Wolfe • Hotchkiss • Pederson • Kozin • Cohen

Green's Operative Hand Surgery

Seventh Edition


HAND


WRIST

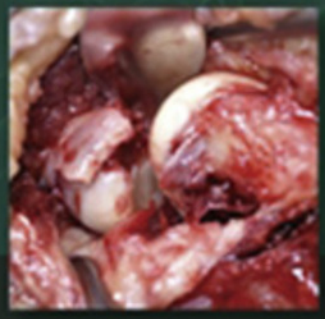
ELBOW


PEDIATRICS

ELSEVIER

Expert CONSULT Built with inkling | E books

Any screen. Any time. Anywhere.



Activate the eBook version
of this title at no additional charge.

Expert Consult eBooks give you the power to browse and find content, view enhanced images, share notes and highlights—both online and offline.

Unlock your eBook today.

1. Visit **expertconsult.inkling.com/redeem**
2. Scratch off your code
3. Type code into "Enter Code" box
4. Click "Redeem"
5. Log in or Sign up
6. Go to "My Library"

It's that easy!

Scan this QR code to redeem your eBook through your mobile device:

Place Peel Off Sticker Here

For technical assistance:
email expertconsult.help@elsevier.com
call 1-800-401-9962 (inside the US)
call +1-314-447-8200 (outside the US)

ELSEVIER

Use of the current edition of the electronic version of this book (eBook) is subject to the terms of the nontransferable, limited license granted on expertconsult.inkling.com. Access to the eBook is limited to the first individual who redeems the PIN, located on the inside cover of this book, at expertconsult.inkling.com and may not be transferred to another party by resale, lending, or other means.

2015v1.0

GREEN'S

OPERATIVE HAND SURGERY

This page intentionally left blank

GREEN'S

OPERATIVE HAND SURGERY

Seventh Edition

Editor in Chief

Scott W. Wolfe, MD
Professor of Orthopaedic Surgery
Weill Medical College of Cornell University;
Emeritus Chief, Hand and Upper Extremity Surgery
Attending Orthopaedic Surgeon
Hospital for Special Surgery
New York, New York

Editors

Robert N. Hotchkiss, MD
Associate Professor of Clinical Orthopaedic Surgery
Weill Medical College of Cornell University;
Associate Attending Orthopaedic Surgeon
Director of Clinical Research
Hospital for Special Surgery
New York, New York

William C. Pederson, MD, FACS
Adjunct Professor of Surgery
The University of Texas Health Science Center;
Fellowship Director
The Hand Center of San Antonio
San Antonio, Texas

Scott H. Kozin, MD
Professor
Department of Orthopaedic Surgery
Temple University School of Medicine;
Chief of Staff
Shriners Hospitals for Children
Philadelphia, Pennsylvania

Mark S. Cohen, MD
Professor
Director, Orthopaedic Education
Director, Hand and Elbow Section
Department of Orthopaedic Surgery
Rush University Medical Center
Chicago, Illinois

ELSEVIER

ELSEVIER

1600 John F. Kennedy Blvd.
Ste 1800
Philadelphia, PA 19103-2899

GREEN'S OPERATIVE HAND SURGERY, SEVENTH EDITION ISBN: 978-1-4557-7427-2

Copyright © 2017 by Elsevier, Inc. All rights reserved.
All contributors retain copyright to the original photographs and video.

No part of this publication may be reproduced or transmitted in any form or by any means, electronic or mechanical, including photocopying, recording, or any information storage and retrieval system, without permission in writing from the publisher. Details on how to seek permission, further information about the Publisher's permissions policies and our arrangements with organizations such as the Copyright Clearance Center and the Copyright Licensing Agency, can be found at our website: www.elsevier.com/permissions.

This book and the individual contributions contained in it are protected under copyright by the Publisher (other than as may be noted herein).

Notices

Knowledge and best practice in this field are constantly changing. As new research and experience broaden our understanding, changes in research methods, professional practices, or medical treatment may become necessary.

Practitioners and researchers must always rely on their own experience and knowledge in evaluating and using any information, methods, compounds, or experiments described herein. In using such information or methods they should be mindful of their own safety and the safety of others, including parties for whom they have a professional responsibility.

With respect to any drug or pharmaceutical products identified, readers are advised to check the most current information provided (i) on procedures featured or (ii) by the manufacturer of each product to be administered, to verify the recommended dose or formula, the method and duration of administration, and contraindications. It is the responsibility of practitioners, relying on their own experience and knowledge of their patients, to make diagnoses, to determine dosages and the best treatment for each individual patient, and to take all appropriate safety precautions.

To the fullest extent of the law, neither the Publisher nor the authors, contributors, or editors, assume any liability for any injury and/or damage to persons or property as a matter of products liability, negligence or otherwise, or from any use or operation of any methods, products, instructions, or ideas contained in the material herein.

Previous years copyrighted: 2011, 2005, 1999, 1993, 1988, 1982

Library of Congress Cataloging-in-Publication Data

Names: Wolfe, Scott W., editor. | Hotchkiss, Robert N., editor. | Pederson, William C., editor. | Kozin, Scott H., editor. | Cohen, Mark S., 1960- , editor.
Title: Green's operative hand surgery / [edited by] Scott W. Wolfe, Robert N. Hotchkiss, William C. Pederson, Scott H. Kozin, Mark S. Cohen.
Other titles: Operative hand surgery
Description: Seventh edition. | Philadelphia, PA : Elsevier, [2017] | Includes bibliographical references and index.
Identifiers: LCCN 2015049498 | ISBN 9781455774272 (hardcover : alk. paper)
Subjects: | MESH: Hand—surgery
Classification: LCC RD559 | NLM WE 830 | DDC 617.5/75059—dc23
LC record available at http://lccn.loc.gov/2015049498

Executive Content Strategist: Dolores Meloni
Content Strategist: Maureen Iannuzzi
Publishing Services Manager: Catherine Jackson
Project Manager: Kate Mannix
Design Direction: Margaret Reid

Printed in China

Last digit is the print number: 9 8 7 6 5 4 3 2 1

Working together to grow libraries in developing countries
www.elsevier.com • www.bookaid.org

CONTRIBUTORS

Brian D. Adams, MD
Professor of Orthopedic Surgery
Baylor College of Medicine
Baylor-St. Luke's Medical Center
Houston, Texas

Julie E. Adams, MD
Associate Professor of Orthopaedic Surgery
Department of Orthopaedic Surgery
Mayo Clinic Health System
Austin, Minnesota

Nidal F. AlDeek, MD, MSc
Department of Plastic and Reconstructive Surgery
Chang Gung Memorial Hospital
Taipei, Taiwan

Edward A. Athanasian, MD
Clinical Professor of Orthopedic Surgery
Weill Cornell Medical College;
Chief, Hand Surgery
Hospital for Special Surgery;
Division of Orthopedics
Department of Surgery
Memorial Sloan Kettering Cancer Center
New York, New York

George S. Athwal, MD, FRCSC
Associate Professor and Consultant
HULC, St. Joseph's Health Care
University of Western Ontario
London, Ontario, Canada

Kodi Azari, MD, FACS
Professor
Orthopaedic Surgery and Plastic Surgery
David Geffen School of Medicine at UCLA
Los Angeles, California

Donald S. Bae, MD
Associate Professor of Orthopaedic Surgery
Department of Orthopaedic Surgery
Harvard Medical School;
Attending Surgeon
Department of Orthopaedic Surgery
Boston Children's Hospital
Boston, Massachusetts

Mark E. Baratz, MD
Vice Chairman
Department of Orthopaedic Surgery
Allegheny General Hospital
Pittsburgh, Pennsylvania

David P. Barei, MD, FRCSC
Professor
Department of Orthopaedic and Sports Medicine
University of Washington;
Director
Orthopedic Trauma Fellowship
Harborview Medical Center
Seattle, Washington

Andrea S. Bauer, MD
Pediatric Hand Surgeon
Department of Orthopaedic Surgery
Shriners Hospital for Children Northern California;
Assistant Clinical Professor
Department of Orthopaedic Surgery
UC Davis School of Medicine
Sacramento, California

Rolfe Birch, MChir, FRCS
Professor
Neurological Orthopaedic Surgery
University College
London, Great Britain

Allen T. Bishop, MD
Professor
Department of Orthopedic Surgery
Mayo Clinic College of Medicine;
Consultant
Division of Hand Surgery
Department of Orthopedic Surgery
Mayo Clinic
Rochester, Minnesota

Paul S. Cederna, MD
Robert O'Neal Collegiate Professor of Plastic Surgery
Section Head, Plastic Surgery
Professor, Department of Biomedical Engineering
University of Michigan School of Medicine
Ann Arbor, Michigan

Neal C. Chen, MD
The Philadelphia and South Jersey Hand Centers, P.C.;
Assistant Professor
Orthopaedic Surgery
Thomas Jefferson University Hospital,
Philadelphia, Pennsylvania

Mark S. Cohen, MD
Professor
Director, Orthopaedic Education
Director, Hand and Elbow Section
Department of Orthopaedic Surgery
Rush University Medical Center
Chicago, Illinois

Roger Cornwall, MD
Associate Professor of Orthopaedic Surgery and Developmental Biology
Clinical Director of Pediatric Orthopaedics
Cincinnati Children's Hospital Medical Center
Cincinnati, Ohio

Timothy R.C. Davis, FRCS, ChM, BSc, MB
Honorary Professor
Nottingham University;
Hand Surgeon
Nottingham University Hospitals
Nottingham, United Kingdom

Charles S. Day, MD, MBA
Associate Professor of Orthopaedic Surgery
Director, Orthopaedic Curriculum
Harvard Medical School;
Orthopaedic Hand and Upper Extremity Surgery
Beth Israel Deaconess Medical Center
Boston, Massachusetts

Rafael J. Diaz-Garcia, MD
Attending Surgeon
Department of Surgery
Division of Plastic Surgery
Allegheny Health Network;
Clinical Assistant Professor
Department of Plastic Surgery
University of Pittsburgh School of Medicine
Pittsburgh, Pennsylvania

George S.M. Dyer, MD
Orthopaedic Hand Surgeon
Department of Orthopaedic Surgery
Brigham and Women's Hospital
Boston, Massachusetts

Charles Eaton, MD
Executive Director
Dupuytren Foundation
Palm Springs, Florida

Bassem T. Elhassen, MD
Assistant Professor of Orthopaedic Surgery
Department of Orthopaedics
Mayo Clinic
Rochester, Minnesota

Paul Feldon, MD
Chief, Hand Surgery Service
Newton Wellesley Hospital
Newton, Massachusetts;
Clinical Associate Professor of Orthopaedic Surgery
Tufts University School of Medicine
Boston, Massachusetts

Jeffrey B. Friedrich, MD, FACS
Associate Professor of Surgery and Orthopaedics
Department of Surgery
University of Washington
Seattle, Washington

Marc Garcia-Elias, MD, PhD
Consultant Hand Surgeon
Hand and Upper Extremity Surgery
Institut-Kaplan
Barcelona, Spain

William B. Geissler, MD
Professor and Chief, Alan E. Freeland Chair of Hand Surgery
Division of Hand and Upper Extremity Surgery
University of Mississippi Health Care
Jackson, Mississippi

Günter Germann, MD, PhD
Professor of Plastic and Hand Surgery
ETHIANUM Heidelberg Clinic for Plastic, Reconstructive, and Aesthetic Surgery, Preventative Medicine
The University of Heidelberg
Heidelberg, Germany

Vidal Haddad, Jr., MD, MSc, PhD
Associate Professor
Department of Dermatology
Botucatu Medical School
São Paulo State University
Botucatu, São Paulo, Brazil

Douglas P. Hanel, MD
Professor
Department of Orthopaedic and Sports Medicine
Director of Orthopaedic Education
University of Washington
Seattle, Washington

Hill Hastings, MD
Past Clinical Professor, Orthopedic Surgery
Indiana University
Telluride, Colorado

James P. Higgins, MD
Chief of Hand Surgery
The Curtis National Hand Center
MedStar Union Memorial Hospital
Baltimore, Maryland

Robert N. Hotchkiss, MD
Associate Professor of Clinical Orthopaedic Surgery
Weill Medical College of Cornell University;
Associate Attending Orthopaedic Surgeon
Director of Clinical Research
Hospital for Special Surgery
New York, New York

Manuel Hrabowski, MD
ETHIANUM Heidelberg Clinic for Plastic, Reconstructive, and Aesthetic Surgery, Preventative Medicine
Heidelberg, Germany

Michelle A. James, MD
Professor of Clinical Orthopaedic Surgery
Chief, Pediatric Orthopaedic Service
UC Davis School of Medicine;
Chief, Orthopaedic Surgery
Shriners Hospital for Children of Northern California
Sacramento, California

Neil F. Jones, MD
Chief of Hand Surgery
University of California Irvine Medical Center;
Professor of Orthopaedic Surgery and Professor of Plastic and Reconstructive Surgery
University of California Irvine School of Medicine
Orange, California;
Attending Hand Surgeon
Shriners Hospital
Los Angeles, California

Jesse B. Jupiter, MD
Hansjörg Wyss Professor of Orthopaedic Surgery
Harvard Medical School;
Hand and Upper Extremity Division
Massachusetts General Hospital
Boston, Massachusetts

Sanjeev Kakar, MD, MRCS
Associate Professor
Department of Orthopaedic Surgery
Mayo Clinic
Rochester, Minnesota

Morton L. Kasdan, MD
Clinical Professor of Plastic Surgery
University of Louisville
Louisville, Kentucky

Simon P. Kay, BA, BM BCh, FRCS (Plas), FRCSE (Hon)
Consultant Plastic Surgeon
Department of Plastic Surgery
Leeds Teaching Hospitals NHS Trust;
Professor of Hand Surgery
University of Leeds
Leeds, Great Britain

Graham J.W. King
Director, Roth McFarlane Hand and Upper Limb Centre
Chief of Surgery
St. Joseph's Health Centre;
Professor of Orthopaedic Surgery and Biomedical Engineering
Western University
London, Ontario, Canada

L. Andrew Koman, MD
Professor and Chair
Department of Orthopaedic Surgery
Wake Forest School of Medicine
Winston-Salem, North Carolina

Scott H. Kozin, MD
Clinical Professor
Department of Orthopaedic Surgery
Temple University School of Medicine;
Chief of Staff
Shriners Hospital for Children
Philadelphia, Pennsylvania

Steve K. Lee, MD
Associate Professor of Orthopaedic Surgery
Weill Cornell Medical College;
Associate Attending Orthopaedic Surgeon
Orthopaedic Surgery
Hospital for Special Surgery
New York, New York

Fraser J. Leversedge, MD
Associate Professor and Vice-Chair
Director, Hand, Upper Extremity, and Microvascular Surgery Fellowship
Department of Orthopaedic Surgery
Duke University
Durham, North Carolina

Nina Lightdale-Miric, MD
Assistant Clinical Professor of Orthopaedic Surgery
Keck School of Medicine
University of Southern California;
Director, Hand and Upper Extremity Surgery
Children's Hospital Los Angeles
Los Angeles, California

Graham D. Lister, MD
Former Professor and Chief
Division of Plastic Surgery
University of Utah School of Medicine
Salt Lake City, Utah

Alberto L. Lluch, MD, PhD
Consultant Hand Surgeon
Hand and Upper Extremity Surgery
Institut-Kaplan
Barcelona, Spain

Dean S. Louis, MD
Professor of Surgery
University of Michigan
Ann Arbor, Michigan

Susan E. Mackinnon, MD, FRCSC
Schoenberg Professor and Chief
Division of Plastic and Reconstructive Surgery
Washington University School of Medicine
St. Louis, Missouri

David B. McCombe, MBBS, MD, FRACS
Senior Lecturer
Department of Surgery
St. Vincent's Hospital
University of Melbourne
Melbourne, Victoria, Australia

Greg Merrell, MD
Indiana Hand to Shoulder Center
Indianapolis, Indiana

Richard Meyer, MD
Associate Professor
Department of Surgery
University of Alabama
Birmingham, Alabama

Lewis H. Millender, MD[†]
Clinical Professor of Orthopaedic Surgery
Tufts University School of Medicine
Boston, Massachusetts

Peter M. Murray, MD
Professor and Chairman
Department of Orthopaedic Surgery
Consultant
Department of Orthopaedic Surgery and Neurosurgery
Mayo Clinic;
Staff Physician
Department of Orthopaedic Surgery
Nemours Children's Clinic
Jacksonville, Florida

Edward A. Nalebuff, MD
Emeritus Surgeon
New England Baptist Hospital;
Emeritus Professor of Orthopaedic Surgery
Tufts University School of Medicine
Boston, Massachusetts

David T. Netscher, MD
Clinical Professor of Plastic Surgery and Orthopedic Surgery
Baylor College of Medicine
Houston, Texas;
Adjunct Professor of Clinical Surgery
Weill Medical College;
Adjunct Professor of Clinical Surgery
Cornell University
New York, New York

Christine B. Novak, PT, PhD
Associate Professor
Division of Plastic and Reconstructive Surgery
University of Toronto;
Scientist and Research Associate
University Health Network
Toronto, Ontario, Canada

Mukund R. Patel, MD, FACS
Chief of Hand Surgery
Associate Clinical Professor, Orthopedic Surgery
New York University Medical Center;
Attending Hand Surgeon
Hospital for Joint Diseases;
Chief of Hand Surgery
Department of Orthopedics
Richmond University Medical Center
New York, New York

William C. Pederson, MD, FACS
Adjunct Professor of Surgery
The University of Texas Health Science Center;
Fellowship Director
The Hand Center of San Antonio
San Antonio, Texas

Tom Quick, MB, MA(Hons)Cantab, FRCS(Tr & Orth)
Consultant Surgeon
Peripheral Nerve Injury Unit
Royal National Orthopaedic Hospital
Middlesex, United Kingdom;
Honorary Consultant
Defence Medical Rehabilitation Centre
Headley Court
Surrey, United Kingdom;
Honorary Consultant Surgeon
Great Ormond Street Hospital for Sick Children;
Honorary Senior Lecturer
Institute of Orthopaedics and Musculoskeletal Science
University College Hospital
London, United Kingdom

David Ring, MD, PhD
Professor of Orthopaedic Surgery
Harvard Medical School;
Chief of Hand Surgery
Massachusetts General Hospital
Boston, Massachusetts

Marco Rizzo, MD
Professor
Department of Orthopedic Surgery
Chair, Division of Hand Surgery
Mayo Clinic
Rochester, Minnesota

Trajano Sardenberg, MD, PhD
Professor of Orthopaedic, Traumatology, and Hand Surgery
Department of Surgery and Orthopaedics
Botucatu Medical School
São Paulo State University
Botucatu, São Paulo, Brazil

John Gray Seiler III, MD
Clinical Professor of Orthopaedic Surgery
Emory University
Georgia Hand, Shoulder, & Elbow Surgery
Atlanta, Georgia

Frances Sharpe
Assistant Clinical Professor of Orthopedics
University of Southern California, Keck School of Medicine;
Orthopedics and Hand Surgery
Southern California Permanente Medical Group
Fontana, California

[†]Deceased.

Alexander Y. Shin, MD
Professor & Consultant
Orthopedic Surgery
Mayo Clinic
Rochester, Minnesota

Beth Paterson Smith, PhD
Professor
Department of Orthopaedic Surgery
Wake Forest School of Medicine
Winston-Salem, North Carolina

Thomas L. Smith, PhD
Professor
Department of Orthopaedic Surgery
Wake Forest School of Medicine
Winston-Salem, North Carolina

Nicole Z. Sommer, MD, FACS
Associate Professor
Department of Plastic Surgery
Southern Illinois School of Medicine
Springfield, Illinois

Robert J. Spinner, MD
Chair, Department of Neurologic Surgery
Burton M. Onofrio Professor of Neurosurgery
Professor of Orthopedics and Anatomy
Mayo Clinic
Rochester, Minnesota

Scott P. Steinmann, MD
Professor of Orthopaedic Surgery
Department of Orthopaedic Surgery
Mayo Clinic
Rochester, Minnesota

Milan V. Stevanovic, MD
Director of the Joseph H. Boyes Hand Fellowship Program
Professor of Orthopedics and Surgery
Department of Orthopedics
University of Southern California Keck School of Medicine
Los Angeles, California

Robert J. Strauch, MD
Professor of Orthopaedic Surgery
Columbia University Medical Center
New York, New York

Andrew L. Terrono, MD
Chief, Hand Surgery Service
New England Baptist Hospital;
Clinical Professor of Orthopaedic Surgery
Tufts University School of Medicine
Boston, Massachusetts

Ann E. Van Heest, MD
Professor and Vice Chair of Education
Department of Orthopedic Surgery
University of Minnesota
Minneapolis, Minnesota

Nicholas B. Vedder, MD
Professor & Chief of Plastic Surgery
Department of Surgery
University of Washington
Seattle, Washington

Peter M. Waters, MD
John E. Hall Professor of Orthopaedic Surgery
Harvard Medical School;
Orthopedic Surgeon in Chief
Children's Hospital
Boston, Massachusetts

Fu-Chan Wei, MD
Department of Plastic and Reconstructive Surgery
Chang Gung Memorial Hospital
Taipei, Taiwan

Scott W. Wolfe, MD
Professor of Orthopaedic Surgery
Weill Medical College of Cornell University;
Emeritus Chief, Hand and Upper Extremity Surgery
Attending Orthopaedic Surgeon
Hospital for Special Surgery
New York, New York

Elaine Yang, MD
Clinical Instructor
Department of Anesthesiology
Weill Cornell Medical College;
Assistant Attending
Department of Anesthesiology and Critical Care Medicine
Hospital for Special Surgery
New York, New York

Dan A. Zlotolow, MD
Associate Professor of Orthopaedics
Temple University School of Medicine;
Attending Physician
Shriners Hospital for Children
Philadelphia, Pennsylvania

FOREWORD FOR THE SEVENTH EDITION

Who would have thought when the first edition of *Operative Hand Surgery* was published in 1982 that nearly three and a half decades later we would be publishing the seventh edition and the book would be sold in more than 50 countries? The success of this book has been due to three main factors: (1) Careful selection of experienced authors with recognized expertise who are willing to invest the huge time and energy commitment that it takes to write an outstanding chapter (and people who are willing to make that commitment are becoming increasingly difficult to recruit); (2) meticulous dissection and critique of each chapter by the editors, another job that requires a mammoth expenditure of hours; and (3) the worldwide explosion of interest in hand surgery and the blossoming of national hand societies throughout the world (56 at last count). In 1982, we were fortunate to be at the right place at the right time.

A huge debt of gratitude is due to the contributors of the seventh edition, who made the decision to write a chapter, which demanded that they forego more pleasurable or financially productive pursuits. I am especially grateful to Scott Wolfe, who picked up the mantle of editor-in-chief and has devoted the time and effort necessary to oversee and direct the last two editions. He has more than justified the confidence we had in choosing him for this job over many other equally qualified hand surgeons. To my good friends and former practice partners, Bob Hotchkiss and Chris Pederson, I cannot thank you enough for what you have done to stick with this book through several editions. Over many years, we have laughed, we have cried, and we have anguished together over the peaks and valleys of bringing to life this large body of work. And to the new editors, Scott Kozin and Mark Cohen, I extend my appreciation for their commitment to this demanding process. Your only reward will be knowing that someone, somewhere will benefit from your efforts.

One other person deserves credit that is long overdue. Lewis Reines was president of the American division of Churchill Livingstone in the late 1970s, and *Operative Hand Surgery* was his idea. I had wanted to do a small book on some topic in hand surgery, but Lew said, "No, do the big book." This text would never have come into being without his foresight, encouragement, and expert guidance during those early years.

David P. Green, MD
San Antonio, TX
September 2016

PREFACE

"See one, do one, teach one" was the mantra of our past generation of surgical mentors. This rubric was emblematic of a surgical apprenticeship style of learning that had been effective for centuries. But implicit in this approach is a trial and error mentality that may only have worked in a day of lower expectations and a more narrow understanding of disease. The last half century has witnessed an explosion of technological advancements, increased scientific knowledge base, and surgical complexity, coupled with parallel changes in health care financing, regulation, and work hour restrictions that challenge our ability to teach effectively.

The average adult learner requires not one, but *seven* exposures to learn a new concept, and retention becomes even more difficult if the learning occurs over a short, intense study period. Similarly, psychological theory holds that it may take as many as 10,000 repetitions to master a technique or a skill. How then can a medical student, or even an accomplished surgeon, master a surgical reconstruction of a disorder that he or she may only see twice in a career? Benjamin Franklin quipped, "Experience keeps a dear school, but fools will learn in no other." Experience alone is not a panacea, however, as one can practice and engrain incorrect techniques. Experience should be accompanied by feedback and reinforcement, such that when skill acquisition is accompanied by reading, learning, and coaching, repetition will lead to mastery.

Enter *Green's Operative Hand Surgery*, a concept that was introduced 35 years and six editions ago, and one that has remained the backbone of hand surgical learning since. David Green invited recognized masters of specific hand surgical techniques to pool their talents to create an enduring resource of expert techniques, a synthesis of current publications and novel research, and the hugely successful guide to success: the *Author's Preferred Technique.* In this book, you can immerse yourself in concise tutorials of what works and what doesn't, learn the evidence and the anecdotes that contribute to success, and enlist the surgical mentoring of nearly a hundred recognized experts in hand surgery. The electronic version of *Green's Operative Hand Surgery,* available at ExpertConsult.com, does not simply duplicate the written content but expands on it, with volumes of illustrative cases, an expert classroom of 60 video techniques, classic chapters from archived editions, and regular online updates of emerging techniques that promise to change the landscape of tomorrow's hand surgery. Through the intensely dedicated work of its five editors, *Green's* can sharpen the skills of hand surgeons worldwide and excite present and future students of hand surgery. Welcome to *Green's Operative Hand Surgery*, seventh edition.

Scott W. Wolfe, MD

ACKNOWLEDGMENTS

Publishing a multimedia reference of this magnitude requires an enormous team effort and unanimity of purpose. I'd first like to thank Dave Green for his confidence in entrusting his brainchild with me and for giving me the amazing opportunity to expand our hand educational borders across the globe. On behalf of our readership, a huge shout-out to our expert authors for their countless hours away from family and work, their exquisite attention to the details and principles of *Operative Hand Surgery*, and their dedication to education. Many of our authors wrote their chapters single-handedly, which, in the spirit of the inaugural edition of *Green's*, gives our readers firsthand exposure to their thoughts, tips, and techniques. What may be less apparent is the luster given to each chapter by our incredible editorial team, whose proficiency and dedication make *Green's* the foundational resource of hand surgery. I am indebted to my trusted colleagues Bob Hotchkiss and Chris Pederson, who have devoted their expertise in microsurgery and elbow reconstruction for more than twenty years and five editions to hone these gems to perfection. We are incredibly fortunate to have attracted Scott Kozin, a thought leader in pediatrics and congenital hand, to complete a comprehensive revision of our pediatric section in the sixth edition. With the seventh edition, I'm delighted to welcome longtime friend and colleague Mark Cohen, also a prolific writer and exemplary educator, as our newest associate editor. Special thanks as well to Jonathan Isaacs and David Dennison, whose innovative ideas and commitment will make the electronic version of *Green's Operative Hand Surgery* a true living, interactive, and fully accessible bridge between the print editions.

I'd particularly like to thank the outstanding staff of Elsevier for assuring the highest quality print and online publications. From its inception six years ago, the content strategy team of Don Scholz, Helene Caprari, and Dolores Meloni have sculpted the first fully integrated print and online edition to ensure that *Green's* is available where you are. I'm indebted to my go-to person and content strategist Maureen Iannuzzi, who choreographed the entire production from its start to its launch, gently coaxing, convincing, and cajoling our writers and editors across the finish line. Special thanks to our illustrator, Wendy Beth Jackelow, for bringing these pages to life with abundant new color drawings, and to our project manager, Kate Mannix, for transforming our concepts and documents into the published multimedia finale.

Most importantly, I want to thank my family: my incredible children, William, Elizabeth, and Christian, for giving me free passes for too many weekends holed up in the office; and most of all, my wife Missy: my best friend, historian, and trusted advisor, whose sacrifice, patience, and wisdom inspired me to complete this work.

Scott W. Wolfe, MD

This page intentionally left blank

CONTENTS

VOLUME 1

PART I Basic Principles

1 **Anesthesia,** 1
Elaine Yang

PART II Hand

2 **Acute Infections of the Hand,** 17
Milan V. Stevanovic and Frances Sharpe
3 **Chronic Infections,** 62
Mukund R. Patel
4 **Dupuytren Disease,** 128
Charles Eaton
5 **Extensor Tendon Injury,** 152
Robert J. Strauch
6 **Flexor Tendon Injury,** 183
John Gray Seiler III
7 **Fractures of the Metacarpals and Phalanges,** 231
Charles S. Day
8 **Dislocations and Ligament Injuries of the Digits,** 278
Greg Merrell and Hill Hastings
9 **Perionychium,** 318
Nicole Z. Sommer
10 **Treatment of the Stiff Finger and Hand,** 338
Robert N. Hotchkiss
11 **Treatment of the Osteoarthritic Hand and Thumb,** 345
Peter M. Murray

PART III Wrist

12 **Wrist Arthrodesis and Arthroplasty,** 373
Marco Rizzo
13 **Wrist Instabilities, Misalignments, and Dislocations,** 418
Marc Garcia-Elias and Alberto L. Lluch
14 **Distal Radioulnar Joint,** 479
Brian D. Adams and Fraser J. Leversedge
15 **Distal Radius Fractures,** 516
Scott W. Wolfe
16 **Fractures of the Carpal Bones,** 588
Steve K. Lee
17 **Wrist Arthroscopy,** 653
William B. Geissler

PART IV Elbow and Forearm

18 **Fractures of the Distal Humerus,** 697
David P. Barei and Douglas P. Hanel
19 **Fractures of the Radial Head,** 734
Graham J.W. King
20 **Fractures of the Proximal Ulna,** 770
George S.M. Dyer and David Ring
21 **Disorders of the Forearm Axis,** 786
Mark E. Baratz
22 **Complex Traumatic Elbow Dislocation,** 813
George S.M. Dyer and Jesse B. Jupiter
23 **Chronic Elbow Instability: Ligament Reconstruction,** 830
Mark S. Cohen
24 **Treatment of the Stiff Elbow,** 843
Robert N. Hotchkiss
25 **Elbow Tendinopathies and Tendon Ruptures,** 863
Julie E. Adams and Scott P. Steinmann
26 **Elbow Arthroscopy,** 885
George S. Athwal
27 **Total Elbow Arthroplasty,** 905
Mark S. Cohen and Neal C. Chen

PART V Nerves

28 **Compression Neuropathies,** 921
Susan E. Mackinnon and Christine B. Novak
29 **Thoracic Outlet Compression Syndrome,** 959
Richard Meyer

VOLUME 2

30 **Nerve Injury and Repair,** 979
Rolfe Birch and Tom Quick
31 **Principles of Tendon Transfers of Median, Radial, and Ulnar Nerves,** 1023
Timothy R.C. Davis
32 **Spasticity: Cerebral Palsy and Traumatic Brain Injury,** 1080
Scott H. Kozin and Nina Lightdale-Miric
33 **Tetraplegia,** 1122
Ann E. Van Heest
34 **Traumatic Brachial Plexus Injury,** 1146
Robert J. Spinner, Alexander Y. Shin, Bassem T. Elhassan, and Allen T. Bishop

PART VI Pediatric Hand

35 **Embryology of the Upper Extremity,** 1208
Scott H. Kozin
36 **Deformities of the Hand and Fingers,** 1217
Simon P. Kay, David B. McCombe, and Scott H. Kozin
37 **Deformities of the Thumb,** 1289
Scott H. Kozin
38 **Malformations and Deformities of the Wrist and Forearm,** 1328
Michelle A. James and Andrea S. Bauer

39 **Arthrogryposis,** 1365
Dan A. Zlotolow
40 **Pediatric Brachial Plexus Palsy,** 1391
Roger Cornwall and Peter M. Waters
41 **Hand, Wrist, and Forearm Fractures in Children,** 1425
Donald S. Bae

PART VII Bone and Soft Tissue Reconstruction

42 **Replantation,** 1476
James P. Higgins
43 **Mangled Upper Extremity,** 1486
Jeffrey B. Friedrich and Nicholas B. Vedder
44 **Nonmicrosurgical Coverage of the Upper Extremity,** 1528
William C. Pederson
45 **Free Flaps to the Hand and Upper Extremity,** 1574
Neil F. Jones and Graham D. Lister
46 **Vascularized Bone Grafting,** 1612
Allen T. Bishop and Alexander Y. Shin
47 **Toe-to-Hand Transplantation,** 1643
Fu-Chan Wei and Nidal F. AlDeek
48 **Thumb Reconstruction,** 1674
Kodi Azari

PART VIII Other Disorders of the Upper Extremity

49 **Digital Amputations,** 1708
Sanjeev Kakar
50 **Major Limb Amputations and Prosthetics,** 1753
Rafael J. Diaz-Garcia and Paul S. Cederna
51 **Compartment Syndrome and Volkmann Ischemic Contracture,** 1763
Milan V. Stevanovic and Frances Sharpe
52 **Management of Venomous Injuries,** 1788
Vidal Haddad, Jr., and Trajano Sardenberg
53 **A Practical Guide for Complex Regional Pain Syndrome in the Acute Stage and Late Stage,** 1797
L. Andrew Koman, Beth Paterson Smith, and Thomas L. Smith
54 **Factitious Disorders,** 1828
Dean S. Louis and Morton L. Kasdan
55 **Rheumatoid Arthritis and Other Connective Tissue Diseases,** 1832
Paul Feldon, Andrew L. Terrono, Edward A. Nalebuff, and Lewis H. Millender
56 **Tendinopathy,** 1904
Scott W. Wolfe
57 **Burned Hand,** 1926
Günter Germann and Manuel Hrabowski
58 **Skin Tumors of the Hand and Upper Extremity,** 1958
David T. Netscher
59 **Bone and Soft Tissue Tumors,** 1987
Edward A. Athanasian
60 **Vascular Disorders of the Hand,** 2036
William C. Pederson

Classic Chapters*

Classic: General Principles
Classic: Radial Nerve
Classic: Stiff Joints
Classic: Principles of Microvascular Surgery
William C. Pederson

Index, I1

*Available on ExpertConsult.com

VIDEO CONTENTS

PART II: Hand

Chapter 4 Dupuytren Disease
4.1 Collagenase injection for Dupuytren contracture—Larry Hurst

Chapter 5 Extensor Tendon Injury
5.1 Subluxation of extensor carpi ulnaris—Robert J. Strauch

Chapter 6 Flexor Tendon Injury
6.1 Flexor tendon repair—Scott W. Wolfe
6.2 Paneva-Holevich technique for chronic tendon laceration—John S. Taras and Robert A. Kaufman

Chapter 11 Treatment of the Osteoarthritic Hand and Thumb
11.1 Volar approach for proximal interphalangeal joint implant arthroplasty—Peter C. Amadio
11.2 Physical examination for osteoarthritis of the thumb—Peter M. McMurray

PART III: Wrist

Chapter 12 Wrist Arthrodesis and Arthroplasty
12.1 Re-motion total wrist arthroplasty—Marco Rizzo
12.2 Radiolunate arthrodesis with ligament-sparing approach—Marco Rizzo

Chapter 13 Wrist Instabilities, Misalignments, and Dislocations
13.1 Dorsal view of a dissected cadaveric wrist set in a jig that allows isometric loading of different tendons—Marc Garcia-Elias and Alberto Lluch
13.2 Dynamic 3D computed tomography (also known as 4D computed tomography) of a patient with a scapholunate dissociation while performing dart thrower's exercises—Marc Garcia-Elias and Alberto Lluch
13.3 Clinical example of a catch-up clunk phenomenon in a patient with carpal instability nondissociative-volar intercalated segmental instability—Marc Garcia-Elias and Alberto Lluch
13.4 Volar approach of a perilunate dislocation—Marc Garcia-Elias and Alberto Lluch

Chapter 14 Distal Radioulnar Joint
14.1 Dynamic ultrasound for tendinopathy—Scott W. Wolfe

Chapter 15 Distal Radius Fractures
15.1 Insertion of a novel intramedullary device for locked fixation of articular fractures—Scott W. Wolfe

Chapter 16 Fractures of the Carpal Bones
16.1 Arthroscopic fixation scaphoid of nonunion—William Geissler and Joseph F. Slade

Chapter 17 Wrist Arthroscopy
17.1 Diagnostic arthroscopy—Scott W. Wolfe

PART IV: Elbow and Forearm

Chapter 19 Fractures of the Radial Head
19.1 Open reduction and internal fixation of the radial head—Graham J.W. King
19.2 Radial head replacement—Wright Medical Technology

Chapter 25 Elbow Tendinopathies and Tendon Ruptures
25.1 Endobutton single-incision repair of the distal biceps tendon—Julie A. Adams and Scott P. Steinmann

PART V: Nerves

Chapter 28 Compression Neuropathies
28.1 Carpal tunnel release—standard—Susan E. Mackinnon, Christine B. Novak, and Andrew Yee
28.2 Carpal tunnel release–extended—Susan E. Mackinnon, Christine B. Novak, and Andrew Yee
28.3 Median nerve forearm decompression–standard—Susan E. Mackinnon, Christine B. Novak, and Andrew Yee
28.4 Median nerve release in the forearm—Susan E. Mackinnon, Christine B. Novak, and Andrew Yee
28.5 Guyon canal and carpal tunnel release–standard—Susan E. Mackinnon, Christine B. Novak, and Andrew Yee
28.6 Submuscular ulnar nerve transposition–standard—Susan E. Mackinnon, Christine B. Novak, and Andrew Yee
28.7 Transmuscular ulnar nerve transposition—Susan E. Mackinnon, Christine B. Novak, and Andrew Yee
28.8 Posterior interosseous nerve release—Susan E. Mackinnon, Christine B. Novak, and Andrew Yee
28.9 Revision carpal tunnel release—Susan E. Mackinnon, Christine B. Novak, and Andrew Yee
28.10 Revision carpal tunnel release, part I—Susan E. Mackinnon, Christine B. Novak, and Andrew Yee

Chapter 29 Thoracic Outlet Compression Syndrome
29.1 Resection with improved pulse—Scott W. Wolfe

Chapter 32 Spasticity: Cerebral Palsy and Traumatic Brain Injury
32.1 Athetoid cerebral palsy—Scott H. Kozin
32.2 Upper extremity examination of hemiplegia—Scott H. Kozin

Chapter 33 Tetraplegia
33.1 Brachioradialis to flexor pollicis longus and extensor carpi radialis longus to flexor digitorum brevis transfers—Scott H. Kozin
33.2 Biceps to triceps transfer—Scott H. Kozin
33.3 Patient outcome video after biceps to triceps, brachioradialis to flexor pollicis longus, and extensor carpi radialis longus to flexor digitorum brevis transfers—Scott H. Kozin

33.4 Additional patient outcome video after biceps to triceps, brachioradialis to flexor pollicis longus, and extensor carpi radialis longus to flexor digitorum brevis transfers—Scott H. Kozin
33.5 Patient outcome video after biceps to triceps, brachioradialis to flexor pollicis longus, and extensor carpi radialis longus to flexor digitorum brevis transfers—Scott H. Kozin
33.6 Additional patient outcome video after biceps to triceps, brachioradialis to flexor pollicis longus, and extensor carpi radialis longus to flexor digitorum brevis transfers—Scott H. Kozin

PART VI: Pediatric Hand

Chapter 36 Deformities of the Hand and Fingers
36.1 Cleft hand—Scott H. Kozin
36.2 Symbrachydactyly—Scott H. Kozin

Chapter 37 Deformities of the Thumb
37.1 Opposition transfer and ulnar collateral ligament reconstruction for type II thumb hypoplasia—Scott H. Kozin and Dan A. Zlotolow
37.2 Thumb reconstruction follow-up 1—Scott H. Kozin
37.3 Thumb reconstruction follow-up 2—Scott H. Kozin
37.4 Pollicization type IIIB thumb hypoplasia with vascularized adipose flap—Dan A. Zlotolow and Scott H. Kozin
37.5 Testimonial: Tucker's story—Scott H. Kozin

Chapter 39 Arthrogryposis
39.1 Stiletto flap metacarpophalangeal joint chondrodesis for the clasped thumb—Scott H. Kozin and Dan A. Zlotolow

Chapter 40 Pediatric Brachial Plexus Palsy
40.1 Brachial plexus examination of the infant—Scott H. Kozin
40.2 Ulnar-to-musculocutaneous nerve transfer (Oberlin transfer)—Scott H. Kozin
40.3 Open joint reduction and latissimus dorsi/teres major tendon transfer—Scott H. Kozin

Chapter 41 Hand, Wrist, and Forearm Fractures in Children
41.1 Closed reduction and percutaneous fixation of a unicondylar fracture—Scott H. Kozin
41.2 Open reduction and screw fixation of scaphoid fracture with distal radial bone graft and superficial volar branch of the radial artery vascular pedicle transfer—Dan A. Zlotolow
41.3 Closed reduction and percutaneous pinning of a distal radius fracture—Scott H. Kozin

PART VIII: Other Disorders of the Upper Extremity

Chapter 49 Digital Amputations
49.1 Flexor digitorum superficialis tenodesis for proximal phalangeal amputation—Sanjeev Kakar

Chapter 51 Compartment Syndrome and Volkmann Ischemic Contracture
51.1 Surgical technique of upper extremity fasciotomy, cadaver demonstration—Milan V. Stevanovic and Frances Sharpe
51.2 Ten-year follow-up on flexor origin slide for "moderate"-type Volkmann contracture—Milan V. Stevanovic and Frances Sharpe
51.3 Eighteen-month follow-up on functional free muscle transfer for finger flexion for "severe"-type Volkmann contracture—Milan V. Stevanovic and Frances Sharpe

Chapter 55 Rheumatoid Arthritis and Other Connective Tissue Diseases
55.1 Metacarpophalangeal arthroplasty in rheumatoid arthritis—Andrew L. Terrono

Chapter 56 Tendinopathy
56.1 Percutaneous trigger finger release—Mukund R. Patel
56.2 Dynamic ultrasound—Scott W. Wolfe

1

Anesthesia

Elaine Yang

Acknowledgments: The author wishes to recognize the work of previous authors Drs. Lauren Fisher and Michael Gordon for their contributions to Green's Operative Hand Surgery *and to this manuscript.*

There are several techniques for providing anesthesia for hand surgery. This chapter provides an overview, illustrating both the risks and benefits of each. General anesthesia will be briefly discussed and regional techniques will be addressed, as well as the unique role that regional anesthesia plays in both operative anesthesia and postoperative analgesia for hand surgery.

GENERAL ANESTHESIA

General anesthesia has long been the technique of choice for surgical procedures, using either traditional endotracheal intubation or the newer laryngeal mask airway. Considered fast and reliable, it is the standard of care at many institutions. Unfortunately, it also has its share of complications, because the systemic administration of medication can cause derangements of other organ systems, including the brain, the heart, the lungs, the airways, and the gastric, endocrine, and renal systems. General anesthesia often calls for airway manipulation, which causes additional associated complications ranging from minor sore throat and hoarseness to more feared, serious complications, including laryngospasm, aspiration, or failed airway. These serious complications are relatively rare; more prevalent are the minor complications of nausea and vomiting, grogginess, or pain requiring further treatment.[47]

REGIONAL ANESTHESIA

Regional anesthesia is the anesthetic of choice at our institution and is especially suited to upper extremity surgery, as most patients are ambulatory. For inpatients, regional anesthesia is associated with less time spent in the recovery room, improved pain control, lower opiate consumption, and less nausea and vomiting.[46] Regional blockade can be used alone as an intraoperative anesthetic or as a supplement to general anesthesia.

Contraindications

Absolute Contraindications

The two absolute contraindications to regional anesthesia are (1) patient refusal and (2) infection at the site of needle insertion. Often patients refuse regional anesthesia because they have been inadequately educated preoperatively or are misinformed about it. However, many common fears regarding regional anesthesia can be dispelled with a forthright discussion.[115] For instance, patient surveys reveal concerns regarding discomfort during needle placement or awareness of the surgical procedure.[28] These concerns are easily allayed with adequate premedication and sedation. In fact, a regional technique would be advantageous to the patient wishing to minimize sedation and remain awake.

Relative Contraindications

Need for Assessing Postoperative Nerve Status or Compartment Syndrome. Because a successful block hinders motor and sensory conduction, nerve testing in the immediate postoperative period is not possible. Therefore, if an immediate postoperative assessment of nerve function is required, a regional block should not be used.

Fear of masking postoperative compartment syndrome is another relative contraindication to regional anesthesia. Compartment syndrome is diagnosed from both the subjective history and objective findings, especially compartment pressure measurements.[49] Pain in the postoperative period is estimated to precede changes in neurovascular status by 7.3 hours but can be masked by the use of nerve blockade provided for analgesia. Even more confusing, there are also reported cases of compartment syndrome being masked by intravenous (IV) morphine administration during patient-controlled analgesia.[118] Concern for the development of compartment syndrome should be conveyed prior to the start of the case and a plan for postoperative pain control determined at that time. Appropriate vigilance is needed and measurement of compartment pressures mandatory if suspicion for increased compartment pressures exists.

Aggravating a Preexisting Nerve Injury. Another concern is the possibility that regional nerve blockade will incite further nerve injury (double-crush phenomenon) in patients with preexisting

nerve injury or paresthesias.[13,83] While this is an understandable concern, experience has shown that regional nerve blockade remains an appropriate option for patients undergoing uncomplicated procedures such as ulnar nerve transposition[50] and the vast majority of elective upper extremity operations.

At our institution, most surgeons and anesthesiologists, in consultation with the patient, opt for the use of regional nerve blockade, even in cases of existing nerve injury or dysfunction. The demonstrated safety of newer techniques (described in the following) and benefit of pain control outweigh the unlikely risk of nerve injury. It is important to discuss the advantages and disadvantages with the patient, allowing him or her to participate in decision making, especially when nerve dysfunction preexists. For patients who appear to fear further nerve injury, we often opt to use general anesthesia with local anesthesia at the surgical site in order to avoid adding a perceived risk and uncertainty to the fears of an already anxious patient.

Anticoagulation Therapy. A relative concern among regional anesthesiologists is performing regional blockade in patients who are taking anticoagulants. More and more patients presenting for surgery are already taking anticoagulants for treatment of underlying coronary artery disease, atrial fibrillation, or cerebrovascular disease or for prevention or treatment of deep venous thrombosis. An injury or even the stress of surgery itself, along with a prothrombotic tissue insult, places anticoagulated patients at risk for development of postoperative deep and superficial venous thrombosis and leads many practitioners to prescribe antithrombotic measures to prevent its occurrence.[90]

Regional neuraxial (spinal or epidural) anesthesia does not contribute to venous thrombosis in patients not receiving anticoagulation therapy and, in fact, has been shown to reduce the rate of blood clots following lower extremity and abdominal surgery, though this advantage has been minimized in recent years with the advent of aggressive and risk-appropriate thromboprophylaxis.[93] Postulated mechanisms include sympathetic blockade leading to improved blood flow and decreased sympathetic stimulation, as well as a direct antithrombotic effect of the local anesthetic solution. However, neuraxial regional anesthesia is contraindicated in the fully anticoagulated patient, given the risk of epidural hematoma and subsequent devastating neural injury. Performance of deep plexus blocks in this setting, though, remains practitioner-dependent. Although few case reports exist of retroperitoneal hematoma following deep lumbar plexus blockade in anticoagulated patients, the relative safety of this technique was confirmed in a large study of 670 patients who underwent continuous lumbar plexus blockade while anticoagulated with warfarin.[15]

In the anticoagulated patient, a perivascular brachial plexus nerve block has the potential to cause excessive bleeding. Yet, several case reports document the safety of peripheral nerve block in the anticoagulated patient, particularly when it is placed under ultrasound guidance.[31] Despite these reassuring findings, the most recent published regional anesthesia guidelines advocate applying the same recommendations for neuraxial anesthesia to patients undergoing deep plexus or perivascular nerve blocks.[54] Patients who have incomplete reversal of their anticoagulation or who possess mild derangements of their coagulation panel for unclear reasons must be approached on a case-by-case basis, and the risks and benefits must be discussed thoroughly with the patient.

Bilateral Procedures. Although there may be instances in which regional anesthesia could be used for bilateral procedures, there are many risks, and it should be avoided if possible. The risk of drug toxicity is higher because the dose must be nearly doubled. Using a lower amount to avoid toxicity raises the probability of block failure.[33] The type of block also influences the risk. Interscalene nerve block commonly results in phrenic nerve paralysis,[111] so bilateral interscalene nerve block is contraindicated because of the risk of respiratory failure. Even supraclavicular blockade has an estimated associated risk of diaphragmatic paralysis of around 50%[81]; this risk, compounding the associated risk of pneumothorax, makes supraclavicular blockade an unreasonable technique for bilateral regional blockade. A safer alternative may be combining techniques of proximal and distal blockade or performing the blocks using low-volume, short-acting local anesthetics in sequence (i.e., performing the block on the second limb only upon completion of the first limb).[33,53]

Relative Indications

Microvascular Surgery Patients

Regional anesthesia with the use of long-acting blocks or continuous/prolonged infusion for digital reimplantation and free flaps is discussed in a later chapter. Continuous sympathetic blockade causes vasodilation and improves blood flow to the digit at risk and reduces neurogenically mediated vasospasm.[105] Improved pain control at the graft site via an effective nerve block also reduces pain-induced sympathetic-mediated vasospasm.[120] While peripheral nerve blockade has been shown to be a safe and effective anesthetic option, it is still unclear whether continuous nerve blockade indeed results in improved graft survival.[105]

Patients with scleroderma undergoing digital sympathectomy and vascular reconstruction also benefit from prolonged anesthetic blockade.[113]

Finally, patients with complex regional pain syndrome who undergo corrective surgery are also likely to benefit from effective prolonged regional anesthesia.[25]

Pediatric Patients

Anesthesia for pediatric patients depends greatly on the age and maturity of the child and the experience of the anesthesiologist. Many techniques combine general anesthesia for the surgical procedure itself with regional anesthesia for postoperative pain control. Many practitioners are comfortable placing blocks in anesthetized children, especially under ultrasound guidance, though the dose of anesthetic agent and the anatomy must be carefully considered.[72] Regional anesthetic technique has been demonstrated to be an effective form of postoperative pain control in children with very low rates of complications[87] and it has opioid-sparing effects. A long-term study looking at the use of continuous peripheral nerve catheters in pediatric patients shows this to be a safe and effective way to provide prolonged analgesia for this population of patients.[45]

Pregnant Patients

While elective procedures are generally not performed during pregnancy, circumstances that require surgery may present.

When possible, a local or regional technique should be used to minimize the effects on maternal physiology as well as reduce the possible pharmacologic exposure of the developing fetus. Ideally, surgical procedures should be deferred to the second trimester to minimize exposure of the fetus to teratogens during the critical period of organogenesis (15 to 56 days) and also limit the risks of preterm labor more prevalent in the third trimester.[55]

An anesthetic plan must provide safe anesthesia for both the mother and the fetus. When surgery is unavoidable in a previable fetus, the American College of Obstetricians recommends monitoring the fetal heart rate by Doppler ultrasound before and after surgery. With regard to a viable fetus, fetal heart rate and contraction monitoring should occur before, during, and after the procedure. The patient should have given consent for emergency cesarean section, and obstetric staff should be on standby in the event of fetal distress.[89]

The pregnant patient has an increased cardiac output, increased minute ventilation, increased risk for gastric aspiration, and increased upper airway edema, which can increase the risk of failed intubation. Fetal safety generally relates to avoidance of teratogenicity, avoidance of fetal asphyxia, and avoidance of preterm labor. While randomized controlled trials examining teratogenicity are not ethically or clinically feasible, local anesthetics, volatile agents, induction agents, muscle relaxants, and opioids are not considered teratogenic when used in clinical concentrations when normal maternal physiology is maintained. Nitrous oxide is probably best avoided given its effects on DNA synthesis and its teratogenic effects in animals.[39]

Patients With Rheumatoid Arthritis

Patients with rheumatoid arthritis are especially suitable candidates for regional anesthesia for upper limb surgery as it decreases the need for airway manipulation and blunts the stress response to surgery. Patients with deformity associated with advanced rheumatoid arthritis require careful positioning on the operating room table to avoid injury to other areas of the body.

This patient population often carries a high potential for airway complications owing to cervical spine immobility, paradoxic atlantoaxial instability, temporomandibular joint ankylosis, and cricoarytenoid arthritis,[96] all of which make endotracheal intubation difficult. Additionally, many rheumatoid patients are maintained on antirheumatic drugs and systemic corticosteroids, which have the potential for causing immunosuppression and a decreased neuroendocrine stress response. Patients consuming at least 20 mg of prednisone a day for more than 3 weeks are considered at significant risk for hypothalamic-pituitary-adrenal suppression.[2] These patients may be considered for stress dose steroid coverage depending on the invasiveness and stress of the procedure, and steroid treatment should be provided in the event of refractory hypotension.

Advantages and Disadvantages (Box 1.1)

A common concern regarding regional anesthesia is the question of whether the block will work. Success depends on the experience and confidence of the practitioner performing the block. At our orthopedic hospital, more than 6300 upper extremity blocks are performed annually, and we are able to achieve a surgical level of anesthesia in 94% to 98% of patients.[71,70]

BOX 1.1 Factors Limiting Use of Regional Anesthesia

In spite of the advantages of regional anesthesia, several factors may prevent its use. Each of these problems can be overcome with appropriate planning.

- Time constraints
- Anesthesiologist's lack of familiarity with the procedure
- Patient's fear of anesthesia failure
- Concern about complications
- Patient's desire to be completely unaware during the procedure

While regional blockade can effectively anesthetize the upper extremity and surgical site, this does not ensure patient comfort. Patients asked to lie motionless on a hard operating room bed might be apt to move to relieve discomfort in the back or knees, therefore disturbing the operative field. We place pillows to support the head and under the knees to reduce low-back strain. Even with adequate motor and sensory blockade, some patients will experience vibration or proprioception, and even vague sensations of pressure in the operative limb. Adequate anxiolysis and sedation will minimize the sensation. Access to the airway should be maintained during surgery in case the block is inadequate or other problems ensue. If the patient's position, such as lying prone, precludes this access intraoperatively, preoperative securing of the airway may be needed.

Duration of the neural blockade is variable, anywhere from 45 minutes to 24 hours after a single injection. The duration can be extended using a peripheral nerve catheter for continuous local anesthetic administration. Catheters have been successfully inserted along various levels of the brachial plexus depending on the desired location of blockade, from above the clavicle, such as interscalene and supraclavicular locations, to below the clavicle, such as infraclavicular and axillary locations.[95] Catheters can be maintained to provide continuous-flow or patient-controlled analgesia for hospitalized patients, and many centers have started home catheter programs for their outpatient population.

Prolonged regional anesthetic blockade provides improved pain relief during immediate postoperative physical therapy, and does not necessarily preclude active participation. In a study comparing continuous patient-controlled perineural infusion with 0.2% ropivacaine with patient-controlled IV narcotic infusion following arthroscopic rotator cuff repair, regional anesthesia techniques resulted in decreased use of supplementary analgesics and had a comparable incidence of motor weakness as did IV patient-controlled analgesia.[101]

The advantages of regional nerve block have been well demonstrated in the ambulatory surgery population. These advantages include lower pain scores, decreased nausea and vomiting, and shorter stays in the postanesthesia care unit.[57,95,101] While these effects are considerable in the immediate postoperative period, studies are ongoing to demonstrate a long-term outcome difference between the different types of anesthetics.[58,103] Evidence supports the finding that in patients undergoing repair of displaced distal radius fracture, regional anesthesia offers decreased pain and improved functional outcomes at 3 and 6 months.[27]

TABLE 1.1 Characteristics of Commonly Used Drugs

	CONCENTRATION (g/dL)			
Generic Name (Trade Name)	Infiltration	Nerve Block	Maximum Dose (mg/kg)*	Approximate Duration
Procaine (Novocain)	0.75	1.5-3	10-14	45-90 min, short-acting
Chloroprocaine (Nesacaine)	0.75	1.5-3	12-15	
Lidocaine (Xylocaine)	0.5	1-2	8-11	1.5-3 hr, medium-duration
Mepivacaine (Carbocaine)	0.5	1-2	8-11	
Tetracaine (Pontocaine)	0.05	0.15-0.2	2	
Bupivacaine (Marcaine)	0.25	0.25-0.5	2.5-3.5	3-10 hr, long-acting
Ropivacaine (Naropin)	0.25	0.25-0.5	2.5-3.5	

*Higher doses with the use of 1:200,000 epinephrine.

BOX 1.2 Prevention of Systemic Toxicity

- Avoid intravascular injection.
- Use epinephrine to slow systemic absorption.
- Use benzodiazepine as a premedication.
- Use ultrasound guidance to fractionate the dose.

Equipment and Pharmacologic Requirements

Medications commonly used in regional anesthesia are listed in Table 1.1.

Regional anesthesia may be administered in a designated block room or preoperative area, in addition to in the operating room. It is crucial to have available appropriate monitoring and resuscitation equipment, including airway management supplies and resuscitative medication, should an acute complication arise. High-flow oxygen, airway management equipment, and suction capability are crucial for emergency airway management in the event of seizure or high or total spinal block. Medications including inotropes, anticholinergics, and vasopressors should be immediately available to treat symptomatic arrhythmias, bradycardias, and hypotensive episodes. Other available medications should include benzodiazepines or propofol to treat seizures and an intralipid to treat bupivacaine-induced cardiovascular collapse (Box 1.2).[4]

Local Anesthetic Additives

In recent years, the use of additives in local anesthetics to increase efficacy and onset of block, as well as overall block duration, has been readily investigated.[5] Historically, sodium bicarbonate has been used to increase onset of sensory and motor blockade in epidural anesthesia through alkalinization of the molecule, thereby facilitating its passage across lipid membranes. When used perineurally, this advantage appears to be more unpredictable for certain types of blocks and may not be clinically significant.[18] Epinephrine, on the other hand, remains one of the most popular adjuncts for prolonging the effect of short- and intermediate-acting local anesthetics by decreasing systemic uptake of the local anesthetic through vasoconstriction. It is also an excellent marker for detection of intravascular injection. The advantage of epinephrine as an adjunctive in long-acting local anesthetic peripheral nerve blocks is not as apparent, especially when juxtaposed with concerns of neurotoxicity in at-risk patients.[114]

Dexamethasone is another additive that has gained popularity in recent years because of its ability to significantly prolong peripheral nerve blockade. Through its proposed ability to inhibit nociceptive C-fibers, dexamethasone has been used with both short- and long-acting local anesthetics in upper extremity surgeries with some success, though recent randomized trials and meta-analyses suggest that this effect can be achieved just as well via IV administration, which has a well-characterized safety profile.[22,24] While investigations into concerns for neurotoxicity with dexamethasone have not yielded conclusive results, we recommend that care be taken when using this adjunct in patients with preexisting nerve injuries.

Alpha-2 selective adrenergic agonists such as clonidine and dexmedetomidine have an analgesic benefit when added to local anesthetics for peripheral blocks.[38,88] By inhibiting current channels that facilitate neurons to return to normal resting potential from a hyperpolarized state, clonidine and dexmedetomidine selectively disable C-fiber neurons from generating subsequent action potentials, resulting in analgesia. The disadvantages of using these additives include dose-dependent systemic effects of sedation, bradycardia, and hypotension.

Opioid agonists such as tramadol and buprenorphine are also used as additives to local anesthetics.[3,9] Tramadol, which acts as a weak mu-opioid agonist while stimulating serotonin release and inhibiting reuptake of norepinephrine, prolongs blockade when given perineurally but does not reliably have a clear advantage over IV or intramuscular administration.[59,61] Buprenorphine, on the other hand, has a fairly consistent record of prolonging block duration and reducing postoperative analgesia when given perineurally, an effect not related to systemic absorption of the drug. The mechanism of action of buprenorphine is an ability to inhibit voltage-gated sodium channels in a fashion similar to local anesthetics.[67] Further studies are needed to elucidate any potential neurotoxic effects of this adjunct.

Finally, additives such as ketamine, midazolam, and magnesium, while showing some promise, do not have an adequately characterized safety profile to be recommended as routine additives to local anesthetics at this time.[64-66]

Historical Techniques

Regional nerve blockade is essentially the deposition of local anesthetic near a nerve. Historically, nerve blocks were blind techniques, performed on the basis of known anatomic relationships to superficial landmarks. Practitioners noted that patients would report paresthesias as the needle advanced, leading to development of the paresthesia technique. This technique required a cooperative and conscious patient capable of providing verbal feedback, as the anesthetic practitioner would intentionally attempt to elicit a paresthesia as a means of nerve localization. Others began experimenting with the use of a nerve stimulator, applying a low-current electrical impulse through the needle near a nerve to stimulate muscle contraction.[14] Studies were unable to demonstrate outcome differences.[85] Though it was hoped that nerve localization using nerve stimulation would decrease actual needle-to-nerve contact, reducing nerve injury, a randomized prospective trial comparing the two techniques was unable to determine a difference in postoperative neurologic symptoms.[69] An advantage of the development of the nerve stimulator was decreased reliance on patient feedback and, therefore, the ability to perform the technique on sedated or even anesthetized patients.

Ultrasound was next used to improve needle placement by means of a portable device in the operating room or holding area. Ultrasound allows visualization of anatomic structures, blood vessels, and nerves, as well as of the advancement of a needle and the distribution of local anesthetic.[60] With satisfactory visualization of target structures, this technique does not require patient feedback and can be used safely after the patient has been given sedation or even general anesthesia.[78] However, when target structures are deep, needle visualization can be difficult; in such cases, it is a standard of safety to engage patient feedback whenever possible. Several studies have demonstrated improved onset and decreased dosing requirements compared with traditional techniques.[76,107] A recent metaanalysis of 16 randomized controlled trials showed that ultrasound decreased the incidence of complete hemidiaphragmatic paresis and vascular punctures and was more likely to result in a successful brachial plexus block when compared with the nerve stimulation technique.[119] Despite these benefits, ultrasound-guided blocks do not appear to decrease the incidence of neurologic injury.[71,119] Certainly, this is an area in need of further study and review as we attempt to maximize results while minimizing risks of complications for our patients.

Continuous Peripheral Nerve Catheters

The use of continuous peripheral nerve catheters has gained favor both in the inpatient setting and the outpatient setting. As mentioned before, the advantages include time-extended, opioid-sparing, and site-specific analgesia with only minimal side effects.[12] Disadvantages include increased anesthesia performance time, dislodgement or malplacement of the catheter leading to ineffective analgesia, and infection.[56] Rarely, brachial plexus peripheral nerve catheters have led to epidural and even intrathecal blockade.[40,112] The incidence of brachial plexus catheter failure on postoperative day 1 is between 19% and 26%.[1] The rate of dislodgement is low (<5%) but is directly correlated with the length of time the catheter has been in place and the extent of upper extremity movement.[74] Though there appears to be a modest clinical benefit to the use of nerve-stimulating catheters over nonstimulating catheters to confirm tip placement, this advantage has been largely minimized by ultrasound guidance.[79] In contrast to epidural catheters, the choice of end-orifice versus multiple-orifice catheters in continuous peripheral nerve blocks does not affect analgesic quality.[35]

Once the patient is at home, peripheral nerve infusion pumps for ambulatory surgery patients are safe and effective for extending the duration of nerve blocks from hours to days. In a study of ambulatory patients comparing general anesthesia with single-shot interscalene nerve blocks with continuous interscalene blocks for 48 hours, during which time the patients went home, the catheter group had lower pain scores both at 48 hours and at 1 week.[95] Rare complications include respiratory compromise in proximal brachial plexus catheters (interscalene and supraclavicular blocks) due to ipsilateral diaphragmatic paralysis, technical problems involving the infusion pump leading to dosing inconsistency, infection due to the indwelling catheter, and catheter coiling leading to block failure or catheter retention.[56] Evidence supports the use of these catheters in children as well as adults.[45]

Minimum Effective Volume

In recent years, efforts to determine the minimum effective volume (MEV) of local anesthetic required to produce an adequate operative and postoperative anesthetic have been made in order to reduce the dose-dependent side effects and the risk of neurotoxicity and systemic absorption without sacrificing time to onset of block and overall duration of effective analgesia. These efforts have been helped enormously by the use of ultrasound. For the upper extremity, low local anesthetic volumes have been established for interscalene blocks and axillary blocks using ultrasound guidance. Although the absolute effect of type and concentration of local anesthetic on minimal volume is not yet elucidated, the MEV to elicit an interscalene blockade that is 90% to 95% successful ranges as low as less than 1 mL.[29,76] Reducing the anesthetic volume in interscalene blocks has the potential advantage of reducing the incidence of hemidiaphragmatic paresis.[92] For axillary blocks, the 90% to 95% MEV averages 1 to 2 mL per nerve.[30,42] On the contrary, the 90% to 95% MEV for supraclavicular and infraclavicular blocks averages above 30 mL.[108,109] We postulate that this discrepancy in the latter blocks may be related to increased variations in injection techniques and anatomy.

Elderly patients generally require lower local anesthetic volumes, an effect likely related to a decrease in the cross-sectional area of the brachial plexus as we age.[84] Similarly, diabetic patients are more likely to have a successful supraclavicular block than their nondiabetic counterparts for a given local anesthetic dose.[41] The authors postulate that this is due either to an increased sensitivity of diabetic nerve fibers to local anesthetic, inadvertent intraneural penetration due to decreased ability to elicit paresthesias, or a preexisting neuropathy leading to decreased sensation to surgical stimulation. Surprisingly, although associated with a higher performance difficulty, an increased body mass index does not necessitate an increased local anesthetic volume.[44,100]

In general, in the absence of additives, decreasing the dose of local anesthetic either by volume or concentration in the peripheral block results in a reduction of block duration and

decreases the time until the patient first requires an analgesic.[36,99] Despite the advantage of decreasing dose-dependent complications and reducing neurotoxicity, our goal in establishing the MEV should always be juxtaposed with the surgical procedure, the patient's particular risk factors, and the expected postoperative pain. In the end, it is also important to remember that the MEV for any given block is heavily influenced by the practitioner and his or her ability to deposit local anesthetic optimally.

Specific Blocks

The goal of regional anesthesia for upper extremity surgery is to provide anesthesia in the localized area of surgery, taking into account other potential painful stimuli, including positioning and the application of a tourniquet. There are many different approaches to nerve blockade, all involving nerves encompassed in the brachial plexus and providing sensory and motor innervation to the upper extremity. The brachial plexus is formed by the ventral rami of C5-T1, occasionally with small contributions by C4 and T2 (Figure 1.1).

There are multiple approaches to blockade of the brachial plexus, beginning proximally with the interscalene approach and continuing distally with the supraclavicular, infraclavicular, axillary, and midhumeral approaches at the terminal branches. The uniting concept is the existence of a sheath encompassing the neurovascular bundle extending from the deep cervical fascia to slightly beyond the borders of the axilla.[32]

Interscalene Block

The interscalene block is the most proximal approach, performed as the brachial plexus courses in the groove between the anterior and middle scalene muscles, traditionally at the level of the cricoid cartilage (Figure 1.2).[117] This block is well suited for procedures of the shoulder, the lateral two thirds of the clavicle, and the proximal humerus. Advantages of this block include rapid and reliable blockade of the shoulder region, as well as relative ease of landmark palpation. Disadvantages of this block traditionally include incomplete coverage of the inferior trunk of the plexus; hence, insufficient anesthesia of the ulnar distribution makes it an unreliable block for forearm or hand procedures. The interscalene block commonly causes transient ipsilateral diaphragmatic paralysis and ipsilateral Horner syndrome because of the proximity of the phrenic nerve and the cervical sympathetic ganglion, respectively. Rare but serious complications include permanent phrenic nerve palsy and cervical epidural and total spinal blockade.[68]

Supraclavicular Block

A supraclavicular approach to the brachial plexus provides profound anesthesia for the entire arm, making it an appropriate block for most upper extremity procedures. Past approaches have used surface landmarks, generally lateral to the lateral border of the sternocleidomastoid muscle and superior to the clavicle, considering the first rib as the safety margin for the cupola of the lung.[63] Proximity to the brachial plexus was

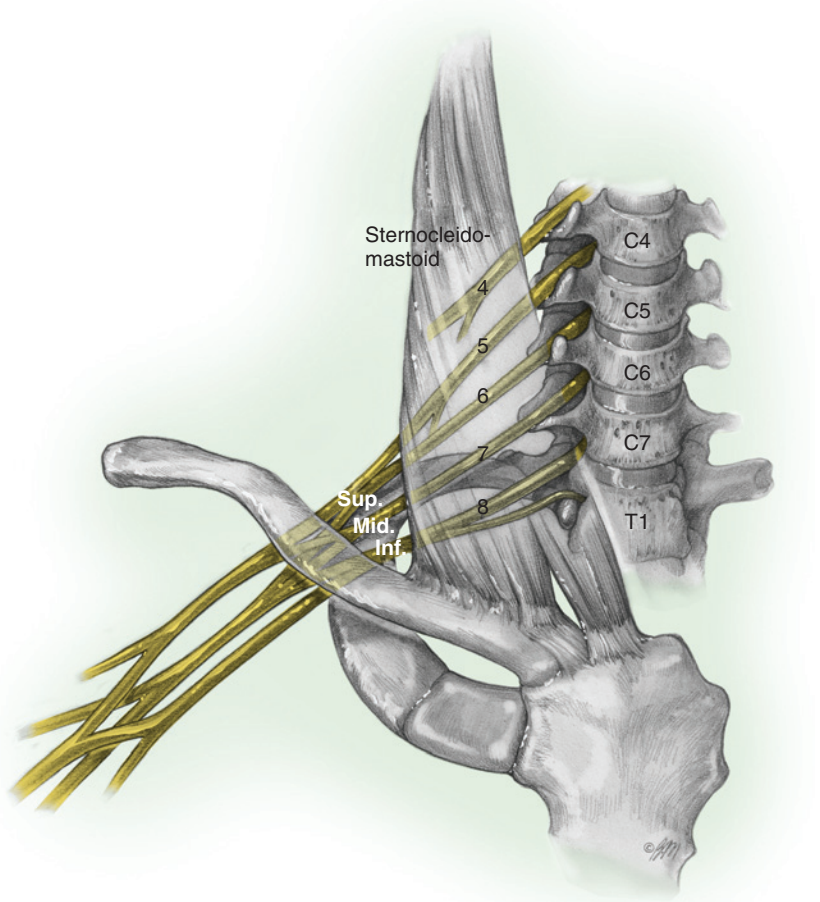

FIGURE 1.1 Brachial plexus, showing the relationship of the roots, trunks, divisions, and cords to bony landmarks. *Inf.*, Inferior; *Mid.*, middle; *Sup.*, superior. (Copyright Elizabeth Martin.)

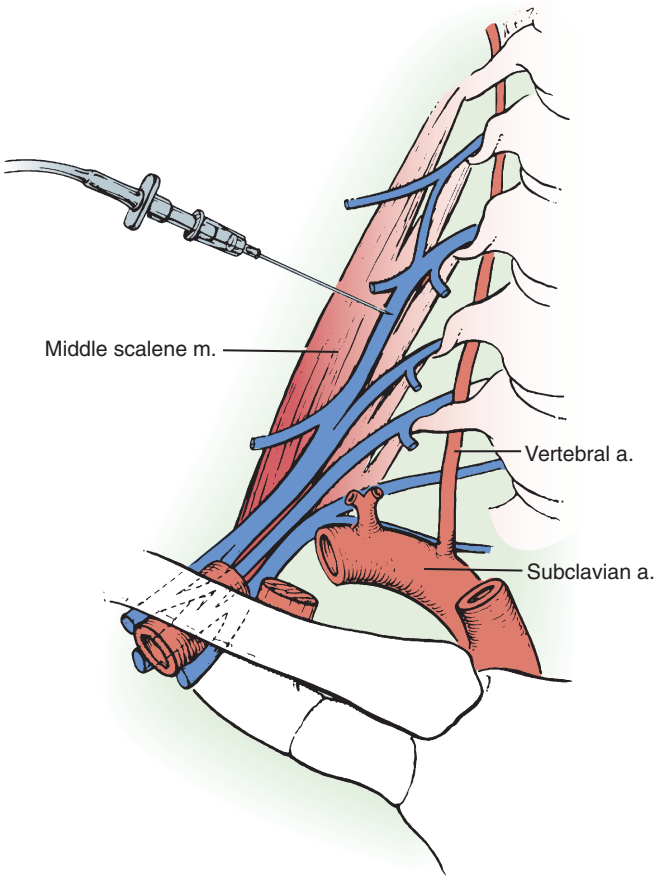

FIGURE 1.2 Interscalene technique. (From Winnie AP: Regional anesthesia. *Surg Clin North Am* 55:861–892, 1975.)

determined using either paresthesia or nerve stimulator techniques.[34] Concern regarding the risk for pneumothorax with traditional techniques (estimated at 1% to 4%) led to the development of an ultrasound-guided technique for supraclavicular brachial plexus blockade (Figure 1.3).[60,116] Ultrasound guidance allows the practitioner to visualize the first rib and the border of the pleura, thereby being able to watch the approach of the needle to help ensure an appropriate distance from these vulnerable structures.[102] Advantages include a compact formation of the plexus at this level and resultant dense blockade of the entire upper extremity. Disadvantages include the remote risk of pneumothorax, suprascapular nerve palsy,[26] and potential for slower block onset.

Infraclavicular Block

The infraclavicular (or coracoid) approach is more distal still, at the level of the cords as they course circumferentially around the subclavian artery, providing dense anesthesia to the entire arm to the fingers. This block does not adequately anesthetize the shoulder but has become the block of choice at our institution for elbow, wrist, and hand surgery. Initial techniques of the infraclavicular block based needle placement on anatomic landmarks and nerve localization with a nerve stimulator,[91] but more recent approaches favor an ultrasound approach (Figures 1.4 and 1.5).[97] The consistent anatomic relationship between the cords and the vascular structures makes it a predictable and

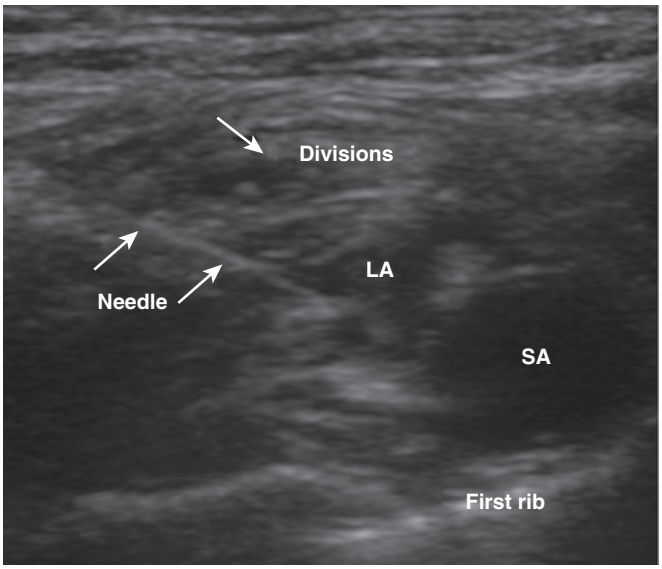

FIGURE 1.3 Ultrasound-guided supraclavicular nerve block. The brachial plexus is approached at the level of the divisions; the needle is entering the view from the lateral aspect at the top left of the screen. The pulsations of the subclavian artery (*SA*) are visualized, as is the spread of local anesthetic (*LA*).

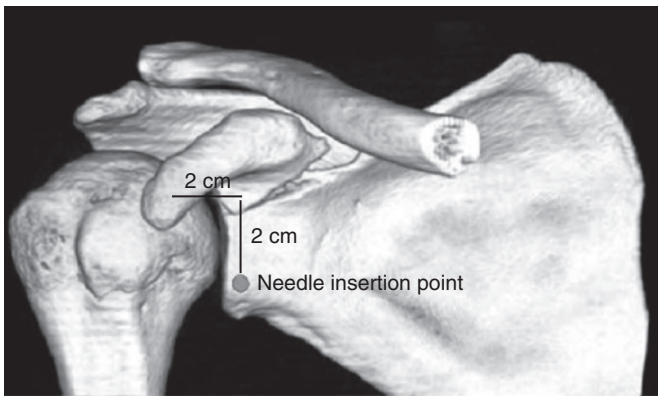

FIGURE 1.4 Landmarks for infraclavicular block.

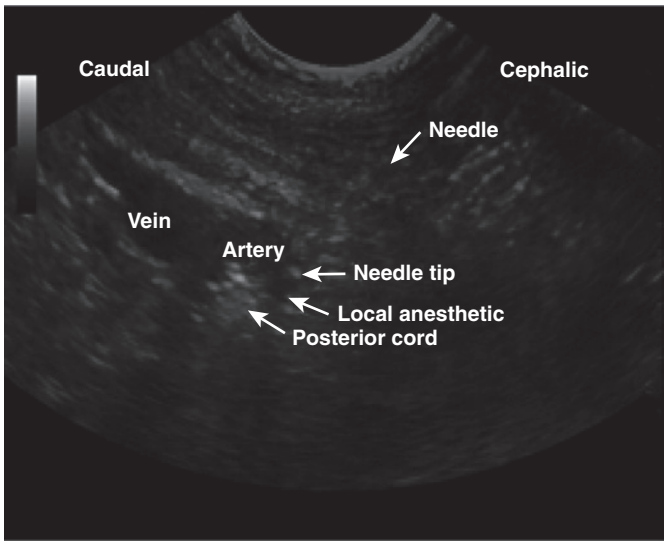

FIGURE 1.5 Ultrasound-guided infraclavicular nerve block; note the perivascular spread of local anesthetic.

reliable block to perform under ultrasound guidance. The lower anatomic location of this block makes it unlikely to encounter phrenic blockade and therefore makes it a more appropriate block for bilateral procedures. Disadvantages include pneumothorax, a risk minimized by performing the block more laterally along the clavicle,[11] and the concern that if the subclavian artery is accidentally punctured in the infraclavicular approach, subsequent compression of the area to tamponade bleeding is difficult.

Axillary Block

The axillary block, the most distal of the brachial plexus blocks before the nerves leave the sheath and divide into their terminal branches, is perhaps one of the oldest and most traditional regional blocks for hand and wrist surgery. Various guidance techniques are described, including ultrasound, anatomic (either transarterial or paresthesia), or nerve stimulator techniques. All begin with palpation of the axillary nerve in the apex of the axilla, with consideration of the reliable anatomic relationship of the nerves to this arterial landmark (Figure 1.6). Because the musculocutaneous nerve frequently leaves the sheath proximal to the intended insertion point of this block, frequently a supplemental injection into the body of the coracobrachialis muscle is needed, especially if a forearm tourniquet is planned. This can be done easily with a blind technique as well as with ultrasound guidance, as the nerve is commonly found in the fascial plane between the coracobrachialis muscle and the biceps. A 2013 Cochrane Database Review showed that a multiple-injection technique led to more effective anesthesia than a single- or double-injection technique; however, no difference in other outcomes could be found.[16] Major risks for this block are largely related to the close proximity of the axillary artery. Risks for minor bruising and tenderness run higher with transarterial techniques, although the risk of hematoma is lower, reported from 0.2%[104] to 8%.[62] Another concern relating to the high vascularity of this area is local anesthetic toxicity related to either intraarterial injection or rapid systemic absorption after injection near an arterial puncture. Rates of systemic toxicity are around 0.2%.[104] Although the end results of these incidental complications were minor and without lasting effect, at our institution the axillary approach to the brachial plexus has largely been replaced by the ultrasound-guided infraclavicular block because of the latter's reliability and low incidence of side effects and the availability of ultrasound at our facility. At other institutions, the axillary plexus block is widely used as the preferred technique for lower arm procedures.

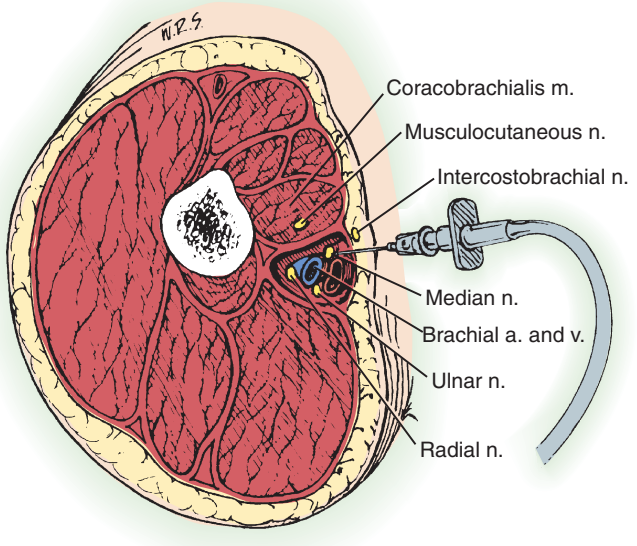

FIGURE 1.6 Cross-sectional view of the axillary nerve block. (From Winnie AP: Regional anesthesia. *Surg Clin North Am* 55:861–892, 1975.)

Supplementary Blocks

Elbow Block

The intercostobrachial nerve arises from T1-T3 and travels superiorly to provide cutaneous sensory innervation to the medial and posterior upper arm.[82] Because this innervation is not part of the brachial plexus, additional blockade in the form of a field block is used for surgery around the medial aspect of the elbow. Subcutaneous distribution of 5 to 10 mL of local anesthetic along the distal portion of the axillary crease will effectively anesthetize this cutaneous distribution.

Blocks around the elbow are rarely performed as a primary technique because the overlap and variation of nerve distribution would necessitate multiple injections in order to obtain anesthesia of a given area. Blocks around the elbow are mainly used to supplement incomplete brachial plexus nerve blockade. While blocks are often performed blindly using bony landmarks, it is also possible to perform blocks based on eliciting paresthesias or nerve stimulation. The median, radial, and ulnar nerves are individually visualized using ultrasound as they course from the elbow to the wrist.[75]

The median nerve may be blocked as it courses posteromedial to the brachial artery superior to the antecubital crease. The nerve is typically blocked using 5 to 10 mL of local anesthetic injected slightly superior to a line connecting the epicondyles. This block can be accomplished using a blind, landmark-based technique, by eliciting paresthesias, or by using a nerve stimulator.

The radial nerve can be blocked 3 to 4 cm above the lateral epicondyle, close to the distal head of the humerus. After the lateral intramuscular septum has been pierced, paresthesias or a nerve stimulator can be used to localize the nerve. An injection of 5 to 10 mL of local anesthetic will provide an adequate nerve block in this location.

The ulnar nerve is largely missed in interscalene blocks, so supplementation is often necessary to obtain complete anesthesia of the arm. The nerve is usually blocked as it runs behind the medial epicondyle. Injection of 3 to 5 mL of local anesthetic is made between the olecranon and the medial epicondyle. Caution must be used to avoid compressing the nerve, because it runs near the bony landmarks.[94]

Wrist Block

Hand surgeons frequently use wrist blocks to produce anesthesia for surgery or supplement plexus nerve blocks. Wrist blocks are relatively simple and reliable to perform based on external landmarks. The nerve supply of the extrinsic muscles of the hand is preserved, thus allowing the patient to move the fingers of the hand, but the intrinsic muscles are paralyzed. Whereas



FIGURE 1.7 Surface anatomy for median nerve block at the wrist. (Reproduced with permission from Chung KC, editor: *Operative Techniques: Hand and Wrist Surgery*, Philadelphia, 2008, Saunders, p 5.)

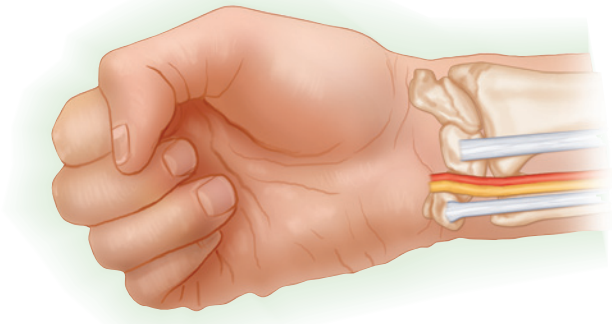

FIGURE 1.8 Surface anatomy for ulnar nerve block at the wrist. (Reproduced with permission from Chung KC, editor: *Operative Techniques: Hand and Wrist Surgery*, Philadelphia, 2008, Saunders, p 6.)

this can be an advantage in a cooperative patient, it is a potential disadvantage and distraction in an uncooperative patient. Additionally, the need for a forearm tourniquet limits the duration of surgery to 20 to 30 minutes in most instances. These blocks are especially efficacious for carpal tunnel release.[23,110]

The median nerve can be blocked as it courses between the palmaris longus and flexor carpi radialis tendons (Figure 1.7). A 1.5-cm, 25-gauge needle is inserted at the level of the ulnar styloid process or the proximal crease of the wrist. In the absence of the palmaris longus tendon, the needle is inserted on the ulnar side of the flexor carpi radialis tendon. After penetration through the flexor retinaculum at a depth of approximately 1 cm, 5 mL of local anesthetic is injected. Injecting 1 mL of local anesthetic above the retinaculum as the needle is withdrawn can block a superficial palmar branch supplying the skin over the thenar eminence.[21,94]

The ulnar nerve is blocked at the wrist at either the radial or the ulnar side of the flexor carpi ulnaris tendon (Figure 1.8). The ulnar approach is preferred so as to avoid intravascular injection, given the location of the ulnar artery on the radial side of the tendon. At the level of the distal ulna, the needle is introduced on the dorsal ulnar side of the flexor carpi ulnaris. Subsequent injection of 5 mL of local anesthetic under the flexor carpi ulnaris will result in anesthesia of this distribution. Additional subcutaneous infiltration of the dorsal ulnar area of the wrist ensures adequate blockade of the dorsal cutaneous branch of the ulnar nerve.[21]

The radial nerve is superficial and divided into branches running in the subcutaneous fat at the level of the radial styloid process (Figure 1.9). It may be blocked using 5 to 10 mL of local



FIGURE 1.9 Surface anatomy for radial nerve block at the wrist. (Reproduced with permission from Chung KC, editor: *Operative Techniques: Hand and Wrist Surgery*. Philadelphia, 2008, Saunders, p 7).

anesthetic injected in a subcutaneous field block at the level of the radial styloid. Initial injection is made using 2 to 3 mL of local anesthetic just lateral to the radial artery at the level of the proximal wrist crease. The needle is then redirected and advanced with subcutaneous injection of 5 to 7 mL of local anesthetic across the proximal border of the snuffbox to the midpoint of the dorsal wrist. Several injections may be necessary to follow the curvature of the wrist and block the many superficial branches.[94]

Digital Block

As the most distal innervation of the hand, four nerve branches—two dorsal and two volar—run along the sides of each digit to supply each digit (Figure 1.10). There are three main recommended approaches for performing digital nerve block—transthecal, transmetacarpal, and subcutaneous. A circumferential ring block along the base of the digit is not recommended because the subsequent pressure can result in gangrene.

Transthecal digital nerve block uses the flexor tendon sheath for anesthetic infusion. At the level of the palmar digital crease, the needle enters the flexor tendon sheath until bony contact is made (Figure 1.11). The needle is then withdrawn slowly until the local anesthetic solution is injected easily into the potential space between the periosteum and the flexor tendon. Two milliliters of local anesthetic is used for digital anesthesia. Advantages of this approach include a single injection and rapid onset[52]; however, patients often complain of prolonged discomfort in the finger after this technique.[73]

Transmetacarpal block is performed at the level of the distal palmar crease. The insertion site is approximately 1 cm proximal to the metacarpophalangeal joint, traditionally on the volar side of the hand (Figure 1.12), though some favor entering the thinner dorsal side for patient comfort. Two milliliters of local anesthetic injected on one side of the metacarpal neck effectively anesthetizes the common digital nerve supplying the finger.[98]

Subcutaneous digital nerve block is accomplished at the level of the distal palmar crease. The needle is inserted vertically into each side of the flexor tendon sheath, and 2 mL of local

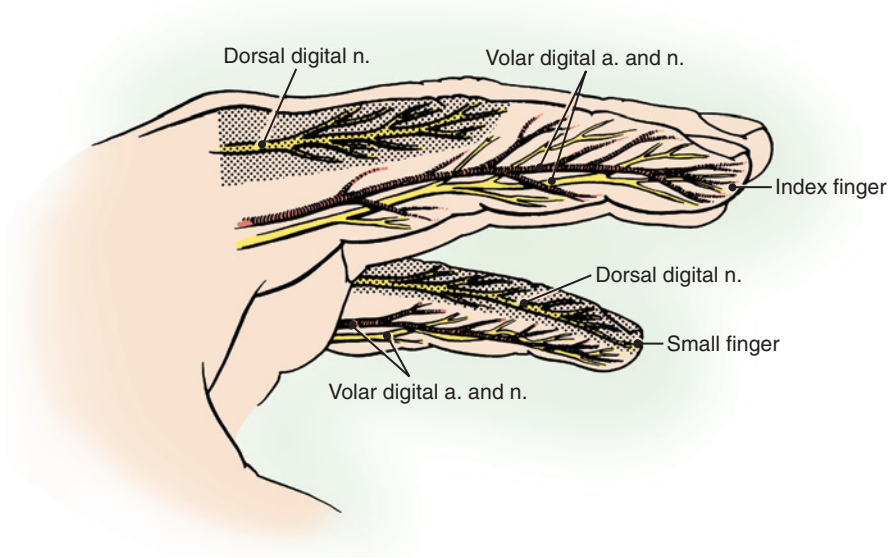

FIGURE 1.10 Relationship and distribution of the digital nerves. Note that in the small finger, the dorsal digital nerve extends to the top of the digit; in the median nerve distribution, the volar nerve supplies the dorsum of the digit distal to the proximal interphalangeal joint. (Copyright Elizabeth Martin.)

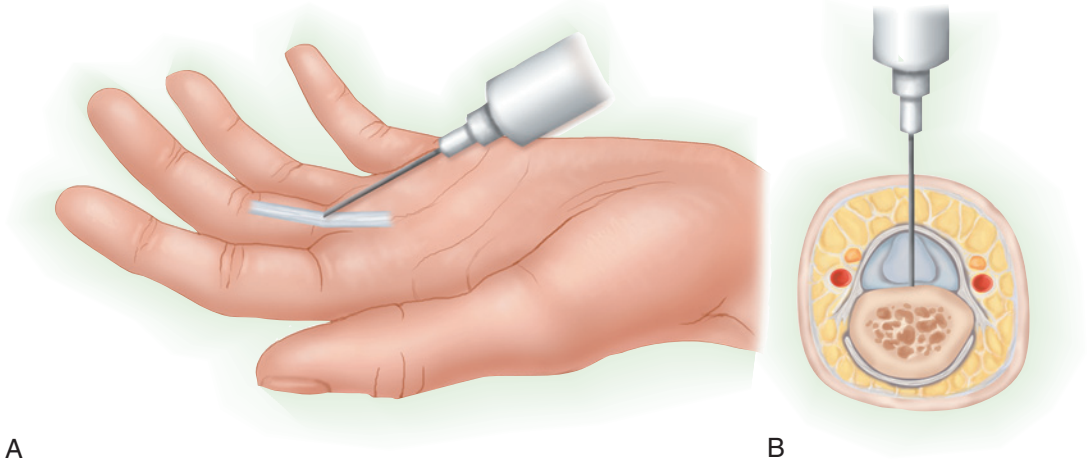

FIGURE 1.11 Transthecal digital nerve block. (Reproduced with permission from Chung KC, editor: *Operative Techniques: Hand and Wrist Surgery.* Philadelphia, 2008, Saunders, p 13.)

anesthetic is injected at each location (Figure 1.13). Alternatively, injection can be made just proximal to the web of the finger using a 1.5-cm, 25-gauge needle, creating a skin wheal superficial to the extensor hood to block the dorsal nerve. The needle is then advanced toward the palm and an additional 1-mL injection is made just under the skin on the volar side to anesthetize the volar digital nerve. The needle is then withdrawn to the skin and redirected toward the opposite side of the finger to place a superficial skin wheal, and the process is repeated on that side. Care must be taken to use small volumes of local anesthetic to avoid creating a circumferential ring. In recent years, clinicians have moved away from the traditional two injections method to a single injection method due to improved patient comfort. With this technique, 2 to 3 mL of local anesthetic are deposited into the subcutaneous space at the middle point of the palmar digital crease.

Use of Epinephrine in Digital Nerve Blockade. Long-standing debate has taken place about the use of epinephrine in digital nerve blocks because of concern regarding vasoconstriction to the digit and subsequent ischemia and necrosis. Several studies and reviews have addressed this issue; Chowdhry and colleagues published a retrospective review in 2010 that reported no adverse events involving digital gangrene in 1111 patients.[19] The authors concluded that the use of local anesthetic with the addition of epinephrine was safe in digital nerve blockade, enabling improved hemostasis and decreasing the need for tourniquet placement.[19]

Intravenous Regional Block

Intravenous regional block, or Bier block, was one of the first techniques of regional blockade, introduced in 1908.[20] Bier block can be used for brief surgical procedures or manipulation of the distal upper extremity. Advantages of this technique include ease of use and rapid onset of anesthesia; disadvantages include the necessity of using a pneumatic tourniquet and the lack of postoperative analgesia.

This technique involves placement of an IV catheter in the dorsum of the hand, followed by exsanguination of the upper

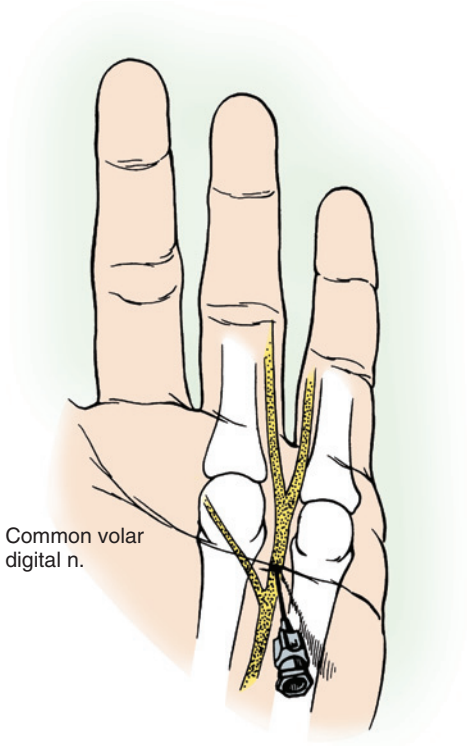

FIGURE 1.12 Transmetacarpal digital nerve block. (Copyright Elizabeth Martin.)

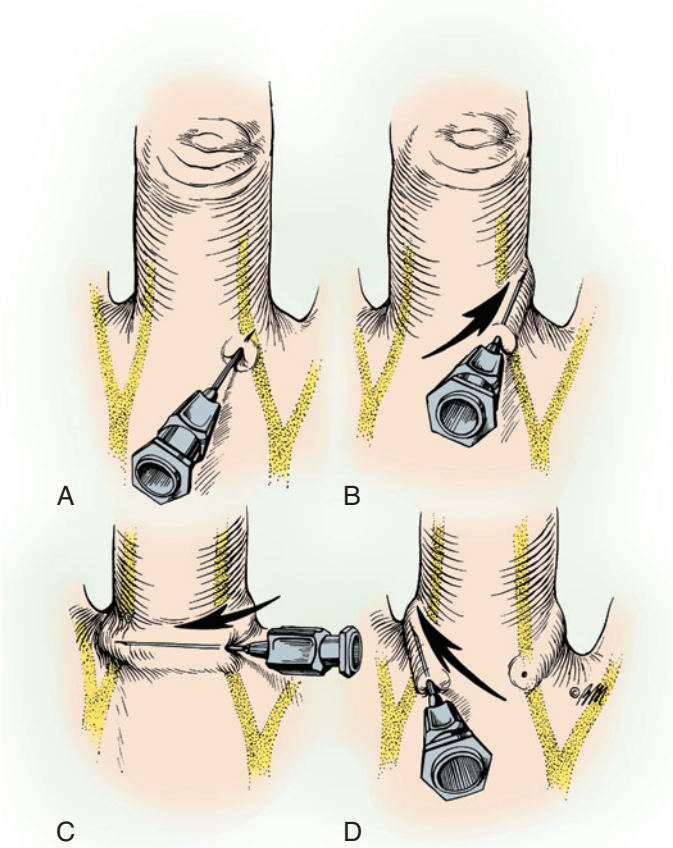

FIGURE 1.13 Subcutaneous digital nerve block. **A,** The needle is inserted along one side of the flexor tendon sheath to block the volar nerve **(B)**. **C,** The dorsal digital nerve is anesthetized with a superficial skin wheal. **D,** The opposite volar nerve is blocked using the same technique. Care is taken to ensure that local anesthetic is not injected fully circumferentially around the finger. (Copyright Elizabeth Martin.)

extremity and inflation of a pneumatic tourniquet. Subsequent injection of local anesthetic into the venous system by means of the IV catheter results in rapid and profound sensory blockade. Plain lidocaine 0.5% in a dose of 3 mg/kg is the typical agent of choice, which results in a volume of 40 mL for the average adult.[20] Other agents such as prilocaine may be used instead[43]; however, bupivacaine is contraindicated in Bier block because of potential cardiac toxicity. While not well studied, additives such as acetaminophen, magnesium, narcotics, and vecuronium have been used in an effort to increase onset and efficacy of the Bier block while reducing the total local anesthetic volume needed to achieve adequate anesthesia.[77]

Contraindications include crush injuries or compound fractures in which the venous system may be interrupted or the extremity difficult to exsanguinate. Bier block is also contraindicated in patients in whom tourniquet use is contraindicated, in patients with local skin infections or cellulitis, or in those with a convincing allergy to local anesthetics. Another limitation to the use of a Bier block is duration of tourniquet application; patients tend to complain of tourniquet pain after 30 minutes. Adding a second distal tourniquet allows prolongation of the block; after tourniquet pain is experienced with the proximal tourniquet, the distal tourniquet is inflated. By using this double-tourniquet technique, the tourniquet time is prolonged up to 1 hour.[86]

Complications associated with Bier block are mainly related to drug effects of the local anesthetic, especially if there is mechanical tourniquet failure leading to early deflation of the cuff. It is recommended that the cuff stay inflated for 20 to 30 minutes after injection in order to minimize local anesthetic effects, particularly on the cardiovascular and respiratory systems.[43] Using incremental deflation, inflation, and deflation again allows for gradual release of the local anesthetic from the isolated limb. Additional complications can arise from the use of the pneumatic tourniquet, including but not limited to ischemic and mechanical crush injuries.

❖ AUTHOR'S PREFERRED METHOD OF TREATMENT: Regional Anesthesia

For surgery of the upper extremity, regional anesthesia is our standard method. Regional anesthesia is associated with decreased morbidity and shorter stays in the postanesthesia care unit.[46,57,95,101]

Our preferred blocks for regional anesthesia of the upper extremity are ultrasound-guided supraclavicular and infraclavicular blocks. They are often faster to perform in less experienced hands, have a faster onset, and allow smaller anesthetic volumes to be used.[76,106,107] Each year nearly 5000 supraclavicular and infraclavicular blocks are performed at our institution. Of these 5000, all but a few are done with ultrasound guidance. This method has proven to be very safe, rapid, and highly successful at anesthetizing the upper extremity.

The type of ultrasound-guided block chosen depends on the surgery involved. For surgery from the shoulder to the elbow and occasionally from the elbow to the hand, the block of choice at our institution is the ultrasound-guided supraclavicular block. For surgery on the more distal upper extremity, the block of choice is most frequently the ultrasound-guided infraclavicular block.

The technique for perivascular blocks involves an in-plane view of the needle at its point of entry just under the skin to its location near the plexus. The needle choice is probably less critical, although we use short-bevel, noninsulated needles, which are more echogenic. In placing the block, our goal is to keep needle movement to a minimum, thereby decreasing the chance for needle-to-nerve trauma. For the supraclavicular block, the needle is placed just inferoposterolateral to the plexus, as in "eight ball in the corner pocket" (see Figure 1.3).[102] The preferred position of the infraclavicular block is the 6 o'clock location relative to the subclavian artery (see Figure 1.4). The goal is to get close to the nerve (plexus or cord) without actually coming into contact with it. Once the fascial plane adjacent to the nerve is reached, a small amount of local anesthetic is injected. The anesthetic will hydrodissect the area and demonstrate local filling in the desired location of the nerve. Again, needle movement is kept to a minimum while injecting the full dose of local anesthetic. We find these locations to be reliable in accomplishing whole-plexus blocks while minimizing needle-to-nerve contact and trauma.

Complications

Neurapraxia (Box 1.3)

Incidence. Temporary postoperative paresthesia, or temporary sensory or motor deficit, is relatively uncommon. Injury can result from needle trauma, local anesthetic irritation, patient positioning, tourniquet compression, or surgical manipulation, to name a few of the confounding variables. Studies attempting to elucidate the relationship between neural anatomy and nerve injury, mainly correlating epineural and intraneural injections with neurologic sequelae, have been largely inconclusive.[17] The majority of these postoperative neuropathies resolve by 4 weeks, and the incidence of prolonged or permanent neurologic deficit is exceedingly rare. Certain patient risk factors have been identified that may increase the risk of neurologic injury after peripheral nerve blockade. These include old age, the use of chemotherapy, and the presence of diabetes mellitus, cervical myelopathy, multiple sclerosis, vascular disease, and any other preexisting neuropathies.[6] A review of recent literature shows the incidence of temporary neurologic complications after peripheral regional anesthesia to be 3% to 8% and of permanent nerve injury as defined by the presence of symptoms after 6 months to be between 0.04% and 0.6%.[7,37] Interestingly, the use of ultrasound guidance rather than the nerve-stimulator technique has not led to a decrease in the incidence of neurologic complications after peripheral nerve blockade.[7,37,80]

Management (Figure 1.14)**.** It is often the surgeon who discovers the existence of residual neurapraxia postoperatively. Management of the patient's concerns and the suspected injury requires thorough communication between the surgeon, anesthesiologist, and patient. A thorough history and physical examination are needed to determine the duration and types of symptoms and the vascular integrity, dermatomal distribution, and correlated motor or sensory deficit. It is important to investigate other confounding factors such as postoperative pain, immobility, edema, positioning, and casting or dressings.

We recommend dividing the findings into minor or major deficits. Minor deficits include positional paresthesias, defined as changes in temperature or light touch sensation without loss of motor function. Sometimes a burning sensation in a dermatomal distribution is present. For minor deficits, reassurance that the deficit will likely resolve in a few weeks will likely allay the patient's anxiety. It is important to closely follow the patient to ensure resolution of symptoms, provide reassurance, and allow early detection of a more serious problem or the need for referral to a neurologist.

Major deficits, such as complete or nearly complete palsy, should prompt early neurologic or neurosurgical consultation, which may be able to guide further diagnostic testing and treatment. If compression is suspected, ultrasound or magnetic resonance imaging should be performed to localize the lesion, followed by prompt surgical decompression.[6] Pain medication should be provided to prevent nerve sensitization and the potential for a complex regional pain syndrome. Nerve conduction studies (NCSs) can detect the presence of a lesion in myelinated nerves. However, because the nerves that transmit pain sensation are mostly unmyelinated nerves, NCSs are inconclusive when the only symptom is pain. A decrease in conduction velocity indicates myelin damage, whereas a decrease in amplitude indicates axonal damage. NCSs can show a lesion 1 to 2 days after injury. If the initial NCS is normal, the patient likely has a neurapraxia that should resolve with time and should be followed clinically, with the NCS repeated if symptoms persist or worsen. If the initial NCS is abnormal, electromyography (EMG) is indicated to find the exact anatomic location of the injury within the plexus. Because EMG changes appear 2 to 4 weeks following injury, many centers choose to perform an initial EMG at the same time as the NCS to obtain a baseline of preexisting nerve damage. Ideally, EMG should then be performed 2 to 4 weeks after injury because delaying it beyond 4 weeks may complicate the picture owing to reinnervation. EMG analysis will indicate the location of the nerve injury and may be able to pinpoint the likely cause.[48]

Allergy and Sepsis

Local anesthetics are categorized into two groups, esters and amides, based on their chemical structure. Esters are rapidly metabolized by plasma pseudocholinesterase, while amides are metabolized intracellularly by the liver. True allergic responses to local anesthetics are rare,[8,10] and often a history of a tachycardic response to added epinephrine can be elicited. True allergies are more likely to be due to the ester group, although some patients have a history of allergy to the preservative methylparaben, which is added to multidose vials of amide anesthetic. There is no evidence for cross-reactivity between the two groups, attributable to the different chemical structures.

Any injection through the skin raises concerns for infection, and regional nerve blockade is no exception. Aseptic technique is recommended, including thorough hand washing and skin

BOX 1.3 Neurologic Complications

- Neurologic complications can occur after regional or general anesthesia.
- Use of ultrasound does not appear to minimize this risk.
- The mechanisms of injury are sometimes obscure.
- With appropriate precautions the frequency of nerve injury after nerve blocks is quite low.

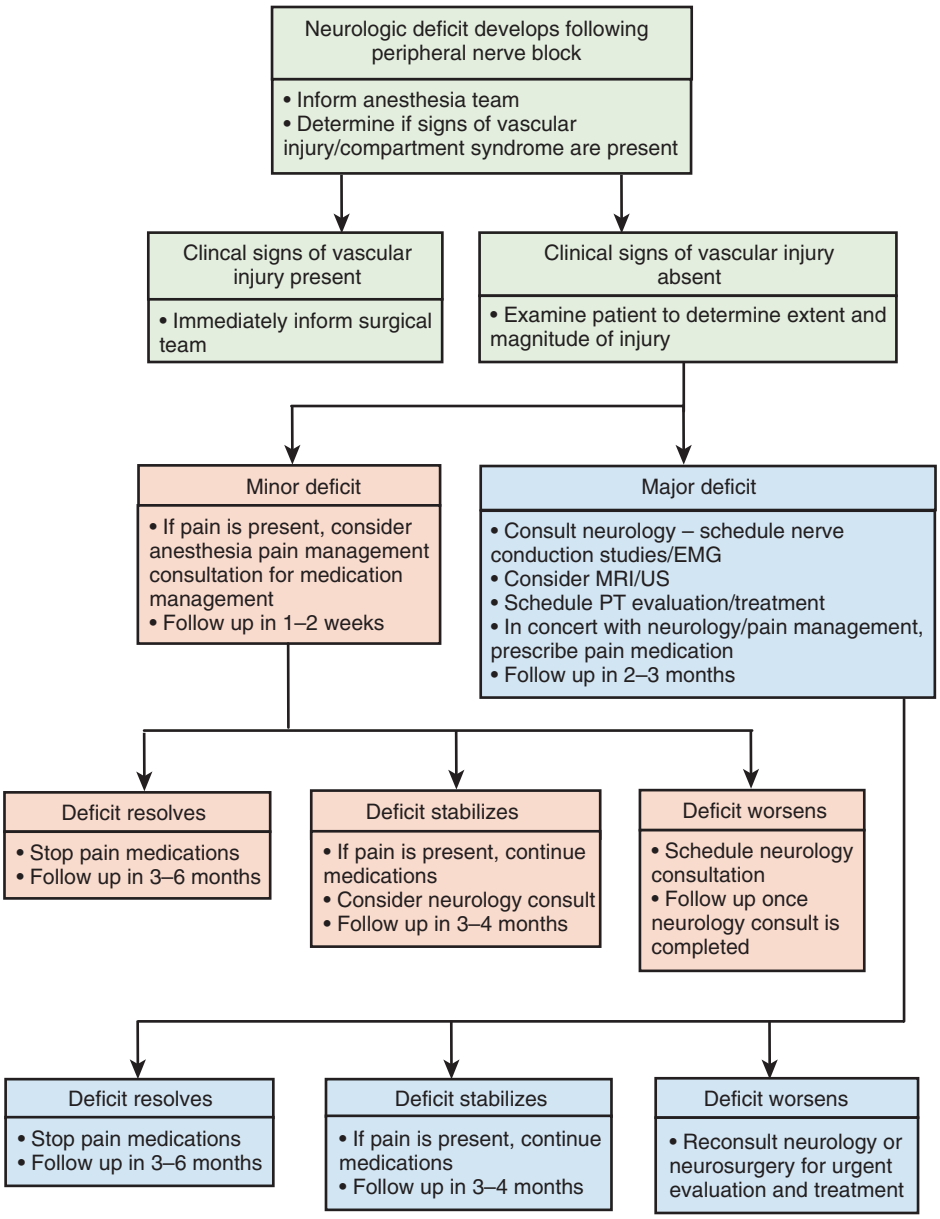

FIGURE 1.14 Management of neurologic deficit following peripheral nerve block. (Reproduced and modified with permission from Hadzic A, editor: *Textbook of Regional Anesthesia and Acute Pain Management*, New York, 2007, McGraw-Hill, p 989.)

cleansing with either povidone-iodine solution or chlorhexidine.[51] The rate of infection is exceptionally low for single-shot techniques, though sporadic case reports can be found in the literature. It is established that indwelling catheters have the potential for colonization; however, the rate of clinical infection, which positively correlates with catheter duration, is negligible.[51]

CRITICAL POINTS *Regional Anesthesia*

- Regional anesthesia for upper extremity surgery may improve the control of postoperative pain, lower opiate consumption, decrease nausea and vomiting, and decrease the hospital stay.
- Among the regional anesthesia techniques of nerve stimulator–guided, paresthesia-guided, or ultrasound-guided nerve block, there is no demonstrated improvement in outcome with any particular technique. However, ultrasound-guided blocks have been shown to improve onset and decrease dosage requirements compared with traditional techniques.
- Absolute contraindications to regional anesthesia are infection at the site of injection and patient refusal. Patient refusal often stems from fear of the unknown, which can be dispelled with a forthright discussion and promise of adequate sedation prior to administering the block.
- The use of additives to local anesthetics can prolong block duration and analgesia while reducing overall local anesthetic dose, but agents should be chosen judiciously to avoid neurotoxicity.
- Continuous peripheral nerve catheters are safe and effective for extending opioid-sparing, site-specific analgesia for adult and pediatric patients in both the inpatient and outpatient settings.
- The incidence of temporary postoperative paresthesias is between 3% and 8%; of that number, most resolve within 4 weeks.
- Prolonged neurapraxias are extremely rare, with an incidence of between 0.04% and 0.6%. In the event of a neurapraxia, a coordinated effort between the anesthesiologist and surgeon is required, as well as thorough communication with the patient. Often, early neurologic consultation will help with further diagnosis and treatment.

REFERENCES

1. Ahsan ZS, Carvalho B, Yao J: Incidence of failure of continuous peripheral nerve catheters for postoperative analgesia in upper extremity surgery. *J Hand Surg* 39(2):324–329, 2014.
2. Akkara Veetil BM, Bongartz T: Perioperative care for patients with rheumatic diseases. *Nat Rev Rheumatol* 8(1):32–41, 2012.
3. Alemanno F, Ghisi D, Fanelli A, et al: Tramadol and 0.5% levobupivacaine for single-shot interscalene block: effects on postoperative analgesia in patients undergoing shoulder arthroplasty. *Minerva Anestesiol* 78(3):291–296, 2012.
4. Aumeier C, Kasdorf B, Gruber M, et al: Lipid emulsion pretreatment has different effects on mepivacaine and bupivacaine cardiac toxicity in an isolated rat heart model. *Br J Anaes* 112(4):735–741, 2014.
5. Bailard NS, Ortiz J, Flores RA: Additives to local anesthetics for peripheral nerve blocks: Evidence, limitations, and recommendations. *Am J Health Syst Pharm* 71(5):373–385, 2014.
6. Barrington MJ, Snyder GL: Neurologic complications of regional anesthesia. *Curr Opin Anaesthesiol* 24(5):554–560, 2011.
7. Barrington MJ, Watts SA, Gledhill SR, et al: Preliminary results of the Australasian Regional Anaesthesia Collaboration: a prospective audit of more than 7000 peripheral nerve and plexus blocks for neurologic and other complications. *Reg Anesth Pain Med* 34(6):534–541, 2009.
8. Batinac T, Sotosek Tokmadzic V, Peharda V, et al: Adverse reactions and alleged allergy to local anesthetics: analysis of 331 patients. *J Dermatol* 40(7):522–527, 2013.
9. Behr A, Freo U, Ori C, et al: Buprenorphine added to levobupivacaine enhances postoperative analgesia of middle interscalene brachial plexus block. *J Anesth* 26(5):746–751, 2012.
10. Bhole MV, Manson AL, Seneviratne SL, et al: IgE-mediated allergy to local anaesthetics: separating fact from perception: a UK perspective. *Br J Anaesth* 108(6): 903–911, 2012.
11. Bigeleisen P, Wilson M: A comparison of two techniques for ultrasound guided infraclavicular block. *Br J Anaesth* 96(4):502–507, 2006.
12. Bingham AE, Fu R, Horn JL, et al: Continuous peripheral nerve block compared with single-injection peripheral nerve block: a systematic review and meta-analysis of randomized controlled trials. *Reg Anesth Pain Med* 37(6):583–594, 2012.
13. Blumenthal S, Borgeat A, Maurer K, et al: Preexisting subclinical neuropathy as a risk factor for nerve injury after continuous ropivacaine administration through a femoral nerve catheter. *Anesthesiology* 105(5):1053–1056, 2006.
14. Chapman GM: Regional nerve block with the aid of a nerve stimulator. *Anaesthesia* 27(2):185–193, 1972.
15. Chelly JE, Szczodry DM, Neumann KJ: International normalized ratio and prothrombin time values before the removal of a lumbar plexus catheter in patients receiving warfarin after total hip replacement. *Br J Anaesth* 101(2):250–254, 2008.
16. Chin KJ, Alakkad H, Cubillos JE: Single, double or multiple-injection techniques for non-ultrasound guided axillary brachial plexus block in adults undergoing surgery of the lower arm. *Cochrane Database Syst Rev* (8):CD003842, 2013.
17. Choquet O, Morau D, Biboulet P, et al: Where should the tip of the needle be located in ultrasound-guided peripheral nerve blocks? *Curr Opin Anaesthesiol* 25(5):596–602, 2012.
18. Chow MY, Sia AT, Koay CK, et al: Alkalinization of lidocaine does not hasten the onset of axillary brachial plexus block. *Anesth Analg* 86(3):566–568, 1998.
19. Chowdhry S, Seidenstricker L, Cooney DS, et al: Do not use epinephrine in digital blocks: myth or truth? Part II. A retrospective review of 1111 cases. *Plast Reconstruct Surg* 126(6):2031–2034, 2010.
20. Colbern E: The Bier block for intravenous regional anesthesia: technic and literature review. *Anesth Analg* 49(6):935–940, 1970.
21. Crystal CS, Blankenship RB: Local anesthetics and peripheral nerve blocks in the emergency department. *Emerg Med Clin North Am* 23(2):477–502, 2005.
22. De Oliveira GS, Jr, Almeida MD, Benzon HT, et al: Perioperative single dose systemic dexamethasone for postoperative pain: a meta-analysis of randomized controlled trials. *Anesthesiology* 115(3):575–588, 2011.
23. Delaunay L, Chelly JE: Blocks at the wrist provide effective anesthesia for carpal tunnel release. *Can J Anaesth* 48(7):656–660, 2001.
24. Desmet M, Braems H, Reynvoet M, et al: I.V. and perineural dexamethasone are equivalent in increasing the analgesic duration of a single-shot interscalene block with ropivacaine for shoulder surgery: a prospective, randomized, placebo-controlled study. *Br J Anaesth* 111(3):445–452, 2013.
25. Detaille V, Busnel F, Ravary H, et al: Use of continuous interscalene brachial plexus block and rehabilitation to treat complex regional pain syndrome of the shoulder. *Ann Phys Rehabil Med* 53(6–7):406–416, 2010.
26. Draeger RW, Messer TM: Suprascapular nerve palsy following supraclavicular block for upper extremity surgery: report of 3 cases. *J Hand Surg* 37(12):2576–2579, 2012.
27. Egol KA, Soojian MG, Walsh M, et al: Regional anesthesia improves outcome after distal radius fracture fixation over general anesthesia. *J Orthop Trauma* 26(9):545–549, 2012.
28. Esaki RK, Mashour GA: Levels of consciousness during regional anesthesia and monitored anesthesia care: patient expectations and experiences. *Anesth Analg* 108(5):1560–1563, 2009.
29. Falcao LF, Perez MV, de Castro I, et al: Minimum effective volume of 0.5% bupivacaine with epinephrine in ultrasound-guided interscalene brachial plexus block. *Br J Anaesth* 110(3):450–455, 2013.
30. Ferraro LH, Takeda A, dos Reis Falcao LF, et al: Determination of the minimum effective volume of 0.5% bupivacaine for ultrasound-guided axillary brachial plexus block. *Braz J Anesthesiol* 64(1):49–53, 2014.
31. Ferraro LH, Tardelli MA, Yamashita AM, et al: Ultrasound-guided femoral and sciatic nerve blocks in an anticoagulated patient. Case reports. *Braz J Anesthesiol* 60(4):422–428, 2010.
32. Franco CD, Rahman A, Voronov G, et al: Gross anatomy of the brachial plexus sheath in human cadavers. *Reg Anesth Pain Med* 33(1):64–69, 2008.
33. Franco CD, Salahuddin Z, Rafizad A: Bilateral brachial plexus block. *Anesth Analg* 98(2):518–520, 2004.
34. Franco CD, Vieira ZE: 1,001 subclavian perivascular brachial plexus blocks: success with a nerve stimulator. *Reg Anesth Pain Med* 25(1):41–46, 2000.
35. Fredrickson MJ: Randomised comparison of an end-hole, triple-hole and novel six-hole catheter for continuous interscalene analgesia. *Anaesth Intensive Care* 42(1):37–42, 2014.
36. Fredrickson MJ, Abeysekera A, White R: Randomized study of the effect of local anesthetic volume and concentration on the duration of peripheral nerve blockade. *Reg Anesth Pain Med* 37(5):495–501, 2012.
37. Fredrickson MJ, Kilfoyle DH: Neurological complication analysis of 1000 ultrasound guided peripheral nerve blocks for elective orthopaedic surgery: a prospective study. *Anaesthesia* 64(8):836–844, 2009.
38. Fritsch G, Danninger T, Allerberger K, et al: Dexmedetomidine added to ropivacaine extends the duration of interscalene brachial plexus blocks for elective

shoulder surgery when compared with ropivacaine alone: a single-center, prospective, triple-blind, randomized controlled trial. *Reg Anesth Pain Med* 39(1):37–47, 2014.
39. Fujinaga M, Baden JM: Methionine prevents nitrous oxide-induced teratogenicity in rat embryos grown in culture. *Anesthesiology* 81(1):184–189, 1994.
40. Gaus P, Heb B, Tanyay Z, et al: Epidural malpositioning of an interscalene plexus catheter. *Anaesthesist* 60(9):850–853, 2011.
41. Gebhard RE, Nielsen KC, Pietrobon R, et al: Diabetes mellitus, independent of body mass index, is associated with a "higher success" rate for supraclavicular brachial plexus blocks. *Reg Anesth Pain Med* 34(5):404–407, 2009.
42. Gonzalez AP, Bernucci F, Pham K, et al: Minimum effective volume of lidocaine for double-injection ultrasound-guided axillary block. *Reg Anesth Pain Med* 38(1): 16–20, 2013.
43. Guay J: Adverse events associated with intravenous regional anesthesia (Bier block): a systematic review of complications. *J Clin Anesth* 21(8):585–594, 2009.
44. Gupta PK, Pace NL, Hopkins PM: Effect of body mass index on the ED50 volume of bupivacaine 0.5% for supraclavicular brachial plexus block. *Br J Anaesth* 104(4):490–495, 2010.
45. Gurnaney H, Kraemer FW, Maxwell L, et al: Ambulatory continuous peripheral nerve blocks in children and adolescents: a longitudinal 8-year single center study. *Anesth Analg* 118(3):621–627, 2014.
46. Hadzic A, Arliss J, Kerimoglu B, et al: A comparison of infraclavicular nerve block versus general anesthesia for hand and wrist day-case surgeries. *Anesthesiology* 101(1):127–132, 2004.
47. Hadzic A, Williams BA, Karaca PE, et al: For outpatient rotator cuff surgery, nerve block anesthesia provides superior same-day recovery over general anesthesia. *Anesthesiology* 102(5):1001–1007, 2005.
48. Hadzic AE: *Textbook of regional anesthesia and acute pain management*, New York, 2007, McGraw-Hill.
49. Halpern AA, Nagel DA: Compartment syndromes of the forearm: early recognition using tissue pressure measurements. *J Hand Surg* 4(3):258–263, 1979.
50. Hebl JR, Horlocker TT, Sorenson EJ, et al: Regional anesthesia does not increase the risk of postoperative neuropathy in patients undergoing ulnar nerve transposition. *Anesth Analg* 93(6):1606–1611, 2001.
51. Hebl JR, Niesen AD: Infectious complications of regional anesthesia. *Curr Opin Anaesthesiol* 24(5):573–580, 2011.
52. Hill RG, Jr, Patterson JW, Parker JC, et al: Comparison of transthecal digital block and traditional digital block for anesthesia of the finger. *Ann Emerg Med* 25(5): 604–607, 1995.
53. Holborow J, Hocking G: Regional anaesthesia for bilateral upper limb surgery: a review of challenges and solutions. *Anaesth Intensive Care* 38(2):250–258, 2010.
54. Horlocker TT, Wedel DJ, Rowlingson JC, et al: Regional anesthesia in the patient receiving antithrombotic or thrombolytic therapy: American Society of Regional Anesthesia and Pain Medicine Evidence-Based Guidelines (Third Edition). *Reg Anesth Pain Med* 35(1):64–101, 2010.
55. Humbyrd CJ, LaPorte DM: Hand surgery: considerations in pregnant patients. *J Hand Surg* 37(5):1086–1089, quiz 1089, 2012.
56. Ilfeld BM: Continuous peripheral nerve blocks in the hospital and at home. *Anesthesiol Clin* 29(2):193–211, 2011.
57. Ilfeld BM, Mariano ER, Girard PJ, et al: A multicenter, randomized, triple-masked, placebo-controlled trial of the effect of ambulatory continuous femoral nerve blocks on discharge-readiness following total knee arthroplasty in patients on general orthopaedic wards. *Pain* 150(3):477–484, 2010.
58. Ilfeld BM, Shuster JJ, Theriaque DW, et al: Long-term pain, stiffness, and functional disability after total knee arthroplasty with and without an extended ambulatory continuous femoral nerve block: a prospective, 1-year follow-up of a multicenter, randomized, triple-masked, placebo-controlled trial. *Reg Anesth Pain Med* 36(2):116–120, 2011.
59. Kaabachi O, Ouezini R, Koubaa W, et al: Tramadol as an adjuvant to lidocaine for axillary brachial plexus block. *Anesth Analg* 108(1):367–370, 2009.
60. Kapral S, Krafft P, Eibenberger K, et al: Ultrasound-guided supraclavicular approach for regional anesthesia of the brachial plexus. *Anesth Analg* 78(3):507–513, 1994.
61. Kesimci E, Izdes S, Gozdemir M, et al: Tramadol does not prolong the effect of ropivacaine 7.5 mg/ml for axillary brachial plexus block. *Acta Anaesthesiol Scand* 51(6):736–741, 2007.
62. Koscielniak-Nielsen ZJ, Hesselbjerg L, Fejlberg V: Comparison of transarterial and multiple nerve stimulation techniques for an initial axillary block by 45 mL of mepivacaine 1% with adrenaline. *Acta Anaesthesiol Scand* 42(5):570–575, 1998.
63. Kulenkampff D: Brachial plexus anaesthesia: its indications, technique, and dangers. *Ann Surg* 87(6):883–891, 1928.
64. Laiq N, Khan MN, Arif M, et al: Midazolam with bupivacaine for improving analgesia quality in brachial plexus block for upper limb surgeries. *J Coll Physicians Surg Pak* 18(11):674–678, 2008.
65. Lee AR, Yi HW, Chung IS, et al: Magnesium added to bupivacaine prolongs the duration of analgesia after interscalene nerve block. *Can J Anaesth* 59(1):21–27, 2012.
66. Lee IO, Kim WK, Kong MH, et al: No enhancement of sensory and motor blockade by ketamine added to ropivacaine interscalene brachial plexus blockade. *Acta Anaesthesiol Scand* 46(7):821–826, 2002.
67. Leffler A, Frank G, Kistner K, et al: Local anesthetic-like inhibition of voltage-gated Na(+) channels by the partial mu-opioid receptor agonist buprenorphine. *Anesthesiology* 116(6):1335–1346, 2012.
68. Lenters TR, Davies J, Matsen FA, 3rd: The types and severity of complications associated with interscalene brachial plexus block anesthesia: local and national evidence. *J Shoulder Elbow Surg* 16(4):379–387, 2007.
69. Liguori GA, Zayas VM, YaDeau JT, et al: Nerve localization techniques for interscalene brachial plexus blockade: a prospective, randomized comparison of mechanical paresthesia versus electrical stimulation. *Anesth Analg* 103(3):761–767, 2006.
70. Liu SS, Gordon MA, Shaw PM, et al: A prospective clinical registry of ultrasound-guided regional anesthesia for ambulatory shoulder surgery. *Anesth Analg* 111(3):617–623, 2010.
71. Liu SS, Zayas VM, Gordon MA, et al: A prospective, randomized, controlled trial comparing ultrasound versus nerve stimulator guidance for interscalene block for ambulatory shoulder surgery for postoperative neurological symptoms. *Anesth Analg* 109(1):265–271, 2009.
72. Lonnqvist PA: Is ultrasound guidance mandatory when performing paediatric regional anaesthesia? *Curr Opin Anaesthesiol* 23(3):337–341, 2010.
73. Low CK, Vartany A, Diao E: Comparison of transthecal and subcutaneous single-injection digital block techniques in cadaver hands. *J Hand Surg* 22(5):897–900, 1997.
74. Marhofer D, Marhofer P, Triffterer L, et al: Dislocation rates of perineural catheters: a volunteer study. *Br J Anaesth* 111(5):800–806, 2013.
75. McCartney CJ, Xu D, Constantinescu C, et al: Ultrasound examination of peripheral nerves in the forearm. *Reg Anesth Pain Med* 32(5):434–439, 2007.
76. McNaught A, Shastri U, Carmichael N, et al: Ultrasound reduces the minimum effective local anaesthetic volume compared with peripheral nerve stimulation for interscalene block. *Br J Anaesth* 106(1):124–130, 2011.
77. Mirkheshti A, Aryani MR, Shojaei P, et al: The effect of adding magnesium sulfate to lidocaine compared with paracetamol in prevention of acute pain in hand surgery patients under intravenous regional anesthesia (IVRA). *Int J Prev Med* 3(9):616–621, 2012.
78. Misamore G, Webb B, McMurray S, et al: A prospective analysis of interscalene brachial plexus blocks performed under general anesthesia. *J Shoulder Elbow Surg* 20(2):308–314, 2011.
79. Morin AM, Kranke P, Wulf H, et al: The effect of stimulating versus nonstimulating catheter techniques for continuous regional anesthesia: a semiquantitative systematic review. *Reg Anesth Pain Med* 35(2):194–199, 2010.
80. Neal JM: Ultrasound-guided regional anesthesia and patient safety: an evidence-based analysis. *Reg Anesth Pain Med* 35(2 Suppl):S59–S67, 2010.
81. Neal JM, Moore JM, Kopacz DJ, et al: Quantitative analysis of respiratory, motor, and sensory function after supraclavicular block. *Anesth Analg* 86(6):1239–1244, 1998.
82. O'Rourke MG, Tang TS, Allison SI, et al: The anatomy of the extrathoracic intercostobrachial nerve. *Aust N Z J Surg* 69(12):860–864, 1999.
83. Osterman AL: The double crush syndrome. *Orthop Clin North Am* 19(1):147–155, 1988.
84. Pavicic Saric J, Vidjak V, Tomulic K, et al: Effects of age on minimum effective volume of local anesthetic for ultrasound-guided supraclavicular brachial plexus block. *Acta Anaesthesiol Scand* 57(6):761–766, 2013.
85. Perlas A, Niazi A, McCartney C, et al: The sensitivity of motor response to nerve stimulation and paresthesia for nerve localization as evaluated by ultrasound. *Reg Anesth Pain Med* 31(5):445–450, 2006.
86. Perlas A, Peng PW, Plaza MB, et al: Forearm rescue cuff improves tourniquet tolerance during intravenous regional anesthesia. *Reg Anesth Pain Med* 28(2):98–102, 2003.
87. Polaner DM, Taenzer AH, Walker BJ, et al: Pediatric Regional Anesthesia Network (PRAN): a multi-institutional study of the use and incidence of complications of pediatric regional anesthesia. *Anesth Analg* 115(6):1353–1364, 2012.
88. Popping DM, Elia N, Marret E, et al: Clonidine as an adjuvant to local anesthetics for peripheral nerve and plexus blocks: a meta-analysis of randomized trials. *Anesthesiology* 111(2):406–415, 2009.
89. American College of Obstetricians and Gynecologists: ACOG Committee Opinion No. 474: Nonobstetric surgery during pregnancy. *Obstet Gynecol* 117(2 Pt 1):420–421, 2011.
90. Prandoni P, Temraz S, Taher A: Direct oral anticoagulants in the prevention of venous thromboembolism: evidence from major clinical trials. *Semin Hematol* 51(2):121–130, 2014.
91. Raj PP, Montgomery SJ, Nettles D, et al: Infraclavicular brachial plexus block: a new approach. *Anesth Analg* 52(6):897–904, 1973.

92. Renes SH, Rettig HC, Gielen MJ, et al: Ultrasound-guided low-dose interscalene brachial plexus block reduces the incidence of hemidiaphragmatic paresis. *Reg Anesth Pain Med* 34(5):498–502, 2009.
93. Rosencher N, Noack H, Feuring M, et al: Type of anaesthesia and the safety and efficacy of thromboprophylaxis with enoxaparin or dabigatran etexilate in major orthopaedic surgery: pooled analysis of three randomized controlled trials. *Thromb J* 10(1):9, 2012.
94. Salam GA: Regional anesthesia for office procedures: Part II. Extremity and inguinal area surgeries. *Am Fam Physician* 69(4):896–900, 2004.
95. Salviz EA, Xu D, Frulla A, et al: Continuous interscalene block in patients having outpatient rotator cuff repair surgery: a prospective randomized trial. *Anesth Analg* 117(6):1485–1492, 2013.
96. Samanta R, Shoukrey K, Griffiths R: Rheumatoid arthritis and anaesthesia. *Anaesthesia* 66(12):1146–1159, 2011.
97. Sandhu NS, Capan LM: Ultrasound-guided infraclavicular brachial plexus block. *Br J Anaesth* 89(2):254–259, 2002.
98. Scarff CE, Scarff CW: Digital nerve blocks: more gain with less pain. *Australas J Dermatol* 48(1):60–61, 2007.
99. Schoenmakers KP, Wegener JT, Stienstra R: Effect of local anesthetic volume (15 vs 40 mL) on the duration of ultrasound-guided single shot axillary brachial plexus block: a prospective randomized, observer-blinded trial. *Reg Anesth Pain Med* 37(3):242–247, 2012.
100. Schroeder K, Andrei AC, Furlong MJ, et al: The perioperative effect of increased body mass index on peripheral nerve blockade: an analysis of 528 ultrasound guided interscalene blocks. *Braz J Anesthesiol* 62(1):28–38, 2012.
101. Shin SW, Byeon GJ, Yoon JU, et al: Effective analgesia with ultrasound-guided interscalene brachial plexus block for postoperative pain control after arthroscopic rotator cuff repair. *J Anesth* 28(1):64–69, 2014.
102. Soares LG, Brull R, Lai J, et al: Eight ball, corner pocket: the optimal needle position for ultrasound-guided supraclavicular block. *Reg Anesth Pain Med* 32(1):94–95, 2007.
103. Srikumaran U, Stein BE, Tan EW, et al: Upper-extremity peripheral nerve blocks in the perioperative pain management of orthopaedic patients: AAOS exhibit selection. *J Bone Joint Surg Am* 95(24):e197, 191–113 (1–13), 2013.
104. Stan TC, Krantz MA, Solomon DL, et al: The incidence of neurovascular complications following axillary brachial plexus block using a transarterial approach. A prospective study of 1,000 consecutive patients. *Reg Anesth* 20(6):486–492, 1995.
105. Su HH, Lui PW, Yu CL, et al: The effects of continuous axillary brachial plexus block with ropivacaine infusion on skin temperature and survival of crushed fingers after microsurgical replantation. *Chang Gung Med J* 28(8):567–574, 2005.
106. Thomas LC, Graham SK, Osteen KD, et al: Comparison of ultrasound and nerve stimulation techniques for interscalene brachial plexus block for shoulder surgery in a residency training environment: a randomized, controlled, observer-blinded trial. *Ochsner J* 11(3):246–252, 2011.
107. Trabelsi W, Amor MB, Lebbi MA, et al: Ultrasound does not shorten the duration of procedure but provides a faster sensory and motor block onset in comparison to nerve stimulator in infraclavicular brachial plexus block. *Korean J Anesthesiol* 64(4):327–333, 2013.
108. Tran de QH, Dugani S, Correa JA, et al: Minimum effective volume of lidocaine for ultrasound-guided supraclavicular block. *Reg Anesth Pain Med* 36(5):466–469, 2011.
109. Tran de QH, Dugani S, Dyachenko A, et al: Minimum effective volume of lidocaine for ultrasound-guided infraclavicular block. *Reg Anesth Pain Med* 36(2):190–194, 2011.
110. Tuzuner T: Median and ulnar nerve block for endoscopic carpal tunnel release. *Adv Ther* 23(6):902–904, 2006.
111. Urmey WF, Talts KH, Sharrock NE: One hundred percent incidence of hemidiaphragmatic paresis associated with interscalene brachial plexus anesthesia as diagnosed by ultrasonography. *Anesth Analg* 72(4):498–503, 1991.
112. Walter M, Rogalla P, Spies C, et al: Intrathecal misplacement of an interscalene plexus catheter. *Anaesthesist* 54(3):215–219, 2005.
113. Ward WA, Van Moore A: Management of finger ulcers in scleroderma. *J Hand Surg* 20(5):868–872, 1995.
114. Weber A, Fournier R, Van Gessel E, et al: Epinephrine does not prolong the analgesia of 20 mL ropivacaine 0.5% or 0.2% in a femoral three-in-one block. *Anesth Analg* 93(5):1327–1331, 2001.
115. Webster F, Bremner S, McCartney CJ: Patient experiences as knowledge for the evidence base: a qualitative approach to understanding patient experiences regarding the use of regional anesthesia for hip and knee arthroplasty. *Reg Anesth Pain Med* 36(5):461–465, 2011.
116. Williams SR, Chouinard P, Arcand G, et al: Ultrasound guidance speeds execution and improves the quality of supraclavicular block. *Anesth Analg* 97(5):1518–1523, 2003.
117. Winnie AP: Interscalene brachial plexus block. *Anesth Analg* 49(3):455–466, 1970.
118. Yang J, Cooper MG: Compartment syndrome and patient-controlled analgesia in children: analgesic complication or early warning system? *Anaesth Intens Care* 38(2):359–363, 2010.
119. Yuan JM, Yang XH, Fu SK, et al: Ultrasound guidance for brachial plexus block decreases the incidence of complete hemi-diaphragmatic paresis or vascular punctures and improves success rate of brachial plexus nerve block compared with peripheral nerve stimulator in adults. *Chin Med J* 125(10):1811–1816, 2012.
120. Zor F, Ozturk S, Usyilmaz S, et al: Is stellate ganglion blockade an option to prevent early arterial vasospasm after digital microsurgical procedures? *Plast Reconstruct Surg* 117(3):1059–1060, 2006.

2

Acute Infections of the Hand

Milan V. Stevanovic and Frances Sharpe

GENERAL PRINCIPLES

Hippocrates' principles for the treatment of hand infections are fundamentally valid today. Wounds were kept clean with frequent changes of wine-soaked dressings. Dressings were kept loose "so as not to intercept the pus, but to allow it to flow away freely."[44] Coupled with these early principles is the pioneering work of Dr. Alan Kanavel, a Chicago general surgeon who treated hand infections in the preantibiotic era. Much of our current understanding of the pathogenesis and treatment of hand infections must be credited to his extensive dissections and innovative injection studies. Through these studies, he demonstrated the potential spaces of the hand and the pathogenesis of infection. From this data, he developed the surgical principles that remain the cornerstone of modern treatment of hand infections.[75]

Hand infections can result in severe disabilities, including stiffness, contracture, and amputation. These complications have been significantly reduced through the introduction of antibiotic therapy in conjunction with surgical treatment. Although antibiotics have dramatically reduced the morbidity associated with hand infections, their use does not supplant the need for expedient and proper surgical intervention. Several factors influence the outcome of hand infections. These include the location of the infection, infecting organism, timing of treatment, adequacy of surgical drainage, efficacy of antibiotics, and health status and immunocompetence of the host. In the words of one of the preeminent United States public health officials, Dr. Charles V. Chapin: "As it takes two to quarrel, so it takes two to make a disease, the microbe and the host."

Host factors play a determining role in the severity and duration of infection. Many medical conditions reduce host defenses. Malnutrition, alcoholism, autoimmune diseases, chronic corticosteroid use, hepatitis, and human immunodeficiency virus (HIV) infection are some of the comorbidities to be considered. The most prevalent disease with associated immunosuppression is diabetes mellitus, which affects up to 11% of the adult population of the United States.[140]

Early and superficial infections may respond to nonsurgical management. However, most acute infections of the hand represent surgical emergencies. Swelling and edema associated with an infection result in increased tissue pressure and can cause ischemia and tissue necrosis by a process resembling compartment syndrome.[139] Furthermore, toxins produced by the offending pathogen can cause vascular thrombosis and tissue death. Patients with necrotizing fasciitis and gas gangrene need *immediate* surgical care.

Types of Infections

Cellulitis is an infection of the subcutaneous tissue, which is often diffuse and can be associated with lymphangitis. It is caused by a single organism, usually *Staphylococcus aureus* or β-hemolytic *Streptococcus*. Lymphangitic streaking is more commonly seen with β-hemolytic streptococcal infections. It generally has a more distal nidus and spreads proximally. It is a non–pus-forming infection and as such is initially treated nonsurgically. If the cellulitis is not responding to intravenous therapy over 12 to 24 hours, this often suggests the formation of pus (*abscess*) and more serious infection. Even in the absence of abscess formation, cellulitis associated with significant swelling resolves more quickly with surgical decompression. Cellulitis often requires hospital admission and close monitoring for response to antibiotic therapy. A specific type of staphylococcal infection is the *staphylococcal scalded skin syndrome*, primarily a disease of young children that results from an exfoliative toxin-producing staphylococcal organism.[85,120] A high index of suspicion and early differentiation of this process from other skin conditions are important to treatment outcome. Although this syndrome is extremely rare in adults, it is associated with a high mortality rate, usually because of serious underlying illness, such as kidney failure or immunosuppression.[120] Detection of the exfoliative toxin is required for diagnosis. New immunologic methods allow for more rapid detection.[81] Prompt antibiotic therapy and local wound care are the mainstays of management. *Necrotizing fasciitis* is a serious life-threatening infection that may initially resemble cellulitis. Although purulence is not present, a watery discharge often described as "dishwater-like fluid" may be seen superficial to the fascia. Most other hand infections are generally pus forming and are discussed in detail throughout the chapter.

The most common infecting organisms are *Staphylococcus* and *Streptococcus* species, with staphylococcal organisms predominating. Many infections, especially those associated with bite wounds, those associated with gross contamination, or

those seen in diabetics, are often caused by mixed species. *Pasteurella multocida* should be considered in most animal bites, and both streptococcal species and *Eikenella corrodens* should be considered in human bite wounds. Anaerobic infection is less common but should be considered more frequently in diabetics or intravenous drug users. Empirical antibiotic therapy should be tailored toward the most likely offending pathogen. The local prevalence of antibiotic-resistant organisms should be considered when starting empirical treatment. An infectious disease specialist is valuable in patient management because he or she is most familiar with the hospital-specific patterns of antibiotic resistance, can direct antibiotic therapy, and can follow outpatient intravenous therapy.

Methicillin-Resistant *Staphylococcus aureus* Infections

The increasing incidence of infection with methicillin-resistant *S. aureus* (MRSA) has been recognized throughout the surgical as well as infectious disease literature. A strain of *S. aureus* resistant to methicillin was mentioned in reports from the United Kingdom in 1961. This strain was soon identified worldwide and was associated with hospital-acquired infections (HA-MRSA).[113] Only a handful of successful HA-MRSA clones are responsible for the majority of infections, and different clones dominate in different geographic locations.[87] However, MRSA infections have been increasingly identified as community-acquired infections (CA-MRSA). There are unique microbiologic and genetic properties distinguishing the hospital-acquired and community-acquired strains. A community-acquired infection is defined as occurring in patients with MRSA identified by culture who have no history of a hospital or medical facility stay within the past year, who have no history of dialysis or surgery occurring within the past year, and in whom no indwelling catheters are present.

CA-MRSA is now the predominant strain in hand infections, found in up to 60% of *S. aureus* infections.[20,25,72,114] The majority of CA-MRSA infections in the United States have been caused by a single clone (USA300). One of the distinguishing features in CA-MRSA is the frequent gene sequence encoding for Panton-Valentine leukocidin (PVL), a potent toxin that leads to the characteristic tissue necrosis commonly seen in the clinical setting.

MRSA infections frequently have a characteristic appearance of a dermonecrotic skin lesion (Figure 2.1). They are often mislabeled as "spider bites" due to their dermonecrotic appearance and may not receive appropriate antibiotic therapy.[160] More recently, we have not seen the extensive tissue necrosis with MRSA infections that we have in the past. Empirical treatment of hand infections has also changed to address potential MRSA infections.[25,41,70,116] Successful treatment requires surgical débridement with excision of necrotic tissue in conjunction with appropriate antibiotic therapy.

Nosocomial Infections

The hand is a very well-vascularized region, making it less vulnerable to postoperative infection than other anatomic sites. *S. aureus* is the most common pathogen in clean surgical procedures.[21,46,141] The use of perioperative intravenous antibiotics within 1 hour preceding surgery has greatly reduced the incidence of postsurgical infections in general orthopedic practice.[27] However, the role of perioperative antibiotics in elective hand surgery is less clear. Several studies suggest that for soft tissue procedures of less than 2 hours' duration, the routine use of prophylactic antibiotics is not indicated.[19,40,64,128,154] Ultimately, the whole patient must be considered. Prophylactic antibiotics in patients with joint arthroplasties are recommended to protect the prosthesis more than to prevent surgical site infection. Patients with an altered immune response may have a potentially greater benefit from prophylactic antibiotics than an immunocompetent host. For surgical procedures that involve exposure of the bone or joint or those involving implants, we routinely give intravenous prophylaxis.*



FIGURE 2.1 Characteristic appearance of MRSA infection with central skin necrosis and surrounding erythema. Purulence is not always present. Soft tissue necrosis is often more extensive than would be expected from a localized infection. (Copyright courtesy of Milan Stevanovic and Frances Sharpe.)

Patient Evaluation

Clinical examination remains the hallmark of diagnosis in hand infections. Pain (dolor), and increased temperature (calor), with or without erythema (rubor), and tenderness remain the prime features of hand infection. Temperature elevation is inconsistent. Abnormalities of the white blood cell (WBC) count and C-reactive protein (CRP) level are uncommon features of a hand infection. In one study, these were normal in

*Editor's note (DPG): I strongly disagree with the practice of giving "prophylactic" antibiotics for all clean bone and joint cases in the wrist and hand. This is not only unnecessary but harmful in the long term, creating superresistant bacteria. In my practice, I do not administer perioperative antibiotics in clean, elective cases unless there is a specific indication to do so. Unfortunately, many orthopedic surgeons give antibiotics indiscriminately purely as a defensive measure, fearing that if the patient does get an infection and no antibiotics were given, a plaintiff's attorney will cite this as inappropriate care. In addition, many hospital policies now require the routine administration of preoperative antibiotics.

75% of patients. The erythrocyte sedimentation rate (ESR) was slightly more useful, with elevation of the ESR found in 50% of patients.[68]

The initial evaluation and management in the emergency department should include a thorough medical history, assessment of risk factors for immunocompromise, and evaluation of tetanus immunization status. Appropriate tetanus prophylaxis should be administered based on immunization history and time of the last booster shot. Tetanus immune globulin (TIG; HyperTET®) and tetanus toxoid booster are given if the patient has not had a series of tetanus immunizations. Clinical evaluation of the affected extremity should include examination for fluctuance, warmth, edema, redness, tenderness, and lymphangitis or lymphadenopathy. Areas of cellulitis should be marked on the skin so that progression or regression of the infectious process can be monitored; if an open draining wound is present, a specimen should be sent for aerobic and anaerobic culture. Blood cultures should be taken in febrile patients. Blood should be drawn for a complete blood cell count (CBC), ESR, CRP, electrolytes, and random blood glucose measurements. Hand infection may be the first presenting complaint of undiagnosed diabetes. Radiographs are obtained to evaluate for the presence of a foreign body, gas within the soft tissues, underlying fracture, septic joint, or osteomyelitis.

When a patient presents with an area of fluctuance, this should be provisionally treated with aspiration or decompression until formal surgical débridement is performed. The fluid should be sent for culture. For patients who do not clearly have an abscess, aspiration may be useful to identify a deep pyogenic infection. Swollen painful joints should be aspirated with caution. The site of aspiration should not be over an area of cellulitis, so as not to seed the joint with bacteria. The aspirated fluid should be sent for culture. Joint fluid analysis with cell count, glucose, and protein levels can be obtained if an adequate specimen is available. If the joint aspirate is not clearly pyogenic and there are not other indicators of infection, antibiotics are withheld. Nonsteroidal antiinflammatory drugs (NSAIDs) may be given to both treat the patient and help distinguish between an inflammatory process and sepsis. If the presentation is suggestive of an inflammatory process, antibiotics are withheld while the response to NSAIDs is observed. When infection is suggested, empirical antibiotic therapy should be started in the emergency department after a culture specimen has been obtained.

Differentiating between an infectious process and an inflammatory process, especially pseudogout, can be difficult. The suspicion of one process over the other depends on many factors, including the patient's history, the presence of underlying diseases, and the clinical presentation. When to withhold antibiotic therapy can be a diagnostic challenge, and the use of antibiotics in some circumstances may be done more to treat the physician's anxiety than the patient's disease. Overnight observation in the hospital while antibiotics are withheld allows the disease process to be closely monitored and allows treatment to be changed if the anticipated improvement is not evident with NSAID therapy alone. When the level of suspicion for an infectious process is low, a corticosteroid dose pack (Medrol DosePak™) may be used. The patient is reevaluated in 24 to 48 hours. The importance of seeing the patient again within 48 hours cannot be overstated. If the process is noninfectious, the symptoms will be nearly resolved. It may take years to develop the clinical experience to recognize these different processes, and even the experienced eye can mistake these two conditions.

Patients with severe infections such as necrotizing fasciitis or gas gangrene or who are immunocompromised, including diabetics, should be immediately treated with broad-spectrum antibiotic therapy and emergent surgical intervention.

Treatment Principles

Surgical drainage should be done through a large incision. The incision should be planned so that it can be extended proximally or distally. Longitudinal incisions across a flexion crease should be avoided.

Excision of all necrotic tissue is imperative for infection control. In the 1800s, Louis Pasteur noted that it is the environment and not the bacterium that allows the propagation of infection. Cultures and surgical pathologic reports should be obtained. Fungal and mycobacterial organisms are slow growing and may be more rapidly identified by staining techniques. Most wounds can be left open, with moist gauze covering the exposed surfaces. Alternatively, large wounds can be managed with a negative-pressure sponge dressing. In an acute infection, these should be changed in 48 hours. Small wounds with a tendency to heal quickly should be kept open with a gauze wick. Multiple débridements may be necessary to control infection. Amputation may be necessary to eradicate infection. Functional results may be improved by amputation of a stiff, contracted, and painful digit. In cases of severe infection such as necrotizing fasciitis or gas gangrene, amputation may be a life-saving procedure.

Postoperatively, loose soft dressings are applied. A short period of immobilization for 24 to 48 hours with a splint may afford some pain relief to the patient. Early mobilization in the first 24 hours, under the guidance of a hand therapist, reduces edema, stiffness, and contracture associated with severe hand infections.

Empirical antibiotic therapy may be started after cultures have been obtained. In the case of cellulitis, where local cultures cannot be obtained, blood cultures may identify an organism and should if possible be obtained prior to initiating antibiotic therapy. The specific empirical therapy should be based on the most commonly encountered organisms for the type of infection being treated. The patient history, such as being exposed to an aquatic or a farm environment or being bitten by an animal, may help tailor the specific treatment to the patient. The relative prevalence of MRSA is increasing in many communities, and empirical treatment for MRSA is now commonplace. An infectious disease specialist is invaluable in guiding antibiotic recommendations for both specific infections and for resistant organisms that may be relatively prevalent in one's community. Table 2.1 lists general antibiotic recommendations for common infections. Dosages should be adjusted for the patient's age, weight, renal function, and allergic status. The duration of therapy depends on the clinical response to treatment, the location and depth of the infection, and the patient's immune status. The use of peripherally inserted central venous catheters (PICC lines) can be a valuable method of providing outpatient parenteral therapy, but it comes with a risk of upper extremity venous thrombosis.

CRITICAL POINTS *Treatment Principles*

Surgical Setup and Incision
- Tourniquet control
- Elevation (not elastic) to exsanguinate the limb
- Surgical incisions long and extensile
- Planned to minimize exposure of blood vessels, nerves, or tendons
- Avoid longitudinal incisions across flexion creases

Débridement
- Excision of all necrotic tissue

Specimens
- Obtain culture specimens from the periphery of an abscess cavity
- Gram-stained smear, aerobic and anaerobic cultures
- Tissue and/or fluid to pathology department and request fungal and mycobacteria stains

Irrigation
- Copious irrigation to reduce bacterial load

Wound Management
- Wounds should be left open
- Negative-pressure dressings should be used
- Do not be overly eager for immediate wound closure
- Delayed primary wound closure or healing by secondary intention

Postoperative Care
- Frequent dressing changes for open wounds
- Dressing changes every other day for negative-pressure wound care
- Early motion to reduce the incidence of tendon adhesions and stiff joints
- Multiple débridements may be needed to control infection
- Amputation may be necessary to eradicate infection
- Empirical antibiotic therapy based on most common organisms and patient history
- Infectious disease consultation for antibiotic recommendations and management very helpful

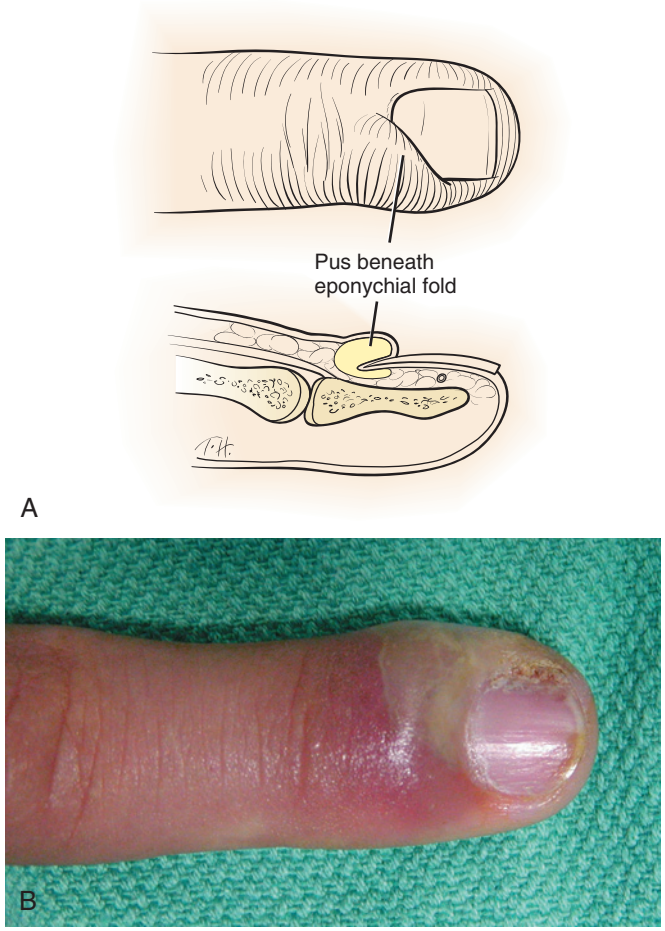

FIGURE 2.2 **A**, Inflamed paronychium and eponychium shown with pus extending below the eponychial fold. **B**, Clinical appearance of a purulent paronychium with partial involvement of the eponychium. (Copyright courtesy of Milan Stevanovic and Frances Sharpe.)

SPECIFIC TYPES OF COMMON HAND INFECTIONS

Acute Paronychia

Paronychia is the most common infection in the hand.[127] It is generally treated by primary care physicians, although refractory cases are often seen by the hand surgeon. Acute paronychia involves the soft tissue fold around the fingernail. It usually results from the bacterial inoculation of the paronychia tissue by a sliver of nail or hangnail, by a manicure instrument, or through nail biting. The disruption of the barrier between the nail fold and the nail plate allows the introduction of bacteria into the tissue bordering the nail (Figure 2.2). Although most paronychias are mixed infections, the most common infecting organism is *S. aureus*.

Clinical Presentation and Preoperative Evaluation

Erythema, swelling, and tenderness immediately adjacent to the nail are the hallmarks of the early clinical presentation. If left untreated, an abscess may form along the nail fold. The abscess may extend below the nail plate, either partially or completely, or it can track volarly into the pulp space. Because of the continuity of the nail fold with the eponychial tissue overlying the base of the nail, the infection can extend into this region and may continue around to the fold on the opposite side of the fingernail. This unusual occurrence is called a "runaround infection." Infection involving the entire eponychium, as well as one lateral fold, is known as an *eponychia*. An eponychia is usually manifested as a collection of pus beneath the proximal portion of the nail in the region of the lunula. It is rare to see both lateral folds and the dorsal tissue infected in the same digit.

Radiographs and laboratory examination are not necessary in uncomplicated cases with early clinical findings. However, patients who have not responded to initial treatment or who present with significant swelling or abscess should be evaluated for underlying systemic diseases such as diabetes. The patient's history and examination will direct the need for wound cultures for atypical organisms, radiographs to evaluate for a foreign body or osteomyelitis, and laboratory evaluation. Patients who do not respond to empirical therapy with a first-generation cephalosporin may also have CA-MRSA infection and may respond to a change in antibiotic therapy.

Pertinent Anatomy

The nail complex consists of the nail bed, nail plate, and perionychium. The nail bed, which lies below the plate, consists of

TABLE 2.1 Antibiotic Recommendations for Common Infections

Infection Type	Most Common Organism	Other Considerations	Initial Antibiotic Therapy
Cellulitis	*Staphylococcus, Streptococcus*	Antibiotic synergy for streptococcal infections with clindamycin	First-generation cephalosporin or penicillin (for *Streptococcus* only)
Abscess (e.g., paronychia, felon, deep space infections)	*Staphylococcus aureus*	Methicillin-resistant *S. aureus* (MRSA) is common now in the community; start therapy for MRSA empirically and change to nafcillin or first-generation cephalosporin if infection is methicillin sensitive	**IV:** Vancomycin or clindamycin for inpatients Linezolid or tigecycline if unable to tolerate vancomycin **Oral:** Trimethoprim/sulfamethoxazole (Bactrim), clindamycin, or doxycycline
Flexor tenosynovitis	*Staphylococcus, S. aureus,* anaerobes	Polymicrobial infections have worse prognosis. Consider multimodal therapy as initial treatment until culture results are available, especially in immunocompromised patients	**IV:** Ampicillin/sulbactam (Unasyn) plus cefoxitin (second-generation cephalosporin) **Oral:** Amoxicillin/clavulanate (Augmentin) If pencillin allergic: Fluoroquinolone (ciprofloxacin or other) plus clindamycin
Pyarthrosis	*Staphylococcus*	Requires parenteral therapy MRSA is common now in the community; start therapy for MRSA empirically and change to nafcillin or first-generation cephalosporin if infection is methicillin sensitive Consider coverage for *Neisseria gonorrheae* in sexually active patients	**IV:** Vancomycin Add ceftriaxone for *N. gonorrheae* coverage Presumptive treatment for MRSA until cultures are available; then change to antibiotic appropriate to organism with the least side effect profile
Human bite	*Staphylococcus, Streptococcus, Eikenella corrodens,* anaerobes		**IV:** Ampicillin/sulbactam (Unasyn) plus cefoxitin **Oral:** Amoxicillin/clavulanate (Augmentin) If pencillin allergic: Fluoroquinolone (ciprofloxacin) plus clindamycin Alternative: Third-generation cephalosporin plus anaerobic coverage with clindamycin or metronidazole **Note:** Quinolones not indicated in children
Animal bites	*Pasteurella multocida, Staphylococcus, Streptococcus*		**IV:** Ampicillin/sulbactam (Unasyn) plus cefoxitin **Oral:** Amoxicillin/clavulanate (Augmentin) If pencillin allergic: Fluoroquinolone plus clindamycin Alternative: Third-generation cephalosporin plus anaerobic coverage with clindamycin or metronidazole **Note:** Quinolones not indicated in children
Suspected CA-MRSA (community-acquired MRSA)		Suspected based on clinical appearance and relative frequency of CA-MRSA seen in community	**IV:** Vancomycin or clindamycin **Oral:** Trimethoprim/sulfamethoxazole (Bactrim), clindamycin
Suspected HA-MRSA (hospital-acquired MRSA)			**IV:** Vancomycin, linezolid, or daptomycin
Necrotizing fasciitis	*Streptococcus* or polymicrobial infection	Treat both until organisms identified	Broad-spectrum beta-lactam (piperacillin/tazobactam; imipenem) plus vancomycin (for MRSA) plus clindamycin (for synergy for *Streptococcus pyogenes*)
Gas in soft tissues	*Clostridium. perfringens* (gas gangrene), polymicrobial infections (anaerobic and facultative anaerobes)	Intravenous drug abusers and diabetics more often have polymicrobial infections; often, gas in the soft tissues	High-dose penicillin plus clindamycin Broad-spectrum beta-lactam (piperacillin/tazobactam; imipenem) plus vancomycin (for MRSA) plus clindamycin (for synergy for *S. pyogenes*)

the germinal and sterile matrices. The germinal matrix is responsible for the majority of nail growth. The proximal portion of the nail sits below the nail fold. The border tissue surrounding the nail is the perionychium. The eponychium is the thin layer of tissue extending from the nail wall onto the nail plate. The hyponychium is the mass of keratin just distal to the sterile matrix, below the distal nail plate. This area of the nail complex is highly resistant to infection.

Treatment Options

In the very early stages, this infection can be treated by soaks in a warm solution, systemic oral antibiotics, and rest of the affected part. If there is a superficial abscess, treatment can be carried out with local anesthesia and should consist of elevation of the cuticle away from the nail plate in the area of erythema and opening the thin layer of tissue over the abscess with a sharp blade directed away from the nail bed and matrix. Drainage of

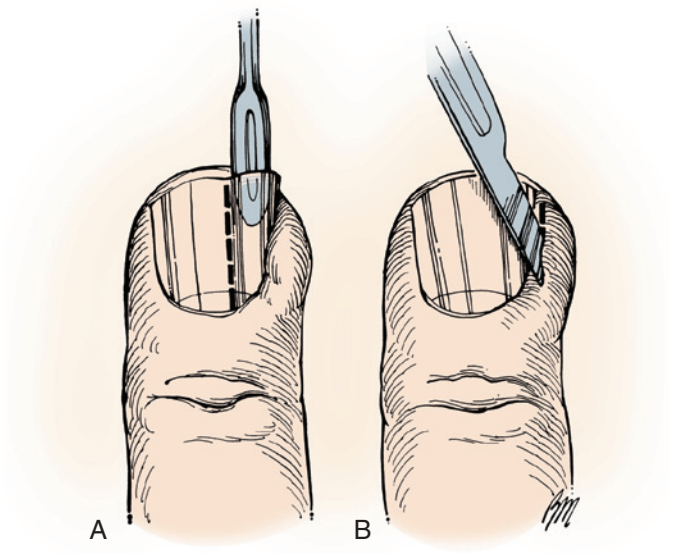

FIGURE 2.3 **A**, Elevation and removal of one fourth of the nail to decompress the perionychium. **B**, Incision of the perionychial fold with the blade directed away from the nail bed and matrix.

the abscess is performed where the abscess most nearly approaches the surface (Figure 2.3). The patient is counseled regarding high-risk activities, such as nail biting and manicures.

More extensive infection requires individualized treatment based on the extent of the lesion. Surgical decompression is best carried out under digital block anesthesia at the level of the metacarpal head with plain lidocaine. If the perionychial fold and the adjacent part of the eponychium are involved, the perionychium and skin adjacent to the nail fold are released. If the perionychial infection tracks volarly and involves the pulp, the incision should be deep enough to fully drain the abscess and allow evaluation of bone involvement of the distal phalanx. Infection that travels below the nail plate requires removal of a portion of the nail. If the entire nail matrix is involved, then the entire nail is removed. Purulence below the nail plate can cause pressure on the germinal matrix, resulting in ischemia of the germinal matrix and temporary or permanent arrest of nail growth.

Operative Methods. The peronychial sulcus is elevated from the nail gently by a flat, blunt instrument such as the flat portion of a malleable or metal probe or a Freer elevator. Sharp incision may be used as well. The incision is directed away from the nail bed to avoid injury to the nail bed and subsequent growth abnormality. The incision may be extended proximally along the nail fold, as far proximally as is necessary (Figure 2.4, *A* and *B*). It is generally sufficient to carry the incision only to the proximal edge of the nail, but it may extend as far proximally as the distal interphalangeal (DIP) joint.

When abscess or fluctuance is found below the eponychium and a single incision does not adequately expose or decompress the involved tissues, a parallel incision along the opposite nail fold is made, allowing the eponychium and nail fold to be elevated and reflected above the nail plate (see Figure 2.4, *C* through *E*).

When the abscess extends below the nail plate, a portion of the nail plate should be removed. The amount and location of nail removal depend on the location and extent of involvement below the nail. If the area of fluctuance lies adjacent to the perionychium, a flat blunt probe or Freer elevator is used to separate the affected portion of the nail plate from the nail bed. The nail plate is then cut with a small scissors and removed. In the rare case where the eponychium is infected and pus is present only below the proximal portion of the nail, the eponychium and nail plate are elevated through a single or double incision. The proximal third of the nail plate is carefully removed. Only when the nail is entirely separated from the underlying matrix is it necessary to remove the entire nail plate. After decompression, the area of abscess is irrigated. The wound is left open with a small thin piece of gauze that allows the wound to stay open and drain.

❖ AUTHORS' PREFERRED METHOD OF TREATMENT

No one treatment should be used exclusively, because there are cases in which each is applicable. We prefer to treat early infections nonsurgically with oral antibiotics and soaks two to three times per day in a solution of warm water and povidone-iodine at a ratio of 10 parts water to 1 part povidone-iodine. If the patient is allergic to topical povidone-iodine, warm normal saline may be used. Antibiotic treatment should cover *S. aureus*.

CRITICAL POINTS *Acute Paronychia*

Indication
- Perionychial or eponychial infection with abscess

Preoperative Evaluation
- None required in healthy individual with acute infection
- Laboratory evaluation in diabetics or immunocompromised patients
- Radiographs if long-standing infection or no improvement with conventional therapy

Pearls
- Careful evaluation for infection residing below the nail plate or in finger pulp

Technical Point
- Incise with blade facing away from nail bed to reduce risk of injury to matrix.

Pitfalls
- Misdiagnosis as herpetic whitlow (see section on herpetic whitlow)
- Failure to recognize underlying osteomyelitis
- Underlying systemic illness or atypical organism leading to refractory infection

Postoperative Care
- Seven to ten days of oral antibiotics
- Daily soaks in dilute povidone-iodine solution
- Early finger range of motion

Surgical treatment depends on the location and extent of the perionychial infection. Generally, we release along the perionychial sulcus, extending proximally to the level of the nail base. Double incisions are reserved for more extensive eponychial involvement, or when removal of the proximal portion of the nail is planned. Removal of any portion of the nail is done only when the area of abscess extends below the nail plate. Removal of the entire nail is necessary only when the entire nail plate is separated from the nail matrix by abscess.

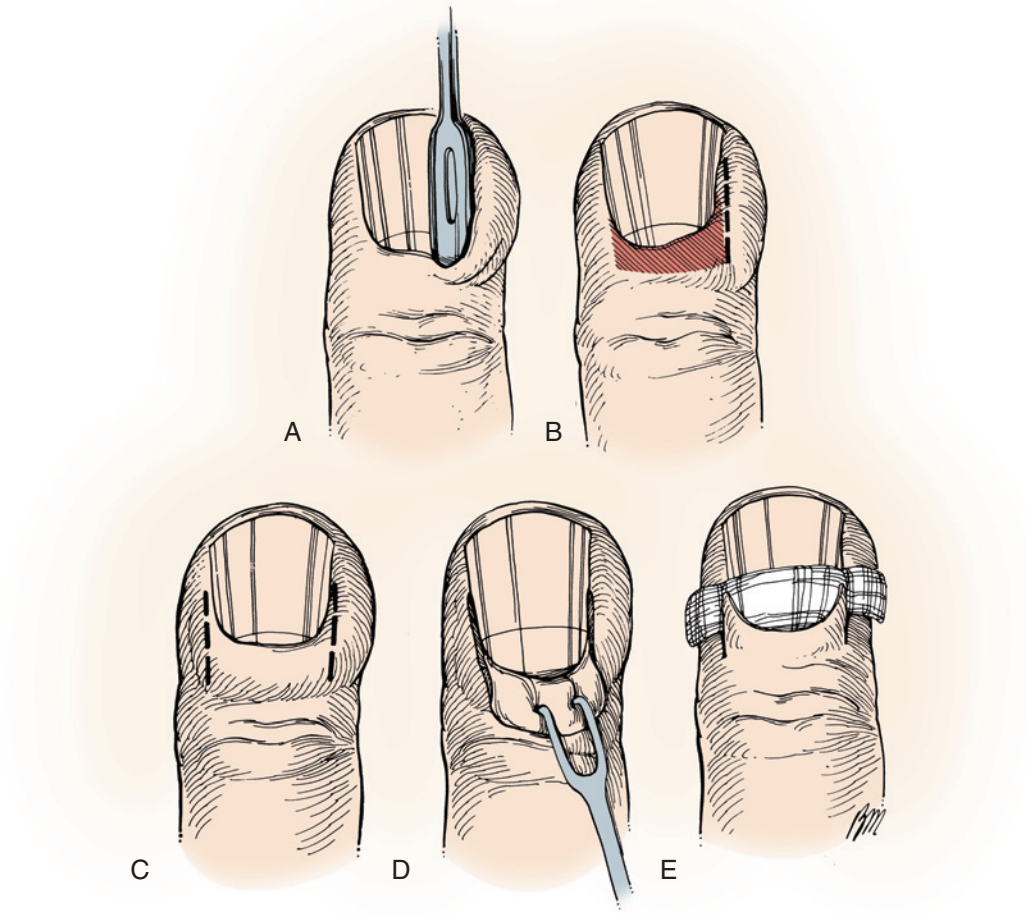

FIGURE 2.4 **A**, Elevation of the eponychial fold with a flat probe to expose the base of the nail. **B**, Placement of an incision to drain the paronychia and elevate the eponychial fold for excision of the proximal third of the nail. **C** to **E**, Incisions and procedure for elevating the entire eponychial fold with excision of the proximal third of the nail. A gauze pack prevents premature closure of the cavity.

Postoperative Management and Expectations

Postoperatively, the patient is given oral antibiotics for 7 to 10 days, depending on the severity of the infection. Dressings are changed two to three times per day, coinciding with soaking of the affected finger in a dilute solution of povidone-iodine for 5 to 10 minutes. We discontinue packing or wicking the wound at 3 to 4 days. Occlusive dressings can lead to skin maceration and should be avoided. Early motion is emphasized to prevent stiffness.

Improvement is noted in most acute cases of paronychia in 3 to 4 days with appropriate management; however, some tenderness and hypersensitivity around the surgical scars can be expected for several months. Nail deformity can occur either as a result of the infection or after minimal surgical injury to the nail matrix. Patients with an underlying medical illness may require a longer time for healing and recovery or require additional surgery. This population likewise has a higher risk of recurrent infection.

Complications are rare but do occur. Nail deformity can occur either from the infection itself or from inadvertent injury to the nail matrix from decompression. The risk of injury is minimized by gently separating the nail plate from the underlying matrix and by directing the scalpel blade away from the matrix when incising around the nail bed. Persistent infection despite appropriate treatment may be due to inadequate surgical decompression and drainage or inadequate antibiotic coverage. If the infection is not resolving at 1 week, radiographs to evaluate for osteomyelitis, cultures with antibiotic sensitivities, and repeat surgical débridement may be necessary. Robbins found that the most frequent complication of a paronychia was extension to the pulp space through a sinus at the side of the nail. This occurred in approximately 13.5% of patients treated in his series from the 1950s.[129] The occurrence of spread to the pulp space today is rare owing to improved antibiotic therapy and more aggressive surgical treatment. In children with long-standing paronychia, infection can lead to bone involvement and epiphyseal separation.

Misdiagnosis of a paronychia can occur, particularly confusion of perionychial infection with herpetic whitlow. Distinguishing herpetic whitlow from a bacterial infection is important. Incision and drainage of herpetic whitlow are contraindicated and can result in systemic viral infection and/or bacterial suprainfection.[7]

Chronic Paronychia

Clinical Presentation and Preoperative Evaluation

Chronic paronychia is characterized by chronically indurated and rounded eponychium and is a distinct clinical problem from acute paronychia. The chronic inflammation is accompanied by repeated episodes of inflammation and drainage. If left untreated, this results in thickening and grooving of the nail

plate. This problem is more common in middle-aged women, with a female-to-male ratio of 4:1.[11] Frequent water immersion, particularly in detergents and alkali solutions, is a predisposing condition. Housewives, bartenders, dishwashers, nurses, swimmers, and children who suck their fingers are often affected. It also more commonly affects patients with diabetes and psoriasis.[11] Cultured organisms include gram-positive cocci, gram-negative rods, *Candida*, and mycobacterial species.[99] Preoperative evaluation includes a thorough history for contributing environmental factors, laboratory evaluation for underlying systemic diseases such as diabetes or immunosuppression, and radiographic evaluation for evidence of a foreign body, osteomyelitis, or lytic or blastic processes in the bone that could indicate a possible tumor. If the lesion is suspicious for a possible tumor, a magnetic resonance imaging (MRI) study may be helpful in distinguishing a chronic paronychia from a tumor.

Pertinent Anatomy and Pathophysiology

Chronic paronychia begins with separation between the nail plate and the dorsal soft tissue covering the nail plate, including the cuticle, eponychium, and nail fold. This leads to colonization, usually by staphylococcal organisms. Subsequent infection, by *Candida albicans* and/or colonic organisms, leads to chronic inflammation and recurrent exacerbations with episodic increased erythema and drainage. This chronic inflammation leads to fibrosis and thickening of the eponychium, with a resultant decrease in vascularity to the dorsal nail fold. The decreased vascularity reduces the resistance to minor bacterial insults, allowing for recurrent episodes of symptomatic exacerbations.[11,78]

Treatment

Conservative therapies for chronic paronychial infection have included topical corticosteroids, oral and topical antibiotics, and oral and topical antifungal agents. Although reducing exposure to moist environments and chemical irritants may be helpful, these treatments alone have been unsuccessful in a large number of cases.[11,78]

Operative Treatment. Eponychial marsupialization is the most common surgical treatment for the chronic paronychium. Under digital block anesthesia and tourniquet control, a crescent-shaped incision is made beginning 1 mm proximal to the distal edge of the eponychial nail fold and extending proximally for 3 to 5 mm. Some authors recommend removal of all thickened tissue. Others have found a 3-mm margin adequate to achieve equal results. The crescent should be symmetrically shaped and extend to the edge of the nail fold on each side (Figure 2.5). The crescent of tissue is removed down to but not including the germinal matrix. The wound is left open and allowed to drain. If nail deformity is present, removal of the nail has been reported to improve the cure rate and reduce the risk of recurrence.[11] Pabari and colleagues have described elevation of the nail fold, inverting the tissue and folding this tissue over a nonadherent gauze and anchoring the inverted skin to proximal suture with nonabsorbable suture. Anchoring sutures are removed between 2 and 7 days, and the nail fold is allowed to return to its original position[118] (Figure 2.6).

❖ AUTHORS' PREFERRED METHODS OF TREATMENT

We have found eponychial marsupialization an effective treatment for this condition. We agree with Bednar and Lane[11] that a 3-mm crescent of tissue is adequate and removal of all thickened tissue is not critical to the outcome. Special care is used to avoid injury to the germinal matrix. The removed tissue is sent for bacterial, fungal, and mycobacterial culture. The remaining tissue is sent for pathologic examination. Nail removal is performed when a nail deformity is present. Wounds are covered with Xeroform™ gauze. When the nail is removed, Xeroform gauze is placed in the nail bed and nail fold as well.

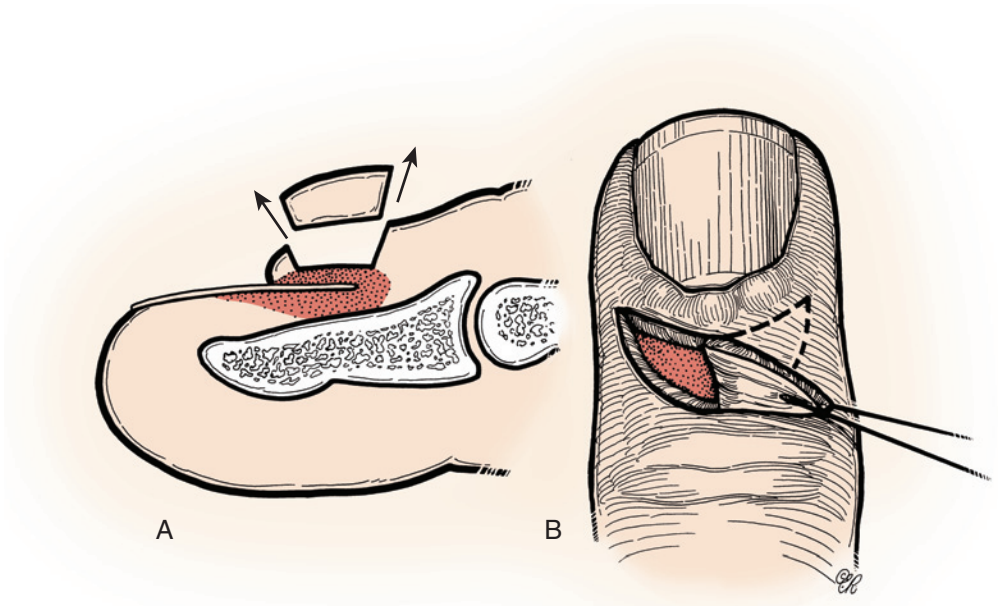

FIGURE 2.5 Eponychial marsupialization for chronic paronychia. **A**, Lateral view showing the area of wedge-shaped excision. Undisturbed matrix is stippled. **B**, Dorsal view of the crescent-shaped area of excision extending to the margins of the nail folds on each side.



FIGURE 2.6 Alternative technique of nail marsupialization for chronic paronychia, the Swiss roll technique. (Copyright courtesy of Milan Stevanovic and Frances Sharpe.)

Patients are counseled regarding exposure to moist environments. Predisposing systemic conditions, such as diabetes and psoriasis, are medically controlled. We evaluate for activities that may lead to mycobacterial exposures, such as home aquariums or terrariums, marine work, or aviary exposure.

Postoperative Management and Expectations

The postoperative dressing is removed at 48 to 72 hours by soaking in 3% hydrogen peroxide solution. The patient is instructed to soak the area three times per day in dilute povidone-iodine solution. This continues until 2 days after all drainage has stopped. Oral antibiotics are given for 2 weeks. If cultures are negative or the organism is not sensitive, the antibiotic therapy is discontinued at 3 to 5 days.

Most chronic paronychial infections resolve with marsupialization. Systemic or topical antibiotics or antifungal agents are often not required. Wound healing by secondary intention occurs over 3 to 4 weeks. Scar sensitivity is more common than in acute paronychia and may persist for several months. Nail deformity is also more common than in treatment of acute paronychia. Six to 12 months may be required for nail growth, and residual deformity cannot be assessed until that time. Recurrence rates are higher if the patient does not correct environmental factors or if systemic diseases are not medically controlled. In the event of recurrence, re-marsupialization and nail removal should be done.

Felon

The term *felon* probably has its roots from the Latin *fel*, meaning "bile" or "venom." A felon is a subcutaneous abscess of the distal pulp of a finger or thumb (Figure 2.7). However, not all abscesses of the distal phalanx are felons. Superficial infections of the most distal part of the pulp skin are known as "apical infections." Apical infections are distinct from the felon in that the palmar pad is not involved. The term *felon* should be reserved for those infections involving multiple septal compartments and causing compartment syndrome of the distal phalangeal pulp. The most commonly cultured organism from felons is *S. aureus*. Infections from gram-negative organisms have also been reported. These are uncommon and more typically seen in immunocompromised patients or diabetics.

CRITICAL POINTS *Chronic Paronychia*

Indication
- Chronic eponychial infection

Preoperative Evaluation
- Thorough workup and social history for contributing factors
- Laboratory evaluation in diabetics or immunocompromised patients
- Radiographs

Pearls
- Nail removal in conjunction with marsupialization if nail deformity is present
- Nail removal and remarsupialization even with normal nail in setting of recurrence

Technical Point
- Protect the germinal matrix during marsupialization.

Pitfalls
- Misdiagnosis with tumor or cyst
- Unrecognized systemic illness
- Failure to correct environmental factors

Postoperative Care
- Ten to fourteen days of oral antibiotics, if cultures are positive and sensitive. Different if mycobacterial organism
- Consider oral antifungal medications
- Daily soaks in dilute povidone-iodine solution
- Early finger range of motion

Clinical Presentation and Evaluation

Felons account for 15% to 20% of all hand infections.[90] A felon is characterized by severe throbbing pain, tension, and swelling of the entire distal phalangeal pulp. The pulp space is exquisitely tender, but the associated swelling does not extend proximal to the DIP flexion crease, unless the joint or tendon sheath is involved. With the progression of swelling and tension, there is compromised venous return, leading to microvascular injury and development of necrosis and abscess formation. There is often a history of penetrating injury, such as a wood splinter, glass sliver, or minor cut, preceding a felon. "Finger-stick felons" can be seen in diabetics, who repeatedly traumatize the fingertip for blood tests. Once the felon has developed, the patient may attempt a decompression with a knife or needle. The pain and swelling usually develop rapidly. The expanding abscess breaks down the septa and can extend toward the phalanx and produce osteitis or osteomyelitis, or it can extend toward the skin and cause necrosis and a sinus somewhere on the palmar surface of the digital pulp. If such spontaneous, although inadequate, decompression does not occur, it is possible that the digital vessels will thrombose and a sloughing of the tactile pulp will result. Other complications of an untreated felon include sequestration of the diaphysis of the distal phalanx, pyogenic arthritis of the DIP joint, and flexor tenosynovitis from proximal extension, although the last is quite rare.[164]

Pertinent Anatomy

Kanavel studied the anatomy of the fingertip through multiple sagittal and coronal sections of cadaveric fingers. He described the anatomy of the distal pulp as a "closed sac connective tissue

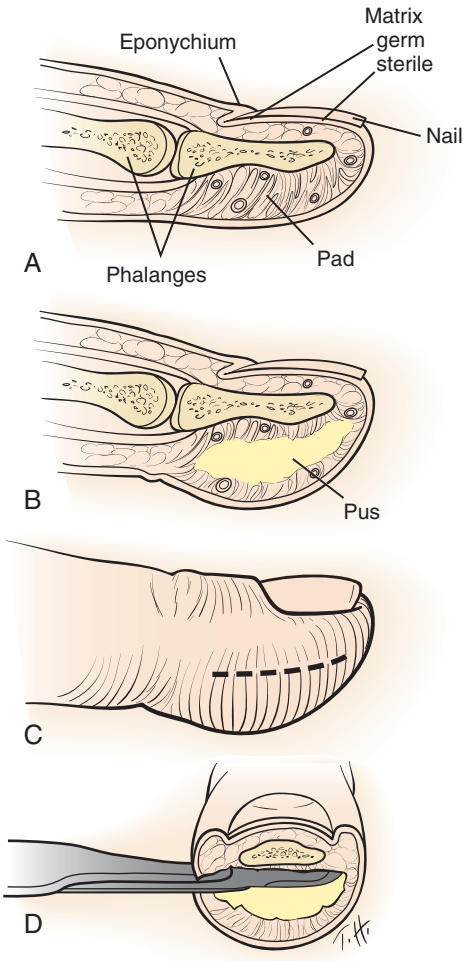

FIGURE 2.7 **A**, Cross section of the distal fingertip, showing the septated anatomy of the pad. **B**, Collection of pus within the finger pulp space. **C**, Incision for drainage of felon. **D**, The incision should include all of the involved septal compartments. (Copyright courtesy of Milan Stevanovic and Frances Sharpe.)

framework, isolated and different from the rest of the finger."[75] Multiple vertical trabeculations divide the pulp of the distal phalanx into a latticework of separate septal compartments. The trabeculae attach the periosteum of the distal phalanx to the epidermis, giving the fingertip structural support and stabilizing the pulp during pinch and grasp. The septal interstices are filled with fat globules and eccrine sweat glands, which open onto the epidermis and provide an access for surface bacteria to enter the pulp space. The digital arteries run parallel to the distal phalanx, giving off a nutrient branch to the epiphysis before entering the pulp space. The diaphysis is supplied principally from volar nutrient vessels from the terminal branches of the digital arteries. The terminal branches of the digital nerve are parallel and palmar to the digital arteries. They arborize extensively within the pulp of the distal phalanx, providing fine tactile discrimination. The highest concentration of sensory receptors in the hand is the volar aspect of the distal phalanx.

Felons may begin with penetrating wounds of the distal pulp or as bacterial contamination of the fat pad through the eccrine sweat glands. Inflammation and cellulitis lead to local vascular congestion, which is aggravated by the closed septal anatomy of the pulp. If left untreated, tissue necrosis and abscess formation follow, resulting in further microvascular impairment. The increased pressure within the pulp as a "closed sac" results in a clinical situation resembling a compartment syndrome. The ischemia of the pulp causes severe ischemic pain in the densely innervated pulp. The blood supply to the periosteum and diaphysis is compromised more than the blood supply to the skin, leading to bone necrosis and sequestration before spontaneous decompression of the felon through the skin. In children, infection or necrosis of the epiphysis is rarely seen, most likely owing to the preservation of the epiphyseal nutrient artery, which arises from the digital artery proximal to the closed space of the distal pulp and is therefore preserved.

Treatment

Treatment of the felon should be directed toward preserving the function of the finger pulp. These functions include fine tactile sensibility and a stable durable pad for pinch. In the early cellulitic phase, it may be possible to treat the felon with elevation, antibiotics, and soaks. Short-term immobilization may make the patient more comfortable. Some authors recommend surgical drainage only in the presence of abscess.[152] In our hands, surgical drainage is indicated when the pulp is very tender, tense, or fluctuant. The basic tenets of all approaches are to avoid injury to the digital nerve and vessels, use an incision that will not leave a disabling scar, provide adequate drainage, and avoid inadvertent violation of the flexor tendon sheath, causing an iatrogenic tenosynovitis.

Operative Treatment. Several surgical incisions have been described (Table 2.2; Figure 2.8); some of these are of historic interest only and are no longer recommended. Surgery may be performed under digital block anesthesia or under general anesthesia. A tourniquet is helpful for visualization. Regardless of the type of incision, surgical decompression requires thorough removal of necrotic tissue, irrigation, and wound management to allow continued drainage of the abscess cavity. To keep the wound open and draining, a gauze wick is placed in the wound. The first dressing change is done at 24 to 48 hours. Authors' opinions vary as to how long the wound is kept open with a wick drainage. Two to 5 days should be adequate for most cases, depending on the severity of infection. Soaking in dilute povidone-iodine solution as described earlier is initiated after the first dressing change and continued until wound healing by secondary intention.

❖ AUTHORS' PREFERRED METHODS OF TREATMENT

Only in the very early presentation of an acute felon should nonsurgical management be considered. The felon is more typically a very rapidly developing process, and by the time of presentation, the pulp is tensely swollen and exquisitely tender. This requires surgical decompression whether fluctuance is present or not. We prefer to perform surgery under digital block anesthetic with sedation. A forearm tourniquet is used. The extremity is exsanguinated by elevation. The surgical incision is made longitudinally. When the point of maximal tenderness is located in the middle of the pulp or when a sinus is present volarly, we use the longitudinal volar incision. When the point of tenderness is on the side of the pulp, we use the unilateral longitudinal incision. Although the incision is preferably placed on the side opposite the pinching surface, the incision should always be placed on the side of maximal tenderness. When

TABLE 2.2 Surgical Incisions for the Treatment of Felon

Incision	Advantages	Disadvantages	Comments and Technical Points
A: Fish-mouth incision (Figure 2.8, *A*)	None	Risks circulation leading to skin slough; unstable pulp; unsightly scar	No place in treatment
B: "J" or hockey-stick incision (Figure 2.8, *B*)	Good for extensive or severe abscess	Incision coming distally into the fingertip can cause painful scar	Adequate débridement and release of septa can be performed without crossing the fingertip (see F)
C: Through-and-through incision (Figure 2.8, *C*)	Wide access to all involved septal compartments	Additional wound; superfluous incision that can compromise circulation to the pulp	Initially described with a "J" incision on the ulnar side with a longitudinal counterincision; extension across the fingertip is *not* necessary; two dorsolateral incisions
D: Volar incision (transverse) (Figure 2.8, *D*)	Most direct access to area of abscess; easy to perform; better maintains structural integrity of palmar pad	Palmar scar; higher risk of digital nerve and vessel injury	Incision 4 to 5 mm made at site of maximal fluctuance; sharp dissection through skin and dermis only, followed by blunt dissection through the pulp; elliptical excision of sinus tract and necrotic tissue (if present)
E: Volar (longitudinal) incision (Figure 2.8, *E*)	Same as above; lower risk of digital neurovascular injury	Palmar scar	Same as above; incision should not cross DIP flexion crease
F: Unilateral longitudinal incision (Figure 2.8, *F*)			Preferred placement on the ulnar side of the index, middle, and ring fingers and on the radial side of the thumb and small fingers

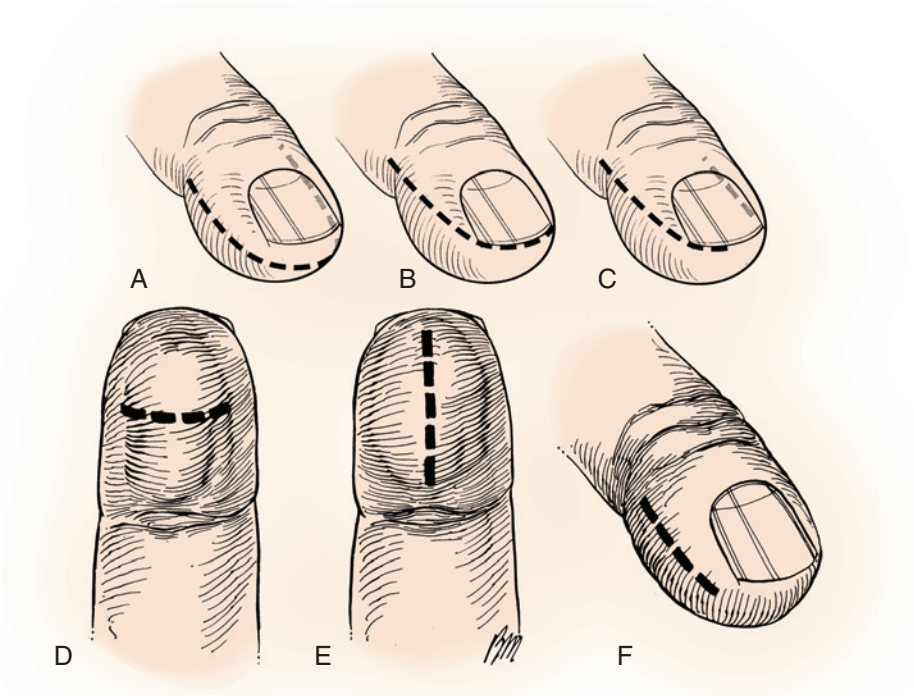

FIGURE 2.8 Incisions for drainage of felons. **A**, Fish-mouth incision. This approach is associated with significant complications and should *not* be used. **B**, Hockey-stick incision. The incision begins in the midaxial line, aims for the corner of the nail, and passes across the finger in the natural line between the skin and nail matrix (see text discussion). **C**, Abbreviated hockey-stick incision with counterincision on the opposite side. An alternative to the full hockey-stick incision is to make this incision shorter and make a second incision on the opposite side of the pulp (*faint dotted line*). **D**, Volar drainage is useful if the abscess points volarward, but this incision risks injury to the digital nerves. **E**, Alternative volar approach. There is less risk to the digital nerves, but the incision should not touch or cross the DIP joint flexion crease. **F**, Unilateral longitudinal approach. This incision is the authors' preferred method for treatment of most felons.

possible, the incision is made on the ulnar side of the second to fourth digits and on the radial side in the thumb and small finger. The incision is started dorsal to and 0.5 cm distal to the DIP joint flexion crease. It is continued distally in line with the volar margin of the distal phalanx, but it does not cross over the fingertip. The incision is deepened along a plane just volar to the palmar cortex of the phalanx until the abscess is entered. The opening in the cavity is enlarged until adequate evacuation is achieved.

All involved septa should be opened, and a wound culture is taken. The flexor tendon sheath should not be violated, unless there are signs of tendon sheath involvement, as this can cause

an iatrogenic tendon sheath infection. The distal phalanx must be examined with a probe. A rough or softened surface indicates bone involvement, which requires débridement of the softened or necrotic bone. After thorough débridement and irrigation, the wound is kept open with a thin gauze wick and a sterile dressing is applied. The first dressing change is done between 12 and 24 hours.

CRITICAL POINTS *Felon*

Indication
- Tense pulp space infection with or without fluctuance

Preoperative Evaluation
- Patient history of recent injury, medical and social history
- Laboratory evaluation in diabetics or immunocompromised patients
- Radiographs to evaluate for foreign body or osteomyelitis

Pearls
- Incision made at point of maximal tenderness

Technical Points
- Avoid incisions crossing the fingertip or DIP flexion crease.
- Protect the digital nerves and vessels.
- Do not violate the flexor tendon sheath.

Pitfalls
- Misdiagnosis as herpetic whitlow
- Unrecognized osteomyelitis
- Incomplete decompression of all involved septa
- Iatrogenic septic flexor tenosynovitis
- Creation of an unstable pulp

Postoperative Care
- Intravenous antibiotic therapy for 5 to 7 days, longer if bone is involved (in hospitalized patients)
- Patients treated in an outpatient setting usually do not require intravenous antibiotics
- Gauze wick for at least 72 hours
- Soaks three times per day in dilute povidone-iodine solution
- Early finger range of motion

Postoperative Management and Expectations

The setting of the drainage procedure (office, emergency department, or operating room) and decision to hospitalize the patient depend on the severity of the infection and the reliability of the patient. In our county hospital patients, we prefer to admit the patients and give intravenous antibiotics until a favorable response to therapy is seen. Oral antibiotics can be used when the infection is controlled. Bone involvement requires longer intravenous therapy. The choice of antibiotic depends on the cultured organism and its antibiotic sensitivity. Because most felons are caused by *S. aureus*, initial antibiotic therapy should address this organism. Factors such as underlying disease, injury mechanism, or contributing occupational or social history may influence antibiotic choice. Dressings are changed two to three times per day. At the time of dressing change, the patient soaks the affected finger in a solution of dilute povidone-iodine for 5 to 10 minutes. Packing or wicking of the wound is discontinued after 3 to 5 days. Occlusive dressings are not used, because they often result in skin maceration. Early motion is emphasized to prevent stiffness.

Most felons recover in 3 to 4 weeks with appropriate management. The length of treatment and recovery depends on the severity of the infection and the presence of bone involvement. Tenderness and hypersensitivity around the surgical scars and of the entire pulp can be expected for several months after surgery. In some patients, this may be a permanent finding. Pulp deformity, most commonly pulp atrophy, occurs frequently and is permanent. Pulp instability can occur in patients where the infection has involved all of the vertical septa, regardless of the incision used. This will often resolve over time but may take 6 months to a year. In cases of osteomyelitis with large bone loss, nail deformity may occur owing to loss of underlying bone support of the nail matrix, resulting in a short finger with a short nail. Nail ablation may be necessary for painful deformities. In some cases with severe bone involvement, amputation of the distal phalanx should be considered.

Complications of treatment include recurrence of infection, usually as a result of inadequate bone débridement. In these cases, repeat surgical débridement and prolonged organism-specific antibiotic therapy will usually be sufficient. Amputation may be necessary for refractory infection. Iatrogenic septic flexor tenosynovitis has been reported. Appropriate treatment involves repeat débridement and surgical decompression and irrigation of the flexor tendon sheath, as described later.

Pyogenic Flexor Tenosynovitis

Pyogenic flexor tenosynovitis is a closed-space infection of the flexor tendon sheath of the fingers or thumb. The purulence within the flexor tendon sheath destroys the tendon gliding mechanism, rapidly creating adhesions that lead to marked limitation of tendon function and severe loss of motion. It can also destroy the blood supply, producing tendon necrosis. Early treatment is of paramount importance in limiting the morbidity associated with this diagnosis. Untreated disease and late diagnosis or presentation can lead to devastating disability in hand function. The incidence and serious sequelae of bacterial tenosynovitis are less frequent, owing to early recognition and the availability of appropriate antibiotic therapy. The most common organisms responsible for disease include *S. aureus* and β-hemolytic *Streptococcus. P. multocida* is frequently cultured in infections caused by animal bites. A wider host of organisms should be considered in immunocompromised patients, who have yielded positive cultures for *E. corrodens, Listeria monocytogenes*, and mixed gram-positive and gram-negative infections.

Clinical Presentation and Preoperative Evaluation

Most patients present with a history of penetrating trauma, typically over the volar aspect of the proximal interphalangeal (PIP) or DIP joint. A small puncture wound, often from a foreign body or animal bite, can inoculate the tendon sheath. Hematogenous septic flexor tenosynovitis is rare. When this occurs, disseminated gonococcal infections should be considered. Levy recommended that hematogenous tenosynovitis should be treated as disseminated gonorrhea until final culture results are available.[84,134]

Kanavel[74] initially described three cardinal signs of acute flexor tenosynovitis. He later added a semiflexed posture of the

digit as the fourth sign.[75] All four signs need not be present, especially in the early course of the disease. Kanavel's four cardinal signs are:

1. A semiflexed position of the finger
2. Symmetric enlargement of the whole digit (fusiform swelling)
3. Excessive tenderness limited to the course of the flexor tendon sheath
4. Excruciating pain on passively extending the finger; the pain should be experienced along the flexor sheath and not localized to a particular joint or abscess.

There are different opinions as to which signs are most clinically useful. Kanavel and others believed that excessive tenderness along the tendon sheath was the most reliable and reproducible clinical sign. Neviaser believed the most reproducible clinical sign was pain with passive extension. Pang and associates noted fusiform swelling of the digit in 97% of patients. Pain on passive extension was noted in only 72% of patients.[32,75,111,119] We believe that all of these findings are useful and in combination help distinguish pyogenic flexor tenosynovitis from local abscess or pyarthrosis. Findings in the thumb and small finger may be more subtle because these fingers have a mechanism of autodecompression through the radial and ulnar bursae.

Laboratory evaluation should include a CBC. The ESR and CRP may be useful in monitoring the disease process. However, these may be elevated in noninfectious inflammatory processes, as well. Radiographs should be taken to evaluate for a retained foreign body, underlying pyarthrosis, osteomyelitis, or unrecognized trauma, such as a fracture.

There are several conditions that may mimic acute pyogenic flexor tenosynovitis. The differential diagnosis includes herpetic whitlow, felon, pyarthrosis, local abscess, and inflammatory diseases such as rheumatoid arthritis or gout or aseptic flexor tenosynovitis. Herpetic whitlow and felon, as already described, present a different clinical picture, typically with more distal findings. Herpetic whitlow is not associated with the tenseness and swelling that are found in pyogenic flexor tenosynovitis and classically presents with small skin vesicles. Pyarthrosis can more closely resemble an infection of the flexor sheath because there is commonly pain with passive joint motion and the digit is held in a flexed posture. Unlike flexor synovitis, the location of the traumatic injury is usually on the dorsal surface of the finger, the swelling is more localized around the joint, and pain with palpation is not present along the entire tendon sheath.

In cases in which the clinical presentation is not clear or there is a clinical suspicion of a nonseptic acute tenosynovitis as may be seen in gout, rheumatoid arthritis, or acute stenosing tenosynovitis, aspiration of the tendon sheath should be done. If the aspiration is negative, NSAID therapy is initiated. The patient should be closely monitored in the first 24 hours. Depending on patient reliability, this can be done on an inpatient or outpatient basis.

Pertinent Anatomy

Knowledge of the anatomy of the flexor tendon sheaths, bursae, and deep spaces of the forearm is important in understanding the presentation and possible spread of infection in the hand. The flexor tendon sheath is a double-walled structure with a visceral layer and a parietal layer. The visceral layer is closely adherent to the tendon and is essentially the epitenon. The parietal layer lies adjacent to the pulley system.[29,35] These two layers are connected proximally and distally, creating a closed system. In the fingers, the sheaths begin in the palm at the level of the metacarpal neck and end distally just proximal to the DIP joint. In the small finger, there is usually continuity between the flexor sheath and the ulnar bursa, which extends to a point just proximal to the transverse carpal ligament. In the thumb, a similar connection is seen with the radial bursa, which also extends proximal to the transverse carpal ligament.[29,35,75,136] Proximally, the radial and ulnar bursae have a potential space of communication through the Parona space, which lies between the fascia of the pronator quadratus muscle and flexor digitorum profundus (FDP) conjoined tendon sheath. This site of connection between the thumb and small fingers through the radial and ulnar bursae gives rise to the *horseshoe abscess*, in which a flexor sheath infection of the thumb or small finger tracks proximally to the wrist and then ascends along the flexor sheath on the opposite side. Although this is the most commonly described connection, many variations of flexor sheath anatomy exit. This was elegantly described by Scheldrup in 1951.[136] These potential variations and sites of interconnection should be kept in mind to direct appropriate treatment.

The flexor tendons receive their nutrient support from a direct vascular supply and diffusion from the synovial fluid. When bacteria inoculate the flexor sheath, the synovial fluid becomes the nutritional source for the bacteria. The host has limited ability to defend against the bacterial proliferation, owing to the poor vascularity within this closed system. The bacterial proliferation leads to increased volume and pressure within the tendon sheath. Schnall and colleagues demonstrated pressures exceeding 30 mm Hg in more than 50% of flexor sheath infections.[139] This high pressure likely contributes to the pathogenesis of the disease process by obstructing the arterial blood supply of the flexor tendons through the vincular system. This can quickly result in tendon necrosis and subsequent rupture. Appropriate and urgent management of flexor tendon sheath infections is imperative in preventing these unwanted complications.

Treatment

There is a narrow range of indications for nonsurgical treatment of pyogenic flexor tenosynovitis. Patients rarely present with early clinical findings, which may be managed with antibiotic therapy. Those patients who present within the first 24 hours of the onset of symptoms, have mild pain and mild swelling, and show only partial expression of one or two of Kanavel's signs may be initially treated with intravenous administration of antibiotics. A dorsal block splint is applied to place the hand at rest. The extremity is elevated. The patient is monitored with close clinical observation in an inpatient hospital setting. If the clinical symptoms are not improving in the first 12 hours, surgical treatment is indicated. Nonsurgical management should seldom be considered in the diabetic or immunocompromised patient.

Before antibiotic therapy is initiated, an aspiration of the tendon sheath is done to obtain material for culture. The aspiration is performed with a 20- to 22-gauge needle. The aspiration can be performed anywhere between the palmodigital crease and the DIP flexion crease. The aspiration should be performed

away from any areas of superficial cellulitis. A small amount of saline may be necessary to lavage the sheath to obtain a specimen for culture. If frank pus is encountered on the aspiration, nonsurgical treatment should not be pursued. Patients who present with a local cellulitis along the volar surface of the finger may also have a septic flexor tendon sheath. If nonsurgical treatment is considered, aspiration should not be performed through the cellulitic subcutaneous tissue, to prevent inadvertent inoculation of the sheath.

Purulent tenosynovitis rapidly destroys the gliding mechanism within the flexor tendon sheath. Delayed or inadequate treatment increases the formation of adhesions within the sheath, permanently limiting tendon excursion and ultimately limiting the finger range of motion.

Operative Treatment. Several surgical approaches have been described for the treatment of pyogenic flexor tenosynovitis. Some of these are of historic interest only. Most describe various incisions for proximal and distal exposure of the flexor tendon sheath and various irrigation methods and solutions.

There have been two principal surgical approaches to treatment of flexor tendon sheath infections. The first is with surgical exposure of the tendon sheath through a midlateral or Brunner incision. We prefer the midlateral incision (Figure 2.9, *A*). Although this allows more direct access to the tendon sheath, it can lead to greater scarring and stiffness of the finger. In the setting of wound healing problems, this leaves the tendon or tendon sheath exposed and more typically requires return to the operating room for delayed primary wound closure.

The second approach developed because of concerns that wide exposure of the tendon sheath led to significant postoperative scarring and stiffness of the involved finger. To address this problem, a number of methods were described that were designed to limit exposure of the tendon sheath (see Figure 2.9, *B* to *D*). Variations included location of incisions, type of irrigants, and continuous methods of irrigation, but all involved limited incisions at the proximal and distal ends of the tendon sheath and proximal to distal irrigation of the sheath.

Neviaser popularized a limited midlateral incision, with opening of the tendon sheath distal to the A4 pulley. The proximal tendon sheath is exposed in the distal palm, and a catheter is placed for continuous irrigation[111] (see Figure 2.9, *D*).

In the technique of closed tendon sheath irrigation, as described by Neviaser, a zigzag incision is made in the distal area of the palm over the proximal end of the sheath. The sheath is opened at the proximal margin of the A1 pulley. A second incision is made on the ulnar midaxial side of the finger in the middle and distal segments. Access to the distal end of the sheath is obtained through a plane dorsal to the digital artery and nerve. The sheath is resected distal to the A4 pulley. A 16-gauge polyethylene catheter with a single opening at its end is inserted under the A1 pulley in the palm for a distance of 1.5 to 2 cm. The catheter is sutured to the skin, and the wound closed around it. The sheath is copiously irrigated with saline. A small drain is placed in the distal incision, making sure to be in the tendon sheath. The drain is sutured to the skin. The wound is closed around the drain. The system is flushed again to test its patency. The hand is dressed and splinted, with the catheter brought out of the dressing and connected to a 50-mL syringe. The dressing is arranged so that the drain can be seen distally. The system is tested just before the patient leaves the

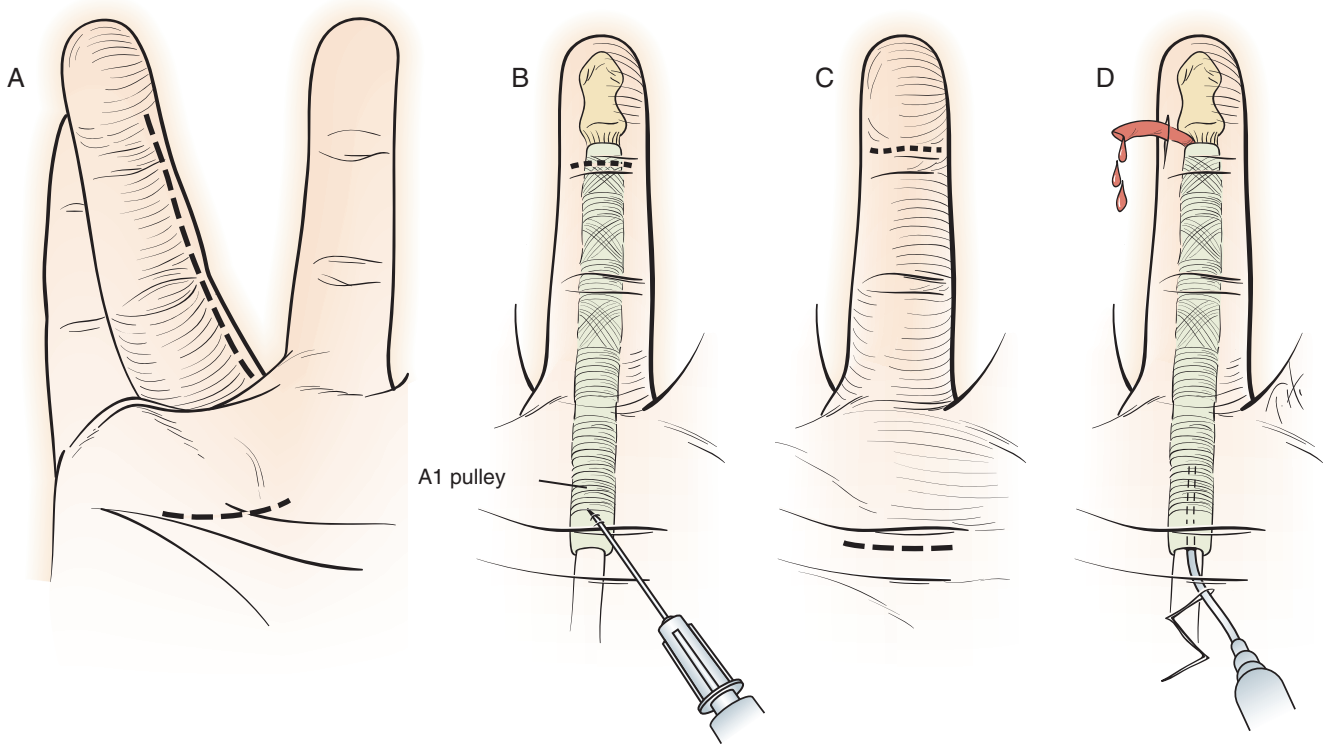

FIGURE 2.9 Incisions for drainage of tendon sheath infections. **A**, Open drainage incisions through the midaxial approach. **B**, Sheath irrigation with distal opening of the sheath and proximal syringe irrigation. **C**, Incisions for intermittent through-and-through irrigation. **D**, Closed tendon sheath irrigation technique (see Neviaser R: Closed tendon sheath irrigation for pyogenic flexor tenosynovitis. *J Hand Surg* 3A(5):462–466, 1978). (Copyright courtesy of Milan Stevanovic and Frances Sharpe.)

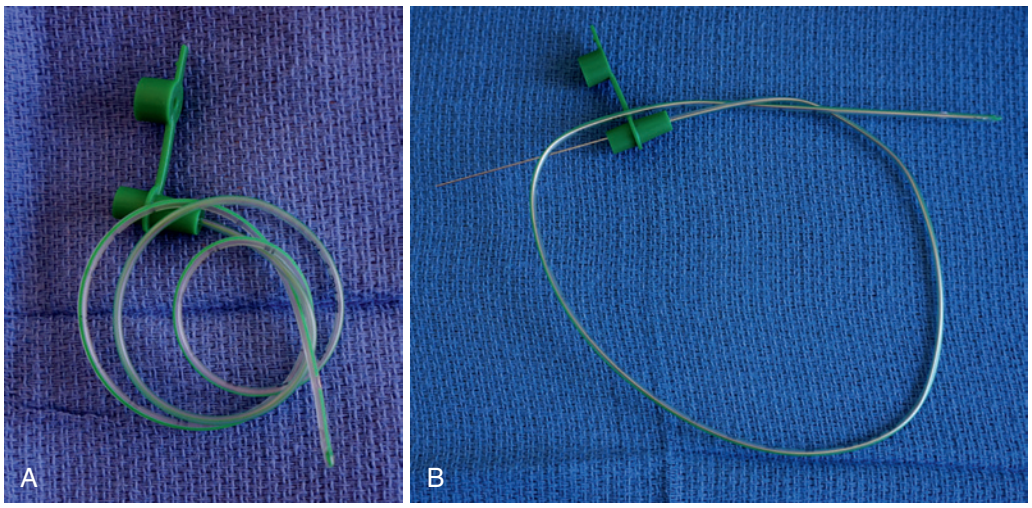

FIGURE 2.10 Cannulation of the flexor tendon sheath with a 5 Fr pediatric feeding tube can be difficult due to the flaccidity of the tube. Use of a 24-gauge wire as an obturator facilitates introduction of the feeding tube into the tendon sheath. (Technique courtesy of Dr. E. Farng.) (Copyright courtesy of Milan Stevanovic and Frances Sharpe.)

operating suite. Postoperatively, the sheath is flushed manually with 50 mL of sterile saline every 2 hours for 48 hours. At this time, the digit is inspected. If signs of infection have abated, the catheter and drain are removed. The wounds are dressed lightly to avoid impeding motion. Exercises to restore finger motion are started. If any doubt exists, the irrigation may be continued for an additional 24 hours.[111] Complete motion can be expected in a week. Several studies support the use of this technique.[32,61] Indwelling catheter placement has not been shown to be necessary and may delay active motion.[86] In our experience, we have not felt that this technique adequately decompresses the flexor tendon sheath or finger. Also, the method of continuous irrigation has often been painful to the patient, the nursing staff, and the on-call physician.

❖ AUTHORS' PREFERRED METHODS OF TREATMENT

Decompression of the septic flexor tendon sheath begins with a midlateral incision. The incisions are designed to avoid scarring on the pinching surface of the fingers. In the index, middle, and ring fingers, the incision is placed on the ulnar border, and in the thumb and small finger, it is placed on the radial side. The incision is made dorsal to Cleland's ligament (see Figure 2.9, *A*). The incision extends from the middle of the distal phalanx to just proximal to the web space. The dissection is carried out dorsal to the neurovascular bundle and down to the flexor tendon sheath. This allows decompression of the swollen finger, decreasing compartment pressure. The tendon sheath is opened distal to the A4 pulley. The sheath must be opened enough to allow the easy egress of fluid or pus, typically 4 to 6 mm. Cultures are taken from the tendon sheath effluent. A 1.5- to 2.0-cm transverse volar incision made proximal to the A1 pulley is usually sufficient to expose the proximal flexor sheath. This incision can be easily extended proximally or distally as a Brunner-type incision to allow greater exposure of the tendon sheath if it is necessary. The tendon sheath is opened proximally. If fluid for culture was not obtained distally, cultures should be taken from the proximal sheath. If hypertrophic synovitis is seen, synovial biopsy is recommended. Pathologic examination should include fungal and mycobacterial stains.

A 14- or 16-gauge intravenous catheter or preferably a No. 5 pediatric feeding tube is introduced into the tendon sheath and advanced 1.5 to 2.0 cm into the sheath (Figure 2.10). Syringe irrigation with copious amounts of antibiotic containing normal saline is done. The fluid should be seen to egress from the distal opening in the tendon sheath. The tendon sheath should be irrigated until clear fluid is seen distally. Irrigation is discontinued if there is too much fluid extravasation into the finger.

If we encounter difficulty in irrigating, the catheter is first repositioned. Mobilizing the superficialis and profundus tendons and placing the catheter dorsal to the tendons may allow easy flow of solution. Thickened tenosynovium may impede flow, and a limited proximal synovectomy or wider exposure of the tendon sheath may be necessary.

Any wounds on the volar surface of the finger should be débrided. Even small puncture wounds, particularly those caused by cat bites, should be débrided and irrigated. In cases in which there is a large volar wound and opening in the tendon sheath at a site of abscess, the irrigant may primarily be flowing out of the abscess site. In this situation, following the débridement of the volar wound, the irrigation catheter can be placed into the tendon sheath at the site of abscess and the distal tendon sheath can be further irrigated (Case Study 2.1).

Postoperative Management and Expectations

Postoperatively, the wounds are left open. A wet gauze wick is placed into the wounds to allow continued drainage. A bulky dressing is applied. The hand is elevated, and intravenous antibiotics are continued. The first dressing change should be done at 12 to 24 hours. At this time, the patient begins soaking in a dilute solution of povidone-iodine, as described earlier. Early motion is initiated. Therapist supervision may be necessary. It is important to keep this wound open to allow drainage. If left alone, the palmar wound will close almost immediately. Therefore, moist gauze wicks are used to keep the wounds open in

CASE STUDY 2.1 Septic Flexor Tenosynovitis

A, A 40-year-old coroner stuck himself with a contaminated sharp instrument at the distal interphalangeal flexion crease. Two days later, he developed severe swelling. Three of Kanavel's cardinal signs were present. Surgical findings included gross pus at the level of the A1 pulley (eFigure 2.1). **B**, A radial midlateral incision was used to decompress the finger and open the tendon sheath distally (eFigure 2.2). **C**, Early range of motion was initiated, and the wound was allowed to heal by secondary intention. Flexion is shown at 5 days in eFigure 2.3. Extension at 5 days is displayed in eFigure 2.4.



eFIGURE 2.1 Copyright Milan Stevanovic and Frances Sharpe.



eFIGURE 2.2 Copyright Milan Stevanovic and Frances Sharpe.



eFIGURE 2.3 Copyright Milan Stevanovic and Frances Sharpe.

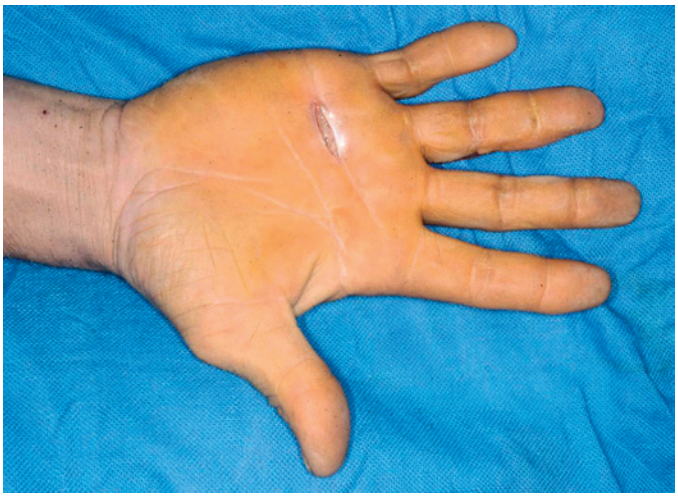

eFIGURE 2.4 Copyright Milan Stevanovic and Frances Sharpe.

CRITICAL POINTS *Pyogenic Flexor Tenosynovitis*

Indication
- Septic flexor tenosynovitis

Preoperative Evaluation
- Clinical examination is the hallmark of diagnosis.
- Laboratory evaluation may include uric acid and rheumatoid factor in addition to CBC, depending on suspicion of nonpyogenic process.
- Radiographs to evaluate for foreign body or fracture, or for joint space widening suggesting joint effusion

Pearls
- Pain with palpation along the flexor tendon sheath and pain with passive extension are most useful in diagnosing early disease.
- Urgent surgical treatment, especially in a patient with diabetes or immunocompromise, reduces the morbidity associated with this infection.

Technical Points
- Perform early decompression with complete midlateral incision of the finger.
- Incise dorsal to Cleland's ligament.
- Irrigate the sheath until the effluent is clear.
- Use wick to keep the proximal and distal incisions open.

Pitfalls
- Delayed surgical treatment
- Inadequate decompression
- Injury of the digital neurovascular structures

Postoperative Care
- Intravenous antibiotics
- Pain management to allow early range of motion
- First dressing change between 8 and 12 hours
- Soaks in dilute povidone-iodine solution three times per day with range-of-motion exercises
- Repeat débridement and irrigation in 48 hours if Kanavel's signs not resolving.

the first 48 to 72 hours. Intravenous antibiotics are continued for 7 to 10 days or until clinical improvement is seen. After this, oral antibiotics are continued to complete a 4-week course of therapy.

If the clinical signs of infection are not improving in the first 24 to 36 hours, the patient is returned to the operating room for a repeat irrigation and débridement. Repeat cultures are obtained, and organism-specific intravenous therapy is continued. A low threshold for return to the operating room should be used in diabetics and immunocompromised patients.

Most patients with pyogenic tenosynovitis, if treated promptly with adequate surgical débridement, appropriate antibiotics, and therapy, will improve rapidly. Patients usually have an almost immediate sense of relief of the severe throbbing pain that was present before treatment. Wound healing of the volar incision occurs quickly as soon as the wicking is discontinued. The midlateral incision heals by secondary intention over the course of 10 to 20 days. When the swelling subsides, Steri-Strips™ can be used to bring the wound edges together, shortening the healing time. Despite healing by secondary intention, the midlateral scar is usually painless. Over time, the scar becomes soft and essentially unnoticeable. The reported range of motion after flexor tendon sheath infection varies. Ten to 20% of patients fail to recover a full range of motion. A more rigorous analysis of motion showed that only two thirds of normal motion was present at 6 weeks. This improved to 80% of normal motion at a 30-month follow-up.[15]

The more severe the initial presentation, the greater is the likelihood of complications and an adverse outcome. Maloon and associates identified three risk factors for a poor prognosis: 1) diabetes, 2) late presentation, and 3) association with a human bite.[94] Pang and colleagues identified five risk factors associated with a poor outcome, including 1) age over 43 years; 2) diabetes mellitus, peripheral vascular disease, or renal failure; 3) presence of subcutaneous purulence; 4) digital ischemia; and 5) polymicrobial infection. Patients with no purulence and no ischemia had no amputations and recovered 80% of the total active range of motion (TROM). Patients with subcutaneous purulence but no ischemia had an 8% risk of amputation. This group recovered 72% of the TROM. Patients with subcutaneous purulence and ischemic changes had an amputation rate of 59% and recovered only 49% of the TROM.[119] Any infection of the flexor tendon sheath may cause scarring and adhesions within the sheath, limiting flexor tendon excursion and gliding. Manipulation under local anesthesia in the first 2 to 4 weeks following treatment may have value in breaking up adhesions before dense scarring occurs. Tenolysis should not be considered until the infection has completely resolved and the patient has failed to improve with occupational therapy. Although we have not had to perform a tenolysis following pyogenic FTS, we would recommend at least 6 months of therapy following resolution of infection to allow for tendon recovery before additional procedures. Passive motion should exceed active motion for a tenolysis alone to improve function. Stiffness of the PIP or DIP joint is not uncommon, particularly if early motion is not initiated or if the patient is noncompliant with therapy. Soft tissue necrosis occurs rarely. Local débridement should be done as needed. When the infection is controlled, healing by secondary intention will occur. If the flexor tendon is exposed, local flap coverage should be considered, especially in patients who have good tendon gliding. Late treatment or severe infection may result in tendon necrosis. This requires excision of the necrotic tendons from the level of the A1 pulley to its distal insertion. In our experience, staged reconstruction of the tendon sheath and tendon grafting is difficult and often has suboptimal outcome. In the index and small finger with tendon necrosis, amputation may be considered, because this is more likely to improve functional outcome and shorten the healing time. Severe flexor tendon sheath infections with tendon necrosis in conjunction with pyarthrosis of any digit except the thumb may best be treated by amputation.

Radial and Ulnar Bursal and Parona Space Infections

Pertinent to the treatment of pyogenic flexor tenosynovitis are infections of the radial and ulnar bursae of the palm and the Perona space at the wrist. Infections in these spaces occur rarely in isolation but are more commonly associated with flexor tendon sheath infections of the small finger or thumb.

Pertinent Anatomy

Radial Bursa. The radial bursa is a continuation of the tendon sheath of the flexor pollicis longus (FPL) tendon. The sheath begins at the base of the distal phalanx of the thumb.

Technically, the sheath ends at the metacarpophalangeal (MP) joint. The radial bursa begins at this level and includes the length of the FPL tendon through the carpal canal. It ends 1 to 2 cm proximal to the proximal edge of the transverse carpal ligament. It is considered a separate bursal space from the FPL tendon sheath, even though in adults it was contiguous with the sheath in 95% of specimens.[136]

Ulnar Bursa. The ulnar bursa begins at the proximal end of the small finger flexor tendon sheath. The bursa widens more proximally, overlapping the mid fourth metacarpal and the proximal base of the third and fourth metacarpals. The bursa lies ulnar to the flexor tendons, which are invaginated into the bursa but not surrounded by it. The relationship of the small finger flexor tendon sheath with the ulnar bursa is less consistent than the relationship between the flexor tendon sheath of the thumb and the radial bursa. Early studies showed direct continuity in only 50% of specimens. Other studies have demonstrated a higher rate of communication, often with an hourglass-type narrowing between the small finger tendon sheath and the ulnar bursa. Communication between the radial and ulnar bursae occurs in 85% of specimens.[136]

Proximal to the transverse carpal ligament, the radial and ulnar bursae lie deep to the FDP tendons and above the fascia of the pronator quadratus muscle. Communication between the radial and ulnar bursae can occur across this space, known as the potential Parona space.[92]

Parona Space

The Parona space is the deep potential space in the distal volar forearm. It lies between the fascia of the pronator quadratus muscle and the sheath of the FDP tendons. It is in continuity with the midpalmar space. Although infections of the Parona space most commonly result from extension of infection from either the radial or ulnar bursa, the Parona space is not in direct continuity with these bursae. Rupture of these bursae due to infection leads to involvement of the Parona space. Also, radiocarpal joint infection may rupture through the volar capsule and spread into the Parona space. Isolated infection of the Parona space can occur after a penetrating injury or, rarely, as a spontaneous (hematogenously spread) deep space infection.

Clinical Presentation and Preoperative Evaluation

Because radial and ulnar bursal infections rarely occur in isolation, the clinical presentations of these infections are similar to those of pyogenic flexor tenosynovitis of the thumb and small finger. In addition to the cardinal signs of Kanavel, there may be swelling and tenderness along the thenar or hypothenar eminence. The adjacent fingers assume a flexed posture, as does the wrist. Although the uninvolved fingers may not be swollen, passive extension is painful. Kanavel believed that the most valuable sign of ulnar bursal infection was the presence of tenderness at the junction of the distal flexion crease of the wrist and the hypothenar eminence. In a similar manner, the most valuable sign for radial bursal infections was tenderness at the junction of the distal wrist flexion crease and the thenar eminence.[75]

Extensive swelling may not be evident, because the bursae rapidly become necrotic. Accumulation of pus does not occur, because the bursae rupture and decompress into the surrounding space. The infection can track into the adjacent bursa through intrabursal communication or across the potential space of Parona. An ascending infection along the opposite border digit can then occur, forming the so-called *horseshoe abscess*. Anatomic variations in the interconnection of the tendon sheaths occur in approximately 15% of patients.[136] Therefore, clinical examination of any flexor tendon sheath infection should include examination of the palm, wrist, and all of the adjacent fingers.

Isolated infections of the Parona space are rare but may present as swelling, tenderness, and, occasionally, fluctuance in the distal volar forearm. Digital flexion is often difficult and painful. Symptoms of numbness and tingling in the median nerve distribution may be present due to swelling or fluid present in the midpalmar space. Diagnostic ultrasound or MRI can be useful in demonstrating fluid within this space. More commonly, Parona space infections are associated with tendon sheath infections of the thumb and small finger. In a series of nine patients, the most common site of spread of infection was from the thumb flexor tendon sheath (seven of nine patients). Interestingly, in this group of patients, β-hemolytic *Streptococcus* was cultured from five of nine specimens.[142]

Treatment

Ulnar and radial bursal infections rarely occur in isolation but are a part of pyogenic flexor tenosynovitis, most commonly of the thumb and small finger. There is no role for nonsurgical treatment of this condition. These infections can cause rapid destruction of the bursal sheath, swelling within the carpal tunnel causing acute median nerve symptoms, and scarring and adhesions between the superficial and deep flexor tendons. Prompt surgical treatment is necessary. The septic flexor tenosynovitis must be treated in conjunction with the bursal infection. There is no general consensus regarding the surgical incision, use of drains, or open versus closed management with catheter irrigation. The following techniques have been described.

Open Treatment. Open treatment of ulnar bursal infections, as described by Boyes, included two separate incisions. The first incision is placed parallel to the proximal edge of the A1 pulley. It can be extended proximally along the radial margin of the hypothenar crease. The proximal end of the bursa in the forearm is exposed through a 3-inch incision, beginning just proximal to the wrist flexion crease. The incision parallels the volar edge of the distal ulna. The flexor carpi ulnaris and the dorsal sensory branch of the ulnar nerve are retracted volarward. By retracting these structures, the pronator quadratus muscle is exposed. The bulge of the ulnar bursa is easily visualized and opened. Cultures should be taken, and the wound is copiously irrigated from proximal to distal. Similarly, treatment of radial bursal infections is done through a distal incision placed at the level of the thumb MP joint. Boyes believed that the radial bursa could best be treated through the same proximal incision as the ulnar bursa, dissecting radially across the volar floor of the pronator quadratus to reach the radial bursa. He described a separate radial incision along the flexor carpi radialis; however, he believed this was superfluous when the ulnar incision was used. For advanced infections, Boyes advocated proximal extension of the palmar incision to include the decompression and drainage of the carpal tunnel. Drains are placed in the bursa and brought out through the skin; they are removed after 48 hours so that exercises can be started.[18]

For isolated Parona space infections, we prefer the incision described for the treatment of the ulnar bursa. Only the proximal incision is necessary. In cases in which there are associated carpal tunnel symptoms or an associated midpalmar infection, an extended carpal tunnel incision is necessary to drain both the midpalmar and Parona spaces.

❖ AUTHORS' PREFERRED METHOD OF TREATMENT

We treat bursal infections by first addressing the flexor tendon sheath infection when present. The exposure of the distal bursa is the same as that described by Boyes.[18] When a tendon sheath infection is present, the same incision used for exposure of the proximal tendon sheath is used for the distal exposure of the bursa. The proximal incision for ulnar bursal infections is a longitudinal incision beginning at the proximal wrist flexion crease. The incision is extended proximally for 5 cm, paralleling the radial margin of the flexor carpi ulnaris. The superficialis and profundus tendons are retracted radially. The flexor carpi ulnaris and ulnar neurovascular structures are retracted ulnarly. The bursa is exposed, opened, and drained. Cultures are taken. Proximal-to-distal irrigation with a 14- or 16-gauge angiocatheter or No. 5 pediatric feeding tube is performed using normal saline. The irrigation is continued until the distal effluent is clear. Radial bursal infections are treated in the same manner. Our incisions are the same as described under through-and-through treatment.

The incisions are left open. A ¼- to ½-inch Penrose drain is placed in the proximal incision site, at the pronator fascia. Distally, a moist gauze wick is used to keep the incision open.

For isolated Parona space infections, we prefer the incision described for the treatment of the ulnar bursa. Only the proximal incision is necessary. If carpal tunnel symptoms or a midpalmar infection are present, an extended carpal tunnel incision is necessary to drain both the midpalmar and Parona spaces.

Postoperative Management and Expectations

The postoperative management of bursal infections is the same as that described for flexor tendon sheath infections. We remove the Penrose drain at 24 to 48 hours.

Outcomes after bursal infections are generally not as favorable as for isolated flexor tenosynovitis. Tendon adhesions, flexion contracture of the fingers and wrist, and restricted motion are more likely to occur. Tenolysis for recalcitrant adhesions may be necessary if therapy does not adequately restore function.

Deep Space Infections

The hand has three anatomically defined potential spaces. These septated spaces lie between muscle fascial planes (Figure 2.11, *A*); they are the *thenar, midpalmar*, and *hypothenar spaces* in the hand. There are three more superficial spaces in the hand, the *dorsal subcutaneous space, dorsal subaponeurotic space*, and *interdigital web space*. Infections of these spaces are different from deep space abscesses in that they do not have well-defined anatomic borders; their presentations are similar to those of deep palmar space abscesses, however. Deep palmar space infections are increasingly rare, likely due to early recognition and surgical treatment of infections and improved antibiotic therapies.

Palmar Space Infections

Clinical Presentation and Preoperative Evaluation. Deep space infections are most commonly caused by penetrating trauma. In thenar and midpalmar space infections, infection can occur from spread from a septic tendon sheath (thumb, index, or long

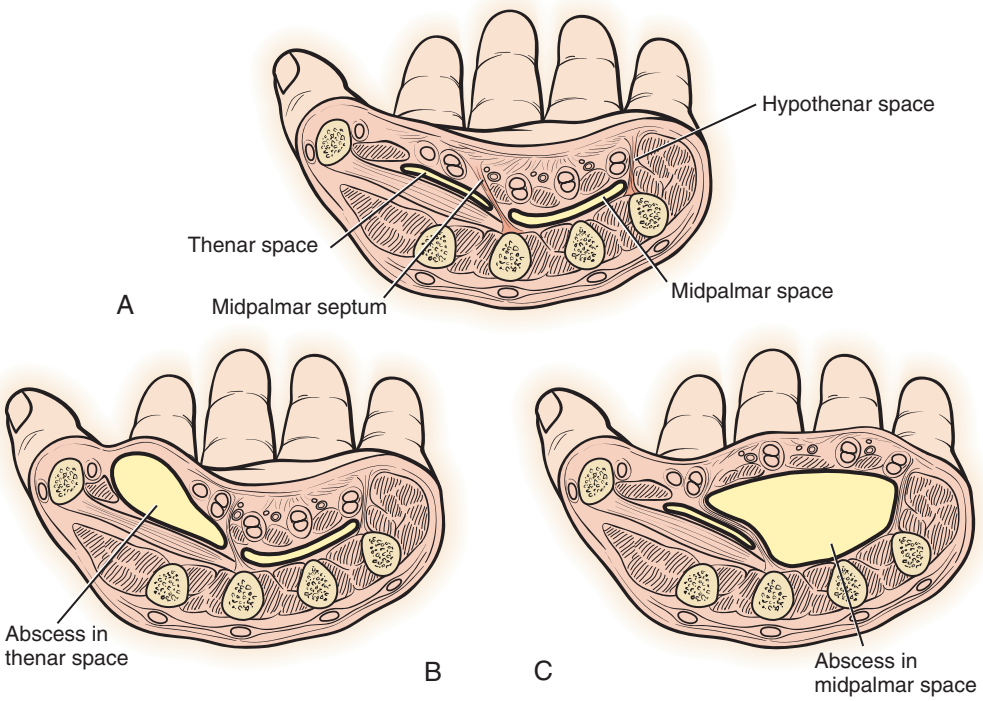

FIGURE 2.11 Deep palmar spaces. **A**, Potential spaces of the midpalm. **B**, Thenar space abscess. **C**, Midpalmar space abscess. (Copyright courtesy of Milan Stevanovic and Frances Sharpe.)

TABLE 2.3 Characteristics of Deep Palmar Space Infections

Space	Thenar Space (Figure 2.11, *A* and *B*)	Midpalmar Space (Figure 2.11, *A* and *C*)	Hypothenar Space (Figure 2.11, *A*)
Characteristics	Most common of deep space infections; can often track dorsally into space between first dorsal interosseous muscle and adductor pollicis muscle; can be confused with dorsal subcutaneous abscess if dorsal extension of abscess cavity	Rare infection	Extremely rare; distinctly separate anatomic space; is not in continuity with any of the flexor tendon sheaths
Boundaries	Dorsal: Fascia of adductor pollicis, second volar metacarpal, and first volar interosseous fascia Volar: Tendon sheath of index finger and radial palmar fascia Radial: Confluence of adductor pollicis fascia and palmar fascia at base of thumb proximal phalanx Ulnar: Midpalmar oblique septum	Dorsal: Fascia overlying second and third volar interosseous muscles and periosteum of third, fourth, and fifth metacarpals Volar: Flexor sheaths of long, ring, and small fingers and palmar aponeurosis Radial: Midpalmar oblique septum Ulnar: Hypothenar septum	Dorsal: Periosteum of fifth metacarpal and fascia of deep hypothenar muscles Volar: Palmar fascia and fascia of superficial hypothenar muscles Radial: Hypothenar septum Ulnar: Fascia of hypothenar muscles
Proximal and distal boundaries	Distal: Deep transverse fascia at level of MC head Proximal: Base of palm	Distal: Deep transverse fascia at level of MC head Proximal: Base of palm	Distal: Deep transverse fascia at level of MC head Proximal: Base of palm
Clinical findings	Swelling and exquisite tenderness of thenar eminence; thumb is abducted; pain with passive adduction	Dorsal swelling predominates; loss of palmar concavity (becomes convex); flexed posture of fingers (long and ring); pain with passive extension of fingers, but less than with septic flexor tenosynovitis	Localized tenderness and swelling of hypothenar eminence; no palmar swelling; no finger or flexor tendon sheath involvement

finger for thenar space and long, ring, or small finger for midpalmar space). Local spread from a subcutaneous abscess that tracks deep into the space can also be a route of infection.

Both thenar and midpalmar space infections often present with swelling involving the entire hand, particularly on the dorsal side. The tight fascia on the palmar surface of the hand limits the amount of volar swelling. The more loosely arranged connective tissue dorsally allows greater expansion of the soft tissue in this area. This dorsal swelling should be distinguished from local dorsal abscess and dorsal cellulitis. All of the deep palmar space infections will have areas of palmar swelling and exquisite tenderness localized over the involved palmar space. Hypothenar infections generally have less dorsal swelling.

Preoperative evaluation includes a careful history of the mechanism of injury and relevant comorbidities. Laboratory evaluation should include a CBC. Radiographs should be routinely obtained to evaluate for a retained foreign body, underlying osteomyelitis, or fracture. Aspiration, ultrasound, or MRI may be useful in identifying an abscess. If the clinical presentation strongly suggests a deep infection, a negative aspiration should not negate surgical exploration.

Pertinent Anatomy. The thenar and midpalmar spaces of the hand are located dorsal to the flexor tendons and volar to the metacarpals and interosseous muscle fasciae. They are divided by the midpalmar (oblique) septum, which extends from the palmar fascia to the volar diaphyseal ridge of the third metacarpal. The midpalmar space is separated from the hypothenar space by the hypothenar septum, which extends from the volar ridge of the fifth metacarpal shaft to the palmar aponeurosis (Table 2.3).

Treatment. There is no role for nonsurgical management of deep space infections. These should be treated as surgical emergencies. Intravenous antibiotics are started, preferably after obtaining a culture either from the site of a draining wound or from an aspirate of the affected palmar space. If the patient cannot be taken immediately to the operating room and cultures cannot be obtained from an aspiration, then antibiotic therapy with good staphylococcal coverage should be initiated.

Thenar Space. Incisions to drain the thenar space should provide adequate exposure of the affected areas. It is also important to make incisions that will not lead to subsequent contracture. Access to the thenar space requires that an incision be placed near neurovascular structures, specifically, the recurrent motor branch of the median nerve, the digital nerves to the thumb and radial side of the index finger, the princeps pollicis artery, and the proper digital arteries. Careful dissection is necessary to avoid injury to these structures.

Drainage of the thenar space abscess has been described through dorsal, volar, or combined volar and dorsal incisions. We avoid the dorsal transverse incision owing to the risk of web space contracture. Combined approaches should not be connected through the web space, as they can also lead to contracture and/or a painful scar.

Volar Approach (Thenar Crease). An incision is made on the palmar surface of the hand just adjacent and parallel to the thenar crease (Figure 2.12, *A*). The incision begins

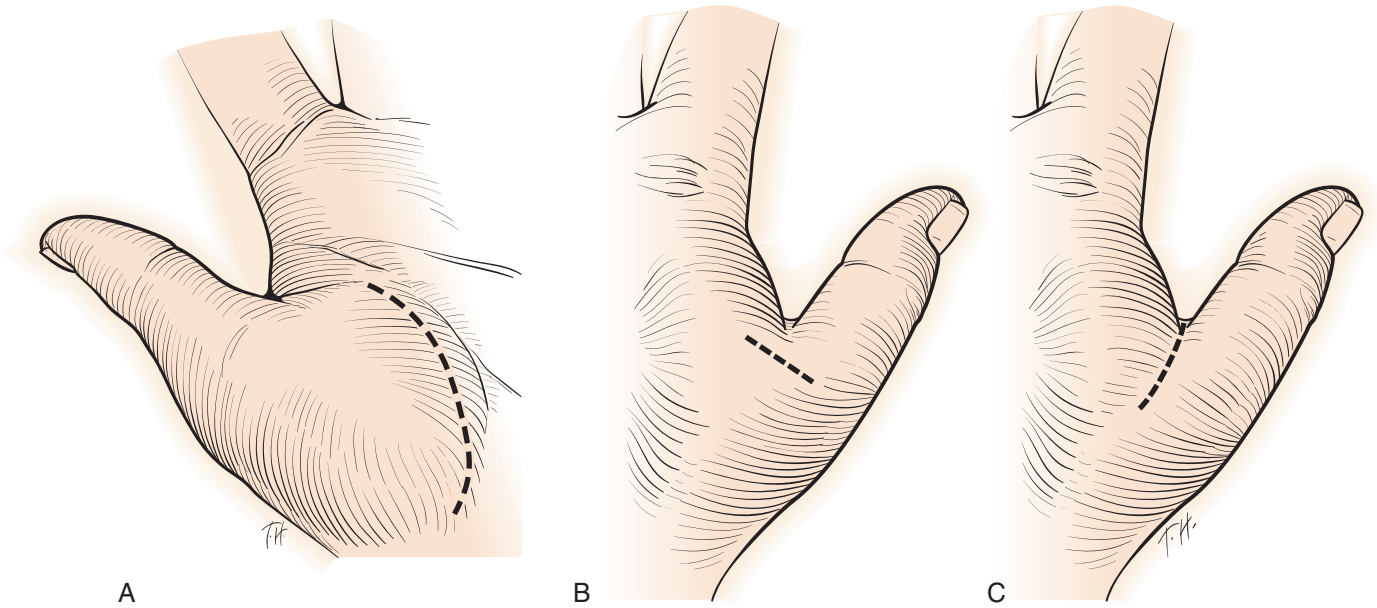

FIGURE 2.12 Incisions for drainage of the thenar space. **A**, Thenar crease approach. Motor recurrent branch of the median nerve is at risk in dissection. **B**, Dorsal transverse approach. Transverse incision is not favored as this can lead to a web space contracture. **C**, Dorsal longitudinal approach. (Copyright courtesy of Milan Stevanovic and Frances Sharpe.)

approximately 1 cm proximal to the web space and continues proximally for 3 to 4 cm. Blunt dissection through the palmar fascia is carried out toward the adductor pollicis muscle until abscess is encountered. In the proximal portion of the deep dissection, particular attention is necessary to protect the motor branch of the median nerve. After the area has been drained adequately, the dissection is extended over the distal edge of the adductor to decompress the first dorsal interosseous space.

Dorsal Longitudinal Approach. A straight or slightly curved longitudinal incision is made in the dorsum of the first web space, starting proximal to the web and extending perpendicular and proximal to the web, bisecting the interval between the first and second metacarpals (see Figure 2.12, *C*). The dissection is continued deeper into the interval between the first dorsal interosseous and the adductor pollicis, at which point pus should be encountered.

Combined Dorsal and Volar Approach. Two incisions are made: one dorsally, which is the slightly curved longitudinal approach described earlier, and one volarly, which parallels the thenar crease. Each approach is used to drain the corresponding half of the space. A separate drain is used for each incision, but through-and-through drains are not used.

Midpalmar Space. Various skin incisions have been described for decompression of the midpalmar space. These include the (1) transverse incision in the distal crease (Figure 2.13, *A*); (2) combined transverse and longitudinal approach (see Figure 2.13, *B*); and (3) curved longitudinal approach (see Figure 2.13, *C*). Whichever skin incision is used, the common digital nerves and arteries as well as superficial palmar arch are protected. The flexor tendons of the ring finger are used as a guide to the midpalmar space. The deep dissection is continued longitudinally on either side of these tendons until the abscess is opened.

Distal Palmar Approach Through the Lumbrical Canal. This approach was described by Kanavel not as a routine approach to midpalmar space infection but as treatment for a special circumstance, when a midpalmar space infection involves the lumbrical canal.[75] A longitudinal incision is made on the palmar surface of the third web space (between the middle and ring fingers). It extends from immediately proximal to the web and ends distal to the midpalmar crease. The incision should not cross the crease (see Figure 2.13, *D*). A clamp is inserted into the wound and directed proximally down the canal of the third lumbrical, dorsal to the flexor tendons, until the midpalmar space is entered and pus is encountered.

Dorsal Approach. A longitudinal incision is made between the middle and ring fingers or between the ring and small fingers. Blunt dissection is done above the periosteum on the ulnar side of the third metacarpal or along the radial or ulnar sides of the fourth metacarpal. Dissection is carried down between the metacarpal and interosseous muscles. Below the interosseous muscles lies the midpalmar space.

Hypothenar Space. The hypothenar space is decompressed through an incision in line with the ulnar border of the ring finger, starting just proximal to the midpalmar crease and continued proximally to 3 cm distal to the wrist flexion crease (Figure 2.14). The incision is deepened to the level of the hypothenar fascia. This layer is divided in the line of the incision. The abscess should be directly beneath it. After the purulence has been evacuated, a gauze dressing and/or Penrose drain is placed in the wound.

Deep Subfascial Space Infections

The deep subfascial spaces include the dorsal subcutaneous space, the dorsal subaponeurotic space, and the interdigital web space. The dorsal subcutaneous space is an extensive area of loose connective tissue without distinct boundaries, in which pus can accumulate over the entire dorsum of the hand. The dorsal subaponeurotic space lies deep to the extensor tendons, above the periosteum of the metacarpals and fascia of the dorsal interosseous muscles. The interdigital web spaces are areas of

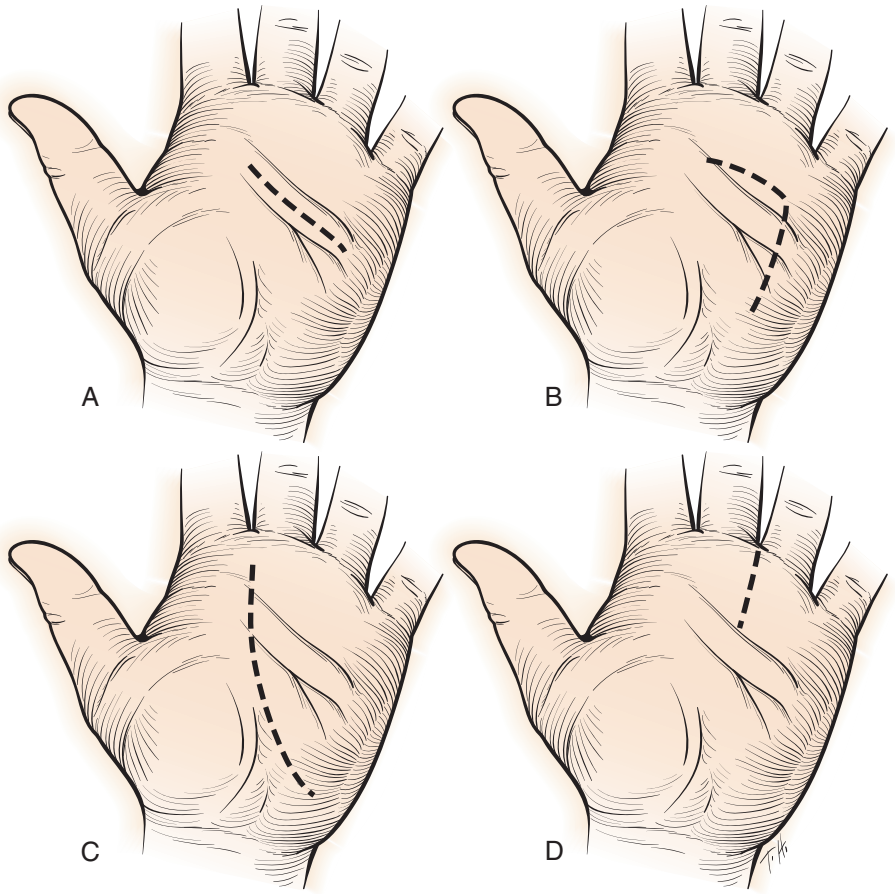

FIGURE 2.13 Incisions for drainage of the midpalmar space. **A**, Transverse incision in the distal crease. **B**, Combined transverse and longitudinal approach. **C**, Curved longitudinal approach. **D**, Distal palmar approach through the lumbrical canal. (Copyright courtesy of Milan Stevanovic and Frances Sharpe.)

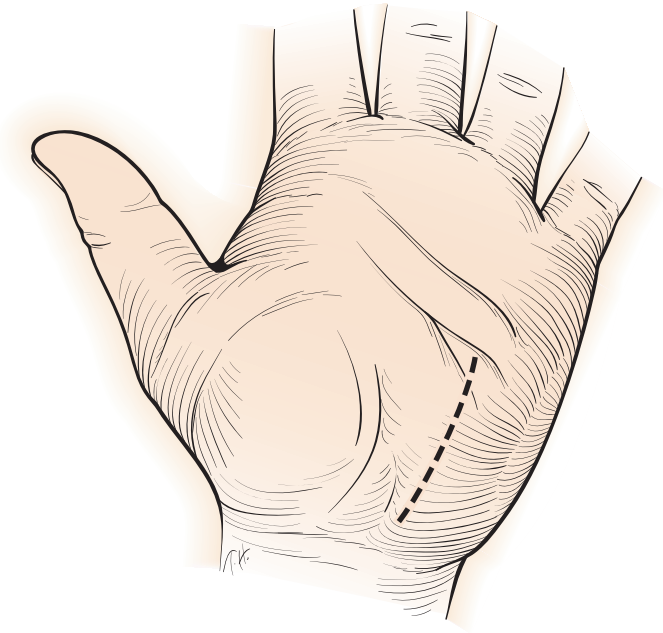

FIGURE 2.14 Approach to the hypothenar space. (Copyright courtesy of Milan Stevanovic and Frances Sharpe.)

loose connective tissue between the fingers. Infection in this area tracks both volarly and dorsally and is commonly called a *collar-button abscess*.

Clinical Presentation and Evaluation

Dorsal Subcutaneous and Dorsal Subaponeurotic Space Abscess. As with most infections of the hand, dorsal subcutaneous and dorsal subaponeurotic space infections typically result from penetrating injuries of the hand. The dorsal aspect of the hand is swollen, warm, and erythematous. The dorsal surface is tender to palpation. Fluctuance may be present. Finger extension may be difficult and is usually painful. Differentiating these infections from cellulitis or other hand infections can be difficult, because most hand infections present with dorsal swelling.

Web Space Abscess (Collar-Button Abscess). The term *collar-button abscess* refers to the hourglass shape of the abscess and the resemblance to the collar buttons used for dress shirts in the early 1900s. An infection in the web space (collar-button or collar-stud abscess) usually occurs through a fissure in the skin between the fingers, from a distal palmar callus, or from extension of an infection in the subcutaneous area of the proximal segment of a finger. The pain and swelling are localized to the web space and distal area of the palm. The adjacent fingers lie abducted from each other (Figure 2.15). The swelling may

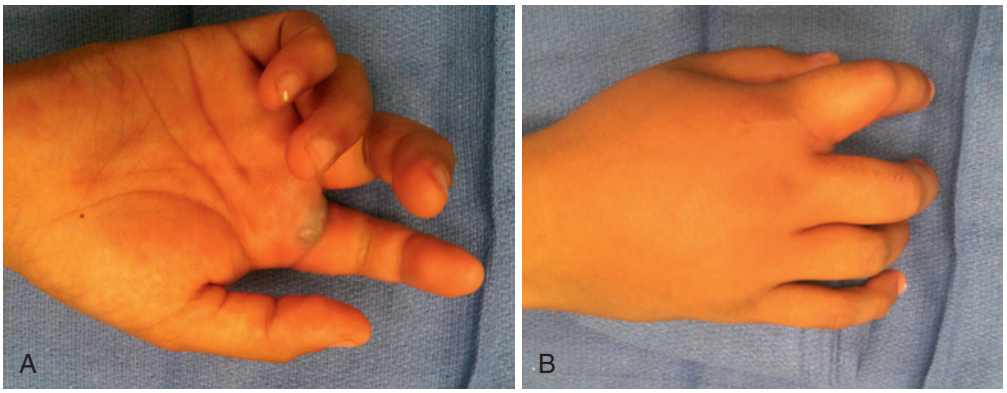

FIGURE 2.15 Clinical appearance of a patient with a collar-button abscess of the second web space, showing the abducted position of the fingers. **A**, Volar. **B**, Dorsal. (Copyright courtesy of Milan Stevanovic and Frances Sharpe.)

be more prominent on either the palmar or dorsal aspect, depending on the extent and location of the infection. Swelling is often greater on the dorsal side. However, one should not be misled into overlooking the more important volar component of this infection (Case Study 2.2).

The position of finger abduction is helpful in differentiating a collar-button abscess from a dorsal subcutaneous infection. In the dorsal subcutaneous infection, the fingers are not abducted, because there is no purulence tracking palmarly between the bases of the adjacent fingers.

Pertinent Anatomy. The dorsal subaponeurotic space is limited on its dorsal surface by the dense aponeurosis of the extensor tendons. On its volar aspect, it is limited by the periosteum of the metacarpals and the dorsal fascia of the interossei. Medially and laterally, the aponeurotic sheet merges with the deep fascia overlying the dorsal interosseous muscles, the periosteum of the first through fifth metacarpals, and the capsules of the first through fifth MP joints. Kanavel described this space as a truncated cone, with the smaller end at the wrist and the larger end toward the MP joints.

The interdigital web spaces consist of the loose areolar connective tissue between the metacarpal heads and around the deep intermetacarpal ligament. The skin of the web space is densely attached to the palmar fascia. A web space infection most commonly begins on the volar surface. The strong attachments of the palmar fascia to the skin limit the volar extension of the abscess. Therefore, the infection track is along the path of least resistance to the dorsal surface.

Treatment

Dorsal Subcutaneous and Subaponeurotic Space Abscess. Exploration of the dorsal subcutaneous and subaponeurotic spaces can be performed through one or two dorsal longitudinal incisions. The first incision is placed over the longitudinal axis of the index metacarpal. The second incision is placed between the fourth and fifth metacarpals. These incisions allow exploration of the infection to determine if this is a superficial or deep infection. The subaponeurotic space can be opened by incising along the margin of the extensor tendon. Advanced infection often involves both the dorsal subcutaneous and subaponeurotic spaces. The use of two incisions allows for good drainage of the abscess cavity, while soft tissue coverage over the extensor tendons is maintained.

Interdigital Web Space (Collar-Button Abscess). Awareness that both volar and dorsal components of infection may be present is critical for proper treatment of this abscess.

Most authors agree with both dorsal and volar incisions for treatment of these abscesses. There is agreement on the use of a dorsal longitudinal incision. The most commonly described volar incisions are the curved longitudinal and zigzag incisions. Both provide access to the volar space.

Curved Longitudinal Incision. The volar incision is begun on the radial side of the affected web space. It is continued proximally and ulnarward, stopping just distal to the midpalmar crease overlying the metacarpal of the ulnar digit involved (Figure 2.16, *A*). After the skin is divided, the subcutaneous tissue is spread with a clamp until pus is encountered. The opening in the abscess is enlarged longitudinally. Compression is applied to the dorsum of the web space by the surgeon while the volar incision is retracted. Increased drainage can be seen in the depth of the wound if there is a deep collar-button abscess.

A second incision is then made on the dorsum. It begins just proximal to the involved web space and extends proximally between the metacarpal heads for a distance of 1 to 1.5 cm or as much as is needed to decompress the abscess (see Figure 2.16, *D*). The deep tissues are divided in a plane toward the palmar abscess. When the dorsal collection is entered, the opening is enlarged in the direction of the wound. After the pus has been evacuated and the wound irrigated, gauze wicks are placed into both wounds.

One modification of this approach is a longitudinal volar incision between the metacarpals, but this provides less adequate exposure to the volar aspect of the abscess.

Volar Zigzag Approach. A zigzag incision is made on the palmar surface, starting just proximal to the web and stopping just distal to the midpalmar crease (see Figure 2.16, *B*). The flaps are reflected and the deep tissues dissected in the web while the digital arteries and nerves are retracted to either side. The superficial transverse metacarpal ligament and other fibers of the palmar fascia are divided to allow ample exposure of the volar and dorsal compartments of the dumbbell-shaped abscess. A 1.5-cm dorsal longitudinal incision is made between the bases of the proximal phalanges. Generous communication between the two incisions is established.

CASE STUDY 2.2 Collar-Button Abscess

A 35-year-old construction worker sustained a puncture wound to the left fourth web space. He presented 1 week after injury with pain, swelling, and discoloration around the web space.

A, Initial presentation (eFigure 2.5).

B, Initial decompression (eFigure 2.6).

C, Proximal Brunner extension into palm to allow for adequate decompression (eFigure 2.7).

D, Dorsal longitudinal incision for débridement of dorsal component of the collar-button abscess (eFigure 2.8).



eFIGURE 2.5 Copyright Milan Stevanovic and Frances Sharpe.

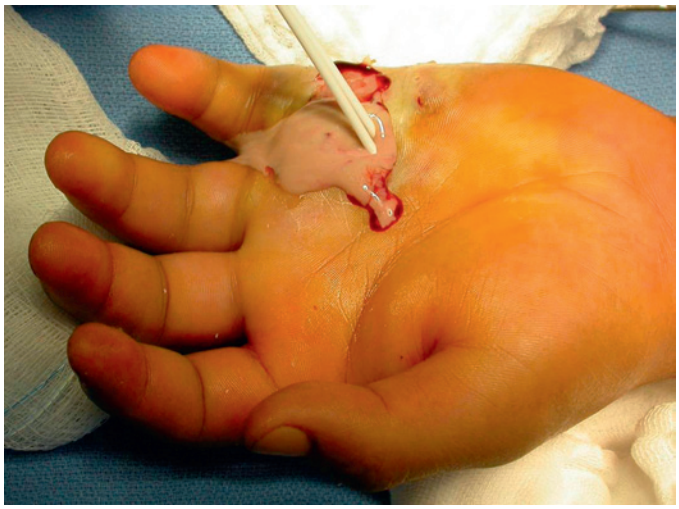

eFIGURE 2.6 Copyright Milan Stevanovic and Frances Sharpe.

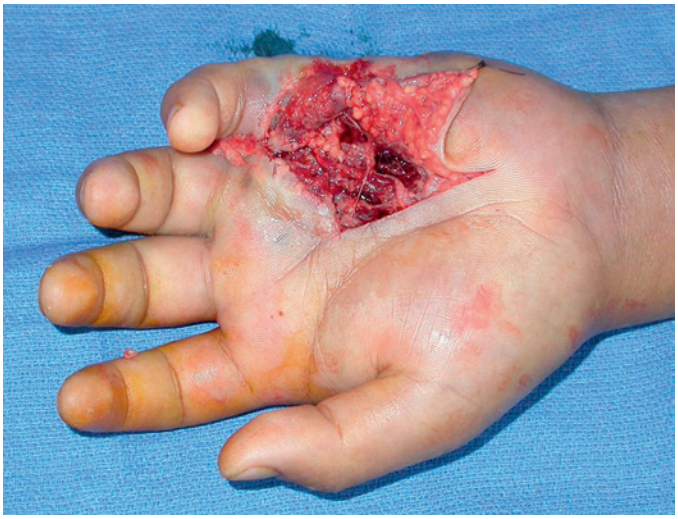

eFIGURE 2.7 Copyright Milan Stevanovic and Frances Sharpe.



eFIGURE 2.8 Copyright Milan Stevanovic and Frances Sharpe.

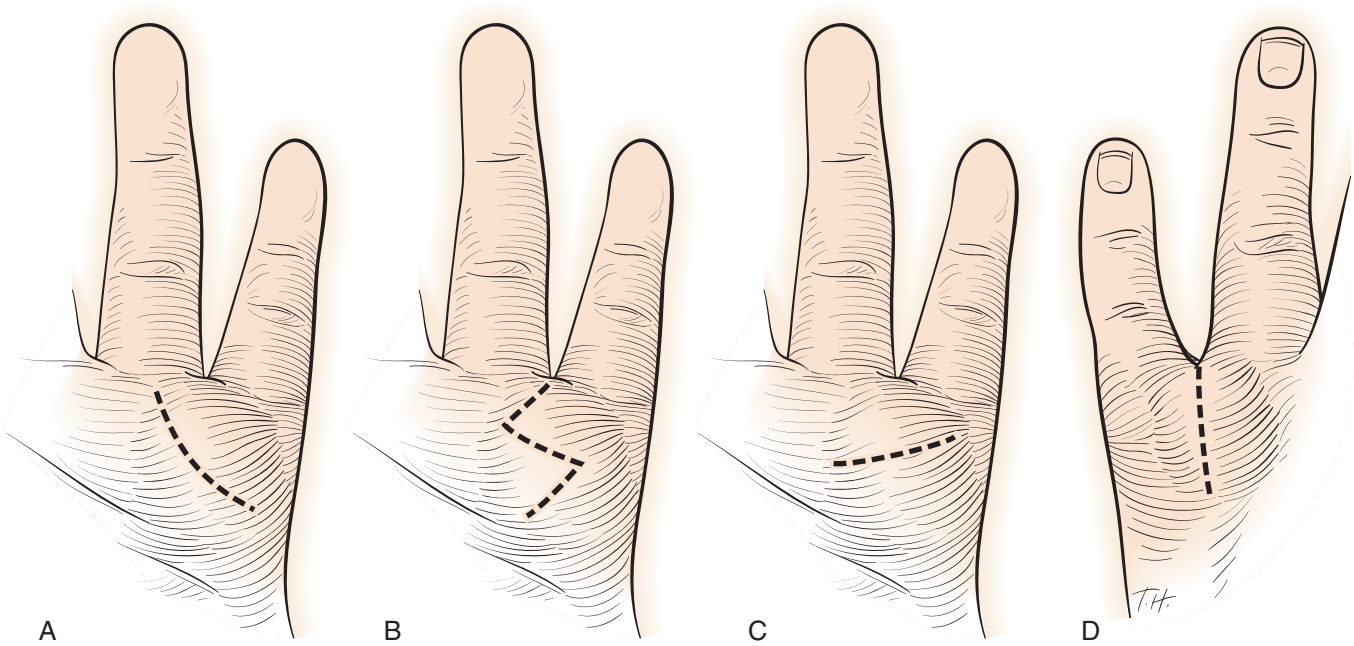

FIGURE 2.16 Incisions for web space abscesses (collar-button abscesses). **A**, Curved longitudinal incision. **B**, Volar zigzag approach. **C**, Volar transverse approach. **D**, Dorsal incision used in conjunction with any of the volar exposures. (Copyright courtesy of Milan Stevanovic and Frances Sharpe.)

Zigzag incisions provide excellent exposure for drainage of infection, but if they are left open, the flaps can retract and cause thick or tender scars. Therefore, if this incision is used, we recommend delayed primary wound closure after the infection has been controlled.

Volar Transverse Approach. Kanavel described a volar transverse incision placed parallel with the distal flexion crease of the palm over the site of maximum swelling (see Figure 2.16, *C*). He believed this was generally adequate for drainage and did not require a second incision.[75] The deep dissection is as previously described. The dorsal approach may be needed as well. One potential disadvantage of this incision is placement of the transverse limb too far distally. If this part of the incision is inadvertently carried too close to the web, a web space contracture can result.

❖ AUTHORS' PREFERRED METHOD OF TREATMENT

Thenar Space. Our preferred method of treatment for the thenar space infections is through combined dorsal and volar approaches, as described earlier. We have found that a single volar incision is not adequate to address the dorsal abscess cavity between the adductor and first dorsal interosseous muscle. Similarly, a single dorsal incision, whether it is transverse or longitudinal, can provide access to the volar abscess, but it is more difficult and we have not been satisfied with our ability to adequately decompress and irrigate the involved space. We leave the wounds open, using a moist gauze wick. We occasionally use a Penrose drain on the volar side for large areas of abscess.

Midpalmar Space. Midpalmar space infections are treated as described earlier under the curved longitudinal approach. This method provides the best exposure of the midpalmar space. It is less likely to result in a severe scar contracture, because it lies adjacent to an anatomic crease. It is an extensile incision and can be used to simultaneously access the thenar space if necessary. We leave the incisions open, using a moist gauze wick as described earlier. Healing by secondary intention occurs rapidly provided the infection is well controlled and necrotic tissue has been removed.

Interdigital Web Space Abscess (Collar-Button Abscess). We use both a dorsal and volar approach to treat these infections. Our preferred incision is the curved longitudinal incision. We find that this incision provides excellent exposure of the abscess, reduces the risk of skin edge necrosis, and provides easier access for wound management. We try to avoid crossing the web space and do not connect the volar and dorsal skin incisions. If the web space is crossed, this should be done with a longitudinal rather than a transverse incision to avoid later web space contracture.

Postoperative Management and Expectations. The same principles of management apply for all deep space infections. Postoperatively, the wounds are left open. A wet gauze sponge is placed into the wounds to allow continued drainage. A bulky dressing is applied. The hand is elevated, and intravenous antibiotics are continued. The first dressing change should be done at 12 to 24 hours. At this time, the patient begins soaking in a dilute solution of povidone-iodine, as described earlier. Early motion is initiated. Therapist supervision may be necessary. Active finger and wrist motion is necessary to reduce problems of stiffness, contracture, and tendon adhesion. Intravenous antibiotics are continued for 14 to 21 days. After this, oral antibiotics are continued to complete a 4-week course of therapy.

If the clinical signs of infection are not improving in the first 24 to 36 hours, the patient is returned to the operating room for a repeat irrigation and débridement. An MRI may be helpful in identifying areas of abscess or joint effusion that need to be surgically assessed. Repeat cultures are obtained if the previous

CRITICAL POINTS *Deep Space Infections*

Indication
- Thenar, midpalmar, and collar-button abscesses

Etiology
- Penetrating injury is the most common source of infection.

Preoperative Evaluation
- Clinical examination features may provide a diagnosis, but diffuse dorsal swelling can cause difficulty in separating cellulitis from abscess.
- Aspiration is useful but can be misleading.
- Radiographs are necessary to evaluate for foreign body or fracture.
- MRI is very helpful in identifying localized abscess.

Pearls
- Thenar space infections present as wide abduction of the thumb and difficulty with opposition.
- Midpalmar space infections result in loss of palmar concavity; fingers are semiflexed.
- Collar-button abscesses are distinguished by abduction of adjacent fingers.
- Urgent surgical treatment, especially in a patient with diabetes or immunocompromise, reduces the morbidity associated with these infections.

Technical Points
- We prefer two incisions for thenar space infections. Use caution for the motor recurrent branch of median nerve.
- Single volar midpalmar incision. Use caution for superficial arch and digital nerves. Deep to the midpalmar space, pay attention to the deep palmar arch and motor branch of ulnar nerve.
- Two incisions are required for collar-button abscess. We prefer not to incise across the web space. If crossing the web space, keep incision longitudinal.
- Use wick to keep incisions open.

Pitfalls
- Delayed surgical treatment
- Inadequate decompression
- Injury of digital neurovascular structures

Postoperative Care
- Intravenous antibiotics
- Pain management to allow early range of motion
- First dressing change between 8 and 12 hours
- Soaks in dilute povidone-iodine solution three times per day
- Repeat débridement and irrigation in 48 hours if symptoms not improving

culture was negative, and organism-specific intravenous therapy is continued. Tissue biopsy with specific staining to diagnose fungal or atypical infections provides information more quickly than fungal and mycobacterial cultures. A low threshold for return to the operating room should be used in diabetics and immunocompromised patients.

Deep space infections are more likely to develop scarring and stiffness of the hand and fingers. With adequate treatment and rehabilitation, 70% to 80% of patients achieve full recovery. Most patients are able to return to their previous occupations.

Complications associated with deep space infections include stiffness and contracture. Extensor lag has been reported after dorsal subcutaneous and dorsal subaponeurotic space infections. Skin necrosis either dorsally or volarly can lead to exposed tendons or neurovascular structures. These problems may require secondary procedures for soft tissue coverage and contracture release. Tendon necrosis is less common with deep space infections but can occur, particularly on the extensor surface when there may be significant soft tissue loss. Painful scar formation along the incision is reduced by proper placement of the incisions and postoperative management with desensitization, scar massage, and early motion.

Nerve injury is uncommon but can occur during treatment. Infection causes soft tissue necrosis and can distort the local anatomy. This can lead to inadvertent placement of the surgical incision. It may be difficult to recognize a nerve or vessel within an ocean of pus and necrotic tissue.

Septic Arthritis

Septic arthritis is characterized by the presence of a purulent exudate within the closed confines of a joint. It is caused by the introduction and proliferation of pyogenic bacteria within the synovium in concentrations greater than 10^5 organisms per microliter, with subsequent production of a purulent exudate. Inoculation of the joint usually occurs from penetrating trauma. *S. aureus* and streptococcal species are the most common organisms. Gram-negative, anaerobic, and mixed infections also occur, especially in the immunocompromised host. A hematogenous origin of septic arthritis should raise suspicion of gonococcal infection. Expedient treatment is important to minimize articular destruction caused by infection.

Clinical Presentation and Patient Evaluation

Abscess within the joint cavity represents a cellular and immunogenic response within the synovium and reticuloendothelial system. Bacteria replicate within the joint cavity, producing toxins. This stimulates an immunogenic response. The responding leukocytes produce bactericidal enzymes that destroy the proteoglycan matrices and collagen of hyaline cartilage. Lymphocytes and related cells form immune complexes, which also can degrade articular surfaces. As the inflammatory response continues, there is increased pressure within the joint. This forces the joint into a position of maximum potential volume, producing pseudoparalysis. The increased volume within the joint further damages the articular cartilage through pressure necrosis. Untreated, pus under pressure may erode through the joint capsule and overlying skin. Alternatively, it may erode into the subchondral bone, resulting in osteomyelitis.

Patients generally present with a history of penetrating trauma, which may be caused by bites or by splinters, thorns, hooks, needles, or any of a variety of penetrating objects. The source of the injury is important in selecting empirical antibiotic therapy for the presumptive infecting organisms. Contiguous spread from an adjacent infection can occur. In the DIP joint, other common mechanisms of occurrence are from infection or direct inoculation of a mucous cyst or from contiguous spread from a felon, paronychia, or purulent flexor tenosynovitis. In the PIP joint, contiguous spread is most commonly related to a purulent flexor tenosynovitis. At the MP joint, infection from a clenched fist injury is frequently encountered. Hematogenous spread, although uncommon, has been reported and is more likely to occur in immunocompromised patients.

The clinical findings associated with septic arthritis are swelling, redness, warmth, and pain around the affected joint.

Active or passive motion produces exquisite pain. Fluctuance within the joint may be demonstrated by ballottement. Systemic signs such as fever, chills, tachycardia, malaise, sweats, and rash may be present but are not common. The presence of systemic symptoms suggesting hematogenous seeding should alert the physician to look for a primary source of infection.

Evaluation of the patient should address any history of penetrating trauma, insect bite, or animal bite or of previous therapeutic joint injection or aspiration, or the possibility of a retained foreign body. A history of immunocompromising conditions or inflammatory conditions that may mimic joint sepsis should be obtained. Many inflammatory conditions can present as an acutely swollen and painful joint of the wrist and hand. These include gout, pseudogout, rheumatoid arthritis, systemic lupus erythematosus, psoriatic arthritis, acute rheumatic fever, sarcoidosis, and Reiter syndrome. In the case of possible hematogenously spread infection, a careful review of systems may reveal the primary nidus of infection. Retained penetrating objects, in particular palm or cactus thorns or sea urchin spines, can create a chemical synovitis that resembles an infectious process. Distinction between infectious and noninfectious processes is difficult. In these circumstances, surgical treatment is necessary, with the difference that it is very important to remove the offending nidus of inflammation if still present. Identification of gout or pseudogout crystals on fluid analysis does not exclude the possibility of a commensurate infection. If the clinical picture supports infection, surgical treatment should be performed.

Laboratory evaluation should include the WBC count, ESR, and CRP. The WBC count is elevated in less than half of patients. The ESR and CRP are usually elevated in nonimmunocompromised patients. Blood cultures should be taken, particularly when systemic symptoms are present. Culture of potential distant primary sources, such as the urine or the urethra or oropharynx, should be considered in the setting of a hematogenously spread infection.

Aspiration of small joints may be difficult, especially when trying to avoid areas of cellulitis. Fluid yields may be low. If only a small volume of fluid is obtained, it is best sent for culture rather than cell count. Radiocarpal joint aspiration is more easily performed and may help differentiate acute infection from other inflammatory processes. Aspiration through cellulitic skin should be avoided. Radiocarpal aspiration is performed through the dorsal skin, just distal to the Lister tubercle. An 18-gauge needle is introduced and directed proximally to accommodate the normal palmar tilt of the distal radius. Aspiration of the midcarpal joint or distal radioulnar joint may be necessary if no fluid is obtained from the radiocarpal joint. If fluid is not easily obtained from either the radiocarpal or midcarpal joint, 1 to 2 mL of sterile saline can be injected into the joint and then aspirated for analysis. The aspirate should be sent for gram-stained smear, crystal analysis, and aerobic and anaerobic cultures. If adequate aspirate is available, cell count, fluid protein and glucose levels, and fungal and mycobacterial cultures should be obtained. The WBC count from the aspirate of more than 50,000/mm^3 suggests joint sepsis. A lower WBC count with a high percentage of polymorphonuclear cells (>90%) can indicate an early joint infection. A high WBC count (>90,000/mm^3), regardless of the percentage of polymorphonuclear cells, should be treated as an acute infection. A synovial fluid glucose value of 40 mg/dL or less than the fasting blood glucose level also supports a septic process.

Radiographs are useful to evaluate for a retained foreign body, osteomyelitis, or gas within the joint or soft tissues indicating clostridial or other anaerobic infections. Initially, radiographs may show joint capsular distention and periarticular soft tissue swelling. Joint space narrowing on radiographs is seen as a late sequela of septic arthritis. MRI, when necessary, is a sensitive and specific technique of identifying a joint effusion.

Treatment

Septic arthritis of the hand or wrist is treated as a surgical emergency. Articular destruction from proteolytic enzymes and toxins that degrade glycosaminoglycans begins in the first 24 hours of infection. The principle of treatment for all septic joints is prompt surgical drainage. Serial aspiration has been proposed as a form of treatment for septic joint infection. In the hand and wrist, aspiration is useful diagnostically but is therapeutically unpredictable. Leslie and colleagues reported superior results with formal arthrotomy of the shoulder joint over serial aspiration. The same principle applies to the hand, where serial aspiration of small joints is more difficult and less reliable.[83] Serial aspiration should only be considered when the patient is not medically stable for formal treatment.

Infections of the Wrist Joint (Radiocarpal, Ulnocarpal, and Midcarpal Joints)

Arthrotomy of the wrist joint may include arthrotomy of the radiocarpal and ulnocarpal joints, as well as the midcarpal and distal radioulnar joints. This can be accomplished through the standard dorsal approach to the wrist joint. This is done through a longitudinal incision centered slightly ulnar to the Lister tubercle. The retinaculum between the third and fourth extensor compartments is opened. The extensor pollicis longus tendon is identified and retracted radially. The underlying joint capsule is exposed. The capsule can be opened longitudinally or with a "T" incision. A longitudinal or T-capsular incision provides adequate exposure of the joint and can easily be left open to allow continued drainage. The ligament-sparing incision is an excellent approach to the wrist joint. In the case of sepsis, the capsular flap does not have to be completed. Transverse incisions to separately open the radiocarpal and midcarpal joints can be used, and capsular windows can be created to allow ongoing drainage. Culture of the joint fluid is obtained. The joint is copiously irrigated with gravity irrigation or bulb syringe. Pulsed lavage is not used, because this can cause additional soft tissue injury. The joint is taken through flexion and extension during the irrigation to maximize removal of purulent material. Articular surfaces are inspected for discoloration, areas of thinning, or softness. Necrotic tissue and inflammatory synovium are removed as indicated. Synovial tissue should be sent for culture and histologic studies. At the completion of irrigation, the joint capsule is left open. A gauze wick is placed down into the capsule to maintain a path for continuous drainage. Alternatively, the capsule may be closed over a drain. The skin incision is left open. One or two loosely placed sutures can be used to keep the skin edges from retracting. If the skin edges are markedly retracted, Steri-Strips can be placed to gently approximate the skin edges as the swelling decreases. A transverse skin incision can also be used to approach the joint, which

results in a more cosmetic scar with less skin edge retraction. However, it is not extensile and may not provide adequate exposure in all circumstances.

Arthroscopic débridement and lavage of the infected radiocarpal joint may be a useful alternative to open débridement. Viewing and working portals are established; usually the 3-4 portal is used for viewing and for fluid ingress. The working portal may be the 6R or the 4-5 portal. An 18-gauge needle attached to intravenous tubing can be placed in the 6U portal for additional fluid egress. Arthroscopic irrigation and débridement has been shown in one study to decrease the number of surgical procedures and hospital stays in those patients with a single septic joint.[133]

Metacarpophalangeal Joint

The MP joint can be opened through a dorsal longitudinal or dorsal curvilinear incision. If a wound is present, the incision is designed to incorporate the wound and excise the wound margins. The skin flaps are elevated, and the extensor mechanism is defined. The joint capsule is exposed either through longitudinal splitting of the extensor tendon hood or through an incision in the sagittal band adjacent to the tendon. The MP joint capsule is often thin and inadvertently opened through the same incision. Once the joint is open, it is copiously irrigated with saline. Longitudinal traction opens the joint space and allows better access of the irrigant to the volar recesses of the joint. The joint should be carefully inspected for any articular surface damage or a retained foreign body, especially in the scenario of MP joint infection resulting from a clenched fist injury, described later under human bite injuries. The joint capsule and wounds are left open and covered with a moist gauze dressing.

Proximal Interphalangeal Joint

Arthrotomy of the PIP joint is performed through a midaxial incision. This incision avoids exposure of an injury to the central extensor tendon slip. The midaxial incision is placed from the distal margin of the interdigital web space and continued in the midaxial line to the level of the DIP joint. In the index finger, the incision is preferentially placed on the ulnar side of the finger. In the small finger, the incision is placed on the radial side. The central two digits can be accessed through either radial or ulnar incisions. If this approach is used for the thumb MP or interphalangeal (IP) joints, a radial incision is preferred. When the incision is correctly placed, the proper digital nerves lie protected in the volar skin flap (Figure 2.17, *A*). However, the dorsal sensory branch of the digital nerves can be jeopardized by this approach. The transverse retinacular ligament is incised, exposing the collateral ligament complex. The PIP joint is entered by excision of the accessory collateral ligament (see Figure 2.17, *B*), followed by capsulectomy. Alternatively, the joint may be exposed through subperiosteal elevation of the proximal origin of the collateral ligament. The joint is thoroughly débrided and irrigated. Inspection of the articular surfaces may be difficult through this incision, but a blunt probe or Freer elevator can be used to palpate the cartilage for areas of erosion or softening. The capsule and wounds are left open and covered with a moist gauze dressing.

Wittels and associates described a combined radial and ulnar midaxial incision for drainage. In conjunction with their functional rehabilitation, this provided very satisfactory results.[170] A dorsal arthrotomy is sometimes necessary due to the presence of a dorsal wound. In these cases, the central extensor slip and dorsal capsule are often injured or disrupted. This frequently leads to the development of a septic boutonnière deformity. When a septic PIP joint is encountered in this setting, the wound is extended proximally and distally. The arthrotomy and capsulectomy are performed adjacent to the central slip, if it is intact.

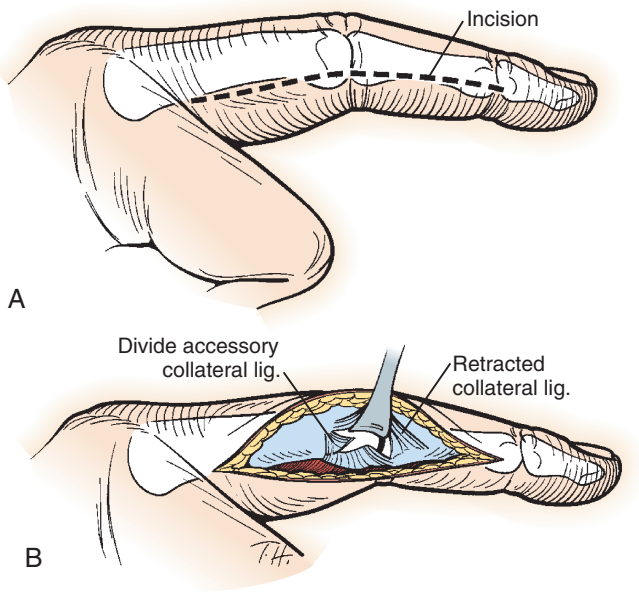

FIGURE 2.17 Lateral approach to the PIP joint. **A**, Skin incision. **B**, Arthrotomy is performed through the lateral ligamentous complex, dividing the accessory collateral ligament. (Copyright courtesy of Milan Stevanovic and Frances Sharpe.)

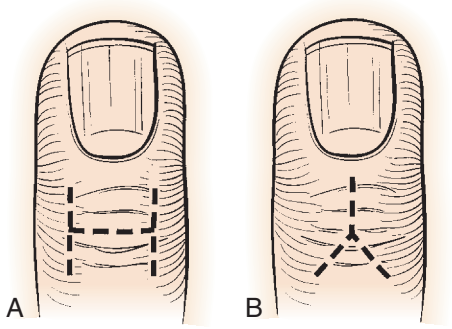

FIGURE 2.18 Dorsal approach to the DIP joint. **A**, "H" incision. **B**, Reverse "Y" or Mercedes incision. (Copyright courtesy of Milan Stevanovic and Frances Sharpe.)

Distal Interphalangeal Joint

The DIP joint is opened through a dorsal "H" incision or through a dorsal reverse "Y" or Mercedes incision (Figure 2.18). Skin flaps are elevated over the terminal extensor tendon. The terminal tendon is retracted to the side, and the capsule is opened. It is important to protect the tendon insertion because injury can result in a mallet finger deformity. Alternatively, the midaxial incision as described for PIP joint arthrotomy can be extended distally and used to expose the DIP joint. The collateral ligament is excised to gain access to the joint. This approach

may be more useful when there is an associated flexor tendon sheath infection. The joint should be adequately débrided and irrigated. The wounds are left open.

Postoperative Management and Expectations

Surgical incisions are left open, with a gauze wick to maintain patency of the capsulectomy and allow for continued wound drainage. Moist gauze dressing changes two to three times per day prevent encrustation of the wound, which results in premature wound closure. Early range of motion is critical to postoperative treatment. This provides mechanical lavage of the joint and reduces the accumulation of pus within the joint. We prefer that patients soak the affected hand in a dilute solution of povidone-iodine, as described previously. Active, active-assisted, and passive range of motion is done during the soaking period.

Empirical intravenous antibiotic therapy is started immediately after obtaining a culture from either an aspirate or surgical culture. Antibiotic selection is then tailored to treat the bacterial pathogen. There is some controversy regarding the duration of antibiotic therapy necessary for septic arthritis. Previous recommendations have included duration of intravenous therapy between 3 and 4 weeks. More recent recommendations use shorter courses of intravenous therapy, with a switch to oral antibiotics after 10 to 14 days. Oral antibiotics are continued to complete a 4- to 6-week course of therapy. We agree with others that intravenous antibiotic therapy should be continued through symptom resolution, followed by oral antibiotics for 4 to 6 weeks. The duration of antibiotic therapy should be based on surgical findings, pathogen virulence, patient compliance, and clinical response to treatment. If clinical improvement is not seen within the first 24 to 48 hours, repeat surgical irrigation and débridement should be considered, and reexamination for underlying bone involvement should be performed. Amputation may be necessary if an infection cannot be eradicated or if an affected finger has a significant negative impact on overall hand function.[18,148] Every effort should be made to preserve the thumb, even if arthrodesis, shortening, or reconstruction is required (Figure 2.19).

Symptom resolution and functional outcome after septic arthritis are correlated with the duration of symptoms before the initiation of treatment.[50,124] Some degree of joint stiffness is expected. In one study, only 13 of 33 infections of the PIP joint treated with early surgical decompression achieved full restoration of motion.[170] Early mobilization reduces the degree of postoperative stiffness but cannot reverse the changes that have occurred in the articular cartilage resulting from sepsis. Joint space narrowing is generally seen after completion of treatment. Joint arthrosis and ankylosis can occur in any setting but are more prevalent in cases in which the presentation or treatment has been delayed.

Complications associated with septic arthritis in the hand and wrist include stiffness of the affected and adjacent joints. Tendon adhesions may occur in association with the swelling and inflammation caused by the infection or as a result of the surgical incision and may require secondary surgery. Osteomyelitis of the adjacent bones may complicate or prolong the course of treatment (Case Study 2.3). Additional surgical débridement, bone resection, resection arthroplasty, or amputation may be necessary. Late complications include arthrosis and arthritis.

Pediatric patients may have associated injury to the epiphysis and growth plate. Septic arthritis of infancy may be difficult to identify and may be complicated by concurrent illnesses resulting in a delay of diagnosis. This can result in partial or complete growth arrest and stiffness.[149]

Salvage of postinfectious arthritis may include arthrodesis, resection arthroplasty, or amputation. Implant arthroplasty in previously infected joints of the hand is very controversial. At the present time, most authors do not favor this treatment.

Septic Boutonnière and Mallet Deformity

Unique complications of septic arthritis occur at the PIP and DIP joints. Septic boutonnière deformity is a complication of pyogenic arthritis of the PIP joint. It occurs in those cases in which a virulent organism has caused rapid tissue destruction or where there has been late presentation or treatment. The intraarticular collection of purulence has reached a volume that can no longer be retained within the joint. The path of least resistance for escape is dorsally. The joint is well supported palmarly by the volar plate, which blends with the accessory collateral ligaments, and by the collateral ligaments on the sides. All these structures are thick and unyielding; therefore, the pus escapes dorsally through the thin dorsal capsule. There, it can destroy the extensor mechanism over the dorsum of the joint. The central slip is attenuated or eroded, allowing the lateral bands to slip volarward. This results in a classic boutonnière deformity. Management of this problem is difficult. However, the first priority is eradication of the joint infection and preservation of full passive range of motion and active flexion. Late boutonnière reconstruction can be done when the infection is resolved and the joint is supple (see Chapter 5). Late PIP joint fusion may be appropriate in cases of severe damage to the articular cartilage or when passive range of motion cannot be recovered.

Mallet finger deformity can occur after DIP joint sepsis. The mechanism of injury is similar to that which occurs in the PIP joint. The terminal extensor tendon is attenuated or destroyed. Delayed DIP joint fusion is the most appropriate treatment after infection is eradicated.

Osteomyelitis

Osteomyelitis is an infection of the bone. Traditionally, it has been believed that once the bone has been infected, it remains infected. In the hand, it may be possible to eradicate infection, because amputation can remove the involved digit or portion of the digit. Moreover, having options for later microvascular reconstruction means that adequate bone débridement can be undertaken with less risk of permanent structural and functional loss. In the hand, osteomyelitis is rare, likely owing to the hand's abundant vascular supply. It has been reported to represent between 1% and 6% of all hand infections.[102,126] It is often related to adjacent soft tissue or joint infection. The most commonly involved bone is the distal phalanx.[8,126]

Osteomyelitis can occur after penetrating trauma, crush injuries, contiguous spread from adjacent soft tissue infections, and hematogenous seeding and in the postsurgical setting. Penetrating trauma is the most common cause of osteomyelitis.[8,90,126] Patients with immunocompromise, vascular impairment, and systemic illness are more susceptible to developing osteomyelitis.

CASE STUDY 2.3 Septic Joint Progression to Osteomyelitis

A 48-year-old woman underwent irrigation and débridement of a cat bite wound over the thumb interphalangeal joint. Three weeks later, she was still having pain and her wound had not healed. Repeat radiographs demonstrated joint space narrowing. The patient was returned to the operating room, where osteomyelitic changes were noted in the condyle of the proximal phalanx and complete loss of articular cartilage was seen.

A, Initial cat bite (eFigure 2.9).

B, Initial radiographs of the thumb (eFigure 2.10).

C, Wound appearance 3 weeks after initial débridement (eFigure 2.11).

D, Radiographs at 3 weeks showing complete loss of joint space (eFigure 2.12).

E, Intraoperative findings showing loss of articular surface and erosion of the condyle of the proximal phalanx (eFigure 2.13).

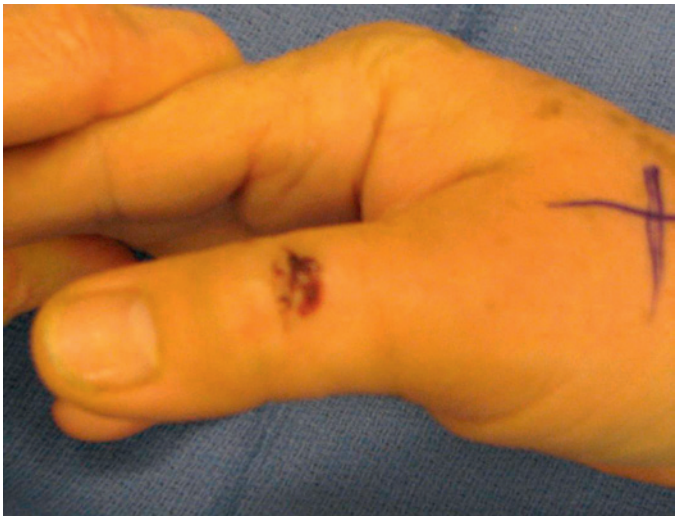

eFIGURE 2.9 Copyright Milan Stevanovic and Frances Sharpe.



eFIGURE 2.10 Copyright Milan Stevanovic and Frances Sharpe.



eFIGURE 2.11 Copyright Milan Stevanovic and Frances Sharpe.



eFIGURE 2.12 Copyright Milan Stevanovic and Frances Sharpe.

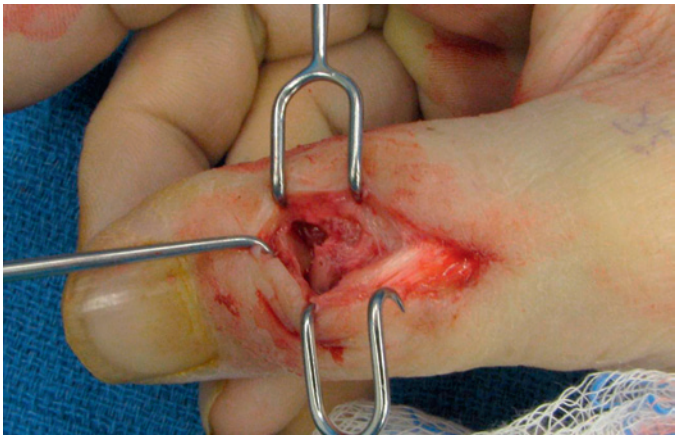

eFIGURE 2.13 Copyright Milan Stevanovic and Frances Sharpe.

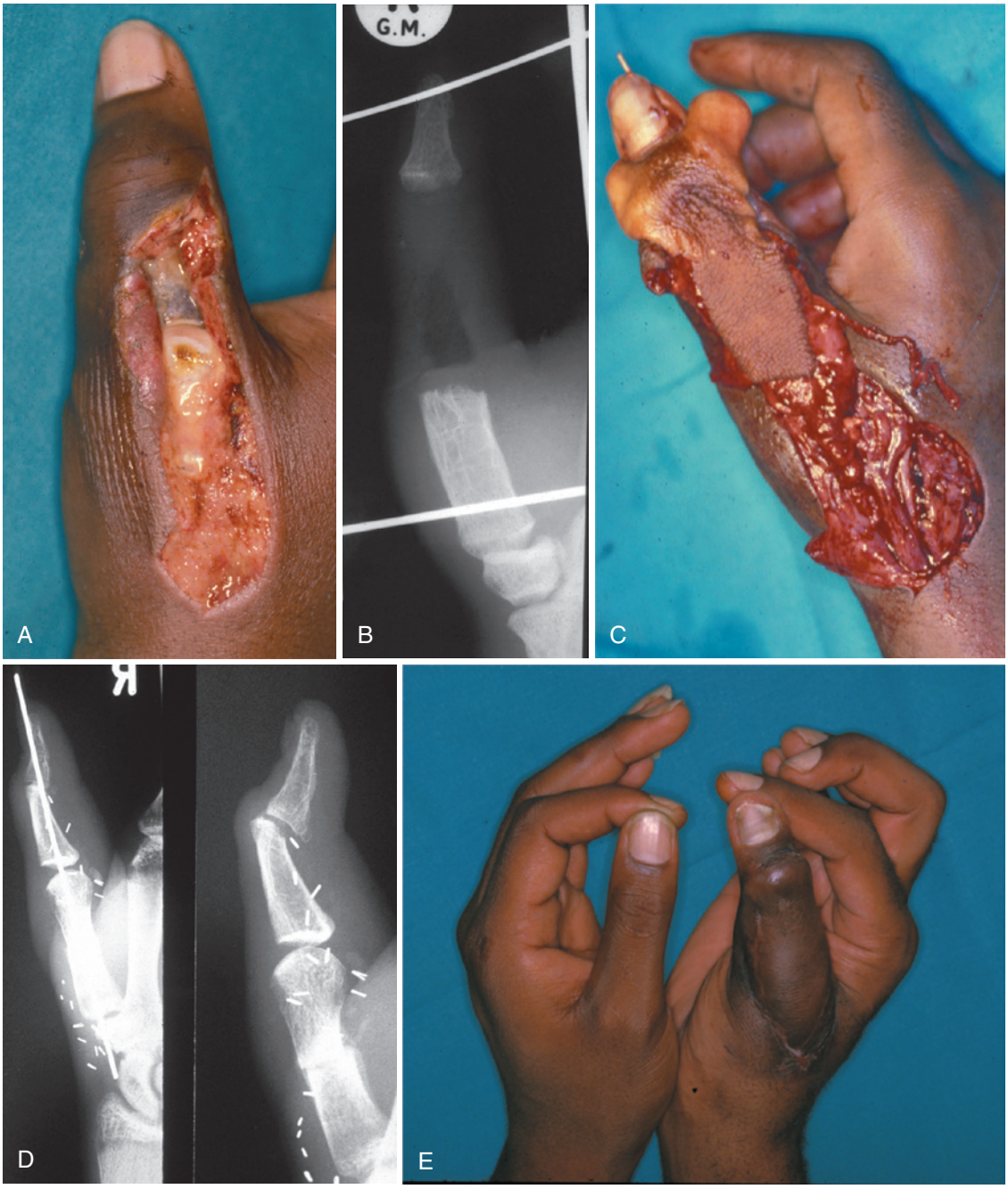

FIGURE 2.19 A 27-year-old man sustained a bite injury to his thumb during an assault. He developed a severe infection of the thumb MP joint, with subsequent spread to the metacarpal head and proximal phalanx. The volar soft tissue, flexor tendon, and neurovascular structures were intact. **A**, Open draining wound with exposed metacarpal head and necrotic proximal phalanx. **B**, Radiograph taken after resection of all necrotic bone. **C**, A free vascularized second toe transfer was used to reconstruct the bone defect, extensor pollicis longus tendon, and soft tissue defect. **D**, Radiographs immediately after surgery with Kirschner wire stabilization and at 1-year follow-up. **E**, Appearance and function of the reconstructed thumb at 1-year follow-up. There is no evidence of recurrent infection. (Copyright courtesy of Milan Stevanovic and Frances Sharpe.)

Hematogenous osteomyelitis of the hand and wrist is rare. Reilly and colleagues reported 13% of their cases were of hematogenous origin. Of those patients, half were immunocompromised.[126] Children are more susceptible to hematogenous osteomyelitis. The susceptibility to infection in the long bones in children is believed to result from the vascular arrangement around the growth plate. The long capillary loops and venous sinusoids in the metaphysis adjacent to the growth plate have a tortuous course, leading to turbulent and sluggish blood flow. These capillary loops are actually terminal branches possessing gaps that allow blood cells and bacteria to pass into the extravascular space. Once in this space, the pathogen may proliferate, causing infection. Contributing to this process is the relative acellularity of this space, decreased oxygen tension, and suboptimal phagocytic activity.[8,162] Until the age of 1 year, there is vascular continuity between the metaphysis and epiphysis via the epiphyseal plate arteries. In infants, this can lead to the spread of infection from the metaphysis into the epiphysis and

subsequently into the joint space. After the age of 1 year, the epiphyseal plate capillaries disappear. This reduces the likelihood of contiguous spread of hematogenous osteomyelitis into the joint space. In immunocompetent children, these infections occur predominantly in the radial and ulnar metaphysis. In sickle cell anemia, the inciting event for hematogenous osteomyelitis is more likely bone infarction, and the location associated with hematogenous osteomyelitis favors the metacarpals and phalanges.[153]

Acute infections after closed fractures are extremely rare,[63] but open fractures of the hand can result in deep infection. McLain and colleagues reported an incidence of deep infection in 11% of patients. Factors associated with infection included grossly contaminated wounds and extensive soft tissue and skeletal injury. *S. aureus* was the dominant organism in only 30% of patients. Polymicrobial infections and enteric organisms were significant pathogens in more than 60% of cultures.[102] Fixation of open or closed fractures with Kirschner wires can lead to a local osteomyelitis along the pin track. The incidence of significant pin track infection has been reported between 0.5% and 5%.[9,16]

The most common organisms responsible for osteomyelitis are *S. aureus* and other skin organisms. Coagulase-negative *Staphylococcus* is commonly associated with infections of implants, such as hardware used for internal fixation after a fracture. Many other organisms have been isolated and reported in the literature. Often, the mechanism of injury and the environment in which the injury occurred may suggest a different infecting pathogen. For example, a penetrating injury from an animal bite would lead to empirical treatment for *Pasteurella multocida*, until definitive culture results are available. *Salmonella* remains the most common organism in hematogenous osteomyelitis in children.[153]

The classification of osteomyelitis was refined by Cierny and Mader in 1985.[26] This classification (Table 2.4) applies to long bones and describes four anatomic sites of infection and three physiologic classes of host, defining 12 clinical types of osteomyelitis (anatomic site plus physiologic class).

TABLE 2.4 Classification of Osteomyelitis

Anatomic Site		
Type 1	Medullary osteomyelitis (endosteal infection)	Associated with hematogenous osteomyelitis or intramedullary implant
Type II	Superficial osteomyelitis (periosteal and cortical involvement)	Often, overlying soft tissue is deficient
Type III	Localized infection	Both medullary and superficial bone involvement; full-thickness sequestrum
Type IV	Diffuse infection	Instability present from injury, infection, or débridement
Physiologic Class (Host Characteristics)		
A host	Normal host with good immune system	
B host	Local or systemic compromise	**Local:** Scarring, radiation, sensory compromise, lymphedema, peripheral vascular disease **Systemic:** Diabetes mellitus, liver or renal disease, malnutrition, malignancy, smoking, autoimmune disease, bariatric surgery with vitamin and mineral deficiency
C host	Markedly compromised host	Treatment of the disease is worse than the disease itself

Clinical Presentation and Evaluation

Clinical signs of infection often include redness, swelling, warmth, and tenderness. Fluctuance and/or drainage may be present. Findings depend in part on the cause of the bone infection. When osteomyelitis has resulted from contiguous spread of infection, it is frequently difficult to differentiate bone infection from soft tissue infection, as might be seen in a felon. Systemic clinical signs such as fever, chills, and malaise are more common in hematogenous osteomyelitis. Waldvogel and colleagues reported that all patients with osteomyelitis of the hand had local signs of inflammation, but only one third of patients had fever and leukocytosis.[163] The presence of systemic symptoms should alert the examiner to the possibility of a remote source of infection. Failure of an apparent soft tissue infection to respond to appropriate treatment should suggest the diagnosis of an underlying osteomyelitis. Children can present a greater diagnostic challenge, leading to delays in diagnosis. Young children may not be able to describe their pain or its location and may present only with pseudoparalysis of a limb. Careful examination may indicate areas of increased warmth, localized bone tenderness, or joint irritability. Older children often present with a history of trauma that may be falsely assumed to be the source of the patient's pain.

Laboratory studies are frequently normal, but evaluation should include a WBC count, ESR, CRP, and blood culture. ESR and CRP are also useful in monitoring the response to treatment. CRP normalizes more rapidly than does ESR. Both levels increase in the first 48 hours after surgery.

Radiographic findings are present in less than 5% of cases of acute osteomyelitis. Soft tissue swelling is one of the first radiographic findings. Metaphyseal rarefaction, osteopenia, osteosclerosis, and periosteal reaction are not noted until 2 to 3 weeks after the onset of infection[38,52] (Figure 2.20). Subacute or chronic osteomyelitis in the hand may be caused by a fragment of dead bone (sequestrum). Persistent drainage in the hand is uncommon and should alert the physician to the possibility of residual necrotic bone. One should always look on the radiograph for a fragment (often tiny) of bone with increased density. (See the following for information on the role of MRI in evaluating for sequestrum.)

Advanced imaging studies such as technetium-, gallium-, and indium-labeled WBC scans can be useful in identifying acute osteomyelitis. These studies are useful in the early stages of infection, when standard radiographs are normal.[52] Ultrasound can be helpful in identifying subperiosteal abscess and directing aspiration. MRI can be a very useful study in the early presentation of osteomyelitis, owing to the contrast it generally provides between the abnormal and normal bone marrow. It can also help identify areas of abscess and necrotic bone (sequestrum). MRI characteristics of osteomyelitis include high signal intensity on T_2-weighted and inversion recovery sequences, as well as regional enhancement in the bone and surrounding soft

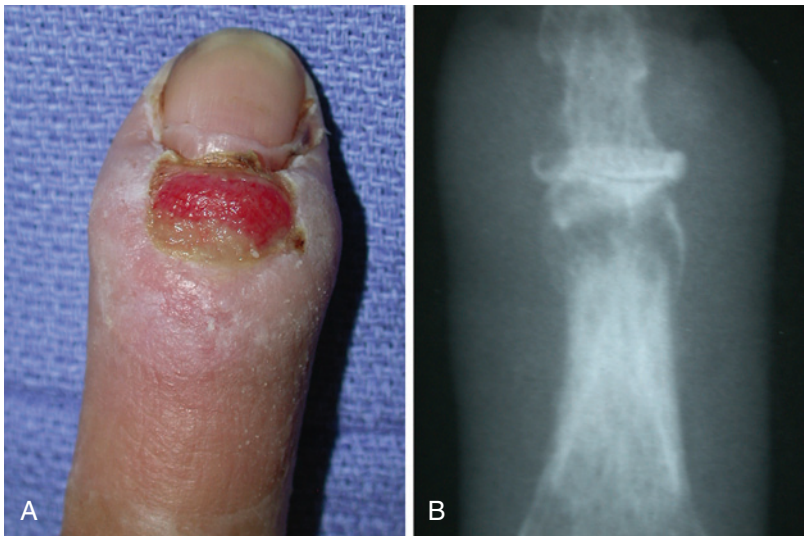

FIGURE 2.20 Osteomyelitis of the middle finger as a complication of pyarthrosis of the DIP joint. **A**, Granulation tissue overlying the DIP joint. **B**, Radiograph shows characteristic metaphyseal rarefaction and osteopenia. (Copyright courtesy of Milan Stevanovic and Frances Sharpe.)

tissues. The sensitivity of MRI in the diagnosis of osteomyelitis has been reported between 82% and 100%.[17]

Aspiration may be useful diagnostically. Subperiosteal pus may be present, typically in the pediatric patient. If pus is not obtained adjacent to bone, metaphyseal aspiration can identify the offending pathogen and direct antibiotic therapy. A negative aspirate should not stop further investigation or suspicion of bone infection.

Treatment

Early diagnosis and treatment lead to an improved functional outcome. Both surgical and medical treatments are necessary in the adult patient. Pediatric patients with osteomyelitis without subperiosteal abscess formation can be treated with antibiotic therapy alone. Adequate surgical débridement is critical to eradication of infection. Débridement of necrotic soft tissue and decompression and curettage of necrotic bone are mandatory. Repeat débridement and culture are necessary when clinical improvement is not seen in the first 72 hours. Wounds are left open and treated with frequent dressing changes or managed with negative-pressure dressings (e.g., VAC™), even though this may leave exposed bone, tendon, or implant. Repeat débridements and use of antibiotic-impregnated beads may help eradicate infection. It is better to plan bone and soft tissue reconstruction once the infection is well controlled than to inadequately débride the wound or attempt a primary closure. Treatment of osteomyelitis of the distal phalanx or of a single finger, particularly osteomyelitis associated with septic arthritis, may be best managed with amputation.[8,18,126]

Osteomyelitis can occur in the setting of an acute fracture. This may be a pin track infection or a deep infection around hardware. Pin track infections can often be managed with oral antibiotics and local wound and pin care. However, if the infection cannot be controlled, removal of the pins may be necessary. Management of deep infections around implanted hardware depends on the stage of fracture healing, host factors, and the stability of fixation. In a healthy patient with stable fixation, it is usually preferable to control the infection with débridement and intravenous or oral antibiotics until the fracture is sufficiently healed to allow hardware removal. If this cannot be achieved, hardware removal and removal of all necrotic bone and tissue are necessary. Provisional stabilization with an external fixator or with an antibiotic-impregnated methylmethacrylate spacer is used until the infection is controlled. Late reconstruction is planned based on the structural and functional deficits.

Prolonged intravenous antibiotic therapy is continued for 4 to 6 weeks and is based on the organism identified at surgical débridement and antibiotic sensitivity. Oral antibiotics that achieve therapeutic levels in bone can be used in conjunction with intravenous therapy. Resistant organisms are seen with increasing frequency. An infectious disease specialist is an invaluable resource in managing this problem.

Complications

Complications of acute osteomyelitis are common. Pain, stiffness, deformity, and loss of strength frequently persist despite successful treatment and eradication of infection. Chronic pain and cold intolerance have also been described, particularly in patients with vascular insufficiency.[8] Bone loss with shortening of the finger may occur. Fracture nonunion or malunion is not infrequent. Infection that requires amputation may result in a functional deficit. However, it is often less debilitating than preservation of a stiff and painful finger. Unresolved acute infection leads to chronic osteomyelitis and the complications associated with this process. Pediatric patients have risks of growth arrest and resultant deformity or shortening of the affected site.

SPECIFIC TYPES OF INFECTIONS AND VECTORS

Animal Bites

Domestic animal bites by dogs and cats are common. An estimated 4.5 million dog bites occur in the United States annually.

Of these, 885,000 (19%) require medical attention.[48] Dog bites represent up to 90% of all animal bites. In more than 70% of cases, the dog is known to the victim.[45,53] Children younger than age 12 years account for 50% of all dog bite injuries. Cat bites less frequently result in emergency room visits, but they are nonetheless estimated to account for 5% to 15% of emergency room animal bite injuries. The remaining 5% include various domestic and wild animal bites.[1,45,53,145]

The bacteria identified from bite wounds reflect the oral flora of the biting animal. The oral flora of the animal is also influenced by the microbiome of its ingested prey or other foods. A minority of pathogenic bacteria are from the victim's skin flora. Of the multiple organisms cultured from the dog mouth, the more common pathogens include *S. aureus, Streptococcus viridans, Bacteroides,* and *P. multocida.* Similar flora is found in the cat mouth.[1,45,48,145,151] Wound cultures often show a polymicrobial infection. Talan and associates cultured an average of five organisms per wound.[151] *P. multocida* is a frequent pathogen causing infection after dog and cat bites. It is more prevalent in cat bite infections. Cellulitis and serous or seropurulent drainage presenting in the first 12 to 24 hours after the bite injury is often caused by *P. multocida*.[1,5,48,145,167] Ulceroglandular tularemia has been reported after cat bites. The cat is thought to become a carrier of *Francisella tularensis* organisms in the mouth or claws through hunting and eating wild rodents or rabbits. The diagnosis of tularemia should be considered when patients with a history of cat bite present with pneumonia and have a soft tissue infection not responding to penicillin therapy. Cat-scratch fever caused by infection with *Bartonella henselae* should also be kept in mind after feline contact. The infection typically begins with a papular skin lesion, usually 4 to 6 days after the inoculation, causing a self-limiting infection characterized by regional lymphadenopathy and fever. Symptoms usually last between 4 and 6 weeks.[1,145] *Capnocytophaga canimorsus* is a rare pathogen in dog bites. It is of particular interest because of the high fatality rate of 23% to 28% associated with this infection. A history of splenectomy, alcoholism, and chronic pulmonary disease is a significant risk factor for *C. canimorsus* infections.[1,45,107]

Although dog bites occur far more commonly than cat bites, they much less commonly become infected. In one report, cat bites were responsible for 76% of infected animal bites. Dog bites accounted for the remaining 24%.[1,45] Cat bites are produced by needle-sharp teeth, which produce a puncture wound. This allows bacteria to be injected deeply into the soft tissues. This soft tissue bed is a fertile medium for anaerobic and facultative anaerobic infections. The dog has blunt teeth and powerful masseter muscles that cause tearing of soft tissues, leaving large open wounds that are less susceptible to infection.

In general, patients present to the emergency room with a dog bite either because of a large wound or concern about the immunization status of an unknown dog. Patients presenting with cat bites are usually not there because of the wound size. They are having pain disproportionate to the wound size and should be treated as having an evolving infection. At the very least, the cat puncture wounds should be opened up and irrigated in the emergency room under local anesthesia, and oral antibiotic therapy should be initiated. Wider involvement or systemic symptoms may require formal surgical débridement and inpatient antibiotic therapy. Factors associated with hospital admissions for cat bites include location of the bite over a joint or tendon, presence of erythema or lymphangitis, wound drainage, and immunocompromised state.[6] All animal bite wounds should be thoroughly irrigated. Necrotic tissue must be débrided. All animal bite wounds should be left open. However, large gaping wounds can be loosely closed after several débridements. Primary reconstruction of soft tissue defects can be considered if the tissue bed appears healthy with no evidence of necrotic tissue or sepsis after the first 48 to 72 hours.

The initial medical treatment includes an update of tetanus immunization if necessary. The rabies immunization status of the animal should be ascertained. Prompt and thorough wound irrigation with soap or povidone-iodine solution reduces the development of rabies by up to 90%.[39,45] Infected wounds should be cultured before irrigation and débridement. Aerobic and anaerobic cultures should be sent. Failure to culture for anaerobic organisms will result in a significant number of missed pathogens and subsequent inadequate antibiotic coverage. Antibiotic treatment depends on the severity of clinical signs and symptoms. Routine prophylactic treatment for an animal bite depends on the timing of presentation and the clinical signs and symptoms.

Other domestic and wild animal bites occur much less frequently. The organisms causing infection are similar to those involved in cat and dog bites.[1,104,132] However, certain infections have been associated with particular animals, such as tularemia seen in rabbit handlers, and *Streptobacillus moniliformis* is associated with rat bites as well as contact with rat feces. *S. moniliformis* is the causative agent of rat-bite fever, which can occur through animal contact, not necessarily requiring an animal bite. Rat-bite fever presents with an eruptive fever with blisters, polyarthritis, and spectacular desquamation of the hands.[59] The increase of exotic domestic pets introduces other species-associated infections that should be considered in determining the treatment of infections.[1,104,132]

Empirical antibiotic treatment should include coverage for gram-positive, gram-negative, and anaerobic organisms. The principles of surgical treatment remain the same. The wound should be opened to expose the depth of the bite. Necrotic or crushed tissue should be sharply débrided, and the wound should be thoroughly irrigated by gravity irrigation. The wounds should be left open and managed with dressing changes. Delayed primary wound closure may be considered when swelling and erythema have subsided and healthy wound base and tissue margins are present. Wound cultures taken 12 to 24 hours after débridement may be a useful diagnostic tool in determining whether a wound should be closed.[138]

Other animal bites and stings, caused by reptiles, arthropods, and marine animals, are associated with inflammation and tissue necrosis. The soft tissue injury results from the injection of toxin-containing venom or from chemical inflammation, such as that seen with sea urchin spines. The swelling associated with these bite injuries can result in compartment syndrome. Secondary infection can occur and requires medical and surgical treatment (see Chapter 52).

Marine Organisms

Multiple pathogens have been associated with an aquatic environment. Contact may occur through occupation or hobby, including home aquariums. *Mycobacterium marinum*, although

commonly associated with aquatic infections, generally presents as a chronic infection. Organisms producing acute infections include species of *Staphylococcus, Streptococcus, Pseudomonas, Aeromonas,* and *Enterobacter*. Infection often occurs through contamination of a break in the skin or through an inadvertent penetrating injury by the bones or the spines of the fish. Relatively minor wounds can be complicated by injection of venom, produced by glands on the dorsal and pectoral spines in some species, notably the catfish. When envenomation occurs, patients experience immediate severe throbbing pain, which may spread through the entire extremity. Muscle spasms and fasciculations may be noted. Over the first few hours, the site of injury may have local pallor that progresses to erythema and swelling. Occasionally, local skin necrosis and skin slough may occur. Swelling of the entire extremity may develop. Secondary infection can lead to death.[95,108]

The most serious aquatic infections associated with fresh or brackish water are the *Aeromonas* species infections. Despite aggressive surgical management, necrotizing infections associated with *Aeromonas* species have a mortality rate of up to 27%.[95,108,155] Another organism associated with brackish water is *Edwardsiella tarda*. Immunocompromised hosts, especially with underlying liver disease, are more susceptible to developing a necrotizing infection that can result in amputation or death.[31]

Serious infections associated with saltwater exposure or raw seafood ingestion are those caused by *Vibrio* species other than *Vibrio cholerae*, particularly *Vibrio vulnificus* and *Vibrio damsela.* Infections due to *Vibrio* species cause an estimated 8000 illnesses annually in the United States. The majority of these occur in the Gulf Coast states. Not all infections result in severe illness. Analysis of 4754 *Vibrio* infections identified 85% of infections with symptoms of cellulitis. Ten percent of infections resulted in amputation, and 17% resulted in death. *Vibrio* is a gram-negative, facultative anaerobic rod. *Vibrio* infections other than *V. cholerae* infections are classified into two types: primary septicemia type and localized wound type. Primary septicemia is usually acquired through the gastrointestinal tract by the ingestion of raw seafood. This typically occurs in patients with underlying liver disease or other immunocompromising disorders. The association with liver disease is thought to result from bypassing the hepatic reticuloendothelial system, as portal blood is shunted around the diseased liver. Also, high levels of serum iron associated with hepatic cirrhosis may increase the susceptibility to *V. vulnificus*, which requires iron for growth.[110] Most cases occur in males over the age of 50 years. The gender specificity has been found to be due to the protective effect of estrogen against the *V. vulnificus* endotoxin.[115] Primary septicemia can cause disseminated infection, manifesting in the extremities as a picture of necrotizing fasciitis. Patients often present with rapidly developing extremity pain, followed by skin lesions with bullae, purpura, and necrosis. The most common site of presentation is the lower extremities. It may also be seen in the upper extremities. The findings are similar to those of necrotizing fasciitis, but unlike necrotizing fasciitis, they are more commonly associated with an elevated serum creatine phosphokinase (CPK) level. In a report of eight patients with *Vibrio* septicemia, an elevated CPK level was found in seven. All patients with an elevated CPK level died. Even with aggressive medical and surgical management, these infections are associated with a very high mortality rate (67% to 88%).[110] The less common type of *Vibrio* infection, described as nonfoodborne *Vibrio* infection, is increasingly recognized; it is identified in up to 25% of reported *Vibrio* infections.[33] This is typically a localized wound infection and occurs equally in immunocompetent and immunocompromised patients. The infection is a localized infection, and most are associated with a puncture wound from a fish spine or bone. *Vibrio* species as causative agents should be considered with a history of a wound infection after exposure to seawater, more specifically warm seawater. There are no distinguishing features for local infections. Diagnosis is made after culture identification of *Vibrio* species. Generally, these are self-limiting infections. Local débridement of necrotic tissue is usually adequate treatment in conjunction with antibiotic therapy. However, development of necrotizing fasciitis has been reported. Aggressive surgical débridement, including amputation, and prolonged intravenous antibiotic therapy are necessary to treat these often fatal infections.[33,115]

Leeches

Iatrogenic animal bite infections have more recently been described with the reintroduction of medicinal leeches, *Hirudo medicinalis*, which are used for salvage of tissue with venous congestion. The pseudomonad *Aeromonas hydrophila* is the organism most commonly associated with the medicinal leech and has been cultured from presumed postoperative flap infections in 18% of cases in which leeches were used.[10] It has been frequently cultured from the intestinal flora of the leech. It can result in cellulitis, myonecrosis, abscess formation, endocarditis, and sepsis. Lineaweaver and associates found that leeches that fed on antibiotic-containing blood had lower or absent intestinal cultures for *A. hydrophila*. Based on those findings, they recommended the use of broad-spectrum prophylactic antibiotics, which include coverage for *Aeromonas* species, before leech application. The increased incidence of ciprofloxacin-resistant organisms should be considered in selecting appropriate antibiotic prophylaxis.[89,91,158,168]

Human Bites

Human saliva contains nearly one billion bacteria per milliliter. It can also contain transmissible viruses, including human immunodeficiency virus (HIV) and hepatitis B and C viruses.[65] The overall incidence of human bite injuries to the hand is unknown, but such injuries are probably third in incidence below dog and cat bites. These injuries are often misdiagnosed or unreported. Frequently, it is the patient who misreports the mechanism of injury to the hand. Patzakis and colleagues reported on admissions to the orthopedic infection ward over a 5-year period: Of 2288 admissions, 10% were due to human bites, specifically clenched fist injuries.[121]

Four mechanisms of human bite injuries to the hand have been described.[36,121] The least frequent is inadvertent self-inflicted injury occurring from nail biting or secondary to sucking an open bleeding wound on the finger or thumb. The second mechanism is a traumatic amputation secondary to a bite injury. This usually occurs through the distal phalanx or the DIP joint. Full-thickness bite wounds into various parts of the hand represent the third mechanism of injury and inoculation. Although this is one of the more frequent modes of injury,

it less commonly results in infection. When infection occurs, it is usually localized around the area of the penetration.[88,121] However, it has been reported to result in a rapidly spreading process continuing up to the forearm and arm, fitting a diagnosis of necrotizing fasciitis. Deaths associated with this condition were reported in the preantibiotic era.[121] The fourth mechanism of injury is a bite injury occurring when the hand strikes another person's mouth with a closed fist, more commonly known as a clenched fist injury or fight bite. The most commonly involved areas are adjacent to the third and fourth metacarpal heads of the dominant hand.[121] This type of bite injury is associated with the highest incidence of complications.

Clenched fist injuries occur as the patient strikes the mouth of another person. The area around the MP joint may be impaled by a tooth, penetrating the skin and deeper structures. At the time of contact, the skin and extensor tendons are stretched tightly over the metacarpal head and a large surface area of the metacarpal head is exposed. Deep structures, including tendons, the joint capsule, and bone, may be penetrated as well. The depth of penetration affects the location of spread of the infection. The dorsal subcutaneous space, the subtendinous space, the joint space, bone, or all of these structures may be involved. The site of the skin injury can be misleading in evaluating for injury to deeper structures. The position of the fingers at the time of impact affects the location of injury to the deeper structures. The more flexed position of the fingers at the time of penetration results in a more proximal injury to the tendon and joint capsule and a more distal injury to the metacarpal head (Figure 2.21).

Patients often present with an innocuous-appearing wound on the dorsum of the hand around the MP joint. This presentation should be considered a human bite until proven otherwise. The patient may be reluctant to provide an accurate history regarding the method of injury and often presents to the emergency department either because of a functional loss, as might be caused by fracture or extensor tendon dysfunction, or because of infection. Pain, localized swelling, and erythema may be present. Drainage from the wound is frequently seen; however, fever, lymphadenopathy, and lymphangitis are rare.

A complete blood cell count, ESR, and CRP are obtained. Often, these results are normal. Radiographs are used to evaluate for fracture, cortical violation, or the presence of a retained foreign body, such as a tooth. These radiographs also provide a baseline for comparison with subsequent films used to evaluate for osteomyelitis. In cases of late presentation, osteomyelitis may already be evident. The patient's tetanus status should be determined and updated as needed. Inquiry as to the viral status of the source should be made. Further guidance by an infectious disease specialist should be sought for those patients at risk.

The underlying injury to the hand is frequently more serious and extensive than the superficial wound and clinical presentation indicate. Patzakis and colleagues described the surgical findings in a group of 191 patients with clenched fist injuries. Seventy-five percent had injury to the deep tissue layers, including tendon, capsule, and bone. Sixty-seven percent had a violation of the joint capsule. Twenty-two percent had cartilage or bone involvement. These findings emphasize the importance of surgical exploration and débridement in the treatment of these injuries.[121] Wide exposure around the traumatic wound is required (Figure 2.22). The tendon, joint capsule, and bone are explored with the hand in a position of flexion. Small penetrations in the joint capsule may be inconspicuous or may have become sealed off. Therefore, even when the joint capsule appears intact, we prefer to open the capsule and inspect the articular surfaces. Cultures should be taken before irrigation. Necrotic tissue must be meticulously removed. Curettage of the affected portion of bone is performed. Softened areas of bone are débrided. Loose fragments of articular cartilage are removed. The wound is left open. No attempt should be made to repair injuries to the extensor tendon or extensor mechanism. Despite the release of the sagittal band to gain access to the joint, we have not seen cases of extensor tendon subluxation associated

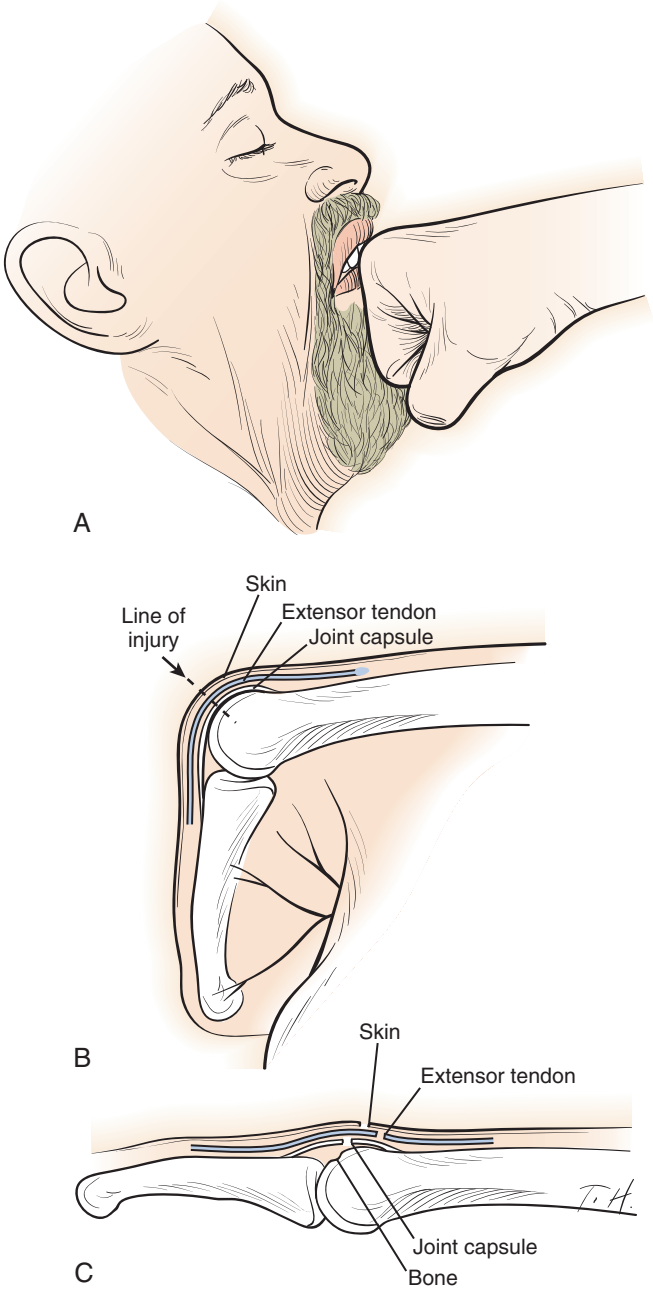

FIGURE 2.21 Clenched fist injury of the MP joint. **A**, Mechanism of injury. **B**, Linear wound track with MP joint flexed. **C**, Position of injured structures in full extension. (Copyright courtesy of Milan Stevanovic and Frances Sharpe.)

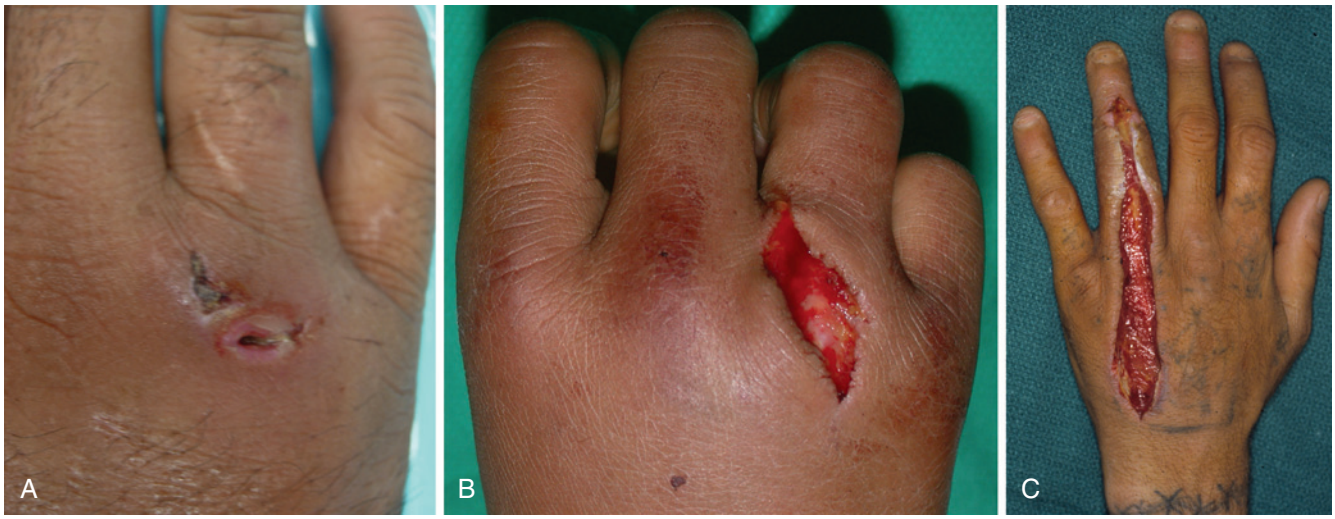

FIGURE 2.22 Clenched fist injury. **A**, Initial traumatic wound. **B**, Typical surgical extension of traumatic wound to allow adequate exposure and débridement of the injury. **C**, More extensively infected clenched fist injury requiring longer surgical exposure. (Copyright courtesy of Milan Stevanovic and Frances Sharpe.)

with these injuries or their treatment. A moist gauze wick is placed in the wound, and a soft bulky dressing is applied. Dressing changes are started at 12 to 24 hours and combined with soaking in dilute povidone-iodine solution and early range of motion as described in previous sections. If clinical symptoms are not improving, repeat radiographs are obtained to evaluate for underlying osteomyelitis, and the patient should be returned to the operating room for repeat irrigation and débridement.

Intravenous antibiotic therapy should cover a broad spectrum of pathogens. Although it is not the most commonly cultured organism, *E. corrodens* is the organism most often associated with human bite infections. It is a gram-negative rod, which is a facultative anaerobe. This is usually treated with high doses of penicillin. However, there are emerging strains of penicillin-resistant organisms. Empirical therapy should also cover *Staphylococcus* and *Streptococcus* species, as well as gram-negative organisms.[1,54,121] Inpatient intravenous therapy should be continued until the clinical appearance is improving. Appropriate consideration of the patient's social situation and ability to comply with outpatient treatment are necessary.

Complications of infected bite wounds include septic flexor tenosynovitis, septic arthritis, osteomyelitis, stiffness, and pain. Toxic shock syndrome and deaths have been reported.[36,165] Amputations or resection arthroplasty may be necessary to eradicate infection and improve function. Complications may be minimized by recognizing the human bite wound as a serious injury and treating even small seemingly innocuous wounds with early and thorough débridement and appropriate antibiotic therapy.[103,165] Educating those physicians involved in the primary care of wounds to suspect human bite infections in the appropriate clinical setting can reduce the delay to treatment and subsequent complications associated with these injuries.[96,97,165]

Prosthetic and Implant Infections

Deep infections around surgical hardware and implants are uncommon but can be difficult to treat. The eradication of infection requires removal of the implant and removal of all nonviable tissue. The presence of subclinical infection may be responsible for what has previously been labeled aseptic nonunion or aseptic loosening of the prosthesis. This presentation is due to the presence of bacterial biofilms.

Prosthetic joint replacements in the hand and wrist are more commonly performed in patients with rheumatoid arthritis. Although this patient population is generally immunocompromised, the infection rate around prosthetic implants is low, ranging from 0.5% to 4%.[37,47,73,105,112,159] When infection occurs, removal of the implant is necessary to control infection. Thorough débridement is done with removal of adjacent areas of necrotic bone. Treatment options include staged reimplantation, resection arthroplasty, or fusion, although arthrodesis after infected total elbow arthroplasty has a high failure rate.[117] In the setting of severe infection or a large dead space, temporary placement of an antibiotic-impregnated methylmethacrylate spacer can be used until the infection is controlled. The choice of intravenous antibiotic is based on the offending organism. The duration of therapy should be the same as that for treatment of osteomyelitis. Rarely is there an indication for prosthetic reimplantation. If reimplantation is considered, the patient should have a normal WBC count, ESR, and CRP. At the time of surgery, a gram-stained smear should be negative for bacteria; a frozen section with less than five polymorphonuclear cells per high-power field suggests adequate eradication of infection. Infection around Silastic® tendon rods can occur. Separate series have reported infection rates of 2% to 4%. Treatment included removal of the silicone rod, irrigation, débridement, and later reconstruction after all signs of infection were resolved and the skin and soft tissues were supple.[67,166]

Bacterial biofilms have been recognized since the 1970s. These bacterial colonies adhere to inert surfaces such as metal, plastic, nonviable bone, or living tissue. They secrete an exopolysaccharide matrix that isolates the bacterial colonies from the surrounding tissues and protects the bacteria from the host defense mechanism. Bacterial growth within the biofilm is characterized by slow growth, difficulty in culturing an organism, and triggering of an inflammatory response. They can be caused

by a single or mixed species of bacteria or by fungi. The microbiologic literature refers to the sessile state of bacteria within a biofilm, which is slow growing and systemically inert. Release of bacteria from the biofilm can result in a "planktonic state," in which the bacteria can rapidly propagate and cause a systemic host response.[30] Sessile bacterial cells release antigens and stimulate the production of antibodies; however, the antibodies are not effective in killing bacteria within the biofilm. The immunologic host response contributes to the localized tissue destruction around the biofilm and can suppress the planktonic state but cannot eradicate the sessile biofilm-protected bacteria. Antibiotics are effective against the planktonic state, but bacterial or fungal cells within a biofilm are resistant to antibiotic concentrations 1000 times higher than that required to kill planktonic bacteria. Detection of bacteria within a biofilm is difficult, and bacteria are not typically identified by growth in agar media. Disturbing findings were reported in 10 cases of aseptic acetabular cup loosening. Despite negative cultures, bacteria were identified within the biofilms under electron microscopy in 8 of 10 patients.[30] This suggests that aseptic loosening may be a misnomer and should be treated as an infection, with complete removal of the implant and staged reconstruction. Newer detection methods include ELISA (enzyme-linked immunosorbent assay), PCR (polymerase chain reaction), and FISH (fluorescent in situ hybridization). More recently, diagnostic tests for biomarkers specific to infection (alpha defensin) show great promise in identifying prosthetic joint infection, with one study showing 100% specificity and sensitivity in its diagnosis.[34]

Treatment of the infection involves complete removal of the biofilm (thus, implant removal and removal of all nonviable tissue). Staged procedures with use of antibiotic-impregnated spacers in conjunction with systemic antibiotic therapy can be effective therapy against chronic infection. Newer technology with improved detection and more sophisticated antibiotic delivery systems will be part of the future treatment of these infections.[30,34]

Shooter's Abscesses: Infections Caused by Parenteral Drug Abuse

One of the most commonly encountered complications of intravenous drug abuse is infections of the skin and soft tissues. The hand and forearm provide easily accessible sites of venous access. Overall, abscesses of the upper extremity account for 40% to 80% of admissions for soft tissue infections.[57,66,137] Multiple sites of abscesses may be present. Many of these patients have underlying medical illnesses, poor medical care, and poor medical compliance. Bergstein and colleagues reported an incidence of hepatitis B seropositivity of 29%. The incidence of hepatitis C may be even higher. The incidence of HIV in patients consenting to serologic testing ranged between 9% and 50%.[13,57,109] Recent studies have correlated the incidence of abscess formation with subcutaneous or intramuscular injection rather than intravenous injection. This may occur inadvertently when the vein is missed and the injected substance extravasates into the extravascular space. It may also occur volitionally. The repeated abuse of intravenous drugs leaves hardened sclerotic veins, which are no longer accessible for injection. Subcutaneous injections (skin popping) or intramuscular injections are used when venous access is difficult. The use of cocaine or of a cocaine-heroin mixture (speedball) predisposes patients to abscess formation by inducing soft tissue ischemia.[109]

The organisms cultured from these abscesses are usually a mixed flora. Staphylococcal and streptococcal species predominate, with an increasing incidence of oxacillin-resistant *S. aureus* (ORSA) noted. In one study, ORSA made up 82% of *S. aureus* infections in 2005, compared with 5% in 1999.[3] Oral and enteric flora are also frequently present.[3,13,57,137,150] Summanen and coworkers isolated oral flora from 67% of abscesses caused by parenteral drug use. This was compared with 25% in abscesses not associated with drug use. This is likely due to the use of sputum to clean either the injection site or the needle.[150] Schnall and colleagues found that gram-negative isolates were more common in patients older than 40 years of age.[137]

The majority of these patients present to the emergency department with complaints of pain and swelling. Most patients do not have an elevated temperature and often do not have an elevated WBC count.[143] Examination may demonstrate fluctuance. Deep abscesses may be more difficult to identify. If abscess is suspected, aspiration with an 18-gauge needle in the area of suspicion may identify the presence of pus. Cultures should be sent from specimens obtained in the emergency department. Radiographs may demonstrate gas in the soft tissues or an underlying osteomyelitis.

Provisional drainage of any area of fluctuance should be performed in the emergency department. Once cultures are obtained, broad-spectrum antibiotics are given. Tetanus status is determined and updated as necessary. Hepatitis and HIV status should be investigated. The patient should be admitted to the hospital. Expedient treatment with formal irrigation and débridement in the operating room can minimize the complications associated with these infections. A longitudinal extensile surgical incision is necessary to adequately drain the abscess cavity. Removal of all necrotic tissue and copious irrigation are performed. The wounds are left open and packed with gauze soaked with dilute povidone-iodine. Wounds may heal by secondary intention. Delayed primary wound closure can also be done and has been shown to reduce the hospital stay.[138] Large wounds with associated skin loss or soft tissue fibrosis that precludes delayed primary wound closure can be skin-grafted when a healthy granulation tissue bed is present.

Large open wounds can also be managed with a vacuum-assisted wound closure (VAC) device. This technique can reduce the size of the wound, so that a smaller skin graft is required, or shorten the time needed for secondary wound healing.

Complications associated with soft tissue abscesses include spread of infection to adjacent potential spaces, such as the flexor tendon sheath or adjacent joint space. Osteomyelitis can occur with long-standing infection. Bacteria and septicemia can spread infection to distant sites. Cardiac examination for murmur suggesting endocarditis should be performed on all patients. The most serious complication of soft tissue abscess is that of necrotizing fasciitis. Although this occurs rarely, it is a life-threatening infection that requires emergent surgical and medical treatment.

Many of these patients require prolonged hospitalization, more often due to social concerns and medical compliance than because of medical necessity. Premature discharge to a situation in which the patient will not have a clean environment or be able to comply with antibiotic therapy and wound management

may lead to more complications, greater morbidity, and higher social and financial costs. Releasing a patient with a history of intravenous drug abuse with an indwelling catheter for home antibiotic therapy is ill advised.

The risk of pathogen exposure to the surgeon and health care team is considerable. Although universal precautions should be exercised with every patient, greater vigilance and attention are necessary to protect the health care providers in managing this patient population.

Septic Thrombophlebitis

Suppurative septic thrombophlebitis of the upper extremity is a rare but potentially life-threatening infection of the superficial and/or deep venous system. Bacteria and purulent material are in direct communication with the vascular system, and septic emboli to distant sites (most commonly the lungs) are a common complication. Causes of peripheral septic phlebitis include venipuncture, central or peripheral venous catheters, intravenous drug abuse, and localized soft tissue lacerations or infections that are in continuity with the venous system. Treatment of these infections is typically performed by vascular surgeons. However, since the initial presentation may be similar to cellulitis or localized abscess, the hand surgeon may be the first consultant called to treat the patient. Surgical findings are characterized by purulence within the venous system. Treatment includes excision of the affected veins. Vascular surgery consultation is recommended, particularly with more proximally tracking infections. Supportive care by an intensive care team and infectious disease consultation and management help to reduce the morbidity and mortality rates of these infections.

Herpetic Whitlow (Herpes Simplex Virus Infection of the Fingers)

Herpetic viral infections of the fingers are commonly misdiagnosed as bacterial infections, such as paronychia or felon. The inappropriate treatment of these conditions as bacterial processes can result in severe complications. It is therefore important to be aware of the diagnosis and clinical presentation to avoid adverse sequelae.

The term *herpetic whitlow* is derived from the viral origin of the process and the middle English term *whitlow*. *Herpes* has a Greek origin, meaning "to creep," as this fits the general pattern of disease progression. Herpes simplex virus (HSV) types 1 and 2 are part of the alpha *Herpesviridae*. Humans are the only natural host. The term *whitlow* is believed to be a misnomer, because whitlow was generally used to describe a suppurative infection of the finger pulp, such as a felon. Other terms used to describe herpetic infection of the fingers include herpetic febrilis of the finger, herpetic paronychia, and aseptic felon. The first reported case of herpetic infection of the finger in the English literature was reported by Adamson in 1909. Since Stern's publication in 1959, this infection has been commonly named herpetic whitlow.[69]

Herpetic infections are seen in both adults and children (Figure 2.23). In a child with herpetic gingivostomatitis, the thumb or finger can become inoculated by sucking. In adults, this infection has been reported as an occupational hazard, affecting those in the medical or dental profession who come into direct contact with saliva from patients who are actively shedding HSV. This is most often infection from HSV type 1.



FIGURE 2.23 Herpetic whitlow in an 18-month-old child. **A**, Isolated long finger involvement. **B**, Oral lesions. (Copyright courtesy of Milan Stevanovic and Frances Sharpe.)

HSV type 1 antibodies have been detected in the saliva of up to 24% of school-aged children.[146] More recent studies emphasize the importance of autoinoculation or inoculation from a sexual partner infected with HSV type 2. HSV type 1 more commonly affects young children and the medical and dental professional in contact with saliva. HSV type 2 infections have been more common in adults.[7,49] Age and profession cannot be exclusively used to differentiate between HSV type 1 and HSV type 2 infections, and there is no difference in their clinical presentations.

Clinical Presentation and Diagnosis

The early symptoms of HSV infection of the hand mimic the presentation of herpetic lesions occurring in other locations. The incubation period of the virus ranges between 2 and 14 days, and a thorough history may provide clues to the diagnosis, possible vector, and viral type. Infection usually involves a single finger. Involvement of more than one finger may suggest another infection, such as coxsackievirus infection.

The index finger and thumb are the most frequently infected digits. However, the infection may occur on any finger or any

location on the hand or integument. In the beginning of the infection, the patient has intense throbbing and pain in the affected digit. Carter reported that one of the early symptoms may be tingling in the affected digit. In the early disease process, the patient's pain is disproportionately severe to the clinical findings.[23,171] Erythema and mild swelling are present; this is followed by the development of 1- to 2-mm clear vesicles. Over several days, these vesicles creep together and coalesce. The vesicle roof usually remains intact. As the vesicles coalesce, a large confluent bulla may form. The fluid within the vesicles is initially clear. It may rapidly become turbid and appear purulent, mimicking a bacterial hand infection. Lymphangitis and adenopathy may be present but are more commonly seen with bacterial suprainfection.

Over the next 7 to 10 days, these signs and symptoms subside. Even though the symptoms are resolving, there is continued viral shedding over the next 12 to 14 days. It is during this time that the patient is most infective. The clinical course is generally self-limited and resolves over a 3-week period.

Early diagnosis depends on clinical suspicion. Distinguishing a viral infection from a bacterial infection is critical to the treatment. Suspicion of a viral infection depends on the patient history, quality and intensity of the pain, softness of the digital pulp, presence of vesicles, and a blood profile that does not fit a pattern of sepsis. Viral cultures definitively establish the diagnosis. However, the culture may take several days to become positive. The virus is sensitive to transport and cultures may be negative, even when transported in viral medium. Lesions that have crusted often do not produce positive cultures.

The Tzanck smear is performed on fresh vesicles. This microscopic examination will show multinucleated keratinocytes with steel-blue homogeneous karyoplasm. The base of the lesion is scraped vigorously with the edge of a scalpel blade. The material is touched to a glass slide and allowed to air dry. The Tzanck smear in all stages of the disease is less sensitive than viral culture. Immunofluorescent serum antibody titers, using type-specific monoclonal anti-HSV antibodies, can confirm the diagnosis and type. HSV blood testing for antibodies to the HSV type-specific G1 and G2 glycoproteins is now available and may provide a rapid diagnosis of HSV infection.[161]

Treatment of herpetic whitlow is essentially nonsurgical. The course of the disease is self-limiting. The main goal of treatment is to prevent autoinoculation or transmission of the infection. The digit should be kept covered with a dry dressing, and all contact with the lesion should be avoided. Unroofing of the vesicles may improve patient comfort. Intravenous, oral, or topical antiviral medication may be useful in shortening the natural course of the infection.[144] Partial nail excision may be indicated for a subungual herpetic lesion causing pressure below the nail plate. Surgical débridement of bacterial suprainfection must be done cautiously. Misdiagnosis of the viral infection as a paronychia or felon, which leads to surgical intervention, may result in disastrous complications. Viral encephalitis and death have been reported as a result of misdiagnosis and treatment of a herpetic infection as a felon.[7,23,77]

Once the disease resolves, the virus becomes latent in the nervous system. The responsible cell in the ganglia or the mechanism of latency is not completely understood. Twenty percent of patients will experience recurrence. The recurrent infection is usually less severe, except in immunocompromised patients, in whom the recurrence rate and infection severity are much higher.[144,146,161]

Upper Extremity Infections Associated With HIV Infection

Upper extremity infections in patients with HIV are more common in those patients with a concomitant history of intravenous drug abuse. The clinical presentation of infection is similar to patients without HIV; however, the clinical course of the infection is often more severe. Gonzalez and coworkers reported on 28 patients with HIV infection. Eight of those patients had acquired immunodeficiency syndrome (AIDS), as defined by the Centers for Disease Control and Prevention guidelines. The most common presentation was that of soft tissue abscess. Patients with AIDS were more likely to present with a spontaneous infection,[58,98] and spontaneous septic arthritis should raise suspicion of underlying immunocompromise.[51,98] The organisms most frequently isolated were streptococcal and staphylococcal species. McAuliffe and Seltzer found *S. aureus* to be the most common pathogen in 74 patients infected with HIV.[98] Pyogenic infections responded well to aggressive débridement and antibiotic therapy. Herpetic viral infections were more commonly seen than in the general population.[51,58,146] The viral infections did not run a self-limited course and often became suprainfected. Oral or intravenous antiviral therapy was necessary to resolve the infection. The incidence of necrotizing fasciitis was also disproportionately high in the patient group reported by Gonzalez and coworkers. Opportunistic infections of the hand have been reported, although less frequently than might be expected.[14]

Pyogenic infections respond well to early and aggressive surgical débridement and culture-directed antibiotic therapy. Viral infections have a prolonged course and do not resolve spontaneously. Intravenous antiviral therapy may be necessary to eradicate the infection. Amputation may be indicated for recalcitrant infection.

Diabetic Hand Infections

Approximately 7% of the adult population of the United States is diagnosed with diabetes mellitus.[22] It has been estimated that the prevalence of undiagnosed diabetes in the adult population older than the age of 50 years is 10%. Among the many complications associated with diabetes is a susceptibility to infection. Diabetics are known to have a higher rate of postsurgical infection, even after minor soft tissue procedures.[22,56] Infection may be the initial presenting complaint in patients previously undiagnosed with diabetes. Cohen and colleagues reported a 17% incidence of undiagnosed diabetes in patients treated for infections of the extremities.[28]

Several different mechanisms have been postulated for the increased susceptibility to infection in diabetics. Many studies have shown immune deficits, particularly lymphocyte dysfunction associated with elevated blood glucose levels. Deficits include decreased chemotaxis, decreased phagocytosis, decreased intracellular bactericidal activity, and decreased opsonic activity.[22,42,130] Overall, the leukocyte is less capable of performing its role of preventing infection and fighting sepsis. It has been further suggested that the local hyperglycemic environment may enhance bacterial proliferation, especially in staphylococcal infections.[42,130] Anatomic factors, notably

peripheral neuropathies and diabetic angiopathy, contribute to poor wound healing and poor oxygen, leukocyte, and antibiotic delivery to the affected area. Wound healing activities, including capillary ingrowth, fibroblast proliferation, and collagen synthesis, have also been shown to be decreased in diabetics.[42]

Infections in diabetics have been separated into superficial and deep infections. The superficial infections include cellulitis and superficial localized abscess. These infections behave more like infections in nondiabetics and respond to broad-spectrum antibiotic therapy and local wound débridement.[123] Deep infections include involvement of bone, the tendon sheath, or deep palmar spaces. Francel and colleagues reported that 73% of patients in their series had deep infections.[42] Gonzalez and coworkers reported that more than 50% of patients with deep infections required more than one surgical procedure.[56] The amputation rate in diabetics with deep infection ranges from 8% to 63%.[56,79,123] Necrotizing fasciitis occurs with greater frequency in diabetics and has been associated with a higher mortality rate.[43] Diabetics with associated renal failure represent a subgroup of patients with even higher morbidity and mortality rates. Francel and colleagues reported a 100% amputation rate in this patient group with upper extremity infections.[42,146] The most common pathogen remains *S. aureus.* However, multiple organisms are present in most infections.[56,60,79,146] Gram-negative organisms were documented in up to 73% of positive cultures.[79]

Treatment includes broad-spectrum antibiotic therapy, careful monitoring and control of blood glucose levels, and aggressive surgical management. Surgical incisions should extend past the area of erythema and should include the length of the areas of indurated skin and soft tissue. Wounds should be left open to heal by secondary intention or can be treated with negative-pressure dressings. Delayed primary wound closure can be performed when the infection is controlled. Secondary procedures for repeat débridement are common. When amputation is necessary, an open amputation is performed if close to the site of infection. The bone is shortened proximal to the level of skin resection. The wound will heal readily by secondary intention as long as the infection is controlled or delayed wound closure can be performed. Primary amputation may be the most appropriate procedure to control the infection, reduce disability, and improve functional outcome.

Necrotizing Soft Tissue Infections and Gas Gangrene

Necrotizing fasciitis is a rapidly advancing necrotizing infection affecting the skin, subcutaneous tissue, and fascia. It characteristically spares the underlying muscle. It is associated with high morbidity and mortality rates and severe systemic sepsis. Whereas necrotizing soft tissue infections (NSTIs) were recognized in earlier literature, Meleney is credited with the first detailed description of the disease process and first recognized the importance of early and extensive surgical débridement. Wilson first applied the term *necrotizing fasciitis*, recognizing that the constant feature of the infection was fascial necrosis.[169]

Two types of necrotizing infections have been described based on the bacteriology of the infection. Type 1 infections are mixed aerobic and anaerobic infections. Facultative anaerobic bacteria and non–group A streptococci are present. This is the most common type and is found in approximately 80% of cases. Type 2 infections are caused by group A *Streptococcus* species alone or in combination with staphylococcal species.[55] Fungal infections are uncommon causes of necrotizing fasciitis. However, the incidence is increasing, principally in immunocompromised patients but also in previously healthy individuals.

The inciting event for the onset of infection may not be known. There may be a history of minor trauma or puncture wound. When seen in intravenous drug abusers, it is postulated that the contamination occurs through use of an unclean needle, use of saliva to clean the needle or injection site, or contamination of the street drug being injected. In the initial presentation, necrotizing fasciitis may resemble cellulitis. There is a swollen erythematous area of exquisite tenderness with an area of extensive cellulitis. Nonpitting edema is present and extends beyond the margins of the erythema, distinguishing this from cellulitis. Beyond the area of cellulitis, the skin may have an orange-peel appearance (peau d'orange skin). As the infection progresses, the skin changes from red and purple to a dusky blue-gray. The skin may be come hypoesthetic or anesthetic. Later, patchy areas of frank necrosis of the skin develop. The skin may slough, owing to thrombosis of the nutrient vessels that traverse the fascial layer and supply the overlying skin and subcutaneous tissue. Bullae form and are either clear or hemorrhagic (Figure 2.24). Soft tissue crepitance may be present but is not common. Radiographs frequently demonstrate the presence of gas in the tissues.

Diagnosis begins with maintaining a high clinical suspicion in all patients, particularly patients with risk factors, including diabetes, immunocompromise, and intravenous drug abuse. (See also the previous discussion regarding *Vibrio* infections and underlying liver disease.) In the early stages, the infection appears more like cellulitis. Marking the area of both cellulitis and edema followed by reexamination within an hour for signs of progression helps distinguish a necrotizing infection from cellulitis. Tenderness beyond the area of erythema is highly suggestive of necrotizing fasciitis. If an open wound is present, the wound can be explored. A probe or finger that dissects easily along the fascia below intact skin is a hallmark finding distinguishing this process from cellulitis. When still in doubt regarding the diagnosis, an incisional biopsy can be performed at bedside. This is done proximal to the area of erythema and over the area of edema. The incision is carried down to the fascia. At least a 1-cm–square section of fascia is obtained for frozen section. Thrombosis obliterans of the perforating vessels and



FIGURE 2.24 Characteristic appearance of necrotizing fasciitis. (Copyright courtesy of Milan Stevanovic and Frances Sharpe.)

massive infiltration of polymorphonuclear cells confirm the diagnosis. This step may delay appropriate surgical treatment. Similarly, MRI has been shown to have distinct characteristics in necrotizing fasciitis, but obtaining this study can result in further delays to treatment.[93]

Patients with necrotizing fasciitis often feel much worse than what would be expected from the initial presentation. They may experience a sense of impending doom. Fever and elevated WBC counts are not universally present. As the infection progresses, systemic signs of sepsis develop. Dehydration, electrolyte disturbance, and hypotension occur owing to the fluid shifts caused by the edema. Disseminated intravascular coagulopathy with rapidly progressing septic shock has been associated with necrotizing fasciitis.

The infection can spread rapidly over hours, involving the entire upper extremity and continuing onto the chest wall. Surgical treatment and broad-spectrum intravenous antibiotic therapy covering gram-positive and gram-negative organisms as well as anaerobic organisms are mandatory. Careful monitoring and correction of fluid and electrolyte status should be done in the intensive care setting. Intubation may be necessary as systemic signs of sepsis progress. Although the patient's medical condition should be optimized, surgical débridement should not be delayed, because this is the most important means of controlling the infection.

The surgical débridement should be extensive. Pus is not usually a component of these infections. A thin, watery exudate may be encountered, sometimes described as "dirty dishwater." The infection dissects along the fascial planes, making easy finger dissection in this plane. The fascia appears gray or grayish green and may be liquefied. Areas of normal-appearing fascia may be seen. However, under microscopic examination, these areas may be involved. Intraoperative frozen sections of the fascia can help guide the extent of débridement. Myonecrosis may be observed in cases of longer duration. In the hand, secondary thrombosis of the digital vessels results in necrotic fingers. Wide débridement of skin, subcutaneous tissue, fascia, and necrotic muscle, if present, is required. Amputation may be necessary, especially if muscle is involved or if the patient's condition is not improving despite aggressive débridement. The wounds should be left open and covered with moist gauze. Burn dressings should be used, and the patient is returned to the intensive care unit. Patient resuscitation should be the same as that used to resuscitate patients with extensive third-degree burns. These patients often require repeat débridement. However, it is the initial débridement that will most influence the treatment outcome. It is mandatory to remove all necrotic tissue at the first surgery. The wound should be reexamined no more than 24 hours after the first surgery. If the patient's clinical course is deteriorating, an earlier reexamination and repeat débridement versus amputation is indicated. The use of hyperbaric oxygen as adjunctive treatment has been reported. In centers where this facility is readily available, there may be some benefit (Case Study 2.4).

When the infection is controlled and the patient is clinically stable, wound coverage with a split-thickness skin graft is necessary. Prolonged occupational therapy is often required for functional recovery. Despite aggressive management, these infections are associated with a high morbidity and mortality rate. Mortality rates range from 9% up to 75% when chest wall involvement is present. Factors associated with an increased mortality rate include age older than 50 years; the presence of diabetes mellitus, truncal involvement, or bacteremia on presentation; and delay to diagnosis and treatment.[43,55,76,100,101,135] Early deaths, defined as those within the first 10 days after initial débridement, were found consequent to sepsis syndrome. Late deaths were attributable to multiple organ system failure.[101]

Fungal necrotizing fasciitis is a rare cause of necrotizing infections but appears to be more common than previously recognized. Zygomycotic (mucormycotic) infections can be seen alone or in conjunction with bacterial species.[62,71] Diagnosis of mucormycosis is most rapidly made by histopathologic diagnosis, showing the characteristic abundance of broad, nonseptated hyphae invading tissue and, particularly, showing vascular invasion.[71] This highlights the importance of routinely taking tissue biopsies of necrotizing infections, as well as including cultures for fungal organisms. In our experience, we have seen three cases of fungal necrotizing fasciitis. These have all been in transplant patients who were receiving high-dose immunosuppressive therapy. Clinically, there is less erythema and swelling, but the tissue is firm and indurated with spotty areas of black necrotic lesions (Figure 2.25).

Gas gangrene is an uncommon infection of the upper extremity. These infections are rare but can be rapidly fatal. There are more than 60 species of *Clostridium*, but six types are known to cause gas gangrene. *Clostridium perfringens* is the most common, particularly in traumatic causes of infection. *Clostridium septicum* infection has been associated with spontaneous gas gangrene. The infection may "metastasize" to a site remote from the suspected portal of infection, such as the upper



FIGURE 2.25 Fungal necrotizing fasciitis. Clinically, there is less swelling and erythema, but the tissue feels woody and indurated. There are superficial areas of black necrotic tissue. **A**, Black necrotic eschar. **B**, Indurated forearm without significant erythema or swelling. (Copyright courtesy of Milan Stevanovic and Frances Sharpe.)

CASE STUDY 2.4 Necrotizing Fasciitis

A 19-year-old intravenous drug abuser presented with sepsis.

A, Crepitance was noted about the posterior shoulder. There was involvement of the dorsal and volar chest wall (eFigure 2.14).

B, Wide débridement was performed of the involved skin and subcutaneous tissue for necrotizing soft tissue infection (eFigure 2.15).

C, Myonecrosis consistent with gas gangrene was noted about the shoulder girdle, requiring emergent forequarter amputation (eFigure 2.16).



eFIGURE 2.14 Copyright Milan Stevanovic and Frances Sharpe.



eFIGURE 2.15 Copyright Milan Stevanovic and Frances Sharpe.

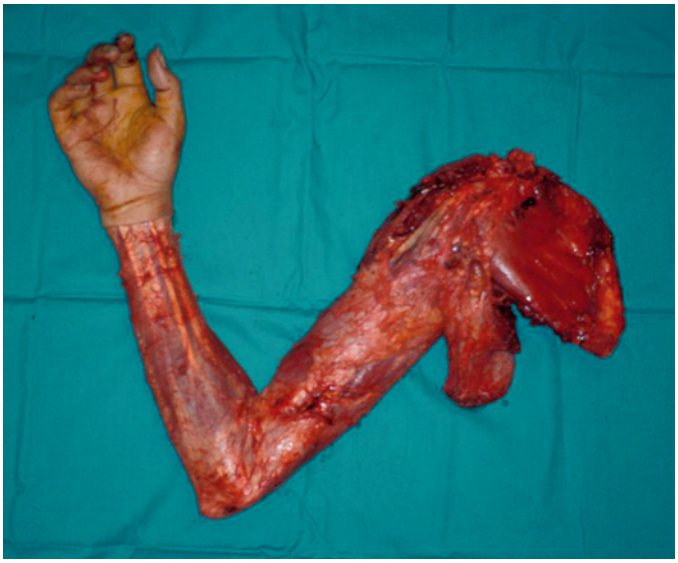

eFIGURE 2.16 Copyright Milan Stevanovic and Frances Sharpe.

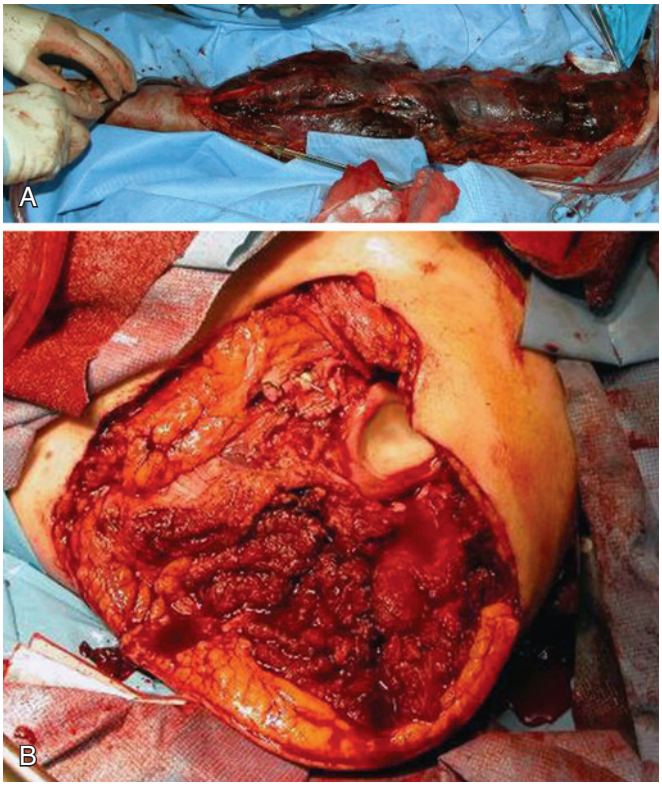

FIGURE 2.26 Spontaneous clostridial myonecrosis in a 54-year-old diagnosed with colorectal cancer 6 months prior to presentation with systemic sepsis. Despite aggressive surgical management, including left hip disarticulation and left arm disarticulation, patient survived only 12 hours after radical débridement. **A**, Myonecrosis of the arm and forearm. **B**, Following disarticulation, the resected muscles of the shoulder girdle have a healthy appearance. (Copyright courtesy of Milan Stevanovic and Frances Sharpe.)

or lower extremity.[80] Nontraumatic gangrene has an 80% association with underlying malignancy, most commonly colorectal cancers and leukemia[157] (Figure 2.26). More than 60% of gas gangrene infections also involve nonclostridial species. Clostridial organisms are obligate anaerobic gram-positive rods. They are spore forming, and the spores are highly resistant to environmental stresses. They survive for long periods and are ubiquitous in the soil. They are also found in the human gastrointestinal tract and in the female genital tract. It may be difficult to isolate *Clostridium* from a wound culture. It must be grown in an anaerobic environment in a medium with a reducing agent such as sodium thioglycolate. Clostridia produce a number of toxins. Among these, alpha toxin is responsible for the myonecrosis, hemolysis, and myocardial depression through the inhibition of the calcium pump. Theta toxin is a hemolysin and is cardiotoxic. Kappa toxin destroys blood vessels through collagenase activity.[55]

Devitalized tissue provides an excellent environment for clostridial growth. Clinical signs occur within hours of inoculation. Endotoxin production quickly produces necrosis of muscles, subcutaneous tissues, and fat. Thrombosis of local vessels further reduces the oxygen tension at the site of infection, continuing to promote a suitable environment for bacterial replication. Hydrogen sulfide and carbon dioxide gas are produced and dissect along the soft tissue planes, causing further tissue destruction. Local and systemic effects of the toxins are present as the infection continues, leading to severe hemolysis, hemoglobinuria, and, ultimately, renal failure. Death has been reported in as short a period as 12 hours after onset of infection.

The clinical findings generally include a history of trauma, often with a crush component. Infections have also occurred in postsurgical wounds and as spontaneous infections. The principal signs of clostridial infection are pain, a closed wound, tachycardia out of proportion to fever or hydration status, and subcutaneous crepitance.

Treatment requires rapid recognition of the infection and emergent surgical débridement, removing all necrotic tissue. It is imperative to leave wounds widely open. This infection is a contraindication for a negative-pressure dressing. Frequent dressing changes are initiated within 6 hours of the initial débridement. Intravenous antibiotic therapy, including high-dose penicillin therapy, is started immediately. Patient resuscitation in the intensive care unit must carefully manage fluid and electrolyte status. Hyperbaric oxygen is a valuable adjunct in the management of this devastating infection.

The principal differential diagnosis of clostridial myonecrosis includes necrotizing fasciitis and streptococcal gangrene, which also represent surgical emergencies. Gas gangrene progresses even more rapidly than necrotizing fasciitis, making early recognition imperative to patient survival. The mortality rate, despite aggressive management, remains high, approximating 25%.[131]

Cutaneous Anthrax Infections

Anthrax infection is caused by the gram-positive aerobic or facultative anaerobic bacterium *Bacillus anthracis*. The black eschar produced by the cutaneous disease gave rise to the name "anthrax," derived from the Greek word *anthrakos,* meaning "coal." The bacillus exists in a vegetative or growing state and in a spore form. In the vegetative state, it is very sensitive to environmental stress. Under these conditions, the cells undergo sporulation. The spore form is very resistant to environmental extremes, including temperature, pH, irradiation, disinfectants, sporicides, and many other stresses. The spore may remain viable in nature for up to 60 years (up to 200 years in one report).[82] Spores are present in the top 6 cm of soil and in animal products. Animals that die of anthrax release massive quantities of spores into the soil that may remain for decades before being ingested again. Burying animal carcasses is probably of little use in disrupting transmission because Pasteur showed that earthworms will carry spores back to the surface. Animal carcasses should be burned, not buried, to prevent long-term environmental contamination.

Anthrax infections have traditionally been transmitted through contaminated soil, animals, or animal products. Cases of cutaneous anthrax still occur in rural environments and in countries with a poorly developed agricultural infrastructure. Anthrax has also been used as a biologic weapon. With the potential threat of bioterrorism, it is important for clinicians to recognize the clinical manifestations of this disease. There are three main manifestations of anthrax. These are cutaneous, gastrointestinal, and inhalational. At present, the cutaneous form remains the most commonly seen, representing 95% of all reported cases worldwide. This form is also the most likely to be encountered by the hand surgeon.[156]



FIGURE 2.27 Cutaneous anthrax. (Courtesy of Dr. Eduardo Gotuzzo, Tropical Medicine Institute, Unversidad Peruana Cayetano Heredia, Lima, Peru.)

Clinical lesions of cutaneous anthrax usually appear within 2 to 7 days of handling sick animals or eating their meat; however, incubation periods of over 8 weeks have been reported. Cutaneous disease begins as a small, painless, red macule that progresses to a papule over 48 to 72 hours. The papule becomes vesicular and ruptures, ulcerates, and forms a brown or black eschar of 1 to 5 cm in diameter (Figure 2.27). Even when the vesicle ruptures and ulcerates, the lesion remains painless. Weeping vesicles and open ulcers should be cultured. If the patient has not received antibiotic treatment, anthrax bacilli may be cultured from the fluid. A gram-stained smear may reveal gram-positive rods. PCR and immunohistochemical staining may help confirm the diagnosis. Lesions are not purulent or painful in the absence of suprainfection. Satellite lesions and significant edema may surround the initial eschar. Depending on the location and severity of disease, edema may be extensive and life threatening, especially if the lesions are close to the chest or neck. Tender regional lymphadenopathy, fever, malaise, and chills may accompany the skin lesion.

Even with prompt antibiotic therapy, cutaneous lesions progress through the eschar phase. Progression of the cutaneous lesion occurs despite antibiotic treatment, because the tissue necrosis and ulceration occur due to the toxin, which is not neutralized by antibiotic therapy. Although antibiotics have no effect on the progression of the skin lesion, they do sterilize the ulcer. Several different antibiotics may be used, including penicillin, quinolones, or doxycycline. Intravenous therapy is used initially. Oral antibiotics are started as the patient shows clinical improvement. The duration of therapy is 60 days. ***Débridement of skin lesions is contraindicated because of the risk of spreading infection.*** Although 80% to 90% of lesions heal spontaneously, 10% to 20% of untreated cases may progress to malignant edema, septicemia, shock, renal failure, and death. Fatalities are uncommon with therapy.[82,156]

High-Pressure Injection Injuries

High-pressure injection injuries can result in extensive soft tissue damage, despite the often benign appearance of the entry wound. Material is injected through the skin at pressures of up to 7000 psi. The nondominant index finger is the most frequently involved digit. The extent of injury is related to the force of the injection and the type and amount of material injected. Mechanical and chemical injury results in local tissue necrosis and vascular occlusion. Oil-based paints and industrial solvents produce a greater degree of tissue necrosis than water-based paints and grease. Mirzayan and colleagues reported an amputation rate of 50% with oil-based paints. No amputations were required in water-based paint injections.[12,106] Emergent surgical decompression and débridement are necessary. Despite wide and aggressive surgical management, it is usually impossible to remove all of the foreign material. Surgical delay of more than 10 hours was found to result in higher rates of amputation.[147] Repeat surgical débridement at 48 to 72 hours may be necessary for wounds with wide contamination for removal of additional necrotic tissue and foreign material. Primary wound closure is often possible. Soft tissue reconstruction may be necessary for critical areas of soft tissue loss.[24]

Infection is not frequently a component of these injuries unless treatment is delayed. These wounds are commonly contaminated with both gram-positive and gram-negative organisms.[12,106,122] The necrotic tissue resulting from the injury provides a good culture medium for the injected bacteria. Broad-spectrum antibiotic coverage is important in the treatment of these injuries.

Mimickers of Infection

A wide range of clinical conditions may mimic an infection of the hand. It is important to recognize these conditions to provide appropriate treatment and prevent unnecessary surgery. The following conditions do not represent an exhaustive list but include those that are more commonly encountered. *Gout* and *pseudogout* represent the crystal arthropathies that may present as a pyarthrosis. Gouty tophi that erupt through the skin may have the appearance of infection with erythema of the skin and drainage. These lesions may also become secondarily infected and require surgical intervention (Figure 2.28). *Acute calcific tendinitis* presents as severe, well-localized pain overlying tendons or ligaments. Erythema and edema are often present. Other signs of infection, such as fever, lymphadenopathy, or abnormal laboratory values, are absent. Radiographs demonstrate characteristic calcific density in the area of tenderness (Figure 2.29). *Pyogenic granuloma* presents as a raised red, friable lesion (Figure 2.30). The friable tissue is sensitive to minor trauma and bleeds easily. In the hand, it is usually on the volar surface of the palm or fingers. The cause remains unclear, possibly related to repetitive irritation or minor trauma. *Pyoderma gangrenosum* is a very rare cutaneous lesion, seen principally in patients with a coexisting systemic disease, especially



FIGURE 2.28 Tophaceous gout. (Copyright courtesy of Milan Stevanovic and Frances Sharpe.)



FIGURE 2.29 Calcinosis clinically presents with acute onset of severe pain, associated with swelling and, often, redness around the site of calcium deposition. (Copyright courtesy of Milan Stevanovic and Frances Sharpe.)

in patients with ulcerative colitis. The disease process begins with small papules that rapidly develop pustules. Central necrosis follows quickly, leaving a central ulcer. The border is raised and violaceous, and it advances from the center at a rate of 1 to 2 cm/day. Treatment includes local wound care. Surgical excision is contraindicated and may exacerbate the disease, resulting in a larger area of necrosis. *Retained foreign bodies* may result in an inflammatory response that mimics an infection. Woody materials can be a significant irritant. Palm thorns are known to cause a chemical irritation of the soft tissues. Intraarticular thorns or thorns that pierce the tendon sheath can result in a chemical synovitis. Removal of the offending irritant is necessary for definitive treatment. *Metastatic* or *primary tumors* on the hand are rare. However, awareness of this possibility is important to prevent a misdiagnosis and emphasizes the importance of tissue biopsy as well as tissue culture.[125] Primary lesions include squamous cell carcinoma, basal cell carcinoma, melanoma, and keratoacanthoma (see Chapter 58) (Case Study 2.5). A metastatic primary tumor is more likel to appear as a chronic infection. Metastatic lesions to the hand and wrist have been reported in all bones of the hand but are usually acral lesions, with more than 50% involving the distal phalanx. Radiographs may help distinguish between tumor and infection. Primary lung tumors are the most common metastatic lesion to the hand. Other sites of primary tumor include the breast, kidney, colon, thyroid, and prostate.[2,4,24]



FIGURE 2.30 Pyogenic granuloma of the thumb. (Copyright Milan Stevanovic and Frances Sharpe.)

For Case Studies, Videos, and more, please visit ExpertConsult.com.

REFERENCES

1. Abrahamian FM, Goldstein EJ: Microbiology of animal bite wound infections. *Clin Microbiol Rev* 24(2):231–246, 2011.
2. Afshar A, Farhadnia P, Khalkhali H: Metastases to the hand and wrist: an analysis of 221 cases. *J Hand Surg [Am]* 39(5):923–932, 2014.
3. Allison DC, Miller T, Holtom P, et al: Microbiology of upper extremity soft tissue abscesses in injecting drug abusers. *Clin Orthop Relat Res* 461:9–13, 2007.

CASE STUDY 2.5 Tumor (Melanoma) Masquerading as an Infection

A 75-year-old gentleman had been treated for 6 months for a chronic paronychia and nail bed infection of the left thumb. After referral to our service, a biopsy was obtained, confirming the presumed diagnosis of malignancy. Final pathologic findings were consistent with malignant melanoma.

A, Clinical presentation (eFigure 2.17).

B, Radiographs of the thumb, showing bone destruction (eFigure 2.18).

C, Treatment of the lesion with amputation of the thumb, with a minimum of 1 cm of clear margin (eFigure 2.19).



eFIGURE 2.17 Copyright Milan Stevanovic and Frances Sharpe.



eFIGURE 2.18 Copyright Milan Stevanovic and Frances Sharpe.

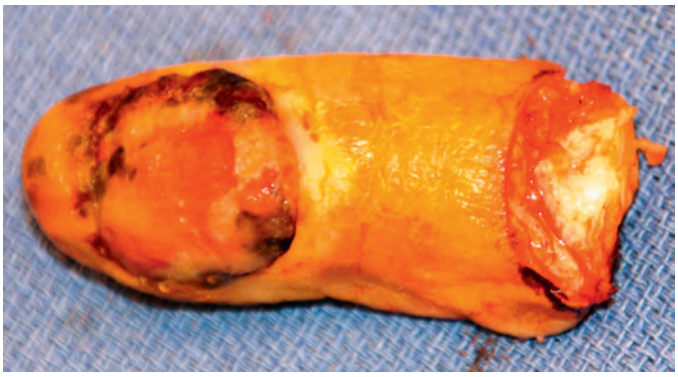

eFIGURE 2.19 Copyright Milan Stevanovic and Frances Sharpe.

4. Amadio P, Lombardi R: Metastatic tumors of the hand. *J Hand Surg* 12A(2):311–316, 1987.
5. Arons M, Fernando L, Polayes I: *Pasturella multocida:* the major cause of hand infections following domestic animal bites. *J Hand Surg* 7(1):47–52, 1982.
6. Babovic N, Cayci C, Carlsen BT: Cat bite infections of the hand: assessment of morbidity and predictors of severe infection. *J Hand Surg [Am]* 39(2):286–290, 2014.
7. Baran R, Haneke E: Infection of the nail apparatus: viral infection. In Krull E, Zook EG, Baran R, et al, editors: *Nail surgery: a text and atlas*, Philadelphia, 2001, Lippincott Williams & Wilkins, pp 201–205.
8. Barbieri R, Freeland A: Osteomyelitis of the hand. *Hand Clin* 14(4):589–603, 1998.
9. Battle J, Carmichael K: Incidence of pin track infections in children's fractures treated with Kirschner wire fixation. *J Pediatr Orthop* 27(2):154–157, 2007.
10. Bauters T, Buyle F, Verschraegen G, et al: Infection risk related to the use of medicinal leeches. *Pharm World Sci* 29(3):122–125, 2007.
11. Bednar M, Lane L: Eponychial marsupialization and nail removal for surgical treatment of chronic paronychia. *J Hand Surg* 16A:314–317, 1991.
12. Bekler H, Gokce A, Beyzadeoglu T, et al: The surgical treatment and outcomes of high-pressure injection injuries of the hand. *J Hand Surg Eur* 32(4):394–399, 2007.
13. Bergstein J, Baker EI, Aprahamian C, et al: Soft tissue abscesses associated with parenteral drug abuse: Presentation, microbiology, and treatment. *Am Surg* 61(12): 1105–1108, 1995.
14. Biviji A, Paiement G, Steinbach L: Musculoskeletal manifestations of human immunodeficiency virus infection. *J Am Acad Orthop Surg* 10(5):312–320, 2002.
15. Boles D, Schmidt C: Pyogenic flexor tenosynovitis. *Hand Clin* 14(4):567–578, 1998.
16. Botte M, Davis J, Rose B, et al: Complications of smooth pin fixation of fractures and dislocations in the hand and wrist. *Clin Orthop* 276:194–201, 1992.
17. Boutin R, Brossmann J, Sartoris D, et al: Update on imaging of orthopedic infections. *Orthop Clin North Am* 29(1):41–66, 1998.
18. Boyes JH: Infections. In Boyes JH, editor: *Bunnell's surgery of the hand*, Philadelphia, 1970, JB Lippincott Company, pp 613–642.
19. Bratzler DW, Dellinger EP, Olsen KM, et al: Clinical practice guidelines for antimicrobial prophylaxis in surgery. *Surg Infect* 14(1):73–156, 2013.
20. Buchanan D, Heiss-Dunlop W, Mathy JA: Community acquired methicillin resistant *Staphylococcus aureus* hand infections: a South Pacific perspective: characteristics and implications for antibiotic coverage. *Hand Surg* 17(3):317–324, 2012.
21. Calkins E: Nosocomial infections in hand surgery. *Hand Clin* 14(4):531–545, 1998.
22. Calvet H, Yoshikawa T: Infections in diabetes. *Infect Dis Clin North Am* 15(2):407–421, 2001.
23. Carter S: Herpetic whitlow: Herpetic infections of the digits. Invited comments. *J Hand Surg* 4(1):93–94, 1979.
24. Chaput B, Nouaille de Gorce H, Courtade-Saidi M, et al: The role of a systematic second look at 48-72 hours in high-pressure injection injuries to the hand: a retrospective study. *Chir Main* 31(5):250–255, 2012.
25. Chung MT, Wilson P, Rinker B: Community-acquired methicillin-resistant *Staphylococcus aureus* hand infections in the pediatric population. *J Hand Surg [Am]* 37(2):326–331, 2012.
26. Cierny G, III, Mader J, Penninck J: A clinical staging system for adult osteomyelitis. *Contemp Orthop* 10(5):17–37, 1985.
27. Classen D, Evans R, Pestotnik S, et al: The timing of prophylactic administration of antibiotics and the risk of surgical wound infection. *N Engl J Med* 326(5):281–286, 1992.
28. Cohen G, Schnall S, Holtom P: New-onset diabetes mellitus in patients presenting with extremity infections. *Clin Orthop Relat Res* 403:45–48, 2002.
29. Cohen M, Kaplan L: Histology and ultrastructure of the human flexor tendon sheath. *J Hand Surg* 12A(1):25–29, 1987.
30. Costerton J: Biofilm theory can guide the treatment of device-related orthopedic infections. *Clin Orthop Relat Res* 437:7–11, 2005.
31. Crosby SN, Snoddy MC, Atkinson CT, et al: Upper extremity myonecrosis caused by *Edwardsiella tarda* resulting in transhumeral amputation: case report. *J Hand Surg* 38A(1):129–132, 2013.
32. Dailiana ZH, Rigopoulos N, Varitimidis S, et al: Purulent flexor tenosynovitis: factors influencing the functional outcome. *J Hand Surg Eur* 33(3):280–285, 2008.
33. Dechet A, Yu P, Koram N, et al: Non-foodborne *Vibrio* infections: an important cause of morbidity and mortality in the United States, 1997-2006. *Clin Infect Dis* 46(7):970–976, 2008.
34. Deirmengian C, Kardos K, Kilmartin P, et al: Diagnosing periprosthetic joint infection: has the era of the biomarker arrived? *Clin Orthop Relat Res* 4:4, 2014.
35. Doyle J: Anatomy of the flexor tendon sheath and pulley system. *J Hand Surg* 13A(4):473–484, 1988.
36. Faciszewski T, Coleman D: Human bite infections of the hand. *Hand Clin* 14(4): 683–690, 1998.
37. Ferlic D, Clayton M, Holloway M: Complications of silicone implant surgery in the metacarpophalangeal joint. *J Bone Joint Surg* 57A(7):991–994, 1975.
38. Fitoussi F, Litzelmann E, Ilharreborde B, et al: Hematogenous osteomyelitis of the wrist in children. *J Pediatr Orthop* 27(7):810–813, 2007.
39. Fleisher G: The management of bite wounds. *N Engl J Med* 340(2):138–140, 1999.
40. Formaini N, Jacob P, Willis L, et al: Evaluating the use of preoperative antibiotics in pediatric orthopaedic surgery. *J Pediatr Orthop* 32(7):737–740, 2012.
41. Fowler JR, Ilyas AM: Epidemiology of adult acute hand infections at an urban medical center. *J Hand Surg* 38A(6):1189–1193, 2013.
42. Francel T, Marshall K, Savage R: Hand infections in the diabetic renal transplant patient. *Ann Plast Surg* 24(4):304–309, 1990.
43. Francis K, Lamaute H, Davis J, et al: Implications of risk factors in necrotizing fasciitis. *Am Surg* 59(5):304–308, 1993.
44. Gahhos F, Ariyan S: Hippocrates, the true father of hand surgery. *Surg Gynecol Obstet* 160:178–184, 1985.
45. Garcia V: Animal bites and *Pasteurella* infections. *Pediatr Rev* 18(4):127–130, 1997.
46. Gaston RG, Kuremsky MA: Postoperative infections: prevention and management. *Hand Clin* 26(2):265–280, 2010.
47. Gellman H, Stetson W, Brumfield R, Jr, et al: Silastic metacarpophalangeal joint arthroplasty in patients with rheumatoid arthritis. *Clin Orthop* 342:16–21, 1997.
48. Gilchrist J, Sacks JJ, White D, et al: Dog bites: still a problem? *Inj Prev* 14(5):296–301, 2008.
49. Gill M, Arlette J, Buchan K: Herpes simplex virus infection of the hand. A profile of 79 cases. *Am J Med* 84:89–93, 1988.
50. Glass K: Factors related to the resolution of treated hand infections. *J Hand Surg* 7(4):388–394, 1982.
51. Glickel S: Hand infections in patients with acquired immunodeficiency syndrome. *J Hand Surg* 13A(5):770–775, 1988.
52. Gold R, Hawkins R, Katz R: Bacterial osteomyelitis: Findings on plain radiography, CT, MR, and scintigraphy. *Am J Roentgenol* 157:365–370, 1991.
53. Goldstein E: Current concepts on animal bites. *Curr Clin Top Infect Dis* 19:99–111, 1999.
54. Goldstein E, Barones M, Miller T: *Eikenella corrodens* in hand infections. *J Hand Surg* 8(5):563–567, 1983.
55. Gonzalez M: Necrotizing fasciitis and gangrene of the upper extremity. *Hand Clin* 14(4):635–645, 1998.
56. Gonzalez M, Bochar S, Novotny J, et al: Upper extremity infections in patients with diabetes mellitus. *J Hand Surg* 24A(4):682–686, 1995.
57. Gonzalez M, Garst J, Nourbash P, et al: Abscesses of the upper extremity from drug abuse by injection. *J Hand Surg* 18A(5):868–870, 1993.
58. Gonzalez M, Nikoleit J, Weinzweig N, et al: Upper extremity infections in patients with the human immunodeficiency virus. *J Hand Surg* 23A(2):348–352, 1998.
59. Graves M, Janda J: Rat-bite fever (*Streptobacillus moniliformis*): a potential emerging disease. *Int J Infect Dis* 5(3):151–155, 2001.
60. Gunther S, Gunther S: Diabetic hand infections. *Hand Clin* 14(4):647–656, 1998.
61. Gutowski KA, Ochoa O, Adams WP, Jr: Closed-catheter irrigation is as effective as open drainage for treatment of pyogenic flexor tenosynovitis. *Ann Plast Surg* 49(4):350–354, 2002.
62. Harada A, Lau W: Successful treatment and limb salvage of mucor necrotizing fasciitis after kidney transplantation with posaconazole. *Hawaii Med J* 66(3):68–71, 2007.
63. Hardy A, Nicol R: Closed fractures complicated by acute hematogenous osteomyelitis. *Clin Orthop* 201:190–195, 1985.
64. Harness NG, Inacio MC, Pfeil FF, et al: Rate of infection after carpal tunnel release surgery and effect of antibiotic prophylaxis. *J Hand Surg* 35A(2):189–196, 2010.
65. Harrison M: A 4-year review of human bite injuries presenting to emergency medicine and proposed evidence-based guidelines. *Injury* 40(8):826–830, 2009.
66. Henriksen B, Albrektsen S, Simper L, et al: Soft tissue infections from drug abuse. A clinical and microbiological review. *Acta Orthop Scand* 65(6):625–628, 1994.
67. Honner R, Meares A: A review of 100 flexor tendon reconstructions with prosthesis. *Hand* 9(3):226–231, 1977.
68. Houshian S, Seyedipour S, Wedderkopp N: Epidemiology of bacterial hand infections. *Int J Infect Dis* 10(4):315–319, 2006.
69. Hurst L, Gluck R, Sampson S, et al: Herpetic whitlow with bacterial abcess. *J Hand Surg* 16A(2):311–313, 1991.
70. Imahara SD, Friedrich JB: Community-acquired methicillin-resistant *Staphylococcus aureus* in surgically treated hand infections. *J Hand Surg* 35A(1):97–103, 2010.
71. Jain D, Kumar Y, Vasishta R, et al: Zygomycotic necrotizing fasciitis in immunocompetent patients: a series of 18 cases. *Mod Pathol* 19:1221–1226, 2006.
72. Janis JE, Hatef DA, Reece EM, et al: Does empiric antibiotic therapy change hand infection outcomes? Cost analysis of a randomized prospective trial in a county hospital. *Plast Reconstr Surg* 133(4):511e–518e, 2014.
73. Jeon IH, Morrey BF, Anakwenze OA, et al: Incidence and implications of early postoperative wound complications after total elbow arthroplasty. *J Shoulder Elbow Surg* 20(6):857–865, 2011.
74. Kanavel A: *Infections of the hand*, ed 4, Phildelphia, 1921, Lea & Febiger.
75. Kanavel A: *Infections of the hand*, ed 7, Philadelphia, 1939, Lea & Febiger, p 503.
76. Kao LS, Lew DF, Arab SN, et al: Local variations in the epidemiology, microbiology, and outcome of necrotizing soft-tissue infections: a multicenter study. *Am J Surg* 202(2):139–145, 2011.

77. Karpathios T, Moustaki M, Yiallouros P, et al: HSV-2 meningitis disseminated from a herpetic whitlow. *Paediatr Int Child Health* 32(2):121–122, 2012.
78. Keyser J, Eaton R: Surgical cure of chronic paronychia by eponychial marsupialization. *Plast Reconst Surg* 58(1):66–70, 1976.
79. Kour A, Looi K, Phone M, et al: Hand infections in patients with diabetes. *Clin Orthop Relat Res* 331:238–244, 1996.
80. Kudsk K: Occult gastrointestinal malignancies producing metastatic *Clostridium septicum* infections in diabetic patients. *Surgery* 112:765–772, 1992.
81. Ladhani S, Cameron J, Chapple D, et al: A novel method for rapid production and purification of exfoliative toxin A of *Staphylococcus aureus. FEMS Microbiol Lett* 212(1):35–39, 2002.
82. LaForce F: Anthrax. *Clin Infect Dis* 19:1009–1014, 1994.
83. Leslie B, Harris J, III, Driscoll D: Septic arthritis of the shoulder in adults. *J Bone Joint Surg* 71A(10):1516–1522, 1989.
84. Levy C: Treating infections of the hand: identifying the organism and choosing the antibiotic. *Instr Course Lect* 39:533–537, 1990.
85. Li MY, Hua Y, Wei GH, et al: Staphylococcal scalded skin syndrome in neonates: an 8-year retrospective study in a single institution. *Pediatr Dermatol* 31(1):43–47, 2014.
86. Lille S, Hayakawa T, Neumeister MW, et al: Continuous postoperative catheter irrigation is not necessary for the treatment of suppurative flexor tenosynovitis. *J Hand Surg* 25B(3):304–307, 2000.
87. Lindsay JA: Hospital-associated MRSA and antibiotic resistance: what have we learned from genomics? *Int J Med Microbiol* 303(6–7):318–323, 2013.
88. Lindsey D, Christopher M, Hollenbach J, et al: Natural course of the human bite wound: incidence of infection and complications in 434 bites and 803 lacerations in the same group of patients. *J Trauma* 27(1):45–48, 1987.
89. Lineaweaver W, Furnas H, Follansbee S, et al: Postprandial *Aeromonas hydrophila* cultures and antibiotic levels of the enteric aspirates from medicinal leeches applied to patients receiving antibiotics. *Ann Plast Surg* 29(3):245–249, 1992.
90. Linscheid R, Dobyns J: Common and uncommon infections of the hand. *Orthop Clin North Am* 6(4):1063–1104, 1975.
91. Mackay D, Manders E, Saggers G, et al: *Aeromonas* species isolated from medicinal leeches. *Ann Plast Surg* 42(3):275–279, 1999.
92. Malenfant J, Walters A, Kralovic S, et al: Francesco Parona (1842-1908) and his contributions to our understanding of surgery through anatomy. *Clin Anat* 26(5): 547–550, 2013.
93. Malghem J, Lecouvet FE, Omoumi P, et al: Necrotizing fasciitis: contribution and limitations of diagnostic imaging. *Joint Bone Spine* 80(2):146–154, 2013.
94. Maloon S, de V de Beer J, Opitz M, et al: Acute Flexor Tendon Sheath Infections. *J Hand Surg* 15A(3):474–477, 1990.
95. Mann J, III, Werntz J: Catfish stings to the hand. *J Hand Surg* 16A(2):318–321, 1991.
96. Mann R: *Infections of the hand,* Philadelphia, 1988, Lea & Febiger, p 190.
97. Mann R, Hoffeld T, Farmer C: Human bites of the hand: twenty years of experience. *J Hand Surg* 2(2):97–104, 1977.
98. McAuliffe J, Seltzer D, Hornicek F: Upper-extremity infections in patients seropositive for human immunodefieciency virus. *J Hand Surg* 22A(6):1084–1090, 1997.
99. McGinley K, Larson E, Leyden J: Composition and density of microflora in the subungual space of the hand. *J Clin Microbiol* 26(5):950–953, 1988.
100. McHenry C, Brandt C, Piotrowski J, et al: Idiopathic necrotizing fasciitis: recognition, incidence, and outcome of therapy. *Am Surg* 60(7):490–494, 1994.
101. McHenry C, Piotrowski J, Petrinic D, et al: Determinants of mortality for necrotizing soft-tissue infections. *Ann Surg* 221(5):563–565, 1995.
102. McLain R, Steyers C, Stoddard M: Infections in open fractures of the hand. *J Hand Surg* 16A(1):108–112, 1991.
103. Mennen U, Howells C: Human fight-bite injuries of the hand. A study of 100 cases within 18 months. *J Bone Joint Surg* 16B(3):431–435, 1991.
104. Meyer CL, Abzug JM: Domestic bird bites. *J Hand Surg* 37A(9):1925–1927, 2012.
105. Millender L, Nalebuff E, Hawkins R, et al: Infection after silicone prosthetic arthroplasty in the hand. *J Bone Joint Surg* 57A(6):825–829, 1975.
106. Mirzayan R, Schnall S, Chon J, et al: Culture results and amputation rates in high-pressure paint gun injuries of the hand. *Orthopedics* 24(6):587–589, 2001.
107. Morgan M: Prophylaxis should be considered even for trivial animal bites. *BMJ* 314:1413, 1997.
108. Murphey DK, Septimus EJ, Waagner DC: Catfish-related injury and infection: Report of two cases and review of the literature. *Clin Infect Dis* 14(3):689–693, 1992.
109. Murphy E, DeVita D, Liu H, et al: Risk factors for skin and soft-tissue abscesses among injection drug users: a case controlled study. *Clin Infect Dis* 33(July):35–40, 2001.
110. Nakafusa J, Misago N, Miura M, et al: The importance of serum creatine phosphokinase level in the early diagnosis, and as a prognostic factor, of *Vibrio vulnificus* infection. *Br J Dermatol* 145(2):280–284, 2001.
111. Neviaser R: Closed tendon sheath irrigation for pyogenic flexor tenosynovitis. *J Hand Surg* 3A(5):462–466, 1978.
112. Nydick JA, Greenberg SM, Stone JD, et al: Clinical outcomes of total wrist arthroplasty. *J Hand Surg* 37A(8):1580–1584, 2012.
113. O'Hara F, Geux N, Word JM, et al: A geographic carian of the *Staphylococcus aureus* Panton-Valentine leukocidin toxin and the origin of community-associated methicillin-resistant *S. aureus* USA300. *J Infect Dis* 197(2):187–194, 2008.
114. O'Malley M, Fowler J, Ilyas AM: Community-acquired methicillin-resistant *Staphylococcus aureus* infections of the hand: prevalence and timeliness of treatment. *J Hand Surg* 34A(3):504–508, 2009.
115. Oliver J: Wound infections caused by *Vibrio vulnificus* and other marine bacteria. *Epidemiol Infect* 133(3):383–391, 2005.
116. Otto M: Community-associated MRSA: what makes them special? *Int J Med Microbiol* 303(6–7):324–330, 2013.
117. Otto RJ, Mulieri PJ, Cottrell BJ, et al: Arthrodesis for failed total elbow arthroplasty with deep infection. *J Shoulder Elbow Surg* 23(3):302–307, 2014.
118. Pabari A, Iyer S, Khoo CT: Swiss roll technique for treatment of paronychia. *Tech Hand Up Extrem Surg* 15(2):75–77, 2011.
119. Pang H-N, Teoh L, Yam A, et al: Factors affecting the prognosis of pyogenic flexor tenosynovitis. *J Bone Joint Surg* 89A(8):1742–1748, 2007.
120. Patel GK, Finlay AY: Staphylococcal scalded skin syndrome: diagnosis and management. *Am J Clin Dermatol* 4(3):165–175, 2003.
121. Patzakis M, Wilkins J, Bassett R: Surgical findings in clenched-fist injuries. *Clin Orthop Relat Res* 220:237–240, 1987.
122. Pinto M, Turkula-Pinto L, Cooney W, et al: High-pressure injection injuries of the hand: review of 25 patients managed by open wound technique. *J Hand Surg* 18A(1):125–130, 1993.
123. Pinzur M, Bednar M, Weaver F, et al: Hand infections in the diabetic patient. *J Bone Joint Surg* 22B(1):133–134, 1997.
124. Rashkoff E, Burkhalter W, Mann R: Septic arthritis of the wrist. *J Bone Joint Surg* 65A(8):824–828, 1983.
125. Rauh MA, Duquin TR, McGrath BE, et al: Spread of squamous cell carcinoma from the thumb to the small finger via the flexor tendon sheaths. *J Hand Surg* 34A(9):1709–1713, 2009.
126. Reilly K, Linz J, Stern P, et al: Osteomyelitis of the tubular bones of the hand. *J Hand Surg* 22A(4):644–649, 1997.
127. Ritting AW, O'Malley MP, Rodner CM: Acute paronychia. *J Hand Surg* 37A(5):1068–1070, 2012.
128. Rizvi M, Bille B, Holtom P, et al: The role of prophylactic antibiotics in elective hand surgery. *J Hand Surg* 33A(3):413–420, 2008.
129. Robbins R: Infections of the hand. *J Bone Joint Surg* 34B(4):567–587, 1952.
130. Robertson H, Polk H: The mechanism of infection in patients with diabetes mellitus: a review of leukocyte malfunction. *Surgery* 75(1):123–128, 1974.
131. Roding B, Groeneveld P, Boerema I: Ten years of experience in the treatment of gas gangrene with hyperbaric oxygen. *Surg Gynecol Obstet* 134(4):579–585, 1972.
132. Rosen T, Jablon J: Infection threats from exotic pets: dermatological implications. *Dermatol Clin* 21(2):229–236, 2003.
133. Sammer DM, Shin AY: Comparison of arthroscopic and open treatment of septic arthritis of the wrist. *J Bone Joint Surg* 91A(6):1387–1393, 2009.
134. Schaefer R, Enzenauer R, Pruitt A, et al: Acute gonococcal flexor tenosynovitis in the adolescent male with pharyngitis. A case report and review of the literature. *Clin Orthop Relat Res* 281:212–215, 1992.
135. Schecter W, Meyer A, Schecter G, et al: Necrotizing fasciitis of the upper extremity. *J Hand Surg* 7A(1):15–20, 1982.
136. Scheldrup E: Tendon sheath patterns in the hand. An anatomical study based on 367 hand dissections. *Surg Gynecol Obstet* 93(1):16–22, 1951.
137. Schnall S, Holtom P, Lilley J: Abscesses secondary to parenteral abuse of drugs. *J Bone Joint Surg* 76A(10):1526–1530, 1994.
138. Schnall S, Thommen V, Allari T, et al: Delayed primary wound closure in upper extremity soft-tissue infections. *Clin Orthop Relat Res* 335:286–291, 1997.
139. Schnall S, Vu-Rose T, Holtom P, et al: Tissue pressures in pyogenic flexor tenosynovitis of the finger. Compartment syndrome and its management. *J Bone Joint Surg* 78B(5):793–795, 1996.
140. Selvin E, Parrinello CM, Sacks DB, et al: Trends in prevalence and control of diabetes in the United States, 1988-1994 and 1999-2010. *Ann Intern Med* 160(8):517–525, 2014.
141. Shapiro D: Postoperative infection in hand surgery. *Hand Clin* 14(4):669–681, 1998.
142. Sharma KS, Rao K, Hobson MI: Space of Parona infections: experience in management and outcomes in a regional hand centre. *J Plast Reconstr Aesthet Surg* 66(7):968–972, 2013.
143. Simmen H, Giovanoli P, Battaglia H, et al: Soft tissue infections of the upper extremities with special consideration of abscesses in parenteral drug abusers. *J Hand Surg* 20B(6):797–800, 1995.
144. Simmons A: Clinical manifestations and treatment considerations of herpes simplex virus infections. *J Infect Dis* 186(Suppl):S71–S77, 2002.
145. Smith P, Meadowcroft A, May D: Treating mammalian bite wounds. *J Clin Pharm Ther* 25(2):85–89, 2000.

146. Spicher VM, Bouvier P, Schlegel-Haueter SE, et al: Epidemiology of herpes simplex virus in children by detection of specific antibodies in saliva. *Pediatr Infect Dis J* 20(3):265–272, 2001.
147. Stark H, Ashworth C, Boyes J: Paint-gun injuries of the hand. *J Bone Joint Surg* 49A(4):637–647, 1967.
148. Stern P, Staneck J, McDonough J, et al: Established hand infections: a controlled prospective study. *J Hand Surg* 8A(5):553–559, 1983.
149. Strong M, Lejman T, Michno P: Septic arthritis of the wrist in infancy. *J Pediatr Orthop* 15(2):152–156, 1995.
150. Summanen P, Talan D, Strong C, et al: Bacteriology of skin and soft-tissue infections: Comparison of infections in intravenous drug users and individuals with no history of drug use. *Clin Infect Dis* 20(Suppl 2):S279–S282, 1995.
151. Talan D, Citron D, Abrahamian F, et al: Bacteriologic analysis of infected dog and cat bites. *N Engl J Med* 340(2):85–92, 1999.
152. Tannan SC, Deal DN: Diagnosis and management of the acute felon: evidence-based review. *J Hand Surg* 37A(12):2603–2604, 2012.
153. Tordjman D, Holvoet L, Benkerrou M, et al: Hematogenous osteoarticular infections of the hand and the wrist in children with sickle cell anemia: preliminary report. *J Pediatr Orthop* 34(1):123–128, 2014.
154. Tosti R, Fowler J, Dwyer J, et al: Is antibiotic prophylaxis necessary in elective soft tissue hand surgery? *Orthopedics* 35(6):e829–e833, 2012.
155. Tsai Y, Hus R, Huang T, et al: Necrotizing soft-tissue infections and sepsis caused by *Vibrio vulnificus* compared with those caused by *Aeromonas* species. *J Bone Joint Surg* 89A(3):631–636, 2007.
156. Tutrone W, Scheinfeld N, Weinberg J: Cutaneous anthrax: a concise review. *Cutis* 69(1):27–33, 2002.
157. Valentine E: Nontraumatic gas gangrene. *Ann Emerg Med* 30(1):109–111, 1997.
158. van Alphen NA, Gonzalez A, McKenna MC, et al: Ciprofloxacin-resistant *Aeromonas* infection following leech therapy for digit replantation: report of 2 cases. *J Hand Surg* 39A(3):499–502, 2014.
159. van der Lugt JC, Geskus RB, Rozing PM: Primary Souter-Strathclyde total elbow prosthesis in rheumatoid arthritis. Surgical technique. *J Bone Joint Surg* 1A(Pt 1): 67–77, 2005.
160. Vetter R, Agac B, Reiland R, et al: Skin lesion in barracks: Consider community-acquired methicillin-resistant *Staphylococcus aureus* instead of spider bites. *Military Med* 171(9):830–832, 2006.
161. Wald A, Ashley-Morrow R: Serological testing for herpes simplex virus (HSV)-1 and (HSV)-2 infection. *Clin Infect Dis* 35(Suppl 2):S173–S182, 2002.
162. Waldvogel F, Medoff G, Swartz M: Osteomyelitis: a review of clinical features, therapeutic considerations and unusual aspects (first of three parts). *N Engl J Med* 282(4):198–206, 1970.
163. Waldvogel F, Medoff G, Swartz M: Osteomyelitis: a review of clinical features, therapeutic considerations and unusual aspects (second of three parts). *N Engl J Med* 282(5):260–266, 1970.
164. Watson PA, Jebson PJ: The natural history of the neglected felon. *Iowa Orthop J* 16:164–166, 1996.
165. Weber B, Rabenau H, Berger A, et al: Seroprevalence of HCV, HAV, HBV, HDV, HCMV, and HIV in high risk groups. *Zentrabl Bakteriol* 282(1):102–112, 1995.
166. Wehbe M, Mawr B, Hunter J, et al: Two-stage flexor tendon reconstruction. Ten-year experience. *J Bone Joint Surg* 68A(5):752–763, 1986.
167. Westling K, Bygdeman S, Engkvist O, et al: *Pasteurella multocida* infection following cat bites in humans. *J Infect* 40(1):97–98, 2000.
168. Whitaker IS, Kamya C, Azzopardi EA, et al: Preventing infective complications following leech therapy: is practice keeping pace with current research? *Microsurgery* 29(8):619–625, 2009.
169. Wilson B: Necrotizing fasciitis. *Am J Surg* 18(4):416–431, 1952.
170. Wittels N, Donley J, Burkhalter W: A functional treatment method for interphalangeal pyogenic arthritis. *J Hand Surg* 9A(6):894–898, 1984.
171. Zuretti A, Schwartz I: Gangrenous herpetic whitlow in a human immunodeficiency virus–positive patient. *Am J Clin Pathol* 93:828–830, 1990.

3

Chronic Infections

Mukund R. Patel

Acknowledgment: Govind Narain Malaviya was the main contributor to the section on leprosy. He was a leader in surgery for Hansen disease in the world and has now retired. I am thankful to Dr. Malaviya for his great contribution to this chapter and dedicate the leprosy section to his legacy.

GENERAL PRINCIPLES

Chronic infections of the hand and upper extremity can be caused by a variety of agents: viruses, bacteria, mycobacteria, fungi, *Prototheca*, protozoa, parasites, and insects (Table 3.1). An infection may be superficial and affect the skin or nails, or it may affect subcutaneous tissue, or it may be deep and affect the nerves, tenosynovium, joints, and bone. Chronic lesions of the hand, both superficial and deep, have a nonspecific presentation and early biopsy and cultures facilitate diagnosis. Early suspicion and diagnosis of a chronic infection is the mainstay of all ensuing treatment principles and is the primary message of this chapter.

Chronic infections of the hand and upper extremity are rare indeed and are primarily a problem of diagnosis. They often are not considered in the differential diagnosis of hand lesions. Many surgeons encounter their first case by surprise unless an unusual diagnosis is considered in the presence of unusual symptoms and signs. One must consider infection in any chronic lesion of the hand. In an immunocompromised patient, infection must always be included in the differential diagnosis. Biopsy and cultures should be considered as a part of a diagnostic workup for atypical lesions.

An infection that does not respond to antibiotics, incision, drainage, or debridement, is suspect. Because infections are rare, diagnosis is often delayed unless a high level of suspicion is maintained. "Culture a tumor and biopsy an infection," is an adage to apply when an unusual lesion is encountered[53,62,88]; otherwise, chronic and emerging infections will continue to elude physicians. With increasing numbers of international travelers, immigrants, and vacationers to endemic areas, we encounter old (i.e., tuberculosis,[46] yaws,[37] leprosy[65]) and exotic (i.e., protozoal,[18] protothecal, and parasitic gnathostomiasis[96]) infections of the hand. With more organ transplants and malignant lesions treated with chemotherapy, new and emerging infections are encountered. Recognition of all of them saves unnecessary surgery for infections that are medically treatable.

This chapter is a reservoir of rare encounters with chronic infections during hand surgery. It may serve as a reference when an unexpected or unfamiliar infection appears on a pathology or microbiology report. Moreso, I hope that it will highlight the need for early biopsy and cultures when a chronic lesion (e.g., tenosynovium, joint, bone, skin or subcutaneous tissue) of the hand and/or upper extremity eludes diagnosis.

The most common chronic hand infection traditionally has been tuberculosis (Hansen disease). Nontuberculous mycobacterial (NTM) infections—initially recognized in the 1950s as atypical or mycobacteria other than tuberculosis (MOTT)—of the hand are now more common[5,15,25,34,52,61,63,64,72,92,112,122] than mycobacterium tuberculosis infections. Tenosynovial infections of both types are far more common than joint and bone infections. In North America, the most common chronic bacterial infection is nocardiosis and the most common fungal infection is sporotrichosis. Hansen disease is the most common chronic infection affecting the hand in developing countries. It infects peripheral nerves, and the level of suspicion should be high when peripheral neuropathy of the ulnar nerve, with or without nerve enlargement, is seen in an immigrant.

Chronic hand infections caused by protozoa, *Prototheca*, and parasites are sporadically encountered in Africa, Asia, and South America but are rare in North America. Since 1981, chronic hand infections due to human immunodeficiency virus (HIV) have become increasingly common in emergency departments and consultation rooms. HIV blood testing and counseling should be considered in acute, recurrent, and chronic infections of the hand. Once a diagnosis is made, it is wise to arrange for consultation with an infectious disease specialist. Pharmacologic treatment of a chronic hand infection requires close monitoring for serious side effects and drug resistance. Recurrence of the infection due to drug resistance may occur because of poor patient compliance or prescription practices. Consultation with an infectious disease specialist, microbiology personnel, and a pathologist improves the accuracy of a diagnosis.

Diagnosis

A presumptive diagnosis of a chronic hand infection is made when one considers it as a possibility in the face of any chronic cutaneous, subcutaneous, tenosynovial, nerve, joint, or bone lesion (i.e., nodule, abscess, ulcer, sinus, fistula, or a nondescript mass) of the hand or upper extremity. Obtaining a careful history is essential and must include details about underlying diseases (e.g., leukemia, aspergillosis, diabetes, and mucormycosis), medications (e.g., corticosteroids with immigrants and reactivation of tuberculosis), occupation (e.g., barbers and interdigital sinuses[89]), immigrant status,[19] and recent travel.[37]

A history of contact with pigeons may suggest a diagnosis of cryptococcosis. A Thai immigrant's ingestion of contaminated pork may suggest a helminth infection. The initial appearance

TABLE 3.1 Etiology, Diagnosis, and Treatment of Chronic Infections of the Hand and Upper Extremity

	Organism	Predilection	Diagnosis	Chemotherapy
Bacteria	*Actinobacillus actinomycetemcomitans*	TS	Actinobacillosis	Ampicillin
	Actinomyces israelii	S, SC, J, B	Actinomycosis	Penicillin
	Bartonella henselae and *Bartonella quintana*	S	Bacillary angiomatosis/CSD	ERY
	Francisella tularensis	S	Tularemia	Streptomycin
	Nocardia species	S, SC, B	Mycetoma (actinomycetoma)	As per C&S
	Treponema pallidum	S, SC	Syphilis	Penicillin
	Treponema pertenue	S	Yaws	Penicillin
	Bacillus anthracis	S	Anthrax	Doxycycline
	Brucella	B, J	Brucellosis	RFM, TC
Fungi	*Aspergillus*	S, SC	Aspergillosis	AB, fluconazole
	Blastomyces dermatitidis	TS, B	Blastomycosis	AB, KTC
	Candida albicans	S, TS	Candidiasis	AB
	Coccidioides immitis	TS, J	Coccidioidomycosis	AB, miconazole
	Cryptococcus neoformans	TS	Cryptococcosis	AB
	Exophiala jeanselmei	Deep abscess	Chromohyphomycosis	None
	Histoplasma capsulatum	TS, J	Histoplasmosis	AB, KTC
	Madurella mycetomatis	S, SC	Mycetoma (eumycetoma)	As per C&S
	Rhizopus arrhizus	SC	Mucormycosis	AB
	Sporothrix schenckii	S, SC	Sporotrichosis	KTC, SSKI, AB
Mycobacterium leprae	*M. leprae*	N	Hansen disease	D, RFM, CFZ, ETH
Tuberculous mycobacteria	*M. tuberculosis*	S, TS, J, B	Typical tuberculosis	INH, RFM, ETH, PZA
	M. bovis	TS	Typical tuberculosis	INH, RFM, ETH, PZA
Nontuberculous mycobacteria	*M. asiaticum*	TS	Atypical tuberculosis	TC, CLAR
	M. avium (MAC or MAI)	SC, TS, J, B	Atypical tuberculosis	AZI, CLAR, ETH, RFB
	M. chelonae	TS	Atypical tuberculosis	AMK, ERY
	M. fortuitum	Deep abscess	Atypical tuberculosis	INH, RFM, MIN
	M. haemophilum	J	Atypical tuberculosis	
	M. kansasii	S, TS, J, B	Atypical tuberculosis	INH, RFM
	M. marinum	S, TS, J, B	Atypical tuberculosis	RFM, TC, MIN, AMK
	M. malmoense	TS, J	Atypical tuberculosis	INH, RFM, ETH, PZA
	M. szulgai	TS, BU	Atypical tuberculosis	INH, RFM, ETH, PZA
	M. terrae	S, SC, T, J	Atypical tuberculosis	ETH, CYCLO
Parasites (worms)	*Gnathostoma spinigerum*	SC	Gnathostomiasis	None
	Onchocerca volvulus	TS	Onchocerciasis	None
Prototheca	*Prototheca wickerhamii*	S, TS	Protothecosis	AB, TC
Protozoa	*Leishmania*	S	Leishmaniasis	Antimony, AB
Mites	*Sarcoptes scabiei*	S	Scabies	Permethrin cream
Viruses	HIV	CD4 lymphocyte	AIDS	NRTI/PI
	HPV	S (epidermis)	Warts (verruca vulgaris)	Topical salicylic acid
	Herpes simplex virus	S	Herpetic whitlow	Acyclovir
	Orf (paravaccinia) virus	S	Orf/milker's nodule	Cidofovir, imiquimod, idoxuridine cream

B, Bone; *BU*, bursa; *C&S*, culture and sensitivity; *CSD*, cat-scratch disease; *J*, joint; *MAC*, *Mycobacterium avium* complex; *MAI*, *Mycobacterium avium-intracellulare*; *N*, nerve; *S*, skin; *SC*, subcutaneous; *TS*, tenosynovium.

Chemotherapeutic drugs are abbreviated as follows: *AB*, amphotericin B; *AMK*, amikacin; *AZI*, azithromycin; *CFZ*, clofazimine; *CHL*, chloromycetin; *CLAR*, clarithromycin; *CYCLO*, cycloserine; *D*, dapsone; *ERY*, erythromycin; *ETH*, ethambutol; *GNT*, gentamicin; *INH*, isoniazid; *KTC*, ketoconazole; *MIN*, minocycline; *NRTI*, nucleoside reverse transcriptase inhibitor; *PI*, protease inhibitor; *PZA*, pyrazinamide; *RFB*, rifabutin (Mycobutin); *RFM*, rifampin (Rifadin); *SSKI*, supersaturated solution of potassium iodide; *Sulfa*, sulfonamides; *TC*, tetracycline.

of the lesion is nonspecific, and a lesion suspected to be an unusual tumor may be just a chronic infection.[54,58,88] Immunocompromised states that predispose patients to chronic hand infections include congenital hypogammaglobulinemia, HIV infection, organ transplantation, hematologic malignancies, pancytopenic anemia, systemic lupus erythematosus, and diabetes. Vascular compromise—that is, arterial injury, venous stasis, lymphangitis, severe scarring, radiation fibrosis—always increases the risk for infection.

The opposite is also true: one must suspect immunodeficiency when a certain fungus, for example, *Aspergillus*, *Cryptococcus*, *Pseudallescheria boydii*, or a Mucorales (formerly called Zygomycete), is encountered in a culture from an infected wound. An infective agent often lives in balance with an immunocompromised host. Reactivation of a latent organism in the hand can occur when malnutrition is present, cytotoxic chemotherapy is administered to treat a malignancy, and/or treatment with immunosuppressive agents (most commonly, corticosteroids) is initiated. Diagnosis is delayed until tissue (e.g., drainage, aspirate, punch biopsy, needle biopsy, open biopsy) is sent for a smear and cultured for bacteria (aerobic and anaerobic), mycobacteria (typical and atypical), and fungus.

Anaerobic organisms, such as *Actinomyces israelii* and *Nocardia* spp., do not grow well unless the specimen is properly transported to the laboratory in anaerobic medium. Organisms in chronic infections are often sparse, and they grow slowly (*M. tuberculosis* divides approximately every 24 h). Some organisms require a specific temperature for growth (e.g., *Sporotrichum schenckii*, *M. marinum*, *M. haemophilum*, *M. chelonae*, and *M. ulcerans* grow at 30°C; *M. xenopi* grows at 42°C). Some organisms do not grow at all unless ideal growth medium is provided (i.e., *M. haemophilum* requires hemoglobin). Improper collection, and/or delay in transportation of specimens, may impair growth of organisms and result in delayed treatment. There is no other area of clinical medicine where specimen selection, collection, and transportation are so important and in which close communication with the pathologist, microbiologist, and infectious disease specialist is imperative.

Laboratory Techniques

Five basic laboratory techniques can be used for the diagnosis of infectious diseases: (1) direct visualization of the organism under a microscope, (2) growth and isolation of the organism in culture, (3) serological testing by detection of microbial antigen and antimicrobial antibody, (4) detection of a specific microbial nucleotide sequence, and (5) gross and microscopic pathology. All require proper collection of the specimen and transportation to a laboratory as the following subsections detail.

Guidelines for Specimen Collection and Handling

The successful identification of a specific pathogen often depends on collection methods, transportation process, and laboratory algorithms suitable for various organisms and samples. The specimen must be kept moist and transported rapidly. In general, the more quickly a specimen is planted onto an appropriate medium, the better the chances for isolating bacterial pathogens. For ideal fungal cultures, specimens should be transported to the microbiology laboratory within 1 h of collection. If a delay is anticipated, the specimen should be refrigerated until prompt next day delivery can be ensured. A sterile container, securely covered, is adequate; bacteriostatic saline or formalin should not be used for microbiology specimens. Biopsied tissue or pus is better as a specimen than swabs for routine anaerobic, mycobacterial, and fungal cultures.

The suspected pathogen must always be communicated to the microbiologist personally and in writing if other than routine bacteria are suspected (e.g., *Nocardia*, *Actinomyces*, *M. marinum*, *M. ulcerans*, *Sporothrix*, *Bartonella*). This facilitates the microbiologist's choice of the best incubation medium, temperature, and period. Because there are many pathogen-specific paradigms for collection–transportation procedures, it is recommended that the surgeon seek advice from the laboratory microbiologist when in doubt about a particular situation. It is absolutely essential that the microbiology laboratory be informed of the site of origin of the sample to be cultured, chronicity of the infection, and possible infectious agents suspected. This information determines the selection of culture medium, temperature of incubation, and the length of time to culture.

Swabs of superficial ulcers from the skin surface of a sinus tract or from open abscesses commonly yield a host of mixed bacterial flora and often do not reflect the organism's true infectious significance. For such infections, every effort should be made to biopsy tissue from the deeper aspects of the lesion or from the margins where the organisms are actively spreading. An adequate quantity of material should be obtained. At least 1 mL of fluid or a 1-g piece of tissue should be obtained for bacterial identification.

For mycobacterial identification, 10 mL of fluid or a tissue as large as possible should be obtained to compensate for the "paucibacillary" nature of the hand infection.[3] For example, swabs are not adequate to detect the sparse organisms of tuberculous infections. Characteristically, chronic lesions contain few organisms, so the swab is likely to obtain much serum and few organisms. To recover the most bacteria, mycobacteria, and fungi, a swab should never be submitted in lieu of curetting, biopsy material, or synovial fluid.

Tissue biopsy is more likely to show the infecting organisms than pus or necrotic detritus. If a swab is used, the patient's interests are best served by vigorous rather than gentle application of the swab to the target tissue. Biopsy from the undermined edge of an ulcer is far superior to a swab culture from the surface. Open biopsy is better than needle aspiration, punch biopsy, or superficial curettage of infected tissue. For meaningful culture results, laboratories prefer surgically obtained tissue samples, aspirates of closed abscesses, or a small amount of pus. Organism concentrations in synovial fluids and pus may be low, so as much fluid as possible should be obtained whenever mycetoma, mycobacterial, or fungal infection is a serious consideration. Specimens for smear and culture should be collected and transported in closed, leakproof, sterile containers.

Organisms are not uniformly distributed in infected tissue; thus, several parts of the lesion should be sampled for smears and cultures to find the infecting organism. Impression smears made by gently pressing a freshly cut surface of the tissue onto a slide increases the chance of organism identification and should be requested from the microbiology laboratory in addition to routine ground tissue smears. This is because tissue

impression smears are easier to read and interpret than those made from material that has been ground or macerated. Gram stains, calcofluor-white, or potassium hydroxide (KOH) stains for fungi, and acid-fast stains for mycobacteria, can also be done on slide impression smears.

If results prove negative but signs and symptoms indicate otherwise, repetition of biopsy, smears, and cultures may be necessary. If antibiotic therapy has been initiated, a direct smear may be the only available guide to the etiology because growth may be inhibited. After biopsy, the tissue specimen is immediately bisected: half of it is sent to the pathologist in formalin, and the other half is sent promptly to the microbiologist for smears and cultures in a sterile container without formalin because it kills organisms.

An "eight-pack" tissue culture is sent to the microbiology laboratory for diagnosis (Table 3.2). The first three packs are sent immediately for staining: gram stain for bacteria, acid-fast stain for mycobacteria, and KOH or stains for fungi (Table 3.2). The next five packs are for cultures: two for aerobic and anaerobic bacteria, two for typical and atypical mycobacteria, and one for fungus. *M. marinum*, *M. haemophilum*, *M. ulcerans*, and *Sporothrix schenckii* grow best at 30°C. The rest of the mycobacteria grow best at 37°C; only one, *M. xenopi*, grows best at 42°C.

The microbiologist needs to know that the specimen is from a chronic lesion so that it can be incubated at an appropriate temperature. The microbiologist also should get the tissue fluid (i.e., pus, synovial fluid, serosanguineous exudate), whenever available, for eight-pack smears and cultures. The laboratory must know which antimicrobial agents, if any, the patient is taking. Whenever possible, the specimen is obtained before intraoperative antimicrobial agents are administered. A sterile tube with a tight-fitting cap is adequate for transporting bodily fluids. A sterile bottle or a jar should be used to transport tissue specimens.

Tissue should be promptly forwarded to the laboratory. For chronic and unusual lesions, more often than not, I deliver the specimen to the microbiologist. This gives me an opportunity to communicate clinical history about the patient and tell the pathologist or microbiologist which organisms I am looking for. Fastidious organisms may not survive prolonged storage. Pus, fluid, and tissue should be placed into a transport vial in which anaerobes can survive for several hours in case the specimen is not delivered to the laboratory promptly. A simple way to collect and transport a fluid specimen, especially for anaerobes, is to aspirate at least 1 mL of it (pus, synovium) with a needle into a syringe, discharge any residual air at the top of the fluid, and seal off the syringe. It is important not to leave any air in the needle before sealing it.

Histoplasma capsulatum, *Cryptococcus neoformans*, *M. bovis*, *M. avium*, *Nocardia*, and *Bartonella* may take more than 6 weeks to grow, and it is imperative to request that the microbiology laboratory not discard the cultures for at least 4 weeks. *M. ulcerans* and *M. malmoense* may take 12 weeks to grow; so to cover all the organisms, I request that the microbiologist not discard the cultures for 12 weeks and to notify me as soon as growth is positive. It is a good idea to seek help from an infectious disease specialist who can closely follow the growth plates in the laboratory. In the care of immunocompromised patients or difficult diagnostic problems, numerous cultures or tests are often requested on the same specimen, for which there may be an inadequate quantity. The clinician should prioritize the test requests for the laboratory based on the highest clinical suspicions.

Four laboratory tests are used for identification of bacteria and mycobacteria: (1) direct visualization of the organism by staining, (2) detection of pathogenic-specific antigens and antibodies, (3) cultures in growth media, and (4) nucleic acid (DNA and RNA) amplification techniques. The fourth test is new and not widely available but is very useful for diagnosing stains, cultures, and serology tests and is very rapid.

TABLE 3.2 The Eight-Pack Tissue Culture for Microbiology Covers Bacteria, Mycobacteria, and Fungi

Biopsy tissue is divided into two parts.
- I. Histopathology: 50% of tissue in formalin
- II. Microbiology: 50% of tissue *without* formalin is divided into 8 parts

Smear and stain
1. Gram stain
2. Acid-fast bacillus stain (Ziehl-Neelsen or Kinyoun)
3. Fungus stains (potassium hydroxide or calcofluor-white stain)

Culture and sensitivity
1. Aerobic (use transport medium, e.g., "Port-A-Cul™")
2. Anaerobic (use transport medium, e.g., "Port-A-Cul")
3. Tuberculous mycobacteria at 37°C
4. Nontuberculous mycobacteria at 30°C (*M. marinum*) and 42°C (*M. xenopi*)
5. Mycotic culture media (Sabouraud dextrose agar or brain–heart infusion agar)

This smear and culture protocol is useful for bacteria, mycobacteria, and fungi from the biopsy specimen. The circulating nurse sends half the biopsy specimen to the pathologist in formalin and the other half as an "eight pack" to the microbiologist in a sterile cup without formalin or saline. The specimen is delivered to the microbiologist immediately at the conclusion of surgery.

Direct Visualization of the Organism by Staining

Gram staining is often the first step used by the hospital microbiology laboratory to identify an unknown bacterium from a clinical specimen. Gram stain differentiates between organisms with thick peptidoglycan cell walls (gram positive) and those with thin peptidoglycan cell walls that can be dissolved with acetone (gram negative). The sensitivity is such that $>10^4$ bacteria per mL are necessary for detection.

An acid-fast stain identifies organisms that retain red carbol fuchsin dye after washing with an acid-alcohol (i.e., "acid fast"). Ziehl-Neelsen and Kinyoun stains are carbol fuchsin-based and stain mycobacteria red. However, fluorescent stains are more sensitive for detection of mycobacteria in direct specimens. The organisms stain brightly and can be clearly distinguished from background material. Slides stained with a fluorescent dye can be examined reliably with an objective lens of lower magnification (×25′) than the oil immersion lens (×100′) required for carbol fuchsin-stained smears; in addition, reading slides is faster and more reliable. This stain is preferred by the Centers for Disease Control and Prevention (CDC). Modification of an

acid-fast stain also allows detection of *Actinomyces*, *Nocardia,* and other weakly acid-fast organisms.

Detection of Pathogenic-Specific Antigens and Antibodies (Serology)

Biochemical methods are used to detect the antigens of newer mycobacterial species from cultures. Diagnosis of cryptococcosis is confirmed by a high cryptococcal antigen titer in the purulent discharge from a cryptococcal skin ulcer. Measurement of serum antibody (i.e., IgG or IgM) provides an indirect marker for past or current infection with a specific pathogen. Testing for the presence of antibody has been successfully used for diagnosis of coccidioidomycosis and histoplasmosis in infections of the hand and elsewhere.

Detection of Specific Microbial Nucleotide Sequences

Nucleic acid amplification technology (i.e., detection and quantitation of specific DNA and RNA base sequences in clinical specimens) has gained widespread use and has become a rapid and powerful tool for diagnosis of viral, bacterial, mycobacterial, fungal, and parasitic infections. The use of nucleic acid tests generally involves lysis of intact cells and denaturation of DNA or RNA to render it single-stranded. Probes, that is, primer sequences complementary to pathogen specific base sequences, then detect the pathogen-specific sequences. Use of nucleic acid polymerase chain reaction (PCR) analysis allows very rapid DNA sequence analysis and direct identification of *M. tuberculosis* in clinical specimens. PCR can detect <10 organisms/mL in a clinical specimen, compared with 100 for cultures and the 10,000 necessary for a positive smear.

PCR analysis provides a useful method when a smear and culture are negative in the presence of a clinical presentation of tuberculosis (TB). The test is generally accessible but is skill-intense and expensive. The potential for nucleic acid amplification testing (i.e., PCR) to enhance patient care is greatest when suspicion of TB is moderate to high and specimens are acid-fast bacillus (AFB) smear negative. At least 2 g of tissue are necessary to do this test. The tissue should be set aside and preserved in 70% alcohol for later processing in case conventional smear and culture tests prove negative.

Two commercial DNA probes approved by the Food and Drug Administration (FDA) are available for the detection of organisms in the *M. tuberculosis* complex. They are used with organisms grown in culture as well as directly on patient specimens. The procedure can be performed and the organism identified within a matter of hours from the time an infection is suspected. Conventional cultures for TB generally take many weeks.

Organism Isolation in Culture and Drug-Susceptibility Testing

Several quantitative studies have shown that a minimum of 10,000 bacilli/mL of specimen is necessary to detect bacteria in stained smears. When host immunity is high and bacterial virulence is low, infected tissue may have far less organisms per mL. In such cases, acid-fast staining may be negative. In contrast, <100 organisms are necessary to grow in culture. Green and Adams suggested that when investigating chronic infections, tissue samples be cultured on blood agar, a Lowenstein-Jensen medium, and a Sabouraud glucose agar.

These three media should allow growth of most bacteria, mycobacteria, and fungi.[44] It is important that the clinician notify the laboratory if a pathogen with specific growth requirements is suspected so that special culturing media can be used. *M. haemophilum* grows best in a selective agar medium enriched with hemoglobin. A major improvement in mycobacteriology has been the development of commercial broth systems that allow for rapid growth and detection of mycobacteria within 1 to 3 weeks, compared to solid media in which growth takes 3 to 8 weeks.

Drug-Susceptibility Tests

Drug-susceptibility tests are performed on initial isolates from all patients with suspected TB to identify what should be an effective drug regimen. To generate rapid testing and faster turnaround time for better patient management, the radiometric BACTEC™ system is used to test the sensitivity of all primary antituberculous drugs (i.e., isoniazid, rifampin, pyrazinamide, and ethambutol).

Additional Evaluation

Isolation of *Aspergillus* or *Nocardia* from a patient without a known immunodeficiency should trigger a workup for an underlying host immune defect. Such a workup should include, at a minimum, evaluation of B cell-mediated humoral immunity (serum immunoglobulins and isohemagglutinins) and T cell–mediated cellular immunity (CBC count and differential, absolute lymphocyte count, peripheral smear, platelet count, and erythrocyte sedimentation rate). The most common cause of immunodeficiency currently is acquired immunodeficiency syndrome (AIDS). AIDS and iatrogenic deficiencies that result from therapies that modulate the immune system (e.g., corticosteroids, posttransplant immunosuppression, and cytotoxic chemotherapy for malignancies) are leading causes of chronic infections. Primary (congenital) immunodeficiency syndrome associated with a hand infection is rare but has been reported.[114]

An algorithm for requesting stains and cultures of biopsy material is useful in the operating room. When tenosynovitis, synovitis, or osteomyelitis is encountered during biopsy, the responsible organism is generally not discernible because the infected tissue does not have pathognomonic characteristics. Rice bodies may be found in rheumatoid arthritis, TB, and fungal infections (e.g., coccidioidomycosis, histoplasmosis, and sporotrichosis). Certain types of tenosynovitis have a high tendency of recurrence unless radical surgical excision is combined with appropriate antibiotics such as in the following infections: actinomycosis, sporotrichosis, coccidioidomycosis, *M. terrae*, and *M. avium*. Thus, complete synovectomy is reasonable at the time of biopsy or surgery because this will reduce the microbial burden for subsequent antibiotic treatment.

An exception to this approach is when the diagnosis of tuberculosis is endemic in a country (e.g., India, Hong Kong) or is known, such as in a patient with positive stains from pus, exudate, synovial fluid, sputum, or gastric washings for mycobacteria. The excised synovium should be sent for special stains (i.e., methenamine silver stains are common to many fungi) and cultures at three temperatures: *M. marinum*, *M. chelonae*, *M. hemophilum*, and *Sporothrix schenckii* grow best at 30°C;

M. xenopi at 42°C; and the rest at 37°C. *M. avium*, *M. fortuitum*, *M. terrae*, and *M. chelonae* require prolonged incubation, and some require special media—*M. hemophilum* grows only in a hemoglobin-reinforced medium, *M. malmoense* requires a pyruvate-containing medium, and *A. actinomycetemcomitans* grows in the presence of CO_2 and an aerobic as well as anaerobic environment. *Actinomyces* spp. and *Nocardia* spp. grow only in anaerobic media.

Treatment

In the war between humans and microbes, the outcome depends on the dose and virulence of the microbe and the immunity of the host. Antibiotics reduce the quantity of the invading organisms, but final elimination of them is determined by innate immunity—that is, phagocytes (neutrophils and macrophages), natural killer lymphocytes, proteins and enzymes of a complement system, and cytokines—and two arms of acquired immunity: humoral and cell mediated. Humoral immunity is conferred by B lymphocytes, which mature to plasma cells and produce immunoglobulin antibodies (i.e., IgG, IgA, IgM, IgE, IgD) that eliminate extracellular organisms. Cell-mediated immunity is mediated by T lymphocyte helper cells ($CD4^+$ T lymphocytes). The helper cells facilitate activation of phagocytes and destroy ingested microbes, and T lymphocyte cytotoxic cells (CTLs = CD^{8+} T lymphocytes) eliminate intracellular organisms by killing the cells that harbor them. Eosinophils produce antibodies against multicellular parasites, and eosinophilia is pathognomonic of a parasitic infection.

When humoral and cellular immunity is depressed, it is critical that three important components of treatment be implemented: antibiotics, surgical debridement of the infected tissue, and improved nutrition. Poor nutrition, whether from alcoholism, cancer, major trauma, or inadequate diet, predisposes the patient to infections that would otherwise be easily combated by healthy individuals. When a patient is therapeutically immunosuppressed and does not respond to adequate antibiotic therapy and surgical debridement, a reduction in immunosuppressive therapy and an improvement in nutrition may upgrade the host immunity to successfully combat the invading organisms (Table 3.3).

TABLE 3.3 Ten Factors That Improve the Outcome of Chronic Infection Treatment

1. The initial appearance of the lesion is nonspecific. Early diagnosis is made if early biopsy is done.
2. Beware of immunocompromised states, which predispose patients to chronic hand infections and may require higher doses of medication. Management of immunosuppressed patients may require upscaling antibiotic therapy and nutrition and downscaling immunosuppressive therapy to control infection.
3. Biopsy specimen should be sent to the microbiology laboratory in a sterile container.
4. Pathology specimen only should be sent in formalin.
5. Alert microbiology staff of the possibility of a chronic infection; they will require special media and may hold cultures for 12 weeks or more, especially in suspected cases of mycobacteria, fungus, or mycetoma.
6. Early consultation with an infectious disease specialist will optimize proper management of specimens and follow-up.
7. Eight-pack tissue for histopathology and cultures improves diagnostic probability (gram stain, acid-fast, KOH, aerobic, anaerobic, mycobacteria, atypical mycobacteria, fungus).
8. Request the laboratory to do cultures at 30°C (*M. marinum*, *M. chelonae*, *M. hemophilum*, *M. ulcerans*, and sporotrichosis), at 37°C (*M. tuberculosis*), and at 42°C (*M. xenopi*).
9. Request special media for cultures as necessary (*M. hemophilum* grows only in a hemoglobin-reinforced medium; *M. malmoense* requires a pyruvate-containing medium, actinomycetemcomitans grows in the presence of CO_2) and anaerobic environment. Actinomyces and *Nocardia* spp. grow only in anaerobic media.
10. Chemotherapy management is best done in conjunction with an infectious disease specialist because of varied and serious drug toxicity and emerging resistance to multiple drugs.

CHRONIC BACTERIAL INFECTIONS

Actinomycosis, botryomycosis, brucellosis, mycetoma (actinomycetoma, eumycetoma), syphilis, and yaws are rare chronic bacterial infections that have been reported to sporadically affect the hand and upper extremity. A newly emerging septic tenosynovitis of the hand is recognized to be caused by actinobacillosis. Pyoderma gangrenosum and neutrophilic dermatoses, although not infectious, are included in this section because (1) they mimic a fulminating infection that will become chronic if incorrectly diagnosed; (2) if mistakenly treated by surgery, the condition gets worse; and (3) oral prednisone remarkably and rapidly cures the conditions. With surgery, pyoderma gangrenosum spreads furiously and centrifugally (so-called pathergic reaction) and has even led to unnecessary amputations. It is important to recognize cutaneous anthrax because it has become a bioterrorism method since the 9/11 attack.

Actinobacillosis

Actinobacillosis is caused by *Actinobacillus actinomycetemcomitans*, a gram-negative bacillus that is part of the endogenous flora of the mouth and can be obtained from about 20% of teenagers and adults. It occurs in association with *A. israelii*, and it behooves physicians to look for the latter when found in infected tissue. *Actinobacillus* infections have emerged only recently.

Clinical Findings

A. actinomycetemcomitans may cause chronic tenosynovitis of dorsal wrist tendons or finger flexor tendons. After an assault, a deep hand laceration from a tooth may cause recurrent abscesses and a draining sinus at the site of original trauma in an adult patient. X-rays may show chronic osteitis of the injured metacarpal.

Diagnosis

Pus from a draining sinus may yield profuse growth of *A. actinomycetemcomitans* if grown in the presence of CO_2. Otherwise, it is difficult to grow and identify the organism.

Treatment

Incision, drainage, and ampicillin may completely eliminate the infection. Tenosynovectomy and intravenous gentamicin or

oral tetracycline may also resolve the infection without further recurrence.

Actinomycosis

Etiology and Epidemiology

Actinomycosis is most commonly caused by *Actinomyces israelii*, a normal inhabitant of the oral cavity. Actinomycosis, by definition, is caused by endogenous human flora while actinomycetoma, described later, is caused by exogenous pathogenic bacteria in soil. Two percent of actinomycosis cases occur in the upper extremity. Most cases of hand actinomycosis have been noted sporadically in case reports.

Clinical Findings

In the hand, a closed-fist injury or a bite is the most common cause of actinomycosis. Oral flora may be implanted over the metacarpophalangeal joint or the metacarpal head on impact. This type of injury is designated as "punch actinomycosis." A dentist can contact it during examination of the mouth without gloves.

Clinical presentations are varied. In the early stages it may appear as nonspecific, painful induration, or as a nontender, mobile nodule. The nodule may later form a draining sinus. Any suppurative inflammatory reaction that stubbornly resists treatment and tends to discharge continuously should lead one to suspect the possibility of actinomycosis, especially if it is at the site of a human bite wound. It may start as an acute abscess, or there may be a painless and persistent swelling of the hand after the acute inflammation from the initial trauma subsides. Subcutaneous tissue may become indurated and adherent to subjacent bone. It may present as a recurrent swelling with sinuses that intermittently discharge purulent fluid.[100] When tendon sheaths are involved, purulent material may contain melon seeds, as in tuberculosis and fungus infections. A recurrent fluctuating palmar abscess may occur.

Once actinomycosis is established locally, it spreads contiguously in a slow but progressive manner, ignoring tissue planes. In the forearm, it may arise as a mass from hematogenous spread and can masquerade as a soft tissue neoplasm. Finally, contiguous invasion of subjacent bones occurs. The bones of the hand and wrist may have cystic and sclerotic or lytic changes. Isolated actinomycosis osteomyelitis is rare and may occur in the proximal phalanx or metacarpal. Infectious destruction may even cross from the dorsal-to-palmar or palmar-to-dorsal side of the hand. Infection of the upper arm can occur but is rare. Axillary nodes may become enlarged.

Diagnosis

The identification of "yellow sulfur granules" of actinomycosis organisms from a draining sinus or pus from an abscess is diagnostic. Sulfur granules are a yellow conglomeration of microorganisms that form only in vivo and characteristically are identified in bandages that cover a draining sinus. Biopsy is necessary to obtain clinical material for diagnosis if a draining sinus is not present. A specimen must be sent and cultured in anaerobic media. Cultures are positive in only 25% of the cases, perhaps because the specimen was not sent to the laboratory in anaerobic media. Histopathology of infected tissue shows the characteristic organisms and diagnosis can be firmly made in the absence of positive cultures.[80]

Treatment

Penicillin is the treatment of choice. Intravenous penicillin must be employed in high doses for several weeks followed by oral penicillin or amoxicillin for 6 to 12 months. Short-term treatment with antibiotics may result in temporary cessation of drainage. When the therapy is discontinued, however, drainage may recur. Without definitive treatment, the infection can persist for several decades and cause extensive deformities. For penicillin-allergic patients, tetracycline, erythromycin, minocycline, and clindamycin are alternatives. If infection recurs, surgical debridement is an essential component of further antibiotic treatment.

Anthrax

Etiology and Epidemiology

In the United States, the annual incidence of anthrax exposure declined from 130 cases in the early to mid 1900s to a single case reported in 1992. It reappeared in the United States as a bioterrorism method in 2001. Ten cases of cutaneous anthrax and 10 cases of pulmonary anthrax (four fatal) were reported within a month after September 11. Of the numerous biologic agents that may be used as weapons, anthrax is one of the most devastating.

Anthrax infection is caused by *Bacillus anthracis*, a gram-positive, encapsulated, spore-forming bacillus. The name *anthrax* (Gk. *anthracis*, "coal") refers to the typical black eschar that is seen on affected areas. Ninety-five percent of patients with cutaneous anthrax are diagnosed when they have a relatively painless necrotic black ulcer. Humans can acquire the disease directly from contact with infected herbivores (i.e., agricultural anthrax); indirectly from contaminated meat, wool, hides, or leather from infected animals (i.e., industrial anthrax), through accidental inoculation in the laboratory (i.e., laboratory-acquired anthrax); or unexpectedly from exposure to "weaponized" spores of bioterrorism (i.e., biocriminal anthrax). The clinical forms include (1) cutaneous anthrax, which accounts for more than 95% of cases; (2) intestinal anthrax, from eating infected meat; and (3) pulmonary anthrax, from inhaling spore-laden dust. Cutaneous anthrax of the hand and upper extremity occurs in approximately one-third of all cases in an epidemic and may be presented to a hand surgeon primarily.

Clinical Findings

Cutaneous anthrax occurs after the deposition of the organism into the skin at the site of a previous cut or abrasion. The lesion may occur on a finger or hand. After an incubation period of 3 days (range, 1-12 days), the skin infection begins as an area of local edema that becomes a pruritic macule or papule. The papule progresses to a vesicle or vesicles, surrounded by erythema, in 1 to 2 days. The vesicle contains clear or bluish fluid (Figure 3.1). Patients may have a fever and regional lymphadenopathy. The vesicles rupture in 2 to 14 days and leave behind a painless black skin ulcer that becomes a black eschar (Figure 3.2). The eschar contracts into an ulcer, usually 1 to 3 cm in diameter, with small, 1- to 3-mm vesicles surrounding the ulcer. A characteristic black necrotic center develops by 4 weeks, often associated with extensive local edema. Unless the disease becomes systemic, the eschar dries, loosens, and falls off in the next 1 to 2 weeks. A lesion on the finger may heal with full mobility. The common clinical description "malignant



FIGURE 3.1 The initial lesion of cutaneous anthrax is a vesicle or vesicles surrounded by erythema. The vesicle contains clear or bluish fluid.

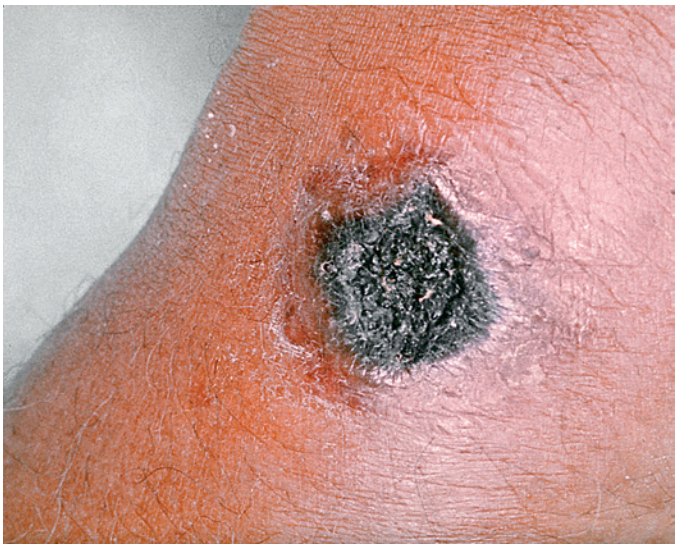

FIGURE 3.2 An anthrax skin ulcer has a black central necrosis. The local lesion is painless but the regional lymph nodes may be enlarged and tender. (From Habif TP: *Clinical dermatology: a color guide to diagnosis and therapy*, ed 5. Philadelphia, 2010, Elsevier; Figure A-3, with permission.)

pustule" is actually a misnomer because the cutaneous lesion is not purulent.

Diagnosis

Anthrax exposure is diagnosed by isolating *B. anthracis* from the vesicular fluid of skin lesions. Gram-staining reveals bacilli in the subcutaneous tissue.

Treatment

About 20% of untreated cases of cutaneous anthrax become systemic and result in death. Antibiotic therapy does not appear to change the course of eschar formation and healing; however, it does decrease the likelihood of systemic disease and death. When treated with appropriate antibiotics, the death rate is <1% and lesions resolve without complications or scarring in 80 to 90% of cases. It is rare for the black eschar on the hand to extend deeper than the dermis and over the whole of the hand's dorsum and distal forearm; if it does, soft tissue coverage may be required.[23] The eschar may extend down to the muscle fascia. In these cases, the eschar is excised, and the defect is grafted using split-thickness skin grafts. Deep eschars in the forearm have been identified to cause severe compression neuropathy of superficial nerves.

Duration of antibiotic treatment for animal-acquired and bioterrorism-acquired anthrax differs. Animal-acquired anthrax is treated with doxycycline (100 mg PO bid), ciprofloxacin (750 mg bid), or amoxicillin (500 mg tid) orally for 7 to 10 days. Lesions become sterile within 24 h and resolve within weeks. Direct person-to-person spread of anthrax is extremely unlikely. There is no need therefore to treat contacts of infected individuals unless they were also exposed to the same primary source of infection. Bioterrorism-acquired anthrax is classified either as anthrax exposure or anthrax infection. Both exposure and infection are treated for 60 days because aerosol inhalation of anthrax is presumed in instances of bioterrorism.

The case fatality rate of 11 treated cases of an inhalational bioterrorism event in 2001 was 45%.[57] A bioterrorist event should be reported to www.bt.cdc.gov, a website that also provides information about clinical diagnosis and management of anthrax and all agents of bioterrorism. In the United States, anthrax vaccine is recommended only for high-risk populations, including military combat personnel, persons who work directly with the organism in a laboratory, those who work with imported animal hides or furs, or those who handle potentially infected animal products in high-incidence areas.

Botryomycosis

Etiology and Epidemiology

Botryomycosis is a rare, chronic, granulomatous, suppurative, bacterial skin and subjacent soft tissue infection that produces loose clumps of bacteria that resemble grains. Among more than 100 cases of botryomycosis reported in the literature, three cases affecting the hand have been identified. The characteristic histologic finding of "granules" in clusters is the origin for the term *botryomycosis* (Gk. *botrys*, "bunch of grapes" in histology; mycosis for its clinical and histologic resemblance to fungal infection). The condition is in fact produced by bacteria and is truly a "granular bacteriosis." *Staphylococcus aureus*, *Pseudomonas vesicularis*, *Moraxella nonliquefasciens*, and tuberculosis have been reported to cause botryomycosis of the hand. The first case of tuberculous botryomycosis was reported in 2014 and was cured by antituberculous chemotherapy.[109]

Diagnosis

Clinically, histologically, and therapeutically this bacterial infection resembles a fungal one.

Treatment

The condition may respond rapidly to oral antibiotics, or it may be resistant to antibiotic therapy and need complete excision and skin grafting to eradicate the infection.

Brucellosis

Etiology and Epidemiology

Brucellosis is named after Sir David Bruce (1855-1931), the Scottish physician who identified the bacterium. Brucellae are gram-negative coccobacilli that chronically infect animals. Virtually all human infections derive from direct or indirect contact with cattle (*B. abortus*) or goats and sheep (*B. melitensis*). Routes of transmission to humans include cuts in the skin, inhalation of infected aerosols, and ingestion of unpasteurized milk. Brucellosis is endemic in the Middle East, South America, and the Mediterranean area. In Texas and California, the epidemiology of brucellosis has changed from a disease associated with exposure to cattle to one linked to ingestion of unpasteurized goat's milk products imported from Mexico.

Clinical Findings

The musculoskeletal system was affected in approximately one-third of 169 cases.[84] Osteomyelitis and septic arthritis involved the upper extremity. Septic arthritis occurred in the sternoclavicular joint in three cases (1.8%), shoulders in eight (5%), elbows in nine (5.3%), and wrists in six (3.5%). Osteomyelitis occurred in four (2.4%) and tendinitis was noted in one (1.2%). Dactylitis may occur with or without osteoarticular brucellosis.

Diagnosis

Diagnosis is made when blood culture or bone needle aspiration culture grow *B. melitensis*. Chronic brucellar olecranon bursitis may occur when synovial fluid and serum are positive for serologic tests and *B. melitensis* grows on chocolate agar.

Treatment

Repeated 4- to 6-week courses of rifampin and tetracycline may cure the patient without a relapse.

Mycetoma (Actinomycetoma and Eumycetoma)

Etiology and Epidemiology

Mycetoma is a twofold disease complex, caused either by large filamentous bacteria (actinomycetoma) or by fungi (eumycetoma) (synonyms: maduromycosis, Madura foot). Eumycetoma is so named because it is caused by the eumycetes group of fungi. Predictably, fungal eumycetoma is more invasive and more difficult to treat than bacterial actinomycetoma. Mycetoma is characterized by a slowly evolving, often painless, cutaneous and subcutaneous destructive inflammatory granuloma, riddled with abscesses; sinuses with interconnecting channels; and fistulas that drain characteristic colonies of the infecting organisms in the form of grains and granules.

The grains are dense clusters of organisms and are the defining characteristic of this infection. The granules, colonies of the organisms, occur in a triad of chronic infections: mycetoma (eumycetoma and actinomycetoma), actinomycosis, and botryomycosis. Only 2 to 12% of all mycetomas involve the hands, whereas the majority (70%) occur in the feet. Twenty-one cases of the hand and arm were reviewed by Moore in 1954,[82] and since then several more hand cases have been reported. In only three recent cases was the disease diagnosed early at a nodular or abscess stage. In all other cases, diagnosis was delayed until it was in the sinusoidal or musculoskeletal stage; therefore, treatment was difficult.

A mycetoma caused by aerobic bacteria, *Actinomyces* spp., is referred to as actinomycetoma. *Actinomyces* spp. are "higher" bacteria with morphologic characteristics between bacteria and fungi. The majority of actinomycetomas in North America are caused by *Pseudallescheria boydii* (its asexual anamorph is *Scedosporium apiospermum*; previous names, *Allescheria* and *Monosporium*). *Nocardia* is another cause of mycetoma in the hand. It is important not to misdiagnose it as actinomycosis on gross and microscopic examination because of the presence of granules in both.[9]

A mycetoma caused by true fungi is referred to as eumycetoma, true mycetoma, maduromycosis, or Madura foot—named after Madura from South India where the first cases were described. More than 30 fungi are known to cause eumycetoma. Distinguishing mycetomas caused by the *Actinomyces* spp. bacteria (actinomycetoma) and fungi (eumycetoma) is extremely important. Actinomycetoma and eumycetoma both clinically look the same but the treatment and prognosis for the two are distinctly different. In contemporary medical mycology, actinomycosis is not classified as an actinomycetoma because the etiologic agents of actinomycosis are anaerobic and endogenous in the oral flora. Conventionally, only infections caused by exogenous aerobic pathogenic bacteria and fungi are called actinomycetoma and eumycetoma. This clearly differentiates actinomycosis from actinomycetoma.

Microbiology

Mycetoma of the hand has been reported to occur from a wide variety of organisms; many of them are being reported for the first time. Major mycetoma bacteria and fungi are found all over the world and are associated with woody plants and soil. The largest number of infected patients live in the tropics. In the United States, several cases of hand mycetoma have been reported, and they are equally divided between actinomycetoma and eumycetoma. Agents of mycetoma differ in various parts of the world. The most common cause of eumycetoma in the United States is *Pseudallescheria boydii* (asexual anamorph, *Scedosporium apiospermum*; previous names *Allescheria*, *Monosporium*, *Petriellidium*) and of actinomycetoma is *Nocardia*. *Madurella mycetomatis*, *Actinomadura madurae* (Figure 3.3), and *Nocardia brasiliensis* are predominant in India. *N. brasiliensis* and *A. madurae* are the most common causes of mycetoma in Mexico and Central and South America. Actinomycetomas represent 97% of mycetomas in Mexico, and 87% of them are caused by *Nocardia brasiliensis*. *Streptomyces somaliensis* and *Actinomadura pelletieri* are seen in Africa. *N. asteroides* and *Scedosporium apiospermum* are reported to predominate in Japan.

A case of hand eumycetoma caused by *Arthrographis kalrae* was reported in Japan and was successfully treated with itraconazole. A case of *S. somaliensis* hand actinomycetoma was reported in the United Kingdom and was sensitive to and treated with co-trimoxazole (trimethoprim/sulfamethoxazole,



FIGURE 3.3 **A,** This 62-year-old woman from Madura, India, presented with a 7-year history of draining sinuses of the right hand several weeks after a scorpion bite. Multiple courses of antibiotics and other treatments helped transiently. Multiple healed sinuses in various stages can be seen on the indurated palm. **B,** Infection crosses over to the dorsum of the hand. A culture grew *Actinomadura madurae*. **C, D,** As the infection crosses from palmar side to dorsal side of the hand, osteomyelitis of the carpals and metacarpals is evident, characterized by sclerosis and lysis of bone.

Bactrim) and streptomycin. A case of actinomycetoma of the hand caused by *Gordona terrae* was reported in the Netherlands and was cured in two weeks by only doxycycline. *Phialophora jeanselmei* (*Torula jeanselmei*) hand eumycetoma was reported in Thailand. *Aspergillus nidulans* rarely causes eumycetoma of the upper extremity. *Leptosphaeria tompkinsii* is a dematiaceous fungus that is rarely reported as an agent of black-grain mycetoma. The first case of mycetoma caused by *Nocardia caviae* was reported in Brazil. At times, granules are identified in the lesion but fail to grow organisms and identification by a polymerase chain reaction is needed. In rare instances, the bacteriological origin of mycetoma cannot be ascertained.

Clinical Findings

A mycetoma is a characteristic clinical triad of tumification, draining sinuses, and granules in the discharging pus in the distal aspect of a limb. Swelling is woody and indurated (tumification), and multiple sinus tracts drain grain-filled pus; the grains are the infecting organisms. Old sinuses heal and new may grow. Characteristic grains in draining sinuses are 0.2 to 5.0 mm in diameter and may be black, white, yellow, pink, or red, depending on the causal organism. Grains may be difficult to locate in histopathologic sections and require multiple cuts through the paraffin-embedded tissue.

Mycetoma, regardless of fungal or bacterial origin, has a similar clinical presentation. The majority of the patients are males between 30 and 60 years old. The male-to-female ratio is 5:1. It is rare in children, and most that occur in children (80%) are eumycetoma. The disease begins following the traumatic implantation of the etiologic agent from the soil, thorn, or wood splinter into a bare hand of a healthy person. The lesions may be restricted to a finger, palm, dorsum of the hand, dorsum of the wrist, forearm, or upper arm. The lesion may be on both sides of the hand when the infection crosses the metacarpals from the dorsal-to-volar or from the volar-to-dorsal side of the hand.

Mycetomal infection begins in the skin and subcutaneous tissues as a nodule or nodules. Mycetoma tends to follow fascial planes as it spreads proximally and laterally, and with increasing depth, it progressively infects and destroys all connective tissues and eventually bone (see Figure 3.3). In the end, the untreated hand is deformed and functionless.

The annual incidence of nocardiosis in the United States has been estimated to be between 500 and 1000 cases, with 36% being cutaneous nocardiosis. The genus *Nocardia* comprises gram-positive, aerobic, acid-fast, and filamentous bacteria of which *N. brasiliensis* is usually associated with cutaneous and subcutaneous infection. The spectrum of nocardiosis of the hand manifests clinically as one of three types: (1) an acute infection consisting of cellulitis or abscesses; (2) lymphocutaneous infection with marching lymphangitis (sporotrichoid infection); (3) typical actinomycetoma stage I with nodules, stage II with purulent A0 or nonpurulent sinuses, stage III with spread to subjacent, and stage IV with metastasis proximal to the limb.

Staging

Mycetoma of the hand has been graded into five stages. Initially, the lesion is a small, firm, painless subcutaneous nodule or nodules under the skin (duration 2-3 months), which may grow to a large size (nodular, stage I). Nodules become abscesses and drain granules through sinuses to the surface of the skin or to the surface of an ulcerated nodule (duration 4-12 months) (sinusoidal, stage II). Sinuses may close after pus and granules have been discharged. Old sinuses heal and new ones crop up. If left untreated, the infection progresses to osteomyelitis (see Figures 3.3, *C,D*; skeletal, stage III).

Finally, limb deformity occurs over the course of a year or more (skeletal, stage IV). Lesions of the hand may metastasize to the axilla and the chest wall (metastatic, stage V). Radiographic signs include thinning of the metacarpals, bone erosions, sclerosis, and periostitis (see Figures 3.3. *A,D*). A network of connected sinuses is present in the soft tissues from the bone

to the skin. Hand mycetoma has been reported to extend through the lymphatics to the chest wall and to the lung after many years (metastatic stage). Constitutional symptoms are absent unless there is superimposed bacterial infection. Pain is not a predominant symptom.

The patient, usually an immigrant, a rural farmer, or a laborer of lower socioeconomic status, postpones seeking medical care until the second or third stage is reached. Granules, which are aggregates of the organism, are discharged through the sinuses. Eventually, the hand and forearm become grossly enlarged, nodular, discolored, indurated, and deformed, although the patient may experience little pain or tenderness. The progression of the disease is marked by remissions and exacerbations. The period necessary for the development of the deformity varies from several months to several years. The extent of soft tissue invasion (staging) may be best evaluated with magnetic resonance imaging (MRI).

Diagnosis

Hematoxylin and eosin stain is adequate to detect the grains. Tissue-gram staining detects fine, branching hyphae within the bacteria of actinomycetoma grain, and Gomori methenamine silver, or periodic acid–Schiff stain detects the larger hyphae of fungus of eumycetoma. Species of the agent can often be recognized by the color, size, compaction, and hematoxylin-staining character of the grains when organisms fail to grow. *Actinomyces* spp. are recognized as 0.5 to 1 μm filaments and fungi by 2 to 5 μm wide hyphae. Culture should be held for at least 4 weeks.

A more exact species diagnosis is made by microscopic observation and culture of a grain, which must be as free as possible from bacterial and fungal contamination. A deep-tissue, wedge-shaped biopsy provides a good specimen for both histological and microbiologic diagnosis and avoids the bacterial contamination of surface cultures. A better strategy is the aspiration of grains directly from an unopened sinus tract because evaluation of spontaneously extruded grains may be composed of dead organisms and contaminated bacteria. Fungi that cause eumycotic mycetoma can be difficult to grow; optimizing growth is an important step. Before being inoculated onto a culture medium, the grains should be rinsed quickly in 70% alcohol and washed several times in sterile saline to eliminate contaminating bacteria.

Biopsy specimens are preferred over discharged grains because such grains may be contaminated with surface organisms or the infecting organism may already be dead. For primary isolation, actinomycetoma grains are grown on a Lowenstein-Jensen medium and fungal grains on blood agar. Sabouraud agar without antibacterial antibiotics is satisfactory for subcultures.

Two sets of cultures are prepared: one is inoculated at 37°C and the other at 26°C. Characteristic colonies are expected to develop within 10 days. Apart from *M. mycetomatis*, which secretes a brown pigment in the medium, all other organisms, both bacteria and fungi, tend to maintain the color of the original grain. Bacterial colonies are usually granular or cribriform, whereas fungal colonies are either velvety or fluffy. Further identification is made by microscopic examination of fungi in a lacto phenol blue preparation and of bacteria in gram and modified Ziehl-Neelsen stains. Actinomycotic granules may be white (*Actinomadura madurae*), pink, or red (*A. pelletieri*); yellow (*Nocardia asteroides*, *Streptomyces somaliensis*); or orange (*N. asteroides*). Black granules are always eumycotic (*Leptosphaeria senegalensis*, *Exophilia jeanselmei*, *Madurella grisea*, *M. mycetomatis*), but eumycotic granules may also be pale (*Pseudallescheria boydii*).

In histologic sections stained with hematoxylin and eosin, involved tissue reveals a suppurative granuloma. Grains are seen embedded in an abscess composed of neutrophils accompanied by an outer epithelioid cell, plasma cell, and multinucleated giant cell reaction intermingled with areas of fibrosis. The size of various grains in sections is so characteristic that it allows specific diagnosis of the causative organism. Eumycetic hyphae within the grain are easy to see at 400× magnification, whereas those of *Actinomyces* spp. are difficult to visualize even at ×800. In electron micrographs, concentric rings of cell wall thickening and coarse cell wall fibrils around cells are seen within eumycetic grains. When stains, cultures, and histology do not help and clinical suspicion is significant, diagnosis is achieved using a panfungal polymerase chain reaction and sequencing technology.

CRITICAL POINTS *For Diagnosis of Mycetoma*

- Obvious grains should be collected and washed in alcohol to eliminate bacterial contamination.
- Deep wedge biopsy is better than collecting superficial exudate and grains.
- Request hematoxylin-eosin stain for *Actinomyces* spp.
- Request acid–Schiff stain for fungi.

Differential Diagnosis

Tentative diagnosis is made in the presence of a chronic cutaneous and subcutaneous lesion that is swollen, indurated, and riddled with nodules, abscesses, sinuses, and fistulas that discharge granules. Grains are seen in actinomycosis, botryomycosis, actinomycetoma, and eumycetoma. The linear, marching lymphangitis typical of *Nocardia* infection can also be seen with infections caused by *Sporothrix*, *M. marinum*, *M. kansasii*, *Leishmania*, *Coccidioides*, *Cryptococcus*, lupus vulgaris, and tularemia.

Treatment

The success of treatment depends not only on the differentiation between actinomycetoma and eumycetoma but also on definitive identification, culture, and sensitivity of the causal organism. Initial treatment of actinomycetoma is medical. Initial treatment of eumycetoma is a wide surgical debridement of acute and chronic necrotic tissues, followed by chemotherapy.

Actinomycetoma. In all cases of actinomycetoma, a combination of two drugs is used to prevent resistance. Streptomycin sulfate (14 mg/kg daily) may be used for the first month and on alternate days thereafter. For patients with *A. madurae* mycetoma (see Figure 3.3), dapsone is given orally (1.5 mg/kg in the morning and evening). Similarly, *S. somaliensis* mycetoma is treated by dapsone first, but if no response appears after 1 month, treatment is changed to trimethoprim-sulfamethoxazole

tablets (23 mg/kg per day of sulfamethoxazole and 4.6 mg/kg per day of trimethoprim in two divided doses). *A. pelletieri* and *N. brasiliensis* mycetoma responds better to streptomycin and trimethoprim-sulfamethoxazole.

Mycetomas caused by *Nocardia* in the Americas may respond well to trimethoprim-sulfamethoxazole alone or in combination with dapsone or amikacin. Because amikacin could have deleterious side effects in patients with renal disease (and because of its high cost in developing countries), it is kept as a second-line treatment when first-line treatment with dapsone fails. Rarely has a case been cured by only doxycycline. Wide excision with skin grafting may be necessary for large lesions. The rate of cure for actinomycetoma is 63 to 95% of the cases.

Eumycetoma. Combined surgical and medical management is the currently recommended approach. Early resection with a wide margin of uninfected tissue results in the most successful outcomes. Surgery is used as a means to remove the lesion's bulk, and treatment is then supplemented with antifungal drugs. Surgical management should include excision to uninfected margins; otherwise, the recurrence rate is as high as 50%. Ketoconazole, itraconazole, and fluconazole are drugs of choice for fungi that cause eumycetoma. Eumycetoma caused by *M. mycetomatis* often responds to ketoconazole (200 mg twice daily) after debulking of the lesion. Miconazole is an option to manage mycetoma caused by *P. boydii*. Rare cases of mycetoma caused by *Acremonium falciforme*, *Aspergillus flavus*, or *Fusarium solani* have responded well to itraconazole in a dose of 200 mg twice daily.

Ketoconazole has revolutionized the treatment of fungal varieties by allowing partial resections compatible with preservation of hand function. Altman and associates successfully used oral fluconazole for 6 months to treat a eumycotic hand infection.[6] In all cases, the treatment is given for at least 6 to 12 months and has been required for up to 3 years in some cases. The cure rate is approximately 50%. Although side effects are few, patients are regularly monitored to assess hematologic, kidney, and liver function.

Syphilis

Etiology

Syphilis has vast and varied clinical presentations and Osler's adage remains relevant: "He who knows syphilis, knows medicine." It has often been called "the great imitator" because so many of the signs and symptoms are indistinguishable from those of other diseases. The illness is caused by slender, motile, spiral bacteria—*Treponema pallidum*. Syphilitic lesions of the hand may be congenital, primary, secondary, or tertiary, and all affect the hand as the following subsections describe.

Clinical Findings

Congenital syphilis may present as bilateral dactylitis and metacarpitis in a newborn. Syphilitic dactylitis is characterized by edema of the hands and fusiform swelling of digits. Metacarpals and phalanges show new bone formation (i.e., reactive sclerosis), bone destruction (i.e., patchy rarefaction), and periosteal new bone formation. Syphilitic dactylitis in the infant may resemble tuberculous *spina ventosa*. Pathologic fractures of the metaphysis can masquerade as pseudoparalysis. Syphilis should be considered in the differential diagnosis of infantile osteomyelitis.

Primary syphilis of fingers is seldom seen now and usually occurs in men who have had contact with genital or anal lesions during sexual encounters. It may be contracted by physicians when examining an infected lesion on a patient. Examination of patients, deliveries, pelvic examinations, needle punctures, and tonsillectomies are the most common procedures performed by physicians who subsequently became infected. Extragenital syphilitic ulcers in adults occur in at least 5% of primary syphilis patients and mostly affect fingers, lips, and nipples. The hand constitutes 14% of extra genital chancres during syphilitic epidemics.

Syphilis may present as syphilitic dactylitis with generalized swelling, induration, and erythema of a finger, or as a painless ulcer within 2 to 3 weeks after exposure. The lesion begins as a rapidly growing solitary nodule on the nail or nail bed, pulp, paronychium, finger, hand, or arm that soon ulcerates and appears as nodular-ulcerative chancre. Early on, the ulcer (chancre) is red and oozing (Figure 3.4, *A*). The base of the ulcer has a firm or "cartilaginous" consistency and is surrounded by erythema and scaling (Figure 3.4, *B*). Edges of the ulcer may be rounded. Paronychia may present as a "discharging horseshoe ulcer" around the nail fold or as inflammatory periungual and



FIGURE 3.4 **A,** Acute syphilitic chancre is red and oozes infected serous fluid. **B,** As the chancre heals spontaneously or with treatment, peripheral skin peels and the chancre shrinks.

subungual papules. Lesions on multiple fingers can occur. A concurrent lesion on the hand and genitalia (i.e., bipolar syphilis) may or may not be present. Enlarged, painless, and nontender epitrochlear and axillary nodes are almost always palpable but rarely unpalpable. There is generally no fever or constitutional symptoms.

Differential Diagnosis of a Hand Ulcer

Differential diagnosis of an ulcer on the hand, in addition to syphilis (Figure 3.4, *A,B*), includes (A-Z) anthrax (see Figure 3.2), aspergillosis, buruli ulcer, *Candida albicans*, cryptococcosis, leishmaniasis (see Figure 3.34), mucormycosis, neutrophilic dermatoses (e.g., classical pyoderma gangrenosum) (see Figures 3.6-3.9), protothecosis, sporotrichosis (see Figures 3.12 and 3.15), tularemia, tuberculosis, and yaws. Interdigital ulcers are typical of a *C. albicans* infection. (Figures 3.6-3.9, 3.12, 3.15, and 3.34 are shown later in this chapter.)

Diagnosis

Diagnosis is confirmed by dark-field microscopic examination of ulcer exudate which almost always shows spirochetes. Diagnosis of syphilis made by using a Venereal Disease Research Laboratory (VDRL) test, a fluorescent treponemal antibody absorption (FTA-ABS) test, and the rapid plasma reagin (RPR) test are presumptive because the tests may be false positive in nonvenereal treponemal infections such as yaws. The nucleic acid amplification test for *T. pallidum* is positive and useful when microscopic examination is negative.

Secondary syphilis may develop 6 to 8 weeks later if a primary syphilitic lesion is not treated. Paronychia or panaritium of the finger may present during secondary syphilis. Secondary syphilitic lesions in the hand may consist of exuberant ulcerated lesions on the palms or hand and wrist. Tertiary syphilis, now relatively rare in the United States, develops after 10 years in about 10% of untreated patients. Tertiary lesions of syphilis in the hand present as gummas—nonspecific, chronic granulomatous lesions that may involve tissues from skin to bone. The skin gumma is a superficial nodule or deep granulomatous lesion that appears as a punched out ulcer. Diagnosis is facilitated by concurrent cardiovascular or neurological syphilis that may be present in 10% of untreated patients after 10 years of onset.

Treatment

Pathologic fractures and dactylitis in congenital syphilis are treated with protective splints in addition to an appropriate dose of penicillin. In primary syphilis, a single dose of 2.4 million units of intramuscular benzathine penicillin G resolves the lesion in 2 weeks without residual scarring. This long-acting antibiotic can be detected in blood up to 4 weeks after injection. The regimen for penicillin-allergic patients is doxycycline (100 mg), administered orally two times daily for 2 weeks. Secondary and tertiary syphilis are treated with benzathine penicillin G, 2.4 million units intramuscularly, given 1 week apart for 3 consecutive weeks. As the lesion heals, it shrinks, skin around it peels away, and the ulcer is covered by crust.

Tularemia

Etiology and Epidemiology

Tularemia, a bacterial zoonosis, is caused by *Francisella tularensis*, one of the most infectious pathogenic bacteria known. It requires inoculation or inhalation of as few as 10 organisms to cause disease. *F. tularensis* is a small, nonmotile, aerobic, gram-negative coccobacillus.

Rabbits, hares, and rodents are especially susceptible. Humans can become infected through several routes, including tick and deer fly (i.e., yellow fly) bites, skin contact with infected animals, ingestion of contaminated water, laboratory exposure, and inhalation of contaminated dusts or aerosols. In addition, humans can be exposed as a result of bioterrorism. In the United States, naturally occurring infections have been reported in all states except Hawaii.

Clinical Presentation

The main form of this disease is ulceroglandular (70%), usually occurring following a tick or deer fly bite or after handling of an infected animal. A skin ulcer appears at the site where the organism entered the body. The ulcer is accompanied by swelling of regional lymph glands, usually in the armpit or groin. Untreated, the disease may progress to include a moderate to high fever, inflammation of the face and eyes, ulcerating lymph nodes, extreme fatigue, loss of appetite, and sepsis; in approximately 1% of cases the disease is fatal.

Diagnostic Testing

Growth of *F. tularensis* in culture is the definitive means of confirming the diagnosis of tularemia. Appropriate specimens include swabs or scrapping of skin lesions, lymph node aspirates or biopsies, pharyngeal washings, sputum specimens, or gastric aspirates, depending on the form of the illness. Paradoxically, blood cultures are often negative.

Physicians who suspect tularemia should promptly alert the laboratory about the need for special diagnostic and safety procedures. Rapid diagnostic testing for tularemia is not widely available and help from the CDC should be sought; check its website for current contact information.

A presumptive diagnosis of tularemia may be made through testing of specimens using direct fluorescent antibody, immunohistochemical staining, or PCR. The diagnosis of tularemia can also be established serologically by demonstrating a fourfold change in specific antibody titers between acute and convalescent sera. Convalescent sera are best drawn at least 4 weeks after illness onset; thus, this method is not useful for clinical management.

Treatment

Streptomycin is the drug of choice. Tetracyclines may be a suitable alternative for patients who are less severely ill. Tetracyclines are static agents and should be given for at least 14 days to avoid relapse.

Yaws

Etiology and Epidemiology

Yaws is an infectious, chronic, relapsing, nonvenereal, treponemal disease caused by *Treponema pallidum* ssp. *pertenue* (*T. p. pertenue*). It is transmitted by direct skin contact with the contagious exudate of an exposed and infected skin lesion. About 75% of those affected are children under 15 years of age, and the peak incidence occurs in children 5 to 10 years old. It is endemic in tropical regions of the world. Humidity and constant warm temperatures are necessary for the treponema to

flourish. It occurs "where the highways end," and there is poverty, overcrowding, low levels of collective hygiene, poor sanitation, scanty clothing, and minimal health care; all of which facilitate the spread of yaws. Many areas of Africa, Southeast Asia, South America, and Oceania are included, and any area of exposed skin is at risk. Yaws is categorized into early and late stages of infection; early yaws consists of the primary and secondary stages and late yaws consists of the tertiary stage.

Clinical Findings

The primary yaws lesion arises in the skin at the site of inoculation. It usually appears 9 to 90 days (average, 21 days) after inoculation and begins as an erythematous papule that turns into a nodules or papillomas. Nodules and papillomas subsequently enlarge into highly infectious, raspberry colored, friable ulcers containing numerous *Treponema*. The lesions may be multiple and bilateral. At initial presentation, papilloma is more common (80%) than the ulcerative lesion (20%). This ulcerative lesion, also called mother yaws, usually heals spontaneously after several weeks to months, leaving an atrophic scar.

The secondary stage of infection typically occurs weeks to months after the appearance of mother yaws. Secondary lesions (called daughter yaws) are smaller than mother yaws but are more widespread. They exude highly infectious serum. The soft tissue skin and subcutaneous lesion eventually invades bone and cartilage. The striking feature of secondary yaws is osteoperiostitis, involving the phalanges, metacarpals,[36] and forearm bones. Periostitis occurs with increased bone density, sclerosis, thickening, and enlargement of the cortex and an increase in the width of the entire shaft (Figure 3.5).[36] Proximal, middle, and distal phalanges are involved in yaws dactylitis in that order of frequency. Tender and fusiform or spindle-shaped soft tissue and bone swelling of fingers and metacarpals is a characteristic clinical presentation in secondary yaws.[36] It may be bilateral and symmetric[36] with considerable finger, hand, and forearm pain. Yaws osteoperiostitis is similar clinically to osteoperiostitis in tuberculous, syphilitic, blastomycotic, and brucellosis dactylitis.

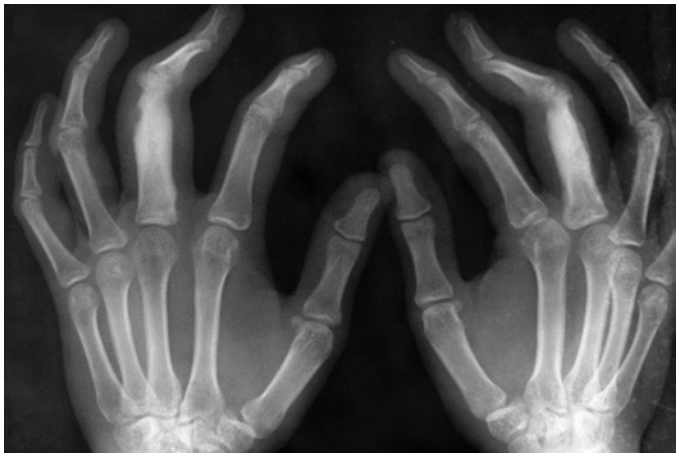

FIGURE 3.5 Yaws. Dactylitis of proximal phalanges of both middle fingers is characterized by osteoperiostitis. There is periosteal reaction, cortical thickening, sclerosis, and scalloping of proximal phalanges of both middle fingers.

Tertiary lesions appear after a latency period of 5 to 10 years in 10% of the cases. Gummas may involve skin and subcutaneous tissues over areas of underlying osteitis. Nodules may develop in the vicinity of joints. The disease is rarely fatal; however, without treatment, it can lead to chronic disfigurement and disability.

Diagnosis

The diagnosis of yaws is primarily based on clinical findings in an epidemiological context.[37] A painless ulcer, in a child below 15 years who lives in an endemic area or who has immigrated from an endemic area, may be diagnosed as yaws.[37] Morphological and serological tests are identical to those for syphilis and are used to diagnose yaws as well. The clinical diagnosis can be confirmed by examining a sample of serum from an ulcerative skin lesion under a microscope with dark field examination. A VDRL test, rapid plasma reagin (RPR) test, a fluorescent treponemal antibody absorption test (FTA-Abs), an agglutination assay for antibodies to *T. pallidum* (TPHA), and a microhemagglutination assay for *T. pallidum* (MHA-TP) can be done and are positive for yaws the same as for syphilis.

Treatment

Penicillin remains the drug of choice. Yaws can be treated with a single dose of benzathine penicillin injection, which cures both the early and late versions. Relapse is very rare. The dose for adults is 1.2 million units and for children <10 years old is 600,000 units. Resistance to penicillin has emerged in rare cases. For those who are allergic or resistant to penicillin, tetracycline, erythromycin, and doxycycline can be used. Spirochetes are usually not detectable by dark-field microscopy within 8 to 10 h of treatment and the lesions resolve in 90% of cases within a month. However, 25% of children show clinical and/or serological evidence of either relapse or reinfection within 2 years.

Neutrophilic Dermatoses and Pyoderma Gangrenosum

Etiology and Epidemiology

Neutrophilic dermatoses are ulcerative dermal diseases in which the ulcer edges are full of neutrophils. Su et al[113] classified ulcers of neutrophilic dermatoses into four types: (1) pyoderma gangrenosum (PG), the classic ulcerative PG[55]; (2) bullous or atypical PG[12]; (3) pustular PG; and (4) vegetative PG.[68] The ulcerative classic form is the most common and the pathognomonic lesion is an ulcer with purplish overhanging border. PG is a progressive, necrotizing, noninfectious, autoimmune, and ulcerative dermatosis that commonly mimics an acute or chronic infection. It is an indicator of an underlying immunological or inflammatory bowel disease (ulcerative colitis, Crohn syndrome) in more than 50% of cases.[55]

Pyoderma gangrenosum was first described as a fulminant streptococcal infection, but it has subsequently been proved to be a noninfectious ulcer. However, the name "pyogenic granuloma" persisted because of the original assumed etiology. It is most common in the lower limbs (70-80%) and rare in the hands and upper extremity (16%).[55] Only 20 cases in the hand and upper extremity were reported in the English literature between 1983 and 2001; all were misdiagnosed initially as

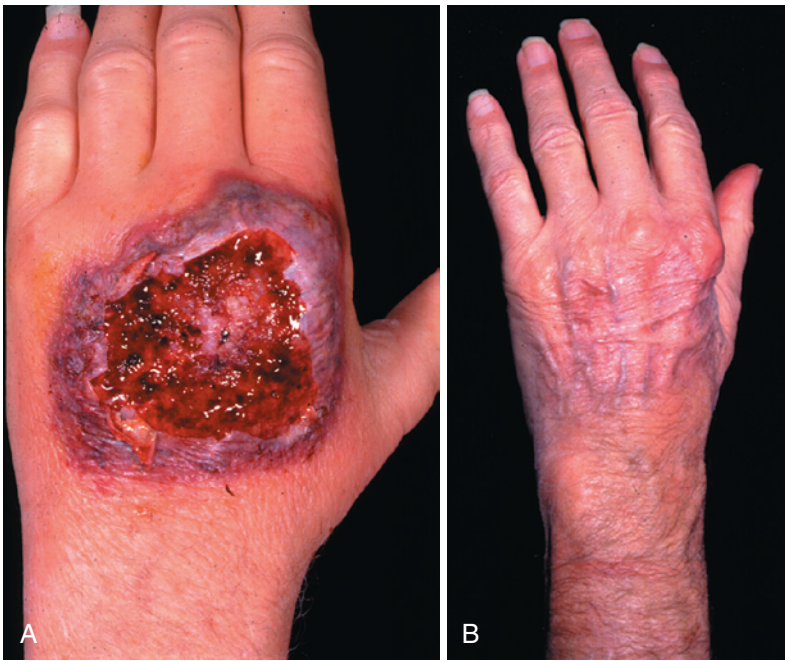

FIGURE 3.6 Pyoderma gangrenosum. **A,** The ulcer is a centrifugally creeping one surrounded by a rough, serpentine, undermining black-blue rim, which is further encircled by a 5- to 10-mm rim of raised purplish erythema and covered by a thin, translucent, graying epidermis. The central portion undergoes wet gangrenous necrosis, oozes, and impersonates infection. **B,** With oral cortisone, skin returns to normal because the deep layers of dermis are still intact.

infections.[55] Since then the condition has been classified under ulcerative neutrophilic dermatoses.[113] The prevalence of PG in ulcerative colitis is about 5%, and in Crohn syndrome it is about 2%.

Bullous or atypical PG is associated with hematological neoplasms (i.e., myeloproliferative diseases[55] such as acute myeloid leukemia, hairy cell leukemia, myelodysplastic syndrome) in 70% of cases.[81] Miyata reviewed 17 cases of bullous PG that have been reported over 20 years, from 1991 to 2011.[81] Unlike the reddish or violaceous halo of classic PG, bullous PG has bulla and bluish-gray halo surrounding the ulcer.[113] Pustular PG is associated with arthralgia, inflammatory bowel disease, and monoclonal gammopathy in 70% of cases.[81] It is considered a *forme fruste* of ulcerative PG in which pustules do not evolve into frank ulcers. Histologically, it shows pustular vasculitis. When bullous PG, pustular PG, and bullous sweet syndrome occurred on the dorsum of both hands, Galaria called it "neutrophilic dermatosis of the dorsal hands"[39] in 2000, and reports of more than 100 cases since then have validated this condition.

Vegetative PG is the most benign, localized, and nonaggressive form of PG and is not associated with systemic diseases, has superficial verrucous and ulcerative lesions, a granulomatous histologic appearance, and responds to minor treatment measures that do not require corticosteroids in most cases. Mixed types of PG also occur,[81] showing that different forms are part of a single clinical spectrum from the nonaggressive vegetative PG to the rapidly destructive classical PG. In all cases, the margin of the ulcer is packed with "noninfectious" neutrophils. In 25% of patients with a generalized category of neutrophilic dermatoses, no known underlying medical condition was found.



FIGURE 3.7 Pyoderma gangrenosum can occur in the upper arm and posterior chest wall. (From en.wikipedia.org/wiki/Pyoderma_gangrenosum #mediaviewer/File:Pyoderma_gangrenosum_01.jpg.)

Clinical Findings

Neutrophilic dermatoses characteristically affect the dorsal surface of a single finger,[55] rarely multiple fingers, hand[55] (Figure 3.6, *A*), wrist, forearm, elbow, or upper arm[55,81] (Figure 3.7). Patients are most often between their third and fourth decades and 4% are children. A centrifugally creeping and weeping ulcer is surrounded with a rough, serpentine, undermining, burrowing, black-blue, violaceous, or gunmetal gray border, which is further encircled by a 5- to 10-mm rim of raised purplish erythema and covered by a thin, translucent graying epidermis (see Figure 3.6, *A*). It spreads 1 to 2 cm/day in a centrifugal pattern.

Pain is a significant symptom in 75% of cases. The central portion undergoes wet gangrenous necrosis, oozes, and impersonates infection. PG does not respond to traditional antibiotics or surgical intervention.

Diagnosis

Neutrophilic dermatosis (mostly characterized by PG) is a clinical diagnosis, and a high clinical suspicion prompts correct diagnosis and treatment. If it is on the dorsum of both hands, the condition is designated as neutrophilic dermatosis of dorsal hands (Figures 3.8 and 3.9) If after debridement of a supposedly infected wound (with pustules, bullae, or ulcerations) there is no improvement, but there is centrifugal extension of the lesions with a "sepsis-like" syndrome and persistent negative cultures, PG is highly probable; in that case, corticosteroids (not antibiotics) are the definitive treatment. Rarely, PG may masquerade as necrotizing fasciitis. PG ulcers appear similar to other cutaneous ulcers, such as aspergillosis, and may lead to misdiagnosis.



FIGURE 3.8 Neutrophilic dermatoses of the dorsal is characterized by pyogenic granuloma-like lesions on the dorsal side of both hands.



FIGURE 3.9 Neutrophilic dermatoses of dorsal hands may extend into the fingers.

Biopsy is of limited diagnostic value as it accelerates the ulcerative process; however, in cases where biopsy is done, "a sea of neutrophils" are characteristic in the marching edge of the ulcer. No laboratory test is confirmatory. In a clinical setting, when an ulcer does not yield infectious organisms and biopsy aggravates the ulceration, a diagnosis of PG is paramount. Dermal neutrophilia in the advancing border of the ulcer confirms that diagnosis.

In a review of 13 cases in the literature and 7 cases added by Huish and colleagues, every patient initially had a misdiagnosis of infection.[55] In a later review of 35 cases of the hand by Wong, 29 were initially treated for infection and 13 were debrided with further deterioration of ulceration. Thirteen misdiagnoses in Huish's series resulted in 16 unnecessary surgeries, including 2 failed skin grafts and 4 amputations. No surgical procedure resulted in clinical improvement, and all were followed by unrelenting extension of the ulcer. Five physicians on an average examined each patient before the final diagnosis of PG was made by a dermatologist. Clinical improvement after correct medical treatment with oral prednisone, azathioprine, or dapsone was dramatic and occurred within a week.[55]

Treatment

Biopsy or wound debridement consistently leads to deterioration of the condition; this so-called idiopathic pathergic response is a hallmark of this disease.[55] Pathergy, first described by Blobner, is a violent inflammatory response of the skin after any intradermal trauma. It is seen in both PG and neutrophilic dermatoses. Pathergic response also explains the occurrence of PG in patients who sustain occupationally induced trauma or develop PG following a hand injury or surgery.

Management includes (1) immunosuppressive therapy with oral administration of corticosteroids (i.e., prednisone, 100 mg/day); (2) treatment of associated medical conditions (i.e., ulcerative colitis, Crohn syndrome, myeloproliferative conditions, or myelodysplastic syndrome); (3) local wound care; and (4) the most important, avoidance of surgical intervention. The administration of corticosteroids is tapered when the ulcers show signs of healing. There is dramatic improvement within 24 h, and within 6 weeks the lesion is completely epithelialized because the deeper layers of the dermis, sweat glands, and hair follicles remain intact (see Figure 3.6, *B*).

PG responds to oral dapsone, azathioprine, topical glucocorticoid ointment, or intralesional steroid injections when oral corticosteroids are contraindicated. Corticosteroid-resistant PG associated with Crohn syndrome rapidly responds to cyclosporine or infliximab. Before the advent of these drugs, the skin lesions healed with an atrophic scar when the underlying disease, such as ulcerative colitis, was controlled.

FUNGAL INFECTIONS

Etiology, Epidemiology, and Classification

Given the increasing number of immunocompromised individuals throughout the world, the incidence of infection caused by fungal and unusual organisms has increased. Fungal (*L. fungosus*, "mushroom") infections are classified into categories based on anatomic location of infection and epidemiology. Anatomic categories that affect the hand are: cutaneous, subcutaneous, and deep. Cutaneous and subcutaneous infections can

cause serious morbidity but are rarely fatal. Deep infections are often fatal without treatment. The epidemiologic categories are endemic and opportunistic.

The endemic mycoses are exogenous infections (e.g., coccidioidomycosis) and are caused by fungal organisms that are not part of the normal human microbial flora and are acquired from the external environment. Endemic mycoses cause severe illness in immunocompetent individuals and more serious infections in immunocompromised patients. Patients acquire infection with endemic fungi almost exclusively by inhalation. The soil is the natural reservoir for the vast majority of endemic mycosis. In contrast, the opportunistic mycoses (e.g., *Candida*, *Aspergillus*) are endogenous and are caused by organisms that are components of normal human flora. Opportunistic fungi cause serious infections when immunity of the host is depressed, allowing the organisms to transition from harmless commensals to invasive pathogens.

The incidence of fungal infections has risen as a consequence of intentional immunosuppression (e.g., organ and stem cell transplantation), administration of cytotoxic chemotherapy for cancers, corticosteroid therapy, and liberal use of antibacterial agents. *Any yeast or mold recovered from an immunocompromised patient should not be dismissed as a "contaminant" or colonizer without first ruling out its role in the patient's disease.* Fungi commonly associated with immunodeficiencies are shown in Table 3.4.

Diagnosis

Three terms used to describe fungi are yeast, mold, and dimorphic varieties. Yeasts (e.g., *Candida* and *Cryptococcus*) are typically round and reproduce by budding. Molds (e.g., *Aspergillus*, Mucorales) are filamentous and grow by branching both at room and body temperature. Dimorphic fungi (e.g., blastomycosis, coccidioidomycosis, histoplasmosis, sporotrichosis) are fungi that grow as yeasts in human tissue but as filamentous forms in the environment at room temperature.

There are two fungal infections, aspergillosis and mucormycosis, that need special cautionary mention because they infect the blood vessels and cause avascular necrosis of dermis and deep tissues. They cause rapid necrosis of the dermis, resulting in a black eschar that may progress to gangrene. Rapid and progressive black eschar formation in an immunocompromised patient should arouse suspicion of angioinvasive fungus and warrant prompt biopsy rather than a culture because the host tissue grows the fungus faster than the petri dish. The definitive diagnosis of these fungal infections requires histopathologic identification of them in the infected tissue, and early diagnosis can prevent unnecessary amputation or mortality. Evidence of inflammatory response in the biopsy tissue is critical for diagnosis of infection by *Aspergillus*, as these species are ubiquitous in air and can contaminate biopsy material, causing false-positive microscopic identification. A high level of suspicion is necessary to make diagnosis of a fungal infection, especially in immunocompromised patients.

Any unusual swelling of the upper extremity should raise suspicion of the more common chronic infections, such as fungus infection, tuberculosis, and actinomycetoma, in addition to aerobic infections (e.g., actinomycosis) and anaerobic infections (e.g., botryomycosis). Fungal hand infections have been reported in patients with AIDS, hematologic malignancies, cancer patients on chemotherapy, those on corticosteroid therapy, recipients of bone marrow and organ transplants, patients with prosthetic finger joint implants, patients with prosthetic arteriovenous shunts and distal steal phenomena, patients with chronic renal failure, diabetics, rheumatoid patients on disease-modifying drugs, alcoholics, and those with severe burns.

Identification of *Aspergillus*, *Nocardia*, *Cryptococcus*, or Mucorales from a patient without a known immunodeficiency is sufficient grounds for pursuing the probability of an underlying immune defect. A biopsy to identify the infecting organism and an appropriate workup to identify the immunodeficiency are then warranted. When a soft tissue, joint, or bone infection presents as a chronic draining sinus that has not responded to usual antibiotics, deep fungal infection should be considered. Surgical wound cultures from chronic lesions that are repeatedly negative for the usual bacteria also raise the possibility of a fungal infection. The main role of the surgeon is to perform an adequate biopsy and request smears and cultures that include fungi, which can often be identified in tissue, even when they do not grow in culture.

The stains most commonly used to identify fungi are periodic acid–Schiff and Gomori silver. India ink preparation is diagnostic for cryptococcosis. Most laboratories now use calcofluor-white staining coupled with fluorescent microscopy to identify fungi in fluid specimens. The histologic finding of a fungus in a biopsy tissue specimen can be more rapidly diagnostic than culture when the mycosis is caused by a slow-growing fungus, which can take weeks to a month or more to grow in the laboratory and may require a special growth medium. Again, a biopsy may provide proof that the fungus is invading tissue and is not just a contaminant (e.g., a saprophyte growing on a skin ulcer). It is important to rapidly transport the specimen to the microbiology laboratory to minimize overgrowth of contaminating bacteria. Most fungi grow within 4 weeks but occasionally take 8 weeks (as is the case with *Sporothrix schenckii* and some of the filamentous fungi); it is wise to request that the microbiology laboratory not discard, usually after 4 weeks, the cultures when fungi are suspected.

TABLE 3.4 Risk Factors and Commonly Associated Fungi

Predisposing Host Risk Factors	Fungi/Infection
Neutropenia (hematogenous malignancies)	*Aspergillus*, mucormycosis
Cell-mediated immune defects, including AIDS	*Cryptococcus*
Malnutrition	*Aspergillus*, mucormycosis
Diabetes	Mucormycosis
Corticosteroids	*Cryptococcus*, *Pseudallescheria boydii* (*Allescheria boydii*, *Petriellidium boydii*), mucormycosis
Cytotoxic chemotherapy	*Aspergillus*
Exposure to pigeons	*Cryptococcus*

The only mycosis for which serodiagnosis (i.e., testing for the presence of antibody) has established a role is coccidioidomycosis. This test is the most frequent means for diagnosis and is highly specific for active coccidioidomycosis. Detection of cryptococcal polysaccharide antigen in serum is the most reliable for diagnosis of cryptococcosis. Correlation of clinical and microbiologic results is always necessary. Some fungi (e.g., *Blastomyces dermatitidis*, *Coccidioides immitis*, *Histoplasma capsulatum*) usually infect immunocompetent hosts while other fungi (e.g., *Aspergillus*, *Rhizopus*, *Cryptococcus*, *Pseudallescheria*) infect immunocompromised hosts. However, the endemic fungi are important causes of infection in seriously immunocompromised hosts such as those with AIDS or heart transplant recipients. Recovery of *Aspergillus* or *Candida* from an otherwise immunocompetent host may not be indicative of invasive disease, but the burden is to consider these seriously before ruling out infection. Many risk factors are specific to certain fungal infections. The differential diagnosis can often be narrowed on the basis of the specific immune defect present (see Table 3.4).

The diagnostic laboratory should be alerted when specimens from patients suspected of having coccidioidomycosis or histoplasmosis are sent for culture. Once these cultures grow in mold form, they can be easily aerosolized if the cultures are not maintained in a biohazard hood. Infection of the laboratory with *H. capsulatum* or *C. immitis* is a well-documented occurrence and can lead to considerable morbidity and even mortality of the infected laboratory worker. With a rare exception (e.g., ringworm), mycoses are not transmissible from patient to patient.

Treatment

Prompt surgical debridement of infected tissue is the keystone of treatment in aspergillosis and mucormycosis, irrespective of the host's immunocompetence. Due to their angioinvasive predilection, these two fungi cause severe and often progressive tissue infarction, necrosis, and gangrene.[93] Removal of nonviable tissue is critical to prevent further invasion and infection of neighboring viable tissue and to increase the success of treatment. If possible, reversal of the underlying immunocompromising predisposition should be vigorously attempted by reducing immunosuppressive therapy.

Amphotericin B (AmB, Fungizone) has been the treatment of choice for patients with fungal diseases from the time of its introduction in 1958 and by default became the gold standard for antifungal therapy of invasive mycoses. It is given intravenously and has serious toxic effects on kidney, liver, and blood. The availability of lipid formulations of AmB, such as Abelcet and AmBisome, has resulted in the ability to administer higher doses of it with significantly fewer side effects.

Currently, there is some controversy concerning whether the lipid formulations should replace Fungizone for most indications. Because these lipid formulations of AmB are rather expensive, many physicians are hesitant to prescribe them, especially when the much less expensive conventional amphotericin B can be used. Consultation with experts in the treatment of invasive fungal diseases is encouraged so that the most effective and least toxic regimen can be recommended. Echinocandins (micafungin, caspofungin) now offer broad spectrum activity against all *Candida* species and has relatively low toxicity. Turbinafine has been as effective as itraconazole in the treatment of onychomycosis and more effective than griseofulvin in the treatment of ringworm infections.

Use of effective oral antifungal therapy with little or no nephrotoxicity for the treatment of invasive mycoses is a relatively recent development. Since the FDA approval of ketoconazole (Nizoral in 1983), fluconazole (Diflucan in 1990), itraconazole (Sporanox in 1994), voriconazole in 2002, and posaconazole in 2006, these synthetic oral antifungal azoles have been increasingly and effectively used as therapy for various systemic mycoses. Unlike AmB, these drugs are fungistatic, not fungicidal. In certain circumstances, they have equivalent efficacy, improved safety, and ease of administration when compared with AmB. Itraconazole has emerged as a possible alternative to amphotericin B in treating several fungal infections, including blastomycosis, coccidioidomycosis, histoplasmosis, pseudallescheriasis, and sporotrichosis. Voriconazole has now superseded AmB as a drug of choice for treatment for aspergillosis.

Posaconazole is uniquely effective against Mucorales and is the only antifungal agent with clinically relevant activity against this group of pathogens. Antifungal agents in current use are shown in Table 3.5. Because of the infrequency of these

TABLE 3.5 Spectrum of Antifungal Agent Activity and Preferred Agent(s) for Most Clinical Infections

	Amphotericin B	Flucytosine	Ketoconazole	Fluconazole	Itraconazole
Aspergillus	+	+	–	–	+
Blastomyces	+	+	+	+	
Candida albicans	+	+	+	+	+
Chromomycosis		+	+	–	+
Cryptococcus	+	+	+	+	+
Coccidioides	+	–	+	+	+
Histoplasma	+	–	+	+	+
Mucormycosis	+	–	–	–	–
Pseudallescheria			+		+
Sporothrix	+	–	+	+	+

In general, acutely ill patients with life-threatening mycosis should be treated with AmB. Azole therapy can follow once the patient's condition is stabilized.

infections, potential hepatotoxicity and the emergence of resistant strains, an infectious disease consultation is advisable. Some drugs (e.g., itraconazole capsules) are erratically absorbed and can have multiple drug interactions. When antifungal agents are used for chronic therapy, serum blood concentration monitoring is necessary and doses adjusted as necessary. The use of flucytosine has diminished in recent years as newer antifungal drugs have been developed.

Cutaneous Fungal Infections

Etiology and Epidemiology

The most common fungal infections of the hand are cutaneous (skin and nail) infections and are commonly treated by dermatologists and primary care physicians. Nail infections (onychomycosis) can be diagnosed by direct smear in 75% and by histology in 80% of the cases.

Cutaneous (superficial) infections are caused by fungi that infect and metabolize keratin (e.g., skin, hair, and nails). Because these organisms depend on keratin for nutrition, they do not invade beneath the skin. Most of the clinical manifestations of skin infections are a consequence of host reaction to fungal metabolic products. Patients with skin and nail infections usually seek medical care from dermatologists. *Candida albicans* and dermatophytes (*Trichophyton*, *Microsporum*, and *Epidermophyton*) are the cause of the majority of chronic cutaneous and nail infections.

Chronic cutaneous *C. albicans* infection occurs in the moist palms and webs of a "clenched fist" in patients with spasticity. Trichophytosis ("ringworm") is the most common cutaneous (and nail) infection. It is more often treated by a family physician or dermatologist, although hand surgeons are now consulted by patients directly and often. The skin diseases associated with *Trichophyton* ringworms in interdigital spaces are also commonly referred to as "tinea." It may occur on the dorsum of the hand (Figures 3.10 and 3.11) and may have typical rings within the lesion (Figure 3.11). Other fungi that infect the skin are *Epidermophyton* and *Microsporum*. "Wristwatch ringworm" occurs in moist skin under a watch or its strap. Tinea nigra palmaris has been reported to be misdiagnosed as malignant melanoma.

Diagnosis

Most of cutaneous fungi are easily identified on wet KOH preparations. They grow hyphae (Greek *hyphos*, "a web") readily on a Sabouraud medium. Skin or nail scrapings from the suspected area are placed in 10% KOH on a glass slide, which can be heated over an alcohol lamp until bubbles are seen. Spores or branching mycelia under the microscope confirm the presence of fungus. Definitive diagnosis requires fungal cultures because the infections caused by *Trichophyton* and *C. albicans* may not be clinically distinguishable and respond to various antifungal agents.

Treatment

Uncomplicated cases of tinea are easily treated with cream or lotion of tolnaftate (Tinactin), miconazole (Monistat), or ciclopirox (Loprox). Widespread lesions require treatment with oral griseofulvin, ketoconazole, fluconazole, or itraconazole. It is probably not necessary to use the newer broad-spectrum triazole derivatives, such as voriconazole, for the treatment of these infections. For the cerebral palsy patient with a clenched fist, tendon or fascial lengthening may be necessary to prevent recurrent infections if routine hand hygiene fails to keep the skin dry.



FIGURE 3.10 Ringworm infection on the dorsum of the hand. (From Habif TP: *Clinical dermatology: a color guide to diagnosis and therapy*, Philadelphia, 2010, Elsevier; Figure 13.29, with permission.)



FIGURE 3.11 Concentric rings can be seen in some lesions of ring worm.

Subcutaneous Fungal Infections

Classification

There are three major subcutaneous fungal infections of the hand: chronic paronychia, sporotrichosis, and phaeomycotic cysts. Chronic paronychia is usually initially misdiagnosed as a bacterial infection. Lack of response to repeated courses of the

usual antibiotics is an important clue to the fungal etiology of this infection. Drainage and debridement may be needed if medical management fails. Sporotrichosis is rare but responds readily to medical treatment. A phaeomycotic cyst is a deep dermal or subcutaneous infection that results from the traumatic implantation of a dematiaceous (pigmented) fungus such as *Exophiala* or *Phialophora*. A subcutaneous soft tissue abscess of the forearm can occur in a patient with refractory acute myeloid leukemia caused by *Scedosporium apiospermum*.

Chronic Paronychia

Etiology and Epidemiology. Chronic paronychia is characterized by a relatively well-localized area of skin inflammation proximal to the cuticle. The skin becomes pink, warm, indurated, glistening, and tense and extends to the cuticle. The cuticle is chronically retracted, rounded, and detached from the nail plate, allowing free passage of moisture and water under the eponychium. It usually affects a female patient who frequently soaks her hands in water, as required either by her job or her domestic duties. Mechanical trauma that damages the cuticle at modern nail salons is responsible for bacterial and fungal invasion of the nail fold. Patients with chronic paronychia have a higher incidence of *Candida* colonization of the mouth, bowel, and vagina than controls. Patients do not routinely have a history of acute paronychia, and surgical exploration does not identify pus deep to the nail plate. Unless the disease process is stopped, secondary thickening, ridging, and discoloration of the nail can occur, eventually resulting in nail loss. Specific diagnosis can be made by gram stain, KOH preparation, and culture.

C. albicans is responsible for the majority (70-97%) of cases of chronic paronychia. Stone and Mullins first reproduced this entity in 1964 by soaking fingers in water until the skin macerated and inoculated either viable or nonviable *Candida* into the cul-de-sac between the base of the nail and eponychium. Inflammatory reaction in the presence of dead *C. albicans* indicated that the exogenous byproducts of fungal organisms caused local chronic inflammation. Chronic maceration of the fingers is accompanied by separation of the cuticle from the nail so that a pocket of water is entrapped under the proximal nail fold. Once this pocket is formed, capillary action retains water in it and transient flora (e.g., *C. albicans* and gram-negative rods) thrive in it. As Stone refers to it, the process forms a "dermatologic cesspool" and cultures yield *C. albicans* and mixed bacterial flora, including *Proteus*, *Streptococcus*, and gram-negative rods (usually *Escherichia coli* and *Pseudomonas*). The condition has been reported in up to 9% of diabetic and in 3% of nondiabetic women older than 20 years. Thumb sucking can be the etiology of chronic paronychia in children. In men, the condition may be occupational. For barbers, chronic paronychia can occur when hair is embedded in the paronychium.

Clinical Findings. The lateral nail fold may show the first signs of chronic swelling, with a separation of this fold from the nail's lateral margin. After weeks or months, the process may progress to the posterior nail fold, the eponychium. The cuticle separates from the nail plate and allows moisture and *C. albicans* to reside in the subeponychial cul-de-sac. Germinal matrix in the eponychial area is eventually invaded and causes irregularities of the dorsum of the nail plate, usually grooving. In 30% of cases, the nail plate becomes greenish owing to secondary colonization by *Pseudomonas aeruginosa*, which are normal colonizers of the hyponychial space between the skin and free edge of the nail. Subacute intermittent flare-ups by secondary bacterial infection may require treatment with oral antibiotics but do not cure the underlying chronic hyponychial candidiasis.



FIGURE 3.12 Sporotrichosis of fifth finger in a gardener simulates a paronychial lesion. Note marching lesions in hand and forearm.

Differential Diagnosis. Other causes of paronychia include syphilis (see Figure 3.4), sporotrichosis (Figure 3.12), blastomycosis, tuberculosis, and herpetic paronychia. Squamous cell carcinoma, subungual keratoacanthoma, leukemia cutis, amyloidosis, and pilonidal sinus around the nail have been reported to mimic chronic paronychia.

Diagnosis. Chronic paronychia is entirely a clinical diagnosis; the visual picture presented is so characteristic as to present no diagnostic difficulties. Ninety-two percent of patients are women; of affected men, 25% are chefs, bartenders, or fishmongers. A chronically indurated, retracted, and rounded eponychium is the hallmark of diagnosis of chronic paronychia. Recurrent episodes cause inflammation, followed by thickening, transverse grooving, and nail deformity. Patients with chronic paronychia complain of a long history of annoying and disfigured thickening of the eponychial skin. If smears of skin and nail scrapings are negative for *C. albicans*, the diagnosis can be established with a culture.

Treatment. Keeping the area as dry as possible and prolonged application of a topical azole antifungal agent, such as clotrimazole (Lotrimin, Mycelex) or econazole, may adequately treat a *C. albicans* infection. Oral therapy with fluconazole, 200 to 400 mg/day, is a more effective alternative, but long-term prognosis of either topical or oral therapy remains unsatisfactory. Approximately 40% of patients remain free of paronychia, 40% heal periodically, and 20% have continuous disease after a year. When medical management does not succeed, eponychial marsupialization should be considered. In this operation, the fibrotic cutaneous and subcutaneous tissue of the eponychium is excised to permit unrestricted drainage of the fungi and their exogenous byproducts so that the infectious and inflammatory processes are reversed.

For additional information on marsupialization, see eFigure 3.1 and the online version of this chapter at www.ExpertConsult.com.

Surgical Technique of Marsupialization. Under digital or wrist block with tourniquet hemostasis, a symmetrical 2- to 3-mm wide crescent-shaped piece of skin and subcutaneous tissue is excised approximately 2 mm proximal to the nail fold of the affected digit (eFigure 3.1 and Figure 9.23). The excision extends to the lateral nail plate margin on both sides. An asymmetrical excision produces an asymmetrical nail margin when it heals. Nail removal should be done when concurrent nail irregularities are seen. Irregularities may indicate that the infection is deeper under the nail, so if the nail is not removed, infection tends to recur.[10] The tourniquet is removed and hemostasis is obtained by several minutes of direct compression.

When the nail plate is removed, a stent should be placed beneath the nail fold for a few days to prevent adhesion to the germinal matrix. This is dressed initially with a nonadherent dressing that is removed on the first postoperative day, warm soaks are initiated, and the wound is redressed. The patient then soaks the wound in hydrogen peroxide periodically and keeps it covered. Epithelialization occurs in 2 weeks and in most cases this is curative. Full-length improvement of the nail plate can take 9 to 12 months. In one study, normal cuticular contour and nail growth resulted in 28 of 31 digits. Keeping the fingers dry and using basic hygiene are essential to prevent recurrence. The mouth, anus, and vagina can provide a reservoir for *C. albicans* from which the nail fold may be reinfected.

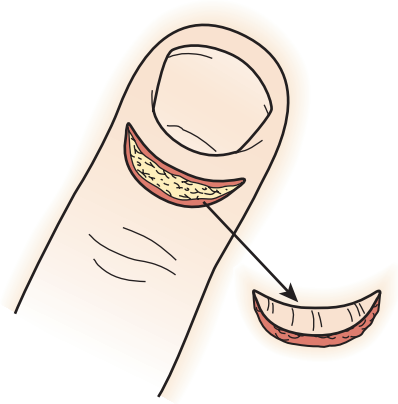

eFigure 3.1 Technique of marsupialization. A symmetric, crescent shaped segment of skin is excised from the dorsum of the distal phalanx while leaving an adequate bridge of skin proximal to the eponychium. (From Keyser JJ, Littler JW, Eaton RG: Surgical treatment of infections and lesions of the peronychium, *Hand Clin* 6:137–153, 1990, with permission.)

Sporotrichosis (Rose Thorn Disease)

Etiology and Epidemiology. Sporotrichosis is the most common cutaneous and lymphatic (lymphocutaneous) fungal infection in North America. If sporotrichosis is promptly diagnosed, it can usually be cured with medical treatment. If unrecognized, the disease can result in progressive disability. Sporotrichosis was first diagnosed by Schenck in 1898 at Johns Hopkins Hospital in a patient with a primary lesion in his finger and secondary lymphatic lesions in the forearm. The infecting organism was a dimorphic fungus and was termed *Sporothrix* (or *Sporotrichum*) *schenckii*. In the United States, the infection in humans is an occupational hazard of rose growers, gardeners, and florists, as well as farmers, horticulturists, and nursery workers. The organism is ubiquitous in soil and frequently inoculated into the skin and subcutaneous tissues by a rose thorn. The majority of cases are reported around the Missouri and Mississippi rivers, but the disease occurs worldwide. The fungus has been recovered from nails of cats, so sporotrichosis should be considered following cat scratches. It is common in Brazil but rare in the United States; only 36 cases were treated at the Mayo Clinic in the 29 years between 1957 and 1986.

Clinical Findings. The infection may be solitary or multiple with marching lymphocutaneous lesions. Solitary cutaneous lesion, so-called a fixed lesion, remains localized to the site of infection, perhaps due to a higher degree of immunity. Lymphocutaneous marching infection accounts for 50 to 80% of cases of sporotrichosis (Figures 3.12 and 3.13), and 80% of infections occur in the upper extremity (see Figures 3.12 through 3.15). It should be suspected in any patient with painless, ulcerative lesions of the skin that are unresponsive to antibacterial treatment. Infection can start at the tip of a finger as paronychia (see Figure 3.12) or as nonhealing ulcer of the pulp, finger, or the hand (see Figures 3.14 and 3.15). The lesion is usually unilateral; however, Haruna et al reviewed 15 cases of bilateral upper extremity sporotrichosis in Japan (see Figure 3.14).[48]

Bilateral cases may be due to autoinoculation or multiple inoculations. The infection is usually nonopportunistic and affects healthy subjects and is rare during childhood. Infection begins when the fungus is inoculated into a site of skin injury on the exposed part of hand or forearm. It produces an erythematous or verrucous nodule that gradually ulcerates. The ulcers develop raised borders. The ulcer closely resembles a syphilitic chancre.

The infection is characterized by linear marching nodules on the forearm and arm, which represent spread through local lymphatic channels (see Figure 3.13). Regional lymph nodes become enlarged, and seropurulent drainage may occur from both the primary lesion and the involved nodes. The lymphocutaneous lesions are typically painless, and a chronic cyclical process of spontaneous healing, nodule formation, ulceration, and drainage may continue for years if untreated. Infection can result in exposure of the tendons and require skin grafting (see Figure 3.15).

Diagnosis. Diagnosis of sporotrichosis is often missed owing to the relative rarity of the disease. The average delay in diagnosis is 4 months.[33] The standard histologic stains may not show the organism. Periodic acid–Schiff or silver staining will highlight the fungus as red or black, respectively. Examination of biopsy specimens reveals a pyogranulomatous response and



FIGURE 3.13 Lymphocutaneous sporotrichosis. A 68-year-old Brazilian housewife presented with a 2-week history of a small ulcer on her right forefinger and palpable erythematous nodules on her right forearm of 4 weeks duration; this occurred after a bite from a domestic cat that had a lesion on its hind foot. The patient had taken an antibiotic (cephalexin) without improvement. An ulcer measured 1 cm in diameter with erythematous borders on her right forefinger. Subcutaneous erythematous nodules extended in a linear and ascending distribution on her right hand and forearm. The fungal culture, performed at 25°C using Sabouraud dextrose agar for 5 days, showed a creamy white-colored colony. Microscopy demonstrated *Sporothrix schenckii*. (From *Dermatology Online Journal* 14(7), 2008.)



FIGURE 3.14 Bilateral sporotrichosis of the hands may be due to simultaneous infection or contralateral inoculation. (From Haruna K, Shiraki Y, Hiruma M, et al: A case of lymphangitic sporotrichosis occurring on both forearms with a published work review of cases of bilateral sporotrichosis in Japan. *J Dermatol* 33:364–367, 2006, with permission.)



FIGURE 3.15 Sporotrichosis. **A,** Skin loss due to cutaneous sporotrichosis can be devastating when it is not diagnosed and treated early. **B,** Skin loss was treated by skin grafting.



FIGURE 3.16 Sporotrichoid erythematous nodular and pustular marching lymphangitis in a Chinese woman during a 2014 *M. marinum* outbreak in New York City. The women cleaned fish without gloves.

is diagnostic if characteristic cigar-shaped yeast forms are seen. Unfortunately, the yeast can be difficult to detect unless multiple sections are examined because characteristically there are very few organisms in infected tissue. A diagnosis is best made by culture of the infected site, although repeated attempts at culture may have to be made. Aspirates or deep cultures are preferable to swabbed specimens because the organisms are sparse. Cultures become positive in a few days to a month and must be incubated at 30°C or room temperature in a modified Sabouraud agar fungal medium. False-negative cultures may result if the specimens are cultured at 37°C. Sporotrichosis should be included in the differential diagnosis of a chronic ulcerated skin lesion (see Figures 3.12 and 3.15).

Among the differential diagnoses of the nodular marching lymphangitis pattern of lymphocutaneous sporotrichosis are nocardiosis, leishmaniasis, and atypical mycobacterial infections, especially *M. marinum* (Figure 3.16 and Table 3.6). The ulceroglandular form of tularemia is usually accompanied by systemic symptoms. Much less often, botryomycosis, *Blastomyces dermatitidis*, *Coccidioides immitis*, *Cryptococcus neoformans*, *Histoplasma capsulatum*, *Mycobacterium kansasii*, *Staphylococcus aureus*, *Streptococcus pyogenes*, *Burkholderia pseudomallei*, *Bacillus anthracis*, and *Vaccinia virus* may also be characterized by nodular lymphangitis.

Treatment. Itraconazole is the drug of choice for lymphocutaneous sporotrichosis. Treatment with 200 mg/day for 3 to 6 months results in complete resolution for most patients. The drug should be administered with a fatty meal or carbonated beverage to enhance absorption. Heat (warm soaks) is considered a useful adjunct to medicinal therapy because the organism grows at temperatures below 37°C. Cutaneous sporotrichosis was treated in the past with a saturated solution of potassium iodide (SSKI, 1 g/mL) and this may still be considered if itraconazole causes hepatotoxic side effects. SSKI may not be convenient because it causes a bitter taste and gastrointestinal upset. It is still the mainstay of treatment in developing countries because SSKI is effective and inexpensive.

Oral terbinafine (125 mg/day) has been shown to be effective against sporotrichosis in Japan. Fluconazole, 400 to 800 mg/day, can also be used. Isolated cutaneous sporotrichosis responds well to medication and has an excellent prognosis. Rarely, sporotrichosis can present as a deep fungal infection in immunocompromised hosts; it is described later. da Rosa et al reviewed 304 cases of sporotrichosis in Brazil over a period of 35 years between 1967 and 2002.[27] Duran et al reviewed 23 cases of sporotrichosis in the United States.[33]

CRITICAL POINTS *Sporotrichosis*

- Sporotrichosis is a cutaneous mycotic infection caused by the dimorphic organism *Sporothrix schenckii.*
- Clinically, sporotrichosis classically presents as subcutaneous nodules at the primary inoculation site and spreads linearly along the lymphatic channels on the hand and forearm.
- Biopsy rarely reveals fungal organisms, but when present, rounded or budding spores, cigar-shaped fungal elements, and asteroid bodies are characteristic.
- Histology alone cannot identify the causative organism, but fungal culture or PCR analysis can confirm a diagnosis of sporotrichosis.
- Itraconazole is used as a first-line treatment for lymphocutaneous or fixed-cutaneous sporotrichosis.
  - Alternative treatment options include other antifungal agents, SSKI, and hyperthermia.

TABLE 3.6 Differential Diagnosis and Treatment for Major Causes of Multiple, Marching, Linear Nodular Lymphangitis

Organism	Exposure History	Diagnosis	Preferred Therapy	Alternative Therapy	Duration of Treatment
Sporothrix schenckii	Gardening, soil contamination, splinters, animal scratches or bites	Biopsy and culture	Itraconazole (Sporanox), 200 mg daily	SSKI, 5 drops in water three times daily, slowly increased to 40-50 drops three times daily as tolerated Terbinafine (Lamisil), 250 mg twice daily	Two months after resolution of lesions
Nocardia brasiliensis	Gardening, soil contamination, splinters	Biopsy and culture	TMP-SMX (Bactrim, Septra), 2 double-strength tablets three times daily	Minocycline (Minocin), 200 mg twice daily See text for additional alternatives	Three months
Mycobacterium marinum	Aquariums; fish handling; swimming in oceans, lakes, or pools	Biopsy and culture	Minocycline, doxycycline	TMP-SMX Rifampin, 10-15 mg/kg daily, with clarithromycin (Biaxin), 30 mg/kg daily	Two to three months after resolution of symptoms
Leishmania brasiliensis	Residence in or travel to endemic areas	Biopsy and culture	Stibogluconate sodium, 20 mg/kg daily, or meglumine antimonate, 20 mg/kg daily	AmB (Fungizone IV), 0.25-1.00 mg/kg daily See text for additional alternatives	20 days

SSKI, Supersaturated potassium iodide; *TMP-SMX*, trimethoprim-sulfamethoxazole.

Phaeomycotic Cysts

A phaeomycotic cyst is a rare deep dermal and subcutaneous cystic infection due to a darkly pigmented fungus such as *Exophiala*, *Phialophora*, or *Bantalis*. It most commonly results from the traumatic implantation of a wood splinter, but it may be nosocomially acquired at the site of an intravenous catheter in an immunocompromised patient. In a review of phaeomycotic cysts from the Armed Forces Institute of Pathology, 25 cases were seen over 19 years.[121] Eleven were on the upper extremity, 12 on the lower extremity, and 2 on the face. The standard of care for this infection is surgical removal. It is not clear whether antifungal therapy alone could be successful.

Deep Fungal Infections

Deep fungal infections are serious clinical problems that often result in significant morbidity and even mortality. Several of the organisms described in the following subsections can also present as cutaneous or superficial infections; both superficial and deep infections are presented together under each fungal infection. Fortunately, deep infections are rare in the hand and upper extremity but may affect the tenosynovium, joints, or bone. The only way to make a diagnosis of hand or upper extremity fungal infection is to include fungal stains and cultures in the biopsy for every presentation of chronic tenosynovitis, arthritis, or osteomyelitis. Infectious disease consultation is recommended for diagnosis and treatment of deep fungal infections. They are difficult to treat because drug therapy is prolonged, drug toxicity is often severe, and recurrences are common in both immunocompetent and immunocompromised patients. The infections are presented in alphabetic order next.

Aspergillosis

Etiology. Aspergillosis of the upper extremity, like cryptococcosis and mucormycosis in an immunocompromised patient, is a devastating disease. Prompt and timely biopsy and treatment prevents serious morbidity. *A. fumigatus* is the most common species recovered from patients with aspergillosis. *A. ustus* was found in a case of forearm abscess in a cardiac transplant patient.

Clinical Findings. *Aspergillus* infections of the hand are rarely encountered in a healthy person and are reported and occur as localized dermal nodules. It may be seen as a necrotic ulcer in a finger, hand, or forearm. As a rule, it infects the immunocompromised and is a major cause of morbidity, hand amputation, and mortality in immunosuppressed patients because it infects blood vessels and causes devastating tissue necrosis as in mucormycosis. Hand infection has been reported in immunocompromised adults with diabetes, in immunocompromised children with acute leukemia,[45] and in cardiac and/or liver transplant patients.

In the upper extremity, primary cutaneous aspergillosis is often associated with burns,[101] sites of IV or catheter insertion in leukemic children, and surgical wounds. It typically presents as minor erythema and induration that rapidly progresses to devastating skin and deep necrosis. Granulocytopenia (<500 polymorphonuclear leukocytes per mL) that results from cytotoxic chemotherapy predisposes children to invasion by *Aspergillus*. A hemorrhagic vesicle, bleb, or necrotic ulcer on the finger, hand, forearm, or arm of a child who is undergoing chemotherapy for acute leukemia should alert the hand surgeon to aspergillosis. Puncture wounds after intravenous infusion are common sites of infection. Infection in an organ transplant patient should arouse a strong suspicion.

Diagnosis. Biopsy is essential to establish a diagnosis; blood cultures fail to reveal the diagnosis. *Aspergillus* species are common contaminants in the bacteriology laboratory but should not be dismissed when the culture is obtained from an immunosuppressed patient. Biopsy of the necrotic lesions shows numerous fungal hyphae on a wet KOH preparation. Definitive diagnosis of *Aspergillus* infection depends on identification of the organism in cultures of the infected biopsy tissue.

Treatment. Rapid radical surgical debridement, intravenous or oral voriconazole, and reversal of underlying host immune

defect with reduction of high doses of immunosuppressive therapy are the mainstays of treatment. Repeated debridement may be necessary due to its invasiveness and tissue necrosis caused by vascular infection. This may be followed by skin grafting. Itraconazole was successful in the treatment of a localized cutaneous *Aspergillus* infection of the hand; however, voriconazole is now considered the drug of choice against aspergillosis. It has replaced AmB because it is more potent and has fewer side effects. Transient and reversible visual disturbance occurs in 30% of patients receiving voriconazole. Without treatment, aspergillosis metastasis to different sites occurs rapidly and generally proves fatal. When necrosis of tendons, joints, and neurovascular bundles occurs, ray amputation may be necessary. In an immunocompetent subject, excision of the lesion is curative.

Blastomycosis

Etiology and Epidemiology. Blastomycosis is caused by *Blastomyces dermatitidis*. It is reported mostly in North America's Ohio and Mississippi River valleys and has a similar distribution as histoplasmosis. It is a disease of immunocompetent hosts who work in contact with soil. The fungus is inhaled and causes a clinical or subclinical lung infection. Primary cutaneous blastomycosis can be caused by direct implantation into the skin or secondarily by dissemination of the fungus from the lungs. Hand infections are rare and only sporadically reported. Traumatic implantation of *B. dermatitidis* may occur in the hand of a veterinarian who handled an infected necropsy specimen. Blastomycosis can occur as a primary infection of the upper extremity[47] or secondarily as part of a systemic infection.[47] Primary inoculation blastomycosis in a finger can occur when there is an accidental inoculation of *Blastomyces dermatitidis*. It can occur in AIDS patients.

Clinical Findings. Clinical findings are nonspecific and multifarious. It may appear as a plaque, ulcer, or nodules on a finger, hand, or forearm.[43] Skin lesions can be in the form of subcutaneous nodules and can be solitary[43] or multiple; they may appear concurrently in the hand or wrist[43] or on separate regions of the same upper extremity, or another extremity, or elsewhere on the body. Blastomycosis may appear as paronychia, nodules on a finger, dorsum of the hand, or forearm. It may appear as a painless soft tissue mass on the forearm. Subcutaneous nodules can develop into abscesses with draining fistulas and finally into ulcers. Lesions may be exudative, suppurative, or granulomatous. Contiguous spread to bone, joint, or flexor tendon of a finger can occur. It may present as a blastomycotic phalangeal osteomyelitis (dactylitis). A localized osteomyelitis of the distal radius that simulates a sarcoma may occur in an otherwise asymptomatic patient. Osteoarticular lesions occur in 60% of patients who have systemic blastomycosis and may include septic arthritis and osteomyelitis in the hand and elbow. Lymphangitis and lymphadenitis may occur.

Diagnosis. Histopathologic diagnosis of biopsy tissue may require special stains, including periodic acid–Schiff or silver stain. The fungus has a characteristic histologic appearance with a double refractile cell wall and broad-based buds between the mother/daughter cells.

Treatment. Ketoconazole and itraconazole are highly effective against *B. dermatitidis*. Surgery is necessary only for diagnostic biopsy. The value of surgical debulking is questionable.

Candidiasis

Etiology and Epidemiology. The increasing incidence of HIV infection and the implantation of prosthetic devices are important in the increasing incidence of local and systemic candidiasis. The most common species recovered from clinical specimens include *C. albicans*, *C. tropicalis*, *C. glabrata*, and *C. parapsilosis*. Many other less common species have also been described. *C. albicans* can cause an interdigital web ulcer.

Clinical Findings. Flexor and extensor tenosynovitis of the hand has been reported in newborns and in AIDS patients. Osteomyelitis and septic arthritis of the wrist with *C. parapsilosis* has been reported. Silicone arthroplasty of the metacarpophalangeal joint may become infected with *C. albicans*.

Diagnosis. Infected prosthetic joints may be aspirated or opened, and staining and culture for the fungus should be included in microbiologic studies.

Treatment. Fluconazole and AmB are the drugs of choice for use in patients with deep candidiasis. For periprosthetic infection, radical synovectomy, tenosynovectomy, and removal of the implant are recommended in addition to chemotherapy combined with amphotericin B and 5-fluorouracil.

Coccidioidomycosis

Etiology and Epidemiology. Coccidioidomycosis is caused by *Coccidioides immitis*. It is a highly infectious fungus that is found only in hot and arid regions of the San Joaquin Valley in California and the US deserts of the southwest, where the infection is endemic.

Clinical Findings. This fungus has a predilection for synovium, and 10% of coccidioidal infections occur in the wrist and hand. Coccidioidal tenosynovitis,[29] joint infection, and osteomyelitis[53] of the hand have been reported. All four cases of coccidioidal osteomyelitis were in children. Coccidioidal osteomyelitis of a metacarpal has been reported to mimic an enchondroma.[53] Patients with tenosynovitis present with chronic diffuse swelling over the dorsal or volar side of the wrist or palm. If untreated, tenosynovitis can lead to extensor tendon rupture and mimic rheumatoid arthritis. Rarely has concurrent pulmonary coccidioidomycosis been diagnosed. Coccidioidomycosis of the hand may occur as a part of disseminated coccidioidomycosis or after traumatic implantation of the fungus.

Diagnosis. Clinical, gross histopathologic (rice bodies and melon seed bodies), and microhistopathologic similarities (noncaseating granulomas) between coccidioidal and other fungal and tuberculous infections are well recognized. Diagnosis is made from positive complement fixation titer, presence of chronic granuloma, microabscesses in the synovial biopsy, and identification of *C. immitis* in synovial stains and cultures. The organism has a characteristic appearance in tissue and can be identified in many cases under a microscope. Histopathology of excised synovium shows the characteristic *C. immitis* spherules in synovium, and the dimorphic fungus grows in synovium culture. The fungus in its hyphal form is highly infectious. The laboratory should be alerted to the presumed diagnosis so that it can handle the specimens and cultures in an appropriate biohazard hood to prevent airborne dissemination.

Treatment. Coccidioidomycosis is one of the most difficult to treat among invasive mycoses because the nonpulmonary infection often requires years to cure, and lifelong antifungal suppressive therapy may be needed. The infection resists aggressive

treatment with synovectomy, tenosynovectomy, and high doses of AmB. Patients may have multiple recurrences of tenosynovitis, even when they are treated with adequate tenosynovectomy and intravenous amphotericin B. The infection flares up during periods of immunosuppression or lowered host resistance. Preexisting and dormant tenosynovitis may suffer flare-up of infection during chemotherapy for leukemia. Complement fixation titers correlate closely with clinical response to therapy and are useful in detecting subclinical recurrences.

Therapy with fluconazole, itraconazole, or AmB may be indicated depending on the patient's condition. The azoles are particularly useful for long-term therapy and have provided many patients with chronic suppression of otherwise relapsing manifestations of the disease. Consultation with a knowledgeable infectious disease consultant is highly recommended because a long-term commitment to therapy and attention to drug side effects, drug interactions, and possibly disease flare-ups is frequently necessary.

Cryptococcosis

Etiology and Epidemiology. Cryptococcosis of the upper extremity, like aspergillosis and mucormycosis, in an immunocompromised patient is a devastating disease and prompt and timely biopsy and treatment will prevent serious morbidity. In immunocompetent patients, primary infection in the lung is rare and is typically asymptomatic and self-limited. In immunocompromised patients, *Cryptococcus* from the lung may be disseminated to many sites, commonly to the skin, brain, and meninges. Cryptococcosis (European blastomycosis, torulosis) is an infection caused by the opportunistic fungus *Cryptococcus neoformans*. It is usually associated with avian habitats and, in particular, with pigeons and pigeon's droppings. There are two varieties of neoformans: *C. neoformans* and *C. gattii*.

Clinical Findings. The skin is the third most common organ affected in *C. neoformans* infections, after the lung and central nervous system. Cutaneous cryptococcosis can present in a variety of ways, including papules, pustules, plaques, cellulitis, abscesses, nodules, sinuses, and ulcers—all of which may present diagnostic problems for the hand surgeon. Opportunistic cryptococcal infections of the hand are reported in patients who are immunodeficient because of renal failure or end-stage renal disease, in renal allograft recipients, in diabetics, in patients with malignancy, and in patients receiving long-term corticosteroids. With HIV, cryptococcosis is listed as an AIDS-defining disease. The hand and entire forearm may be bullous in an immunocompromised patient.

Cryptococcal tenosynovitis may present as a sausage finger and was reported in a rheumatoid patient treated with the disease-modifying drug adalimumab. *Cryptococcus* species very rarely cause disease of the upper extremity in an immunocompetent patient, and having it is an exception to the rule. Primary cutaneous cryptococcosis presenting as a hemorrhagic pustular lesion and an abscess and osteomyelitis of the proximal phalanx are reported in immunocompetent patients.[4] A patient may develop a finger infection after accidental inoculation with an cryptococcal-contaminated needle. The most common radiological presentation of cryptococcal osteomyelitis is a lytic lesion with or without a periosteal reaction. Thick and tenacious pus in the wound should arouse suspicion of cryptococcal infection, especially when thorough surgical debridement fails to clear the infection.

Diagnosis. The simple procedure of mixing together India ink and biologic fluids from sinus, ulcer, or abscess identifies capsulated yeast and remains a rapid and effective method for identifying *Cryptococcus* infection. Diagnosis is confirmed by a high cryptococcal antigen titer and growth of the fungus from biopsy specimens within 48 h on most routine agar media. Histology is an effective way to establish diagnosis of cryptococcosis as the organism is easily and readily identified in the biopsy specimen. Draining material, deep skin biopsy, or curettage from the bone show granulomatous inflammation and encapsulated yeasts.

Treatment. Fluconazole, itraconazole, and flucytosine are all effective in eradicating the infection. Treatment of hand infections with a minimum of 12 weeks of therapy with fluconazole (400 mg/day or more) should control most of these infections. Alternatives include flucytosine, itraconazole, or the newer azoles (e.g., voriconazole). If the patient is immunosuppressed, long-term antifungal therapy is recommended. Patients with diabetes, end-stage renal failure, and uremia who develop infection of the hand with ipsilateral synthetic arteriovenous fistula do not resolve with AmB, 5-flucytosine, and repeated surgical drainages until the graft is removed. Early therapy with fluconazole prevents infection in injuries incidentally caused by needles contaminated with viable *C. neoformans*.

Histoplasmosis

Etiology and Epidemiology. Histoplasmosis is caused by *Histoplasma capsulatum*. It is a highly infectious fungus endemic in the Mississippi and Ohio River valleys.

Clinical Findings. Histoplasmosis may present as cutaneous infection, tenosynovitis, tendon ruptures, carpal tunnel syndrome, arthritis, and in severe burns of the upper extremity with fatal necrotizing myofascitis. A case of recurrent osteomyelitis of capitate bone with 10-year latency between initial inadequate curettage and clinical recurrence has been reported. African histoplasmosis may cause fungating shoulder and elbow swellings with lytic destruction of lateral clavicle and distal humerus, respectively. Infected synovial tissue is red-brown, contains many rice bodies, and undergoes active caseous granulomatous inflammation.

Diagnosis. The diagnosis of histoplasmosis is difficult because the clinical syndrome is nonspecific, and it may be difficult to isolate *H. capsulatum* from clinical specimens. It is revealed in the biopsy tissue if Grocott silver stain is specified. *H. capsulatum* is difficult to grow; it can take several weeks. Close collaboration between surgeon, rheumatologist, infectious disease specialist, pathologist, and microbiologist is paramount in the diagnosis and treatment of these cases. Since the late 1940s, serology has been important in the diagnosis of infection with *H. capsulatum*. Complement fixation test is reliably and commonly used in the clinical laboratory. For complement fixation of antibodies, a titer of 1 : 8 is considered presumptive and a titer of more than 1 : 32 is significantly suggestive of active infection. Sensitivity of antibody tests may be lower in immunocompromised hosts. An antigen test can help in diagnosis of histoplasmosis and gauge the efficacy of antifungal therapy.

Treatment. Combined medical and surgical treatment is critical to prevent recurrence. A combination of complete

tenosynovectomy, bone debridement, and prolonged systemic antifungal therapy (e.g., oral ketoconazole or itraconazole or intravenous AmB) is used. The drug of choice for long-term therapy is 200 mg of itraconazole twice daily. Fluconazole, 400 to 800 mg/day, can serve as an alternative. The histoplasmosis reference laboratory in Indianapolis, Indiana (histodgn @indyunix.lupui.edu), provides services in histoplasmosis antigen testing and itraconazole serum levels.

Mucormycosis

Etiology and Epidemiology. Mucormycosis of the upper extremity in an immunocompetent (in context of trauma) as well as immunocompromised patient (especially diabetes) is a devastating disease, and prompt biopsy and earliest possible treatment prevent serious morbidity (amputation) and mortality. Mucormycosis is an acute and chronic fungal infection characterized by vascular infection, arterial and venous thrombosis, and gangrenous tissue infarction and necrosis. These infections are highly invasive and relentlessly progressive and among the most aggressive, destructive, and necrotizing of all fungal infections. It has a higher rate of morbidity and mortality (>40%) than many other infections. In mucormycosis, necrotizing fasciitis carries a mortality rate approaching 80%. It rapidly infects the blood vessels at the site of infection and quickly spreads to adjacent and subjacent soft tissues all the way to the bone. There is rapid onset of local and widespread tissue necrosis and gangrene, all while the physician struggles to make a diagnosis because of its rarity.

Recent reclassification has abolished the class Zygomycetes. Although called phycomycosis and zygomycosis in the past, the infection is caused by fungi of the class Mucoromycotina and order Mucorales and is now called mucormycosis. *Rhizopus* species are the most commonly isolated agents of mucormycosis, followed by *Rhizomucor*. *Mucor* species, despite its name, is a rare cause of mucormycosis. *Mucor hiemalis*, a common soil inhabitant, was recovered from a diabetic gardener with a localized subcutaneous infection of a finger.

Mucorales are opportunistic fungi that are angioinvasive like *Aspergillus*. Cutaneous mucormycosis can result from external implantation of the fungus or conversely from hematogenous dissemination. External implantation–related infection has been described in the setting of heavy soil contamination of open wounds (e.g., in high-energy severe motor vehicle accidents), penetrating injury from plant material (e.g., a thorn), injections of medications (e.g., insulin or corticosteroids), catheter insertion, contaminated surgical dressings, and use of tape to secure endotracheal tubes or oxygen-monitoring devices. Cutaneous mucormycosis is a common infection in immunocompromised patients and remains rare in the immunocompetent patient outside the setting of major trauma.[83] Cutaneous infections represent <10% of all *Mucor* cases. Cutaneous mucormycosis predominantly involves the epidermis and dermis (eschar), and tissue necrosis and gangrene develop secondary to vascular invasion of subcutaneous tissues and major arteries, respectively.

Clinical Findings. *Rhizopus* and *Mucor* infection of the hand is usually cutaneous and subcutaneous. The upper extremity is involved in 24% of all cutaneous and subcutaneous cases. As an isolated lesion it can occur in the hand,[111] forearm, upper arm,[111] or shoulder.

Fifty percent of cases of primary cutaneous mucormycosis occur in immunocompetent patients with severe trauma where a large and open extensive soft tissue wound is heavily contaminated by soil. Moran et al. have wisely warned that hand surgeons should have a high level of suspicion of *Mucor* infections in high-energy automobile and agricultural injuries with open, contaminated, extensive soft tissue wounds involving the upper extremity in immunocompetent patients.[83] All seven of their patients had an average of 10 surgical debridements (range, 4-20) and four resulted in amputations: one partial hand amputation, one below the elbow, one above the elbow, and one at the glenohumeral joint. Cutaneous mucormycosis of the wrist can occur after an arterial puncture in an immunocompetent host. Infection may start as a blister at the puncture site and progress to a large eschar that needs a large skin graft. If the diagnosis is not made with biopsy, waiting for cultures may result in an amputation and/or loss of life.

The other 50% of the *Mucor* infections occur in immunodeficient patients. Of the 50%, most patients have diabetes (20%), leukemia or aplastic anemia (9%), chronic kidney failure (5%), organ transplants (4%), and rarely alcoholic encephalopathy.[93] An infection of the forearm may occur at an intravenous infusion site, at the arterial line,[93] or follow an intramuscular corticosteroid injection in immunocompromised patients. Persistent and progressive thrombophlebitis at the site of an intravenous line in an immunocompromised diabetic should arouse suspicion of mucormycosis.

The disease occurs as a devastating and often fatal infection in severe burns of the upper extremity. Whereas some mild and localized cases have been described in the hand, the disease more often results in devastating tissue necrosis. Al-Qattan rightly recognized cutaneous and subcutaneous infections of the upper extremity in three stages: dermal plexus (black eschar), subcutaneous vessels (bleeding ulcer), and deep extension to major subjacent arteries (digital and hand gangrene).[2] It is critical to recognize the infection when it is limited to the dermal plexus as a black eschar with progressive necrosis of the wound margin.

Diagnosis. The most important criteria to remember that may point to diagnosis of mucormycosis is a triad of rapid cutaneous and subcutaneous gangrenous destruction, diabetes, and blood vessel thrombosis (i.e., arterial or venous). Enlarging black skin eschars and gangrene should lead one to consideration of advanced mucormycosis, both in immunocompetent and immunocompromised hosts. The diagnosis may be difficult to make because the infectious lesions can be confused with ischemic pathology in patients with multiorgan failure.[93] It may behave like necrotizing fasciitis with rapid necrosis of subcutaneous tissue. Progressive gangrene has prompted finger, hand, below-elbow, above-elbow, and shoulder amputation.

Mucormycosis is notorious for its tendency to invade deep tissues, although mucormycosis osteomyelitis in the hand is rare. Extension of pathology across tissue planes, dermis-to-subcutaneous tissue to vascular invasion of a major artery strongly suggests a mucoral etiology and urgent need for a biopsy. Biopsy and histopathologic examination remain the most sensitive and specific modality for definitive diagnosis. Cultures are positive in less than half of the cases of mucormycosis.

Biopsy specimens taken from the center of the lesion down to the subcutaneous fat are most likely to reveal presence of fungus. The organisms are scattered within a large area of necrosis. Biopsy and smears often reveal the organisms when cultures are negative. Cultures from an excised ulcer may grow *Rhizopus*, *Mucor*, or *Absidia*, as well as other Mucorales (e.g., *Cunninghamella* and *Apophysomyces*). They grow abundantly in 1 to 7 days on routine fungal media when the biopsy material is sampled from deep tissue.

Histopathology for diagnosis of fungus in the infected tissue is immediate and reliable and waiting for cultures may be too late to prevent extremity amputation or death. For histopathologic examination, the laboratory must be alerted as to the nature of the lesion because certain fungal media contain cycloheximide, which suppresses growth of Mucorales species. Yield on superficial swab cultures is low and not recommended.

Treatment. Rapid diagnosis and radical debridement of all necrotic tissues are essential to preserve tissues and prevent limb amputation and loss of life, both in immunocompetent and immunocompromised patients. Successful treatment of mucormycosis requires four steps:

1. Early biopsy
2. Prompt and aggressive surgical debridement of necrotic tissue
3. Rapid initiation of effective, high-dose systemic lipid formulation of amphotericin B
4. Reversal of any underlying predisposing systemic factors; that is, rapid restoration of euglycemia in diabetes, and reducing the dose of immunosuppressive medications if possible helps eliminate the infection

With older patients, tissue necrosis may be so extensive that major debridement and multiple skin grafts are necessary. Intravenous lipid formulations of AmB remain the drugs of choice for the treatment of mucormycosis and should be given in full dose without the delay of increasing dose titration. High doses of these agents are necessary for patients who are at risk of dying of this infection, despite their known nephrotoxicity.

Cutaneous and subcutaneous mucormycosis that is more localized has a much better prognosis (mortality, 15%) than deep-seated infections (mortality, 40%). Mortality of cutaneous mucormycosis is higher in immunocompromised patients than immunocompetent patients, especially when early and aggressive surgery is undertaken.[83] For patients receiving immunosuppressive therapy, secondary antifungal prophylaxis is continued for as long as the immunosuppressive regimen is administered. *Mucor* and *Aspergillus* infection of burns and bones is devastating and is considered separately in the following. Al-Qattan,[1] Prabhu et al,[90] Moran et al,[83] and Spellberg et al[108] recently reviewed mucormycosis comprehensively.

Deep (Extracutaneous) Sporotrichosis

Etiology and Epidemiology. Extracutaneous sporotrichosis is rare and usually occurs within the musculoskeletal system of an immunocompromised host. The organism frequently enters the body through the lungs, and a concomitant pneumonia is often present. Deep sporotrichosis infection may localize to the bones, joints, or tenosynovium in the hand. Sporotrichal osteomyelitis may present as multifocal subchondral and periarticular erosions of the hand's bones. Among articular lesions, wrist joint and hand joints are the most commonly involved.

Diagnosis. A joint infection with a sinus should arouse suspicion. Tenosynovial lesions can occur on the dorsal wrist tendons. Extensor tenosynovitis may cause rupture of an extensor tendon. Sporotrichal flexor tenosynovitis can result in carpal tunnel syndrome or ulnar nerve entrapment. Bursal sporotrichosis can occur in the olecranon bursa. Sporotrichal myositis of the biceps muscle can occur without skin or lymphatic involvement.

A high level of suspicion is needed to make the diagnosis of sporotrichal arthritis, osteomyelitis, and tenosynovitis. The diagnosis of sporotrichal arthritis is often delayed for two reasons: (1) *Sporothrix schenckii* is an uncommon cause of arthritis and (2) sporotrichal arthritis often occurs in the absence of the clinically familiar cutaneous lesions. Eighty-four percent of sporotrichal joint infections presented as monoarthritis. Sporotrichosis should be considered in the differential diagnosis when granulomatous synovitis is recognized by histologic examination.

Sporotrichal osteomyelitis is equally rare. Infected patients have localized swelling, local sinus tract formation, and concomitant arthritis. Roentgenographic findings in osseous sporotrichosis are nonspecific and include destruction of bone without reactive sclerosis or periosteal reaction. Tenosynovial swelling of sporotrichosis is clinically similar to rheumatoid tenosynovitis and on gross examination proliferative tenosynovium is similar to rheumatoid tenosynovium. Rice bodies may be found in the inflamed tenosynovium, as is common in tenosynovitis due to rheumatoid arthritis, tuberculosis, and many other causes.

Olecranon bursal sporotrichosis has been reported.*** Even when biopsy is done expeditiously, diagnosis can be missed on histopathologic examination unless multiple sections are diligently examined. *S. schenckii* may grow from aspirated pus or from tenosynovium, or not grow on repeated cultures. Delay in diagnosis can range from 2 to 12 months. Repeated synovial fluid cultures and synovium biopsies may be necessary before a diagnosis is made. Cultures usually grow in 4 weeks, but growth may be delayed up to 8 weeks.[30] Histologic examination typically reveals a nonspecific pyogranulomatous response or a noncaseating granuloma. It is diagnostic only when characteristic cigar-shaped yeasts are seen and *Sporothrix schenckii* grow on culture.

Treatment. Aggressive chemotherapy in combination with surgical debridement is necessary to cure deep sporotrichosis. For bone, joint, and tenosynovial sporotrichosis, SSKI is not adequate because it is for the treatment of cutaneous and lymphocutaneous sporotrichosis. Amphotericin B is the drug of choice, and 2-hydroxystilbamidine, ketoconazole, itraconazole, and fluconazole have all been used successfully. If surgical debridement in conjunction with chemotherapy does not eradicate the infection, arthrodesis or amputation may be necessary. Appropriate use of antifungal agents, however, should make such radical surgery less likely. Osteoarticular sporotrichosis may require prolonged therapy but is not life threatening.

Fungal infections of burns and fungal osteomyelitis are described separately in the following subsection because they are exceedingly devastating, resulting in morbidity and mortality.

CRITICAL POINTS *Diagnosis and Treatment of Mucormycosis*

- Beware of an eschar (mucormycosis, aspergillosis).
- Fungus grows faster in host than in petri dish.
- Biopsy gives faster diagnosis than cultures.
- Waiting for culture result can cost limb or life.
- Excise infected tissues to healthy margins.

Fungal Infections Following Large Upper Extremity Burns

Fungal infections following large upper extremity burns are rare but devastating. They are best reviewed by Salisbury et al.[101] Seven out of 16 patients died in spite of correct diagnosis and treatment with AmB and radical surgery including amputations in four. The extent of the burns in the patients averaged 50%. The presence of invasive fungal infection was diagnosed from 3 to 27 days from the occurrence of the burns. There were only two invading organisms: mucormycosis (Phycomycetes) in 13 and *Aspergillus* species in 3. Suspicious signs included: (1) inflammation, (2) a rapidly progressive change in color of the wound to violaceous or black, and (3) earlier separation of eschar.

There was rapid progression of clinical disease, compared to slow and inconsistent growth of fungi on cultures. Thus, histological examination of a burn wound suspected of fungal invasion should be carried out promptly because the fungus is easily visible in biopsy tissue. The fungus may be on the surface of the wound (contamination), may colonize on the wound surface, may colonize partial eschar, may colonize entire eschar, may infect subeschar, and finally may invade the muscle locally or extensively. Prompt and radical excision of infected tissue including muscle combined with AmB is the treatment of choice. Three levels of invasion necessitated amputation: (1) widespread muscle invasion, (2) bone involvement, and (3) vascular invasion.

Fungal Osteomyelitis

Clinical aspects of mycotic infections of bone are well reviewed by Rhangos and Chick.[97] The three major causes of fungal osteomyelitis are blastomycosis, coccidioidomycosis, and histoplasmosis. Coccidioidomycosis and histoplasmosis are asymptomatic or moderate in 75% of the infections. Bone lesions due to *C. immitis* may be expected in 10% of severe infections caused by it.

The most important factor in diagnosis of a mycotic infection is a high level of suspicion. Without this, the proper diagnostic steps may never be taken. The skin tests done with fungal antigens of *H. capsulatum* and *C. immitis* are simple diagnostic tools and are performed in the same way as the Mantoux PPD test for tuberculosis. Five millimeters or more of induration after 48 h indicates present or past infection. A negative test rules out infection by either of these two organisms. Serologic tests provide useful information in that the presence of a positive titer indicates active infection.

Serial determinations are a precise method of following the extent of the infection. The complement fixation test is most widely applied with *Histoplasma*, *Coccidioides*, and *Blastomyces*. Skin and serologic tests provide a presumptive diagnosis. Diagnosis is verified by demonstration of fungus in a culture, but that takes up to 4 or more weeks. A more rapid diagnosis of *B. dermatitidis*, *C. immitis*, and *C. neoformans* is provided by biopsy material in which the fungus is identified. The best all-purpose stain is methenamine silver, which will demonstrate all of the preceding fungi that involve bone.

In blastomycosis, about half the cases infect bone, and carpal bone infection has been reported. Radiologically, there is sharp, well-defined bone destruction. In *Coccidioides*, about 20% of the cases involve bones and joints. Infection of the wrist and elbow are favorite sites in the upper extremity. Radiologic examination shows sharply demarcated cystic lesions. In cryptococcosis, 20% of 200 cases had bone involvement. Radiologically, lesions resemble osteomyelitis with eventual breakdown of soft tissues and formation of a draining sinus. The radiographic appearance is again that of a discrete osteolytic lesion surrounded by a zone of dense bone.

Mucormycosis osteomyelitis in the hand is a rare occurrence, but occurs commonly in diabetics. Inoculation happens from trauma with soil contamination, burns, and intramuscular injection. Zygomycotic *Apophysomyces elegans* fungus was the infecting organism in 3 of Stevanovic's 9 cases. They are angioinvasive and lead to tissue necrosis by vascular thrombosis and amputation was necessary in 4 of 9 cases reviewed by Stevanovic et al.[111]

Newly Emerging Hand Fungal Infections

Etiology and Epidemiology

In recent years, a number of emerging fungal infections have become apparent. This category includes resurgent organisms that had previously declined in prevalence, as well as newly identified organisms. Such fungal infections are generally rare and often of low grade, causing encapsulated cysts localized to subcutaneous tissue.

Hand infections with several new fungi have been reported. Pheohyphomycosis (i.e., chromomycosis, chromohyphomycosis, chromoblastomycosis) is the general term for infections caused by dematiaceous (e.g., pigmented, yellow-brown, light brown, black) fungi, commonly seen in tropical and subtropical climates. These infections should be suspected in a visitor from or traveler to such regions. Such infections are being reported at an increasing rate. Pheomycotic cyst or subcutaneous pheohyphomycosis is the most common type of pheohyphomycosis.

Among the pheohyphomycosis cases reported in the hand, many rare fungi have been reported, including *Phaeoacremonium aleophilum*, *Curvularia*, *Pyrenochaeta romeroi*, *Exophilia dermatitidis*, *Exophiala jeanselmei*, *Geotrichum candidum*, *Phialophora richardsiae*, *Cladophialophora carrionii*, *Alternaria alternata*, *C. bantiana*, *Fonsecaea pedrosoi*, *Rhinocladiella aquaspersa*, *Cladosporium*, *Actinomucor elegans*, *Microsporum persicolor*, *Scedosporium apiospermum*, *Fusarium oxysporum*, *Moraxella lacunata*, and *Paecilomyces lilacinus*. *Pseudallescheria boydii* is known to cause mycetoma in immunocompetent subjects. Rare *Leptosphaeria tompkinsii* was reported to cause mycetoma of the hand. *P. richardsiae* is a rare fungus found in wood pulp and has been known to cause two infections in the upper extremity, one in the hand, and one in the olecranon bursa. Splinters may cause pheomycotic cysts of the finger.

Treatment

These fungi are relatively less virulent and invoke minimal inflammation and result in formation of a thick capsule that allows easy excision, which is generally curative. No antibiotics are necessary if the entire encapsulated mass of fungus is excised. The cysts should not be opened while dissecting them because the fungus from within them will spill into virgin tissue and cause recurrence. If a cyst filled with fungus is opened, it is essential to irrigate the wound before the tourniquet is released to prevent hematogenous dissemination of live fungi.

One case recurred when surgical excision was not complete. *Pseudallescheria boydii* is known to cause infection of hand, wrist joint, tendons, and soft tissues of the forearm in immunocompromised patients. The infections respond to itraconazole, although surgical excision is an important adjunct for treatment of this infection. These fungi are inherently resistant to AmB and may be less sensitive to azoles as well. Treatment with voriconazole, high-dose fluconazole, or itraconazole is the preferred strategy. Long-term therapy (>3 months) is likely to be necessary.

Consultation with the CDC's mycotic disease branch in Atlanta (www.cdc.gov) or fungus testing laboratory at the University of Texas, Health Sciences Center, San Antonio (rinaldi@uthscsa.edu), may help with choosing the latest diagnostic and therapeutic laboratory tests and treatment.

MYCOBACTERIAL INFECTIONS (TUBERCULOUS AND NONTUBERCULOUS)

Tubercle bacillus was identified, isolated, and grown in 1872 by Robert Koch, for which he received a Nobel Prize in 1905. Almost 150 years after Koch, *M. tuberculosis* continues to affect an estimated 2 billion people (i.e., one-third of the world's population). Worldwide, it is second only to AIDS as a cause of death resulting from a single infectious agent. Globally, in 2012, approximately 8.6 million became ill with TB, and 1.3 million died from the disease.

In the United States, after the resurgence of it during 1985 to 1992 as a result of the AIDS epidemic, the annual TB rate decreased steadily. In 2011, a total of 10,528 new US cases (3.4/100,000) were reported. This represents a decline of 60.5% from 1992 due to retroviral treatment of AIDS. Unfortunately, multidrug-resistant TB (MDR TB) has become a threat, and extensively drug-resistant TB (XDR TB) is an emerging threat. Racial and ethnic minorities and foreign-born individuals continue to account for the largest number of TB cases in the United States. In 2011, 84% of all reported cases occurred in racial and ethnic minorities: 30% in Asians, 29% in Hispanics, 23% in African Americans, whereas 16% of cases occurred in non-Hispanic whites.

The percentage of recorded TB cases for foreign-born people increased from 28% in 1990 to 62% in 2011. Among the foreign-born, 46% were Asian, 34% were Hispanic or Latino, 13% were non-Hispanic black or African American, and 5% were non-Hispanic white. In 2011, the seven top countries reported 61% of the total cases, with Mexico having 22%, the Philippines 11.6%, Vietnam 8.4%, India 7.7%, China 5.8%, Haiti 2.9%, and Guatemala 2.5%. People from more than 135 other countries accounted for the rest (39%) of US foreign-born individuals with TB. Approximately 65% of the immigrants affected developed tuberculosis in the United States within 5 years of their arrival. Five states (i.e., California, Florida, Illinois, New York, and Texas) recorded for more than half of all TB cases. Understandably, the most common chronic infection of the hand is tuberculosis.

The number of MDR TB cases (i.e., resistant to >1 agent and at least isoniazid or rifampin) worldwide was about a half million in 45 countries. In the United States, primary drug resistance was first reported in 1993. Resistance to at least isoniazid in 2011 was 9.2%. Multidrug-resistant TB in 2011 was 1.3%. Drug resistance is also higher in foreign-born individuals; the percentage of isoniazid resistance was approximately two times higher among the foreign-born than among US-born individuals in 2010. Cases of XDR TB (i.e., resistant to isoniazid and rifampin, plus resistant to any fluoroquinolone and at least 1 of 3 injectable second-line anti-TB drugs) have been reported in 17 countries almost every year, including the United States and all G8 countries. Six cases of XDR TB were reported in the United States in 2011. (For further information about the preceding discussion, see www.cdc.gov/tb/statistics/surv/surv2011/slides/surv21.htm.)

Tuberculous tenosynovitis, arthritis, and bursitis simulate rheumatoid synovitis but are localized to a few tendons, a joint, or a bursa. Absence of generalized findings of rheumatoid arthritis or proliferative tenosynovitis of unknown origin should alert the clinician to the possibility of tuberculosis. Biopsy for histopathology and microbiology is always necessary for definitive diagnosis. The sine qua nonhistologic hallmark of a tuberculous infection is the granuloma (tubercle). A granuloma is a minute aggregation of cell-mediated T lymphocytes, macrophages, epithelioid cells, and Langhans giant cells that limit the multiplication and spread of the tubercle bacillus. The tuberculosis granuloma can be distinguished from those of NTM by its characteristic central necrosis or caseating granuloma.[24]

NTM, however, in rare cases can cause a caseating granuloma, and organism identification is necessary for definitive diagnosis.[24,122] Caseated material represents host cells composed of tubercle bacilli that are killed by cytotoxic lymphocytes (CTLs) and a chronic delayed type hypersensitivity immune reaction (type 2 hypersensitivity reaction) to the residual and persisting dead tubercle bacillus wall antigens. If an initial biopsy does not yield a positive culture, a repeat biopsy may help to establish a diagnosis because the organisms are often sparse and grow with difficulty. Ultrasonography can detect soft tissue extension of the bony lesions and can guide drainage or biopsy procedures.

All mycobacterial hand infections reported before 1960 were attributed to *M. tuberculosis*. Since 1960, reported cases of *M. tuberculosis* of the hand are few and reported hand infections caused by NTM[5,15,34,52,64,72,92] are more frequent. Nontuberculous mycobacteria may be either slow growing (>7 days to grow) or fast growing (<7 days to grow) (Table 3.7). Currently there are more than 120 species of NTM, of which approximately 60 are human pathogens. Of the 60 known human NTM, only 19 have been reported to cause hand infections. *M. marinum* is the most widespread cutaneous tuberculosis and *M. avium*, *M. chelonae*, and *M. haemophilum* are the most common AIDS-related mycobacterial infections in the United States.

The clinical presentation of tuberculous and NTM infections is indistinguishable. Mycobacterial identification is paramount

TABLE 3.7 Growth Rates of Mycobacteria

Slowly Growing	Intermediately Growing	Rapidly Growing (<7 days)
M. avium complex (*M. avium* and *M. intracellulare*)	*M. marinum*	*M. fortuitum*
M. kansasii	*M. gordonae*	*M. chelonae*
M. xenopi		*M. smegmatis*
M. szulgai		*M. abscessus*
M. scrofulaceum		
M. malmoense		
M. terrae		
M. haemophilum		
M. asiaticum		

Growth rates have become a practical means of grouping the species within laboratories.

because the virulence, growth requirements, drug sensitivity, and treatment of the various species differ greatly. The constitutional symptoms present in pulmonary tuberculosis are notoriously lacking in extrapulmonary tuberculosis. The erythrocyte sedimentation rate (ESR) may be normal or only slightly elevated in infection with *M. tuberculosis* but is almost invariably normal in immunocompetent patients with NTM infections.

A higher ESR occurs in patients with lower immunity with more inflammatory disease and indicates a more severe infection. It may necessitate diagnostic workup for an active primary focus and multicentric tuberculosis. Regional lymphadenopathy is usually absent. A positive tuberculin skin test is not indicative of a currently active infection, is positive in people who had BCG vaccination or subclinical infection, is negative in debilitated and anergic patients, and is not useful for diagnosis. Pulmonary disease does not generally accompany mycobacterial infection of the hand[11] unless immunity is low in an inadequately nourished patient.

Surgical findings of TB and NTM infection are indistinguishable. Acid-fast bacillus (AFB) smears of sampled granuloma may not show any organisms or reveal only sparse bacilli after painstaking scrutiny. The purulent aspirate from an infected joint often shows the organisms on a smear. Cultures most often grow the organism in 1 to 12 weeks on a Lowenstein-Jensen medium. *M. marinum*, *M. haemophilum*, *M. chelonae*, and *M. ulcerans* grow at 30°C (room temperature), whereas *M. tuberculosis* and other NTM grow at 37°C (body temperature). *M. xenopi* grows best at 42°C. It is wise and critical to request incubation at three temperatures in a suspected chronic hand infection because many laboratories do not routinely incubate mycobacterial cultures at 30°C and 42°C.

The TB and NTM infections differ in their prognosis, and their sensitivity to antimicrobial drugs varies widely. The clinical course of NTM infections varies from self-healing cutaneous lesions to highly resistant deep lesions, resistant both to surgical debridement and chemotherapy. *M. avium*, *M. chelonae*, and *M. malmoense* infections are tenacious, resistant, and recurrent, often requiring amputation. Some grow readily on cultures and others (e.g., *M. avium*, *M. chelonae*, and *M. malmoense*) do not. Some grow quickly in 7 to 10 days (fast-growing mycobacteria) and others take 7 to 12 weeks (*M. avium*, *M. malmoense*).

Sites of tuberculous and NTM infections in the upper extremity are the skin, subcutaneous tissues, tenosynovium, bursa, joints, and bone. A combination of the preceding may be seen in immunocompromised patients. The three most common *M. tuberculosis* infections of the hand are flexor tenosynovitis, wrist joint infection, and phalangeal osteomyelitis (dactylitis). Of 32 cases of the tuberculosis of the hand seen over a 4-year period by Kotwal et al,[66] 12 had bony infection and 20 had soft tissue infection. Out of the 20 soft tissue infections, 14 had flexor or extensor tenosynovitis. Out of the 12 bony infections, about half had dactylitis (i.e., phalangeal or metacarpal infections). Of the 6 joint infections, all involved the wrist.[66]

Rarely, mycobacterial infections can cause a midpalmar space abscess, a large soft tissue forearm abscess, fasciitis, compartment syndrome in the forearm due to expanding purulent caseation, or a cold abscess in a muscle. Cold abscess of muscle may occur in deltoid, brachialis, or biceps brachii muscles. Corticosteroids can cause reactivation of a latent focus of extrapulmonary tuberculosis in an immigrant from an endemic country or after organ transplantation.

Cutaneous Tuberculosis

Clinical Findings

The most common TB infection of the hand involves the skin; 80% of cutaneous tuberculosis affects the hand and the upper extremity. It is rare in childhood even in countries with a high burden of tuberculosis. It may be acquired in the skin in one of the following ways: by inoculation from an exogenous source through a breach in the skin, inoculation by tattoo needles, by acupuncture needles, by BCG vaccination, by contiguous spread from bone to skin (scrofuloderma), or by hematogenous spread to skin from a pulmonary or extrapulmonary focus (lupus vulgaris). *M. marinum* (*M. balnei*) is the most commonly reported NTM skin infection of the hand in Western countries and *M. tuberculosis* in Eastern countries. An underlying disease that compromises host immunity may be found in up to 30% of cases. Cutaneous tuberculosis of the hand in AIDS patients occurs in rare cases.

Skin infections can be caused in medical personnel by accidental primary inoculation with a cannulated needle withdrawn from an infected patient, primary inoculation of a surgeon from a blade that operated on tuberculous tissue, accidental injection of infected fluid in the laboratory, or mycobacterial infection from autopsy material (i.e., prosector's paronychia). Tuberculous paronychia has been reported in a nurse caring for a patient with active pulmonary tuberculosis. The disease is usually self-limited if host immunity is high, but chemotherapy expedites cure and reduces morbidity. Surgical excision of the lesion is clearly indicated for one caused by accidental inoculation by a known drug-resistant organism.

The most common nontuberculous mycobacterial skin infection is caused by *M. marinum* (see Figure 3.16). Fish tank exposure is the most frequent source of cutaneous *M. marinum* infections and can be prevented by use of waterproof gloves by anyone with an open skin lesion. The cutaneous infections by *M. kansasii* may heal spontaneously over a period of time, but chemotherapy may be given to expedite healing and prevent scarring. A TB skin gumma can occur on the hand after a contaminated skin venipuncture. *M. bovis* skin infection can occur occupationally in butchers (butcher's wart).

Diagnosis

The most common presentation is a node, abscess, ulcer, or a plaque lesion on the finger, hand, or forearm. A nontender nodule gradually progresses to single or multiple abscesses that drain clear liquid. Nodules do not heal with antibiotics and soaks. Less common presentations include erythema, swelling, cellulitis, crusting, verrucous plaque, verrucous nodule, sporotrichoid lesion, and ulceration. Cortisone exacerbates the disease. Signs of lymphatic spread are evident in 70% of cases. Multiple, marching, linear lesions may be seen along the lymphatics on the hand, wrist, and forearm (i.e., sporotrichoid type) (see Figure 3.17).

Most patients have lesions for 2 months or more before they seek care, and there is usually a substantial delay between initial consultation and correct diagnosis because of the rarity of the condition. Patients infected with *M. marinum* give a history of a puncture wound involved with a fish, fish tank, or swimming pool in more than half the cases. Such a lesion is aptly known as "fish tank granuloma," "fish tank finger," "fish fancier's finger," "swimming pool granuloma," and "fish breeder's granuloma." To this list we can add "fish cleaner's finger."

An outbreak of *M. marinum* occurred in 2014 in New York among Chinese housewives who cleaned fish without gloves (see Figure 3.16). A pustular or nodular phase may subsequently ulcerate to form a "tuberculous chancre"; rarely it may present as marching plaques. Regional lymphadenopathy develops in 3 to 4 weeks after the primary skin lesion is noted. The tuberculous chancre and affected regional lymph nodes constitute the "tuberculous primary complex" of the skin, akin to the classic Ghon lesion in the lung. Organisms may not be seen on AFB staining, and cultures may not grow mycobacteria. Under these circumstances, the detection of mycobacteria by PCR to analyze nucleic acid sequences is recommended, useful, and diagnostic.

Differential Diagnosis

The linear, marching lymphangitis typical of *Sporothrix* infection can also be seen with infections caused by *M. marinum*, *M. kansasii*, *Leishmania*, *Coccidioides*, *Cryptococcus*, *Nocardia*, and tularemia. Tuberculous cutaneous infection of the hand can also be confused with infection by blastomycosis, histoplasmosis, syphilis, and yaws. Final diagnosis of TB infection requires skin biopsy with mycobacterial culture.

Treatment

The US researcher Selman Waksman was awarded a Nobel Prize in 1952 for his discovery of streptomycin—the first antibiotic demonstrated to be effective against tuberculosis. To avoid resistance, *M. tuberculosis* infection is treated with a combination of bactericidal drugs, including isoniazid and rifampin taken daily for at least 6 months, as well as ethambutol and pyrazinamide for the first 2 months. Prompt chemotherapy is curative.

Treatment of NTM infection differs from treatment of tuberculosis. Optimal treatment of cutaneous *M. marinum* infection is not well established. Mild infection resolves spontaneously but complete resolution may take up to 2 years. A two drug combination is recommended to prevent resistance. *M. marinum* is sensitive to clarithromycin, rifampicin, ethambutol, minocycline, and levofloxacin. Resistance to tetracycline, minocycline, doxycycline, and rifampin is emerging. Thus, results of antimicrobial sensitivity tests are essential in guiding chemotherapy. Treatment of *M. kansasii* cutaneous infection is usually effective with the standard antituberculous drugs, erythromycin and cotrimoxazole. Drug sensitivity testing against *M. kansasii* is recommended because resistance to rifampin is known.

Current concepts of cutaneous *M. tuberculosis* treatment have been reviewed by Sehgal.[103] Large series of *M. marinum* and *M. kansasii* skin infections of the hand have been reviewed by Breathnach et al.[15] When the infection is caused inadvertently by inoculation of drug-resistant *M. tuberculosis*, surgical excision of the lesion is important.

Subcutaneous Tuberculosis

Mycobacterium Ulcerans (Buruli Ulcer)

Etiology and Epidemiology. By far the most common cause of subcutaneous infection is *M. ulcerans* (buruli ulcer). After *M. tuberculosis* and *M. leprae* infections, *M. ulcerans* infection is the third most common TB disease in the world. It has been diagnosed in US immigrants from endemic countries. Buruli ulcer was first described in 1948 in six Australian patients, who each had a single ulcerative lesion on an arm or leg. In the 1960s, many patients in the Buruli district of Uganda, near the Nile River, had ulcers that were caused by *M. ulcerans*.

The disease has since become known as buruli ulcer (BU) and is prevalent in West and Central Africa; however, it has been reported to occur in 32 other countries. In Japan, about half of the 19 cases appeared in the upper extremity. The first case in the United States was reported in 1974 in an immigrant physician from Nigeria who developed a chronic ulcer around the elbow. Necrosis of subcutaneous fat is the pathologic hallmark of BU. Inoculation into subcutaneous tissue usually occurs through penetrating skin trauma. Secretions of toxins by the organisms (e.g., mycolactone, phospholipase C) cause extensive subcutaneous fatty tissue necrosis resulting in extensive fibrosis.

Clinical Findings. A lesion usually starts as a painless subcutaneous edema and progresses to a subcutaneous nodule that secondarily ulcerates with a characteristic undermined edge. The ulcers may vary from few centimeters to a large part of the arm. The ulcers may be very large because the entire ulcerative phase is painless and available medical facilities are limited. The disease progresses in four stages: edema, subcutaneous nodule, ulceration, and end-stage scar formation with deformity. A painless ulcer that has undermined edges and a necrotic center with hyperpigmented and shiny surrounding skin is pathognomonic of a buruli ulcer. If untreated, the infection can invade all subjacent tissues including the bones. Infections invading phalanges, metacarpals, and ulna have been reported (Figure 3.17).

Diagnosis. There are five laboratory methods to confirm the disease.

- *Direct smear examination*—An examination done on swabs from ulcers or smears from tissue biopsies that can be promptly conducted at local health facilities where TB microscopy is also done. The exam is conducted using the acid-fast (Ziehl-Neelsen) stain procedure. Nevertheless, the sensitivity of this method is low (~40%) because *M. ulcerans* numbers tend to decrease over time. It is important to

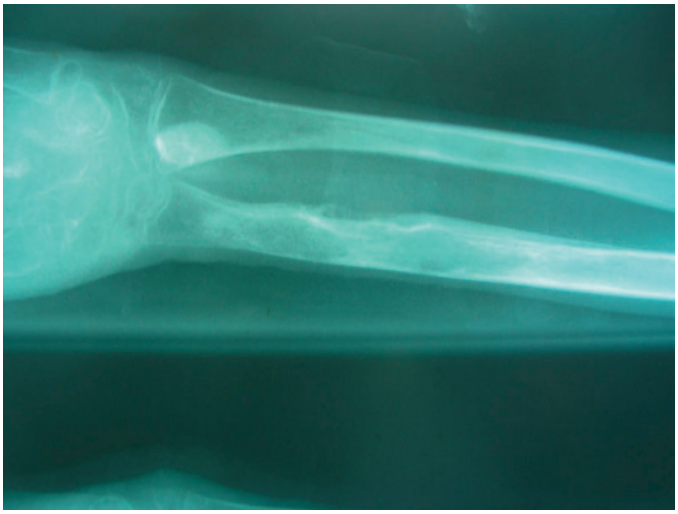

FIGURE 3.17 Buruli osteomyelitis of radius and ulna. The patient's absence of pain and inadequate health care access led in this case to advanced lesions. Note osteolysis, osteosclerosis, scalloping, and periosteal reaction.

emphasize that the positivity of the test varies with the clinical form of the disease. It is more useful in the ulcerative stage, but if the lesion is not ulcerated, a skin biopsy of the nodule is sufficient for the examination. In the nodular form, positivity can reach 60% and in the edematous form, it can reach up to 80%, both in the direct examination and culture. It is considered by many the easiest and most accessible method to arrive at a diagnosis.

- *Culture of* M. ulcerans—A procedure done on swabs from ulcers or tissue biopsies through the Lowenstein-Jensen medium that takes 6-8 weeks or more; sensitivity is approximately 20 to 60%. It is especially difficult to culture *M. ulcerans* when the sample is taken from bone tissue. *M. ulcerans* grows at 30°C. It is difficult to grow and up to 3 months of incubation are required, and the laboratory should be alerted not to discard the medium prematurely.
- *Polymerase chain reaction (PCR)*—This is a test from which results can be obtained within two days on swabs of ulcers or tissue biopsies; sensitivity is around 98%.[2,7] The positivity of PCR and histopathological tests does not vary with the clinical form of the disease.
- *Histopathology*—Tissue biopsies are sensitive in about 90% of cases and are useful for differential diagnoses when the results of other methods are negative. It should be done with a scalpel, thus avoiding the use of punches. The incision should cover the border of the lesion and extend into the subcutaneous tissue.
- *Fine-needle aspiration*—This technique is used in cases of nodular lesions and allows the collection of material for direct examination and culture.

Treatment. Current WHO recommendations for treatment are as follows. A combination of rifampicin and streptomycin/amikacin for eight weeks as a first-line treatment for all forms of the active disease. Clarithromycin and rifampin were successfully used in 19 cases in Japan. Nodules or uncomplicated cases can be treated without surgery. Surgery is done mainly to remove necrotic tissue, cover skin defects, and correct deformities. A necrotic ulcer should be excised to normal healthy tissue to prevent recurrence from residual bacilli and the defect can be skin grafted.

Deep Infections

Deep infections most commonly involve tenosynovium, less commonly joints, and least commonly bone.

Mycobacterial Tenosynovitis

Etiology and Epidemiology. Mycobacterial tenosynovitis is rare. However, it is the most common form of tuberculosis of the hand. Mycobacteria have more predilection for tenosynovium than joints, bone, subcutaneous tissue, or nerve. Flexor tendons of the fingers (Figure 3.18, *A,B*), palm, wrist, and forearm are affected more often than extensor tendons (Figure 3.19, *A-C*). Tuberculous tenosynovitis of flexor carpi ulnaris, abductor pollicis longus, and biceps tendon are rare. Nontuberculous mycobacterial tenosynovitis is more common than TB mycobacterial tenosynovitis.[122] More than half of the reported hand NTM tenosynovial infections are due to *M. marinum* (see Figure 3.18).

The second most common infecting organism is *M. kansasii*, and the ratio of *M. kansasii* and *M. marinum* is 1:5. The third most frequent infecting organism is *M. avium-intracellulare* complex. The less common tenosynovial infections caused by NTM are *M. scrofulaceum* (Figure 3.20), *M. szulgai*,[112] *M. terrae*,[71] *M. fortuitum*,[95] *M. chelonae*,[67] *M. abscessus*, *M. malmoense*,[38] and *M. xenopi*.[26] Reports of *M. tuberculosis* tenosynovitis since 1960 have been sporadic compared with a larger series in prior years. Infection may follow cortisone injection due to reactivation of dormant infection or proliferation of an active infection.

Clinical Findings. Nontuberculous mycobacterial tenosynovitis is more common than tuberculous tenosynovitis and appears to occur more frequently during the fourth to seventh decades of life. Tenosynovitis caused by tuberculous mycobacteria and nontuberculous mycobacteria is clinically similar. The most common presentation of all mycobacterial tenosynovitis is digital flexor tenosynovitis. The physician may feel rice bodies, millet seeds, or melon seeds glide beneath the examining fingers. Flexor tenosynovitis produces three classic presentations: a sausage finger (see Figures 3.18, *A,B*), compound palmar ganglion, and rice body-laden carpal tunnel syndrome (see Figure 3.20). Of the TB tenosynovitis in the carpal tunnel, 90% show thick synovium laden with large rice bodies. The patient is generally healthy and constitutional symptoms are lacking. Inflammatory signs (e.g., erythema, warmth, tenderness) are absent (cold abscess).

Coexistent pulmonary or extrapulmonary tuberculosis is rare. Wrist and hand radiographs are almost always normal. Late in the disease, tendons may rupture and the infection can spread to adjacent joints or bone. The ESR may be elevated in multifocal *M. tuberculosis* infection and is almost always normal in NTM infections but rarely may be elevated. The delay between the onset of symptoms and diagnosis is lengthy—one year in a survey of 32 cases by Kozin et al.[67] Early diagnosis is important because tendon rupture, wrist infection, or secondary osteomyelitis can be prevented. When treatment with steroid injection aggravates the condition, it should raise suspicion of tuberculosis or fungal infection.



FIGURE 3.18 *Mycobacterium marinum* flexor tenosynovitis caused a sausage finger in a Chinese housewife during an outbreak in New York City. This finger was completely stiff in extension. **A,** Dorsal view. **B,** Volar view.

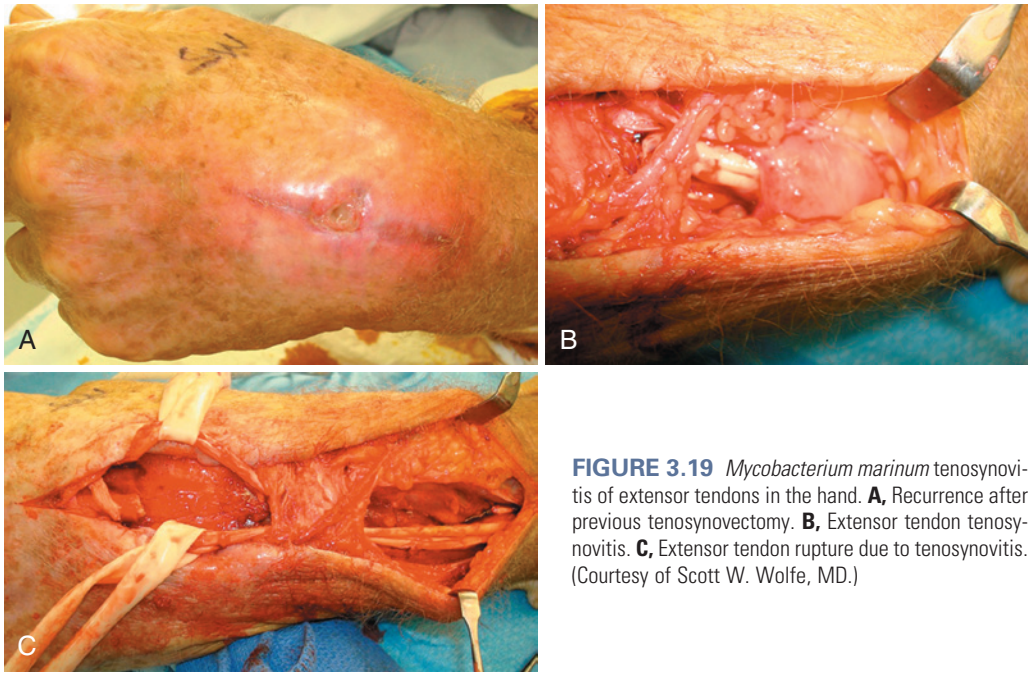

FIGURE 3.19 *Mycobacterium marinum* tenosynovitis of extensor tendons in the hand. **A,** Recurrence after previous tenosynovectomy. **B,** Extensor tendon tenosynovitis. **C,** Extensor tendon rupture due to tenosynovitis. (Courtesy of Scott W. Wolfe, MD.)

Diagnosis. The old dictum that tuberculosis (and syphilis) can mimic almost any other disease entity remains true today. Hand surgeons who are aware of this and perform an early biopsy are more likely to make a correct diagnosis, treat early on, and prevent a bad outcome.

Delay in diagnosis and misdiagnosis can cost the patient an amputation. Lau described two patients with *M. chelonae* infection that required amputation owing to the delay in diagnosis and treatment.[69] Three patients underwent finger amputations for a missed diagnosis of *M. marinum* infection. Delay in diagnosis occurs for several reasons. Clinically, the disease pattern is nonspecific. Pain is conspicuously absent until late in the disease. It starts insidiously and becomes indolent. Other than the hand lesion, the patient is healthy. The diagnosis is not suspected because the tenosynovitis resembles nonspecific or rheumatoid tenosynovitis. Carpal tunnel syndrome can be an initial manifestation of tuberculosis and when proliferative tenosynovitis with or without rice bodies or melon and millet

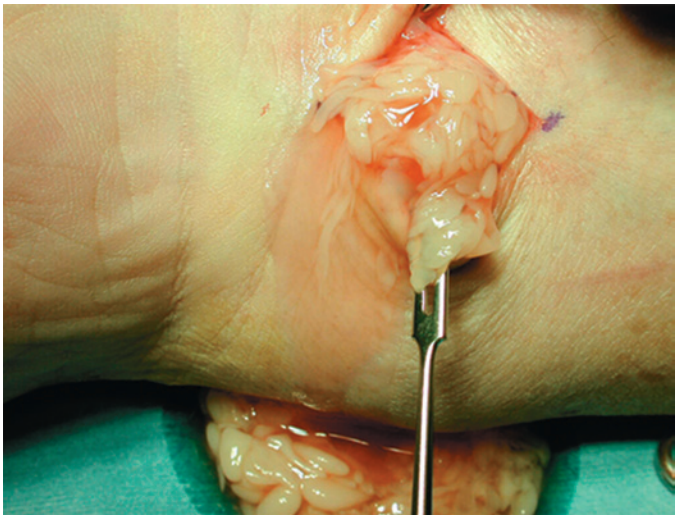

FIGURE 3.20 *Mycobacterium scrofulaceum* tenosynovitis and rice bodies in flexor tendons of the palm. (Courtesy of Scott W. Wolfe, MD.)

seeds is encountered, biopsy and cultures most likely will reveal the correct diagnosis. Smears of fluid aspirated from the lesion may provide the first clue to diagnosis, but this is often not done. Tenosynovial biopsy is often not done at the time of carpal tunnel release. When biopsy is done, tissue is often sent for histopathology but not for microbiology.

Histopathology shows poorly or noncaseating granuloma and may be misinterpreted as sarcoidosis. When biopsy tissue is sent for culture, it can be mistakenly sent in formalin. Even when properly done, histopathology studies reveal only scanty bacilli after painstaking scrutiny. Hand tuberculosis is a paucibacillary lesion and smears and cultures are frequently negative. When tenosynovitis is not clinically visible or palpable, MRI of fingers, hand, and wrist show inflammation around the flexor and extensor tendons. Inflammatory changes are demonstrated and margins of the extensor tendons lose clear delineation compared to those of adjacent fingers. Cultures may not be requested for or not done at 30°C for *M. marinum* at some hospitals. Polymerase chain reaction to confirm tuberculosis is essential to make a diagnosis when stains and cultures are negative. The disease may present in one of four stages depending on the duration of the infection and host immunity.

1. A thin synovitis with free synovial fluid may be seen.
2. For up to 2 years, granulation tissue, thick tenosynovial proliferation, and rice bodies appear.
3. Infection invades the tendon; they may be frayed, infiltrated, ruptured, or caseated into a fungoid mass. Fraying of tendons occurs at an average of 3 years and rupture of tendons occurs at an average of 4 years from the onset of tenosynovitis.
4. Only very late, the infection spreads to the adjacent joints or bone and a sinus may be present with or without superimposed pyogenic infection.

Histologic sections are first examined with the hematoxylin and eosin stain. This is best done as a rapid intraoperative biopsy (frozen section). If granulomas are observed, even if poorly formed, additional stained specimens with Ziehl-Neelsen stain (for AFB) and Gomori methenamine silver stain (for fungi) are examined. *M. tuberculosis* forms caseated granulomas but nontuberculous mycobacteria form mostly noncaseated granulomas.

Failure to demonstrate AFB by staining the synovium does not rule out tuberculosis because cultures may be positive when smears are negative. Only 30% of patients with NTM infection have positive acid-fast stains. Definitive diagnosis can be made by culturing infected synovium or rice bodies. Rice bodies are tubercles in the synovial tissue that become detached and contain live mycobacteria that grow on culture, but only 40% of 166 patients with *M. marinum* yielded positive cultures. Rice bodies are a feature of both *M. tuberculosis* and NTM. A bacteriologic diagnosis can often be made by smearing and culturing drainage from a sinus.

Treatment. The treatment algorithm suggested by Zenone et al is useful.[122] The first step in it is to treat chronic tenosynovitis with thorough tenosynovectomy because tenosynovitis due to pernicious mycobacteria (i.e., *M. avium*, *M. chelonae*, *M. malmoense*, and *M. terrae*) is indistinguishable from other mycobacterial infections. If the patient is immunocompromised, "aggressive synovectomy" becomes essential and helps to reduce the mycobacterial load. Tenosynovectomy should be done from musculotendinous junction to the tendon insertion into the bone.

Chow and colleagues recommend that the role of synovectomy in an immunocompetent patient, in areas where *M. tuberculosis* is endemic, is a "minimal" biopsy to make a diagnosis with removal of enough synovium for histopathology, smears, and cultures.[22] If the diagnosis is established through a "minimal" biopsy or through culture of drainage material, treatment may be successful with chemotherapy without synovectomy. When the patient is on immunosuppressive therapy, in addition to chemotherapy and thorough synovectomy, the physician may be forced to decrease the dose of immunosuppressive drugs to control the infection.

It is reasonable to start chemotherapy based on positive smear staining or histopathology and revise chemotherapy if necessary when results of culture and sensitivity become available. Multidrug therapy with four antituberculous antibiotics remains the cornerstone of treatment for *M. tuberculosis*. Before the development of effective antituberculous therapy, fewer than one half of patients with tuberculous tenosynovitis were cured by complete surgical extirpation of all infected synovium if immunity was adequate.

The most effective empirical combination of chemotherapy for NTM infections is rifampin, isoniazid, and ethambutol. Because of extensive resistance of many nontuberculous mycobacteria, the empirical addition of clarithromycin in a multidrug regimen would probably be appropriate for most nontuberculous mycobacteria causing tenosynovitis[122] (see Figure 3.18, *A,B*). A variety of antibiotic regimens have been used successfully in the treatment of *M. marinum* in two of the largest series. A rifampicin and ethambutol combination was successfully used by Cheung and colleagues in 70 of 75 patients.[20]

Clarithromycin in combination with doxycycline or minocycline or rifampin or ofloxacin or ethambutol is the drug of choice for treatment of *M. marinum* infections. It is important to remember that *M. marinum* is resistant to isoniazid and can be discontinued once culture results or identification by PCR are available. The optimum duration of treatment is unknown and controversial. Average duration of therapy was 7.2 months according to Cheung[20] and 10 months in a survey from the Mayo Clinic.[67] The worst outcome was in patients who were

misdiagnosed for more than 2 months and were mistakenly treated with cortisone injections preoperatively.

Untreated, tuberculous tenosynovitis in the finger and wrist eventually leads to painless tendon attrition and rupture. Flexor tendon grafting restores finger flexion, if the infection is contained within the flexor tendon sheath and the sheath and underlying joints are spared. When a tendon ruptures in the palm or carpal tunnel or distal forearm, the ruptured tendon's distal end can be "piggybacked" to an adjacent functional tendon. When infection spreads from a tendon sheath in a finger to adjacent joint and bone, chemotherapy controls the infection but mobility is lost. Reactivation of a dormant tuberculous infection of the hand may recur many years after it is successfully treated with tenosynovectomy and multidrug therapy (MDT) if the patient's immunity is decreased for any reason, such as immunosuppressive therapy or cytotoxic therapy.

Tuberculous Bursitis

Tuberculous bursitis is uncommon. Most frequent bursa infected by tuberculosis in the upper extremity is subdeltoid bursa followed by olecranon bursa and bicipitoradial bursa. Calcification of the bursal sac is seen in approximately one third of the cases. If the diagnosis is delayed, an adjacent joint may become infected. Early incision and drainage facilitates diagnosis and chemotherapy is curative.

Tuberculous Arthritis

Osteoarticular tuberculosis of the extremities is rare and occurs in only 1% of patients with extrapulmonary tuberculosis. The wrist is the most commonly infected joint by *M. tuberculosis* in the upper extremity. Tuberculous infection of the wrist can be seeded by a blood-borne infection or may spread from untreated flexor tenosynovitis. The infection has been demonstrated to spread from flexor tendons across the wrist joint to the dorsal tenosynovium and result in a swelling on both sides of the wrist. The elbow and interphalangeal joint infections are less common. Wilson[118] published results of 31 cases of elbow tuberculosis in adults. Dix-Peek et al[31] published facts from 10 cases of tuberculosis of the elbow in children between the ages of 1 and 11 and concluded that elbow infections generally start from the olecranon, the lower end of the humerus, or the olecranon bursa.

Clinical Findings. The earliest manifestation of tuberculous arthritis is pain, swelling, and limitation of joint motion. The joint may be held in flexion. Tuberculous arthritis may be suspected when drainage persists from an infected elbow, wrist, or finger joint despite multiple courses of antibiotics and multiple drainage procedures. Most joint infections are monoarticular and may strongly resemble a case of monoarticular rheumatoid arthritis. Concurrent pulmonary or extrapulmonary tuberculosis is uncommon. Skoll and Hudson have classified and graded the radiological findings in osteoarticular tuberculosis.[107]

Roentgenographic hallmarks of early joint infection are soft tissue swelling and periarticular osteoporosis (Figure 3.21, *A*). In the second phase, the hyaline cartilage is invaded, and joint space is reduced or lost (Figure 3.21, *B*) and pannus causes subchondral cysts on both sides of the joint. Finally, in the third stage, there is gross destruction, deformity, dislocation, or ankylosis of the joint (Figure 3.21, *C,D*). The Phemister triad of radiographic findings—juxtaarticular osteoporosis, subchondral cysts, and gradual narrowing of the cartilage space—are part of this classification.

NTM also causes joint infection. The clinical difference between joint infections with *M. tuberculosis* and *M. marinum* is that *M. marinum* infections are positively associated with traumatic exposure to a fish bone, saltwater, a fish tank, or a swimming pool in 80% of the cases. Of the 166 patients treated by Cheung, 50% were fishermen or fishmongers and 15% were seafood handlers at work or home.[20] Diagnosis is made with biopsy and culture. Cultures are positive between 2 and 6 weeks of incubation at 30°C on a Lowenstein-Jensen medium. In *M. marinum* infections, a finger joint is infected in three-fourths of the cases and the wrist is infected in the rest. Infections are typically monoarticular. Symptoms usually begin within 1 to 2 weeks after the initial trauma.

The mean time from onset of symptoms to bacteriologic diagnosis is 8 months (range, 3 months to 3 years). The pain is mild, but swelling of the involved joint is marked and boggy. Organisms may be stained from draining joint fluid, aspirated joint fluid, or synovial biopsy in 75% of cases. Mycobacterial cultures are positive in almost all (95%) of synovial fluid and synovial biopsy specimens. A severely immunocompromised patient (e.g., from chemotherapy, corticosteroids, systemic lupus) may develop a multicentric *M. marinum* mycobacteriosis that may include bones, joints, tendons, and skin.

Diagnosis. In the absence of coexistent extraarticular tuberculosis, diagnosis of *M. tuberculosis* joint infection almost always requires arthrocentesis or biopsy. Synovial fluid aspirate may show AFB on smear, and cultures are generally positive. Granulomas with caseation are present in three-fourths of the biopsy specimens. Clinical confusion may occur when *M. tuberculosis* infects joints previously involved with rheumatoid arthritis or gouty arthritis.

Treatment. Treatment of *M. tuberculosis* septic arthritis consists of chemotherapy and prevention of deformity by splinting during the first and second stages. Intermittent active exercises for the elbow, forearm, wrist, and finger joints should be encouraged as pain permits. Although total or partial synovectomy has been performed at the time of biopsy, the value of it is controversial. Some favor chemotherapy after debridement once diagnosis is confirmed. Benkeddache and Gettesman[11] recommend biopsy only for diagnosis and chemotherapy for treatment. In its earliest stage almost all infected joints recover fully with chemotherapy and without surgical debridement. In the second stage, painful joints are fused.

If the source of pain can be localized to the distal radioulnar joint, resection of the distal end of the ulna, synovectomy of distal radioulnar joint, and chemotherapy may be required. In patients with an unfavorable response within 3 months, or with recurrence of infection, Tuli recommends surgical debridement.[116] Unfavorable therapeutic response can occur if the organism is marginally sensitive to drugs or if host resistance is low due to malnutrition, drug immunosuppression, or an underlying immune deficiency disease. In the third stage, a painful, dislocated, unstable, ankylosed, or deformed joint requires fusion, excisional arthroplasty, or corrective osteotomy. Fusion is delayed until progressive bone destruction is halted and bone is sufficiently vascularized after chemotherapy. Chemotherapy is given for 9 months.

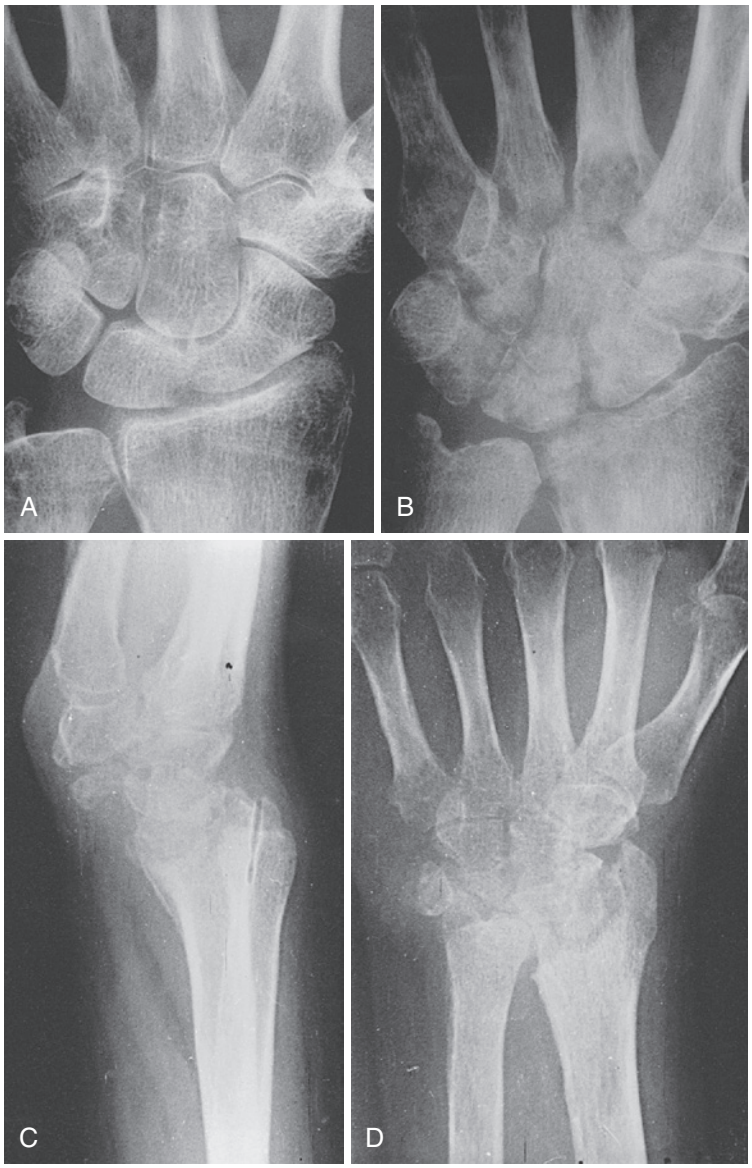

FIGURE 3.21 **A,** Tuberculosis of the wrist joint can start in the synovium and cause subchondral erosions in the carpal bones. **B,** Gradually the hyline cartilage is destroyed, the joint space is reduced, and the bones become osteopenic. **C, D,** Finally, there is destruction of supporting ligaments and volar subluxation of the radiocarpal joint. (Courtesy of S. M. Tuli, New Delhi, India.)

Successful outcome with this method (i.e., biopsy for diagnosis and chemotherapy for treatment) has been confirmed in the treatment of tuberculosis of the elbow and the wrist.[116] *M. marinum* arthritis does not have as favorable a therapeutic response to chemotherapy as *M. marinum* tenosynovitis. A combination of chemotherapy and synovectomy is preferred in the treatment of *M. marinum* arthritis. Patients with involvement for more than 6 months had worse results. *M. marinum* strains are uniformly resistant to isoniazid but are sensitive to rifampin, ethambutol, and ciprofloxacin. Monotherapy with minocycline and trimethoprim-sulfamethoxazole has been effective for superficial infections, but combination chemotherapy is recommended for *M. marinum* arthritis to prevent resistance. Rifampin–ethambutol combination is the most successful in past reports. Chemotherapy for a minimum of 6 months, or for at least 2 months after complete resolution of joint infection, is recommended for all NTM joint infections.

Brashear et al[14] and Tsai et al[115] reviewed *M. tuberculosis* infections of the wrist joint. Wilson and Dix-Peek et al[31] reviewed the largest number of elbow tuberculosis. The largest numbers of deep NTM infections of the hand are reported and reviewed by Hurst,[56] Chow,[22] Kozin,[67] Hellinger,[52] and Zenone.[122] The largest number of cases of *M. marinum* joint infections of the hand have been reviewed by Alloway and colleagues.[5]

Tuberculous Osteomyelitis

Etiology and Epidemiology. Extrapulmonary tuberculosis accounts for almost 20% of all cases of tuberculosis in the general population and 72% of all cases in US AIDS patients. In the United States, skeletal tuberculosis is 1% of all tuberculosis and 10% of all extrapulmonary tuberculosis. Of skeletal tuberculosis, approximately 50% occurs in the spine, 33% in the lower extremity (12% in pelvis, 10% in hip and femur, 10% in knee and tibia, 1% in ankle and foot), 7% in the ribs, and 10% in the

upper extremity; that is, 1% in shoulder and humerus, 2% in elbow, forearm, and wrist, 4% in hand and fingers, and an additional 3% in the hand accompanied by multifocal sites elsewhere.[11] Tuberculosis of the bones of the hand is less common than tuberculosis of the tenosynovium and joints of the hand. It typically occurs in the phalanges (i.e., tuberculous dactylitis) and metacarpals.

Diagnosis. Clinical presentation of skeletal tuberculosis of the hand in children and adults is different and has changed in character over the years based on health and immunity of the affected group.

Tuberculous Osteomyelitis of Children's Hands. The highest incidence of skeletal tuberculosis of the hand before the era of antituberculous therapy was in infants and children. In children, two-thirds of the patients were age 2 or younger. It was uncommon after age 5 and scarce after 10 years. The natural course of the disease was often self-limiting but was accompanied by residual deformity. *M. bovis* was then the main infecting organism, and with pasteurization of milk it is rarely reported in children today. Adult cases currently are reported more often and are caused by *M. tuberculosis* or NTM.[116] Concurrent pulmonary infection and multifocal skeletal tuberculosis was common in the past but is rare today both in children and adults.[116]

Of 37 cases of tuberculous dactylitis reviewed by Ritz et al, only 20% had concurrent pulmonary tuberculosis.[98] It also may follow previously treated pulmonary tuberculosis. Tuberculosis of phalanges (tubercular dactylitis) and metacarpals is the most common form of skeletal tuberculosis in infants and children. The proximal phalanx, middle phalanx, distal phalanx, and metacarpals are involved in that order. The second, third, and fourth fingers are involved most frequently. From a clinical viewpoint, there are three types of dactylitis.

- One group consists of those individuals who have generalized tuberculous infection and tuberculous dactylitis is a manifestation of the whole.
- The second group consists of patients whose dactylitis is the presenting symptom and who have no evidence of generalized tuberculous infection.
- The third group consists of multifocal tuberculous dactylitis with coexistent musculoskeletal tuberculosis in additional fingers of the same hand (Figure 3.22) and/or opposite hand, or in other parts of the same extremity or in another extremity.[46]

Thirty percent of children who have tuberculous dactylitis have multifocal tuberculosis. In all cases, symptoms begin with a painless, nonsuppurative, and insidious swelling on the fingers (phalangeal infection) or the hand (metacarpal infection). On examination, there is a typical fusiform swelling of a finger or a diffuse swelling on the dorsum of the hand. There is practically no tenderness or local heat, but the part may appear taut and shiny. It is not easily diagnosed at this early stage because the presentation is nonspecific and may simulate a tumor.[49,58]

The swelling often reaches considerable size, doubling the digital girth. In late cases, an abscess may form with skin discoloration and fluctuation. The abscess may burst and leave a sinus that drains a cheesy, yellowish exudate. Multiple discharging sinuses occur with disseminated dactylitis. Where secondary infection of a sinus occurs, the condition closely resembles a subacute osteomyelitis of pyogenic origin. Radiographs are characterized by endosteal resorption of bone and progressive subperiosteal hyperplasia.



FIGURE 3.22 Tuberculous dactylitis can be single-digital or multidigital in the same hand, bilateral, or associated with tuberculosis of other joints in the same or other extremities. This child has tubercular dactylitis of the proximal phalanx of index finger and middle phalanges of index, middle, and ring fingers. (From Kumar V, Kumar M: Multiple discharging sinuses with disseminated dactylitis. *Indian Pediatr*, 48:583–584, 2011, with permission.)

During infancy and childhood, the short tubular bones have a lavish blood supply through a large nutrient artery entering in the middle of the bone. The agent lodges in the center of the marrow cavity, and the interior of the short tubular bone is converted into a virtual granuloma. This leads to a spindle-shaped expansion and inflated shape of the bone. Endosteal resorption of bone is followed by progressive subperiosteal hyperplasia and has been termed as *spina ventosa* by Dupuytren (Latin *spina*, "spine"; *ventosa*, "distended with air").[32]

Metaphyseal tuberculous osteomyelitis may be the initial pathology and then the infection crosses the epiphyseal plate into the joint and there may be telltale enlargement of epiphysis. Transphyseal spread of infection is more commonly seen in tuberculous than in nontuberculous osteomyelitis. Syphilitic dactylitis has a similar radiographic appearance, but serology distinguishes the two clinically. Early in the course of a TB infection, the epiphysis is spared because of its rich blood supply, but in late cases it is invaded and causes shortening or deformity of the digit. Radiographic findings of tuberculosis in children include joint effusion, periarticular osteopenia, joint space narrowing, endosteal thinning with cortical irregularity, lytic lesions, periosteal new bone formation, and advanced epiphyseal maturity.

Diagnosis cannot be made without a biopsy. Singh et al showed that fine-needle aspiration cytology reveals granulomas with or without necrosis in a third of cases and staining showed AFB in all their eight cases of tuberculous dactylitis.[105] If the biopsy shows granulomatous inflammation on frozen section, AFB staining of the tissue should be requested because it may show tubercle bacilli. A high level of suspicion for tuberculosis in a chronic bone lesion and an eight-pack culture at the time of biopsy expedite the diagnosis.

Tuberculous Osteomyelitis of Adult Hands. Tuberculosis osteomyelitis in the adult occurs more commonly in fingers than metacarpals; more in middle and ring fingers than index and small fingers; and more in the proximal, middle, and distal

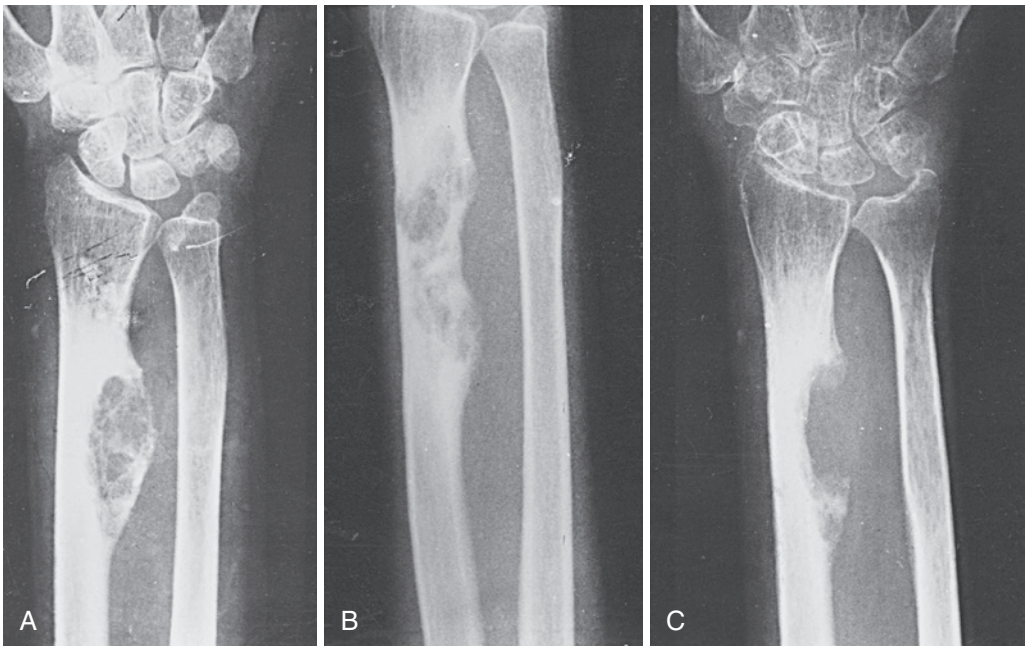

FIGURE 3.23 Tuberculous osteomyelitis of the radial shaft. **A,** This resembles a tumorous lesion of the bone; there is bone destruction and cultures grew *Mycobacterium tuberculosis*. **B,** Mixed cystic-sclerotic pattern. **C,** The lesion heals with reossification in response to oral antituberculous chemotherapy. (Courtesy of S. M. Tuli, New Delhi, India.)

phalanges in that order. Tuberculosis osteomyelitis of carpal bones is rare. A single bone lesion that appears to be a bone tumor (e.g., a GCT of distal radius[88]) may be tuberculosis. In patients with skeletal tuberculosis, only 20% have a pulmonary lesion and 10% have abdominal disease. In 70% of the patients with skeletal tuberculosis, no primary focus can be demonstrated. Therefore, the presence of osteoarticular lesions without pulmonary or abdominal lesions does not exclude diagnosis of tuberculosis.

Multifocal tuberculosis involving the hand may include multiple digits or it may be part of generalized multifocal and systemic tuberculosis. Failure to consider tuberculosis in the differential diagnosis of multifocal skeletal lesions can substantially delay diagnosis. It may be suspected in a patient coming from a region endemic for tuberculosis. Constitutional symptoms, rare in solitary skeletal tuberculosis, may be present in multifocal tuberculosis with fever, chills, anorexia, and loss of weight. Discharging lesions are more common in multiple lesions than in solitary lesions. Multifocal lesions are more common in immunosuppressed patients, including those with AIDS. Elevated ESR and positive PPD, rare in solitary lesions, may also be present. Technetium-99m helps to detect multifocal tuberculosis when radiographs have not yet become positive. ESR is elevated in multifocal cases more than solitary ones, presumably because multifocal disease occurs with reduced immunity. In multifocal tuberculosis, pulmonary and abdominal lesions are more common than in solitary skeletal tuberculosis. Multicentric tuberculosis can be mistaken for a malignant metastatic disease. Tuberculous dactylitis may coexist with another extrapulmonary nonskeletal focus of tuberculosis such as tuberculosis of the cervix.

Local discomfort and swelling are the usual presenting findings. A pathologic fracture of a metacarpal or a phalanx may occur. A draining sinus or fistula forms in untreated cases. Al-Qattan et al,[3] who reviewed the literature on radiological patterns of tuberculous osteomyelitis in the hand and wrist, found six patterns:

1. In early cases, there is soft tissue swelling followed by periosteal reaction and metaphyseal osteoporosis. This is followed by a well-defined cystic lesion that simulates a bone cyst.
2. Bone destruction with honeycombing, shown in Figure 3.23, *A*. It may resemble a GCT when it is near the metaphysis.[88]
3. A mixed cystic-sclerotic pattern with a lytic lesion that is surrounded by a sclerotic rim (Figure 3.23, *B*).
4. A diaphyseal lytic lesion that crosses the epiphyseal plate; this pattern is classic of pediatric tuberculous osteomyelitis.
5. Spina ventosa, as described earlier.
6. Bony lytic lesion with bone destruction that resembles bacterial osteomyelitis.[3]

Increased bone density and sequestra may be seen if staphylococcal osteomyelitis is superimposed. MRI of the digit can show that the draining sinus is continuous with the bone marrow through a cortical defect. Radiographically, the cystic lesion is replaced by bone with antibiotics (Figure 3.23, *C*). Osteomyelitis as a result of *M. marinum*, *M. kansasii*, and *M. scrofulaceum* is clinically and radiologically similar but treatment should be different.

Diagnosis is made by biopsy, which should be taken from the granulomatous area where a cyst is apparent on the radiograph or the histological results may be equivocal.

Differential diagnosis of tuberculous dactylitis should include other causes of dactylitis; it can occur in infections that include yaws,[35,36] syphilis, leishmaniasis, brucellosis, blastomycosis,[40] leprosy, and blistering distal dactylitis. Noninfectious causes of dactylitis are sarcoidosis, sickle cell anemia, and celiac

disease. Spondyloarthritis causes dactylitis that looks like a sausage digit.[85] Osteomyelitis may be caused by nontuberculous mycobacteria in AIDS and has been reported to be caused by *M. szulgai*.[72]

Treatment. Tuli's approach of "do not operate when antibiotics can do the job and operate when you must" is based on experience with thousands of cases of musculoskeletal tuberculosis treated over three decades. MDT is the keystone of treatment of tuberculosis.[116] Curettage is chosen by the treating surgeon at the time of biopsy because it is easy and removes pathologic tissue. It does reduce the bacterial dose when chemotherapy begins. Because of the efficacy of available chemotherapy today, curettage is not essential if a diagnosis is established with biopsy or staining and culture of draining material. On the other hand, if the organism is resistant, or if the host is immunosuppressed or there is evidence of bone sequestrum, surgical debridement of infected bone is essential. Histological findings compatible with tuberculosis (i.e., chronic granuloma, with or without caseation) in the presence of negative fungal cultures warrant MDT.

Before the advent of chemotherapy, many infants and children with localized TB dactylitis without generalized active tuberculosis recovered without surgical debridement in 1 to 3 years. When tuberculous dactylitis occurs in an infant or a child as a part of severe generalized tuberculosis, it does not resolve spontaneously. When it occurs in an adult patient and remains untreated, it progresses slowly and may necessitate amputation. Benkeddache and Gettesman treated all their skeletal cases with surgical biopsy for diagnosis and antimycobacterial drugs for treatment without further surgical debridement.[11] Kotwal et al had success with biopsy and conservative treatment in 75% of their 32 tuberculous hand infections.[66] In early stages, treatment with chemotherapy results in complete resolution. The immune status of the host is an overwhelming predictor of eventual outcome. In the immunocompromised patient population, less than half of the patients have resolution of a deep infection with surgery as well as chemotherapy.[67]

Antituberculous Drugs and Multidrug Therapy Regimens

The modern era of tuberculosis began in 1944 with the demonstration of the efficacy of streptomycin in humans by Waksman in New Jersey. In 1952, the more effective bactericidal drug isoniazid (INH) became available at Seaview Hospital on Staten Island in New York, making tuberculosis curable in the great majority of patients. In 1970, the bactericidal drug rifampin (RMP) attained equal status to INH. In 1993, rifabutin (RFB) became available for *M. tuberculosis* associated with HIV infection.[51] Rifapentine is the latest (1999) rifamycin that is not only long-acting but also more potent, allowing less frequent dosage and a shorter duration of therapy for *M. tuberculosis*. The duration of chemotherapy progressively decreased from approximately 2 years with streptomycin and INH, to 9 months with INH and RMP given together, to 6 months using MDT that includes INH, RMP, pyrazinamide (PZA), and ethambutol (EMB).

INH is bactericidal and is the cornerstone of therapy. It is included in all regimens until resistance is established on cultures. It can cause hepatitis and peripheral neuropathy. Pyridoxine (50 mg PO daily) is given conjointly with INH to minimize peripheral neuropathy. RMP is also bactericidal and is the second major antituberculous agent. The most important complication of RMP is hepatitis. Rifabutin is a semisynthetic derivative of rifamycin that shows good activity against *M. intercellulare* and about one-third of rifampin-resistant strains of *M. tuberculosis*. PZA is an essential component of all MDT regimens. It is bacteriostatic, and its beneficial effect is mostly limited to the first 2 to 3 months of treatment. It can cause hepatitis and hyperuricemia. EMB is also bacteriostatic and is an initial component of most regimens. The most important complication of EMB is optic neuritis, which may require its removal from the regimen. Blurring and acuity of vision are determined at baseline and reviewed monthly.

Because of side effects and emerging resistance to the first line of antituberculous drugs, tuberculosis should be treated in collaboration with an infectious disease specialist. Second-line agents (e.g., fluoroquinolones, three injectable drugs [amikacin, kanamycin, capreomycin], ethionamide, and cycloserine) are less efficacious and more toxic than the first-line drugs. Drug resistance to one or more antituberculous drugs has developed and remains a challenge. Multiple drug-resistant strains of tuberculosis both to RMP and INH have been seen. Directly observed therapy (DOT) is the five-component treatment strategy developed by the World Health Organization to prevent emergence of drug-resistant strains and is now the US standard of care. In 2009, 60% of all the patients received their therapy entirely as DOT and 90% received at least some portion of their treatment as DOT in the United States.

Indications for Treatment

Histologic findings compatible with tuberculosis (i.e., granulomatous synovitis, with or without caseation) warrant chemotherapy, although other chronic infections can cause an identical clinical and histologic picture. This is best to establish it on a frozen section of biopsy material. The differential diagnosis of granulomatous synovitis includes TB and NTM infections, fungus, foreign bodies, brucellosis, sarcoidosis, and Crohn syndrome, among others. In the presence of negative fungal smears and cultures, a diagnosis of tuberculosis is presumed when caseating granuloma is histologically confirmed with an intraoperative frozen section. Once sensitivity results are reported by the laboratory, chemotherapy is revised to use appropriate drugs. In early stages, treatment with chemotherapy results in complete resolution.

Regimens

Modern tuberculosis therapy guidelines by the CDC and the American Thoracic Society are summarized in Table 3.8. The basic principles that underlie treatment of pulmonary tuberculosis apply to extrapulmonary forms of the disease. Although relatively few studies have examined treatment of extrapulmonary tuberculosis, increasing evidence suggests that 4 months of INH and RMP or 6 months of INH and ethambutol are effective for soft tissue infections. In bone and joint disease, 9 to 12 months of cumulative chemotherapy is advised. The first 2 months include a four-drug regimen of INH, RMP, PZA, and EMB. After the initial regimen, a two-drug regimen (i.e., INH and RMP or INH and ethambutol) may be resumed if the bacillus is sensitive to both RMP and ethambutol. Patients with initial resistance to RMP or INH (XDR TB) are treated with at

TABLE 3.8 Antituberculous Drugs Used in the United States

Drug	Adult Daily Dosage	Pediatric Daily Dosage	Main Drug Toxicity
First-Line Drugs			
Isoniazid[a,d]	300 mg PO, IM	10-20 mg/kg (max, 300 mg)	Hepatic toxicity, peripheral neuropathy
Rifampin[a,b,c] (rifadin, rifocin, rimactane) or rifapentine	600 mg PO, IV	10-20 mg/kg (max, 600 mg)	Hepatic toxicity, flu-like syndrome
Pyrazinamide[e]	1.5-2.5 g PO	15-30 mg/kg (max, 2 g)	Arthralgia, hepatic toxicity, hyperuricemia
Ethambutol (Myambutol)	15-25 mg/kg PO	15-25 μγ per κγ ΠΟ	Optic neuritis
Second-Line Drugs (in Alphabetical Order)			
Capreomycin (Capastat)	15 mg/kg IM	15-30/μγ per κγ	Auditory, vestibular, and renal toxicity
Cycloserine[g] (Seromycin)	250-500 mg bid PO or 1 g in a single dose	10-20 mg/kg	Psychiatric symptoms, seizures
Ethionamide/prothionamide (Trecator-SC)	250-500 mg bid PO or 1-g single dose	15-20 mg/kg	Gastrointestinal and hepatic toxicity
Gatifloxacin			
Kanamycin (Kantrex)	15 mg/kg IM, IV (max, 1 g/day)	15-30/μγ per κγ	Auditory and renal toxicity
Levofloxacin			
Moxifloxacin			
Para-aminosalicylic acid	4-6 g bid PO or 12-g single dose	75 mg/kg bid	Gastrointestinal disturbance
Streptomycin	15 mg/kg IM	20-30 mg/kg	Vestibular toxicity, renal toxicity

[a]Intravenous preparations of isoniazid and rifampin are available.
[b]Pyridoxine, 10-25 mg, should be given to prevent neuropathy in malnourished or pregnant patients and in those with HIV infection, alcoholism, or diabetes. For intermittent use after initial daily therapy for a few months, the dosage is 15 mg/kg (max, 900 mg) twice a week for adults.
[c]For intermittent use after a few months of daily therapy, the dosage is 600 mg twice a week.
[d]Rifabutin is effective against 30% of rifampin-resistant *M. tuberculosis*. It is the drug of choice against *M. avium* infections.
[e]For intermittent use after the first 8 weeks of daily therapy, the dosage is 2.5-3.5 g twice a week.
[g]May recommend pyridoxine, 50 mg for every 250 mg of cycloserine, to decrease the incidence of adverse neurologic effects.

least four drugs that are shown by culture to be effective and should be continued for at least 18 months. All patients with organisms resistant to either INH or RMP should receive DOT.

The four-drug regimen can be administered three times a week for 6 months if the therapy is directly observed. Only ~30% of XDR cases can be cured using combinations of the previously described medications for 24 months. Concurrent pulmonary tuberculosis with chronic tuberculous hand infection is rare but infrequent concurrent pulmonary tuberculosis must be ruled out in every case because cases with positive sputum smears or positive sputum cultures are highly infectious. Every patient who has hand tuberculosis must have chest radiography. Patients receiving chemotherapy become noninfectious within 2 weeks. If the chest radiograph and sputum are positive, isolation for the first 2 weeks of treatment is recommended to control the spread of tuberculosis. No isolation is necessary for extrapulmonary tuberculosis without active pulmonary tuberculosis.

Special Features and Treatment of Nontuberculous Mycobacteria

Of the more than 100 species of NTM mycobacteria that are currently considered to be potential sources of disease, only 18 have been reported to cause infection of the hand and upper extremity (Table 3.9). NTM infection occurs in both immunocompetent and immunodeficient patients. When NTM infection is encountered, a cause for underlying immunodeficiency should be sought. *M. marinum* is an increasingly common opportunistic infection in patients treated by anti-TNF-α biologic therapy. Postmarketing FDA surveillance through January of 2007 noted 239 atypical mycobacterial infections in patients on anti-TNF-α therapy, and 12 different species of mycobacterium were implicated. There is a wide range of clinical presentation, virulence, and drug sensitivity among NTM species, which makes chemotherapy and treatment of NTM different from that of *M. tuberculosis*. Atypical mycobacterial infections in immunosuppressed patients may show delayed response to antibiotics and surgery and portend serious morbidity.

❖ AUTHOR'S PREFERRED METHOD OF TREATMENT

The most common manifestation of tuberculosis and mycosis in the hand is chronic tenosynovitis. Arthritis and osteomyelitis come next in that order of frequency.

If chronic tenosynovitis is nonspecific (i.e., no indication of rheumatoid arthritis), is made worse by cortisone injection, reoccurs after tenosynovectomy, or is accompanied by sinus formation, tuberculosis or fungal infection may be ruled out with biopsy. At the time of biopsy, the specific diagnosis may not be discernible because the tissues do not have pathognomonic characteristics. Rice bodies may be found in rheumatoid arthritis, tuberculosis, and fungal infections such as coccidioidomycosis, sporotrichosis, and histoplasmosis.

TABLE 3.9 Diagnosis and Treatment of Nontuberculous Mycobacterial Hand Infections

NTM	Year Identified	Tissue Affected	Growth	Effective Chemotherapy
M. abscessus		T	Takes 6 weeks to grow	Clarithromycin, ciprofloxacin
M. asiaticum	1965	T	Radical tenosynovectomy	Minocycline, clarithromycin
M. avium-intracellulare complex[89]	1943	T	Most resistant, tenacious, and troublesome May take 8 weeks to grow Radical tenosynovectomy necessary	Clarithromycin, rifabutin, and ethambutol
M. chelonae		T, SQ	Difficult growth delays diagnosis Multiple biopsies may be necessary for diagnosis	Clarithromycin, erythromycin, doxycycline, kanamycin
M. fortuitum	1972	T		
M. gordonae		T		
M. haemophilum	1978	S	Grows at 30°C with hemoglobin media Fastidious, slow growing Occurs in AIDS	Difficult to treat because of underlying immune deficiency
M. kansasii	1953	T, S	Generally low-grade infections	Erythromycin, ethambutol, rifampin, isoniazid
M. malmoense	1977	T, SQ	Diagnosis delayed because organism takes 12 weeks to grow	Isoniazid, rifampin, ethambutol, pyrazinamide
M. marinum	1926	C, T, S	Grows at 30°C. Easily treated with antibiotics alone[81]	Clarithromycin, minocycline, trimethoprim-sulfamethoxazole, ethambutol, rifampin
M. monacense	2008	SQ		Clarithromycin, levofloxacin
M. scrofulaceum	1956	T, B		
M. simiae		C		
M. smegmatis (M. goodii)	2001	OB		
M. terrae complex (*M. terrae, M. nonchromogenicum, M. triviale*, radish bacillus)	1950	SQ, T, S, B		
M. ulcerans (buruli ulcer)	1930	SQ	Grows at 30°C. Difficult to grow, failure in more than half of all cases Up to 3 months of incubation required	None
M. xenopi	1957	T	Grows at 42°C	
M. szulgai	1972	T, OB		Isoniazid, rifampin, ethambutol, pyrazinamide

B, Bone; *C*, cutaneous; *OB*, olecranon bursitis; *S*, synovium; *SQ*, subcutaneous; *T*, tenosynovium.

Certain chronic infections have a high tendency of recurrence unless radical surgical excision is combined with appropriate antibiotics, as with *M. avium*, *M. chelonae*, *M. malmoense* and *M. terrae*, *Sporothrix*, *Actinomyces*, and *Coccidioides*. Thus, complete synovectomy is reasonable at the time of biopsy or surgery because this will reduce the microbial burden for subsequent antibiotic treatment. An exception to this approach is when the diagnosis is known, as in a patient with positive stains from pus, exudate, synovial fluid, sputum, or gastric washings for mycobacteria.

At surgery, I divide the excised tissue and save half the specimen without formalin for the microbiology laboratory; the other half is sent to the histopathology laboratory in formalin. The pathologist is asked to look for granuloma in the frozen section and permanent sections. If a granuloma is reported on frozen section, the need for multiple smears and cultures is reinforced. In addition to biopsy, I send the fluids (e.g., pus, synovial fluid, exudates) for smears and cultures and request three smears (gram, AFB, and KOH fungus) on the biopsy tissue as well as the fluid. I request six cultures (i.e., aerobic and anaerobic bacteria [*Actinomyces* spp. and *Nocardia* spp. are anaerobic], tuberculous and NTM, and fungi and mycetoma) on the tissue specimen as well as fluids. The cultures need to be done at three temperatures, held for more than three months, and inoculated on special media for *M. haemophilum*.

I request the mycobacterial cultures at 30°C for *M. marinum*, *M. haemophilum*, *M. ulcerans*, and *Sporothrix*, at 37°C for the rest of the mycobacteria, and at 42°C for *M. xenopi*. More often than not, I personally take the specimen to the microbiology laboratory and urge the microbiologist not to discard the cultures for 4 to 6 months because that covers the slowest-growing *M. ulcerans* species. I alert the microbiologist and the

pathologist of possible chronic infections in the hand and request the infectious disease specialist to participate in the identification and treatment of the infectious agent. This partnership improves the chances of laboratory diagnosis of these rare, unexpected, and newly emerging infections.

Treatment. If there is histopathologic evidence of granuloma, caseating, or noncaseating, I start treatment for tuberculosis with four drugs (i.e., isoniazid, rifampin, pyrazinamide, ethambutol) until the cultures and sensitivities become available. Pyridoxine is added to combat INH neurotoxicity. Histologic findings compatible with tuberculosis warrant MDT, although other chronic infections (e.g., mycetoma, fungi, and NTM) can cause identical clinical and histologic pictures. It may be difficult to distinguish between granuloma of various mycobacteria and fungi, and it is reasonable to start treatment for nontuberculous mycobacterial infection because this is the most common granulomatous hand infection.

Cultures may take 1 to 12 weeks depending on the organism (e.g., *T. ulcerans*). Once the sensitivity of the organism is determined, I revise the chemotherapy. Wounds generally heal without complications while mycobacteria are being cultured. It is important to seek the help of an infectious disease specialist because the drugs are toxic to liver and kidneys among other tissues, and drug resistance may develop at any time owing to inadequate drug compliance. I monitor therapy with monthly examinations. Bone and joint lesions on chemotherapy are monitored with radiographs every 3 months for improvement or deterioration. If improvement is not seen, surgical debridement is considered again, especially in immunocompromised patients. I consider surgical treatment of a tuberculous mass for certain cases of XDR TB when chemotherapy is not an option.

Additional Information on *M. Tuberculosis*. Recent recommendations on treatment of tuberculosis are available from the CDC, Division of Tuberculosis Elimination at www.cdc.gov. For management of drug-resistant tuberculosis, the website lists current contact information.

HANSEN DISEASE (LEPROSY)

Hansen disease (HD) is a chronic neurologic and dermatologic disease with immunological overtones. The ulnar, median, and radial nerves, usually in that order, are affected in the upper extremity in 70% of active and relapsing cases of leprosy. The nerves suffer a triple blow from *M. leprae*: infective neuropathy, immunologic neuropathy, and compressive neuropathy (intraneural and extraneural compression). The bacteria preferentially infect nerves in the cooler parts of the body: the fine terminal dermal nerves, small subcutaneous nerves, and the superficially located large nerve trunks. Sensory loss almost always precedes motor loss because superficial dermal nerve damage precedes deeper nerve trunk damage. Nonmyelinated and thinly myelinated fibers are affected before myelinated fibers. Untreated peripheral neuropathy leads to the characteristic deformities of Hansen disease. Sensory damage and sensory loss lead to gradual and progressive absorption and autoamputation of fingers from recurrent injury and infection; autonomic damage causes loss of protective sudomotor and vasomotor functions, and, finally, motor damage causes muscle imbalance, leading to flexible and subsequently fixed deformities.

Etiology

Gerhard Armauer Hansen from Norway identified the acid-fast bacillus *M. leprae* in 1873, 10 years before Robert Koch, his contemporary, described *M. tuberculosis*. *M. leprae* was the first bacterium to be implicated as a cause of a human infection. Leprosy is now officially called Hansen disease to remove the stigma of the words "leper" and "leprosy." HD is curable with outpatient oral chemotherapy. Fear of the disease is no longer justified by the lay public or the medical profession. Dapsone renders the patient noncontagious in less than 6 weeks and rifampin in 2 days. Treated early, it is cured; treated late, infection is cured but the nerve damage lingers. The care of HD patients is now firmly integrated into general outpatient health care services.

Epidemiology

Leprosy, one of the most ancient, feared, and disabling diseases of humankind, is almost on the verge of elimination (<1 new case/10,000 population), if not eradication. Since 1985, the prevalence rate of the disease has dropped by 90%—from 21.1/10,000 inhabitants to <1/10,000 inhabitants in 2000. This is because treatment with MDT has been successful without discernible resistance and is provided by WHO free to all. There has been a dramatic decrease in the global disease burden from 5 million cases in 1985 to 180,000 at the end of 2011. Leprosy has been eliminated from 119 countries out of 122 where the disease was considered as a public health problem in 1985. India (134,000), Brazil (38,000), and Indonesia (17,000) had the highest number of cases in the world in 2010.

In the United States, there are approximately 6500 cases of leprosy, 90% of which are in immigrants from countries where leprosy is endemic. Asians and Latinos comprise the majority of the cases. The number of cases with active disease that require drug treatment is approximately 600. There are 200 to 250 new leprosy cases reported each year, with about 175 of these being first-time occurrences; 80% of US cases were reported in Hawaii, Puerto Rico, California, Texas, Louisiana, Florida, and New York. The island populations in Hawaii and Puerto Rico have the highest incidence and prevalence of HD in the United States. The National Hansen's Disease Program in Baton Rouge, Louisiana, is exclusively devoted to the disease. Most patients in the United States are treated under US Public Health Service grants at clinics in major cities.

In terms of reservoirs, most consider that HD is largely a human disease. In Texas and Louisiana, 15% of wild armadillos are infected with *M. leprae*. One-quarter of 175 new cases of Hansen disease in the United States occur in US-born people who have never traveled to endemic countries; the cases are thought to be a result of contact with infected armadillos because the genomes of *M. leprae* in them and the native whites match in 80% of the cases. The most commonly held view of transmission of HD is that it spreads from human to human, primarily as a nasal droplet infection. Skin-to-skin contact is unproven. Incidence rates rise to a peak between 10 and 20 years of age and then decline. About 20% of HD patients are children who develop the disease below the age of 10 and 50% as young adults.

Clinical Pathology

HD is essentially an infection of the peripheral nerves—the only bacillary infection of the nerves. Only a few cases of tuberculoma (i.e., tubercular infection of ulnar nerve) have recently been described.[94] Schwann cells are where *M. leprae* preferentially proliferate in the peripheral nerve. Some patients develop peripheral neuropathy before the appearance of skin lesions (pure or primary neuritic leprosy), some develop it after starting therapy (infectious and immunologic neuritis), and others continue to develop neuropathies well after therapy is stopped (immunologic neuritis or relapse). HD causes mononeuritis or mononeuritis multiplex. There is always nerve damage with HD because there is no such thing as nonneural leprosy.

From onset, the cutaneous nerves and fine intradermal nerve fibers are involved in all forms of HD, and sensory loss is the first and most devastating manifestation of it. Skin lesions and sensory loss develop more or less simultaneously; when skin lesions are present, the underlying dermal nerves are always infected. Although it is the skin lesions that bring one to the doctor, it is the nerve lesions that cripple the patient. About 30% of sensory fibers must be destroyed before evidence of sensory impairment can be detected. Thus, by the time an anesthetic skin patch is detected, the nerve infection is well advanced. According to Ridley and Jopling, if a skin lesion is found to be insensitive, and/or an adjacent subcutaneous nerve is visible or palpable, HD can confidently be suspected.[59]

The bacillary load in the nerves is always higher than that observed in the skin in all stages and all types of HD. The first and the earliest change observed in lepromatous (LL) HD is the presence of *M. leprae* inside the Schwann cells. In tuberculoid HD, the bacilli are found in 70% of the nerves but are almost never found in the skin. At the time of diagnosis of HD, 50% of patients have nerve impairment or disability, both motor and/or sensory. An additional 10 to 20% develop nerve impairment during and after completion of treatment. Of new patients who have no nerve disability at diagnosis, 10% develop it within 2 years of treatment.

Nerve lesions are the result of infection of the nerves and are compounded by the immune reactions that continue in them long after the patient is rendered free of living bacteria. Dead bacterial remnants persist in the nerves after a full course of antibiotic treatment. The presence of these antigens causes intraneural inflammation and fibrosis indefinitely.

The maximum concentrations of bacilli, and thus the greatest damage, are found in the fine dermal nerves, subcutaneous nerves, and the superficially located nerve trunks. In all types of HD, the infected nerve is ultimately replaced by hyalinized fibrous tissue. *M. leprae* conveniently hide in the fibrous tissue and are not reached by drugs. There is the possibility of relapse of the disease from persistent *M. leprae* in the fibrosed nerves. Profound loss of sensation allows uncontrolled and progressive tissue damage from unrecognized injury and infection. With repeated tissue necrosis and self-debridement, the fingers and toes may shorten to form mitten hands and feet. Antia has described three patterns of sensory loss in HD[7]: (1) anesthetic patch from infection of a dermal or subcutaneous nerve, (2) regional loss from infection of a nerve trunk in tuberculoid disease, and (3) a glove-and-stocking pattern due to confluent involvement of sensory nerves in lepromatous disease.

The incubation period of HD is not accurately known; 2 to 7 days is considered usual. Ninety percent of the people who are exposed to *M. leprae* infection have a natural immunity to it. Most who are infected with *M. leprae* develop a subclinical infection and recover naturally without having symptoms or signs of disease. In the remainder, HD progresses slowly over months and years.

Most of the serious sequelae are the result of infection of the peripheral nerves. Bacterial multiplication occurs within Schwann cells, and they spread intraneurally to adjacent Schwann cells. A stage is reached when intraneural infection is "recognized" by the host immune system and the nerve is invaded by lymphocytes and macrophages to combat *M. leprae*. A granuloma forms and fibrosis occurs within the epineurium, perineurium, and endoneurium. Enlargement of peripheral nerves results not from initial infection but instead from subsequent immunologic reaction and caseation. Enlarged nerves are pathognomonic of HD. They are present in 25% of newly diagnosed cases, and neurologic deficit is present with 95% of patients with enlarged nerves. Outside the peripheral nerves, the pathology of HD is largely confined to the skin, eyes, upper respiratory tract, and testes.

Classification

The clinical manifestations of HD vary, depending on the host's resistance or immunity. At one end of the spectrum, a patient may have high cell-mediated immunity and ability to resist, fight, and contain bacteria. Of infected patients, 95% do not develop a clinically diagnosable disease. At the other end of the spectrum, a patient may have complete tolerance to *M. leprae* due to lack of any detectable cell-mediated immunity against the microbe. These patients are actually teeming with bacteria, so the host becomes a perfect culture medium for *M. leprae*. Between these two ends of the spectrum, the borderline group encompasses most patients.

The three main clinical types of HD are tuberculoid (TT, high immunity), lepromatous (LL, low immunity), and borderline (BB, intermediate immunity); BB can fluctuate in either direction. In tuberculoid HD, a cell-mediated immune response to *M. leprae* rapidly destroys both the bacillus and the host Schwann cell in which it resides and leads to early caseous necrosis with total destruction of the nerve. In lepromatous HD, because there is very little immune response to the bacillus, *M. leprae* multiply freely in the Schwann cells, producing a slow fibrosis over many years. Histoid leprosy and Lucio leprosy are variants of lepromatous leprosy. For research purposes, in 1966 Ridley and Jopling divided the borderline cases into three immunologic subsets: BL, BB, and BT (Table 3.10).[59]

Ridley further divided TT and LL into polar (LLp, TTp) and subpolar (LLs, TTs) groups. In 1982, the World Health Organization recommended a simplified, clinical, and operational classification of HD into paucibacillary (PB) and multibacillary (MB) for treatment purposes based on the result of slit-skin smears. When a skin smear is positive, the disease is classified as MB. Under this classification, most of indeterminate (I), TT, and BT cases are PB, but any of them showing smear positivity are classified as MB for purposes of drug therapy. The smears are positive in LL, BL, and usually in BB cases and are classified as multibacillary. The number of drugs and length of therapy are more for multibacillary than for paucibacillary disease.

TABLE 3.10 Clinical, Bacteriologic, Histologic, and Immunologic Features of HD

Lesions and Tests	TYPE OF HANSEN DISEASE				
	TT	BT	BB	BL	LL
Number of skin lesions	Usually single	Single or few, may be distant	Several	Many	Very many
Size of skin lesions	Variable	Variable	Variable, mixed large and small lesions	Variable	Small
Surface of skin lesions	Very dry, sometimes scaly	Dry	Slightly shiny	Shiny	Shiny
Sensation in skin lesions	Absent	Moderately to markedly diminished	Slightly to moderately diminished in large lesions	Slightly diminished in large lesions	Not affected
Loss of hair and sweating in skin lesions	Absent	Markedly diminished	Moderately diminished	Slightly diminished	Not affected
AFB in skin lesions	Nil	Nil or scanty	Moderate numbers	Many	Very many (plus globi)
AFB in nasal scrapings or nose blows	Nil	Nil	Nil	Usually nil	Very many (plus globi)
Nerve lesions	Nerve may be thickened (one or two nerves only)	Thickening of several nerves	Thickening of several nerves	Thickening of several nerves, bilateral	Nerve thickening mild; may not be obvious until late stages
Histology	Dermal nerves are destroyed and cannot be recognized AFB not seen Foci of lymphocytes, epithelioid cells, and giant cells invading the skin indicative of host cell-mediated immunity Cutaneous nerves are greatly swollen because of epithelioid cell granuloma; they may caseate or are destroyed Nerve abscess more common	In BT there is a tuberculoid reaction more diffuse than in TT AFB may or may not be seen	In BB there is a diffuse epithelioid cell granuloma with occasional foam cells AFB in small numbers	In BL there is a granuloma composed of macrophages with lymphocytes in clumps or sheets AFB present	Diffuse leproma of foamy macrophages with few lymphocytes and plasma cells indicative of poor cell-mediated immunity Cutaneous nerves may show slight cellular infiltrate with foam cells AFB seen in clumps Nerve abscess less common
Lepromin test	Strongly positive (+++)	Moderately or weakly positive (++ or +)	Negative	Negative	Negative

AFB, Acid-fast bacillus; *BB*, borderline; *BL*, borderline lepromatous; *BT*, borderline tuberculoid; *LL*, lepromatous; *TT*, tuberculoid.

When a slit smear is not possible, a patient can be classified clinically by the number of skin lesions, but this is not ideal. A patient with >6 lesions is classified as MB, and one with less than six lesions as PB, with a reasonable balance between sensitivity and specificity. PB patients are further classified into those with a single lesion and those with 2 to 6 lesions because the treatment of the two differs in drugs used. The limitation of using a purely clinical classification is that a single-lesion, or paucilesional smear-positive, case may be falsely classified as PB and will receive inadequate chemotherapy, with the risk of relapse and resistance, because approximately 3% of single-lesion patients and 1% of paucilesional smear-positive cases are multibacillary.

Clinical characteristics, skin and nerve lesions, bacteriology, histology, and immunology of HD in its spectrum are summarized earlier in Table 3.10. It remains unknown why certain individuals develop HD and others do not.

Early Diagnosis

Early diagnosis of HD can usually be made by clinical examination supported by slit-skin smear and is conducive to cure and normal life.

Cardinal Signs

WHO has emphasized three cardinal signs for clinical diagnosis of HD: an anesthetic skin patch, nerve thickening, and a hypopigmented skin lesion. The diagnosis must be confirmed by bacteriologic examination. A skin smear positive for HD bacilli confirms the diagnosis. At least two of the first three cardinal signs, or the fourth (positive bacteriological examination), should be present for the diagnosis of HD to be made. Sensory loss in hands and feet should be accompanied with nerve trunk thickening for diagnosis of leprosy. In the absence of nerve thickening one has to be cautious to label a patient

suffering from leprosy because of the emotional trauma associated with it. Such cases are kept under observation and periodically examined for the confirmation of disease.

Anesthetic Skin Patch. There are numerous diseases that produce patches on the skin, and there are varied neurologic conditions that cause sensory loss. Demonstrable loss of sensation restricted to a skin patch is unique and pathognomonic of HD. The tests (slit-skin smears) help further treatment classification of the disease.[7] Patients seldom complain of numbness because they adapt to gradual loss of sensation. Anesthesia may be patchy in the distribution of the dermal and cutaneous nerves, regional in the distribution of the peripheral nerve trunks, or in a diffuse glove-and-stocking pattern when damage has occurred to the dermal, subcutaneous, and the main nerve trunk, as seen in lepromatous HD.

The first tests to show and quantitate sensory nerve function impairment are moving two-point discrimination and Semmes-Weinstein monofilament testing. A painless burn may be the presenting symptom or sign of HD. In lepromatous HD a period of pruritus (formication) may precede all other symptoms very early in the course of the disease.

Thickened Nerves. Thickened nerves at the site of predilection are pathognomonic of HD (Figure 3.24). The ulnar nerve is always the first nerve trunk to be involved in the upper extremity and is the most commonly affected with or without skin lesions. In an immigrant from an endemic region of the world who presents with an ulnar nerve enlargement or carpal tunnel syndrome,[65] one must consider HD as a possible diagnosis.[86]

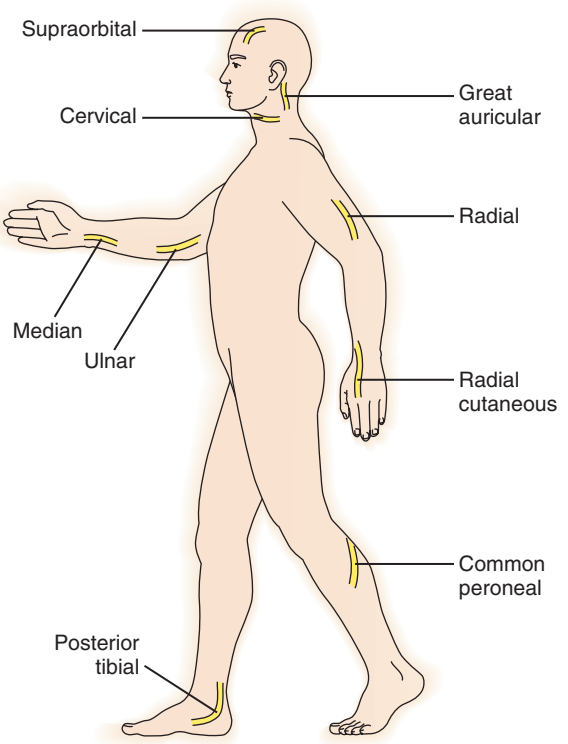

FIGURE 3.24 Hansen disease. The common sites of nerve involvement ("sites of predilection") in the upper extremity are the ulnar nerve at the elbow, the median nerve just proximal to the carpal tunnel, and the sensory branch of the radial nerve. These nerves are closer to the skin and thus reside in colder temperatures. *M. leprae* preferentially infect nerves in the cooler parts of the body. (From Hastings RC: *Leprosy*, ed 2, New York, 1994, Churchill Livingstone, with permission.)

There are four clinical stages of nerve infection in HD:

I. *Parasitization*—Bacteria invade the Schwann cells; clinically the nerve is normal but 50% of the patients have neurologic deficit.
II. *Inflammation*—Adhesion of the nerve to the perineurium is noted with inability to roll the nerve during palpation.[8]
III. *Enlargement*—The nerve is palpably enlarged (nerve caseation without or with an abscess). Ninety-five percent of these patients have a neurologic deficit.
IV. *Destruction*—The nerve is irreversibly damaged and converted to a cord of scar tissue.

Of the newly identified cases, 25% have one or more enlarged nerves. The enlarged nerves may be palpable but not visible, palpable and visible, or palpable and fluctuant. The nerve may be soft (parasitization), not rollable (inflammation), firm (caseation), or hard (fibrosed).

Thickening of nerve trunks occurs most often in the borderline, lepromatous, and pure neuritic types of HD. Pain in one or several nerves may be the presenting symptom even before skin lesions appear. In the beginning, the nerve may be normal in size but may be tender. As granuloma, edema, and fibrosis occur in the nerves, they become enlarged and firm. Enlarged nerves may or may not be tender. Caseation may follow and progress to a solitary tuberculoid nerve lesion or a cold nerve abscess with or without sinus formation. Finally, the nerve is calcified.[75]

If the body's cellular immunity anchors the infection within one or more nerves, the patient may present initially with clinical nerve deficit but no skin lesions and negative slit-skin smears. This is called "pure neuritic" or "primary neuritic" HD.[59,117] Mean prevalence rate of pure neuritic HD varies from 0.8 to 18%. In pure neuritic HD, commonly one nerve is involved, typically the ulnar nerve at the elbow, or the patient may have polyneuropathy. The most common clinical presentation is with numbness or weakness; wasting, deformity, and pain/tingling can also be presenting symptoms in a small minority of cases. The nerve is palpable or visible in 80% of patients with pure neuritic HD.

An early and accurate diagnosis of pure neuritic HD is essential to avoid mismanagement and should be suspected in an immigrant with an enlarged nerve from an endemic region. In absence of anesthetic skin patches or AFB in slit-skin smears, fine-needle nerve aspiration or an open nerve biopsy can establish a diagnosis. Histopathology of pure neuritic lesions reveals a spectrum from paucibacillary (tuberculoid) to multibacillary (lepromatous) type. When it is not possible to biopsy a nerve in pure neuritic HD, three factors help to decide the classification and choice of treatment regimen. First, a pure mononeuritic case generally responds well to a PB regimen. However, it is reasonable to consider HD involving multiple nerves on both sides of the body (i.e., mononeuritis multiplex) as multibacillary. Second, a clinically mononeuritic case may show multiple nerve involvement on electrophysiologic studies, indicating a more widespread involvement and need for a MB regimen. Third, the lepromin reaction is helpful in both mononeuritis and mononeuritis multiplex in determining the patient's position on the immunologic spectrum.

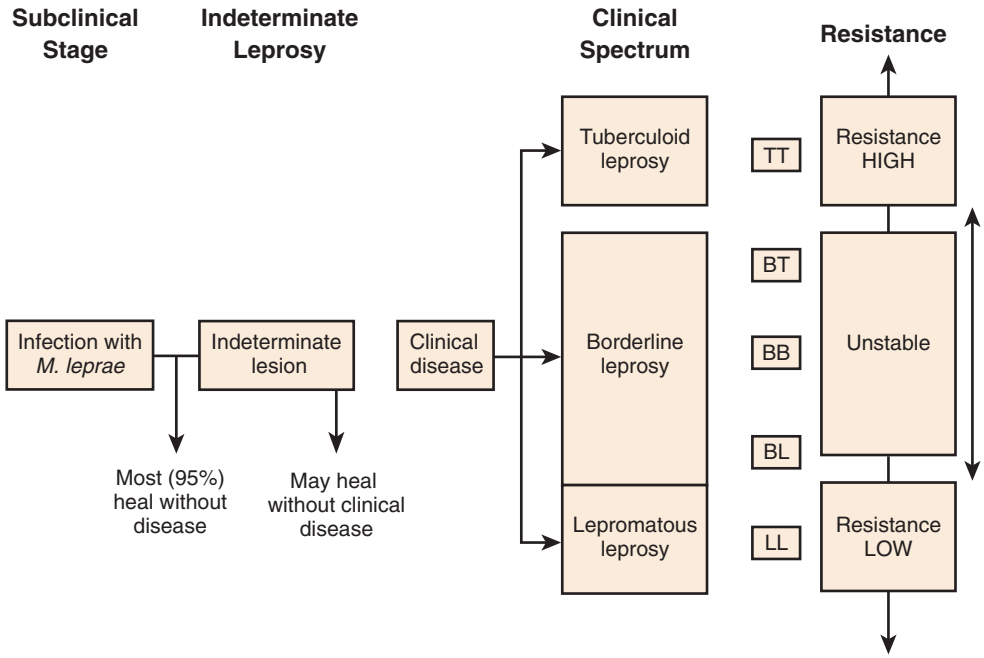

FIGURE 3.25 The course of leprosy after infection with *Mycobacterium leprae*. Clinical disease manifests in <5% of the infected individuals. Clinical spectrum of the disease depends on the immunity of the patient.

Skin Lesions. Skin lesions may become visible at any time during the course of primary neuritic HD. The patient's body should be examined for pigmented or hypopigmented patches and nodules in light that should preferentially fall on the patient from behind the shoulders of the examiner. Classically, the first lesion is a symptomless, ill-defined, slightly hypopigmented macule that is commonly seen on the face, trunk, or limbs. Sensation is only slightly impaired or normal. Bacilli are difficult to find, and diagnosis depends on careful, continuing observation. This lesion is called "indeterminate"; it may heal or progress to one of the three determinate types: tuberculoid, borderline, or lepromatous HD. An I lesion most often heals spontaneously. Only about 30% of indeterminate lesions progress to a determinate type (Figure 3.25).[59] Only 5% of all infected people ever develop clinical symptoms.

The most common and earliest clinical manifestation in HD is a hypopigmented, numb patch of the skin. Discolored skin lesions occur in numerous diseases and numbness of skin occurs in many nerve disorders, but a discolored skin lesion that is anesthetic occurs only in HD. When such a lesion is encountered, diagnosis of HD is clinically confirmed. Increasing anesthesia and elevation of the margins of the skin lesion indicate movement toward the tuberculoid pole. An increase in the number of the lesions and central elevation of the skin lesion indicate movement toward the lepromatous pole. On light skin, the lesions are copper colored; on dark skin, they are hypopigmented. In MB disease the skin lesions are multiple and symmetrical whereas in PB disease the lesions are fewer and asymmetrical (Figure 3.26). A hyperpigmented palmar lesion is a rare presentation of HD.

The diagnosis of HD occasionally can be difficult, as in the following three situations: (1) there is a skin lesion without sensory loss, (2) there is a sensory loss without a skin lesion, and (3) there is an enlarged nerve without motor or sensory loss and a skin lesion is absent (i.e., primary neuritic HD).

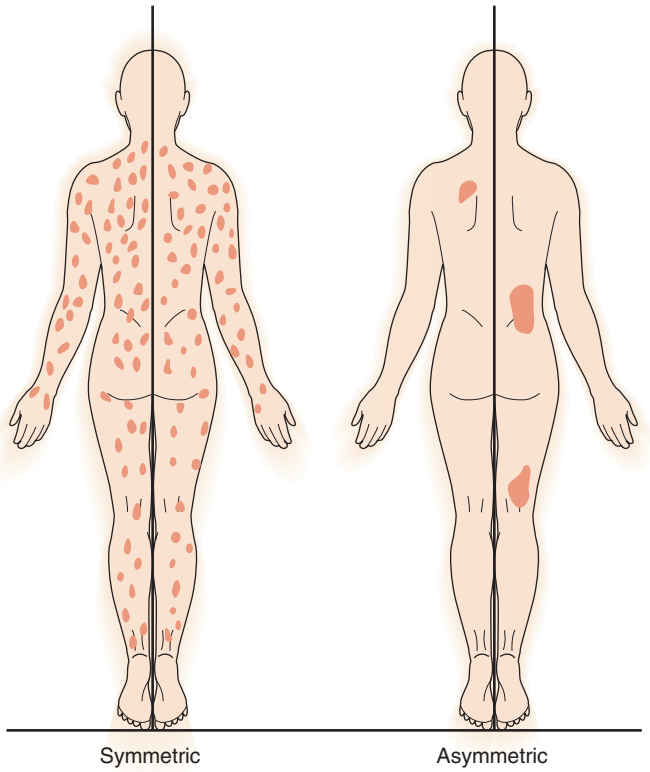

FIGURE 3.26 The lesions of MB Hansen disease are multiple and symmetrical and those of PB disease are few and asymmetric. (From Hastings RC: *Leprosy*, ed 2, New York, 1994, Churchill Livingstone, with permission.)

Diagnostic Tests

Lepromin Skin Test. A majority of individuals exposed to *M. leprae* get infected but only a small percentage of these go on to develop the disease. The lepromin test is positive in people who develop subclinical infection because their inherent resistance

is high. It is thus positive in the majority of healthy individuals in endemic areas and is not a diagnostic test for HD. It is of great value in classifying a case of HD once the diagnosis has been made because it essentially indicates the host resistance (immunity) of the patient.

Patients on the tuberculoid side of the spectrum have higher resistance and show a positive reaction, whereas those on the lepromatous side have lower resistance and show a negative reaction. The lepromin reaction is helpful in distinguishing silent mononeuritis from silent mononeuritis multiplex in determining the patient's position on the immunologic spectrum to determine paucibacillary or multibacillary status of the HD and treatment.[8]

Slit-Skin Smears. Slit-skin smear is the gold standard for diagnosis of HD. This is the simplest and most important investigation that helps not only in diagnosing but also in classifying the HD into PB and MB disease for appropriate treatment.[59] Presence of AFB in slit-skin smears confirms the diagnosis of HD but a negative result does not rule out the diagnosis. In pure (primary) neuritic HD, skin lesions are absent and nerve aspiration or open nerve biopsy can be considered if the clinical diagnosis of HD is not certain.[117]

Slit-skin smears are made from a suspect lesion, as well as from sites commonly affected in lepromatous HD, which include skin from the dorsum of proximal phalanges of fingers and extensor surfaces of the forearms. In lepromatous patients, nodules are the preferred sites for slit-skin smears, but they also can be obtained from the trunk, buttocks, or ear lobes. In tuberculoid patients, rims of skin lesions should be sampled.

Slit-Skin Smear Technique. The skin lesion is cleansed with isopropyl alcohol and is pinched between the thumb and index finger of the left hand to squeeze the blood off the raised skin fold. With a No. 15 scalpel, the skin is slit between the thumb and finger (~5 mm long) and deep enough (~3 mm) to get well into, but not through, the infiltrated layer of the dermis. The blade is then used several times to scrape the cut edges of dermis so that tissue fluid and dermal pulp, but not blood, collects on one side of the blade; this is gently smeared onto a glass slide. The smear is fixed over a flame before being sent for staining. A total of six or eight smears should be made.

Skin Biopsy. When a slit-skin smear is negative, a skin biopsy may be considered if the clinical diagnosis is in doubt. The probability of finding bacilli in an HD patient is greater in skin biopsy than slit-skin smears. A biopsy in HD must include the full depth of the dermis together with a portion of subcutaneous fat to include a dermal nerve. It is difficult to opine on a section that fails to show a dermal nerve.

Skin Biopsy Technique. A deep skin biopsy at the active edge of a lesion is done that includes deep dermal nerves entering the deep surface of the dermis and/or a nerve in the subcutaneous tissue. The biopsy can be preserved in a suitable preservative (e.g., 10% formaldehyde) for further processing. A portion of the skin can be saved in 70% ethyl alcohol so that PCR can be done if bacilli are not found in the skin. PCR can detect as few as 10 to 100 bacilli in a skin sample of an early or TT lesion. When a biopsy is being sent for a mouse footpad test, it should be placed in a small sterile bottle without any additive and kept at 4°C in a flask containing ice.

Viable *M. leprae* are solid, are nonfragmented, and stain uniformly, whereas dead bacilli are fragmented and stain irregularly. The percentage of solidly staining bacilli, termed the *morphologic index* (MI), is useful for assessing viability of the bacilli in skin and tissue sections. It tells whether the patient is still infective and gives valuable information as to response to treatment if the disease is still active. It also provides an early indication of bacterial resistance to treatment or of noncompliance with chemotherapy. The total number of bacilli in the dermis, the bacteriologic index (BI),[59] includes both live (solid) and dead (fragmented) bacteria and is useful in assessing the number of bacteria at the onset of diagnosis (Table 3.11); it classifies the patient into PB or MB disease, which determines his or her respective treatment regimens. Using the WHO definition, paucibacillary refers to a patient with a BI of 0 on the Ridley scale at all skin smear sites, and multibacillary refers to a patient with a BI of 1+ or more at any site.

Nerve Biopsy. Neuritic pain with an enlarged nerve and without a skin lesion may be the first symptom/sign of HD. In this type of nerve lesion, called pure or primary neuritic HD, in the absence of skin lesions, fine-needle nerve aspiration cytology or open biopsy may be the only way to confirm the diagnosis of HD. Nerve aspiration cytology is simple and rapid; material obtained is abundant, absence of trauma and scarring are appreciated by the patient, and an operating room visit for nerve biopsy is avoided. A thickened pure sensory nerve with minimal functional deficit (e.g., sural, radial sensory, supraclavicular) is suitable. When *M. leprae* is not visible on microscopy in the nerve, as in pure neuritic HD or TT disease, PCR, which is positive in 80% of cases, is the last resort to find *M. leprae* in the nerve or the skin.

Fine-Needle Nerve Aspiration Technique. The nerve is palpated and the most obvious site is noted. Skin is anesthetized 1 cm proximal to the site of aspiration. A 22-gauge, 4-cm needle fixed to a 10-mL disposable syringe is used, and aspiration is

TABLE 3.11 Method of Grading the Bacteriologic Index in a Slit-Skin Smear or in a Skin or Nerve Biopsy Specimen

Bacterial Index	Average Number of Bacilli per (100>) Field	WHO Classification
0	0 in 100 fields	Paucibacillary
1	1-10 in 100 fields	Multibacillary
2	1-10 in 10 fields	Multibacillary
3	1-10 per field	Multibacillary
4	10-100 per field	Multibacillary
5	100-1000 per field	Multibacillary
6	>1000 per field	Multibacillary

Classification of patients into paucibacillary (BI = 0) and multibacillary (BI > 0) for treatment purposes makes detailed computing unimportant in diagnosis. The index is nevertheless useful in monitoring improvement or deterioration of the disease (drug compliance and drug resistance). The morphologic index calls for consistently high standards of staining, fixation, and microscopy, which are rarely available outside research and scientific units.

performed using a single puncture. The direction of the needle is always kept parallel to the length of the nerve. The material aspirated is smeared on glass slides. Hematoxylin and eosin and AFS are done. Of the aspirated nerves, 65% showed inflammatory cells, 25% showed granulomas consistent with the diagnosis of HD, and 24% showed AFB. No neurologic deficit was identified at 1-year follow-up.

Open Nerve Biopsy Technique. Biopsy of one or two fascicles of a palpable, thickened, and superficially placed sensory nerve is recommended, preferably under magnification so as to select the most likely affected fascicles. If the nerve is severely damaged and fascicles are obliterated, a small longitudinal wedge of nerve can be removed. A 2-cm-long nerve biopsy provides enough length for histology and electron microscopy.[8] It is important to identify proximal and distal ends of the nerve for the pathologist. The excised portion is immediately immersed in a fixative (10% buffered formalin or 70% alcohol).

Electrophysiological Studies. Nerve conduction studies and electromyography are not specific in the diagnosis of HD but are useful in confirming the site of compression neuropathy before surgery and in assessing the extent of nerve damage in early stages of leprosy.

Imaging Studies. Magnetic resonance imaging can localize a mass, fluctuating or not, in a nerve and facilitate early diagnosis of a nerve abscess or calcification.

Treatment

The patient is classified based on the lepromin test, skin smears, skin biopsy, or nerve biopsy. Based on this, chemotherapeutic agents and duration of treatment are decided. The primary aim in managing patients with HD is to prevent deformities in those who do not have them and to reduce disabilities or arrest their progression in those with them. If treated early, the disease leaves no residual marks. The diagnosis should not be made by exclusion or by therapeutic trial. No one should be treated for HD unless a diagnosis is established. A mistaken diagnosis may cause severe social complications. The objectives of treatment of HD include:

- Elimination of infecting bacteria (multidrug therapy)
- Relief of pain (antiinflammatory medications and nerve decompression)
- Preservation of sensation (corticosteroids, thalidomide, and nerve decompression)
- Restoration of sensation (innervated skin flaps, nerve transfer, nerve decompression, sensory reeducation)
- Treatment of deformities: flexible and fixed (hand therapy and reconstructive surgery)
- Rehabilitation (psychological, social, vocational, and avocational)

Elimination of Infecting Bacteria With MDT

In the 1940s, dapsone was shown to cure patients with HD and was the first landmark in its treatment. Monotherapy with dapsone led to drug resistance. In 1982, WHO recommended multidrug therapy to combat resistance to drugs. Dapsone, which is bacteriostatic, makes the patient noninfective in 6 weeks, and rifampin, which is bactericidal for *M. leprae*, makes the patient noninfective in 2 days. MDT is very effective in the prevention of drug resistance in leprosy, but it has not been possible to reduce the length of treatment substantially and resistance of *M. leprae* to rifampin is emerging.

Since the mid-1980s, bactericidal activities of ofloxacin, minocycline, and clarithromycin have provided treatment for rifampin-resistant *M. leprae*. Mouse footpad antibiotic sensitivity testing should be done on all MB patients whenever possible. In vitro techniques are being developed to identify resistant strains of *M. leprae* in suspected cases. Lately, mouse footpad and genomic studies on *M. leprae* obtained from leprosy patients have begun to show occurrence of *M. leprae* resistance to more than one drug. Isolation of *M. leprae* resistant to a combination of dapsone, rifampicin, ofloxacin and sparfloxacin has been reported.

Paucibacillary Hansen Disease. Paucibacillary HD is treated with two drugs: dapsone, 100 mg once daily, orally, unsupervised; and rifampin, 600 mg once a month, orally, supervised. The drugs are given orally on an ambulatory basis, and WHO recommends treatment for 6 months. In developing countries, rifampin is given once a month because it is very expensive. US recommendations include rifampin in a "full" dosage of 600 mg daily.

A single dose of a three-drug bactericidal combination of rifampin, 600 mg, plus ofloxacin, 400 mg, plus minocycline, 100 mg (i.e., the ROM regimen) is shown to kill 99% of viable *M. leprae*. In 1997, WHO endorsed the use of single-dose ROM for the treatment of patients with single-lesion paucibacillary HD but some reports are now challenging the efficacy of this drug schedule.

Multibacillary Hansen Disease. Multibacillary HD is treated with three drugs: dapsone, 100 mg daily, orally, unsupervised; rifampin, 600 mg once monthly, orally, supervised; and clofazimine, 300 mg once a month, orally, supervised and 50 mg daily, orally, unsupervised. WHO recommends treatment for 12 months. If the skin smears remain positive, the treatment is continued until the smears become negative. Patients in the urban United States often refuse to take clofazimine because it discolors the skin. Rifampin is hepatotoxic, and its use must be monitored with periodic liver function tests. An elevation of serum bilirubin and serum aspartate transaminase (AST or SGOT) is an indication to stop rifampin. It should not be prescribed during the first 3 months of pregnancy.[16]

Drug resistance, persistence of viable *M. leprae* in the tissues for many years after effective therapy (persisters), and resulting relapses after release from treatment (RFT) make eradication of HD difficult. Persisters relapse when their immunity falls for any reason. Relapse rate after MDT is about 0.6% 5 years after RFT. Relapses are more often in MB than PB patients after both monodrug therapy and MDT. Relapses in multibacillary patients occur more often in patients who have a higher bacillary load (BI >4 before MDT).

Relief of Pain

Neuritic pain in HD occurs secondary to nerve infection, nerve reactions due to immunologic defense mechanisms,[16] nerve compression in fibroosseous tunnels, and nerve abscess. Nonneuritic pain in HD may arise from dermatitis, tenosynovitis (Figure 3.27, *A*,*B*), arthritis, dactylitis (Figure 3.27, *C*), and myositis. Chronic regional pain syndrome has been described as a cause of pain in leprosy that responds effectively to

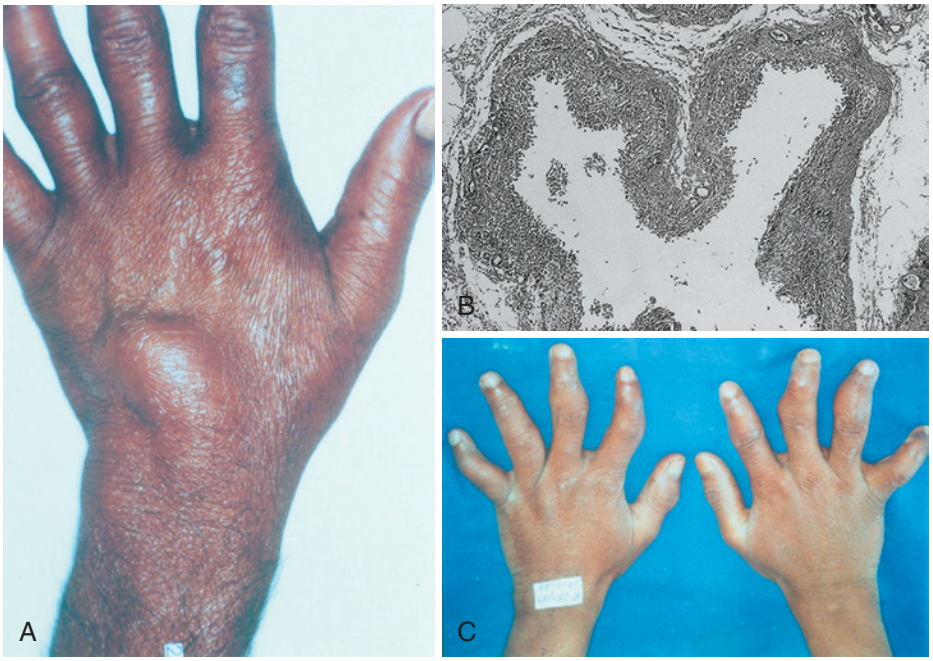

FIGURE 3.27 Rare initial presentations of Hansen disease. **A,** Tenosynovitis is manifested as a moderately painful swelling on the dorsum of one or both wrists, hands, or fingers. By comparison, idiopathic and rheumatoid extensor tenosynovitis is often painless. **B,** Histology shows proliferative tenosynovial tissue. **C,** Arthritis and joint deformities in type 2 reaction in fingers. (Courtesy of G. N. Malaviya, India.)

sympathetic blocks and drugs traditionally used for complex regional pain syndrome (CRPS).

Reactions. The term *reaction* is used to describe the sudden exacerbations in the manifestations of HD that may occur before, during, or after a course of MDT. Reactional episodes are said to be brought about by alterations in immunologic balance. They are antigen-antibody reactions to *M. leprae* polysaccharides and proteins. In the upper extremity, they manifest with acute inflammation in the skin, nerves, tenosynovium, and joint. The patient suffers pain from tender nerves, skin, joints, and tenosynovitis. Swelling of the joints is symmetric and occurs mainly in the wrist, metacarpophalangeal joints, and proximal interphalangeal joints and resembles rheumatoid arthritis. All are precursors to edema and stiffness. The shoulder–hand–finger syndrome can develop in the reactive phases of HD as an edematous, painful, stiff upper extremity and has been called the "stasis hand" of leprosy.

Much of the nerve damage in HD takes place during the reactive phase, which produces intraneural caseous necrosis in tuberculoid disease and microabscesses in lepromatous disease. Reaction neuritis is a medical emergency. Unless it is treated immediately, sensory loss can become devastating and irreversible. A reaction may be the initial manifestation of HD. Reactions plague the patient before treatment, during treatment, and long after MDT has practically eliminated all viable organisms from the body. New deformity or disability occurs in 5% of MB patients during therapy and 2.5% after RFT during the surveillance period as a result of leprae reactions. They continue to disable and deform the patient for life. HD is thus truly an immunologic peripheral nerve disease. Three types of reactions occur in HD: reversal reaction (type 1), erythema nodosum leprosum (type 2), and the Lucio reaction (Table 3.12).

Reversal Reaction (Leprae Type 1). Sometimes there is a rapid increase in cell-mediated immunity when a patient is under adequate and regular treatment, which increases the immunologic resistance, and is associated with a reaction characterized as an "upgrading reaction" or "reversal reaction" (RR). These type 1 reactions are most common in borderline and tuberculoid patients. Clinically, reaction is manifested in the skin, nerves, and tendons. It may be mild and manifested by dull pain or with severe neuritic pain, skin lesions, and tenosynovitis.

ENL Reaction (Leprae Type 2). Leprae type 2 reactions affect mainly lepromatous (LL > BL) patients. In contrast to a reversal reaction, erythema nodosum leprosum is a generalized process involving several organ systems, concurrently or sequentially. The patient is often ill with fever and granulocytosis. The process takes its name from crops of painful, red, cutaneous, and subcutaneous nodules that develop all over the face, limbs, and trunk. Joints may become swollen and tender. Neuritis occurs in 20% of cases owing to formation of microabscesses. Periostitis, tendinitis, and myositis are sometimes observed. It has been hypothesized that a high bacterial antigen load leads to an immune reaction in which immune complexes cause vasculitis—the histologic hallmark of ENL (see Table 3.12).

Lucio Reaction. The Lucio reaction is a necrotizing skin reaction associated with nonnodular diffuse lepromatous HD. The Lucio reaction is common in Mexico and Central America. Large recurrent, sloughing cutaneous ulcerations occur that heal inadequately. It may present as intense hand and foot edema. Necrosis, ulceration, and purulent exudate are superimposed on purpuric cutaneous plaques on hands and feet. There may be rapid and profound deterioration of health, and delay in diagnosis causes high morbidity and mortality. This is

TABLE 3.12 Classification of Lepra Reaction in Leprosy

Type	Type of Leprosy Involved	Main Clinical Features	Main Histologic Features	Main Hematologic Findings
Type 1	1. Borderline (BT < BB < BL)	Erythema and swelling of some or all leprosy skin lesions	With an upgrading reaction there is edema, reduced bacilli, and increased defensive cells (e.g., lymphocytes, epithelioid, and giant) With a downgrading reaction there is an increase in bacilli and defensive cells are replaced by macrophages	Nil
Reversal (RR)		New lesions may appear		
Increased hypersensitivity to *M. leprae*		Edema of extremities Neuritis		
Type 2 (ENL reaction) Immune complex formation	1. LL 2. BL	Fever, skin eruptions, ENL with any of the following, singly or in various combinations: *Hand*—neuritis, bone pain, joint pain, dactylitis, tenosynovitis, lymphadenitis *Systemic*—fever, malaise, rhinitis, epistaxis, iritis, epididymo-orchitis, proteinuria	In ENL lesions there is edema, neutrophil infiltration, and vasculitis (veins and arterioles)	Polymorphonuclear leukocytosis Raised ESR Thrombocytosis Raised IgG, IgM, complement 2, and complement 3 Normocytic normochromic anemia
		In severe cases (e.g., erythema necroticans), skin lesions may become vesicular or bullous and break down	In erythema necroticans there is obliterative angiitis and endarteritis Bacilli are fragmented and granular	
Lucio	Lucio leprosy (in Mexico and South America)	Small pink lesions on the skin become large; bullae develop, become necrotic, and cause large painful ulcers	Necrosis of superficial blood vessels Deposits of immunoglobulin and complement in vessel walls Abundant AFBs	High titers of circulating immune complexes and cryoglobulins

AFB, Acid-fast bacillus; *BL*, borderline lepromatous; *ENL*, erythema nodosum leprosum; *ESR*, erythrocyte sedimentation rate; *LL*, lepromatous.

TABLE 3.13 Treatment of Lepra Reaction

Type	Corticosteroids	Clofazimine	Thalidomide
1	At least 60-80 mg prednisone daily Initially attempt to taper over a 2-3-month period For chronic reactions, try to taper to every other day	300 mg daily until controlled without corticosteroids; then taper to 100 mg daily Increase as needed if reaction recurs	Ineffective
2	Usually 60 mg of prednisone daily Initially attempt to taper over a 2-3-month period For chronic reactions, try to taper to every other day	300 mg daily until controlled without corticosteroids; then taper to 100 mg daily Increase as needed if reaction recurs	100 mg four times daily tapered after reaction controlled For chronic reaction, maintenance level of 100 mg every other day to 100 mg twice daily Try to discontinue after 6 months
Lucio	At least 60 mg of prednisone daily Initially attempt to taper over a period of several weeks For chronic reactions, try to taper to every other day	Value questionable except as antileprosy therapy	Ineffective

considered to be a type of HD reaction associated with necrosis of arterioles, the endothelium of which is massively invaded by *M. leprae* (see Table 3.12).

Treatment of Reactions. Leprosy is cured but nerves die, unless reactions are prevented or treated early (Table 3.13). Mild reactions are accompanied by nagging pain without neurologic deficit. Aspirin is adequate for this type of mild to moderate pain and is the drug of choice. More severe reactions are best managed by resting the nerve (i.e., splinting the affected joint) and oral corticosteroid therapy. Prednisone reduces

edema virtually overnight and decreases postinflammatory scarring.

In reversal reactions, corticosteroids may be needed for 6 months or longer to prevent relapses, and use for up to 5 years has shown very beneficial results. In ENL, clofazimine and thalidomide help to reduce the corticosteroid dose once acute pain subsides. Acute tenosynovitis is treated with oral cortisone, hand elevation, and a balanced combination of splinting and mobilization of the joints.

In the Lucio reaction, debridement of sloughing skin and skin grafting are indicated early, particularly when joints are exposed. It is also necessary to provide immunosuppressive drug therapy and MDT. Hands affected by reactive phases of HD do well if occupational and physical hand therapists prevent "frozen hands" and "frozen shoulders."

Compression Neuropathy. There may be internal compression of the nerves where the nerve fibers are strangulated by the thickened epineurium because of intraneural edema ("acute nerve compartment syndrome") or intraneural granuloma formation and caseation ("chronic nerve compartment syndrome") or external compression from the fibroosseous tunnel that contains it. Surgical decompression is complementary to, and not a substitute for, treatment of acute neuritis. Nerve compression is surgically decompressed (1) when nerve pain is severe even after function may have been lost for months or years and (2) when there is recent and/or progressive loss of nerve function (motor or sensory) after adequate cortisone treatment from 3 days to 3 weeks.

Those with extensive surgical experience in HD, including Brand,[13] Antia,[8] and Srinivasan,[110] found that when unrelenting pain was the main problem, ulnar nerve decompression was a satisfying operation for the patient and the surgeon. Both extraneural pressure release (fibroosseous tunnel) (Figure 3.28, *A*) and intraneural pressure release (epineurotomy) (Figure 3.28, *B*) are essential parts of the surgery. Varying grades of motor and sensory recovery were additional benefits in 50% of the patients when surgery was done early.

Results of carpal tunnel release are mixed. The decompression of the median nerve is beneficial. Pain relief is dramatic, sensory recovery is seen in 90% of cases, and muscle strength improves in 45% of cases. Srinivasan and Palande observed motor recovery in 75% of patients with median nerve palsy if operated on within 2 months of paralysis.[110] Results of radial nerve release in the nerve groove of humerus are equivocal. The number of cases requiring any nerve decompression have been significantly reduced after using cortisone, clofazimine, and thalidomide to control acute leprous reactions.

Nerve Abscess. Nerve abscess may be (1) the initial presenting problem in HD, (2) seen during therapy, or (3) appear during post-MDT surveillance after RFT. A nerve abscess may appear as a single swelling (Figure 3.29), multiple swellings on a single nerve (Figure 3.30), or multiple swellings on multiple nerves. Children and teenagers accounted for 47% of 145 nerve abscesses and occur across the entire spectrum of HD. The abscess may be fluctuant, nonfluctuant, subcutaneous, deep, painless, painful, collar-stud, moderate in size, giant in size, without a sinus, with an impending sinus (see Figure 3.30), with a draining sinus, with a dried sinus, without calcification, or with calcification (Figure 3.31, *A*,*B*).[75] It is most frequently seen in the ulnar nerve (58%) and rarely in the median (7%) or the radial nerves and can be unilateral or bilateral. Abscesses may occur along one or more cutaneous nerves of the arm and forearm (Figure 3.32). Medial cutaneous nerves of arm and forearm account for 35% of abscesses.

Treatment of a Nerve Abscess. A painless abscess may subside with oral corticosteroid therapy. If a painful and

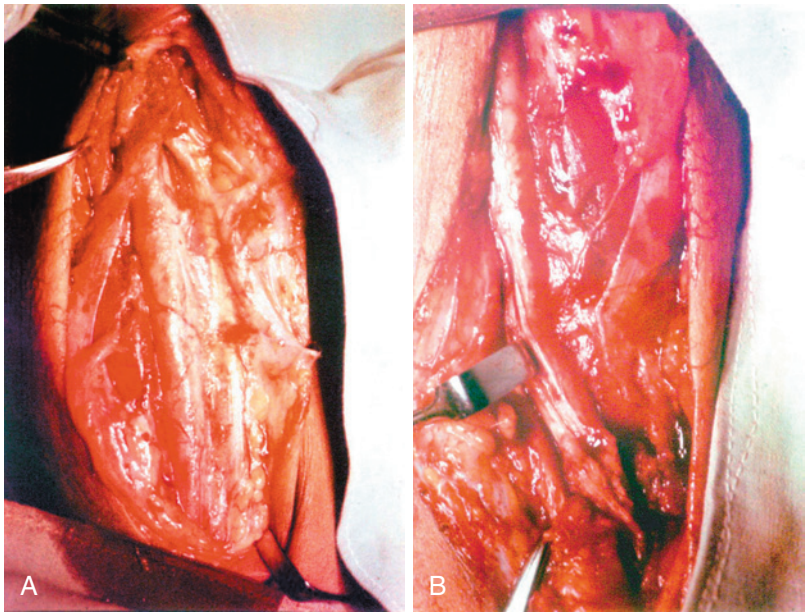

FIGURE 3.28 Surgical exposure of the ulnar nerve at the elbow in a case of Hansen disease. **A,** The incision is made in the upper arm over the palpable nerve at least 10 cm proximal and distal to the medial epicondyle. Extraperineurial pressure over the fibroosseous tunnel containing the enlarged nerve is decompressed. **B,** More importantly, intraepineurial pressure in the ulnar nerve due to infection is released by longitudinal epineurotomy along the entire enlarged nerve. Epineurotomy is limited to the exposed side of the nerve and the nerve is left intact in the bed to preserve compromised circulation to the nerve due to perineurial fibrosis. (Courtesy of G. N. Malaviya, India.)

fluctuating abscess does not respond to oral corticosteroid therapy, it is drained to debulk the caseous granulation tissue and to decompress the surviving nerve fascicles. This relieves pain and may prevent further deterioration of nerve function.[76]

Nerve Abscess Drainage Technique. A painless and fluctuating abscess without progressive nerve deficit can simply be aspirated under sonography. An abscess with progressive neurologic deficit is drained with a single longitudinal epineurotomy. Caseous material is drained and nerve fascicles are not disturbed, and the epineurium is not closed. The skin can be primarily closed over a drain that is removed 24 to 48 h after surgery. A chronic sinus secondary to a discharged nerve abscess can be treated by excision of the sinus tract along with necrotic nerve tissue. In cases of complete nerve trunk palsy, a course of rifampin and isoniazid may heal the sinus in about 6 months.



FIGURE 3.29 Clinical features of a nerve abscess caused by Hansen disease are highly variable. A single swelling is the most common finding. Ultrasound is helpful for making a diagnosis of nerve abscess. Of abscesses, 58% are seen in the ulnar nerve. (Courtesy of G. N. Malaviya, India.)

Preservation of Sensation

Infection of the peripheral nerve in HD impairs pain perception. Loss of pain allows the patient to injure himself or herself. Fingertips undergo "terminal absorption" due to recurrent trauma and infection. Shortening of the fingers results in "mitten" hands.



FIGURE 3.30 There are two abscesses on one nerve shown here. A nerve abscess with an impending sinus may need early incision and drainage to prevent formation of a chronic sinus and more perineurial fibrosis. (Courtesy of G. N. Malaviya, India.)

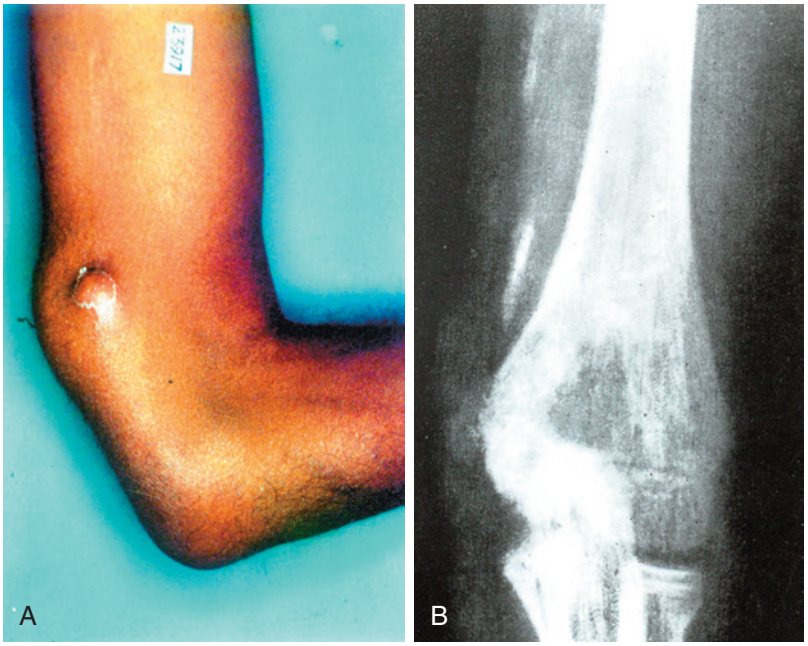

FIGURE 3.31 **A,** A nerve abscess can become calcified. **B,** Calcified nerve can be seen on a radiograph as a longitudinal opacity corresponding to the location of the nerve. (Courtesy of G. N. Malaviya, India.)



FIGURE 3.32 Cutaneous nerve abscesses can be seen along one or more cutaneous nerves in the upper arm and forearm. The medial cutaneous nerve of the upper arm and of the forearm account for 35% of nerve abscesses. (Courtesy of G. N. Malaviya, India.)

Sensory loss occurs in HD from several causes, but the basic pathology is a varying mixture of segmental demyelination and axonal degeneration. There is swelling of vascular endothelium in leprous vasculitis and this causes narrowing of lumina and nerve ischemia. Progressive nerve fibrosis converts it into a fibrous cord. Complete and early elimination of bacteria by MDT may cure the patient. Reactions are treated by prompt administration of corticosteroids. For patients with recent loss of sensation who do not respond to corticosteroids, surgical decompression of the involved nerve is indicated.[8] Surgery done no later than 3 months after the onset of nerve damage has been shown to be beneficial.

Silent Neuritis. Silent neuritis occurs with neurologic loss (sensory and motor) but without neuropathic pain or tenderness and in absence of a leprae reaction (i.e., types 1, 2, or Lucio) in a large HD population. In 67 to 75% of those who developed deformities, patients gave no history of reactions; 95% of those with pure neuritic HD did not give a history of neuritic pain. The nerves are silently damaged by Schwann cell destruction and segmental demyelination during continuous or recurrent subclinical types 1 and 2 reactions. In silent neuritis, corticosteroids are beneficial in reversing motor weakness, but their benefit in impaired sensibility is not known.

Restoration of Sensibility

Antia reported that 20 to 30% of patients develop irreversible nerve damage in HD.[8] Restoring sensibility in anesthetic extremities of HD patients is the next surgical frontier. The minimum desirable level of sensibility in Hansen disease is protective sensibility. This prevents self-mutilation of the hand. Surgery is successful if the patient can resume "injury-free" hand activities. The recovery of sensory abilities therefore will help in "normalization" of the activities of the patients.[73,74] Procedures to restore sensibility should be delayed until all indicated tendon transfers have been done and the patient has supple tissues with an established range of motion. The following possibilities have currently been used in HD with varying success.

Ozkan and associates have described restoration of sensibility in leprosy-affected hands by transferring a sensory branch of the radial nerve to appropriate median or ulnar nerve branches.[87] Frozen skeletal muscle bridge grafts have been used to replace damaged nerve segments. After freezing, muscle fibers degenerate and leave their sarcolemmal tubes intact. These tubes act as a framework, along and through which the regenerating axon sprouts can migrate distally toward the receptors. Muscles such as sartorius and gracilis that have a parallel arrangement of fibers are preferred as grafts. Ability to sweat in the affected area was also restored in 1 of 9 hands.

Sensory reeducation is useful for all patients with HD with sensory loss, with or without surgery. Some patients who have undergone reconstructive surgery of the hand have been observed to get some "feeling" in their hands 2 to 3 years after surgery, especially when the hand has been put to considerable use.

Treatment of Deformities

The horror and stigma of the disease are rooted in the deformity it can cause. The normal-appearing but infected HD patient moves about freely in society. The deformed but noncontagious patient is an outcast. To the deformed patient, appearance means the difference between being an outcast and having a normal work and social life. With HD, the appearance of the hand is as important as its function. The correction of deformity is often indicated even if it does not substantially restore hand function because it restores a patient's dignity.

The ulnar nerve damage is responsible for 50% of the primary hand deformities. The ulnar claw hand is the most common paralytic deformity in HD. The second most common deformity is because of a combined ulnar and median nerve paralysis, the complete claw hand, with simian deformity. Deformities that are a result of radial nerve paralysis are rare, occurring only in 1 to 2% of the deformed cases. Radial nerve palsy is usually a part of a "triple nerve paralysis." Pure median and radial nerve involvement is rarely encountered in HD. Surgical treatment of hand deformities from muscle imbalance due to nerve palsy is reviewed extensively in Chapter 31.

In cases of ulnar palsy, the atrophy of first dorsal interosseous muscle results in a deep gutter in the first web space. Although it does not lead to any functional deficit, patients at times request that this gap be filled for cosmetic reasons. This problem has not been given much attention by hand surgeons. Several attempts have been made in the past to fill it with silicone gel, dermal grafts, dermofat grafts, and structured autologous fat grafts with varying success. An adipofascial flap raised from the forearm, based on cephalic vein and distal perforators of the radial artery, has been satisfactory for correcting this deformity because it is a vascularized substitute.[91]

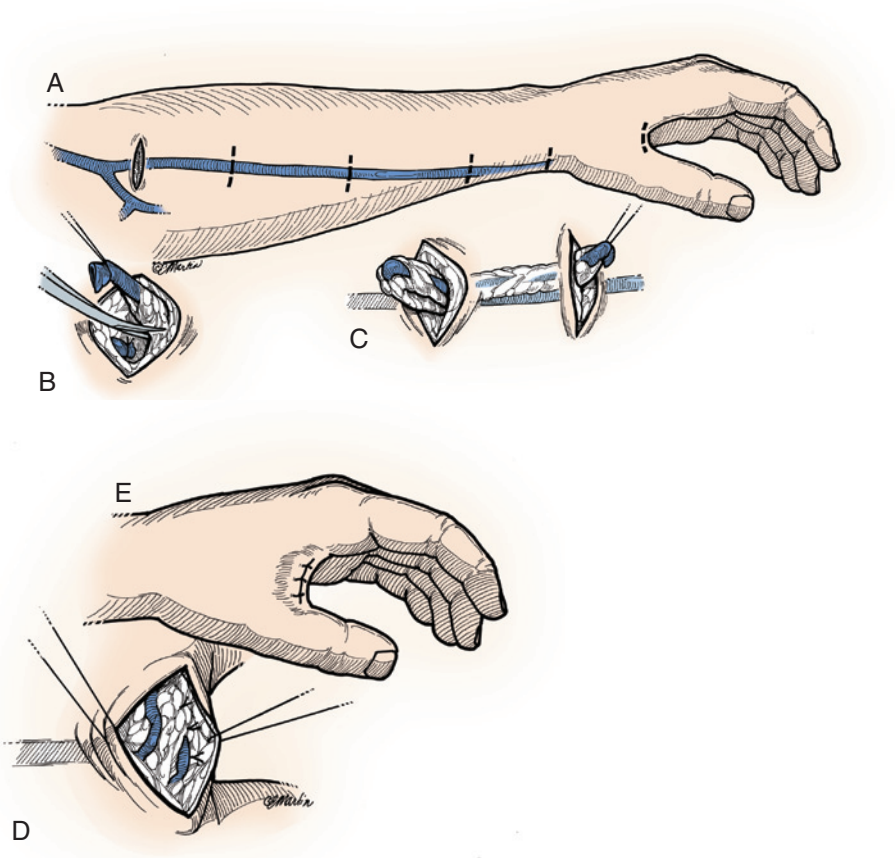

FIGURE 3.33 Reconstruction of first dorsal interosseous gutter. **A,** Dorsal first web space gutter as a result of atrophy of the first dorsal interosseous muscle. **B,** Incisions used to design an adipofascial flap. **C,** Dissection of the adipofascial flap. **D,** Dissected flap. **E,** Thumb web space after in-setting of the flap. (Copyright © Elizabeth Martin.)

Overcorrection is required because 50% of the bulk may be lost in about 6 months to a year, as reported by the authors (Figure 3.33, *A-E*).

Rehabilitation

Psychiatric morbidity is common in HD patients. One must therefore evaluate the deformity a patient has as well as the person who has it. For them to make a decision about treatment, it is essential that patients know what kind of surgery is available and what is expected during the postoperative period. Patients with HD have to face three different sets of problems: overuse, misuse, and protected use. The entire rehabilitation process depends on patients' understanding of those problems, acceptance of residual disability, and desire to adapt to the new situation. Among these, acceptance of disability is the most important and the most difficult. It is patients who need rehabilitation, not the hand alone.

It is important that the surgeon assemble a multidisciplinary team to follow the patient, including an infectious disease specialist, a physical and occupational therapist, and a social worker. Rehabilitation of the patient's psychological, social, vocational, and avocational life restores his or her self-esteem. These are the final and most important milestones in restoring social acceptability and dignity to the dejected and stigmatized HD patient. In his enthusiasm for surgery and research, Brand never forgot the person behind the disease.[13]

Resource Materials

For the latest guidelines on diagnosis and treatment of HD, National Hansen's Disease Program (Baton Rouge, LA) maintains a referral service to several federally funded ambulatory HD centers; they are located in Boston; Chicago; Los Angeles, Martinez, and San Diego, California; Miami; New York; Phoenix; Puerto Rico; Seattle; and Dallas, Harlington, Houston, and San Antonio, Texas.

Several texts on medical and surgical treatment have been published by physicians[16,50,59] and surgeons[7,8,110] experienced in HD. Two journals (*Indian J. Lepr.* and *Lepr. Rev.*) are dedicated to basic and clinical HD research in English. The publication of the *International Journal of Leprosy* and *Acta leprologica* has been discontinued. The International Congress of Leprosy first met in 1897 and convenes every fifth year under the auspices of the International Leprosy Association to update research and clinical information; it last met in 2012 in New York.

CRITICAL POINTS *For Diagnosis of Hansen Disease*

Two of the following three clinical signs are needed for clinical diagnosis:

- A hypopigmented skin patch
- An anesthetic skin patch
- An enlarged nerve (ulnar nerve at elbow, median nerve at wrist, sensory branch of radial nerve)

A smear positive for *M. leprae* from the skin or nerve biopsy is diagnostic when only one of the three signs is positive. Smear is done for (1) diagnosis, (2) selection of a PB or MB treatment regimen, and (3) prognosis by determining bacteriological level.

CRITICAL POINTS *Indications for Steroids in Leprosy Reactions*

- Impending or recent muscle paralysis
- Recent loss of sensation
- Painful neuritis
- Moderate to severe type 1 reactions
- Moderate to severe erythema nodosum leprosum, especially when associated with neuritis, arthritis, and orchitis or uveitis

PROTOTHECAL, PROTOZOAL, AND PARASITIC INFECTIONS

Protothecosis (Algae Infections)

Etiology and Epidemiology

Human protothecosis is a rare infection caused by members of the genus *Prototheca*. *Prototheca* species are generally considered to be achlorophyllous (colorless) algae and are ubiquitous in nature. *Prototheca* spp. exist in the environment as ubiquitous detritus inhabitants and contaminants of various substrates. *Prototheca wickerhamii* and *Prototheca zopfii* have been associated with human disease. It is often classified as a fungus because the organisms are frequently preliminarily identified in tissue biopsy as yeast. It was first identified in 1894, but the first case of human protothecosis was not described until 1964. Since then, 50 cases have been reported and reviewed up to 1992 and 80 cases up to 2006.[120] Of the first 50 cases, 28 were in the upper extremity (i.e., 3 in fingers, 1 in palm, 1 on dorsum of hand, 2 in wrist, 2 in forearm, 16 in olecranon bursa, and 4 in upper arm).

About half the cases were cutaneous/subcutaneous and the other half were bursitis, tenosynovitis, and fasciitis. The cutaneous/subcutaneous cases occurred in immunocompromised patients, mainly due to systemic corticosteroid administration, diabetes, renal failure, and topical application of corticosteroids at the site of infection.

Clinical Findings

The most common form of protothecosis in the upper extremity is olecranon bursitis. *P. wickerhamii* is the most frequent alga infection in the upper extremity. The occurrence of protothecosis can be local or disseminated and acute or chronic, with the latter being more common. Diseases have been classified as (1) cutaneous lesions, (2) olecranon bursitis, and (3) disseminated-systemic manifestations. Infections can occur in both immunocompetent and immunosuppressed patients. More severe and disseminated infections tend to occur in immunocompromised individuals.

The most common presentations of protothecosis in the upper extremity are olecranon bursitis and tenosynovitis. Protothecosis deserves to be included in the differential diagnosis of recurrent olecranon bursitis. Most olecranon bursitis occurs after trauma, several days to several weeks prior to infection. In the skin, the typical lesion is a painless, slowly progressive, and well-circumscribed plaque or papulonodular lesion that may become ulcerated.

The skin and soft tissue lesions typically enlarge over a period of weeks to months with no tendency for self-healing. The infection follows minor trauma, corticosteroid injection, or wounds exposed to soil or water. Incision and drainage of an infected abscess generally are complicated by recurrence.

Diagnosis

Diagnosis can only be made by open biopsy. Protothecosis is best diagnosed on histologic study. Most such infections are probably caused by traumatic inoculation into subcutaneous tissues. Olecranon bursitis and localized cutaneous infections are more common in immunocompetent patients, whereas dissemination and visceral involvement mainly affect patients with compromised host immunity.

An abscess wall from the olecranon bursa, tenosynovitis, or skin and subcutaneous tissue shows foci of chronic granulomatous inflammation and small, refractile, and morula-like oval objects in epithelioid cells. The inflammatory response shows both microabscesses and granulomas, both with multinucleated giant cells. *Prototheca* cells usually range from 8 to 20 mm in diameter, stain well with Gomori methenamine silver or periodic acid–Schiff, and often contain 2 to 8 tightly packed endospores in each cell or sporangium. *Prototheca* species from skin lesions grow well on routine laboratory media such as a Sabouraud dextrose agar; however, only half of the synovial protothecosis can be isolated by culture.[78,106] When the organisms grow, white opaque colonies appear in a few days on a Sabouraud agar. Recognition of *Prototheca* cells in host's living tissue is essential to making the diagnosis of protothecosis. When histopathologic material is not available, repeated isolation from clinical material may be necessary to confirm protothecal etiology.

Treatment

Usually, treatment involves combined medical and surgical approaches; treatment failure is not uncommon. Protothecosis has little, if any, tendency toward self-healing. Surgical excision of lesions is successful when it is meticulous and complete. Prolonged therapy with ketoconazole, itraconazole, or fluconazole should be added in immunosuppressed patients. A case of cutaneous protothecosis of the hand in an immunocompromised patient that did not respond to high doses of itraconazole treatment showed complete resolution in 2 months after thermal adjuvant therapy with a disposable body warmer; it provided 55°C average heat over clothes used every day without recurrence at 2 years.

Protozoal Infections

Leishmaniasis Infection

Etiology and Epidemiology. Leishmaniasis is transmitted by the bite of small insects called sand flies. Exposed hands, feet, and face are thus sites of infection. Leishmaniasis threatens 350 million people in 88 countries where the disease is endemic. The estimated yearly incidence is 1 to 1.5 million cases of the

cutaneous variety and 500,000 cases of visceral leishmaniasis (kala azar). Of these cases, 90% occur in Saudi Arabia, Afghanistan, Peru, Brazil, and Iran. From 2002 to 2004, 522 new cases of cutaneous leishmaniasis were reported among troops stationed in Afghanistan, Iraq, and Kuwait, mostly due to *L. major*. More than 80% of a total of 12 million infected patients live in Brazil (New World leishmaniasis) and 20% live in Tunisia, Syria, Iran, and Afghanistan (Old World leishmaniasis).

Kabul is considered to be the largest center of cutaneous leishmaniasis in the world, with approximately 67,500 cases in 2004. The disease is endemic in southern Texas because of its proximity to Mexico. Travelers to Costa Rica and Central America are the most common importers of leishmanial ulcers to the United States. It should be included in the differential diagnosis of skin lesions on exposed upper extremity in personnel returning from the military in endemic areas. Leishmaniasis is an intracellular infection caused by the protozoa *Leishmania*. Rodents and canines are the normal reservoirs, humans are the hosts, and the vector is the sandfly. Humans can also act as reservoirs when they are actively infected. The parasite multiplies in the macrophages, which then rupture and release the *Leishmania* organisms into the bloodstream.

Clinical Findings. There are three anatomic sites affected by leishmaniasis: cutaneous, mucocutaneous, and visceral. Cutaneous leishmaniasis (e.g., Baghdad boil, Delhi boil, tropical sore, oriental sore, Balkan sore, chiclero ulcer, Saldana) is the most common form and of interest to upper extremity surgeons because 80% of the lesions are located on exposed body sites of the upper extremity and the lower extremity and face.

In the finger, it may present as a node, whitlow,[4] chronic paronychia, or an ulcer that has not responded to a variety of treatments. It may occur on the finger, hand, wrist, forearm, elbow, or upper arm. In an AIDS patient, uncontrolled infection of a fingertip can cause necrosis of the distal phalanx. The initial lesion is a red-brown papule or a nodule at the bite site. It gradually enlarges to a 2- to 4-cm painless, chronic ulcer within 6 months. The ulcer has a necrotic base and indurated margin and is covered by a firmly adherent crust. It has a "pizza-like" appearance with a raised outer margin.

A solitary lesion occurs in 76% of cases, two lesions in 15%, three lesions in 6%, and four lesions in 1%. Multiple ulcers occur in immunocompromised patients. Without treatment, the ulcer begins to heal over the course of a year, eventually leaving a characteristic cribriform scar. Lymphadenopathy is absent. The lesion may present as a marching lymphocutaneous sporotrichoid abscesses. Basal cell carcinoma or squamous cell carcinoma may develop in an untreated, neglected, chronic leishmaniasis ulcer.

Diagnosis. A chronic nonhealing ulcer in the exposed part of the upper extremity of a traveler, immigrant, or military personnel from an endemic country (e.g., Brazil, Middle East) should arouse suspicion of a leishmanial ulcer. A nonhealing nodular ulcer is an indication to carry out a smear, culture, or biopsy. Final diagnosis is usually delayed unless the level of suspicion is high. In a series of 28 patients, the diagnosis of leishmaniasis was delayed an average of 125 days despite an average of three physicians' examinations.

Diagnosis is made by identification of the parasite from smear, fine-needle aspiration cytology, or biopsy specimen. The first smear may be positive in 80% of cases, and a second smear may be positive in an additional 10% of cases. Smears taken from the center of the ulcer have a greater sensitivity than those from its edge. Before a biopsy sample is immersed in formaldehyde, an impression smear of tissue should be made and a prolonged Giemsa stain (45 min) should be performed on the smear. PCR is the most accurate test for identification of the *Leishmania* species but is limited to specialized laboratories. The microorganism has to be cultivated from biopsy material on a special medium (i.e., Novy-MacNeal-Nicolle) and a positive culture can take a month to grow.

Treatment. Treatment minimizes scar formation and may ultimately avert formation of carcinoma. Topical therapy with paromomycin and methylbenzethonium chloride has been used successfully for the treatment of Old World leishmaniasis in a randomized, controlled, double-blind study. Intralesional injection of antimony compounds is successful in 76% of cases. Therapy was carried out using intralesional injection of 1 mL/cm^2 of meglumine antimoniate or sodium stibogluconate once a week. The average number of injections was 11.

As a preventive measure for travelers to endemic countries, the CDC recommends (1) avoidance of outdoor activities from dawn to dusk when sand flies are most active, (2) wearing long sleeve shirts and pants when out between dawn and dusk, and (3) application of repellent with diethyltoluamide (DEET) to exposed skin and edges of clothing to prevent sand flies from biting.

Parasitic Worm (Nematode) Infection

Parasitic worm (nematode) infections of the upper extremity have been reported due to three worms: two roundworms, *Gnathostoma spinigerum* and *Onchocerca volvulus*, and a tapeworm, *Taenia solium*. The T_H2 subsets of helper T lymphocytes recognize helminthic antigens and stimulate IgE antibodies. Eosinophils adhere to and attain defenses against helminths, and Eosinophilia is pathognomonic of helminthic infections.

Gnathostomiasis (Round Worm) Infection

Gnathostomiasis is a subcutaneous infection caused by a roundworm (nematode), Gnathostoma spinigerum. It is a chronic, cutaneous "migrating" larval infection. It is common in Thailand, Southeast Asia, and Japan, where people eat uncooked fish or raw pork. Daengsvang et al alluded to five cases of gnathostomiasis occurring in the fingers.[28] In the United States, a patient is likely to be an immigrant. Multiple migrating episodes of swelling and pain can occur in the hand, foot, shoulder, and face over several years as larva migrate subcutaneously. Eosinophilic count is typically high because eosinophils are specifically effective against helminthic parasites. A skin test and a serum precipitin test are useful in confirming the clinical diagnosis. Exploration, recognition, and removal of the larva that are 1 cm × 1 mm from the infected part of the hand is curative. Drug therapy is not necessary once the larvae are removed.

Onchocerciasis (Onchocercosis, Filarial, Round Worm) Infection

Onchocerciasis is a rare parasitic infection of the soft tissues caused by a roundworm (nematode), *Onchocerca volvulus*.

Onchocerciasis of the flexor tendons of finger, wrist, carpal tunnel, and forearm have been reported in North America. Eosinophilia is pathognomonic of parasitic infestations. Synovectomy is curative. Drug therapy is not necessary if all the parasites are removed with the infected tissue.

Tapeworm (Cysticercosis, *Taenia Solium*) Infection

The tapeworm (*Taenia solium*) can infect a muscle and present as a mass that can be mistaken clinically for malignant sarcoma. Tapeworm infections of the upper extremity have been reported in the triceps muscle and flexor digitorum profundus muscle. Tapeworm infection is acquired by ingestion of inadequately cooked and infected pork. The differential diagnosis of a muscle mass should include cysticercosis. The diagnosis is made by fine-needle aspiration of the cyst. Simple surgical excision cures the condition.

OCCUPATIONAL INFECTIONS

Barber's interdigital pilonidal sinus, shearer's disease, milker's interdigital granuloma, and slaughterer's interdigital granuloma are foreign-body occupational hand infections caused by penetration of human or animal hair into skin. Anthrax, *M. marinum*, tuberculous paronychia, herpetic paronychia, prosector's wart, milker's nodule, human orf, and viral warts are also infectious occupational diseases of the hand and are described in detail in the bacterial, tuberculous, and viral infection sections.

Barber's Interdigital Pilonidal Sinus

Etiology and Epidemiology

Barber's interdigital pilonidal sinus of the hand is a foreign-body hair granuloma.[89] The term *pilonidal* is derived from the Latin terms *pilos*, which means "hair," and *nidus*, which means "nest." Interdigital pilonidal sinus in barbers was first described in 1942 as a foreign-body reaction or a granuloma of the customer's hair implanted in the barber's interdigital skin. Since then, cases have been described as hair-bearing sinus, barber's interdigital pilonidal sinus, barber's disease, and interdigital sinus. Interdigital pilonidal sinus is a disease of male barbers and hairdressers only. It has never been reported in female hairdressers. It rarely affects the pulp of a finger. The condition is not a congenital cyst because hair roots are not seen in the sinus or the cyst, and the hairs are not immature, curly, or fine like those found in a congenital pilonidal cyst.

Clinical Findings and Diagnosis

Clinically, a pit or sinus develops in the interdigital web space dorsally. The sharp snipped hair ends enter the soft skin of the digital webs when barbers or hairdressers use their fingers to comb the customer's hair. Constant rubbing of the fingers against each other exacerbates the problem. Once inside the web space the hairs cause a foreign-body reaction and sinus formation. As more hairs enter the web space through the sinus, a cyst can form. In time, the sinus or the cyst becomes infected and an abscess forms that intermittently discharges purulent fluid with pieces of hair. Histologically, the lesion reproduces the features of a nonspecific inflammatory granuloma.[89]

Several loose and easily removable hairs, of different lengths, color, and texture, generally protrude from the sinus. They have sharp, pointed ends and are consistently thick, stiff, and straight, essentially the male type. This may explain why the condition occurs in men's hairdressers. Women's hair is generally soft and thin, and the ends are more likely to bend rather than penetrate. Rarely is more than one interdigital web space affected. The order of predilection is the third web space followed by the second and fourth. The first web space has been reported to be involved only once.

Treatment

Excision of the lesion and primary wound closure results in a less obvious scar than incision and drainage.

Shearer's Disease

A similar and related condition to barber's interdigital sinus occurs in the interdigital spaces of sheep shearers and is caused by wool. Small tufts of wool may protrude from the sinus. Symptoms are made worse after shearing lambs because newer, finer wool tufts enter the open sinus with ease. It can result in a recurrent subungual pilonidal sinus and can cause chronic osteomyelitis of the subjacent phalanx. The foreign-body hair granuloma is a well-recognized occupational hazard in dog groomers in the United Kingdom as well.

Milker's Interdigital Granuloma

The hairs of cattle, barbed at an angle, can penetrate skin of milker's hands and migrate slowly and deeply under the skin and cause a foreign-body reaction. Milker's interdigital granuloma is a painful, red, granulating, discharging, vegetating lesion found in the hands of milkers. It can vary from pea size to nut size, and the surface may be irregular and riddled with sinuses. The second and third interdigital spaces of the dominant hand are the usual location. Treatment is removal of all hair and control of the inflammatory process. A persistent granuloma should be excised.

Slaughterman's Interdigital Granuloma

Slaughterhouse employees can develop a pilonidal sinus in the interdigital space from hair of the animals they slaughter. The lesion persists with conservative treatment until it is completely excised.

SCABIES

The discovery of the itch mite in 1687 marked scabies as the first disease of humans with a known cause.

Etiology and Epidemiology

Scabies is not an infection but an infestation of the epidermis and dermis by a microscopic eight-legged mite, the *Sarcoptes scabiei*. Each mite is less than half a millimeter long, and under a magnifying glass mites can be seen on skin as black dots. Typically, an affected host is infested by only about 10 to 12 adult mites. After mating, the male dies. The female mite burrows into the epidermis and dermis of the skin where she lives, lays up to 3 eggs each day for her 1- to 2-month lifetime, and dies.

Development from egg to adult scabies mite takes 10 to 21 days. They are highly contagious and can be spread by close, skin-to-skin contact. Institutions (e.g., nursing homes, extended-care facilities, and prisons) are often sites of scabies

outbreaks. People who have a decreased immune system sometimes develop a more severe form of scabies known as Norwegian scabies, which refers to a particularly severe form of scabies that is also known as crusted scabies. Crusted scabies is called Norwegian scabies because the condition was first described in Norway in the mid-19th century.

Clinical Findings

Any area of the body can be affected, but the interdigital regions of hands and feet, the groin, and popliteal fossa are the more common sites. Infected individuals usually develop a pimple-like rash and intense itching. If it is the first time a person has had scabies, he or she may not develop symptoms for up to 6 weeks. During this period, those infected are contagious despite not having symptoms. Scabies can spread easily among people who have close physical contact with an infected person; the longer the skin-to-skin contact, the more likely the spread. Crusted (Norwegian) scabies is a more severe, more contagious form of infestation that occurs in people who are debilitated or have a weak immune system.

Diagnosis

Each mite is less than half a millimeter long and this makes them very difficult to spot. To the naked eye, they may look like tiny black dots on the skin. A microscope can identify mites, eggs, or fecal matter from a skin scraping.

Treatment

Treatment is needed to get rid of scabies and prevent it from spreading to others. It will not go away on its own. Treatment consists of killing the mites, symptom control, and decontamination. In the United States, permethrin cream, 5% (Elimite), is used to treat scabies by killing the mites. Treatment should be considered for all those who have had skin-to-skin contact with an infected individual. Vigorous scratching can lead to a bacterial infection requiring treatment with an antibiotic. Although the rash may not be present all over the body, patients are usually instructed to apply the cream to all areas of the body except the face. If infants are being treated, directions may include application of the cream to the scalp and head. A second application of medication may also be needed in some cases. Attention to the area under the fingernails is necessary. If the scabicide medication is used correctly, it usually kills the mites relatively quickly.

A particular danger of scabies is that these lesions often predispose to the development of secondary infections, as with *Staphylococcus* bacteria. Like typical scabies, Norwegian scabies is treated with topical permethrin cream and the oral medication ivermectin (Stromectol). Treatment of crusted scabies can require oral medications along with multiple applications of scabicide cream. After effective treatment, no new rashes will develop. Although the mites are killed, itching can still persist for a few weeks.

Prevention

Home care involves cleaning and removing the mites from areas of the home that the infected person may have come into contact with. This helps prevent reinfection and spreading of the infection to others. Clothes, bedding, and towels need to be washed in hot water to kill mites. The infected person should avoid skin-to-skin contact with others until after treatment. With the correct use of medication and proper home care, scabies can be effectively treated and spread of the condition prevented.

VIRAL INFECTIONS

Chronic viral infections of the hand include AIDS, human orf, milker's nodules, and warts. AIDS is associated with infections and tumors of the hand secondary to suppressed immunity. Orf is self-limiting in immunocompetent subjects but in an immunodeficient patient attains "giant" size and can be misdiagnosed and mistreated as a malignancy. Warts are often seen by hand surgeons and most are managed conservatively. Larger warts, those that do not respond to conservative treatment, and periungual and subungual warts may need surgical excision. I consider surgery on patients who wish immediate eradication of warts and do not want prolonged conservative treatment.

Acquired Immunodeficiency Syndrome

Etiology and Epidemiology

Although two serotypes of human immunodeficiency virus (HIV) are currently recognized, namely HIV-1 and HIV-2, the term *HIV* is generally used to designate HIV-1, which is the major virus. Less than 100 cases of HIV-2 infections are reported in the United States. AIDS syndrome is defined by the development of serious opportunistic infections, neoplasms, or other life-threatening manifestations that result from progressive HIV-induced immunosuppression. AIDS has affected approximately 60 million people globally. In 2010, approximately 1.1 million over the age of 13 were living with AIDS in the United States alone. To learn more about the etiology and epidemiology and classification and clinical diagnosis, please visit Expert-Consult.com.

Clinical Manifestations of AIDS Infection in the Hands

Ching and coworkers,[21] Gonzalez and coworkers,[42] McAuliffe et al,[79] and Seltzer and associates[104] described hand infections in patients with HIV disease in the late 1990s. Approximately 10% of the patients who presented with hand infections in metropolitan hospital emergency departments had HIV infection. Of the intravenous drug users who presented with hand and upper extremity infections, 80% had HIV infection. Glickel suggests that diagnosis of AIDS should be considered when there is an unusual hand infection.[41] It should be taken into consideration for any patient who needs a repeat drainage or debridement procedure. Fingers of those with AIDS may be red with painless erythema and periungual telangiectasia. Nails may be blue or show clubbing. Ching and colleagues noted that among 14 AIDS patients with hand infections, almost one-third needed multiple debridements and resulted in amputation of a finger or hand.[21]

McAuliffe et al,[79] in a review of 74 HIV-seropositive patients who were treated for upper extremity infections, found that intravenous drug use was the most common risk factor for HIV infection as well as the most common cause of the infection necessitating admission. These 74 patients were admitted a total of 97 times for treatment of 89 different infections and underwent 120 surgical procedures. Twenty-six (29%) infections required more than 1 operation, and 11 (12%) resulted in

Since the beginning of the epidemic, more than 60 million people have been infected with HIV and nearly 30 million people have died of HIV-related causes. Globally, in 2011, approximately 34 million people were living with HIV/AIDS, a total of 2.7 million more people acquired HIV infection, and approximately 1.8 million people died of AIDS. Sub-Saharan Africa remains by far the most affected region; approximately 70% of HIV-positive individuals in the world live here, but the area contains only 10% of the global population. One-third of those currently living with HIV/AIDS in the world are between the ages of 15 and 24 and 7% are children below the age of 15. Women account for more than half of new HIV infections in adults worldwide. Sexual behavior is the most important determinant of HIV spread. Factors that can increase the risk of HIV transmission through sex are oral ulcers, bleeding gums, genital sores, and the presence of other sexually transmitted diseases.

In the United States at the beginning of 2010, an estimated 1.1 million individuals aged 13 and older were living with HIV infection; this included ≈200,000 (18%) whose infections had not been diagnosed but were contagious. There were an estimated 47,500 newly acquired HIV infections. Of these, approximately 22,000 (46%) were in blacks, 14,000 in whites, 10,000 in Hispanics, and 800 in Asians. The largest majority of the cases (≈29,000, 60%) were from male-to-male sexual contact and ≈4000 (8%) in drug users. Five states—California, Florida, New York, New Jersey, and Texas—have reported about half of all US AIDS cases. AIDS deaths have declined from 1998 due to increasing use of simultaneously administered (i.e., combination of more than one) highly active antiretroviral therapy (HAART). Statistics on HIV/AIDS are constantly updated at www.cdc.gov/hiv/topics/surveillance/basic.htm and www.cdc.gov/hiv/.

Classification and Clinical Diagnosis

The current CDC classification for HIV infection is based on clinical conditions associated with HIV infection (eTable 3.1) and CD4$^+$ T lymphocyte counts (eTable 3.2). Thus, there are three clinical grades based on three ranges of CD4$^+$ cell counts (see eTable 3.2.). This combination grades HIV infection into nine mutually exclusive categories as shown in the table. Current clinical staging approaches favor use of CD4$^+$ lymphocyte counts and plasma viral load assays.

After initial infection, the human immunodeficiency virus enters various types of cells in the body, including CD4$^+$ lymphocytes, dendritic cells, mononuclear phagocytes, and others. Once in intracellular locations, the virus is safe from antibody neutralization. The symptoms of AIDS do not usually occur until the blood count of CD4$^+$ T cells is below 200/mm^3. The patients in all categories whose CD4 cell count is <200/mm^3 are now considered as having AIDS. Most patients with truly opportunistic infections have CD4 counts <100/mm^3. Those with CD4 counts <50/mm^3 are at high risk of death from serious life-threatening opportunistic infections.

There are three clinical categories of HIV infection relevant to hands and upper extremities.

- Category A—Asymptomatic HIV infection, persistent generalized lymphadenopathy, acute (primary) HIV infection with accompanying flu-like syndrome (acute retroviral syndrome).
- Category B—Bacillary angiomatosis, herpes zoster with at least two episodes or in more than one dermatome.
- Category C—The deficiencies in T-cell mediated immunity in patients with AIDS leads to impaired immunity to viruses, fungi, and Protozoa, which otherwise are easily controlled by a normal immune system.

Many of the malignancies that are frequent in patients with AIDS are associated with oncogenic viruses. Kaposi sarcoma is associated with the human herpes virus 8 infection. Many of the lymphomas that occur in patients with AIDS are associated with the Epstein-Barr virus. Lots of the skin and cervical carcinomas that occur in patients are associated with the human papillomavirus. Bacterial infections, multiple or recurrent, coccidioidomycosis, cryptococcosis, herpes simplex virus infection for longer than 1 month, histoplasmosis, Kaposi sarcoma, *Mycobacterium tuberculosis*, nontuberculous mycobacteria, and

eTABLE 3.1 AIDS Indicator Conditions Relevant to Hand Surgery

Clinical Grade	Clinical Findings
A	Asymptomatic, PGL, acute retroviral syndrome
B	Bacillary angiomatosis, herpes zoster
C	Bacterial infections, multiple or recurrent Coccidioidomycosis, extrapulmonary Cryptococcosis, extrapulmonary Herpes simplex Histoplasmosis, extrapulmonary Kaposi sarcoma *Mycobacterium avium-intracellulare* complex or *Mycobacterium kansasii*, extrapulmonary *Mycobacterium tuberculosis*, any site (pulmonary or extrapulmonary) *Mycobacterium*, other species or unidentified species, extrapulmonary Wasting syndrome of HIV infection

PGL, Persistent generalized lymphadenopathy.

eTABLE 3.2 Grading for AIDS Based on Clinical Conditions and CD4$^+$ Lymphocyte Count

	CLINICAL CATEGORIES		
CD4$^+$ T-Cell Count	A—Asymptomatic or Acute (Primary) HIV or PGL	B—Symptomatic, Not A or C Conditions	C—AIDS Indicator Conditions[a]
500/μL	A1	B1	C1
200-499/μL	A2	B2	C2
<200/μL	A3	B3	C3

[a]Clinical conditions in category C listed in Table 3.1.
PGL, Persistent generalized lymphadenopathy.
(This is the 1993 Revised Classification System for HIV Infection With Expanded AIDS Surveillance Case Definition for Adolescents and Adults.)

wasting syndrome of HIV infection are indicator conditions of infections relevant to hand surgery.

Cellular Immune Responses. CD4 T cell dysfunction, both quantitative and qualitative, is the hallmark of HIV disease. Abnormalities in all limbs of the immune system, including T and B lymphocytes, natural killer cells, and neutrophils invariably occur. In the advanced stage of disease there is almost total dissolution of the lymphoid tissue architecture. The opportunistic infection observed with advanced disease is primarily because of a decrease in CD4 T cells. Most patients with truly opportunistic infections have CD4 counts $<100/mm^3$.

Among the conditions included in the 1993 AIDS Surveillance Case Definition by the CDC, those of particular importance to hands and upper extremity disease are listed earlier in eTable 3.1. Nine clinical stages of the disease based on clinical findings and $CD4^+$ T-lymphocyte count are shown in eTable 3.2.

Clinical Features. The spectrum of HIV infection ranges from (1) initial asymptomatic stage (incubation period); to (2) acute symptoms of primary infection (acute retroviral syndrome); to (3) chronic persistent lymphadenopathy with prolonged clinical latency up to 10 years (category A); to (4) severe immunodeficiency associated serial secondary infections, neoplasms, and severe wasting with loss of more than 10% of body weight (categories B and C). It is during this time that conditions described in the following subsections are encountered.

amputation. Patients with AIDS were significantly more likely to present with spontaneous infection than were those who were HIV seropositive. The infections may be seen early in the course of the disease, and in one-half of the patients, they preceded the diagnosis of AIDS. Gonzalez et al, in a study of 28 patients, found 5 who had necrotizing fasciitis; all needed more than one debridement, and one required forequarter amputation.[42]

Herpes Simplex Virus. Herpes simplex virus type 2 (HSV-2) infection of the hand is clinically diagnosed when characteristic multiple vesicular lesions on an erythematous base are present. It generally resolves within 3 weeks in non-HIV infected patients. Although HSV-2 can recur in nonimmunosuppressed hosts, it recurs more frequently and for prolonged periods in patients with HIV infection. When it lasts longer than 3 weeks, a level of suspicion for immunosuppression or AIDS should be raised. In an occult or overt HIV infection, herpes simplex may present as a chronic granulating hand infection that does not respond to routine antibiotics and may progress to finger necrosis or gangrene. Staining of scrapings from the base of the lesions with Wright, Giemsa (Tzanck preparation), or Papanicolaou stain demonstrates characteristic giant cells or intranuclear inclusions of HSV infection. These cytological techniques are often useful as quick procedures to confirm the diagnosis.

Direct immunofluorescent antibody and indirect immunoperoxidase staining are equally sensitive and specific for the detection of HSV antigen. In the eyes of most virologists, viral cultures remain the gold standard by which other methods of diagnosis of HSV are judged. For treatment of cutaneous HSV infections, acyclovir and its related compounds, famciclovir and valacyclovir, have been the mainstay of therapy. Treatment with intravenous acyclovir is followed by oral acyclovir (200 mg q 4-5 h) to prevent recurrences. Famciclovir and valacyclovir have more convenient dosing schedules (three times daily) compared with acyclovir (five times daily). Necrotic and gangrenous parts of the hand are excised. Acyclovir-resistant strains of HSV are being identified with increasing frequency in HIV-infected individuals.

Isolation of HSV from persisting lesions despite adequate dosages of acyclovir should raise the suspicion of acyclovir resistance. Therapy with the intravenous foscarnet (Foscavir) and topical cidofovir gel (Forvade), trifluorothymidine ointment, and vidarabine speeds healing of acyclovir-resistant herpes. Herpetic infections of the pulp in AIDS patients should not be mistaken for felons or paronychia and should not be violated with incision and drainage. If inappropriately treated with surgery, local secondary bacterial bone lysis or metastatic viral encephalitis can occur.

Bacillary Angiomatosis. Bacillary angiomatosis was first described in 1983 in AIDS patients and is an infectious, cutaneous, vascular, tumor-like disorder found almost exclusively in HIV-positive individuals. The lesion may be a pea-sized nodule with or without plaques when first noticed (Figure 3.34). It may be nonpedunculated or pedunculated, and the lesions can occur anywhere on the body and have solitary (Figure 3.34) or multiple nodules. When punctured by a needle or scalpel, the lesion may bleed profusely. It may resemble a benign pyogenic granuloma or present as an ulcer (Figure 3.35).



FIGURE 3.34 Early lesions of bacillary angiomatosis in an AIDS patient may be nodular.



FIGURE 3.35 Bacillary angiomatosis can present as a large ulcer with necrotic areas in an AIDS patient.

Histologically, it is characterized by vascular perforation, hemorrhage, and necrosis of skin. The disease is caused by the bacteria species *Bartonella henselae* and *Bartonella quintana* and is transmitted by cats, ticks, fleas, and lice. The diagnosis of bacillary angiomatosis is best made by fine-needle aspiration biopsy. Warthin-Starry stains show perivascular accumulations of bacilli; these findings may be confirmed by electron microscopy, although this is not usually necessary. The diagnosis can also be established by culture of the organism in several special media or by detection of *Bartonella* DNA by polymerase chain reaction. Serologic assays for anti-*Bartonella* antibodies are available through the special pathogens branch of the CDC.

If left untreated, bacillary angiomatosis follows a progressive and potentially fatal course. Once it is properly identified, treat-

ment consists of prolonged therapy with erythromycin or doxycycline, which prevents recurrence of bacillary angiomatosis. Fluoroquinolones, other macrolides, and trimethoprim-sulfamethoxazole also have activity against *Bartonella*.

Kaposi Sarcoma. Kaposi sarcoma (KS) is a vascular disorder that in the United States is seen predominantly in HIV-infected men. Human herpes virus type 8 is transmitted sexually. It may present as a solitary nodule or multiple nodules or as plaques. Lesions of KS are often difficult to distinguish from those of bacillary angiomatosis; biopsy is required for diagnosis.

KS may occur in the hand[60] and may need punch or open biopsy or excision for histologic confirmation. The skin is the most common first site of presentation. The lesions are generally painless and nonpruritic and appear as firm, slightly raised nodular tumors. In light-skinned individuals, the lesions are typically violaceous in color. In dark-skinned individuals, the lesions appear more brownish or black. More information about Kaposi sarcoma can be found online at ExpertConsult.com.

Treatment. The natural history of AIDS-related KS is variable and difficult to predict. Kaposi sarcoma does not commonly cause death of patients with HIV infection. Despite the relative lack of mortality associated with KS, morbidity associated with a more advanced disease is considerable. KS is staged as (1) cutaneous, locally indolent; (2) cutaneous, locally aggressive with or without regional lymph node enlargement; (3) generalized mucocutaneous with or without regional lymph node enlargement; and (4) visceral. The patient with limited disease and controlled HIV infection does reasonably well. In the setting of uncontrolled HIV viral replication, KS progresses rapidly. It is a systemic disease and mandates a systemic approach with MDT (highly active antiretroviral therapy).

Vascular lesions other than KS occur as serious complications of the hand in HIV infection. Symptoms of Raynaud phenomenon develop in HIV-infected patients when treated with bleomycin and vincristine. Digital gangrene can occur from vasculitis, obliteration of digital arteries, and vascular injury resulting from chemotherapy. HIV-induced thrombocytopenia may cause compartment syndrome of the forearm.

Treatment of AIDS

Currently most patients on their initial antiretroviral regimen take a combination of two nucleoside reverse transcriptase inhibitors with either a protease inhibitor or a nonnucleoside reverse transcriptase inhibitor. Before the availability of these drugs, the median survival after the diagnosis of AIDS was 12 to 18 months. Now antiretroviral treatment leads to a near-normal life expectancy.

Warts

A wart is a cauliflower-like, raised, demarcated, grayish mass with an irregular surface traversed by many projections. It was a century ago that warts were first provoked in the skin of volunteers by injection of appropriately filtered wart tissue, suggesting that it is a viral infection. Half a century ago the causal virus was demonstrated under an electron microscope and was subsequently included under the group of human papillomaviruses (HPVs).

Classification

Two types of cutaneous warts are widespread in hands. Common verrucated warts, *Verruca vulgaris* (*L. verruca*, "a little hill"), represent 95% of cutaneous hand warts. The second most common warts are flat or plane (verruca plana) (5%). Both types are seen predominantly in children but also affect adolescents and young adults. Adults at high risk for the development of warts are veterinary surgeons, butchers, meat packers, fowl handlers, poultry processors, and fish handlers—all occupations in which hands are frequently exposed to moisture.

Pathogenesis of Human Papillomavirus

The incubation period of HPV disease is 1 to 3 months. The virus infects only the epidermis. Warts have a characteristic histologic appearance, showing acanthosis, papillomatosis, hyperkeratosis, and parakeratosis.

Diagnosis

Common Verrucated Wart. The clinical appearance of a common verrucated wart is quite characteristic and usually consists of a single lesion on the hand, fingers, or around the nail. It is a cauliflower-like, raised, demarcated, and grayish mass, with an irregular surface traversed by many projections (Figure 3.36, *A*). It is often painless, and the adjacent skin is healthy. Warts in the palm may be painful because of pressure during grip. If untreated, the common wart can multiply and infect the surrounding skin or the opposite hand. When multiple, there may be several dozen "seed lesions" surrounding a larger and older "mother wart." A cluster of closely spaced papules can coalesce into a large "mosaic wart." "Kissing warts" are seen in areas of skin contact (web spaces) and may represent direct inoculation. Filiform warts are slender, finger-like papules. Periungual warts can extend into the nail bed under the nail plate (subungual warts) and can persist for many years in spite of conservative treatment.

Flat (Plane) Warts. Flat (plane) warts are minimally elevated papules that are 2 to 5 mm in diameter. They appear as multiple lesions with a smooth surface. They have an enhanced likelihood of spontaneous involution. Flat warts in adults are more common in women.

Multiple Warts. Common warts rarely if ever transform into squamous cell carcinoma. Immunosuppressed patients with an inherited defect, such as epidermodysplasia verruciformis, acquired defects in immunity (renal transplant recipients), lymphoproliferative disorders, or those on chemotherapeutic drugs may develop multiple warts. These warts can transform into squamous cell carcinoma. Biopsy is indicated when the diagnosis is doubtful.

Treatment

No antiviral chemotherapy is available for HPV warts. They are a cosmetic nuisance in most cases and often disappear spontaneously; this seems to occur in 50% of children within a year and 90% within 5 years. Fluctuations in immunity to human papillomavirus may be responsible for spontaneous regression or resurgence of preexisting warts. If left untreated, however, some may persist for many years and become larger. A periungual wart can lead to bone destruction of distal phalanx. Rarely does a wart transform into a carcinoma.

Moritz Kaposi first described the entity Kaposi sarcoma (KS) in 1872. KS is a skin tumor caused by a sexually transmitted virus. Chang and coworkers discovered human herpes virus type 8 in KS lesions. It has been identified in all types of Kaposi sarcomas including classic KS, African or endemic KS, transplant-associated KS, and AIDS-related KS. The virus is found in peripheral blood mononuclear cells in patients with KS, and this frequently precedes the development of it in AIDS patients. KS appears in the advanced stages of AIDS.

In the early 1980s, cases of KS in young, homosexual men helped alert the medical community to the AIDS epidemic. In New York City, KS was the initial AIDS diagnosis in 50% of homosexual men diagnosed between 1981 and 1983. Precipitous decline of KS has occurred since 1995 due to more widespread use of HAART. The number of new KS cases decreased from 25/1000 patient-years in the early 1990s to 7.5/1000 patient-years in 1996 to 1997.

The histopathology of KS is characterized by proliferation of abnormal vascular structures. Three histologic variants have been reported: spindle cell, anaplastic, and mixed cell. The mixed-cell variant is the most common of the three seen in AIDS patients. Three features characterize this variant:

1. Proliferation within the tumor of vascular structures often lined by abnormally large, malignant-appearing endothelial cells
2. Proliferation of surrounding spindle cells
3. Extravasation of erythrocytes

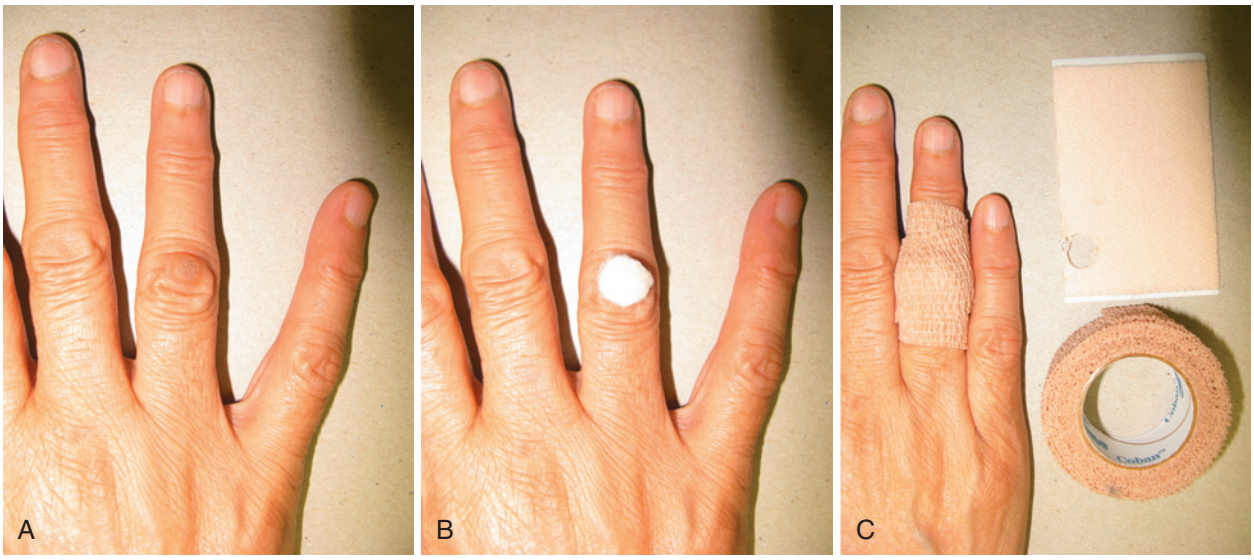

FIGURE 3.36 **A,** Typical wart in the hand of a woman who frequently immerses her hands in water. **B,** A piece of medicated adhesive tape (Mediplast) slightly larger than the diameter of the wart is applied over the lesion. **C,** The tape is secured in place with waterproof tape (Coban).

Conservative treatment remains the hallmark for management of common warts. When they do not respond to conservative treatment or are too large and cosmetically unacceptable, surgical excision is a good option that cures the problem. Multiplicity of treatments for warts attests to the lack of any single satisfactory therapy method. Cooperation and preference of the patient or parent and experience of the physician determine the appropriate treatment modality.

Most therapeutic modalities consist of chemical or physical destruction of warts. Surgical excision of large isolated lesions can be successful. In contrast, warts in immunosuppressed adults are likely to be progressive, recalcitrant, recurrent, and unresponsive to all but the most aggressive therapy and are more likely to become malignant. Infectious disease and dermatology specialists should be consulted for treatment recommendations. Patients with verrucated warts usually seek treatment for cosmetic reasons. Patients with flat warts usually do not seek treatment.

Keratolytic Therapy. Keratolytic therapy is simple, inexpensive, painless, and preferred because it is as effective as cryotherapy, with a success rate of approximately 70% and a minimal recurrence rate of 4%. Treatment is just as successful as more invasive methods. Less aggressive therapy for common warts in childhood is preferred because of the increased likelihood of spontaneous resolution[77] and lack of tolerance to painful ablative treatments. Salicylic acid is the most commonly used ingredient in the chemical destruction of the lesion and the virus it harbors. Local applications of keratolytic agents result in chemical debridement of the infected epidermal cells. The most used method is a self-applied paint of salicylic acid with lactic acid in collodion (1:1:4). A drop of the solution (e.g., Duofilm, Occlusal, Paplex) is placed over the wart and left in place for a few minutes. The area is then soaked in warm water, and white sloughing keratin is mechanically debrided gently with a cloth. This is repeated daily; it takes a few days to a few weeks to "melt" a wart.

A cure rate of 70% within 12 weeks was reported in a randomized trial by Bunney,[17] and the treatment was as effective as cryotherapy. Compliance is a major limitation. A high-potency 26% salicylic acid can reduce the treatment period to 2 weeks. Forty percent salicylic acid is available as a thin layer applied on a tape (Mediplast) and is an excellent alternative in my experience. A small piece of the tape, which is a little larger than the wart, is cut, then the protective plastic that covers the salicylic acid on the tape is peeled off. The tape firmly adheres to the wart (Figure 3.36, *B*) and is left in place for a day or two. On a finger, it may be reinforced with waterproof 3M tape (Figure 3.36, *C*). When taking a shower, it is removed, sloughed epidermis is scrubbed off, and a new tape is applied over dry skin. Slow tissue necrosis removes the infected epidermis over a few days to few weeks. Irritation of normal skin surrounding the wart rarely occurs. This treatment is painless, convenient, and safe. Patient compliance is good, and self-treatment is inexpensive.

Periungual warts are difficult to treat when they extend under the nail plate and are inaccessible to salicylic acid treatment. Application of plain adhesive tape to the entire finger distal to the proximal interphalangeal joint is another option. The patient is instructed to remove the tape in 6.5 days, scrub off the necrotic skin, and reapply the tape after 12 h. The process is repeated for 6 to 9 weeks. Additional fingers with warts can be taped similarly.

Cryotherapy. Liquid nitrogen or carbon dioxide without local anesthesia has been used for the management of warts. Burning pain associated with cryotherapy is well tolerated by adults but not children. Children's adverse reactions have included premature closure of the distal phalangeal physis, angular deviation of the distal interphalangeal joint, and destruction of the proximal interphalangeal joint.

Intralesional Injection of Bleomycin. Intralesional injection of bleomycin (0.1-0.2 mL of 1 unit/mL) has been used in the treatment of recalcitrant warts and found to be successful in 88% of

patients.[3] The Raynaud phenomenon is reported in digits injected with bleomycin.

Electrosurgery. Electrosurgery includes electrocautery, electrocoagulation, electrodesiccation, and laser ablation. Ablation of the wart can be done with a diathermy knife under local anesthesia or under general anesthesia for multiple lesions. There is risk of recurrence of warts in and around the site of treatment. Concerns about laser therapy include risk to the operator and paramedics from the dispersion of virus in the plume of vapor generated by the laser.

Surgical Excision. A wart can be curetted out with a small curette. No controlled studies have been published, but gratifying results have been reported. To prevent recurrence, it is safe to apply a tape with a keratolytic agent (e.g., Mediplast) to debride the curetted margins of the wart. Simple surgical excision has not been prospectively studied. I have had success with it and have not encountered recurrences after removal of more than 30 warts in 5 years. It is important to excise the wart through a wide margin, generally at least 1 mm, to prevent recurrence. If the excision is incomplete, recurrence in the suture tracts can occur. Periungual warts creeping under the nail plate infect the nail bed (subungual warts); they respond poorly to keratolytic therapy, cryotherapy, and electrosurgery due to inaccessibility and often require removal of nail plate and surgical excision.

Prognosis. Prognosis in general depends in part on the age and immunity of the patient, as well as on the type, location, number, and chronicity of warts. Warts in children respond to treatment more readily than in adults. Immunodeficiency inhibits the response to treatment. Mosaic and plane warts are more resistant to treatment. Single warts disappear more rapidly than multiple warts, and chronic warts tend to be more recalcitrant to treatment. Warts should not be considered cured until at least a 6-month period has elapsed.

❖ AUTHOR'S PREFERRED METHOD OF TREATMENT

I use 40% acetylsalicylic acid keratolytic therapy with Mediplast as my first choice of treatment. It is acceptable to patients, is simple to execute, and is effective for a large percentage of patients. When a patient does not want to undertake prolonged treatment and the wart is large, I surgically excise it with a 1- to 2-mm margin. In cases of periungual and subungual warts, I remove the nail plate and excise the superficial surface of the infected nail bed.

Human Orf (Farm Yard Pox, Milker's Nodule, Ecthyma Contagiosum, Contagious Pustular Dermatitis)

Human orf infection is important to a hand surgeon because it causes a large tumor-like lesion in immunodeficient hosts that resolves with simple topical cidofovir application. Misdiagnosis has led to unnecessary excisions, multiple excisions, and even amputation.[102] Four cases of human orf were reported in the United States between 2009 and 2011 from household exposure to lamb and goat slaughter.

The word "orf" is an old Anglo-Saxon name for cattle, and the disease is endemic in sheep and goats. Orf is caused by a large paravaccinia DNA virus that belongs in the subgroup of pox viruses. It is common in humans who have direct contact with infected sheep and goats or with products or objects that come in contact with sheep and goats. The virus can persist for long periods on such objects as fences, barn doors, and feeding troughs from which the disease is indirectly transmitted to a susceptible host. In one year, 1.4% of 16,484 sheep and goat handlers in New Zealand were infected.[99] The risk was highest (4%) with mutton slaughterers. It occurs on the exposed parts of the body, especially the hands. Human orf is an occupational disease in "risk populations" such as shepherds, sheep shearers, butchers, and veterinary surgeons.

There is a yearly outbreak of orf infection of the hand in Saudi Arabia. Two million people visit there for "Hajj" every year, and hundreds of thousands of sheep are slaughtered by nongloved hands at the end of the ceremony. Inoculation occurs in preexisting or incidental new injuries of the hand from the infected animals. Outbreaks in Turkey and Belgium occur 2 to 3 weeks after the Islamic "Feast of Sacrifice" (Aid el-Kebir or Eid el-Adha) in men who bleed the sheep and in women who handle their skin and meat. The epidemic is predictable 9 weeks after the end of Ramadan every year and 75% of patients are Islamic.

Clinical Findings

Ninety-five percent of the lesions are on the finger (Figure 3.37, *A,B*), hand, wrist, or forearm—the area of contact with infected animals. The lesion is usually unilateral, rarely bilateral. The lesions may be single (Figure 3.37, *A*) or multiple (Figure 3.37, *B*). It may occur as paronychia and is distinguished from bacterial paronychia by the presence of a nodule with central red discoloration, a middle bluish-white ring, and peripheral erythematous or violaceous halo (Figure 3.37, *A*). There is a history of exposure to sheep or goats, a goat/sheep bite, or handling of goat/sheep for "sacrifice." After an incubation period of 3 to 7 days, the infected skin lesion erupts clinically. In humans, orf is commonly known as ecthyma contagiosum or contagious purulent dermatitis (CPD), but this is in part a misnomer because pustules are not purulent (ecthyma = purulent pustules) in human orf.

Leavell described the lesion in six clinical stages in a study of 19 cases of human orf.[70] Each stage lasts approximately a week, and the disease resolves without treatment in approximately 6 weeks (range, 14-72 days). The first stage is characterized by an erythematous macule or papule. In the second (target stage) the lesion turns into a nodule. The lesion may be bullous at this stage (Figure 3.37, *B*). The third, or the weeping, stage is characterized by a weeping surface on a nodule. The fourth stage consists of a thin yellow crust with underlying black dots over the nodule. The fifth (papillomatous stage) consists of small surface papillomas and finger-like projections of the epidermis. The sixth and final stage is characterized by reduction in the size of the lesion and formation of a thick crust that looks like an ulcer before final healing. Lesions do not always correspond to these stages and may present as an erythematous nodule, a tense bullous lesion, a giant lesion, or a felon. In a felon there is an absence of local pain and drops of clear fluid may exude from the lesion.

Diagnosis

The diagnosis is based on clinical features and contact with goats or sheep. Orf may be confirmed by electron microscopy



FIGURE 3.37 Orf can infect one or two fingers simultaneously. **A,** The lesion has an umbilicated red center, a white middle, and a peripheral violaceous halo. **B,** The lesion may be bulbous and affect multiple fingers. (**A,** From Karabay O, Goksugur N: Red-blue, umbilicated nodules on the fingers. *Am Fam Physician* 76:119–120, 2007, with permission. **B,** From http://quizlet.com/8107530/viruses-flash-cards/.)

of negatively stained suspensions from lesions, which is the most rapid laboratory method available. Provisional diagnosis can be made in an hour compared with several weeks when tissue culture techniques are used. The virus survives without preservatives in crusts, vesicular fluid, or biopsy of suspected lesions for as long as 30 days and can be safely saved and mailed to a distant electron microscopic facility for identification. A scab from the surface of the lesion is usually sufficient to establish the diagnosis because these contain large amounts of orf virus and characteristic large multiple oval viral particles can be seen within the keratinocytes under an electron microscope. In most cases, however, the clinical appearance of the lesion on a finger, hand, wrist, or forearm and a history of contact with sheep or goats are sufficient to make a diagnosis of human orf.

In an immunocompromised patient, the lesion may attain a large size. Immunosuppressed patients with chronic lymphatic leukemia, patients on immunosuppressive medication for a lymphoma, and renal and heart-lung transplant patients have been reported with "giant" orf lesions on their fingers or palms. The lesion may recur several times after thorough excision, and skin grafting may be necessary. It may assume giant proportions in atopic dermatitis. Giant orf in a normal individual is rare, and immunologic workup is in order when one is encountered. A giant orf on dorsum of proximal interphalangeal can weaken the extensor mechanism and cause swan neck deformity. It has been erroneously stated that infection with the orf virus confers lifelong immunity. Many cases of reinfection in immunocompetent patients have been reported. Person-to-person transmission is rare.

Differential Diagnosis

Orf and milker's nodule are essentially identical on clinical, histologic, and virologic examination. Orf is diagnosed if the patient has been in contact with sheep or goats, whereas milker's nodule is suspected if the patient has been manually milking cows or buffaloes. Frequently the patient can remember seeing a scabby mouth lesion on a sheep or a crusting pseudocowpox lesion on an udder. In the absence of such history, diagnosis of "farmyard pox" or "parapox infection" affords the clinician a diagnosis based on common clinical and electron microscopic findings. Arnaud et al have wisely warned that orf infection of pulp that is superinfected must be differentiated from a felon. Presence of drops of clear liquid from the lesion and absence of local pain contribute to a correct diagnosis of orf.

Treatment

An orf lesion is self-limiting in 6 weeks and does not require antiviral treatment in immunocompetent patients. If an orf nodule does not undergo spontaneous healing in 6 weeks, the nodule continues to rapidly evolve into an ulcer or a pyogenic granuloma-like lesion, assumes tumoral proportion, or recurs after multiple and radical excisions and skin grafts, immunocompromise should be suspected and investigated. If the patient is immunosuppressed due to organ transplantation (kidney or heart–lung) or has hematogenous malignancy (e.g., lymphoma, lymphocytic leukemia), treatment should include local antiviral therapy (e.g., cidofovir cream, imiquimod cream, idoxuridine 40% cream) and a reduction in immunosuppression or cytotoxic chemotherapy to control the infection.[119] Otherwise, the lesion may grow and become more resistant to treatment.

Multiple surgical excisions and even an amputation[102] have been described when (1) correct diagnosis is not made, (2) correct antiviral treatment is not initiated, and/or (3) immunosuppression has not been reduced in an immunocompromised patient. With correct diagnosis and treatment, the nodular lesion in an immunocompetent patient or even the giant lesion in an immunodeficient patient resolves in 6 weeks without further recurrence.

Milker's Nodule (Paravaccinia Virus, Pseudocowpox)

Paravaccinia virus that infects sheep and goats also infects cows. In humans, nodules on the hand caused by this virus are called

milker's nodules because milkers acquire hand infections from the cow's infected udder through direct contact or indirectly through contaminated objects. Milker's nodule is usually regarded as an occupational disease of dairy farm workers.

The initial lesion is on the exposed part of the hand and upper extremity in more than 50% of cases. The incidence of milker's nodule has fallen since the majority of cows are now milked by machine. It has been reported in a healthy young cattle veterinarian. The bovine virus is morphologically indistinguishable from the ovine orf virus. When the animal source is unknown, it is not possible to clinically differentiate between ovine (sheep and goat) and bovine (cow) nodular lesions on the exposed hand and upper extremity and under the electron microscope. Diagnosis of the disease is based for the most part on knowledge of the animal source. Rarely, the lesion of pseudocowpox presents as a black necrotic ulcer clinically indistinguishable from anthrax. Large eosinophilic intracytoplasmic inclusions within epidermal cells and DNA sequencing to match paravaccinia can quickly distinguish the two when anthrax has to be ruled out promptly.

Treatment

Milker's nodule is easily recognized by those working with cows. The understanding that the disease spontaneously resolves in 6 weeks inclines many workers not to seek medical attention. When a physician who is unaware of such a lesion encounters one, misdiagnosis and unnecessary treatment may occur.

CONCLUSION

In the coming years, physicians will continue to see four types of chronic infections of the hand.

- There will be infections of known organisms that have not yet caused chronic infections of the hand. As an example, atypical mycobacterial hand infections were not recognized until the 1960s. These are, however, easy to diagnose as long as biopsy, staining, serology, cultures, and sequencing methods are routinely used for diagnosis.
- More elusive infections may be those that arise from organisms that have not been previously suspected. Herpes virus was not recognized as a cause of Kaposi sarcoma until 1986 because detection and quantitation of specific DNA and RNA base sequences in clinical specimens had not yet became available.
- Physicians will see chronic infections that are caused by newly recognized organisms. Fungal infections are on the rise and recently identified fungal infections are reported more frequently. Many of these fungal infections respond inadequately to currently available antifungal antibiotics.
- Finally, chronic infections will continue to increase as worldwide travel and immigration brings older and exotic organisms into the United States.[37] Cases of leishmaniasis trickle into Texas from Mexico and into all parts of the United States from those who vacation in Costa Rica.

Awareness of the characteristics of chronic hand infections, and vigilant use of biopsy and culture techniques, should be able to reveal and control such infections in the upper extremity.

For Case Studies, Videos, and more, please visit ExpertConsult.com.

REFERENCES

1. Al-Qattan MM: Opportunistic mycotic infections of the upper limb. A review. *J Hand Surg* 21B:148, 1996.
2. Al-Qattan MM, al Mazrou AM: Mucormycosis of the upper limb. *J Hand Surg [Br]* 21:261, 1996.
3. Al-Qattan MM, Bowen V, Manktelow RT: Tuberculosis of the hand. *J Hand Surg [Br]* 19:234, 1994.
4. Allegue F, de Lis MP, Perez-Alvarez R: Primary cutaneous cryptococcosis presenting as a whitlow. *Acta Derm Venereol* 87:443, 2007.
5. Alloway JA, Evangelisti SM, Sartin JS: *Mycobacterium marinum* arthritis. *Semin Arthritis Rheum* 24:382, 1995.
6. Altman DT, Lubahn JD, Kuhn PJ: A case report and review of mycetoma of the hand: a diagnostic and therapeutic challenge. *J Hand Surg* 19A:998, 1994.
7. Antia NH, Enna CD, Daver BM: *The surgical management of deformities in leprosy*, Bombay, 1992, Oxford University Press.
8. Antia NH, Shetty VP: *The peripheral nerve in leprosy and other neuropathies*, New Delhi, 1997, Oxford University Press.
9. Becton J, Neibauer J: Nocardia infection of the hand. *J Bone Joint Surg* 52A:1443, 1970.
10. Bednar MS, Lane LB: Eponychial marsupialization and nail removal for surgical treatment of chronic paronychia. *J Hand Surg* 16A:314, 1991.
11. Benkeddache Y, Gettesman H: Skeletal tuberculosis of the wrist and hand: a study of 27 cases. *J Hand Surg* 7:593, 1982.
12. Bennett ML, Jackson JM, Jorizzo JL, et al: Pyoderma gangrenosum. A comparison of typical and atypical forms with an emphasis on time to remission. Case review of 86 patients from 2 institutions. *Medicine (Baltimore)* 79:37, 2000.
13. Brand PW, Fritschi E: Rehabilitation in leprosy. In Hastings R, editor: *Leprosy*, New York, 1985, Churchill Livingstone.
14. Brashear HR, Winfield HG: Tuberculosis of the wrist: a report of ten cases. *South Med J* 68:1345, 1975.
15. Breathnach A, Levell N, Munro C, et al: Cutaneous *Mycobacterium kansasii* infection: case report and review. *Clin Infect Dis* 20:812, 1995.
16. Bryceson A, Pfaltzgraff RE: *Leprosy*, New York, 1990, Churchill Livingstone.
17. Bunney MH, Benton C, Cubie HA: *Viral warts. Biology and treatment*, Oxford, 1992, Oxford University Press.
18. Charters AD, Staer PA: Cutaneous leishmaniasis of long incubation period in an Italian immigrant in Western Australia. *Med J Aust* 2:278, 1970.
19. Charters AD, Staer PA: Cutaenous leishmaniasis of long incubation period in an Italian immigrant in Western Australia. *Med J Aust* 2:278, 1970.
20. Cheung JP, Fung B, Ip WY, et al: *Mycobacterium marinum* infection of the hand and wrist. *J Orthop Surg (Hong Kong)* 20:214, 2012.
21. Ching V, Ritz M, Song C, et al: Human immunodeficiency virus infection in an emergency hand service. *J Hand Surg* 21A:696, 1996.
22. Chow SP, Ip FK, Lau JH, et al: *Mycobacterium marinum* infection of the hand and wrist. Results of conservative treatment in twenty-four cases. *J Bone Joint Surg* 69:1161, 1987.
23. Coban YK, Balik O, Boran C: Cutaneous anthrax of the hand and its reconstruction with a reverse-flow radial forearm flap. *Ann Plast Surg* 49:109, 2002.
24. Collins RJ, Chow SP, Ip FK, et al: Synovial involvement by *Mycobacterium marinum*. A histopathological study of 25 culture-proven cases. *Pathology* 20:340, 1988.
25. Colville A, Ispahani P: Non-tuberculous mycobacterial tenosynovitis. *Lancet* 2: 1161, 1989.
26. Coombes GM, Teh LS, Denton J, et al: *Mycobacterium xenopi*—an unusual presentation as tenosynovitis of the wrist in an immunocompetent patient. *Br J Rheumatol* 35:1008, 1996.
27. da Rosa AC, Scroferneker ML, Vettorato R, et al: Epidemiology of sporotrichosis: a study of 304 cases in Brazil. *J Am Acad Dermatol* 52:451, 2005.
28. Daengsvang S, Sangsingkeo P, Ayudhya BSN: A case of gnathostomiasis of a finger. *Southeast Asian J Trop Med Pub Health* 4:260, 1973.
29. Danzig LA, Fierer J: Coccidioidomycosis of the extensor tenosynovium of the wrist. *Clin Orthop* 129:245, 1977.
30. Dehaven KE, Wilde AH, O'Duffy JD: Sporotrichosis arthritis and tenosynovitis: report of a case cured by synovectomy and amphotericin B. *J Bone Joint Surg* 54-A:874, 1972.
31. Dix-Peek SI, Vrettos BC, Hoffman EB: Tuberculosis of the elbow in children. *J Shoulder Elbow Surg* 12:282, 2003.
32. Dupuytren G: The Classic: On osteo-sarcoma, spina-ventosa, and tubercles in bone. Injuries and Diseases of Bones; 1847: 416-433. *Clin Orthop Relat Res* 450:17, 2006.

33. Duran RJ, Coventry MB, Weed LA: Sporotrichosis: a report of 23 cases in the upper extremity. *J Bone Joint Surg* 39A:1330, 1957.
34. Edwards MS, Huber TW, Baker CJ: Mycobacterium terrae synovitis and osteomyelitis. *Am Rev Respir Dis* 117:161, 1978.
35. Engelkens HJ, Ginai AZ, Jadanarso J, et al: Case report 274. *Skeletal Radiol* 21:194, 1992.
36. Engelkens HJ, Ginai AZ, Judanarso J, et al: Radiological and dermatological findings in two patients suffering from early yaws in Indonesia. *Genitourin Med* 66:259, 1990.
37. Engelkens HJ, Orange AP, Stolz E: Early yaws imported in the Netherlands. *Genitourin Med* 65:316, 1989.
38. Gabl M, Pechlaner S, Hausdorfer H: Tenosynovitis in the hand caused by *Mycobacterium malmoense*: a case report. *J Hand Surg* 22:338, 1997.
39. Galaria NA, Jenkins-Hopkins JM, Kligman D, et al: Neutrophilic dermatosis of the dorsal hands: pustular vasculitis revisited. *J Am Acad Dermatol* 43:870, 2000.
40. Gelman MI: Blastomycotic dactylitis. *Radiology* 107:331, 1973.
41. Glickel SZ: Hand infections in patients with acquired immunodeficiency syndrome. *J Hand Surg* 13:770, 1988.
42. Gonzalez MH, Nikoleit J, Weinzweig N, et al: Upper extremity infections in patients with the human immunodeficiency virus. *J Hand Surg [Am]* 23:348, 1998.
43. Graham WR, Callaway JL: Primary inoculation blastomycosis in a veterinarian. *Am Acad Dermatol* 7:785, 1982.
44. Green WO, Adams TE: Mycetoma in the United States. *Am J Clin Pathol* 42:75, 1964.
45. Grossman ME, Fithian EC, Behrens C, et al: Primary cutaneous aspergillosis in in six leukemic children. *J Am Acad Dermatol* 12:313, 1985.
46. Haider N, Khan AQ, Zulfiqur M: Tubercular dactylitis and multifocal osteoarticular tuberculosis—two rare cases of extrapulmonary tuberculosis. *BMJ Case Reports* 10:1, 2011.
47. Hankins CL: Blastomycotic hand infections. *Scand J Plast Reconstr Surg Hand Surg* 43:166, 2009.
48. Haruna K, Shiraki Y, Hiruma M, et al: A case of lymphangitic sporotrichosis occurring on both forearms with a published work review of cases of bilateral sporotrichosis in Japan. *J Dermatol* 33:364, 2006.
49. Hassan FO: Tuberculous dactylitis pseudotumor of an adult thumb: a case report. *Strategies Trauma Limb Reconstr* 5:53, 2010.
50. Hastings RC: *Leprosy*, New York, 1994, Churchill Livingstone.
51. Hauser AR: Antibiotic basics for clinicians. Philadelphia, Wolters Kluwer, 2013.
52. Hellinger WC, Smilack JD, Greider JL, Jr, et al: Localized soft-tissue infections with *Mycobacterium avium* / *Mycobacterium intracellulare* complex in immunocompetent patients: granulomatous tenosynovitis of the hand or wrist. *Clin Infect Dis* 21:65, 1995.
53. Huang JI, Seeger LL, Jones NF: Coccidioidomycosis fungal infection in the hand mimicking a metacarpal enchondroma. *J Hand Surg* 25B:475, 2000.
54. Huang JI, Seeger LL, Jones NF: Coccidioidomycosis fungal infection in the hand mimicking a metacarpal enchondroma. *J Hand Surg [Br]* 25:475, 2000.
55. Huish SB, de la Paz EM, Ellis PR, III, et al: Pyoderma gangrenosum of the hand: a case series and review of the literature. *J Hand Surg* 26A:679, 2001.
56. Hurst LC, Amadio PC, Badalamente MA, et al: *Mycobacterium marinum* infections of the hand. *J Hand Surg* 12:428, 1987.
57. *Iowa State University, The Center for Food Security and Public Health.* <www.cfsph.iastate.edu/Factsheets/pdfs/anthrax.pdf>, March 2007.
58. Jensen CM, Jensen CH, Paerregaard A: A diagnostic problem in tuberculosis dactylitis. *J Hand Surg* 16B(2):202, 1991.
59. Jopling WH, McDougall AC: *Handbook of leprosy*, New Delhi, 1996, CBS Publishers.
60. Keith JE, Jr, Wilgis EF: Kaposi's sarcoma in the hand of an AIDS patient. *J Hand Surg* 11A:410, 1986.
61. Kelly PJ, Weed LA, Lipscomb PR: Infection of tendon sheaths, bursae, joints and soft tissues by acid-fast bacilli other than tubercle bacilli. *J Bone Joint Surg* 45A:327, 1963.
62. Khan K, Bandyopadhyay A: A rare case of chondromyxoid fibroma mimicking spina ventosa. *J Surg Tech Case Rep* 4:43, 2012.
63. Kiely JL, O'Riordan DM, Sheehan S, et al: Tenosynovitis due to mycobacteria other than tuberculosis: a hazard of water sports and hobbies. *Respir Med* 89:69, 1995.
64. Kim JE, Sung H, Kim MN, et al: Synchronous infection with *Mycobacterium chelonae* and Paecilomyces in a heart transplant patient. *Transpl Infect Dis* 13:80, 2011.
65. Koss SD, Reardon TF, Groves RJ: Recurrent carpal tunnel syndrome due to tuberculoid leprosy in an Asian immigrant. *J Hand Surg* 18:740, 1993.
66. Kotwal PP, Khan SA: Tuberculosis of the hand: clinical presentation and functional outcome in 32 patients. *J Bone Joint Surg Br* 91:1054, 2009.
67. Kozin S, Bishop A: Atypical Mycobacterium infections of the upper extremity. *J Hand Surg* 19A:480, 1994.
68. Langan SM, Powell FC: Vegetative pyoderma gangrenosum: a report of two new cases and a review of the literature. *Int J Dermatol* 44:623, 2005.
69. Lau JHK: Hand infection with *Mycobacterium chelonei*. *Br Med J* 292:444, 1986.
70. Leavell UW, McNamara MJ, Muelling R: Orf. Report of 19 human cases with clinical and pathological observations. *JAMA* 203:657, 1968.
71. Love GL, Melchior E: *Mycobacterium terrae* tenosynovitis. *J Hand Surg* 10:730, 1985.
72. Luque AE, Kaminski D, Reichman R, et al: *Mycobacterium szulgai* osteomyelitis in an AIDS patient. *Scand J Infect Dis* 30:88, 1998.
73. Malaviya GN: Towards restoring sensibility in anesthetic extremities of leprosy patients. *Acta Leprol* 9:111, 1995.
74. Malaviya GN: Rehabilitation of insensitive hands. *Indian J Lepr* 74:151, 2002.
75. Malaviya GN, Mishra B, Girdhar BK, et al: Calcification of nerves in leprosy—report of three cases. *Indian J Lepr* 57:651, 1985.
76. Malaviya GN, Mukherjee A, Ramu G: Nerve abscess in lepromatous leprosy. *Lepr India* 54:123, 1982.
77. Massing AM, Epstein WL: Natural history of warts. A two year study. *Arch Dermatol* 87:306, 1963.
78. Matsuda T, Matsumoto T: Protothecosis: a report of two cases in Japan and a review of the literature. *Eur J Epidemiol* 8:397, 1992.
79. McAuliffe JA, Seltzer DG, Hornicek FJ: Upper-extremity infections in patients seropositive for human immunodeficiency virus. *J Hand Surg [Am]* 22:1084, 1997.
80. Mert A, Bilir M, Bahar H, et al: Primary actinomycosis of the hand: a case report and literature review. *Int J Infect Dis* 5:112, 2001.
81. Miyata T, Yashiro M, Hayashi M, et al: Bullous pyoderma gangrenosum of the bilateral dorsal hands. *J Dermatol* 39:1006, 2012.
82. Moore M: Mycetoma of hand and arm caused by *Madurella*; report of a case with a review of the literature. *Am J Trop Med* 3:303, 1954.
83. Moran SL, Strickland J, Shin AY: Upper-extremity mucormycosis infections in immunocompetent patients. *J Hand Surg [Am]* 31:1201, 2006.
84. Mousa AR, Muhtaseb SA, Almudallal DS, et al: Osteoarticular complications of brucellosis: a study of 169 cases. *Review Infect Dis* 9:531, 1987.
85. Olivieri I, Scarano E, Padula A, et al: *Dactylitis*, a term for different digit diseases. *Scand J Rheumatol* 35:333, 2006.
86. Ooi WW, Moschella SL: Update on leprosy in immigrants in the United States: status in the year 2000. *Clin Infect Dis* 32:930, 2001.
87. Ozkan T, Ozer K, Gulgonen A: Restoration of sensibility in irreparable ulnar and median nerve lesions with use of sensory nerve transfer: long-term follow-up of 20 cases. *J Hand Surg [Am]* 26:44, 2001.
88. Pan KL, Ibrahim S: Tuberculosis of the distal end of the radius mimiking a giant-cell tumor. *Med J Malaysia* 55:105, 2000.
89. Patel MR, Bassini L, Nashad R, et al: Barber's interdigital pilonidal sinus of the hand: a foreign body hair granuloma. *J Hand Surg* 15A:652, 1990.
90. Prabhu RM, Patel R: Mucormycosis and entomophthoramycosis: a review of clinical manifestations, diagnosis and treatment. *Clin Microbiol Infect* 10:31, 2004.
91. Prakash V, Husain S, Malaviya GN: Adiposubcutaneous flap for reconstruction of first web space depression in ulnar paralysis in leprosy patients. *Plast Reconstr Surg* 102:2519, 1998.
92. Raffi F, Moinard D, Drugeon HB: Non-tuberculous mycobacterial tenosynovitis. *Lancet* 335:613, 1990.
93. Raizman NM, Parisien M, Grafe MW, et al: Mucormycosis of the upper extremity in a patient with alcoholic encephalopathy. *J Hand Surg [Am]* 32:384, 2007.
94. Ramesh Chandra VV, Prasad BC, Varaprasad G: Ulnar nerve tuberculoma. *J Neurosurg Pediatrics* 11:751, 2013.
95. Randall G, Smith PW, Korbitz B: Carpal tunnel syndrome caused *Mycobacterium fortuitum* and *Histoplasma capulatum*. *J Neurosurg* 56:299, 1982.
96. Raturi U, Burkhalter W: Gnathostomiasis externa: a case report. *J Hand Surg* 11A:751, 1986.
97. Rhangos WC, Chick EW: Mycotic infections of bone. *South Med J* 57:664, 1964.
98. Ritz N, Connell TG, Tebruegge M, et al: Tuberculous dactylitis—an easily missed diagnosis. *Eur J Clin Microbiol Infect Dis* 30:1303, 2011.
99. Robinson AJ, Peterson GV: Orf virus infection of workers in the meat industry. *N Z Med J* 96:81, 1983.
100. Rushforth GF, Susannah JE: Actinomycosis of the hand. *Hand* 14:194, 1982.
101. Salisbury RE, Silverstein P, Goodwin MN, Jr: Upper extremity fungal invasions secondary to large burns. *Plast Reconstr Surg* 54:654, 1974.
102. Savage J, Black MM: "Giant" orf of finger in a patient with a lymphoma. *Proc R Soc Med* 65:766, 1972.
103. Sehgal VN: Cutaneous tuberculosis. Current concepts. *Int J Dermatol* 29:237, 1990.
104. Seltzer DG, McAuliffe J, Campbell DR: AIDS in the hand patient: the team approach. *Hand Clin* 7:433, 1991.
105. Singh S, Gupta R, Jain S, et al: Tubercular dactylitis: Fine needle aspiration cytology as a diagnostic modality. *Acta Cytol* 50:669, 2006.
106. Sirikulchayanonta V, Visuthikosol V, Tanphaichitra D, et al: Protothecosis following hand injury. *J Hand Surg* 14B:88, 1989.

107. Skoll PJ, Hudson DA: Tuberculosis of the upper extremity. *Ann Plast Surg* 43:374, 1999.
108. Spellberg B, Ibrahim A: Mucormycosis. In Kasper DL, Fauci AS, editors: *Harrison's infectious diseases*, New York, 2013, McGraw-Hill Education.
109. Sreekanth R, Pallapati SCR, Thomas BP: Tuberculous *Botryomycosis* of the hand: case report. *J Hand Surgery* 39(9):1810–1812, 2014.
110. Srinivasan H, Palande DD: *Essential surgery in leprosy. Techniques for district hospitals,* Geneva, 1997, World Health Organization.
111. Stevanovic MV, Mirzayan R, Holtom PD, et al: Mucormycosis osteomyelitis in the hand. *Orthopedics* 22:449, 1999.
112. Stratton CW, Phelps DB, Reller LB: Tuberculoid tenosynovitis and carpal tunnel syndrome caused by *Mycobacterium szulgai. Am J Med* 65:349, 1978.
113. Su WP, Davis MD, Weening RH: Pyoderma gangrenosum: clinicopathologic correlation and proposed diagnostic criteria. *Int J Dermatol* 43:790, 2004.
114. Tan ST, Blake GB, Chambers S: Recurrent orf in an immunocompromised host. *Br J Plast Surg* 44:465, 1991.
115. Tsai MS, Liu JW, Chen WS, et al: Tuberculous wrist in the era of effective chemotherapy: an eleven-year experience. *Int J Tuberc Lung Dis* 7:690, 2003.
116. Tuli SM: *Tuberculosis of the skeletal system*, New Delhi, 1991, Jaypee Brothers Medical Publishers (P) Ltd.
117. Uplekar MW, Antia NH: Clinical and histopathological observations on pure neuritic leprosy. *Indian J Lepr* 58:513, 1986.
118. Wilson JN: Tuberculosis of the elbow; a study of thirty-one cases. *J Bone Joint Surg Br* 35-B:551, 1953.
119. Zaharia D, Kanitakis J, Pouteil-Noble C, et al: Rapidly growing orf in a renal transplant recipient: favourable outcome with reduction of immunosuppression and imiquimod. *Transpl Int* 23:e62, 2010.
120. Zaitz C, Godoy AM, Colucci FM, et al: Cutaneous protothecosis: report of a third Brazilian case. *Int J Dermatol* 45:124, 2006.
121. Zeifer A, Connor DH: Pheomycotic cyst: a clinicopathologic study of twenty-five patients. *Am J Trop Med Hyg* 29:901, 1980.
122. Zenone T, Boibieux A, Tigaud S, et al: Non-tuberculous mycobacterial tenosynovitis: a review. *Scand J Infect Dis* 31:221, 1999.

4

Dupuytren Disease

Charles Eaton

These videos may be found at *ExpertConsult.com:*
4.1 Collagenase injection for Dupuytren contracture

Dupuytren disease (DD) is the most common heritable disorder affecting connective tissues. It is an inherited, benign, chronic progressive condition that results in fibrotic changes of the palmar and digital fascia and adjacent soft tissues. DD causes tissues to shorten along lines of mechanical tension, limiting digit extension. *Dupuytren contracture* (DC) is the end result of DD. There is not yet an effective treatment for DD. Primary treatment options for DC range from soft tissue release (i.e., collagenase injection, open or percutaneous needle fasciotomy) to excision (i.e., fasciectomy, dermofasciectomy). Because current treatments address only the contracture not its cause, both *recurrence* (reappearance of clinical disease in a treated area) and *extension* (posttreatment appearance of disease in untreated areas) are common.

Treatment of both primary and recurrent disease should be individualized, based on a person's risk factors and disease history. Treatment is empiric, and many aspects of DD lack clarity: enigmatic biology; unpredictable natural history; lack of standard terminology either for severity, outcome, recurrence, or patient satisfaction; lack of an animal model; lack of a unique biomarker; variation in biologic aggressiveness; or slow progression, often over the course of years. Proper management can be very rewarding, and treatment options have grown in the last decade, yet "… two issues remain unsolved relevant to Dupuytren's disease: its cause and its cure."[87]

DEMOGRAPHICS

DD has the highest prevalence in senior Caucasian men with blue or green eyes[13] who have a family history of the condition. DD is uncommon in those under the age of 40, but prevalence increases with age, as shown in Figure 4.1. Mean prevalence in Western countries is 12% at age 55, 21% at age 65, and 29% at age 75.[63] Pediatric DD has been reported sporadically,[56] but the diagnosis cannot be confirmed with certainty because of a lack of a unique biomarker. The most common age range at diagnosis is early fifties to early sixties. Incidence in women parallels that of men, but lags by an average of 10 to 15 years,[65] resulting in a male : female prevalence ratio that decreases with age.

Some studies have reported that prevalence in men decreases after the age of 70 and in women after the age of 80, thought to reflect attrition from increased mortality rates of patients with DD compared to the general population,[39] as well as higher mortality rates of men compared to women in the general population. The average patient has two or three affected rays; the ring or little finger are most commonly involved.[26] Overall, half of patients have bilateral disease,[64] but this varies with age; DD presents bilaterally in only 20% of patients, but over time increases to at least 70%.[48] The overall prevalence of Dupuytren *contracture* accounts for less than one-fifth of all patients with Dupuytren disease.[64]

Clinical behavior stratifies patients into four biologic groups. In order of increasing risk of needing future treatment for DC, these groups are those *without* clinical DD, those *with* DD but no contracture, those with *untreated* DC, and those with *treated* DC. Unfortunately, because diagnostic codes prior to the 10th revision of the International Statistical Classification of Diseases and Related Health Problems (ICD-10) did not differentiate Dupuytren *disease* from *contracture*, data for these groups have often been mingled.

Heritability

Inheritance patterns of DD appear to follow an autosomal dominant pattern with variable penetrance.[52,65] Despite reports of a northern European concentration, recent studies suggest that it is common in Caucasians in general, common throughout Europe and less common in Asia, as shown in Figure 4.2. Definitive prevalence data are lacking from Africa, Russia, India, and China. African Americans have just less than one-fifth the prevalence of Caucasian Americans,[92] similar to the average percent Caucasian heritage of African Americans.[83] Hispanic Americans have one-third and Asian Americans one-tenth the prevalence of Caucasian Americans.[92] Prevalence reported in family history studies is often underestimated because of the combination of late onset and lack of awareness of mild involvement in senior relatives.[65] Nearly half of patients with DD have a relative who is known to have the disease.[65,48]

Positive family history is the single strongest predictor of the disease and is associated with both earlier age of onset and earlier age of first treatment.[7,48] A family history involving both parents is associated with younger age of onset than a history of only one affected parent.[7] An affected sibling triples one's risk of developing DD.[48] Although these findings strongly suggest a genetic basis, a specific locus has yet to be identified. It is not clear whether DD is one condition or, like diabetes, the common destination of several different starting points.

Associated Conditions

DD has been associated with comorbidities including hypercholesterolemia, diabetes,[37] smoking tobacco,[14] excessive alcohol use, epilepsy, antiepileptic medication, regional trauma,[33]

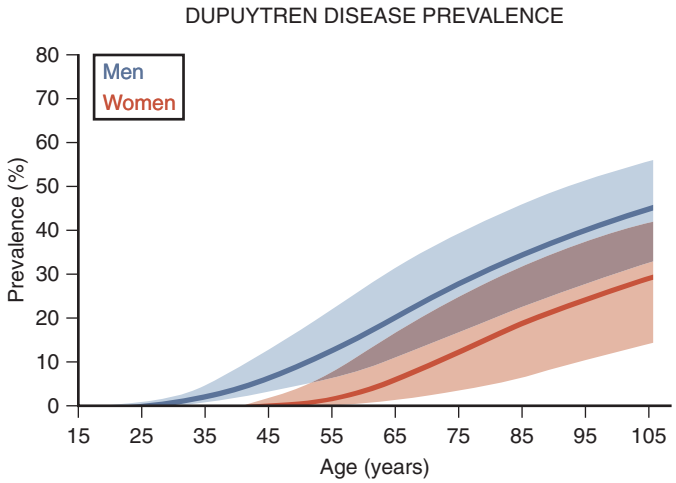

FIGURE 4.1 Summary of Dupuytren disease prevalence data in 11 high-quality studies selected from 199 reviewed publications.[63] Lines represent mean values; shaded areas are 95% confidence intervals. Prevalence in women parallels that of men, but lags by about 15 years.

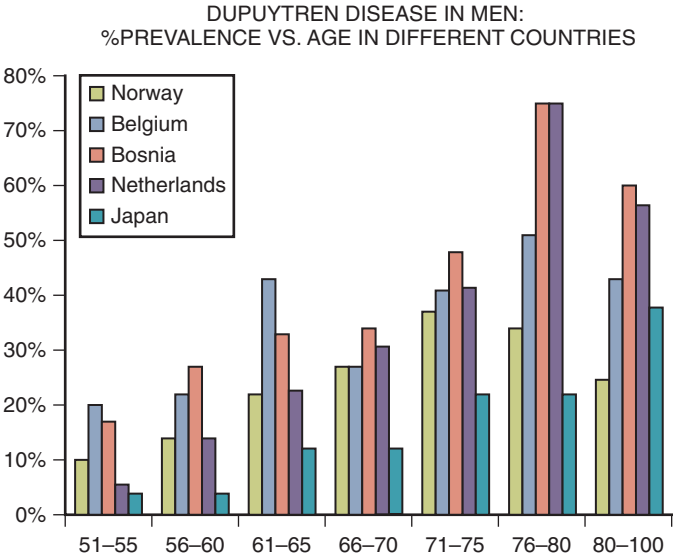

FIGURE 4.2 Prevalence of Dupuytren disease in men reported in studies from five different countries.[23,32,64,73,118] In these, prevalence in northern and southern Europe is similar; both are greater than the incidence in Japan.

chronic heavy manual labor,[25] and a lower-than-average body mass index.[41] The literature is far from clear on this topic and lack of association has also been reported for each of these factors. False association bias with other medical disorders may exist in that DD is more likely to be diagnosed in patients who have more medical office visits for other conditions.[37] The volume of evidence suggests that these conditions are probably *associated but not causative* of DD.

GENETIC BIOMARKERS

Efforts to characterize gene expression associated with disease activity have identified cellular regulatory abnormalities associated with DD. Dupuytren tissue is *not* a monoclonal neoplastic process.[16] The largest genome-wide association study to date identified nine genetic loci associated with genetic susceptibility to DD.[30] Genetic markers specific to DD have been identified in profibrotic pathways involving regulation of transforming growth factor beta one (TGFβ1); cell differentiation; proliferation and apoptosis[85]; metalloproteinase activity[115]; fibroblast growth factor[3]; vascular endothelial growth factor[50]; hypoxia inducible factor alpha[50]; and, in particular, proteins in the Wnt-signaling pathway.[30] HLA studies have identified an increased incidence of HLA-DRB1*01 genotype[58] in Caucasians with DD, and HLA-B7 haplotype in both Peyronie disease and DD.[80]

DD gene expression studies face many challenges. The *physical setup* of cell culture affects gene expression and cytokine response[94] and may not replicate the mechanical environment that influences gene expression in vivo.[111] The *site of tissue origin* affects mechanoregulation of gene expression in otherwise similar tissues.[51] Finally, the *genetic relationship of DD and gender* is complex: palmar fascia has overexpression of androgen receptors[82]; *TIMP-1*, the gene that expresses tissue inhibitor of metalloproteinase 1 (a collagenase implicated in DD), is located on the X-chromosome[82]; estrogen suppresses both collagen synthesis[43] and matrix metalloproteinase gene expression in response to acute mechanical stress.[101] Compared to men, incidence in women is delayed until after the average age of menopause.

PREOPERATIVE EVALUATION

Physical Examination

Early Dupuytren disease is commonly overlooked and underreported.[28] The earliest signs of Dupuytren *disease* takes the form of skin tightness (i.e., exaggerated blanching with finger extension), contour changes (i.e., skin crease deformation, dimples), nodules, cords without contractures, or prominence of the palmar monticuli, as shown in Figure 4.3. Nodules are the first change noticed by about 6 out of 10 patients.[28] Nodules are flattened round or ovoid areas of subdermal firmness, fixed to the dermis, typically 0.5 to 1.5 cm in diameter with indistinct peripheral margins. The dermal papillae overlying nodules may be prominent or may be longitudinally compressed, different from the type of papillary ridge stretching and flattening seen with other slowly growing tumors (Figure 4.4). Uncommonly, nodules are initially erythematous, tender, or itchy. Skin crease deformation or dimples are the first change noticed in about 1 out of 10 patients.[28]

Dorsal Dupuytren nodules (DDN), also called *Garrod pads* or *knuckle pads*, are firm masses on the extensor aspect of the digital joints, and histologically resemble palmar nodules (Figure 4.5). DDN most commonly affect the proximal interphalangeal (PIP) joints, but occasionally the distal interphalangeal (DIP), metacarpophalangeal (MCP), or interphalangeal (IP) joint of the thumb, or rarely the extensor mechanism.[53] DDN are fixed to the superficial paratenon of the extensor mechanism and involve overlying subcutaneous tissue and retinacular fibers to a variable degree. Secondary skin involvement may occur. DDN can be confused with *dorsal cutaneous pads*: local dorsal joint skin thickening and hyperkeratosis that only involves the skin. DDN are found in one in five DD patients, often precede palmar DD, and are associated with more aggressive biology.[54]

In contrast, dorsal cutaneous pads are *not* associated with Dupuytren disease and are equally common with and without

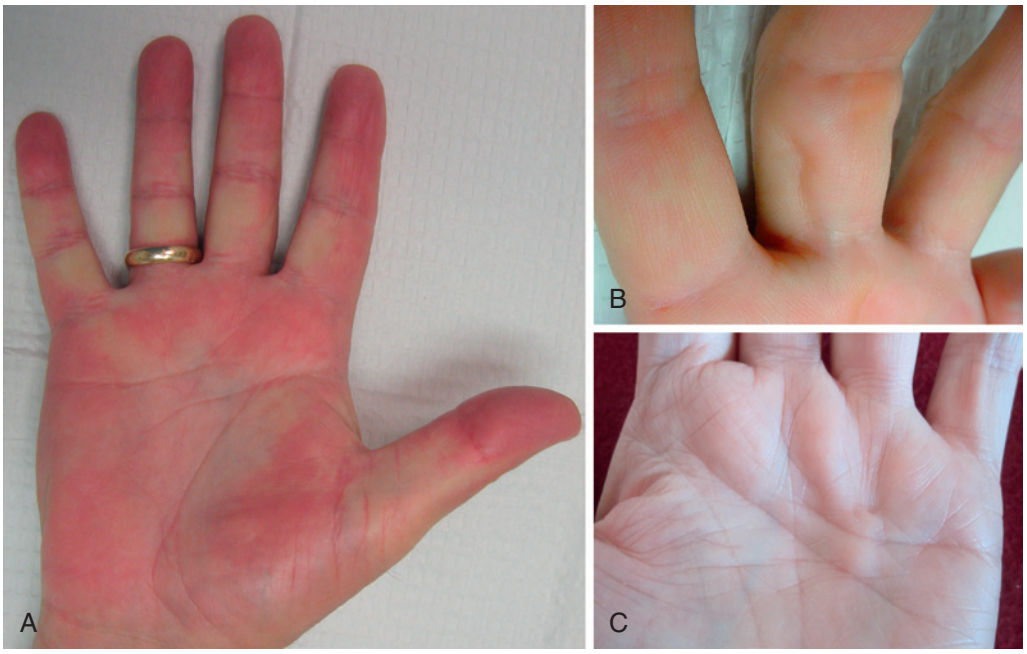

FIGURE 4.3 Earliest signs of Dupuytren disease in patients with Dupuytren contracture on the opposite hand. **A,** Palmar skin tightness, blanching in the digits with neutral extension; **B,** dimpling of the lateral digit; **C,** prominence of the interdigital palmar monticuli in the distal palm from central band tightness. This hand also demonstrates a ring finger nodule with adjacent distal skin retraction.



FIGURE 4.4 This patient has diffuse nodular skin involvement of Dupuytren disease, but no contractures. The dermal papillae are abnormally prominent over the nodules of the middle and ring rays, almost resembling fingerprints. Dimples and nodules are also visible at the base of the index finger and thumb as well as the first-web space.

DD.[86] Occasionally, the earliest sign of a DDN is a tethered depression of the extensor skin creases[54] (see Figure 4.5). Palpated *cords* feel like strings beneath the skin, and vary from a few millimeters to greater than a centimeter in width. Although they may be found independent of each other, nodules and cords are usually arranged as beads on a string. Nonnodular cords, unlike nodules, feel firm only when placed under tension, have well-defined margins, and are not fixed to the dermis. There is often overlap of nodules and cords[112]; that is, nodular cords share nodular aspects of dermal adherence and firmness unrelated to joint position. All of these early changes may go unnoticed by the patient.

It is likely that the majority of patients with only mild Dupuytren disease will not progress to Dupuytren contracture. Reilly[89] followed patients who initially presented with only nodules. At an average of nearly 9 years, about 1 in 10 had progressed to contracture; 1 in 10 had nodule regression; 4 in 10 had progressed to cord without contracture; and 4 in 10 had neither progressed nor regressed. Gudmundsson[40] reported that almost two-thirds of 75 patients presenting with a nodule or cord without contracture did not progress to contracture over an 18-year period of observation. Conversely, patients may develop contractures without noticing nodules: cords or contractures are the sentinel finding in nearly one-quarter of patients.[28]

Because the diagnosis is made by clinical examination, the differential diagnosis of palmar nodules also includes fibrosarcoma, fibrous histiocytoma, giant cell tumor, synovial sarcoma, calcifying aponeurotic fibroma, epithelioid sarcoma, and other less common tumors. For this reason, the patient presenting with an isolated palmar mass diagnosed as DD should be seen for scheduled follow-up to confirm that the mass does not undergo unexpected changes.

The earliest appearance of Dupuytren *contracture* is passive extension deficit due to a contracted cord, most often affecting the MCP and PIP joints of the fingers. Almost all cords can be palpated with fingertip pressure. Because nonnodular cords feel firm only when under tension, the key to cord palpation is to feel for a change from soft to firm as the finger is passively ranged from flexion to extension. Most cords develop along recognizable lines of mechanical tension produced by passive extension or abduction. Patients with aggressive Dupuytren biology or who have had prior treatment are more likely to vary from these common patterns.

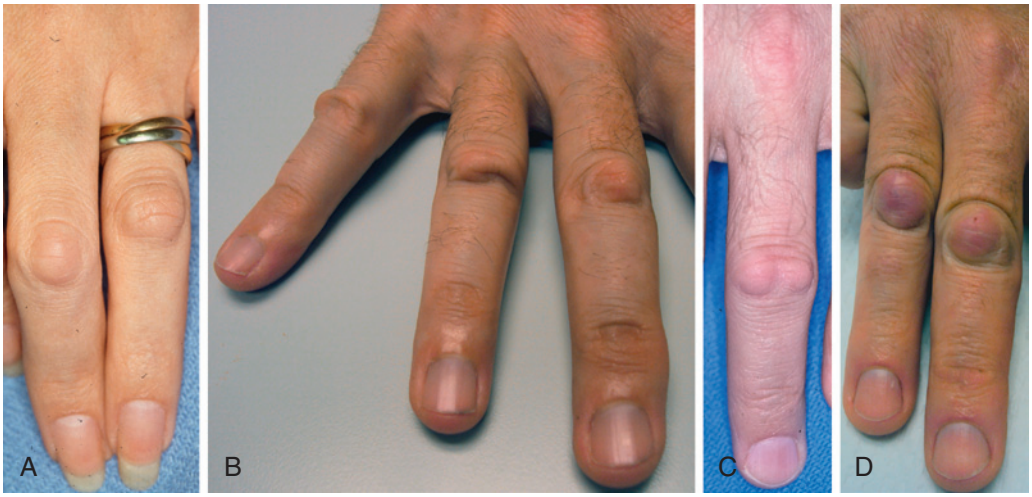

FIGURE 4.5 Variations of dorsal Dupuytren nodules. **A,** No skin involvement; **B,** dimpling with or without nodule; **C,** prominence over the condyles; **D,** inflammatory with diffuse skin tethering.

Cords may result in isolated flexion contractures of the MCP, PIP, or DIP joints or combinations of these. Thumb involvement may result in carpometacarpal (CMC) MCP or IP flexion contractures and/or radial or palmar adduction contractures. Natatory ligament contractures that adduct the fingers may be masked by the adducting effect of MCP joint contractures. Contractures on the ulnar border of the palm may produce little finger MCP flexion/abduction contractures.

Staging

There is no universally accepted system for either describing the quality or quantifying the severity of DC. Objective multifactorial tests, such as the Sollerman test and Rosenbloom joint mobility assessment, and other measures have been used for evaluation of DD but are not disease-specific. Because DC is usually painless, the inclusion of pain questions dilutes the value of subjective tests such as the Disabilities of the Arm, Shoulder, and Hand (DASH) and Michigan Hand Outcomes (MHQ); neither correlate well with range-of-motion measurements.[120] Range-of-motion measurements are the most common assessment, but often cannot be compared because of incompatible formats such as individual versus multiple joints, active versus passive measurements, and other author-defined measures. Range-of-motion measurements alone do not correlate well with hand function.[31,57]

Other systems exist, incorporating grip strength, flexion deficit, sensibility, scarring, improvement, satisfaction, and other measures specific to postoperative evaluation. The Unité Rhumatologique des Affections de la Main scale (URAM) questionnaire[6] and Southampton Dupuytren's Scoring System (SDSS)[77] have been developed as disease-specific staging systems, but neither has yet gained wide adoption. Each of the following subsections focuses on common classification schemes for a specific portion of the overall picture.

Luck Classification and Related Histology

Luck[67] described a progression of three histologic stages: *proliferative*, *involutional*, and *residual,* roughly corresponding to nodules, nodular cords, and nonnodular cords, respectively. The *key cell* is the *myofibroblast*, which under light microscopy resembles a fibroblast but has ultrastructural differences: stress fibers, cell membrane adhesion complexes, fibronectin fibers, smooth muscle α-actin, and other unique characteristics. The *proliferative* cellular stage is characterized by highly cellular, mitotic histology with randomly oriented myofibroblasts and sparse, randomly oriented collagen fibrils. Specimens of the *involutional* fibrocellular stage are less cellular with no mitoses, and show some parallel orientation of myofibroblasts and collagen fibrils. *Residual* fibrotic stage histology is characterized by relatively acellular collagen with flattened cells within areas of uniformly oriented densely packed collagen bundles. Occluded microvessels and basal lamina thickening are also present in cords, nodules, and perinodular areas.

Luck staging correlates with collagen type. Normal palmar fascia has little or no type III collagen. Abnormally high levels of type III collagen exist in the palmar fascia of DD patients even in the absence of contracture.[11] The ratio of type III to type I collagen is highest in the proliferative stage (>35%).[62] This ratio decreases to the range of 20 to 35% in involutional specimens, and to less than 20% in residual specimens.[62] Type III collagen persists in affected tissues: the involutional stage is static, but not normal.

Luck staging correlates with recurrence rate after fasciectomy. Balaguer et al[4] analyzed outcomes at 8 to 9 years after fasciectomy and reported that proliferative histology more than doubled recurrence compared to involutional histology and more than tripled recurrence compared to residual histology. This Luck stage parallels clinical assessment of nodularity and may prove applicable for preoperative recurrence prediction or for procedures performed without tissue sampling.

Tubiana Staging

The Tubiana stage is an index of composite flexion contracture. The composite MCP + PIP joint flexion contracture of each ray is placed in a group of 45-degree increments:

- Stage 0: no contracture
- Stage 1: 0 to 45 degrees
- Stage 2: 45 to 90 degrees

- Stage 3: 90 to 135 degrees
- Stage 4: greater than 135 degrees

DIP joint angles are not included.

This classification has been modified to include notations for the presence of nodules or distal IP hyperextension for each ray, and a summary number for the entire hand as well as other notations[46]; however, the most common use is as a quick descriptor—the stage number of the affected finger. This classification has the unique advantage of summarizing contractures from cords that span both MCP and PIP joints and complements individual joint measurements. A variation of the Tubiana stage is the total contracture index (TCI), which is the composite MCP + PIP flexion contracture in degrees.

Individual Joint Measurements

Range-of-motion measurement of individual joints using a goniometer might seem to be the most objective documentation. However, two DD-specific issues can result in a pattern of bias affecting individual joint measurements. First, limited joint motion from Dupuytren cords may produce static or dynamic contractures. Cords spanning sequential joints produce *dynamic contractures* via fasciodesis: measurements at one joint are linked to the position of the adjacent spanned joint. Grotesman[38] found dynamic contractures in more than one-third of rays having combined MCP + PIP contractures, primarily affecting a PIP joint.

This is consistent with the report of correction of untreated PIP contractures in more than one-third of combined MCP + PIP contractures in which only the MCP joint was treated with collagenase clostridium histolyticum (CCH) injection.[44] Cords extending to the proximal palm are affected by CMC joint position, which cannot easily be measured and can affect both MCP and PIP joint measurements in a zigzag fashion (Figure 4.6). Second, although cords themselves are inelastic, they arise from soft tissues that have elastic attachments: passive range-of-motion measurements are subject to examiner bias from the force applied to the finger.

Location of Disease

Although much has been written regarding the anatomical basis of cords, not all cord areas have been named, and published reports lack a precise, standard system to tag cord and nodule locations in the palm based on physical examination. A diagram developed for this purpose based on skin landmarks and common patterns of DD is shown in Figure 4.7. Forms based on this are available at http://dupuytrens.org/research-publications/forms-for-documentation, and these allow documentation of initial evaluation disease location, joint measurements, and treatment details.

Diathesis Score and Severity

Biologic severity affects the clinical course both before and after treatment. Biologic severity is reflected both in the rate of progression from diagnosis to the need for treatment and the risk of recurrence, extension, stiffness, and inflammatory reaction after treatment. Biologic severity varies greatly between individuals and is *not* simply contracture severity. One index of biologic severity is association with specific fibrotic conditions: that is, DDN, Peyronie, Ledderhose, frozen shoulder. Despite conflicting reports, each of these is probably associated with increased risk of DD and vice versa. Why is this?

Each of these conditions occurs where *inelastic fascial structures* are subjected to *high peak shearing* or *traction forces*. The author's opinion is that there is an underlying connective tissue disorder triggered by the mechanics at each of these sites, which would explain the observed overlap of risk factors; *family history* of DD increases the risk both of Ledderhose and of DDN.[42] In contrast, other fibrotic conditions, such as keloid or scleroderma, are *not* associated with increased DD risk and appear to have different molecular pathways.[9,55]

Diathesis factors predict biologic severity. Diathesis factors include bilateral palmar disease, DDN, Ledderhose disease, positive family history, age of onset younger than 50, male gender,[47] first ray disease,[1] and involvement of more than two digits.[22] There has not been full agreement on the relative

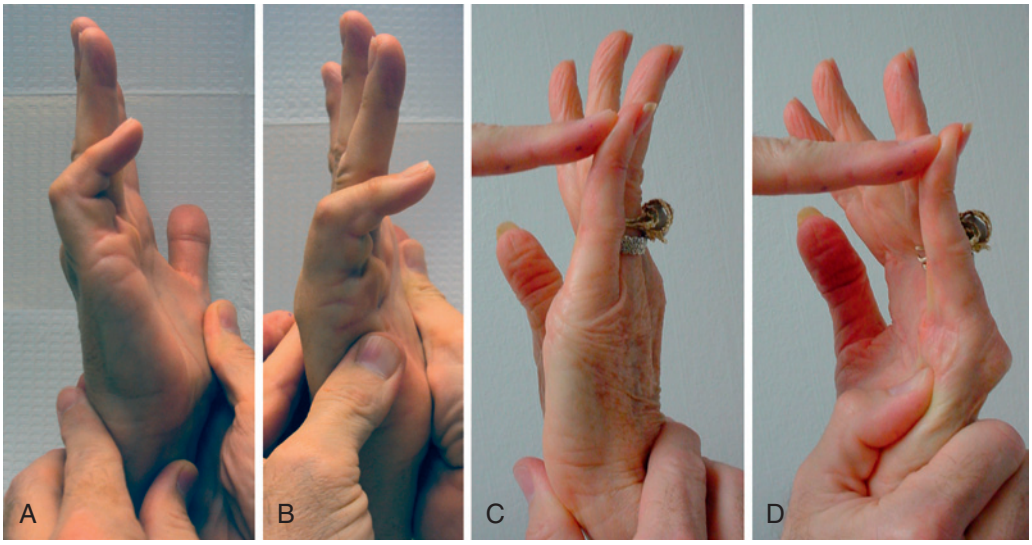

FIGURE 4.6 Demonstration of dynamic contractures with carpometacarpal (CMC) fasciodesis. **A,** Patients use a trick motion to compensate for tight fascia, flexing their ring and small CMC joints to allow metacarpophalangeal (MCP) extension. **B,** CMC flexion allows 10 degrees of active MCP hyperextension. **C,** When CMC flexion is blocked, active MCP extension is limited to 20 degrees, which in turn improves active proximal interphalangeal extension by 10 degrees. **D,** blocking CMC flexion changes passive MCP extension from 0 to 65 degrees.

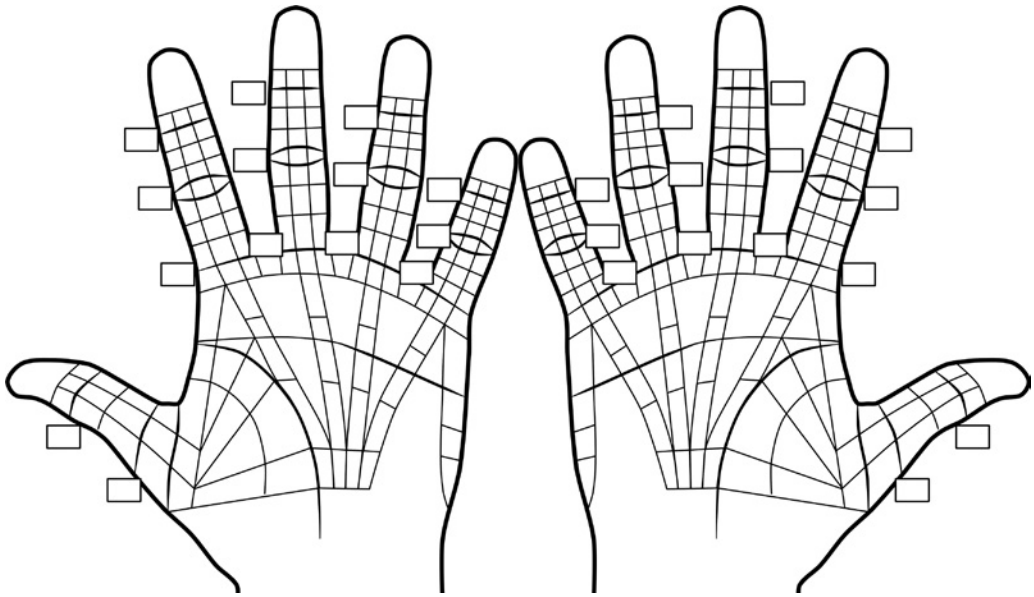

FIGURE 4.7 This diagram is based on common zones of involvement and allows standard documentation of the location of physical findings, procedures, and joint measurements. PDF versions of this as evaluation and procedure forms are available at http://dupuytrens.org/research-publications/forms-for-documentation.

importance of each, but in general, the greater the number of diathesis factors, the higher the recurrence rate after surgery. The strongest predictor of greater biologic severity is younger age of onset.[7,29]

Similarly, rate of recurrence drops with greater age at the time of first treatment.[109] Some factors, such as frozen shoulder[99] and Peyronie disease,[79] increase the incidence risk of DD but not the rate of recurrence after surgery.[22,47] This paradox might be explained by the effect of index event bias on interpretation of recurrence data,[100] and more clarification is needed. Diathesis factors share genetic markers. Patients with early age of onset, DDNs, and a positive family history were found to have a greater likelihood of having a high genetic risk score based on a profile of single nucleotide polymorphisms associated with DD.[29]

Documentation of DD biologic severity should include diathesis factors: family history of DD in siblings or parents; gender; age of onset of DD; current age; age of first treatment; bilaterality of DD; number of digits involved; thumb involvement; presence of nodules; presence of DDNs; presence of Ledderhose disease; presence of Peyronie disease; and history of frozen shoulder. A high diathesis score implies three or more of these factors: age of onset younger than 50, positive family history, DDN, bilateral disease, Ledderhose.

Treatment Outcome Score

Outcome assessment is most meaningful in the context of the initial contracture. Two useful objective comparative outcome measures are the *Thomine coefficient* ([degrees of improvement]/[degrees of initial contracture]) and *CCH success* ([number of joints corrected to 5 degrees or less]/[number of treated joints]). The fact that neither adequately reflects functional change in all patients reflects the difficulty of this issue. Consider, for example, a patient with a 40-degree contracture and a patient with a 140-degree contracture. For these patients, complete correction would give the same outcome score by either measure, despite very different changes in function. A 30-degree improvement would not be considered a CCH success for either, but the first patient would likely be happier than the second. Patient satisfaction correlates poorly with range-of-motion measurements regardless. Roush and Stern[90] reported results of surgery for recurrence in which 95% of patients were "unconditionally satisfied and stated that they would have the procedure again" despite lack of improvement in average total active motion.

Recurrence Assessment

Because recurrence is a lifetime issue, recurrence percentages are meaningless unless duration is also specified. Recurrence is most accurately described as a *percent per year rate*, not simply a percent, and also not an average of a broad range of follow-up intervals. Many definitions of recurrence exist. Quantitative definitions include need for repeat treatment, loss of a defined percent of initial correction, or loss of a defined number of degrees of correction. Different metrics cannot be easily compared. For example, recurrence as defined in CCH studies excludes the subset of treated patients not corrected to within 5 degrees of complete extension, a group known to have a higher recurrence rate[84]; this skews recurrence results favorably compared to other recurrence definitions. In addition, many published studies define recurrence qualitatively or not at all.

Not all contracture recurrence is Dupuytren recurrence. Contracture recurrence falls into three categories: early, progressive, and late (Table 4.1). *Early recontracture* develops during the first 3 postoperative months, followed by a plateau.[27] This pattern is not recurrent Dupuytren contracture. It is due to incomplete correction of secondary pathology at the time of treatment. Central slip laxity, oblique retinacular ligament

TABLE 4.1 Patterns of Recontracture After Treatment of Dupuytren Contracture

Type	Begins	Course	Cause
Early	1–2 weeks posttreatment	Plateau after 6–12 weeks	Residual secondary pathology
Progressive	6–12 weeks posttreatment	Progressive	Residual primary pathology
Late	After posttreatment plateau lasting 12 months or longer	Progressive	New disease activity (true recurrence)

tightness, mild PIP anterior cruciate ligament (ACL), or capsular tightness may not prevent improvement at the time of treatment, but their persistent effects result in loss of initial gains over the following weeks. Because these are static influences, their effects plateau. *Progressive recontracture* is a steady worsening of contracture that continues to progress *after* the first 3 postoperative months. This is due to inadequate treatment of primary pathology: inadequate fasciotomy/ectomy of all mechanically important cord(s).

Both severe contractures and diffuse disease are more likely to have multiple cords affecting the same joint,[105] some of which may escape treatment. Residual cords with soft tissue attachments may stretch without becoming discontinuous and remain biologically active and contractile during the early postoperative period. *Late recontracture* develops after an initial period of stability lasting a year or more after treatment.

Similar to extension of disease after treatment, late recontracture is due to progression of new Dupuytren activity and represents *true recurrence*. Failure to clearly separate these groups has led to confusion regarding outcomes. The author recommends the definition of recurrence published by the international Dupuytren Delphi group: "an increase in joint contracture in any treated joint of at least 20 degrees at 1 year posttreatment compared to 6 weeks posttreatment."[59]

Diagnostic Imaging

Diagnosis is made by physical examination. Although there are objective findings *consistent* with Dupuytren disease, there is neither laboratory result, imaging finding, nor a biomarker *unique* to DD. Plain x-rays may be helpful in determining presence and extent of degenerative joint changes or heterotopic ossification of cords.[93] Ultrasound imaging[106] or Doppler ultrasound examination may help identify neurovascular displacement from a spiral cord.[35] MRI can be used to evaluate the cellularity of disease[117] and, in theory, the Luck stage—however, it has not yet been widely adopted for this use.

PERTINENT ANATOMY

Normal Anatomy

DD produces progressive changes in the palmar fascia, its attachments, adjacent subcutaneous tissues, and dermis. Normal anatomy is diagrammed in Figure 4.8.

Palm

The *superficial palmar fascia* lies in a coronal plane deep beneath the palmar subcutaneous tissue and covers a triangular area of the central palm, the proximal corner facing directly proximal. The *palmaris longus* tendon, when present, terminates in continuity with the fibers of this proximal corner. From this common point, four *central bands* of fascia extend distally toward each of the fingers. There is no central band for the thumb. Confluent proximally, these bands separate and diverge at the distal edge of the underlying transverse retinacular ligament, each following the path of the underlying ray. At the level of the distal palmar crease, the central bands are bridged transversely by the *superficial transverse palmar ligament*. At the radial border of the index central band, the superficial transverse palmar ligament is in continuity with the *proximal first-web-space ligament*, which continues to a point roughly superficial to the radial sesamoid of the thumb MCP joint. Although the superficial transverse palmar ligament appears to lie deep beneath the central bands, fibers from the central bands pass above, below, and through it.[49] At this level, each central band branches in the following three directions.

- *Superficial fibers* track superficially to merge with vertical retinacular fibers at the undersurface of the dermis in the distal palm in areas between skin flexion creases, where nodules commonly arise.
- *Intermediate fibers* split transversely into two sections, which extend toward the lateral border of the base of the digit. This track of fibers is called the *spiral band* because fibers track *around* the neurovascular bundle: proximally, they are central and superficial to the bundle; distally, lateral and deep beneath it. Neurovascular spiral bundles result from involvement of these fibers.
- *Deep fibers* continue dorsally to merge with the sagittally oriented interosseous fascia and pierce the transverse MP ligament to merge with fibers of the sagittal bands of the extensor mechanism. These fibers are rarely involved in contractures.

Web Spaces

A subdermal fascial layer borders the periphery of the web spaces from thumb to little finger. Fascial fibers follow the direction of this layer. The section of this structure spanning the fingers is referred to as the *natatory ligament*; its continuation across the first-web space is referred to as the *distal first-web-space ligament*. It crosses the thumb to join fibers of the proximal first-web-space ligament over the radial sesamoid area. Fibers from the natatory ligament extend distally at the lateral base of each finger in continuity with the Grayson ligament and the lateral digit dermis.

Digits

Contradictory descriptions exist of the digital fascia anatomy because of difficulties inherent in dissecting fascial structures in the digits[119]: fibrous strands less than 1-mm thick follow oblique curved paths; distortion from release of skin attachments are needed for exposure; distortion when fingers preserved in flexion are later straightened for dissection. Zwanenburg et al.[119] recently reported a clarification of anatomy, as shown earlier in Figure 4.8. The digital neurovascular structures are circumferentially enveloped within thin layers of fascia.

The traditional name for components of this envelope *dorsal* to the neurovascular bundle is *Cleland ligament*, and the traditional name for components *palmar* to the neurovascular

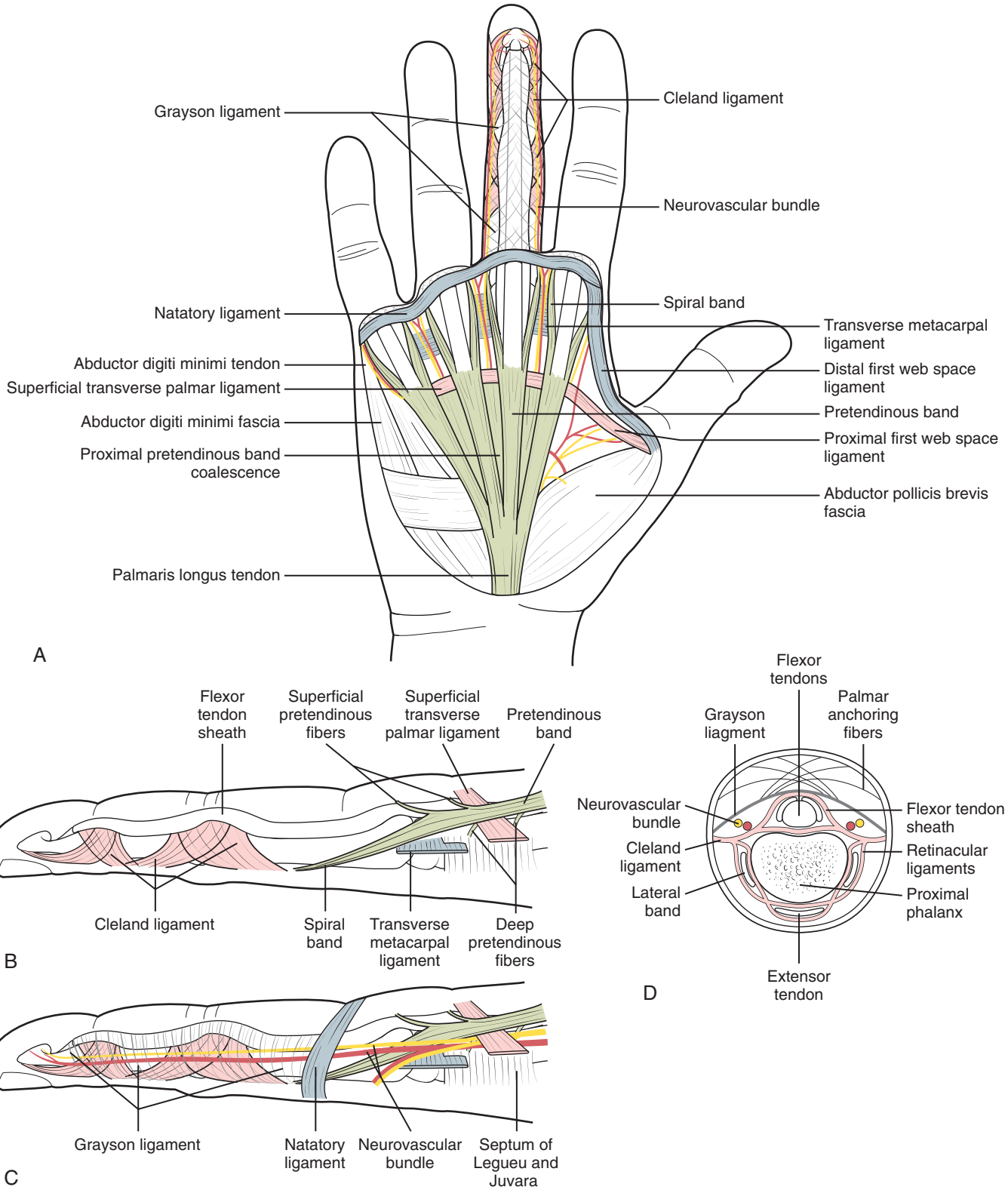

FIGURE 4.8 Normal fascial anatomy. **A,** Palmar view of structures beneath skin and subcutaneous tissues of the palm and finger. **B,** Lateral view of the deeper structures of the distal palm and finger. **C,** Lateral view of the more superficial structures of the distal palm and finger. **D,** Axial cross sectional view of finger proximal to the proximal interphalangeal joint.

bundle is *Grayson ligament*. These "ligaments" are actually a loose meshwork of multiple layers of crossing oblique curved fibers. There is a common zone of origin of these fibers in continuity with the retinacular ligaments of the fingers, the floor of the flexor tendon sheath, and the network of retinacular fibers that attach to the palmar digital skin. On the ulnar border of the small finger, this pattern of lateral fascial attachments continues in continuity with the abductor digiti minimi fascia and tendon.[114] What has been described in the digits as the *retrovascular band* is actually a dissection artifact created by releasing skin attachments of this lateral fascial complex.

PATHOLOGIC ANATOMY

Primary Pathology

Core elements of Dupuytren biology are shared with other fibrotic diseases: myofibroblasts, collagen, cytokines, and mechanical stress on the extracellular matrix. *Nodules* are the most active sites of this process. Nodules arise on the palmar surface of the fascia in areas where shear forces from gripping are resisted by retinacular fibers that anchor dermis to fascia and result in local mechanical strain. Typical light microscopic changes are described in the earlier discussion of the Luck classification. The known process begins as fibroblasts in an extracellular matrix subjected to mechanical stress and in the presence of TGFβ1 differentiate into myofibroblasts.[110]

Myofibroblast gene expression results in the appearance of new intracellular α-SMA microfilaments, large cell-matrix attachments, and intercellular junctions. Cell-matrix attachments (focal adhesions) of collagen strands to myofibroblast cell membranes signal myofibroblasts to contract in response to mechanical stress on the extracellular matrix. Individual collagen strands are folded by myofibroblast contraction, and extracellular matrix enzymes crosslink across these folds[15] (Figure 4.9).

This process progressively shortens the extracellular collagen matrix at a rate up to 1 cm/month and stiffens the extracellular matrix through collagen crosslinking.[15] The stiffened matrix transmits mechanical forces to adjacent tissues, which then undergo the same process. Under normal conditions, myofibroblast presence is temporary, limited by myofibroblast dedifferentiation or apoptosis triggered by loss of mechanical and cytokine stimulation. However, in DD, myofibroblasts persist through periods of diminished stimulation. The mechanism by which myofibroblasts resist apoptosis remains unknown.

It is believed that cords develop as a reactive process along lines of mechanical stress in susceptible tissues.[60] The reason for individual susceptibility is unknown, but the profile of Dupuytren-type abnormalities found in phenotypically normal areas of palmar fascia prior to clinical disease include abnormally increased levels of type III collagen,[11] abnormal mechanical stress–strain curves,[74] abnormal tension-related contraction,[10] DNA alterations,[97] and some,[95] but not all,[88] Dupuytren-related gene expression markers.

Mechanical[10] and gene expression[111] characteristics of nodules, cords, and macroscopically normal palmar fascia in

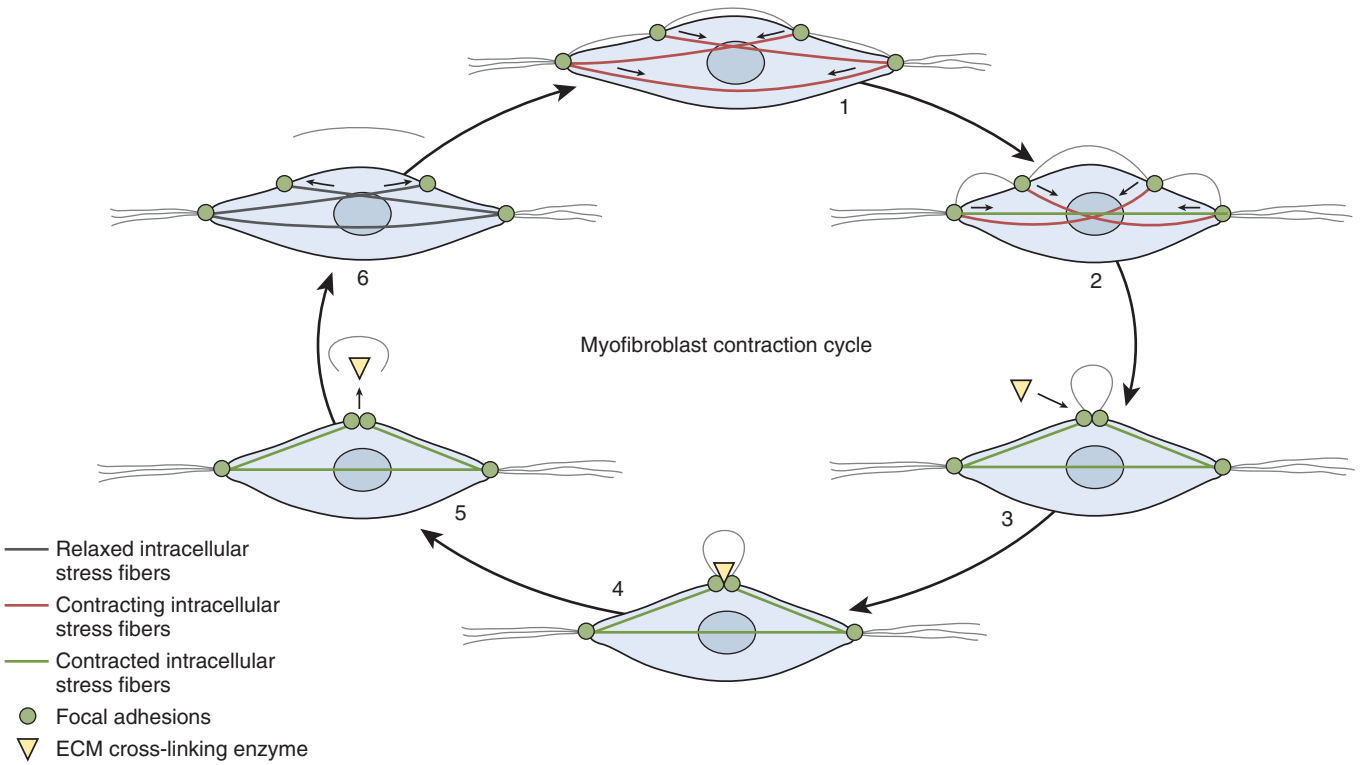

FIGURE 4.9 Myofibroblast cycle of extracellular matrix (ECM) remodeling.[15] Relaxed (*green lines*) and contracting (*red lines*) intracellular stress fibers are joined to extracellular collagen strands via focal adhesions (*green circles*) in the cell membrane. *1:* Mechanical stress on the ECM triggers global contraction of all stress fibers. *2:* This generates slack in individual collagen strands along lines of mechanical tension. *3:* The slack collagen strands are repositioned by individual stress fibers, creating a loop. *4:* ECM crosslinking enzymes (yellow triangle) join the base of the loop and trim the redundant strand. *5:* The strand is released into the ECM. *6:* The shortened strand then stress shields the stress fibers, allowing the cell to return to its prior state and repeat the cycle.

Dupuytren patients are all abnormal, but to different degrees. There is growing understanding of the biomechanics of fascial response to strain,[96] age,[61] and the cause-and-effect relationships of type III collagen to DD. The starting point could be the abnormal presence of type III collagen, mechanically different than type I, triggering abnormal mechanoregulatory stimulation of gene expression. Alternatively, the priming event might be abnormal mechanoregulation of gene activation resulting in overexpression of type III collagen.[51]

Patterns of contracture may have more to do with collagen crosslinking than myofibroblast contraction. Some locations (i.e., distal palm, palmar digit) produce clinical contractures, but other common locations (i.e., DDN, Ledderhose) do not, despite the fact that biopsy tissue from each contracts similarly in vitro. A possible explanation is that Dupuytren biology fixes tissues in their resting position.[72] The biology of collagen deposition and remodeling is activated by mechanical stress, but then continues during periods of rest. At rest, activated myofibroblasts and collagen crosslinking enzymes in the extracellular matrix shorten redundant collagen fibrils. At rest, this process remodels collagen length to match the resting dimension—similar to contracture of the PIP volar plate, which occurs after injury and prolonged flexion.

Such a process would be expected to produce contractures resembling the resting posture of the hand—flexion and adduction—which is what is seen in the vast majority of cases. It would also explain why knuckle pads and Ledderhose rarely develop contractures, because the IP joints rest in flexion and the metatarsophalangeal joints of the toes rest in extension.

Most patterns of DC can be explained as transformation of existing fascial structures through Luck's stages into fibrous cords, guided by stress and stress shielding. In the process of cord formation, there is a reorientation of collagen fibers parallel to lines of mechanical stress. Any palmar fascial structure subjected to mechanical stress may contribute to Dupuytren cords. Stress shielding reduces the risk of contracture of certain locations, some of which have only minimal case reports of involvement. Structures rarely involved because of stress shielding include the Cleland ligament (shielded by adjacent phalanx); longitudinal fibers deep beneath the transverse superficial palmar ligament (shielded by the central band); transverse superficial palmar ligament (shielded by the transverse metacarpal ligament); and the septa of Legueu and Juvara (shielded by adjacent metacarpal). Stress shielding also provides the endpoint for disease progression.

As contractures progress, stress shielding from lack of use or from secondary capsuloligamentous joint contractures permanently removes mechanical stress from the cord; in the end, this allows myofibroblast apoptosis and progression to the final, involutional, static stage of disease.[112]

Common cord patterns are shown in Figure 4.10. Cords may be confined to the palm, the digit, or span both. Unlike cords

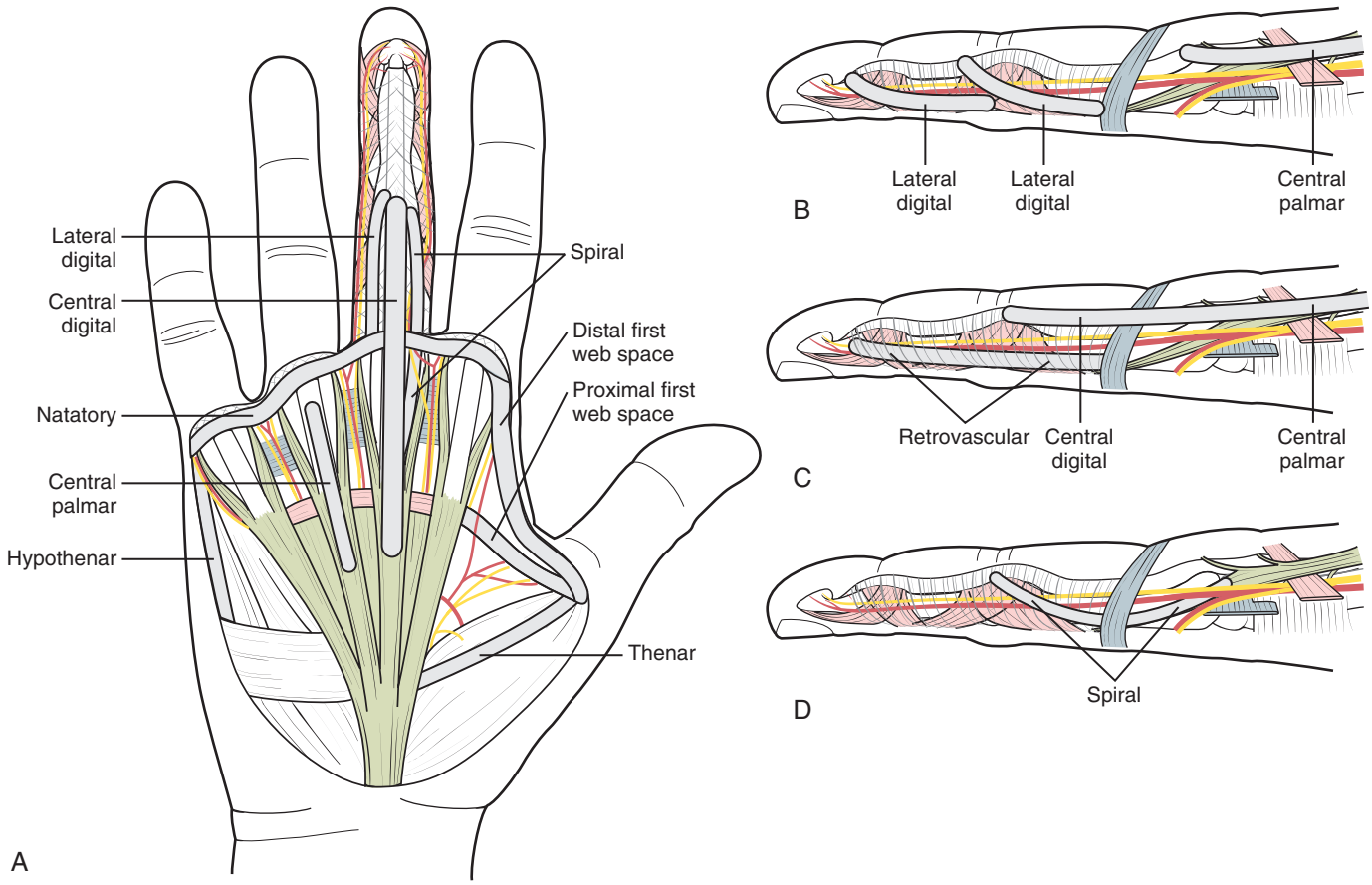

FIGURE 4.10 Common cord patterns. **A,** Central digital, central palmar, distal first-web space, hypothenar, **(B)** lateral digital, **(C)** retrovascular, **(D)** spiral.

that arise in the palm, cords isolated to a digit may have both proximal and distal bony attachments, making them more difficult to palpate.

Common *central palm cords* are *central palmar*, *spiral*, and *proximal first web*. Common *border palm cords* are *natatory*, *distal first web*, *hypothenar*, and *thenar*. Thenar and hypothenar cords are uncommon and are usually associated with diffuse disease or aggressive biology. The majority of MCP joint contractures are a result of the effect of an isolated central cord. In contrast, the majority of PIP contractures are due to multiple *digital cords*, which, in order of frequency, are *central digital*, *retrovascular*, and *spiral* or *lateral.*[105] Multiple cords can exist at the same longitudinal level in either palm or digit.

Secondary Pathology

Over time, flexed posture results in anatomic changes of joints and tendons independent of the causative cord. These issues are more likely to develop with more severe primary contractures. The PIP joint is particularly vulnerable to such changes. Contractures of the accessory collateral ligament are more common in PIP joint contractures greater than 45 degrees.[105] Central slip attenuation contributes to extension deficit for PIP contractures greater than 60 degrees,[98] which are less likely to achieve full correction than those with less severe contractures.[75] Boutonnière, sagittal band rupture, or mallet deformity may develop secondary to chronic contractures. Sagittal band rupture can be difficult to diagnose in the context of a fixed MCP flexion contracture, but a key clue is MCP abduction–supination in the absence of a responsible palmar cord. Chronic rotational or lateral deformities from digital cords often persist after treatment of the primary disease.

Synergistic Pathology

Postural abnormalities from prior injury, chronic flexor tendinitis, osteoarthritis, peripheral neuropathy, intrinsic weakness, or mild spasticity are common in the senior demographic population and must be kept in mind in evaluation because they affect outcome expectations. Dupuytren disease is less common in rheumatoid patients,[2] but it can coexist. This author has seen all of these conditions concurrent with DC, often not previously diagnosed.

Neurovascular Spiral Bundle

A neurovascular spiral bundle (i.e., spiral cord, or spiral nerve) is common in DC. Tissues that form a cord may initially describe a longitudinal path that spirals around a straight neurovascular bundle (see Figure 4.10). When this path tightens and straightens, the neurovascular bundle is displaced into a spiral path, raising a section of the bundle into a subcutaneous position that is superficial to the cord. If the neurovascular fat pad surrounding the bundle is displaced as well, this presents as an area where a palpable subdermal cord passes beneath a soft subcutaneous mass beneath soft skin. Such a finding is associated with a spiral bundle in the majority of cases, but lack of this finding is not predictive of absence of a spiral bundle.[108]

Spiral bundles have been reported in nearly half of Dupuytren finger contractures.[108] Superficial displacement is most common between the distal palmar crease and the flexion crease of the PIP joint. Variations occur, including cords that pass between the digital nerve and a dorsal branch, double spirals,[45] and spirals at the level of the middle phalanx. Spiral bundles are at risk for inadvertent injury during open or percutaneous procedures.

Little Finger PIP Joint

Little finger PIP joint contractures have a worse prognosis and higher recurrence rate than other PIP joints, independent of surgical technique. Abductor digiti minimi (ADM) tendon involvement, common in little finger contractures, is *not* an independent risk factor for either inferior outcome or higher recurrence,[113] and similar intrinsic tendon involvement can occur in any digit. ADM fascia involvement may explain loss of little finger supination frequently seen by this author with mild contractures.

HISTORICAL REVIEW

Percutaneous fasciotomy and open fasciotomy were the most common procedures performed for DC in the early 1800s. Fasciectomy became the dominant procedure in the late 1800s, facilitated by the introduction of general anesthesia and then sterile technique. Radical fasciectomy, developed in the early 1900s, became the recommended procedure until the mid-1900s, when it became clear that it led to more morbidity but was not more effective. A trend to conservative treatment followed, paralleling development of minimally invasive techniques in all surgical specialties. Percutaneous needle fasciotomy and enzymatic fasciotomy, both pioneered in France during the mid-1900s, entered the mainstream of US practice in the early 2000s. As of this writing, fasciectomy is the most common procedure performed in the United States for DC, and by extension is the current standard of care. Additional historical data points are listed in Table 4.2.

TYPES OF OPERATIONS

Current treatments fall into four categories: minimally invasive, fasciectomy, dermofasciectomy, and salvage. Choice is based on the desires of both patient and surgeon. All existing DC procedures are palliative and prone to recurrence. The following are three unsolved issues with Dupuytren surgery:

1. The core *biology* resembles that of wound contracture and can be provoked by the wounding process of fasciectomy. One consequence of this is the postfasciectomy *flare reaction*: disproportionate and prolonged swelling, stiffness and pain, and worsening several weeks after an initially uneventful postop course and continuing for months thereafter. Postfasciectomy flare reaction occurs in about 1 in 10 patients and leads to permanent stiffness in about 1 in 20.[24] Average postfasciectomy edema and stiffness are greater both after more extensive dissection and in overweight patients.[5] Minimally invasive procedures are not commonly associated with flare reaction.
2. The *anatomy* is distorted and some normal tissue planes are obliterated, increasing the risk of iatrogenic neurovascular injury compared to that for other elective procedures. Digital nerve injury has been reported in at least 3% of primary fasciectomy procedures; the risk is more than five times greater in fasciectomy for recurrence.[24]

TABLE 4.2 Historical Points in the Treatment of Dupuytren Contracture

Year	Author	Significance
1614	Plater	Clinical description
1777	Cline	Suggested fasciotomy
1822	Cooper	Percutaneous fasciotomy
1831	Dupuytren	Open fasciotomy
1834	Goyrand	Fasciectomy
1875	Busch	Open fasciotomy and skin graft
1906	Keen	Radical fasciectomy
1908	Ombrédanne	PIP arthrectomy for PIP contracture
1919	Griffith	Fasciectomy and transposition flaps
1919	Davis	Fasciectomy and full-thickness skin graft
1922	Eckstein	Proximal phalanx-shortening osteotomy for PIP contracture
1931	Lexer	Radical dermofasciectomy and full-thickness skin graft
1932	Palmén	Fasciectomy and Y–V-plasty
1948	McIndoe	Fasciectomy and Z-plasty
1957	De Seze and Debeyre	Steroid injection and needle fasciotomy
1959	Luck	Histologic staging
1963	Hueston	Diathesis concept
1964	McCash	Open palm technique
1965	Bassot	Enzymatic fasciotomy with trypsin and other enzymes
1972	Gabbiani	Myofibroblast identified in DC
1996	Moermans	Segmental fasciectomy
2002	Agee	Skeletal extension torque for PIP contractures
2009	Degreef	Tamoxifen reduces recurrence after fasciectomy in high-risk patients
2010	Hurst and Badalamente	CCH approved by FDA as contracture treatment

CCH, Collagenase clostridium histolyticum; *DC*, Dupuytren contracture; *PIP*, proximal interphalangeal.

3. Optimum *timing* of surgery for best outcome is unknown.
   a. Operations should be performed before the severity of contracture compromises the chance of an excellent result, which is about 40 degrees at the PIP joint.[105]
   b. For lesser contractures, defer procedures until the patient has functional problems to minimize the number of lifetime procedures. A commonly recommended window of opportunity is between the tabletop test (cannot place the palm flat on a table) and the pocket test (difficulty slipping a hand into one's pants pocket).
   c. Ideally, avoid treatment during the proliferative phase to reduce postoperative recurrence rate.[4] This parallels historical advice to postpone surgery until disease is no longer "active" (nodular). Unfortunately, activity may persist until contractures are past the point of expectation of a satisfactory surgical result, which explains why there is also traditional advice that contradicts this—that is, to operate if the contracture is rapidly getting worse.

The three procedures for primary disease have similar outcomes in terms of initial correction of deformity[78,81,104] but differ in terms of cost effectiveness, length of recovery, morbidity, and recurrence (Table 4.3). Relative indications for different procedures are listed in Table 4.4.

Patient choice of DC treatment is influenced by social networking. Individuals may seek treatment for early DD because they fear progression or have heard that someone was told by their surgeon that they had "waited too long" for treatment. Conversely, patients may avoid treatment for advanced DC because of fear or have heard of a long, difficult ordeal after fasciectomy. Patients are deterred by the memory of fasciectomy: patients with recurrence after fasciectomy are less likely to opt for repeat treatment than those with recurrence after minimally invasive treatment.[109] Patients who seek treatment but are put off by the prospect of fasciectomy will choose minimally invasive treatment with full knowledge that recurrence rates are higher.

Minimally Invasive Procedures

The most commonly performed minimally invasive procedures are enzymatic fasciotomy and percutaneous needle fasciotomy. These are indicated when the benefit of shorter recovery

TABLE 4.3 Comparison of Various Procedures

Procedure	Cost Effectiveness	Length of Recovery	Most Common Treatment-Specific Complications	Recurrence (%/year)
Needle fasciotomy	Best	Week–weeks	>1%: skin tears <1%: nerve, tendon injury	10–20
Enzymatic fasciotomy	Next best	Week–weeks	>1%: extensive bruising, skin tears <1%: tendon rupture, pulley rupture	10–20
Local fasciectomy, ± skin graft	Worse	Month–months	>1%: prolonged inflammation, delayed healing, nerve injury, loss of flexion <1%: amputation for ischemia	5–10
Dermofasciectomy	Worse	Months	>1%: prolonged inflammation, delayed healing, nerve injury, loss of flexion <1%: amputation for ischemia	2

TABLE 4.4 Indications and Options for Various Clinical Scenarios

Indication	Best Options
Nodule only	Observe *or* steroid injection
Primary presentation + low diathesis score	Minimally invasive procedure
Recurrence + low diathesis score	Repeat initial procedure *or* fasciectomy
Multiple recurrence/severe recurrence	Dermofasciectomy
High diathesis score	Dermofasciectomy
Insufficient longitudinal skin or diffuse skin involvement	Fasciectomy + skin flap/graft *or* dermofasciectomy
Isolated MCP *or* MCP + PIP contracture	Any procedure
Primary isolated PIP contracture	Any procedure
Recurrent isolated PIP contracture	Stronger consideration of skeletal extension torque ± fasciectomy/dermofasciectomy *or* skeletal shortening
Composite contracture < 90 (Tubiana I or II)	Any procedure
Composite contracture > 90 (Tubiana III or IV)	Consider staged procedures: staged releases *or* preliminary skeletal extension torque followed by definitive procedure

MCP, Metacarpophalangeal; *PIP*, proximal interphalangeal.

outweighs the disadvantage of higher recurrence rate. These two approaches have similar outcomes[81] and compared to fasciectomy are similar in terms of length of recovery (shorter), morbidity, complication rate (less), and recurrence rate (greater). (See Video 4.1 for a review of collagenase injection.)

Percutaneous Needle Fasciotomy

Indications. The minimum requirement for percutaneous needle fasciotomy (PNF) is a cooperative patient with joint contracture(s) due to a palpable, tensionable cord with adequate skin reserve.

Contraindications. PNF is contraindicated for patients who cannot tolerate an awake procedure or who have tight skin or scars preventing extension, diffuse skin involvement, lack of a palpable cord, rapid recurrence in a young patient, or healing wounds or infection in the area of the procedure.

Preoperative Planning. PNF can be performed as a single visit office procedure under local anesthesia. Cords are identified by inspection and palpation.

Technique. Local prep and field sterility (as for IV cannula insertion) are used. Needle entry sites ("portals") are injected with *intradermal anesthetic*. A small gauge hypodermic needle is inserted through a portal and, with the cord maintained under tension, the needle tip is used to progressively sever cord fibers until the cord "gives" at that level. The procedure is then repeated for all areas of palpable cords, ideally in a distal to proximal sequence. Nerve status and tendon status are checked repeatedly throughout the procedure.

After all palpable cords have been released, final passive extension is performed and light bandages are applied. The patient may discontinue bandage use when wounds are dry, usually the same day. The other hand can be treated the following day. Neither therapy nor splinting is routinely used. Strenuous gripping and forceful use of the hand are to be avoided for 1 week.

Enzymatic Fasciotomy With Collagenase Clostridium Histolyticum

Indications. Indications are the same as for PNF.

Contraindications. Collagenase clostridium histolyticum (CCH) is contraindicated for patients with a history of severe allergic reaction to CCH or to collagenase used in any other therapeutic application or application method. The safety of CCH is unknown in patients who are pregnant, plan to become pregnant, are breastfeeding, plan to begin breastfeeding, have a bleeding problem, have other medical conditions, are on any anticoagulant medications, or are less than 18 years old.[116] Otherwise, contraindications are the same as for PNF.

Preoperative Planning. CCH injection is performed over the course of two closely spaced office visits, typically 2 consecutive days per hand, with additional injections spaced a minimum of 30 days apart. An area of clearly palpable cord responsible for a specific joint contracture is chosen for injection. For the little finger, the manufacturer recommends limiting needle penetration to a maximum depth of 3 mm and avoiding injection more than 4 mm distal to the palmar flexion crease at the base of the finger. The drug must be maintained under constant refrigeration until use.

Technique. Of all procedures, CCH is the easiest and least time-consuming option for the surgeon. CCH is reconstituted with the accompanying diluent solution immediately before use according to package directions. Using a sterile technique, the central substance of the chosen cord segment is injected at three closely spaced points with the recommended dose of the reconstituted drug. After injection, the hand is wrapped in a soft immobilizing bandage. The patient is instructed to keep the hand elevated and avoid moving the fingers until the next office visit. Manipulation is performed by the physician on postinjection days 1 through 4, optionally using local anesthetic. The patient is then fitted with a static extension splint to wear for 1 month while sleeping, given a set of active range-of-motion exercises to perform during the day, and instructed to avoid strenuous activities with the treated hand until instructed otherwise, usually after several weeks.

Open Surgical Procedures

Fasciectomy

There are two current approaches to fasciectomy. *Segmental fasciectomy* involves minimal dissection to remove short segments of cords. *Regional fasciectomy* (also called local fasciectomy) is removal of all diseased fascia. Currently, segmental fasciectomy is more popular in Europe than in the United States. These two procedures have similar outcomes.[76] *Radical fasciectomy* is removal of *all* palmar fascia, including paratendinous septa, subcutaneous and subfascial fatty tissue, and fat pads of the palmar monticuli. Radical fasciectomy is no longer recommended because of greater morbidity and lack of any

TABLE 4.5 Comparison of Fasciectomy Technical Options

Technique		Pros	Cons
Incision	Longitudinal zigzag (either primary zigzag or straight incision converted to zigzag with Z-plasties at closure)	Most extensile exposure for a single ray	Greater risk of marginal wound ischemia; challenging for multiple adjacent rays in palm
	Transverse	Wide exposure for adjacent rays in the palm; closure optional; can be converted to zigzag	Visibility more challenging; not extensile
	Combined: finger zigzag + transverse palm	Most extensile for multiple rays	No advantage for single ray
Adding skin	Local flap (Z-plasty, Y–V-plasty)	Lowers recurrence vs. longitudinal closure[19]	Risk of flap loss
	Regional flap (homodigital lateral digit, cross finger)	More durable than skin graft	Limited donor sites
	Skin graft addition for closure	Allows closure	Doesn't change recurrence rate, requires immobilization
	Dermofasciectomy: skin excision and replacement with skin graft	Lowest recurrence rate[12,103]	Longest recovery
Ligament or pulley release	Flexor tendon sheath	May avoid need for joint release	May require coverage: FTSG if <1 cm^2, flap, or dermal substitute followed by skin graft
	Accessory collateral	Does not destabilize joint	Does not correct the dorsal joint changes that result in early recontracture
	Checkrein/volar plate	Often allows full intraoperative correction	Same as ACL and destabilizes joint, risks postop snapping swan neck
Immobilization	Delayed until a few days postop	More comfortable	Not applicable for skin graft
	Intraoperative splint	Stabilize skin graft	May increase risk of flap or wound-margin ischemia
	PIP transarticular pin	Stabilize skin graft spanning PIP joint	Does not improve outcome of joint release[8]
Closure	Open	Less pain	Appearance stressful for some patients
	Closed	Shorter bandage duration	Suture removal; increased risk of marginal necrosis

ACL, Anterior cruciate ligament; *FTSG*, full-thickness skin graft; *PIP*, proximal interphalangeal.

additional benefit. Relative indications for different technical choices in fasciectomy are listed earlier in Table 4.5.

Indications. Fasciectomy is indicated for failed minimally invasive treatment, for diffuse disease, for concurrent treatment of secondary pathology, or surgeon/patient preference.

Contraindications. Fasciectomy is contraindicated for patients for whom a long operation, a long recovery, or proper postoperative therapy is not possible. Segmental fasciectomy is contraindicated for cases in which skin shortage itself is severe enough to limit extension or if treatment of secondary pathology requires wide exposure. Regional fasciectomy is contraindicated for hands that have diffuse skin tightness or skin shortage greater than what local flaps could be expected to correct. Dermofasciectomy and skin grafting should be considered for such cases and for patients with a high diathesis score.

Preoperative Planning. Fasciectomy is performed as an outpatient procedure in a surgical setting. The procedure is performed either under general or regional anesthesia with tourniquet control or use of the wide awake local anesthetic no tourniquet (WALANT) technique. Provisional incisions should be considered for skin graft, lateral digital, or cross finger flap coverage of exposed flexor tendons in the event that a flexor tendon sheath breach results in a large area of exposed flexors that cannot be covered by primary wound closure. An alternative is to have available acellular dermal matrix to cover exposed tendons, followed by skin grafting as a secondary procedure.[34] Splinting is scheduled for fabrication during the first postoperative week.

Technique

Segmental Fasciectomy. This is performed using multiple short transverse or longitudinal "C"-shaped incisions (Figure 4.11). If nodules exist in continuity with cords, incisions are planned directly over the nodules. Otherwise, incisions are centered over points of maximum cord bowstringing. Nodules and cord segments are excised through these incisions to restore extension. No attempt is made to remove all cord pathology. The skin is closed, and a soft bandage is applied.

Regional Fasciectomy. This is performed through either longitudinal, longitudinal zigzag, or transverse incisions. Combinations of incisions are used for exposure of multiple fingers that converge in the palm (see Figure 4.11). Local flaps (Z- or Y–V-plasty) can be incorporated into the primary skin incisions (Figure 4.11). Incisions can be either contiguous or separate, but deep dissection is contiguous across the entire length of each excised cord and all visibly diseased tissue is removed. Helpful tips to minimize neurovascular injury consequences include the following:

- Search for spiral cords preoperatively.
- Transect cord(s) proximally to allow extension and improve early exposure.
- Follow neurovascular structures from uninvolved areas—proximal, distal, or retrovascular[66]—toward the diseased areas ("known to unknown").
- Use sharp rather than spreading (tearing) dissection: neurovascular structures will tear before cords.

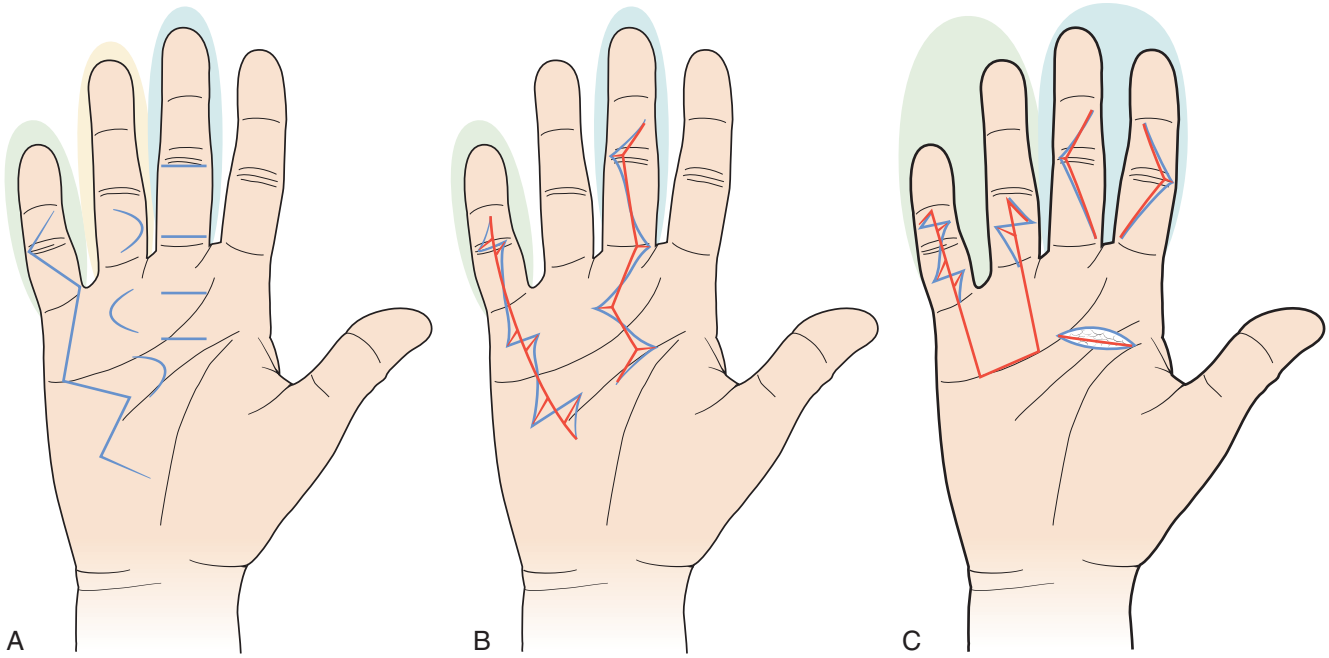

FIGURE 4.11 Common fasciectomy incisions. For flaps, initial incisions are red; blue lines are final closure. **A,** Incisions without skin rearrangement: zigzag (*little finger*), C (*ring finger*), transverse (*middle finger*); the C and transverse incisions are typical for segmental fasciectomy. **B,** Z-plasty (*little finger*), Y–V-plasty (*middle finger*). **C,** Combined incisions for multiple fingers: in continuity, with closure (*ring and little fingers*), discontinuous, with open palm technique (*index and middle fingers*).

- Don't skeletonize or strip the fat from the neurovascular bundles.
- Have microvascular equipment and microscope available.

Longitudinal incisions should always be converted to zigzag ones using Z-plasties at the time of closure. Zigzag incisions and flap insets are sutured. The *open palm* method is regional fasciectomy through transverse incisions, which are not closed, healing by wound contracture over the next 3 to 4 weeks.

Following this principle, transverse incisions or transverse limbs of zigzags may be closed or left open. Flaps or grafts may be used to achieve full closure, but the addition of small gap-filling skin grafts do not improve early outcome or later recurrence rates.[107] Splints are incorporated into the operative dressing to protect skin grafts; transarticular PIP joint pins may be placed to immobilize grafted joints. Otherwise, only a soft bandage is applied and splinting is initiated during the first postoperative week.

Dermofasciectomy

Dermofasciectomy is not simply fasciectomy augmented with skin graft, but rather functional unit replacement of skin and regional nonessential palmar soft tissues with full thickness skin graft. Recurrence rates are lower for dermofasciectomy than fasciectomy.[12] Replacement of skin with full thickness skin graft both changes soft tissue mechanics and inhibits myofibroblast activity.[91] Duration of recovery after dermofasciectomy averages 50% longer than fasciectomy.[103]

Indications. Dermofasciectomy is indicated for:

- Longitudinal skin shortage beyond the capacity of local flaps to correct
- Recurrent contracture with diffuse skin involvement or extensive scarring
- Skin irretrievably devascularized during surgery
- First procedure in selected young patients with strong diathesis profile

Contraindications. Dermofasciectomy is contraindicated in patients for whom a long operation, a long recovery, or proper postoperative therapy is not possible and in patients for whom skin grafting is not advisable.

Preoperative Planning. Setting and anesthesia are the same as for fasciectomy. In primary dermofasciectomy, skin excision in the palm is planned as a truncated ellipse centered over the distal palmar crease, and in the fingers as a rectangular palmar hemicircumference of the pulp space (Figure 4.12). Incisions can be left separate or connected with access incisions planned in tension-free lines for wide extensile exposure. Plans are modified as needed to incorporate scarred or shortened skin. If possible, skin graft is avoided over the palmar prominences of the metacarpal heads to avoid durability and sensitivity issues.

Incisions are planned such that the healed junctions of graft and normal skin will follow tension-free lines. *Full thickness* skin graft donor sites are planned in hairless areas, if available (e.g., the proximal medial ipsilateral forearm or the groin crease lateral to the femoral triangle). Full thickness skin grafts may be used to cover up to 1 cm^2 of exposed flexor tendon if the periphery of the graft lies on a well-vascularized bed. Larger areas of flexor tendon exposure should be covered with a local flap or acellular dermal matrix, as described for fasciectomy.

Technique. Dermofasciectomy as a primary procedure is styled after regional fasciectomy with wide extensile exposure. Dermofasciectomy for recurrence after fasciectomy can be performed similar to segmental fasciectomy, limiting exposure to the areas planned for excision, avoiding dissection through scarred tissues other than as needed for exposure for skin

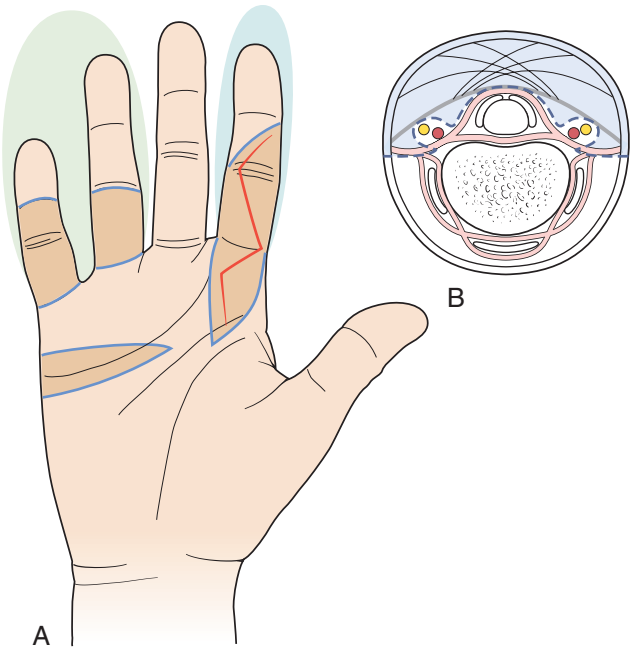

FIGURE 4.12 Dermofasciectomy variations. **A,** Segmental replacement (*ring and little fingers*), extensile, excising prior scarred skin (*index finger*). **B,** Block of tissue excision including Cleland ligaments for digital dermofasciectomy.

excision. In the digit, all lateral digital fascia including Cleland ligament tissues are excised (see Figure 4.11). For little finger involvement, the abductor digiti minimi fascia is also excised.

After all zones of skin replacement are excised, the tourniquet is released, hemostasis is achieved, vascularity is confirmed, and access incisions are closed. Transarticular PIP joint pins can be placed to immobilize grafted joints. Skin graft templates of the defects are then created and used to plan and harvest full thickness skin grafts. After donor site closure, skin grafts are inset, and the hand is bandaged, incorporating a resting splint.

Special Cases

Dorsal Dupuytren Nodules. Most DDN do not require treatment, but occasionally are tender, painful, or a cosmetic concern. They may tether the extensor mechanism, limiting flexion, or they may spontaneously regress. Steroid injections are particularly helpful for relieving symptoms of pain, tenderness, and extensor tightness, for example, 5 mg triamcinolone or equivalent using a lateral approach, angling the needle tangential to the skin, aiming for the center of the nodule. Steroid injections have a high response rate, but also at least 50% recurrence and a common finding of temporary poststeroid pink shiny skin at the injection site. Because there is no plane between the extensor mechanism and the similar appearing nodule tissue, attempts at excision risk extensor tendon injury with secondary boutonnière. Most patients do well after excision, but recurrence or persistent tenderness is common. DDN excision is indicated only in selected cases.

Severe PIP Contracture. Fixed PIP contractures greater than 60 degrees are often associated with secondary extensor mechanism laxity, capsuloligamentous tightness, and flexor tendon sheath tightness. Surgery often results in palmar skin tightness even if scars are well planned. Treatment of severe PIP contractures with inadequate palmar skin reserve requires either *soft tissue lengthening* or *skeletal shortening*.

A staged approach with preliminary *skeletal extension torque* followed by fasciectomy or dermofasciectomy has been shown to have better outcomes than single-stage release and fasciectomy.[20] Boutonnière associated with severe recurrent PIP contractures is most predictably managed with DIP arthrodesis in addition to treatment of the PIP contracture. Skeletal shortening (i.e., PIP arthrodesis, middle phalangectomy, amputation) (Figure 4.13) is an option when soft tissue lengthening is not possible. PIP arthrodesis is predictable, but results in a flexion arc mismatched with the rest of the fingers. *Middle phalangectomy* constructs an IP joint between proximal and distal phalanges, which maintains a normal flexion arc at the PIP level.[102]

Amputation is an option for patients who have failed results with other options. DC is the most common indication for elective finger amputation, and has high patient satisfaction for those who request, rather than simply consent to the procedure. If amputation is selected, *ray amputation* is indicated for combined PIP + MCP contractures, and *PIP disarticulation* is appropriate for isolated PIP contractures with full MCP extension. *PIP implant arthroplasty* and fasciectomy has been reported as a salvage procedure, but has not achieved popularity. Middle phalanx extension osteotomy is not recommended; the author's experience is that gains made by osteotomy are negated by additional joint flexion, which simply reduces the flexion arc without improving extension.

Severe Composite Contracture. Composite MCP + PIP contractures greater than 135 degrees (Tubiana stage IV) present unique problems beyond secondary joint and tendon changes.

Skin maceration is common and may not be obvious without thorough examination. If present, the affected areas should be treated to reduce risk of postoperative infection. An effective routine is cleansing with rubbing alcohol, using cotton-tipped applicators for inaccessible areas, and drying with a thin towel and a hair dryer set on cool, four times a day for several days preoperatively.

Limited access to the digits may be addressed in stages, first to open the palm and MCP joints and second to treat the digits 3 months later. This approach is appropriate for both open and minimally invasive procedures and may be necessary for intractable skin maceration. Alternatively, PNF may be used as a first step to improve exposure for fasciectomy at the same setting.[36]

Cortical reorganization may occur with chronic severe contractures. In such cases, when the patient attempts to straighten his or her fingers, the "reorganized" digits actively flex as the others actively extend. Functionally, this mimics amputation—an improvement for fingers that otherwise only extend enough to be a nuisance. This is a contraindication to treatment aimed at restoring function of the affected digit(s).

❖ AUTHOR'S PREFERRED METHOD OF TREATMENT

PNF is the least expensive and least complicated treatment option, and has high patient satisfaction. PNF should be considered as the first intervention for Dupuytren disease in patients with a low diathesis score for whom a shorter recovery is more important than early recurrence. PNF can be performed as an office procedure and does not require changes in medication or diet. With proper planning, it may be performed at the

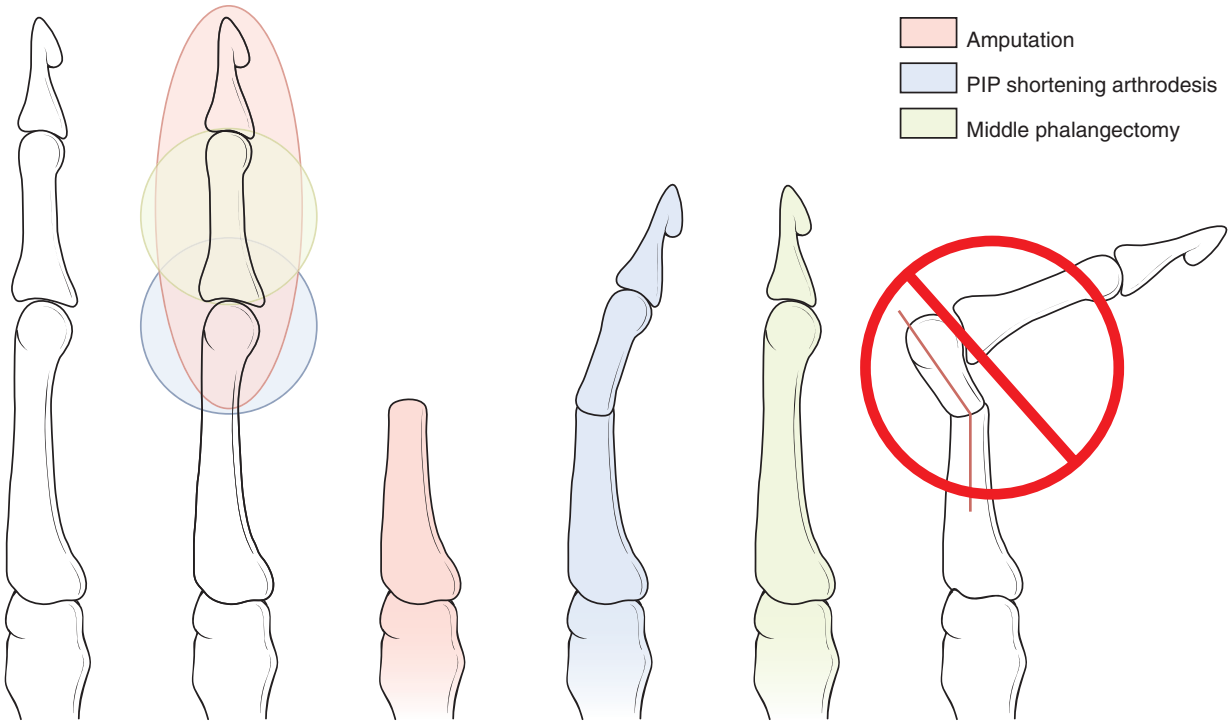

FIGURE 4.13 Skeletal-shortening procedures for severe recurrent proximal interphalangeal (PIP) contractures includes amputation (*red*), PIP-shortening arthrodesis (*blue*), and middle phalangectomy (*green*). Extension osteotomy (*far right*) results in increased PIP joint flexion, which limits its usefulness.

time of the patient's first office visit and does not require scheduled follow-up.

Patient Instructions

Before the Procedure

If PNF is planned for the first office visit, patients should have a previsit screening to confirm suitability for PNF. For patients traveling to have PNF on their first office visit, the diagnosis of Dupuytren contracture and suitability for PNF should be assessed by having them send or email images of their hands for review prior to booking a date. When setting a procedure date, patients should be instructed that on arrival, the hand to be treated must be free of recent or healing injuries; they should plan to avoid strenuous gripping for 1 week postprocedure. Prior to the office visit, rings should be removed from affected fingers. Patients who normally take an anxiolytic medication for routine dental work should plan to do the same for this procedure.

During the Procedure

Best results require the patient to follow these guidelines as an active participant during the procedure.

1. Patients should be instructed to consciously relax their fingers while you are working. This aids your ability to palpate tethering cords and avoids bowstringing the flexor tendons in the areas where the work is being done.
2. Patients should be instructed to report any uncomfortable sensations and to describe both their location (whether it's where the needle is or out at the fingertip) and quality (sharp vs. electrical). This will help you assess whether or not the sensation represents digital nerve stimulation from needle proximity.
3. Patients should be instructed and asked to demonstrate "scratching" movement (short arc active finger flexion and extension), as you may ask them to do this again during the procedure to check proximity of the needle to flexor tendons. This also serves as a preoperative check for active finger flexion, which might otherwise be missed in the evaluation of a severe contracture or boutonnière deformity.
4. Patients should be asked to alert you if at any point they feel any numbness or tingling during the procedure.

After the Procedure

Expectations discussed with the patient prior to the procedure should include the following. The patient should remove bandages the same day to prevent maceration. Skin tears occur in a minority of patients, but on occasion can be dramatic. Skin tears are managed with bandages changed frequently enough to avoid maceration and can be expected to heal within a week or two. Patients are encouraged to chill and elevate the operated hand for the first 36 hours after the procedure. Strenuous or sports-related gripping should be avoided for 1 week, including golf, tennis, biking, rowing, gripping during weight training, push-ups, pull-ups, shoveling, and so on. It's important to be very specific about this because there is often little or no pain with these activities, but they may provoke a delayed inflammatory reaction that can mimic infection and may last for days.

Typical immediate outcome is up to 90 degrees improvement of composite (MCP + PIP) extension and an average of 50% improvement of PIP extension. It is common for partial corrections to improve for several months after release, with or without splinting. Recurrence significant enough to require a repeat procedure occurs at a rate of 8% per year.[68] Repeat

procedures are usually possible and reasonable if the initial release worked well, the release lasted at least one year, the recontracture is due to a palpable cord, or adequate skin reserve remains. Repeat release can be expected to result in similar improvement as the prior release, with some diminishing returns and less predictability. There are no clear data to either support or discourage splinting after PNF. Soft indications for splinting include preoperative isolated PIP with MCP hyperextension, preoperative composite contracture of 90 degrees or greater, postoperative extensor lag, and patient request.

Planning

Planning Portals

Ideal needle entry areas are over tensionable cords palpable beneath mobile skin. Portals may be marked preoperatively or intraoperatively. Single portals are best planned directly over the most prominent area of the cord. Dual portals on each side of the cord are used for broad cords in the palm and for bowstringing lateral digital cords to improve safe access, and in areas where skin tethering is thought to pose an increased risk for skin tear. Avoid planning portals in areas of poor skin reserve, including areas in which the skin blanches on stretch. Avoid portals in areas of skin tethering from skin creases, scars, dimples, or nodules.

Some nodules resemble cords, but can be distinguished by lack of softening when the finger is flexed. Cords may have nodular involvement, and it may not be possible to avoid nodules altogether. Portals proximal to Kaplan's line should also be avoided if possible because this area may remain sensitive for weeks, similar to "pillar pain" after open carpal tunnel release. Proximal or distal interphalangeal portals are planned a few millimeters offset from the flexion creases, and oblique needle paths may be used to detach the crease dermis from the underlying cord, which improves release gains and reduces the chance of a crease tear.

Dimples

Skin dimples are due to traction from retinacular fibers attached to contracted cords. The depth of dimples should be confirmed by direct inspection or with the use of a probe. A disposable dental floss passer works well as a probe and can be used as a dipstick: povidone iodine is placed into the dimple, and the level of iodine remaining on the withdrawn probe indicates depth. Dimples may be associated with deep needle sensitivity, as discussed in the following. Dimple sinuses may extend deep and follow a path tangential to the skin, posing a risk for transection by needle release adjacent to the visible dimple.

Digital Cords

The biggest concern in treating digital cords is the location of the neurovascular bundle. In most cases, the neurovascular bundle lies deep beneath cords at the PIP joint. Away from the PIP joint, the neurovascular bundle usually lies central to lateral and spiral cords and lateral to central cords[70] (Figure 4.10). Doppler ultrasound is useful in this context.

Spiral Bundles

Spiral bundles should be suspected if there are areas in which a subdermal cord is in continuity with a cord segment lying beneath bulky subcutaneous tissue. The vascular pulse of a spiral cord is occasionally palpable, and the displaced digital nerve is occasionally tender to firm, direct pressure while passively tensioning the cord. Doppler probe is a more definitive examination tool of these fleshy areas and should be pointed to areas where the neurovascular bundle should not normally lie. For example, the Doppler tip may be angled tangential to the skin to listen to areas more superficial than the normal course of the neurovascular bundle. Portals should not be used at the direct level of an identified spiral cord, but taking advantage of the spiral anatomy, may be planned 8 to 10 millimeters proximal or distal to the area in which the bundle has been identified as most superficial. Ultrasound imaging may also be useful in this context.

Procedure

Positioning

During the procedure, the patient may rest in a supine or semirecumbent position. If the patient is seated, there should be a simple mechanism to either have the chair recline or transfer the patient to a supine position in the event of a vasovagal reaction.

Assistance

Because sterile gloves are not required, this is not mandatory, but an assistant is helpful.

Antisepsis

Immediately prior to the procedure, the patient should wash his or her hands to clean and degrease the skin. The procedure may be performed using *field sterility*, similar to starting an intravenous line. The area of interest is prepped with a povidone iodine solution or other topical antiseptic solutions. Sterile drapes and sterile gloves are not needed. Needles are handled in a manner to preserve sterility of the metal portion of the needle. A mask and eye cover are recommended to protect the surgeon in the event of backspray during anesthetic injection or joint manipulation.

Anesthetic

The goal is *superficial intradermal anesthetic injection*, avoiding subcutaneous spread and potential digital nerve conduction block. Plain lidocaine buffered 1:10 with sodium bicarbonate given via a 30-gauge needle on a 3-cc syringe reduces injection pain. To confine anesthetic to the dermis, the needle tip is placed about 1 mm into the dermis and injection is given as the needle is withdrawn. Pinpoint local anesthesia develops immediately with this technique and lasts 15 to 30 minutes. Lidocaine with epinephrine or bupivacaine may be used, but their prolonged effect is a disadvantage if a conduction block develops. If a block develops that precludes desired work, plain lidocaine effect usually wears off rapidly enough to resume during the same setting; long-lasting anesthetics may require deferring completion to the following day.

Bleeding during the procedure is minimal and does not justify the need for epinephrine. Ideally, digital nerve block is avoided and the fingertip remains sensate throughout the procedure. Tip sensitivity is checked prior to each anesthetic injection, prior to beginning each new portal, and at regular intervals between injections. Anesthetic joint injections and management of finger numbness are discussed in later sections.

Needle Size

The tip of a hypodermic needle has two short scalpel-sharp cutting edges. Needle-tip proportions are such that the length of each cutting edge measures slightly less than twice the diameter of the needle. Any needle gauge can be used; the author recommends a short 25-gauge needle. An 18-gauge needle has a terminal blade length of 2.6 mm; a 25-gauge needle has a diameter of 0.5 mm and a terminal blade length of 0.8 mm.

Smaller-gauge needles require more passes to divide cords but have the advantage of greater control and less likelihood of inadvertently severing a digital nerve with a single pass. Smaller needles are more flexible, and using the shortest possible needle gives the best control of the tip. Some surgeons hold a hypodermic needle directly with their fingertips, but mounting the needle on a 3-cc Luer-lock syringe is recommended for control and sterility.

Portal Sequence

An important safety factor of needle aponeurotomy is the ability to monitor digital nerve function through the procedure. For this reason, the safest approach is to begin distally and work proximally. That way, if a digital nerve block develops, the procedure may be continued at the more proximal portal level, where the nerve is still sensitive to local irritation. By the same logic, if several fingers are being treated at the same sitting, completing all work on the digits before moving into the palm prevents an unexpected common digital nerve block from affecting an adjacent digit before its release.

Needle Maneuvers

Needle bevel alignment should be maintained perpendicular to the cord; otherwise the needle may not cut the fibers. It's helpful to note the bevel orientation in relation to the syringe markings to reference while the tip is inserted and out of view. The three basic needle maneuvers are (1) clear, (2) perforate, and (3) sweep (Figure 4.14). After initial needle insertion through the dermis, a local exploration is performed to define the surface of the cord by feel. The needle is used to divide vertical retinacular fibers and clear a path superficial to the cord the width of the cord. The needle is then used to perforate into the cord a millimeter or two in depth at multiple points across this transverse line. This divides fibers and also reveals unexpectedly displaced nerves. If no unexpected tenderness is encountered with perforation, the needle is then used to graze or sweep the surface of the cord transversely to the previously perforated depth.

It is possible to divide cords entirely by continuing to perforate through the depth of the cord, but sweeping is more efficient, requires fewer needle passes, and leaves the smallest internal wound. The process of perforating and then sweeping is then repeated to divide the cord progressively from superficial to deep. While sweeping, needle depth insertion is critical (Figure 4.15). If the needle tip is inserted to a depth beyond the terminal cutting edge, the blunt needle shaft proximal to the tip will engage the cord, preventing the needle edge from cutting until enough force is exerted that the needle tip suddenly pops out of the area of cord entry, cutting as it exits. This type of uncontrolled motion can be avoided by estimating the depth of insertion by feel and using a light touch. The syringe should be held with a light grip to avoid an unexpected shish-kabab event if the patient makes a sudden move.

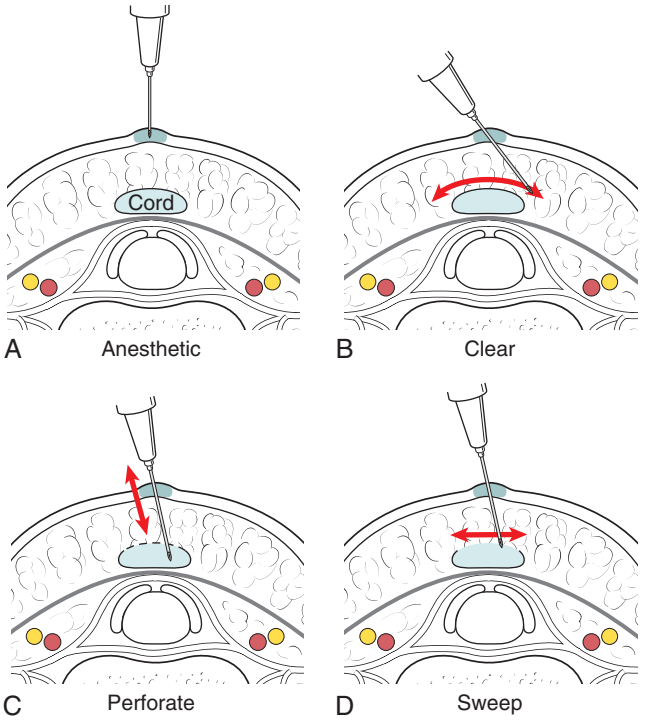

FIGURE 4.14 Maneuvers for percutaneous fasciotomy. **A,** Anesthetic is limited to the dermis to reduce the chance of a conduction block. **B,** The needle tip is used to clear a working area superficial to the cord. **C,** The needle perforates a line of points across the cord using a reciprocating motion. **D,** The bevel of the needle scores the surface of the cord to progressively divide fibers from superficial to deep.

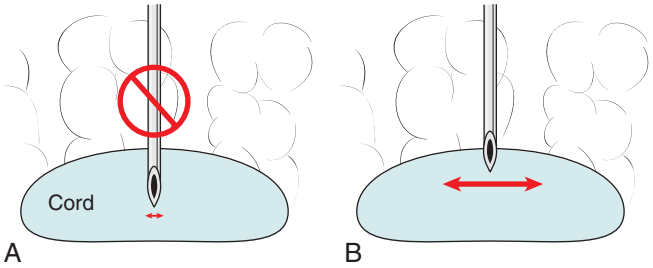

FIGURE 4.15 Needle depth penetration is important for sweeping motion. **A,** Cord penetration beyond the bevel prevents lateral motion. **B,** Optimum placement for scoring the surface of the cord is with only the distal needle bevel engaged.

Cord Traction

Cord fibers are cut most efficiently while under constant tension, which also provides constant feedback regarding the status of cord division. Cords may be tensioned by pulling the finger into extension, but this also tensions the flexor tendons, potentially pulling them into harm's way. There are two alternatives to passive composite pull. The first is to passively extend the most affected joint, but flex the adjacent joint (or, at least, not pull on it). For example, while working on a cord contracting the MCP joint, flex the PIP joint and extend the MCP joint; for cords affecting the PIP joint, flex the DIP joint while extending the PIP joint.

The second option is to take advantage of the anatomic fact that cords are tethered to the dermis: using your fingertip to create traction on the skin proximal or distal to the portal in a direction away from the portal will also tension the cord from its attachment to the skin. This is also a helpful alternative if joints are painful to passive extension. Finally, it's worth checking that the patient isn't unconsciously flexing his or her fingers against your pull, which both bowstrings flexors and prevents assessment of cord release.

Needle Problems

If the needle bends, you are using too much force, most likely because the needle tip is inserted too deeply, as previously described. An advantage of using a 25-gauge needle is that it is the most sensitive indicator of this. Replace the needle. Needle edges dull quickly and can burr easily; expect to replace the needle for every portal or two. Signs of a dull needle edge include slow progress dividing the cord, drag, catching, and unexpected tenderness. When in doubt, replace the needle. A 25-gauge needle costs 11 cents.

Flexor Tendon Issues

Flexor tendons are at risk for injury. The patient should be reminded to relax his or her fingers ("just let them go limp") to avoid tensioning the flexors. Bowstring the cord, not the flexors. In addition, active posturing by the patient—either flexion or extension—makes it more difficult to palpate cords and contractures. If there is any question regarding flexor proximity, check by having the patient gently perform short arc "scratching motion" finger flexion and extension with the needle in place, cautioning the patient to not make a fist.

Needle contact with a moving tendon will either produce a gritty feel of the needle or will visibly move the needle, depending on whether the needle tip is on or in the tendon. If there is a confirmed breach of the flexor tendon sheath, use of that portal should be discontinued, and the tendon should be checked for continuity, triggering, and pain with flexion against resistance. If there is evidence or strong suspicion of a mechanically significant tendon injury, that issue assumes management priority. If not, the procedure may be continued at a different level and the patient should be cautioned to avoid strenuous gripping for 1 month to reduce the chance of provoking tendinitis.

Nerve Issues

Distal to proximal portal sequence should be followed, including finishing the fingers before starting in the palm, as described previously. Fingertip sensitivity should be checked: prior to each anesthetic injection, prior to starting each new portal, and at regular intervals in between. Even with careful technique, digital nerve block may develop from anesthetic diffusion or digital nerve contusion and may appear without any precedent event or patient awareness of it developing. If the patient develops a digital nerve block, the safest step is to continue only *proximal* to the last anesthetized portal.

Pain or Paresthesia With Needle Movement

Patients may experience pain with needle maneuvers, and this should always be evaluated. Cords are insensate and do not require anesthetic. The capsuloligamentous structures and associated cruciate pulleys of the proximal[18] and distal[17] interphalangeal joints have at least proprioceptive sensory innervation, which may confer sensitivity to needle contact. It is not known if there is sensory innervation of the other zones of the flexor tendon sheath or of the annular pulleys.

Following intradermal injection, needle maneuvering is usually painless. Pain during the procedure may be due to contact of the needle tip with unanesthetized adjacent deep dermis; joint capsule or cruciate pulley areas, neurovascular bundle or adjacent Pacinian corpuscles; or pressure on any of these structures from the needle shaft with lateral motion. If the patient has unexpected pain with needle maneuvering, follow the evaluation protocol shown in Figure 4.16. Traction on deep dermis from retinacular fiber involvement may result in subdermal tenderness deep beneath or adjacent to skin creases or dimples. If so, anesthetic injection into the dermis at the level of the crease or dimple usually relieves this needle tenderness (Figure 4.17).

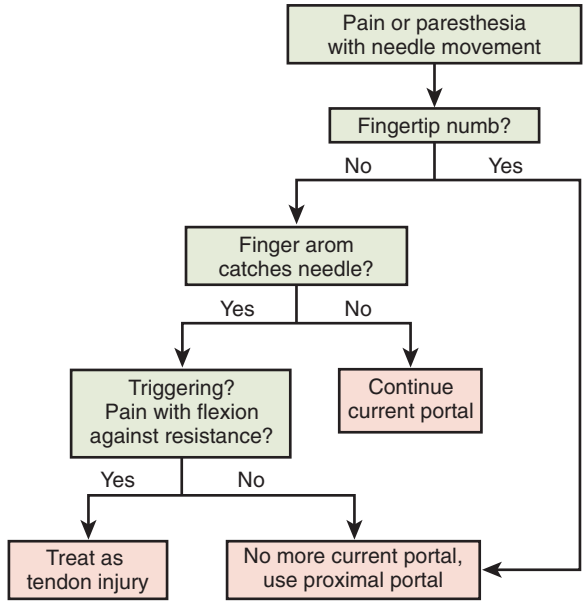

FIGURE 4.16 Management algorithm for pain or paresthesia during percutaneous fasciotomy.

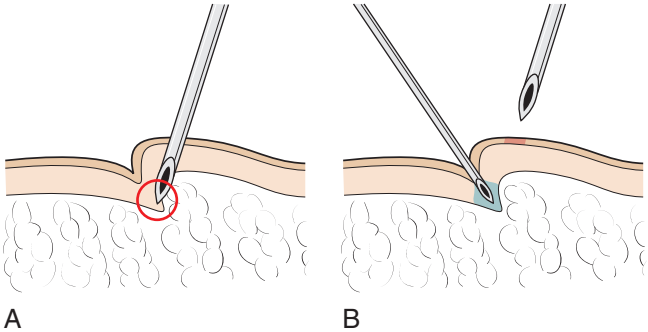

FIGURE 4.17 **A,** Deep tenderness adjacent to a dimple may be due to innervated deep dermis of a dimple pulled into the path of the needle. **B,** After checking the depth of the dimple to confirm that there is not a dimple sinus in harm's way, the dermis at the depth of the dimple may be anesthetized and the procedure continued without pain.

Uncommonly, a cord may remain tender to needle penetration despite these steps. If there is no possibility of dimple-related tenderness, this may represent nerve end organ or digital nerve tethering from the cord. An option in this situation is to inject the cord itself with 0.1 to 0.2 cc local anesthetic directly in the area of sensitivity. Following this, check the fingertip for sensibility, and if the fingertip is not numb, return to cord division at the current portal. If a conduction block develops, discontinue work at this level and proceed to the next most proximal level (Figure 4.16).

Portal-Level Goal

Release at a given portal level is continued until the cord releases or the cord is no longer tensionable or palpable. Progress is often incremental, a few degrees at a time: a definitive "pop" or "snap" may or may not occur.

Needling the PIP

PIP contractures have concurrent involvement of multiple structures more often than MCP contractures.[105] It's helpful to approach PIP release in a stepwise sequential fashion, releasing the most obvious palpable cord and then reassessing to identify additional constraints that were not initially palpable. Cords producing PIP contractures traverse the PIP flexion creases but may only be palpable proximal to the crease. Portals placed distal to the PIP flexion creases may be used to allow an oblique needle path from distal to proximal deep beneath the PIP flexion creases (Figure 4.18). During PIP release, it's important to continue checking fingertip sensibility and for the possibility of flexor tendon contact.

Joint Anesthetic Injection

Intraarticular anesthetic joint injection improves comfort and the effectiveness of interphalangeal joint manipulation. A predictable technique for interphalangeal joint injection is to use a 30-gauge needle directly through the flexor tendon and volar plate via a midline approach with the joint flexed (Figure 4.18).[69] Anesthetic placement can be confirmed by palpating dorsal joint capsule distention during injection. The advantages of this approach are greater predictability of achieving intraarticular infiltration and less likelihood of inadvertent digital nerve or sheath block. Joint anesthesia usually develops within 2 minutes of injection.

Manipulation

Final manipulations are performed after all releases are complete and interphalangeal anesthetic joint injections are performed. Because multiple cord locations are common at the PIP joint, a series of stretching maneuvers are performed in sequence. Because cords are midpalmar and palmar-lateral, the joint is stretched in the opposite directions of each: straight dorsal, dorsal–ulnar, and dorsal–radial. These maneuvers are first performed individually on each joint, leaving the adjacent joints slack, and then performed as composite stretches of all joints.

Postprocedure

Postprocedure care was described earlier, in the "Patient Instructions After the Procedure" section.

CRITICAL POINTS

- The ideal patient has well-defined cords, supple skin, and is able to tolerate an awake procedure.
- Preoperative discussion should include the patient's role in relaxing, reporting pain or numbness, and moving his or her fingers when asked.
- Portals are planned at cord levels where the skin is soft and the cord is subdermal.
- Use intradermal anesthetic, avoiding subcutaneous injection.
- Release through distal-to-proximal portals, and avoid working in an area with a nerve block.
- Check nerve and tendon status before each portal and regularly in between.
- Caution patient to avoid strenuous gripping for 1 week postprocedure, even if the patient has no pain (which is usually the case).

THE FUTURE

Dupuytren disease has parallels with rheumatoid arthritis. Both are systemic conditions that commonly lead patients to hand surgeons. Both have inspired a diverse array of innovative procedures with impressive early outcomes but high long-term

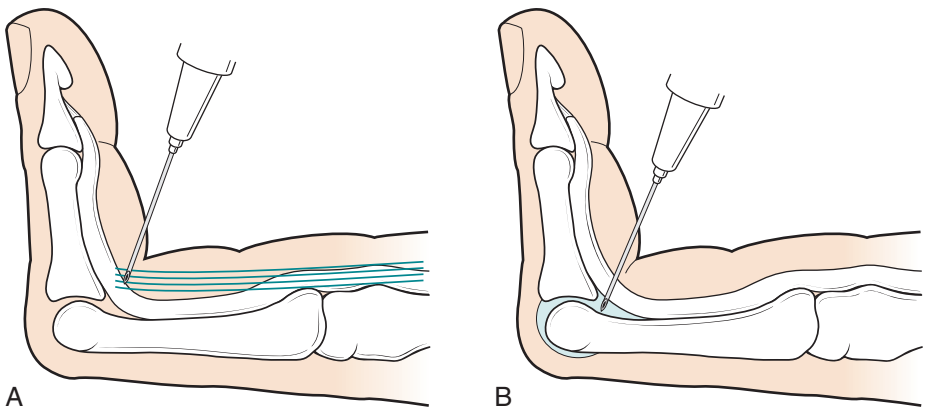

FIGURE 4.18 Palmar approaches to the proximal interphalangeal (PIP) joint. **A,** Cords producing PIP contractures often cross beneath the PIP skin flexion crease and may be approached distal to this crease. **B,** Intraarticular anesthetic may be given with a small gauge needle through the flexor tendon and volar plate to anesthetize the joint, but not the rest of the finger, helpful to reduce pain during manipulation.

failure rates. Senior hand surgeons will recall when this resemblance abruptly changed: anti-TNF drugs suddenly reduced the need for rheumatoid hand surgery, proof that they modified the disease biology—a first. A parallel change is needed for Dupuytren disease, which is a medical, not a surgical, condition.

Minimally invasive treatments have recently gained popularity despite higher recurrence rates, largely because the morbidity of fasciectomy makes it an unpopular choice with patients, a scenario that also occurred in the late 1800s and again in the mid-1900s. This is change without progress, a persistent theme in the history of this disease. Collagen is not the culprit; it is simply the footprint left by the primary biology.

A 1990 treatment review included diagrams of 67 different incisions recommended for fasciectomy,[71] and many more have been described since. This alone is testimony that local treatment is the wrong focus of effort. Because hand surgeons are the primary caregivers for this disease, the responsibility to our patients is to change this focus to the development of disease-modifying interventions by engaging colleagues in the fields of molecular biology, genomics, and fibrosis research. Tamoxifen has been shown to reduce recurrence rates[21] after fasciectomy in high-risk patients, proof that it is possible to modify DD biology—a first.

Treatment with microRNA or SiRNA to downregulate the production of TGFβ1 or its receptors, identification of molecules that inhibit or bind to TGFβ1 or other implicated cytokines (the strategy used to develop anti-TNF drugs), and molecular stenting to prevent excessive collagen crosslinking are the types of approaches that must be explored to change the landscape of Dupuytren disease. Absent this, the cycle will continue to repeat.

For Case Studies, Videos, and more, please visit ExpertConsult.com.

REFERENCES

1. Abe Y, Rokkaku T, Ofuchi S, et al: An objective method to evaluate the risk of recurrence and extension of Dupuytren's disease. *J Hand Surg [Br]* 29:427–430, 2004.
2. Arafa M, Steingold RF, Noble J: The incidence of Dupuytren's disease in patients with rheumatoid arthritis. *J Hand Surg [Br]* 9:165–166, 1984.
3. Baird KS, Crossan JF, Ralston SH: Abnormal growth factor and cytokine expression in Dupuytren's contracture. *J Clin Pathol* 46(5):425–428, 1993.
4. Balaguer T, David S, Ihrai T, et al: Histological staging and Dupuytren's disease recurrence or extension after surgical treatment: a retrospective study of 124 patients. *J Hand Surg Eur* 34:493–496, 2009.
5. Barclay TL: Edema following operation for Dupuytren's contracture. *Plast Reconstr Surg Transpl Bull* 23(4):348–360, 1959.
6. Beaudreuil J, Allard A, Zerkak D, et al: Unité rhumatologique des affections de la main (URAM) scale: development and validation of a tool to assess Dupuytren's disease-specific disability. *Arthritis Care Res (Hoboken)* 63:1448–1455, 2011.
7. Becker K, Tinschert S, Lienert A, et al: The importance of genetic susceptibility in Dupuytren's disease. *Clin Gen* 87:483–487, 2015.
8. Belusa L, Buck-Gramcko D, Partecke BD: Results of interphalangeal joint arthrolysis in patients with Dupuytren disease. *Handchir Mikrochir Plast Chir* 29(3):158–163, 1997.
9. Bhavsar S, Nimigan A, Hackam DG, et al: Keloid scarring, but not Dupuytren's contracture, is associated with unexplained carotid atherosclerosis. *Clin Invest Med* 32:E95–E102, 2009.
10. Bisson MA, Mudera V, McGrouther DA, et al: The contractile properties and responses to tensional loading of Dupuytren's disease-derived fibroblasts are altered: a cause of the contracture? *Plast Reconstr Surg* 113:64–611, 2004.
11. Brickley-Parsons D, Glimcher MJ, Smith RJ, et al: Biochemical changes in the collagen of the palmar fascia in patients with Dupuytren's disease. *J Bone Jt Surg Am* 63:787–797, 1981.
12. Brotherston TM, Balakrishnan C, Milner RH, et al: Long-term follow-up of dermofasciectomy for Dupuytren's contracture. *Br J Plast Surg* 47(6):440–443, 1994.
13. Brouet JP: Etude de 1000 dossiers de maladie de Dupuytren. In Tubiana R, Hueston JT, editors: *La maladie Dupuytren*, ed 3, Paris, 1986, Expansion Scientifique, pp 98–105.
14. Burge P, Hoy G, Regan P, et al: Smoking, alcohol and the risk of Dupuytren's contracture. *J Bone Joint Surg Br* 79(2):206–210, 1997.
15. Castella LF, Buscemi L, Godbout C, et al: A new lock-step mechanism of matrix remodelling based on subcellular contractile events. *J Cell Sci* 123:1751–1760, 2010.
16. Chansky HA, Trumble TE, Conrad EU, et al: Evidence for a polyclonal etiology of palmar fibromatosis. *J Hand Surg [Am]* 24(2):339–344, 1999.
17. Chikenji T, Berger RA, Fujimiya M, et al: Distribution of nerve endings in human distal interphalangeal joint and surrounding structures. *J Hand Surg [Am]* 36(3): 406–412, 2011.
18. Chikenji T, Suzuki D, Fujimiya M, et al: Distribution of nerve endings in the human proximal interphalangeal joint and surrounding structures. *J Hand Surg [Am]* 35(8):1286–1293, 2010.
19. Citron N, Hearnden A: Skin tension in the aetiology of Dupuytren's disease: a prospective trial. *J Hand Surg [Br]* 28(6):528–530, 2003.
20. Craft RO, Smith AA, Coakley BB, et al: Preliminary soft-tissue distraction versus checkrein ligament release after fasciectomy in the treatment of Dupuytren proximal interphalangeal joint contractures. *Plast Reconstr Surg* 128:113–1107, 2011.
21. Degreef I, De Smet L: Dupuytren disease: on our way to a cure? *Acta Orthop Belg* 79:243–249, 2013.
22. Degreef I, De Smet L: Risk factors in Dupuytren's diathesis: is recurrence after surgery predictable? *Acta Orthop Belg* 77:27–32, 2011.
23. Degreef I, De Smet LA: High prevalence of Dupuytren's disease in Flanders. *Acta Orthop Belg* 76(3):316–320, 2010.
24. Denkler K: Surgical complications associated with fasciectomy for Dupuytren's disease: a 20-year review of the English literature. *Eplasty* 10:e15, 2010.
25. Descatha A, Jauffret P, Chastang JF, et al: Should we consider Dupuytren's contracture as work-related? A review and meta-analysis of an old debate. *BMC Musculoskelet Disord* 12:96, 2011.
26. Dias JJ, Braybrooke J: Dupuytren's contracture: an audit of the outcomes of surgery. *J Hand Surg [Br]* 31(5):514–521, 2006.
27. Dias JJ, Singh HP, Ullah A, et al: Patterns of recontracture after surgical correction of Dupuytren disease. *J Hand Surg [Am]* 38:1987–1993, 2013.
28. Dibenedetti DB, Nguyen D, Zografos L, et al: Prevalence, incidence, and treatments of Dupuytren's disease in the United States: results from a population-based study. *Hand* 6(2):149–158, 2011.
29. Dolmans GH, de Bock GH, Werker PM: Dupuytren diathesis and genetic risk. *J Hand Surg [Am]* 37:2106–2111, 2012.
30. Dolmans GH, Werker PM, Hennies HC, et al: Wnt signaling and Dupuytren's disease. *N Engl J Med* 365(4):307–317, 2011.
31. Draviaraj KP, Chakrabarti I: Functional outcome after surgery for Dupuytren's contracture: a prospective study. *J Hand Surg [Am]* 29:88–804, 2004.
32. Egawa T, Senrui H, Horiki A: Epidemiology of the oriental patient. In *Dupuytren's dis. biol. treat*, New York, 1990, Churchill Livingstone, pp 239–245.
33. Elliot D, Ragoowansi R: Dupuytren's disease secondary to acute injury, infection or operation distal to the elbow in the ipsilateral upper limb—a historical review. *J Hand Surg [Br]* 30(2):148–156, 2005.
34. Ellis CV, Kulber DA: A cellular dermal matrices in hand reconstruction. *Plast Reconstr Surg* 130(5 Suppl 2):256S–69S, 2012.
35. Elsahy NI: Doppler ultrasound detection of displaced neurovascular bundles in Dupuytren's contracture. *Plast Reconstr Surg* 57:104–105, 1976.
36. Erne HC: Downgrading severe stages of Dupuytren's contracture to simplify partial aponeurectomy using percutaneous needle fasciotomy. *Plast Reconstr Surg* 133:79e–80e, 2014.
37. Geoghegan JM, Forbes J, Clark DI, et al: Dupuytren's disease risk factors. *J Hand Surg [Br]* 29(5):423–426, 2004.
38. Grotesman A: *Clinical assessment in Dupuytren's disease. Presentation at Dupuytren's Disease Symposium*, New York, Stony Brook University Medical Center, Stony Brook. 4/17/2010.
39. Gudmundsson KG, Arngrímsson R, Sigfússon N, et al: Increased total mortality and cancer mortality in men with Dupuytren's disease: a 15-year follow-up study. *J Clin Epidemiol* 55(1):5–10, 2002.
40. Gudmundsson KG, Arngrimsson R, Jónsson T: Eighteen years follow-up study of the clinical manifestations and progression of Dupuytren's disease. *Scandinavian J Rheumatol* 30(1):31–34, 2001.
41. Gudmundsson KG, Arngrimsson R, Sigfusson N, et al: Epidemiology of Dupuytren's disease: clinical, serological, and social assessment. The Reykjavik Study. *J Clin Epidemiol* 53(3):291–296, 2000.
42. Gudmundsson KG, Jónsson T, Arngrimsson R, et al: Association of Morbus Ledderhose with Dupuytren's contracture. *Foot Ankle Int* 34(6):841–845, 2013.

43. Hansen M, Koskinen SO, Petersen SG, et al: Ethinyl oestradiol administration in women suppresses synthesis of collagen in tendon in response to exercise. *J Physiol* 586:316–3005, 2008.
44. Hayton MJ, Bayat A, Chapman DS, et al: Isolated and spontaneous correction of proximal interphalangeal joint contractures in Dupuytren's disease: An exploratory analysis of the efficacy and safety of collagenase clostridium histolyticum. *Clin Drug Investig* 33(12):905–912, 2013.
45. Hettiaratchy S, Tonkin MA, Edmunds IA: Spiralling of the neurovascular bundle in Dupuytren's disease. *J Hand Surg Eur Vol* 35:103–108, 2010.
46. Hindocha S, Stanley JK, Watson JS, et al: Revised Tubiana's staging system for assessment of disease severity in Dupuytren's disease-preliminary clinical findings. *Hand (NY)* 3:6–80, 2008.
47. Hindocha S, Stanley JK, Watson S, et al: Dupuytren's diathesis revisited: Evaluation of prognostic indicators for risk of disease recurrence. *J Hand Surg [Am]* 31:1626–1634, 2006.
48. Hindocha S, John S, Stanley JK, et al: The heritability of Dupuytren's disease: familial aggregation and its clinical significance. *J Hand Surg [Am]* 31(2):204–210, 2006.
49. Holland AJ, McGrouther DA: Dupuytren's disease and the relationship between the transverse and longitudinal fibers of the palmar fascia: a dissection study. *Clin Anat* 10:97–103, 1997.
50. Holzer LA, Cor A, Pfandlsteiner G, et al: Expression of VEGF, its receptors, and HIF-1α in Dupuytren's disease. *Acta Orthop* 84(4):420–425, 2013.
51. Hsieh AH, Tsai CM, Ma QJ, et al: Time-dependent increases in type-III collagen gene expression in medical collateral ligament fibroblasts under cyclic strains. *J Orthop Res* 18:220–227, 2000.
52. Hu FZ, Nystrom A, Ahmed A, et al: Mapping of an autosomal dominant gene for Dupuytren's contracture to chromosome 16q in a Swedish family. *Clin Genet* 68(5):49–424, 2005.
53. Hueston JT: Dorsal Dupuytren's disease. *J Hand Surg [Am]* 7:384–387, 1982.
54. Hueston JT: Some observations on knuckle pads. *J Hand Surg [Br]* 9(1):75–78, 1984.
55. Igarashi A, Nashiro K, Kikuchi K, et al: Connective tissue growth factor gene expression in tissue sections from localized scleroderma, keloid, and other fibrotic skin disorders. *J Invest Dermatol* 106:729–733, 1996.
56. Izadpanah A, Viezel-Mathieu A, Izadpanah A, et al: Dupuytren contracture in the pediatric population: A systematic review. *Eur J Pediatr Surg* 25:151–154, 2015.
57. Jerosch-Herold C, Shepstone L, Chojnowski A, et al: Severity of contracture and self-reported disability in patients with Dupuytren's contracture referred for surgery. *J Hand Ther* 24:6–10, 2011.
58. Jónsson T, Gudmundsson KG, Bjarnadóttir K, et al: Association of HLA-DRB1*01 with Dupuytren's disease. *Scandinavian J Rheumatol* 42(1):45–47, 2013.
59. Kan HJ, Verrijp FW, Hovius SER—the Dupuytren Delphi Group: *An international multidisciplinary Delphi-based consensus definition of recurrence after Dupuytren treatment*. Presentation A-0655 at XIXth FESSH Congress Paris, France 18th-21st June 2014.
60. Kim A, Lakshman N, Petroll WM: Quantitative assessment of local collagen matrix remodeling in 3-D culture: the role of Rho kinase. *Exp Cell Res* 312(18):3683–3692, 2006.
61. LaCroix AS, Duenwald-Kuehl SE, Brickson S, et al: Effect of age and exercise on the viscoelastic properties of rat tail tendon. *Ann Biomed Eng* 41:1120–1128, 2013.
62. Lam WL, Rawlins JM, Karoo ROS, et al: Re-visiting Luck's classification: a histological analysis of Dupuytren's disease. *J Hand Surg Eur Vol* 35:37–312, 2010.
63. Lanting R, Broekstra DC, Werker PMN, et al: A systematic review and meta-analysis on the prevalence of Dupuytren disease in the general population of Western countries. *Plast Reconstr Surg* 133:593–603, 2014.
64. Lanting RR, van den Heuvel ER, Westerink BB, et al: Prevalence of Dupuytren disease in the Netherlands. *Plast Reconstr Surg* 132:394–403, 2013.
65. Ling RS: The genetic factor in Dupuytren's disease. *J Bone Joint Surg Br* 45(4):709–718, 1963.
66. Lo S, Pickford M: Retrovascular fasciectomy: an approach that facilitates dissection of the neurovascular bundles in Dupuytren's fasciectomy. *J Hand Surg Eur Vol* 36:705–707, 2011.
67. Luck JV: Dupuytren's contracture: a new concept of the pathogenesis correlated with surgical management. *J Bone Joint Surg Am* 41A:635–664, 1959.
68. Matton A: *Long-term retreatment rate of Dupuytren's disease after percutaneous needle fasciotomy*, Thesis, 2012, University of Groningen.
69. McClelland WB, Jr, McClinton MA: Proximal interphalangeal joint injection through a volar approach: anatomic feasibility and cadaveric assessment of success. *J Hand Surg [Am]* 38(4):733–739, 2013.
70. McFarlane RM: Patterns of the diseased fascia in the fingers in Dupuytren's contracture. Displacement of the neurovascular bundle. *Plast Reconstr Surg* 54(1):31–44, 1974.
71. McGrouther DA: An overview of operative treatment. In McFarlane RM, McGrouther DA, Flint MH, editors: *Dupuytren's disease biology and treatment*, Edinburg, 1990, Churchill Livingstone, pp 295–310.
72. Meinel AG: Dupuytren contracture—how fibromatosis remodels the palmar subcutaneous tissue and its fibrous environment. *Adv Surg Sci* 1:11–16, 2013.
73. Mikkelsen OA: The prevalence of Dupuytren's disease in Norway. A study in a representative population sample of the municipality of Haugesund. *Acta Chir Scand* 138(7):695–700, 1972.
74. Millesi H: Basic thoughts on Dupuytren's contracture. In Eaton C, et al, editors: *Dupuytren's disease and related hyperproliferative disorders*, Berlin, 2012, Springer-Verlag, pp 21–26.
75. Misra A, Jain A, Ghazanfar R, et al: Predicting the outcome of surgery for the proximal interphalangeal joint in Dupuytren's disease. *J Hand Surg [Am]* 32:240–245, 2007.
76. Moermans JP: Long-term results after segmental aponeurectomy for Dupuytren's disease. *J Hand Surg [Br]* 21:797–800, 1996.
77. Mohan A, Vadher J, Ismail H, et al: The Southampton Dupuytren's Scoring Scheme. *J Plast Surg Hand Surg* 48:28–33, 2014.
78. Naam NH: Functional outcome of collagenase injections compared with fasciectomy in treatment of Dupuytren's contracture. *Hand* 8(4):410–416, 2013.
79. Nugteren HM, Nijman JM, de Jong IJ, et al: The association between Peyronie's and Dupuytren's disease. *Int J Impot Res* 23:15–142, 2011.
80. Nyberg LM, Bias WB, Hochberg MC, et al: Identification of an inherited form of Peyronie's disease with autosomal dominant inheritance and association with Dupuytren's contracture and histocompatibility B7 cross-reacting antigens. *J Urol* 128(1):48–51, 1982.
81. Nydick JA, Olliff BW, Garcia MJ, et al: A comparison of percutaneous needle fasciotomy and collagenase injection for Dupuytren disease. *J Hand Surg [Am]* 38(12):2377–2380, 2013.
82. Pagnotta A, Specchia N, Greco F: Androgen receptors in Dupuytren's contracture. *J Orthop Res* 20:163–168, 2002.
83. Parra EJ, Marcini A, Akey J, et al: Estimating African American admixture proportions by use of population-specific alleles. *Am J Hum Genet* 63(6):1839–1851, 1998.
84. Peimer CA, Blazar P, Coleman S, et al: Dupuytren contracture recurrence following treatment with collagenase clostridium histolyticum (CORDLESS study): 3-year data. *J Hand Surg [Am]* 38:12–22, 2013.
85. Ratkaj I, Bujak M, Jurišic D, et al: Microarray analysis of Dupuytren's disease cells: the profibrogenic role of the TGF-β inducible p38 MAPK pathway. *Cell Physiol Biochem* 30(4):927–942, 2012.
86. Rayan GM, Ali M, Orozco J: Dorsal pads versus nodules in normal population and Dupuytren's disease patients. *J Hand Surg [Am]* 35:1559–1571, 2010.
87. Rayan G: Dupuytren's disease. *Hand Clin* 15(1):xiii, 1999.
88. Raykha C, Crawford J, Gan BS, et al: IGF-II and IGFBP-6 regulate cellular contractility and proliferation in Dupuytren's disease. *Biochim Biophys Acta* 1832:1511–1519, 2013.
89. Reilly RM, Stern PJ, Goldfarb CA: A retrospective review of the management of Dupuytren's nodules. *J Hand Surg [Am]* 30:1014–1018, 2005.
90. Roush TF, Stern PJ: Results following surgery for recurrent Dupuytren's disease. *J Hand Surg [Am]* 25:291–296, 2000.
91. Rudolph R: Inhibition of myofibroblasts by skin grafts. *Plast Reconstr Surg* 63:473–480, 1979.
92. Saboeiro AP, Porkorny JJ, Shehadi SI, et al: Racial distribution of Dupuytren's disease in Department of Veterans Affairs patients. *Plast Reconstr Surg* 106(1):71–75, 2000.
93. Sadideen H, Athanasou N, Ashmore A, et al: Heterotopic ossification in Dupuytren's disease: clinical and histological significance. *J Bone Joint Surg Br* 93: 1676–1678, 2011.
94. Satish L, LaFramboise WA, Johnson S, et al: Fibroblasts from phenotypically normal palmar fascia exhibit molecular profiles highly similar to fibroblasts from active disease in Dupuytren's contracture. *BMC Med Genomics* 5:15, 2012.
95. Satish L, O'Gorman DB, Johnson S, et al: Increased CCT-eta expression is a marker of latent and active disease and a modulator of fibroblast contractility in Dupuytren's contracture. *Cell Stress Chaperones* 18:397–404, 2013.
96. Schleip R, Duerselen L, Vleeming A, et al: Strain hardening of fascia: static stretching of dense fibrous connective tissues can induce a temporary stiffness increase accompanied by enhanced matrix hydration. *J Bodyw Mov Ther* 16:94–100, 2012.
97. Shih BB, Tassabehji M, Watson JS, et al: Genome-wide high-resolution screening in Dupuytren's disease reveals common regions of DNA copy number alterations. *J Hand Surg [Am]* 35:1172–1183, 2010.
98. Smith P, Breed C: Central slip attenuation in Dupuytren's contracture: a cause of persistent flexion of the proximal interphalangeal joint. *J Hand Surg [Am]* 19:840–843, 1994.
99. Smith SP, Devaraj VS, Bunker TD: The association between frozen shoulder and Dupuytren's disease. *J Shoulder Elbow Surg* 10:149–151, 2001.
100. Smits LJM, van Kuijk SMJ, Leffers P, et al: Index event bias—a numerical example. *J Clin Epidemiol* 66:192–196, 2013.

101. Sullivan BE, Carroll CC, Jemiolo BB, et al: Effect of acute resistance exercise and sex on human patellar tendon structural and regulatory mRNA expression. *J Appl Physiol* 106:75–468, 2009.
102. Teboul F, Sabri E, Goubier J-N: Case report: middle phalanx resection as an alternative treatment to amputation of recurrent Dupuytren's contracture of the fifth digit. *Eur J Plast Surg* 35:901–903, 2012.
103. Tonkin MA, Burke FD, Varian JP: Dupuytren's contracture: a comparative study of fasciectomy and dermofasciectomy in one hundred patients. *J Hand Surg [Br]* 9:156–162, 1984.
104. Toppi JT, Trompf L, Smoll NR, et al: Dupuytren's contracture: an analysis of outcomes of percutaneous needle fasciotomy versus open fasciectomy. *ANZ J Surg* 1–5, 2014.
105. Trickett RW, Savage R, Logan AJ: Angular correction related to excision of specific cords in fasciectomy for Dupuytren's disease. *J Hand Surg Eur* 39:472–476, 2014.
106. Uehara K, Miura T, Morizaki Y, et al: Ultrasonographic evaluation of displaced neurovascular bundle in Dupuytren disease. *J Hand Surg [Am]* 38:23–28, 2013.
107. Ullaha S, Dias JJ, Bhowal B: Does a "firebreak" full-thickness skin graft prevent recurrence after surgery for Dupuytren's contracture? a prospective, randomised trial. *J Bone Jt Surg Br* 91:374–378, 2009.
108. Umlas ME, Bischoff RJ, Gelberman RH: Predictors of neurovascular displacement in hands with Dupuytren's contracture. *J Hand Surg [Br]* 19:664–666, 1994.
109. van Rijssen AL, ter Linden H, Werker PMN: Five-year results of a randomized clinical trial on treatment in Dupuytren's disease: percutaneous needle fasciotomy versus limited fasciectomy. *Plast Reconstr Surg* 129:469–477, 2012.
110. Vaughan MB, Howard EW, Tomasek JJ: Transforming growth factor-beta1 promotes the morphological and functional differentiation of the myofibroblast. *Exp Cell Res* 257:180–189, 2000.
111. Verhoekx JS, Beckett KS, Bisson MA, et al: The mechanical environment in Dupuytren's contracture determines cell contractility and associated MMP-mediated matrix remodeling. *J Orthop Res* 31(2):34–328, 2013.
112. Verjee LS, Midwood K, Davidson D, et al: Myofibroblast distribution in Dupuytren's cords: correlation with digital contracture. *J Hand Surg [Am]* 34:194–1785, 2009.
113. Walton MJ, Pearson D, Clark DA, et al: The prognosis of fasciectomy for abductor digiti minimi and pretendinous cords in Dupuytren's disease of the little finger. *Hand Surg* 14(2–3):89–92, 2009.
114. White S: Anatomy of the palmar fascia on the ulnar border of the hand. *J Hand Surg [Br]* 9:50–56, 1984.
115. Wilkinson JM, Davidson RK, Swingler TE, et al: MMP-14 and MMP-2 are key metalloproteases in Dupuytren's disease fibroblast-mediated contraction. *Biochim Biophys Acta* 1822(6):897–905, 2012.
116. Xiaflex.com: *Xiaflex Prescribing Information*. <www.xiaflex.com/_assets/pdf/XIAFLEX-PI-and-MedGuide-Combined-20131206-ver-e.pdf>.
117. Yacoe ME, Bergman AG, Ladd AL, et al: Dupuytren's contracture: MR imaging findings and correlation between MR signal intensity and cellularity of lesions. *Am J Roentgenol* 160:813–817, 1993.
118. Zerajic D, Finsen V: Dupuytren's disease in Bosnia and Herzegovina. An epidemiological study. *BMC Musculoskelet Disord* 5:10, 2004.
119. Zwanenburg RL, Werker PMN, McGrouther DA: The anatomy and function of Cleland's ligaments. *J Hand Surg Eur* 39:482–490, 2014.
120. Zyluk A, Jagielski W: The effect of the severity of the Dupuytren's contracture on the function of the hand before and after surgery. *J Hand Surg Eur* 32:326–329, 2007.

5

Extensor Tendon Injury

Robert J. Strauch

Acknowledgments: The author gratefully acknowledges the outstanding previous chapters on these topics in prior editions of Green's Operative Hand Surgery, written by James R. Doyle, Richard I. Burton, Julie A. Melchior, Mark E. Baratz, Christopher C. Schmidt, and Thomas B. Hughes.

These videos may be found at *ExpertConsult.com*:
5.1 Subluxation of extensor carpi ulnaris

In contrast to zone 2 flexor tendon injuries, most extensor tendon repairs are liberated from the confines of a fibroosseous tunnel. Conversely, standard core flexor tendon sutures become technically impossible when dealing with the thin, flat extensor mechanism over the phalanges. These are just some of the differences between injuries of the flexor and extensor tendons. This chapter reviews issues concerning the evaluation and treatment of acute and chronic extensor tendon injuries.

ANATOMY

As in most areas of the hand, an understanding of extensor tendon anatomy is crucial to analyzing and treating injuries to this system.

Muscles

The extensor tendons originate from the finger extensor muscle bellies of the extensor digitorum communis (EDC), extensor indicis proprius (EIP), extensor pollicis longus (EPL), extensor digiti minimi (EDM), abductor pollicis longus (APL), and extensor pollicis brevis (EPB); the radial wrist extensor muscle bellies of the extensor carpi radialis longus and brevis (ECRL and ECRB); and the extensor carpi ulnaris (ECU). All of these muscles are innervated by branches from either the radial nerve or the posterior interosseous nerve.

Anatomic Variations of Extensor Muscles

Wrist Extensors. The most common anatomic variations are accessory muscles and tendons associated with the wrist extensors. The extensor carpi radialis intermedius, reported to be found in 12% of limbs, may arise superficial and radial to or between the ECRL and ECRB.[122] The significance of this accessory muscle is that it may be harvested for use as a tendon transfer in paralytic disorders when donor muscles are lacking. Anomalous tendons originating from the radial wrist extensors have been described inserting on the index or middle metacarpal base. These accessory tendons and interconnections may need to be released during tendon transfer procedures to achieve full excursion.

Finger Extensors. The extensor medii proprius can be considered to be an EIP of the middle finger, found in 10% of hands, and has recently been used in reconstruction of chronic sagittal band injuries.[6] The insertion is typically ulnar to the EDC insertion on the middle finger, as is the usual arrangement of the EIP with respect to the EDC index tendon and the EDM with respect to the small finger EDC tendon. The extensor indicis et medii communis is a variation of the EIP that inserts into the middle and index fingers.[113]

The extensor digitorum brevis manus muscle (EDBM) is an anomalous muscle on the dorsum of the hand, found in 3% of hands, usually arising between the index and middle finger metacarpals and inserting on the extensor hood of the index or middle fingers with or without anomalies of the EIP. Ogura and associates[73] described five types of EDBMs, depending on the insertion and relationship to the EIP. The clinical significance of the EDBM is that it can be mistaken for a dorsal wrist ganglion cyst; it becomes firm when the wrist is slightly flexed and the fingers are extended. It may also be a source of dorsal wrist pain and can be completely excised if needed (Figure 5.1).

Tendons at the Wrist Level

The musculotendinous junction is usually approximately 4 cm proximal to the wrist joint, although muscle fibers of the EIP often continue to the wrist joint level. At the level of the wrist, the tendons course through six individual, synovial-lined, fibroosseous sheaths, known as the six extensor tendon compartments (Figure 5.2, *A*). The fifth extensor compartment is technically a fibrous tunnel only because it does not insert on bone. The sixth extensor tendon compartment, containing the ECU tendon, has a subsheath that maintains the relationship of the tendon to the underlying ulna, and rupture or injury of this subsheath may result in symptomatic ECU tendon subluxation (Figure 5.3 and Video 5.1).[100] (Case Study 5.1; also see Chapter 13.)

Juncturae Tendinum

Proximal to the metacarpophalangeal (MP) joint level, stout interconnecting bands exist between the ring EDC and the small and middle fingers, and there is a less substantial band from the middle to the index finger. The importance of these juncturae tendinum is that finger extension can be preserved if the EDC is lacerated proximal to a juncture tendinum that connects that finger to an intact extensor tendon.[117] The juncturae tendinum also restrict independent extension of the ring and

CASE STUDY 5.1

A 45-year-old man with ulnar-sided wrist pain notices a clicking sensation on the ulnar side of the wrist, which developed after he played tennis. See Video 5.1.

What is the diagnosis?

ANS: ECU instability

Which structure has been injured to allow ECU subluxation to occur?

ANS: ECU subsheath

In the acute situation, how should the forearm and wrist be immobilized for nonoperative treatment?

ANS: Remember that the ECU subluxates with supination, wrist flexion, and ulnar deviation. Therefore, the position of pronation, wrist extension, and radial deviation is most likely to relocate the tendon.



FIGURE 5.1 Extensor digitorum brevis manus (EDBM) muscle. Extension of the fingers increases the prominence of this anomalous muscle.

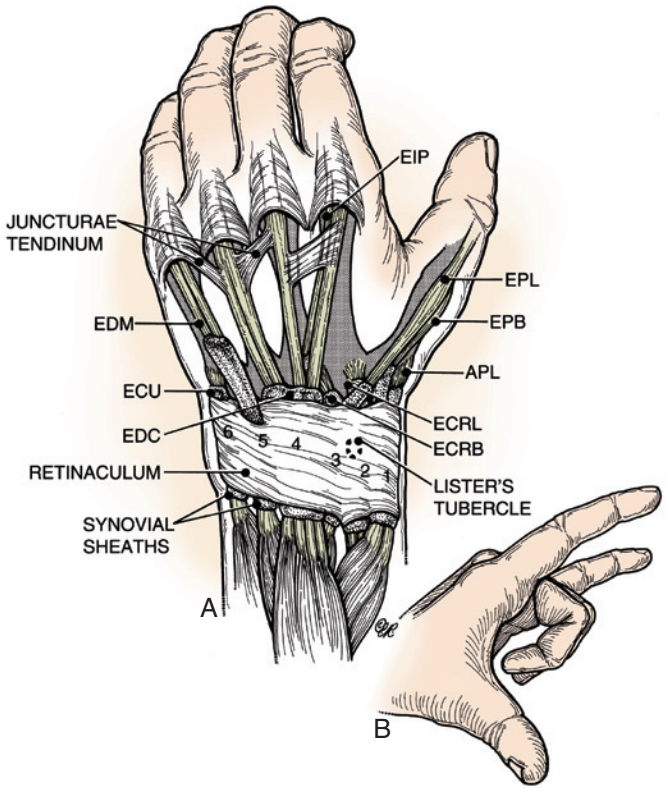

FIGURE 5.2 **A,** Extensor tendons gain entrance into the hand from the forearm through a series of six canals, five fibroosseous canals and one fibrous canal (the fifth dorsal compartment, which contains the EDM). The first compartment contains the APL and EPB; the second, radial wrist extensors; the third, the EPL, which angles around the Lister tubercle; the fourth, the EDC to the fingers and EIP; the fifth, the EDM; and the sixth, the ECU. The communis tendons are joined distally near the MP joints by fibrous interconnections called juncturae tendinum. These juncturae are found only between the communis tendons and may aid in surgical recognition of the proprius tendon of the index finger. The proprius tendons are usually positioned to the ulnar side of the adjacent communis tendons, but variations may be present that alter this arrangement (see text discussion). Beneath the retinaculum, the extensor tendons are covered with a synovial sheath. **B**, Proprius tendons to the index and little fingers are capable of independent extension, and their function may be evaluated as depicted. With the middle and ring fingers flexed into the palm, the proprius tendons can extend the ring and little fingers. Independent extension of the index finger is not always lost after transfer of the indicis proprius, however, and is less likely to be lost if the extensor hood is not injured; and is probably never lost if the hood is preserved and the juncturae tendinum between the index and middle fingers is excised. This figure represents the usual anatomic arrangement found over the wrist and hand, but variations are common, and the reader is referred to the section on anatomic variations. (Copyright Elizabeth Martin.)

middle fingers when the other digits are flexed at the MP joints. Varying morphologic views of juncturae tendinum have been described by Hirai and colleagues[36] (see Figure 5.2).

Independent Extension of the Index and Small Fingers

The EIP and EDM allow independent extension of the index and small fingers, although loss of the EIP because of tendon transfer or injury does not eliminate the ability to extend the index finger independently at the MP joint. This is true as long as the extensor hood at the index MP joint level is not injured. Isolated loss of the EDM can lead to loss of independent extension of the small finger, however, because the anatomic structure of the EDC to the small finger is highly variable, and it may be replaced exclusively by a juncturae tendinum from the ring finger (see Figure 5.2).

Variations of Extensor Tendons of the Fingers

The typical arrangement of finger extensor tendons is as follows: (1) single EIP inserting ulnar to the EDC tendon of the index finger; (2) single tendon from the EDC to the index and middle fingers; (3) double tendon from the EDC to the ring finger; (4) absent EDC to the small finger but usually a substantial juncturae tendinum from the ring EDC to the EDM; and (5) double EDM tendon to the little finger with a double insertion into the MP joint hood (see Figure 5.2).[113] Variations of extensor tendons have been noted, including a double slip of the EIP; an EIP inserting volar or radial to the EDC; and, rarely, absence of the EDC and juncturae tendinum to the small finger, in which case harvesting the EDM would lead to small finger MP joint extensor lag.

Sagittal Bands

The extensor tendon at the MP joint level is maintained in a central position by the sagittal bands, which arise from the volar plate of the MP joint and the intermetacarpal ligaments, to insert on the extensor hood. Injury to the sagittal bands may result in subluxation of the EDC.

Extensor Digitorum Communis Insertion

The mechanism by which extension of the MP joint is achieved by the pull of EDC tendons is not related to a direct insertion of the tendon on the base of the proximal phalanx. Van Sint Jan and colleagues[112] showed that although there is a "central slip" on the base of the middle phalanx, there is no such structure on the base of the proximal phalanx. Instead, there is loose connective tissue between the EDC and the base of the proximal

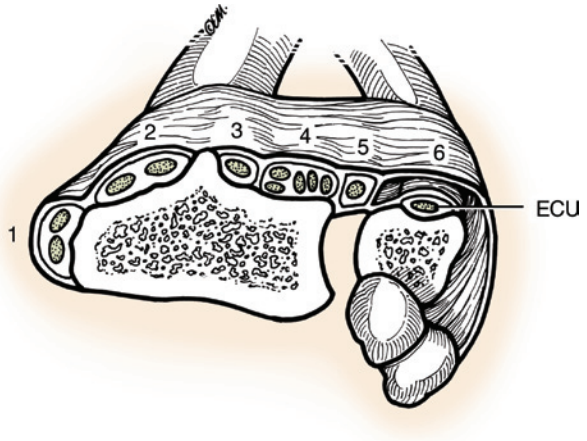

FIGURE 5.3 ECU lies in a separate fibroosseous tunnel, or subsheath. The extensor retinaculum lies superficial to and does not attach to the ulna but swings around and attaches to the pisiform and triquetrum. (From Spinner M, Kaplan EB: Extensor carpi ulnaris: its relationship to the stability of the distal radio-ulnar joint, *Clin Orthop Relat Res* 68:124, 1970. Copyright Elizabeth Martin.)

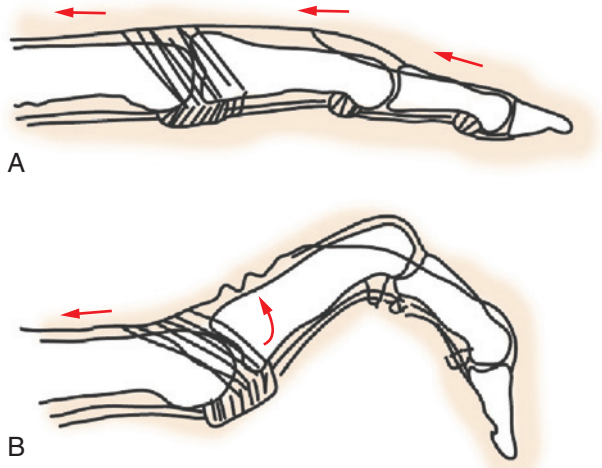

FIGURE 5.4 **A**, EDC allows extension of MP joint via insertion onto the sagittal bands, which "lasso" around the base of the proximal phalanx. There is usually no tendinous insertion of EDC to the dorsal base of the proximal phalanx. When MP joint hyperextension is prevented, EDC is capable of extending MP, PIP, and DIP joints even in the absence of intrinsic muscle function. **B**, When MP joint hyperextension is allowed, as with intrinsic paralysis, "slack" develops in EDC system distal to the sagittal bands, in addition to increased tone in the flexor system, all producing a flexion posture at the PIP and DIP joints, or claw finger.

phalanx. Extension of the MP joint is transmitted by the pull of the EDC tendon through the sagittal bands (Figure 5.4). When the sagittal band system is damaged, and the EDC tendon subluxates or dislocates off the central axis of the finger, MP joint extension is compromised.

Anatomy of the Extensor Mechanism Over the Proximal Phalanx

The anatomy of the extensor mechanism is an intricate and layered system that changes geometry as the finger flexes and extends, allowing the lateral bands to displace volarly in flexion and return to the dorsum of the finger in extension. The intrinsic tendons from the lumbricals and interossei form the lateral bands, which join the extensor mechanism at the proximal third of the proximal phalanx. The lumbrical muscle functions both to flex the MP joint and to extend the IP joints owing to its insertion on the lateral band. The lumbrical also contracts during IP and MP extension in order to "relax" the profundus tendon by pulling it distally through its proximal origin from the FDP.[120] The EDC trifurcates proximal to the proximal interphalangeal (PIP) joint, with the central component becoming the central slip and the lateral components joining up with the lateral bands.[88] These conjoined lateral bands coalesce over the middle phalanx and continue distally to become the terminal tendon (Figure 5.5).

Anatomy of the Extensor Mechanism Over the Middle Phalanx

The lateral bands are maintained in position by the triangular ligament, which unites them dorsal and distal to the PIP joint, and the transverse retinacular ligaments, which stabilize them to the flexor tendon sheath. The primary function of the triangular ligament is to prevent palmar subluxation of the lateral bands during PIP joint flexion, which can occur in the boutonnière deformity as a result of triangular ligament incompetence. The primary function of the transverse retinacular ligament is to prevent dorsal subluxation of the lateral bands during extension, as can occur in a swan neck deformity. There is a normal dorsal-palmar translation of the lateral bands with respect to the PIP joint axis of rotation during flexion and extension, which must be preserved to retain normal extensor function. The central slip insertion on the base of the middle phalanx helps to initiate extension of the PIP joint; however, PIP joint extension is possible even in the absence of the central slip, provided that the triangular ligament, lateral bands, and transverse retinacular ligaments are functioning normally (Figures 5.6 and 5.7). Distal to the triangular ligament, the lateral bands converge to form the terminal tendon, which inserts onto the base of the distal phalanx. The germinal nail matrix, which creates the nail plate, arises approximately 1.2 mm distal to the terminal tendon insertion.[94]

Extension of the Fingers

Extension of the fingers at the MP joint is exclusively a function of the extrinsic extensor tendons. Extension of the PIP joints, although primarily a function of the intrinsic interossei and lumbrical muscles, can also occur through the extrinsic tendon extensor system, provided that MP joint hyperextension is blocked. When intrinsic palsy allows the MP joint to hyperextend, the extrinsic extensor system becomes insufficient to extend the interphalangeal (IP) joints, and a "claw finger" results. This deformity occurs because of "slack" in the extensor mechanism distal to the sagittal bands and the increased flexor tone in this position (see Figure 5.4).

Extension at the MP joint is possible regardless of the position of flexion of the PIP and distal interphalangeal (DIP) joints, so the "intrinsic plus" and "hook grip" are both tenable positions. It is physically impossible, under normal circumstances, to extend or flex the PIP and DIP joints independent of one another (i.e., to extend the PIP joint without simultaneously extending the DIP joint). Only in individuals who can

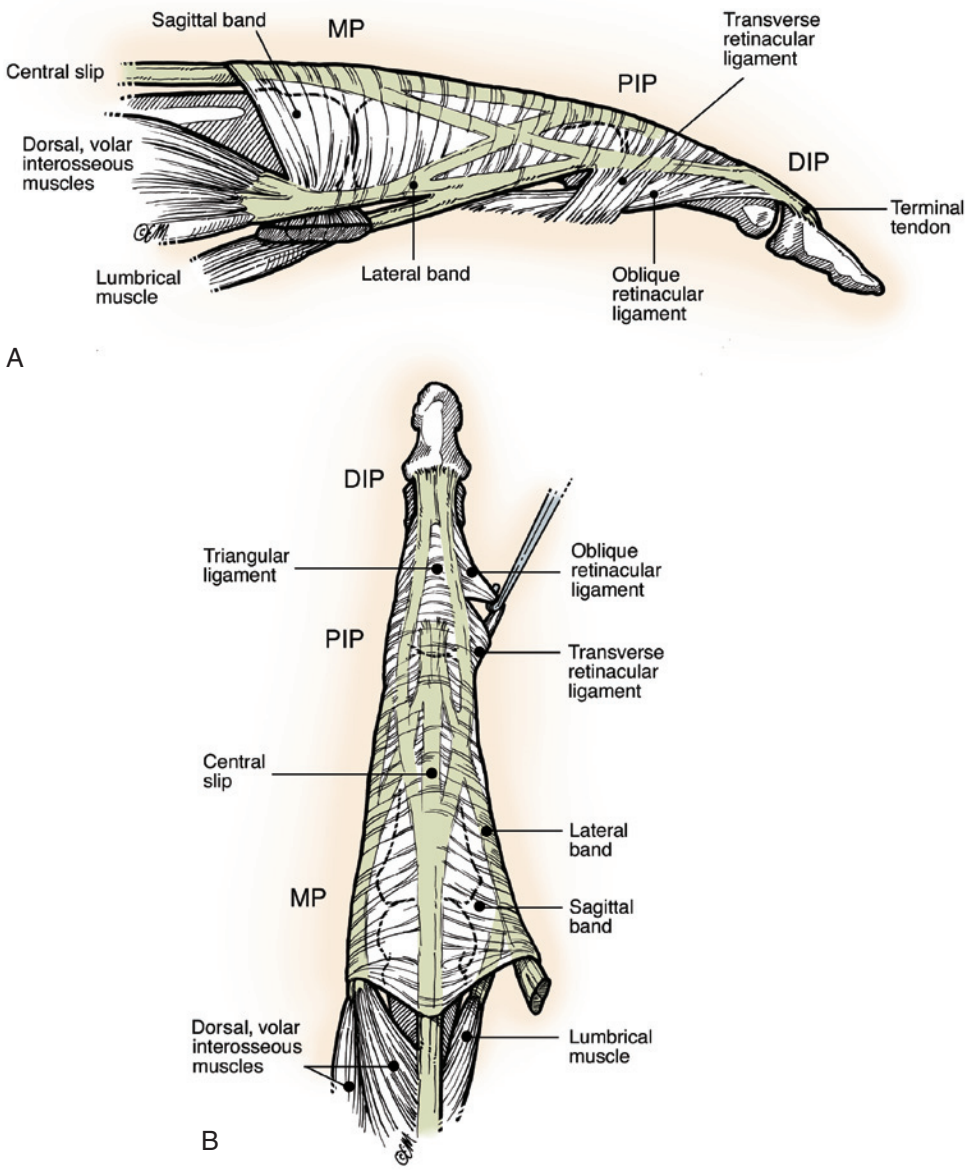

FIGURE 5.5 **A** and **B**, Extensor tendon at MP joint level is held in place by the transverse lamina or sagittal band, which tethers and centers the extensor tendons over the joint. This sagittal band arises from the volar plate and the intermetacarpal ligaments at the neck of the metacarpals. Any injury to this extensor hood or expansion may result in subluxation or dislocation of the extensor tendon. Intrinsic tendons from lumbrical and interosseous muscles join the extensor mechanism at about the level of the proximal portion and midportion of the proximal phalanx and continue distally to the DIP joint of the finger. Extensor mechanism at PIP joint is best described as a trifurcation of the extensor tendon into the central slip, which attaches to the dorsal base of the middle phalanx, and the two lateral bands. These lateral bands continue distally to insert at the dorsal base of the distal phalanx. Extensor mechanism is maintained in place over PIP joint by transverse retinacular ligaments. (Copyright Elizabeth Martin.)

voluntarily or involuntarily lock their PIP joints in hyperextension or when the PIP joint is passively held in full extension, can DIP joint flexion be accomplished independently using the flexor digitorum profundus tendon.

Testing the Anatomic Integrity of the Central Slip: Elson Test

When the PIP joint is passively flexed completely, the central slip insertion is pulled distally along with its proximal attachments, and "slack" is created between the lateral band insertions on the terminal tendon and the lateral connections of the central slip to the lateral band. This slack can be easily appreciated by manually assessing the resistance to passive flexion of the DIP joint with the PIP joint fully extended versus fully flexed. This elegant mechanism permits full flexion of the DIP joint when the PIP joint is maximally flexed (Figure 5.8, *A* and *B*). A corollary is that active extension of the DIP joint becomes impossible when the PIP joint is fully flexed because of the slack in the lateral bands (see Figure 5.8, *C* and *D*).

When the central slip is injured or incompetent, it is possible to generate extensor force at the DIP joint with maximal passive PIP joint flexion, which is the basis of the Elson test for detecting acute central slip rupture.[23] As described by Elson,[23] the examiner passively flexes the PIP joint to 90 degrees over a

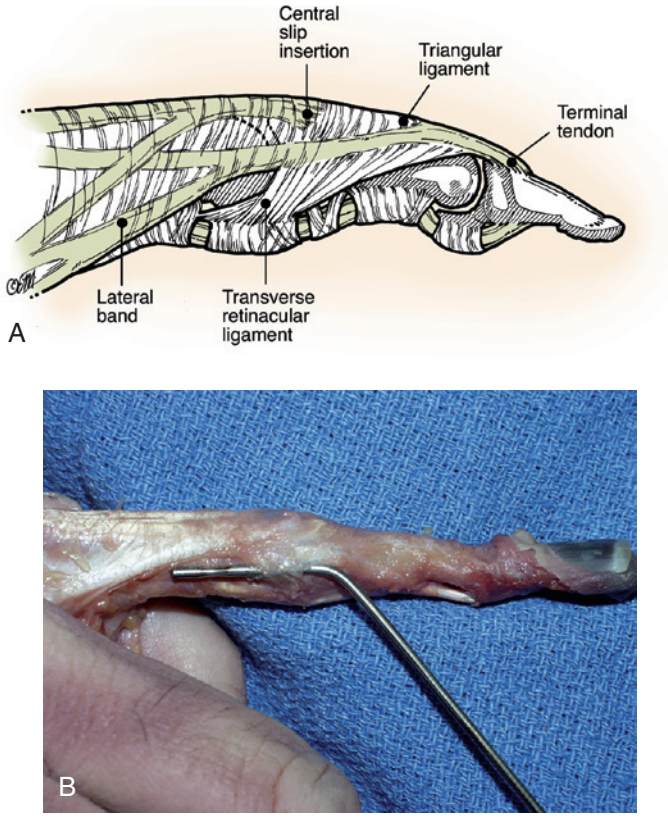

FIGURE 5.6 **A**, Illustration of extensor mechanism at PIP joint level. **B**, Cadaver finger dissection showing probe beneath transverse retinacular ligament at level of PIP joint. (**A**, From Yu HL, Chase RA, Strauch B, editors: *Atlas of Hand Anatomy and Clinical Implications,* St Louis, 2004, Mosby, p 343. Redrawn by Elizabeth Martin.)

tabletop and asks the patient to attempt active extension of the PIP joint while the examiner resists PIP joint extension. When acute rupture of the central slip occurs, no extension power is felt at the PIP joint but significant extension power, or hyperextension, is produced at the DIP joint. This test has been found to be the most sensitive physical examination test to detect acute central slip rupture.[87]

In practice, I find that the Elson test is best performed under a digital block to eliminate any pain that may arise from a concomitant injury to the PIP joint. The hand is supinated, and the examiner passively maximally flexes the injured PIP joint with one hand and then asks the patient to attempt PIP joint extension as the examiner assesses extension force at the DIP joint by gently flexing the DIP joint with the other hand. If the examiner feels DIP joint extension with force compared with the adjacent or contralateral noninjured digits held in the same position, the central slip is incompetent. Boyes[11] described another test for central slip integrity in 1970, in which the PIP joint is held in extension while the examiner assesses resistance to passive DIP joint flexion. This test is not helpful in acute situations, and it becomes positive only as a boutonnière deformity develops because of chronic retraction of the lateral bands.

Oblique Retinacular Ligament

Landsmeer[55] described the oblique retinacular ligament (ORL) (also termed the *Landsmeer ligament*) as originating from the flexor sheath at the volar aspect of the PIP joint and inserting dorsally into the terminal tendon (see Figure 5.5). The ORL theoretically tightens with extension of the PIP joint and extends the DIP joint during PIP joint extension. The existence and function of the ORL have been the subject of debate.[89]

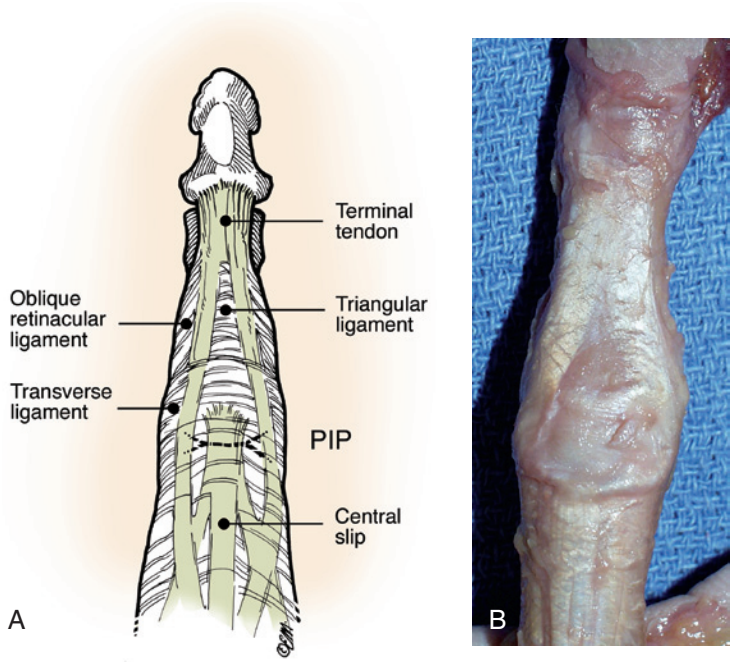

FIGURE 5.7 **A**, Triangular ligament. **B**, Cadaver triangular ligament. (**A**, Copyright Elizabeth Martin.)

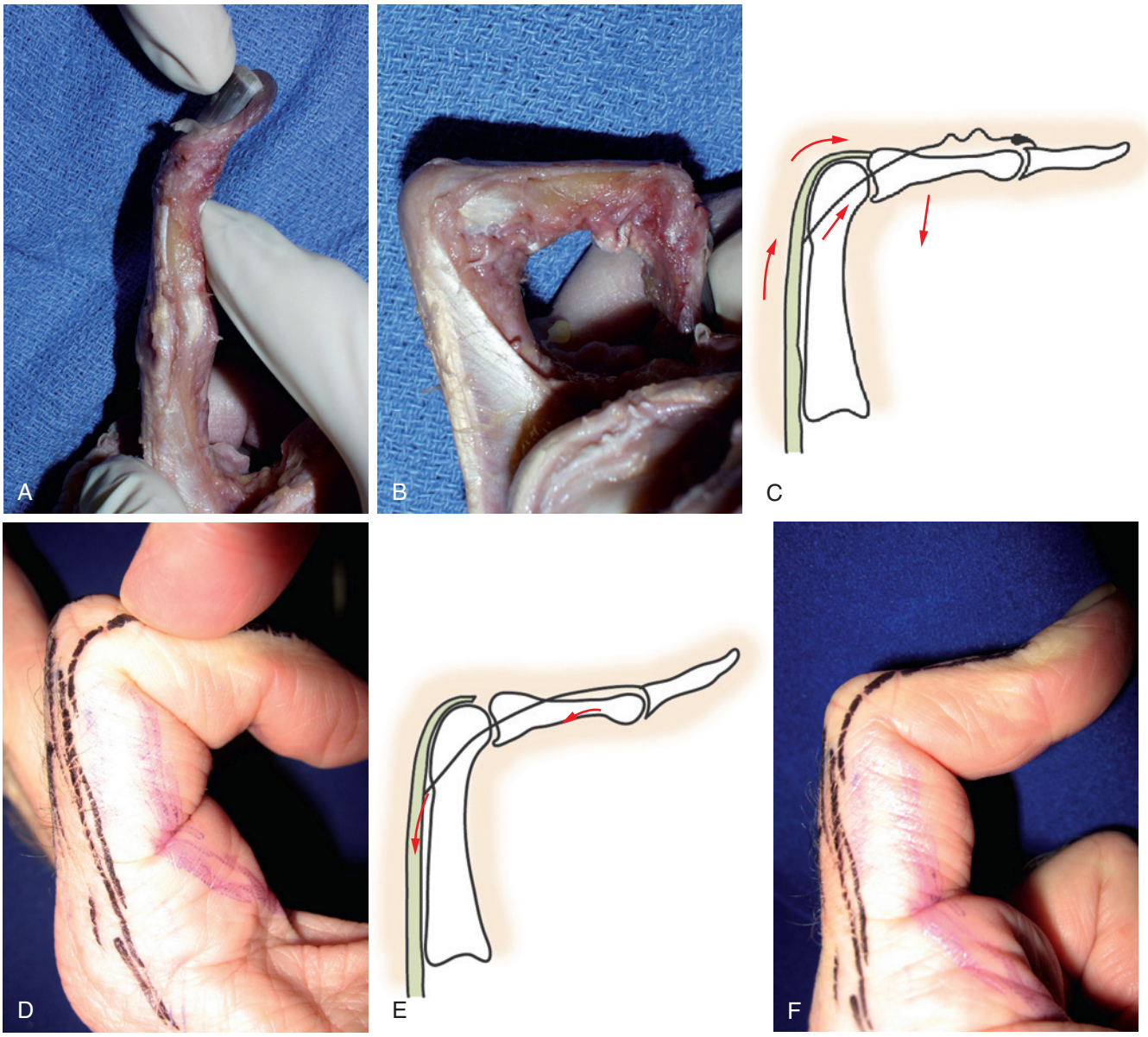

FIGURE 5.8 **A**, Maximal passive PIP joint extension prohibits full DIP joint flexion by normal tension in lateral bands. **B**, Full PIP joint flexion allows slack in the lateral bands, permitting full DIP joint flexion. **C**, Maximal passive flexion of PIP joint induces slack in the lateral bands via proximal interconnections, resulting in loss of power of active DIP joint extension and increased DIP joint flexion. **D**, Finger maximally flexed prohibits any ability to extend DIP joint actively. **E**, Injury to central slip eliminates the slack in the lateral bands produced by passive PIP joint flexion and allows extensor tension to be generated at DIP joint. This is the basis for the Elson test. **F**, With central slip injury, DIP joint can be actively extended with maximum PIP joint flexion.

Shrewsbury and Johnson[92] showed that it is present less than 50% of the time except on the ulnar side of the ring finger, where it is found more than 90% of the time. Excision of the ORL has not been shown to cause an extensor deficit at the DIP joint.

An alternative explanation to Landsmeer's theory is that the collateral ligaments of the DIP joint alone can account for the "spring back" tendency of the DIP joint in the absence of an ORL. Shrewsbury and Johnson[93] noted that a complete extensor lag does not occur when the terminal tendon is intentionally sectioned, as in the treatment of the DIP joint hyperextension posture of a boutonnière deformity. In practice, identification and preservation of the ORL, if present, would be prudent. Shrewsbury and Johnson[93] believed the presence of a functioning terminal tendon alone is sufficient to account for full extension of the DIP joint, and that the ORL was of no practical functional importance. Ueba and colleagues[110] found the ORL present in 38 of 40 cadaver fingers in an anatomic and biomechanical study; the ORL contributed up to 30% of passive resistance to DIP joint flexion, with a maximum at 30 degrees of PIP joint flexion. Regardless of its presence or absence, the *concept* of the ORL is useful in surgically creating a passive tendon "checkrein" to enable simultaneous DIP and PIP joint extension in the setting of a chronic mallet finger.

BIOMECHANICS OF FINGER EXTENSION

Boyes[11] suggested that the amplitude of tendon excursion for the wrist extensors is 3.3 cm and the amplitude of tendon excursion for the finger extensors and EPL is 5 cm; however, most of this excursion occurs over the forearm, wrist, and dorsal hand. The amplitude of tendon excursion over the dorsum of the finger is extremely small; this explains why small tendon gaps, overtightening of tendon repairs, or small amounts of bony shortening or angulation can lead to dramatic extensor lags or restriction of flexion at the PIP and DIP joints. Vahey and associates[111] found that an experimental 12-degree PIP joint extensor lag was produced with every 1 mm of tendon lengthening over the proximal phalanx. Schweitzer and Rayan[90] showed that 1 mm of terminal tendon lengthening resulted in a 25-degree DIP joint extensor lag and that 1 mm of terminal tendon shortening severely restricted DIP joint flexion.

Over the dorsum of the hand, it has been shown experimentally that relative lengthening of the extensor tendon by 2 mm produces an extensor lag of approximately 7 degrees at the MP joint. Because most MP joints had a "reserve" of hyperextension ability of about 35 degrees, however, 5 to 6 mm of relative extensor tendon lengthening in this zone may not produce a clinically relevant lack of extension.[102]

ZONES OF INJURY

The classification of extensor tendon injuries proposed by Kleinert and Verdan[51] ended at zone 8 (the forearm). Doyle[21] added a ninth zone for the muscular area of the extensor mechanism at the middle and proximal forearm. The classification is easy to recall if one remembers that the joints are odd numbered; from distal to proximal, the DIP joint is zone 1, PIP joint is zone 3, and so forth. The thumb IP joint is zone 1, and the MP joint is zone 3 (Figure 5.9).

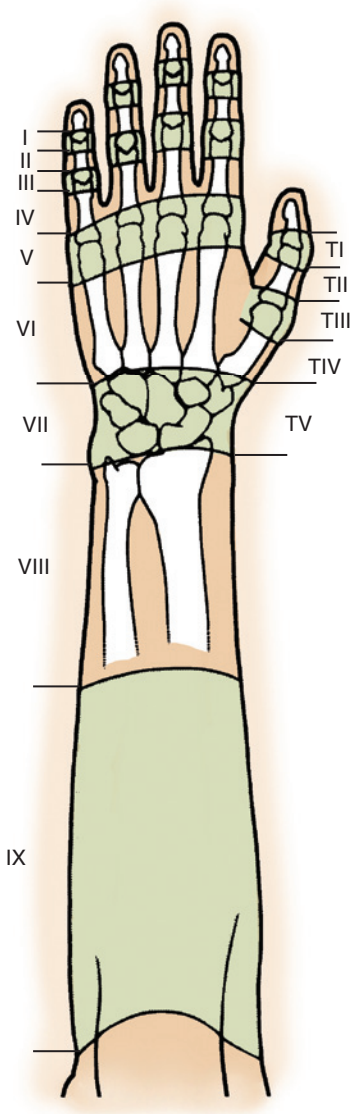

FIGURE 5.9 Zones of extensor tendon injury.

TREATMENT OF EXTENSOR TENDON LACERATIONS

Suture Repair Techniques

There are few published studies on the strength of various suture techniques for extensor tendon injuries compared with the plethora of studies concerning flexor tendon repair techniques. One problem concerns the variability in the thickness of the extensor tendon as it changes from proximal to distal. Proximally, at the forearm and wrist level, the tendons are thicker and more capable of holding core sutures, and at the finger level, the tendons become broader but quite thin, and are incapable of holding standard core sutures. Doyle[21] measured the thickness of the extensor mechanism in the fingers to be within a range of 1.75 mm in zone 6 (dorsal hand) to 0.65 mm at zone 1. A similar range was found at the thumb level.

In 1992, Newport and Williams[72] found the Kleinert modification of the Bunnell repair to be the strongest technique in a cadaver study of zone 6 extensor tendon repairs performed with 4-0 polypropylene (Prolene) suture material. In 1995, Newport and coworkers[71] reported that the Kleinert-modified Bunnell technique and the modified Kessler techniques were the strongest techniques for zone 4 injuries, and were suitable for dynamic or active range of motion under controlled conditions and in short arcs.

In 1997, Howard and colleagues[38] compared the MGH, modified Bunnell, and modified Krackow-Thomas repairs in cadaveric zone 6 extensor tendon lacerations and found the MGH technique to be superior. In a 2005 study of zone 4 extensor tendon repairs with 4-0 nonabsorbable, braided polyester (Ticron) suture, Woo and coworkers[121] found the modified Becker technique to be the strongest repair, with a significantly greater resistance to a 1- and 2-mm gap and the greatest ultimate strength. Lee and colleagues[56] compared the augmented Becker technique, the modified Bunnell technique, and a new, running interlocking horizontal mattress technique and found the newer technique to be stiffer, to produce less shortening, and to be faster to accomplish than the other techniques, without a significant difference in the ultimate load to failure. This newer technique, termed the *corset suture,* does not require the placement of core sutures and was found to have good to

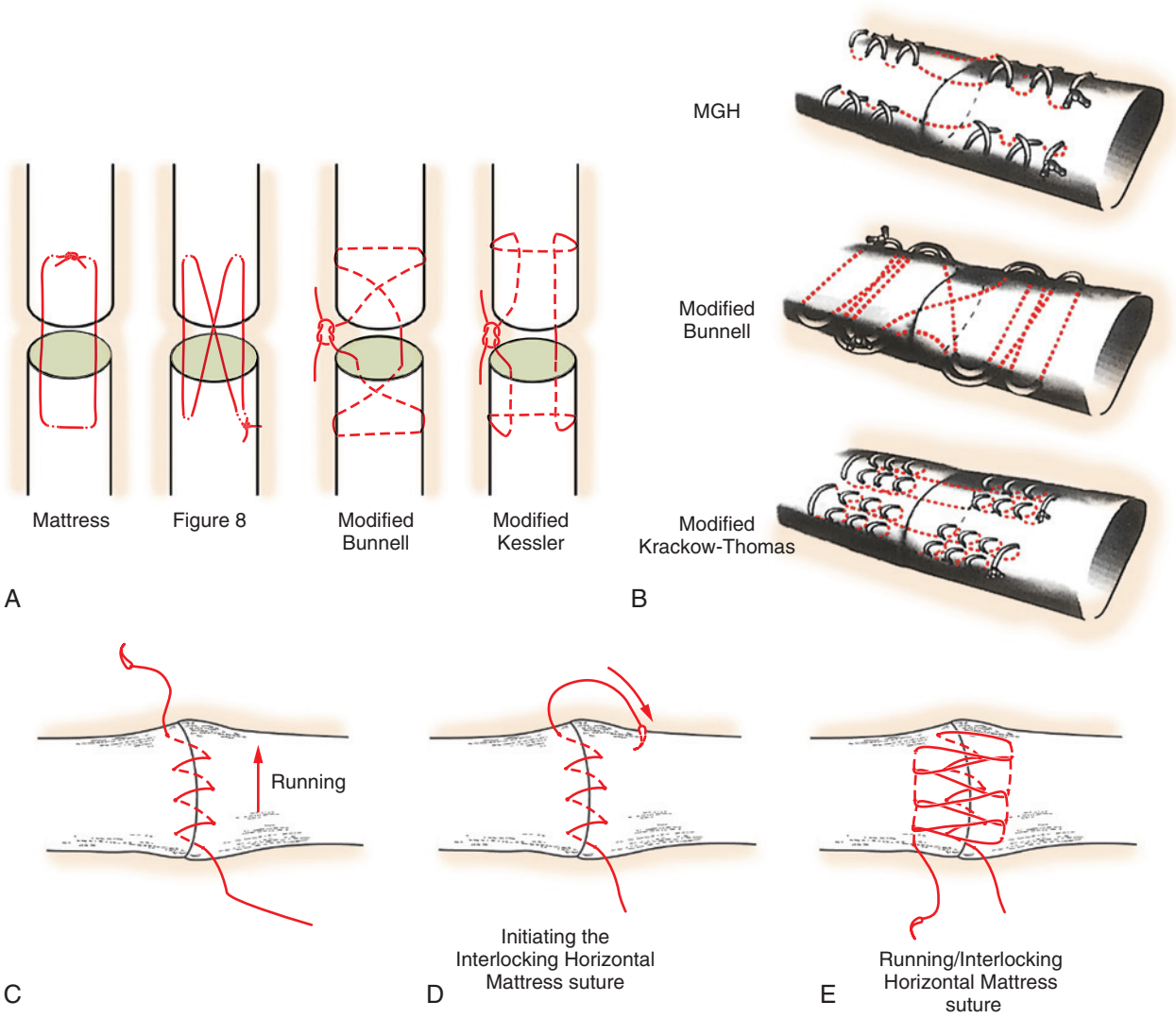

FIGURE 5.10 **A**, Modified Bunnell suture was the strongest suture with the least loss of MP or PIP joint motion. **B**, Schematic representation of four-strand MGH, modified Bunnell, and modified Krackow-Thomas repairs. **C**, Starting running suture of corset suture. This suture configuration was evaluated in zone 6 but may be used in any zone. It does not employ any core sutures. **D**, Initiating the interlocking horizontal mattress suture. **E**, Completed running interlocking horizontal mattress suture. (**A,** From Newport ML, Williams CD: Biomechanical characteristics of extensor tendon suture techniques. *J Hand Surg Am* 17:111–119, 1992, with permission from The American Society for Surgery of the Hand; **B,** From Howard RF, Ondrovic L, Greenwald DP: Biomechanical analysis of four-strand extensor tendon repair techniques. *J Hand Surg Am* 22:838–842, 1997, with permission from The American Society for Surgery of the Hand; **C** to **E,** From Lee SK, Dubey A, Kim BH, et al: A biomechanical study of extensor tendon repair methods: introduction to the running-interlocking horizontal mattress extensor tendon repair. *J Hand Surg Am* 35:19–23, 2010, with permission from The American Society for Surgery of the Hand.)

excellent clinical results in a study of zones 4 and 5 extensor tendon lacerations[3] (Figure 5.10).

Doyle[21] proposed the following techniques for extensor tendon repair:

Zone 1 (DIP joint): Running suture incorporating skin and tendon.

Zone 2 (middle phalanx): Running 5-0 stitch near cut edge of tendon, completed with a "basket-weave" or "Chinese finger trap" type of cross-stitch on the dorsal surface of the tendon (Figure 5.11).

Zones 3 through 5 in fingers, and zones 2 and 3 in thumb: Modified Kessler suture of 4-0 synthetic material in the thickest portion of the tendon. A 5-0 cross-stitch tied to itself at the beginning and end is run on the dorsal surface of the tendon (Figures 5.12, 5.13, and 5.14).

Zones 6 and 7: Same as for zones 3 through 5, except the cross-stitch is run around the entire circumference of the tendon, if feasible.

❖ AUTHOR'S PREFERRED TREATMENT

I agree with Doyle's recommendations except that I usually use two modified Kessler core suture repairs for zones 3 through 5 complete tendon lacerations, on either side of the tendon, to avoid "bunching up" of the tendon. For zone 1 injuries, I do a running suture of 5-0 polypropylene supplemented by a transarticular Kirschner wire in full extension for 6 weeks, instead of a "roll" suture incorporating skin and tendon; sometimes I will use several interrupted and buried figure-of-eight 5-0 polypropylene sutures to anatomically reapproximate the tendon in zones 1 to 4, if the tendon laceration is jagged.

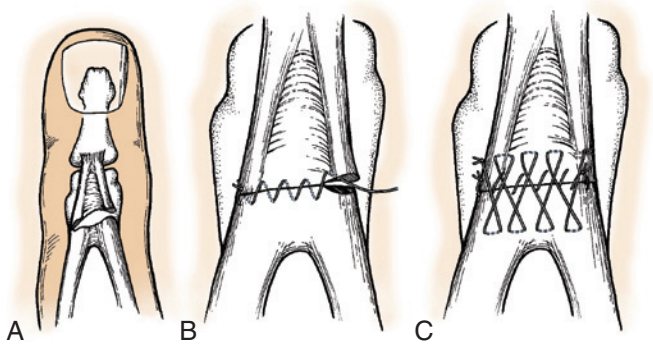

FIGURE 5.11 Relatively thin extensor tendon just proximal to DIP joint can be repaired with this technique. **A**, Sharp laceration in zone 2 of the extensor tendon. **B** and **C**, Laceration repaired with a running suture (**B**) and oversewn with a Silfverskiöld cross-stitch (**C**).

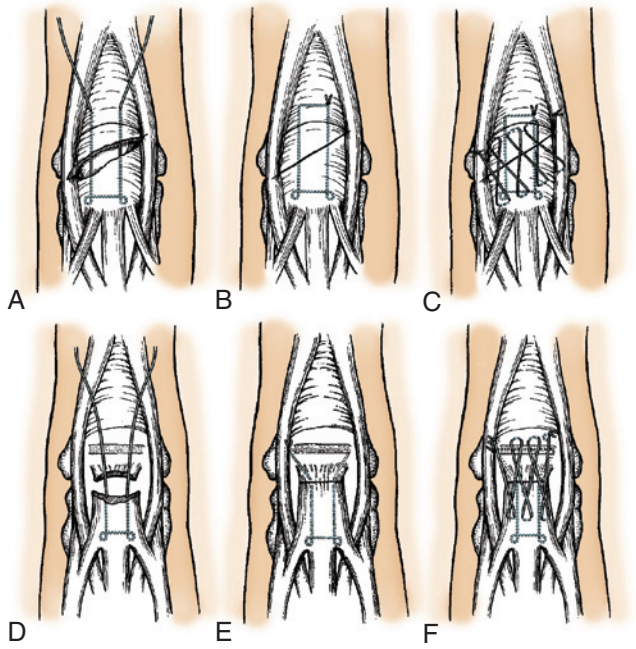

FIGURE 5.12 Doyle's preferred technique for repair of zone 3 lacerations. **A** to **C**, Central slip laceration with sufficient tendon to repair with core suture and oversew with Silfverskiöld epitendinous stitch. **D** to **F,** Core stitch can be passed through trough in the base of the middle phalanx when the tendon laceration is distal, leaving a small stump of central slip.

Postoperative Management

The traditional postoperative program for extensor tendon repairs in zones 1 and 2 is 6 weeks of immobilization with either splint or Kirschner wire fixation of the DIP joint, and this generally remains the preferred regimen. Zones 3 through 5 repairs have historically been protected with the wrist in 40 degrees of extension, slight flexion at the MP joint, and extension at the PIP joints for 4 weeks. Zones 6 and 7 repairs have usually been managed with similar wrist and MP joint extension, allowing full active motion at the IP joints for 4 weeks.[21] As in the rehabilitation of flexor tendon injuries, the main concern after repair is to maintain the integrity of the repair while limiting adhesion formation. The concept of early protected range of motion has been investigated for extensor tendon injuries, as it has been for flexor tendon injuries.

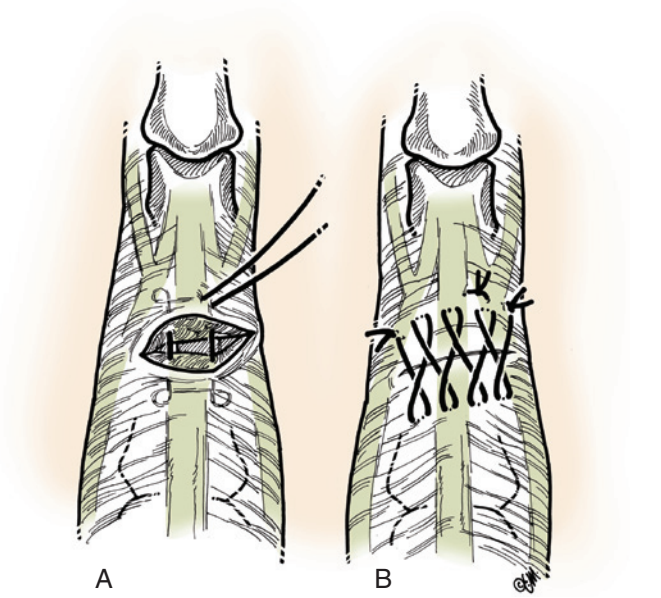

FIGURE 5.13 The author's recommended technique for suture of zone 4 extensor tendon injuries. **A**, Modified Kessler suture is centered over the laceration and tied with suitable tension to avoid gapping or undue shortening of the tendon. The distance between longitudinal components of the suture is adjusted to avoid side-to-side "bunching" or shortening. Alternatively, two modified Kessler core sutures may be placed to avoid bunching of the repair. The relative increased thickness of lateral bands is used for placement of the longitudinal portions of the suture to obtain maximal holding power. **B**, The suture is "finished" with a cross-stitch to augment the repair further. This repair is well suited to the curvature of the extensor tendon over the proximal phalanx and the relative thinness of the tendon. (Copyright Elizabeth Martin.)

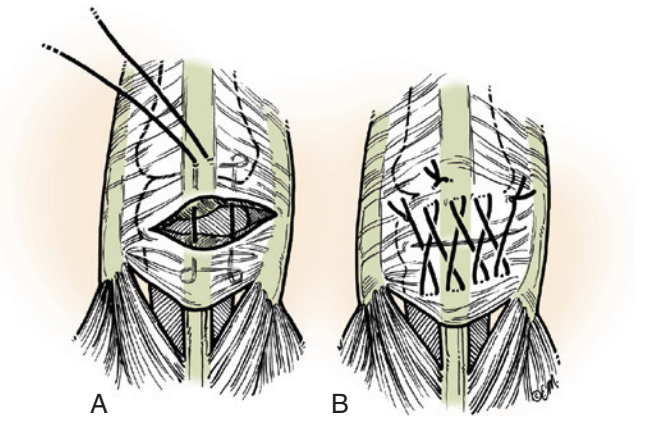

FIGURE 5.14 Lacerations over MP joint (zone 5) are in a region of increased thickness and substance compared with the extensor tendon mechanism distally. **A** and **B**, The author's preferred technique for repair of lacerations in this zone includes the modified Kessler (**A**), followed by the cross-stitch (**B**). (Copyright Elizabeth Martin.)

The ideal candidate for early range of motion (dynamic splinting) is a motivated patient with a complex injury involving more than one structure (e.g., tendon, bone, nerve). The concept of early passive motion for extensor tendon rehabilitation is that by moving joints through a controlled arc of motion, extensor tendon gliding of 3 to 5 mm may limit adhesion formation. Evans and Burkhalter[24] found that 30 degrees of MP joint flexion created 5 mm of EDC glide in zones 5 through 7. The EPL glides approximately 5 mm at the Lister tubercle with 60 degrees of thumb IP joint flexion. The Evans and Burkhalter

TABLE 5.1 Studies of Postoperative Dynamic, Static, or Active Splinting

Study	Year	Zones of Injury	Comparison	Results
Browne and Ribik[11a]	1989	Zones 4-7	Dynamic splinting only	Full flexion in all. No tendon ruptures
Hung et al[39]	1990	Zones 2-5; prospective study	Dynamic splinting only	Poor results distal to MP joint
Saldana et al[87b]	1991	Zone 3 only	Dynamic splinting only	Most good or excellent. One mild boutonnière deformity
Evans[23a]	1994	Zone 3	Static extension splinting versus early active short arc motion	Short arc motion is better
Sylaidis et al[103a]	1997	Zones 4-7	CAM; not dynamic splinting	Excellent results in 22 of 24 cases
Purcell et al[80a]	2000	All zones	Static splinting only	76% excellent, 24% good results
Khandwala et al[48a]	2000	Zones 5-6	Dynamic splinting versus CAM	No difference between groups. Prefer CAM as simpler and less expensive
Chester et al[16a]	2002	Zones 4-8; prospective randomized study	Dynamic splinting versus CAM	Dynamic splinting better
Russell et al[87a]	2003	Zones 5-8	Dynamic splinting versus static splinting	Prefer static splinting because results similar
Mowlavi et al[57]	2005	Zones 5-6; prospective randomized study	Dynamic versus static splinting	Dynamic better at 4, 6, and 8 weeks but not at 6 months
Bulstrode et al[12]	2005	Zones 5-6; prospective comparative trial	Static splinting of MP and IP joints versus static splinting allowing IP motion only versus Norwich regimen	Motion in static group worse at 4 weeks but equal at 12 weeks
Kitis et al[50]	2012	Zones 5-7; prospective randomized trial	Dynamic versus static splinting	Dynamic better at 12 weeks and 6 months
Patil and Koul[78]	2012	Zone 5-8; prospective randomized trial	Static versus early active motion	Active better at 12 weeks but equal at 6 months

CAM, Controlled active mobilization.

method of postoperative rehabilitation for extensor tendon repair in zones 5 through 7 starts with dynamic splinting 3 days postoperatively to allow MP joint flexion to about 30 degrees, keeping the wrist in 45 degrees of extension. Dynamic splinting involves passive joint extension with a dynamic outrigger device, with flexion limited by the confines of the palmar splint (see Figure 5.27). Controlled active mobilization involves active joint extension, limiting joint flexion with a palmar splint. Short arc motion protocol involves passive extension splinting with intermittent, splint-assisted passive flexion and active extension. Table 5.1 summarizes studies done on various postoperative splinting protocols.

TABLE 5.2 Miller Criteria for Assessing Extensor Tendon Function

Result	Total Extension Lag (degrees)	Total Flexion Loss (degrees)
Excellent	0	0
Good	≤10	≤20
Fair	11-45	21-45
Poor	≥45	≥45

From Miller H: Repair of severed tendons of the hand and wrist. *Surg Gynecol Obstet* 75:693–698, 1942.

Outcomes

In 1942, Miller[67] suggested criteria for assessing extensor tendon repair outcomes, which were later endorsed by Newport and associates[70] (Table 5.2). This rating system takes into account extension lag and loss of flexion secondary to extensor adhesions and stiffness in terms of total active motion. In 1990, Newport and colleagues[70] reported on the long-term results of extensor tendon repair treated with static splinting. Of patients without associated injury, 64% achieved good or excellent results, whereas only 45% of patients with associated injuries achieved good or excellent results. More fingers lost the ability to flex fully than lost the ability to extend. Injuries in zones 1 through 4 had a worse outcome than injuries in the more proximal zones. Fair or poor results were found in 7 of 12 zone 1 injuries, 6 of 6 zone 2 injuries, 10 of 14 zone 3 injuries, and 4 of 7 zone 4 injuries. These injury zones were associated with total extensor lags of the PIP and DIP joints of 11 to 45 degrees or more, and loss of flexion of 21 to 45 degrees or more. Zones 5 through 7 usually regained approximately 80% or more of normal motion.[58] In a prospective randomized trial of dynamic versus static splinting for uncomplicated zones 5 and 6 lacerations, Mowlavi and coworkers[68] found total active motion of 250 degrees for both groups at 6-month follow-up, with grip strength of 80% of normal in the dynamic group and 73% of normal in the static group. A systematic review of the literature in 2012 noted that both static and early motion protocols resulted in favorable results, but neither technique could be shown to be superior owing to variability in outcome measure reporting.[33]

I employ dynamic splinting and controlled active motion for extensor tendon injuries in zones 4 through 7 in compliant patients, or when multiple structures are involved in certain patients with injuries in zones 2 and 3. There is no level I evidence that accelerated rehabilitation confers any long-term advantage in outcome over static splinting.

Complications After Extensor Tendon Repair

Adhesions are the most frequent complication of extensor tendon repair and can cause an extension lag and loss of flexion. An extensor tenolysis may be considered if, after 6 months,

progress is considered to be unsatisfactory by the patient. Tenolysis of the extensor mechanism over the hand and finger may require concomitant joint releases and flexor tenolysis, either simultaneously or in a staged fashion. In the ideal situation, full passive motion should be present before tenolysis because this implies that there are no secondary capsular or ligamentous contractures. Lack of full passive motion after an appropriate course of therapy is not a contraindication to surgery, but the patient should be aware of the diminished expectations when joint release and mobilization are necessary. Creighton and Steichen[18] reported the results of tenolysis after fracture and found only a 31% improvement in total active motion overall, 50% improvement in extensor lag if only a tenolysis was required, and 21% improvement in total active motion if a dorsal capsulotomy was required with no improvement of the active extensor lag.

CRITICAL POINTS *Extensor Tendon Repair*

- "Bunching up" the flat extensor tendon over the phalanges with one large core suture should be avoided.
- Repairs in zones 1 through 3 are not usually amenable to early motion protocols.
- Dynamic splinting may be used for injuries proximal to the PIP joints, but may not produce better outcomes than static or early active motion rehabilitation.

Expected Outcomes

- Loss of digital flexion may be greater than residual loss of extension.
- Repairs in zones 1 through 4 typically have worse motion than more proximal injuries.

SPECIFIC EXTENSOR TENDON INJURIES

Acute Mallet Finger Injury (Zone 1: Distal Interphalangeal Joint Level) (Case Study 5.2)

Mallet finger injury is characterized by discontinuity of the terminal extensor tendon resulting in an extensor lag at the DIP joint with or without compensatory hyperextension at the PIP joint (*swan neck deformity*). The injury has also been termed *drop finger* or *baseball finger*. Mallet fingers are classically described as "soft tissue" (tendon rupture) or "bony" (avulsed fragment of bone). For a seemingly simple injury, a lengthy, tedious treatment course is often required to obtain a satisfactory result. Poor outcomes are not unusual and can be a considerable source of frustration for the patient and the surgeon.

Mechanism of Injury

Mallet finger may be caused by open injuries or more commonly by closed rupture of the terminal tendon with or without associated fracture of the distal phalanx. Closed injuries are more common and are typically unnoticed at the moment of injury. Snagging the extending finger on a pants cuff, a bedsheet, or other object that suddenly flexes the extending DIP joint is a frequent cause. Less commonly, a forceful hyperextension injury of the DIP joint may result in a large fracture of the base of the distal phalanx involving one third or more of the articular surface. Elderly patients with osteoarthritis of the DIP joint may have "mallet" deformities that are not related to trauma, and individuals with hyperlax joints may have multiple pseudomallet swan neck postures that are unrelated to trauma.

Incidence

The most frequently involved digits are the small, ring, and middle fingers of the dominant hand, with a male predominance.[32] Tendinous mallet fingers have been reported to occur from age 11 onward. In skeletally immature individuals, a transepiphyseal plate fracture may be seen. According to Jones and Peterson,[44] who noted 20 mallet fingers in 7 family members, there may be a familial predisposition to mallet fingers.

ANATOMY

The radial and ulnar lateral bands merge to form the terminal tendon distal to the triangular ligament over the dorsum of the middle phalanx. Warren and associates[115] suggested that an area of avascularity in the area of the terminal tendon may predispose it to rupture. The extensor mechanism over the dorsum of the middle phalanx is proximally tethered by its anatomic connections. Katzman and colleagues[47] showed that PIP joint motion and intrinsic tendon tension did not cause a tendon gap in a transected terminal tendon. If the DIP joint is fully extended, the gap closes; if the DIP joint is flexed, the gap opens. The position of the DIP joint alone dictates the gap at the site of healing of a torn terminal tendon, regardless of the position of the PIP joint. Theoretically, PIP joint flexion should advance the extensor mechanism distally through interconnections between the central slip and lateral bands, and some historical treatments did immobilize the PIP joint in flexion along with DIP joint extension. PIP joint flexion is not currently recommended in the treatment of mallet fingers.

The posture of the DIP joint is exquisitely sensitive to changes in the length of the terminal tendon. Lengthening of the extensor mechanism over the middle phalanx or DIP joint by 1 mm may result in a DIP joint extensor lag of 25 degrees, and lengthening of 0.5 mm results in a lag of 10 degrees.[90] This finding helps to explain why mallet finger injuries frequently result in residual extensor DIP joint lags and why such prolonged immobilization is required. Twenty percent of patients may have a residual extensor DIP joint lag of 10 degrees or more.[17]

Individuals with the ability to hyperextend the PIP joint because of volar plate laxity (either traumatic or congenital) may develop a secondary swan neck deformity after a mallet injury, as the central slip overcompensates at the PIP joint. The small finger is especially prone to this deformity.

Mallet fingers associated with large fragments of bone from the dorsal base of the distal phalanx may result in volar subluxation of the distal phalanx because the collateral ligaments remain attached to the fracture fragment and are incapable of resisting the volar translation moment of the flexor profundus. Fracture fragments that are less than 43% of the distal phalanx articular surface usually do not allow volar subluxation, whereas fragments involving more than 52% of the joint surface consistently allow subluxation.[40]

Classification

Doyle[21] has classified mallet finger deformities as four types (Table 5.3). The most common injury is type I. Patients presenting within 4 weeks of injury are considered to have acute injuries; patients presenting later than 4 weeks are considered to have chronic injuries. X-rays are always recommended for mallet injuries to assess for fractures.

CASE STUDY 5.2

A 45-year-old woman is kicked by a horse. Her left small finger DIP joint is subluxated volarly and deviated radially (eFigure 5.1, *A* and *B*).

The injury is not passively correctable. There is a "springy" feel when full extension of the joint is attempted.

Surgical exploration includes:

- Ulnar collateral ligament of DIP joint torn and flipped into joint
- Extensor mechanism torn 90% from ulnar to radial (eFigure 5.2)

Treatment:

- Interposed ligament extracted and repaired
- DIP joint pinned in neutral
- Extensor mechanism repaired with interrupted 5-0 polypropylene sutures
- Pins removed 6 weeks postoperatively (eFigure 5.3)

Outcome at 1 year postoperatively:

- 10-degree extensor lag
- Full flexion

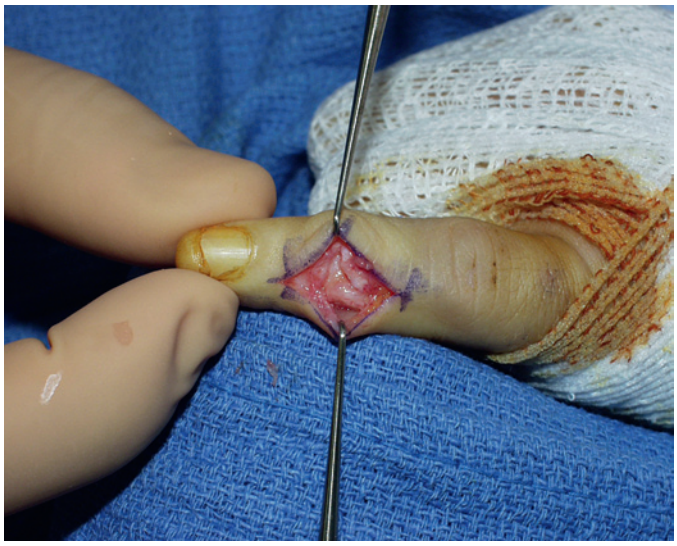

eFigure 5.2





eFigure 5.1

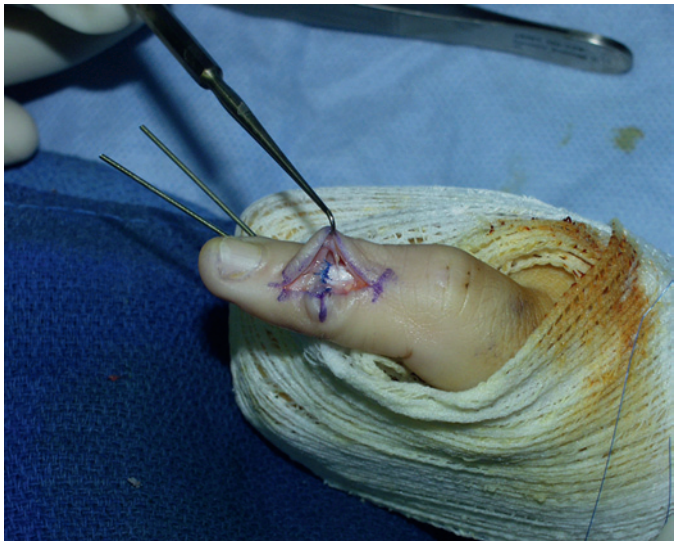

eFigure 5.3

TABLE 5.3 Classification of Mallet Fingers

Type I	Closed injury, with or without small dorsal avulsion fracture
Type II	Open injury, laceration of tendon
Type III	Open injury with loss of skin, subcutaneous cover, and tendon substance
Type IV	Mallet fracture
A	Transepiphyseal plate fracture in children
B	Hyperflexion injury with fracture of articular surface of 20% to 50%
C	Hyperextension injury with fracture of the articular surface >50% and with early or late volar subluxation of distal phalanx

From Doyle JR: Extensor tendons: acute injuries. In Green D, editor: *Green's operative hand surgery*. ed 4, New York, 1999, Churchill Livingstone, pp 195–198.
Doyle, JR: Extensor tendons: acute injuries. In Green DP, Hotchkiss RN, Pederson WC, et al, editors: *Green's operative hand surgery*. ed 5, New York, 1999, Churchill Livingstone, pp 195–197.

Management of Type I Acute Mallet Injuries

The DIP joint is splinted in full extension for 6 to 8 weeks, followed by progressive weaning of the splint. Mallet fingers manifesting several months after injury have been found to be amenable to successful splint treatment.

Nonoperative Treatment. Methods of immobilizing the DIP joint in extension include aluminum foam splints applied palmarly or dorsally, premade plastic splints, or custom-molded thermoplastic splints. Using a premade plastic splint, Okafor and colleagues[75] noted an average DIP joint extensor lag of 8.3 degrees at 5-year follow up in 31 patients. Using a dorsal DIP joint thermoplastic splint, Foucher and colleagues[26] noted an extensor lag of 5 degrees at 5 years after the injury. Using a premade plastic splint for 8 weeks, Crawford[17] noted that 20% of patients had an extensor lag of more than 10 degrees, and these tended to be patients who were noncompliant with proper splinting. Pike and colleagues[79] found no difference in clinical outcomes in a blinded, prospective randomized trial comparing volar or dorsal aluminum foam splints and custom splints; increased extensor lags were seen after discontinuation of splinting.

Historical methods of treatment involved plaster casting the finger with the PIP joint in flexion and DIP joint in extension, although now it is appreciated that the PIP joint need not be immobilized to obtain tendon coaptation. Plaster casting has been reported to be helpful with children or noncompliant patients, but this technique has largely fallen out of favor.

Operative Treatment

Tendon Suture. In 1930, Mason[63a] recommended immediate operative repair of closed mallet finger injuries; however, treatment has evolved such that immediate repair is neither necessary nor desirable for type I mallet injuries. This change in thinking is due to the difficulty of obtaining adequate tendon repair at the level of the paper-thin terminal tendon and the relative success of nonoperative treatment. Even with operative repair, prolonged immobilization of the DIP joint in extension is still required to allow tendon healing without gapping.

Kirschner Wire Fixation. Kirschner wire fixation has historically been recommended for patients who are unable to work wearing a splint, such as surgeons. Axial or oblique Kirschner wire fixation of the DIP joint, without directly repairing the tendon, has been advocated in these cases for 6 to 8 weeks, followed by 2 to 4 weeks of part-time splinting. Typically, 0.045- or 0.035-inch Kirschner wires are used depending on the size of the joint. The advantage of oblique Kirschner wires is that if they are passed through the opposite cortex of the middle phalanx, they may be extracted in the event of breakage, as opposed to a broken centrally placed Kirschner wire in the DIP joint, which is quite difficult to extricate. Instead of Kirschner wire fixation, surgeons with acute mallet fingers may use the aluminum foam splint without the foam portion (moleskin applied to the aluminum), creating a thin splint that can be protected with a sterile wrap and easily fits into a sterile glove.

Management of Types II and III Open Mallet Finger Injuries

Open lacerations of the terminal tendon are typically managed by débridement and tendon suture. Type III injuries involving loss of skin and tendon substance may require skin coverage procedures, with or without tendon grafts. Theoretically, there is no reason why closed treatment for type II injuries should not be successful (suture skin only and splint the DIP joint), and in late presentations of open injuries this may be preferable. So long as the tendon ends are approximated, an equally successful result with closed treatment should be expected. The open nature of the acute injury necessitates surgical cleansing of the contaminated joint and lends itself well to immediate tendon repair.

Management of Type IV Mallet Finger Injuries

Mallet fractures in children differ from their adult counterparts because the fractures are transepiphyseal rather than articular (Seymour fracture).[91] The extensor tendon inserts on the epiphysis and the flexor tendon inserts on the metaphysis and spans the fracture. Al Qattan[2] noted, as did Seymour, that most of these injuries were located 1 to 2 mm distal to the growth plate, and he recommended fixing the fracture with a longitudinal Kirschner wire spanning the DIP joint. I concur with axial Kirschner wire fixation of this injury. The physician should be vigilant for the frequent open nature of this injury; the nail plate can be avulsed proximally from beneath the eponychial fold. Failure to recognize this injury and treat with appropriate irrigation and antibiotic coverage can result in osteomyelitis of the terminal tuft.

The treatment of large fracture fragments in adults with or without volar subluxation of the DIP joint is controversial.[7,21,118] Intuitively, operative anatomic restoration of a large articular fragment at the DIP joint would seem preferable to nonoperative treatment and acceptance of a gap of several millimeters in the joint surface. Experience has shown that successful results are obtainable with splint treatment of these injuries.

Nonoperative Treatment. Wehbe and Schneider[118] recommended nonoperative treatment for all mallet fractures, including injuries with volar subluxation of the distal phalanx, citing the complications of operative treatment and the satisfactory results obtained with closed treatment. They found that remodeling of the articular surface occurred even with volar subluxation, leading to a near-normal painless joint despite persistent joint subluxation and a dorsal prominence. King, Shin, and Kang[49] noted a 41% incidence of complications following operative treatment of mallet fractures, the most common of which was skin necrosis.

Crawford[17] found that splint treatment of mallet fractures was usually successful, but that in some cases with large fracture fragments, the DIP joint should not be immobilized in hyperextension because this might encourage volar subluxation of the distal phalanx. Operative treatment was recommended by Crawford only for cases involving volar subluxation of the distal phalanx.[17] Kalainov and associates[45] reviewed 22 mallet fractures involving more than one third of the articular surface treated with 5.5 weeks of splinting; 13 were associated with volar DIP joint subluxation. An average DIP joint extensor lag of 9 degrees and flexion of 59 degrees resulted, and most had degenerative joint changes. All patients expressed some dissatisfaction with the final appearance of the digit because of residual dorsal joint prominence, swan neck deformity, or extensor lag. Pain was negligible, but there was overall high satisfaction with finger function and minimal difficulties with work and activities of daily living. A delay in treatment of 1 month after initial injury did not adversely affect outcome.[45] A Cochrane analysis of four randomized clinical trials found insufficient evidence to support operative over nonoperative treatment of mallet fractures.[34]

Operative Treatment. Open and closed methods of reduction of large articular fragments have been described. Open operative reduction is technically difficult and frequently results in comminution of the small piece of bone. Closed reduction and Kirschner wire pinning or "extension block pinning" has been described by several authors with different techniques.[65,105] The DIP joint is maximally flexed, and a 0.045- or 0.035-inch Kirschner wire is introduced into the head of the middle phalanx at a 45-degree angle to create an extension block for the bony fragment. Alternatively, the Kirschner wire may be inserted using a Kapandji-like technique, to lever the fragment down into flexion. A second Kirschner wire is placed axially from distal to proximal across the DIP joint to maintain extension and reduction. The pins are removed at 4 to 6 weeks postoperatively. Tetik and Gudemez[105] reported all fractures healed with this technique, and a congruent joint was obtained in 17 of 18 patients (Figure 5.15).

Complications. Stern and Kastrup[101] reported a 45% complication rate in digits treated with extension splinting and a 53% complication rate in digits treated surgically. Splinting complications were minor and included skin-related problems, whereas most of the surgical complications were major, including four DIP joint fusions and one amputation.

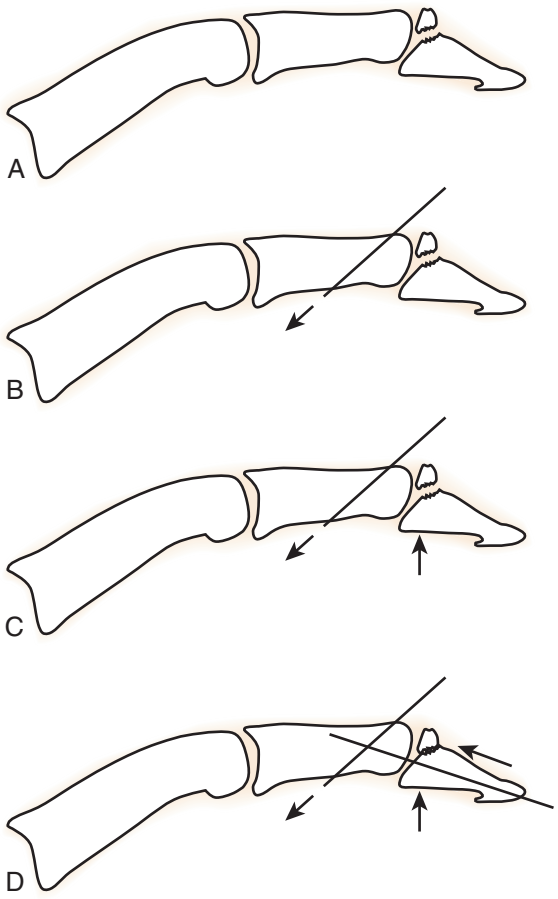

FIGURE 5.15 Extension block pinning of mallet fractures. **A**, Large mallet fracture in preparation for extension block pinning. **B**, A 0.045- or 0.035-inch Kirschner wire introduced at 45-degree angle to "block" the fragment and enable the volar piece to be reduced to it, after "levering" it down in a Kapandji-like technique, or after maximally flexing DIP joint. **C**, Volar fracture piece is reduced to dorsal fragment. **D**, Axial or oblique Kirschner wire is introduced from the distal to the middle phalanx to maintain the reduction.

❖ AUTHOR'S PREFERRED METHOD OF TREATMENT OF ACUTE MALLET INJURIES

Type I Injuries. I prefer aluminum foam splints with or without the foam, applied dorsally for 8 weeks of full-time splinting, followed by 4 weeks of night-time splinting; during this time, for the first 2 weeks the splint is worn half-time during the day. If the foam portion of the splint is completely removed, moleskin may be applied to the aluminum for skin comfort; alternatively, the foam portion can be thinned with a scissors. Slight hyperextension is built into the splint to improve tendon coaptation. I have not seen skin problems with slight hyperextension of the DIP joint, although some authors have reported vascular compromise of the skin as a complication.[82] The splint is changed every 3 days or so to check the skin, with care taken to ensure the DIP joint remains extended. Active flexion is allowed after splint removal, and passive manipulation of the DIP joint into flexion is avoided to prevent elongation of the healed tendon. Full DIP joint flexion may require 4 additional months. The skin over the DIP joint and the distal middle phalanx may remain swollen and slightly red for several months after splint cessation, which may be a reaction to the prolonged splinting and underlying tendon thickening (Figure 5.16). Patients are counseled that a 5- to 10-degree extension lag is common, and that unsatisfactory results may occur in 10% of patients despite optimal splint treatment.

Types II and III Injuries. Open repair of the extensor tendon with a running 5-0 polypropylene suture, or placement of multiple interrupted and buried figure-of-eight 5-0 polypropylene sutures, is performed; an oblique or axial 0.045-inch Kirschner wire is placed across the DIP joint in full extension to protect the repair and removed 1 month later, followed by full-time splinting for 2 weeks and night-time splinting for 1 month.

Type IV Injuries (Mallet Fractures). Unless volar subluxation is present, extension splinting for 5 to 6 weeks is my treatment of choice. I currently recommend treating large fragments associated with volar subluxation with extension block pinning as described previously, although I have had success with

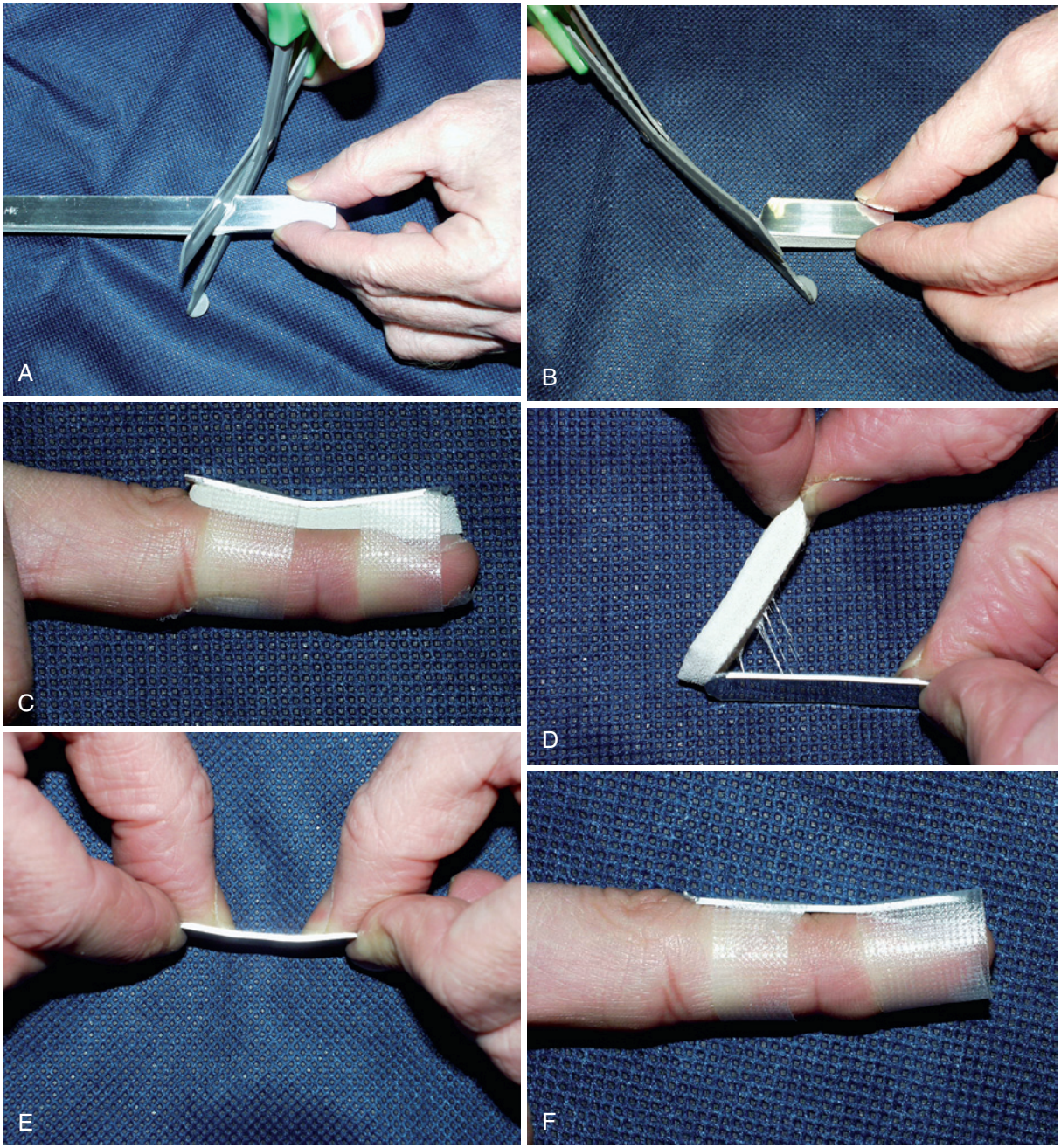

FIGURE 5.16 Author's preferred splinting regimen for mallet fingers. **A**, Cutting aluminum foam finger splint. **B**, It is important to ensure that sharp edges on the splint edge are trimmed off. **C**, Slight hyperextension is applied to splint to encourage tendon approximation. **D**, For compliant patients desiring a thinner splint, the foam can be removed. The "shiny," nonsticky side faces the skin. **E**, Slight bending of the splint into extension is performed. **F**, The "thin" splint easily fits into gloves. Care must be taken to ensure that the skin tolerates the splint in all cases using padded or nonpadded splints.

operative and nonoperative treatment of these injuries. Either splint treatment or extension block splinting is acceptable based on the current literature for mallet fractures, including fractures with volar subluxation. Patients are always advised that they may have a permanent dorsal bump with either surgical or nonsurgical treatment.

Chronic Mallet Injuries

Mallet deformities manifesting several months after the injury have been successfully treated with an extension splinting protocol.[28] Surgical options involve direct tendon repair or skin imbrications (or both),[42] tendon rebalancing with a central slip tenotomy (Fowler tenotomy),[10,31] or creating an ORL using a lateral band or tendon graft.[52,106] Arthrodesis is a salvage procedure for patients with resistant fixed or painful mallet deformities associated with arthritic changes. Tendon grafting has also been recently reported with a tendon-bone construct harvested from the ECRB–third metacarpal junction with a mean residual extensor lag of 4 degrees in 28 fingers.[114] Suh and Wolfe[103] reviewed the outcomes of various treatment options for chronic

CRITICAL POINTS *Acute Mallet Finger Splinting*

- A splint is worn full-time for 8 weeks, with weaning off of the splint over 1 month.
- Night-time splinting is implemented for 4 weeks after full-time splint wear.
- Full PIP joint flexion exercises are encouraged to prevent stiffness and to slacken lateral band tension.
- Mallet fractures may be treated nonoperatively with 5 to 6 weeks of splinting. Acute mallet fractures associated with volar subluxation of the DIP joint are treated with extension block pinning, although excellent functional results can also result from splint treatment.

Expected Outcomes

- A 10-degree residual extensor lag is common.
- The dorsal skin may remain pink and tender for 1 to 2 months after splint cessation.

mallet finger and noted generally less than 10 degrees of residual extensor lag in small studies involving splinting, tenodermodesis, palmaris longus grafting, central slip tenotomy, and ORL reconstruction.

Technique of Skin Imbrication

Tenodermodesis involves an elliptical wedge resection of skin and scarred tendon with suturing of the skin and tendon as a single unit.[42] A Kirschner wire is used to maintain the DIP joint in full extension for 4 to 6 weeks.

Technique of Fowler Tenotomy

The Fowler central slip tenotomy relies on a mature terminal tendon that has healed with slight elongation resulting in a persistent extensor lag. Typically, at least 6 to 12 months have passed since injury to allow full tendon maturation. The passage of time also allows most patients to realize that they no longer desire surgical correction because finger function is adequate. The procedure allows the extensor mechanism to slide proximally at the PIP joint by removing the tethering effect of the central slip insertion; this effectively takes up the "slack" induced by elongation at the terminal tendon. A boutonnière deformity is not created, because the triangular ligament is not injured, so long as the central slip is released from *underneath* the extensor mechanism, as described subsequently.

The finger is exposed via a midlateral incision centered over the PIP joint, performed under a local digital block with sedation. The transverse retinacular ligament is incised, and a Freer elevator is inserted under the extensor mechanism proximal to the central slip and underneath the lateral bands distal to the central slip. A tenolysis may need to be performed over the middle phalanx to break up any adhesions of the tendon to bone. The triangular ligament is left intact. The insertion of the central slip is visualized deep to the extensor mechanism. The insertion is divided by sliding a scalpel from proximal to distal underneath the extensor mechanism, and active extension of the DIP joint is attempted. A dorsal view of the extensor mechanism would not reveal any discontinuity in the tendon anatomy. Usually a near-full correction is obtained with preoperative extensor lags of up to 35 degrees.[16] The ability to extend the DIP joint actively is now better with the PIP joint held passively in flexion as opposed to extension (the reverse of normal, where DIP joint extension is limited by PIP joint flexion—the basis of the Elson test) owing to increased tension in the extensor mechanism.

The skin is closed, and a dorsal splint is applied over a thin dressing to hold the PIP joint in about 20 degrees of flexion and the DIP joint fully extended, the idea being to maximize tension on the extensor mechanism at the DIP joint. Two separate dorsal aluminum splints are applied 2 to 3 days postoperatively, one to keep the DIP joint in full extension and the second as an extension block splint for the PIP joint of about 20 degrees. The dorsal blocking splint over the PIP is discarded 2 weeks postoperatively (although PIP joint hyperextension should not be allowed), and the DIP joint extension splint is removed several times daily to allow active flexion exercises, although it is worn full-time otherwise. At 4 weeks postoperatively, the DIP joint extension splint is removed all day, although it is still worn at night for another month (Figure 5.17).

Results of Fowler Tenotomy. In a series of 20 patients, Grundberg and Reagan[31] noted an average preoperative DIP joint extensor lag of 37 degrees corrected to an average of 9 degrees at most recent follow-up using an immediate motion postoperative protocol. Houpt and colleagues[37] noted that 26 of 35 patients regained full extension, 8 patients had a residual 10- to 20-degree lag, and 1 patient had a residual 30-degree lag using an immediate motion postoperative protocol. Lucas[61] reported 11 cases of which 8 had an extensor lag of 10 degrees or less; one patient who had a mallet deformity for only a few weeks had a poor result with a 30-degree lag. Lucas[61] used a postoperative protocol of splinting the PIP joint in flexion and the DIP joint in extension for 2 weeks, followed by a Stack splint for another 2 weeks, then full motion. Bowers and Hurst[10] reported five patients; four obtained full DIP joint extension, and one had a residual lag of 10 degrees. One patient had a PIP joint lag of 12 degrees. Preoperative DIP joint extension lags ranged from 45 to 70 degrees. The postoperative splinting protocol involved splinting the PIP joint at 45 degrees of flexion and the DIP joint in full extension for 2 weeks, followed by full motion except for PIP joint flexion, which was not allowed past 45 degrees for an additional 2 weeks. I have been more pleased with respect to maintenance of the mallet correction with a progressive postoperative splinting regimen (as described previously) than by allowing full active immediate motion without any splinting, which was my previous postoperative protocol.

Treatment of Swan Neck Deformity Associated With Chronic Mallet Injury

Swan neck deformity may result from chronic mallet injury provided that the PIP joint is capable of hyperextension. PIP hyperextension results from innate or acquired laxity of the volar plate combined with increased tension in the central slip and lateral bands owing to elongation of the terminal tendon. The swan neck deformity may also arise (not due to terminal tendon injury) from overactivity of the extrinsic or intrinsic extensor mechanism due to spasticity or intrinsic contracture, and can result from insufficiency of the volar stabilizers of the PIP joint, such as volar plate incompetence or flexor digitorum superficialis injury.[108] Swan neck deformity may become symptomatic due to locking of the PIP joint in hyperextension (pseudotriggering) upon initiating PIP flexion from the hyperextended position, as well as the cosmetic deformity of the

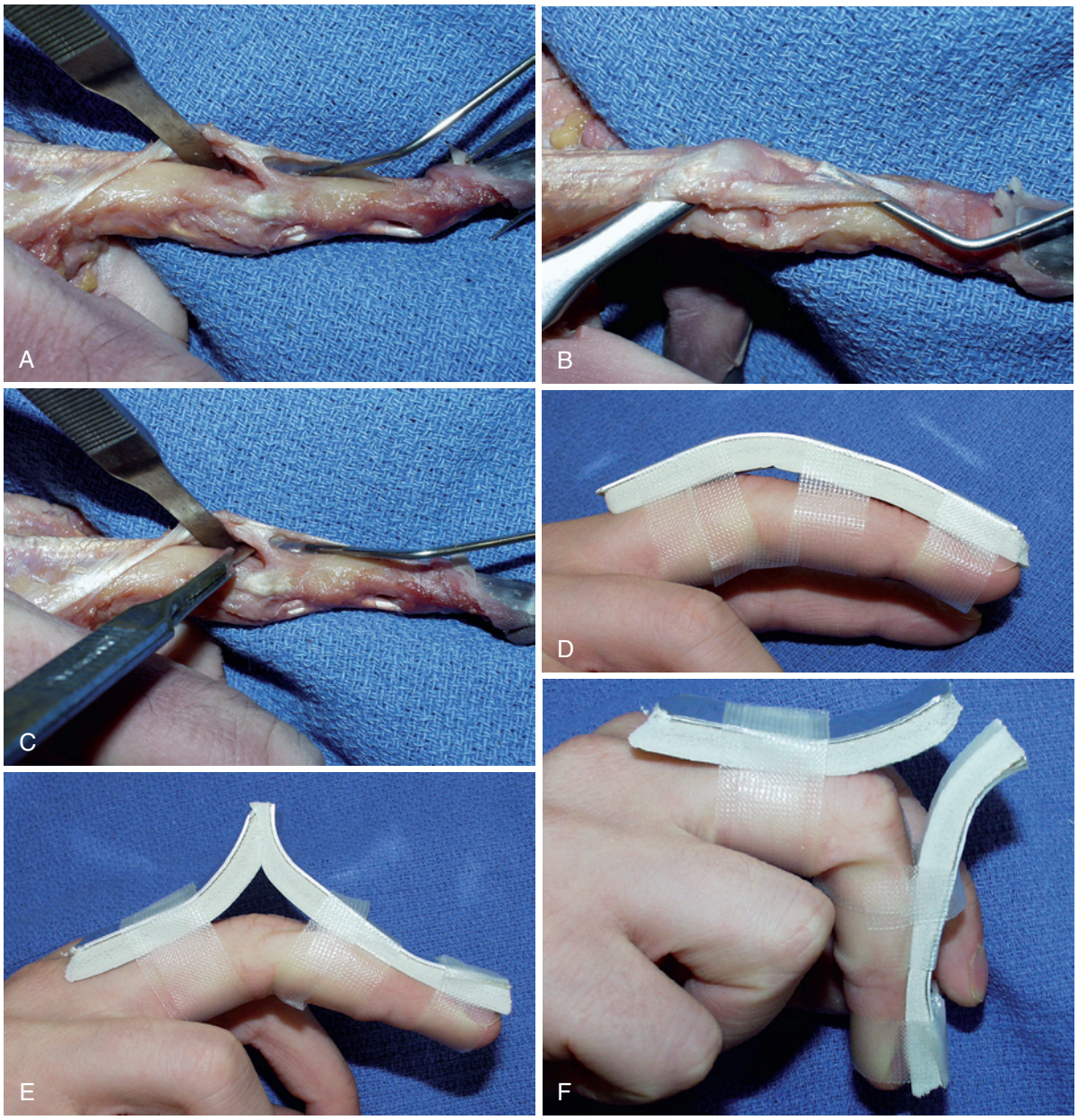

FIGURE 5.17 Fowler tenotomy for mallet finger. **A**, Midlateral incision is used. Transverse retinacular ligament is incised. The extensor mechanism over the proximal and middle phalanges is freed from any adhesions, and the central slip is identified. **B**, Dorsal view showing that the triangular ligament and dorsal extensor mechanism are not violated when the central slip insertion is transected. **C**, Central slip is transected with scalpel at its insertion into the middle phalanx base, allowing the extensor mechanism to slide proximally, reliably correcting up to a 35-degree extensor lag. **D**, Postoperatively, the finger is immobilized in PIP joint flexion and DIP joint extension for approximately 3 days. **E**, At 3 days postoperatively, a dorsal PIP joint extension block splint is applied until 2 weeks postoperatively. During this time, the DIP joint is kept in full extension. **F**, PIP joint flexion is allowed in the splint. At 2 weeks postoperatively, the proximal splint is removed, and full PIP joint motion is allowed, restricting hyperextension at PIP joint, if it was present preoperatively. The DIP joint extension splint is removed three to four times daily to allow motion; otherwise, it is kept on all the time. At 4 weeks postoperatively, the DIP joint splint is left off all day but used at night for another month.

finger. Some individuals are able to voluntarily put the finger in the swan neck position and this is physiologic in the absence of symptoms.

If PIP laxity is the primary cause, preventing PIP hyperextension will correct the DIP extensor lag associated with the swan neck deformity. A physical examination maneuver that will distinguish between swan neck deformity caused primarily by PIP laxity or mallet finger is to manually block PIP hyperextension; if full DIP extension is possible, blocking PIP hyperextension will suffice to correct the swan neck deformity (Figure 5.18). This may be considered a "distal Bouvier-type maneuver." If this maneuver corrects the mallet deformity, restricting PIP hyperextension may be accomplished through figure-of-eight splinting or surgical means, such as volar plate imbrication, flexor digitorum superficialis (FDS) tenodesis, or lateral band translocation.[108] Should this maneuver not result in correction of the DIP extensor lag, surgically increasing the extensor force at the DIP joint is required in addition to restricting PIP

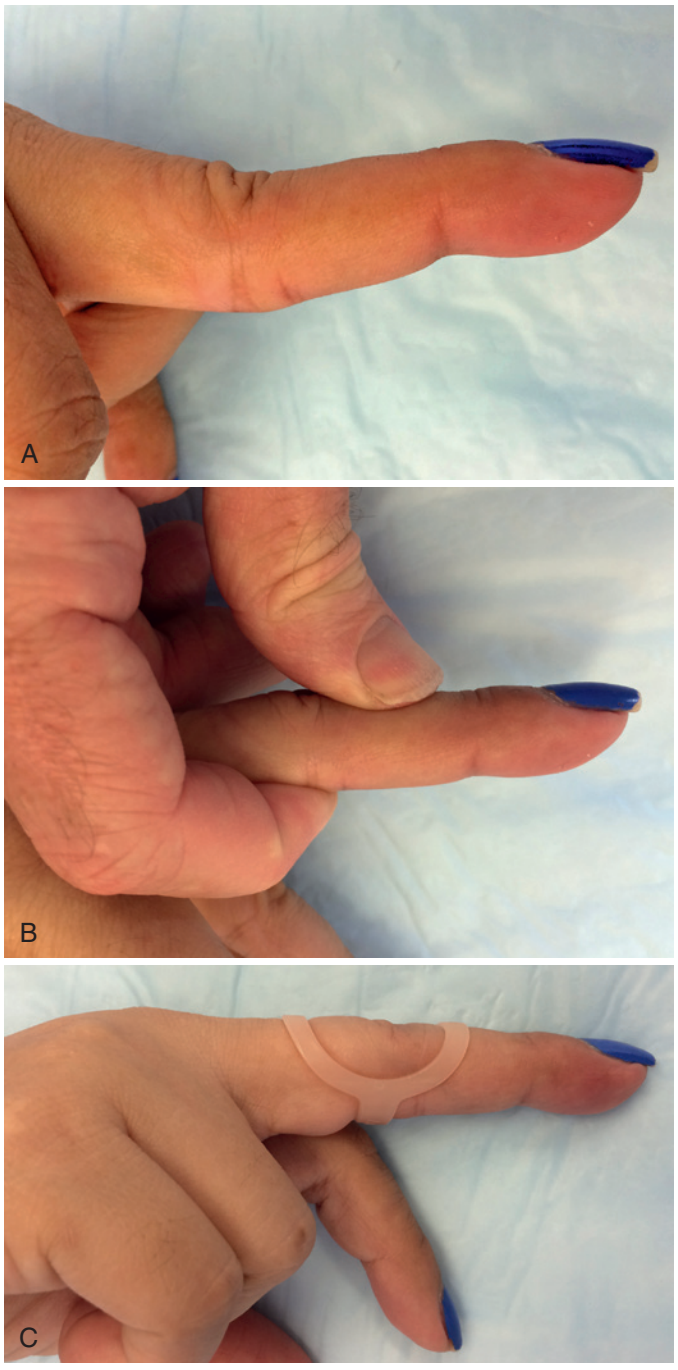

FIGURE 5.18 Physical examination maneuver to distinguish swan neck deformity due to mallet finger from other causes. **A**, Swan neck deformity due to congenital PIP joint laxity. Note the PIP hyperextension with DIP extensor lag. **B**, Manual blocking of PIP hyperextension by the examiner eliminates the DIP extensor lag, indicating that the primary problem is at the PIP joint. **C**, Figure-of-eight splint that blocks PIP hyperextension eliminates the swan neck deformity while allowing full finger flexion. This was sufficient for this patient; after wearing the splint for a few months, her symptomatic locking in hyperextension was no longer bothersome.

hyperextension. Both of these goals can be achieved by surgical reconstruction of an ORL, either by using one of the existing lateral bands[58,108] or by tendon graft procedures.[52,106] Correction of the swan neck deformity can also be accomplished via the Fowler tenotomy, which reduces central slip tone while increasing extensor force at the DIP joint.[10]

Technique of Spiral Oblique Retinacular Ligament Reconstruction

The concept of the ORL as a dynamic tenodesis linking the volar flexor sheath to the lateral aspect of the terminal tendon provides a mechanism for automatic DIP joint extension with active PIP joint extension. An ORL can be surgically created in several ways. Littler[58] described a technique to correct the swan neck deformity that divided the lateral band proximally and rerouted it palmar to the axis of PIP joint rotation, securing it to the flexor tendon sheath. Theoretically, if bridging scar tissue is stable enough to support the Fowler tenotomy concept for mallet fingers, it should work for the Littler procedure as well, although in this situation a much thinner piece of scar tissue is being relied on to extend the DIP joint. Oh and colleagues[74] found no clinical differences with the use of one lateral band (Littler's original procedure[58]) or a tendon graft (spiral ORL reconstruction) in the treatment of mallet finger in a series of 27 patients.

In 1978, Thompson and colleagues[106] described the spiral ORL, which is a procedure creating an ORL with a free palmaris or plantaris tendon graft (Figure 5.19). The tendon graft was placed through gouge holes in the distal phalanx and then directed in a spiral fashion around the middle phalanx, deep to the neurovascular bundles, over the flexor sheath, and transversely through the base of the proximal phalanx. Graft tension was adjusted with the PIP and DIP joints in neutral extension by securing the proximal end with a button or hemoclips, or both. Care is taken to avoid overtightening, which could create a boutonnière deformity. Kirschner wire fixation was not used, and active motion was begun 3 weeks postoperatively. Most patients fully corrected their preoperative mallet deformities, and one patient required slight graft lengthening for 20 degrees of DIP joint hyperextension.

In 1984, Kleinman and Petersen[52] modified the Thompson procedure, terming it the *ORL reconstruction*, and demonstrated its efficacy in 12 patients, 8 of whom had a concomitant swan neck deformity. The modifications involved axial Kirschner wire pinning of the DIP joint in neutral and pinning of the PIP joint in 10 to 15 degrees of flexion with an oblique Kirschner wire. The proximal pin is removed 3 weeks postoperatively, and the distal pin is removed 4.5 weeks postoperatively, with splinting of the DIP joint in extension for another 1.5 weeks. Additionally, Kleinman and Petersen[52] secured the graft to the dorsal distal phalanx with a 4-0 Bunnell steel pull-out wire, and the proximal juncture was attached to the palmar flexor tendon sheath with nonabsorbable sutures. This technique resulted in normal DIP joint extension in 9 of 12 cases, and slight active hyperextension of 10 to 25 degrees was seen in 3 of 12 patients. One patient required flexor tenolysis for adhesions, and one patient developed a 35-degree PIP joint flexion contracture that responded to step-cut lengthening of the graft (see Figure 5.18).

❖ AUTHOR'S PREFERRED TREATMENT OF CHRONIC MALLET INJURY

Because there is little downside to a trial of splinting, I attempt an 8-week trial of full-time extension splint treatment for neglected mallet deformities of up to 6 months' duration. For patients with an extensor lag of less than 35 to 40 degrees, more than 6 months after the injury, I find Fowler's central slip tenotomy effective; greater degrees of extensor lag may not correct

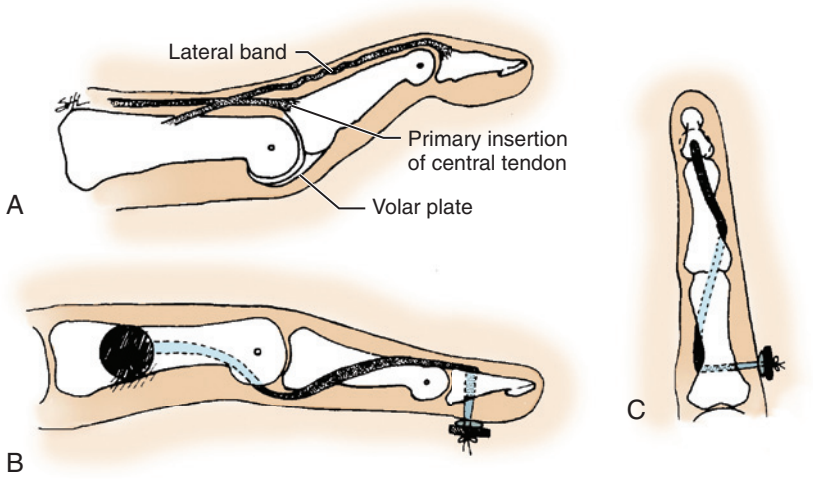

FIGURE 5.19 Spiral oblique retinacular ligament reconstruction. **A**, Schematic representation of the mallet deformity with compensatory swan neck deformity. **B** and **C**, The tendon graft is fixed to the distal phalanx, in this case using a pull-out suture. The graft is passed between the flexor sheath and the neurovascular bundles palmar to the PIP joint. The graft is tensioned and anchored into the shaft of the proximal phalanx.

as well, and alternative procedures should be considered.[16] Fowler's tenotomy also reduces PIP joint extension moment by disinserting the central slip and usually improves a swan neck deformity. For mallet fingers with extensor lags greater than 45 degrees, when there is an associated swan neck deformity, or where there is no tendon continuity at all between the retracted terminal tendon and the distal phalanx, I recommend the ORL reconstruction procedure, with or without a tendon graft.

Mallet Thumb Injury

Excellent results have been reported with nonoperative (splint) and operative treatment of closed mallet thumb injuries.[1,77] Generally, I treat closed mallet thumbs with the same splinting protocol used for type I mallet fingers and repair open tendon injuries. I have successfully treated several cases with late presentation of open mallet thumb injuries (1 to 2 weeks following the injury) with a splinting protocol in patients who have refused surgical repair.

Zone 2 Extensor Tendon Injuries

Lacerations over the dorsal aspect of the middle phalanx involve injury to one or both lateral bands or the triangular ligament that unites them (or both). One functioning lateral band is sufficient to achieve full extension of the DIP joint, and lacerations involving 50% of the extensor mechanism may be treated without tendon repair.[21] Local wound care for 1 to 2 weeks followed by active motion is sufficient. Lacerations involving more than 50% of the extensor mechanism may be repaired using a running suture of 5-0 polypropylene followed by a cross-stitch of 5-0 polypropylene, as described by Doyle[21] (see Figure 5.12). Core sutures are not technically feasible in this zone, because the tendon is too thin. Postoperatively, static splinting or pinning of the DIP joint in extension for 6 weeks is recommended, allowing PIP joint motion. Thumb zone 2 lacerations are treated in a similar manner. Chronic zone 2 injuries may be treated with a tendon graft as described previously, using the spiral ORL reconstruction.[52]

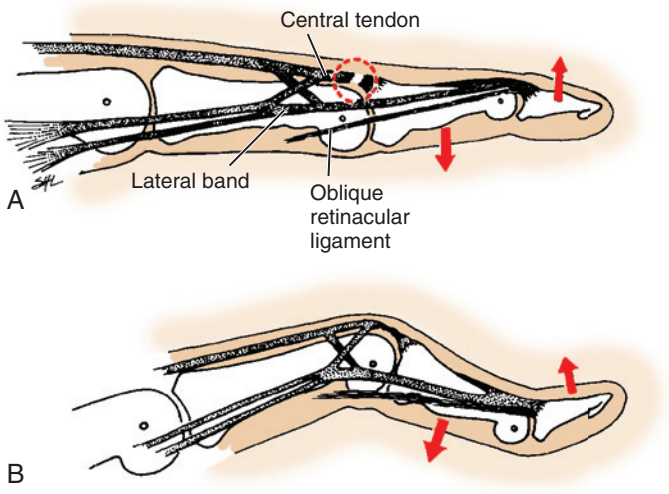

FIGURE 5.20 Pathomechanics of the boutonnière deformity. **A**, Attenuation of the central slip results in unopposed flexion at the PIP joint. **B**, With PIP joint flexion, the lateral bands drift palmar to the axis of rotation at the PIP joint. The lateral bands stay in the palmar position owing to loss of dorsal support from the attenuated triangular ligament and contracture of the transverse retinacular ligament.

Zone 3 (Proximal Interphalangeal Joint) Injuries (Case Study 5.3)

Closed or open injury to the extensor mechanism over the PIP joint may injure the central slip or the lateral bands (or both) and result in a PIP joint extensor lag and DIP joint hyperextension, termed a *boutonnière deformity* (Figure 5.20). Causes of a closed boutonnière deformity include blunt trauma to the dorsum of the PIP joint and volar dislocation of the PIP joint that results in an avulsion of the central slip, with or without a piece of bone.[99]

As noted earlier in the section on the Fowler tenotomy, an isolated, surgically created, central slip injury would not cause

CASE STUDY 5.3

A 35-year-old man experiences a chronic small finger PIP flexion contracture of 30 degrees from an old basketball injury. He jams his small finger again and is unable to extend the PIP joint actively. The Elson test shows a central slip injury. A trial of splinting for 3 weeks is unsuccessful due to the previous PIP contracture, and he develops increased DIP extensor tone in the meantime (eFigure 5.4, *A* and *B*).

What is the diagnosis?

ANS: Acute boutonnière injury superimposed on chronic PIP flexion contracture

Treatment:

Operative exploration (the patient understood that the PIP contracture would likely not be improved)

- The incision is shown in eFigure 5-5
- The extensor mechanism shows central slip scarring (eFigure 5-6, *A* and *B*)
- The DIP joint is open following débridement of injury (eFigure 5-7)
- The central slip is repaired and the joint pinned in neutral for 5 weeks (eFigure 5-8)

Outcome:

- Over a span of 6 months, full flexion of the DIP joint was regained
- A residual extensor lag of 25 degrees of the PIP joint was seen; full PIP flexion was present

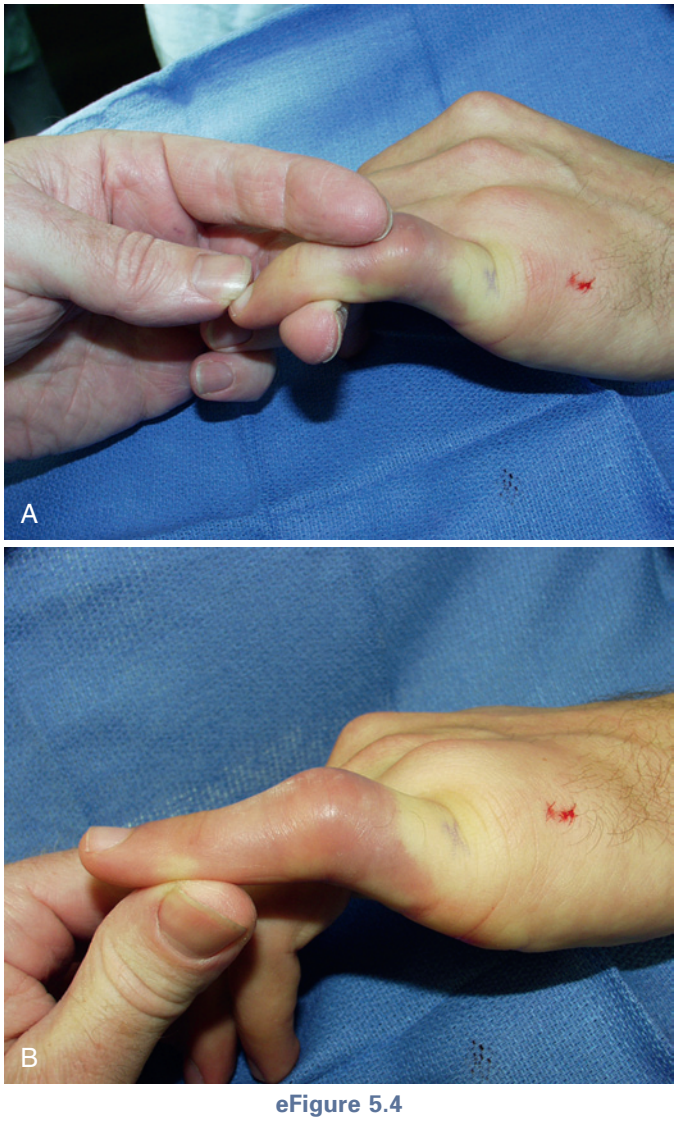

eFigure 5.4



eFigure 5.5

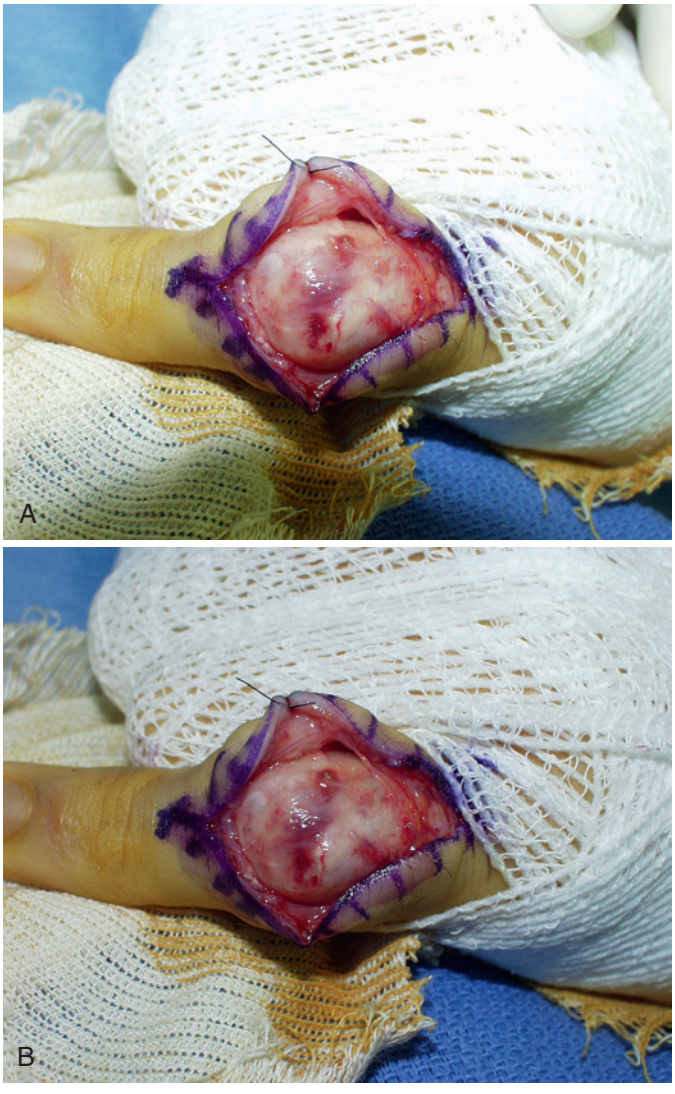

eFigure 5.6

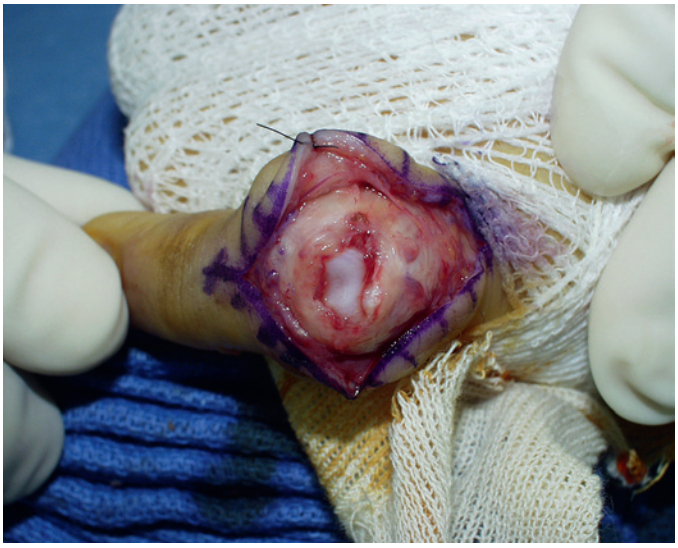

eFigure 5.7

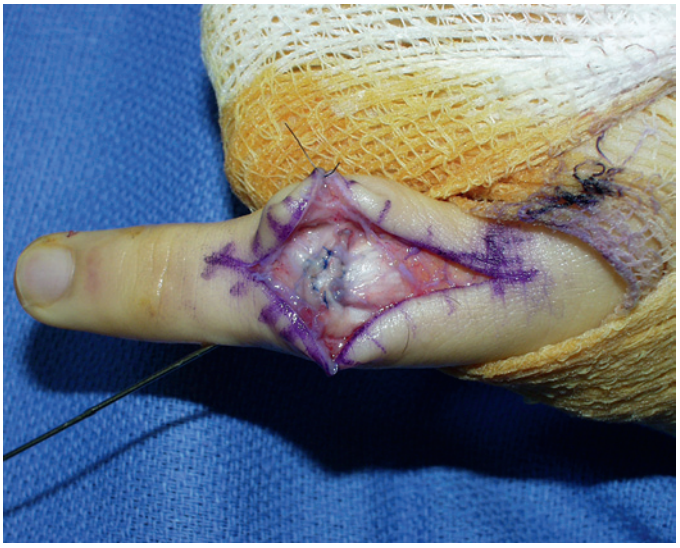

eFigure 5.8

a PIP joint extensor lag, although it would allow increased proximal extensor tension at the DIP joint, especially when the PIP joint is flexed. This increased proximal extensor tension permits correction of a mallet finger but causes DIP joint hyperextension in an uninjured finger. If the lateral bands are also cut over the PIP joint, or if the triangular ligament is injured, allowing volar subluxation of the lateral bands, a PIP joint extensor lag would result.[10] After an acute central slip injury, the classic boutonnière deformity is usually not present, and full range of motion of the PIP joint is possible. The Elson test (see Figure 5.8) should be used to diagnose central slip disruption in suspected injuries.[23,87] Within 2 to 3 weeks after untreated central slip disruption, development of PIP joint flexion and DIP joint hyperextension deformities occurs as the triangular ligament stretches out and the lateral bands migrate palmarly. All tendons crossing the PIP joint now lead to increased PIP joint flexion (the two flexor tendons and the two lateral bands) (see Figure 5.20).

Treatment of acute central slip injury consists of splinting or pinning the PIP joint in full extension for approximately 6 weeks to allow the central slip to heal, during which time active DIP joint flexion exercises are performed hourly to draw the lateral bands into the correct dorsal alignment (Figure 5.21). The exercises also stretch the increased lateral band tone that is secondary to proximal migration of the extensor apparatus. Intermittent and night splinting follows for an additional 4 to 6 weeks.

Occasionally, the central slip is avulsed with a piece of bone. Small fragments that are not displaced are treated nonoperatively, as previously described. Larger fragments that are displaced by 2 mm or more can be repaired with Kirschner wire or screw fixation. Alternatively, small or comminuted fragments can be excised, and the tendon can be repaired directly to bone using a pull-out wire or suture anchor.[21]

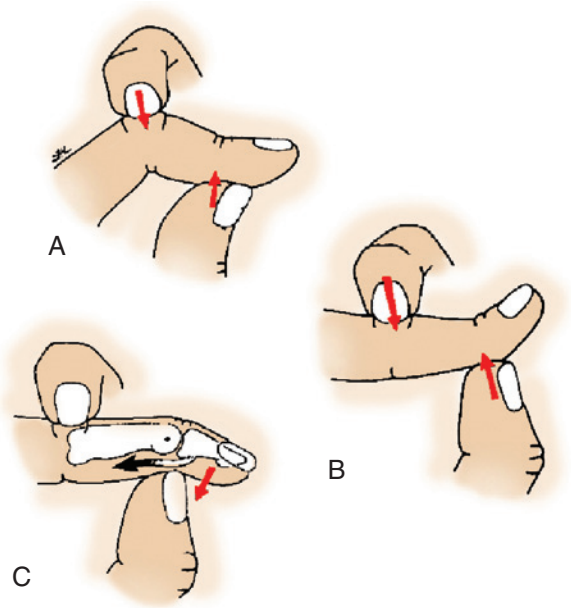

FIGURE 5.21 Exercise program for boutonnière deformity. Many patients with boutonnière deformity respond well to a carefully structured exercise and splinting program. The exercise is done in three steps. **A**, The patient is instructed to place the index finger of the opposite hand on the dorsum of PIP joint of the involved finger. The thumb of the uninvolved hand is placed on flexor aspect of DIP joint. **B**, PIP joint is passively extended by the patient as far as can be tolerated. This passively corrects the deformity at the proximal joint but increases the tone in the lateral bands and ORL, increasing hyperextension at DIP joint. **C**, The patient actively flexes DIP joint over the thumb of the opposite hand, stretching the ORLs and lateral bands (see text discussion).

A "pseudoboutonnière deformity" is one in which there is a PIP joint flexion contracture that typically follows PIP joint hyperextension injury, or PIP joint collateral ligament sprains, without concomitant increased DIP joint extensor tendon tone.[55] In this case, the lateral bands and central slip remain competent but a flexion contracture of the joint has resulted from collateral ligament and volar plate scarring. Treatment is aimed at ameliorating the PIP joint flexion contracture, usually with dynamic splinting and serial static casting techniques.

Open Injuries

Acute open zone 3 injuries typically enter the PIP joint, and appropriate wound management and irrigation should be performed. Injury to one lateral band or 50% or less of the central slip does not require operative repair and may be treated with wound care and early motion. Complete transection of the central slip warrants open repair. Surgical repair of central slip lacerations may be done with reattachment to bone using a suture anchor, to a bone tunnel, or to the insertion itself, if sufficient tendon remains distally. A cross-stitch may be used to supplement the repair (see Figure 5.12). Doyle and Atkinson[22] noted that although the average thickness of the central slip just proximal to the PIP joint is 0.5 mm, this thickness doubles as a result of the fibrocartilaginous dorsal plate at the insertion of the central slip, providing better suture purchase. If there is sufficient tendon remaining distally, one or two core sutures of 4-0 or 5-0 followed by a 5-0 cross-stitch may be performed. The PIP joint must be maintained in extension during healing, and often this is facilitated by use of a transarticular 0.045-inch Kirschner wire.

❖ AUTHOR'S PREFERRED METHOD OF TREATMENT OF ZONE 3 INJURIES

In the setting of an injured, acutely tender PIP joint, the Elson test is performed with a digital block, as previously described, to evaluate for the presence of central slip injury. If the central slip is found to be injured, splinting the PIP joint in extension using an aluminum foam splint similar to mallet treatment (except placed over the dorsal PIP joint) is employed for 6 weeks, followed by part-time and night-time wear for another 4 to 6 weeks. DIP joint active and passive flexion exercises are performed hourly with the PIP joint fully extended during the entire splinting and rehabilitation course.

When treating subacute open zone 3 injuries, if the wound was sutured in the emergency department and the extent of tendon injury is unknown at the time of presentation (a common scenario), there are several options. An obvious PIP joint extensor lag would indicate the need for open repair. If there is no PIP joint extensor lag but the history indicates that a tendon was noted to be lacerated, surgical exploration generally provides the best method to assess the extent of injury (e.g., 90% laceration of the central slip versus 5%) and guide the necessity for tendon repair. The Elson test, performed in the office (under digital block), assesses the integrity of the central slip; if disruption is evident, operative repair is recommended. Because closed central slip disruptions are treated

nonoperatively, an argument could be made for splint treatment of open central slip injuries as well; however, I prefer open surgical repair of the lacerated tendon in this situation using a suture anchor or cross-stitch suture. If the central slip is intact based on the Elson test and the patient has full active extension against resistance (a digital block may be necessary to assess the strength of resistance free of pain), active motion is allowed, with a reexamination in 1 week to ensure that a partial tendon laceration did not propagate. If a PIP joint lag or loss of extension power develops, surgical exploration is recommended.

After operative repair, I usually place a 0.045-inch Kirschner wire obliquely across the joint in full extension to protect the repair for 5 to 6 weeks, followed by pin removal and range-of-motion exercises with interval splinting for another 2 to 4 weeks. Some authors recommend early motion or dynamic splinting. Lateral band lacerations may be repaired and rehabilitated similarly. Gentle active DIP joint motion is permitted if motion on the operating table does not stress or gap the lateral band repair. When there is loss of tendon substance, the gap in the tendon may be overcome using a graft, or the method of Snow, who used a proximally based flap of central slip tendon and rotated it distally to reconstruct the central slip (Figure 5.22).[97,96]

Open Thumb Metacarpophalangeal Joint Lacerations (Zone 3 Lacerations). Zone 3 lacerations over the MP joint of the thumb may involve the EPL or EPB, or both. In this location, a standard core type of suture may be used (I use a 4-0 or 3-0 locked Kessler suture on either side of the tendon to avoid bunching), augmented by a 5-0 cross-stitch. The underlying MP joint capsule is repaired separately. I either place a 0.045-inch Kirschner wire across the joint in full extension or splint the MP and IP joints in full extension for 4 weeks. If the EPB only is lacerated, the IP joint may be left free.

Congenital absence of the EPB occurs without thumb MP joint extensor lag, and if an isolated EPB laceration occurs in the setting of an intact EPL with full extension of MP and IP thumb joints, EPB repair may not be required. In patients presenting late to the office in this situation, the EPB laceration is likely to be overlooked; however, if a complete EPB laceration is noted acutely during the course of wound exploration, I recommend repairing the EPB to avoid potential late MP joint extensor lag.

CRITICAL POINTS *Acute Boutonnière Deformity Treatment*

- Recognize the injury by using the Elson test.
- Splint the PIP joint in full extension for 6 weeks.
- Perform active and passive DIP joint flexion exercises hourly to stretch out the lateral bands.

Expected Outcome

- Some tendency toward DIP joint hyperextension usually remains, along with a slight PIP joint extensor lag, even if splint treatment is initiated promptly.

Chronic Zone 3 Closed Injuries (Chronic Boutonnière Deformities)

Flexible boutonnière deformities can be successfully managed with splints several months after injury.[59] It is postulated that

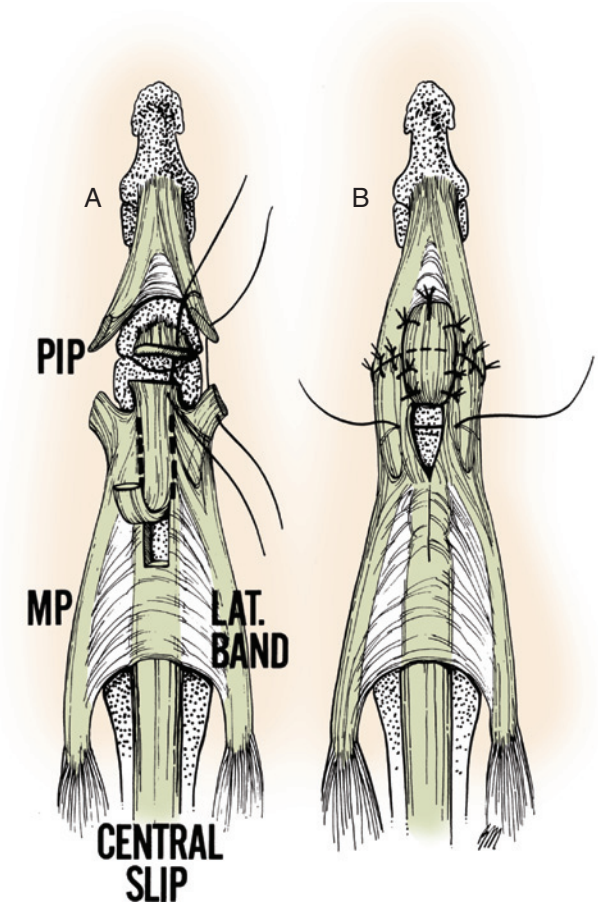

FIGURE 5.22 Acute boutonnière deformities associated with loss of substance of the extensor mechanism at PIP joint are difficult to treat. **A** and **B**, In an attempt to solve this problem, Snow took a retrograde flap from the central slip of the extensor (**A**) and applied it as a reinforcing batten over the central slip repair. The retrograde flap is carefully sutured into place over the repair site to act as a reinforcement in the area of repair. The defect in the central slip is closed with interrupted sutures (**B**). (Copyright Elizabeth Martin.)

late splint treatment allows the lateral bands to realign themselves by stretching out the tight transverse retinacular ligaments, resulting in correction of the deformity despite central slip discontinuity. Chronic boutonnière deformity is distinguished by the presence of fixed PIP joint or DIP joint contractures (or both). The central slip may have been traumatically disrupted or may have attenuated because of inflammatory synovitis, because of osteoarthritis, or through prolonged flexion contracture as is seen with Dupuytren contracture, flexor pulley disruptions, or burns.[62] In the presence of fixed contractures, treatment and successful results are far more difficult because both flexor tendons and the subluxated lateral bands are deforming forces. Despite the PIP joint contracture, however, many patients have functional complaints related to the inability to flex the DIP joint.

Burton[13] classified chronic boutonnière deformity into three stages:

Stage I: Supple, passively correctable deformity
Stage II: Fixed contracture, contracted lateral bands
Stage III: Fixed contracture, joint fibrosis, collateral ligament and palmar plate contractures
Stage IV is added to this classification, which is stage III plus PIP joint arthritis.

Stages I and II can be treated with a therapy regimen consisting of splinting to achieve full PIP joint extension by means of serial casting, splinting, or dynamic splinting. When full PIP joint extension is achieved, it is maintained for at least 6 to 12 weeks with splints. The entire time, active and passive DIP joint flexion exercises are performed. If full passive PIP joint extension is not achievable through nonoperative means, surgical PIP joint release of contracted collateral ligaments may be necessary. If PIP joint passive extension is achieved but an active extensor lag remains, there are myriad surgical procedures designed to address the chronic boutonnière deformity. Deformities of 30 degrees or less are quite difficult to improve with surgery. Burton[13] proposed seven principles when dealing with chronic boutonnière deformity that are "required reading" for anyone undertaking this problem:

1. The operations must be precisely done and should not be attempted by a surgeon who only occasionally operates on the hand.
2. Operative treatment should rarely be necessary in a supple boutonnière deformity because this condition usually responds to conservative management.
3. The procedure should be done within the context of a preoperative and postoperative exercise program. The exercises and splints are needed for several months after surgery.
4. The tendon procedure is best done after the joint has full passive mobility. In some difficult problems with a very stiff joint, the surgical correction must be done in two stages. The first stage is the release of the joint, and the second is the tendon reconstruction. In many patients, after the joint release is completed and the exercise program is resumed, the extensor mechanism rebalances with the conscientious performance of the two-stage exercise program and the splinting or cast support of the PIP joint. In these patients, the second stage is not required.
5. If radiograph shows significant arthritic changes, extensor mechanism rebalancing must be combined with implant arthroplasty or with PIP joint fusion.
6. Most patients with a boutonnière deformity retain full flexion and full grip function; even with this deformity, most patients have good function. As surgery is planned, the surgeon must be constantly aware of the need not to jeopardize flexor function in an attempt to gain extension.
7. All procedures involve a rebalancing of the extensor system, decreasing the tone at the distal joint and diverting it to the proximal joint.

Surgical Techniques to Correct Supple Boutonnière Deformity

Terminal Tendon Tenotomy (Distal Fowler or Dolphin Tenotomy). The concept of terminal tendon tenotomy is that operatively creating a "mallet finger" would decrease the extensor tone at the DIP joint, allowing DIP joint flexion and permitting the extensor mechanism to slide proximally to increase the extensor tension at the PIP joint. This procedure is designed for patients with full passive PIP joint extension and is contraindicated in patients with a fixed PIP joint flexion deformity. A dorsal incision is made over the middle phalanx, and the extensor mechanism is divided transversely over the junction of its middle and proximal thirds, distal to the triangular ligament. Care is taken to identify and preserve ORLs, if present (see Case Study 5.4). Why a mallet finger does not usually develop is unknown. It is possible that the DIP joint capsule and ligaments have chronically tightened so that rebound joint extension occurs after the joint is flexed. Postoperatively, a DIP joint extension splint is removed for active range-of-motion exercises several times a day for 6 to 8 weeks.[20,27,69]

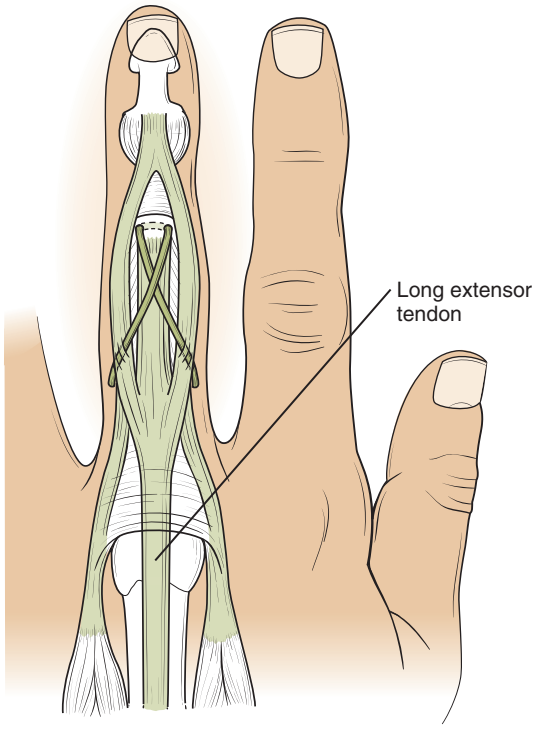

FIGURE 5.23 The Littler tendon graft technique. A thin graft is woven through the base of the middle phalanx and through the extensor tendon to restore extensor tone to the PIP joint.

Tendon Grafts. Tendon grafts have been employed, as in the figure-of-eight tendon graft through the extensor mechanism into the base of the middle phalanx described by Littler[57] (Figure 5.23). Full passive mobility of the PIP joint is required for success.

Lateral Band Mobilization and Relocation. The lateral bands normally move in a dorsal-palmar direction with PIP joint flexion and extension. Dividing them distally and suturing them to the central slip insertion has been used to restrict PIP joint flexion, with mixed results.[30,59,64,98,116]

❖ AUTHOR'S PREFERRED METHOD: The Curtis Staged Reconstruction

There are three stages of the Curtis procedure, depending on the correction obtained at each step (Figure 5.24).[19] All are done under a local anesthetic, and all rely on full passive preoperative PIP joint motion. The use of local anesthetic allows the surgeon to test active extension at each stage.

In stage I, a lazy "S" incision is made centered on the PIP joint. The transverse retinacular ligament is freed distally and proximally, and a tenolysis of the extensor tendon is performed. If full extension is present, the operation stops.

CASE STUDY 5.4 Boutonnière Deformity

The normal anatomy can be reviewed in Figure 5.5; the pathoanatomy is shown in Figure 5.4.

Patient History:

- Chief complaint: Righ small finger deformity
- History of present illness: An otherwise healthy 18-year-old male who presents with painful right small finger deformity. He states that he had injured the finger in grade school in multiple incidents. In the past few years, the finger has become more deformed, hyperextended at the DIP.

Clinical photos of the preoperative examination are presented in eFigure 5.9, *A* and *B*. The distal Fowler tenotomy (or "dolphin" tenotomy) is illustrated in eFigure 5.10. The surgical result is displayed in Video 5.2.

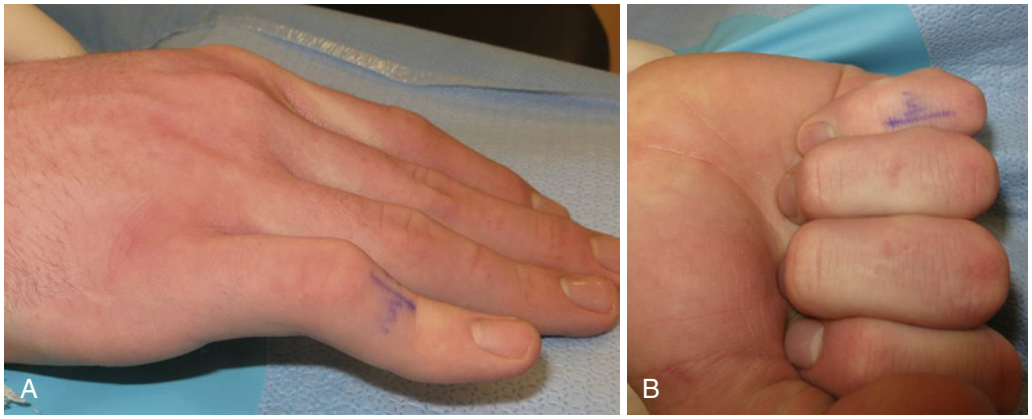

eFigure 5.9 Preoperative examination. (Copyright Scott W. Wolfe, MD.)

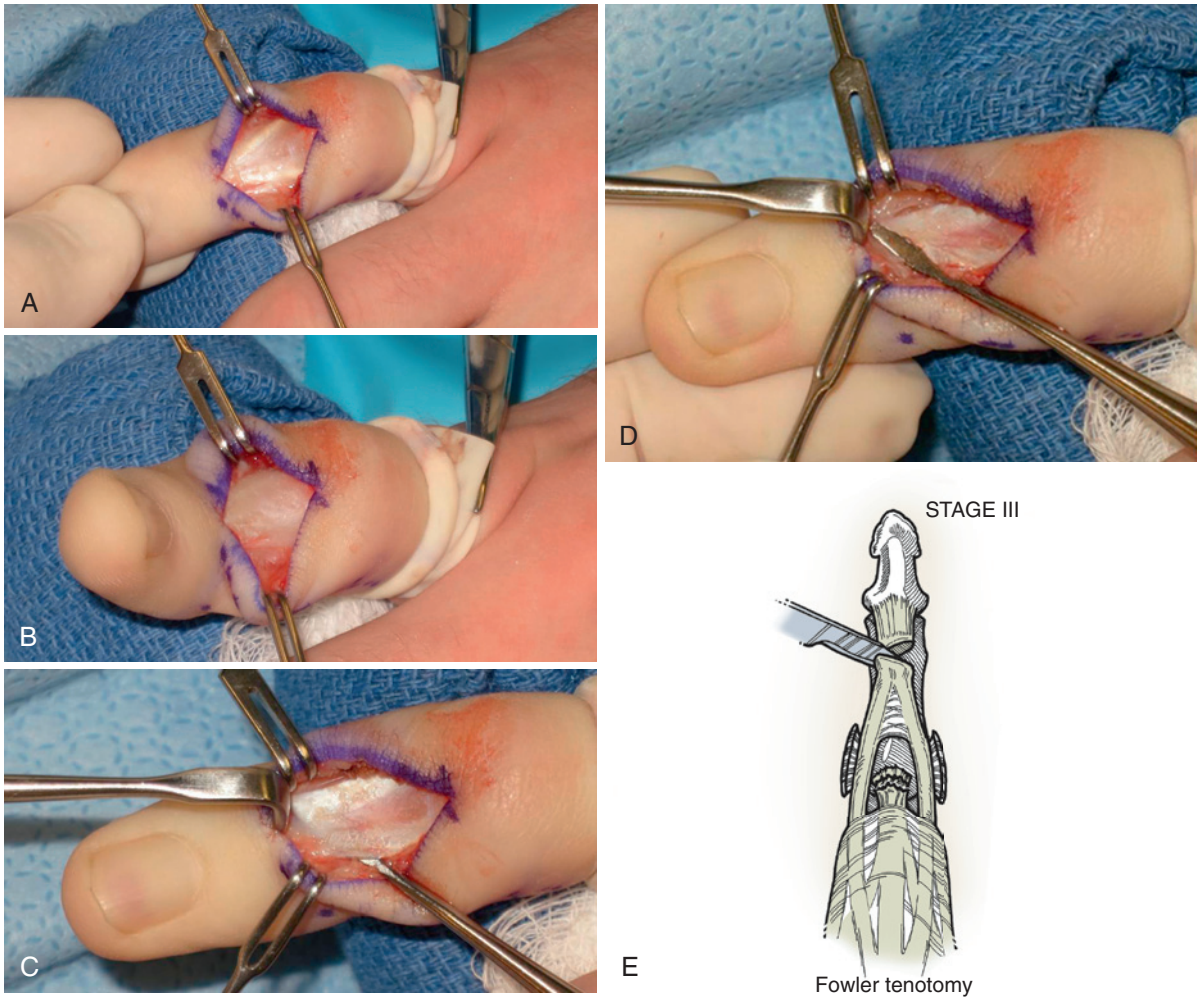

eFigure 5.10 Distal Fowler tenotomy. **A**, Incision. **B** through **D**, Exposure. **E**, Diagram illustrating a distal Fowler tenotomy (or "dolphin" tenotomy). A longitudinal incision is made over the middle phalanx. The oblique retinacular ligaments are protected, and the terminal tendon is cut. (Copyright Scott W. Wolfe, MD.)

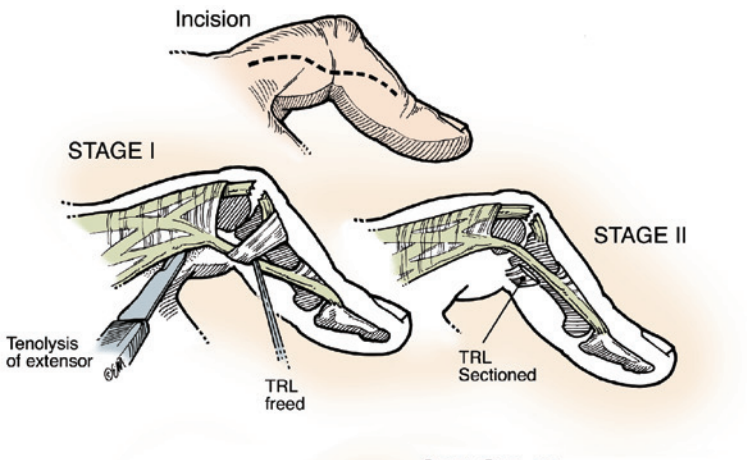

A

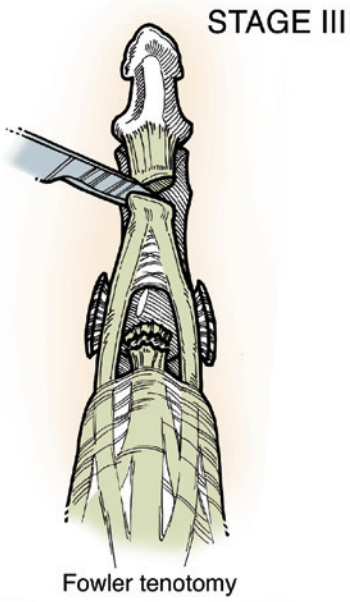

B

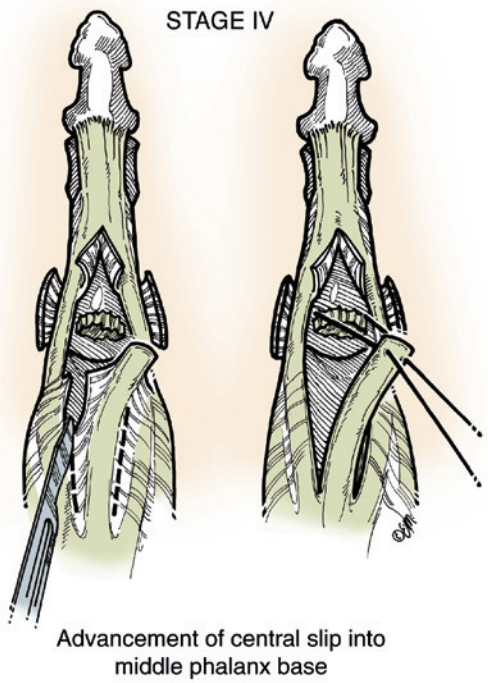

C

FIGURE 5.24 The Curtis staged reconstruction of boutonnière deformity. This operation relies on full preoperative passive mobility of PIP joint. **A**, Stages I and II: The transverse retinacular ligament is freed and transected if necessary, allowing the lateral bands to swing dorsally. **B**, Stage III: If full correction is not obtained after stage II but PIP joint extensor lag is less than 20 degrees, a Fowler tenotomy is performed. If PIP joint extensor lag is significant and more than 20 degrees after stage II, this step is skipped, and one proceeds directly to stage IV. **C**, Stage IV: The central slip is advanced into the middle phalanx base after removing 4 to 6 mm of intervening scar tissue between the native tendon and its insertion. (From Curtis RM, Reid RL, Provost JM: A staged technique for the repair of the traumatic boutonniere deformity, *J Hand Surg Am* 8:167–171, 1983. Copyright Elizabeth Martin.)

In stage II, if full extension is not achieved, the transverse retinacular ligament is sectioned, allowing the lateral bands to swing dorsally. If full extension is achieved (seen in 30% to 40% of cases), the MP joint is splinted at 70 degrees of flexion, the PIP and DIP joints are splinted at 0 degrees for 1 week, and then dynamic PIP joint splinting is performed.

In stage III, if there is still a 20-degree or smaller lag after stage II, a distal Fowler tenotomy is performed. Curtis recommended a "step-cut lengthening" of the lateral bands to prevent a mallet finger. I usually just obliquely transect the extensor mechanism distal to the triangular ligament. If full extension is present, the operation stops.

If an extensor lag of more than 20 degrees is still present after stage II, Curtis recommended proceeding directly to stage IV (necessary in 38% of his cases). The central tendon is dissected free and advanced about 4 to 6 mm into a drill hole in the dorsal base of the middle phalanx. The lateral bands, now slack, are loosely sutured to the central tendon.

Curtis's results at 1 year of follow-up revealed a 10-degree PIP joint lag, with an average 31-degree improvement from the preoperative status.[19] For patients requiring stage IV reconstruction with an average PIP joint preoperative lag of 55 degrees, a 17-degree lag persisted postoperatively. All but 3 of 23 patients showed improved flexion after the procedure.

CRITICAL POINTS *Treatment of Chronic Boutonnière Deformity*

- Exhaust the splinting protocol before surgical correction.
- Ensure full passive PIP joint motion before embarking on any tendon rebalancing or reconstructive procedure.
- A stepwise approach (Curtis procedure) is a rational solution to the problem.

Expected Outcomes

- A 20-degree persistent extensor lag is common, and surgery for PIP joint extensor lags of 20 to 30 degrees may not result in significant improvements. Although flexion loss is possible postoperatively, it is uncommon using the stepwise approach (Curtis procedure).

Zone 4 Injuries

Because of the convex bony contour of the proximal phalanx, dorsal lacerations are frequently associated with partial tendon injuries. Fractures of the proximal phalanx are commonly seen in association with these injuries. Similar to tendon injuries in other locations, the ideal method of evaluating the extent of injury is by surgical exploration. Partial lacerations of greater than 50% and complete tendon lacerations are repaired with one or two modified Kessler 4-0 core braided polyester sutures and a 5-0 cross-stitch on the dorsal side of the tendon.[5,21] The core suture should be placed into the relatively thicker area of the lateral bands to obtain maximal purchase (see Figure 5.13). Early motion protocols to prevent adhesions to the proximal phalanx involve the use of a dynamic extension splint to allow PIP joint flexion. The postoperative splint includes a dorsal outrigger with elastic straps to provide passive PIP joint extension (see Figure 5.29). The degree to which the PIP joint can be safely flexed is determined during surgery by observing repair site tension. Accelerated rehabilitation protocols generally begin within the first week of repair. If treated with immobilization, the PIP and MP joints are maintained in extension for 4 weeks, followed by range-of-motion exercises.

Zone 4 in the thumb lies over the metacarpal. In this zone, the tendons are typically wide and round enough to perform a standard core-type repair with a 3-0 or 4-0 suture, followed by a 5-0 cross-stitch.

❖ AUTHOR'S PREFERRED METHOD OF ZONE 4 REPAIRS

The repair is performed as described previously. I assess the tension on the repair site with isolated MP and PIP joint flexion to determine the safe zone of motion postoperatively. In compliant patients, I begin hand therapy and dynamic extension splinting as noted previously. In less compliant patients, I splint the wrist in 20 degrees of extension, splint the MP joints in full extension, and mold a palmar splint to allow PIP joint flexion to a degree that does not permit visual tension or gapping at the repair site; I have the patient perform passive extension of the PIP joint, limiting flexion with the splint for 4 weeks, followed by active range-of-motion exercises.

Zone 5 Injuries

Human Bite Wounds

Open tendon injuries over the MP joint often result from striking someone in the mouth with a clenched fist. The tendon laceration is frequently partial, and the wound often communicates with the MP joint. These injuries initially appear innocuous and may be unrecognized until the joint becomes infected.[29,63,109] The dominant middle finger MP joint is most often involved. A high index of suspicion is required, and an x-ray is required to exclude a fracture or foreign body. The wound should be irrigated, appropriate antibiotics should be started, and the wound should be left open. Partial tendon injuries do not require repair; however, complete or complex tendon lacerations may be repaired secondarily after the wound is deemed to be clean.

Lacerations

Clean tendon lacerations at the MP joint level may be repaired with one or two core-type 3-0 or 4-0 sutures, followed by a 5-0 nylon or polypropylene cross-stitch. Assuming there is no gap formation at the repair site at the time of repair during PIP joint motion, patients may be treated with MP joint extension splinting for 4 weeks, allowing active PIP joint motion, or with dynamic extension splinting within the limits defined at surgery.

Sagittal Band Lacerations

Although rare, sagittal band lacerations may cause extensor tendon subluxation to the opposite side of the MP joint. Koniuch and associates[54] showed extensor tendon instability after laceration involving the proximal two thirds of the sagittal band. Subluxation is particularly common after radial sagittal band injuries to the ring and middle digits. Repair of the sagittal band may be performed with simple sutures of 4-0 or 5-0 (with or without a cross-stitch) if there is evidence of EDC subluxation. Postoperatively, the repair may be subject to gentle range of motion (depending on the visible intraoperative tension caused by flexion and extension) and "buddy taping" the finger to the adjacent finger.

Closed Sagittal Band Rupture

Closed sagittal band ruptures are more common than open lacerations and usually involve the radial sagittal band of the middle or ring finger following resisted extension ("flicking") of the finger, or direct trauma to the dorsum of the MP joint.[43] The condition may be mistaken for a trigger finger because of a snapping sensation that occurs when the extensor tendon shifts back and forth between the ulnar groove and its normal position over the metacarpal head. Consequently, early treatment may be delayed. Often, MP joint extension cannot be initiated from the flexed position of the joint, and the involved finger is abducted ulnarly. When passively positioned in full extension, the reduced position can be actively maintained. The middle finger may be more frequently involved because of its exposed position and the looser anchoring of the middle EDC tendon to the sagittal band. Rarely, radial extensor tendon subluxation secondary to ulnar sagittal band injury has been reported.[86] Individuals with hyperlaxity may have nonpathologic subluxation of the middle and ring finger EDC tendons at the MP joints with flexion, and this does not warrant treatment; it is important to evaluate the opposite side for comparison when dealing with this condition to ensure that an actual injury is not present (Figure 5.25).

Ishizuki[43] identified superficial and deep layers of the sagittal band and noted disruption of the superficial layer only in "spontaneous" cases caused by "flicking" of a finger or "crumpling" up of paper. The deep and superficial layers were disrupted in traumatic cases involving a direct blow or forced MP joint flexion from a contusion or fall (Figure 5.26).

Rayan and Murray[83] classified sagittal band injuries into three types. Type I is a contusion without tear of the sagittal bands and without instability. Type II involves tearing of the sagittal bands with snapping of the extensor tendon but without complete dislocation. Type III consists of tendon dislocation into the groove between the metacarpal heads.

Sagittal band injuries that do not cause EDC subluxation may be treated with buddy taping to an adjacent digit for 4 weeks, but pain in the area may persist for 1 year.[83] If pain, swelling, and loss of MP joint motion persist for 3 months after direct MP joint trauma, consideration should be given to surgical exploration. Koniuch and colleagues[54] reported nine patients undergoing exploration because of persistent MP joint pain and swelling without EDC subluxation and repaired a partial tear of the ulnar sagittal band in seven and radial sagittal band in four; 25% of the patients also had MP joint pathologic conditions, including synovitis, loose bodies, chondral injuries, and palmar plate disruption. Postoperatively, patients were begun on dynamic passive extension and active flexion splinting, with eight of nine patients returning to full activities. All patients experienced pain relief. Posner and Ambrose[80] termed this entity *boxer's knuckle* and noted that sagittal band injuries without instability could be a cause of chronic pain in the area of the involved MP joint.

Sagittal band injuries with EDC subluxation that are seen within 3 weeks of injury may be treated nonoperatively.[4,14,39,83,86] An MP joint flexion block splint, or "sagittal band" splint, may be used to limit MP joint flexion of the involved finger and allow healing of the torn tendon. The splint is applied to hold the injured MP joint in 25 to 35 degrees of hyperextension compared with the adjacent MP joints. It is recommended that the splint be worn full-time for 8 weeks.[15] Active motion of the MP and IP joints is permitted with the splint in place (Figure 5.27). Using this technique, Catalano and colleagues[15] found a full range of flexion and extension in 10 patients; 8 patients had no pain, and 3 had moderate pain. Three of the 10 patients had persistently symptomatic EDC subluxation, and one required sagittal band reconstruction. Alternatively, the involved and neighboring fingers can be casted or splinted for 4 weeks with the MP joints extended and the IP joints free.

Patients presenting later than 2 to 3 weeks after injury or patients in whom splinting has been unsuccessful are candidates for surgical repair. The ulnar sagittal band may need to be partially released to allow the tendon to be centralized. The involved (usually radial) sagittal band is examined to see whether or not it is amenable for repair. If a primary repair is impossible, there are many methods of sagittal band reconstruction (Figure 5.28).[14,48,66,119]

Atraumatic, acquired, ulnar subluxation of the EDC at the MP joints has been described predominantly in elderly women. If the subluxation is symptomatic, extensor tendon reconstruction may be required.[60]

❖ AUTHOR'S PREFERRED METHOD OF TREATMENT OF CLOSED SAGITTAL BAND DISRUPTION

Patients with EDC subluxation who present within 3 weeks of injury are treated with a sagittal band splint, as described previously. Patients presenting late or who remain symptomatic despite a trial of splinting are candidates for sagittal band reconstruction. I have no experience with late repair of the radial sagittal band for these injuries, and I prefer the reconstructive technique described by Carroll and associates,[14] wherein a distally based radial slip of tendon is harvested from the EDC, passed around the radial collateral ligament of the involved MP joint, and sutured to itself to centralize the EDC mechanism. I also use this technique for elderly women with chronically attenuated radial sagittal bands of the middle and ring fingers, resulting in symptomatic EDC subluxation (see Figure 5.28, *E*).

Thumb Zone 5 Injuries (Carpometacarpal Joint)

Lacerations in zone 5 involve the EPB, APL, and, rarely, EPL. Repair at this level is by core suture and a cross-stitch. Either static splinting or active motion may be employed postoperatively. Imai and colleagues[41] described closed ulnar subluxation of the EPB at the MP joint level (zone 3), resulting from gripping a racquet tightly. Persistent flexion at the thumb MP joint resulted and was effectively treated with EPB centralization.

Finger Zone 6 Injuries at the Metacarpal Level (Case Study 5.5)

Zone 6 injuries over the dorsal hand area usually have a favorable prognosis for several reasons, as noted by Doyle[21]:

1. They are unlikely to be associated with a joint injury.
2. There is greater tendon excursion, which means that slight limitation of motion would not lead to the significant loss of joint motion seen with injuries over the phalanges.
3. Increased subcutaneous tissue lessens the chances of adhesion formation.
4. Core sutures may be easily placed.
5. Dynamic splinting can be easily performed.

CASE STUDY 5.5

The patient suffered a glass laceration in the dorsal first web space. The emergency room staff believed the EPL to be intact because the patient was able to extend the thumb IP joint to neutral. In retrospect, the abductor pollicis brevis (APB) expansion was allowing partial IP extension.

At surgical exploration, a complete EPL laceration was found, as well as a laceration of the sensory branch of the radial nerve (SBRN) (eFigure 5-11, *A* and *B*).

The EPL laceration was repaired using two core sutures of 3-0 Ticron. The SBRN laceration was repaired, as well.

Outcome at 6 months postoperatively:

- Excellent extension and flexion of the thumb IP joint (eFigure 5-12, *A* and *B*)

Take-home points:

- EPL function is tested by seeing whether the patient is able to elevate the thumb off a tabletop and/or allow thumb IP joint hyperextension
- Extending the thumb IP joint to neutral may be accomplished through extensor expansion of the abductor pollicis brevis (APB)

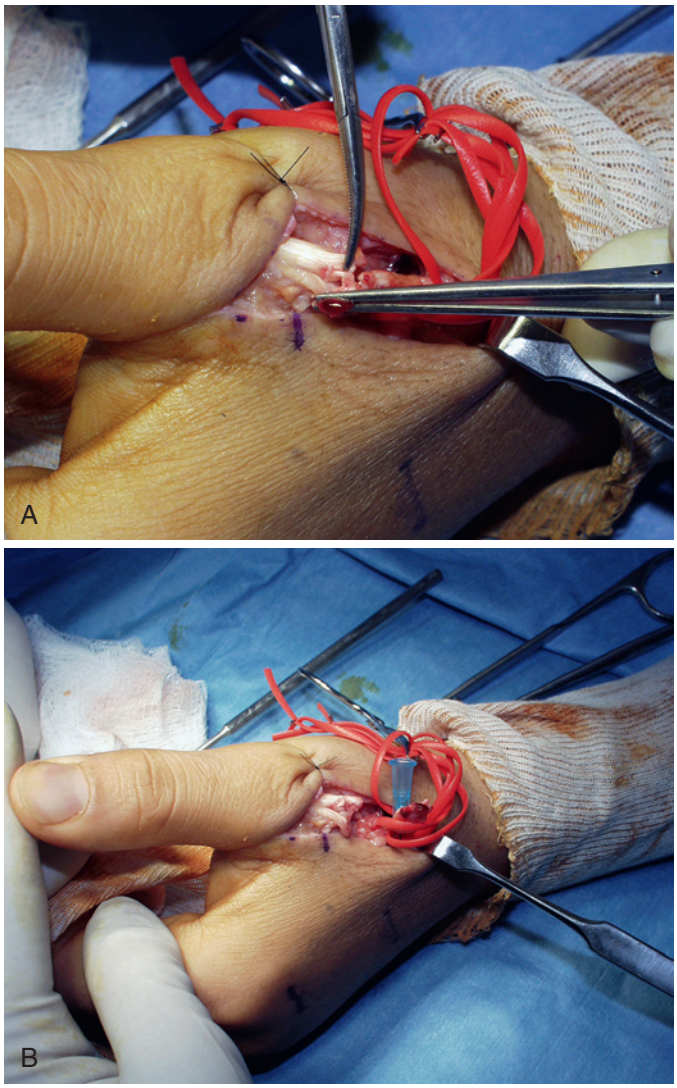

eFigure 5.11

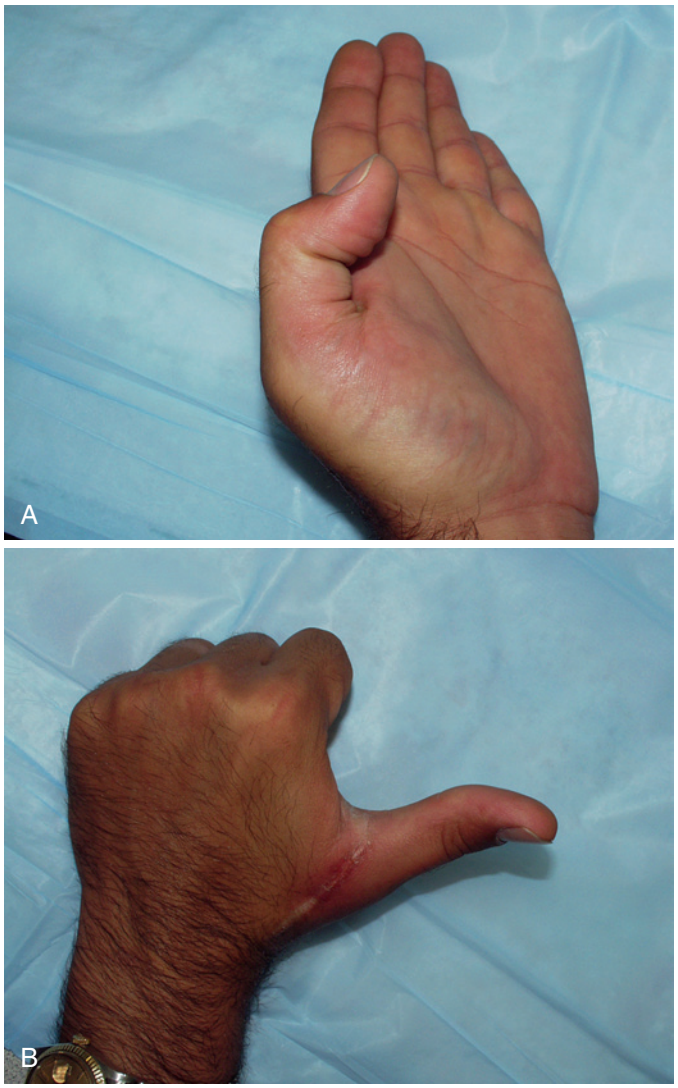

eFigure 5.12

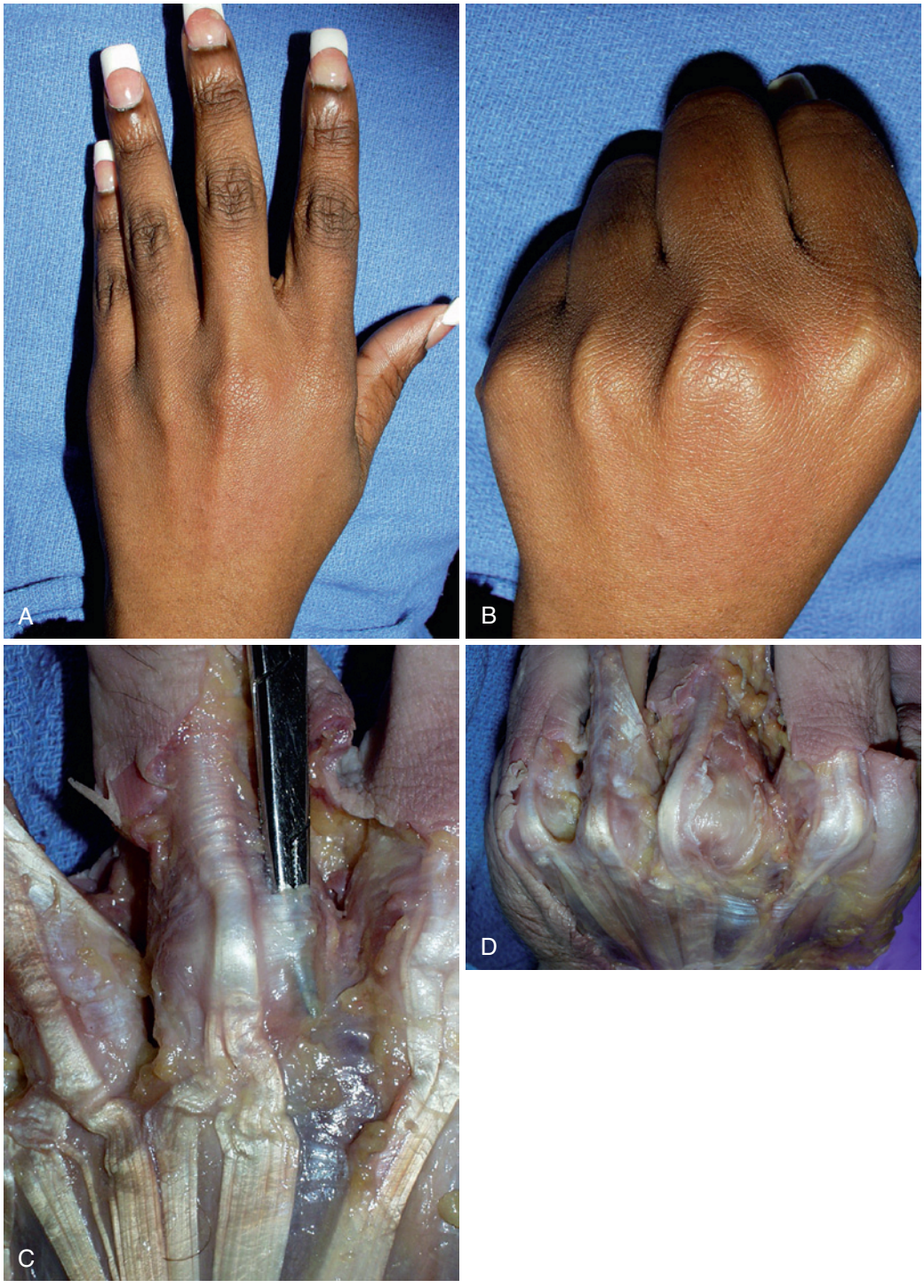

FIGURE 5.25 Closed sagittal band rupture. **A**, In extension, slight ulnar deviation of middle finger is noted because of radial sagittal band rupture of middle finger MP joint. **B**, In flexion, middle finger sagittal band subluxates into the groove between the middle and ring fingers. **C**, Cadaver dissection showing probe underneath intact radial sagittal band of middle finger. **D**, Cadaver dissection showing dislocation of extensor mechanism after sectioning of radial sagittal band.

As noted in the anatomy section, complete EDC lacerations may not result in MP joint extensor lag because of the tethering effect of the juncturae tendinum connections. As is the case for all extensor tendon lacerations, exploration is helpful to guide treatment, and a laceration of 50% or more may be repaired with core sutures of 3-0 nonabsorbable material. A 5-0 cross-stitch may be performed at the discretion of the surgeon. Postoperatively, either static or dynamic splinting may be employed. Static splinting involves wrist extension of 30 to 45 degrees, MP joints at neutral to 15 degrees of flexion, and IP joints free for active range of motion. Dynamic splinting involves wrist extension, dynamic rubber band MP joint extension, and passive MP joint flexion to the level of repair tension determined at the time of surgery (Figure 5.29).

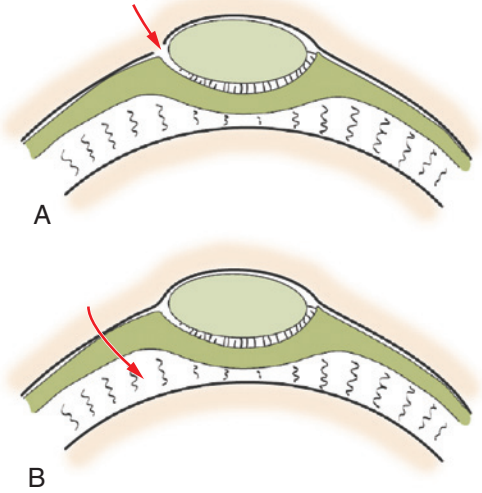

FIGURE 5.26 Anatomy of sagittal band injury. **A**, The Ishizuki interpretation of a spontaneous dislocation, in which the superficial layer of the sagittal band is disrupted. **B**, Traumatic dislocation is shown in which superficial and deep layers are torn. (From Ishizuki M: Traumatic and spontaneous dislocation of extensor tendon of the long finger. *J Hand Surg Am* 15:969, 1990, with permission from The American Society for Surgery of the Hand.)

❖ AUTHOR'S PREFERRED METHOD OF TREATMENT OF ZONE 6 INJURIES

I have employed various core sutures over the years and found equal success with a Newport modified Bunnell repair or a modified locked Kessler (Strickland) repair, as described earlier (see Figures 5.12 through 5.14). The tendons at this level are usually large enough to accommodate a core suture of 3-0 caliber. A cross-stitch may be used to supplement the repair. Dynamic splinting is employed in compliant patients.

Chronic Zone 6 Injuries

Lacerations. Lacerated extensors over the metacarpal may remain tethered in position by the juncturae tendinum, permitting delayed repair several weeks after injury. If direct repair is impossible, side-to-side transfer or intercalary tendon grafts may be performed. In severe cases of tendon loss, a two-stage reconstruction with silicone rods may be considered when the soft tissue envelope is adherent.[107] In long-standing cases of tendon loss, scar tissue may intervene, and some individuals may have adequate function even with total loss of the EDC over the dorsum of the hand, especially if the MP joints are stiff in extension.[81,107]

Chronic Blunt Trauma to the Dorsal Hand: Secretan Disorder. A factitious illness characterized by dorsal hand edema and fibrosis, *Secretan disorder* is a self-inflicted condition in which the patient is intentionally causing the signs and symptoms.[84,85,95] The cause is likely repetitive intentional blunt trauma[17] or other self-inflicted trauma to the dorsal hand area. It may sometimes mimic EDC tenosynovitis. Recognition of the disorder is paramount. After exclusion of underlying rheumatic or neoplastic conditions with magnetic resonance imaging (MRI), the condition characteristically responds temporarily to full-hand casting, but it often recurs when the behavior is repeated after cast removal. Confrontation is usually not helpful and may lead to violent outbursts on the part of the patient. Psychotherapy is encouraged, although this is often not accepted by the patient. Surgery must be avoided because nonhealing wounds and multiple reoperations may ensue. Factitious illnesses such as Secretan disorder are extremely frustrating and difficult conditions for the physician to treat because the patient is actively contributing to the problem.

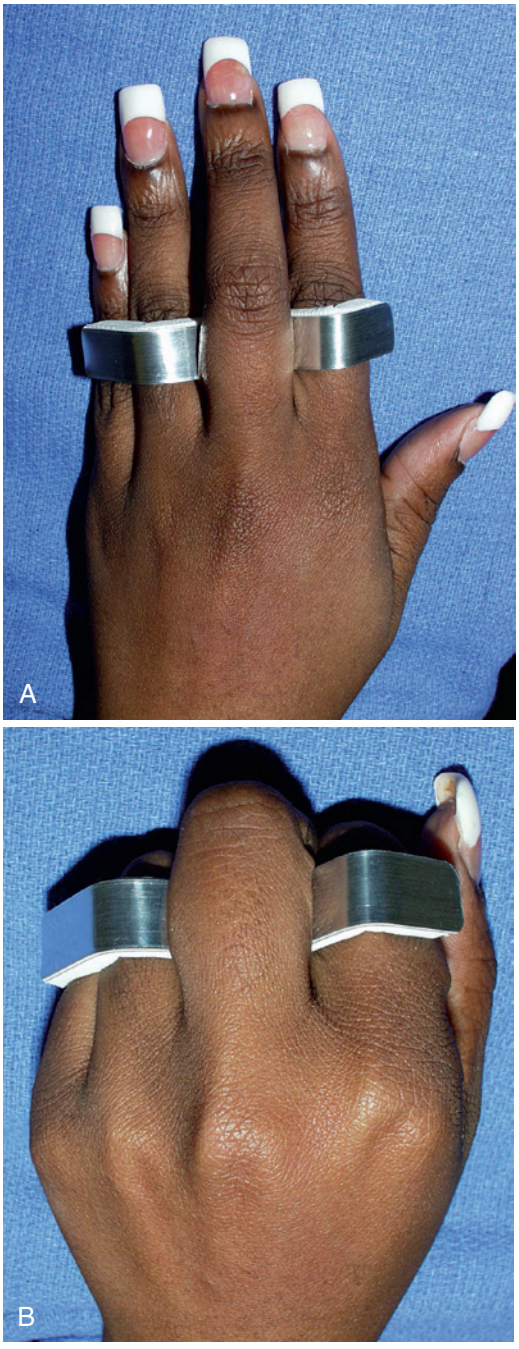

FIGURE 5.27 Sagittal band splint. **A**, Aluminum foam finger splint or splint custom made by a hand therapist is used for 8 weeks full-time to allow the injured sagittal band to heal. Splint should hold injured MP joint in about 25 degrees of extension relative to adjacent digits. **B**, Full active motion of MP and IP joints is allowed with splint in place.

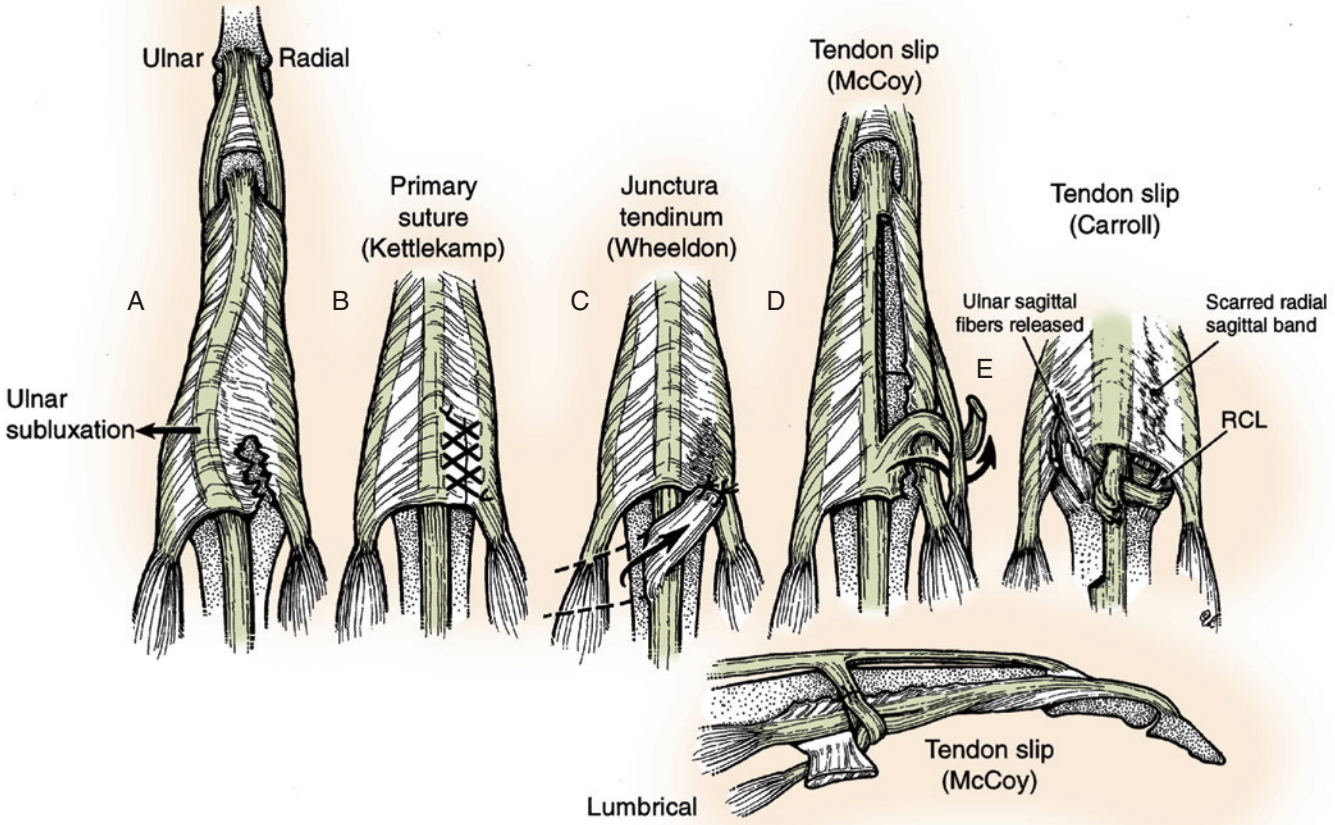

FIGURE 5.28 Methods of sagittal band reconstruction (left middle finger). **A**, Ulnar subluxation of EDC tendon caused by torn radial sagittal band. **B**, Primary suture of radial sagittal band centering EDC tendon. **C**, Ulnar junctura tendinum is released from the adjacent tendon and sutured to the palmar radial sagittal band remnant of the deep intermetacarpal ligament. **D**, Distal tendon is splinted on the radial side and wrapped around the lumbrical muscle. **E**, Ulnar, distally based slip of EDC is looped around the radial collateral ligament (RCL). (Copyright Elizabeth Martin.)

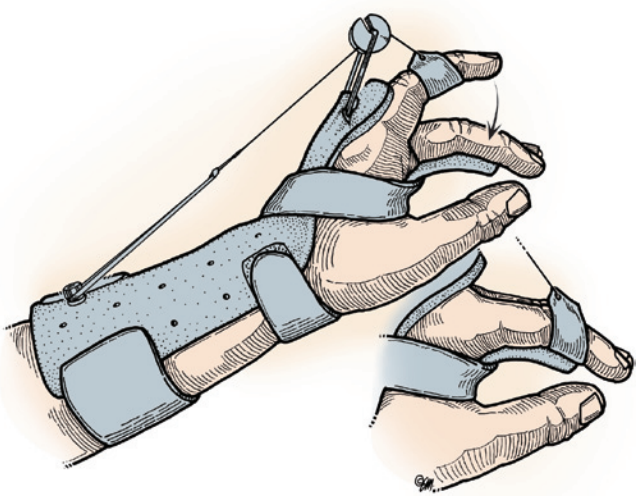

FIGURE 5.29 Dynamic splint for early motion of extensor tendon injuries. Elastic traction maintains fingers in extension. Excursion of the repaired extensor tendon is achieved by active flexion. Splinting is started 3 to 5 days after surgery and is maintained for 5 weeks. Active flexion is performed 10 times an hour. See text for details. (Copyright Elizabeth Martin.)

Zone 7 Injuries (Dorsal Wrist Injuries)

Zone 7 injuries are similar to zone 2 flexor tendon injuries in that the repaired tendon may lie in a synovial-lined tunnel beneath the extensor retinaculum. Although the extensor retinaculum prevents extensor tendon bowstringing, excision of portions of the retinaculum overlying the extensor tendon repair site do not seem to cause harm and may facilitate tendon gliding. In contrast to A2 and A4 pulleys, which are nearly impossible to repair if they are sacrificed during the course of flexor tendon repair, the extensor retinaculum may be incised to allow exposure and repaired primarily or by means of relaxing incisions. It is usually also possible to preserve sufficient retinaculum to prevent bowstringing while excising the retinacular portion over the repair site to prevent adhesions.

In contrast to lacerations over the metacarpals, tendon lacerations in this zone frequently retract into the forearm, and patients should be advised that counterincisions in the forearm or longer extensions of the original incision may be required to retrieve retracted proximal stumps. In this zone, core sutures of 3-0 or 2-0 diameter are easily placed, and a cross-stitch may be added at the surgeon's discretion.

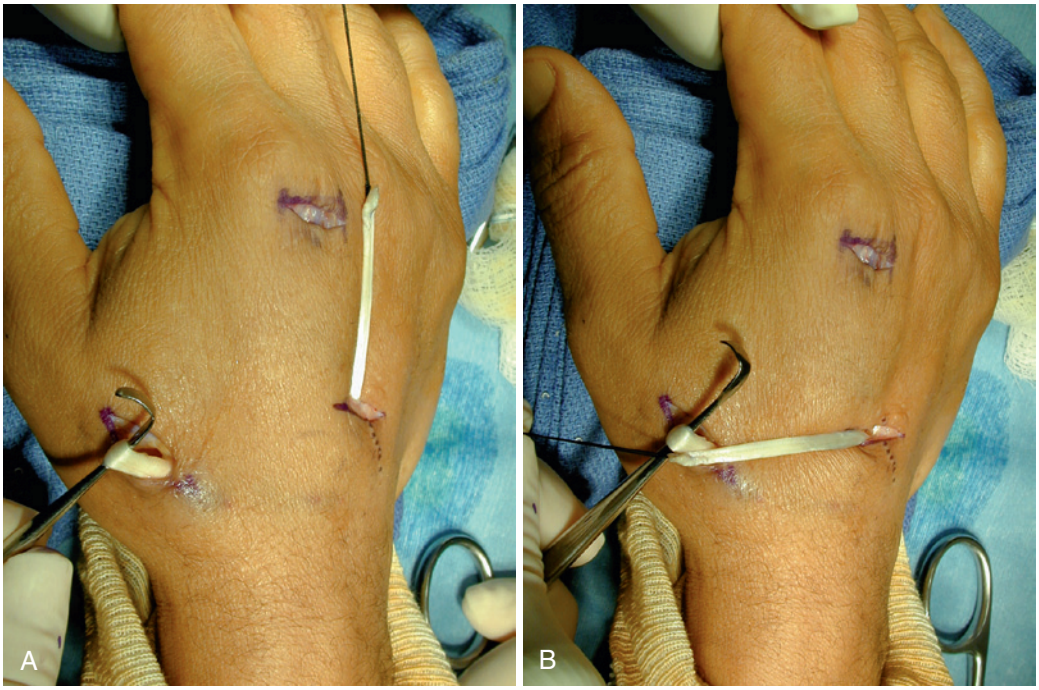

FIGURE 5.30 EIP to EPL tendon transfer. **A**, EIP, which is the most ulnar tendon at the index MP joint, is transected proximal to the sagittal bands. It is withdrawn through a transverse incision located at the distal edge of the extensor retinaculum. **B**, EIP is tunneled subcutaneously (shown here on top of the skin for demonstration) to the distal end of nonfunctioning EPL tendon. It is unnecessary to dissect out proximal EPL tendon. A Pulvertaft weave is performed with the thumb in full extension and the wrist in 20 degrees of extension. It is important to ensure that the transferred tendon does not "wrap up" EDC of the index MP joint during its passage.

Chronic Injuries and Ruptures in Zone 7

Nondisplaced distal radius fractures may be associated with late rupture of the EPL tendon. The cause for this rupture is unclear, but it has been suggested that extravasation of blood and fracture debris into a tight third dorsal compartment may constrict the EPL and lead to late attritional rupture.[35] It has been postulated that there exists a relative "watershed" zone of intrinsic vascular supply to the tendon beneath the extensor retinaculum, which may predispose the tendon further to rupture. The condition is usually treated by transfer of the EIP tendon to the EPL tendon with excellent results (Figure 5.30).

Transfer of the Extensor Indicis Proprius Tendon to the Extensor Pollicis Longus Tendon. A transverse incision is made just proximal to the index MP joint, and the EIP tendon, which is the ulnar tendon, is identified and freed up subcutaneously to the level of the wrist retinaculum. It is transected proximal to its insertion on the extensor hood. A second transverse incision is made overlying the EIP tendon just distal to the retinaculum, and the tendon is withdrawn to this location. A third incision is made longitudinally overlying the EPL tendon at the metacarpal level, close to the MP joint. The EIP tendon is passed subcutaneously to the EPL tendon, with care taken not to ensnare any EDC tendons in the passage. The EIP tendon is sutured in a Pulvertaft weave with several 3-0 nonabsorbable sutures. The repair is tensioned with the wrist in 30 degrees of extension and at the thumb in extension at the carpometacarpal and IP joints and in neutral at the MP joint. A thumb spica splint is placed full-time for 4 weeks, at which time active motion is allowed with a removable thumb spica splint for another 2 weeks.

❖ AUTHOR'S PREFERRED METHOD OF TREATMENT OF ZONE 7 INJURIES

I prefer to window the extensor retinaculum over the extensor tendon repair site to prevent adhesion formation. I prefer sutures of 2-0 caliber for the wrist extensors and of 3-0 caliber for the digital extensors. I usually employ a four-strand core suture repair using either a locked modified Kessler suture plus a horizontal mattress or a locked four-strand cruciate repair. A 5-0 circumferential cross-stitch may be added. Postoperative splinting with the wrist in extension and the MP and IP joints free is done for wrist extensor lacerations for 4 weeks, followed by active range of motion, and finger extensors are splinted with the MP joints in extension and IP joints free. I employ dynamic extension splinting in well-motivated patients.

Zone 8 Injuries (Distal Forearm Injuries) (Case Study 5.6)

Injuries in zone 8 involve the musculotendinous junction, and repairs in this zone may have tenuous holding power in the muscle tissue. Musculotendinous juncture closed ruptures are rare but have been reported as a consequence of violent resisted wrist or finger extension.[104] The EDC tendons to the middle and ring fingers are reported to be the most commonly injured. When repair to the muscle fascia is flimsy, a side-to-side tendon transfer may be the best option.[104]

Zone 9 Injuries (Proximal Forearm Injuries)

Zone 9 is the site of the muscle bellies of the extensor tendons in the proximal half of the forearm. Penetrating trauma, as with knife or glass injuries, is the most frequent cause of injury in

CASE STUDY 5.6

An 18-year-old man was waterskiing and received a rope burn when the boat took off unexpectedly while the tow line was wrapped around his forearm. He suffered median and ulnar nerve deficits, but no compartment syndrome was seen (eFigure 5-13, *A* and *B*).

The wound was débrided. All nerves and tendons were intact. The wound was loosely closed; the nerves recovered.

Outcome after 1 year:

- The one deficit was hyperextension of the index finger only when the wrist was flexed
- Extension of the index finger at the PIP and DIP joints with MP flexion of the index finger
- The patient was able to flex the index finger fully with the wrist in extension (eFigure 5-14, *A* and *B*)

What was the diagnosis?

ANS: Zone 8 injury of the EIP muscle and tendon
Tight EIP

Treatment:

- Surgical exploration revealed a fibrotic EIP muscle and tendon.
- The EIP was excised, with full motion obtained.





eFigure 5.13

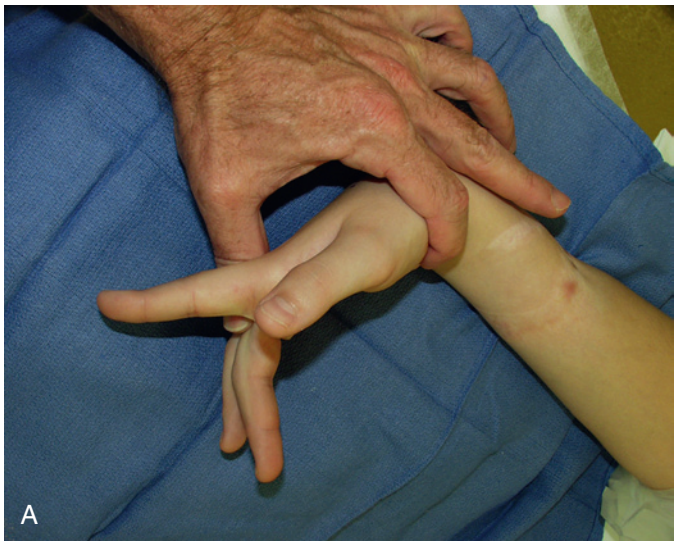



eFigure 5.14

this zone. Loss of finger or wrist extension may result from muscle transection or nerve injury, or both.[25] Surgical exploration reveals the extent of injury, and muscle belly wounds may be repaired with multiple figure-of-eight sutures. Botte and colleagues[9] noted that tendon grafting was an effective method of overcoming defects in this area and used the palmaris longus or toe extensors as graft material. Indications for this procedure were laceration of two or more muscle bellies with laceration of at least 50% of the muscle substance. Patients with less severe lacerations had epimysial repair with interrupted figure-of-eight sutures using absorbable sutures. Most patients in Botte's series had lacerations with 100% of the muscle substance disrupted, a gap of 2 cm at the laceration site, and concomitant nerve and arterial injuries.[9] Patients who present a week or two after injury and who demonstrate mild to moderate extensor lag of one or more digits may be considered for extension splinting for 3 to 4 weeks, as this may allow muscle healing and return to function.

Nerve injuries to the posterior interosseous nerve may be difficult to localize and repair in the substance of the muscle bellies. Chronic nerve injuries may be treated with tendon transfers.

For Case Studies, Videos, and more, please visit ExpertConsult.com.

REFERENCES

1. Abouna JM, Brown H: The treatment of mallet finger. The results in a series of 148 consecutive cases and a review of the literature. *Br J Surg* 55:653–667, 1968.
2. Al-Qattan MM: Extra-articular transverse fractures of the base of the distal phalanx (Seymour's fracture) in children and adults. *J Hand Surg [Br]* 26:201–206, 2001.
3. Altobelli GG, Conneely S, Haufler C, et al: Outcomes of digital zone IV and V and thumb zone TI to TIV extensor tendon repairs using a running interlocking horizontal mattress technique. *J Hand Surg [Am]* 38:1079–1083, 2013.
4. Araki S, Ohtani T, Tanaka T: Acute dislocation of the extensor digitorum communis tendon at the metacarpophalangeal joint. A report of five cases. *J Bone Joint Surg Am* 69:616–619, 1987.
5. Baratz ME, Schmidt CC, Hughes TB: Extensor tendon injuries. In Green DP, Hotchkiss RN, Pederson WC, et al, editors: *Green's operative hand surgery*, ed 5, New York, 2005, Churchill Livingstone.
6. Beck JD, Riehl JT, Klena JC: Anomalous tendon to the middle finger for sagittal band reconstruction: report of 2 cases. *J Hand Surg [Am]* 37:1646–1649, 2012.
7. Bendre AA, Hartigan BJ, Kalainov DM: Mallet finger. *J Am Acad Orthop Surg* 13:336–344, 2005.
8. Blue AI, Spira M, Hardy SB: Repair of extensor tendon injuries of the hand. *Am J Surg* 132:128–132, 1976.
9. Botte MJ, Gelberman RH, Smith DG, et al: Repair of severe muscle belly lacerations using a tendon graft. *J Hand Surg [Am]* 12:406–412, 1987.
10. Bowers WH, Hurst LC: Chronic mallet finger: the use of Fowler's central slip release. *J Hand Surg [Am]* 3:373–376, 1978.
11. Boyes JH, editor: *Bunnell's surgery of the hand*, ed 5, Philadelphia, 1970, Lippincott.

11a. Browne EZ, Jr, Ribik CA: Early dynamic splinting for extensor tendon injuries. *J Hand Surg [Am]* 14:72–76, 1989.

12. Bulstrode NW, Burr N, Pratt AL, et al: Extensor tendon rehabilitation: a prospective trial comparing three rehabilitation regimes. *J Hand Surg [Br]* 30:175–179, 2005.
13. Burton RI: Extensor tendons: late reconstruction. In Green DP, Hotchkiss RN, Pederson WC, et al, editors: *Green's operative hand surgery*, ed 5, New York, 1988, Churchill Livingstone, pp 2073–2116.
14. Carroll C, 4th, Moore JR, Weiland AJ: Posttraumatic ulnar subluxation of the extensor tendons: a reconstructive technique. *J Hand Surg [Am]* 12:227–231, 1987.
15. Catalano LW, 3rd, Gupta S, Ragland R, 3rd, et al: Closed treatment of nonrheumatoid extensor tendon dislocations at the metacarpophalangeal joint. *J Hand Surg [Am]* 31:242–245, 2006.
16. Chao JD, Sarwahi V, Da Silva YS, et al: Central slip tenotomy for the treatment of chronic mallet finger: an anatomic study. *J Hand Surg [Am]* 29:216–219, 2004.

16a. Chester DL, Beale S, Beveridge L, et al: A prospective, controlled, randomized trial comparing early active extension with passive extension using a dynamic splint in the rehabilitation of repaired extensor tendons. *J Hand Surg [Br]* 27:283–288, 1984.

17. Crawford GP: The molded polythene splint for mallet finger deformities. *J Hand Surg [Am]* 9:231–237, 1984.
18. Creighton JJ, Jr, Steichen JB: Complications in phalangeal and metacarpal fracture management. Results of extensor tenolysis. *Hand Clin* 10:111–116, 1994.
19. Curtis RM, Reid RL, Provost JM: A staged technique for the repair of the traumatic boutonniere deformity. *J Hand Surg [Am]* 8:167–171, 1983.
20. Dolphin JA: Extensor tenotomy for chronic boutonnière deformity of the finger: report of two cases. *J Bone Joint Surg Am* 47:161–164, 1965.
21. Doyle JR: Extensor tendons: acute injuries. In Green DP, Hotchkiss RN, Pederson WC, et al, editors: *Green's operative hand surgery*, ed 5, New York, 1999, Churchill Livingstone, pp 195–1987.
22. Doyle JR, Atkinson RE: Rupture of the radial collateral ligament of the metacarpophalangeal joint of the index finger: a report of three cases. *J Hand Surg [Br]* 14:248–250, 1989.
23. Elson RA: Rupture of the central slip of the extensor hood of the finger. A test for early diagnosis. *J Bone Joint Surg Br* 68:229–231, 1986.

23a. Evans RB: Early active short arc motion for the repaired central slip. *J Hand Surg [Am]* 10:991–997, 1994.

24. Evans RB, Burkhalter WE: A study of the dynamic anatomy of extensor tendons and implications for treatment. *J Hand Surg [Am]* 11:774–779, 1986.
25. Fischer CR, Tang P: Lacerations to zones VIII and IX: it is not just a tendon injury. *Adv Orthop* 2010. [Epub September 14, 2010].
26. Foucher G, Binhamer P, Cange S, et al: Long-term results of splintage for mallet finger. *Int Orthop* 20:129–131, 1996.
27. Fowler SB: The management of tendon injuries. *J Bone Joint Surg Am* 41:579–580, 1959.
28. Garberman SF, Diao E, Peimer CA: Mallet finger: results of early versus delayed closed treatment. *J Hand Surg [Am]* 19:850–852, 1994.
29. Gonzalez MH, Papierski P, Hall RF, Jr: Osteomyelitis of the hand after a human bite. *J Hand Surg [Am]* 18:520–522, 1993.
30. Grundberg AB: Anatomic repair of boutonniere deformity. *Clin Orthop Relat Res* 153:226–229, 1980.
31. Grundberg AB, Reagan DS: Central slip tenotomy for chronic mallet finger deformity. *J Hand Surg [Am]* 12:545–547, 1987.
32. Hallberg D, Lindholm A: Subcutaneous rupture of the extensor tendon of the distal phalanx of the finger: "mallet finger": brief review of the literature and report on 127 cases treated conservatively. *Acta Chir Scand* 119:260–267, 1960.
33. Hammond K, Starr H, Katz D, et al: Effect of aftercare regimen with extensor tendon repair: a systematic review of the literature. *J Surg Orthop Adv* 21:246–252, 2012.
34. Handoll HH, Vaghela MV: Interventions for treating mallet finger injuries. *Cochrane Database Syst Rev* (3):CD004574, 2004.
35. Helal B, Chen SC, Iwegbu G: Rupture of the extensor pollicis longus tendon in undisplaced Colles' type of fracture. *Hand* 14:41–47, 1982.
36. Hirai Y, Yoshida K, Yamanaka K, et al: An anatomic study of the extensor tendons of the human hand. *J Hand Surg [Am]* 26:1009–1015, 2001.
37. Houpt P, Dijkstra R, Storm van Leeuwen JB: Fowler's tenotomy for mallet deformity. *J Hand Surg [Br]* 18:499–500, 1993.
38. Howard RF, Ondrovic L, Greenwald DP: Biomechanical analysis of four-strand extensor tendon repair techniques. *J Hand Surg [Am]* 22:838–842, 1997.
39. Hung LK, Chan A, Chang J, et al: Early controlled active mobilization with dynamic splintage for treatment of extensor tendon injuries. *J Hand Surg [Am]* 15:251–257, 1990.
40. Husain SN, Dietz JF, Kalainov DM, et al: A biomechanical study of distal interphalangeal joint subluxation after mallet fracture injury. *J Hand Surg [Am]* 33:26–30, 2008.
41. Imai S, Kikuchi K, Matsusue Y: Posttraumatic recurrent dislocation of extensor pollicis brevis tendon over the metacarpophalangeal joint. *J Hand Surg [Am]* 30:147–150, 2005.
42. Iselin F, Levame J, Godoy J: A simplified technique for treating mallet fingers: tenodermodesis. *J Hand Surg [Am]* 2:118–121, 1977.
43. Ishizuki M: Traumatic and spontaneous dislocation of extensor tendon of the long finger. *J Hand Surg [Am]* 15:967–972, 1990.
44. Jones NF, Peterson J: Epidemiologic study of the mallet finger deformity. *J Hand Surg [Am]* 13:334–338, 1988.
45. Kalainov DM, Hoepfner PE, Hartigan BJ, et al: Nonsurgical treatment of closed mallet finger fractures. *J Hand Surg [Am]* 30:580–586, 2005.
46. Katzman SS, Gibeault JD, Dickson K, et al: Use of a Herbert screw for interphalangeal joint arthrodesis. *Clin Orthop Relat Res* 296:127–132, 1993.

47. Katzman BM, Klein DM, Mesa J, et al: Immobilization of the mallet finger. Effects on the extensor tendon. *J Hand Surg [Br]* 24:80–84, 1999.
48. Kettelkamp DB, Flatt AE, Moulds R: Traumatic dislocation of the long-finger extensor tendon. A clinical, anatomical, and biomechanical study. *J Bone Joint Surg Am* 53:229–240, 1971.
48a. Khandwala AR, Webb J, Harris SB, et al: A comparison of dynamic extension splinting and controlled active mobilization of complete divisions of extensor tendons in zones 5 and 6. *J Hand Surg [Br]* 25:140–146, 2000.
49. King HJ, Shin SJ, Kang ES: Complications of operative treatment for mallet fractures of the distal phalanx. *J Hand Surg [Br]* 26:28–31, 2001.
50. Kitis A, Ozcan RH, Bagdatli D, et al: Comparison of static and dynamic splinting regimens for extensor tendon repairs in zones V to VII. *J Plast Surg Hand Surg* 46:267–271, 2012.
51. Kleinert HE, Verdan C: Report of the Committee on Tendon Injuries (International Federation of Societies for Surgery of the Hand). *J Hand Surg [Am]* 8:794–798, 1983.
52. Kleinman WB, Petersen DP: Oblique retinacular ligament reconstruction for chronic mallet finger deformity. *J Hand Surg [Am]* 9:399–404, 1984.
53. Deleted in review.
54. Koniuch MP, Peimer CA, VanGorder T, et al: Closed crush injury of the metacarpophalangeal joint. *J Hand Surg [Am]* 12:750–757, 1987.
55. Landsmeer JM: Anatomy of the dorsal aponeurosis of the human finger and its functional signficance. *Anat Rec* 104:31–44, 1949.
56. Lee SK, Dubey A, Kim BH, et al: A biomechanical study of extensor tendon repair methods: introduction to the running-interlocking horizontal mattress extensor tendon repair technique. *J Hand Surg [Am]* 35:19–23, 2010.
57. Littler JW: The digital extensor-flexor system. In Converse J, editor: *Reconstructive plastic surgery*, Philadelphia, 1964, WB Saunders, pp 1612–1632.
58. Littler JW: Restoration of the oblique retinacular ligament for correcting hyperextension deformity of the proximal interphalangeal joint. In Tubiana R, editor: *La main rheumatoide*, Paris, 1966, Expansion Scientifique Francaise, pp 159–167.
59. Littler JW, Eaton RG: Redistribution of forces in the correction of Boutonniere deformity. *J Bone Joint Surg Am* 49:1267–1274, 1967.
60. Love GJ, MacLean JG: Ulnar subluxation of the extensor tendons in elderly osteoarthritic females: a neglected diagnosis. *J Hand Surg Eur Vol* 32:45–49, 2007.
61. Lucas GL: Fowler central slip tenotomy for old mallet deformity. *Plast Reconstr Surg* 80:92–94, 1987.
62. Maisels DO: The middle slip or boutonniere deformity in burned hands. *Br J Plast Surg* 18:117–129, 1965.
63. Mann RJ, Hoffeld TA, Farmer CB: Human bites of the hand: twenty years of experience. *J Hand Surg [Am]* 2:97–104, 1977.
63a. Mason ML: Rupture of the tendons of the hand. *Surg Gynecol Obstet* 50:611–624, 1930.
64. Matev I: Transposition of the lateral slips of the aponeurosis in treatment of longstanding "boutonnière deformity" of the fingers. *Br J Plast Surg* 17:281–286, 1964.
65. Mazurek MT, Hofmeister EP, Shin AY, et al: Extension-block pinning for treatment of displaced mallet fractures. *Am J Orthop (Belle Mead NJ)* 31:652–654, 2002.
66. McCoy FJ, Winsky AJ: Lumbrical loop operation for luxation of the extensor tendons of the hand. *Plast Reconstr Surg* 44:142–146, 1969.
67. Miller H: Repair of severed tendons of the hand and wrist. *Surg Gynecol Obstet* 75:693–698, 1942.
68. Mowlavi A, Burns M, Brown RE: Dynamic versus static splinting of simple zone V and zone VI extensor tendon repairs: a prospective, randomized, controlled study. *Plast Reconstr Surg* 115:482–487, 2005.
69. Nalebuff EA, Millender LH: Surgical treatment of the boutonniere deformity in rheumatoid arthritis. *Orthop Clin North Am* 6:753–763, 1975.
70. Newport ML, Blair WF, Steyers CM, Jr: Long-term results of extensor tendon repair. *J Hand Surg [Am]* 15:961–966, 1990.
71. Newport ML, Pollack GR, Williams CD: Biomechanical characteristics of suture techniques in extensor zone IV. *J Hand Surg [Am]* 20:650–656, 1995.
72. Newport ML, Williams CD: Biomechanical characteristics of extensor tendon suture techniques. *J Hand Surg [Am]* 17:1117–1123, 1992.
73. Ogura T, Inoue H, Tanabe G: Anatomic and clinical studies of the extensor digitorum brevis manus. *J Hand Surg [Am]* 12:100–107, 1987.
74. Oh JY, Kim JS, Lee DC, et al: Comparative study of spiral oblique retinacular ligament reconstruction techniques using either a lateral band or a tendon graft. *Arch Plast Surg* 40:773–778, 2013.
75. Okafor B, Mbubaegbu C, Munshi I, et al: Mallet deformity of the finger. Five-year follow-up of conservative treatment. *J Bone Joint Surg Br* 79:544–547, 1997.
76. Patel MR, Desai SS, Bassini-Lipson L, et al: Painful extensor digitorum brevis manus muscle. *J Hand Surg [Am]* 14:674–678, 1989.
77. Patel MR, Lipson LB, Desai SS: Conservative treatment of mallet thumb. *J Hand Surg [Am]* 11:45–47, 1986.
78. Patil RK, Koul AR: Early active mobilisation versus immobilisation after extrinsic extensor tendon repair: a prospective randomised trial. *Indian J Plast Surg* 45:29–37, 2012.
79. Pike J, Mulpuri K, Metzger M, et al: Blinded, prospective, randomized clinical trial comparing volar, dorsal, and custom thermoplastic splinting in treatment of acute mallet finger. *J Hand Surg [Am]* 35:580–588, 2010.
80. Posner MA, Ambrose L: Boxer's knuckle: dorsal capsular rupture of the metacarpophalangeal joint of a finger. *J Hand Surg [Am]* 14:229–236, 1989.
80a. Purcell T, Eadie PA, Murugan S, et al: Static splinting of extensor tendon repairs. *J Hand Surg [Br]* 25:180–182, 2000.
81. Quaba AA, Elliot D, Sommerlad BC: Long term hand function without long finger extensors: a clinical study. *J Hand Surg [Br]* 13:66–71, 1988.
82. Rayan GM, Mullins PT: Skin necrosis complicating mallet finger splinting and vascularity of the distal interphalangeal joint overlying skin. *J Hand Surg [Am]* 12:548–552, 1987.
83. Rayan GM, Murray D: Classification and treatment of closed sagittal band injuries. *J Hand Surg [Am]* 19:590–594, 1994.
84. Reading G: Secretan's syndrome: hard edema of the dorsum of the hand. *Plast Reconstr Surg* 65:182–187, 1980.
85. Redfern AB, Curtis RM, Wilgis EF: Experience with peritendinous fibrosis of the dorsum of the hand. *J Hand Surg [Am]* 7:380–383, 1982.
86. Ritts GD, Wood MB, Engber WD: Nonoperative treatment of traumatic dislocations of the extensor digitorum tendons in patients without rheumatoid disorders. *J Hand Surg [Am]* 10:714–716, 1985.
87. Rubin J, Bozentka DJ, Bora FW: Diagnosis of closed central slip injuries. A cadaveric analysis of non-invasive tests. *J Hand Surg [Br]* 21:614–616, 1996.
87a. Russel RC, Jones M, Grobbelaar A: Extensor tendon repair: moblise or splint? *Chir Main* 22:19–23, 2003.
87b. Saldana MJ, Choban S, Westerbeck P, et al: Results of acute Zone III extensor tendon injuries treated with dynamic extension splinting. *J Hand Surg [Am]* 16:1145–1150, 1991.
88. Schultz RJ, Furlong J, 2nd, Storace A: Detailed anatomy of the extensor mechanism at the proximal aspect of the finger. *J Hand Surg [Am]* 6:493–498, 1981.
89. Schweitzer TP, Rayan GM: The terminal tendon of the digital extensor mechanism: Part I, anatomic study. *J Hand Surg [Am]* 29:898–902, 2004.
90. Schweitzer TP, Rayan GM: The terminal tendon of the digital extensor mechanism: Part II, kinematic study. *J Hand Surg [Am]* 29:903–908, 2004.
91. Seymour N: Juxta-epiphysial fracture of the terminal phalanx of the finger. *J Bone Joint Surg Br* 48:347–349, 1966.
92. Shrewsbury MM, Johnson RK: A systematic study of the oblique retinacular ligament of the human finger: its structure and function. *J Hand Surg [Am]* 2:194–199, 1977.
93. Shrewsbury MM, Johnson RK: Ligaments of the distal interphalangeal joint and the mallet position. *J Hand Surg [Am]* 5:214–216, 1980.
94. Shum C, Bruno RJ, Ristic S, et al: Examination of the anatomic relationship of the proximal germinal nail matrix to the extensor tendon insertion. *J Hand Surg [Am]* 25:1114–1117, 2000.
95. Smith RJ: Factitious lymphedema of the hand. *J Bone Joint Surg Am* 57:89–94, 1975.
96. Snow JW: Use of a retrograde tendon flap in repairing a severed extensor in the PIP joint area. *Plast Reconstr Surg* 51:555–558, 1973.
97. Snow JW: A method for reconstruction of the central slip of the extensor tendon of a finger. *Plast Reconstr Surg* 57:455–459, 1976.
98. Souter WA: The problem of boutonniere deformity. *Clin Orthop Relat Res* 104:116–133, 1974.
99. Spinner M, Choi BY: Anterior dislocation of the proximal interphalangeal joint. A cause of rupture of the central slip of the extensor mechanism. *J Bone Joint Surg Am* 52:1329–1336, 1970.
100. Spinner M, Kaplan EB: Extensor carpi ulnaris. Its relationship to the stability of the distal radio-ulnar joint. *Clin Orthop Relat Res* 68:124–129, 1970.
101. Stern PJ, Kastrup JJ: Complications and prognosis of treatment of mallet finger. *J Hand Surg [Am]* 13:329–334, 1988.
102. Strauch RJ, Rosenwasser MP, Lunt JG: Metacarpal shaft fractures: the effect of shortening on the extensor tendon mechanism. *J Hand Surg [Am]* 23:519–523, 1998.
103. Suh N, Wolfe SW: Soft tissue mallet finger injuries with delayed treatment. *J Hand Surg [Am]* 38:1803–1805, 2013.
103a. Syladis P, Youatt M, Logan A: Early active mobilization for extensor tendon injuries: the Norwich regime. *J Hand Surg [Br]* 22:594–596, 1997.
104. Takami H, Takahashi S, Ando M, et al: Traumatic rupture of the extensor tendons at the musculotendinous junction. *J Hand Surg [Am]* 20:474–477, 1995.
105. Tetik C, Gudemez E: Modification of the extension block Kirschner wire technique for mallet fractures. *Clin Orthop Relat Res* 404:284–290, 2002.
106. Thompson JS, Littler JW, Upton J: The spiral oblique retinacular ligament (SORL). *J Hand Surg [Am]* 3:482–487, 1978.
107. Tomaino MM, Plakseychuk A: Two-stage extensor tendon reconstruction after composite tissue loss from the dorsum of the hand. *Am J Orthop* 29:122–124, 2000.

108. Tonkin MA, Hughes J, Smith KL: Lateral band translocation for swan-neck deformity. *J Hand Surg [Am]* 17:260–267, 1992.
109. Tonta K, Kimble FW: Human bites of the hand: the Tasmanian experience. *ANZ J Surg* 71:467–471, 2001.
110. Ueba H, Moradi N, Erne HC, et al: An anatomic and biomechanical study of the oblique retinacular ligament and its role in finger extension. *J Hand Surg [Am]* 36:1959–1964, 2011.
111. Vahey JW, Wegner DA, Hastings H, 3rd: Effect of proximal phalangeal fracture deformity on extensor tendon function. *J Hand Surg [Am]* 23:673–681, 1998.
112. Van Sint Jan S, Rooze M, Van Audekerke J, et al: The insertion of the extensor digitorum tendon on the proximal phalanx. *J Hand Surg [Am]* 21:69–76, 1996.
113. von Schroeder HP, Botte MJ: Anatomy of the extensor tendons of the fingers: variations and multiplicity. *J Hand Surg [Am]* 20:27–34, 1995.
114. Wang L, Zhang X, Liu Z, et al: Tendon-bone graft for tendinous mallet fingers following failed splinting. *J Hand Surg [Am]* 38:2353–2359, 2013.
115. Warren RA, Norris SH, Ferguson DG: Mallet finger: a trial of two splints. *J Hand Surg [Br]* 13:151–153, 1988.
116. Weeks PM: The chronic boutonniere deformity: a method of repair. *Plast Reconstr Surg* 40:248–251, 1967.
117. Wehbe MA: Junctura anatomy. *J Hand Surg [Am]* 17:1124–1129, 1992.
118. Wehbe MA, Schneider LH: Mallet fractures. *J Bone Joint Surg Am* 66:658–669, 1984.
119. Wheeldon FT: Recurrent dislocation of extensor tendons in the hand. *J Bone Joint Surg Br* 36:612–617, 1954.
120. Whillis J, Channell GD: The action of the lumbrical and interosseous muscles in some of the movements of the digits. *J Anat* 83:60, 1949.
121. Woo SH, Tsai TM, Kleinert HE, et al: A biomechanical comparison of four extensor tendon repair techniques in zone IV. *Plast Reconstr Surg* 115:1674–1681, discussion 1682–1683, 2005.
122. Wood VE: The extensor carpi radialis intermedius tendon. *J Hand Surg [Am]* 13:242–245, 1988.

Flexor Tendon Injury

John Gray Seiler III

Acknowledgments: The author would like to acknowledge the assistance of Dr. Mihir Desai in the preparation of these works on flexor tendon repair and flexor tendon grafting.

The author acknowledges the work of Drs. James Strickland, Lawrence Schneider, and Martin I. Boyer, whose outstanding chapters in previous editions have been modified, combined, and updated. Their contributions to our understanding of repair and reconstruction of the damaged flexor tendon system have greatly advanced our ability to care for these injuries.

The author also acknowledges the contributions of Mr. Daniel Acker, OT, CHT, to the rehabilitation portion of this chapter.

These videos may be found at *ExpertConsult.com:*
6.1 Flexor tendon repair
6.2 Paneva-Holevich technique for chronic tendon laceration

REPAIR OF ACUTE FLEXOR TENDON INJURIES

In the 1960s, initial clinical reports began to emerge that suggested primary tendon repair was possible and desirable.[112-115,134,136,236] Since that time, there have been major advances in the understanding of intrasynovial flexor tendon anatomy, biology, mechanisms of response to injury, and methods of repair.* Pioneering work by Lundborg validated primary adhesion-free intrasynovial tendon repair in experimental and clinical studies.† More recent research has focused on improvements in surgical and aftercare methods that can achieve a reliable flexor tendon repair site and are associated with satisfactory digital motion.‡ These advances coupled with improvements in suture design, optical magnification, and rehabilitation methods have made primary flexor tendon repair the preferred operative treatment for lacerated tendons in zone 2.§ Table 6.1 summarizes research relevant to flexor tendon repair.

The goals of surgical treatment of a lacerated intrasynovial flexor tendon have remained constant: accurate coaptation of the tendon ends in such a manner as to allow application of a postoperative rehabilitation protocol that encourages tendon gliding, inhibits the formation of peritendinous adhesions, stimulates restoration of the gliding surface, allows for primary healing of the repair site, and ultimately restores normal range of motion to the finger.[214-218]

*References 1, 4-6, 16, 18, 32, 36, 45-49, 67-76, 78, 97, 126-131, 141, 162-166, 185, 187, 197, 225, 226, 240, 245-248, 250.
†References 11-13, 20-23, 42-44, 51, 85, 90, 92, 143-159.
‡References 73, 75, 111, 135, 137, 138, 142, 168, 174, 220.
§References 78, 80, 203-218, 223, 251, 252.

Preoperative Evaluation

A thorough patient history and physical examination of the injured hand are performed as a part of the initial evaluation and before the administration of local anesthesia or sedation so that any potential neurologic or vascular injuries can be accurately detected. Generally, a systematic method of examining each system in the hand is most effective in documenting the components of the injury. This primary evaluation is important to planning the nature and timing of future medical and surgical treatments.

Systematic Examination

Integument Examination. The integrity of the skin on the volar and dorsal aspects of the injured digit is examined to ascertain the presence or absence of additional injuries. The nature of each skin injury should be recorded.

Musculoskeletal Examination. Obvious angular or rotational deformity of the digit signifies either a fracture or a ligamentous injury that requires further assessment. Realignment of a fracture or reduction of a dislocation may be required before the evaluation of flexor tendon integrity or the presence of digital neurovascular injury. If the flexor tendons are lacerated, the digit loses its inherent flexor tone and assumes an extended posture at the proximal interphalangeal (PIP) and distal interphalangeal (DIP) joints. If the tendons are completely transected, there is no active flexion and the tenodesis effect (normal increase in flexor tone) is lost with passive wrist extension.

The tendons should be examined individually in each finger. To isolate the flexor digitorum superficialis (FDS) tendon (Figure 6.1), the adjacent digits are held in full extension or in mild hyperextension by the examiner at the metacarpophalangeal (MP), PIP, and DIP joints. Active flexion of the PIP joint is evaluated for each digit, and its presence indicates that the fibers of the FDS tendon are intact. The presence of active flexion does not rule out partial FDS tendon injury, however. Pain on active flexion may suggest a partial tendon injury. The flexor digitorum profundus (FDP) tendon examination is done by positioning the finger in full extension, stabilizing the middle phalanx against the examining surface, and asking the patient to flex the DIP joint actively.

Neurologic Examination. An assessment of light touch and static two-point discrimination is preferred; loss of sensation in

TABLE 6.1 Contributions to Our Understanding of Flexor Tendon Repair

Author	Publication Activity	Main Area of Contribution	Significance
Bunnell	1918-1951	Surgical technique of tendon repair, grafting	Stressed importance of gentle, precise surgical technique as having a direct effect on results
Mason et al	1932-1959	Animal model study of repair site healing	Classic in vivo study of repair site healing and accrual of strength
Boyes et al	1947-1989	Surgical technique of tendon repair, grafting	Detailed techniques and results of intrasynovial flexor tendon grafts
Peacock et al	1957-1987	Tendon biology, healing	Stressed contribution of surrounding sheath to tendon repair site healing
Verdan et al	1960-1987	Primary tendon repair	First report of successful primary tendon repair within digital sheath
Potenza et al	1962-1986	Tendon biology, healing	Stressed the contribution of surrounding sheath to repair site healing
Kleinert et al	1967-present	Early motion rehabilitation	Reported technique of reliable and reproducible postoperative "rubber band" rehabilitation. Also first valid report in United States of primary zone 2 repair
Burner	1967-1975	Skin incisions	Zigzag volar approach to digital sheath
Kessler et al	1969-1987	Primary tendon repair	Core suture technique
Ketchum et al	1971-1985	Biology and biomechanics of tendon repair	Experimental study of tendon repair and healing
Lundborg et al	1975-present	Tendon healing, vascularity, nutrition	Advocated concept of "intrinsic" tendon healing, detailed vascularity of flexor tendon
Duran et al	1975-1990	Early motion rehabilitation	Passive motion rehabilitation protocol
Manske et al	1977-present	Tendon biology, biomechanics	Classic studies of tendon nutrition, repair site biology, and biomechanics
Leddy et al	1977-1993	FDP avulsion injuries	Classification of FDP avulsions
Lister et al	1977-1986	Rehabilitation, pulley reconstruction	Clinical studies of pulley reconstruction and handling of digital sheath
Gelberman et al	1980-present	Tendon biology, biomechanics, rehabilitation	Classic experimental and clinical studies of tendon repair site biology, biomechanics, vascularity, and rehabilitation
Strickland et al	1982-present	Tendon repair, rehabilitation	Classic clinical and experimental studies of flexor tendon repair and rehabilitation
Silfverskiöld et al	1983-1994	Tendon repair, rehabilitation	Clinical and experimental study of repair site gap formation and rehabilitation
Amadio et al	1984-present	Tendon and pulley biology, biomechanics, rehabilitation	Classic experimental studies of tendon repair site biology, biomechanics, and rehabilitation
Hitchcock et al	1987	Tendon biology, rehabilitation	Experimental study of biologic effect of passive motion rehabilitation
Doyle	1988	Flexor pulley system	Relative importance of each pulley
Mass et al	1989-present	Tendon biomechanics	Experimental study of in vitro repair site biomechanics
Abrahamsson et al	1989-present	Growth factors in tendon healing	In vitro studies of growth factor synthesis during repair site healing and their effects
Seiler et al		Biology of tendon repair	Identification of growth factors in repair, suture methods in tendon repair
Schuind et al	1992-present	In vivo flexor tendon forces	Classic study documenting in vivo flexor forces during digital motion
Diao et al	1996-present	Core and circumferential suture techniques	Experimental study of role of circumferential suture in time-zero repair site strength
Sandow and McMahon	1996-present	Core suture technique	Improved time-zero core suture technique
Boyer et al	1997-present	Tendon biology, biomechanics, rehabilitation	Experimental studies of tendon repair site biology, biomechanics, vascularity, and rehabilitation
Wolfe et al	1999-present	Core suture technique	Core suture technique
Taras	1999-present	Core suture technique	Core suture technique
Leversedge	2000-present	Tendon vascularity and neovascularization after repair	Experimental studies of tendon repair site and insertion site vascularity

a digital nerve dermatome after a sharp laceration represents a nerve transection until proven otherwise.

Vascular Examination. Capillary refill of the volar digital pulp and the nail bed is assessed. When necessary, a digital Allen test can be done. Delayed capillary refill or poor turgor may suggest a digital artery laceration.

After a complete evaluation of the skin, skeleton, tendons, nerves, and vascular supply, the evaluating physician can make a judgment regarding the timing and nature of the anticipated surgical repair. The surgeon must be prepared, however, to treat any findings that could be encountered during surgical exploration.

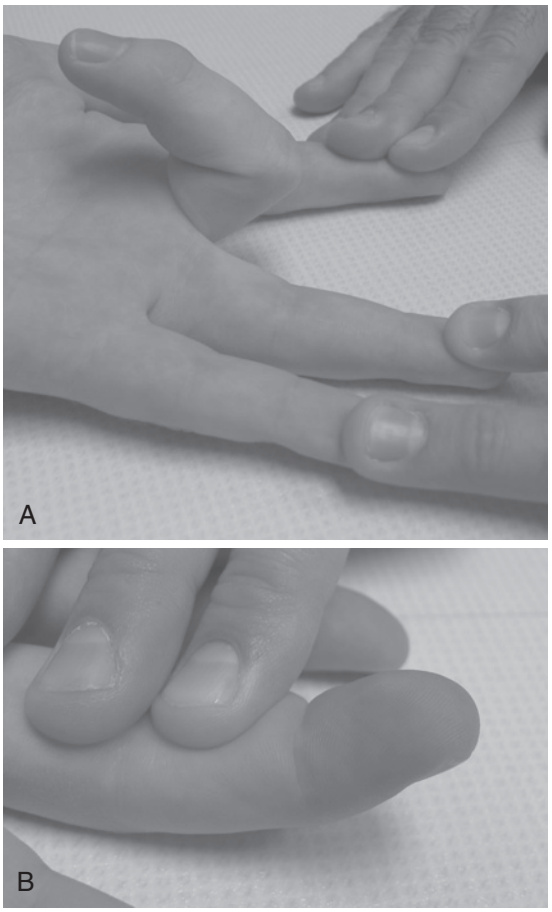

FIGURE 6.1 **A,** Continuity of FDS tendon is evaluated by asking the patient to flex the finger actively while holding MP joints of the uninvolved fingers in hyperextension, and PIP and DIP joints of the uninvolved fingers in full extension. This effectively eliminates the profundus and allows the superficialis action to be evaluated. **B,** Middle phalanx is held firmly, and active flexion at DIP joint is carried out. This shows continuity of FDP tendon.

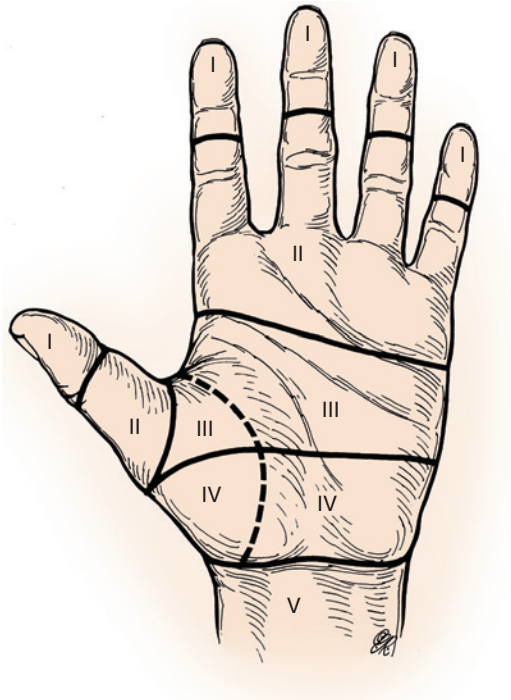

FIGURE 6.2 Flexor system has been divided into five zones or levels for the purposes of discussion and treatment. Zone 2, which lies within the fibroosseous sheath, has been called "no man's land" because it was previously believed that primary repair should not be done in this zone. (Copyright Elizabeth Martin.)

Diagnostic Imaging

Plain radiographs are usually obtained at the time of initial assessment while the patient is in the emergency department. Diagnostic ultrasound may be useful when the continuity of a flexor tendon is in question, or to assess a suspected partial laceration. Intraoperative fluoroscopic images may be useful, especially if indicated by the findings of surgical exploration.

ANATOMY

The FDS muscle has two heads of origin. The ulnar head arises from the anterior aspect of the medial epicondyle, the ulnar collateral ligament of the elbow, the medial aspect of the coronoid process, and the proximal ulna. The radial head arises from the proximal radius immediately distal to the insertion of the supinator muscle and lies deep to the pronator teres. The median nerve is loosely adherent to the deep surface of the FDS muscle. At the level of the midforearm, the FDS muscle divides and sends tendons to the middle and ring fingers (superficial) and the index and small fingers (deep). The innervation of the FDS muscle is from the median nerve. The blood supply is from the radial and the ulnar arteries.

The FDP muscle belly arises from the volar and medial aspects of the proximal three fourths of the ulna and from the interosseous membrane. In the deepest layer of the volar forearm, the FDP muscle lies adjacent to the flexor pollicis longus muscle. The ulnar nerve innervates the muscle-tendon units of the ring and small fingers. The anterior interosseous branch of the median nerve innervates the FDP muscle-tendon units of the index and middle fingers. The blood supply to the FDP muscle is largely from the ulnar artery.

The flexor pollicis longus (FPL) tendon arises from the volar aspect of the middle third of the radial shaft and from the lateral aspect of the interosseous membrane. The anterior interosseous branch of the median nerve innervates the FPL muscle belly in the proximal forearm or midforearm. The blood supply of the FPL muscle is predominantly from the radial artery.

The tendons of the nine digital flexors enter the proximal aspect of the carpal tunnel in a fairly constant relationship. The most superficial tendons are the FDS tendons to the long and ring fingers. Immediately beneath them are the FDS tendons to the index and little fingers. In the deepest layer are four FDP tendons and the FPL.

Kleinert and colleagues[115] and Verdan[236] used their knowledge of anatomy to facilitate classification of tendon injuries into five anatomic zones (Figure 6.2). Zone 5 extends from the muscle-tendon junction to the proximal aspect of the carpal tunnel, and zone 4 describes the flexor tendons within the carpal tunnel. Distal to the transverse carpal ligament at approximately the level of the superficial palmar vascular arch, the lumbrical tendons take their origin from the FDP tendons. Zone 3 denotes the origin of the lumbricals from the FDP tendon. The proximal aspect of the A1 pulley is the entrance to zone 2, or "no man's land." Zone 1 is distal to the insertion of the FDS tendon. A laceration in zone 1, by definition, injures

only the tendon of the FDP. This classification of tendon injury, by anatomic zone, is still in use today.

In each finger, the FDS tendon enters the A1 pulley and divides into two equal halves that rotate laterally and then dorsally (180 degrees) around the FDP tendon (Figure 6.3). The two slips rejoin deep to the FDP tendon over the distal aspect of the proximal phalanx and the palmar plate of the PIP joint at the Camper chiasm, and then insert as two separate slips on the volar aspect of the middle phalanx.

Zones 1 and 2 of the FDS and FDP tendons are described by the fibroosseous digital sheath (Figure 6.4). Within this sheath, the flexor tendons are covered by a layer of flattened fibroblasts termed the *epitenon*. This specialized surface is the crucial gliding surface that must be restored for flexor tendon repair to be successful.

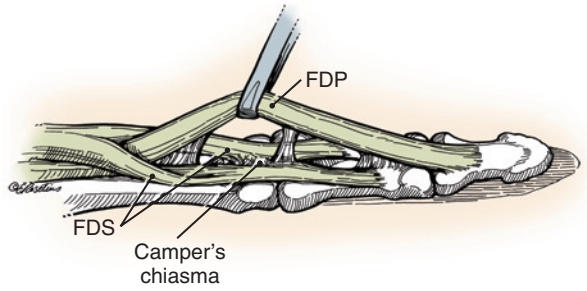

FIGURE 6.3 In the proximal part of the flexor sheath, FDS tendon divides into two slips, which encircle the FDP tendon first at the volar aspect, then at the radial and ulnar aspects, and finally at the dorsal aspect. The two portions of the FDS tendon reunite at the Camper chiasm and redivide before inserting onto the middle three fifths of the volar aspect of the middle phalanx, forming the floor of the flexor sheath in this area. (Copyright Elizabeth Martin.)

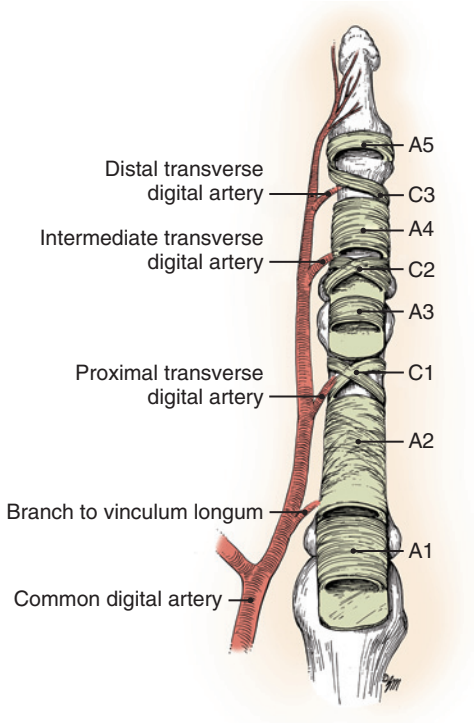

FIGURE 6.4 Fibrous retinacular sheath starts at the neck of the metacarpal and ends at the distal phalanx. Condensations of the sheath form the flexor pulleys, which can be identified as five heavier annular bands and three filmy cruciform ligaments (see text). (Copyright Elizabeth Martin.)

The pulley mechanism of the flexor sheath consists of thicker annular pulleys and thinner, more flexible cruciform pulleys.[39,40,45] The annular pulleys are stiffer and keep the tendon closely applied to the underlying bone.[175] Their form and function allow an economical amount of tendon excursion to effect a significant amount of joint angular rotation, improving the efficiency of the flexor apparatus.[230,231] Structural analysis of these pulleys has suggested that each of the three layers of the pulley has a strategic purpose. The innermost layer secretes hyaluronic acid and is designed to facilitate gliding. The middle layer, rich in collagen, resists palmar translation of the tendons. The outer areolar layer facilitates nutrition of the pulley. The cruciform pulleys are collapsible and can "accordion" to allow for digital flexion to occur without significant deformation of the annular pulley system (see Figure 6.4). The A1, A3, and A5 pulleys take origin from the palmar plates of the MP, PIP, and DIP joints. The A2 pulley originates from the proximal third of the proximal phalanx, and the A4 pulley originates from the middle phalanx.

The dual nutritional supply of the digital flexor tendons in zone 2 is from vascular perfusion and synovial diffusion (Figure 6.5).[140,240] The parietal paratenon[230] allows for passive nutrient delivery to, and waste removal from, the flexor tendon within the flexor sheath by means of diffusion. The flexor tendons receive a direct arterial supply from the well-developed vincular system, osseous bony insertions, reflected vessels from the tendon sheath, and longitudinal vessels from the palm. The system of blood supply allows delivery of nutrients and removal of wastes.

Surgical Treatment

Preoperative Considerations

Optimal timing of flexor tendon repair depends on the findings of a thorough history and physical examination. Emergency repair of the lacerated tendons is indicated only in the setting of altered digital perfusion that requires microvascular repair

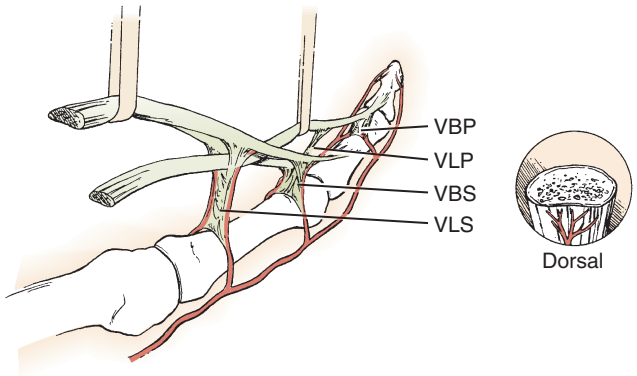

FIGURE 6.5 Blood supply to flexor tendons within the digital sheath. The segmental vascular supply to the flexor tendons is via long and short vincular connections. The vinculum brevis superficialis (VBS) and the vinculum brevis profundus (VBP) consist of small triangular mesenteries near the insertion of the FDS and FDP tendons. The vinculum longum to the superficialis tendon (VLS) arises from the floor of the digital sheath of the proximal phalanx. The vinculum longum to the profundus tendon (VLP) arises from the superficialis at the level of the PIP joint. *Cutaway view* depicts relative avascularity of the palmar side of the flexor tendons in zones 1 and 2 compared with the richer blood supply on the dorsal side, which connects with the vincula.

or reconstruction. If digital perfusion is compromised, or if the mechanism of injury is consistent with injury to arteries, urgent exploration and tendon repair with microvascular digital artery and nerve repair are indicated.

Primary repair done within days of the injury allows for preparation of the patient and ensures optimal conditions for the procedure. Basic science and clinical evidence suggest that it is preferable to perform tendon repair early after injury. Undue delay can be associated with changes in the tendon ends and proximal muscle that make primary tendon repair difficult. Done promptly after injury, the wound is easier to manage and the tendon ends are fresh for the repair.

In some cases of delayed presentation, or when the patient provides an unreliable history, the interval between injury and diagnosis may be unknown. In these cases, adequate preoperative consideration should be given to the possible need for tendon reconstruction and tendon repair. These more complicated cases may require the use of a primary tendon graft or placement of a tendon spacer.

In some settings, repair of both tendons is impossible. If the tendon ends are severely injured, unclean, or ragged, or if there is insufficient tendon for repair, excision of the FDS tendon and isolated repair of the FDP tendon may be the best alternative.[52,118,245] Isolated repair of the FDP tendon creates a simpler finger and is generally associated with diminished adhesion formation in a severely traumatized digit. In cases where only repair of the FDS tendon is possible, FDP tenodesis to the middle phalanx or DIP joint fusion may be necessary. Generally, repair of both tendons is preferable for optimal gliding and strength. In select cases, excision of one slip of the FDS tendon may be necessary to diminish the bulk of the repair and facilitate gliding through the tendon sheath. The need for repair of the flexor sheath is controversial.[168,223]

Repair of Zone 1 Tendon Lacerations or Avulsions

Laceration of the FDP tendon distal to the insertion of the FDS tendon or avulsion from its insertion at the base of the proximal aspect of the distal phalanx is a zone 1 injury. If the tendon is lacerated and the distal tendon stump is less than 1 cm long, FDP tendon advancement and primary repair to bone is usually indicated. If more than 1 cm of FDP stump is available for suture, primary tenorrhaphy is usually done because shortening of the FDP tendon by more than 1 cm may result in a "quadriga effect" on the intact FDP tendons. The term *quadriga* (*quadri* meaning "four" and *jungere* meaning "to yoke") refers to a Roman chariot pulled by four horses abreast. When excessive advancement of a tendon is done for the purpose of repair, it also creates tension in the other "yoked" tendons of the FDP muscle. Because of this increased tension, diminished flexion occurs in the other fingers when the injured finger is flexed.

Tendon-to-Bone Repair. The many techniques for tendon-to-bone repair can be divided into two general types: traditional pull-out suture methods and internal suture methods. Traditional methods of FDP tendon repair to bone call for the placement of a core suture in the proximal tendon and using the free ends of the suture to secure the cut end of the tendon into a small trough in the distal phalanx. The free ends of the sutures are passed through or around the distal phalanx and through the sterile matrix and nail plate, and tied over the dorsum of the fingernail (see Figure 6.11, *C*, and Figure 6.27). This "pull-out suture" usually is removed approximately 6 weeks after the procedure. All internal suture methods use suture anchors or other methods to affix the tendon directly to the bone. The development of miniature anchors, appropriate for deployment into the distal phalanx, has improved our ability to use newer core suture types, that is, four-strand tendon repairs, so as to fix the tendon to the distal phalanx in a stable manner. Whatever technique is used, it is essential that the FDP stump be secured directly to the footprint in the distal phalanx when the knot is secured.

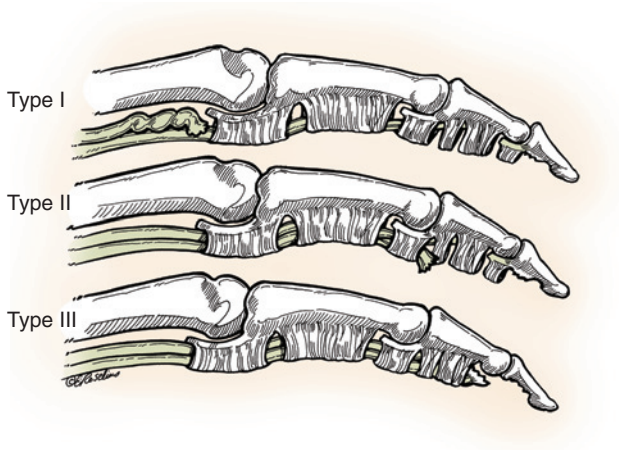

FIGURE 6.6 Leddy and Packer classification of profundus avulsions. *Type I*: The FDP tendon is avulsed from its insertion and retracts into the palm. *Type II*: The profundus tendon is avulsed from its insertion, but the stump remains within the digital sheath, implying that the vinculum longum profundus is still intact. *Type III*: A bony fragment is attached to the tendon stump, which remains within the flexor sheath. Further proximal retraction is prevented at the distal end of the A4 pulley. (Copyright Elizabeth Martin.)

Flexor Digitorum Profundus Avulsion. Leddy and Packer[123] classified FDP avulsions into three types (Figure 6.6). In type I avulsions, the FDP tendon retracts into the palm and the vincular blood supply of the tendon has been disrupted. These injuries are best treated by urgent surgical repair. In type II avulsions, the tendon stump retracts to the level of the PIP joint and some vincular blood supply is preserved. In some type II cases, a primary tendon repair may be done 6 weeks after injury. A large bone fragment is attached to the stump of the FDP tendon in type III injuries. This fragment usually prevents tendon retraction proximal to the distal edge of the A4 pulley. Fracture repair using Kirschner wire or miniature screw fixation is necessary for treatment of this injury. Since Leddy and Packer's description was created, a fourth type of injury has been identified.[229] A type IV injury is defined as a fracture *and* avulsion of the FDP tendon from the fracture fragment. The stump may be located either within the tendon sheath or within the palm. Suspicion of this injury can be confirmed with advanced digital imaging; either ultrasound or magnetic resonance imaging (MRI) is appropriate. Repair of the fracture is done first, after which the tendon is advanced and affixed to the distal phalanx. In some cases with a small fracture fragment, the bone may be excised, and the tendon may be advanced and sutured into the distal phalanx. Generally, this type IV injury is more severe and may be associated with a less optimal outcome. Because the initial radiographic findings may be inconsistent with the proximal location of the flexor tendon, I recommend

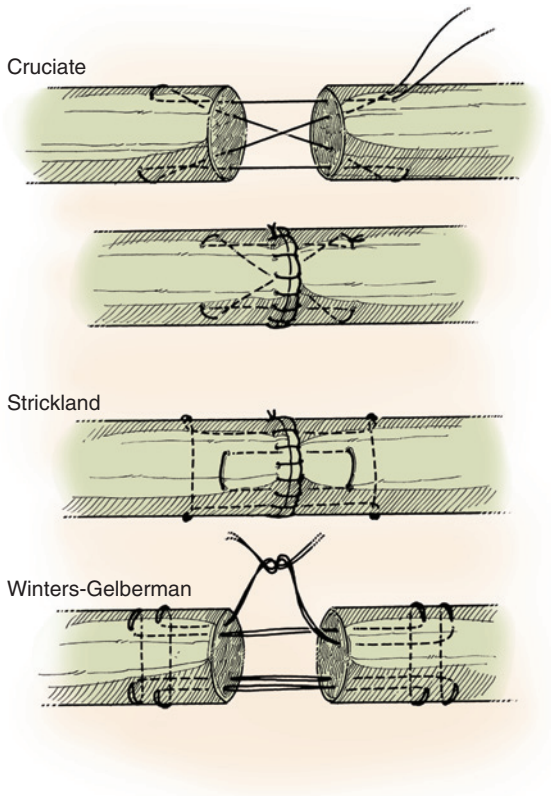

FIGURE 6.7 Commonly used techniques for end-to-end flexor tendon repair. (Copyright Elizabeth Martin.)

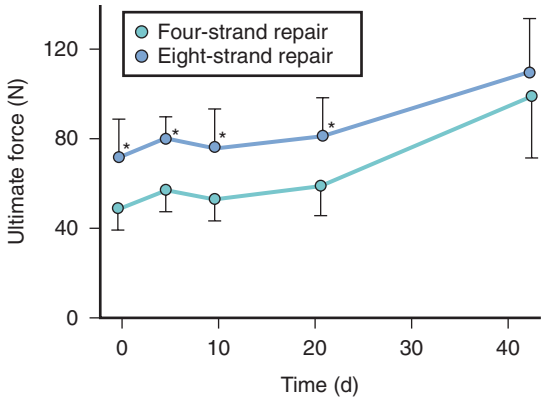

FIGURE 6.8 Comparison of ultimate force versus time between suture techniques from 0 to 21 days. The repairs with the eight-strand technique were significantly stronger than the repairs that used the four-strand technique. *Asterisks* denote a significant difference between the eight-strand and four-strand techniques at $P < .05$. (Redrawn from Boyer MI, Gelberman RH, Burns ME, et al: Intrasynovial flexor tendon repair: an experimental study comparing low and high levels of in vivo force during rehabilitation in canines, *J Bone Joint Surg [Am]* 83:891–899, 2001.)

that all flexor tendon avulsion injuries be treated by early repair when possible.

Repair of Zone 2 Tendon Lacerations

Attempts to improve the strength of flexor tendon repairs have focused on strategies to vary the material properties of the suture, the suture caliber, and the suture technique to coapt the tendon ends accurately. A smooth tendon suture is important for restoration of a low-friction gliding surface and facilitates tendon rehabilitation. Generally, surgeons need to master a method that allows for atraumatic suture placement and stable, accurate coaptation of the tendon ends. The method of tendon coaptation must be strong enough to allow early digital mobilization.

Core Sutures. Ex vivo and in vivo investigations in clinically relevant models have suggested that core suture configurations with the greatest tensile strength are those in which there are multiple sites of tendon-suture integration. Although two-strand suture methods (Kessler and modified Kessler and Tajima techniques) still enjoy widespread acceptance, newer multistrand suture methods (Strickland, cruciate, Becker, Savage, and Winters) are being used with increasing frequency because they are stronger and have increased resistance to repair site gapping (Figures 6.7 and 6.8 and Video 6.1). These more modern methods of core tendon suture placement have not only been shown to offer greater initial repair site tensile strength but also to improve strength 6 weeks postoperatively.

It is well accepted that core suture strength is related to the type of suture material, the caliber of the suture, and the number of suture strands crossing the repair site. This concept holds true in time-zero mechanical studies and in clinical studies for the first 6 weeks after repair. The practical limitation of the more esoteric repairs is the time required and the complexity of suture placement in a small space using a minimally traumatic technique. Most surgeons choose the suture size based on the caliber of the tendon to be repaired because a 3-0 suture shows increased strength compared with a 4-0 suture. Ex vivo studies have shown that the loop of the core suture that is positioned to "lock" rather than "grasp" the tendon stumps shows greater time-zero strength. Similarly, increasing the number of locks or grasps increases the time-zero tensile strength (Figure 6.9).

The placement of the suture knot either within or away from the repair site has not been shown to have an independent effect on tensile strength. Greater quantity of suture within the repair site may increase repair site bulk, increase the work of flexion, and diminish the surface area available for repair.[167] External knot placement distant to the repair site may also adversely affect tendon gliding within the flexor tendon sheath by causing increased friction or knot trapping between tendon and sheath.[166,175]

Epitendinous Suture. Initially proposed as a method to smooth the site of tendon repair, epitendinous, or *circumferential,* suture has been shown to augment repair site strength. Diao and colleagues[43] and others have shown that by making the suture deeper or by altering the configuration, there is some improvement in repair site strength.[117,238] Although the circumferential suture can increase the initial and early postoperative strength of the repair site, it remains an adjunct to core tendon suture. In some cases, placement of the circumferential suture first (at least in the dorsalmost aspect of the tendon repair) can facilitate tendon orientation and make placement and tensioning of the core suture easier.[182]

Gap Formation. There is a negative effect of early repair site gap formation on tendon healing and accrual of repair site strength. An in vivo canine study showed that tendons healing without repair site gaps, or with gaps of less than 3 mm, acquire strength 6 weeks after repair. In this same study, if there was a

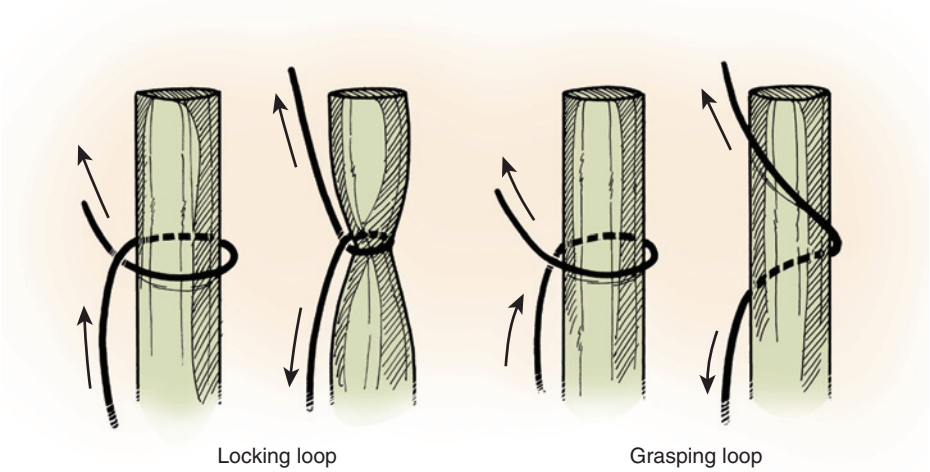

FIGURE 6.9 Relationship between the longitudinal and transverse intratendinous components of the core suture defines whether the suture is "locking" or "grasping." When the transverse component passes within the tendon superficial to the longitudinal component, the suture "locks" a bundle of tendon fibers. When the transverse component passes deep to the longitudinal component, however, the suture does not "lock" a bundle of tendon fibers but pulls through the tendon. (Copyright Elizabeth Martin.)

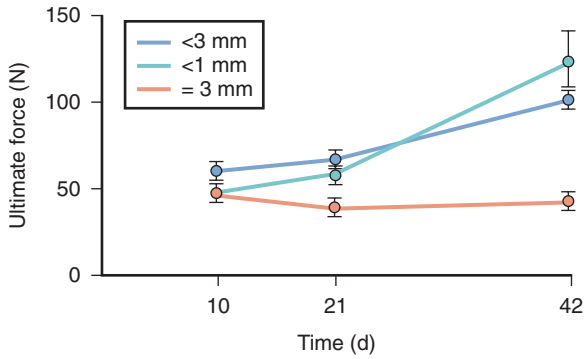

FIGURE 6.10 Ultimate tensile strength is plotted as function of time. Tendons with repair site gaps less than 3 mm accrue strength during the fourth to sixth week postoperatively, whereas tendons with repair site gaps greater than 3 mm show no significant increase in ultimate tensile strength during the early postoperative period. (Redrawn from Gelberman RH, Boyer MI, Brodt MD, et al: The effect of gap formation at the repair site on the strength and excursion of intrasynovial flexor tendons: an experimental study on the early stages of tendon-healing in dogs, *J Bone Joint Surg [Am]* 81:965–982, 1999.)

repair site gap greater than 3 mm, significant accrual of repair site strength did not occur. Repair site gaps that develop early in the postoperative period pose a greater risk of rupture as rehabilitation progresses after 3 weeks (Figure 6.10).

Biologic Considerations. Since Lundborg's important observation that intrinsic tendon healing was possible, large strides have been made in the investigation of the biologic processes occurring at the repair site during the postoperative period. The process of flexor tendon repair can be divided into three general phases: early inflammatory, intermediate active repair, and late remodeling. The area within 1 cm of the repair site is the most active and is characterized by early cellular proliferation and migration to the repair site. Although suture methods maintain the position of the tendon ends, the biology of the repair response is the ultimate arbiter of outcome. Increased synthesis of type I collagen mRNA and protein has been shown within repair site cells and cells within the adjacent epitenon early in the postoperative period. Fibronectin, an abundant extracellular matrix protein involved in cell-matrix communication, and $\alpha_5\beta_1$ and $\alpha_v\beta_3$ integrins, cell surface compounds involved in the binding of fibroblasts to extracellular matrix, are also upregulated during the early postoperative period.[21-23]

Role of Postoperative Passive Motion Rehabilitation. Despite advances in suture methods and understanding of the biology of the repair site, the formation of adhesions between the tendon and the surrounding fibroosseous sheath with resultant digital stiffness remains one of the most common complications after intrasynovial flexor tendon repair. In vivo studies have suggested that the formation of these restrictive intrasynovial adhesions at the repair site and at remote sites between tendon and sheath may be obviated if a sufficient amount of tendon excursion is achieved during passive motion rehabilitation. In vivo canine studies have shown that repaired tendons need only be moved passively 1.6 mm or more during postoperative rehabilitation to prevent clinically relevant adhesion formation.[22,23]

In an effort to improve the accrual of strength at the tendon repair site, investigators have advocated rehabilitation methods that generate increased levels of applied in vivo force across the repair. Although some level of force application is valuable, Boyer and colleagues[22,23] showed that increasing levels of applied force during postoperative rehabilitation from 5N to 17N did not accelerate the accrual of repair site strength after placement of a multistrand repair and may risk gap or rupture.

Future Concepts. Recent studies have explored the use of fibrin glue in the flexor tendon repair. Fibrin glue has been used in a variety of surgical procedures to promote hemostasis and tissue bonding and as a cell carrier for stem cells on tendons. Using a rabbit model, He and associates[87] reported improved range of motion in digits following zone 2 tendon repair augmented with fibrin glue at 3 weeks compared with controls. At 8 weeks there was no difference in the range of motion between the two groups. There was no change in the biomechanical properties of the repair in the experimental group. A recent cadaveric study examined the effect of fibrin glue augmentation following zone 2 repairs. The authors compared a standard four-strand core repair plus fibrin glue augmentation with a standard

four-strand core repair with epitendinous sutures. They reported a significantly higher gliding resistance in the fibrin glue group compared with the epitendinous suture group.[256]

Vitamin C has become a hot topic in preventing reflexive sympathetic dystrophy following distal radius fractures. Its use as an antioxidant has been examined in flexor tendon repair. Tissue damage and hemorrhage can disturb redox regulation, thereby favoring fibrotic responses in the flexor tendon repair site. Hung and colleagues[96] used a chicken model to examine the effects of local vitamin C following flexor tendon injury and repair. They reported improved gliding resistance, reduced fibrotic size, and fewer histologic peritendinous adhesions 6 weeks following repair compared with saline controls.

Flexor Pollicis Longus Lacerations. Intrasynovial lacerations of the FPL tendon may pose a unique difficulty in that the proximal tendon stump frequently retracts deep to the thenar musculature, making retrieval of the proximal end more difficult.[23,79,114] If the proximal stump has retracted proximal to the distal edge of the thenar musculature, it can be localized through a separate incision in the carpal canal or distal forearm.

Repair of Tendon Lacerations in Zones 3, 4, and 5

The principles for operative exploration and repair of flexor tendon injuries proximal to the A1 pulley are similar to injuries in zone 2, though the potential for disruptive adhesion formation postoperatively is considerably reduced. Generally, repair of lacerations in these zones has an improved prognosis. The preoperative planning for these repairs should account for the possible need for microsurgical nerve and arterial repair. Techniques and considerations for the placement of the core and circumferential sutures and postoperative rehabilitation are the same as those described for zone 2 injuries.

Repair of Partial Tendon Lacerations

There has been considerable debate about the appropriate management of partial tendon lacerations. Partial flexor tendon lacerations can progress to late tendon rupture and tendon entrapment or triggering. For lacerations that are more than 50% of the tendon cross-sectional area, I usually repair the tendon using a core suture method and a circumferential suture. If the cross-sectional area lacerated is less than 50%, the tendon is either repaired or débrided to avoid entrapment and triggering of the tendon. My preference is to explore wounds where there is high probability on physical examination that a tendon injury has occurred. Advanced imaging can be useful in select cases for decision making but is unlikely to take the place of exploration in the majority of cases.

❖ AUTHOR'S PREFERRED TECHNIQUE: Zone 1 Tendon-to-Bone Repair

The patient is placed supine on the operating table, and the arm lies at a right angle to the long axis of the body. A well-padded brachial tourniquet is placed on the arm. The arm is prepared using a povidone-iodine (Betadine) scrub and paint. A surgical pause or "time out" is done. The limb is exsanguinated using an elastic bandage, and the tourniquet is inflated to a pressure that is 100 mm Hg greater than the systolic blood pressure. Prior to insufflation of the tourniquet, a first-generation cephalosporin or other appropriate antibiotic(s) is administered as determined by the nature of the injury.

When possible, an extensile midlateral incision is used to expose the flexor apparatus. This may be extended with Bruner incisions proximally and distally as needed (Figure 6.11; see also Figure 6.14). After the exposure is completed, assessment of the entire injury is possible and the sequence of repair is determined. The tendon stump is located proximally and drawn into the distal wound by any of the techniques described for zone 2 injuries (see Figure 6.11). The tendon is then transfixed to the annular pulleys and the digital soft tissues with a 25-gauge needle.

It is often difficult to deliver the flared-out stump of the FDP tendon through the A4 pulley after it has avulsed from the distal phalanx and retracted proximally, particularly if several days or weeks have elapsed. Several techniques are available for this difficult situation. Sequential dilation of the A4 pulley using pediatric cervical sounds or dilators can be effective. The edges of the stump may be trimmed so that the width of the stump does not exceed that of the pulley. After sequential dilation of the pulley, a core suture is placed in the stump, and the suture strands are delivered in a proximal-to-distal direction through the pulley. With the sutures placed, gentle traction is applied to the suture ends, and the tendon can be guided through the pulley using a small flat elevator as a proximal skid. A truncated pediatric red-rubber catheter can also be used in this situation; the flared end of the catheter is cut at a width just slightly larger than the tendon and A4 pulley. The tendon core suture end may be drawn into the flared end, and the whole composite can be slid through the pulley, simultaneously dilating and passing the avulsed tendon end. In some cases, the A4 pulley must be vented at the proximal end to allow passage of the tendon. Lieber and associates[128,129] and Tang[222] have presented convincing mechanical and clinical evidence that the A4 pulley can be divided as needed to promote tendon gliding without adverse effects on work of flexion or functional outcome.

The bone at the volar base of the distal phalanx is exposed to establish a repair footprint for the tendon reinsertion. If the distal phalanx is large enough to accept a miniature suture anchor, I place an anchor in the center of the distal phalanx.[29] Next, I place two corner sutures at the edge of the phalanx in the osteoperiosteal sleeve using 5-0 polypropylene. I use these sutures to seat the tendon into the footprint, and then secure the tendon into final position using the anchor suture ends. Using this technique, the tendon can be seated securely and then the grasping core suture can be more easily placed and appropriately tensioned. Two- or four-strand core suture methods can be used with this technique,[125] and I prefer incorporating a Becker type of suture (Figure 6.12).[174] When the distal phalanx is not large enough to accommodate an anchor, I use a traditional pull-out suture. Placement of the corner sutures is still useful, however, to guide and reinforce the repair site. The pull-out sutures (a modified Kessler type of 3-0 polypropylene suture) are passed through the distal phalanges using straight Keith needles that are drilled through the footprint at the base of the distal phalanx and are tied over a button placed on the nail plate dorsally (see Figure 6.25). It is preferable to have the needles exit the nail plate beyond the lunula (and beyond the germinal matrix) to avoid nail deformity or eponychial injury. The button and suture are left in place for 6 weeks.

The rehabilitation protocol generally follows the same progression as described for zone 2 injuries (see later).

CRITICAL POINTS *Zone 1 Repair*

Surgical Timing

- Leddy type I injuries require early (within 3 weeks) diagnosis and treatment.
- Although all flexor tendon avulsion injuries are best treated early, Leddy type II and III injuries may be amenable to later repair. Careful exploration is useful here.

Pearls

- Direct tendon repair is preferable if there is at least 1 cm of distal tendon stump.
- Tendon repair to bone is done if there is less than 1 cm of distal tendon stump. Either suture anchors or pull-out suture and button constructs may be used.
- The tendon-bone site should be observed directly before final knot-tying to ensure the tendon is well seated on the repair footprint (distal phalanx).

Pitfalls

- A tendon that is advanced too far and inserted too tightly leads to quadriga.
- Two-strand repair techniques may be insufficient for rehabilitation programs that employ early active range of motion.

Technical Points

- Identify and prepare the bony insertion site.
- Ensure the tendon is seated in the footprint when the knot is secured.
- Place additional peripheral sutures that guide and secure the tendon.

Postoperative Care

- Apply a dorsal splint with wrist and MP joints flexed and PIP and DIP joints at 0 to 10 degrees.
- Use a graded rehabilitation protocol under supervision of a qualified therapist.

Return to Activities

- The patient may return to full activity at 4 to 6 months after surgery.

❖ AUTHOR'S PREFERRED TECHNIQUE: Primary Tendon Repair in Zones 1 and 2

After the initial evaluation has been done and a decision has been made in favor of early repair, the wound is irrigated with an antibiotic solution and closed with a fine monofilament suture. For clean wounds and healthy patients, I administer a weight-based dosage (1-2 g) of a first-generation cephalosporin and a tetanus toxoid when necessary. For patients who have not been immunized and for patients whose immunization status is uncertain, passive immunization may be indicated. Passive immunization is not a substitute for wound débridement. Patients who are at risk for methicillin-resistant *Staphylococcus aureus* or have a highly contaminated injury may require a more formal irrigation and débridement and/or broader-spectrum antibiotic coverage. A dorsal splint that includes all digits is applied. For cases that do not require urgent repair, I prefer to repair the tendon within 7 days of injury.

The patient is prepped and draped as above. The initial wound is examined, and then incisions are planned that would predictably allow access to both tendon ends. A midlateral incision is preferred because it gives wide exposure and places intact skin and subcutaneous fat directly over the flexor tendon sheath. When the laceration is complex, a midlateral approach may not be practical, and in those instances I incorporate the existing laceration into the approach to the tendon sheath (Figures 6.13 and 6.14). The goal of the exposure should be to provide maximum visualization while maintaining useful durable skin flaps over the area of the tendon repair. The skin and subcutaneous fat are raised off of the tendon sheath as a single thick layer. Separation of these tissues must be avoided because skin perfusion is by random vascular supply, and thinning of the skin flap can cause decreased perfusion at the distalmost aspect of the flap. I generally design the longitudinal limb of the incision to be associated with the nerve and artery that may require repair.

The wound is completely examined to define the nature and elements of the injury. After a thorough lavage, the sequence of repairs can be determined. The laceration of the sheath is identified, and a limited débridement of the hemorrhagic ends of the sheath is performed. Exposure of the tendons is done by reflecting a radial- or ulnar-based flap of sheath within repair "windows" between the A2 and A4 annular pulleys. Sheath venting and excision should be limited to that necessary for visualization and repair, as excessive sheath division can lead to bowstringing.

If the digit was in a position of significant flexion at the time of injury, the distal stump usually lies distal to the skin laceration and may rest beneath or distal to the A4 pulley with the finger in extension. The distal tendon stump may often be delivered by passive flexion of the DIP and PIP joints. If the tendon does not pass readily, gentle sequential dilation of the A4 pulley with pediatric cervical sounds or dilators may be beneficial. Often, I place half of the core suture in the tendon distal to the pulley, and then pass the sutures and tendon end proximally beneath the pulley to complete the repair. Partial or complete A4 pulley division, pulley venting, and pulley lengthening may occasionally be necessary. I prefer to obtain a smooth repair, with full excursion on intraoperative range-of-motion testing without additional alteration of the annular pulleys when possible. Some newer studies find that this is easily done with local anesthetic methods that may facilitate intraoperative examination of tendon excursion and digital range of motion.[89]

The proximal tendon stumps may be visible within the fibro-osseous sheath. The proximal tendon end may be retrieved using a variety of methods. If the tendon is immediately accessible, I gently grasp the endotenon of the FDP and pull the tendons distally; usually the FDS tendon comes into the wound with distally applied traction on the FDP tendon.[252] The tendon position is maintained by placement of a 25-gauge, 5/8-inch needle through the tendon and one of the proximal annular pulleys.

For tendons that are not locally accessible, I milk the tendon ends into the wound using a proximal-to-distal massage of the digit. The tendon is grasped directly on its cut end (the endotenon) with nontoothed forceps and is held in position using a 25-gauge needle. If the proximal tendon stump is not visible and cannot be delivered by milking into the wound, the wound is extended or a counterincision is made in the palm to retrieve the proximal tendon end. Repeated blind passes into the digital sheath using a hemostat or similar device in an attempt to grasp the tendon end can be associated with additional injury to the tendon sheath and should not be done. Because there is some evidence that epitendinous injury can be associated with peritendinous adhesion formation, I try to limit contact with the



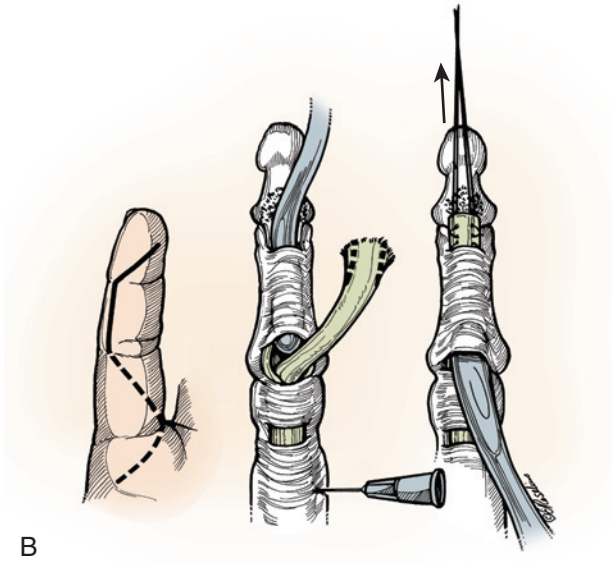

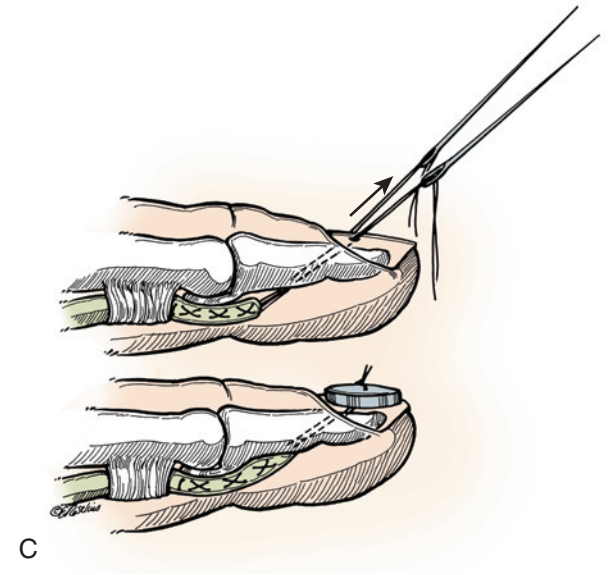

FIGURE 6.11 Author's preferred technique for FDP tendon reattachment to bone. **A,** Clinical photograph of a patient without active DIP joint flexion. **B,** Midlateral exposure over middle phalanx is preferred. This incision may be extended diagonally over the pulp of the finger distally and into a Bruner incision proximally. Sourmelis-McGrouther technique of proximal stump retrieval is preferred. The stump of the profundus tendon may be delivered under the A4 pulley after sequential dilation of the pulley with pediatric cervical sounds of increasing diameter. A modified Becker grasping stitch core suture is placed within the tendon stump. **C,** Straight Keith needles are drilled from the volar proximal base of the distal phalanx in a distal dorsal direction to exit the nail plate through the sterile matrix (distal to the lunula and eponychial fold). The individual grasping core sutures are delivered to the dorsum of the finger after placement of the needles through the holes in the button. The sutures are tied while holding the tendon directly to bone using forceps. (**B** and **C,** Copyright Elizabeth Martin.)

epitenon during tendon repair and grasp the tendon by the endotenon whenever possible.

Although there are several methods for acquisition of the proximal tendons, the method advocated by Sourmelis and McGrouther[209] is reliable and effective. A small pediatric feeding tube or similar device is passed in a retrograde manner through the digital sheath. The tube should enter at the site of the laceration and exit in the palm proximal to the A1 pulley. The flexor tendons are left in situ in the sheath, and, through a midpalmar incision, the catheter is sutured to both tendons several centimeters proximal to the A1 pulley. The catheter is pulled distally, delivering the tendon stumps into the distal repair site easily. A 25-gauge, 5/8-inch needle is used to secure the tendons to adjacent soft tissues at the repair site. In situations in which the tendons have retracted proximal to the A1 pulley, an incision is made just proximal to the A1 pulley and the lacerated tendons and adjacent neurovascular structures are identified. The proximal stumps are delivered distally by the catheter method when possible. A Freer elevator or one of several commercial instruments may be used to "shoehorn" the tendon atraumatically into the flexor sheath beneath the A1 pulley.

It is crucial to reestablish the proper anatomic relationship of the FDS and FDP tendons in the palm and at the site of the repair. In some complex lacerations, orientation of the tendons and repair of all injured tendons may be impractical. In those cases, I resect one slip of the FDS tendon and repair one slip. This repair strategy facilitates gliding of the repairs within the sheath and simplifies tendon orientation.

If the tendon is lacerated proximal to the FDS decussation, a core suture is often used (see Figure 6.7). I base the core suture method on the caliber of the tendon that is available for repair. The more robust, thicker FDP tendon is ideal for core suture placement within zones 1 and 2. I prefer a 3-0 braided caprolactam looped (double-strand) suture affixed to a curved, tapered needle end. A four-strand modified Kessler core suture with locked loops offers a substantial improvement in time-zero repair site tensile strength and stiffness over traditional two-strand core suture techniques.

For smaller tendons, I use a four-strand modified Kessler suture that is placed with a 4-0 braided caprolactam looped suture. The suture may be placed simply in both ends and results in a strong four-strand repair. For larger tendons or

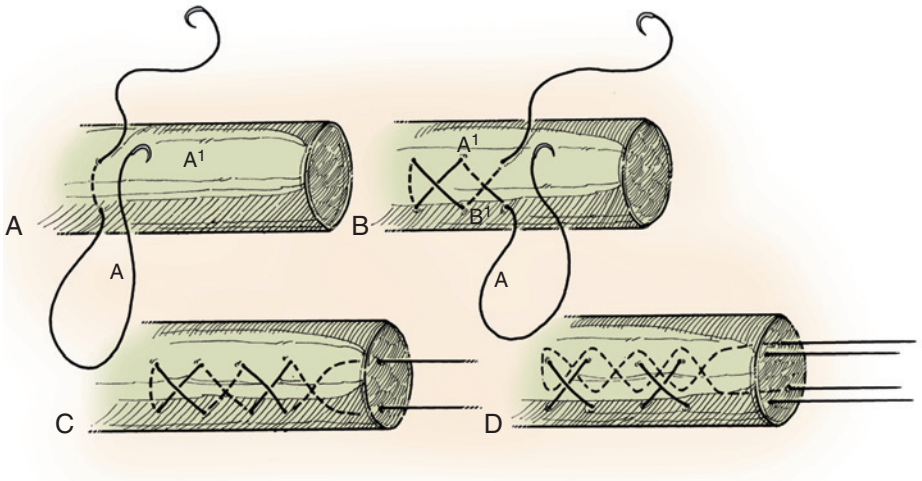

FIGURE 6.12 **A to D,** Four-strand modified Becker repair (see text). (Copyright Elizabeth Martin.)

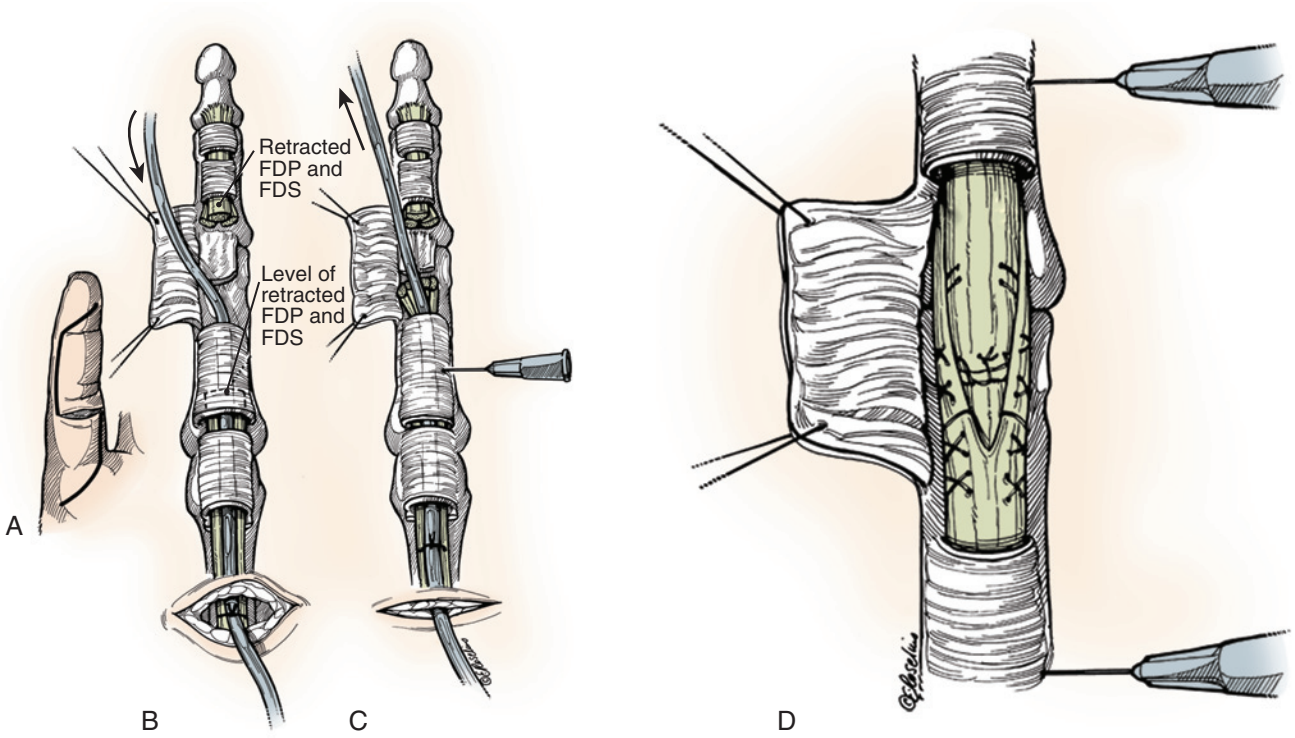

FIGURE 6.13 Author's technique of flexor tendon repair in zone 2. **A,** Knife laceration through zone 2 with digit in full flexion. The distal stumps retract distal to the skin incision with digital extension. **B,** Radial and ulnar extending incisions are used to allow wide exposure of the flexor tendon system. Note appearance of the flexor tendon system of the involved fingers after the retraction of skin flaps. The laceration occurred through the C1 cruciate area. Note the proximal and distal position of the flexor tendon stumps. Retraction of small flaps (windows) in the cruciate portion of synovial sheath allows the distal flexor tendon stumps to be delivered into the wound by passive flexion of DIP joint. The profundus and superficialis stumps are retrieved proximal to the wound by passive flexion of DIP joint. The profundus and superficialis stumps are retrieved proximal to the sheath by the use of a small catheter or infant feeding gastrostomy tube. **C,** Proximal flexor tendon stumps are maintained at the repair site by means of a transversely placed small-gauge hypodermic needle, allowing repair of the FDS slips without tension. **D,** Completed repair of FDS and FDP tendons is shown with DIP joint in full flexion. Extension of DIP joint delivers the repair under the intact distal flexor tendon sheath. Wound repair is done at the conclusion of the procedure. (Copyright Elizabeth Martin.)

where a stronger repair is desirable, I use two continuous modified Kessler sutures placed with a 3-0 looped suture made of braided caprolactam (eight strands). Using this method, the sutures lie side by side within the tendon. Because of the increase in suture volume, care must be taken to prevent impaling the transverse suture limb when passing the suture out of the cut end of the tendon. Locking loops of suture are not used. When using a single suture, the core suture is tensioned to bring the stumps together before beginning the second core component. When using looped suture, care must

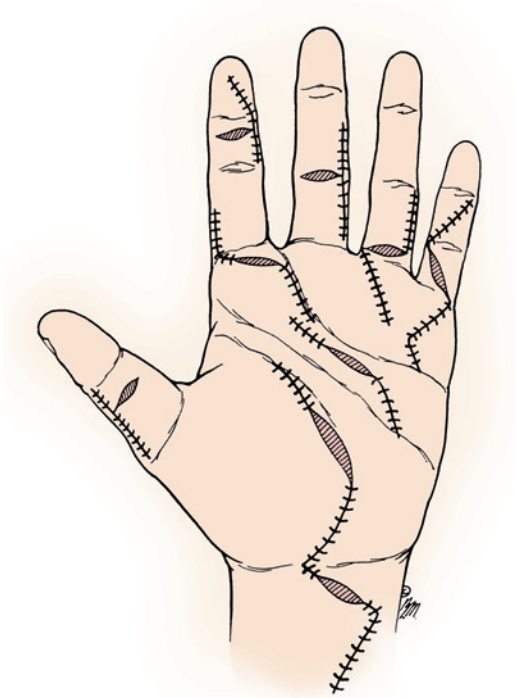

FIGURE 6.14 Incision options for wound extension during flexor tendon repair. (Copyright Elizabeth Martin.)

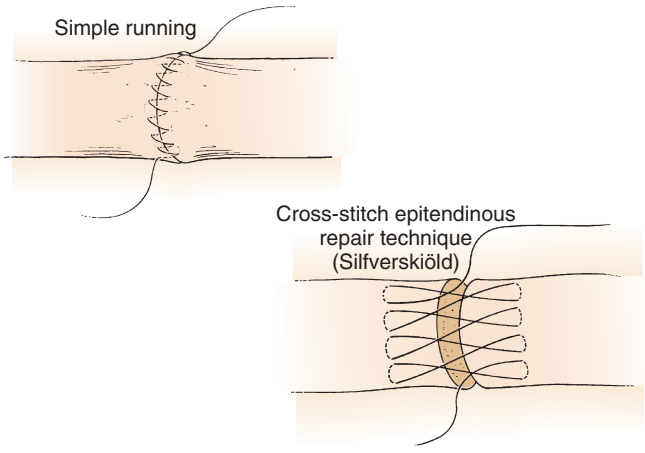

FIGURE 6.15 Circumferential epitendinous suture techniques.

be taken to maintain even tension in all limbs of the suture; this allows the setting of an evenly tensioned suture knot. To finish the repair, a 6-0 polypropylene suture is used for a deep, running circumferential suture. This suture is started on a volar corner of the repair site and is placed circumferentially around the tendon over the repair site. When the stitch is started, I invert the first pass to facilitate inversion of the suture knot into the repair site. I leave one tail long when the suture is cut so that the running suture may be tied to itself when the suture is completed (Figure 6.15).

More distally, the FDS tendon repair is made difficult by the thin, flat shape of the tendon slips as they wrap around the FDP tendon. A traditional core suture may not be possible in the flattened FDS tendon slips near the PIP joint; these tendons may best be repaired using one of the zone 2 to 4 extensor tendon techniques.[124] It is preferable to use a smaller needle along with a smaller-caliber suture to minimize tissue trauma. A 4-0 or 5-0 braided polyester suture affixed to a small, tapered needle at each end is effective.

After completion of all tendon sutures, I evaluate the stability of the repairs throughout a full range of digital motion and ensure satisfactory gliding of the repairs through the fibroosseous tunnel. Sheath closure is done only if it does not impair tendon gliding. These intraoperative observations may be valuable to clinicians in making decisions about aftercare regimens.

I prefer to repair the tendons first and then repair the injured nerves and arteries. Often the arterial repair is done last, with the tourniquet deflated using standard microsurgical dissection and repair methods. This also provides a satisfactory length of time for hemostasis to occur. Bipolar electrocautery is critical to prevent postoperative hematoma formation, and primary wound closure is performed in clean wounds using simple 5-0 nylon sutures. I believe that meticulous hemostasis limits postoperative swelling, diminishes postoperative pain, and facilitates rehabilitation.

A well-padded compressive, nonconstrictive dressing with a dorsal plaster slab is applied from the fingertips to the proximal forearm to hold the wrist, MP, PIP, and DIP joints in slight flexion to minimize passive myostatic tension on the repair site. All digits are included in the postoperative dressing. If the FPL tendon is repaired, the plaster splint overlies the dorsal aspect of the thumb to hold the carpometacarpal, MP, and interphalangeal (IP) joints in slight flexion.

Surgical Techniques for Tendon Repairs in Zones 3, 4, and 5. Tendon repairs in zones 3, 4, and 5 are performed with suture techniques similar to those used in zone 2. Because of the nature of penetrating injuries in these zones, an extensile approach is essential to complete identification of the injury. Arterial and nerve injuries in these areas are common, and the surgeon should be prepared to repair these injuries at the time of wound irrigation, débridement, and tendon repair. I prefer a longitudinal extensile approach that allows for the potential need for fasciotomy and allows each tendon to be identified at each end of the wound. Intraoperatively, the digits should be completely flexed and extended to identify the lacerated tendon ends. These operations generally are done in the following sequence:

- Wound exposure
- Wound débridement
- Identification of injured structures
- Repair of injured structures

For the forearm, I prefer to perform the arterial repairs first, the tendon repairs second, and the nerve repairs last. The tendon repairs are started from the deepest tendon that is lacerated, and the progression of repairs is to the most superficial tendon that is lacerated. If arterial repair is necessary or if the swelling in the forearm seems significant, I will consider a forearm fasciotomy prior to skin closure. For the specific repair method, I use a 3-0 looped, braided caprolactam suture and a modified Kessler four-strand technique. In these zones, it is often useful to place a simple suture in the corners of the tendon ends to begin the approximation and then place the core suture. This simple step eliminates the need to set the tension in the suture after suture passage and limits any gap formation between the tendon ends. I do not routinely use epitendinous sutures in these areas.

CRITICAL POINTS *Zone 2 Repair*

Surgical Timing

- Emergency repair is indicated if both digital nerves and arteries are lacerated. Tendon repair is done in conjunction with digit revascularization.
- Routine tendon repairs are preferably done no later than 7 days after injury.
- After 6 weeks, primary repair is unlikely to be possible.

Pearls

- A multistrand core suture method with a running circumferential suture is preferred when the caliber of the tendon is sufficient.
- A pediatric No. 8 feeding tube should be ready if retrieval is required (Sourmelis technique).
- Knowledge of the patient's history and the nature of the injury and observation of the repair should guide the approach to rehabilitation.

Pitfalls

- The importance of patient compliance with aftercare strategies should be emphasized.

Technical Points

- Enter sheath between distal A2 pulley and proximal A4 pulley.
- Retrieve proximal stump by milking, feeding tube, or direct exposure.
- Deliver distal stump by passive DIP hyperflexion.
- Stabilize the tendon ends for repair by transfixation using a 25-gauge, 5/8-inch needle. For some cases, single inverted simple sutures can provide temporary tendon alignment while the core suture is being placed.
- The caliber of the tendon and the probable method of aftercare determine the choice of repair method.
- Use at least a four-strand core suture technique (3-0 or 4-0 suture) with a running 6-0 polypropylene circumferential suture (nonlocked, deep bites into tendon).
- Repair both the FDS and FDP tendons. Excise a single slip of the FDS tendon if it is excessively bulky or gliding is impaired.
- Examine the intraoperative range of motion to guide therapy considerations.
- Sheath repair is optional.
- Ensure adequate hemostasis before closure.

Postoperative Care

- The postoperative dressing should be applied to position the wrist in flexion (20 to 30 degrees), the MP joints in flexion (50 to 70 degrees), and the PIP and DIP joints at zero or slight flexion. Apply the dressing so that it is well padded and nonconstricting and does not have any fulcrum effect in the palm.
- Use a graded rehabilitation protocol under supervision of a qualified hand therapist.
- Use synergistic wrist motion to increase excursion.

Return to Activities

- The patient may return to unrestricted activity at 4 to 6 months after surgery.

Expected Outcomes of Flexor Tendon Repair

The outcome after flexor tendon repair is variable and depends on the nature of the injury, the patient's individual biologic response to injury, the timing of repair, the method of repair, and the ability of the patient to participate in a program of postoperative occupational therapy. If satisfactory tendon repair can be obtained and if the patient can participate in a tendon repair aftercare program, forearm tendon repair is generally associated with a good functional outcome.

The most common complication after tendon repair is digital stiffness related to peritendinous adhesion formation or digital joint contracture. Repair site rupture occurs uncommonly and can often be related to noncompliance with the suggested aftercare program. An early second attempt at repair can be performed successfully with the anticipation of good outcome, provided the patient is compliant and has access to supervised hand therapy. Pulley rupture with resultant tendon bowstringing, quadriga, digital triggering, swan neck digital deformity, and lumbrical-plus fingers can occur but are less common provided the mechanical and anatomic relationships of the tendons and the pulley system are maintained.

Postoperative Management: Rehabilitation

❖ AUTHOR'S PREFERRED TECHNIQUE: Postoperative Rehabilitation of Repairs in Zones 1 and 2

Philosophically, I believe the tendon rehabilitation program has to be constructed to try to improve the function of the entire hand and facilitate differential incorporation of the injured soft tissues (Figures 6.16 to 6.18). Generally, the method of rehabilitation is significantly influenced by the compliance of the patient, the nature of the wound, and the method and location of the repair. Although we still employ general time guidelines for implementation of various therapeutic interventions, we also accelerate and decelerate patients' regimens based on their individual response to treatment. In this environment, there is no substitute for an experienced, energetic, meticulous hand therapist.

Therapists are encouraged to choose a postoperative program that controls the amount of *force* to the repair site, while promoting *excursion* of the tendon proximally and distally. Improvements in tendon excursion are thought to be associated with improvements in range of motion and patient outcome. The rationale for applying any force to the healing tendon during a postoperative rehabilitation program is to promote a small amount of proximal excursion and not to accelerate healing.[38,253] Excessive force during rehabilitation can lead to tendon gapping or rupture. The force that is applied to the repair site is controlled during an aftercare program by exercise and the position of the wrist, MP, and IP joints.

Excursion, measured in millimeters, is best described as the total amount of glide that a point on the tendon travels during range of motion. In the original Duran and associates protocol,[51] the authors reported that 3 to 5 mm of tendon excursion was sufficient to prevent restrictive adhesions after repair. This concept has been widely accepted and incorporated into tendon rehabilitation programs over the last 30 years. More recently, authors have concluded that 6 to 9 mm of excursion was the maximal limit of therapeutic excursion during a postoperative program, and that further excursion was not beneficial.[202] Low force and moderate excursion programs have traditionally been effective and should continue to be effective in the future.

The first 4 weeks of therapy are the most important phase in the patient's rehabilitation. Although each patient's situation is generally similar, the particular therapy program must be individualized. Many factors influence decision making in the aftercare regimen, including patient compliance, edema (which increases the work of flexion), suture size and configuration,

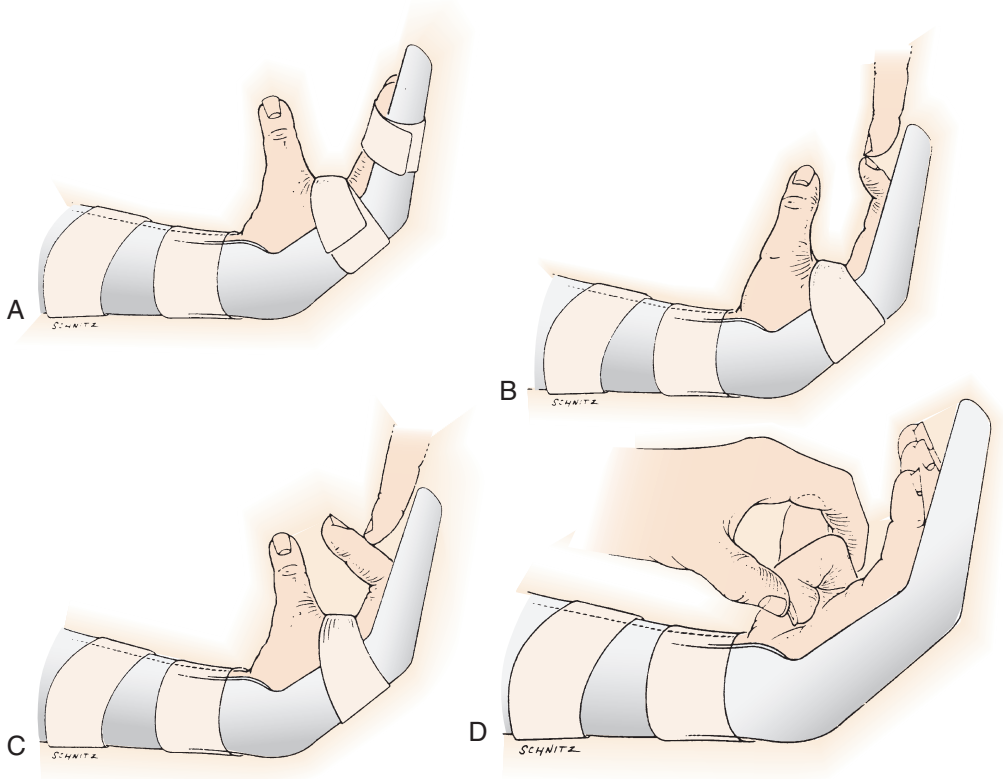

FIGURE 6.16 Controlled passive motion method. **A,** Orthoplast dorsal blocking splint is used to hold wrist in mild flexion, MP joints in about 45 degrees of flexion, and PIP and DIP joints in nearly full extension. **B,** Full isolated passive flexion of DIP joint. **C,** Full isolated passive flexion of PIP joint. **D,** Full passive flexion of MP, PIP, and DIP joints.

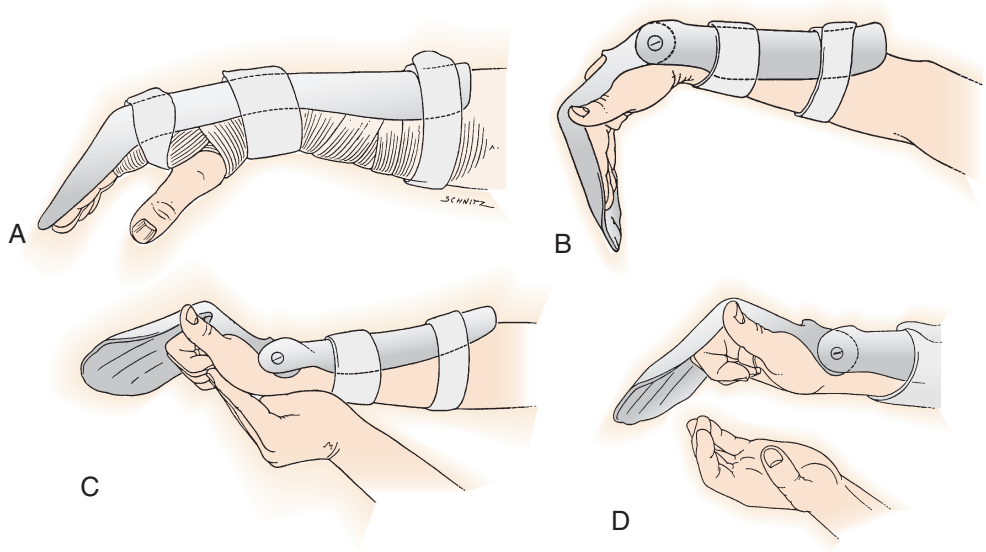

FIGURE 6.17 Controlled place-and-hold motion after flexor tendon repair protocol. **A,** After removal of the surgical bandage, a traditional dorsal blocking splint that positions the wrist in 20 degrees of palmar flexion, MP joints in 50 degrees of flexion, and IP joints in extension is applied. **B,** A tenodesis splint with a wrist hinge is fabricated to allow for full wrist flexion, wrist extension of 30 degrees, and maintenance of MP joint flexion of at least 60 degrees. **C,** After composite passive digital flexion, the wrist is extended and passive flexion is maintained. **D,** The patient actively maintains digital flexion and holds that position for about 5 seconds. Patients are instructed to use the lightest muscle power necessary to maintain digital flexion.

wound complications, tight wound dressings, systemic conditions, or concomitant injury. With these factors in mind, our center categorizes and treats postoperative patients in two general categories: patients who are appropriate for an accelerated rehabilitation program, and patients who are not. That decision is usually made with the input of the surgeon and the therapist.

Before beginning therapy, it is important for the therapist to have information from the operating surgeon about the type of repair that was done and whether other structures were injured.

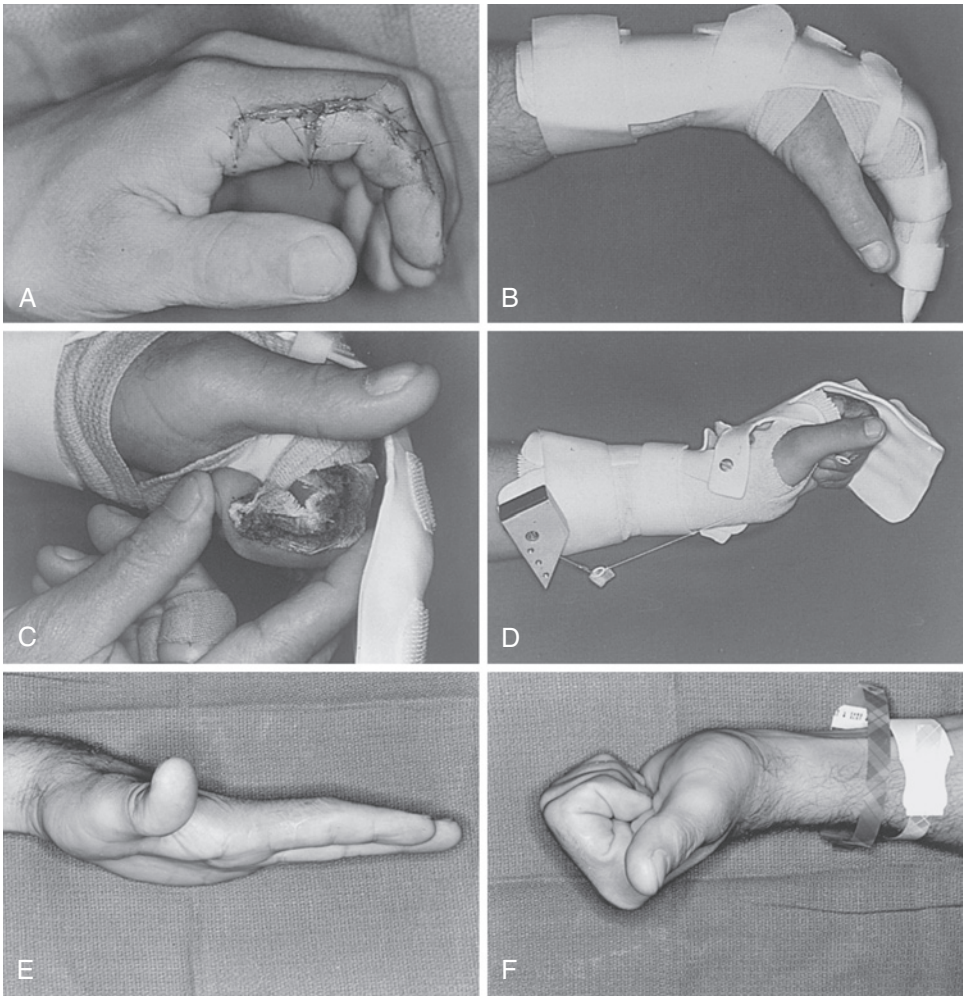

FIGURE 6.18 Clinical examples of the author's program following flexor tendon repair. **A,** Index finger after a four-strand repair of FDS and FDP tendons. **B,** Resting splint with wrist and MP joints flexed and IP joints extended. **C,** Finger is passively flexed with the wrist in flexion. **D,** Wrist is extended while maintaining passive digital flexion. The patient holds this position with light active flexion. **E,** Extension at 3 years. **F,** Flexion at 3 years. (Courtesy of James W. Strickland, MD.)

If a high-strength tendon repair technique was successfully performed in a compliant patient, the patient is placed in a more aggressive early motion program that employs individual decision making based on patient progress. Therapy typically begins 1 to 5 days after surgery. On the initial visit, a wrist-neutral dorsal blocking orthosis is applied. The MP joints are positioned at 50 degrees of flexion, a position that promotes gentle stretch on the collateral ligaments of the MP joints and prevents excessive stretch on the flexor tendons.

The patient is taught an hourly home exercise program that consists initially of passive positioning of the fingers in a fist for 3 minutes, with the splint in place. Next, within the confines of the orthosis, the patient performs the exercise of passive flexion of the affected finger to the palm, followed by actively extending the finger to the orthosis: 15 passive flexion and active extension movements to the bib of the splint are done in each hour. Finally, the patient removes the splint and performs a tenodesis program. The fingers are passively flexed into the palm using the unaffected hand, and the wrist is actively extended to a comfortable end range. The patient gently contracts the flexor muscles, removes the unaffected hand, and actively holds the fist position for 5 seconds. After 5 seconds, the patient releases wrist extension and the wrist falls into flexion, and as it does, the fingers passively extend. The tenodesis cycle is repeated 10 times.

When not exercising, the patient straps the fingers into the bib of the splint, positioning the MP joints in flexion and the IP joints at −10 to 0 degrees of extension. Based on the patient's comfort with the program and any complicating factors, components of the program can be decelerated, accelerated, or discontinued by the therapist. The patient is counseled to stretch the PIP joint gently and passively with the MP joints held in flexion to avoid joint contracture. Wounds are dressed with loose-fitting 1/2-inch tube gauze. Edema is addressed in the first 2 weeks with elevation, the gentle pumping action of the exercises, and the gentle compression of the gauze. After 2 weeks postoperatively, compressive bandages can be applied as needed.

At 3 weeks postoperatively, the dorsal protective splint is removed for isolated and composite active joint range-of-motion exercises that are done hourly. The timing and type of active exercises prescribed at this point in the aftercare program are based on the physiologic healing response of the injured hand. Our decision to prescribe more forceful exercises has been adapted from the work of Groth,[80] who analyzed and reported

the results of differing wrist and hand positions coupled with passive and active movements to create a pyramid of progressive force application to the healing tendon. Groth defined "high" or "low" physiologic tissue responses and suggested clinical approaches to each. Accelerated wound healing, edema, and dense scar resulting in the formation of peritendinous adhesions characterize a "high" physiologic response. Ultimately with a "high" physiologic response, there is significant loss of flexor tendon excursion. Patients who exhibit a "high" response are progressed through the pyramid of exercises quickly to promote force and prevent further adhesions. During this time, the clinical evaluation for the formation of peritendinous adhesions that limit tendon excursion is done. The nonresistive exercises of the pyramid are ranked in ascending order of increased force, which includes place-and-hold, composite-fist, straight-fist, and isolated joint motion with joint blocking exercises.

Conversely, a "low" physiologic response is characterized by slower wound healing, limited edema, and minimal discrepancy between the patient's active and passive finger flexion measurements. These patients generally have improved flexor tendon excursion, and less risk is required in therapy to maintain the range of motion. These patients may not have as robust a repair response, so progression to resistive exercises may be delayed, and patients are counseled not to use the hand in strength activities until cleared to do so by their surgeon.

The dorsal protective splint usually is discontinued at approximately 6 to 8 weeks postoperatively. If any flexion contractures of the IP joints are present, they are addressed with a static progressive device at that time. Isolated strength exercises are gradually introduced at 10 weeks postoperatively.

For more complicated cases, for patients with limited understanding, or for cases where compliance with the program is questionable, we use a passive mobilization program. The same dorsal protective splint is used, with the wrist in neutral and the MP joints in 50 degrees of flexion. A passive range-of-motion program (Duran type of program) of isolated IP and MP joint passive motion is taught. This program requires that the patient passively flex and extend the PIP joint of the affected finger while holding the DIP and MP joints flexed, and then passively move the DIP joint into extension and flexion with the MP and PIP joints flexed. All of the exercises are performed within the confines of the splint. The patient's wounds and edema are addressed as described previously. The progression of force application after 4 weeks of passive motion is similar to that described previously, but delayed for 2 to 3 weeks.

When children or adolescents have sustained a lacerated tendon and subsequent repair, the surgeon must make a decision with help from the parents and treating therapist as to whether or not the patient is a candidate for an early motion program. A basic tenet of any early motion flexor tendon rehabilitation program is that the patient be an active participant in aftercare. For this reason, the surgeon, parents, and child all must agree that the child is mature enough to perform the essential functions of rehabilitation safely. If the decision is not to allow an early motion program, the patient's wrist and hand are immobilized for 4 to 6 weeks in a cast positioning the wrist in neutral, the MP joints in 70 degrees of flexion, and the IP joints straight. After the initial period of immobilization, the patient is referred to therapy for careful initiation and progression of range-of-motion exercises for the next 6 weeks. Although the advantages of increased repair site tensile strength, decreased peritendinous adhesions, and better functional outcomes associated with early motion programs are well documented, immobilizing a child's hand after flexor tendon repair has not been found to be as deleterious as it is for adults.[162]

If participants agree that the patient is a candidate for an early protected range-of-motion program, the tenodesis aftercare program discussed previously is employed. The treating therapist must frequently monitor the patient's compliance by having the patient attend therapy at least two times a week for the first 6 to 8 weeks. If more complicated forceful movements need to be eliminated from the child's aftercare program, movements such as tenodesis with place-and-hold therapy or simply place-and-hold therapy alone can be reduced to passive flexion/active extension movements within the splint. Progression through the phase of therapy is done based on both the injury and the patient's individual physiologic response to the injury.

Recent research has described the use of ibuprofen at anti-inflammatory doses (2400 mg/day) to decrease peritendinous adhesions following zone 2 flexor tendon repairs. In their study, Rouhani and colleagues[183] found that patients who received ibuprofen following tendon repair had a better range of motion compared with their control group. There were no reported complications.

Complications Following Flexor Tendon Repair

Despite continued improvement in surgical care and rehabilitation of flexor tendon injuries, complications still occur and may have devastating effects on hand function.[139,216] Infection, skin flap necrosis, tendon repair rupture, and tendon adherence all adversely affect digital function after injury. The greatest protection against repair site rupture is a well-done multistrand core suture, complemented by a running circumferential repair, and early institution of high-quality hand therapy. Should rupture occur up to 3 weeks postoperatively, repeat repair is done. At time periods longer than 3 weeks postoperatively, the chance of a successful repeat repair is less likely. If rupture occurs, it is crucial that the condition be diagnosed and treated within days of the event, before scarring and retraction prevent successful repeat repair. Patients should be counseled regarding the possibility of tendon reconstruction with a silicone rod or tendon graft.

The repaired tendons may become adherent and fail to glide sufficiently to restore unimpeded digital function. The decision to proceed with tenolysis is made after serial joint measurements fail to show improved active digital motion despite continued therapy.[251] A prerequisite for successful tenolysis is that full or nearly full passive digital flexion has been achieved. Tenolysis is a surgical strategy that should be considered 4 to 6 months after tendon repair for patients who have significant loss of tendon excursion.

Interphalangeal joint contracture can occur after flexor tendon repair, especially among patients treated with elastic traction. Early identification and treatment of the contracture usually result in satisfactory outcomes using nonsurgical strategies. Generally, these contractures can be resolved using passive stretching exercises and static progressive splints as needed. Patients with recalcitrant contractures that limit hand function at 4 to 6 months after tendon repair can be considered for small joint release.

CRITICAL POINTS *General Principles of Flexor Tendon Repair*

- Extensile exposure in a controlled setting with optical magnification allows the extent of the injury to be defined.
- Tendon retrieval is done using atraumatic techniques and windows through noncrucial areas of the flexor tendon sheath.
- Handling of the tendon should be minimal.
- The tendon must be accurately oriented.
- The core tendon sutures should be placed to allow for accurate coaptation of the tendon ends. The suture method should provide a stable, smooth repair that is freely gliding within the tendon sheath.
- Circumferential suture is used to "finish" the repair and add strength to the repair.
- Sheath closure is necessary only if it improves tendon gliding.

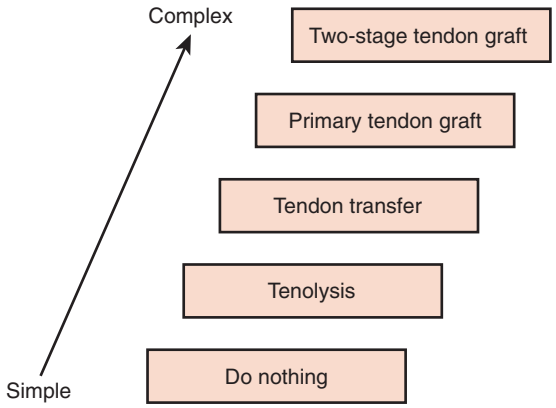

FIGURE 6.19 Ladder of tendon reconstruction options.

Acknowledgments: The authors acknowledge the work of Dr. John S. Taras and Dr. Robert A. Kaufmann, whose outstanding chapters in previous editions have been modified, combined, and updated. Their contributions to our understanding of repair and reconstruction of the damaged flexor tendon system have greatly advanced our ability to care for these injuries. The authors also acknowledge the contributions of Mr. Daniel Acker, OT, CHT, to the rehabilitation portion of this chapter.

FLEXOR TENDON RECONSTRUCTION

With improvements in flexor tendon repair methods, the need for flexor tendon reconstruction has substantially diminished. Still, flexor tendon reconstruction is a necessary and important procedure for failed and neglected tendon repairs. Prior to Lister's report detailing a successful method for zone 2 flexor tendon repair, tendon transection in the finger had been treated using tendon grafting as the preferred method for the reconstruction of finger flexion. Restoration of satisfactory digital function after an unrepaired flexor tendon laceration or a failed repair remains one of the most difficult challenges in hand surgery.[105,152-154,157,158,217]

In this section, we review the indications and methods for primary tendon grafting, staged tendon grafting, select tendon transfers, pulley reconstruction, and tenolysis. These cases remain among the most challenging in hand surgery; advances in repair methods and postoperative rehabilitation strategies have improved the results of flexor tendon reconstruction, however. Research that focuses on surface cell modulation, scaffold seeding, other tissue engineering methods, and biochemical agents that may decrease adhesion formation and facilitate graft survival will likely improve surgical strategies in the future.

Patient Selection

Proper patient selection is essential for the success of flexor tendon reconstruction. Before proceeding with surgery, the nature and number of procedures as well as the extent of postoperative therapy should be outlined for the patient. Finsen[61] reported that a significant number of patients underestimate the impact of the reconstruction process. The patient must be willing and able to adhere to the aftercare regimen to optimize outcome. A number of patient variables have been identified that affect the need for and outcome after tendon grafting:

1. *Age of the patient*. Younger patients typically do better than elderly patients; however, in very young patients, technical difficulties and difficulties with rehabilitation compliance may compromise the outcome.
2. *Mechanism and extent of trauma*. Crushing injuries, fractures, joint disruption, nerve and artery damage, skin loss, and infection contribute to a poorer prognosis after reconstructive surgery.
3. *Level of tendon laceration*. As a rule, tendons injured outside the digital flexor sheath yield better results than tendons injured within zone 2.
4. *Healing response of the patient*. The patient's innate healing response to injury is likely to influence the end result more than the actual technique of suturing, the type of suture material chosen, or the timing of the procedure.

The timing of and nature of reconstructive procedures play a role in contributing to the success of the care plan. Reconstruction of the flexor tendon system can be viewed as a management ladder, with each rung representing a need to address greater impairment (Figure 6.19). For patients with early tendon repair site disruption, we still recommend an early reattempt at repair if possible. For patients who have previously undergone repair, we recommend 4 to 6 months of occupational therapy and rehabilitation to restore normal tendon gliding and joint mobility prior to considering tenolysis and joint release. If, upon exploration, tendon grafting is necessary, primary tendon grafting can be done from palm to fingertip when the palm and fibroosseous tunnel are satisfactory. If extensive adhesions have formed in the fibroosseous tunnel, a staged tendon grafting procedure should be started using a temporary silicone spacer to recreate a gliding space and the tendon graft implanted at a second procedure.

Flexor Tenolysis

Preoperative Evaluation

Full smooth finger motion is, in part, the result of normal flexor tendon excursion within the digital sheath. Any source of significant peritendinous adhesion formation will limit tendon excursion and, consequently, active digital motion. Tendon adhesions occur whenever the surface of a tendon has been compromised either by the injury itself or by surgical manipulation.[145,146] Failed primary tendon repairs, crush injuries,

fractures, inflammatory conditions, and infections can all cause peritendinous adhesions to the adjacent tendon, skin, neurovascular structure, or bone. Additionally, adhesions may form at the juncture between the graft and the native tendon after a grafting procedure. If the adhesions are mild, an organized occupational therapy program can often restore full gliding. When a patient's progress has plateaued and a substantial difference exists between passive and active range of digital motion, a tenolysis may be considered. Surgical release of restrictive adhesions has been shown to be an excellent salvage procedure when tendon and pulley integrity are maintained and the involved joints are supple.[25,58,109,190,213,217,246]

Flexor tenolysis is often technically demanding and can be associated with significant complications, including tendon repair site and graft juncture rupture. If unsuccessful, the patient's hand function may be even worse than before surgery. Tenolysis is usually considered approximately 4 to 6 months after the index procedure and when the soft tissues have recovered sufficiently to allow another attempt at restoration of motion. The best candidate for tenolysis is a patient with limited active but full passive range of motion, supple soft tissues, and a tendon repair with localized adhesions that limit tendon gliding (Figure 6.20). It is paramount that the patient can begin occupational therapy immediately. When surgical release of this region has been accomplished successfully, full or near full range of motion is usually regained. Commonly, adhesions have formed over a long segment of the involved tendon and require extensive exposure for release.

Because optimizing results after tenolysis requires immediate mobilization, any concomitant surgery that requires immobilization (i.e., repair of nonunion or skin coverage) in the postoperative period should be done in a staged manner prior to tenolysis. Joint contracture is frequently seen in patients requiring tenolysis. These patients may also require a capsulectomy, which complicates the problem further and results in diminished gains.[235] Prognostic indicators that are associated with a poorer outcome include patient age older than 40 years, nerve repair or graft, late tenolysis (>1 year postoperatively), and tenolysis requiring a prolonged operative time.[235]

Although opinions vary on the best timing of tenolysis, almost all surgeons agree that a reasonable time should be allowed for durable tendon repair, wound softening, and spontaneous remodeling of adhesions and scar tissue. Fetrow,[60] after reviewing Pulvertaft's cases, stated that 6 months should elapse before tenolysis after a free tendon graft to lessen the risk of graft rupture and suggested that a minimum of 3 months of healing be allowed before tenolysis after primary tendon repair. Rank and Wakefield[180] originally waited 3 months, but later advocated a delay of 6 to 9 months before considering tenolysis. Weeks and Wray[242] reported that most of the active digital function obtained after a tendon graft occurred by the 22nd postoperative week. Based on these reports, we usually consider tenolysis at 4 postoperative months in motivated patients with loss of active motion, full passive motion, stable soft tissues, and healed fractures. The patients need to be both willing and able to work with an occupational therapist after the surgery to obtain the best outcome and must accept the potential risk of tendon rupture following surgery.

The effect of patient age on functional improvement after tenolysis in children was investigated in a report by Birney and Idler.[17] These authors noted that tenolysis in children younger than 11 years resulted in only minimal gains, whereas older children benefited from tenolysis even when it was done more than 1 year after the original operation.

Agents That May Limit Adhesion Formation

Several authors have investigated the use of agents to block restrictive adhesion formation after tenolysis or tendon repair.[109] Steroid preparations have been locally instilled to alter wound healing in the belief that adhesion formation would be less robust. Whitaker and colleagues,[246] James,[108] Carstam,[33,34] Rank and associates,[181] and Wrenn and coworkers[255] suggested locally administered steroids to be of some value, whereas Verdan[235] and Fetrow[60] concluded that steroids do not improve the results of tenolysis. Bora and colleagues[19] found that many of these materials promoted additional scarring. Using a rabbit model, Tan and associates[221] reported that oral ibuprofen administration limited adhesion formation after FDP repair. Other authors have reported on the potential benefits of 5-fluorouracil[2,260] and hyaluronic acid[31] surface treatments in limiting adhesion formation following tenolysis and tendon repair in animal models.

❖ AUTHORS' PREFERRED TECHNIQUE: Tenolysis

Schneider and Hunter and coworkers[101,102,193,195] advocated local anesthesia and intravenous sedation to allow the patient's active participation during tenolysis (see the section on neuroleptanalgesia in Chapter 2). In our practice we often use local blocks for tenolysis. After the procedure is completed, the patient can easily demonstrate the range of motion that can be the postoperative goal. Recently, Lalonde and colleagues[119] have advocated "wide-awake" surgery done without tourniquet (WALANT). These methods of anesthesia have improved our ability to verify that the tenolysis is complete and the extent to which the patient can activate the tendon.

We reserve regional or general anesthesia for anxious patients and patients with extensive scarring where the procedure time would be extended. When a patient is under a regional nerve block or general anesthesia, the surgeon must be certain to extend the tenolysis proximal and distal to the zone of injury to ensure that all adhesions are released. Whitaker and

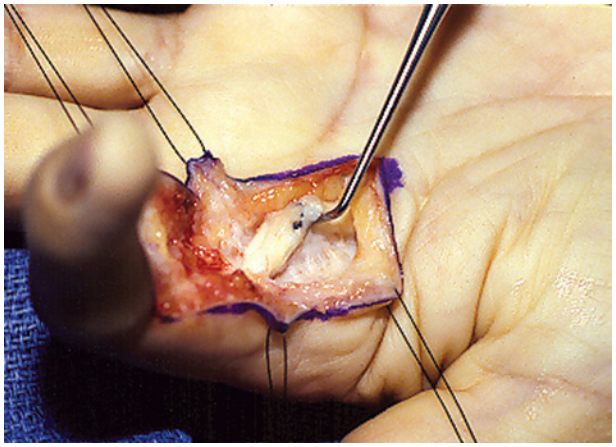

FIGURE 6.20 Localized area of tendon adhesion permits simple tenolysis to restore full tendon gliding.

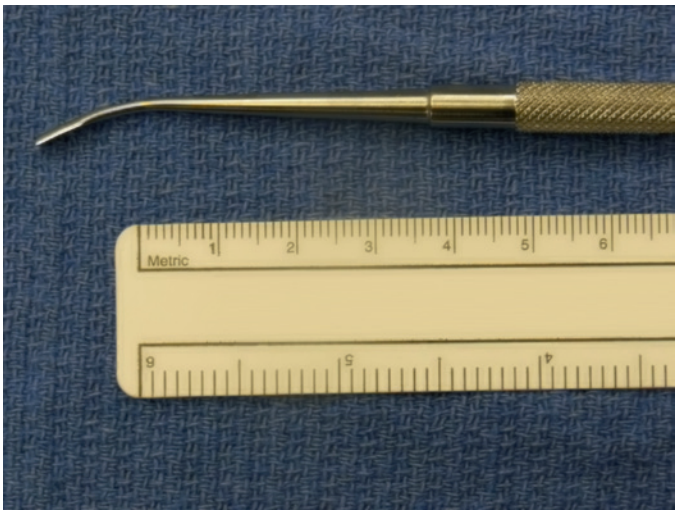

FIGURE 6.21 Specially designed tenolysis blades are invaluable in cleaving dense tendon adhesions.

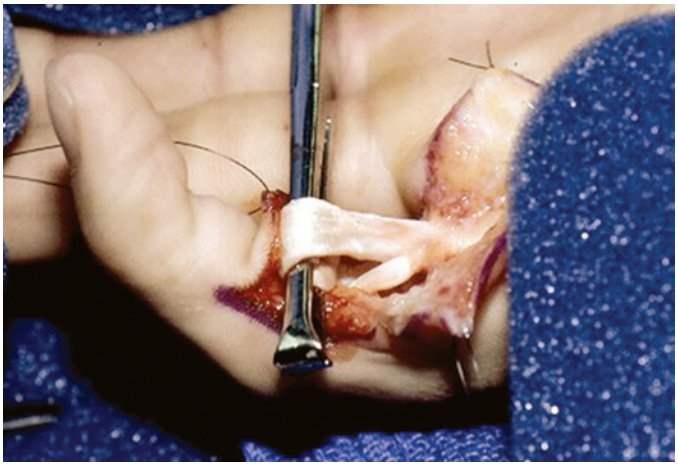

FIGURE 6.22 By gently twisting the tendons with an Allis clamp, tendon excursion can be confirmed during tenolysis.

colleagues[246] recommended a "traction flexor check" by pulling on the involved tendon through a separate incision at the wrist; this provides an estimate of the potential range of motion and has the additional benefit of breaking up any adhesions that may have been missed.

The involved flexor system is approached through an incision sufficiently long to uncover the entire length of the adhesions. Preoperative planning should ensure that the entire flexor apparatus can be exposed if necessary. Flexibility of the surgical approach may be required to use previous surgical scars. Beginning in a proximal area without adhesion formation and using careful dissection methods, all peritendinous adhesions are methodically excised. The tendon surface should be carefully identified proximally and distally to make it easier to define the areas of dense scar tissue formation. Optical magnification and specialized instrumentation may facilitate this process. Fine Beaver blades (Beaver-Visitec, Waltham, MA) (#6300, 6400, and 6900) or specialized tenolysis knives (Meals Tenolysis Knives; George Tiemann and Company, Hauppauge, NY) are particularly useful to cleave tendon adhesions (Figure 6.21). The dissection is continued along the tendon surfaces until all adhesions are removed or a need for tendon grafting is determined. Traction on the proximal end of the tendon and finger flexion and extension during the procedure will help the surgeon evaluate for additional areas of adhesion formation (Figure 6.22). It is imperative to preserve crucial elements of the pulley system, especially the A2 and A4 pulleys. If this preservation is impossible, new pulleys can be constructed at the time of tenolysis,[133] but we believe that this practice greatly reduces the probability of success.

A staged tendon implant should be considered when the tendon sheath is obliterated over a long section or an adequate pulley system cannot be preserved and must be reconstructed at the time of tenolysis. A poor-quality tendon can rupture during a tenolysis, forcing the surgeon "up the reconstructive ladder" to consider tendon grafting (see Figure 6.19).

After the tourniquet is released, intraoperative hemostasis is helpful in limiting hematoma formation, which facilitates aftercare. Wound closure is also a critical step. Using fine sutures to evert the skin edges for a nice closure is important to the success of the operation. A major benefit of using anesthesia that allows the patient to remain awake or using the WALANT method is the opportunity to allow the patient to witness the improved active digital flexion gained at surgery and establish rehabilitation goals. Final intraoperative range-of-motion measurements are useful to both the patient and occupational therapist as a method of setting the goals for rehabilitation.

Postoperative Care Following Tenolysis

After closure, a nonconstrictive dressing is placed so that immediate flexion can be performed within the bandage to maintain the gains made at surgery. Active finger motion is begun under the supervision of a hand therapist on the first postoperative day. Active range-of-motion exercises must be the primary therapeutic modality after tenolysis.[59,62] To help the patient get through the difficult and often painful first week after tenolysis, an indwelling polyethylene catheter can be left in the involved area at the time of surgery. The catheter is inserted percutaneously so that the catheter tip lies below the proximal extent of the incision. A specialized continuous inflow device (ON-Q pump, Halyard Health, Alpharetta, GA) can provide up to 5 days of local anesthesia. Alternatively the catheter can be injected or a new block administered prior to therapy on the first few visits to improve discomfort during the session.

Continuous passive motion devices can be useful when joint contracture releases are performed concomitantly after tenolysis,[149] but passive motion devices cannot substitute for immediate active pull-through exercises of the lysed tendon system. Continuous passive motion devices may impart a false impression of success if they are used without active-assisted exercises.

Expectations Following Tenolysis

Tenolysis is a tedious and complicated procedure that, if successful, has a high likelihood of improving the discrepancy between the patient's active and passive ranges of motion. The procedure has the following risks: neurovascular injury; tendon rupture; impaired healing; development of a cold, insensitive, and/or painful finger; and recurrence of adhesion. Some of these complications could provoke a need for digit amputation.

Having cautiously optimistic patients who understand the complexities and expect the unexpected is perhaps the healthiest mind-set for the treating surgeon and the patient. One series reported an increase in active PIP joint and DIP joint range of motion of 70 degrees in 80% of patients, no change in 10% of patients, and loss of motion of 25 degrees in 10% of patients.[62]

CRITICAL POINTS *Tenolysis*

Indication
- Tendon adhesions

Preoperative Evaluation
- A discrepancy exists between passive (full) and active (limited) range of motion after progress at hand therapy has plateaued.

Pearls
- Do not operate earlier than 4 months following repair or grafting.

Technical Points
- Use a block, the WALANT method, or neuroleptanesthesia, if possible. Perform a proximal "traction check" through an additional wrist incision.
- Use an extensile approach that allows for exposure of the entire flexor apparatus.
- Start in an area of normal tendon to help with identification of the tendon surface when scar tissue is thick.
- Specialized tenolysis blades may help divide adhesions without compromising pulley function.

Pitfalls
- Concurrent capsulectomy, concurrent osteotomy, age older than 40 years, and a 1-year delay contribute to a worse prognosis.

Postoperative Care
- Maintain digital anesthesia with a lidocaine pump for several days.
- Supervised occupational therapy and active range-of-motion exercises should begin immediately.

Single-Stage Flexor Tendon Grafting: Flexor Digitorum Profundus and Flexor Digitorum Superficialis Tendons Disrupted

Single-stage free tendon grafting after flexor tendon injury remains one of the most elegant and difficult procedures in the hand surgeon's armamentarium. The injured tendons are excised and replaced with a suitable tendon graft secured to the base of the distal phalanx at the FDP insertion and joined to a proximal motor in the palm or distal forearm. The palm-to-fingertip tendon graft (Figure 6.23) is usually performed in fingers that have had both flexor tendons severed in zone 2. Important surgical principles include the following:

- Reconstruct only one tendon in each finger.
- Never sacrifice an intact FDS tendon.
- Use a graft of small caliber.
- Perform the junctions outside of the tendon sheath.
- Ensure adequate graft tension.

Indications for Tendon Grafting

Flexor tendon grafting is indicated in the following clinical situations[10,81,24,83,239]:

1. Failure of flexor tendon repair.
2. Injuries resulting in segmental tendon loss.
3. Delay in repair that obviates primary repair. Late referral or a missed diagnosis may preclude primary treatment. Lacerations that have been neglected for more than 3 to 6 weeks show tendon degeneration accompanied by scarring within the tendon sheath.
4. Patients in whom the surgeon believes delayed grafting is the better treatment alternative for a zone 2 injury (e.g., segmental or extensive tendon injury).
5. Occasionally, for delayed presentation of FDP avulsion injuries associated with significant tendon retraction.

Before flexor tendon reconstruction surgery is considered, the soft tissues should be healed, mobile, and stable; the joints should be free of contracture; and the finger should, ideally, have full passive motion (Boyes' grade 1) (Table 6.2).[25] Pulvertaft[178] emphasized that "The hand [must be] in good overall condition. There is no extensive scarring. Passive movements are full or nearly full. The circulation is satisfactory. At least one digital nerve in the affected digit is intact." Prior to considering flexor tendon reconstruction, the surgeon should be prepared for and the patient advised of the need for additional reconstruction procedures after initial exploration. For example, at the time of initial exploration joint release, pulley reconstruction, tenolysis, and nerve reconstruction may be necessary, in addition to silicone rod implantation.

Initial Exploration

Initial exploration is usually done using a midlateral incision. This incision allows wide exposure of the digit and allows a nice thick flap of skin to be placed over the flexor tendon sheath. Sometimes, prior incisions dictate the operative approach. At the time of exploration it is crucial to make full assessment of the condition of the digit and reconstruct any injury that will facilitate the ultimate outcome of the reconstructive effort. For example, joint release, tenolysis, and pulley reconstruction should be done at the time of initial exploration. After exploration the surgeon can determine the best method for distal tendon juncture and the location and method for proximal tendon juncture. The length of the tendon graft can then be determined by measuring the extended finger from the distal juncture to the proximal juncture and adding 4 to 6 cm depending on the method of juncture that is anticipated.

TABLE 6.2 Boyes' Preoperative Classification

Grade	Preoperative Condition
1	Good: Minimal scarring with mobile joints and no trophic changes
2	Cicatrix: Heavy skin scarring because of injury or prior surgery; deep scarring because of failed primary repair or infection
3	Joint damage: Injury to joint with restricted range of motion
4	Nerve damage: Injury to digital nerves resulting in trophic changes in finger
5	Multiple sites of damage: Involvement of multiple fingers with combination of above problems

From Boyes JH: Flexor tendon grafts in the fingers and thumb: an evaluation of end results, *J Bone Joint Surg Am* 32:489–499, 1950.

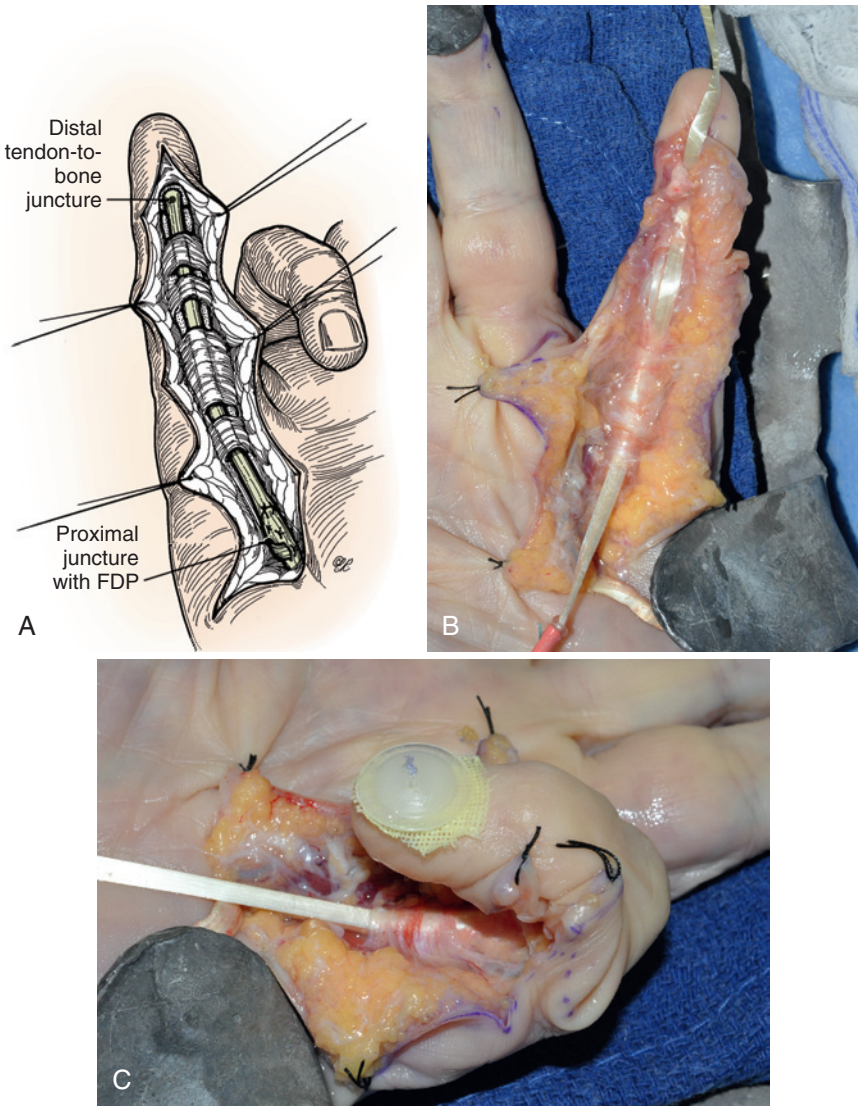

FIGURE 6.23 **A,** Flexor tendon graft. Tendon junctures are placed outside the confines of the flexor sheath (zone 2). **B,** In this clinical case, the graft has been passed from distal to proximal using a red-rubber catheter beneath the intact pulley system. **C,** Following distal junction repair with an "around-the-bone" pull-out suture, the graft is tensioned before the proximal juncture. (**A,** Copyright Elizabeth Martin; **B** and **C,** Copyright Scott W. Wolfe.)

Biology of Tendon Graft Incorporation

Using a clinically relevant canine model, basic science investigators have reported on the incorporation of free tendon grafts when placed into the specialized environment of the digital synovial sheath. They have found that intrasynovial donor tendons seem adapted to survive transplantation to the digital sheath and can incorporate without the formation of peritendinous adhesions. This adhesion-free or minimal adhesion incorporation is associated with improved functional characteristics (tendon excursion and angular joint range of motion). In contrast, extrasynovial donor tendons undergo considerable peritendinous necrosis, which is associated with the formation of dense peritendinous adhesions during tendon graft incorporation. These adhesions limit tendon graft excursion and joint range of motion.[127,199]

Obtaining Donor Tendon Grafts

The most popular tendon grafts are the palmaris longus for palm-to-fingertip reconstruction and the plantaris for forearm-to-fingertip reconstruction. Other sources of graft material include the long extensors of the three middle toes, the toe flexors, the extensor indicis proprius, and one slip of the extensor digiti minimi. The selection of a graft in any specific case is determined by the particular demands of the surgical procedure. Several authors have investigated the use of intrasynovial toe flexor grafts. These grafts healed with fewer adhesions in animal models compared with extrasynovial grafts, but their clinical superiority has not been shown to date. All tendon grafts should be harvested and handled with the utmost care. A harvested tendon should be placed in a sponge moistened with saline or lactated Ringer solution to protect it from drying. Allis-type clamps or suture on each end can be used to facilitate handling of the graft.

Palmaris Longus Tendon. Generally, we prefer the palmaris longus tendon for use in the palm-to-fingertip graft because it is in the same field of surgery and is accessible.[160] The presence of the palmaris longus tendon is easily determined during preoperative examination. The patient is asked to oppose the

thumb to the little finger while flexing the wrist against resistance. The palmaris longus tendon should be readily visible, superficial, and palpable in the midline of the wrist. While there is some difference among populations, the palmaris longus tendon is present in at least 75% to 85% of the population.

Technique of Palmaris Longus Tendon Harvest. A 1- to 2-cm transverse incision is made at the wrist crease that is centered over the long axis of the long finger. The palmaris longus tendon is identified just beneath the skin. Care is taken to identify and protect the immediately subjacent median nerve and its palmar cutaneous branch during harvest of the palmaris longus tendon. Inadvertent median nerve harvest during this procedure has been reported.[241] If there is any question as to the identification of the palmaris longus versus the median nerve, a counterincision is made in the midforearm to confirm the structure prior to harvest. After its identification and distal dissection, the tendon may be harvested through several transverse forearm incisions or with the use of a tendon stripper that allows the entire tendon to be removed with only one or two small incisions. After transection at the wrist crease, the distal end of the graft is held with a 4-0 suture or Kocher clamp. The tendon is mobilized, under direct vision, for 6 to 8 cm and threaded through a circular tendon stripper (Figure 6.24). With firm, gentle tension held on the graft at its distal end with a clamp, the stripper is slowly advanced with a slight twisting motion. As the stripper advances into the proximal region of the forearm, the muscle belly fills the circular cutting blade and is divided; this allows the tendon to be withdrawn through one incision. Occasionally, a second proximal incision is made over the stripper in the proximal forearm if undue resistance to the stripper is experienced.

Plantaris Tendon. When multiple grafts are needed, or one long distal forearm-to-fingertip graft is required, it is necessary to harvest tendons in the lower extremity. The presence of the plantaris tendon cannot be predicted clinically, but ultrasound or MRI can reliably identify its presence. Although it is said to be absent in only 7% of cadavers, Harvey and associates[84] found that the tendon was present in only 80% of limbs. It is also unusable sometimes because of variations in its girth or by virtue of attachments to the triceps surae, which make its removal in one length impossible. When robust, the plantaris tendon is an excellent graft, however, and can supply two and occasionally three palm-to-fingertip grafts or one long distal forearm-to-fingertip graft.

Technique of Plantaris Tendon Harvest. A 5-cm vertical incision is made just anterior to the medial aspect of the Achilles tendon, starting at the insertion and proceeding proximally.[27] The tendon is identified, bluntly dissected anterior to the Achilles tendon, and divided near its insertion (Figure 6.25, *D*). With a holding suture securely fixed in its cut end, the tendon is

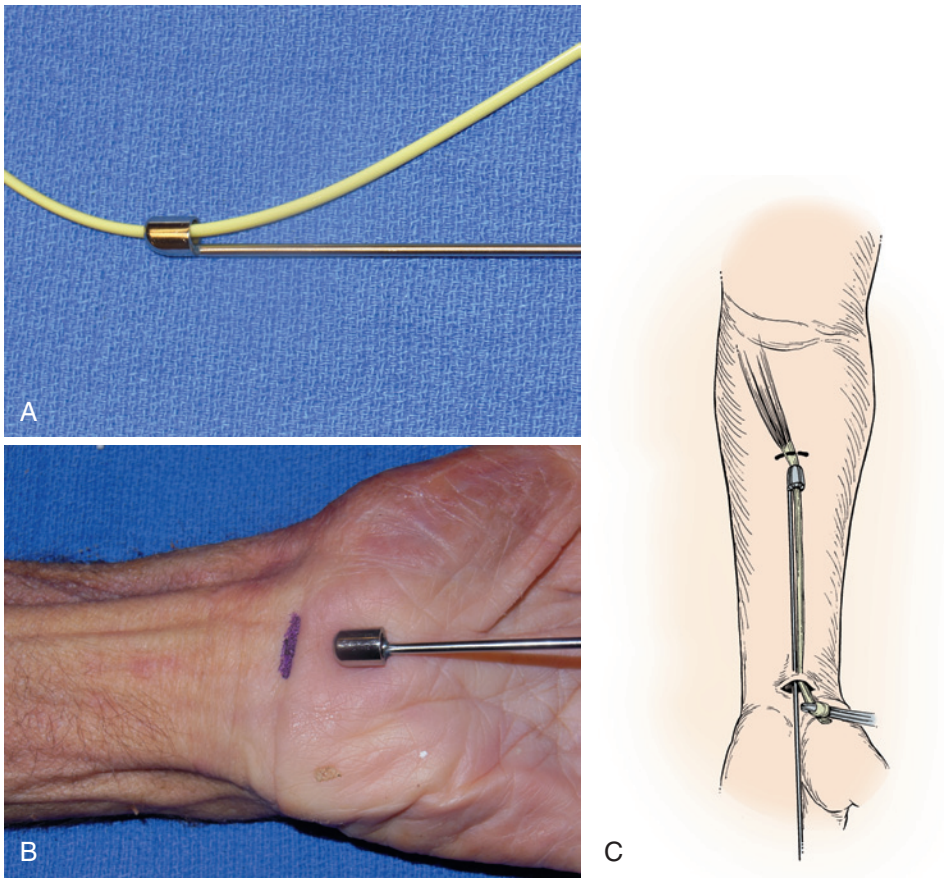

FIGURE 6.24 Palmaris longus graft. Our preferred technique for obtaining the graft uses a tendon stripper, which is a circular knife passed along the surface of the tendon. **A,** Tendon stripper. **B,** Placement of stripper. **C,** Stripper is advanced until it cuts off the graft at the muscle belly, or a second proximal incision can be used to obtain the proximal end of the tendon graft. (**A** and **B,** Copyright John Seiler; **C,** Copyright Elizabeth Martin.)

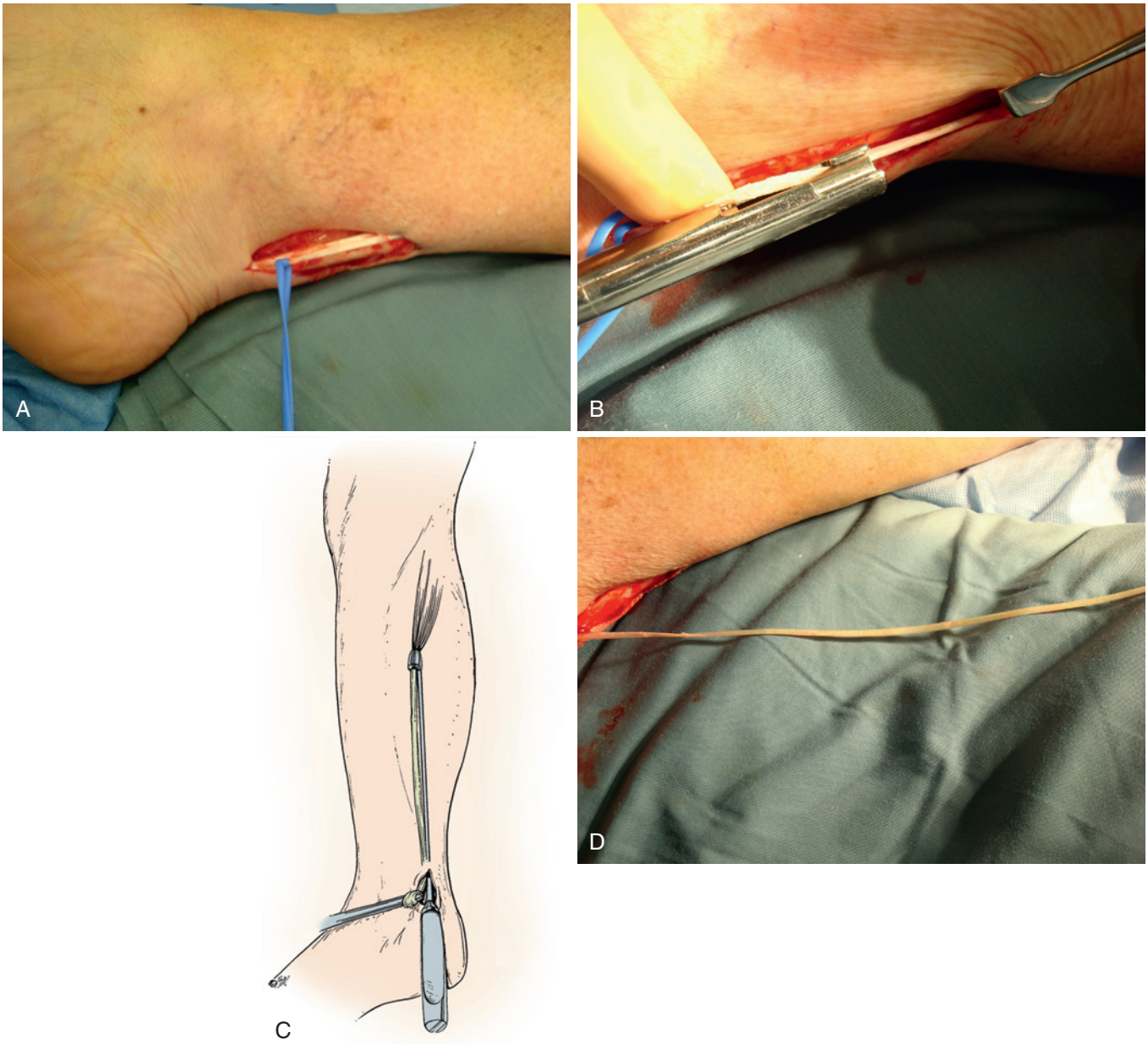

FIGURE 6.25 Plantaris graft. **A,** Tendon is located anterior and medial to Achilles tendon. After division distally, it is passed through circular stripper. **B,** Stripper is advanced up the leg. **C,** When stripper engages the muscle belly, it divides it, and the surgeon can withdraw the tendon. **D,** Plantaris graft can supply two fingertip-to-palm grafts. (**A, B,** and **D,** Copyright Scott W. Wolfe; **C,** Copyright Elizabeth Martin.)

mobilized as far as possible under direct vision; this gives the tubular stripper through which the tendon is threaded a straight course up the leg. The stripper should be held parallel to the leg and advanced with a gentle twisting motion while the tendon graft is held under tension. The knee should be extended. When the belly of the plantaris muscle fills the stripper, the muscle is divided to allow the entire plantaris tendon to be withdrawn from the wound. Alternatively, the tendon stripper can be palpated in the proximal leg and then a second incision made to allow for direct section of the proximal tendon. Care must be taken to keep the stripper parallel to the long axis of the tendon, or the tendon may be severed prematurely. Compartment syndrome after plantaris harvest has been reported; therefore, we recommend palpation of the calf at the conclusion of the procedure to assess for bleeding and excessive calf swelling.[227]

Long Toe Extensor Tendon. The long toe extensors can provide excellent grafts. Their presence is never in doubt, and their diameter is adequate for most needs. Three long tendon grafts can be acquired when the tendons to the second, third, and fourth toes are harvested. A frequent problem is that the individual tendons may fuse distal to the ankle, and three long grafts may be unobtainable. Although some authors advise their removal through a large longitudinal incision, we recommend the use of a tendon stripper and/or multiple transverse incisions to harvest these tendons.

Technique of Long Toe Extensor Tendon Harvest. A generous transverse incision is made on the dorsum of the forefoot at the level of the metatarsophalangeal joint (Figure 6.26). The long toe extensor is isolated proximal to the extensor hood and prepared for harvest by placing a holding suture in the tendon

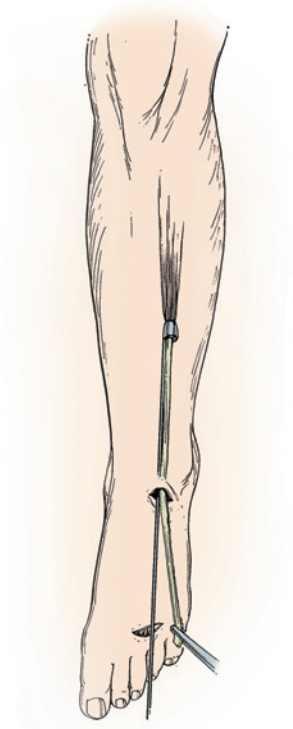

FIGURE 6.26 Long toe extensors. These tendons are best obtained through multiple transverse incisions on the foot. Graft is obtainable when the long toe extensor is used. When proximal to ankle, stripper can be advanced up the leg until the muscle is severed. More incisions than the two shown may be required. (Copyright Elizabeth Martin.)

and transecting it. After mobilization, a small stripper is advanced proximally, but stopped when resistance is encountered. A second transverse incision is made at this level, and the cause of obstruction is checked under direct vision. Further direct dissection can be done, the tendon withdrawn into this second wound, and the stripper used again. Just distal to the ankle level, the cruciate crural ligament encloses the tendons, and often this must be opened. It is imperative to make as many transverse incisions as necessary to minimize premature transection of the graft by forcing the stripper through this area. From the ankle proximally, the tendon can be stripped up into the lower leg. In some cases, all the long extensors will become confluent in the lower leg or ankle area, making it impossible to obtain a high-quality, long graft. When this problem is encountered, extensile incisions are used, and the tendons are dissected out individually. This approach creates "raw" or cut surfaces along the sides of the graft which may be associated with increased peritendinous adhesion formation after placement of the graft.

Extensor Proprius Tendons. The extensor indicis proprius and extensor digiti minimi tendons are both suitable as grafting material, and have the advantage of ease of access to the operative site. Each tendon is long enough for one palm-to-fingertip graft.

Technique of Extensor Indicis Proprius Tendon Harvest. The tendon is exposed through a transverse incision over the MP joint of either the index or the little finger. The extensor indicis proprius tendon is ulnar to the index extensor digitorum communis tendon and is transected about 1 cm proximal to the extensor hood. The tendon is mobilized subcutaneously, and a second incision is made over the musculotendinous junction proximal to the wrist (often the tendon can be identified as the lowest-lying muscle belly here). The tendon can usually be pulled into the second wound and transected. If the tendon does not withdraw easily, an interval incision between the first and second incisions may be necessary. Using these windows, any synovial connections or juncturae can be released under direct vision. The extensor digiti minimi tendon is harvested in a similar manner. At the metacarpophalangeal joint (MPJ) level it is the ulnar of the two tendons and is released just proximal to the extensor hood of the MPJ. The proximal dissection is similar to that for the extensor indicis proprius tendon. The extensor digiti minimi tendon is smaller in caliber and shorter in length. It is composed of two slips; Snow has recommended that only the ulnar half be used as a graft.[206]

Flexor Digitorum Longus Tendon of the Foot. Experiments on intrasynovial toe flexors have shown that these grafts heal with fewer restrictive adhesions than extrasynovial grafts.[199,201] The long flexors of the second to fifth toes can be sacrificed with minimal complications, and their clinical application has been shown in a small series.[127]

Technique of Flexor Digitorum Longus Tendon Harvest. The toe flexor is first identified at the distal phalanx of the toe through a small transverse incision or modified Bruner incision. If only one tendon is required, we prefer to use the second toe flexor because the intrasynovial section is longest in anatomic studies.[200] Next, a 6-cm longitudinal incision is curved over the non–weight-bearing portion of the midfoot. The selected tendon is identified and carefully dissected from the coalescence of the toe flexors. Care must be taken not to injure the neurovascular structures traversing this region. Resection of the toe flexor from midfoot to toe is suitable for palm-to-fingertip grafts. The entire system of toe flexors can be harvested for grafting multiple digits, leaving the coalescence of the toe flexors intact. This harvesting requires more extensive dissection through the tarsal tunnel and posterior to the medial malleolus (Figure 6.27).

Distal Tendon Juncture

The distal tendon juncture is usually done first; there must be a durable union between the grafted tendon and the distalmost FDP stump or volar base of the distal phalanx. If the distal juncture is completed first, the graft length and graft tension may be adjusted when the proximal juncture is completed. There are several techniques for attaching the tendon graft to the distal phalanx, and these are based primarily on the length and condition of the distal FDP stump. If enough profundus stump is available, the graft can be sutured to the profundus stump or woven through the stump as in an end-weave juncture.

When there is not sufficient profundus tendon available for primary repair, the traditional method is a modification of the classic Bunnell tendon-to-bone pull-out technique (Figure 6.28). A drill hole is made in the volar cortex of the distal phalanx into which Keith needles are passed through the nail plate. Many surgeons employ a sterile button tied over a stent on top of the nail plate for securing the pull-out suture. Currently, suture anchors are commonly used in patients with good bone quality and may be combined with a pull-out suture for the increased strength of a multistrand repair.

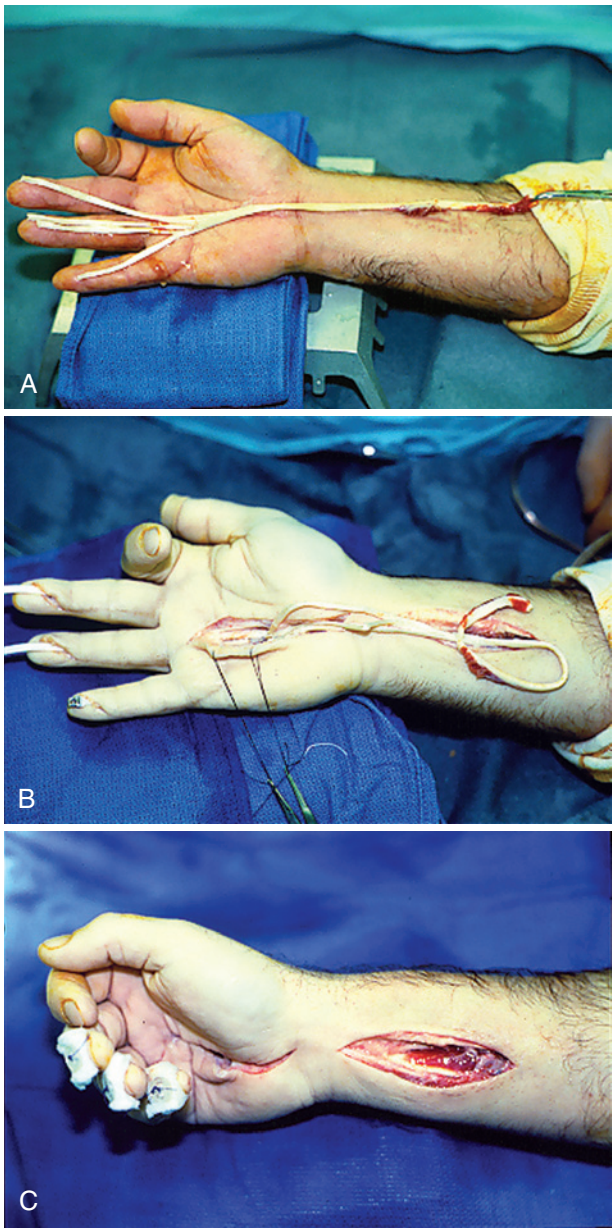

FIGURE 6.27 **A** to **C,** Toe flexor grafts. Multiple digits can be grafted using toe flexors, as illustrated by this case. The ulnar three digits were grafted using the entire long toe flexor tendons after silicone implants. (Courtesy of David Zelouf, MD.)

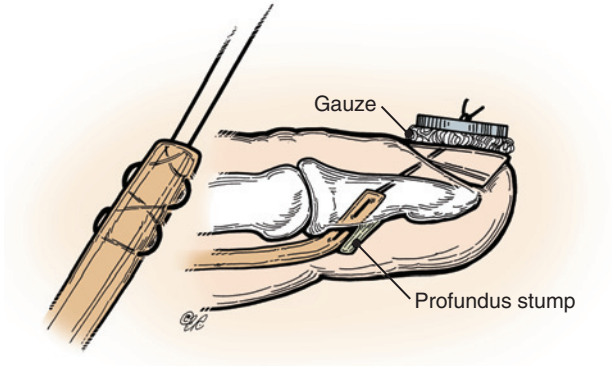

FIGURE 6.28 Modified Bunnell distal juncture technique. Pull-out sutures are passed through the distal phalanx. (Copyright Elizabeth Martin.)

CRITICAL POINTS *Obtaining Tendon Grafts*

Indications

- The need for a tendon graft is noted during flexor tendon reconstruction.
- Graft selection is determined by the donor's presence, the anticipated length of graft material necessary to secure the graft, and the demands of the procedure.

Preoperative Evaluation

- The presence of the palmaris longus tendon is easily determined through opposition of the thumb to the little finger as the wrist is flexed against resistance.
- The most common donor tendon for palm-to-fingertip reconstruction is the palmaris longus tendon, and the most common donor tendon for forearm-to-fingertip reconstruction is the plantaris tendon.
- Prior to use of the plantaris tendon, consider preoperative imaging to determine its presence.
- Other graft options are long extensors of the three middle toes, toe flexors, extensor indicis proprius tendon, and extensor digiti minimi tendon.

Pearls

- Intrasynovial grafts are associated with fewer adhesions in animal models.
- Keep harvested graft material in a moist saline sponge and handle it with the utmost care.

Technical Points

- Make a transverse incision just proximal to the wrist crease and in line with the long finger metacarpal centered over the palmaris longus tendon. The dissection is subcutaneous at this point, and the tendon is readily identifiable.
- Underneath this incision, use direct inspection to mobilize the tendon proximally 6 to 8 cm.
- Place a suture in the free distal tendon end, and thread the tendon through a circular tendon stripper.
- If a stripper is unavailable, use a multiple-incision method.

Pitfalls

- Identify and protect the median nerve at the time of palmaris longus tendon graft harvest. Careful subcutaneous dissection just proximal to the wrist flexion crease should allow identification of the tendon and, if necessary, the median nerve. The palmaris longus tendon is present in only 75% to 85% of people.
- Consider preoperative imaging for identification of the plantaris tendon. It is difficult to identify on physical examination, and imaging can confirm its presence prior to the procedure. The plantaris tendon is present in about 80% of people.

Pull-Out Sutures (Around the Bone)

Some surgeons prefer passing the pull-out suture around instead of through the distal phalanx (Figure 6.29, *A* to *D*). If the distal profundus stump has been preserved, it is reflected to its insertion on the volar lip of the distal phalanx. A 3-0 polypropylene pull-out core suture is placed in one end of the graft using a crisscrossed Bunnell technique. The sutures and graft are passed through the FDP stump and the pull-out sutures are threaded onto Keith needles. With the use of a needle holder, the Keith needles are passed around both sides of the distal phalanx and through the middle third of the nail plate (see Figure 6.29, *C*). An effort should be made to avoid the germinal nail matrix; the ideal point of exit through the nail plate should be 3 to 4 mm distal to the lunula and approximately 2 mm from the midline. The tails of the suture may be tied directly over the

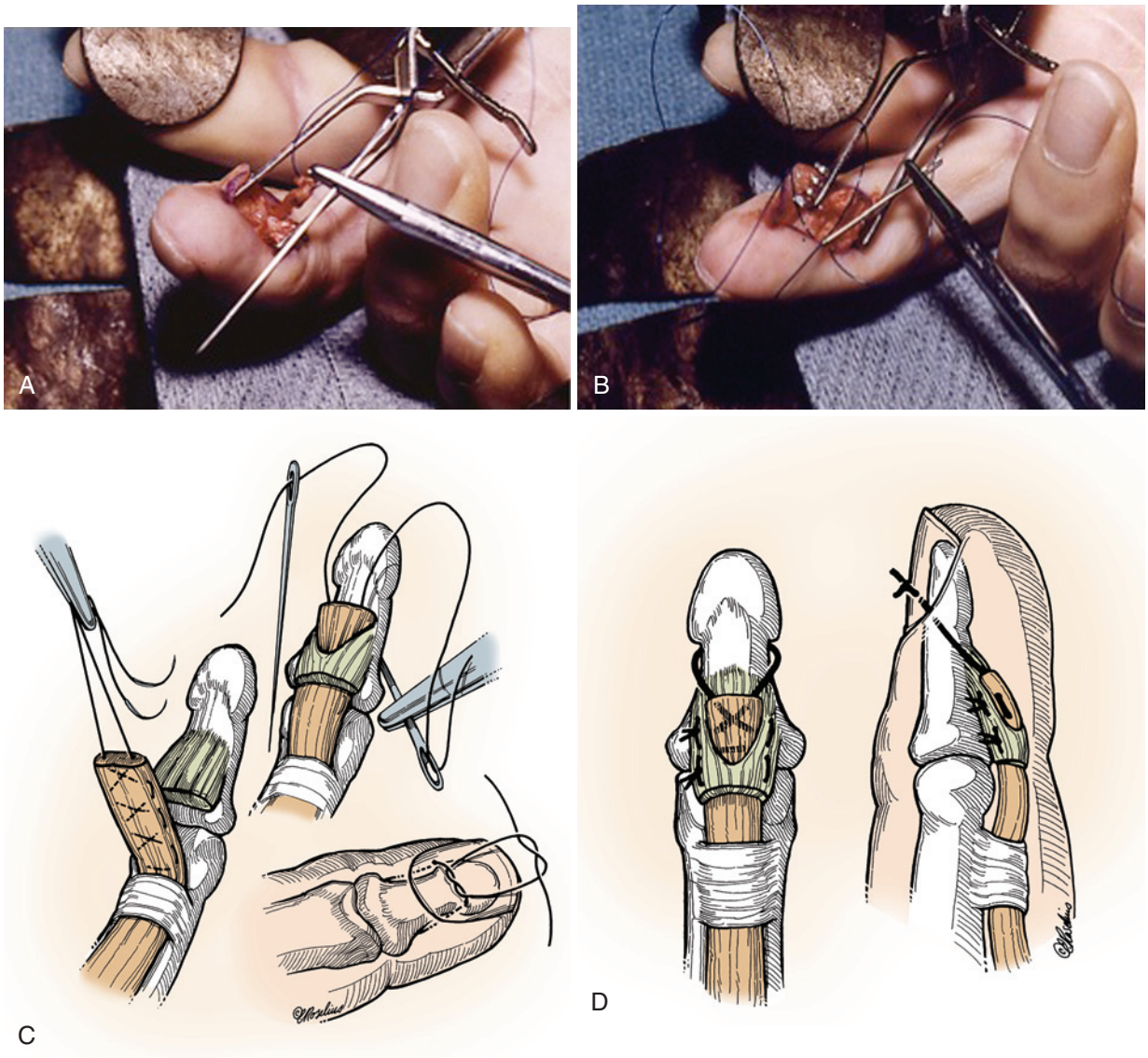

FIGURE 6.29 **A** and **B,** Pull-out suture for distal juncture of securing a tendon graft is passed around both sides of distal phalanx with aid of Keith needles. **C,** Diagram of technique. The sutures pass through the nail bed and are tied directly over the nail plate. **D,** Completed repair. (**C** and **D,** Copyright Elizabeth Martin.)

nail plate (see Figure 6.29, *D*) or over a button (see Figure 6.27). At least two 3-0 or 4-0 nonabsorbable mattress sutures reinforce the FDP-graft juncture.

When the distal FDP stump is insufficient to allow braiding, or in children with open physes, the distal stump may be split longitudinally and the graft laid within the split. The graft is drawn through the pulp with a large needle, and the projecting graft is temporarily clamped at the fingertip (Figure 6.30, *A*), allowing for precise tension adjustment. Nonabsorbable 3-0 or 4-0 sutures are placed between the graft and the FDP stump through which it was passed. If the surgeon is confident in the strength of the horizontal mattress sutures, the tendon may be trimmed (see Figure 6.30, *B*). For additional strength and security, the tendon may also be temporarily fixed at the fingertip with a padded button for 4 to 6 weeks (see Figure 6.30, *C*).

Another technique places a transverse drill hole across the base of the distal phalanx, with the graft threaded through and sutured to itself (Figure 6.31).[156,176] This technique allows for graft tension judgment but is technically more difficult, as the graft must be thin to pass through the bony tunnel; an articular fracture of the distal phalanx is possible.

Proximal Tendon Juncture

A Pulvertaft tendon weave is our preferred method of repair for proximal tendon graft juncture completed in zones 3, 4, and 5. This type of juncture is stronger than the end-to-end suture techniques, and it has the advantage of allowing the surgeon to adjust the graft tension at the time of the first tendon pass (Figure 6.32).[176,177,228] A human cadaveric analysis of this technique by Gabuzda and coworkers[65] demonstrated that repair strength increased significantly with additional weaves and recommended using as many as four or five weaves. We prefer to use at least two passes to create a strong juncture.

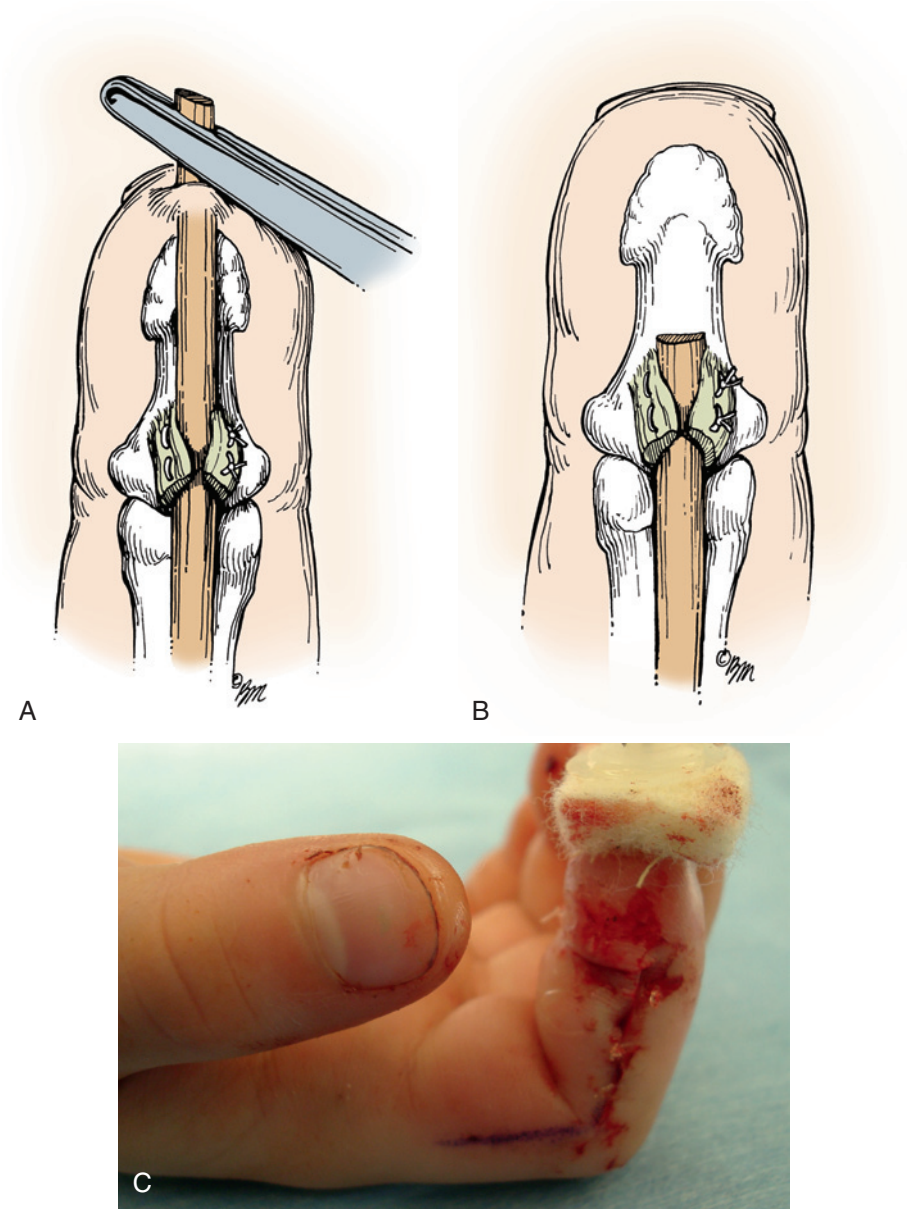

FIGURE 6.30 Distal juncture technique. **A,** Graft is drawn through the pulp, and after tension adjustments are made, is sutured to profundus stump. **B,** In this tendon-to-tendon technique, an interweave suture is used to fix graft to stump of FDP tendon. **C,** In this 6-year-old child, the graft was temporarily secured to the fingertip with a padded button. (**A** and **B,** Copyright Elizabeth Martin; **C,** Copyright Scott W. Wolfe.)

❖ AUTHORS' PREFERRED TECHNIQUE: Single-Stage Grafting Technique

All flexor tendon surgery should be done under tourniquet control. When possible, we prefer a midlateral incision for several reasons: This exposure gives wide access to the digital sheath, it places a thick flap of essentially normal skin over the tendon sheath at the time of wound closure, and it is durable during the rehabilitation process. After exposure, a thorough assessment of the injury is performed. The proximal and distal ends of the remaining tendon are identified. If the digital sheath is in good condition and a suitable proximal motor tendon can be identified, we prefer to proceed with single-stage tendon graft reconstruction. If the tendon sheath is severely damaged or contracted, making tendon graft passage impractical, staged tendon reconstruction is indicated. At this time, a decision must also be made about the need for nerve repair or reconstruction, pulley reconstruction, joint release, and arterial repair or reconstruction. The area of tendon rupture and interval tendon is excised from the digital sheath. The margins of the resection should allow the tendon graft junctures to be done distal to the A4 pulley and proximal to the A2 pulley. Approximately 1 to 2 cm of the FDP stump is preserved distally to strengthen the distal juncture. Proximally, the FDP tendon is sectioned just distal to the lumbrical origin in the palm.

In most cases, neither of the digital flexor tendons is functioning. When this is true, the proximal stump of the FDS tendon is pulled distally and the tendon is transected, allowing the remaining stump to retract proximally. The distal FDS tendon is excised sharply, but 1 to 2 cm of its insertion is left

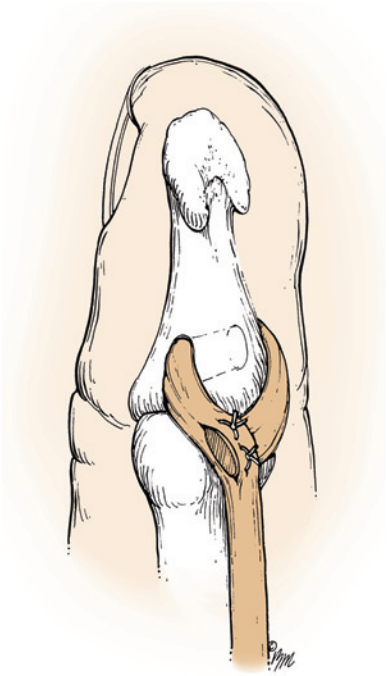

FIGURE 6.31 Distal juncture technique. Tendon graft, which must be thin, is passed through transverse drill hole in distal phalanx. (Copyright Elizabeth Martin.)

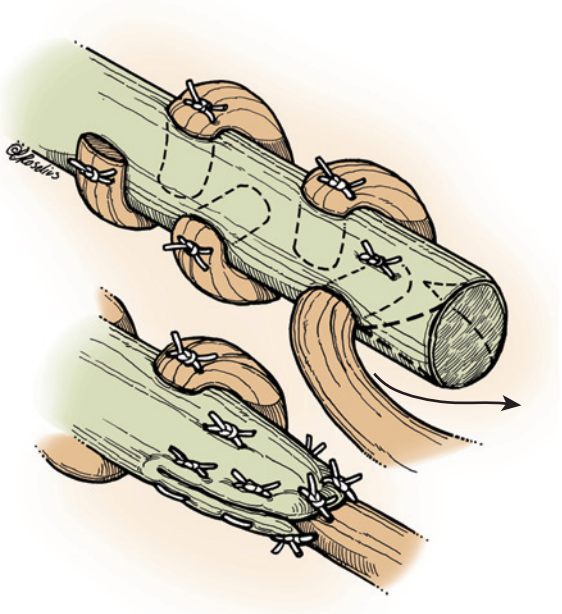

FIGURE 6.32 Modified Pulvertaft end-weave technique. The graft is secured to the proximal motor tendon via multiple weaves through the motor tendon held in place with 3-0 polyester sutures. (Copyright Elizabeth Martin.)

undisturbed because this provides a more favorable dorsal bed for the graft; also, the presence of the FDS tail provides stability at the PIP joint, helping to prevent a hyperextension (swan neck) deformity, a problem occasionally seen in fingers without an FDS tendon.[232]

The intact proximal FDP tendon is preferred as the graft "motor," unless it is of poor quality, in which case the transected FDS tendon of the injured digit may be used. Occasionally, the FDP tendon of an uninjured neighboring digit may be used as an end-to-side proximal transfer if both proximal motors are unsuitable.

For surgical sequencing, the graft is harvested only after the digit is prepared and found to be appropriate for tendon grafting. After the tendon graft is harvested, it is prepared by placing sutures in the ends of the graft to facilitate passing the graft. The graft is wrapped in saline-soaked gauze and placed on the back table until it is time to implant it. In an effort to limit any surface irregularities in the graft, the graft is handled with care and not manipulated with forceps.

Placement of the Graft

Various techniques can be used to pass the graft. Leddy[122] and Sourmelis and McGrouther[209] used a flexible rubber catheter (e.g., pediatric feeding tube, red-rubber catheter) as a passer. It is directed beneath the pulleys in a distal-to-proximal direction. The holding suture attached to the grafted tendon is sutured to the catheter and then pulled distally. A flexible silicone tendon implant or a Swanson disposable suture passer (Smith & Nephew, Memphis, TN) to which the graft is sutured can also be used as a tendon passer. Regardless of which method is used, care must be taken to minimize trauma to the intact sheath. A clamp is placed at the proximal end of the graft to prevent inadvertent withdrawal.

Distal Juncture Technique

Usually the distal juncture is done first. For patients with good bone quality, we prefer a metallic suture anchor method and the use of a nonabsorbable suture. Basic science studies have shown metallic anchors to be sufficient to provide stable fixation of the graft to the distal phalanx, and this method avoids potential complications inherent in all pull-out suture methods. Metallic anchors are preferred to avoid the possible complication of osteolysis associated with bioabsorbable anchors. By measuring the thickness of the distal phalanx on the lateral view, an anchor can be chosen that will fit within the bone. To prepare the distal phalanx, the previous FDP stump is lifted to expose the base of the distal phalanx and the cortical surface roughened to bleeding bone. A suture anchor hole is drilled obliquely and the anchor embedded into the distal phalanx. The end of the tendon graft is passed through the previous FDP stump. The anchor sutures are passed through the tendon using one of the locking suture techniques and secured. Horizontal reinforcing sutures are passed between the FDP stump and the tendon graft. For patients with poor bone quality, a pull-out suture method is advised (see Figure 6.28).[15,66,121,144]

Proximal Juncture Technique

For proximal repairs in zones 3 and 5, we prefer to join the graft to the FDP tendon (just distal to the lumbrical origin in zone 3) using a Pulvertaft end-to-side weave method with three mattress sutures of 3-0 nonabsorbable suture material (see Figure 6.32). We perform the proximal repair after the distal repair is complete.[53] This repair sequence allows stable repair of the tendon ends and also allows the graft to be tensioned appropriately. The tension in the graft (and flexor positioning of the finger) is best set after the first pass of the graft through the proximal "motor" tendon. After the tension is established, the finishing sutures can be inserted and the Pulvertaft weave completed. General recommendations have been (and we agree)

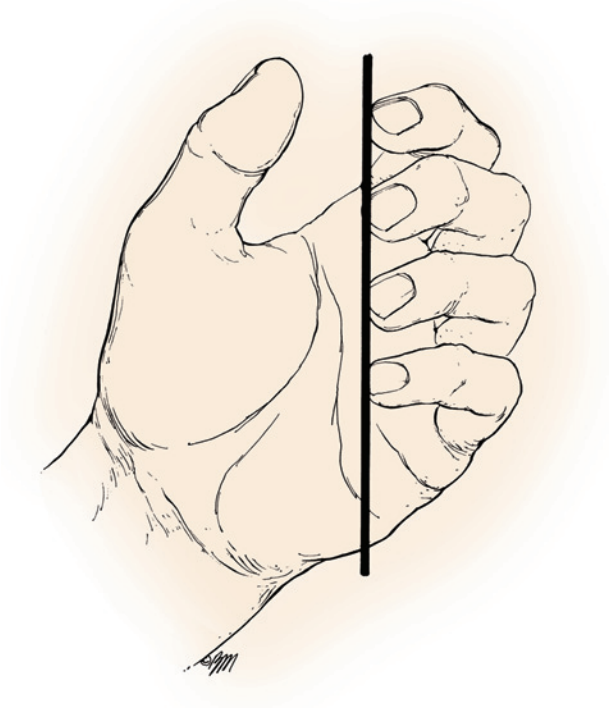

FIGURE 6.33 Determining tension in a reconstructed flexor system at the time of suturing the proximal juncture. With the wrist in neutral position, each finger falls into slightly less flexion than its ulnar neighbor. (Copyright Elizabeth Martin.)

that the tendon graft tension should be such that the digital flexor cascade is reproduced or slightly increased for the finger requiring tendon grafting (Figure 6.33).

Postoperative Care

Postoperative care of tendon grafts has undergone a transformation[10] that favors early motion protocols[212] over the more traditional cast immobilization.

Accelerated rehabilitation protocols are as valuable in the setting of tendon grafting as they are in primary flexor tendon repair because they improve tendon excursion and also joint mobility in the early postoperative period. Our early active motion protocol is used for compliant patients with secure tendon junctures and is directed by an occupational hand therapist. The protocol should be used only when the surgeon is confident that the graft junctures are strong enough to withstand the additional tensile stresses of this regimen. The postoperative splint that we prefer is a static dorsal blocking splint, with the wrist positioned in neutral, the MP joints in 45 degrees of flexion, and the IP joints in neutral. This splint is applied early in the postoperative period and worn for protection until 6 weeks after surgery.

Therapist-guided protected passive range-of-motion exercise can be instituted at the first postoperative visit 2 to 3 days after surgery. At 2 weeks after surgery, gentle place-and-hold flexion exercises and active short-arc digital flexion and extension exercises are added to the therapy program. Blocked flexion of the MP or PIP joint enables increased active flexion at the distal joints but puts additional stress on the junctures. Despite this tensile stress, the blocked flexion exercise method optimizes tendon gliding and is instituted actively at 4 weeks and with resistance at 6 weeks. Flexion contractures are treated with protected passive stretching and specific splinting techniques. Patient education is of paramount importance, and judgment must be used in restraining more active patients and prodding reluctant patients.

Graft Incorporation

If a grafted tendon is explored after 6 or more months, it often has a normal appearance and may resemble a histologic replica of the original tendon. Whether the tendon is, in reality, the original graft or a repopulation of a tendon scaffolding is a question studied by a number of basic science research efforts. Seiler and Gelberman and colleagues have reported on the incorporation of various types of tendon grafts in a clinically relevant canine model.[199] Traditional extrasynovial grafts, such as palmaris longus or plantaris tendon grafts, undergo a significant cellular necrosis when transplanted to the digital sheath and are repopulated by fibroblasts donated through the formation of peritendinous adhesion or through the proximal tendon juncture sites. Similarly, studies of tendon graft neovascularization show new vessels growing to the tendon graft through adhesion formation and also through the tendon junctures. These newly donated fibroblasts are responsible for producing collagen that will strengthen the graft over time. Intrasynovial grafts have, in basic science study and limited clinical study, showed an improved capacity to survive transplantation to the digital sheath. They have a surface that is designed to allow for synovial fluid imbibition and that may promote nutrition and cellular survival. It may also explain the ability of these grafts to incorporate with much less cellular necrosis or adhesion formation and with maintenance of the critical gliding surface.[199]

Single-Stage Flexor Tendon Grafting: Flexor Digitorum Profundus Tendon Disrupted, Flexor Digitorum Superficialis Tendon Intact

Indications

In patients with transection of the FDP tendon but an intact FDS tendon, early direct FDP repair is the preferred treatment method. When more than 4 weeks have elapsed from the time of injury, tendon grafting may be necessary and, depending on the status of the tendon sheath, can be done as a one- or two-stage procedure. When the FDS tendon is functional, caution must be exercised in offering a free tendon graft to restore distal joint function.[192]

Useful digital motion is maintained when the FDS tendon is functional (Figure 6.34). Most patients with a severed FDP tendon but an intact FDS tendon adapt nicely and may require no treatment; this is especially true if the DIP joint is stable. An appropriate preoperative explanation of the considerable risk of worsening function after attempted reconstruction of the isolated FDP laceration is essential. Most surgeons advise nonoperative treatment, especially in older patients or heavy laborers.[91] In patients troubled by instability at the DIP joint or weakness of grip, stabilization of the DIP joint by tenodesis or arthrodesis is a good solution. Despite the difficulties and considerable risks, outstanding results with FDP grafting in carefully selected patients have been reported.[35,77,106,107,150,177,184,211] Some of the variability in patient results may be attributed to different methods of patient evaluation.[192]

CRITICAL POINTS *Single-Stage Tendon Grafting: Flexor Digitorum Profundus and Flexor Digitorum Superficialis Tendons Disrupted*

Indication
- Definitive repair has been delayed or ruptured, and direct repair is impossible or impractical.

Preoperative Evaluation
- Joint contractures need correction before grafting.

Pearls
- The Pulvertaft weave technique allows easy graft tensioning when creating the proximal juncture.
- Graft tension is correct when, with the wrist in neutral, the grafted finger shows a slight increase in flexor tone (or slightly more flexion in the flexor cascade).

Technical Points
- Use a midlateral incision.
- Preserve the crucial pulleys.
- When flexor tendon grafting is chosen, clear the flexor sheath of unnecessary tendon but preserve the FDP tendon distal to the A4 pulley for the distal juncture.
- Pass the graft using a small pediatric feeding tube or silicone rod.
- Create the distal juncture with a suture anchor or suture pull-out technique.
- Proximally, use the FDP tendon of the involved finger as the graft motor. The proximal juncture should be just distal to the lumbrical origin when possible
- Set the tension in the graft by passing the graft through the motor and creating the desired flexor cascade.
- Use two or more right angle passes of the graft by means of a Pulvertaft technique and nonabsorbable sutures to complete the proximal juncture.

Pitfalls
- A two-stage tendon graft is needed if there is extensive scarring, pulley incompetence, or joint contracture.
- Handle the graft carefully. Careless handling, pinching, or probing of the graft may increase surface irregularities and, therefore, the number and density of adhesions.

Postoperative Care
- Use an early range-of-motion protocol if graft junctures are strong.
- Apply a static dorsal blocking splint (4 to 6 weeks) with the wrist in neutral position, the MP joints at 45 degrees, and the IP joints in neutral position.
- Treat flexion contractures with passive stretching and splinting (6 to 8 weeks).

We restrict this procedure to young patients with supple joints and a reasonable need for active DIP joint function. The graft may have more potential benefit to patients with ring and small finger injury who require a power grip (Figure 6.35).

Single-Stage Grafting Technique With an Intact Flexor Digitorum Superficialis Tendon (Zone 1 Injuries)

The technique is similar to the technique for free tendon grafting described in the previous section. A thinner graft is easier to pass, making a palmaris longus, extensor digiti quinti, or plantaris graft an excellent choice. The graft must be passed accurately and glide easily through the intact FDS tendon

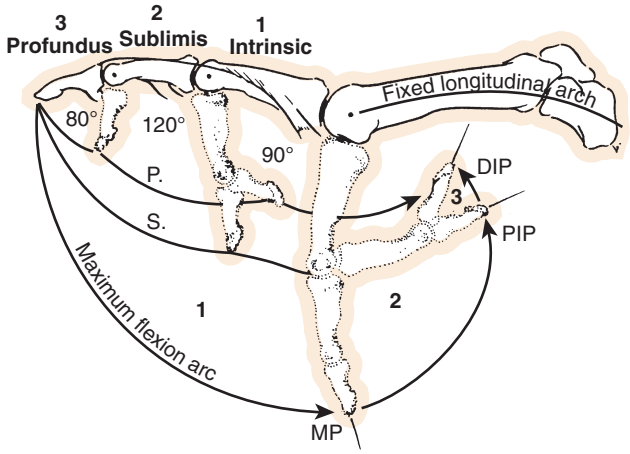

FIGURE 6.34 Flexion arc. In isolated injuries to the FDP tendon when the FDS tendon is fully functional, the greatest part of the flexion arc is maintained (*stippled areas 1 and 2*). Restoration of active profundus function provides only that portion of the arc denoted by the small *stippled area 3*. (From Littler JW: The physiology and dynamic function of the hand, *Surg Clin North Am* 40:259, 1960.)

decussation in order to obtain an optimal outcome. An intact, fully functioning FDS tendon should not be removed, although concomitant tenolysis may be useful to improve independent tendon excursion. Harrison[82] suggested removal of one tail of the FDS tendon to facilitate graft passage and gliding. The procedure occasionally has been performed in two stages,[41,77,237,249] with a tendon implant placed at the first stage, particularly if there has been some element of injury to the FDS tendon, flexor tendon bed, or pulley system. A staged tendon graft has been gratifying when appropriately used in fingers with a poor sheath.[41,219]

Postoperative Care of Tendon Grafts With an Intact Flexor Digitorum Superficialis Tendon (Zone 1 Injuries)

We favor early active range-of-motion protocols to maintain normal FDS tendon function, particularly because Schneider[192] noted that, despite careful preoperative patient selection, numerous patients required subsequent tenolysis. To help limit tendon adhesion formation, we favor exercises designed to facilitate independent tendon gliding, including short-arc active extension and finger flexion exercises. Within the first postoperative week, we begin gentle place-and-hold and straight-fist flexion exercises in compliant patients.

Expectations

We counsel patients that grafting to restore FDP tendon function when the FDS tendon is intact can be associated with significant digital stiffness and is usually best done to meet specific functional demands, such as playing a musical instrument or doing specialized work.

Two-Stage Flexor Tendon Reconstruction

Indications

In 1965, Hunter first published his personal experience with tendon implants; in 1971, Hunter and Salisbury[100] presented more than 10 years' experience with staged tendon reconstruction using an implant reinforced with silicone and Dacron. The

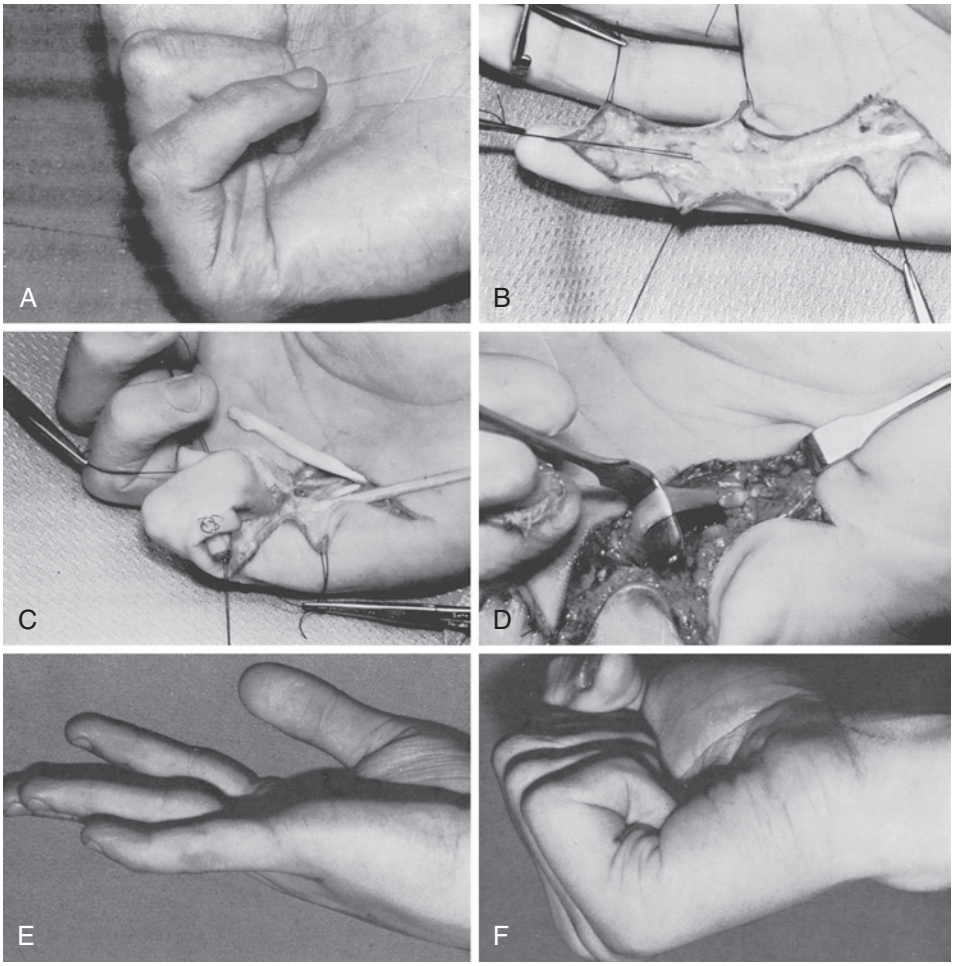

FIGURE 6.35 Tendon graft through intact FDS tendon. **A,** A 17-year-old boy had ruptured the FDP tendon and had incomplete function of the FDS tendon 3 months after injury. **B,** FDP tendon was retrieved and mobilized, but it was impossible to advance it to the insertion. A tendon graft was placed. **C,** The graft in place. The finger is to be closed before completing the proximal juncture. **D,** Interlace juncture in the palm using the FDP tendon as the motor. **E** and **F,** End result at 1 year. There is a flexion deformity at the tip, but 50 degrees of strong flexion has been gained at the DIP joint.

next four decades witnessed significant advances in the ability to restore flexor tendon function to badly scarred digits. The first procedure of a staged reconstruction employs a thorough digital exploration, reconstruction of associated injuries, and placement of a passive silicone tendon implant. This allows for correction of any joint contracture, reconstruction of critical pulleys, and formation of a pseudosheath around the silicone rod. The index procedure is followed by placement of a tendon graft at a second operation, which is usually done 6 to 12 weeks after the index operation.

Tissue Response to a Silicone Implant. The nature of the sheath formed by silicone and other materials has received significant investigation. Hunter's group,[103,104] working in the late 1960s, observed an orderly pattern of cellular organization on the surface of the implant when silicone implants were placed in the paravertebral soft tissues of dogs. A parallel study evaluated the response to an actively gliding implant in the extensor system of dogs and showed that the system could function as a physiologic sheath capable of supporting a long tendon graft initially by synovial fluid nutrition and subsequently via mobile vascular adhesions. Urbaniak and colleagues[232] performed experiments in the flexor system and confirmed revascularization of tendon in dogs by intratendinous vessels within the sheath. Farkas and colleagues[58] reported ultrastructural evidence of a normal-appearing reconstituted tendon sheath in chickens, and also concluded that motion was important for remodeling.

The nature of the sheath created in response to a flexible silicone implant used in a passive-gliding program in humans is still debated. Some of the varying observations may be a result of different species and experimental conditions. Most commonly the silicone rod placement is associated with the formation of a soft, flexible, translucent sheath, which is suitable for supporting the purpose of tendon grafting. In a series of 109 digits, the reported complications from silicone rod implantation during stage 1 included rod buckling, rupture of the distal end of the rod, rod migration, synovitis, and infection.[208]

Alternative Techniques. Other researchers have investigated alternative techniques for reconstruction.[257] In the staged technique published by Paneva-Holevich in 1969,[169] the damaged tendons are removed from the flexor sheath and transected in the palm (Video 6.2). The cut ends of the FDS and FDP tendons are sutured in the palm to create the proximal tendon juncture. Approximately 6 weeks later at a second stage, the FDS tendon

CRITICAL POINTS *Single-Stage Tendon Grafting: Flexor Digitorum Profundus Tendon Disrupted, Flexor Digitorum Superficialis Tendon Intact (Chronic Zone 1 FDP Injury)*

Indications
- Young person with supple joints and a reasonable need for active DIP joint function.
- More useful on the ulnar side of the hand for power grip.
- DIP joint that is unstable but supple.

Preoperative Evaluation
- Document absence of FDP function.
- Evaluate the DIP joint for instability.
- If on exploration the FDP tendon position is maintained, early direct repair is indicated.
- Later repair is possible if a short vinculum to the FDP tendon maintains the tendon in a distal location.
- MRI or ultrasound may be useful to determine the location of the proximal FDP stump.

Pearls
- Never remove an intact, fully functioning FDS tendon in an effort to place a graft.
- Tenolysis of the FDS tendon may be necessary.
- The procedure may be done in one or two stages, depending on the condition of the flexor tendon sheath.
- The graft must be accurately oriented through the decussation of the FDS tendon.
- The proximal motor for the graft is usually the FDP tendon of the same finger, with the proximal juncture done just distal to the lumbrical origin.
- For some cases a more proximal tenolysis of the FDP motor must be done to improve the tendon excursion.

Technical Points
- Use a similar technique as in free tendon grafting.
- Know that a thinner graft is easier to pass (plantaris).
- Pass the graft through the FDS tendon decussation.
- One FDS tail can be removed for tendon graft passage if the graft is too bulky to pass.

Pitfalls
- Patients should be selected for the goal of restoring the specific function of grip.
- Patients with an intact FDS tendon usually adapt nicely and require no treatment.
- Digital scarring can be heavy and result in adhesions, loss of motion, and further functional impairment.

Postoperative Care
- Apply a static dorsal blocking splint (4 to 6 weeks) with the wrist in neutral position, MP joints at 45 degrees, and IP joints in neutral position.
- Use an early motion protocol if the graft juncture is strong.
- Treat flexion contractures with passive stretching and splinting (6 to 8 weeks).

is severed at the muscle-tendon junction in the forearm and passed distally through the tendon sheath to be attached to the distal phalanx or distal FDP tendon. Although this procedure results in a finger with one tendon, it has the advantage of requiring a single distal repair at the second stage and may transplant an intrasynovial tendon segment of the FDS to the digital sheath. This can be a good solution for severely injured fingers, especially in patients with limited tendon donor options. Later, this method was combined with implantation of a silicone prosthesis during the first stage to prepare a bed for the subsequent distal pedicle transfer[3,14,28,161] (Figure 6.36). The relatively larger size of the FDS tendon compared with a conventional tendon graft may require the use of a silicone rod with a larger diameter.

Composite Tissue Transfer Methods. Peacock[171] showed that a transplanted allograft of the entire flexor system, tendon, and sheath was well tolerated in three digits in four patients, but no range-of-motion details were provided. Hueston and colleagues[94] also presented a clinical series of three cases using homografts, although no clinical results were reported, and the technique was not widely adopted. In 1974, Chacha[35] used autologous composite grafts from the toe to the flexor system of the hand with only modest results. More recently, Asencio and associates[9] implanted human composite flexor tendon allografts into two fingers with irreparable injuries of the flexor tendon system. Although none of these methods has current clinical applicability, they are interesting to consider and may represent fertile ground for future tissue engineering research. Some of the biggest future improvements will likely come from tissue engineering strategies.

Permanent (active) tendon implants varying in size, shape, material, and type of end device for distal and proximal fixation have been reported in the literature. Unfortunately, biologically durable bonding between the tendon implant distal to bone and proximal to native tendon has not been reliably achieved. Basic science researchers continue to search for a permanent active tendon implant.[84]

❖ AUTHORS' PREFERRED TECHNIQUE: Staged Tendon Grafting: Stage I

The flexor system of the involved finger is exposed through a midlateral incision. The annular pulleys are dissected and preserved. An assessment is made as to the need for pulley reconstruction. The injured flexor tendons are excised. If a 2-cm FDS tail can be preserved, it is left attached to the middle phalanx for stability. A second curvilinear incision is made proximal to the wrist crease in the ulnar half of the volar forearm. The involved FDS tendon is identified, drawn into the wound, and divided near the musculotendinous junction. Excised tendon material is set aside in moist sponges for possible use in pulley reconstruction.

The proximal FDP tendon is transected at the lumbrical origin level; if the lumbrical is scarred, it is also excised. Fixed flexion deformities are corrected with capsulectomy and volar plate and accessory collateral ligament release.

A trial set of silicone tendon implants is useful to determine the appropriate size needed. Men generally can accommodate a tendon implant of up to 5 or 6 mm, but we usually use a smaller 4-mm implant. This implant is closer in size to the expected tendon graft and creates a nice fit through the tendon sheath. When threaded into the pulley system, the implant should glide freely. The integrity of the pulley system is assessed. A minimal requirement is the presence of A2 and A4 pulleys; however, when possible, a four-pulley system is preferable. The pulleys must be strong and snug but not binding, so that passive gliding of the implant is possible.

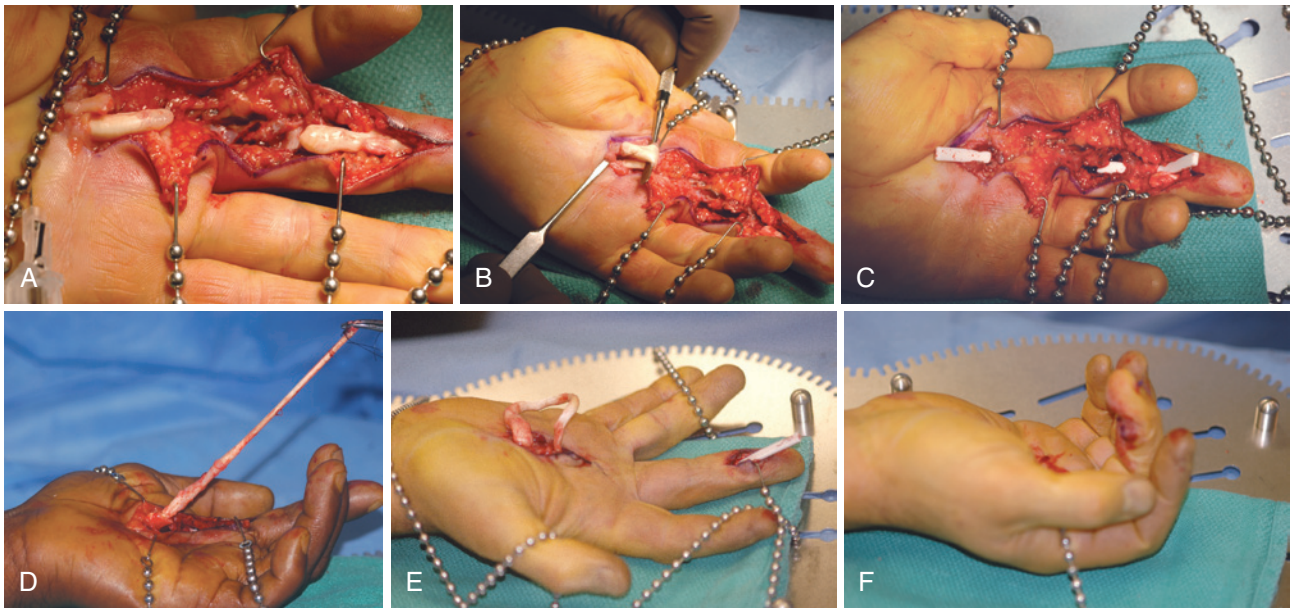

FIGURE 6.36 FDS-FDP Paneva-Holevich reconstruction. **A,** Tendon injury requiring graft reconstruction. **B,** *Stage I:* FDS and FDP loop sewn together with four-strand repair. **C,** Silastic spacer placed in finger, preserving critical pulleys. **D,** *Stage II:* FDS tendon cut at musculotendinous junction and withdrawn into site of previous FDS-FDP juncture. Tenolysis of juncture is required. **E,** FDS tendon tied to Silastic spacer and drawn into finger. **F,** FDS tendon tension set slightly greater than natural cascade of digits.

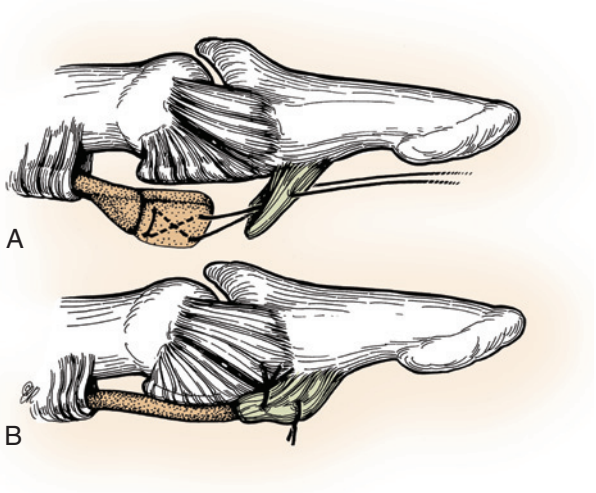

FIGURE 6.37 Stage I flexor reconstruction. **A** and **B,** In the distal juncture wire suture technique, a figure-of-eight suture of 3-0 polypropylene is placed in the implant and sutured to the profundus stump. Additional sutures are placed on each side of the implant. (Copyright Elizabeth Martin.)

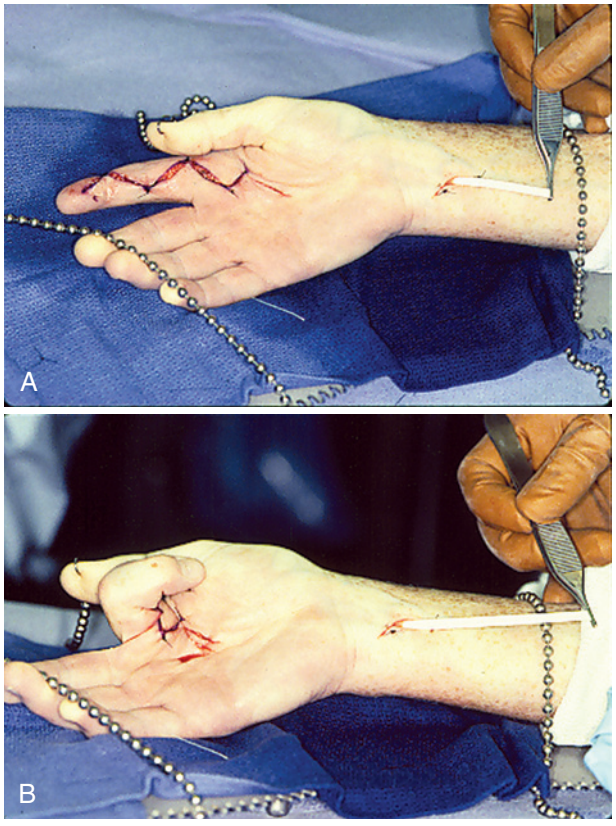

FIGURE 6.38 **A** and **B,** Potential of the planned graft is tested by pulling the implant proximally. A bowstring posture of the implant indicates the need for pulley reconstruction.

The silicone implant is removed from its sterile package, and care is taken to handle the implant with smooth forceps using a "no touch" technique. Handling the rod with standard surgical gloves may lead to talc adherence to the implant and increase the likelihood of an inflammatory reaction. The silicone tendon spacer is placed in the tendon sheath and affixed distally to the distal phalanx with 3-0 polypropylene sutures or wire (Figure 6.37). Proximally, the spacer is placed adjacent to the intended motor for the tendon graft and may be trimmed to end in the palm or threaded across the carpal tunnel and into the distal forearm. At this point the pulley integrity is assessed by traction on the implant (Figure 6.38). Bowstringing of the implant indicates the need for pulley reconstruction. Pulley reconstruction is done over the silicone rod using a variety of pulley techniques and using excised tendon material whenever possible (Figure 6.39, *A* and *B*). The A2 pulley is reconstructed on the proximal half of the proximal phalanx. If a tendon belt loop technique is used, the graft is passed beneath the dorsal extensor apparatus. The A4 pulley is reconstructed on the middle of the middle

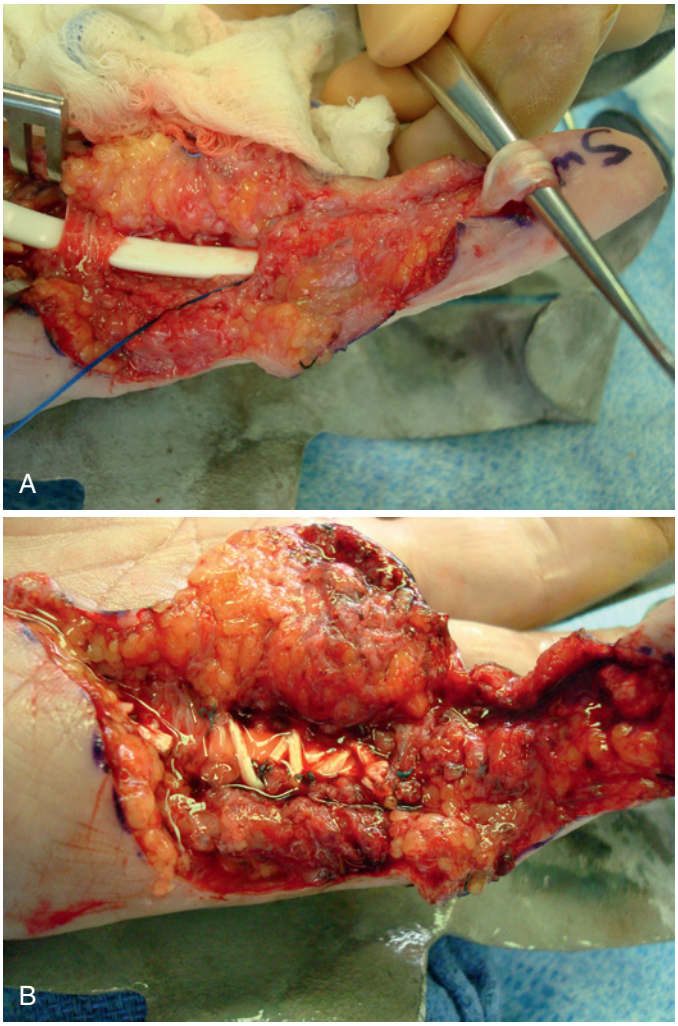

FIGURE 6.39 At the time of implant placement, deficiencies in the pulley system are addressed by pulley reconstruction. **A,** A2 to A3 pulley reconstruction in small finger. **B,** A Weilby repair of the pulley system is performed over the silicone rod. (Copyright Scott W. Wolfe.)

phalanx, and if a belt loop technique is used, it is passed dorsal to the extensor apparatus.

Postoperative Care

After wound closure, a bulky dressing is applied with a posterior plaster splint, so that the wrist is maintained in about 35 degrees of flexion. This splint ensures more proximal placement of the implant, which creates a longer proximal extension of the sheath, giving the implant more room to move without buckling during the passive range-of-motion program between stages I and II. The splint should extend past the fingertips, with the MP joints kept in 60 to 70 degrees of flexion and the IP joints relaxed in the extended position.

Passive motion is started on the first postoperative visit 2 to 3 days after surgery. Patients are taught passive range-of-motion exercises, including the use of trapping with adjacent normal fingers to regain passive range of motion of the operated finger. When there is a concomitant nerve laceration, we prefer nerve reconstruction that allows for full digital motion. Often this can be done with a conduit or allograft to avoid tension at the repair site, allowing immediate mobilization of the digit. Patients who also require contracture release will require intensive occupational therapy. The goal is to recover full passive range of motion and to have a stable soft tissue environment prior to implantation of the tendon graft.

The appropriate interval between stages I and II is the time needed for wound healing and the development of a gliding sheath in response to the implant. We usually wait 6 weeks before considering stage II tendon graft implantation and prefer that the patient has maintained full passive range of motion. Because these cases are complex, the specific timing of the second procedure is individualized to the needs of the patient. Any inflammatory reaction to the implant should be controlled prior to stage II, and patients should have achieved full passive range of motion of the involved digit.

Stage II

Technique. After approximately 6 weeks, the second stage can be done and smaller incisions are necessary. The silicone rod is identified using a small incision at the distal phalanx, and care is taken not to disrupt the A4 pulley.

If the proximal juncture is to be done in the forearm, the proximal incision is opened and the soft, thin, translucent pseudosheath identified. The sheath is incised; the proximal implant is exposed; and the common profundus mass tendon is selected most frequently as the motor. For index finger reconstruction, the independent FDP tendon to the index finger is preferable. The superficialis muscle can be used if the FDP tendon is unsuitable. If the hand is uninjured and has compliant tissues, the proximal juncture may be done in the palm; in this case, the FDP motor is exposed in the palm and a tenolysis done to ensure normal gliding. The wounds are packed, and the tourniquet is deflated while a tendon graft is obtained (see Figures 6.24 to 6.26). If the proximal juncture is in the forearm, the palmaris longus is sufficiently long, and either the plantaris (preferred) or a toe extensor must be used.

After hemostasis is achieved, the tourniquet is reinflated and the graft is sutured to the proximal end of the implant and pulled through the pseudosheath by gentle traction on the distal implant (Figures 6.40 and 6.41). The distal juncture is created using the surgeon's preference and based on the presence or absence of the FDP stump. The distal wound is closed.

Attention is now directed to the proximal juncture. The graft is woven into the motor tendon or tendons (see Figure 6.39, *B*). When only one motor is used, an end-weave technique is advised (see Figure 6.30). In cases in which the profundus mass of the long, ring, and little fingers is chosen as a common motor, an interweave juncture (see Figure 6.39, *B*) is created to the common origin of these tendons. It is important to choose a juncture site that enables full simultaneous extension of the digits and wrist without impingement on the flexor retinaculum. Tensioning is performed following the first weave to gain an appropriate flexion cascade (eFigure 6.1).

In the less common instance in which the palm is not compromised by trauma or through prior surgery, a shorter graft can be used, motored by the FDP tendon at the lumbrical origin. A sufficiently proximal juncture is necessary to avoid impingement on the flexor tendon sheath when the finger is in full extension. The option of using an adjacent FDS tendon as a motor is also available within the palm if the FDP tendon is deemed inadequate. The wound is closed by careful eversion of

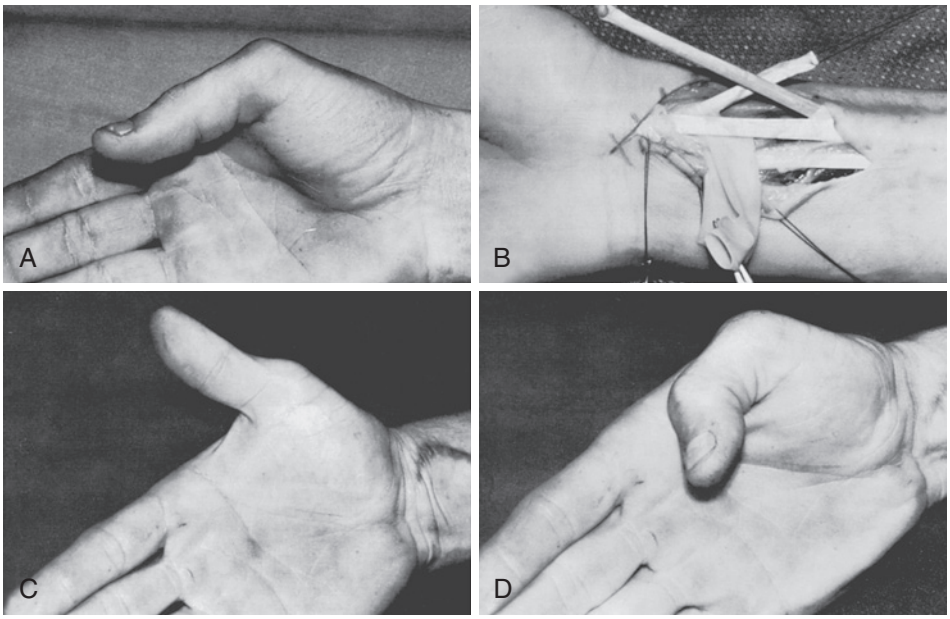

eFIGURE 6.1 FPL reconstruction using FDS tendon from ring finger. **A,** Loss of active flexion at IP joint of the right thumb in a 28-year-old machinist with an old zone 5 laceration. **B,** Distal FPL stump is obtained; FDS is brought over into the same wound. An interlace juncture is used. **C** and **D,** Range of extension and flexion after 6 months. FDS tendon is long enough to use for any level of laceration of FPL, even out at the insertion.

CRITICAL POINTS ***Two-Stage Flexor Tendon Reconstruction: Stage I***

Indications
- Extensive peritendinous adhesion and failure of tendon repair.
- Crush injuries associated with an underlying fracture or overlying skin damage.
- Failure of previous operations.
- Damaged pulley system.
- Joint contracture.
- Nerve or artery reconstruction.
- Repair of nonunion.

Contraindications
- Recent or remote septic tenosynovitis.
- Patients with severe neurovascular impairment are poor candidates.
- Arthrodesis or amputation may be a better alternative.

Preoperative Evaluation
- The patient must understand the necessity of the prolonged postoperative therapy program.

Pearls
- A range-of-motion and scar-softening therapy program is important to attain maximal preoperative passive range of motion and to evaluate the patient's willingness to participate in postoperative therapy.

Technical Points
- Preserve potential pulley material, injured or uninjured.
- Transect the proximal FDP tendon at the level of the lumbrical origin.
- Correct joint flexion deformities.
- Make a second incision in the distal forearm.
- Identify the involved FDS tendon, draw it into the wound, and transect it near the musculotendinous junction.
- Determine the appropriate size of the silicone implant.
- Assess the integrity of the pulley system; the presence of the A2 and A4 pulleys is a minimum requirement.
- Affix the silicone implant to the distal phalanx with 3-0 polypropylene sutures.
- Exert traction on the proximal end of the implant to observe the range of motion.
- If there is significant bowstringing at A3, it must be corrected at this stage with additional pulley reconstruction.

Pitfalls
- Ensure that the tendon implant does not buckle with passive flexion.

Postoperative Care
- Apply a splint with the wrist in 35 degrees of flexion, MP joints at 60 to 70 degrees of flexion, and IP joints extended.
- Start passive motion on the first postoperative visit.
- Contracture releases may benefit from dynamic splinting (6 to 8 weeks).

the skin edges, and a short-arm dorsal blocking splint is applied, with the wrist in neutral position, the MP joints flexed 45 degrees, and the IP joints in neutral position.

Postoperative Care. Protected passive range of motion and an early controlled active motion program are begun within days of surgery. At 2 weeks after surgery, short-arc active extension and flexion and place-and-hold flexion exercises can be added to the therapy program. Resistance is added to the exercise regimen at 4 to 6 weeks after surgery based on the strength of the repair and the degree of adhesion formation. Dynamic splinting may also be employed at 6 to 8 weeks to combat joint contracture. Therapy must be more aggressive, with active and resisted exercises being instituted earlier in cases where tendon adhesion is observed. Therapy should be supervised and reinforced on a regular basis.

For less compliant patients and children, the hand may be immobilized initially, followed by active and passive range-of-motion exercises at 3 weeks and blocking at 4 weeks. The program is continued as in the early mobilization program described previously.

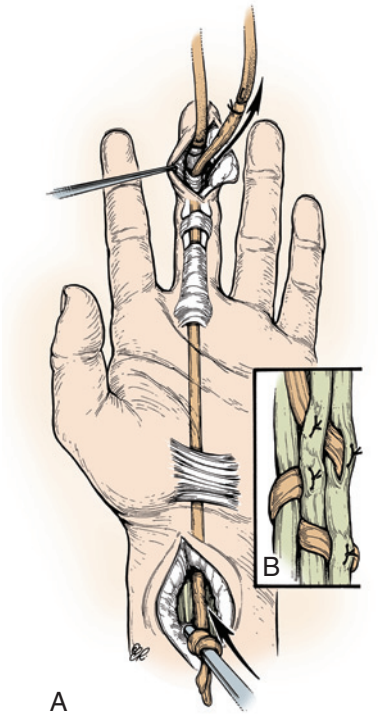

FIGURE 6.40 Stage II flexor reconstruction. **A,** Distal portion of finger wound and distal forearm wound are opened, and both ends of the implant are located. Tendon graft is now sutured to the proximal end of the implant and drawn into the newly created sheath. **B,** Proximal juncture is either an interweave of the graft into the adjacent FDP motor in the case of the long, ring, and little fingers or an interlace into the FDP tendon of the index finger. (See Figure 6.33 for the Pulvertaft end-weave technique.) (Copyright Elizabeth Martin.)

Thumb Flexor Tendon Reconstruction

The flexor system of the thumb is less complicated than the flexor system of the fingers. The thumb contains one fewer joint than the fingers, and only one tendon (the FPL tendon) is involved. When the FPL tendon is reconstructed, a more modest recovery of 30 to 40 degrees of active IP joint flexion is associated with excellent thumb function. For these reasons, reconstruction of the FPL is often indicated after failure of repair or neglected injury.

Indication

Direct repair at all levels of injury may be possible 3 to 6 weeks after injury and even later in cases in which the tendon ends have not widely separated.[7,151,233] Reconstruction for FPL tendon injuries is indicated when satisfactory passive IP joint motion is established and primary repair is no longer possible.

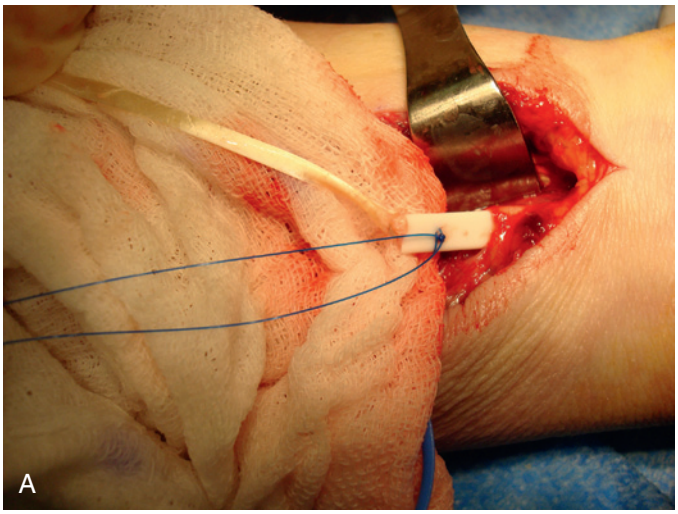

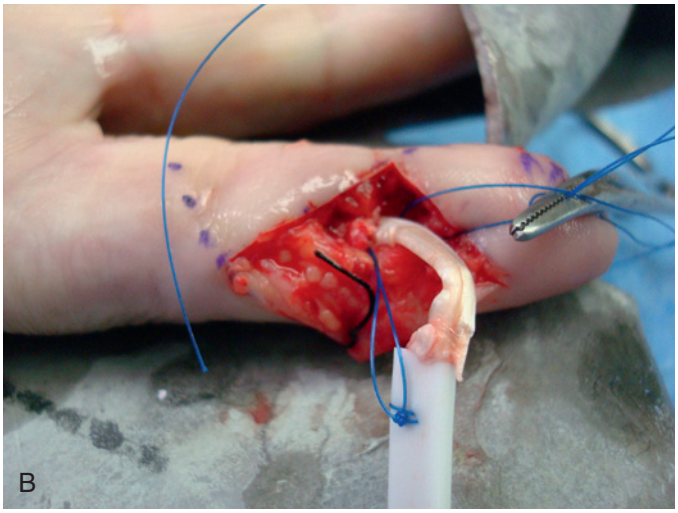



FIGURE 6.41 Stage II. **A,** Plantaris tendon graft is secured to the proximal end of the implant in the distal forearm. **B,** Implant is removed from distal incision, pulling the graft into place. The graft is sutured distally and proximally. **C,** Tension is adjusted following distal fixation with a pull-out suture and before completing the proximal Pulvertaft weave to attain an appropriate flexion cascade. (Copyright Scott W. Wolfe.)

CRITICAL POINTS *Two-Stage Flexor Tendon Reconstruction: Stage II*

Indication
- Patient who underwent stage I of flexor reconstruction process.

Preoperative Evaluation
- The interval between stages I and II is at least 6 weeks.
- The hand wounds should be soft and durable, and the joints should be fully mobile.

Pearls
- The newly formed sheath is disturbed as little as possible.
- Proximal juncture is placed in the forearm: a longer graft is needed (plantaris or toe extensor), motored by the FDP tendon.
- Proximal juncture is placed in the palm (palm not involved in trauma): a shorter graft can be used (palmaris), motored by the FDP tendon at the lumbrical origin.

Technical Points
- Open the distal portion of the finger incision to the middle of the middle phalanx.
- Locate the implant at its attachment to the distal phalanx.
- Reopen the proximal incision in the distal forearm or the midpalm.
- Excise the forearm fascia, and incise the sheath.
- Select the motor.
- Obtain the tendon graft.
- Suture the graft to the proximal end of the implant and pull it distally through the sheath. It should pass smoothly.
- Fix the distal juncture.
- Create the proximal juncture with a slight increase in the flexor cascade for the grafted finger.

Pitfalls
- Proper tension on the graft and proximal tendon excursion are essential for success.

Postoperative Care
- Apply a short-arm dorsal blocking splint (wrist in neutral position, MP joints at 45 degrees, and IP joints in neutral position).
- Begin therapy in a formal setting.
- Start protected passive range-of-motion and early controlled motion program.
- Use dynamic splinting for contractures.

Reconstruction can be done by intercalary tendon grafting (single- or two-stage grafting) or by tendon transfer.

Thumb Free Tendon Graft

Technique. The same basic technique is used as has been described for free tendon grafting in the fingers. The flexor system is approached through a volar zigzag incision from the distal phalanx to the MP joint. The essential oblique pulley is preserved with care, and the injured tendon is excised. Incompetence of the pulley system is an indication to proceed to a two-stage grafting procedure with a silicone tendon spacer. A second 6-cm incision is made in curvilinear fashion at the volar-radial aspect of the distal end of the forearm. The musculotendinous junction of the FPL tendon is identified, and the transected tendon is pulled into this incision. The palmaris longus or plantaris tendon is obtained and threaded through

the pulley system with a tendon passer. The distal juncture is performed, preferably using a weave or docking repair to bone with suture anchors. A distal pull-out suture technique can also be employed when necessary. The distal wound is closed. The graft is interwoven into the proximal tendon of the FPL using a Pulvertaft weave (see Figure 6.32). The graft tension should be adjusted at the time of forming the proximal juncture such that with the wrist in neutral, the thumb IP joint is in approximately 30 degrees of flexion.

After wound closure and dressing, a dorsal splint is applied with the wrist in neutral to 5 degrees of flexion and the thumb protected in about 30 degrees of abduction at the carpometacarpal joint. The MP and IP joints are positioned in 20 to 30 degrees of flexion in the dorsal splint. We use a similar program of immediate passive mobilization and early active mobilization for the grafted tendon when the repairs are durable and the patient is compliant with the hand therapy program. At 6 weeks, more strenuous activities, including blocking techniques, are allowed.

Flexor Digitorum Superficialis Tendon Transfer

An alternative method to tendon grafting, particularly indicated when the FPL muscle is not a useful motor, is use of the ring finger FDS tendon transfer.[173,196]

This method of tendon reconstruction can be particularly useful after rupture of the FPL tendon following treatment of distal radius fractures by plate fixation.

Technique. The zigzag volar approach to the flexor system of the thumb is used, along with a second vertical incision in the distal region of the forearm (eFigure 6.1). The injured tendon is removed with preservation of as much of the pulley system as possible. A transverse incision is made at the base of the ring finger, and the FDS tendon is identified, a tagging suture is placed in one tail, and the tendon is transected about 2 cm proximal to the PIP joint. The tendon is located as the ulnarmost of the two superficial digital flexors in the forearm wound and withdrawn proximally; this may be difficult because of synovial thickenings and tendinous interconnections. A second incision in the palm is used as needed to free these connections. The proximally retracted FDS tendon is passed distally into the thumb flexor sheath, and a distal juncture is done (see earlier in this chapter). Critical tension is more difficult to establish at the distal juncture, especially if a tendon-to-bone technique is planned. For this reason, we prefer the distal juncture interweave technique, in which the graft is woven through the stump of the FDP, allowing more precise distal juncture tensioning (see Figure 6.29).

The repair is fixed with one suture, and tension is evaluated before completion of the juncture. After confirming that satisfactory tension has been established, the distal repair is completed. The rehabilitation protocol postoperatively is similar to that used in free tendon grafting. Mobilization of the transfer by combining active ring finger flexion with thumb flexion helps patients who are learning to use the transfer.

Staged Tendon Reconstruction in the Thumb

In patients in whom it is imperative to restore active thumb flexion and in whom prior surgery has failed, or in whom there is a severely scarred tendon bed, staged flexor tendon reconstruction offers an opportunity to salvage thumb function. This approach becomes even more of a necessity when the retinacular pulley system has been destroyed. Pulley reconstruction over the implant at the level of the proximal half of the proximal phalanx usually suffices if the oblique pulley has been destroyed.

Technique. Details of the technique are similar to those of the technique performed in the fingers. In the thumb, the surgeon can use either a free graft or an FDS transfer at stage II.[127,199]

Other Options After Loss of Flexor Pollicis Longus Function

In patients who have lost FPL tendon function but have a stable distal joint, no additional treatment may be necessary, especially if the carpometacarpal and MP joints are functioning normally. This approach is reasonable in less active patients. When more stable pinch is required, especially in the presence of articular damage at the IP joint or in patients with a hyperextensile IP joint, arthrodesis is a useful alternative.

Secondary Reconstruction of Tendon Injuries in Zones 3, 4, and 5

Indications

When flexor tendons are injured in the palm, wrist, carpal tunnel, or distal forearm, direct repair at an early date is desirable. When primary repair fails, secondary reconstruction carries a more favorable prognosis for these proximal levels than does reconstruction in zone 2. Before secondary tendon surgery, the wounds should be well healed and the hand should be soft and fully mobile. Generous longitudinal, curvilinear incisions are needed to identify and repair the injured structures. The operation is technically easier to do through ample exposure, and the likelihood of additional damage is lessened if all structures are first identified proximally and distally in unscarred areas of normal anatomy and then carefully dissected into the zone of injury using optical magnification. If synovial connections and adhesions have prevented proximal migration of the tendons, direct end-to-end repairs can occasionally be performed. When the tendons cannot be brought together without undue tension, three techniques have proved useful for zones 3, 4, and 5.

Interposition Graft

When trying to reunite the FDP tendon ends in the palm or wrist after delay, the surgeon often finds that a gap of 2 to 5 cm needs to be bridged to bring the tendons to normal functional length. A short tendon graft may be interposed using a segment of the injured FDS or palmaris longus tendon and a bridging suture technique (Figure 6.42).[210] In this setting there is no particular advantage to any particular donor tendon, so the

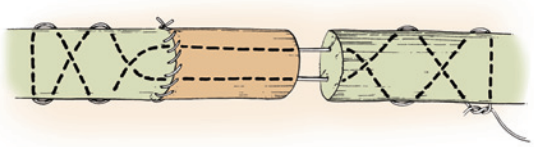

FIGURE 6.42 Interposition graft. By using short segments of available graft material, a gap can be closed in the late repair of zone 3, 4, or 5 injuries. (Copyright Elizabeth Martin.)

CRITICAL POINTS *Thumb Flexor Tendon Reconstruction*

Indications
- Repair of the FPL tendon is delayed or soft tissue trauma does not allow repair.
- Satisfactory preoperative range of passive IP joint motion.

Preoperative Evaluation
- Free tendon graft: similar indications as for fingers.
- Assess the patient for the presence of a suitable donor tendon.
- Superficialis transfer: alternative to free tendon graft.
- Two-stage tendon reconstruction: severely scarred synovial sheath or destroyed pulley system, or both.
- IP joint arthrodesis: when stable pinch is required, especially in the presence of articular damage at the IP joint or in patients with hyperextensile IP joint.

Pearls
- Recovery of 30 to 40 degrees of active IP joint flexion may provide a well-functioning thumb.
- Tension is crucial.
- Tension is estimated by placing the wrist in neutral position, the thumb in palmar abduction in front of the index metacarpal, and the IP joint in 30 degrees of flexion.
- Pulley reconstruction over the implant at the level of the proximal half of the proximal phalanx usually suffices if the oblique pulley has been destroyed. This pulley reconstruction is usually done as a belt loop method passed dorsally underneath the extensor apparatus.

Technical Points
Free Tendon Graft
- Extensile exposure of the thumb is crucial to assess the nature of the injury and the preferred reconstructive method.
- Preserve the pulleys as the damaged tendon tissue is removed.
- Preserve enough distal FPL tendon to allow for a tendon weave method for the distal juncture when possible.
- Make a second incision in the distal forearm.
- Identify the musculotendinous junction of the FPL tendon.
- Obtain the graft, and thread it through the pulley system.
- Fashion the distal juncture by means of a distal pull-out suture technique.
- Interweave the graft into the FPL tendon to create the proximal juncture.

Superficialis Tendon Transfer
- Use a zigzag volar approach to the thumb.
- Make a longitudinal incision in the distal forearm.
- Remove the injured tendon with preservation of the uninjured pulley system.
- Make a transverse incision at the base of the ring finger.
- Flex the finger and divide the FDS tendon distally to allow for sufficient tendon harvest to reach to the distal phalanx of the thumb.
- Transect the FDS tendon 2 cm proximal to the PIP joint.
- Withdraw the tendon into the proximal wound.
- Create a distal juncture as in a free tendon graft.

Pitfalls
- Proper tension is difficult to create with FDS transfer.

Postoperative Care
- Apply a dorsal splint with the wrist in neutral position, the thumb in 30 degrees of abduction at the carpometacarpal joint, and the MP and IP joints in 20 to 30 degrees of flexion.
- Limit passive flexion and active extension with a splint for the first 2 weeks.
- Begin active flexion and extension at 2 weeks.
- At 6 weeks, begin blocking techniques.

most expendable and available donor tendon is selected. Pulvertaft weave methods can also be used for bridging larger gaps with tendon graft and are tensioned so that the appropriate resting posture of the finger is obtained. Proper tension is crucial here, and local or WALANT anesthesia with active cooperation of the patient can facilitate determination of appropriate tension.

Flexor Digitorum Superficialis Tendon Transfer

A tendon gap at the palm or wrist level can be overcome by intercalary tendon grafting or by transfer of an adjacent intact FDS tendon passed deep to the neurovascular bundle or median nerve and sewn to the distal segment of the injured tendon (Figure 6.43 and eFigure 6.2). Any of the techniques described for end-to-end tendon repair can be used. Tension is crucial, and the use of regional or local anesthesia can be helpful for this process.

End-to-Side Flexor Digitorum Profundus Tendon Juncture

It may be possible to attach the distal end of a severed FDP tendon to the side of an intact adjacent FDP tendon, which is best done with an interweave technique (Figure 6.44). Although the technique is more useful in the zone 5 area (forearm), it can also be used in the distal portion of zone 3 (palm). Excursion must be carefully assessed in all positions because the juncture can impinge on the A1 pulley in extension. A1 pulley division should be formed as needed.

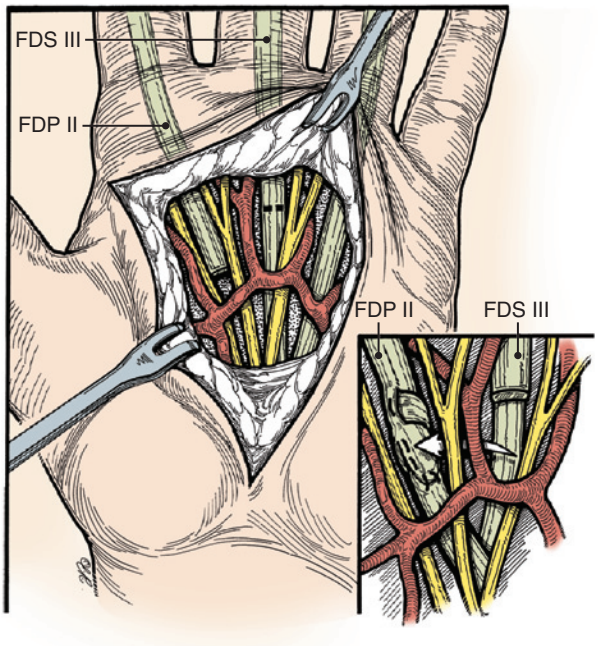

FIGURE 6.43 FDS transfer for FDP injuries in another finger. See eFigure 6.2. (**A,** Copyright Elizabeth Martin.)

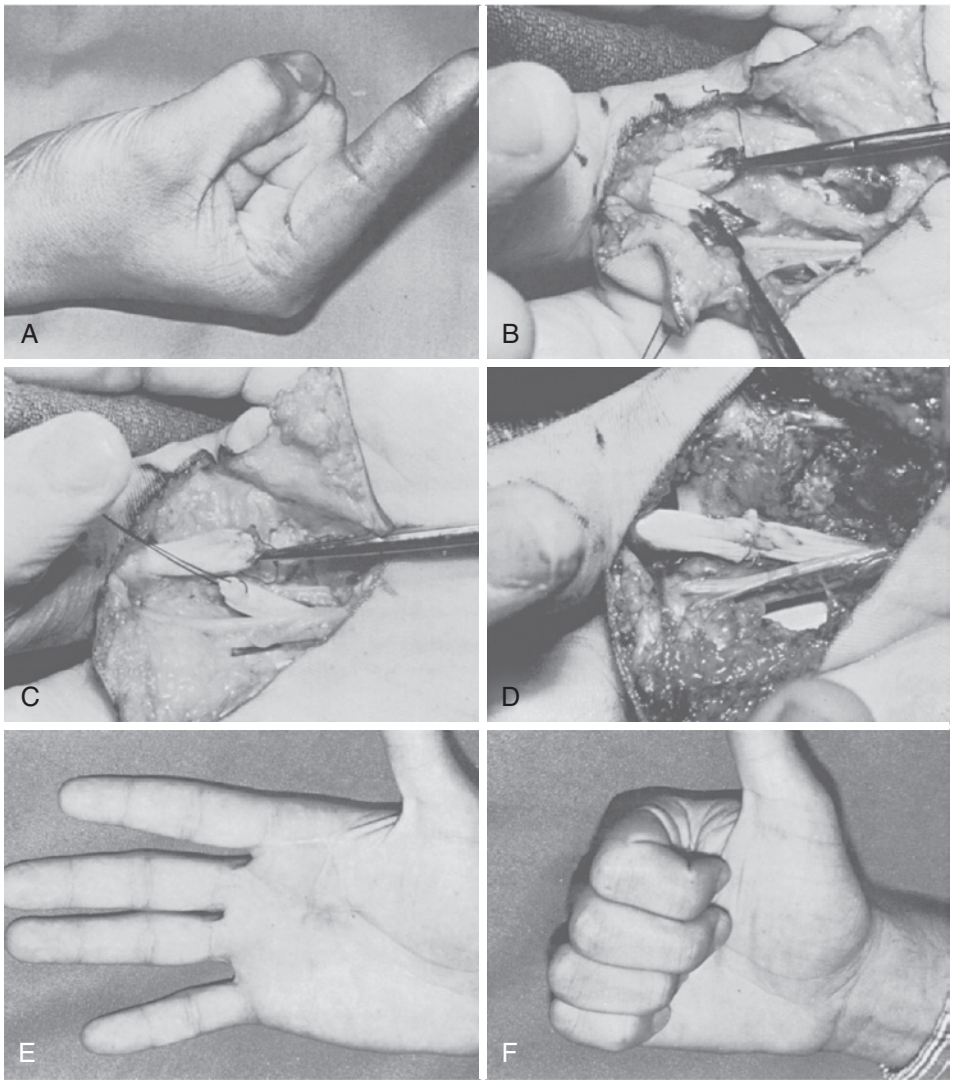

eFIGURE 6.2 FDS transfer for FDP injuries in another finger. **A,** Long-standing injury to flexor tendons in zone 3 in a 20-year-old man. There is no active motion at IP joints. **B,** Distal tendon stumps have been recovered at A1 pulley level. There is good distal pull-through of tendons within the retinacular system. **C,** Superficialis tendon of long finger is transected and brought over to the profundus of the index finger. **D,** End-to-end juncture has been created. **E** and **F,** Extension and flexion at 6 months postoperatively.

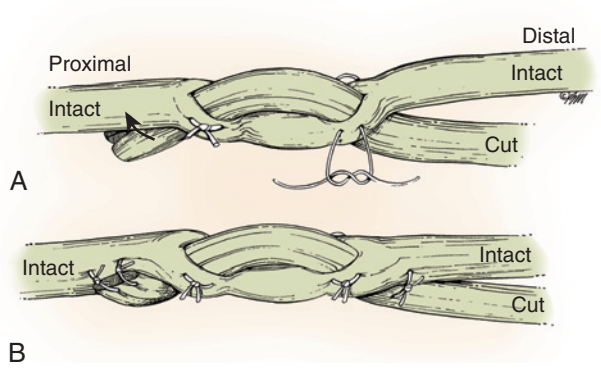

FIGURE 6.44 **A** and **B,** End-to-side interweave suture technique useful in zone 5 injuries. (Copyright Elizabeth Martin.)

Postoperative Care

A short-arm posterior molded plaster splint is applied from the fingertips to below the elbow. The wrist is maintained in neutral position, the MP joints in 40 to 50 degrees of flexion, and the IP joints in neutral position. A program of controlled active range of motion (passive flexion followed by active extension to the limits of the dorsal splint) and protected passive range of motion is begun at the first postoperative visit. Flexion contractures can develop rapidly if full extension at the PIP joint is not achieved early. The patient should be followed closely for development of contractures so that adjustments can be made to the splint and therapy regimen. Active range of motion is introduced early after surgery. Often these repairs are more durable and we will start active motion sooner in the rehabilitation program. Splint protection is discontinued at 4 weeks. Resisted exercise and blocking techniques at each of the IP joints are allowed 4 to 5 weeks after the repair.

Expectations

In general, the outcomes after flexor tendon grafting are inferior to the results of primary flexor tendon repair. Using intrasynovial tendon grafts and early active range-of-motion rehabilitation, Leversedge and colleagues[127] reported that the active motion recovery was 64% for single-stage reconstructions and 55% for multiple-stage reconstructions. Single-digit reconstructions had the best outcomes, with a total active motion recovery of 73% of normal. Coyle and Leddy[41] reported on a fingertip-to-palm reconstruction using a two-stage method and reported an active motion recovery that averaged 91% of the preoperative range of motion. The differences in reporting methods and in the nature of the injury likely account for the differences reported in these two series. Finsen reported on a cohort of 43 patients treated with a two-stage tendon grafting method and found the time away from work was 44 days after the first procedure and 104 days after the second procedure. Furthermore, the author reported that tertiary procedures were needed in 42% of patients and that 28% of patients would not have had the procedure done if they had had to do it again. By their estimation, 28% of patients had a poor outcome. These series highlight the difficult nature of these procedures.[24,41,61,120,127,205,243]

Reconstruction of the Pulley System

Successful reconstruction of the flexor tendon system depends not only on treatment of the tendon itself but also on the important structural aspects of the pulley system.[4,172,242] Because the flexor muscles have a maximum shortening capability, only a certain amount of tendon excursion can be created. The purpose of the annular pulleys is to maintain the tendons in proximity to the joint center of rotation such that an economical amount of tendon excursion can create the desired amount of angular joint rotation. Competent pulleys prevent palmar tendon translation (clinically referred to as "bowstringing"), which may lead to a fixed flexion contracture and limited flexion of the finger. When two or more contiguous annular pulleys are disrupted, decreased range of motion and a PIP joint flexion contracture generally results.

The relative importance of the individual pulleys has been studied by Doyle and Blythe,[45-47] Hunter and colleagues,[98,99] and others.[26,50,130,132,186,207] They confirmed the work of Barton, who stated that at least two pulleys (A2 and A4) need to be retained or reconstructed. If it is determined by direct inspection that flexor tendon bowstringing has occurred despite intact A2 and A4 pulleys, consideration should be given to pulley reconstruction to optimize the efficiency of digital flexion.[95]

Indications

Intraoperative assessment of pulley function during flexor tendon reconstruction is crucial. If a one-stage tendon graft is planned, all uninjured pulley material is retained[100] to encourage flexor tendon healing within the uninjured sheath. If pulley material is absent because of injury or prior surgery, reconstruction must be done, at which time a two-staged tendon reconstruction is recommended.[194] During a two-stage reconstruction, it may be acceptable to repair an injured pulley by suturing the ends over the implant. Damaged pulleys that are structurally intact are also useful in two-stage reconstructions because they would not adhere to the implant as they would to a tendon graft. For this reason, all pulley material is saved at the first stage of the two-stage reconstruction. If a pulley is constricted, the tissue may be dilated, often using a cylindrical probe or small uterine sound so that it can be enlarged sufficiently to accept the implant.

Pulley Reconstruction Using a Free Tendon Graft

When doing a two-stage tendon reconstruction, sufficient tendon material generally may be available after tendon graft harvest to reconstruct the annular pulleys (Figure 6.45). If additional donor material is necessary for pulley reconstruction, we usually use the palmaris longus tendon. There may be a theoretical advantage to the use of the intrasynovial section of the flexor digitorum longus tendon for tendon gliding in a heavily scarred bed.

Many pulley reconstruction techniques have been proposed and tested mechanically. Bunnell advocated encircling the phalanx with a free tendon graft.[30] In his original description, the pulley graft was placed superficial (dorsal) to the extensor apparatus in the middle phalanx and deep to the extensor mechanism in the area of the proximal phalanx. Although this type of pulley reconstruction may be bulky, it has the advantage of being easier to tension and, in our experience, does not seem to have an adverse effect on the extensor system.

Several methods can facilitate wrapping of tendon graft around the phalanx. A curved suture passer may be used to pull sutures placed into the tendon graft around the phalanx. A

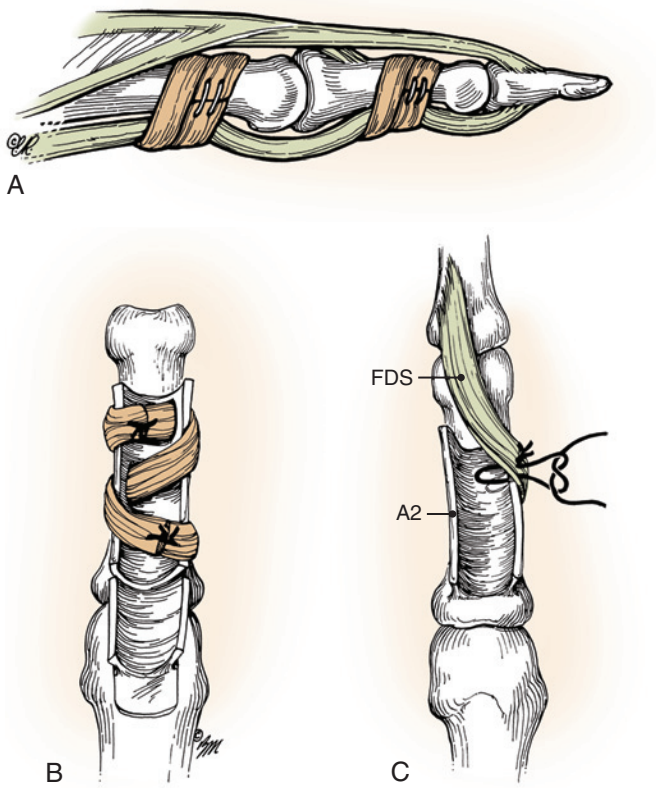

FIGURE 6.45 Methods of reconstruction of pulley system. **A,** Free tendon graft pulleys encircling the phalanx deep to the extensor mechanism at proximal and middle phalanges. **B,** Free tendon graft pulley can be constructed by suturing graft material to the rim of the destroyed pulley. This can take the form of an interweave into the rim, or if the rim is inadequate, the graft can be sutured through drill holes in the bone (not shown). **C,** Tail of FDS tendon, when left attached to its insertion, can be sutured over implant to the periosteum or to the rim of the original A2 pulley. (Copyright Elizabeth Martin.)

Penrose drain that is passed with a right-angled hemostat can also be used. We use a custom instrument designed for this purpose to facilitate both dissection and passage of the tendon graft (Seiler personal data).

Given that the double-loop method has been considered strong enough for early active protected motion,[66,254] encircling the phalanx and tendons twice is a reasonable balance between pulley strength and pulley width. In a study by Lin and coworkers,[130] it was reported that this type of reconstruction using three loops around the proximal phalanx approached the strength of a normal annulus in vitro.[66,254] After the graft is passed, an assessment of the finger is made in both flexion and extension to ensure that the pulley is both appropriately tensioned and approximates the flexor tendon to the phalanx. The reconstructed pulley should be sufficient to resist palmar translation of the flexor tendon when proximal traction is placed on the tendon.

Other methods proposed for pulley reconstruction include Kleinert and Bennett's[116] "ever-present rim" technique. This method weaves a thin graft back and forth through the remaining rim of the pulley system (see Figure 6.45, *B*). Doyle and Blythe[47] described a technique in which the graft is passed through a drill hole in the phalanx and then sutured back to itself. While durable, this technique may weaken the phalanx, creating a possibility for intraoperative or postoperative phalangeal fracture.

Different pulley reconstruction techniques were compared in an elegant in vitro study using intrasynovial and extrasynovial tissue sources. Intrasynovial grafts such as the extensor retinaculum or FDS tendon showed lower resistance to tendon gliding than extrasynovial sources such as the palmaris longus or extensor digitorum communis tendon. Among extrasynovial sources, the extensor tendon had more favorable characteristics than the palmaris longus tendon. An encircling method was recommended over tendon weaving through pulley remnants.[163]

Pulley Reconstruction Using a Flexor Digitorum Superficialis Tendon

The FDS tendon tail may be used as a pulley if it is long enough (see Figure 6.45, *C*). In this technique, the distal attachment is preserved, and the free proximal end is sutured over the implant onto the contralateral side. It may be sutured to either periosteum or the original pulley rim, or fastened via small holes drilled into bone. This makes an excellent pulley in the A3 area.

Pulley Reconstruction Using the Extensor Retinaculum

Lister[133] described good results with a technique in which a segment of the extensor retinaculum from the dorsum of the wrist is passed around the phalanx for pulley reconstruction. The advantages of this technique are that (1) the undersurface of the retinaculum is an ideal gliding surface (the broad fourth dorsal compartment segment of the retinaculum is rotated into a position overlying the flexor tendon or silicone implant), and (2) the new pulley is strong enough to allow early motion (e.g., after tenolysis). The major disadvantage is that harvesting the 6- to 8-cm length of retinaculum is technically difficult and time-consuming and requires a separate incision. Tang and associates[224] used the sheath of the first dorsal compartment to reconstruct the digital sheath with good results in delayed tendon repairs.

Pulley Reconstruction Using the Volar Plate

Karev[110] described a technique that creates slits in the volar plate for pulley reconstruction. More recent articles have suggested that this "belt-loop" technique is nearly as strong as a normal annular band but does not attain normal joint motion.[66,254] Widstrom and coworkers[247] published an excellent comparison of different pulley reconstruction techniques. They showed that among six methods studied in cadaver limbs, the technique of Karev was the most mechanically effective, but an encircling technique was the strongest and most resistant to failure.

Pulley Reconstruction Using Artificial Materials

Artificial materials have been used in the reconstruction of pulleys. These materials include knitted Dacron arterial graft,[254] silicone rubber sheeting, xenograft materials, polytetrafluoroethylene, woven nylon and fascia lata, and porcine collagen and peritoneum. The use of artificial materials is not routine at this time.

❖ AUTHORS' PREFERRED TECHNIQUE: Pulley Reconstruction

We prefer to create a circumferential pulley using the method of Bunnell. Our choice, however, is to place the graft deep to the extensor at the proximal and middle phalangeal levels (see

Figure 6.45, *A*). We prefer to use the palmaris longus tendon for our donor tendon and consider using the flexor digitorum longus tendon in complex cases.

At the proximal phalanx level, the tendon graft is placed inside the neurovascular bundles and deep to the dorsal extensor mechanism to prevent compression of the intrinsic system. To best simulate the biomechanics of the A2 and A4 pulleys, we use a minimum of two circumferential wraps for A2 and A4. Each wrap is passed around the phalanx under direct vision, and the repair is finished and tensioned using a modified Pulvertaft-type method, passing the graft through itself and tensioning it sufficiently to maintain the tendons in position. The repair is secured with a nonabsorbable mattress suture, and then the entire repair can be rotated away from the volar surface of the digit to minimize the impact of the repair on the volar tendon reconstruction. If the entirety of the A2 pulley requires reconstruction (which is normally 18 to 20 mm in length), this may require three to four tendon wraps. In the A4 region, two wraps create a pulley approximately 10 mm in length and should adequately simulate the biomechanics of the native pulley (Figure 6.46). For severely damaged tendon sheaths, a combination of strategies and donor grafts may be necessary to reconstruct the pulleys sufficiently to withstand the stresses of digital flexion. For reference, approximately 6 to 8 cm of graft is required to encircle the phalanx one time.

Postoperative Care

Postoperatively, splinting should include an external protective pulley ring, worn for 4 to 6 weeks. This ring can be rigid and fabricated from moldable plastic or flexible and formed from a simple elastic wrap. The therapist should be apprised of the pulley reconstruction so that this area can be supported manually during active and resisted exercise.

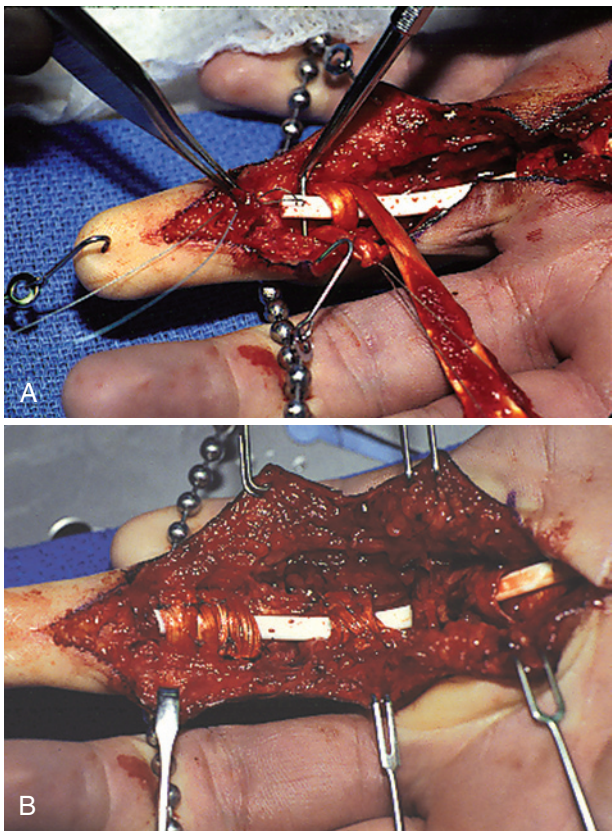

FIGURE 6.46 **A** and **B,** Pulley reconstruction. Resected FDS tendon is used to create a circumferential-type pulley around the silicone tendon implant by the phalanx technique.

CRITICAL POINTS *Pulley Reconstruction*

Indication
- Inadequate pulley function or bowstringing.

Preoperative Evaluation
- During a two-stage reconstruction, it may be acceptable to repair an injured pulley by suturing the ends over the implant.
- The most popular method of pulley reconstruction is the Bunnell encircling method.
- Other options include the Kleinert technique of weaving the graft into a remnant of the pulley rim, the Karev volar plate belt-loop technique, and the Lister extensor retinaculum pulley reconstruction.

Pearls
- The reconstructed pulley must be vigorously tested under direct visualization on the operating table.
- The tendon must be held as close to underlying bone as possible without restricting gliding.

Technical Points
- The encircling method requires a 16-cm graft for A2 reconstruction (phalanx encircled twice).
- Place the graft inside the neurovascular bundles and deep to the extensor mechanism at all levels.

Pitfall
- When encircling the phalanx with the graft, protect the neurovascular bundle.

Postoperative Care
- Wear a protective external ring for 4 to 6 weeks to protect the reconstruction.

Flexor Tendon Reconstruction in Children

Indications

Flexor tendon injuries in children can be particularly difficult to diagnose and treat. Careful observation and the use of various tricks geared to stimulate withdrawal of the fingers into flexion assist in the diagnosis of flexor tendon disruption. Children heal rapidly, and contractures rarely develop unless the joint has been directly injured. Generally, if wound conditions permit, direct early repair at all ages and all levels of injury is encouraged.[55,88,191] Flexor tendon grafting in young children is particularly difficult, and the appropriate timing for this procedure has been debated. Although loupe magnification helps eliminate technical difficulties, the physically small size of the tendon or silicone graft does not always hold sutures well, and repair site gapping may occur after primary repair. The inability of children to cooperate in postoperative care and rehabilitation has also been cited as a reason for poorer results.[176] Although one study concluded that age was not a contraindication to grafting,[61] and grafts have been successfully placed in young children,[8] we advocate a conservative approach and encourage waiting until the patient is age 7 years or older.

❖ AUTHORS' PREFERRED TECHNIQUE: Tendon Graft in Children

The technique for tendon graft in children is essentially the same as that in adults except that the distal juncture is not generally placed through the distal phalangeal bone. Our method in children and adults is the "around-the-bone technique," woven through the FDP stump, if available. Another technique involves placement of the graft through a split in the FDP stump that is then passed through the fingertip (see Figure 6.30, *C*). If no distal stump is present, the graft may be secured directly to bone with nonabsorbable sutures through drill holes placed *distal* to the physeal plate.

The preferred graft material is the palmaris longus or FDS tendon of the injured finger. A plantaris tendon in a child may be too thin to hold sutures adequately, so informed consent should enable use of other sources. As the child grows, a successfully placed flexor tendon graft is likely to grow with the child's hand. This clinical observation was questioned by Hage and Dupius,[81] however, who reported that, despite good function, the involved finger remained slightly smaller than the uninjured fingers.

Flexor tendon injuries are difficult problems for the child and the surgeon. The difficulties encountered with grafting make direct repair a better procedure than late reconstruction.[25,170] As with hand injuries in other children, the use of absorbable skin sutures makes aftercare more pleasant.

CRITICAL POINTS *Tendon Reconstruction in Children*

Indication
- Same as in adults.

Preoperative Evaluation
- Direct repair is preferable to late reconstruction.
- Reconstruction should be deferred until the patient is 7 years old or older.

Pearls
- Skin suture is done with absorbable material.
- Children heal rapidly, and contractures rarely develop unless the joint is directly injured.
- The plantaris tendon is too thin.

Technical Points
- Use the same technique in children as in adults except for distal juncture.
- Do not violate the distal phalanx epiphysis.
- Pass distally out of the fingertip and/or weave into the distal FDP stump.
- For graft material, the palmaris longus or FDS tendon of the injured finger is preferred.

Pitfalls
- Children present difficulties with diagnosis.
- Because of its small size, the tendon or silicone graft does not hold sutures well.
- Young children cooperate poorly in postoperative care and rehabilitation.

Postoperative Care
- The flexor tendon graft should grow with the child's hand.
- The involved finger may remain slightly smaller than uninjured fingers.

Complications Following Flexor Tendon Grafting

Adhesion Formation

The most common problem after flexor tendon grafting, as in all flexor tendon surgery, is adhesion formation. This formation may occur at any level of the graft reconstruction. To help reduce this problem, the surgeon must practice gentle handling of the tissues, use fine instruments, and adhere to proven surgical indications. Each injury to the surface of the tendon results in an adhesion at that level. The assistance of a good hand therapy program often helps mobilize adhesions and guide the patient through the critical 8-week period after surgery. Tenolysis (stage III) can improve tendon graft excursion in patients with adhesion formation, provided that the patient has reached a plateau and at least 3 to 6 months have elapsed since the grafting procedure.[60] Tenolysis can also be associated with tendon graft failure.

Mechanical Failure of the Implant

Breakdown of the distal juncture during stage I of a two-stage reconstruction is rare.[249] Dacron-reinforced silicone is recommended to prevent suture pull-out. The proximal end should not be sewn to a muscle motor in an attempt to create an "active" implant. This juncture usually disrupts and creates additional irritation and scarring in the forearm. If this unnecessary proximal juncture is stronger than the distal juncture, the distal end may rupture.

Graft Rupture

Breakdown at the proximal or distal juncture of a tendon graft has been seen in primary tendon grafting and staged tendon reconstruction. Adherence to excellent surgical technique and a closely supervised hand therapy program has made this a rare complication. When rupture at the graft juncture does occur, the patient can usually determine the location of the rupture. If recognized early, the situation can be salvaged by early reoperation. This complication occurs more frequently at the distal juncture. If the tendon cannot be advanced to the original insertion, the end of the graft can be attached to the middle phalanx, and an FDS-only finger can be created. Attenuation of the graft interweave can manifest as a proximal graft rupture. Early exploration of the distal forearm often leads to successful reattachment. Although most failures occur within the first few months after surgery, late intratendinous rupture has been reported.[57]

Pulley Disruption

Pulley failure is confirmed by a reduction of previously regained range of motion combined with bowstringing of the tendon graft. Early blocking support of the flexor tendon using the patient's contralateral hand, a wooden block, or an external ring helps maintain necessary tendon gliding while consideration for secondary pulley reconstruction is undertaken. The complication of reconstructed pulley disruption has been virtually eliminated in our practice with the use of an encircling method.

Quadriga Syndrome

Quadriga syndrome manifests as a decrease in flexion of an adjacent normal finger when an FDP tendon has been shortened or becomes adherent due to injury, repair, or

reconstruction.[189] It was first described by Bunnell[30] and later by Verdan[234]; the term *quadriga* is derived from the Roman four-horse chariots driven by one charioteer who controlled all four horses with a common rein. If injury or a surgical procedure prevents normal proximal excursion of a single FDP tendon, a tethering effect is experienced by the other FDP tendons that share a common musculotendinous origin. The adjacent FDP tendons cannot fully flex their respective digits, and the injured finger develops a flexion deformity.

The quadriga syndrome may occur in numerous settings, as when one FDP tendon is advanced too far distally in a reattachment procedure in zone 1. Other causes include a tendon graft that is too short, a distal finger amputation in which the flexor is sutured over the tip to the extensor tendon, or an amputation in which the FDP tendon adheres to the proximal phalanx. Treatment is tendon lengthening, tenolysis, or severing of the offending tendon to allow the other normal adjacent fingers to flex fully.

Hyperextension of the Proximal Interphalangeal Joint

Absence of the FDS tendon in a grafted finger may result in a hyperextension deformity at the PIP joint.[170] It manifests as a swan neck deformity with difficulty initiating flexion at the PIP joint and is more apt to occur in patients with hyperextensile, loose joints. A tenodesis with one slip of the FDS tendon across the PIP joint may prevent or resolve the deformity.

Lumbrical-Plus Finger

The reverse of the quadriga effect is the lumbrical-plus finger described by Parkes,[170] seen when a graft is placed with insufficient tension.[54,56] This complication occurs because the lumbrical origin is normally pulled proximally with proximal movement of the FDP tendon. If an FDP tendon graft is too long, traction is exerted on the lumbrical muscle, which paradoxically causes extension of the IP joints. This problem can be avoided by ensuring proper length at the time of placement of the graft.

Synovitis

Synovitis after stage I is characterized by increased warmth, crepitus, and swelling secondary to fluid accumulation within the sheath. It is associated with a thickened, less pliable sheath at stage II (eFigure 6.3). Its incidence was initially believed to be 15% to 20%, but more recently synovitis was identified in 8% of patients after stage I surgery.[14] This serious complication is often, but not always, followed by a less successful end result after stage II. Cultures for bacteria in the fluid found within these sheaths have consistently shown no growth.

Although the inciting cause for this inflammatory reaction is not always apparent, certain circumstances are implicated. Breakdown of the distal juncture after stage I is often followed by a clinical picture of synovitis. Rigid fixation of the tendon implant to the distal FDP stump and use of a Dacron-reinforced implant have all but eliminated this cause of mechanical sheath irritation. Buckling or binding of the implant because of tight or inadequate pulleys is another cause for synovial irritation. Appropriate pulley reconstruction should eliminate this problem. Intraoperative finger motion at the time of stage I surgery usually shows the need for either further dilation or reconstruction of a pulley. Postoperative lateral radiographs in flexion and extension identify the amount of implant excursion and often show buckling if present.

An effort to minimize implant handling and careful cleansing of the surgeon's gloves reduce the likelihood that foreign materials such as talc may induce synovitis. When synovitis is recognized, the patient's exercise program should be limited to short periods of passive range of motion, and resting splints should be employed. An earlier stage II procedure may be advisable if the problem is not controllable.

Infection

As in any implant procedure, postoperative infection after stage I is a disastrous complication. When confronted with infection in the sheath, antibiotic irrigation with small-bore catheters has been attempted. Established infection generally necessitates removal of the implant, with a healing period of 3 to 6 months and then, if feasible, placement of a new implant.

Late Flexion Deformity

A late flexion deformity may develop in the postoperative period and may be related to an incompetent pulley system, splinting difficulties, or wound contracture. These problems require early intervention and are rarely seen in patients with good initial motion after stage I. When noticed early, splinting the digits in extension between therapy sessions and at night can correct this problem. This program combined with gentle stretching exercises may continue for 1 year. Chronic deformities may require capsular release and flexor tenolysis. Flexion deformity may also be caused by an inadequate annular pulley system and resultant bowstringing. Joint contracture release at stage I and the construction of strong pulleys are of paramount importance.

Future Concepts

Investigators reporting on current concepts in tissue engineering have found that the flexor tendon is a tissue type amenable to various methods of tissue engineering. Allograft tendons and engineered tissue avoid any potential complications with autograft harvest and address the issue of graft availability in multiple-digit tendon reconstructions. Chong and colleagues, using a rabbit model, found that grafts can be satisfactorily acellularized and that acellularized tendon grafts provide high-strength scaffolding for tendon grafting.[37] Furthermore, it may be possible to seed these grafts with cells and to modify their surfaces, which creates a tendon graft optimized for gliding within the specialized synovial spaces of the hand.[93] Chang has worked extensively with stem cells derived from adipose tissue and with certain growth factors to delineate their use in seeding allografts for tendon grafting.[179,188] With improvements in these methods, it may be possible to engineer tissue that is optimized for the purpose of tendon grafting. Numerous investigators are examining the use of surface modifications to allograft tendons to reduce adhesions and gliding ability following tendon reconstruction. Using a canine model, Zhao, Amadio, and colleagues found that carbodiimide-derivatized hyaluronic acid and gelatin-modified intrasynovial allografts had less mean work of flexion and reduced gliding resistance compared with saline controls.[259] Follow-up in vivo canine studies have shown that resurfacing allograft tendons with carbodiimide-derivatized hyaluronic acid combined with lubricin resulted in fewer

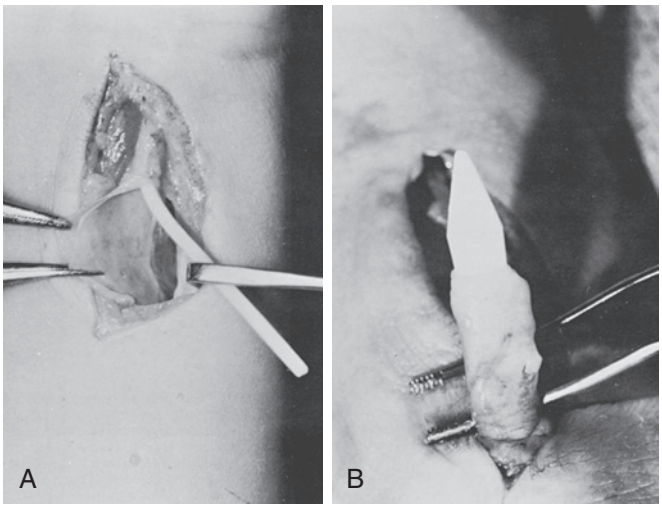

eFIGURE 6.3 Sheath formed in response to the implant as seen at stage II. **A,** Soft, translucent sheath seen at 3 months in a patient with a benign postoperative course. **B,** Thickened sheath seen in a patient with synovitis after stage I.

adhesions, less resistance, and less work of flexion. This surface modification resulted in inferior healing at the tendon-bone repair site as seen on histologic studies, however.[258]

With growing concerns about failure at the tendon-bone interface at the distal juncture, bone-block tendon allografts theoretically allow bone-to-bone healing versus tendon-to-bone healing. Biomechanical studies have addressed the ability to use bone-block tendon grafts for distal repair. Using a cadaveric model, Wei and colleagues compared the mechanical force of three distal juncture techniques: a suture pull-out technique, a suture anchor technique, and a suture pull-out with an FDP allograft with the distal bony attachment intact.[244] The authors found no difference in the load to failure and the stiffness in reconstructions using the suture pull-out or suture anchors. The group treated with the bony attachment had a significantly higher tensile strength compared with the group treated with tendon-to-bone attachment. Other cadaveric studies have shown no significant difference in the tensile strength of these tendon-to-bone composite allografts even after decellularization processes.[63]

Flexor Digitorum Superficialis Finger: Salvage Procedure

In flexor tendon reconstruction, an effort is usually made to restore active motion in the PIP and DIP joints. Occasionally, under specific conditions, efforts are directed at regaining motion only in the PIP joint in a more modest attempt to salvage function. This procedure has been called the FDS finger, although most of these reconstructions, in our experience, have been motored by the FDP tendon inserted into the middle phalanx. Perhaps the term *PIP joint finger* would be more appropriate.

The following three clinical scenarios involve flexor tendon disruption without reasonable likelihood of achieving acceptable DIP joint motion. Under these circumstances, restoration of motion at the PIP joint alone might be considered:

- *Type I*: Digits in which the DIP joint is inadequate because of either articular damage or extensor mechanism dysfunction (i.e., DIP arthrodesis).
- *Type II*: Digits with a poorly functioning flexor system because of tendon bowstringing secondary to pulley absence or failure despite one or more attempts at pulley reconstruction.
- *Type III*: Digits in which the distal insertion ruptured after tendon grafting.

Technique

In type I, a standard tendon graft is performed as described earlier, but the graft is inserted into the middle phalanx by the pull-out technique as used in the standard tendon graft. Particular attention is directed to padding placed between the button and the skin to distribute skin pressure over as wide an area as possible. Alternatively, the graft can be sutured by various techniques: to the middle phalanx via use of the pulley remnants; to the FDS tail, through the use of suture anchors; or to the local periosteum (Figure 6.47). With the patient anesthetized, tension must be adjusted so that with the wrist in neutral, the finger adopts a flexion posture at the PIP joint similar to that of the adjacent fingers. Whenever possible, we prefer to do this procedure with local sedative anesthesia so that the patient can cooperate directly in the setting of distal juncture tension at the middle phalangeal level. In situations in which the distal joint is unstable, arthrodesis or tenodesis in 20 to 30 degrees of flexion is also done.

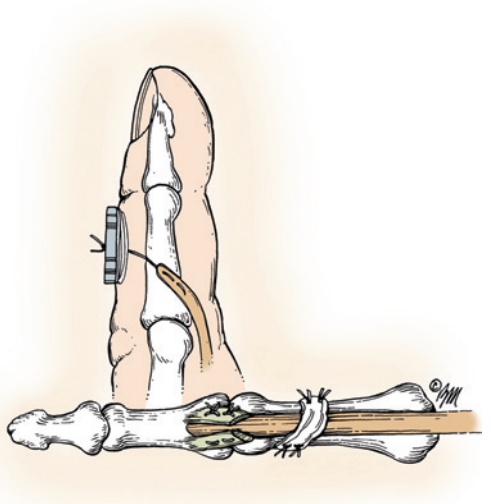

FIGURE 6.47 FDS finger. Graft is inserted into middle phalanx by one of several techniques. If the distal joint is unstable, tenodesis or arthrodesis of the DIP joint can be carried out at the same operation. (Copyright Elizabeth Martin.)

In types II and III, the FDP tendon is identified through a volar approach to the finger and reattached, preferably to bone. The technique is the same as in type I cases except that pulley reconstruction is needed in type II cases. The use of local anesthesia to allow active participation of the patient is useful.

Postoperative Care

Tendon grafts (type I) are treated exactly as a standard graft would be treated. In types II and III, early unresisted motion is allowed in a protective dorsal splint, which may be combined with gentle rubber band traction on the fingernail, according to the surgeon's preference. The MP joints are placed in 70 degrees of flexion, with the posterior splint allowing full PIP joint extension. The wrist is flexed approximately 30 degrees. When a pulley is reconstructed, a molded plastic ring splint measuring about 2 cm in width is fabricated and worn to protect the pulley. At 3 to 4 weeks, the splint is removed, but the rubber band, attached to a wrist cuff, is continued for a total of 6 weeks. The ring is worn for at least 8 weeks postoperatively.

For Case Studies, Videos, and more, please visit ExpertConsult.com.

REFERENCES

1. Abrahamsson SO: Matrix metabolism and healing in the flexor tendon: experimental studies on rabbit tendon. *Scand J Plast Reconstr Surg Hand Surg Suppl* 23: 1–51, 1991.
2. Akali A, Khan U, Khaw PT, et al: Decrease in adhesion formation by a single application of 5-fluorouracil after flexor tendon injury. *Plast Reconstr Surg* 103: 151–158, 1999.
3. Alms A: Pedicle tendon graft for flexor tendon injuries of the fingers. *J Bone Joint Surg Br* 55:881, 1973.
4. Amadio PC, Hunter JM, Jaeger SH, et al: The effect of vincular injury on the results of flexor tendon surgery in zone 2. *J Hand Surg [Am]* 10:626–632, 1985.
5. Amiel D, Ishizue K, Billings E, Jr, et al: Hyaluronan in flexor tendon repair. *J Hand Surg [Am]* 14:837–843, 1989.

6. Aoki M, Manske PR, Pruitt DL, et al: Work of flexion after tendon repair with various suture methods: a human cadaveric study. *J Hand Surg [Br]* 20:310–313, 1995.
7. Apfelberg DB, Maser MR, Lash H, et al: "I-P flexor lag" after thumb flexor reconstruction: causes and solution. *Hand* 12:167–172, 1980.
8. Arons MS: Purposeful delay of the primary repair of cut tendons in "some man's land" in children. *Plast Reconstr Surg* 53:638–642, 1974.
9. Asencio G, Abihaidar G, Leonardi C: Human composite flexor tendon grafts. *J Hand Surg [Br]* 21:84–88, 1996.
10. Bakalim G: Primary mobilization after secondary flexor tendon surgery. *Scand J Plast Reconstr Surg* 9:240–244, 1975.
11. Barrie KA, Tomak SL, Cholewicki J, et al: The role of multiple strands and locking sutures on gap formation of flexor tendon repairs during cyclical loading. *J Hand Surg [Am]* 25:714–720, 2000.
12. Barrie KA, Wolfe SW, Shean C, et al: A biomechanical comparison of multistrand flexor tendon repairs using an in situ testing model. *J Hand Surg [Am]* 25:499–506, 2000.
13. Becker H: Primary repair of flexor tendons in the hand without immobilization: preliminary report. *Hand* 10:37–47, 1978.
14. Beris AE: Two-stage flexor tendon reconstruction in zone II using a silicone rod and a pedicled intrasynovial graft. *J Hand Surg [Am]* 28:652–660, 2003.
15. Bertelli JA, Santos MA, Kechele PR, et al: Flexor tendon grafting using a plantaris tendon with a fragment of attached bone for fixation to the distal phalanx: a preliminary cohort study. *J Hand Surg [Am]* 32:1543–1548, 2007.
16. Bidder M, Towler DA, Gelberman RH, et al: Expression of mRNA for vascular endothelial growth factor at the repair site of healing canine flexor tendon. *J Orthop Res* 18:247–252, 2000.
17. Birney HB, Idler RS: Flexor tenolysis in children. *J Hand Surg [Am]* 20:254–257, 1995.
18. Boardman ND, 3rd, Morifusa S, Saw SS, et al: Effects of tenorrhaphy on the gliding function and tensile properties of partially lacerated canine digital flexor tendons. *J Hand Surg [Am]* 24:302–309, 1999.
19. Bora FW, Lane JM, Prockop DJ: Inhibitors of collagen biosynthesis as a means of controlling scar formation in tendon injury. *J Bone Joint Surg Am* 54:1501–1508, 1972.
20. Boulas HJ, Strickland JW: Strength and functional recovery following repair of flexor digitorum superficialis in zone 2. *J Hand Surg [Br]* 18:22–25, 1993.
21. Boyer MI, Ditsios K, Gelberman RH, et al: Repair of flexor digitorum profundus tendon avulsions from bone: an ex vivo biomechanical analysis. *J Hand Surg [Am]* 27:594–598, 2002.
22. Boyer MI, Gelberman RH, Burns ME, et al: Intrasynovial flexor tendon repair: an experimental study comparing low and high levels of in vivo force during rehabilitation in canines. *J Bone Joint Surg Am* 83:891–899, 2001.
23. Boyer MI, Strickland JW, Engles D, et al: Flexor tendon repair and rehabilitation: state of the art in 2002. *Instr Course Lect* 52:137–161, 2003.
24. Boyes JH, Stark HH: Flexor tendon grafts in the fingers and thumb: a study of factors influencing results in 1000 cases. *J Bone Joint Surg Am* 53:1332–1342, 1971.
25. Boyes JH: Flexor tendon grafts in the fingers and thumb: an evaluation of end results. *J Bone Joint Surg Am* 32:489–499, 1950.
26. Brand PW, Cranor KC, Ellis JC: Tendon and pulleys at the metacarpophalangeal joint of a finger. *J Bone Joint Surg Am* 57:779–784, 1975.
27. Brand PW: Tendon grafting. *J Bone Joint Surg Br* 43:444–453, 1961.
28. Brug E, Stedtfeld HW: Experience with a two stage pedicled flexor tendon graft. *Hand* 11:198–205, 1979.
29. Buch BD, Innis P, McClinton MA, et al: The Mitek Mini G2 suture anchor: biomechanical analysis of use in the hand. *J Hand Surg [Am]* 20:877–881, 1995.
30. Bunnell S: Reconstructive surgery of the hand. *Surg Gynecol Obstet* 34:259–274, 1924.
31. Burns JW, Skinner K, Colt MJ, et al: A hyaluronate based gel for the prevention of postsurgical adhesions: evaluation in two animal species. *Fertil Steril* 66:814–821, 1996.
32. Bynum DK, Gilbert JA: Avulsion of the flexor digitorum profundus: anatomic and biomechanical considerations. *J Hand Surg [Am]* 13:222–227, 1988.
33. Carstam N: Prevention of experimental tendon adhesions by cortisone. *Acta Orthop Scand* 22:15–24, 1953.
34. Carstam N: The efforts of cortisone on the formation of tendon adhesions and on tendon healing. *Acta Chir Scand Suppl* 182:1–111, 1953.
35. Chacha P: Free autologous composite tendon grafts for division of both flexor tendons within the digital theca of the hand. *J Bone Joint Surg Am* 56:960–978, 1974.
36. Chang J, Thunder R, Most D, et al: Studies in flexor tendon wound healing: neutralizing antibody to TGF-beta1 increases postoperative range of motion. *Plast Reconstr Surg* 105:148–155, 2000.
37. Chong AK, Riboh J, Smith RL, et al: Flexor tendon tissue engineering: acellularized and reseeded tendon constructs. *Plast Reconstr Surg* 123:1759–1766, 2009.
38. Chow SP, Stephens MM, Ngai WK, et al: A splint for controlled active motion after flexor tendon repair: design, mechanical testing, and preliminary clinical results. *J Hand Surg [Am]* 15:645–651, 1990.
39. Coert JH, Uchiyama S, Amadio PC, et al: Flexor tendon-pulley interaction after tendon repair: a biomechanical study. *J Hand Surg [Br]* 20:573–577, 1995.
40. Cohen MJ, Kaplan L: Histology and ultrastructure of the human flexor tendon sheath. *J Hand Surg [Am]* 12:25–29, 1987.
41. Coyle MP, Jr, Leddy TP, Leddy JP: Staged flexor tendon reconstruction fingertip to palm. *J Hand Surg [Am]* 27:581–585, 2002.
42. Cribb AM, Scott JE: Tendon response to tensile stress: an ultrastructural investigation of collagen:proteoglycan interactions in stressed tendon. *J Anat* 187(Pt 2): 423–428, 1995.
43. Diao E, Hariharan JS, Soejima O, et al: Effect of peripheral suture depth on strength of tendon repairs. *J Hand Surg [Am]* 21:234–239, 1996.
44. Dinopoulos HT, Boyer MI, Burns ME, et al: The resistance of a four- and eight-strand suture technique to gap formation during tensile testing: an experimental study of repaired canine flexor tendons after 10 days of in vivo healing. *J Hand Surg [Am]* 25:489–498, 2000.
45. Doyle JR: Anatomy of the finger flexor tendon sheath and pulley system. *J Hand Surg [Am]* 13:473–484, 1988.
46. Doyle JR, Blythe W: The finger flexor tendon sheath and pulleys: anatomy and reconstruction. In *AAOS symposium on tendon surgery in the hand*, St. Louis, 1975, Mosby, pp 81–87.
47. Doyle JR, Blythe WF: Anatomy of the flexor tendon sheath and pulleys of the tendon sheath and pulleys of the thumb. *J Hand Surg [Am]* 2:149–151, 1977.
48. Duffy FJ, Jr, Seiler JG, Gelberman RH, et al: Growth factors and canine flexor tendon healing: initial studies in uninjured and repair models. *J Hand Surg [Am]* 20:645–649, 1995.
49. Duffy FJ, Seiler JG, Hergrueter CA, et al: Intrinsic mitogenic potential of canine flexor tendons. *J Hand Surg [Br]* 17:275–277, 1992.
50. Dunlap J, McCarthy JA, Manske PR: Flexor tendon pulley reconstructions: a histological and ultrastructural study in non-human primates. *J Hand Surg [Br]* 14: 273–277, 1989.
51. Duran R, Houser R, Coleman C, et al: A preliminary report in the use of controlled passive motion following flexor tendon repair in zones II and III [abstract]. *J Hand Surg [Am]* 1:79, 1976.
52. Elliot D, Khandwalla A, Ragoowansi R: The flexor digitorum profundus demitendon: a new technique for passage of the flexor profundus tendon through the A4 pulley. *J Hand Surg [Br]* 26:422–426, 2001.
53. Engles D, Diao E, Seiler JG, III, et al: Reconstruction after flexor tendon injury: state of the art. *Instr Course Lect* 58:561–572, 2009.
54. Enna CD, Dyer RE: Tendon plasticity: a property applicable to reconstructive surgery of the hand. *Hand* 8:118–124, 1976.
55. Entin MA: Flexor tendon repair and grafting in children. *Am J Surg* 109:287–290, 1965.
56. Entin MA: Flexor tendon surgery in children. In *AAOS symposium on tendon surgery in the hand*, St. Louis, 1975, Mosby, pp 132–144.
57. Eshman SJ, Posner MA: Intratendinous rupture of a flexor tendon graft many years after staged reconstruction: a report of three cases. *J Hand Surg [Am]* 25:1135–1139, 2000.
58. Farkas LG, McCain WG, Sweeney P, et al: An experimental study of the changes following Silastic rod preparation of a new tendon sheath and subsequent tendon grafting. *J Bone Joint Surg Am* 55:1149–1158, 1973.
59. Feldscher SB, Schneider LH: Flexor tenolysis. *Hand Surg* 7:61–74, 2002.
60. Fetrow KO: Tenolysis in the hand and wrist: a clinical evaluation of two hundred and twenty flexor and extensor tenolyses. *J Bone Joint Surg Am* 49:667–685, 1967.
61. Finsen V: Two-stage grafting of digital flexor tendons: a review of 43 patients after 3 to 15 years. *Scand J Plast Reconstr Surg Hand Surg* 37:159–162, 2003.
62. Foucher G, Lenoble E, Ben Youseff K, et al: A post-operative regime after digital flexor tenolysis. *J Hand Surg [Br]* 18:35–40, 1993.
63. Fox PM, Farnebo S, Lindsey D, et al: Decellularized human tendon-bone grafts for composite flexor tendon reconstruction: a cadaveric model of initial mechanical properties. *J Hand Surg [Am]* 38:2323–2328, 2013.
64. Franko OI, Lee NM, Finneran JJ, et al: Quantification of partial or complete A4 pulley release with FDP repair in cadaveric tendons. *J Hand Surg [Am]* 36(3):439–445, 2011.
65. Gabuzda GM, Lovallo JL, Nowak MD: Tensile strength of the end-weave flexor tendon repair. *J Hand Surg [Br]* 19:397–400, 1994.
66. Galano GJ, Jiang KN, Strauch RJ, et al: Inflammatory response with osteolysis related to a bioabsorbable anchor in the finger: a case report. *Hand* 5:307–312, 2010.
67. Gelberman RH: Flexor tendon physiology: tendon nutrition and cellular activity in injury and repair. *Instr Course Lect* 34:351–360, 1985.
68. Gelberman RH, Amiel D, Harwood F: Genetic expression for type I procollagen in the early stages of flexor tendon healing. *J Hand Surg [Am]* 17:551–558, 1992.

69. Gelberman RH, Botte MJ, Spiegelman JJ, et al: The excursion and deformation of repaired flexor tendons treated with protected early motion. *J Hand Surg [Am]* 11:106–110, 1986.
70. Gelberman RH, Boyer MI, Brodt MD, et al: The effect of gap formation at the repair site on the strength and excursion of intrasynovial flexor tendons: an experimental study on the early stages of tendon-healing in dogs. *J Bone Joint Surg Am* 81:975–982, 1999.
71. Gelberman RH, Khabie V, Cahill CJ: The revascularization of healing flexor tendons in the digital sheath: a vascular injection study in dogs. *J Bone Joint Surg Am* 73:868–881, 1991.
72. Gelberman RH, Manske PR, Akeson WH, et al: Flexor tendon repair. *J Orthop Res* 4:119–128, 1986.
73. Gelberman RH, Nunley JA, 2nd, Osterman AL, et al: Influences of the protected passive mobilization interval on flexor tendon healing: a prospective randomized clinical study. *Clin Orthop* (264):189–196, 1991.
74. Gelberman RH, Siegel DB, Woo SL, et al: Healing of digital flexor tendons: importance of the interval from injury to repair: a biomechanical, biochemical, and morphological study in dogs. *J Bone Joint Surg Am* 73:66–75, 1991.
75. Gelberman RH, Vande Berg JS, Lundborg GN, et al: Flexor tendon healing and restoration of the gliding surface: an ultrastructural study in dogs. *J Bone Joint Surg Am* 65:70–80, 1983.
76. Gelberman RH, Vandeberg JS, Manske PR, et al: The early stages of flexor tendon healing: a morphologic study of the first fourteen days. *J Hand Surg [Am]* 10(6 Pt 1):776–784, 1985.
77. Goldner JL, Coonrad RW: Tendon grafting of the flexor profundus in the presence of a completely or partially intact flexor sublimis. *J Bone Joint Surg Am* 51:527–532, 1969.
78. Greenwald DP, Randolph MA, Hong HZ, et al: Augmented Becker versus modified Kessler tenorrhaphy in monkeys: dynamic mechanical analysis. *J Hand Surg [Am]* 20:267–272, 1995.
79. Grobbelaar AO, Hudson DA: Flexor pollicis longus tendon injuries in children. *Ann R Coll Surg Engl* 77:135–137, 1995.
80. Groth G: Pyramid of progressive force exercises to the injured flexor tendon. *J Hand Ther* 17:31–42, 2004.
81. Hage J, Dupius CC: The intriguing fate of tendon grafts in small children's hands and their results. *Br J Plast Surg* 18:341–349, 1965.
82. Harrison SH: Repair of digital flexor tendon injuries in the hand. *Br J Plast Surg* 14:211, 1961.
83. Harrison SH: Delayed primary flexor tendon grafts. *Hand* 1:106–107, 1969.
84. Harvey FJ, Chu G, Harvey PM: Surgical availability of the plantaris tendon. *J Hand Surg [Am]* 8:243–247, 1983.
85. Hatanaka H, Zhang J, Manske PR: An in vivo study of locking and grasping techniques using a passive mobilization protocol in experimental animals. *J Hand Surg [Am]* 25:260–269, 2000.
86. Hatano I, Suga T, Diao E, et al: Adhesions from flexor tendon surgery: an animal study comparing surgical techniques. *J Hand Surg [Am]* 25:252–259, 2000.
87. He M, Gan AWT, Lim AYT, et al: The effect of fibrin glue on tendon healing and adhesion formation in a rabbit model of flexor tendon injury and repair. *J Plast Surg Hand Surg* 47:509–512, 2013.
88. Herndon JH: Treatment of tendon injuries in children. *Orthop Clin North Am* 7:717–731, 1976.
89. Higgins A, Lalonde DH, Bell M, et al: Avoiding flexor tendon repair rupture with intraoperative total active movement examination. *Plast Reconstr Surg* 126(3):941–945, 2010.
90. Hitchcock TF, Light TR, Bunch WH, et al: The effect of immediate constrained digital motion on the strength of flexor tendon repairs in chickens. *J Hand Surg [Am]* 12:590–595, 1987.
91. Honnor R: The late management of the isolated lesion of the flexor digitorum profundus tendon. *Hand* 7:171–174, 1975.
92. Howard RF, Ondrovic L, Greenwald DP: Biomechanical analysis of four-strand extensor tendon repair techniques. *J Hand Surg [Am]* 22:838–842, 1997.
93. Huang D, Balian G, Chhabra AB: Tendon tissue engineering and gene transfer: the future of surgical treatment. *J Hand Surg [Am]* 31:693–704, 2006.
94. Hueston JJ, Hubble B, Rigg BR: Homografts of the digital flexor tendon system. *Aust N Z J Surg* 36:269–274, 1967.
95. Hume EL, Hutchinson DT, Jaeger SA, et al: Biomechanics of pulley reconstruction. *J Hand Surg [Am]* 16:722–730, 1991.
96. Hung LK, Fu SC, Lee YW, et al: Local vitamin-C injection reduced tendon adhesion in a chicken model of flexor digitorum profundus tendon injury. *J Bone Joint Surg Am* 95:e41–e47, 2013.
97. Hunter J: Anatomy of flexor tendons: pulley, vincular, synovia, and vascular structures. In Spinner M, editor: *Kaplan's functional and surgical anatomy of the hand*, Philadelphia, 1984, JB Lippincott, pp 65–92.
98. Hunter JM, Cook JF, Jr: The pulley system: rationale for reconstruction. In Strickland JW, Steinchen JB, editors: *Difficult problems in hand surgery*, St. Louis, 1982, Mosby, pp 94–102.
99. Hunter JM, Cook JF, Ochiai N, et al: The pulley system. *Orthop Trans* 4:4, 1980.
100. Hunter JM, Salisbury RE: Flexor tendon reconstruction in severely damaged hands: a two-stage procedure using a silicone Dacron reinforced gliding prosthesis prior to tendon grafting. *J Bone Joint Surg Am* 53:829–858, 1971.
101. Hunter JM, Schneider LH, Dumont J, et al: A dynamic approach to problems of hand function using local anesthesia supplemented by intravenous fentanyl-droperidol. *Clin Orthop* 104:112–115, 1974.
102. Hunter JM, Seinsheimer F, Mackin EJ: Tenolysis: pain control and rehabilitation. In Strickland JW, Steinchen JB, editors: *Difficult problems in hand surgery*, St. Louis, 1982, Mosby, pp 312–318.
103. Hunter JM, Steindel C, Salisbury R, et al: Study of early sheath development using static non-gliding implants. *J Biomed Mater Res* 5:155, 1974.
104. Hunter JM, Subin D, Minkow F, et al: Sheath formation in response to limited active gliding implants (animals). *J Biomed Mater Res* 5:155, 1974.
105. Hunter JM, Taras JS, Mackin EJ, et al: Staged flexor tendon reconstruction using passive and active tendon implants. In Hunter JM, Mackin EJ, Callahan AD, editors: *Rehabilitation of the hand: surgery and therapy*, St. Louis, 1995, Mosby, pp 477–514.
106. Ipsen T, Barfield T: Early mobilization after flexor tendon grafting for isolated profundus tendon lesions. *Scand J Plast Reconstr Surg* 22:163, 1988.
107. Jaffe S, Weckesser E: Profundus tendon grafting with the sublimis intact: the end result of thirty patients. *J Bone Joint Surg Am* 49:1298–1308, 1967.
108. James JIP: The use of cortisone in tenolysis. *J Bone Joint Surg Br* 41:209–210, 1959.
109. James JIP: The value of tenolysis. *Hand* 1:118–119, 1969.
110. Karev A: The "belt loop" technique for the reconstruction of pulleys in the first stage of flexor tendon grafting. *J Hand Surg [Am]* 9:923–924, 1984.
111. Kato H, Minami A, Suenaga N, et al: Long-term results after primary repairs of zone 2 flexor tendon lacerations in children younger than age 6 years. *J Pediatr Orthop* 22:732–735, 2002.
112. Ketchum LD, Martin NL, Kappel DA: Experimental evaluation of factors affecting the strength of tendon repairs. *Plast Reconstr Surg* 59:708–719, 1977.
113. Kleinert H, Cash S: Management of acute flexor tendon injuries in the hand. *Instr Course Lect* 34:361–372, 1985.
114. Kleinert H, Cash S: Current guidelines for flexor tendon repair within the fibroosseous tunnel: indications, timing and techniques. In Hunter J, Schneider L, Mackin E, editors: *Tendon surgery in the hand*, St. Louis, 1987, Mosby, pp 118–125.
115. Kleinert H, Kutz J, Ashbell T, et al: Primary repair of lacerated flexor tendons in "no man's land." *J Bone Joint Surg Am* 49:577, 1967.
116. Kleinert HE, Bennett JB: Digital pulley reconstruction employing the always present rim of the previous pulley. *J Hand Surg [Am]* 3:297–298, 1978.
117. Kubota H, Aoki M, Pruitt DL, et al: Mechanical properties of various circumferential tendon suture techniques. *J Hand Surg [Br]* 21:474–480, 1996.
118. Kwai Ben I, Elliot D: "Venting" or partial lateral release of the A2 and A4 pulleys after repair of zone 2 flexor tendon injuries. *J Hand Surg [Br]* 23:649–654, 1998.
119. Lalonde DH, Martin AL: Wide-awake flexor tendon repair and early tendon mobilization in zones 1 and 2. *Hand Clin* 29:207–213, 2013.
120. LaSalle WB, Strickland JW: An evaluation of the two-stage flexor tendon reconstruction technique. *J Hand Surg [Am]* 8:263–267, 1983.
121. Latendresse K, Dona E, Scougall PJ, et al: Cyclic testing of pullout sutures and micro-mitek suture anchors in flexor digitorum profundus tendon distal fixation. *J Hand Surg [Am]* 30:471–478, 2005.
122. Leddy JP: Flexor tendons: acute injuries. In Green DP, editor: *Operative hand surgery*, Edinburgh, 1982, Churchill Livingstone, pp 1347–1373.
123. Leddy JP, Packer JW: Avulsion of the profundus tendon insertion in athletes. *J Hand Surg [Am]* 2:66–69, 1977.
124. Lee SK, Dubey A, Kim BH, et al: A biomechanical study of extensor tendon repair methods: introduction to the running-interlocking horizontal mattress extensor tendon repair technique. *J Hand Surg [Am]* 35(1):19–23, 2010.
125. Lee SK, Fajardo M, Kardashian G, et al: Repair of flexor digitorum profundus to distal phalanx: a biomechanical evaluation of four techniques. *J Hand Surg [Am]* 36(10):1604–1609, 2011.
126. Leversedge FJ, Ditsios K, Goldfarb CA, et al: Vascular anatomy of the human flexor digitorum profundus tendon insertion. *J Hand Surg [Am]* 27:806–812, 2002.
127. Leversedge FJ, Zelouf D, Williams C, et al: Flexor tendon grafting to the hand: an assessment of the intrasynovial donor tendon: a preliminary single-cohort study. *J Hand Surg [Am]* 25:721–730, 2000.
128. Lieber RL, Amiel D, Kaufman KR, et al: Relationship between joint motion and flexor tendon force in the canine forelimb. *J Hand Surg [Am]* 21:957–962, 1996.
129. Lieber RL, Silva MJ, Amiel D, et al: Wrist and digital joint motion produce unique flexor tendon force and excursion in the canine forelimb. *J Biomech* 32:175–181, 1999.
130. Lin GT, Amadio PC, An KN, et al: Biomechanical analysis of finger flexor pulley reconstruction. *J Hand Surg [Br]* 14:278–282, 1989.
131. Lin GT, Amadio PC, An KN, et al: Functional anatomy of the human digital flexor pulley system. *J Hand Surg [Am]* 14:949–956, 1989.

132. Lin G-T, Cooney WP, Amadio PC, et al: Mechanical properties of human pulleys. *J Hand Surg [Br]* 15:429–434, 1990.
133. Lister GD: Reconstruction of pulleys employing extensor retinaculum. *J Hand Surg [Am]* 4:461–464, 1979.
134. Lister GD, Kleinert HE, Kutz JE, et al: Primary flexor tendon repair followed by immediate controlled mobilization. *J Hand Surg [Am]* 2:441–451, 1977.
135. Lundborg G: Experimental flexor tendon healing without adhesion formation: a new concept of tendon nutrition and intrinsic healing mechanisms: a preliminary report. *Hand* 8:235–238, 1976.
136. Lundborg G, Rank F: Experimental intrinsic healing of flexor tendons based upon synovial fluid nutrition. *J Hand Surg [Am]* 3:21–31, 1978.
137. Lundborg G, Rank F: Experimental studies on cellular mechanisms involved in healing of animal and human flexor tendon in synovial environment. *Hand* 12:3–11, 1980.
138. Lundborg G, Rank F: Tendon healing: intrinsic mechanisms. In Hunter J, Schneider L, Mackin E, editors: *Tendon surgery in the hand*, St. Louis, 1987, Mosby, pp 54–60.
139. Mackin E: Flexor tenolysis. In Hunter J, Schneider L, Mackin E, editors: *Tendon surgery in the hand*, St. Louis, 1987, Mosby.
140. Manske P, Lesker P: Diffusion as a nutrient pathway to the flexor tendon. In Hunter J, Schneider L, Mackin E, editors: *Tendon surgery in the hand*, St. Louis, 1987, Mosby, pp 86–90.
141. Manske PR, Gelberman RH, Vande Berg JS, et al: Intrinsic flexor-tendon repair: a morphological study in vitro. *J Bone Joint Surg Am* 66:385–396, 1984.
142. Manske PR, Lesker PA, Gelberman RH, et al: Intrinsic restoration of the flexor tendon surface in the nonhuman primate. *J Hand Surg [Am]* 10:632–637, 1985.
143. Mass DP, Tuel RJ: Intrinsic healing of the laceration site in human superficialis flexor tendons in vitro. *J Hand Surg [Am]* 16:24–30, 1991.
144. Matsuzaki H, Zaegel MA, Gelberman RH, et al: Effect of suture material and bone quality on the mechanical properties of zone I flexor tendon-bone reattachment with bone anchors. *J Hand Surg [Am]* 33:709–717, 2008.
145. Matthews P, Richards H: Factors in the adherence of flexor tendons after repair. *J Bone Joint Surg Br* 58:230–236, 1976.
146. May H: Tendon transplantation in the hand. *Surg Gynecol Obstet* 83:631–638, 1946.
147. May EJ, Silfverskiöld KL, Sollerman CJ: Controlled mobilization after flexor tendon repair in zone II: a prospective comparison of three methods. *J Hand Surg [Am]* 17:942–952, 1992.
148. May EJ, Silfverskiöld KL: Rate of recovery after flexor tendon repair in zone II: a prospective longitudinal study of 145 digits. *Scand J Plast Reconstr Surg Hand Surg* 27:89–94, 1993.
149. McCarthy JA, Lesker PA, Peterson WW, et al: Continuous passive motion as an adjunct therapy for tenolysis. *J Hand Surg [Br]* 11:88–90, 1986.
150. McClinton MA, Curtis RM, Wilgis EFS: 100 tendon grafts for isolated flexor digitorum profundus injuries. *J Hand Surg [Am]* 7:224–229, 1982.
151. McCollough FH: Repair of the flexor pollicis longus tendon. *U S Armed Forces Med J* 2:1579–1591, 1951.
152. McCormack RM, Demuth RJ, Kindling PH: Flexor tendon grafts in the less-than-optimal situation. *J Bone Joint Surg Am* 44:1360–1364, 1962.
153. McFarlane RM, Lamon R, Jarvis G: Flexor tendon injuries within the finger: a study of the results of tendon suture and tendon graft. *J Trauma* 8:987–1003, 1968.
154. McKenzie AR: Function after reconstruction of severed long flexor tendons of the hand: a review of 297 tendons. *J Bone Joint Surg Br* 49:424–439, 1967.
155. McLarney E, Hoffman H, Wolfe SW: Biomechanical analysis of the cruciate four-strand flexor tendon repair. *J Hand Surg [Am]* 24:295–301, 1999.
156. McNally TA, Hamman JJ, Heminger H, et al: The strength of distal fixation of flexor digitorum profundus tendon grafts in human cadavers. *J Hand Surg [Am]* 27:599–604, 2002.
157. Meals RA: Flexor tendon injuries: current concepts review. *J Bone Joint Surg Am* 67:817–821, 1985.
158. Millar R, Dickie WR, Colville J: The results of long delayed flexor tendon grafting. *Hand* 4:261–262, 1972.
159. Miller L, Mass DP: A comparison of four repair techniques for Camper's chiasma flexor digitorum superficialis lacerations: tested in an in vitro model. *J Hand Surg [Am]* 25:1122–1126, 2000.
160. Morrison WA, Schlicht SM: The plantaris tendon as a tendon osseous graft. II: Clinical studies. *J Hand Surg [Br]* 17:471–475, 1992.
161. Naam NH: Staged flexor tendon reconstruction using pedicled tendon graft from the flexor digitorum superficialis. *J Hand Surg [Am]* 22:323–327, 1997.
162. Nietosvaara Y, Lindfors N, Palmu S, et al: Flexor tendon injuries in pediatric patients. *J Hand Surg [Am]* 32:1549–1557, 2007.
163. Nishida J, Amadio PC: Flexor tendon-pulley interaction after pulley reconstruction: a biomechanical study in a human model in vivo. *J Hand Surg [Am]* 23:665–672, 1998.
164. Nishida J, Amadio PC, Bettinger PC, et al: Flexor tendon-pulley interaction after pulley reconstruction: a biomechanical study in a human model in vitro. *J Hand Surg [Am]* 23:665–672, 1998.
165. Nishida J, Seiler JG, Amadio PC, et al: Flexor tendon-pulley interaction after annular pulley reconstruction: a biomechanical study in a dog model in vivo. *J Hand Surg [Am]* 23:279–284, 1998.
166. Noguchi M, Seiler JG, 3rd, Gelberman RH, et al: In vitro biomechanical analysis of suture methods for flexor tendon repair. *J Orthop Res* 11:603–611, 1993.
167. Norris SR, Ellis FD, Chen MI, et al: Flexor tendon suture methods: a quantitative analysis of suture material within the repair site. *Orthopedics* 22:413–416, 1999.
168. O'Connell SJ, Moore MM, Strickland JW, et al: Results of zone I and zone II flexor tendon repairs in children. *J Hand Surg [Am]* 19:48–52, 1994.
169. Paneva-Holevich E: Two-stage tenoplasty in injury of the flexor tendons of the hand. *J Bone Joint Surg Am* 51:21–32, 1969.
170. Parkes A: The "lumbrical plus" finger. *J Bone Joint Surg Br* 53:236–239, 1971.
171. Peacock EE: Homologous composite tissue grafts of the digital flexor mechanism in human beings. *Plast Reconstr Surg* 25:418–421, 1960.
172. Peterson WW, Manske PR, Bollinger BA, et al: Effect of pulley excision on flexor tendon biomechanics. *J Orthop Res* 4:96–101, 1986.
173. Posner MA: Flexor superficialis tendon transfers to the thumb: an alternative to the free tendon graft for treatment of chronic injuries within the digital sheath. *J Hand Surg [Am]* 8:876–881, 1998.
174. Pribaz JJ, Morrison WA, Macleod AM: Primary repair of flexor tendons in no-man's land using the Becker repair. *J Hand Surg [Br]* 14:400–405, 1989.
175. Pruitt DL, Aoki M, Manske PR: Effect of suture knot location on tensile strength after flexor tendon repair. *J Hand Surg [Am]* 21:969–973, 1996.
176. Pulvertaft RG: Tendon grafts for flexor tendon injuries in the fingers and thumb: a study of technique and results. *J Bone Joint Surg Br* 38:175–194, 1956.
177. Pulvertaft RG: The treatment of profundus division by the free tendon graft. *J Bone Joint Surg Am* 42:1363–1371, 1960.
178. Pulvertaft RG: Indications for tendon grafting. In *AAOS symposium on tendon surgery in the hand*, St. Louis, 1975, Mosby, p 123.
179. Raghavan SS, Woon CY, Kraus A, et al: Optimization of human tendon tissue engineering: synergistic effects of growth factors for use in tendon scaffold repopulation. *Plast Reconstr Surg* 129:479–489, 2012.
180. Rank BK, Wakefield AR: *Surgery of repair as applied to hand injuries*, ed 2, Edinburgh, 1960, E & S Livingstone.
181. Rank BK, Wakefield AR, Hueston JJ: *Surgery of repair as applied to hand injuries*, ed 4, Baltimore, 1973, Williams & Wilkins.
182. Rispler D, Greenwald D, Shumway S, et al: Efficiency of the flexor tendon pulley system in human cadaver hands. *J Hand Surg [Am]* 21:444–450, 1996.
183. Rouhani AR, Barzgar H, Ghavidel E, et al: Effects of non-steroidal anti-inflammatory drugs on flexor tendon rehabilitation after laceration repair. *J Am Sci* 9:98–100, 2013.
184. Sakellarides HT, Papadopoulos G: Surgical treatment of the divided flexor digitorum profundus tendon in zone 2, delayed more than 6 weeks, by tendon grafting in 50 cases. *J Hand Surg [Br]* 21:63–66, 1966.
185. Sandow M, McMahon M: Single cross-grasp six-strand repair for acute flexor tenorrhaphy: modified Savage technique. *Atlas Hand Clin* 1:41–64, 1996.
186. Savage R: The mechanical effect of partial resection of the digital fibrous flexor sheath. *J Hand Surg [Br]* 15:435–442, 1990.
187. Schlenker JD, Lister GD, Kleinert HE: Three complications of untreated partial laceration of flexor tendon-entrapment, rupture, and triggering. *J Hand Surg [Am]* 6:392–398, 1981.
188. Schmitt T, Fox PM, Woon CY, et al: Human flexor tendon tissue engineering: in vivo effects of stem cell reseeding. *Plast Reconstr Surg* 132:567e–576e, 2013.
189. Schneider LH: *Flexor tendon injuries*, Boston, 1985, Little, Brown.
190. Schneider LH: Flexor tenolysis. In Hunter JM, Schneider LH, Mackin EJ, editors: *Flexor tendon surgery in the hand*, St. Louis, 1986, Mosby, pp 348–361.
191. Schneider LH: Injuries to tendons in children. In Bora FW, editor: *The pediatric upper extremity*, Philadelphia, 1986, WB Saunders, pp 91–119.
192. Schneider LH: Treatment of isolated flexor digitorum profundus injuries by tendon grafting. In Hunter JM, Schneider LH, Mackin EJ, editors: *Flexor tendon surgery in the hand*, St. Louis, 1986, Mosby, pp 518–525.
193. Schneider LH, Hunter JM: Tendon injuries in the hand. In Cotler J, editor: *Cyclopedia of medicine, surgery and specialities*, Philadelphia, 1975, FA Davis, p 723.
194. Schneider LH, Hunter JM: Flexor tendons: late reconstruction. In Green DP, editor: *Operative hand surgery*, New York, 1982, Churchill Livingstone, pp 1375–1440.
195. Schneider LH, Mackin EJ: Tenolysis. In Hunter JM, Schneider LH, Mackin EJ, et al, editors: *Rehabilitation of the hand*, St. Louis, 1978, Mosby, pp 229–234.
196. Schneider LH, Wiltshire D: Restoration of flexor pollicis longus function by flexor digitorum superficialis transfer. *J Hand Surg [Am]* 8:98–101, 1983.
197. Schuind F, Garcia-Elias M, Cooney WP, 3rd, et al: Flexor tendon forces: in vivo measurements. *J Hand Surg [Am]* 17:291–298, 1992.
198. Seiler JG, Chu CR, Amiel DA, et al: Autogenous flexor tendon grafts: biologic mechanisms for incorporation. *Clin Orthop Relat Res* 345:239–247, 1997.

199. Seiler JG, Gelberman RH, Williams CS, et al: Autogenous flexor-tendon grafts: a biomechanical and morphological study in dogs. *J Bone Joint Surg Am* 75:104–114, 1993.
200. Seiler JG, Reddy AS, Simpson LE, et al: The flexor digitorum longus: an anatomic and microscopic study for use as a tendon graft. *J Hand Surg [Am]* 20:492–495, 1995.
201. Seiler JG, Uchiyama S, Ellis F, et al: Reconstruction of the flexor pulley: the effect of tension and source of the graft in an in vitro dog model. *J Bone Joint Surg Am* 80:669–703, 1998.
202. Silfverskiöld KL, May EJ: Gap formation after flexor tendon repair in zone II: results with a new controlled motion programme. *Scand J Plast Reconstr Surg Hand Surg* 27:263–268, 1993.
203. Silfverskiöld KL, May EJ, Oden A: Factors affecting results after flexor tendon repair in zone II: a multivariate prospective analysis. *J Hand Surg [Am]* 18:654–662, 1993.
204. Silfverskiöld KL, May EJ, Tornvall AH: Flexor digitorum profundus tendon excursions during controlled motion after flexor tendon repair in zone II: a prospective clinical study. *J Hand Surg [Am]* 17:122–131, 1992.
205. Smith P, Jones M, Grobbelaar A: Two-stage grafting of flexor tendons: results after mobilization by controlled early active movement. *Scand J Plast Reconstr Surg Hand Surg* 38:220–227, 2004.
206. Snow JW: Ulnar half of extensor digiti-quinti proprius tendon for flexor grafts. *Plast Reconstr Surg* 42:603–604, 1968.
207. Solonen KA, Hoyer P: Positioning of the pulley mechanism when reconstructing deep flexor tendons of the fingers. *Acta Orthop Scand* 38:321–328, 1967.
208. Soucacos PN, Beris AE, Malizos KN, et al: Two-stage treatment of flexor tendon ruptures: Silicon rod complications analyzed in 109 digits. *Acta Orthop Scand Suppl* 275:48–51, 1997.
209. Sourmelis SG, McGrouther DA: Retrieval of the retracted flexor tendon. *J Hand Surg [Br]* 12:109–111, 1987.
210. Stark HH, Anderson DR, Boyes JH, et al: Bridge grafts of flexor tendons. *Orthop Trans* 7:44, 1983.
211. Stark HH, Zemel NP, Boyes JH, et al: Flexor tendon graft through intact superficialis tendon. *J Hand Surg [Am]* 2:456–461, 1977.
212. Steelman P: Treatment of flexor tendon injuries: therapist's commentary. *J Hand Ther* 12:149–151, 1991.
213. Strickland JW: Flexor tenolysis: a personal experience. In Hunter JM, Schneider LH, Mackin EJ, editors: *Tendon surgery in the hand*, St. Louis, 1987, Mosby, pp 216–233.
214. Strickland JW: Flexor tendon injuries. I: Foundations of treatment. *J Am Acad Orthop Surg* 3:44–54, 1995.
215. Strickland JW: Flexor tendon injuries. II: Operative technique. *J Am Acad Orthop Surg* 3:55–62, 1995.
216. Strickland JW: Flexor tendon repair. *Hand Clin* 1:55–68, 1985.
217. Strickland JW: Flexor tendon surgery. II: Free tendon grafts and tenolysis. *J Hand Surg [Br]* 14:368–382, 1989.
218. Strickland JW, Glogovac SV: Digital function following flexor tendon repair in zone II: a comparison of immobilization and controlled passive motion techniques. *J Hand Surg [Am]* 5:537–543, 1980.
219. Sullivan DJ: Disappointing outcomes in staged flexor tendon grafting for isolated profundus loss. *J Hand Surg [Br]* 11:231–233, 1986.
220. Szabo RM, Younger E: Effects of indomethacin on adhesion formation after repair of zone II tendon lacerations in the rabbit. *J Hand Surg [Am]* 15:480–483, 1990.
221. Tan V, Nourbakhsh A, Capo J, et al: Effects of nonsteroidal anti-inflammatory drugs on flexor tendon adhesion. *J Hand Surg [Am]* 35:941–947, 2010.
222. Tang JB: Indications, methods, postoperative motion and outcome evaluation of primary flexor tendon repairs in zone 2. *J Hand Surg Eur Vol* 32(2):118–129, 2007.
223. Tang JB, Ishii S, Usui M, et al: Flexor sheath closure during delayed primary tendon repair. *J Hand Surg [Am]* 19:636–640, 1994.
224. Tang JB, Zhang QG, Ishii S: Autogenous free sheath grafts in reconstruction of injured digital flexor tendon sheath at the delayed primary stage. *J Hand Surg [Br]* 18:31–32, 1993.
225. Taras J: Primary flexor tendon repair. *Oper Tech Orthop Surg* 3:270–277, 1993.
226. Taras J, Skahen J, James R, et al: The double-grasping and cross-stitch for acute flexor tendon repair: applications with active motion. *Atlas Hand Clin* 1:13–28, 1996.
227. Taras JS, Fitzpatrick MJ: Compartment syndrome of the leg after plantaris tendon harvest: a case report. *J Hand Surg [Am]* 26:1135–1137, 2001.
228. Taras JS, Marion M, Culp RW: Staged flexor tendon reconstruction with Hunter implants. In Osterman AL, editor: *Atlas of hand clinics: flexor tendon repair*, St. Louis, 1996, Mosby, pp 129–152.
229. Trumble TE, Vedder NE, Benirschke SK: Misleading fractures after profundus tendon avulsions: a report of 6 cases. *J Hand Surg [Am]* 17:902–906, 1992.
230. Uchiyama S, Amadio PC, Coert JH, et al: Gliding resistance of extrasynovial and intrasynovial tendons through the A2 pulley. *J Bone Joint Surg Am* 79:219–224, 1997.
231. Uchiyama S, Amadio PC, Ishikawa J, et al: Boundary lubrication between the tendon and the pulley in the finger. *J Bone Joint Surg Am* 79:213–218, 1997.
232. Urbaniak JR, Bright DS, Gill LH, et al: Vascularization and the gliding mechanism of free flexor tendon grafts inserted by the silicone rod method. *J Bone Joint Surg Am* 56:473–482, 1974.
233. Urbaniak JR, Goldner JL: Laceration of the flexor pollicis longus tendon: delayed repair by advancement, free graft or direct suture. *J Bone Joint Surg Am* 55:1123–1148, 1973.
234. Verdan C: Syndrome of the quadriga. *Surg Clin North Am* 40:425, 1960.
235. Verdan C: Tenolysis. In Verdan C, editor: *Tendon surgery of the hand*, Edinburgh, 1979, Churchill Livingstone, pp 137–142.
236. Verdan CE: Half a century of flexor-tendon surgery: current status and changing philosophies. *J Bone Joint Surg Am* 54:472–491, 1972.
237. Versaci AD: Secondary tendon grafting for isolated flexor digitorum profundus injury. *Plast Reconstr Surg* 46:57–60, 1970.
238. Wade PJ, Wetherell RG, Amis AA: Flexor tendon repair: significant gain in strength from the Halsted peripheral suture technique. *J Hand Surg [Br]* 14:232–235, 1989.
239. Wakefield AR: Late flexor tendon grafts. *Surg Clin North Am* 40:399, 1960.
240. Weber E: Nutritional pathways for flexor tendons in the digital theca. In Hunter J, Schneider L, Mackin E, editors: *Tendon surgery in the hand*, St. Louis, 1987, Mosby, pp 91–99.
241. Weber RV, Mackinnon SE: Median nerve mistaken for palmaris longus tendon: restoration of function with sensory nerve transfers. *Hand* 2:1–4, 2007.
242. Weeks PM, Wray RC: Rate and extent of functional recovery after flexor tendon grafting with and without silicone rod preparation. *J Hand Surg [Am]* 1:174–180, 1976.
243. Wehbe MA, Hunter JM, Schneider LH, et al: Two-stage flexor-tendon reconstruction: ten-year experience. *J Bone Joint Surg Am* 68:752–763, 1986.
244. Wei Z, Thoreson AR, Amadio PC, et al: Distal attachment of flexor tendon allograft: a biomechanical study of different reconstruction techniques in human cadaver hands. *J Orthop Res* 31:1720–1724, 2013.
245. Weidrich T: Acute repairs of zone II flexor digitorum profundus lacerations, with excision of the flexor digitorum superficialis. *Atlas Hand Clin* 5:131–148, 2000.
246. Whitaker JH, Strickland JW, Ellis RK: The role of flexor tenolysis in the palm and digits. *J Hand Surg [Am]* 2:462–470, 1977.
247. Widstrom CJ, Doyle JR, Johnson G, et al: A mechanical study of six digital pulley reconstruction techniques. II: Strength of individual reconstructions. *J Hand Surg [Am]* 14:826–829, 1989.
248. Widstrom CJ, Johnson G, Doyle JR, et al: A mechanical study of six digital pulley reconstruction techniques. I: Mechanical effectiveness. *J Hand Surg [Am]* 14:821–825, 1989.
249. Wilson RL, Carter MS, Holdeman VA, et al: Flexor profundus injuries treated with delayed two-staged tendon grafting. *J Hand Surg Am* 5:74–78, 1980.
250. Winters SC, Gelberman RH, Woo SL-Y, et al: The effects of multiple-strand suture methods on the strength and excursion of repaired intrasynovial flexor tendon: a biomechanical study in dogs. *J Hand Surg [Am]* 23:97–104, 1998.
251. Winters SC, Seiler JG, 3rd, Woo SL, et al: Suture methods for flexor tendon repair: a biomechanical analysis during the first six weeks following repair. *Ann Chir Main Memb Super* 16:229–234, 1997.
252. Woo SL, Gelberman RH, Cobb NG, et al: The importance of controlled passive mobilization on flexor tendon healing: a biomechanical study. *Acta Orthop Scand* 52:615–622, 1981.
253. Wray RC, Jr, Moucharafieh B, Weeks PM: Experimental study of the optimal time for tenolysis. *Plast Reconstr Surg* 61:184–189, 1978.
254. Wray RC, Weeks PM: Reconstruction of digital pulley. *Plast Reconstr Surg* 53:534–536, 1974.
255. Wrenn RN, Goldner JL, Markee JL: An experimental study of the effect of cortisone on the healing process and tensile strength of tendons. *J Bone Joint Surg Am* 36:588–601, 1954.
256. Xu NM, Brown PJ, Plate JF, et al: Fibrin glue augmentation for flexor tendon repair increases friction compared with epitendinous suture. *J Hand Surg [Am]* 38:2329–2334, 2013.
257. Yajima H, Inada Y, Shono M, et al: Radical forearm flap with vascularized tendons for hand reconstruction. *Plast Reconstr Surg* 98:328–333, 1996.
258. Zhao C, Hashimoto T, Kirk RL, et al: Resurfacing with chemically modified hyaluronic acid and lubricin for flexor tendon reconstruction. *J Orthop Res* 31:969–975, 2013.
259. Zhao C, Sun YL, Ikeda J, et al: Improvement of flexor tendon reconstruction with carbodiimide-derivatized hyaluronic acid and gelatin-modified intrasynovial allografts: study of a primary repair failure model. *J Bone Joint Surg Am* 92:2817–2828, 2010.
260. Zhao C, Zobitz ME, Sun YL, et al: Surface treatment with 5-fluorouracil after flexor tendon repair in a canine in vivo model. *J Bone Joint Surg Am* 91:2673–2682, 2009.

7

Fractures of the Metacarpals and Phalanges

Charles S. Day

Acknowledgment: I would like to acknowledge Dr. Peter Stern for all of his contributions to this chapter in this and previous editions of Green's Operative Hand Surgery.

Fractures of the metacarpals and phalanges are the most common fractures of the upper extremity, totaling approximately 600,000 in 1998.[22,69] Roughly 70% of all metacarpal and phalangeal fractures occur between the ages of 11 and 45.[112]

Until the early part of the 20th century, these fractures all were managed nonoperatively, and most continue to be managed successfully without surgery today. Most fractures are functionally stable either before or after closed reduction and fare well with protective splints and early mobilization.[99] Certain fractures require operative fixation (Box 7.1). Selection of the optimal treatment depends on many factors, including fracture location (articular versus extraarticular), fracture geometry (transverse, spiral or oblique, comminuted), deformity (angular, rotational, shortening), whether the fracture is open or closed, whether osseous and soft tissue injuries are associated, and intrinsic fracture stability. Additional considerations include the patient's age, occupation, and socioeconomic status; the presence of systemic illnesses; the surgeon's skill; and the patient's compliance. Despite the numerous treatment options, Swanson[116] aptly stated, "Hand fractures can be complicated by deformity from no treatment, stiffness from overtreatment, and both deformity and stiffness from poor treatment."

Over the past three decades, operative fixation of hand fractures has gained increasing popularity[11,114] for the following reasons:

1. Improved materials, implant designs, and instrumentation: Traditionally, implants have been made of 316L stainless steel. Although this metal is fully acceptable for fracture fixation, some surgeons prefer titanium, which has a modulus of elasticity that approximates bone. Self-tapping and miniature screws, with an outer diameter of 1 mm, are now available and in selected cases can be inserted percutaneously. Plates for the metacarpals and phalanges are low profile, easy to contour and cut, and available in various configurations.
2. Better understanding of the biomechanical principles of internal fixation
3. More demanding public expectations
4. Radiographic imaging: Cross-sectional imaging, particularly computed tomography (CT), permits multiplanar analysis of any fracture and may be useful in the assessment of articular fractures. In the operating room, portable minifluoroscopy units have been shown to reduce operating time substantially. Such units have eliminated much of the guesswork in fracture reduction, are helpful when inserting pins and screws (especially percutaneously), and allow assessment of fracture reduction and fixation in multiple planes. Radiation exposure is minimal.
5. Availability of specialists in hand surgery
6. Anesthesia: Many fractures, particularly of the phalanges, can be managed by local nerve blocks and sedation with monitored anesthesia care. In addition, a sterile forearm tourniquet with appropriate sedation can be comfortably inflated for 60 to 75 minutes.
7. Therapy: Hand therapists play an integral role in the operative and nonoperative management of hand fractures. Wound management, edema and scar control, fabrication of thermoplastic splints, supervision of therapeutic modalities, and structuring an exercise program all contribute to improved outcomes.

Prolonged immobilization should be avoided because of the risk of permanent stiffness; however, overly aggressive attempts at internal fixation may lead to soft tissue damage, tendon adhesions, infection, and the necessity for a secondary procedure for implant removal. Operative fixation must be used judiciously and with the expectation that the ultimate outcome will be as good as, and optimally better than, the outcome after nonoperative management.

METACARPAL FRACTURES (EXCLUDING THE THUMB)

Metacarpal Head Fractures

Fractures of the metacarpal head are rare and are usually articular. McElfresh and Dobyns[87] reported on 103 metacarpal head fractures. The injury involved the index metacarpal most frequently, presumably because it is a border digit, and its carpometacarpal (CMC) joint is relatively immobile. Fractures were classified into several categories (Box 7.2). Comminuted fractures occurred most commonly. Half of the comminuted fractures had loss of more than 45 degrees of flexion at the metacarpophalangeal (MP) joint. Articular defects may remodel with time; in contrast to weight-bearing joints, an incongruous MP joint may function satisfactorily with painless motion.

Articular fractures of the metacarpal head can also occur with complex dorsal MP dislocations. These fractures may need open reduction and internal fixation (ORIF) through a dorsal approach.

BOX 7.1 Indications for Fixation of Metacarpal and Phalangeal Fractures

Irreducible fractures
Malrotation (spiral and short oblique)
Articular fractures
Subcapital fractures (phalangeal)
Open fractures
Segmental bone loss
Polytrauma with hand fractures
Multiple hand or wrist fractures
Fractures with soft tissue injury (vessel, tendon, nerve, skin)
Reconstruction (i.e., osteotomy)

BOX 7.2 Types of Fractures of the Metacarpal Head

Epiphyseal fractures (all nondisplaced Salter-Harris type III fractures)
Ligamentous avulsions
Osteochondral shear fractures
Three-part fractures occurring in different planes (sagittal, coronal, axial)
Comminuted fractures
Boxer fractures with articular extension
Fractures with substance loss
Occult compression fractures with subsequent avascular necrosis

Radiographic evaluation requires three views: posteroanterior, lateral, and oblique. The lateral view is difficult to interpret because of the adjacent overlying metacarpal heads. The Brewerton view (MP joint flexed 65 degrees with the dorsum of the fingers lying flat on the x-ray plate and the tube angled 15 degrees in an ulnar-to-radial direction) profiles the articular contour better.

Treatment of these fractures must be individualized. Displaced ligament avulsion fractures and osteochondral fractures can be satisfactorily managed by ORIF (Figure 7.1).[85] Kumar and Satku[73] emphasized that small osteochondral fragments should not be discarded or independently fixed with hardware, but instead "trapped in place" by larger fragments. Two-part coronal, sagittal, and oblique articular fractures are best managed by ORIF with Kirschner wires or interfragmentary screws.[55,87] Shewring and Thomas[108] examined 19 patients with collateral ligament avulsion fractures from the metacarpal heads, including displaced and nondisplaced fractures, and found that the fractures are prone to symptomatic nonunion even when treated conservatively and may require subsequent surgery. Good results were seen for internal fixation of displaced fractures using a single lag screw through a dorsal approach. A 3-month delay in operative treatment of nondisplaced fractures can still lead to good radiographic and functional outcomes.

Occasionally, an injury occurs with partial loss of a metacarpal head. Boulas and colleagues[11] reported successful short-term results in five patients with osteochondral autografts taken from a similarly sized metatarsal.

A comminuted articular fracture is the most difficult fracture to treat. It is often associated with soft tissue injuries and metaphyseal impaction or bone loss. ORIF may be frustrating, if not impossible. Alternative forms of treatment include skeletal traction or joint arthroplasty. The most common complication of articular metacarpal head fractures is stiffness. This stiffness may result from extensor tendon adhesions, collateral ligament or dorsal capsular contracture, devascularization of small articular fragments, or articular incongruity.

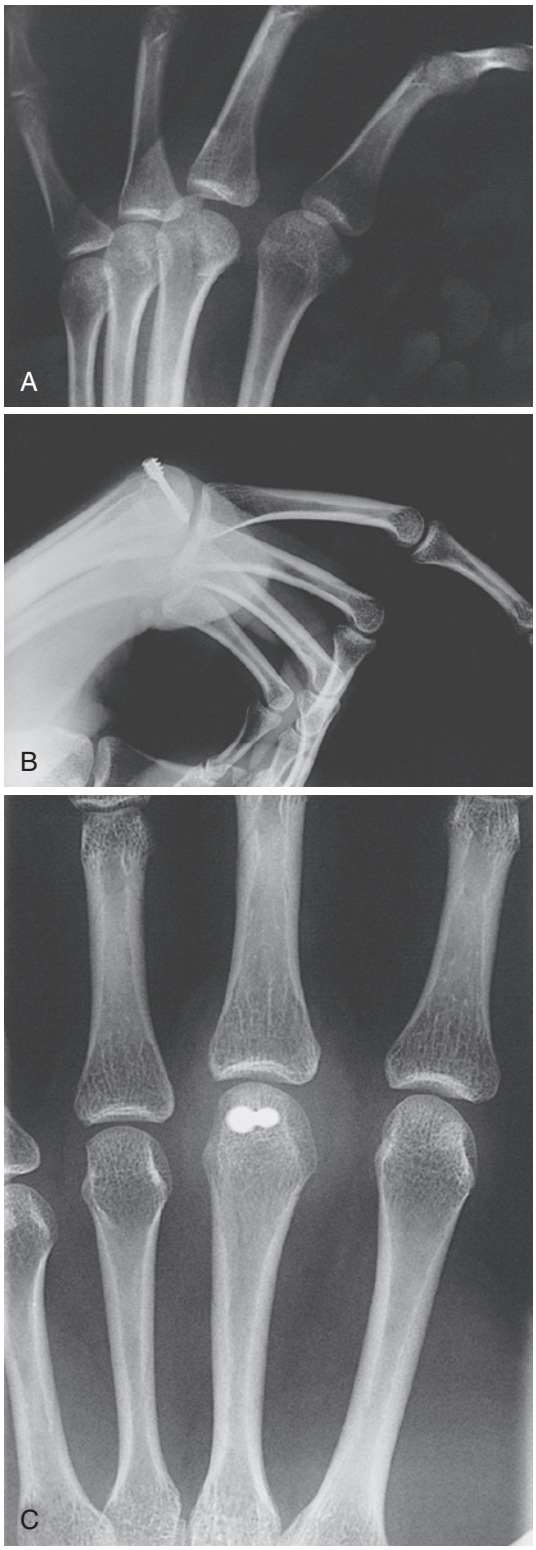

FIGURE 7.1 **A,** Displaced, articular sagittal slice fracture of middle finger metacarpal head. **B** and **C,** Postoperative posteroanterior (**B**) and lateral (**C**) views show anatomic reduction and fixation with headless screw. Full MP mobility was restored.

❖ AUTHOR'S PREFERRED METHOD OF TREATMENT

Noncomminuted, displaced fractures that constitute more than 25% of the articular surface or exhibit more than 1 mm of articular step-off are treated operatively. We approach these fractures through a dorsal longitudinal incision that splits the extensor tendon to expose the joint. Two-part articular fractures are usually amenable to fixation with headless screws. Fixation with Kirschner wires, although easier, is less rigid and requires immobilization for 3 to 4 weeks.

Open fractures of a metacarpal head secondary to a clenched fist injury should be presumed to have oral contamination and are treated by formal irrigation and débridement. The wound is generally left open, and internal fixation, if necessary, is delayed until the wound shows no sign of infection.

Comminuted fractures are problematic. Direct fracture fixation with multiple Kirschner wires or cerclage wires can be effective in stabilizing tenuous reductions of these fractures. Unstable reductions may require immobilization for 2 to 3 weeks before range-of-motion exercises are begun. Often these joints need a delayed tenolysis and capsulotomy procedure to improve the functional outcome. If Kirschner wires or cerclage wires fail to stabilize the fracture and maintain the reduction, we prefer immobilization for 2 to 3 weeks with the MP joint flexed 70 degrees, followed by intensive range-of-motion exercises. Skeletal traction or external fixation may be needed if there are associated comminuted fractures of the adjacent base of the proximal phalanx. For open comminuted head fractures, especially fractures with bone loss, prosthetic arthroplasty is a reasonable alternative, but it should not be done under the following circumstances:

1. Fracture of the head of the index finger because shear stresses from pinch predictably result in implant failure
2. Inadequate soft tissue coverage
3. Excessive metacarpal bone loss because excessive shortening and instability occur

MP arthrodesis is a salvage procedure and should seldom be done acutely because of the risk of excessive shortening or nonunion.

Metacarpal Neck Fractures

Metacarpal neck fractures (boxer's fracture) are common and usually involve the ring and small metacarpals. "Boxer's fracture" is really a misnomer. Fractures of the fifth metacarpal neck are rarely seen in professional boxers; they are far more common in brawlers and in people who hit solid objects such as walls. The term *boxer's fracture* seems to be deeply ingrained in the orthopedic literature, however. These fractures invariably occur when a clenched MP joint strikes a solid object and angulates with its apex dorsal. Apex dorsal angulation occurs because (1) the impact occurs on the dorsum of the metacarpal head and causes comminution of the volar metacarpal neck, and (2) the intrinsic muscles that cross the MP joint lie volar to its axis of rotation and maintain a flexed metacarpal head posture.

Controversy exists regarding the optimal treatment of this fracture, which varies from nonoperative treatment to various internal fixation techniques. Nonunion is uncommon; however, malunion occasionally can be a problem. Patient complaints may include a loss of prominence of the metacarpal head, diminished range of motion, a palpable metacarpal head in the palm, and, occasionally, rotatory malalignment.

When deciding on treatment, the following factors must be considered: (1) which metacarpal neck is fractured, (2) the degree of angulation, and (3) presence of a rotational deformity. The ring and small finger CMC joints have 20 to 30 degrees of mobility in the sagittal plane, whereas the index and middle CMC joints have less mobility. Angulation can be better compensated for in the ring and small fingers.

Although the reliability of measurement of angulation on plain films is low, it may be unimportant, because several surgeons believe that considerable angulation of a small finger metacarpal neck fracture is acceptable without compromising hand function. Hunter and Cowen[61] and Kuokkanen and colleagues[74] noted no significant disability with 70 degrees of angulation. Hunter and Cowen[61] did not attempt manipulation of fractures with less than 40 degrees of angulation and noted no increase in angulation during healing. Hansen and Hansen[53] prospectively compared casting, a functional brace, and an elastic bandage in patients with less than 60 degrees of angulation. They found no difference in patient satisfaction, but recommended a functional brace because patients became mobile faster and experienced less pain. Statius Muller and associates[113] prospectively treated 40 patients exhibiting angulation less than 70 degrees with either an ulnar gutter plaster cast for 3 weeks followed by mobilization or a pressure bandage for 1 week and immediate mobilization. They found that immediate mobilization yielded satisfied patients. There were no statistical differences with regard to range of motion, pain perception, and patients' satisfaction between these two treatments for boxer's fractures.

In a prospective series of 73 small finger metacarpal neck fractures, Lowdon[82] noted no relationship between the presence of symptoms and residual angulation. McKerrell and associates[88] studied two statistically comparable groups of patients with fifth metacarpal neck fractures treated conservatively and operatively. Failure to correct dorsal angulation was not associated with functional disability despite residual dorsal angulation in the nonoperative group. Tavassoli and coworkers[118] examined the difference between immobilizing the MP joint in extension or flexion for metacarpal neck fractures and found no significant functional and radiographic difference between the two casting groups. Because of the lack of compensatory CMC motion, there is almost universal agreement that residual angulation greater than 10 to 15 degrees in fractures of the index and middle metacarpal necks should not be accepted.[66]

Closed Reduction of Metacarpal Neck Fractures

Jahss[64] recognized that flexing the MP joint to 90 degrees relaxed the deforming intrinsic muscles and tightened the collateral ligaments, allowing the proximal phalanx to exert a dorsal force on the metacarpal head. He applied a cast in two parts: first immobilizing the proximal metacarpal fragment with the MP flexed, and subsequently pushing dorsally on the flexed proximal interphalangeal (PIP) joint while applying the second part. The Jahss maneuver (Figure 7.2) remains the best technique of closed reduction; however, fingers should never be immobilized in the "Jahss position" (MP and PIP joints flexed 90 degrees) because of the risk of skin necrosis over the dorsum of the PIP joint or permanent PIP stiffness.

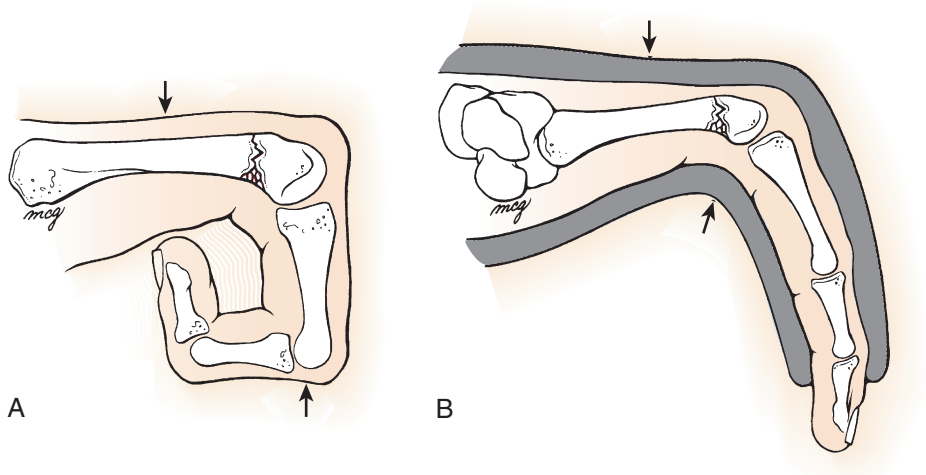

FIGURE 7.2 **A,** Jahss maneuver for reduction of metacarpal neck fracture. *Arrows* indicate direction of pressure application for fracture reduction. **B,** After reduction, fingers are held in intrinsic-plus (safe) position in ulnar gutter splint with molding as indicated by *arrows*.

With regard to cast immobilization, Hofmeister and colleagues[58] demonstrated that immobilization of the fifth metacarpal fracture in extension rather than flexion (as in the Jahss maneuver) did not affect fracture healing. However, the extension cast was faster to apply and showed greater improvement of angulation.

Maintenance of closed reduction by percutaneous longitudinal or crossed Kirschner pin fixation of the fractured metacarpal neck is a popular method of treatment for metacarpal neck and shaft fractures. Percutaneous transverse Kirschner wire fixation to the adjacent metacarpal has also been used for these fractures. Percutaneous fixation has the advantage of being minimally invasive, with a decreased likelihood of postoperative swelling and stiffness that may follow ORIF. The disadvantage is that it does not provide rigid fixation and requires some form of external immobilization for 2½ to 3 weeks. Galanakis and associates[42] reported excellent functional and anatomic outcomes in treatment of closed metacarpal neck fractures by transverse percutaneous pinning, using two Kirschner wires distally and one proximally. Active flexion-extension exercises of the fingers were started at 1 week after surgery. These investigators reported no fixation failures. Transarticular Kirschner wire fixation may be also used to hold a reduction adequately.

Foucher[35] reported excellent results with the use of "bouquet" osteosynthesis in the management of displaced small finger metacarpal neck fractures (Figure 7.3). The fracture is reduced in closed fashion; a hole is made in the proximal ulnar metaphysis of the metacarpal; and three blunt prebent Kirschner wires are passed antegrade down the medullary canal, across the fracture, and into the subchondral bone of the metacarpal head. This antegrade fixation technique has the advantage of avoiding the fracture site, but it can be technically difficult, and pins can migrate either proximally or distally. Using a similar antegrade intramedullary Kirschner wire fixation technique, Kelsch and Ulrich[68] reported satisfactory 1-year radiographic and functional results in 35 patients. The fractures were immobilized for 2 to 6 weeks, depending on patient compliance.

As the antegrade intramedullary fixation technique has gained in popularity, multiple studies have compared this technique with traditional Kirschner wire fixation. In a retrospective study of 30 patients with displaced neck fractures of the fifth metacarpal that compared retrograde crossed pinning with antegrade intramedullary fixation, Schadel-Hopfner and colleagues[105] found significantly decreased motion of the MP joint in the retrograde cohort. There was decreased shortening of the metacarpal after antegrade fixation, suggesting that intramedullary fixation was preferable. When comparing antegrade intramedullary pinning with transverse Kirschner wire fixation, Wong and associates[134] found no statistical difference in the effectiveness, functional outcome, or complications, concluding that both methods are comparable in treating small finger metacarpal neck fractures.

Facca and colleagues[30] demonstrated no benefit of locked dorsal plate fixation and immediate motion when compared with intramedullary fixation. Both techniques had a high complication rate (>30%), and the authors concluded that the intramedullary pinning technique should be continued as the fixation standard for displaced fractures of the fifth metacarpal neck.

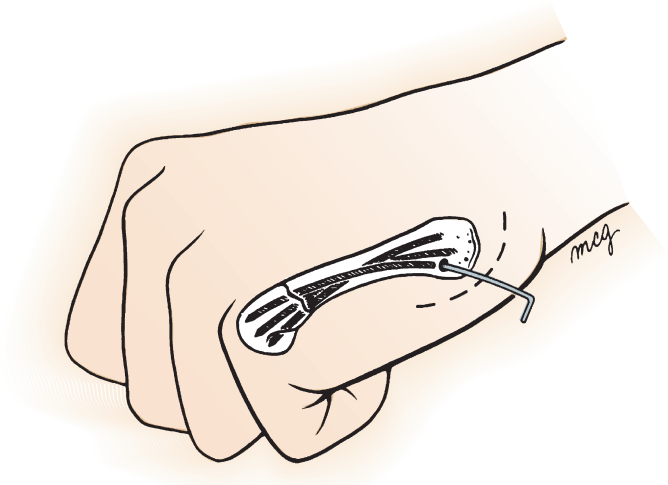

FIGURE 7.3 Technique for antegrade fixation of metacarpal neck fracture with multiple prebent Kirschner wires. Exposure of fracture site is avoided.

Open Reduction of Metacarpal Neck Fractures

Malunions of the fifth metacarpal neck rarely result in significant disability. Open reduction is occasionally indicated when manipulation fails to restore acceptable angulatory or rotational alignment. Following reduction, any number of techniques can stabilize the reduction adequately, including wires or tension band or miniplate fixation.

❖ AUTHOR'S PREFERRED METHOD OF TREATMENT

Most closed metacarpal neck fractures (especially of the ring and small fingers) should be treated nonoperatively. In the absence of pseudoclawing or rotational malalignment, metacarpal neck fractures produce minimal, if any, functional problems despite angulation on the lateral radiograph and shortening in the frontal projection. The term *pseudoclawing* refers to compensatory hyperextension of the MP joint and flexion of the PIP joint caused by excessive metacarpal neck flexion; the relative metacarpal shortening creates an imbalance between the longer extrinsic extensors and the short intrinsics. If pseudoclawing is not present on attempted digital extension, we prefer to use a functional brace. A forearm-based, dorsal-ulnar gutter splint using thermoplastic material is fabricated such that the wrist is extended 30 degrees, and the proximal phalanges of the ring and small fingers are splinted in approximately 70 degrees of flexion. "Buddy taping" is used to secure the digits to one another. Active range of motion is encouraged. The splint is worn for 2 weeks and is discontinued when pain has resolved.

Reduction of metacarpal neck fractures is clinically indicated when there is pseudoclawing or when there is a rotational deformity. After appropriate anesthesia, a closed manipulation of the metacarpal neck fracture is performed by the Jahss maneuver (see Figure 7.2). This maneuver is accomplished by flexing the MP and PIP joints to 90 degrees and exerting upward pressure through the flexed proximal phalanx and simultaneous downward pressure on the metacarpal shaft. Particular attention is paid to correcting any rotational deformity by using the flexed proximal phalanx as a crank. A forearm-based ulnar gutter plaster cast is applied and includes the adjacent, stable finger. The wrist is placed in 30 degrees of extension, the MP joints are maximally flexed, and the PIP joints are held extended (see Figure 7.2, *B*).

Radiographs are obtained to check the accuracy of reduction. Angulation greater than 15 degrees is unacceptable for fractures of the index and middle metacarpal necks. Angulation of 30 to 40 degrees is acceptable in the ring finger, and angulation of 50 or 60 degrees is acceptable in the small finger. Patients who use their hands extensively for gripping (e.g., professional athletes, carpenters) may generate discomfort, however, from the flexed metacarpal head of the small finger in their palm. In these patients, we would typically not accept flexion greater than 40 degrees. Immobilization usually can be discontinued after 12 to 14 days, and a program of active range of motion and intermittent splinting is initiated. The patient may return to sports and unrestricted activity at 4 to 6 weeks. Manipulation is not usually worth attempting if the fracture is older than 7 to 10 days.

In fresh metacarpal neck fractures, closed reduction is usually possible; however, reduction may be difficult to maintain because of volar comminution and intrinsic muscle pull. If an acceptable reduction cannot be maintained, we prefer percutaneously inserted crossed Kirschner wires (Figure 7.4) or antegrade intramedullary fixation under fluoroscopic guidance. After closed reduction, the pins are inserted into the nonarticular portion of the metacarpal head and drilled proximally into the metacarpal shaft. Alternatively, two pins can be percutaneously inserted in a transverse fashion from the fractured metacarpal head and fixed to the adjacent intact metacarpal (Figure 7.5). Care should be taken not to induce lateral translation of the fractured metacarpal head.

If open reduction is necessary, we prefer crossed Kirschner pins. Alternatively, a dorsal tension band wire with a supplemental Kirschner pin or a laterally applied minicondylar plate

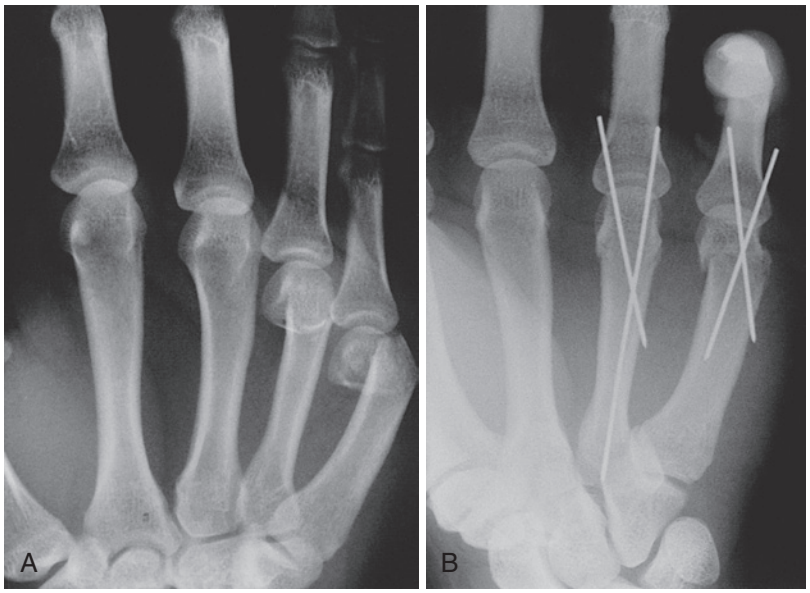

FIGURE 7.4 **A,** Severely displaced neck fractures of ring and small metacarpals. **B,** Closed reduction using Jahss maneuver and percutaneous crossed pins.

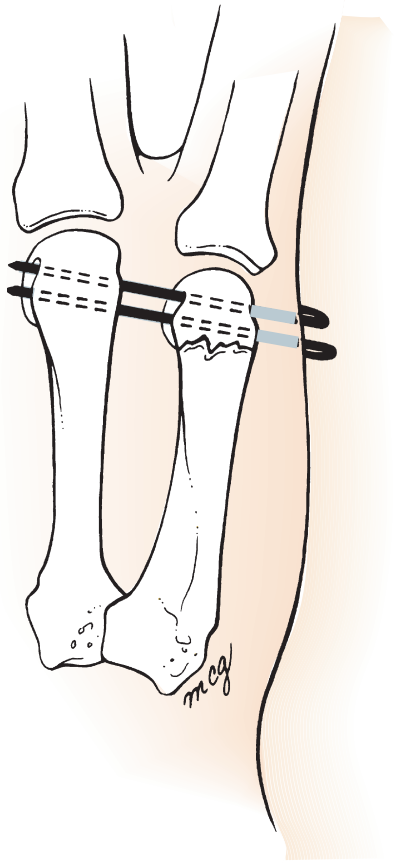

FIGURE 7.5 Percutaneous transverse pinning of displaced metacarpal neck fracture. After closed reduction, significantly angulated metacarpal neck fracture can be held with two percutaneous pins extending into adjacent intact metacarpal.

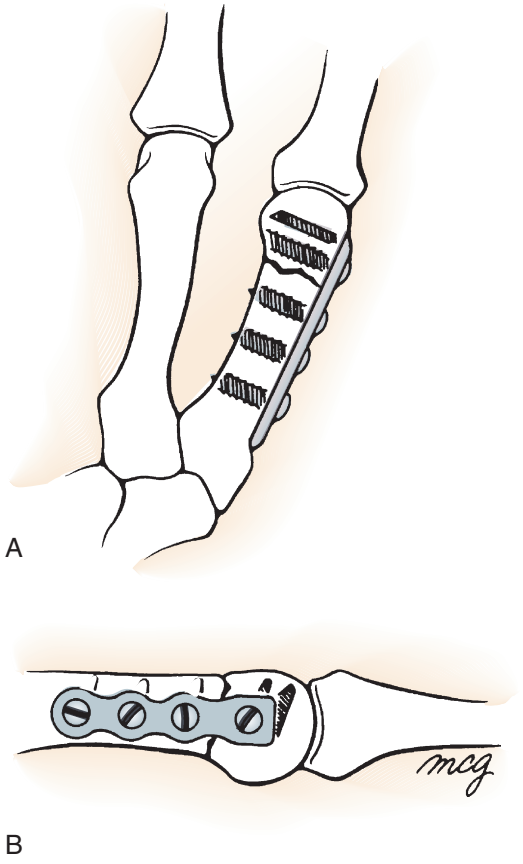

FIGURE 7.6 Laterally applied 2-mm minicondylar plate for stabilization of metacarpal neck fracture. **A,** Anteroposterior view. **B,** Lateral view.

(Figure 7.6) can be applied. Plate application requires more dissection, however, which may result in tendon adherence and MP stiffness, and should be used as a last resort. Plates require intracapsular positioning and may interfere with tendon gliding and collateral ligament function, all of which can adversely affect MP joint mobility.

Postoperatively, the operated digit is immobilized in an intrinsic-plus position for 5 to 7 days. Radiographs are taken to verify hardware position and fracture alignment, and, if satisfactory, protected active range-of-motion exercises are initiated after internal fixation. Immobilization in an ulnar gutter splint is usually maintained for 2 to 3 weeks after percutaneous pin fixation. If MP joint transarticular pins have been placed, immobilization is maintained until the pins are removed at 3 weeks postoperatively. Edema control with an elastic garment is also recommended.

Metacarpal Shaft Fractures

Metacarpal shaft fractures are broadly classified into three types: transverse, oblique/spiral, and comminuted. Each fracture type presents characteristic deformities that may lead to complications if unrecognized or improperly treated. Although most metacarpal fractures are readily diagnosed with standard biplanar views, oblique views may be helpful when there is clinical suspicion of a fracture.

Transverse fractures are usually produced by axial loading and angulate with the apex dorsal; the interosseous muscles are the deforming force. Dorsal angulation is better tolerated in the ring and small metacarpals. Dorsal angulation has several undesirable effects, however, as follows:

1. The metacarpal head becomes prominent in the palm and may cause pain on grasping.
2. There may be compensatory hyperextension at the MP joint that results in a secondary pseudoclaw deformity with digital extension.
3. Patients find the dorsal prominence aesthetically displeasing.
4. There is metacarpal shortening; if great enough, the intrinsic muscles may be unable to accommodate and are consequently weakened.

Although opinions vary, reduction generally is required for angulation greater than 30 degrees in the small finger, angulation greater than 20 degrees in the ring finger, and any angulation in the middle and index fingers. Likewise, opinions vary as to the degree of acceptable shortening. Most surgeons accept shortening of 2 to 5 mm, provided there is no pseudoclawing.

Oblique and spiral fractures are usually the result of torsional forces and can cause rotational malalignment. Malrotation is poorly tolerated and is difficult to assess on plain radiographs. It is best judged clinically by asking the patient to flex all the fingers *simultaneously*.[16] If scissoring or malrotation is present with composite digital flexion, open reduction should be considered.

CRITICAL POINTS *Operative Management of Boxer's Fractures*

Indications
- Angulation greater than 60 degrees (small finger) on lateral view
- Rotatory malalignment
- Associated fractures in fifth ray of hand
- Open fractures with associated soft tissue injury (excluding human bites)
- Presence of pseudoclawing

Preoperative Evaluation
- Inquire as to the mechanism of injury (e.g., human bite).
- Obtain anteroposterior and true lateral radiographs.
- Assess active range of motion, and check for presence of pseudoclawing (compensatory MP hyperextension and PIP flexion).

Pearls
- Less invasive techniques are preferred.
- Use closed reduction and percutaneous pinning.
- Many patients with this fracture are unreliable, and this may compromise outcome.

Technical Points
- Reduction is accomplished with the Jahss maneuver (see Figure 7.2).
- Under fluoroscopic guidance, insert two 0.9-mm retrograde crossed Kirschner wires from the lateral or dorsal (nonarticular) portion of the metacarpal head into the shaft (see Figure 7.4). The pins may cross the joint surface if necessary.
- Pins should exit through the dorsal metacarpal shaft.

Other Options
- Two transverse pins from small to intact ring metacarpal head (see Figure 7.5)
- "Bouquet" osteosynthesis: percutaneous antegrade insertion of prebent Kirschner wires from small finger metacarpal base into head (see Figure 7.3)
- ORIF with a lateral minicondylar plate (see Figure 7.6); least desirable treatment option because stiffness may occur

Postoperative Care
- Immobilize in ulnar gutter cast for 3 weeks.
- Begin protected active range-of-motion exercises stressing MP flexion. Extension of the MP joint may be impossible because of the location of the wires.
- Control edema with use of an elastic garment.

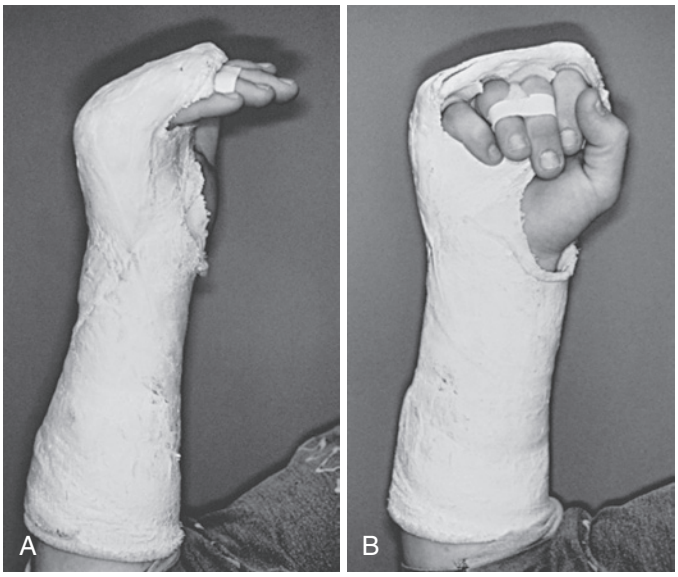

FIGURE 7.7 **A** and **B,** Clam-digger cast for metacarpal shaft fracture. Wrist is extended 30 degrees, MP joints are flexed 80 to 90 degrees, and IP joints are extended. Active range of motion is encouraged, and supplemental "buddy taping" can help control rotation.

Comminuted fractures are usually produced by direct impact, are often associated with soft tissue injury, and may produce shortening. There is considerable controversy regarding the amount of shortening that is acceptable. Regardless of fracture geometry, certain situations may influence the surgeon to perform operative fixation (eTable 7.1). These include the presence of multiple fractures (especially spiral and oblique); open fractures, especially with bone loss or concomitant soft tissue injury; and fractures in polytrauma victims who cannot cooperate or tolerate cast immobilization.

Closed Reduction and Plaster Immobilization

Closed reduction with plaster immobilization works well for most metacarpal shaft fractures, and overtreatment is to be avoided. Many metacarpal fractures are inherently stable and may be treated with minimal or no immobilization. In athletes, Rettig and associates[103] reported that 82% of the fractures were minimally displaced or nondisplaced, and the average time lost from practice or competition was 13.7 days. Burkhalter[15] advocated closed treatment for fractures that showed no rotational malalignment on clinical examination. He used a short-arm cast with the wrist in 30 to 40 degrees of extension and added a dorsal extension block to hold the MP joints flexed 80 to 90 degrees and the interphalangeal (IP) joints extended. Composite active MP and IP flexion was initiated, and the cast was maintained for 4 weeks.

When the PIP joints are extended in this splint, the hand assumes the intrinsic-plus or clam-digger[132] position (Figure 7.7). This position limits joint contractures and maintains the intrinsics in a relaxed position. In a retrospective study examining 263 patients, Tavassoli and coworkers[118] compared three different casting techniques for metacarpal neck or shaft fractures and found that positioning the MP joints in flexion or extension or the IP joints free or immobilized resulted in no difference in motion, grip strength, or fracture alignment. They recommended immobilizing the MP joints in extension and allowing full motion of the IP joints. A recent study performed by Westbrook and colleagues[130] in Britain examined the functional and aesthetic outcomes of operative and nonoperative treatment of little finger metacarpal fractures in 262 patients. The authors concluded that up to 40 degrees of flexion of the metacarpal shaft can be safely managed nonoperatively, although the patient must be warned that a visible deformity is possible.

Closed Reduction and Percutaneous Pinning

Antegrade or retrograde percutaneous pinning can be successfully employed as above; if cut and bent outside the skin, short-term immobilization is necessary. Buried intramedullary Kirschner wire fixation for unstable metacarpal fractures has

eTABLE 7.1 Fracture Stabilization Techniques

Technique	Indications	Advantages	Disadvantages
Kirschner wires	Transverse Oblique Spiral Longitudinal	Available and versatile Easy to insert Minimal dissection Percutaneous insertion	Lacks rigidity May loosen May distract fracture Pin track infection Requires external support Splint and therapy awkward
Intraosseous wires	Transverse fractures (phalanges) Avulsion fractures Supplemental fixation (butterfly fragment)	Available Low profile Relatively simple	May cut out (especially osteopenic bone)
Composite wiring	Transverse Oblique Spiral	More rigid than Kirschner wires Low profile Simple and available	Pin or wire migration Secondary removal (sometimes) Exposure may be significant
Intramedullary device	Transverse Short oblique	No special equipment Easy to insert No pin protrusion Minimal dissection	Rotational instability Rod migration
Interfragmentary fixation	Long oblique Spiral	Low profile Rigid	Special equipment Little margin for error
Plates and screws	Multiple fractures with soft tissue injury or bone loss Markedly displaced shaft fracture (especially, border metacarpals) Articular and periarticular fractures Reconstruction for nonunion or malunion	Rigid (stable) fixation Restore or maintain length	Exacting technique Special equipment Extensive exposure May require removal Refracture after plate removal Bulky
External fixation	Restore length for comminution or bone loss Soft tissue injury or loss Infection Nonunion	Preserves length Allows access to bone and soft tissue Percutaneous insertion Direct manipulation of fracture avoided	Pin track infections Osteomyelitis Overdistraction: nonunion Neurovascular injury Fractures through pin holes Loosening

been advocated and is greatly facilitated by the use of image intensification.[31,45] Using an awl, a cortical window is made at the ulnar base of the fifth metacarpal 1 cm distal to the CMC joint. Three or four prebent (≈30 degrees) 0.9-mm pins are inserted and buried within the medullary canal (Figure 7.8).

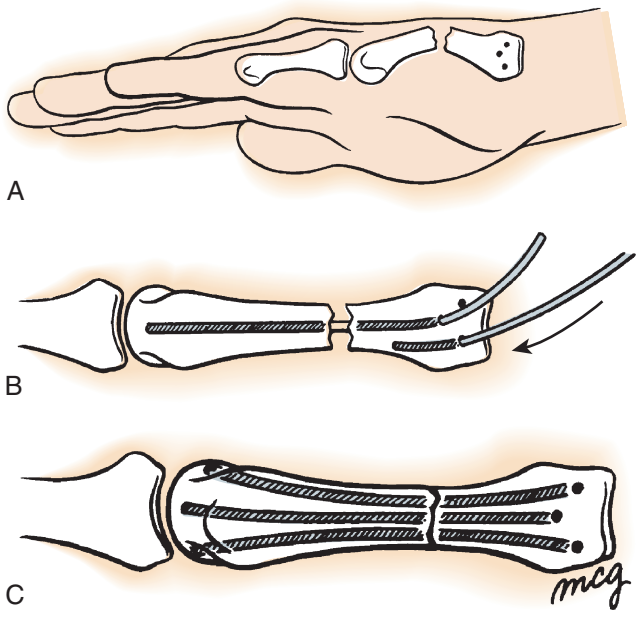

FIGURE 7.8 Intramedullary pins are inserted in antegrade fashion through multiple drill holes. Technique is facilitated by fluoroscopy. **A,** Fifth metacarpal shaft fracture. **B,** Antegrade pin insertion. **C,** Pins cut so that they are buried within medullary canal.

Open Reduction

A small percentage of metacarpal fractures were irreducible by closed manipulation or percutaneous pinning and require open reduction. Absolute indications for open reduction include the following:

1. Open fractures are associated with bone loss, contamination, or soft tissue injury.
2. Multiple fractures: In such cases, the stabilizing effect of the adjacent metacarpals is lost.
3. Unstable fractures: Fractures of the border metacarpals tend to be more unstable and more difficult to control than fractures of the central metacarpals because of the lack of support for soft tissue on both sides.
4. Malalignment: Rotational malalignment is unacceptable and is characteristically seen in spiral and oblique fractures. When correction of a rotational deformity by closed techniques or percutaneous pinning is unsatisfactory, open reduction is indicated.

Techniques of Open Reduction. See eTable 7.1.

Kirschner Wires. Kirschner wires may be used in nearly any fracture pattern (Figure 7.9). Pin fixation is technically easy, requires minimal dissection, and is universally available. Pin configurations can be either single or multiple and may be crossed,[29] transverse, longitudinal (intramedullary), or in combination. They can be used to supplement other forms of fracture fixation and can be used as a "bailout" if more complicated fixation has failed. Kirschner wires are not rigid; may loosen or even migrate; and, if improperly inserted, may distract fracture fragments. Pin track infections may develop secondary to skin irritation or loosening, and pin protrusion may make therapy and splinting awkward. Botte and associates[10] reviewed a series

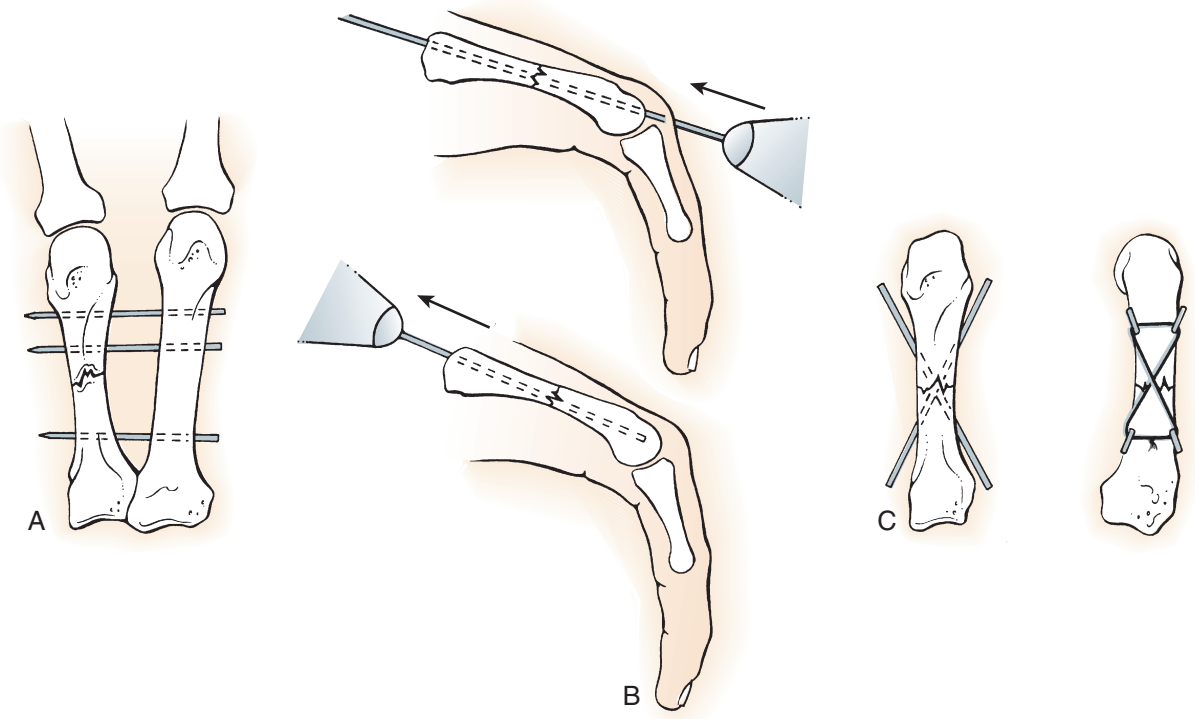

FIGURE 7.9 Techniques for Kirschner pin fixation of metacarpal shaft fractures. **A,** Transverse pins may be inserted percutaneously or open. **B,** Retrograde intramedullary fixation. Pin can be backed out so that they do not remain in MP joint. **C,** Crossed pins (*left*) and supplemental 25-gauge stainless steel wire (composite wiring) (*right*).

of 422 Kirschner wires placed in the hand and wrist and reported an 18% complication rate.

For longitudinal fixation, the pin can be drilled in antegrade fashion from the fractured end out the dorsal radial aspect of the metacarpal head. After reduction, the pin can be drilled in a retrograde fashion back down the shaft through the reduced fracture. Antegrade drilling of the proximal fragment through the fracture site is also possible with the wrist acutely flexed. Retrograde pins can also be introduced directly into the metacarpal head on either side of the extensor tendon and driven down the metacarpal shaft to engage subchondral bone at the CMC joint. Transarticular pins are generally bent outside the skin and left in place for 3 weeks. One or more supplemental transverse pins are generally recommended for unstable or transverse fractures in border digits when using this technique.

Composite (Tension Band) Wiring. Composite wiring for metacarpal fractures is a combination of Kirschner wires (0.035-inch or 0.045-inch diameter) and monofilament stainless steel wire (24-gauge or 26-gauge). The stainless steel wire is inserted as a tension band through a small transverse drill hole in the distal fragment and crossed around the Kirschner wires at the bone interface proximally (see Figure 7.9, *C*). Composite wiring provides additional stability and fracture compression and superior strength, stiffness, and approximation compared with crossed Kirschner wires alone. Little, if any, additional dissection is necessary. The technique is rigid enough to permit early motion. The technique is contraindicated when there is bone loss, comminution, or osteopenia.

Cerclage and Interosseous Wiring. Cerclage (circumferential) wiring with 24-gauge stainless steel wire can be successfully employed for oblique and spiral metacarpal shaft fractures (see Figure 7.38), but the technique is not widely popular. The technique was originally described to include scoring of the cortical bone with a side-cutting bur so that wire migration would not occur.[80] Al-Qattan and Al-Lazzam[3] showed that cerclage wire fixation can be sufficient without scoring of bone or finger immobilization for midshaft oblique or spiral fractures in 19 cases.

Gingrass and colleagues[44] achieved six excellent or good results in seven metacarpal fractures treated by double 26-gauge interosseous wires placed in a dorsal-volar direction. A single Kirschner pin was added in five of seven cases to augment stability. These authors suggest that interosseous wiring done without supplemental Kirschner pin fixation is generally unsuitable for metacarpal shaft fractures because wire loosening and subsequent loss of reduction are real possibilities. In contrast, Al-Qattan[2] reported treatment of 36 metacarpal shaft fractures with interosseous loop wire fixation alone and concluded that interosseous wiring without Kirschner wire fixation is rigid enough for immediate postoperative finger mobilization. Of 36 patients, 34 regained full range of motion. It is prudent to use supplementary Kirschner wires if the fracture is comminuted or if bone is missing.

Intramedullary Fixation. Open reduction and intramedullary fixation are applicable for transverse fractures, are easy to perform, and allow early active motion (Figure 7.10). There are no exposed pins, and secondary removal is unnecessary. In 1981, Grundberg[51] reported one nonunion in 27 metacarpals treated by open reduction and permanent intramedullary fixation with a large Steinmann pin. Potential disadvantages include rotational instability, pin migration, and occasional fracture distraction. The technique is not recommended for spiral or long oblique fractures.

The technique involves determining the diameter of the medullary canal using a smooth Steinmann pin and drilling one size larger. Next, the pin is introduced into the proximal fragment (blunt end first to avoid penetration of the subchondral

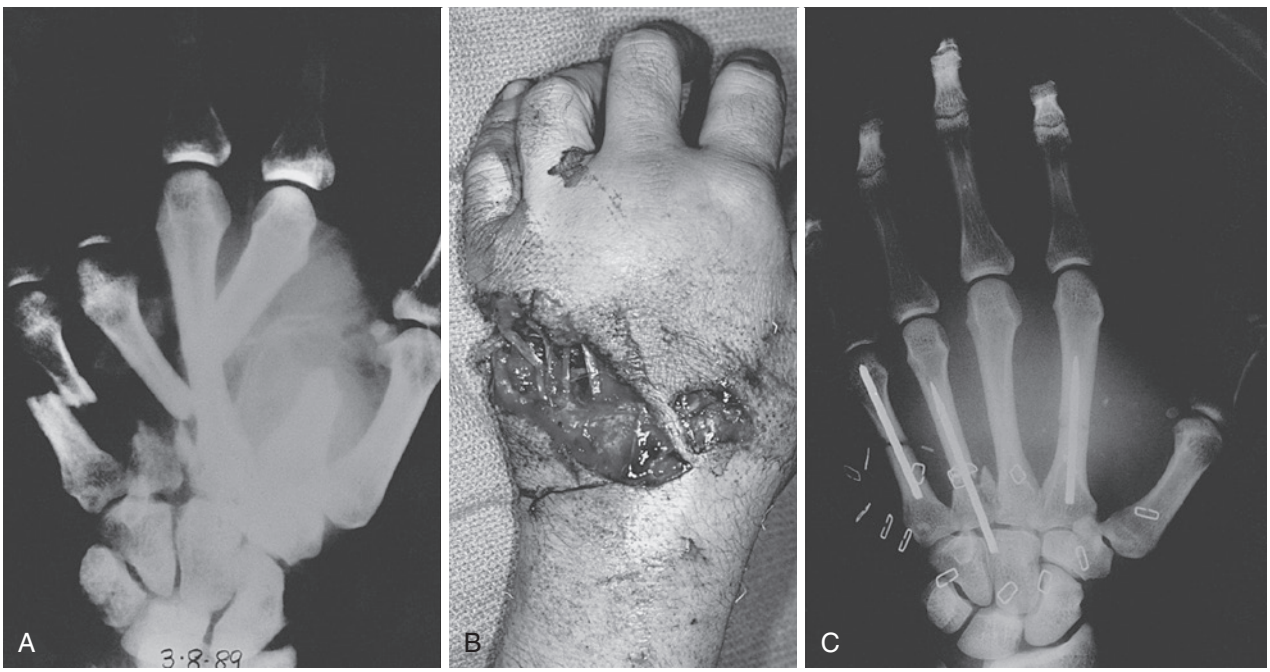

FIGURE 7.10 Intramedullary fixation. **A,** Displaced open metacarpal shaft fractures. **B,** Clinical appearance of dorsum of hand. **C,** Intramedullary Steinmann pin fixation. Pin in ring metacarpal extends into carpus for more secure fixation.

bone) and cut so that it protrudes 1.5 cm. The fracture is distracted, and the pin is introduced into the distal fragment. Finally, the fracture is impacted to achieve rotational stability.

When segmental bone loss is present and the soft tissue sleeve is largely intact, locked intramedullary fixation with rods[5,45] or plates with bone grafting is recommended.[5] In this situation, the rod or plate acts as an internal spacer while the defect is bridged with corticocancellous autogenous bone graft. One or more supplementary Kirschner wires may be necessary.

Interfragmentary Compression Screws. Interfragmentary compression screws provide stable fixation and are primarily indicated for long oblique and spiral shaft fractures (Figure 7.11). Interfragmentary screw fixation is stable enough to allow early active range of motion. To ensure success, the fracture length must be a minimum of twice the bone diameter. The fracture is reduced by manipulating it into alignment and holding the reduction with provisional Kirschner wires or a fracture reduction forceps, followed by placement of two or three interfragmentary compression screws (see Figure 7.11). A dorsal miniplate can be applied to neutralize the fracture if stability of the fracture is questionable.

To optimally resist axial and torsion loading, the screw should be placed in a plane bisecting the fracture plane and longitudinal axis. In large patients, at least two 2.7-mm screws are necessary, and in smaller individuals three 2.4-mm or 2-mm screws are necessary. To avoid fragmentation, the screw hole should be a minimum of two screw diameters from the fracture margin.[56]

Interfragmentary screw fixation (2.7-mm) of a metacarpal fracture involves six sequential steps (see Figure 7.11). There is little tolerance for technical error with this technique; if the screw is inserted through the near cortex and is misdirected such that it strikes the endosteal surface of the far cortex, the fracture is distracted, and the reduction lost. Any resistance to screw tightening should alert the surgeon to stop and redirect the screw.

Plate Fixation. Dorsal metacarpal plating with or without an interfragmentary screw provides more stable fixation than crossed Kirschner wires, an interosseous wire loop alone, or an

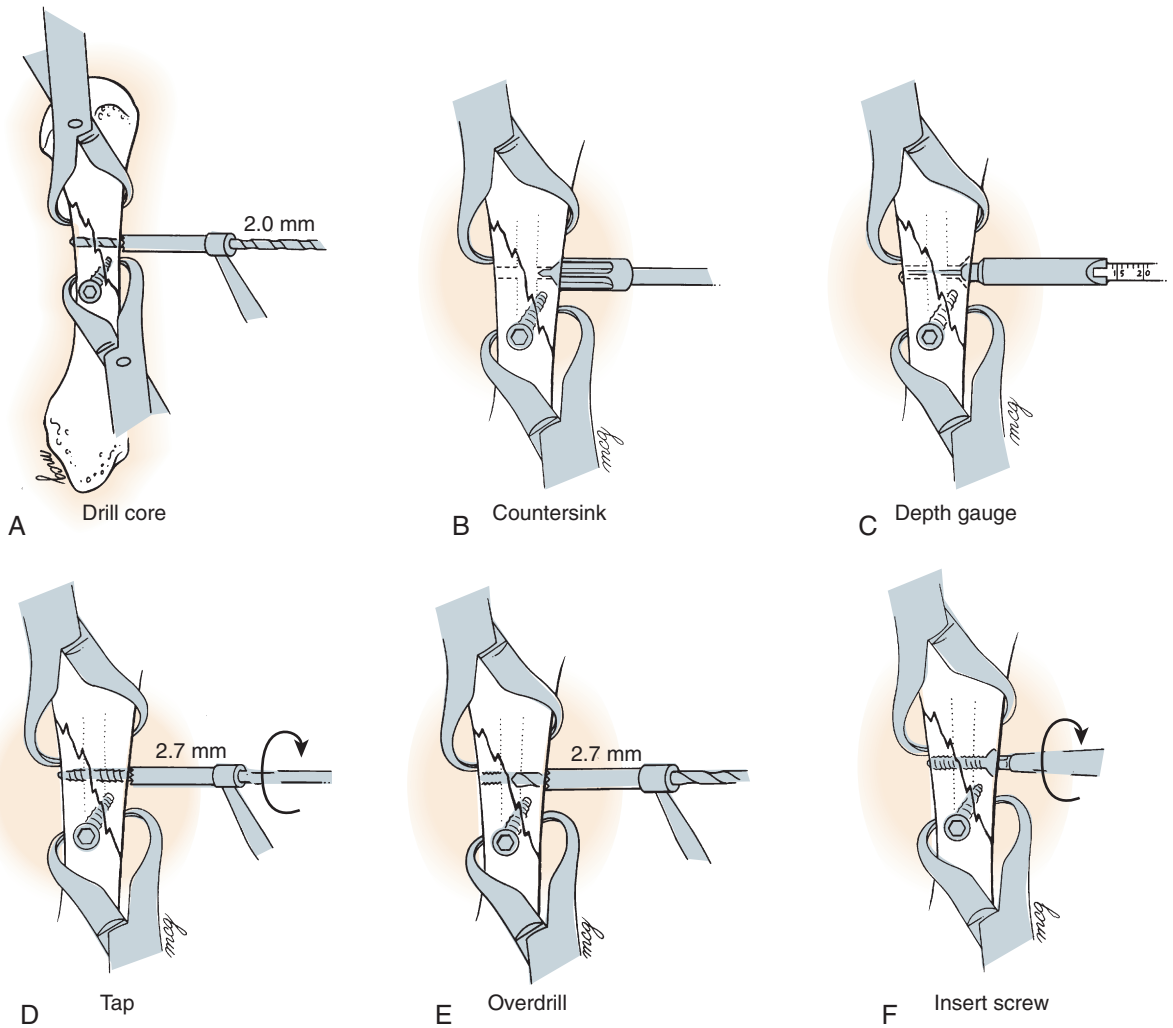

FIGURE 7.11 Fixation of spiral metacarpal fracture with 2.7-mm lag screws. **A,** A 2-mm bicortical hole is drilled. **B,** Near hole is countersunk to accept truncated screw head and distribute compression. **C,** Screw length is determined with depth gauge. **D,** Precision use of the 2.7-mm tap is critical, as failure to engage the far cortical drill hole can disrupt fracture reduction. Most modern screws are self-tapping. **E,** The near (gliding) hole is overdrilled with a 2.7-mm drill bit. **F,** Insertion of screw, engaging far hole and compressing the fracture.

interosseous wire with a Kirschner pin. The amount of strength required for stable fixation in the clinical setting has not been determined; fixation should be customized to the particular fracture.

Page and Stern[93] reported multiple complications of metacarpal fracture plating, however, including malunion, nonunion, and stiffness (articular and tendon adhesions). Complications were more frequent when there was associated bone loss, soft tissue injury, and open fractures. Fusetti and colleagues[41] assessed 81 patients treated with plate fixation and reported complications in 28 (35%). Complications included difficulty with fracture healing (15%), stiffness (10%), plate loosening or breakage (8%), complex regional pain syndrome, and infection. In another study, Fusetti and Della Santa[40] reported significant correlation between a transverse fracture pattern and nonunions when treated with plate fixation.

Most implants are made of either stainless steel or titanium. Although titanium is more expensive, some advantages of titanium include generally lower incidence of corrosion and allergic reactions, ease of contouring, and a modulus of elasticity that approaches that of bone.[83] Some studies have shown, however, that use of titanium plates may still lead to significant corrosion and release of metal debris.[70] No clinical difference in outcomes has been shown with the use of titanium implants. Great care must be taken when using titanium implants; screws may break, especially when being removed, and plates can break if excessively contoured before application.

Successful use of small titanium maxillofacial plates has been reported.[20] Screws are self-tapping, and diameters range from 0.8 to 1.7 mm. Because the plates are low profile (≈1 mm), the periosteum can often be closed over the plate to reduce adhesion formation. Fracture stabilization was adequate to allow early mobilization with a low incidence (3%) of hardware failure or plate breakage in a series of 36 patients treated for metacarpal and phalangeal fractures after acute and complex hand injury.[20]

Bioabsorbable plates and screws are not widely used in the United States, and clear advantages of such plates over metal implants have not been demonstrated.

External Fixation. The advantages of external fixation were enumerated by Schuind and coworkers[107]: "There is respect of bone biology." Fracture fragments are not stripped of periosteal blood supply and further devascularized. External fixators are adjustable, and there is adequate stability to permit early mobilization. When there has been concomitant soft tissue injury, external fixation permits ready access to the wound for débridement and for reconstruction of tendons, nerves, and blood vessels.[4]

Hastings[54] identified numerous complications of external fixation, including pin track infection, osteomyelitis, fracture through pin holes after removal, neurovascular injury during insertion, overdistraction with subsequent nonunion, loss of reduction, impairment of tendon gliding and motion, and interference with adjacent digits by the fixator. In weighing the advantages and disadvantages of external fixation, the technique is primarily indicated for severe fractures when anatomic reconstitution of the skeleton is not feasible. Examples include highly comminuted open shaft fractures with or without bone loss; displaced, comminuted articular fractures; and fractures with injury or loss of soft tissue structures. In addition, external fixation can be used to stabilize septic nonunions after débridement.[4]

❖ AUTHOR'S PREFERRED METHOD OF TREATMENT

Most metacarpal shaft fractures can be managed nonoperatively. Stable fractures that do not require reduction can be treated in a clam-digger cast or thermoplastic splint until the fracture is clinically nontender. The fractured finger is "buddy taped" to an adjacent finger, and immediate finger flexion is initiated.

Transverse shaft fractures are usually easy to reduce, but maintenance of acceptable alignment may be difficult. To achieve reduction, a palmarly directed load is applied to the dorsal apex at the fracture site with a dorsally directed force to the flexed MP joint (see Figure 7.2). A well-molded, forearm-based cast extending to the IP joints and holding the MP joints in 60 degrees of flexion is applied. Special attention must be paid to ensure satisfactory rotational alignment. The fracture is monitored with radiographic imaging at weekly intervals, and guarded active range-of-motion exercises can be initiated at 3 to 4 weeks. Marked swelling, which is often present in acute metacarpal shaft fractures, does not preclude manipulation and casting. The cast should be changed at 5 to 7 days when the swelling subsides.

Closed manipulation and percutaneous treatment are indicated when the fracture can be reduced but cannot be maintained in plaster or when concomitant soft tissue injury requires dressing changes and inspection. Fluoroscopy is invaluable to confirm fracture reduction and assist in placement of fixation devices. Reduction can sometimes be facilitated by placing a small incision over the fracture and inserting an elevator to manipulate the fragments. I pin transverse fractures of the fifth or fourth metacarpal to the neighboring intact metacarpal using two parallel transverse pins into the distal fragment and one through the proximal fragment (see Figure 7.9, *A*).

Open reduction is indicated for transverse shaft fractures that either are significantly displaced or have residual angulation of more than 10 degrees in the second and third metacarpals, 20 to 30 degrees in the ring metacarpal, and 30 to 40 degrees in the small finger metacarpal. ORIF using Kirschner wires or interfragmentary screws is indicated for most spiral and oblique fractures, particularly if there is evidence of a rotational deformity on physical examination, because fracture reduction is difficult to maintain by closed techniques. ORIF is nearly always indicated when there are multiple metacarpal fractures or when the fracture is open and associated with soft tissue injury or bone loss.

Fracture exposure is accomplished through a longitudinal incision just to one side of the extensor tendon overlying the involved metacarpal. If all four metacarpals require reduction, two longitudinal incisions are used: one between the fourth and fifth metacarpals and one between the second and third metacarpals. Care is taken to preserve cutaneous nerves and the paratenon surrounding the extensor tendons. Occasionally, one of the juncturae tendinum requires division for better fracture visualization; if this is necessary, the junctura should be repaired after fixation. The fracture ends are exposed, and fracture hematoma is removed. Reduction is accomplished by applying longitudinal traction and is maintained with reduction clamps.

Although infrequently used in the United States, bioabsorbable implants are commonly used in Europe. Biomechanical testing in cadaveric metacarpal and phalangeal bone shows that the implants provide fixation stability that is comparable to that of metal implants. Bioabsorbable platings resulted in higher torsional rigidity than 1.7-mm titanium plating and in failure torque comparable with 2.3-mm titanium plating.[126] The advantage of absorbable plates is that removal is unnecessary.

The first-generation bioabsorbable implants in the 1990s consisted mostly of polyglycolic acid, which led to a noninfectious inflammatory response 7 to 30 weeks after fracture fixation in 5% to 25% of cases.[9] A newer generation of bioabsorbable implants using poly-L-lactide implants is now being evaluated.[27] Dumont and coworkers[27] used this new plate in 12 patients (14 fractures) with displaced, unstable metacarpal fractures. The plates were molded and placed laterally on the bone to reduce irritation to the extensor tendon. Lag screws were used as needed. At 26 weeks, the authors found that 25% of the patients had keloid formation and soft tissue swelling. Swelling resolved after 6 months. It is unclear whether the new generation of bioabsorbable implants diminishes the inflammatory response.

Fixation options include Kirschner wires, composite wiring, an intramedullary rod, multiple interfragmentary screws, or a plate and screws. The choice of implant is dictated by the fracture configuration and experience of the surgeon (see eTable 7.1).

Kirschner wire fixation can be used for nearly all fracture configurations. Kirschner wire fixation alone is not rigid and may require immobilization postoperatively. If wire placement or fracture alignment is initially unacceptable, reinsertion is a simple matter. Multiple passes with the wires should be avoided, however, because this may lead to thermal necrosis of bone and increase the incidence of pin track infection. In addition, wires may loosen or distract a fracture, and pin track infection may necessitate premature removal.

I prefer K-wire fixation for isolated short oblique and transverse fractures and when possible supplement the pins with composite wiring to increase rigidity of fixation.[49] The pins, when placed percutaneously, are left in place for 3.5 to 4 weeks, and protected range of motion is initiated at the first postoperative visit (5 to 7 days after fixation). Patients should be instructed that if there is drainage, early pin removal may be necessary.

I find intramedullary fixation using precut Steinmann pins or commercially available rods particularly useful for multiple open transverse shaft fractures (see Figure 7.10). In this situation, there may be injury to the intrinsic muscles that allows the fracture to be easily distracted, facilitating pin insertion. Intramedullary fixation is easy and takes little time, but rotational stability may be a problem, particularly if the fracture ends fail to interdigitate. If the adjacent metacarpal is not fractured, a transverse wire can be added to control rotation.

Spiral and long oblique fractures are well suited for interfragmentary fixation. The fracture length should be at least twice, and preferably three times, the diameter of the bone at the level of the fracture. Reduction is achieved by anatomically interdigitating the proximal and distal apex of the fracture into its corresponding fragment under direct visualization. The reduction is held with two bone clamps, and the screws are inserted. Fixation may be achieved by using two 2.7-mm screws or three 2-mm or 2.4-mm screws. The diameter of the bone and configuration of the fracture may dictate mixing screws of different diameters in the same fracture.

I generally reserve plate and screw fixation for complex situations such as open fractures, multiple metacarpal shaft fractures, or when there is a combination of diaphyseal bony loss or comminution associated with significant soft tissue injury (Figure 7.12). Successful plate application is technically gratifying, provides stable fixation, and maintains length when there has been comminution or bone loss. Plate application is demanding, however, and there is no margin for error. Application requires considerable soft tissue mobilization, and the plates are bulky. Removal is often necessary, and a fracture can occur through a screw hole or at the "original" fracture site. I prefer a 2-mm or 2.4-mm plate that allows screw fixation of at least four cortices, proximal and distal to the fracture, to ensure

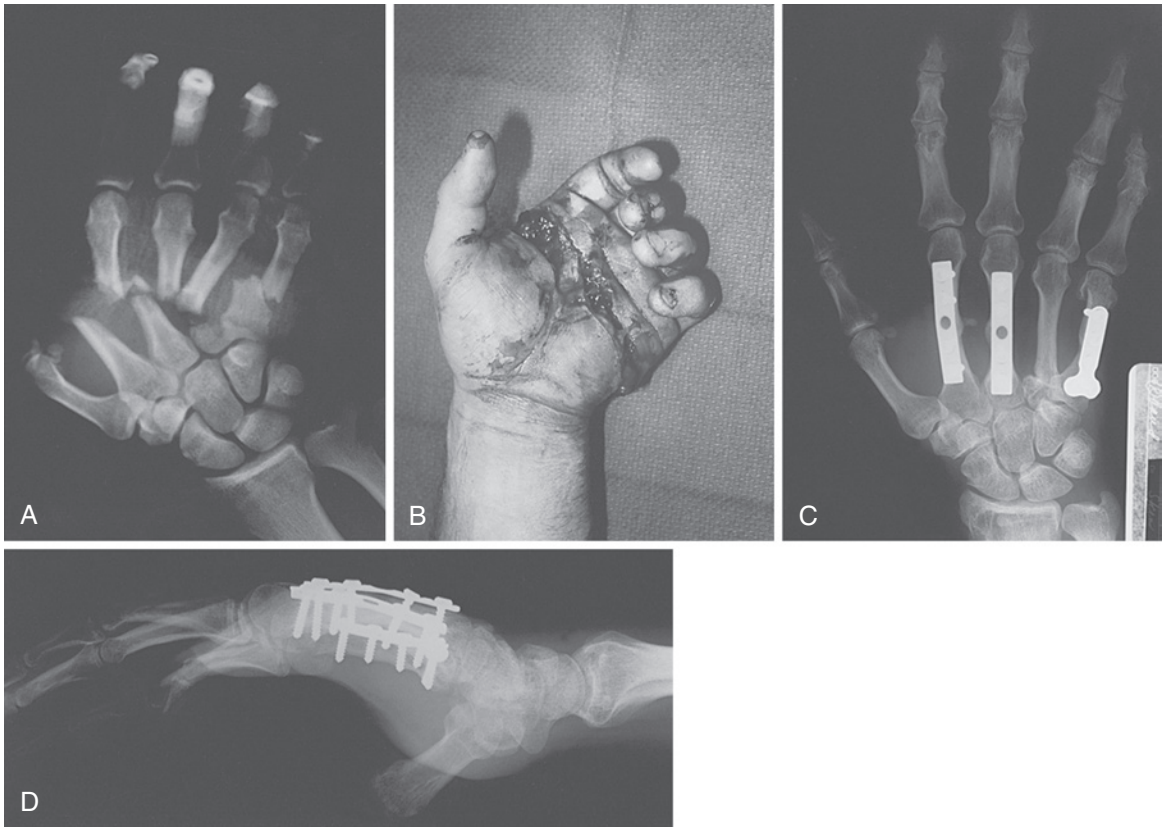

FIGURE 7.12 Plate fixation for metacarpal shaft fractures. **A,** Shaft fractures of all four metacarpals. **B,** Fractures were open, and revascularization was required. **C,** Anteroposterior radiograph showing healed fractures. Plate fixation provided stable framework for microvascular repairs. **D,** Lateral view.

stable fixation. Supplemental fixation with an interfragmentary screw (for transverse and short oblique fractures) placed either through a hole in the plate or obliquely across the fracture significantly enhances fracture stability. Larger 2.7-mm locking plates are not routinely indicated. Such plates may be indicated in osteopenic bone or for reconstruction of nonunions or malunions. Plate fixation is undesirable if the fracture cannot be covered by local soft tissue or flaps. In such situations, I prefer external fixation.

Whenever possible, after ORIF the periosteum is approximated with an absorbable suture. A forearm-based plaster splint with bulky dressing is applied for 4 to 7 days. Assuming stable reduction, active range of motion is initiated. The wrist is splinted in a slightly extended position. Restoration of full MP flexion may be difficult because of edema, intrinsic muscle injury, and subsequent MP collateral ligament contracture. To maximize MP flexion, elastic garments are worn for edema control, and the IP joints are splinted in extension during MP flexion exercises.

Hardware removal depends on the type of implant. Kirschner wires may be removed 3 to 6 weeks after fixation. The AO-ASIF group recommends screw and plate removal approximately 6 months after fixation. Despite the aforementioned admonitions, I do not routinely remove plates. If the plate is perceived as bulky or is irritating, or if there are restrictive adhesions and a tenolysis and capsulotomy procedure is indicated, I remove the plate. Patients should be informed that refracture may occur after plate removal.

Expected Outcomes: Metacarpal Shaft Fractures

Most metacarpal shaft fractures are inherently stable and can be treated conservatively with acceptable functional outcomes. In a comparison study of three casting techniques, no difference was found in motion, grip strength, or fracture alignment between the treatments.[116] Open reduction and internal fixation can be accomplished using numerous techniques, including Kirschner wire fixation, composite and cerclage wiring, intramedullary fixation, screw fixation, and plate fixation. Kirschner wire fixation has been reported to result in an 18% complication rate.[10] Outcomes of cerclage wiring (although more technically demanding) have generally been positive, with full range of motion reported in 34 of 36 patients.[2] Intramedullary fixation allows for early active motion, with only one nonunion in 27 fractures reported in a single cohort study.[51] Screw fixation also typically results in successful outcomes, especially in long oblique and spiral shaft fractures. Plate fixation shows good to excellent outcomes, but has been associated with a complication rate of 35%.[41] Cerclage wiring, screw fixation, and plate fixation are typically rigid enough to allow for early range of motion. Generally, the least invasive method that can reliably restore and maintain anatomic alignment of metacarpal shaft fractures is preferable for successful outcomes.

Segmental Metacarpal Loss

Restoration of metacarpal stability and function after segmental bone loss is a challenge. This situation occurs after an open injury and is nearly always associated with varying degrees of soft tissue injury or loss. Restoration of hand function is usually staged and begins with thorough débridement of devitalized tissue. A discussion of the timing of the soft tissue reconstruction is beyond the scope of this chapter, but it should not begin until a stable osseous framework has been achieved.

There are two philosophies regarding the management of acute metacarpal bone loss. The traditional viewpoint advocates maintaining metacarpal length with transverse intermetacarpal Kirschner wires or external fixation devices, with soft tissue coverage performed as a primary or delayed procedure. Bone grafting is performed only after joint motion is regained and healed wounds have matured. External fixation has been used successfully, but little information has been provided to help surgeons choose the most appropriate construct for a specific injury.

Freeland and Jabaley[36,37] believed that the best time to restore osseous stability with a bone graft and internal fixation is within the first 10 days of injury ("the golden period of wound repair"). Initial wound care consists of débridement and temporary skeletal stabilization. The wound is reinspected 3 to 7 days later, and if it is judged to be ready for closure or coverage, definitive fracture stabilization, bone grafting, and skin flap coverage (if required) are performed. Calkins and colleagues[18] reported satisfactory functional results in 9 of 10 patients who had traumatic segmental bone defects of the hand. Corticocancellous grafts were inserted within 2½ weeks of injury. The soft tissue wounds were left open, there were no cases of infection, and all grafts went on to incorporate. The authors believed that stable fixation combined with bone grafting promoted optimal return of function by allowing for early mobilization to minimize chronic swelling, pain, tendon adhesions, and articular stiffness.

Along similar lines, Gonzalez and colleagues[46] reported excellent results in the treatment of 64 metacarpal fractures secondary to low-velocity gunshot wounds treated with early débridement and stabilization (1 to 7 days). Fracture fixation was performed with an intramedullary rod, and the bone void was filled with autogenous iliac graft. There were no deep infections. The average range of motion at the MP joint was 65 degrees.

Reconstitution of osseous stability involves two steps:

1. Provisional stabilization (Figures 7.13 and 7.14): Maintenance of metacarpal length can be accomplished by numerous techniques, including transfixation pins,[76] external fixation,[4,36] methyl methacrylate spacers,[79] and combinations of these techniques.
2. Bone grafting with or without internal fixation (Figure 7.15): Most defects can be bridged with autogenous iliac corticocancellous graft. If more than one metacarpal has segmental loss, a single curved iliac crest graft designed to fit the defects in all metacarpals is useful.

❖ AUTHOR'S PREFERRED METHOD OF TREATMENT: Segmental Loss

Generally, when there is metacarpal bone loss, there are associated soft tissue defects and contamination. After thorough débridement, osseous stability is achieved with an external fixator. Additional débridements are carried out over the next 2 to 5 days until the wound is surgically clean. At that time, a corticocancellous or cancellous bone graft is harvested from the iliac crest and fashioned to fit into the defect. Stabilization is accomplished with an appropriately contoured dorsal plate.

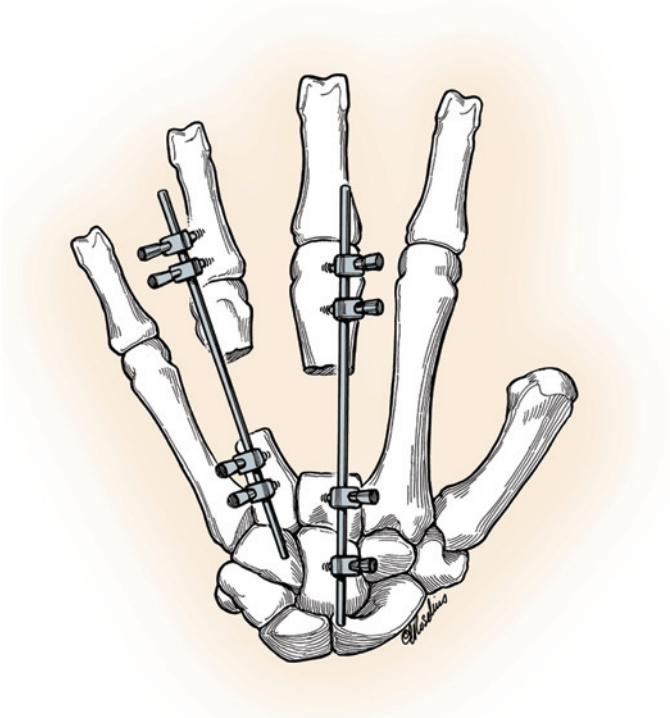

FIGURE 7.13 External fixator is ideal treatment for metacarpal bone loss. Pins may be placed in carpus or phalanges when necessary. (Copyright Elizabeth Martin.)

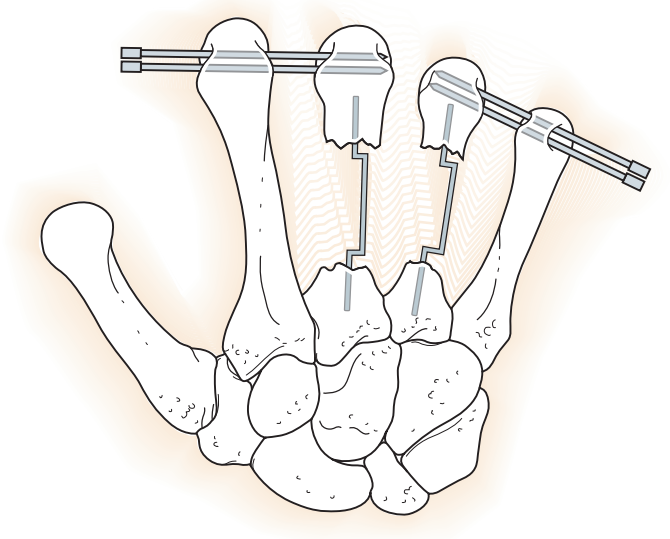

FIGURE 7.14 Transfixation pins and spacer wires are useful as temporary treatment for metacarpal bone loss.

When there is bone loss from multiple metacarpals, I prefer to use a monoblock of corticocancellous or pure cancellous graft, rather than individual metacarpal bone reconstruction. Soft tissue coverage is obtained with a regional, distant, or free flap. I prefer staged tendon reconstruction in which silicone rods are inserted at the time of flap coverage and replaced later with free tendon grafts.

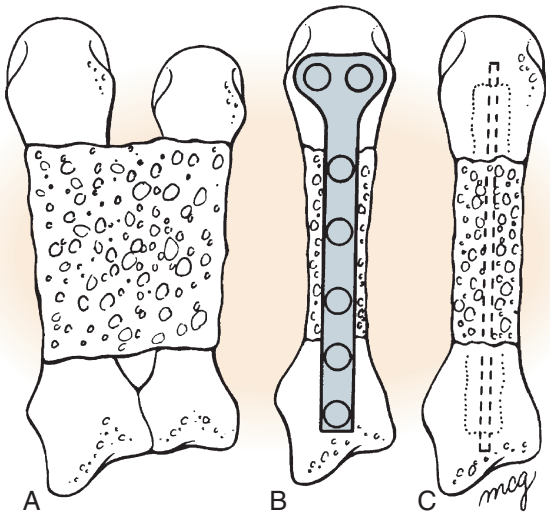

FIGURE 7.15 Techniques of corticocancellous or cancellous bone graft after metacarpal loss. **A,** A block of iliac crest graft is especially useful when there is bone loss in more than one metacarpal. **B,** Corticocancellous graft and plate fixation. **C,** Littler's technique using corticocancellous dowel and intramedullary Kirschner pin.

Metacarpal Base Fractures and Carpometacarpal Fracture-Dislocations

Avulsion Fractures of the Second and Third Metacarpal Bases

Isolated articular fractures of the base of the second and third metacarpals are rare because of the lack of motion in these joints, and there is no consensus regarding optimal treatment. These fractures are usually the result of a fall on a flexed wrist. Avulsion fractures from the dorsal base of the index or middle metacarpals have been successfully managed operatively and nonoperatively. Justification for surgical reattachment includes restoration of the integrity of the extensor carpi radialis longus or brevis, reconstitution of the articular surface of the CMC joint, and elimination of a potentially irritating fragment of dorsal bone.

Fracture-Dislocations of the Ring Finger Carpometacarpal Joint

Ring finger CMC joint dislocations are uncommon, may be associated with a metacarpal fracture, and may be missed at presentation. Isolated ring finger metacarpal fractures should raise the possibility of an associated CMC joint injury and prompt careful examination of various radiographic views. Computed tomography may be helpful to better delineate articular fragments.

Fracture-Dislocations of the Small Finger Carpometacarpal Joint

Articular fractures of the hamate–fifth metacarpal joint are common and are usually associated with proximal and dorsal subluxation of the metacarpal. The hamate articulates with the ring and small metacarpals by two concave facets separated by a ridge. The base of the fifth metacarpal consists of a concave-convex facet that articulates with the hamate and a flat radial facet that articulates with the fourth metacarpal base. Dorsal

and palmar intermetacarpal ligaments and an interosseous ligament stabilize the intermetacarpal joint. The injury results from a longitudinally directed force along the fifth metacarpal resulting in proximal and dorsal subluxation of the metacarpal base. The displacement is accentuated by the pull of the extensor carpi ulnaris.

Because the extent of the injury is frequently missed on routine radiographs, Bora and Didizian[7] recommended an anteroposterior view with the forearm pronated 30 degrees from the fully supinated position. A 30-degree pronated lateral view is also helpful to profile the subluxated metacarpal. For difficult visualization or assessment of articular comminution, CT scan is occasionally warranted.

There is no consensus regarding optimal treatment of these fractures. Options run the gamut from closed reduction and cast immobilization to ORIF. Bora and Didizian[7] found that weakness of grip was the major functional disability resulting from inadequate reduction or lost reduction. These authors recommended closed reduction and percutaneous pin fixation of the fifth metacarpal to the fourth metacarpal or carpus for maintenance of reduction.

Petrie and Lamb[94a] treated 14 fracture-dislocations of the fifth metacarpal–hamate joint by immediate, unrestricted motion and reviewed them at 4.5 years. Despite persistent metacarpal shortening, incongruity in the articular surface, and widening of the joint, only one patient had enough pain to affect work. These investigators believed that the case for surgical treatment was not strong because arthrodesis of the joint could always be performed for persistent pain. Kjaer-Petersen and colleagues[71] reported that regardless of the method of treatment (closed, percutaneous, or open), 19 of 50 (38%) patients had some symptoms at a median follow-up of 4.3 years. They believed that restoration of the articular surface should be the goal of treatment. Cain and associates[17] noted that fracture-dislocations of the fourth and fifth CMC joints, in association with comminuted dorsal hamate fractures or coronal shear fractures through the hamate, were particularly unstable, and ORIF was uniformly necessary. For single large hamate shear fractures, screw fixation to the body serves to treat the fracture and the dislocation.

Multiple Carpometacarpal Dislocations

Multiple CMC dislocations are high-energy injuries that nearly always require ORIF.[78,116] Lawlis and Gunther[78] reported on 20 patients, 14 of whom had multiple CMC dislocations. Closed reduction was uniformly unsuccessful because of redislocation or subluxation, and reduction with Kirschner pin fixation was recommended. Open reduction is necessary only if closed reduction is unsuccessful. At 6.5 years' follow-up, patients with isolated second and third CMC dislocations or concomitant ulnar nerve injury did poorly. Lawlis and Gunther[78] indicated that it was unclear why these patients did poorly compared with patients with dislocations of all four CMC joints. It is possible that these patients had fractures that were unreduced or had recurrent subluxation. Clendenin and Smith[23] reported relief of symptomatic arthritis of the hamate–fifth metacarpal joint when treated by arthrodesis using an iliac crest bone graft.

❖ AUTHOR'S PREFERRED METHOD OF TREATMENT

Fracture-dislocations of the fifth CMC joint are inherently unstable, and closed reduction and cast immobilization can be risky. Redislocation may not be appreciated because radiographic imaging is difficult as a result of bony overlap and plaster artifact. For unstable fracture-dislocations of the fifth CMC joint, we prefer closed reduction and percutaneous pinning. With appropriate anesthesia, longitudinal traction is applied, and palmar pressure is exerted on the base of the fifth metacarpal. Under image intensification, the fifth metacarpal shaft is pinned into the fourth metacarpal. A second pin can be obliquely directed across the fifth metacarpal–hamate joint (Figure 7.16). When multiple fragments or comminution exists, preoperative CT may be useful.

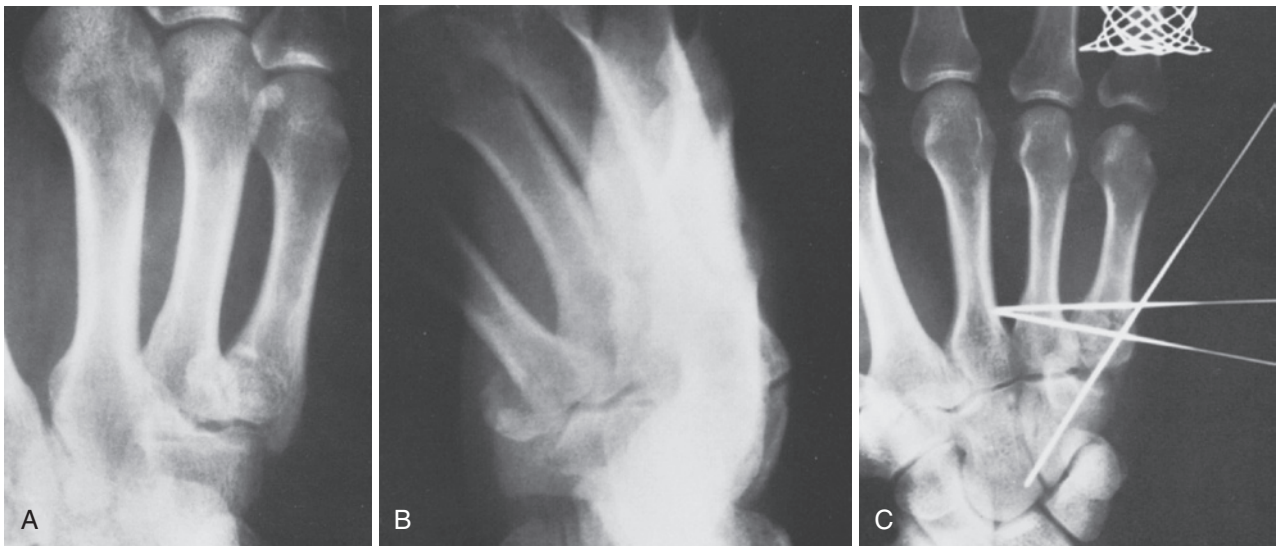

FIGURE 7.16 **A,** Articular fracture of base of fifth metacarpal with proximal and dorsal subluxation of carpometacarpal (CMC) joint. **B,** Oblique view taken with hand pronated 30 degrees from fully supinated position shows extent of articular injury. **C,** Reduction was obtained by longitudinal traction and lateral pressure on displaced bone. Firm fixation with transarticular pin and transfixation pins into adjacent metacarpal allowed early motion.

If ORIF is elected, a dorsal ulnar incision is used to visualize the joint. Care must be taken to protect the dorsal sensory branch of the ulnar nerve. The joint is débrided of loose fracture fragments, the articular surface is reduced, and reduction is maintained with multiple Kirschner wires or small screws. Articular comminution may be so extensive that ORIF is impossible; in such cases, percutaneous reduction of the dislocated metacarpal may be a safer option. Postoperatively, a forearm-based ulnar gutter splint is applied. Digital motion is started at 10 to 14 days, and the internal fixation pins are removed at 6 weeks.

For multiple CMC joint dislocations, closed reduction and percutaneous pinning or ORIF is nearly always indicated. The dislocated joints are well visualized through a dorsal longitudinal incision. Reduction is usually simple and can be maintained with Kirschner wires extending from the metacarpals into the carpus.

If a fracture-dislocation of the fifth CMC joint is seen more than 3 weeks after the injury, we prefer to accept the alignment. If symptomatic arthritis develops, secondary arthrodesis can be performed.

For patients with symptomatic CMC joint arthritis, the arthrodesis is accomplished by removing the articular surfaces down to subchondral cancellous bone, and fixation is accomplished with Kirschner wires extending from the hamate to the fifth metacarpal shaft. If graft is needed for the arthrodesis, we prefer using a corticocancellous slot graft from the iliac crest (Figure 7.17). Fusion of this joint does not significantly compromise hand function.

Complications of Metacarpal Fractures

Malunion

Extraarticular malunions may be angulatory, usually as a result of a malunited transverse shaft fracture; rotational, as a result of a spiral or oblique fracture; or shortened, as a result of a crush injury with bone loss. After crush injuries or open fractures, there may be shortening and associated soft tissue problems, such as tendon adhesions, poor skin coverage, and neurologic deficit. In such cases, one may elect to perform an osteotomy and correct the soft tissue problem simultaneously.

Dorsal Angulation. Metacarpal malunion after a transverse fracture results in apex dorsal angulation in the sagittal plane. Healing of second and third metacarpals with moderate to severe angulation is particularly bothersome cosmetically (pseudoclawing) and functionally (i.e., prominent metacarpal head in the palm resulting in painful and weak grip). With the use of plates and screws, corrective osteotomies have union rates that approach 100% and result in a high degree of clinical satisfaction for isolated malunions and fractures that involve an adjacent joint or extensive soft tissue injury, or both.[122] Correction can be accomplished through either an opening or a closing wedge osteotomy. A closing wedge osteotomy (Figure 7.18) is simpler[47] than an opening wedge osteotomy, and geometrically little, if any, shortening results because length is gained by correction of the angulation. Preoperatively, the size of the wedge is calculated by using a template, and the volar periosteum is left intact to act as a hinge intraoperatively. We prefer fixation with a 2.4-mm or 2.7-mm dorsal plate and supplemental cancellous bone graft. In malunions with metacarpal osteoporosis or insufficient bone stock to achieve at least four cortices of screw fixation proximally and distally, a locking plate should be considered.

If the metacarpal is appreciably shortened because of bone loss, an opening wedge osteotomy (Figure 7.19) with a trapezoid interpositional iliac crest bone graft is preferable. Stable fixation to allow early motion is accomplished with a dorsal plate.

Malrotation. Rotational malunion of a metacarpal results in overlapping of the affected finger over an adjacent finger (scissoring). It usually results from a malunited spiral or oblique fracture. The cosmetic deformity is often marked, and grip

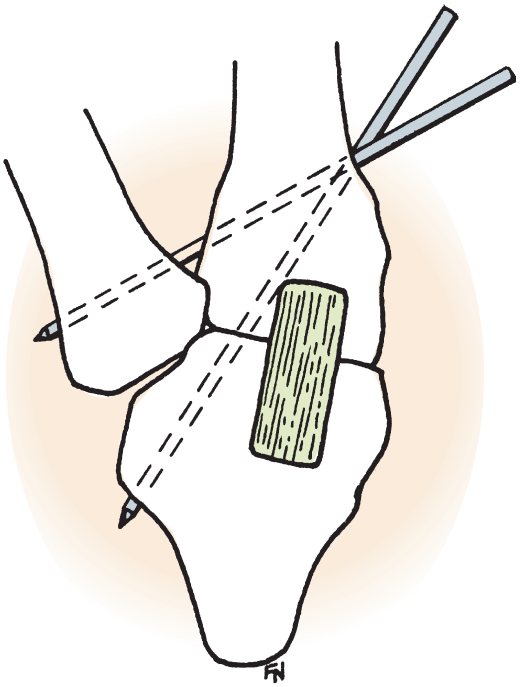

FIGURE 7.17 Method of arthrodesis of fifth carpometacarpal (CMC) joint with inlay graft and pins.

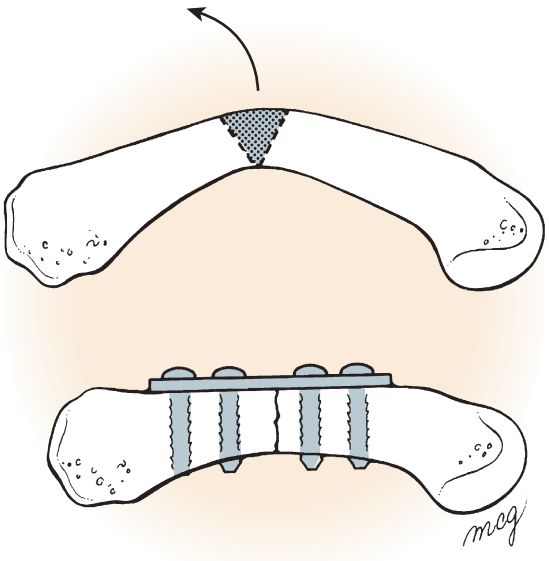

FIGURE 7.18 Metacarpal closing wedge osteotomy for malunion. Volar periosteum is left intact, a precisely calculated triangular wedge is removed, and fixation is provided with dorsal plate.

is impaired. Weckesser[128] advocated a corrective osteotomy through the base and was able to correct 25 degrees in each direction. Fixation was accomplished with Kirschner wires. Gross and Gelberman[50] noted that the maximal correction obtained in fresh cadaveric metacarpal osteotomies was 18 to 19 degrees for the index, long, and ring fingers and 20 to 30 degrees for the small finger. The transverse metacarpal ligament limited the maximal rotation obtained, but the orientation of the MP joint did not limit its motion.

We have been pleased with the results achieved when the osteotomy is performed through the metaphyseal base with the technique (Figure 7.20) described by Weckesser.[128] After rotational correction, the osteotomy is transfixed with a provisional Kirschner pin. Correction is assessed by observing the tenodesis effect of passive wrist flexion and extension, evaluating the plane of the fingernails, and checking for alignment of the fingertips to the scaphoid tuberosity. Final fixation is performed with multiple pins. This fixation technique is appealing because it is simple and forgiving, and union usually occurs rapidly. Alternatively, fixation can be secured with a T-plate, L-plate, or minicondylar plate. This procedure is technically more demanding, and care must be taken not to lose correction when the plate is being applied and to ensure that there is good contact between the bony surfaces.

Articular Malunions. Articular malunions are rarely amenable to corrective osteotomy. If the fracture line can be visualized, and bone quality is satisfactory, osteotomy with reconstitution of the articular surface is the optimal treatment.

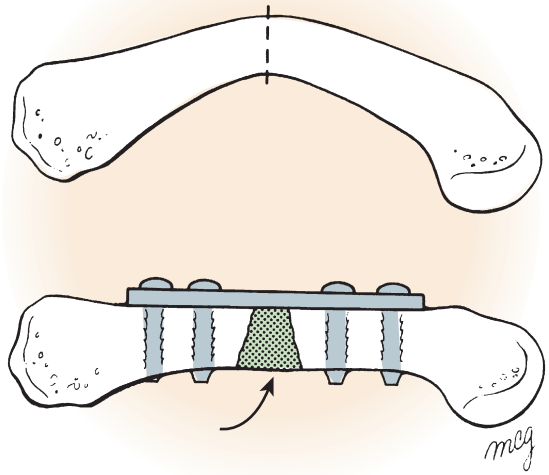

FIGURE 7.19 If there is significant metacarpal shortening, opening wedge osteotomy and plate fixation would reconstitute metacarpal length, although a bone graft would be required.

Osteomyelitis

Osteomyelitis occurring after metacarpal fracture fixation is uncommon, and treatment must be individualized. In a review of osteomyelitis of the tubular bones of the hand, delay in treatment of more than 6 months or performance of more than three procedures was associated with a very high amputation rate.[102] For metacarpal shaft osteomyelitis, the following is recommended:

1. Obtain cultures, remove loose implants, and generously débride bone and soft tissue. Stabilize the proximal and distal segments with an external fixator. The void can be filled with a block of antibiotic-impregnated polymethyl methacrylate, which also provides a spacer for insertion of a future bone graft.
2. Appropriate systemic antibiotics are recommended for at least 4 to 6 weeks. Débride the wound repeatedly until it is surgically clean, and allow wound closure by secondary intention.
3. When sepsis has cleared, insert cancellous or corticocancellous bone graft, preferably with plate and screw fixation.

Nonunion

Nonunion after closed metacarpal fractures is uncommon. Hypertrophic nonunions are rare in the hand; most are atrophic and hypovascular. Recommended treatment in these cases

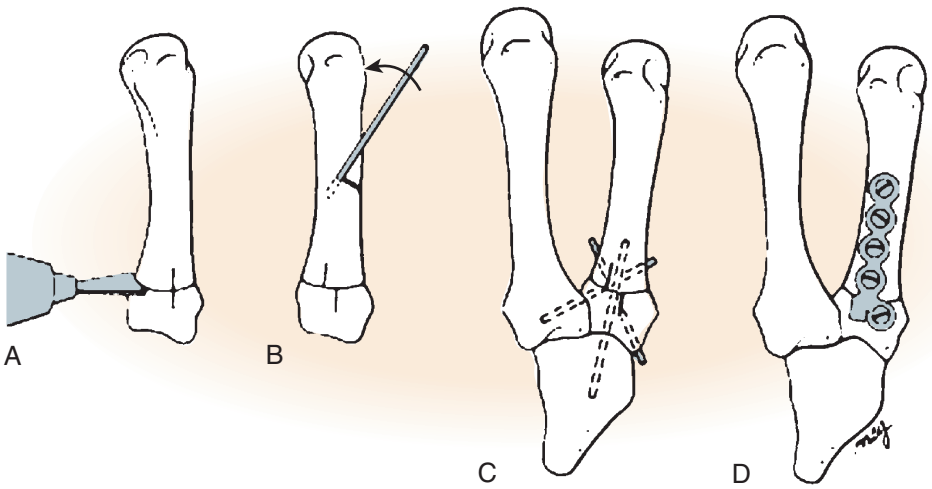

FIGURE 7.20 Metacarpal osteotomy for rotational malunion. **A,** Before osteotomy, a longitudinal mark is placed on metaphysis with osteotome. Osteotomy is made with oscillating saw perpendicular to mark. **B,** Kirschner pin in the shaft acts as joystick for correction. **C** and **D,** Fixation is accomplished with multiple Kirschner wires (**C**) or plate (**D**).

requires resection of the pseudarthrosis, bone grafting, and stable internal fixation.

Nonunions usually occur after bone loss, osteomyelitis, inadequate immobilization, or poor fixation (i.e., a metacarpal fracture pinned in distraction).[67] Jupiter and associates[67] reported 25 nonunions in 23 patients, and advised surgical intervention at 4 months. Nine nonunions occurred in metacarpals, most of which had previously been fixed with Kirschner wires. Six of nine nonunions were treated, and all healed after bone grafting. Three were fixed with a plate and screws, two were fixed by Kirschner wires, and one had no fixation. Rigid internal fixation was preferred because it enabled early active motion and permitted concomitant procedures such as capsulotomy and tenolysis.

Other Complications

Complications are the result of the fracture itself, treatment of the fracture, or a combination of both. Tendon adhesions occurring after closed metacarpal fractures are uncommon. Usually, adhesions follow tendon lacerations or crush injuries and are most frequently seen between the extensor tendons and the underlying bone. Initial treatment should consist of therapy and include dynamic MP flexion splinting. If initial treatment fails, tenolysis with or without MP capsulotomy is indicated.

Intrinsic muscle dysfunction can occur under the following circumstances: loss of innervation, loss of muscle substance, or secondary to contracture. Significant loss of intrinsic muscle substance or denervation can result in clawing, and treatment may require tendon transfers. Intrinsic contractures may also occur, especially after a closed crushing injury associated with an unrecognized hand compartment syndrome, and may require intrinsic releases to improve function (see Chapter 32).

PHALANGEAL FRACTURES

Fractures of the Distal Phalanx

Distal phalangeal fractures are the most commonly encountered fracture in the hand. Distal phalangeal fractures are classified as tuft fractures, shaft fractures, or articular injuries (eTable 7.2).

Tuft Fractures

Tuft fractures usually occur secondary to a crushing injury and are often associated with laceration of the nail matrix or pulp, or both. Closed tuft fractures are frequently associated with a painful subungual hematoma. Decompression provides dramatic pain relief and can be accomplished with a small drill bit, heated paper clip, or battery-powered electrocautery unit. A short period of immobilization (10 to 14 days) is indicated for symptomatic relief. Comminuted tuft fractures rarely require internal fixation. Instead, attention should be focused on carefully approximating associated lacerations of the pulp and nail matrix. The nail should be removed if an injury to the nail matrix is suspected, especially if the nail plate is fractured and displaced. Repair of the nail bed decreases the likelihood of subsequent nail abnormalities. These fractures often fail to unite but are invariably stabilized by a fibrous union. If the nail plate is intentionally perforated to decompress a hematoma or removed to perform a nail bed repair, a closed fracture is theoretically converted to an open fracture, and a short course of oral antibiotic therapy can be considered.

Shaft Fractures

There are two types of shaft fractures: transverse and longitudinal. Nondisplaced transverse fractures are sufficiently stabilized by the surrounding soft tissue and do not require internal fixation. Displaced transverse fractures may be open and are often associated with a transverse laceration of the overlying nail matrix. Longitudinal Kirschner pin fixation and nail matrix repair should be considered.

Epiphyseal Fractures of the Distal Phalanx

Epiphyseal injuries of the distal phalanx result from hyperflexion. Failure to recognize and treat this injury, especially in a toddler, can result in a foreshortened digit that has decreased range of motion at the distal interphalangeal (DIP) joint.[127] The injury may be manifested as an open mallet deformity and mistaken for DIP joint dislocation. The terminal tendon is attached to the proximal epiphyseal fragment and the profundus insertion on the distal fragment, causing apex dorsal angulation at the fracture site. In children, there is nearly always a transverse laceration of the nail matrix, and the avulsed nail plate lies superficial to the proximal nail fold (Figure 7.21). There is some risk in discarding the nail plate because it is useful in maintaining fracture reduction. Simple reduction without treatment of the soft tissue injury results in loss of reduction and infection. Appropriate treatment consists of irrigation and débridement, fracture reduction, repair of the lacerated nail matrix, and replacement of the nail plate beneath the proximal

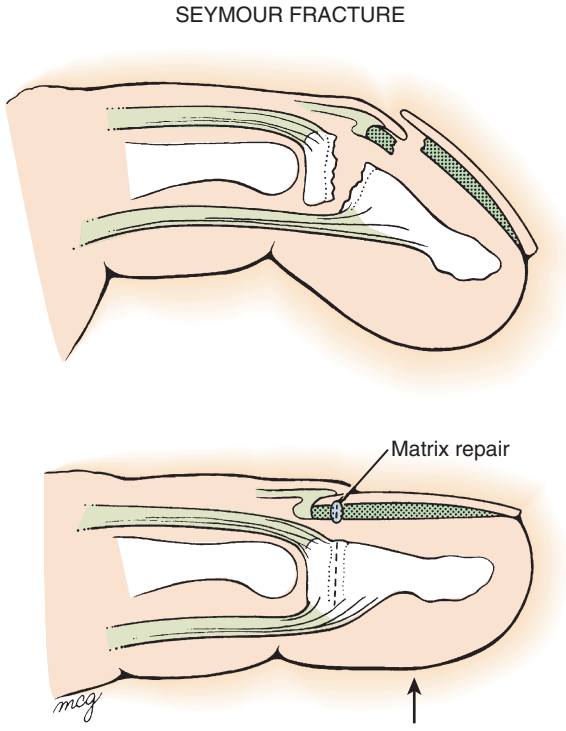

FIGURE 7.21 Open epiphyseal fracture of distal phalanx in a child. *Top,* Note matrix disruption (*stippled*); nail plate has been avulsed and is dorsal to proximal nail fold. *Bottom,* Reduction requires matrix repair and replacement of nail plate beneath proximal nail fold.

eTABLE 7.2 Classification of Distal Phalangeal Fractures

Tuft Fractures	Shaft Fractures	Articular Fractures
Simple	Transverse	Volar (profundus avulsion)
Comminuted	Stable	Epiphyseal
	Unstable	Child (Salter-Harris type I or II fracture)
	Longitudinal	Adolescent (Salter-Harris type III fracture)
		Dorsal (mallet fractures)

Modified from Schneider LH: Fractures of the distal phalanx, *Hand Clin* 4:537–547, 1988.

nail fold to act as a stent in maintaining the reduction. Failure to recognize the injury or inadequate primary treatment may result in acute osteomyelitis or septic arthritis, or both. Postoperatively, a splint is applied to hold the distal fragment in extension.

Complications of Distal Phalangeal Fractures

Symptomatic nonunion of distal phalangeal fractures occurs occasionally. Itoh and coworkers[63] reported six patients with nonunions of the waist of the distal phalanx successfully treated with crossed Kirschner wires and bone graft with exposure through a palmar midline approach. Late presentation of a pediatric epiphyseal fracture is characterized by a dorsal bump secondary to continued growth of the dorsally displaced epiphysis.

Fractures of the Middle and Proximal Phalanges

Phalangeal fractures that are stable and nondisplaced can be effectively managed by "buddy taping" or splint immobilization. Improper treatment of unstable fractures often leads to stiffness and deformity.

In studies by Strickland and colleagues,[115] several factors had a deleterious effect on ultimate digital mobility (eBox 7.1). These investigators pointed out that if an extraarticular fracture occurred in persons in the first 2 decades of life, 88% of the mobility was restored; however, in persons in the sixth and seventh decades, less than 60% of total active motion was restored. In addition, older patients are more likely to have chronic diseases or underlying osteoarthritis that could contribute to residual stiffness. Uncooperative and noncompliant patients must be identified. These patients require heavy-duty splints and casts that are not removable, and if surgery is performed, rigid fracture fixation is recommended.

Articular injury has a major influence on the ultimate result. Because these joints are not subjected to heavy loads, stability and alignment are likely more important than articular congruency in determining outcome. There is a low incidence of late symptomatic osteoarthritis in conservatively treated articular fractures; articular reconstitution over time is often observed in the small joints of the hand. Likewise, comminuted fractures, fractures associated with bone loss, and unstable fractures with considerable deformity are also prone to residual disability regardless of the method of treatment.

Injury to the soft tissue sleeve, usually the result of a crushing injury, may severely compromise digital mobility.[62,99] Duncan and coworkers[28] reviewed 140 open fractures at an average time past surgery of 17 months. They found that there was a direct correlation between the severity of the soft tissue injury and the final range of motion at follow-up. In addition, they found that fractures located in flexor tendon zone 2 had the worst prognosis. Huffaker and coworkers[60] concluded that flexor tendon injuries have a more serious effect on recovery of digital mobility than do extensor tendon injuries, and prolonged immobilization has a detrimental influence. Strickland and colleagues[115] pointed out that if immobilization after a phalangeal fracture was less than 4 weeks, final active motion was 80% of normal. If immobilization exceeded 4 weeks, total active motion declined to 66% of normal. A successful outcome depends on selection of the appropriate treatment and must be tailored to the individual patient and fracture.

It is convenient to divide phalangeal fractures into articular and nonarticular injuries. Articular fractures include condylar fractures; comminuted fractures; dorsal, volar, or lateral base fractures; fracture-dislocations; and shaft fractures extending into the joint. Nonarticular fractures include fractures of the neck, shaft, or base.

Articular Fractures of the Phalanges

Condylar Fractures. Condylar fractures can be classified into three categories. Type I fractures consist of stable fractures without displacement; type II fractures include unicondylar, unstable fractures; and type III fractures are bicondylar or comminuted fractures. In addition to standard anteroposterior and lateral radiographs, oblique radiographs are mandatory to visualize the fracture geometry properly and assess stability and displacement better.

Weiss and Hastings[129] developed a useful classification for unicondylar fractures of the proximal phalanx (Figure 7.22) and made two important observations. First, even initially nondisplaced fractures are inherently unstable (Figure 7.23). Nonoperative management warrants extremely close follow-up. Second, fixation with a *single* Kirschner pin is inadequate. Displaced unicondylar fractures usually require ORIF.[55,65] The two most popular techniques of fixation are (1) Kirschner wires and (2) a lag screw. Of these, multiple Kirschner wires provided the best final range of motion at the PIP joint. Postoperatively, a 20- to 30-degree PIP extensor lag was frequent. Some correction of this problem can be obtained by dynamic extension splinting.

Bicondylar fractures and comminuted articular fractures can be very difficult to fix. Buchler and Fischer used a minicondylar plate.[12] Regardless of the fixation method, PIP joint stiffness frequently occurs.

Other Fractures of the Head of the Phalanx. Displaced collateral ligament avulsion fractures of the head of the proximal phalanx may be symptomatic if nonunion or fibrous union results. Open reduction or repair of these injuries should be done if the injuries are associated with lateral instability.

Extensively comminuted phalangeal head fractures may preclude satisfactory open reduction. These fractures are frequently associated with considerable damage to the soft tissue sleeve and are best treated nonoperatively. Treatment must be individualized.

Dorsal, Volar, or Lateral Base Fractures. Avulsion fractures of the dorsal base of the middle phalanx represent detachment of the insertion of the central tendon and are usually the result of an anterior PIP joint dislocation. If the avulsed fragment is displaced more than 2 mm, accurate reduction and internal or percutaneous pin fixation are necessary to prevent extensor lag and subsequent boutonnière deformity (Figure 7.24).

Fractures of the lateral volar base of the proximal or middle phalanx usually represent collateral ligament avulsion injuries. Minimally displaced lateral corner fractures that do not compromise joint stability or result in an incongruous articular surface can be treated by splinting for comfort measures only and accompanied by early range of motion. Significantly displaced lateral corner fractures may compromise joint stability and may need ORIF. Kuhn and colleagues[72] recommended a volar approach for internal fixation of proximal phalangeal base fractures. They reported 11 avulsion fractures; at final follow-up,

eBOX 7.1 Factors Influencing the Outcome After Phalangeal Fractures

Patient Factors

- Age
- Associated diseases and arthritis
- Socioeconomic status
- Motivation and compliance

Fracture Factors

- Location
- Articular fractures
- Geometry
- Simple, comminuted, impacted, bone loss
- Transverse, oblique, spiral, avulsion
- Deformity: angulation, shortening, rotation
- Stability
- Injury to soft tissue sleeve
- Associated injuries
- Tendon, ligament, joint, vessel, nerve, other digits

Management Factors

- Diagnosis and recognition
- Reduction and maintenance
- Length of immobilization
- Recognition and management of complications

Modified from Strickland JW, Steichen JB, Kleinman WB, et al: Phalangeal fractures: factors influencing digital performance, *Orthop Rev* 11:39–50, 1982.

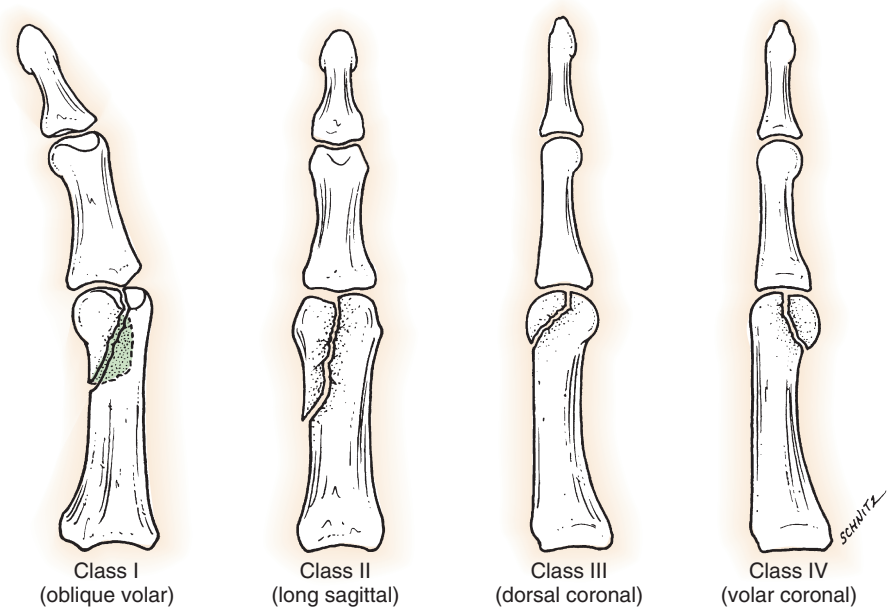

FIGURE 7.22 Weiss-Hastings classification of unicondylar fractures of proximal phalanx. These fractures are nearly all unstable and nearly always require operative fixation. (From Weiss APC, Hastings HH: Distal unicondylar fractures of the proximal phalanx, *J Hand Surg [Am]* 18:594–599, 1993.)

CRITICAL POINTS *Operative Management of Unicondylar Fractures of the Proximal Phalanx*

Indication
- Any displaced condylar fracture

Preoperative Evaluation
- Evaluate for angulation or malrotation with flexion.
- Obtain an anteroposterior radiograph to assess articular step-off.
- Check a lateral radiograph to see if the fractured condyle is displaced palmarly.
- Check an oblique radiograph for orientation of the fracture line.

Pearls
- This is a highly unstable fracture; err on the side of operative intervention.
- Internal fixation *always* requires two screws or two Kirschner wires, or one of each.

Technical Points
- Closed reduction by application of longitudinal traction is worth a try.
- If reduction is achieved, provisionally hold it with one or two towel clips.
- Confirm reduction with fluoroscopy.
- Percutaneously fix the fracture with two Kirschner wires (0.7 mm or 0.9 mm).
- If closed reduction fails, proceed to open reduction.
- Make a dorsal longitudinal incision on the side of the fracture.
- Enter the PIP joint by incising between the lateral band and central tendon.
- Take care not to detach the central tendon.
- Expose the condylar fragment from its apex proximally to its articular surface distally.
- When mobilizing the condylar fragment, take care not to detach the collateral ligament.
- Reduction must be anatomic at the articular surface and proximally so that the condylar apex keys into the phalanx.
- Provisionally maintain reduction with a Kirschner pin or drill bit to be replaced later by a screw.
- Fix with two Kirschner wires (0.7 mm or 0.9 mm) or two (lag) screws (2 mm or 1.5 mm [1.3 mm]).
- Confirm reduction with radiographs (three views).

Pitfalls
- One screw or pin may result in loss of reduction from either rotation or loosening.
- Detachment of the collateral ligament may produce instability or osteonecrosis of the condylar fragment.

Postoperative Care
- At 5 to 7 days, initiate active range of motion.
- Splint the PIP joint in full extension when not exercising.
- Remove Kirschner wires at 3 to 4 weeks.

all digits had full range of motion and a stable MP joint. To expose the fracture, the A1 and proximal portion of the A2 pulley are completely divided, and the flexor tendons are retracted to expose the volar plate (Figure 7.25). The volar plate is longitudinally split in its midline and detached distally from the proximal phalanx on the side of the fracture. The avulsed fragment is now well visualized and reduced. Fixation is accomplished with either 1.5-mm screws or Kirschner wires. The volar plate is repaired, and the digit is splinted in partial flexion. With secure screw fixation, protected active range of motion is initiated at the first postoperative visit.

Hastings and Carroll[55] brought attention to lateral plateau fractures of the base of the middle phalanx. They postulated that these are compression injuries that result in articular depression and metaphyseal bony compaction. Open reduction with cancellous bone grafting and tension band fixation demonstrates satisfactory results.[133]

Comminuted articular fractures, particularly fractures at the base of the middle phalanx, have been termed *pilon fractures*. The fracture is the result of an axial load that causes central articular depression and variable splay of the articular margins. Stern[114] reported 20 injuries treated in three ways: splinting,

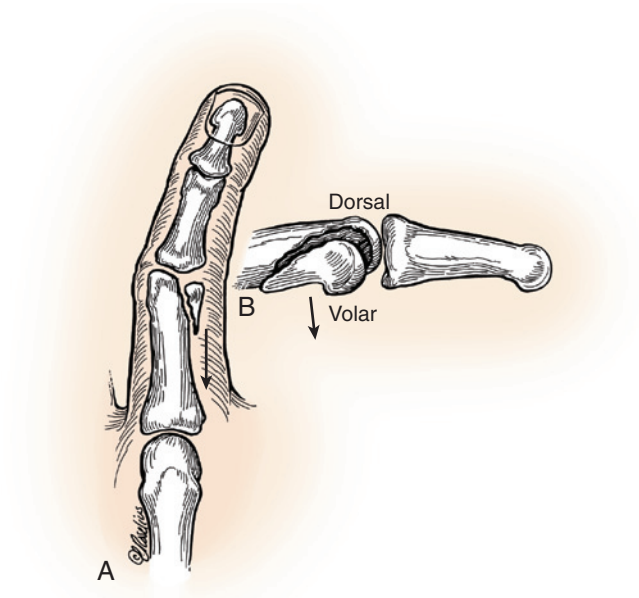

FIGURE 7.23 Inherent instability of a unicondylar fracture. **A,** Anteroposterior appearance of a condylar fracture. Note the articular step-off. **B,** Lateral view. Note volar displacement of the condylar fragment. (Copyright Elizabeth Martin.)

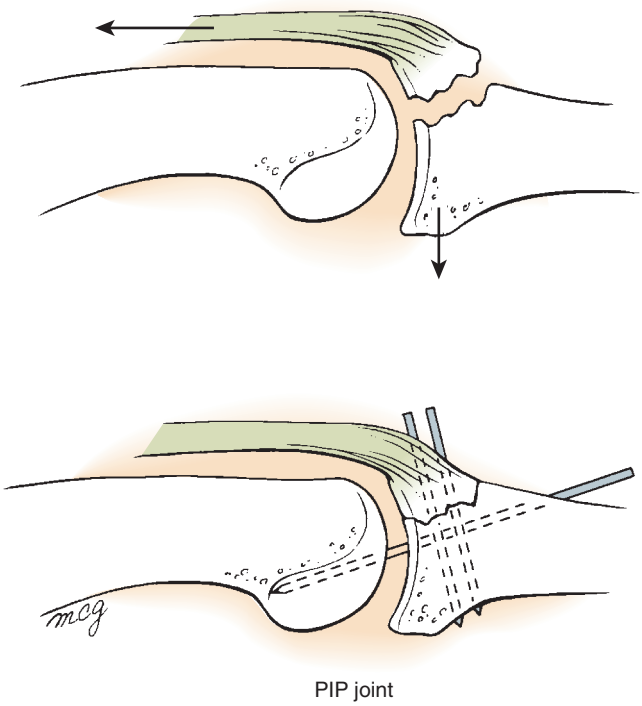

FIGURE 7.24 Anterior PIP fracture-dislocation. *Top,* Avulsion fracture from dorsal base of middle phalanx results in anterior displacement of middle phalanx. *Bottom,* Open reduction with Kirschner wires and transarticular pinning (for 3 weeks) is necessary for fracture and joint reduction.

traction through the middle phalanx, and open reduction. Splinting resulted in considerable stiffness. Skeletal traction through the middle phalanx (Figure 7.26) and ORIF had similar results. Anatomic articular restoration was not accomplished in any case, and no patient regained full mobility. Regardless of the treatment, there was significant articular remolding over time. Hamilton and coworkers[52] evaluated nine patients who were retrospectively identified as having been treated with open reduction and screw fixation for unstable dorsal fracture–dislocations to the PIP joint. Their results indicated that PIP range of motion is usually compromised, and they advised careful selection of candidates for ORIF screw fixation.

Because of the unpredictable outcome associated with treatment of this injury, various dynamic external fixation devices have been developed.[55] These devices are hinged and span the PIP joint to allow early protected range of motion, while maintaining reduction of the joint. Majumder and associates[85] reported their experience with the "pins and rubber traction system," originally introduced by Slade and colleagues,[109] for the treatment of articular base fractures in 14 patients. The traction system was left in for 4 to 7 weeks, and range-of-motion exercises began early. Majumder and associates[85] found an average of 74 degrees at the PIP joint and total active motion of 196 degrees.

As an alternative to dynamic distraction-fixation, ORIF with an autologous "hemihamate" osteoarticular graft can be performed for PIP joint fracture-dislocations in which more than 50% of the base of the middle phalanx is fractured with an intact dorsal cortex. Williams and associates[131] achieved satisfactory results after treating 13 patients with PIP joint fracture-dislocations using a hemihamate autograft and screw fixation. Motion was initiated approximately 1 week after surgery.

Shaft Fractures Involving the Joint. A long spiral fracture of the proximal (and sometimes middle) phalanx may project into the retrocondylar space of the IP joint and can be a mechanical block to flexion. ORIF is usually necessary. If the fracture is unreduced and heals with a residual spike that blocks PIP flexion, the bony projection can be removed to improve flexion.

❖ AUTHOR'S PREFERRED METHOD OF TREATMENT: Articular Fractures

Nondisplaced unicondylar fractures are potentially unstable. Immobilization in a splint is risky, and displacement should be anticipated. If nonsurgical treatment is selected, careful and frequent radiographic follow-up is mandatory to avoid a malunion with articular incongruity.

Displaced unicondylar fractures of the proximal phalanx are best managed operatively (Figure 7.27). The fracture is exposed through either a dorsal radial or dorsal ulnar longitudinal incision. The joint is entered between the central tendon and lateral band. The central tendon should not be detached from its insertion into the dorsal base of the middle phalanx. Fracture hematoma is removed, with care taken not to detach the condyle from its attachment to the collateral ligament. Under direct visualization, the fracture is anatomically reduced with a bone tenaculum, and the reduction is confirmed fluoroscopically. The condylar fragment is fixed with two parallel Kirschner wires (0.028-inch or 0.035-inch) drilled through the fragment into the intact bone. Interfragmentary screw fixation with two 1.5-mm or 1.3-mm screws can be used if the fracture fragment is two and a half to three times the external diameter of the screw. The dorsal extensor apparatus is reapproximated. Postoperatively, early active motion is initiated, and the PIP joint is splinted in extension to avoid extensor lag. Kirschner wires are removed at 3 to 4 weeks. Screws do not require removal unless they are symptomatic.

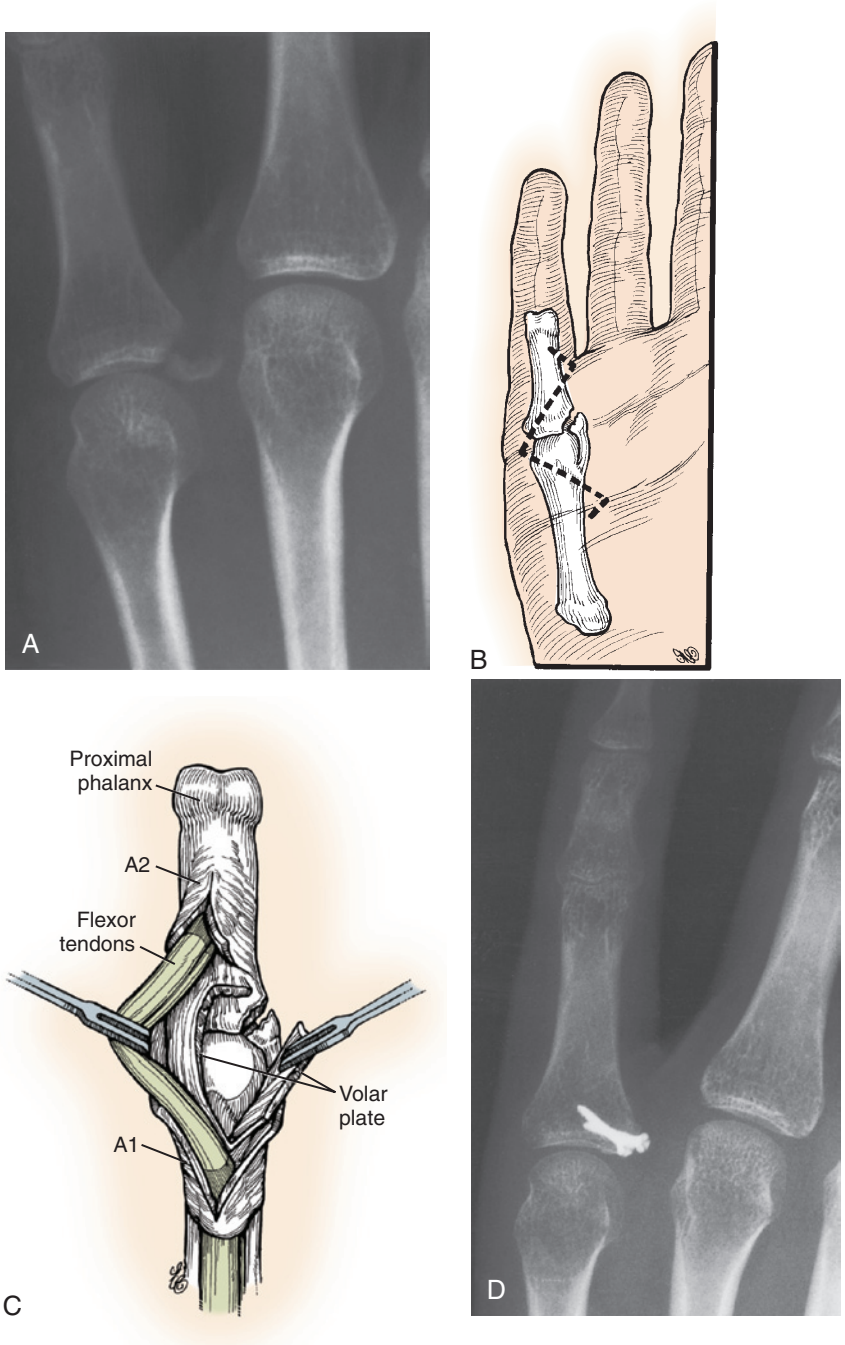

FIGURE 7.25 **A,** Radiograph showing displaced avulsion fracture from radial base of proximal phalanx. **B,** Zigzag incision used to expose fracture. **C,** A1 pulley (not shown) and proximal part of A2 pulley are divided. Volar plate is split longitudinally and detached distally from its insertion on base of proximal phalanx to expose fracture. **D,** Radiograph showing fracture reduction and fixation with two mini-screws. (***B*** and ***C,*** Copyright Elizabeth Martin.)

Although ORIF is the standard of care for the management of condylar fractures, closed reduction and percutaneous pin fixation can also be considered within 5 days from the injury (Figure 7.28). Using a mini C-arm, a pin is placed into the condylar fragment and used as a joystick to manipulate the fragment into its anatomic position. Finger trap traction is sometimes helpful to assist in reduction and to free the surgeon's hands for fragment manipulation and fixation. The reduction is provisionally maintained with a bone tenaculum, and the reduction is verified radiographically. Fixation is secured with two to three appropriately sized Kirschner wires. Small cannulated screws are also available for percutaneous management of these fractures. This technique has the advantage of minimizing soft tissue damage, but can be tedious and does not allow direct visualization of the fracture to verify anatomic reduction. One must also be cautious that the joystick pin and the bone tenaculum do not inadvertently fragment the fractured condyle.

Bicondylar fractures of the proximal phalangeal head are nearly always displaced and often comminuted. Anatomic

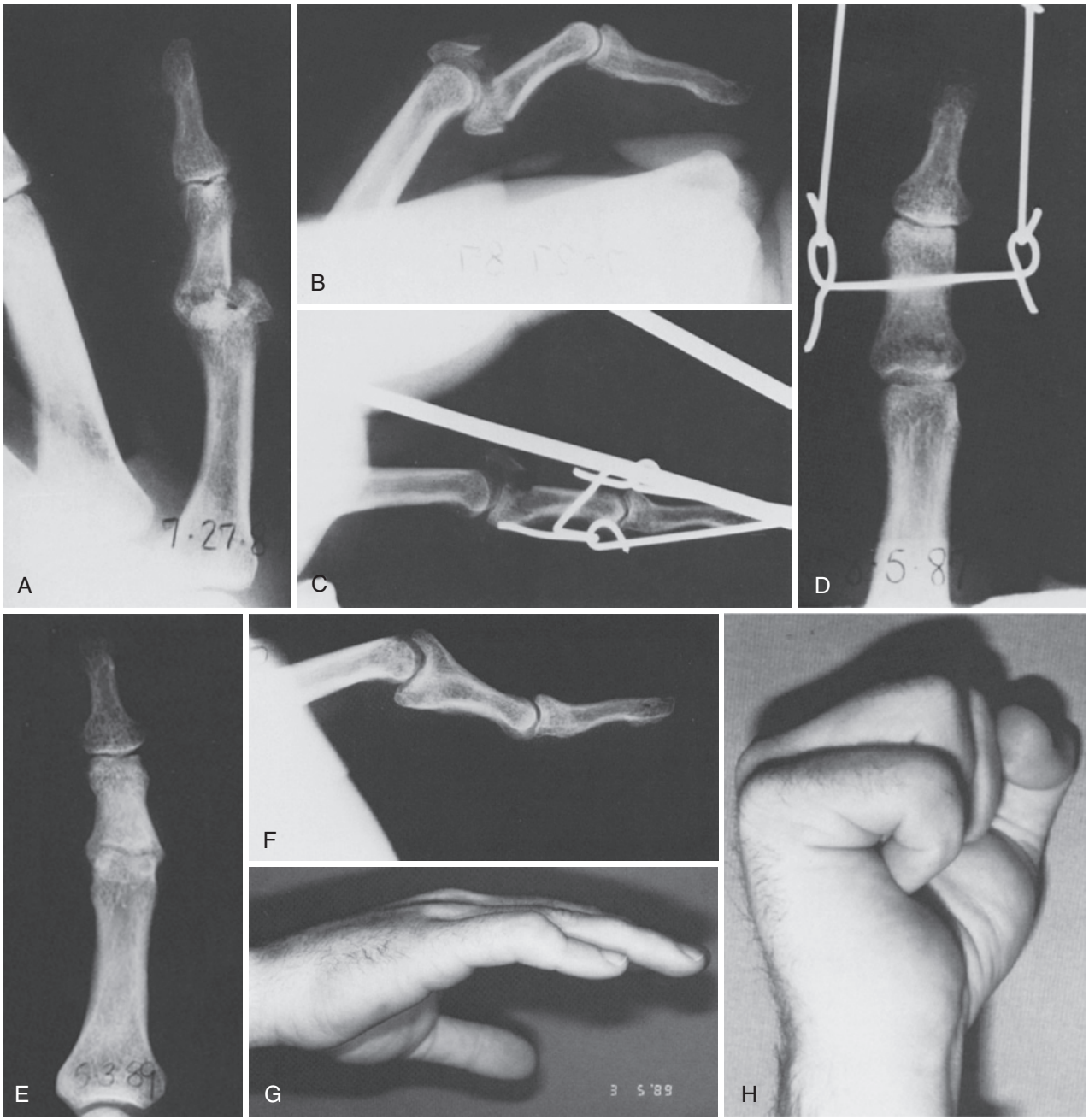

FIGURE 7.26 Pilon fracture of PIP joint treated by skeletal traction. **A** and **B,** Radiographs of fracture show severe joint disruption. **C** and **D,** Radiographs after 7 days of skeletal traction. Note correction of palmar subluxation but persistent displacement of dorsal fragment. **E** and **F,** There has been consolidation of fracture fragments and articular remodeling 21 months after injury. **G** and **H,** At 21 months' follow-up, there is excellent flexion. There is persistent PIP joint swelling and loss of extension, however. (From Stern PJ, Roman RJ, Kiefhaber TR, et al: Pilon fractures of the proximal interphalangeal joint, *J Hand Surg [Am]* 16:844–850, 1991.)

restoration of articular congruency usually cannot be accomplished by closed manipulation. Open reduction using the same approach as for unicondylar fractures is advised (Figure 7.29). First, the two condyles are reduced and fixed to each other with either a screw or Kirschner wires. Next, the head fragment is secured to the shaft in a similar fashion. Postoperatively, range of motion within 3 weeks is encouraged; however, residual stiffness or extensor lag, or both, are common. When there is significant comminution, open reduction may be frustrating, and restoration of the articular surface may be impossible. In such circumstances, skeletal traction or external fixation can be applied for 3½ to 4 weeks. Fracture consolidation can be anticipated, and some articular remodeling occurs. Restoration of full motion is unlikely. Primary arthrodesis is unpredictable and may result in excessive shortening.

Untreated displaced (>2 mm) fractures of the dorsal base of the middle phalanx can lead to a boutonnière deformity. Open reduction through a dorsal approach between the central tendon and the lateral band is recommended. Fixation can be accomplished with two small Kirschner wires or miniscrews. The fixation should be protected with a transarticular Kirschner pin for 3 weeks.

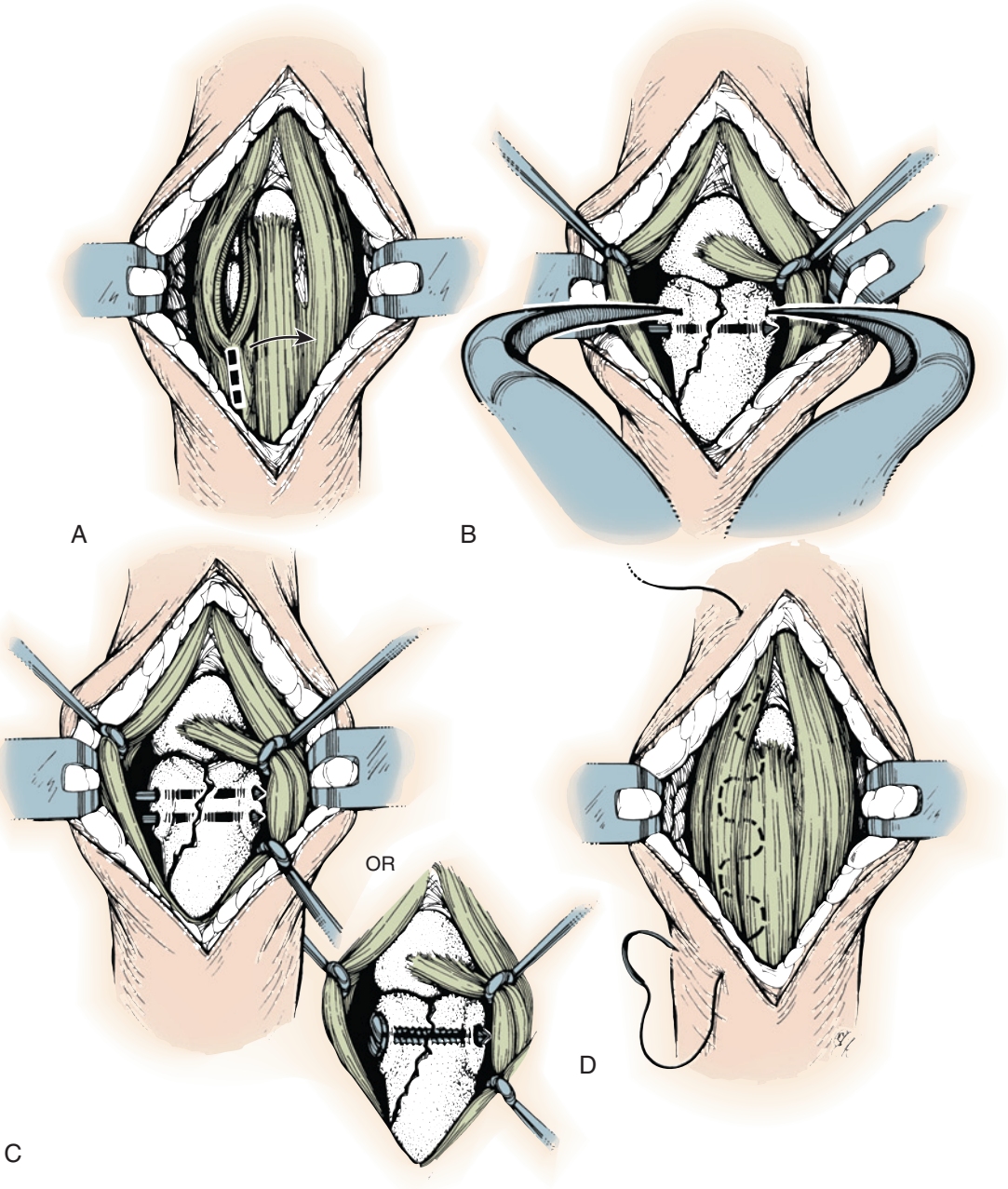

FIGURE 7.27 Method of open reduction of condylar fracture of proximal phalanx. **A,** Fracture is exposed between central tendon and lateral band. Care must be taken not to disrupt insertion of central slip from middle phalanx and origin of collateral ligament from condylar fragment. **B,** Fracture is reduced and held with towel clips (specially designed cannulated clamp may also be used). **C,** Internal fixation is accomplished with two transverse Kirschner wires or small screws. **D,** Central slip and lateral band are reapproximated with running 4-0 suture. (Copyright Elizabeth Martin.)

Displaced fractures of the base of the proximal phalanx require open reduction. I prefer a volar approach in which the A1 and proximal portion of the A2 pulley are divided followed by splitting the volar plate longitudinally. The fracture is easily visualized, and anatomic reduction can usually be achieved and preferably held with small screws. Isolated fractures of the base of the middle phalanx are unusual. There can be an impaction fracture to the articular surface, however, resulting in a depressed plateau type of fracture. These fractures typically need ORIF, with or without subchondral bone grafting.[133]

Pilon fractures of the base of the middle phalanx involve articular impaction and splay of the dorsal/palmar and radial/ulnar margins of the bone. I do not believe that ORIF is possible, and autograft replacement (hemihamate autograft) is precluded because the dorsal cortex is usually fractured. I prefer dynamic distraction fixation for these injuries combined with supervised range of motion of the IP joints. PIP joint arthritis or stiffness can be addressed surgically at a later time.

Because loss of DIP joint mobility is less disabling, bicondylar fractures of the head of the middle phalanx can sometimes

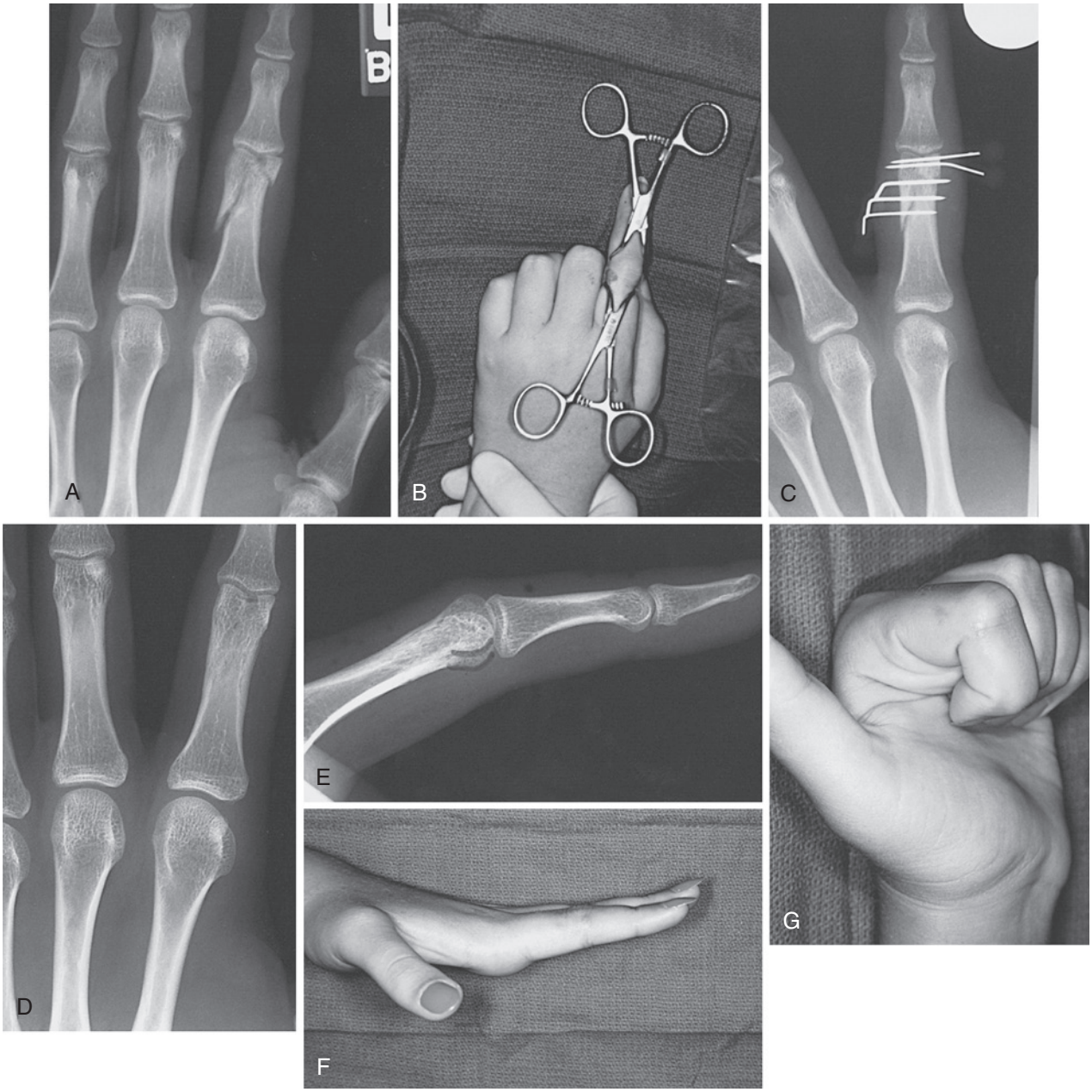

FIGURE 7.28 Percutaneous fixation of unstable bicondylar proximal phalangeal fracture. **A,** Preoperative radiograph. **B,** Fluoroscopically assisted reduction held with towel clips. **C,** Percutaneous pin fixation. **D,** Anteroposterior view of healed fracture. Note small central-radial depression. **E,** Lateral view. Volar condylar surfaces (*outlined*) should be colinear. They were not in this case. **F** and **G,** Final extension and flexion.

be treated by closed reduction, molding, and early protected motion at around 2 weeks, especially if minimally displaced. If open reduction is necessary, a dorsal lateral approach with mobilization of the conjoined lateral bands allows sufficient exposure to perform ORIF with either Kirschner wires or screws. Diminished motion of the DIP joint should be anticipated.

Nonarticular Fractures of the Phalanges

Neck Fractures. Neck fractures (subcapital or subcondylar) of the phalanges are uncommon in adults and can usually be managed in closed fashion by reduction and splinting or by percutaneous crossed Kirschner wires. Neck fractures of the proximal or middle phalanx are common in toddlers and result when the child violently attempts to withdraw a finger trapped in a closing door (Figure 7.30). The serious nature of the neck fracture may be missed unless a true lateral radiograph is obtained. In this view, displacement of the head fragment is best visualized. With lack of tendon attachment, the head fragment displaces dorsally and rotates 90 degrees such that the fracture surface faces palmarly and the cartilaginous surface faces dorsally. These fractures are deceptive and have little capacity to remodel.

Displaced neck fractures usually require open reduction. Fractures involving the head of the middle phalanx can be approached radial or ulnar to the conjoined lateral band,



FIGURE 7.29 Open reduction of displaced bicondylar proximal phalangeal fracture. **A,** Note articular component and angular deformity. **B,** Anatomic reduction with three lag screws. (Courtesy T. R. Kiefhaber.)

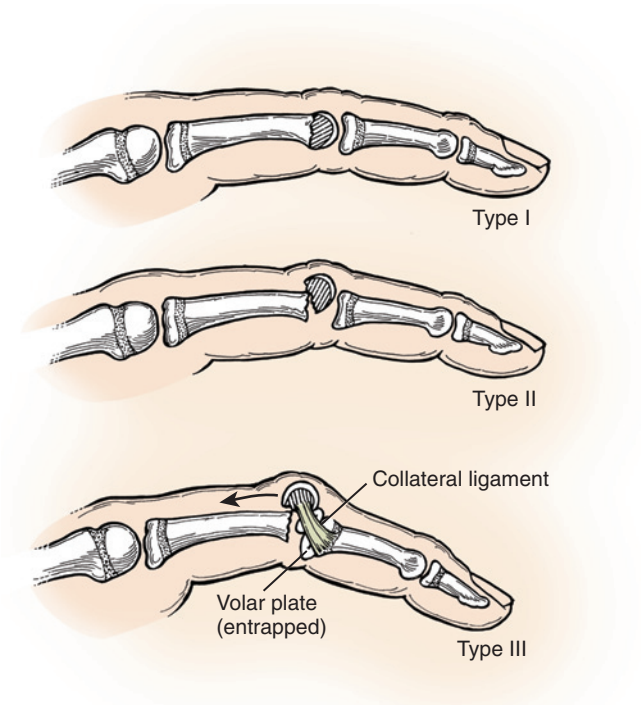

FIGURE 7.30 Classification of fractures of neck of proximal phalanx in a child. *Type I*: Nondisplaced fracture. *Type II*: Displaced with some bone-to-bone contact. *Type III*: Completely displaced, no bone-to-bone contact; may rotate 180 degrees. (Modified from Al-Qattan MM: Phalangeal neck fractures in children: classification and outcome in 66 cases, *J Hand Surg [Br]* 26:112-121, 2001. Redrawn by Elizabeth Martin.)

reduced, and pinned with a single Kirschner pin extending longitudinally from the distal phalanx, across the DIP joint and head fragment, and into the middle phalanx. Fractures of the proximal phalanx are approached between the lateral band and central tendon, reduced, and immobilized with one or two Kirschner wires, preferably avoiding the base of the middle phalanx. In either case, the pins are left in place for 4 to 5 weeks. Complications[1] include persistent angulation in either the frontal plane or the sagittal plane, limited extension secondary to injury to the extensor tendon, limited flexion secondary to a bony block, and nonunion.

Delayed open reduction can be successfully done 4 weeks after injury; a Freer elevator is used to pry the fracture apart, followed by reduction and pin fixation. If the fracture is healed but PIP flexion is lacking, an ostectomy (Figure 7.31) of the protruding spike of the proximal fragment can be done through a lateral approach.

Shaft Fractures. Phalangeal fractures can be transverse, oblique or spiral, and comminuted. Spiral and oblique fractures are more common in the proximal phalanx, whereas transverse fractures tend to be more common in the middle phalanx. Proximal phalangeal fractures have apex volar angulation, the proximal fragment being flexed by the strong interosseous muscle insertion. Angulation of middle phalangeal fractures is variable.

Healing Time

Many authors have commented on the lack of correlation between radiographic and clinical signs of union of phalangeal fractures. Smith and Rider[110] studied phalangeal (toes and hands) fracture healing and found that the average time for complete bony healing was approximately 5 months, and that the clinical healing time when the patient could return to work was about one fourth of this.

Closed Reduction With a Cast or Splint

Traditionally, digital stiffness was an almost inevitable sequela of phalangeal fractures. James[65] realized the importance of maintaining 70 degrees of MP flexion to avoid the contracture of the collateral ligaments that occurs with MP extension. The PIP joints are held in nearly full extension to prevent collateral ligament and volar plate contracture that may otherwise occur in flexion (Figure 7.32).

Burkhalter and Reyes[16] advocated treatment of proximal phalangeal shaft fractures by closed reduction and positioning in a short-arm cast with the wrist held in 30 to 40 degrees of

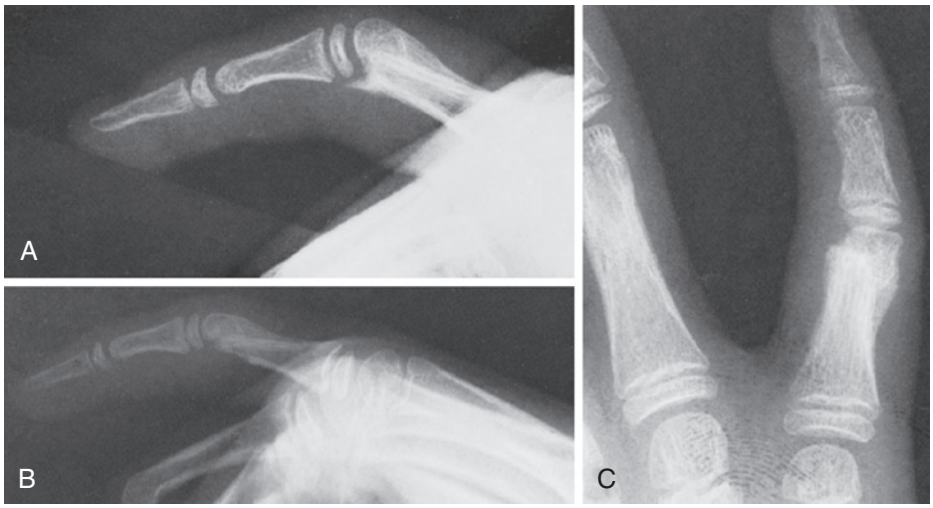

FIGURE 7.31 **A** and **B,** Malunion of neck fracture of proximal phalanx in an adolescent. Flexion was blocked by volar spike at 30 degrees. **C,** Ostectomy of volar spike restored 95 degrees of flexion.

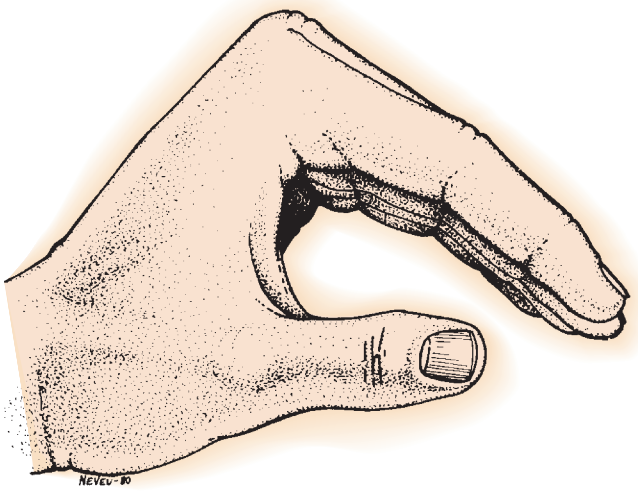

FIGURE 7.32 Safe or intrinsic-plus position of James for hand immobilization.

extension. A dorsal plaster extension block is added to hold the MP joints in maximal flexion and to allow full IP extension (intrinsic-plus position). These authors believed that the dorsal apparatus overlying the proximal phalanx acted as a tension band, and similar positioning of the adjacent digits controlled rotation and angulation. A program of immediate active flexion was then initiated. Reyes and Latta[104] reported 92% satisfactory results using this technique. Rajesh and associates[101] also implemented an MP block splint in a dynamic mobilization program and reported excellent or good results in 94% of patients. Borgeskov[8] stressed the value of early motion and recorded a good functional result in 68% of 485 metacarpal and phalangeal fractures treated without internal fixation.

Closed Reduction and Percutaneous Pinning

Percutaneous Kirschner pin fixation[6] has the advantage of stabilizing the fracture and allowing early motion while minimizing injury to the soft tissue sleeve. This technique is particularly useful in shaft fractures that are transverse, spiral, or oblique in orientation.

Various pin configurations have been described to stabilize transverse fractures (Figure 7.33). Belsky and colleagues[6] used a technique for extraarticular transverse shaft fractures at various levels of the proximal phalanx with wrist block anesthesia. The fracture is reduced by flexing the MP joint. Next, an anterograde pin is driven through the metacarpal head across the MP joint and across the fracture. The fracture is immobilized for approximately 3 weeks, at which time the pin is removed; however, PIP joint motion can be initiated within the first week. Good and excellent results were reported in 90% of fractures treated within 5 days of injury. Green and Anderson[48] achieved full range of motion in 18 of 22 patients with 26 long oblique fractures of the proximal phalanx treated by closed reduction and two or three percutaneous pins (midlateral) perpendicular to the fracture (Figure 7.34). They left the pins in for 3 weeks and protected the finger by "buddy taping" for an additional 3 weeks.

Freeland and Sennett[38] introduced the technique of percutaneous screw fixation for spiral phalangeal fractures. After closed reduction (maintained with bone tenaculum), a self-tapping screw is inserted with fluoroscopic guidance through a very small incision. The value of this technique is that it minimizes soft tissue dissection and provides more stable fixation than Kirschner wires. The technique is exacting and difficult given the small fragments; cannulated screws simplify the process by simultaneously fixing the fracture and aligning the screw for maximum purchase.

Open Reduction and Internal Fixation

If an unstable proximal and middle phalangeal fracture cannot be reduced, or if percutaneous pinning is impossible, ORIF becomes an option. Ip and colleagues[62] showed that if operative fixation is undertaken, rigid constructs have significantly better outcomes than nonrigid constructs because immediate mobilization is possible.

Surgical Approaches

Many authors[62] have stressed the desirability of exact anatomic reduction and solid internal fixation to permit early motion. Pratt[97] exposed the shaft of the proximal phalanx by splitting

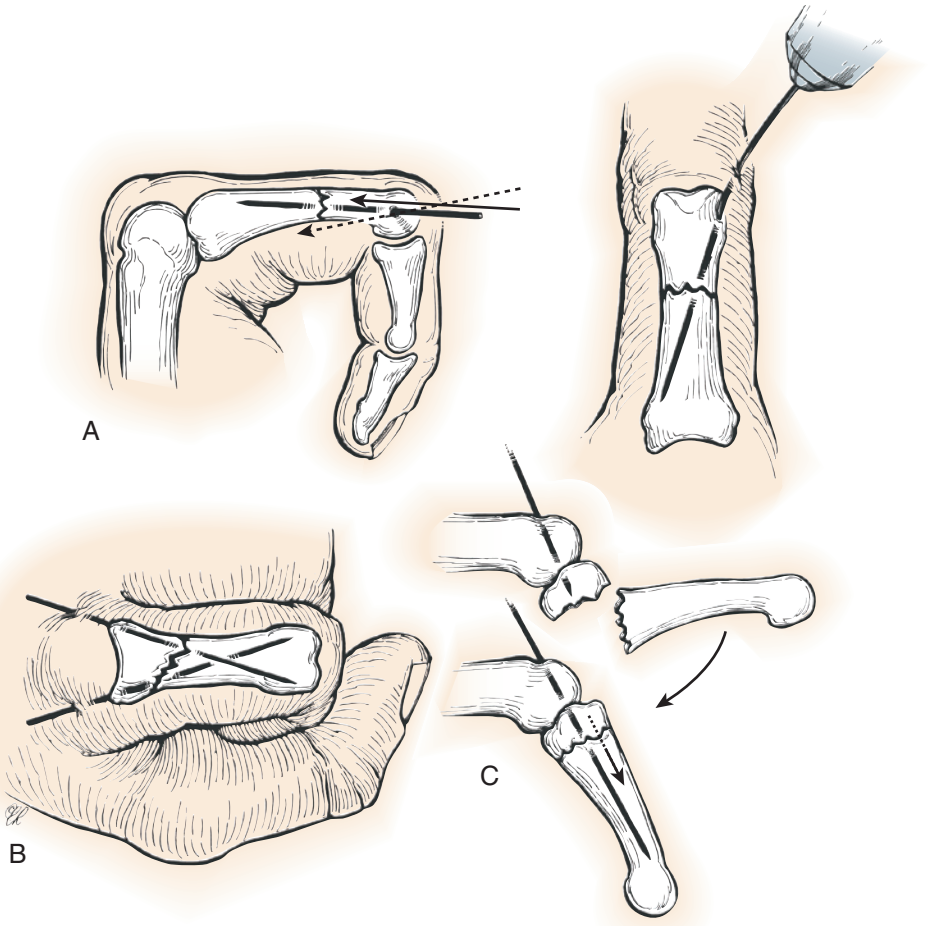

FIGURE 7.33 Three methods of closed reduction and percutaneous pinning of transverse phalangeal fracture. **A,** Fracture is reduced in 90-90 fixed position, and Kirschner wire is introduced in retrocondylar fossa of proximal phalanx. Slight reverse bowing of pin while it is being drilled is often necessary. Normal dorsal bow of proximal phalanx necessitates slight dorsal direction of pin. **B,** Alternative method of percutaneous pinning for fractures of proximal half of shaft. **C,** Technique for closed reduction and percutaneous pin fixation useful for extraarticular fractures near base of proximal phalanx. This method requires plaster immobilization for 3 weeks because Kirschner pin crosses MP joint.

the dorsal apparatus longitudinally and closing it with a running pull-out wire suture (Figure 7.35). This approach has the potential disadvantage of causing scarring of the dorsal apparatus to the skin and bone. Posner[96] used a midlateral incision and excised one of the lateral bands to expose the fracture. He opened the finger on the side to which the distal fragment had shifted (Figure 7.36). Field and associates[33] recommended a midaxial approach to the proximal phalanx. They argued that scarring of the dorsal apparatus is less likely and PIP extensor lag is minimized.

Open Reduction With Pin Fixation

Smooth Kirschner wires have been the most popular technique of maintaining fracture reduction. A pin can be inserted with minimal soft tissue stripping, preserving the blood supply to bone and enhancing the potential for healing. In addition, Kirschner wires are less bulky compared with a plate or screws, may be inserted so that the dorsal apparatus is not impaled, and allow for easy closure of soft tissue.

Pins are acceptable for nearly all fracture configurations. They have been used longitudinally or obliquely in the medullary canal for transverse or short oblique fractures. Placement perpendicular to the fracture or bone is recommended for long oblique fractures, and crossed Kirschner wires are best for transverse fractures; however, distraction may be a problem if the bone ends are not firmly impacted during pin insertion.

Considerable disagreement exists regarding whether the ends of the pins should be allowed to protrude through the skin or should be cut off beneath the skin. In a series of 590 Kirschner pin fixations, Stahl and Schwartz[111] noted no difference in the infection rate between buried and protruding pins. The authors did not indicate the method of immobilization for these cases.

Kirschner wires are not a panacea. Pins do not provide stable fixation, and the necessary cast or splint immobilization may result in tendon adhesion and stiffness after open reduction. Pun and coworkers[99] prospectively reported on 109 unstable digital fractures treated with Kirschner pin fixation. Nearly 70% had fair or poor results. Open fractures, comminuted fractures, and associated significant soft tissue injuries were unfavorable prognostic signs. These authors did not condemn Kirschner wire fixation but emphasized that there are many determinants of outcome, including stable fracture fixation.

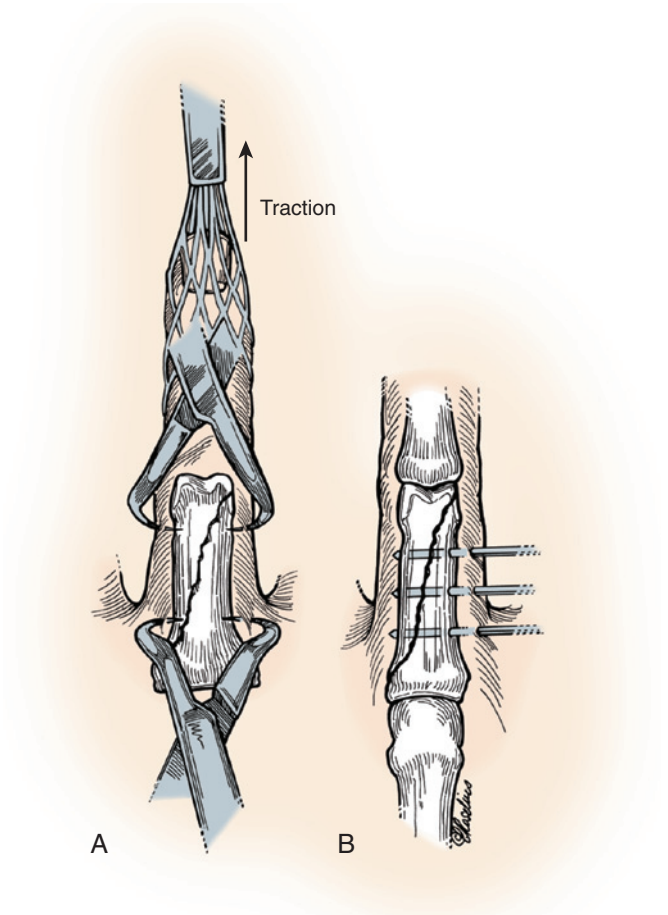

FIGURE 7.34 **A,** Closed reduction and percutaneous pinning of oblique phalangeal fracture. Fracture is reduced by longitudinal traction and compressed with towel clip or reduction clamp. **B,** Next, Kirschner wires are drilled transversely across fracture. (Copyright Elizabeth Martin.)

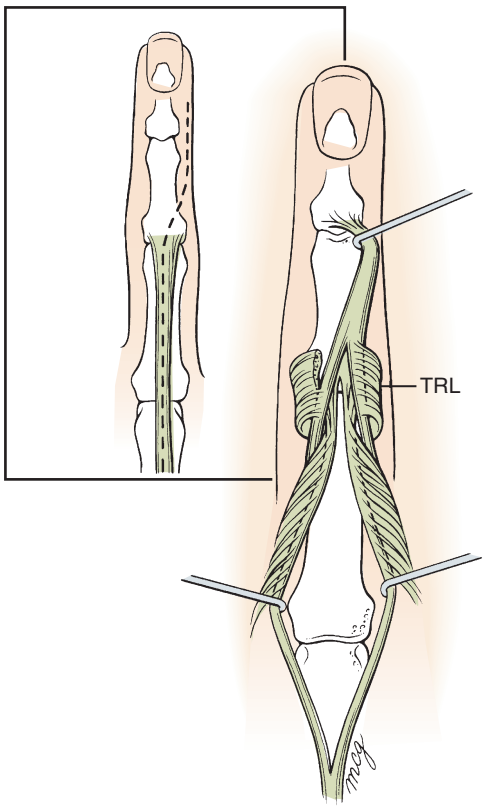

FIGURE 7.35 Author's preferred incision for exposure of proximal and middle phalangeal fractures. For proximal phalangeal exposure, central tendon is longitudinally split. Care must be taken not to detach its insertion into dorsal base of middle phalanx. For middle phalangeal exposure, transverse retinacular ligament (TRL) is divided at its insertion into dorsal apparatus, and fracture is exposed by retracting conjoined tendon radially or ulnarly.

Greene and colleagues[49] showed that fracture stability is enhanced when Kirschner wires are supplemented with stainless steel (26-gauge) composite (or tension band) wiring (Figure 7.37). This technique is particularly useful in spiral and oblique fractures; it should be avoided in comminuted fractures. As the stainless steel wire, which is looped under the pins, is cinched down, compression at the fracture site can be achieved. The Kirschner wires are cut so that there is a 2-mm to 3-mm tail. Pehlivan and coworkers[94] used tension band wiring of unstable phalangeal shaft fractures in 20 patients, and all fractures healed. The mean range of motion for a proximal phalanx fracture was 92%, and the mean range of motion for a middle phalanx fracture was 76%.

Interosseous wiring (Figure 7.38) can be used alone or as a supplement to Kirschner pin fixation (eTable 7.3). It requires minimal exposure, is less prominent than screws and plates, and theoretically minimizes the risk of adhesions to overlying tendons. The technique is most frequently used for transverse phalangeal fractures and in digital replantation.[44,80,133]

Intramedullary Fixation

Orbay and Touhami[91] retrospectively reviewed 150 cases involving flexible intramedullary nails inserted percutaneously through the base of the fractured phalanx in an antegrade direction. Phalangeal fractures were treated with either two nonlocked nails or one locked nail. They found a residual angulation of 9 degrees and shortening of 1.5 mm in the nonlocking group compared with 10 degrees and 1.6 mm in the locking group. Orbay and Touhami[91] concluded that intramedullary nailing is a minimally invasive technique that provides good functional results; they advised locked nails for unstable spiral and comminuted fractures.

Screw Fixation

Because a single, longitudinal Kirschner pin does not provide rotational stability, and crossed pins may distract the fracture, more rigid methods of fixation have been sought. Interfragmentary screw fixation enhances stability by using the lag technique to achieve compression. A minimum of two screws is necessary, and they should be inserted at least two screw diameters from the fracture edge. Generally, 2-mm and 1.5-mm screws are used in the proximal phalanx and 2-mm, 1.5-mm, and 1.3-mm screws are used in the middle phalanx. Even smaller-diameter self-tapping screws of 1 mm to 0.75 mm may be useful.

In a prospective randomized study, Horton and associates[59] compared treatments for spiral or long oblique fractures of the proximal phalanx. One group was treated by closed reduction

eTABLE 7.3 Interosseous Wiring

Author	Comments
Lister[80]	Supplement to Kirschner pin fixation of phalangeal fractures; wiring alone unsuitable in unstable, comminuted fractures, especially with associated bone loss
Gingrass et al[44]	Used for articular, comminuted, and transverse fractures; few complications; can supplement with Kirschner pin
Zimmerman and Weiland[135]	90-90 wiring for transverse fractures, replantation, and arthrodesis

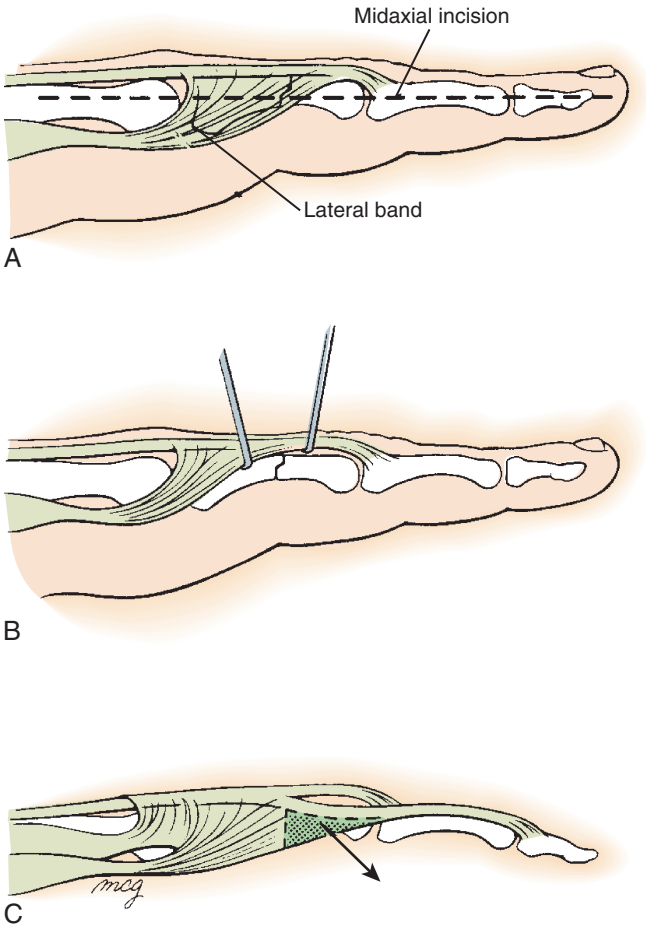

FIGURE 7.36 A, Midaxial incision is an approach to proximal phalanx. **B,** Lateral band is retracted dorsally to expose fracture. **C,** Alternatively, triangular portion of distal lateral band can be excised to facilitate exposure.

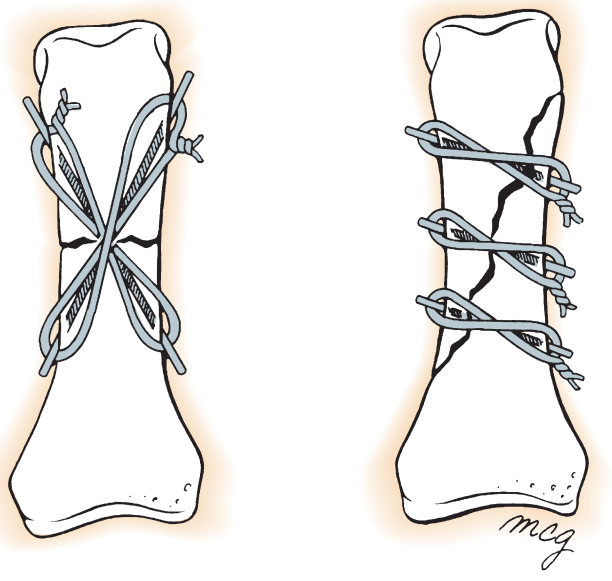

FIGURE 7.37 Technique of composite wiring in proximal phalanx with 0.035-inch Kirschner wires and 26-gauge to 28-gauge stainless steel wire. Pins are left protruding from bony cortex 2 to 3 mm. *Left,* Transverse fracture. *Right,* Spiral fracture.

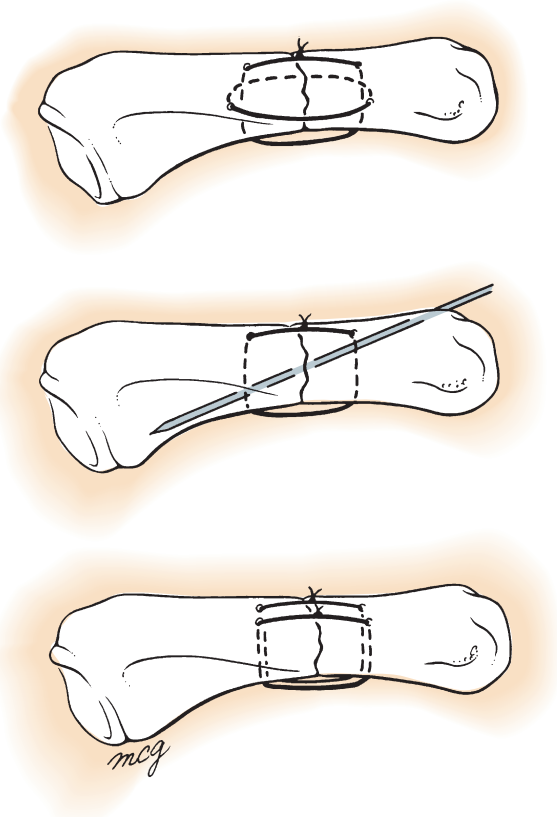

FIGURE 7.38 Intraosseous wire configurations. *Top,* 90-90 wires. *Middle,* Single loop with supplemental Kirschner pin. *Bottom,* Parallel loops.

and Kirschner pin fixation, and the other was treated by open reduction and lag screw fixation. They found no statistical difference in outcomes.

Plate Fixation

Plate and screw stabilization of phalangeal fractures has the advantage of providing stable fixation, permitting early range of motion. Page and Stern[93] reported frequent complications, however, after plate fixation with AO (Arbeitsgemeinschaft für Osteosynthesefragen) minifragment plates for phalangeal fractures. Total active digital motion was less than 180 degrees in 62% of fractures, and open fractures carried a particularly poor prognosis.

Pun and colleagues[99] prospectively analyzed 42 unstable fractures treated by AO minifragment plate fixation. Results were good in 26%, fair in 33%, and poor in 41% of the fractures. When there was considerable soft tissue injury, good results were seen in only 5% of the fractures. When the investigators compared these results with results of a similar series from their institution treated by Kirschner pin fixation,[99] there was no statistically significant difference in the outcome of these two fixation techniques. In 1987, Buchler and Fischer[12] introduced a laterally placed minicondylar plate for the stabilization of periarticular phalangeal (1.5-mm) and metacarpal (2-mm) fractures. Technical errors occurred in 18% of the cases, and secondary surgery was frequently necessary. Subsequent biomechanical studies showed that lateral application of this plate resulted in less PIP flexion loss than dorsally applied plates.[90] Ouellette and Freeland[92] used this plate for metacarpal and

phalangeal fractures and noted a high complication rate secondary to technical errors and the severity of the fractures they treated.

Puckett and colleagues[98] applied thinner maxillofacial miniplates and microplates (0.8-mm screws) with excellent results. The screws are self-tapping; less periosteal stripping is required for application; and the plates are low profile, which may result in less interference with extensor tendon excursion. Supplemental Kirschner pin fixation can be used if the construct is deemed unstable.

External Fixation

External fixation is indicated for open fractures, especially fractures with concomitant soft tissue injury, such as gunshot wounds, highly comminuted diaphyseal fractures, severely comminuted articular fractures, and fractures with significant loss of bone stock.[4] Advantages include ease of insertion, minimal dissection and devascularization of soft tissue and bone, and preservation of bony length. External fixation provides access for additional soft tissue care.

Ashmead and coworkers[4] reported a 90% union rate when using external fixation for acute hand fractures. There were no cases of hardware failure and no iatrogenic tendon or neurovascular injuries; there was one pin track infection; and the device was well tolerated psychologically. Freeland[36] emphasized that external fixation is particularly useful in comminuted fractures that require concomitant management of soft tissue injury.

❖ AUTHOR'S PREFERRED METHOD OF TREATMENT: Phalangeal Shaft Fractures

I consider four factors when determining appropriate fracture management:

1. *Stability.* Phalangeal fracture stability is determined clinically and radiographically. Fractures with the potential to rotate, angulate, or shorten are unstable. Rotation is difficult to judge radiographically and is best assessed clinically by having patients actively flex their fingers simultaneously while the examiner looks for digital overlap (scissoring). Angulatory malalignment is radiographically apparent in either the coronal or the sagittal plane. Clinical angulation in the coronal plane results in digital overlap on flexion. Angulation (apex volar) in the sagittal plane of the proximal phalanx produces compensatory hyperextension at the MP joint and an extensor lag at the PIP joint (pseudoclawing). Shortening, typically seen in comminuted fractures, is assessed radiographically and clinically.
2. *Open versus closed.* Open phalangeal shaft fractures usually result from direct high-energy trauma and tend to be unstable.
3. *Associated injuries.* Fractures with injuries to adjacent structures, such as nerves, vessels, the soft tissue sleeve, or tendons, are usually open and generally require internal stabilization. Concomitant fractures either in the same ray or in the hand also necessitate operative fixation because it is difficult to maintain satisfactory alignment of multiple fractures by closed means.
4. *Fracture geometry.* Three basic fracture patterns occur: transverse, oblique and spiral, and comminuted. Transverse fractures tend to produce angulatory deformities in the lateral and frontal views. Oblique fractures produce rotational deformities, but they may also angulate or shorten. Comminuted fractures nearly always shorten and may also malrotate or angulate.

Nondisplaced and Stable Fractures of the Phalanges

Management of nondisplaced and stable fractures is nonoperative. The "safe" position of 70 degrees of MP flexion and nearly full IP extension should be used whenever possible when treating phalangeal fractures. A forearm-based splint with the wrist extended facilitates maintenance of this position. Protected range of motion should be initiated within 3 weeks. If there is minimal pain, immediate motion with "buddy splinting" can be initiated. Follow-up radiographs should be obtained at weekly intervals to ensure that alignment remains satisfactory.

Displaced Fractures: Stable After Closed Reduction

Displaced fractures that are malaligned can often be manipulated into alignment and stabilized. Transverse fractures of the proximal and middle phalanx are especially amenable to closed reduction. First, flex the MP joint maximally to stabilize the proximal fragment, and then flex the distal fragment to correct the volar angulation. Particular attention should be paid to rotation by comparing the planes of the nails. The reduction can be maintained with a clam-digger or short-arm cast (wrist in neutral or slightly extended), with a dorsal plaster extension block holding the MP joints flexed 70 to 90 degrees and the IP joints extended (see Figure 7.7). The extension block splint should include the adjacent digits with "buddy taping" to help control fracture alignment. Serial x-rays should be taken to monitor for fracture displacement. Active flexion of the digit should begin approximately 3 weeks after reduction and should include supervised hand therapy with customized splinting to optimize the final outcome. The splint is maintained for approximately 3 weeks; "buddy taping" is continued an additional 2 weeks after splint removal.

Spiral and oblique fractures often displace and shorten after reduction and casting and frequently require fixation. These fractures require careful scrutiny if treated with splinting alone. Radiographs can be especially deceptive and difficult to interpret. In addition, after the digit has been immobilized, rotational malalignment is almost impossible to assess.

The position for immobilization of spiral fractures is similar to the position for transverse fractures. Initiation of early motion often results in loss of reduction, however. For the rare stable spiral fracture, immobilization for 3 to 3½ weeks is recommended, followed by mobilization in an extension block cast or "buddy taping" for approximately 2 weeks. Repeated attempts at closed treatment are not warranted. If loss of reduction occurs or if anatomic alignment cannot be realized, we recommend operative fixation.

Displaced Fractures: Unstable After Closed Reduction

Spiral and Oblique Fractures. Closed pinning works particularly well for spiral and oblique fractures treated within 3 to 4 days of injury. We prefer wrist block anesthesia with conscious sedation so that the patient can actively flex the digits to assess rotational alignment after pinning. Provisional reduction is accomplished by applying longitudinal traction and squeezing

Biomechanical Testing

The results of biomechanical testing on various implants may be difficult to compare because investigators use different testing conditions, different bones, dissimilar implant constructs, different fracture patterns, and a variety of loads in different modes. We currently do not have enough information to determine how much stability is needed for a given fracture configuration to permit gentle active motion.

Viegas and colleagues[124] biomechanically tested various Kirschner pin fixations in oblique and transverse human cadaveric phalangeal fractures. They concluded that four crossed 0.028-inch Kirschner wires provided the highest rigidity for transverse fractures and three oblique 0.035-inch Kirschner wires provided the highest rigidity in oblique phalangeal fractures. Massengill and colleagues[86] analyzed various Kirschner pin fixation configurations using pig metacarpals by subjecting the constructs to single four-point bending tests using an electrohydraulic bending machine. They concluded that Kirschner wires fail as the result of loosening and sliding within the bone. The pins were rated low in overall fixation strength. Plate and screw fixation had maximum bending moments that approached those of intact bone. They noted that volar or lateral plate and screw fixation was considerably stiffer and stronger than any configuration of the wire loop or the Kirschner wires.

the fracture fragments together with reduction clamps (see Figure 7.34). Fluoroscopy greatly facilitates fracture reduction and pin placement. Two or three 0.035-inch or 0.045-inch Kirschner wires are inserted at right angles to the fracture and should be placed as far apart as possible and engage both sides of the fracture. For additional stability, the pins should not be placed precisely parallel to one another.

After pin insertion, rotational alignment should be checked by asking the patient to actively flex and extend the digits. If malalignment persists (clinically or radiographically), either the pins should be removed and another effort should be made at closed reduction or open reduction should be pursued. It is unwise to make more than two or three attempts at closed pinning. In such situations, we proceed to open reduction.

A straight dorsal skin incision is our preferred method for exposure of proximal and middle phalangeal shaft fractures (see Figure 7.35). A midaxial incision may make visualization of the other side difficult and may necessitate either a second midaxial incision or more soft tissue mobilization, including a longer incision (see Figure 7.36). Generous skin flaps can be elevated, with care taken to preserve the dorsal longitudinal venous system. The extensor tendon is split longitudinally for exposure of proximal phalangeal fractures. Fractures of the middle phalanx are satisfactorily approached by dividing the transverse retinacular ligament and mobilizing the dorsal apparatus without splitting it. Next, the periosteum is longitudinally incised and elevated to expose the fracture.

To reduce spiral and oblique fractures anatomically, one must expose the sharp proximal and distal fracture spikes, key them into the corresponding fragment, and provisionally maintain the reduction with reduction clamps or towel clips. Fixation is accomplished with either interfragmentary screws or Kirschner wires. Acceptable results can be achieved with both techniques, and I have no preference as long as a stable anatomic reduction is achieved. If interfragmentary screws are used, two or three 2-mm screws are placed in proximal phalanx fractures, and two 1.5-mm or 1.3-mm screws are used for middle phalangeal fractures. Ideally, the screws should be inserted in the plane that bisects the long axis of the bone and the fracture plane and at least two screw diameters from the fracture line. The screws should be lagged for interfragmentary compression and countersunk to prevent interference with tendon gliding. After screw or pin insertion, an attempt is made to close the periosteum with absorbable sutures. If the dorsal apparatus over the proximal phalanx has been divided, it is reapproximated with either a running 4-0 nonabsorbable suture or interrupted inverted sutures.

Postoperatively, after stable fixation of the fracture, a bulky dressing is applied for 3 to 5 days and is followed by active mobilization. When not exercising, a splint maintaining the MP joint in flexion and the IP joints extended is preferred to counteract extrinsic deforming forces and minimize extensor lag at the PIP joint. Soft tissue swelling is minimized with an elastic sleeve or Coban self-adherent wrap. If pins have been inserted, the patient is immobilized in a protective gutter splint, and I begin active motion of joints proximal to the fracture within a week. Pins are removed 3 to 4 weeks after insertion, and supervised motion of joints distal to the fracture is initiated.

Transverse Fractures. Percutaneous cross-pinning of unstable transverse fractures is difficult even with an image intensifier. The goal is to insert two pins in crossed fashion and avoid the MP and PIP joints. Closed percutaneous cross-pinning of these fractures can be frustrating. An alternative percutaneous technique is to insert the pin through the flexed MP joint into the medullary canal of the proximal phalanx (see Figure 7.33, *C*). The pin penetrates the metacarpal head to either the radial or the ulnar side of the extensor tendon and should be driven into the subchondral region of the proximal phalangeal head. Although this technique does not provide rotational stability, it is simple and effective. The hand should be splinted or casted in the intrinsic-plus position. Active range of motion of the IP joints is encouraged. At $3\frac{1}{2}$ to 4 weeks, the pin is removed, and range of motion of the MP joint is initiated.

Some unstable phalangeal shaft fractures require open reduction to facilitate management of concomitant injuries, or because closed reduction and percutaneous pinning failed. In such cases, the fracture can be fixed with two bicortical Kirschner wires inserted in the coronal plane by one of two methods: retrograde cross-pinning or cross-pinning of the reduced fracture. Regardless of the technique, image intensification greatly facilitates the procedure.

In the retrograde cross-pinning method, after the fracture surfaces are exposed, a trial reduction is accomplished (Figure 7.39). A preview pin held over the dorsal surface of the reduced fracture before pinning helps plan the entrance site of the first pin in one fragment and the exit site of the pin in the other fragment. Either the proximal or the distal fragment may be drilled first; however, the distal fragment is usually easier to pin because the adjacent digits can be flexed out of the way of the distally protruding pin. An elevator placed beneath the volar cortex is used to lift the fragment up and make the medullary canal accessible. The pin is drilled in the coronal plane through the middle of the medullary canal. Care must be taken not to angle the pin more than 30 degrees from the long axis of the phalanx because it would not engage adequate cortex of the proximal fragment. Sometimes the pin bounces off the endosteal cortex when drilling the first fragment. The pin is drilled through the cortex and out through the skin, and, ideally, the extensor mechanism is retracted dorsally so that it is not impaled. A second pin is inserted on the other side of the first fragment in a similar fashion; both pins are backed up flush to the fracture surface, and the fracture is reduced. To prevent distraction, the fracture ends are compressed firmly together while the two pins are drilled retrograde into the fragment. It helps to stabilize the proximal fragment by holding it with a towel clip while the pins are drilled.

In another method, the fracture is held reduced while two crossed Kirschner wires are drilled obliquely from the outside across the fracture (Figure 7.40). This method is more difficult because it is challenging to maintain fracture reduction and drive pins simultaneously. Regardless of the technique, pin placement and fracture reduction are confirmed with biplanar radiographs, and closure is accomplished as noted earlier.

Intraosseous wires (25-gauge or 26-gauge) work well for the fixation of unstable transverse shaft fractures (see Figure 7.38). The holes for the wire should be drilled at least 3 to 4 mm from the fracture edge so that the wire does not cut out when it is being tightened. In addition, caution should be exercised to avoid kinking because tightening becomes impossible. Intraosseous wire fixation is particularly useful in open or severely

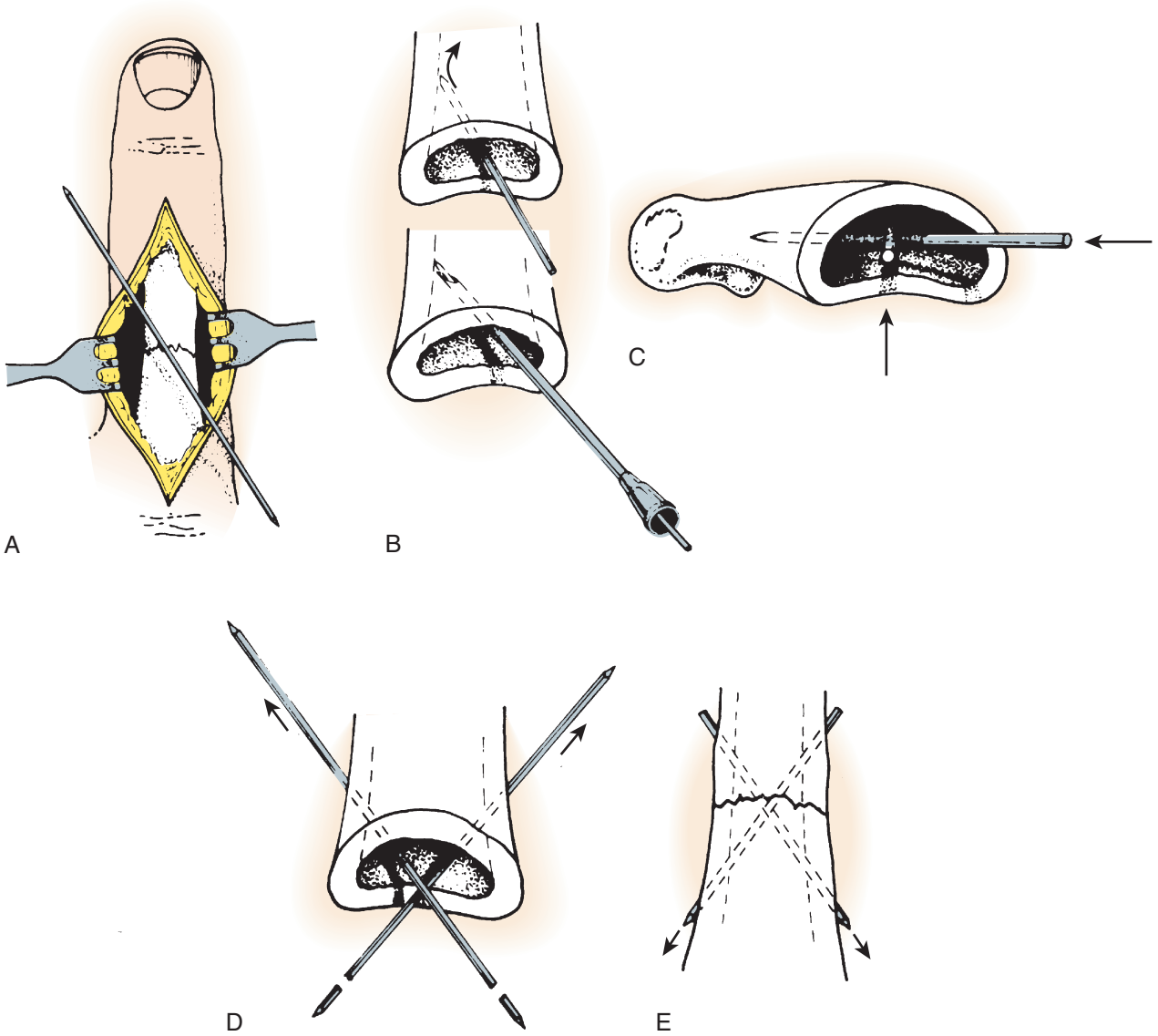

FIGURE 7.39 Open reduction with retrograde cross-pinning of transverse phalangeal fracture. **A,** Preview pin held over reduced fracture helps plan pin direction and angle of entry. **B,** Use of 14-gauge needle as drill guide to prevent pin from sliding off endosteal surface of cortex. **C,** Pins are drilled so that they are through middle of medullary canal in coronal plane. **D,** Pins are drilled through cortex and backed up flush to fracture surface. **E,** Fracture is reduced and fracture ends are compressed, while two pins are drilled retrogradely into other fragment. (From Edwards GS Jr, O'Brien ET, Heckman MM: Retrograde cross pinning of transverse metacarpal and phalangeal fractures, *Hand* 14:141-148, 1982.)

displaced fractures in which the fracture has already been circumferentially exposed (secondary to the trauma) because wire passage is facilitated. Supplemental fixation with an oblique Kirschner pin may provide additional stability, particularly in the phalangeal diaphysis, where the bending moment is greatest.

Occasionally, we employ a 1.5-mm minicondylar plate[12,92] (Figure 7.41) or a T-plate to stabilize periarticular phalangeal fractures. The technique is exacting and should not be attempted without full knowledge of the implant system.

Plate fixation of noncomminuted unstable transverse phalangeal shaft fractures is technically demanding, and there is no margin for error. Considerable exposure is necessary, there is a considerable complication profile, including tendon excursion and stiffness, and secondary removal may be necessary. Despite the secure fixation that plates provide, Kirschner wires, intraosseous wires, and combinations of the two are my preferences for such fractures.

Displaced Fractures: Unstable and Comminuted

Unstable and comminuted fractures are usually open and often associated with soft tissue injury. Instability patterns include angulation, malrotation, and shortening. Fracture stabilization is necessary to restore length and alignment and to facilitate management of concomitant soft tissue injuries. Operative intervention is necessary in nearly all cases.

My preferred treatment is application of a mini–external fixation device. It provides stabilization, allows access to open wounds, and does not risk devitalization of small fracture fragments, which may have a tenuous blood supply. Two transverse

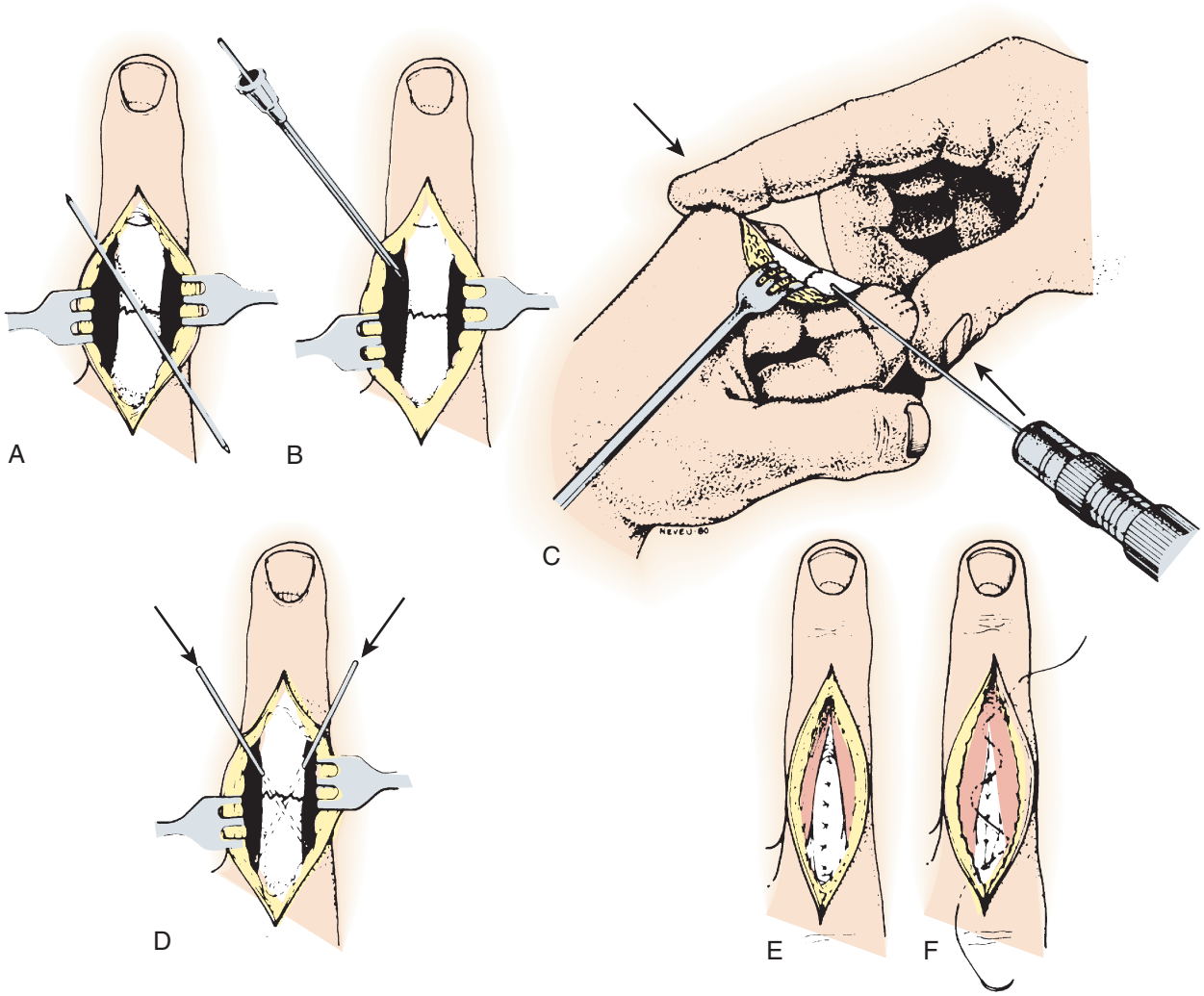

FIGURE 7.40 Open reduction with cross-pinning of reduced transverse phalangeal fracture. **A,** Preview pin held over reduced fracture to plan pin direction and angle of entry. **B,** Use of 14-gauge needle as drill guide for Kirschner wire. **C,** Fracture must be compressed while pins are drilled. **D,** Crossed pins drilled across fracture. **E,** Periosteum closed with interrupted 4-0 absorbable sutures. **F,** Extensor tendon is reapproximated with running nonabsorbable suture.

pins are placed proximal and distal to the fracture and inserted through midaxial or dorsolateral incisions. Fluoroscopy facilitates pin insertion, minimizes the risk of articular penetration, and diminishes the chance of further fracture comminution during multiple drill passes. After insertion of the transverse pins, the connecting rods and swivel clamps are applied. With the image intensifier, the fracture is reduced, and the swivel clamps are tightened to maintain reduction. Usually, stability can be maintained with a single half-frame; if necessary, a second half-frame can be applied. Supplemental Kirschner wires and intraosseous or cerclage wires may also increase stability. If there is an osseous void, bone grafting can be considered, assuming that the wound is clean and there is adequate soft tissue coverage. The fixator is left in place for 4 weeks, during which time active mobilization of uninvolved joints is encouraged. In fractures with extensive comminution or instability, the fixator may need to remain in place an additional 2 to 3 weeks. On removal, an intensive hand therapy program is initiated. Secondary surgery, including tenolysis and capsulotomy, is frequently necessary, but should be delayed until there is solid bony union and the soft tissue sleeve is mature and pliable.

Plates and screws are a popular alternative to external fixation. Several caveats are warranted: Additional soft tissue mobilization is usually necessary, the plate may interfere with tendon gliding, and soft tissue coverage (without a flap) may be impossible. For these reasons, plate fixation is not my first choice for stabilization of comminuted or open phalangeal shaft fractures.

Expected Outcomes: Phalangeal Shaft Fractures

The time for complete bony healing of phalangeal shaft fractures is typically 5 months, although patients can return to work in about 6 weeks.[110] A satisfactory treatment rate of 92% to 94% has been reported with closed reduction and casting or splinting of these fractures.[101,104] Most closed reduction and casting procedures provide sufficient stability to enable early mobilization. Mobilizing the finger within the first 4 weeks is critical to

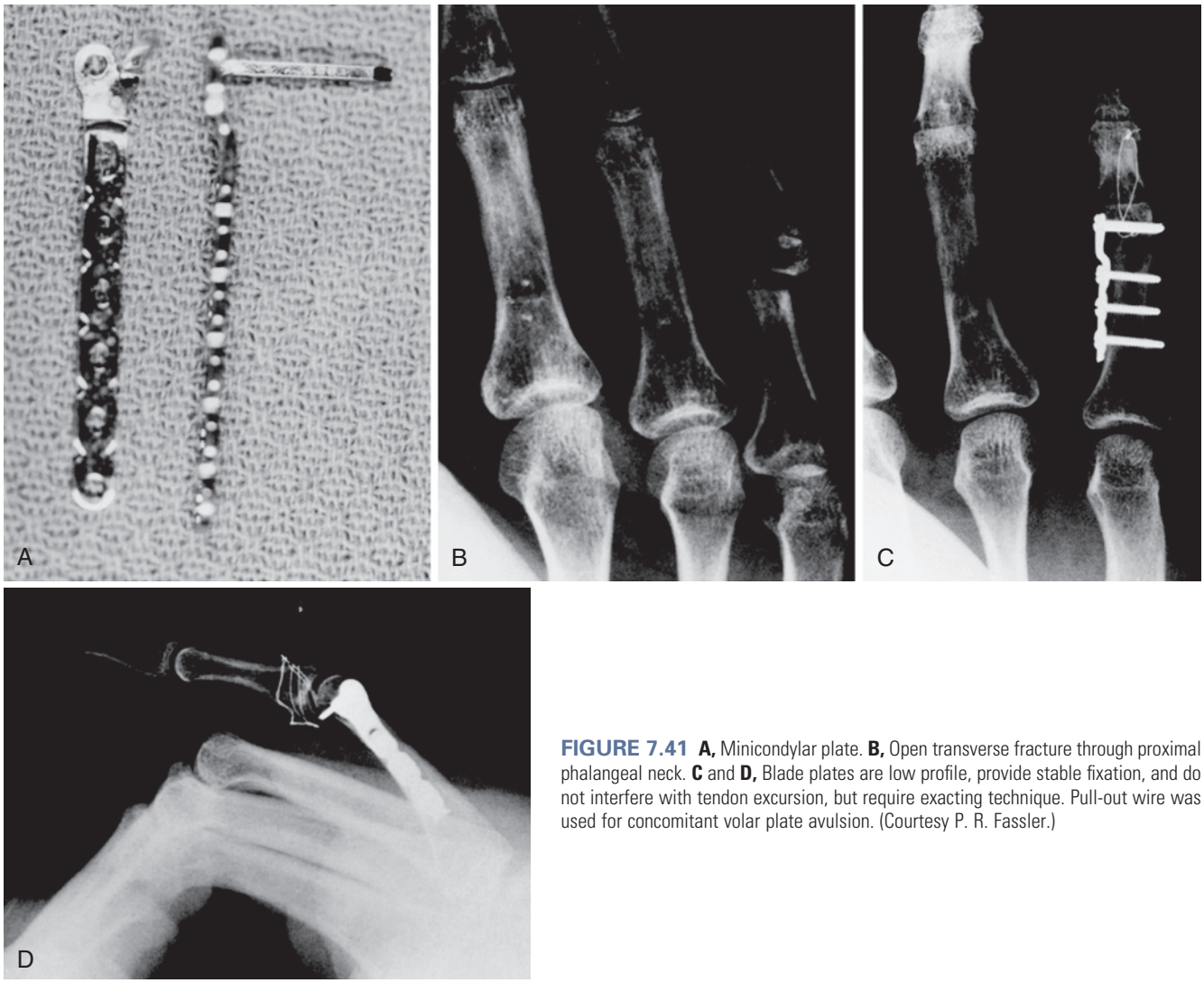

FIGURE 7.41 **A,** Minicondylar plate. **B,** Open transverse fracture through proximal phalangeal neck. **C** and **D,** Blade plates are low profile, provide stable fixation, and do not interfere with tendon excursion, but require exacting technique. Pull-out wire was used for concomitant volar plate avulsion. (Courtesy P. R. Fassler.)

preventing hand stiffness. Closed reduction percutaneous pinning has led to 90% good and excellent results when fracture was treated within 5 days of injury.[6] Active range of motion was fully restored in 82% of patients treated using this technique.[48] In patients treated using tension band wiring, range-of-motion recovery was 92% for the proximal phalanx and 76% for the middle phalanx.[94] Screw fixation typically enhances stability and is associated with earlier mobilization. Intramedullary fixation is a minimally invasive procedure that has been reported with 84% recovery of range of motion and 89% recovery of grip strength.[91] Finally, although plate and screw fixation provides the stability to permit early range of motion, it has also been associated with frequent complications. In a prospective study of fractures treated using miniplates, results were good in 26% and fair or poor in 74%.[100]

Base Fractures of the Proximal Phalanx

Extraarticular fractures at the base of the proximal phalanx occur at the metaphyseal-diaphyseal junction. The fracture is usually comminuted dorsally, is impacted, and has apex volar angulation. There also may be mild angulation in the frontal plane; rotational deformity is rare.

Oblique views may be deceptive and may lead the surgeon to underestimate the severity of the fracture. Coonrad and Pohlman[24] pointed out that malunion was associated with loss of reduction, secondary to immobilization of the digit in insufficient flexion at the MP joint. A malunion may produce pseudoclawing (see Author's Preferred Method of Treatment: Phalangeal Shaft Fractures). In younger children, 30 degrees of apex volar angulation is acceptable, but uncorrected angulation of 25 degrees or more in adults causes loss of motion and may necessitate corrective osteotomy. This fracture is reduced by flexing the MP joint maximally to stabilize the proximal fragment and relax the intrinsic muscles and then correcting the volar angulation by flexing the distal fragment. Immobilization with the MP joint flexed 70 degrees and the PIP joint extended for 3 to 4 weeks is recommended. Closed reduction with intermedullary pinning, as described by Belsky and colleagues,[6] is an excellent technique to maintain reduction. A Kirschner pin is drilled through the flexed MP joint into the proximal fragment to stabilize it. After the distal fragment is reduced onto the proximal fragment, the Kirschner pin is drilled across the fracture into the distal fragment. This percutaneous pinning for extraarticular base fractures can also be performed with crossed

K-wires inserted percutaneously. Faruqui and colleagues[32] retrospectively compared the outcomes of 25 patients using each technique and found no differences in range of motion between the two cohorts. Both methods were equally effective in maintaining radiographic alignment; however, both methods were also associated with a high rate of complications and an average loss of flexion arc at the PIP joint of 35 degrees.

Complications of Phalangeal Fractures

Malunion

Malunion (eBox 7.2) is a common complication of phalangeal fractures and may involve several different planes of deformity: malrotation, apex volar angulation, lateral angulation, and shortening.

Malrotation

Malrotation is usually seen after oblique or spiral fractures of the proximal and middle phalanges. It may be difficult to assess radiographically and is best assessed by having the patient make a fist and looking for digital overlap. Small amounts of malrotation may be acceptable to many patients. Greater degrees of malrotation result in functional impairment, pain from joint malalignment, and diminished grip strength.[13] Osteotomy is usually required, preferably through the phalanx. Phalangeal osteotomy offers the advantages of correcting the malunion at its site of origin, allowing for multiplanar correction and permitting concomitant soft tissue procedures such as tenolysis and capsulotomy. The risk of postoperative adhesions between the dorsal apparatus and phalanx is considerable and may result in digital stiffness. It is simplest to create a transverse osteotomy[39] with a power saw with a thin blade. Transverse osteotomies can be held with a miniplate or Kirschner wires.

Before the development of secure internal fixation, malrotation was corrected by an osteotomy through the metacarpal base. Gross and Gelberman[50] experimentally determined that correction of 18 to 19 degrees can be obtained by osteotomy of the index, long, and ring fingers and that 20 to 30 degrees of correction can be achieved in the small finger. Although this osteotomy is technically easier, the amount of rotational correction is limited, and multiplanar correction is impossible. If concomitant tenolysis and capsulotomy are planned, exposure of the malunion is necessary anyway, which may obviate the simplicity of a metacarpal correction.

I prefer phalangeal osteotomy using plate fixation. The use of a supplemental bone graft is individualized. Postoperatively, an early and intensive range-of-motion program is necessary to minimize stiffness.

Apex Volar Angulation

Malunion of adult basilar proximal phalangeal fractures of more than 25 to 30 degrees results in pseudoclawing. This deformity may compromise dexterity, is often aesthetically unacceptable, and can result in a fixed PIP flexion contracture.[47] An osteotomy may be performed with an oscillating saw by making an opening or closing wedge at the level of the malunion. If shortening is a concern, an opening osteotomy with insertion of a corticocancellous wedge-shaped graft is recommended. Otherwise, a closing wedge osteotomy (apex dorsal, base volar) is preferred because it is simpler than an opening osteotomy and does not require an intercalated bone graft. Preoperatively, a template of the malunited phalanx is made to assess accurately the dimensions of the wedge to be removed. Fixation is accomplished with Kirschner wires, plates and screws, or intraosseous wires. We prefer to use plates and screws (Figure 7.42) for this procedure, with early range of motion initiated at 5 to 7 days postoperatively.

Lateral Angulation

Lateral angulation can be corrected by either an opening or a closing wedge osteotomy. A closing osteotomy can be done with an oscillating saw or power burs, as described by Froimson.[39] Alternatively, corrective opening wedge osteotomy can be accomplished (Figure 7.43). It is preferable to leave the opposite cortex intact, use either a pure cancellous or a corticocancellous graft, and obtain fixation with a laterally applied

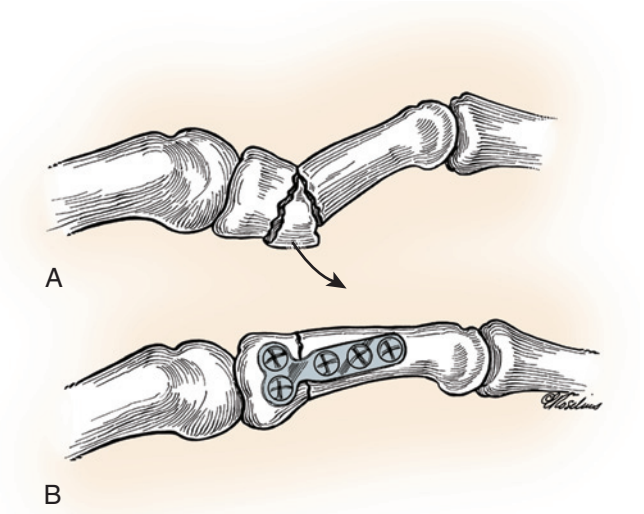

FIGURE 7.42 Closing wedge osteotomy for correction of malunion of the proximal phalanx with volar angulation. **A,** Demonstrating the osteotomy lines for correcting the volar angulation of the malunion. **B,** Plate and screw fixation once the wedge osteotomy bone is removed.

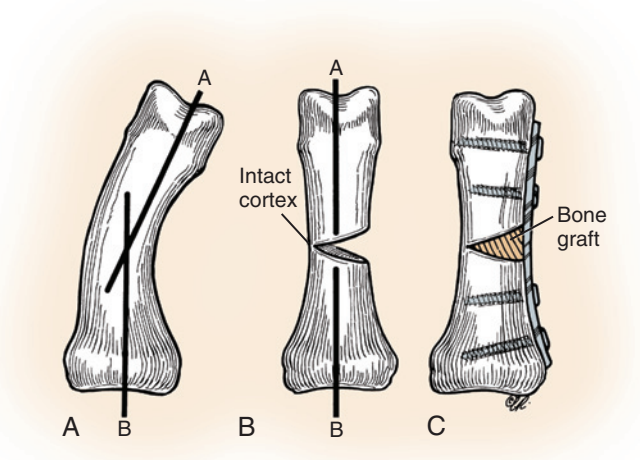

FIGURE 7.43 Technique for lateral opening phalangeal osteotomy. **A,** Angulatory deformity in frontal plane. Lines *A* and *B* show alignment of proximal and distal portions of phalanx. **B,** Corrective osteotomy leaving opposite cortex intact. **C,** Corticocancellous graft inserted with lateral plate fixation. (Copyright Elizabeth Martin.)

eBOX 7.2 Phalangeal Malunion

Treatment Variables

Location: Proximal vs. middle phalanx; digit involved; level with affected phalanx; articular vs. extraarticular
Complexity: Isolated malunion vs. prior combined injury (compromised integrity of soft tissue sleeve, tendons)
Nature of deformity: Angulation, rotation, shortening, translation, gap, step
Bone loss
Functional impairment

Modified from Buchler U: Osteotomy for phalangeal malunion, *Tech Hand Upper Ext Surg* 2:158–165, 1998.

plate. Although closing wedge osteotomy is technically easier and does not require bone grafting, I lean toward opening wedge osteotomy if there is concern for loss of phalangeal length and extensor lag.

Shortening

Shortening may occur after a comminuted fracture that is allowed to heal in a collapsed fashion or after a long spiral fracture. Restoration of phalangeal length alone is rarely indicated because of the inherent risks of osteotomy and interposition bone grafting. When there is a concomitant rotational or angular deformity, diaphyseal osteotomy with an appropriately fashioned intercalated graft may be indicated.

Occasionally, a spiral fracture of the proximal phalanx heals in a shortened position such that the distal spike on the proximal fragment protrudes into the retrocondylar space of the PIP joint and acts as a flexion block. In such instances, digital flexion can be restored by removing the spike through a volar approach. This procedure is best performed by using local anesthesia with sedation so that the patient can actively flex the affected digit intraoperatively to ensure that full digital flexion has been restored. Care must be taken not to be overzealous in bony removal because an iatrogenic fracture can occur. Malunited subcondylar fractures through the neck of the proximal phalanx can result in a block to active and passive PIP flexion. Correction can be attained through a volar approach by removing the bony block. We recommend against osteotomy because of its difficulty and the increased risk of avascular necrosis of the head fragment.

Articular Malunion

Unreduced condylar fractures that extend into the PIP joint may produce pain, angulatory deformity, stiffness, and, ultimately, degenerative arthritis. Treatment options include corrective articular or juxtaarticular osteotomy, arthrodesis, or arthroplasty. Juxtaarticular osteotomy corrects alignment but does not address the articular step-off.

In young patients who do not have posttraumatic arthritis, I prefer an articular osteotomy for uniplanar deformities. Patients should be informed that proper alignment can be corrected but restoration of full mobility is unlikely. Degenerative arthritis can develop in the future.

Outcomes. Buchler and colleagues[13] reviewed 59 extraarticular phalangeal malunions treated by phalangeal osteotomy. Full correction was achieved in 76% of the digits, and 89% showed increased range of motion. For digits with an isolated malunion, 83% had excellent results and 13% had good results. For digits with additional soft tissue injuries, there were only 45% excellent results and 19% good results. Along similar lines, Trumble and Gilbert[120] reported excellent results in 11 patients using an in situ closing wedge osteotomy to correct either uniplanar or multiplanar deformities. They used a 1.3-mm or 1.5-mm dorsally applied plate for fixation and reported no major complications. More recently, Del Pinal and associates[26] treated 10 patients with malunited phalangeal base fractures with an opening wedge osteotomy, insertion of a distal radius bone graft, and fixation using titanium lag screws or cerclage wires, or both. All patients had good results and achieved functional range of motion in the PIP joint, although decreased DIP joint motion was common.

CRITICAL POINTS *Osteotomy for Phalangeal Malunion*

Indications
- Angulatory or rotatory deformity with or without stiffness
- Pain, weakness

Preoperative Evaluation
- Assess the plane of deformity.
- Assess the integrity of the soft tissue sleeve and flexor and extensor tendons.
- Obtain anteroposterior, lateral, and oblique radiographs.
- Assess bone loss (determine whether opening wedge and bone graft are necessary).

Pearls
- Use miniplate and screw fixation whenever possible.
- Maintain phalangeal length rather than shorten it.
- Consider other options (arthrodesis or amputation) when associated with joint stiffness, unstable soft tissue coverage, or history of osteomyelitis.

Pitfalls
- Inadequate correction
- Poor fixation precluding early range-of-motion exercises
- Shortening more than 3 mm is unacceptable.

Technical Points
- Use template to assess length, opening versus closing wedge, or rotational osteotomy.
- Make a dorsal incision; preserve veins in skin flaps.
- Place longitudinal line on phalanx to assess rotational correction or temporary Kirschner wires perpendicular to coronal and sagittal planes.
- Create an osteotomy with a thin saw blade or osteotome.
- If lateral or volar angulation is present, consider an incomplete opening wedge (leave opposite cortex intact) and bone graft.
- Adjust alignment and temporarily hold with Kirschner pin.
- Apply low-profile plate (minimum four cortices above and below osteotomy) on lateral surface if possible.
- Perform tenolysis and/or capsulotomy if necessary.

Postoperative Care
- Apply bulky dressing for 4 to 7 days.
- Begin intensive active and gentle passive range-of-motion exercises.
- Edema control is done with an elastic garment.
- Splint IP joints in extension when not exercising.

Nonunion

Nonunion of phalangeal fractures is uncommon, although delayed union is seen quite often. Jupiter and colleagues[67] advised operative intervention for fractures that had not healed within 4 months of injury. They reported eight nonunions of the proximal phalanx, four of which were treated with plate fixation. Union was achieved in all patients. The earlier motion allowed in the rigid fixation (plate) group resulted in significantly greater total range of motion than in the group fixed with Kirschner wires. Two phalangeal nonunions were treated by arthrodeses, and one required a ray deletion. These procedures were performed in patients with substantial soft tissue problems or joint contractures.

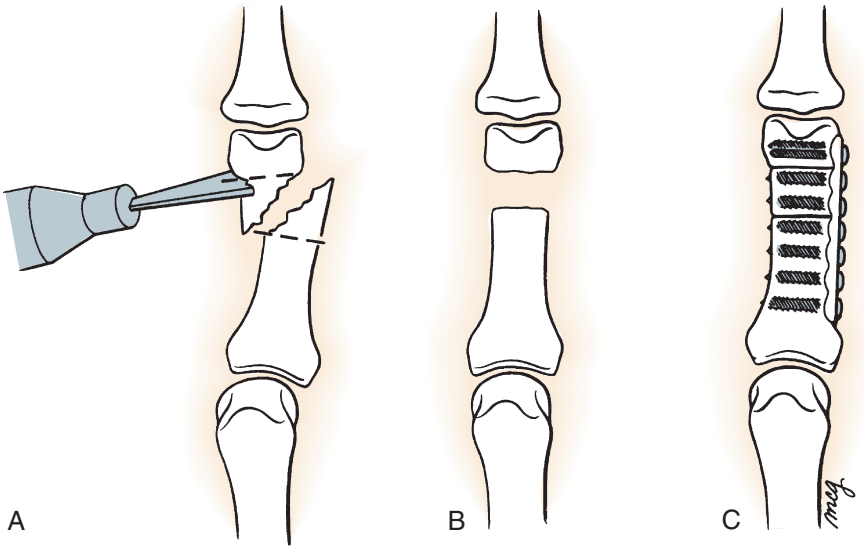

FIGURE 7.44 Technique for treatment of atrophic nonunion. **A,** Nonunion is resected with oscillating saw. **B,** Osseous gap after resection. **C,** Gap is filled with corticocancellous graft, and stabilization is accomplished with laterally applied plate.

Surgical preparation of the nonunion site is just as important as the method of fixation for phalangeal nonunions (Figure 7.44). Fibrous tissue must be removed until there are freshened fracture ends. If a resultant gap produces unacceptable shortening, intercalated corticocancellous bone grafting is indicated. Plate fixation has the advantage of being stable and affords the opportunity for concomitant tenolysis and capsulotomy when indicated (Figure 7.45). It is nevertheless a difficult procedure and requires exacting technique.

Loss of Motion

Stiffness of the PIP joint may result from intraarticular incongruity, arthrofibrosis, tendon adherence, or ligament contracture. Stiffness may be exacerbated by the choice of fixation. Kurzen and colleagues[75] retrospectively reviewed 54 patients who had plate fixation for phalangeal fractures and found that stiffness was the most frequent complication. Immobilization for longer than 4 weeks, associated joint injury, more than one fracture per finger, crush injury, and soft tissue injury all are contributing factors to decreased mobility of a fractured digit. In a prospective study of 245 open phalangeal fractures, Chow and colleagues[21] noted that the results directly correlated with the extent of injury to soft tissue, tendon, and nerve. If the fracture was associated with a laceration or isolated digital nerve injury, 40% of the results were good and 25% were poor. If there was an associated extensor tendon injury or extensive skin loss, 18% of the results were good and 50% were poor. If there was an injury to the flexor tendon or more than one component of soft tissue damage, 80% of the results were poor and good results were rare.

The treatment of stiffness should include an intensive program of hand therapy, with active and passive motion exercises and dynamic splinting. In addition, swelling should be controlled with compressive garments. When there has been a plateau in motion and soft tissue induration and edema have been minimized, surgical intervention can be considered. Extensor tendon adhesions restrict passive PIP joint flexion and limit active extension. Passive extension is not usually limited. Extensor tendon adherence is best treated by tenolysis of the dorsal apparatus.

Schneider[106] pointed out that the use of tenolysis and capsulotomy after phalangeal fractures must be individualized. He recommends using local anesthesia with sedation. Initially, extensor tenolysis over the proximal phalanx is performed; if PIP passive flexion is limited (<90 degrees), a dorsal PIP capsulotomy and collateral ligament release are usually needed. When full passive PIP flexion has been achieved, the patient is asked actively to flex and extend the digit. If there is a discrepancy between active and passive flexion (i.e., if passive flexion exceeds active flexion) flexor tenolysis is performed. Creighton and Steichen[25] found that addition of a dorsal PIP capsulotomy to an extensor tenolysis did not improve the gains in active PIP extensor function.

When there is combined joint stiffness and tendon adhesions, surgical results can be disappointing. Arthrodesis of the PIP joint in a functional position or ray deletion is an option when severe contractures or stiffness persists.

Proximal Interphalangeal Joint Extensor Lag

Extensor lag at the PIP joint is commonly encountered after proximal phalangeal fracture. Causes include adhesions of the dorsal apparatus to the proximal phalanx, shortening of the proximal phalanx, and an angulatory (apex volar) deformity of the proximal phalanx. Vahey and colleagues[121] noted in a cadaveric study that for an average apex volar angulation of 16 degrees, 37 degrees, and 46 degrees, a PIP lag resulted of 10 degrees, 24 degrees, and 66 degrees, respectively. With respect to proximal phalangeal shortening, for each 1 mm of shortening, there was a 12-degree lag. Clinically, the intrinsic and extrinsic muscles are capable, however, of compensating for some degree of bone shortening.

Ideally, prevention of extensor lag is the management of choice. Isolated fractures of the proximal phalanx treated operatively and nonoperatively should have the PIP joint statically



FIGURE 7.45 **A,** Index finger atrophic nonunion. **B,** Anteroposterior view after resection of nonunion, application of corticocancellous graft, and plate fixation. Tenolysis and PIP capsulotomy were done simultaneously. **C,** Lateral view. **D,** Clinical result showing full extension. **E,** Flexion.

splinted in extension. If an extensor lag is noted, a dynamic PIP extension splint, including a lumbrical bar to prevent metacarpophalangeal joint hyperextension, should be applied.

Late management of an extensor lag depends on the cause and the degree of the lag. Most individuals tolerate a lag of less than 15 to 20 degrees. The Elson test should be performed to rule out disruption of the central slip. A dynamic ultrasound may be helpful to identify the site and degree of tendon adherence. If the lag is symptomatic, the central slip is intact, and adhesions are suspected, extensor tenolysis should be considered.

Flexor Tendon Rupture or Entrapment

Flexor tendon rupture is uncommon and usually iatrogenic, secondary to attritional rupture from screws that penetrate the fibroosseous sheath. Entrapment of flexor tendons between fracture fragments is likewise unusual.

Infection

Infection after fracture treatment is rare. The incidence of infection in open fractures ranges from 2.04%[21] to 11%.[89] Infection usually occurs after an open injury in which there has been a delay in treatment, a comminuted fracture, immune compromise, or contamination.

Swanson and associates[117] reviewed 200 open hand fractures in 121 patients. They classified fractures into two types, as follows:

Type I
A. Clean wounds without significant contamination or delay in treatment
B. No significant systemic illness

Type II
A. Gross contamination (animal bite, grossly dirty, or barnyard injury)
B. Delay in treatment of more than 24 hours
C. Significant systemic illness

The infection rate in type I injuries was 1.4% and in type II injuries was 14%. The incidence of infection was not related to the presence of internal fixation, high-energy injury, or concomitant soft tissue injuries. Swanson and associates[117] recommended primary closure for type I injuries and delayed closure for type II injuries.

Role of Antibiotics in the Management of Phalangeal Fractures

The role of antibiotics in the management of phalangeal fractures is controversial. Hoffman and Adams[57] recommended antibiotic treatment in situations involving open wound contamination, extensive soft tissue and bony injury, and soft tissue reconstructive procedures with large flaps. For elective hand surgeries, Platt and Page[95] recommended prophylactic antibiotics when procedures are more than 2 hours long, when surgery involves implants or percutaneous Kirschner wires, or when patients have certain preexisting conditions such as diabetes. I use broad-spectrum antibiotics for open phalangeal fractures because the organisms isolated from open fractures include various gram-positive and gram-negative organisms, anaerobes, and occasional fungi. I prefer a first-generation cephalosporin in the emergency department and a combination of a first-generation or second-generation cephalosporin with an aminoglycoside for the first 24 postoperative hours. For grossly contaminated fractures (farm injuries), penicillin is added for the potential of anaerobic contamination.

Treatment of Infected Phalangeal Fractures

Management of infected fractures includes three goals: (1) eradicating sepsis, (2) obtaining fracture union, and (3) regaining a functional extremity. Sepsis is eliminated by thorough débridement of the infected bone and soft tissue, initiation of appropriate antibiotic therapy, and stabilization of the fracture. We have found external fixation to be helpful in stabilization of infected diaphyseal fractures after débridement. After the infection has been eliminated, bone grafting and rigid internal fixation may be accomplished.

Established phalangeal osteomyelitis may be difficult, if not impossible, to eradicate. Several operative procedures may be necessary, and the final result is often a painful, stiff, useless digit. In such circumstances, amputation must be considered.

FRACTURES OF THE THUMB

Because of the compensatory movement of the adjacent joints, the thumb is more forgiving of residual deformity than the fingers. Malrotation is rarely a problem. Angulatory deformities in the frontal plane of less than 15 to 20 degrees are functionally acceptable, although cosmetically they may be bothersome. Likewise, angulation of less than 20 to 30 degrees in the lateral plane usually causes no functional deficit. Articular fractures must be reduced anatomically to avoid loss of motion and posttraumatic arthritis.

Thumb Phalangeal Fractures

Extraarticular Thumb Fractures

Fractures of the proximal and distal phalanx of the thumb are often the result of direct trauma and are less common than fractures of the thumb metacarpal. These fractures can be divided into tuft, transverse shaft, and longitudinal shaft fractures.

Tuft fractures are usually comminuted and are nearly always associated with an injury to the nail matrix or pulp, or both. The fracture rarely requires reduction or fixation. Treatment should consist of evacuation of the painful subungual hematoma and repair of dermal and nail matrix lacerations when indicated. Splint immobilization is used for 3 to 4 weeks.

Distal phalangeal transverse shaft fractures are potentially unstable. The fracture angulates with its apex anterior secondary to the pull of the flexor pollicis longus on the proximal fragment. If reduction cannot be held in a splint, it is reasonable to insert a longitudinal Kirschner wire percutaneously across the fracture and into the head of the proximal phalanx.

Longitudinal extraarticular fractures of the distal phalanx are uncommon. When displaced, the fracture can usually be reduced and percutaneously pinned.

Head and neck fractures of the proximal phalanx are treated according to the same principles used in treating similar injuries in the fingers. Displaced spiral or oblique fractures may be treated by percutaneous pinning or by open reduction with either Kirschner wires or interfragmentary screws. Transverse fractures angulate the apex volarly secondary to the pull of the thenar intrinsics on the proximal fragment and the extensor pollicis longus on the distal fragment. Closed reduction is usually stable. More than 20 to 30 degrees of angulation in the lateral plane is unacceptable because an extensor lag of the IP joint would result. If open reduction of a fracture of the proximal phalanx is required, the fracture is exposed through a dorsal "Y"-shaped incision with the extensor pollicis longus insertion left intact (Figure 7.46).

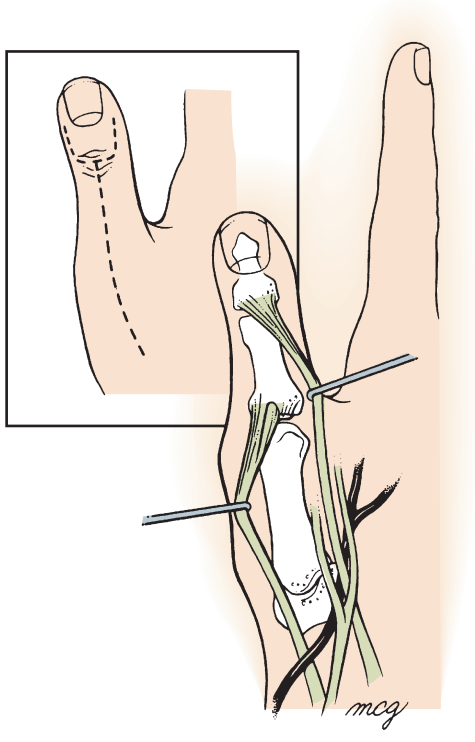

FIGURE 7.46 Exposure of thumb metacarpal and phalanges. Interval between extensor pollicis longus and extensor pollicis brevis is divided, with both tendons left intact. When exposing thumb, care must be taken not to injure terminal branches of superficial radial nerve or radial artery in anatomic snuffbox.

Articular Fractures and Avulsions of the Thumb

Articular fractures of the IP or MP joint may constitute a single fragment (a sign of a ligament or avulsion injury) or may be significantly comminuted. Comminuted fractures usually occur after blunt trauma. Ideally, articular congruity should be restored. If symptomatic arthritis ensues, IP or MP arthrodesis can be accomplished with little functional impairment.

Avulsion fractures of the dorsal base of the distal phalanx are designated a "mallet thumb." Unless there is volar subluxation of the distal phalanx, treatment should consist of continuous extension splinting of the IP joint for 6 weeks. Avulsion fractures of the volar lip of the base of the distal phalanx usually represent impaction fractures after a dorsal IP dislocation or, rarely, avulsion of the flexor pollicis longus. Avulsion fractures from the ulnar base of the proximal phalanx usually represent disruption of the ulnar collateral ligament (gamekeeper's or skier's thumb). If the fragment is displaced more than 2 mm and the MP joint is unstable to stress, stability needs to be restored surgically. If the fracture fragment is small or breaks during internal fixation, it can be removed and the ligament reinserted with a pull-out wire or suture anchor. Larger fragments can be fixed with either Kirschner wires or a small screw. The repair is protected with a transarticular smooth K-wire and thumb spica cast immobilization for 4 to 6 weeks. Avulsion fractures of the radial side represent a radial collateral ligament injury. When the fracture is displaced, open reduction is necessary to ensure joint stability.

Fractures of the Thumb Metacarpal

Metacarpal Head Fractures

Metacarpal head fractures are unusual because the longitudinally directed force that produces them is usually dissipated at the proximal metaphysis or trapeziometacarpal joint. Displaced articular fractures require anatomic reduction. Fixation can be obtained with percutaneous Kirschner wires or by open reduction. The fracture is approached by splitting the dorsal apparatus between the extensor pollicis longus and extensor pollicis brevis (see Figure 7.46) With pin fixation, the thumb is immobilized for 2 to 3 weeks before initiating motion. With screw fixation, motion is initiated at 5 to 7 days postoperatively.

Shaft Fractures of the Thumb

Fractures of the thumb metacarpal occur in three locations: shaft, base, and articular fractures. Extraarticular fractures through the base are common and are usually transverse or mildly oblique. They generally occur at the proximal metaphyseal-diaphyseal junction and are referred to as *epibasal.* The fracture is angulated with its apex dorsal such that the distal fragment is adducted and flexed (Figure 7.47). A true lateral radiograph is necessary to evaluate the degree of angulation, and radiographs must be carefully evaluated to rule out an articular component. Adequacy of the lateral radiograph should be verified by superimposition of the thumb MP joint sesamoids.

Closed reduction of epibasal thumb fractures is usually easy to accomplish by longitudinal traction, downward pressure on the apex of the fracture, mild pronation of the distal fragment, and thumb extension. The reduction is often unstable because of the deforming force of the abductor pollicis. If cast treatment is chosen, the reduction should be closely monitored for displacement. Angulation of less than 30 degrees is usually well compensated because of the abundant motion at the trapeziometacarpal joint. Angulation of more than 30 degrees results in compensatory hyperextension of the MP joint, however, and may be unacceptable (Figure 7.48). In fractures angulated more than 30 degrees, I prefer closed reduction and percutaneous pinning. Open reduction for these epibasal fractures is rarely necessary.

Comminuted thumb metacarpal shaft fractures are usually the result of direct trauma and are often associated with soft tissue injury. Fracture stabilization must be individualized.

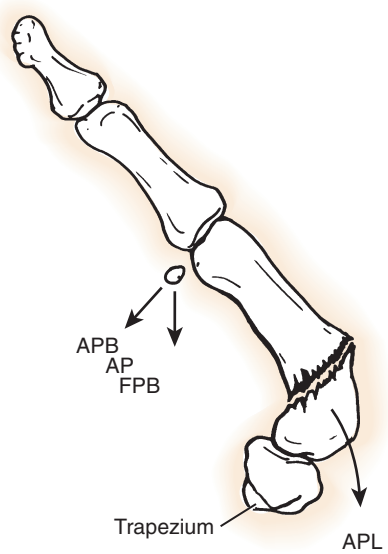

FIGURE 7.47 Deforming forces of thumb metacarpal shaft fracture. Abductor pollicis brevis (*APB*), adductor pollicis (*AP*), and flexor pollicis brevis (*FPB*) flex distal fragment, and abductor pollicis longus (*APL*) extends proximal fragment.

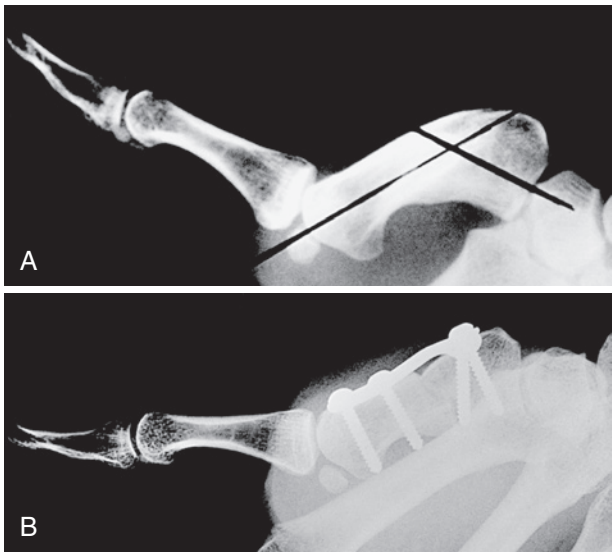

FIGURE 7.48 **A,** Hyperextension deformity after malunion of thumb metacarpal shaft fracture. **B,** Correction by closing wedge osteotomy and plate fixation. Note postural correction of previously hyperextended MP joint.

Open shaft fractures may require an external fixator to prevent metacarpal shortening and to allow soft tissue healing. Extension of the frame to the index metacarpal helps prevent a thumb/index finger web contracture.

Articular Fractures of the Thumb Metacarpal Base: Bennett Fracture

An articular fracture of the base of the thumb metacarpal consisting of a single, variable-sized, volar-ulnar fracture fragment is termed *Bennett fracture*. Many methods of treatment have been advocated, with no consensus on the best technique.

Bennett fracture is really a fracture subluxation. The injury occurs when the thumb metacarpal is axially loaded and partially flexed. The Bennett fragment is of variable size, is pyramidal in shape, and consists of the volar-ulnar aspect of the metacarpal base. The anterior oblique ligament, which runs from the fractured fragment to the trapezium, holds the fragment in anatomic position. The remaining metacarpal base subluxates radially, proximally, and dorsally.

Before the 1970s, nonoperative management was the rule, and controversy regarding the need for anatomic reduction persists today. Most authors recommend an attempt at improvement of the metacarpal subluxation with percutaneous or open reduction. Cannon and coworkers[19] evaluated patients nearly 10 years after nonoperative management and noted little evidence of symptomatic arthritis despite imperfect reduction. Kjaer-Petersen and colleagues[71] noted a higher incidence of symptomatic arthritis when articular incongruity persisted after reduction. Livesley[81] observed 17 patients for 26 years after closed reduction and casting. All patients had diminished mobility and strength, and most had radiographic evidence of degenerative arthritis and joint subluxation. Livesley[81] concluded that this fracture should not be managed conservatively.

Numerous techniques for closed reduction and percutaneous fixation have been recommended. Closed reduction and fluoroscopically guided percutaneous pinning from the thumb metacarpal into the trapezium without anatomic restoration of the metacarpal articular surface has become increasingly popular. Another technique is Kirschner pin fixation between the first and second metacarpals (intermetacarpal pinning) as advocated by van Niekerk and Ouwens.[123]

Timmenga and associates[119] observed patients nearly 11 years after percutaneous or open reduction of a Bennett fracture. They concluded that exact reduction should be the aim of treatment. Most of their patients had some degenerative changes radiographically, but there was no correlation with symptoms. Lutz and associates[84] assessed the long-term functional outcome of 32 patients with Bennett fractures with an articular step-off of less than 1 mm. They noted no difference in clinical outcome or incidence of osteoarthritis between percutaneous and open reduction in treatment of Bennett fractures. They recommended percutaneous reduction for fracture-dislocations with a large beak fragment and open reduction for irreducible fractures. If the Bennett fragment is of adequate size, internal fixation with a screw can be performed.

❖ AUTHOR'S PREFERRED METHOD OF TREATMENT

Although some patients with malunited Bennett fractures remain relatively asymptomatic despite radiographic incongruity and degenerative changes, anatomic reduction is the most reliable method of achieving a satisfactory result. When the Bennett fragment is less than 15% to 20% of the articular surface, we prefer closed reduction and percutaneous pinning of the CMC joint. Under regional or general anesthesia, the thumb metacarpal is extended and pronated, while longitudinal traction and downward pressure are applied to the metacarpal base (Figure 7.49). While the reduction is held, a Kirschner wire is drilled obliquely across the trapeziometacarpal joint under fluoroscopic guidance. The reduction, articular congruity, and pin position are checked with the image intensifier. If the metacarpal is reduced to the Bennett fragment and there is less than 2 mm of articular step-off, we accept the reduction and immobilize the digit in a thumb spica cast.

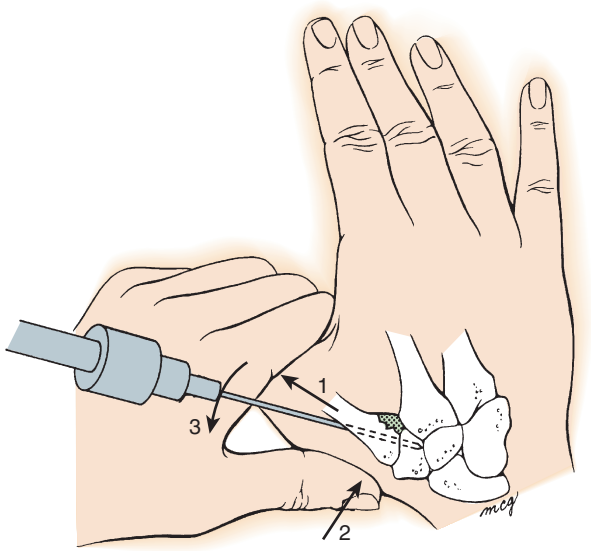

FIGURE 7.49 Percutaneous pin fixation of a Bennett fracture. Reduction is performed by longitudinal traction (*1*), pressure at thumb metacarpal base (*2*), and pronation (*3*). Pin is passed from metacarpal to trapezium. It is unnecessary to pin the Bennett fragment.

If the Bennett fragment is irreducible, we prefer ORIF. The joint is approached through a Wagner[125] incision (Figure 7.50, *A*). The longitudinal limb of this incision is over the subcutaneous border of the thumb metacarpal (between the abductor pollicis longus and the thenar muscles) and is extended proximally and ulnarly to the radial border of the flexor carpi radialis. The thenar muscles are reflected subperiosteally, the joint capsule is incised, and the fracture is visualized. When articular congruity has been restored, the articular fragment is held reduced with either reduction forceps or a small bone hook. Fixation of large fragments is secured with either a 1.5-mm or 2-mm lag screw (Figure 7.51), as suggested by Foster and Hastings.[34] For smaller fragments, 0.035-inch Kirschner wires can be placed across the fracture (see Figure 7.50, *B*). With pin fixation, it is advisable to protect the reduction with an additional transarticular pin.

Postoperatively, if pins are used, the thumb is immobilized in a thumb spica cast for 4 weeks, and the transarticular pin is removed. The pins holding the fracture fragment are removed at 6 weeks. Screw fixation, although technically more demanding, is more secure, and active range of motion may be initiated 5 to 10 days postoperatively.

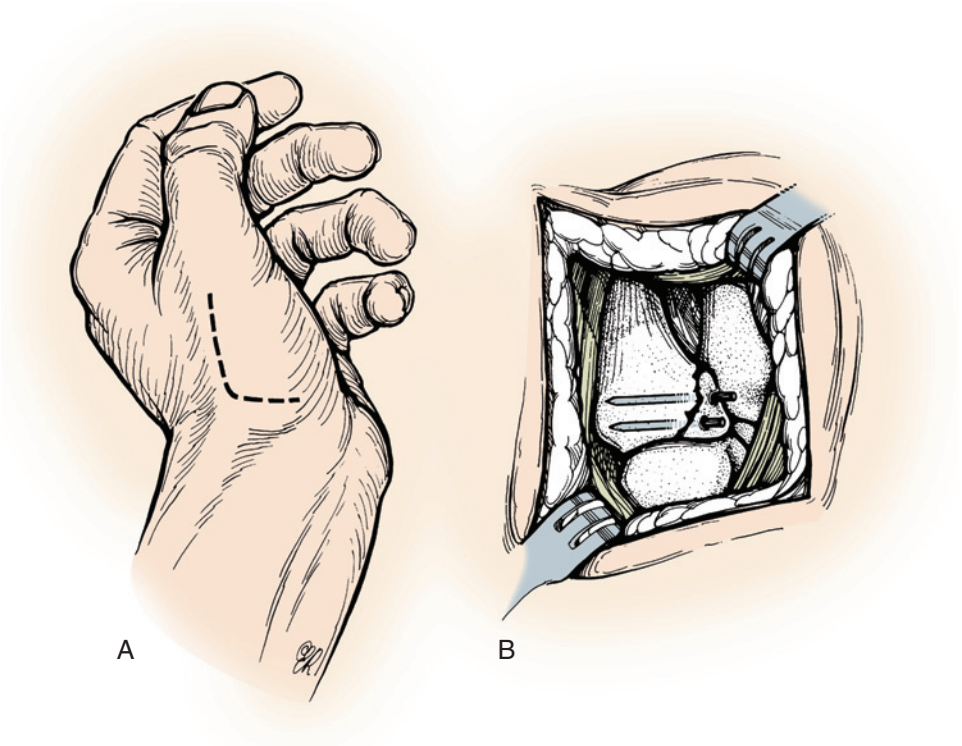

FIGURE 7.50 Incision (**A**) and technique (**B**) of open reduction and pin fixation of a Bennett fracture. (Copyright Elizabeth Martin.)

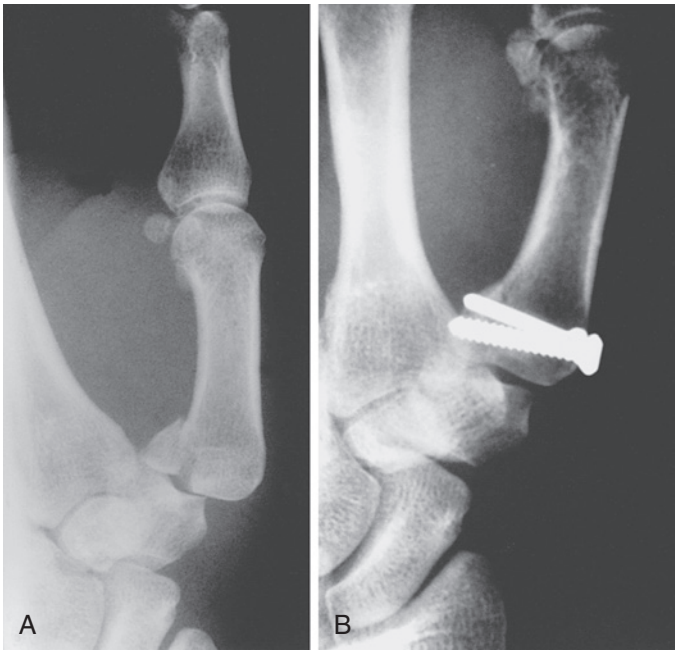

FIGURE 7.51 **A,** Displaced Bennett fracture. **B,** Fixation with lag screws.

Complications. Long-standing instability with painful arthritis is best treated by a trapeziometacarpal joint arthrodesis. Nonunion is practically unknown. A contracture of the first web can result if the thumb metacarpal has been immobilized in an adducted position.

Expected Outcomes for Bennett Fractures. There is some controversy over the outcomes of imperfect reduction resulting from nonmanagement of Bennett fractures. A low incidence of symptomatic arthritis has been reported in a 10-year follow-up study of conservatively treated fractures.[19] In a 26-year follow-up of patients with closed reduction and casting, the authors reported diminished mobility and strength, degenerative arthritis, and joint subluxation.[81] Surgical techniques for treatment of Bennett fractures include closed reduction and percutaneous pinning and ORIF. There is typically no significant difference in clinical outcome between the two techniques, as long as anatomic alignment can be achieved.[84] Long-term degenerative changes may become evident radiographically after closed percutaneous or open reduction of Bennett fractures.[118]

Rolando Fractures of the Thumb

The term *Rolando fracture* includes any comminuted articular fracture of the base of the thumb metacarpal. Techniques of open reduction include multiple Kirschner wires and plate fixation.[34] Successful closed reduction with percutaneous pinning is usually difficult to accomplish in this fracture because of the difficulty of reducing all the articular fragments. Articular reduction is most likely to be successful when there are two fragments with minimal comminution. The surgical exposure for plate fixation is the same as for Bennett fractures. Longitudinal traction is applied, and a provisional reduction of the two articular fragments is held with Kirschner wires or a reduction clamp, or both. Articular congruity of the metacarpal base is verified by radiographs and by direct visualization. A 2.4-mm to 2.7-mm L-plate or T-plate is applied (Figure 7.52).

For comminuted articular fractures, Gelberman and coworkers[43] recommended oblique traction (Figure 7.53) through the thumb metacarpal. This technique is appealing for its simplicity and low complication rate. A 1-cm incision is made just distal to the abductor pollicis longus insertion and radial and volar to

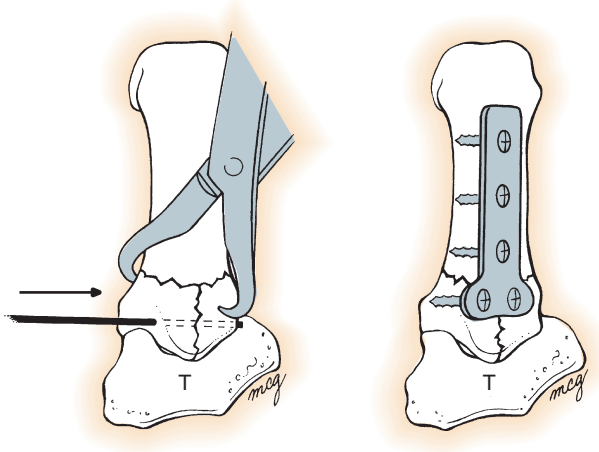

FIGURE 7.52 Rolando fracture. *Left,* Provisional reduction is held with clamp and Kirschner pin. *Right,* Final reduction maintained with T-plate.

CRITICAL POINTS *Operative Management of Bennett Fracture*

Indications
- Displacement of the Bennett metacarpal shaft or a CMC articular step-off of more than 2 mm.

Preoperative Evaluation
- Obtain *true* anteroposterior (Betts and Roberts views) and lateral radiographs.
- CT is unnecessary unless comminution is suspected.

Pearls
- Anatomic articular restoration is probably unnecessary, but reduction of dislocation is mandatory.

Technical Points
- For a reducible Bennett fracture-dislocation, use closed reduction and percutaneous pinning.
- Use general or regional anesthesia.
- Apply longitudinal traction, and with downward pressure at base of the thumb metacarpal, position the metacarpal in pronation.
- Fluoroscopy greatly facilitates accurate pin placement.
- Insert two or three 0.9-mm or 1.1-mm pins from thumb metacarpal into trapezium or index metacarpal.
- For irreducible fracture-dislocation, use ORIF.
- Use Wagner (volar) approach along subcutaneous border of metacarpal.
- Elevate thenar musculature off thumb metacarpal.
- Anatomically reduce fracture with skin hooks or dental probe.
- Provisionally pin in a reduced position with 0.7-mm pin.
- Fix the Bennett fragment to the metacarpal with two 2-mm or 1.5-mm screws using lag technique if feasible.
- Verify articular reduction with fluoroscopy.
- Ensure screws have not penetrated articular surface.

Pitfalls
- Avoid inappropriately placed pins or fracture malreduction.
- Use radiography to properly classify the fracture and extent of comminution.

Postoperative Care
- If percutaneous pin fixation is used, immobilize for 4 to 5 weeks in thumb spica cast before removing pins.
- If ORIF is used, begin range-of-motion exercises at first postoperative visit.

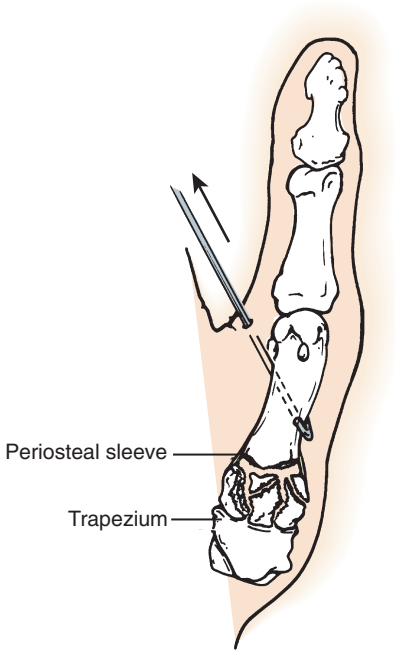

FIGURE 7.53 Oblique skeletal traction for comminuted fracture of thumb metacarpal base. Through small incision, 0.062-inch Kirschner pin is drilled obliquely through proximal metacarpal shaft; it exits distally through thumb web. Pin is crimped proximally, and distal traction is applied through banjo outrigger.

the extensor pollicis brevis tendon. A 0.062-inch Kirschner pin is drilled obliquely through the thumb metacarpal in a distal and ulnar direction with a slight volar tilt so that it exits in the thumb/index finger web space. The proximal end of the pin is bent 90 degrees, and the incision is closed. A forearm cast with a banjo outrigger is applied with exclusion of the thumb web, and rubber band traction is maintained for 4 to 6 weeks. A satisfactory outcome can usually be anticipated.

For comminuted fractures, Buchler and colleagues[14] recommended the application of a quadrilateral mini–external fixation device placed between the thumb and index metacarpal, followed by limited open reduction with Kirschner wires or screws and a cancellous bone graft as needed (Figure 7.54). At nearly 3 years later, nine patients had a good result and one had a fair result. Focal articular incongruity was common.

❖ AUTHOR'S PREFERRED METHOD OF TREATMENT

The choice of treatment depends primarily on the degree of comminution. Rolando fractures can appear deceptively benign on plain radiographs. CT may be helpful in assessing the comminution and extent of articular disruption. If a classic three-part Rolando fracture exists, we prefer ORIF with either multiple Kirschner wires or a plate. One should be prepared to use bone graft if there is a metaphyseal void secondary to compaction of the cancellous subchondral bone. If there is significant comminution, open reduction may be frustrating and unproductive. Buchler's technique of using quadrilateral external fixation, articular reduction with Kirschner wires, and cancellous bone grafting is a reasonable alternative. Anatomic reduction is not usually possible, and prolonged attempts to attain perfect reduction may result in devascularization of the osteochondral fragments and further articular injury.

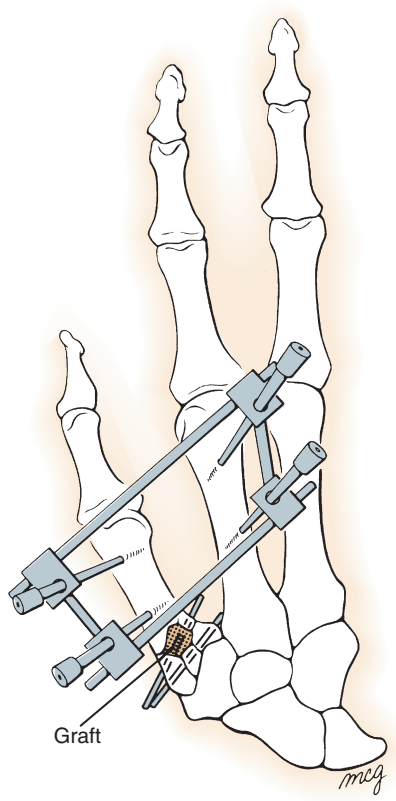

FIGURE 7.54 Quadrilateral frame for comminuted fracture of base of thumb. Two pins each are inserted into thumb and index finger metacarpals and interconnected with rods and swivel clamps. Thumb metacarpal articular surface is reduced and held with Kirschner wires, and metaphysis is grafted with cancellous bone.

After operative management, if there is persistent pain, we prefer no further intervention for a minimum of 6 months. If pain persists and there is radiographic evidence of articular incongruity, we recommend an arthrodesis of the trapeziometacarpal joint.

For Case Studies, Videos, and more, please visit ExpertConsult.com.

REFERENCES

1. Al-Qattan MM: The cartilaginous cap fracture. *Hand Clin* 16:535–539, 2000.
2. Al-Qattan MM: Metacarpal shaft fractures of the fingers: treatment with interosseous loop wire fixation and immediate postoperative finger mobilisation in a wrist splint. *J Hand Surg [Br]* 31:377–382, 2006.
3. Al-Qattan MM, Al-Lazzam A: Long oblique/spiral mid-shaft metacarpal fractures of the fingers: treatment with cerclage wire fixation and immediate post-operative finger mobilisation in a wrist splint. *J Hand Surg Eur Vol* 32:637–640, 2007.
4. Ashmead DT, Rothkopf DM, Walton RL, et al: Treatment of hand injuries by external fixation. *J Hand Surg [Am]* 17:954–964, 1992.
5. Bach HG, Gonzalez MH, Hall RF, Jr: Locked intramedullary nailing of metacarpal fractures secondary to gunshot wounds. *J Hand Surg [Am]* 31:1083–1087, 2006.
6. Belsky MR, Eaton RG, Lane LB: Closed reduction and internal fixation of proximal phalangeal fractures. *J Hand Surg [Am]* 9:725–729, 1984.
7. Bora FW, Jr, Didizian NH: The treatment of injuries to the carpometacarpal joint of the little finger. *J Bone Joint Surg Am* 56:1459–1463, 1974.
8. Borgeskov S: Conservative therapy for fractures of the phalanges and metacarpals. *Acta Chir Scand* 133:123–130, 1967.
9. Bostman OM: Absorbable implants for the fixation of fractures. *J Bone Joint Surg Am* 73:148–153, 1991.
10. Botte MJ, Davis JL, Rose BA, et al: Complications of smooth pin fixation of fractures and dislocations in the hand and wrist. *Clin Orthop Relat Res* 276:194–201, 1992.
11. Boulas HJ, Herren A, Buchler U: Osteochondral metatarsophalangeal autografts for traumatic articular metacarpophalangeal defects: a preliminary report. *J Hand Surg [Am]* 18:1086–1092, 1993.
12. Buchler U, Fischer T: Use of a minicondylar plate for metacarpal and phalangeal periarticular injuries. *Clin Orthop Relat Res* 214:53–58, 1987.
13. Buchler U, Gupta A, Ruf S: Corrective osteotomy for post-traumatic malunion of the phalanges in the hand. *J Hand Surg [Br]* 21:33–42, 1996.
14. Buchler U, McCollam SM, Oppikofer C: Comminuted fractures of the basilar joint of the thumb: combined treatment by external fixation, limited internal fixation, and bone grafting. *J Hand Surg [Am]* 16:556–560, 1991.
15. Burkhalter WE: Closed treatment of hand fractures. *J Hand Surg [Am]* 14(2 Pt 2): 390–393, 1989.
16. Burkhalter WE, Reyes FA: Closed treatment of fractures of the hand. *Bull Hosp Jt Dis Orthop Inst* 44:145–162, 1984.
17. Cain JE, Jr, Shepler TR, Wilson MR: Hamatometacarpal fracture-dislocation: classification and treatment. *J Hand Surg [Am]* 12(5 Pt 1):762–767, 1987.
18. Calkins MS, Burkhalter W, Reyes F: Traumatic segmental bone defects in the upper extremity: treatment with exposed grafts of corticocancellous bone. *J Bone Joint Surg Am* 69:19–27, 1987.
19. Cannon SR, Dowd GS, Williams DH, et al: A long-term study following Bennett's fracture. *J Hand Surg [Br]* 11:426–431, 1986.
20. Chen SH, Wei FC, Chen HC, et al: Miniature plates and screws in acute complex hand injury. *J Trauma* 37:237–242, 1994.
21. Chow SP, Pun WK, So YC, et al: A prospective study of 245 open digital fractures of the hand. *J Hand Surg [Br]* 16:137–140, 1991.
22. Chung KC, Spilson SV: The frequency and epidemiology of hand and forearm fractures in the United States. *J Hand Surg [Am]* 26:908–915, 2001.
23. Clendenin MB, Smith RJ: Fifth metacarpal/hamate arthrodesis for posttraumatic osteoarthritis. *J Hand Surg [Am]* 9:374–378, 1984.
24. Coonrad RW, Pohlman MH: Impacted fractures in the proximal portion of the proximal phalanx of the finger. *J Bone Joint Surg Am* 51:1291–1296, 1969.
25. Creighton JJ, Jr, Steichen JB: Complications in phalangeal and metacarpal fracture management: results of extensor tenolysis. *Hand Clin* 10:111–116, 1994.
26. Del Pinal F, Garcia-Bernal FJ, Delgado J, et al: Results of osteotomy, open reduction, and internal fixation for late-presenting malunited articular fractures of the base of the middle phalanx. *J Hand Surg [Am]* 30:1039, 2005.
27. Dumont C, Fuchs M, Burchhardt H, et al: Clinical results of absorbable plates for displaced metacarpal fractures. *J Hand Surg [Am]* 32:491–496, 2007.
28. Duncan RW, Freeland AE, Jabaley ME, et al: Open hand fractures: an analysis of the recovery of active motion and of complications. *J Hand Surg [Am]* 18:387–394, 1993.
29. Edwards GS, Jr, O'Brien ET, Heckman MM: Retrograde cross-pinning of transverse metacarpal and phalangeal fractures. *Hand* 14:141–148, 1982.
30. Facca S, Ramdhian R, Pelissier A, et al: Fifth metacarpal neck fracture fixation: locking plate versus K-wire? *Orthop Traumatol Surg Res* 96(5):506–512, 2010.
31. Faraj AA, Davis TR: Percutaneous intramedullary fixation of metacarpal shaft fractures. *J Hand Surg [Br]* 24:76–79, 1999.
32. Faruqui S, Stern PJ, Kiefhaber TR: Percutaneous pinning of fractures in the proximal third of the proximal phalanx: complications and outcomes. *J Hand Surg [Am]* 37(7):1342–1348, 2012.
33. Field LD, Freeland AE, Jabaley ME: Midaxial approach to the proximal phalanx for fracture fixation. *Contemp Orthop* 25:133–137, 1992.
34. Foster RJ, Hastings H, 2nd: Treatment of Bennett, Rolando, and vertical intraarticular trapezial fractures. *Clin Orthop Relat Res* 214:121–129, 1987.
35. Foucher G: "Bouquet" osteosynthesis in metacarpal neck fractures: a series of 66 patients. *J Hand Surg [Am]* 20(3 Pt 2):S86–S90, 1995.
36. Freeland AE: External fixation for skeletal stabilization of severe open fractures of the hand. *Clin Orthop Relat Res* 214:93–100, 1987.
37. Freeland AE, Jabaley ME: Stabilization of fractures in the hand and wrist with traumatic soft tissue and bone loss. *Hand Clin* 4:425–436, 1988.
38. Freeland AE, Sennett BJ: Phalangeal fractures. In Peimer CA, editor: *Surgery of the hand and upper extremity*, New York, 1996, McGraw-Hill, pp 921–937.
39. Froimson AI: Osteotomy for digital deformity. *J Hand Surg [Am]* 6:585–589, 1981.
40. Fusetti C, Della Santa DR: Influence of fracture pattern on consolidation after metacarpal plate fixation. *Chir Main* 23:32–36, 2004.
41. Fusetti C, Meyer H, Borisch N, et al: Complications of plate fixation in metacarpal fractures. *J Trauma* 52:535–539, 2002.
42. Galanakis I, Aligizakis A, Katonis P, et al: Treatment of closed unstable metacarpal fractures using percutaneous transverse fixation with Kirschner wires. *J Trauma* 55:509–513, 2003.
43. Gelberman RH, Vance RM, Zakaib GS: Fractures at the base of the thumb: treatment with oblique traction. *J Bone Joint Surg Am* 61:260–262, 1979.

44. Gingrass RP, Fehring B, Matloub H: Intraosseous wiring of complex hand fractures. *Plast Reconstr Surg* 66:383–394, 1980.
45. Gonzalez MH, Hall RF, Jr: Intramedullary fixation of metacarpal and proximal phalangeal fractures of the hand. *Clin Orthop Relat Res* 327:47–54, 1996.
46. Gonzalez MH, McKay W, Hall RF, Jr: Low-velocity gunshot wounds of the metacarpal: treatment by early stable fixation and bone grafting. *J Hand Surg [Am]* 18:267–270, 1993.
47. Green DP: Complications of phalangeal and metacarpal fractures. *Hand Clin* 2:307–328, 1986.
48. Green DP, Anderson JR: Closed reduction and percutaneous pin fixation of fractured phalanges. *J Bone Joint Surg Am* 55:1651–1654, 1973.
49. Greene TL, Noellert RC, Belsole RJ, et al: Composite wiring of metacarpal and phalangeal fractures. *J Hand Surg [Am]* 14:665–669, 1989.
50. Gross MS, Gelberman RH: Metacarpal rotational osteotomy. *J Hand Surg [Am]* 10:105–108, 1985.
51. Grundberg AB: Intramedullary fixation for fractures of the hand. *J Hand Surg [Am]* 6:568–573, 1981.
52. Hamilton SC, Stern PJ, Fassler PR, et al: Mini-screw fixation for the treatment of proximal interphalangeal joint dorsal fracture-dislocations. *J Hand Surg [Am]* 31:1349–1354, 2006.
53. Hansen PB, Hansen TB: The treatment of fractures of the ring and little metacarpal necks: a prospective randomized study of three different types of treatment. *J Hand Surg [Br]* 23:245–247, 1998.
54. Hastings H, 2nd: Open fractures and those with soft tissue damage: treatment by external fixation. In Barton NJ, editor: *Fractures of the hand and wrist*, Edinburgh, 1988, Churchill Livingstone, pp 145–172.
55. Hastings H, 2nd, Carroll CT: Treatment of closed articular fractures of the metacarpophalangeal and proximal interphalangeal joints. *Hand Clin* 4:503–527, 1988.
56. Hastings H, 2nd, Cohen MS: Screw fixation of the diaphysis of the metacarpals. In Blair WF, editor: *Techniques in hand surgery*, Baltimore, 1996, Williams & Wilkins, pp 246–254.
57. Hoffman RD, Adams BD: The role of antibiotics in the management of elective and post-traumatic hand surgery. *Hand Clin* 14:657–666, 1998.
58. Hofmeister EP, Kim J, Shin AY: Comparison of 2 methods of immobilization of fifth metacarpal neck fractures: a prospective randomized study. *J Hand Surg [Am]* 33(8):1362–1368, 2008.
59. Horton TC, Hatton M, Davis TR: A prospective randomized controlled study of fixation of long oblique and spiral shaft fractures of the proximal phalanx: closed reduction and percutaneous Kirschner wiring versus open reduction and lag screw fixation. *J Hand Surg [Br]* 28:5–9, 2003.
60. Huffaker WH, Wray RC, Jr, Weeks PM: Factors influencing final range of motion in the fingers after fractures of the hand. *Plast Reconstr Surg* 63:82–87, 1979.
61. Hunter JM, Cowen NJ: Fifth metacarpal fractures in a compensation clinic population: a report on one hundred and thirty-three cases. *J Bone Joint Surg Am* 52:1159–1165, 1970.
62. Ip WY, Ng KH, Chow SP: A prospective study of 924 digital fractures of the hand. *Injury* 27:279–285, 1996.
63. Itoh Y, Uchinishi K, Oka Y: Treatment of pseudoarthrosis of the distal phalanx with the palmar midline approach. *J Hand Surg [Am]* 8:80–84, 1983.
64. Jahss SA: Fractures of the metacarpals: a new method of reduction and immobilization. *J Bone Joint Surg Am* 20:178–186, 1938.
65. James JI: Fractures of the proximal and middle phalanges of the fingers. *Acta Orthop Scand* 32:401–412, 1962.
66. Jupiter JB, Belsky MR: Fracture and dislocations of the hand. In Browner BD, Jupiter JB, Levine AM, et al, editors: *Skeletal trauma*, Philadelphia, 1992, WB Saunders, pp 925–1024.
67. Jupiter JB, Koniuch MP, Smith RJ: The management of delayed union and nonunion of the metacarpals and phalanges. *J Hand Surg [Am]* 10:457–466, 1985.
68. Kelsch G, Ulrich C: Intramedullary K-wire fixation of metacarpal fractures. *Arch Orthop Trauma Surg* 124:523–526, 2004.
69. Kelsey JL, Pastides H, Kreiger N, et al, editors: *Upper extremity disorders: a survey of their frequency and cost in the United States*, St. Louis, 1980, Mosby.
70. Kim YK, Yeo HH, Lim SC: Tissue response to titanium plates: a transmitted electron microscopic study. *J Oral Maxillofac Surg* 55:322–326, 1997.
71. Kjaer-Petersen K, Langhoff O, Andersen K: Bennett's fracture. *J Hand Surg [Br]* 15:58–61, 1990.
72. Kuhn KM, Dao KD, Shin AY: Volar A1 pulley approach for fixation of avulsion fractures of the base of the proximal phalanx. *J Hand Surg [Am]* 26:762–771, 2001.
73. Kumar VP, Satku K: Surgical management of osteochondral fractures of the phalanges and metacarpals: a surgical technique. *J Hand Surg [Am]* 20:1028–1031, 1995.
74. Kuokkanen HO, Mulari-Keranen SK, Niskanen RO, et al: Treatment of subcapital fractures of the fifth metacarpal bone: a prospective randomised comparison between functional treatment and reposition and splinting. *Scand J Plast Reconstr Surg Hand Surg* 33:315–317, 1999.
75. Kurzen P, Fusetti C, Bonaccio M, et al: Complications after plate fixation of phalangeal fractures. *J Trauma* 60:841–843, 2006.
76. Lamb DW, Abernethy PA, Raine PA: Unstable fractures of the metacarpals: a method of treatment by transverse wire fixation to intact metacarpals. *Hand* 5:43–48, 1973.
77. Lane CS: Detecting occult fractures of the metacarpal head: the Brewerton view. *J Hand Surg [Am]* 2:131–133, 1977.
78. Lawlis JF, 3rd, Gunther SF: Carpometacarpal dislocations: long-term follow-up. *J Bone Joint Surg Am* 73:52–59, 1991.
79. Levin LS, Condit DP: Combined injuries—soft tissue management. *Clin Orthop Relat Res* 327:172–181, 1996.
80. Lister G: Intraosseous wiring of the digital skeleton. *J Hand Surg [Am]* 3:427–435, 1978.
81. Livesley PJ: The conservative management of Bennett's fracture-dislocation: a 26-year follow-up. *J Hand Surg [Br]* 15:291–294, 1990.
82. Lowdon IM: Fractures of the metacarpal neck of the little finger. *Injury* 17:189–192, 1986.
83. Lowka K: Plates and screws. In Bruser P, editor: *Bone and joint injuries*, London, 1999, Martin Dunitz, pp 17–22.
84. Lutz M, Sailer R, Zimmermann R, et al: Closed reduction transarticular Kirschner wire fixation versus open reduction internal fixation in the treatment of Bennett's fracture dislocation. *J Hand Surg [Br]* 28:142–147, 2003.
85. Majumder S, Peck F, Watson JS, et al: Lessons learned from the management of complex articular fractures at the base of the middle phalanges of fingers. *J Hand Surg [Br]* 28:559–565, 2003.
86. Massengill JB, Alexander H, Langrana N, et al: A phalangeal fracture model—quantitative analysis of rigidity and failure. *J Hand Surg [Am]* 7:264–270, 1982.
87. McElfresh EC, Dobyns JH: Articular metacarpal head fractures. *J Hand Surg [Am]* 8:383–393, 1983.
88. McKerrell J, Bowen V, Johnston G, et al: Boxer's fractures—conservative or operative management? *J Trauma* 27:486–490, 1987.
89. McLain RF, Steyers C, Stoddard M: Infections in open fractures of the hand. *J Hand Surg [Am]* 16:108–112, 1991.
90. Nunley JA, Kloen P: Biomechanical and functional testing of plate fixation devices for proximal phalangeal fractures. *J Hand Surg [Am]* 16:991–998, 1991.
91. Orbay JL, Touhami A: The treatment of unstable metacarpal and phalangeal shaft fractures with flexible nonlocking and locking intramedullary nails. *Hand Clin* 22:279–286, 2006.
92. Ouellette EA, Freeland AE: Use of the minicondylar plate in metacarpal and phalangeal fractures. *Clin Orthop Relat Res* 327:38–46, 1996.
93. Page SM, Stern PJ: Complications and range of motion following plate fixation of metacarpal and phalangeal fractures. *J Hand Surg [Am]* 23:827–832, 1998.
94. Pehlivan O, Kiral A, Solakoglu C, et al: Tension band wiring of unstable transverse fractures of the proximal and middle phalanges of the hand. *J Hand Surg [Br]* 29:130–134, 2004.

94a. Petrie PW, Lamb DW: Fracture-subluxation of base of fifth metacarpal. *Hand* 6:82–86, 1974.

95. Platt AJ, Page RE: Post-operative infection following hand surgery: guidelines for antibiotic use. *J Hand Surg [Br]* 20:685–690, 1995.
96. Posner MA: Injuries to the hand and wrist in athletes. *Orthop Clin North Am* 8:593–618, 1977.
97. Pratt DR: Exposing fractures of the proximal phalanx of the finger longitudinally through the dorsal extensor apparatus. *Clin Orthop* 15:22–26, 1959.
98. Puckett CL, Welsh CF, Croll GH, et al: Application of maxillofacial miniplating and microplating systems to the hand. *Plast Reconstr Surg* 92:699–707, discussion 708–709, 1993.
99. Pun WK, Chow SP, So YC, et al: A prospective study on 284 digital fractures of the hand. *J Hand Surg [Am]* 14:474–481, 1989.
100. Pun WK, Chow SP, So YC, et al: Unstable phalangeal fractures: treatment by A.O. screw and plate fixation. *J Hand Surg [Am]* 16:113–117, 1991.
101. Rajesh G, Ip WY, Chow SP, et al: Dynamic treatment for proximal phalangeal fracture of the hand. *J Orthop Surg (Hong Kong)* 15:211–215, 2007.
102. Reilly KE, Linz JC, Stern PJ, et al: Osteomyelitis of the tubular bones of the hand. *J Hand Surg [Am]* 22:644–649, 1997.
103. Rettig AC, Ryan R, Shelbourne KD, et al: Metacarpal fractures in the athlete. *Am J Sports Med* 17:567–572, 1989.
104. Reyes FA, Latta LL: Conservative management of difficult phalangeal fractures. *Clin Orthop Relat Res* 214:23–30, 1987.
105. Schadel-Hopfner M, Wild M, Windolf J, et al: Antegrade intramedullary splinting or percutaneous retrograde crossed pinning for displaced neck fractures of the fifth metacarpal? *Arch Orthop Trauma Surg* 127:435–440, 2007.
106. Schneider LH: Tenolysis and capsulectomy after hand fractures. *Clin Orthop Relat Res* 327:72–78, 1996.
107. Schuind F, Cooney WP, 3rd, Burny F, et al: Small external fixation devices for the hand and wrist. *Clin Orthop Relat Res* 293:77–82, 1993.

108. Shewring DJ, Thomas RH: Collateral ligament avulsion fractures from the heads of the metacarpals of the fingers. *J Hand Surg [Br]* 31:537–541, 2006.
109. Slade JF, Baxamusa TH, Wolfe SW: External fixation of proximal interphalangeal joint fracture-dislocations. *Atlas Hand Clin* 5:1–29, 2000.
110. Smith FL, Rider DL: A study of the healing of one hundred consecutive phalangeal fractures. *J Bone Joint Surg Am* 17:91–109, 1935.
111. Stahl S, Schwartz O: Complications of K-wire fixation of fractures and dislocations in the hand and wrist. *Arch Orthop Trauma Surg* 121:527–530, 2001.
112. Stanton JS, Dias JJ, Burke FD: Fractures of the tubular bones of the hand. *J Hand Surg Eur Vol* 32:626–636, 2007.
113. Statius Muller MG, Poolman RW, van Hoogstraten MJ, et al: Immediate mobilization gives good results in boxer's fractures with volar angulation up to 70 degrees: a prospective randomized trial comparing immediate mobilization with cast immobilization. *Arch Orthop Trauma Surg* 123:534–537, 2003.
114. Stern PJ: Management of fractures of the hand over the last 25 years. *J Hand Surg [Am]* 25:817–823, 2000.
115. Strickland JW, Steichen JB, Kleinman WB, et al: Phalangeal fractures: factors influencing digital performance. *Orthop Rev* 11:39–50, 1982.
116. Swanson AB: Fractures involving the digits of the hand. *Orthop Clin North Am* 1:261–274, 1970.
117. Swanson TV, Szabo RM, Anderson DD: Open hand fractures: prognosis and classification. *J Hand Surg [Am]* 16:101–107, 1991.
118. Tavassoli J, Ruland RT, Hogan CJ, et al: Three cast techniques for the treatment of extra-articular metacarpal fractures: comparison of short-term outcomes and final fracture alignments. *J Bone Joint Surg Am* 87:2196–2201, 2005.
119. Timmenga EJ, Blokhuis TJ, Maas M, et al: Long-term evaluation of Bennett's fracture: a comparison between open and closed reduction. *J Hand Surg [Br]* 19:373–377, 1994.
120. Trumble T, Gilbert M: In situ osteotomy for extra-articular malunion of the proximal phalanx. *J Hand Surg [Am]* 23:821–826, 1998.
121. Vahey JW, Wegner DA, Hastings H, 3rd: Effect of proximal phalangeal fracture deformity on extensor tendon function. *J Hand Surg [Am]* 23:673–681, 1998.
122. van der Lei B, de Jonge J, Robinson PH, et al: Correction osteotomies of phalanges and metacarpals for rotational and angular malunion: a long-term follow-up and a review of the literature. *J Trauma* 35:902–908, 1993.
123. van Niekerk JL, Ouwens R: Fractures of the base of the first metacarpal bone: results of surgical treatment. *Injury* 20:359–362, 1989.
124. Viegas SF, Ferren EL, Self J, et al: Comparative mechanical properties of various Kirschner wire configurations in transverse and oblique phalangeal fractures. *J Hand Surg [Am]* 13:246–253, 1988.
125. Wagner CJ: Method of treatment of Bennett's fracture dislocation. *Am J Surg* 80:230–231, 1950.
126. Waris E, Ashammakhi N, Happonen H, et al: Bioabsorbable miniplating versus metallic fixation for metacarpal fractures. *Clin Orthop Relat Res* 410:310–319, 2003.
127. Waters PM, Benson LS: Dislocation of the distal phalanx epiphysis in toddlers. *J Hand Surg [Am]* 18:581–585, 1993.
128. Weckesser EC: Rotational osteotomy of the metacarpal for overlapping fingers. *J Bone Joint Surg Am* 47:751–756, 1965.
129. Weiss AP, Hastings H, 2nd: Distal unicondylar fractures of the proximal phalanx. *J Hand Surg [Am]* 18:594–599, 1993.
130. Westbrook AP, Davis TR, Armstrong D, et al: The clinical significance of malunion of fractures of the neck and shaft of the little finger metacarpal. *J Hand Surg Eur Vol* 33(6):732–739, 2008.
131. Williams RM, Kiefhaber TR, Sommerkamp TG, et al: Treatment of unstable dorsal proximal interphalangeal fracture/dislocations using a hemi-hamate autograft. *J Hand Surg [Am]* 28:856–865, 2003.
132. Wilson RL, Carter MS: Management of hand fractures. In Hunter JM, Schneider LH, Mackin EJ, et al, editors: *Rehabilitation of the hand*, St. Louis, 1978, Mosby, pp 180–194.
133. Wolfe SW, Katz LD: Articular impaction fractures of the phalanges. *J Hand Surg [Am]* 20:327–333, 1995.
134. Wong TC, Ip FK, Yeung SH: Comparison between percutaneous transverse fixation and intramedullary K-wires in treating closed fractures of the metacarpal neck of the little finger. *J Hand Surg [Br]* 31:61–65, 2006.
135. Zimmerman NB, Weiland AJ: Ninety-ninety intraosseous wiring for internal fixation of the digital skeleton. *Orthopedics* 12:99–103, discussion 103–104, 1989.

8

Dislocations and Ligament Injuries of the Digits

Greg Merrell and Hill Hastings

This chapter will cover the following injuries in order, divided into subsections based on the joint involved:

Proximal interphalangeal joint
- Proximal interphalangeal (PIP) joint dislocations (dorsal, lateral, and volar)
- PIP joint fracture-dislocations, acute
- Chronic PIP joint injuries
- Flexion contractures of the PIP joint

Distal interphalangeal joint
- Finger distal interphalangeal (DIP) joint injuries

Thumb interphalangeal joint
- Thumb interphalangeal (IP) joint injuries

Metacarpophalangeal joint of the fingers
- Metacarpophalangeal (MP) joint dislocations of the fingers
- MP collateral ligament injuries of the finger
- Locked MP joints

Metacarpophalangeal joint of the thumb
- Thumb ulnar collateral ligament (UCL) injury, acute
- Thumb UCL injury, chronic
- Thumb radial collateral ligament (RCL) injury
- Thumb MP joint dislocations

Carpometacarpal joint
- Carpometacarpal (CMC) joint dislocations
- Thumb CMC joint dislocation

PROXIMAL INTERPHALANGEAL JOINT

PERTINENT ANATOMY

The PIP joint is a hinge joint with stability derived from the bony articular contours, collateral ligaments, and volar plate. Slight asymmetry of the condyles imparts up to 9 degrees of supination through the complete arc of PIP motion.[78]

The collateral ligaments arise from a concave fossa on the lateral aspect of each condyle and pass obliquely and volarly to their insertions. The collateral ligaments have proper and volar accessory components. They are anatomically confluent but distinguished by their points of insertion. The proper collateral ligament, which has both a dorsal and a volar component, inserts on the volar third of the base of the middle phalanx, whereas the accessory collateral inserts on the volar plate.[78] The collateral ligaments are the primary restraints to radial and ulnar joint deviation.

The volar plate forms the floor of the joint and is suspended laterally by the collateral ligaments. The thick fibrocartilaginous distal portion inserts across the volar base of the middle phalanx. This insertion is only densely attached at its lateral margins, where it is confluent with the insertion of the collateral ligament. It is thinner centrally and blends with the volar periosteum of the middle phalanx.[12] Laterally, the proximal part of the volar plate thickens to form a pair of checkrein ligaments. The checkrein ligaments originate from the periosteum of the proximal phalanx, just inside the walls of the second annular (A2) pulley at its distal margin, and are confluent with the proximal origins of the first cruciate (C1) pulley.[12] The resulting paired, cordlike structures prevent hyperextension of the joint while permitting full flexion, thereby providing remarkable stability with minimum bulk. The volar plate is a secondary stabilizer against lateral deviation, especially with the PIP joint extended, but only when the collateral ligaments are incompetent or torn.[71]

The key to PIP joint stability is this boxlike complex, secured laterally by the collateral ligaments and volarly by the volar plate and volar base of the middle phalanx (Figure 8.1). This configuration produces a three-dimensional construct that strongly resists PIP displacement. For displacement of the middle phalanx to occur, the ligament-box complex must be disrupted in at least two planes.

Typically, collateral ligaments fail proximally while the volar plate avulses distally, although variable failure patterns have been reported.

Preoperative Evaluation of the Injured PIP Joint

PIP joint injury is the most common ligamentous injury in the hand. The spectrum of injury can vary from a simple sprain and jammed finger to very challenging fracture-dislocations. Radiographic and clinical evaluation will help differentiate the following differential diagnoses: collateral ligament sprain, volar plate avulsion, central slip disruption, dislocations (which may include disruptions of collateral ligaments or the volar plate, or both), fracture-dislocations, and impacted pilon-type injuries.

Radiographic Evaluation

Dedicated posteroanterior and true lateral radiographs of the digit or magnified views of the joint itself must be obtained to determine if recent or preexisting articular involvement is present. Radiographs of the hand alone are not adequate. A subtle fracture or subluxation may otherwise be missed. Keep in mind that the joint may have spontaneously reduced, masking the pathologic situation of a dislocation. Look for the "V" sign dorsally to identify incongruent or dorsally subluxated joints (Figure 8.2). Pronated and supinated oblique radiographs can

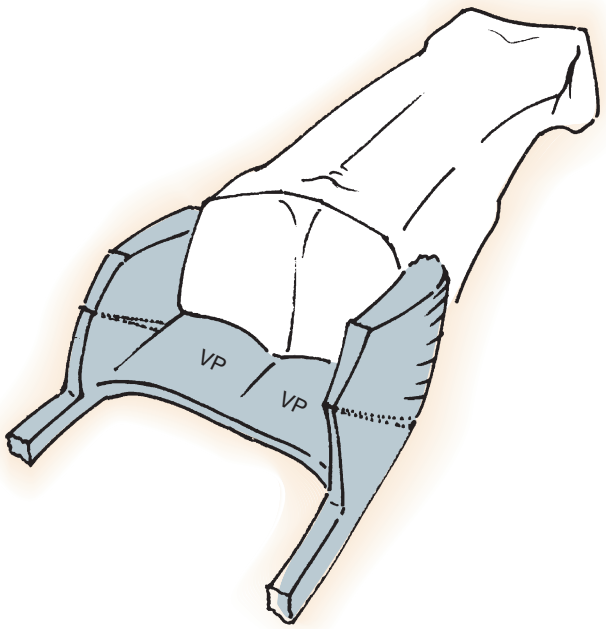

FIGURE 8.1 Three-dimensional ligament-box complex provides strength with minimal bulk. At least two sides of this box must be disrupted for displacement of the joint to occur. *VP,* Volar plate.

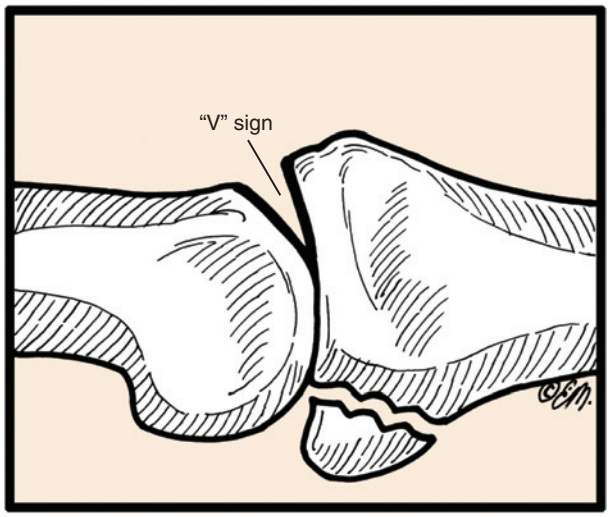

FIGURE 8.2 Subtle proximal interphalangeal joint subluxation is recognized by dorsal joint widening known as the "V" sign. (Copyright © Elizabeth Martin.)

also be helpful in evaluating fractures at the base of the middle phalanx.

Clinical Evaluation

The ultimate determinant of treatment is whether the joint remains concentrically reduced with active motion. This requires adequate pain control from a digital block. Functional stability may be determined by the following two-phase test, after a nerve block.[30]

1. *Active stability.* The patient voluntarily moves the digit through its normal range of motion. Completion of a full or nearly full range indicates that, despite ligament disruption, adequate joint stability remains. Redisplacement with motion, however, indicates significant ligament disruption (i.e., at least two sides of the "box"). The position at which displacement occurs is a clue to the specific site of ligament injury, as well as the optimum position for joint immobilization.
2. *Passive stability.* A final assessment of stability is determined by passive manipulation. Examine the uninjured side first to establish the baseline level of ligamentous laxity in the patient. Gentle lateral stress is applied to each collateral ligament in full extension and 30 degrees of flexion. The flexion examination tests primarily the collateral ligaments. The examination in extension gives an indication of the secondary stability afforded by the bony anatomy, accessory collateral ligaments, and volar plate. Dorsovolar stability is tested by shearing the joint surfaces dorsally and volarly.

Collateral ligament injury with the corresponding stability is classified into three grades:

Grade I: Pain, but no laxity
Grade II: Laxity, but a firm end point and stable arc of motion
Grade III: Gross instability, but no firm end point

Dislocations of the Proximal Interphalangeal Joint

The PIP joint may dislocate in one of three directions: dorsal, lateral, or volar. The terms refer to the position of the middle phalanx with respect to the proximal phalanx.

Acute Dorsal Proximal Interphalangeal Dislocations

The mechanism of injury in dorsal dislocations is usually PIP joint hyperextension combined with some degree of longitudinal compression, most frequently exemplified by a ball striking a fingertip. The greater the longitudinal force, the more likely it is that the volar lip of the middle phalanx will be sheared off or impacted, producing a fracture-dislocation. In a pure dislocation, the collateral ligaments are torn, but after reduction they remain functionally intact whereas the volar plate is sheared off the base of the middle phalanx. A small avulsion fracture of the base of the middle phalanx is common with dorsal dislocations (44% in one series of 57 hyperextension dislocations)[64] and does not change the diagnosis or treatment.

A simple dorsal dislocation presents in one of two ways: A type I injury is a hyperextension deformity with joint surfaces still touching, and a type II injury is in a bayonet position. Type III injuries are fracture-dislocations and are discussed later. The hyperextension deformity typically reduces very easily with a small amount of force directed volarly and in flexion after a digital block. In a bayonet dislocation, after digital block, extension stress should be applied to the middle phalanx and the examiner's thumb can be used to hook the base of the middle phalanx back over the head of the metacarpal. If pure longitudinal traction is used, it can trap the condyles by the collateral ligaments and pull the volar plate into the joint, turning a reducible dislocation into an irreducible dislocation. The stability examination, as described previously, is performed after reduction. If the joint is stable through a full range of motion, immediate motion should be encouraged with protection via buddy taping. Stiffness from prolonged immobilization is the most common complication from treating these injuries.

If the joint is unstable, it is placed in an extension block splint at 10 degrees more flexion than the point at which it begins to subluxate. Each week the splint is extended 10 degrees. The goal is to have patients out of splints by 3 weeks or sooner. A cadaveric study suggests that extension block splinting in slight flexion reliably places the avulsed volar plate in a nearly anatomic position to facilitate healing.[80] If the digit requires flexion past 30 degrees to maintain congruency and stability, operative repair should be considered. Patients should be counseled to expect occasional pain, swelling, and stiffness for at least 6 months because recovery is typically prolonged.

Open Reduction. On rare occasions, the volar plate ruptures proximally and can become interposed between the head of the proximal phalanx and the base of the middle phalanx. This can result in an irreducible dislocation requiring an open reduction.[37] Open reduction can sometimes be performed through a limited dorsal incision. A dorsal incision of 5 to 10 mm can be made between the central slip and the lateral band. The capsule can be incised with just enough space to pass a Freer elevator. The Freer elevator can be used to push the volar plate out of the joint and gently lever the joint into a reduced position. If this works, it can speed recovery and minimize the risk of flexor adhesions. If this fails, the injury is best approached through a Bruner extensile volar incision, with reflection of the A3 pulley and flexor tendons and removal of the volar plate from the joint. If possible, the volar plate is repaired to provide immediate improvement in stability and prevent reentrapment. Positioning in the immediate postoperative period is dictated by the degree of stability identified intraoperatively.

Lateral Proximal Interphalangeal Dislocations

The critical anatomic lesions in a lateral dislocation of the PIP joint are rupture of one collateral ligament and at least partial avulsion of the volar plate from the middle phalanx. More than 20 degrees of deformity on gentle static lateral testing in extension indicates complete collateral ligament disruption and injury to at least one other secondary stabilizer.[71] This is a major disruption of the four-sided ligamentous box, but with few exceptions the ligaments heal when the joint is reduced and early controlled motion begun.[111] The joint should be protected with buddy tapes to an adjacent uninjured digit. Irreducible lateral dislocations typically demonstrate interposition of the lateral band on operative exploration.

Repair of the ruptured collateral ligaments has been frequently reported after PIP dislocations in general and lateral dislocations in particular. Most of these series involve athletes, and it has been suggested that surgery will enable a faster return to sport. Kato and colleagues reported on 11 primary repairs of acute PIP joint collateral ligament tears in athletes and manual laborers.[68] Suture anchors were used in the repair, active motion was initiated at 2 to 3 weeks, and unlimited activities were allowed at 6 weeks. Nevertheless, because the usual sequela of ligament injury of the PIP joint is stiffness and not instability, the surgical trauma of ligament repair may have an adverse effect on the ultimate range of motion after lateral dislocations.

Volar Proximal Interphalangeal Dislocations

Volar dislocations of the PIP joint are rare injuries. The base of the middle phalanx may dislocate volarly without rotation (volar dislocation) or may rotate on one intact collateral ligament so that the opposite side subluxates in a volar direction (volar rotatory subluxation). Appreciating the difference between these two related injuries and identifying them clinically can help ensure appropriate management.

A typical mechanism of injury involves catching a digit in a clothes dryer that has not stopped spinning.[12] As the middle phalanx displaces volarly, the proximal phalangeal condyle ruptures through the extensor mechanism, usually between the central slip and the ipsilateral lateral band. The lateral band may entrap the condyle, creating a situation in which traction and joint extension further tighten the noose and block reduction.

When a volar dislocation occurs without a rotatory component, the central slip is ruptured. If the dislocation is irreducible, there is a high likelihood of an interposed structure such as the central slip, a collateral ligament, or a fracture fragment. Puckering of surrounding skin is suggestive of a joint that still has soft tissue interposition. If the joint reduces easily, one must still be wary of a central slip disruption, and the ability to actively extend the digit fully must be confirmed. If there is any doubt about the integrity of the extensor mechanism, immobilization in PIP extension is mandatory.

Volar fracture-dislocations are quite rare. Injuries with a large dorsal fragment should be treated with open reduction and internal fixation (ORIF) via minifragment lag screw fixation to allow early motion. Open reduction will permit inspection or repair of the central slip insertion. Tekkis and coworkers reported two such cases with excellent clinical outcomes.[116] Care must be taken to avoid screw extension into the flexor sheath. Dorsal screw head prominence may require later screw removal. Another option is to secure the fragment with a wire loop.[126] Volar fracture-dislocations with smaller fracture fragments but an intact central slip and concentric joint can be splinted in extension for 1 to 3 weeks followed by active range-of-motion exercises.

The management of chronic volar dislocations of the PIP joint is complex and requires the simultaneous surgical correction of an incongruous and contracted joint as well as an incompetent extensor mechanism.[94] There may be degeneration of the articular cartilage; if so, the prospect of restoring normal joint function is greatly diminished. Therefore, it is important to recognize a volar PIP joint dislocation at the time of injury and adequately treat the disrupted extensor mechanism. Peimer and colleagues also recommended repair of the ruptured collateral ligament.[94] In this relatively large series of 15 patients with volar PIP dislocation, inspection at the time of surgery revealed disruption of the extensor mechanism, the volar plate, and one collateral ligament in all patients. In each, the extensor mechanism and collateral ligament were repaired, the joint was pinned in extension, and motion with therapy was started at 4 weeks after removal of the Kirschner wire. Although all patients had painless, stable PIP motion, no patient achieved preinjury PIP motion.

❖ AUTHORS' PREFERRED METHOD OF TREATMENT OF VOLAR ROTATORY DISLOCATION

Technique of Closed Treatment of Volar Rotatory Proximal Interphalangeal Dislocation. The management of volar rotatory dislocations of the PIP joint is controversial. Volar rotatory dislocation has been described as irreducible or trapped by

many authors and one that necessitates open reduction.[43,63,97] Open reduction is advocated not only to reduce the interposed extensor mechanism but also to repair the rent in this mechanism. Others have reported that it is necessary to repair the torn ligaments and volar plate as well.[83] However, I believe that open reduction is necessary only if closed reduction fails.

The reduction can be done with a digital anesthetic block. The majority of volar rotatory dislocations can be reduced without surgery by applying gentle traction while holding both of the MP and PIP joints flexed. This maneuver relaxes the volarly displaced lateral band so that with a gentle rotatory motion the intraarticular portion can be disengaged from behind the condyle and reduction accomplished. If necessary, relaxation of the extensor mechanism can be achieved by moderate wrist extension. Once the joint is reduced, active motion is tested. When the joint is reduced, the ligaments are usually restored to their anatomic alignment. Postreduction radiographs should confirm congruous reduction. After reduction of a volar rotatory dislocation, full active extension is usually possible because the contralateral lateral band and at least a portion of the central slip usually remain intact. If the patient cannot actively extend to neutral, the PIP joint should be immobilized in full extension for 6 weeks, just as one would treat a closed boutonnière deformity. The only indication for open reduction, therefore, would be failure to obtain a completely congruous reduction, confirmed by radiographs, and presumably due to the presence of a ligament, capsule, or extensor mechanism trapped within the joint.

In volar dislocations without a rotatory component, the reduction is easily accomplished under a digital block. Typically there is a central slip injury. If extension cannot be maintained, the patient is similarly treated in full PIP extension for 6 weeks, allowing and encouraging active DIP flexion.

Technique of Open Reduction of Volar Rotatory Proximal Interphalangeal Dislocation. Open reduction is approached through a dorsolateral incision on the side of the ligament disruption. The lateral band is atraumatically extricated from the joint and reduction is easily accomplished. With the patient under local or wrist block anesthesia, it is possible to test active extension. If the lateral band is torn but not severely traumatized, it may be carefully repaired. Should the band be ragged, it is best to excise it because the normal contralateral lateral band is sufficient to provide intrinsic extensor power. If full extension and a stable joint are demonstrable on examination, active range of motion can be initiated. Repair of the extensor mechanism would require a zone 3 tendon repair protocol (see Chapter 5). I avoid cross-pinning of the joint if the soft tissue repair/reduction provides adequate stability.

Expected Outcomes. The literature contains only a few case reports and results vary substantially, but an 80-degree arc of motion with a 10-degree extensor lag would be a reasonable expectation.[94]

Dorsal Dislocations and Fracture-Dislocations of the Proximal Interphalangeal Joint

There are two fundamental parameters that guide treatment of these injuries: stability and joint congruity. These parameters are the basis for the treatment algorithm seen in Figure 8.3.

Stable fracture-dislocations have a volar fragment that represents less than 30% of the volar articular surface and a

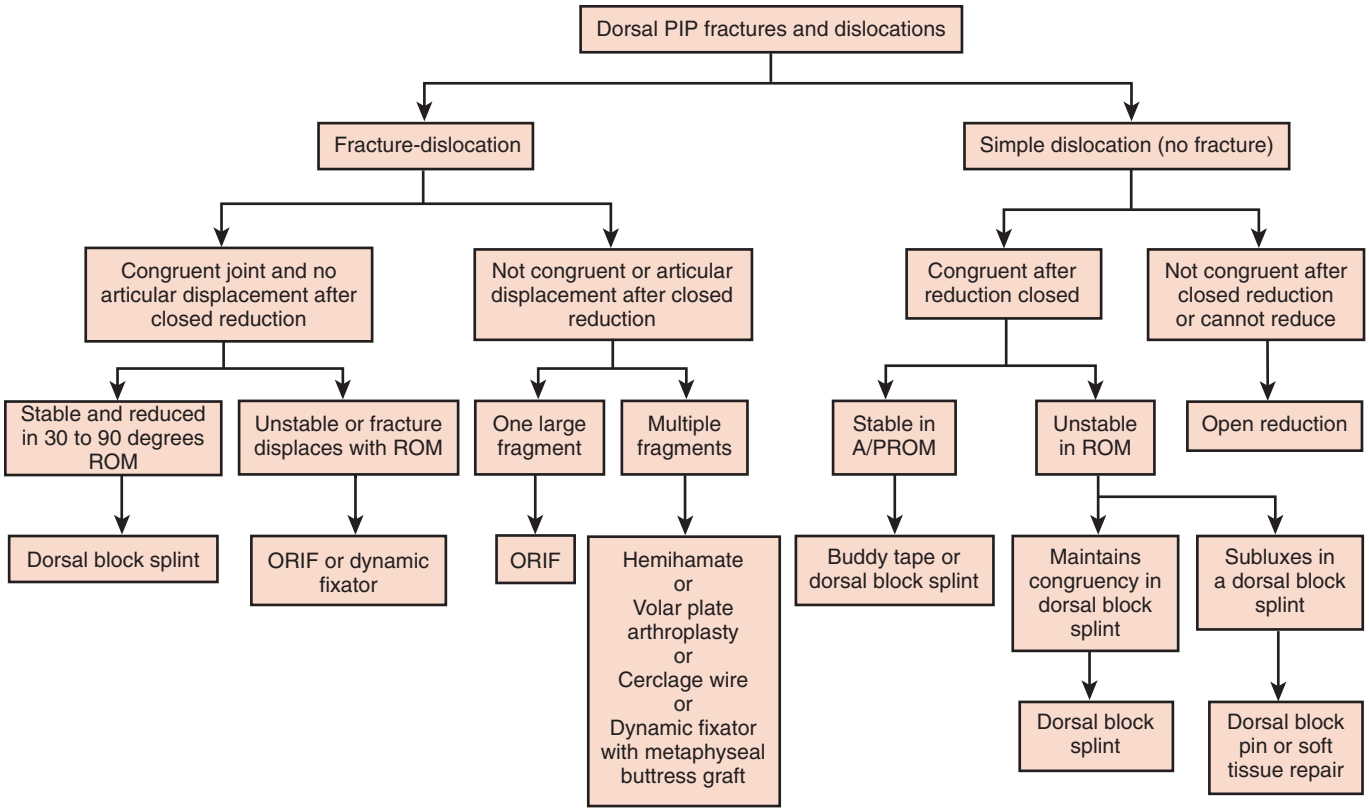

FIGURE 8.3 Treatment algorithm for proximal interphalangeal (PIP) joint fractures and dislocations. *A/PROM*, Active/passive range of motion; *ORIF*, open reduction and internal fixation; *ROM*, range of motion.

concentric joint after reduction. In this case, the disruption occurs through the base of the phalanx rather than at the insertion of the volar plate. Sufficient volar bone remains to render the joint stable. The collateral ligaments, torn or not, do not influence the stability of the reduction other than by contributing to lateral stability on stress. These usually behave like a simple dorsal dislocation. Radiographs tend to underestimate the percentage of volar fracture involvement, as frequently the fracture will involve a greater amount of one middle phalanx articular facet than the other. Stable fracture-dislocations can generally be treated conservatively with 3 weeks of dorsal block splinting, allowing range-of-motion exercises while the splint is worn. It is important to check both active and passive motion (described in the previous examination section) because the volar fracture fragment may become trapped within the flexor sheath and inhibit motion.[34] Fluoroscopy after a digital block can help determine how much extension is possible while fracture and joint reduction is maintained. Many patients will require formal hand therapy to regain full motion and function.

Tenuously stable fracture-dislocations involve 30 to 50% of the volar buttress and reduce with less than 30 degrees of flexion. In cases with less than 40% of volar articular involvement, the joint is usually stable in all positions. With 40 to 60% volar articular involvement, progressively greater flexion is required to render the joint stable.[49]

Unstable fracture-dislocations demonstrate greater than 60% involvement of the volar articular surface. Beyond 60% involvement, joints tend to be unstable in all positions or require more than 60 degrees of flexion to obtain a congruent reduction.[49] Accurate closed reduction is difficult to achieve and even more difficult to maintain. The main element contributing to instability is the loss of the buttressing effect of the volar margin of the middle phalanx that partially cups the proximal phalangeal condyles (Figure 8.4).

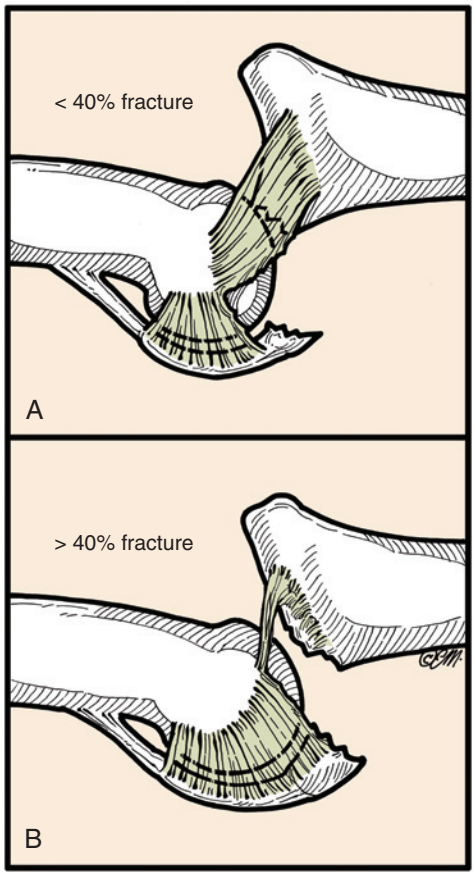

FIGURE 8.4 **A,** Fracture-dislocation with less than 40% of proximal articular surface allows some collateral ligament attachment to middle phalanx. **B,** A fracture-dislocation with more than 40% involvement of the middle phalangeal articular surface ensures that the collaterals are attached only to the fragment and not to the phalanx. The injury is unstable without operative fixation. (Copyright © Elizabeth Martin.)

Pilon Fracture

When a high-energy axial compressive force is delivered to a fully extended digit, a pilon fracture of the PIP joint may occur. There is often widening of the base of the middle phalanx as dorsal and volar fragments are driven apart and more central cartilage surfaces are impacted into the cancellous bone.

Depression of the concave articular fossae of the middle phalangeal base mimics certain tibial plateau fractures. Angular deformities are common, especially if only one facet is involved. These fractures are subtle on plain radiographs of the involved digit, and the clinician should maintain a low threshold for obtaining a CT scan of the PIP joint to better visualize the articular depression. Operative reduction is usually necessary, however, and excellent results are difficult to achieve[123] (Figure 8.5, *A* and *B*).

Treatment of Unstable Proximal Interphalangeal Fracture-Dislocation and Pilon Injuries

Unstable PIP fracture-dislocations and PIP pilon fractures are some of the most challenging injuries treated by hand surgeons. Patients should be counseled about the severity of the injury and the possibility of residual stiffness and arthritis because they often consider a "broken finger" to be a relatively minor injury from which they will recover completely. There are a variety of treatments described, because no single technique has demonstrated clear superiority. The techniques of extension block splinting or pinning, ORIF, dynamic traction, hemihamate autogenous grafting, cerclage wiring, hemiarthroplasty,[50] and volar plate arthroplasty can all be difficult and may be appropriate for different types of cases. Detailed step-by-step guidelines follow for each of these techniques.

Extension Block Splinting. Closed treatment is recommended if there is no articular incongruity, there is some retained lateral stability, and the joint is stable with no more than a 30-degree extension block. These conditions are more important than the size of the fracture fragment, although the fragment typically represents less than 40% of the articular surface. McElfresh and colleagues reported good results with active flexion using a dorsal splint to block extension beyond the point of potential redisplacement.[84] The PIP joint is brought into extension incrementally by modifying the splint 10 to 15 degrees per week. However, in their series of 17 fingers, only four patients had a fragment size greater than 30% of the articular surface. Hamer and Quinton prospectively followed 27 patients with fracture-dislocations involving an average of 50% of the articular surface treated by extension block splinting for less than 2 years.[44] They reported a mean of 87 degrees of active PIP motion and good



FIGURE 8.5 **A** and **B,** Unicondylar depression fracture of the proximal interphalangeal joint. **C** and **D,** The depressed phalangeal "plateau" was elevated with a Kleinert/Kutz elevator, supported by bone graft, and fixed with a Kirschner wire tension band construct. (Courtesy Scott W. Wolfe, MD.)

results in 70% of patients. If more than 30 degrees of flexion is required to achieve stability, the risk for late flexion contracture is dramatically increased; consequently, other treatment options should be considered. Short, small, or very swollen fingers make the fixation of the extension block splint more difficult and may increase the risk of subluxation. Serial radiographs must be obtained to document the ongoing efficacy of this technique.

Extension Block Pinning. This technique is advocated in rare cases when the injury might be amenable to closed treatment but either the digit is too short and swollen to maintain a splint or there are questions with splint compliance. The technique involves placement of a Kirschner wire into the head of the proximal phalanx at an angle that mechanically blocks extension of the PIP joint and prevents dorsal subluxation of the middle phalanx.[118] The pin must be placed obliquely between the central tendon and lateral bands to allow gentle active motion. Even with a pin in place the joint should be splinted in a single-digit or hand-based splint to decrease the risk for pin migration, loosening, or pin tract infection. Reports of this technique include only a small number of cases, and its clinical efficacy must be substantiated through further study. A modification of this technique has been reported using intramedullary fixation,[120] and the technique has been combined with percutaneous volar pin fixation of the middle phalanx.[119]

Dynamic Skeletal Traction. This technique refers to the use of ligamentotaxis to achieve joint and fracture reduction by the application of Kirschner wire external fixators or various commercial fixators. We use dynamic skeletal traction most frequently in pilon injuries and in tenuously unstable injuries with several small fragments constituting 30% to 50% of the joint surface. When ligamentotaxis is insufficient to achieve an adequate reduction (seen commonly with pilon injuries with depressed fragments), it can be combined with either an open reduction or a percutaneous reduction of the joint surface. The fixator can also be combined with volar plate arthroplasty, ORIF, or hemihamate reconstruction to allow earlier active motion with those reconstructions.[75] A fixator can help maintain joint reduction while allowing motion and can neutralize joint reaction forces to minimize the potential for settling of articular fragments that may not be amenable to fixation. A relative contraindication is serious injury to adjacent digits. The fixators can be somewhat cumbersome to wear and can interfere with the care and mobilization of adjacent swollen digits.

Open Reduction With Internal Fixation. ORIF has many advocates and is most likely to be successful in acute cases with a single, large volar fragment. Anatomic restoration of the articular surface is technically difficult, especially because the remaining articular contour may be disrupted secondary to impaction of subchondral cancellous bone. Even excellent anatomic reduction can still lead to problems of flexion contracture, decreased arc of motion, and cold intolerance.[5] The joint can be approached from either a dorsal or a volar direction. The dorsal technique is described well by Lee and colleagues.[77] The volar technique is described in detail in the following. Results vary widely in reported series. It is advisable to caution patients that there will be decreased flexion, an extensor lag, and possibilities of persistent pain, swelling, and cold intolerance.

Cerclage Wiring. For pilon or comminuted fractures with fragments too small for individual screw fixation, one may

consider elevation and grafting of depressed fragments followed by cerclage wiring to prevent widening of the articular surface (Figure 8.6). This technique is most appropriate for the rare case where there is minimal joint subluxation but significant comminution of the joint surface. In a series of 12 patients, Weiss demonstrated an average range of motion of 89 degrees with an 8-degree extensor lag.[121] The technique is described in detail in the following text.

Volar Plate Arthroplasty. Multiple authors have reported on the technique and efficacy of using the distal aspect of the fibrocartilaginous volar plate to resurface the comminuted volar articular surface of the middle phalanx, especially when other techniques are not feasible.[26,81] There is little consensus on the percentage of volar articular involvement that is amenable to volar plate arthroplasty. As a variation on the theme of volar plate arthroplasty, Wiley proposed débridement of the fragments and insertion of a slip of flexor superficialis tendon into the defect to reduce the displacement by active tendon tone.[122] The irregularity of the articular surface was not specifically corrected in his series. Volar plate arthroplasty is most likely to succeed in cases with less than 40% volar articular involvement or when there is minimal impaction of the volar rim, in which case thickness of the interposed volar plate may correct for the buttress effect that has been lost. It is not recommended when volar articular involvement exceeds 40% of the joint surface. A full description of the technique follows.

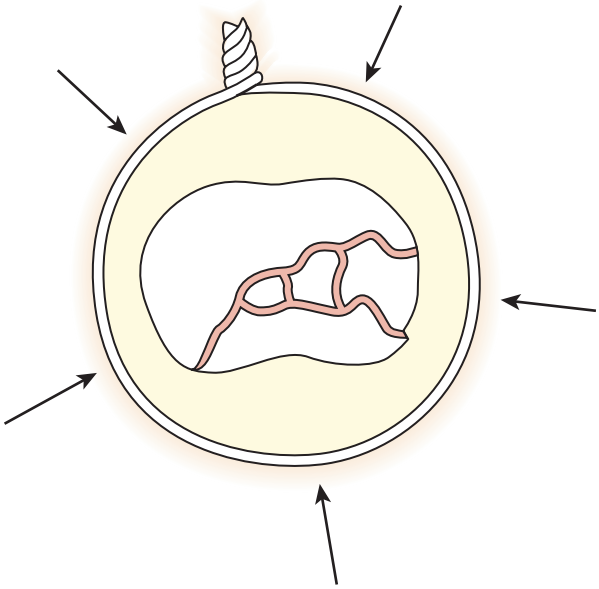

FIGURE 8.6 After shotgun exposure of joint, fragments are managed with elevation and bone graft as needed. Cerclage wire is passed around proximal end of phalanx, preventing typical dorsal/volar expansion in pilon-type injuries and holding small fragments that otherwise may not be amenable to interfragmentary fixation. (Technique courtesy of Dr. A.P.C. Weiss. From Weiss AP: Cerclage fixation for fracture dislocation of the PIP joint, *Clin Orthop Relat Res* (327):21–28, 1996.)

Hemihamate Autogenous Grafting. Using a novel technique introduced by Hastings in 1999,[48] Williams and associates reported on 13 consecutive patients treated with a hemihamate autograft. The autograft is harvested from the dorsal distal aspect of the hamate centered at the fourth and fifth CMC articulations, spanning approximately half of each in both the radioulnar and dorsovolar planes. The graft is rotated 180 degrees in two planes, keyed into the prepared bed at the volar base of the middle phalanx, and stabilized with two or three minifragment lag screws. The authors expressed cautious optimism as to the longevity of the procedure. Calfee and associates[15] reported 4.5-year follow-up results on 22 patients and found little functional impairment. Disabilities of the Arm, Shoulder, and Hand (DASH) scores and visual analog scale (VAS) measurements of pain and function were slightly inferior for cases reconstructed for chronic deformity compared with acute cases. The authors concluded that the hemihamate graft is a viable alternative to volar plate arthroplasty for PIP volar fracture-dislocations with extensive articular comminution, and demonstrates a decreased risk of resubluxation. The technique is described in detail in the following.

❖ AUTHORS' PREFERRED METHODS OF TREATMENT

For less severe fracture-dislocations, we have found extension block splinting to be quite effective for cases where there is a congruent joint following reduction and the articular involvement is less than 40% (Figure 8.7). Care must be taken to ensure that dorsal subluxation (loss of reduction) does not occur during the course of treatment with the splint in place. If the PIP joint injury is amenable to extension block splinting but

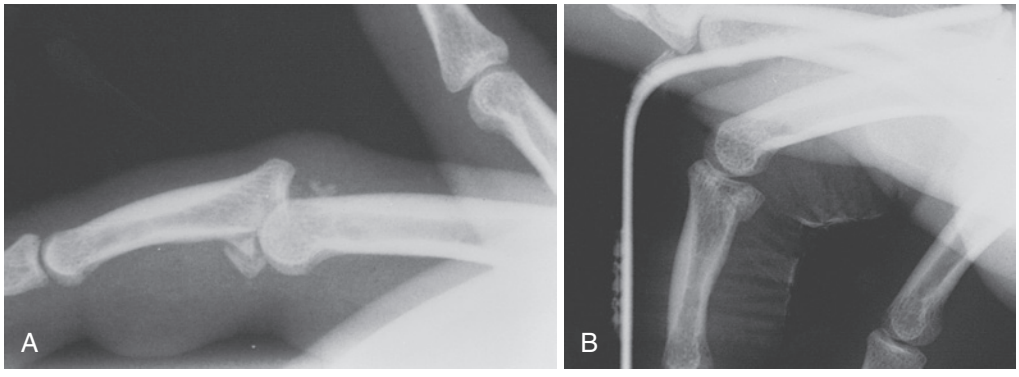

FIGURE 8.7 **A,** Type III fracture-dislocation of proximal interphalangeal (PIP) joint in which approximately 40% of volar articular surface is displaced with fracture fragment. **B,** Fracture-dislocations with 40% or less of articular surface involved may be successfully treated with dorsal extension block splinting. The patient is allowed to actively flex the PIP joint, which is progressively extended over approximately 4 weeks. The key to this mode of treatment is concentric reduction of the PIP joint.

the digit is too short, stocky, or swollen for such treatment, I will occasionally use an extension block pin. In general, if a fracture is unstable enough to warrant pinning over a simple splint, the fracture fragment is likely large enough to warrant operative fixation.

Several satisfactory options exist for the treatment of unstable PIP joint fracture-dislocations, but none is perfect. The authors are not wedded to a particular modality of treatment and allow the injury characteristics to guide the approach (see algorithm in Figure 8.3).

The hand surgeon will often see a PIP fracture-dislocation after it has been initially treated elsewhere, and the true nature of this complicated injury may not have been appreciated or conveyed to the patient. The patient must understand from the outset that while normal PIP joint function is possible, it is highly unlikely. Patients must also be told that the best functional result will only be possible with extensive and dedicated compliance with postoperative hand therapy. Overall results diminish as the time from injury to treatment increases, even with a delay beyond 2 weeks, but especially beyond 6 weeks.[22,42]

Dynamic Skeletal Traction. Dynamic skeletal traction is useful in select cases, especially with increased comminution and fracture lines extending dorsally (pilon) or distally through the base of the middle phalanx. The fracture is viewed under traction using fluoroscopy to get a sense of the amount of reduction possible and to consider whether the fracture may be more amenable to a different technique (Figure 8.8). Although many fixators have been described, in the authors' opinion the easiest, least expensive, and most effective is a fixator constructed in the operating room using three Kirschner wires and dental rubber bands. The fixator requires 9-inch Kirschner wires (check ahead of time because many centers stock only short Kirschner wires). The fixator is assembled by placing two Kirschner wires perpendicular to the digit along the midaxial plane through the proximal and middle phalangeal condyles (Figure 8.9). It is critical for the initial wire to be placed in the center of rotation of the proximal phalangeal condyles. The proximal phalanx wire is bent distally and fashioned into hooks. The second wire is inserted through the center of rotation of the middle phalangeal head, and this condylar wire is also bent

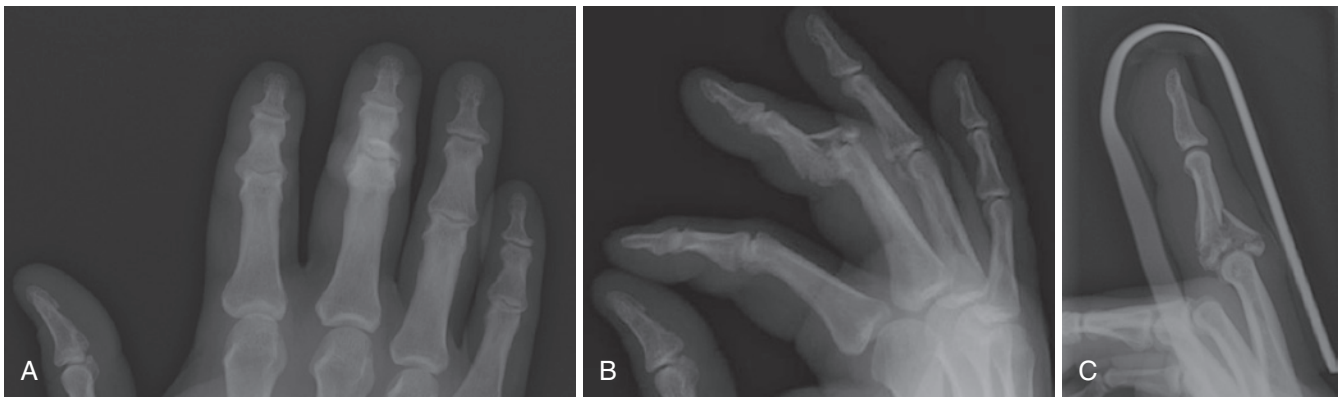

FIGURE 8.8 **A,** Anteroposterior radiograph of pilon proximal interphalangeal joint injury with distal extension, shortening, and subluxation. **B,** Lateral radiograph of same injury before traction. **C,** Lateral radiograph after closed reduction.

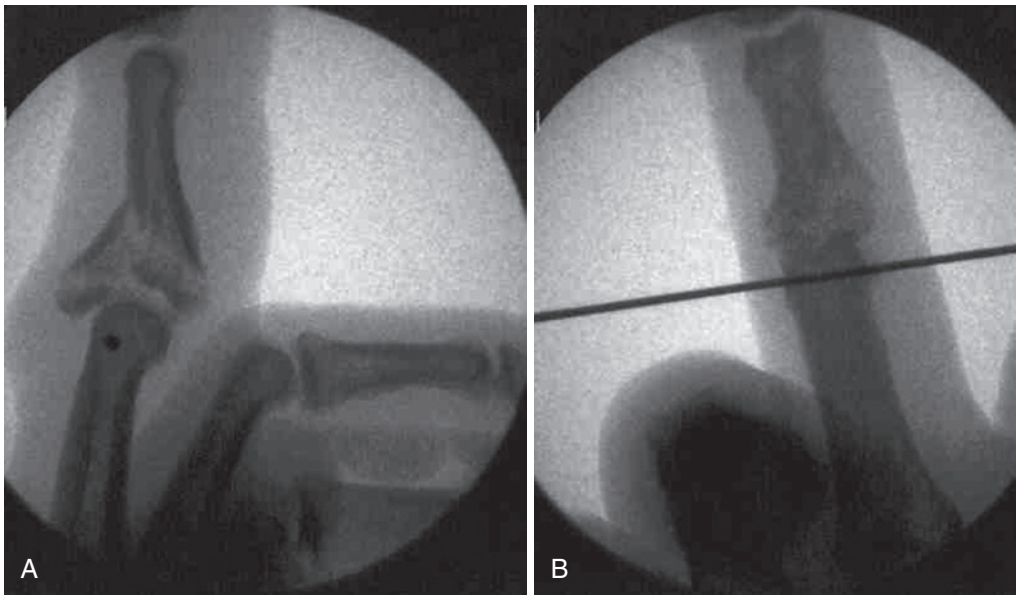

FIGURE 8.9 **A,** Lateral radiograph of proximal wire placement in center of rotation. **B,** Anteroposterior radiograph of proximal wire placement transverse to longitudinal axis of finger.

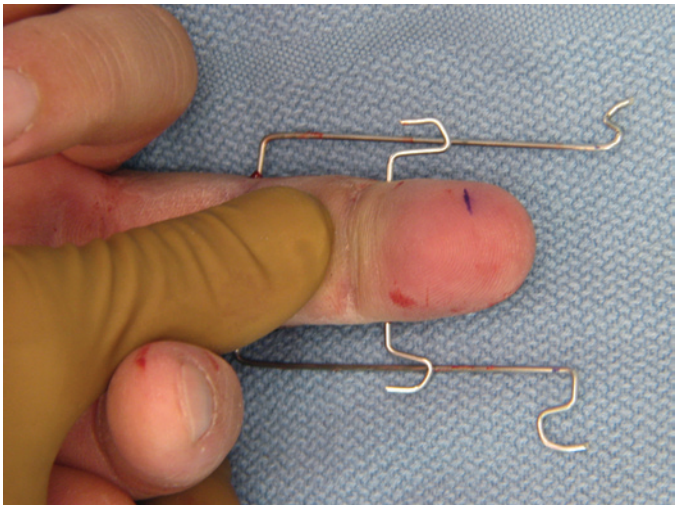

FIGURE 8.10 Demonstration of wire placement with hooks made for dental rubber bands.

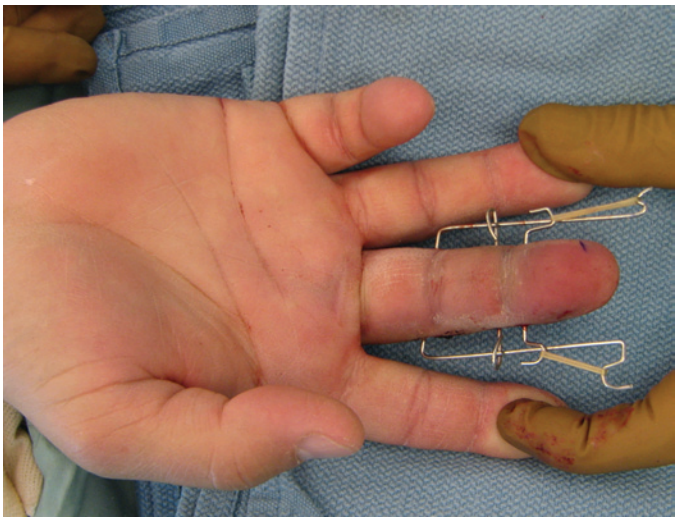

FIGURE 8.12 A third wire is added in middle axial line through middle phalanx. By placing this dorsal to the proximal phalangeal wire, a volar-directed moment is applied to the joint to prevent dorsal subluxation without excessive traction.

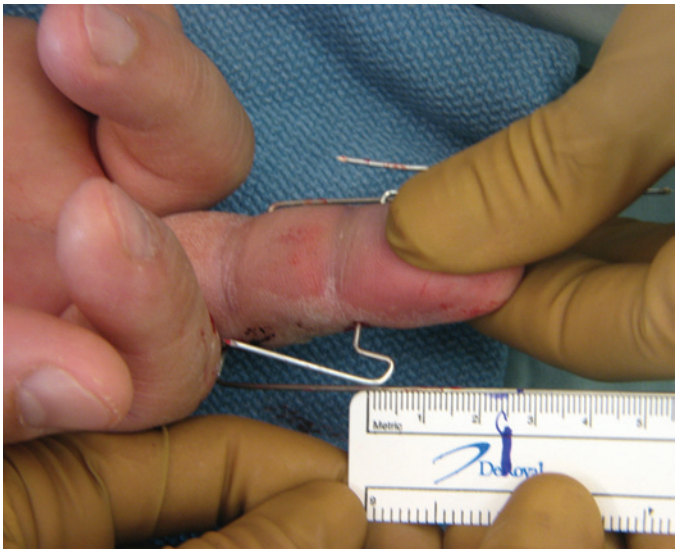

FIGURE 8.11 Hooks are bent such that there is 2.5 cm between proximal and distal hooks, a typically reliable amount of traction.

and fashioned into hooks (Figure 8.10). The distance between the proximal and distal hooks is approximately 2.5 cm (Figure 8.11), which allows for an adequate but not excessive distraction force by dental rubber bands. Give extra rubber bands to the patient to take home in case one ruptures. Prior to applying the rubber bands, a third midaxial wire is placed in the middle phalanx, which acts as fulcrum, blocking dorsal dislocation of the PIP joint (Figure 8.12). This third wire is not seen in all publications on the subject but is crucial in unstable pilon-type fractures to provide joint reduction in the sagittal plane without excessive distraction force. Typically, two rubber bands are applied to each set of hooks. Intraoperative fluoroscopy is used to confirm concentric reduction through a full arc of motion (Figure 8.13), and additional rubber bands are applied as necessary to tailor the distraction. If impacted central fragments remain, one can consider open reduction and bone grafting, or alternatively, an 18-gauge needle or Kirschner wire can be directed fluoroscopically into the fracture site to tamp up the impacted fracture fragment (Figure 8.14).

CRITICAL POINTS *Dynamic Skeletal Traction*

Preoperative Planning

- The construct requires long 0.045-inch Kirschner wires; short Kirschner wires are insufficient.
- Sterilizable dental rubber bands of 3/8 inch are used.
- Less effective if neighboring digits are injured, given width of the construct
- Excellent technique for unstable injuries with comminuted fragments

Technical Points

- Careful placement of the proximal phalanx Kirschner wire in the center of rotation of the condyle is needed, as viewed on posteroanterior and lateral radiographs.
- Add a third Kirschner wire to prevent dorsal subluxation and minimize the needed distraction force.
- Measure 2.5 cm between anchor points for rubber bands on proximal and distal wires.
- Confirm motion and reduction in flexion and extension (it helps to advise the hand therapist).

Postoperative Planning

- Give the patient extra rubber bands to take home in case some break.
- Patient dedication is required in the rehabilitation process.

Postoperative protocol. Patients are instructed to elevate and rest the hand for 2 to 3 days to decrease swelling before beginning hand therapy. Patients are permitted both active and passive range of motion as tolerated. Postoperative motion with the fixator in place is typically less than what was demonstrated in the operating room. Pins are swabbed with half-strength

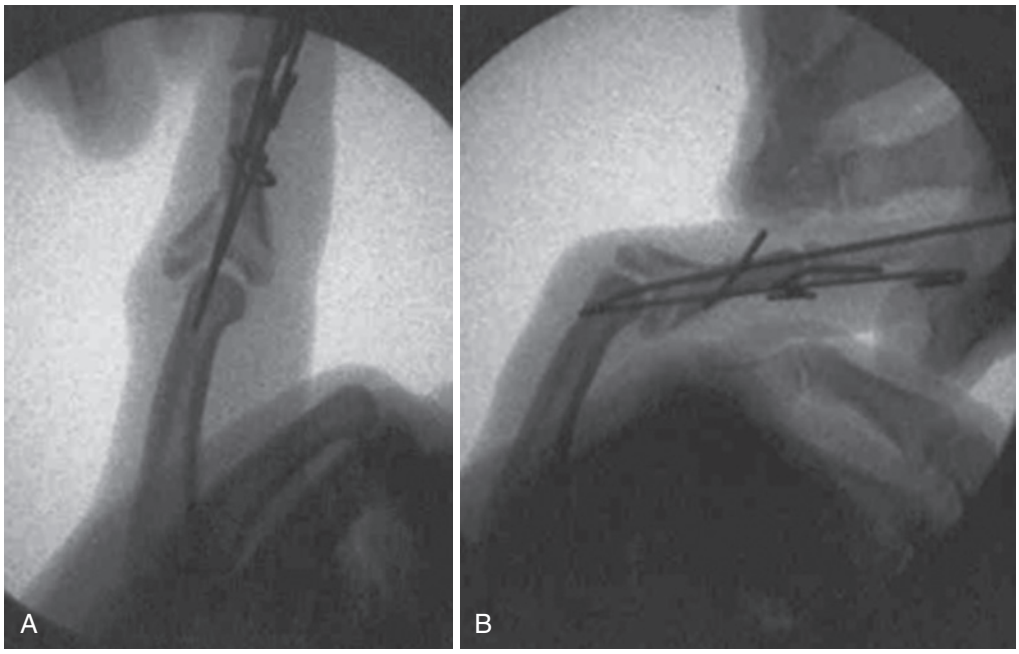

FIGURE 8.13 Full extension is typically the most unstable position. **A,** Lateral radiograph shows some overall widening or cupping at the joint, but no subluxation or secondary incongruity. **B,** Lateral view with joint flexed also shows congruity.

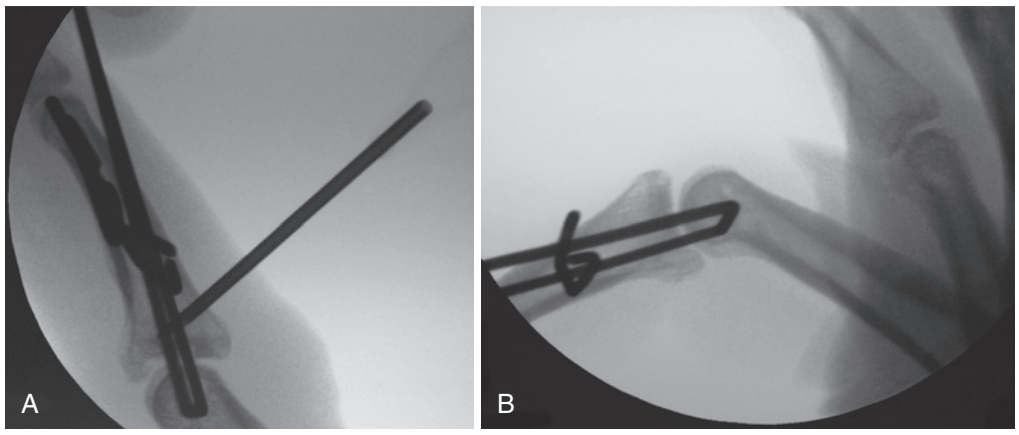

FIGURE 8.14 **A,** Percutaneous introduction of 18-gauge needle to elevated impacted fragments. **B,** Reduction after tension is applied to the dynamic fixator and joint is reduced percutaneously.

peroxide for the first week twice a day and thereafter only if they have drainage. Patients are permitted to get the fixator wet in the shower once wounds are sealed and benign in appearance. Pin tract redness, swelling, or drainage is treated with antibiotics and rest. Radiographs are taken at 1 week to ensure that fracture and joint reduction are maintained. Distraction can be adjusted with rubber band application or removal as indicated by radiographs; ideally, the joint should be only minimally distracted when compared with neighboring PIP joints. After 4 weeks, adequate healing is confirmed by removing the dental rubber bands and obtaining lateral radiographs of the digit in flexion and extension. Fixator removal as early as 3 weeks has been reported with successful results.[23] If there is evidence of fracture healing and the joint stays congruent, the fixator is removed; otherwise, it is rechecked in 1 to 2 weeks.

Expected outcomes. A review of several recent reports showed an average range of motion of approximately 85 degrees at follow-up after 1 to 2 years.[23,33,61,88,100,114] Superficial pin tract infections are present in 10 to 30% of cases, but they typically resolve without incident. Patients demonstrate 92% grip strength on average. Only a few patients in these series have reported residual pain. On subset analysis, patients with significant joint comminution or a delay to surgery perform less well.

Our own results, although good for this difficult injury, have had more instances of residual pain than these case series may suggest. Perhaps the degree of joint comminution was more than the case examples shown in radiographs presented in these papers.

Open Reduction and Internal Fixation. ORIF is an excellent form of treatment when there is a single large volar fragment. The procedure is performed through a volar zigzag incision; the flap is based radially in the index and long fingers and ulnarly in the ring and small fingers to reduce the potential for contact hypersensitivity. The A3 pulley is excised or everted for later

repair. The flexor tendons are retracted. A self-retaining operative tray with ball-and-chain hooks or an aluminum or lead hand may be helpful to retract the neighboring digits. The PIP joint is entered in the A2 to A4 interval between the flexor sheath, and the sheath is excised or everted for later reattachment. It is important to fully visualize the articular surface to ensure anatomic reduction, which may require a "shotgun" hyperextension approach (Fig 8.15, *A* and *B*). To do this, the neurovascular bundles are mobilized to prevent traction injury, the flexor tendons are protected and retracted with a Penrose drain, and the collateral ligaments that remain attached to the middle phalanx are excised except for the most volar remnants. These are preserved for later use in the procedure to suture each corner of the volar plate margin. The volar plate is generally left attached to the volar fracture fragment but can be detached as necessary. Although preservation of the volar plate insertion on the fragment will maintain the blood supply, fracture healing is usually not dependent upon this. Detaching the collateral ligaments allows the joint to be maximally hyperextended, as one would open a shotgun. With both articular surfaces completely exposed, the feasibility of reduction and fixation of the fragments can be determined. Impacted fragments of the dorsal articular surface may be elevated with a dental pick or Freer elevator, and the subchondral void filled with a small autologous or allograft cancellous crouton.

If the volar fragment is large, the joint is reduced and the fragment held with one or two 1-mm lag screws, the goal being an anatomic, stable reduction. In hard bone, the small screw head(s) are countersunk to minimize flexor sheath irritation, and care is taken to avoid screw tips extending beyond the dorsal cortex where they may irritate the extensor mechanism. Release of the collateral ligament attachments to the fragment greatly improves visualization and eases manipulation. When there is comminution of the volar fragment(s), a 1.3-mm volar buttress plate can be applied. The flexor digitorum superficialis inserts laterally, so a centrally placed plate is well tolerated. Protected early motion is the goal.

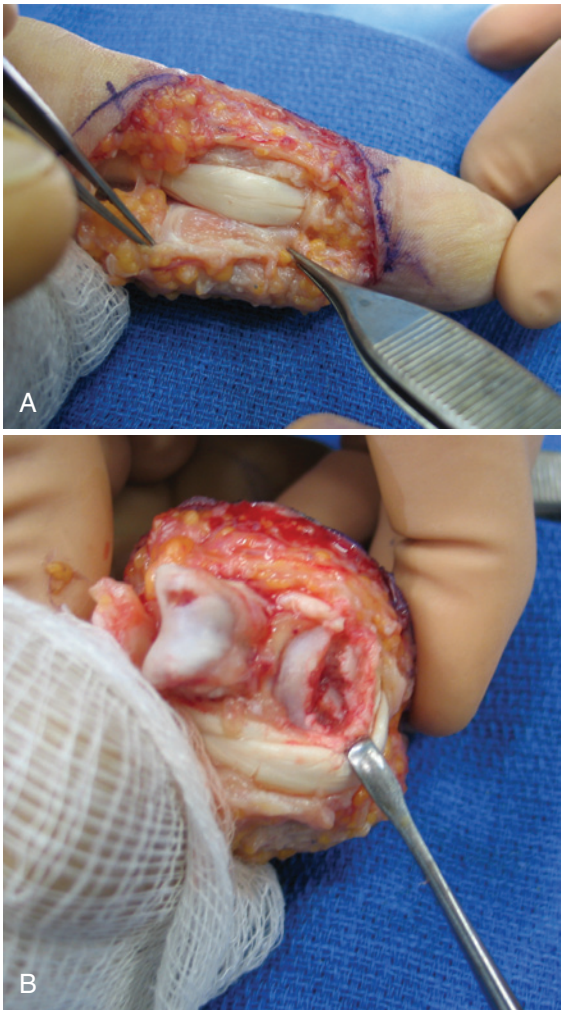

FIGURE 8.15 Shotgun approach for proximal interphalangeal joint exposure. **A,** Flexor sheath between A2 and A4 pulleys is incised along one edge and elevated. When closing, it can be passed under the tendon to prevent adhesions at repair site. **B,** After recession of collaterals, joint can be "shotgunned" open. (Courtesy Hill Hastings, MD.)

CRITICAL POINTS *Open Reduction and Internal Fixation*

Preoperative Considerations

- Have a backup plan (i.e., hemihamate autograft or dynamic skeletal fixation) because comminution is often worse than demonstrated on preoperative radiographs.
- The technique is best for a single, large fragment pattern, but smaller implant systems with 1-mm screws and 1.3-mm plates can render stable reduction with certain fracture types.

Technical Points

- Sharp dissection with meticulous handling of soft tissues cannot be overemphasized.
- Inspect the dorsal surface carefully to make sure it is anatomic, and elevate impacted fragments and bone graft as needed.
- After fixation, check a lateral in flexion and extension to make sure the joint maintains a congruent reduction and does not subluxate in extension.

Postoperative Planning

- Construct must be sufficiently stable to permit early motion. If unstable, consider adding an additional Kirschner wire fixator to maintain stability during early motion. Avoid overdistraction.

Postoperative protocol. Patients begin immediate active range-of-motion movements of the joint. Between exercises the digit is immobilized in a gutter splint with the PIP joint maintained in full extension (as long as there is no joint subluxation) to prevent flexion contracture. Passive range-of-motion movements and dynamic splints are started based on the surgeon's assessment of the integrity of the repair; we prefer to start as soon as possible.

Expected outcomes. Four recent case series of 54 patients who had undergone volar miniscrew ORIF demonstrated PIP motion of 55 to 115 degrees (average, 80 degrees) with a 10-degree flexion contracture. Strength averaged 85% of the uninjured side.[20,42,45,60]

Volar Plate Arthroplasty. The PIP joint is exposed using a radially based flap through a chevron-shaped incision with its apex at the ulnar midaxial point. The flexor sheath is excised between the A2 and A4 pulleys, and the flexor tendons are

atraumatically retracted with a Penrose drain. The articular surfaces are very difficult to assess with the joint reduced. Hyperextension of the joint will usually expose the distal edge of the fracture fragment, facilitating entrance into the joint. A shotgun joint is exposed using a radially based flap through to gain access and to release any preexisting joint contracture.

Congruous reduction may not be possible if the fracture fragments are markedly comminuted or impacted. Loose bone fragments and the segment attached to the volar plate are excised and saved for potential bone graft material. The defect in the volar rim of the middle phalanx is shaped into a transverse groove perpendicular to the long axis of the phalanx. Deeply impacted fragments should be left undisturbed to serve as a buttress for the volar plate. The interval between the volar plate and both collateral ligaments is incised, and the fibrocartilaginous plate is mobilized if necessary to allow its advancement 4 to 6 mm distally into the defect in the middle phalanx. The more recent the injury, the more easily the plate will advance. In late cases, it is usually necessary to partially release (Figure 8.16) the proximal checkrein ligaments to gain sufficient length for advancement.

The volar plate is advanced into the middle phalangeal defect by means of a pull-out wire or suture, which spirals along the lateral margins of the volar plate and is passed through drill holes in the lateral margins of the middle phalangeal defect (Figure 8.17). The holes are made by drilling a Keith needle from volar to dorsal, and the needles are threaded with the suture and pulled out dorsally. These holes should be as proximal as possible (immediately deep to the remaining dorsal subchondral plate) to draw the plate against the edge of the remaining articular cartilage. They should exit the dorsum of the middle phalanx more centrally through the triangular ligament of the extensor mechanism to avoid binding down the lateral bands. The DIP joint should be flexed 30 degrees as the suture is passed through the extensor mechanism to avoid tethering the tendon. Traction on the sutures emerging from the dorsum of the middle phalanx facilitates reduction of the joint as the plate is advanced into the defect.

Lateral radiographs are obtained before tying the sutures, to confirm that a congruous reduction throughout a full arc of motion has been achieved. Maintenance of the reduction with

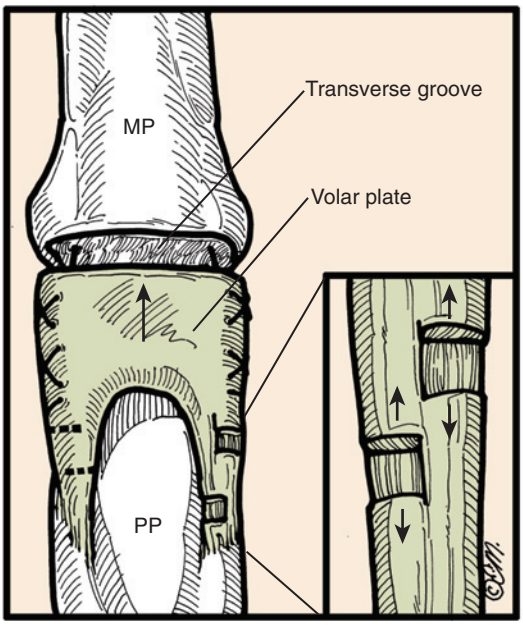

FIGURE 8.16 Step-cuts can be made along checkrein ligaments to allow distal advancement of volar plate into the defect. *MP*, Metacarpophalangeal; PP, proximal phalanx. (Copyright © Elizabeth Martin.)

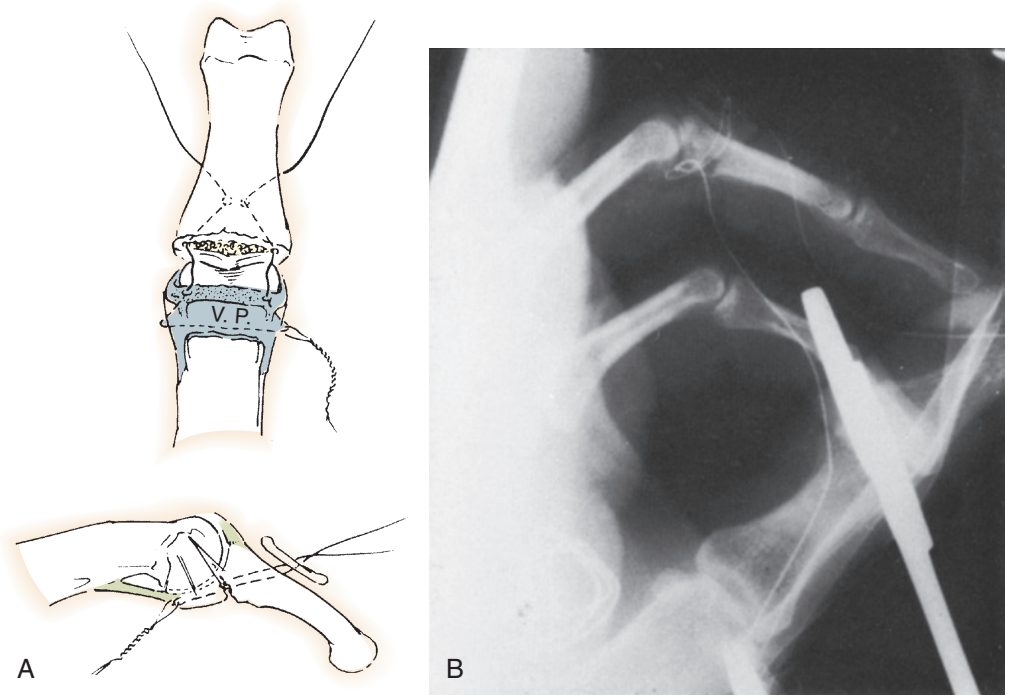

FIGURE 8.17 **A,** Volar plate advanced into defect of reduced joint and held with pull-out wires over a button. **B,** Radiograph showing a reduced joint with volar plate advancement.

articular gliding through the flexion arc (as opposed to hinging on the dorsal articular surface) must be documented. This is particularly true in chronic fracture-dislocations with dorsal adhesions. If hinging is present, additional release is necessary, usually of the dorsal capsule, which may have become scarred and inelastic over time. Once a congruous reduction and arc of motion are ensured, the pull-out sutures are tied over felt and a button. Alternatively, a small incision can be made dorsally and sutures tied down just distal to the central slip insertion, taking care to avoid the lateral bands. A secondary suture is placed between each lateral margin of the volar plate and its adjacent remaining collateral ligament remnant. This reestablishes three-dimensional stability and ensures broad coverage of the condyles and phalangeal base. If there is too much laxity in the volar plate with the joint reduced, additional tightening sutures may be placed to further imbricate the sides of the volar plate to the accessory collateral ligaments, although this is rarely necessary. An oblique Kirschner wire is used to maintain the reduced joint in 20 to 30 degrees of flexion. In large defects, bone graft should be applied deep to the advanced volar plate to reduce the chance for recurrent subluxation.

Postoperative management. DIP joint motion is started immediately. Three weeks after surgery, the Kirschner wire is removed and active, unlimited flexion of the PIP joint is begun using a dorsal extension block splint. Unrestricted active extension is permitted at 4 weeks after surgery, and dynamic extension splinting is begun if full active extension is not regained by 5 weeks after surgery. Unlimited sports activities are allowed at 8 weeks with buddy taping, and buddy taping is continued for 4 to 6 months. Swelling may persist for several months, and it may take up to 6 to 8 months to achieve final range of motion.

Eaton and Malerich reported on 24 patients who underwent volar plate arthroplasty for both acute and chronic PIP fracture-dislocations, with a 10-year average follow-up.[31] The seven procedures performed within 6 weeks of injury attained an average of 95 degrees of motion and a 6-degree flexion contracture. In contrast, the 17 patients with chronic injuries (>6 weeks after injury) achieved 78 degrees of motion and 12 degrees of contracture. Only 3 patients reported pain, and only with strenuous use. Other reports have also noted good results in most patients.[10,28] Our own experience has not been as optimistic. The procedure is more appropriate for patients with volar articular involvement of less than 40 to 50%, and it has failed when we have used it for joints with greater involvement.

Complications

Redisplacement. Failure to achieve a stable reduction, pull-out suture failure, or inadequate protection during mobilization may result in recurrent dorsal subluxation. One cause of pull-out suture failure is damage from the transarticular Kirschner wire fixation. This complication may be obviated by prepositioning of the wire in the middle phalanx after Keith needle passage but before the sutures are pulled through. With close clinical and radiographic follow-up, such problems can be more expeditiously addressed and their effects minimized.

Angulation. Asymmetric impaction of the base of the middle phalanx or failure to create a trough for the volar plate that is perpendicular to the long axis of the middle phalanx will occasionally result in angulation of the middle phalanx. Although postoperative angular deformity is usually mild and not functionally significant, patient satisfaction may be compromised and secondary corrective osteotomy at the base of the middle phalanx may become necessary.

Flexion contractures. Immobilization of the PIP joint in more than 30 degrees of flexion and failure to begin dynamic extension splinting by 5 weeks may result in lack of full extension. Recognition of this potential and common problem should help minimize it. Even with early motion and formal hand therapy, a certain percentage of patients will develop a PIP flexion contracture.

Distal interphalangeal joint stiffness. Failure to flex the DIP joint approximately 30 degrees or impaling the lateral bands while passing the pull-out suture through the extensor mechanism on the dorsum of the middle phalanx may cause limitation of DIP flexion. Modifications in the technique help to decrease the risk of DIP stiffness. These include using two separate sutures for each side of the volar plate, tying the suture knots beneath the skin dorsally, or using small suture anchors in lieu of the pull-out suture. It is imperative to start DIP motion immediately postoperatively to regain the maximal motion possible.

CRITICAL POINTS *Volar Plate Arthroplasty for Dorsal Fracture-Dislocations of the Proximal Interphalangeal Joint*

Preoperative Evaluation

- Determine whether the remaining dorsal articular surface is anatomic or impacted.
- Appropriate for unstable fracture-dislocations unsuitable for ORIF; indicated for fractures in which 40% or less of the articular surface is involved and in occasional cases with articular depression of more than 40% but less than 1.5 to 2 mm; not advised for volar fracture involvement exceeding 40% to 50%

Technical Points

- Use volar approach with chevron incision
- "se volar approach with chevron incisionnatomic or impact
- Excise comminuted fragments and elevate dorsal, impacted articular surface
- Place holes for pull-out sutures as proximal as possible and avoid lateral bands dorsally
- Establish ideal length of volar plate with joint reduced
- Reduce joint, tie sutures with DIP flexed, and document congruency radiographically in flexion and extension
- Pin in 20 to 30 degrees of flexion for 3 weeks only

Pitfalls

- Leaving stable but impacted dorsal articular surface unaddressed
- Impaling lateral bands with pull-out sutures
- Failing to spread volar plate broadly across condyles
- Failing to identify hinged versus gliding flexion via dorsal adhesions
- Applying technique to fracture-dislocations with more than 40% volar articular involvement (failure is likely)

Postoperative Care

- Immobilize joint with Kirschner wire and splint for 3 weeks.
- Remove pin at 3 weeks and obtain radiographs after pin removal.
- Use extension block flexion for 1 to 3 weeks and then unlimited extension.
- Use a dynamic extension splint at 5 to 6 weeks as needed.

Cerclage Wiring. A volar chevron incision is made from the MP joint to the DIP joint. The neurovascular bundles are mobilized away from the flexor sheath to avoid traction injury during the shotgun approach (previously). A dental pick is used to align and elevate fragments. Bone grafting of impacted subchondral bone is done as needed. Sharp dissection is used to clear the proximal 1 to 2 mm of the middle phalanx from the periosteum to allow the wire to be seated. A loop of 24-gauge wire is formed and twisted on itself, placed around the bone, and gently tightened (see Figure 8.6). The joint is gently distracted and reduced. The joint is placed through a range of motion to assess congruency and stability. A "V"-shaped wedge is removed from the volar plate and the lateral edges are repaired (Figure 8.18). This prevents hyperextension but eliminates bulk under the flexor apparatus. This also decreases tension on the repair, allowing for immediate full or nearly full extension in therapy.

Postoperative protocol. Therapy is initiated after 2 to 4 days to allow for edema control. Active and passive motion is allowed with interval gutter splinting. Dynamics are added at 2 weeks if motion is slow to progress.

❖ AUTHORS' PREFERRED TECHNIQUE FOR HEMIHAMATE RECONSTRUCTION

A midaxial incision is made centered on the PIP joint and extended obliquely across the proximal and middle phalanges (Figure 8.19). Sharp dissection passes superficial to the neurovascular bundle down to the flexor sheath, elevating the subcutaneous tissue off the sheath and including the neurovascular bundle on the hinge side of the retracted flap (see Figure 8.15). Incise the sheath between the A2 and A4 pulleys, and retract the flexor tendons. The accessory collateral insertion into the volar plate should be incised longitudinally from the volar plate. The volar plate is divided transversely at its distal insertion and elevated to its proximal insertion. Release the collateral ligaments from their proximal insertion as much as needed until the joint can be shotgunned open. In chronic cases, a Freer elevator may be required to free dorsal capsular or extensor adhesions. Confirm on fluoroscopy that the dorsal residual intact articular base of the middle phalanx reduces anatomically with the head of the proximal phalanx. After exposing the articular base of the middle phalanx fracture, measurements are taken for the replacement graft with respect to the radioulnar width, anteroposterior height, and proximodistal length. It is best to harvest the hamate graft prior to final preparation of the recipient bed to preserve as much of the middle phalanx as possible and maximize the ability to properly position the graft.

Next a longitudinal incision is made over the bases of the fourth and fifth metacarpals, taking care to protect the ulnar sensory nerve branches. Retract the extensors to the fifth finger ulnarly and the fourth finger radially. Incise and elevate the capsule to expose the hamate and metacarpal articulation. Measure and mark the appropriate size for the donor graft, adding a few extra millimeters. The proximal end of the graft should be thicker than the articular portion to allow the graft to re-create the volar lip and appropriate buttress (Figure 8.20).

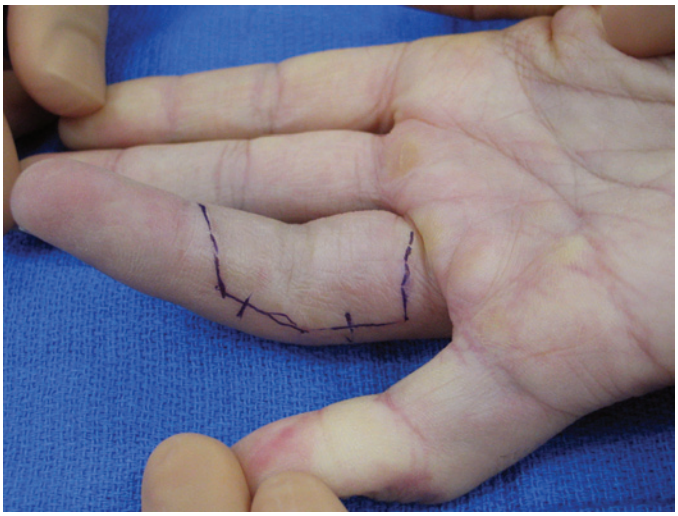

FIGURE 8.19 Incision for hemihamate arthroplasty extends obliquely proximally and distally, but continues along midaxial line at proximal interphalangeal joint to maximize exposure. (Courtesy Hill Hastings, MD.)

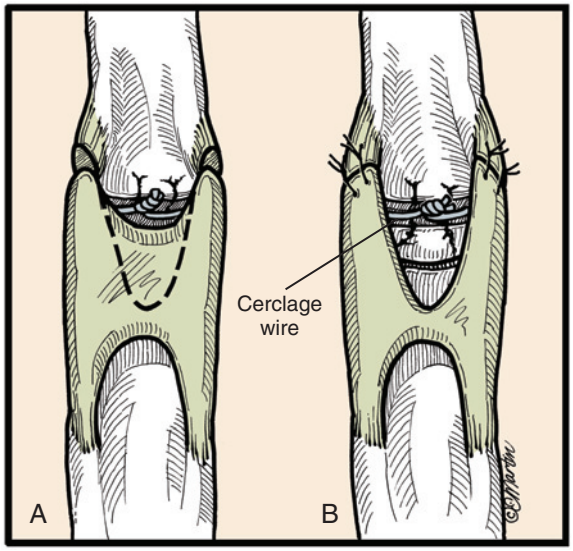

FIGURE 8.18 **A,** "V"-shaped segment is removed from volar plate. **B,** Edges are repaired to minimize bulk while allowing volar stabilization. (From Weiss AP: Cerclage fixation for fracture dislocation of the PIP joint, *Clin Orthop Relat Res* (327):21–28, 1996. Redrawn by Elizabeth Martin.)

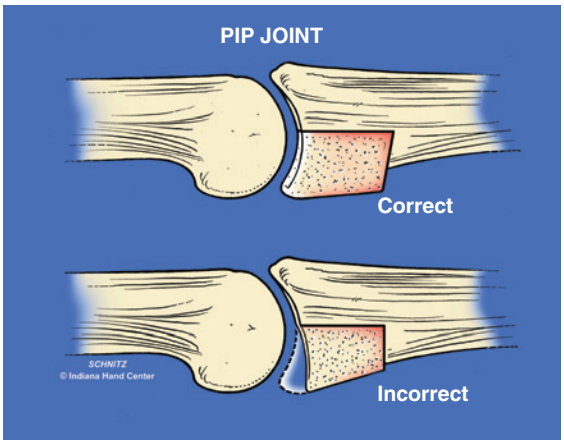

FIGURE 8.20 Graft is planned to be shaped such that when in place it tilts to re-create volar lip. *PIP,* Proximal interphalangeal. (From Strickland JW, Graham TJ, editors: *Master techniques in orthopaedic surgery: the hand,* 2nd ed, Philadelphia, Lippincott Williams & Wilkins, 2004.)

To harvest the hamate graft, mark the required dimensions on the dorsal surface of the hamate. Usually it will extend all the way to the ulnar border of the hamate. Place a Freer elevator in the fourth/fifth CMC joint to lever the joint open slightly. Use a thin sagittal saw blade to make sagittal cuts in the hamate radially and ulnarly, being sure that the depth of each cut is slightly greater than the needed anteroposterior thickness of the recipient defect. Be sure that the cuts extend distally though the articular surface of the hamate into the CMC joint. Make a similar transverse cut proximally at least 2 to 3 mm deeper than the axial cuts. The graft can be harvested in one of two ways. The goal is to create a coronal plane cut from the articular surface into the more proximal hamate in a direction that passes from distal into a more volar direction proximally. This will provide a graft that has a greater dorsal/volar depth or thickness proximally than distally. A curved osteotome is placed within the CMC joint to an appropriate depth that conservatively exceeds the required anteroposterior height of the desired graft. Once it is driven through the chondral and subchondral articular surfaces, a cleavage plane will usually propagate proximally through the bed of the prepared graft dimensions (Figure 8.21). The second, and perhaps safest, method is to make a coronal plane cut with a sagittal saw directed from the ulnar border of the hamate to the radial side. In most cases, in order to obtain a wide enough graft, harvest to the far ulnar side of the hamate will be required. This method provides the best control for ensuring that the plane of osteotomy is from a distal dorsal to a proximal volar direction. The shape of the graft obtained will ensure that the volar buttress of the articular base of the middle phalanx is properly restored (Figure 8.22).

Conservatively trim the recipient defect into a rectangularly shaped bed with a small oscillating saw (Figure 8.23). The graft should first be trimmed to re-create a proper "tip," such that the graft is slightly angled in the sagittal plane to re-create the volar lip buttress of the middle phalangeal base. Once a proper "tip" has been created, the graft is sequentially shortened or the recipient bed enlarged to align the articular surface of the graft with the intact dorsal articular surface.

Hold the graft in place with a provisional 0.028-inch Kirschner wire, and use two 1-mm screws in lag fashion to secure the graft on either side of the provisional Kirschner wire. Remove the provisional Kirschner wire and replace it with a third screw (Figure 8.24). In cases requiring replacement of more than 60% of the joint surface, consider adding a 1.3-mm buttress plate to support the graft. Repair the medial and lateral edges of the volar plate back to the accessory collateral ligaments or proximal edge of the A4 pulley to prevent a swan neck deformity. Check the joint stability and the conformity in flexion and extension. At the surgeon flexion and the previously opened

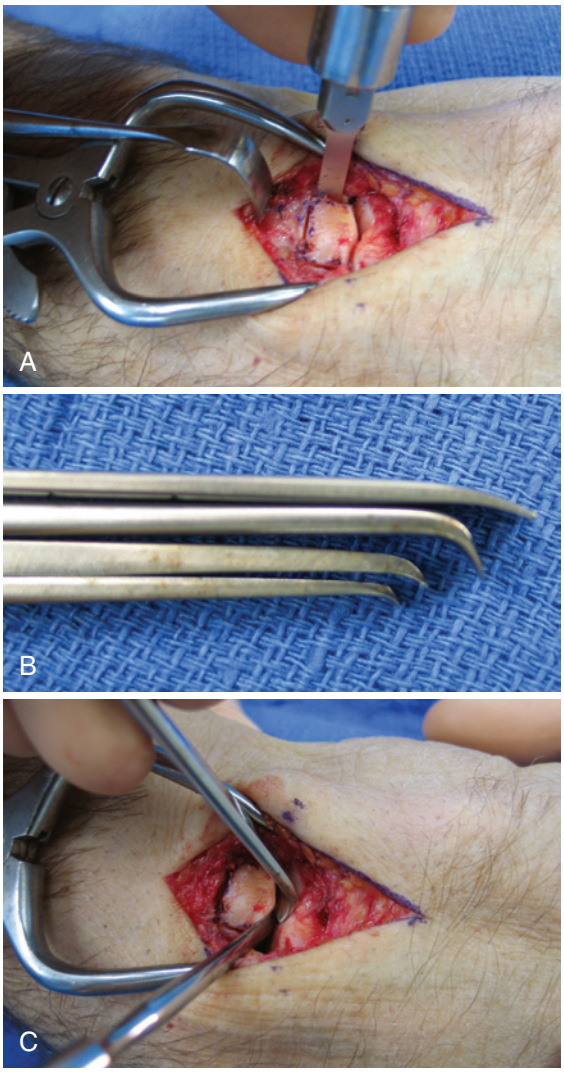

FIGURE 8.21 **A,** A 4-mm sagittal saw is used to free sides of graft. **B,** Custom-made osteotomes to assist with graft harvest. **C,** Small curved osteotomes are used to make coronal split in graft. (Courtesy Hill Hastings, MD.)

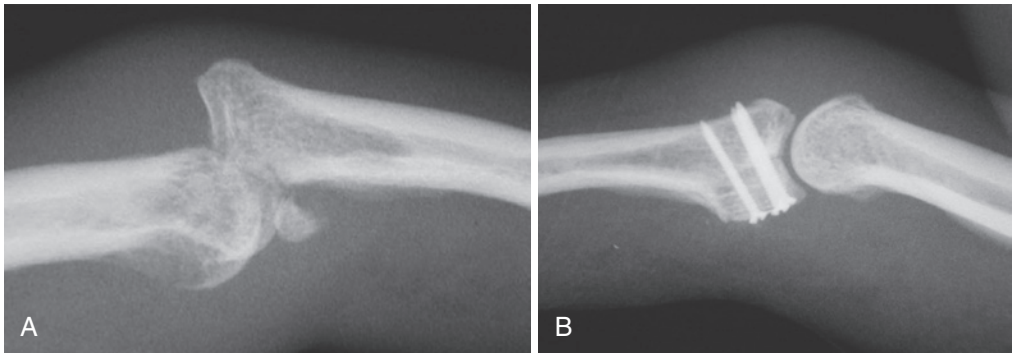

FIGURE 8-22 **A,** Preoperative lateral radiograph showing injury. **B,** Postoperative lateral radiograph showing reconstruction and congruent joint with volar buttress in place due to appropriate angling of graft. (Courtesy Hill Hastings, MD.)

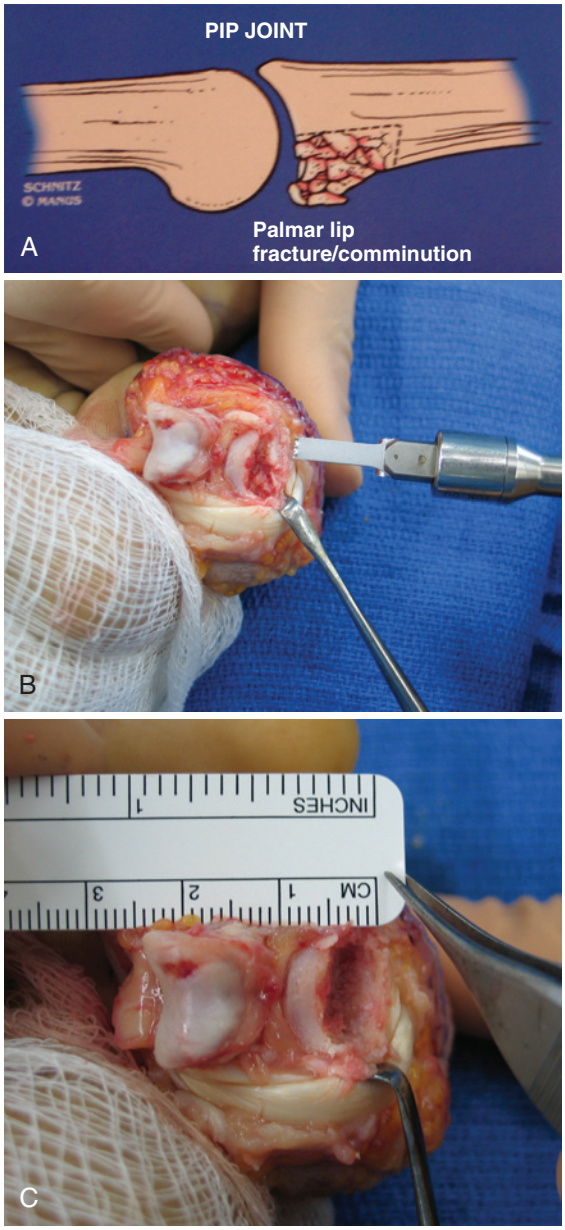

FIGURE 8.23 **A,** Diagram showing transverse and coronal cuts made to remove all comminuted fragments. **B,** Intraoperative photograph showing initial resection of fragments using 4-mm saw. **C,** This leaves a boxlike defect, where the remaining joint surface is structurally sound. *PIP,* Proximal interphalangeal. (**A,** From Strickland JW, Graham TJ, editors: *Master techniques in orthopaedic surgery: the hand,* 2nd ed, Philadelphia, Lippincott Williams & Wilkins, 2004. **B** and **C,** Courtesy Hill Hastings, MD.)

flexor sheath may be transposed beneath the flexor tendons to reinforce the volar plate and prevent adhesions (Figure 8.25).

Postoperative protocol. Patients are splinted with the PIP joint in 10 to 20 degrees of flexion and the MP joints in flexion. On postoperative days 2 to 4, a dorsal block splint for the PIP in 20 degrees of flexion is fitted and patients are instructed to perform full active and passive flexion exercises. A digital anesthetic block may be required to ensure that nearly full motion is established on this first therapy visit. The splint is removed at 4 weeks, and dynamic splints may be applied at 6 weeks as needed to address difficulties with flexion or extension. Radiographs are performed in the flexed and extended lateral positions to confirm joint congruency during the postoperative period (Case Study 8.1).

CRITICAL POINTS *Hemihamate Reconstruction*

Indications
- Acute or chronic unstable PIP fracture-dislocations with extensive joint impaction or comminution
- An option for previously failed external fixation, ORIF, or other treatments

Technical Points
- Preserve the flexor sheath between A2 and A4 on a hinge so that it can be transposed at the end of the procedure under the flexor tendon, to reinforce the repair site and minimize flexor tendon adhesions.
- Small comminuted fragments of volar bone are removed to make a precise box-shaped defect for reconstruction.
- The graft is harvested to be thicker proximally, in order to "tip" the chondral surface appropriately and reconstitute the natural joint curvature of the volar buttress.

Postoperative Plan
- The PIP joint is flexed 10 to 20 degrees for the first 4 weeks to allow volar plate healing.
- Patients should be advised to expect a mild flexion contracture at the final outcome.

Expected outcomes. All 22 patients in this study had unstable dorsal PIP fracture-dislocations of more than 50% of the middle phalangeal articular base that were not amenable to open reduction and fixation. At a mean follow-up of 4.5 years, active PIP motion averaged 70 degrees. The mean flexion contracture was 19 degrees (range, 0 degrees to 80 degrees). The mean VAS score for digit pain was 1.4 (acute, 0.7; chronic, 2.5). A mean DASH score of 5 (acute, 2; chronic, 9) and VAS functional score of 1.9 (acute, 1.4; chronic, 2.6) indicated little functional impairment (acute, 2; chronic, 9). Grip strength averaged 95% of the opposite hand. One dissatisfied patient required revision surgery.[15]

Chronic Proximal Interphalangeal Fracture-Dislocations

Occasionally, fracture-dislocations of the PIP joint remain untreated or the initial closed reduction is lost, resulting in a fixed dorsal subluxation with a malunited or nonunited volar buttress of the middle phalanx. Stiffness and progressive pain are inevitable.

Open reduction with a corrective osteotomy with or without bone graft of malunited fractures has been advocated.[125] Success of this technique is predicated on the accurate reduction of the joint and presence of reasonable chondral surfaces in chronic injuries, two conditions that may not be attainable. Resurfacing an IP joint with costal cartilage and perichondrium (perichondrial arthroplasty) has been used in a small number of chronic PIP joint fractures.[47,69] Free vascularized joint replacement with DIP joints or toe IP joints has also been reported.[51] The efficacy of these techniques for chronic fracture-dislocations has not been convincing to this author. Other treatment options include implant arthroplasty and arthrodesis, both of which are less than ideal in the relatively young patient population in whom this problem most often occurs.

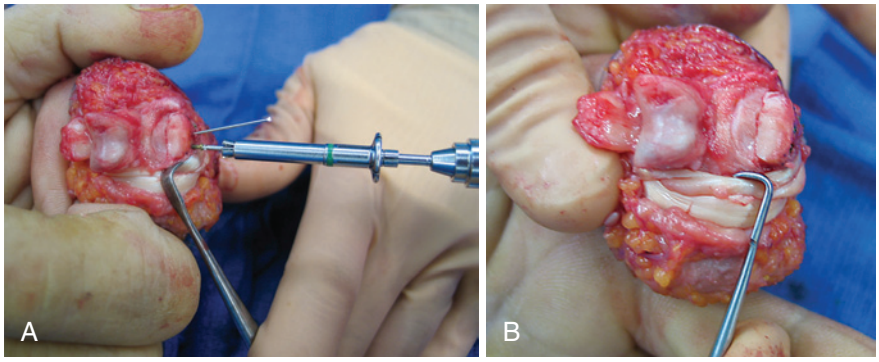

FIGURE 8.24 **A,** Graft is placed and held with provisional Kirschner wire while secured with 1-mm screws. **B,** Intraoperative photograph showing reconstructed joint. (Courtesy Hill Hastings, MD.)

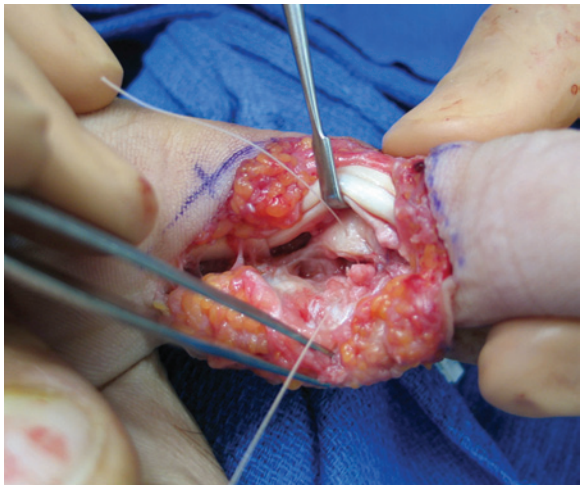

FIGURE 8.25 The flexor sheath between the A2 and A4 pulleys is transposed beneath the flexor tendons to prevent adherence at repair site. (Courtesy Hill Hastings, MD.)

Volar plate arthroplasty is a consideration for these injuries only when there is less than 40% volar articular involvement. The success of the procedure mainly depends on restoring proper reduction of the joint and less so on restoring the volar plate. Adequate advancement of the volar plate may require fractional lengthening of the proximal checkrein ligaments by making several 2- to 3-mm incisions in both lateral margins at intervals along their length. Complete *excision* of both PIP collateral ligaments is essential to achieve adequate exposure, a congruous joint reduction, and maximal postoperative motion.

❖ AUTHORS' PREFERRED METHOD OF TREATMENT

Hemihamate arthroplasty restores a smooth cartilaginous surface to the base of the middle phalanx and maintains a stable reduction. This technique can be used for PIP reconstruction provided there is enough intact articular surface on the dorsum of the base of the middle phalanx with which to form a congruous articulating facet and anchor the graft. In long-standing dislocations, a release of the dorsal capsule may be needed to regain flexion. Surgical technique and rehabilitation are the same as for acute fracture-dislocations. Surgical outcomes are less predictable for chronic injuries and in general less robust.[15]

Chronic Proximal Interphalangeal Subluxations (Hyperextension)

Untreated or underdiagnosed type I (hyperextension) injuries can result in PIP hyperextension or a swan neck deformity. It is important to compare the affected digit with neighboring digits and the opposite side, particularly for patients with ligamentous laxity. Patients may complain of pain from snapping lateral bands as they move to and from the hyperextended position. In swan neck deformities, the examiner must distinguish primary volar plate laxity from extensor mechanism imbalance, such as that after an untreated mallet finger. The distinction can usually be made by stabilizing the PIP joint in full extension as the patient attempts to actively extend the distal joint. A lag in active distal extension when the PIP joint is stabilized in neutral indicates incompetence of the extensor mechanism. If the distal joint extends normally, the problem is primarily with the volar support of the PIP joint.

Treatment

For minimally symptomatic PIP hyperextension deformity, custom or commercially available figure-of-eight splints provide a functional alternative to surgery. Splinting will not correct the problem and the splint must be worn full time to be effective. Surgical correction of these deformities involves either late reattachment/reconstruction of the volar plate or a tenodesis procedure.

Reattachment procedures include direct repair or advancement of the avulsed volar plate with sutures, a pull-out wire, or a bone anchor, following scarification of the base of the middle phalanx. Less severe deformities may be stabilized by advancement of the accessory collateral ligaments into the volar plate.[73]

Reconstruction of the volar plate by tenodesis can be achieved with one or both slips of the flexor digitorum superficialis[91] or by rerouting of one of the lateral bands. Use of both flexor digitorum superficialis slips is reserved for hyperextension deformities created by a severe chronic imbalance of forces, as in cerebral palsy, or in cases when the flexor digitorum superficialis slips may be quite thin. Lateral band tenodesis is a simple procedure that does not interfere with the flexor mechanism.

Technique of Lateral Band Tenodesis. A 2-cm ulnar-sided midlateral incision is made centered on the PIP joint. The Cleland ligament is incised to allow access to the neurovascular bundle and the flexor sheath. The neurovascular bundle is gently

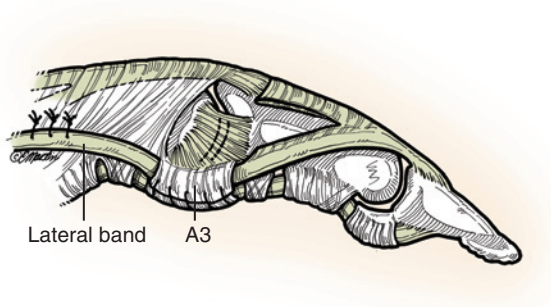

FIGURE 8.26 Treatment of flexible swan neck deformity by volar transposition of lateral band. (Copyright © Elizabeth Martin.)

retracted. The lateral band's relationship to the lumbrical is left undisturbed as it is incised from the extensor apparatus along its dorsal margin, keeping its distal attachment intact. It is mobilized palmar to the PIP joint. Several options exist for rerouting of the lateral band. I prefer to suture the intact lateral band to the lateral edge of the A3 pulley, taking care to avoid the flexor tendons. Another technique is to open the A3 pulley with a step-cut and sew it over the top of the lateral band, trapping it inside the pulley (Figure 8.26). Alternatively, one can release the ipsilateral flexor digitorum superficialis slip distally, interpose the lateral band between it and the volar plate, and reattach the flexor digitorum superficialis to the volar plate distally. The joint should rest in 20 to 30 degrees of flexion and on passive extension should still have a 5- to 10-degree flexion contracture. This allows for some stretching out of the soft tissue repair while still allowing for maintenance of the correction. Some prefer to approach the joint through a volar Bruner incision, divide the lateral band proximally, pass it beneath the Cleland ligament and the neurovascular bundle, and secure it to the A2 pulley on the opposite side of the finger.

Postoperative Management. On the first postoperative day a dorsal extension block splint is applied in 10 to 20 degrees of PIP flexion to allow immediate active flexion. After 3 weeks the extension block is reduced to 5 degrees. Unrestricted motion is permitted at 6 weeks, and unlimited sports activities are possible at 8 to 10 weeks with buddy taping until 3 months after the surgery.

Expected Outcomes. Patients seek treatment for PIP hyperextension deformities because of dysfunction in daily activities. We have found lateral band tenodesis to be reliable with generally good results. Immediate postoperative pain is mild, and recovery is brief with a rapid return to function. There are no published data for lateral band tenodesis that we know of to guide patient and surgeon expectations. Flexor digitorum superficialis tenodesis is another reliable option; in a series of 12 patients, 5 had excellent results, 5 had good results, and 2 had fair results, and all patients returned to their original occupations and recreational activities.[18] Two patients, both of whom were noncompliant with postoperative therapy, had flexion contractures of 30 and 60 degrees.

Complications. In spite of good-quality tissue and fixation, the final tenodesis position may not correspond to that which was set at surgery. There is more of a tendency toward a flexion contracture than residual hyperextension because the procedure weakens the extensor moment while providing a mechanical block to hyperextension. Therefore, it is important to set the tension on the tenodesis to no more than 5 or 10 degrees short of full extension and to monitor the patients carefully postoperatively.

Posttraumatic Fibrosis and Contracture of the Proximal Interphalangeal Joint

Flexion Contracture

When nonoperative treatment and dynamic splinting have failed, operative treatment options for flexion contractures run the gamut from soft tissue release to distraction external fixation.

Collateral ligament excision and, if necessary, a distal volar plate release have demonstrated good results.[1,24,82] Abbiati and associates recommended sparing the proper collateral ligaments while releasing the volar plate and accessory collateral ligaments.[1] Mansat and Delprat recommended a technique in which the volar plate and capsule are released and then the origins of the collateral ligaments are incised but not excised.[82] Diao and Eaton demonstrated no long-term collateral ligament insufficiency after complete excision of the collateral ligaments during joint release.[24] For severe contractures that may involve a postoperative skin deficiency, advancement flaps should be carefully planned to place skin graft over a defect in the palm rather than over the released joint; in cases with compromised volar tissue, a cross-finger flap may be useful.[35]

Concerns for PIP joint instability after collateral ligament excision are unfounded. A review of 16 patients who had total ligament excision and volar plate release for isolated posttraumatic PIP fibrosis showed an increase in total active motion from 38 degrees preoperatively to 78 degrees postoperatively at 1-year follow-up. In all patients, the joints were stable to lateral stress in all positions of flexion by 3 weeks.[24]

Preoperative Evaluation. The three requirements for successful treatment of a flexion contracture are absence of degenerative disease, a functional extensor mechanism, and a motivated and compliant patient. Conservative measures such as dynamic extension splints should be exhausted first. Radiographs should demonstrate a congruent, preserved joint space without mechanical block due to osteophytes. In that setting, release of the contracture, even if mild (<20 degrees), is quite reliable.

For more severe contractures, distraction external fixation achieved extension gains averaging 65 degrees in one series with a unilateral fixator and an average of 42 degrees with a compass hinge fixator.[56] Work by Houshian and Chikkamuniyappa also assessed different distraction rates and demonstrated equal results from an accelerated program with an average fixator time of only 17 days.[55]

An external device that uses extension torque was introduced in 2001 (Digit Widget, Hand Biomechanics Lab, Sacramento, CA).[4] This employs a dorsal bar fixed to the middle phalanx with two threaded pins and connected to a hand-based outrigger device with rubber bands (Figure 8.27). The device provides torque to progressively extend the PIP joint and is well tolerated because the patient can modulate the extension torque with different grades of rubber bands, as well as application times. It is important to control MP joint hyperextension when the device is being worn because this will limit gains in PIP extension (see Chapter 10).

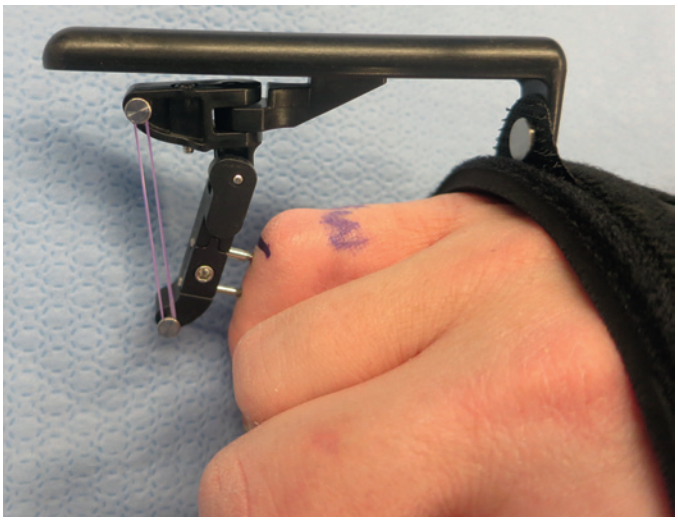

FIGURE 8.27 Digit Widget device (Hand Biomechanics Lab, Sacramento, CA) provides patient-controlled extension torque to a proximal interphalangeal contracture through dorsal rubber bands connected to a fixed dorsal outrigger. Metacarpophalangeal joint hyperextension can be controlled with an accessory strap. (Copyright © Scott W. Wolfe, MD.)

❖ AUTHORS' PREFERRED METHOD OF TREATMENT

The recent reports of external fixation PIP distraction are encouraging and worthy of further investigation.[4,55] At this time, we continue to achieve good results with open soft tissue release, although the time to return to full function may be longer than via a closed means of treatment. The PIP joint is approached through a Bruner style of volar incision. This is more expedient and safer because the bundles are easily identified, both the collaterals and the volar plate are easily accessed, and flexor tenolysis is accessible if needed. A midaxial incision has been shown in one series to produce better results and could be considered, although it is technically more demanding.[14] A tray with self-retaining ball-and-chain hooks facilitates retraction. The A3 pulley is released on one side, and this may be subsequently repaired or excised at the surgeon's discretion. The flexor tendons are gently retracted to allow exposure of the volar plate. Care is taken to protect the distal flexor digitorum superficialis insertion. The authors have never encountered a stiff PIP joint made unstable by full release of collaterals, accessory collaterals, and the volar plate. "Springy" PIP joints that have not had full release of all the aforementioned structures may not progress well postoperatively. A full release of all structures is typically necessary; however, one should proceed in a stepwise fashion, checking motion between steps. A Beaver blade is used to release the collaterals, starting in the joint and working proximally. The volar plate and checkrein ligaments are elevated off the proximal phalanx. There are often fibrotic bands from the volar plate that extend laterally upward dorsally under the neurovascular bundles, which also need to be removed. I have not found that excision of the collaterals is required; full release off the proximal condyles is all that is needed.

At this point in most cases, the digits achieve full extension with little flexor tone. If not, check the flexor tendons for adhesions and treat as needed. In long-standing severe contractures, one may have to consider the trade-offs of flexor digitorum superficialis release if it appears that tendon contractures contribute to an inability to achieve full extension. Also in severe contractures, advancement flaps or skin grafts may be needed for coverage.

Postoperative Management. The digit is splinted in full extension for 2 to 3 days and elevated. This allows for some edema control prior to initiating therapy for active and passive flexion exercises. Static extension splinting is continued between exercises. Dynamic extension splinting is rarely needed if the surgical release was complete. The patient is weaned from daytime extension splinting after a few weeks, but nighttime extension splinting is continued for 3 months.

Expected Outcomes. Ghidella and associates reported on 68 PIP joint contracture releases in 44 patients at minimal 2-year follow-up. Some results were sobering, with an average of only 8 degrees of improvement overall (range, 35-degree loss to 70-degree gain).[38] Younger patients, those with less severe contractures, those without a diagnosis of complex regional pain syndrome or crush injury, and those who had not had prior revascularization did better. Bruser and coworkers reported better overall results in 45 fingers, especially when the surgeon used a midlateral incision instead of a volar incision.[14] With a median contracture of 50 degrees, they achieved nearly 0 degrees of contracture at a 1.5-year follow-up. Careful patient selection is certainly important.

CRITICAL POINTS *Proximal Interphalangeal Contracture Release*

Indications

- Functional deficit secondary to a mature contracture in a compliant patient with no arthritic changes in the joint

Technical Points

- Midaxial incisions may produce better results but are technically more difficult.
- With full release of the collateral ligaments and proximal attachment of the volar plate and checkrein ligaments, instability will not be a problem.
- The joint should lay flat on the table at the end of the procedure and not be "springy."
- After sharp release of contracted structures, gently hyperextend the finger to release any remaining adhesions.

Postoperative Care

- Apply extension splinting between exercises.
- Initiate active and passive range-of-motion movements at postoperative day 2 to 3 to allow for some edema control initially.
- Apply dynamic splinting early if the patient is struggling to achieve full extension.

DISTAL INTERPHALANGEAL JOINTS OF THE FINGER AND INTERPHALANGEAL JOINTS OF THE THUMB

The ligamentous anatomy of the distal articulation of the finger and thumb is analogous to that of the PIP joint of the finger. However, due to the shorter lever arm of the distal phalanx and the enhanced stability provided by the adjacent insertions of the flexor and extensor tendons, dislocations are not as frequent.

Dislocations of the DIP joint are usually dorsal or lateral and often associated with an open wound because of the snug soft tissue envelope about the joint.

Treatment of these dislocations consists of closed reduction under digital or wrist block anesthesia. The reduction maneuver consists of longitudinal traction, direct pressure on the dorsum of the distal phalanx, and manipulation of the distal phalanx into flexion. If the dislocation is open, the joint is contaminated by definition, and treatment should include thorough irrigation and débridement in a controlled, sterile setting. After reduction, joint stability should be tested actively with range of motion by the patient and passively by the examiner to gently stress the collateral ligaments. Postreduction radiographs are mandatory to confirm congruous reduction. Instability after pure dislocations is rare, and the joint is immobilized in slight flexion using a dorsal splint for 2 to 3 weeks. After the first week, the patient should be encouraged to remove the distal tape or Velcro fixation of the splint and actively flex the DIP joint while avoiding the last 20 degrees of extension.

DIP and thumb IP dislocations are rarely irreducible. When they do occur, it is most commonly the result of proximal disruption of the volar plate, which then becomes interposed between the head of the digital middle or thumb proximal phalanx and the base of the distal phalanx, preventing reduction (Figure 8.28).[92] Interposition of the flexor tendon,[102] a fracture fragment,[113] digital nerves,[103] and a sesamoid bone[72] have also been reported, and the condyles of the middle phalanx can become entrapped in a longitudinal rent in the flexor digitorum profundus tendon.[39] Irreducible dislocations require surgical removal or manipulation of the offending anatomic structure(s) to facilitate reduction. It is sometimes possible to approach these cases with a small dorsal incision, thereby avoiding a larger volar dissection. A Freer elevator is introduced to push interposed structures out of the joint in an atraumatic manner and lever the joint back into position.

Rarely, a dorsal dislocation may be associated with a fracture of the volar lip of the distal phalanx, akin to a PIP joint dorsal fracture-dislocation.[54] If the volar fragment is not avulsed with the flexor digitorum profundus tendon, the goal of treatment remains a stable closed reduction. If the profundus tendon is avulsed, however, it must be reattached surgically. Even when the flexor digitorum profundus is intact, a volar fracture fragment may be large enough to render the joint unstable. If mild to moderate flexion of the DIP joint is insufficient to keep the joint reduced and especially if more than 40% of the articular surface has been fractured, a volar plate arthroplasty is indicated.

Volar plate arthroplasty can be an effective treatment for this problem. One series of 10 patients (4 thumb IP joints and 6 finger DIP joints) who underwent volar plate arthroplasty for chronic dorsal fracture-subluxation had an average of 51 degrees and 42 degrees, respectively, of stable active motion. All patients had a flexion contracture, which averaged 12 degrees. Patient satisfaction was high, and there were no complications.[99]

Dorsal dislocation of both IP joints of a single digit, most often the small finger, has also been reported.[6] The force required to cause this double dislocation implies more extensive soft tissue injury. Aggressive hand therapy is instituted soon after stable reduction to maximize the range of motion.

Pure volar dislocations of the DIP joint are rare and probably spontaneously reduce. These are essentially mallet injuries and require splinting in full extension for 6 weeks, followed by progressive mobilization. However, an irreducible volar dislocation of a DIP joint has been reported in which the extensor mechanism was longitudinally split and the terminal tendon interposed, preventing reduction.[62]

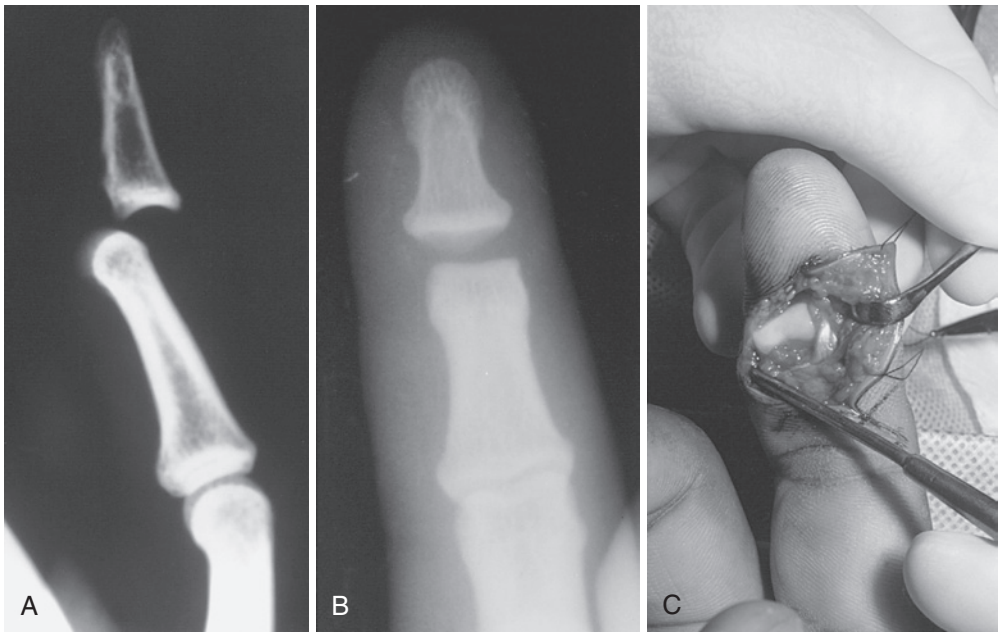

FIGURE 8.28 **A,** Irreducible dorsal dislocation of index distal interphalangeal joint. **B,** Posteroanterior view shows wide gap between middle and distal phalanges suggestive of soft tissue interposition. **C,** These injuries are commonly open, and, at exploration, the head of the middle phalanx was seen ulnar to the displaced flexor tendon. The volar plate was interposed between base of distal phalanx and head of middle phalanx.

METACARPOPHALANGEAL JOINT OF THE FINGER

ANATOMY

The MP joints of the fingers are relatively resistant to ligament injury and dislocation because of their intrinsic ligamentous structure, the surrounding tendons, and their protected position at the base of the fingers. They are most vulnerable to injury from forces directed ulnarly and dorsally. The articular surfaces form a condyloid joint. The metacarpal head is narrow dorsally, with a widened volar flare; this shape results in progressively more contact with the base of the proximal phalanx with increasing flexion.

The capsule of the MP joint extends from the metacarpal neck to the base of the proximal phalanx and is reinforced by specialized structures on all sides. The capsule is composed of areolar tissue dorsally and is reinforced by the loose insertion of the common extensor tendon. On the volar side, the joint is supported by the volar plate, which is continuous laterally with the deep transverse metacarpal (intervolar plate) ligament (Figure 8.29). The volar plate has a thick fibrocartilaginous distal portion and a thin membranous proximal portion. It does not have strong proximal checkrein ligaments comparable to those of the PIP joint. Lateral reinforcement for the volar plate is afforded by the collateral and intervolar plate ligaments, which insert into its lateral margins to produce linked support from one MP joint to the next.[85] The sagittal bands and the tendons of the intrinsic muscles provide additional, secondary support.[95] The collateral ligaments are more taut in flexion than in extension because of the cam effect created by the nonspherical shape of the metacarpal head, which has a longer dorsovolar axis than proximodistal axis (Figure 8.30). There is also broader and more stable articular contact between the metacarpal head and the base of the proximal phalanx beyond 70 degrees of flexion. Therefore, the joint is stable laterally in full flexion but allows some abduction and adduction in full extension.

Dorsal Metacarpophalangeal Dislocations

Dorsal dislocations of the MP joints of the fingers are relatively uncommon injuries. The most frequently involved digit is the index finger followed by the small finger. With exceptions,[90] dorsal dislocation of the central digits is usually seen only with concomitant dislocation of a border digit. Dorsal dislocation of a DIP joint and an MP joint in the same finger has been reported.[58]

The mechanism of injury is usually forced hyperextension of the digit as might occur from falling on an outstretched hand. The pathologic findings of complete dislocation of the index finger and the small finger are similar but not identical. In both instances, the volar plate ruptures in its membranous proximal portion and becomes interposed dorsally between the base of the proximal phalanx and the dorsal metacarpal head. If this were the only structure blocking reduction, reduction could be accomplished by using traction sufficient to draw the proximal edge of the volar plate over the metacarpal head. This is not possible, however, because the medial and lateral structures draw tightly around the narrow metacarpal neck and become even more taut with traction.

ANATOMY

Kaplan, in 1957, described the pathomechanics of the volar structures that block reduction of the dislocated MP joint.[66] The anatomic basis for complete, irreducible dislocation of the MP joint involves the following structures: the volar plate, the Al pulley, the flexor tendons, the lumbricals, and, in the small finger, the abductor and flexor digiti quinti. As the volar plate is drawn distally over the metacarpal head by the dislocating proximal phalanx, the periarticular tendons are drawn dorsally past the metacarpal head. In this manner, a tendon noose forms around the metacarpal head and tightens further with traction. In the index finger, these structures include the lumbrical muscle radially and the flexor tendons ulnarly. The latter remain in the proximal flexor pulleys, which are attached to the dorsally

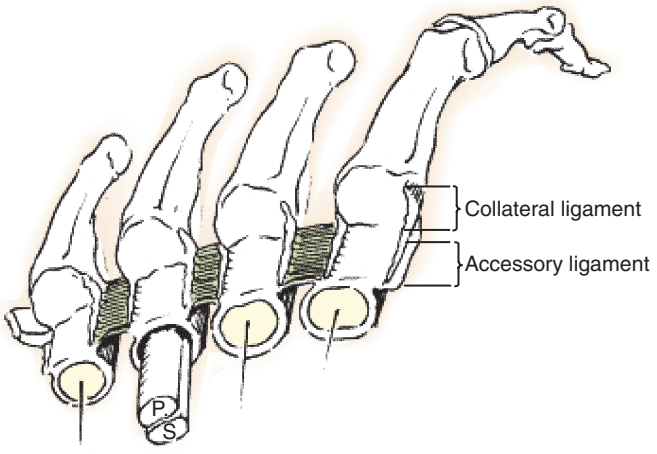

FIGURE 8.29 Intervolar plate ligaments that reinforce the ligament-box complex at each metacarpophalangeal joint. Because the volar plate is most securely attached to the proximal phalanx, this transverse ligament primarily supports the proximal phalanges. (From Eaton RG, Littler JW: Joint injuries and their sequelae, *Clin Plast Surg* 3:85–98, 1976.)

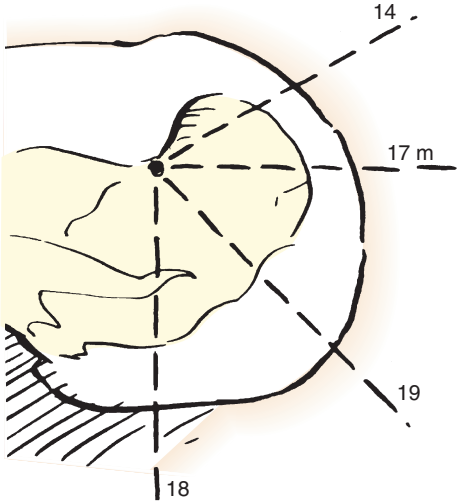

FIGURE 8.30 Diagram of cam effect of metacarpal head contour and relative length of collateral ligaments with increasing flexion. Shortening or loss of elasticity of collateral ligaments limits flexion. Metacarpophalangeal joint must be splinted in at least 50 degrees of flexion to maintain ligament length.

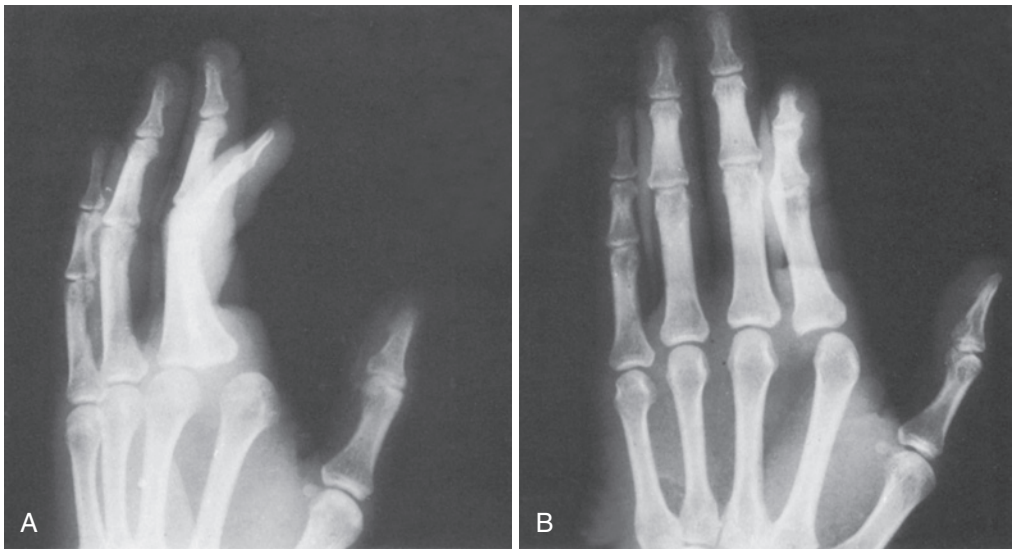

FIGURE 8.31 Radiographs of dorsal irreducible (complex) dislocation. **A,** Oblique view shows dorsal dislocation and a widened joint space caused by interposition of the volar plate. **B,** Ulnar shift of proximal phalanx suggests rupture of the radial collateral ligament.

displaced volar plate. In the small finger, the entrapping structures include the common tendon of the abductor digiti quinti and the flexor digiti minimi ulnarly and the lumbrical muscle and flexor tendons radially. The tendons are also drawn taut by the dorsally displaced volar plate and pulley.

Distinction must be made between subluxation (simple) and complete (complex) dorsal dislocations. Understanding this anatomic distinction is important in planning treatment, because the former is reducible by closed means whereas the latter is not. Similarly, an incomplete or simple dislocation can be converted into a complete or complex dislocation by an inappropriate attempt to reduce the finger by exaggerating the hyperextension deformity.

Simple Metacarpophalangeal Subluxation

Subluxation differs anatomically from complete dislocation because the volar plate is draped over the metacarpal head instead of entrapped within the joint, and the base of the proximal phalanx is postured in 60 to 80 degrees of hyperextension. If either hyperextension or traction is employed as part of the reduction maneuver of this incomplete lesion, it is possible to draw the entire volar plate dorsally, where it becomes folded between the base of the proximal phalanx and the metacarpal head, converting a subluxation into a complete or irreducible dislocation. The reduction maneuver for incomplete dislocations should therefore be performed by flexing the wrist to relax the flexor tendons and applying simple distally and volarly directed pressure to the dorsal base of the proximal phalanx. This *slides* the proximal phalanx and its attached volar plate over the metacarpal head into a reduced position. Early range of motion is encouraged, with a dorsal extension block splint to prevent extension beyond the neutral position.

Complete (Complex) Metacarpophalangeal Dislocation

Preoperative Evaluation. In contrast to the hyperextended proximal phalanx of a simple subluxation, patients with complete (complex) dislocations present with the MP joint of the digit held in slight extension; flexion is impossible. The distal joints are slightly flexed, and the digit itself is mildly deviated toward the adjacent, more central digit. A prominence is felt in the palm corresponding to the metacarpal head, and the adjacent skin may be puckered. Dorsally, a hollow can be palpated proximal to the base of the proximal phalanx.

Posteroanterior radiographs of complete dislocations show widening of the joint space (Figure 8.31). The identification of a sesamoid within the joint confirms the presence of an entrapped volar plate. In the lateral view, the dorsal dislocation is obvious and a large osteochondral shearing fracture from the metacarpal head may be identified. A Brewerton view may help demonstrate a fracture of the metacarpal head. This radiographic view is produced by placing the palm up and the dorsum of the MP joints against the radiograph plate. With the MP joints flexed approximately 65 degrees, the radiograph beam is tilted 15 degrees in an ulnar-to-radial direction. Be mindful on preoperative radiographs, as well as during surgical exploration, of the presence of osteochondral fragments that may need fixation or excision depending on size and location.

Surgical Techniques

MP dislocations can be approached either dorsally or volarly or in a combined approach. The dorsal technique popularized by Becton uses a straight dorsal incision to expose the extensor tendon and joint capsule, which are split longitudinally to gain access to the interposed volar plate.[9] After dividing the volar plate longitudinally in the midline, the two halves fall away as the proximal phalangeal base is gently reduced onto the metacarpal head.

The longer a dorsal dislocation remains unreduced, the more likely is the development of degenerative arthritis and the less satisfactory the result of surgery in terms of pain and ultimate range of motion. That notwithstanding, fair results have been reported after open reduction as long as 5 months after the original dislocation. This generally also requires a combined volar and dorsal approach to release the contracted collateral ligaments.

❖ AUTHORS' PREFERRED METHOD OF TREATMENT

A volar approach allows excellent visualization of any entrapped structures and the ability to extricate and repair them as needed. A regional brachial block is helpful to relax the extrinsic flexors. The index finger is exposed through an oblique volar incision running between the proximal and distal volar creases and extending as needed along the radial midaxial line of the affected proximal phalanx. A mirror image incision is used for the small finger, extending to the ulnar midaxial line. The radial neurovascular bundle is invariably tented over the protruding index metacarpal head and lies immediately beneath the skin. It may be easily damaged if the incision is not made with great care. Similarly, the ulnar neurovascular bundle is displaced in dislocations of the small finger MP joint. Once the skin is incised, the metacarpal head is immediately obvious in the subcutaneous tissue, herniated between the entrapping structures.

The main deterrent to reduction is the tension in the previously described muscle-tendon noose around the narrow metacarpal neck. This tension is maintained by the dorsal displacement of the flexor tendon that remains within the flexor sheath, which has been displaced dorsally with the volar plate. Reduction can be accomplished atraumatically by releasing the Al pulley. This relaxes the tension of one tendon limb of the noose mechanism and allows the proximal phalanx and the attached volar plate to fall back or be gently manipulated into the normal anatomic position.

Postoperative Management

Immobilization of the joint in 30 degrees of flexion is continued for 2 weeks, after which active range of motion is begun using a removable 10-degree dorsal extension block splint. At 4 weeks the splint is used only for protection and at 6 weeks is discontinued. Unlimited activity is allowed at 12 weeks.

Complications

Complex dorsal MP joint dislocations are not uncommon in children. Closure of the metacarpal head physis has been reported as a rare sequela of this injury.[79] Therefore, the family should be warned of this possibility at the time of treatment.

Repeated attempts at closed reduction, traumatic open reduction (i.e., prying the proximal phalanx volarly), or late reduction may lead to degenerative arthritis and, occasionally, osteonecrosis of the metacarpal head.[40] Failure to recognize the very superficial position of the neurovascular bundle tented over the metacarpal head may lead to its division during surgical exposure of the joint. Prolonged immobilization, late reduction, or severe adjacent tissue injury may produce excessive fibrosis and reduce the final range of motion. However, motion may continue to improve for as long as 6 to 8 months.

Expected Outcomes

Timely open treatment of irreducible MP dislocations is the single most important factor in determining patient outcomes and will lead to good results in a majority of patients.

Volar Metacarpophalangeal Dislocations

Irreducible volar dislocations of the MP joints of the fingers have been reported but are extremely uncommon. Four different anatomic structures that may prevent reduction have been reported. The dorsal capsule may be avulsed from the metacarpal proximally and become interposed between the base of the proximal phalanx and the metacarpal head. The distal insertion of the volar plate and/or collateral ligament can be avulsed and become lodged between the dislocated articular surfaces and prevent reduction.[87] In a border digit, a junctura tendinum may slip distal and volar to the metacarpal neck, also leading to an irreducible MP joint.[93] Successful closed reduction has been described and should be attempted under adequate anesthesia; failure necessitates an open reduction through a dorsal approach.

CRITICAL POINTS *Volar Approach to Complex Metacarpophalangeal Dislocations*

Preoperative Evaluation

- Document sensibility, because digital nerves are at risk in this approach.
- Obtain standard radiographs as well as Brewerton views (see text).

Technical Points

- Make an oblique volar incision over the metacarpal head.
- Incise *skin* only to avoid division of nearby digital nerves.
- Use blunt dissection to identify and retract nerves.
- Release the A1 pulley.
- Inspect for osteochondral lesions and address as needed.
- Use a blunt elevator or hemostat to leverage tendons away from the metacarpal head as the joint is reduced.
- No soft tissue repair is necessary; close the skin.

Postoperative Care

- Immobilize the joint in 30 degrees of flexion for 2 weeks.
- Begin active motion with an extension block splint at 10 degrees of MP flexion for 2 more weeks.
- Buddy tape the digit to the adjacent digit at 8 weeks.
- Unlimited use is allowed at 12 weeks.

Isolated Radial Collateral Ligament Ruptures of the Metacarpophalangeal Joints

Although isolated MP ulnar collateral ligament (UCL) ruptures are extremely rare, isolated radial collateral ligament (RCL) ruptures of the MP joints of the fingers are not. The mechanism of injury is forced ulnar deviation with the MP joint flexed. Patients will often present late for evaluation and treatment owing to persistent swelling and pain in a "jammed finger" that is not improving. The clinician should first examine the contralateral digit to determine normal tension in the RCL with the MP joint in both extension and flexion. Differential tension in the two positions is normal due to the aforementioned cam effect of the metacarpal head. In the injured digit, there will be tenderness along the radial aspect of the joint at either the origin or the insertion of the ligament (in a series of 12 patients with complete tears, 7 were avulsed from the metacarpal and 5 from the proximal phalanx; none was a midsubstance rupture).[65] Passive MP flexion of the injured digit will usually cause pain; forced ulnar deviation of the proximal phalanx will demonstrate gross instability and exacerbate the pain. Radiographic evaluation should include a Brewerton view to look for avulsed bone fragments, which are not uncommon.[76] Magnetic resonance imaging (MRI) has been suggested to help identify

the nature and location of the ligament disruption, although we have not found this necessary.

Like other ligament injuries, treatment depends entirely on the grade of injury. A grade I sprain is pain without laxity; a grade II injury demonstrates an endpoint to passive stress testing in 60 degrees of flexion; and a grade III injury represents avulsion with no endpoint to passive stress. Grades I and II injuries will heal with favorable outcomes when treated with splinting.[37] Grades III tears in two case series have worse outcomes with conservative treatment.[37,65] A digital block can be used to fully assess ligamentous integrity if the examination is too limited by pain.

Initial treatment for grades I and II injuries usually consists of immobilization of the joint in 30 degrees of flexion for 3 weeks for comfort. Alternatively, some physicians encourage immediate protected motion with a buddy strap to the ulnar adjacent digit. Clinical reassessment with gentle RCL stress is performed at 3 weeks, and if notable tightening or stability of the RCL is appreciated and the patient confirms a decrease in symptoms, primary healing of the ligament is likely. Further splinting or buddy taping is adjusted on an individual basis. Patients should be counseled that even with a stable MP joint, pain with maximal MP flexion and forceful gripping may continue for up to a year. If instability or pain is not markedly improved at 6 weeks, despite an endpoint, surgical repair or reconstruction may be considered and will give satisfactory results.

Grade III injuries or those with avulsion fragments and instability in the young and active patient should be repaired primarily. In these cases, there is no advantage to a trial of conservative care.[37,65] A dorsal radial incision is made over the joint. Sensory nerves are protected. The extensor hood is divided along the radial aspect of the tendon. The capsule is similarly divided. The injured ligament is identified and mobilized. The site of reattachment is cleared to bleeding bone and a minisuture anchor is placed, directed obliquely away from the joint. The ligament is tensioned with the MP joint in at least 45 degrees of flexion. The capsule and extensor hood are repaired separately with 4-0 suture. The joint is immobilized for 5 to 6 weeks in 45 degrees of flexion. A range of motion of 0 to 80 degrees without pain in acute repairs could be expected.[65]

Patients with grade I or II injuries do not tend to present late because most of these injuries eventually heal. If a patient presents with a subacute or chronic complete RCL injury, conservative treatment is not recommended. In one case series of nine chronic presentations (average, 28 weeks; maximum, 150 weeks), primary ligament repair was possible and all patients improved following surgery.[65] Some authors have preferred tendon graft reconstruction for chronic RCL injuries.[37]

Locked Metacarpophalangeal Joints

Locking of the MP joint of a finger is an unusual entity characterized by a moderate flexion deformity of the joint but normally functioning PIP and DIP joints. The locked MP joint must be differentiated from a locked trigger finger. This should not be difficult, because in a locked trigger finger, full active extension of the IP joints is not possible.

Although various causes have been reported, such as sesamoid entrapment or periarticular exostoses,[98] the usual cause of locking is the restriction of collateral or accessory collateral ligament excursion by a prominent metacarpal head radial condyle or actual impalement on a marginal degenerative osteophyte.[96] The condition can be degenerative or idiopathic. In the former group, the patients tend to be older, and oblique or specialized radiographs will usually demonstrate degenerative changes and a marginal osteophyte. Although any finger may be involved, the long finger is the most frequently affected. In the idiopathic group, the patients are younger and have no degenerative disease. The index finger is usually involved, and the pathologic structure is a very prominent radial condylar margin of the metacarpal head that entraps the RCL.

Most cases can be resolved with the following technique.[124]

1. Inject 2 mL of normal saline dorsally into the MP joint. Lidocaine can be used, but it may increase the risk of fracture due to an anesthetic joint. The injection is hypothesized to distend the joint capsule and displace the ligament laterally enough to disengage it.
2. Flex the joint.
3. Perform radial deviation and external rotation of the joint, with the goal of disengaging a ligament that is still entrapped.
4. Gently extend the digit. The joint is kept in an extension splint for 1 week after which normal motion is allowed. Recurrence has been reported.[124]

If this maneuver is unsuccessful, or if there has been a previous episode of locking, it is necessary to explore the joint and remove the offending osteophyte or condylar margin. Occasionally, a patient will present with a chronically locked MP joint. Because the collateral ligaments are at full length in flexion, good to excellent motion is still usually achieved after surgery.

METACARPOPHALANGEAL JOINT OF THE THUMB

ANATOMY

The primary arc of motion of the thumb MP joint is in the flexion/extension plane, with secondary, minor arcs of abduction/adduction and pronation/supination. The radial condyle of the metacarpal head has greater dorsovolar height than the ulnar condyle, which allows an element of conjunct rotation in pronation with increasing flexion. The range of motion of the thumb MP joint is the most variable of any joint in the body, resulting from different radii of curvature of metacarpal heads. There is some evidence for an inverse relationship between the range of motion and the incidence of injury (i.e., limited range of motion is associated with an increased frequency of joint injury).[104]

Because of the relatively large radius of curvature of the base of the proximal phalanx, the MP joint of the thumb has little intrinsic stability and depends instead on a complex arrangement of capsular, ligamentous, and musculotendinous structures. It is supported laterally by the strong proper collateral ligaments, which arise from the lateral condyles of the metacarpal and pass obliquely to insert on the volar third of the proximal phalanx. The accessory collateral ligaments originate from a more volar site on the metacarpal head and insert on the volar plate and sesamoids on either side of the joint. The proper collateral ligaments are tight in flexion and loose in extension, and,

conversely, the accessory collateral ligaments are tight in extension and loose in flexion. The floor of the joint is formed by the volar plate, creating a three-sided ligament-box configuration similar to that described previously at the PIP joint. However, it differs from the PIP complex because there is no flexor sheath proximal to the plate and, consequently, no strong checkrein ligaments are present. In addition to the fibrocartilaginous plate, volar support is provided by the thenar intrinsic muscles that insert into a pair of sesamoid bones, embedded in the thickened distal volar plate. The adductor pollicis inserts on the ulnar sesamoid, and the flexor pollicis brevis and abductor pollicis brevis insert on the radial sesamoid. Both muscles also have secondary insertions into the extensor mechanism via the adductor and abductor aponeuroses, which provide additional dynamic lateral stability.

The anatomy of the ulnar and RCL origins is important when considering surgical repair. Carlson and colleagues[17] demonstrated that the UCL origin is 4.2 mm from the dorsal edge and 5.3 mm from the joint. Its insertion is 2.8 mm from the volar lip and 3.4 mm from the joint. The RCL origin is 3.5 mm from the dorsal margin and 3.3 mm from the articular surface. The radial collateral insertion is 2.8 mm from the volar lip and 2.6 mm from the joint line. Because these are average measurements on a large cohort of male and female cadavers, it is important to know that the metacarpal origin of the ligaments is approximately a third of the distance volar from the dorsal cortex, and the proximal phalangeal insertions are approximately 25% dorsal to the volar cortex. These origin and insertion sites differ substantially from those in the published literature.[17]

Acute Ulnar Collateral Ligament Injuries (Skier's Thumb)

Preoperative Evaluation

Injuries to the ulnar collateral ligament (UCL) of the MP joint of the thumb are common, particularly among skiers and ball-handling athletes. Moberg and Stener[86] noted UCL injuries to be 10 times more common than RCL injuries. The mechanism of injury is sudden, forced radial deviation (abduction), often resulting from a fall on an outstretched hand with the thumb abducted. In skiing, if a person falls while gripping the ski pole, the handle abducts the thumb. Most modifications in ski pole design, including elimination of the strap, have not been shown to substantially reduce the incidence of thumb injuries.[36] Snowboarders also catch a thumb during falls and turns. Associated injuries include tears of the dorsal capsule and ulnar aspect of the volar plate and occasionally a rent in the adductor aponeurosis. Volar subluxation of the MP joint may result from concomitant tears of the dorsal capsule and UCL. Distal tears of the UCL at its insertion are more common than proximal tears. Ruptures within the substance of the ligament or avulsion of the ligament from the metacarpal head occasionally occur.

Smith[107] observed that not only do the collateral ligaments of the thumb MP joint afford lateral stability but they also resist volar subluxation. If one ligament is torn, the proximal phalanx tends to rotate volarly on the side of the tear, with the opposite intact ligament serving as the axis. In the case of an isolated UCL rupture, the proximal phalanx rotates in supination around the intact RCL. Conversely, if the RCL is torn, the proximal phalanx pronates relative to the metacarpal.

Several fracture patterns may be associated with UCL injuries. An avulsion fracture of the ulnar base of the proximal phalanx at the insertion of the ligament is most common. Typically, the fracture fragment is small and includes little of the articular surface. Fractures involving more than 10% of the articular surface can occur and may require fixation if they are displaced 2 mm or more and associated with articular incongruity. Somewhat surprisingly, there is incomplete agreement about the optimal treatment for small, minimally displaced or nondisplaced avulsion fractures. Cast immobilization is generally believed to be adequate, but one series found that nine of nine patients with small avulsion fractures and displacement of less than 2 mm had persistent pain after immobilization, and all required secondary ORIF.[25] Avulsion fractures from the metacarpal head and intraarticular shearing fractures of the volar surface of the radial condyle of the metacarpal head have also been reported.[110] An interesting fracture pattern that is rare but potentially problematic is one in which there is an avulsion of the UCL with or without an avulsion fracture attached to the ligament and a simultaneous articular shear fracture of the proximal phalangeal base.[67] If attention is directed solely to the shear fracture, a complete tear of the UCL might be missed. In the skeletally immature individual, isolated rupture of the UCL without a Salter fracture of the proximal phalanx is rare but does occur.

Stener Lesion

In 1962, Stener[109] described the lesion that has come to bear his name, which he observed in 25 of 39 cases of complete rupture of the UCL of the thumb (Figure 8.32). At surgery he found the adductor aponeurosis interposed between the distally avulsed ligament and its insertion into the base of the proximal phalanx. He concluded that without contact at the site of rupture, ligament healing would be imperfect and would result in ulnar laxity regardless of the period of immobilization.

Adductor aponeurosis interposition does not occur in partial ruptures. Therefore, it is critical to distinguish between acute complete and partial ruptures of the UCL. That differentiation can usually be made clinically, although there is no absolute consensus in the literature concerning the criteria for making the diagnosis. Biomechanical modeling suggests the ligament is under maximum tension at 40 degrees of flexion, which would therefore be the best position for testing the proper collaterals.[46]

Patients with injuries to the UCL usually have tenderness, ecchymosis, and swelling along the ulnar border of the joint. Most authors use the criteria of 30 degrees of laxity of the ulnar side of the joint when stressed radially in MP extension and 40 degrees of flexion, as well as 15 degrees more laxity when compared with the contralateral thumb. The examination in flexion is far more relevant to the diagnosis of a complete tear because the volar plate will provide substantial lateral stability in full extension. It is hard to imagine that clinical testing is sufficiently precise to determine the difference between 30 and 35 degrees of laxity. I find it more helpful to assess instability by the presence or absence of an endpoint to valgus stress. If the ligament is completely torn, the joint can be manually opened without resistance and without a clear endpoint. A partially torn

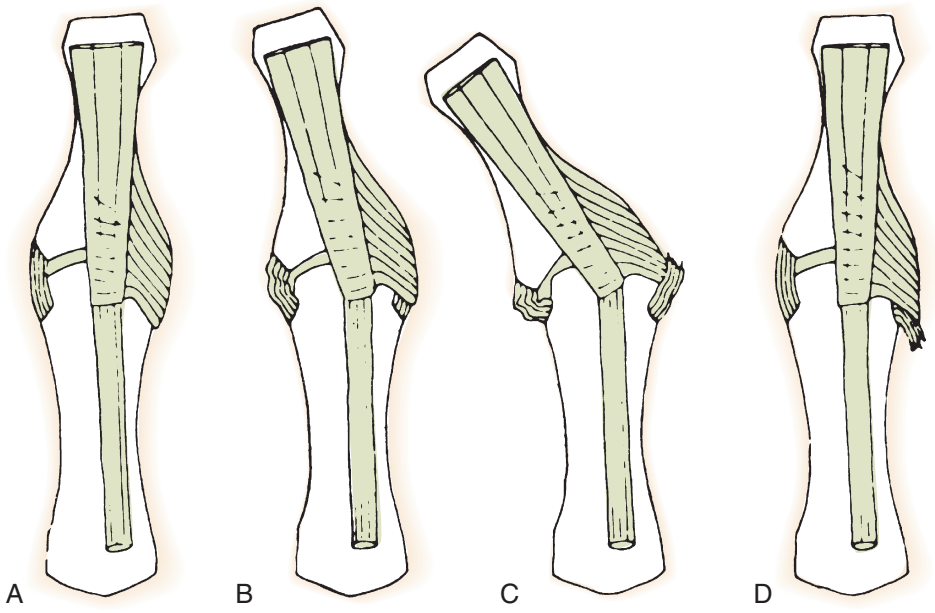

FIGURE 8.32 Diagram of the displacement of the ulnar collateral ligament of a thumb metacarpophalangeal joint. **A,** Normal relationship with the ulnar ligament covered by the adductor aponeurosis. **B,** With slight radial angulation, proximal margin of the aponeurosis slides distally and leaves a portion of ligament uncovered. **C,** With major radial angulation, the ulnar collateral ligament ruptures at its distal insertion. In this degree of angulation, the aponeurosis has displaced distal to the rupture and permitted the ligament to escape from beneath it. **D,** As the joint is realigned, the proximal edge of the adductor aponeurosis sweeps free end of the ligament proximally and becomes interposed between the ligament and its insertion (Stener lesion). Unless surgically restored, the ulnar ligament does not heal properly and is unstable to lateral stress. (From Stener B: Skeletal injuries associated with rupture of the ulnar collateral ligament of the metacarpophalangeal joint of the thumb: a clinical and anatomic study, *Acta Chir Scand* 125:583–586, 1963.)

ligament (grade II sprain) has a discrete endpoint even if there is some laxity with stress. Rarely, patients have too much pain and guarding to allow an adequate assessment of stability. In that case, the MP joint can be anesthetized with a local nerve block before stressing the joint.

Standard posteroanterior, lateral, and oblique radiographs should be obtained in all patients with suspected UCL injury to identify an accompanying avulsion or condylar fracture. Radiographs should be done before stressing the joint. In the absence of a fracture, the posteroanterior view is usually normal. A rare exception is when the joint is so unstable that there is radial deviation of the proximal phalanx at rest. Volar subluxation of the proximal phalanx in the lateral view suggests an associated dorsal capsular tear or extensor insertion injury that may require repair. For some patients with generalized ligament laxity, a small degree of volar subluxation is normal. To be certain that the subluxation is pathologic, comparison should be made with radiographs of the contralateral thumb. We have not found stress radiographs helpful in the diagnosis or treatment algorithm. A diagnosis of a torn UCL remains primarily a clinical diagnosis. The use of diagnostic ultrasound and MRI has received considerable attention in recent years, particularly in the radiology literature. In one series, ultrasound accurately diagnosed the Stener lesion in 32 of 39 patients in whom there was operative confirmation of the findings. There were four false-positive results and three false-negative results.[52] MRI is slightly more accurate but considerably more expensive.[108]

Historical Review

Campbell[16] described the injury as a "gamekeeper's thumb," although the pathologic process that he was describing was chronic repetitive attenuation of the ligament by a radially directed force on the ulnar side of the thumb among Scottish gamekeepers who fractured the necks of rabbits between their thumbs and index fingers. The phrase *gamekeeper's thumb* describes chronic instability of the UCL, although it has been repeatedly misapplied in the literature when referring to any instability of the UCL, acute or chronic.

Treatment

There is general agreement that acute partial ruptures of the UCL can be effectively treated by a 4-week period of continuous immobilization in a thumb spica cast or splint to immobilize only the MP joint while leaving the IP joint free. This is followed by an additional 2-week period of splint immobilization, during which active range-of-motion exercise is begun. Because the injured ligament maintains its normal anatomic relationship, healing with full recovery can be expected. Strenuous activity with the thumb is avoided for 3 months after the injury. It is common for patients to have a degree of aching pain on the ulnar side of the MP joint for 6 or more months after the injury despite having no laxity on examination. Athletes with minor injuries to the UCL can be returned to play after 2 to 4 weeks of immobilization with a protective "playing splint."

Operative intervention is recommended for repair of complete tears as a more predictable and perhaps quicker path to recovery. Clinical diagnosis of a Stener lesion is difficult. Therefore if conservative treatment is even to be considered it is incumbent on the physician to rule out a Stener lesion, usually with advanced imaging. Conversely, if after clinical examination, a diagnosis of a complete tear requiring operative repair is made, MRI or ultrasound imaging is unnecessary.

Types of Operations

The technique used for repair of complete tears of the UCL depends, in part, on the location of the tear within the ligament. Intrasubstance tears are less common and can be fixed by direct suture of the ligament to itself or to the periosteum. The more common distal avulsion of the ligament necessitates reattachment of the ligament to its bony insertion using any of a number of techniques, including a pull-out suture or bone anchor.

Arthroscopic treatments have also been described. Ryu and Fagan monitored eight patients in whom complete tears of the UCL were treated successfully by arthroscopic reduction of Stener lesions without suture repair.[101] The results were good, but the series was small. Slade and Gutow[106] performed arthroscopic-assisted repair of the ligament using a bone anchor for bony reattachment or direct arthroscopic suture for midsubstance tears. The theoretical advantage of arthroscopic repair is the decreased manipulation of the adductor aponeurosis and capsule, which may result in less postoperative scarring and more rapid restoration of motion. A potential disadvantage includes the limited visualization of the dorsal sensory nerve branches, which are susceptible to injury. Introduction of arthroscopic instruments into a small joint by an inexperienced operator has the potential to traumatize the articular cartilage. There are no comparative studies to assess whether the technique is time efficient or clinically advantageous.

❖ AUTHORS' PREFERRED METHOD OF TREATMENT

In patients having less than 30 degrees of laxity of the UCL, less than a 15-degree differential in laxity compared with the contralateral side, and a discrete endpoint to joint opening, the assumption is that the tear is incomplete. Nonoperative treatment consists of immobilization of the MP joint for 4 weeks in neutral alignment and slight flexion. Adams and Muller have shown that excessive flexion and premature range of motion increase the strain on the healing ligament.[3] The IP joint is left free and IP range of motion is encouraged to avoid adherence of the extensor tendons to the injured MP joint capsule. The MP joint can be immobilized either with a custom-molded splint or a cast. The splint may be a short opponens splint that extends to a point just proximal to the thumb CMC joint or a shorter splint that leaves the CMC joint completely free. Take care when molding the spica cast to avoid the natural tendency to abduct the thumb ray and to be certain that no radial deviation occurs through the unstable MP joint. The functional results of splint and cast immobilization have been shown to be comparable, and most patients prefer splinting.[2]

Technique of Open Repair of the Thumb Metacarpophalangeal Ulnar Collateral Ligament. If clinical evaluation confirms that an acute complete rupture of the UCL is present, surgical repair is indicated. A lazy-"S"–shaped incision is used that parallels the ulnodorsal border of the thumb metacarpal to the MP joint, curving sharply in a volar direction to parallel the joint and extending distally along the ulnar midaxial line (Figure 8.33). The distal limb of the incision should be sufficiently volar to give easy access to the volar base of the proximal phalanx and the volar plate. Branches of the superficial radial nerve lying in the deep subcutaneous plane should be identified and protected. The proximal edge of the adductor aponeurosis is identified. When a Stener lesion is present, it appears as an edematous, rounded mass that may obscure this otherwise well-defined proximal border (Figure 8.34). A longitudinal incision is made at the dorsal margin of the sagittal bands incorporating 1 to 2 mm of the ulnar edge of the extensor pollicis longus tendon to facilitate repair of the sagittal bands at the end of the procedure. The aponeurosis is reflected to expose the ulnar aspect of the MP joint, including the volar base of the proximal phalanx. The joint should be examined to inspect the articular cartilage. A small cartilaginous shear fragment will occasionally be found and should be removed if loose.

Tears in the middle two thirds of the ligament can be reapproximated with interrupted figure-of-eight or horizontal mattress sutures using nonabsorbable 4-0 braided synthetic suture material. However, the ligament is usually avulsed distally and can be approximated to the distal stump or into the bone defect from which it was avulsed with a pull-through suture technique

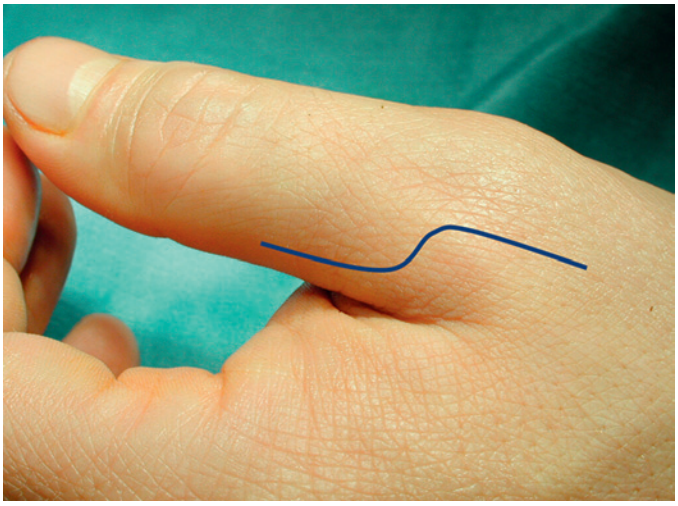

FIGURE 8.33 Incision for repair or reconstruction of ruptured ulnar collateral ligament of metacarpophalangeal joint of thumb. Exposure is excellent, and healing leaves almost imperceptible scar.

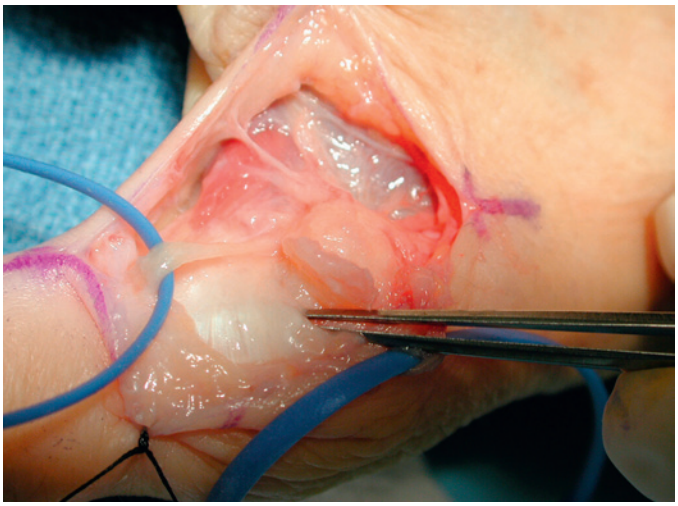

FIGURE 8.34 Displaced edematous end of ulnar collateral ligament lying proximal to edge of adductor aponeurosis, creating a palpable mass, which was noted preoperatively. Forceps is beneath the aponeurosis; the radial sensory nerve is protected with a loop. (Copyright © Scott Wolfe, MD.)

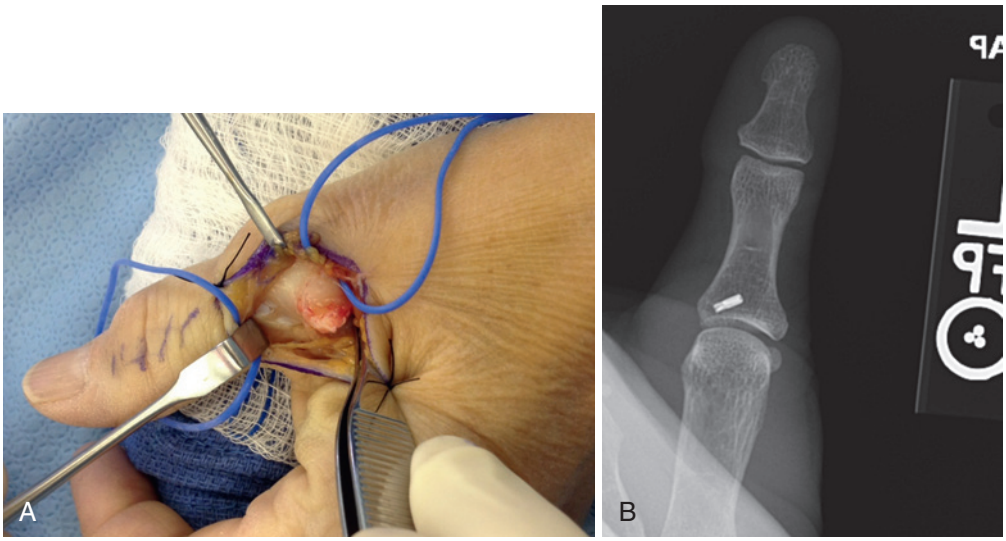

FIGURE 8.35 Ulnar collateral ligament (UCL) repair with bone anchor. **A,** Acute distal UCL disruption with Stener lesion. Vessel loop is around the dorsal sensory nerve branch. **B,** Postoperative posteroanterior radiograph demonstrating anchor in the ulnar base of the proximal phalanx and restoration of alignment and congruency of the metacarpophalangeal joint.

or a small bone anchor (Figure 8.35, *A* and *B*). In either case, the repair is performed with the joint flexed at 45 degrees to avoid overtightening.

Secure fixation of the ligament to bone can be achieved by a pull-through suture technique after scarifying the bone at the site of reattachment with a curet or rongeur. A 2-0 nonabsorbable suture is placed in the proximal stump of the UCL with a Krakow stitch. Keith needles are drilled using a Kirschner wire driver across the base of the proximal phalanx in an ulnoradial direction, exiting on the radial side with a small bone bridge between the needles. The ends of the suture in the UCL stump are threaded through the eye of the Keith needles, which are then pulled through the proximal phalanx. The ligament is pulled up to the shallow trough previously made in the ulnar base of the phalanx, and the ends of the suture are tied over the bone bridge through a small radial incision. The repair is robust and can be tensioned easily. The repair can be supplemented by suturing the proximal stump of the ligament to any remnants of the distal stump or periosteum. If I am concerned about the quality of the collateral ligament to hold a stitch, I find the Krakow stitch in this technique may work better than the simpler stitches used typically with a bone anchor repair.

When the collateral ligament tear extends volarly to also involve the accessory collateral ligament, sutures should be preplaced for accessory collateral ligament repair prior to reattachment of the proper collateral ligament.

Most ligament avulsions are repaired using a bone anchor. The pilot hole for the anchor is drilled in the ulnar base of the proximal phalanx after the reattachment site is cleared of soft tissue. The anatomic attachment site for a distal avulsion of the UCL is 25% dorsal from the volar surface of the proximal phalanx.[17] A single anchor is placed volar to the axis of the joint. The anchor is advanced into the drill hole, and one suture is securely locked into the proximal stump of the ligament. The second suture (the "post") glides through the eyelet in the anchor such that the tension will "dock" the ligament into the repair site The second suture is passed through the ligament at its insertion point, separated as widely as possible from the first to spread out the ligament. A single simple throw may be placed in the suture and tightened down to check the range of motion and ensure satisfactory tension on the repair before completing the knots.

A few additional steps should be considered before closure. First, a suture should be placed between the distal volar portion of the repaired ligament and the volar plate to secure this vital three-dimensional complex. Second, if there is a large capsular tear and joint subluxation or rotation, the tear should be repaired. Third, gentle radial stress is applied to the joint to test the stability of the repair. A Kirschner wire across the MP joint can be used to secure the joint and can be placed dorsal to the repair site.

If a fragment of bone accompanies the avulsed ligament, the repair depends on the size of the fragment. If the fragment is small (>10% to 15% of the articular surface), it may be excised and the ligament inserted directly into the defect with a pull-out suture or anchor. If the fragment is large, it is reduced anatomically into the defect with a pull-out suture, Kirschner wires, one or more minifragment screws, or an interosseous wire.

The adductor aponeurosis is repaired with braided nylon suture, with care taken to avoid capturing the capsule with the repair. The skin is reapproximated with a running subcuticular suture of 4-0 monofilament suture. The thumb is immobilized in a thumb spica molded splint or cast with the IP joint left free to prevent adhesions of the extensor mechanism during healing. Immobilization is continued for 4 weeks, after which a hand-based thermoplastic splint is used to protect the repair. The splint is removed approximately four times per day for controlled active range-of-motion exercise, preferably under the supervision of a hand therapist. Some biomechanical studies suggest that the load during active motion is one third of the failure load of a suture anchor repair, so that active range of motion might be able to be initiated earlier than 4 weeks in

compliant patients.[46] Splint protection is discontinued 6 to 8 weeks postoperatively. Activities that stress the UCL are avoided, and unrestricted use is not recommended for 3 to 4 months after surgery. Vague discomfort and some tenderness and thickening on the ulnar side of the joint can be expected to persist for as long as 1 year.

Postoperative Management and Expectations

We advise patients that when rehabilitation is begun 4 weeks postoperatively, they will be stiff and that it will take several weeks to work out that stiffness with therapy and exercise. Ultimately, they can expect range of motion of the MP joint averaging 80 to 90% of the uninjured thumb and nearly full range of motion of the IP joint. Pinch and grip strength are usually regained to within 5 to 10% of the contralateral side. Patients are often concerned about whether they will be able to return to preinjury sporting activities. In the majority of cases, full athletic participation, including contact sports, can be resumed by approximately 4 months postoperatively. Selective return to recreational activities can be considered sooner, but only if the thumb is protected with a splint and/or taped securely.

After 4 weeks of immobilization, MP and IP flexion and extension and full range of motion in the CMC joint and wrist are encouraged. Radially directed force on the tip of the thumb and resisted activities with the thumb are prohibited. The splint is worn full time except for during bathing and exercise.

During the ensuing 2 weeks (weeks 6 to 8) the patient gradually weans from the splint. During the first week, it is off primarily at mealtimes and during sedentary activity. In the second week, nonstrenuous activities at home and in an office are allowed and patients begin light resisted activities such as manipulating zippers and buttons. Flexion of the IP joint against slight resistance is begun with the therapist. By the seventh postoperative week, full active range of motion of the thumb is encouraged.

By 9 to 10 weeks postoperatively, the patient should have regained nearly full active range of motion. Focused exercises compensate for any deficit in that range. The patient is expected to have between 60 and 75% of normal pinch strength. The only activities that are restricted are forceful torque and radially directed pressure on the thumb tip. Full, unrestricted activity is allowed at 3 months, with the exception of contact sports, which can be played, if necessary, with taping or semirigid splinting of the MP joint.

The most common complication of UCL repair is neurapraxia of the crossing branches of the dorsal sensory branch of the radial nerve. Manipulation and traction on the nerve during the procedure can cause numbness and tingling on the dorsoulnar aspect of the thumb in 10 to 15% of patients, and they should be counseled about this possibility preoperatively. These symptoms are usually self-limited but can last from days to weeks and can be disconcerting, particularly if the patient is not forewarned. The likelihood of the problem arising can be diminished by fully mobilizing the nerve during the exposure and retracting it gently. If vessel loops are used for retraction, a suture should be used to secure the loop rather than an instrument. Another potential complication is stiffness, which can result from reattaching the ligament in a nonanatomic location, particularly one too dorsal relative to the axis of the joint (see previously).

CRITICAL POINTS *Repair of Complete Acute Ulnar Collateral Ligament Tears*

Preoperative Evaluation

- Physical examination is usually adequate for diagnosis; look for lack of a firm endpoint to valgus stress.
- Obtain posteroanterior, lateral, and oblique radiographs to assess for osteochondral lesions or fractures.
- Consider advanced imaging to assess for a Stener lesion if nonoperative treatment of a complete UCL tear is elected.

Technical Points

- Avoid injury to the dorsal sensory nerve branch that crosses the operative field.
- Intrasubstance tears are sutured with 3-0 or 4-0 braided synthetic suture, but consider a longer period of immobilization than with a repair to bone.
- Reattach the ligament avulsions at their anatomic insertion site[17] with a bone anchor or pull-out suture.
- Remember that avulsion fractures and ligament tears have been reported together, so if the fracture is repaired, check the ligament origin and insertion as well.
- Tie down sutures with the joint flexed at 45 degrees to avoid overtightening.
- Repair the accessory collateral component using additional sutures to the volar plate.
- Repair the adductor aponeurosis with 4-0 absorbable suture.
- Avoid stress on the repair when molding a splint or cast.

Postoperative Care

- The joint is immobilized for 4 weeks following operation.
- Apply a thermoplastic splint for 2 to 4 additional weeks.
- Begin range-of-motion exercises at 4 weeks.
- Avoid radially directed stress on the thumb tip for 12 weeks.

Chronic Ulnar Collateral Ligament Injuries (Gamekeeper's Thumb)

Preoperative Evaluation

Causes of chronic instability of the UCL include an untreated acute tear, failure to recognize a Stener lesion, or progressive attenuation of the ligament. Patients with chronic instability usually present with pain, swelling, and weakness of the involved thumb. The pain tends to be exacerbated by forceful pinch and activities requiring torsional motions of the hand, such as unscrewing jar tops. Holding large objects like a half-gallon container of milk may be painful and may cause a feeling of instability or lack of power because of the thumb's inability to resist counterpressure.

Preoperative evaluation of patients with chronic instability of the UCL is similar but less challenging than that of patients with acute instability. The resting posture of the thumb should be observed for volar subluxation or radial deviation of the MP joint. Chronic instability is manifested by gross instability to valgus stress with no endpoint. The presence of a Stener lesion in chronic instability is a moot point, because symptomatic chronic tears likely require repair or reconstruction. Crepitus with active motion suggests degenerative disease.

Radiographic assessment includes posteroanterior, lateral, and oblique views of the thumb. Specific attention should be paid to the presence of degenerative disease, as well as volar and/

or radial subluxation of the joint. Stress views occasionally help clarify the degree of laxity when clinical examination is not definitive. Advanced imaging studies are not indicated to define a Stener lesion.

In all but the most sedentary patients, in whom a splint may suffice, repair, reconstruction, or joint fusion will be necessary.

Types of Operations

Increased time from injury to treatment may decrease the likelihood of direct repair, and the patient and surgeon must be prepared preoperatively for either repair or reconstruction. In many cases, repair is still possible by mobilizing the retracted ligament from the surrounding and scarred soft tissue bed. If augmentation of a local tissue repair is required, the adductor tendon can be split longitudinally and left attached distally, and the volar half can be swung into place proximally to reconstitute or reinforce local tissue. If no local tissue is available, UCL reconstruction is most commonly performed with a free tendon graft. There are technical variations as to how grafts are passed through or attached to the metacarpal and proximal phalanx.

Smith[107] treated chronic UCL instability with reconstruction using a free tendon graft. The ulnar aspect of the MP joint is exposed with a midaxial incision. The adductor aponeurosis is incised longitudinally and mobilized from the underlying soft tissue, exposing the capsule. A 2.8-mm hole is drilled in the ulnar base of the proximal phalanx in the area of the anatomic insertion of the UCL[7,17] (Figure 8.36). A tendon graft is obtained (Smith preferred the palmaris longus), and a figure-of-eight suture is placed in the free end of the graft. The two ends of that suture are placed on needles and passed through the holes in the base of proximal phalanx and through the radial cortex, where the sutures are brought out through the skin and tied over a button; alternatively, the tendon graft can be woven through a channel in the base of the proximal phalanx (see Figure 8.36), The torn UCL is identified and dissected free of surrounding scar tissue. If a proximal stump of ligament remains on the metacarpal head, the graft is woven into the ligament remnant through parallel longitudinal incisions. If there is no usable remnant of ligament, the tendon graft is fixed to the metacarpal through drill holes in the metacarpal head at its anatomic origin[7,17] (Figure 8.37, *A* and *B*). Graft positioning is essential because even small variations from the anatomic origin and insertion sites will limit motion (see previously). The abductor aponeurosis is repaired and the skin is reapproximated. A thumb spica cast is worn for 4 weeks postoperatively. Thereafter, the thumb is protected for an additional 5 weeks in a splint.

The only absolute contraindication to reconstruction is osteoarthritis of the MP joint, in which case arthrodesis is a dependable option, with rapid pain relief and recovery of function. A relative contraindication to ligament reconstruction is marked volar subluxation and/or supination of the MP joint,

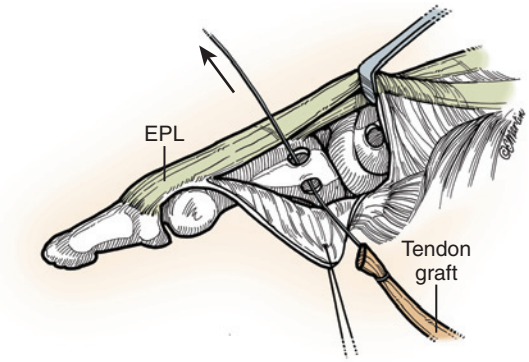

FIGURE 8.36 Method for reconstruction of the ulnar collateral ligament with a free tendon graft. Gouge holes are made at the 1 o'clock and 5 o'clock positions on the ulnar base of the proximal phalanx. A second gouge hole is made slightly obliquely across the metacarpal neck. *EPL,* Extensor pollicis longus. (Copyright © Elizabeth Martin.)

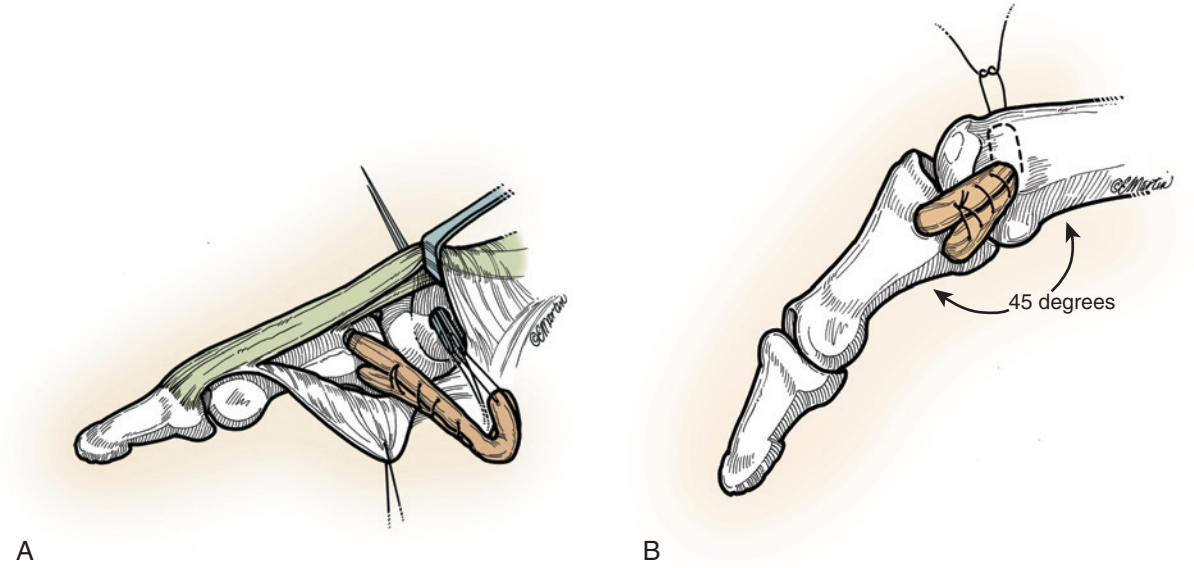

FIGURE 8.37 Free tendon graft tensioning. **A,** The ends of the free graft are whipstitched, and the suture ends are passed on straight needles through radial cortex. **B,** Graft is tensioned into the docking hole in the metacarpal head, and the suture is tied down over the radial cortex through a small counterincision. (Copyright © Elizabeth Martin.)

which may not be adequately addressed by these reconstructive procedures.

❖ AUTHORS' PREFERRED METHOD OF TREATMENT

The authors use 6 weeks as a general criterion for distinguishing between acute and chronic UCL injuries. It is certainly the case that local tissue can sometimes be used for repair of injuries that occurred more than 6 weeks earlier. The remnant of the torn ligament must be supple. Characteristically, the proximal stump of the ligament is shortened, retracted, and surrounded with a layer of fibrous tissue. To use the ligament for repair, that layer of fibrous tissue needs to be mobilized and the substance of the ligament brought out to its physiologic length. It is reattached to the base of the proximal phalanx with a bone anchor. If the local tissue is of questionable length or quality, a primary repair should not be done. This is typically the case in surgery performed more than 6 to 12 weeks after injury; this time frame is not absolute, however; it is the character of the tendon that should be the main guide for decision making.

My preferred technique for late reconstruction of an incompetent UCL is to replace the static restraint with a free tendon graft anchored in the medullary canals of both the metacarpal and the proximal phalanx.[41] The technique of passage of the tendon graft very nearly recapitulates the normal anatomy of the UCL and attempts to resist the volar and rotatory translation by repair of surrounding capsular and volar plate tissues. The exposure is the same as that described earlier for repair of acute ligament ruptures. The adductor aponeurosis is exposed, and an attempt is made to preserve the sagittal fibers of the extensor mechanism. A volar-based triangular flap of the adductor aponeurosis distal to the sagittal band is reflected to expose the MP joint and base of the proximal phalanx. The scarred, redundant UCL and capsule are resected from the concavity of the metacarpal head to the base of the proximal phalanx. A unicortical 2.5-mm hole is made in the proximal phalanx 3 mm from the joint and 3 mm from the volar cortex. Another unicortical hole is made in the metacarpal at the anatomic UCL origin. This hole is approximately 7 mm from the joint line and 5 mm from the dorsal cortex of the metacarpal.[17] A Kirschner wire is driven across the joint after joint reduction in 30 degrees of flexion, making sure to correct positioning in coronal and sagittal planes. The wire can be placed dorsal to the drill hole on the proximal phalanx and can run volar to the drill hole in the metacarpal.

A palmaris longus tendon graft is obtained if available. In the absence of the palmaris longus, a longitudinal strip of the flexor carpi radialis, extensor carpi radialis longus, long toe extensor, or abductor pollicis longus may be used. A 2-0 nonabsorbable stitch is placed in Krakow fashion in one end of the graft. Using Keith needles, the suture ends are passed through the radial cortex of the metacarpal head with a small bone bridge and tied over periosteum through a radial incision, drawing the graft down into the drill hole. The graft is measured and cut to length to allow it to pass just into the proximal phalangeal drill hole. The free end of the graft is stitched with a second Krakow suture; the sutures are passed with Keith needles through the drill hole in the proximal phalanx and out a bone bridge radially. This construct allows the surgeon to pull quite strongly on the graft to make sure it is tight and docked, and the suture strands are then tied radially over a bone bridge. It is recommended that a small counterincision be made to avoid injuring the sensory nerve. Various anchors or tenodesis screws can also be used to avoid making a counterincision, although I like the tensioning effect of pulling a graft into a bone tunnel; it also obviates the risk of a tenodesis screw fracture.

Postoperative Management and Expectations. The MP joint is immobilized for 6 weeks, after which motion is started with protective interim splint wear. Full-time splinting is weaned at 8 weeks. Full activity, including contact sports, should be postponed for at least 4½ months postoperatively.

Typically, the thumb is stabilized by the reconstruction; two thirds of patients have no pain postoperatively, and one third have mild, occasional pain. Approximately 80% of the motion of the MP joint and more than 90% of the motion of the IP joint are regained when compared with the contralateral side.[41] There is mild loss of key pinch strength and mild weakness with radially directed pressure on the ulnar aspect of the thumb tip. The overall satisfaction rate among patients who have had the procedure is high.

CRITICAL POINTS *Chronic Ulnar Collateral Ligament Repair*

Preoperative Evaluation

- Indicated for any complete tear (no endpoint) or partial symptomatic tear
- Rule out degenerative joint changes with radiographs.

Technical Points

- Avoid injury to the dorsal sensory branch of the radial nerve.
- Incise the adductor aponeurosis.
- Resect the remnant of the collateral ligament.
- Make a 2.5-mm hole in the base of the proximal phalanx 3 mm from the volar cortex and 3 mm from the joint.
- Make another 2.5-mm hole in the metacarpal head 7 mm from the joint and 5 mm from the dorsal cortex.
- Dock the tendon into the metacarpal drill hole with 2-0 nonabsorbable suture on Keith needles.
- Cut the tendon graft to length.
- Dock the tendon into the proximal phalanx hole by using Keith needles to pass the suture ends through the radial cortex.
- Tension and tie suture ends over bone using a small radial incision.
- Repair capsular tissue if possible and then the adductor.

Postoperative Care

- Apply a short-arm thumb spica cast or splint for 6 weeks of full-time wear with no MP motion.
- Use a thermoplastic splint for 2 additional weeks while starting MP exercises.
- Avoid radially directed stress on the thumb tip for 12 weeks.

Radial Collateral Ligament Injuries

Injuries to the RCL are much less common but may be as debilitating as tears of the UCL. The principles of diagnosis and treatment of RCL and UCL injuries are similar and therefore only their differences will be highlighted in this discussion.

ANATOMY

The principal difference between the anatomy on the radial and the ulnar sides of the thumb is that the abductor aponeurosis is broad and covers most of the radial side of the MP joint

whereas the adductor aponeurosis is a narrower sheet of tissue that is easily interposed between the torn UCL and its insertion (i.e., the Stener lesion). There is little potential for an interposition lesion on the radial side comparable to the Stener lesion, although it has been reported.[21] The mechanism of RCL injuries is forced adduction or torsion on the flexed MP joint. The ligament is torn proximally or distally with about equal frequency and, somewhat more commonly than the UCL, is ruptured in its midsubstance.[27] The abductor aponeurosis may be torn as well. A tear in the RCL, as noted previously for the UCL, creates a rotatory deformity of the MP joint in which the proximal phalanx shifts volarly on the radial side and rotates around the intact UCL into pronation. This is responsible for dorsoradial prominence of the metacarpal head, a common physical finding seen with RCL rupture.

Preoperative Evaluation

Partial tears of the RCL are characterized by swelling, tenderness, and sometimes ecchymosis over the radial side of the joint and metacarpal head. There is little or no laxity with stress of the RCL, but if laxity is present there usually remains a clear end point to opening of the joint. Laxity of 30 degrees in flexion or extension or 15 degrees of increased laxity when compared with the contralateral thumb are guidelines indicating a complete tear. The most dependable diagnostic finding is the absence of a firm endpoint to varus stress.

Radiographic evaluation should include standard posteroanterior, lateral, and oblique views. Volar subluxation of the proximal phalanx, best detected on the lateral radiograph, usually accompanies the more extensive radial ligament tears and is strongly suggestive of an extension of the tear into the dorsal capsule. Volar subluxation is reported more frequently in RCL injuries than in UCL injuries, being seen in as many as 86% of complete tears.[21] The posteroanterior radiograph occasionally shows ulnar angulation of the proximal phalanx at rest and suggests gross instability. Avulsion fractures are best seen on the posteroanterior view. Stress radiographs, MRI studies, or ultrasound images offer little additional information for the guidance of diagnosis or treatment.

Treatment

Partial tears of the RCL can be treated the same as partial tears of the UCL, with a cast or splint. For complete acute tears, most authors advocate early surgical repair as a more predictable way of achieving good results.[19] For chronic instability without arthritic changes, surgical repair (when possible) or reconstruction (more likely) is necessary. For chronic instability with arthritic change, arthrodesis is preferable.

Types of Operations

Acute repairs typically involve the use of a suture anchor. Treatment options for reconstruction of chronic radial instability are either direct ligament repair (documented as late as 10 years from injury),[21] abductor advancement, or free tendon grafting.

The technique of abductor advancement is a mirror image of Neviaser adductor advancement, either alone or in combination with repair and/or reefing of the remnant of the RCL.[89] In these techniques, any ligament remnant that can be mobilized is repaired. This is reinforced by advancement of the extensor pollicis brevis tendon into a drill hole in the proximal phalanx 1 cm from the articular surface and tied over bone on the ulnar side of the thumb.[27]

Two recent technique articles describe dorsal advancement of the abductor pollicis brevis origin on the metacarpal head with encouraging results.[53,59]

The abductor advancement procedures have the same potential shortcomings as the adductor advancement for UCL instability: it is a dynamic reconstruction that is used to replace a static restraint. The procedure involves ligamentous or capsular reefing, which may compensate for the dynamic component of the reconstruction.

❖ AUTHORS' PREFERRED METHOD OF TREATMENT

The principles of treatment are similar to those for the UCL. Partial tears of the RCL are best treated by immobilization of the MP joint full time for 4 to 5 weeks in either a thumb spica cast or splint. A splint is worn the majority of the time for an additional 2 weeks during which active range-of-motion movement in flexion and extension is begun. The literature does not resolve the question of whether all complete tears of the RCL need to be repaired, although I do routinely offer surgical repair when there is lack of a firm endpoint or significant laxity on examination. Complete tears with volar subluxation of the MP joint should be repaired. Patients with symptomatic chronic RCL instability are also offered surgery unless they are elderly or sedentary and are satisfied with a splint.

For acute repairs, the radial side of the MP joint is exposed, using a lazy-"S" incision in which the proximal limb is along the dorsoradial aspect of the thumb metacarpal and the central limb extends from dorsal to volar and parallel to the joint line. The distal limb parallels the radial volar base of the proximal phalanx in the midaxial line. A longitudinal incision is made in the abductor aponeurosis just radial to the extensor pollicis brevis. The aponeurosis is reflected volarly to expose the radial side of the joint. Midsubstance tears are repaired with figure-of-eight or mattress sutures using a 3-0 or 4-0 braided synthetic suture. Avulsions of the ligament from the metacarpal or proximal phalanx can be fixed with a bone anchor. Subluxation of the proximal phalanx must be reduced and the dorsal capsule accurately repaired without overtightening. If present, disruption of the insertions of the extensor pollicis brevis and the extensor mechanism at the base of the proximal phalanx must also be repaired. In the setting of marked volar subluxation of the joint, the repair can be supplemented with a 0.045-inch Kirschner wire to transfix the joint. The thumb MP joint is immobilized for 5 weeks in a splint or cast.

The treatment of chronic complete ruptures is similar to that for UCL ruptures. Unlike the UCL, the torn RCL almost always lies beneath the abductor aponeurosis. Consequently, it is more likely that the ends of the RCL can be mobilized and repaired in the chronic situation by using the same technique as described for acute tears. The joint should be immobilized for an additional week because healing of a chronically torn ligament is not as rapid or as strong as with a ligament repaired acutely. If the ruptured RCL is too fibrotic or shortened to be repaired, ligament reconstruction with a free tendon graft is performed (Figure 8.38). The technique of reconstruction is the mirror image of that described earlier for the ulnar side. The sagittal band is incised longitudinally along with the abductor

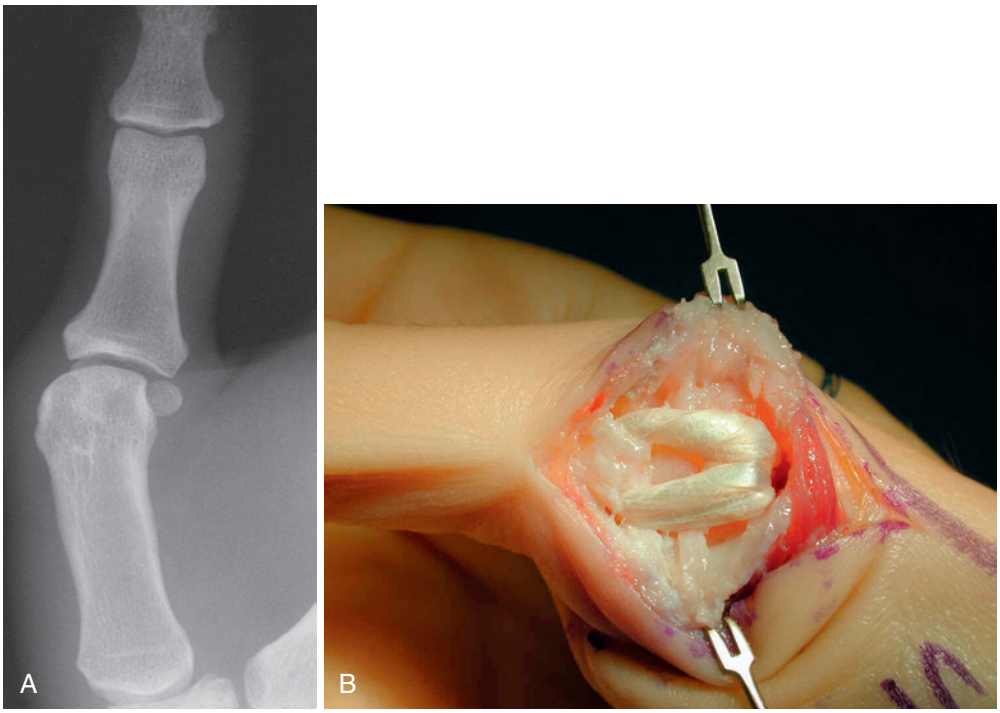

FIGURE 8.38 **A,** Typical radiographic appearance of chronic radial collateral ligament (RCL) instability demonstrates ulnar deviation of proximal phalanx even at rest. **B,** Chronic RCL instability may be reconstructed with a free tendon graft by using a mirror-image technique similar to that described for ulnar collateral ligament instability.

aponeurosis and repaired at the end of the procedure. The holes in the proximal phalanx and route of passage of the tendon are the same.

Postoperative Management and Expectations

The postoperative management of acute RCL repairs and RCL reconstructions is identical to that described previously for UCL repairs and reconstructions, with the single exception that the acute RCL repairs are immobilized for an additional week, beginning rehabilitation at 5 weeks postoperatively. Chronic UCL and RCL reconstructions are immobilized for 6 weeks before beginning the therapy protocol.

Postoperative expectations are also similar to those for UCL repair and reconstruction. Patients should be advised that they may have a persistent prominence of the radial side of the thumb metacarpal head postoperatively. This results from fibrosis of the soft tissue in the area of the repair or reconstruction. It may represent a mild degree of laxity of the ligament that, however, has not, in our experience, been a functional problem. Expectations for acute repairs can be guided by a report of long-term follow-up on 38 patients: 87% were symptom-free, 92% had normal pinch and grip strength, and 79% had full range of motion.[21] Although these results are encouraging, patients should be advised that some motion and strength will be lost.

Metacarpophalangeal Dislocations

Historical Perspective

Most dislocations of the thumb MP joint are dorsal, although volar dislocation has been reported and may be irreducible.[115] The mechanism of dorsal dislocation is hyperextension, with

CRITICAL POINTS *Chronic Radial Collateral Ligament Repair*

Preoperative Evaluation

- Physical examination usually adequate for diagnosis
- Posteroanterior, lateral, and oblique radiographs to rule out degenerative joint changes

Technical Points

- Avoid injury to the dorsal sensory branch of the radial nerve.
- Incise the abductor aponeurosis.
- Resect the remnant of collateral ligament.
- Make holes in the base of the proximal phalanx similar to the procedure for UCL reconstruction.
- Make a 4-mm hole in the metacarpal head.
- Pass a tendon graft through the distal holes.
- Whipstitch the tendon ends with nonabsorbable suture.
- Dock in the proximal hole using Keith needles to pass suture through the radial cortex.
- Set tension on the graft with the joint flexed 45 degrees.
- Tie down sutures on the ulnar side of the thumb over bone.
- Repair the abductor aponeurosis.
- Transfix the MP joint with a 0.045-inch Kirschner wire if needed.
- Avoid stress on the repair when molding a splint or cast.

Postoperative Care

- Apply a short-arm thumb spica cast for 6 weeks.
- Use a thermoplastic splint for 2 additional weeks.
- Begin range-of-motion exercises when the cast is removed.
- Avoid forceful pinch, torsional activities, and ulnarly directed stress on the thumb tip for 12 weeks.

complete rupture of the volar plate, capsule, and at least part of the collateral ligaments. Rupture of the volar plate usually occurs proximally but can be through or distal to the sesamoid bones. Most dorsal dislocations are reducible, although some are more complex injuries and are irreducible. Reduction is blocked typically by the volar plate and less commonly by the flexor pollicis longus. The flexor pollicis longus tendon more often remains within the flexor tendon sheath and displaces to the ulnar side of the metacarpal head, creating a "noose" around the metacarpal neck together with the radially displaced thenar intrinsic musculature. Volar dislocations have been described and in some cases can be reduced without surgery.[8]

Preoperative Evaluation

Diagnosis of an MP joint dislocation is generally not difficult. Clinically, the MP joint has an obvious hyperextension deformity and the metacarpal is adducted. There may be dimpling of the skin on the volar aspect of the MP joint that is suggestive of a complex dislocation. Radiographs typically show the MP joint to be hyperextended, with the proximal phalanx dorsal and sometimes lying in "bayonet" apposition to the metacarpal. There may be an increased space between the metacarpal head and the proximal phalanx suggestive of interposed soft tissue. Interposition of the sesamoids between the metacarpal head and the proximal phalanx is evidence of a complex, irreducible dislocation.

Treatment Options

The majority of dorsal dislocations can be easily reduced without surgery. Simple longitudinal traction as a reduction maneuver should be avoided because it might convert a simple dislocation into an irreducible complex one. The preferred reduction technique is hyperextension of the MP joint, followed by direct pressure on the dorsal base of the proximal phalanx to gently push it over the metacarpal head.

Less severe hyperextension injuries can cause dorsal subluxation of the MP joint rather than frank dislocation. This may present as a locked MP joint in which the joint cannot be flexed actively or passively. The pathoanatomy is thought to be entrapment of the radial condyle in a tear of the radial part of the volar plate, proximal to the sesamoid. Closed reduction may be attempted with regional anesthesia or a lidocaine block of the MP joint. The examiner applies volar-directed pressure on the proximal phalanx while twisting it on the metacarpal head.[74] If closed reduction fails, open reduction may be necessary and can be done through several approaches.

The surgical approach may be dorsal, volar, or lateral. Bohart and Gelberman and colleagues[11] prefer the dorsal approach because of its simplicity. A longitudinal skin incision exposes the extensor tendons. The interval between the extensor pollicis longus and extensor pollicis brevis tendons is developed. The dorsal capsule is incised. The tissue interposed in the joint is identified and mobilized using blunt instruments such as hooks, forceps, and periosteal elevators. The tissue is pushed over the metacarpal head and the joint is reduced. Occasionally, a dorsal MP dislocation will present with a volar laceration that necessitates débridement and extension of the volar wound. The proximal phalanx is hyperextended, and the interposed soft tissue is extricated from the joint. The advantage of the volar approach is that it allows the interposed structures to be pulled from within the joint and affords an excellent view of the neurovascular bundles, tendons, and affected structures.[57] Once reduced, the joint is usually stable, but if not, ligament and volar plate repair can be performed.

❖ AUTHORS' PREFERRED METHOD OF TREATMENT

Closed reduction is usually successful with the following technique. Under radial and median nerve wrist block or Bier block anesthesia, distally directed pressure is applied to the base of the proximal phalanx with the metacarpal in a position of flexion and adduction. This maneuver relaxes the noose that the thenar muscles and flexor pollicis longus occasionally create around the metacarpal neck. If necessary, flexing the IP joint and the wrist will relax an entrapped flexor pollicis longus tendon that is blocking reduction. After reduction, collateral ligament stability is tested and a congruous reduction confirmed by radiographs. Stability is assessed by extending the joint to determine the point at which it starts to subluxate. The thumb should be fitted with a dorsal block splint in 10 degrees more of flexion than the point of instability. This can be extended 10 degrees per week. If there is significant collateral ligament instability, consideration should be given to immobilization of the MP joint for 4 weeks or open collateral ligament repair. Open reduction is required when closed reduction fails. If the case presents within 24 hours of injury, we make a small dorsal incision, insert a Freer elevator, and try to push interposed tissue from within the joint. If that fails or if the dislocation is more than 24 hours old, the joint is exposed through a volar zigzag incision. Interposed or entrapped structures are reduced with blunt instruments, avoiding injury to the metacarpal head. Stabilization of the joint in 25 degrees of flexion with a Kirschner wire should be done if the joint is unstable. If the volar plate is detached from the base of the proximal phalanx, surgical repair using bone anchors or repair of surrounding soft tissue is recommended after closed reduction.

Postoperative Management and Expectations

Patients are advised that they will most likely have a stable joint after closed or open reduction. However, stiffness is possible after any dislocation, and the chance of stiffness is greater if surgery is required. Recovery of motion can be slow and require several weeks of therapy. Patients should be counseled at the time of injury that stability is a more important consideration than full range of motion of the MP joint. The protocol for rehabilitation is similar to that for acute collateral ligament injury of the MP joint, with a focus on avoidance of forceful extension while the volar plate is healing during the initial 6 to 8 weeks after the injury.

Chronic Volar Instability of the Thumb Metacarpophalangeal Joint

Preoperative Assessment

Chronic laxity of the thumb MP joint occurs most commonly in the context of generalized ligament laxity and is rarely symptomatic. Symptomatic laxity may be a manifestation of systemic conditions such as collagen vascular disease, congenital or acquired paralytic disorders, collapse deformity secondary to basal joint arthritis, or trauma. Posttraumatic hyperextension of the MP joint is infrequent and may be the consequence of

an unrecognized or undertreated volar plate injury or MP dislocation. Patients with instability caused by generalized ligament laxity are able to volitionally maintain the joint in flexion during pinch and grip, whereas those with posttraumatic laxity cannot, and the resultant collapse of the joint causes pain and weakness. Radiographs are usually normal but may show an avulsion fleck of bone at the site of the volar plate injury.

Types of Operations

If there has been a relatively recent hyperextension injury of the MP joint, it may be possible to reattach the volar plate to its metacarpal origin. A zigzag incision is used to expose the volar aspect of the MP joint. The volar plate is identified and mobilized. Its proximal end is minimally débrided and reattached to the volar aspect of the metacarpal neck with two bone anchors. The MP joint is immobilized in a cast for 1 month, after which range of motion with a 20-degree extension block splint is encouraged for an additional 2 weeks. The procedure is unlikely to be successful if the injury is chronic and the volar plate attenuated.

Several techniques have been described to treat chronic symptomatic hyperextension of the MP joint. Kessler[70] transected the extensor pollicis brevis proximally and reconstructed the volar plate with the distally attached segment. The graft was directed in a dorsovolar direction along the radial side of the MP joint and passed along the volar aspect of the joint in a radioulnar direction. The tendon was passed through a hole in the metacarpal neck from ulnar to radial and again passed across the volar aspect of the MP joint to the ulnar side, where it was sutured to the adductor tendon. The reconstruction creates a static restraint to hyperextension, while simultaneously removing the extensor pollicis brevis extension moment on the MP joint. Tonkin[117] reported good results with sesamoid arthrodesis to the metacarpal head for 42 thumbs in 37 patients with either cerebral palsy or osteoarthritis of the CMC joint. Eaton and Floyd[32] used a volar capsulodesis as an adjunct to basal joint arthroplasty for osteoarthritis in patients with MP hyperextension of 30 degrees or more.

The joint is approached through a volar Bruner incision and an interval between the volar plate and the RCL. The cortex of the retrocondylar fossa is decorticated, one or two suture anchors are placed, and the volar plate is advanced proximally. The RCL is sutured to the volar plate and the joint transfixed with a 0.045-inch Kirschner wire for 4 weeks, after which range-of-motion movement is begun. The joint is protected in a splint for 2 more weeks.

THUMB CARPOMETACARPAL JOINT

Carpometacarpal Joint Dislocations

ANATOMY

The articular surfaces of the CMC joint of the thumb resemble two reciprocally opposed saddles with perpendicular transverse axes. The CMC joint has motion in three principal planes: flexion-extension, abduction-adduction, and pronation-supination (or opposition-retropulsion). There is an element of conjunct rotation in pronation that results from the asymmetric height of the radial and ulnar condyles of the trapezial articulating surface. These concavoconvex contours by themselves produce a degree of intrinsic stability, but the ligaments and joint capsule play the principal role in stabilization. There are four major ligaments: volar (anterior oblique), intermetacarpal, dorsoradial, and dorsal oblique (posterior oblique). The volar oblique ligament, which passes from the trapezium to the volar beak of the thumb metacarpal (Figure 8.39), has traditionally been considered to provide the primary restraint to dorsal subluxation force that is inherent with pinch. The dorsal ligament is thin but is reinforced by the expanded insertion of the abductor pollicis longus.

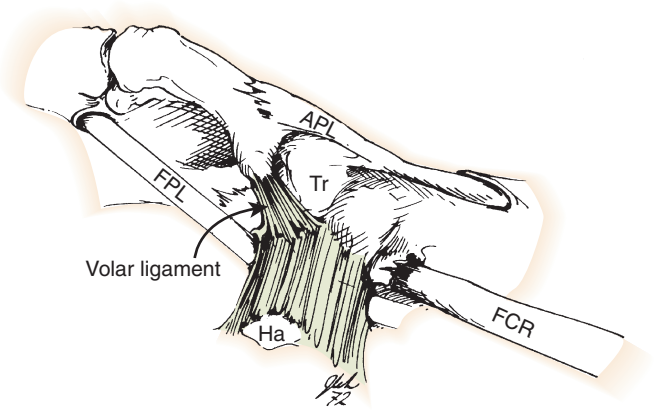

FIGURE 8.39 Essential anatomy of thumb carpometacarpal joint. A key structure is the volar oblique ligament, a short reflection of the transverse carpal ligament that maintains the thumb metacarpal within the biconcave contour of trapezium. *APL,* Abductor pollicis longus; *FCR,* flexor carpi radialis; *FPL,* flexor pollicis longus; *Ha,* hamate; *Tr,* trapezium. (From Eaton RG, Littler JW: Joint injuries and their sequelae, *Clin Plast Surg* 3:85–98, 1976.)

Historical Review

All reported CMC dislocations have been dorsal. It is generally believed that the mechanism of injury is axial compression on a flexed thumb metacarpal, driving the metacarpal base out dorsally. There is some disagreement concerning which ligaments must be injured to allow complete dislocation to occur. It has been suggested that the dorsoradial ligament has to be torn for a dorsal dislocation to occur but that the volar ligament is often sheared off its insertion on the metacarpal base as well. Strauch and colleagues[112] made observations using a ligament-cutting cadaver model and concluded that the dorsoradial ligament had to be disrupted for a complete dislocation to occur and that the volar ligament was insufficient to resist dislocation.

Preoperative Evaluation

Injuries to the ligaments of the thumb CMC joint may be complete or partial. Complete rupture permits the thumb metacarpal to dislocate dorsally (Figure 8.40). Partial rupture of the ligaments permits varying degrees of displacement. The more extensive the tear, the greater the displacement and, hence, the more obvious the diagnosis. Less severe tears are particularly difficult to diagnose because the contours of the joint tend to maintain gross alignment of the metacarpal base within the concavity of the trapezium. There may be minimal detectable dorsal translation of the metacarpal on clinical and radiographic examination. The difference between normal mobility and hypermobility is difficult to measure because these structures are at least partially enclosed within the thenar muscles.



FIGURE 8.40 Dislocations of the thumb carpometacarpal joint are uncommon; they are invariably dorsal and usually unstable. The thumb is generally adducted.

Standard posteroanterior and true lateral radiographs must be taken to rule out existing joint pathologic developments and the relatively more frequent Bennett fracture-dislocation. Widening of the joint space or a slight dorsoradial shift of the metacarpal may be apparent on these routine radiographs. A useful diagnostic technique is the stress radiograph, which is a posteroanterior view of both thumbs positioned parallel to the radiograph plate with the distal phalanges pressed firmly together along their radial borders. This tends to lever the base of the metacarpal laterally, and in the presence of a capsular tear or laxity, radial shift of the metacarpal on the trapezium will occur. Because both thumbs are included on the film, a comparison with the uninjured joint is possible.

Treatment

Because acute complete dislocations are quite rare and partial tears of the CMC joint are rarely recognized, the relevant literature is composed largely of case reports with few specific recommendations about the management of these injuries. Simonian and Trumble[105] reported persistent instability in four of eight patients after closed reduction and percutaneous Kirschner wire fixation of acute CMC dislocations and significantly better results with early ligament reconstruction. The commonly used techniques for ligament reconstruction are those described by Eaton and Littler[29] and Brunelli and associates.[13]

❖ AUTHORS' PREFERRED METHOD OF TREATMENT

Patients with acute posttraumatic pain in the CMC joint of the thumb but without gross clinical instability or radiographic subluxation should be considered to have a partial volar ligament tear and immobilized in a long opponens or thumb spica splint with the metacarpal in palmar abduction and extension for 4 to 6 weeks. The thumb should be positioned to prevent its tip from opposing the digits, which would create axial compression along the thumb ray.

Patients with a documented dislocation or with clinical instability and radiographic subluxation require special consideration. If postreduction radiographs show the metacarpal to be well reduced initially and maintained at 5 to 7 days, cast immobilization may be adequate treatment. However, if the metacarpal is not well seated radiographically or is clinically lax, surgical reduction is indicated. In light of the study by Simonian and Trumble,[105] the indications for closed reduction under anesthesia with percutaneous Kirschner wire fixation of the CMC joint should be narrow. A possible exception might be a patient in whom closed reduction resulted in a stable joint, suggesting that there is no interposed soft tissue. The joint may then be transfixed with a percutaneous 0.045-inch Kirschner wire down the medullary canal or obliquely across the base of the metacarpal. When the pin is driven across the joint, the metacarpal should be held in abduction and extension as the joint is held manually reduced. Pressure at its dorsoradial base seats the metacarpal and approximates the metacarpal beak to the volar ligament, to encourage ligament healing. If the metacarpal will not reduce congruously but remains dorsally or laterally translated, or if the joint continues to feel unstable, it must be assumed that soft tissue is interposed or that a small, undetected bony or chondral fragment is preventing reduction. Open reduction is indicated, and the volar ligament should be reconstructed with a tendon graft.

Technique of Volar Ligament Reconstruction of the Thumb Carpometacarpal Joint. The CMC joint of the thumb is exposed through a modified Wagner volar approach that curves ulnarly into the distal wrist flexion crease. Care is taken to avoid injury to the palmar cutaneous branch of the median nerve, the superficial radial artery, and branches of the lateral antebrachial cutaneous and radial nerves. The thenar muscles are elevated extraperiosteally. The intact volar and radial capsule is incised, and any interposed tissue is removed from the joint. The flexor carpi radialis tendon is identified at the wrist flexion crease and unroofed distally as far as the midportion of the trapezium.

Reconstruction of the volar ligament is begun by first creating a channel in the base of the metacarpal in a sagittal plane perpendicular to the thumbnail. A small incision is made in the dorsal periosteum through which a hole is made in the metacarpal base and enlarged with progressively larger handheld gouges. It emerges just distal to the volar beak, at the site of the volar ligament insertion. A 28-gauge stainless steel wire is placed through this channel for subsequent passage of the tendon graft used for ligament reconstruction (Figure 8.41).

The radial half of the flexor carpi radialis is mobilized, beginning 6 to 8 cm proximal to the wrist through one or more short transverse incisions. Alternatively, a looped monofilament suture or an arthroscopic suture passer can be passed from the incision at the wrist crease, beneath the skin bridge, to emerge through a proximal forearm incision and thereby avoid the need for multiple incisions on the forearm. The loop of the suture or the suture passer is placed through a split in the flexor carpi radialis tendon and firmly pulled distally into the distal wound to continue the split longitudinally. The distal end is left in continuity with the index metacarpal insertion, and the transected proximal end is passed through the channel in the volar

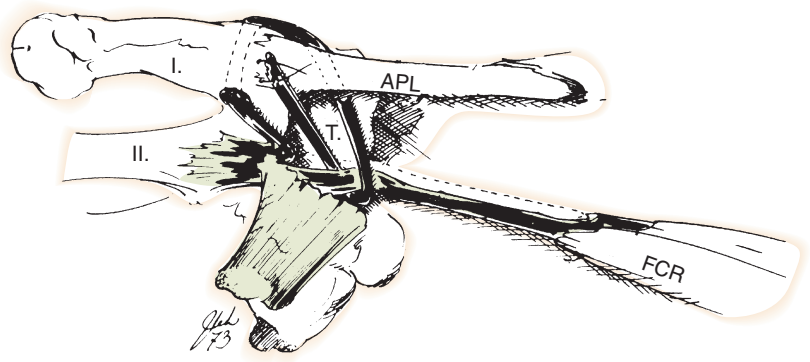

FIGURE 8.41 Schema for routing of the flexor carpi radialis tendon in a reconstruction of the volar ligament of carpometacarpal joint of the thumb. Volar, dorsal, and radial capsules are reinforced by this routing. *APL,* Abductor pollicis longus; *FCR,* flexor carpi radialis; *I,* thumb; *II,* index finger; *T,* trapezium. (From Eaton RG, Littler JW: Ligament reconstruction for the painful thumb carpometacarpal joint, *J Bone Joint Surg Am* 55:1655–1666, 1973.)

base of the metacarpal to emerge dorsally. The metacarpal is held reduced under direct vision as the tendon is drawn tight to remove any kinks along its passage, and then traction is relaxed slightly to keep the reconstruction from being too tight. The tendon is sutured to the dorsal periosteum to set proper tension in the new ligament, and its free end is passed deep to the insertion of the abductor pollicis longus on the metacarpal base. It is sutured at this point to reinforce the dorsal capsule. The free end is further passed volarly around the intact flexor carpi radialis tendon and finally reflected distally across the radial aspect of the joint, where it is sutured to a remnant of the capsule. Kirschner wire fixation of the trapeziometacarpal joint is optional. It is important that the new volar ligament not be sutured with excessive tension, which may restrict joint motion, particularly rotation. The thenar muscles are reattached. Immobilization is continued for 4 weeks, at which time the cast and Kirschner wire are removed and gentle progressive motion is begun.

Postoperative Management and Expectations

During the 4 weeks of immobilization after volar ligament reconstruction, patients are encouraged to move the digits and thumb IP joint within the limits of the cast. The cast and Kirschner wire are removed after 4 weeks, and patients are referred to a hand therapist. A custom-molded thermoplastic long opponens splint is worn for 2 weeks and removed for range-of-motion exercises. Patients are encouraged to oppose the tip of the thumb to the index and long fingers during the first 2 weeks. In the ensuing 2 weeks (beginning at 6 weeks postoperatively), they oppose the tip of the thumb to the ring and small fingers. Strengthening of the thenar musculature begins 2 months postoperatively and strengthening of pinch and grasp at 10 to 12 weeks postoperatively. It is important that the therapist not be overly aggressive with strengthening during the first 2 months postoperatively, because this may contribute to the reconstruction "stretching out." Patients are allowed essentially full use of the thumb at 3 months.

Patients are advised that volar ligament reconstruction predictably stabilizes the unstable basal joint, whether due to dislocation, subluxation, or atraumatic laxity of the basal joint, provided there is no degenerative disease. The vast majority of patients who have undergone CMC ligament reconstruction are

CRITICAL POINTS *Volar Ligament Reconstruction*

Indications

- Acute, irreducible dislocation of the thumb CMC joint
- Redislocation of the CMC joint after reduction
- Subacute or chronic posttraumatic instability
- Chronic symptomatic atraumatic laxity
- Persistent pain despite conservative treatment

Technical Points

- Use a modified Wagner incision.
- Avoid injury to the dorsal sensory branch of the radial nerve.
- Elevate the thenar musculature extraperiosteally.
- Inspect the CMC joint through a transverse arthrotomy.
- Make a dorsovolar hole in the metacarpal base perpendicular to the plane of the thumbnail. The hole should exit just distal to the volar beak at the insertion point of the volar oblique ligament.
- Place a 28-gauge stainless steel wire through the hole for later passage of the tendon graft.
- Harvest a distally based slip of the flexor carpi radialis tendon, starting ulnarly so that as it spirals it ends radially.
- Tie the volar end of a 28-gauge wire to the proximal end of the flexor carpi radialis tendon slip.
- Pull the tendon through the hole from volar to dorsal.
- Position the thumb in abduction and extension.
- Set tension on the flexor carpi radialis graft by pulling tightly and then relaxing 2 to 3 mm.
- Suture the graft to the periosteum adjacent to the dorsal hole with 3-0 braided polyester suture.
- Place the free end of the graft beneath the abductor pollicis longus to which it is sutured.
- Loop the graft around the intact flexor carpi radialis and then back dorsally.
- Reattach the thenar musculature.

Postoperative Care

- Apply a short-arm thumb spica cast for 4 weeks.
- Use a thermoplastic long opponens splint for 2 additional weeks.
- Begin range-of-motion exercises when the cast is removed.
- Begin gentle strengthening at 8 weeks.
- Avoid strenuous pinch and torsional motions for 3 months.

either pain free or have mild, intermittent pain postoperatively. It is very unlikely for laxity or pain to recur in the short and intermediate term, and patients should have essentially full function of their thumb and hand and be able to participate in all activities, including athletics. However, dislocation of the thumb CMC joint represents a significant injury not only to the ligaments but to the articular cartilage as well and raises the possibility of long-term degenerative arthritis. Postoperative mild limitation in range of motion of the basal joint is not uncommon, including the possibility the patient will not be able to fully flatten the palm on a countertop. This can usually be avoided by ensuring that the reconstruction is not overly tightened.

Patients commonly have some numbness on the dorsal radial aspect of the thumb after volar ligament reconstruction. It is most often due to traction on the branch of the dorsal sensory branch of the radial nerve that crosses the operative field. This complication can be avoided by being particularly attentive to identification and gentle retraction of the nerve throughout the procedure. Clamps attached to vessel loops around the nerve should be avoided. Occasionally, the nerve can become entrapped in scar tissue at the site of the fixation of the flexor carpi radialis tendon slip to the periosteum of the thumb metacarpal base. Neurapraxia resulting from traction almost invariably resolves completely over weeks to months. Rarely, entrapment of the nerve in scar tissue may require neurolysis and transposition of the nerve away from the previous point of fixation.

For Case Studies, Videos, and more, please visit ExpertConsult.com.

REFERENCES

1. Abbiati G, Delaria GE, Saporiti E, et al: The treatment of chronic flexion contractures of the proximal interphalangeal joint. *J Hand Surg [Br]* 20:385–389, 1995.
2. Abrahamsson SO, Sollerman C, Lundborg G, et al: Diagnosis of displaced ulnar collateral ligament of the metacarpophalangeal joint of the thumb. *J Hand Surg [Am]* 15:457–460, 1990.
3. Adams BD, Muller DL: Assessment of thumb positioning in the treatment of ulnar collateral ligament injuries: A laboratory study. *Am J Sports Med* 24:672–675, 1996.
4. Agee JM, Goss BC: The use of skeletal extension torque in reversing Dupuytren contractures of the proximal interphalangeal joint. *J Hand Surg [Am]* 37(7):1467–1474, 2012.
5. Aladin A, Davis TR: Dorsal fracture-dislocation of the proximal interphalangeal joint: a comparative study of percutaneous Kirschner wire fixation versus open reduction and internal fixation. *J Hand Surg [Br]* 30:120–128, 2005.
6. Andersen MB, Andersen-Ranberg F: Dislocation of the distal interphalangeal and the metacarpophalangeal joints in the same finger: A case report. *J Hand Surg [Am]* 20:574–575, 1995.
7. Bean CHG, Tencer AF, Trumble TE: The effect of thumb metacarpophalangeal ulnar collateral ligament attachment site on joint range of motion: An in vitro study. *J Hand Surg [Am]* 24:283–287, 1999.
8. Beck JD, Klena JC: Closed reduction and treatment of 2 volar thumb metacarpophalangeal dislocations: report of 2 cases. *J Hand Surg [Am]* 36(4):665–669, 2011.
9. Becton JL, Christian JD, Goodwin HN, et al: A simplified technique for treating the complex dislocation of the index metacarpophalangeal joint. *J Bone Joint Surg Am* 57:698–700, 1975.
10. Bilos ZJ, Vender MI, Bonavolonta M, et al: Fracture subluxation of proximal interphalangeal joint treated by volar plate advancement. *J Hand Surg [Am]* 19:189–196, 1994.
11. Bohart PG, Gelberman RH, Vandell RF, et al: Complex dislocations of the metacarpophalangeal joint. *Clin Orthop Relat Res* 164:208–210, 1982.
12. Bowers WH, Wolf JW, Jr, Nehil J, et al: The proximal interphalangeal joint volar plate: I. An anatomical and biomechanical study. *J Hand Surg [Am]* 5:79–88, 1980.
13. Brunelli G, Monini L, Brunelli F: Stabilisation of the trapeziometacarpal joint. *J Hand Surg [Br]* 14:209–212, 1989.
14. Bruser P, Poss T, Larkin G: Results of proximal interphalangeal joint release for flexion contractures: Midlateral versus volar incision. *J Hand Surg [Am]* 24:288–294, 1999.
15. Calfee RP, Kiefhaber TR, Sommerkamp TG, et al: Hemi-hamate arthroplasty provides functional reconstruction of acute and chronic proximal interphalangeal fracture-dislocations. *J Hand Surg [Am]* 34(7):1232–1241, 2009.
16. Campbell CS: Gamekeeper's thumb. *J Bone Joint Surg Br* 37:148–149, 1955.
17. Carlson MG, Warner KK, Meyers KN, et al: Anatomy of the thumb metacarpophalangeal ulnar and radial collateral ligaments. *J Hand Surg [Am]* 37(10):2021–2026, 2012.
18. Catalano LW, Skarparis AC, Glickel SZ, et al: Treatment of chronic traumatic hyperextension deformities of the proximal interphalangeal joint with flexor digitorum superficialis tenodesis. *J Hand Surg [Am]* 28:448–452, 2003.
19. Catalano LW, 3rd, Cardon L, Patenaude N, et al: Results of surgical treatment of acute and chronic grade III (corrected) tears of the radial collateral ligament of the thumb metacarpophalangeal joint. *J Hand Surg [Am]* 31:68–75, 2006.
20. Cheah AE, Tan DM, Chong AK, et al: Volar plating for unstable proximal interphalangeal joint dorsal fracture-dislocations. *J Hand Surg [Am]* 37(1):28–33, 2012.
21. Coyle MP, Jr: Grade III radial collateral ligament injuries of the thumb metacarpophalangeal joint: treatment by soft tissue advancement and bony reattachment. *J Hand Surg [Am]* 28:14–20, 2003.
22. Deitch MA, Kiefhaber TR, Comisar BR, et al: Dorsal fracture-dislocation of the proximal interphalangeal joint: Surgical complications and long-term results. *J Hand Surg [Am]* 24:914–923, 1994.
23. Deshmukh SC, Kumar D, Mathur K, et al: Complex fracture-dislocation of the proximal interphalangeal joint of the hand. Results of a modified pins and rubbers traction system. *J Bone Joint Surg Br* 86:406–412, 2004.
24. Diao E, Eaton RG: Total collateral ligament excision for contractures of the proximal interphalangeal joint. *J Hand Surg [Am]* 18:393–402, 1993.
25. Dinowitz M, Trumble T, Hanel D, et al: Failure of cast immobilization for thumb ulnar collateral ligament avulsion fractures. *J Hand Surg [Am]* 22:1057–1063, 1997.
26. Dionysian E, Eaton RG: The long-term outcome of volar plate arthroplasty of the proximal interphalangeal joint. *J Hand Surg [Am]* 25:429–437, 2000.
27. Durham JW, Khuri S, Kim MH: Acute and late radial collateral ligament injuries of the thumb metacarpophalangeal joint. *J Hand Surg [Am]* 18:232–237, 1993.
28. Durham-Smith G, McCarten GM: Volar plate arthroplasty for closed proximal interphalangeal joint injuries. *J Hand Surg [Br]* 17:422–428, 1992.
29. Eaton RG, Lane LB, Littler JW, et al: Ligament reconstruction for the painful thumb carpometacarpal joint: A long-term assessment. *J Hand Surg [Am]* 9:692–699, 1984.
30. Eaton RG, Littler JW: Joint injuries and their sequelae. *Clin Plast Surg* 3:85–98, 1976.
31. Eaton RG, Malerich MM: Volar plate arthroplasty for the proximal interphalangeal joint: A ten-year review. *J Hand Surg [Am]* 5:260–268, 1980.
32. Eaton RG, Floyd WE, III: Thumb metacarpophalangeal capsulodesis: An adjunct procedure to basal joint arthroplasty for collapse deformity of the first ray. *J Hand Surg [Am]* 13:461–465, 1988.
33. Ellis SJ, Cheng R, Prokopis P, et al: Treatment of proximal interphalangeal dorsal fracture-dislocation injuries with dynamic external fixation: a pins and rubber band system. *J Hand Surg [Am]* 32:1242–1250, 2007.
34. Failla JM: Extrusion of fracture fragment into flexor sheath following proximal interphalangeal joint fracture-dislocation: A case report. *J Hand Surg [Am]* 21:253–255, 1996.
35. Fei X, Feng S, Gao S: Microsurgery for severe flexion contracture of proximal interphalangeal joint. Article in Chinese. *Zhongguo Xiu Fu Chong Jian Wai Ke Za Zhi* 26(7):803–805, 2012.
36. Fricker R, Hintermann B: Skier's thumb. Treatment, prevention and recommendations. *Sports Med* 19:73–79, 1995.
37. Gaston RG, Lourie GM: Radial collateral ligament injury of the index metacarpophalangeal joint: an underreported but important injury. *J Hand Surg [Am]* 31:1355–1361, 2006.
38. Ghidella SD, Segalman KA, Murphy MS: Long-term results of surgical management of proximal interphalangeal joint contracture. *J Hand Surg [Am]* 27:799–805, 2002.
39. Ghobadi F, Anapolle DM: Irreducible distal interphalangeal joint dislocation of the finger: A new cause. *J Hand Surg [Am]* 19:196–198, 1994.
40. Gilsanz V, Cleveland RH, Wilkinson RH: Aseptic necrosis: A complication of dislocation of the metacarpophalangeal joint. *AJR Am J Roentgenol* 129:737–738, 1977.
41. Glickel SZ: Thumb metacarpophalangeal joint ulnar collateral ligament reconstruction using a tendon graft. *Tech Hand Up Extrem Surg* 6:133–139, 2002.
42. Grant I, Berger AC, Tham SK: Internal fixation of unstable fracture dislocations of the proximal interphalangeal joint. *J Hand Surg [Br]* 30:492–498, 2005.

CASE STUDY 8.1 Hemihamate Reconstruction

A 26-year-old man was injured when his left ring finger was struck by a basketball. A splint was applied. The patient presents for further evaluation and treatment 6 weeks after injury. He complains of pain and limited motion. An examination shows swelling and deformity of the proximal interphalangeal (PIP) joint. The PIP joint has nearly full extension, but flexion is limited to 30 degrees (eFigure 8.1).

What treatment would you advise?

A. Dynamic skeletal traction
B. Open reduction and internal fixation
C. Hemihamate reconstruction
D. Volar plate arthroplasty
E. Corrective osteotomy and bone grafting

Answer: C. Hemihamate reconstruction (arthroplasty). At 6 weeks the healed, impacted fracture fragments and joint subluxation will not reduce by traction. The radiographs suggest that open reduction will be difficult to obtain because of the small impacted fragments. Volar plate arthroplasty is likely to fail with joint involvement greater than 40%. Corrective osteotomy is best applied to cases with single, larger, palmar fragment impaction/displacement.

The mechanism of this injury to the PIP joint was likely:

A. Hyperextension
B. Lateral deviation
C. Forced flexion
D. Axial compression with lateral deviation
E. Pure axial compression with the joint in slight flexion

Answer: D. Axial compression with lateral deviation. Compression and fragmentation have been more extensive on the palmar radial portion of the articular base of the middle phalanx than on the ulnar side. Lateral radiographs tend to underestimate the percentage of involvement of the articular base of the middle phalanx.

The outcome 10 weeks after hemihamate reconstruction is shown in eFigure 8.2. Note that the palmar osteochondral graft has been fixed with three screws and shows "tip" of the graft for restoration of an adequate palmar buttress. (AP, Lateral in extension, lateral in flexion.)

Clinical flexion at 10 weeks following surgery is displayed in eFigure 8.3.

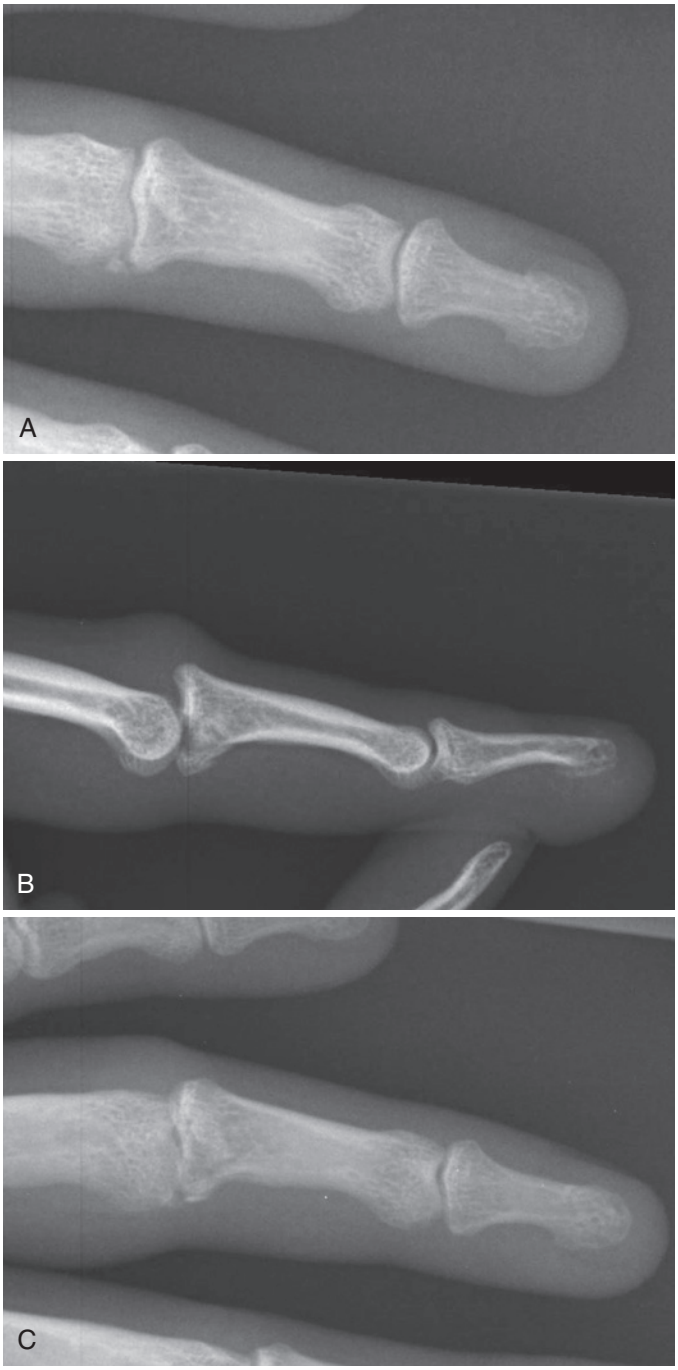

eFIGURE 8.1 **A** to **C,** Radiographs of 26-year-old male with proximal interphalangeal dorsal fracture-dislocation of the left ring finger that occurred 6 weeks earlier.

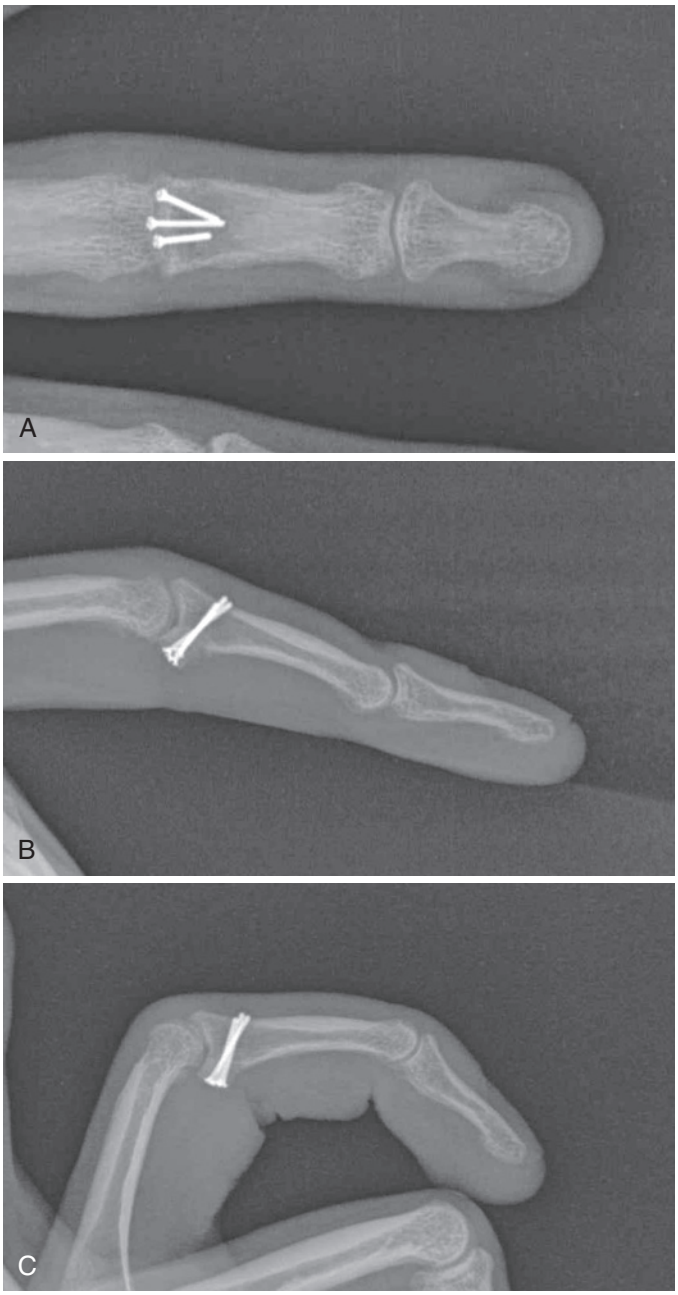

eFIGURE 8.2 **A** to **C,** Postoperative anteroposterior, lateral extension, and lateral flexion radiographs at 10 weeks.



eFIGURE 8.3 Postoperative range of motion at 10 weeks shows nearly full flexion.

43. Grant IR: Irreducible rotational anterior dislocation of the proximal interphalangeal joint: A spin drier injury. *J Hand Surg [Br]* 18:648–651, 1993.
44. Hamer DW, Quinton DN: Dorsal fracture subluxation of the proximal interphalangeal joints treated by extension block splintage. *J Hand Surg [Br]* 17:586–590, 1992.
45. Hamilton SC, Stern PJ, Fassler PR, et al: Mini-screw fixation for the treatment of proximal interphalangeal joint dorsal fracture-dislocations. *J Hand Surg [Am]* 31:1349–1354, 2006.
46. Harley BJ, Werner FW, Green JK: A biomechanical modeling of injury, repair, and rehabilitation of ulnar collateral ligament injuries of the thumb. *J Hand Surg [Am]* 29:915–920, 2004.
47. Hasegawa T, Yamano Y: Arthroplasty of the proximal interphalangeal joint using costal cartilage grafts. *J Hand Surg [Br]* 17:583–585, 1992.
48. Hastings H, Stern PJ, Capo JT, et al: *Hemicondylar hamate replacement arthroplasty (HHRA) for PIP fracture/dislocation*. Paper presented at 54th Annual Meeting of The American Society for Surgery of the Hand, September 2–4, 1999, Boston, MA.
49. Hastings J, III, Hamlet WP: *Critical assessment of PIP joint stability after palmar lip fracture dislocations*. Presented at the 56th Annual Meeting of The American Society for Surgery of the Hand, October 3–6, 2001, Baltimore, MD.
50. Henry M: Prosthetic hemiarthroplasty for posttraumatic articular cartilage loss in the proximal interphalangeal joint. *Hand (N Y)* 6(1):93–97, 2011.
51. Hierner R, Berger AK: Long-term results after vascularised joint transfer for finger joint reconstruction. *J Plast Reconstr Aesthet Surg* 61:1338–1346, 2008.
52. Hoglund M, Tordai P, Muren C: Diagnosis by ultrasound of dislocated ulnar collateral ligament of the thumb. *Acta Radiol* 36:620–625, 1995.
53. Horch RE, Dragu A, Polykandriotis E, et al: Radial collateral ligament repair of the thumb metacarpophalangeal joint using the abductor pollicis brevis tendon. *Plast Reconstr Surg* 117:491–496, 2006.
54. Horiuchi Y, Itoh Y, Sasaki T, et al: Dorsal dislocation of the D.I.P. joint with fracture of the volar base of the distal phalanx. *J Hand Surg [Br]* 14:177–182, 1989.
55. Houshian S, Chikkamuniyappa C: Distraction correction of chronic flexion contractures of PIP joint: comparison between two distraction rates. *J Hand Surg [Am]* 32:651–656, 2007.
56. Houshian S, Gynning B, Schroder HA: Chronic flexion contracture of proximal interphalangeal joint treated with the compass hinge external fixator: A consecutive series of 27 cases. *J Hand Surg [Br]* 27(4):356–358, 2002.
57. Hughes LA, Freiberg A: Irreducible MP joint dislocation due to entrapment of FPL. *J Hand Surg [Br]* 18:708–709, 1993.
58. Hutchison JD, Hooper G, Robb JE: Double dislocations of digits. *J Hand Surg [Br]* 16:114–115, 1991.
59. Iba K, Wada T, Hiraiwa T, et al: Reconstruction of chronic thumb metacarpophalangeal joint radial collateral ligament injuries with a half-slip of the abductor pollicis brevis tendon. *J Hand Surg [Am]* 38(10):1945–1950, 2013.
60. Ikeda M, Kobayashi Y, Saito I, et al: Open reduction and internal fixation for dorsal fracture dislocations of the proximal interphalangeal joint using a miniplate. *Tech Hand Up Extrem Surg* 15(4):219–224, 2011.
61. Inanami H, Ninomiya S, Okutsu I, et al: Dynamic external finger fixator for fracture dislocation of the proximal interphalangeal joint. *J Hand Surg [Am]* 18:160–164, 1993.
62. Inoue G, Maeda N: Irreducible volar dislocation of the distal interphalangeal joint of the finger. *J Hand Surg [Am]* 12:1077–1079, 1987.
63. Isani A: Small joint injuries requiring surgical treatment. *Orthop Clin North Am* 17:407–419, 1986.
64. Jespersen B, Nielsen SN, Bonnevie BEB, et al: Hyperextension injury to the PIP joint or to the MP joint of the thumb: A clinical study. *Scand J Plast Reconstr Hand Surg* 32:317–321, 1998.
65. Kang L, Rosen A, Potter HG, et al: Rupture of the radial collateral ligament of the index metacarpophalangeal joint: diagnosis and surgical treatment. *J Hand Surg [Am]* 32:789–794, 2007.
66. Kaplan EB: Dorsal dislocation of the metacarpophalangeal joint of the index finger. *J Bone Joint Surg Am* 39:1081–1086, 1957.
67. Kaplan SJ: The Stener lesion revisited: A case report. *J Hand Surg [Am]* 23:833–836, 1998.
68. Kato H, Minami A, Takahara M, et al: Surgical repair of acute collateral ligament injuries in digits with the Mitek bone suture anchor. *J Hand Surg [Br]* 24(1):70–75, 1999.
69. Katsaros J, Milner R, Marshall NJ: Perichondrial arthroplasty incorporating costal cartilage. *J Hand Surg [Br]* 20:137–142, 1995.
70. Kessler I: A simplified technique to correct hyperextension deformity of the metacarpophalangeal joint of the thumb. *J Bone Joint Surg Am* 61:903–905, 1979.
71. Kiefhaber TR, Stern PJ, Grood ES: Lateral stability of the proximal interphalangeal joint. *J Hand Surg [Am]* 11:661–669, 1986.
72. Kitagawa H, Kashimoto T: Locking of the thumb at the interphalangeal joint by one of the sesamoid bones: A case report. *J Bone Joint Surg Am* 66:1300–1301, 1984.
73. Kleinert HE, Kasden ML: Reconstruction of the chronically subluxated proximal interphalangeal finger joint. *J Bone Joint Surg Am* 47:958–964, 1965.
74. Kojima T, Nagano T, Kohno T: Causes of locking metacarpophalangeal joint of the thumb and its nonoperative treatment. *Hand* 11:256–262, 1979.
75. Krakauer JD, Stern PJ: Hinged device for fractures involving the proximal interphalangeal joint. *Clin Orthop Relat Res* 327:29–37, 1996.
76. Lane CS: Detecting occult fractures of the metacarpal head: the Brewerton view. *J Hand Surg [Am]* 2:131, 1977.
77. Lee JY, Teoh LC: Dorsal fracture dislocations of the proximal interphalangeal joint treated by open reduction and interfragmentary screw fixation: indications, approaches and results. *J Hand Surg [Br]* 31:138–146, 2006.
78. Leibovic SJ, Bowers WH: Anatomy of the proximal interphalangeal joint. *Hand Clin* 10:169–178, 1994.
79. Light TR, Ogden JA: Complex dislocation of the index metacarpophalangeal joint in children. *J Pediatr Orthop* 8:300–305, 1988.
80. Lutz M, Fritz D, Arora R, et al: Anatomical basis for functional treatment of dorsolateral dislocation of the proximal interphalangeal joint. *Clin Anat* 17:303–307, 2004.
81. Malerich MM, Eaton RG: The volar plate reconstruction for fracture-dislocation of the proximal interphalangeal joint. *Hand Clin* 10:251–260, 1994.
82. Mansat M, Delprat J: Contractures of the proximal interphalangeal joint. *Hand Clin* 8:777–786, 1992.
83. McCue FC, Honner R, Johnson MC, et al: Athletic injuries of the proximal interphalangeal joint requiring surgical treatment. *J Bone Joint Surg Am* 52:937–956, 1970.
84. McElfresh EC, Dobyns JH, O'Brien ET: Management of fracture-dislocation of the proximal interphalangeal joints by extension-block splinting. *J Bone Joint Surg Am* 54:1705–1711, 1972.
85. Minami A, An KN, Cooney WP, et al: Ligament stability of the metacarpophalangeal joint: A biomechanical study. *J Hand Surg [Am]* 10:255–260, 1985.
86. Moberg F, Stener B: Injuries to the ligaments of the thumb and fingers: Diagnosis, treatment and prognosis. *Acta Chir Scand* 106:166–186, 1953.
87. Moneim MS: Volar dislocation of the metacarpophalangeal joint: Pathologic anatomy and report of two cases. *Clin Orthop Relat Res* 176:186–189, 1983.
88. Morgan JP, Gordon DA, Klug MS, et al: Dynamic digital traction for unstable comminuted intraarticular fracture-dislocations of the proximal interphalangeal joint. *J Hand Surg [Am]* 20:565–573, 1995.
89. Neviaser RJ, Wilson JN, Lievano A: Rupture of the ulnar collateral ligament of the thumb (gamekeeper's thumb): Correction by dynamic repair. *J Bone Joint Surg Am* 53:1357–1364, 1971.
90. Nussbaum R, Sadler AH: An isolated, closed, complex dislocation of the metacarpophalangeal joint of the long finger: a unique case. *J Hand Surg [Am]* 11:558–561, 1986.
91. Palmer AK, Linscheid RL: Chronic recurrent dislocation of the proximal interphalangeal joint of the finger. *J Hand Surg [Am]* 3:95–97, 1978.
92. Palmer AK, Linscheid RL: Irreducible dorsal dislocation of the distal interphalangeal joint of the finger. *J Hand Surg* 2:406–408, 1977.
93. Patel MR, Bassini L: Irreducible volar metacarpophalangeal joint dislocation due to junctura tendinum interposition: A case report and review of the literature. *J Hand Surg [Am]* 25:166–172, 2000.
94. Peimer CA, Sullivan DJ, Wild DR: Volar dislocation of the proximal interphalangeal joint. *J Hand Surg [Am]* 9:39–48, 1984.
95. Posner MA, Langa V, Ambrose L: Intrinsic muscle advancement to treat chronic volar instability of the metacarpophalangeal joint of the thumb. *J Hand Surg [Am]* 13:110–115, 1988.
96. Posner MA, Langa V, Green SM: The locked metacarpophalangeal joint: diagnosis and treatment. *J Hand Surg [Am]* 11:249–253, 1986.
97. Posner MA, Wilenski M: Irreducible volar dislocation of the proximal interphalangeal joint of a finger caused by interposition of an intact central slip: a case report. *J Bone Joint Surg Am* 60:133–134, 1978.
98. Quinton DN: Dorsal locking of the metacarpophalangeal joint. *J Hand Surg [Br]* 12:62–63, 1987.
99. Rettig ME, Dassa G, Raskin KB: Volar plate arthroplasty of the distal interphalangeal joint. *J Hand Surg [Am]* 26:940–944, 2001.
100. Ruland RT, Hogan CJ, Cannon DL, et al: Use of dynamic distraction external fixation for unstable fracture-dislocations of the proximal interphalangeal joint. *J Hand Surg [Am]* 33:19–25, 2008.
101. Ryu J, Fagan R: Arthroscopic treatment of acute complete thumb metacarpophalangeal ulnar collateral ligament tears. *J Hand Surg [Am]* 20:1037–1042, 1995.
102. Salamon PB, Gelberman RH: Irreducible dislocation of the interphalangeal joint of the thumb: Report of three cases. *J Bone Joint Surg Am* 60:400–401, 1978.
103. Shah SR, Bindra R, Griffin JW: Irreducible dislocation of the thumb interphalangeal joint with digital nerve interposition: case report. *J Hand Surg [Am]* 35(3):422–424, 2010.
104. Shaw SJ, Morris MA: The range of motion of the metacarpophalangeal joint of the thumb and its relationship to injury. *J Hand Surg [Br]* 17:164–166, 1992.

105. Simonian PT, Trumble TE: Traumatic dislocation of the thumb carpometacarpal joint: early ligamentous reconstruction versus closed reduction and pinning. *J Hand Surg [Am]* 21:802–806, 1996.
106. Slade JF, Gutow AP: Arthroscopy of the metacarpophalangeal joint. *Hand Clin* 15:501–526, 1999.
107. Smith RJ: Post-traumatic instability of the metacarpophalangeal joint of the thumb. *J Bone Joint Surg Am* 59:14–21, 1977.
108. Spaeth HJ, Abrams RA, Bock GW, et al: Gamekeeper thumb: differentiation of nondisplaced and displaced tears of the ulnar collateral ligament with MR imaging. *Radiology* 188:553–556, 1993.
109. Stener B: Displacement of the ruptured ulnar collateral ligament of the metacarpophalangeal joint of the thumb: a clinical and anatomical study. *J Bone Joint Surg Br* 44:869–879, 1962.
110. Stener B: Hyperextension injuries to the metacarpophalangeal joint of the thumb: rupture of ligaments, fracture of sesamoid bones, rupture of the flexor pollicis brevis: An anatomical and clinical study. *Acta Chir Scand* 125:275–293, 1963.
111. Stern PJ: Stener lesion of the lateral dislocation of the proximal interphalangeal joint: indication for open reduction. *J Hand Surg [Am]* 6:602–604, 1981.
112. Strauch RJ, Behrman MJ, Rosenwasser MP: Acute dislocation of the carpometacarpal joint of the thumb: an anatomic and cadaver study. *J Hand Surg [Am]* 19:93–98, 1994.
113. Stripling WD: Displaced intraarticular osteochondral fracture: cause for irreducible dislocation of the distal interphalangeal joint. *J Hand Surg [Am]* 7:77–78, 1982.
114. Suzuki Y, Matsunaga T, Sato S, et al: The pins and rubbers traction system for treatment of comminuted intraarticular fractures and fracture-dislocations in the hand. *J Hand Surg [Br]* 19:98–107, 1994.
115. Tajima K, Sasaki T, Yamanaka K: Vertical locking of the metacarpophalangeal joint of the thumb. *Hand Surg* 10:279–284, 2005.
116. Tekkis PP, Kessaris N, Gavalas M, et al: The role of mini-fragment screw fixation in volar dislocations of the proximal interphalangeal joint. *Arch Orthop Trauma Surg* 121:121–122, 2001.
117. Tonkin MA, Beard AJ, Kemp SJ, et al: Sesamoid arthrodesis for hyperextension of the thumb metacarpophalangeal joint. *J Hand Surg [Am]* 20:334–338, 1995.
118. Viegas SF: Extension block pinning for proximal interphalangeal joint fracture dislocations: Preliminary report of a new technique. *J Hand Surg [Am]* 17:896–901, 1992.
119. Vitale MA, White NJ, Strauch RJ: A percutaneous technique to treat unstable dorsal fracture-dislocations of the proximal interphalangeal joint. *J Hand Surg [Am]* 36(9):1453–1459, 2011.
120. Waris E, Alanen V: Percutaneous, intramedullary fracture reduction and extension block pinning for dorsal proximal interphalangeal fracture-dislocations. *J Hand Surg [Am]* 35(12):2046–2052, 2010.
121. Weiss APC: Cerclage fixation for fracture dislocation of the proximal interphalangeal joint. *Clin Orthop Relat Res* 327:21–28, 1996.
122. Wiley AM: Instability of the proximal interphalangeal joint following dislocation and fracture dislocation: Surgical repair. *Hand* 2:185–194, 1970.
123. Wolfe SW, Katz LD: Intra-articular impaction fractures of the phalanges. *J Hand Surg [Am]* 20:327–333, 1995.
124. Yagi B, Yamanaka K, Yoshida K, et al: Successful manual reduction of locked metacarpophalangeal joints in fingers. *J Bone Joint Surg Am* 82:366–371, 2000.
125. Zemel NP, Stark HH, Ashworth CR, et al: Chronic fracture dislocation of the proximal interphalangeal joint: treatment by osteotomy and bone graft. *J Hand Surg [Am]* 6:447–455, 1981.
126. Zhang X, Yang L, Shao X, et al: Treatment of bony boutonniere deformity with a loop wire. *J Hand Surg [Am]* 36(6):1080–1085, 2011.

9

Perionychium

Nicole Z. Sommer

Acknowledgment: Thank you to Richard E. Brown and Elvin G. Zook for their past contributions to the creation of this chapter.

The fingernail serves many functions that are taken for granted in everyday use of the hand. The nail protects the fingertip, helps in regulation of peripheral circulation, and contributes to tactile sensation that assists us in picking up small objects. An abnormal nail is a functional and a cosmetic problem. Because of the prominence of the nail on the tip of the finger, the perionychium is the most frequently injured part of the hand.

ANATOMY

The anatomic landmarks of the nail are shown in Figure 9.1. The perionychium includes the nail bed, nail fold, eponychium, paronychium, and hyponychium. The nail bed, the soft tissue beneath the nail, includes the germinal matrix proximally and the sterile matrix distally. The nail fold, which is the most proximal extent of the perionychium, consists of a dorsal roof and a ventral floor. The ventral floor is the germinal matrix portion of the nail bed. Paronychium refers to the skin on each side of the nail, and hyponychium refers to the skin distal to the nail bed. The eponychium is the skin proximal to the nail that covers the nail fold. Extending distally from the eponychium onto the nail is the nail vest or cuticle. The white arc of the nail just distal to the eponychium, known as the lunula, is the distal extent of the germinal matrix.

The germinal matrix produces about 90% of the nail,[65] an important point in reconstruction of the nail bed. The sterile matrix adds a thin layer of cells to the undersurface of the nail, keeping the nail adherent to the nail bed.[12,29,53] Scarring of the germinal matrix leads to absence of the nail, whereas injury to the sterile matrix leads to nail deformity. The dorsal roof of the nail fold produces the shine on the nail.

The blood supply of the perionychium comes from the terminal branches of the radial and ulnar volar digital arteries and capillary loops (Figure 9.2).[47] The veins drain into the proximal nail bed and nail fold, then course randomly over the dorsum of the finger.[73,103] Sensation to the nail bed is supplied by dorsal branches of the volar radial and ulnar digital nerves and the most distal extent of the dorsal radial digital nerve branches.[99]

The numerous lymphatics of the nail bed roughly parallel the veins. The hyponychium contains the greatest density of lymphatics of any dermal area in the body,[93] which aids in deterring infection in this frequently exposed area.[102]

PREOPERATIVE EVALUATION

In the case of fingertip injuries, evaluation of the perionychium usually begins in the office or emergency department with the patient history. Evaluation of an injured perionychium includes assessment for associated injuries. We recommend a radiograph of the involved finger because of the 50% chance of fracture with a nail bed injury.

Doors are the most common source of trauma to the perionychium, followed by smashing the finger between two objects and lacerations from yard or workshop tools. Patients are most often older children or young adults. The long finger is most frequently injured because of its increased exposure distal to the other digits. Similarly, the most distal part of the nail bed is the most frequently injured part of the perionychium, and often the hyponychium is involved as well.

Most nail bed trauma falls into the classification of simple lacerations, stellate lacerations, severe crush, or avulsions (Figure 9.3).[44,104] These injuries occur in the same order of frequency. A fifth category of injury is subungual hematoma. Because of the inability to see the extent of the nail bed laceration, subungual hematomas can be the most challenging injury to treat.

TYPES OF OPERATIONS

Subungual Hematoma

Compression of the nail onto the underlying distal phalanx can lead to a laceration in the nail bed and bleeding beneath the nail, known as subungual hematoma. If the nail is intact, the pressure of the blood within this confined space frequently causes severe throbbing pain, and evacuation of the hematoma is indicated.

Before evacuation of the hematoma, the finger should be surgically prepared. Surgical preparation is essential to decrease the chance of bacterial inoculation of the subungual space on trephination of the nail. We prefer a povidone-iodine (Betadine) soap scrub. Trephination of the nail has been performed with drills, needles, and paperclips heated in an open flame until red hot. We prefer a battery-powered microcautery unit, available in most emergency departments (Figure 9.4). The heated tip is passed through the nail and is cooled by the hematoma, avoiding injury to the nail bed. The hole must be large enough to allow continued drainage; otherwise, the hematoma recurs if a clot seals the hole.

In the past, we recommended removal of the nail and repair of the nail bed if greater than 25% to 50% of the nail was undermined by blood.[97,107] However, a prospective 2-year study of 48 patients with hematomas showed no complications of nail deformity with drainage only, regardless of hematoma size or the presence of a distal phalangeal fracture.[88] Our cutoff for nail removal and repair subsequently became greater than 50%. At

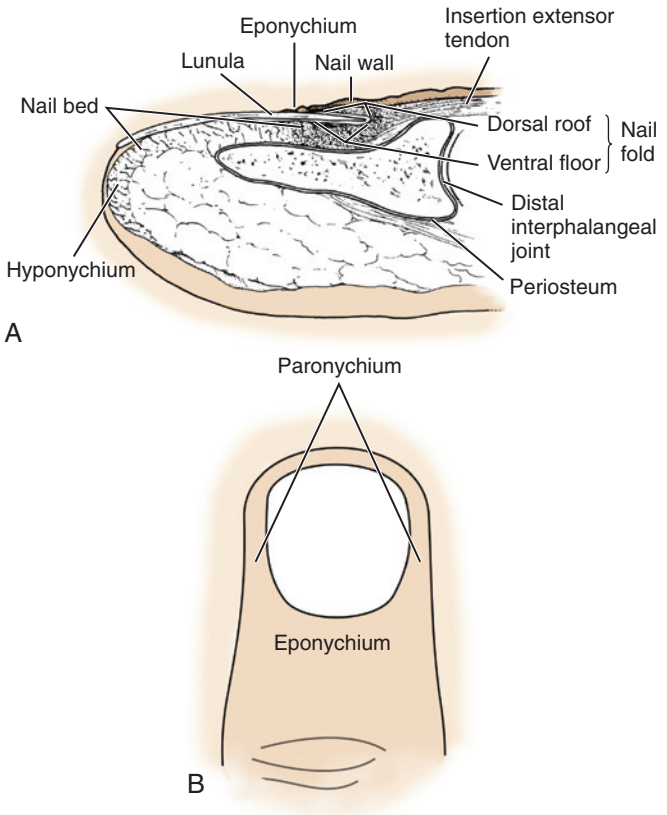

FIGURE 9.1 **A,** Anatomy of the nail bed shown in sagittal section. **B,** The perionychium includes the paronychium, eponychium, hyponychium, and nail bed.

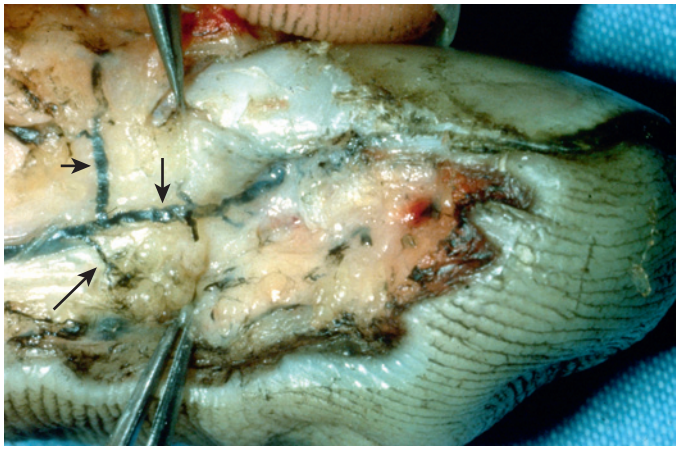

FIGURE 9.2 *Small arrow* shows common volar digital artery, *medium arrow* indicates dorsal branch to the nail fold, and *large arrow* shows artery that progresses along the perionychium and sends branches to the nail bed. The terminal branch to the pad of the finger is not shown.

the present time, the decision for removal of the nail is based primarily on evaluation of the nail edges, rather than the percentage of hematoma. Generally, if the nail edges are intact, we recommend drainage only. If the nail is broken or the edges are disrupted, we recommend removal of the nail with exploration and repair of the nail bed.

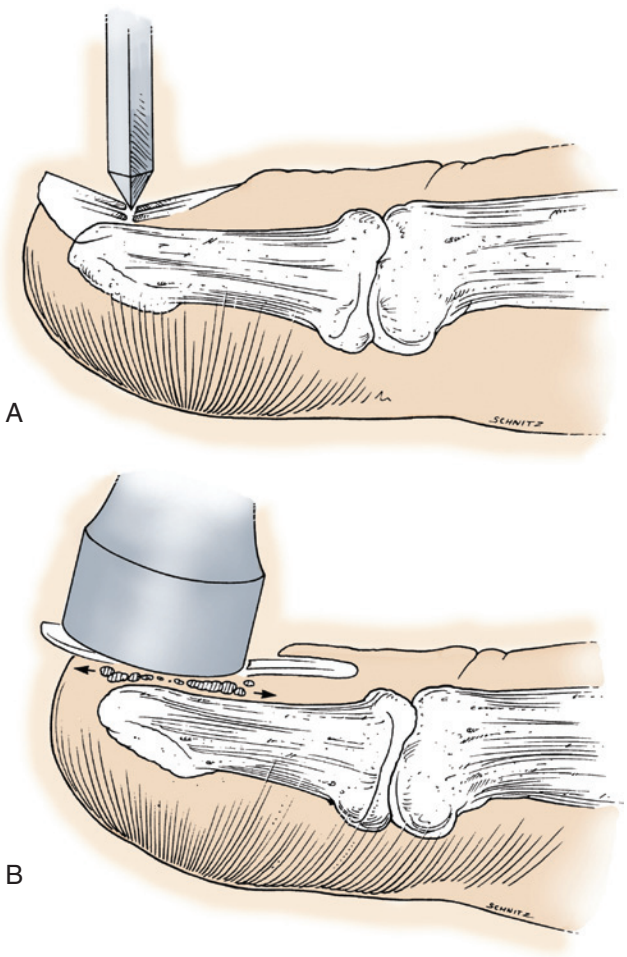

FIGURE 9.3 **A,** A relatively sharp object compressing the nail between the nail and bone causes a splitting laceration (simple). **B,** A wider area of compression of the nail bed between the nail and the bone causes an exploding-type injury that results in multiple fragments (stellate or crush).

Nail Bed Repair

This discussion on nail bed repair includes the various points pertinent for treatment of simple lacerations, crush injuries, and avulsion injuries. A finger block is performed with 1% plain lidocaine. Lidocaine with epinephrine (1:100,000) has also been shown to be safe for digital blocks.[25] The finger and often the entire hand are surgically prepared and draped. After exsanguination, a finger tourniquet is placed around the proximal phalanx to allow for hemostasis and adequate visualization of the nail bed. The nail is removed with a periosteal elevator or iris scissors. The scissors are inserted beneath the free edge of the nail and gently opened and closed working them proximally. If curved scissors are used, the tips are pointed superficially toward the nail to avoid injury to the nail bed. Caution must be used with an elevator because blunt force can tear the nail bed. We recommend a Kutz elevator because it is smaller than a Freer elevator and does less damage to the nail bed. The nail is cleaned by scraping the undersurface to remove the residual fibrinous tissue and soaked in povidone-iodine during the repair of the nail bed laceration.

The nail bed is examined under loupe magnification. Irregularities of the edges are trimmed if it is possible to do so without

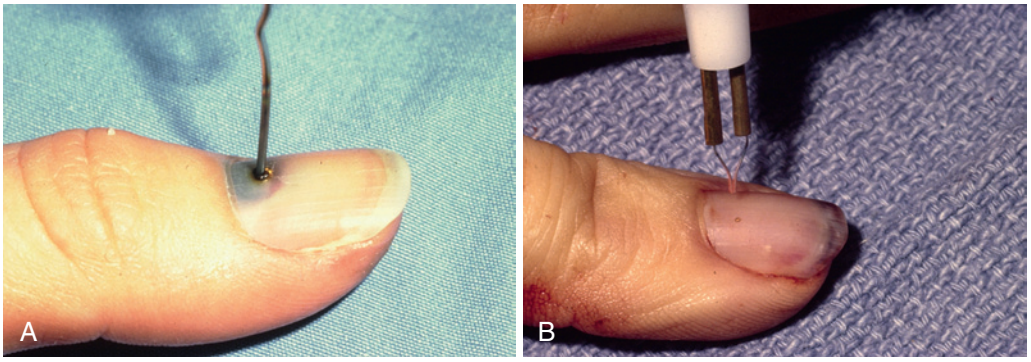

FIGURE 9.4 **A,** A time-honored method of burning a hole through the nail is with a heated paperclip. **B,** The authors' preferred method of burning a hole through the nail is with an ophthalmic battery-powered cautery.

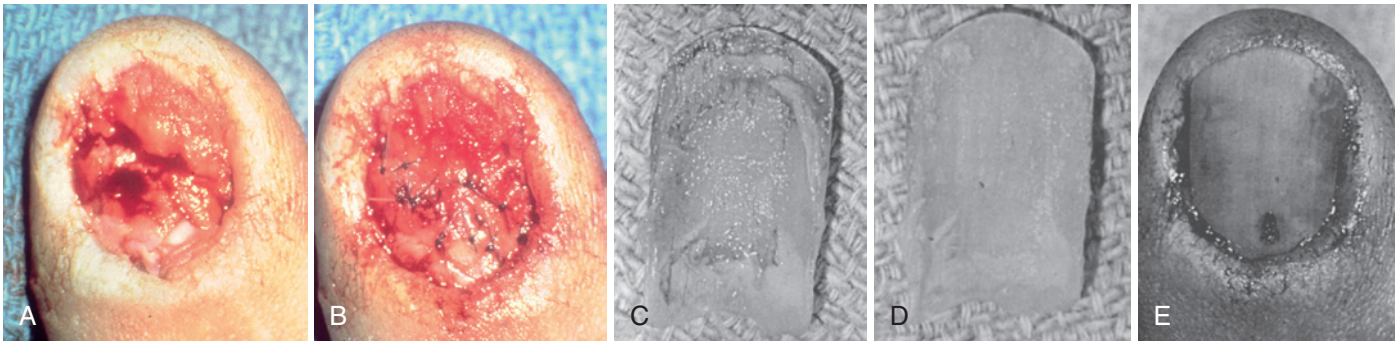

FIGURE 9.5 **A,** Stellate laceration of nail bed is visible after the nail is removed. **B,** The lacerations are approximated with fine 7-0 chromic sutures under loop magnification. **C,** The undersurface of the nail after it has been removed from the nail bed shows the residual soft tissue that is usually present. **D,** The undersurface of the nail after it has been cleaned and soaked. **E,** A hole large enough to allow drainage has been burned through the nail, and the nail has been inserted back into the nail fold. (**C** through **E,** From Zook EG: The perionychium: anatomy, physiology and care of injuries. *Clin Plast Surg* 8:21–31, 1981, with permission.)

compromising the repair. Débridement must remain conservative, however. The nail bed is adherent to the distal phalanx and difficult to mobilize. Undermining the edges approximately 1 mm allows for slight eversion, but minimal to no mobilization. It is better to leave contused edges in place if there is doubt of closure, rather than to leave a defect from aggressive débridement. The wound is copiously irrigated with normal saline. The nail bed is repaired with a 7-0 chromic suture on a micropoint spatula, double-arm, GS-9 ophthalmic needle (Ethicon). The curve of this needle allows easier passage through the nail bed, which is adherent to the periosteum. The double needle provides a spare in case one is bent or broken. Simple nonburied sutures are placed.

With stellate lacerations and especially with crush injuries, the nail is often fragmented. The nail is removed very cautiously to avoid injury to the small segments of adherent nail bed. With meticulous approximation of the multiple segments, stellate lacerations have a good outcome (Figure 9.5). Crush injuries have a poorer prognosis likely because of the presence of greater contusion along with the complicated laceration.

After repair of simple or complex lacerations (or placement of a nail bed graft, when needed), the nail bed must be protected. The best option is the native nail if this is available. The nail also acts as a perfect mold for the repaired nail bed.[85] The nail is removed from the povidone-iodine soak and irrigated with normal saline. A hole is cut in the nail with a pair of fine scissors or burned with a battery-operated cautery to allow

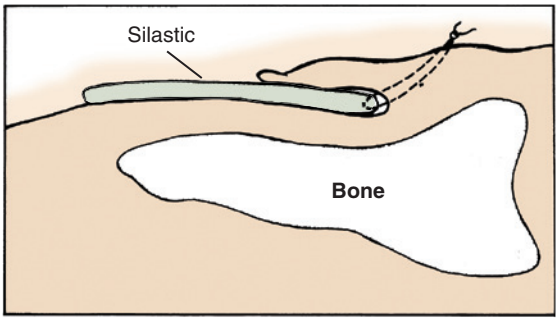

FIGURE 9.6 Horizontal mattress suture through the nail wall is used to hold a silicone sheet in the nail fold.

drainage of serum or hematoma from the subungual space. We prefer to place the hole away from the repair when possible. The nail is secured in place with a 5-0 nylon mattress suture through the nail and nail fold or a simple suture through the edge of the nail and hyponychium. The nail prevents scar formation between the ventral and dorsal surface of the nail fold. The nail stiffness prevents it from flipping out of the nail fold when the hyponychium suture is used. Dermal adhesives[45,94] have been advocated for nail adhesion, but we have no experience with this technique. If the nail is unavailable or is too badly damaged, a nail-shaped piece of 0.020-inch reinforced silicone sheeting may be substituted. Silicone is less stiff and requires a nail fold suture to hold it in place beneath the nail fold (Figure 9.6). We

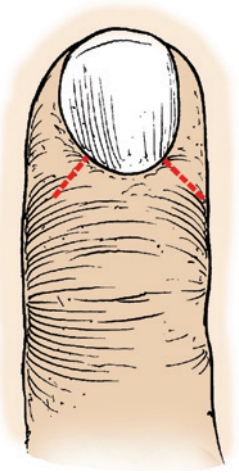

FIGURE 9.7 When incisions are made in the eponychium, they should be made at 90-degree angles from the eponychium to prevent deformity.

believe that the silicone is able to mold the edges of the repair more accurately than firmer prosthetic materials recommended by Ogunro.[78] If neither nail nor silicone is available, a single thickness of nail-shaped nonadherent gauze or suture packet material may be placed in the nail fold.

The finger is wrapped in nonadhesive gauze and small gauze bandages and wrapped with a small gauze roll. We recommend a four-prong or volar aluminum splint for protection of the repair and reduction of pain. The splint is worn for 2 to 3 weeks, or longer if a fracture is present. Immobilization of the distal interphalangeal (DIP) joint is necessary only if a significant distal phalanx fracture is present. Patients are instructed to keep the finger and dressing dry until follow-up and to keep the hand elevated. If a nail bed graft is taken, the donor site is treated in a similar fashion with replacement and stabilization of the nail and a protective dressing.

Avulsion

Nail bed avulsion often leaves a fragment of nail bed attached to the undersurface of the avulsed nail and often involves most of the nail bed. An avulsion commonly manifests as laceration of the nail bed within the nail fold with the nail bed attached distally. In a child, avulsion of the nail bed out of the nail fold suggests a Salter I fracture. Radiographic evaluation, especially in the lateral view, is recommended.

Adequate visualization and repair require an incision in the eponychium. The incision is made perpendicular to the lateral curved portion of the eponychial fold and may be necessary on both sides (Figure 9.7). The nail bed is repaired under direct visualization, and the eponychial incisions are closed with 6-0 nylon.

An attempt should be made to find the nail if it does not accompany the patient. The avulsed nail bed is replaced as a nail bed graft with the nail acting as an optimal graft bolster. If the fragment is large, the nail is trimmed back 1 to 2 mm from the outer edge of the nail bed to allow suturing of the nail bed (Figure 9.8). Small fragments of nail bed are removed from the nail and replaced as nail bed grafts. A graft 1 cm in diameter usually takes by inosculation and vascular ingrowth from the periphery. The distal phalanx is one of the few sites where a

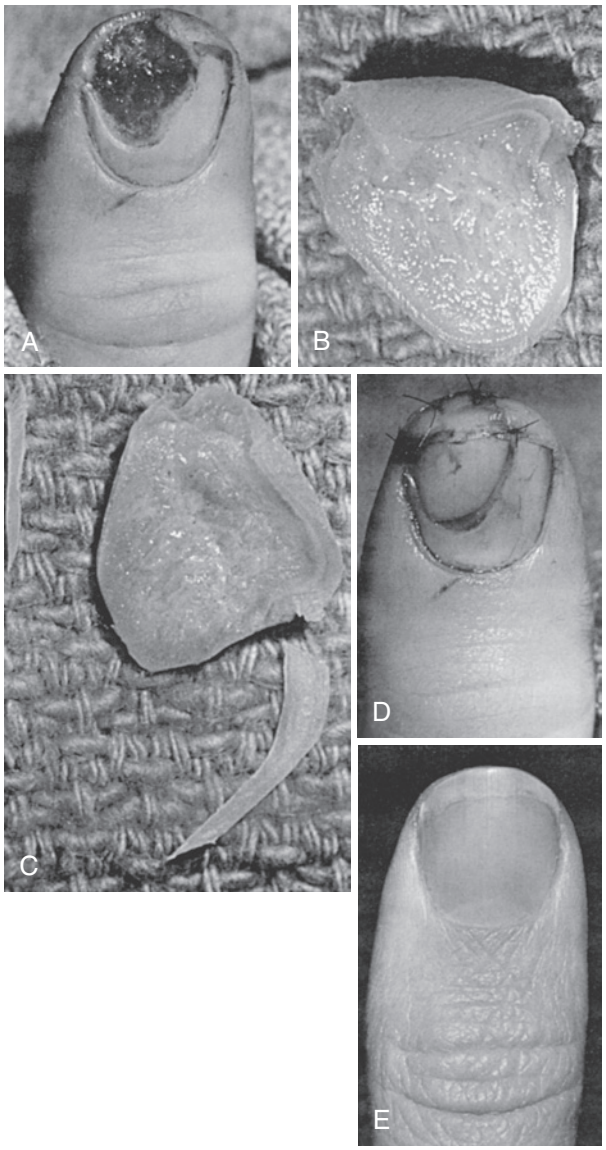

FIGURE 9.8 **A,** Avulsion of a small portion of the nail and nail bed. **B,** Undersurface of the nail fragment with attached nail bed. **C,** Only that portion of the nail that is overhanging the nail bed is removed. **D,** The nail with attached nail bed is accurately approximated and held in place with a few fine chromic sutures. **E,** Nail bed 12 months after injury.

graft can survive on bare cortex. Very small nail bed fragments may be more difficult to remove. Although rarely the case, if there is concern about further injury to the nail bed fragment on attempted removal, the entire nail is replaced without separation of the nail bed fragment from the nail or suturing of the nail bed.

Nail Bed Defect

A split-thickness injury of the nail bed regenerates and does not need closure. Small areas of full-thickness nail bed loss have been left to heal by secondary intention; however, this generally results in scarring and nail deformity. Johnson[52] advocated releasing incisions in the lateral paronychial folds with advancement of the germinal matrix toward the center of the nail. Favorable features that increase success of this lateral mobilization include a defect less than one third of the nail width, good

condition of the matrix to be mobilized, and careful elevation and advancement of the matrix.[3] We have found this technique useful in the acute setting with a defect of 3 to 5 mm.

There are other options for closure of sterile matrix defects, including split-thickness or full-thickness nail bed grafts.[84] Use of a split-thickness nail bed graft[90] allows for harvest of nail bed from adjacent uninjured nail bed without altering nail growth at the donor site. It has been our experience that if there is inadequate undamaged area on the injured nail bed from which to harvest, such as a defect greater than 50% of the nail bed, the nail bed graft should be harvested from an adjacent finger or toe. Patients often choose to have a graft harvested from the toe rather than another finger. From a clinical standpoint, the toe is likely a better option, owing to the small risk of donor site nail deformity if the graft is harvested too deeply (Figure 9.9).

Full-thickness nail bed grafts are rarely used except when there are salvageable spare parts that would otherwise be discarded. Otherwise, a full-thickness graft would leave a deformity of the nail at the donor site. A full-thickness nail bed graft is necessary, however, when replacing lost germinal matrix. Another situation in which full-thickness grafts are chosen involves injury to the perionychium surrounding the nail bed. Zaias[100] determined that there are no living cells in split-thickness nail bed grafts, and the recipient site is resurfaced with cells from the surrounding hyponychium, eponychium, and paronychium. If the surrounding perionychium is also missing, a full-thickness nail bed graft, which possesses living cells, would yield superior results compared with a split-thickness graft.

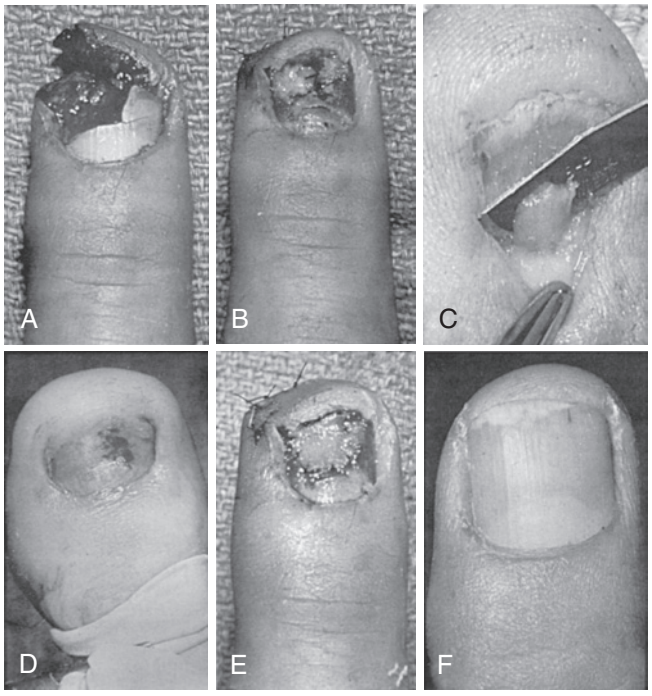

FIGURE 9.9 **A,** Nail bed and fingertip injury with avulsion of approximately 25% of the nail bed. **B,** Tip skin and nail bed surrounding the avulsion have been repaired. The white area at the distal left portion of the nail bed is bare cortical bone of the distal tuft. **C,** Technique of harvesting a small, split-thickness nail bed graft. **D,** Large toe after the nail has been removed and a split-thickness graft has been removed from the sterile matrix. The germinal matrix should not be included in a split-thickness graft. **E,** Split-thickness graft of sterile matrix is sutured in place on the nail bed. **F,** Fingernail 1 year later.

Sugamata treated a small series of nail bed wounds with artificial dermis. The artificial dermis was placed as a substitute for the missing part of nail bed in patients without an available amputated piece or unwilling to sacrifice another digit for the nail bed graft. Although he does not specify if the nail bed wound involved the sterile versus germinal matrix, all patients regenerated nail and were satisfied with the result.[95] We suspect this technique would be less successful if the germinal matrix portion were involved.

Harvest of Nail Bed Graft

The finger or toe to be used as the donor is anesthetized with a digital block. After exsanguination, a digital tourniquet is placed for hemostasis, and the nail is removed. If possible, only a portion of the nail is removed, leaving the proximal nail intact within the nail fold. If a sterile marking pen is available, it is helpful to mark the area of graft needed on the donor site. A split-thickness nail bed graft (approximately 0.010 inch thick) is harvested with a No. 15 scalpel (see Figure 9.9, *C*). Harvesting must be done carefully and slowly. The scalpel is placed parallel to the nail bed, and a back-and-forth sawing motion is used. To ensure thinness of the graft, we recommend visualization of the blade through the graft. It is better for the graft to be too thin than too thick. If a thick graft results in full-thickness donor loss, donor site deformity is likely. A large graft is more difficult to harvest because of the curve of the nail bed and increases the chance of an accidental full-thickness harvest. To avoid this possibility, we use the tip of the blade while picking up the edge of the graft with fine forceps. The graft is sutured into the defect with 7-0 chromic sutures.

Fracture

An associated distal phalanx fracture occurs with 50% of nail bed injuries.[104] Nondisplaced fractures and distal tuft fractures are treated with repair of the nail bed and replacement of the nail as a splint. The curve of the nail and its close approximation to the underlying bone makes an excellent splint to maintain fracture reduction. A tension band suture over the replaced nail can provide further stability to the fracture (Figure 9.10).[15] If



FIGURE 9.10 Figure-of-eight stitch holds nail in place and adds stability to fracture.

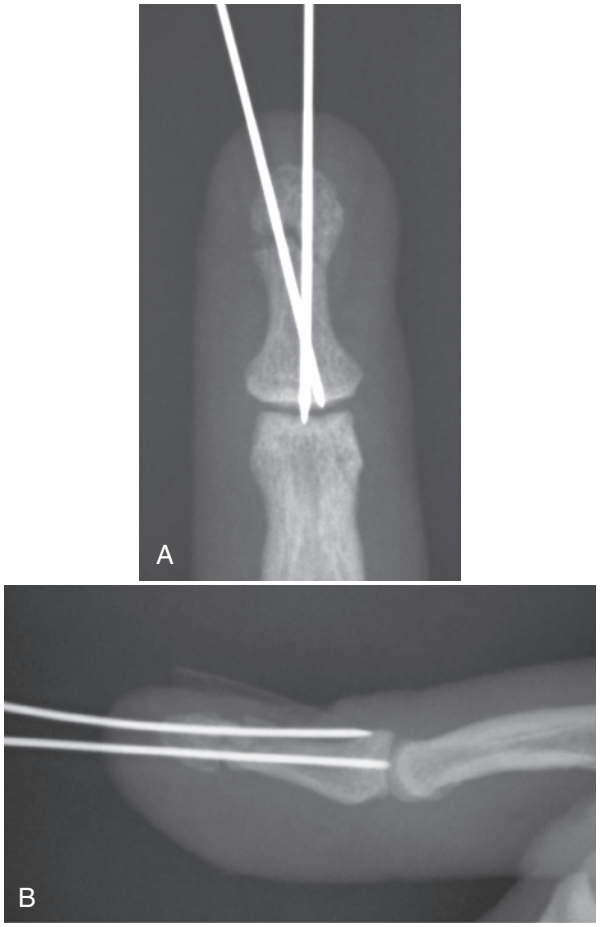

FIGURE 9.11 **A** and **B,** Distal phalanx fractures with Kirschner wire fixation. (From Brown RE: Acute nail bed injuries. *Hand Clin* 18:561–575, 2002.)

the nail is missing, the fracture may need to be pinned for better stabilization.

Displaced fractures, especially fractures proximal to the nail fold, are accurately reduced and fixed with 0.028-inch longitudinal or crossed Kirschner wires (Figure 9.11). The use of a single wire is not recommended. Although a single wire can reduce the fracture, it cannot eliminate axial rotation. If only a small nail bed laceration is present, wires are passed in a retrograde fashion. However, with large nail bed lacerations, the wires are passed antegrade through the distal fragment, then retrograde into the proximal fragment. Crossing the DIP joint should be avoided if possible. With crush injuries, the distal phalanx fracture is often comminuted with small fractured pieces adherent to the nail bed. In this case, the bony fragments are reduced with reapproximation of the nail bed using the nail as a splint. If the nail is unavailable for use as a splint, a piece of reinforced silicone is recommended. The goals of distal phalanx reduction are bony union and an even dorsal cortex. An uneven cortex would impair nail bed healing and lead to a nail deformity.

Salter I fractures are often reduced with repair of the nail bed alone. Pinning of the fracture should be avoided unless it is unstable. The patient and parents should be informed that growth of the distal phalanx may be affected, even with adequate reduction.

Amputation

Amputation can be treated in multiple ways, usually based on the remaining proximal tissue and the presence and quality of the amputated piece. Options include revision amputation, closure with flaps and grafts, or replantation. Our preference for treatment is discussed for a distal to proximal direction of injury.

On the rare occasion that the distal phalanx is covered by a layer of soft tissue, the amputated piece can be defatted and replaced as a skin or nail bed graft, or the area can be left to heal by secondary intention, especially if less than 1 to 1.5 cm in size. If the distal phalanx is exposed, the options consist of trimming back the bone to allow for primary closure or rotation of local or regional skin flaps to preserve length. In both cases, when suturing the fingertip skin to the distal nail bed, tension should be avoided. Tension at the closure causes volar curvature of the distal nail bed and plate, leading to a hook nail. If a portion of the distal phalanx is absent, the nail bed should be shortened to the end of the remaining distal phalanx before repair to avoid hooking of the nail from loss of bony support.

More proximal amputations involving the midportion of the nail bed can be managed with local and regional flaps.[20] We use local volar and lateral "V-Y" advancement flaps and regional cross-finger and thenar flaps to provide tip coverage (Figures 9.12 and 9.13).[18,5,39] "V-Y" advancement flaps cannot be advanced more than 5 to 10 mm.[18] These flaps can be used to close defects primarily involving the volar and distal fingertip or can be used with nail bed grafts to reconstruct the entire fingertip. Such flaps provide excellent coverage and can be deepithelialized to provide a vascularized bed for placement of the nail bed graft. Full-thickness nail bed grafts from the amputated part or a split-thickness nail bed graft from an adjacent finger or toe may be used. Eponychial advancement flaps or cutaneous translation flaps have been successfully used to advance the nail distally in reconstruction of amputation defects.[7] The eponychial flap is used in conjunction with a volar flap to preserve length of the digit.[35]

Amputations through the eponychium may be replanted, but success is variable. We tend to perform revision amputation at the level of the eponychium. If 25% or greater of the nail bed distal to the eponychium is present, the patient benefits from maintaining that nail. If less than 25% remains, however, we recommend resection of the remaining nail bed. This resection requires removal of the dorsal roof and ventral floor of the nail fold. The eponychial skin is left intact to use for coverage. Netscher and Meade[76] described success with the use of full-thickness graft of hyponychium, nail bed, and paronychium for amputations between the midportion of the nail and just proximal to the eponychium. In several cases, the distal phalanx was replaced as a graft and covered with regional flaps. The graft was placed onto the deepithelialized flaps. This would allow for preservation of length when successful.

Replantation is most successful when the amputation is proximal to the area of the paronychium through the proximal aspect of the distal phalanx. Amputations through the nail bed are less successful because of the size of the vessels.

In children, the tip of the finger is often avulsed with the nail bed. In these cases, we approximate the edges of the nail bed

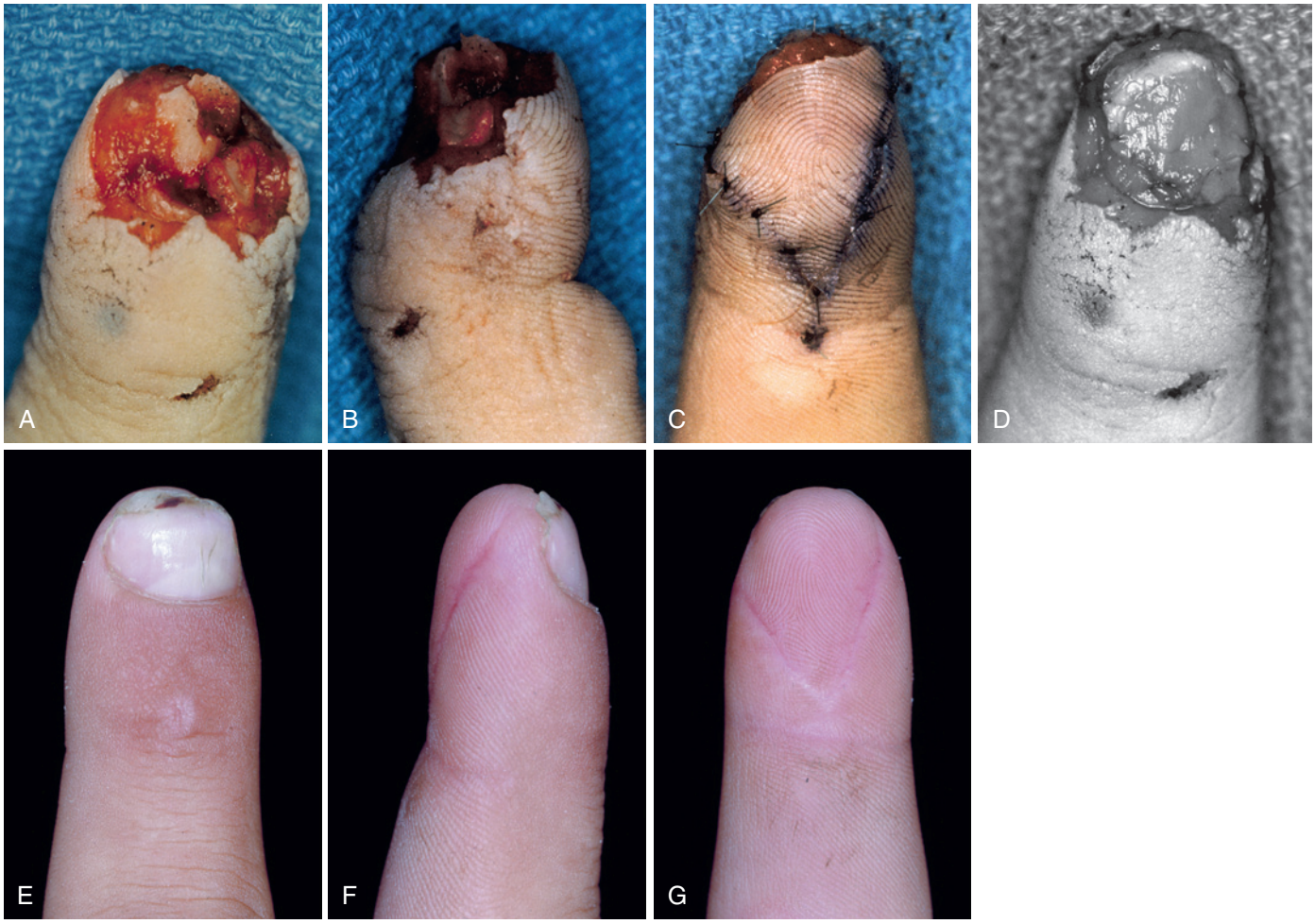

FIGURE 9.12 **A,** Fingertip injury with avulsion of nail bed. **B,** Dorsal tip defect with intact volar skin. **C,** "V-Y" volar advancement flap for coverage and nail bed support. **D,** Nail bed replaced as graft. **E** to **G,** Results after partial nail regrowth. (**D,** From Brown RE, Zook EG, Russell RC: Fingertip reconstruction with flaps and nail bed grafts. *J Hand Surg [Am]* 24:345–351, 1999.)

and fingertip skin as a composite graft. Débridement of this composite graft is minimal to allow for maximal inosculation effect. Longitudinal or crossed pins are used to hold the bone in place. With young children, we occasionally use hypodermic needles in place of Kirschner wires for the bony reduction. The younger the child, the better chances for "take" of a composite graft of skin and nail bed. Our greatest success rate is for children 3 years old and younger. Alternatively, in an older child, a "cap" graft[83] is likely to have greater success. This procedure includes removal of the bone fragment and defatting of the skin for use of the piece as a full-thickness skin or nail bed graft.

Delayed Treatment of Acute Injuries

Occasionally, a nail bed injury is seen hours or days after the injury, with or without previous treatment. The first decision must be whether the initial care was adequate and, if it was not, whether more should be done. If there is any question, the nail bed is explored and accurately approximated; this can usually be done 7 days after injury. Any untreated or maltreated distal phalangeal fractures should also be treated appropriately, and the patient should be placed on perioperative antibiotics. Although the chance of infection may be greater with delayed treatment, a nail deformity occurs if nothing is done. We believe the risk is worth taking.

POSTOPERATIVE MANAGEMENT

Patients are seen at 5 to 7 days after surgery. It is usually necessary to soak the finger with normal saline and peroxide to remove the dressing. The bandage is removed gently and slowly to protect the repair. This removal is especially difficult when nonadherent gauze alone is used for the nail fold because it adheres to the nail bed. If it does not loosen, we instruct the patient to perform warm soapy soaks at home several times a day. It generally separates as the nail grows.

The nail is checked for subungual seroma or hematoma. If either is present, the hole is reopened, or the nail is very gently raised at the edge to permit drainage. The suture used to hold the nail or silicone sheet in place within the nail fold should be removed 5 to 7 days after injury to avoid a sinus tract formation through the nail fold. Sutures placed through the hyponychium or the paronychium (lateral skin) may be left in longer and removed in 10 to 14 days as would be customary for sutures in the hand. The old nail is likely to adhere to the nail bed for 1 to 3 months until pushed off by the new nail. Silicone sheeting will fall off sooner.

The nail bed repair is protected, and distal phalangeal fractures are immobilized with a splint dressing for the first 3 to 4 weeks. After this time, a bandage is adequate for protection of

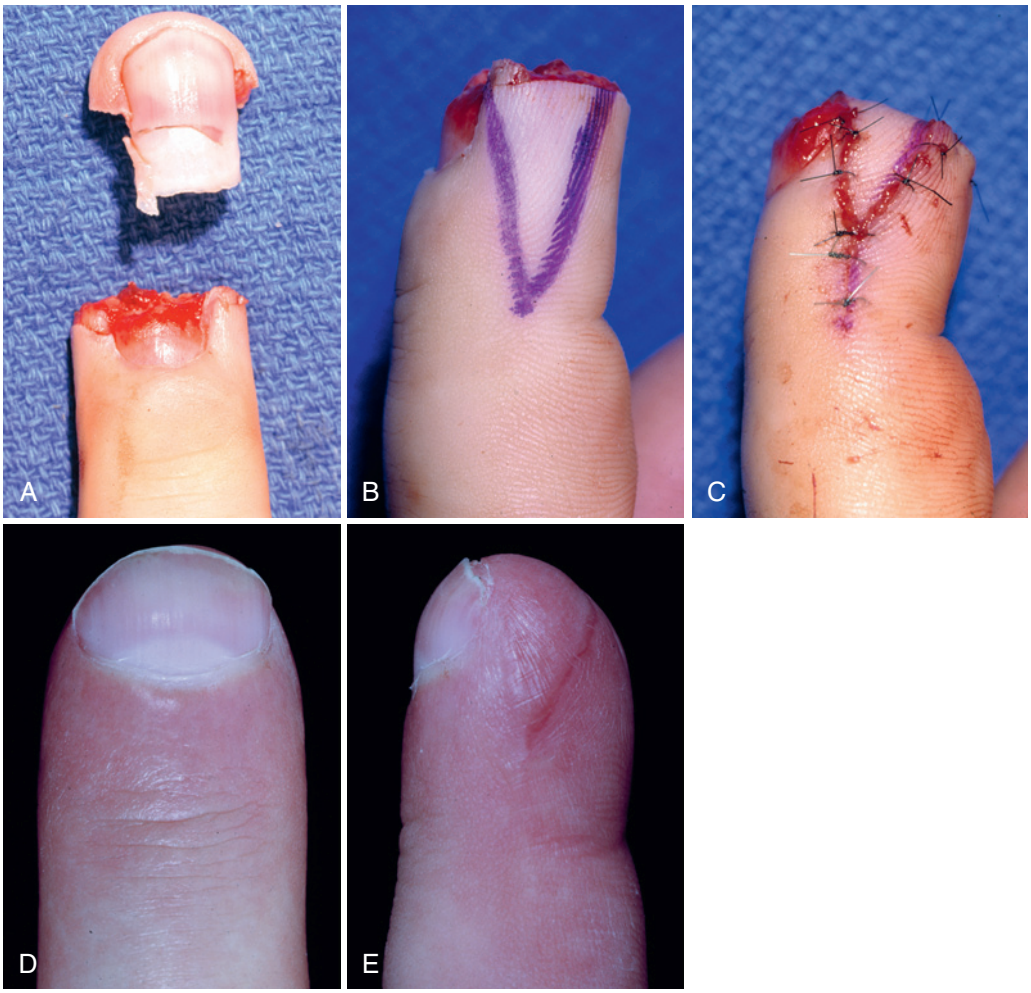

FIGURE 9.13 **A,** Fingertip amputation through the sterile matrix. **B,** Outline of bilateral "V-Y" advancement flaps for soft tissue coverage of fingertip. **C,** Flaps advanced and sutured together in midline. **D** and **E,** Appearance after regrowth of nail.

the repair and for assisting in retention of the old nail. Retention of the nail protects the nail bed and creates a much less tender fingertip while the new nail grows. Distal phalanx fractures are followed by x-ray evaluation at 3 to 4 weeks and clinical resolution of pain.

Scarring of the nail bed is reduced with surgical repair, and growth of a normal new nail is expected. Nail bed scarring and nail deformities do occur, however, and the patient should be reminded of this at the postoperative visit.

The nail grows at approximately 0.1 mm per day[6] or 2 to 3 mm per month. After removal of the nail for nail bed repair, there is a delay of new growth for 3 to 4 weeks.[6] If the proximal nail was uninjured and left in place during repair of a distal nail bed injury, growth of that nail occurs at a normal rate without delay. As the nail grows, there is a bulge on the leading edge. This distal end is expected to reach the distal finger at 6 to 9 months after injury. Toenail growth occurs four times more slowly than fingernail growth.[79]

COMPLICATIONS

Postoperative complications can be divided into problems at the site of nail growth (i.e., the germinal and sterile matrix and nail fold) and the site of nail support, the distal phalanx. Scar within the sterile matrix results in various deformities, including notching, splitting, elevation, and nonadherence, because the nail does not grow over or adhere to a nail bed scar.[48] Scar within the germinal matrix may lead to absence of nail growth. Splitting or absence of the nail may also be caused from scarring of the nail fold dorsal roof to the ventral floor, which again emphasizes the importance of placing the nail or a silicone sheet under the nail fold after acute repair. All of these deformities can be functional and cosmetic. Bony complications include an uneven dorsal cortex and loss of bony support secondary to overdébridement of the distal phalanx, nonunion of the distal phalanx, or osteomyelitis.

Late reconstruction of the nail bed is commonly not as successful as the surgeon or the patient would desire. These less than satisfactory results have discouraged and hindered progress in reconstruction of the perionychium. Every reconstructive problem of the nail bed is different and must be approached individually. A thorough understanding of the anatomy and physiology of the nail bed of the fingers and toes is essential to devise and carry out a treatment plan.

Nail Ridges

Nail ridges are caused by an uneven dorsal cortex or scar beneath the nail bed. Because nail growth follows the shape of

the nail bed, an uneven surface beneath the nail bed leads to an irregular nail bed and a subsequent nail ridge. A transverse nail ridge can raise the nail off of the nail bed preventing distal adherence. Ridging is typically a cosmetic problem except in the instance of nonadherence, where the free nail edge can catch on objects such as clothing, making this a functional problem as well. Correction requires elevation of the nail bed off of the distal phalanx and surgical excision of the scar or leveling of the uneven dorsal cortex to create a flat nail bed.[4,96]

We have noted minor transverse ridges of the nail after general hypoxic illness and local hypoxia from use of an arm tourniquet for upper extremity procedures. Hypoxia leads to temporary abnormality of germinal matrix cells; the ridges resolve as the nail grows.

Split Nail

A split nail may be caused by a longitudinal ridge or scar in the germinal or sterile matrix. Because scar does not produce nail cells, there is a blank area between the regions of normal nail production, producing a split.

If the split is due to scar in the germinal matrix with lack of nail production, the scar must be removed, and the nail bed must be repaired or replaced. The eponychium is elevated with incisions at right angles to the corners to expose the germinal matrix. The nail is removed, and under loop magnification, the scar is identified and resected. Rarely, the defect is small enough (<2 mm) to be closed primarily. If there is any tension, a nail bed graft should be used instead. We have found lateral mobilization of the matrix,[53] as mentioned earlier, to be mostly unsuccessful in the case of late reconstruction owing to scar interfering with flap rotation.

A larger defect must be closed with a nail bed graft. We prefer to use a germinal matrix graft from a toe that is similar in size and shape to the resected scar (Figure 9.14). The germinal matrix must be taken as a full-thickness graft for it to produce nail at the recipient site. Because a full-thickness graft frequently requires the elimination of nearly an entire toenail bed, the second toenail is more acceptable to most individuals, rather than having a significant deformity of the large toenail.[26] The third through fifth toes usually do not have enough germinal matrix available for a graft.

If the scar involves the sterile matrix, it can rarely be treated with resection and primary closure. In our experience, the scar is frequently too wide to approximate the edges without significant tension and recurrence of the scar and subsequent split. We recommend resection of the scar and replacement with a split-thickness nail bed graft. A defect in the sterile matrix does not require a full-thickness graft as does the germinal matrix. Harvest of the graft should cause no donor site deformity.[81,91] Donor site options include adjacent nail on the injured finger, an adjacent finger, or the first or second toe (Figure 9.15).

Nonadherence

The sterile matrix adds nail cells to the undersurface of the nail, resulting in adherence of the nail to the nail bed. Scars within the sterile matrix do not produce nail cells, allowing for loosening of the nail attachments. The nail is lifted off of the nail bed by transverse and diagonal scars and is unable to adhere distally. Resection of the scar is essential for correction. For replacement, we prefer a split-thickness sterile matrix graft from either an adjacent area of the nail bed or a toenail bed (Figure 9.16).[81,101,106]

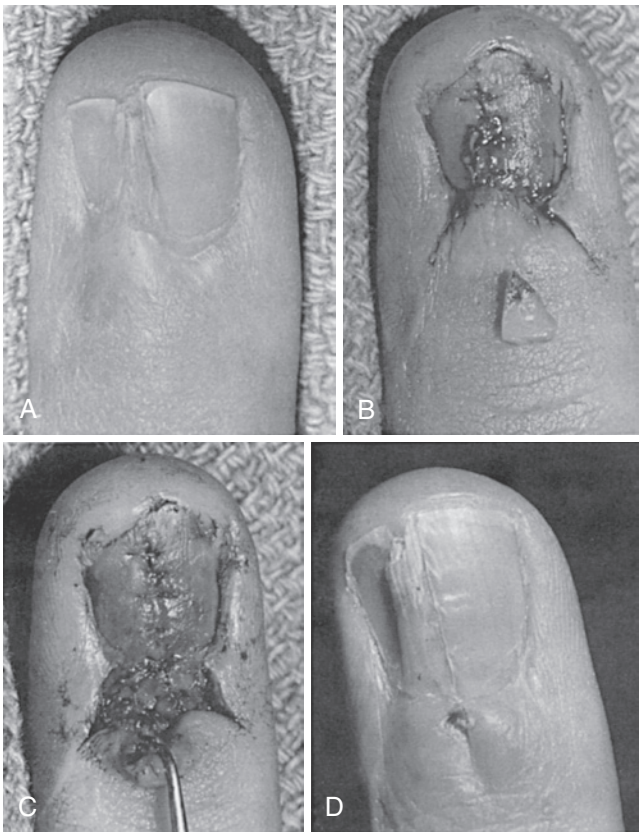

FIGURE 9.14 **A,** Split nail with a pterygium caused by scarring of the germinal matrix. **B,** Scar of the germinal matrix has been removed, and a fragment of germinal matrix from the second toe has been cut to shape to fit the defect. **C,** Germinal matrix graft sutured in place. **D,** Nail can be seen growing from the germinal matrix graft 6 months later.

Chronic nonadherence of the nail to the distal nail bed can also occur with repetitive trauma, such as using the fingernails to pry open objects. Cutting back or avoiding the activity is advised. If no improvement is seen, replacement of this distal nail bed segment with a split-thickness sterile matrix graft is recommended.

Absence

Absence of a nail may be congenital or may result from avulsion, severe crush, infection, or burn, and is a disconcerting deformity to the patient. Absence may be partial or complete. Absence of nail distal to the germinal matrix is treated with removal of the scar and replacement with a split-thickness sterile matrix nail bed graft. Lemperle and associates[64] reported success with serial excisions of 4-mm wide, crescent-shaped, full-thickness scars at 2-month intervals that resulted in distal migration of the nail bed by wound contraction. This technique seems to eliminate morbidity of a donor graft site, while increasing the number of procedures required in serial excision.

Complete absence of nail is more difficult to reconstruct, especially when the proximal nail fold is absent along with the germinal matrix. A simple but suboptimal treatment is resection of an area of skin in the shape of a slightly larger than normal nail.[46] A full-thickness or split-thickness skin graft is

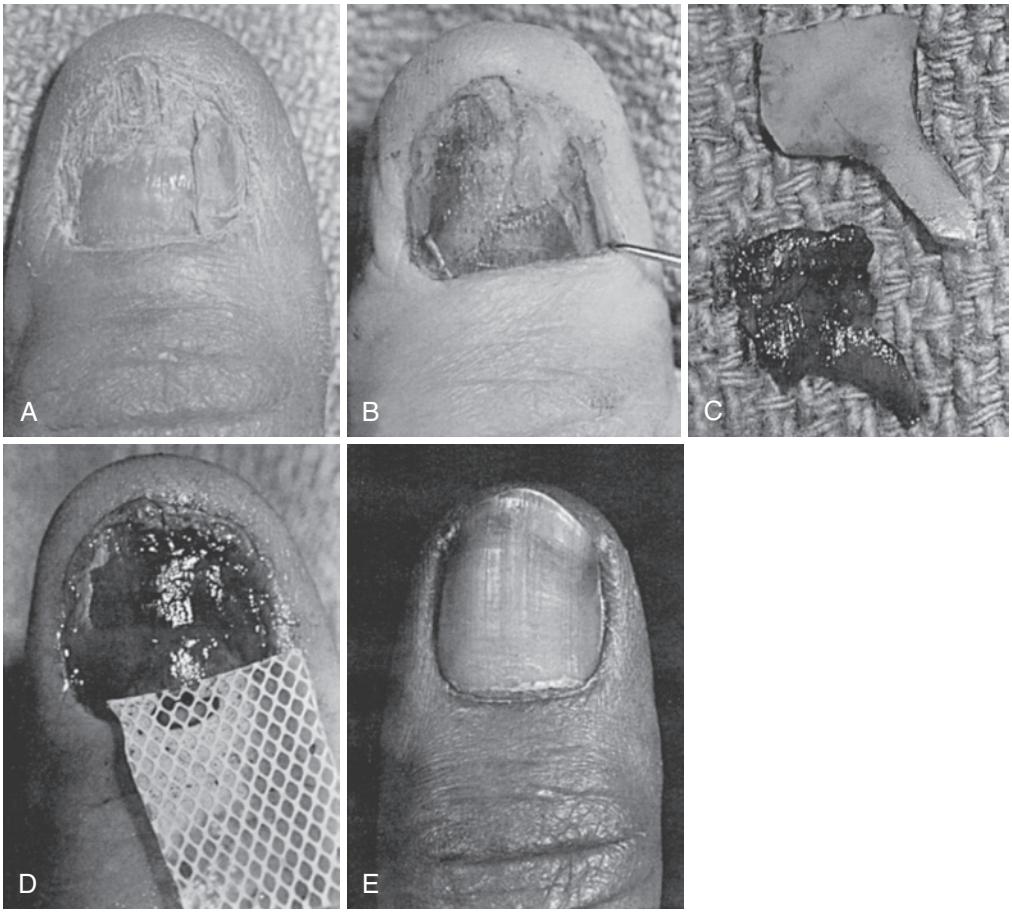

FIGURE 9.15 **A,** Preoperative view of a thumbnail after injury by a car door. The nail grows out and becomes nonadherent every 2 to 3 months. **B,** Nail remnant has been removed, and scar can be seen in the nail bed on the right side. **C,** An exact template in the configuration of the scar is used to shape a split-thickness nail bed graft from sterile matrix of the toe. **D,** Split-thickness nail bed graft has been sutured in place, and a silicone sheet has been placed over it and into the nail fold. **E,** The nail 11 months postoperatively with complete adherence of the nail.

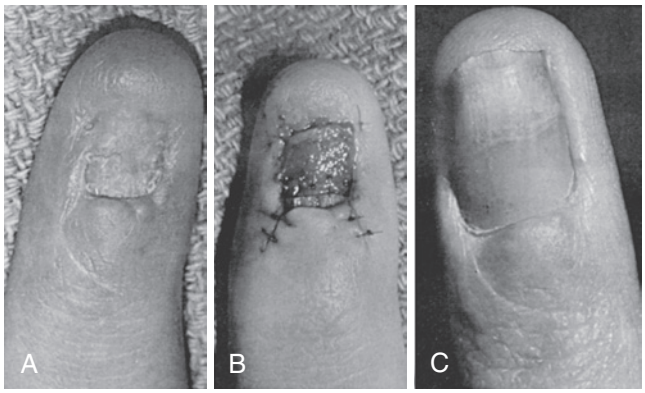

FIGURE 9.16 **A,** Finger with normal germinal matrix, but absent sterile matrix and nonadherence of the nail. The patient had had repeated infections beneath the nail. **B,** Scarred nail bed has been removed, and a full-thickness sterile matrix graft from the second toe has been used to replace it. **C,** Nail 1 year later adheres to the full-thickness toenail graft, but does not adhere to the distal scar. (From Zook EG: The perionychium: anatomy, physiology and care of injuries. *Clin Plast Surg* 8:21–31, 1981, with permission.)

used to mimic the appearance of a nail. Artificial nails applied with glue have been unsuccessful.[13] Buncke and Gonzalez[22] advocated reconstruction of a nail fold pouch to aid in artificial nail adherence. As time passes, the pouch becomes obliterated, however, and no longer holds the edge of the prosthetic nail.[13]

Baruchin and colleagues[12a] described the use of titanium implants inserted into the distal phalanx as a method of artificial nail fixation. A small patient series showed favorable results with this simple, cost effective and sustainable procedure.

Composite toenail grafts that include germinal and sterile matrix and the dorsal roof have been used for nail reconstruction (Figure 9.17). The few reported cases have produced unpredictable results. In our experience, the results do not seem to be directly related to patient age or size of the graft.[66] We inform the patients of the expected toenail deformity and the potentially suboptimal fingernail outcome. In selecting a donor site for composite grafts, we prefer to use the second toe because it is usually approximately the width of the fingernail. A toenail is not as long as a fingernail, however, and a split-thickness sterile matrix graft from another toe needs to be placed distal to the composite graft to lengthen the attachment area. The large toenail or a portion of it is necessary for thumbnail reconstruction with composite grafts.

The most reliable treatment to produce a growing nail is a free microvascular transfer of the dorsal tip of the toe, including the nail bed (Figure 9.18).[34,71,72,92,98] This procedure requires very skilled microvascular technique, has some risk of failure, and leaves significant scars on the foot, toe, and finger. Nakayama[75] and Iwasawa and coworkers[50] described microsurgical transfers of small toenail flaps that result in less donor and defect site

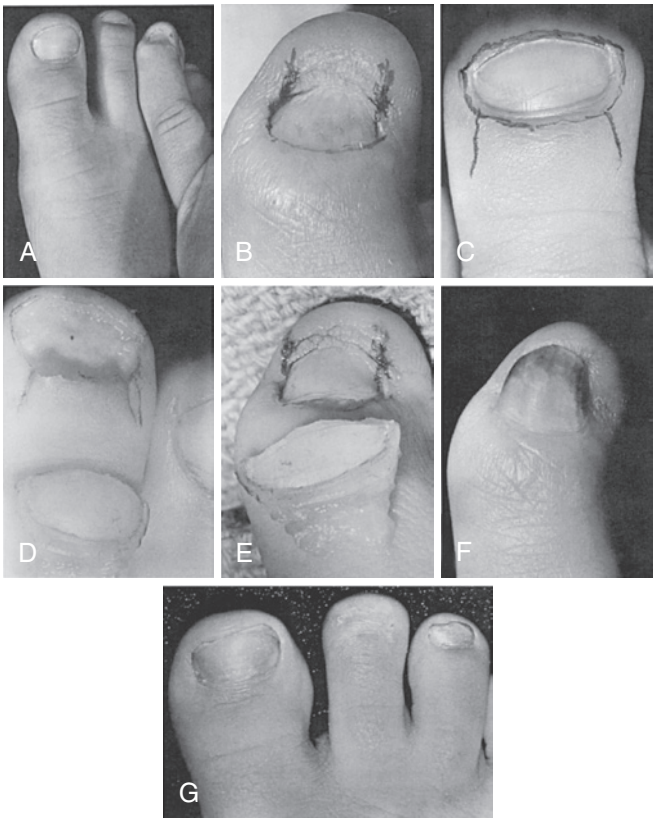

FIGURE 9.17 **A,** A 7-year-old child with posttraumatic absence of the index nail; the width of the fingernail is compared with that of the second toenail. **B,** Nail bed is seen close-up at the time of surgery. **C,** Second toe is marked for removal of the composite nail and nail bed graft. **D,** Composite graft is excised. **E,** Composite graft is placed on the dorsum of the finger after the nail fold has been created. The toenail does not have as much length as a normal fingernail. The sterile matrix was advanced distally to create a recipient site for the graft. **F,** Nail 1 year postoperatively. **G,** Postoperative view of second toe. A split-thickness skin graft was applied to the periosteum.

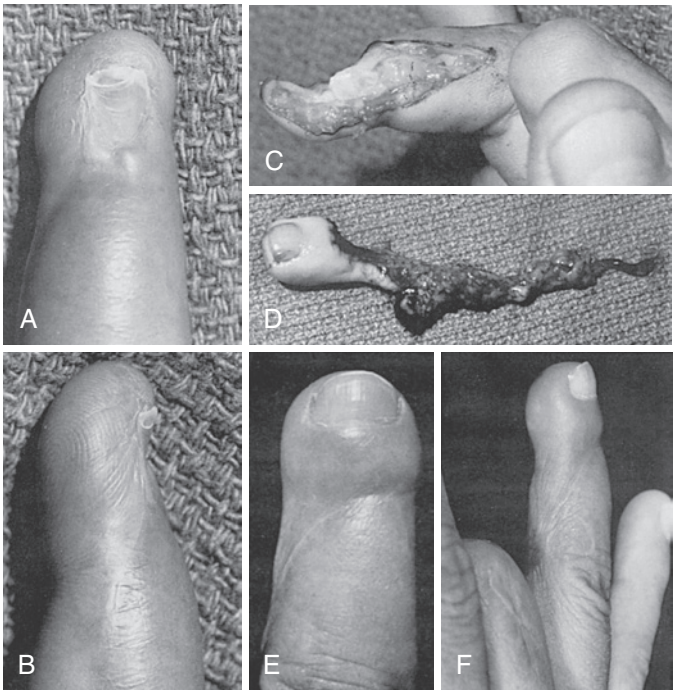

FIGURE 9.18 **A** and **B,** Minimal nail growth and soft tissue loss after oblique amputation of ring fingertip. **C,** Defect after excision of the scarred nail bed and tip. **D,** Partial second toe free flap. **E** and **F,** Postoperative appearance of ring finger.

morbidity than the larger wraparound flaps. Nakayama[75] successfully transferred a venous flap based on the venous system only, and Iwasawa and coworkers[50] reported a case of a venous flap anastomosed to a digital artery and vein. Nail flaps with short vascular pedicles have been reported for decreased scarring owing to less dissection at both sites, but these require expert microsurgical skill because of the small size of the vessels.[27,32,33,61]

Nail Spikes, Cysts, and Cornified Nail Bed

Nail cysts most commonly occur from failure to remove the entire germinal matrix from the nail fold during revision amputation. The skin is closed over the germinal matrix, producing a cyst wall, which continuously produces nail. They manifest as painful, enlarging masses at the site of the previous nail fold. Treatment consists of complete resection of the nail cyst and wall (Figure 9.19).

Nail spikes also result from incomplete removal of the germinal matrix. They are unenclosed and produce nail, which grows distally. They are a frequent occurrence after removal of the side of the nail and nail bed for an ingrown toenail. Treatment is complete removal of the spike and the residual germinal matrix.

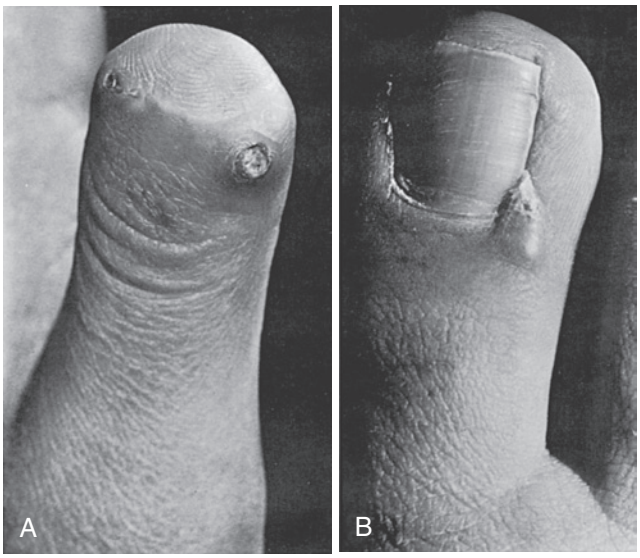

FIGURE 9.19 **A,** Nail cysts after amputation of fingertip without complete removal of the nail bed. **B,** Nail spike resulting from incomplete removal of nail bed after resection of an ingrown toenail.

A cornified nail bed occurs in patients whose germinal matrix has been removed to eliminate nail growth, but the sterile matrix has been left intact. The nail bed does not produce nail, but the sterile matrix continues to produce the keratinizing material, which in a normal nail bed maintains nail adherence. To relieve this, the sterile matrix is excised, and a split-thickness skin graft is applied.

Eponychial Deformities

Traumatic loss of the eponychium exposes the proximal nail and leads to loss of the nail shine, which is produced by the dorsal roof of the nail fold. This is commonly an aesthetic defect only because there is no abnormality in actual nail growth. Notching of the eponychium is often a primarily aesthetic concern, but can be functional if the free edge is frequently caught on objects. Notching is usually secondary to loss of part of the eponychium or failure to repair an eponychial laceration.

Scarring of the eponychium and nail fold to the nail bed, also known as pterygium, leads to functional and aesthetic deformities, such as absence of nail growth and splitting of the nail. This webbing between the eponychium and the nail bed most commonly occurs secondary to trauma, but has also been associated with ischemia and collagen vascular diseases. In trauma, scarring is minimized with precise repair of the nail bed within the fold and separation of the dorsal and ventral layers of the nail fold during healing, as previously mentioned. Scarring remains a possible complication, however. Absence or splitting of the nail occurs with scarring of the eponychium to the germinal matrix. The nail is unable to grow in the area of scar, leading to absence, or the nail grows around the scar, leading to splitting.

For a persistent pterygium of the eponychium, we recommend freeing the dorsal roof of the nail fold from the nail and inserting a small piece of silicone sheet into the nail fold with a horizontal mattress suture. The undersurface of the nail fold epithelializes preventing readherence. If this procedure is unsuccessful, it may be necessary to separate the dorsal roof from the nail and to place a thin split-thickness sterile matrix graft on the undersurface of the eponychium to prevent the adherence.[89] The nail bed must also be examined for scarring, especially in patients with absence of nail growth.

An eponychial defect may be reconstructed by a composite toe eponychial graft,[66] the helical rim of the ear,[82] or rotation flaps.[1] We recommend use of a composite eponychial graft from an appropriate toe to replace missing eponychium. A template of the eponychial defect is used to plan the composite graft of eponychium and underlying dorsal roof. With this graft, there is only a small area of raw surface on the proximal end for revascularization. To improve the chance of graft take, we harvest a larger area of dorsal skin with the graft that corresponds to a deepithelialized area on the finger, which lies just proximal to the defect. This leaves a slightly larger area on the toe that is left to heal secondarily. The resultant toe deformity has been minimal.

Eponychial deformities from burn injury result in contracture of soft tissue proximal to the eponychium. Donelan and Garcia have found a reliable treatment for this proximal retraction of the eponychium with a distally based bipedicle flap which unfurls the nail fold advancing the eponychium distally and replacing the resultant soft tissue defect with a skin graft.[30]

Hyponychial Deformities

Pterygia can also occur within the hyponychium secondary to trauma. Other sources of scarring within the hyponychium include denervation and ischemia. The tip of the finger may become painful and tender. We recommend removal of the distal 5 mm of nail from the nail bed and hyponychial area. A narrow strip of nail bed and hyponychium, 3 to 4 mm wide, is resected and replaced by a split-thickness skin graft. This procedure causes nonadherence in the hyponychial area and usually provides relief of pain.



FIGURE 9.20 Hooked-nail deformity caused partially by loss of distal bony support but primarily from the nail bed being pulled over the tip to close the amputation.

Hooking of the nail occurs with tight closure of a fingertip amputation or loss of bony support under the nail bed, which leads to curving of the matrix in a volar direction (Figure 9.20). Because the growing nail follows the nail matrix, any alteration in the support of the distal finger would alter the direction of nail growth. To avoid this alteration in nail growth, the nail should not be pulled over the distal phalanx. Acutely, when the distal bone is absent, it must be replaced, or the nail bed must be trimmed back to the end of the bone so the nail bed does not curve over the end.

After a hooked nail has developed, a decision must be made whether to shorten the bone or attempt to add support to the nail bed. If the distal nail bed had been pulled over the end of the finger, a "V-Y" advancement flap, cross-finger flap, or full-thickness skin graft can be used to replace the soft tissue for the tip and allow replacement of the nail bed onto the dorsum of the bone.[63] This procedure usually improves the hook, although complete correction is uncommon. Correction of a hooked nail with maintenance of nail length requires replacement of the distal phalanx or tuft with a bone graft. Additional tip soft tissue before or at the time of bone grafting may be required. Initially, bone grafts support the nail bed satisfactorily, but as with most bone grafts that do not have bone apposition on both ends, in time they tend to resorb, and the correction is lost. A free vascularized transfer of second toe tip, including the distal phalanx and nail, is the best, although most complex, solution.[60] A prosthesis, rather than reconstruction, is a simple solution that may give very satisfactory results.[13]

Hyponychial nonadherence occurs with loss of the hyponychial barrier from exposure of the fingertips to acids or alkali or chronic exposure to liquid. Without the barrier, fungus, bacteria, and dirt have direct access to the subungual space, causing nonadherence of the nail. If removing the cause does not result



FIGURE 9.21 **A** and **B,** Pincer nail deformity with tubing of nail. **C,** Removal of nail. **D,** Elevation of sides of nail bed from underlying distal phalanx. **E,** Placement of dermal graft into created tunnel. **F,** Improvement of pincer nail 1 year after surgery.

in readherence, it is usually secondary to the presence of keratinous material. The nail is removed to a point just proximal to the nonadherence and the keratin is scraped from the nail bed to allow for adherence as the nail grows distally. The nail may need to be scraped multiple times as the nail grows to the desired length.

Dull Nail

A dull nail is another minor complication that is cosmetic in nature. The dorsal roof of the nail fold is responsible for the shiny surface to the nail. Scar within the dorsal roof may lead to a dull streak within the nail.[103] No treatment is necessary as long as there are no associated functional problems.

PINCER NAIL

Although the pincer or trumpet nail deformity has been attributed to several causes, the exact etiology of this deformity is uncertain. It consists of excess transverse curvature of the nail and progressive pinching off of the soft tissue of the distal fingertip with resultant pain and an unaesthetic deformity. Although partial or complete nail ablation may provide symptomatic relief, various nail-preserving methods have been reported. Kosaka and Kamiishi[59] showed satisfactory success in treatment of severe pincer deformity with a contracted hyponychium. This method involves a fish-mouth incision near the nail margin, elevation of the nail bed, flattening of the distal phalanx dorsal surface, widening of the contracted hyponychium, and a "W"-plasty type of closure between the distal nail bed flap and hyponychium. Our preferred treatment consists of nail plate removal, elevation of the sides of the nail bed from the distal phalanx, and placement of autogenous dermal grafts[21] or AlloDerm under the lateral portions of the nail bed, between the nail bed and periosteum (Figure 9.21).[105]

ACUTE INFECTIONS

Fungal Infections

Perionychial infections of the subungual area are the most common infections in the hand. These are most frequently onychomycosis or chronic fungal infections (although superimposed bacterial infections may occur) and are usually treated medically by primary care physicians or dermatologists.[10] Treatment usually starts with topical therapy with nail lacquer placed over the nail. Systemic treatments are started if this is unsuccessful after 6 months. Options include terbinafine (250 mg/day

CRITICAL POINTS *Pincer Nail Treatment*

Indications
- Painful nail
- Disfigured nail

Technical Points
- Use a digital block and apply a tourniquet to finger.
- Remove the nail with an elevator or curved iris scissors.
- Perform stab incisions to the radial and ulnar hyponychium.
- Place a Kleinert-Kutz elevator into stab incisions.
- Carefully elevate the nail bed from the underlying periosteum.
- Harvest dermal graft or prepare AlloDerm.
- Cut graft or AlloDerm to length and tube.
- Perform a stab incision to the ulnar and radial proximal eponychium.
- Pass the dull end of a Keith needle proximal to distal beneath the nail bed, leaving the needle within the wound.
- Thread 5-0 nylon suture through the end of graft or AlloDerm.
- Thread suture into the Keith needle.
- Pull the needle proximally to pull the graft or AlloDerm into the space beneath the nail bed.
- Close stab incisions with superficial stitches.

Pitfall
- Tearing the radial or ulnar paronychium on nail bed elevation may occur.

for 6 weeks for fingernails and 12 weeks for toenails), itraconazole (200 mg twice a day for 1 week every month for 2 months for fingernails and 200 mg once daily for 12 weeks for toenails), or fluconazole (150 to 300 mg once a week for 3 to 6 months for fingernails and 6 to 12 months for toenails). Surgical intervention is required in 25% of patients who do not respond to systemic treatment.[10]

We most commonly see patients after these first lines of treatment have been unsuccessful. At this point, we recommend removal of the nail and application of 4% Mycolog-nystatin, triamcinolone acetonide cream twice a day to the nail bed until the nail has completely regrown. This approach allows for exposure of the subungual fungal infection and, if needed, debulking of the onychomycosis for improved penetration. Occasionally, we have performed total ablation of the nail for recurrent or persistent fungal infections.[103]

Recently, gentian violet solution has been found to be successful in treatment of chronic fungal infections without the need for removal of the nail (verbal correspondence, Wyndell Merritt, MD). This age-old drug has reemerged in the field of dermatology as well as a potentially simple option for a difficult problem.[68]

Bacterial Infections

Bacterial infections of the nail most commonly involve the paronychium. The dermal and epidermal layers of the paronychium are arranged in an overlapping fashion, similar to the shingles of a house. When one of these layers is pulled up, an open wound (hangnail) is created. Subsequent infection produces a paronychia. *Staphylococcus aureus* is the most frequent organism isolated.[69]

If the infection involves the paronychium, but is above the nail, it can be drained by lifting the paronychium away from the nail, followed by soaks to encourage adequate drainage. If the infection and purulence have progressed beneath the edge

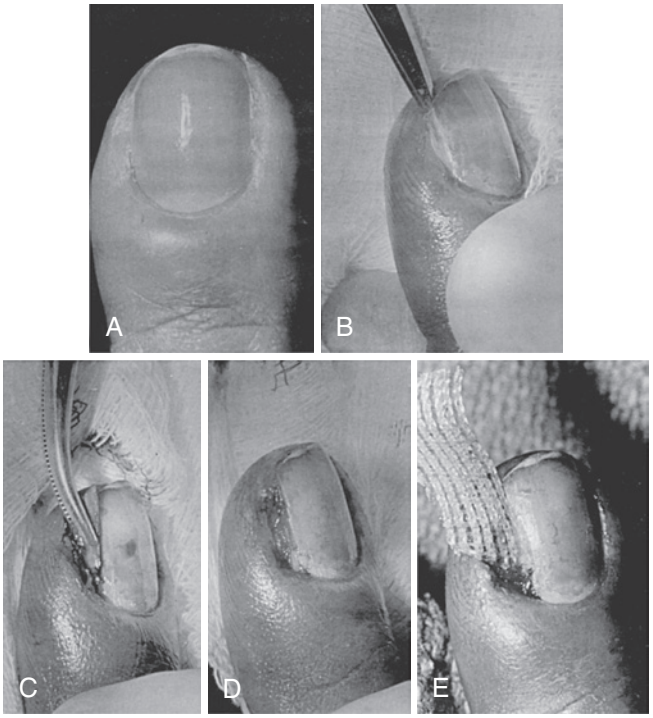

FIGURE 9.22 **A,** Paronychia is seen on the left side of this nail, with pus extending beneath the nail. **B,** Fine pair of iris scissors is used to elevate the side of the nail from the nail bed and the eponychium from the dorsum of the nail. **C,** Loosened fragment of nail is split longitudinally and removed from nail fold. **D,** Adequate drainage is performed after partial removal of the nail. **E,** Small wick of gauze is used to promote drainage.

of the nail, a portion of the nail must be removed to permit drainage (Figure 9.22). Local anesthesia is used, but commonly does not bring complete anesthesia because of the underlying infection. If a tourniquet is to be used for hemostasis, the finger should not be exsanguinated to avoid proximal spread of infection. The nail is dissected from the underlying nail bed and the overlying proximal eponychium with fine scissors or a periosteal elevator. The nail is split longitudinally, and the undermined portion is removed to allow drainage. Adequate open drainage is maintained by soaking the digit in warm soapy water three to four times per day. Antibiotics are indicated if tissue cellulitis is present. If the abscess dissects beneath the dorsal roof of the nail fold or beneath the nail in the nail fold, the proximal portion of the nail must be removed. The distal portion of the nail may be left in place to decrease discomfort. Incisions should not be made in the eponychium to drain the infection. Such incisions frequently do not heal primarily in the presence of infection, and a notch or square corner in the eponychium may result. We have never seen a paronychia or abscess that required incision in the eponychium for adequate drainage.

CHRONIC INFECTIONS

Chronic paronychia usually occurs between the nail and the dorsal roof of the nail fold and results in a tender, erythematous, and swollen fingertip. The infection is most commonly caused by gram-negative organisms and fungus, primarily *Candida*.[9] They are often seen in diabetic patients, immunocompromised patients, and patients whose jobs involve frequent hand soaking

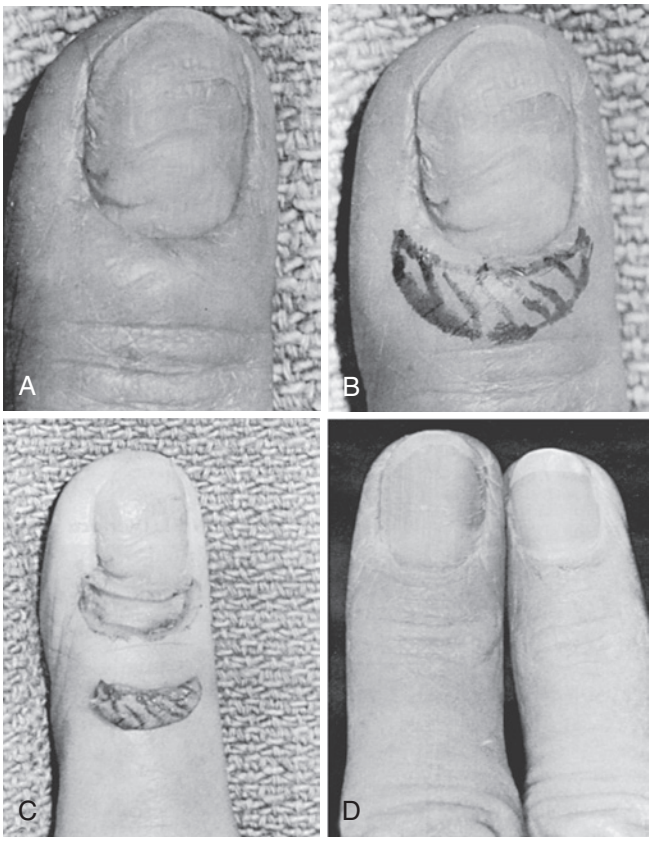

FIGURE 9.23 **A,** Chronic paronychia that has been present for 2 years. **B,** Area on the dorsal roof is marked for excision. **C,** Dorsal roof of nail fold has been removed down to the nail. **D,** Appearance 1 year after injury with no further infection.

in water. Treatment involves topical or oral antifungal agents and preventive measures such as avoidance of moisture, trauma from cuticle treatments, and irritants such as citrus fruits and cosmetic nail products.[100] For resistant cases, treatment is a Keyser-Eaton marsupialization of the nail fold.[1,14,54,55] A 3- to 4-mm–wide crescent is excised from the proximal nail fold, preserving the cuticle. The skin and dorsal roof of the nail fold are excised down to the nail, taking care not to injure the germinal matrix (Figure 9.23). The wound is allowed to heal secondarily. We have found this treatment generally successful (see Chapter 3).

TUMORS OF THE PERIONYCHIUM

Benign Tumors

Pyogenic Granuloma

Pyogenic granulomas manifest as rapidly growing lesions with a round, red, elevated area similar to granulation tissue, growing through the nail. They are usually the result of perforations of the nail by trauma or iatrogenic causes (Figure 9.24). The most common treatment is repeated silver nitrate cauterization, which may result in some nail deformity. Excision is also an option, but is likely to require a nail bed graft for closure. Differential diagnosis for these lesions includes squamous cell carcinoma and amelanotic melanoma. If the lesion is persistent or recurrent after cauterization, biopsy is needed.



FIGURE 9.24 Pyogenic granuloma growing through the nail after perforation of nail with cuticle scissors.

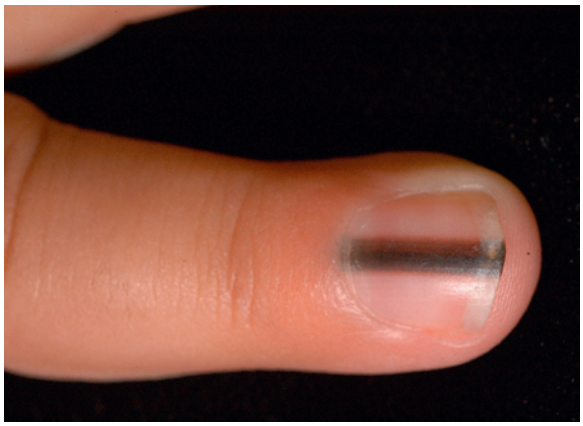

FIGURE 9.25 Pigmented nevus of fingernail.

Subungual Nevi

Nevi of the nail bed are common. The nail produced by a nail bed with a pigmented nevus is also pigmented because the nevus cells are added to the nail as it grows distally (Figure 9.25). Roughening of the nail surface usually does not occur, but elevation and ridging of the nail may. A nevus is frequently present at birth and first noticed in childhood. As years pass, it may become lighter or darker.

In the past, nevi of the nail bed were commonly observed owing to the potential deformity of the nail on nail bed biopsy. Because of a greater potential for malignant degeneration within the nail bed, we generally recommend incisional biopsy of the nevi. Watching the nevi for changes and delaying the biopsy until the child is older is also a reasonable option. We discuss the options with the patient and parents. On biopsy, if atypical cells are present, the involved portion of the nail bed is removed, and the nail bed is reconstructed as needed.[37]

It is important to remember the other causes of subungual pigmentation, including melanonychia striata and hematoma. Melanonychiae are benign longitudinal bands of pigmentation most often seen in African Americans and are usually present on multiple nails. They can be difficult to diagnose; Glat and colleagues[40] recommend biopsy in whites with any longitudinal

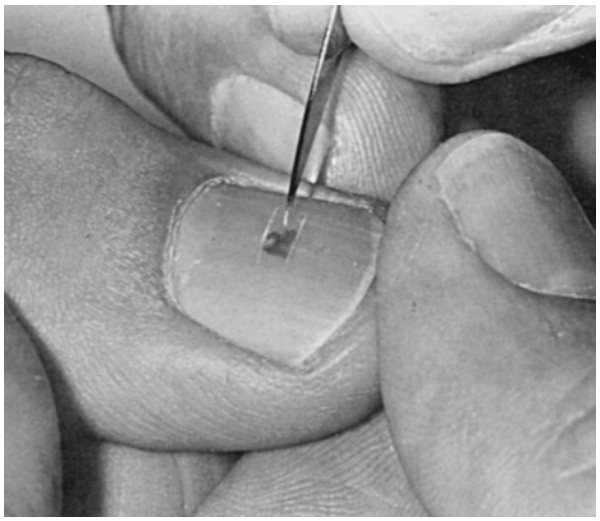

FIGURE 9.26 Marking the nail over a pigmented area to monitor pigment growth in relation to nail growth (see text Subungual Nevi in text).

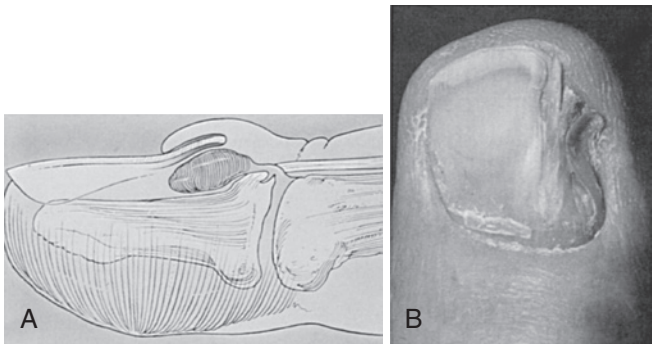

FIGURE 9.27 **A,** Dissection of a ganglion between the periosteum of the distal phalanx and the nail bed. **B,** Typical (but extreme) longitudinal groove deformity that results when the ganglion is located as shown in **A**.

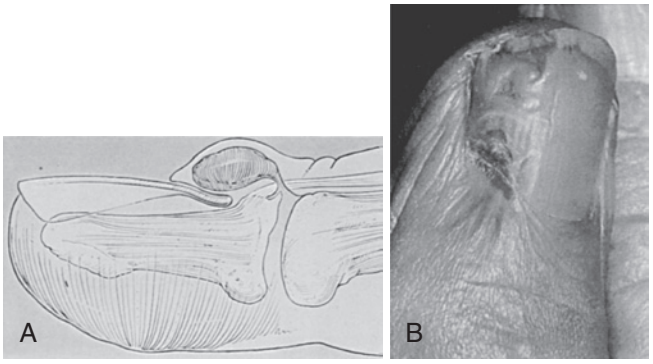

FIGURE 9.28 **A,** Dissection of ganglion into the dorsal roof of the nail fold compresses the nail bed volarly. **B,** Irregular breakup of the nail (or a longitudinal groove) is the deformity frequently caused by a ganglion.

pigmented band and in African Americans if only one digit is involved. A subungual hematoma is the most common cause of subungual pigmentation in an adult, even when there is no history of trauma. These areas of pigmentation should be monitored closely for resolution. We make a scratch into the surface of the nail at the proximal and distal borders of the pigmented area (Figure 9.26) and monitor the pigment in relation to the scratches for approximately 3 weeks. If the pigment is from a hematoma, it progresses toward the free edge of the nail with the scratches. If the pigment is nevus or melanoma in the nail bed, the scratches progress distally away from the area of pigmentation, necessitating a biopsy.

Verruca Vulgaris

Hand surgeons usually see patients with verruca vulgaris (viral warts) of the perionychium after they have been treated by their primary physician or dermatologist. We recommend laser therapy for patients with persistent warts. The keratin outer layer is shaved off to allow better penetration, and a pulsed dye laser is used to target the vessels within the wart. To avoid injury to the nail bed, laser treatment should remain superficial. Multiple treatments may be necessary. Our estimated success with this has been upwards of 75% resolution. Schellhaas and colleagues have seen a remission of 89% with the pulsed dye laser treatment, with only 4% failure.[87]

We also see patients with nail deformity that occurred from treatment of the wart. The resulting scar tissue in the nail bed prevents return of normal nail growth. Reconstruction consists of surgical excision of the nail bed scar and nail bed grafting, usually from the toes, as previously discussed.

Ganglion

Ganglions of the DIP joint, incorrectly known as mucous cysts, are the most common tumors that deform the nail bed. Kleinert and coworkers[58] reported a communication between these cysts and the DIP joint in the area of an arthritic spur (osteophyte). When the cystic expansion of the ganglion is between the floor of the nail and the periosteum, upward pressure on the nail bed causes a ridged, curved, or ragged nail (Figure 9.27). If the cyst lies dorsal to the nail bed within the nail fold, the pressure is downward on the nail, causing grooving, thinning, or roughening of the nail (Figure 9.28).

If there is severe nail deformity, we believe that the best treatment is removal of the nail followed by débridement of the DIP osteophytes and drainage of the cyst through a "T"-shaped incision over the joint (Figure 9.29). A piece of 0.020-inch silicone sheet is placed into the nail fold to help mold the nail bed back into its normal position. For minor grooves or flattening, removal of the deformed nail is unnecessary. In our early experience, débridement of the osteophytes and removal of the cyst wall resulted in a residual minor nail deformity in 36% of cases.[19] Our more recent experience with only débridement of the osteophytes and drainage of the cyst through the incision resulted in minor nail deformity in 10% with no recurrence of the cyst.[38] We believe that osteophyte débridement is the key to preventing recurrence. Removal of the cyst wall is unnecessary and increases the risk of nail deformity owing to possible nail bed damage.

Ganglions occasionally rupture and drain through the nail fold of the overlying skin. If infection occurs, permanent nail deformity and limitation of joint motion may result. If the ganglion ruptures, the appropriate treatment is antibiotics until the skin is closed, followed by surgical removal of the osteophyte before the ganglion ruptures again. A ganglion should not be surgically treated while it is actively draining because of an increased risk of subsequent infection and deformity.

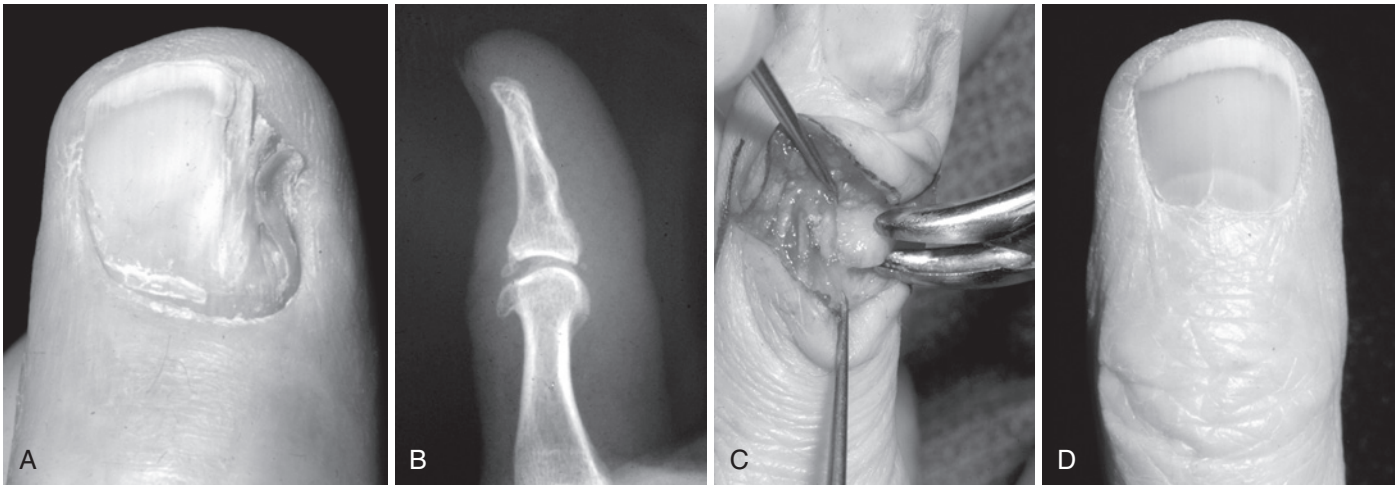

FIGURE 9.29 **A,** Distal interphalangeal (DIP) joint ganglion causing nail deformity. **B,** Radiographic evidence of osteophytes of DIP joint. **C,** Offending osteophyte is excised, and ganglion is decompressed. **D,** Normal nail growth at 1-year follow-up. (From Sommer N, Neumeister MW: Tumors of the perionychium. *Hand Clin* 18:673–689, 2002.)

CRITICAL POINTS *Treatment of Distal Interphalangeal Joint Ganglion*

Indications
- Pain
- Recurrent ganglion rupture or infection
- Significant nail deformity

Pearls
- Nail deformity resolves with removal of osteophyte and ganglion drainage.
- Chance of nail deformity is decreased with drainage rather than excision of ganglion.
- Infection of draining cyst must be resolved before definitive treatment.

Technical Points
- Use a "T"-shaped or "H"-shaped incision over dorsal DIP joint.
- Elevate and retract the extensor tendon without disrupting the insertion.
- Identify and drain the ganglion.
- Excise the osteophyte with a small rongeur.
- Irrigate the joint and wound with normal saline.
- Use superficial interrupted closure of skin.
- Apply a volar DIP joint digital splint for comfort.

Pitfalls
- Extensor lag may develop with extensor tendon elevation that is too aggressive.
- Patients must be willing to accept a lengthy recovery with a painful joint and swollen finger.
- Healing difficulties may occur at the "T" junction.

Postoperative Care
- Use a splint for 1 week if there is only minimal traction of the extensor tendon.
- Use a splint for 3 to 4 weeks if the extensor tendon is attenuated during retraction.
- Begin active range-of-motion exercises after the splint is removed.

Glomus Tumor

A glomus tumor arises from the glomus body that regulates blood flow and temperature in the finger.[11] Although not limited to the nail bed, 50% occur subungually. Proliferation of this angiomatous tissue within the confined space of the nail bed results in exquisite pain. On presentation, the patient may have a bluish discoloration beneath the nail. The nail may be exquisitely tender to pressure and sensitive to temperature changes, especially cold. An ice cube held over the nail bed may reproduce the pain. Ultrasound[24] and magnetic resonance imaging (MRI)[31] have been reported as highly successful in identifying subungual glomus tumors.

Treatment consists of removal of the nail, identification of the glomus tumor or tumors, and surgical excision. The entire nail bed should be carefully examined for multiple tumors after the nail is removed. A longitudinal incision is made over the glomus tumor, and the tumor is dissected out from the surrounding tissue. The tumor frequently "shells out," similar to a lipoma (Figure 9.30); this allows primary closure of the nail bed incision. Alternatively, the nail bed may be raised up as a flap from distal to proximal to provide exposure for tumor excision.

Malignant Tumors

Basal cell carcinoma is rare in the hand and even more so in the finger. Only 11 cases have been reported.[56] Basal cell carcinoma most frequently occurs after radiation exposure or other chronic trauma or exposure. Arsenic exposure is also thought to be a risk factor.[56] Complete resection of the tumor with frozen section examination of the margins is recommended to ensure complete removal. If the distal phalanx is involved, amputation at the DIP joint level is recommended. Repair consists of nail reconstruction with a split-thickness nail bed graft or skin graft closure.

Squamous cell carcinomas, although uncommon, are the most common malignant tumor of the perionychium[51] and can be secondary to radiation exposure (Figure 9.31).[2,23,67] In the past, dentists' hands were commonly affected, owing to chronic

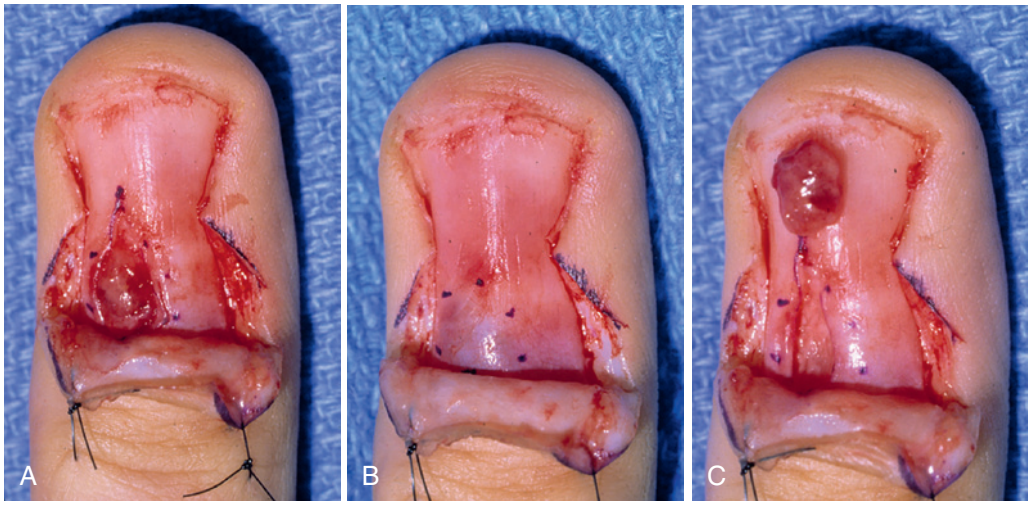

FIGURE 9.30 **A,** Perpendicular incisions at the eponychium expose a glomus tumor at the junction of the germinal and sterile matrices. **B,** Approach is through a longitudinal incision in the nail bed. **C,** Appearance after excision.



FIGURE 9.31 A veterinarian with many years of radiation exposure to his fingers contracted squamous cell carcinoma of the perionychium.



FIGURE 9.32 Malignant melanoma of the nail bed.

radiation exposure; this became much less common with the knowledge of radiation-induced tumor formation. Other predisposing factors include repeated trauma, infection, arsenic exposure, or presence of human papillomavirus.[23,74,86] In a retrospective review at the Cleveland Clinic of 12 patients in 10 years with squamous cell carcinoma of the nail, only two causes were clearly defined: human papillomavirus and radiation.[43]

Squamous cell carcinomas may manifest as a raised, red, sometimes ulcerated, bleeding lesion or as a simple nail deformity. They are slow growing and are frequently misdiagnosed as paronychia. Carroll[23] showed that the average length of time between appearance and treatment was 4 years. This tumor is seen more commonly in men and usually involves the thumb. A lesion without bony involvement requires resection of the entire lesion with adequate margins, frequently requiring a nail bed or skin graft. If the carcinoma has been present for a long time, is large, or involves the bone, amputation at the DIP joint or even more proximally is indicated. Node dissection is indicated only if the nodes do not disappear after amputation because most nodal enlargements are inflammatory.

Melanomas of the hands and feet have a poorer prognosis than melanomas elsewhere on the body.[28] They are almost always pigmented and may or may not have nail deformity (Figure 9.32). Fungal infection, paronychia, warts, pyogenic granuloma, foreign bodies, subungual hematoma, and melanonychiae striata may mimic a melanoma of the perionychium. Consequently, the diagnosis is often missed initially and delayed 2 to 3 years.[62,70]

Any pigmented lesion that does not advance with nail growth, such as the case with subungual hematoma, should raise suspicion. If the lesion has not changed in 4 to 6 weeks, biopsy with permanent pathologic examination is recommended.[17] Margins of excision are based on thickness of the skin melanoma, but thickness is difficult to determine in cases of subungual melanoma.[36] We recommend complete excision with clear margins for lesions with dysplasia or atypia. Melanoma in situ requires excision with 5-mm margins. For invasive melanoma, early studies recommended metacarpal ray amputation for stage I (local) disease.[16,42] More recent recommendations include more conservative amputation[36] at the proximal interphalangeal joint[49] or at the joint just proximal to the nail bed melanoma[41] with preservation of as much function as possible.[77]

Evaluation for metastatic disease should include physical examination of the regional lymph nodes, a chest radiograph, and liver function tests. Opinions have varied regarding the advisability and timing of lymph node dissections in subungual melanoma. As in other areas of the body, elective lymph node dissection in the absence of palpable nodes is controversial and is still being evaluated, whereas therapeutic lymph node dissection is indicated for palpable nodes. Glat and colleagues[40] recommended lymph node dissection for lesions greater than

1 mm in thickness, which is in line with the recommendation for intermediate cutaneous melanomas (1 to 4 mm). The use of sentinel node biopsies has shown promising results for the detection of lymph node metastases, while potentially preventing unnecessary nodal dissections. With a negative sentinel node, the chance of regional lymph node metastasis was found to be less than 1%.[8]

Survival rates for subungual melanomas are varied. Park and colleagues[80] found a poorer 5-year survival for subungual melanomas (41%) versus cutaneous melanomas (72%). Klausner and coworkers[57] reported 5-year survival rates of 28% to 30% and 10-year survival rates of 0% to 13%.

REFERENCES

1. Achauer BM, Welk RA: One stage reconstruction of the postburn nailfold contracture. *Plast Reconstr Surg* 85:937–940, 1990.
2. Alport LI, Zak FG, Werthamer S: Subungual basal cell epithelioma. *Arch Dermatol* 106:599, 1972.
3. Antony AK, Anagnos DP: Matrix-periosteal flaps for reconstruction of nail deformity. *Plast Reconstr Surg* 109:1663–1666, 2002.
4. Ashbell TS, Kleinert HE, Putcha SM, et al: The deformed fingernail, a frequent result of failure to repair nail bed injuries. *J Trauma* 7:177–190, 1967.
5. Atasoy E, Iokamidis E, Kasdan ML, et al: Reconstruction of the amputated fingertip with a triangular volar flap: a new surgical procedure. *J Bone Joint Surg Am* 52:921–926, 1970.
6. Baden HP: Regeneration of the nail. *Arch Dermatol* 91:619–620, 1965.
7. Bakhach J, Demiri E, Guimerteau JC: Use of the eponychial flap to restore the length of a short nail: a review of 30 cases. *Plast Reconstr Surg* 116:478–483, 2005.
8. Balch CM: The role of elective lymph node dissection in melanoma: rationale, results and controversies. *J Clin Oncol* 6:163–169, 1988.
9. Baran R: Onychia and paronychia of mycotic, microbial and parasite origin. In Pierre M, editor: *The nail, GEM monograph series*, vol 5, New York, 1981, Churchill Livingstone.
10. Baran R: Nail fungal infections and treatment. *Hand Clin* 18:625–628, 2002.
11. Barre JA, Masson PV: Anatomy—clinical study of certain painful subungual tumors (tumors of the neuromyoarterial glomus of the extremities). *Bull Soc Fr Dermatol Syph* 31:148, 1924.
12. Barron JN: The structure and function of the skin of the hand. *Hand* 2:93–96, 1970.

12a. Baruchin AM, Nahlieli O, Vizethum F, et al: Harnessing the osseointegration principle for anchorage of fingernail prosthesis. *Hand Clinic* 18(4):647–654, 2002.

13. Beasley RW, deBeze GM: Prosthetic substitution for fingernails. *Hand Clin* 6:105–111, 1990.
14. Bednar MS, Lane LB: Eponychial marsupialization and nail removal for surgical treatment of chronic paronychia. *J Hand Surg [Am]* 16:314–317, 1991.
15. Bindra RR: Management of nail bed fracture-lacerations using a tension-band suture. *J Hand Surg [Br]* 21:1111–1113, 1996.
16. Booher RJ, Pack GT: Malignant melanoma of the feet and hands. *Surgery* 42:1084–1121, 1957.
17. Briggs JC: Subungual melanoma: a clinico-pathological study of 24 cases. *Br J Plast Surg* 38:174–176, 1985.
18. Brown RE: Acute nail bed injuries. *Hand Clin* 18:561–575, 2002.
19. Brown RE, Zook EG, Russell RC, et al: Fingernail deformities secondary to ganglions of the distal interphalangeal joint (mucous cysts). *Plast Reconstr Surg* 87:718–725, 1991.
20. Brown RE, Zook EG, Russell RC: Reconstruction of fingertips with combination of local flaps and nail bed grafts. *J Hand Surg [Am]* 24:345–351, 1999.
21. Brown RE, Zook EG, Williams J: Correction of pincer-nail deformities using dermal grafting. *Plast Reconstr Surg* 105:1658–1661, 2000.
22. Buncke HJ, Jr, Gonzalez RI: Fingernail reconstruction. *Plast Reconstr Surg* 30:452–461, 1962.
23. Carroll RE: Squamous cell carcinoma of the nail bed. *J Hand Surg* 1:92–97, 1976.
24. Chen SH, Chen Y, Cheng M, et al: The use of ultrasonography in preoperative localization of digital glomus tumors. *Plast Reconstr Surg* 112:115–120, 2003.
25. Chowdhry S, Seidenstricker L, Cooney DS, et al: Do not use epinephrine in digital blocks: myth or truth? Part II. A retrospective review of 1111 cases. *Plast Reconstr Surg* 126:2031–2034, 2010.
26. Clark WE, Buxton LHD: Studies in nail growth. *Br J Dermatol* 50:221–235, 1938.
27. Dautel G, Corcella D, Merle M: Reconstruction of fingertip amputations by partial composite toe transfer with short vascular pedicle. *J Hand Surg [Br]* 4:457–464, 1998.
28. Day CL, Jr, Lew RA, Mihm MC, Jr, et al: A multivariate analysis of prognostic factors for melanoma patients with lesions greater than or equal to 3.65 millimeters in thickness. *Ann Surg* 195:44–49, 1982.
29. DeBerker D, Mawhinney B, Sviland L: Quantification of regional matrix nail production. *Br J Dermatol* 134:1083–1086, 1996.
30. Donelan MB, Garcia JA: Nailfold reconstruction for correction of burn fingernail deformity. *Plast Reconstr Surg* 117:2303–2308, 2006.
31. Drape JL, Idy-Peretti I, Goettmann S, et al: Subungual glomus tumors: evaluation with MR imaging. *Radiology* 195:507–515, 1995.
32. Endo T, Nakayama Y: Short pedicle vascularized nail flap. *Plast Reconstr Surg* 97:656–661, 1996.
33. Endo T, Nakayama Y: Microtransfers for nail and fingertip replacement. *Hand Clin* 18:615–622, 2002.
34. Endo T, Nakayama Y, Soeda S: Nail transfer: evolution of the reconstructive procedure. *Plast Reconstr Surg* 100:907–913, 1997.
35. Fakin RM, Biraima A, Klein H, et al: Primary functional and aesthetic restoration of the fingernail in distal fingertip amputations with the eponychial flap. *J Hand Surg Eur Vol* 39(5):499–504, 2014.
36. Finley RK, Driscoll DL, Blumenson LE, et al: Subungual melanoma: an eighteen year review. *Surgery* 116:96–100, 1994.
37. Fleegler EJ, Zeinowicz RJ: Tumors of the perionychium. *Hand Clin* 6:113–136, 1990.
38. Gingrass MK, Brown RE, Zook EG: Treatment of finger nail deformities secondary to ganglions of the distal interphalangeal joint. *J Hand Surg [Am]* 20:502–505, 1995.
39. Gharb BB, Rampazzo A, Armijo BS, et al: Tranquilli-Leali or Atasoy flap: an anatomical cadaveric study. *J Plast Reconstr Aesth Surg* 63:681–685, 2010.
40. Glat PM, Shapiro RL, Roses DF, et al: Management considerations for melanonychia striata and melanoma of the hand. *Hand Clin* 2:183–189, 1995.
41. Glat PM, Spector JA, Roses DF, et al: The management of pigmented lesions of the nail bed. *Ann Plast Surg* 37:125–134, 1996.
42. Goldsmith HS: Melanoma: an overview. *CA Cancer J Clin* 29:194–215, 1979.
43. Guitart J, Bergfeld WA, Tuthill RJ, et al: Squamous cell carcinoma of the nail bed: a clinicopathological study of 12 cases. *Br J Dermatol* 123:215–222, 1990.
44. Guy RJ: The etiologies and mechanisms of the nail bed injuries. *Hand Clin* 6:9–21, 1990.
45. Hallock GG, Lutz DA: Octyl-2-cyanoacrylate adhesive for rapid nail plate restoration. *J Hand Surg [Am]* 25:979–981, 2000.
46. Hanraham EM: The split-thickness skin graft as a covering following removal of a fingernail. *Surgery* 20:398–400, 1946.
47. Hasegawa K, Pereira BP, Pho R: The microvasculature of the nail bed, nail matrix, and nail fold of a normal human fingertip. *J Hand Surg [Am]* 26:283–290, 2001.
48. Hashimoto H: Experimental study of histogenesis for the nail and its surrounding tissue. *Niigate Med J* 82:254, 1971.
49. Heaton KM, el-Naggar A, Ensign LG, et al: Surgical management and prognostic factors in patients with subungual melanoma. *Ann Surg* 219:197–204, 1994.
50. Iwasawa M, Furuta S, Noguchi M, et al: Reconstruction of fingertip deformities of the thumb using a venous flap. *Ann Plast Surg* 28:187–189, 1992.
51. John HG: Primary skin cancer of the fingers stimulating chronic infection. *Lancet* 1:662, 1956.
52. Johnson RK: Nailplasty. *Plast Reconstr Surg* 47:275, 1971.
53. Johnson M, Shuster S: Continuous formation of nail along the bed. *Br J Dermatol* 128:277–280, 1993.
54. Keyser JJ, Eaton RG: Surgical care of chronic paronychia by eponychial marsupialization. *Plast Reconstr Surg* 58:66–70, 1976.
55. Keyser JJ, Littler JW, Eaton RG: Surgical treatment of infections and lesions of the perionychium. *Hand Clin* 6:137–157, 1990.
56. Kim H, Kim Y, Suhr K, et al: Basal cell carcinoma of the nail bed in a Korean woman. *Int J Dermatol* 39:397–398, 2000.
57. Klausner JM, Inbar M, Gutman M, et al: Nail-bed melanoma. *J Surg Oncol* 34:208–210, 1987.
58. Kleinert HE, Kutz JE, Fishman JH, et al: Etiology and treatment of the so-called mucous cyst of the finger. *J Bone Joint Surg* 54:1455–1458, 1972.
59. Kosaka M, Kamiishi H: New strategy for the treatment and assessment of pincer nail. *Plast Reconstr Surg* 111:2014–2019, 2003.
60. Koshima I, Moriguchi T, Umeda N, et al: Trimmed second toetip transfer for reconstruction of claw nail deformity of the fingers. *Br J Plast Surg* 45:591–594, 1992.
61. Koshima I, Soeda S, Takase T, et al: Free vascularized nail grafts. *J Hand Surg [Am]* 13:29–32, 1988.
62. Krige JE, Hudson DA, Johnson CS, et al: Subungual melanoma. *S Afr J Surg* 33:10–14, 1995.

63. Kumar VP, Satku K: Treatment and prevention of "hook nail" deformity with anatomic correlation. *J Hand Surg [Am]* 18:617–620, 1993.
64. Lemperle G, Schwarz M, Lemperle SM: Nail regeneration by elongation of the partially destroyed nail bed. *Plast Reconstr Surg* 111:167–172, 2003.
65. Lewis BL: Microscopic studies of fetal and mature nail and surrounding soft tissue. *AMA Arch Dermatol* 70:732–747, 1954.
66. Lille S, Brown RE, Zook EG, et al: Free nonvascularized composite nail grafts: an institutional experience. *Plast Reconstr Surg* 105:2412–2415, 2000.
67. Lumpkin LR, Rosen T, Tschen JA, et al: Subungual squamous cell carcinoma. *J Am Acad Dermatol* 11:735–738, 1984.
68. Maley AM, Arbiser JL: Gentian violet: a 19th century drug re-emerges in the 21st century. *Exp Dermatol* 22:775–780, 2013.
69. McGinley KJ, Larson EL, Leyden JJ: Composition and density of microflora in the subungual space of the hand. *J Clin Microbiol* 26:950–953, 1988.
70. Metzger S, Ellwanger U, Stroebel W, et al: Extent and consequences of physician delay in the diagnosis of acral melanoma. *Melanoma Res* 8:181–186, 1998.
71. Morrison WA: Microvascular nail transfer. *Hand Clin* 6:69–76, 1990.
72. Morrison WA, O'Brien BM, McLeod AM: Thumb reconstruction with a free neurovascular wrap-around flap from the big toe. *J Hand Surg [Am]* 5:575–583, 1980.
73. Moss SH, Schwartz KS, von Drasek-Ascher G, et al: Digital venous anatomy. *J Hand Surg [Am]* 10:473–482, 1985.
74. Moy RL, Eliezri YO, Nuovo GJ, et al: Human papillomavirus type DNA in periungual squamous cell carcinomas. *JAMA* 261:2669–2673, 1989.
75. Nakayama Y: Vascularized free nail grafts nourished by arterial inflow from the venous system. *Plast Reconstr Surg* 85:239–245, 1990.
76. Netscher DT, Meade RA: Reconstruction of fingertip amputations with full-thickness perionychial grafts from the retained part and local flaps. *Plast Reconstr Surg* 104:1705–1712, 1999.
77. Nguyen JT, Bakri K, Nguyen EC, et al: Surgical management of subungual melanoma: Mayo Clinic experience of 124 cases. *Ann Plast Surg* 71:346–354, 2013.
78. Ogunro EO: External fixation of injured nail bed with the INRO surgical nail splint. *J Hand Surg [Am]* 14:236–241, 1989.
79. Pardo-Castello V: *Disease of the nail*, ed 3, Springfield, IL, 1960, Charles C Thomas.
80. Park KGM, Blessing K, Kernohan NM: Surgical aspects of subungual malignant melanomas. *Ann Surg* 216:692–695, 1992.
81. Pessa JE, Tsai T-M, Li Y, et al: The repair of nail deformities with the nonvascularized nail bed graft: indications and results. *J Hand Surg [Am]* 15:466–470, 1990.
82. Rose EH: Nailplasty utilizing a free composite graft from the helical rim of the ear. *Plast Reconstr Surg* 66:23–29, 1980.
83. Rose EH, Norris MS, Kowalski TA, et al: The "cap" technique: non-microsurgical reattachment of fingertip amputations. *J Hand Surg [Am]* 14:513–518, 1989.
84. Saito H, Suzuki Y, Fujino K, et al: Free nail bed graft for treatment of nail bed injuries of the hand. *J Hand Surg [Am]* 8:171–178, 1983.
85. Schiller C: Nail replacement in fingertip injuries. *Plast Reconstr Surg* 19:521–530, 1957.
86. Schwartz GB: Subungual squamous cell carcinoma of a nail bed. *Orthop Rev* 17:884–885, 1988.
87. Schellhaas U, Gerber W, Hammes S, et al: Pulsed dye laser treatment is effective in the treatment of recalcitrant viral warts. *Dermatol Surg* 34:67–72, 2008.
88. Seaberg DC, Angelos WJ, Paris PM: Treatment of subungual hematomas with nail trephination: a prospective study. *Am J Emerg Med* 9:209–210, 1991.
89. Shepard GH: Treatment of nail bed avulsions with split thickness nail bed grafts. *J Hand Surg [Am]* 8:49–54, 1983.
90. Shepard GH: Nail grafts for reconstruction. *Hand Clin* 6:79–102, 1990.
91. Shepard GH: Perionychial grafts in trauma and reconstruction. *Hand Clin* 18:595–614, 2002.
92. Shibata M, Seki T, Yoshizu T, et al: Microsurgical toenail transfer to the hand. *Plast Reconstr Surg* 88:102–109, 1991.
93. Smith DO, Oura C, Kimura C, et al: The distal venous anatomy of the finger. *J Hand Surg [Am]* 16:303–307, 1991.
94. Stanislas JM, Waldram MA: Keep the nail plate on with histoacryl. *Injury* 28:507–508, 1997.
95. Sugamata A: Regeneration of nails with artificial dermis. *J Plast Surg Hand Surg* 46:191–194, 2012.
96. Tajima T: Treatment of open crushing type industrial injuries of the hand and forearm: degloving, open circumferential, heat press and nail bed injuries. *J Trauma* 14:995–1011, 1974.
97. Wei FC, Epstein MD, Chen HC, et al: Microsurgical reconstruction of distal digits following mutilating hand injuries: results in 121 patients. *Br J Surg* 46:181–186, 1993.
98. Wilgis EF, Maxwell GP: Distal digital nerve graft: clinical and anatomical studies. *J Hand Surg [Am]* 4:439–443, 1979.
99. Yates YJ, Concannon MJ: Fungal infections of the perionychium. *Hand Clin* 18: 631–642, 2002.
100. Zaias N: *The nail in health and disease*, ed 2, Norwalk, CT, 1990, Appleton & Lange.
101. Zook EG: The perionychium: anatomy, physiology and care of injuries. *Clin Plast Surg* 8:21–31, 1981.
102. Zook EG: Fingernail injuries. In Strickland JW, Steichen JB, editors: *Difficult problems in hand surgery*, St. Louis, 1982, Mosby.
103. Zook EG: Discussion of "nail fungal infections and treatment." *Hand Clin* 18:629, 2002.
104. Zook EG: Reconstruction of a functional and aesthetic nail. *Hand Clin* 18:577–594, 2002.
105. Zook EG, Chalekson CP, Brown RE, et al: Correction of pincer-nail deformities with autograft or homograft dermis: modified surgical technique. *J Hand Surg [Am]* 30:400–403, 2005.
106. Zook EG, Guy RJ, Russell RC: A study of nail bed injuries: causes, treatment and prognosis. *J Hand Surg [Am]* 9:247–252, 1984.
107. Zook EG, Van Beek AL, Russell RC, et al: Anatomy and physiology of the perionychium: a review of the literature and anatomic study. *J Hand Surg [Am]* 5:528–536, 1980.

10

Treatment of the Stiff Finger and Hand

Robert N. Hotchkiss

Acknowledgments: The author gratefully acknowledges the extensive analysis and expertise of previous authors of this chapter, including Peter Amadio, MD, Alex Shin, MD, and Richard J. Smith, MD.

This chapter is intended to provide guidance regarding the treatment of a stiff digit following trauma, primarily with a focus on the metacarpophalangeal (MP) and proximal interphalangeal (PIP) joints. There are numerous resources, including several sections in this book, dedicated to preventing stiffness and maximizing motion and mobility after specific injuries such as fractures, tendon lacerations, or burns. This chapter will not supplant or replace this specific guidance. Instead, this discussion is dedicated to the surgical treatment of a stiff digit caused by trauma, including the timing, methods, potential pitfalls, and expectations of operation.

Curtis's elegantly simple work from 1954[15] and Smith's[45] elucidation of intrinsic tightness cannot be improved upon. The detailed, granular record provided by Curtis is an accurate reflection of the complexity and variability of every patient. Reading this work removes any illusions about surgical formulas and reinforces the need for careful analysis and strategies that are designed for each individual. If the reader simply put down this volume and concentrated on those two masterpieces, little more would be required for a conceptual grasp of the digit's anatomy, pathologic findings, and reliable strategies for treatment.

You can learn more about the anatomy of the MP joint online at ExpertConsult.com.

PATHOPHYSIOLOGIC FINDINGS

The initial response to nearly any injury to the hand or finger is edema.[8,12,39] The injured hand and digit are bathed in a macrophage- and protein-rich fluid that not only encompasses the injured structure but surrounds and bathes adjacent uninjured structures. Accumulation of edema fluid or hematoma within the layers of tendons, sheaths, and capsular structures of the joint or within the synovial spaces physically limits mobility.[3,7,8,12] The swollen hand assumes a characteristic posture that maximizes the capacity of the joint and comfort of the hand; for the MP joint, this is full extension, and for the PIP joint, this is flexion[51] (Figure 10.1).

In contrast to the MP joint, the capacity of the interphalangeal joints is affected little by joint position and is minimally affected by the hydrostatic effect of edema, although skin tension does have some limiting effect. The posture of resting MP extension following injury has a reciprocal influence on the PIP joint, by tipping the finely tuned balance between the extrinsic flexors and extensors in favor of a flexed position. Without intervention, this can become fixed and often does.

DIGIT FUNCTION AND MOBILITY

The functional demands of the hand obviously vary depending on activity, task, and occupation. However, the basic functions of pinch, grasp, and grip form the contextual basis for considering the need for motion, stability, and strength in the digits. For effective pinch, a stable, well-positioned thumb is crucial. Extremes of movement of the thumb interphalangeal or MP joint are less important for effective pinch than is stability in a functional position at these joints. Some movement of the carpometacarpal (CMC) joint of the thumb may be advantageous but is not crucial.[28] Meeting the thumb at the tip requires MP motion of the index and long fingers, with less motion needed at the PIP joints of these two radial digits. In contrast, power grip requires the composite motion of the MP and PIP joints, especially the ulnar three digits. Therefore before embarking on complex and challenging operative attempts to improve mobility of a given digit or joint, a full assessment of need and impact must be undertaken.

The highest priority of function combined with the highest probability of success is seen with attempts to improve *flexion* at the MP and PIP joints following trauma. Improvement of active and passive flexion of the joints is usually more likely than improvement of extension (e.g., patients with fixed contractures resulting from intrinsic tightness are excellent candidates for improvement following surgery).

Musicians present a unique and interesting challenge, because different instruments place vastly different demands on the fingers and hands and require an individualistic analysis. Pianists, who play with both hands, can adapt so that little PIP motion is needed. In contrast, musicians who play string instruments need both strength and mobility, especially of the fingering or fretting hand and even out to the DIP joint.

TREATMENT

Evaluation and Planning

Status of the Articular Surface of the Metacarpophalangeal and Proximal Interphalangeal Joints

If the joint shows signs of posttraumatic arthritis or articular malalignment, the likelihood of improvement with capsular release is quite poor. Although implant arthroplasty following

ANATOMY

Metacarpophalangeal Joint

The MP joint is a multiaxial condyloid joint that permits flexion, extension, abduction, adduction, and a slight degree of circumduction.[33] The joint consists of a capsule, two collateral ligaments, two accessory ligaments, and a volar plate (eFigure 10.1). The capsule about the joint is loose and is attached to the crest surrounding the articular surface of the head of the metacarpal and at the base of the proximal phalanx. The redundant capsule allows extensive motion of the proximal phalanx on the metacarpal head and also allows distraction and a minimal amount of rotation.

The collateral ligaments are situated on the radial and ulnar aspects of the joint and are quite substantial, 1.5 to 3 mm thick and 4 to 8 mm wide. The collateral ligament arises from the depression in the subcapital area of the dorsal metacarpal head, courses distally toward the volar proximal phalanx, and has a length of 12 to 14 mm. The accessory ligament courses volar to the origin of the collateral ligament on the metacarpal head, fans out to blend in with the collateral ligament, and attaches to the proximal phalanx and the volar plate.

The volar plate of the MP joint is composed of crisscrossing fibers that can collapse from a fully extended position to a fully flexed position, so that its longitudinal length is diminished by a third to half when in full flexion.[51] The volar plate is the structure that ultimately restrains hyperextension. Normally, some degree of hyperextension is possible, but this varies considerably from one person to the next.

The shape of the metacarpal head is that of a cam with a volar flare. As the proximal phalanx is flexed, the cam and volar flare displace and lengthen the collateral ligaments and thus place them in the position of greatest tension and the joint in its position of greatest stability.[51] Although the contours of the cam vary slightly from digit to digit, an understanding of this cam effect is essential to understanding MP joint pathologic conditions.

Proximal Interphalangeal Joint

The PIP joint is a hinge or ginglymus joint, the configuration of which facilitates a wide arc of flexion and extension while resisting motion in the coronal plane. The stability of the joint is afforded not only by the geometry of the articular surfaces but also by the collateral ligaments and the volar plate (eFigure 10.2). The PIP joint is supported laterally by two layers of soft tissues. The superficial layer is thin and made of the transverse and oblique fibers of the retinacular ligament of Landsmeer. The deeper and stouter layer is made of the collateral ligaments, which arise from the small recess in the proximal phalanx head and insert into the volar third of the middle phalanx and the volar plate. The accessory ligaments follow a similar path but run more obliquely and insert onto the sides of the volar plate. Unlike the MP joint, there is no cam or volar flare of the proximal phalanx head, and the tension of the collateral ligaments is uniform throughout the arc of motion. The volar plate of the PIP joint is also different from that of the MP joint (eFigure 10.3). There are two distinct regions of the volar plate of the PIP joint.[37,38] The distal portion is the articular portion, which

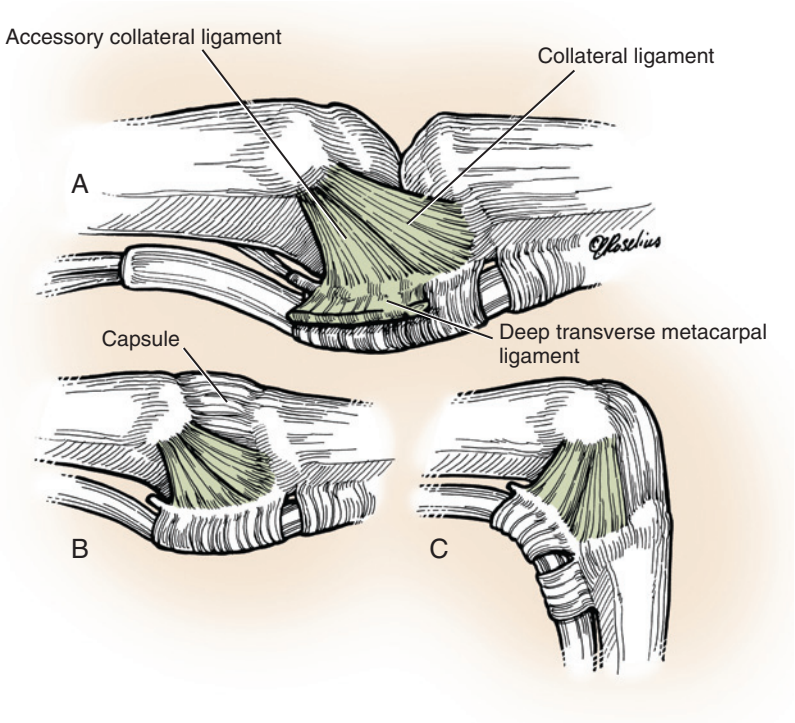

eFIGURE 10.1 Ligamentous anatomy of the metacarpophalangeal (MP) joint. **A,** The MP joint has an accessory and a proper collateral ligament on the radial and ulnar aspect of the joint. A capsule covers the dorsal aspect of the joint. In extension, the proper collateral ligament is lax, as is the dorsal capsule **(B),** whereas in flexion, the proper collateral ligament and dorsal capsule are taut **(C).** (Copyright © Elizabeth Martin.)

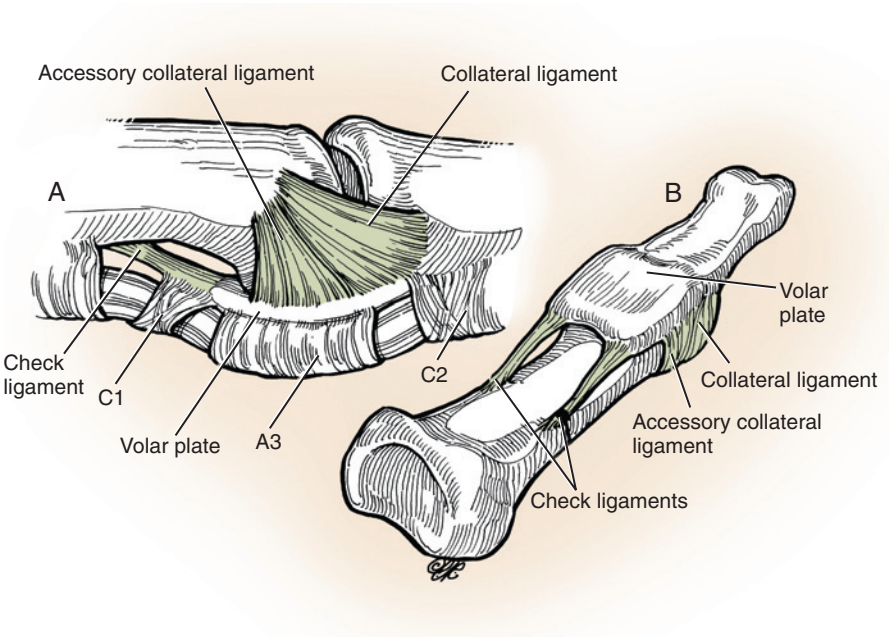

eFIGURE 10.2 Anatomy of the proximal interphalangeal (PIP) joint. **A,** Similar to the metacarpophalangeal joint, the PIP joint has an accessory and a proper collateral ligament. **B,** The volar plate of the PIP joint is more defined and has two proximal extensions called checkrein ligaments. (Copyright © Elizabeth Martin.)

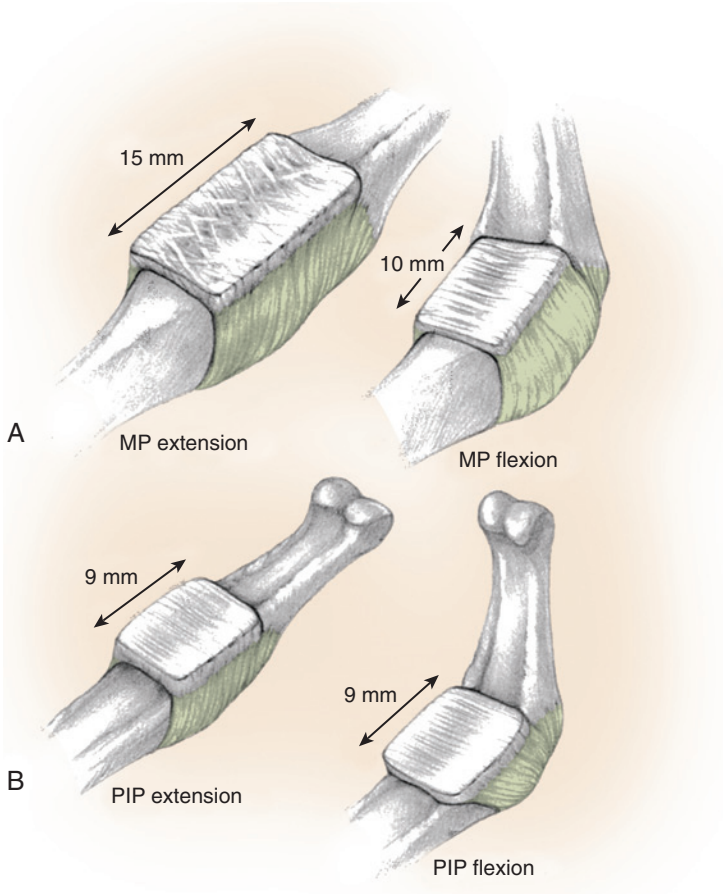

eFIGURE 10.3 The volar plate. **A,** The volar plate of the metacarpophalangeal (MP) joint is composed of crisscrossing fibers that have the ability to collapse from the fully extended to the fully flexed position. In flexion, the volar plate collapses from a third to a half of its length in full extension. The volar plate pocket behind the MP volar plate is smaller than at the proximal interphalangeal (PIP) joint; thus, there is no tendency for the development of checkreins. (Sagittal microscopic views demonstrate these bundles of fibers as compared with the more homogeneous collagenous arrangement in the PIP volar plate.) **B,** The PIP joint volar plate is similar to a unit in a suit of armor. It slides proximally and distally and protects the joint. The volar plate is thick, which allows extreme external loading over the joint. The pocket behind the proximal volar plate is large. The excursion of the volar plate between flexion and extension is significant, and collapse of the volar plate itself between extension and flexion is minimal. Any limitation or fixation of the proximal volar plate, as with the development of checkreins, produces a significant restriction in extension of the PIP joint. (Copyright © Elizabeth Martin.)

is fibrocartilaginous and quadrangular in shape, and the proximal portion is thin and membranous. The distal lateral portions of the quadrangularly shaped volar plate form a confluence that anchors the collateral ligament and volar plate to the middle phalanx. On either side of the volar plate, there is an expansion that extends proximally and onto the volar margins of the proximal phalanx. These proximal extensions cross the transverse digital artery just proximal to the PIP joint and are variously referred to as checkreins, check ligaments, or swallowtail extensions.[17,50] This volar plate, unlike that of the MP joint, does not contract with flexion but rather slides proximally and distally with flexion and extension of the joint.[6] Thus, any limitation or adhesions of the proximal volar plate or contraction of the checkrein ligaments can result in significant limitation to extension of the PIP joint. Moreover, because the checkrein structure limits hyperextension much more effectively than does the looser arrangement of fibers at the MP joint, the interphalangeal joints typically hyperextend much less than the MP joints do. Finally, dorsally, the joint capsule is closely connected to the central tendon, which provides a dorsal stabilizing force. The relationship is so intimate that the undersurface of the central tendon undergoes fibrocartilaginous metaplasia and serves as an additional articulating structure for the proximal phalangeal head in flexion.[36,40]

Distal Interphalangeal Joint

The distal interphalangeal (DIP) joint is also a hinge or ginglymus joint (eFigure 10.4). The capsule surrounding the DIP joint is reinforced laterally by collateral ligaments that insert into the sides of the head of the middle phalanx and run in a distal and volar direction to insert into the volar lateral tubercle of the distal phalanx. The accessory ligaments are more volar and extend from the sides of the middle phalanx head to the sides of the volar plate. The volar plate serves as an accessory insertion point for the flexor digitorum profundus. Proximally, the plate extends and is attached to the neck of the middle phalanx, but unlike the PIP joint, it does not have lateral volar extensions. Not having checkrein ligaments, the volar plate of the DIP joint can hyperextend.[33] The dorsal aspect of the joint has no reinforcing ligament, but the terminal portion of the extensor mechanism attaches from the dorsal edge of one collateral ligament to the other and blends into the capsular fibers and the periosteum of the distal phalanx.

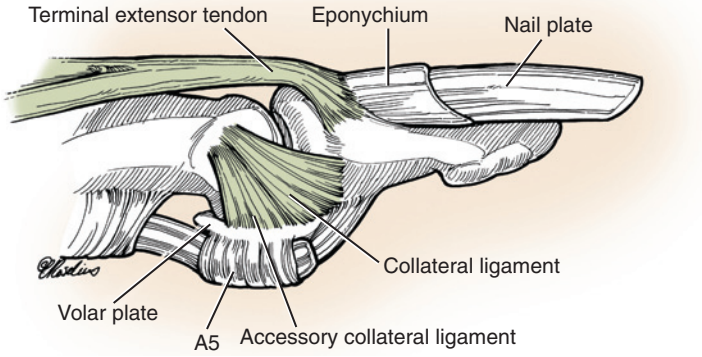

eFIGURE 10.4 Anatomy of the dorsal interphalangeal (DIP) joint. The DIP joint is bound on the radial and ulnar side by the accessory and proper collateral ligaments. The dorsal aspect of the joint is covered by the terminal extensor tendon, which inserts onto the distal phalanx. (Copyright © Elizabeth Martin.)

Interosseous and Hypothenar Muscles

The anatomy of the hand does not change. Although our understanding of the meaning and fine details of that anatomy does change, the classic description of the intrinsic system of the hand by the late Richard J. Smith, MD, in previous editions of this textbook remains, in our opinion, the gold standard. In tribute to Dr. Smith's enduring contribution to hand surgery, we have preserved his description of the anatomy of the intrinsic system here, in his words.

There are seven interosseous muscles, four dorsal and three volar (eFigure 10.5). The dorsal interossei are abductors. Because the anatomic axis of the hand coincides with the axis of the third metacarpal, the dorsal interossei lie to the radial side of the index and middle fingers and the ulnar side of the middle and ring fingers. The little finger is abducted by the abductor digiti quinti, which functions like an interosseous muscle. The volar interossei are adductors and lie to the ulnar side of the index finger and the radial side of the ring and little fingers. The middle finger therefore has two dorsal interossei (abductors) and no volar interossei (adductors) because the central axis of the hand lies within it.[33,48]

Each *dorsal interosseous muscle*, with the exception of the third, has two muscle heads. The *superficial head* arises most dorsally from the shaft of the contiguous metacarpals and is inserted deeply by a *medial tendon* onto the lateral tubercle of the base of the proximal phalanx. The superficial head abducts and weakly flexes the proximal phalanx. It has no direct effect on the middle or distal phalanges. The *deep head* of each dorsal interosseous muscle forms a *lateral tendon*, or *lateral band*, at the level of the MP joint. The deep head flexes and weakly abducts the proximal phalanx and extends the middle and distal phalanges. At the level of the middle of the proximal phalanx, *transverse fibers* arch dorsally from each lateral band to join each other over the dorsum of the finger. These fibers flex the proximal phalanx. More distally, *oblique fibers* (spiral fibers) from the lateral bands sweep over the distal third of the proximal phalanx to insert onto the lateral tubercles at the base of the middle phalanx. The oblique fibers extend the middle phalanx. More distally, the lateral bands are joined by the *lateral slips* of the extensor tendon to form the *conjoined lateral band*. The two conjoined lateral bands to each finger unite at the distal third of the middle phalanx to form the *terminal tendon*. The terminal tendon inserts at the base of the distal phalanx to extend it (eFigures 10.6 and 10.7).[35]

The *flexor digiti quinti brevis* is structurally and functionally similar to the deep head of the dorsal interossei. It forms the ulnar lateral band of the little finger.

The three *volar interossei* arise from adjacent surfaces of contiguous metacarpal shafts. Unlike the dorsal interossei, each volar interosseous muscle has only one muscle head; none of them inserts onto the proximal phalanx. The volar interossei form the ulnar lateral band of the index finger and the radial lateral band of the ring and little fingers. As with the lateral bands of the dorsal interossei, transverse fibers arch over the dorsum of the proximal phalanx and join those of the opposite lateral band to flex the proximal phalanx. All send oblique or

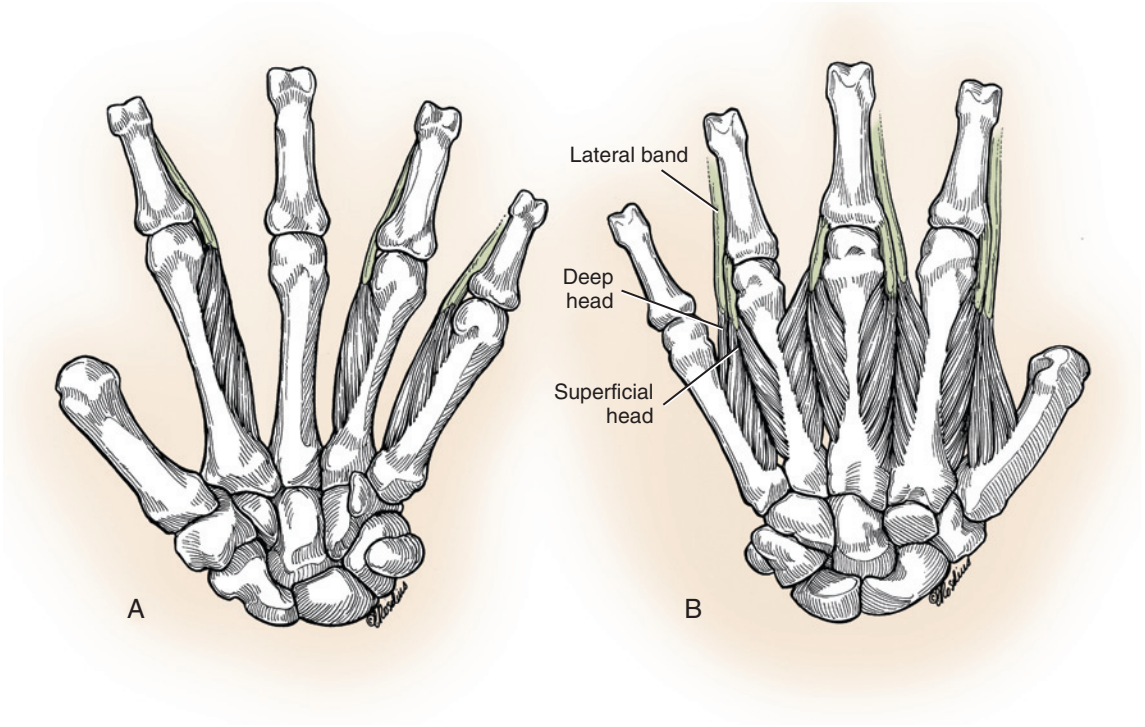

eFIGURE 10.5 Anatomy of the interosseous muscles. **A,** The palmar interosseous muscles are located on the ulnar side of the index metacarpal and on the radial aspect of the ring and small metacarpals and extend to the lateral bands of their respective digits. The middle finger has no palmar interosseous muscles. **B,** The dorsal interosseous muscles are bipennate muscles originating from the adjacent metacarpals of each web space. (Copyright © Elizabeth Martin.)

spiral fibers that insert onto the base of the middle phalanx at its lateral tubercle. All lateral bands are joined by the lateral slips of the extensor tendon to form a conjoined lateral band and finally a terminal tendon that extends to the distal phalanx.

Of the *hypothenar muscles*, the *abductor digiti quinti* and *flexor digiti quinti brevis* have been described. These muscles are similar in both structure and function to the superficial and deep heads of the dorsal interossei, respectively, and arise from the fifth metacarpal. The abductor inserts onto the ulnar lateral tubercle at the base of the proximal phalanx of the little finger. The flexor digiti quinti forms the ulnar lateral band. A third muscle, the *opponens digiti quinti*, lies deepest. It arises from the pisohamate ligament and the hook of the hamate and inserts onto the ulnar side of the diaphysis of the fifth metacarpal, which it flexes and supinates.

Lumbrical Muscles

The lumbrical muscles arise from the flexor digitorum profundus tendons in the palm. The lumbricals to the index and middle fingers arise from the radial side of the profundus tendons to these fingers (eFigure 10.8). The lumbricals of the ring and little fingers arise from the profundus tendons of adjacent fingers. The tendon of each lumbrical passes volar to the deep transverse metacarpal ligament and joins the radial lateral band at the middle of the proximal phalanx. The lumbricals extend the PIP and DIP joints. They also assist in flexing the MP joint. When a lumbrical muscle contracts, it pulls the profundus tendon distally and the lateral band proximally. Thus, lumbrical contraction decreases the force of flexion of the flexor digitorum profundus on the distal phalanx, and it can more effectively extend the interphalangeal joints.[5,33] By contrast, when the flexor profundus contracts and the lumbrical contracts as well, interphalangeal joint flexion may be limited (see eFigure 10.8).

Extrinsic Extensors

The *extrinsic extensors* join the dorsal aponeurosis at the level of the MP joint (eFigure 10.9).[26] The four extensor digitorum communis tendons and the extensor indicis proprius and extensor digiti quinti proprius tendons are the only extensors of the proximal phalanges. These tendons are loosely tethered to the dorsal joint capsule and the base of the proximal phalanx by a short leash of articular fibers that help hold the extensors at the midline of the MP joint. Normally, the articular fibers have little effect on MP joint extension.[33] In the region of the MP joint, a sling of sagittal (transverse) fibers, the *sagittal bands*, pass toward the palm from the extensors to insert onto the volar plate and the volar base of the proximal phalanx. The sagittal bands lie deep to the lateral tendons of all the interossei and are superficial to the medial tendon of the dorsal interossei and the joint capsule. When the extensor communis muscle contracts, the extensor tendons lift the proximal phalanx into extension through the sling of sagittal bands. Hyperextension of the proximal phalanx is restricted by the volar plate and the normal tone of the intrinsic muscles of the fingers.

On dissecting the dorsum of the finger, one might confuse the sagittal bands with the transverse fibers. Both structures are directed transversely and both lie in approximately the same plane at the dorsum of the finger. However, the sagittal bands arise from the extensor tendon at the MP joint and pass volarly

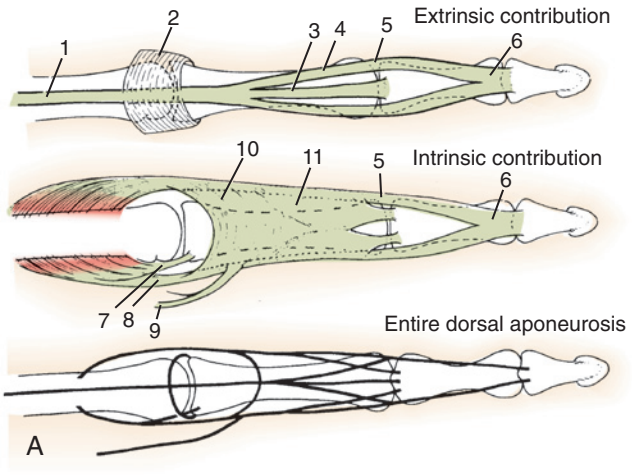

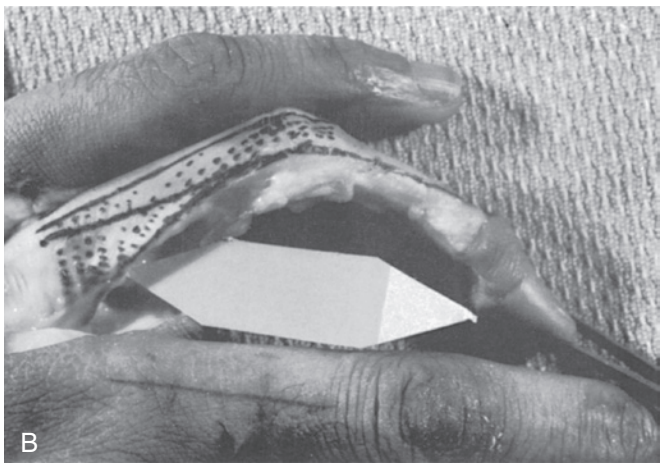

eFIGURE 10.6 Lateral view of the dorsal aponeurosis of the finger. **A,** Diagrammatic representation of the extrinsic contribution, the intrinsic contribution, and the entire dorsal aponeurosis of the finger. *1*, Extensor tendon; *2*, sagittal band; *3*, central slip; *4*, lateral slip; *5*, conjoined lateral band; *6*, terminal tendon; *7*, superficial head and medial tendon of the dorsal interosseous; *8*, deep head and lateral tendon of the dorsal interosseous; *9*, lumbrical muscle and tendon; *10*, transverse fibers of the dorsal aponeurosis; *11*, oblique fibers of the dorsal aponeurosis. **B,** Dissected specimen showing the dorsal aponeurosis of the finger. The *cardboard arrow* points to the lateral band lying between the lateral tendon and the conjoined lateral band. The transverse and oblique fibers are *dotted*. The central slip, lateral slip, lateral band, and conjoined lateral band are identified by the *continuous dark lines*. The sagittal bands lie proximal to the *dotted* transverse fibers of the dorsal aponeurosis.

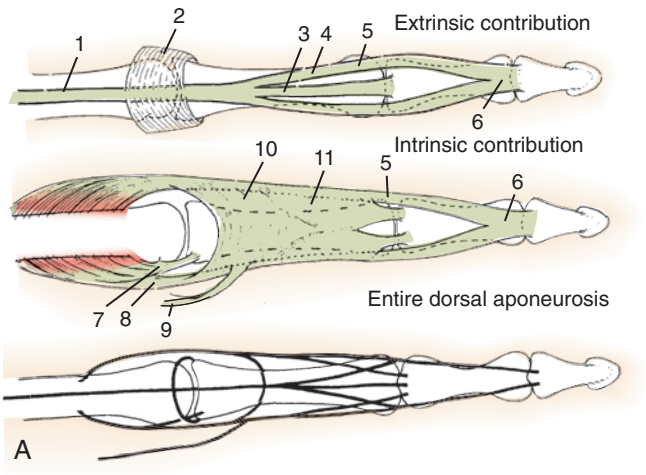

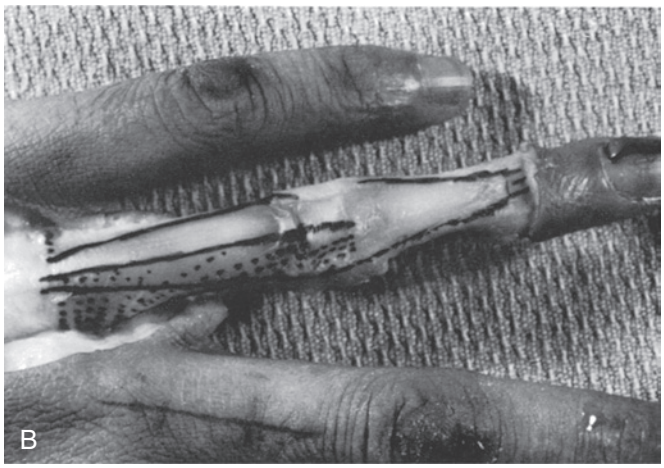

eFIGURE 10.7 Dorsal view of the dorsal aponeurosis of the finger. **A,** Diagrammatic representation of the extrinsic and intrinsic contributions of the dorsal aponeurosis. *1*, Extensor tendon; *2*, sagittal band; *3*, central slip; *4*, lateral slip; *5*, conjoined lateral band; *6*, terminal tendon; *7*, superficial head and medial tendon of the dorsal interosseous; *8*, deep head and lateral tendon of the dorsal interosseous; *9*, lumbrical muscle and tendon; *10*, transverse fibers of the dorsal aponeurosis; *11*, oblique fibers of the dorsal aponeurosis. **B,** Dissected specimen showing the dorsal aponeurosis of the finger. The central slip, lateral slips, lateral band, and conjoined lateral band are identified by *solid lines* over the proximal phalanx. The conjoined lateral bands and terminal tendons are identified by *continuous lines* over the middle phalanx. The *dotted lines* represent the transverse fibers (proximally) and oblique fibers (distally) of the dorsal aponeurosis overlying the proximal phalanx.

into the volar plate and the base of the proximal phalanx; they extend the finger. The transverse fibers, more distally, arch dorsally from the lateral bands. They are not inserted onto bone, and they flex the proximal phalanx.[45]

Distal to the MP joint, the extensor tendon divides into three slips (see eFigure 10.9). The *central slip* inserts onto the base of the middle phalanx to extend it. The two *lateral slips* diverge beneath the oblique fibers of the dorsal aponeurosis and join the lateral bands at the distal end of the proximal phalanx. The combined tendon distal to the juncture of the lateral slip and the lateral band is called the *conjoined lateral band*. The two conjoined lateral bands of each finger join each other proximal to the DIP joint and form the terminal tendon. The conjoined lateral bands are held dorsally by the *triangular ligament* that passes between them. Thus, the borders of the triangular ligament include the medial and lateral tubercles at the base of the middle phalanx and the conjoined lateral bands at its sides. The apex of the triangle is the juncture of the conjoined lateral bands, where they form the terminal tendon. Laterally, the *transverse retinacular ligament* prevents the bands from bowstringing dorsally. These ligaments extend from the lateral sides of the conjoined bands to the fibroosseous tunnel.[35,44,49]

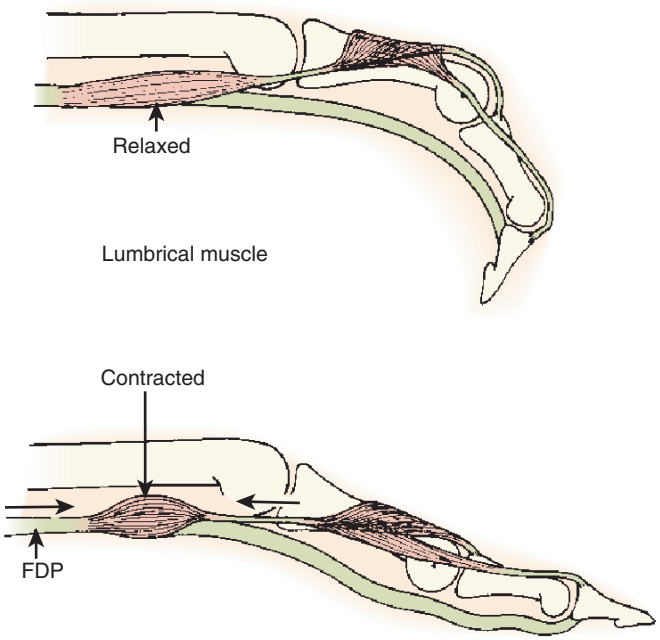

eFIGURE 10.8 The lumbrical muscle arises from the flexor digitorum profundus (FDP) tendon. When the lumbrical is relaxed and the FDP contracts, the interphalangeal joints flex. When the lumbrical contracts, it extends the interphalangeal joints both through relaxation of the profundus tendon distal to the lumbrical origin and through proximal pull on the lateral band and dorsal aponeurosis. (From Smith RJ: Intrinsic muscles of the fingers: function, dysfunction and surgical reconstruction. *Instr Course Lect* 24:200–220, 1975, with permission.)

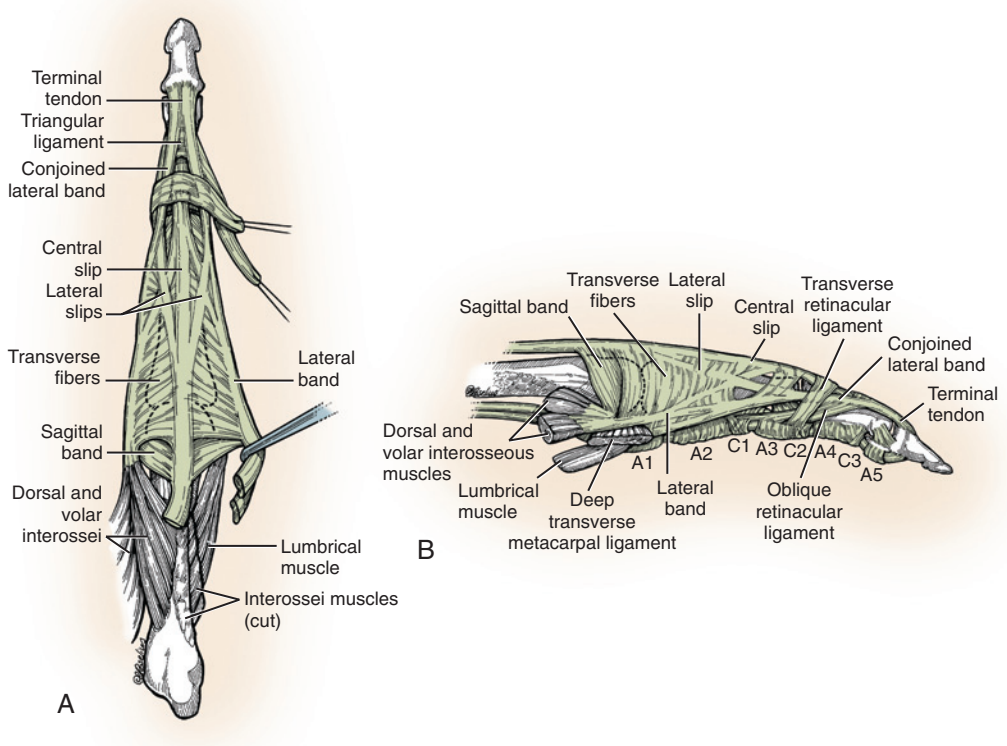

eFIGURE 10.9 Dorsal **(A)** and lateral **(B)** extensor tendon anatomy. (Copyright © Elizabeth Martin.)

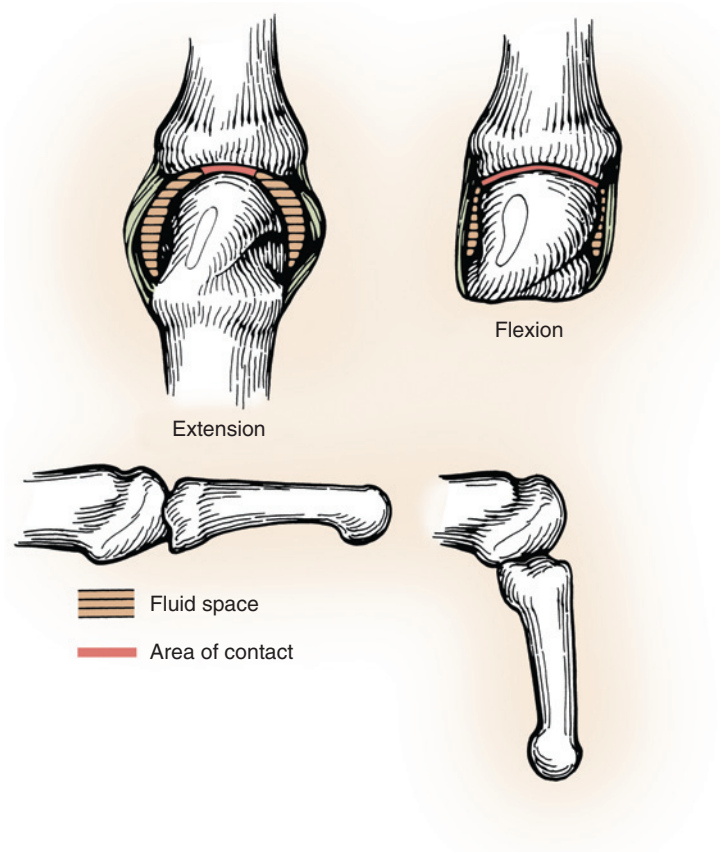

FIGURE 10.1 The anatomy of the extended metacarpophalangeal (MP) joint differs significantly from that of the fully flexed MP joint. In extension, the bone contact surface area is minimal. The collateral ligaments are loose, intracapsular fluid space is at a maximum, and the joint is relatively unstable. The proximal phalanx rotates, abducts, and adducts on the metacarpal. In full flexion, the metacarpal condylar surface is broad and the contact area is maximal between the metacarpal and proximal phalanx. The collateral ligaments are tight secondary to a cam effect and the necessity of the collaterals to pass around the metacarpal head prominences. The intracapsular fluid space is minimal, and the joint is highly stable because of the bone and ligament configurations in the flexed position. (Copyright © Elizabeth Martin.)

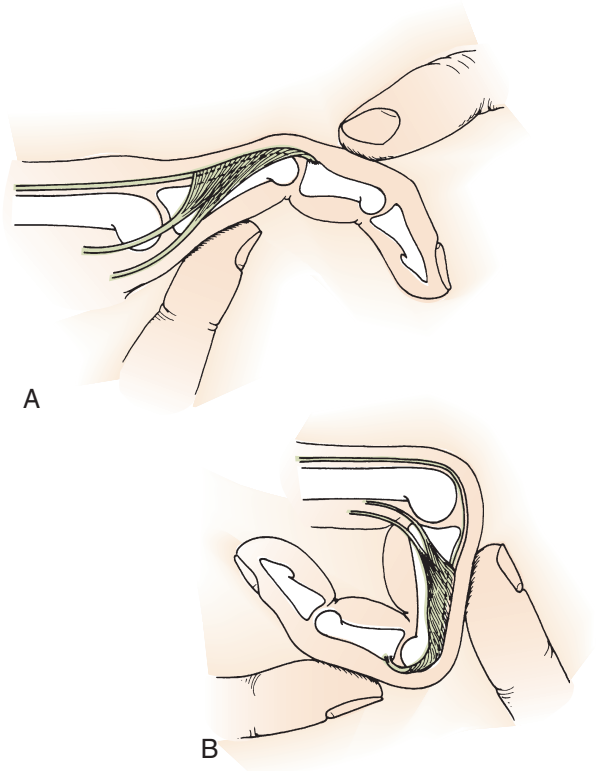

FIGURE 10.2 Intrinsic tightness test. In most cases of intrinsic tightness, there is less flexion of the proximal interphalangeal joint when the metacarpophalangeal (MP) joint is held extended **(A)** than when the MP joint is flexed **(B)**. (From Smith RJ: Intrinsic muscles of the fingers: function, dysfunction and surgical reconstruction. *Instr Course Lect* 24:200–220, 1975, with permission.)

posttraumatic stiffness has been successful in the hip, knee, and elbow, this has not been the case for the MP or PIP joints. The reported motion gain is minimal, and implant failure is quite common.[20] Therefore if the joint is in poor condition, contracture release surgery should be avoided. Although some limited success has been reported for distraction arthroplasty, at this time a general recommendation regarding this procedure cannot be made.[30]

Capsular Contracture, Tendon Adherence, and Extrinsic and Intrinsic Assessment

The examination of the stiff joint requires a fundamental understanding of the interdependence and relative roles of the joint capsule, extrinsic tendon adherence, and intrinsic function (see Anatomy of the Intrinsics on ExpertConsult.com). It is vital to distinguish between active and passive motion and to determine the position of the adjacent joint in which these parameters are measured.

If the joint cannot be moved at all, it is difficult to tell whether the problem is due to joint incongruity, capsular contracture, or tendon adhesions or to some combination of factors. If active motion and passive motion are equal but diminished, the joint capsule or articular surface is likely to be a primary limiting factor. However, tendon adherence or dysfunction cannot be ruled until the joint is fully or maximally mobilized. If passive motion exceeds active motion, the musculotendinous unit is incompetent or adherent, or both. The adequacy of a motor unit or tendon can only be fully assessed once the joint contracture is resolved. Manual motor testing can identify any element of motor weakness.

After testing active and passive motion, a test of the extrinsic/intrinsic system is required. To test for extensor tendon tightness, the wrist and the MP joints are flexed, and passive flexion of the interphalangeal joints is assessed. In the normal state there is easy passive flexion of the interphalangeal joints. If extensor adhesions or tightness exists, flexion of the interphalangeal joints will be difficult. Similarly, if interphalangeal extension is less with the wrist and MP joints extended, extrinsic flexor tightness may be the problem.

Because the intrinsic system spans both the MP and PIP joints, testing requires fixing the position of the one joint when testing the other. The *Bunnell intrinsic tightness test* examines the effect of MP joint position on PIP joint flexion (Figure 10.2). The test is considered positive when there is less flexion of the PIP joint when the MP joint is held extended than when the MP joint is flexed. A positive intrinsic test indicates that there is some element of intrinsic muscle tightness contributing to the finger stiffness.

It is not possible with this test to determine whether the tightness is due to a pathologic condition of the interosseous muscle alone or to a pathologic problem of both the lumbrical and interosseous muscles.[14] It is useful to test for tightness of the PIP joint with the MP joint in ulnar or radial deviation. If the tightness is symmetric, the lumbrical is not the only muscle involved. If there is more tightness with ulnar deviation, however, a component of lumbrical tightness can be suspected. Additional information on lumbrical tightness can also be obtained if the Bunnell test is normal. Limited active finger flexion may be present in the absence of a passive joint contracture as a result of lumbrical tightness alone because the lumbrical fibers are most palmar. Thus, lumbrical tightness can be evaluated by passively flexing not just the PIP joint, as in the Bunnell test, but also the distal joint by making a passive hook grip. If this lumbrical tightness test is positive and the Bunnell test is normal, a specific contracture of the lumbrical muscle may be present.

To summarize, the following assessment should be carried out to gain insight into the causes of stiffness and limitation of motion:

1. Active versus passive motion of the MP and PIP joints
2. Active versus passive motion of the MP and PIP joints with the wrist extended or flexed
3. Active versus passive motion of the PIP joint (Bunnell test) with the MP joint extended or flexed, in radioulnar deviation

Nonoperative Intervention

Edema can often be diminished and mobilization promoted by applying low-load, prolonged stress during active exercise to encourage functional use of the hand in light and moderate activities. It has been estimated that 87% of MP and PIP joint contractures can be successfully managed nonoperatively.[52] As long as there is positive progress, nonoperative treatment should continue. Only when a plateau in active and passive range of motion has been reached and the result is functionally unacceptable should surgical options be considered.

For more information on nonoperative treatment of joint contractures, see ExpertConsult.com.

Operative Intervention

Before developing and implementing an operative approach to joint stiffness, it is essential to confirm that a compliant patient and competent therapist will be permitted to work together and that the postoperative therapy visits are indeed recognized by all concerned parties as being an essential part of the treatment plan. If all three conditions (willing patient, capable therapist, and third-party approval when required) are not met, the surgery should not be performed.

For more information on skin and soft tissue intervention, please see ExpertConsult.com.

Anesthesia

When possible, local anesthesia with intravenous sedation is optimal for contracture release and tenolysis. It permits the patient to have active motion without pain and allows the surgeon to assess active motion intraoperatively. If sedation is used, the anesthesiologist can often titrate the timing and degree of sedation, so that the patient is more sedated at the beginning of the case and is later able to flex and extend the joint when asked to do so. The upper arm tourniquet can be alternated with a forearm tourniquet, both for comfort and to avoid the temporary palsy of tourniquet pressure.

If regional or general anesthesia is used, a proximal incision for traction on the flexors may be needed. It is surprising how much can be accomplished under local anesthesia using a combination of bupivacaine and lidocaine.

Release of Metacarpophalangeal Joint Extension Contracture

A dorsal approach to a stiff, extended MP joint is best because it allows both extensor tenolysis and dorsal capsulectomy. The extensor tendon is split sharply and elevated off the capsule, and the extensor tendon and sagittal band are reflected to either side.

A preliminary extensor tenolysis can be performed at this point by sliding an elevator both proximal and distal to the MP joint. The tenolysis may need to be extended further proximally and distally once the capsulectomy is complete and the range of motion is tested. A transverse incision is made in the dorsal capsule, and the dorsal capsule is excised, with inclusion of the most dorsal fibers of the collateral ligaments. As the joint is passively flexed, the surgeon must judge if more ligament must be incised. There is no absolute angle of flexion, but at least 70 degrees of flexion should be the goal. If the remaining collateral ligament is unable to pass over the condyles of the metacarpal head, it is detached from its origin on the metacarpal head. Although satisfactory flexion can be obtained by detaching the ulnar collateral ligament alone, it is often necessary to detach both collateral ligaments to prevent abnormal rotation as flexion occurs.

Once the collateral ligaments have been released, an elevator is used to free any adhesions between the volar plate and the volar capsule. It is best to keep testing passive motion, releasing more collateral ligament tissue as needed. Occasionally, the MP joint will jump or trigger as the joint reaches full extension. In such cases, any remaining accessory collateral ligament should be divided. Following release, the extensor tendons are again examined for excursion and any adhesions. The tourniquet is used sparingly to eliminate any degree of tourniquet palsy, and the patient is asked to actively move the affected finger. If a block or general anesthesia has been used, a second incision and proximal traction on the tendons will be necessary. In either case, if the extensor tendons do not glide freely, tenolysis may need to be extended.

Decisions Regarding When to Stop Excising and Releasing Tissue. In every one of these cases, one must decide when the "law of diminishing returns" should be invoked. For instance, there is no value in releasing the MP joint to the point of instability because immobilization or pin fixation of an unstable joint will defeat any gains in motion achieved. Instead, if one has achieved improvement in passive and active flexion from 0 to 60 degrees, excising more tissue may risk destabilizing the joint and the necessary smooth articulating movement.

The use of pin fixation is not necessarily a poor choice, especially in severe cases of global trauma, but if used, the timing of pin removal for activation of the mobilization program has to be carefully considered and individualized. Removal may take place as early as 5 to 7 days following the original procedure.

Four types of splints are available to a surgeon or therapist treating joint contractures in the hand. *Static splints* are used to maintain the hand and digits in one position. They may be worn continuously to support healing tissue or may be removed periodically to exercise the injured hand. They are effective in minimizing external stress; when they are used as blocking splints, they may confine movement within a specified range. *Serial static splints* are applied with the tissue at its maximum excursion and are worn for a period of time. The splint is removed after the tissues have accommodated to it, and additional stretching force is applied. A new splint is then applied again with the tissues at their new maximum excursion. *Dynamic splints* apply some sort of elastic traction, typically either with springs or with rubber bands, and thus apply load while permitting motion. Dynamic splinting is the treatment of choice when passive motion is responsive to manual stretch and inflammation has subsided.[12] *Static progressive splints* are similar to dynamic splints, except that motion is not possible within the splint. These splints often use the principle of three-point application of force (eFigure 10.10).

Nonoperative Treatment of Metacarpophalangeal Joint Contractures

Splinting the MP joint in the flexed position results in diminished intrasynovial space and increased collateral ligament and capsular tension, so that the length of the collateral ligaments is effectively maintained. Thus, the best treatment for reducing the risk for extension contracture of the MP joint is aggressive control of edema, splinting (or occasionally even pinning) of the joint in flexion, and controlled mobilization once the soft tissues and skeletal structures are stabilized. The converse problem of flexion contracture is much less common at the MP joint. When flexion contractures do occur, however, they are typically secondary to external abnormalities such as intrinsic muscle tightness, extensor tendon adhesions, or other extraarticular causes.

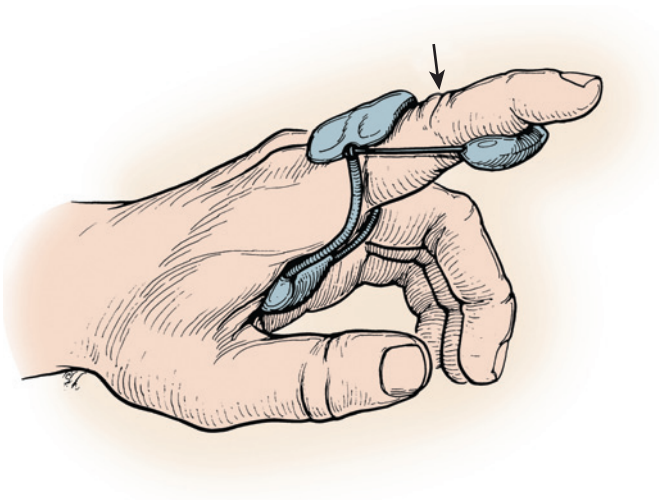

eFIGURE 10.10 The LMB spring finger extension splint exerts its action solely on the proximal interphalangeal joint. Because it is less bulky than some other splints, it may be more acceptable for daytime use in an active or employed individual. Single or multiple splints of this type can be worn either as the sole splint or in conjunction with the Joint-Jack, with the latter being used at night. (Copyright © Elizabeth Martin.)

When confronted with a contracture of the MP joint that suggests fibrosis of the collateral ligament or capsule, aggressive hand therapy plus splinting is the first line of treatment. A combination of dynamic daytime and static progressive nighttime splinting, when used by a diligent patient and implemented by a knowledgeable therapist, can have dramatically successful results. Weeks and colleagues evaluated the conservative management of 212 patients with 789 stiff joints of the hand, 336 of which were MP joint contractures, by exercise and dynamic splinting.[52] A total of 173 patients, or 82%, responded favorably within 2 weeks of starting therapy, with no further treatment necessary. Of the MP joints, the index finger MP joint gained an average of 35 degrees (42 degrees before treatment, 77 degrees after treatment), the long finger MP joint gained an average of 40 degrees (43 degrees before treatment, 83 degrees after treatment), the ring finger MP joint gained an average of 11 degrees (39 degrees before treatment, 50 degrees after treatment), and the small finger MP joint gained an average of 42 degrees (33 degrees before treatment, 75 degrees after treatment). Provided that the interphalangeal joints are supple, it is unusual for a patient whose MP joints can flex as much as 60 degrees to request or benefit from surgical release. Somewhat less flexion can be tolerated in the radial digits than in the ulnar ones.

Nonoperative Treatment of Proximal Interphalangeal Joint Contractures

Limited extension or flexion contractures of the PIP joint can result from a variety of causes, including scarring of the volar surface of the finger, contractures of the superficial fascia of the finger (as in Dupuytren disease), contraction of the flexor tendon sheath within the finger, adherent flexor tendons or contracted flexor muscles, adherence of the retinacular ligaments of Landsmeer to the collateral ligaments, contraction of the volar plate, adherence of the collateral ligaments with the finger in the flexed position, or a bony block or exostosis.[15] Treatment of Dupuytren contractures and flexor tendon injuries and their complications is detailed in Chapters 4 and 6, respectively. Regardless of the cause, however, the most common final pathway to flexion contracture is pathologic changes of the volar plate complex. The anatomy of the volar plate of the PIP joint is unique in that its fibers are transverse and there is little to no excursion of the volar plate in flexion or extension. On the margins of the volar plate are proximodistal expansions known variously as swallowtail ligaments or checkrein ligaments. After injury, these ligaments form thick collagenous bands linking the volar plate and the proximal phalanx and thus restrict extension of the joint.[50] Any injury that causes even slight shortening of these capsular structures can result in fibrosis and contracture[12] despite the most rigid attention to proper splinting and hand therapy protocols.[15,16]

Splinting with dynamic techniques or serial casting is the mainstay of conservative treatment of PIP joint contractures. Although there are many splint designs, all work on the principle that applied tension alters cell proliferation and the elasticity of contracted tissues.[8,34,54] These splints vary in design, but the principle of proper use is invariable: slow, steady application of an extension force perpendicular to the position of the flexed middle phalanx (which means constant adjustment of the line of pull as the contracture improves). Dynamic splinting should

be applied for at least 1 hour several times per day. Pain that limits dynamic splinting to shorter times or that requires narcotic medication for control is a reliable indication that the applied load is too large and the scar is being torn rather than stretched.

Static splinting is useful at night to maintain the gains achieved in the daytime. It is not advisable to wear dynamic splints at night because the position may slip during sleep and pressure sores may develop. As long as there is measurable progress, splinting should continue. As time passes, the force needed to achieve extension diminishes, and flexion deformity of the digit occurs more slowly and less severely. Frequently, splinting for several months is needed to achieve maximal correction.

An alternative nonoperative approach to a difficult flexion contracture is *serial casting*. Casts should be applied with sufficient force to achieve some correction but not so much that the digit is painful. The casts should be changed every few days as long as progress is being made.

The results of nonoperative management of the PIP joint have been reported by several authors. Weeks and coworkers reported on 453 PIP joint flexion contractures treated by active, passive, and resistive exercises in addition to dynamic and static splinting.[52] Eighty-seven percent of the joints responded to treatment such that no further treatment was necessary. The pretreatment arc of motion of the index PIP joint was 42 degrees, as compared with a posttreatment arc of 84 degrees. The long finger arc of motion was 42 degrees preoperatively and 76 degrees postoperatively. The ring and small finger preoperative arc of motion was 40 degrees and 39 degrees, respectively, and the posttreatment arc was 75 and 71 degrees, respectively.

Prosser reported an outcome study of 20 patients with PIP joint flexion contractures who followed a program of dynamic splinting with two different splint types.[41] The average pretreatment contracture was 39 degrees and the final extension after treatment averaged 21 degrees, an 18-degree improvement. Although there was no statistical difference between splint types, there was a statistically significant relationship between splinting time and final range of motion.

Hunter and colleagues treated 61 flexion contractures of the PIP joint with an average pretreatment range of motion of 24 degrees to 67 degrees.[31] Twenty-nine patients underwent exercises alone, 27 patients underwent serial splinting, 5 had thermoplast splints applied, and 5 had dynamic splints applied. The average posttreatment arc of motion was 90 degrees, demonstrating the efficacy of conservative treatment.

Extensor tendon adhesions are the most common cause of extension contractures and are detailed in Chapter 5. Other factors that may limit flexion include scar contractures of the skin over the dorsum of the finger, dorsal capsular fibrosis, contracted or adherent intrinsic muscles and tendons, and bony deformity.[15] Clinical examination will elucidate whether there are skin problems, extensor tendon adherence, or intrinsic tightness, whereas radiographs will determine whether there is a bony block to flexion.

Although PIP extension contractures are not uncommon, there are few published reports of the results of conservative management.[31,52] If the contracture is due solely to capsular or intrinsic muscle adhesions, nonoperative therapy may be helpful. As with flexion contractures, a combination of static and dynamic splints and stretching exercises is often helpful. The interosseous muscles can be stretched by putting the hand in the intrinsic-minus position of MP extension and interphalangeal joint flexion. Both isolated PIP and combined PIP and DIP joint flexion stretches can be used.

Skin and Soft Tissue

If the skin overlying the MP or PIP joint is thin, adherent, and lacks mobility, a separate procedure, including local or free flap coverage over the joint, may be needed. There is no point in performing tenolysis procedures with capsular releases if the skin and soft tissue are so damaged that motion will not be permitted. The soft tissue coverage should be adequate before the surgeon considers contracture release and tenolysis.

There is no substitute for experience in these cases, and consultation with colleagues is strongly encouraged, no matter the age or track record of the surgeon.

Closure and Postoperative Management. Once the release is complete, repair the extensor mechanism and skin in layers using 4-0 nonabsorbable sutures. The degree of flexion can be retested, being careful not to rupture the repaired extensor mechanism. The hand is placed in a bulky dressing, with dorsal and volar plaster splints holding the MP joints at 70 degrees of flexion and the PIP joints in extension.

The hand should be elevated for 24 to 36 hours and mobilization initiated in 2 to 3 days, if possible. The use of removable static splints and dynamic splints is dictated by individual circumstance and opportunity.

Methylprednisolone (Medrol Dosepak, Pfizer, New York) can effectively reduce swelling and pain in the immediate postoperative period in many cases and should be strongly considered if progress appears to have stalled.

Expectations and Complications. Most patients do not maintain the degree of improvement observed in the operating room, despite intensive and persistent rehabilitation programs; every patient needs to be fully informed of this difficulty. In general, patients with direct trauma and extensive local scarring do less well than patients with the sequelae of chronic regional pain syndrome.

Complications include wound separation and lack of skin pliability, especially in the first 2 weeks after release. It may be necessary to suspend rehabilitation for a few days until the skin and wound better tolerate flexion. At 10 to 12 days following operation the wounds can better tolerate mobilization and direct pressure. Diligent attention to the patient and rehabilitation program is an absolute necessity.

More information on this topic can be found online at ExpertConsult.com.

Release of Flexion Contractures of the Proximal Interphalangeal Joint

The primary challenge in the treatment of fixed flexion contracture of the PIP joint, after accounting for the health of the articular cartilage of the joint, is the integrity and function of the extensor mechanism. If there is attenuation of or injury to the extensor, release of the volar contracture tissue alone will not restore active extension. Instead, a plan to release the joint, including the volar collateral ligament, and reconstruction of the extensor mechanism must be considered.[1,23]

Surgical approaches to the PIP joint have been well described in the literature. All use either the volar zigzag Bruner incision or the midaxial approach. The use of local anesthesia with intravenous sedation is preferred to allow the patient to actively flex and extend the joint after release of contractures. This enables immediate evaluation of the effectiveness of the procedure, and any fine-tuning or additional releases can be performed if full extension is not achieved. If local anesthesia with sedation is not possible, an arm block or general anesthesia can be used, but in this case the effectiveness of the releases cannot be thoroughly evaluated intraoperatively without an additional proximal incision and applied traction to the affected motors.

For information on the volar surgical approach, please see ExperConsult.com.

❖ AUTHOR'S PREFERRED APPROACH: Proximal Interphalangeal Flexion Contractures

Under local anesthesia, a midlateral skin incision is made that extends from the midshaft of the proximal phalanx to the midshaft of the middle phalanx (Figure 10.3). The neurovascular bundle is identified and retracted palmarly. The transverse retinacular ligament is divided and the accessory collateral ligament and volar plate are visualized. Although a unilateral incision is preferred, a bilateral incision can be used if exposure of the contralateral collateral ligament is difficult. Once exposure is achieved, the checkrein ligament is released and the accessory collateral ligament is completely excised as necessary. The exposure can be extended to the dorsal side as needed for extensor tenolysis or central slip reconstruction. This situation is not substantially different from release and reconstruction of the chronic, fixed boutonniére reconstruction (see Chapter 5).

The dressing is removed at 3 days following operation and active motion is encouraged under the supervision of a hand therapy specialist. Two splints are made at that time, one for extension and one for flexion, and they are alternated as needed. Static splinting in extension is continued at night for up to 6 months.

For expectations and outcomes of PIP flexion contracture release, please see ExpertConsult.com.

External Fixation Devices for Proximal Interphalangeal Joint Contractures. External fixation provides a sustained forceful moment and exerts control through the bone, as opposed to pressure on the skin, thus offering a promising way of both stabilizing and mobilizing the PIP joint.[2,19,29,30]

Though several devices have been reported to have successful outcomes, the Digit Widget (Hand Biomechanics Laboratory, Sacramento, CA) is a unique device that uses extension torque rather than a distractive force, is controlled entirely by the patient, and has a reasonably low profile. This device allows a range of motion of the PIP joint during the application of extension torque on the contracted joint, via a series of rubber bands that are applied to the device (Figure 10.4, *A* to *E*). The device may be applied for a wide variety of reasons, is simple to apply and maintain, and "burns no bridges" should further reconstructive procedures be required (Case Study 10.1).

Release of Posttraumatic Proximal Interphalangeal Joint Extension Contractures

Surgery for extension contractures of the PIP joint is best performed under local anesthesia with sedation. This enables testing of the contracture release via the patient's voluntary control and allows fine-tuning. The operative approach for extension contractures can be from a dorsal or dorsolateral approach (Figure 10.5). The extensor mechanism is exposed, and the transverse fibers of the retinacular ligament are identified and longitudinally divided on either side of the central tendon. The extensor tendon is then elevated, with care taken to avoid injury to the central slip insertion. This provides exposure of the dorsal capsule and the collateral ligaments. Extensor tenolysis is performed, and the surgeon can continue as far proximally and distally as needed to free the tendon from underlying bone and overlying skin. The dorsal capsule is excised, and the range of motion of the joint is assessed. If full flexion is not possible, the dorsalmost fibers of the collateral

In 1974, Buch described the anatomic characteristics of the MP joint and ligaments and detailed the technique of capsulotomy and collateral ligament release.[10] Buch's technique uses a dorsal exposure to divide the sagittal band off the extensor tendon and expose the capsule. A capsulotomy is performed and the volar pouch is re-created with an elevator. The collateral ligaments are detached from their attachments to the metacarpal head, and the joint is flexed to 90 degrees. Meticulous closure is performed while care is taken to maintain centralization of the extensor tendon. Postoperatively, the MP joints are splinted in flexion. Mobilization is started 5 to 7 days after surgery.

Young, Wray, and Weeks described a technique that involved the use of Kirschner wire fixation of the joint in flexion for 2 weeks after the operation.[55] They described both volar and dorsal approaches. Their dorsal technique is similar to Buch's, with the exception that the extensor tendon is split longitudinally and the volar half of the collateral ligaments and the accessory collateral ligaments are preserved to maintain joint stability. The joint is pinned with a transarticular Kirschner wire in 90 degrees of flexion for 2 weeks, after which time it is removed and therapy is initiated. Their volar technique is used if the dorsal skin is moderately deficient but adequate to preclude skin grafting, flexor tenolysis is required, or later extensor tendon reconstructive surgery is planned. The volar technique uses a 2-cm longitudinal incision between the metacarpal heads. The lateral bands are traced proximally to the MP joint. The insertions of the collateral ligaments are detached and a segment is excised. In comparing the dorsal and volar approaches, Weeks and associates reported that 44% of the joints treated via the volar approach gained more than 50 degrees of active motion as compared with just 16% treated via the dorsal approach.[53]

Gould and Nicholson evaluated 105 MP joint capsulotomies performed in 37 patients with a dorsal approach similar to Buch's technique.[24] The average gain in flexion was 21 degrees. When only fracture and crush injuries were considered, the average gain in flexion was 18 degrees even though 90 degrees of flexion was obtained at the time of surgery. They concluded that although their results have modified their expectations of capsulotomy of the MP joint, the functional gains that allow better prehension are still significant.

Volar Surgical Approach. A standard Bruner incision is made from the distal phalangeal crease to the digital-palmar skin crease, and the skin flaps are elevated while care is taken not to devitalize the corner. The radial and ulnar neurovascular bundles are identified and protected. The flexor tendon sheath is opened on a lateral hinge from the distal aspect of the A2 pulley to the proximal aspect of the A4 pulley, and the flexor tendons are carefully retracted while preserving the vincula. The checkrein ligaments are identified (eFigure 10.11).[50] An anatomic landmark for identifying the checkrein ligaments is the transverse digital artery, which passes underneath the checkrein ligament 3 mm proximal to the joint. The checkrein ligaments are released while the transverse digital arteries are spared. An attempt at passive extension of the joint is then made. If full passive extension is not achieved, a capsular release is performed to release the volar plate complex and accessory collateral ligaments. If the contracture still persists, the rest of the collateral ligament is detached from the proximal phalanx. It is very valuable at this point to check active motion, provided the patient has agreed to surgery under local anesthesia with sedation. It is impossible to know whether extensor tenolysis will be needed in the presence of a flexion contracture. Thus, active extension always needs to be checked after flexion contracture release, and the patient must be advised preoperatively of the possible need for extensor tenolysis.

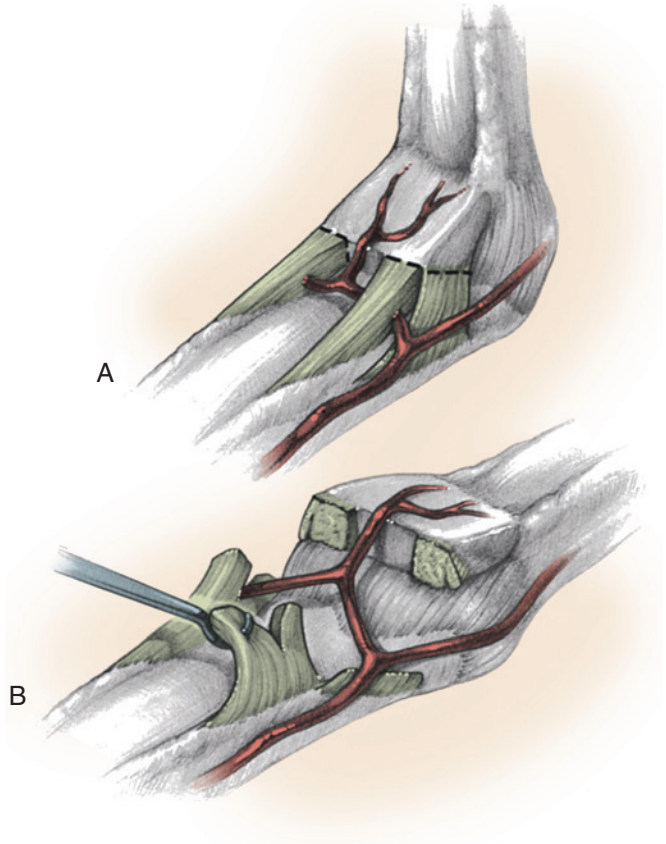

eFIGURE 10.11 Checkrein pathologic bands. **A,** The checkreins attach proximally to the assembly line and distally to the volar plate on both the radial and ulnar sides. The transverse communicating vessels traverse the collagen band approximately 2 mm proximal to the volar plate. **B,** Complete excision of the checkreins often requires resection dorsal as well as volar to the transverse communicating vessels. These vessels should be preserved. (Copyright © Elizabeth Martin.)

The tourniquet is deflated, and hemostasis is achieved. Any hematoma will encourage the formation of a new contracture, and the swelling will impair postoperative rehabilitation. The vascularity of the digit must be carefully monitored during closure and postoperative positioning because overstretching of neurovascular tissues may result in spasm and an ischemic digit.[51] Postoperatively, the finger should be splinted in the maximum safe extension position for 3 to 5 days. Kirschner wire fixation of the joint in extension is occasionally used to maintain the release for a few days while the soft tissues become accommodated to the new position. If there is excessive pressure to maintain extension on the joint, placement of a Kirschner wire can result in cartilage necrosis or cartilage overgrowth on the distal end of the proximal phalanx.[18,21,22]

After the dressings are removed, a light dressing is applied and active motion exercises are begun. Dynamic and static resting splints are fabricated and used for 3 to 4 months or until the correction plateaus.

Expectations and Outcomes of Proximal Interphalangeal Joint Flexion Contracture Release. In 1954, Curtis reported on 25 patients with PIP flexion contractures treated by midlateral exposure, capsulectomy, excision of the collateral ligaments, and elevation of the volar plate, followed by Kirschner wire fixation for 5 to 7 days.[15] He reported that the more anatomic structures involved in the limitation of motion, the poorer the end result. If the only limiting factor was the capsular ligaments, release of the collateral ligaments gave a good result. Curtis summarized his findings by stating that restoration of complete motion with his technique is not expected but that improvement of function can be expected. Typically, about half the intraoperative gain is maintained. Using Curtis's technique, Rhode and Jennings were able to obtain similar results.[42] Sprague was not as enthusiastic in his reports of the Curtis technique[46,47] but echoed Curtis's finding that the more structures involved, the worse the outcome.[4,15,16,46,47] In joints that underwent capsulotomy and excision of the collaterals, volar plate, and extensor mechanism to release adhesions, the results were disheartening. The initial gain intraoperatively was just 30 degrees, 90% of which was lost in the postoperative period. Sprague concluded, and others have agreed, that surgical release of a severely contracted PIP joint yields unpredictable results and should be considered only when both the surgeon and patient clearly understand its limitations.[27,43,46,47]

Bruser and associates compared the use of a midlateral incision with a palmar incision for contracture releases of the PIP joint in 1999.[9] Their study of 45 joints demonstrated an average of 30 to 50 degrees of increased motion at 1.5 years' follow-up. The group in whom a midlateral incision had been used had an average improvement of 50 degrees, whereas the group in whom a volar incision had been used had an increase of 30 degrees. The differences were found to be statistically significant.

To identify which demographic, preoperative, and intraoperative factors affected the outcome of contracture release, Ghidella and coworkers performed a review of 68 PIP joints that had been released.[23] The average improvement with a minimum of 24 months of follow-up was 7.5 degrees. Based on their analysis, the best candidates for surgical release were younger than 28 years with an uncomplicated contracture and a preoperative maximum flexion of less than 43 degrees.

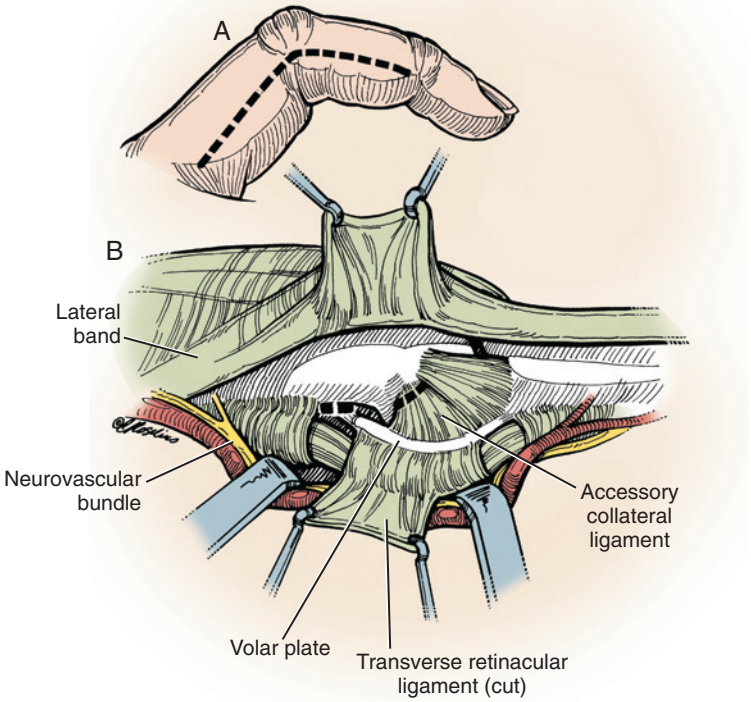

FIGURE 10.3 **A,** Flexion contracture release at the proximal interphalangeal joint as performed via a midlateral approach. Though technically easier, the results of a volar Bruner approach have been shown to result in less favorable outcomes. **B,** The transverse retinacular ligament is divided and the lateral aspect of the joint is visualized. The volar plate checkrein ligaments are released, as well as the accessory collateral ligament at its origin on both the radial and ulnar aspects of the joint. If motion is not improved, the proper collateral ligament is also released. (Copyright © Elizabeth Martin.)

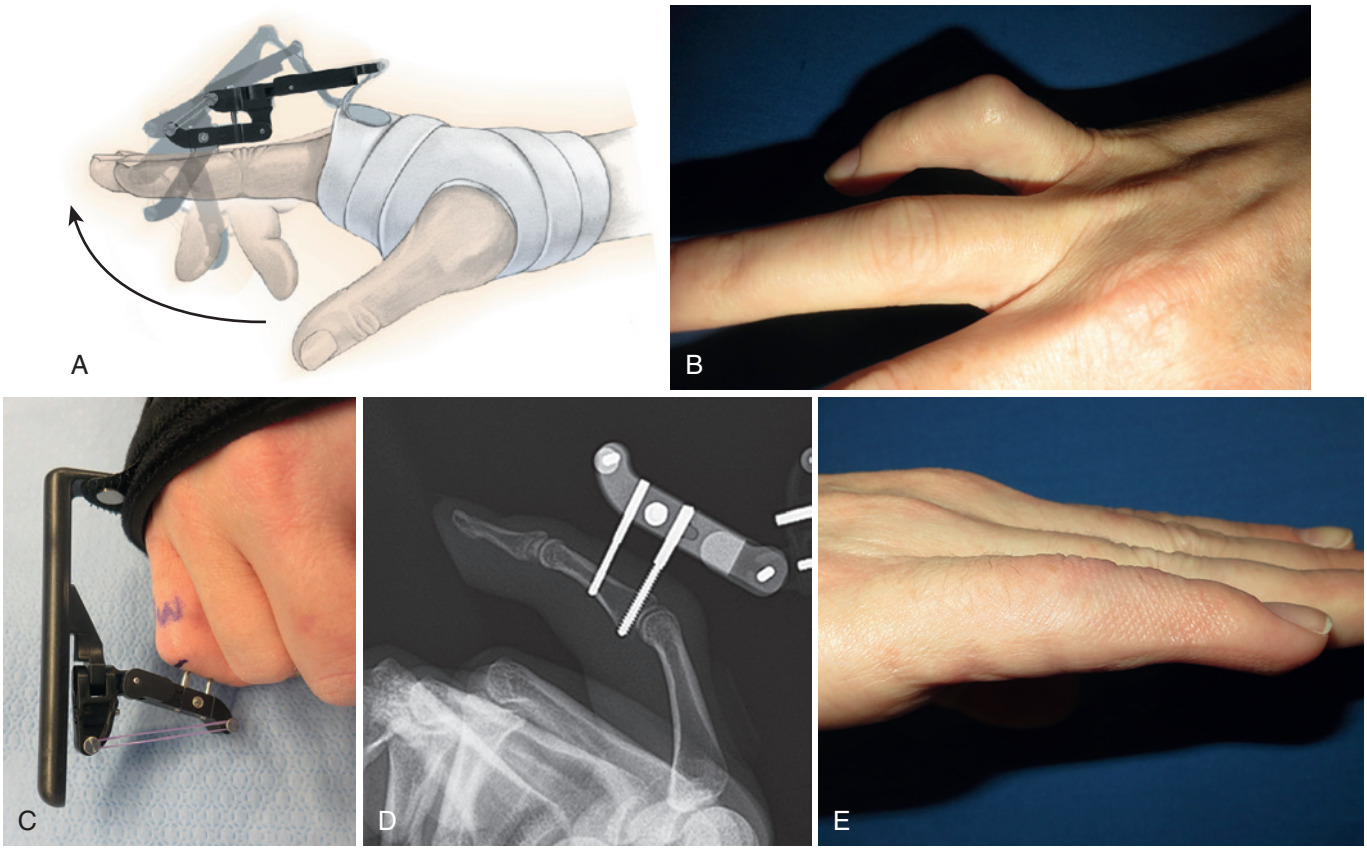

FIGURE 10.4 **A,** The Digit Widget, a device that uses extension torque rather than a distractive force, was introduced in 2001 (Hand Biomechanics Laboratory, Sacramento, CA). **B,** A 38-year-old woman 1 year after flexor tendon repair complicated by a 90-degree flexion contracture. **C,** The device allows range of motion while extension torque is applied via rubber bands with different grades of elasticity. **D,** Radiographs 4 weeks following application of device. **E,** Active extension 3 months following removal and vigorous splinting protocol.

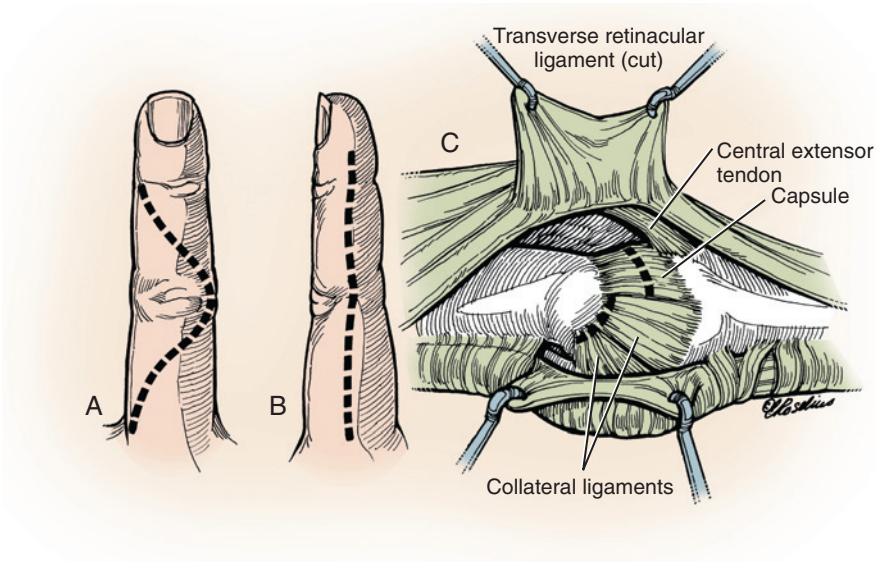

FIGURE 10.5 **A** to **C,** Extension contracture release of the PIP joint can be performed through a dorsal curvilinear or midlateral approach. Once the skin is elevated and mobilized, the transverse retinacular ligament is divided to expose the joint. Extensor tenolysis is performed, and a dorsal capsulotomy is made. The collateral ligaments are then released at their insertion on the proximal phalanx. (Copyright © Elizabeth Martin.)

ligaments should be released. If full flexion is still not obtained, the rest of the collateral ligaments are released off the proximal phalanx origin. Once passive flexion is satisfactory, the patient is asked to voluntarily flex the digit to determine whether there are any extrinsic causes of blocked flexion. It is impossible to know whether flexor tenolysis will be needed in the presence of an extension contracture. Thus, active flexion always needs to be checked after release of the contracture, and the patient must be advised preoperatively of the possible need for flexor tenolysis. If the patient does not tolerate local anesthesia with sedation, the procedure can be done under regional or general anesthesia, and a proximal counterincision must be made in the distal part of the forearm to apply traction to the flexor tendons.

No discussion of PIP extension contractures is complete without mentioning the possibility of intrinsic contractures. After surgical release is completed, the Bunnell intrinsic tightness test is performed to determine whether there is residual contracture of the intrinsics. If the test is positive, release of the intrinsics should be performed as described by Dr. Richard J. Smith (see ExpertConsult.com). If the patient is awake, the active hook grip should be tested following release, to detect more subtle degrees of intrinsic tightness that will respond to stretching postoperatively.

An alternative to capsulotomy is release of the lateral bands on either side of the central slip, followed by the gentle passive flexion maneuver described by Inoue.[32] In this technique, the passive flexion breaks up adhesions of the extensor tendon and intraarticular adhesions. A dorsal extension block with a Kirschner wire prevents active extension beyond the desired flexed position, and active flexion exercises are initiated immediately postoperatively. The wire is removed at 2 weeks, and vigorous flexion exercises are initiated with a dynamic flexion splinting device. The results in 10 patients treated in this manner demonstrated an average gain of 47.5 degrees of flexion without complications.

The results of release of extension contractures have been reported by Mansat and Delprat.[37,38] In a multicenter study involving 10 institutions in France, 246 contracture releases of the PIP joint were performed, of which extension contractures accounted for 45% of cases. The average improvement in flexion was 28 degrees, with a preoperative range of motion of 19 to 34 degrees as compared with a postoperative range of motion of 8 to 62 degrees.

For Case Studies, Videos, and more, please visit ExpertConsult.com.

REFERENCES

1. Abbiati G, Delaria G, Saporiti E, et al: The treatment of chronic flexion contractures of the proximal interphalangeal joint. *J Hand Surg [Br]* 20(3):385–389, 1995.
2. Agee JM, Goss BC: The use of skeletal extension torque in reversing Dupuytren contractures of the proximal interphalangeal joint. *J Hand Surg [Am]* 37(7):1467–1474, 2012.
3. Akeson WH, Amiel D, Woo SLY: Immobility effects on synovial joints. The pathomechanics of joint contracture. (Third International Congress of Biorheology: Symposium on Soft Tissues Around a Diarthrodial Joint.) *Biorheology* 17:95–110, 1980.
4. Allieu Y, Ould Ouali A, Gomis R, et al: Simple arthrolysis for flexor rigidity of the proximal interphalangeal joint. *Ann Chir Main* 2:330–335, 1983.
5. Backhouse KM, Catton WT: An experimental study of the function of the lumbrical muscles in the human hand. *J Anat* 88:133–141, 1954.
6. Bain GI, Mehta JA, Hepinstall RJ, et al: Dynamic external fixation for injuries of the proximal interphalangeal joint. *J Bone Joint Surg Br* 80:1014–1019, 1998.
7. Brand PW: Drag. In *Clinical mechanics of the hand*, St. Louis, 1985, Mosby, pp 61–87.
8. Brand PW: Mechanical factors in joint stiffness and tissue growth. *J Hand Ther* 8:91–96, 1995.
9. Bruser P, Poss T, Larkin G: Results of proximal interphalangeal joint release for flexion contractures: midlateral versus palmar incision. *J Hand Surg [Am]* 24:288–294, 1999.
10. Buch VI: Clinical and functional assessment of the hand after metacarpophalangeal capsulotomy. *Plast Reconstr Surg* 53:452–457, 1974.
11. Bunnell S: Ischaemic contracture, local, in the hand. *J Bone Joint Surg Am* 35:88–101, 1953.
12. Bunnell S: *Surgery of the hand*, ed 3, Philadelphia, 1956, JB Lippincott.

Release of Intrinsic Contracture After Trauma. The classic description of the surgical treatment of intrinsic contractures of the hand by the late Richard J. Smith, MD, in previous editions of this textbook remains in our opinion the gold standard on this subject. Again, in tribute to Dr. Smith's enduring contributions to hand surgery, we have included his description of the surgical techniques for release of intrinsic contractures of the hand, in his own words.

Posttraumatic interosseous contracture is usually caused by edema, prolonged immobilization, or muscle ischemia. *Hematoma* and *edema* fluid envelop the interosseous muscles after severe hand injuries. This fluid fills the interosseous muscle compartment and is trapped by the firm dorsal and volar interosseous fascia. Capillary compression and venous stasis add to the congestion. The fingers move little because of pain. If a compressive bandage or circular cast further impedes venous drainage, the interossei develop a myostatic contracture in their viscid environment. When the edema finally subsides, fibrosis supervenes.

Late Posttraumatic Intrinsic Contracture of the Proximal Interphalangeal Joint. Several months after injury to the wrist or hand, many patients will have persistent limited flexion of the PIP joints. The surgeon may suspect that the limited motion is due to intraarticular or periarticular adhesions or posttraumatic synovitis. Frequently, the cause is residual intrinsic contracture. To flex the MP joints, the intrinsics must stretch the collateral ligaments. With diffuse edema, these ligaments are tight and resist stretching. However, there is no resistance to PIP extension, because the collateral ligaments relax with extension. The swollen collateral ligaments of the injured finger therefore resist MP flexion but not PIP extension. The MP joint is unaffected. There is an extension contracture at the PIP joint, and the intrinsic tightness test is positive.

It is not necessary to release the entire intrinsic aponeurosis in these patients. Because only PIP joint flexion is limited, just the oblique fibers of the lateral bands are resected. This is known as a *distal intrinsic release* (eFigure 10.12).[25]

Technique of distal intrinsic release. Local anesthesia is infiltrated dorsal to the proximal phalanx. A longitudinal incision is made along the dorsal midline of the distal half of the proximal phalanx. The lateral bands, oblique fibers, and central and lateral slips of the dorsal aponeurosis are identified. The lateral band and oblique fibers are resected at the distal third of the proximal phalanx. The central slip, the lateral slips of the extensor tendon, and the transverse fibers of the intrinsic aponeurosis should not be resected.[25] Postoperatively, the MP joints are splinted in extension for 3 weeks. Active and passive-assisted interphalangeal flexion exercises are begun within 1 day of surgery.

Late Posttraumatic Interosseous Contracture of the Metacarpophalangeal and Proximal Interphalangeal Joints. Severe, prolonged deep-space edema of the hand will cause interosseous muscle necrosis and fibrosis.[11,13] With unrelenting contracture of the scarred muscle remnant, deformities develop at both the MP and interphalangeal joints. When there has been extensive edema of the hand, the collateral ligaments of the MP joints are swollen and resist stretching. Thus, it is only with the most severe interosseous muscle contracture that the shortened collateral ligaments yield and permit the proximal phalanx to be pulled into flexion. The PIP joint is held in extension by the

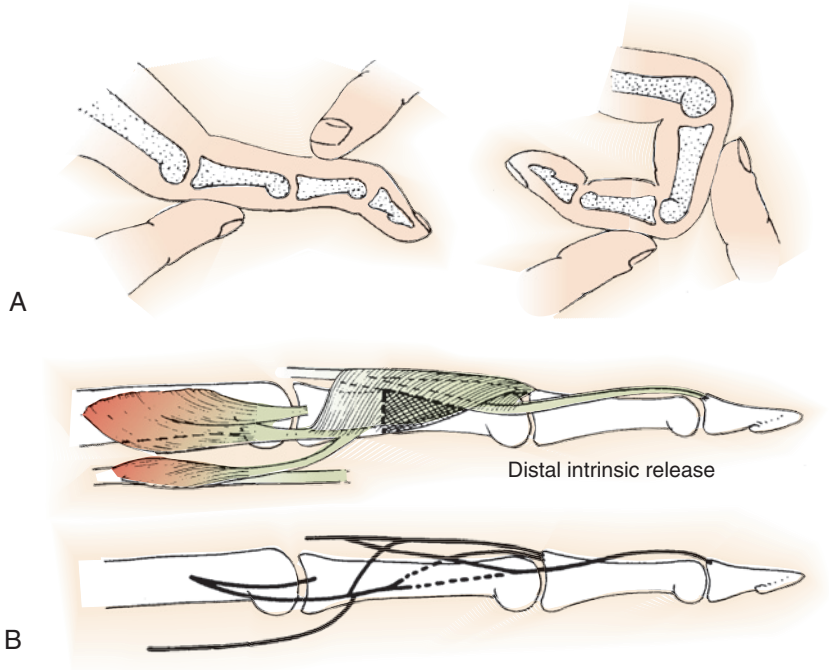

eFIGURE 10.12 Distal intrinsic release. For late posttraumatic interosseous contracture with proximal interphalangeal joint stiffness, the intrinsic tightness test is positive and a distal intrinsic release is usually indicated. **A,** The lateral band and oblique fibers of the dorsal aponeurosis are removed proximal to the juncture of the lateral band with the lateral slip of the extensor tendon. Strong metacarpophalangeal flexion and dorsal interphalangeal extension are preserved by the distal intrinsic release. **B,** In this dissected specimen, the portion of the dorsal aponeurosis that was removed with the distal intrinsic release is *blackened.*

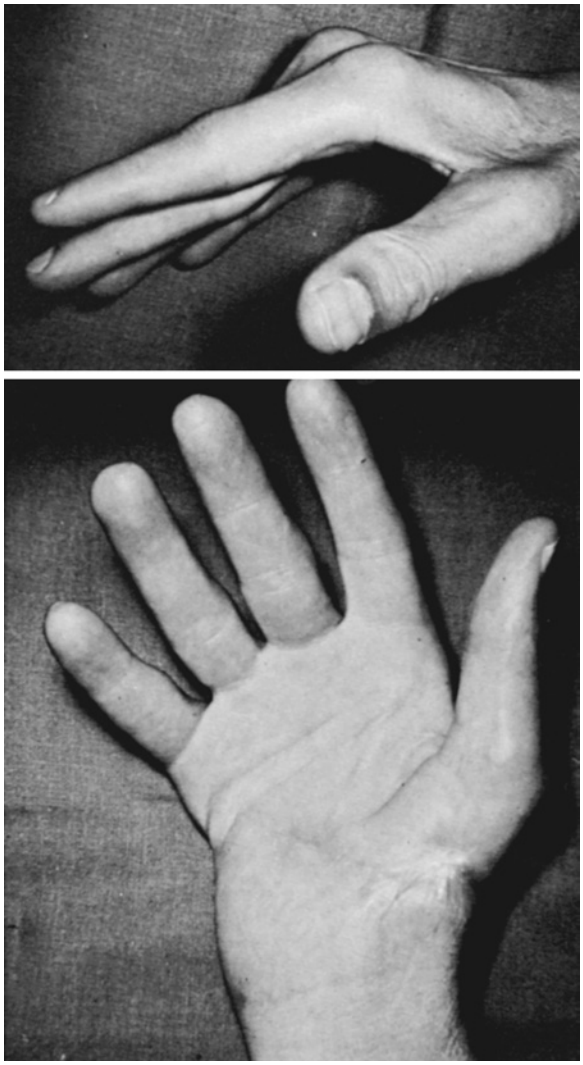

eFIGURE 10.13 Late posttraumatic interosseous contracture involving the metacarpophalangeal (MP) and proximal interphalangeal joints is often associated with interosseous ischemia and necrosis. The fingers are flexed at the MP joints and extended at the interphalangeal joints. The contracture in this patient was due to severe edema after the application of a tight cast for a fracture of the wrist.

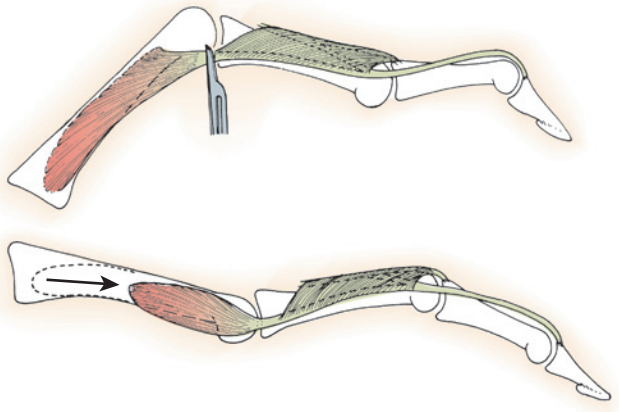

eFIGURE 10.14 Metacarpophalangeal (MP) and proximal interphalangeal deformity after late posttraumatic interosseous contracture may be relieved by transecting the lateral tendon proximal to the MP joint *(top)* if the muscles are necrotic. If some function remains, the muscles may be relaxed by performing an interosseous muscle slide *(bottom)*.

oblique fibers of the contracted interossei. Secondary paraarticular changes may include contracture of the volar plate and accessory collateral ligaments of the MP joints and contracture of the collateral ligaments of the PIP joints. This deformity causes serious disability. Large objects cannot fit in the palm, the grip is weak, and pulp-to-pulp pinch is impossible (eFigure 10.13).

To correct severe intrinsic contractures that involve both the MP and interphalangeal joints, extensive release of the dorsal aponeurosis is necessary. If the interossei retain their contractility but are fibrotic and tight, they may be released with a muscle slide. With more severe ischemia, the interossei are necrotic and nonfunctional. Lumbrical function may be preserved and the interosseous muscle contracture released by transecting the interosseous tendons proximal to the MP joints (eFigure 10.14).

Any paraarticular structures that have become secondarily contracted are also transected to improve passive motion of the MP and interphalangeal joints. The surgeon need not fear overcorrection or a claw deformity. MP joint hyperextension rarely develops even with the most thorough soft tissue release.

Technique of release of severe posttraumatic intrinsic contractures with muscle fibrosis. A dorsal transverse incision is made just proximal to the MP joints. The lateral tendons of all the interosseous muscles and the abductor digiti quinti tendon are resected at the level of the MP joints. If the MP joints remain flexed, the sagittal bands are retracted distally and each accessory collateral ligament is divided at its insertion into the volar plate. The volar plate is freed from its attachments to the base of the proximal phalanx. With a blunt probe, any adhesions between the volar plate and the head of the metacarpal are separated. If it is difficult to maintain extension of the proximal phalanx after soft tissue release, a Kirschner wire is inserted obliquely through the MP joint in maximum extension. When the phalanx is extended, it is important to be certain that the base of the proximal phalanx articulates properly with the metacarpal head before inserting the Kirschner wire. If passive PIP flexion is incomplete with the MP joint extended, the lateral bands are resected at the distal half of the proximal phalanx through a separate dorsal incision. Postoperatively, passive and active PIP flexion exercises should begin within 1 day of surgery. The Kirschner wire is usually removed at about 3 weeks.

Case Study 10.1

A 38-year-old right-handed woman injured herself when separating frozen hot dogs with a knife. She was seen at 6 months following R 5th profundus repair through an intact superficialis (eFigure 10.15, *A* to *D*). An MRI (eFigure 10.16, *A* to *D*) demonstrates an intact A2 pulley and intense scar formation around the repaired tendon at A1 and zone 2.

The PIP flexion contracture is 90 degrees, signifying that no improvement has taken place with 6 months of therapy and serial casting has been ineffective. Ultrasound study documents intact tendons, fibrosis over the proximal phalanx, and gliding of the flexor digitorum profundus.

What do you advise?

A. Flexor tenolysis alone
B. Joint contracture release
C. Joint contracture release and tenolysis in one procedure
D. Joint contracture release and tenolysis in separate procedures
E. Application of the Digit Widget

ANS:

E, Application of the Digit Widget (eFigure 10.17, *A* to *C*).

The patient's postoperative clinical photos and radiographs are displayed in eFigures 10.18, *A* and *B*, 10.19, *A* and *B*, and 10.20, *A* and *B*.

Two months after application of the device, the patient demonstrates excellent active extension and flexion. You perform a trial of rubber band removal, and the contracture begins to recur at 48 hours (eFigure 10.21). You recommend:

A. Removing the device and performing serial casting
B. Reapplying the bands and waiting another month
C. Reapplying the bands and providing an MP hyperextension block
D. Removing the fixator and performing A2 pulley reconstruction
E. Surgically releasing the collateral ligaments

ANS:

C, Reapplying the bands and providing an MP hyperextension block.

MP hyperextension can increase the tone of the digital flexors and place the intrinsic PIP extensors at a mechanical disadvantage.

Six weeks later, the patient is able to control MP hyperextension, and the device is removed (eFigure 10.22).

MP hyperextension blocks were used for 2 additional months (eFigure 10.23, *A* and *B*). By 16 months following the injury, the patient returned to a fully active lifestyle, without splints or any residual contracture (eFigure 10.24).

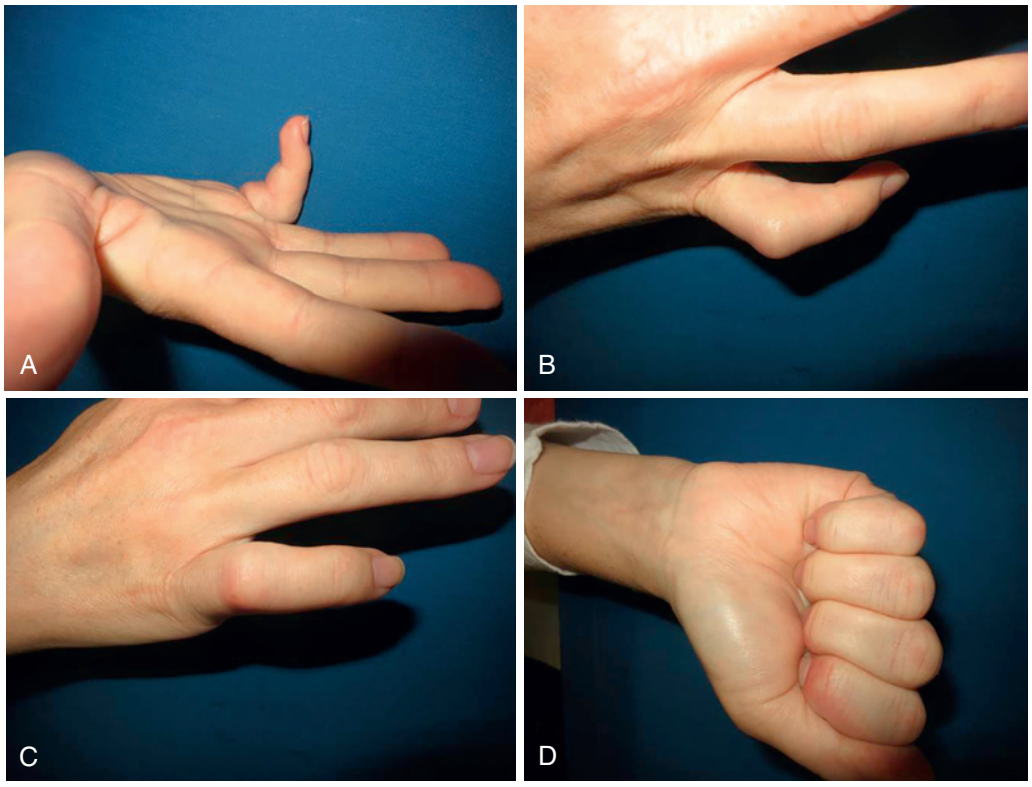

eFIGURE 10.15 **A** to **D,** Clinical photos.

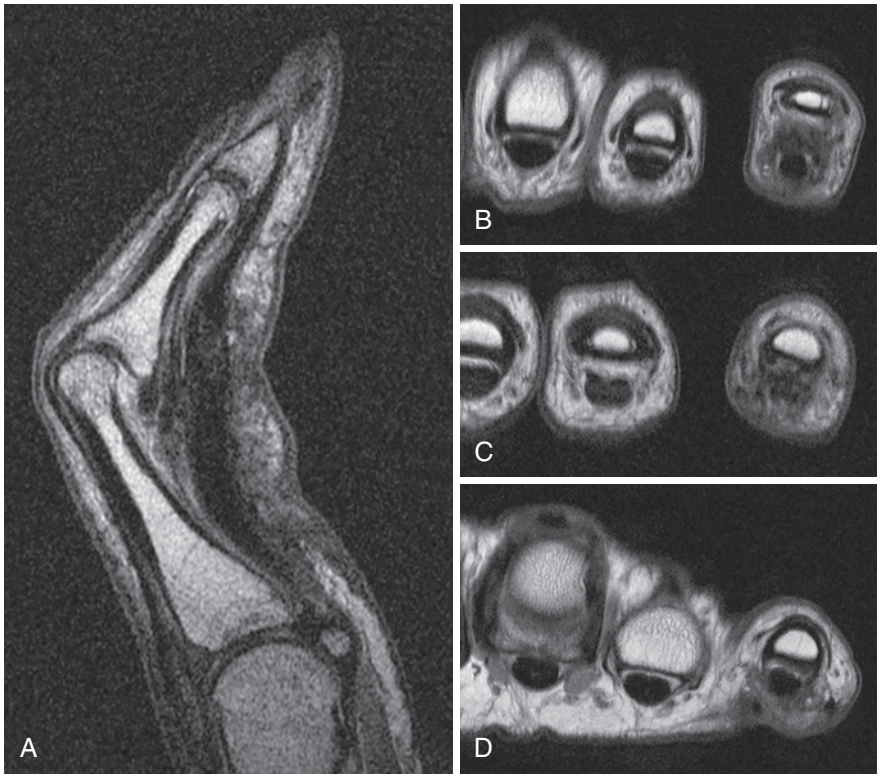

eFIGURE 10.16 **A** to **D,** Magnetic resonance images of injury.



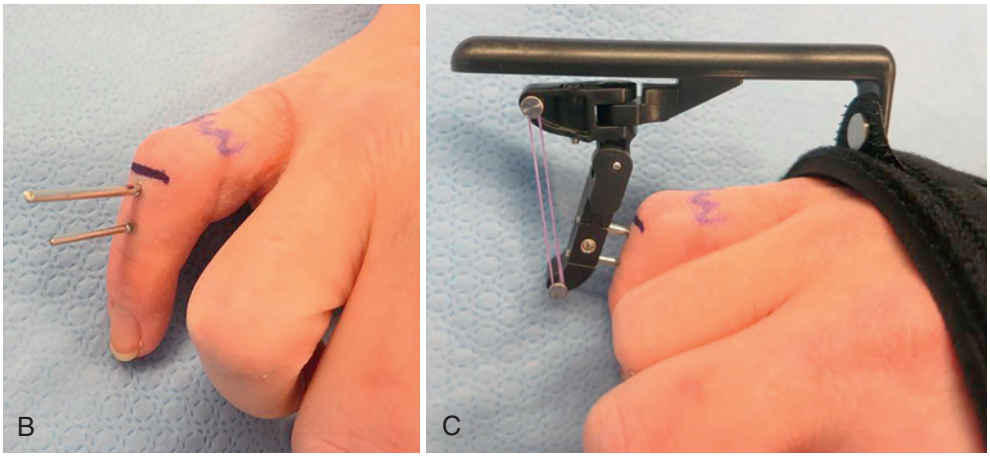

eFIGURE 10.17 **A** to **C,** Application of Digit Widget.

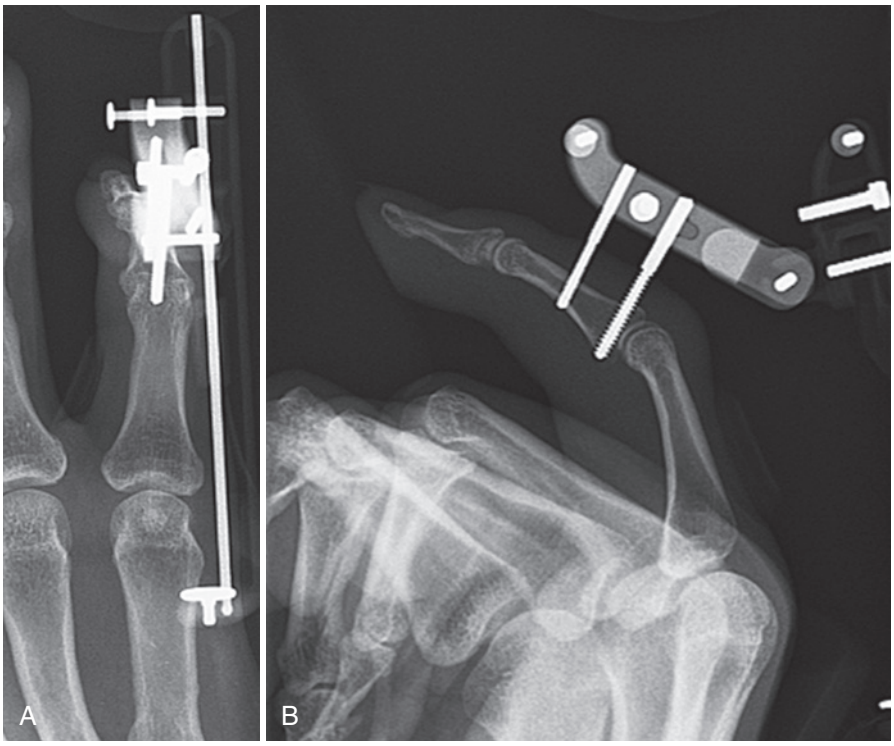

eFIGURE 10.18 A and B, Radiographs ten days following operation.

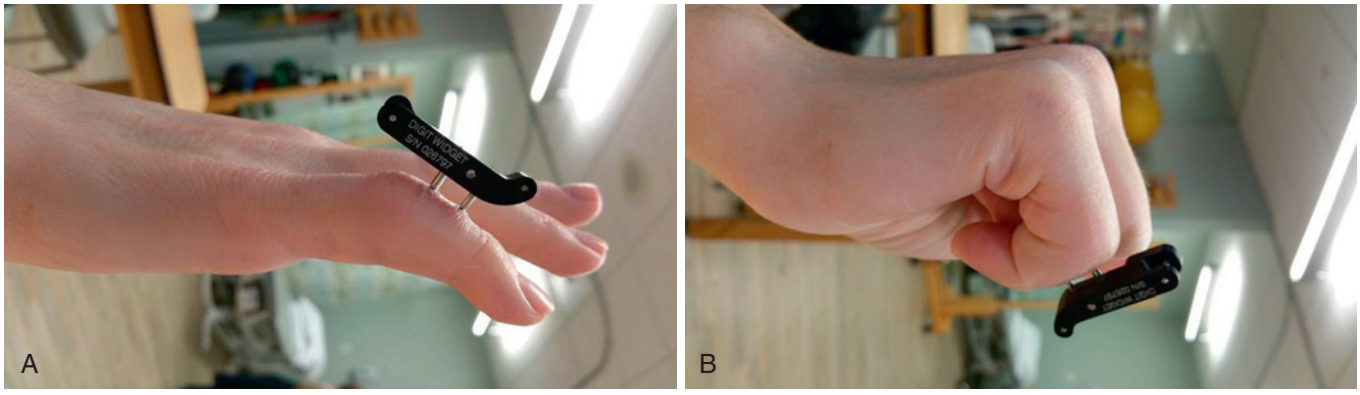

eFIGURE 10.19 **A** and **B,** Photographs four weeks following operation.

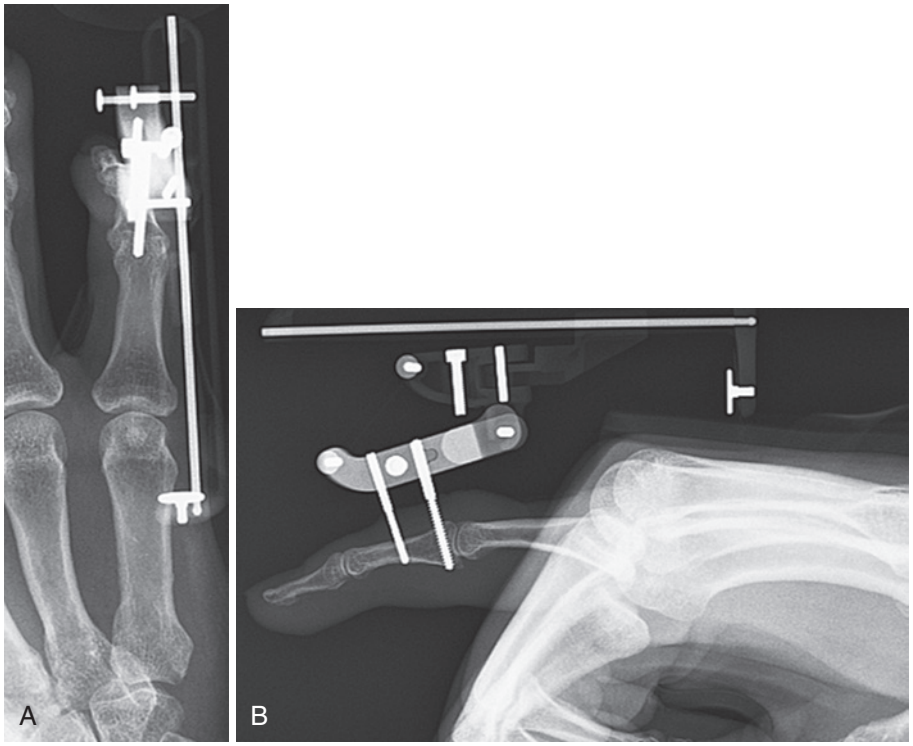

eFIGURE 10.20 **A** and **B,** Radiographs two months following operation.



eFIGURE 10.21 Contracture has recurred by 48 hours after bands were removed.



eFIGURE 10.22 Photographs six weeks following operation.

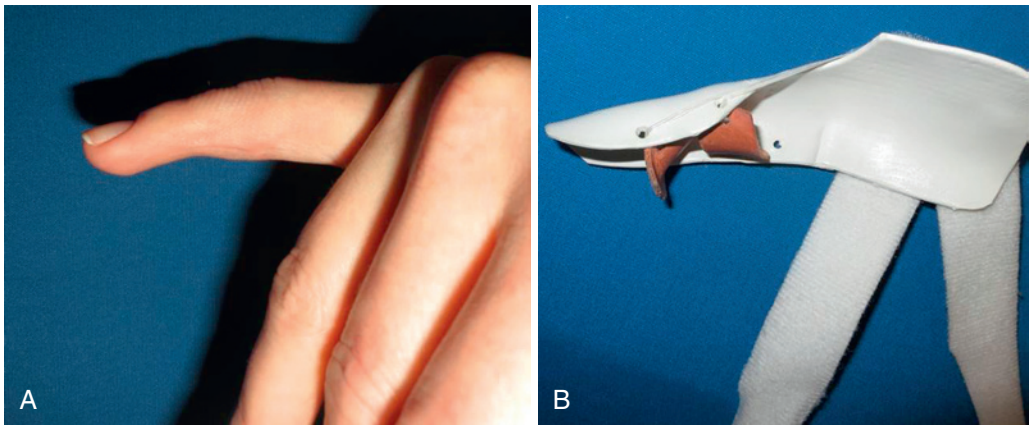

eFIGURE 10.23 **A** and **B,** Metacarpophalangeal hyperextension blocks.



eFIGURE 10.24 Photograph sixteen months following injury.

13. Bunnell S, Doherty DW, Curtis RM: Ischemic contracture, local, in the hand. *Plast Reconstr Surg* 3:424–433, 1948.
14. Colditz JC, Erdmann D, Levin LS: *Differential testing and stretching of the interosseous and lumbrical muscles: clinical implications*. Paper presented at the 25th Annual Meeting of the American Society of Hand Therapists, 2002, Ottawa, Canada.
15. Curtis RM: Capsulectomy of the interphalangeal joints of the fingers. *J Bone Joint Surg Am* 36:1219–1232, 1954.
16. Curtis RM: Surgical restoration of motion in the stiff interphalangeal joints of the hand. *Bull Hosp Jt Dis* 31:1–6, 1970.
17. Eaton RG, Littler JW: Joint injuries and their sequelae. *Clin Plast Surg* 3:85–98, 1976.
18. Enna CD, Zimny M: A scanning electron microscopy study of articular cartilage obtained from contracted joints of denervated hands. *Hand* 6:65–69, 1974.
19. Feldscher SB, Blank JE: Management of a proximal interphalangeal joint fracture dislocation with a compass proximal interphalangeal joint hinge and therapy: a case report. *J Hand Ther* 15(3):266–273, 2002.
20. Field J: Two to five year follow-up of the LPM ceramic coated proximal interphalangeal joint arthroplasty. *J Hand Surg Eur Vol.* 33(1):38–44, 2008.
21. Field PL, Hueston JT: Articular cartilage loss in long-standing flexion deformity of the proximal interphalangeal joints. *Aust N Z J Surg* 40:70–74, 1970.
22. Field PL, Hueston JT: Articular cartilage loss in long-standing immobilization of interphalangeal joints. *Br J Plast Surg* 23:186–191, 1970.
23. Ghidella SD, Segalman KA, Murphey MS: Long-term results of surgical management of proximal interphalangeal joint contracture. *J Hand Surg [Am]* 27:799–805, 2002.
24. Gould JS, Nicholson BG: Capsulectomy of the metacarpophalangeal and proximal interphalangeal joints. *J Hand Surg [Am]* 4:482–486, 1979.
25. Harris C, Jr, Riordan DC: Intrinsic contracture in the hand and its surgical treatment. *J Bone Joint Surg Am* 36:10–20, 1954.
26. Harris C, Jr, Rutledge GL, Jr: The functional anatomy of the extensor mechanism of the finger. *J Bone Joint Surg Am* 54:713–726, 1972.
27. Harrison DH: The stiff proximal interphalangeal joint. *Hand* 9:102–108, 1977.
28. Hartigan BJ, Stern PJ, Kiefhaber TR: Thumb carpometacarpal osteoarthritis: arthrodesis compared with ligament reconstruction and tendon interposition. *J Bone Joint Surg Am* 83(10):1470–1478, 2001.
29. Houshian S, Chikkamuniyappa C: Distraction correction of chronic flexion contractures of PIP joint: comparison between two distraction rates. *J Hand Surg [Am]* 32(5):651–656, 2007.
30. Houshian S, Jing SS, Kazemian GH, et al: Distraction for proximal interphalangeal joint contractures: long-term results. *J Hand Surg [Am]* 38(10):1951–1956, 2013.
31. Hunter E, Laverty J, Pollack R, et al: Nonoperative treatment of fixed flexion deformity of the proximal interphalangeal joint. *J Hand Surg [Br]* 24:281–283, 1999.
32. Inoue G: Lateral band release for post-traumatic extension contracture of the proximal interphalangeal joint. *Arch Orthop Trauma Surg* 110:298–300, 1991.
33. Kaplan EB: *Functional and surgical anatomy of the hand*, Philadelphia, 1965, JB Lippincott, pp 53–86.
34. Kottke FJ, Pauley DL, Ptak RA: The rationale for prolonged stretching for correction of shortening of connective tissue. *Arch Phys Med Rehabil* 10:345–352, 1966.
35. Landsmeer JMF: The anatomy of the dorsal aponeurosis of the human finger and its functional significance. *Anat Rec* 104:31–44, 1949.
36. Lewis AR, Ralphs JR, Kneafsey B, et al: Distribution of collagens and glycosaminoglycans in the joint capsule of the proximal interphalangeal joint of the human finger. *Anat Rec* 250:281–291, 1998.
37. Mansat M, Delprat J: Contractures of the proximal interphalangeal joint. *Hand Clin* 8:777–786, 1992.
38. Mansat MF: Volar aspect of the proximal interphalangeal joint. An anatomical study and pathological correlations. *Bull Hosp Jt Dis Orthop Inst* 44:309–317, 1984.
39. Merritt WH: Written on behalf of the stiff finger. *J Hand Ther* 11:74–79, 1998.
40. Milz S, Putz R, Ralphs JR, et al: Fibrocartilage in the extensor tendons of the human metacarpophalangeal joints. *Anat Rec* 256:139–145, 1999.
41. Prosser R: Splinting in the management of proximal interphalangeal joint flexion contracture. *J Hand Ther* 9:378–386, 1996.
42. Rhode CM, Jennings WD, Jr: Operative treatment of the stiff proximal interphalangeal joint. *Am Surg* 37:44–59, 1971.
43. Salafia A, Chauhan G: Joshi External Stabilising System (JESS) in proximal interphalangeal joint (PIP) contractures in leprosy. *Indian J Lepr* 69:331–339, 1997.
44. Shrewsbury MM, Johnson RK: A systemic study of the oblique retinacular ligament of the human finger. Its structure and function. *J Hand Surg [Am]* 2:194–199, 1977.
45. Smith RJ: Balance and kinetics of the fingers under normal and pathological conditions. *Clin Orthop Relat Res* 104:92–111, 1974.
46. Sprague BL: Proximal interphalangeal joint injuries and their initial treatment. *J Trauma* 15:380–385, 1975.
47. Sprague BL: Proximal interphalangeal joint contractures and their treatment. *J Trauma* 16:259–265, 1976.
48. Stack HG: Muscle function in the fingers. *J Bone Joint Surg Br* 44:899–909, 1962.
49. Tubiana R, Valentin P: The anatomy of the extensor apparatus of the fingers. *Surg Clin North Am* 44:897–906, 1964.
50. Watson HK, Light TR, Johnson TR: Checkrein resection for flexion contracture of the middle joint. *J Hand Surg [Am]* 4:67–71, 1979.
51. Watson HK, Weinzweig J: Stiff joints. In Green DP, Hotchkiss RN, Pederson WC, editors: *Green's operative hand surgery*, Philadelphia, 1999, Churchill Livingstone, pp 552–562.
52. Weeks PM, Wray RC, Jr, Kuxhaus M: The results of non-operative management of stiff joints in the hand. *Plast Reconstr Surg* 61:58–63, 1978.
53. Weeks PM, Young VL, Wray RC, Jr: Operative mobilization of stiff metacarpophalangeal joints: dorsal versus volar approach. *Ann Plast Surg* 5:178–185, 1980.
54. Wynn Parry CB: Management of the stiff joint. *Hand* 3:169–171, 1971.
55. Young VL, Wray RC, Jr, Weeks PM: The surgical management of stiff joints in the hand. *Plast Reconstr Surg* 62:835–841, 1978.

11

Treatment of the Osteoarthritic Hand and Thumb

Peter M. Murray

These videos may be found at *ExpertConsult.com:*

11.1 Volar approach for proximal interphalangeal joint implant arthroplasty

11.2 Physical examination for osteoarthritis of the thumb

Osteoarthritis of the hand and thumb is one of the most common symptomatic conditions of the hand, particularly for people over the age of 75 years. Osteoarthritis of the thumb, for example, occurs in one of three females and in one of eight males.[5] Ring and colleagues have studied the prevalence of thumb carpometacarpal (CMC) arthritis in a consecutive series of patients and found the condition present in 91% of patients over the age of 80 years, with complete joint destruction present three times more often in females.[118] Osteoarthritis affects the small joint of the hand more commonly than any other location in the body and is among the leading conditions for which surgery of the hand is performed.[101]

Although the cause of osteoarthritis of the hand still engenders much debate, mechanical stress is supported by many. In a study of over 2500 individuals in China, Hunter and associates found that chopstick use accounted for 19% of thumb arthritis cases in men and 36% in women.[46] Interestingly and perhaps counterintuitively, handedness has not been shown to influence the development of osteoarthritis of the hand.

The indications for surgical reconstruction of the rheumatoid hand have declined over the last three decades, but the need for reconstruction of the osteoarthritic hand has remained constant, with reconstruction of the thumb CMC among the most commonly performed hand surgery procedures. A number of successful procedures have been employed for reconstruction of the arthritic thumb CMC joint. Traditionally, reconstruction for arthritis of the small joints of the hand has primarily involved arthrodesis. In recent decades, joint arthroplasty procedures have been used with increasing frequency and success.

OSTEOARTHRITIS OF THE SMALL JOINTS OF THE HAND

Preoperative Evaluation

Physical Examination

Physical examination of the hand begins with a careful inspection of the dorsal and palmar surfaces. Several distinguishing characteristics may be obvious in the osteoarthritic hand. At the metacarpophalangeal (MCP) joints, swelling and volar subluxation may be present, with an associated flexion contracture or extension lag. Likewise, the proximal interphalangeal (PIP) joints may display flexion contractures; a more common distinguishing characteristic is the Bouchard node. Similarly, inspection of the osteoarthritic distal interphalangeal (DIP) joint is heralded by the presence of Heberden nodes, which signifies swelling and periarticular osteophyte formation. Additionally, mucous cyst formation may occur in relation to an osteoarthritic DIP joint.

Palpation of the acutely inflamed osteoarthritic MCP, PIP, or DIP joint will elicit tenderness as well as a fullness about the joint and loss of the typical bony contour of the joint. While gently holding the joint between the dominant thumb and index finger, the examiner can carefully apply a small amount of pressure to detect tenderness and synovitis. The range of motion of each joint may be limited due to a superimposed flexion contracture. The digital range of motion is often expressed in terms of total active range of motion, approximately 250 degrees, but individual ranges are also often measured: The MCP joint has 0 to 90 degrees, the PIP joint 0 to 100 degrees, and the DIP joint 0 to 60 degrees.

Tendon integrity may be compromised in the osteoarthritic hand. Pathologic conditions of the flexor tendon may uncommonly occur, generally because chronic tenosynovitis of the flexor tendon sheath has caused a zone 2 flexor digitorum superficialis (FDS) or flexor digitorum profundus (FDP) tendon rupture. More commonly, the extensor tendons are involved, with ulnar subluxation of these tendons occurring at the level of the MCP joints owing to failure of the sagittal bands. The result is ulnar drift and flexion positioning of the digits at the level of the MCP joints. In the acute phase of this condition, extensor tendon subluxation and ulnar drift/MCP flexion may be passively correctable and amenable to individual digital splinting. In the more chronic situation, the only treatment option is surgical release of the sagittal bands, with or without intrinsic releases and extensor tendon realignment.

Erosive or inflammatory osteoarthritis is an uncommon variant of osteoarthritis first described in 1966 by Peter and coworkers.[101,104] Like primary osteoarthritis, it is more common in women and the symptoms appear abruptly and interestingly involve the joints on the radial aspect of the hand while sparing the joints on the ulnar side (Figure 11.1). The DIP joint is the most commonly affected joint, but the PIP joint is most



FIGURE 11.1 51-year-old right hand–dominant female with a 1-year history of right index finger pain located at the MCP joint.

commonly the symptomatic joint. In some patients, erosive osteoarthritis will seroconvert to rheumatoid arthritis at a later time.

Diagnostic Imaging

Plain PA, lateral, and oblique radiographic views can adequately image the osteoarthritic hand. Further detail can be obtained by directly imaging the individual digit, with an attempt made to center the radiograph beam over the joint in question (i.e., the MCP, PIP, or DIP joint). Further definition of the MCP joints can be obtained with a Brewerton view radiograph. Originally described for the rheumatoid hand, this view is obtained by placing the supinated hand on the cassette and flexing the MCP joints 45 to 60 degrees. This view may also be helpful in imaging the hand with osteoarthritis or erosive osteoarthritis. Advanced imaging such as computed tomography (CT) scanning and magnetic resonance imaging (MRI) is seldom necessary for osteoarthritis of the small joints of the hand; however, it may be helpful in the early stages of the condition, showing synovial changes in the joint along with effusion.

PERTINENT ANATOMY AND BIOMECHANICS

The PIP joint is a simple uniaxial hinge joint, stabilized by the extensor mechanism, the collateral and accessory collateral ligaments, the volar plate and articular contact between the bicondylar proximal phalangeal head, and the articular surface of the middle phalanx. The center of rotation of the PIP joint is within the condylar area of the proximal phalanx.[136] Minamikawa and coworkers[85] have shown that in the normal state, the PIP joint may deviate 5 degrees in the radioulnar plane and supinate 9 degrees when subjected to lateral stress. This may increase to 20 degrees of deviation following complete sectioning of the collateral ligaments, with laxity greatly reduced when the PIP joint is in full extension and complete flexion. The primary stabilizer of the PIP joint is the lateral collateral ligament, and stability of the joint is maintained as long as half of this ligament remains intact.[85]

There are several unique characteristics of the MCP joints of the hand that can affect their surgical reconstruction and rehabilitation. In the sagittal plane, the metacarpal head has an elliptical shape that influences the arc of motion of the MCP joint such that a cam effect occurs during flexion and extension. The radial and ulnar collateral ligaments of the MCP joint originate along recesses of the metacarpal heads and course obliquely to insert along the base of the proximal phalanx. By virtue of the sagittal elliptical shape of the metacarpal head, the radial and ulnar collateral ligaments of the MCP joints are lax in extension and taut in full flexion. This integrity of the collateral ligament system has certain implications when it comes to joint immobilization, given the tendency for joint contracture of the MCP when immobilized in full extension.

Historical Review

Moberg and colleagues[87] and Carroll and Hill[19] reported on some early experiences with interphalangeal (IP) joint arthrodesis, citing a low pseudarthrosis rate. Since these early experiences, many authors have reported successful results using a variety of techniques (Table 11.1).

The first reported attempt at prosthetic replacement of the PIP joint was made by Burman using a Vitallium cap for arthroplasty in 1940.[12] In 1959, Brannon and Klein from Lackland Air Force Base, Texas, published the first series of digital total joint replacements. This was a hinged prosthesis initially indicated in PIP joint fractures and fracture-dislocations.[12] Flatt reported on a more rotationally stable device with two intermedullary prongs as opposed to the single-pronged Brannon prosthesis[36] (Figure 11.2). In 1979, Linscheid and Dobyns developed the surface replacement arthroplasty (SRA) for the PIP joint.[70] The development of these linked and unlinked metal arthroplasty designs were paralleled by the development of the Swanson silastic implant in the 1960s, which has been successful for management of osteoarthritis in both the MCP and PIP joints.[125] Carroll and Taber[20] reported on soft tissue interposition techniques for management of osteoarthritis of the IP joints of the hand.

Distal Interphalangeal Joint Arthrodesis

Indications and Contraindications

The main indication for DIP joint arthrodesis is primary osteoarthritis or posttraumatic arthritis. The patient should have pain referable to the DIP joint and static deformity or instability that interferes with activities of everyday living. The symptomatic digit may become less painful and the deformity less of an impairment with time, rendering the need for surgery less imperative. Therefore, it is advisable to treat the patient nonoperatively with analgesics, hand therapy modalities, a removable finger-based splint, and a period of prolonged observation prior to deciding to proceed with surgery. DIP joint arthrodesis may

TABLE 11.1 Studies of Interphalangeal Arthrodesis Fixation and Outcomes

Study	Fixation Technique	Time to Union (weeks)	Failure Rate (%)
McGlynn et al[79]	Cup and cone, Kirschner wire	~8	0
Lewis et al[66]	Tension and mortise, Kirschner wire	~8	2
Khuri[57]	Tension band wire	7	0
Hogh and Jensen[45]	Kirschner wire/ cerclage	8	7-16
Granowitz and Vainio[42]	Crossed Kirschner wire	—	7
Carroll and Hill[19]	Cup and cone, Kirschner wire	6-8	10 (all cases)
Lister[72]	Intraosseous wire	10	13
Burton et al[17]	Kirschner wire	8	0
Buchler and Aikin[16]	Plate	—	8
Ayres et al[6]	Herbert screw	—	2
Moberg and Henrickson[87]	Bone peg	~6	6
Allende and Engelem[4]	Tension band wire	—	0
Wright and McMurtry[149]	Plate	—	0
Potenza[105]	Bone peg and Kirschner wire	7	—
Ijsselstein et al[47]	Kirschner wire	≈6	8
Ijsselstein et al[47]	Tension band wire	—	3
Stern and Fulton[121]	Kirschner wire	—	12
Stern and Fulton[121]	Interosseous wire	—	12
Stern and Fulton[121]	Herbert screw	—	11
Katzman et al[56]	Herbert screw	8	0
Stern et al[122]	Tension band wire	—	3
Braun and Rhoades[13]	External fixator	≈8	0
Seitz et al[117]	External fixator	6	9
Teoh et al[131]	Compression screw	8.2	4
Watson and Shaffer[145]	Kirschner wire	6	0
Leibovic and Strickland[64]	Kirschner wire	10	21
Leibovic and Strickland[64]	Tension band wire	11	5
Leibovic and Strickland[64]	Herbert screw	9	0
Leibovic and Strickland[64]	Plate	12	>50

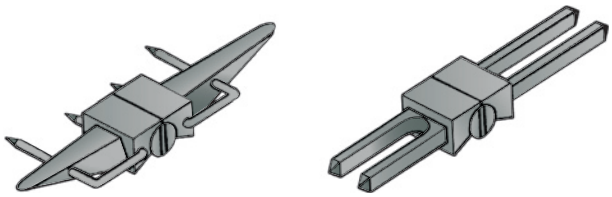

FIGURE 11.2 Drawing of the dual-pronged Flatt proximal interphalangeal (PIP) joint arthroplasty on the right and the single-prong Brannon PIP joint arthroplasty on the left.

be done following joint degeneration because of remote septic arthritis.

Contraindications for DIP arthrodesis include active infection of the finger, septic arthritis of the DIP joint, or an open wound in the proximity of the joint. Other potential contraindications include unhealthy atrophic skin over the joint, as may occur following long-term steroid usage. Patients with compromised blood flow or ischemic fingers should not undergo DIP joint arthrodesis.

Preoperative Planning

Critical to the preoperative assessment of the patient and planning for care are dedicated PA and lateral radiographs of the finger. It is important to identify the appropriate implant for arthrodesis based on the size of the distal phalanx. It is also important to identify any periarticular degenerative cyst formation or bone loss that may necessitate bone graft augmentation.

Technique

DIP joint arthrodesis can be performed under regional anesthesia or even digital block anesthesia using finger tourniquet control. The technique involves a dorsal exposure of the joint, followed by removal of all remaining articular cartilage. The natural contour of the head of the middle phalanx may be retained if it matches well with the resulting contour of the base of the distal phalanx following removal of articular cartilage. Typically, a reasonable fit is obtainable, but bone defect causing shortening may be encountered, which may require either allograft or autograft supplementation. Alternatively, the head of the middle phalanx and the base of the distal phalanx may be contoured into a cup and cone match.[19] Full extension to slight flexion is desirable for positioning of the joint and is limited due to fixation considerations. Fixation techniques for DIP joint arthrodesis include percutaneous pin fixation or low-profile, variable-pitch compression screw fixation.

Percutaneous pin fixation configurations include crossed pinning of the arthrodesis site or percutaneous longitudinal pinning with two parallel Kirschner wires. Longitudinal pinning is best done by advancing two 0.045-inch wires antegrade through the distal phalanx articular surface and exiting the tuft of the distal phalanx. The arthrodesis site is reduced. The wires are recovered beyond the skin of the fingertip and sequentially advanced in a retrograde manner such that the arthrodesis site is stabilized (Figure 11.3, *A* to *F*).

If a headless variable-pitch screw is chosen for fixation, attention must be paid to the dimension of the distal phalanx because the diameter of the bone in smaller individuals, particularly of the small finger, may not accommodate the caliber of the screw. This technique is detailed below.

❖ AUTHOR'S PREFERRED METHOD OF TREATMENT

DIP joint arthrodesis is accomplished through the extensile "H" incision (Figure 11.4). Full- thickness skin flaps are elevated and the terminal tendon is exposed. The terminal tendon is incised transversely, exposing the articular surfaces of the joint. Hyperflexion of the joint facilitates exposure of the articular surfaces. I avoid excessive shortening of the finger by using a 2-mm high speed bur to remove the remaining articular cartilage, preferably following the natural contours of the head of the middle

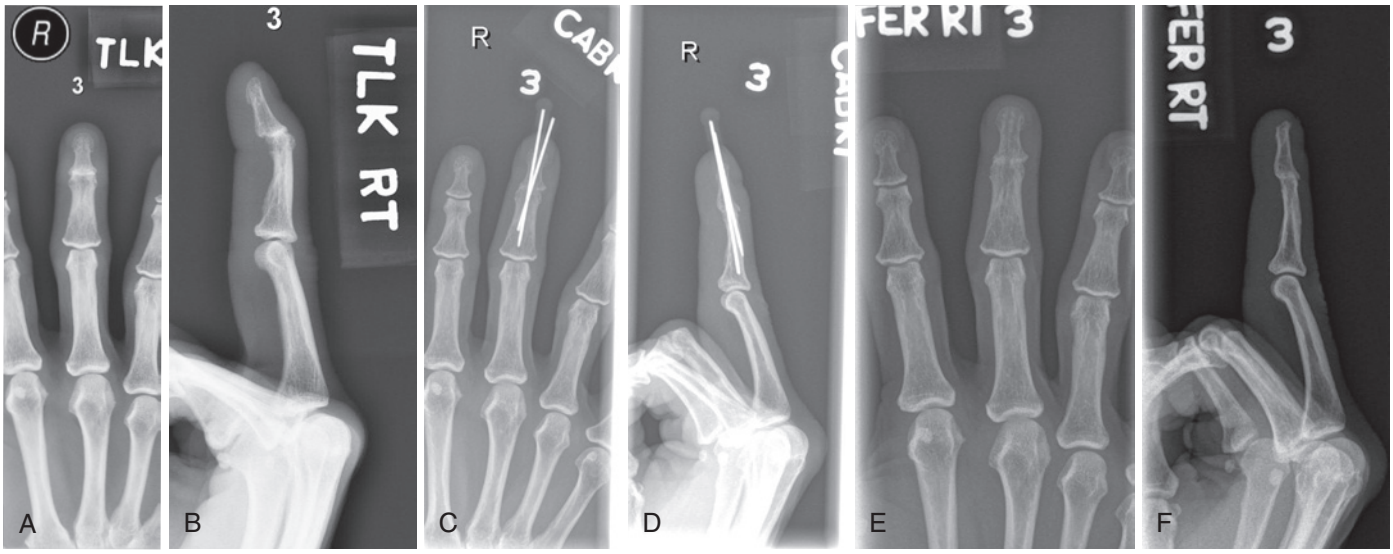

FIGURE 11.3 **A** and **B,** Preoperative radiographs of a 55-year-old female with distal interphalangeal (DIP) joint destruction following septic arthritis caused by an infected mucous cyst. **C** and **D,** Postoperative radiographs following DIP joint arthrodesis with K-wire stabilization. **E** and **F,** Final follow-up radiographs of healed DIP joint arthrodesis.

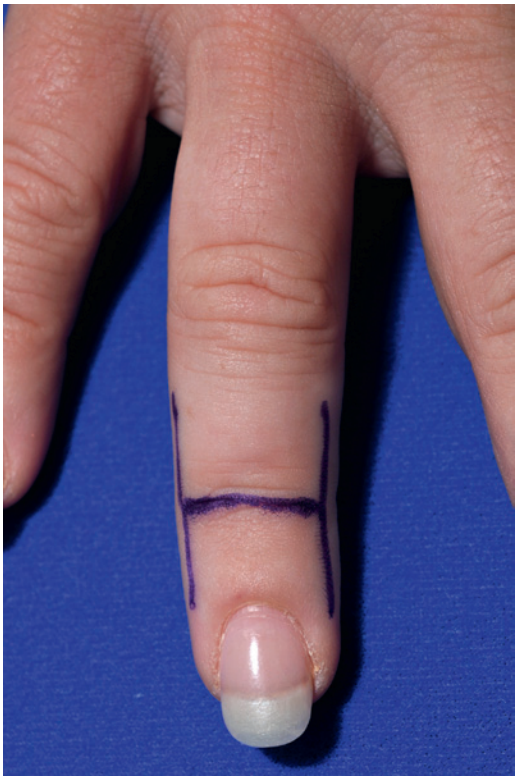

FIGURE 11.4 "H" incision for arthrodesis of the distal interphalangeal joint of the finger.

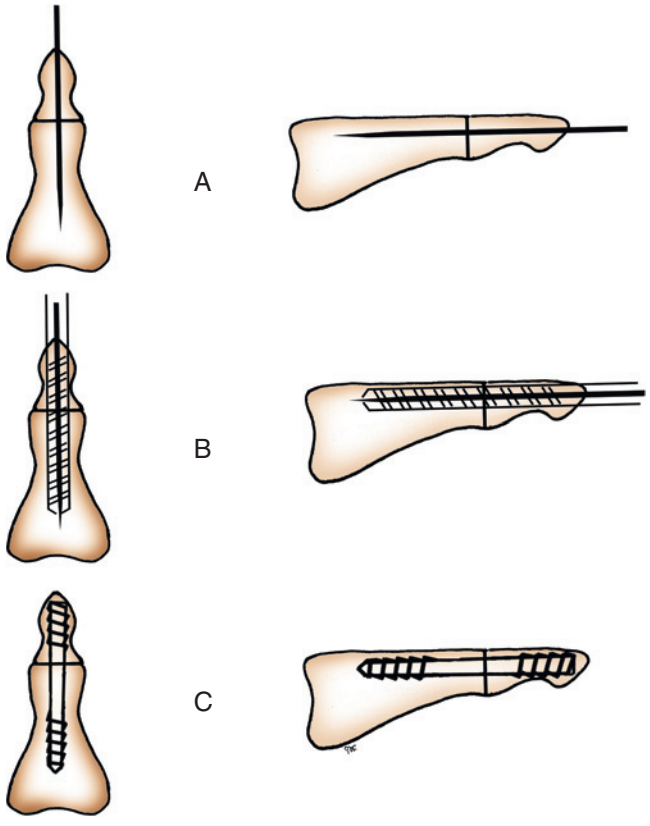

FIGURE 11.5 Arthrodesis of the distal interphalangeal joint with the use of a cannulated, low-profile headless compression screw. **A,** Guidewire placement. **B,** Placement of cannulated drill. **C,** Headless, variable-pitch compression screw placement. (© Mayo Clinic, Rochester, MN. Modified with permission.)

phalanx and the articular base of the distal phalanx. Though desirable, a tight, flush contact of surfaces is often not achieved; the arthrodesis site can be supplemented with a small portion of autograft or allograft material of choice. The position of full extension is generally preferred.

For fixation, I prefer a variable-pitch, headless compression screw no larger than 2.4 mm in diameter. This affords immediate, stable fixation and is available from a variety of different manufacturers. Initially, a guidewire is driven retrograde to the level of the subchondral bone of the base of middle phalanx (Figure 11.5). A cannulated drill is advanced over the guidewire, and a screw of appropriate length is advanced across the arthrodesis. Care is taken to avoid inside-out contact with the

nail bed. It is also important that the distal aspect of the compression screw be completely buried in the tuft of the distal phalanx so there is no screw prominence.

If inside-out contact with the nail bed occurs during placement of the compression screw, screw fixation is abandoned in favor of fixation with a 0.062-inch percutaneous pin placed longitudinally across the arthrodesis site in a retrograde fashion. To the extent possible, the drill track is packed with autograft or allograft bone substitute material. Placement of percutaneous pins or the cannulated drill bit and variable-pitch screw is done using biplanar fluoroscopy.

CRITICAL POINTS *Distal Interphalangeal Joint Arthrodesis*

Indications
- Osteoarthritis
- Posttraumatic arthritis
- Postseptic arthritis

Technique
- "H" incision
- Articular cartilage removed and joint surfaces matched (alternative is cup and cone technique)
- Fixation with headless screw or K-wires in extension or slight flexion
- Headless screws can cut out into nail bed if distal phalanx is of a small diameter.

Rehabilitation
- Immediate motion of the finger is permitted following headless screw fixation.

Outcomes
- High union rates can be anticipated with either head compression screw devices or K-wire fixation.
- Preoperative planning is important to avoid nail bed complications and prominent hardware.

Postoperative Management and Expectations

At 5 days following operation, the dressings are removed and the wound is inspected. Following DIP arthrodesis with a variable pitch, headless compression screw, a removable finger-based splint is fabricated by a hand therapist. The splint may be removed and immediate motion initiated. This should include active and passive range-of-motion exercises of the PIP, MCP, and wrist joints. Radiographs are obtained at 6- to 8-week intervals, and the splint is maintained until radiographic healing is evident.

If DIP arthrodesis is performed with percutaneous pin fixation, the wires are cut at the surface of the pulp of the finger and left in place for 8 weeks. The patient is treated with a nonremovable finger-based splint for 4 weeks, allowing active and passive MCP and wrist motion only. This is followed by fabrication of a removable finger-based splint allowing PIP motion at 4 weeks following operation. Radiographs are followed until solid fusion is achieved, at which time unrestricted activity is resumed.

Expected Outcomes. DIP joint arthrodesis is considered a reliable procedure. Accordingly, high rates of union and patient satisfaction can be expected.[144] Burton and coworkers reported a 100% union rate using K-wire fixation,[17] and in 1984 Faithfull and Herbert originally reported on successful union using a headless compression screw.[33] More recently, Cox and colleagues and Matsumoto and associates have reported 94% and 97% union rates, respectively, for different compression screw devices at 12 months and 35 months of follow-up.[27,78] Alternatively, successful union has been reported using obliquely placed headless compression screws to avoid nail bed complications (96%)[48] as well as using fixation with a small plate placed laterally (100%).[75]

Complications. Mismatch between the caliber of the variable-pitch, headless compression screw and the diameter of the distal phalanx can result in inside-out damage of the nail bed, particularly in small individuals and particularly involving the small finger.[121] Furthermore, variable rates of nonunion, infection, and hardware prominence at the fingertip have been reported.[48,78] Stern and Fulton, for instance, in a study published in 1992, reported a nonunion rate of 12% and a complication rate of 21%.[121] Less common complications include malunion, cold intolerance, reflex sympathetic dystrophy, paresthesias, PIP joint stiffness, and skin necrosis.[121]

Proximal Interphalangeal Joint Arthrodesis

Indications and Contraindications

The principle indication for PIP joint arthrodesis is painful primary osteoarthritis or posttraumatic osteoarthritis that is refractory to nonoperative measures. Patients will often complain of diminishing motion of the joint in conjunction with aching pain with use. Other indications are unreconstructable fractures, fracture-dislocations, or chronic instability of the joint.

Contraindications for the procedure are recent infection or a poor soft tissue envelope. A relative indication for PIP joint arthrodesis is a history of septic arthritis. Patients with residual articular destruction following chronic septic arthritis may under certain circumstances be considered for arthrodesis, assuming that the level of pain and functional loss warrant the intervention. Bone loss is a relative indication for arthrodesis in that bone can often be reconstructed in such a way as to achieve arthrodesis when the appropriate fixation is used.

Preoperative Planning

Critical to preoperative assessment and planning are dedicated, high-quality PA and lateral radiographs of the finger. It is important to identify the appropriate implant for arthrodesis; surgeon preference is the deciding factor in most circumstances. In cases of trauma where bone loss has occurred, fixation must be planned in order to best accommodate the bone deficiency. It is also important to identify any periarticular degenerative cyst formation, which may necessitate bone graft augmentation and fixation modification.

Technique

Arthrodesis of the PIP joint is performed under regional anesthesia and upper arm or forearm tourniquet control. A dorsal longitudinal incision can be used in most patients. In patients with atrophic or compromised skin, a longitudinal incision can create insufficient skin margins for closure. A carefully designed serpentine incision over the dorsal aspect of the affected digit

creates a flap well positioned to cover the hardware and arthrodesis site. The articular surfaces are exposed, and an osteotomy of the head of the proximal phalanx and the base of the middle phalanx is performed so that two flush bony surfaces are achieved. This requires the removal of the entire articular surface of the head of the proximal phalanx and the entire articular base of the middle phalanx. Positioning of the PIP joint arthrodesis is critical. The index finger PIP arthrodesis is positioned in 30 degrees of flexion, and the arthrodesis position of each successive finger should be in approximately 10 degrees more of flexion (Figure 11.6). Realistically, accuracy of arthrodesis positioning cannot often be scrutinized to the 10-degree level; an arthrodesis position of 30 to 40 degrees is preferred for the index and long fingers and 50 to 60 degrees for the ring and small fingers in most cases.

Several fixation techniques are available for stabilization of the arthrodesis. Options include K-wire fixation with or without tension band wiring; variable-pitch, headless compression screw fixation; or small joint plate fixation. Tension band wire fixation will be detailed in the following section. Variable-pitch, headless compression screw fixation requires adequate bone stock and accurate screw placement. A 2.4-mm cannulated screw is preferred. Plate fixation uses a 2-inch low-profile plate, bent to accommodate the bone contours and desired angle of the arthrodesed digit. In general, it is desirable to achieve six cortices of fixation on both sides of the arthrodesis. Immediate mobilization of the finger is possible following tension band wiring, screw fixation, and plate fixation. The compression screw has a low profile and usually does not cause irritation, as some hardware might. Plate fixation of an arthrodesis is generally reserved for situations in which trauma-related bone loss has occurred and a corticocancellous bone graft is needed to fill the defect.

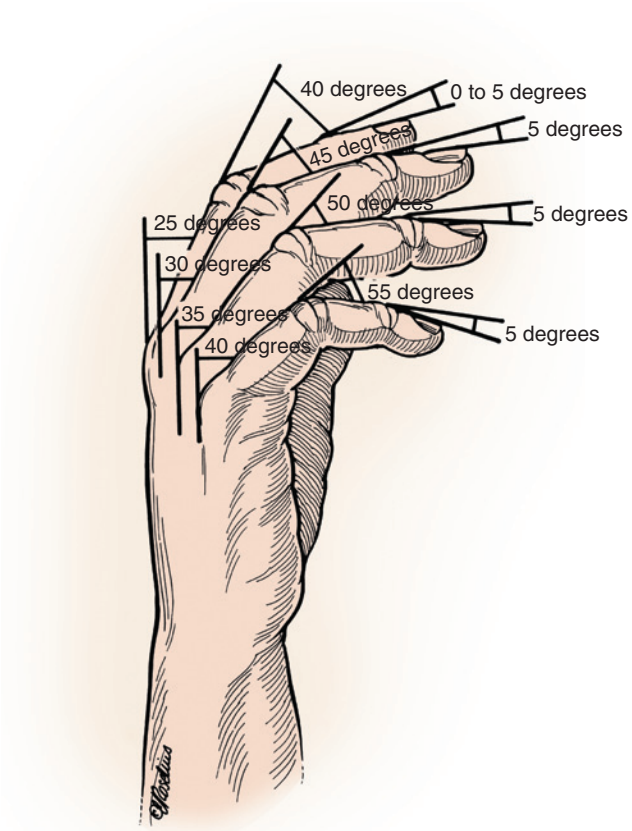

FIGURE 11.6 Drawing displaying the progressive degree of proximal interphalangeal joint arthrodesis flexion.

❖ AUTHOR'S PREFERRED METHOD OF TREATMENT

The extensor mechanism is incised longitudinally and the articular surfaces exposed subperiosteally. The collateral ligaments are released, providing further PIP joint flexion and enabling correction of any joint contracture. Using a handheld oscillating saw, the articular surfaces of the PIP joint are removed just proximal to the condylar flares of the proximal phalanx and just distal to the articular surface of the middle phalanx. The angle of the arthrodesis is imparted on the bony cut of the proximal phalanx. Beginning with the index finger at 30 degrees, the long, ring, and small fingers are positioned at 40, 50, and 60 degrees, respectively. The oscillating saw is used to create the thin middle phalanx cut, just proximal to the articular base. It is important to make these cuts perpendicular to the longitudinal axis of the digit; otherwise, an angulated digit will result.

Once the bony surfaces are prepared, irrigated, and dried, the arthrodesis is stabilized. The author's preferred method is a K-wire tension band technique (Figure 11.7, *A* to *D*). Using fluoroscopic guidance, two parallel 0.035-inch K-wires are drilled in a retrograde fashion perpendicular to the osteotomy cut at the distal aspect of the proximal phalanx. This is necessary in order that the K-wires, when driven antegrade, migrate down the center of the middle phalanx. It is important that the tips of the K-wires stop about 5 mm shy of the distal articular aspect of the middle phalanx because they will be advanced further later to capture the figure-of-eight tension band. Once the articular surfaces are stabilized, another 0.035-inch K-wire is drilled transverse to the axis of the middle phalanx through the dorsal cortex at the junction of the proximal and middle thirds of the shaft. Through this transverse hole, the 22-gauge wire is passed and then passed in a figure-of-eight fashion beneath the K-wires, which are still exposed beyond the dorsal cortex of the proximal phalanx. The 22-gauge wire is twisted several times on the radial or ulnar aspect of the digit prior to cutting and burying the twist. Although sometimes difficult, the twist of the wire can be turned down around the side of the digit to prevent prominence of the material beneath the skin. Next, the exposed K-wires are cut approximately 1 cm superficial to the dorsal cortex of the proximal phalanx and are bent 90 degrees in order to capture and secure the figure-of-eight wires. The figure-of-eight wire is gently driven down over the middle phalanx with a small bone tamp and mallet with the aid of fluoroscopic imaging. Bone grafting is usually not necessary (see Figure 11.7, *A* to *D*). The extensor mechanism is closed over the hardware, and the skin reapproximated. The wounds are sterilely dressed and placed in a forearm-based resting hand splint.

Postoperative Management and Expectations

The wounds are inspected at postoperative day 5, and a rigid finger-based splint supporting the affected digits is created by a hand therapist. The patient is allowed to remove the hand from the fabricated splint and begin gentle active range of motion. At 4 weeks following operation, most activities of daily living are resumed. Radiographs are assessed at 6 weeks and 12 weeks for healing of the arthrodesis. Once healing has been achieved



FIGURE 11.7 **A** and **B,** An 80-year-old male with gradual onset of index finger pain and limited mobility. **C** and **D,** Index finger with fresh interphalangeal joint arthrodesis.

CRITICAL POINTS *Proximal Interphalangeal Joint Arthrodesis*

Indications
- Osteoarthritis
- Inflammatory arthritis
- Posttraumatic arthritis
- Postseptic arthritis (relative)

Technique
- Dorsal midline incision
- Articular surfaces prepared so the angle of the arthrodesis is achieved on the proximal phalanx
- Angle of the arthrodesis for the index, long, ring, and small fingers is 30, 40, 50, and 60 degrees, respectively.
- Variety of fixation techniques available

Rehabilitation
- Immediate motion possible with most fixation techniques

Outcome
- High union rates can be expected using either K-wires and tension band wiring or headless compression screw fixation.
- Hardware removal is not unusual following fixation with K-wires and tension band wiring.

radiographically, the patient is released to full activity. The rationale behind tension band wiring of the PIP joint arthrodesis is that active flexion of the digit enhances compression of the arthrodesis surface.[62] Caution should be exercised in the patient with osteopenia or osteoporosis.

Expected Outcomes. High union rates have been reported using a number of fixation methods for PIP joint arthrodesis, including headless compression screws, K-wire fixation, and tension band wiring/K-wire techniques.[64,122] Carroll reported on 635 IP arthrodeses and found only a 5% nonunion rate.[19] Stern has reported a 97% fusion rate among 290 consecutive MCP and PIP joint arthrodeses using a tension band wiring technique.[122] A 98% union rate with the use of a headless compression screw has been reported by Ayres and colleagues.[6]

Throughout the arc of PIP joint flexion and extension, 5 degrees of adduction and 9 degrees of supination are anticipated.[85] Loss of this degree of freedom, as would be expected with PIP joint arthrodesis, has been shown to alter precision pinch in the index finger PIP joint.[31]

Complications. Nonunion, malunion, hardware prominence, fracture, infection, skin necrosis, and complex regional syndrome have been described as complications following arthrodesis of the PIP joint.[6,64,122] Ayres and associates reported fracture of the proximal phalanx following headless compression screw insertion.[6] Leibovic and Strickland reported on 3 of 224 PIP arthrodesis patients who ultimately required amputation, 1 for osteomyelitis and the other 2 for complications following the development of RSD.[64] Hardware removal can be anticipated in up to 9% of patients following PIP arthrodesis with K-wire and tension band wiring.[122]

Metacarpophalangeal Joint Arthrodesis

Indications and Contraindications

MCP joint arthrodesis is not typically recommended for osteoarthritis of the index, long, ring, and small fingers. It is, however, performed on the thumb MCP joint in cases of primary osteoarthritis or posttraumatic arthritis. Like the other arthrodeses, the procedure should not be performed in the setting of active or recent infection or in patients with a poor skin envelope. Reconstruction of chronic arthritis following a history of remote septic arthritis is considered a relative indication.

Preoperative Planning

Critical to the preoperative assessment and planning are dedicated PA and lateral radiographs of the thumb. An appropriate fixation technique is chosen based on surgeon preference. It is important to identify any periarticular degenerative cyst formation or bone loss that may necessitate bone graft augmentation of the arthrodesis or dictate the fixation technique.

Technique

Arthrodesis of the thumb MCP joint is accomplished through a dorsal longitudinal incision. The extensor mechanism is incised in line with the skin incision and the arthritic joint exposed. As in the PIP joint, the proximal phalanx and the metacarpal head are prepared with a handheld oscillating saw. The preferred position for arthrodesis is 20 degrees of flexion. As previously described for preparation of the PIP joint arthrodesis surfaces, a transverse osteotomy of the base of the middle phalanx is accomplished just proximal to the subchondral bone of the proximal articular surface of the thumb proximal phalanx. Next, the flexion angle of the arthrodesis is accomplished by orienting the oscillating saw 20 degrees volar, just proximal to the metacarpal head. The two bony surfaces are approximated and secured by any of several fixation techniques, including the tension band technique described for arthrodesis of the PIP joint. Alternatively, two crossing percutaneous K-wires placed from distal to proximal can be used. The K-wires can be removed in 8 weeks but are preferably maintained, if possible, until bony union is achieved. Fixation can also be achieved with a 2.0 dorsal plate, obtaining six cortices proximal and six cortices distal to the arthrodesis site. Variable-pitch, cannulated headless screw fixation with one or two screws is another option. Alternatively, use of a standard cortical screw and washer has been described. The extensor mechanism is closed and the skin approximated. A sterile dressing is applied, followed by a thumb spica splint.

CRITICAL POINTS *Metacarpophalangeal Joint Arthrodesis*

Indications
- Osteoarthritis
- Inflammatory arthritis
- Posttraumatic arthritis
- Postseptic arthritis (relative)

Technique
- Dorsal midline incision
- Articular surfaces prepared so that the angle of arthrodesis is achieved on the proximal phalanx
- Desired angle of arthrodesis is 20 degrees.
- Fixation techniques available include tension band wiring, screw fixation, and plate fixation.
- Bone graft may be required in some posttraumatic situations.

Rehabilitation
- Immediate motion is possible with most fixation techniques.

Outcome
- A high union rate can be expected using either the K-wire and tension band technique or the headless compression screw technique.
- The need for hardware removal following the K-wire fixation and tension band technique is relatively common.

Postoperative Management and Expectations

At 5 days following operation, the dressing and splint are removed, a removable forearm-based thumb spica splint is fabricated, and gentle active motion is initiated. For reasons stated previously, active motion, including pinch, is encouraged for patients with stabilization using the tension band wire or headless compression screw technique. Protective splinting is maintained, however, until radiographic healing is seen, at which time activity without restriction may resume.

Expected Outcomes. High union rates can be expected with arthrodesis of the MCP joint of the thumb, irrespective of the form of fixation. Breyer and colleagues compared healing rates of thumb MCP arthrodesis using either a tension band wiring technique or a headless compression screw technique. The

union rate among 28 patients with the tension band technique was 92.8%, whereas the union rate among the 28 patients treated with a headless compression screw was 85.7%. Overall, there was no significant difference in healing rates.[15]

Complications. Much like arthrodesis of the PIP joint, complications following arthrodesis of the thumb MCP joint can include nonunion, malunion, hardware prominence, infection, and fracture. Breyer and associates found no significant differences in the incidence of nonunion, delayed union, infection, or intraoperative fracture when comparing arthrodesis using tension band wiring or headless compression screw fixation. However, 25% of patients in the tension band wiring group (7/28) required hardware removal, compared with no patients in the headless compression screw group. This reached statistical significance.[15]

Proximal Interphalangeal Joint Arthroplasty

Indications and Contraindications

Indications for use of the PIP surface replacement arthroplasty (SRA) include primary degenerative osteoarthritis or posttraumatic arthritis in elderly patients. Ideally, this would include less active patients who desire to maintain PIP joint motion in deference to arthrodesis. Relative indications include severe fractures or fracture-dislocations of the PIP joint in older, less active patients. Contraindications for use of PIP arthroplasty include current or chronic infection, loss of extensor mechanism integrity such that the patient has a boutonnière deformity, with either PIP joint extension lag or fixed flexion contracture, or complete absence of extensor function. Additional contraindications include poor or absent flexor tendon function, a poor soft tissue envelope including atrophic skin on the dorsum of the digit, absent PIP collateral ligament function, and incompetence of the PIP joint volar plate rendering the PIP joint unstable or creating a swan neck deformity.

Preoperative Planning

The preoperative evaluation should include a thorough assessment of patient expectations and a clear articulation of the activity restriction imposed by this procedure. Documentation should include PIP range of motion, angular deformity, joint stability, and soft tissue integrity. Dedicated PA and lateral radiographs of the digit centered over the PIP joint are necessary for templating purposes. Seldom do radiographs of the entire hand suffice. Irrespective of the device chosen for implantation, template devices are available from the device manufacturer.

Success has been reported with a variety of PIP joint implant arthroplasties, including the silicone, pyrocarbon, and surface replacement implants. Choice of the implant is largely left to surgeon preference and experience; evidence suggests that a semiconstrained implant is advantageous in the index PIP joint for resisting enhanced forces encountered during thumb-index pinch maneuvers.[68,71,85,90]

Technique

PIP implant arthroplasty can be performed using one of three surgical approaches, each having advantages and disadvantages: dorsal, lateral and anterior.[21,68,116] With the dorsal approach, care is taken to preserve the extensor tendon insertion at the base of the middle phalanx. Complications with this approach can include extensor tendon dysfunction and the development of a boutonnière deformity. The volar plate must be repaired following the volar or anterior approach. Failure to do so may result in PIP joint hyperextension instability and the development of a swan neck deformity (Video 11.1). With the lateral approach, the ulnar collateral ligament must be repaired in order to prevent PIP joint instability.

With the pyrocarbon and surface replacement arthroplasties, the proximal phalanx is prepared in such a way that the collateral ligaments of the PIP joint are preserved, although it has been shown that up to 50% of the radial or ulnar collateral ligament can be sacrificed without compromising stability of the joint.[85] With the silicone implant, a more generous phalangeal osteotomy is required, which sacrifices the radial and lateral collateral ligament origins. Merle and coworkers have reported on a lateral approach technique for silicone implant placement that advances, embrocates, and repairs the ulnar and radial collateral ligaments following initial sectioning for exposure.[82] Their study discusses 51 arthroplasties in 43 patients with a mean follow-up of 36 months, finding an average axial deviation of 17 degrees. The middle phalanx is prepared in order to accept the stem of either the middle phalanx component or the stem of the silicone implant. The canals are prepared with device-specific broaches and, not uncommonly, are further modified with a high-speed bur. Implantation of undersized components is a common mistake in implant arthroplasty of the digits and can result in limited motion because of subsidence and subsequent bony impedance to flexion.[89,90]

Most authors currently recommend fixation of the pyrocarbon implant using a press-fit technique.[24,80,96,126,128] Tagil and Geijer and colleagues reported subsidence of up to 8% of the prosthetic length of the proximal phalanx component and up to 7% of the prosthetic length of the middle phalanx component.[128] Sweets and Stern reported a 48% radiographic loosening rate in their series of 31 patients, followed up at a minimum of 2 years.[126] Silicone is implanted as a spacer and, therefore, is stabilized with neither a cement nor a press-fit technique.

Debate continues concerning the use of cement for implantation of the SRA of the PIP joint. Originally, the PIP surface replacement was designed for implantation using cement,[70,71] but more recently there have been reports about a cementless version of the prosthesis and a press-fit technique.[74,90] Jennings and Livingstone reported that the majority of loosening complications in their series of 43 arthroplasties in 25 patients with an average follow-up of 37 months were the result of inadequate cement technique.[49] At an average follow-up of 4 years, Johnstone and associates compared the results of 18 patients with 27 cemented PIP SRAs, with 18 patients having 21 joint replacements using the uncemented PIP surface replacement version of the prosthesis with an average length of follow-up of 4 years. They reported a very strong association between cementless implantation and prosthetic subsidence. However, there was no correlation with the use of cement and postoperative pain, range of motion, or joint failure.[51] In a study of 67 PIP SRAs in 47 patients with a follow-up averaging 8.8 years, Murray and colleagues[90] showed no correlation with cement use and overall implant survival. Implant subsidence and radiolucencies about the prosthesis bore no clinical association with the patients' final results in their series. A dorsal incision is

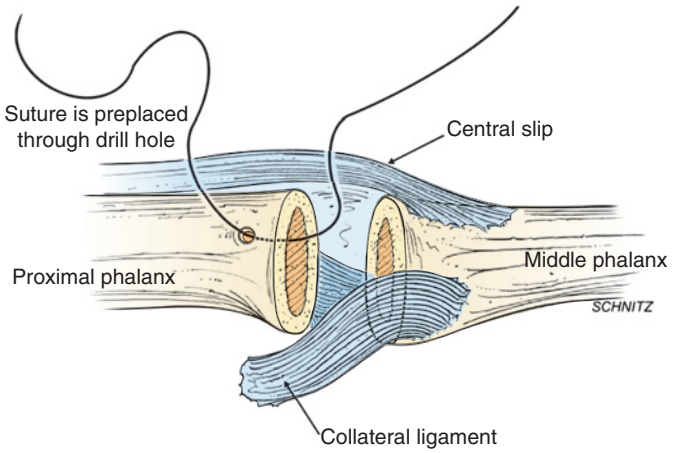

FIGURE 11.8 Dorsal approach for silastic implant arthroplasty of the proximal interphalangeal joint demonstrating the interval between the extensor mechanism and the ulnar collateral ligament. The ulnar collateral ligament is released and repaired in order to achieve the proper proximal phalanx cut. (From Bickel KD: The dorsal approach to silicone implant arthroplasty of the proximal interphalangeal joint. *J Hand Surg [Am]* 32(6):909–913, 2007.)

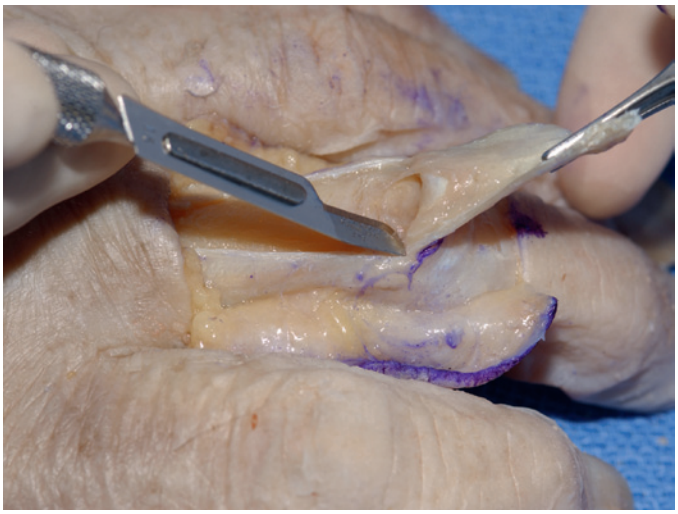

FIGURE 11.9 Chamay central-slip distally based flap dorsal approach to the proximal interphalangeal joint. (From Chamay A: A distally based dorsal and triangular tendinous flap for direct access to the proximal interphalangeal joint. *Ann Chir Main* 7(2):179–183, 1988.)

generally preferred for silicone spacer implantation of the PIP joint.[9] However, success has been reported with the use of the anterior approach as well as with the lateral approach as described by Segalman.[68,116] Merle and associates reported on 51 NeuFlex silicone spacers in 43 patients with a mean follow-up of 36 months. They found improvement in pain and function scores.[82] The primary technical distinction with silicone PIP arthroplasty is the more extensive proximal phalanx and middle phalanx bone resections required (Figure 11.8). The proximal phalanx cut is made just proximal to the articular head of the phalanx after the radial and collateral ligaments are released from the proximal phalanx (with either the anterior or dorsal approach) or the ulnar collateral ligament alone when using the lateral approach.

Whether approaching the joint laterally, where the ulnar collateral ligament only is taken down; anteriorly or dorsally, where both ligaments are taken down; or between the extensor mechanism and the ulnar collateral ligament, repair of the collateral ligaments is imperative. This is accomplished with the use of a 3-0 braided suture. Under most circumstances a cutting needle housing the suture can be used to penetrate the cortices of the proximal or middle phalanges. Alternatively, a free needle, a 2-mm drill bit, or a 0.045-inch K-wire can be used. The suture is first passed through the proximal phalanx and a Bunnell stitch is placed in the collateral ligament. Once the needle is passed back out of the ligament, it is again advanced through the proximal phalanx until it is taut and tied over the cortical bridge between the two holes in the cortex. If a drill or free needle is used to penetrate the cortex of the proximal phalanx, the needle is removed from the suture after it is passed through the ligament and the free ends are passed through the holes in the proximal phalangeal cortex and tied as before.

❖ AUTHOR'S PREFERRED METHOD OF TREATMENT

The bulk of my clinical experience with PIP joint arthroplasty has been with PIP SRA (Small Bone Innovations, New York, NY). I prefer a dorsal, midline approach to the PIP. The extensor mechanism is incised and reflected according the technique described by Chamay[21] (Figure 11.9).

Remnants of the dorsal PIP joint capsule are identified and incised longitudinally.

As the joint is hyperflexed to expose the articular surfaces, it is imperative to protect the radial and ulnar collateral ligaments using small, narrow Hohmann retractors. Placement of the retractors will bring the articular surfaces of the proximal and middle phalanges into view, facilitating the bone cuts (Figure 11.10, *A* and *B*).

The proximal phalangeal head is prepared by accomplishing a perpendicular osteotomy just proximal to the most proximal extent of the articular surface. This cut is also perpendicular to the long axis of the proximal phalanx. Again, it is important to protect the proximal origin of the radial and ulnar collateral ligaments while using the handheld oscillating saw. At times, it may be necessary to release a small distal portion of the proximal phalangeal origin of the collateral ligaments to facilitate the proximal phalangeal osteotomy and subsequent prosthesis insertion. One biomechanical study has shown that up to 50% of the radial or ulnar collateral ligament may be undermined or released with little biomechanical consequence.[85] In some patients with heterotopic bone adjacent to the collateral ligaments, proximal release of the collateral ligament with repair back to the proximal phalanx may be necessary to facilitate prosthetic implantation. It has been, however, the author's experience that any release of the radial or ulnar collateral ligaments should be done cautiously and subsequently repaired.

A "chamfer" back cut of the proximal phalanx is necessary so the proximal phalanx can adequately accept the proximal phalangeal component (Figure 11.11). This important cut can be done with an oscillating saw, but the use of the saw may place the flexor tendons, volar plate, digital nerves, and arteries at risk. Alternatively, while protecting the volar plate with a small retractor, a high-speed 2-mm bur or a small rongeur can be used to make this cut.

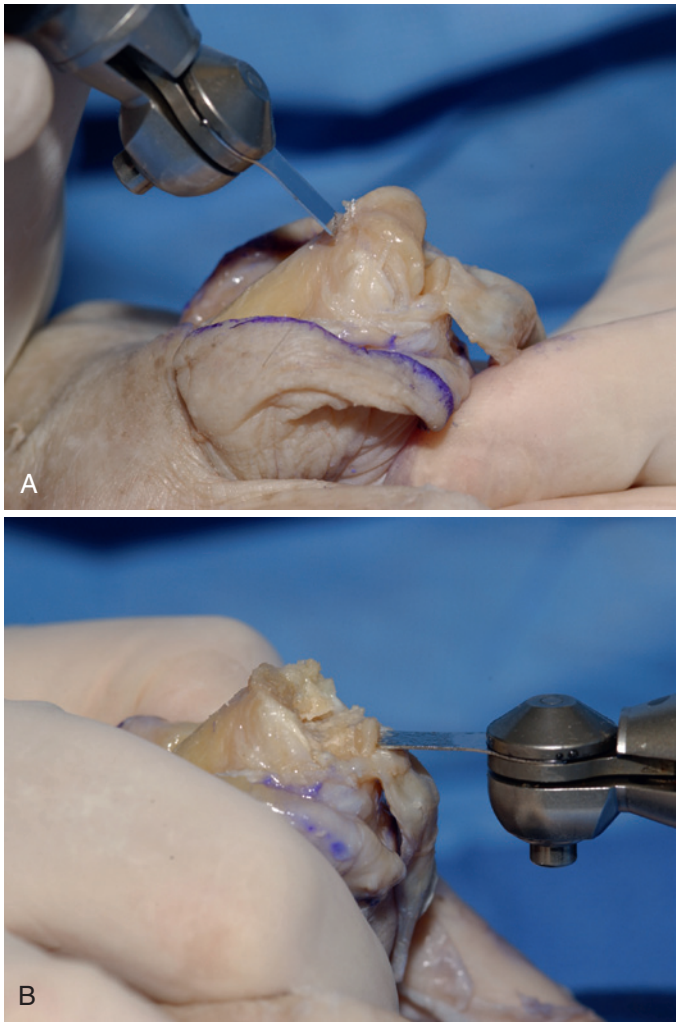

FIGURE 11.10 **A** and **B,** Proximal phalanx cut and middle phalanx articular "wafer" cut.



FIGURE 11.11 Chamfer back cut of proximal phalanx. This cut is necessary for placement of the proximal phalanx component.

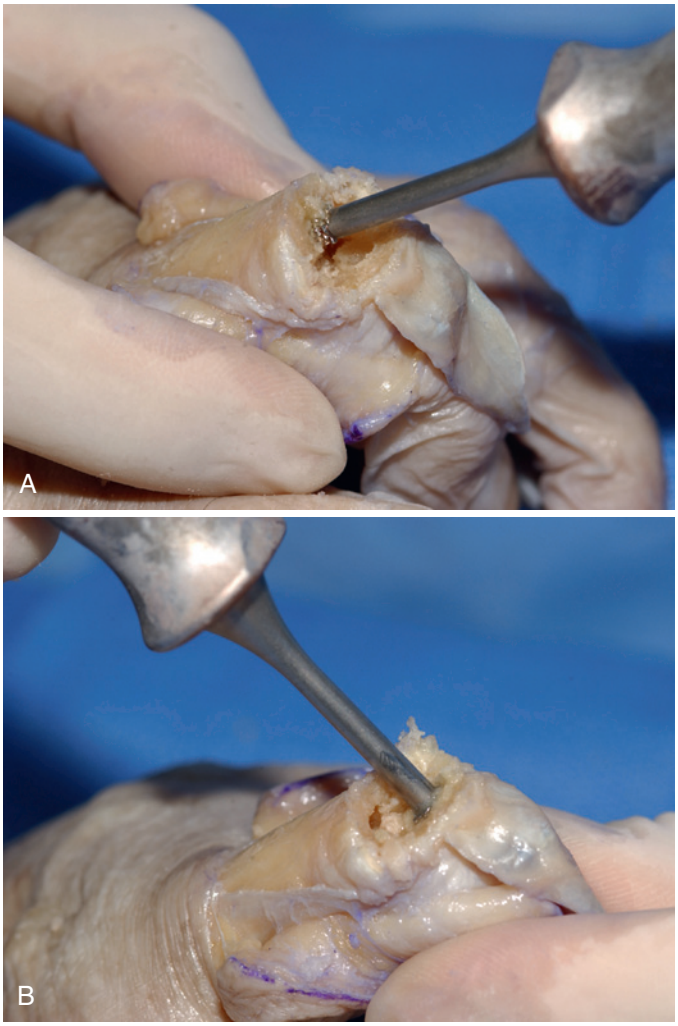

FIGURE 11.12 **A** and **B,** Broaching of the proximal phalanx and distal phalanx.

After the proximal phalanx has been prepared, an oscillating saw is again used to make an osteotomy at the base of the middle phalanx, perpendicular to its long access. This is done while exercising caution not to violate the insertion of the central slip on the middle phalanx. Similar to the way in which the origin of the collateral ligaments on the proximal phalanx was protected, the collateral ligament insertions are protected with Hohmann retractors or simply by hyperflexion of the digit, bringing the base of the middle phalanx into full view. This osteotomy should be no more that 1 to 2 mm thick. Under circumstances of severe articular erosion or bone loss, adequate preparation of the bone surface may be accomplished with the use of a small rongeur, whereby the remaining articular cartilage is removed and subchondral bone exposed and an oscillating saw cut is not necessary.

Next, the proximal and middle phalanges are broached with the device-specific instrumentation. Specific proximal phalanx broaches and middle phalanx broaches are used (Figure 11.12, *A* and *B*). It is sometimes necessary to initially locate the intermedullary canal of the proximal or middle phalanx with a high-speed 2-mm bur. It is imperative to broach and then trial the proximal and middle phalanges to the largest size accepted by

these bones. Failure to do so results in the implantation of undersized components, a common technical error.

Trial components are inserted next. Proximal and middle phalanx-specific impactors are available for trial component insertion. With the trial components in place, the digit is examined for range of motion and stability. If bony impingement occurs between the posterior cortices of the proximal and middle phalanges, the trial components are removed and their sizes reassessed or the canals are rebroached such that the largest trial components are accepted. Posterior osteophyte removal is sometimes necessary.

Once permanent components are chosen, they are delivered to the back table and kept in their protective packing. It remains my preference to insert the final components with a press-fit technique using clean gloves and the "no touch technique" whereby the implants are handled only with forceps. Using the proximal and middle phalanx component-specific impactors, the permanent components are seated. I reserve the use of cement for cases of osteoporosis or overly capacious canals. Patients who have substantial preoperative bone loss from degenerative cyst formation or following trauma may also require prosthesis implantation with cement. Alternatively, bone graft augmentation may be used in these patients. The extensor mechanism is repaired with a 3-0 nonabsorbable suture (Figure 11.13, *A* and *B*).

Postoperative Management and Expectations

Immediately following the operation, a volar plaster splint is placed with the MCP and PIP joints held in full extension. After 5 to 7 days, the initial dressing is removed and the patient is placed in a dynamic extension splint, affording active flexion and passive extension. During the first 6 weeks, the amount of active flexion is gradually increased every 2 weeks in the following progression: 30 degrees for the first 2 weeks, 60 degrees for the next 2 weeks, and 90 degrees for the next 2 weeks. At the end of 6 weeks, full digital flexion and extension are permitted without the splint. The dynamic outrigger device is continued for an additional 6 weeks if an extension lag is present.

CRITICAL POINTS *Proximal Interphalangeal Joint Surface Replacement Arthroplasty*

Indications
- Osteoarthritis
- Posttraumatic arthritis
- Inflammatory arthritis (relative)

Technique
- Dorsal, volar, or lateral incision
- Preservation of the radial and ulnar collateral ligaments
- Broach and trial components to the largest allowable size
- Assess for bony impingement
- Components press fit
- Cement reserved for overly capacious canals or patients with osteoporosis

Rehabilitation
- Early motion allowed with constraints based on surgical approach
- Extension outrigger for passive extension or flexion block is used following dorsal approach
- Unrestricted range of motion is permitted at 6 weeks postoperative
- Nighttime extension splinting may be necessary after 6 weeks if extension lag present

Outcome
- Good pain relief and modest improvement in range of motion and function expected
- Similar results are found irrespective of surgical approach
- Controversy exists regarding the use of cement
- 16% failure rate at 15 to 25 years has been reported

Expected Outcomes

Surface Replacement Arthroplasty. Linscheid and Dobyns first reported on SRA for the PIP joint in 1979. Since this original



FIGURE 11.13 **A** and **B,** Postoperative radiographs showing proximal interphalangeal-surface replacement arthroplasty implanted with press-fit technique.

report, there has been general agreement that patient satisfaction is good and function is improved.[70] In 1997, Linscheid and Murray reported on 66 PIP joint SRA implants in 47 patients over a 14-year period, with a mean follow-up of 4.5 years. Results were good in 32 fingers, fair in 19, and poor in 15. Results in this study were better in patients with the dorsal approach. There was a 12-degree increase in range of motion in these patients.[71] Jennings and Livingstone reported on 43 SRA implants in 25 patients with an average follow-up of 37 months. They found a nominal increase in range of motion; 26 patients were very satisfied and 12 fairly satisfied; 5 were not satisfied. There were 11 failures, which were attributed to the lack of cement use in these joints.[49] Luther and colleagues reported on 24 PIP SRAs in 23 patients followed for an average of 27 months.

There was an average increase of range of motion of 21 degrees. Seventy percent of the patients were satisfied overall with the result of the operation; however, 58% of the patients needed a reoperation.[74]

Murray and associates[90] provided further follow-up on their original 1997 series from the Mayo Clinic with a report on 67 SRA PIP implants in 47 patients followed for a mean of 8.8 years. The mean range of motion was 40 degrees. The failure rate was found to increase from 3% at 1 year to 8% at 3 years, 11% at 5 years, and 16% at 15 to 25 years. Prostheses implanted through a volar approach failed more often than those implanted through a dorsal approach. Failure rates did not differ among patients with degenerative arthritis, rheumatoid arthritis, or posttraumatic arthritis. The use of cement also did not affect results.[90] Johnstone and coworkers[51] compared 18 patients who had 27 cemented PIP SRA implants with 18 patients who had 21 uncemented PIP SRA implants with a follow-up of 4 years and 6 years, respectively. Although functional results were not significantly different, there were 13 implants in the uncemented group with subsidence and loosening compared with 1 in the cemented group, leading the authors to favor the use of cement for the implantation of this prosthesis.

Other areas of controversy exist regarding the outcomes of the SRA implants. Despite earlier reports citing superior results with the dorsal approach, Stoecklein and coworkers have reported good results with significant improvements using the volar approach in six patients with an average follow-up of 35 months.[71,89,90,124] In another study that included 91 SRA implants, Pritsch and Rizzo reported that 26 reoperations were necessary; extensor mechanism dysfunction was identified as the most common reason for failure.[107] Daecke and colleagues[28] recently reported a prospective multicenter study involving 62 PIP SRAs among 43 patients followed up at 35 months. They noted comparable results among pyrocarbon, SRA, and silicone devices, with a tendency toward greater early range of motion in the pyrocarbon and SRA devices compared with the silicone devices. There were significantly more complications with the pyrocarbon and SRA devices compared with the silicone devices. Adams and associates published a metaanalysis finding that the dorsal approach produced the most successful result.[1]

Pyrocarbon Implant. Nunley and colleagues[96] reported disappointing results with the pyrocarbon PIP implant, with no real improvement postoperatively with respect to scores on the Disabilities of the Arm, Hand, and Shoulder (DASH) scale and pain scale. The range of motion actually decreased at an average 17-month follow-up.[96] Subsequent studies have been more encouraging. Bravo and associates[14] reported on 50 implants in 35 patients at a minimum follow-up of 27 months, finding an overall patient satisfaction rate of 80% and a revision rate of 8%. Similarly, Mashhadi, McGuire, and Tagil and Geijer and their colleagues, each with midterm follow-up, reported improvements in pain and function as well as good patient satisfaction.[77,80,128] Osteolysis and implant subsidence in 40% of joints have been reported.[80,128] Wijk and associates have reported on 53 joints in 43 patients with an average follow-up of 24 months. On average, rates of pain at rest, pain with activity, patient satisfaction, and occupational performance as well as DASH scores all improved. There were seven reoperations, and the range of motion and grip strength did not improve.[147]

Sweets and Stern reported on their experience with pyrocarbon arthroplasty of the PIP joint in a series of 31 arthroplasties in 17 patients with an average follow-up of 55 months. They found a decrease in average range of motion postoperatively from 57 degrees to 31 degrees. Six joints required a reoperation, and implant migration was severe for seven proximal phalanx implants and three distal phalanx implants.[126] Although Ono and coworkers[97] reported improvement in pain on average and good patient satisfaction, they found a complication rate of 42.9% in their series of 21 implants in 13 patients. Presumably in an earlier report on the same cohort of patients, Chung and colleagues[24] noted implant squeaking in three patients and implant dislocation in three patients.

Silastic Implant. Success with the use of the silicone PIP joint spacer has been reported by many investigators. Swanson and colleagues[125] reported on 424 implants with a minimum of 1 year of follow-up. In this series, the majority of digits had at least 40 degrees of range of motion. Lin and associates analyzed 69 silicone PIP spacers at an average follow-up of 3.4 years. Pain was improved in 67 of the 69 digits. Range of motion was not improved following operation.[68] Takigawa and associates[130] reviewed 70 implants in 48 patients at an average follow-up of 6.5 years. They found no significant change in the active range of motion or correction of deformity, but pain had been relieved in 70% of patients.

Recently, several comparative studies involving the silicone spacer have been published. One study compared the NeuFlex implant (Small Bone Innovations, New York, NY) and Swanson implant, finding better objective results with the Swanson implant but better patient satisfaction with the NeuFlex implant at 34 months of follow-up.[120] Chan and coworkers[22] compared pyrocarbon arthroplasty with silicone implants in a systemic analysis. In this study, 35 citations were identified, and the authors found no clear superiority of pyrocarbon arthroplasty over silicone implants; they expressed concern over the number of identified complications in the pyrocarbon implants. Branam and colleagues[11] reviewed 41 arthroplasties in 22 patients, comparing results of silicone implants and pyrocarbon implants. At an average of 45 months of follow-up, the results were comparable, although 8 of the 19 pyrocarbon joints squeaked. Interestingly, Adams and associates[1] concluded in a recent metaanalysis that in general, the effectiveness of PIP joint arthroplasty has not been adequately established, citing short-term follow-up and insufficient data as limiting the value of current evidence.



FIGURE 11.14 Proximal interphalangeal-surface replacement arthroplasty implant has failed because of extensor mechanism incompetence.

Complications. Complications from implant or spacer arthroplasty of the PIP joint are largely dependent on the surgical approach and device used. Extensor mechanism failure is a complication with the dorsal approach and in one study, accounted for the majority of indications for reoperation[107] potentially leading to the development of a boutonnière deformity (Figure 11.14). Alternatively, the anterior approach can lead to failure of the volar plate and the development of a swan neck deformity.

For the purpose of clarity, complications specific to the individual devices have been mentioned in the outcomes section above. Silicone spacer devices are known to fracture over time but may remain in service even if fractured. Stern and Ho have cautioned about the use of silicone spacer implants because of concerns about the development of instability with pinch.[123] Problems encountered with the pyrocarbon implant osteoplasty include squeaking, osteolysis, prosthesis migration, and dislocation.[24,80,97] Interestingly, infection has only rarely been reported among implant arthroplasty series of the hand, perhaps because the vasculature supply of the hand is robust.

Metacarpophalangeal Joint Arthroplasty

Indications and Contraindications

Most indications for MCP arthroplasty are in patients with rheumatoid arthritis, and the vast majority of published reports involve rheumatoid patients. Osteoarthritis of the MCP joint can be seen primarily in the index and long fingers as well as the thumb. Nonoperative measures such as splinting, medication with nonsteroidal antiinflammatory drugs (NSAIDs), activity modifications, and injections are often helpful in primary osteoarthritis or posttraumatic osteoarthritis. When nonoperative measures fail, arthroplasty may be indicated for the relief of pain but generally not for functional improvement. For MCP arthroplasty to be considered, adequate bone stock is necessary as well as a stable soft tissue envelope. For the nonconstrained pyrocarbon or metal-on-plastic surface replacement implants, this means preservation of the radial and ulnar collateral ligaments.

Contraindications to arthroplasty include compromised or atrophic skin as well as acute infection and a local open wound. A relative indication is a remote history of infection, but in certain well-controlled circumstances, replacement of a degenerative joint following a remote history of MCP joint septic arthritis may be indicated. Situations such as these should be scrutinized on a case-by-case basis.

The operative technique for MCP arthroplasty, including preoperative planning and postoperative management, will be discussed in Chapter 55.

Expected Outcomes

Pyrocarbon Implant. It is generally recognized that nonconstrained pyrocarbon implants have better material properties than silicone implants; however, limited follow-up data are available for the treatment of MCP joint osteoarthritis.[26,107] Parker and colleagues have reported on 21 MCP joints treated with pyrocarbon arthroplasty in the context of a study involving 142 total implants, with an average of 17 months of follow-up. Amid the osteoarthritis group, pain and function improved as did the arc of motion (from 44 degrees before operation to 58 degrees following operation), oppositional pinch (126% improvement), and grip (40% improvement).[100]

Silastic Implant. Silastic implant arthroplasty remains the standard for reconstruction of the MCP joints.[107,125] Rettig and Luca[109] reported on 13 MCP silicone implants in 12 patients, finding good or excellent overall improvement in all patients at an average of 40 months of follow-up. Increases in joint flexion were seen, but grip strength at follow-up was well below average. Neral and coworkers[93] reported on 30 patients with 38 MCP silicone implant arthroplasties at a follow-up of 56 months. They found improvement in range of motion and function and less pain. As with Rettig and Luca, no difference was found for grip strength. Overall, 73% were satisfied with the outcome of surgery. Namdari and Weiss have also reported good results with the use of a silicone implant for MCP joint osteoarthritis at 4 years of follow-up.[92]

Other Procedures. A surface replacement, metal-on-plastic MCP arthroplasty device has been developed as another option. The anatomic design of this implant (Small Bone Innovations, New York, NY) as well as its material properties are intriguing. To date, no series has reported on the clinical results of this implant, and currently its use is relegated to experimental protocols. Pain relief has been reported with the Tupper resection-interposition volar plate arthroplasty in one recent small series of patients, which included two patients with posttraumatic osteoarthritis of the MCP joint.[69]

Complications

Deformity and fracture of silicone implant arthroplasties following years of service are well recognized. Trail and coworkers found an implant fracture rate of 66% at 17 years among 1000 implants reviewed retrospectively.[135] Periprosthetic erosions have been reported, as have radiolucent lines surrounding pyrocarbon implants; the latter have been considered benign.[100] Ulnar drift with extensor tendon subluxation can complicate the use of either implant. Implant squeaking can occur with pyrocarbon implants.

OSTEOARTHRITIS OF THE CARPOMETACARPAL JOINT OF THE THUMB

Epidemiologic Findings

The prevalence of osteoarthritis of the thumb CMC joint is striking, with the condition affecting up to 10% of women in the middle years of life. Postmortem studies have found thumb CMC arthritis in 75% of cases.[98] In a study by Armstrong and colleagues, 143 postmenopausal women were found to have a 25% prevalence of thumb CMC osteoarthritis; 55% of patients with combined CMC and scaphotrapezial osteoarthritis of the thumb had pain.[5] The condition is regarded as a major cause of disability in the aging population.

Evaluation

Physical Examination

Patients with osteoarthritis of the thumb CMC joint may present with varied complaints of pain localized to the area or more vague complaints of throbbing or even burning in the radial aspect of the hand. A thorough physical examination of the joint begins with inspection. Patients with more advanced osteoarthritis will often display a thumb adduction contracture and a compensatory thumb MCP joint hyperextension deformity. Examination of the thumb MCP joint in these patients will show laxity of the joint in hyperextension. The degree of MCP joint instability can have implications for surgical management of the arthritic CMC joint when trapeziectomy procedures are indicated. This will be discussed in more detail later in this chapter.

After inspection, the CMC joint is evaluated using the grind test and joint subluxation test. To perform the CMC grind test, the examiner faces the patient, rests the patient's hand on a hand examining table, stabilizes the wrist with one hand, and applies an axial load to the thumb axis. Pain may be elicited as well as crepitus as the degenerative articular surfaces are compressed. The CMC subluxation test is done in a similar fashion, although the objective is to gently force the CMC joint to sublux; the examiner determines whether this elicits a pain response. Crepitus may also be apparent. Additionally, pinch strength testing, such as the two-point key pinch test or three-point chuck pinch test using a dynamometer, may be helpful when absolute values are compared with those of the contralateral side (Video 11.2). Pinch maneuvers such as the two-point or lateral pinch test may increase forces across the CMC joint by a factor of 12. The examiner should be aware that the association of carpal tunnel syndrome with CMC osteoarthritis approaches 30%.

Diagnostic Imaging

Radiographs to profile the thumb CMC joint include PA, lateral, and oblique views of the hand or, alternatively, PA and lateral views of the wrist. A Robert view of the thumb CMC joint is also helpful because it is a true PA view of the joint (Figure 11.15). The Robert view requires special positioning of the arm and hand that some patients may find difficult, particularly if they have limited or painful motion of the shoulder. The Robert view is obtained with the arm and hand in a combination of positions, including shoulder flexion, shoulder internal rotation, and wrist hyperpronation, so that the dorsal surface of the thumb can be placed directly on the radiograph cassette. Advanced imaging studies such as MRI or CT scanning are seldom necessary for operative procedures or surgical decision making about the thumb CMC joint.



FIGURE 11.15 Robert's true PA radiograph of the thumb carpometacarpal (CMC) joint of a 52-year-old female with stage III CMC osteoarthritis.

Eaton and colleagues have described a widely accepted radiographic staging system for thumb CMC joint degenerative arthritis[32]:

- *Stage I:* Normal or slight widening of the joint shadow due to synovitis
- *Stage II:* Mild joint shadow narrowing with osteophyte formation of 2 mm or less
- *Stage III:* Marked joint shadow narrowing with osteophyte formation of more than 2 mm
- *Stage IV:* Stage III disease with scaphotrapezialtrapezoidal osteoarthritis

Although helpful for radiographic description and explanation, this staging system has never shown correlation with the intraoperative extent of disease or treatment outcome, irrespective of the treatment chosen.

ANATOMY AND BIOMECHANICS

The thumb CMC joint evolved as an unstable articulation providing prehension, opposition, and circumduction, which distinguished human hand function from that of the higher-order mammals. The joint is a biconcave, reciprocating saddle joint with little inherent stability. What stabilization it has is provided

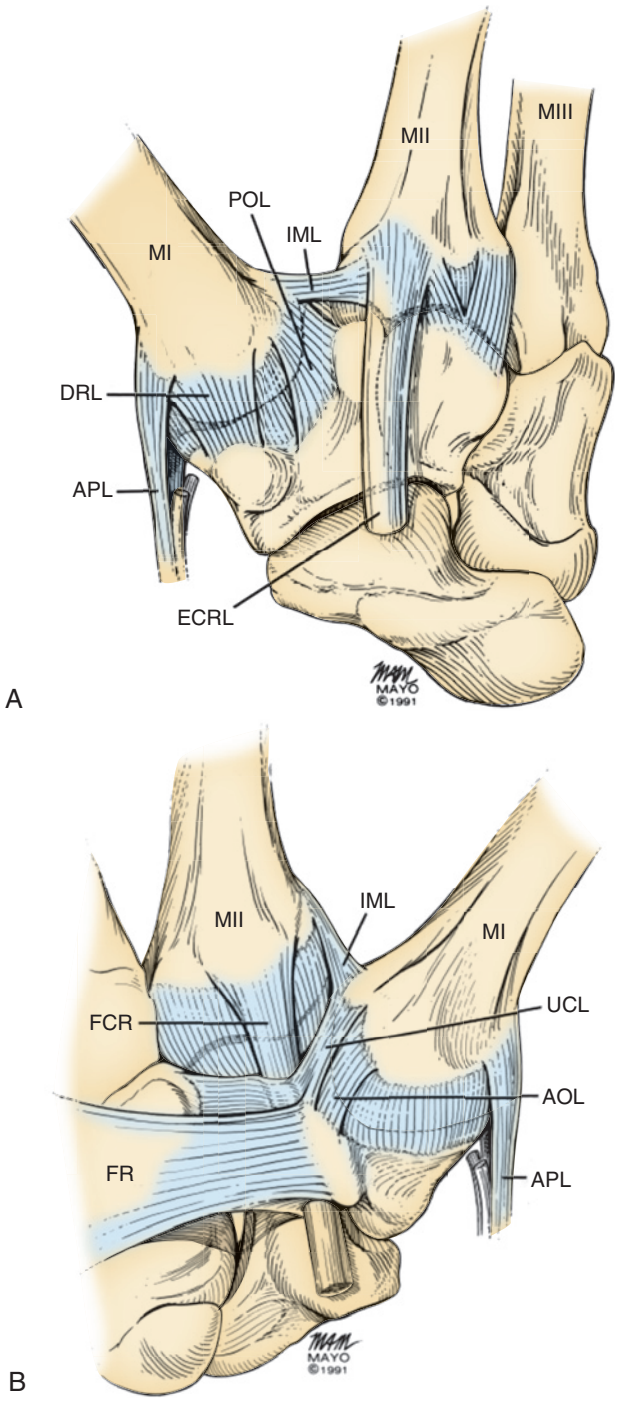

FIGURE 11.16 **A,** Posterior view and **B,** anterior view showing ligamentous anatomy of the thumb carpometacarpal joint. *APL,* Abductor pollici longus; *AOL,* anterior oblique ligament; *DRL,* dorsal radial ligament; *ECRL,* extensor carpi radialis longus; *FCR,* flexor carpi radialis; *FR,* flexor radialis; *IML,* intermetacarpal ligament; *MI,* metacarpal I; *MII,* metacarpal II; *MIII,* metacarpal III; *POL,* posterior oblique ligament; *UCL,* ulnar collateral ligament. (© Mayo Clinic, Rochester, MN. Modified with permission.)

by 16 ligaments, and it rests in pronation (Figure 11.16, *A* and *B*). There is a discrepancy in articular diameter; the thumb metacarpal articular surface is 34% smaller than the distal articular surface of the trapezium.

The primary stabilizer of the thumb CMC joint is the deep anterior oblique ligament, or palmar "beak" ligament. The deep anterior oblique ligament is an intracapsular ligament emanating from the volar tubercle of the trapezium and inserting on the ulnar volar aspect of the first metacarpal. The ligament tightens with pronation, abduction, and extension, preventing ulnar translation and dorsal translation of the first metacarpal relative to the trapezium. The ligament's obliquely oriented fibers serve to create a center of rotation about which the CMC joint may rotate. The superficial anterior oblique ligament tightens with pronation and extension of the thumb.

Other ligaments that contribute substantially to thumb CMC joint stability include the dorsoradial ligament and posterior oblique ligament, which stabilize and inhibit dorsal translation and ulnar translation of the joint, respectively. The dorsal intermetacarpal ligament of the thumb prevents radial translation of the thumb metacarpal as well as proximal migration of the thumb metacarpal following trapeziectomy.

Ultrastructurally, Mobargha and associates have noted in 11 patients with osteoarthritis that the deep anterior oblique ligament was composed of disorganized connective tissue, with little evidence of collagen fibers and few signs of innervation. Mechanoreceptors were identified in the dorsoradial ligament, and it was found to be innervated to a much greater extent than the anterior oblique ligament. In contrast, the collagen bundles of the dorsoradial ligament were found to be better organized. No association was noted with ligament innervation patterns and patient age.[86]

High compressive forces occur across the thumb CMC during pinch; they may reach in excess of 12 times the applied load and may approach 20 times the applied load during maximum grasp. Cantilever bending occurs with these applied forces such that shear forces are created that are highest at the volar half of the joint's articular surface. These forces are enhanced with CMC flexion, whereas the volar portion of the trapezial metacarpal joint is relatively unloaded.[88] Pellegrini has shown an association with degeneration of the volar half of the thumb CMC joint as the integrity of the deep anterior oblique ligament diminishes. Consequently, the dorsal cartilage is relatively spared, even in cases of advanced osteoarthritis.[102] In another study, Pellegrini showed that articular degeneration consistently involved a greater portion of the surface area of the trapezium compared with the metacarpal by a ratio of 3:1, and a decrease in this ratio was associated with more advanced disease.[103]

Treatment

Indications and Contraindications

Nonoperative Treatment. The first phase of management for patients with osteoarthritis of the thumb CMC joint is nonoperative treatment. This may include thumb spica splinting, which may be forearm or hand based but preferably leaves the thumb IP joint free for patient comfort. In addition to splinting, NSAIDs may be used orally or topically, depending on patient tolerance or physician preference. Outpatient hand therapy may consist of ultrasound, paraffin wax, heat, and deep tissue massage, along with activity modifications. The success of hand therapy protocols in these situations is variable. Sustained benefit from splinting and corticosteroid injections has been demonstrated by several authors[30,54]; however, one randomized, controlled, blinded trial has shown no difference in scores on

the visual analog pain scale at 24 weeks when comparing a group treated with a thumb CMC joint steroid injection and another group treated with saline injection.[81]

First Metacarpal Osteotomy. Forces across the thumb CMC joint lead to cantilever bending and result in high concentrations of shear forces across the volar half of the joint. These forces are believed to be causative in the preferential development of osteoarthritis of this segment of the thumb CMC joint. Therefore, a 30-degree closing wedge, extension osteotomy of the thumb metacarpal has been theorized to unload the volar segment of the thumb CMC joint by redistributing the load through the more dorsal segment of the joint. The first metacarpal osteotomy is indicated for patients with stage I or II disease but contraindicated in patients with hypermobility, fixed subluxation, or hyperextension of the joint.

Tomaino[134] reported on 12 patients with stage I disease treated with extension osteotomy of the thumb metacarpal. All osteotomies healed within 7 weeks; 11 of the 12 were satisfied with the outcome, and all had increased grip and pinch strength at 2 years of follow-up. Parker and colleagues reviewed eight patients with stage I, II, or III disease at an average of 9 years of follow-up. They found that pinch and grip strength had improved and excellent functional outcomes were obtained in six of the eight patients.[99]

Ligament Reconstruction. For patients with stage I or II disease of the thumb CMC joint, ligament reconstruction alone may be preferred over other salvage techniques. Instability of the volar ligamentous complex of the joint, particularly the deep anterior oblique ligament, has been forwarded as a potential cause of osteoarthritis of the joint.[37] In a biomechanical study, Koff and coworkers have shown that ligament reconstruction improved stability of the joint.[60] It has generally been felt that ligament reconstruction be reserved for patients with very mild articular changes and that it is contraindicated in patients with stages III and IV disease.[98]

Resection Arthroplasty. The majority of reconstructive procedures for thumb CMC osteoarthritis involve resection arthroplasty of the trapezium, with removal of the articular base of the first metacarpal with or without ligament reconstruction and with or without interposition of autograph material. This procedure is typically reserved for patients with stage III or IV disease, although durability of this procedure has been reported in a younger population with stage I disease.[148] In 1984, Burton and Pellegrini described a technique for "advanced osteoarthritis of the thumb CMC joint," in part based on the procedure described by Eaton and Littler for reconstruction of the deep anterior oblique ligament.[18] This procedure involves resection of the trapezium and base of the first metacarpal, along with a stabilization procedure they termed the *flexor carpi radialis sling suspension interposition,* in which, similar to the Eaton and Littler procedure, a portion of the flexor carpi radialis (FCR) tendon is used to reconstruct the deep anterior oblique ligament (or perhaps more accurately, the intermetacarpal ligament) and to create an interposition arthroplasty, filling the void left by trapezium resection. Theoretically, this interposition and deep anterior oblique ligament reconstruction provides support and resists subsidence of the thumb metacarpal.

A number of different approaches to advanced thumb CMC arthritis have been described, centered on the concept of resection arthroplasty. Weilby has reported on a technique which involves passing half of the FCR tendon around the abductor pollicis longus (APL) tendon, making a suspension lattice in the void created by the trapezium resection.[142,143] Routing a slip of the APL tendon around the extensor carpi radialis longus (ECRL)[23] or passing half of the FCR around the ECRL has also been described to gain suspension and may be beneficial in revision procedures.

Kuhns and colleagues have described a procedure whereby no interposition material or ligament reconstruction was employed. Temporary K-wire stabilization is performed. They termed the procedure the *hematoma and distraction arthroplasty*.[35,43,63] Excision of the trapezium alone without stabilization of any kind has been reported by Gervis as well as others.[29,41]

Carpometacarpal Thumb Arthrodesis. Arthrodesis of the thumb CMC joint has historically been indicated for the young, high-demand laborer in whom stability and grip strength are considered a premium. More recently, the indications have been expanded to include older, less active patients, as an alternative to trapeziectomy with ligament reconstruction.[112] It is generally agreed that advanced osteoarthritis of the scaphotrapeziotrapezoidal (STT) joint is a contraindication to CMC joint arthrodesis, but there is less agreement about the relevance of mild or moderate osteoarthritis of the STT articulation. One challenge with CMC arthrodesis is the need for prolonged immobilization because notable nonunion rates have been reported.[112] Nevertheless, most continue to indicate this procedure in the young active individual.

Carpometacarpal Thumb Arthroplasty. Implant arthroplasty of the thumb CMC joint has met with varied, if not unpredictable, results. Several devices have been developed and used. These include the de la Caffinière prosthesis; Guepar implant; Elektra and Braun-Cutter implants and surface replacement arthroplasty (Small Bone Innovations, New York, NY); and Orthosphere implant (Wright Medical Technology, Memphis, TN). Among the most used and evaluated thumb CMC prostheses is the de la Caffinière prosthesis, which is a semiconstrained ball and socket design with both components cemented. The metacarpal component is made of cobalt chromium, and the trapezium component is a polyethylene cup. The Guepar prosthesis is also a cemented prosthesis with a cobalt chrome metacarpal component that snap-fits into a polyethylene trapezium component and functions in a constrained fashion. The Elektra prosthesis is a modular design made of cobalt chrome and threads into the trapezium. The Braun prosthesis is a cemented design that consists of a metallic metacarpal and a polyethylene socket. The Avanta SR TMC prosthesis is a cemented total joint surface replacement with matching sloped, saddle-shaped components approximating the natural contours of the base of the first metacarpal and the articular surface of the trapezium, with the trapezium component made of cobalt chrome and the first metacarpal component made of polyethylene.[7,65] Polycarbon has been used to develop replacement arthroplasties and hemiarthroplasties of the thumb CMC joint, including the pyrolytic carbon anatomic interposition arthroplasty, the pyrocarbon implant (BioProfile/Tornier, Montbonnot Saint Martin, France), the Pyrodisk (Integra Life Sciences, Plainsboro, NJ), and the pyrocarbon interposition implant (Pi2), which is a pyrolytic carbon interpositional disk (BioProfile/Tornier). The

pyrolytic carbon hemiarthroplasty is a resurfacing implant with a stem that press-fits into the thumb metacarpal (NuGrip, Integra Life Sciences). This prosthesis has been used in patients with stage II or III disease. Confidence in many of these devices is hampered by its relatively recent use and high loosening rates.[44,108,139,140]

The most experience with implant arthroplasty of the thumb CMC joint is with silicone implants such as the Swanson implant (Wright Medical Technology) or Niebauer implant. In longer-term analysis of these implants, problems identified included breakage, subluxation/dislocation, bone erosion, and silicone synovitis; therefore, these implants are no longer available.[18,84,129] Regarding particulate debris synovitis, no clear best treatment alternative has been identified.[91] Interestingly, Umarji and colleagues[137] have recently reported their experience with 10 patients who had revision surgery with a silastic finger joint implant spacer following failure of simple trapeziectomy. At an average follow-up of 53 months, 9 of the 10 patients reported improvement in pain and were generally satisfied with their function.

Other Procedures and Devices

Artelon Implant. Porous polyurethane-urea (Artelon, Small Bone Innovations, Morrisville, PA) has been extensively trialed as an interpositional material following trapeziectomy. Multiple studies have called into question its efficacy, however. In a retrospective study, Blount and colleagues have reported that 37% of patients had their implants explanted, largely due to pain or extrusion of the implant.[10] Jorheim and associates, in a matched cohort study, were unable to show any advantage of the spacer over a tendon suspension procedure.[53] Similarly, Nilsson and coworkers could not show superior results with the implant compared with tendon interposition procedures.[94] Robinson and Muir, in a report of three cases, have described a histologic foreign body reaction that caused pain requiring removal of the implant.[113] Based on these recent series, use of this implant is generally not recommended.

Carpometacarpal Arthroscopy. Small joint arthroscopy procedures have been advocated by some for limited synovectomy and ligament stabilization through thermal shrinkage for stage I disease; however, outcome data are limited.[98] Arthroscopy has also been advocated for partial resection of the thumb CMC joint and the STT joint with reported success.[2,25]

Operative Techniques

First Metacarpal Osteotomy. The first metacarpal is approached through a dorsal longitudinal incision and exposed subperiosteally in the interval between the extensor pollicis longus (EPL) and extensor pollicis brevis (EPB) tendons. This requires elevation of the thenar muscles off of the radial aspect of the metacarpal. Care is taken to protect branches of the radial sensory nerve. In the ulnar proximal aspect of the wound, the deep branch of the radial artery is identified, along with two accompanying veins. These structures are retracted with the aid of a small vessel loop. Two curved Hohmann retractors are placed radially and ulnarly around the first metacarpal in order to fully expose the base of the first metacarpal. A location for the osteotomy is chosen approximately 1 cm distal to the trapezial metacarpal joint. The joint may be identified by making a small incision through the trapezium and first metacarpal joint capsule. A microsagittal saw is used to accomplish a transverse osteotomy, perpendicular to the axis of the first metacarpal and parallel to its base (Figure 11.17). The saw is stopped at the level of the volar cortex and removed, but the saw blade is left in place. A second saw blade is used to make a second cut approximately 2 mm distal to the first cut, and the two saw blades are converged at the level of the volar cortex. This will accomplish the desired 15-degree apex volar osteotomy.[99] A variety of different fixation options may be used to stabilize the first metacarpal, including crossed K-wires, crossed wires with a tension wire, or a small "T"-plate.

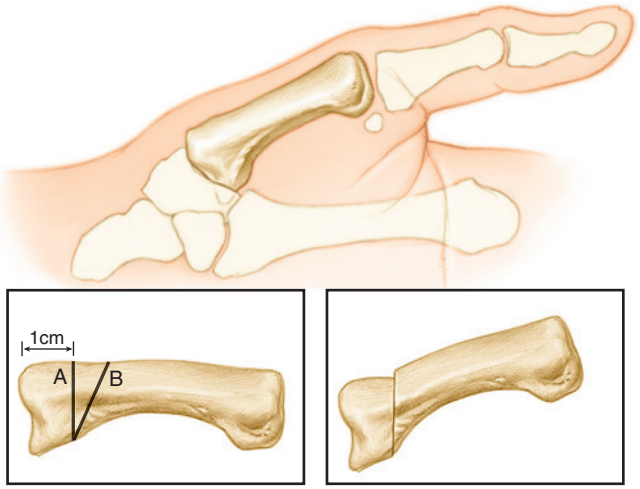

FIGURE 11.17 Wilson first metacarpal osteotomy for stage I and II carpometacarpal osteoarthritis. (© Mayo Clinic, Rochester, MN. Modified with permission.)

The author prefers to pass a 20-gauge surgical steel wire through drill holes made in the distal and proximal portions of the osteotomized metacarpal and then twist-tie the wires together, compressing the osteotomy surfaces. The wire twist is cut and bent beneath the thenar musculature on the radial aspect of the metacarpal. Drill holes through the metacarpal to accommodate the 20-gauge wire can be made with a 0.045-inch K-wire advanced perpendicular to the osteotomy sites in the proximal and distal portions of the metacarpal. Ideally the drill holes are made 5 mm proximal and distal to the osteotomy sites. The tension wire fixation is further augmented by a crossing 0.045-inch K-wire placed in a retrograde, oblique direction using fluoroscopy.

Following routine postsurgical wound inspection and management, a thumb spica cast is applied for 6 weeks; the percutaneous K-wire is removed when the cast is removed. The patient is transitioned to a removable forearm-based thumb spica splint and followed radiographically until healing occurs. At this time, the splint may be discontinued and full activity resumed.

Ligament Reconstruction. The standard volar (Wagner) approach is used. The thenar muscles are sharply dissected extraperiosteally from the underlying metacarpal, trapezium, and trapeziometacarpal (TMC) and scaphotrapezoid joints.

The deeper dissection begins at the transverse fascial fibers overlying the FCR tendon and continues distally along the overhanging ulnar border of the trapezium, from which the transverse carpal ligament attaches.

The proliferative synovium is débrided while preserving the joint capsule. The TMC joint is manually reduced to ensure that a concentric reduction is possible. The terminal branch of the superficial radial nerve courses along the dorsum of the metacarpal superficial and parallel to the EPB tendon. The nerve and EPB tendon are retracted, and the periosteum is incised parallel and volar to the EPB tendon 1 cm distal to the TMC joint. This is just distal to the abductor pollicis brevis insertion. The arthrotomies are closed with interrupted 3-0 braided nonabsorbable suture.

A volar-to-dorsal gouge tract of progressively larger diameters is created across the base of the metacarpal, parallel to the TMC joint and perpendicular to the metacarpal long axis. In harder bone, a 0.062-inch K-wire can be used to establish the initial tract orientation and facilitate gouge usage. The volar aspect of the gouge tract must be cleared of soft tissue and bone fragments to allow the smooth passage of the FCR tendon graft. A 28-gauge stainless steel wire is fed through the gouge tract, and the ends are clamped. Only half of the FCR tendon width is needed. The FCR tendon is identified at the proximal-ulnar extent of the primary incision.

The proximal tendon is isolated with blunt dissection and cleared of distal muscle fibers. A suture passer is gently bent at the tip and placed within the FCR sheath distally. As it is pushed proximally along the sheath, digital palpation ensures that the nylon loop remains volar to the tendon. The loop is delivered into the smaller proximal incision. A No. 2 monofilament suture is passed through the midportion of the tendon, and the needle is cut off. The two free ends of the suture are placed into the loop of the suture passer, which is drawn distally, bringing the monofilament suture limbs out of the distal end of the FCR sheath. The monofilament suture ends are grasped with a hemostat, and then with steady force the stitch is teased along the FCR tendon distally, splitting the tendon in half. The ulnar half of the tendon is used for the procedure; this ensures that the harvested tendon is in close apposition to the volar beak of the metacarpal. The ulnar portion of the FCR tendon is divided proximally, and the proximal free end of the FCR graft is delivered into the primary incision.

The FCR graft is held in a moist sponge and pulled distally just beyond the distal trapezium as it is separated from the intact tendon with a probe or fingertip. A loop is made in the previously placed 28-gauge wire and tightened around the last 2 mm of the tendon graft free end. The wire with tendon is drawn through the gouge tract from volar to dorsal. Using 3-0 braided nonabsorbable suture, a series of stay sutures are placed beginning with the periosteum of the dorsal metacarpal. During suturing, the joint is held reduced by an assistant. With the aid of a small hemostat, the free graft end is passed through and deep to the broad APL tendon insertion and across the volar capsule and sutured at both places. Finally, the FCR tendon graft is looped around the remaining FCR tendon and sutured to itself. It is important not to overtighten the graft. The thenar musculature is repaired anatomically with absorbable suture, beginning with the tagged slip of the APL tendon.

Gentle activities, including writing and typing, are allowed immediately as tolerated. The cast or splint is removed at 3 weeks, and progressive use and range-of-motion exercises are begun. Unlimited activities, including sports, are permitted at 6 weeks postoperatively.

Resection Arthroplasty. The trapeziectomy for thumb CMC osteoarthritis is essentially a resection arthroplasty procedure. In this procedure, a complete subperiosteal dissection is achieved so that the bone can be osteotomized with a small osteotome and removed in a piecemeal fashion. Next the base of the first metacarpal is prepared by removing the articular surface with a microsagittal saw. It should be noted that the osteotomy of the base of the first metacarpal requires removal of only a small wafer of bone of the first metacarpal should be removed. The trapeziectomy portion of this procedure has also been successfully performed with the small joint arthroscope; however, this technique generally involves resection of the distal half of the trapezium.[25]

Management of the CMC joint resection arthroplasty has been accomplished using a variety of methods:

1. *Hematoma:* The remaining capsule is closed over the defect and blood is allowed to fill the defect. A modification of this technique is to place thrombin-soaked Gelfoam in the defect.
2. *FCR sling suspensionplasty:* This classic method of reconstruction involves harvesting half or all of the FCR tendon, the base of which inserts on the base of the second metacarpal. The FCR is passed through the base of the first metacarpal, and the excess tendon is sutured together to create a ball, which in theory is used to provide a stable support for the thumb. It is important to understand that the FCR tendon may be absent, diminutive, or ruptured in some patients, and, in such cases, an alternative procedure would be necessary. Further details of this procedure are provided under Author's Preferred Technique.
3. *Weilby sling:* In this technique,[146] half of the FCR tendon is harvested and a lattice is created to support the thumb metacarpal by weaving the FCR back and forth in a figure-of-eight fashion between the APL and the remaining FCR (Figure 11.18).
4. *Thompson APL sling:* The entire APL is harvested at its musculotendinous junction, passed through a bone tunnel at the first metacarpal articular base, and passed through a transverse drill hole at the base of the second metacarpal. The remaining portion of the tendon is

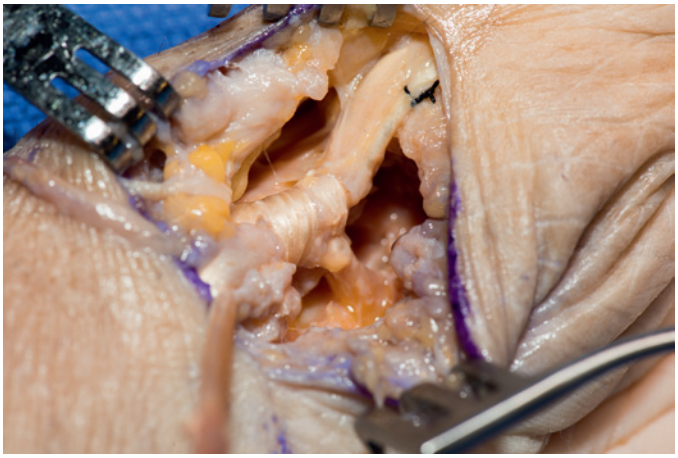

FIGURE 11.18 Weilby technique of flexor carpi radialis/abductor pollicis longus sling suspension.

woven around the ECRL tendon, in theory providing suspension to the first metacarpal. No interpositional material is placed into the void created by the trapeziectomy, according to Thompson's original description.[23] Chang and Chung have described a modification of the APL sling procedure whereby the most radial APL slip is released at the musculotendinous junction and advanced in a figure-of-eight fashion around the ECRL tendon, creating a sling for the first metacarpal of the thumb.

Carpometacarpal Arthrodesis. Exposure of the thumb CMC joint is gained through a dorsal longitudinal incision directly over the joint. Branches of the radial sensory nerve are identified and protected. The radial artery and accompanying veins are identified just proximal and ulnar to the thumb CMC joint and are retracted with a vessel loop. The interval between the EPB and the APL is used to expose the base of the first metacarpal and, subsequently, the trapezium in a subperiosteal fashion. The articular base of the first metacarpal and the distal articular surface of the trapezium are prepared by removing any remaining articular cartilage back to bleeding bone. The joint preparation is done in such a way that the contours of the opposing joint ends match and any voids are filled with autologous bone graft from the distal radius. The resultant fusion of the bone ends is stabilized by crossing 0.045-inch K-wires (Figure 11.19), which are placed percutaneously. Alternatively, a 2.4-mm low-profile "T"-plate can be used.

The thumb is placed in a thumb spica cast for 6 weeks, and the K-wires are removed at 6 weeks following operation. The patient is transitioned to a removable splint until radiographic arthrodesis can be determined. At that time, full activity may be resumed.

Carpometacarpal Arthroscopy. Thumb CMC arthroscopy involves the use of a 1.9-mm arthroscope inserted through either a 1R portal (positioned radial to the APL tendon) or a 1U portal (positioned ulnar to the EPB tendon).[3] The thumb may be suspended with a traction tower, with 5 to 10 pounds of traction applied. The 1R portal is helpful in visualizing the deep anterior oblique ligament insertion. A 25-gauge needle with a small amount of saline may be used to inflate the thumb CMC joint through the 1U portal. With the scope through the 1R portal, the thumb CMC joint may be visualized. A 2.0-mm shaver may be inserted through the 1U portal for joint débridement. A 2.9-mm bur may also be inserted through the 1U portal to remove the distal articular surface of the trapezium. It is desirable to remove up to 4 mm of the distal trapezium in this fashion. Further details of small joint arthroscopy are described in Chapter 17. Once the partial trapeziectomy is complete, interpositional material such as autologous palmaris longus tendon or FCR tendon, Gelfoam, or GrafJacket (Wright Medical Technology, Memphis, TN) can be inserted.[3] Artelon has also been used in this manner, but recent studies question the predictability of its use.[10,53,94]

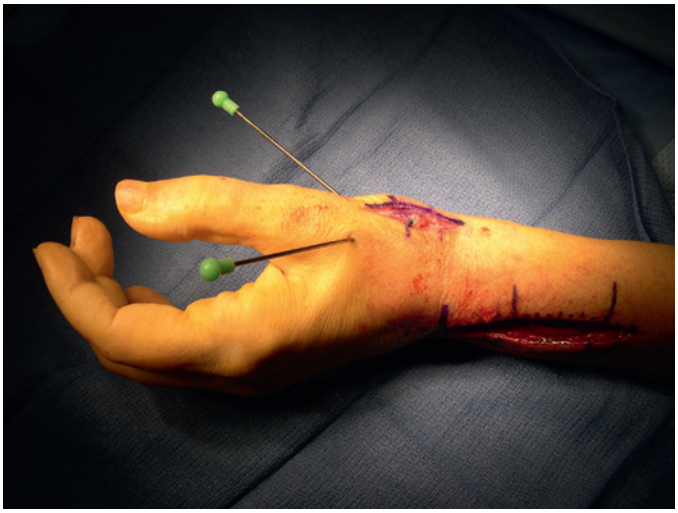

FIGURE 11.19 Carpometacarpal arthrodesis stabilized with cross K-wire technique.

❖ AUTHOR'S PREFERRED METHOD OF TREATMENT

For patients with stage III or IV osteoarthritis of the thumb CMC joint, I prefer the trapeziectomy with the FCR sling suspension arthroplasty procedure. I have occasionally used the same procedure for older, less active patients with stage II disease, but in my experience, most patients with stage I and early stage II disease can be treated nonoperatively.

The patient is placed supine on the operating room table with the affected arm positioned comfortably on a hand table extension. After regional anesthesia is achieved, a well-padded upper arm tourniquet is applied and padding is also placed beneath the elbows, knees, and heels. The arm is prepped and draped, the limb exsanguinated, and the tourniquet inflated.

A longitudinal incision is made over the dorsum of the thumb CMC joint (alternatively, a volar radial or Wagner incision can be used) (Figure 11.20, *A* to *C*). The deep branch of the radial artery is identified and protected by placing a vessel loop around the artery and the accompanying veins. The dorsoradial sensory nerve branches to the thumb are also identified and protected. The dorsal capsule of the thumb CMC joint is incised in line with the skin incision. The trapezium is exposed in a subperiosteal fashion. Using a Hoke osteotome, the trapezium is osteotomized into four segments and removed piecemeal with a small rongeur, with care being taken to protect the FCR tendon at its insertion at the base of the second metacarpal. It is important to recognize that the FCR tendon is immediately deep to the trapezium and can be damaged with removal of the trapezium, particularly when overzealous attempts are made to remove osteophytes enshrouding the tendon. The trapezoid is also identified, as is the distal pole of the scaphoid. Care should be exercised not to violate the articular surface of these structures; however, they are carefully inspected for advanced osteoarthritis and treated accordingly. If there are advanced osteoarthritic changes at the scaphotrapezoidal articulation, resection of the proximal half of the trapezoid is performed with a one-quarter-inch osteotome and mallet. Interposition material is not used. With a 0.4-mm oscillating saw, the base of the first metacarpal is osteotomized, exposing subchondral bone. Next, using a curet and a 2-mm bur, an oval window is created over the dorsoradial aspect at the base of the first metacarpal, which communicates to the base of the first metacarpal and exits into the space previously occupied by the trapezium. During exposure of the base of the first metacarpal as well as during creation of the oval window, it is important to avoid the insertion of the APL tendon on the dorsal radial aspect of the

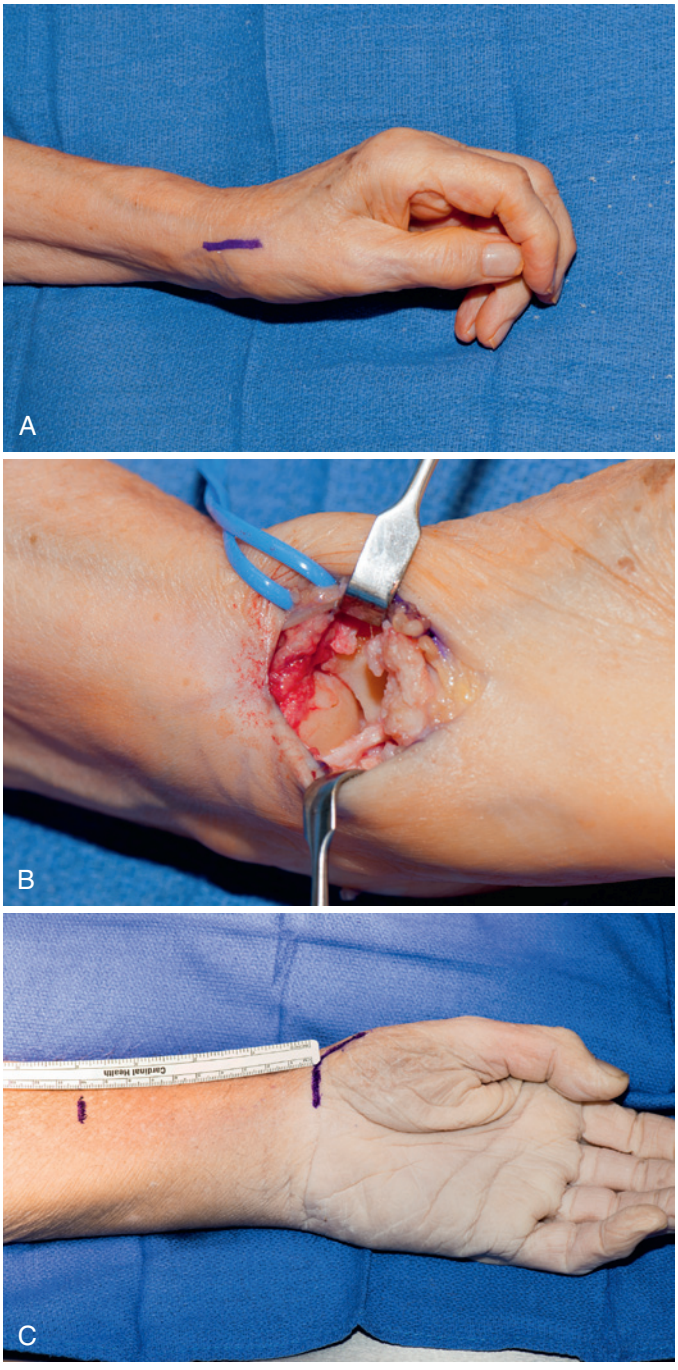

FIGURE 11.20 **A,** Dorsal approach with longitudinal incision for exposure of the thumb carpometacarpal joint. **B,** Following trapeziectomy. **C,** Wagner incision with transverse incision for flexor carpi radialis harvest positioned 10 cm proximal to the distal wrist flexion crease.

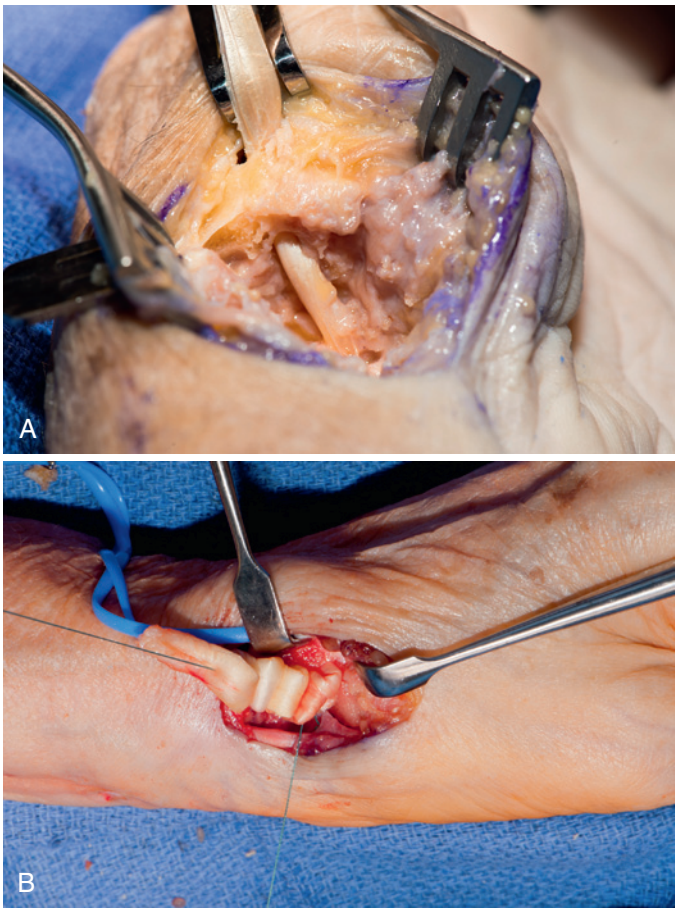

FIGURE 11.21 **A,** Flexor carpi radialis (FCR) tendon passed through osteotomized base of first metacarpal. **B,** FCR tendon anchovy achieved by placement of an alternating 2-0 nonabsorbable suture.

base of the first metacarpal. Using a 1-cm transverse incision in the forearm approximately 10 cm proximal to the wrist flexion crease, the myotendinous junction of the FCR tendon is identified (see Figure 11.20, C). This is released sharply, and the FCR tendon is delivered into the distal wound. Thrombin-soaked Gelfoam can be placed in the base of the void created by the trapeziectomy. A 2-0 suture is placed in the proximal stump of the FCR tendon for the purpose of passing the tendon, and the FCR is delivered through the base of the first metacarpal and through the oval window with the aid of a small right angle. It is tacked back upon itself using 2-0 nonabsorbable suture. A second nonabsorbable 2-0 suture is placed in the ulnar aspect of the capsule, deep in the wound. This 2-0 nonabsorbable suture is woven through the remaining FCR tendon so that it can be collapsed in accordion fashion into the void left by the trapeziectomy; the resulting FCR tendon "anchovy" is anchored into place, being secured with the limb of 2-0 nonabsorbable suture previously placed in the deep aspect of the void (Figure 11.21). The dorsal capsule of the thumb CMC joint is closed using a 4-0 absorbable suture.

At this point, the thumb MCP joint is assessed for stability. If more than 30 degrees of hyperextension instability is present, I favor some form of stabilization for the joint (Figure 11.22). This can include volar capsulodesis or MCP joint arthrodesis (described earlier in this chapter). Other described procedures include pinning of the MCP joint in flexion, sesamoid arthrodesis, or free palmaris longus tendon graft to the thumb MCP joint.[58]

The tourniquet is released prior to closure so hemostasis can be achieved. The wound is closed in layers using interrupted 4-0 absorbable suture for the CMC joint and subcutaneous tissue and 4-0 absorbable suture for the skin in a subcuticular fashion. A sterile dressing is applied. A thumb spica plaster splint is applied prior to leaving the operating room. See Case Studies 11.1 through 11.3.

CASE STUDY 11.1

A 74-year-old right-hand dominant retired pilot who has had a 7-year history of left thumb pain and left hand numbness experiences night time paresthesias that include the thumb, index, and long finger. Physical examination finds pain with left thumb carpometacarpal (CMC) grind test and with left thumb pinch strength testing, as well as with a positive left wrist carpal tunnel compression test. Subsequent nerve conduction velocity/electromyographic studies showed left carpal tunnel syndrome with delays in the distal motor latency. Radiographs showed advanced CMC degenerative arthritis as well as scaphotrapezoidal and scaphotrapezial degenerative arthritis (eFigure 11.1). Following failure of nonoperative care, the patient underwent a trapeziectomy and flexor carpi radialis sling suspension arthroplasty as well as a partial trapezoidectomy and carpal tunnel release (eFigure 11.2).

Postoperatively, he was treated with a 2-week period of immobilization followed by supervised mobilization by hand therapy. He returned to unrestricted activity at 3 months postoperative.

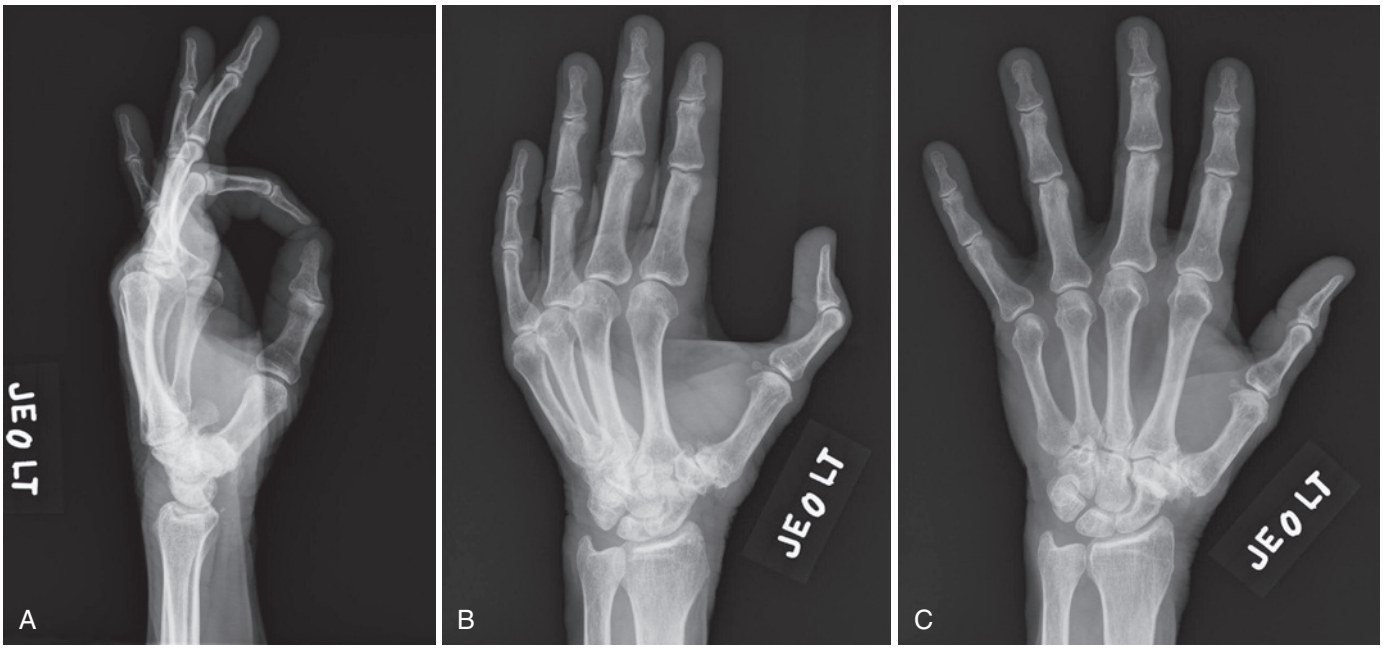

eFIGURE 11.1 Preoperative radiographs of left thumb. **A,** Lateral. **B,** Oblique. **C,** Posteroanterior.

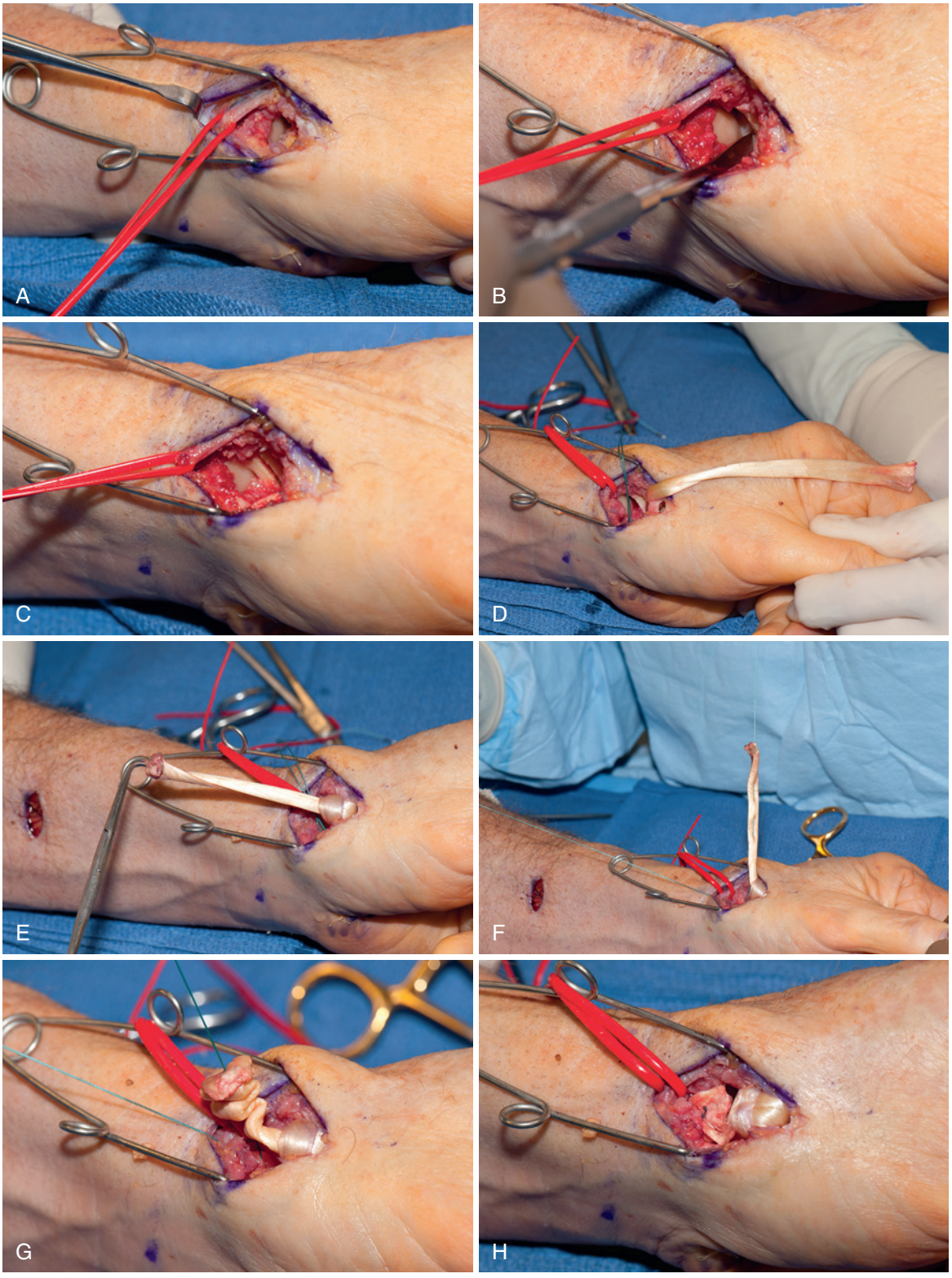
A
B
C
D
E
F
G
H

eFIGURE 11.2 Intraoperative photographs of trapeziectomy and flexor carpi radialis (FCR) sling suspension arthroplasty with a partial trapezoidectomy and carpal tunnel release. (For a complete discussion of the procedure, please see the Author's Preferred Method of Treatment under the section on CMC Arthroscopy.) A longitudinal incision is made over the dorsum of the thumb carpometacarpal (CMC) joint (alternatively, a volar radial or Wagner incision can be used). The deep branch of the radial artery is identified and protected by placing a vessel loop around the artery and the accompanying veins **(A).** The dorsoradial sensory nerve branches to the thumb are also identified and protected. The dorsal capsule of the thumb CMC joint is incised in line with the skin incision. The trapezium is then exposed in a subperiosteal fashion and, using a Hoke osteotome, the trapezium is osteotomized into four segments and then removed piecemeal with a small rongeur, being careful to protect the FCR tendon at its insertion at the base of the second metacarpal. It is important to recognize that the FCR tendon is immediately deep to the trapezium and can be damaged with removal of the trapezium, particularly when overzealous attempts are made to remove osteophytes enshrouding the tendon. The trapezoid is also identified, as is the distal pole of the scaphoid **(B).** Care should be exercised not to violate the articular surface of these structures; however, they are carefully inspected for advanced osteoarthritis and treated accordingly. If there are advanced osteoarthritic changes at the scaphotrapezoidal articulation, then resection of the proximal half of the trapezoid is performed with the use of a quarter osteotome and mallet **(C).** Interposition material is not used. Using a 0.4-mm oscillating saw, the base of the first metacarpal is osteotomized, exposing subchondral bone. Next, using a curet and a 2-mm burr, an oval window is created over the dorsoradial aspect at the base of the fiest metacarpal, which communicates to the base of the first metacarpal and exits into the space previously occupied by the trapezium. During the exposure of the base of the first metacarpal and the creation of the oval window, it is important to avoid the insertion of the abductor pollicis longus tendon on the dorsal radial aspect of the base of the first metacarpal. Using a 1-cm transverse incision in the forearm approximately 10 cm proximal to the wrist flexion crease, the myotendinous junction of the FCR tendon is identified. This is released sharply, and then the FCR tendon is delivered into the distal wound **(D).** Thrombin-soaked Gelfoam can be placed in the base of the void created by the trapeziectomy. A 2-0 suture is placed in the proximal stump of the FCR tendon for the purpose of passing the tendon, and the FCR is delivered through the base of the first metacarpal, then through the oval window with the aid of a small right angle. It is then tacked back upon itself using 2-0 nonabsorbable suture **(E, F).** A second nonabsorbable 2-0 suture is placed in the ulnar aspect of the capsule, deep in the wound. This 2-0 nonabsorbable suture is then weaved through the remaining FCR tendon such that it can be collapsed in accordion fashion into the void left by the trapeziectomy, and the resulting FCR tendon "anchovy" is anchored into place, secured with the other limb of the 2-0 nonabsorbable suture previously placed in the deep aspect of the void **(G, H).** The dorsal capsule of the thumb CMC joint is then closed using a 4-0 absorbable suture.

CASE STUDY 11.2

A 70-year-old right hand dominant female presented with a 2-year history of progressive pain and disability of the right thumb. She experiences pain with opening doors and jars. She has had to give up knitting because of her right thumb pain and she complains that she drops objects around the house. She has been treated with paraffin wax, heat, splints, and antiinflammatory medications and injections without lasting relief. Physical examination revealed pain with carpometacarpal (CMC) compression testing, and it was also noted that she had limited and painful right thumb palmar abduction. Radiographs showed moderate right thumb CMC joint degenerative arthritis without apparent involvement of the scaphotrapezoidal joint (eFigure 11.3). Subsequently, she underwent a right thumb trapeziectomy and flexor carpi radialis sling suspension arthroplasty. At time of surgery, her scaphotrapezoidal joint was inspected and no degenerative arthritis was noted.

Postoperatively, she was treated with a 2-week period of immobilization followed by supervised mobilization by hand therapy. She returned to unrestricted activity at 3 months postoperative.

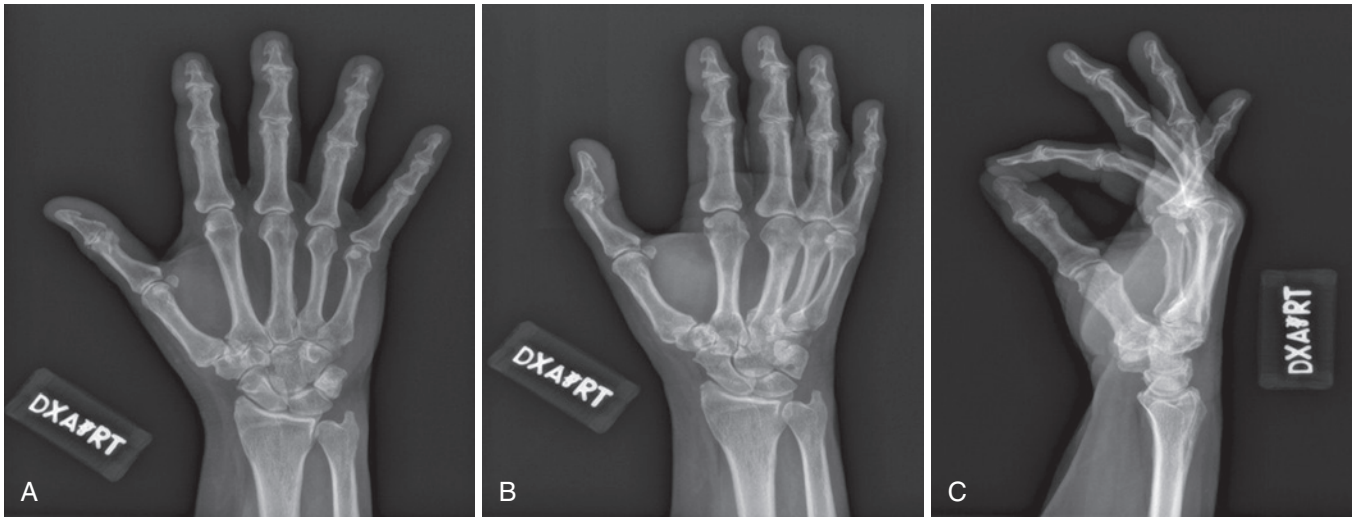

eFIGURE 11.3 Radiographs showing moderate right thumb carpometacarpal joint degenerative arthritis without apparent involvement of the scaphotrapezoidal joint.

CASE STUDY 11.3

A 68-year-old right hand dominant retired female presented with a 5-year history of right small finger pain. The small finger pain interferes with activities of daily living, particularly gripping activities. The small finger pain will also awaken her at night from time to time. She has had multiple corticosteroid injections into the right small finger proximal interphalangeal (PIP) joint, which has given her limited relief. She has had no history of injury but has recently had a right thumb carpometacarpal (CMC) trapeziectomy and flexor carpi radialis sling suspension arthroplasty with a right thumb metacarpophalangeal (MCP) joint arthrodesis for thumb CMC degenerative arthritis with thumb MCP joint instability.

On physical examination, the patient had right small finger PIP joint range of motion of 30 to 65 degrees with pain. There is also pain with PIP joint compression and distraction. Radiographs show advanced degenerative arthritis of the right small finger PIP joint (eFigure 11.4).

The patient underwent a right small finger PIP joint arthroplasty using a Chamay dorsal approach (eFigure 11.5). Postoperatively, she was treated with a volar wrist bases orthosis that prevented active PIP joint flexion in a graduated fashion. At 6 weeks postoperative, she returned to all activities of daily living without restriction.

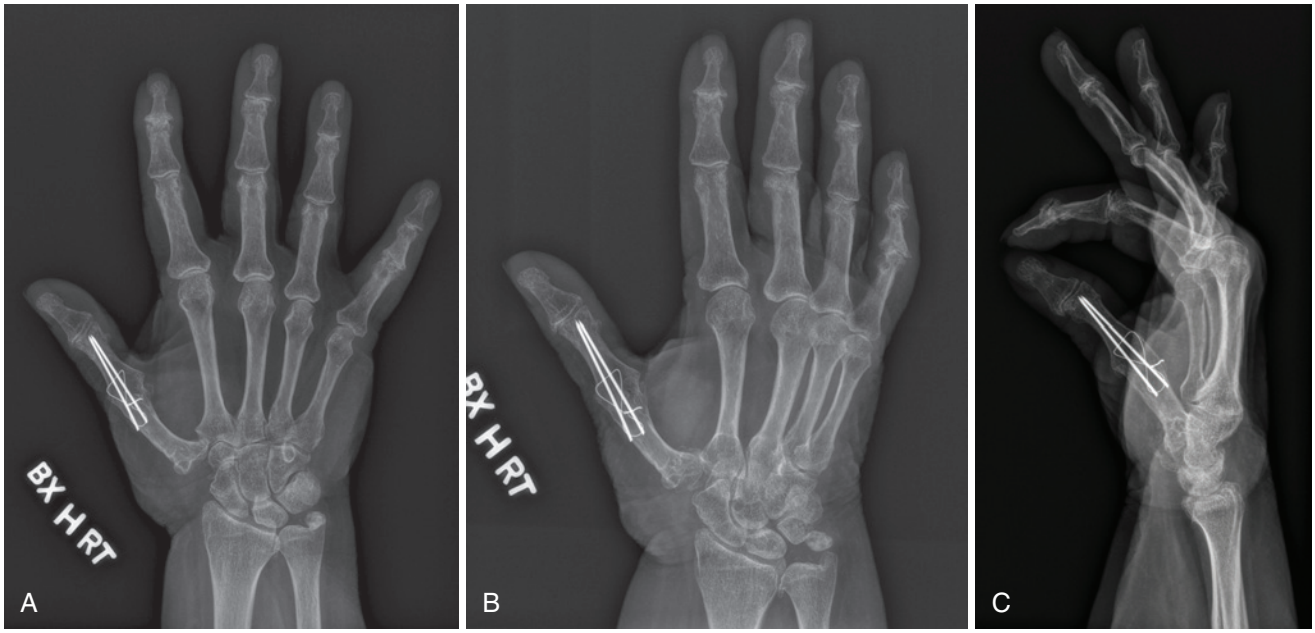

eFIGURE 11.4 Radiographs showing advanced degenerative arthritis of the right small finger proximal interphalangeal joint.

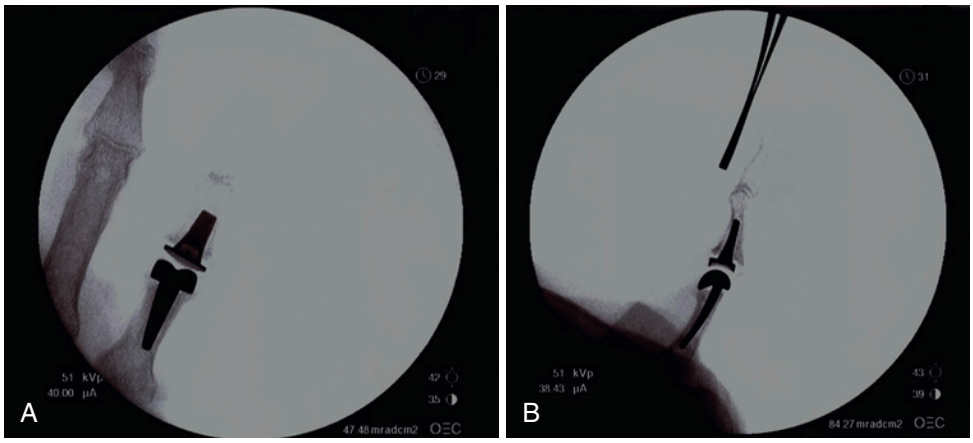

eFIGURE 11.5 Right small finger proximal interphalangeal joint arthroplasty using a Chamay dorsal approach.

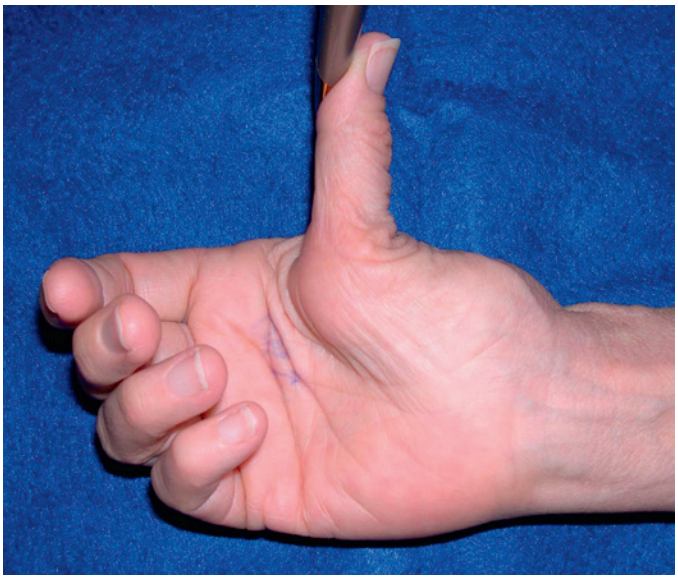

FIGURE 11.22 Hyperextension instability of the thumb MCP joint in the setting of advanced carpometacarpal osteoarthritis.

CRITICAL POINTS *Trapeziectomy and Flexor Carpi Radialis Sling Suspension Arthroplasty (LRTI)*

- A dorsal incision provides wide exposure to the trapezium.
- Identify the dorsal sensory nerve branches and the deep branch of the radial artery.
- Osteotomize the trapezium into pieces for removal with a rongeur.
- Using a 2-mm bur, create an oval window on the dorsal proximal aspect of the first metacarpal, avoiding the APL.
- Remove the articular surface of the base of the first metacarpal and a sliver of subchondral bone with a microsagittal saw.
- Carefully inspect the scaphotrapezoidal articulation for osteoarthritis and treat with resection of the proximal half of the trapezoid, if indicated.
- Protect the FCR tendon in the depths of the wound during extraction of the trapezium.
- Locate the FCR myotendinous junction 10 cm proximal to the wrist flexion crease.
- Harvest the entire FCR tendon and deliver the tendon into the trapeziectomy wound.
- Create an oval window and metacarpal base osteotomy of sufficient size to accommodate passage of the entire FCR tendon.
- Use the "anchovy procedure" for the remaining FCR tendon, securing it in the depths of the trapeziectomy wound with 2-0 nonabsorbable suture.

Postoperative Management and Expectations

Five to 7 days following surgery, provided the wound is in suitable condition, the patient is fitted for a removable custom forearm-based thumb spica splint with the thumb IP joint free. The splint is maintained for 6 weeks; it is removed daily for digital and wrist range-of-motion movements as well as hygienic care. This is followed by 6 weeks of strengthening, adaptation to activities of daily leaving, and occupational-related activities as needed. Return to full activities is anticipated at 12 weeks following operation.

Expected Outcomes

First Metacarpal Osteotomy. Although studies are few and small in size, first metacarpal osteotomy is reliable in restoring thumb function and strength. Tomaino prospectively reported on 12 patients with stage I disease with follow-up at 2.1 years. All osteotomies had healed, and 11 of the 12 patients were satisfied with the outcome. Grip and pinch strength had both increased. Parker and colleagues,[99] in a longer-term follow-up, retrospectively reported on eight patients with a mean follow-up of 9 years. Excellent functional outcomes were reported in six of the eight patients, and the authors concluded that first metacarpal osteotomy is a durable procedure that has a predictable outcome in patients with early- to moderate-stage disease.

Resection Arthroplasty. Resection of the trapezium with or without ligament reconstruction and interposition has been shown by many authors to provide favorable results (Table 11.2), irrespective of the technique. More recently, different authors have published results comparing not only different technique modifications for traditional trapeziectomy and FCR sling suspension/interposition arthroplasty procedures but also suspension procedures using different tendons and, in some cases, synthetic material for the traditional trapeziectomy and FCR suspension/interposition procedure.

Davis and Pace compare in a prospective fashion the results of trapeziectomy and FCR ligament reconstruction and tendon interposition (LRTI) with or without K-wire stabilization and casting. At 1 year following surgery, clinical outcome measures did not differ among the two groups.[29] Field and Buchanan examined 65 patients randomized into two groups. One group had trapeziectomy alone and the other had FCR suspensionplasty. Patient satisfaction among the two groups was similar.[34] Gangopadhyay and associates[39] studied 174 thumbs in three groups: trapeziectomy alone, trapeziectomy with palmaris longus interposition, and trapeziectomy with suspensionplasty using half of the FCR tendon. At a minimum of 5 years of follow-up, they found no difference in pain relief, grip strength, pinch strength, and range of motion, causing them to conclude that there is no benefit from tendon interposition or ligament reconstruction following trapeziectomy for thumb CMC osteoarthritis.[39] In another study from the same group, Salem and Davis evaluated 114 thumbs in a randomized prospective series with a mean follow-up of 6.2 years, comparing trapeziectomy alone versus trapeziectomy and ligament reconstruction using FCR suspensionplasty and K-wire stabilization. Again, the authors found no difference in any subjective or objective outcome measures, causing them to conclude that evidence does not support the use of the LRTI procedure and K-wire stabilization following trapeziectomy.[114] Garcia-Mas and Sole Molins[40] compared the results of 94 thumbs that had been treated with partial trapeziectomy and FCR suspensionplasty with 18 thumbs treated with total trapeziectomy and FCR suspensionplasty and found no difference in outcome at a minimum of 3 years of follow-up.

It is worth noting that the partial trapeziectomy group included patients with stages II and III thumb CMC osteoarthritis, whereas all patients in the total trapeziectomy group had stage IV disease.[40] The approach to trapeziectomy was studied

TABLE 11.2 Studies of Carpometacarpal Arthroplasty

Technique	Study	Mean Follow-up Time (months)	Number of Procedures	Good to Excellent Outcome	Fair to Poor Outcome	Number of Complications	Male-to-Female Ratio	Level of Evidence
Double interposition	Barron,1998[8]	34	21	95%	5%	4	8:12	IV
trapeziectomy, LRTI (FCR)	Burton, 1986[18]	24	25	92%	8%	2	3:21	IV
trapeziectomy, LRTI (APL)	Chang, 2008[23]	12	21	NA	NA	3	4:14	IV
trapeziectomy, LRTI (APL)	Kochevar, 2011[59]	66	25	94%	6%	0	1:17	IV
trapeziectomy, acellular matrix	Kokkalis, 2009[61]	30	82	NA	NA	6	15-67	IV
trapeziectomy	Kuhns, 2003[63]	24	26	96%	4%	2	7:19	II
trapeziectomy	Gray, 2007[43]	25	22	100%	0%	2	5:17	II
trapeziectomy, LRTI (APL-ECRL)	Sammer, 2009[115]	9	42	90%	10%	7	7:41	IV
trapeziectomy, LRTI (APL)	Soejima, 2006[119]	33.3	21	86%	14%	NA	2:16	IV
trapeziectomy, suture anchor/graft	Taghinia, 2008[127]	48	46	93%	7%	3	7:31	III
trapeziectomy, LRTI (FCR)	Tomaino, 1995[133]	108	24	95%	5%	3	3:19	IV
trapeziectomy, LRTI (Weilby)	Vadstrup, 2009[138]	12	106	83%	17%	18	18:87	II
trapeziectomy, LRTI (Weilby)	Vermeulen, 2009[143]	12	20	90%	10%	4	2:17	II
trapeziectomy	Wollstein, 2009[148]	86	8	100%	0%	NA	1:7	IV
trapeziectomy, FCR screw fixation	Wysocki, 2010[150]	19	29	NA	NA	1	5:24	IV
trapeziectomy, suture button suspension	Yao, 2013[152]	34	21	NA	NA	2	NA	IV
trapeziectomy, partial	Noland, 2012[95]	108	16	92%	7%	NA	4:9	IV

APL, Abductor pollicis longus; *ECRL*, extensor carpi radialis longus; *FCR*, flexor carpi radialis; *LRTI*, ligament reconstruction and tendon interposition.

by Ritchie and Belcher.[111] In this randomized study, they evaluated the results of trapeziectomy performed through either an anterior incision or a dorsal radial incision to the thumb CMC joint in 40 hands at a median follow-up of 33 months. They found that trapeziectomy performed through the anterior approach had better outcomes for power, scar tenderness, and overall patient satisfaction. The findings of these studies have been further amplified by Li and coworkers,[67] who published a systematic literature review that used electronic databases to identify previously published randomized controlled trials, including several of the previously mentioned studies, comparing trapeziectomy alone versus trapeziectomy with some form of FCR suspensionplasty and temporary K-wire stabilization. They concluded that neither procedure provided a clear benefit over the other.

Poulter and Davis[83,106] were unable to show any difference in outcome at 1 year for MCP joint hyperextension deformity of up to 30 degrees. For hyperextension beyond that, they showed that correction of the deformity was successful but were unable to draw definitive conclusions on how this affected outcomes. They did find value in volar plate advancement with suture anchors for correcting the MCP hyperextension deformity and found little sustainable postoperative correction with simple, temporary K-wire fixation of the MCP joint.

In a follow-up questionnaire study comparing thumb CMC implant arthroplasty with trapeziectomy and FCR sling suspension arthroplasty, no significant difference could be demonstrated between the two. The device used was the de la Caffinière prosthesis (Stryker, Kalamazoo, MI) or Roseland prosthesis (DePuy Synthes, Warsaw, IN). Questionnaires regarding 89 CMC prosthetic implants were received, as well as questionnaires regarding 233 thumbs treated with trapeziectomy and the FCR sling suspension procedure. Given the cost of the implant and the fact that clear superiority of the implant could not be shown, the authors recommend trapeziectomy and FCR sling suspension as the preferred procedure for the treatment of thumb CMC osteoarthritis.[141]

In a randomized controlled study of 79 women over the age of 40 years with stage IV osteoarthritis of the thumb CMC joint, Vermeulen and colleagues[142] compared the clinical outcomes of trapeziectomy with the FCR sling suspension arthroplasty (Burton and Pellegrini technique) and the clinical outcomes of the FCR-APL suspension procedure (Weilby technique). At 3 months after surgery, the group treated with the Burton and

Pellegrini procedure demonstrated significant improvement in the Patient-Rated Wrist and Hand Function Evaluation, but by 12 months, no significant differences were seen in outcome scores or in rates of strength, return to work, patient satisfaction, or complications. The results led the authors to conclude that the trapeziectomy with the FCR suspension procedure using a bone tunnel offered a quicker initial recovery but by 1 year the results of the two procedures were similar.

A nuance of trapeziectomy with or without LRTI is the identification of scaphotrapezoidal involvement or the presence of stage IV disease. Tomaino and associates[134] have reported a sensitivity of radiographic diagnosis of 44% for scaphotrapezoidal disease and recommended visual inspection of the joint at the time of surgery. In the same study, the authors evaluated the results of proximal trapezoidal resection in 14 patients; they found no morbidity from the procedure and recommended its use in patients with trapezoidal osteoarthritis in the setting of thumb CMC osteoarthritis in order to prevent residual symptoms.

Carpometacarpal Arthrodesis. In a retrospective study of 59 trapezial metacarpal arthrodeses followed up at 7 years, Stern and Fulton[38] reported four nonunions following a technique that involved K-wire fixation and distal radius bone graft. Pain was assessed as an average of 1.5 on a scale of 10. In a more recent experience, the authors concluded that trapezial metacarpal arthrodesis in patients older than 40 years of age was successful for isolated trapezial metacarpal osteoarthritis. In a more recent, larger retrospective report, Rizzo and coworkers[112] reviewed 126 thumbs following trapezial metacarpal arthrodesis for osteoarthritis at an average follow-up of 11 years. Although they reported 17 nonunions, the oppositional pinch, grip strength, and pain scores of the entire group had significantly improved. Even though there was progression of osteoarthritis at the scaphotrapezoidal joint and MCP joint in 39 and 16 thumbs, respectively, over the study period, only 8 thumbs became symptomatic. The authors concluded that trapezial metacarpal arthrodesis improved functional results and resulted in excellent patient satisfaction despite the concomitant development of scaphotrapezoidal and first MCP osteoarthritis.

Carpometacarpal Arthroplasty. A number of implant arthroplasties have been designed for thumb CMC osteoarthritis. Perhaps the most widely used implant has been the de la Caffinière implant; however, it is no longer available. Johnston and colleagues[50] reported on 39 implants reviewed at 19 years. Survivorship was 73.9%, and patients continued to be satisfied with the implant arthroplasty. Lemoine and associates[65] reported on the Guepar prosthesis. In a retrospective review of 84 prostheses at 50 months, 92% of patients were satisfied with their results and more than 80% remained pain free. The authors concluded that use of this prosthesis for thumb metacarpal trapezial osteoarthritis is effective for improving strength and motion as well as providing a high degree of pain relief. However, it should be noted that less than half of patients had what would be typically considered advanced osteoarthritis of the thumb CMC joint. The authors go on to state that success with the use of this implant is dependent on compliance with the details of surgical technique. Badia and Sambandam[7] retrospectively reported on the results of the use of the Braun prosthesis in 26 thumbs with stages III and IV osteoarthritis of the thumb CMC joint. Ninety-six percent of patients reported complete pain relief. The most widely used pyrolytic carbon device for the thumb CMC joint is the hemiarthroplasty. Martinez de Aragon and coworkers[76] have reported on 54 pyrolytic hemiarthroplasty implants; at 1.8 years, the survival rate was 80% and 71% of patients were pain free, but there was a high complication rate. Hansen and Snerum[44] reported on 17 Elecktra prostheses for the thumb CMC joint with a 35-month follow-up. Seven of the 10 prostheses had failed. Van Rijn and Gosens[140] reported on the results of the Avanta SR-TMC prosthesis (Small Bone Innovations, New York, NY) in 15 thumbs at a follow-up of 36 months. The range of motion and strength had not improved, but pain had subsided significantly.

Complications. The most common complication encountered with the first metacarpal osteotomy and the thumb CMC arthrodesis is nonunion. Fortunately, this complication is unusual, as is development of infection. Complications seen with implant joint replacement arthroplasty are loosening and subluxation. However, long-term studies for these implant arthroplasty procedures are not currently available. Implant subluxation is more often seen in the pyrocarbon hemiarthroplasty as reported by Martinez de Aragon and colleagues.[76] Kaszap and associates[55] have performed 15 secondary trapeziectomies following failure of trapeziometacarpal joint implant arthroplasty. Using subjective and objective evaluation measures, there was no difference in outcome when comparing secondary trapezium resection for revision surgery following failed CMC joint implant arthroplasty and primary trapeziectomy using a matched-pair analysis.

Following trapeziectomy, postoperative radiographic phenomena have been observed. Metacarpal subsidence has been demonstrated in excess of 30% with lateral pinch; however, this has not been shown to correlate with functional outcomes (Figure 11.23, *A* and *B*).[151] Yuan and coworkers[153] have reported on the development of carpal collapse following trapeziectomy. In a review of 33 wrists following surgery, they documented the increased presence of a dorsal intercalated segment instability deformity from 27% before operation to 50% following operation, noting an even greater tendency in patients with stage IV disease. Salem and Davis[114] have also shown the progression of degenerative changes in the pseudarthrosis site between the base of the first metacarpal and the scaphoid; however, these changes were not deemed clinically relevant in 25 thumbs at 6 years of follow-up.

Low and Hales[73] have reported a 25% incidence of FCR tendonitis 2 to 10 months following trapeziectomy and APL suspensionplasty, leading to persisting postoperative pain. Sixty percent of these patients required surgery, with some experiencing FCR rupture and pseudotendon formation. Jones and colleagues[52] have evaluated the consequences of and salvage options for complete FCR rupture during primary trapeziectomy and FCR sling suspensionplasty, including use of the partially ruptured FCR tendon or part of the ECRL tendon. Herniation of the tendon interposition material has been reported but can usually be treated with restabilization or excision of the material.[110]

Umarji and associates[137] have shown improvements in pain, pinch, activities of daily living, and overall satisfaction following silastic interposition finger arthroplasty treatment for failed trapeziectomy. This was a small series of 10 patients with an average follow-up of 53 months.



FIGURE 11.23 **A** and **B,** First metacarpal subsidence following trapeziectomy.

For Case Studies, Videos, and more, please visit ExpertConsult.com.

REFERENCES

1. Adams J, Ryall C, Pandyan A, et al: Proximal interphalangeal joint replacement in patients with arthritis of the hand: a meta-analysis. *J Bone Joint Surg Br* 94(10): 1305–1312, 2012.
2. Adams JE: Does arthroscopic debridement with or without interposition material address carpometacarpal arthritis? *Clin Orthop Relat Res* 472(4):1166–1172, 2014.
3. Adams JE, Steinmann SP, Culp RW: Bone-preserving arthroscopic options for treatment of thumb basilar joint arthritis. *Hand Clin* 27(3):355–359, 2011.
4. Allende BT, Engelem JC: Tension-band arthrodesis in the finger joints. *J Hand Surg [Am]* 5(3):269–271, 1980.
5. Armstrong AL, Hunter JB, Davis TR: The prevalence of degenerative arthritis of the base of the thumb in post-menopausal women. *J Hand Surg [Br]* 19(3):340–341, 1994.
6. Ayres JR, Goldstrohm GL, Miller GJ, et al: Proximal interphalangeal joint arthrodesis with the Herbert screw. *J Hand Surg [Am]* 13(4):600–603, 1988.
7. Badia A, Sambandam SN: Total joint arthroplasty in the treatment of advanced stages of thumb carpometacarpal joint osteoarthritis. *J Hand Surg [Am]* 31(10): 1605–1614, 2006.
8. Barron OA, Eaton RG: Save the trapezium: double interposition arthroplasty for the treatment of stage IV disease of the basal joint. *J Hand Surg [Am]* 23(2):196–204, 1998.
9. Bickel KD: The dorsal approach to silicone implant arthroplasty of the proximal interphalangeal joint. *J Hand Surg [Am]* 32(6):909–913, 2007.
10. Blount AL, Armstrong SD, Yuan F, et al: Porous polyurethaneurea (Artelon) joint spacer compared to trapezium resection and ligament reconstruction. *J Hand Surg [Am]* 38(9):1741–1745, 2013.
11. Branam BR, Tuttle HG, Stern PJ, et al: Resurfacing arthroplasty versus silicone arthroplasty for proximal interphalangeal joint osteoarthritis. *J Hand Surg [Am]* 32(6):775–788, 2007.
12. Brannon EW, Klein G: Experiences with a finger-joint prosthesis. *J Bone Joint Surg Am* 41(1):87–102, 1959.
13. Braun RM, Rhoades CE: Dynamic compression for small bone arthrodesis. *J Hand Surg [Am]* 10(3):340–343, 1985.
14. Bravo CJ, Rizzo M, Hormel KB, et al: Pyrolytic carbon proximal interphalangeal joint arthroplasty: results with minimum two-year follow-up evaluation. *J Hand Surg [Am]* 32(1):1–11, 2007.
15. Breyer JM, Vergara P, Parra L, et al: Metacarpophalangeal and interphalangeal joint arthrodesis: a comparative study between tension band and compression screw fixation. *J Hand Surg Eur Vol* 40(4):374–378, 2015.
16. Buchler U, Aiken MA: Arthrodesis of the proximal interphalangeal joint by solid bone grafting and plate fixation in extensive injuries to the dorsal aspect of the finger. *J Hand Surg [Am]* 13(4):589–594, 1988.
17. Burton RI, Margles SW, Lunseth PA: Small-joint arthrodesis in the hand. *J Hand Surg [Am]* 11(5):678–682, 1986.
18. Burton RI, Pellegrini VD, Jr: Surgical management of basal joint arthritis of the thumb. Part II. Ligament reconstruction with tendon interposition arthroplasty. *J Hand Surg [Am]* 11(3):324–332, 1986.
19. Carroll RE, Hill NA: Small joint arthrodesis in hand reconstruction. *J Bone Joint Surg Am* 51(6):1219–1221, 1969.
20. Carroll RE, Taber TH: Digital arthroplasty of the proximal interphlangeal joint. *J Bone Joint Surg Am* 36(5):912–920, 1954.
21. Chamay A: A distally based dorsal and triangular tendinous flap for direct access to the proximal interphalangeal joint. *Ann Chir Main* 7(2):179–183, 1988.
22. Chan K, Ayeni O, McKnight L, et al: Pyrocarbon versus silicone proximal interphalangeal joint arthroplasty: a systematic review. *Plast Reconstr Surg* 131(1):114–124, 2013.
23. Chang EY, Chung KC: Outcomes of trapeziectomy with a modified abductor pollicis longus suspension arthroplasty for the treatment of thumb carpometacarpal joint osteoarthritis. *Plast Reconstr Surg* 122(2):505–515, 2008.
24. Chung KC, Ram AN, Shauver MJ: Outcomes of pyrolytic carbon arthroplasty for the proximal interphalangeal joint. *Plast Reconstr Surg* 123(5):1521–1532, 2009.
25. Cobb T, Sterbank P, Lemke J: Arthroscopic resection arthroplasty for treatment of combined carpometacarpal and scaphotrapeziotrapezoid (pantrapezial) arthritis. *J Hand Surg [Am]* 36(3):413–419, 2011.
26. Cook SD, Beckenbaugh RD, Redondo J, et al: Long-term follow-up of pyrolytic carbon metacarpophalangeal implants. *J Bone Joint Surg Am* 81(5):635–648, 1999.
27. Cox C, Earp BE, Floyd WE, 4th, et al: Arthrodesis of the thumb interphalangeal joint and finger distal interphalangeal joints with a headless compression screw. *J Hand Surg [Am]* 39(1):24–28, 2014.
28. Daecke W, Kaszap B, Martini AK, et al: A prospective, randomized comparison of 3 types of proximal interphalangeal joint arthroplasty. *J Hand Surg [Am]* 37(9):1770–1779, 2012.
29. Davis TR, Pace A: Trapeziectomy for trapeziometacarpal joint osteoarthritis: is ligament reconstruction and temporary stabilisation of the pseudarthrosis with a Kirschner wire important? *J Hand Surg Eur Vol* 34(3):312–321, 2009.

30. Day CS, Gelberman R, Patel AA, et al: Basal joint osteoarthritis of the thumb: a prospective trial of steroid injection and splinting. *J Hand Surg [Am]* 29(2):247–251, 2004.
31. Domalain M, Evans PJ, Seitz WH, Jr, et al: Influence of index finger proximal interphalangeal joint arthrodesis on precision pinch kinematics. *J Hand Surg [Am]* 36(12):1944–1949, 2011.
32. Eaton RG, Lane LB, Littler JW, et al: Ligament reconstruction for the painful thumb carpometacarpal joint: a long-term assessment. *J Hand Surg [Am]* 9(5):692–699, 1984.
33. Faithfull DK, Herbert TJ: Small joint fusions of the hand using the Herbert Bone Screw. *J Hand Surg [Br]* 9(2):167–168, 1984.
34. Field J, Buchanan D: To suspend or not to suspend: a randomised single blind trial of simple trapeziectomy versus trapeziectomy and flexor carpi radialis suspension. *J Hand Surg Eur Vol* 32(4):462–466, 2007.
35. Fitzgerald BT, Hofmeister EP: Treatment of advanced carpometacarpal joint disease: trapeziectomy and hematoma arthroplasty. *Hand Clin* 24(3):271–276, vi, 2008.
36. Flatt A: Restoration of rheumatoid finger-joint function: interim report on trial of prosthetic replacement. *J Bone Joint Surg Am* 43:753–774, 1961.
37. Freedman DM, Eaton RG, Glickel SZ: Long-term results of volar ligament reconstruction for symptomatic basal joint laxity. *J Hand Surg [Am]* 25(2):297–304, 2000.
38. Fulton DB, Stern PJ: Trapeziometacarpal arthrodesis in primary osteoarthritis: a minimum two-year follow-up study. *J Hand Surg [Am]* 26(1):109–114, 2001.
39. Gangopadhyay S, McKenna H, Burke FD, et al: Five- to 18-year follow-up for treatment of trapeziometacarpal osteoarthritis: a prospective comparison of excision, tendon interposition, and ligament reconstruction and tendon interposition. *J Hand Surg [Am]* 37(3):411–417, 2012.
40. Garcia-Mas R, Sole Molins X: Partial trapeziectomy with ligament reconstruction: tendon interposition in thumb carpo-metacarpal osteoarthritis: a study of 112 cases. *Chir Main* 28(4):230–238, 2009.
41. Gervis WH, Wells T: A review of excision of the trapezium for osteoarthritis of the trapezio-metacarpal joint after twenty-five years. *J Bone Joint Surg Br* 55(1): 56–57, 1973.
42. Granowitz S, Vainio K: Proximal interphalangeal joint arthrodesis in rheumatoid arthritis. A follow-up study of 122 operations. *Acta Orthop Scand* 37(3):301–310, 1966.
43. Gray KV, Meals RA: Hematoma and distraction arthroplasty for thumb basal joint osteoarthritis: minimum 6.5-year follow-up evaluation. *J Hand Surg [Am]* 32(1):23–29, 2007.
44. Hansen TB, Snerum L: Elektra trapeziometacarpal prosthesis for treatment of osteoarthrosis of the basal joint of the thumb. *Scand J Plast Reconstr Surg Hand Surg* 42(6):316–319, 2008.
45. Hogh J, Jensen PO: Compression-arthrodesis of finger joints using Kirschner wires and cerclage. *Hand* 14(2):149–152, 1982.
46. Hunter DJ, Zhang Y, Nevitt MC, et al: Chopstick arthropathy: the Beijing Osteoarthritis Study. *Arthritis Rheum* 50(5):1495–1500, 2004.
47. Ijsselstein CB, van Egmond DB, Hovius SE, et al: Results of small-joint arthrodesis: comparison of Kirschner wire fixation with tension band wire technique. *J Hand Surg [Am]* 17(5):952–956, 1992.
48. Iwamoto T, Matsumura N, Sato K, et al: An obliquely placed headless compression screw for distal interphalangeal joint arthrodesis. *J Hand Surg [Am]* 38(12): 2360–2364, 2013.
49. Jennings CD, Livingstone DP: Surface replacement arthroplasty of the proximal interphalangeal joint using the PIP-SRA implant: results, complications, and revisions. *J Hand Surg [Am]* 33(9):1565, 2008.
50. Johnston P, Getgood A, Larson D, et al: De la Caffiniere thumb trapeziometacarpal joint arthroplasty: 16-26 year follow-up. *J Hand Surg Eur Vol* 37(7):621–624, 2012.
51. Johnstone BR, Fitzgerald M, Smith KR, et al: Cemented versus uncemented surface replacement arthroplasty of the proximal interphalangeal joint with a mean 5-year follow-up. *J Hand Surg [Am]* 33(5):726–732, 2008.
52. Jones DB, Jr, Rhee PC, Shin AY, et al: Salvage options for flexor carpi radialis tendon disruption during ligament reconstruction and tendon interposition or suspension arthroplasty of the trapeziometacarpal joint. *J Hand Surg [Am]* 38(9):1806–1811, 2013.
53. Jorheim M, Isaxon I, Flondell M, et al: Short-term outcomes of trapeziometacarpal Artelon implant compared with tendon suspension interposition arthroplasty for osteoarthritis: a matched cohort study. *J Hand Surg [Am]* 34(8):1381–1387, 2009.
54. Joshi R: Intraarticular corticosteroid injection for first carpometacarpal osteoarthritis. *J Rheumatol* 32(7):1305–1306, 2005.
55. Kaszap B, Daecke W, Jung M: Outcome comparison of primary trapeziectomy versus secondary trapeziectomy following failed total trapeziometacarpal joint replacement. *J Hand Surg [Am]* 38(5):863–871 e863, 2013.
56. Katzman SS, Gibeault JD, Dickson K, et al: Use of a Herbert screw for interphalangeal joint arthrodesis. *Clin Orthop Relat Res* (296):127–132, 1993.
57. Khuri SM: Tension band arthrodesis in the hand. *J Hand Surg [Am]* 11(1):41–45, 1986.
58. Klinefelter R: Metacarpophalangeal hyperextension deformity associated with trapezial-metacarpal arthritis. *J Hand Surg [Am]* 36(12):2041–2042, quiz 2043, 2011.
59. Kochevar AJ, Adham CN, Adham MN, et al: Thumb basal joint arthroplasty using adductor pollicis longus tendon: an average 5.5 year follow up. *J Hand Surgery [Am]* 36A:1326–1332, 2011.
60. Koff MF, Shrivastava N, Gardner TR, et al: An in vitro analysis of ligament reconstruction or extension osteotomy on trapeziometacarpal joint stability and contact area. *J Hand Surg [Am]* 31(3):429–439, 2006.
61. Kokkalis ZT, Zanaros G, Weiser RW, et al: Trapezium resection with suspension and interposition arthroplasty using acellular dermal allograft for thumb carpometacarpal arthritis. *J Hand Surg [Am]* 34(6):1029–1036, 2009.
62. Kovach JC, Werner FW, Palmer AK, et al: Biomechanical analysis of internal fixation techniques for proximal interphalangeal joint arthrodesis. *J Hand Surg [Am]* 11(4):562–566, 1986.
63. Kuhns CA, Emerson ET, Meals RA: Hematoma and distraction arthroplasty for thumb basal joint osteoarthritis: a prospective, single-surgeon study including outcomes measures. *J Hand Surg [Am]* 28(3):381–389, 2003.
64. Leibovic SJ, Strickland JW: Arthrodesis of the proximal interphalangeal joint of the finger: comparison of the use of the Herbert screw with other fixation methods. *J Hand Surg [Am]* 19(2):181–188, 1994.
65. Lemoine S, Wavreille G, Alnot JY, et al: Second generation GUEPAR total arthroplasty of the thumb basal joint: 50 months follow-up in 84 cases. *Orthop Traumatol Surg Res* 95(1):63–69, 2009.
66. Lewis AR, Ralphs JR, Kneafsey B, et al: Distribution of collagens and glycosaminoglycans in the joint capsule of the proximal interphalangeal joint of the human finger. *Anat Rec* 250(3):281–291, 1998.
67. Li YK, White C, Ignacy TA, et al: Comparison of trapeziectomy and trapeziectomy with ligament reconstruction and tendon interposition: a systematic literature review. *Plast Reconstr Surg* 128(1):199–207, 2011.
68. Lin HH, Wyrick JD, Stern PJ: Proximal interphalangeal joint silicone replacement arthroplasty: clinical results using an anterior approach. *J Hand Surg [Am]* 20(1):123–132, 1995.
69. Lin SY, Chuo CY, Lin GT, et al: Volar plate interposition arthroplasty for posttraumatic arthritis of the finger joints. *J Hand Surg [Am]* 33(1):35–39, 2008.
70. Linscheid RL, Dobyns JH: Total joint arthroplasty. The hand. *Mayo Clin Proc* 54(8):516–526, 1979.
71. Linscheid RL, Murray PM, Vidal MA, et al: Development of a surface replacement arthroplasty for proximal interphalangeal joints. *J Hand Surg [Am]* 22(2):286–298, 1997.
72. Lister G: Intraosseous wiring of the digital skeleton. *J Hand Surg [Am]* 3(5):427–435, 1978.
73. Low TH, Hales PF: High incidence and treatment of flexor carpi radialis tendinitis after trapeziectomy and abductor pollicis longus suspensionplasty for basal joint arthritis. *J Hand Surg Eur Vol* 39(8):838–844, 2014.
74. Luther C, Germann G, Sauerbier M: Proximal interphalangeal joint replacement with surface replacement arthroplasty (SR-PIP): functional results and complications. *Hand* 5(3):233–240, 2010.
75. Mantovani G, Fukushima WY, Cho AB, et al: Alternative to the distal interphalangeal joint arthrodesis: lateral approach and plate fixation. *J Hand Surg [Am]* 33(1):31–34, 2008.
76. Martinez de Aragon JS, Moran SL, Rizzo M, et al: Early outcomes of pyrolytic carbon hemiarthroplasty for the treatment of trapezial-metacarpal arthritis. *J Hand Surg [Am]* 34(2):205–212, 2009.
77. Mashhadi SA, Chandrasekharan L, Pickford MA: Pyrolytic carbon arthroplasty for the proximal interphalangeal joint: results after minimum 3 years of follow-up. *J Hand Surg Eur Vol* 37(6):501–505, 2012.
78. Matsumoto T, Nakamura I, Miura A, et al: Distal interphalangeal joint arthrodesis with the reverse fix nail. *J Hand Surg [Am]* 38(7):1301–1306, 2013.
79. McGlynn JT, Smith RA, Bogumill GP: Arthrodesis of small joint of the hand: a rapid and effective technique. *J Hand Surg [Am]* 13(4):595–599, 1988.
80. McGuire DT, White CD, Carter SL, et al: Pyrocarbon proximal interphalangeal joint arthroplasty: outcomes of a cohort study. *J Hand Surg Eur Vol* 37(6):490–496, 2012.
81. Meenagh GK, Patton J, Kynes C, et al: A randomised controlled trial of intra-articular corticosteroid injection of the carpometacarpal joint of the thumb in osteoarthritis. *Ann Rheum Dis* 63(10):1260–1263, 2004.
82. Merle M, Villani F, Lallemand B, et al: Proximal interphalangeal joint arthroplasty with silicone implants (NeuFlex) by a lateral approach: a series of 51 cases. *J Hand Surg Eur Vol* 37(1):50–55, 2012.
83. Miller NJ, Davis TR: Palmar plate capsulodesis for thumb metacarpophalangeal joint hyperextension in association with trapeziometacarpal osteoarthritis. *J Hand Surg Eur Vol* 39(3):272–275, 2014.

84. Minami A, Iwasaki N, Kutsumi K, et al: A long-term follow-up of silicone-rubber interposition arthroplasty for osteoarthritis of the thumb carpometacarpal joint. *Hand Surg* 10(1):77–82, 2005.
85. Minamikawa Y, Horii E, Amadio PC, et al: Stability and constraint of the proximal interphalangeal joint. *J Hand Surg [Am]* 18(2):198–204, 1993.
86. Mobargha N, Ludwig C, Ladd AL, et al: Ultrastructure and innervation of thumb carpometacarpal ligaments in surgical patients with osteoarthritis. *Clin Orthop Relat Res* 472(4):1146–1154, 2014.
87. Moberg E, Henrikson B: Technique for digital arthrodesis. A study of 150 cases. *Acta Chir Scand* 118:331–338, 1960.
88. Moulton MJ, Parentis MA, Kelly MJ, et al: Influence of metacarpophalangeal joint position on basal joint-loading in the thumb. *J Bone Joint Surg Am* 83(5):709–716, 2001.
89. Murray PM: New-generation implant arthroplasties of the finger joints. *J Am Acad Orthop Surg* 11(5):295–301, 2003.
90. Murray PM, Linscheid RL, Cooney WP, 3rd, et al: Long-term outcomes of proximal interphalangeal joint surface replacement arthroplasty. *J Bone Joint Surg Am* 94(12):1120–1128, 2012.
91. Murray PM, Wood MB: The results of treatment of synovitis of the wrist induced by particles of silicone debris. *J Bone Joint Surg Am* 80(3):397–406, 1998.
92. Namdari S, Weiss AP: Anatomically neutral silicone small joint arthroplasty for osteoarthritis. *J Hand Surg [Am]* 34(2):292–300, 2009.
93. Neral MK, Pittner DE, Spiess AM, et al: Silicone arthroplasty for nonrheumatic metacarpophalangeal joint arthritis. *J Hand Surg [Am]* 38(12):2412–2418, 2013.
94. Nilsson A, Wiig M, Alnehill H, et al: The Artelon CMC spacer compared with tendon interposition arthroplasty. *Acta Orthop* 81(2):237–244, 2010.
95. Noland SS, Saber S, Endress R, et al: The scaphotrapezial joint after partial trapeziectomy for trapeziometacarpal joint arthritis: long-term follow-up. *J Hand Surg [Am]* 37(6):1125–1129, 2012.
96. Nunley RM, Boyer MI, Goldfarb CA: Pyrolytic carbon arthroplasty for posttraumatic arthritis of the proximal interphalangeal joint. *J Hand Surg [Am]* 31(9):1468–1474, 2006.
97. Ono S, Shauver MJ, Chang KW, et al: Outcomes of pyrolytic carbon arthroplasty for the proximal interphalangeal joint at 44 months' mean follow-up. *Plast Reconstr Surg* 129(5):1139–1150, 2012.
98. Parker WL: Evidence-based medicine: thumb carpometacarpal arthroplasty. *Plast Reconstr Surg* 132(6):1706–1719, 2013.
99. Parker WL, Linscheid RL, Amadio PC: Long-term outcomes of first metacarpal extension osteotomy in the treatment of carpal-metacarpal osteoarthritis. *J Hand Surg [Am]* 33(10):1737–1743, 2008.
100. Parker WL, Rizzo M, Moran SL, et al: Preliminary results of nonconstrained pyrolytic carbon arthroplasty for metacarpophalangeal joint arthritis. *J Hand Surg [Am]* 32(10):1496–1505, 2007.
101. Pellegrini V: Hand osteoarthritis. In Glickel S, Bernstein S, editors: *Arthritis of the hand and upper extremity: a master skills publication*, Rosemount, IL, 2011, American Society for Surgery of the Hand, pp 167–176.
102. Pellegrini VD, Jr: Osteoarthritis of the trapeziometacarpal joint: the pathophysiology of articular cartilage degeneration. I. Anatomy and pathology of the aging joint. *J Hand Surg [Am]* 16(6):967–974, 1991.
103. Pelligrini VD, Jr: Osteoarthritis of the trapeziometacarpal joint: the pathophysiology of articular cartilage degeneration. II. Articular wear patterns in the osteoarthritic joint. *J Hand Surg [Am]* 16(6):975–982, 1991.
104. Peter JB, Pearson CM, Marmor L: Erosive osteoarthritis of the hands. *Arthritis Rheum* 9(3):365–388, 1966.
105. Potenza AD: Brief note. A technique for arthrodesis of finger joints. *J Bone Joint Surg Am* 55(7):1534–1536, 1973.
106. Poulter RJ, Davis TR: Management of hyperextension of the metacarpophalangeal joint in association with trapeziometacarpal joint osteoarthritis. *J Hand Surg Eur Vol* 36(4):280–284, 2011.
107. Pritsch T, Rizzo M: Reoperations following proximal interphalangeal joint nonconstrained arthroplasties. *J Hand Surg [Am]* 36(9):1460–1466, 2011.
108. Regnard PJ: Electra trapezio metacarpal prosthesis: results of the first 100 cases. *J Hand Surg [Br]* 31(6):621–628, 2006.
109. Rettig LA, Luca L, Murphy MS: Silicone implant arthroplasty in patients with idiopathic osteoarthritis of the metacarpophalangeal joint. *J Hand Surg [Am]* 30(4):667–672, 2005.
110. Rhee PC, Shin AY: Complications of trapeziectomy with or without suspension arthroplasty. *J Hand Surg [Am]* 39(4):781–783, quiz 784, 2014.
111. Ritchie JF, Belcher HJ: A comparison of trapeziectomy via anterior and posterior approaches. *J Hand Surg Eur Vol* 33(2):137–143, 2008.
112. Rizzo M, Moran SL, Shin AY: Long-term outcomes of trapeziometacarpal arthrodesis in the management of trapeziometacarpal arthritis. *J Hand Surg [Am]* 34(1):20–26, 2009.
113. Robinson PM, Muir LT: Foreign body reaction associated with Artelon: report of three cases. *J Hand Surg [Am]* 36(1):116–120, 2011.
114. Salem H, Davis TR: Six year outcome excision of the trapezium for trapeziometacarpal joint osteoarthritis: is it improved by ligament reconstruction and temporary Kirschner wire insertion? *J Hand Surg Eur Vol* 37(3):211–219, 2012.
115. Sammer D, Shah H, Shauver M, et al: The effect of ulnar styloid fractures on patient-related outcomes after volar locking plating of distal radius fractures. *J Hand Surg [Am]* 34:1595–1602, 2009.
116. Segalman KA: Lateral approach to proximal interphalangeal joint implant arthroplasty. *J Hand Surg [Am]* 32(6):905–908, 2007.
117. Seitz WH, Jr, Sellman DC, Scarcella JB, et al: Compression arthrodesis of the small joints of the hand. *Clin Orthop Relat Res* 304:116–121, 1994.
118. Sodha S, Ring D, Zurakowski D, et al: Prevalence of osteoarthrosis of the trapeziometacarpal joint. *J Bone Joint Surg Am* 87(12):2614–2618, 2005.
119. Soejima O, Hanamura T, Kikuta T, et al: Suspensionplasty with the abductor pollicis longus tendon for osteoarthritis of the thumb. *J Hand Surgery [Am]* 31A:425–428, 2006.
120. Stahlenbrecher A, Hoch J: [Proximal interphalangeal joint silicone arthroplasty: comparison of Swanson and NeuFlex implants using a new evaluation score]. *Handchir Mikrochir Plast Chir* 41(3):156–165, 2009.
121. Stern PJ, Fulton DB: Distal interphalangeal joint arthrodesis: an analysis of complications. *J Hand Surg [Am]* 17(6):1139–1145, 1992.
122. Stern PJ, Gates NT, Jones TB: Tension band arthrodesis of small joints in the hand. *J Hand Surg [Am]* 18(2):194–197, 1993.
123. Stern PJ, Ho S: Osteoarthritis of the proximal interphalangeal joint. *Hand Clin* 3(3):405–413, 1987.
124. Stoecklein HH, Garg R, Wolfe SW: Surface replacement arthroplasty of the proximal interphalangeal joint using a volar approach: case series. *J Hand Surg [Am]* 36(6):1015–1021, 2011.
125. Swanson AB: Silicone rubber implants for replacement of arthritis or destroyed joints in the hand. *Surg Clin North Am* 48(5):1113–1127, 1968.
126. Sweets TM, Stern PJ: Pyrolytic carbon resurfacing arthroplasty for osteoarthritis of the proximal interphalangeal joint of the finger. *J Bone Joint Surg Am* 93(15):1417–1425, 2011.
127. Taghinia AH, Al-Sheikh AA, Upton J: Suture anchor suspension and fascia lata interposition arthroplasty for basal joint arthritis of the thumb. *Plast Reconstr Surg* 122:497–504, 2008.
128. Tagil M, Geijer M, Abramo A, et al: Ten years' experience with a pyrocarbon prosthesis replacing the proximal interphalangeal joint. A prospective clinical and radiographic follow-up. *J Hand Surg Eur Vol* 39(6):587–595, 2013.
129. Tagil M, Kopylov P: Swanson versus APL arthroplasty in the treatment of osteoarthritis of the trapeziometacarpal joint: a prospective and randomized study in 26 patients. *J Hand Surg [Br]* 27(5):452–456, 2002.
130. Takigawa S, Meletiou S, Sauerbier M, et al: Long-term assessment of Swanson implant arthroplasty in the proximal interphalangeal joint of the hand. *J Hand Surg [Am]* 29(5):785–795, 2004.
131. Teoh LC, Yeo SJ, Singh I: Interphalangeal joint arthrodesis with oblique placement of an AO lag screw. *J Hand Surg [Br]* 19(2):208–211, 1994.
132. Thompson JS: Complications and salvage of trapeziometacarpal arthroplasties. *Instr Course Lect* 38:3–13, 1989.
133. Tomaino MM, Pellegrini VD, Jr, Burton RI: Arthroplasty of the basal joint of the thumb. Long-term follow-up after ligament reconstruction with tendon interposition. *J Bone Joint Surg Am* 77(3):346–355, 1995.
134. Tomaino MM, Vogt M, Weiser R: Scaphotrapezoid arthritis: prevalence in thumbs undergoing trapezium excision arthroplasty and efficacy of proximal trapezoid excision. *J Hand Surg [Am]* 24(6):1220–1224, 1999.
135. Trail IA, Martin JA, Nuttall D, et al: Seventeen-year survivorship analysis of silastic metacarpophalangeal joint replacement. *J Bone Joint Surg Br* 86(7):1002–1006, 2004.
136. Uchiyama S, Cooney WP, 3rd, Linscheid RL, et al: Kinematics of the proximal interphalangeal joint of the finger after surface replacement. *J Hand Surg [Am]* 25(2):305–312, 2000.
137. Umarji SI, Arnander MW, Evans DM: The use of Swanson silastic interposition arthroplasty in revision thumb-base surgery for failed trapeziectomy: a case series of 10 patients. *J Hand Surg Eur Vol* 37(7):632–636, 2012.
138. Vadstrup LS, Schou L, Boeckstyns ME: Basal joint osteoarthritis of the thumb treated with Weilby arthroplasty: a prospective study on the early postoperative course of 106 consecutive cases. *J Hand Surg Eur Vol* 34(4):503–505, 2009.
139. van Cappelle HG, Elzenga P, van Horn JR: Long-term results and loosening analysis of de la Caffiniere replacements of the trapeziometacarpal joint. *J Hand Surg [Am]* 24(3):476–482, 1999.
140. van Rijn J, Gosens T: A cemented surface replacement prosthesis in the basal thumb joint. *J Hand Surg [Am]* 35(4):572–579, 2010.
141. Vandenberghe L, Degreef I, Didden K, et al: Long term outcome of trapeziectomy with ligament reconstruction/tendon interposition versus thumb basal joint prosthesis. *J Hand Surg Eur Vol* 38(8):839–843, 2013.

142. Vermeulen GM, Brink SM, Slijper H, et al: Trapeziometacarpal arthrodesis or trapeziectomy with ligament reconstruction in primary trapeziometacarpal osteoarthritis: a randomized controlled trial. *J Bone Joint Surg Am* 96(9):726–733, 2014.
143. Vermeulen GM, Brink SM, Sluiter J, et al: Ligament reconstruction arthroplasty for primary thumb carpometacarpal osteoarthritis (Weilby technique): prospective cohort study. *J Hand Surg [Am]* 34(8):1393–1401, 2009.
144. Villani F, Uribe-Echevarria B, Vaienti L: Distal interphalangeal joint arthrodesis for degenerative osteoarthritis with compression screw: results in 102 digits. *J Hand Surg [Am]* 37(7):1330–1334, 2012.
145. Watson HK, Shaffer S: Concave-convex arthrodesis in joints of the hand. *Plast Reconstr Surg* 46(4):368–371, 1970.
146. Weilby A: Tendon interposition arthroplasty of the first carpo-metacarpal joint. *J Hand Surg [Br]* 13(4):421–425, 1988.
147. Wijk U, Wollmark M, Kopylov P, et al: Outcomes of proximal interphalangeal joint pyrocarbon implants. *J Hand Surg [Am]* 35(1):38–43, 2010.
148. Wollstein R, Watson HK, Martin RT, et al: Long-term durability of tendon arthroplasty with excision of the trapezium in stage 1 osteoarthritis of the thumb CMC joint. *Ann Plast Surg* 62(4):358–360, 2009.
149. Wright CS, McMurtry RY: AO arthrodesis in the hand. *J Hand Surg [Am]* 8(6):932–935, 1983.
150. Wysocki RW, Cohen MS, Shott S, et al: Thumb carpometacarpal suspension arthroplasty using interference screw fixation: surgical technique and clinical results. *J Hand Surg [Am]* 35(6):913–920, 2010.
151. Yang SS, Weiland AJ: First metacarpal subsidence during pinch after ligament reconstruction and tendon interposition basal joint arthroplasty of the thumb. *J Hand Surg [Am]* 23(5):879–883, 1998.
152. Yao J, Song Y: Suture-button suspensionplasty for thumb carpometacarpal arthritis: a minimum 2-year follow-up. *J Hand Surg [Am]* 38(6):1161–1165, 2013.
153. Yuan BJ, Moran SL, Tay SC, et al: Trapeziectomy and carpal collapse. *J Hand Surg [Am]* 34(2):219–227, 2009.

12

Wrist Arthrodesis and Arthroplasty

Marco Rizzo

Acknowledgment: The author and editors wish to acknowledge and thank John K. Stanley, MD, who contributed this chapter to the sixth edition. This work is built on his foundation.

These videos may be found at *ExpertConsult.com:*
12.1 Re-motion total wrist arthroplasty
12.2 Radiolunate arthrodesis with ligament-sparing approach

A pain-free, stable wrist joint is essential for normal function of the hand. Pain arising from a traumatized, arthritic, or unstable wrist will, through the unconscious spinal reflex, inhibit the function of the forearm musculature and result in weakness. Intermittent pain and instability result in an unreliable grasp that can fail capriciously and without warning. In addition to pain and instability, the problems of restricted range of motion and deformity may be present and may have an added adverse impact on function.[33]

Primary osteoarthritis of the wrist is a relatively uncommon cause of pain and is exemplified by degenerative changes at the scaphotrapeziotrapezoid (STT) joint. More commonly, arthritis ensues after trauma, instability and dislocation, crystalline deposition, or inflammatory processes. Less common causes include cerebral palsy, penetrating wounds, hemophilia, infection, or chondrolysis. On occasion, bone lesions, such as giant cell tumors or distal radius or synovial chondromatosis of the wrist, can be a source of pain and may require excision and/or wrist reconstruction.

A variety of surgical procedures are available for the management of the painful, unstable, degenerate, or stiff wrist. The choice of treatment depends on the cause and the pattern of the effects of the causative pathology and is dependent on the integrity of the articular cartilage. There are some minimally invasive surgical options that try to maintain motion, including partial denervation or metaphyseal decompression. The more extensively performed surgical procedures may be grouped into two principal treatment options: partial or total wrist arthrodesis and wrist arthroplasty.

The aim of any treatment is to provide a pain-free, stable, and functional wrist, and each patient will have a pattern of problems that guide the surgeon toward the appropriate treatment for that individual. Some patients cannot tolerate the loss of range of motion engendered by total wrist arthrodesis and will press for a motion-preserving procedure.[116] Therefore, careful assessment of the patient's needs and requirements is important.

Because the normal wrist enjoys considerable range of motion, loss of any of that range is perceived as an impairment that may give rise to a disability. However, a number of studies have been performed to examine the requirements for wrist motion for a variety of normal activities, and it is clear that most of the activities of daily living can be performed with quite a restricted range of motion of the wrist.

Palmer and colleagues[78] suggested that the functional range of wrist motion is 30 degrees of extension, 5 degrees of flexion, 15 degrees of ulnar deviation, and 10 degrees of radial deviation; these values were derived from a study in which they evaluated 52 standardized tasks involving activities of daily living and some aspects of work. Brumfield and Champoux found that in performing 15 activities of daily living, 10 degrees of wrist flexion was required and 35 degrees of wrist extension was used.[12] A later study by Ryu and colleagues evaluated a smaller number of activities of daily living and identified an ideal range of motion that they described as 60 degrees of extension, 54 degrees of flexion, 17 degrees of radial deviation, and 40 degrees of ulnar deviation.[89] They went on to state that the majority of hand placement and range-of-motion tasks studied in their project could be accomplished with 70% of maximum range of wrist motion, that is, 40 degrees each of wrist flexion and extension and 40 degrees of combined radial and ulnar deviation. Nelson demonstrated with use of a splint to mimic stiffness that 123 activities of daily living could be performed successfully with limited motion consisting of 5 degrees of flexion, 6 degrees of extension, 7 degrees of radial deviation, and 6 degrees of ulnar deviation.[73] This probably represents considerable coping strategies, compensatory motion of the shoulder and elbow, and modification of activity by the individuals in the study. Their study concluded that although having a wide range of motion is of great value, only a small arc of motion in each direction is *required* to maintain independence of existence. However, life involves a combination of hobbies, pastimes, and work, each of which may require a specific range of motion, and these must be considered when assessing

an individual patient for treatment. Franko and associates highlighted the issues surrounding the capacity of volunteers to adapt to and compromise limitations of wrist motion.[33] The authors found that severe restriction of wrist motion with the use of splints gave rise to only a modest impairment in function of the wrist in activities of daily living. However, when some motion was allowed, there was a significant improvement in the ease of performance of the same tasks and a significant improvement in the *range* of tasks that could be performed. This study highlights the general need of patients to have some movement at the wrist but the fact that individual requirements will differ. Therefore, when patients seek advice and treatment for a painful, unstable wrist, it is important to identify not only the wrist impairment but also the net effect of that impairment on functional ability. This will be unique to each patient and will have a great influence on the choice of surgical procedure. With a thorough history, one can determine which activities are inhibited by the painful or unstable wrist and choose the correct motion-preserving procedure, such as limited arthrodesis or arthroplasty, or motion-ablating procedure, such as arthrodesis. Other factors, such as the patient's age, ipsilateral shoulder and elbow pathologic findings, and occupation may well affect the choice between arthroplasty and arthrodesis.[71] Preoperative assessment must include a detailed physical examination and a full radiographic analysis to determine bone quality, residual bone stock, and the pattern of the disease. Additional investigations may be needed to identify the underlying pathologic condition (e.g., whether the condition is due to an inflammatory or degenerative disease process), as well as any comorbidity that might prejudice the outcome of a surgical procedure. Scoring of the function, disability, and pain will facilitate measurement of the outcome of the intervention. It is important to evaluate the patient's willingness and ability to comply with the postoperative instructions and therapy program; such evaluation is essential to a successful outcome for most surgical procedures involving the wrist.

PREOPERATIVE ASSESSMENT

The preoperative assessment consists of four discrete elements.

1. Identification of the impairment or loss of faculty. *Impairment* is defined as the parameters that can be measured and includes range of motion, grip strength, deformity, and stability.
2. Assessment of *pain*, which by definition is a symptom and therefore cannot be objectively measured. The most reliable assessment tool for pain is the visual analog scale. A visual analog chart should be scored for pain at rest and pain with activity.
3. Identification of the presence of a disability, which is a condition that limits a person's ability to perform normal tasks and may include pain. The term *disability* includes the effects of pain and the limitations generated by the loss of faculty on an individual. The assessment identifies the activities of daily living that are affected and the areas of significant difficulty within patients' lives that they wish to resolve.
4. Radiographic assessment to determine which procedures may be possible as indicated by the patient's residual bone stock and pattern of degenerative changes.

Physical Examination of the Wrist

Examination of the wrist is necessary to establish the baseline values of movement, strength, deformity, and stability.[99,107] In addition, visual inspection will allow the physician to observe local swelling, scars, evidence of current or previous infection, and the patient's reaction to movement or provocative stress testing of the joint or joints. The associated physical signs of inflammatory joint disease may well be apparent, including multiarticular involvement, deformity, swelling, and effusion. The presence or absence of scaly patches and nail changes must be noted to rule out psoriasis. A patient with psoriasis must be warned of the *Koebner phenomenon*,[117] in which acute psoriatic plaques may develop along the length of a scar engendered by surgery. The presence of vasculitis or active rheumatoid disease may be a contraindication to any surgery until the condition is controlled.

Radiographic Evaluation

X-rays, including the standard posteroanterior (PA), oblique, and lateral views, should be the basis for the initial radiographic examination. Gross changes can be seen on these three standard views with the shoulder held at 90 degrees of abduction, the elbow at 90 degrees of flexion, and the hand placed flat on the radiographic plate. This gives a reproducible PA view in neutral rotation with the beam centered over the capitate and including the distal radioulnar joint (DRUJ). Marked changes, as seen in the scapholunate advanced collapse (SLAC) pattern of arthritis, the scaphoid nonunion advanced collapse (SNAC) pattern, and carpal coalitions, are easily identified. STT arthrosis may be associated with deposition of calcium pyrophosphate (Figure 12.1, *A* and *B*), and in this condition the radiolunate joint may well be involved (see Figure 12.1, *C*). Less obvious and more difficult to assess is arthrosis between the capitate and the lunate and between the head of the hamate and the lunate. In these circumstances, the so-called six-shot series includes a PA view of the wrist in full radial and full ulnar deviation, which is valuable in identifying elements of instability in patients with scapholunate injury. An anteroposterior (AP) grip view completes the series and can magnify carpal collapse or scapholunate diastasis and show whether there is impingement between the hamate head and the hamate facet on the lunate (Figure 12.2, *A* to *C*).[97] The recently described "pencil-grip" PA view profiles both scapholunate joints simultaneously and demonstrates scapholunate diastasis favorably when compared with other radiographic stress views.[58]

Specific x-rays are indicated by the history and examination. They may include, for example, a pisotriquetral skyline view (a lateral view with the wrist in 10 degrees of supination) (Figure 12.3, *A*) to exclude osteoarthritis of this joint, which can coexist with other areas of arthritis in the wrist and, if not identified, can give rise to residual symptoms that may overshadow any improvement after other surgical procedures.

Computed tomography (CT) scans and magnetic resonance imaging (MRI) may also be helpful in evaluating patients with arthritis. CT scans will better discern the bone quality and joint disease when compared with plain films (see Figure 12.3, *B* and *C*). MRI will be most helpful in confirming the vascularity of the carpus, identifying bone marrow changes, and delineating pathologic conditions of the soft tissues such as synovitis and

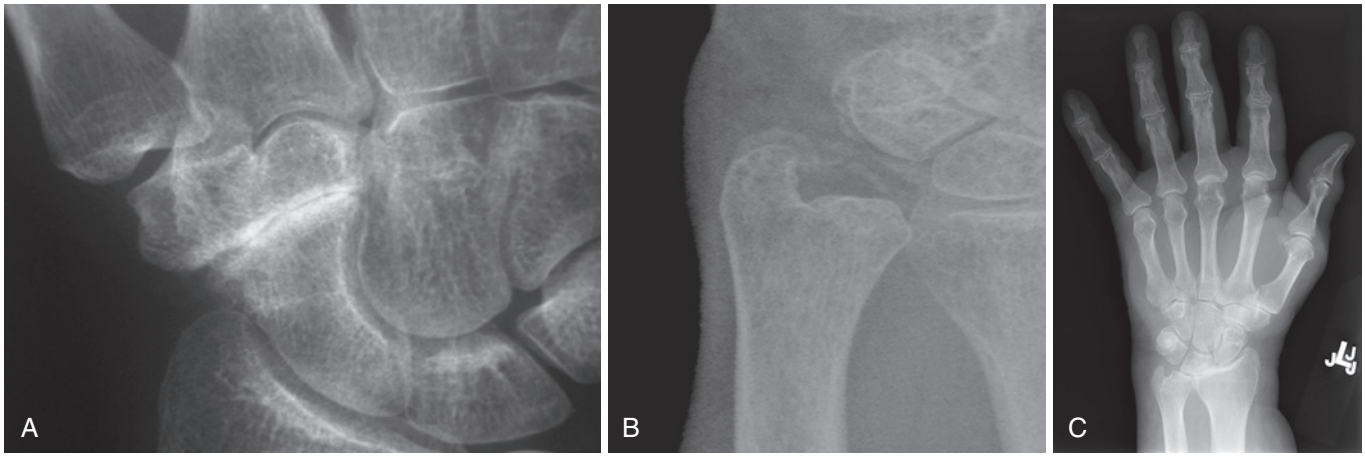

FIGURE 12.1 **A,** Scaphotrapeziotrapezoidal arthrosis may be localized to only one hand, although the majority of patients suffer from bilateral disease. **B,** The association with calcium pyrophosphate deposition disease (CPDD) is obvious in this patient with calcific changes in the triangular fibrocartilage complex. **C,** Figure demonstrates a posteroanterior view of a patient with known CPPD and obvious joint space narrowing at the radiolunate joint.

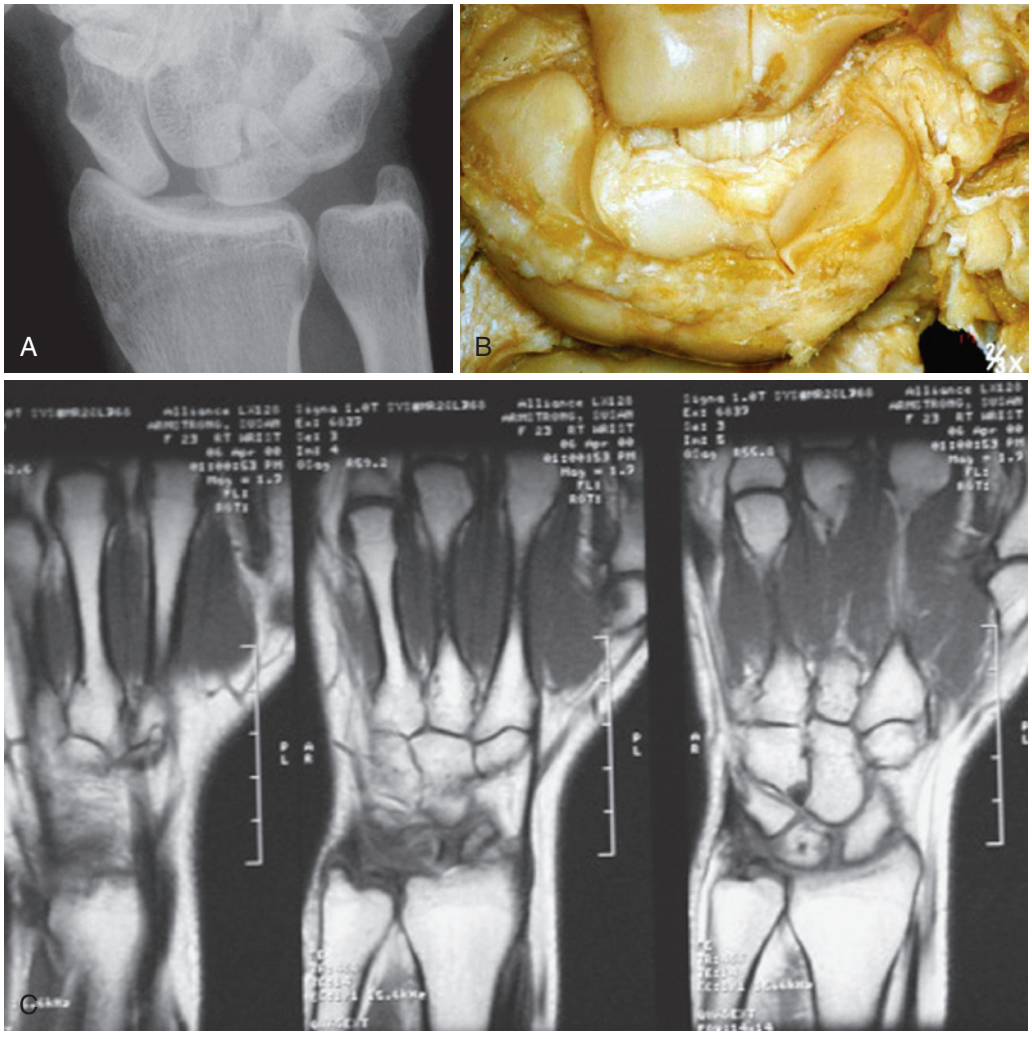

FIGURE 12.2 **A,** This radiograph of a wrist under axial load clearly demonstrates scapholunate dissociation but is also suggestive of hamolunate impingement. **B,** This cadaveric specimen demonstrates hamolunate impaction, which can occur and may compromise radiolunate and radioscapholunate arthrodesis. **C,** The most appropriate investigation is magnetic resonance imaging, which shows significant bone edema at the tip of the hamate.

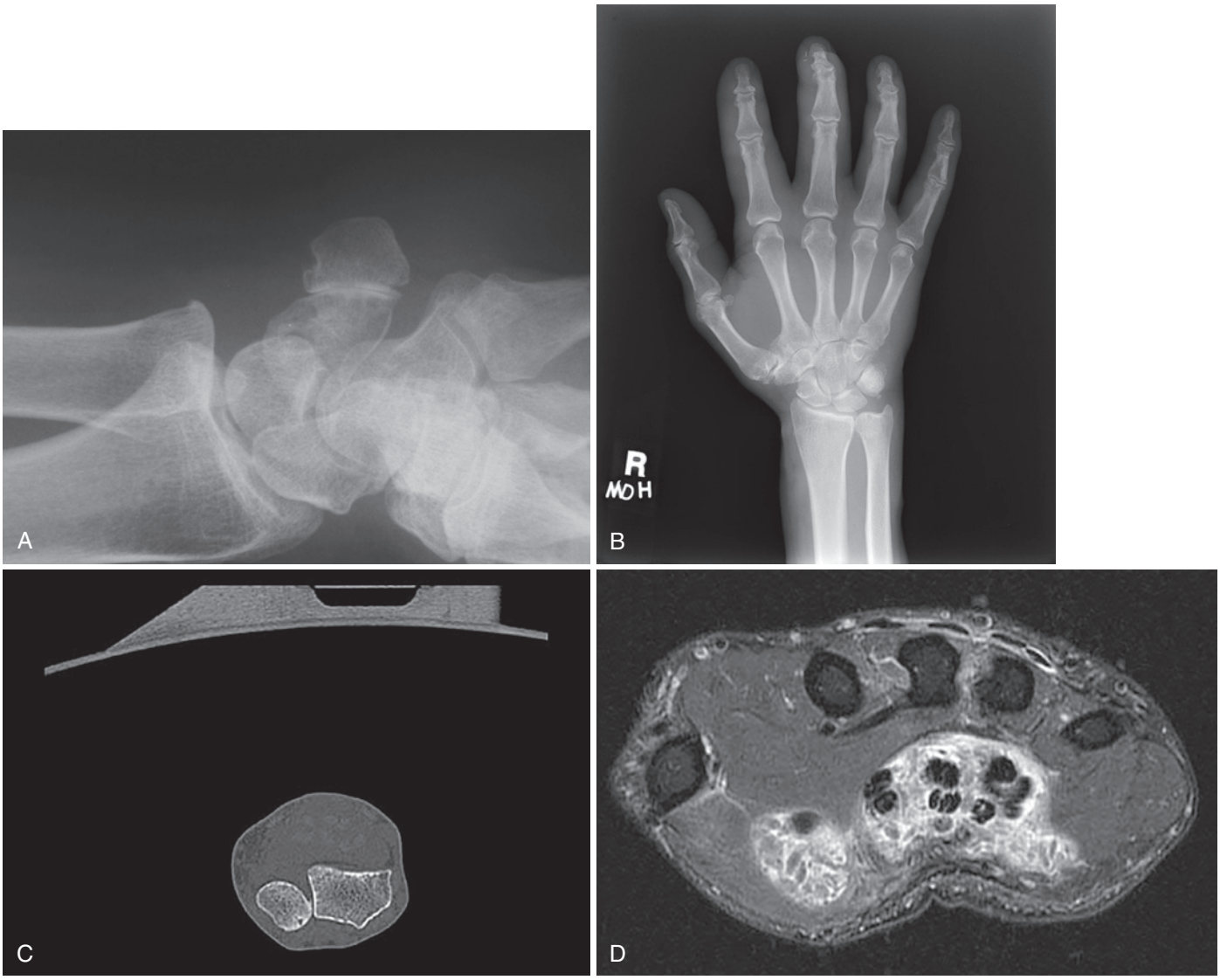

FIGURE 12.3 **A,** If not recognized preoperatively, pisotriquetral arthrosis can be painful, irritate the ulnar nerve in the canal of Guyon, and detract from an otherwise successful surgical wrist procedure. **B,** Posteroanterior radiograph of a patient with pain at the distal radioulnar joint and radiographic suspicion of arthritis. **C,** An axial computed tomographic scan of the same patient illustrates more clearly the arthritic process, demonstrating joint space narrowing; note also the subchondral cysts and volar osteophyte of the ulnar head. **D,** An axial T2-weighted image of a patient with inflammatory arthritis. Note the extensive flexor tendon tenosynovitis.

tenosynovitis associated with inflammatory diseases (see Figure 12.3, *D*).

Common Radiographic Patterns of Disease

Osteoarthritis. In osteoarthritis, a common pattern of the progression of degenerative change has been defined by Watson and Ballet as the SLAC pattern (Figure 12.4).[108] Vender and coworkers have described the SNAC pattern (Figure 12.5).[102]

Rheumatoid Arthritis. Because the variable picture seen in the inflammatory arthropathies such as rheumatoid arthritis does not lend itself to either of these classifications, treatment must be individualized. The following discussion is based on the Wrightington classification of rheumatoid wrist radiographs, which may be useful when considering surgical possibilities for various patterns of joint damage and residual bone stock.[47]

The Conservative Wrist. In general in the early stages of rheumatoid disease, x-rays show minor erosions but no significant bone loss or ligament injury and also show normal joint spaces. In these circumstances, simple synovectomy with disease-modifying drugs, splintage, and other measures may be all that is required. This would be called the conservative wrist (Figure 12.6, *A*).

The Restorative Wrist. As the disease progresses, localized loss of joint space becomes apparent in the radiocarpal joint (see Figure 12.6, *B*). There may be secondary changes consisting of translation and translocation of the carpus. Provided that the midcarpal joint is well preserved, patients at this stage are suitable candidates for radiolunate[17] or radioscapholunate fusion.[4,38,92]

The Reconstructive Wrist. Progression of the disease can lead to widespread loss of the joint surface, including the midcarpal joint, but if the bone stock is preserved, the surgical choices are total wrist replacement or total wrist arthrodesis (see Figure 12.6, *C*).



FIGURE 12.4 Scapholunate advanced collapse pattern of arthrosis of the wrist. Localized arthrosis of the scaphoid fossa begins at the styloid tip (stage I), proceeds to the proximal scaphoid fossa (stage II), and is followed by capitolunate arthrosis (stage III). The lunate may fall into dorsiflexion (dorsal intercalated segment instability [DISI]) and the scaphoid into flexion as seen here, but the integrity of the radiolunate articulation is preserved until late in the process.



FIGURE 12.5 Scaphoid nonunion advanced collapse (SNAC) pattern of arthrosis of the wrist. Degenerative changes develop in the distal segment of the scaphoid (stage I), and the proximal segment is spared. As in this case, excision of the proximal pole of the nonunited scaphoid will precipitate a combination of instability and SNAC. The scaphocapitate joint deteriorates in stage II. (See Watson HK, Fink JS, Monacelli DM: Use of triscaphe fusion in the treatment of Kienbock's disease. *Hand Clin* 9(3):493–499, 1933.)

The Salvage Wrist. When the wrist has been so damaged by the disease process that a significant amount of bone stock has been lost, the only surgical procedure that is reasonably reliable is arthrodesis, and this is often the only practical course of action. Particular attention should be paid to the lateral x-ray of the wrist; it may show significant volar subluxation of the lunate, which will give rise to some difficulties in reducing the wrist and could precipitate carpal tunnel syndrome as the wrist is relocated and realigned (see Figure 12.6, *D*).

SURGICAL TECHNIQUES

Partial Wrist Fusions

History of Limited Wrist Arthrodesis

- Peterson and Lipscomb, 1967: Intercarpal arthrodesis[80]
- Chamay and colleagues, 1983: Radiolunate arthrodesis[17]
- Watson and Ballet, 1984: Surgical correction of the SLAC wrist[108]
- Pisano and associates, 1991: Scaphocapitate (SC) arthrodesis[81]
- Minamikawa and coworkers, 1992: The ideal sagittal scaphoid angle for STT and SC arthrodesis[67]
- Calandruccio and colleagues, 2000: Capitolunate fusion with excision of the scaphoid and triquetrum[14]

Much effort has gone into determining the most appropriate intercarpal arthrodesis for a given condition, and there is a wide range of opinions on the best options for particular patterns of disease and pathologic findings. The choices are described in the following sections.

Radiolunate Fusion

Indications

Localized degenerative change secondary to rheumatoid arthritis is the most common cause of isolated radiolunate arthritis. The indications for radiolunate fusion[10,17,94] are volar translation, ulnar carpal translocation (Figure 12.7, *A*), complex carpal instabilities, and localized radiolunate arthritis (see Figure 12.7, *B*), commonly seen in patients with rheumatoid arthritis but also noted in those with die punch fractures within the lunate fossa. This latter injury causes a disorder of normal mechanics, scapholunate dissociation, flexion of the scaphoid, and, ultimately, degenerative arthritis. Frequently, an ulnar abutment syndrome will accompany the situation because of subsidence of the lunate within the lunate fossa, and there may be associated damage to the DRUJ. This complex injury can be improved by radiolunate fusion, provided that carpal height is restored.

Technique for Radiolunate Fusion

Preparation of the bone surface is sometimes awkward and time-consuming because of the nature and shape of the lunate and the radial fossa, the presence of eburnation of subchondral bone in osteoarthritic patients, and the distortion of the anatomy as seen in rheumatoid disease (Figure 12.8). The lunate must be restored to its anatomic height, and this involves the use of iliac crest, distal radius, or ulnar head bone graft material if available and sufficient. Fixation can be accomplished with Kirschner wires, staples, miniature pin plates, blade plates, or screws. Headless cannulated or other compression screws passed through the dorsal horn of the lunate can also be used to achieve rigid fixation (Figure 12.9, *A* and *B*).

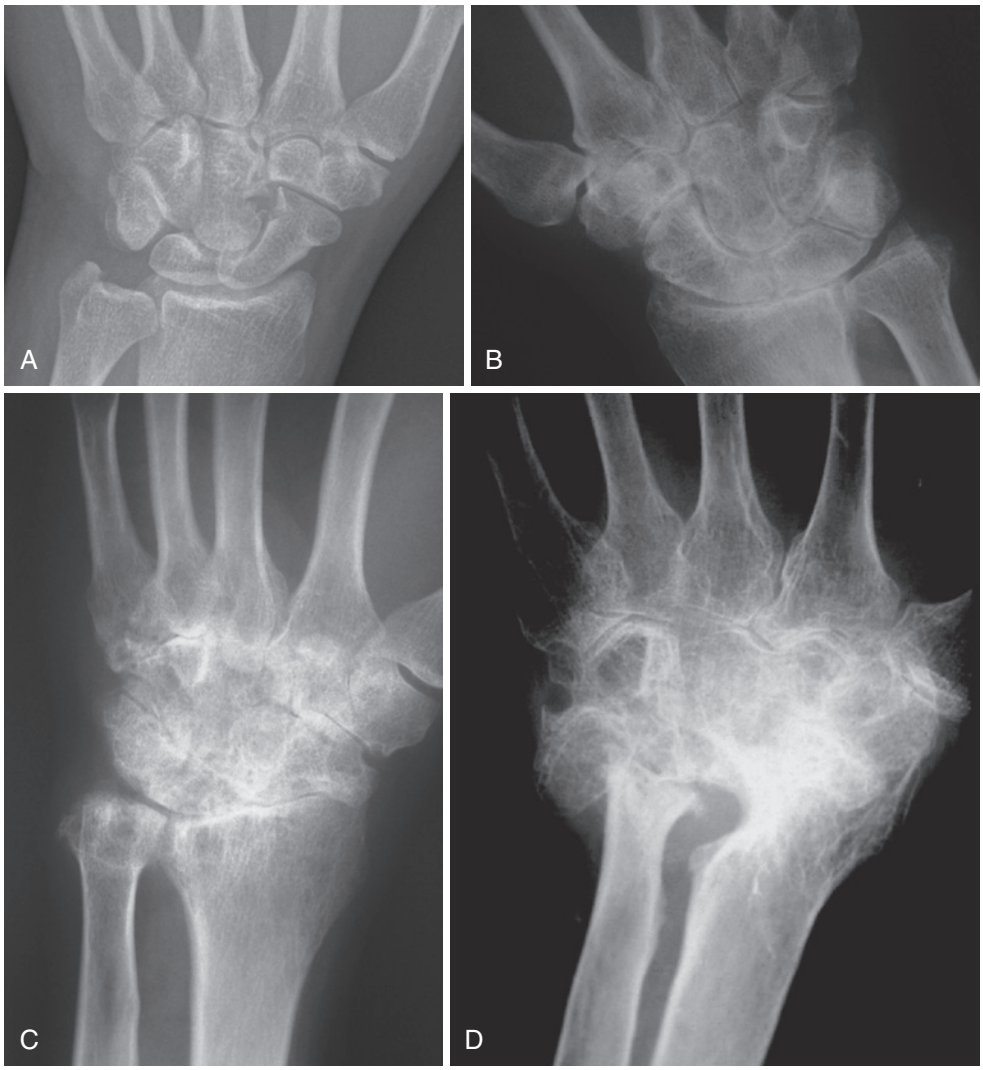

FIGURE 12.6 **A,** The conservative wrist. Integrity of the ligament and joint surfaces characterizes this phase of the disease, although erosions may be seen. **B,** The restorative wrist. The secondary arthrosis is principally confined to the lunate fossa and suggests that radiolunate fusion is an appropriate option. In this radiograph, the presence of translocation and radioscaphoid arthritis indicates that radioscapholunate fusion is the preferred option. **C,** The reconstructive wrist. Bony stock is well preserved, although all joints are significantly affected; wrist replacement may be considered as an option. **D,** The salvage wrist. Very poor bone stock remains, and with marked bone loss, arthrodesis remains the most likely choice, although each case must be taken on its merits.

❖ AUTHOR'S PREFERRED METHOD OF TREATMENT: Radiolunate Arthrodesis

The wrist is exposed through a standard longitudinal incision approximately 8 cm long in line with the third metacarpal and bisected by the radiocarpal joint line (Figure 12.10, *A* and *B*). The flaps are raised deep to the superficial fascia to preserve the vessels and cutaneous nerves while obtaining an excellent view of the extensor retinaculum. At this point, the Lister tubercle is identified by palpation and the extensor retinaculum is opened over the third compartment just to the ulnar side of the Lister tubercle while taking care not to damage the extensor pollicis longus (EPL). The digital extensor tendons contained within the fourth compartment are raised in the envelope created by the extensor retinaculum superficially and the capsule of the wrist on the deep surface. This prevents specific damage to the extensor tendons. The posterior interosseous nerve can be identified lying to the ulnar side of the Lister tubercle, and a neurectomy can be performed to help with postoperative pain and prevent scarring of the nerve.[60,114] A ligament-sparing approach to the wrist involves making an incision along the lines of the dorsal radiocarpal and dorsal intercarpal ligaments to expose the radiocarpal and midcarpal joints (see Figure 12.10, *C*). The capitolunate joint should be inspected; if it has degenerated, one would consider a full wrist arthrodesis (although some authors suggest that mild degenerative changes of the capitate head are acceptable).[96] Upon confirmation that the midcarpal joint is intact, the radiolunate joint is identified and the cartilage of the lunate fossa and the proximal lunate surface is denuded from the bone with curets, rongeurs, and limited use of a bur. A graft is taken from the area deep to the Lister tubercle if carpal height has been maintained. However, if carpal height needs to be restored, a corticocancellous bone graft is taken from the iliac crest with a trephine through a small

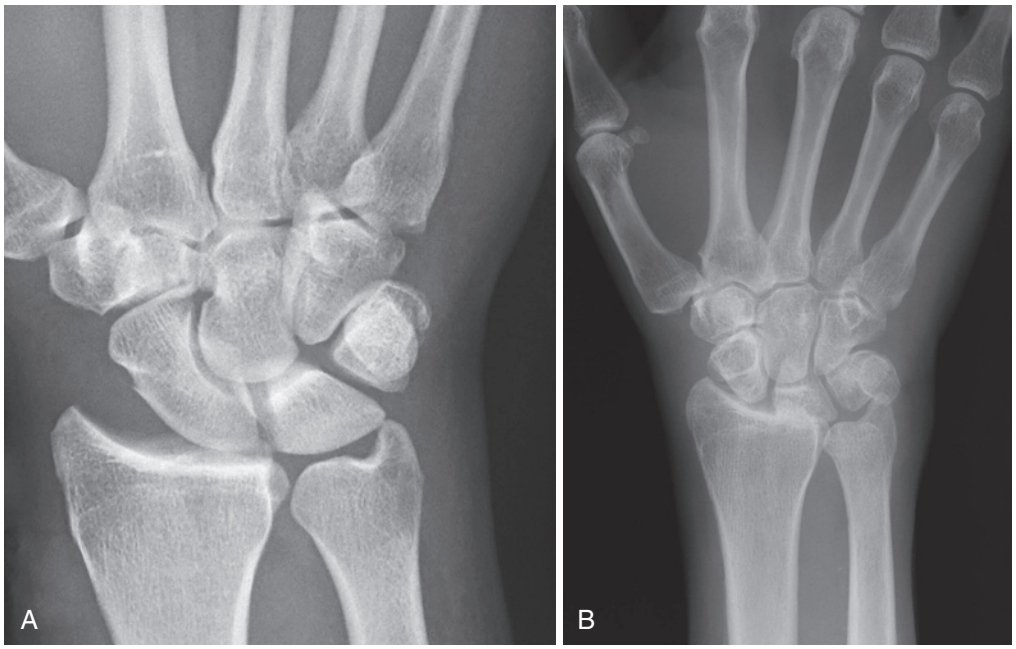

FIGURE 12.7 **A,** Posteroanterior (PA) view of the wrist demonstrating ulnar translocation of the lunate and carpus. **B,** PA view of the wrist illustrating significant radiolunate arthritis.



FIGURE 12.8 Volar subluxation of the lunate in a patient with inflammatory joint disease creates a new, more proximal pseudolunate fossa. This accentuates the supination deformity of the carpus and causes profound collapse of the scaphoid. Isolated radiolunate fusion in this patient would not be indicated.

incision. Care should be taken not to overcorrect the height of the proximal carpal row, because this has been associated with increased loading and progression of arthritis of the midcarpal joint.[24] If the ulnar head has been removed as part of the procedure, it may also be fashioned into a suitable graft (Figure 12.11, *A* and *B*). This yields a corticocancellous graft that may be shaped so that it can be inserted to restore carpal height, particularly if a die punch fracture has previously occurred (Figure 12.12).

In a patient with extension of the lunate, as seen in dorsal intercalated segment instability (DISI) deformity and SLAC/SNAC wrist or distal radius malunion with nondissociative carpal instability,[118] this must be corrected to achieve proper balance of the remaining carpus. Fixation of the lunate in extension during radiolunate arthrodesis will predictably result in impingement of the capitate with wrist flexion. To correct the extended lunate, one can fully flex the wrist and pass a 0.062-inch Kirschner wire through the dorsal aspect of the radius into the repositioned lunate. When the wrist is brought back to neutral flexion-extension, the lunate is in the correct position as seen in the sagittal view (Figure 12.13, *A* to *C*). Gentle manipulation of the wrist into extension stretches the anterior capsule, and this process can be repeated through two or three iterations. Extension of the wrist is then improved and arthrodesis can be completed. After preparation of the bone surface and grafting, fixation with Kirschner wires through the distal dorsal aspect of the radius into the lunate with the lunate in neutral rotation allows the position to be checked with intraoperative radiographs or fluoroscopy. The midcarpal joint should be carefully assessed to rule out hardware penetration. In patients with better bone quality, a cannulated headless bone screw or osseous staple can be inserted and the provisional wire removed. If the lunate does not lend itself readily to fixation with Kirschner wires through the dorsal horn, consideration can be given to

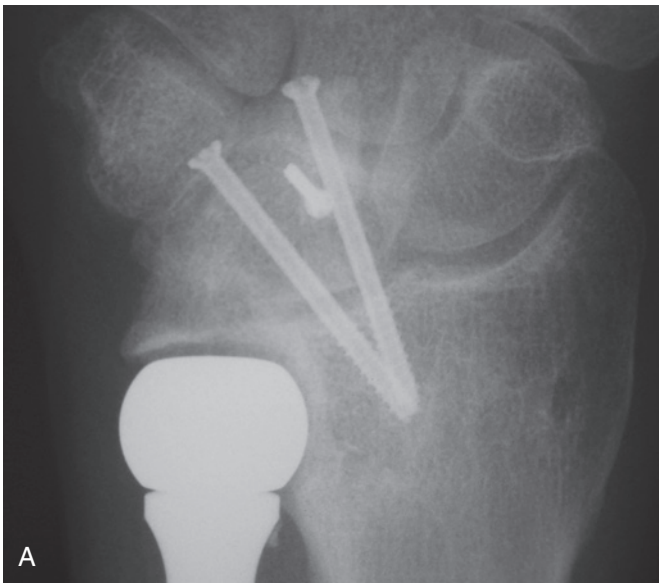

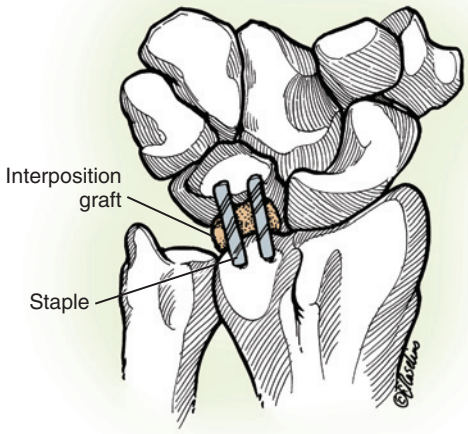

FIGURE 12.9 **A,** Crossed screws are used here as the construct, the ulnar head has been replaced, and it is imperative that adequate clearance between the lunate graft and the implant be maintained to minimize the potential for the development of an ulnar abutment syndrome. **B,** Staples may provide a simpler method of fixation. (**B,** Copyright © Elizabeth Martin.)

removal of the proximal pole of the triquetrum. This maneuver reveals the ulnar aspect of the lunate and allows a Kirschner wire or headless bone screw to be inserted through the lunate into the radius from the ulnar side. This ensures better fixation, may increase the range of motion, and helps to prevent translocation.

Pitfalls

1. Failure to appreciate that the posterior interosseous nerve can be damaged or become scarred following surgery, resulting in traction pain or neuroma in continuity. A relatively straightforward solution is to simply excise 1 cm of the nerve proximal to the joint. This will prevent problems associated with scarring of the tethered posterior interosseous nerve.[60] In addition, performing a posterior interosseous neurectomy has been shown to relieve pain in many patients with arthritis. Thus, it is my preference to routinely perform a posterior interosseous neurectomy.[114]
2. Fusion of the lunate in an excessively dorsiflexed position (DISI). This restricts the range of motion in flexion considerably, and a neutral or 10-degree dorsiflexed position of the lunate in relation to the radius is essential.
3. Failure to restore carpal height, leading to a permanently flexed scaphoid and unnecessary restriction of the range of motion. However, overcorrection has been shown to increase loading of the midcarpal joint, and thus a proper balance needs to be achieved.
4. Problems related to hardware, such as violation of the capitolunate joint by wires or hardware extending from the radius into the lunate. In addition, dorsally prominent hardware can result in tendon or soft tissue irritation and pain.

Postoperative Management

Use of a bulky dressing with immobilization for 10 to 14 days with the hand elevated whenever possible allows the swelling to subside and the sutures to be removed. A short-arm cast immobilizes the wrist for a period of 5 to 6 weeks. At that point, early rehabilitation should be restricted to using the dart thrower's motion only, namely, radial deviation and extension to ulnar deviation and flexion. This prevents excessive forces from acting on the radiolunate arthrodesis. After a further period of 4 weeks, full mobilization can take place, provided that radiographs confirm the presence of union. Strengthening exercises for finger motion should start early. At 3 months it is appropriate to remove the splint entirely, but avoidance of contact sports for 2 to 3 additional months is recommended. Excessive attempts to mobilize the midcarpal joint can result in an increased risk for nonunion.

Net Analysis of the Literature

A nonunion rate of approximately 10%[56] and a 50% reduction in range of motion in flexion and extension are reported. Some authors have noted an increased risk of nonunion associated with staples and better union rates with the use of miniplates with oblique screws.[39,40]

Scaphocapitate Arthrodesis

Indications

Scaphocapitate (SC) fusion is considered an alternative to STT fusion for stabilization of the scaphoid.[68] Accordingly, indications include dynamic or rotatory subluxation of the scaphoid, nonunion of the scaphoid, Kienböck disease,[41,49] and midcarpal instability. It is particularly advantageous with chronic scaphoid nonunion to address the instability and to expand the area of bone healing from distal to proximal scaphoid to capitate.

Most authors believe that there are no significant loading differences between SC and STT fusion. Watson felt that better motion is achieved with STT fusion than with SC fusion. Two cadaveric laboratory studies found essentially no differences in motion between the two.[27,65] The authors noted that after both STT and SC fusion there is diminished joint reactive force at the radiolunate and capitolunate joints. The amount of restriction of motion very much depends on proper reduction of the scaphoid to an intermediate position of flexion with respect to the radius.

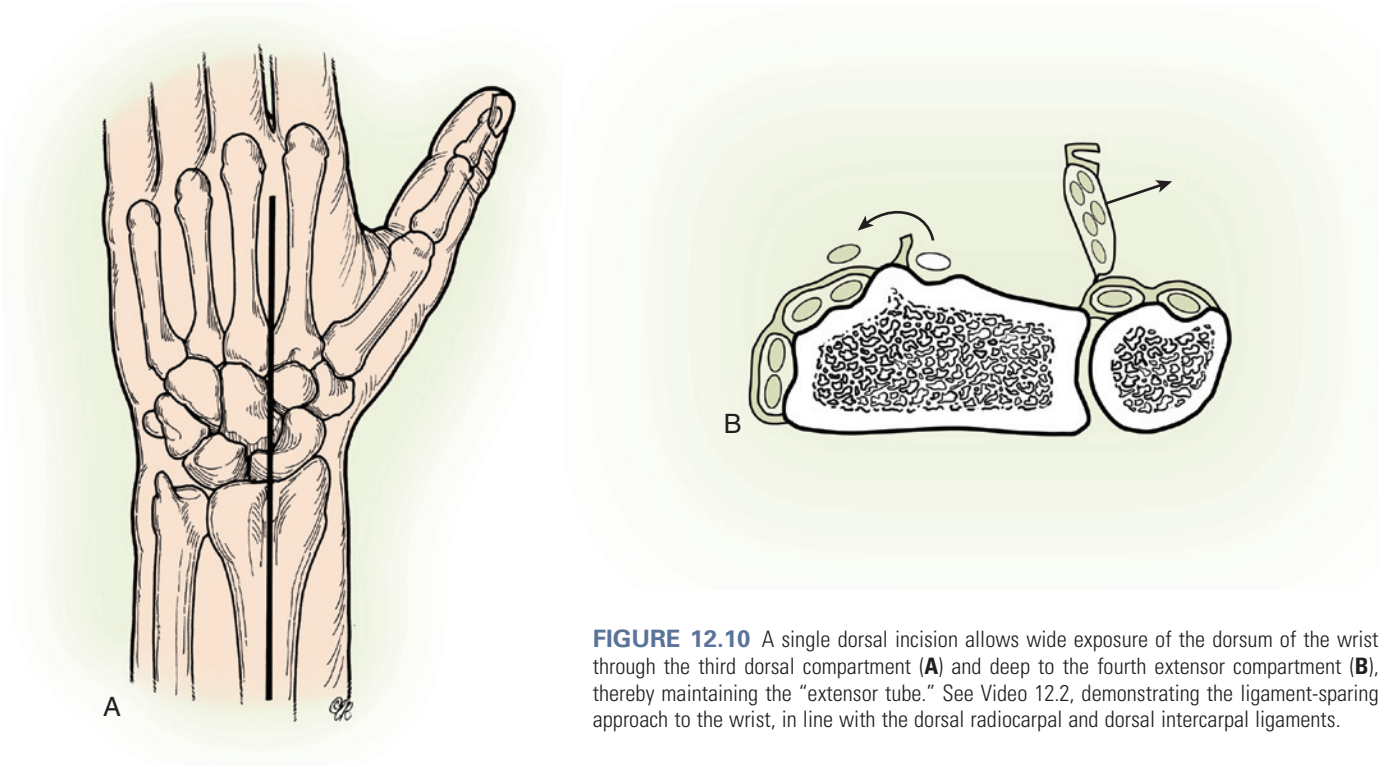

FIGURE 12.10 A single dorsal incision allows wide exposure of the dorsum of the wrist through the third dorsal compartment (**A**) and deep to the fourth extensor compartment (**B**), thereby maintaining the "extensor tube." See Video 12.2, demonstrating the ligament-sparing approach to the wrist, in line with the dorsal radiocarpal and dorsal intercarpal ligaments.

CRITICAL POINTS *Radiolunate Arthrodesis*

Indications

- Isolated cases of radiolunate arthritis, which usually arise as a result of localized die punch fractures or from rheumatoid arthritis
- Instability of the proximal row of the carpus in translation
- Severe nondissociative carpal instability with painful clunk[12,35,118]
- Failed soft tissue reconstruction of scapholunate dissociation[77,98,103]

Contraindications

- The presence of significant degenerative changes in the midcarpal joint or radioscaphoid joint

Radiographic Evaluation

- Assessment of the preoperative x-rays is essential to ensure that the midcarpal and radioscaphoid joints are free of any degenerative changes, there is no residual degenerative arthritis in the DRUJ or pisotriquetral joint, and the DRUJ is stable.

Pearls

- Maintain the fourth compartment "tube" intact to minimize the risk of tendon injury.
- Perform a posterior interosseous neurectomy to help with pain and avoid problems with scarring and traction pain of the nerve.
- Reduction of the lunate extension is very important; therefore, for reduction, fully flex the wrist, drive a Kirschner wire through the distal radius into the lunate, and extend the wrist to reduce the lunate to the remainder of the carpus.
- During the procedure, temporary fixation of the lunate to the radius followed by intraoperative radiographs helps identify whether adequate height has been achieved and whether the position of the lunate is not excessively extended with regard to the capitate and radius. In addition, the lunate must be placed so that it comes to lie underneath the capitate, not to the ulnar side of it.
- Excision of the proximal part of the triquetrum can provide easier access for screw fixation if there has been significant ulnar translocation of the lunate.
- Restoration of carpal height is important in injuries due to trauma and, to a lesser extent, in wrists affected by rheumatoid arthritis.
- When using a bur, care should be taken to irrigate to avoid overheating the bone and inviting osteonecrosis.

Expectations

- There will be permanent loss of some range of motion, usually 50% or slightly less than the range of a normal wrist.
- Full recovery may take 9 to 12 months; the patient will need to learn to adapt to the new situation, and coping strategies may be developed in conjunction with the hand therapist.
- Not all pain will be relieved, and aching may occur after heavy use.
- There is a risk for deterioration over time with the development of degenerative changes within the midcarpal joint. This may require further surgery in the future.

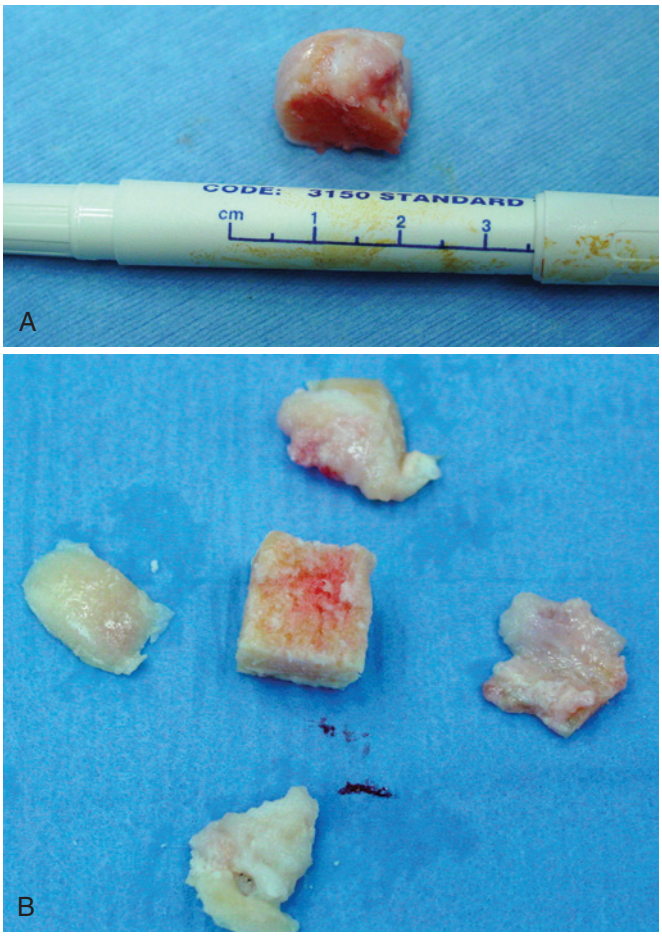

FIGURE 12.11 **A,** If the ulnar head is carefully excised as part of the procedure, it can, in many circumstances, be a sufficient graft to perform radiolunate or radioscapholunate arthrodesis. **B,** The head is held in a gauze sponge and the anterior, posterior, and medial surfaces are removed with an oscillating saw sequentially. The remaining cortical bone on the distal face provides a strong structural element for the graft.

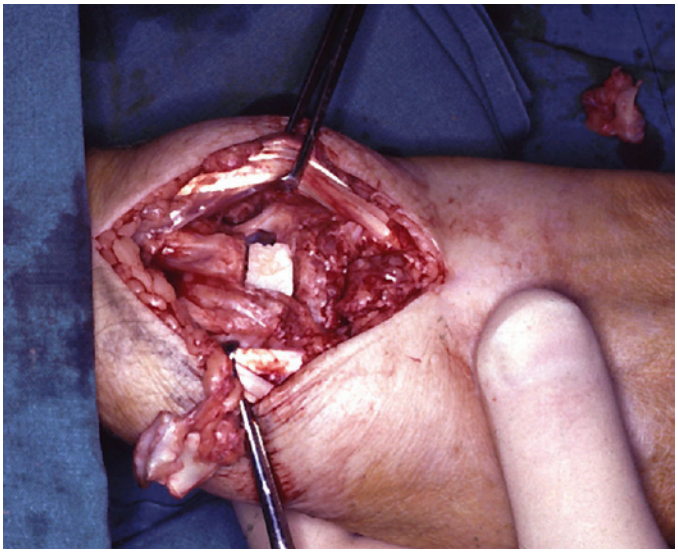

FIGURE 12.12 The size of the graft will often allow restoration of carpal height and is sufficiently robust to permit screw or staple fixation.

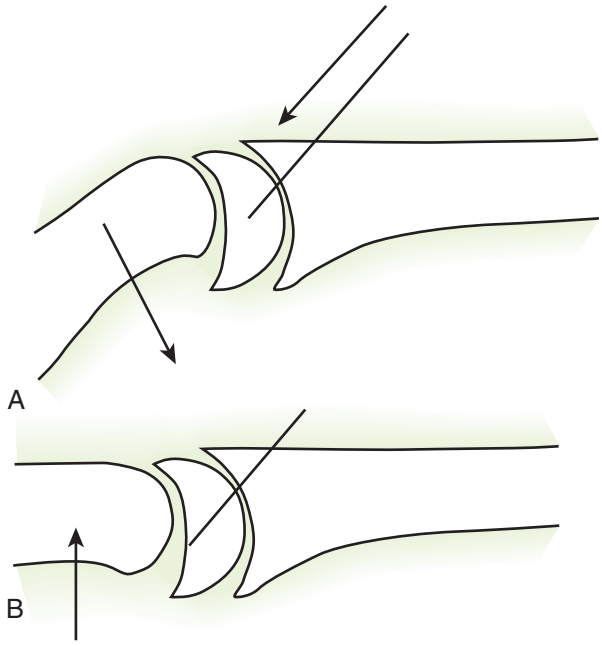

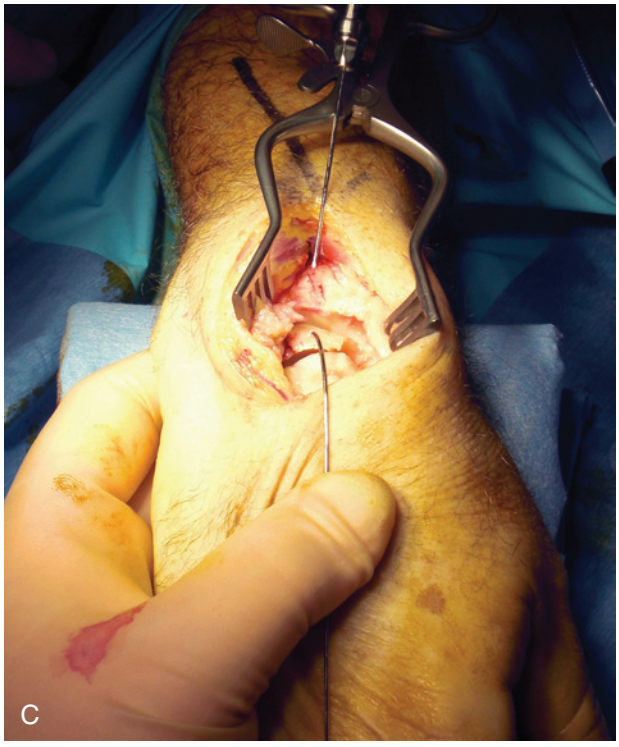

FIGURE 12.13 **A,** The wrist is fully flexed and a smooth 1.1-mm Kirschner wire is inserted into the distal radius to fix the lunate in neutral to slight flexion. If the wrist is moved into ulnar deviation and flexed before transfixion, the maneuver reduces both the translocation and flexion deformities. **B,** When the wrist is brought into neutral, the position of the lunate remains reduced and the capitate is in appropriate alignment with the lunate. **C,** A joystick in the lunate facilitates proper reduction of the lunate posture before transfixion.

Contraindications

Contraindications, as in STT fusion, include any abnormality of the radioscaphoid joint that would be susceptible to increased degeneration and symptoms because of the altered or increased loading through the radioscaphoid joint after SC fusion. Similarly, STT degenerative changes would be a contraindication to SC fusion.

Fixation

Fixation can be accomplished with Kirschner wires, staples, screws, or plates and screws (Figure 12.14). Safe hardware insertion requires identification and protection of the radial artery and the dorsal sensory radial nerve branches. Provided that normal intercarpal spacing is maintained by decorticating only the dorsal 75% of the articular surfaces and by packing the resultant space with bone graft, compression screws may be used between the scaphoid and capitate to hold the scaphoid in a 40- to 50-degree radioscaphoid angle.

❖ AUTHOR'S PREFERRED METHOD OF TREATMENT: Scaphocapitate Arthrodesis

The wrist is exposed through a longitudinal incision similar to that for a radiolunate fusion from the Lister tubercle to the base of the index metacarpal. The dorsal sensory radial nerve branches are identified and protected. The capsule is incised using a ligament-sparing approach within the fibers of the dorsal radiocarpal and dorsal intercarpal ligaments. When necessary for exposure, this approach can be extended radially along the radiocarpal joint to better expose the radioscaphoid interval. Both the radioscaphoid and capitolunate joints are inspected for healthy cartilage and protected. I prefer to use cannulated compression screws for fixation (Figure 12.15, *A* and *B*). These can be placed in a radial to ulnar direction either percutaneously or directly within the exposure of the wound, depending on the visualization and access to the radial side of the scaphoid. Care is taken to ensure that the superficial branch of the radial nerve and dorsal branch of the radial artery are safely protected. The nerve can be visualized just deep to the

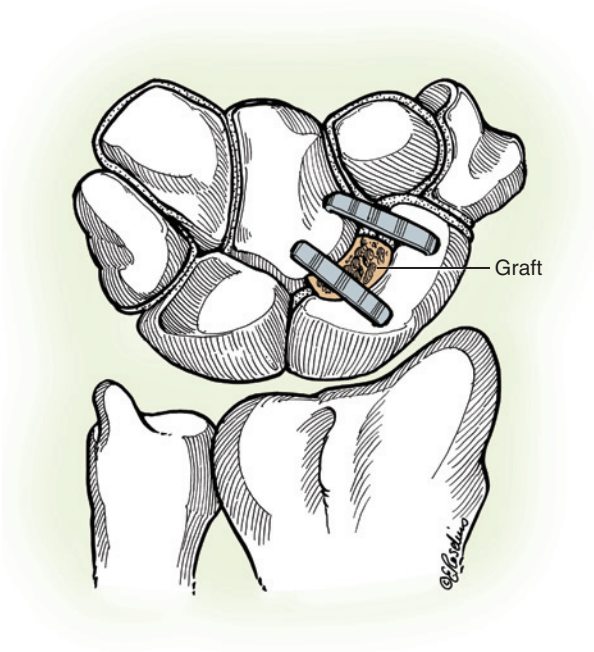

FIGURE 12.14 Scaphocapitate fusion with staples. Normal space between the scaphoid and capitate is maintained by preserving the volar 25% articulation of both bones. (Copyright © Elizabeth Martin.)

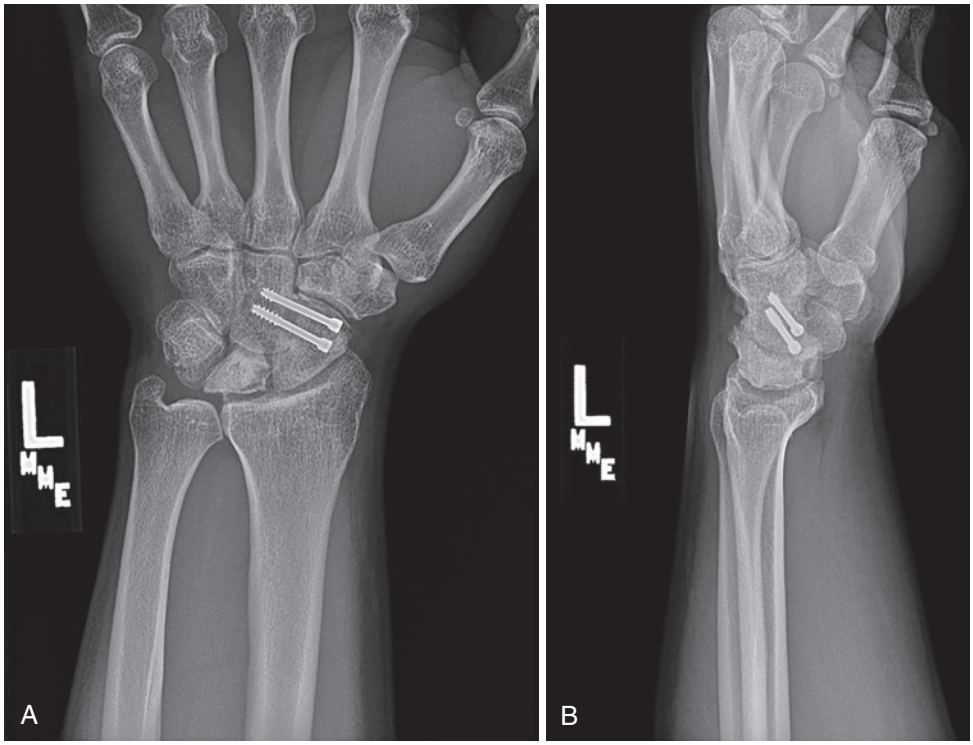

FIGURE 12.15 Figure shows (**A**) posteroanterior and (**B**) lateral views of a patient 5 years following scaphocapitate fusion using headless compression screws for the treatment of Kienböck disease.

skin to protect it from penetration or torsional damage by the guide pins. The artery will be deeper and needs to be seen to ensure it is safely out of the way. Reduction of a malrotated scaphoid is required. Similarly, if the lunate is tilted dorsally, this angulation must be corrected to ensure normal alignment of the fused capitate. For reduction, the proximal scaphoid pole is depressed and the distal pole of the scaphoid elevated with a 0.062-inch Kirschner wire "joystick," supplemented as needed with a large skin hook applied around the distal scaphoid. Correct capitolunate posture can be restored by the application of a palmar-directed load on the capitate until the lunate is restored to its normal tilt.

The guidewires are advanced into the capitate, and reduction to a 40- to 50-degree radioscaphoid angle is confirmed by fluoroscopy with the wrist in neutral alignment. If this is difficult to achieve within the wound, the guidewires can be placed through a small incision just distal to the radial styloid, with care taken to protect the dorsal radial artery and superficial branch of the radial nerve. Excessive scaphoid extension will impede radial deviation and extension. Any adjustments in scaphoid position are made before decortication of the joint surfaces. The dorsal 80% of the SC joint is decorticated down to cancellous bone, including the dorsal apposing edges. This can be done with curets, rongeurs, and/or a high-speed bur. Care is taken to avoid penetration of the capitolunate joint. Cancellous bone graft is harvested through a cortical window made just proximal to the Lister tubercle and is packed into the fusion space. Upon achieving appropriate reduction of the interval and bony preparation, the guide pins are inserted. Fluoroscopy is used to confirm the appropriate position of the proposed fusion and hardware placement. Drilling over the pins is then performed. I prefer to drill and place a screw in the first guide pin, prior to drilling over the second guide pin to maintain a point of fixation to resist rotation or loss of reduction. Take care not to overcompress the interval and not to overclose the normal intercarpal spacing with the compression screws. The provisional Kirschner wires are removed, and the capsule is closed with 3-0 braided absorbable suture. Alternatively, two staples 15 mm wide and 10 to 13 mm deep are inserted by power across the SC joint (see Figure 12.14). The skin is closed with a 4-0 polypropylene (Prolene) interrupted skin suture or subcuticular 3-0 polypropylene monofilament, followed by Steri-Strips. The hand and wrist are immobilized with a noncompressive short-arm bulky dressing and thumb spica splint.

Postoperative Management

At 10 days, the sutures are removed and a short-arm thumb spica cast is applied. At 6 to 8 weeks, radiographs are checked, and if satisfactory, a short-arm wrist splint is applied for intermittent protection. Active range of motion is initiated. Strengthening is usually deferred until 10 to 12 weeks postoperatively.

Postoperative Expectations

The range of motion should approximate 50% to 60% of the opposite side. Sennwald and Ufenast reported a flexion-extension arc of 62 degrees.[90] Viegas and associates reported a range of motion of 50% of the opposite side.[103] Grip strength will be approximately 80% of the opposite side; Pisano and coworkers reported 74% of the opposite side,[81] while Sennwald and Ufenast documented 83% of the opposite side.[90] Nonunion rates of 6% to 28% can be expected, with a 95% confidence interval.[56]

CRITICAL POINTS *Scaphocapitate Arthrodesis*

Indications
- Dynamic or static rotatory subluxation of the scaphoid
- Chronic scaphoid nonunion
- Kienböck disease

Preoperative Evaluation
- Evaluate scaphoid stability with the scaphoid shift test (see Chapter 13)
- Obtain a supinated AP radiograph to evaluate the scapholunate joint for increased gap and to be sure that the radioscaphoid and STT joints are free of degenerative changes.
- Obtain a lateral radiograph to evaluate the scapholunate angle.
- Obtain a hyperpronated AP radiograph to evaluate the STT joint.

Pearls
- Preserve the volarmost cartilage surfaces between the scaphoid and lunate to maintain normal anatomic relationships.
- It is easier to reduce the scaphoid before decortication.
- When using a bur, irrigation should be done to avoid overheating the bone and inviting osteonecrosis.

Technical Points
- Protect the radial sensory nerve branches and radial artery by using a small drill guide during Kirschner wire placement.
- Confirm by fluoroscopy or radiographs proper reduction of the scaphoid to a 40- to 50-degree radioscaphoid angle. Separate lunate reduction is not required.

Pitfalls
- Avoid overreduction (extension > 50 degrees) of the scaphoid, which will limit motion, particularly radial deviation and extension.
- Avoid overcompression at the SC interval.

Postoperative Care
- The initial dressing should be bulky but noncompressive to avoid postoperative pain. Apply a short-arm thumb spica splint.
- At 10 days, apply a well-molded short-arm thumb spica cast.
- At 6 to 8 weeks, check radiographs and initiate active range-of-motion exercises.

Expectations
- Fifty percent to 60% range of motion in comparison to the opposite wrist
- Eighty percent grip strength
- Fifteen percent nonunion rate
- Minimum 4-month recovery time before sports participation

Athletic Participation

Athletic use of the involved extremity is precluded for at least 8 weeks. Nonloaded use is allowed at 8 weeks. Full use and any exposure to sudden force should be avoided for at least 10 to 13 weeks after surgery. Patients should not expect strong, relatively symptom-free wrist performance until at least 4 months after surgery.

What Patients Should Be Told

Patients are advised that pain relief is predictable and they will lose 40 to 50% of wrist motion but should still have a very

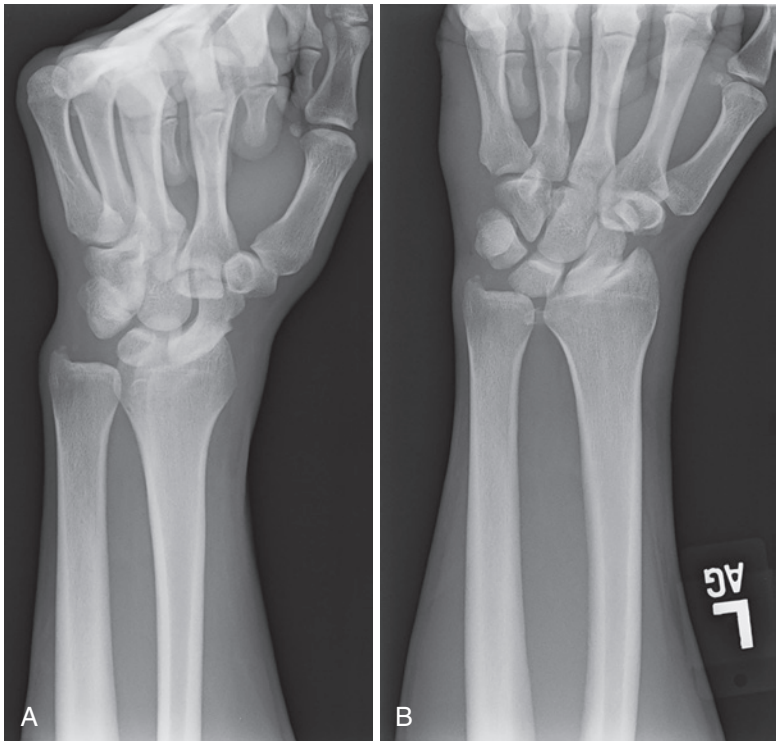

FIGURE 12.16 **A,** PA and **B,** oblique plain films of a patient who had prior trauma and now has degenerative changes in the radiocarpal joint as well as ulnar translation of the carpus.

functional arc. They may experience postoperative transient tingling over the dorsoradial aspect of the wrist or hand, which will resolve over time. Although the wrist will never feel "normal," almost all patients will feel improvement and regain 70 to 80% of grip strength. Patients who smoke are strongly advised to discontinue it preoperatively because smoking is associated with a higher likelihood of nonunion. Nonunion in other patients is unlikely but can occur in 15% of cases.

Radioscapholunate Arthrodesis

Indications and Contraindications

One indication for radioscapholunate arthrodesis is proximal row destruction, which is most commonly seen in posttraumatic patients (Figure 12.16, *A* and *B*) in whom there has been extensive intraarticular damage. It is also seen after chondrolysis, infection, or inflammatory arthritis (Figure 12.17). In fact, it is rare for patients with rheumatoid arthritis or osteoarthritis to have isolated radiolunate arthritis. Thus, in my experience it is more often necessary to perform a radioscapholunate arthrodesis.[4,38]

Preservation of midcarpal motion while dealing with painful radiocarpal motion is another indication for radioscapholunate arthrodesis. Contraindications include the presence of active infection or degenerative changes in the midcarpal joint.



FIGURE 12.17 Patient with rheumatoid arthritis and severe articular destruction of the radiocarpal joint.

❖ AUTHOR'S PREFERRED METHOD OF TREATMENT: Radioscapholunate Arthrodesis

Through a central longitudinal dorsal incision, full-thickness skin flaps are raised to identify the extensor retinaculum. The Lister tubercle is identified and an incision made in the extensor retinaculum in a line between the third and fourth compartments. The EPL tendon is dislocated from its groove. The Lister tubercle is removed with an osteotome. The retinaculum can be raised through the second compartment radially and (if necessary for exposure) the fifth compartment ulnarly. The extensor carpi radialis brevis (ECRB) and extensor carpi radialis longus (ECRL) are retracted to the radial side. Deep to the fourth

compartment, a posterior interosseous neurectomy may be performed. The joint is exposed through a ligament-sparing approach, and the proximal radial exposure (if necessary) can be extended by elevating the capsule off the distal radius, leaving a cuff on the radius for reapproximation on closure.

Inspection of the midcarpal joint to ensure that there is adequate cartilage on the surface is the first prerequisite of this procedure. Any malalignment of the proximal row must be corrected by reduction of the lunate into the neutral position and reduction of the scaphoid into 45 degrees of radioscaphoid flexion, as determined by image intensification. The articular surfaces are excised down to cancellous bone. The space is filled with bone graft, which may be taken from the distal radius through a small defect created by removal of the Lister tubercle (Figure 12.18). Once the graft is in situ and the positions are satisfactory, memory staples can be used to maintain and compress the scaphoid-radial and lunate-radial interfaces (Figure 12.19, *A* to *D*). Alternative methods of fixation such as Kirschner wires, compressive screws, or plates can also be used. Once reduction and fixation of the arthrodesis have been achieved, the range of motion should be assessed. Because the scaphoid is fixed at 45 degrees of flexion, flexion-extension may be limited and radial deviation is particularly limited. The resultant motion is almost entirely in the dart thrower's plane of radial extension to ulnar flexion. When necessary or helpful, excision of the distal pole of the scaphoid can be performed to enable further radial deviation.[37,38,45] Separately, additional investigators have recommended removal of the triquetrum, in addition to the distal scaphoid, to enable a better ulnar-radial arc of motion of the wrist.[4,79]

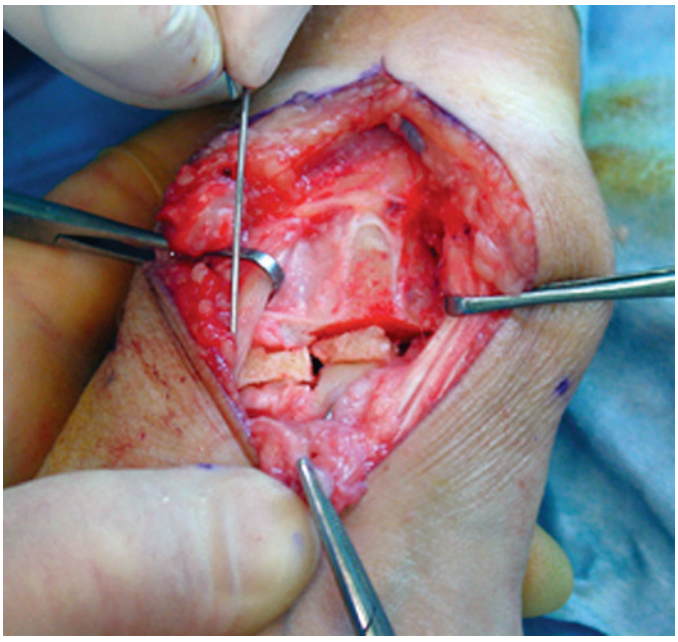

FIGURE 12.18 Example of radioscapholunate fusion. The diseased ulnar head has been excised and prepared in this case as the two grafts that are necessary to achieve restoration of carpal height and to ensure that the lunate is neutral in flexion and extension. Normally, it is our practice to excise the distal 20% of the scaphoid initially and then check during the dart thrower's range of motion that clearance is adequate. Further excision can be done until the surgeon is comfortable with the range of motion. Excision of the triquetrum follows the same principle.

Complications

Shin and Jupiter commented on the problems of nonunion after attempted radioscapholunate arthrodesis and the problems of using Kirschner wires or cannulated screws.[92] They reported successful use of 2.4-mm distal radial plates to provide locking plate stabilization of their radioscapholunate fusions. Nagy and Büchler identified two patients who exhibited secondary midcarpal degenerative joint disease.[72] Hamate-lunate impaction syndrome can occur in patients with a type II lunate and may be secondary to activities that require frequent flexion and ulnar deviation (see Figure 12.2, *B*).[97] Hamate-lunate impaction syndrome can be treated with amputation of 2 to 3 mm of the tip of the proximal hamate, which can be performed concurrently with radioscapholunate fusion. This causes no instability in the wrist and can ensure that impaction does not lead to pain and the late development of midcarpal degenerative joint disease. Arthrosis of the capitolunate joint is a contraindication to radioscapholunate arthrodesis, but Taleisnik suggested that mild arthrosis is acceptable and reported encouraging results with a motion-preserving adjunctive capitate interposition arthroplasty for patients with more severe capitolunate disease.[96]

Postoperative Care

As is standard for any fusion, initial immobilization in a bulky dressing for 10 to 14 days with the hand elevated whenever possible allows the swelling to subside. At 10 to 14 days a short-arm cast that allows finger and thumb motion is applied for 4 to 6 weeks. Once union is confirmed at 6 to 8 weeks, therapy is commenced with 1 to 2 weeks of dart thrower's motion, followed by 4 weeks of additional flexion-extension and radial-ulnar deviation exercises. Strengthening exercises with avoidance of heavy activities are then initiated for 4 to 6 weeks. Contact sports are not permitted for 4 to 5 months postoperatively.

What Patients Should Be Told

Provided union occurs (and even in select cases of pseudarthrosis), successful pain relief is predictable. There will be restricted range of motion, as identified by Garcia-Elias and colleagues.[36] The overall arc of flexion-extension and radioulnar deviation should be approximately half of the normal side, as one joint of a two-row system has been eliminated. Nagy and associates documented an average postoperative range of motion of 32 degrees of flexion, 35 degrees of extension, 14 degrees of radial deviation, and 19 degrees of ulnar deviation.[72] A metaanalysis from the mid 1990s documented a nonunion rate of 30%[56]; however, more recent investigations using more rigid fixation (e.g., compression screws, staples) and modification of technique to include distal scaphoid as well as triquetral excision have reported excellent union rates.[4,8,38,92] In addition, as previously mentioned, if it occurs, nonunion is not always painful (Figure 12.20). Recovery may require 9 to 12 months in some patients with poor bone stock, nonrigid fixation, or inflammatory disease. Patients should be warned that they are at some risk for midcarpal arthritis because of the altered wrist biomechanics and loads at that joint. Radioscapholunate fusion is an excellent motion-preserving procedure for radiocarpal arthrosis.



FIGURE 12.19 **A,** Posteroanterior (PA) and **B,** lateral x-rays of a 62-year-old female with significant radiocarpal arthritis. Note that the midcarpal joint has a fairly well maintained joint space. The patient underwent radioscapholunate (RSL) fusion using memory staples and intraoperative PA **(C)** and lateral **(D)** fluoroscopy images demonstrate the initial fixation. **E,** PA and lateral **(F)** radiographs 3 months after surgery show stable alignment and consolidation across the fusion mass.

Scapholunate Arthrodesis

Because motion of the scaphoid varies from individual to individual, the results of scapholunate arthrodesis[48] are unpredictable. In the hypermobile group of patients, the scaphoid will pronate and flex considerably with a small amount of translation. At the other extreme, the scaphoid does not flex or pronate in radial deviation.[23] In patients with hypermobile scaphoids, scapholunate arthrodesis is contraindicated. Nonunion rates are high, the ability to achieve union is low, and the results are unpredictable. Because of nonunion rates of 50 to 85%,[48,56] this procedure has not proved to be a satisfactory treatment option for scapholunate dissociation.

Lunotriquetral Arthrodesis

Indications and Contraindications

Indications for lunotriquetral arthrodesis[51] include painful partial coalition of the lunotriquetral joint and symptomatic

CRITICAL POINTS *Radioscapholunate Arthrodesis*

Indications
- Radioscaphoid or radioscapholunate joint arthritic deformity after distal radial articular fractures
- Rheumatoid arthritis with relative sparing of the midcarpal joint
- Translocation of a carpus that is arthritic and/or irreducible

Preoperative Evaluation
- CT scanning or MRI can be helpful as an adjunct to standard x-rays to better delineate the nature of the midcarpal joint and, in particular, identify the presence or absence of a type II lunate facet.

Pearls
- There must be absent or minimal degenerative joint disease within the midcarpal joint.
- A 2- to 3-mm amputation of the impacting part of the head of the hamate must be performed if there is a significant type II joint on the lunate.
- Displacement of the ECRB and ECRL to the radial side gives adequate exposure.
- Excision of the distal pole of the scaphoid can be performed to allow better radial deviation of the wrist.
- Decortication of the posterior two thirds of the scaphoid, lunate, and radius preserves longitudinal alignment and length, and the area can be grafted quite readily. The use of a rongeur and/or a bur is most helpful in preparing the surfaces.
- When using a bur, copious irrigation is needed to avoid overheating and osteonecrosis.
- A posterior interosseous neurectomy can help with postoperative pain and avoid problems with scarring or tethering of the nerve with wrist range of motion.

Pitfalls
- Failure to recognize that a type II lunate is preventing full ulnar deviation of the midcarpal joint and therefore that excision of the proximal tip of the hamate is necessary
- Failure to adequately excise the distal pole of the scaphoid when distal scaphoid excision is performed
- Violation of the capitolunate joint
- Failure to recognize ulnar abutment between the ulnar head and triquetrum
- Irritation of a nerve, artery, or tendon caused by hardware. This is especially relevant when wires are placed from the radial side of the wrist percutaneously.

Expectations
- Seventy-degree arc of flexion-extension, 35-degree arc of radioulnar deviation
- As with other partial carpal fusions, incomplete relief of pain
- Prolonged recovery in some series
- Possible late-onset midcarpal degenerative changes



FIGURE 12.20 Posteroanterior x-ray at 9 months following surgery in a patient with rheumatoid arthritis who underwent attempted radioscapholunate fusion and developed nonunion. Despite nonunion, she remains symptom free with functional motion.

lunotriquetral dissociative instability. Contraindications include the presence of midcarpal arthritis, nondissociative ulnar midcarpal instability, or lunotriquetral dissociation with ulnocarpal impingement.

❖ AUTHOR'S PREFERRED METHOD OF TREATMENT: Lunotriquetral Arthrodesis

A longitudinal dorsal wrist incision is used. The lunotriquetral joint is approached through the fifth dorsal extensor compartment, and the extensor digiti minimi is dislocated toward the radial side. The triquetrum is identified through a longitudinal capsular incision, and the fourth compartment is raised subperiosteally off the distal radius to identify the lunotriquetral interval. Care is taken during this exposure to avoid injury to the dorsal radioulnar ligament origin on the radius. The triquetrolunate joint is decorticated with osteotomes and a rongeur. A distal radius bone graft is harvested as above. The fusion site is packed with bone graft while normal intercarpal spacing is maintained. Two 0.045-inch Kirschner wires are placed for fixation, and fluoroscopy is used to confirm the reduction and appropriate alignment. One Kirschner wire may be used to guide a cannulated drill or reamer and prepare for the insertion of a single cannulated headless bone screw; this can give rise to substantial compression of the joint, which is then usually stable. If there are any doubts about stability, the second Kirschner wire can be left in place and cut flush with the triquetrum.

Postoperative Management

Healing is somewhat less predictable and, in my experience, takes longer than with radiocarpal or four-corner arthrodesis. This is likely due to the small fusion area. Most patients require 6 to 10 weeks of immobilization. At this point the patient may be mobilized gently with flexion-extension and dart-throwing exercises. If the x-rays show satisfactory union, strengthening and more resistive activities can be started at 12 weeks. Heavy activities and contact sports should be avoided for 4 to 5 months.



FIGURE 12.21 Headless bone screws are ideal for triquetrolunate (TL) fusion. A trial of TL fusion can be performed by percutaneous insertion of a TL screw.

Pearls

Because the effect of lunotriquetral fusion is unpredictable, temporary stabilization of the joint with a headless bone screw can be performed percutaneously through a small stab incision while taking care to avoid the dorsal branch of the ulnar nerve. After inserting a Kirschner wire and confirming its position with fluoroscopy, a cannulated drill and tap are used, followed by insertion of a headless bone screw across the joint (Figure 12.21). The patient can "try out" the fusion for the next 4 to 6 weeks; if successful, as a definite open procedure, the screw can be loosened, the joint prepared, the bone graft inserted, and the screw recompressed. Failure of the temporary fixation to improve the patient's symptoms indicates that the screw should be removed and the status quo should be reestablished. Further workup and consideration about management of the patient's condition are warranted.

Pitfalls

The dorsal branch of the ulnar nerve is highly vulnerable to percutaneous hardware insertion on the ulnar side of the wrist, and injury may give rise to a neuroma of this nerve and altered sensation on the dorsal-ulnar aspect of the hand. This complication causes considerable distress to patients and significantly detracts from any benefits of this procedure. To avoid this problem, a small skin incision should be made as is practiced in arthroscopy of the wrist, blunt dissection performed down to the triquetrum, and a drill sleeve used to protect the soft tissues.

Preoperative x-rays in full ulnar deviation and full axial compression of the forearm should identify whether there is abutment between the ulnar head and the triquetrum. Ulnar impaction is the leading cause of lunotriquetral disruption; it may also be a cause of significant pain. Treatment involves an isolated or combined wafer procedure[29] or ulnar-shortening osteotomy.

What Patients Should Be Told

There is a nonunion rate of 30%,[56] there will always be a loss of 30% to 40% of the range of motion, the results are somewhat unpredictable, and recovery takes 9 to 12 months. The pain may not be entirely relieved.

Triquetrohamate Fusion

Triquetrohamate fusion[85] is a less common intercarpal fusion; its primary indication is for treatment of painful midcarpal instability. Much like scapholunate arthrodesis, the complication rates are significant. Rao and Culver reported an almost 50% failure rate in providing relief of symptomatic midcarpal instability with triquetrohamate fusion[85]; therefore, this operation is not recommended. The author's experience mirrors that of these investigators.

Scaphotrapeziotrapezoidal Fusion

Indications

There are several indications for scaphotrapeziotrapezoidal fusion.[54,113] The presence of degenerative arthrosis localized to the STT joint is often associated with calcium pyrophosphate deposition disease. Primary osteoarthritis of this joint is not uncommon. Painful radial deviation and pain on gripping and when performing heavier tasks are the usual complaints of patients with scaphotrapeziotrapezoidal (STT) arthritis, and failure of conservative measures including corticosteroid injection is an indication for surgical intervention. STT arthrodesis (called triscaphe arthrodesis by Watson[109]) has also been used to treat selected cases of dynamic or static rotatory subluxation of the scaphoid, nonunion of the scaphoid, Kienböck disease,[41,109] scapholunate dissociation,[111] midcarpal instability, and congenital synchondrosis of the STT joint.

Contraindications

Contraindications primarily include radiographic narrowing or degenerative change of the radioscaphoid joint, which will become increasingly degenerative and symptomatic after the increased load transfer associated with STT fusion. The presence of thumb carpometacarpal (CMC) joint arthritis would also be considered a contraindication.

Preoperative evaluation should include radiography of the STT joint with full ulnar deviation views and full radial deviation views to identify whether the scaphoid moves. If the scaphoid is highly mobile, as characterized by considerable flexion and pronation during radial deviation, an STT fusion condemns patients to painful radioscaphoid subluxation each time they move into radial deviation. In this case, one should consider some form of interpositional arthroplasty or excisional arthroplasty rather than arthrodesis. Similarly, if there is substantial gap formation at the STT joint on full ulnar deviation that closes on radial deviation, there may be chronic bone loss involving the distal pole of the scaphoid. These patients have less satisfactory results with arthrodesis and in the author's experience are better served by excision of the distal pole of the scaphoid.[37]

❖ AUTHOR'S PREFERRED METHOD OF TREATMENT: Scaphotrapeziotrapezoid Fusion

The STT joint is approached through a dorsal radial curvilinear transverse wrist incision of 6 to 8 cm centered over the STT joint just distal to the radial styloid. The dorsal veins and branches of the superficial branch of the radial nerve are preserved. Care must be taken to identify and preserve the dorsal radial artery. The radial styloid is exposed through an incision in the capsule, and the distal 5 mm is removed with a rongeur. A transverse incision in the dorsal capsule is made, and the radioscaphoid joint is inspected. If significant degenerative disease is identified, the procedure of choice is proximal row carpectomy (if the capitate has a healthy articular surface) or scaphoid excision and four-corner fusion (if both the scaphoid fossa and head of the capitate show degenerative wear).

The distal aspect of the extensor retinaculum is opened along the EPL, and the STT joint is approached through a transverse capsular incision between the ECRL and ECRB tendons. The entire articular surfaces of the scaphoid, trapezium, and trapezoid are removed with a rongeur while taking care to remove the proximal half of the trapezium-trapezoid articulation only. It is mandatory that the subchondral hard cancellous bone also be removed and the softer cancellous surfaces exposed. The dorsal cortex of the trapezium and trapezoid is likewise removed to broaden the surface area for fusion. The volar lip of the scaphoid is decorticated by inserting a dental rongeur deep into the joint and levering the handle distally. Cancellous bone graft is then harvested from the distal radius at the Lister tubercle. Two 0.045-inch Kirschner wires are driven percutaneously from the distal aspect of the dorsal trapezoid proximally into the prepared space without crossing it. The first, radially positioned Kirschner wire is passed to the point of just touching the surface of the scaphoid. The second, ulnarly positioned Kirschner wire is passed proximally to the point of entering the scaphotrapezoid space. The wrist is placed in full radial deviation and 45 degrees of dorsiflexion while the scaphoid tuberosity is reduced by the surgeon's thumb to prevent overcorrection of the scaphoid (Figure 12.22, *A*). A 5-mm spacer, usually the handle of a small instrument, is placed into the scaphotrapezoid space to maintain the original external dimensions of the STT joint, and the radial Kirschner wire is driven into the scaphoid while avoiding placement into the radioscaphoid joint. The spacer is removed, and the ulnar Kirschner wire is similarly driven into the scaphoid (see Figure 12-22, *B*). After pinning, the scaphoid should lie at approximately 55 degrees of flexion relative to the long axis of the radius when seen from the lateral view. This ensures optimal radioscaphoid congruity and maximizes the postoperative range of motion. It is not necessary to correct any abnormal rotation of the lunate. Excessive extension of the scaphoid will limit the motion obtained after surgery. Cancellous bone is densely packed into the spaces between the scaphoid, trapezium, and trapezoid. The pins are cut beneath the skin level, and the wrist capsule and extensor retinaculum are simply realigned without suturing. The skin incisions are closed with a single-layer subcuticular monofilament suture. The postoperative dressing consists of a bulky noncompressive wrap incorporating a long-arm plaster splint. The hand is placed in a protected position with the wrist in slight extension and radial deviation, the forearm neutral, and the elbow at 90 degrees.

Postoperative Management

An above-elbow bulky dressing and splint including the thumb are applied for the first 2 to 3 weeks following surgery. Following suture removal, a long-arm thumb spica cast is applied. Following 4 additional weeks of above-elbow immobilization, a short-arm thumb spica cast can be added for an additional 2 to 3 weeks. If using Kirschner wire fixation, the proximal carpal row is easily immobilized by casting the forearm and arm, but it is difficult to adequately maintain the position of the distal carpal row. Therefore, Watson recommended casting the metacarpophalangeal (MP) joints of the index and middle fingers in 80 to 90 degrees of flexion (the so-called Groucho Marx cast) with the interphalangeal joints left free. When radiographic union is seen, the pins are removed in the office and the patient is referred to the hand therapy department for full wrist mobilization. A splint may occasionally be used for an additional 1 or 2 weeks if there is any doubt about the status of bone healing.

Alternative Techniques

Staple Fixation

Power-inserted staples can simplify the fixation process and prevent complications related to Kirschner wire irritation and potential infection. After provisional fixation in the appropriate position with Kirschner wires, staples are driven across the scaphotrapezial and scaphotrapezoid joints. The provisional Kirschner wires can then be removed. Postoperative care is as outlined earlier, although it is seldom necessary to include the index and middle digits in a cast when modern fixation techniques are employed.

Circular Plate Fixation

Small circular plates, commonly used in the management of four-corner fusions, may also be used for fixation of an STT arthrodesis. Most plate systems carry a smaller version that can be centered at the STT joint dorsally. The bone ends are prepared as in the above-mentioned technique and provisional Kirschner wires can be placed to hold the construct in reduction. Most systems use reamers to inset the plate into the fusion mass.

Screw Fixation

The STT joint should be reduced and provisionally held by two guidewires and checked by fluoroscopy. The length is measured, and an appropriate-length cannulated screw can be inserted over each wire.

What Patients Should Be Told

Watson has reported excellent functional results and pain-free, stable wrists after STT arthrodesis. In a review of over 800 STT fusions, the average range of motion has usually been 70 to 80% of that of the contralateral normal wrist and the grip strength has averaged 70 to 90% of that of the unaffected wrist.[113] Long-term radiographic follow-up has revealed only rare instances of progressive radioscaphoid or intercarpal degenerative changes, and they occurred only in patients who had some evidence of disease in these joints at the time of surgery. However, radial styloid-scaphoid impingement can occur and may be painful; styloidectomy is thus an important element of the procedure.[88] The nonunion rate is greater than 20% (Figure 12.23). Loss of

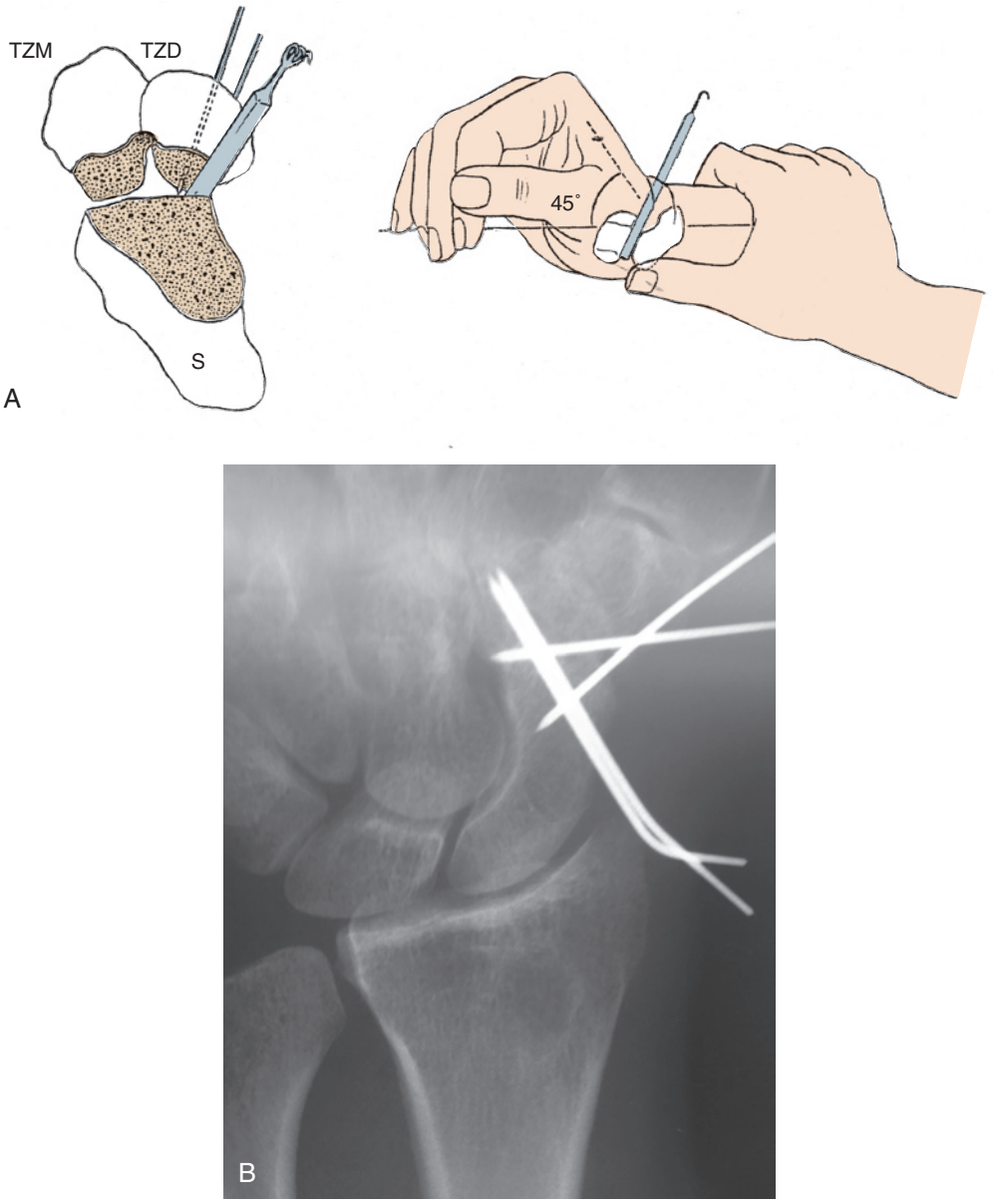

FIGURE 12.22 **A,** These diagrammatic representations of the preparation and positioning of the scaphoid highlight the requirement of ensuring that the scaphoid must lie in a flexed position at 45 to 55 degrees to the long axis of the radius before insertion of the Kirschner wires. **B,** Posteroanterior radiograph demonstrating scaphotrapezotrapezoidal arthrodesis with K-wire fixation. *S,* Scaphoid, *TZD,* trapezoid; *TZM,* trapezium.

wrist range of motion is unpredictable. Recovery takes 9 to 12 months, and pain relief may not be complete.

Few authors have reported results as successful as those reported by Watson and colleagues following STT arthrodesis. Kleinman and Carroll reported a 52% complication rate in 47 wrists monitored for 10 years and highlighted the need for precise positioning of the fused scaphoid.[54]

Reconstruction of Wrists With Scapholunate/ Scaphoid Nonunion Advanced Collapse (Scaphoid Excision, Capitate-Lunate-Hamate-Triquetrum Fusion)

The SLAC and SNAC patterns of arthritis generally spare the radiolunate articulation, and therefore capitate-hamate-lunate-triquetrum arthrodesis (the four-corner fusion with scaphoid excision) has become the procedure of choice, particularly if the midcarpal joint is arthritic.[21,52,55,102,110,112] Excision of the scaphoid must include stabilization of the remaining carpus to prevent gross instability, and this is achieved effectively either through arthrodesis of the capitate, lunate, triquetrum, and hamate or by capitolunate fusion alone. Capitolunate arthrodesis reduces the area of cancellous bone exposed and may be less reliable than four-corner fusion.

Indications

The presence of degenerative changes in the radioscaphoid joint and the midcarpal joint identifies the pattern as SLAC wrist stage III (Figure 12.24). If the capitolunate joint is preserved, proximal row carpectomy is an alternative to four-corner



FIGURE 12.23 Posteroanterior view of the hand demonstrates a patient who had undergone attempted scaphotrapeziotrapezoid fusion 1 year earlier and now had a painful nonunion.



FIGURE 12.24 Stage III scapholunate advanced collapse wrist as seen on a radiograph. The prolonged scaphoid flexion and the deepening radial erosion force the lunate into extension, which becomes very difficult to reduce because of an associated anterior capsular contracture. Reduction, however, is essential to permit extension of the wrist, which after a four-corner fusion, occurs solely at the radiolunate articulation.

fusion.[21,25,105] However, long-term outcomes with proximal row carpectomy have shown poorer results in patients less than 40 years of age.[105] Scaphoid nonunion or avascular necrosis of the scaphoid with the SNAC pattern of arthritis may lead to significant symptomatic wrist arthritis, and four-corner fusion is an option.

Contraindications

The lunate fossa must be intact and free of disease such as crystalline or inflammatory arthropathy for four-corner fusion or capitolunate fusion to succeed.

❖ AUTHOR'S PREFERRED METHOD OF TREATMENT: Scaphoid Excision and Four-Corner Fusion

A longitudinal incision is made in the line of the third metacarpal. The extensor retinaculum is incised over the third compartment, and the fourth and second compartments are exposed over the carpus. Posterior interosseous neurectomy is performed by excising a 1-cm segment of the nerve proximal to the dorsal rim of the radius. The ligament-sparing capsulotomy is performed to expose the joint. Visual inspection of the lunate and the lunate fossa must confirm intact articular cartilage. On occasion, in more severe SLAC wrists and in wrists with extreme extension of the lunate, there may be some dorsal chondromalacia of the lunate and the dorsal rim of the lunate fossa. Because the lunate alignment will be corrected with the procedure, some of this is acceptable, but if it is too extensive, an alternative procedure, such as a complete wrist fusion, should be considered. The ECRL and ECRB are retracted to allow extension of the capsulotomy more radially for exposure of the scaphoid. The scaphoid is removed with a rongeur. The palmar radioscaphocapitate and long radiolunate ligaments are protected. The remaining cartilage and subchondral bone are removed from the surfaces of the capitate, distal lunate, hamate, and distal triquetrum until a broad cancellous surface is obtained. Bone graft is harvested from beneath the Lister tubercle. Next, 0.045-inch Kirschner wires are percutaneously preset through the capitate, hamate, and triquetrum so that they line up with the more proximal lunate. A fourth wire is passed into the triquetrum directed toward the capitate. Cancellous graft is packed into the deep interval between the capitate and lunate. The most important step in this procedure is to reduce the dorsiflexed position of the lunate in relation to the radius. A Kirschner wire inserted into the dorsal lunate is used as a joystick for reduction. With the lunate reduced into neutral alignment or very slight extension, the capitate is translated ulnarward to restore its normal position on the lunate in the coronal plane. It is important not to overcorrect the capitate position on the lunate, because the palmar extrinsic ligaments will tighten and limit ulnar deviation. The preset Kirschner wires are passed across the capitolunate, capitohamate, triquetrocapitate, and triquetrolunate joints under fluoroscopic guidance. The intervals between the bones are packed with cancellous bone harvested from the distal radius. Although I have no strong feelings about the hardware selection for fusion, I prefer a radiolucent circular plate (Figure 12.25, *A* and *B*). A reamer is used to inset the plate so that it will not impinge with extension of the wrist. Typically, I will try to place at least two screws into each bone; tightening the screws applies compression across the fusion mass. Each hole is drilled and the screw placed. I prefer to place subsequent

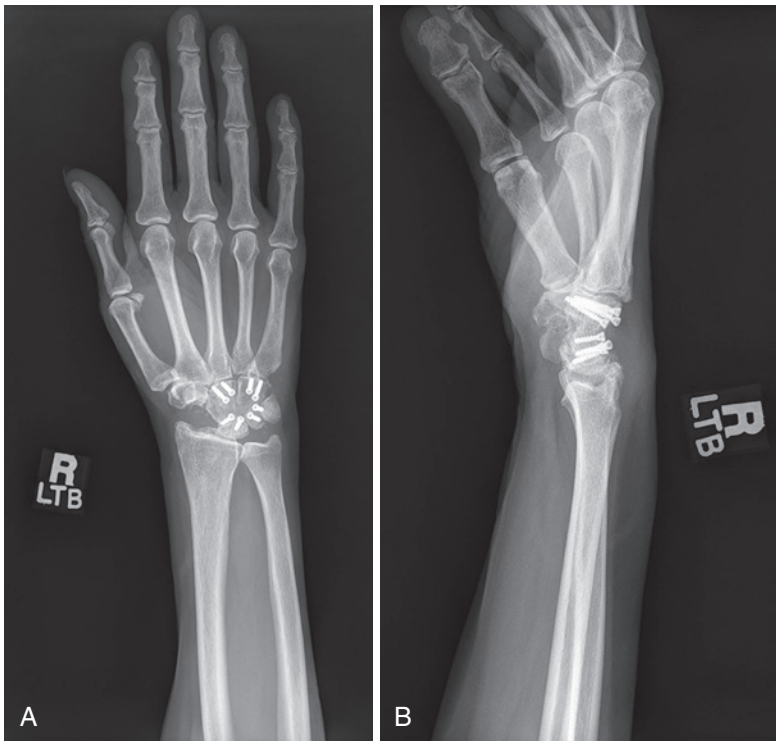

FIGURE 12.25 **A,** Posteroanterior view following a four-corner fusion using a radiolucent circular plate. Note the center of the plate is slightly distal to the four-bone center, which will minimize risk of plate impingement. **B,** Also, it is important to reduce the lunate from its extended position. Recessing the plate will also help to reduce the risk of impingement with extension, but care must be taken to avoid overrecessing because it will limit the strength of fixation.

screws opposite from the previous screw to maintain the balance of the plate and its position. I find that placing the center of the plate a bit distally from the center of the four bones provides a better position for the hardware (see Figure 12.25, *B*). Care should be taken to avoid penetration of the far cortex in the triquetrum and lunate as that would invite irritation of the pisotriquetral and radiolunate joints. Fluoroscopy should be used to confirm appropriate reduction of the lunate and carpus, as well as the hardware position and appropriate screw lengths. Upon completion of the construct, the wrist should be extended to confirm that there is no hardware impingement (Figure 12.26, *A* and *B*). The wires are removed after securing the plate. The capsule is closed, the retinaculum is repaired, the subcutaneous tissues are approximated, and the skin is closed with subcuticular sutures.

Postoperative Management

The extremity is immobilized in a bulky conforming dressing and splint in neutral to 20 degrees of extension. The fingers are left free for exercises. At 2 weeks the sutures are removed and a short-arm cast is applied. At 6 to 8 weeks after surgery, the patient is assessed clinically and radiographically, a lightweight removable splint is applied, and remedial exercises are commenced. In patients younger than 55 years, a more cautious approach consisting of the application of a long-arm cast for the first 5 weeks may be indicated. Some authors have allowed for earlier motion with the use of compression staples, circular plates, and compression screws. However, my preference is to protect the patient for approximately 6 weeks.

Alternative Methods of Fixation

In recent years a number of internal fixation devices have been designed and applied to limited wrist fusion in an attempt to provide more rigid fixation.

Kirschner Wire Fixation

Kirschner wires are a simpler method of fixation for maintaining the four-bone mass alignment and reduction (Figure 12.27). The pins are typically removed approximately 6 to 8 weeks following surgery. One can leave the pins out in the skin or bury the pins subcutaneously in case there is a need to leave them in longer. The pins have the advantage of being more forgiving in placement; also, there is no potential for problems with retained hardware.

Staple Fixation

Power fixation devices have facilitated placement of staples with both improved accuracy of placement and improved biomechanical properties.[7,91] The capitate, lunate, hamate, and triquetrum are prepared as described earlier and provisionally held with Kirschner wires. One staple is placed between the capitate and hamate, a second between the hamate and triquetrum, and a third between the lunate and capitate (Figure 12.28). Staples measuring 13 mm wide and 10 mm deep are normally chosen.

Screw Fixation

The development of headless compression screws has facilitated internal fixation of carpal bones by burying the screw within

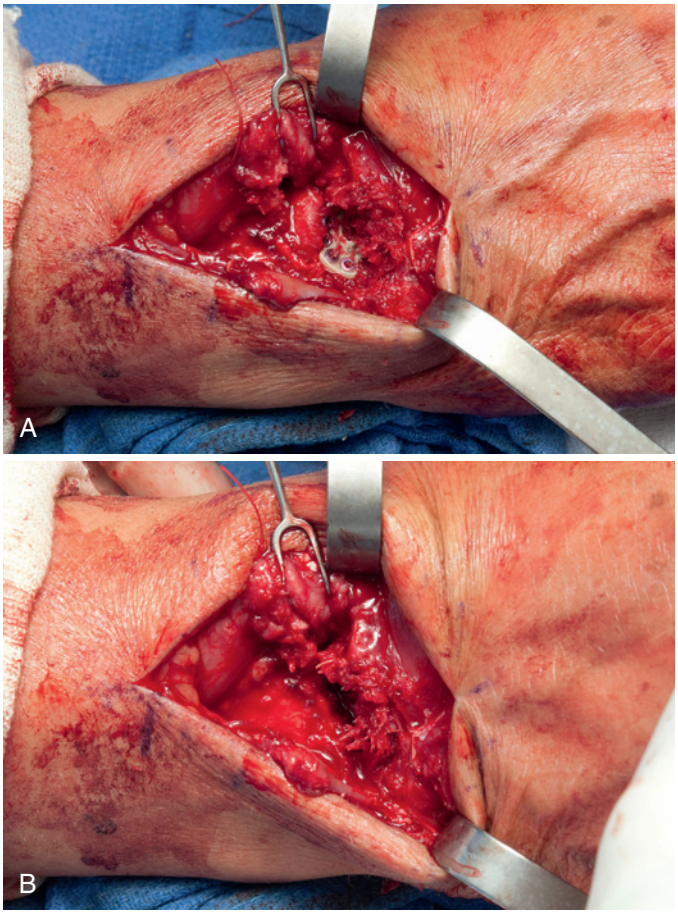

FIGURE 12.26 **A,** Intraoperative images following plate fixation and the use of a circular plate with the wrist in neutral. **B,** Note that in extension the plate glides without impingement on the dorsal lip of the radius.

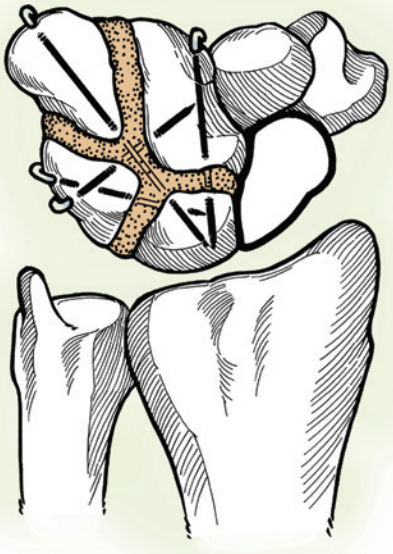

FIGURE 12.27 Kirschner wires fixing a four-corner fusion. (Copyright © Elizabeth Martin.)

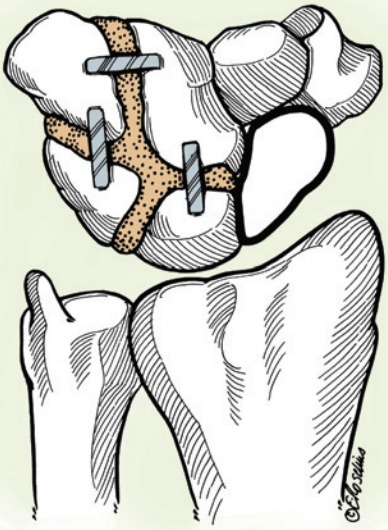

FIGURE 12.28 Diagram of staple fixation. (Copyright © Elizabeth Martin.)

the carpus. Several manufacturers have designed appropriate headless cannulated screws. Screw fixation affords the opportunity for initiation of earlier range of motion because a more reliable and rigid fixation can be achieved.

What Patients Should Be Told

When the procedure is successful, pain relief has been excellent. Neubrech and colleagues reviewed nearly 600 four-corner fusions, with over 100 followed for nearly 15 years.[74] Graduation to total wrist fusion was necessary in less than 7% of patients. The nonunion rate was 11%. Flexion-extension and radioulnar motions were 62% and 68%, respectively, of the motions of the contralateral sides. Grip strength was nearly 90% of that of the contralateral side. Subjective outcomes were generally excellent. Although some previous studies have shown that more rigid fixation methods were associated with earlier graduation to range of motion, these methods also had increased complication rates.[100] However, newer analyses have shown that with proper technique, success can be achieved with the newer-generation circular plates, headless compression screws, or staples.[3,5,76] I conclude again that the method of fixation is less important than the reduction of the fusion mass and appropriate bone preparation. In addition, I have found that with immobilization for 6 weeks following surgery, the rates of long-term motion are similar to those of the Neubrech and colleagues study.

Scaphoid Excision With Capitolunate Arthrodesis

Stabilization (fusion) of the midcarpal joint for reconstruction of a SLAC wrist can also be achieved by isolated capitolunate fusion (Figures 12.29 and 12.30).[2,14,50,52] Because there is no theoretical difference in motion between the two options, four-bone fusion has been recommended to enlarge the fusion surfaces and improve the rate of union. With the availability of more rigid methods of fixation, isolated capitolunate fusion has been used as a simpler procedure that requires only limited

CRITICAL POINTS *Scaphoid Excision and Four-Corner Fusion*

Indications
- SLAC or SNAC stage II or III
- Four-corner fusion is preferred over proximal row carpectomy in patients younger than 45 years of age

Preoperative Evaluation
- CT scanning or MRI can be helpful as an adjunct to standard x-rays to evaluate the cartilage of the radiolunate joint and confirm the SLAC stage.

Pearls
- There must be no degenerative joint disease at the radiolunate joint.
- A posterior interosseous neurectomy should be incorporated as part of the procedure.
- Protect the volar radial supporting ligaments and radioscaphocapitate ligament during the scaphoidectomy and scaphoid excision. This will minimize the risk of ulnar translation of the carpus.
- Proper bone preparation is critical to ensure a successful fusion. Decortication of the lunate-capitate-hamate-triquetral surfaces down to healthy cancellous bone is important. In patients with severe or long-standing SLAC III wrists, the lunate-capitate interval may be quite sclerotic, and denuding down to healthy cancellous bone may be challenging. A high-speed bur can be used to create "craters" on the surfaces that help to maintain the length of the fusion mass but also allow access to the healthy bleeding bone that helps facilitate fusion.
- When using a bur, copious irrigation is needed to avoid overheating and osteonecrosis.
- When choosing the fixation method, have fallback options or a plan B because the position of the four bones and their reduction may be somewhat different than originally expected.
- I feel strongly that the method of fixation is not as important as the application of meticulous carpentry in preparing the bone ends and bone grafting.

Pitfalls
- Avoid leaving prominent dorsal hardware because this may invite impingement with wrist extension.
- Do not overreduce the capitate in the coronal plane because this will tighten the extrinsic ligaments and reduce the ulnar deviation.
- Failure to adequately reduce the lunate from its extended position will invite impingement and result in limited wrist extension.
- With circular plates, avoid screws that penetrate the far cortex in the lunate and triquetrum. Inadequate bone preparation and denuding of cartilage down to cancellous bone will invite a higher risk of nonunion.

Expectations
- There will be 50 to 60% of contralateral flexion-extension and radioulnar deviation.
- The nonunion rate is 10 to 15%.
- Relief of pain is incomplete.
- The recovery time is 9 to 12 months.
- Late-onset radiolunate degenerative changes are possible.

bone graft, which can be obtained from the excised scaphoid. Screw fixation permits earlier initiation of range of motion. Some authors recommend triquetral excision at the time of capitolunate fusion and have had results comparable to those of four-corner arthrodesis and improved motion in the radioulnar direction.[31]

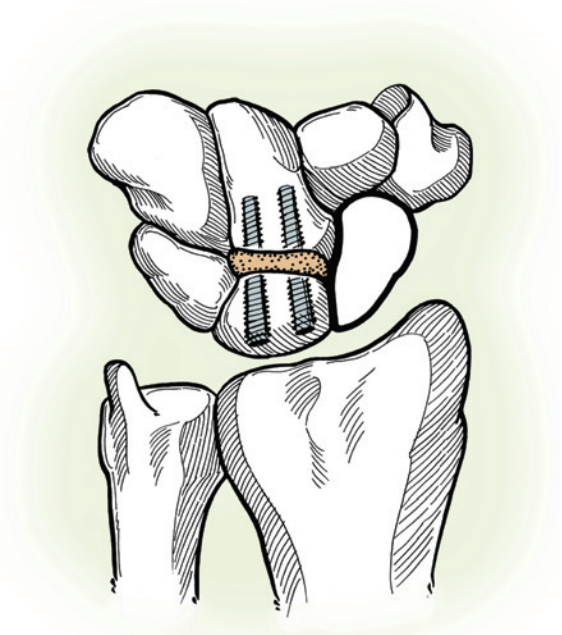

FIGURE 12.29 Excision of the scaphoid and localized capitolunate fusion fixed with headless bone screws. (Copyright © Elizabeth Martin.)

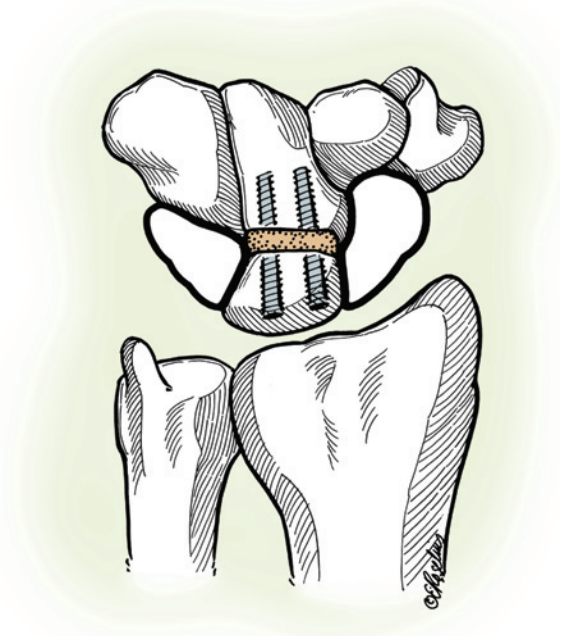

FIGURE 12.30 Excision of the scaphoid and triquetrum occasionally requires an additional capitohamate arthrodesis in the small group of patients with a mobile capitohamate joint. (Copyright © Elizabeth Martin.)

Total Wrist Arthrodesis

When the wrist has been so damaged by the disease process that significant bone stock has been lost, the only reliable surgical procedure is arthrodesis, and this is often the only practical course of action. Particular attention should be paid to the lateral x-ray of the wrist; it may show significant volar subluxation of the lunate, which will give rise to some difficulties in reducing the wrist and could precipitate carpal tunnel syndrome as the wrist is relocated and realigned. From a patient satisfaction perspective, I think it wise to have the patient wear

a brace continuously in order to "simulate" a wrist fusion. It will help temper expectations and more appropriately prepare the patient for the loss of function and adjustments necessary following successful arthrodesis.

History of Wrist Arthrodesis

- Steindler, 1918: Wrist arthrodesis for stabilization in patients with polio and spastic hemiparesis
- Ely, 1920: Arthrodesis for tuberculosis
- Gill, 1923: Devised a method of corticocancellous grafting to provide stability
- Smith-Peterson, 1940: Described an ulnar approach with distal ulnar excision[93]
- Evans, 1955: Wedge arthrodesis[28]

Plates, Wires, and Staples

- Wood, 1987: Introduced a modification of the Gill technique involving compression wire fixation[119]
- Larsson, 1974: AO (Arbeitsgemeinschaft für Osteosynthesefragen) plating[57]
- Benkeddache and associates, 1984: Multiple staples[7]
- Hastings and coworkers, 1993/1996: Modified AO plate with compression[45]

Intramedullary Fixation

- Robinson and Kayfetz, 1952: Intramedullary rods in rheumatoid patients[87]
- Clayton, 1965: Outlined techniques without fixation in rheumatoid patients[18]
- Mannerfelt and Malmsten, 1971: Introduced the Rush pin technique[62]
- Millender and Nalebuff, 1973: Popularized the use of a Steinmann pin and sliding graft[66]

❖ AUTHOR'S PREFERRED METHOD OF TREATMENT: Total Wrist Arthrodesis

My preferred method of stabilizing the wrist for fusion is to use a dorsal wrist fusion plate applied using AO fixation principles.[45,116,120] Specially made plates that fix the radius with 3.5-mm screws and the metacarpal with 2.7-mm screws fit quite nicely and span the radiocarpal, intercarpal, and CMC joints nicely (Figure 12.31, *A* and *B*). Many fixation systems use precontoured plates that conveniently facilitate fixation and compression. Straight plates that one can customize are available for patients with severe disease or a shortened carpus resulting from a prior proximal row carpectomy. In addition, the newer-generation implants afford locking technology, which has been quite helpful in patients with weaker bone stock or bone deficits, such as those with severe rheumatoid arthritis or for whom arthroplasty has failed. As a result, I rarely use Steinmann pins or intramedullary fixation for total wrist fusion.

A standard longitudinal incision is begun in the midmetacarpal area and centered on the third metacarpal (Figure 12.32, *A*). The incision passes across the Lister tubercle and ends over the dorsum of the distal radius just proximal to the muscle belly of the adductor pollicis longus. The radial side of the incision is raised as a flap directly off the dorsal surface of the retinaculum and contains the superficial branch of the radial nerve. The dorsum of the retinaculum is opened by incising the third compartment (EPL) (see Figure 12.32, *B* and *C*) or through a Z-plasty of the fourth compartment retinaculum (see Figure 12.32, *D*). The EPL is mobilized from the compartment proximally and distally and transposed radially. The distal radius is exposed subperiosteally, and the longitudinal incision in the



FIGURE 12.31 **A,** Posteroanterior and **B,** lateral x-rays of a patient with rheumatoid arthritis who underwent arthrodesis with a precontoured dorsal wrist fusion plate.

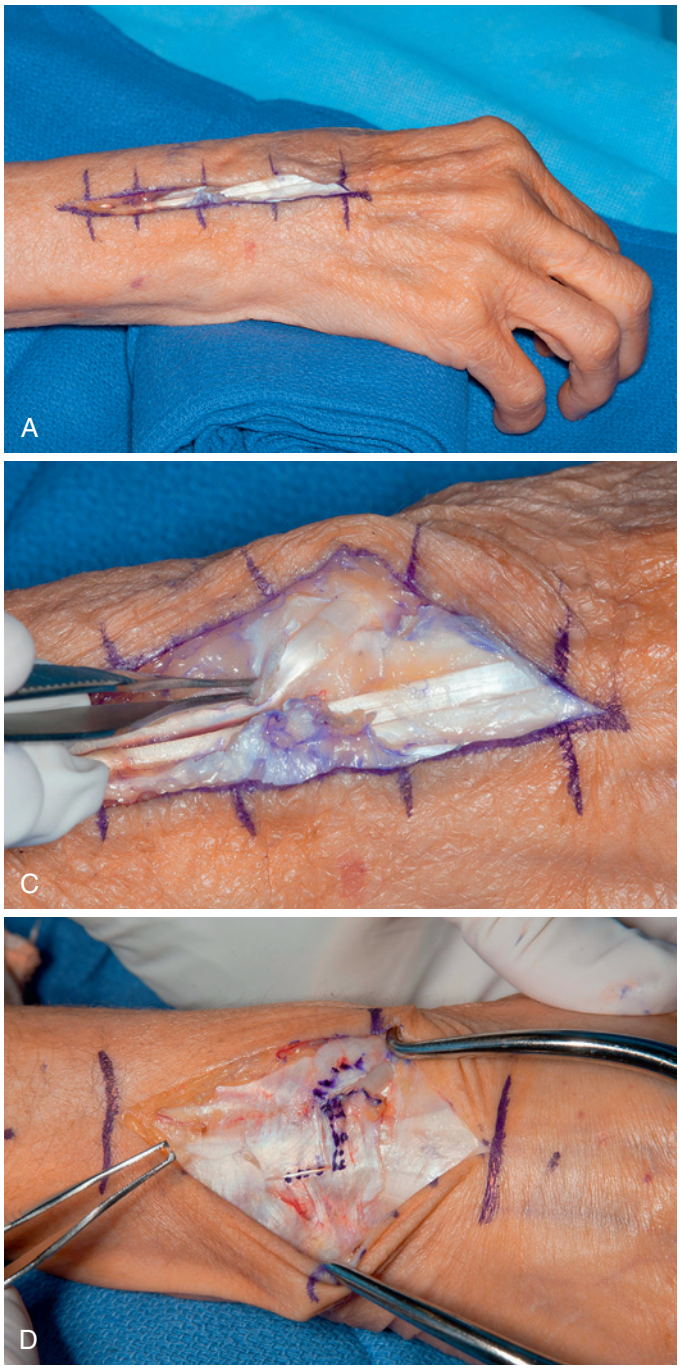

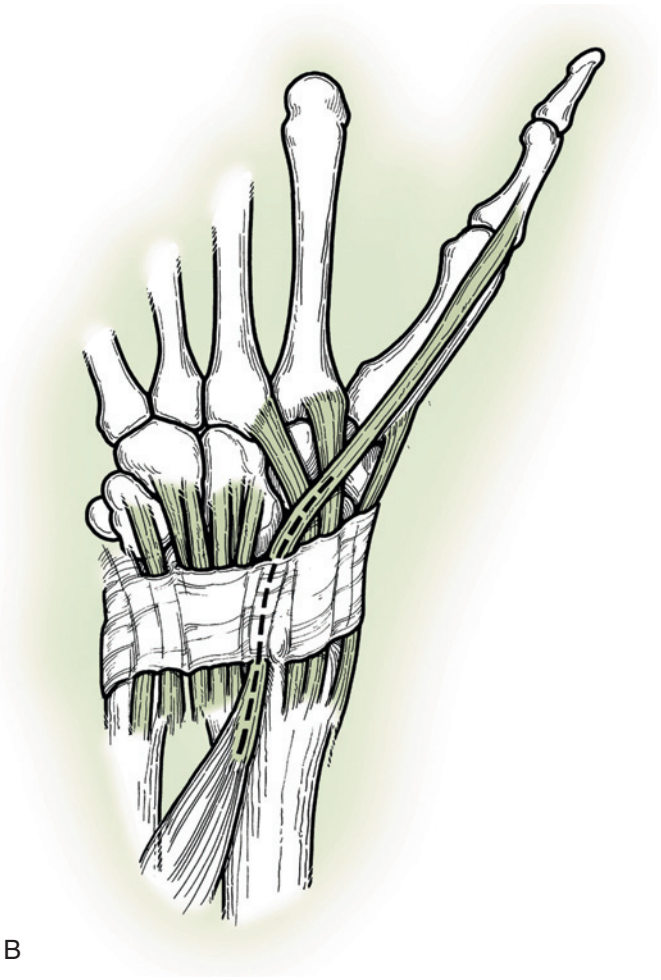

FIGURE 12.32 **A,** A dorsal approach to the wrist centered over the 3 to 4 compartments proximally and in line with the third metacarpal distally. **B** and **C,** A schematic drawing and an operative photo show the approach through the retinaculum in line with the EPL tendon. The obliquity of the retinacular exposure allows for adjustments in tension on closure. **D,** An alternative approach through the retinaculum is via a Z-plasty through the fourth compartment. I prefer to leave the extensor pollicis longus superficial to the retinaculum on closing. (**B,** Copyright © Elizabeth Martin.)

periosteum is extended distally through the capsule out to the radial base of the third metacarpal. A 1- to 2-cm portion of the posterior interosseous nerve is excised just proximal to the articular surface of the radius. The insertion of the ECRB is subperiosteally elevated by scalpel dissection and reflected radially. An incision is made in the interosseous fascia on the radial side of the third metacarpal. The dorsal surface of the third metacarpal is exposed without disturbing the intrinsic musculature on either side. A scalpel blade is used to elevate the two flaps of capsule from the carpus. The second dorsal compartment is elevated subperiosteally from the radius and reflected radially with its underlying capsule. If evaluation or resection of the DRUJ is necessary, the retinaculum should be elevated through the fifth compartment; deep to that compartment, access to the distal radioulnar joint is afforded via an "L"-shaped capsular incision (Figure 12.33). The DRUJ is left undisturbed unless distal ulnar resection is needed for degenerative arthritis. To allow flat apposition of the plate on the radius, the Lister tubercle is removed with an osteotome. This also allows for access to a distal radius bone graft. The dorsal cortices of the base of the third metacarpal and the carpal bones are removed to give excellent visual access to all the joints to be included in the fusion.

Five articulations are generally necessary to facilitate a successful fusion: radiolunate, radioscaphoid, lunocapitate, scaphocapitate and the third CMC joints. The bone ends are

prepared with curets, rongeurs, and high-speed burs (Figure 12.34). I pack the bone graft from the distal radius and the ulna, if a distal ulnar resection is performed. Cortical bone is generally not necessary when a contoured plate is used, but if used, the low-contour fit of the plate may be compromised. I would recommend a straight plate in these cases and customization of the contour. A purely cancellous graft is incorporated faster and has been shown to be associated with lower donor site morbidity.[45] Additional cancellous bone can be harvested from within the distal radius through a cortical window made radial to the intended plate position and 1.5 to 2 cm proximal to the wrist joint (Figure 12.35). All joints to be fused are packed with cancellous bone before plate fixation (Figure 12.36). In the rare instances in which local bone graft is judged inadequate, I prefer mixing the bone graft with cancellous allograft with demineralized bone matrix or cancellous bone harvested from the olecranon or from a window in the superior aspect of the iliac crest without stripping it of its musculature. Any remaining allograft can be packed into the defect of the distal radius.

Different plate sizes are available with shorter or longer bends depending on the preoperative deformity of the wrist and whether the proximal row is retained or excised. These plates do not typically require contouring and they position the wrist in slight extension. A straight version is used when large segmental carpal traumatic or tumor defects require corticocancellous intercalary graft replacement. When desired, a slight extension bend can easily be created with plate benders. If precontoured or 3.5/2.7-mm plates are not available, a straight 3.5-mm limited contact dynamic compression plate may be similarly contoured to follow the dorsal radius, carpal sulcus, and dorsal third metacarpal. One version has a distal taper so as to have a lower profile on the metacarpal. In small individuals, a nine-hole, 3.5-mm reconstruction plate is optimal. In persons with extremely small hands, a 2.7-mm reconstruction plate may be necessary. However, even in some of the smaller wrists with severe rheumatoid arthritis, it has generally been possible to secure the 3.5/2.7-mm plates (Figure 12.37, *A* and *B*).

The plate is affixed to the third metacarpal with 2.7-mm screws while taking care to ensure central drilling in its narrow isthmus. The distal metacarpal hole is drilled first and secured



FIGURE 12.33 When necessary, exposure to the ulnar head is performed through the floor of the fifth compartment and the joint can be exposed via an "L"-shaped capsular incision.

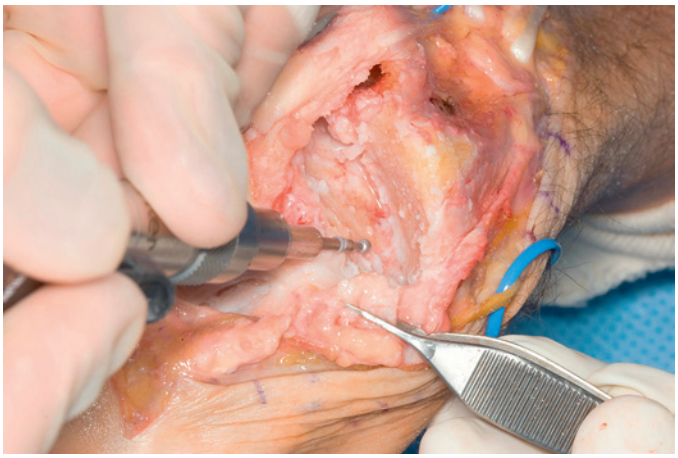

FIGURE 12.34 The use of curets, rongeurs, and, occasionally, burs, especially in hard sclerotic bony surfaces, is necessary to appropriately prepare the surfaces for bone grafting and fusion. This is arguably the most important aspect of surgery to help ensure fusion. When using a high-speed bur, liberal irrigation is needed to minimize heat-related damage to the bony surfaces.

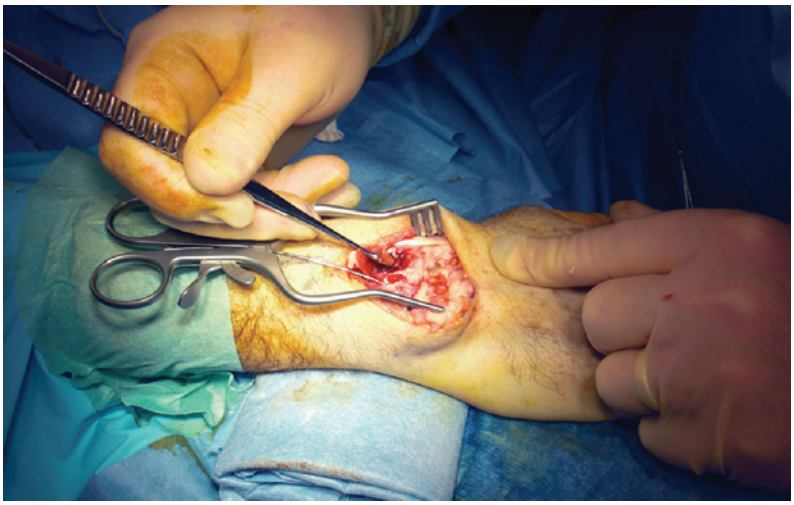

FIGURE 12.35 Cancellous graft is harvested from the distal radius through a window created by excision of the Lister tubercle.

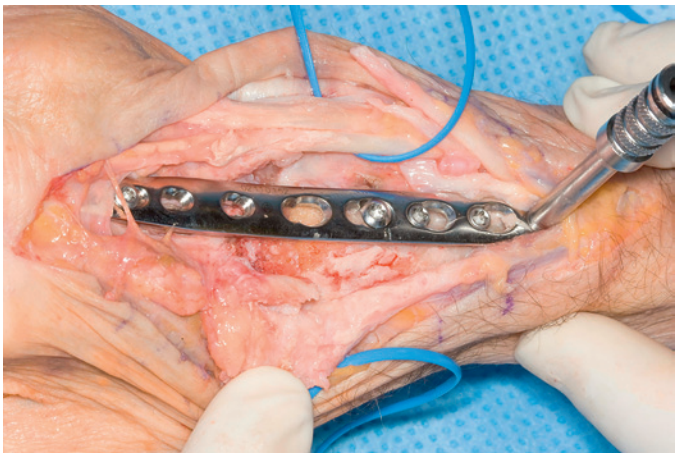

FIGURE 12.36 Placement of cancellous bone graft beneath the plate. Cortical screws help secure the plate to the bone and afford compression. In patients with severe rheumatoid arthritis and/or poor bone quality, locking screws can be added to enhance stability of the construct.

with a cortical screw to enable fine-tuning of the position and compression of the plate to the bone. Accurate alignment of the plate in the dorsal midline of the metacarpal is essential to avoid malrotation and maximize grip strength potential.[82] Upon confirmation of adequate reduction and alignment of the wrist, a second screw may be placed in the metacarpal to ensure the plate will not rotate with compression prior to moving to the radius, or if I am comfortable with the bone quality and confident that the distal fixation is secure to the bone and will not rotate with compression, I will next fix the plate proximally in the radius with a 3.5-mm cortical screw in compression mode. Further compression at the fusion mass may be achieved with a second screw in the radius. After drilling the second compression screw, it is important to start the second screw; the tension from the first radial compression screw is released prior to securing the second screw, allowing for the further compression. The first radial screw can be retightened and secured. Because the radial screws are larger, better compression is achieved from them compared with the 2.7-mm metacarpal screws. The remaining screw holes in the metacarpal, capitate, and radius are filled in no-compression mode, or if the bone quality is poor, locking screws may be used to provide strength to the overall construct (Figure 12.38, *A* and *B*). The use of fluoroscopy will be most helpful during positioning for confirming appropriate plate/screw placement and screw lengths.

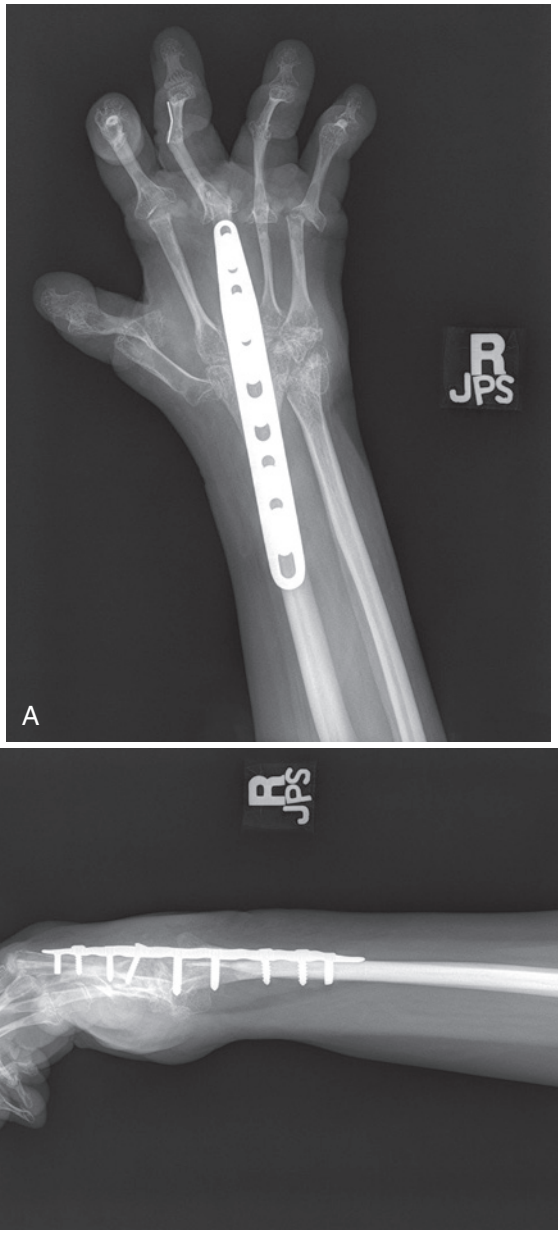

FIGURE 12.37 **A,** Posteroanterior and **B,** lateral radiographs of a 43-year-old female with juvenile rheumatoid arthritis and smaller bone structure who underwent arthrodesis for severe deformity and pain. Despite the smaller bone structure, fixation with the plate was feasible and fusion successful. Note that the most proximal screw was the smallest available and had to be cut so as not to be too prominent volarly.

Closure

A small suction drain is routinely used and brought out proximally. The capsule is closed to the best extent possible to cover the plate with absorbable interrupted braided suture. The retained radial and ulnar flaps of the previously opened retinaculum are approximated, with the EPL left transposed radially out of the Lister canal to minimize potential irritation of the tendon (Figure 12.39).

Postoperative Management

A bulky short-arm dressing incorporating a volar plaster splint is applied. If a distal ulnar resection is performed, I will likely place a sugar-tong splint to prevent pronation and supination. At week 2 the wrist is placed into a cast for an additional 2 to 4 weeks. If clinical healing is confirmed, the patient is graduated to a removable splint for support. Full active use of the hand and digits is allowed, but resistance or lifting is limited to 1 kg. The splint is discontinued at 8 to 10 weeks after surgery. Full use of the hand is allowed by the 10th week. Radiographic healing is to be expected by 8 to 10 weeks.

Complications

A union rate of nearly 100% can be expected when using a precontoured compression plate and local bone graft. Larsson reported a 0% nonunion rate in 23 cases,[57] and Weiss and

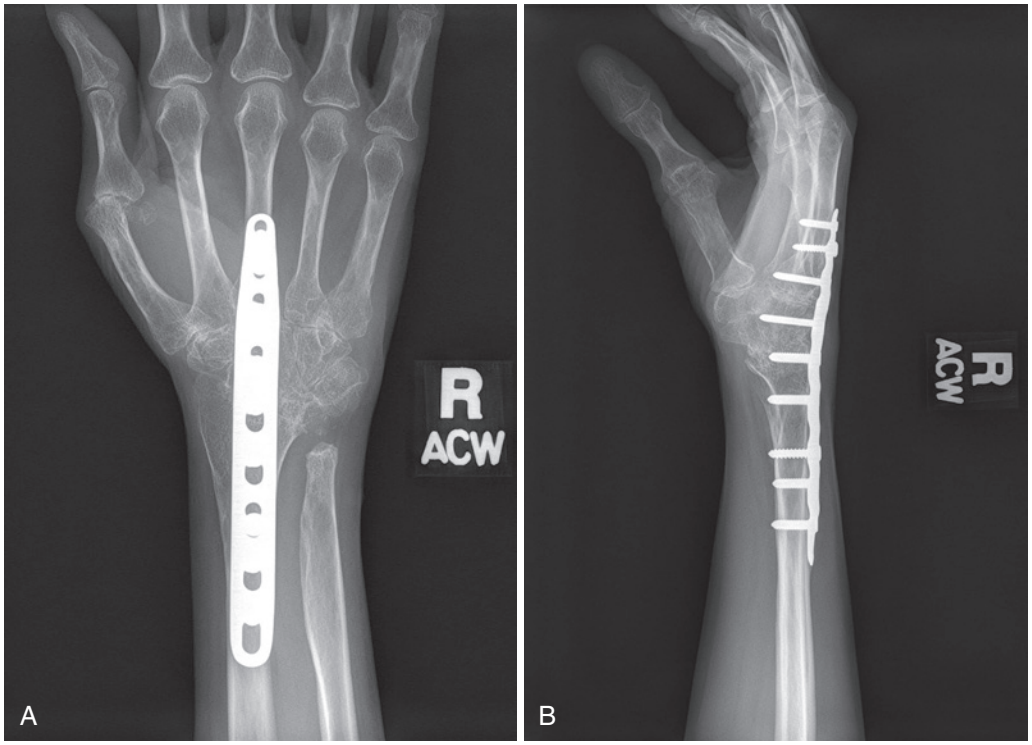

FIGURE 12.38 **A,** Posteroanterior and **B,** lateral x-rays of a 75-year-old female with severe rheumatoid arthritis and poor bone quality who underwent successful arthrodesis 1 year earlier. To enhance the rigidity and strength of the construct, the majority of screws placed were locking after securing the construct distally with a cortical screw and compressing it proximally with a 3.5-mm cortical screw.

CRITICAL POINTS *Plate Fixation for Wrist Arthrodesis*

Indications

- Pancarpal arthrosis of the radiocarpal and midcarpal joints
- Failed past limited arthrodesis
- Failed total joint or previous arthroplasty[86]
- Paralysis of the wrist or hand (with the potential for using functioning tendons for transfer)
- Reconstruction after segmental tumor resection, infection, or traumatic segmental bone loss of the distal radius and carpus[70]
- Inflammatory arthritis with healthy bone stock[45]

Pearls

- Decorticate the dorsal 80% of the third CMC joint.
- Remove the dorsal distal radius for improved plate fit.
- Harvest a distal radius metaphyseal bone graft and apply to the fusion site.
- In a patient with rheumatoid arthritis and ulnar translation, remove part of the radial styloid to facilitate realignment of the wrist.
- Fluoroscopy is helpful in ensuring that the plate position, wrist alignment, compression at the fusion mass, and screw lengths are appropriate.

Technical Points

- Transpose the EPL.
- Decorticate the third CMC joint, capitate, proximal hamate, and distal radius.
- Place graft in the third CMC joint.
- Fix the plate to the metacarpal first.
- Reduce the wrist and fix the plate to the radius in compression mode.
- Fill in any remaining screw holes in the metacarpal, capitate, and radius in neutral mode.
- In patients with poorer bone stock, locking screws will help strengthen the construct.
- Add additional graft from the dorsal distal aspect of the radius and excised carpal bones to the fusion area.
- The triquetrum can be removed if ulnocarpal impingement is of concern.

Pitfalls

- The drill hole through the metacarpal portion of the plate must be in the sagittal plane. If not, the plate will lie rotated on the metacarpal. Subsequent radius fixation will cause rotational deformity of the third metacarpal.
- If the capitate does not contact the undersurface of the plate and is lagged up to the plate, the screw may end up being too long and protrude into the carpal canal. Check screw length with fluoroscopy.
- If non–self-tapping screws are used, be careful to avoid excessive penetration of the tip through the metacarpal, which may injure the deep motor branch of the ulnar nerve as it crosses radially.
- If the ulna is not resected, failure to reduce the lunate to the lunate fossa may invite ulnocarpal impingement.

Postoperative Care

- Immobilize the hand and wrist in a bulky dressing and splint for 10 to 14 days.
- Apply a short-arm cast for 2 to 4 weeks longer.
- At 4 to 6 weeks, graduate to a removable splint.
- At 8 to 10 weeks, begin strengthening.
- Allow full use at 10 to 12 weeks.

Athletic Participation

- Patients are given a 5-lb weight limit for the first 8 weeks.
- Full use is allowed after 10 weeks as symptoms and radiographs permit.

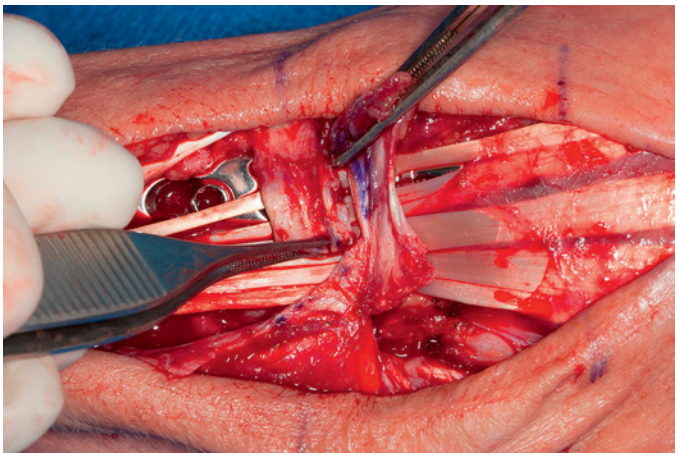

FIGURE 12.39 Repair of the retinaculum following fusion of the wrist. Even in cases of increased tension/volume due to hardware, bone graft, and/or correction of deformity, the Z-plasty affords reapproximation of a functional pulley. Note that the extensor pollicis longus in the most radial aspect of the wound is left superficial to the retinacular closure.

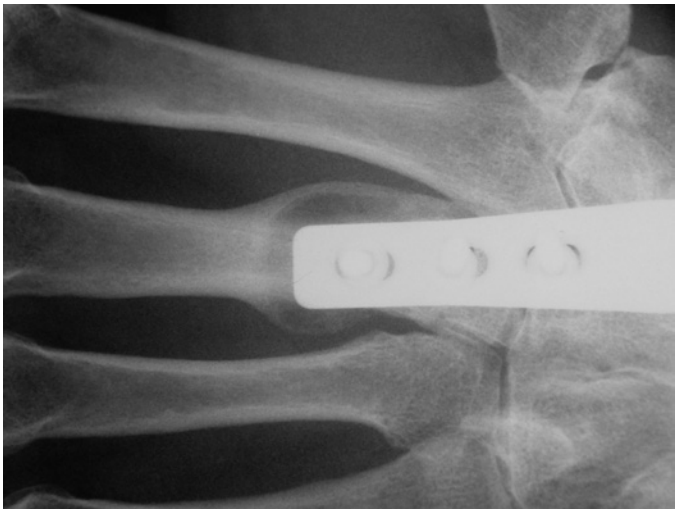

FIGURE 12.40 Failure to achieve sound arthrodesis at the third carpometacarpal joint in an active individual may give rise to loosening of the plate from the metacarpal as shown here, with subsequent painful swelling and diminished function.

Hastings also had a 0% nonunion rate in 28 patients with a plate and local bone graft.[116] When partial nonunion occurs, it most commonly occurs at the third CMC joint (Figure 12.40). With stabilization of the radiocarpal and midcarpal joints, stress may be concentrated distally, and micromotion can lead to fibrous union. Prevention depends on careful and complete decortication of the dorsal 80% of the third CMC joint down to cancellous bone. Although some authors have advised against attempts to formally include the third CMC joint in the fusion, subsequent plate removal is then mandatory to prevent hardware loosening or fatigue fracture. When not included in the fusion, the second and third CMC joints may be at risk for the later development of symptomatic degenerative changes. Standard 3.5-mm plates have been reported to have hardware complication rates of 19%, the majority at the metacarpal level. The incidence of plate removal for tenderness has been 12%.[45] The lower-profile precontoured wrist fusion plate uses smaller 2.7-mm screws distally at the metacarpal level and has tapered edges, and the screws are recessed flush with the dorsal plate surface. With use of this lower-profile plate, symptoms requiring implant removal are rare. The incidence of carpal tunnel syndrome after AO plate fusion is as high as 10.5%, with approximately 67% requiring carpal tunnel release.[45] The surgeon must carefully assess for preoperative carpal tunnel symptoms that may become symptomatic postoperatively. Ideally, the three-dimensional architecture of the carpal canal should not be altered significantly by fusion. Although wrist fusion is generally predictable in providing pain relief, unexplained pain can persist despite successful fusion. This is most commonly seen in patients who have previously undergone multiple failed surgical procedures. When this is the case, selective wrist nerve blocks may be indicated to determine whether wrist denervation would be helpful.[13,114] DRUJ pain can occur after fusion in a small percentage of individuals.[19,115] In a series of 85 wrist fusions, new pain in the DRUJ was seen in just one case and resolved after injection of the joint with 1 mL of betamethasone. Plate fixation of the radius to the third metacarpal usually "radializes" the wrist and protects against impingement of the distal end of the ulna and carpus. Ulnocarpal abutment can occur when there is a discrepancy between the combined height of the radius and radial carpus and that of the ulna and ulnar part of the carpus.[34] When the surgeon chooses to maintain and incorporate the proximal row into the fusion, visual and radiographic means must be used to ensure that the triquetrum does not interfere with the distal end of the ulna. If insufficient space exists between the distal ulna and the triquetrum, the triquetrum should be excised (see Figure 12.30). Some surgeons first perform a proximal row carpectomy, fusing just the radial-capitate and third CMC intervals, simplifying the procedure and avoiding ulnocarpal impingement (Figure 12.41, *A* and *B*).[61]

Intramedullary Pin Fusion for Patients With Rheumatoid Arthritis

Intramedullary pin arthrodesis is an established technique for patients with rheumatoid arthritis and poor bone quality. This method of fusion was first described by Clayton[18] and further popularized by Millender and Nalebuff[66] uses a Steinmann pin, which is inserted down the third metacarpal shaft and into the radius (Figure 12.42). The technique is both technically simple and effective.

This technique is not without potential complications, because the third MP joint will have to be violated. In addition, because these patients have multijoint rheumatoid involvement, surgery will probably be needed to replace the third MP joint. The Steinmann pin may be difficult to countersink, and if there is a failure of union of the third CMC joint, continued motion at the joint may cause the pin to work loose and migrate distally. For these reasons, some surgeons prefer to place the pin retrogradely through the carpus and out the second intermetacarpal web space. The pin can then be redirected in an antegrade fashion down the shaft of the radius. The intermetacarpal pin position places the hand in a position of slight ulnar deviation, which is advantageous mechanically.

To counteract these problems and to improve the security of intramedullary fixation, the Wrightington unit developed a

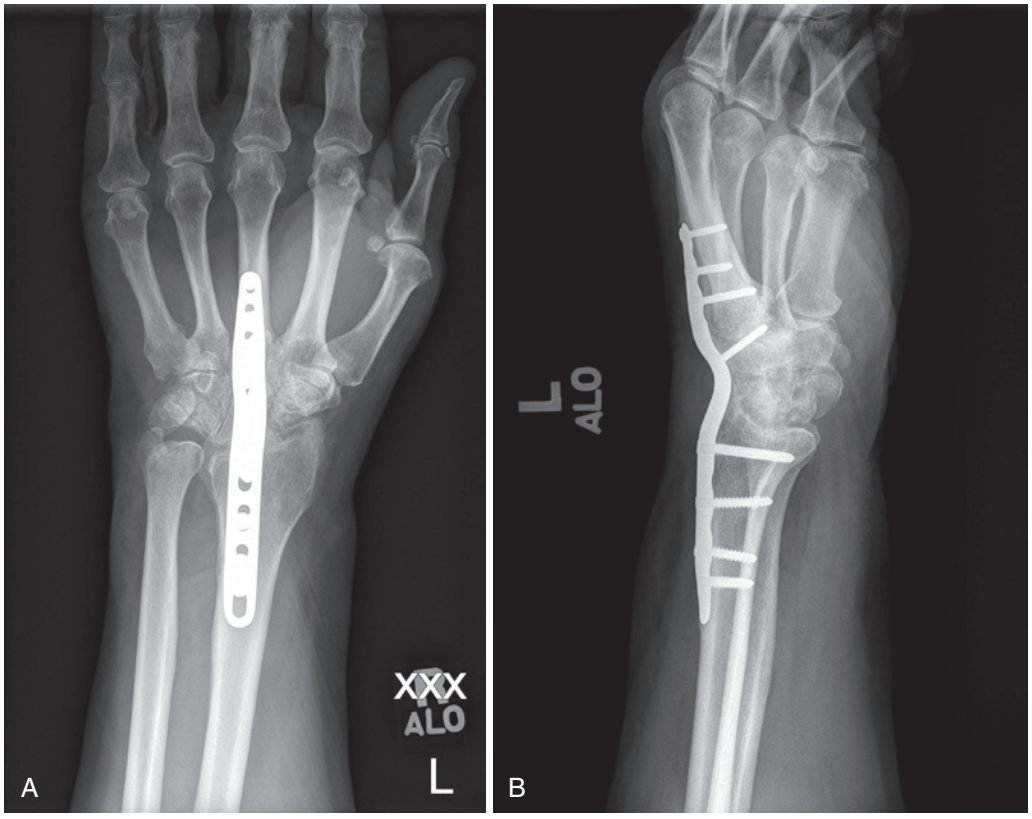

FIGURE 12.41 **A,** Posteroanterior and **B,** lateral x-rays of a patient following successful arthrodesis done with concomitant proximal row resection. This minimizes the risk of ulnocarpal impingement in this wrist with positive ulnar variance.



FIGURE 12.42 Introduction of intramedullary pins through the head of the third metacarpal is rapid and effective fixation for radiocarpal arthrodesis.



FIGURE 12.43 Three lengths of pins in two diameters for placement in the third metacarpal shaft are shown here. The introducer and countersink driver are also demonstrated.

specialized instrument kit consisting of modified pins, a driver, and a countersink driver (Osteotec Ltd, Christchurch, Dorset, UK). The tip of each pin has a flat cutting edge with a chip breaker so that it may be used as a drill when mounted on a hand drill piece. There are a variety of sizes and lengths (Figure 12.43). Preoperative radiographs must be assessed to identify the diameter of the third metacarpal so that the correct size and length of pin can be chosen. It is important that volar subluxation of the lunate be reduced, and any large anterior shelf of the distal radius should be excised when present to avoid postoperative median nerve compression (Figure 12.44).

In general, a single pin is all that is required unless there has been significant loss of bone, in which case two-pin fixation

may be necessary (Figure 12.45, *B*). Rotational stability must be checked, and if there is any rotational movement, an additional 3-mm pin or a staple may be used to prevent rotation. Morselization of the carpus generates adequate bone stock to stimulate the healing process for fusion. If the ulnar head has been excised, it can be converted to a corticocancellous graft to lay on the surface of the radius and carpus (Figure 12.46, *A* and *B*).

What Patients Should Be Told

Most patients experience significant swelling requiring bed rest and strict hand elevation. Patients are told that they will be immobilized in a bulky dressing for 10 days followed by a removable splint until 6 weeks postoperatively and that they can expect a 98.5% union rate. Although full use is allowed at 10 weeks, they will not feel really adapted until 6 months after surgery. Complete pain relief cannot be guaranteed if the patient has undergone multiple previous surgeries. Grip strength will take a year to plateau and will approximate 72% of normal.[45] Bolano and Green found no significant difference in grip strength between fusion with retention of the proximal row and fusion with excision of the proximal row.[9] Patients should expect a 6-month period of learning and adaptation to the fusion. Ninety-two percent of tasks will be performed in a normal manner without undue delay. The greatest functional



FIGURE 12.44 If the lunate is translated in the palmar direction, fusion in situ carries the risk of pin perforation into the flexor aspect of the forearm. Reducing the lunate to the radius without excision of the anterior shelf risks postoperative median nerve compression. The presence of marked arterial calcification indicates that excessive manipulation should be avoided.



FIGURE 12.45 **A,** Once a stable construct is achieved, the driver is removed and the countersink tool is applied into the dimple at the base of the pin, which is driven into the metacarpal for a distance of approximately 1 inch. **B,** Two pins can be used if a single pin fails to prevent rotational stability.

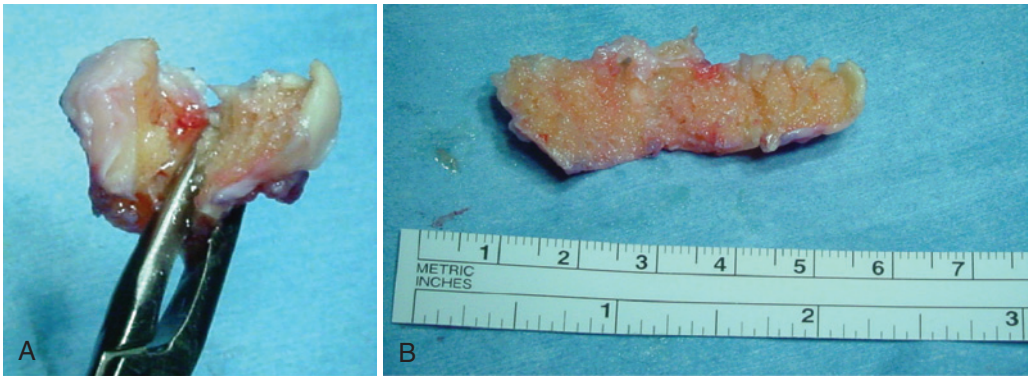

FIGURE 12.46 The extraperiosteal excised ulnar head can be used as a corticocancellous graft. **A,** The head is opened into a graft with a narrow bone rongeur. **B,** The softer bone of a rheumatoid patient is ideal for this technique. The periosteum holds the fragments together, and the graft remains a viable supplement to the main morselization of the carpus and distal radius.

CRITICAL POINTS *Wrist Arthrodesis With Intramedullary Pins*

Indications
- Pancarpal arthrosis of the radiocarpal and midcarpal joints
- Failed previous partial fusion
- Failed total joint or previous arthroplasty
- Significant bone loss of the distal radius and carpus[45]
- Other inflammatory arthritic disability or deformity[18,62]

Pearls
- Carefully assess preoperative carpal tunnel symptoms and perform a concomitant release, even for mild symptoms.
- Decorticate the dorsal 80% of the third CMC joint.
- Remove the ulnar head in one piece if indicated for additional source of graft.
- Morselize the dorsal two thirds of the scaphoid, lunate, and capitate and the entire radial articular surface, including the distal dorsal rim.
- When there is significant ulnar translation, remove part of the radial styloid to facilitate realignment of the wrist.
- Remove the anterior lunate fossa shelf if present.

Pitfalls
- Insufficient removal of the anterior shelf
- Acute carpal tunnel syndrome
- Pain from incomplete fusion of the third CMC joint
- Insufficient countersinking of the pin past the isthmus of the third metacarpal

Postoperative Care
- Immobilize the hand and wrist in a bulky dressing and splint for 10 days.
- Protect against excessive use with a removable short-arm splint until 6 weeks postoperatively.
- At 6 weeks, discontinue the splint.
- At 8 weeks, begin strengthening.

problems will be perineal care, lifting a glass or can from a low table, and horizontal use of a screwdriver. These potential concerns can be mitigated preoperatively by having the patient wear a splint day and night during all activities for a period of time. This will help the individual better understand the functional expectations following fusion. Further surgery for plate removal is unlikely with the low-profile precontoured plates.

Wrist Arthrodesis After Failed Total Wrist Arthroplasty

Fusion after failed total wrist arthroplasty can be challenging, and patients are often left with a sizable defect following implant resection (Figure 12.47, *A*), debris removal, and bone preparation. Although some investigators had encouraging union results with fusion following failed wrist arthroplasty,[15] others have had significantly higher nonunion rates ranging from 35% to 50%.[6,86] In these circumstances there is considerable loss of bone substance, and our preferred technique involves the use of morselized femoral head allograft that has been prepared with a bone mill (Figure 12.48, *A* and *B*). This can be included with an off-the-shelf graft as well as iliac crest (see Figure 12.48, *C*). The implants and cement, if present, are removed and the absence of infection confirmed. After three passages through the bone mill (to make the size of the fragments appropriate for the radius and carpus), the allograft femoral head is introduced

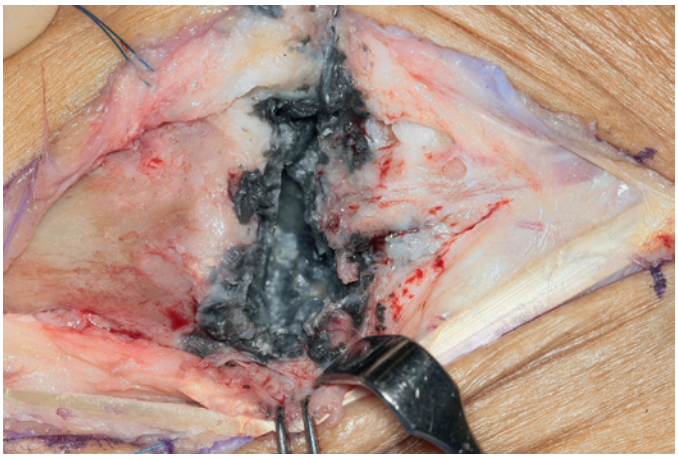

FIGURE 12.47 Patient following total wrist arthroplasty resection; note the metallosis and bony defect. Following debris removal and bone preparation, a sizable defect remained.

into the defect and impact grafted into the distal radius and into the defect within the carpus with bone tamps. Two pins are used for the second and third metacarpals to lock the carpus and hand in alignment with the radius. Any remaining gap may be filled with autologous bone from iliac crest if thought to be necessary. Structural bone graft may also be fashioned with tricortical iliac crest to maintain wrist length. An alternative to Steinmann pins is the use of locking wrist fusion plates (see Figure 12.48, *D* and *E*).

Total Wrist Replacement

Although total wrist arthrodesis yields significant pain relief, stability, and power grasp, immobility of the wrist requires compensatory motion of the elbow and shoulder to accurately place the hand in space and, more particularly, to allow the thumb, index finger, and middle finger to perform fine activities with precision. Therefore, loss of wrist motion can give rise to significant dysfunction in occupational, self-care, and recreational activities.[33,73] However, the individual patient's capacity to adapt, compromise, and develop coping strategies, coupled with support and assistance from family members, requires careful assessment and counseling to ensure the proper choice of surgical reconstruction. In individual patients, a decision has to be made whether to preserve motion at the expense of some residual pain or to remove motion and improve the pain considerably. For some patients, the choice is very easy and obvious; for others, loss of mobility of the wrist may be associated with difficulties with the shoulder and elbow, as seen in patients with inflammatory arthritis. Many patients with a wrist arthrodesis report significant impairment in fine dexterous activities, although they learn to cope. In our practice, patients who have undergone wrist arthrodesis on one side and wrist replacement on the other prefer the wrist replacement to the wrist fusion and state that they find preservation of some motion of considerable importance, particularly in activities of daily living.[69]

Normal wrist motion is accomplished by a complex interaction of multiple articulations involving the radius, ulna, and carpal bones. Total wrist arthroplasty cannot duplicate this intricate system, but it can potentially produce a stable, pain-free joint with a functional range of motion. Achieving a functional and durable outcome requires appropriate patient



FIGURE 12.48 **A** and **B,** Femoral head allograft can be reamed as shown to yield sizable amounts of cancellous bone. **C,** It can be packed into the medullary canal and mixed with structural iliac crest (*left*) and off-the-shelf allograft (*right*) to span the defect. **D,** Posteroanterior and **E,** lateral radiographs of the patient shown in previous figures who underwent bone grafting and stabilization with a locking wrist fusion plate.

selection, preoperative planning, and accurate surgery. Because arthroplasty poses greater risks than arthrodesis does, low-demand patients with special needs or a desire for wrist motion are the best candidates. Recently, patients with degenerative arthritis are seeking to have replacement rather than fusion as they gain greater awareness of the surgical options. Careful patient selection is critical to a good outcome, and caution is advised when advising patients with high demands and perhaps unrealistic expectations.

History of Modern Total Wrist Arthroplasty

- Swanson, 1972: Flexible-hinge silicone arthroplasty[95]
- Volz, 1976: AMC/Volz prosthesis, a highly constrained implant[104]
- Meuli, 1980: The Meuli implant, a ball-and-socket design[64]
- Guepar, 1988: The first distal screw fixation device[1]
- Figgie and associates, 1988: Trispherical wrist[32]
- Ferlic and Clayton, 1995, The CFV wrist, a reverse-polarity implant[30]
- Cobb and Beckenbaugh, 1996: Biaxial wrist, ingrowth fixation into the radius and third metacarpal[20]
- Menon, 1998: Universal I, screw fixation of the distal component into the second metacarpal and hamate[63]
- Divelbiss, Sollerman, and Adams, 2002: Universal II (Integra Life Sciences, Plainsboro, NJ), change in design to reduce the risk for dislocation[26]
- Levadoux and Legré, 2003: Destot prosthesis[59]
- Radmer and colleagues, 2003: ATW/APH prosthesis[83]



FIGURE 12.49 Imbalance of the wrist aggravated by ulnar translation of the common extensor tendons resulted in a high attrition rate of the silicone implant with consequent deterioration in function.

- Rahimtoola and Rozing, 2003: RWS implant[84]
- Palmer and associates, 2005: Maestro (Biomet Orthopaedics, Warsaw, IN), a design with alignment with the lunate fossa[75]
- Gupta, 2008: Re-Motion (Small Bone Innovations, Morrisville, PA), an implant with 10 degrees of pronation-supination of the components[43]

Swanson, in the late 1960s and early 1970s, developed a flexible-hinge silicone arthroplasty of the wrist,[95] similar to the successful MP joint implants. Patients initially had extremely good results, with a high level of pain relief and functional range of motion. Although the early results were encouraging, it became apparent over time that balance of the wrist was an important issue. Failure of the implant at its distal stem, when inserted into the carpus and third metacarpal, was a common feature, with loss of the ulnar shoulder (Figure 12.49) of the implant. This frequently occurred in association with ulnar deviation of the wrist and caused significant functional problems, and a number of implants fractured and/or had to be removed (Figure 12.50). The long-term results of Swanson arthroplasty showed that those that survived and were well balanced continued to give good pain relief, although with a gradually decreasing range of motion.[32] Even reports published within the last 10 years have concluded that for very low demand elderly patients with inflammatory arthritis, use of a Swanson flexible-hinge implant may still be considered.[53] However, the development of metal-on-plastic hip replacements encouraged many to attempt to reproduce this success at the wrist joint, and a number of implants were designed, including the early Volz,[104] Meuli,[64] and Guepar group implants.[1] Subsequently, the Mayo Clinic introduced the biaxial wrist.[20] All of these implants had



FIGURE 12.50 Excised fractured silicone wrist arthroplasty.

their particular foibles with difficulty in balancing the wrist. In 1998, Menon presented the first reports of the ellipsoid Universal I wrist design, which is composed of a metallic radial component and a polyethylene carpal component fixed to a metal carpal base plate.[63] The implant was a departure from the normal distal stem and cement fixation and instead relied on screw fixation in the second and fourth metacarpals and a central peg in the capitate. The particular design of this implant was attractive, and a number of these procedures were performed. The Universal I results as reported by Menon, however, identified a significant dislocation rate, and it became apparent that design modifications were required.[63] The Universal II implant restored the normal radial inclination of the distal radius and altered the shape and conformity of the implant with a subsequent reduction in the instability rate to 1% to 2%.[42] Short-term outcomes with the Universal II implant were encouraging.[26] Medium-term results focusing on rheumatoid patients have been published as well. Unfortunately, the authors noted a substantial loosening rate of the distal component necessitating revision surgery in 40%.[106] However, they went on to conclude that if the implant remained radiographically stable, the clinical results and patient satisfaction were generally excellent.

Further developments and designs have also been introduced and include the Re-Motion and Maestro designs. The Re-Motion design was introduced in 2003, and the design rationale, indications, and technique were described by Gupta with encouraging preliminary results.[43] It differs slightly from the Universal II device in that there is a 10-degree axial rotation of the carpal component allowing for some degree of intercarpal supination and pronation (Figure 12.51). In addition, the articular rims of the radius are preserved during preparation and placement of the Re-Motion implant so that the capsular attachments are preserved. The range of motion to be expected is 20 degrees of flexion, 30 to 40 degrees of extension, and an arc of motion of 25 degrees of radial and ulnar deviation. It is possible that marked distortion of the distal radius articular surface, as seen on occasion in rheumatoid arthritis, may make seating of the Re-Motion radial component more difficult.

Herzberg and coworkers prospectively reported their results in using the Re-Motion implant in over 200 wrists performed in a multicenter prospective trial.[46] Sixty percent of their patients



FIGURE 12.51 The Re-Motion total wrist replacement (Small Bone Innovations, Morrisville, PA).



FIGURE 12.52 The Maestro total wrist replacement (Biomet Orthopaedics, Warsaw, IN).

had rheumatoid arthritis. Results at an average 4-year follow-up demonstrated improvement in subjective patient assessments such as pain scores and disability of shoulder arm and hand (DASH) scores. Although there was no significant difference in the range of motion postoperatively, grip strengths did improve. A total of 11 patients (6 in the group with rheumatoid arthritis and 5 in the group without rheumatoid arthritis) underwent revision to either fusion or revision total wrist arthroplasty (TWA).

The Maestro (Figure 12.52) implant is designed to mimic proximal row carpectomy and depends on replacement primarily of the capitate head; articulation is achieved with a polyethylene proximal component seated in the radius. Nydick and colleagues retrospectively published their results using the Maestro total wrist arthroplasty in 23 cases.[75] Short-term follow-up at an average of 28 months demonstrated excellent pain relief and patient-related outcomes (DASH and Mayo Wrist Scores). One wrist failed secondary to infection and was successfully revised to a fusion.

Cooney and associates described a retrospective review comparing the outcomes of the newer-generation (Universal II and Re-Motion) implants with the previous-generation biaxial design implants.[22] The authors found that both designs were associated with excellent pain relief and functional motion; however, lower rates of complications and reoperation were noted with the newer-generation designs.

Preoperative Evaluation

Clinical Examination. Examination must include an accurate range of active and passive motion, most particularly to determine whether there is subluxation or dislocation of the carpus and whether the DRUJ is stable. The status of the flexor and extensor tendons of the wrist and hand must be assessed. Functional assessment of the patient should be performed and a detailed history taken of the patient's activities, including home circumstances, hobbies, and pastimes. Patients who live alone have no one to assist them with important activities of daily living. Some patients with a sedentary occupation can have quite high-demand leisure activities that are a balance to their lives. Joint-preserving procedures should be considered in a patient who finds a trial period of splint immobilization unacceptable.

Surgical Technique (Universal II Implant)

Perioperative antibiotics are used, and fluoroscopy is an integral part of the procedure. The dorsal aspect of the wrist is exposed through a longitudinal central incision with reflection of the extensor retinaculum either through the fourth compartment Z-plasty or radially from the first compartment across through to the sixth compartment. The extensor tendons of the fourth compartment are retracted ulnarly and those of the third and second compartments to the radial side. A segment of the posterior interosseous nerve can be excised just proximal to the radiocarpal joint at the discretion of the surgeon. The distal radius is identified, and the dorsal capsule of the radiocarpal joint is defined and raised (Figure 12.53, *A* and *B*). Two methods can be used for this: (1) raising the capsule either in one or two distally based flaps with a "U" or an inverted "T" incision or (2) an ulnar-based flap by raising the dorsal radiolunotriquetral ligament from the rim of the radius, incising along the distal edge of the dorsal intercarpal ligament fibers, and detaching the fibers on the radial side and leaving them attached to the hamate and triquetrum on the ulnar side. The object of preserving the capsule is to provide cover for the implant and to place a layer of tissue between the implant and the extensor tendons. The proximal half of the scaphoid, the lunate, and the triquetrum is excised. During proximal scaphoid excision and sizing of the carpal component, it is helpful to temporarily pin the distal scaphoid to the distal carpal row. The distal radius is examined for bone loss, particularly in the lunate fossa. A central guide pin is introduced through the dorsal radial quadrant of the radius 5 mm below and in line with the Lister tubercle. This is

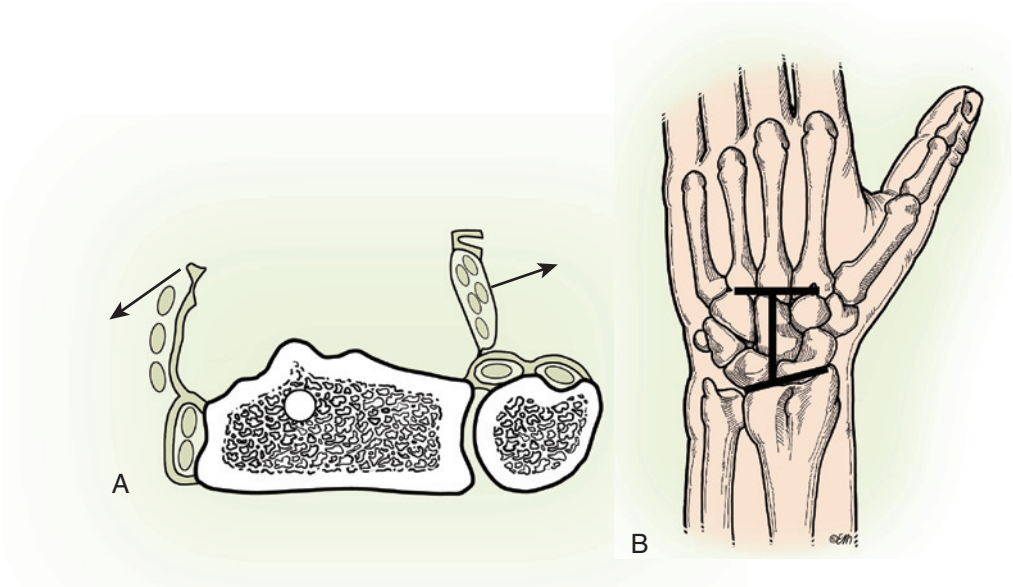

FIGURE 12.53 The incision is along the line of the third metacarpal and may be extended proximally and distally to facilitate exposure of the wrist. **A,** The fourth compartment is raised as for wrist fusion. The second compartment must be raised as shown. When the retinaculum has been raised in this manner, it can be passed deep to the extensor carpi radialis longus, extensor carpi radialis brevis, and extensor pollicis longus and, with a hemostat, can be used to maintain radial displacement of the radial-side tendons to facilitate the exposure. **B,** The dorsal capsule is raised as shown. (Copyright © Elizabeth Martin.)

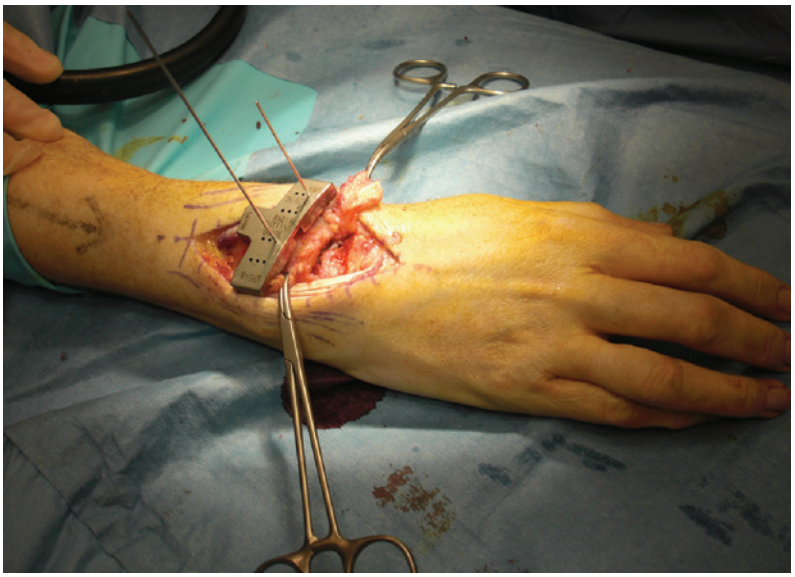

FIGURE 12.54 The cutting guide temporarily held in place by Kirschner wires after removal of the intramedullary guide rod. If a satisfactory position is achieved, as seen on intraoperative radiographs, the distal radial articular surface can be excised with an oscillating saw.

checked on the image intensifier to ensure that it is correctly located parallel to the cortices in both the sagittal and coronal planes. Introduction of a cutting guide along the central pin allows the radial cutting guide to be located and fixed with temporary Kirschner wires. Removal of the central pin allows the radial guide to be checked for position with intraoperative radiographs. The distal radius is cut and removed (Figure 12.54). Reinsertion of the medullary guide pin allows introduction of the cannulated reamers, and reaming of the shaft can proceed (Figure 12.55, *A* and *B*). A trial radial component of the appropriate size is inserted. Having completed preparation of the radius, preparation of the distal component may be performed.

A Kirschner wire is introduced through the head of the capitate and into the third metacarpal with use of the wire guide. This again is checked on the intensifier to ensure that its placement within the third metacarpal and the capitate is, in fact, aligned in both the sagittal and coronal planes (Figure 12.56, *A* and *B*). A cannulated drill is introduced along the guidewire and drilled to the appropriate depth as marked on the drill. The wire and drill are removed and the distal alignment guide is placed in the drill hole. The cutting guide is placed on the

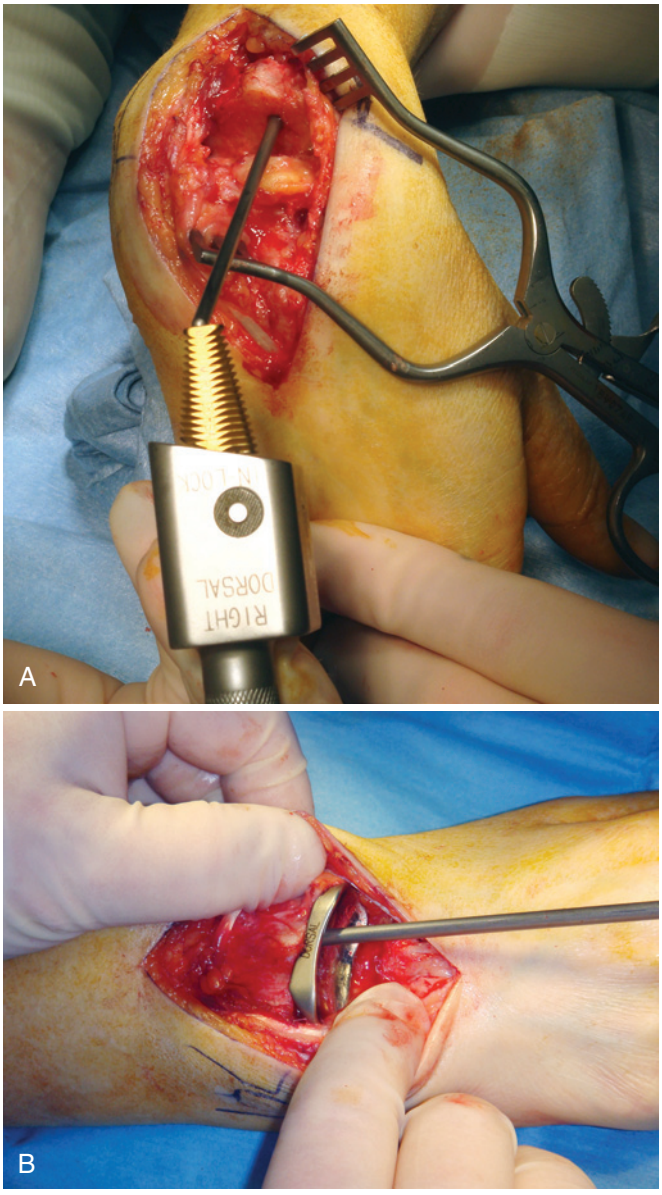

FIGURE 12.55 **A,** With the guide pin reinserted, the medullary canal can be reamed. **B,** The trial radial component is then inserted.

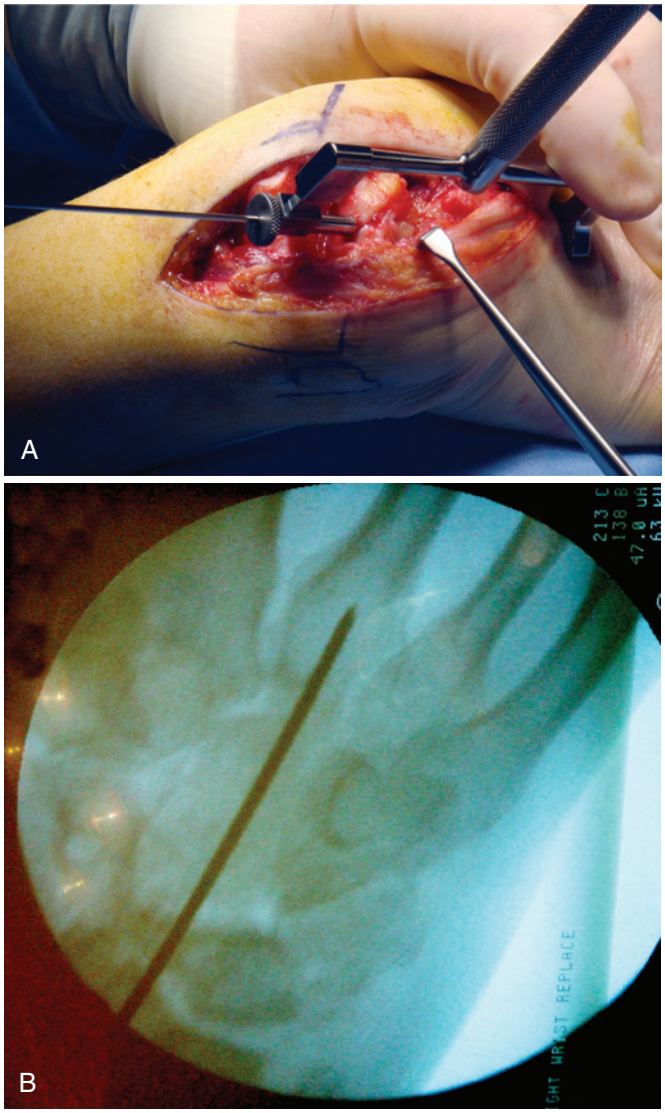

FIGURE 12.56 **A,** A Kirschner wire is inserted into the capitate and passed through to the third metacarpal. **B,** The position of the Kirschner wire must be assessed with intraoperative radiographs or fluoroscopy.

alignment guide, and temporary Kirschner wires are inserted through the cutting guide (Figure 12.57). The position is checked with a radiograph. With the cutting guide in place, the appropriate amount of capitate head, residual scaphoid, and, if necessary, part of the hamate is removed. The distal trial implant is inserted after removal of the guides (Figure 12.58). The metacarpal alignment guide is placed on the second metacarpal to guide introduction of the screws through the plate and into the second metacarpal. A similar process allows introduction of the screw into the hamate by alignment with the fourth metacarpal guides (Figure 12.59). The screw must be in the hamate but must not cross the fourth CMC joint (which is mobile). The polyethylene central component is attached (Figure 12.60, *A* and *B*), and the range of motion and stability are assessed. It is particularly important to assess axial distraction to ensure that there is no excessive laxity within the joint that would encourage dislocation. The distal component has modular sizes so that appropriate tension can be attained. However, if the component is too large and prevents extension, a smaller component should be inserted. If this is not possible, 2 mm must be removed from the distal radius.

When satisfied with the sizing, the trial components can be removed and the final components implanted. The components may be inserted with or without cement. It is important to complete an intercarpal fusion of the distal row bones for support of the carpal component plate. After confirmation of adequate range of motion, particularly in extension, the wounds are closed, the capsule is closed, and the extensor tendons are examined. Provided that the common extensors are suitably centralized and aligned, closure of the superficial fascia and skin is all that is required. If there is a tendency for the tendons to lie to the ulnar side of the long axis of the implant, they should be centralized to properly balance the implant (see later).

The patient is immobilized in plaster for a period of 2 weeks for wound healing. The sutures are removed at 2 weeks, at

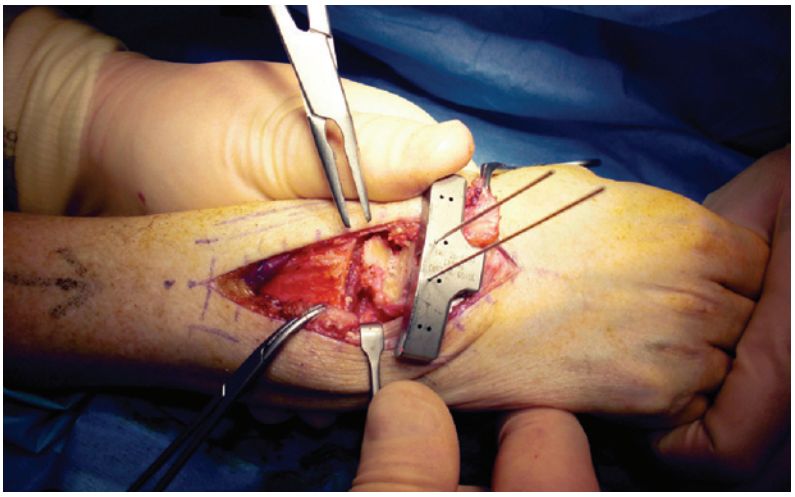

FIGURE 12.57 The distal cutting guide is held with two Kirschner wires and the position checked and adjusted if necessary.



FIGURE 12.58 The distal implant must lie in contact with the cut surface of the capitate, scaphoid, and triquetrum, and the central stem of the implant should remain within the body of the capitate.

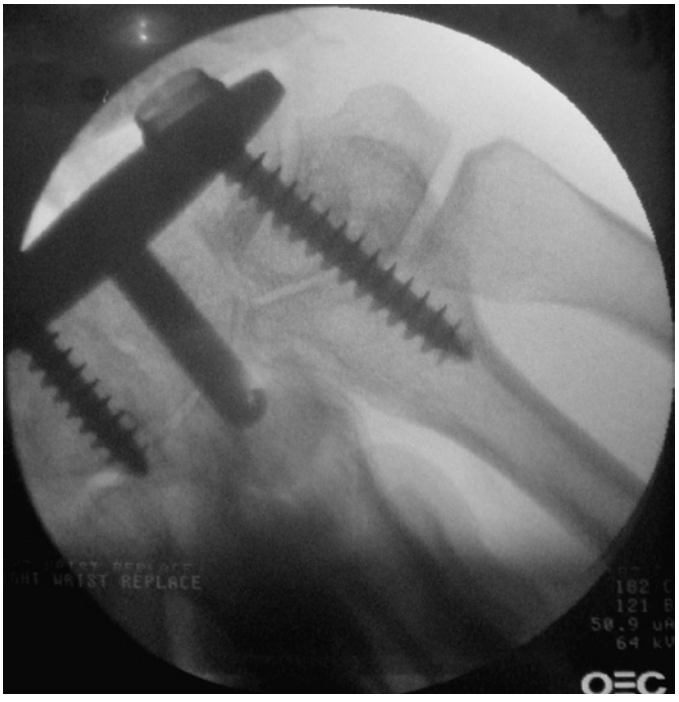

FIGURE 12.59 Seating of both components is followed by placing the trial screws into the second metacarpal and hamate.

which time early controlled motion in the form of flexion-extension and some radial-ulnar deviation is allowed. Over a period of 3 months, the wrist range of motion recovers and plateaus.

Surgical Technique (Re-Motion Implant) (Video 12.1)

The approach and exposure are similar to those for the Universal II implant, and differences or deviations from the above approach are mentioned below. The Re-Motion system has a carpal alignment guide that can be centered in the lunate fossa to allow for proper positioning in preparation for the carpal cut at the level of the capitate head (Figure 12.61, *A* and *B*). In addition, it allows for a radial alignment guide to be attached to ensure proper positioning of the anticipated proximal component, and this can be confirmed radiographically (see Figure 12.61, *C*). A carpal bone resection guide is situated in line with the lunate (when reduced) and lines up with the third metacarpal distally (Figure 12.62). The anticipated carpal cut should be made at the level of the proximal capitate. Upon confirmation of appropriate alignment, the proximal carpal cut can be performed (Figure 12.63, *A* and *B*). A proximal radius alignment guide appropriately positioned, centered on the radius, will allow for preparation of the distal radius surface and properly align in the center of the medullary canal. The radial surface is

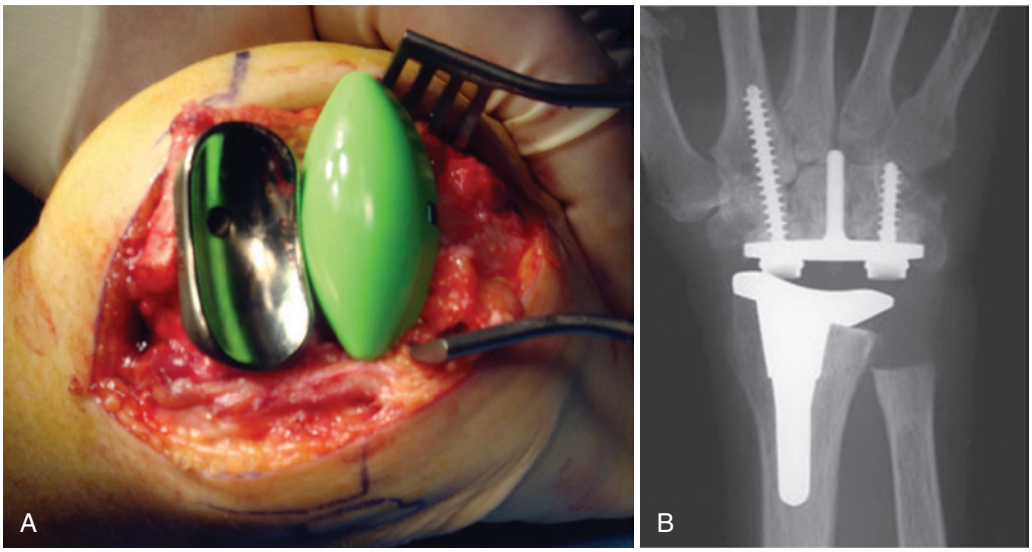

FIGURE 12.60 **A,** A trial central polyethylene bearing surface is placed. **B,** Verification with radiographs.

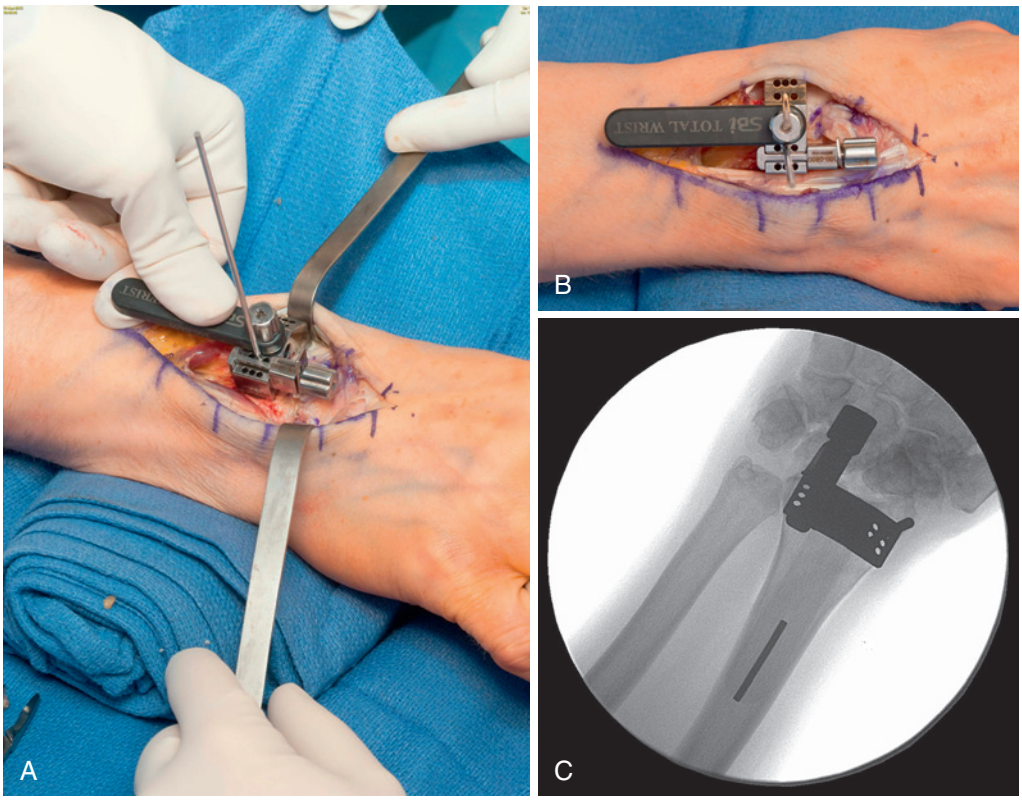

FIGURE 12.61 **A,** Placement of the radial alignment guide and **B,** securing it with two Kirschner wires. The distal attachment slides proximal to the lunate and sits on the lunate fossa. **C,** The black portion of the guide has a radiopaque rod to help confirm appropriate alignment. Fluoroscopy will help confirm alignment in the anteroposterior and lateral planes.

prepared using the appropriately sized high speed bur (Figure 12.64, *A*). The surgeon may also use the bur in a freehand position to fine-tune the preparation of the radial surface (see Figure 12.64, *B*). The next step involves placement of the intramedullary radial alignment guide and insertion of a medullary pin into the shaft of the radius (Figure 12.65). The Lister tubercle is a good landmark for the centering drill hole, and in the axial plane, it should sit in the middle-distal third junction of the radius. Upon fluoroscopic confirmation that the guide pin is appropriately aligned, the radial canal can be reamed, broached, and trialed (Figure 12.66).

The carpal side can be prepared. The trial guide is based on the center of the capitate and a Kirschner wire is used to locate its center (Figure 12.67), followed by broaching to the correct size. The broach into the capitate has three slots on it corresponding to small, medium, and large, and much like the

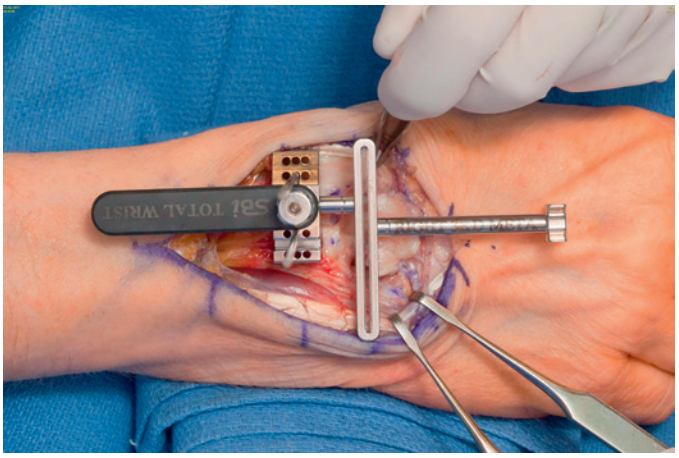

FIGURE 12.62 The carpal cutting guide attaches to the radial alignment guide as shown. It has three notches to correspond with the appropriate size.

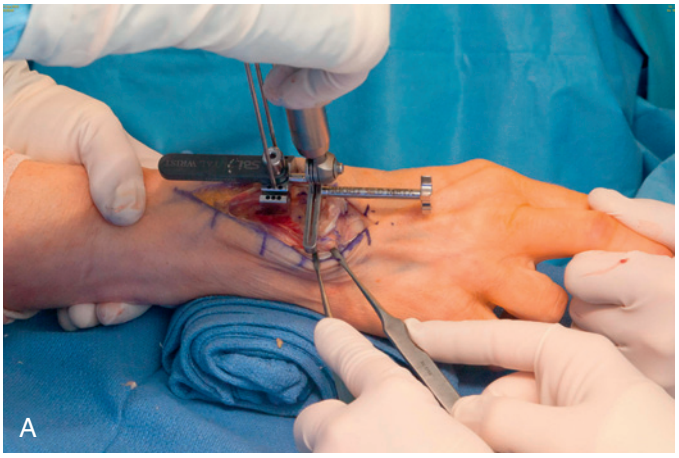

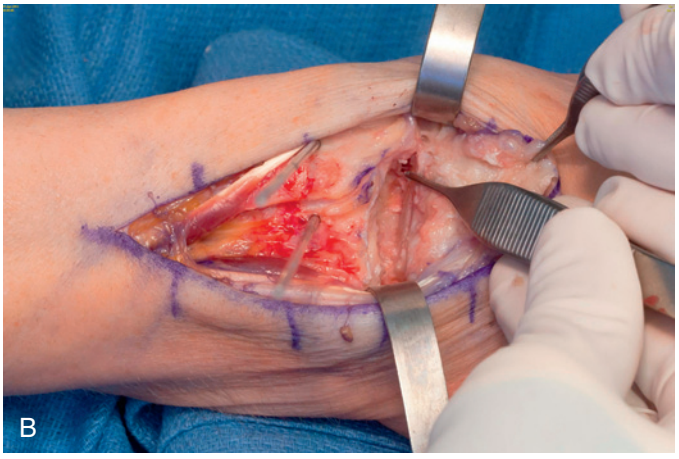

FIGURE 12.63 **A,** An oscillating saw is used to initiate the carpal cut. The cut should be made to remove only the tip of the capitate head. **B,** The cut should be perpendicular to the long axis of the capitate and long finger metacarpal.





FIGURE 12.64 **A,** Another attachment with a large bur is used to prepare the radius. The aim is to smooth out the articular surface but preserve the subchondral bone. **B,** In my experience, freehand use of the bur is often necessary to appropriately prepare the radial surface.

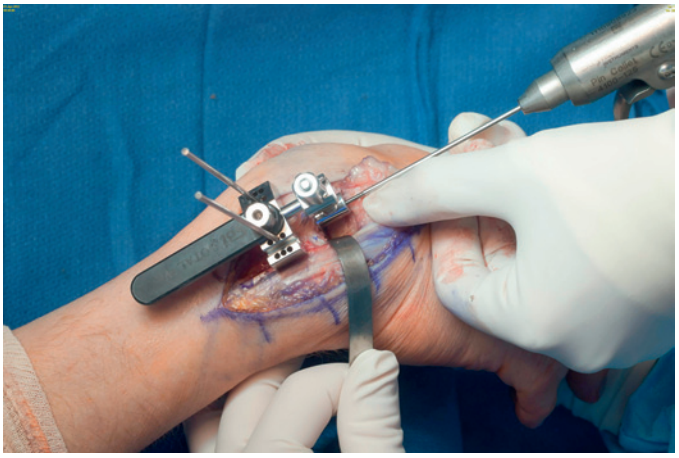

FIGURE 12.65 After preparing the radial surface, the intramedullary guide is placed into the radius. The Lister tubercle is a good marker for alignment in the coronal plane, and in the sagittal plane the guide pin should sit in the mid to distal third junction of the radial surface.

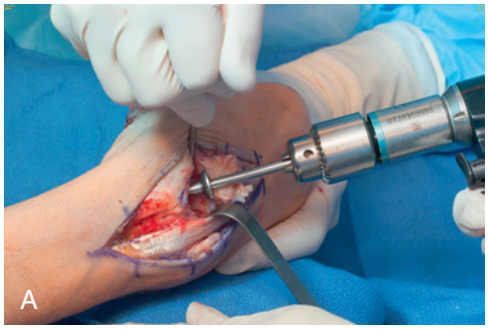





FIGURE 12.66 Upon confirmation of adequate alignment, the radius is drilled (**A**), broached (**B**), and trialed (**C**).

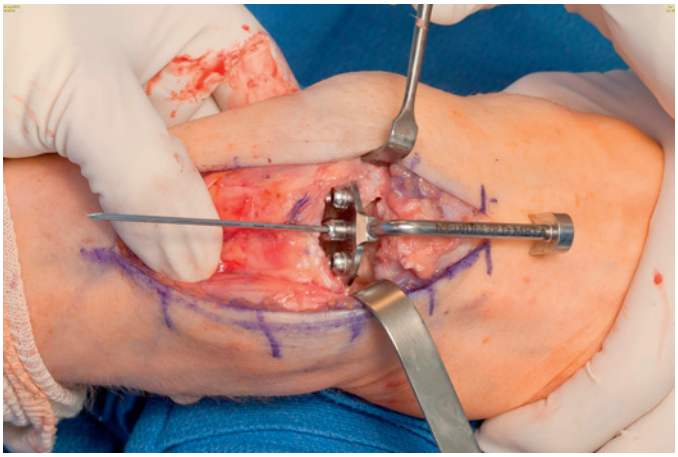

FIGURE 12.67 Attention turns to the carpal component. The drill guide is centered into the capitate and stabilized as shown.

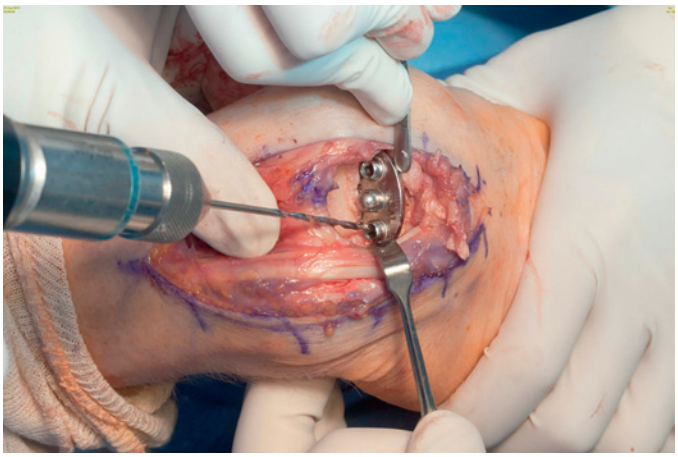

FIGURE 12.68 Drilling for the second metacarpal and hamate screws can be done with the alignment guide or after placement of the final component. It is acceptable to cross the carpometacarpal (CMC) joint with the radial screw, but if possible, the ulnar screw should not cross the fourth CMC joint.

Universal II, the distal trial has a peg for the capitate with holes for the 4.5-mm radial and ulnar carpal screws (Figure 12.68). The radial screw lines up with the second metacarpal distally, while the ulnar screw typically lies in line with the fourth metacarpal. Use of a depth gauge will help ensure appropriate screw lengths. Upon completing the distal trial the proximal trial is inserted and the trial liner is secured (Figure 12.69). The wrist is assessed for stability, range of motion, and laxity. The wrist should be stable to 40 degrees of flexion and 40 degrees of extension, and the gap should be 2 to 3 mm with distraction. The radial and carpal components are placed, and the polyethylene ball snaps on the carpal component. Radiographs confirm that the implant size and placement and the wrist alignment are appropriate (Figure 12.70, *A* and *B*).

Centralization of the Extensor Tendons

When the extensor tendons do not align in the midline of the wrist, they should be centralized to provide appropriate extension moments across the implant. Centralization is achieved by

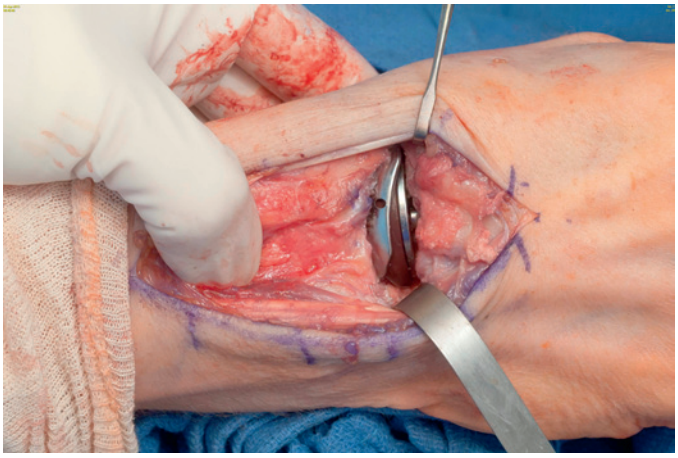

FIGURE 12.69 The wrist can be trialed one last time to ensure that it is stable to flexion and extension of 80 degrees and radial-ulnar deviation of 40 degrees. In addition, gapping of 2 to 3 mm with distraction should be appreciable.

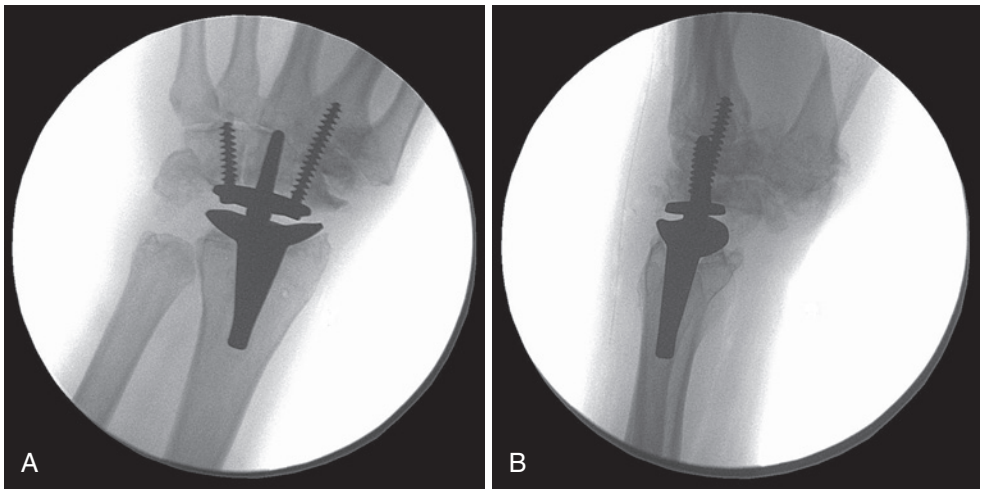

FIGURE 12.70 **A,** Posteroanterior and **B,** lateral fluoroscopy images show appropriate alignment of the wrist and screw lengths as well as implant position.



FIGURE 12.71 Use of half of the extensor carpi radialis longus (ECRL) tendon to align and stabilize the common extensor tendons is achieved by harvesting part of the tendon proximally to distally and leaving the tendon strip attached distally. The strip of tendon is taken deep to the common extensors and woven into the remaining ECRL to create an open loop. The tension in this loop is judged to be correct when the common extensors are aligned with the longitudinal axis of the implant. Similarly, the extensor carpi ulnaris (ECU) tendon is brought up to the dorsum by bringing the extensor retinaculum deep to the tendon. The free edge of the retinaculum is brought over the ECU tendon and sutured to itself under appropriate tension to realign the tendon dorsally.

performing a hemitransection of the ECRL proximally, raising a strip to its insertion on the base of the second metacarpal, and threading it deep to the ECRB and the common extensor tendons.[16] This should not include the extensor digiti minimi. The strip of ECRL is taken superficial to the common extensors and woven through the ECRB. The loop that has been generated maintains the extensor tendons in the proper alignment (Figure 12.71). This is very often necessary in a rheumatoid patient when preservation of the tube of the fourth compartment is not always possible and when extensor tenosynovectomy may be necessary.

What Patients Should Be Told

The results of wrist replacement for a patient with inflammatory arthritis are very good for pain relief, but attempts at restoration of a normal range of motion are undesirable because this increases the risk of dislocation and loosening. The range to be expected is 25 to 35 degrees of extension, 30 to 40 degrees of flexion, 10 degrees of radial deviation, and 15 degrees of ulnar deviation; however, these ranges can be highly variable. For patients with severe rheumatoid disease, the outcome in terms of range of motion may be less predictable, but the motion obtained is of great value in improving the capacity for activities of daily living.[33] The recovery period after the acute surgical phase is 6 to 8 weeks, but the wrist will continue to improve for up to 1 year after implantation of the prosthesis. The midterm (1 to 5 years) risk for instability of the implant is reported to be 15%.[69] The loosening rate is dependent on time and the level of activity.

The early results are very encouraging, but as always with all implants, some failures are inevitable and the patient and treating physician should be aware of the potential risks associated with implant arthroplasty. The surgical technique should be meticulous and cutting guides used to ensure accuracy of bone preparation. Repeated intraoperative radiographs are important to ensure correct alignment to minimize the risk for early and midterm mechanical failure. Longer-term results will better help us understand the indications and limitations of these implants.

Wrist Hemiarthroplasty

One of the primary concerns regarding total wrist arthroplasty is distal component loosening; consequently, some investigators have proposed the concept of radial hemiarthroplasty as an alternative motion-preserving procedure for wrist disease.[11,24,44,101] The concept and rationale were introduced by Boyer and Adams in a case report whereby a proximal row carpectomy was performed with replacement of the proximal articulation with the radial component of the Universal II

CRITICAL POINTS *Total Wrist Arthroplasty*

Indications

- Pancarpal arthrosis of the radiocarpal and midcarpal joints in patients with low demand
- Failed past limited arthrodesis
- Rheumatoid wrist arthritis and other inflammatory arthritis or deformity with radiocarpal ulnar translocation instability
- SLAC pattern of arthritis in older low-demand patients
- Avascular necrosis of the carpal bones

Pearls and Technical Points

- Carefully assess for preoperative carpal tunnel symptoms, and perform a concomitant release, even for mild symptoms.
- Template the preoperative radiographs to guide selection of the appropriate implant size.
- In the event that it is difficult to raise a continuous capsuloperiosteal tube containing the fourth compartment tendons for adequate exposure (see Figure 12.10), the fourth compartment extensor retinaculum can be released and taken off the tendons and the tendons allowed to be retracted to the ulnar side.
- It is important to see the entire distal end of the radius when opening the capsule, and on occasion the extensor tendons can interfere with such visualization. Be generous with your exposure to minimize the risk of malpositioning the implant.
- Expose the distal radius and free the first compartment.
- Removal of the proximal row and the proximal half of the scaphoid and part of the triquetrum will expose both the distal radius and the distal row of the carpus.
- Check the alignment of the guide pin within the radius in the sagittal and coronal planes on intraoperative radiographs.
- Measure *three* times; cut *once*.
- In rheumatoid arthritis with ulnar translation, remove part of the radial styloid to facilitate realignment of the wrist.
- Check the insertion of the radial component with radiographs.
- Check the alignment of the carpal guide with radiographs.
- Preparation of the distal row includes very accurate placement of the central peg and accurate placement of the screws.
- The carpal screws may cross at the second CMC joint, but whenever possible, they should not cross the fourth CMC joint.
- Intercarpal arthrodesis is helpful to ensure stability of the distal component.
- Cement fixation is an option, but it is not commonly used.
- The range of motion to aim for is 40 degrees of extension, 20 degrees of flexion, 10 degrees of radial deviation, and 15 degrees of ulnar deviation.

Pitfalls

- Overstuffing the joint causes significantly restricted range of motion.
- Failure to remove and deal with the anterior lunate fossa lip can lead to acute carpal tunnel syndrome if the wrist is then relocated into its normal position.
- A very large lunate fossa defect gives rise to poor support of the implant of whatever type.
- Extreme palmar subluxation of the carpus on preoperative lateral radiographs and rupture of the radial and ulnar wrist extensor tendons are contraindications to total wrist arthroplasty.
- On completion of surgery, an x-ray must be taken before closure to ensure that there is no likelihood of ulnar abutment between the head of the ulna and the implant on the radius. If there is, a wafer type of procedure can be performed, and in a rheumatoid patient one may consider distal ulnar excision.

Postoperative Care

- Immobilize for 3 to 5 days in a bulky conforming dressing.
- Immobilize in a splint for 10 to 14 days.
- Begin an active supervised gentle exercise program for 4 to 6 weeks with a rest splint used between exercise periods for comfort.
- At 6 to 8 weeks, increase mobilization but permanently avoid repeated forceful activities (e.g., hammering) and avoid heavy manual work and contact sports.
- Further postoperative care includes encouraging patients to develop the appropriate range of motion for their lifestyle by encouraging them to perform tasks at an early stage in a planned, progressive, and purposeful fashion with a structured rehabilitation program of activities.

Joint Protection

- Advice regarding avoidance of stressful and staccato activity is crucial for long-term survival of the implants.

implant.[11] Culp and coworkers performed radial hemiarthroplasty in 10 patients, with an average 19-month follow-up, and reported a myriad of complications.[24] Unfortunately, there was a 30% rate of osteolysis and a significant incidence of wrist contracture and stiffness and diminished grip strength postoperatively. In addition, when polyethylene had been used, its erosion was a problem. The authors concluded that better materials and techniques were necessary. Wolfe introduced the first implant intended specifically for radial hemiarthroplasty (KinematX, Extremity Medical, Parsippany, NJ). The implant has a pronounced radial aspect to better emulate the distal carpal row. In addition, it maintains an anatomic center of motion while preserving the dart thrower's motion arc. Preliminary short-term results were published for nine patients with an average 31-week follow-up.[101] Most patients did not have rheumatoid arthritis, and both subjective and objective outcomes were excellent, with few or no complications.

The technique has the advantage of being simpler than a total wrist arthroplasty. A longitudinal incision is made, the proximal row of the carpus is removed, and the retinaculum is elevated between the third and fourth compartments. A posterior interosseous neurectomy is performed. The wrist can be exposed through a proximally based "U"-shaped flap and the proximal carpal row excised. The volar ligaments of the wrist can be preserved. The radial surface can be prepared or cut. An intramedullary alignment guide is used to confirm alignment within the radius. The distal radius is drilled, broached, and trialed. The final component is press-fit and the capsule closed with interrupted braided absorbable sutures. The retinaculum is reapproximated with the EPL translocated superficial to the retinaculum. The skin is closed over a drain, if necessary. Postoperatively, the recovery is similar to if not faster than that for a total wrist arthroplasty.

A hemiarthroplasty design that does not require proximal row carpectomy has been developed by Liverneaux (Prosthelast, Argomedical GmbH, Cham, Switzerland). The rationale and use have been to treat cases of irreparable distal radius fractures or lesions of the distal radius such as giant cell tumor of bone.[44] Although no reports have been published, carpal hemiarthroplasty designs are being developed.

The capitate component of the Maestro system has been suggested as a hemiarthroplasty in rheumatoid patients, but no formal reports have been published to date.

Longer-term studies and analysis will better help validate the use of hemiarthroplasty in the treatment of early arthritis of the wrist. Wrist hemiarthroplasty is not currently approved by the Food and Drug Administration for use in the United States.

For Case Studies, Videos, and more, please visit ExpertConsult.com.

REFERENCES

1. Alnot JY: [Guepar's total arthroplasty of the wrist in rheumatoid polyarthritis]. *Acta Orthop Belg* 54(2):178–184, 1988.
2. Alnot JY, Bruchou F, Couturier C: [Lunocapitate shortening arthrodesis after scaphoid and triquetrum resection: treatment of Watson stage III advanced scaphoid periarthrosis]. *Rev Chir Orthop Reparatrice Appar Mot* 88(2):125–129, 2002.
3. Bain GI, McGuire DT: Decision making for partial carpal fusions. *J Wrist Surg* 1(2):103–114, 2012.
4. Bain GI, Ondimu P, Hallam P, et al: Radioscapholunate arthrodesis: a prospective study. *Hand Surg* 14(2–3):73–82, 2009.
5. Bedford B, Yang SS: High fusion rates with circular plate fixation for four-corner arthrodesis of the wrist. *Clin Orthop Relat Res* 468(1):163–168, 2010.
6. Beer TA, Turner RH: Wrist arthrodesis for failed wrist implant arthroplasty. *J Hand Surg [Am]* 22(4):685–693, 1997.
7. Benkeddache Y, Gottesman H, Fourrier P: Multiple stapling for wrist arthrodesis in the nonrheumatoid patient. *J Hand Surg [Am]* 9(2):256–260, 1984.
8. Biswas D, Wysocki RW, Cohen MS, et al: Radioscapholunate arthrodesis with compression screws and local autograft. *J Hand Surg [Am]* 38(4):788–794, 2013.
9. Bolano LE, Green DP: Wrist arthrodesis in post-traumatic arthritis: a comparison of two methods. *J Hand Surg [Am]* 18:786–791, 1993.
10. Borisch N, Haussmann P: Radiolunate arthrodesis in the rheumatoid wrist: a retrospective clinical and radiological longterm follow-up. *J Hand Surg [Br]* 27(1):61–72, 2002.
11. Boyer JS, Adams B: Distal radius hemiarthroplasty combined with proximal row carpectomy: case report. *Iowa Orthop J* 30:168–173, 2010.
12. Brumfield RH, Champoux JA: A biomechanical study of normal functional wrist motion. *Clin Orthop Relat Res* (187):23–25, 1984.
13. Buck-Gramcko D: Denervation of the wrist joint. *J Hand Surg [Am]* 2(1):54–61, 1977.
14. Calandruccio JH, Gelberman RH, Duncan SF, et al: Capitolunate arthrodesis with scaphoid and triquetrum excision. *J Hand Surg [Am]* 25(5):824–832, 2000.
15. Carlson JR, Simmons BP: Wrist arthrodesis after failed wrist implant arthroplasty. *J Hand Surg [Am]* 23(5):893–898, 1998.
16. Cerovac S, Stanley JK: The centralization of extensor tendons during wrist surgery. *Tech Hand Up Extrem Surg* 12(3):188–190, 2008.
17. Chamay A, Della Santa D, Vilaseca A: Radiolunate arthrodesis. Factor of stability for the rheumatoid wrist. *Ann Chir Main* 2(1):5–17, 1983.
18. Clayton ML: Surgical treatment at the wrist in rheumatoid arthritis: a review of thirty-seven patients. *J Bone Joint Surg Am* 47:741–750, 1965.
19. Clendenin MB, Green DP: Arthrodesis of the wrist: complications and their management. *J Hand Surg [Am]* 6:253–257, 1981.
20. Cobb TK, Beckenbaugh RD: Biaxial total-wrist arthroplasty. *J Hand Surg [Am]* 21(6):1011–1021, 1996.
21. Cohen MS, Kozin SH: Degenerative arthritis of the wrist: proximal row carpectomy versus scaphoid excision and four-corner arthrodesis. *J Hand Surg [Am]* 26(1):94–104, 2001.
22. Cooney W, Manuel J, Froelich J, et al: Total wrist replacement: a retrospective comparative study. *J Wrist Surg* 1(2):165–172, 2012.
23. Craigen MA, Stanley JK: Wrist kinematics. Row, column or both? *J Hand Surg [Br]* 20(2):165–170, 1995.
24. Culp RW, Bachoura A, Gelman SE, et al: Proximal row carpectomy combined with wrist hemiarthroplasty. *J Wrist Surg* 1(1):39–46, 2012.
25. DiDonna ML, Kiefhaber TR, Stern PJ: Proximal row carpectomy: study with a minimum of ten years of follow-up. *J Bone Joint Surg Am* 86(11):2359–2365, 2004.
26. Divelbiss BJ, Sollerman C, Adams BD: Early results of the Universal total wrist arthroplasty in rheumatoid arthritis. *J Hand Surg [Am]* 27(2):195–204, 2002.
27. Douglas DP, Peimer CA, Koniuch MP: Motion of the wrist after simulated limited intercarpal arthrodeses. An experimental study. *J Bone Joint Surg Am* 69(9):1413–1418, 1987.
28. Evans DL: Wedge arthrodesis of the wrist. *J Bone Joint Surg Br* 37(1):126–134, 1955.
29. Feldon P, Terrono AL, Belsky MR: Wafer distal ulna resection for triangular fibrocartilage tears and/or ulna impaction syndrome. *J Hand Surg [Am]* 17(4):731–737, 1992.
30. Ferlic DC, Clayton ML: Results of CFV total wrist arthroplasty: review and early report. *Orthopedics* 18(12):1167–1171, 1995.
31. Ferreres A, Garcia-Elias M, Plaza R: Long-term results of lunocapitate arthrodesis with scaphoid excision for SLAC and SNAC wrists. *J Hand Surg Eur Vol* 34(5):603–608, 2009.
32. Figgie HE, 3rd, Ranawat CS, Inglis AE, et al: Preliminary results of total wrist arthroplasty in rheumatoid arthritis using the Trispherical total wrist arthroplasty. *J Arthroplasty* 3(1):9–15, 1988.
33. Franko OI, Zurakowski D, Day CS: Functional disability of the wrist: direct correlation with decreased wrist motion. *J Hand Surg [Am]* 33(4):485–492, 2008.
34. Friedman SL, Palmer AK: The ulnar impaction syndrome. *Hand Clin* 7(2):295–310, 1991.
35. Garcia-Elias M: The non-dissociative clunking wrist: a personal view. *J Hand Surg Eur Vol* 33(6):698–711, 2008.
36. Garcia-Elias M, Cooney WP, An KN, et al: Wrist kinematics after limited intercarpal arthrodesis. *J Hand Surg [Am]* 14(5):791–799, 1989.
37. Garcia-Elias M, Lluch A: Partial excision of scaphoid: is it ever indicated? *Hand Clin* 17(4):687–695, x, 2001.
38. Garcia-Elias M, Lluch A, Ferreres A, et al: Treatment of radiocarpal degenerative osteoarthritis by radioscapholunate arthrodesis and distal scaphoidectomy. *J Hand Surg [Am]* 30(1):8–15, 2005.
39. Gaulke R, O'Loughlin PF, Kendoff D, et al: Radiolunate fusion in the rheumatoid wrist via three point fixation with a mini-titanium-T-plate and oblique screw. *Technol Health Care* 17(4):345–351, 2009.
40. Gaulke R, Suppelna G, Hildebrand F, et al: Radiolunate fusion in the rheumatoid wrist with Shapiro staples: clinical and radiological results of 22 cases. *J Hand Surg Eur Vol* 35(4):289–295, 2010.
41. Graner O, Lopes EI, Carvalho BC, et al: Arthrodesis of the carpal bones in the treatment of Kienbock's disease, painful ununited fractures of the navicular and lunate bones with avascular necrosis, and old fracture-dislocations of carpal bones. *J Bone Joint Surg Am* 48(4):767–774, 1966.
42. Grosland NM, Rogge RD, Adams BD: Influence of articular geometry on prosthetic wrist stability. *Clin Orthop Relat Res* 421:134–142, 2004.
43. Gupta A: Total wrist arthroplasty. *Am J Orthop* 37(8 Suppl 1):12–16, 2008.
44. Hariri A, Facca S, Di Marco A, et al: Massive wrist prosthesis for giant cell tumour of the distal radius: a case report with a 3-year follow-up. *Orthop Traumatol Surg Res* 99(5):635–638, 2013.
45. Hastings H, 2nd, Weiss AP, Quenzer D, et al: Arthrodesis of the wrist for posttraumatic disorders. *J Bone Joint Surg Am* 78(6):897–902, 1996.
46. Herzberg G, Broekstyns M, Sorensen AI, et al: "Remotion" total wrist arthroplasty: preliminary results of a prospective international multicenter study of 215 cases. *J Wrist Surg* 1(1):17–22, 2012.
47. Hodgson SP, Stanley JK, Muirhead A: The Wrightington classification of rheumatoid wrist X-rays: a guide to surgical management. *J Hand Surg [Br]* 14(4):451–455, 1989.
48. Hom S, Ruby LK: Attempted scapholunate arthrodesis for chronic scapholunate dissociation. *J Hand Surg [Am]* 16(2):334–339, 1991.
49. Iwasaki N, Genda E, Barrance PJ, et al: Biomechanical analysis of limited intercarpal fusion for the treatment of Kienbock's disease: a three-dimensional theoretical study. *J Orthop Res* 16(2):256–263, 1998.
50. Kadji O, Duteille F, Dautel G, et al: [Four bone versus capito-lunate limited carpal fusion. Report of 40 cases]. *Chir Main* 21(1):5–12, 2002.
51. Kirschenbaum D, Coyle MP, Leddy JP: Chronic lunotriquetral instability: diagnosis and treatment. *J Hand Surg [Am]* 18(6):1107–1112, 1993.
52. Kirschenbaum D, Schneider LH, Kirkpatrick WH, et al: Scaphoid excision and capitolunate arthrodesis for radioscaphoid arthritis. *J Hand Surg [Am]* 18(5):780–785, 1993.
53. Kistler U, Weiss AP, Simmen BR, et al: Long-term results of silicone wrist arthroplasty in patients with rheumatoid arthritis. *J Hand Surg [Am]* 30(6):1282–1287, 2005.
54. Kleinman WB, Carroll CT: Scapho-trapezio-trapezoid arthrodesis for treatment of chronic static and dynamic scapho-lunate instability: a 10-year perspective on pitfalls and complications. *J Hand Surg [Am]* 15(3):408–414, 1990.
55. Krakauer JD, Bishop AT, Cooney WP: Surgical treatment of scapholunate advanced collapse. *J Hand Surg [Am]* 19(5):751–759, 1994.
56. Larsen CF, Jacoby RA, McCabe SJ: Nonunion rates of limited carpal arthrodesis: a meta-analysis of the literature. *J Hand Surg [Am]* 22(1):66–73, 1997.

57. Larsson SE: Compression arthrodesis of the wrist. A consecutive series of 23 cases. *Clin Orthop Relat Res* (99):146–153, 1974.
58. Lee SK, Desai H, Silver B, et al: Comparison of radiographic stress views for scapholunate dynamic instability in a cadaver model. *J Hand Surg [Am]* 36(7): 1149–1157, 2011.
59. Levadoux M, Legré R: Total wrist arthroplasty with Destot prostheses in patients with posttraumatic arthritis. *J Hand Surg [Am]* 28(3):405–413, 2003.
60. Loh YC, Stanley JK, Jari S, et al: Neuroma of the distal posterior interosseous nerve. A cause of iatrogenic wrist pain. *J Bone Joint Surg Br* 80(4):629–630, 1998.
61. Louis DS, Hankin FM, Bowers WH: Capitate-radius arthrodesis: an alternative method of radiocarpal arthrodesis. *J Hand Surg [Am]* 9(3):365–369, 1984.
62. Mannerfelt L, Malmsten M: Arthrodesis of the wrist in rheumatoid arthritis: a technique without external fixation. *Scand J Plast Reconstr Surg* 5:124–130, 1971.
63. Menon J: Universal total wrist implant: experience with a carpal component fixed with three screws. *J Arthroplasty* 13(5):515–523, 1998.
64. Meuli HC: Arthroplasty of the wrist. *Clin Orthop Relat Res* 149:118–125, 1980.
65. Meyerdierks EM, Mosher JF, Werner FW: Limited wrist arthrodesis: a laboratory study. *J Hand Surg [Am]* 12(4):526–529, 1987.
66. Millender LH, Nalebuff EA: Arthrodesis of the rheumatoid wrist: an evaluation of sixty patients and a description of a different surgical technique. *J Bone Joint Surg Am* 55:1026–1034, 1973.
67. Minamikawa Y, Peimer CA, Yamaguchi T, et al: Ideal scaphoid angle for intercarpal arthrodesis. *J Hand Surg [Am]* 17(2):370–375, 1992.
68. Moy OJ, Peimer CA: Scaphocapitate fusion in the treatment of Kienbock's disease. *Hand Clin* 9(3):501–504, 1993.
69. Murphy DM, Khoury JG, Imbriglia JE, et al: Comparison of arthroplasty and arthrodesis for the rheumatoid wrist. *J Hand Surg [Am]* 28(4):570–576, 2003.
70. Murray JA, Schlafly B: Giant-cell tumors in the distal end of the radius. Treatment by resection and fibular autograft interpositional arthrodesis. *J Bone Joint Surg Am* 68(5):687–694, 1986.
71. Murray PM: Current status of wrist arthrodesis and wrist arthroplasty. *Clin Plast Surg* 23(3):385–394, 1996.
72. Nagy L, Buchler U: Long-term results of radioscapholunate fusion following fractures of the distal radius. *J Hand Surg [Br]* 22(6):705–710, 1997.
73. Nelson DL: Functional wrist motion. *Hand Clin* 13(1):83–92, 1997.
74. Neubrech F, Mühldorfer-Fodor M, Pillukat T, et al: Long-term results after midcarpal arthrodesis. *J Wrist Surg* 1(2):123–128, 2012.
75. Nydick JA, Greenberg SM, Stone JD, et al: Clinical outcomes of total wrist arthroplasty. *J Hand Surg [Am]* 37(8):1580–1584, 2012.
76. Ozyurekoglu T, Turker T: Results of a method of 4-corner arthrodesis using headless compression screws. *J Hand Surg [Am]* 37(3):486–492, 2012.
77. Palmer AK, Dobyns JH, Linscheid RL: Management of post-traumatic instability of the wrist secondary to ligament rupture. *J Hand Surg [Am]* 3(6):507–532, 1978.
78. Palmer AK, Werner FW, Murphy D, et al: Functional wrist motion: a biomechanical study. *J Hand Surg [Am]* 10(1):39–46, 1985.
79. Pervaiz K, Bowers WH, Isaacs JE, et al: Range of motion effects of distal pole scaphoid excision and triquetral excision after radioscapholunate fusion: a cadaver study. *J Hand Surg [Am]* 34(5):832–837, 2009.
80. Peterson HA, Lipscomb PR: Intercarpal arthrodesis. *Arch Surg* 95(1):127–134, 1967.
81. Pisano SM, Peimer CA, Wheeler DR, et al: Scaphocapitate intercarpal arthrodesis. *J Hand Surg [Am]* 16(2):328–333, 1991.
82. Pryce JC: The wrist position between neutral and ulnar deviation that facilitates the maximum power grip strength. *J Biomech* 13(6):505–511, 1980.
83. Radmer S, Andresen R, Sparmann M: Total wrist arthroplasty in patients with rheumatoid arthritis. *J Hand Surg [Am]* 28(5):789–794, 2003.
84. Rahimtoola ZO, Rozing PM: Preliminary results of total wrist arthroplasty using the RWS prosthesis. *J Hand Surg [Br]* 28(1):54–60, 2003.
85. Rao SB, Culver JE: Triquetrohamate arthrodesis for midcarpal instability. *J Hand Surg [Am]* 20(4):583–589, 1995.
86. Rizzo M, Ackerman DB, Rodrigues RL, et al: Wrist arthrodesis as a salvage procedure for failed implant arthroplasty. *J Hand Surg Eur Vol* 36(1):29–33, 2011.
87. Robinson RF, Kayfetz DO: Arthrodesis of the wrist; preliminary report of a new method. *J Bone Joint Surg Am* 34(1):64–70, 1952.
88. Rogers WD, Watson HK: Radial styloid impingement after triscaphe arthrodesis. *J Hand Surg [Am]* 14(2 Pt 1):297–301, 1989.
89. Ryu JY, Cooney WP, III, Askew LJ, et al: Functional ranges of motion of the wrist joint. *J Hand Surg [Am]* 16(3):409–419, 1991.
90. Sennwald GR, Ufenast H: Scaphocapitate arthrodesis for the treatment of Kienbock's disease. *J Hand Surg [Am]* 20(3):506–510, 1995.
91. Shapiro JS: Power staple fixation in hand and wrist surgery: new applications of an old fixation device. *J Hand Surg [Am]* 12(2):218–227, 1987.
92. Shin EK, Jupiter JB: Radioscapholunate arthrodesis for advanced degenerative radiocarpal osteoarthritis. *Tech Hand Up Extrem Surg* 11(3):180–183, 2007.
93. Smith-Petersen MN: A new approach to the wrist joint. *J Bone Joint Surg* 22:122–124, 1940.
94. Stanley JK, Boot DA: Radio-lunate arthrodesis. *J Hand Surg [Br]* 14(3):283–287, 1989.
95. Swanson AB: Flexible implant resection arthroplasty. *Hand* 4(2):119–134, 1972.
96. Taleisnik J: Combined radiocarpal arthrodesis and midcarpal (lunocapitate) arthroplasty for treatment of rheumatoid arthritis of the wrist. *J Hand Surg [Am]* 12(1):1–8, 1987.
97. Thurston AJ, Stanley JK: Hamato-lunate impingement: an uncommon cause of ulnar-sided wrist pain. *Arthroscopy* 16(5):540–544, 2000.
98. Trumble T, Bour C, Edwards GS, et al: [Partial arthrodesis of the wrist for internal instability of the wrist]. *Rev Chir Orthop Reparatrice Appar Mot* 74(Suppl 2):147–149, 1988.
99. Tubiana RT, Thomine JM, Mackin E: *Examination of the hand and wrist*, St. Louis, 1996, Mosby.
100. Vance MC, Hernandez JG, DiDonna ML, et al: Complications and outcome of four-corner arthrodesis: circular plate fixation versus traditional techniques. *J Hand Surg [Am]* 30(6):1122–1127, 2005.
101. Vance MC, Packer G, Tan D, et al: Midcarpal hemiarthroplasty for wrist arthritis: rationale and early results. *J Wrist Surg* 1(1):61–68, 2012.
102. Vender MI, Watson HK, Wiener BD, et al: Degenerative change in symptomatic scaphoid nonunion. *J Hand Surg [Am]* 12(4):514–519, 1987.
103. Viegas SF, Patterson RM, Peterson PD, et al: Evaluation of the biomechanical efficacy of limited intercarpal fusions for the treatment of scapho-lunate dissociation. *J Hand Surg [Am]* 15(1):120–128, 1990.
104. Volz RG: The development of a total wrist arthroplasty. *Clin Orthop Relat Res* 116:209–214, 1976.
105. Wall LB, DiDonna ML, Kiefhaber TR, et al: Proximal row carpectomy: minimum 20-year follow-up. *J Hand Surg [Am]* 38(8):1498–1504, 2013.
106. Ward CM, Kuhl T, Adams BD: Five- to ten-year outcomes of the Universal total wrist arthroplasty in patients with rheumatoid arthritis. *J Bone Joint Surg Am* 93(10):914–919, 2011.
107. Watson HK, Ashmead DT, Makhlouf MV: Examination of the scaphoid. *J Hand Surg [Am]* 13(5):657–660, 1988.
108. Watson HK, Ballet FL: The SLAC wrist: scapholunate advanced collapse pattern of degenerative arthritis. *J Hand Surg [Am]* 9(3):358–365, 1984.
109. Watson HK, Fink JA, Monacelli DM: Use of triscaphe fusion in the treatment of Kienbock's disease. *Hand Clin* 9(3):493–499, 1993.
110. Watson HK, Goodman ML, Johnson TR: Limited wrist arthrodesis. Part II: Intercarpal and radiocarpal combinations. *J Hand Surg [Am]* 6(3):223–233, 1981.
111. Watson HK, Ryu J, Akelman E: Limited triscaphoid intercarpal arthrodesis for rotatory subluxation of the scaphoid. *J Bone Joint Surg Am* 68(3):345–349, 1986.
112. Watson HK, Weinzweig J, Zeppieri J: The natural progression of scaphoid instability. *Hand Clin* 13(1):39–49, 1997.
113. Watson HK, Wollstein R, Joseph E, et al: Scaphotrapeziotrapezoid arthrodesis: a follow-up study. *J Hand Surg [Am]* 28(3):397–404, 2003.
114. Weinstein LP, Berger RA: Analgesic benefit, functional outcome, and patient satisfaction after partial wrist denervation. *J Hand Surg [Am]* 27(5):833–839, 2002.
115. Weiss AC, Wideman G, Jr, Quenzer D, et al: Upper extremity function after wrist arthrodesis. *J Hand Surg [Am]* 20(5):813–817, 1995.
116. Weiss AP, Hastings H, 2nd: Wrist arthrodesis for traumatic conditions: a study of plate and local bone graft application. *J Hand Surg [Am]* 20(1):50–56, 1995.
117. Weiss G, Shemer A, Trau H: The Koebner phenomenon: review of the literature. *J Eur Acad Dermatol Venereol* 16(3):241–248, 2002.
118. Wolfe SW, Garcia-Elias M, Kitay A: Carpal instability nondissociative. *J Am Acad Orthop Surg* 20(9):575–585, 2012.
119. Wood MB: Wrist arthrodesis using dorsal radial bone graft. *J Hand Surg [Am]* 12(2):208–212, 1987.
120. Wright CS, McMurtry RY: AO arthrodesis in the hand. *J Hand Surg [Am]* 8(6):932–935, 1983.

13

Wrist Instabilities, Misalignments, and Dislocations

Marc Garcia-Elias and Alberto L. Lluch

These videos may be found at *ExpertConsult.com*:

13.1 Dorsal view of a dissected cadaveric wrist set in a jig that allows isometric loading of different tendons. The entire scapholunate (SL) ligament complex has been sectioned. When the extensor carpi ulnaris (ECU) tendon is loaded, the distal row pronates and pulls the scaphoid away from the lunate. By contrast, loading of the extensor carpi radialis longus (ECRL) and abductor pollicis longus closes the SL gap. Certainly, the latter, and not the ECU; are the muscles that need to be emphasized when performing proprioceptive exercises for SL dissociations. *(Courtesy of Marc Garcia-Elias and Alberto L. Lluch.)*

13.2 Dynamic 3D computed tomography (also known as 4D computed tomography) of a patient with a scapholunate dissociation while performing dart thrower's exercises. Note that the scaphoid no longer behaves as a proximal row bone. It moves as if it were an extension of the distal carpal row; thus, the formation of a large gap in ulnarflexion. *(Courtesy of Marc Garcia-Elias and Alberto L. Lluch.)*

13.3 Clinical example of a catch-up clunk phenomenon in a patient with carpal instability nondissociative–volar intercalated segmental instability. *(Courtesy of Marc Garcia-Elias and Alberto L. Lluch.)*

13.4 Volar approach of a perilunate dislocation. The distal surface of the lunate bone may be seen before the dislocation is reduced. *(Courtesy of Marc Garcia-Elias and Alberto L. Lluch.)*

The wrist has often been described as an irrelevant articulation that can be fused without causing much functional impairment to the upper extremity. Undoubtedly, patients with a fused wrist may recover enough grip strength so as to return to their previous occupation; their hands, however, will never be completely normal.[77] A stiff wrist does not allow, for instance, washing one's own back, dusting a low surface, turning a steering wheel, or beating an egg without overloading the adjacent upper limb articulations. If the wrist is fused, the hand can reach distant objects, but it cannot be properly oriented to grasp, push, or manipulate them effectively. Certainly this is one of the most important roles of the wrist: to place the hand in the position that ensures its maximal efficiency with minimal energy cost.

If properly identified and treated, wrist injuries tend to heal without sequelae, with a very low complication rate. When there is a complication, the carpus may remain aligned or it may collapse in a variety of ways. The articular cartilage may deteriorate or remain normal and asymptomatic. Identifying which injuries will evolve into significant dysfunctions is not always easy. How does one prevent an injured wrist from becoming unstable? How does one differentiate between carpal instability and carpal misalignment? There are no good answers to these questions; certainly, the more these subjects are analyzed, the more unknowns arise, leading to the realization that further research is needed.

Progress is being made, however, and the proof can be found in this chapter. Only 5 years have passed since the sixth edition of this book was published, yet most chapters have had to be extensively rewritten. The goals have been: (1) to incorporate new knowledge acquired during this period, (2) to propose changes to the classification of carpal disorders, (3) to question misleading terminology, and (4) to eliminate concepts that the test of time has proved obsolete. The book's title itself has been modified to emphasize the fact that not all carpal misalignments are necessarily unstable, and that normal alignment does not guarantee stability.[2]

Undeniably, there is a growing interest in the wrist. What follows is an earnest attempt to respond to that interest by offering an updated description of how to assess and treat the various disorders of the wrist, truly one of the most complex joints of the human body.

Terminology. Most terms used to describe carpal misalignment and wrist instability were introduced in the 1970s, when these subjects were discussed for the first time.[57] Some of them have passed the test of time and are still useful and widely utilized; others have been proven less effective, if not misleading or totally incorrect, and need to be revised. The following are some suggestions in this regard. The goal is to improve the clarity of what is taught and to avoid misinterpretation of the facts.

The term *rotary (or rotatory) instability of the scaphoid*,[116] used to describe the advanced stage of carpal collapse where the scaphoid has lost its oblique alignment relative to the radius, is not correct: The scaphoid not only undergoes flexion and pronation but also translates dorsolaterally. There is never a pure rotation as implied by the adjective "rotary" or "rotatory." Furthermore, such an advanced stage of misalignment involves not only a complex displacement of the scaphoid but also of the lunate, which should be mentioned as well.

The terms *dorsal intercalated segment instability* (DISI) and *volar intercalated segment instability* (VISI)[42] seem quite appropriate for cases where the entire proximal carpal row adopts a position of abnormal extension or flexion in relation to the long axis of the radius. However, its use to define deformities secondary to dissociative carpal instabilities may create some

confusion: only the lunate is in DISI not the scaphoid, which goes into flexion and pronation. Both are intercalated bones, and the deformity of each should be defined separately to prevent confusion; the scaphoid flexes and pronates, while the lunate extends.

While reading the literature, it is not uncommon to find confounding descriptions of wrist pathology that are a sign of a limited understanding of the basic principles of its mechanics. A typical example would be the use of redundant expressions such as "rotation into flexion" or "rotation into extension"—"flexion" or "extension" is enough. Another example is the use of "dorsiflexion" or "palmar-flexion." The first is a contradiction and the second is another redundancy; "extension" and "flexion" need no embellishments.

Although radial and ulnar *deviation* are widely accepted expressions, following the recommendations of the Committee on Standardization of Nomenclature of the International Federation of Societies for Surgery of the Hand (IFSSH),[58] they should be replaced by radial and ulnar *inclination*. An inclination is a mathematical term used to define the angle between two lines or planes. The term deviation is to be used when something departs from an acceptable standard or norm, and this is not what happens when the wrist is moved.

The inclination of the distal articular surface of the radius in relation to its longitudinal axis is frequently referred to as *radial tilt*, an expression that could be misinterpreted as an inclination toward the radial side. We suggest using the term *ulnar tilt of the radius*; for the same reason, it is best to use the term *volar tilt* to refer to the anterior inclination of the radius.

By consensus, wrist joints are termed by juxtaposing the names of the bones that meet in that articulation in an orderly manner, from proximal to distal and from radial to ulnar. Ligaments are named in a similar way. Based on this, the central midcarpal articulation should not be called "capitolunate" but "lunocapitate," and the ligaments connecting the triquetrum to the lunate should not be called "triquetrolunate" but "lunotriquetral."

WRIST ANATOMY

Carpal disorders cannot be properly diagnosed without a first-rate understanding of what is normal and what is abnormal in a symptomatic wrist. This requires a thorough knowledge of both the anatomy and mechanics of the normal wrist. This section reviews the former. The terminology used from here on is in accordance with the recommendations made by the IFSSH,[58] as well as by the International Wrist Investigators' Workshop (IWIW).[42] A list of abbreviations used in this chapter is shown in Table 13.1.

Osseous Anatomy

The wrist is a complex, composite joint formed by 20 interdependent articulations binding 15 bones: radius, ulna, 8 carpal bones, and the bases of 5 metacarpals. In the frontal (coronal) plane, the carpus is arranged in two rows (proximal and distal). The distal carpal row consists of 4 tightly bound bones (i.e., trapezium, trapezoid, capitate, hamate) with little mobility between them. The proximal carpal row, by contrast, exhibits substantial intercarpal mobility. It consists of three bones (i.e., scaphoid, lunate, triquetrum), interconnected by two intercarpal joints: scapholunate (SL) and lunotriquetral (LTq) (Figure 13.1). The pisiform, usually considered a proximal row bone, is actually a sesamoid bone that increases the lever arm of the flexor carpi ulnaris (FCU) tendon.

The radiocarpal joint is an oval-shaped glenoid articulation that connects the proximal convexities of the scaphoid, lunate

TABLE 13.1 Abbreviations Used in This Chapter

Acronym	Definition
AAOS	American Academy of Orthopedic Surgeons
AIN	Anterior interosseous nerve
APL	Abductor pollicis longus
ASSH	American Society for Surgery of the Hand
CIC	Carpal instability complex
CID	Carpal instability dissociative
CIND	Carpal instability nondissociative
CMC	Carpometacarpal
DASH	Disabilities of the arm, shoulder, and hand
DISI	Dorsal intercalated segment instability
DRUJ	Distal radioulnar joint
DT	Dart thrower's
ECRB	Extensor carpi radialis brevis
ECRL	Extensor carpi radialis longus
ECU	Extensor carpi ulnaris
EPL	Extensor pollicis longus
FCR	Flexor carpi radialis
FCU	Flexor carpi ulnaris
FPB	Flexor pollicis brevis
FPL	Flexor pollicis longus
FR	Flexor retinaculum
L	Lunate
LC	Lunocapitate
LTq	Lunotriquetral
RASL	Reduction association scapholunate
RL	Radiolunate
RS	Radioscaphoid
RSC	Radioscaphocapitate
RSL	Radioscapholunate
S	Scaphoid
SC	Scaphocapitate
SL	Scapholunate
SLD	Scapholunate dissociation
SLIL	Scapholunate interosseus ligament
SNAC	Scaphoid nonunion advanced collapse
STT	Scaphotrapeziotrapezoid
TFCC	Triangular fibrocartilage complex
Tq	Triquetrum
TqC	Triquetrocapitate
TqH	Triquetrohamate
VAS	Visual analog scale
VISI	Volar intercalated segment instability

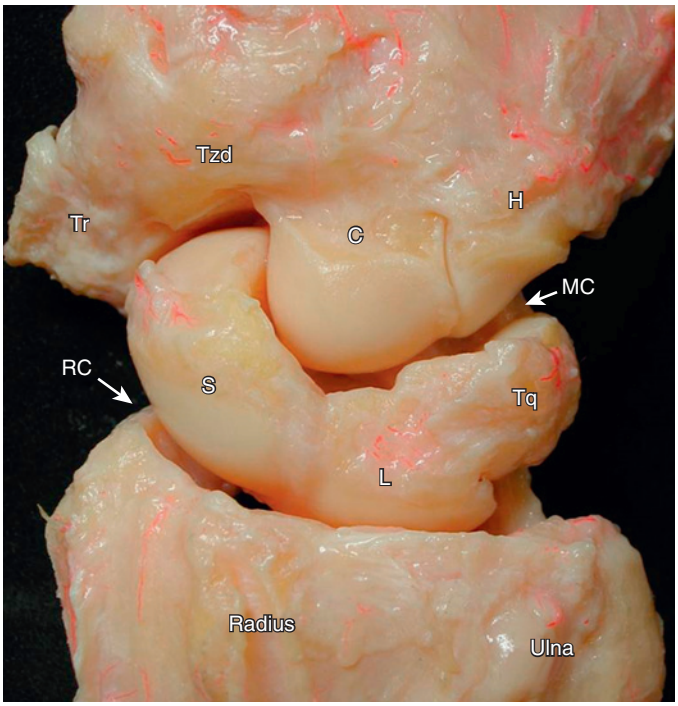

FIGURE 13.1 Dorsal view of a dissected cadaver specimen. The proximal row behaves as an intercalated segment between the radiocarpal (RC) and the midcarpal (MC) joints. *C*, Capitate; *H*, hamate; *L*, lunate; *S*, scaphoid; *Tq*, triquetrum; *Tr*, trapezium; *Tzd*, trapezoid.

and triquetrum—the so-called "carpal condyle"—with the antebrachial glenoid formed by the shallow concavities of the distal radius and triangular fibrocartilage complex (TFCC). The distal radius is tilted in two planes: the sagittal plane, where there is an average 10 degrees inclination toward the palm, and the frontal plane, where there is an average inclination toward the ulna of 24 degrees.[95] The proximal joint surface of the scaphoid is more curved than that of the lunate. To ensure articular congruency, the radius has two articular facets (i.e., scaphoid and lunate fossae), often separated by a cartilaginous sagittal ridge (i.e., interfacet prominence).

The midcarpal joint is a combination of three types of articulations. On the radial side, the convex distal surface of the scaphoid articulates with the concavity formed by the trapezium and the trapezoid—the scaphotrapeziotrapezoid (STT) joint. This is also known as the radial column. The central portion of the midcarpal joint is concave proximally and convex distally and has two sectors: the scaphocapitate (SC) and lunocapitate (LC) joints. The column formed by the lunate and capitate is also known as the central column. The lunate may have only one distal facet articulating with the capitate (lunate type I) or have two distal facets to articulate with the capitate and proximal pole of the hamate (lunate type II).[82,112] On the ulnar side, the triquetrum articulates with the hamate through the helicoidally shaped triquetrohamate (TqH) joint. This is known as the ulnar column.

The bones of the central column are collinear in the sagittal plane in only one-third of cases. In another 30%, the lunate is slightly flexed relative to the longitudinal axis of the forearm, while in the remaining 40% is slightly extended.[34] The scaphoid is placed obliquely in ~45 degrees of flexion in relation to the radius (range 30-60 degrees) to provide support to the thumb metacarpal, which is located anteriorly to the plane of the capitate.[6]

In the axial (transverse) plane, the carpus forms the carpal tunnel, a palmar concavity, enclosed by the transverse carpal ligament (also known as the flexor retinaculum). The narrowest portion of the carpal tunnel is located at the level of the distal carpal row.

Ligamentous Anatomy

The bones of the wrist are interconnected by a complex arrangement of ligaments[7,23,81,86] (Figure 13.2, *A–C*). Some ligaments are mechanically important structures, formed by tightly packed collagen fibers with a minimal amount of sensory corpuscles. Others are sensorially important structures with a rich population of Ruffini, Pacini, or Golgi corpuscles embedded within a less dense structure of collagen fibers.[35,91] The former are static structures designed to hold the bones together. The latter provide the necessary proprioceptive information that the sensorimotor system uses to guarantee joint stability.[84]

The ligaments are extracapsular or intracapsular. Only three are extracapsular: the transverse carpal ligament, and the two ligaments that connect the pisiform to the hook of the hamate and to the base of the fifth metacarpal. All other ligaments are contained within the depth of the capsule, surrounded by sheaths of loose connective tissue.

Two categories of intracapsular ligaments exist: extrinsic and intrinsic. Extrinsic ligaments connect the forearm with the carpus, whereas intrinsic ligaments originate and insert within the carpus[23,86] (Figure 13.3, *A, B*). Histological and biomechanical differences exist between the two types. Extrinsic ligaments are mostly inserted onto bone, whereas intrinsic ligaments insert mostly onto cartilage. The extrinsic ligaments are more elastic and less resistant to traction (i.e., lower yield strength) than most intrinsic ligaments. Not surprisingly, the extrinsic ligaments tend to sustain midsubstance ruptures, whereas the intrinsic ligaments are more frequently avulsed than ruptured. The best way to assess the intracapsular ligaments is to use an arthroscope.[20,31,100] Inside the joint, most extrinsic ligaments can be identified under a thin synovial sheath.

Extrinsic Ligaments

There are four palmar radiocarpal ligaments: radioscaphoid (RS), radioscaphocapitate (RSC), long radiolunate, and short radiolunate ligaments (long RL and short RL).[7,23] The first three originate from the anterolateral margin of the distal radius and take an oblique course to insert onto the proximal edge of the scaphoid tuberosity (RS ligament), the palmar aspect of the capitate (RSC ligament), and the palmar surface of the lunate (long RL ligament). The short RL ligament originates from the anteromedial margin of the distal radius and has a vertical direction until merging with fibers of the long RL ligament. The RSC ligament courses around the palmar concavity of the scaphoid, forming a sling over which the scaphoid rotates. Between the two diverging RSC and long RL ligaments is the so-called "interligamentous sulcus" (i.e., space of Poirier), which represents a weak zone through which perilunate dislocations frequently occur.[45,94]

There are three palmar ulnocarpal ligaments: one superficial (ulnocapitate) and two deep (ulnotriquetral and ulnolunate).[7,23,69] The ulnocapitate ligament arises from a rough

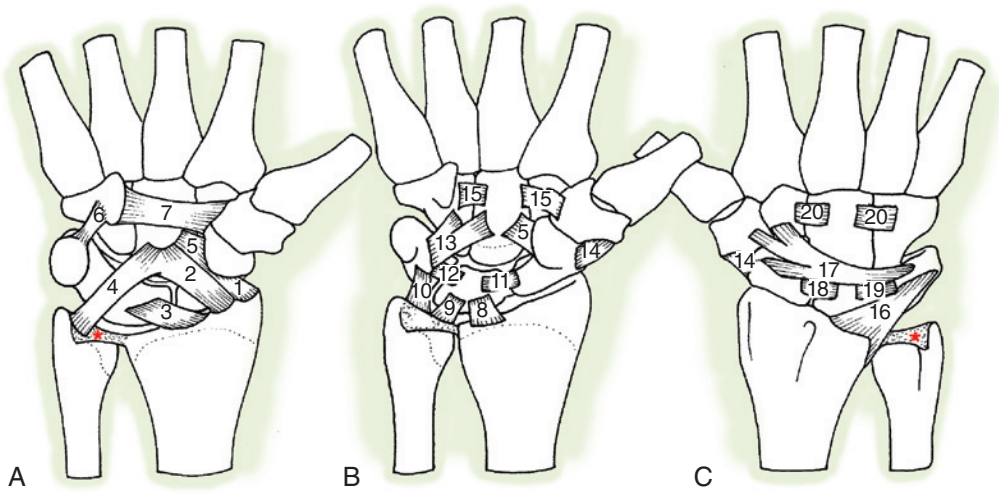

FIGURE 13.2 Schematic representation of wrist ligaments. These drawings do not replicate the exact shape and dimensions of the actual ligaments or their frequent anatomic variations. **A,** Palmar superficial ligaments: radioscaphoid (*1*), radioscaphocapitate (*2*), long radiolunate (*3*), ulnocapitate (*4*), scaphocapitate (*5*), pisohamate (*6*), and flexor retinaculum or transverse carpal ligament (*7*). **B,** Palmar deep ligaments: short radiolunate (*8*); ulnolunate (*9*); ulnotriquetral (*10*); palmar scapholunate (*11*); palmar lunotriquetral (*12*); triquetral–hamate–capitate, also known as the ulnar limb of the arcuate ligament (*13*); dorsolateral STT (*14*); and palmar transverse intercarpal ligaments of the distal row (*15*). **C,** Dorsal ligaments: radiotriquetral, also referred to as dorsal radiocarpal (*16*); triquetrum–scaphoid–trapeziotrapezoid, also known as the dorsal intercarpal ligament (*17*); dorsal scapholunate (*18*); dorsal lunotriquetral (*19*); and dorsal transverse intercarpal ligaments of the distal row (*20*). *Red asterisk*, triangular fibrocartilage complex.

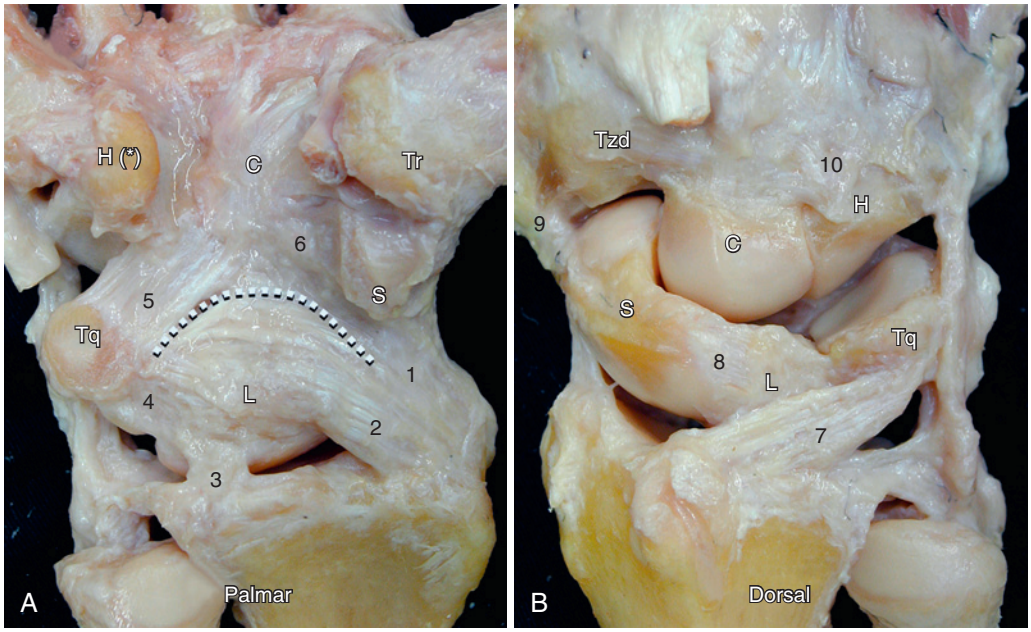

FIGURE 13.3 Human cadaver wrist dissected to show the relationship of some ligaments with the underlying joint surfaces. **A,** Palmar view: radioscaphocapitate (*1*); long radiolunate (*2*); short radiolunate (*3*); palmar lunotriquetral (*4*); triquetral–hamate–capitate (*5*); scaphocapitate (*6*). The so-called "space of Poirier" (*white dotted line*) is a relatively weak interligamentous sulcus through which most perilunate dislocations occur. **B,** Dorsal view: radiotriquetral (*7*); dorsal scapholunate (*8*); scaphoid–trapeziotrapezoid (*9*); dorsal transverse intercarpal ligaments (*10*). *Asterisk*, hook of the hamate. *C*, Capitate; *H*, hamate; *L*, lunate; *S*, scaphoid; *Tq*, triquetrum; *Tr*, trapezium; *Tzd*, trapezoid. (Not shown: dorsal intercarpal ligament.)

surface at the base of the ulnar styloid (i.e., the basistyloid fovea) and courses distally to attach onto the neck of the capitate. The ulnotriquetral and ulnolunate ligaments are deep fascicles that emerge from the palmar edge of the TFCC and run toward their distal insertions onto the anterior aspects of the lunate and triquetrum. The distal insertions of the ulnocapitate ligament blend with those of the triquetrocapitate ligament before inserting onto the capitate. That combined ligament, together with the RSC ligament, form the "distal V" ligament, also known as arcuate ligament.

There is only one dorsal extrinsic ligament binding the radius to the carpus—the dorsal radiotriquetral ligament, also

known as the dorsal radiocarpal ligament. It is a wide ligament that emerges from the dorsal edge of the distal radius and courses obliquely toward its distal insertion onto the dorsal ridge of the triquetrum.[76,86,100] This ligament may have fibers inserted onto the lunate, but rarely onto the scaphoid. There are no dorsal ligaments between the ulna and the carpus.

Because the wrist is not a hinge joint, there are no longitudinal ligaments between the radial and ulnar styloid processes and the medial and lateral corners of the carpal condyle. The absence of collateral ligaments is substituted for by the dynamic actions of the extensor carpi ulnaris (ECU) medially and the abductor pollicis longus (APL) laterally.[92] Although long considered an extrinsic palmar ligament, the radioscapholunate (RSL) ligament of Testut-Kuentz is not a true ligament, but a bundle of loose connective tissue containing vessels that supply the palmar corner of the proximal pole of the scaphoid.[7]

Intrinsic Ligaments

There are two types of intrinsic carpal ligaments: transverse intercarpal and midcarpal. The former interconnect bones from the same carpal row, while the latter link bones across the midcarpal joint.[7,11,23,81,86]

The SL joint is stabilized by two distinct transverse intercarpal ligaments (palmar and dorsal) and the proximal fibrocartilaginous membrane uniting both of them. The latter follows the arc of the proximal edges of the two bones from dorsal to palmar, separating the radiocarpal and midcarpal joint spaces. The dorsal SL ligament is located in the depth of the dorsal capsule and connects the dorsal–distal corners of the scaphoid and lunate bones. It is formed by a thick collection of fibers, slightly obliquely oriented, and plays a key role in scaphoid stability. Its anterior counterpart, the palmar SL ligament, has longer, more obliquely oriented fibers, which allow substantial flexion and extension of the scaphoid relative to the lunate. The dorsal SL ligament has the greatest yield strength, 260 newtons (N) on average, followed by the palmar SL ligament (118 N) and the proximal membrane (63 N).[7] The proximal membrane is formed by fibrocartilaginous tissue that is often perforated in older individuals (Figure 13.4).

The LTq joint also has two transverse intercarpal ligaments (palmar and dorsal) connecting the palmar and dorsal aspects of the two bones, and a fibrocartilaginous membrane closing the joint proximally. In contrast to the SL ligaments, the palmar LTq ligament is thicker and stronger than its dorsal counterpart (average yield strengths: 301 N and 121 N) with the proximal portion being the weakest (64 N).[54,87] Unless perforated by age or injury, this proximal membrane prevents communication between the radiocarpal and midcarpal joint spaces. The fibers of the two LTq ligaments are under greater tension through all ranges of motion than the fibers of the SL ligaments. The most distal fibers of palmar and dorsal LTq ligaments are often connected to the distal fibers of the SL ligaments, forming the palmar and dorsal scaphotriquetral ligaments.[113] These structures, as well as the interdigitating fibers of the dorsal intercarpal ligament, contribute to the stability of the LC joint by increasing the depth of the midcarpal fossa.[27,118]

The distal carpal row bones are strongly bound to each other by stout transverse intercarpal ligaments (i.e., dorsal, palmar,

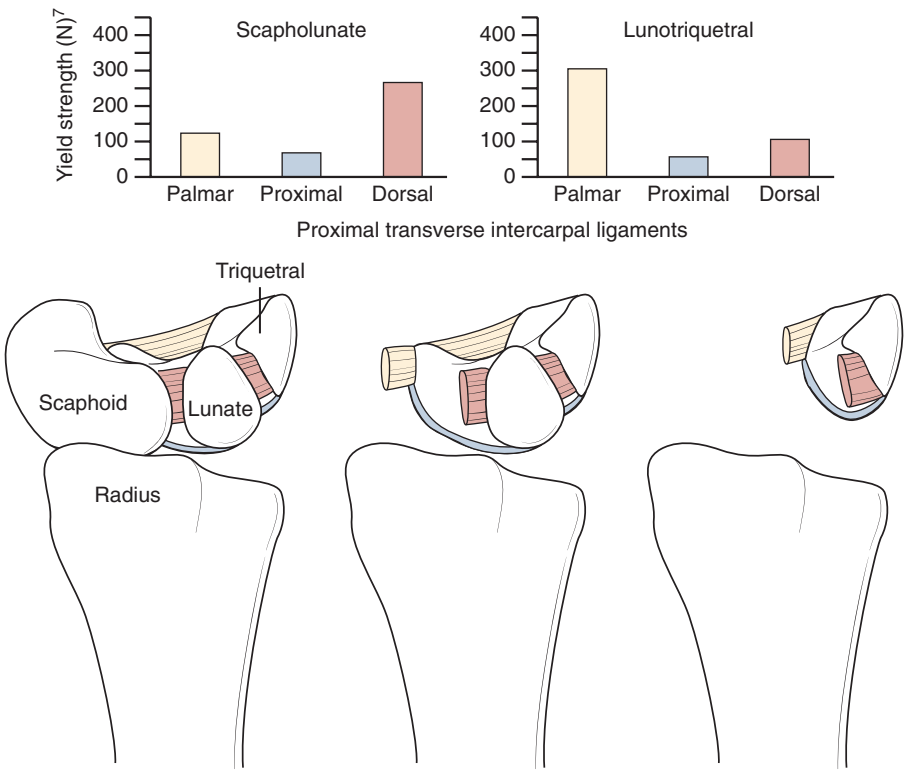

FIGURE 13.4 Schematic representations of the scapholunate (SL) and lunotriquetral (LTq) ligamentous complexes. At both levels there are one proximal fibrocartilaginous membrane (*in blue*) and two transverse intercarpal ligaments: palmar (*in yellow*) and dorsal (*in red*). The dorsal SL ligament has the greatest yield strength of the three components of the SL joint (*upper left bar chart*), whereas the palmar LTq ligament is stronger than it dorsal counterpart (*upper right bar chart*).[7]

intraarticular). They are essential to ensure the rigidity of the transverse carpal arch and to protect the carpal tunnel contents.[80]

The midcarpal joint is crossed by three palmar ligaments (i.e., triquetrohamate [TqH], triquetrocapitate [TqC], and scaphocapitate), one dorsolateral STT ligament, and one dorsal intercarpal ligament.[11,23,56] The TqH and TqC ligaments are thick structures, variable in size and shape, that play an important role in the stabilization of the midcarpal joint.[27,118] Their anatomy varies according to the type of lunate (I or II).[23,82,112] The TqC ligament is also known as the ulnar arm of the arcuate ligament.[56] Laterally, the scaphoid tuberosity is linked to the distal row by the anteromedial SC ligament and the dorsolateral STT ligament. These two ligaments behave as collateral ligaments for the STT joint.[70]

The only ligament crossing the dorsum of the midcarpal joint is the dorsal intercarpal ligament.[11,76,113] On the ulnar side, it arises from the dorsal ridge of the triquetrum and courses transversely along the dorsal edges of the proximal row bones, distal to the scaphotriquetral ligament. At the level of the scaphoid, this ligament fans out to insert onto the dorsal rim of the scaphoid, the trapezium, and the trapezoid. There are no ligaments, palmar or dorsal, between the lunate and capitate.

WRIST BIOMECHANICS

The wrist is a highly mobile, composite articulation that links the two forearm bones and the hand, characterized by its ability to sustain substantial amounts of load in all positions.[46,57] To achieve this, there must be appropriate interaction between wrist motor tendons, joint surfaces, and soft tissue constraints.[35,84] What follows is a brief description of how the wrist moves (i.e., kinematics) and how it withstands loads without yielding (i.e., kinetics).

Carpal Kinematics

The wrist can be moved passively by an external force, or actively by contracting muscles with a tendon crossing the joint. None of these tendons inserts onto the proximal carpal row; all of them insert distal to the midcarpal joint.[18,76,99] Consequently, when these muscles contract, the distal carpal row is the first to move. The bones of the proximal row do not start rotating until the midcarpal ligaments become taut and pull them into motion. In other words, around the neutral position, the only joint that moves is the midcarpal articulation.[18,29,67]

Flexion–Extension

In the sagittal plane, the scaphoid rotates more than the lunate, owing to differences in the shape of their proximal and distal articulating surfaces and surrounding ligamentous anatomy (Figure 13.5). From neutral-to-maximal wrist flexion, the scaphoid and lunate contribute 70% and 46%, respectively, to the total range. Similarly, during maximal wrist extension, the scaphoid and lunate contribute 72% and 42%, respectively.[67,76] The shape of the two bones also deserves a comment: the scaphoid is obliquely oriented relative to the longitudinal axis of the forearm; because of that, it is easier for it to flex than to extend.

The lunate, by contrast, has an inherent tendency to extend as it is narrower dorsally than palmarly. With this in mind, it is easy to understand why the contribution of the radiocarpal and midcarpal joints to the total range of wrist flexion–extension is different in the central column (55% of the total range takes

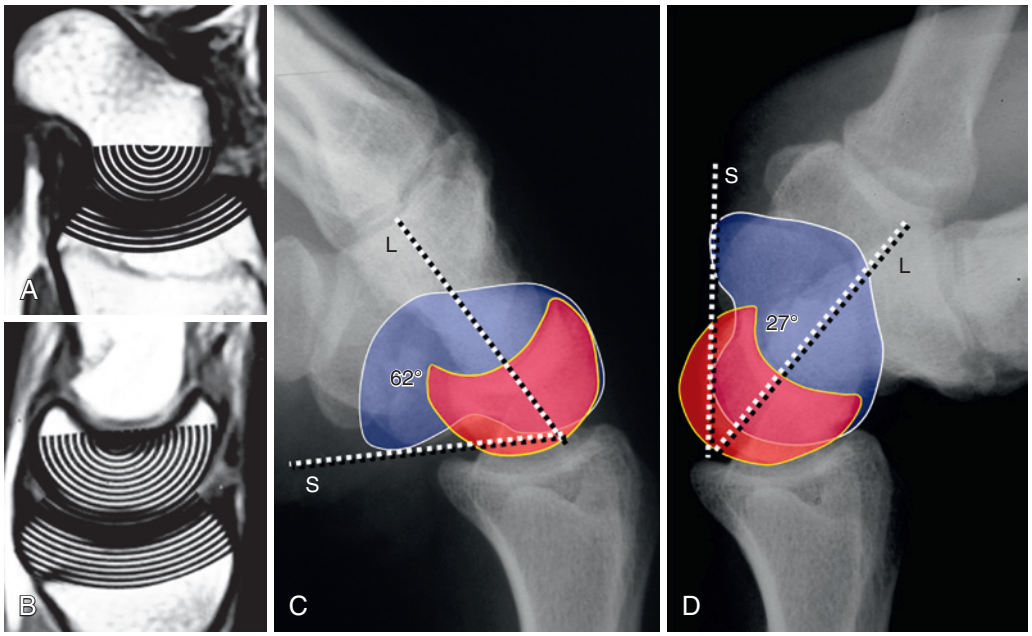

FIGURE 13.5 Sagittal computed tomography scans of the scaphoid **(A)** and lunate **(B),** covered by a transparent card with concentric circle scale marks. Indeed, the radii of curvature of the lunate (L) is longer than that of the scaphoid (S). Because of this, the scaphoid needs to rotate more than the lunate to get to the limits of flexion–extension. Unlike the distal row, where the four bones form a fixed unit with little motion between them, the proximal row exhibits substantial SL and lunotriquetral (LTq) rotations. The proof of this may be found by comparing the SL angle in full flexion **(C)** and full extension **(D).** In this particular case the scaphoid rotates 35 degrees more than the lunate.

place in the midcarpal joint) than in the radial column (70% of motion happens at the RS joint).[34]

Radioulnar Inclination

When the wrist moves along the frontal (i.e., coronal) plane, both the proximal and distal rows go into radial and ulnar inclination, but the proximal carpal row also flexes and extends. In radial inclination, the trapezium and trapezoid approximate to the radius and therefore the scaphoid has to flex because the space is reduced, and its longitudinal axis becomes almost perpendicular to that of the radius. The lunate and triquetrum also flex, although to a lesser degree.[67,105]

When the wrist goes into ulnar inclination the scaphoid extends, pulled by the trapezium and trapezoid, with its longitudinal axis becoming practically collinear to that of the radius. The lunate and triquetrum also extend during ulnar inclination, although to a lesser degree. For this reason, if the wrist is ulnarly inclined when a plain radiograph or a sagittal tomogram is obtained, one may erroneously think that the extended position of the lunate is secondary to misalignment.[59]

Dart-Thrower's Motion

The orthogonal (i.e., frontal and sagittal) planes of motion are seldom utilized in activities of daily living. The most commonly used plane of motion goes from extension and radial inclination to flexion and ulnar inclination.[9,18] Fisk described this plane as "when someone is casting a fly or throwing a dart"; thus, hand surgeons use the term "dart-thrower's" (DT) motion.[70]

When the wrist is in radial inclination, the scaphoid and lunate are flexed. If the wrist is then brought into extension, the lunate recovers its initial alignment, as when the wrist was in neutral. When the wrist goes into ulnar inclination, the scaphoid and lunate extend, but they regain that neutral position when the wrist is flexed while in ulnar inclination.[30] In other words, when the wrist moves along an oblique plane going from extension and radial inclination to neutral, and finally into flexion and ulnar inclination, the scaphoid and lunate remain in neutral position. Indeed, during DT motion, most wrist mobility takes place at the midcarpal joint.[18,30,70]

The obliquity of the DT plane of motion is unique to each individual, ranging from 37 to 59 degrees from the sagittal plane, according to various authors.[9,18,30,70] This oblique plane of wrist motion, generated by the pull of two wrist extensors—extensor carpi radialis longus (ECRL) and extensor carpi radialis brevis (ECRB)—and one wrist flexor, the FCU, is one of the most frequently used in activities of daily living.

Reversed Dart-Thrower's Motion

The opposite rotation, from extension–ulnar inclination to flexion–radial inclination has been referred to as the "reversed dart-thrower's" motion. It is a rotation mediated by the FCR on the volar side and the ECU on the dorsal side of the wrist. As opposed to what happens during DT rotation, the contribution of the midcarpal joint to the reversed dart-thrower's type of rotation is minimal: only the radiocarpal joint is mobilized. Based on this, the wrist can be compared to a universal (i.e., cardan) type of articulation with two axes of rotation: one for the midcarpal joint and another for the radiocarpal joint. The midcarpal dart-throwing axis and the radiocarpal reversed DT axis do not coincide in space: the first would be located at about the center of the head of the capitate, while the second would be more proximally located at about the LC joint.[18]

Needless to say, this way of describing wrist motion is an oversimplification. In reality, each bone has its own center of rotation that changes in location and orientation as the wrist moves. There are substantial synergies between the bones of each row that make this simplified model useful for the clinician, however. In fact, this model is the first to provide a convincing explanation of how the wrist is able to transmit pronosupination torques, from distal-to-proximal or vice versa, in all wrist positions, without losing stability (Figure 13.6).

Intracarpal Pronosupination

Most axial rotation of the hand takes place in the forearm, with the radius rotating around a slightly oblique longitudinal axis running from the center of the head of the radius to the center of the head of the ulna. However, some pronation and supination also take place in the wrist, mainly at the midcarpal joint. Passive intracarpal pronation and supination are greater than active rotation.

The mechanism of active intracarpal pronosupination has recently been elucidated[91,92] and can be explained as follows. Distal to the extensor retinaculum, most wrist motor tendons change direction, taking an oblique path to their distal insertion. The ECU tendon, for instance, from a dorsal position at the level of the ulnar head, courses obliquely toward its distal insertion onto the volar–ulnar corner of the fifth metacarpal. The ECRL and the APL also have an oblique course but in the opposite direction, toward the lateral border of the wrist.

All of them are dorsal at the radiocarpal level but diverge distally toward their ulnar or radial insertions. If the wrist is in a neutral position, isolated isometric contraction of any of these muscles will generate a pronation or supination moment to the distal row: ECU muscle contraction will cause intracarpal pronation, whereas the ECRL and APL muscles will induce a supination moment to the distal row.[91,92]

Carpal Kinetics

Hand function generates a considerable amount of force that is transmitted across the carpometacarpal (CMC) joints into the carpus.[63,99,112] At the distal row, loads are distributed among the midcarpal joints with the SC and LC joints transmitting ~50%, the STT joint ~30%, and the TqH joint ~20%.[112] The fact that most synovial cysts emerge from the SL interval proves this to be a particularly overloaded area; indeed, ganglions tend to appear on the surface of chronically strained ligaments.

Once in the proximal row, 50% of the total load is transmitted across the RS joint (scaphoid fossa), 35% across the RL joint (lunate fossa), and 15% across the TFCC into the ulna.[63,112] The average pressure values within the radiocarpal joint may be as high as 5.6 MPa, which is approximately 0.5 N/mm^2 or 810 lb/in^2. These figures vary substantially with wrist position. The lunate fossa is increasingly loaded with ulnar inclination, the scaphoid fossa with radial inclination. When the wrist is in the "position of function" (i.e., slightly extended and radially inclined), the lunate tends to carry more load than the scaphoid.[63]

When axially loaded, the carpal bones become displaced following specific patterns.[2] The magnitude and direction of displacement depend on the shape of the articular surfaces, the

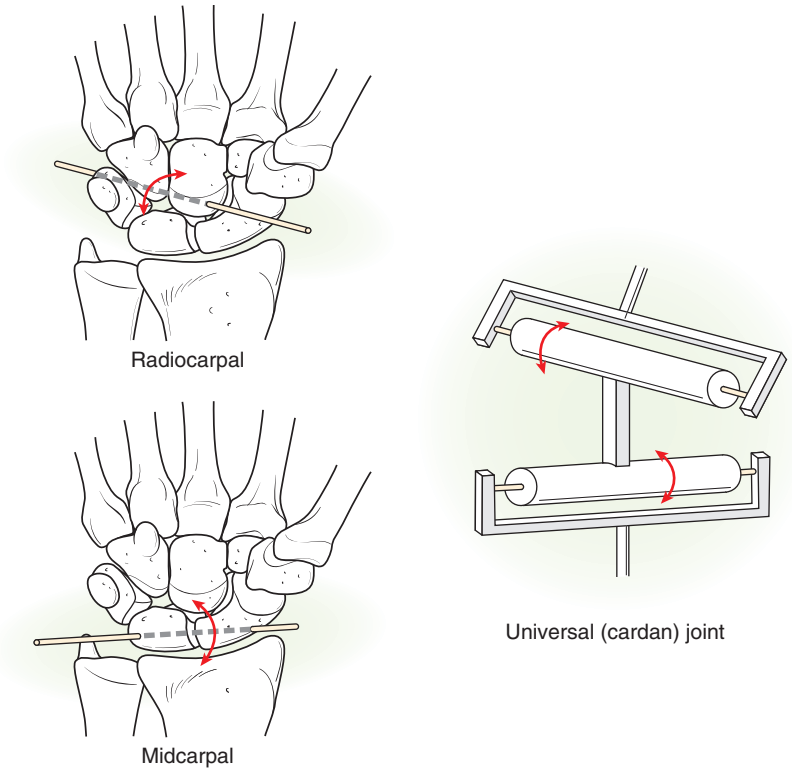

FIGURE 13.6 The wrist is a universal (cardan) type of articulation, able to transmit torques across the proximal row in all wrist positions without losing stability. Henle was the first to describe this phenomenon in 1871.[21]

orientation and point of application of the incoming loads, and the status of the various soft tissue constraints (i.e., capsule, ligaments, muscles).

A wrist is stable when it is able to sustain physiological loads in all positions without experiencing abnormal carpal displacement.[2] When a stable wrist is loaded, the carpal bones do not displace beyond normal limits. For this to happen, the articular surfaces must be normally oriented and congruous, the ligaments must be all present and active; and the forces generated by the muscles acting on the carpal bones must be balanced.

The Role of Ligaments in Carpal Stabilization

The proximal carpal row, truly an intercalated segment between the radius and distal carpal row, is inherently unstable. If not for the capsule, ligaments, and muscles, the three bones would collapse when compressed by the distal carpal row against the radius. The obliquely oriented scaphoid would rotate into flexion and pronation, while the wedge-shaped (thinner dorsally than palmarly) lunate and triquetrum would collapse into extension and supination[34] (Figure 13.7).

In theory, if the SL ligaments were all intact, the flexion tendency of the scaphoid would be counteracted by the opposite tendency of the loaded lunate and triquetrum to rotate into extension, and stability would be achieved. In practice, these ligaments cannot do that alone.[7] The tensile forces involved in most hand activities are far too high for these ligaments to be the only wrist stabilizers. To achieve stability, ligaments need to be protected by muscles.[35,91,92]

To ensure a timely and protective muscle response, the carpal ligaments contain mechanoreceptors providing the proprioceptive information required by the sensorimotor system to activate that response.[84] In other words, the ligaments provide the first line of defense against instability, but the muscles are the ultimate stabilizers.[35,91]

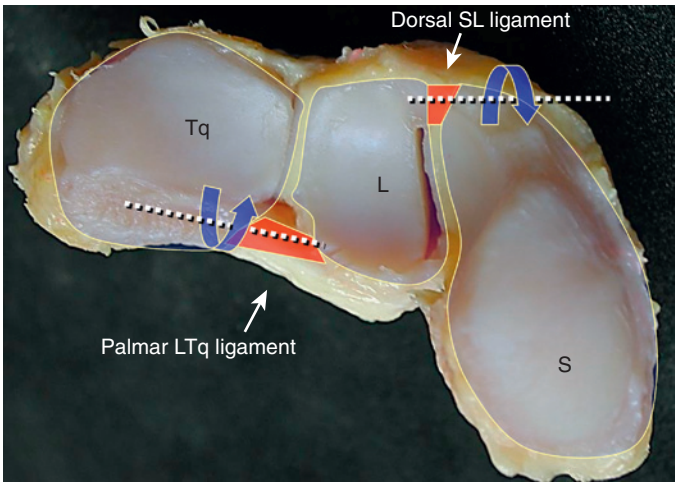

FIGURE 13.7 Human wrist dissected to show the distal articular surfaces of the proximal row and the transverse intercarpal ligaments. The main role of the dorsal scapholunate (SL) ligament is to avoid excessive flexion–pronation of the scaphoid (S; *blue curved arrows*), whereas the palmar lunotriquetral (LTq) ligament is responsible for the neutralization of the extension tendency of the triquetrum (Tq) under load. *L*, Lunate.

The Role of Muscles in Carpal Stabilization

Until recently, muscles were considered to have a negative influence on carpal stability. Instability was assumed to be a ligament insufficiency problem made worse by muscle contraction. Now

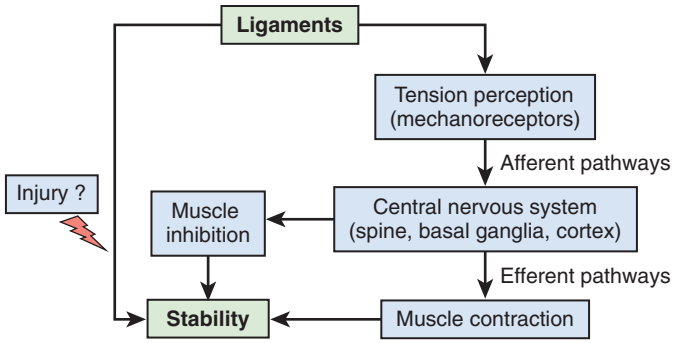

FIGURE 13.8 Schematic representation of the mechanism of carpal stabilization. Ligaments are the primary stabilizers. When one ligament is seriously injured, a secondary neuromuscular reflex develops to compensate for the defect. This entire mechanism is mediated by the central nervous system and, depending on which ligament is injured, involves contraction of some muscles, and inhibition of others muscles.

we know that the assumption is wrong: muscles play an important stabilizing role[35,91,92] (Figure 13.8).

The mechanisms of muscle stabilization of the wrist are based on the previously mentioned ability of some muscles to pronate or supinate the distal carpal row.[91,92] When the intracarpal supinators (ECRL or APL) contract, the trapezium displaces dorsally, thus tightening the STT ligament. If the STT ligament is taut, the scaphoid cannot collapse into flexion and pronation. The intracarpal supinators, therefore, protect against excessive flexion–pronation of the scaphoid[92] (see Video 13.1). In contrast, when the ECU contracts, the distal row pronates, tightening the TqH ligament and preventing the proximal row from collapsing into flexion.[54] Thus, the supinators are useful in the treatment of scaphoid instabilities, and the pronators in the treatment of most ulnarside carpal instabilities.[35] Again, muscles are the ultimate carpal stabilizers.[84]

WRIST DISORDERS

Wrist function may be altered in a variety of ways. A change in the shape of the articulating bones, a rupture or insufficiency of specific ligaments, and/or a loss of the stabilizing effect of specific muscles can explain most carpal disorders. The resulting malfunction may be present at birth (i.e., congenital disorders); may appear slowly as a result of abnormal growth (i.e., developmental disorders); or be the consequence of violent trauma, repetitive stress, or a joint damaging disease (i.e., acquired disorder). This chapter discusses the assessment and treatment of most acquired disorders of the wrist.

With time, most wrist disorders evolve into carpal misalignment. In theory, the most misaligned wrists should all be unstable. In practice, this is not always true. Instability is a multifactorial phenomenon that may or may not be associated with an alteration of the carpal alignment.[2] The misalignment of the so-called "adaptive wrists", for instance, is not a sign of ligament-related instability, but an adaptation of a normal carpus to compensate for an extracarpal bone deformity.[1] Another example is the constitutional hyperlax wrist: It may appear misaligned, yet it frequently remains asymptomatic, able to handle most activities of daily living, and seldom requires treatment. Chronic unreduced perilunate dislocations are also examples of malaligned, but not unstable wrists. Certainly, if a dislocation is left unreduced, the joint will be unstable for a while until it undergoes a process of arthrofibrosis and becomes stiff, and stiffness is the opposite of being unstable. Indeed, a normally aligned carpus may behave as an unstable articulation; and vice versa, a grossly misaligned wrist may behave as if it was a completely stable structure.[1]

With these considerations in mind, this chapter differentiates the unstable carpus secondary to intracarpal pathology from the misaligned, yet normal carpus secondary to extracarpal pathology, and from the misaligned but stiff wrist secondary to posttraumatic arthrofibrosis. What follows is a review of some aspects that are common for these three clinical conditions.

Pathomechanics

Carpal derangements may result from a direct or an indirect mechanism of injury. In direct mechanisms, the destabilizing force is applied directly to the dislocating bone, whereas indirect mechanisms involve a force applied at a distance from the injured joint. A typical direct mechanism occurs when the wrist is crushed by a power press or a wringer-type machine.[80] If the dislocating force is applied over a large surface area of the hand, a carpal derangement may follow. In contrast, if the dislocating force is exerted over a small surface area, a localized fracture–dislocation may occur.

Wrist extension is the primary component of injuries causing distal radial fractures, scaphoid fractures, or perilunate dislocations. Differences in bone stock, the direction and magnitude of the deforming forces, and/or the position of the wrist at the time of incident may explain which type of injury occurs.

Perilunate dislocations are complex carpal derangements, usually the result of a combination of loaded hyperextension and intracarpal axial rotation.[43,64] A typical case would be a head-on motorbike collision, where the hand gets pinned to the handlebar while the body is violently projected forward. The wrist, in such instances, becomes the pivot point about which the body rotates. When this happens, carpal destabilization undergoes a quite consistent four-stage pattern called "progressive perilunar instability," described by Mayfield et al.[44,45,64] The stages shown in Figure 13.9 are described in the following subsections.

Stage I: SL Dissociation or Scaphoid Fracture

When the wrist is violently twisted into extension and intracarpal supination, if the STT and SC ligaments are intact, the scaphoid extends and supinates, dragged by the trapezium. The lunate, in contrast, stays behind, constrained by the two long and short RL ligaments. With this, an increasing SL torque is created. When this torque reaches a certain level, progressive tearing of the SL intercarpal membrane and ligaments tends to occur. Usually, this happens from palmar-to-dorsal.

The end stage would be a complete SL dissociation. If the same process happens when the wrist is radially inclined (i.e., when the proximal pole of the scaphoid is powerfully constrained by the RSC ligament), instead of SL dissociation, an scaphoid fracture is likely to occur. More rarely, the lunate may suffer a coronal fracture, the volar portion of it remaining attached to the radius while the dorsal fragment follows the scaphoid and distal row in their dorsal displacement.[5]

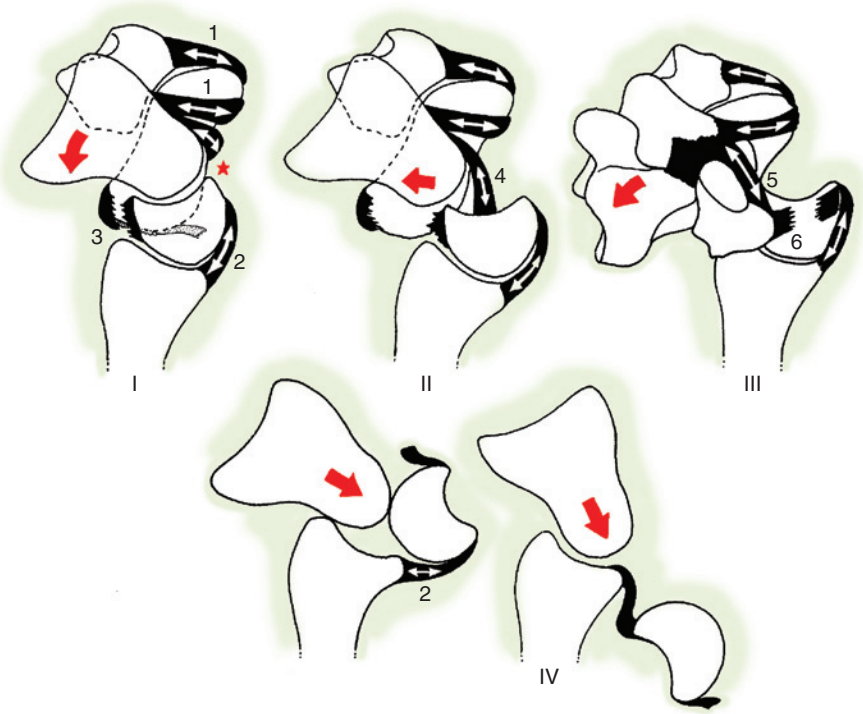

FIGURE 13.9 Schematic representation of the four stages of perilunate instability, viewed from the ulnar side. Stage I: As the distal carpal row is forced into hyperextension (*red arrows*), the scaphotrapezoid–capitate ligaments (*1*) pull the scaphoid (S) into extension, opening the space of Poirier (*asterisk*). The lunate (L) cannot extend as much as the scaphoid because it is directly constrained by the short RL ligament (*2*). When SL torque reaches a certain value, the SL ligaments may fail, usually from palmar to dorsal. A complete SL dissociation is defined by the rupture of the dorsal SL ligament (*3*). Stage II: When dissociated from the lunate, the scaphoid–distal row complex may dislocate dorsally relative to the lunate (*red arrow*). The limit of such dorsal translation is determined by the radioscaphocapitate (RSC) ligament (*4*). Stage III: If hyperextension persists, the ulnar limb of the arcuate ligament (*5*) may pull the triquetrum (Tq) dorsally, causing failure of the lunotriquetral (LTq) ligaments (*6*). Stage IV: Finally, the capitate may be forced by the still-intact RSC ligament (*4*) to edge into the radiocarpal space and push the lunate palmarward until it dislocates into the carpal canal in a rotary fashion. (Modified from Mayfield JK, Johnson RP, Kilcoyne RK: Carpal dislocations: pathomechanics and progressive perilunar instability. *J Hand Surg Am* 5:226–241, 1980.[64])

Stage II: Perilunate Dislocation

Once the SL joint is disrupted, if the destabilizing force continues, the capitate may leave the lunate concavity, leading to a dorsal perilunate dislocation. If instead of SL dissociation there is a scaphoid fracture, the wrist will suffer a transscaphoperilunate dislocation. Less commonly, the capitate may undergo a fracture. In such cases, only the body of the capitate dislocates dorsally with the rest of the distal row. The head of the capitate stays behind, sometimes completely rotated. In most instances, the displacement of the distal row is associated with a midsubstance stretching injury of the RSC ligament.

Stage III: LTq Disruption or Triquetrum Fracture

As the distal row dislocates dorsally, the TqH and TqC ligaments become extremely taut, generating an extension/dorsal translation vector to the triquetrum. This may result either in the separation of the triquetrum from the lunate, owing to tearing of the LTq ligaments, or a sagittal fracture of the triquetrum.

Stage IV: Lunate Dislocation

When all perilunate ligaments are torn, only the dorsal capsule and palmar RL ligaments can hold the lunate in place. In such circumstances, the dorsally displaced capitate, propelled by the forearm muscles, may enter the radiocarpal joint and push the lunate palmarly, out of the lunate fossa. This results in an anterior dislocation of the lunate. Such a dislocation is often associated with a variable degree of lunate flexion into the carpal tunnel.

Depending on the amount of lunate rotation, lunate dislocation has been subdivided into three categories: type I, in which the lunate exhibits greater than 90 degrees of flexion deformity; type II, in which the lunate is flexed >90 degrees around an intact, undisrupted, palmar RL capsule and ligament; and type III, which is a complete palmar enucleation of the lunate with rupture of the palmar capsule.[38]

There are cases where the carpal derangement starts at the ulnar side and proceeds radially around the lunate. Usually, this happens as a result of a backward fall on the outstretched hand with the upper limb externally rotated. In such circumstances, the disrupting load is applied to the hypothenar area, the triquetrum being forced by the pisiform to displace dorsally relative to the lunate. Since the lunate cannot displace in the same direction because it is constrained by the radius, an increasing shear stress develops between the two bones. In such cases, complete rupture of the LTq ligaments would be stage I of a reversed perilunate destabilization pattern of the wrist,

ulnocarpal ligament rupture plus LC dislocation would be stage II, and SL dissociation would be stage III. This alternative mechanism has recently been confirmed in the laboratory.[71]

Diagnosis of Wrist Disorders

Wrist disorders present in a great variety of ways. From the patient who has suffered a violent trauma such as a fall from a height or a crush injury to the wrist, presenting with a major fracture or dislocation of the upper limb, to the patient with a symptomatic malfunctioning wrist without a clear recollection of what caused the problem. In the former, the diagnosis of a major carpal derangement may be obvious; however, in the latter, identification of the true nature of the problem may not be easy. This section discusses clinical and radiographic assessments of both acute and chronic dysfunctions. Supplemental information on the particular features of each type can be found in Rhee et al[83] and Sauvé et al.[93]

Clinical Examination

Physical examination always needs to be preceded by a thorough investigation of the patient's medical history, with special emphasis on the mechanism of injury. The patient should be asked details about the location, duration, and characteristics of any pain including aggravating and relieving factors, and previous treatments, if any. With chronic problems, it is also important to inquire about the patient's jobs and hobbies, and whether there has been exposure to repetitive stress, vibrating tools, or potentially dangerous instruments.

The next step is inspection. Except in cases with an open dislocation, the external appearance of most wrist dislocations may not be dramatic. Swelling is generally moderate, and bone displacements may be evident only if the patient is seen immediately after experiencing the trauma. If there has been a delay since the accident, swelling may have increased significantly, making visualization of the displaced bones more difficult. When present, skin abrasions, contusions, or ecchymosed areas may be helpful in determining the mechanism of injury and the potential areas of damage.

Palpation for areas of maximal tenderness is one of the most useful tools in the diagnosis of wrist pathology, especially in patients with chronic dysfunctions.[83,93] In acute dislocations, because of extensive soft tissue damage, tenderness is seldom elicited at specific points, but rather in a diffuse manner. Nonetheless, palpation should always be performed in a methodical way.

Acutely, range of motion is usually limited by pain, whereas it may be reduced or normal in more chronic cases. In the latter, passive mobilization of the joints is valuable not only in determining the presence of abnormal motion or crepitus but also in reproducing the patient's pain. Grip and pinch strength also need to be measured for chronic problems to uncover underlying pathology. Strength may be reduced due to muscle atrophy or by pain inhibition. A local injection of anesthetic within the affected joint may normalize the dynamometer readings in the latter.

A careful assessment of neurovascular status is imperative, with particular attention being paid to the median and ulnar nerves, which may be injured by direct contusion at the moment of impact, by compression from displaced bones, or by swelling in the carpal canal.

Radiological Examination

Routine Radiograph Views. The initial radiographic examination of a patient with a suspected carpal injury should include four images of the wrist. If some of these are omitted, or of inadequate quality, the likelihood of missing important information increases.[59,120]

Posteroanterior (Palm Down) Projection. The posteroanterior (PA) view should be obtained with the hand placed flat over the radiograph film, the shoulder abducted 90 degrees, the elbow flexed 90 degrees, and the forearm in neutral rotation. One can determine whether it is a true PA radiograph by checking that the ECU groove is projected radial to the axis of the ulnar styloid. In the PA view of a normal wrist, the proximal and distal outlines of the proximal row, as well as the proximal outline of the distal row (i.e., the so-called "Gilula's lines") are smooth, without breaks in their continuity (Figure 13.10). Any step-off of these lines indicates abnormality at the site where the arc is broken.[120]

Normally articulating bones have parallel opposing surfaces separated by 2 mm or less. Any overlap between well-profiled carpal bones definitely suggests an intercarpal abnormality. Joint diastasis should not be interpreted as a sign of joint disruption unless it is asymmetric. Contralateral wrist radiographs are mandatory for a ligament injury workup.

In the PA view of a wrist in neutral, the normal lunate has a trapezoidal configuration. It is possible to differentiate a flexed from an extended lunate based on the shape of its contour (Figure 13.11). To do so, it is important to remember that, in the transverse plane, the lunate is wider palmarly than dorsally. Therefore, when abnormally extended, the lunate has an ovoid configuration due to the distal displacement of the wider anterior horn. Conversely, when abnormally flexed the lunate is triangular shaped, often with a half moon-like configuration, with its concavity facing toward the scaphoid.[34,82]

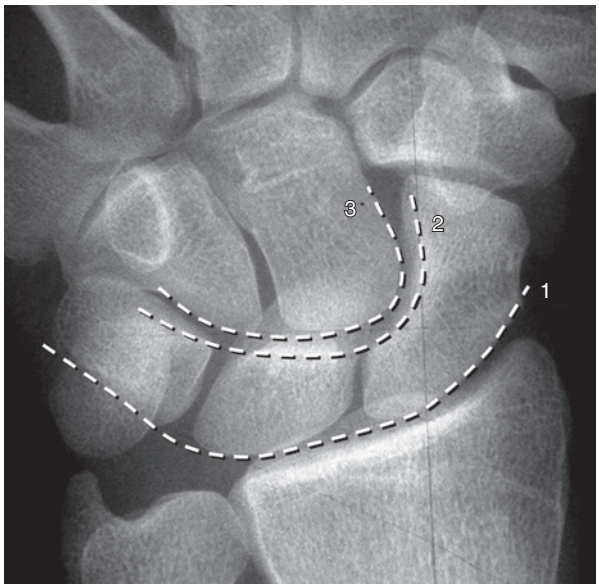

FIGURE 13.10 Gilula[120] defined three smooth, curved lines (*1*, *2*, and *3*) joining the proximal and distal cortical surfaces of the carpal bones that help assess normal carpal relationships. A disruption or step-off in any one of these lines may indicate a major carpal derangement.

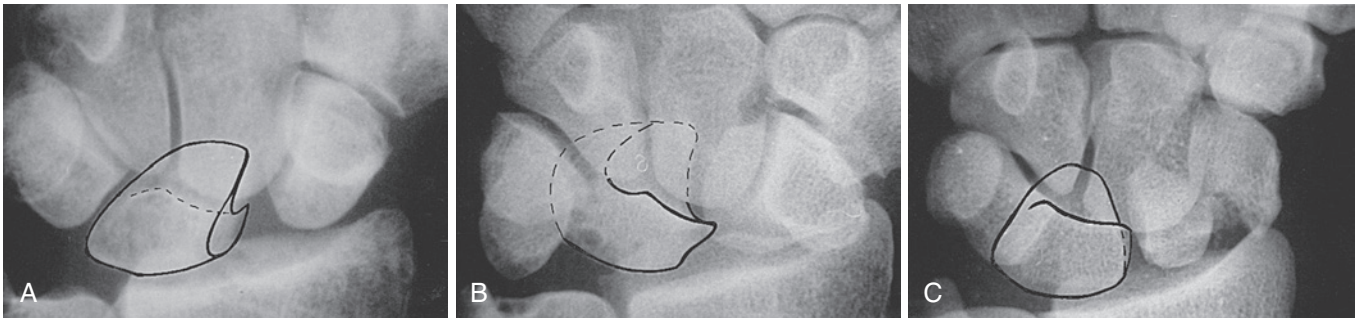

FIGURE 13.11 The shape of the lunate (L) on a posteroanterior view may help differentiate a dislocated from a malaligned lunate. **A,** The lunate in a dorsal intercalated segment instability (DISI) position tends to have an ovoid configuration, with a prominent ulnar corner pointing toward the medial aspect of the wrist. **B,** The lunate in volar intercalated segment instability (VISI) has a "C"-shaped or moonlike appearance. **C,** In dorsal perilunate dislocations, the subluxed lunate appears as an isosceles triangle pointing distally.

Lateral Projection. The lateral view must be taken with the arm adducted to the patient's side, and with both the forearm and the wrist in neutral rotation. For a lateral projection to be correct, the axis of the third metacarpal needs to be parallel to that of the radius, and the palmar outline of the pisiform needs to be located between (and equidistant to) the palmar surfaces of the scaphoid tuberosity and the capitate head.[120]

Scaphoid Projection. The best projection to confirm a scaphoid fracture is a PA view centered on it, with the wrist in ulnar inclination and the fingers fully flexed.

Semipronated (Oblique) Projection. A 45-degree semipronated oblique view profiling the anterolateral and posteromedial corners of the carpus is useful to investigate the presence of fractures of the dorsal ridge of the triquetrum and of the scaphoid tuberosity.

Additional Radiograph Views. When routine radiographs do not confirm the suspected diagnosis, obtaining additional views is recommended. The following are the most commonly used projections for the wrist.

- *Anteroposterior (palm up) view with a clenched fist:* Alternatively, get radiographs with a longitudinal compression force applied to the wrist by an assistant, which may accentuate the gap that often appears in SL dissociation (Figure 13.12). It is preferable to obtain this view without wrist extension or flexion. Correct positioning can be objectively evaluated by looking at the third CMC joint. When the wrist is in neutral, the joint's surfaces are parallel.
- *PA (palm down) view with 10 degrees of tube angulation from ulna toward radius:* This view is ideal to assess the SL interval. Measurement of its separation (SL gap) is made at the midportion of the joint where its anatomy is more consistent. The spacing should be compared with the opposite wrist and with the surrounding carpal articulations.
- *Clenched-pencil view:* This is one of the best ways to demonstrate SL dissociation because it optimally profiles the joint while it is being separated with some grip force. It consists of a PA view of both wrists while the two hands are gripping one pencil tightly, with the index fingers apposed and the thumb metacarpals lying flat on the radiographic cassette. The technique provides comparison of both wrists at the same time.[51a]
- *Oblique view at 20 degrees of pronation from the lateral position:* This view is used to visualize the dorsum of the triquetrum, where avulsion fractures frequently occur, and to evaluate the distal tuberosity and waist of the scaphoid. It is ideal for fracture–subluxations of the fifth CMC joint.
- *Oblique view at 30 degrees of supination from the lateral position:* The pisotriquetral relationship is best seen with this view.
- *Lateral view with the wrist radially inclined:* The palmar outline of the hook of the hamate can be seen on a lateral view with the wrist radially inclined and the thumb in maximal anteposition. It places the hook of the hamate between the bases of the first and second metacarpals.
- *Carpal tunnel view:* By profiling the carpal concavity of the wrist, a clearer view of the hook of the hamate, the pisiform, and the palmar ridge of the triquetrum can be obtained. In patients with acute injuries, however, pain produced by extending the wrist may not allow the radiograph to be taken.



FIGURE 13.12 Compression of the carpus by having the patient make a fist (*large arrow*) may accentuate the gap in complete scapholunate dissociation (*small arrows*).

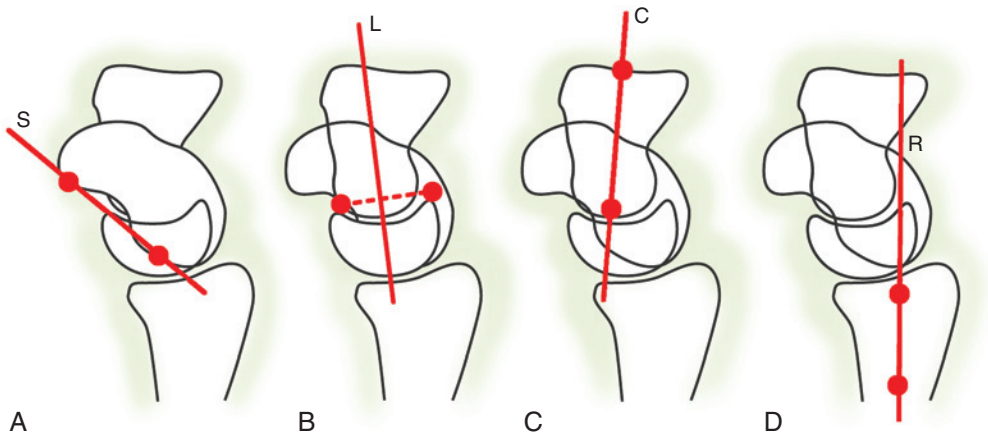

FIGURE 13.13 Carpal angle determination is based on tracing axes to the carpal bones on true lateral radiographs. The most reproducible methods of axis determination are as follows: **A,** The scaphoid (S) is represented by a tangential line that connects the two palmar convexities of the bone. **B,** The lunate (L)-axis is perpendicular to a line that joins the two distal horns of the bone. **C,** The capitate (C)-axis is determined by the center of the two proximal and distal articular surfaces. **D,** The axis of the radius (R) is obtained by tracing perpendicular lines to its distal third and connecting the center of these lines.

- *Static motion views:* For patients suspected of having carpal instability, a routine "motion" series may be needed. It should include PA and anteroposterior views in radial and ulnar inclination, in addition to lateral views in extension and flexion.

Carpal Bone Alignment Measurement. Carpal misalignment has traditionally been determined by measuring specific distances and angles on PA or lateral radiographs.[57,120] When interpreting these data, however, one must be aware that the normal ranges for these parameters are quite diverse. Also, reproducibility is low and small errors in rotational positioning of the hand at the time of radiograph exposure may result in substantial variation in angle determination. The following are the most frequently used measurements to define carpal bone alignment (Figure 13.13).

- *LC angle:* This is helpful to quantify midcarpal misalignment. The axis of the lunate is a line perpendicular to a line connecting the palmar and dorsal tips of it. The capitate axis is identified by connecting a point in the center of the convexity of its head to a point at the center of the third CMC joint. A normal LC angle should be 0 ± 15 degrees with the wrist in neutral.[120]
- *SL angle:* This angle, formed by a line tangential to the proximal and distal convexities of the scaphoid's palmar aspect and that of the lunate, has been quoted extensively in the literature as one of the major determinants of SL dissociation. Normal values range from 30 to 60 degrees (average, 47 degrees).[57,120] Although angles greater than 80 degrees indicate SL ligament disruption, lower readings do not rule out this pathology. Values less than 30 degrees are not unusual for patients with STT joint osteoarthritis.
- *RL angle:* This gives objective evidence of the dorsal or palmar tilt of the lunate. The normal RL angle should be 0 ± 15 degrees.[120]
- *Ulnar variance:* The relative lengths of the radius and ulna, or "ulnar variance," and the possible effects of this parameter on various carpal disorders have long been investigated.[95] Ulnar variance is usually measured on standard PA radiographs, although lateral radiographic projections also offer very accurate readings. The usual way to assess ulnar variance is to measure the distance between two lines perpendicular to the longitudinal axis of the radius. One is tangential to the most distal point of the ulnar dome, and the other is tangential to the distal articular surface of the lunate fossa. When the ulna is shorter than the radius, the ulnar variance is negative, and when longer, it is positive.
- *Carpal height ratio:* This is another parameter in the evaluation of carpal collapse. The term *carpal height* refers to the distance between the base of the third metacarpal and the distal articular surface of the radius measured along the proximal projection of the axis of the third metacarpal. The ratio (carpal height ÷ length of third metacarpal) was found to be 0.54 ± 0.03 in normal wrists.[95] Because wrist radiographs often do not include the entire third metacarpal, some authors have proposed using the length of the capitate instead (i.e., carpal height ÷ capitate length), with a normal range of 1.57 ± 0.05[120] (Figure 13.14).
- *Ulnar translocation ratio:* In some instability conditions, there is an ulnar shift of the carpal bones. The amount of translocation can be quantified using a variety of techniques. The more commonly used one measures the perpendicular distance from the center of the head of the capitate to a line from the radial styloid, which extends distally and parallel to the longitudinal axis of the radius. The carpal translocation ratio (calculated as the ratio of this distance to the length of the third metacarpal) in normal wrists is 0.28 ± 0.03.[8] Other techniques use the axis of the ulna or the axis of the radius as a reference (Figure 13.15). However, they may not be as accurate as the ulnar translocation ratio.

Other Diagnostic Tests

Computed Tomography. Computed tomography (CT) scans are usually taken at 1- to 2-mm intervals along the axial, sagittal, and coronal planes, or any plane in which the structure of interest can be best visualized. CT scan images following the longitudinal axis of the scaphoid, at approximately 45 degrees to the long axis of the radius, are best at showing the amount of collapse in a "humpback" scaphoid deformity. CT is also useful in

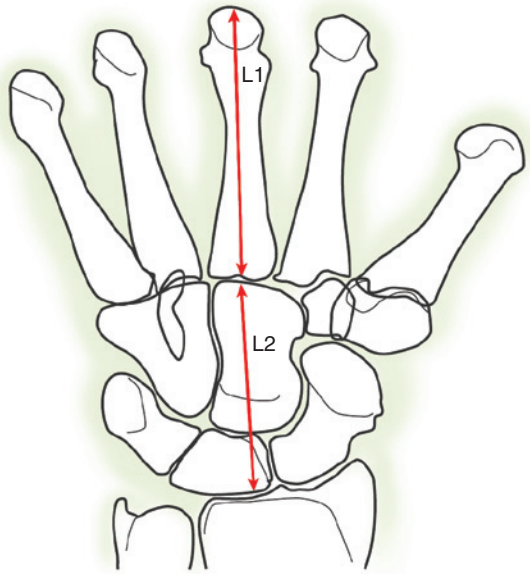

FIGURE 13.14 Carpal height ratio is calculated by dividing the carpal height (*L2*) by the length of the third metacarpal (*L1*). The normal ratio is 0.54 ± 0.03.117.

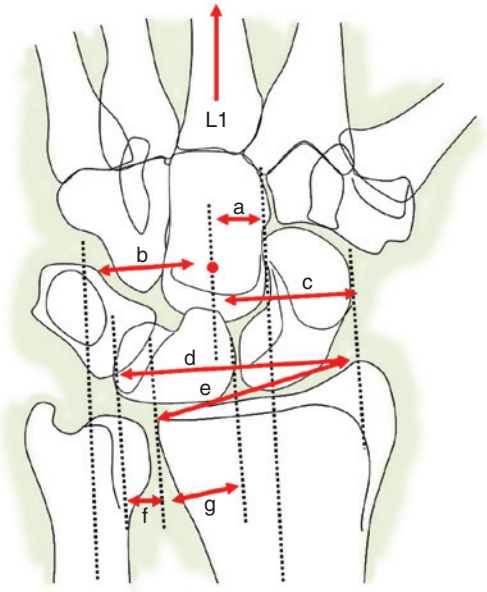

FIGURE 13.15 Ulnar translocation of the carpus can be quantified in different ways according to various authors.[8,64,78,95,120] McMurtry and colleagues[64] suggested using the axis of the ulna as a reference to determine whether there is an ulnar shift of the center of the capitate head. In normally positioned wrists, the distance *b* divided by the length of the third metacarpal (*L1*) should equal 0.3 ± 0.003. According to Chamay and coworkers, a vertical line extending distally from the radial styloid offers a more reliable reference to measure the ulnar shift of the capitate. Normal values for the distance *c* divided by L1 are 0.28 ± 0.03. A similar method was described by Di Benedetto and colleagues by using the longitudinal axis of the radius as a reference. The distance divided by L1 should be 0.015 ± 0.024. The so-called "lunate (L)-uncovering index" has been suggested by Linn and colleagues as another method to determine the relative position of the lunate with respect to the radius. According to Schuind and associates,[95] the ratio between the length of uncovered lunate (*f*) and the maximal transverse width of this bone (*f/g*) should equal 32.6 ± 11. To measure lunate translocation, Bouman and associates found it more reproducible to use the ratio *e/d*, which in normal wrists equals 0.87 ± 0.04. The last two methods are more likely to detect ulnar translocations of the lunate than the first three methods, at the expense of being strongly dependent on the wrist being precisely positioned in neutral. Even minor degrees of radial or ulnar inclination may significantly alter the results.

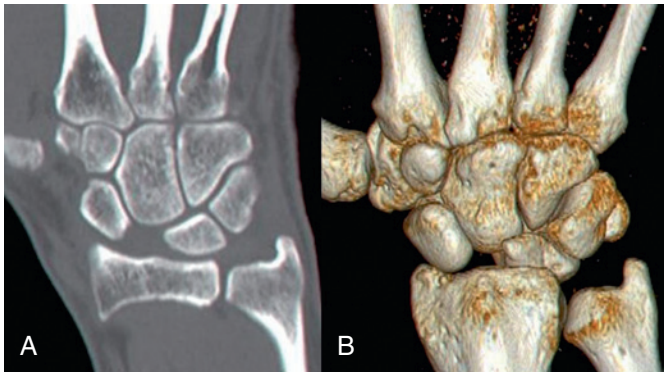

FIGURE 13.16 Computed tomography provides information about the amount and direction of carpal bone displacement **(A).** For a better visualization of the deformity, a 3D rendering of bone surfaces is recommended **(B).**

evaluating the union of fractures or arthrodeses, although in many instances the image can be altered by the presence of retained hardware.

CT has the added advantage of allowing computer manipulation to obtain three-dimensional (3D) images of the carpal bones, which help visualize the structure to be analyzed. When surgery is planned on a malunited scaphoid or a complex carpal dislocation, a 3D reconstruction provides excellent visual information about the amount and direction of the displacement (Figure 13.16). However, it is important to note that all the information provided by such a reconstruction is already present in the original CT image.[59,120]

The recent introduction of ultrafast CT scans has substantially reduced image-acquisition time to a fraction of a second.[30] By observing a sequence of 3D representations of the wrist, one can get the impression of seeing it in motion (see Video 13.2). This is called "dynamic 3D," also known as "four dimensions–computed tomography" (4D-CT scan). Although promising, this technology needs to be used with caution owing to the higher dose of radiation involved.[30]

Distraction Views. In patients with acute fracture–dislocations, the four routine views described earlier may be difficult to interpret because of the overlapping of displaced carpal bones. In such cases, obtaining anteroposterior and lateral radiographs with the hand suspended in finger traps is recommended. Distraction views may reveal intraarticular fracture fragments or joint dissociations in the form of a step-off that cannot be seen on routine films.

Stress Views. In some instances, obtaining radiographs while stressing the joints in various directions may help visualize the abnormality[120] (Figure 13.17). A commonly used technique consists of taking PA projections of the wrist while forcing it into maximal radial or ulnar inclination. Lateral views while applying a dorsal or palmar force to the distal carpal row ("drawer test") are also helpful to identify midcarpal instabilities.

Lateral radiographs, while extending a fully flexed wrist against resistance ("resisted extension test"), may reveal dynamic dorsal subluxation of the proximal scaphoid. In this case, if the SL ligaments are disrupted, the lunate will remain in a neutral or extended posture, substantially increasing the previously measured SL angle.

http://e-surg.com

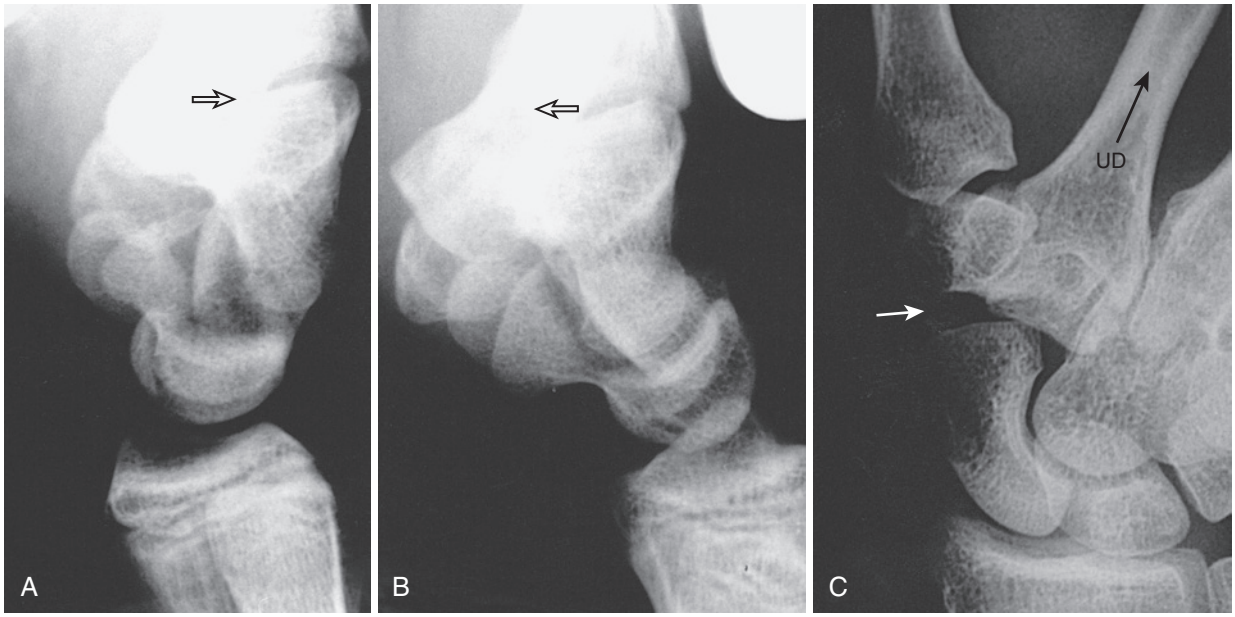

FIGURE 13.17 Stress views are particularly important to assess dynamic instabilities. **A,** In this 15-year-old girl with hyperlax wrists, dorsal stress (*white arrow*) shows the existence of a multilevel (radiocarpal and midcarpal) joint subluxation. **B,** A palmarly directed force (*white arrow*) in the same patient seems to be better tolerated, without any noticeable subluxation. **C,** In a 23-year-old patient, a combination of traction (*black arrow*) and ulnar inclination (UD) showed an increased scaphotrapezial gap (*white arrow*), which was not present on the contralateral side. Because this finding coincided with the location of major tenderness, a ligament injury was suspected and treated nonoperatively.

Cineradiography. Dynamic cineradiographic examination of the wrist provides considerable information for the evaluation of patients with altered kinematics ("clunking" wrists).[30,105] Cineradiography routinely includes observation of active motion from a radial-to-ulnar inclination in PA views; flexion and extension in lateral views, and radial and ulnar inclination in lateral views. If the patient has a painful clunk, the true nature of the subluxation can be identified by observing the moving wrist under an image intensifier. Provocative stress maneuvers may be of help to document the location of maximal dysfunction. In a recent study, cineradiography has been found to have a sensitivity of 90%, a specificity of 97%, and a diagnostic accuracy of 93% in detecting SL dissociation.[105]

Arthrography. Although long considered the gold standard in the assessment of intercarpal derangements, wrist arthrography is now rarely performed as an isolated procedure. The technique was originally introduced based on the assumption that any flow of dye from the radiocarpal to the midcarpal space or vice versa was pathologic. Since then, it has been proven that asymptomatic degenerative tears of the proximal SL or LTq membranes are not unusual, especially in older adults.

Nonetheless, arthrography still has some potential, particularly in association with high-resolution tomography (i.e., arthroscan), to assess cartilage defects and ligament injuries. When injecting the joint, it is important to watch the pattern of dye flow because this facilitates detection and estimation of the size of communicating defects.[12]

Magnetic Resonance Imaging. Compared with arthroscopy, traditional MRI without dedicated wrist coils shows reduced sensitivity and specificity (63% and 86%, respectively) in the diagnosis of SL ligament injury. When intravenous contrast medium is injected, these parameters may slightly improve,[12,88] and this technique is increasingly being used. Technical improvements and advanced wrist imaging algorithms enable accurate measurement of the articular cartilage thickness, the length and integrity of specific ligaments, as well as injuries of the TFCC.[12,88]

Because of its superior soft tissue contrast, direct multiplanar acquisition, and lack of ionizing radiation, MRI is an effective means to evaluate the ligaments of the wrist. High-resolution noncontrast techniques have proven efficacious in the evaluation of the TFCC and intrinsic ligaments, but require a dedicated wrist coil and slice thickness of no more than 1 mm.[88]

Ultrasonography. This is gaining a well-deserved reputation in the assessment of both intrinsic and extrinsic wrist ligaments.[81] High-frequency linear transducers have been shown to have great potential. Ultrasonography is considerably less expensive than MRI, is real time (permitting dynamic evaluation of kinematic instabilities), and does not require intraarticular injection of a contrast medium or the use of ionizing radiation. No doubt, in the near future, ultrasonography will be incorporated into clinical practice as an inexpensive and safe method to get most of the information required to make accurate treatment decisions.

Arthroscopy. Wrist arthroscopy provides the technical capabilities to examine and treat intraarticular abnormalities without an arthrotomy.[17,20,31,100] As well as allowing direct visualization of the articular surfaces, synovial tissues, and intercarpal ligaments, arthroscopy has proved to be a useful adjunct in the management of various acute and chronic wrist lesions. Arthroscopy is an important wrist surgery tool; indications for its use are mentioned throughout this chapter and reviewed in detail in Chapter 17.

http://e-surg.com

Carpal Instability

Definition

Injuries to the wrist that induce carpal misalignment have long been recognized in the medical literature. In 1968, Fisk was the first to use the term "carpal instability" to describe a zigzag pattern of carpal misalignment present in some fractured scaphoids.[21] In 1972, a landmark article by Linscheid and coworkers[57] helped define specific patterns of carpal malalignment secondary to carpal ligament injury. Unfortunately, an oversimplified interpretation of those publications propagated the incorrect view that all carpal misalignments are unstable. As emphasized earlier, the term *instability* cannot be used as a synonym for *misalignment*, and an alteration of carpal alignment is not always pathologically unstable.[1]

From a mechanical point of view, stability can be defined as the ability of a joint to avoid subluxations or dislocations under physiologic loads in all wrist positions.[2] Stability not only implies the capacity to transfer loads without yielding (i.e., kinetic stability) but also the ability to maintain smooth carpal rotations without sudden, unexpected changes in bone position and/or alignment (i.e., kinematic stability). However, it is important to emphasize from a mechanical point of view, that the presence of symptoms and carpal instability are not synonymous. In fact, asymptomatic instabilities are frequent and many do not require treatment.

Analysis of Carpal Instability

Carpal instability is a multifactorial phenomenon that is difficult to diagnose and treat unless there is a thorough understanding of all the factors contributing to each individual case. What follows is an analytical scheme developed by Larsen et al[50] to help the clinician in the assessment and interpretation of patients with carpal instability (Table 13.2). According to this scheme, any carpal instability can be characterized by investigating the following five features.

- *Chronicity:* Traditionally, ligament injuries have been classified depending on the time elapsed from injury to diagnosis into three categories: acute, subacute, and chronic. In acute injuries, diagnosed within a week, the ligament-healing potential is likely to be optimal. In subacute injuries, diagnosed between 1 and 6 weeks, the deformity is still easily reducible but the ligaments may have reduced healing potential because of retraction and/or necrosis. After 6 weeks, or in chronic cases, the possibility of achieving an acceptable reduction and primary ligament healing, although possible, is unlikely. The exception would be some ligament avulsions where the ligament is detached but not resorbed; it remains capable of being repaired with good healing potential beyond the time limit quoted for mid-substance ligament ruptures.
- *Severity:* Any carpal instability can be analyzed according to the severity of the resulting subluxation. If carpal misalignment appears only under high stress in specific wrist positions, the case is less severe than if it were permanently present. Based on this idea, three groups of instabilities exist: occult (partial ligament tears with no misalignment under stress), dynamic (complete ruptures exhibiting carpal misalignment only under certain loading conditions), and static (complete ruptures with permanent alteration of carpal alignment).[116]
- *Etiology:* Although most instability problems are caused by trauma, certain diseases (e.g., inflammatory arthritis) may also be responsible for a similar constellation of radiographic findings. In traumatic cases, especially if diagnosed early, effective repair of the ruptured ligaments is possible. If ligament rupture results from rheumatoid arthritis, strong remaining ligament tissue is unlikely.
- *Location:* It is important to investigate the location of the most important dysfunctions (e.g., subluxation or joint gapping), which may or may not coincide with the location of the primary lesion. This is especially important in the nondissociative instabilities in which treatment depends on which joint (i.e., radiocarpal or midcarpal) is more unstable under stress. It is also important to consider whether the pathology affects only one or several joints.
- *Direction:* When present, the direction of the carpal misalignment is an important factor to consider; several patterns have been recognized (Figure 13.18). The most common are: (1) DISI, when the lunate is regarded as an intercalated segment and appears abnormally extended relative to the radius and capitate; (2) VISI, when the lunate appears abnormally flexed; (3) ulnar translocation, when a portion of, or the entire proximal row, is (or can be) displaced ulnarly beyond normal limits; (4) radial translocation, when the proximal row can be passively displaced radially beyond normal, usually in the context of a radially malunited distal radius fracture; (5) dorsal translocation, when the carpal condyle, often as a result of a dorsally malunited fracture of the radius, is (or can be) displaced in a dorsal direction.[42]

TABLE 13.2 Analysis of Carpal Instability

Category I: Chronicity	Category II: Constancy	Category III: Etiology	Category IV: Location	Category V: Direction
Acute, >1 week (maximum primary healing potential)	Occult	Congenital	Radiocarpal	VISI rotation
Subacute, 1–6 weeks (some healing potential)	Dynamic	Traumatic	Proximal intercarpal	DISI rotation
Chronic, >6 weeks (little healing potential)	Static reducible	Inflammatory	Midcarpal	Ulnar translation
	Static irreducible	Neoplastic Iatrogenic	Distal intercarpal	Dorsal translation
		Miscellaneous	CMC	Other
			Specific bones	

CMC, Carpometacarpal; *DISI,* dorsal intercalated segmental instability; *VISI,* volar intercalated segmental instability.
Modified from Larsen et al.[50]

http://e-surg.com

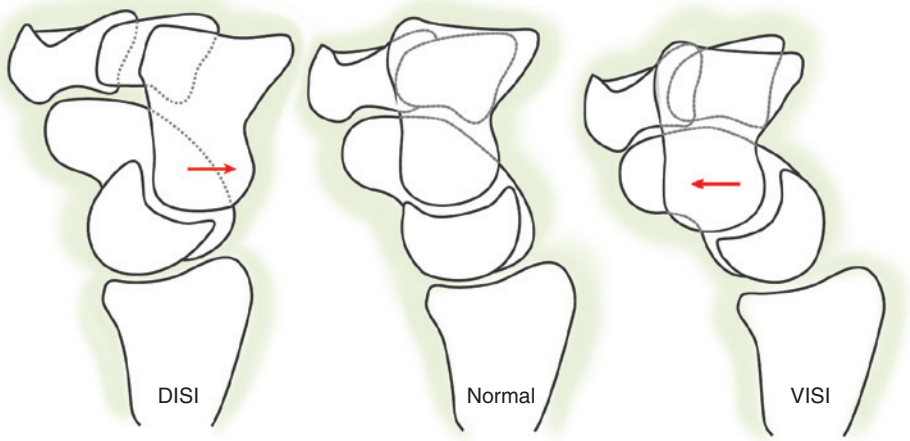

FIGURE 13.18 Views of the two major patterns of sagittal malalignment as described by Linscheid and coworkers.[57] In dorsal intercalated segment instability (DISI) and volar intercalated segment instability (VISI; also known as PISI, for palmar) the lunate (L) and triquetrum (Tq) rotate abnormally in a dorsal or volar direction, respectively (*red arrows*).

Classification of Carpal Instability

Classifying the great variety of conditions that can cause carpal instability depends in large part on the findings from the preceding analysis.[29] Many classification systems exist based on the location of the predominant disorder, the direction of the abnormal alignment, and the severity of the misalignment itself. However, none of these systems is exhaustive enough to allow categorization of all types of carpal instability or simple enough to be easily remembered and used clinically. Despite its limitations, the Mayo Clinic classification is the most commonly used by the majority of wrist specialists and therefore, it is recommended.[50]

Having clarified that neither adaptive misalignments nor all types of fracture–dislocations are necessarily unstable,[1] there are three major instability patterns of the wrist. The first group includes the so-called "dissociative carpal instabilities," also known as carpal instability dissociative (CID), in which the predominant dysfunction (i.e., ligament rupture or insufficiency) occurs between bones of the same carpal row.[29] Most CIDs occur between the scaphoid and lunate, and less often between the lunate and triquetrum.[48,87] Dissociative instabilities between the bones of the distal carpal row are rare, usually the result of a violent dorsopalmar crushing mechanism.[80]

The second group includes the nondissociative carpal instabilities, also known as carpal instability nondissociative (CIND).[28,56,118,119] This group includes radiocarpal, midcarpal, and combined radiocarpal–midcarpal instabilities. If the entire carpus is malaligned (translocated) with respect to the radius in any direction, this is radiocarpal instability.[8,78] If the proximal carpal row as a unit collapses and becomes unstable, either in flexion or extension, this is a combined radiocarpal–midcarpal instability, a condition that is also known as nondissociative instability of the proximal carpal row.[119] Less frequently, there are cases where there is only a dysfunction at the midcarpal level, the radiocarpal joint being normal. Only these cases can be called true midcarpal instabilities.[29]

The third group of instabilities is formed by the so-called "carpal instability complex" (CIC), where there are features of both CID and CIND types. Carpal dislocations, if treated inadequately, may generate complex (i.e., CIC) patterns of instability where the dysfunction affects both the radiocarpal and the proximal intercarpal joint. With time, however, the untreated or suboptimally reduced carpal derangement may evolve into a stiff misaligned joint. When this happens, the wrist may no longer be considered unstable, but stiff, and stiffness is the opposite of instability. This is why, in this edition, carpal dislocations are discussed in a section different from that of true carpal instabilities.

Dissociative Carpal Instability

In this group of instabilities, the misalignment occurs between two adjacent bones of the proximal carpal row, such as between the scaphoid and lunate or between the lunate and triquetrum.[29,48,50] Dissociative instabilities seldom occur between the bones of the distal carpal row, as there is little mobility between them.

Scapholunate Dissociation. Although this condition was recognized in the early 20th century,[21] it was not until 1972 that the clinical features of SL dissociation were described by Linscheid and associates.[57] SL dissociation is the most frequent carpal instability[48,88] and can appear either as an isolated injury or in association with other local injuries (e.g., distal radial fractures, perilunate injuries, or displaced scaphoid fractures).

Pathomechanics of SL Dissociation. A fall on the outstretched hand with the wrist in extension and ulnar inclination and associated with midcarpal supination may cause a wide spectrum of injuries, from minor SL sprains to complete perilunar dislocations. Although apparently different, these clinical conditions are stages of the same progressive perilunar destabilization process described earlier.[64]

Different authors have investigated the kinematic and kinetic consequences of having a complete SL dissociation.[30,72,99] In the cadaver, if only the palmar SL ligament and the proximal membrane are sectioned, minor kinematic alterations may appear. The SL joint, however, does not show an acutely detectable gap, not even under stress (occult instability). Scapholunate

http://e-surg.com

kinematics is altered, however, and heavy mechanical activity may cause symptoms. When painful, this may be due to the presence of joint synovitis and may improve with rest and anti-inflammatory agents.[88]

Complete sectioning of the SL ligaments results in substantial alterations of wrist kinematics and force transmission parameters, but acutely does not result in carpal misalignment. Immediate carpal misalignment only occurs if there is concomitant rupture of the secondary scaphoid stabilizers; that is, the palmar RSC, the palmar SC, and the anterolateral STT ligament.[99] These ligaments may gradually attenuate with time and lead to secondary malrotation and carpal collapse. In these cases, the dissociated lunate and triquetrum rotate into extension under load. The scaphoid and the lunate separate in the coronal plane and adopt opposite deformities. The scaphoid flexes around the RSC ligament, while pronating and translocating toward the radial side.[30] As a result of the scaphoid collapsing into flexion and pronation and the lunate and triquetrum into extension, the distal row is forced to rotate into pronation (Figure 13.19).

It seems evident that axial loads will increase the normal flexed stance of the scaphoid. However, there is controversy regarding the mechanisms causing the lunate to go into extension. According to Kauer,[46] the unconstrained lunate has a natural tendency toward displacing into extension owing to its configuration (with the dorsal horn being narrower than its palmar counterpart), but also to the fact that it is set onto a radial surface that is volarly inclined. Other authors believe that the lunate, when free from the constraints of the scaphoid, tends to follow the triquetrum toward extension under the influence of the helicoid TqH joint surfaces.[21,107]

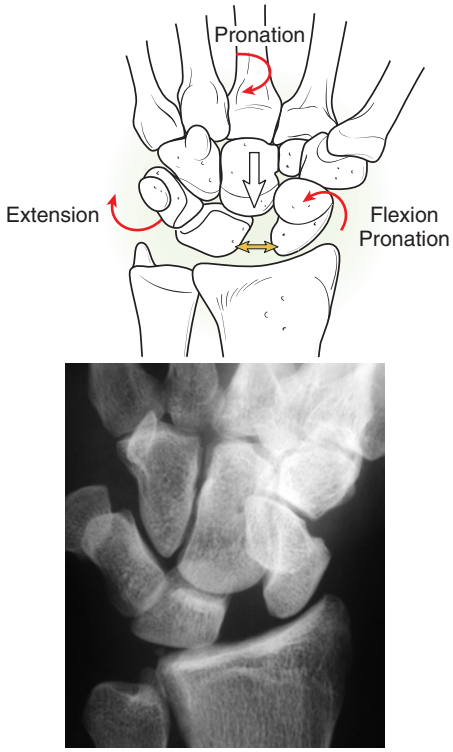

FIGURE 13.19 Schematic representation (*left*) and a case example (*right*) of the most frequent displacements (*red curved arrows*) exhibited by a static SL dissociation under axial load (*white arrow*): the scaphoid tends to rotate into flexion and slight pronation; the unconstrained triquetrum (Tq) and lunate (L) extend (dorsal intercalated segment instability [DISI] pattern of misalignment); the distal carpal row pronates and a gap appears between the scaphoid and lunate (*yellow double arrow*).

When the SL joint is completely dissociated, with the proximal pole of the scaphoid subluxed dorsoradially, the forces crossing the wrist cannot be distributed normally.[72,99] An increased compressive and shear stress appears on the dorsal and lateral aspect of the radioscaphoid fossa, a situation that Watson and associates[115,116] compared to two spoons sitting on top of each other with the handles out of alignment. Such peripheral contact may explain the frequent development of degenerative changes at the dorsolateral corner of the RS fossa. The lunate extends but remains stable with the radius because both opposing articular surfaces have the same radius of curvature. This explains why the RL joint is seldom affected by the degenerative process.

The term scaphoid–lunate advanced collapse (SLAC) has been proposed by Watson and associates[5,116] to define the progression of degenerative changes secondary to SL dissociation. Although only three stages were initially proposed, a recent investigation by Lluch[57a] identified five stages: stage I, radioscaphoid; stage II, scaphocapitate; stage III, lunocapitate; stage IV, triquetrohamate; and stage V, radiolunate.[57a] In stage I, the earliest osteoarthritic changes will differ among SLAC and scaphoid nonunion advanced collapse (SNAC) wrists. In SLAC wrists, osteoarthritis includes the proximal scaphoid and the dorsal rim of the radius. In SNAC wrists, osteoarthritis develops between the distal scaphoid and the radial styloid, while the proximal fragment of the scaphoid remains free of pathology.

Diagnosis of SL Dissociation. A history of a fall on an outstretched hand should warn the clinician about the possibility of an SL injury, sometimes masked by fractures of the scaphoid or the distal radius. SL dissociation is frequently missed at presentation, especially in isolated partial lesions, or when it is masked by other, more obvious injuries.[48] When SL dissociation is static or results from a perilunate dislocation, the diagnosis is more obvious. According to Geissler and colleagues,[31] up to 30% of distal radial fractures are associated with variable degrees of carpal ligament disruption. Aside from wrist trauma, iatrogenic SL injury can occur with excessive capsular excision when removing dorsal ganglions, or after ligament attenuation from rheumatoid, metabolic, or septic arthritis. Although SL dissociation is rare in children, diagnosis is more problematic because it is not easy to clearly identify bone axes in an immature skeleton and performing a careful clinical examination is difficult.

In both children and adults, a high index of suspicion is needed to avoid missing this injury. The symptoms of SL dissociation vary markedly depending on the magnitude of the ligament rupture, the extent of the associated injuries, and the time elapsed since the accident. Poor grip strength, limited mobility, dorsoradial swelling, and point tenderness over the dorsal aspect of the SL interval are the most common findings.[48,93] Pain is common and is usually aggravated by intense use of the hand. The patient may report a clunking sensation during wrist movement due to dislocation or reduction of a dorsally subluxed proximal scaphoid.

Physical examination. On inspection, there may be minimal or no changes in the appearance of the wrist with SL instability. Even in the acute phase, swelling may be moderate. Palpation

http://e-surg.com

at the areas of maximal tenderness is useful in the diagnosis of wrist pathology, especially for patients with chronic SL instability. By flexing the wrist and palpating the dorsum of the capsule distal to the Lister tubercle, one can obtain important information about the SL joint. If sharp pain is elicited by pressing this area, the probability of either a recent injury or a chronic localized synovitis is high. Most of these patients also have tenderness in the anatomical snuffbox and over the palmar scaphoid tuberosity. In acute cases, range of motion is usually limited by pain, whereas it may be normal in chronic cases.

Scaphoid shift test. Passive mobilization of an unstable SL joint is valuable not only in determining the presence of abnormal scaphoid subluxation but also in reproducing the patient's pain. A positive scaphoid shift test, as described by Watson and colleagues,[115] is said to be diagnostic of SL dissociation. The examiner places four fingers behind the radius, and the thumb on the scaphoid tuberosity (distal pole). The other hand is used to move the wrist passively from ulnar-to-radial inclination. In ulnar inclination, the scaphoid is extended and assumes a position more in line with the forearm. In radial inclination, the scaphoid is flexed. Pressure on the tuberosity while the wrist is moved from ulnar-to-radial inclination prevents the scaphoid from flexing. If the SL ligaments are completely ruptured or elongated, the proximal pole subluxes dorsally out of the radius, inducing pain in the dorsoradial aspect of the wrist (Figure 13.20). When pressure is released, a typical clunking may occur, indicating self-reduction of the scaphoid over the dorsal rim of the radius.

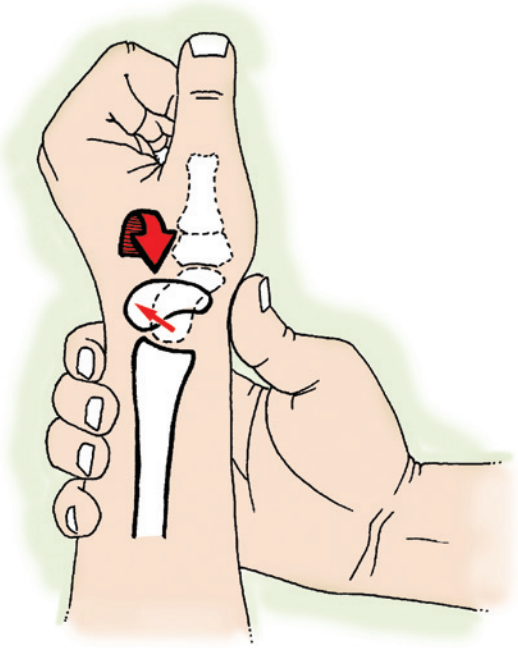

FIGURE 13.20 Watson and colleagues[115] described the scaphoid shift test. Firm pressure is applied to the palmar tuberosity of the scaphoid while the wrist is moved from ulnar-to-radial inclination (*curved arrow*). In normal wrists, the scaphoid cannot flex because of the external pressure by the examiner's thumb. This may produce pain on the dorsal aspect of the scapholunate (SL) interval owing to synovial irritation. A "positive" test is seen in a patient with an SL tear or in a patient with a lax wrist; the scaphoid is no longer constrained proximally and subluxes out of the scaphoid fossa (*straight arrow*). When pressure on the scaphoid is removed, it goes back into position and typically a clunk occurs.

When performing the scaphoid shift test, one should be aware of its low specificity. If the SL ligaments are intact, but there are other local problems inducing local synovitis (e.g., occult ganglion or dorsal RS impingement), this test may also provoke sharp pain, making it difficult to discern whether there is an abnormally subluxable proximal scaphoid. Alternatively, patients with generalized laxity may exhibit painless clunks during this maneuver, which most likely emanate from the midcarpal joint. Comparison of the two sides is important, although sometimes the opposite "asymptomatic" wrist has a painful scaphoid shift test as well.[74,115] Experience with this test is necessary before it can be interpreted with confidence.

Resisted finger extension test. The ability of the proximal pole of the scaphoid to carry a load without producing pain can be explored by asking the patient to extend the index and middle fingers fully against resistance with the wrist partially flexed.[115] In the presence of an injury or insufficiency of the dorsal SL ligament, a sharp pain is elicited in the SL area, probably due to the presence of synovitis at the RS joint. This maneuver is very sensitive but not specific for this pathology.

SL Ballottement Test. The lunate is firmly stabilized with the thumb and index finger of one hand, while the scaphoid, held with the other hand (i.e., thumb on the palmar tuberosity and index on the dorsal proximal pole) is displaced dorsally and palmarly. The test is positive when there is pain, crepitus, and excessive mobility of the scaphoid.

Radiological examination. On standard radiographs, SL dissociation is suspected in the presence of one or more of the features described in the following subsections. Dynamic instabilities require special projections or loading conditions for these features to be observed.

Increased SL joint space. The "Terry Thomas sign," named by Frankel after the English film comedian's dental diastema,[21,48] is considered positive when the space between the scaphoid and lunate appears abnormally wide compared with the contralateral side (Figure 13.21). The SL gap should be measured in the middle of the flat ulnar facet of the scaphoid.[120] A unilateral gap greater than 5 mm is diagnostic of SL dissociation. If there is no history of a specific traumatic episode, and yet there is an obvious SL diastasis, one must consider either a constitutionally increased SL gap, usually bilateral, with or without hyperlax ligaments. Other less common causes include rheumatoid arthritis, gout, and calcium pyrophosphate deposition disease.[48] To rule out the presence of an occult asymptomatic SL ligament injury, a comparative radiographic examination is critical (Figure 13.22).

Scaphoid ring sign. When the scaphoid has collapsed into flexion, it has a foreshortened appearance in the anteroposterior view.[93] In such circumstances, the scaphoid tuberosity is shown in the PA projection in the form of a radiodense circle or ring over the distal two-thirds of the scaphoid (see Figure 13.21). This is the "ring sign" and is present in all cases where the scaphoid is abnormally flexed, regardless of the cause. The presence of this sign does not always indicate SL dissociation, as both the scaphoid and lunate can be flexed with the SL ligaments remaining intact.

Increased SL angle. In the lateral view, if the scaphoid lies more perpendicular to the long axis of the radius and the lunate appears normally aligned or abnormally extended, SL dissociation should be suspected. In such circumstances, the

http://e-surg.com

SL angle is greater than the usual 45 to 60 degrees (Figure 13.23). This angle will progressively increase as the lunate extends to accommodate the loss of height of the radial column, causing a dorsal subluxation of the capitate.

Palmar V sign. In the lateral view of a normal wrist, a wide "C"-shaped line can be drawn by joining the palmar margins of the scaphoid and radius. When the scaphoid is abnormally flexed, the palmar outline of it intersects the palmar margin of the radial styloid at an acute angle, forming a sharper, "V"-shaped pattern.[107]



FIGURE 13.21 Posteroanterior view of the wrist of a 35-year-old man who sustained a hyperextension injury 4 months before seeking medical attention. Note the foreshortened scaphoid (S) with the ring sign (*arrowheads*), representing the frontal projection of the palmar tuberosity, and the increased scapholunate (SL) joint space (*white double arrow*), indicating the presence of SL dissociation with carpal malalignment.

Advanced imaging. When the patient's history, clinical examination, and radiographs are inconclusive, magnetic resonance imaging, computed arthrotomography,[12] or diagnostic arthroscopy[20,31,100,113] may be helpful to assess the degree of injury to the intercarpal ligaments, the secondary supporting ligaments, and the articular cartilage.

Treatment of SL Dissociation. Numerous factors may explain why the treatment of SL dissociation is difficult and not always predictable.[19,48,68,88,101,107] When the initial injury is a partial SL ligament derangement, radiographs are usually normal, and the injury is frequently missed at presentation. Even if diagnosed early, the ligament remnants are short and difficult to repair. Because the SL ligament is exposed to

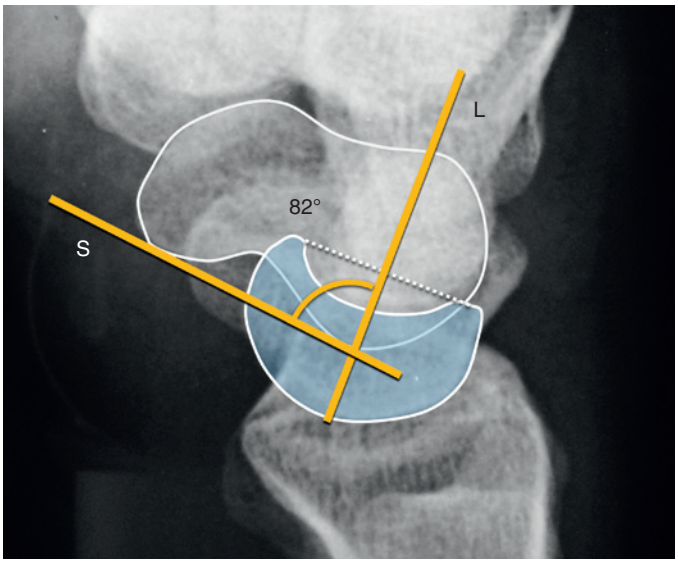

FIGURE 13.23 Lateral view of the same patient shown in Figure 13.22. The scapholunate (SL) angle is abnormally wide (82 degrees) as a result of an abnormally flexed scaphoid and a slightly extended lunate. *L*, Lunate axis; *S*, scaphoid axis.

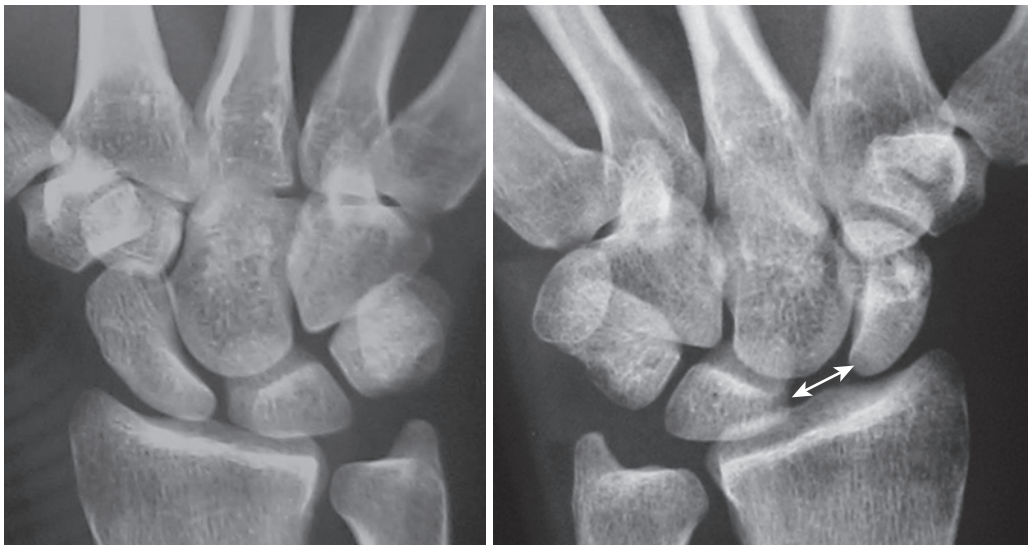

FIGURE 13.22 Bilateral radiographic scapholunate (SL) widening is not uncommon. True traumatic SL disruption is less common. To rule out this possibility, it is imperative to obtain comparative radiographs of both sides. In this case, a closed fist radiograph was obtained from both sides but only one had substantial widening of the SL joint (*white double arrow*), a finding known as the Terry Thomas sign.[21]

http://e-surg.com

considerable tension and torsion, it is not unusual for successful repairs to deteriorate with time. There is no guarantee that a repaired SL ligament will retain good functional strength and adequate stabilizing capability, even with early diagnosis and proper treatment.

More commonly, SL dissociation is discovered in the subacute or chronic phase, when carpal malalignment is evident on plain radiographs. This occurs because abnormal SL kinematics gradually attenuate the secondary ligamentous stabilizers under load. At this stage, the underlying pathology no longer involves a single structure but consists of a complex multilevel ligament injury. Some ligament remnants are retracted, whereas others are attenuated and/or insufficient to stabilize the joint.[3] Furthermore, if substantial time has elapsed since the initial injury, degenerative arthritis may have set in, making an acceptable outcome from ligament repair less likely.[19,48,88]

For these reasons, treating the injury in the acute phase, when the healing potential is greatest, is generally more rewarding than trying to treat chronic or degenerative injuries. It is important to carefully consider the patient's age, occupation, recreational demands, and level of symptoms prior to embarking on a treatment plan.[88] To facilitate patient selection and appropriate treatment, Garcia-Elias[27,29] has recently modified a previously published algorithm for the treatment of SL dissociation, based on the six questions listed in the following Critical Points box.

CRITICAL POINTS ***Six Questions to Consider When Evaluating an SL Injury***

- Is the dorsal SL ligament intact and functional?
- If the ligament has ruptured, does it have good integrity for repair?
- Is the scaphoid alignment normal?
- Is radiolunate alignment still retained?
- Are abnormal carpal alignments easily reducible?
- Is the articular cartilage normal?

The answers to these questions enable categorization of the SL dissociation into seven stages (Table 13.3). An increased number of negative answers indicates progression from a minor problem (Stage I) to a global dysfunction (Stage VII). In theory, all SL dissociations sharing similar features could be treated similarly. In practice, it is wise to tailor treatment to the specific peculiarities of each individual case. The following subsections describe all the stages in turn, including the most commonly used treatment for each.

Stage I: partial SL ligament injury. In stage I, the SL ligament is only stretched or partially disrupted. These patients still have an uninjured dorsal and/or volar SL ligament. Arthrography may suggest this diagnosis, but most commonly this is made arthroscopically or with high-resolution MRI. The degree of SL ligament incompetence varies from minimal distention (Geissler grade I; see Table 17.1) to a partial rupture of the proximal membrane without gross instability (Geissler grade II or III; see Table 17.1).[31] The European Wrist Arthroscopy Society (EWAS) suggested modifying Geissler's classification to include subtypes of SL ligament disruption, and the authors recommend this[66] (Table 13.4). At this stage, wrists do not exhibit misalignment or widening of the SL joint space on standard or stress radiographs. Based on this finding, some authors have suggested using the term predynamic or occult

TABLE 13.3 Staging of SL Instability

	Stage I	Stage II	Stage III	Stage IV	Stage V	Stage VI	Stage VII
Partial injury	Yes	No	No	No	No	No	No
Repairable	Yes	Yes	No	No	No	No	No
Normal RS angle	Yes	Yes	Yes	No	No	No	No
Lunate aligned	Yes	Yes	Yes	Yes	No	No	No
Reducible	Yes	Yes	Yes	Yes	Yes	No	No
Normal cartilage	Yes	Yes	Yes	Yes	Yes	Yes	No

Modified from Garcia-Elias.[29]

TABLE 13.4 Arthroscopic EWAS Staging of Scapholunate Interosseous Ligament Ruptures

Stage	Description	Arthroscopic Testing of Scapholunate Joint From the Radial Midcarpal Portal
I	Elongation	No passage of the probe
II	Rupture of the proximal SL membrane	Passage of the tip of the probe in the SL space without widening
IIIA	II + disruption of the volar SL ligament	Volar SL joint widening when tested with the probe (anterior laxity)
IIIB	II + disruption of the dorsal SL ligament	Dorsal SL joint widening when tested with the probe (posterior laxity)
IIIC	II + rupture of the volar and dorsal SL ligaments	Global widening of SL space, reducible with removal of probe
IV	IIIC + SL gap (no misalignment)	SL diastasis without radiographic abnormalities; arthroscope may enter the radiocarpal space
V	IV + carpal misalignment	Wide SL gap with radiographic anomalies

SL, Scapholunate.
Modified from Messina et al.[66]

http://e-surg.com

instability to refer to such cases.[116] Dysfunction derives from increased motion between the two bones, generating abnormal cartilage loading and painful local synovitis.

If a subtotal ligament rupture (Geissler II or III; EWAS II or IIIA) is diagnosed in the acute phase, when the healing potential of the disrupted ligaments is greatest, a percutaneous or arthroscopically guided K-wire fixation is recommended.[31] For acute complete scapholunate interosseus ligament (SLIL) tears without carpal malalignment (Geissler grade III; EWAS Grades IIIB and IIIC), open repair should be considered in young patients. In chronic incomplete SLIL tears, three different approaches have been proposed: proprioception reeducation and strengthening of the intracarpal supination muscles, arthroscopic debridement of the torn ligament edges, and electrothermal ligament shrinkage. There are few data on the long-term clinical or radiographic outcomes of these techniques. Arthroscopic techniques for acute and chronic stage I instability are discussed in Chapter 17.

Percutaneous Kirschner wire fixation of the SL joint. Acute partial ruptures of the SL ligaments without carpal misalignment may benefit from pinning the joint with Kirschner (K) wires and a period of rigid joint immobilization to enable ligament healing. Obviously, the ligament remnants will only heal if there is no carpal malalignment (i.e., secondary stabilizers are intact), and there is close contact between the two edges of the injured ligament. To ensure this, K-wire insertion should be done under arthroscopy or fluoroscopy control.[31,100] However, open repair can also be done in these cases because it will provide more precise information on the degree and extent of the lesion.

Sometimes, a slight rotational displacement may keep the two ends of a disrupted ligament apart. To solve this, it is helpful to introduce two percutaneous K-wires into the dorsal aspects of the scaphoid and lunate to be used as "joysticks." If there is no soft tissue interposition, minimal displacement may be reduced by pulling the scaphoid wire proximally and ulnarly while the lunate wire is directed distally and radially.

To avoid injuring the dorsal sensory branches of the radial nerve, a small incision is made distal to the radial styloid. Blunt dissection of the subcutaneous tissue with a hemostat allows safe introduction of a soft tissue protector directly onto the scaphoid. Two or more 1.2-mm K-wires are inserted across the SL joint to keep the two bones together during the ligament-healing process. To ensure maximal stability, a third wire transfixing the SC joint can be used.

The wrist is immobilized in a below-elbow cast for 8 to 10 weeks, at which time the K-wires are removed. Physical therapy with range-of-motion exercises of the fingers is initiated immediately. The wrist is protected with a removable splint for an additional 4 weeks. Range-of-motion and grip-strength exercises of the wrist are begun at 3 months. Strenuous activities are discouraged for the first 6 months.

Reeducation of wrist proprioception. As stated previously, the muscles are the ultimate carpal stabilizers.[35,91] Without their protection, most wrist-stabilizing ligaments would not resist the amount of tension and torque generated in most accidents, and ligament ruptures would be even more common. To remain stable, the wrist does not need powerful muscles, but ones that are able to react quickly to protect the underlying ligaments. Even if some ligaments have failed, however, promptly reacting muscles may succeed in maintaining relatively normal kinematics of mildly unstable joints, avoiding the development of cartilage wear and reactive synovitis. Thus, the immediate goal of proprioception reeducation is not to increase grip strength but to optimize the "latency time" (i.e., the time taken by the stabilizing muscles to react to any potentially damaging force).[84]

Under axial load, the scaphoid tends to flex and pronate. That tendency can be counteracted by supinating the distal row. Indeed, if the STT capsule and ligaments are intact, a distal row supination will draw the trapezium dorsally, thus preventing the scaphoid from collapsing into flexion and pronation. Laboratory studies have shown ECRL and APL to be distal row supination muscles, while ECU is a pronation muscle.[54,92] If properly trained, the former may become effective dynamic scaphoid stabilizers. Isometric contraction of ECU, by contrast, increases scaphoid misalignment and widens the SL gap (see Video 13.1). A quick response of the intracarpal supinators (i.e., ECRL and APL), on one side, and avoidance of the ECU, on the other, may explain why many dynamic SL dissociations remain asymptomatic for a long time.

The FCR has also been said to have a positive effect on SL stability owing to its ability to close the SL gap by supinating the scaphoid. Indeed, if the dorsal SL ligament is not completely torn, the FCR also may be counted as a dynamic scaphoid stabilizer.[91,92]

As more research is being published, it appears that avoidance of the ECU's deleterious effects on SL stability, combined with adequate proprioception reeducation of FCR, APL, and ECRL will play an important role in the control of dynamic SL instabilities. What is not known is which of the many protocols being currently tested will prove to be the most useful, and in what circumstances.[35] In all cases, adequate evaluation of the extent of ligament damage is a prerequisite for this type of approach.

In recent years, special attention has been drawn to the fact that, during DT motion, the majority of carpal motion occurs at the midcarpal joint, the proximal row remaining relatively stationary. Based on these findings, it has been suggested that, after a SL ligament repair, early dart-throwing mobilization of the midcarpal joint could have a beneficial effect on stiffness, while avoiding tension on the repair. This is not entirely correct, and caution is warranted. Recent studies using dynamic 3D CT of patients with SL dissociations have shown that, once disconnected from the lunate, the scaphoid no longer behaves as a proximal row bone but follows the capitate as if it was a distal row element.[30] Certainly, unless the dorsal SL ligament is fully competent, or the repair is protected with additional fixation, DT exercises are not recommended, at least not in the early stages of healing.

Arthroscopic debridement of torn ligament edges and electrothermal ligament shrinkage. Debridement of the irregular edges of a torn SL proximal membrane has proved to be beneficial in the treatment of dynamic SL dissociation. Eliminating unstable flaps may help prevent joint synovitis and pain.[31,52,100] Another alternative is to shrink them with radiofrequency under arthroscopic control (see Chapter 17). Although one should not expect long-lasting results from the latter technique, acceptable results at an average follow-up of 53 months have been published by Lee et al.[52]

http://e-surg.com

Stage II: complete SL ligament injury, repairable. This stage is characterized by complete disruption of the SL ligamentous complex, with good healing potential because of a repairable dorsal component.[28] The carpal bones are minimally displaced without cartilage degeneration. The distal–palmar connections of the scaphoid to the distal row (i.e., STT and SC ligaments) are still intact. The scaphoid is not abnormally flexed, the RS angle is normal, and there is little or no SL gap.

According to Andersson et al,[3] there are four major types of dorsal SL ligament ruptures: avulsion from the scaphoid (42% of all dorsal SL ligaments), avulsion from the lunate (18%), midsubstance rupture (20%), and partial rupture plus elongation (22%).[10] If the remnants and vascular supply of the disrupted SL ligament are preserved, one option is an arthroscopy-guided closed reduction and percutaneous fixation (Figure 13.24); another is a direct repair of the disrupted ligaments. In general, the second is recommended. If the ligament is avulsed, with or without a small piece of bone, successful reattachment of it can be expected beyond the time limits of what could be expected from a ligament rupture.

Proprioceptive reeducation of the intracarpal supinator muscles is no longer adequate in stage II as an isolated treatment. Indeed, if the dorsal SL ligament is disrupted, supination of the distal carpal row does not reduce the SL joint; however, it creates an unconstrained dorsally directed vector that promotes scaphoid dorsal subluxation of its proximal pole. Certainly, proprioceptive exercises of the intracarpal supinator muscles are only recommended in EWAS II and IIIA partial injuries, where the dorsal SL ligament is intact.

Open reduction, internal fixation, and dorsal SL ligament repair. This approach offers the same advantages as when treating acute ligament injuries in other joints, provided the subluxation is reduced. A direct, solid repair of torn ligaments should be carefully performed and all associated osteochondral injuries explored and repaired. Most failures may be explained by the excessive forces produced by the capitate trying to separate the SL joint, the poor healing potential of chronic or devascularized ends of the disrupted ligaments, and the prolonged immobilization required after surgery. Despite these factors, we agree with authors who believe there is a place for acute primary repair in properly selected patients.[16,75]

Several biomechanical studies in cadaveric specimens concluded that only the dorsal SL ligament needs to be repaired to achieve relatively normal carpal kinematics.[99] Other authors claim better results by repairing both the palmar and dorsal SL ligaments, through a double palmar and dorsal approach, despite the obvious difficulty of getting access to the palmar component without damaging the palmar extrinsic ligaments. In this regard, the short-term results obtained after arthroscopic dorsal SL ligament repair and capsuloplasty by Wahegaonkar and Mathoulin[113] and the arthroscopic repair of the palmar SL ligament by Piñal[20] are truly encouraging. See arthroscopic techniques in Chapter 17.

Open dorsal ligament repair is performed as follows. The skin incision may be longitudinal, "Z"-shaped, or transverse, with the last two incisions resulting in a more aesthetic scar (Figure 13.25). The extensor retinaculum is divided longitudinally at the level of the Lister tubercle, being careful not to injure the extensor pollicis longus (EPL) tendon, running on its ulnar side. The author recommends visualizing the dorsal capsule by creating two retinacular flaps: one radial-based, uncovering the second extensor compartment; and the other ulnar-based, exposing the third, fourth, and fifth extensor compartments.

Next, the floor of the fourth compartment is explored, and if the posterior interosseous nerve is found to be normal, a proximally based capsular flap sparing the nerve is recommended. The incision starts at the dorsal rim of the lunate fossa. It takes a distal-oblique course following the fibers of the dorsal radiotriquetral ligament until its distal insertion on the dorsal ridge of the triquetrum. Another vertical incision is made from the tip of the radial styloid to the lateral corner of the STT joint. The distal ends of the two incisions are then connected by a third transverse incision that splits the fibers of the dorsal intercarpal ligament. This flap is carefully elevated by sectioning its



FIGURE 13.24 Unless controlled arthroscopically, closed reduction and percutaneous Kirschner (K)-wire fixation cannot ensure that the two ends of the disrupted ligaments are in contact so that they can heal (*black arrow*). If there is no ligament healing, the intraarticular fibrosis that forms between the two bones is seldom enough to maintain stability. The case shown would not be an ideal indication for closed reduction and percutaneous K-wire fixation.

http://e-surg.com

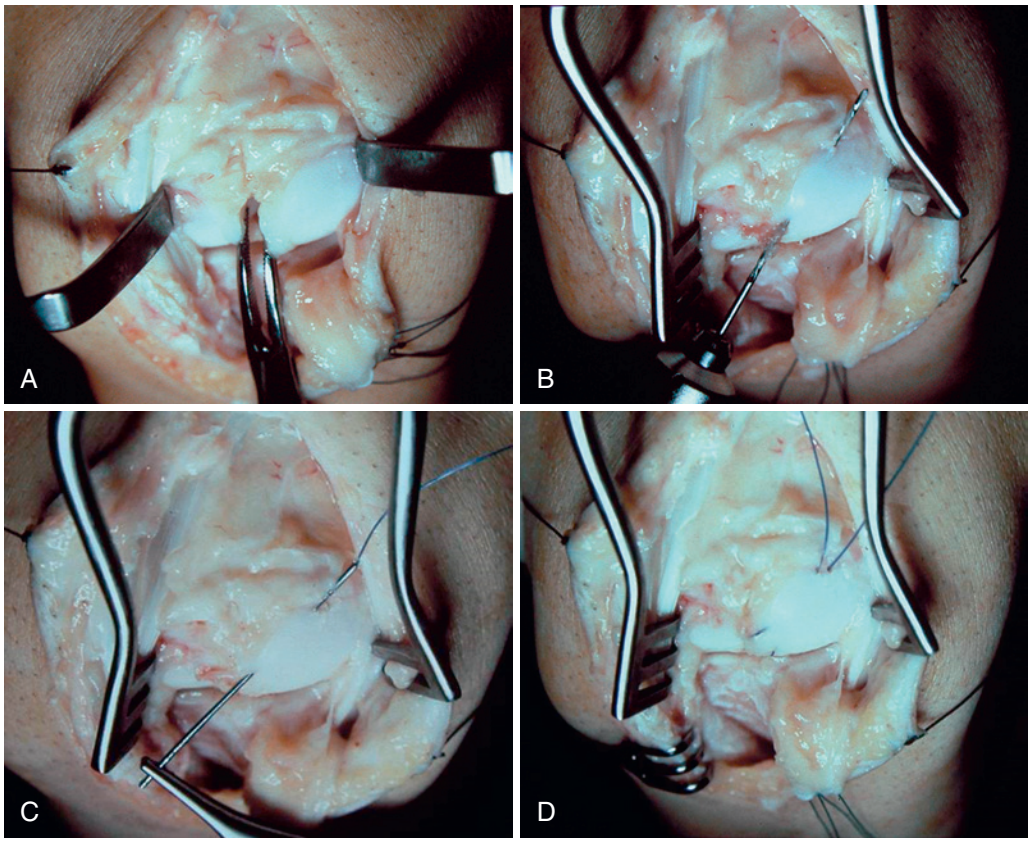

FIGURE 13.25 Open reduction and scapholunate (SL) ligament repair in a 27-year-old man who sustained SL dissociation 6 weeks before surgery. **A,** Through a dorsal approach and the wrist in flexion, the SL interval may be opened, allowing inspection of the anterior aspect of the joint. **B,** Fine drills are used to create tunnels connecting the dorsal edge of the scaphoid to the origin of the disrupted ligament. **C,** Transosseous sutures are passed through the perforations. **D,** Sutures are finally tied to bring the two ends of the ruptured ligament into contact. Previously, two Kirschner wires have been inserted to secure adequate immobilization of the reduced carpal bones.

connections to the dorsal edge of the three bones of the proximal row. Care is taken to leave enough dorsal radial triquetrum ligament attached to the triquetrum to facilitate capsular repair later.

If the posterior interosseous nerve is felt to be nonfunctional, damaged, or irregularly thick, a laterally based capsulotomy, following the "fiber-splitting" concept described by Berger[7] is recommended. This starts at the tip of the radial styloid and proceeds medially along the dorsal edge of the radius until it meets the center of the origin of the radiotriquetral ligament. From there it follows an oblique course toward the dorsal rim of the triquetrum and returns back to the lateral edge of the wrist, splitting the fibers of the dorsal intercarpal ligament. In these cases, the posterior interosseous nerve should be excised proximal to the joint; otherwise, a neuroma may develop leading to painful wrist flexion from traction on the nerve.

Frequently, when operating early on a torn dorsal SL ligament, there is sufficient ligamentous tissue to permit a reasonable repair. If the ligament is not ruptured but avulsed, the repair is more effective and consists of reattaching the avulsed ligament, with or without a bone fragment, to the freshened dorsal edge of the scaphoid or lunate. Transosseous sutures[16] or suture anchors[89] are used. The repair is protected by transfixing the SL and SC joints with K-wires. Several authors recommend reinforcing the repair with a dorsal capsulodesis, as will be described in the following.[48] The wires are maintained for 8 to 10 weeks with protection in a removable splint for an additional 4 weeks.

Several series of patients with SL dissociation treated by means of direct repair have been published.[16,25,75,88] By combining the data from 100 reported cases, with an average follow-up of 37 months, pain was absent or significantly reduced in 70% of patients, with more than 80% grip strength and 75% wrist motion compared with the normal contralateral side. Radiographs showed degenerative changes in one-third, but the condition had not progressed to an advanced collapse pattern except for those who had placed high demands on the wrist on a daily basis.[48,116]

Stage III: complete SL ligament injury, nonrepairable, normally aligned scaphoid and lunate. Stage III is characterized by complete rupture of the SL ligament, with poor healing capacity at its dorsal component.[28] When the dorsal SL ligament is disrupted through its mid-substance, the two ends tend to degenerate quite rapidly, thus diminishing the chance of a successful repair.[3] Carpal misalignment is not yet present because the scaphoid is constrained by the anterolateral STT ligament, volar capsule, and dorsal intercarpal ligaments.[11] No permanent misalignment exists at this stage, and an increased SL gap may appear only under specific loading conditions. However, the wrist may yield or give way when attempting tasks in certain wrist positions. From a radiologic point of view, stages II and III are "dynamic" instabilities.[116]

http://e-surg.com

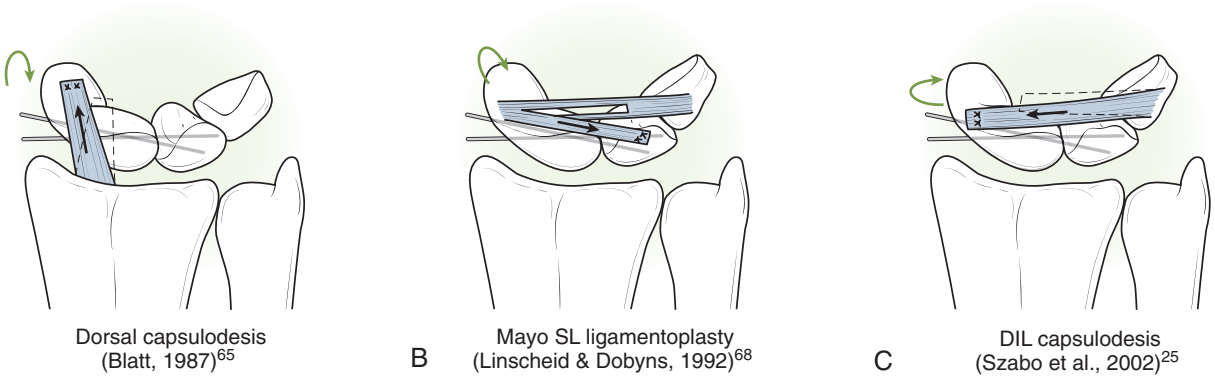

FIGURE 13.26 Schematic representation of three capsulodeses described to stabilize the wrist with complete, but reducible, scapholunate (SL) dissociation: **(A)** proximally based dorsal capsulodesis described by Blatt[65] to prevent scaphoid flexion, **(B)** laterally based dorsal intercarpal ligamentoplasty (DIL) described by Linscheid and Dobyns,[68] and **(C)** medially based DIL described by Szabo et al.[106] Although similar in final results, they all aim to correct different aspects of carpal misalignment (*green curved arrows*): Blatt's procedure[65] aims at preventing scaphoid flexion; Szabo's technique prevents scaphoid pronation, whereas the Linscheid and Dobyns method attempts to correct both flexion and pronation using the lunate as a reference.

If the dorsal ligament cannot be repaired, one alternative is to reconstruct it, either by using local tissues from adjacent ligaments[11,68] or by using a bone–ligament–bone autograft.[37,101] Another commonly used method is to perform a capsulodesis.[25,106] Closed reduction and cast immobilization is not an acceptable treatment for complete SL disruption in active patients.

Dorsal capsulodesis. When detached from the lunate, the scaphoid has a natural tendency to collapse into flexion and pronation. To prevent this, several forms of dorsal capsulodesis have been recommended.[68,106] The most commonly used technique was popularized by Blatt[65,71a] and consists of tightening the RS capsule to prevent excessive palmar rotation of the scaphoid (Figure 13.26, *A*). A 1-cm-wide capsular flap is created, leaving its proximal edge attached to the dorsal rim of the radius. After the scaphoid is reduced by manipulation and stabilized with one or two K-wires passed obliquely from the distal pole of the scaphoid into the capitate, the flap is tightly inserted into a notch created on the dorsum of the neck of it, just distal to its axis of rotation. Sutures within the capsular flap are passed through the scaphoid using Keith needles and tied on a button over the thenar skin. Bone-anchored sutures are favored by some surgeons. A thumb spica cast should be worn for 2 months, followed by protected active range-of-motion exercises. The K-wires may be left in place for an additional month.

Various modifications of Blatt's technique have been published. The so-called "Mayo Clinic SL ligamentoplasty" was first suggested by Linscheid and Dobyns.[58] It uses one-half of the dorsal intercarpal ligament, released from the triquetrum and freed from the dorsal rim of the lunate (see Figure 13.26, *B*). This ligament flap is redirected and pulled on to the dorsum of the lunate, where it is securely anchored. Another option is "dorsal intercarpal ligamentoplasty," first described by Szabo and colleagues[25,106] (see Figure 13.26, *C*). It consists of advancing the scaphoid insertion of the dorsal intercarpal ligament from its dorsal ridge to a more radial position at the scaphoid neck to control the pronation component of SL instability.

According to the study of Megerle et al,[65] at an average of 8 years' follow-up, most of the 59 patients who underwent Blatt's dorsal capsulodesis for this condition had acceptable wrist function. The mean range of flexion–extension was 88 degrees, and the mean disabilities of the arm, shoulder, and hand (DASH) and Mayo wrist scores were 28 and 61, respectively. This technique could not prevent progressive carpal collapse. After significant postoperative improvement in the carpal alignment, the mean SL angle returned to the preoperative value of 70 degrees at final follow-up, with more than two-thirds of patients having radiological evidence of degenerative arthritis. Radiology aside, the overall results are satisfactory when used in dynamic instabilities.[25,65] Similar findings have been published for the other two capsulodesis options, none being superior to the other.[25,68,106] These methods can be done successfully in the skeletally immature carpus without adverse effects on growth.

Soft tissue reconstruction of the dorsal SL ligament. More recent publications have reported acceptable results in the treatment of dynamic SL instabilities by replacing the nonrepairable dorsal SL ligament with a strip of either the dorsal intercarpal ligament or the dorsal radiocarpal ligament.[25,61,68,106] Both methods involve using a portion of dense connective tissue, preserving its triquetral attachment. The free end of the ligament flap is tightly reinserted onto the dorsal and ulnar corner of the proximal scaphoid. Bone-anchored sutures should be used to facilitate incorporation of the ligament into the previously denuded dorsal and distal cortices of the scaphoid and lunate. Both techniques are very appealing in their simplicity and low local morbidity. Early results are said to be satisfactory, but they should be used with caution until further long-term results are available.[25,106]

Bone–ligament–bone grafts. Based on the proven success of replacing knee ligaments with bone–ligament–bone grafts, several investigators addressed the in vitro feasibility of using allografts to replace a dorsal SL ligament. Weiss[101] reported transferring a bone-retinaculum–bone autograft harvested from the region of the Lister tubercle. Harvey and associates[37] advocated the use of the third metacarpal–capitate dorsal ligament. The surgical approach is the same as used for a direct repair. After the scaphoid and lunate are reduced and transfixed by wires, a deep trough is carved on either side of the SL joint,

http://e-surg.com

and a bone–ligament–bone graft is impacted and fixed with miniature screws, small wires, or interference screws.

Theoretically, by providing tissue with similar elasticity and strength as the original ruptured ligament, there is a better chance of achieving an adequate SL linkage. However, the following three problems may arise. First, the proximal scaphoid is poorly vascularized and so healing of the bone graft may be delayed. Second, after a long period of postoperative immobilization, the mechanical properties of the ligament in the graft may deteriorate and fail from heavy use of the hand. Finally, reconstructing the dorsal SL ligament alone does not solve the palmar–distal ligament insufficiency present in complete SL ruptures. The early clinical results are encouraging in dynamic instabilities, when the secondary stabilizers are still preserved.[37,101] The reported failures of this technique, when used in static instabilities, makes this technique less desirable.

Dynadesis. First suggested by Seradge et al,[96] the so-called "dynadesis" (i.e., *dynamic ECRL tendon transfer to the distal scaphoid plus volar FCR tenodesis*) procedure consists of passing two-thirds of the ECRL tendon through a 3.5-mm tunnel drilled across the distal pole of the reduced scaphoid and anchoring the end to the FCR tendon (Figure 13.27). The portion of FCR distal to the scaphoid becomes a check-rein that tightens with contraction of the ECRL. In the 2014 meeting of the American Society for Surgery of the Hand (ASSH), Seradge et al[96] reported their experience with this procedure: out of 18 patients followed for an average of 20 years, complete relief of pain was obtained in 14 and 11 had excellent functional results according to Mayo wrist score. Whether such outstanding results can be replicated by other authors is not known.

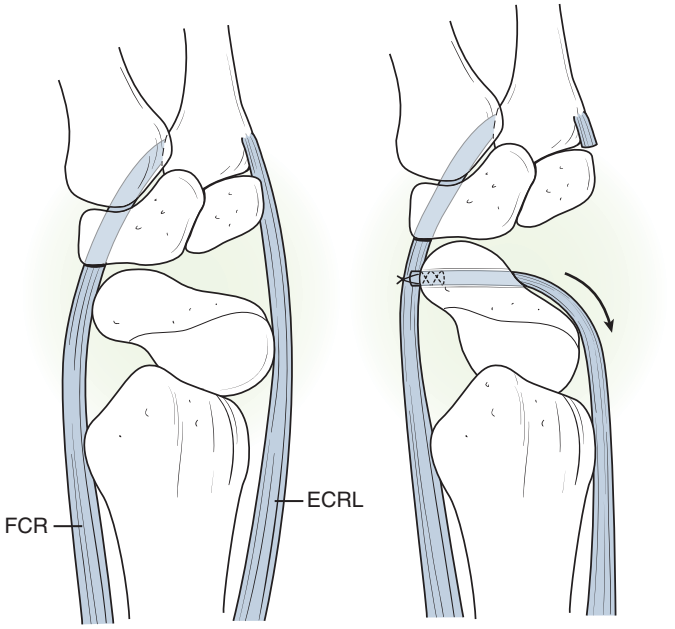

FIGURE 13.27 Schematic representation of the so-called "dynadesis" procedure described by Seradge et al.[96] A large anteroposterior tunnel across the distal scaphoid (S) is used to suture a strip of extensor carpi radialis longus (ECRL) to the flexor carpi radialis (FCR) tendon. In theory, the ECRL becomes a dynamic extensor of the scaphoid, whereas the FCR is converted into a static tether that inhibits scaphoid flexion. An average 20-year follow-up study presented recently by the authors demonstrates this method to be very efficient in dynamic scapholunate dissociations.

Stage IV: complete SL ligament injury, nonrepairable, reducible flexion deformity of the scaphoid. Stage IV is characterized by complete loss of the proximal and distal scaphoid stabilizers. The scaphoid subluxates dorsally over the dorsolateral rim of the radius and increases its flexed position, showing an RS angle greater than 45 degrees. The lunate extends only slightly but does not translocate toward the ulnar side. For this to occur, there must be normal functioning of the long- and short-palmar RL ligaments.[29] The scaphoid misalignment is easily reduced, and there is no cartilage deterioration as yet. Because the misalignment is at rest, stage IV is categorized as a static instability. Clunking secondary to self-reduction of the subluxation is a common finding.

Two different treatments have been proposed for this stage: reconstruction of the disrupted ligaments with tendon grafts and reduction-association of the SL joint (i.e., RASL procedure).

SL ligamentoplasty using a tendon graft. The use of tendon grafts to reconstruct disrupted ligaments in the wrist has evolved considerably since their first description in 1972.[21,57,107] The initial technique was simple: anteroposterior bone tunnels were drilled across the lunate and proximal pole of the scaphoid along the margins of the joint, and a strip of tendon, usually the ECRL, was threaded through these tunnels to form a loop that closed the SL gap. These techniques involved large drill holes across poorly vascularized areas, so bone fractures and joint degeneration were not unusual. As such, the technique was abandoned in the early 1980s in favor of partial fusions.

In the 1990s, there was renewed interest in tendon reconstruction resulting in the publication of more complex and theoretically safer alternatives.[21] The technique described by Brunelli and Brunelli received great attention.[10] The goal was to provide sagittal stability to the scaphoid by reconstructing both the palmar–distal connections to the distal row and the dorsal–proximal connections to the radius. To achieve that, a strip of FCR tendon was obtained from the ipsilateral wrist, leaving its distal end attached to the second metacarpal. Through a separate dorsal incision, all fibrous tissue filling the STT joint was removed and the scaphoid reduced and neutralized with Kirschner wires (Figure 13.28). A 3.2-mm tunnel, perpendicular to the main axis of the scaphoid, was drilled from the center of the scaphoid tuberosity to the neck and the strip of FCR passed through it. Once at the dorsum, the split tendon was pulled taut proximally and anchored to the dorsal rim of the distal radius at the level of the origin of the dorsal radiocarpal ligament. This technique offered excellent stabilization of the scaphoid. Unfortunately, it resulted in a marked reduction in wrist flexion, and with time, an increased rate of RS osteoarthritis.

In 2005, Van den Abbeele and associates[110] proposed modifying the Brunelli technique in two ways to avoid this complication. First, the transscaphoid drill hole was placed slightly oblique rather than perpendicular to the axis of the scaphoid with its end coinciding with the insertion of the dorsal SL ligament; and second, the tendon did not cross the radiocarpal joint, but used the dorsal radiocarpal ligament as an anchor point for the tendon to be tensioned before being sutured onto itself. With further refinements, this technique was published with a new name: *three-ligament tenodesis*[27] (Figure 13.29).

According to its proponents, this procedure is indicated when the SL joint is easily reducible, the cartilage is undamaged,

http://e-surg.com

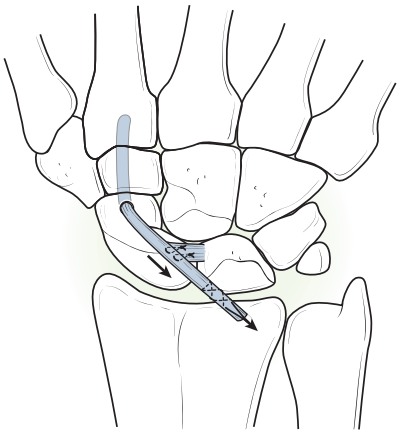

Scaphotrapezoid tenodesis
(Brunelli & Brunelli, 1995)[10]

FIGURE 13.28 Despite the initial discouraging results obtained after the first attempts to reconstruct the scapholunate (SL) linkage using tendons (*black arrows*),[21] the technique described by Brunelli and Brunelli[10] was the first to be successful in reducible SL dissociations for ligaments that cannot be optimally repaired (stage IV, SL dissociation). Unlike previous tendon reconstructions of the SL linkage, this technique was successful because it was based on the stabilization of both the proximal and the distal ends of the subluxating scaphoid, without creating bone holes in the vicinity of the vascularly compromised SL joint.

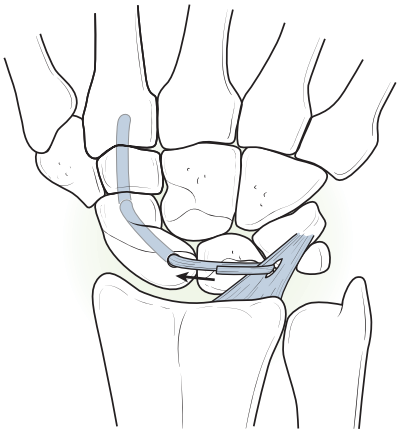

Three-ligament tenodesis
(Garcia-Elias et al., 2006)[27]

FIGURE 13.29 Schematic representation of "three-ligament tenodesis." This technique was designed to stabilize nonrepairable, easily reducible scapholunate (SL) dissociations.[27,110] A strip of flexor carpi radialis (FCR) tendon is passed obliquely from the palmar scaphoid (S) tuberosity to the dorsal ridge of the scaphoid where the dorsal SL ligament inserts. The tendon is buried in a trough created on the dorsum of the lunate by means of an anchor suture. To adjust the tension of the graft, a slit in the distal portion of the dorsal radial triquetrum ligament is made through which the tendon is looped around and sutured onto itself (*black arrow*).

and the lunate is stable relative to the radius (see the following Critical Points box). The series published by Garcia-Elias et al,[27] with an average follow-up of 46 months, indicated that 28 out of 38 patients had complete pain relief. Compared to the contralateral side, the operated wrist had a 24% reduction in global motion and a 35% reduction in grip strength. Recurrence of carpal collapse with an SL gap wider than 5 mm was frequently seen at follow-up (Figure 13.30). However, a recent publication by Sousa et al[103] has shown that in most cases this is asymptomatic. Indeed, the window of opportunity for this technique to be successful is quite narrow.[61] When the technique is used in poorly reducible subluxations, in cases with an ulnarly translocated lunate, or in cases with preexistant degenerative arthritis the results are consistently disappointing.[19]

CRITICAL POINTS *SL Stabilization With Three-Ligament Tenodesis*

Indications

- Dynamic SL dissociation, reducible, with normal cartilage (stage III)
- Static SL dissociation, reducible, with normal cartilage (stage IV)

Preoperative Evaluation

- Routine radiograph examination
- Clenched-fist view
- Fluoroscopic evaluation of abnormal carpal motion
- MRI to check integrity of FCR tendon if injury or discontinuity suspected
- Arthroscopy or MRI to rule out cartilage degeneration, LTq injury, or both

Technical Points

- Perform a dorsal (zigzag, lazy scaphoid, or longitudinal) approach centered at the Lister tubercle.
- Incise the extensor retinaculum along the third compartment.
- Open septa between II and III, III and IV, and IV and V; coagulate intraseptal arteries.
- If the posterior interosseous nerve is intact, perform a proximal-based, nerve-sparing capsulotomy[91]; if it is not intact, perform a dorsal capsulotomy with the fiber-splitting technique by Berger.[7]
- Reducibility is checked by traction or by direct manipulation with K-wires as joysticks.
- Enter the scaphoid with a 2.7-mm cannulated drill hole at the point of insertion of the dorsal SL ligament.
- Direct the drill hole along the axis of the scaphoid aiming at the palmar tuberosity.
- Make a 1-cm palmar incision over the scaphoid tuberosity and release the FCR tendon sheath.
- Obtain a distally based 8-cm strip of tendon (0~3 mm).
- Retrieve the tendon strip from the dorsum using a wire or a tendon passer.
- Carve a transverse trough over the dorsum of the lunate with a rongeur (see Figure 13.30, *C*).
- Insert a 1.8-mm anchor suture into the lunate.
- Localize the dorsal radial triquetrum ligament, and loop the tendon strip around its distal insertion.
- While tensioning the tendon using the radial triquetrum ligament as a pulley, transfix the SL and SC joints (usually two 1.5-mm K-wires are used; eventually three are used) (see Figure 13.30, *E*).
- Without releasing the tendon tension, use the anchor suture to bury the tendon against the lunate cancellous bone in the previously created trough.
- Suture the tendon loop onto itself.
- Close the capsule over the tendon strip carefully.
- Reconstruct the extensor retinaculum.

Postoperative Treatment

- Short arm thumb spica cast for 6 weeks; change at 10 days for stitch removal and radiographs
- Removal of wires at 6 weeks and protection in a removable splint for an additional 4 weeks
- Rehabilitation after cast removal to regain motion and grip strength
- Contact sports not allowed until 6 months postoperatively
- Probable outcome: a painless wrist with 20 degrees loss of flexion and 75% grip strength

http://e-surg.com

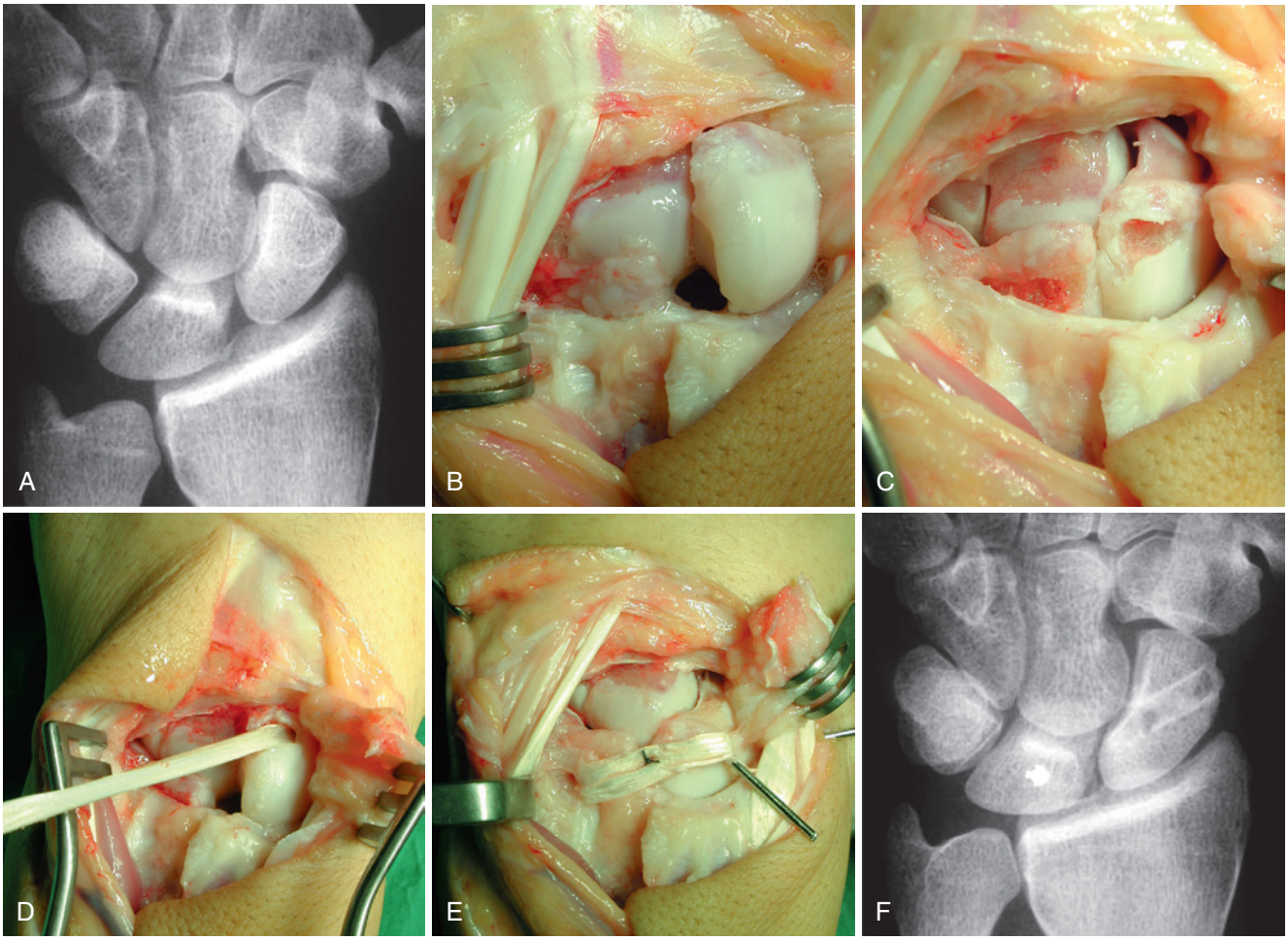

FIGURE 13.30 A 32-year-old lawyer sustained an injury to his left wrist while playing soccer 8 months ago. **A,** Posteroanterior (PA) radiograph showing relatively shortened scaphoid (S) with mildly increased scapholunate (SL) interval. **B,** The scaphoid viewed from the dorsum could easily sublux because the entire SL ligamentous complex was ruptured and could not be repaired (static reducible SL dissociation). **C,** A transverse trough was created on the dorsal aspect of the lunate (L). To ensure that the tendon would be permanently in contact with the lunate cancellous bone, an anchor suture was placed in the trough. **D,** A strip of flexor carpi radialis was harvested at the palmar side but left attached distally. Its proximal end was passed through a tunnel emerging at the distal–medial corner of the scaphoid. **E,** The tendon used the dorsal radial triquetrum ligament as an anchor point for adequate tension before being sutured onto itself. Two Kirschner wires were used to immobilize the reconstructed ligament for 6 weeks, with 4 more weeks in a removable splint. **F,** PA view obtained 8 months postoperatively. The patient had resumed his former sport activity at 6 months. At 18 months, the wrist remained stable and pain-free with 90% grip strength and 85% motion compared with the contralateral side.

To ensure better functional and radiographic results, several modifications to the technique have been proposed. In 2014, Ross et al[95] recommend drilling two tunnels: one across the scaphoid, as for the three-ligament tenodesis, and another across the lunate and triquetrum, from the lunate insertion site of the SL ligament to the medial corner of the triquetrum (Figure 13.31). The tendon strip is passed through these tunnels and secured using an interference screw in the triquetrum. The dorsal intercarpal ligament is then reinforced with the remnants of the tendon graft. A prospective series of 11 patients demonstrated good early radiological and clinical outcomes.

Corella et al[17] recommend a minimally invasive, arthroscopic, controlled technique to reconstruct both the dorsal and palmar SL ligaments (Figure 13.32). Two small incisions are placed at each end of the scaphoid, and a strip of FCR is passed through a tunnel similar to the one used for the three-ligament tenodesis. A second dorsopalmar tunnel is drilled across the lunate, again through a small incision, and the tendon graft is passed

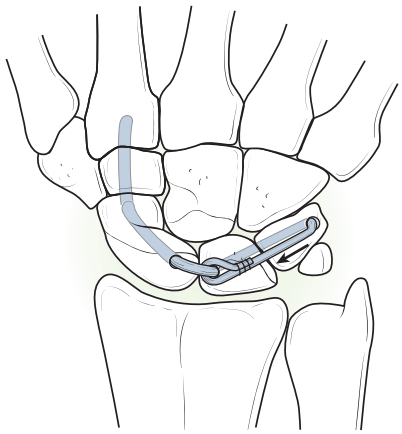

Scapholunotriquetral tenodesis
(Ross et al., 2014)[90]

FIGURE 13.31 Schematic representation of the scapholunotriquetral tenodesis suggested by Ross et al[90] to avoid recurrence of gap formation after tendon reconstruction of the dorsal scapholunate ligament (*black arrow*).

http://e-surg.com

from dorsal-to-palmar. To facilitate this, a tendon passer is introduced between the FCR and the median nerve and used to retrieve the graft and tension it while it is being secured by two interference screws—one in the lunate and the other in the scaphoid. Once in the volar surface of the lunate, the remnant of the tendon graft is reattached to the volar surface of the proximal scaphoid to augment the volar component of the SL ligament. There have been no long-term results published for these recently described methods of SL stabilization, so their true efficacy is unknown.

It is important to emphasize that the use of a strip of tendon to stabilize unstable segments of the wrist is feasible but not ideal. The elastic properties of a tendon will never match those of a ligament. Also, the resultant neoligament probably will never contain mechanoreceptors, so will not participate in one of the most important functions of these ligaments—that is, to provide the necessary information required by the sensorimotor system to activate proper muscle stabilization of the joint.

Before deciding on one of the preceding techniques, it is imperative not to forget that stability cannot be built on an unstable foundation. If the lunate is unstable, reestablishing the SL ligament connections will not solve the problem. Indeed, for the techniques just discussed to be successful, the lunate must be stable. If it is not, the options described later for stage V are recommended (Figure 13.33).

Reduction-association of the SL joint. Based on the observation that failed SL fusions tend to do better clinically than successful fusions,[104] the "reduction-association of the scapholunate" (RASL) procedure was proposed as a novel approach to static SL instabilities[60,101a] (Figure 13.34). Before repairing the ligament remnants, the articular cartilage between the scaphoid and lunate is removed and the joint is reduced and transfixed with one headless screw for 12 months or more. The goal is to create a fibrous union of the SL joint and allow loading these bones without fear of recurrent joint widening. Early results have been encouraging, with most patients exhibiting excellent ranges of motion and a strong grip.[60]

Unfortunately, as reported by Larson and Stern,[51] the screw often becomes loose, and the outcomes tend to deteriorate with

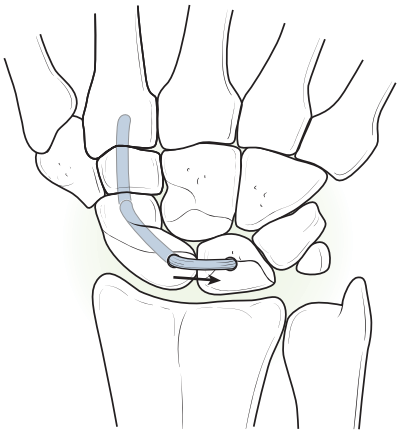

Dorsal and volar SL ligament
(Corella et al., 2013)[17]

FIGURE 13.32 Arthroscopically guided tendon reconstruction of both dorsal and volar scapholunate (SL) ligaments using a strip of flexor carpi radialis tendon (*arrow*), as described by Corella et al.[17]

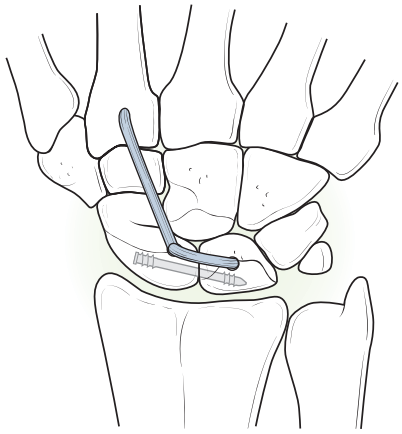

ECRL ligamentoplasty and RASL
(Fernandez DL, 2014)

FIGURE 13.34 Reduction-association of the scapholunate joint, the so-called "RASL procedure,"[60] has been suggested to avoid the problem of recurrent diastasis after an SL ligament repair. DL Fernandez has recently reported good results by combining the RASL procedure with an extensor carpi radialis tenodesis, as illustrated in this figure. *ERCL,* Extensor radialis carpi longus.

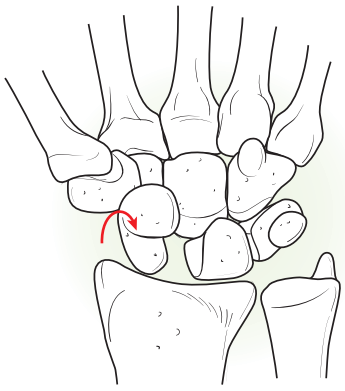

SL instability without ulnar translation
(Taleisnik type 1)

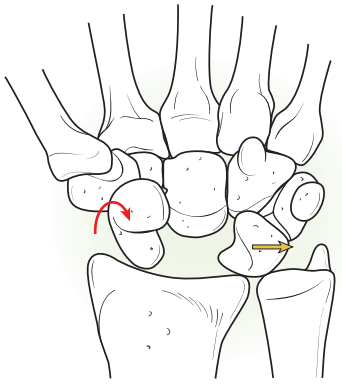

SL instability with ulnar translation
(Taleisnik type 2)

FIGURE 13.33 Tendon reconstructions of scapholunate (SL) dissociations can only be effective if the lunate is stable. An associated radiocarpal instability is the cause of most failures.[29] When evaluating an SL dissociation, therefore, it is imperative to rule out this problem, as emphasized by Taleisnik in 1988.[108] The *red arrows* indicate subluxation of the scaphoid and the *yellow arrows* indicate ulnar translocation of the lunate.

http://e-surg.com

time, resulting in frequent recurrences of the misalignment once the screw is removed. To avoid these complications several alternatives have been proposed. One is to introduce a specially designed jointed screw into the SL interval that allows some rotation of the scaphoid about the lunate (SLIC screw, Acumed®, Hillsboro, OR). Another is to insert a tendon autograft along the axis of SL rotation that will act as a flexible biological link between the two bones (SL-axis method, Arthrex®, Naples, FL).[53] Yet another technique is to associate the RASL procedure with a more solid tendon reconstruction of the SL ligaments (Fernandez, DL, personal communication, 2014) (see Figure 13.34). Whether these alternatives will avoid the complications observed with current techniques is unknown, but that are certainly worth investigating.

Stage V: reducible carpal collapse due to chronic SL ligament injury, plus instability of radiolunate joint and normal joint cartilage. As stated earlier, rupture of both the primary and secondary ligament stabilizers of the scaphoid is frequently associated with distention or rupture of the RL ligaments. In such instances, both the scaphoid and lunate are unstable (see Figure 13.33). In general, it is accepted that an unstable segment cannot be stabilized using another unstable segment. If the lunate is unstable, most reconstructions of the SL ligaments are bound to fail. In those cases, stability is only possible if the reconstruction is based on the radius. This is the rationale for "spiral tenodesis"[13] (Figure 13.35).

Spiral Tenodesis. As described in the kinetic section of this chapter, under axial load the distal row tends to pronate, the scaphoid to flex and pronate, and the lunate to translocate ulnarly down the ulnar inclination of the radius. To constrain all these displacements, a number of ligaments need to be ruptured and/or attenuated, including: the long and short RL, the dorsal radiotriquetral (RTq), the palmar and dorsal LTq, the dorsal SL, the dorsal intercarpal, and the palmar SC ligaments. Except for the dorsal RTq ligament, all these structures spiral around the central column so as to prevent excessive pronation of the distal row under load. The so-called "antipronation spiral tenodesis," described by Chee et al,[13] was aimed at reconstructing this spiral arrangement of ligaments using one single strip of FCR (see Figure 13.35).

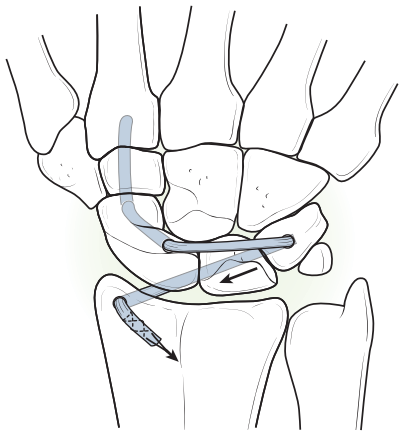

Antipronation spiral tenodesis
(Chee et al., 2012)[13]

FIGURE 13.35 Schematic representation of the so-called "antipronation spiral tenodesis" (*arrows*) described by Chee et al.[13] It is recommended for reducible scapholunate dissociation with instability of the radiolunate articulation.

The technique begins the same as for the three-ligament tenodesis. However, once on the dorsum of the triquetrum, the FCR is threaded through a dorsopalmar tunnel across it to exit at the floor of the carpal tunnel. From there, it is brought under the flexor digitorum profundus (FDP) to emerge in a separate incision over the radial styloid where it is inserted. This procedure is only indicated if the instability is easily reducible and there is no cartilage damage. The early results in the index patient obtained with this new alternative are encouraging (Figure 13.36).

Stage VI: irreducible carpal collapse due to chronic SL ligament injury, with normal joint cartilage. This stage is defined by the presence of carpal misalignment that cannot be reduced easily owing to deformation of the subluxed joint surfaces, fibrosis formation within the empty spaces left by the subluxing bones, and capsular retraction. If the joint cartilages are normal despite this, then the criteria for stage VI SL dissociation are fulfilled.

When cases are symptomatic, the most frequently recommended treatment is a partial carpal fusion. Compared to a total wrist fusion, the advantages of only arthrodesing the destroyed joint have long been recognized.[104] What follows is a brief description of the most commonly used partial fusions for the treatment of SL dissociation. Further details about these techniques and their results are provided in Chapter 12.

Scaphoid–trapezium–trapezoid arthrodesis. The goal of this procedure is to reduce the proximal pole of the scaphoid into the scaphoid fossa, restoring RS congruency and decreasing the chance of developing degenerative changes.[104,116] When planning, it is important that the external dimensions and alignment of the resultant fused block are the same as the external dimensions of the bones in the normal wrist. Underreduction (scaphoid flexed) fails to close the SL gap correctly, and overreduction (scaphoid extended) may result in more restricted motion and more severe RS impingement postoperatively.

As experience with STT joint fusion has increased, complications and long-term outcomes have been reported.[104] The average rate of nonunion among all the reported series is 14%. Postoperatively, range of motion and strength are frequently decreased, and the results in terms of pain relief are not uniformly predictable. Painful RS impingement is a frequent problem, owing to the fact that in radial inclination the distally fused scaphoid can no longer rotate into flexion, resulting in increased pressure on the scaphoid fossa. To solve this problem, Watson and coworkers[5,116] recommended incorporating a dorsolateral radial styloidectomy as part of the STT joint fusion. This is likely to prevent peripheral, but not central, RS impingement. Any preexisting cartilage degeneration between the scaphoid and radius is a formal contraindication to STT joint fusion.

SL arthrodesis. Previously believed to be the ideal method of treating SL dissociation, fusion of the SL joint has proved to be one of the least reliable treatments for this condition.[73,104] The small surface area of the articular surfaces coming into contact and the magnitude of forces transmitted by the capitate, tending to separate the two bones, make this fusion difficult to achieve. After this procedure, the mutual shifting that occurs between the two bones is no longer possible, resulting in increased demands on the arthrodesis, predisposing the fusion to refracture. Bony union occurs in only 50% of cases.[73,104] However, the nonunions may have created enough fibrosis between the scaphoid and lunate to decrease the patient's symptoms.[104]

http://e-surg.com

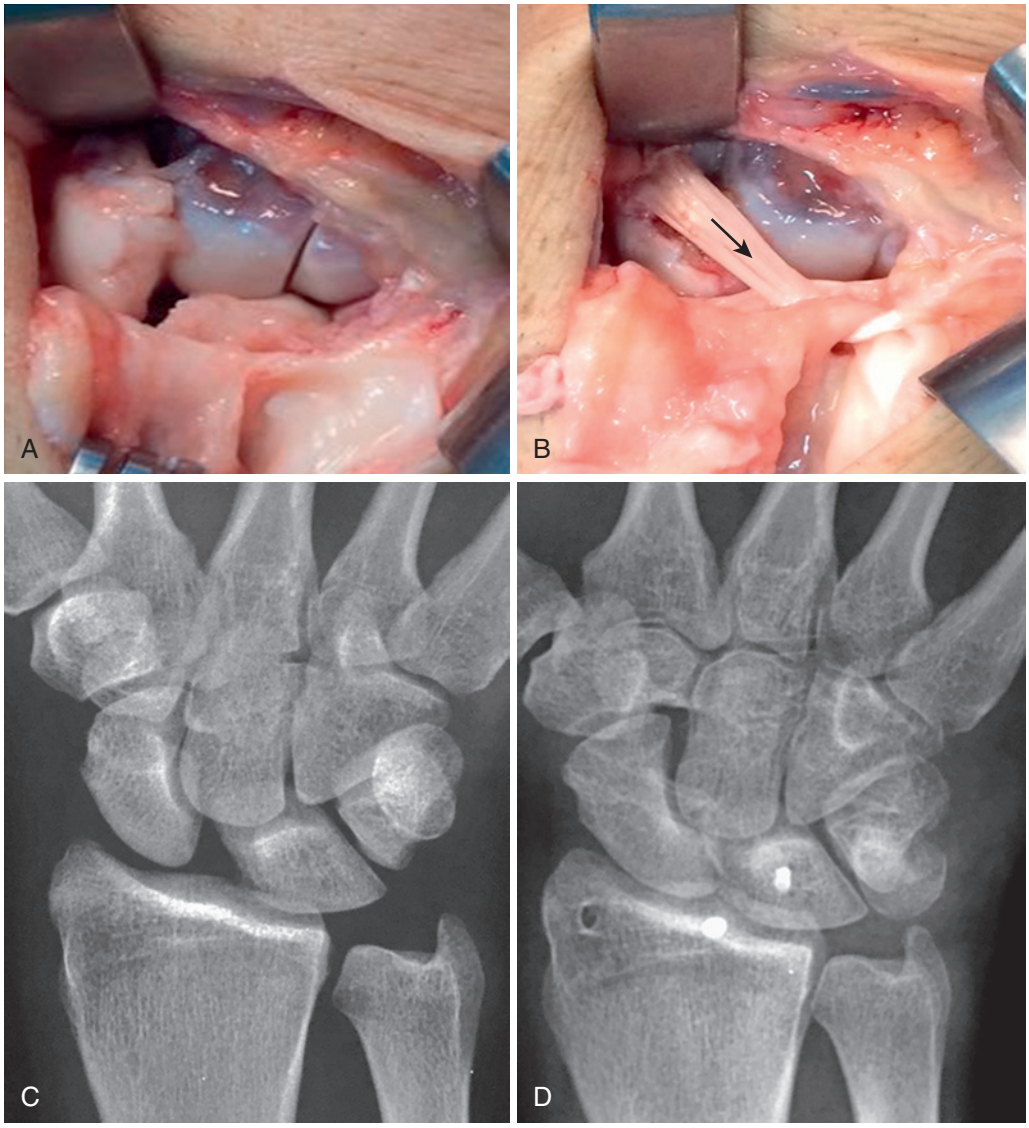

FIGURE 13.36 A 33-year-old male, after a motor vehicle accident, was diagnosed with scapholunate (SL) dissociation. A more detailed radiographic assessment under stress, however, showed the lunate to be excessively displaceable toward the ulna. Under the diagnosis of a combined radiocarpal–intracarpal derangement, he was scheduled for an antipronation spiral tenodesis, as described by Chee et al.[13] **A, B,** Photographs taken during surgery. Dorsal view of the SL dissociated joint, before and after the tendon graft (*arrow*) replaced the dorsal SL ligament. **C,** Posteroanterior radiograph before surgery. **D,** A radiograph obtained 8 months after surgery shows full restoration of the normal alignment. The patient was able to resume his occupation without limitations 4 months after surgery.

Scaphoid–capitate arthrodesis. Theoretically, SC fusion should have consequences similar to STT joint fusion. In the laboratory, the kinematic and kinetic carpal behavior after both types of fusion is similar—that is, both cause abnormal transfer of load and significant loss of midcarpal joint motion, especially in radial and ulnar inclinations. Watson and coworkers[104] found less of a reduction of motion after STT joint fusion than after SC fusion, probably because of increased rotation at the trapezoid–capitate joint. The long-term results of this procedure are quite acceptable, with more than two-thirds of patients satisfied, with minimal disability, although approximately 30% of patients develop degenerative changes at the RS joint.[62]

Scaphoid–lunate–capitate arthrodesis. Adding the lunate to the scaphoid–capitate fusion offers a method of controlling both the scaphoid and the lunate misalignment at the expense of a 50% reduction in wrist motion.[62,104] This is indicated in patients with severe fixed misalignment without degenerative changes of the proximal pole of the scaphoid and the opposing articular surface of the radius. The recommendation is that this procedure be combined with a generous dorsoradial styloidectomy.

Radioscaphoid–lunate fusion and distal scaphoidectomy. As stated in the preceding, most activities of daily living involve motion along the dart-thrower's plane-of-wrist rotation, going from extension and radial inclination to flexion and ulnar inclination. This motion occurs mainly at the midcarpal joint.[9,70] Consequently, if the cartilage of that joint is normal, and the fixed misalignment or degenerative arthritis of the scaphoid and lunate requires an arthrodesis, it is reasonable to fuse only

http://e-surg.com

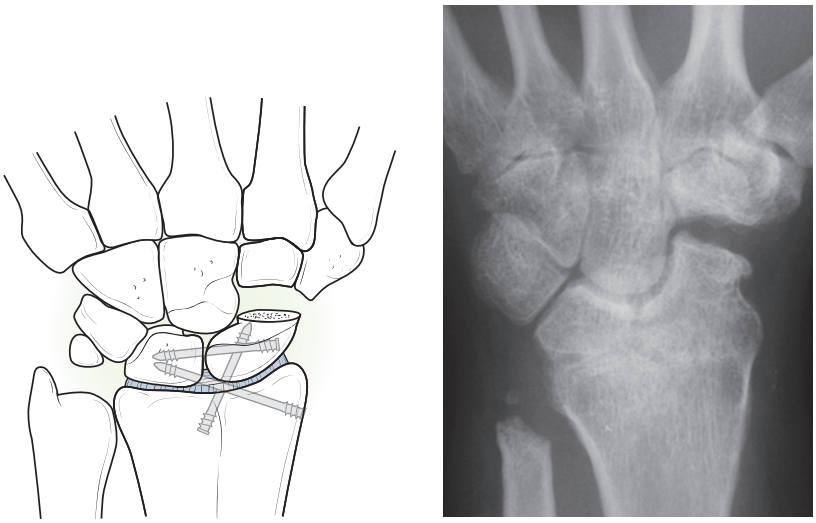

FIGURE 13.37 Schematic representation (*left*) and case example (*right*) of the technique that is preferred when a scapholunate dissociation is not easily reducible but the cartilage at the midcarpal joint is intact: radioscapholunate fusion plus distal scaphoidectomy to allow wider radial inclination.

the RSL joint. Fusing it eliminates pain induced by degenerative arthritis, while stabilizing the proximal component (i.e., SL acetabulum) of the midcarpal joint. After this fusion, the STT joint may degenerate with time and become painful due to the inability of the scaphoid to flex during wrist flexion and radial inclination, creating a local impingement.

To avoid this complication, and to increase the resultant motion, Garcia-Elias et al[26] suggested excision of the distal third of the scaphoid (Figure 13.37). Other authors have also recommended excising the triquetrum.[10a] With this modified technique, the midcarpal ball-and-socket articulation is freed from its lateral constraint, allowing more than 50% of overall wrist motion. Furthermore, the chances of achieving an RSL arthrodesis are improved due to the loss of distal scaphoid constraint.

Despite the published and encouraging early results, it is important to note that, by resecting the distal scaphoid, the area of contact between the proximal and distal rows is reduced substantially. If the joint is not misaligned, however, that reduction of contact should be well tolerated. Indeed, if the lunate is arthrodesed in a proper axial alignment, dorsal dislocation of the capitate will not occur, preserving full joint contact, thus preventing degenerative arthritis of the LC joint. Needless to say, the operation should not be performed if the LC cartilage is not normal.

Stage VII: complete SL ligament injury with irreducible misalignment and cartilage degeneration. Long-lasting carpal misalignment, with irreducible subluxation of the scaphoid, will cause joint cartilage destruction. This is secondary to decreased joint contact areas, which prevent successful ligament repair or reconstruction. Stage VII is the beginning of a pattern of progressive joint degeneration known as SLAC wrist.[5,116] The cartilage wear begins between the tip of the radial styloid and the adjacent surface of the scaphoid and progresses proximally until the entire RS joint is involved. At a later stage, the midcarpal joint may also degenerate, usually starting at the LC joint. In advanced cases, the rest of the carpus may be involved, with the exception of the RL joint, which is usually spared. The following subsections contain a brief review of the surgical alternatives that exist to tackle these conditions. Detailed information about most of these procedures is provided in Chapters 12, 16, and 17.

Arthroscopy. Wrist arthroscopy plays a limited role in patients with SLAC wrist. It can be used to evaluate the degree and extent of articular degeneration to decide which salvage procedure is best. Wrist arthroscopy can be a valuable adjunct in determining the status of the radial and capitate articular cartilages, particularly in the decision-making process between a four-corner fusion or proximal row carpectomy.

Radial styloidectomy. This is one of the oldest procedures used to relieve wrist pain caused by an impingement between the tip of the radial styloid and a misaligned distal scaphoid. Despite removing the degenerated radial styloid process, the SLAC wrist sequence will continue to progress. When performing a radial styloidectomy through an open lateral approach, caution is required to protect the dorsolateral branches of the superficial radial nerve. At its palmar margin, it is important to avoid detaching the origin of the radiocarpal ligaments, which would lead to further instability.[7] For individuals who desire minimal surgical intervention, arthroscopic radial styloidectomy may be an option.

Scaphoidectomy and midcarpal fusion. Popularized by Watson and coworkers[116] the SLAC procedure (i.e., scaphoid excision plus capitate–lunate–triquetrum–hamate fusion; also known as four-corner fusion) has gained an excellent reputation for the treatment of chronic SL dissociation. For the operation to be successful, good articular cartilage at the RL level is required. A frequent complication is the development of dorsal impingement between the dorsal edge of the radius and the capitate. An important step to avoid this is to fully correct the extension deformity of the lunate before stabilizing the midcarpal joint. Several new implants, including circular or square plates, staples, and locking screws have been designed to be countersunk below the dorsal intersection of the four carpal bones so that radial impingement is avoided.

In selected cases, fusion is limited to the LC joint, and reported results have been comparable.[10a] In patients with ulnar-positive variance (in which an excessively rigid triquetrum could precipitate ulnocarpal abutment), or in cases with

http://e-surg.com

chronic combined SL and LTq instability, the scaphoid and triquetrum can be excised before fusing the LC joint.

Proximal row carpectomy. This is another salvage operation in which the scaphoid, lunate, and triquetrum are excised, creating a neoarticulation between the capitate and lunate fossa of the radius.[114] In most published series, this procedure is said to be good in terms of pain relief, restoration of functional wrist motion, and grip strength, with high overall patient satisfaction.

In mechanical terms, this operation converts a complex composite articulation into a single ball-and-socket joint with nonmatching articular surfaces. The wrist can adjust to such an incongruity only if there is a good articular cartilage on the proximal pole of the capitate and in the lunate fossa of the radius. Compared with midcarpal arthrodesis, this technique avoids long immobilization and the risk of nonunion. It has the added advantage of being able to be converted into a wrist arthrodesis or arthroplasty if at a later date it evolves into a painful osteoarthritis. Long-term radiocapitate degeneration, although often asymptomatic, is present in about one-third of patients with more than 10 years of follow-up. In one series, 6 out of 17 patients at 20 years follow-up had been reoperated on.[114] With a success rate (65%), Walls et al[114] recommends adequate preoperative counseling of this increased failure risk when this procedure is offered to patients younger than 35 years old.

Total wrist arthroplasty. Advances in total joint replacement of the wrist have made this option a reasonable treatment for patients who place low demands on the wrist. Most patients with late posttraumatic instability are young and active individuals or manual laborers, for whom a joint prosthesis is seldom an acceptable choice (see Chapter 12). If the cartilage of the proximal surface of the capitate is preserved, there is the option of replacing only the proximal row by a hemiarthroplasty.[48]

Total wrist arthrodesis. Although many surgeons believe that a total wrist arthrodesis should rarely be considered in patients with a posttraumatic unstable osteoarthritis, arthrodesis is still the procedure of choice for patients who perform heavy manual work. According to some sources, complete pain relief can be expected in 85% of patients with 65% of them returning to their former occupations.[77] As shown in many clinical series, most patients with total wrist fusion are able to accomplish all daily tasks by learning to compensate for the loss of wrist motion.

❖ AUTHORS' PREFERRED METHOD OF TREATMENT: SL Dissociation

Partial ruptures of the SL ligamentous complex (i.e., stage I, occult SL dissociation) may respond well to physiotherapy. Particularly promising are the results of proprioception reeducation of the wrist muscular stabilizers, promoting the combined action of the APL and ECRL muscles by asking them to extend and radially incline wrists against resistance. In more advanced partial injury, we believe in arthroscopic debridement of the unstable remnants of the disrupted membrane, plus percutaneous pinning of the SL joint with two or more Kirschner wires for 8 weeks. It is always important to check for the integrity of the dorsal SL ligament. If insufficient or torn, but repairable (stage II, SL dissociation), we prefer the open technique of joint reduction, ligament repair, and dorsal capsulodesis as proposed by Cohen[16] (see Figure 13.25).

Although recognizing its potential use, we no longer use bone–ligament–bone grafts in stage III SL dissociation because it stiffens the radiocarpal articulation too much. In our opinion, isolated reconstruction of the dorsal SL ligament is not indicated in more advanced stages where the secondary stabilizers are lost and the scaphoid has already yielded into flexion and pronation. We no longer consider SL ligament repair, even if repairable, when there is substantial lunate misalignment. Indeed, the presence of DISI indicates a more global problem that can hardly be solved by addressing only the dorsal SL ligament.

If the subluxation is easily correctable (stage IV, SL dissociation) and no cartilage defect exists, we have had very acceptable results with the three-ligament tenodesis (see Figure 13.29; see also Critical Points: SL Stabilization). However, in recent years, we have paid more attention to the level of RL instability than we have admitted in previous editions of this book. In our experience, one cannot build SL instability on an unstable lunate. If the lunate is ulnarly translocated, or if it exhibits substantial sagittal misalignment (stage V, SL dissociation), we look for reducibility. If it is easily reducible, we trust the recently described spiral tenodesis (see Figure 13.35).

When the misalignment is irreducible (stage VI, SL dissociation), but no cartilage damage is present, we have achieved good results by fusing the radiocarpal joint and excising the distal third of the scaphoid[26] (see Figure 13.37). In our experience, most midcarpal-crossing arthrodeses provide excellent short-term results but poor long-term outcomes. When the radioscaphoid and the midcarpal joints are involved by the arthritic process (stage VII, SL dissociation, SLAC wrist), we prefer to do a total scaphoidectomy plus a midcarpal fusion. Being skeptical of the long-term viability of a joint with mismatched articular surfaces, we perform proximal row carpectomies only occasionally.

Lunotriquetral Dissociation. Posttraumatic or degenerative LTq dissociations are not unusual. The literature may be scarce and often misleading, but disruptions of the LTq joint are not infrequent. The first case of a LTq dissociation was identified in the early 20th century,[21] but it was not until the 1970s, following the work of Reagan and associates,[79] that the problem became more widely recognized. Since then, this problem has become better understood and treatment results have improved. Yet, the chance that this condition is missed or confused with other ulnar-sided wrist problems (e.g., midcarpal instabilities or TFCC injuries) remains high.[15,83]

Pathomechanics of LTq Dissociation. Most isolated injuries to the LTq ligaments are secondary to a backward fall onto the outstretched hand, with the arm externally rotated, the forearm supinated, and the wrist extended and radially inclined. In such circumstances, the impact is concentrated on the hypothenar area, and particularly on the pisiform, which acts as a punch against the extended triquetrum.[71] Such a dorsally directed force to the triquetrum induces its dorsal displacement. The lunate does not follow the triquetrum because it is constrained by the radius and the volar long RL ligament. As a result of this, substantial shear stress is created at the LTq joint, causing progressive stretching and ultimately tearing of the three components of the LTq ligaments (i.e., volar, dorsal, and proximal).

http://e-surg.com

If, aside from this, there is a violent rotation of the distal row into further pronation, the palmar TqHC ligament adds the extra destabilizing force required for the palmar LTq ligament to fail. Supporting this explanation is the fact that the two ligaments (i.e., palmar LTq and TqHC) are rarely disrupted simultaneously.

Injury to the LTq ligaments is often associated with peripheral tears of the TFCC and a distal avulsion of the ulnotriquetral ligament.[71] The mechanism of these combined injuries is similar to the mechanism discussed for the isolated LTq injury, except for the predominance of radial inclination and pronation as torque-inducing vectors. In this respect, any ligament avulsion of the palmar rim of the triquetrum should be interpreted as a sign of a combined ulnocarpal and LTq injury.

In other cases, a perilunate destabilization process, as postulated by Mayfield and colleagues,[64] may lead to LTq instability. In such instances, the wrist has undergone violent extension, ulnar inclination, and midcarpal supination, usually from motorcycle accidents or falls from a height. Rupture of the SL ligaments (stage I) occurs first, followed by LC dislocation (stage II), and finally rupture of the LTq ligaments (stage III). If the SL ligament lesion is successfully treated, but the LTq lesion remains, symptoms from LTq instability may require treatment.

The LTq joint may become progressively disrupted as the result of a long-standing ulnocarpal abutment. In the presence of an ulnar-plus variant, attritional degeneration of the proximal membranous portion of the LTq joint is frequent and should never be confused, or treated, as if it was the result of an isolated traumatic event.

In the laboratory, several attempts to ascertain the consequences of LTq ligament disruptions have been made.[87] When the LTq and dorsal radiotriquetral ligaments were experimentally sectioned in axially loaded cadaveric wrists, the flexion moment of the scaphoid became unconstrained, causing a conjoint flexion of the scaphoid and lunate, with secondary anterior subluxation of the capitate (Figure 13.38). This represents the more advanced stage of the disease, resulting in a static VISI pattern of instability. By contrast, when only the palmar and dorsal LTq ligaments were sectioned, increased mobility of the LTq joint was detected (dynamic instability), but not a complete destabilization of the carpus. These findings may explain the relatively low incidence of radiocarpal arthrosis in late static LTq dissociations. This is probably because the scaphoid and lunate maintain their normal alignment with the radius.

Diagnosis of LTq Dissociation. LTq dissociation manifests as a spectrum of clinical conditions, ranging from asymptomatic partial tears to a painful complete dissociation with static carpal collapse. Although the former does not deform the wrist, the latter may exhibit a reversed "fork-like" or "bayonet" deformity. This is similar to the deformity seen in volarly displaced distal radius fractures, except that the carpal sag is distal and not lateral to the prominent distal ulna.[81] Some patients describe painful crepitus as they incline the hand ulnarly.[57] Symptomatic injuries invariably exhibit point tenderness directly over the dorsal aspect of the joint. Pain is usually aggravated with ulnar inclination of the wrist and supination of the forearm. Wrist motion is seldom diminished except in the more advanced cases with carpal collapse. Patients frequently complain of weakness and a sensation of the wrist giving way, and some may also have ulnar nerve paresthesias.

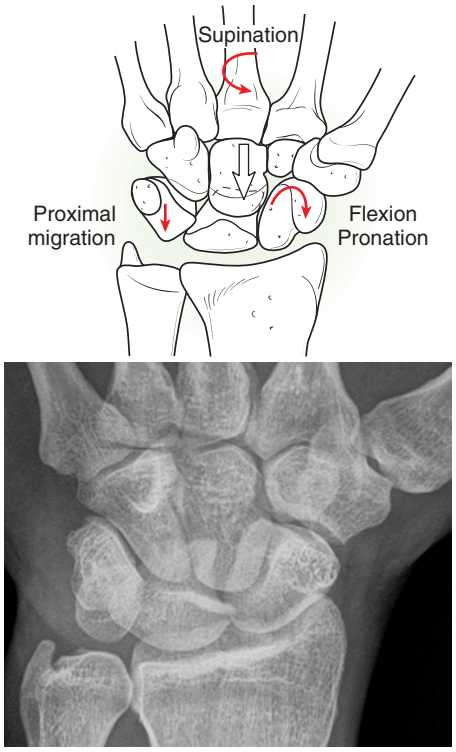

FIGURE 13.38 Schematic representation and radiograph of typical carpal bone displacements (*curved arrows*) that occur when the extrinsic and intrinsic lunotriquetral-supporting ligaments have failed. The scaphoid and lunate as a unit fall into flexion; the unconstrained triquetrum migrates proximally, especially in ulnar inclination (*straight arrows*); and the distal row supinates.

Physical examination. A pathognomonic finding is a positive ballottement test, as described by Reagan and coworkers.[79] The lunate is firmly stabilized with the thumb and index finger of one hand, while the triquetrum and pisiform are displaced dorsally and palmarly with the other hand. A positive result elicits pain, crepitus, and abnormal displacement of the joint. The so-called "shear test" described by Kleinman[83] is a variation of the ballottement test that can be done with a single hand: By stabilizing the dorsal aspect of the lunate with the index finger, the pisiform is loaded by the thumb in a dorsal direction, creating a shear force at the LTq joint that causes pain (Figure 13.39).

The Derby test reported by Christodoulou and Bainbridge is also useful in the reducible LTq dissociation without a fixed VISI type of deformity.[83] This test starts by realigning the lunate and scaphoid relative to the radius. This is done by placing the wrist in extension and at a slight ulnar inclination. If, in that position, we reduce the LTq joint by pushing the pisiform dorsally, the feeling of instability disappears immediately, and grip strength increases as long as pressure over the pisiform is maintained.

Most of these provocative maneuvers are of reasonable sensitivity but poor specificity. Painful ulnar-sided conditions that may elicit a pain from these tests include: LTq synchondrosis, fracture of an incomplete congenital coalition; triquetrum–hamate impingement and degeneration; avulsion fractures of the dorsal triquetrum; pisotriquetral arthropathy; traumatic or degenerative TFCC tears; ulnocarpal impaction syndrome; ECU tenosynovitis; and entrapment of the dorsal branch of the

http://e-surg.com

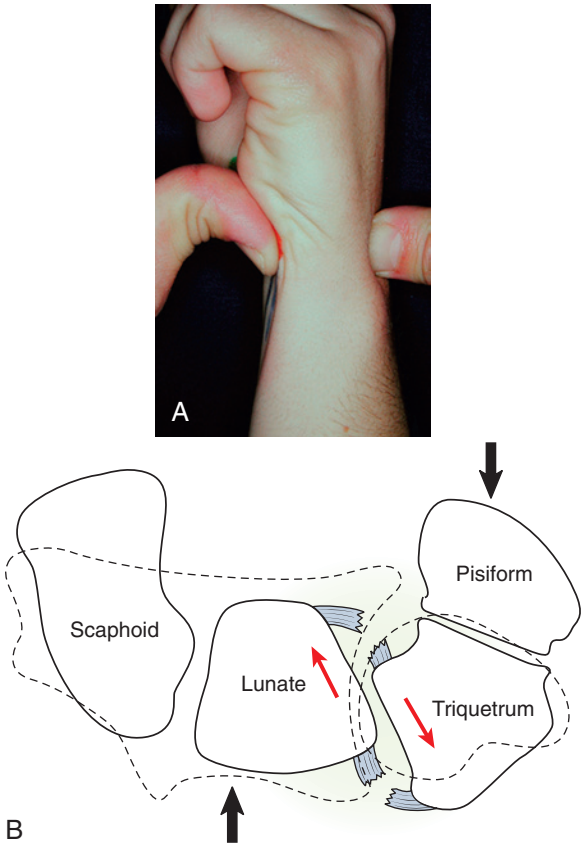

FIGURE 13.39 **A,** The "shear test" as described by Kleinman[83] is similar to the ballottement test described by Reagan and coworkers.[79] **B,** Opposite force (*black arrows*) is applied to induce abnormal displacement (*red arrows*) to a lunotriquetral (LTq) joint suspected of ligament injury. This test is painful for a patient with a sprain or instability in the LTq joint.

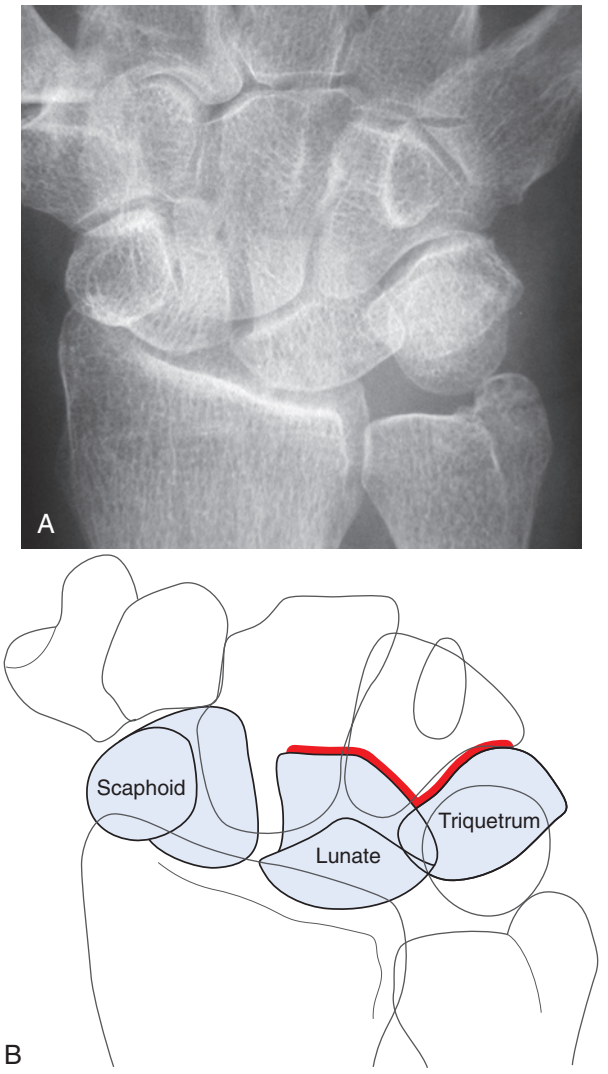

FIGURE 13.40 **A,** Posteroanterior view of a static lunotriquetral (LTq) dissociation in a 44-year-old lawyer who had suffered a fall from a height 2 years before, without apparent consequences. Six months after the accident, he complained of painful snapping during lateral inclinations. **B,** Note the moonlike configuration of the lunate in volar intercalated segmental instability and the "seagull"-appearing outline of the distal LTq border (*red line*). The scapholunate joint was slightly widened probably the result of the palmar fibers of this joint being longer than the dorsal ones.

ulnar nerve. Indeed, careful differential diagnosis is mandatory before deciding on a treatment for ulnar-sided pain.[12]

Radiographic examination. Standard wrist views appear normal in most patients with partial tears of the LTq interosseous membrane. Occasionally, in chronic dynamic instabilities, a slight narrowing of the LTq joint with subchondral cyst formation on the opposing sides of the joint may appear. This finding should not be confused with similar features seen in patients with a fracture of an incomplete LTq coalition.[120]

When there is a static VISI pattern of misalignment secondary to complete rupture of both intrinsic and extrinsic LTq supporting ligaments, radiographic diagnosis is obvious. Most characteristic is the disruption of the normal convex arc of the proximal carpal row (the Gilula line) in the PA radiograph projection. A "moon-like" lunate facing a foreshortened scaphoid is also typical of this condition (see Figures 13.15 and 13.40). In such cases, the lunate's dorsal pole is superimposed on the distal part of the capitate, implying an abnormal flexion of the bone. It is also pathognomonic of this problem, the so-called "seagull sign"—the distal outlines of the lunate and triquetrum adopt the form of a flying seagull (Figure 13.40). A widened SL joint is paradoxically common in LTq dissociations. It is important to note, however, that the gap does not represent a rupture of the SL ligaments, but is instead the result of an axial load being applied to the most palmar SL ligament fibers. These fibers are longer and obliquely oriented, allowing an increased, but normal, separation of the two bones.[46] None of these radiographic findings changes with the wrist in ulnar inclination, except for an increased proximal displacement of the triquetrum relative to the rest of the proximal carpal row (Figure 13.41). In collapsed cases, the carpal height ratio may be diminished.

In the lateral projection, aside from the VISI pattern of misalignment, it is sometimes possible to find a decreased LTq angle. According to Reagan et al,[79] the average LTq angle is 14 degrees. Assessment of this angular measurement requires films of excellent quality and considerable practice taking them because the longitudinal axis of the triquetrum is difficult to identify. Yet, identifying the relative position of the triquetrum axis relative to the lunate axis may help to discriminate between a CIND–VISI and an LTq dissociation (Figure 13.42). Both in normal as in CIND–VISI wrists, the triquetrum-axis is palmar

http://e-surg.com

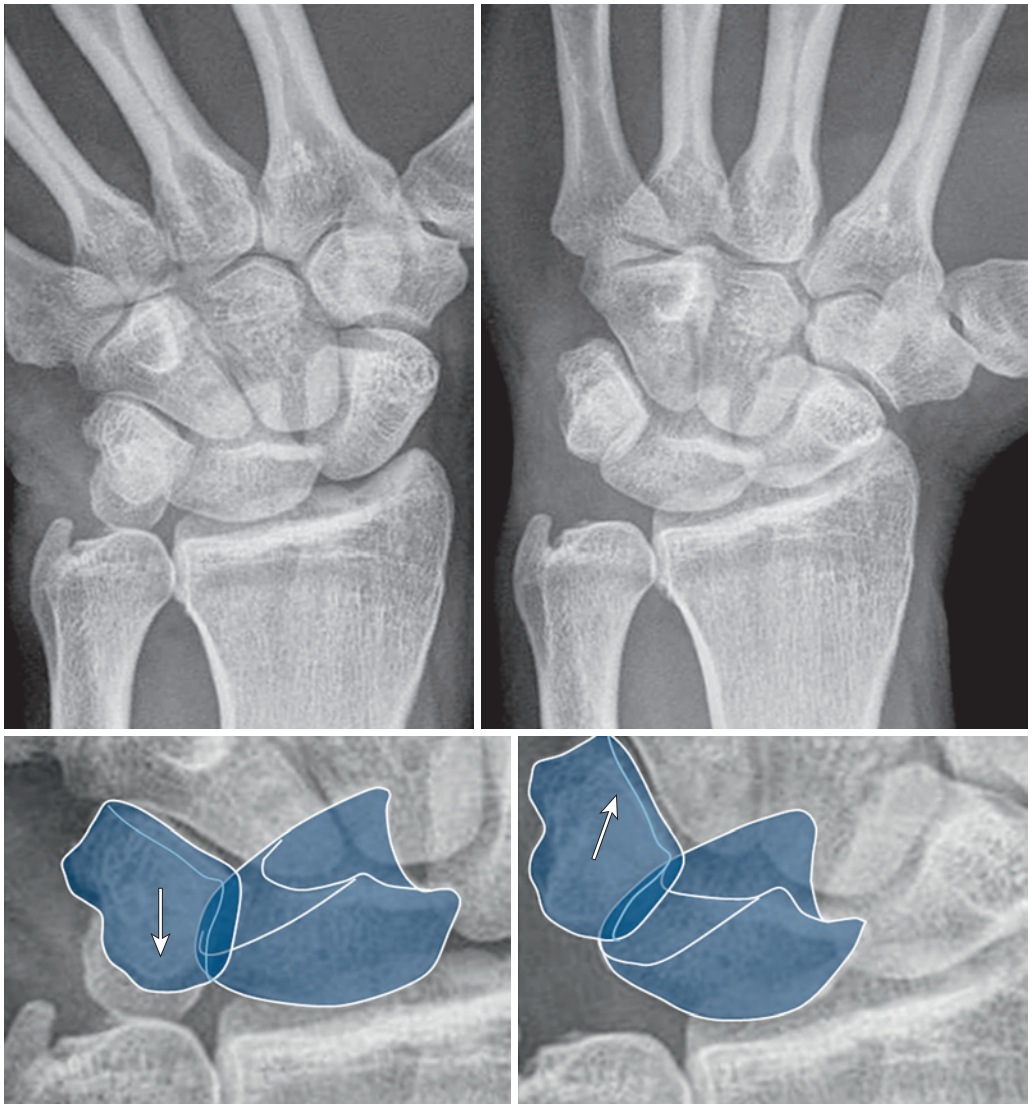

FIGURE 13.41 Dynamic radiographs of static lunotriquetral dissociation. During radial inclination (*right*), the scaphoid (S) and the lunate (L) are abnormally palmar flexed, but the triquetrum (Tq) is normally aligned relative to the lunate (*up arrow*). During ulnar inclination (*left*), there is a significant step-off between the lunate and the triquetrum (*down arrow*). Note the scaphoid and lunate remain in the flexed position, despite the ulnar inclination of the wrist.

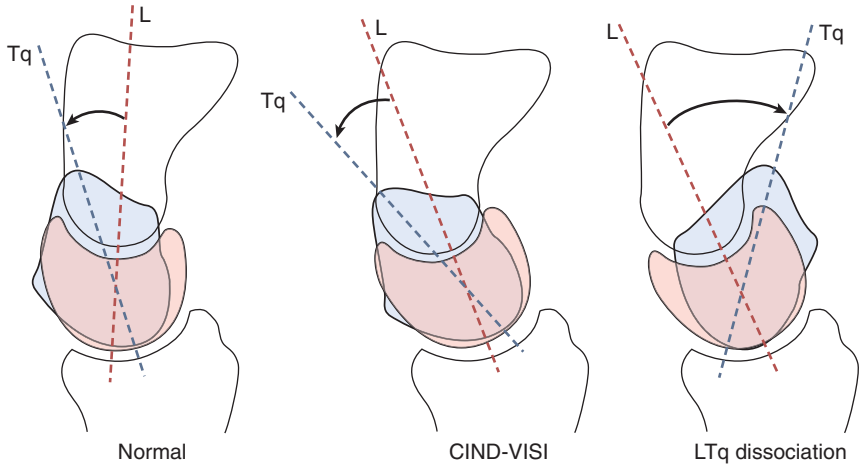

FIGURE 13.42 The lunotriquetral (LTq) angle is difficult to identify in a lateral radiograph, and its quantification difficult to reproduce. Yet, identifying the relative position of the triquetrum (Tq) axis relative to the lunate (L) axis may be of help to discriminate between a carpal instability nondissociative (CIND)–volar intercalated segmental instability (VISI) and an LTq dissociation. Both in normal wrists (*left*) and in CIND–VISI (*center*) wrists, the triquetrum-axis is palmar to the lunate-axis. In the LTq dissociated wrist (*right*), by contrast, the triquetrum-axis is always dorsal to the lunate-axis.

http://e-surg.com

to the lunate-axis. In the LTq dissociated wrist, by contrast, the triquetrum-axis is always dorsal to the lunate-axis.

Other diagnostic tests. Advanced imaging is particularly useful when there is doubt about the etiology of a chronic LTq tear. If the injury is due to a chronic ulnocarpal impingement, a bone scan or MRI frequently shows an area of increased uptake in the lunate. In pure LTq instabilities, the scan is seldom positive.

Arthrography may show a communication of dye between the radiocarpal and midcarpal joints. An arthrographic communication is nonspecific and may result from a traumatic injury, a chronic age-related perforation, or ligament degeneration caused by ulnocarpal impaction syndrome.[12]

Cineradiography may be very helpful and is always recommended.[105] In relatively acute situations, the wrist may still exhibit a sudden reduction of the abnormally flexed lunate during ulnar inclination, manifesting as a clunk. However, such self-reducing capability is rapidly lost, and the VISI misalignment becomes static (Figure 13.43). In such instances, as the wrist moves from radial-to-ulnar inclination, the triquetral–hamate joint is always engaged, and the SL complex remains in the flexed position in ulnar inclination.

Arthroscopy has become an increasingly important diagnostic and therapeutic tool for the evaluation of lesions on the ulnar side of the carpus, and it may identify previously unrecognized types of ligamentous disruptions.[105] Further technical details are provided in Chapter 17.

LTq Dissociation Treatment. As with all other forms of carpal instability, treatment of LTq instability needs to be individualized according to the patient's age, occupation, recreational demands, and intensity of symptoms. LTq injuries may be acute or chronic. They may involve only the LTq interosseous ligaments and maintain normal bony alignment, or they may have a more global intrinsic and extrinsic ligament insufficiency resulting in carpal collapse. An injury may appear as an isolated ulnar-sided problem or be part of a perilunate instability. There are different clinical conditions in which there is substantial damage to the LTq supporting ligaments, each having its own



FIGURE 13.43 Images of a 56-year-old retired man who fell from a height 8 years before, without short-term consequences. Treated conservatively, he did well until 10 months ago when a mild sprain triggered an increasingly dysfunctional process characterized by wrist pain, progressive loss of motion, and increasing weakness. Plain radiographs **(A, B)** disclosed the presence of a static carpal collapse secondary to lunotriquetral dissociation, a diagnosis that was made fully evident by a 3D rendering of the bones' surfaces **(C, D).**

http://e-surg.com

prognosis and treatment. A description of the treatment of the five most common forms of LTq ligament injury seen in clinical practice follows. Cases in which there is degeneration of the lunotriquetral proximal membrane as a result of a chronic ulnocarpal abutment are not included in this section (see Chapter 14).

Acute LTq injury without carpal collapse. The so-called "dynamic or occult LTq instability" is usually diagnosed by arthroscopy. The degree of LTq ligament incompetence varies from a minimal disruption to complete rupture of the proximal membrane and both volar and dorsal LTq ligaments; yet, the wrist does not exhibit misalignment because the extrinsic ligaments are not injured. The condition may be painful as a result of increased motion between the two bones, generating shear stress and local synovitis.

In the past, most authors agreed that acute LTq injuries should be treated conservatively, with the wrist immobilized in a carefully molded cast or splint, with a pad beneath the pisiform and over the dorsum of the distal radius to maintain optimal alignment.[79] Failures using that approach, however, were not unusual. Unless pronosupination is blocked by including the elbow in the cast, the amount of motion that occurs in the LTq joint during forearm rotation is substantial, owing to the "pistonage" effect of the ulna against the carpus through the TFCC. Such micromotion prevents proper connective tissue formation at the repair site. Thus, should conservative treatment for an acute LTq ligament be chosen, an above-elbow cast is imperative.

The introduction of arthroscopy as a routine exploration in wrist trauma allowed earlier recognition of the extent of these lesions, and an increased awareness of their potential risk. To avoid an above-elbow cast, some authors recommend multiple percutaneous pinning of the acutely injured joint. The arthroscopic method of pinning the joint is discussed in Chapter 17. Postoperatively, it is important to remember the positive stabilizing effects of the ECU muscle in preventing VISI.[54] Thus, adequate proprioceptive reeducation of this muscle is recommended during rehabilitation.

Chronic LTq injury without carpal collapse. LTq instability is considered chronic when the two ends of the disrupted ligaments have degenerated, diminishing the chances for successful healing. If the extrinsic ligaments maintain their secondary stabilizing efficacy, carpal alignment may still be normal. In symptomatic cases, a more aggressive approach is necessary to reestablish the synchronicity of motion between the triquetrum and lunate.

A variety of strategies have been proposed including simple arthroscopic debridement, electrothermal shrinkage, ligament reconstruction using a strip of the ECU tendon, and LTq arthrodesis.[87,98] None of these methods has attained consistent success for chronic injuries.

The various arthroscopic techniques for the management of chronic tears of the lunotriquetral interosseous ligament are reviewed in Chapter 17. These include debridement of the frayed ends of the disrupted proximal membrane, capsular shrinkage, or closing the interval between the ulnolunate and ulnotriquetrum ligaments with sutures under arthroscopic control.[100]

Complete disruption of the LTq ligaments associated with reducible chronic instability is best treated by ligament reconstruction with a tendon graft (Figure 13.44). The technique recommended by Shin et al[98] consists of reconstructing the LTq linkage with a strip of ECU tendon, left attached distally and passed through holes in the lunate and triquetrum. By tightly looping the tendon graft around the LTq joint, immediate stability is achieved. The reconstruction is further secured by transfixing the joint with one or two Kirschner wires for 8 weeks, followed by 4 more weeks in a protective splint. A group of 8 patients treated with this technique showed encouraging results.[98]

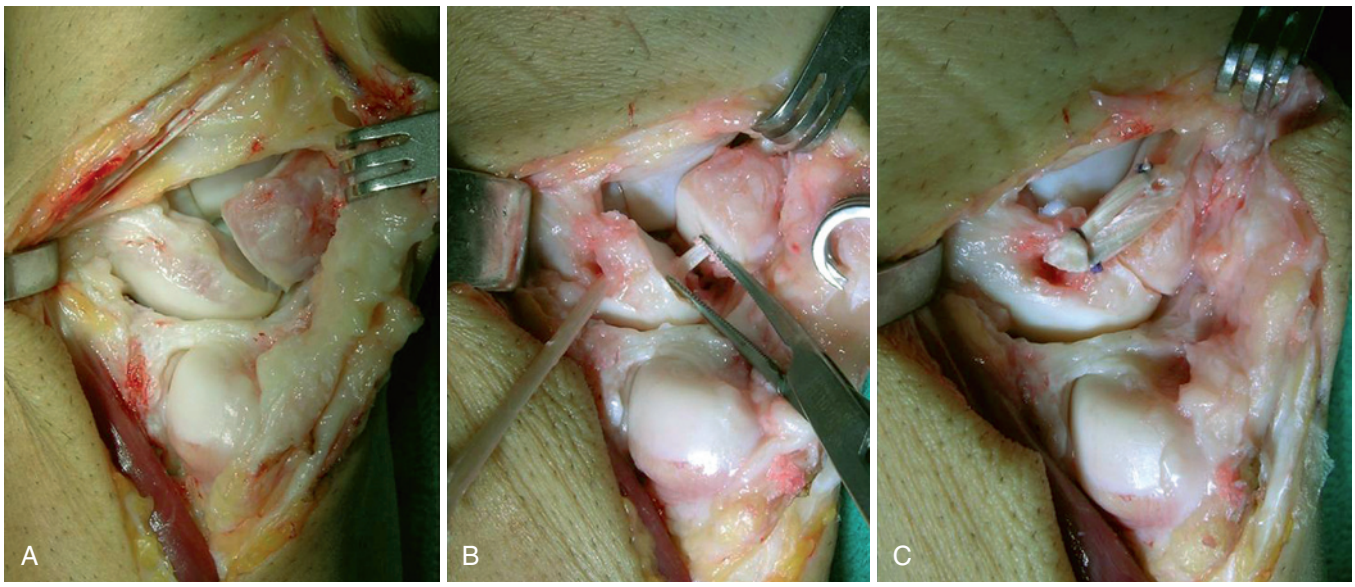

FIGURE 13.44 A 44-year-old policeman who was injured in a fight had painful chronic dynamic lunotriquetral (LTq) dissociation. A complete nonrepairable LTq injury was found arthroscopically **(A)**, so it was decided to perform an open tendon reconstruction of the palmar **(B)** and dorsal **(C)** LTq ligaments using a slip of the extensor carpi ulnaris tendon, according to Shin and colleagues.[98] The patient had regained normal hand function 6 months after surgery with 35% reduced flexion but a strong and painless grip.

http://e-surg.com

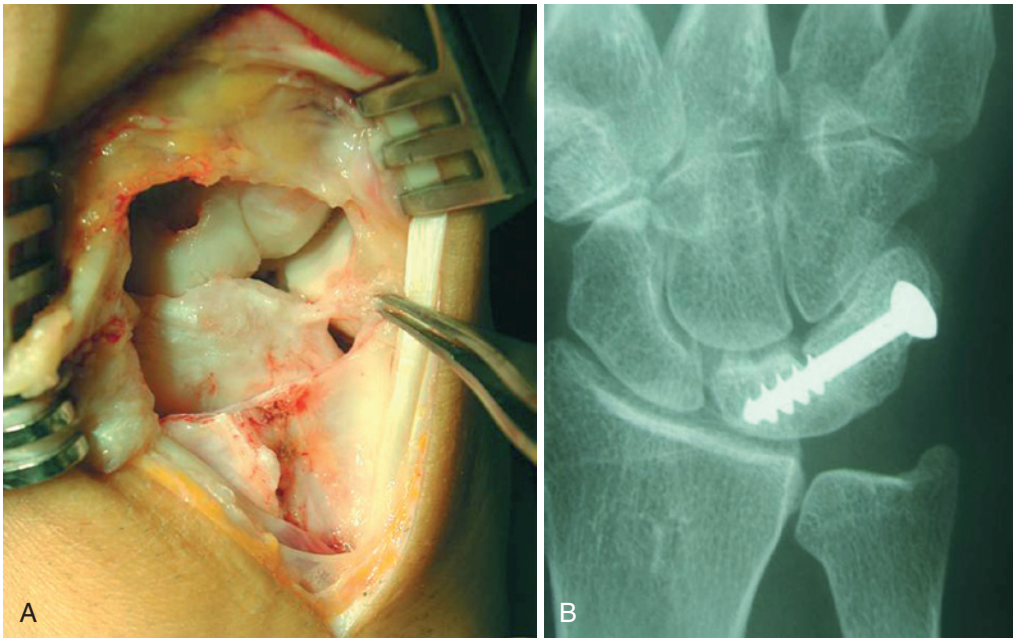

FIGURE 13.45 A 28-year-old woman, who could not recall any traumatic event, had chronic ulnar-side wrist pain. **A,** Increased hypermobility and complete rupture of the lunotriquetral intercarpal ligaments were shown at operation, so a local fusion was done. Following publication by Guidera and colleagues,[33] we tend to use compression screws to improve the chances of healing. **B,** The fusion was solid 15 months after surgery, but some tenderness persisted.

Shahane and coworkers[97] published a slightly different approach, also using a strip of ECU tendon, to tether the dorsal aspects of the triquetrum–hamate joint. This approach seems to control the abnormal triquetral motion and provides good pain relief and acceptable function in most patients with isolated chronic LTq dissociations.

Fusing the unstable LTq joint is another alternative. The procedure has met with variable success due to a relatively high nonunion rate[98,104] (Figure 13.45). According to Guidera et al,[33] most complications of LTq fusion result from technical problems. By using cancellous bone graft to fill a biconcave space created in the adjoining bones and stabilizing the joint with multiple Kirschner wires, these authors reported a 100% consolidation rate (see the following Critical Points box). In their series of 26 patient wrists, postoperative flexion–extension averaged 78% of the range measured on the contralateral side, with good or excellent pain relief in 83% of the cases and with 88% of patients returning to their previous occupations.[33] A meta-analysis of 143 LTq fusions, however, demonstrated that lunotriquetral fusions are not without problems, particularly if they have been incorrectly planned or executed. A nonunion rate of 26% and a complication rate of 43%, mostly in the form of persistent pain, were reported.[104] The procedure should not be performed in the presence of a VISI deformity.

The only study comparing ligament reconstruction with LTq fusion has been reported by Shin and colleagues.[98] They retrospectively reviewed 57 patients with an average postoperative follow-up of 9.5 years. Patients who underwent tendon reconstruction of the LTq ligaments had higher subjective and objective outcomes and a much lower complication rate than patients having an arthrodesis.

Chronic LTq dissociation with carpal collapse. LTq dissociation with carpal collapse is secondary to complete disruption of the intrinsic LTq ligaments and attenuation or disruption of the extrinsic stabilizing ligaments—dorsal and palmar radiocarpal ligaments. As a result of such a global ligament insufficiency, the carpus collapses into a dissociative VISI pattern of misalignment. The underlying pathology involves the intrinsic and extrinsic ligaments, so partial carpal fusion of the lunate and triquetrum is unsuccessful in controlling the misalignment. Neither an isolated fusion of the LTq joint nor any sort of tendon reconstruction is likely to reliably correct such a complex unstable condition. Halikis and associates[36] suggested adding an RL fusion to the LTq fusion. As an alternative, the ulnar midcarpal joint, between triquetrum and hamate, may be included in the fusion site. There is little guidance in the literature about this condition.

Acute perilunate instability (combined SL and LTq instability). Stage III perilunate instabilities involve a combination of injuries around the lunate, including complete rupture of the SL and LTq interosseous ligaments. If the LTq injury is not treated, carpal instability is more likely to result, and the outcome will be worse than that of an isolated injury. Owing to their inherent instability, all perilunate dislocations are best managed surgically. Treatment of perilunate dislocations is discussed in more detail later in this chapter.

Chronic perilunate instability (SL plus LTq instability). When not adequately addressed, most perilunate injuries evolve into a state of permanent misalignment (i.e., carpal collapse into either VISI or DISI) with reduced wrist motion, decreased grip strength, progressive joint degeneration, and painful synovitis.

There is little information in the literature about this specific problem. Generally, when the proximal row presents with a combined SL and LTq dissociation, most authors recommend a proximal row carpectomy.[114] Alternatively, excision of the

http://e-surg.com

CRITICAL POINTS *LTq Arthrodesis*

Indications

- Dynamic LTq instability secondary to complete intrinsic ligament rupture in the absence of an ulnocarpal abutment syndrome (i.e., normal TFCC) and normal midcarpal joint
- Perilunar SL and LTq instability
- No radiographic evidence of VISI

Preoperative Evaluation

- Positive LTq ballottement test
- Fluoroscopic evaluation of abnormal proximal–distal shift of the triquetrum during radioulnar inclination
- Arthroscopy to rule out TFCC degeneration or triquetrum–hamate impingement

Technical Points

- Perform a dorsal (e.g., zigzag, lazy "S," or longitudinal) incision centered at the IV–V septum.
- Perform a longitudinal incision of the extensor retinaculum along the V compartment.
- Open the septum between IV–V; coagulate intraseptal artery.
- Perform a Z capsulotomy creating two flaps following the fiber-splitting concept.[10]
- Complete section of the remnants of LTq ligaments.
- Open the LTq as a book and remove the adjacent articular surfaces with a dental rongeur to expose cancellous bone. Do not excise the rim of the opposing cortical edges to preserve the normal intercarpal separation.
- Harvest cancellous bone from the radius through a window created under the infratendinous sheath at the floor of compartment IV.
- Two 1.5-mm nonparallel K-wires are preset in the ulnar aspect of the triquetrum. Bone graft is densely packed in the biconcave cavity.
- The joint is reduced, and two K-wires are driven into the lunate and their position verified.
- One wire is used to insert a headless cannulated compression screw. Beware of the dorsal branch of the ulnar nerve.
- Cut the second wire below the skin's surface.
- Perform standard capsular and retinacular closure.

Postoperative Regimen

- Short arm thumb spica cast for 6 weeks, changed at 10 days for stitch removal and radiographs
- At 6 weeks, cast removal, radiographs, and new cast applied
- Out-of-cast radiographs until healing is obvious, at which point wires are removed under local anesthesia
- Rehabilitation after cast removal to regain motion and grip strength
- Contact sports not allowed until 6 months postoperatively
- Probable outcome: 75% of patients have a painless wrist with 80% of global motion and 75% grip strength

scaphoid and triquetrum, while fusing the LC joint, may also give good results. The long-term comparative outcomes of these approaches are unknown. A less radical, motion-sparing solution for this problem is spiral tenodesis, described by Chee et al in 2012[13] (Figure 13.46).

❖ AUTHORS' PREFERRED METHOD OF TREATMENT: LTq Dissociation

We believe that acute tears of the LTq ligaments are best treated by percutaneous LTq joint fixation with Kirschner wires and cast immobilization. The good ligament healing obtained outweighs the minimal morbidity from pinning the joint. By ensuring complete immobilization of the joint with wires, the wrist can be mobilized earlier (at 4 weeks), which allows a much faster recovery of motion.



FIGURE 13.46 Late degenerative changes of static lunotriquetral (LTq) dissociation. Note the typical step-off in the LTq interval, a break in Gilula's line (*arrow*), and the midcarpal (hamate–lunate) articular deterioration involving cystic formation within the head of the capitate. Radioscaphoid–lunate joints are usually spared.

For chronic instability without carpal collapse, we have had very encouraging experience with the ECU tendon reconstruction suggested by Shin and colleagues[98] (see Figure 13.44). It is an anatomically sound solution for chronic, dynamic LTq dissociation because it replaces the most important stabilizer of the joint—the palmar LTq ligament.

We seldom perform LTq fusions, owing to the substantial rate of complications. When there is no other alternative than fusing the joint, we prefer the method described by Guidera et al,[33] in which the empty space left in the LTq joint, after resecting cartilage and subchondral bone from the central portion of the two articular surfaces, is filled with abundant, tightly packed cancellous bone graft from the distal radius. Thus, the joint is stabilized by multiple K-wires or a compression screw (see Figure 13.45). We believe it is important to check to see whether there is a relatively long ulna because, if there is an ulna-plus variant, lunate–triquetrum fusions tend to remain symptomatic. In such instances, it is better to add a "wafer" procedure or an ulnar shortening to the LTq fusion. We do not recommend an LT fusion if there is static carpal misalignment (i.e., VISI) or a chronic SL and LTq dissociation. Our first choice for the former would be fusion of the RL and LTq joints and, for the latter, an RSL fusion plus a distal scaphoidectomy.

Nondissociative Carpal Instability

As stated previously, a painful wrist is said to have a CIND pattern of instability when there is dysfunction of the radiocarpal and/or the midcarpal joints with complete integrity of the ligaments connecting the bones of the proximal and distal rows.[8,28,50,56,118,119] Depending on which joints are affected the most, CIND problems can be further subdivided into

http://e-surg.com

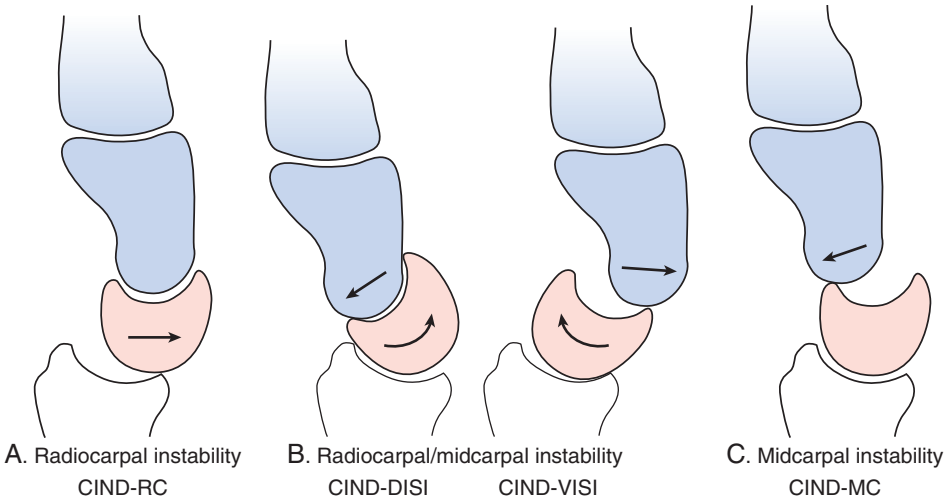

FIGURE 13.47 Simplified representation of the four types of carpal instability nondissociative (CIND), and the most common displacements involved (*arrows*). **A,** Radiocarpal instability (CIND–RC), in which the entire carpus is dissociated from the radius and ulna and may be displaced in different directions, most commonly ulnarly. **B,** Combined radiocarpal and midcarpal, also known as proximal row instability, where there is instability at both levels: the proximal row rotating either volarly (CIND–VISI) or dorsally (CIND–DISI). **C,** Pure midcarpal instability (CIND–MC): this is an uncommon type in which only the midcarpal joint is unstable, the radiocarpal joint being normal, or following fusion to the radius.

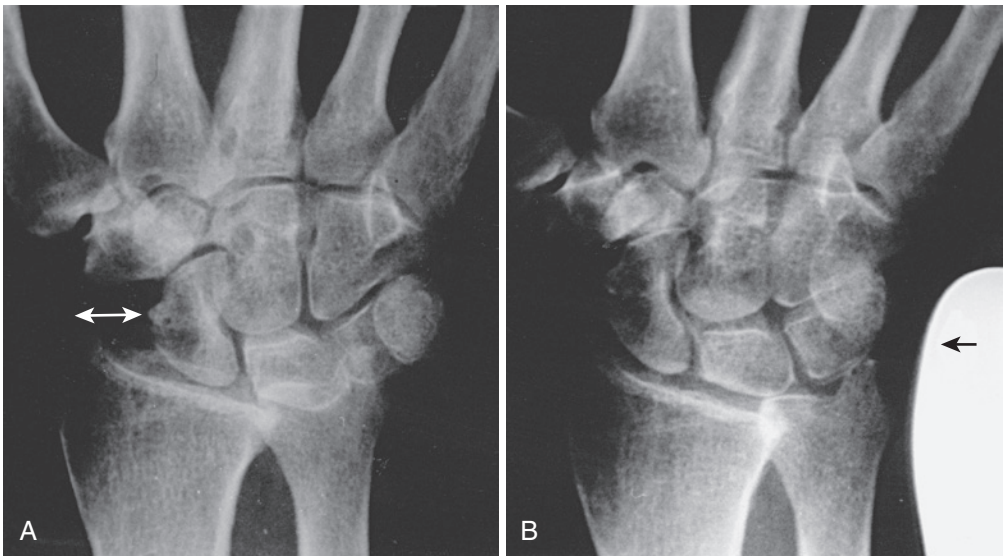

FIGURE 13.48 Ulnar translocation in a 50-year-old woman with rheumatoid arthritis. **A,** Widened radial styloid–scaphoid space (*white double arrow*). **B,** This unstable situation can be easily reduced by laterally directed pressure (*black arrow*).

radiocarpal, midcarpal, and combined radiocarpal–midcarpal (Figure 13.47). Combined radiocarpal–midcarpal instability is also known as "proximal row instability" and has two distinct varieties: CIND–VISI (i.e., flexion rotation of the proximal row with a tendency of the capitate to sublux volarly) and CIND–DISI (i.e., extension rotation of the proximal row with a dorsal capitate sublux tendency).

Radiocarpal Instability. Radiocarpal CINDs occur in patients with excessive laxity, insufficiency, or rupture of the radiocarpal ligaments. In these cases, the carpal condyle can be easily displaced beyond normal limits down the slope of the radius. With time, further stretching of the capsule may occur, and the carpus becomes permanently translocated.[8,78] This condition is commonly seen in rheumatoid patients or in patients with developmental deformities such as the Madelung deformity (Figure 13.48). Posttraumatic radiocarpal instability is less frequent, most often associated with a distal radial malunion or the result of a pure radiocarpal dislocation.[22] In rheumatoid patients, the radiocarpal ligaments fail as a result of the attritional effects of synovitis. The displacement is not always anteromedial; if the instability is due to a malunion, the carpus may displace in a dorsal or dorsoradial direction, depending on the direction of the deformity. The most common form of radiocarpal CIND, however, is ulnar translocation.

The first traumatic ulnar translocation of the carpus caused by complete disruption of the extrinsic ligaments was described

http://e-surg.com

by Rayhack and associates.[78] There are two types of ulnar translocations. Type I involves displacement of the entire carpus, including the scaphoid, and the distance between the radial styloid process and the scaphoid is widened.[13,108] In type II, the relationship between the distal row, the scaphoid, and the radius remains normal. The SL space is widened and the LTq complex is ulnarly translocated.

The distinction between type I and type II is important for various reasons. Conceptually, type I is a true CIND instability, whereas type II is a combined SL and RL injury—a condition already discussed as stage V SL dissociation.[13] In practice, distinguishing between the two types is essential because different ligaments are involved that require differing treatment; type I injuries result from failure of all radiocarpal ligaments, including the RS and RSC. In type II injuries, neither the RSC ligament nor the RS ligament is ruptured; however, there is complete SL and RL ligament disruption. When presented with a widened SL joint, the possibility of an ulnar translation of the LTq complex (type II injury) must be kept in mind to avoid misdiagnosis. If a type II ulnar translocation is treated by stabilizing only the apparent SL dissociation, the underlying radiocarpal instability remains unresolved. If easily reducible, type II is an excellent choice for spiral tenodesis (see SL dissociation, stage V, and Figure 13.35).

As described in the discussion of the radiographic examination of carpal instabilities, a variety of methods for assessing ulnar translation have been reported. None is universally reliable. The indices using the center of the capitate head as a carpal reference should not be used in type II injuries because in those cases only the LTq complex is significantly displaced.[120] On the other hand, when using the lunate as a reference, if the wrist is slightly radially or ulnarly inclined, the measurements may be unreliable. Dynamic stress views under fluoroscopy are useful in the assessment of this type of instability. When the joint is axially loaded in radial inclination, the proximal row is brought into maximal flexion. If the dorsal radiocarpal ligament is disrupted or elongated, the axial load induces abnormal ulnar translation of the lunate beyond the sigmoid notch of the radius.

Rayhack and associates[78] reported a single series of eight patients with traumatic ulnar translocation of the carpus. Their experience indicates that this is a difficult problem to treat. They had disappointing results with delayed ligament repairs and suggested that probably a radiocarpal fusion is the only reliable alternative for such patients[28,36] (see Figure 13.37).

Isolated Midcarpal Instability. Strictly speaking, the term *midcarpal instability* should only be used to describe cases where the midcarpal joint is unstable but not the radiocarpal joint. In reality, most unstable midcarpal joints are associated to a variable degree of radiocarpal instability. One condition with potential for developing a pure midcarpal instability would be the wrist with incompetent midcarpal ligaments after radiocarpal fusion or a hemiimplant arthroplasty.[118] When loaded in full flexion, those wrists could exhibit capitate subluxations or even dislocations over the edge of the fixed proximal row. This is a theoretical possibility, however, that has not been published yet.

Volar Instability of the Proximal Row (CIND–VISI). Often referred to as "palmar (or anterior) midcarpal instability," this condition was first described in 1934 by Mouchet and Belot.[21] It is usually seen in patients with attenuation or rupture of the palmar midcarpal ligaments associated with insufficiency of the dorsal radiocarpal ligament. The proximal row remains flexed (i.e., VISI) until near the end of ulnar inclination, where it suddenly rotates into extension. This phenomenon has been termed the "catch-up" clunk[27,56,118] (see Video 13.3).

Pathomechanics. As discussed previously, under axial compressive load, the proximal row tends to rotate into flexion and pronation, a tendency that is normally constrained by the palmar midcarpal crossing ligaments.[7,23] Especially important stabilizers are the palmar TqH ligament, the palmar TqC ligament, the dorsolateral STT ligament, and the SC ligament. These ligaments not only play a key kinetic role in preventing midcarpal collapse but also are essential to ensure a smooth, progressive transition of the proximal row from flexion to extension as the wrist inclines ulnarly. Consequently, any injury or condition resulting in increased laxity of the TqH, TqC, STT, and SC ligaments is likely to have two consequences: (1) a kinetic instability (i.e., loss of the ability to transfer loads adequately without collapsing); and (2) a kinematic problem in which the transition of the proximal row from flexion to extension is sudden and sometimes painful, rather than smooth and progressive, when the wrist reaches a certain amount of ulnar inclination (Figure 13.49). In the laboratory, several studies have addressed the intricate mechanism of stabilization of the proximal row. The consequences of sectioning the midcarpal crossing ligaments are better understood but, comparatively, little is known about what causes these ligaments to fail.

Diagnosis. Proximal row instability seldom results from injury of one specific ligament. Most have congenital laxity with poor neuromuscular control, plus some sort of repetitive stress initiating the symptoms. In these cases, there is an obvious sag

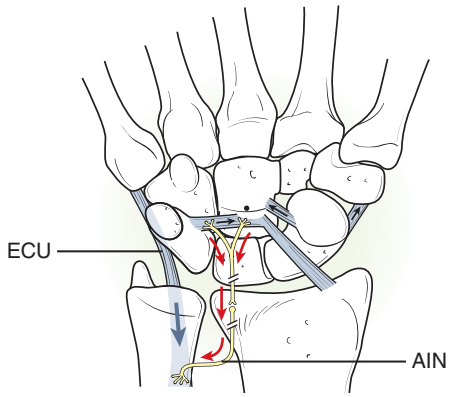

FIGURE 13.49 When the wrist inclines ulnarly, the proximal row undergoes a progressive extension. In some cases, however, that extension is not smooth and progressive—that is, the proximal row suddenly rotates at the end of ulnar inclination. What follows is a tentative explanation of why this happens. Because the wrist's center of rotation during radioulnar inclination lies around the center of the head of the capitate, all ligament fibers inserted proximal or radial to it are likely to increase in tension (*small arrow*) as the wrist inclines ulnarly. These fibers contain mechanoreceptors able to detect changes in tension. When taut, they send afferent messages (*red arrows*) through different nerves, here represented by the anterior interosseous nerve (AIN). These messages return in the form of efferent orders to those muscles (here represented by the extensor carpi ulnaris [ECU]) in which contraction (*blue arrow*) most effectively can realign with the proximal row. When this feedback mechanism fails, the proximal row does not extend until the hamate comes into contact with the lunate, forcing its sudden extension. It is the so-called "catch-up clunk."

http://e-surg.com

of the wrist in the palmar direction, indicating a palmar translation plus supination of the distal row relative to the forearm—a misalignment that corrects itself in ulnar inclination.[28,118]

The role of arthroscopy in the diagnosis and grading of nondissociative instability is minimal. Under traction, the elongated palmar capsule allows greater joint separation than normal, but the palmar ligaments usually look normal.[52] In long-standing cases, recurrent subluxation may have caused degenerative changes at the proximal pole of the hamate, which can be assessed and often treated arthroscopically with debridement or drilling.

Physical examination. A useful maneuver to determine the amount of midcarpal joint laxity is the midcarpal shift test, described by Lichtman and colleagues.[56] It consists of reproducing the painful clunk by passive palmar translation and ulnar inclination of the wrist in pronation. Based on how much force is necessary to maintain the wrist palmarly subluxed in ulnar inclination, wrists are classified into five grades. In grade I, the palmar midcarpal ligaments are so tight that the distal row can hardly be displaced palmarly. Grades II and III can still be found in normal individuals and represent increasing levels of midcarpal laxity allowing the palmar sag to be obtained in ulnar inclination, although it reduces when the applied force is removed. In grade IV, subluxation is easily achieved, and the wrist remains subluxed after removal of the external force. Grade V instability occurs when the patient can actively reproduce and maintain the palmar sag in ulnar inclination without assistance from the examiner.

Radiographic examination. Radiographs usually show a VISI pattern of misalignment, especially on unsupported lateral views compared with the opposite wrist. In the frontal view, the scaphoid is foreshortened and exhibits the ring sign, whereas the lunate has a moon-like appearance, its concave surface facing the scaphoid.

Cineradiography is always helpful in cases where there is a predominant kinematic disorder, as in this one. In a normal wrist, there is synchronized motion of the proximal carpal row from flexion to extension as the wrist inclines ulnarly. In the wrist with CIND–VISI, the proximal carpal row remains flexed throughout the entire range of motion except when the wrist reaches a certain ulnarly inclined position, at which point it suddenly snaps into an extended position, sometimes with an audible clunk.

Stress views are useful to determine the degree of laxity or ligament insufficiency of the various radiocarpal–midcarpal joint stabilizers. A traction view is useful to rule out disruptions between the bones of the proximal row. The anterior drawer view[20] is recommended under fluoroscopic visualization. In this test, the distal row is translated palmarly, and the relationship between the scaphoid, lunate, and distal row is observed. If the STT joint widens palmarly (i.e., the so-called "yawning sign"), the STT and SC ligaments are probably stretched or excessively lax (see Figure 13.17). If there is also palmar LC subluxation, the ulnar midcarpal ligaments must be somehow incompetent. It is important to compare such findings with the contralateral normal side.

Differential diagnosis. When the radiographs of a clunking wrist reveal abnormal flexion of the proximal row (i.e., VISI), the differential diagnosis must include LTq instability. The diagnosis can be established by using the LTq ballottement and shear maneuvers.[79,82] Both tests are negative in nondissociative instabilities and induce pain and a typical grinding sensation when there is LTq dissociation. Radiographically, the SL and LTq angles are normal in nondissociative instabilities, whereas they may be altered in wrists with dissociative instability (see Figure 13.42). When the LTq ligaments are completely torn, the triquetrum appears proximally migrated relative to the lunate in the ulnar inclination stress test; this does not occur in a wrist with nondissociative instability. When in doubt, arthroscopy is recommended. Inspection with a probe shows a tightly closed LTq intercarpal space in nondissociative instabilities and a space easily opened up if there is substantial ligament damage of the LTq-stabilizing ligaments.[100]

Treatment. Several strategies have been recommended for the painful CIND–VISI. Patients should initially be treated by splint immobilization, antiinflammatory medication, and avoidance of activities that reproduce the painful clunk. In the initial inflammatory phase, the wrist should be protected by the so-called "pisiform boost splint," a gutter splint with padding to the volar surface of the pisiform that maintains the proximal row neutrally aligned (Figure 13.50). When symptoms have subsided, a supervised therapy program to reestablish adequate proprioceptive control of the wrist may help eliminate further symptoms.[35]

Excessive flexion of the proximal row can be dynamically controlled by the coupled action of the FCU and ECU muscles. Isometric contraction of the FCU muscle generates a dorsally directed force onto the triquetrum via the pisiform, which helps stabilize the proximal row in a neutral position.[54] Concomitant isometric contraction of the ECU pronates the distal row relative to the proximal row, further promoting reduction of the VISI misalignment. Poor proprioception and inadequate neuromuscular control are probably what differentiates symptomatic from asymptomatic wrists.[35,54,118]

When all conservative measures have failed to control the symptoms of patients with CIND–VISI, the following three options exist: capsular shrinkage, ligament reconstruction, and limited intercarpal arthrodesis.

- *Capsular shrinkage:* Based on experience with other joints, electrothermal shrinkage of insufficient or stretched ligaments has been proposed for the stabilization of CIND–VISI.[52] Local heat is applied to the loose palmar midcarpal and dorsal radiocarpal capsule to create areas of collagen damage.[100] Fibroblasts grow into the injured tissues, building a new structure simulating normal tissue. Despite some promising reports, the use of capsular shrinkage in this field is still considered experimental. See Chapter 17 for further details about this technique.
- *Soft tissue reconstruction of the midcarpal ligaments:* In the past, most attempts to resolve CIND–VISI through a soft tissue procedure were based on the assumption that the underlying pathology was an elongation of both TqH and TqC ligaments.[56,104,118] In most instances, surgery consisted of reefing or advancing the portion of capsule that contains these ligaments. Most attempts, however, failed and symptoms persisted.[56] Recreation of the palmar TqC and dorsal radiocarpal ligaments with a tendon graft was also proposed (Figure 13.51); however, no long-term results are ready to be published.[118] Again, it is implausible that a tendon graft can adequately simulate the mechanical properties of these

http://e-surg.com



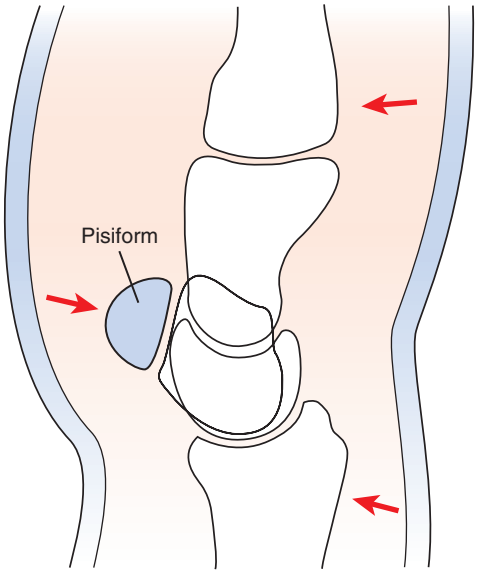

FIGURE 13.50 In the initial inflammatory phase, wrists with a painful carpal instability nondissociative–volar intercalated segmental instability should be protected by the so-called "pisiform boost splint"—a three point (*red arrows*) gutter splint (*left*) with padding on the volar surface of the pisiform that maintains the proximal row neutrally aligned (*right*).

highly specialized and tensioned ligaments over a prolonged period and heavy use.

- *Limited intercarpal arthrodesis:* Limited midcarpal arthrodeses (mostly triquetrum–hamate fusions) have also been recommended for this type of instability[32,56] (Figure 13.52). In a study comparing the results of fusions with those of a variety of soft tissue reconstructions, Lichtman and colleagues[56] confirmed the advantage of the former in the treatment of patients with CIND–VISI. All of them were able to return to their normal level of activity with less than one-third loss of motion and no clunking. However, later publications have been less enthusiastic about such an approach.[32] Although this type of procedure is effective in eliminating the carpal clunking, this is achieved at the expense of creating a painful RS impingement. Furthermore, when the midcarpal joint is fused, DT motion is unnaturally performed by the radiocarpal joint[18,70]; this eventually results in either a dorsolateral overload of the scaphoid fossa or a progressive deterioration of the LTq.

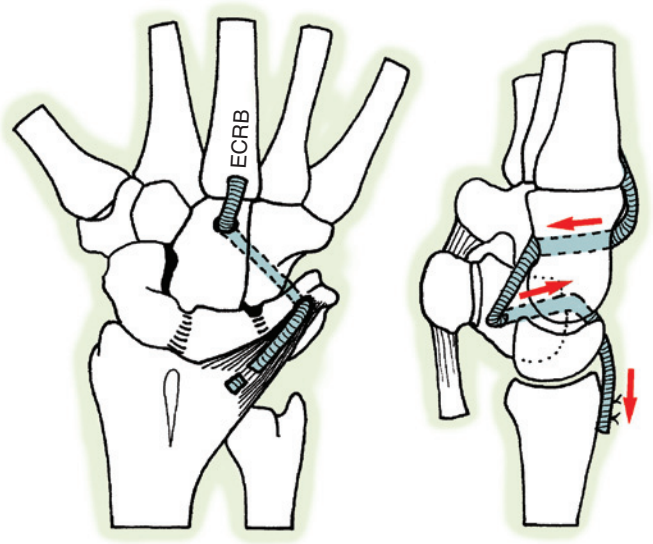

FIGURE 13.51 The author's preferred tenodesis procedure to reinforce the two major ligament problems in cases of a carpal instability nondissociative–volar intercalated segmental instability. A distally attached strip of the extensor carpi radialis brevis (ECRB) tendon is raised and passed through holes in the capitate and triquetrum (*red arrows*) to recreate the ulnar limb of the arcuate ligament (triquetrum–capitate fascicles) and the dorsal radial triquetrum ligament.

More recently, it has been suggested that carpal clunking may also be eliminated by fusing the RL joint instead of the midcarpal joint.[28,36,118] By fixing the lunate to the radius, the cornerstone of the carpus is placed in a neutral position, allowing more stable midcarpal motion. The lunate is fused with crossed K-wires and a corticocancellous graft to preserve normal carpal height, allowing the scaphoid and triquetrum to move normally. Not only does the clunking disappear but also the wrist retains a substantial amount of motion, mostly along the dart-throwing plane. Certainly, RL fusion allows a more natural way of moving the wrist.[28]

Dorsal Instability of the Proximal Row. In dorsal instability of the proximal row (i.e., CIND–DISI), the wrist appears normally aligned except in ulnar inclination, where a dorsal subluxation of the capitate may appear, often with a clunk. These are often called "dorsal midcarpal instability" or "capitate-lunate instability pattern" (CLIP) wrists.[44] The posterior drawer test is useful to assess this type of condition.

If the capitate can be passively translocated beyond the dorsal edge of the lunate with manual dorsal translation of the hand while stabilizing the radius, the dorsal intercarpal ligament is attenuated, lax, or congenitally deficient. The RSC ligament is generally stretched in this condition as well. In ulnar inclination, slight subluxation of the capitate may occur. In normal wrists, the alignment should return to normal after the dorsally directed force is removed. When minimal force is necessary to dislocate the capitate in neutral position, a posterior midcarpal instability is likely.[28,56,118] The posterior drawer test is also useful to assess radiocarpal instability.[120] A dorsal tilt of the lunate causing anterior widening of the joint is indicative of a lax palmar RL ligament (see Figure 13.17).

http://e-surg.com

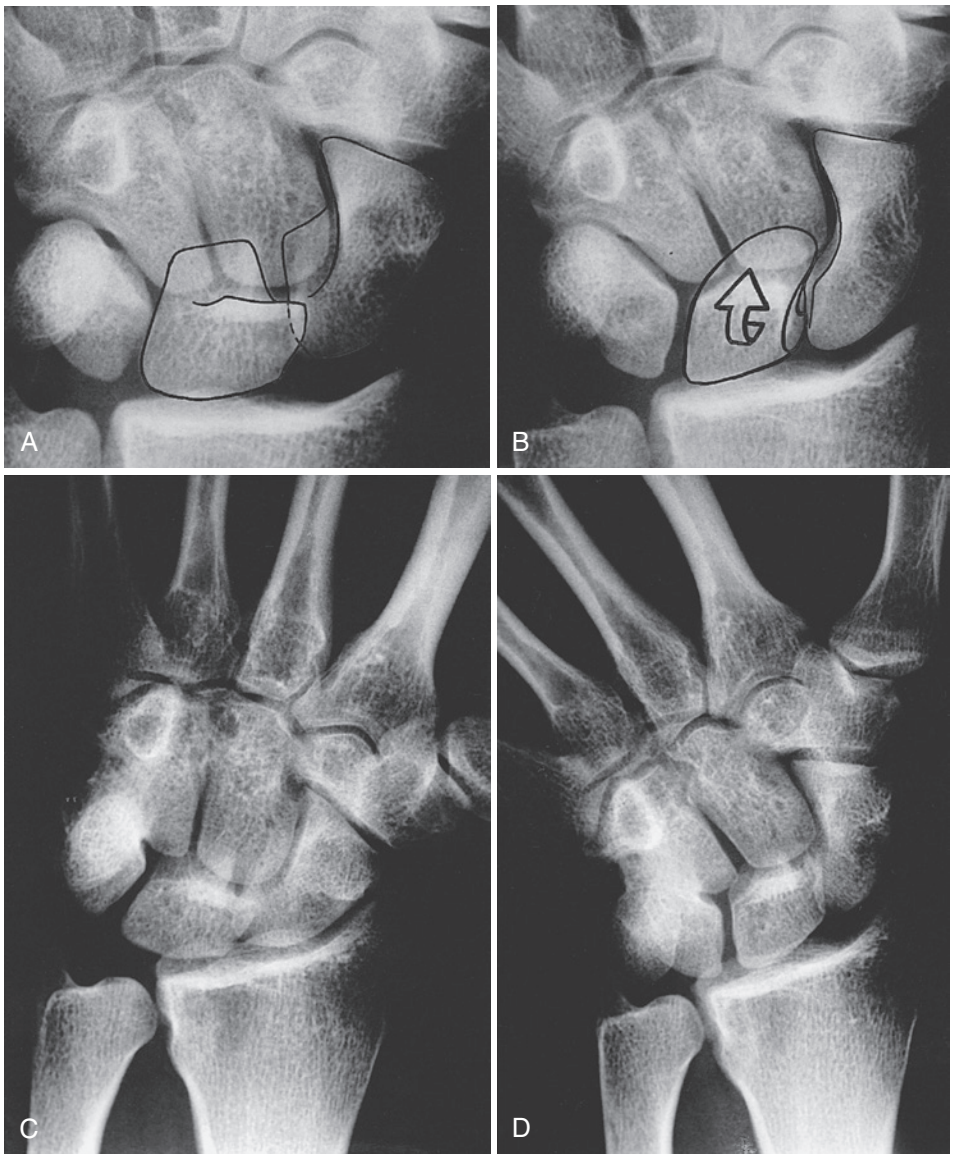

FIGURE 13.52 A 21-year-old man sustained a hyperextension injury to the right wrist 2 years earlier. Since then, there has been painful clunking during radioulnar inclinations. Dynamic radiographs showed a sudden shift (*arrow*) of the lunate and scaphoid from a flexed **(A)** to an extended **(B)** position as the wrist reached a certain degree of ulnar inclination. Conservative treatment did not succeed in relieving the patient's symptoms, and a triquetrum–hamate fusion was performed. Four months after surgery, the patient was back to his former occupation without any complaint. At 18 months of follow-up, the clunking had not recurred but an obviously altered carpal kinematics was evident. From radial **(C)** to ulnar **(D)** inclination, little midcarpal motion exists. Whether such increased radiocarpal shear will result in early degeneration is unknown, but it is a good possibility.

Patients with CIND–DISI should always undergo a dedicated program of physical rehabilitation. In this case, hand therapy should emphasize proprioceptive reeducation of the ECU, ECRL, and ECRB muscles. When these muscles contract, an extension moment to the distal row is generated that results in a shift of the midcarpal joint contact forces from a dorsal position to a more palmar one. Such compressive forces prevent excessive extension of the proximal row.

Failing proprioceptive reeducation, one option is the surgical procedure described by Johnson and Carrera.[44] Through an extended anterior approach to the carpal tunnel, the sulcus that exists between the long RL and RSC ligaments (i.e., space of Poirier) is obliterated with sutures to avoid dorsal translocation of the capitate. According to its proponents, most patients obtain good or excellent results with little loss of motion, especially in extension. Alternatively, a transverse dorsal midcarpal capsulodesis to reinforce the dorsal intercarpal ligament, similar to the one suggested by Gajendran and colleagues,[25,106] may be as effective.

❖ AUTHORS' PREFERRED METHOD OF TREATMENT: Nondissociative Instability

Our assessment of painful clunking wrists is mostly based on a thorough physical examination, plus cineradiography and stress views. The goal is to rule out CID and determine the location and characteristics of the predominant dysfunction. In case of

http://e-surg.com

doubt, occasionally arthroscopy is used. In our setting, most nondissociative disorders respond well to conservative treatment. This consists of splinting, avoidance of activities that produce the painful snapping, plus a controlled hand therapy program aimed at maximizing the stabilizing action of the ECU and FCU. Surgery is only indicated when the conservative protocol fails to control the patient's symptoms.

We are reluctant to recommend capsular shrinkage as an option in hyperlax individuals with CIND. By creating zones of stiff scarred tissue, radiofrequency may provide some static stability to the joint, but not a long-term solution. Indeed, by applying heat to the capsule, we neutralize the intracapsular mechanoreceptors that provide the proprioceptive information required by the sensorimotor system to ensure long-lasting stability. Without proprioception, a hypermobile wrist is bound to suffer continuous subluxations, cartilage damage, and synovitis, and the condition will ultimately deteriorate rather than improve. In the past at our institution, most patients with a clunking wrist were treated by fusing the triquetral–hamate joint. We have failed to reproduce the encouraging results reported by Lichtman and colleagues.[56] Some patients complained of RS impingement, whereas others disliked not being able to move the hand naturally because midcarpal fusion blocked the DT motion.

Some time ago, we designed a tenodesis procedure that is able to recreate the TqC ligament and augment the dorsal radiocarpal ligament (see Figure 13.51). Two longitudinal incisions (i.e., dorsal and palmar) are used. Two drill holes, 3.2 mm in diameter are made: (1) one from the dorsal aspect of the capitate into the carpal canal and (2) another from the palmar aspect of the triquetrum into its dorsal ridge. A strip of ECRB tendon is passed through the capitate hole, retrieved palmarly, and passed again through the triquetrum hole. The tendon is pulled taut, and sutures reinforcing the remnants of the palmar TqC and TqH ligaments are placed. On the dorsum, the tendon is tightly sutured to the origin of the dorsal–radiocarpal ligament. Generally, K-wires are used to stabilize the construct further.

The results obtained in seven patients have been promising, with minimal discomfort, excellent grip strength, and minimal loss of motion. All patients returned to their occupations without clunking. Nowadays, this option is used only when the dysfunction is easily reducible, with perfectly normal cartilages. In all other instances, we recommend an RL arthrodesis.

Our experience with the use of RL fusion for the treatment of combined radiocarpal and midcarpal instability, although limited in number, has been most satisfying. Not only were nearly all patients able to return to their previous activities but also the range of flexion–extension at follow-up was only slightly reduced, grip strength was normal, and no clunking recurred.[28] Indeed, patients are happy after an RL fusion because pain and instability disappear at the expense of losing only a moderate portion of wrist mobility.

When surgery is required for dorsal midcarpal instability, we no longer believe in obliterating the space of Poirier with nonabsorbable sutures; such an intervention would excessively decrease the midcarpal extension. In our experience, a dorsal reinforcement of the midcarpal capsule by using the capsulodesis technique[25,106] is less morbid, and it is as effective as other soft tissue procedures.

Carpal Misalignments

The introduction of this chapter emphasizes that ligament injury, wrist instability, and carpal misalignment, although frequently associated, are independent events—the presence of one does not necessarily imply the presence of the other two.[2] Indeed, not all wrists with a ligament injury develop carpal instability, and not all unstable wrists are misaligned. The previous section discussed carpal instabilities secondary to ligament injuries. This section reviews the "adaptive misalignments" (i.e., the carpal misalignment that is not caused by a ligament injury).

The concept of adaptive misalignment was introduced in 1984 by Allieu[1] to refer to those conditions where carpal misalignment is not a sign of instability but a way to preserve global joint congruity in the presence of a deformed bone. An adaptive carpus is a normal joint that adjusts its alignment to compensate for extracarpal defects. The adaptive misalignment is there to preserve joint coherence.[1,28] Usually, if the bone deformity is corrected, the misalignment disappears and no ligament reconstruction is needed. However, if the misalignment continues for a prolonged period of time, the taut ligaments may stretch and progress toward a true carpal instability problem. In other words, if the cause of an adaptive misalignment is not corrected early enough, the wrist may deteriorate and become unstable with time. Thus, early detection and correction of the deformity that is causing an adaptive misalignment are always recommended. What follows is a review of the most common adaptive misalignments of the carpus.

Carpal Misalignment Secondary to Deformity of the Distal Radius

If not properly reduced and immobilized, distal radial fractures may heal significantly misaligned. Of all possible deformities, the most frequent involves radial shortening plus extension, radial deviation, and supination misalignment of the distal fragment relative to the radial shaft. No matter how inclined the distal radial surface is, patients always try to realign the hand along the longitudinal axis of the forearm. Obviously, this implies forcing the wrist into considerable misalignment.

If the distal radial surface is for the most part tilted dorsally, the defect will be compensated for by flexion of the midcarpal joint. Prolonged flexion of that joint, however, tends to distend the dorsal capsule.[27,108] This, together with the lack of tension experienced by the volar midcarpal ligaments when the wrist is flexed, explains the frequent clunking that occurs during ulnar inclination.[108] Similar to the catch-up clunk of nondissociative instabilities, this clunking indicates the presence of a recurrent dorsal subluxation of the capitate over the dorsal edge of the midcarpal socket.

It is important to note that the primary cause of this type of kinematic dysfunction is not ligament insufficiency but radial deformity; there is no ligament repair that will correct this. The misalignment is an adaptive phenomenon that tends to disappear when the radial deformity is corrected. As stated earlier, if the normal alignment of the distal radius is not restored early enough, some ligaments may stretch out, and some portions of capsule may contract. In these circumstances, the wrist may become progressively unstable (i.e., CIND–DISI or CIND–VISI, depending on radius malunion direction), and a corrective osteotomy may not be enough to solve the dysfunction.

http://e-surg.com

If the predominant deformity involves mostly the coronal plane, as when the frontal inclination of the radius is excessively steep or too shallow, a lateral (closing or opening) wedge osteotomy of the distal radius may be indicated. If, aside from radial misalignment, there is excessive radioulnar length discrepancy, a leveling procedure may be required as well. By doing so, the tendency of the carpal condyle to translate ulnarly will be inhibited as a result of the TFCC being pushed against the ulnar corner of the lunate.

When the deformity involves misalignment in more than one plane, as in the Madelung congenital deformity, a tailored corrective osteotomy addressing all rotations and translations is mandatory. Additional soft tissue procedures are seldom necessary. Aside from the clunking phenomenon, patients with distal radius malunion may also complain of pain in the dorsoradial corner of the wrist. This is typically due to midcarpal synovitis induced by the recurrent subluxation of the capitate. With time, if the misalignment is not corrected, permanent damage to the attenuated ligaments may occur, resulting in more pain and nondissociative radiocarpal instability.

In 1985, Taleisnik and Watson[108] reported on a series of 13 patients with a clunking wrist secondary to a distal–radial malunion. A distal–radial osteotomy was performed for 9, and all attained an excellent result. The only failure occurred in one patient who underwent a soft tissue stabilization of the midcarpal joint without correction of the radial deformity. Clearly, this patient was misdiagnosed as a CIND–VISI. Detailed information about the planning and execution of the corrective osteotomy is provided in Chapter 15 .

Carpal Misalignment Secondary to Deformity of the Scaphoid

When an unstable wrist is axially loaded, the scaphoid prevents what Fisk termed *concertina deformity* (i.e., carpal collapse).[21] Not only is scaphoid alignment important but also its own geometry needs to be normal so as not to create a global carpal destabilization. If the scaphoid has fractured into two or more unstable fragments, the distal portion has a tendency to follow the motion of the distal row, whereas the proximal fragment acts in concert with the proximal row.[6] Under such circumstances, the necessary coordinated motion of the two carpal rows is lost, resulting in an abnormal kinematics of the midcarpal joint. When fractured, the scaphoid cannot transfer load normally and acts as an imperfect kinetic linkage between the two rows. Under load, its proximal part tends to follow the unconstrained lunate and triquetrum by rotating into extension, whereas the distal fragment is forced into flexion by the axial force exerted by the trapezoid and trapezium.[6]

If not properly reduced and stabilized, the fractured scaphoid is likely to develop a pseudarthrosis. Stable nonunions rarely have global mechanical consequences. If the nonunion is unstable and motion occurs at the nonunion site, the scaphoid may undergo resorption of its palmar cortex at the fracture site. In these instances, a "humpback" deformity may appear—the distal scaphoid fragment becomes flexed and inclined ulnarward with respect to the proximal fragment. The resultant misalignment can be categorized as CID because the disruption occurs within the proximal row and typically progresses into a DISI pattern of carpal misalignment. In the presence of a scaphoid fracture, DISI should be regarded as an indirect sign of a fracture displacement.

If the scaphoid fracture finally heals, but in a deformed palmar-flexed posture, its external dimensions will not be normal, and the orientation and congruency of its articular facets will be inadequate to perform its important stabilizing role. Scaphoid malunions can be the source of painful instability, weakness, and reduced motion, especially wrist extension.

Surgery for an unstable scaphoid is technically demanding. The surgeon must be aware of the necessity of obtaining fracture consolidation and, most important, of reestablishing the normal length and shape of the scaphoid so that the anatomic relationship between the bone and the rest of the carpus is normalized. A thorough description of the techniques to achieve these goals is provided in Chapter 16.

Carpal Misalignment Secondary to STT Arthritis

Another rather frequent condition that causes scaphoid deformity, and secondarily carpal misalignment, is STT osteoarthritis.[59] For unknown reasons, it begins as an isolated degenerative phenomenon, often bilateral, and rapidly erodes the cartilage and subchondral bone of the distal scaphoid. In such circumstances, the shorter the scaphoid, the more the proximal row extends to compensate for the defect. In the early stages, the resultant misalignment should not be confounded with carpal instability: it is merely an adaptive phenomenon that can become asymptomatic when the normal length of the lateral column is restored, for instance, by means of an interposition implant.

Needless to say, if the misalignment continues long enough, the taut extrinsic volar radiocarpal ligaments may deteriorate and even disrupt, the dorsal RS capsule may contract, and the space of Poirier may become fibrotic. In such circumstances, restoring the scaphoid normal length may not restore the normal alignment. This would be an example of CIND–DISI.

Carpal Misalignment Secondary to Deformity of the Lunate. Although Kienböck disease is discussed fully in Chapter 16, a brief comment here about the peculiar features of the carpal instability that appears when the diseased lunate collapses is pertinent. One of the prognostic factors of Kienböck disease is the absence (stage 3A) or presence (stage 3B) of abnormal flexion and pronation deformity of the scaphoid. In stage 3A, the carpus remains relatively stable, whereas in stage 3B, it has collapsed. Fragmentation of the lunate results not only in loss of the mechanical strength of the central column but also in a disruption of the kinematic linkage of the proximal row, secondary to slackening of the SL and LTq ligaments. In such circumstances, the loaded scaphoid is apt to follow its natural tendency and progressively collapse into flexion, whereas the triquetrum migrates proximally. Conceptually, the resultant misalignment would be categorized as a CID pattern. Depending on which part of the bone is most involved (i.e., palmar, dorsal, or global), the resultant lunate misalignment may range from neutral to VISI or DISI.

In the past few years, numerous limited intercarpal arthrodeses have been found to be beneficial in the treatment of late stage Kienböck disease. Some of them, especially procedures eliminating motion between the scaphoid and the distal carpal row (i.e., STT and SC joints), are said to be the most effective at unloading the lunate. Despite controversies about their effects on lunate load, these interventions have proved valuable in preserving carpal stability by preventing scaphoid rotary subluxation.

http://e-surg.com

Wrist Dislocations and Fracture–Dislocations

Definition

According to the Mayo Clinic classification, when there is complete rupture of the ligaments binding bones of the same row, the resultant instability fulfills the criteria of a CID.[27,50] If the carpal derangement has preserved the ligaments that connect the bones of the same row, but not the ones that stabilize the radiocarpal and/or midcarpal ligaments, it fulfills the criteria of a CIND. When a carpal derangement shares features of both CID and CIND, the instability can be categorized as a "complex instability of the carpus" (CIC). Acute carpal fracture–dislocations are examples of CIC.

It is important to note that a dislocation is only unstable in the early stages of the injury, particularly if it has not been reduced. With time, the unreduced dislocation becomes stiff, and stiffness is the opposite of instability.[41,43,94,103] Indeed, chronic unreduced fracture–dislocations should not be classified as a carpal instability problem but as a more complex injury that tends to progress to stiffness and degenerative disease.

There are six types of wrist dislocations[94]: dorsal perilunate, lesser arc; dorsal perilunate fracture–dislocations, greater arc; palmar perilunate, lesser or greater arc; radiocarpal; axial; and isolated carpal bone. The first two groups have in common a carpal derangement occurring around the lunate; the first as a pure ligament disruption problem, the second involving one or more fractures of the adjacent bones. The third group, although perilunate, results from a different mechanism producing a palmar displacement of the distal row relative to the lunate. The fourth and fifth groups are nonperilunate dislocations, usually the result of high-energy trauma.

Dorsal Perilunate Dislocations (Lesser-Arc Injuries)

Under the diagnosis of dorsal perilunate dislocation, there are various forms of carpal injury, all confined to a relatively vulnerable area around the lunate (Figure 13.53). They can be pure ligamentous injuries or in combination with fractures of the bones around the lunate (see Chapter 16). Johnson[43] suggested using the term *lesser-arc injuries* to refer to pure perilunate dislocations, as opposed to *greater-arc injuries*, in which one or several bones around the lunate have a concomitant fracture.

Bain et al[5] have expanded this concept further by including the translunate arc, a particular type of wrist dislocation where the lunate has suffered a coronal fracture—the dorsal portion of it displaces together the distal row. This section focuses on lesser-arc injuries: dorsally displaced perilunate dislocations without an associated fracture.

Throughout the literature, there has been a tendency to consider dorsal perilunate dislocations and palmar–lunate dislocations as separate and distinct entities. In reality, as discussed in the pathomechanics section of this chapter, the two conditions represent different stages of the same injury—the so-called "progressive perilunate instability" pattern.[64] When one attempts to reduce a palmarly dislocated lunate, a dorsal perilunate dislocation can be easily reproduced. In other words, the position of the bones when the patient is seen in the emergency department does not reflect the degree of instability or the full extent of the ligamentous damage. Perilunate and lunate dislocations are pathogenically equivalent lesions, and their management is almost identical.

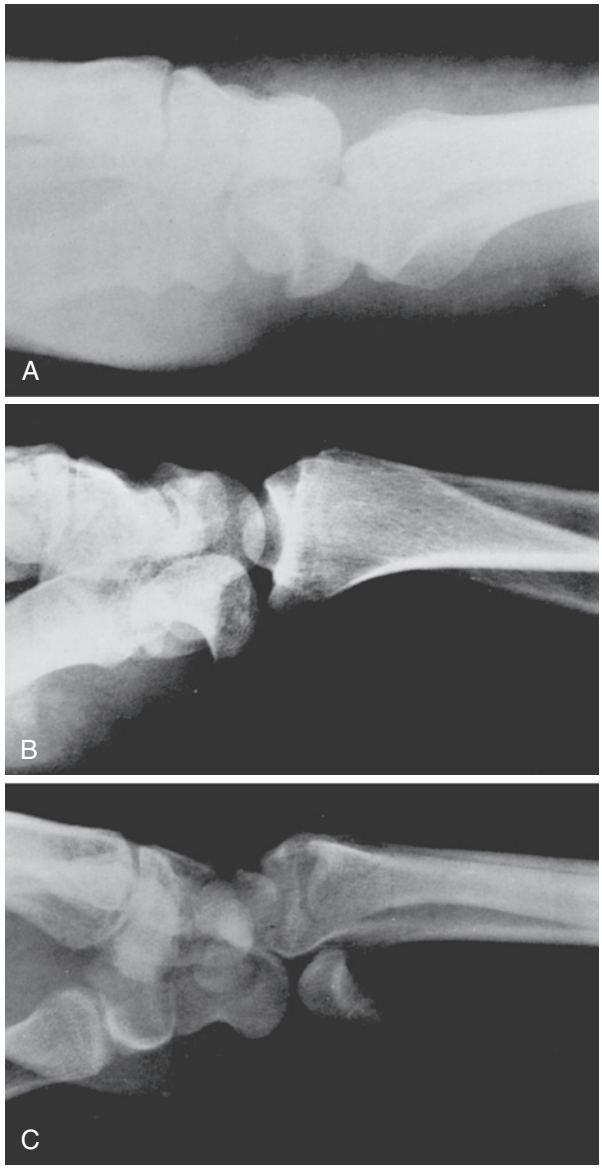

FIGURE 13.53 Carpal dislocations constitute a spectrum of injury, and the initial lateral radiograph in a patient with carpal dislocation may depict a configuration at any point on that spectrum. **A,** "Pure" dorsal perilunate dislocation. **B,** Intermediate stage. **C,** "Pure" volar lunate dislocation.

Another frequent misconception is that when the LC joint dislocates (i.e., the Mayfield stage II), the scaphoid has either fractured or torn its ligamentous attachments to the lunate, but not both. In the literature, perilunate dislocations with a simultaneous scaphoid fracture and SL dissociation have been reported, showing that the two lesions are not mutually exclusive.[14] Most experimentally produced scaphoid fractures have an associated partial SL intercarpal ligament failure. In a multicenter study of 166 perilunate dislocations, Herzberg and coworkers[38] found 6 cases (3.8%) with a concomitant scaphoid fracture and SL dissociation (Figure 13.54).

Treatment of Perilunate Dislocations. In the literature, three major methods of treating carpal dislocations have been suggested: closed reduction and cast immobilization, closed

http://e-surg.com

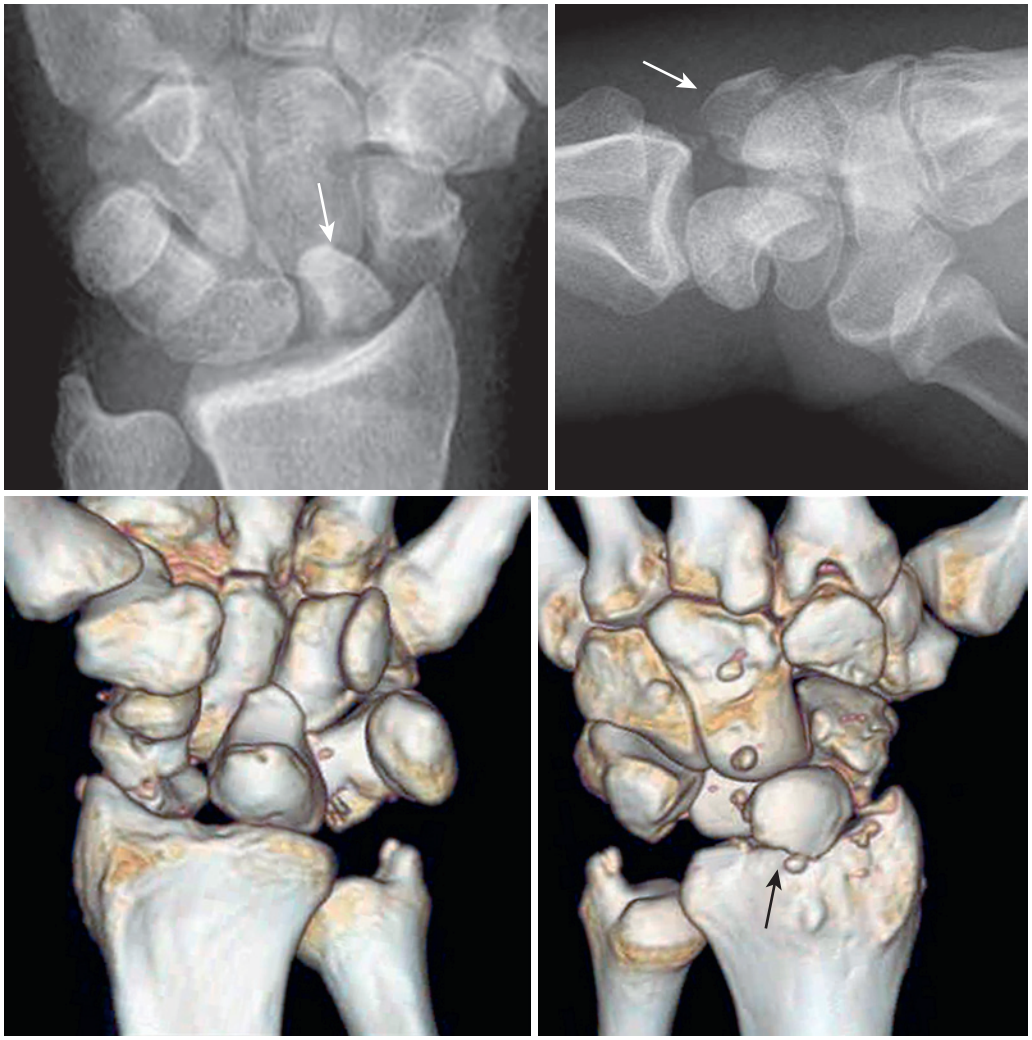

FIGURE 13.54 Posteroanterior (*upper left*) and lateral (*upper right*) radiographs, as well as 3D reconstruction of a computed tomography scan seen from both the volar (*lower left*) and dorsal (*lower right*) sides of the wrist of a patient who sustained a transscaphoid perilunate dislocation with dorsal enucleation of the proximal pole of the scaphoid.

reduction and percutaneous pinning under arthroscopy control, and open reduction and internal fixation.[39,94]

Closed Reduction and Cast Immobilization. Since the 1920s, when case reports of lunate dislocations began to appear, many methods have been suggested for closed reduction. Of importance is the contribution by Böhler, who emphasized the necessity of prolonged continuous traction before attempting to reduce the dislocation.[21] Some authors even considered the use of an external fixator spanning the wrist in old unreduced dislocations to neutralize muscle contraction and apply ligamentotaxis.[102]

Complete muscle relaxation is essential for an atraumatic reduction of a carpal dislocation. General anesthesia, axillary block, and intravenous regional anesthesia (i.e., Bier block) all provide satisfactory muscle relaxation. Local anesthesia or a "hematoma block" does not. An initial period of 10 minutes of uninterrupted traction with the elbow flexed 90 degrees is helpful before reduction begins. During traction, PA and lateral radiographs with the carpus distracted are obtained. These films are valuable in delineating the full extent of carpal damage. When the wrist has been distracted for 10 minutes, traction is released, and the method of reduction described by Tavernier is attempted as follows[21,94] (Figure 13.55).

With one hand, the patient's wrist is extended (maintaining longitudinal traction), while the thumb of the other hand stabilizes the lunate on the palmar aspect of the wrist. Gradual flexion of the wrist allows the capitate to snap back into the lunate concavity. To facilitate this maneuver, the operator's thumb stabilizes the lunate to prevent it from being displaced forward by the capitate. When the LC joint is reduced, and without releasing traction, the wrist is extended gradually while the lunate is pushed dorsally with the thumb, and a full reduction is usually achieved. The sooner after injury this technique is performed, the easier it is to do the reduction.

Postreduction radiographs are taken. It is imperative to take enough different views and to assess "very critically" the relationship of the capitate and lunate and the position of the scaphoid. An SL angle greater than 80 degrees and an SL gap greater than 3 mm have been shown to indicate a poor prognosis if not corrected.[38,43] The wrist may be initially immobilized with a dorsal short arm and thumb spica plaster splint with the wrist in neutral. Unless operative treatment is

http://e-surg.com

medically contraindicated, surgery should be done expeditiously. In the few cases in which closed reduction alone is indicated, most authors recommend at least 12 weeks of immobilization, with weekly radiographic reassessment of the reduction for at least the first 3 weeks. Closed treatment should be continued only when medical reasons contraindicate surgical intervention.

Closed Reduction and Percutaneous Fixation Under Arthroscopic Control. Percutaneous pin fixation is acceptable only if the reduction achieved by closed manipulation of all the perilunate joints is completely anatomic. Minor degrees of scaphoid malrotation would prevent the SL ligaments from being in contact for proper healing, leading to later SL or LTq instability, or both (Figure 13.56). The introduction of arthroscopy to ensure proper reduction of the carpal displacements has made this alternative more attractive. The technique of percutaneous fixation is as follows.

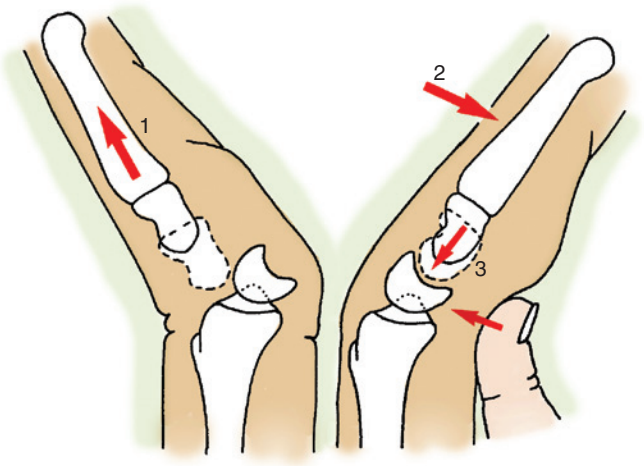

FIGURE 13.55 Schematic representation of Tavernier's method[21,94] of reduction of dorsal perilunate dislocations. With the wrist slightly extended, gentle manual traction is applied (*1*). Without releasing such traction, and while the lunate (L) is stabilized palmarly by the surgeon's thumb, the wrist is flexed until a snap occurs (*2*). This indicates that the proximal pole of the capitate has overcome the dorsal horn of the lunate. At this point, traction is released, and the wrist is brought back to neutral (*3*).

The hand is prepared with standard surgical preparation. The procedure starts by inserting from two K-wires dorsally, one into the lunate and one into the scaphoid; they are used as joysticks to manipulate and align the carpus into an anatomic reduction. Arthroscopy is performed in the radiocarpal and midcarpal joints to verify carpal bone alignment and carpal posture with the image intensifier.[117] While a knowledgeable assistant holds the lunate wire in the reduced position relative to the radius, a 1.2- or 1.5-mm oblique pin from the radial aspect of the radial metaphysis is inserted across the RL joint under fluoroscopy.

The scaphoid joystick wire is used to reduce the SL joint anatomically, and two slightly divergent pins are inserted transversely from the dorsoulnar corner of the lunate across the SL joint. These wires also can be introduced across the anatomical snuffbox; however, the wires should be placed through a small open incision using drill sleeves to minimize risk to the radial artery and radial sensory nerve branches. The wrist is then inclined somewhat radially to bring the triquetrum up into a reduced position relative to the lunate, and two more K-wires are inserted through a small incision from the anteromedial corner of the triquetrum across the LTq joint. Arthroscopy can be utilized to ensure that wires are intraosseous, and that the SL and LTq joints are anatomically coapted.

Lunocapitate joint mobility is inspected under fluoroscopy. If there is a tendency for the capitate to sublux dorsally in flexion, a further pin is passed across the SC joint. The K-wires are left protruding through the skin, bent at right angles, or cut just under the skin to facilitate later removal. A padded thumb

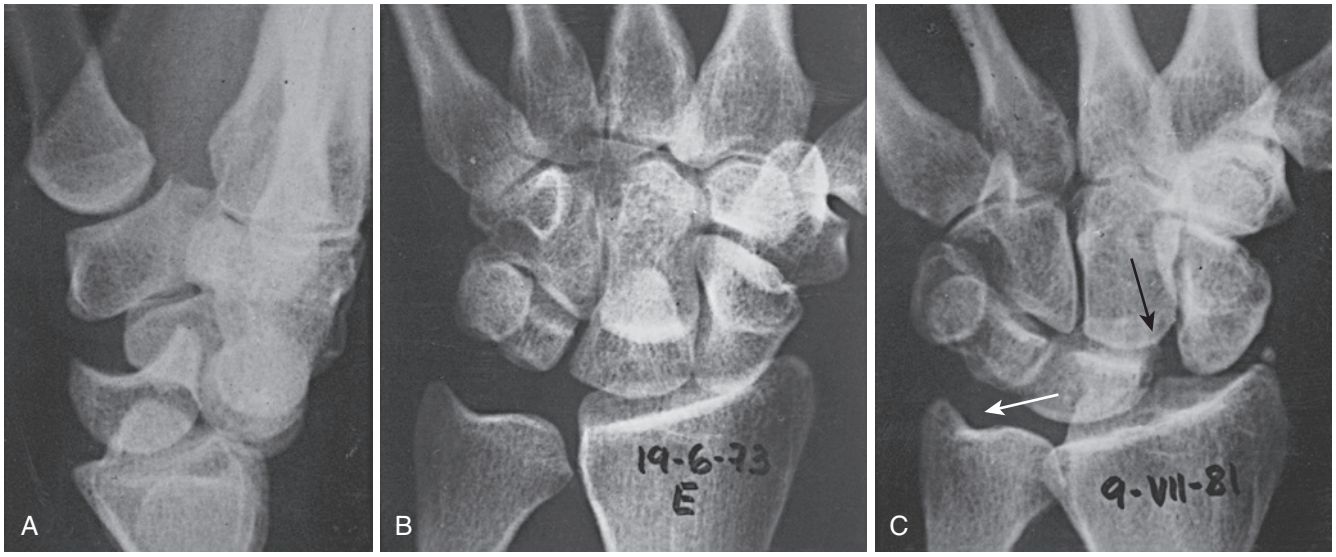

FIGURE 13.56 Nonoperative treatment of this dorsal perilunate dislocation, which consisted of reduction, cast immobilization for 7 weeks, and physical rehabilitation, was considered successful until the patient was assessed 8 years after the injury. **A-C,** Chronic scapholunate dissociation (*black arrow*) associated with ulnar translation of the lunate (*white arrow*) was the result of this suboptimal reduction. The wrist was not unstable, however, it continued to be stiff and painful.

http://e-surg.com

spica splint is applied immediately after the final radiographs have been obtained. This is converted to a thumb spica cast at 7 to 10 days after swelling has subsided and assuming the pin tracts are free of infection. Radiographs are taken in the new cast to ensure proper maintenance of reduction.

The cast and pins are removed at 8 weeks, and immobilization in a dorsal splint is continued for an additional 4 weeks, for a total of 12 weeks after reduction. Until long-term results become available to critically appraise this procedure, a strictly percutaneous technique should be used with some caution. One can be sure though that the most significant drawback of this technique is the fact that it does not address the disruption of the critical dorsal component of the SL ligament, a factor that has been shown to lead to diminished long-term outcomes.[38,109]

Suboptimal reductions of perilunate dislocations will inevitably lead to poor long-term results[38] (see Figure 13.54). Even when an acceptable restoration of the anatomy has been obtained, one must consider the benefits of an open procedure to ensure adequate repair of the dorsal SL interosseous ligament, and to avoid missing osteochondral defects and loose intraarticular bone or cartilage fragments that may lead to poor outcomes.

Open Reduction and Internal Fixation. Generally, open surgery of a carpal dislocation is likely to achieve better results than closed treatment because it allows: (1) complete recognition of all bone and soft tissue damage, (2) removal of interposed soft tissue, (3) removal of unstable chondral fragments, (4) an accurate reduction of bone displacement, and (5) suture of repairable ligaments (Figure 13.57). Many long-term follow-up studies have shown the superiority of open reduction, ligament repair, and percutaneous K-wire fixation over any other alternative in the treatment of perilunate dislocations.[38,109,117] Although some authors still prefer using only a dorsal approach to treat perilunate dislocations,[94] the alternative of combining a dorsal and a palmar approach to allow repair of the palmar LTq ligament, while assessing the reduction and repair of the dorsal SL ligament from the dorsum, is gaining wider recognition.[109]

Some authors recommend using an external fixator to facilitate exposure while protecting the repair.[102] This is especially indicated in longstanding dislocations with extensive fibrosis. In these cases, several days of progressive joint stretching may facilitate surgery. A description of dual-approach treatment of a perilunate dislocation follows in the Critical Points box.

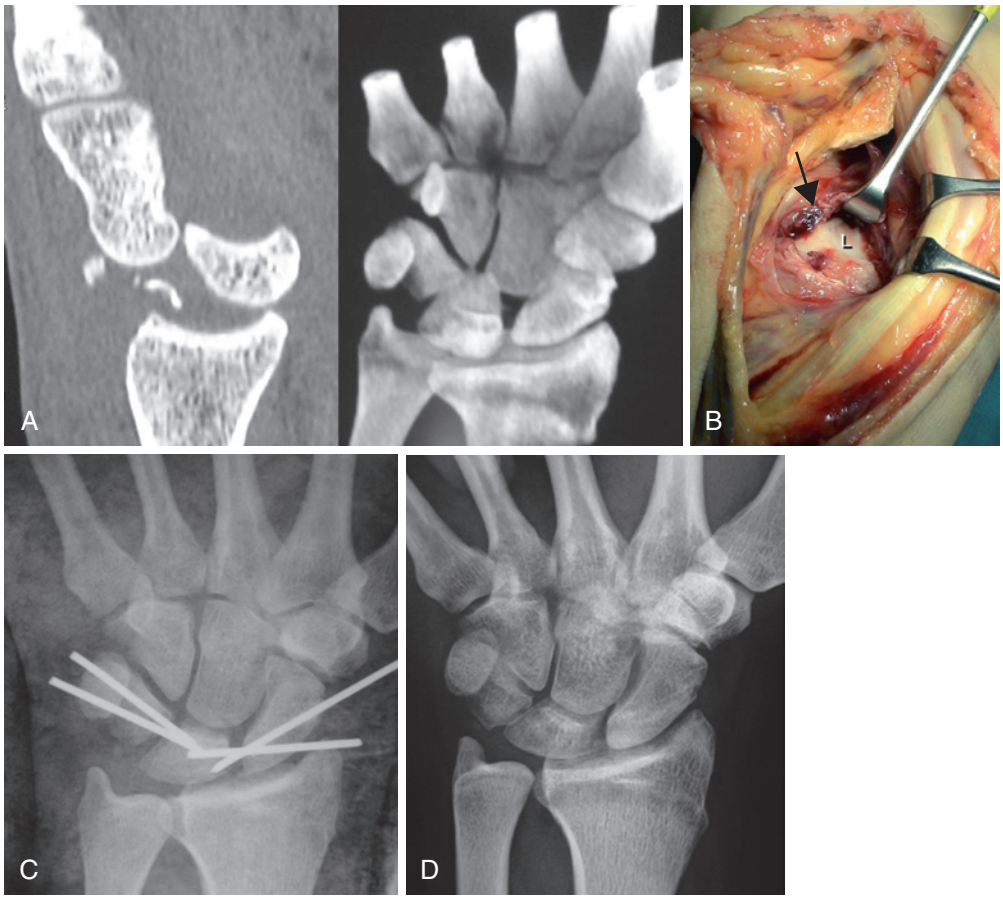

FIGURE 13.57 A 31-year-old male professional motorcycle racer fell during a race. **A,** Computed tomography scan and 3D reconstruction of unreduced perilunate dislocation obtained 3 days after the injury. The dislocation had been missed at presentation. **B,** Surgical approach using an extended carpal tunnel incision allows visualization of the distal surface of the lunate (L). After reduction, the disrupted palmar lunotriquetral (LTq) ligament (*arrow*) was repaired adding further stability to the proximal row. **C,** Placement of stabilizing Kirschner wires across the scapholunate and LTq joints. **D,** Posteroanterior view obtained 8 months after injury. The patient had resumed his racing activities with about a 25% reduction of wrist motion.

http://e-surg.com

CRITICAL POINTS *Perilunate Dislocations: Technique for Open Reduction and K-wire Fixation (Combined Dorsal and Palmar Approach)*

Indication
- All perilunate dislocations, unless unstable medical condition contraindicates surgery

Preoperative Evaluation
- Under axillary block, the dislocation is reduced in the emergency department (Tavernier's maneuver) (Figure 13.55).
- During reduction, traction views are obtained.
- The forearm is elevated in a well-padded above-elbow cast until definitive surgery is possible.

Surgical Approach
- Perform a dorsal 6-cm straight incision centered on the Lister tubercle.
- Open the extensor retinaculum along the third compartment, and expose the second through fourth compartments. Elective neurectomy of the posterior intercarpal nerve may be performed.
- Perform a palmar carpal tunnel incision, extending proximally across the wrist in a zigzag fashion. Flexor tendons and the median nerve are retracted radially.

Usual Findings
- The dorsal capsule is generally found avulsed off the radius. If the dislocation has not been reduced, an obvious empty space between the capitate and radius appears.
- Exploration of the palmar capsule reveals a consistent arciform rent, coinciding with the space of Poirier, coursing along the sulcus between the radiocarpal and long RL ligaments, and ulnarly curving across the palmar LTq ligament (see Figure 13.58). If the dislocation is unreduced, one can see the distal articular surface of the lunate through this rent.

Reduction and Fixation
- The lunate can be easily reduced under direct vision by manually pushing it back in between the capitate and radius, while applying gentle longitudinal traction on the hand.
- The ulnar portion of the capsular rent (i.e., disrupted palmar LTq ligament) is repaired with 3-0 nonabsorbable sutures.
- The lateral portion of the palmar capsular derangement does not need to be repaired because it is an anatomic defect—the interligamentous sulcus between the long RL ligament and the RSC ligament.
- Through the dorsal approach, reduce the LTq joint, stabilize it with a K-wire, and repair the dorsal ligaments.
- Reduce, stabilize, and carefully repair the dorsal SL ligament.
- If the LC joint feels unstable, stabilize it with two crossed K-wires—one through the scaphoid and the other across the triquetrum.
- Obtain radiographs, and assess the quality of the reduction and the purchase of the pins.
- Except for the flexor retinaculum (FR), all anatomic planes are closed with sutures, leaving drains.

Important Tips
- Even if repair of the dorsal ligaments is impossible, their remnants should be tacked back into position; suboptimal repairs may still result in acceptable function.
- Make sure that no osteochondral fragments are left inside the articulation.
- If there is substantial damage of the lunate's cartilage, proximal row carpectomy may be an acceptable solution.
- When present, radial styloid fractures should be reduced anatomically and held with additional K-wire or screw fixation. If the fracture is comminuted, do not excise the unstable fragments so as not to destabilize the radiocarpal ligaments. Molding the fragments back into place as anatomically as possible is recommended.

Postoperative Regimen
- A short arm thumb spica cast is worn for 6 weeks; it is changed at 10 days for stitch removal and radiographs.
- At 8 weeks, cast and wires are removed and rehabilitation to regain range of motion and grip strength starts. A protective removable splint is used between sessions.
- Most patients have some permanent limitation of motion, and several months of rehabilitation are required to regain function. Return to heavy labor is rarely possible before 6 months and more commonly requires up to 12 months.

The dorsal capsule is exposed through a longitudinal incision centered on the Lister tubercle, dividing the extensor retinaculum between the second and third compartments. The fourth compartment is also opened by sectioning the septum between the third and fourth compartments. The capsule often is found disrupted or avulsed at its proximal insertion on the radius. This tear is extended medially following the fibers of the dorsal radiocarpal ligament, and a distally based capsular flap is elevated to uncover the radiocarpal and midcarpal joints.

The palmar approach consists of a carpal tunnel incision extended proximally in a zigzag fashion. The flexor tendons and median nerve are carefully elevated and protected. This allows inspection of the floor of the carpal tunnel, where an lunate-shaped transverse capsular rent along the sulcus between the RSC and long RL ligaments is identified. This capsular rent typically curves proximally across the palmar LTq ligament. Through this rent, the distal articular surface of the lunate can be easily inspected by carefully reproducing the dislocation (see Video 13.4). Before reducing the dislocation, all unstable remnants of the capsule are removed, and the joints are freed from any interposed soft tissue. The lunate is reduced under direct vision by manually pushing it in a dorsal direction while gentle longitudinal traction is applied to the hand. The ulnar corner of the capsular rent, which contains the disrupted palmar LTq ligament, is repaired with nonabsorbable sutures (Figure 13.58).

The carpus is then inspected through the dorsum, and the SL and LTq joints are reduced and stabilized as described previously for the closed percutaneous fixation. Some authors use cerclage wire around the SL joint to provide further stability and allow earlier mobilization. Others insert a headless screw across the SL joint as described for the RASL joint.[60] When possible, direct repair of the dorsal SL and LTq intercarpal ligaments using nonabsorbable sutures is recommended.[39,61]

A reduction clamp to approximate the dissociated bones and facilitate a more reliable ligament repair may be useful. The two ends of all disrupted ligaments are intimately approximated to ensure healing. If there is an associated radial styloid fracture, the dorsal approach is used to reduce it anatomically and to fix

http://e-surg.com

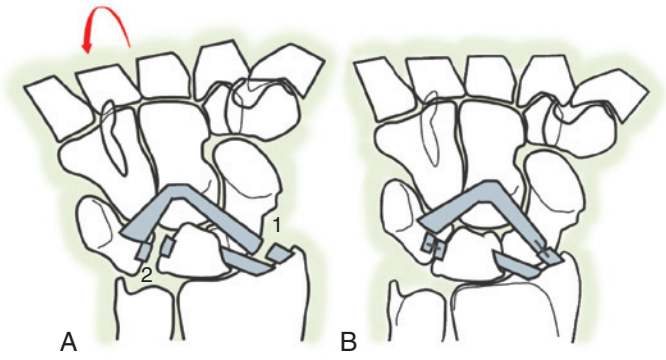

FIGURE 13.58 A, Schematic representation of the two levels of ligament disruption that need to be addressed when approaching a perilunate dislocation (*red arrow*) palmarly: the origin of the radioscaphocapitate (RSC) ligament may have avulsed off the radial styloid (1), and the palmar lunotriquetral ligament often is disrupted through its midsubstance (2). **B,** When properly reduced, the two ligament injuries need to be repaired to recreate or reinforce the distal portion of the ulnar limb of the arcuate ligament (triquetrum-capitate fascicles), and the dorsal radiotriquetral ligament. The apparent rent that exists between the avulsed RSC ligament and the long radiolunate ligament needs no repair because it is an anatomic sulcus (space of Poirier).

it with an additional screw. The postoperative regimen for open treatment of perilunate dislocations is identical to the closed method. If screws are used for fixation of the SL or LTq joints, they should be removed 3 to 5 months after insertion.

Frequently, during the first months after reduction, the lunate may show increased radiodensity. This finding should not be interpreted as posttraumatic Kienböck disease, however, because it tends to progress toward slow recovery without bone collapse in most cases.

According to a multicenter study by Herzberg and colleagues,[38] functional results of open reduction, ligament repair, and K-wire fixation are significantly better than the outcomes with other alternatives, with an average Green and O'Brien wrist functional score of 86 points in stages II and III and 79 points in stage IV (normal score = 100). Similar results have been published by others.[94,40a,109] Patients require a long period of rehabilitation to regain their maximal possible range of motion (~70% of their normal side) and grip strength. Less than one-third of patients are able to return to heavy manual work. With a minimum of 10 years' follow-up, only 8 out of 18 patients treated by Forli et al[24] exhibited a good or excellent clinical outcome; the main problems among the unsuccessful cases were wrist stiffness and articular degeneration.

❖ AUTHORS' PREFERRED METHOD OF TREATMENT: Perilunate Dislocations

All perilunate dislocations need to be reduced by closed means in the emergency department as soon as possible. The reason for such urgency is to decompress the median nerve and to release tension on the vascular supply to the displaced carpal bones. When the dislocation has been reduced, a well-padded bandage is applied, and the forearm is elevated until a definitive surgical treatment can be initiated. If the dislocation has been reduced, delaying the definitive treatment several hours or even a few days to get the right equipment and trained personnel is not a problem, as long as the patient is comfortable with proper analgesia.

We strongly recommend a double-approach open reduction—dorsal SL and palmar LTq ligament repair—and SL and LTq K-wire fixation. I have not used the alternative of reducing displacements anatomically under arthroscopic guidance and stabilizing the SL and LTq joints with temporary screw fixation, as is done in the RASL procedure for SL dissociation. We believe that surgery is always indicated, regardless of the quality of reduction obtained by closed means, unless an underlying medical condition contraindicates it. If the patient is reluctant to allow open surgical treatment, or if an unstable medical condition is likely to persist for more than a week, closed reduction and percutaneous fixation need to be considered. Operative treatment for dorsal perilunate (the Mayfield stage II or III) and palmar lunate (stage IV) dislocations is identical.

Dorsal Perilunate Fracture–Dislocations

Most perilunate fracture–dislocations (i.e., greater-arc injuries) combine ligament ruptures, bone avulsions, and fractures in various clinical forms. The most frequent is the dorsal transscaphoid perilunate dislocation.[38] Much less common, but interesting from a pathomechanic point of view, are dislocations involving a displaced fracture of the capitate[55,111] and dislocations with a displaced fracture of the triquetrum in the sagittal plane.

Transscaphoid Perilunate Fracture–Dislocations. According to most study series, approximately 60% of all perilunate dislocations are associated with a displaced scaphoid fracture, usually in the middle third.[38,94] Most often, the proximal fragment remains connected to the lunate, even if this has undergone a palmar dislocation. The exceptions are rare instances in which there is a concomitant SL dissociation, with the proximal scaphoid being extruded dorsally.[14]

The initial management of transscaphoid perilunate dislocations, including the need for adequate anesthesia and preliminary traction, is identical to the management described for dorsal perilunate dislocations. Radiographs taken with the hand suspended in finger traps are particularly helpful in the assessment of bone damage and should be obtained routinely. Rigid screw fixation of the scaphoid fracture simplifies treatment and rehabilitation because motion can begin before complete healing of the scaphoid fracture. Alternative methods of treatment are as follows.

Closed Reduction and Cast Immobilization. According to Herzberg and associates,[39] the average healing time reported for this injury is 16 weeks when treated with closed reduction and immobilization. The rate of nonunion after treatment approaches 50%.[38] Although not recommended as definitive treatment, the technique for closed reduction is the same regardless of whether the lunate is palmarly displaced or normally aligned, and it is almost identical to that described for lesser-arc injuries. While maintaining some longitudinal traction, the surgeon stabilizes the lunate by pressing the palmar aspect of the wrist with the thumb. From extension, the wrist is gradually flexed. Unless there is some soft tissue interposition, this maneuver brings the capitate back into the concavity of the lunate, sometimes with a snap. The wrist is held in slight flexion and radial inclination, and a padded thumb spica cast is applied.

At this point, it is important to take enough radiographic views to assess the scaphoid fracture reduction. Not only must the scaphoid be anatomically reduced but also the DISI

http://e-surg.com

deformity has to be corrected. If one of these two factors is not completely resolved (usually because of capsular interposition between the two scaphoid fragments), open treatment should be performed.

Closed Reduction and Percutaneous Fixation. If surgery is contraindicated, or the patient refuses open treatment, and provided that the dislocation has been acceptably reduced by closed means, percutaneous treatment is an alternative to avoid progressive loss of reduction. Two or more percutaneous K-wires are driven across the fracture, and two additional ones are used to stabilize the LTq joint. If available, arthroscopically guided percutaneous screw fixation may achieve improved results over those obtained using only the fluoroscope.[117] No long-term results have been published, however, to compare these techniques.

Open Reduction and Internal Fixation. Open reduction and internal fixation is the recommended treatment for achieving anatomic reduction of the many structures that need to be repaired (Figure 13.59). The dorsal approach that is used in lesser-arc injuries is utilized. Palmarly, the Russe approach, as described for grafting scaphoid nonunions, is adequate. This approach is mostly used to free the scaphoid fracture from interposed soft tissue, to apply bone graft if necessary, to address palmar comminution, and to repair the capsular tear that typically coincides with the scaphoid fracture.

The sequence of joint reduction is identical to that described earlier. Usually, bone reduction is better controlled from the dorsum by using K-wires as joysticks. If the fracture is to be stabilized with a headless compression screw, this can be done from either approach. Many surgeons prefer free-handed insertion of the screw from the dorsal aspect of the proximal pole aiming at the palmar–distal scaphoid tuberosity.

Different outcome studies using this open approach have been published.[38,94] According to Herzberg and Forissier,[39] the average Mayo wrist function score obtained at 8 years of follow-up in 14 transscaphoid perilunate dislocations treated with early surgery was 79 points, which is considered a good outcome. Most authors agree that this approach allows recovery of ~110 degrees of active flexion–extension and 75% of grip strength. Most reports emphasize, however, that fixation of the scaphoid alone is insufficient. Poor results may ensue from insufficient stabilization of the LTq joint or from an ulnar translation of the carpus. The worst outcomes are found among more severely displaced dislocations (stage IV), especially if the diagnosis was missed or treatment was delayed for any reason.

Transscaphoid–Transcapitate–Perilunate Fracture–Dislocations. The scaphocapitate syndrome consists of a variation of a greater-arc dislocation in which the scaphoid and the capitate are fractured, the latter being displaced with the proximal pole rotating 90 or 180 degrees.[4,111] Although not fully understood, the capitate fracture seems to be produced by direct impact of the bone against the dorsal lip of the radius when the wrist is hyperextended and ulnarly inclined (Figure 13.60). Rotation of the proximal fragment seems to occur secondarily, forced by the distal fragment as it returns to the neutral position.

Because radiographic interpretation of this injury may be confusing, films with the hand suspended in finger trap traction should be obtained routinely. The squared-off end of the proximal capitate is easily seen in this view. Many of these fractures are not recognized at presentation, however. Fenton[4] advocated excision of the proximal pole of the capitate as primary treatment because he believed that avascular necrosis and nonunion were inevitable. Rarely does the proximal capitate fragment heal in its malrotated position, but this is the distinct exception, and numerous necrotic nonunions have been reported in patients treated nonoperatively. By contrast, most cases treated by open reduction through a dorsal approach and internal fixation with K-wires or screws healed uneventfully 2 to 6 months after surgery.[111]

In comminuted cases, primary bone grafting may be indicated. Vance and coworkers[111] recognized six forms of displacement and recommended that the first step in the operative

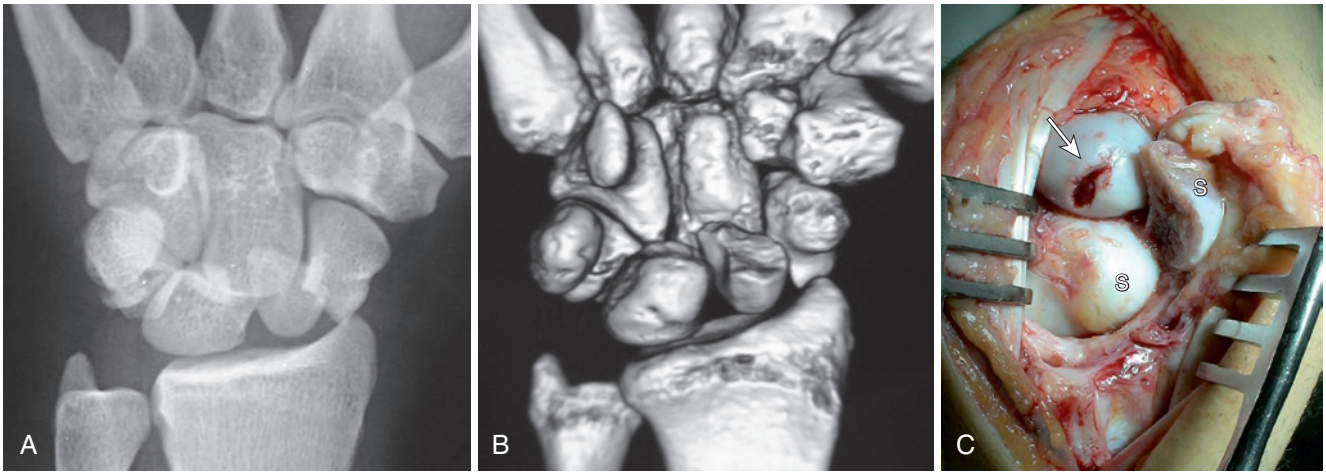

FIGURE 13.59 A 19-year-old man sustained trauma in a motorcycle accident. **A,** Posteroanterior view of wrist shows a transscaphoid perilunate dislocation. **B,** 3D reconstruction of computed tomography scan obtained soon after confirms the injury. **C,** Dorsal surgical approach provided excellent visualization of the structures involved. The two fragments of the scaphoid were completely displaced to each other. Cartilage injury to the proximal pole of the capitate (*arrow*) is quite frequent with this sort of injury, explaining why some patients rapidly develop midcarpal degenerative arthritis. *S,* Scaphoid.

http://e-surg.com

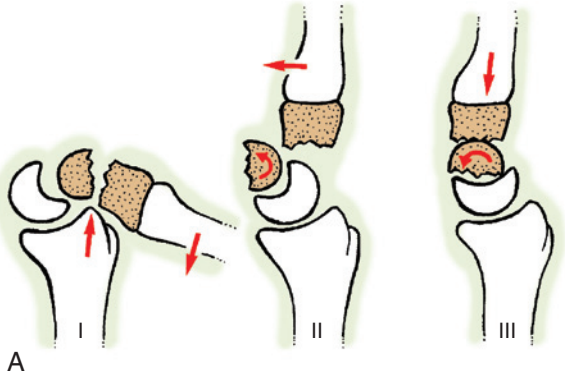



FIGURE 13.60 **A,** Probable mechanism of fracture–dislocation of the capitate as part of the scaphocapitate syndrome, popularized by Fenton.[21] Extreme wrist hyperextension can result in impaction of the neck of the capitate against the dorsal lip of the radius, causing its fracture (*I*). When the wrist is brought back into neutral position, the roughened surface of the fracture may contribute to further displacement of the unconstrained proximal pole of the capitate in a rotatory fashion (*II*). In some cases, the subsequent axial compression can displace the proximal fragment further, which now appears fully (180 degrees) rotated (*III*). **B,** Posteroanterior view of a wrist with scaphocapitate syndrome, with the proximal capitate fragment fully rotated, its articular portion facing distally (*arrow*).

treatment be reduction and fixation of the capitate fracture. The capitate is generally fixed with a headless screw. If capitate fixation is not done, the distal fragment of the scaphoid tends to migrate medially, making its reduction and stabilization difficult. It is equally important to achieve anatomic reduction and stabilization of the scaphoid and lunate using the techniques previously described. Transient avascular changes in the proximal pole of the capitate are common, but healing usually occurs. The overall long-term results after open reduction and internal fixation have been good.

Transtriquetrum–Perilunate Fracture–Dislocations. As previously explained, the third stage of the Mayfield "progressive perilunate instability" is defined by the occurrence of LTq dissociation.[45,64] The lunate is constrained by the two strong RL ligaments (i.e., long and short), and a sudden extension moment is exerted by the dislocating distal row via the triquetrum–hamate–capitate ligaments. Such opposing forces usually result in rupture or avulsion, from palmar-to-dorsal, of the LTq ligaments. In about one-fourth of patients, instead of ligament derangement there is either a sagittal fracture of the body of the triquetrum or a proximal pole avulsion fracture, representing a ligament detachment (Figure 13.61). During the open procedure, this fragment should not be excised but replaced carefully in its original position to ensure correct LTq ligament stability. The triquetrum is a well-vascularized bone, and necrosis or nonunion reports have seldom been published after a wrist dislocation.

Late Treatment of Unreduced Fracture–Dislocations. Despite increased awareness of their clinical and radiological features, the diagnosis of perilunate dislocation is still frequently missed at presentation (in 16-25% of the cases, according to a different series), resulting in chronic wrist disorders and degenerative arthritis.[38] Delay in treatment has repeatedly been found to be an important factor influencing the long-term outcome for patients.

Even though it is unclear how late an open reduction can be accomplished, successful cases have been reported 35 weeks after injury[41] (Figure 13.62). This repair generally requires dorsal and palmar approaches. The use of wrist distraction with an external fixator for a week before surgery seems to facilitate open reduction of old dislocations.[102] If the bones can be reduced and fixed anatomically, satisfactory results can be expected. If reduction cannot be accomplished, or if there is significant cartilage damage, either a proximal row carpectomy or a total wrist arthrodesis is indicated. The results of isolated excision of only the lunate are uniformly poor.[41]

Palmar–Perilunate Dislocations

A palmar dislocation of the capitate relative to the lunate is a very rare injury, representing less than 3% of all wrist dislocations[94] (Figure 13.63). They may occur in association with a fracture of the lunate in the frontal plane,[5] or as a result of a progressive perilunate instability induced by a combination of forced hyperflexion and supination of the wrist relative to the radius.[45] In the former, the capitate subluxation is mild and the consequence of the dorsally displaced lunate fracture. In these circumstances, closed treatment is seldom effective, owing to the fracture's inherent instability. Open reduction using palmar and dorsal approaches and internal fixation of the lunate fracture with wires or screws is the method of choice.

In palmarly displaced perilunate dislocations without a lunate fracture, either SL dissociation or a scaphoid fracture is inevitably present. One or the other typically has a very unstable vertical orientation in the frontal plane, making recognition of it difficult on a standard PA view; a diagnosis is more readily apparent on the lateral view. Reported cases with concomitant rupture of extensor tendons suggest that the mechanism of injury is violent. In acute injuries, closed reduction using finger trap traction should be the initial step in management. Although successful treatment has been reported with closed reduction alone, these are exceedingly unstable injuries; in most cases, the only reliable way to realign and stabilize the scaphoid and perilunate injury is operative treatment.

http://e-surg.com

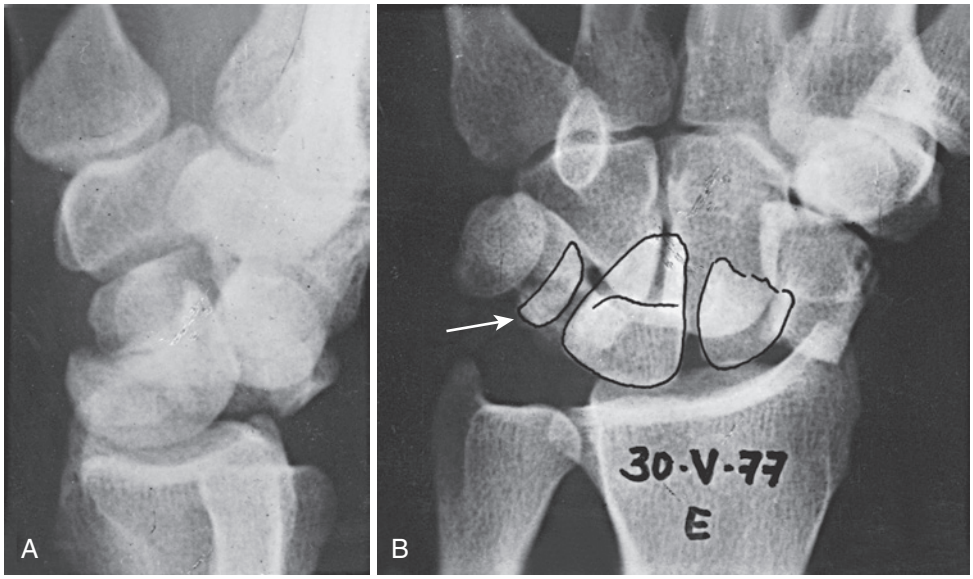

FIGURE 13.61 Lateral **(A)** and posteroanterior **(B)** radiographs of a transscaphoid, transtriquetrum, perilunate dislocation. In this case, there is a sagittal fracture of the triquetrum (*arrow*). The intercarpal lunotriquetral ligaments are probably intact.

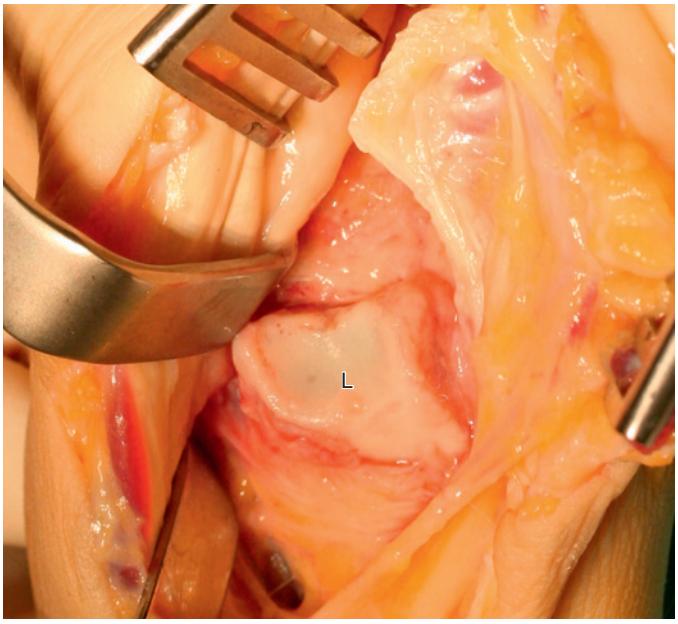

FIGURE 13.62 Volar lunate (L) dislocation was not diagnosed at presentation until median nerve symptoms forced reexamination of the initial radiographs. The wrist was explored at 8 weeks' postinjury with volar and dorsal approaches. The enucleated lunate, surrounded by scar tissue, is demonstrated in the carpal tunnel. The injury was treated with reduction, ligament repair, and Kirschner wire stabilization for 3 months. The final outcome was acceptable, with less than 25% loss of grip strength and 20% loss of range of motion.

Radiocarpal Dislocations

According to Dumontier and coworkers,[22] there are two types of radiocarpal dislocations. Type I includes patients with a pure radiocarpal dislocation, without an associated fracture of the distal radius. Type II involves a radiocarpal dislocation with an avulsion fracture of the radial styloid, which contains the origin of the palmar RS and RSC ligaments. This first type is exceedingly rare; no more than 20 cases have been reported; usually, they are the result of severe shear and rotational injury in young subjects. Associated neurovascular damage is not unusual. Reduction is easy by external manipulation, but maintenance of reduction is difficult because of the loss of radiocarpal ligament attachments. Type II radiocarpal dislocations, with an associated avulsion fracture of the radial styloid, have been reported more frequently. These have a much better prognosis provided that the styloid fracture, which contains the avulsed radiocarpal ligaments, is anatomically reduced and fixed.

Axial Fracture–Dislocations

When the palmar concavity of the carpus is involved in a high-energy dorsal–palmar compression (crush mechanism), a longitudinal disruption of the carpal arch may occur.[80] In most instances, the wrist splits into two axial columns, one remaining normally aligned with the radius and the other shifting in a radial or ulnar direction (Figure 13.64). The metacarpals usually follow the displacement of their corresponding carpal bones, causing an intermetacarpal derangement. As the carpal arch flattens, the FR may either disrupt or avulse from its lateral insertions. Because carpal derangement appears more or less parallel to the long axis of the forearm, Cooney and associates[21] coined the term "axial dislocation" to describe these injuries. Other descriptive terms, such as longitudinal disruption, sagittal splitting, or intercarpal diastasis, may also be appropriate.

Axial dislocations are common in developing countries, where safety measures for wringer-type machines, roller presses, and molding presses are not available. Because of the high energy involved, most patients present with severe associated soft tissue damage, including disruption of the FR with traumatic decompression of the carpal tunnel and subsequent nerve and vascular injuries.

Two major groups of dislocation injuries have been described: axial ulnar and axial radial. In the former, the carpus splits into two columns, with the radial column aligned and stable with respect to the radius, and the ulnar column unstable and displaced proximally and ulnarly (Figure 13.65). In the latter, the

http://e-surg.com

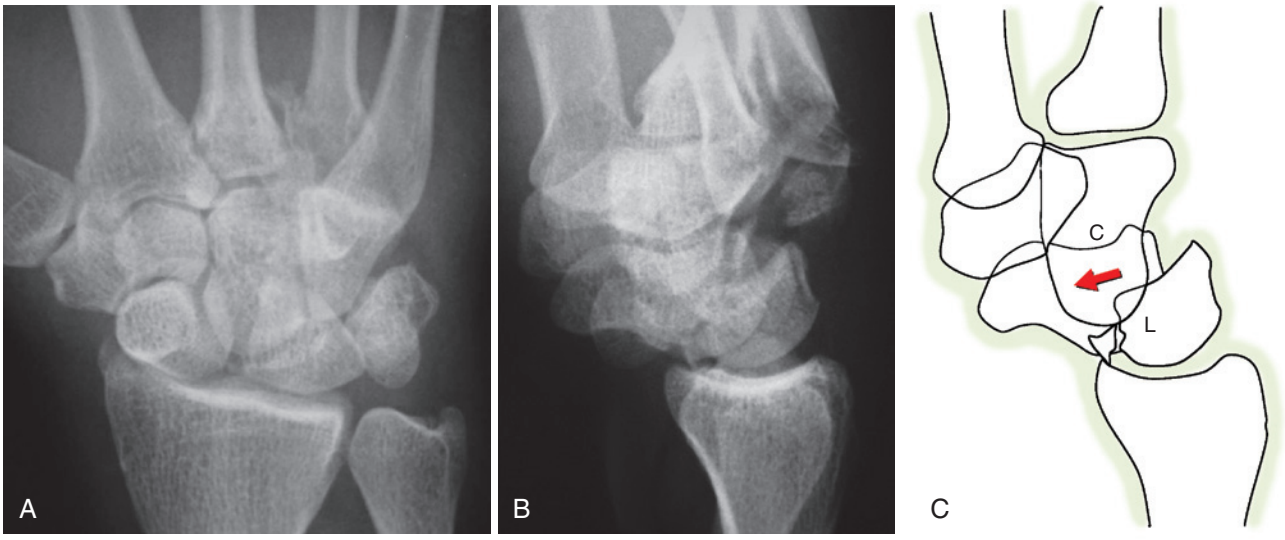

FIGURE 13.63 Example of a rare translunate anterior dislocation of the wrist. **A,** Initial posteroanterior view could be easily diagnosed as a static lunotriquetral dissociation because the lunate (L) shows the typical moonlike configuration. **B,** Careful assessment of the lateral view shows the presence of a fracture of the palmar lip of the lunate and an anterior dislocation of the distal row. **C,** Schematic representation of the sagittal view, demonstrating a capitate subluxation relative to the fractured lunate (*red arrow*).

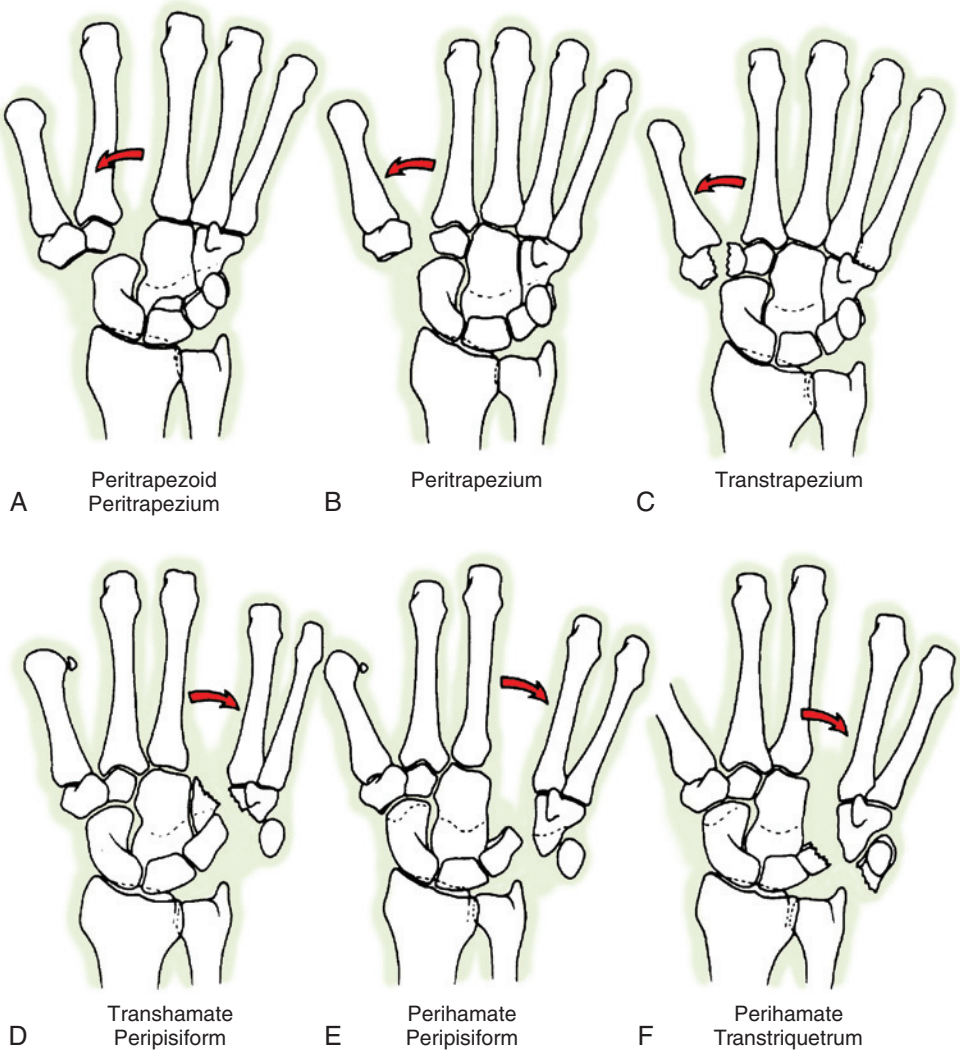

FIGURE 13.64 Schematic representation of the most frequently reported axial fracture–dislocations. **A-C,** In axial–radial dislocations, there is an unstable segment displaced in a radial direction. **D-F,** The opposite instability is seen among the axial–ulnar derangements. (From Garcia-Elias M, Dobyns JH, Cooney WP, III, et al: Traumatic axial dislocations of the carpus. *J Hand Surg [Am]* 14:446–457, 1989.[80])

http://e-surg.com



FIGURE 13.65 Perihamate, peripisiform axial–ulnar dislocation. Vertical disruption involves the distal carpal row and the base of the third and fourth metacarpals. The pisiform is ulnarly displaced because it remains attached to the flexor carpi ulnaris tendon complex.



FIGURE 13.66 Anterolateral dislocation of the scaphoid, type I (without concomitant hamate-capitate axial–ulnar dislocation). (Courtesy of Dr. Fabio Urraza.)

ulnar part of the carpus remains normally aligned with the radius, and the radial aspect of the carpus is displaced and unstable.

The tendons within the carpal tunnel have divergent directions when they emerge into the palm. If their corresponding muscles contract, the flexor tendons of the little finger force the hook of the hamate toward the ulnar side. This force would be opposite in direction to the force generated when the FPL contracts against the inner surface of the triquetrum. Such opposing forces tend to open the palmar carpal concavity (i.e., trapezium toward the radial side, hamate toward the ulnar side) if it were not for the presence of the FR and the strong and taut transverse intercarpal ligaments of the distal carpal row. Their annular disposition maintains adequate transverse stability to the carpal arch. Catastrophic failure of these intrinsic carpal ligaments creates a particular type of carpal instability, termed *axial* or *longitudinal*, with the tunnel splitting into two or more unstable columns and moving in divergent directions.

When dealing with these complex fracture–dislocations, a careful assessment of the associated neurovascular and musculotendinous injury is necessary. A radical debridement of devitalized muscle, subcutaneous tissue, and skin is critical. Closed reduction and percutaneous fixation of the displaced bones may be successful, but open reduction and K-wire or screw fixation has yielded more reliable results. A dorsal approach to control bone reduction and an extended palmar approach to assess associated soft tissue injuries are usually required. Repair of the damaged intercarpal ligaments is seldom possible because of the high energy of the injury and ligamentous shredding. In many instances, decompression of the carpal tunnel is unnecessary because the FR has been disrupted or avulsed already by the trauma. In case of doubt, however, inspection of the carpal tunnel is recommended. Immobilization in a cast for 6 to 8 weeks, depending on the extent of injury, is advisable. Early intensive physical and occupational therapy facilitate rehabilitation. The long-term results are not good, in the most part because of associated tendon and neurovascular involvement.

In less severe dorsal–palmar compressions of the carpal concavity, complete rupture of the transverse intercarpal ligaments between bones of the distal row may occur. If not properly healed, patients may complain of localized discomfort and lack of stability at the dissociated site.

Isolated Carpal Bone Dislocations

When a localized, direct or indirect force is concentrated over a single bone of the wrist, the resulting pressure may be sufficient to cause a localized fracture–dislocation.[47,49] Although the bones of the radial column appear to be more vulnerable to this type of aggression, each carpal bone has been reported to be dislocated. In contrast to axial disruptions, isolated carpal bone dislocations do not imply a global carpal derangement. Actually, except for the lunate and scaphoid, the carpal disorder created by removing the enucleated bone seems to be well tolerated.

Palmar dislocation of the scaphoid is a rare injury, with less than 40 cases reported in the literature.[47] Two clinical forms have been described: isolated anterolateral dislocation of the proximal pole of the scaphoid (type I) and scaphoid dislocation associated with an axial derangement of the capitate–hamate joint (type II) (Figure 13.66). The most probable mechanism of type I injuries involves a violent hyperpronation injury to an extended and ulnarly inclined wrist, causing SL dissociation first, followed by the enucleation of the proximal pole of the scaphoid around the RSC ligament. These injuries also may be the result of a self-reduced palmar–perilunate dislocation, the scaphoid having been left unreduced by capsular interposition.

http://e-surg.com

Type II injuries are thought to involve a high-energy axial compressive load along the third and fourth metacarpals, creating enough shear stress to the capitate–hamate joint to disrupt its strong ligament attachments. None of these mechanisms has been established, however. Diagnosis of the condition is straightforward. An abnormal bony prominence adjacent to the radial styloid has been described frequently. In PA and lateral views, the proximal scaphoid appears enucleated forward and outward, whereas its distal end remains attached to the triquetrum. In type II dislocations, there is also a proximal migration of the capitate and an obvious derangement of the capitate–hamate joint. Closed reduction is easily accomplished by traction and direct manual pressure in most acute cases, all with good results. More recent publications have advocated an open reduction through a dorsal approach, however. Avascular necrosis of the scaphoid has not been reported.

Most reported cases of trapezium dislocation can be described as peritrapezium axial–radial dislocations; that is, the triquetrum appears displaced together with the first metacarpal. Complete enucleations with proximal and distal joint disruption are very rare[40]; usually they are the result of a blow to the dorsolateral aspect of the wrist or a consequence of a hyperextension–supination injury to the radial-inclined wrist. Although some reported cases were openly reduced, excision seems to be a reasonable solution, as shown by the many instances in which trapeziectomy alone has been done, with good patient satisfaction, for the treatment of trapeziometacarpal (TM) arthritis.

Most trapezoid dislocations described in publications manifested with a concomitant displacement of the second metacarpal. According to a literature review by Koenig and West,[49] dislocations of the trapezoid without other associated fractures or dislocations of adjacent bones are very rare. Palmar dislocations may cause attritional rupture of flexor tendons. There is no clear explanation as to how a wedge-shaped bone (wider dorsally) dislocates palmarly. It is plausible that a direct blow, associated with hyperextension of the midcarpal joint, is involved. Successful closed reduction of the dislocated bone has been achieved only in dorsal dislocations. Most volar dislocations of the trapezoid underwent bone excision and localized fusion with acceptable results.

For Case Studies, Videos, and more, please visit ExpertConsult.com.

REFERENCES

1. Allieu Y: Carpal instability—ligamentous instabilities and intracarpal malalignments–explication of the concept of carpal instability. *Ann Chir Main* 3:366–367, 1984.
2. Anatomy and Biomechanics Committee of the International Federation of Societies for Surgery of the Hand: Definition of carpal instability. *J Hand Surg [Am]* 24:866–867, 1999.
3. Andersson JK, Garcia-Elias M: Dorsal scapholunate ligament injury: a classification of clinical forms. *J Hand Surg Eur Vol* 38:165–169, 2013.
4. Apergis E: Scaphocapitate fracture-dislocation. In Garcia-Elias M, Mathoulin C, editors: *Articular injury of the wrist*, Stuttgart, 2014, Thieme, pp 61–65.
5. Bain GI, McGuire DT: Decision making for partial carpal fusions. *J Wrist Surg* 1:103–104, 2012.
6. Berdia S, Wolfe SW: Effects of scaphoid fractures on the biomechanics of the wrist. *Hand Clin* 17:533–540, 2001.
7. Berger RA: The ligaments of the wrist: a current overview of anatomy with considerations of their potential functions. *Hand Clin* 13:63–82, 1997.
8. Berschback JC, Kalainov DM, Husain SN, et al: Traumatic ulnar translocation of the carpus: early recognition and treatment. *J Hand Surg Eur Vol* 37:755–764, 2012.
9. Brigstocke GH, Hearnden A, Holt C, et al: In-vivo confirmation of the use of the dart thrower's motion during activities of daily living. *J Hand Surg Eur Vol* 39:373–378, 2014.
10. Brunelli GA, Brunelli GA: Carpal instability with SL dissociation treated using the flexor carpi radialis and scapho-trapezoid ligament repair: foundations, technique and results of preliminary series. *Rev Chir Orthop Reparatrice Appar Mot* 89:152–157, 2003.

10a. Calandruccio JH, Gelberman RH, Duncan SF, et al: Capitolunate arthrodesis with scaphoid and triquetrum excision. *J Hand Surg [Am]* 25(5):824–832, 2000.

11. Camus EJ, Van Overstraeten L: Dorsal scapholunate stabilization using Viegas' capsulodesis: 25 cases with 26 months follow-up. *Chir Main* 32:393–402, 2013.
12. Cerezal L, de Dios Berná-Mestre J, Canga A, et al: MR and CT arthrography of the wrist. *Semin Musculoskelet Radiol* 16:27–41, 2012.
13. Chee KG, Chin AY, Chew EM, et al: Antipronation spiral tenodesis—a surgical technique for the treatment of perilunate instability. *J Hand Surg [Am]* 37:2611–2618, 2012.
14. Cheng CY, Hsu KY, Tseng IC, et al: Concurrent scaphoid fracture with scapholunate ligament rupture. *Acta Orthop Belg* 70:485–491, 2004.
15. Christodoulou L, Bainbridge LC: Clinical diagnosis of triquetrolunate ligament injuries. *J Hand Surg [Br]* 24:598–600, 1999.
16. Cohen MS: Scapholunate acute repair techniques. In Shin AY, Day CS, editors: *Epub-Advances in scapholunate ligament treatment*, Chicago IL, 2014, American Society for Surgery of the Hand, pp 75–83.
17. Corella F, Del Cerro M, Ocampos M, et al: Arthroscopic ligamentoplasty of the dorsal and volar portions of the scapholunate ligament. *J Hand Surg [Am]* 38: 2466–2477, 2013.
18. Crisco JJ, Heard WM, Rich RR, et al: The mechanical axes of the wrist are oriented obliquely to the anatomical axes. *J Bone Joint Surg Am* 93:169–177, 2011.
19. de Smet L, Goeminne S, Degreef I: Failures of the three-ligament tenodesis for chronic static scapholunate dissociation are due to insufficient reduction. *Acta Orthop Belg* 77:595–597, 2011.
20. del Piñal F: Arthroscopic volar capsuloligamentous repair. *J Wrist Surg* 2:126–128, 2013.
21. Dobyns JH, Linscheid RL: A short history of the wrist joint. *Hand Clin* 13:1–12, 1997.
22. Dumontier C, Meyer ZU, Reckendorf G, et al: Radiocarpal dislocations: classification and proposal for treatment: a review of twenty-seven cases. *J Bone Joint Surg Am* 83:212–218, 2001.
23. Feipel V, Rooze M: The capsular ligaments of the wrist: morphology, morphometry and clinical applications. *Surg Radiol Anat* 21:175–180, 1999.
24. Forli A, Courvoisier A, Wimsey S, et al: Perilunate dislocations and transscaphoid perilunate fracture-dislocations: a retrospective study with minimum ten-year follow-up. *J Hand Surg [Am]* 35:62–68, 2010.
25. Gajendran VK, Peterson B, Slater RR, Jr, et al: Long-term outcomes of dorsal intercarpal ligament capsulodesis for chronic SL dissociation. *J Hand Surg [Am]* 32:1323–1333, 2007.
26. Garcia-Elias M: Classification of scapholunate injuries. In Shin AY, Day CS, editors: *Epub-Advances in scapholunate ligament treatment*, Chicago IL, 2014, American Society for Surgery of the Hand, pp 52–62.
27. Garcia-Elias M: The non-dissociative clunking wrist: a personal view. *J Hand Surg Eur Vol* 33:698–711, 2008.
28. Garcia-Elias M, Alomar Serrallach X, Monill Serra J: Dart-throwing motion in patients with scapholunate instability: a dynamic four-dimensional computed tomography study. *J Hand Surg Eur Vol* 39:346–352, 2014.
29. Garcia-Elias M, Lluch L, Ferreres A, et al: Treatment of radiocarpal degenerative osteoarthritis by radioscapholunate arthrodesis and distal scaphoidectomy. *J Hand Surg [Am]* 30:8–15, 2005.
30. Garcia-Elias M, Lluch AL, Stanley JK: Three-ligament tenodesis for the treatment of SL dissociation: indications and surgical technique. *J Hand Surg [Am]* 31:125–134, 2006.
31. Geissler WB: Arthroscopic management of scapholunate instability. *J Wrist Surg* 2:129–135, 2013.
32. Goldfarb CA, Stern PJ, Kiefhaber TR: Palmar midcarpal instability: the results of treatment with 4-corner arthrodesis. *J Hand Surg [Am]* 29:258–263, 2004.
33. Guidera PM, Watson HK, Dwyer TA, et al: Lunotriquetral arthrodesis using cancellous bone graft. *J Hand Surg [Am]* 26:422–427, 2001.
34. Gupta A: Factors affecting the sagittal alignment of the lunate. *J Hand Surg Eur Vol* 32:155–159, 2007.
35. Hagert E: Proprioception of the wrist joint: a review of current concepts and possible implications on the rehabilitation of the wrist. *J Hand Ther* 23:2–16, 2010.
36. Halikis MN, Colello-Abraham K, Taleisnik J: RL fusion: the forgotten partial arthrodesis. *Clin Orthop Relat Res* 341:30–35, 1997.

http://e-surg.com

37. Harvey EJ, Berger RA, Osterman AL, et al: Bone-tissue-bone repairs for SL dissociation. *J Hand Surg [Am]* 32:256–264, 2007.
38. Herzberg G, Comtet JJ, Linscheid RL, et al: Perilunate dislocations and fracture-dislocations: a multicenter study. *J Hand Surg [Am]* 18:768–769, 1993.
39. Herzberg G, Forissier D: Acute dorsal trans-scaphoid perilunate fracture-dislocations: medium-term results. *J Hand Surg [Br]* 27:498–502, 2002.
40. Ichikawa T, Inoue G: Complete dislocation of the trapezium: case report. *Scand J Plast Reconstr Surg Hand Surg* 33:335–337, 1999.
40a. Inoue G, Kuwahata Y: Management of acute perilunate dislocations without fracture of the scaphoid. *J Hand Surg [Br]* 22(5):647–652, 1997.
41. Inoue G, Shionoya K: Late treatment of unreduced perilunate dislocations. *J Hand Surg [Br]* 24:221–225, 1999.
42. International Wrist Investigators' Workshop (IWIW), Terminology Committee: Wrist: terminology and definitions. *J Bone Joint Surg Am* 84(Suppl 1):1–69, 2002.
43. Johnson RP, Carrera GF: Chronic capitolunate instability. *J Bone Joint Surg Am* 68:1164–1176, 1986.
44. Johnson RP: The acutely injured wrist and its residuals. *Clin Orthop Relat Res* 149:33–44, 1980.
45. Jones DB, Jr, Kakar S: Perilunate dislocations and fracture dislocations. *J Hand Surg [Am]* 37:2168–2173, 2012.
46. Kauer JM: Functional anatomy of the wrist. *Clin Orthop Relat Res* 149:9–20, 1980.
47. Kennedy JG, O'Connor P, Brunner J, et al: Isolated carpal scaphoid dislocation. *Acta Orthop Belg* 72:478–483, 2006.
48. Kitay A, Wolfe SW: Scapholunate instability: current concepts in diagnosis and management. *J Hand Surg [Am]* 37:2175–2196, 2012.
49. Koenig TR, West OC: Palmar dislocation of the trapezoid. *Skeletal Radiol* 32:95–98, 2003.
50. Larsen CF, Amadio PC, Gilula LA, et al: Analysis of carpal instability, I: description of the scheme. *J Hand Surg [Am]* 20:757–764, 1995.
51. Larson TB, Stern PJ: Reduction and association of the scaphoid and lunate procedure: Short-term clinical and radiographic outcomes. *J Hand Surg [Am]* 39:2168–2174, 2014.
51a. Lawand A, Foulkes GD: The "clenched pencil" view: a modified clenched fist scapholunate stress view. *J Hand Surg [Am]* 28(3):414–418, 2003.
52. Lee JI, Nha KW, Lee GY, et al: Long-term outcomes of arthroscopic debridement and thermal shrinkage for isolated partial intercarpal ligament tears. *Orthopedics* 35:e1204–e1209, 2012.
53. Lee SK, Zlotolow DA, Yao J: Scapholunate axis method. In Shin AY, Day CS, editors: *Epub-Advances in scapholunate ligament treatment*, Chicago IL, 2014, American Society for Surgery of the Hand, pp 124–135.
54. León-Lopez MM, Salvá-Coll G, Garcia-Elias M, et al: Role of the extensor carpi ulnaris in the stabilization of the lunotriquetral joint. An experimental study. *J Hand Ther* 26:312–317, 2013.
55. Leung YF, Ip SP, Wong A, et al: Transscaphoid transcapitate transtriquetral perilunate fracture-dislocation: a case report. *J Hand Surg [Am]* 31:608–610, 2006.
56. Lichtman DM, Wroten ES: Understanding midcarpal instability. *J Hand Surg [Am]* 31:491–498, 2006.
57. Linscheid RL, Dobyns JH, Beabout JW, et al: Traumatic instability of the wrist: diagnosis, classification, and pathomechanics. *J Bone Joint Surg Am* 54:1612–1632, 1972.
57a. Lluch A: Osteoarthritis of the wrist and DRUJ. In Trail IA, Fleming ANM, editors: *Disorders of the hand*, Volume 3: Inflammation, arthritis and contractures, London, 2015, Springer-Verlag, pp 41–69.
58. Lluch AL, Garcia-Elias M, Lluch AB: Arthroplasty of the scaphoid-trapezium-trapezoid and carpometacarpal joints. *Hand Clin* 29:57–68, 2013.
59. Lluch A, Hooper G, Kapandji A, et al: *Terminology for hand surgery*. Nomenclature Committee of the International Federation of Societies for Surgery of the Hand. London: Hartcourt Health Sciences, 2011.
60. Lombardi JM, Rodriguez RR, Rosenwasser MP: Reduction and association of scaphoid and lunate for scapholunate instability. In Shin AY, Day CS, editors: *Epub-Advances in scapholunate ligament treatment*, Chicago IL, 2014, American Society for Surgery of the Hand, pp 153–162.
61. Luchetti R, Atzei A, Cozzolino R, et al: Current role of open reconstruction of the scapholunate ligament. *J Wrist Surg* 2:116–125, 2013.
62. Luegmair M, Saffar P: Scaphocapitate arthrodesis for treatment of scapholunate instability in manual workers. *J Hand Surg [Am]* 38:878–886, 2013.
63. Majima M, Horii E, Matsuki H, et al: Load transmission through the wrist in the extended position. *J Hand Surg [Am]* 33:182–188, 2008.
64. Mayfield JK, Johnson RP, Kilcoyne RK: Carpal dislocations: pathomechanics and progressive perilunar instability. *J Hand Surg [Am]* 5:226–241, 1980.
65. Megerle K, Bertel D, Germann G, et al: Long-term results of dorsal intercarpal ligament capsulodesis for the treatment of chronic scapholunate instability. *J Bone Joint Surg Br* 94:1660–1665, 2012.
66. Messina JC, van Overstraeten L, Luchetti R, et al: The EWAS classification of scapholunate tears: An anatomical arthroscopy study. *J Wrist Surg* 2:105–109, 2013.
67. Moojen TM, Snel JG, Ritt MJPF, et al: In vivo analysis of carpal kinematics and comparative review of the literature. *J Hand Surg [Am]* 28:81–87, 2003.
68. Moran SL, Ford KS, Wulf CA, et al: Outcomes of dorsal capsulodesis and tenodesis of SL instability. *J Hand Surg [Am]* 31:1438–1446, 2006.
69. Moritomo H, Apergis EP, Garcia-Elias M, et al: International Federation of Societies for Surgery of the Hand 2013 Committee's report on wrist dart-throwing motion. *J Hand Surg [Am]* 39:1433–1439, 2014.
70. Moritomo H, Murase T, Arimitsu S, et al: Change in the length of the ulnocarpal ligaments during radiocarpal motion: possible impact on triangular fibrocartilage complex foveal tears. *J Hand Surg [Am]* 33:1278–1286, 2008.
71. Murray PM, Palmer CG, Shin AY: The mechanism of ulnar-sided perilunate instability of the wrist: a cadaveric study and 6 clinical cases. *J Hand Surg [Am]* 37:721–728, 2012.
71a. Nathan R, Blatt G: Rotatory subluxation of the scaphoid revisited. *Hand Clin* 16(3):417–431, 2000.
72. Omori S, Moritomo H, Omokawa S, et al: In vivo 3-dimensional analysis of dorsal intercalated segment instability deformity secondary to scapholunate dissociation: a preliminary report. *J Hand Surg [Am]* 38:1346–1355, 2013.
73. Petterson K, Wagnsjö P: Arthrodesis for chronic static SL dissociation: a prospective study in 12 patients. *Scand J Plast Reconstr Surg Hand Surg* 38:166–171, 2004.
74. Picha BM, Konstantakos EK, Gordon DA: Incidence of bilateral scapholunate dissociation in symptomatic and asymptomatic wrists. *J Hand Surg [Am]* 37:1130–1135, 2012.
75. Pomerance J: Outcome after repair of the SL Intercarpal ligament and dorsal capsulodesis for dynamic SL instability due to trauma. *J Hand Surg [Am]* 31:1380–1386, 2006.
76. Rainbow MJ, Crisco JJ, Moore DC, et al: Elongation of the dorsal carpal ligaments: a computational study of in vivo carpal kinematics. *J Hand Surg [Am]* 37:1393–1399, 2012.
77. Rauhaniemi J, Tiusanen H, Sipola E: Total wrist fusion: a study of 115 patients. *J Hand Surg [Br]* 30:217–219, 2005.
78. Rayhack JM, Linscheid RL, Dobyns JH, et al: Posttraumatic ulnar translation of the carpus. *J Hand Surg [Am]* 12:180–189, 1987.
79. Reagan DS, Linscheid RL, Dobyns JH: LTq sprains. *J Hand Surg [Am]* 9:502–514, 1984.
80. Reinsmith LE, Garcia-Elias M, Gilula LA: Traumatic axial dislocation injuries of the wrist. *Radiology* 267:680–689, 2013.
81. Renoux J, Zeitoun-Eiss D, Brasseur JL: Ultrasonographic study of wrist ligaments: review and new perspectives. *Semin Musculoskelet Radiol* 13:55–65, 2009.
82. Rhee PC, Moran SL, Shin AY: Association between lunate morphology and carpal collapse in cases of scapholunate dissociation. *J Hand Surg [Am]* 34:1633–1639, 2009.
83. Rhee PC, Sauvé PS, Lindau T, et al: Examination of the wrist: ulnar-sided wrist pain due to ligamentous injury. *J Hand Surg [Am]* 39:1859–1862, 2014.
84. Riemann BL, Lephart SM: The sensorimotor system, part I: the physiologic basis of functional joint stability. *J Athl Train* 37:71–79, 2002.
85. Rikli DA, Honigmann P, Babst R, et al: Intra-articular pressure measurement in the radioulnocarpal joint using a novel sensor: in vitro and in vivo results. *J Hand Surg [Am]* 32:67–75, 2007.
86. Ringler MD: MRI of wrist ligaments. *J Hand Surg [Am]* 38:2034–2046, 2013.
87. Ritt MJPF, Linscheid RL, Cooney WP, et al: The LTq joint: kinematic effects of sequential ligament sectioning, ligament repair, and arthrodesis. *J Hand Surg [Am]* 23:432–445, 1998.
88. Rohman EM, Agel J, Putnam MD, et al: Scapholunate interosseous ligament injuries: a retrospective review of treatment and outcomes in 82 wrists. *J Hand Surg [Am]* 39:2020–2026, 2014.
89. Rosati M, Parchi P, Cacianti M, et al: Treatment of acute scapholunate ligament injuries with bone anchor. *Musculoskelet Surg* 94:25–32, 2010.
90. Ross M, Peters SE, Couzens GB: Scapho-luno-triquetral tenodesis. In Shin AY, Day CS, editors: *Epub-Advances in scapholunate ligament treatment*, Chicago IL, 2014, American Society for Surgery of the Hand, pp 111–123.
91. Salva-Coll G, Garcia-Elias M, Hagert E: Scapholunate instability: proprioception and neuromuscular control. *J Wrist Surg* 2:136–140, 2013.
92. Salva-Coll G, Garcia-Elias M, Leon-Lopez MT, et al: Effects of forearm muscles on carpal stability. *J Hand Surg Eur Vol* 36:553–559, 2011.
93. Sauvé PS, Rhee PC, Shin AY, et al: Examination of the wrist: radial-sided wrist pain. *J Hand Surg [Am]* 39:2089–2092, 2014.
94. Scalcione LR, Gimber LH, Ho AM, et al: Spectrum of carpal dislocations and fracture-dislocations: imaging and management. *AJR Am J Roentgenol* 203:541–550, 2014.
95. Schuind FA, Linscheid RL, An KN, et al: A normal data base of PA roentgenographic measurements of the wrist. *J Bone Joint Surg Am* 74:1418–1429, 1992.
96. Seradge H, Baer C, Dalsimer D, et al: Treatment of dynamic scaphoid instability. *J Trauma* 56:1253–1269, 2004.

http://e-surg.com

97. Shahane SA, Trail IA, Takwale VJ, et al: Tenodesis of the extensor carpi ulnaris for chronic, post-traumatic LTq instability. *J Bone Joint Surg Br* 87:1512–1515, 2005.
98. Shin AY, Weinstein LP, Berger RA, et al: Treatment of isolated injuries of the LTq ligament: a comparison of arthrodesis, ligament reconstruction and ligament repair. *J Bone Joint Surg Br* 83:1023–1028, 2001.
99. Short WH, Werner FW: The biomechanics of the scapholunate joint. In Shin AY, Day CS, editors: *Epub-Advances in scapholunate ligament treatment*, Chicago IL, 2014, American Society for Surgery of the Hand, pp 21–33.
100. Slutsky DJ: Current innovations in wrist arthroscopy. *J Hand Surg [Am]* 37:1932–1941, 2012.
101. Soong M, Merrell GA, Ortmann F, 4th, et al: Long-term results of bone-retinaculum-bone autograft for scapholunate instability. *J Hand Surg [Am]* 38:504–508, 2013.
101a. Souer JS, Rutgers M, Andermahr J, et al: Perilunate fracture-dislocations of the wrist: comparison of temporary screw versus K-wire fixation. *J Hand Surg [Am]* 32(3):318–325, 2007.
102. Sousa HP, Fernandes H, Botelheiro JC: Pre-operative progressive distraction in old transscapho-peri-lunate dislocations. *J Hand Surg [Br]* 20:603–605, 1995.
103. Sousa M, Aido R, Freitas D, et al: Scapholunate ligament reconstruction using a flexor carpi radialis tendon graft. *J Hand Surg [Am]* 39:1512–1516, 2014.
104. Stewart DT, Froelich JM, Shin AY: Intercarpal arthrodeses. *J Hand Surg [Am]* 39:373–377, 2014.
105. Sulkers GS, Schep NW, Maas M, et al: The diagnostic accuracy of wrist cineradiography in diagnosing scapholunate dissociation. *J Hand Surg Eur Vol* 39:263–271, 2014.
106. Szabo RM: Dorsal intercarpal ligament capsulodesis. In Shin AY, Day CS, editors: *Epub-Advances in scapholunate ligament treatment*, Chicago IL, 2014, American Society for Surgery of the Hand, pp 84–96.
107. Taleisnik J: Current concepts review. Carpal instability. *J Bone Joint Surg Am* 70:1262–1268, 1988.
108. Taleisnik J, Watson HK: Midcarpal instability caused by malunited fractures of the distal radius. *J Hand Surg [Am]* 9:350–357, 1984.
109. Trumble T, Verheyden J: Treatment of isolated perilunate and lunate dislocations with combined dorsal and volar approach and intraosseous cerclage wire. *J Hand Surg [Am]* 29:412–417, 2004.
110. Vance RM, Gelberman RH, Evans EF: Scaphocapitate fractures: patterns of dislocation, mechanisms of injury, and preliminary results of treatment. *J Bone Joint Surg Am* 62:271–276, 1980.
111. Van den Abbeele KLS, Loh YC, Stanley JK, et al: Early results of a modified Brunelli procedure for SL instability. *J Hand Surg [Br]* 23:258–261, 1998.
112. Viegas SF, Patterson RM, Todd PD, et al: Load mechanics of the midcarpal joint. *J Hand Surg [Am]* 18:14–18, 1993.
113. Wahegaonkar AL, Mathoulin CL: Arthroscopic dorsal capsulo-ligamentous repair in the treatment of chronic scapho-lunate ligament tears. *J Wrist Surg* 2:141–148, 2013.
114. Wall LB, Didonna ML, Kiefhaber TR, et al: Proximal row carpectomy: minimum 20-year follow-up. *J Hand Surg [Am]* 38:1498–1504, 2013.
115. Watson HK, Ashmead D, IV, Makhlouf MV: Examination of the scaphoid. *J Hand Surg [Am]* 13:657–660, 1988.
116. Watson HK, Weinzweig J, Zeppieri J: The natural progression of scaphoid instability. *Hand Clin* 13:39–49, 1997.
117. Weil WM, Slade JF, 3rd, Trumble TE: Open and arthroscopic treatment of perilunate injuries. *Clin Orthop Relat Res* 445:120–132, 2006.
118. Wolfe SW, Garcia-Elias M, Kitay A: Carpal instability nondissociative. *J Am Acad Orthop Surg* 20:575–585, 2012.
119. Wright TW, Dobyns JH, Linscheid RL, et al: Carpal instability non-dissociative. *J Hand Surg [Br]* 19:763–773, 1994.
120. Yin Y, Gilula LA: Imaging of the symptomatic wrist. In Watson HK, Weinzweig J, editors: *The wrist*, Philadelphia, 2001, Lippincott-Raven, pp 61–82.

http://e-surg.com

Distal Radioulnar Joint

Brian D. Adams and Fraser J. Leversedge

These videos may be found at *ExpertConsult.com:*
14.1 Dynamic ultrasound for tendinopathy. (Copyright © Scott W. Wolfe.)

The distal radioulnar joint (DRUJ) is a diarthrodial, synovial articulation that provides the distal link between the radius and the ulna and a pivot for pronation and supination (Figure 14.1). Because the radii of curvature of the articular surfaces of the radius and ulna are different, the soft tissues are critical for guiding and restraining the joint; pathologic alterations of the soft tissues can adversely influence joint motion or stability. During normal forearm motion, the DRUJ moves synchronously with the proximal radioulnar joint, and any injury or deformity involving the radius or ulna can alter the function of both joints.

The DRUJ and ulnocarpal joint are anatomically and functionally integrated, so both are affected by traumatic and arthritic conditions. Because of these interdependences, evaluation and treatment of the DRUJ are challenging. This chapter presents the relationships between anatomy, function, injury, and disease that affect the DRUJ and ulnocarpal joint and explains how these relationships influence the rationale for and technique of treatment options for these various conditions.

ANATOMY AND BIOMECHANICS

The sigmoid notch of the radius is a shallow concavity that articulates with the ulnar head. In anatomic studies, the radius of curvature of the sigmoid notch averaged 15 to 19 mm compared with only 10 mm for the ulnar head. The dorsal and palmar rims of the sigmoid notch contribute substantially to DRUJ stability. Typically, the dorsal bony rim is angled acutely, whereas the palmar rim is more rounded and is augmented by a fibrocartilaginous lip, which is prominent in 80% and more subtle in 18% (Figure 14.2). The importance of these rims has been shown clinically and in biomechanical investigations in which posttraumatic deficiencies substantially reduce joint stability.[1,156,162,171]

The articular contour of the DRUJ varies considerably among individuals in both the coronal and transverse planes. In the coronal plane, the slopes of the opposing articular surfaces of the notch and ulnar head may be parallel (55%), oblique (33%), or reverse oblique (33%) relative to the long axis of the radius and ulna.[162] Although slope has no proven impact on joint function in its natural state, acquired changes in length of the radius or ulna can alter peak DRUJ articular pressures. A shortening osteotomy through the ulnar shaft for the treatment of ulnar impaction syndrome in a patient with a reverse oblique slope of the DRUJ has the potential to increase articular pressures at the proximal edge of the notch and the opposing surface of the ulnar head.[135]

In the transverse plane, the average sigmoid notch subtends an arc of approximately 50 degrees (see Figure 14.2). Based on an anatomic study of 50 cadavers, four different sigmoid notch shapes were found: flat face (42%), ski slope (14%), "C" type (30%), and "S" type (14%) (Figure 14.3).[162] The shape has potential implications for risk of traumatic instability and its treatment alternatives. A flat sigmoid notch may be more prone to instability and less responsive to treatment by soft tissue repair alone.[162]

The ulna is the stable unit of the forearm and supports loads transmitted from the radius and carpus. The ulnar head serves as the articular seat around which the radius rotates via the sigmoid notch. The surface of the ulnar head that faces the sigmoid notch forms a slightly asymmetric, partial cylinder of about a 130-degree arc. The articular cartilage coverage of this arc ranges from 50 to 130 degrees and is located on the dorsal, lateral, palmar, and distal surfaces.[3] Due to a slight asymmetry in its curvature, there is a small cam effect at the DRUJ during forearm rotation. The articular surface is generally inclined and shaped to match the slope of the sigmoid notch, but a radiographic appearance of a mismatch is common.

In a radiographic study, the mean inclination of the sigmoid notch was found to be 8 degrees, ranging from −24 to 27 degrees, whereas the inclination of the opposing ulnar head surface averaged 21 degrees, ranging from −14 to 41 degrees.[135] These differences in inclination may partially explain why symptoms can develop after ulnar shortening or changes in radial length following distal radius fracture.[135]

The distal articular surface of the ulna (also called the "dome" or "pole" of the ulna[78]) that articulates with the articular disk of the triangular fibrocartilage complex (TFCC) varies in shape from a partial sphere to nearly flat. A semilunar distribution of cartilage covers much of the dome, which articulates with the articular disk of the TFCC. At the base of the styloid and encompassing the geometric center of the ulnar head is a shallow concavity called the "fovea" that is devoid of cartilage and replete with vascular foramina that supply vessels to the TFCC (Figure 14.4). The fovea is the primary attachment site for the radioulnar and ulnocarpal ligaments. The ulnar styloid is a continuation of the subcutaneous ridge of the ulna, projecting 2-6 mm distal to the dome of the distal ulna. It provides an increased area for soft tissue attachments, including the extensor carpi ulnaris (ECU) tendon sheath and the secondary attachments of the radioulnar ligaments. The dorsal (nonarticular) aspect of the head has a groove for the ECU tendon.

http://e-surg.com

Ulnar variance is the term used to relate the difference in lengths of the radius and ulna. Ulna plus (or positive) and ulna minus (or negative) describe the ulna as longer or shorter than the radius, respectively. In a radiographic study of 120 normal Caucasian subjects, ulnar variance averaged –0.9 mm (range, –4.2-2.3 mm) with no differences between genders.[142]

The *TFCC*, named by Palmer and Werner,[120] is the term used most commonly to describe the interconnected soft tissues that span and support the DRUJ and ulnocarpal articulations. The TFCC is inclusive of other terms that have been used to emphasize either its fibrocartilage components (e.g., triangular cartilage, articular disk) or its ligament components (e.g., triangular ligament, ulnocarpal ligament complex). The TFCC is formed by the: (1) palmar and dorsal radioulnar ligaments; (2) triangular fibrocartilage proper, or articular disk; (3) floor of the ECU sheath; (4) ulnocarpal meniscal homologue; and (5) palmar ulnocarpal ligaments.[120] The primary functions of the TFCC are to (1) extend the smooth articular surface of the distal radius to cover the ulnar head; (2) transmit axial force across

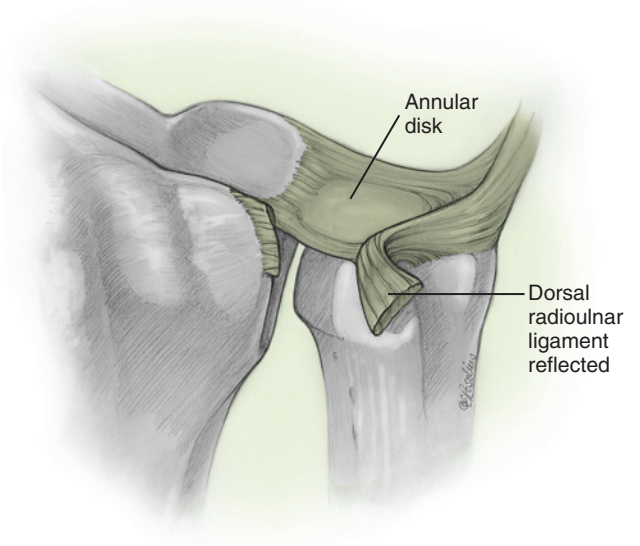

FIGURE 14.1 Distal radial ulnar joint with triangular fibrocartilage complex. (Copyright © Elizabeth Martin.)

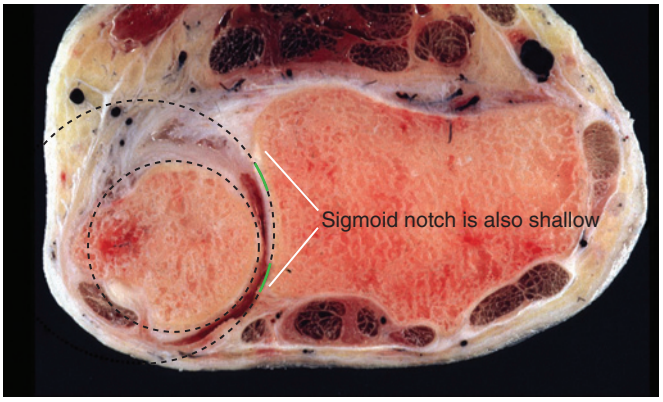

FIGURE 14.2 Cross section through distal radial ulnar joint in a cadaver. The rims of the sigmoid notch are augmented by fibrocartilaginous lips. The sigmoid notch is shallow, and its radius at curvature is substantially larger than at the ulnar head.

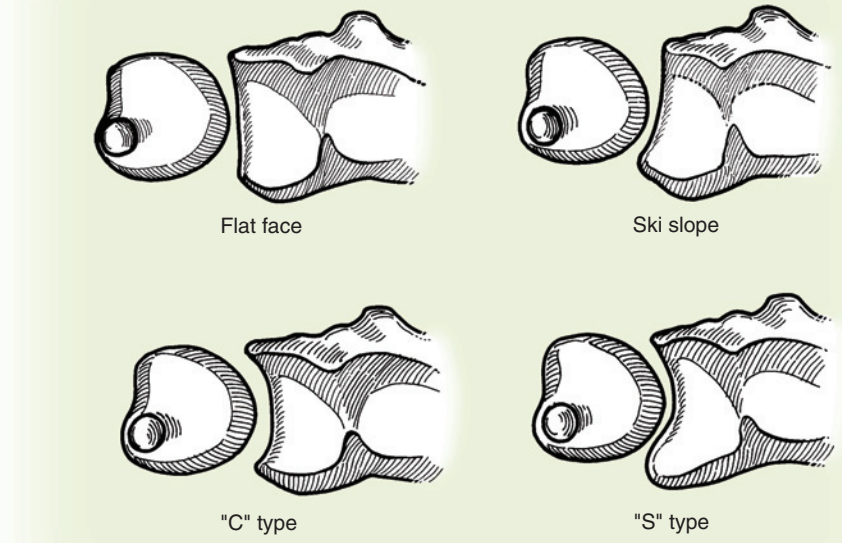

FIGURE 14.3 Various shapes of the articular surfaces of distal radial ulnar joint exist in the transverse plane. The shapes influence its stability. (Redrawn by Elizabeth Martin from Tolat AR, Stanley JK, Trail IA: A cadaveric study of the anatomy and stability of the distal radioulnar joint in the coronal and transverse planes. *J Hand Surg Br* 21:587–594, 1996.)

http://e-surg.com

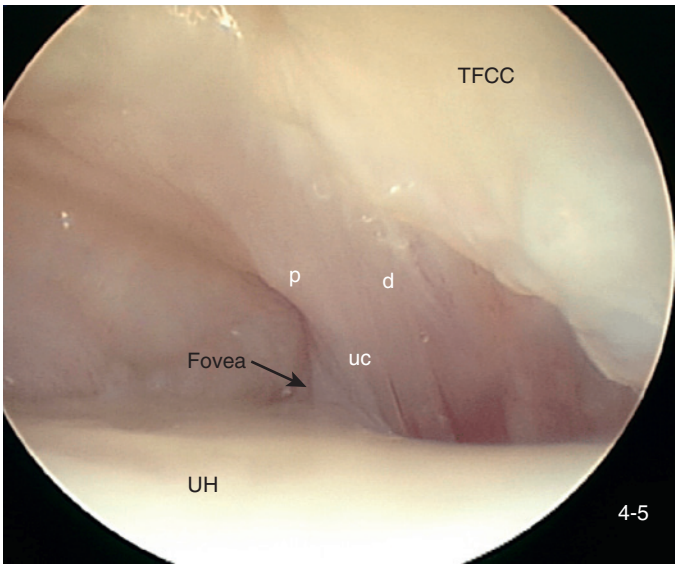

FIGURE 14.4 Arthroscopic evaluation of the ulnocarpal joint in the interval between the triangular fibrocartilage complex (TFCC) and ulnar head (UH). The inserting fibers of the deep limbs of the palmar (p) and dorsal (d) radioulnar ligaments converge as they insert into the foveal region of the distal ulna. The ulnar collateral ligament (uc) is considered a capsular condensation along the midsagittal aspect of the ulnocarpal joint. (Copyright David Slutsky. Reprinted with permission.)

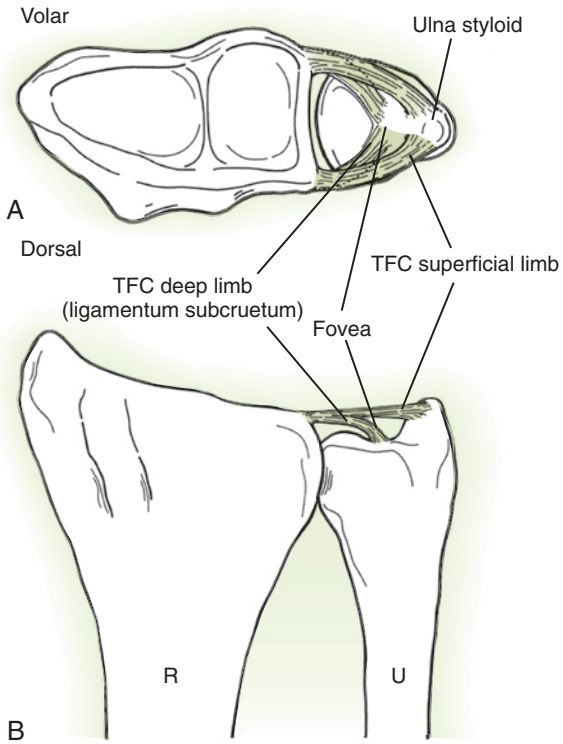

FIGURE 14.5 **A, B,** Normal division of dorsal and palmar radioulnar ligaments into superficial (distal) limbs that attach to the ulnar styloid and deep (proximal) limbs that attach at the fovea of the ulnar head. *R,* Radius; *TFC,* triangular fibrocartilage; *U,* ulna. (From Adams B: Distal radioulnar joint. In Trumble TE, editor: *Hand surgery update 3: Hand, elbow, and shoulder*, Rosemont, IL, 2003, American Society for Surgery of the Hand, pp 147–157.)

the ulnocarpal joint, while partially absorbing the load; (3) provide a strong but flexible connection between the distal radius and ulna that allows forearm rotation; and (4) support the ulnar portion of the carpus through connections to the ulna and the radius. Its anatomic complexity and multiple functions place the TFCC at substantial risk for injury and degeneration.

The radioulnar ligaments are the primary stabilizers of the DRUJ. The palmar and dorsal radioulnar ligaments are located at the common juncture of the articular disk, DRUJ capsule, and ulnocarpal capsule. These ligaments are composed of longitudinally oriented lamellar collagen to resist tensile loads and have a rich vascular supply to allow healing. The palmar and dorsal radioulnar ligaments extend from the palmar and dorsal distal margins of the sigmoid notch, respectively, and converge in a triangular configuration to attach to the ulna. As each radioulnar ligament courses ulnarly, it divides in the coronal plane into two limbs. The deep or proximal limbs attach to the fovea, just medial to the pole of the distal ulna, and are referred to as the *ligamentum subcruetum*.[77]

The superficial or distal limbs attach to the base and midportion of the ulnar styloid[9,77,110] (Figure 14.5). Stability of the DRUJ and treatment considerations, therefore, can be influenced by the location of an ulnar styloid fracture. A basilar styloid fracture imparts mechanical discontinuity to the superficial limbs and signifies potential disruption of the deep limbs because of its proximity to their foveal attachments.

The articular disk extends from the ulnar edge of the lunate fossa at the distal rim of the sigmoid notch and blends peripherally with the radioulnar ligaments. There is an inverse relationship between central disk thickness and ulnar variance.[118] The disk is composed of fibrocartilage, and its interweaving and obliquely oriented fibers are arranged to bear compressive loads through its central portion.[21] In biomechanical cadaveric studies, approximately 20% of the load transmitted through the wrist passed through the ulna.[121] The transmitted force varied with wrist position and increased with ulnar deviation and pronation by up to 150%. Alterations in ulnar variance and the presence of the articular disk also affect load transmission. Shortening the ulna by 2.5 mm decreased ulnar load to 4%, whereas increasing ulnar length by 2.5 mm increased the load to 42%. Removal of two-thirds or more of the disk reduced ulnar load to 3%.[122]

Although the articular disk transmits and absorbs compressive forces, it provides minimal constraint to DRUJ translation.[2] The compression borne by the disk is converted partially to tensile forces that splay the TFCC.[141] These tensile forces are resisted by the radioulnar ligaments. The disk undergoes substantial deformation during forearm rotation. Increased strains are concentrated in its radial portion during axial loading of the wrist, especially in pronation.[2] This region corresponds to the junction of the radially oriented collagen fibers and the obliquely arranged fibers in the central region. These mechanical and histologic findings explain the frequency of traumatic tears near the disk's radial attachment.

The ECU sheath is a stout structure that extends from the dorsal groove in the ulnar head and the dorsal radioulnar ligament to the carpus. It augments the dorsal capsule and provides its own stabilizing effect separate from the ECU tendon.[110] There are three palmar ulnocarpal ligaments that are part of the TFCC. The ulnotriquetral and ulnolunate ligaments originate

http://e-surg.com

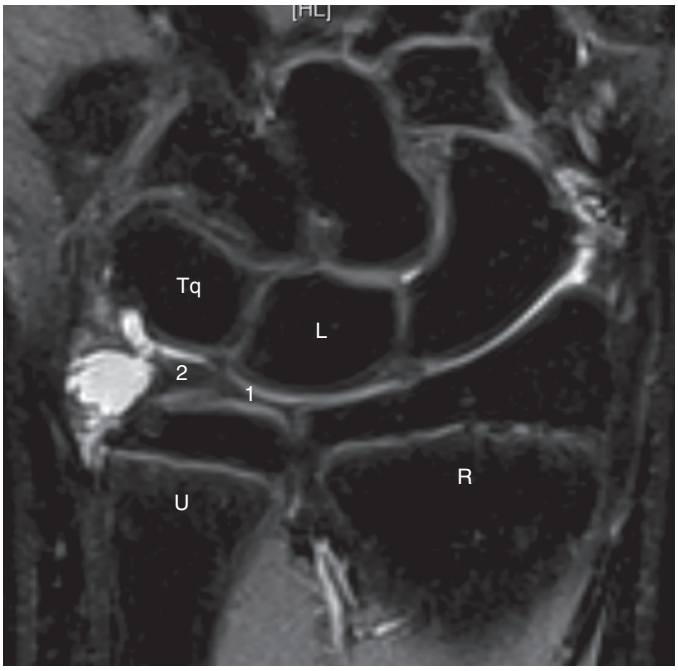

FIGURE 14.6 Meniscus homologue is an irregularly shaped soft tissue structure that variably fills the space between the ulnar capsule, disk, and proximal aspect of the triquetrum. *L*, Lunate; *R*, radius; *Tq*, triquetrum; *U*, ulna; *1*, articular disk of triangular fibrocartilage; *2*, meniscus homologue.

from the palmar radioulnar ligament and insert on their respective carpal bones. The ulnocapitate ligament, which lies just palmar to the other ulnocarpal ligaments, originates from the volar margin of the ulnar head and inserts on the capitate.[9,110] The contribution of the ulnocarpal ligaments to DRUJ stability is controversial. Because these ligaments have a common origin with the radioulnar ligaments, injuries or disease affecting soft tissue attachments at the fovea can affect DRUJ and ulnocarpal stability. This situation is seen commonly in inflammatory conditions, such as rheumatoid arthritis, in which synovitis around the fovea results in subluxation of the radioulnar joint and a supination deformity of the ulnocarpal joint.

The soft tissue structure between the ulnocarpal capsule, articular disk, and proximal aspect of the triquetrum has been referred to as the *meniscus homologue*[120] (Figure 14.6). Although its prevalence and function have not been defined precisely, it consists of well-vascularized loose connective tissue that is derived most likely from synovium. The size, shape, and distal insertion of the meniscus homologue can vary. There is a consistent insertion of the meniscal homologue into the triquetrum, but there is a broader insertion into the fifth metacarpal. In addition, occasionally there is an insertion into the articular surface of the triquetrum and/or into the lunotriquetral ligament that may obscure arthroscopic visualization of the lunotriquetral interosseous ligament.[111]

Several soft tissue structures are considered to be secondary stabilizers of the DRUJ, including the pronator quadratus, ECU, interosseous membrane (IOM), DRUJ capsule, and articular disk. The relative contributions of these structures to joint stability are controversial, but there is common agreement that gross instability requires disruption of multiple structures.[157] The pronator quadratus and ECU musculotendinous units provide dynamic stability. The pronator quadratus coapts the joint during active pronation and passive supination.[88] In pronation, ECU contraction elevates the ulnar carpus dorsally and depresses the ulnar head palmarly.[69,88]

The IOM contributes substantially to the mechanical integrity of the forearm. Complete radioulnar dissociation at the DRUJ does not occur unless the IOM is incompetent. The central band of the IOM that is part of the middle ligamentous complex runs proximally from the radius to its distal attachment on the ulna. The central band provides 71% of the soft tissue contribution to longitudinal forearm stiffness and is the main structure that resists proximal migration of the radius when the radial head is damaged or removed. The distal oblique bundle (DOB) was identified in all of a series of cadaver dissections, although its thickness varied widely among specimens.

The DOB originates from the ulna near the proximal border of the pronator quadratus muscle and courses distally toward the DRUJ to blend into its capsular tissue and to insert into the inferior rim of the sigmoid notch of the radius. Also, some fibers course farther distally to insert on the anterior and posterior ridges of the sigmoid notch and to become continuous with the dorsal and palmar radioulnar ligaments.[112] Based on a cadaver model, the presence of the DOB may confer increased dorsal–palmar translational stability on the DRUJ when evaluated in a cadaver model.[76] This stabilizing effect of the distal IOM appears to influence DRUJ stability following ulnar-shortening osteotomy; osteotomy performed proximal to the distal IOM improves DRUJ stability compared to one done distal to the distal IOM.[103] Also, alterations in the anatomic relationships of the distal radius and ulna, such as following a displaced distal radius fracture, may compromise the stabilizing effect of the DOB on the DRUJ.[35]

The TFCC has a lesser role in dorsoulnar forearm stability. Traditionally, the DRUJ capsule has been considered too redundant and weak to provide effective joint stabilization. Although biomechanical studies have not emphasized the contribution of the capsule,[172] histologic studies show a well-defined fiber orientation and suggest a potential stabilizing role of the capsule.[78] The palmar capsule has a prominent, redundant fold extending from the inferior radial aspect to the distal ulna border that forms a pocket for the ulnar head in supination and helps to limit translation. The dorsal capsule is thinner and homogeneous with a transverse orientation, indicating less potential to provide stability.

The precise roles of the radioulnar ligaments have been debated. There are two clinically relevant themes concerning their stabilizing functions.[140] First, the ligaments act together with the morphologic boundaries of the sigmoid notch to constrain the joint. Second, both ligaments are necessary for normal joint stability in both palmar and dorsal directions.[156,172] Ligament tension peaks at the extremes of translation and rotation as the ulnar head simultaneously compresses against a rim of the notch creating both a tether and a buttress to resist dislocation. In one view of the functions of these ligaments, the dorsal ligament restrains the ulna from dorsal displacement during pronation and the palmar ligament prevents palmar displacement during supination. Supporters of this theory tested the joint with a passive rotation force applied to the joint and measured strain within the ligaments. The major restraining ligament was deemed the one with the greatest strain.[2,140,172]

http://e-surg.com

In the opposing view, the palmar ligament prevents dorsal displacement in pronation, and the dorsal ligament restrains palmar displacement in supination. These results were found by testing the joint with a passive translation force and observing bone displacements.[3,156] Both theories have merit in the clinical management of instability, and the discrepancy can be considered by appreciating the dual insertions of each ligament on the fovea and ulnar styloid. Despite one ligament possibly providing the dominant restraint under a specific condition, the other ligament provides a secondary restraint, and both must be injured to allow complete dislocation.[172] In patients with bidirectional or severe unidirectional instability, injury of both ligaments should be suspected. From a clinical perspective, the foveal attachments of the radioulnar ligaments are the critical stabilizers of the DRUJ.

Improved understanding of the neurovascular supply to the TFCC has been developed using modern imaging and immunohistochemical staining studies. The vascular supply to the articular disk is variable and plays a central role in its healing potential and treatment options. The TFCC vascular supply is primarily via the anterior interosseous and ulnar arteries.[8] The anterior interosseous artery provides palmar and dorsal branches to the DRUJ. The dorsal branch supplies most of the dorsal periphery, and the palmar branch supplies the volar periphery near the radius. Dorsal and palmar branches of the ulnar artery supply the styloid area and ulnar part of the volar periphery. Vascular penetration into the disk extends only to its outer 15%, leaving the central portion hypovascular, or essentially avascular[8,21] (Figure 14.7). The vascular supply of the peripheral articular disk decreases with age.[95]

Based on these findings, a central disk injury has little or no possibility to heal, whereas injuries at the periphery have good healing potential. The neural supply of the TFCC is concentrated in the dense and loose connective tissues deep in the prestyloid recess and has been traced from the dorsal sensory branch of the ulnar nerve and inconsistently from the medial antebrachial cutaneous nerve, posterior interosseous nerve, anterior interosseous nerve, superficial branch of the ulnar nerve, and the palmar cutaneous branch of the median nerve.[82,146] Selective denervation of the TFCC has been suggested based on an algorithm associated with sequential nerve blocks.[82]

The normal arc of pronation and supination ranges among individuals from 150 to 180 degrees. Additional rotation of up to 30 degrees occurs through the radiocarpal joint. The axis of forearm motion varies during rotation, especially under load, but generally passes near the cross-sectional centers of the radial head proximally and ulnar head distally. At the level of the DRUJ, the axis of motion shifts slightly dorsally with pronation and slightly palmarly with supination. During forearm rotation, translation occurs between the ulnar head and sigmoid notch, resulting in a combination of rolling and sliding movements at the articular surface. The radius slides palmarly with forearm pronation and dorsally with supination.

Total dorsal–palmar translation with the forearm in neutral rotation was measured at 8 to 9 mm in normal cadaveric joints subjected to externally applied forces, although in vivo studies suggest that the actual amount of translation may be considerably less. Nonetheless, when the unloaded forearm is in the neutral position, articular contact is maximal, reaching 60% of the available surface area. At the extremes of pronation and supination, there may be only 2 mm of articular contact at the margins of the sigmoid notch (<10% of the articular surface area).[3] Translation can occur because the sigmoid notch is shallow, and its radius of curvature is 50 to 100% greater than that of the ulnar head.

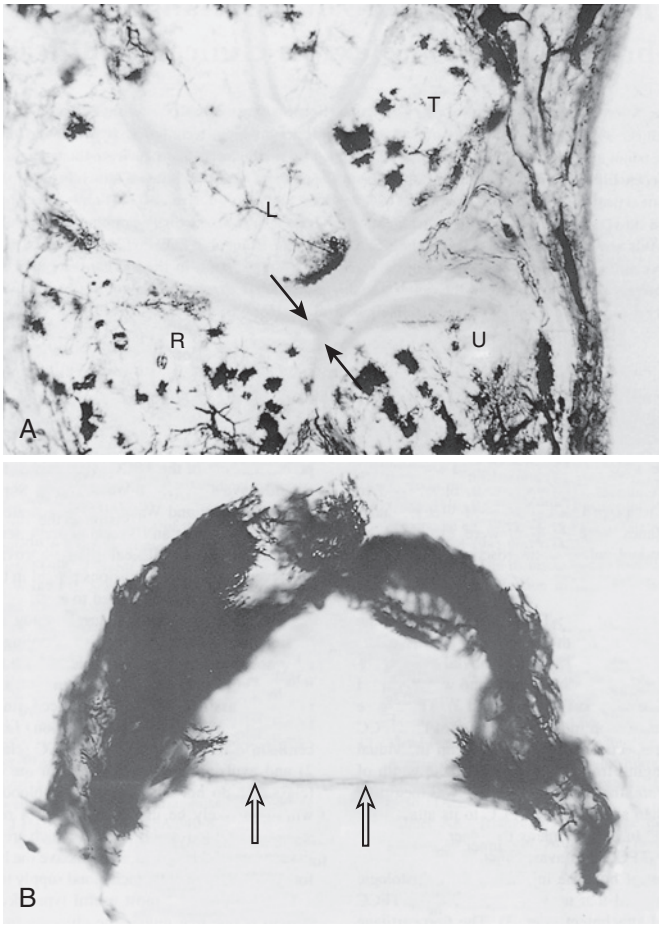

FIGURE 14.7 Triangular fibrocartilage complex (TFCC) is well vascularized in its periphery, whereas only the outer 15% of the disk has vascular penetration. *Arrows* in (**A**) and (**B**) identify avascular regions of TFCC at its attachment to radius. **A,** Coronal section through wrist. **B,** Axial view of TFCC. *L,* Lunate; *R,* radius; *T,* triquetrum; *U,* ulna. (From Bednar MS, Arnoczky SP, Weiland AJ: The microvasculature of the triangular fibrocartilage complex: its clinical significance. *J Hand Surg Am* 16:1101–1105, 1991.)

PHYSICAL EXAMINATION

A global examination of the involved upper extremity is warranted to evaluate for local and remote causes of wrist symptoms, and comparison with the contralateral limb is beneficial. The impact of elbow and forearm pathologic conditions, in particular those of the proximal radioulnar joint (PRUJ), on DRUJ function is necessary to avoid pitfalls and optimize treatment. Vascular or neurogenic causes, including cervical radiculopathy or ulnar neuropathy should be considered.

Inspect the upper limb for swelling and asymmetry with the other side. The evaluation progresses from a general inspection, to active and passive range of motion, strength, tenderness, and provocative maneuvers. Diagnostic injection can be useful in

http://e-surg.com

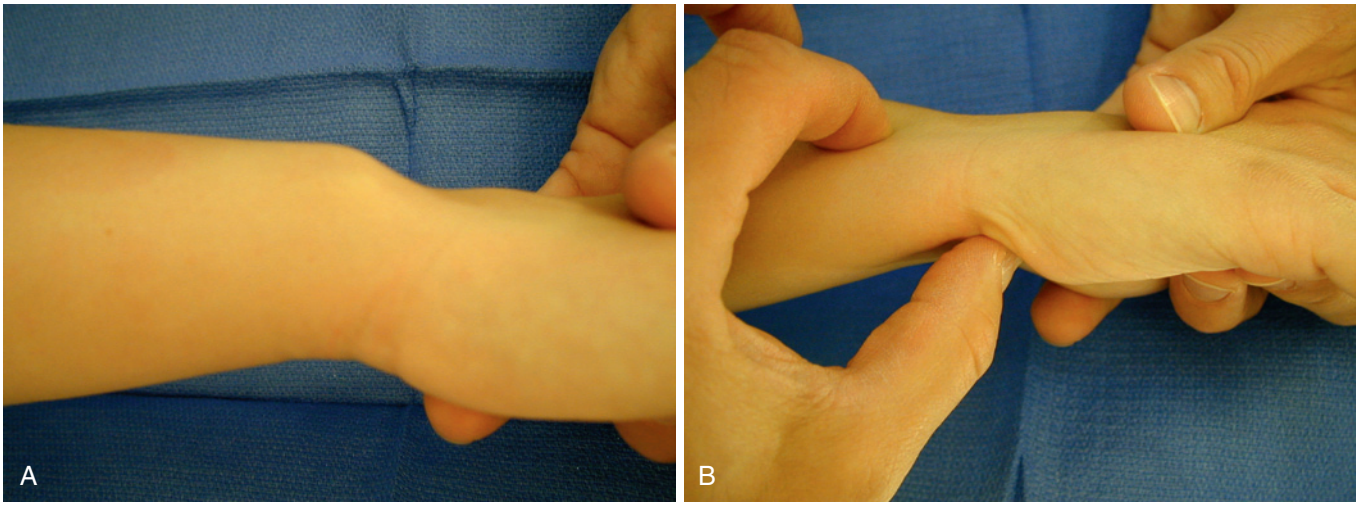

FIGURE 14.8 **A,** Appearance of the right distal ulnar forearm and wrist demonstrating the dorsal prominence of the ulnar head associated with volar subluxation of the distal radius and carpus. **B,** The examiner is able to reduce the wrist by placing the index and long fingers on the dorsal distal ulna and using the thumb to apply a dorsally directed force on the pisiform.

the evaluation. Evaluate for point tenderness using a single palpating fingertip at the distal radius and ulna, DRUJ, radiocarpal and ulnocarpal joints, ulnar styloid, proximal triquetrum, pisotriquetral joint, hook of the hamate, and the scapholunate and lunotriquetral intervals. Tenderness in the soft depression between the flexor carpi ulnaris (FCU) tendon, ulnar styloid, and triquetrum is suggestive of a TFCC injury.[160] Tenderness and or crepitus of the ECU and FCU tendons indicates possible tenosynovial hypertrophy or tendinopathy. A benign mass (e.g., lipoma or ganglion cyst) is not uncommon. An effusion at the ulnocarpal joint or radioulnar joint may indicate degenerative or inflammatory arthritis, especially when associated with dorsal prominence of the ulnar head. Symptoms elicited during provocation tests of the DRUJ may indicate instability, TFCC injury, or arthritic conditions of the DRUJ.

Active and passive motion of the wrist and forearm are measured and compared with the opposite side. Decreased motion and/or crepitus during pronation–supination are signs of DRUJ arthritis; pain may be heightened by manually compressing the joint. ECU tendinitis and lunotriquetral ligament tears can mimic DRUJ symptoms. ECU instability and subluxation is most apparent with forearm supination, flexion, and ulnar deviation of the wrist. The lunotriquetral joint is assessed with the shear or ballottement test. In this test, the examiner stabilizes the lunate between the thumb and index finger of one hand while manually shearing the triquetrum against the lunate articular surface in a dorsal–palmar direction with the thumb and index finger of the other hand. Distinguish between DRUJ conditions and pain associated with pisotriquetral arthritis by palpating the pisotriquetral interval and by pressing and manipulating the pisiform.

Several variations of ulnocarpal stress testing are useful when attempting to reproduce symptoms of ulnocarpal instability caused by disk tears or ulnocarpal degeneration. The patient's forearm is positioned vertically on the examination table and the examiner grasps the hand and applies an axial load through the wrist. The wrist is moved passively through radial and ulnar deviation while being moved through an arc of pronation and supination.[41,107] Alternatively, the wrist is moved passively through a flexion and extension arc in different forearm positions while maintaining an ulnar deviation posture under axial load. Another maneuver involves placing the wrist in passive ulnar deviation while creating increased central loading of the disk and ulnar dome by simultaneously depressing the ulnar head volarly with the index and long fingers and pushing the pisiform dorsally (pisiform boost) with the thumb on its palmar surface. This maneuver is most effectively performed with the forearm in neutral rotation where the DRUJ is the most lax (Figure 14-8, *A*, *B*).

Increased anteroposterior translation of the radius on the ulna during passive manipulation is evidence of DRUJ instability. Because joint translation varies with forearm position and among individuals, the test should be done in all forearm positions and should be compared with the opposite side. A piano-key sign describes the relative hypermobility of the ulnar head with the forearm in full pronation and a positive test is defined by pain elicited following release of the ulnar head after transient palmar depression.[48] A DRUJ ballottement test, used to evaluate relative instability of the ulnar head with the forearm in neutral position, and the ulnocarpal stress test[107] are done with comparison to the contralateral side.

Clinical evaluation for DRUJ instability is challenging due to the subjective nature of the examination and the variability in "normal" DRUJ mobility, even with and without the influence of dynamic stabilizers. In a cadaveric model, one biomechanical study comparing these three clinical assessments suggested that the ballottement test was more accurate in detecting DRUJ instability following TFCC release at the fovea and base of the ulnar styloid.[105] Dynamic loading of the ulnocarpal joint by the patient can be done using the press test.[84] In this test, the patient grasps the arm of a chair and pushes up toward a standing position.

IMAGING

Radiography

Radiographic evaluation of the DRUJ should begin with standard posteroanterior, oblique, and lateral views. A standard

http://e-surg.com

posteroanterior radiograph (i.e., neutral forearm rotation) is taken with the shoulder abducted 90 degrees, the elbow flexed 90 degrees, the forearm and palm flat on the cassette, and the wrist in neutral flexion–extension and neutral radioulnar deviation. The position of the ECU groove can be used to determine whether the posteroanterior view is acceptable. When the cortical outline of the concavity of the groove is radial to the long axis of the ulnar styloid, the posteroanterior view is acceptable for measuring ulnar variance.[85]

A neutral rotation position has been recommended to standardize ulnar variance measurement, but a more recent study found minimal change in ulnar variance throughout the range of forearm rotation, differing only 0.6 mm between pronation and supination.[187] Although changes in variance can be subtle, a posteroanterior view with the forearm pronated,[38] or with the patient making a power grip,[42] or with combined pronation and grip can promote positive ulnar variance.[163]

Several techniques have been described to measure ulnar variance on the posteroanterior view.[117] In a study comparing three commonly used methods, differences were very small and not likely to be of clinical significance.[155] The method of perpendiculars is the most popular. In this method, a line is drawn through the volar sclerotic line of the distal radius perpendicular to its longitudinal axis. The distance between this line and the distal cortical rim of the ulnar dome is measured (Figure 14.9).

The standard lateral radiograph is taken with the shoulder at the patient's side (0 degrees abduction), the elbow flexed 90 degrees, and the wrist in a neutral position. An accurate lateral view is confirmed by the palmar surface of the pisiform visualized midway between the palmar surfaces of the distal pole of the scaphoid and the capitate (i.e., the so-called SPC lateral).[186] Other evidence of correct alignment includes superimpositions of the lesser four metacarpals, the proximal pole of the scaphoid on the lunate, and the radial styloid on the center of the lunate.

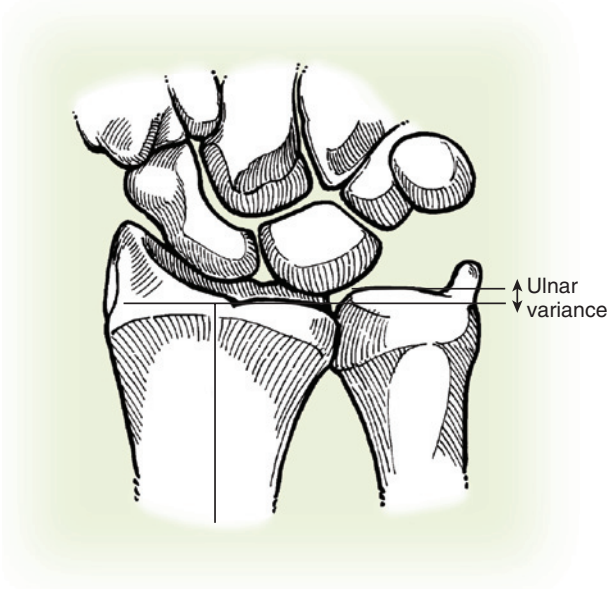

FIGURE 14.9 Ulnar variance is measured by drawing a line through the volar sclerotic line of the distal radius perpendicular to its longitudinal axis. Variance is the distance between this line and the distal cortical rim of the ulnar dome. (Copyright © Elizabeth Martin.)

Despite attention to detail of positioning, the lateral view is imprecise for the diagnosis of DRUJ subluxation. Mino and associates showed that with 10 degrees of supination or pronation, subluxation appeared reduced and dislocation appeared subluxated.[101]

Several radiographic findings may support the diagnosis of DRUJ instability. Ulnar styloid fracture displacement greater than 2 mm associated with distal radius fractures may be consistent with DRUJ instability.[93] Arthroscopically confirmed foveal avulsions of the distal radioulnar ligaments in a group of 29 patients with displaced distal radius fractures were observed to have increased radial translation and radial shortening, decreased radial inclination, or 4 mm or greater ulnar styloid fracture displacement.[108] In the absence of bony abnormalities, however, DRUJ instability secondary to soft tissue deficiency may be highlighted through the use of radiographic stress views.

Several cadaveric studies have demonstrated DRUJ instability with dynamic stress testing following division of the dorsal and palmar distal radioulnar ligaments.[144,150] Clinically, Iida et al. demonstrated a significant increase in DRUJ gap compared to the uninjured side using a clenched-fist posteroanterior (PA) view with the forearm in pronation.[64] Evidence of DRUJ instability following Darrach excision can be accentuated in a lateral stress view in which the patient holds a 5-lb weight with the forearm in pronation and the x-ray beam is directed "cross-table"[138] (Figure 14.10). Semisupinated and semipronated radiographic views improve visualization of the palmar and dorsal rims of the sigmoid notch and the ulnar head and are useful to evaluate for fractures and arthritis. Osteophyte formation at the proximal margin of the ulnar head is an early sign of arthritis.

Ultrasonography

The reliability of ultrasound in the evaluation of DRUJ instability has not been demonstrated due to several confounding factors including its user-dependent nature, although recent work indicates the potential to assess DRUJ instability in a study comparing patients with and without TFCC injuries.[59] Ultrasound may also be helpful in the dynamic assessment of ECU instability.

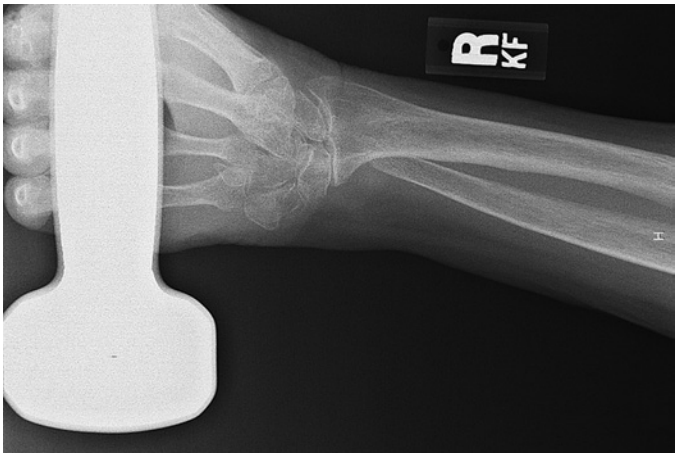

FIGURE 14.10 Weighted radiograph of the pronated forearm to demonstrate radioulnar convergence following distal ulna resection.

http://e-surg.com

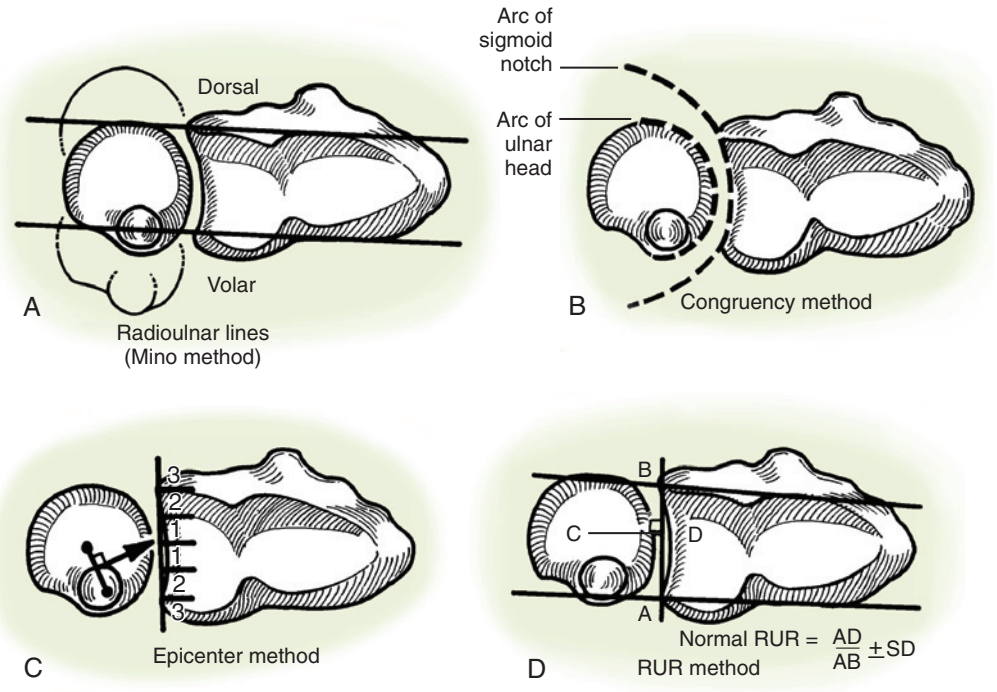

FIGURE 14.11 Measurement methods for assessing distal radial ulnar joint instability on axial computed tomography images. **A,** Radioulnar lines (Mino method). **B,** Congruency method. **C,** Epicenter method. **D,** Radioulnar ratio (RUR) method. (Redrawn by Elizabeth Martin from Adams BD: Distal radioulnar joint instability. In Berger RA, Weiss APC, editors: *Hand surgery* (vol 1). Philadelphia, 2004, Lippincott Williams & Williams, pp 337–354.)

Arthrography

Previously, wrist arthrography played an important role in assessing lesions of the TFCC[131] but was criticized subsequently because its findings showed poor clinical correlation and a low sensitivity compared with arthroscopy.[26] A high incidence of TFCC perforations is detected in asymptomatic wrists, including young adults. Generally, noninvasive magnetic resonance imaging (MRI) and arthroscopy have replaced arthrography. Despite these limitations, a negative arthrogram can be useful as a screening tool. In a retrospective study of patients with ulnar-sided wrist pain who had an inconclusive physical examination, normal standard radiographs, and a negative wrist arthrogram, most of the patients improved over time and few had persistent substantial disability.[67]

Computed Tomography

Computed tomography (CT) is a valuable tool for evaluating fractures, developmental deformities of the sigmoid notch and ulnar head, and degenerative arthritis. Rozental and associates evaluated a series of distal radius fractures with CT and identified displacement of sigmoid notch fractures that were not recognized on standard radiographs.[131] This radiographic study did not correlate radiographic results with patient outcome to determine the findings' clinical significance.

CT is a common method of imaging for DRUJ instability. To optimize its value, the forearms should be aligned with the axis of the gantry. When evaluating for DRUJ instability, it is important to image both wrists in identical forearm positions, including neutral, supination, and pronation. Several measurement methods have been utilized, including use of dorsal and palmar radioulnar lines described by Mino and associates,[101] epicenter and congruency methods proposed by Wechsler and colleagues,[177] and radioulnar ratio described by Lo and coworkers[89] (Figure 14.11).

Wechsler and colleagues found the congruency and epicenter methods to be more sensitive and accurate than the radioulnar lines method.[177] Lo and coworkers claimed that all three methods overestimated and underestimated the extent of subluxation.[89] They found the congruency method to be simple and easy, but highly subjective, with 90% of cases deemed subluxated whether in a normal or abnormal wrist. The radioulnar ratio method was more reliable, but was thought to be too cumbersome in the clinical setting. Its use was recommended when subluxation was not clearly evident on side-to-side visual comparison with the unaffected wrist. Pirela-Cruz and colleagues found applied stress to the DRUJ during CT could identify subtle signs of instability.[126] A combination of methods should be used when instability is subtle, but conclusions must correlate with physical findings and overdiagnosis is to be avoided.

Magnetic Resonance Imaging

Improving technologies and associated increases in image resolution, as well as the use of adjuvant contrast-enhanced arthrography, have improved the sensitivity, specificity, and accuracy of MRI in the diagnosis of TFCC tears (Figure 14.12) (see Chapter 15). Similar to CT, MRI can be used to assess DRUJ instability through anatomic measurements.[37] Dynamic

http://e-surg.com

imaging may become an important tool to identify lesions and instability of the ulnocarpal joint and DRUJ.

Scintigraphy

Scintigraphy (bone scan) has a limited role in assessing the DRUJ but may be useful when the diagnosis is in question or concurrent problems are suspected. It is most useful in diagnosing ulnar impaction syndrome, in which the ulnar head, lunate, and triquetrum may show increased uptake consistent with chronic inflammation in the bone and soft tissues.

Arthroscopy

Arthroscopy is sensitive for identifying traumatic TFCC tears or degeneration in the central portion of the disk, chondromalacia, and ulnocarpal ligament injuries. In several studies, arthroscopy was more sensitive and more accurate than noninvasive imaging modalities.[26] Incomplete peripheral TFCC tears are more difficult to detect, however, and their severity is more complicated to judge. Scar and vascular invasion along the TFCC periphery and tears of the lunotriquetral interosseous ligament or ECU sheath are evidence of previous injury. A lax or hypermobile TFCC under direct probing—the so-called "trampoline effect"—is indicative of an unstable TFCC[58] although reduced tension in the TFCC does not establish the diagnosis of DRUJ instability.

In the assessment of DRUJ instability, arthroscopy can permit visualization of the foveal insertion of the deep fibers of the distal radioulnar ligaments[148] and guide arthroscopically assisted, transosseous repair techniques for foveal TFCC avulsion injuries.[147] Also, arthroscopy can facilitate the evaluation and treatment of secondary conditions that might contribute to the patient's symptoms, especially if these can be treated by arthroscopic debridement alone. A complete discussion of wrist arthroscopy is presented in Chapter 17.



FIGURE 14.12 Magnetic resonance image of ulnar-peripheral tear of triangular fibrocartilage complex, shown by high-intensity signal on T2-weighted image (*arrow*). (From Adams B: Distal radioulnar joint. In Trumble TE, editor: *Hand surgery update 3: Hand, elbow, and shoulder*, Rosemont, IL, 2003, American Society for Surgery of the Hand, pp 147–157.)

TRIANGULAR FIBROCARTILAGE COMPLEX LESIONS

Palmer's classification divides TFCC lesions into two broad categories: traumatic and degenerative[116] (Table 14.1 and Figure 14.13). Traumatic TFCC injuries are classified further according to location of the tear. Most traumatic tears result from an acute rotational injury to the forearm, a combined axial load and distraction injury to the ulnar border of the forearm, or a fall on the pronated outstretched hand. Although Palmer's classification provides an accurate anatomic description of traumatic tears, it does not guide treatment or indicate prognosis. Additionally, the scheme implies that each type occurs in isolation, whereas clinical studies have found that multiple components of the TFCC may tear in the same injury.[94]

Most acute, isolated TFCC tears do not require early treatment. Although the incidence of TFCC injuries associated with distal radius fractures is estimated to be 13 to 60% using imaging methods or surgical inspection, the incidence of persistent problems related to these injuries is much less.[86,106,115,130] The necessity of treatment for TFCC tears depends on the presence of persistent joint pain from mechanical irritation or synovitis caused by the tear, associated fractures or malunions, or posttraumatic instability of the DRUJ. Diagnosis and treatment of isolated traumatic TFCC injuries are presented separately from associated injuries or DRUJ instability (see also Chapters 15 and 17).

A degenerative TFCC tear can result from chronic, excessive loading through the ulnocarpal joint and is a component of ulnar impaction syndrome. It is important to recognize, however, that natural degeneration of the ulnocarpal joint also occurs. In cadaveric examinations, TFCC perforations and chondromalacia of the ulnar head, lunate, and triquetrum were found in 30 to 70% of specimens.[95,120] Those with ulnar-negative

TABLE 14.1 Palmer's Classifications of Triangular Fibrocartilage Complex Lesions

Class	Lesions
1: Traumatic	A: Central perforation
	B: Ulnar avulsion
	With styloid fracture
	Without styloid fracture
	C: Distal avulsion (from carpus)
	D: Radial avulsion
	With sigmoid notch fracture
	Without sigmoid notch fracture
2: Degenerative (Ulnar Impaction Syndrome)	A: TFCC wear
	B: TFCC wear
	Plus lunate or ulnar head chondromalacia
	C: TFCC perforation
	Plus lunate or ulnar head chondromalacia
	D: TFCC perforation
	Plus lunate or ulnar head chondromalacia
	Plus lunotriquetral ligament perforation
	E: TFCC perforation
	Plus lunate or ulnar head chondromalacia
	Plus lunotriquetral ligament perforation
	Plus ulnocarpal arthritis

http://e-surg.com

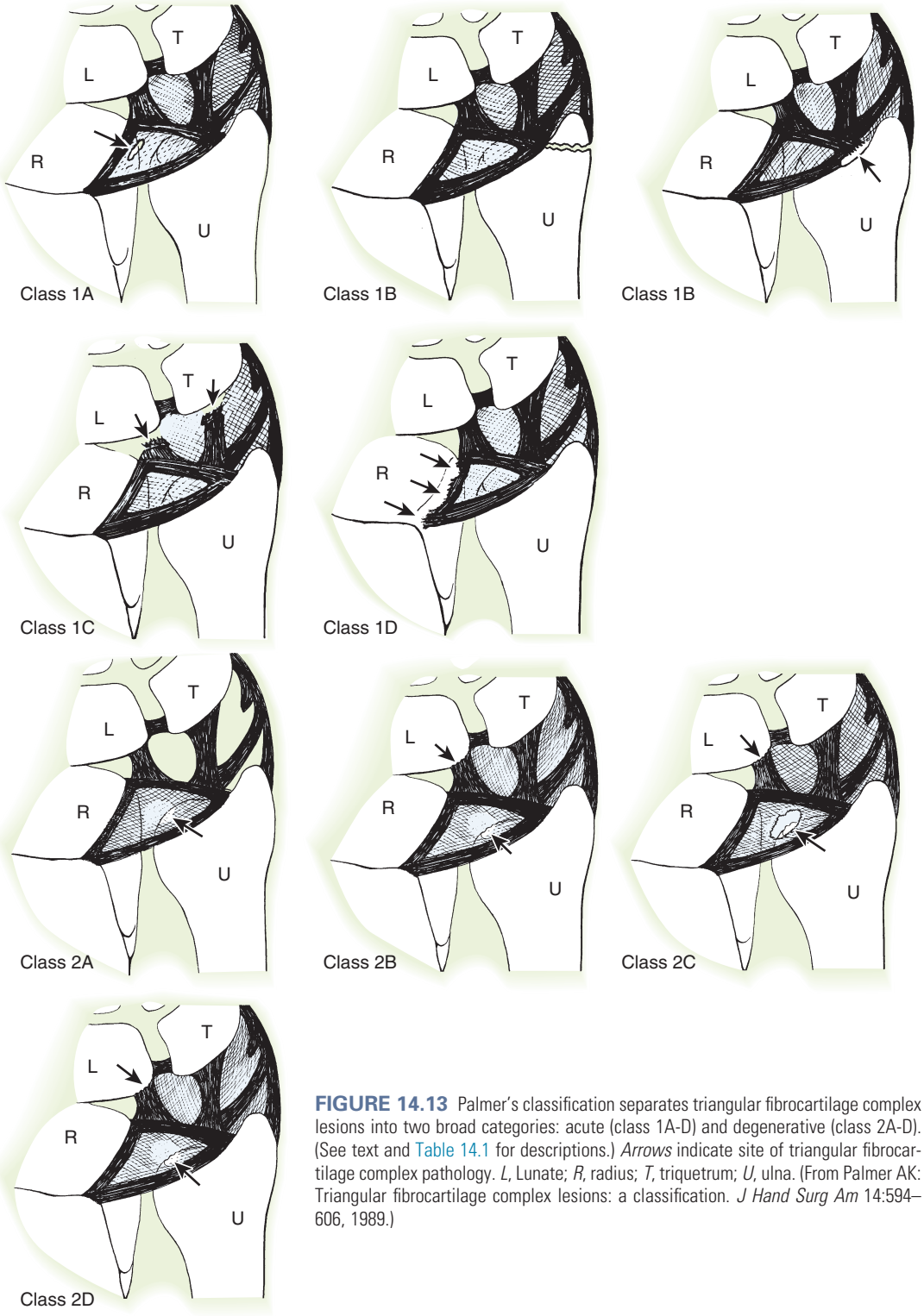

FIGURE 14.13 Palmer's classification separates triangular fibrocartilage complex lesions into two broad categories: acute (class 1A-D) and degenerative (class 2A-D). (See text and Table 14.1 for descriptions.) *Arrows* indicate site of triangular fibrocartilage complex pathology. *L*, Lunate; *R*, radius; *T*, triquetrum; *U*, ulna. (From Palmer AK: Triangular fibrocartilage complex lesions: a classification. *J Hand Surg Am* 14:594–606, 1989.)

variance had less severe degenerative changes.[120] Palmer classified degenerative lesions by the location and severity of degeneration involving the TFCC, ulnar head, and carpus.[116]

Although Palmer's classification implies a specific progression of degeneration among the structures, involvement and severity of degenerative changes in the articular disk, lunate, triquetrum, lunotriquetral interosseous ligament, and ulnar head vary widely in this condition, with any one structure or combination of structures having various stages of degenerative changes. Treatment of degenerative TFCC lesions should consider: (1) debridement of the joint, (2) reduction of load across the ulnocarpal joint, (3) DRUJ stability, (4) DRUJ articular congruity, and (5) presence of developmental or acquired skeletal deformities.

http://e-surg.com

Palmer's Classification of TTFC Lesions

Class 1A Tear

A class 1A tear typically manifests as ulnar-sided wrist pain that is aggravated by power grip, especially with ulnar deviation or forearm rotation. It is a relatively common injury that can cause pain and mechanical symptoms, such as clicking, but does not cause DRUJ instability. Typically, this tear is confined to the disk, located 2 to 3 mm ulnar to its radial attachment, and oriented volar to dorsal. Initially, these injuries should be managed conservatively using rest; immobilization; antiinflammatory medications; and, occasionally, a corticosteroid injection. Patients with ulnar-positive wrists may be less likely to respond to conservative management.

When symptoms persist despite conservative management of traumatic TFCC tears, arthroscopic debridement is the preferred treatment and is discussed in Chapter 17. If a disk tear is identified during an open wrist procedure for another indication, the tear should be debrided to a clean and stable margin. It is important that the peripheral 1 to 2 mm of the articular disk be preserved to avoid injury to the radioulnar ligaments. Outcomes following debridement of the radial remnant of the disk and concomitant repair to the radius are controversial, particularly in light of the relatively good outcomes following arthroscopic debridement alone; this more complex technique is discussed later for the class 1D tear.

Class 1B Tear

A class 1B injury is a partial or complete avulsion of the TFCC from its ulnar attachments, with or without an ulnar styloid fracture. DRUJ instability may or may not be present. A fracture through the base of the styloid that can disrupt both the deep and superficial limbs of the TFCC is more predictive of DRUJ instability than the more common fracture through the shaft or tip.[57] However, most ulnar styloid fractures do not cause DRUJ instability, which is partially related to the dual ulnar attachments of the TFCC.[74,93,185] The ulnar styloid provides attachments for portions of the ulnocarpal ligaments,[9,104] ECU tendon sheath,[104] and superficial limbs of the radioulnar ligaments, whereas the deep limbs insert into the fovea of the ulnar head. The styloid tip is devoid of soft tissue attachments. In addition, a complete avulsion of the radioulnar ligaments and gross instability can occur without a styloid fracture.[94] Occasionally, a small fleck of bone is avulsed from the fovea indicating disruption of the deep limbs of the radioulnar ligaments. Recognition of these injury variations may prevent insufficient treatment.

Symptoms and physical findings associated with a class 1B tear are similar to those of a class 1A tear, although a click is usually absent and point tenderness is characteristically volar to the ulnar styloid. This localized tenderness coincides anatomically with the fovea and, appropriately, tenderness located here has been termed the *fovea sign*.[160] Evaluation of DRUJ stability, as described earlier, is likely to produce pain even if the DRUJ is stable.

Because these tears can progress to a destabilizing injury of the TFCC and DRUJ, initial treatment should restrict forces acting at the TFCC by protective above-elbow immobilization for 4 to 6 weeks with the forearm in neutral rotation. Subsequent treatment should be directed toward gradual recovery of motion and strength. Most of these injuries respond to conservative measures, with surgery indicated for persistent symptoms or evidence of DRUJ instability. Arthroscopic treatment of peripheral TFCC tears has evolved rapidly over the past few years. Symptomatic, complete tears can be repaired by arthroscopic-assisted techniques including transosseous or direct capsular suture repair[109,147,166,184] (see Chapter 17). An open repair is considered in grossly unstable or a chronic injury, provided there is good remaining ligamentous tissue. Chronic basistyloid nonunions associated with DRUJ instability can be addressed with surgical repair of the nonunion fragment (see section on acute DRUJ instability).

Class 1C Tear

A class 1C injury is a partial or complete tear of the ulnocarpal ligaments, either as an intrasubstance rupture or as an avulsion from their carpal insertion. These injuries can occur in combination with class 1B tears or lunotriquetral ligament tears, or both.[94] They are reported much less frequently than other TFCC injuries, probably because they are more difficult to diagnose. Contributions of the ulnocarpal ligaments to DRUJ stability are unclear. The most obvious sign of injury is a volar "sag" of the carpus relative to the ulnar head, analogous to the "caput ulnae" syndrome in rheumatoid arthritis (Figure 14.14). Generally, such injuries should be managed conservatively unless mechanical instability is present. Open repair has been reported in a few cases and arthroscopic-assisted techniques for suture repair or thermal capsular shrinkage have been described, but experience is limited (see Chapter 17).

Class 1D Tear

A class 1D tear is a partial or complete avulsion of the TFCC from the radius, with or without a bone fragment, and may involve one or both radioulnar ligaments. Some reports have confused class 1A and 1D repairs; it is important to reserve the class 1D designation for true radial detachments. Frequently, class 1D injuries are associated with a distal radius fracture and usually respond to accurate fracture reduction of the radius. In the absence of DRUJ instability, symptoms and physical findings are similar to other traumatic TFCC injury types.



FIGURE 14.14 Example of the volar translation of the ulnar carpus and dorsal prominence of the ulnar head associated with rheumatoid arthritis.

http://e-surg.com

Repair of the torn disk to the rim of the radius has been described[22] using open and arthroscopic techniques (Figure 14.15). A crucial concept underlying a successful repair is to provide a biologic environment conducive to healing by promoting vascular invasion from the bony rim. Various arthroscopic techniques have been described, including the use of specialized jigs.[7,22,166]

Open reduction and repair are indicated for large displaced avulsion fractures of the radius involving the rim of the sigmoid notch because the bony and ligament restraints are incompetent. Loss of the buttressing effect of the volar rim (e.g., with a displaced palmar lunate facet fracture) can be particularly destabilizing to the DRUJ. In most cases, these injuries are components of a more extensive distal radius fracture and are stabilized by fracture reduction and fixation (see Chapter 15). Special attention is warranted if DRUJ widening or substantial instability persists after reduction and stabilization of the radius.

❖ AUTHORS' PREFERRED METHOD OF TREATMENT: Open Triangular Fibrocartilage Complex Repair ± Ulnar-Shortening Osteotomy for Class 1B Tear

A 5-cm skin incision, centered over the ulnar head, is made between the fifth and sixth extensor compartments (Figure 14.16). The extensor digiti quinti (EDQ) sheath is opened, and the tendon is retracted. The DRUJ is exposed through an "L"-shaped capsulotomy. The longitudinal limb begins at the ulnar neck and extends to the distal edge of the sigmoid notch. Care should be taken to preserve the dorsal radioulnar ligament's origin at the sigmoid notch. The transverse limb is made by incising along the proximal edge of the dorsal radioulnar ligament and extends to the radial margin of the ECU sheath. The capsule is elevated and retracted proximally to expose the ulnar head and neck.

The proximal surface of the TFCC is inspected for injury, especially at its foveal attachment. If the dorsal and palmar radioulnar ligaments are suitable for repair, the distal surface of the articular disk is exposed through a transverse ulnocarpal capsulotomy made along the distal edge of the dorsal radioulnar ligament. A 0.045-in Kirschner wire is used to create 2 to 3 holes in the distal ulna extending from the dorsal aspect of the

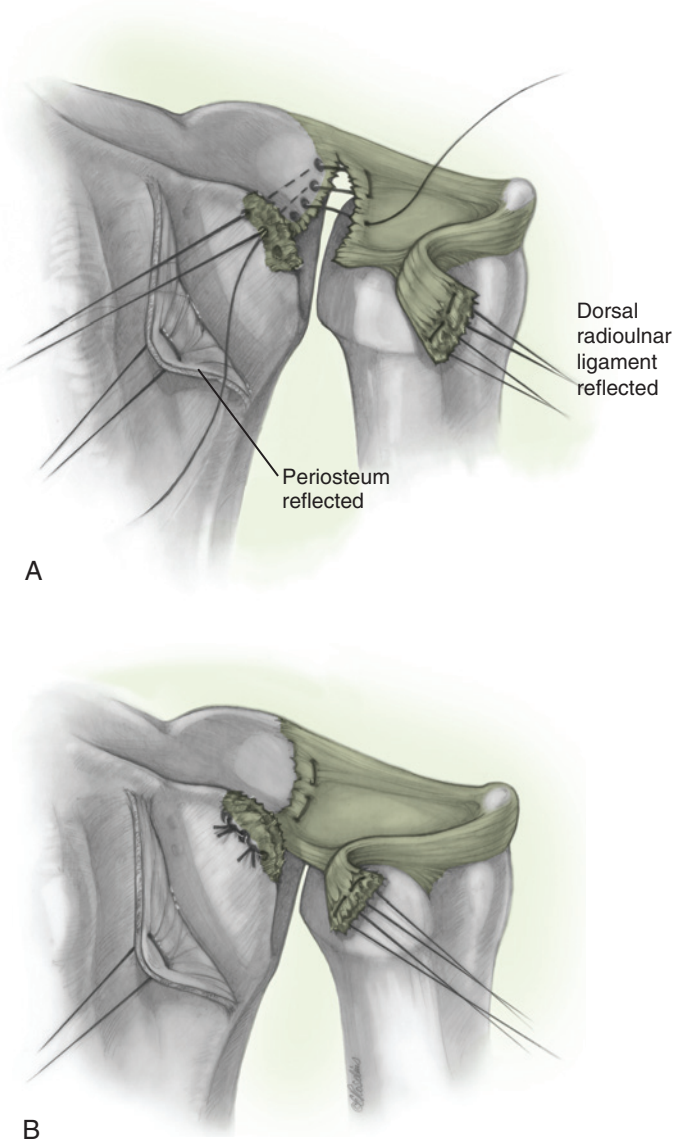

FIGURE 14.15 **A, B,** Class 1D injury involving dorsal radioulnar ligament can be repaired by an open technique using transosseous sutures. (Redrawn by Elizabeth Martin from Cooney WP, Linscheid RL, Dobyns JH: Triangular fibrocartilage tears. *J Hand Surg Am* 19:143–154, 1994.)

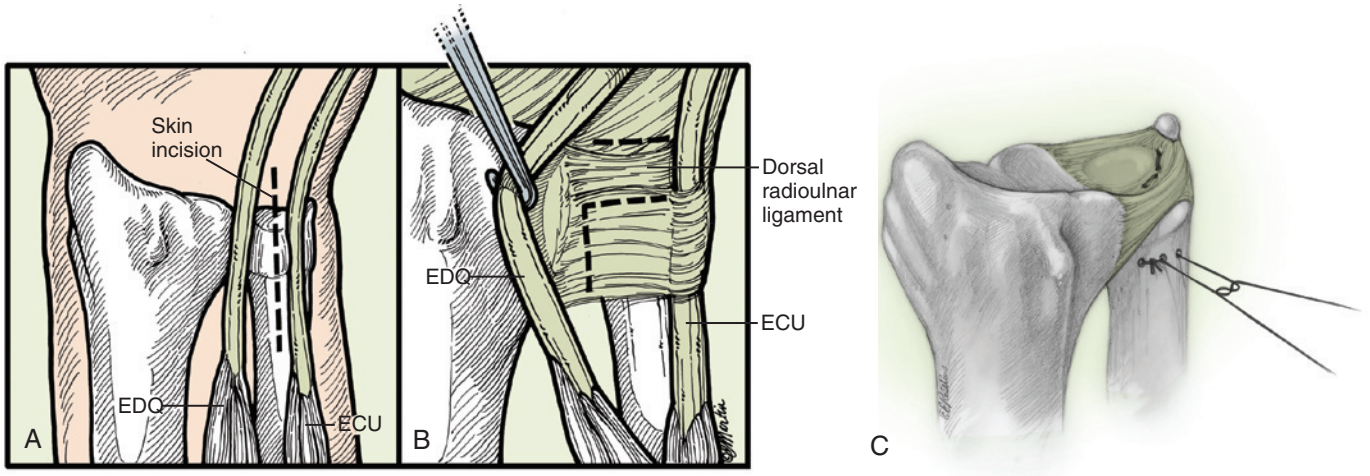

FIGURE 14.16 **A-C,** Open repair of class IB tear is performed through a dorsal approach, "L"-shaped capsulotomy, and horizontal transosseous mattress sutures through the ulnar neck. *ECU*, Extensor carpi ulnaris; *EDQ*, extensor digiti quinti. (Copyright © Elizabeth Martin.)

http://e-surg.com

ulnar neck to the fovea. This site for the holes reduces irritation from suture knots compared with the subcutaneous ulnar border. Two horizontal mattress sutures (2-0 absorbable monofilament) are passed from distal to proximal through the ulnar periphery of the TFCC, which lies near the fovea, by entering through the ulnocarpal capsulotomy and exiting through the DRUJ capsulotomy. With the use of a straight needle or a small suture passer, they are passed through the bone holes. The sutures are tied over the ulnar neck with the joint reduced and the forearm in neutral rotation.

The dorsal DRUJ capsule and extensor retinaculum are either closed as separate layers or as a single layer together; the capsule should not be imbricated to avoid a potential loss of pronation. The EDQ is left superficial to the retinaculum to reduce the risk of peritendinous adhesions. A long-arm splint is applied with the forearm rotated 45 degrees toward the most stable joint position (e.g., supination for dorsal instability). At 2 weeks, the splint is converted to a long-arm cast for 4 weeks, followed by a well-molded short-arm cast for an additional 2 to 3 weeks. A removable splint is used for 4 weeks while motion is regained. Strengthening and resumption of activities are postponed until near-painless motion is possible. The surgical technique for ulnar-shortening osteotomy is described later in this chapter.

Outcomes

Hermansdorfer and Kleinman reported generally good results for open ulnar styloid nonunion excision with TFCC repair although patients with ulnocarpal joint arthritis responded less favorably.[58] For patients with instability and concomitant ulnar-positive variance, ulnar-shortening osteotomy should be considered. Trumble and colleagues reported satisfactory results after open TFCC repair, with some patients also undergoing simultaneous ulnar-shortening osteotomy.[166] The effectiveness of ulnar-shortening osteotomy alone for the treatment of class 1B tears was also reported with good results.[123] The role of ulnar-shortening osteotomy for patients with persisting symptoms following suture repair of a TFCC injury was demonstrated in selected patients.[182] This may be due to the tensioning effect of ulnar-shortening osteotomy on secondary stabilizers, including the DOB.[76] In selected pediatric patients with TFCC injuries, generally good results from repair were reported, although few studies are available.[6]

ACUTE DISTAL RADIOULNAR JOINT INSTABILITY

Although the radius and the carpus together make up the mobile unit of the DRUJ, by convention DRUJ dislocation or instability is described by the position of the ulnar head relative to the distal radius. A general classification of acute DRUJ instability can be considered based on anatomic sites of injury or deformity and is useful in guiding treatment.

Dorsal DRUJ dislocations are the most common and are caused by hyperpronation and wrist extension, as occurs in a fall on the outstretched hand. Conversely, volar dislocations occur with axial loading through a supinated forearm or from a direct blow to the ulnar aspect of the forearm (Figure 14.17). Although the most frequent cause for DRUJ instability is a distal radius fracture, instability after accurate reduction and fixation of the distal radius is uncommon. Initial radiographic findings of wide displacement of the DRUJ and severe radial shortening are the most important risk factors for persistent DRUJ instability. The radioulnar ligaments can tolerate no more than 5 to 7 mm of radial shortening before one or both ligaments tear. In the absence of a displaced sigmoid notch fracture, the TFCC typically tears at its ulnar attachments.[94]

In most cases, the integrity of the secondary stabilizers of the DRUJ, including the IOM, the DOB, the ECU subsheath, ulnocarpal ligaments, and lunotriquetral interosseous ligament,

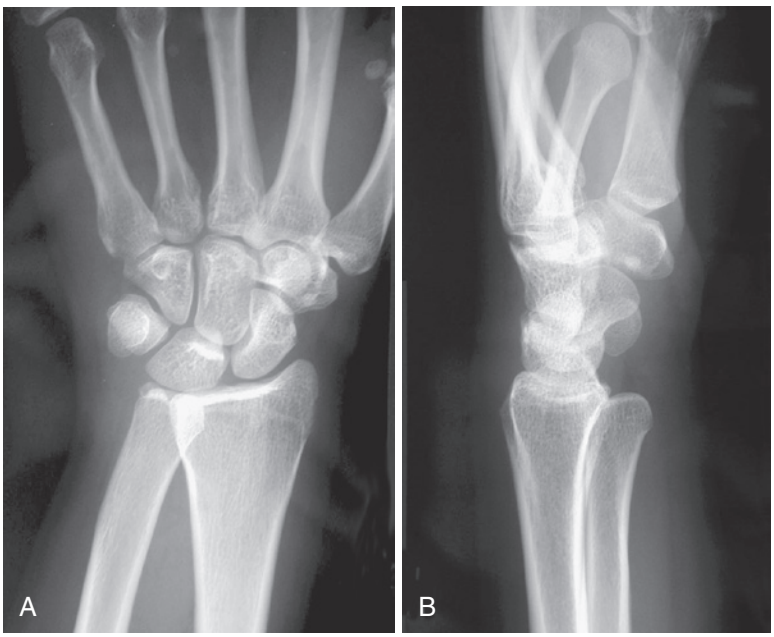

FIGURE 14.17 Radiograph of volar dislocation of distal radial ulnar joint shows overlap of ulnar head and sigmoid notch on posteroanterior view (**A**) and volar displacement of ulnar head on lateral view (**B**).

http://e-surg.com

are preserved, thereby maintaining joint stability. However, as injury severity increases with progressive disruption of the secondary stabilizers, there is progressive instability of the DRUJ. Anatomic reduction of the radius is essential to facilitate DRUJ stability. In a series of articles evaluating young patients with distal radius fractures, unrepaired peripheral tears of the TFCC were a common cause of persistent symptomatic instability.[86,87]

It is important to evaluate DRUJ stability critically after treatment of a distal radius fracture. If instability persists after fracture repair, there are several options to promote a stable joint: (1) temporary immobilization of the forearm in the period of maximum stability using a sugar tong splint or long-arm cast and (2) percutaneous pinning of the ulna to the radius. Typically, the second option is done with one or two large pins (minimum of 0.062 in to resist breakage) driven proximal to the DRUJ from the palpable subcutaneous border of the ulna into the radius. When choosing this treatment, it is important to engage all four cortices of the radius and ulna, so that the pins are accessible should one or both break.

When treating open radius fractures with concomitant DRUJ instability, external fixation of the wrist, with an outrigger attached to the ulna in the position of maximum joint stability, may be considered.[133] When severe or bidirectional instability exists, ulnar styloid fixation or open TFCC repair, combined with radioulnar pinning, should be considered.

Ulnar head fractures and sigmoid notch fractures with or without a complex distal radius fracture pose additional challenges for restoring a congruous and stable DRUJ. Although distal radius fractures frequently involve the sigmoid notch, especially the dorsal rim, the extent of involvement is probably underestimated on standard radiographs and characterized more accurately by CT.[131,159] The clinical implication of residual incongruity of the sigmoid notch has not been studied sufficiently; however, anatomic and biomechanical studies and case reports[102,171] suggest that restoration of the sigmoid notch is essential for joint stability.

In Galeazzi fracture-dislocations of the forearm, a class 1B TFCC injury is present almost inevitably, although there may be a spectrum of DRUJ instability (Figure 14.18). Several studies demonstrated that the risk of DRUJ instability associated with a Galeazzi-type injury increases with a more distal fracture of the radial diaphysis; fractures in the distal one-third, or within 7.5 cm of the distal radius articular surface, have a higher risk of injury to the key soft tissue constraints of the DRUJ.[80,129]

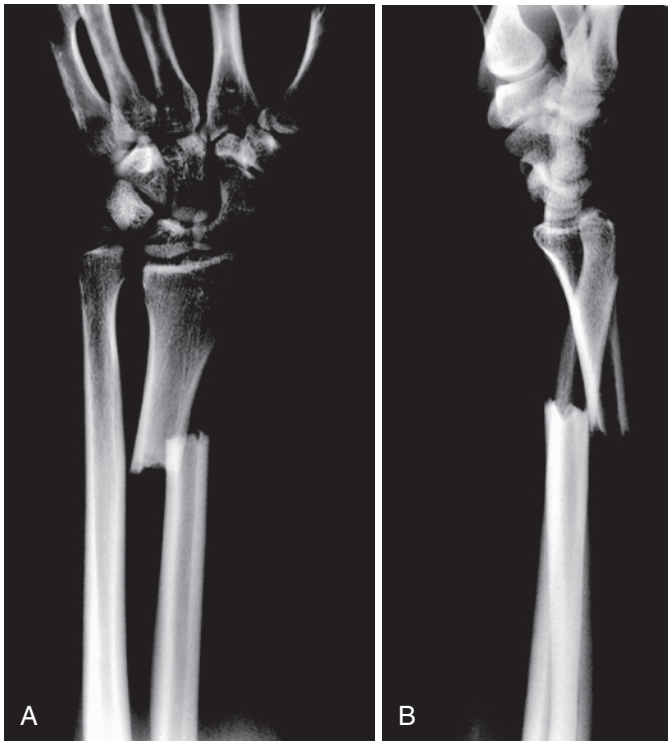

FIGURE 14.18 **A, B,** Galeazzi fracture disrupts distal radial ulnar joint (DRUJ) to varying degrees. After anatomic reduction of the radius, DRUJ stability is assessed and treated if necessary.

Evaluation

An acute dislocation usually produces an obvious deformity with the ulnar head locked over a rim of the sigmoid notch. Local tenderness, swelling, and limited motion are the characteristic findings on presentation. Deep tenderness along the IOM and swelling or pain at the proximal radioulnar joint may indicate a concomitant Essex-Lopresti injury. Instability after reduction is marked by increased translation of the ulnar head in neutral forearm rotation and may be present in supination or pronation depending on the injured soft tissue stabilizers.

Accurate assessment of a DRUJ injury associated with a diaphyseal fracture of the radius or ulna is challenging and is usually impossible until the fracture is reduced and stabilized. Standard radiographs may show subluxation of the ulnar head on the lateral view or partial overlap of the radius and ulna on the posteroanterior view. CT is useful to identify avulsion fractures of the rim of the sigmoid notch and to assess the adequacy of DRUJ reduction; postreduction images can be obtained through splinting or casting material.

Simple Dislocations

An isolated dorsal DRUJ dislocation is more common than a palmar dislocation. When a DRUJ dislocation is recognized acutely, reduction is accomplished easily, unless there is interposed soft tissue (e.g., ECU tendon). Under appropriate anesthesia, gentle pressure is applied over the ulnar head while the radius is rotated toward the prominent ulna. After reduction, joint stability should be evaluated over the full range of forearm rotation to determine the stable arc. Typically, joint reduction following a dorsal dislocation is most stable in supination and a palmar dislocation is most stable in pronation. If the joint is stable only in extreme pronation or supination, additional treatment, such as radioulnar pinning in the position of greatest stability or TFCC repair, should be considered. The TFCC is ruptured nearly always from the ulna.[58,94] If the joint is stable in an acceptable position of forearm rotation, it is treated with an above-elbow cast in this position for 3 to 4 weeks followed by use of a well-molded short-arm cast for 2 to 3 weeks. Interval evaluation with radiographs and/or fluoroscopy is recommended to ensure a stable reduction in the cast.

TFCC Repair (Class 1B Injury)

Peripheral TFCC tears can be diagnosed and sutured to the capsule using arthroscopic-assisted techniques; however, the indications for this technique in the treatment of acute

http://e-surg.com

dislocations of the DRUJ are not defined.[166] If the arthroscopic repair does not reconnect the TFCC to its anatomic attachments on the fovea or the ulnar styloid, it may not be as effective as an open repair in this situation. Ulnar-shortening osteotomy may be considered in conjunction with either an open or an arthroscopic TFCC repair to reduce the loads on the TFCC, especially in patients with positive ulnar variance (see later in the chapter for a description of ulnar-shortening osteotomy).[123,166,182]

Ulnar Styloid Fractures

In his classic article, Frykman reported that ulnar styloid fractures occurred in approximately 61% of distal radius fractures.[43] Most of these fractures are not associated with DRUJ instability or long-term symptoms. Fractures through the tip of the styloid do not require intervention because they do not cause DRUJ instability and are associated with a good prognosis.[18,29,46,81,152,180,188] Fractures through the styloid base, especially when displaced, are associated with a higher risk of DRUJ instability because of the increased potential for disruption of the inserting fibers of the deep limbs of the radioulnar ligaments.[57]

When the DRUJ remains unstable following anatomic fixation of the radius, fixation of an unstable basilar styloid fracture restores DRUJ stability through the restoration of radioulnar ligament integrity, provided that the TFCC is not otherwise damaged. Various methods have been described to fix fractures of the ulnar styloid, including the use of Kirschner wires, tension band wiring, compression screws, variable-pitch headless screws, mini-fragment plates, and suture anchors (Figure 14.19). The size of the ulnar styloid fragment influences fixation options. Soft tissue irritation associated with hardware prominence may require subsequent hardware removal.

Surgical exposure of the ulnar styloid can be accomplished by a dorsal approach if other procedures are being performed; however, the preferred approach is along the subcutaneous border just volar to the ECU tendon. The dorsal sensory branch of the ulnar nerve (DSBUN) is protected as it courses from volar to dorsal, typically crossing the midsagittal aspect of the wrist over the ulnocarpal joint. The ECU sheath is preserved. The ulnar styloid fracture is identified and cleared of any interposed soft tissue.

When using a tension band technique, one or two oblique Kirschner wires are passed through the tip of the ulnar styloid. A 24-gauge stainless-steel wire or heavy suture is passed around the tip of the wire and through a hole in the ulnar neck in a figure-of-eight fashion (see Figure 14.19, *A*). Multiple Kirschner wires or a screw can be used for larger fragments. Suture anchor fixation of the ulnar styloid is preferred by one author (B.D.A.) to minimize the potential to comminute the styloid and to reduce hardware irritation.

With this technique, a bone anchor is inserted into the fracture site and is seated well below the fracture line into the ulnar neck. The attached sutures are passed through drill holes in the styloid fragment if it is very large or passed around the fragment if smaller. The sutures are crossed over the subcutaneous surface of the ulna and one end is passed through a transverse drill hole made near the ulnar neck to create a figure-of-eight configuration. When the suture ends are tied, a combined interosseous compression and a tension band is created (see Figure 14.19, *C*).

Outcomes

The size and degree of displacement of the ulnar styloid fracture fragment are usually good predictors of DRUJ stability.[93] Although fracture union is not consistently achieved with any technique, sound fibrous healing in a good position is generally consistent with resolution of symptoms and DRUJ stability.[18,29,81,152,180,188] Independent of the presence and treatment of injuries of the ulna and TFCC, anatomic reduction and stability of the radius fracture and, in particular the sigmoid notch, are essential to achieve good DRUJ function.

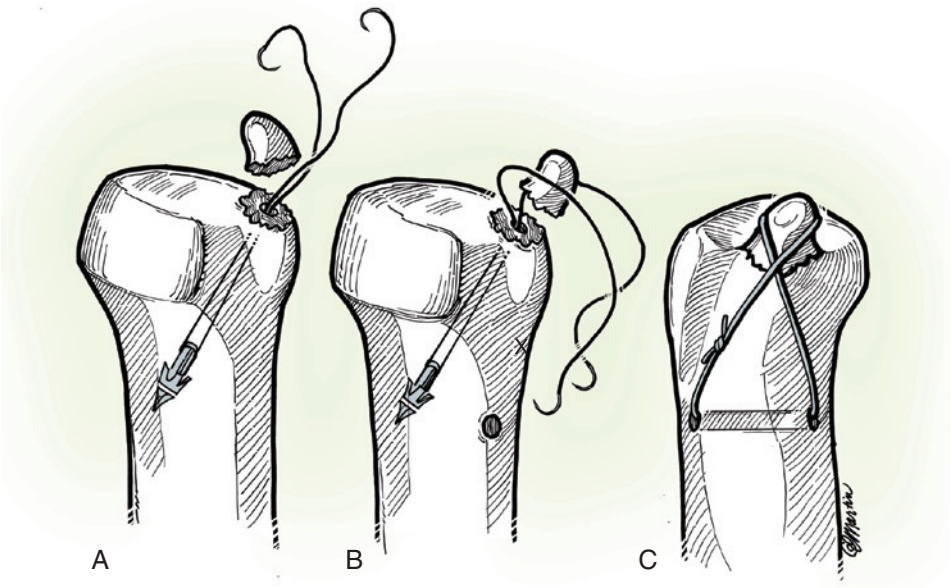

FIGURE 14.19 **A-C,** Several methods are available to fix a ulnar styloid fracture depending partially on the size of styloid fragment. Suture anchor technique is authors' preference (**C**). (Redrawn by Elizabeth Martin from Trumble TE, Culp R, Hanel DP, et al: Intra-articular fractures of the distal aspect of the radius. *J Bone Joint Surg Am* 80:595, 1998.)

http://e-surg.com

CHRONIC DISTAL RADIOULNAR JOINT INSTABILITY

Symptomatic dysfunction of the DRUJ after wrist injury, especially after a distal radius malunion, is common. Residual dorsal angulation of the distal radius of greater than 20 to 30 degrees is associated with increased loading of the distal ulna, radioulnar incongruity, TFCC distortion, and palmar DRUJ instability.[4,28,62] In patients with a distal oblique bundle of the interosseous membrane, a coronal translation, or shift, of 2 mm or greater can also adversely influence DRUJ instability.[35]

DRUJ instability after a distal radius or forearm malunion usually manifests as loss of forearm rotation, prominence of the ulnar head, and ulnar-sided wrist pain. Symptoms are caused by a combination of effects of the malunion on the radiocarpal joint, ulnocarpal joint, and DRUJ. In isolation, loss of radial length is associated less frequently with a substantial loss of rotation or instability but causes a proportionate increase in ulnar load and symptoms of ulnar impaction.[17,127] Conversely, angular deformities of the distal radius or forearm are more likely to cause gross instability and unidirectional loss of motion.[127] Chronic length discrepancies caused by skeletal deficiencies in the proximal forearm (e.g., an Essex-Lopresti injury) are associated with IOM injuries and produce symptoms in the entire forearm axis.[145] Developmental skeletal deformities (e.g., Madelung deformity) behave similarly to their posttraumatic counterparts; however, the symptoms typically progress more slowly.[34]

Chronic posttraumatic DRUJ instability can occur in the absence of a distal radius fracture. A common history involves a fall on the outstretched hand or an unexpected forcible rotation of the wrist (e.g., a jammed power drill). Typically, the patient complains of intermittent ulnar-sided wrist swelling and pain that is aggravated by forearm and wrist motion, particularly with axial loading through an extended wrist or torsional activities against resistance. Untreated, pain at rest and swelling usually improve, but activity-related pain, perceived weakness, and mechanical symptoms persist. The distal ulna may remain tender and appear prominent. In mild instability, pain and weakness occur only with activities that require active rotation of the forearm during forceful gripping (e.g., turning a screwdriver). In the more severe cases, a palpable and painful clunk may occur during unresisted forearm rotation; a decreased arc of rotation may occur from chronic DRUJ subluxation. Chronic instability rarely improves spontaneously, and it is unknown whether DRUJ instability predisposes to arthritis.

DRUJ instability in children usually is associated with a previous fracture of the distal radius or forearm and often manifests later, sometimes years after the fracture.[4] Fracture remodeling and longitudinal growth can make it difficult to characterize a malunion in children accurately. Loss of forearm motion is variable, but the instability is often obvious. Clinical and radiographic evaluation should include a comparison to the noninjured side because angular and rotational deformities of the radius or ulna can be subtle in appearance; however, they can have a profound influence on function, leading to chronic ligament attenuation and associated DRUJ instability (Figure 14.20, *A-D*).

Evaluation

Chronic DRUJ instability can be demonstrated by reproducible clunking, both visible and palpable during active or passive forearm rotation as the ulnar head reduces into the sigmoid notch from a dislocated position. Passive manipulation of the joint is occasionally necessary to complete the dislocation, and compression across the joint may accentuate the clunk. Subtle DRUJ subluxation may be more difficult to detect. In palmar subluxation, a slight prominence of the ulnar head is seen on the palmar aspect of the wrist, and a depression of the soft tissues may be seen on the dorsal side (dimple sign). Tenderness is present diffusely around the distal ulna, but particularly over the fovea of the ulnar head, located in the natural depression between the FCU tendon and ulnar styloid.

Increased translation with passive force is nearly always present in at least one position of forearm rotation. Passive laxity should be assessed by holding the radius and carpus with one hand, while using gentle force with the examiner's opposite hand on the distal ulna with the forearm in neutral, supination, and pronation. Translation is normally greater in neutral compared to the extremes of pronation or supination. It is essential to compare findings with the contralateral extremity because the normal range of motion and laxity of the DRUJ vary considerably among individuals. Resisted forearm rotation, especially at the extremes of pronation and supination, is often painful.

A modification of the press test,[84] originally described to diagnose TFCC tears, is useful for evaluating suspected DRUJ instability.[1] In this modified test, the patient rises from a chair using the hands for assistance by pushing against a tabletop located to his or her front. Instability is shown by greater "depression" of the ulnar head on the affected side and is often coupled with pain. Tenderness over the ulnar styloid may signify an unstable nonunion. In a dorsally angulated malunion of the distal radius, the ulnar head is prominent volarly, especially with supination. Children are unlikely to have at rest pain and are more likely to complain of wrist pain and popping that interferes with recreational activities.

The most specific radiographic signs of instability include a widened DRUJ and a prominent ulnar head volar or dorsal to the radius. Indirect radiographic signs include a malunited distal radius, deformities of the radial or ulnar shafts, displaced basilar fracture of the ulnar styloid, and a displaced fleck fracture from the fovea. CT imagaing in supination, pronation, and neutral is the most accurate modality to evaluate the DRUJ for instability.[89,126,177] (See Imaging section earlier in the chapter.)

Treatment

Nonoperative management of severe, chronic DRUJ instability usually fails unless the individual is willing to use a splint that restricts forearm rotation. A 4- to 6-week trial of forearm splinting or long-arm casting and antiinflammatory medications is indicated for mild instability, particularly in a low-demand patient.[97] Coexistent conditions (e.g., ECU tendinitis or ulnar impaction syndrome) should be identified and treated accordingly. Special consideration needs to be given to patients with symptoms of instability who have a flat sigmoid notch and bilateral DRUJ hypermobility because these patients respond less predictably to reconstructive surgery.

http://e-surg.com

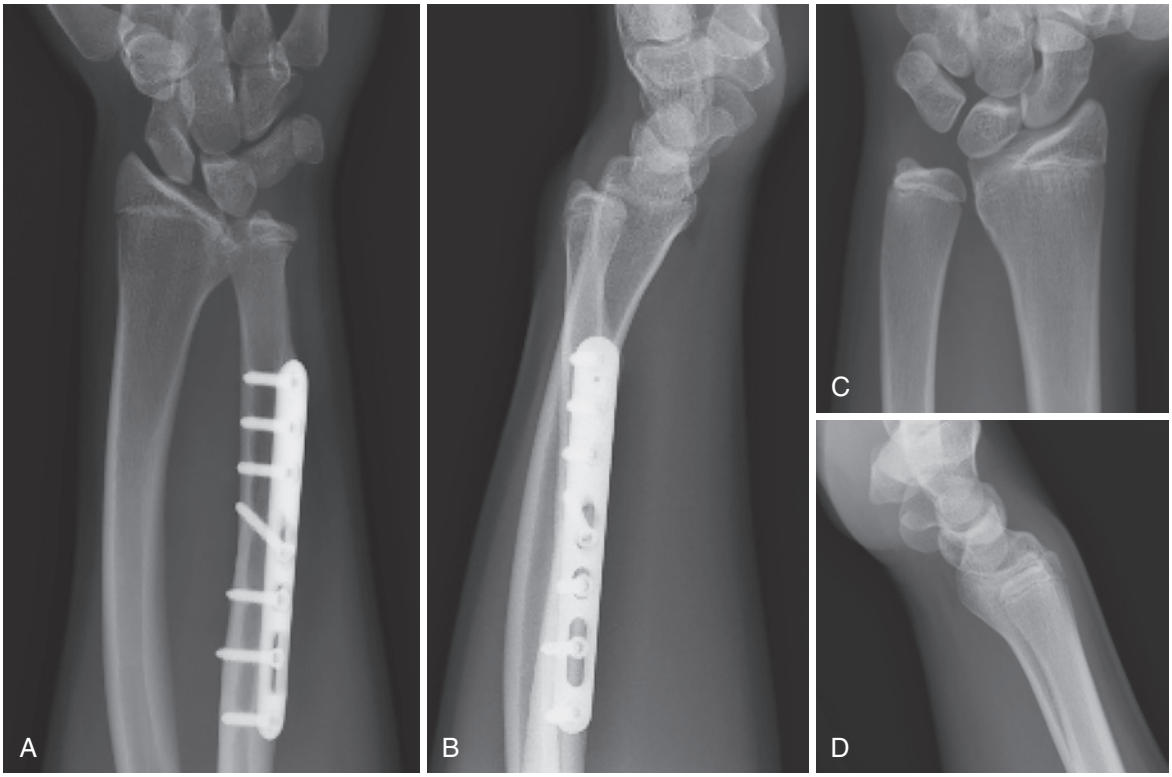

FIGURE 14.20 A 16-year-old female with a history of mild bilateral Madelung deformity and left forearm fracture treated with open reduction and internal fixation of the ulna and closed management of the radius. She complained of persistent instability and pain localized to the distal radial ulnar joint (DRUJ) and ulnocarpal joints. Posteroanterior (**A**) and lateral (**B**) radiographs of the left distal forearm demonstrate relative ulnar-positive variance and DRUJ subluxation. Comparison radiographs (**C, D**) of the contralateral extremity contrast the DRUJ alignment, despite mild morphologic changes of the distal radius.

To take advantage of dynamic DRUJ stabilizers, a strengthening program for the forearm and wrist, along with supportive soft bracing or taping during activities, can be considered. Recurrent dislocations may cause further attenuation of the soft tissue restraints and predispose to degeneration of the articular cartilage and the rims of the sigmoid notch. With young patients, it may be appropriate to accept intermittent dislocations and follow them regularly until skeletal maturity to avoid the potential for iatrogenic physeal injury with reconstructive surgery.

Restoration of stability and a full, painless arc of motion are the goals of surgical treatment for a posttraumatic unstable DRUJ. The anatomic derangements underlying the instability must be identified correctly, including bony deformity, ligament injury, and combinations. In established DRUJ instability without malunion or arthritis, late repair of a class 1B TFCC tear is an option if its radioulnar ligament components are otherwise robust, with the goal to restore their mechanical integrity.[58] Soft tissue repair or reconstruction in the presence of marked bony deformity, however, is likely to fail.

Symptomatic nonunion of the ulnar styloid is an uncommon problem that is usually best treated by simple subperiosteal excision. If the fragment is large, and the TFCC is unstable, it's repaired to the styloid base after fragment excision with transosseous sutures.[57] Alternatively, the nonunion can be repaired; although, fixation of a basilar ulnar styloid nonunion alone in chronic instability can be ineffective because the soft tissues may be attenuated.

A soft tissue reconstructive procedure is indicated when the TFCC is irreparable and the sigmoid notch is competent. Reconstructive techniques can be classified into three categories: (1) a direct radioulnar tether that is extrinsic to the joint, (2) an indirect radioulnar link via an ulnocarpal sling or a tenodesis,[16,60,168] or (3) reconstruction of the distal radioulnar ligaments.[1,70,138] The techniques in the first two categories may improve symptoms but are not anatomic; and in laboratory studies, they have not been shown to restore normal joint stability or mechanics.[124] Nonetheless, these reconstructions may be the only option in some cases and are occasionally used in conjunction with a Darrach excision of the distal ulna or to stabilize a previously resected distal ulna.[52]

An indirect radioulnar link is created using techniques described by Boyes and Bunnell[15] (Figure 14.21) and by Hui and Linscheid[60] (Figure 14.22) to reconstruct the volar ulnocarpal ligaments using a distally based strip of the FCU tendon. Such techniques are particularly applicable when ulnocarpal instability is the primary problem, and DRUJ instability is of a lesser concern.

Reconstruction of the distal radioulnar ligaments is the most anatomical approach and has the potential to restore stability without substantial loss of rotation or strength. The procedure is dependent on a mechanically competent sigmoid notch to provide a buttress effect for proper ligament function. If the notch is not competent, either an osteoplasty of the sigmoid notch (described later in this chapter) must be done concurrently, or another surgical option needs to be considered.

http://e-surg.com

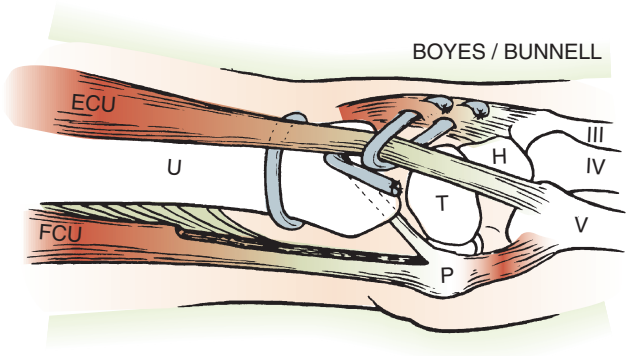

FIGURE 14.21 Technique described by Boyes and Bunnell for chronic distal radial ulnar joint instability reconstructs volar ulnocarpal ligaments and creates a tether between the distal radius and ulna. *ECU,* Extensor carpi ulnaris; *FCU,* flexor carpi ulnaris; *H,* hamate; *P,* pisiform; *T,* triquetrum; *U,* ulna; *III,* long finger metacarpal; *IV,* ring finger metacarpal; *V,* small finger metacarpal. (From Petersen MS, Adams BD: Biomechanical evaluation of distal radioulnar reconstructions. *J Hand Surg Am* 18:328–334, 1993.)

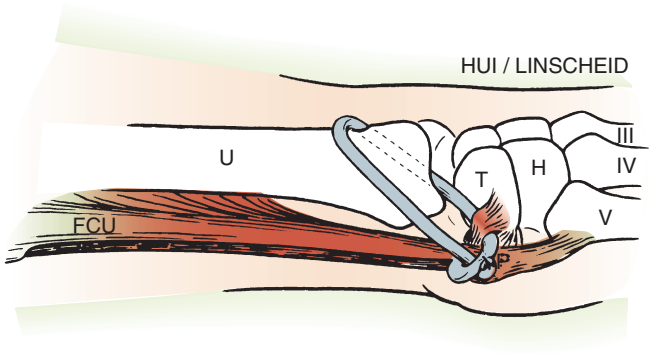

FIGURE 14.22 Hui and Linscheid procedure reconstructs volar ulnocarpal ligament using strip of flexor carpi ulnaris tendon. It is particularly useful for primary ulnocarpal instability and secondary distal radial ulnar joint instability. *FCU,* Flexor carpi ulnaris; *H,* hamate; *P,* pisiform; *T,* triquetrum; *U,* ulna; *III,* long finger metacarpal; *IV,* ring finger metacarpal; *V,* small finger metacarpal. (From Petersen MS, Adams BD: Biomechanical evaluation of distal radioulnar reconstructions. *J Hand Surg Am* 18:328–334, 1993.)

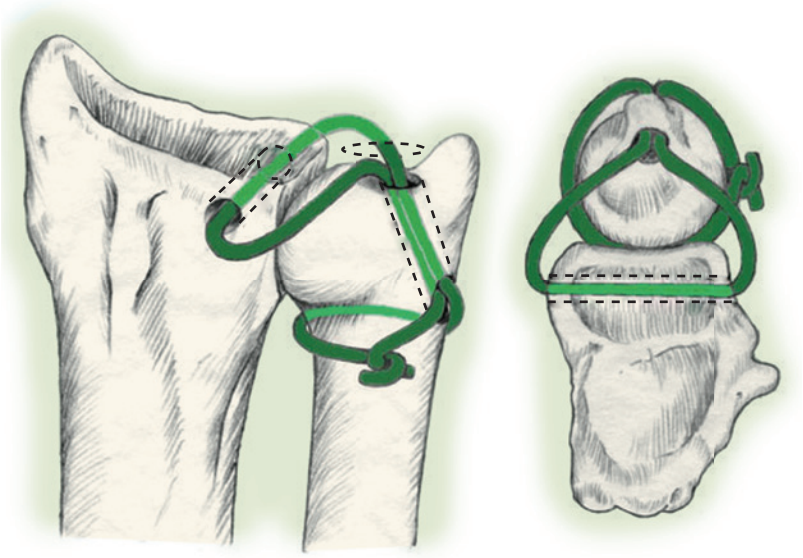

FIGURE 14.23 Method of reconstruction of both distal radioulnar ligaments that uses palmaris longus tendon graft passed through bone tunnels in distal radius and ulnar head is illustrated. Location of bone tunnels and route of tendon graft also are shown.

Scheker and associates described a technique for reconstruction of the dorsal radioulnar ligament using a tendon graft.[138] Three drill holes are placed in the distal radius and ulna, and the graft is woven and tied onto itself. Johnston Jones and Sanders described a technique for reconstruction of both radioulnar ligaments with a palmaris tendon graft.[70] A technique developed by the senior author reconstructs the anatomic origin and insertion of the palmar and dorsal radioulnar ligaments (Figure 14.23); it is presented next.[1]

❖ AUTHORS' PREFERRED METHOD OF TREATMENT: Distal Radioulnar Ligament Reconstruction

A 5-cm incision is made between the fifth and sixth extensor compartments over the DRUJ. Care is taken to preserve the dorsal sensory branch of the ulnar nerve and full-thickness soft tissue flaps are elevated off of the extensor retinaculum. The fifth extensor compartment is opened over the radioulnar joint, and the EDQ tendon is retracted (Figure 14.24, *A*). An "L"-shaped DRUJ capsulotomy is made with the longitudinal limb along the dorsal rim of the sigmoid notch, leaving enough capsule attached to the rim for later repair, and the transverse limb just proximal to the dorsal radioulnar ligament (Figure 14.24, *B*).

The ECU sheath is not opened or dissected from the ulnar groove during the procedure. If the TFCC is irreparable, radioulnar ligament reconstruction is performed. Scar is debrided from the fovea, but the functioning remnants of the TFCC are retained. If an ulnar styloid nonunion is present, the fragment is resected subperiosteally through the same incision. A palmar exposure is made through a 3- to 4-cm longitudinal incision extending proximally from the proximal wrist crease in the interval between the ulnar neurovascular bundle and finger flexor tendons.

Although the palmaris longus is the easiest tendon graft to harvest, it is often too short and therefore the surgeon should be prepared to obtain an alternative graft (e.g., the plantaris, toe

http://e-surg.com

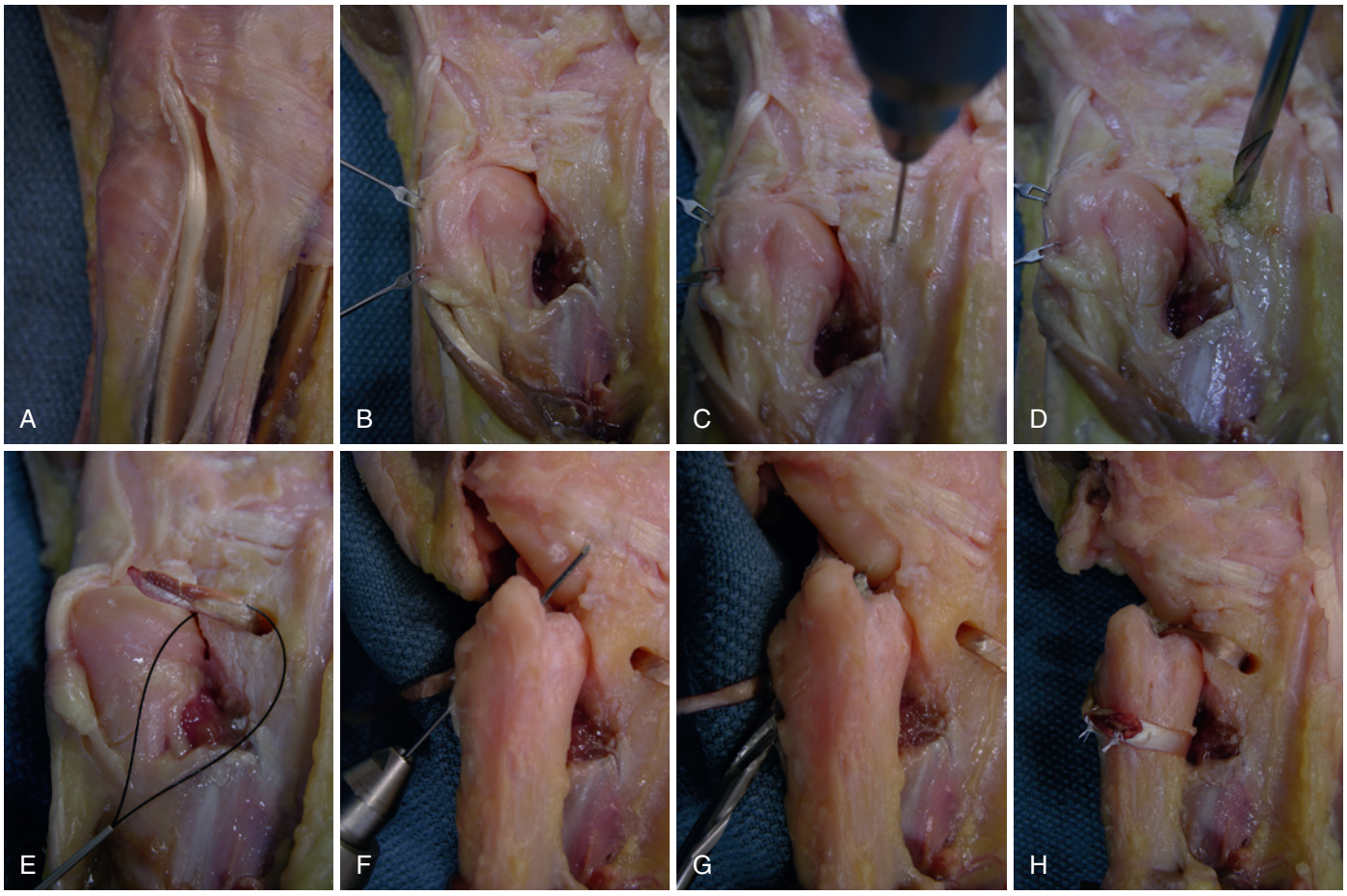

FIGURE 14.24 Surgical steps for the completion of a distal radioulnar ligament reconstruction demonstrated in a left wrist: **A,** Dorsal exposure and incision of the fifth extensor compartment. **B,** A dorsal capsulotomy using an L-shaped incision, preserving the dorsal radioulnar ligament. **C,** Dorsal-to-volar guide pin placement. **D,** Cannulated drilling of the osseous tunnel in the distal radius. **E,** Passage of the palmaris longus tendon graft using a Hewson tendon passer. **F,** The guide pin for the ulnar osseous tunnel may be placed from the ulnar neck with its trajectory toward the fovea, or from the fovea directed to the ulnar neck. **G,** Passage of the tendon graft from volar-to-dorsal within the distal radius before passing through distal ulnar osseous tunnel. **H,** The completed tendon graft passed through the distal radius and ulna, attempting to recreate the distal radioulnar ligaments. (**A–H:** Reprinted with permission: copyright © 2009, Leversedge FJ.)

extensor, or strip of the FCU or FCR)[66]; a narrow FCU strip is the authors' preferred choice because it can be harvested through the same palmar incision used for the reconstruction and a long graft can be obtained. The periosteum beneath the fourth dorsal extensor compartment is elevated sharply from the dorsal margin of the sigmoid notch. A guidewire for a 3.5-mm cannulated drill bit is driven through the radius several millimeters proximal to the lunate fossa and radial to the articular surface of the sigmoid notch. The wire is inserted parallel to the articular surfaces and located so that the tunnel can be made large enough to accommodate the graft without disrupting the subchondral bone of the lunate fossa or sigmoid notch (see Figure 14.24, *C*).

Fluoroscopic imaging is used to confirm proper guidewire position and the tunnel is made with a cannulated drill, exiting carefully through the palmar incision (see Figure 14.24, *D*). If a corrective osteotomy for a distal radius malunion is planned in conjunction with the ligament reconstruction, it is easier to create the tunnel before performing the osteotomy; however, tendon graft insertion and tensioning should not be done until the bony correction is completed. If a sigmoid notchplasty is planned, the tunnel should be created prior to the notchplasty, but the tendon graft is not passed until the notchplasty is completed.

A second tunnel is created in the distal ulna between the fovea and ulnar neck. A 4- to 5-mm diameter drill hole is made in the ulnar neck at its subcutaneous border. A guidewire is inserted in the hole and driven through the fovea under direct visualization. Alternatively, the wrist is flexed, and the guidewire is driven through the fovea and out the ulnar neck. A 3.5-mm cannulated drill bit is used to create the tunnel. If necessary, it is enlarged further with larger drill bits or gouges to accommodate both limbs of the graft.

A suture retriever is passed through the tunnel in the radius from dorsal to palmar, and one end of the graft is pulled back through it (see Figures 14.24, *E-G*). Through the dorsal incision, a hemostat is passed over the ulnar head, adjacent to the ulnar styloid but proximal to the remaining TFCC, and pushed through the palmar DRUJ capsule. The other end of the graft is grasped with the hemostat and pulled back along this tract. Both graft limbs are passed through the ulnar tunnel to exit the ulnar neck. The limbs are passed in opposite directions around

http://e-surg.com

the ulnar neck, one passing radially and deep into the ECU sheath and the other passing palmarly. With the forearm in neutral rotation and the DRUJ manually compressed, the limbs are pulled taut, tied together, or passed through in a belt-loop fashion and secured with sutures (see Figure 14.24, *H*).

If the graft is too short to pass around the ulnar neck, alternative methods of graft fixation include making an additional hole in the neck dorsally and tying the graft over the bony bridge, or using a suture anchor or an interference screw. When the graft is too short, the senior author's preferred method is to tie the limbs around a broad, robust strip of elevated periosteum on the dorsum of the ulnar neck, typically located beneath the ECU tendon. The ECU sheath is opened at the level of the ulnar neck but not over the ulnar head, then one graft limb is passed under and then back over the periosteum through longitudinal splits but beneath the ECU tendon. The limbs are pulled taut around the periosteum and tied to each other.

The dorsal DRUJ capsule and extensor retinaculum are closed together as a single layer with 3-0 sutures, leaving the EDQ subcutaneous. The extremity is immobilized in a long-arm cast with the forearm in neutral rotation for 4 weeks, followed by use of a short-arm cast for 2 weeks. A wrist splint is used while motion and strength are gradually recovered. Near full activity is usually permitted after 4 months, but heavy lifting and impact loading are discouraged until 6 months postoperatively.

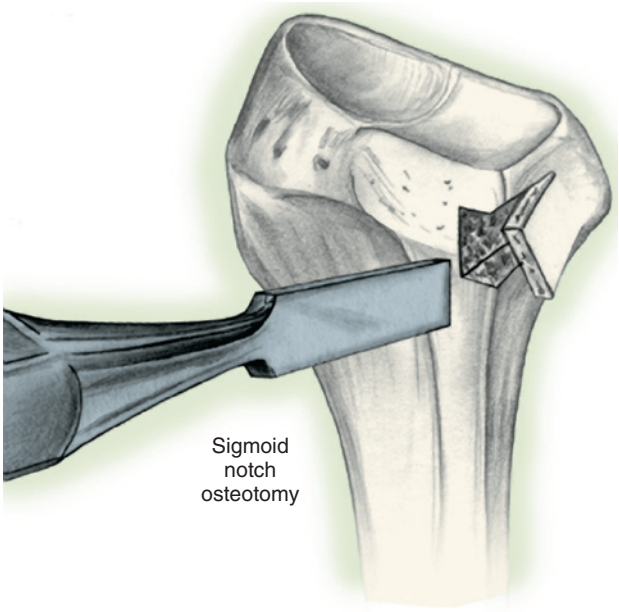

FIGURE 14.25 Sigmoid notch osteoplasty used for distal radial ulnar joint instability that is caused partially by deficiency of a rim of the notch. Bone graft is inserted beneath osteochondral flap. (From Adams B: Distal radioulnar joint. In Trumble TE, editor: *Hand surgery update 3: Hand, elbow, and shoulder,* Rosemont, IL, 2003, American Society for Surgery of the Hand, pp 147–157.)

Outcomes

Scheker and associates reported complete resolution of pain in 12 of 14 patients at an average follow-up of 1.5 years with their technique.[138] Near full range of rotation and 76% increase in grip strength were achieved. Johnston Jones and Sanders reported 13 of 14 patients were satisfied at an average follow-up of 26 months.[70] Of these patients, 12 returned to their previous occupations and showed no evidence of recurrent instability; 2 patients had early failure of stability. No patient had loss of motion >10 degrees of supination or pronation.

Adams and Berger reported restoration of stability in 12 of 14 patients and resumption of previous work, sports, and avocations without limitations.[1] Recovery of strength and motion averaged 85%. Recurrent palmar instability occurred in one patient who had a posttraumatic defect in the palmar rim of the sigmoid notch and another patient had persistent ulnocarpal instability. The authors concluded that the procedure is effective for DRUJ instability but requires a competent sigmoid notch and does not fully correct ulnocarpal instability. If the notch is deficient, a sigmoid notch osteoplasty should be considered in conjunction with ligament reconstruction.

Osteoplasty of the Sigmoid Notch and Ulna

CT is helpful to evaluate the sigmoid notch in patients with a history of a fracture involving it, a suspected deformity of the DRUJ, or a developmentally flat notch. To improve the mechanical buttressing effect of the sigmoid notch's rim, an osteoplasty can be considered as an isolated procedure or to complement ligament reconstruction. In the procedure described by Wallwork and Bain, parallel osteotomies are made, with one just proximal to the lunate fossa and the other at the proximal margin of the sigmoid notch[171] (Figure 14.25).

A third osteotomy is made in the sagittal plane 5 mm from the articular surface of the notch and between the first two cuts; an osteotome placed in this longitudinal cut is carefully advanced, and at each increment it is levered in an ulnar direction to produce a thin, slightly curved osteocartilaginous flap. The wedge-shaped defect is filled with a bone graft harvested from the distal radius and fixed as necessary with Kirschner wires or sutures. When performed in conjunction with a ligament reconstruction, the tendon graft passes around the bone graft and the osteocartilaginous flap to stabilize the construct.

Published results about the procedure are limited, but the concept seems sound. It produced a good result when used as a sole procedure to treat palmar instability in a patient with a flat sigmoid notch.[171] The senior author uses it in conjunction with a radioulnar ligament reconstruction when the sigmoid notch is relatively flat and has been satisfied with the results.

An alternative osteoplasty is an angular osteotomy of the ulna. A closing wedge osteotomy is made in the distal third of the ulna to tilt the ulnar head toward the sigmoid notch with the forearm in the position of instability. The osteotomy is fixed with a compression plate. Preoperative planning, patient selection, and intraoperative assessment must be accurate to achieve a good result with this technique. It may be best utilized in patients with a preexisting ulnar deformity.

DISTAL RADIUS AND FOREARM MALUNIONS

In evaluating a patient with a distal radius malunion, both the radiocarpal joint and the DRUJ must be considered. Biomechanical studies have shown multiple effects of malunion on DRUJ function, with angulation and shortening of the radius more problematic than loss of radial inclination.[28] Isolated soft

http://e-surg.com

tissue reconstruction for instability fails when there is substantial radial deformity. Similarly, a Darrach resection of the distal ulna can result in instability of the residual ulnar stump if performed in the presence of a significant radial malunion.[47]

An osteotomy to correct angular deformity of the radius usually restores the sigmoid notch's orientation and DRUJ stability; however, radioulnar length discrepancy also must be addressed to improve carpal position and to prevent later development of an ulnar impaction syndrome. A trapezoidal graft to the radius can correct angulation and length discrepancy simultaneously. In malunions with severe length discrepancy, this approach can be difficult because of the need for a large intercalated bone graft and the potential for delayed union.

As an alternative, leveling of the joint can be accomplished with concurrent ulnar-shortening osteotomy. If radial shortening is the only substantial deformity, and articular alignment of the radius and carpus is satisfactory, ulnar-shortening osteotomy is effective[154] (Figure 14.26). When bony realignment does not restore stability through a full arc of forearm rotation tested during surgery, TFCC repair or a soft tissue stabilization procedure is necessary (Figure 14.27). If DRUJ arthritis is present, one of the arthroplasty procedures described later in this

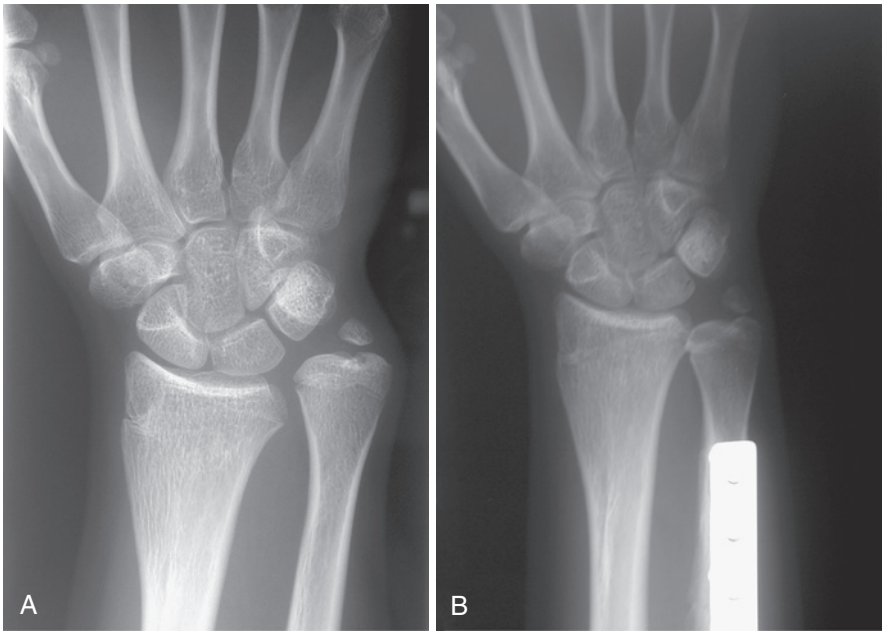

FIGURE 14.26 **A, B,** Radial shortening with disruption of distal radial ulnar joint can be effectively treated by ulnar shortening alone if joint widening is not present.

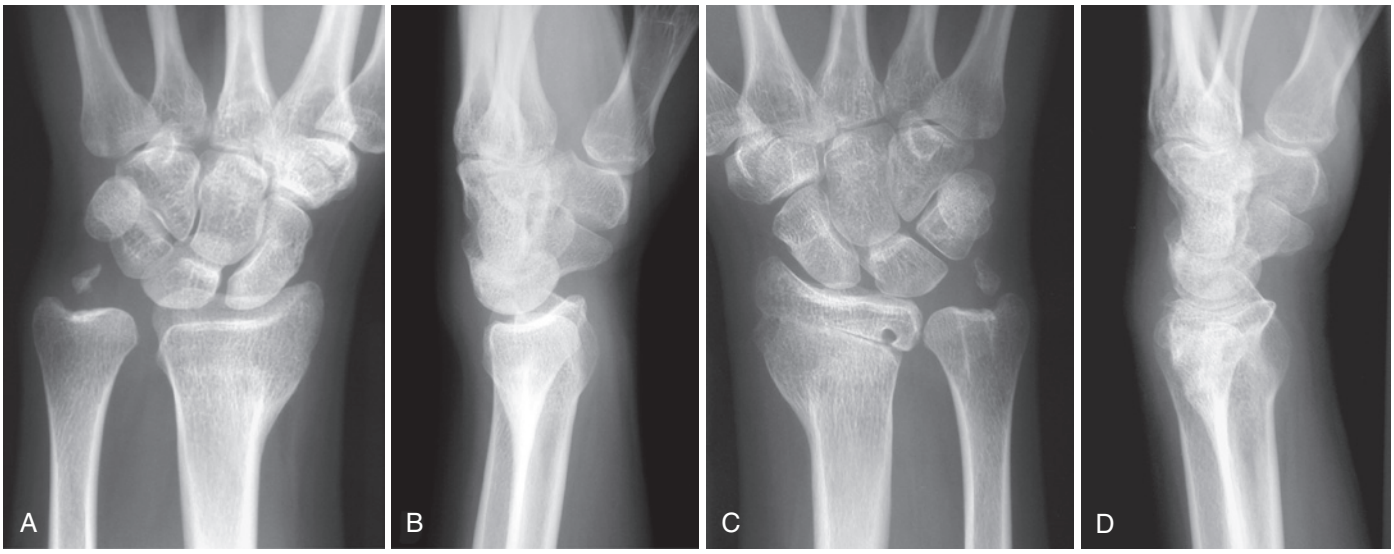

FIGURE 14.27 **A, B,** Views of distal radius malunion with distal radial ulnar joint (DRUJ) instability (i.e., angulation of the radius, DRUJ widening, and displaced fleck fracture from fovea). **C, D,** Treatment was by distal radius osteotomy and distal radioulnar ligament reconstruction as shown in Figure 14.20.

http://e-surg.com

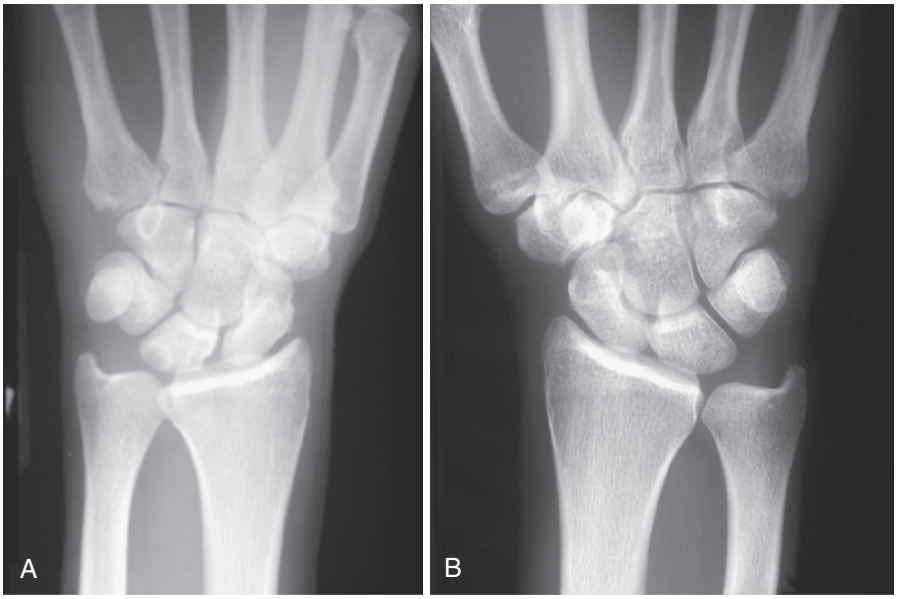

FIGURE 14.28 Comparison radiographs showing positive-ulnar variance with ulnar impaction syndrome (note cystic lesions in lunate) caused by premature physeal closure of distal radius (**A**) and opposite unaffected wrist (**B**). (From Adams B: Distal radioulnar joint. In Trumble TE, editor: *Hand surgery update 3: Hand, elbow, and shoulder*, Rosemont, IL, 2003, American Society for Surgery of the Hand, pp 147–157.)

chapter can be performed; however, radioulnar length discrepancy still needs to be corrected to prevent impingement between the ulnar styloid and the carpus.[14]

Forearm malunion can cause DRUJ instability in addition to loss of rotation. The deformity may manifest initially as limited forearm rotation, and instability may develop later as the soft tissues attenuate. Soft tissue stabilizing procedures alone fail in the presence of a forearm malunion. Conversely, corrective osteotomy with plate fixation often is sufficient to restore stability; TFCC repair or a reconstructive procedure is usually unnecessary.[165] The deformity may involve the radius and the ulna and require osteotomy of both bones. Angulation is corrected through the site of malunion whenever possible to attain anatomic alignment. A rotational deformity can be corrected simultaneously when an angular deformity is treated. Unless there is DRUJ arthritis, resection of the distal ulna should be avoided.

Preoperative planning is important to estimate the desired correction, but the final determination must be made intraoperatively. Temporary bony fixation can be used to assess the effect of the correction. If stability is not restored through a full arc of forearm rotation, a soft tissue stabilization procedure or DRUJ-salvage procedure may be combined with the corrective osteotomy. Operative techniques for correction of malunions are discussed in Chapter 15.

ULNAR IMPACTION SYNDROME

The ulnocarpal joint transmits a substantial load through a relatively small contact area and is at high risk for articular degeneration. This degenerative process is commonly called *ulnar impaction syndrome*, which implies that chronic compressive overloading is the primary cause. Shear forces over the articular surfaces and tensile forces through the soft tissues undoubtedly contribute to joint deterioration.

Acquired ulnar-positive variance is a known risk factor for ulnar impaction syndrome because of the associated increase in ulnocarpal loading. A 2.5-mm increase in ulnar variance increased ulnocarpal loading by 42% in a cadaveric study.[121] In a similar study, changing the tilt of the distal radius from normal to 40 degrees of dorsal tilt increased the ulnar load from 21 to 65%.[179a] Common causes of acquired positive variance include radial shortening from a distal radius fracture, Essex-Lopresti injury, and acute or chronic physeal injury[161] (Figure 14.28).

Although biomechanical studies have not shown increased load transmission through the ulnocarpal joint in developmentally ulnar-positive wrists, these wrists can still develop ulnar impaction syndrome for other reasons. In a cadaveric study, 73% of ulnar-neutral or ulnar-positive wrists had TFCC perforations, whereas only 17% of ulnar-negative wrists had perforations.[120] The thickness of the disk can play a role because there is an inverse relationship between ulnar variance and disk thickness; ulnar-positive wrists are associated with a thinner disk that may be more susceptible to perforation.[118] Also, physiologic increases in ulnar variance of 2 mm can occur during power grip, especially when the forearm is pronated. Palmer identified several additional structures at risk for degeneration in this process, including the ulnar head, lunate, triquetrum, and lunotriquetral interosseous ligament.[116]

Evaluation

Ulnar impaction syndrome is characterized by ulnar wrist pain, localized swelling, and occasional limitation of motion. The history and physical findings are similar to an acute TFCC tear. Pain is exacerbated by ulnar deviation during power grip, especially when combined with active pronation and supination. There is tenderness around the volar and dorsal aspects of the ulnar head and the triquetrum. Passive and active ulnar deviation produces pain, which is intensifed by the examiner

http://e-surg.com

simultaneously depressing the ulnar head and elevating the ulnar carpus (pisiform boost).

This maneuver better reproduces the joint reaction forces during power grip activities, which load the more central portions of the ulnar dome, TFCC disk, lunate, and triquetrum. While the wrist is loaded in this manner, the forearm can be rotated manually to add a shear force to the joint, which can increase pain and occasionally produces crepitus. The examiner should consider other diagnoses involving the ulnar side of the wrist that can manifest with similar findings or coexist, particularly arthritis of the DRUJ.

Standard wrist radiographs can be obtained to assess for arthritis involving the carpus and DRUJ and to measure ulnar variance. Because ulnar variance is dynamic, stress posteroanterior views can help. A pronated view,[38,117] a grip view,[42] or a view with combined pronation and grip[163] may reproduce dynamic increases in ulnar variance. In a study of 22 patients who presented with ulnar wrist pain, the pronated grip view resulted in statistically significant increases in ulnar variance with an average of 2.5 mm.[163]

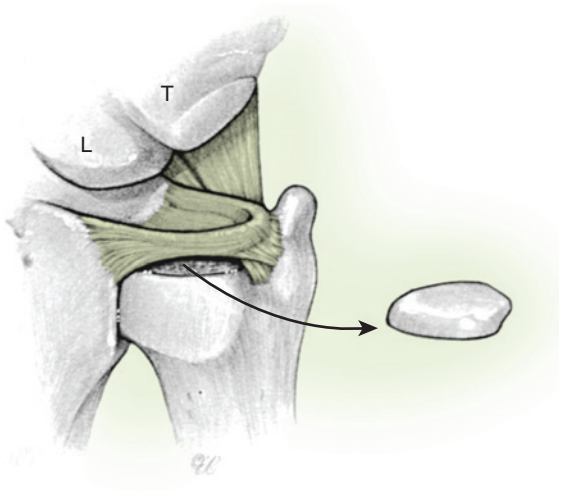

FIGURE 14.29 Resection of distal dome of ulnar head (wafer procedure) decompresses ulnocarpal joint for ulnar impaction syndrome. *L,* Lunate; *T,* triquetrum. (Copyright © Elizabeth Martin.)

Treatment

In treating ulnar-sided wrist pain, it is imperative to remember that degeneration is a common and natural occurrence in the ulnocarpal joint. Several months of conservative management are appropriate before proceeding to surgery. Options include modification of activities to avoid repetitive loading with the wrist in ulnar deviation, antiinflammatory medications, wrist splinting, and corticosteroid injections. Surgery is indicated for patients with clinical and radiographic evidence of ulnocarpal impaction without DRUJ arthritis whose symptoms do not resolve adequately despite conservative measures. The goal of surgery is to reduce ulnocarpal loading.

For a patient with negative or neutral ulnar variance, arthroscopic debridement of the articular disk, chondral surfaces, and lunotriquetral interosseous ligament can be effective. When static or dynamic ulnar-positive variance is present, decreased ulnar loading can be accomplished by a diaphyseal or metaphyseal[53,55] osteotomy, or a partial distal ulnar resection. Some surgeons prefer arthroscopic distal ulnar resection instead of open procedures because it avoids the potential for hardware irritation and the risk of nonunion (see Chapter 17). It is important to understand that distal ulnar-shortening osteotomies have no effect on tensioning of the secondary stabilizers of the DRUJ; consequently, when concern for subtle instability coexists with ulnar impaction syndrome, a diaphyseal osteotomy may be preferable.[76]

Partial Distal Ulnar Resection (Wafer Procedure)

Feldon and colleagues described the "wafer procedure" in which the distal 2 to 4 mm of the ulnar head is excised.[39] Although explained as an open procedure, it can be performed arthroscopically as well (see Chapter 17). The procedure is designed to retain the ulnar styloid and foveal attachments of the TFCC. It is not intended to disrupt the articular surfaces of the DRUJ, so no more than 3 to 4 mm of the distal ulna should be removed.

A dorsal approach to the DRUJ is used as described for distal radioulnar ligament reconstruction (see Figures 14.24, *A*, *B*). The distal 2 to 4 mm of the ulnar dome is resected with an osteotome or oscillating saw, taking care to preserve the TFCC's ulnar attachments (Figure 14.29). If the TFCC becomes detached at the fovea, it is repaired using transosseous sutures as described for TFCC repair. The proximal surface of the disk is inspected and tears are debrided. The dorsal capsule is repaired, but not imbricated to avoid stiffness. A sugar tong splint is applied, with conversion to a removable wrist splint at the first postoperative visit. Digital, wrist, and forearm motion are started early, but full activity is not recommended for 8 to 12 weeks.

Outcomes. In a retrospective review of 13 cases by Feldon and associates, all achieved good or excellent results, and none required secondary procedures.[39] In a separate series of 26 patients, 23 were completely satisfied and obtained improved grip with this method. Two other smaller studies also reported positive results.[11,143] Despite such good final results, the procedure commonly requires a long recovery time. In comparison studies of ulnar-shortening osteotomy and the wafer procedure, outcomes were nearly identical, although reoperation, primarily for plate removal, was more frequent in the osteotomy group.[25,149]

Diaphyseal and Metaphyseal Ulnar-Shortening Osteotomy

Ulnar-shortening osteotomy (diaphyseal) has the advantage of preservation of the ulnar dome articular cartilage and does not violate the DRUJ or ulnocarpal joint. In cases of posttraumatic ulnar-positive variance, ulnar-shortening osteotomy may improve DRUJ congruity, improve forearm rotation, and reduce the risk of arthritis. The ulnocarpal ligaments are tightened by the procedure, and this may have a salutary effect on associated lunotriquetral or DRUJ instability.

An anatomical study of the interosseous membrane demonstrated the presence of a distal oblique bundle—a thickening of the IOM—in approximately 40% of specimens. The DOB originates from the distal 15% of the ulna diaphysis at approximately the proximal margin of the pronator quadratus, and it courses distally to insert into the capsular fibers of the DRUJ and the inferior rim of the sigmoid notch.[112] Based on its anatomic attachments, an ulnar-shortening osteotomy created proximal to the origin of the DOB may improve the stability of the DRUJ through its tensioning of the capsular structures.

http://e-surg.com

An ulnar-shortening osteotomy through the distal metaphysis has been described to take advantage of improved metaphyseal bone healing and reduced risk of hardware prominence or need for subsequent removal.[55] The closing-wedge osteotomy does change the orientation of the distal articular surface of the ulna, and the clinical consequences of this alteration in DRUJ contact stresses are not known.[53]

Possible adverse effects should be recognized when considering ulnar-shortening osteotomy. Although the articular surfaces of the native DRUJ are not fully congruent and usually tolerate some change in joint alignment, radiographic and cadaveric studies have shown that 2 mm of shortening decreases joint contact area and increases pressures in the DRUJ regardless of its shape and inclination.[53,135,162,179] Some DRUJ morphologic types may be more susceptible to developing problematic incongruity after ulnar-shortening osteotomy.[135] A joint with a reverse oblique inclination in the coronal plane or a substantial articular mismatch between the sigmoid notch and ulnar head develops the greatest incongruity, with joint contact concentrated at the proximal margin of the notch. Similar changes occur in a joint with a deep sigmoid notch. Predicting the clinical outcome of surgically created DRUJ incongruity is difficult because it either may stimulate DRUJ remodeling or may cause arthritis.

Ulnar shortening was originally described by Milch in 1941 for the treatment of ulnar-positive variance after radial shortening from a Colles fracture.[96] Milch used a wire suture to fix the osteotomy. Although the principle remains the same, current methods include the use of an oblique osteotomy and techniques of osseous compression, with or without the use of special compression devices[20,178] or commercial plates designed specifically for this procedure.[128] An oblique osteotomy using a compression clamp and an interfragmentary screw increases compression and stability and may improve bone healing.[23,91]

❖ AUTHORS' PREFERRED METHOD OF TREATMENT: Ulnar-Shortening Osteotomy

The authors prefer the technique described by Chun and Palmer[23] (Figure 14.30). For patients with ulnar-positive variance, the amount of bone to be resected to obtain a final ulnar variance of 0 or −1 mm is determined on the posteroanterior radiograph. A 2- to 3-mm shortening is planned for patients with ulnar-neutral wrists. A skin incision is made along the subcutaneous border of the ulna extending proximally from its neck for 10 cm. The fascia is incised between the ECU and the FCU.

The dorsal sensory branch of the ulnar nerve typically lies volar and distal to the exposure and should be carefully protected. Minimal subperiosteal elevation is performed, so as not to strip the limited blood supply of the ulna. A 6- or 7-hole, 3.5-mm dynamic compression plate or specialty ulnar-shortening plate is contoured if necessary and applied to the ulna, with its distal edge about 1 cm proximal to the sigmoid notch. The two most distal screws are inserted in the neutral mode.

Electrocautery is used to make a mark on the ulna at the osteotomy site, which should lie opposite the third or fourth hole in the plate. A longitudinal mark is also made to ensure proper rotational alignment after osteotomy. When using the dynamic compression plate, the most distal screw is loosened and the other screw is removed to allow the plate to be swung away from the ulna. At 45 degrees to the coronal plane, an oblique cut is made through 75% of the ulna. A complete second cut is made parallel to the first. The kerf (i.e., width of bone it removes) of the saw blade is accounted for when making the second cut.

The first cut is completed and the resected bone is removed. The plate is swung back in place and the previously inserted screws are replaced and tightened. Axial compression is applied manually to the ulna to oppose the osteotomy, and the plate is clamped to the ulna proximally. In completing the plate fixation, one or two of the proximal screws are inserted eccentrically in the dynamic compression mode. At the osteotomy site, a compression screw is inserted through a gliding hole and across the oblique osteotomy using a standard interfragmentary compression technique.

In the senior author's experience, placement of the plate on the dorsal surface of the ulna reduces hardware irritation and the need for plate removal.[31] Commercially available systems incorporating a specialty plate and cutting jigs are commonly used for efficiency and accuracy; however, knowledge of the specific system is imperative to optimize its advantages. Postsurgery, an ulnar gutter splint is applied for 2 weeks. A removable splint is used with early forearm, wrist, and digital motion, but strenuous activity is restricted until bony union.

Outcomes. Several studies reported a high percentage of success with ulnar-shortening osteotomy. Combining the results using standard technique and equipment, 79 of 90 (88%) patients achieved good or excellent results with regard to pain relief and recovery of function with only one nonunion (1%).[20,23,30,178] Delayed union and symptomatic hardware prominence leading to plate removal are the most common

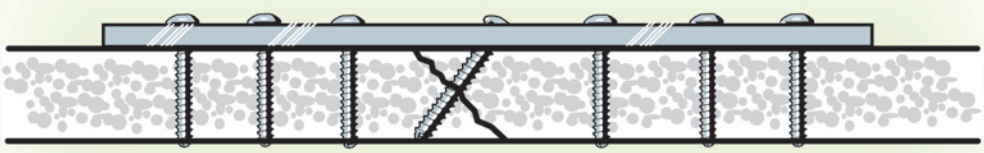

FIGURE 14.30 Ulnar-shortening osteotomy through the shaft is shown using oblique skeletal cut, compression plate, and interfragmentary screw. (Copyright © Elizabeth Martin.)

http://e-surg.com

problems. Ulnar-shortening osteotomy has been used in conjunction with delayed repairs of traumatic TFCC injuries[166] and after failed arthroscopic debridement of central disk tears and incomplete avulsions of the TFCC.[61] The goal is to reduce the load on the injured TFCC. Ulnar shortening is reported as an effective treatment for Madelung deformity as well; remodeling of the joint may still occur even when performed in adolescents.[34]

DISTAL RADIOULNAR JOINT ARTHRITIS

Degeneration of the DRUJ can be caused by posttraumatic arthritis, inflammatory arthritis, osteoarthritis, but rarely by long-standing DRUJ instability. Differentiating between DRUJ arthritis and ulnocarpal impaction syndrome is important when treating degenerative conditions of the ulnar wrist. In some cases, both conditions are present and both require treatment to improve symptoms. Pain and swelling, decreased grip strength, and stiffness are the most common symptoms of DRUJ arthritis. Point tenderness is elicited directly over the DRUJ. Pain is exacerbated by forearm rotation, especially when the joint is manually compressed.

Early radiographic signs of degenerative arthritis of the DRUJ typically occur in the proximal portion of the joint. Osteophytes form along the proximal margin of the ulnar head, whereas the sigmoid notch often is spared. Based on these findings of localized articular involvement, nonablative procedures have been described. Ulnar shortening, which shifts the proximal margin of the ulnar head out of the sigmoid notch, was reported to relieve symptoms in early DRUJ posttraumatic arthritis.[139] Open surgical resection of the proximal one-third of the articular surface of the ulna around its entire circumference and 2- to 3-mm deep also has been employed. The procedure, called a modified arthroplasty, was reported to relieve pain and preserve motion and stability in 10 of 11 patients.[175] Although experience with these procedures is limited, similar approaches have been used successfully in other joints.

In more advanced arthritis, surgical treatments are designed to eliminate the articulation between the distal ulna and radius by resecting all or a portion of the distal ulna, fusing the joint, or replacing the distal ulna. Each of the many techniques described has advantages and disadvantages that should be considered when selecting treatment. Surgical options include the Darrach procedure, the Sauvé-Kapandji operation, hemiresection–interposition technique, implant arthroplasty, wide distal ulnar resection, and a one-bone forearm procedure. The last two options are reserved for ultimate salvage, particularly for a failed distal ulnar resection. Because these procedures do not restore normal anatomy, some compromised function and incomplete pain relief should be expected.

Operative Technique

Hemiresection–Interposition Arthroplasty

Because instability is occasionally associated with the Darrach procedure, Bowers designed a surgical procedure that removes the articular surface of the ulnar head and retains the critical ulnar attachments of the TFCC.[14] The procedure, which Bowers called the hemiresection–interposition technique, was derived from Dingman, who found the best clinical results of the Darrach procedure occurred in patients who had minimal distal ulnar resection that was followed by regeneration within the retained periosteal sleeve.[33]

The primary indication for the hemiresection–interposition technique is posttraumatic or degenerative arthritis of the DRUJ. It may be useful also in patients with severe DRUJ contractures complicated by articular degeneration that may not be discovered until the surgical release. Caution should be observed before using this procedure for the treatment of combined DRUJ arthritis and instability because often the instability can be exacerbated.

Resection procedures in younger patients are less reliable because it may help to relieve pain but may result in loss of support for the ulnar carpus over time. Because some convergence of the radius and ulna occurs after partial resection of the ulnar head, ulnar-positive variance is a relative contraindication because it increases the likelihood of impingement between the ulnar styloid and triquetrum. Also, ulnar carpal translation is a contraindication to partial or complete excision of the ulnar head because the resection may exacerbate the translation. Irreparable damage to the TFCC is a relative contraindication because the hemiresection–interposition technique provides no theoretical benefit over a Darrach procedure.

In his original and modified techniques, Bowers created several retinacular flaps to reconstruct the capsule and to stabilize the ECU.[14] The arthroplasty can be augmented with a tendon or muscle interposition when local soft tissue is insufficient. The matched distal ulnar resection described by Watson and Gabuzda is a similar alternative.[174] Even though these authors do not stress preservation of the TFCC and ulnocarpal ligaments, it is advisable to do so. The concept is to remove all of the articular cartilage and subchondral bone on the radial and dorsal margins of the distal ulna so as to prevent radioulnar impingement during forearm rotation. An intact periosteal sleeve is preserved to maintain continuity with the ulnar carpus, and the exposed cancellous bone encourages very good healing of the surrounding soft tissue sleeve.

❖ AUTHORS' PREFERRED METHOD OF TREATMENT: Hemiresection-Interposition Technique Arthroplasty

The authors prefer a slight modification of Bowers' procedure, in which there is less resection of the ulnar head and the retinaculum and capsular flaps are secured within the resection site to create both interposition and stabilization (Figure 14.31). By resecting less ulnar head, the amount of radioulnar convergence that can occur is reduced. The seemingly increased risk of developing distal radioulnar bony contact is offset by the increased stability imparted from capturing a larger circumference of the distal ulna with a large capsular–retinacular flap, and it does not preclude adding free soft tissue for further interposition when desired.

The DRUJ is approached dorsally through the fifth extensor compartment in a manner similar to that described earlier for TFCC repair and distal radioulnar ligament reconstruction. An ulnar-based retinacular flap extending to the radial edge of the ECU sheath is elevated; its proximal margin is at the ulnar neck, and its distal margin is at the level of the ulnar styloid. The dorsal capsule is raised similarly as a large rectangular flap, with its base extending from the radial edge of the ECU sheath. (Note: The ECU sheath is not opened during this procedure.) The flap begins over the ulnar neck, continues along the rim of

http://e-surg.com

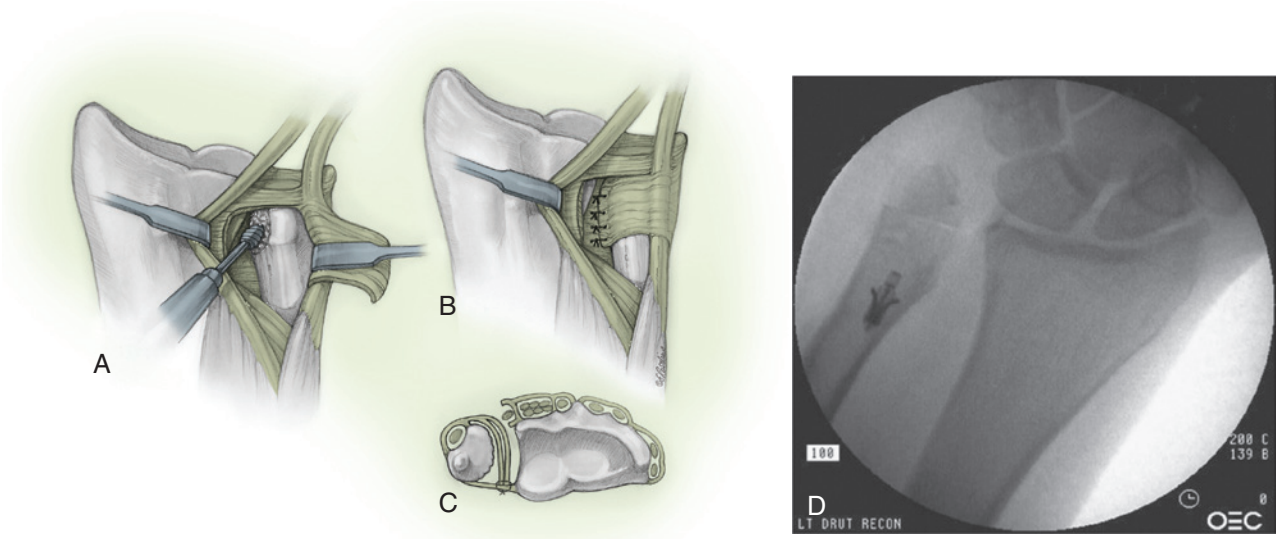

FIGURE 14.31 **A-C,** Hemiresection arthroplasty of distal ulna with soft tissue interposition for arthritis of distal radial ulnar joint (DRUJ). In this modification of the procedure described by Bowers, a single, broad dorsal flap composed of extensor retinaculum and dorsal DRUJ capsule is used for interposition and stabilization (see text). **D,** Concomitant interarticular ulnar-shortening osteotomy has been fixed with embedded suture anchor. (**A–C,** Copyright © Elizabeth Martin.)

the sigmoid notch, and courses ulnarly just proximal to the dorsal radioulnar ligament. Care should be taken not to cut the dorsal radioulnar ligament.

There is no need to expose the distal surface of the TFCC or carpus, unless symptomatic pathology is suspected. Small rongeurs and a bur are used to resect the surface of the ulnar head that articulates with the sigmoid notch to a depth of 3 to 7 mm; the depth of resection is guided by the size of the ulnar head. The head is shaped to resemble a dowel with approximately the same diameter as the ulnar neck. Slight distal tapering is done, but the fovea is not violated and the TFCC insertion is preserved. To reach the volar portion of the head, the radius and ulna are spread with strong retraction, or a laminar spreader is placed proximal to the DRUJ. The TFCC's proximal surface and the remaining ulnar dome are inspected for degeneration and debrided if necessary.

At this point, a decision about ulnar shortening is made. Usually, no more than 2 to 3 mm of ulnar-positive variance is accepted to avoid impingement between the triquetrum and the residual ulnar head or styloid. Similarly, in rare instances, an unusually long ulnar styloid may cause stylocarpal impingement.[164] An assessment for ulnar styloid impingement is done intraoperatively by compressing the radius and ulna while rotating the forearm with the wrist in ulnar deviation. If ulnar shortening is necessary, it can be done through the ulnar shaft, the base of the styloid, or the distal ulna. The goal is to create 1 to 2 mm of ulnar-negative variance. If styloid shortening is done, particular care is required not to cut the TFCC foveal attachment or release the TFCC from the styloid. A distal osteotomy can be repaired with wire or heavy nonabsorbable sutures using a figure-of-eight tension band or an interosseous compression loop.

We prefer to shorten the ulna through the midportion of the residual ulnar head because it can be done through the same incision, avoids the risk of injuring the TFCC foveal attachment, requires minimal fixation, and is in the metaphysis with good bone healing potential. With this technique, a slice is removed with an oscillating saw at its midportion. The osteotomy can be fixed using a standard tension band technique with two parallel 0.045-in Kirschner wires passed obliquely across the osteotomy and a figure-of-eight wire suture. The Kirschner wires are bent over and tapped into the bone. Because the wires often create irritation and require removal, the authors prefer to fix the osteotomy using either a large suture anchor inserted deep into the ulnar neck as described earlier for fixation of ulnar styloid fractures or a headless cannulated screw (see Figure 14.31, *D*). To provide an interposition and to stabilize the joint, the ulnar edges of the retinacular and capsular flaps are sutured simultaneously to the volar DRUJ capsule. The EDQ tendon is left in a subcutaneous position.

Outcomes. Bowers reported on 38 patients, most of whom had rheumatoid arthritis.[14] Patient outcomes were generally good for pain relief and improved motion. Results were excellent in patients with degenerative or posttraumatic arthritis. Often, failures were related to residual ulnocarpal impaction. Bowers now recommends this procedure only in the early stages of rheumatoid arthritis when the stabilizing soft tissues are still effective. According to Bowers, the procedure is particularly valuable in posttraumatic arthritis and osteoarthritis if ulnocarpal impaction is avoided.[14] Fernandez found the procedure to be effective when used in conjunction with a radial osteotomy for malunited distal radius fractures.[40] It has been reported to also be successful in conjunction with repairs of the TFCC in patients with ulnar-positive variance.[99]

Sauvé-Kapandji Procedure

In 1936, Sauvé and, later, Kapandji described a procedure consisting of a radioulnar joint arthrodesis and creation of a pseudarthrosis proximal to the fusion (Figure 14.32). The procedure was developed as an alternative to resection of the distal ulna. Indications are similar to the Darrach procedure, including posttraumatic DRUJ arthritis, rheumatoid arthritis, and osteoarthritis. It has an advantage over a distal ulnar resection in patients with rheumatoid arthritis because it retains support for

http://e-surg.com

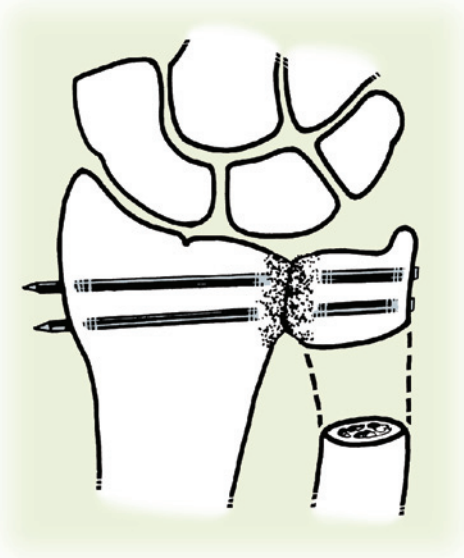

FIGURE 14.32 Sauvé-Kapandji procedure forms a fusion between ulnar head and sigmoid notch and creates a pseudarthrosis through ulnar neck. One or two cannulated screws are used instead of Kirschner wires if bone stock is adequate. (Copyright © Elizabeth Martin.)

the ulnar carpus and reduces the risk of ulnar translation. Some authors have suggested that the Sauvé-Kapandji procedure may be a better one for the treatment of posttraumatic arthritis in active young patients.[72] Potential complications include instability of the ulnar stump and regeneration of the resected segment resulting in loss of motion.

❖ AUTHORS' PREFERRED METHOD OF TREATMENT: Sauvé-Kapandji Procedure

To improve visualization of the articular surfaces of the DRUJ and to avoid levering out the head fragment, we prefer a dorsal exposure. Some surgeons prefer an ulnar approach. A longitudinal incision is made over the sixth extensor compartment extending from the level of the ulnar styloid proximally for 5 to 6 cm. The fifth extensor compartment is opened and the EDQ tendon is retracted. The extensor retinaculum and DRUJ capsule are raised as an ulnar-based flap. The choice of fixation depends on the size and quality of the bone. If bone quality is sufficient, cannulated screw fixation is planned. Two parallel guidewires are inserted into the head just beneath the ECU sheath. The periosteum is excised around the ulnar neck, and 1 cm of the neck is resected with an oscillating saw. If there is ulnar-positive variance, a correspondingly greater segment of ulna is removed so that when the head is depressed to neutral variance the resulting gap is 1 cm. The opposing articular surfaces of the ulnar head and sigmoid notch are denuded to cancellous bone. The ulnar head is held against the sigmoid notch in neutral rotation and at the proper longitudinal position. The wires are driven into the radius, and acceptable alignment is confirmed with fluoroscopy.

Two 3.5-mm cannulated screws are inserted using a lag technique to gain compression, but tilting of the ulnar head must be avoided. If two screws cannot fit, one 3.5-mm and a smaller diameter screw, or one of the guidewires, can be used for additional fixation. Prior to definitive fixation, a small portion of resected cancellous bone is placed into the arthrodesis site. The pronator quadratus muscle is detached from its ulnar insertion and advanced into the osteotomy site and sutured in place to the ECU sheath, followed by a layered wound closure.

To gain additional stability of the proximal ulnar stump in a young patient with posttraumatic arthritis, the FCU tenodesis technique described by Fernandez is used.[40] A distally based strip of FCU tendon is raised and passed into the exposed medullary canal of the ulnar stump and out through a drill hole in it. It is sutured back onto itself under tension. The pronator quadratus is brought into the gap and sutured in place. A long-arm splint is used for 2 to 4 weeks, followed by a short-arm cast until there is radiographic evidence of fusion.

A modified technique described by Fujita and colleagues is useful for patients with advanced rheumatoid disease and in whom the ulnar head is severely eroded. Therefore, a standard Sauvé-Kapandji procedure is not feasible.[44] In their modification, the ulnar osteotomy is made approximately 2 cm proximal to the head, the head–neck segment is rotated 90 degrees from its normal orientation; then, the neck is inserted into a large hole drilled in the sigmoid notch. A screw is inserted through the head, down the neck's medullary canal into the distal radius to stabilize the construct. Although the technique creates an articular surface with the nonarticular part of the ulna, it does construct a strong support for the ulnar carpus.

Outcomes. Goncalves reported on 22 patients whose results were "consistently better" than historical results with the Darrach procedure.[50] Taleisnik reported elimination of pain, restoration of forearm rotation, and few complications in 24 patients with a minimum 1-year follow-up.[158] Predictable complications of an unstable proximal ulnar stump were observed in only 3 of the 24 patients. Other authors have found instability of the ulnar stump more common, although not always symptomatic. A number of authors have expressed general satisfaction with the procedure.[40,51,72,98,100] Stern and colleagues reported unpredictable results in 12 patients—one underwent hardware removal and one underwent a Darrach procedure for persisting pain, with resolution of symptoms.[47]

Distal Ulnar Resection (Darrach Procedure)

Although Darrach's name has become synonymous with resection of the distal ulna, this technique was described by several others before him.[93] The general indication for a distal ulnar resection is any condition that causes incongruity or arthritis of the DRUJ, with resultant pain or stiffness. The procedure is particularly effective for a low-demand patient with an incongruous or degenerative sigmoid notch owing to the sequelae of an intraarticular fracture.

Probably more has been written about the Darrach procedure than any other operation concerning the DRUJ, with a wide variation of technical modifications, results, and opinions (Figure 14.33). Dingman[33] and, more recently, DiBenedetto and colleagues,[32] Nolan and Eaton,[113] and Tulipan and colleagues[169] reviewed the procedure with regard to the technical points of extraperiosteal or subperiosteal resection, the obliquity of the cut, whether to remove the styloid, and the amount of bone to be resected. Dingman's study suggested that none of these factors, other than the amount of bone resection, correlated with patient outcomes. He recommended that only the ulna

http://e-surg.com

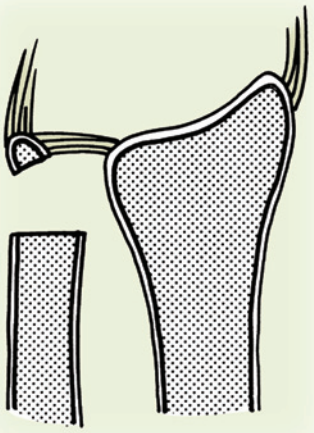

FIGURE 14.33 Darrach procedure resects distal ulna through ulnar neck. The ulnar styloid and its attachments can be retained. Various techniques have been described to help stabilize the ulnar stump. (Adapted from Dingman P: Resection of the distal end of the ulna (Darrach operation): an end result study of twenty-four cases. *J Bone Joint Surg Am* 34:893–900, 1952. Redrawn by Elizabeth Martin.)

adjacent to the sigmoid notch be resected and that subperiosteal resection was ideal because patients in whom regeneration had occurred seemed to have had better results. Dingman also preferred to retain the ulnar styloid. Although controversial, many surgeons would recommend that the procedure be combined with a soft tissue stabilization technique.

❖ AUTHORS' PREFERRED METHOD OF TREATMENT: Distal Ulnar Resection

An incision is extended 5- to 6-cm proximally from the ulnar styloid process along the midsagittal aspect of the distal ulna. The bone is approached just volar to the ECU sheath, with care taken to avoid the dorsal cutaneous branch of the ulnar nerve. The periosteum is incised and reflected from the distal 3 cm of the ulna, but the attachments to the ulnar styloid are retained. Fluoroscopy is used to confirm the preferred osteotomy site; a transverse ulnar osteotomy is made at the level corresponding to the proximal margin of the sigmoid notch. The distal fragment is dissected free, and the ulnar styloid process is osteotomized at its base and left in situ. The periosteal sleeve is closed to provide a firm attachment for the styloid and to help stabilize the ulnar stump.

We typically perform a soft tissue stabilization procedure as an adjunct to the resection (see next section). The wound is closed in layers. Darrach did not use a splint and allowed active motion within 24 h; however, the authors prefer to use a short-arm splint to support the wrist for 2 to 4 weeks to prevent full forearm rotation until the patient has recovered good digital motion and pain and swelling are minimal.

Outcomes. Regardless of the diagnosis, most patients achieve satisfactory pain relief and restoration of function.[52] Instability of the ulnar stump in the anteroposterior and coronal planes can develop and produce substantial weakness and pain. Convergence of the proximal ulnar stump can develop into radioulnar impingement and painful crepitus.[56] The amount of instability and impingement is more common with increasing amounts of bony resection. Outcomes are generally worse in patients with higher demands.[14,56,174] For patients with rheumatoid arthritis and those with active synovitis and wrist laxity, there is a risk of developing progressive ulnar translation of the carpus from a loss of support by the head of the ulna.

For these reasons the Darrach procedure should be used selectively. It may be useful in low-demand patients with severe DRUJ incongruity, arthritis, or ulnar impaction syndrome when an ulnar-shortening osteotomy or hemiresection arthroplasty is unlikely to be successful. In patients with rheumatoid arthritis, consideration should be given to concomitant partial or complete wrist fusion.

Stabilization of the Resected Distal Ulna

To reduce the instability of the proximal ulnar stump created by the Darrach excision, various soft tissue stabilization techniques have been described. Leslie and colleagues,[83] O'Donovan and Ruby,[114] and Webber and Maser[176] tethered the stump with a distally based strip of ECU tendon. Spinner and Kaplan[153] transposed the ECU over the dorsum of the ulnar stump using a flap of retinaculum. Kessler and Hecht[73] created a dynamic sling for the ulnar stump by looping a strip of tendon around the distal ulnar stump and the ECU. Goldner and Hayes[49] passed a proximally based strip of the ECU through a drill hole in the ulnar stump with the forearm in supination. Breen and Jupiter used a combination of half FCU and half ECU, both threaded into the medullary canal of the stump.[16]

Tsai and coworkers used a distally based portion of the FCU tendon to stabilize the ulnar stump and looped this tendon over it also to stabilize the ECU.[167] Tsai and Stilwell[168] reported using the ECU in a similar manner. Hunter and Kirkpatrick[63] used Mersilene tape to bind the radius and ulna together. Watson and colleagues[173] lengthened the short ulnar stump to approximate the appearance of a successfully done partial ulnar resection. Advancement and dorsal redirection of the pronator quadratus was used by Johnson[68] as a soft tissue interposition and as a dynamic stabilizer for the proximal ulnar stump. Ruby and coworkers[132] described a similar use of the pronator quadratus. Blatt and Ashworth sutured a flap of volar capsule to the dorsal aspect of the ulnar stump, which is particularly useful in severe rheumatoid arthritis.[13] Insertion of soft tissue allograft with suture fixation to the ulna and radius was reported by Sotereanos and associates.[151]

❖ AUTHORS' PREFERRED METHOD OF TREATMENT: Stabilization of Resected Distal Ulna

In an elderly, low-demand, or rheumatoid patient, we prefer to stabilize the ulnar stump with a broad flap created from the palmar portion of the ulnocarpal capsule. The flap is transferred to the dorsum of the ulna and attached with sutures through drill holes in the dorsal cortex. The ECU tendon is positioned over the dorsum of the ulna using a sling made from the retinaculum, as described in the section on ECU tendon instability. In patients for whom the capsular tissue is attenuated or of poor quality, tenodesis using one-half of the ECU tendon or both the ECU and FCU tendons by Breen and Jupiter[16] is performed, as discussed next.

For patients with higher demands or patients presenting with an unstable previously resected distal ulna, we prefer to

http://e-surg.com

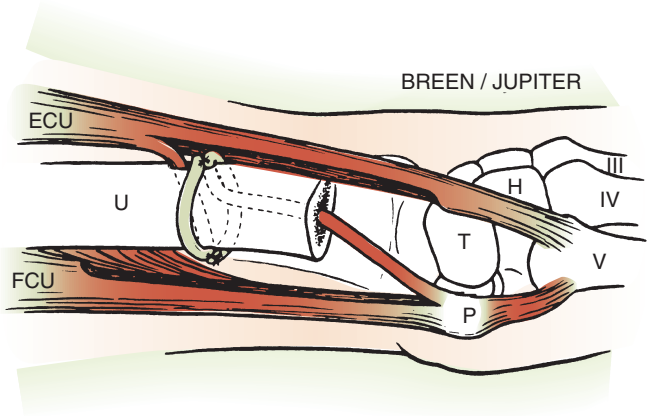

FIGURE 14.34 Tenodesis for stabilization of resected distal ulna using strips of flexor carpi ulnaris and extensor carpi ulnaris tendons as described by Breen and Jupiter. *ECU,* Extensor carpi ulnaris; *FCU,* flexor carpi ulnaris; *H,* hamate; *P,* pisiform; *T,* triquetrum; *U,* ulna; *III,* long finger metacarpal; *IV,* ring finger metacarpal; *V,* small finger metacarpal. (From Petersen MS, Adams BD: Biomechanical evaluation of distal radioulnar reconstructions. *J Hand Surg Am* 18:328–334, 1993.)



FIGURE 14.35 Radiograph showing excision and consequent radioulnar impingement after Darrach procedure. Note remodeling of radius at site of impingement.

stabilize the ulnar stump with a tenodesis using the technique described by Breen and Jupiter because it offers theoretical bidirectional control of the ulnar stump[16] (Figure 14.34). With this technique, a distally based strip of the FCU is passed into the canal of the ulna stump and out through a prepared bone hole in the ulnar shaft. A proximally based ECU strip is passed through the same hole, and both strips are wrapped around the shaft and sutured to each other. If the pronator quadratus has not been damaged previously, it is transferred to augment the stabilization and to provide soft tissue interposition to reduce radioulnar impingement. The muscle is detached from the palmar aspect of the ulna, routed through the radioulnar space, and attached to the dorsum of the distal ulna.[68] All of these procedures have been used successfully to reduce symptoms in small numbers of patients. Complete pain relief and restoration of full function are rare, however.

FAILED DISTAL ULNAR RESECTION

Instability of the distal ulna after a resection can develop early or late. Weakness and pain are associated with excessive dorsal–palmar translation and radioulnar convergence. Convergence can progress to impingement of the ulnar stump against the radius, producing crepitus and pain with forearm rotation (Figure 14.35). Although severe instability of the distal ulna is associated most commonly with the Darrach procedure, it also occurs after hemiresection or the Sauvé-Kapandji procedure. Typically, a history of painful crepitus around the distal ulna can be reproduced during the physical examination by manually compressing the radius against the ulna while passively rotating the forearm. A posteroanterior radiograph shows that the distal ulna touches the radius, which can be accentuated by having the patient hold a weight with the forearm in neutral rotation while the radiograph is taken in a "cross-table" direction (see Figure 14.10).

Treatment of radioulnar impingement is extremely difficult. Bieber and coworkers reported that patients failing a Darrach procedure continued to do poorly despite undergoing up to seven additional operations.[10] Several of the ligament reconstructions described earlier have been used with varying success, but the techniques may need modification to produce a better mechanism to prevent recurrent impingement. If a tenodesis or soft tissue interposition was not used in the primary procedure, a revision using one, or a combination of the techniques, can be effective. A careful review of the patient's previous operation record provides important information regarding available tissues such as the volar DRUJ capsule, pronator quadratus, ECU, and FCU. Kleinman and Greenberg combined longitudinal intramedullary ECU tenodesis, dorsal transfer of the pronator quadratus, and temporary pinning of the distal radius and ulna.[79]

In a modestly active patient with adequate soft tissue and proper motivation for rehabilitation, the authors' preferred technique is ulnar head implant arthroplasty. This procedure is presented in the next section. When implant arthroplasty is contraindicated, we prefer to use the combined method of Breen and Jupiter[16] to stabilize the ulnar stump via tenodesis along with soft tissue interposition using the pronator quadratus when available or Achilles tendon interposition allograft.

In the challenging scenario where previous stabilization of the ulnar stump has failed, the allograft interposition arthroplasty described by Sotereanos and colleagues is a reasonable option because it has demonstrated favorable results for up to 10 years' follow-up.[151] Technically, it is important to secure the allograft tendon to the ulnar border of the distal one-third radius using multiple suture anchors and separate sutures fixing the allograft to the distal ulna using transosseous tunnels to reduce the risk of an ulnar stress fracture.

For patients who have had repeated failed surgeries, wide ulnar resection and creating a one-bone forearm are alternatives, but these procedures should be used with caution. Usually, extensive resection of the distal ulna is reserved for treatment of tumors,[27] but one study[183] reported generally favorable results

http://e-surg.com

in patients after failed DRUJ reconstruction. Range of motion and grip strength averaged 75 to 90%, but radioulnar instability and convergence led to failure in two cases. Radiocarpal instability and ulnar carpal translocation were rare. The surgical approach is straightforward; the ulna is exposed along its subcutaneous border, and subperiosteal resection of 25 to 30% of the ulnar length is recommended. Previous traumatic disruption of the interosseous membrane is an absolute contraindication to the procedure.[183]

The ultimate salvage for the dysfunctional forearm following attempts at surgical reconstruction of the radioulnar functional relationship is the creation of a one-bone forearm through a radioulnar fusion. A complete loss of forearm motion is what is sacrificed to reduce pain and to restore forearm stability. A preoperative test of immobilization in various positions of forearm rotation allows the patient to decide whether the procedure is appropriate and to determine the optimal position for fusion.

One study of 30 normal subjects determined that 63% of them preferred a neutral forearm position for activities of daily living. The procedure is indicated for end-stage radioulnar instability that is recalcitrant to surgical stabilization; paralytic instability; and, rarely, spastic contractures. The fusion can be accomplished by making osteotomies through the radial and ulnar shafts, discarding the proximal radius and the distal ulna, and transposition of the radius to the ulna with plate fixation. Alternatively, the radius and ulna can be collapsed against each other and fixed together with lag screws or a bridging plate. Iliac crest bone graft is recommended. Typically, the osteotomy is fixed with the forearm in neutral or slight pronation. Successful fusion was achieved in 60 of 65 cases in one study series with a distal radioulnar fusion fixed with dual lag screws. Complications are common, and the nonunion rate in one series was 32%.[125]

DISTAL ULNAR HEAD IMPLANT ARTHROPLASTY

Normal stability and function of the forearm rotation axis require an intact ulnar head, making implant arthroplasty an attractive concept for the treatment of ulnar head deficiencies and arthritis. Outcomes of soft tissue stabilization procedures for the treatment of the unstable, resected distal ulna are unpredictable. Successful ulnar head replacement arthroplasty would function to alleviate radioulnar impingement and replicate load transmission. Although a silicone implant, combined with soft tissue reconstruction, temporarily relieved symptoms and restored stability,[157] inevitable failure of the implant led to recurrence of symptoms and silicone synovitis. Silicone ulnar head implants therefore have been abandoned.

Various implant designs have become commercially available and can be divided into the following types: total ulnar head with or without an extended collar, partial ulnar head, unlinked total DRUJ arthroplasty, and linked DRUJ arthroplasty. None of these implants has had long-term clinical follow-up; however, biomechanical laboratory studies have shown excellent kinematic performance, and early clinical results are encouraging. Indications for ulnar head arthroplasty have expanded beyond the treatment of failed resection arthroplasty and include primary treatment of arthritis and irreparable ulnar head fractures.

van Schoonhoven and associates reported on the use of a ceramic head fixed to a porous-coated titanium stem inserted in the ulnar medullary canal.[170] The head is spherical in the transverse plane and features a concave distal surface to decrease pressure across the ulnocarpal joint. Modularity with three different head and collar sizes accommodates anatomic variations and a range of bony defects. The investigators treated 23 patients with chronic painful instability following ulnar head resection after an average of three previous operations. Symptoms were significantly improved in all patients. Stability was achieved initially in all cases, but two developed recurrent instability; both patients were treated successfully by revising the implant. Slight remodeling of the sigmoid notch and 1 to 2 mm of resorption beneath the collar occurred in all patients but was not progressive. These authors were cautiously optimistic with the short-term results.

A metallic ulnar head implant with a modular head and stem, including an extended collar for ulnar neck deficiencies has been developed.[92,181] The implant is indicated for use in acute ulnar head fractures, posttraumatic DRUJ arthritis, rheumatoid arthritis, and failed previous partial or complete resections of the distal ulna, including failed silicone implants. The implant head has a site for reattachment of the TFCC, ECU sheath, and ulnocarpal ligaments to help stabilize the DRUJ. Cement fixation of the stem is not typically necessary. In a prospective study of 19 implants in 17 patients treated for radioulnar convergence, impingement, or arthritis, results showed pain scores diminished by 50%, grip strength improved by 16%, and forearm rotation was unchanged. Many of these patients had multiple previous operations. Two failures occurred at 7 and 14 months postoperatively.[181]

A partial ulnar head replacement arthroplasty was designed for primary treatment of arthritis of the DRUJ, irreparable acute ulnar head fractures, and failed partial ulnar head resections. The concept is to replace only the articular surfaces of the ulnar head and to preserve the soft tissue restraints of the DRUJ. The implant is contraindicated for patients with substantial positive ulnar variance in which proper DRUJ congruity cannot be obtained or stylocarpal impingement would result, and for patients with a previous complete ulnar head resection. In a cadaveric study, the implant provided a close match to the native ulnar head and good joint stability.[24]

Scheker and associates designed a linked implant that replaces the ulnar head and the sigmoid notch, which they considered a total replacement of the DRUJ.[137] It is a ball-and-socket concept that allows some axial displacement of the radial component on the ulnar component to accommodate changes in ulnar variance during forearm rotation. The sigmoid notch component consists of a plate with a socket attached to its distal end and fixed to the distal radius by a peg and screws. The ulnar component is a polyethylene ball fitted on a peg that extends from a long stem fixed into the ulnar medullary canal. The ball can slide axially on the peg but cannot translate.

The purpose of this more complex implant is to stabilize the distal radioulnar relationship in cases with loss of skeletal and ligament support. The prosthesis was used in patients who had partial or complete destruction of the DRUJ, including loss from gunshot injuries, motor vehicle accidents, and excessive surgical resection of the distal ulna for posttraumatic arthritis. A dorsal surgical approach is used, and release of the distal IOM

http://e-surg.com

is occasionally performed to achieve proper motion. A long-arm splint is applied for 3 weeks for immobilization, after which active range-of-motion exercise is initiated.

Scheker and associates treated 23 patients who had at least one previous surgery with partial or complete distal ulna resection.[137] Mean follow-up was 15 months, with a maximum of 40 months. Complete pain relief was reported for all patients, and lifting capacity ranged from 2 to 50 lb with an average of 14 lb; however, a 25-lb lifting limit was recommended to reduce the risk of loosening. Normal pronation and supination were observed. The authors reported no complications; however, one prosthesis was removed for suspected infection.

Operative Technique for Ulnar Head Arthroplasty

A total ulnar head replacement is implanted through a dorsal approach. An ulnar-based flap, including the capsule and extensor retinaculum, is raised from the ulnar head with care to preserve the integrity of the ECU sheath. The amount of soft tissue release from the ulnar head and neck depends on the implant being used and the laxity of the joint. In the presence of a malunited radius, a corrective osteotomy is recommended before implant arthroplasty to achieve radioulnar stability. It is important to contour the sigmoid notch surgically when substantially misshapen by trauma or arthritis; however, breaching the subchondral bone can increase the risk of implant erosion into the radius.

The prosthetic head size is chosen to tension the soft tissues properly, but overstuffing the joint should be avoided. Typically, the implant is inserted without cement. The capsular and retinacular flaps are advanced on the radius as necessary during closure to create prosthetic stability. A long-arm splint is applied for 2 weeks, followed by a short-arm cast for 2 weeks, then a removable splint for another 4 weeks to allow sufficient soft tissue healing for joint stability and bone ongrowth for stem fixation. Strengthening and activities are advanced as wrist and forearm motion improves.

In previously operated cases, the senior author prefers an ulnar surgical approach between the FCU and ECU for ease of implantation and to preserve the capsule. The ECU sheath is elevated subperiosteally from the distal ulna along with the TFCC and ulnocarpal ligaments. The option exists to secure the confluence of the TFCC, ECU sheath, and ulnar wrist capsule with sutures placed through holes in the peripheral part of the implant head to gain joint stability. Rehabilitation is the same as described for the dorsal approach.

A partial ulnar head replacement can be implanted with less exposure than for a total head. A dorsal longitudinal skin incision is made over the ulnar head between the fifth and sixth extensor compartments. The fifth extensor compartment is opened from 2 cm proximal to the ulnar neck to 2 cm distal to the ulnar styloid. The EDQ tendon is retracted to expose the DRUJ dorsal capsule. A rectangular-shaped capsulotomy is made in the dorsal DRUJ capsule, with the longitudinal limb beginning at the ulnar neck and extending parallel to the attachment of the capsule at the sigmoid notch but stopping short of the dorsal radioulnar ligament.

The proximal transverse limb runs across the ulnar neck to the ECU tendon. The distal transverse limb runs parallel to the proximal edge of the dorsal radioulnar ligament and extends ulnarward to the ECU sheath. It is unnecessary to open the ECU sheath. To deliver the ulnar head dorsally, the foveal attachments of the TFCC are sharply released, but the remaining attachments are preserved. A small Hohmann retractor is placed beneath the ulnar head to lift it dorsally. The ulnar shaft is entered through the fovea with an awl. Serial reamers are used until there is cortical contact in the medullary canal. A cutting guide is applied to the reamer handle and properly aligned using the ulnar border of the ulna. The articular surfaces are resected using a small oscillating saw. The resected portion of the ulnar head is matched to the implant trials for proper size. The implant is inserted with a press-fit. The DRUJ capsule and retinaculum are closed in layers, with the EDQ tendon left subcutaneous over the DRUJ (Figure 14.36).

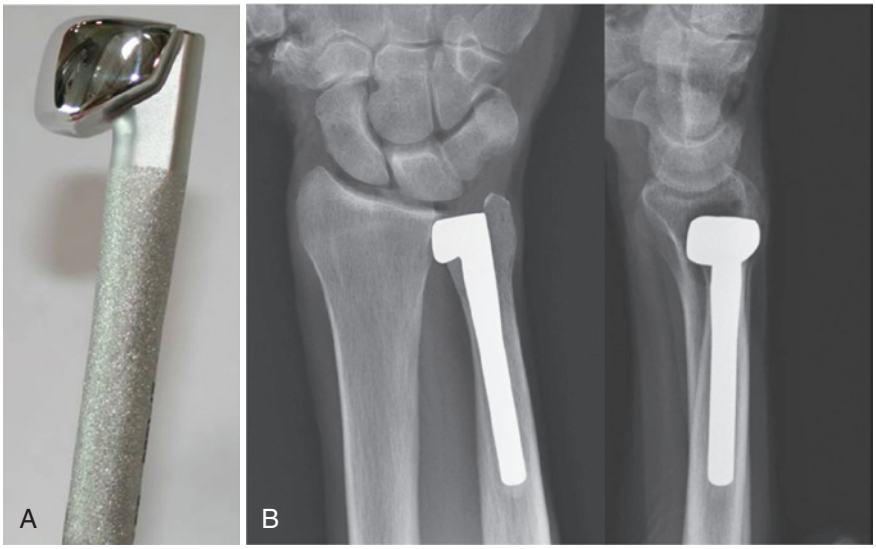

FIGURE 14.36 **A,** Partial ulnar head replacement prosthesis is designed to resurface only the articulating portion of distal ulna (Ascension Orthopedics, Austin, TX). **B,** Posteroanterior and lateral radiographs showing partial ulnar head replacement.

http://e-surg.com

Outcomes

Experience with distal ulna implants is gradually increasing. Biomechanical testing shows that the implants restore DRUJ kinematics to near-normal.[92] The implants are particularly attractive for use for patients with radioulnar impingement after a failed partial or complete distal ulnar resection. In our experience, however, pain and instability are improved, with occasional minor pain and swelling being common after strenuous activities. Achieving a good, well-balanced soft tissue envelope around the implant can be challenging in a patient who has undergone multiple operations or poor-quality soft tissue constraints due to inflammatory arthritis. A substantial improvement in pain and range of motion in patients with rheumatoid arthritis was reported by Galvis et al.[45] Outcomes of ulnar head arthroplasty in patients with previous attempts at DRUJ reconstruction are worse than for primary arthroplasty.[134] Despite these concerns, implant arthroplasty results in less morbidity and appears to be more predictable in short-term follow-up than one-bone forearm or wide excision for radioulnar impingement (Figure 14.37).

In the absence of soft tissue constraints to support an implant arthroplasty, a linked total joint arthroplasty has been used. In this challenging condition, where a one-bone forearm reconstruction may otherwise be the only option, the linked prosthesis has shown promising early results. Several studies detailed good outcomes for decreased pain, forearm motion, and patient satisfaction, with no reported implant failures to date.[12,71,136] Kachooei et al. reported good outcomes for 14 prostheses with no implant failures and secondary procedures in only two patients for debridement of the radial screw tip at a mean follow-up of 60 months (range, 2-102 months).[71] Longer follow-up studies are needed to assess its full value.

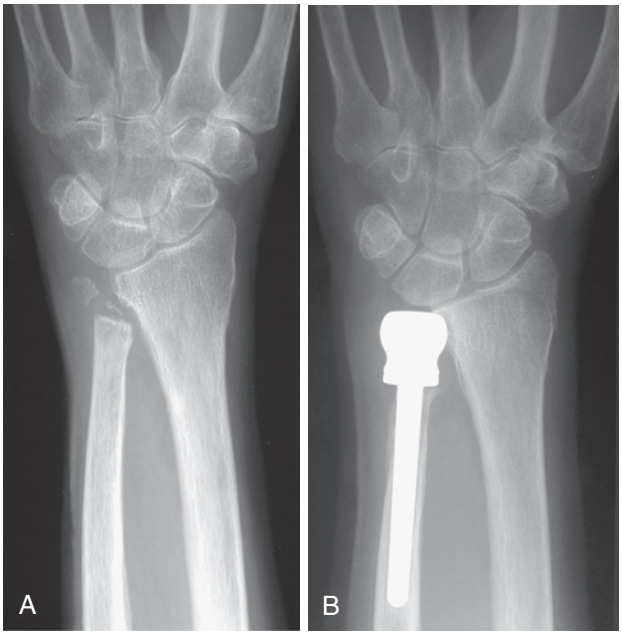

FIGURE 14.37 **A, B,** Radiographs of distal ulna implant arthroplasty (uHead; Avanta Orthopedics, San Diego) for treatment of radioulnar impingement. Note restoration of radioulnar alignment.

DISTAL RADIOULNAR JOINT CONTRACTURE

Acquired contractures of the DRUJ can be the result of trauma, arthritis, or spasticity. Conditions that mimic DRUJ contractures include forearm synostosis, radial head dislocation, and dysplastic congenital conditions. Posttraumatic contractures of the DRUJ capsule are common, especially loss of supination after a distal radius fracture. Physical therapy, including a splinting program, should be used for at least 4 to 6 months before considering surgery. Arthritis and DRUJ subluxation are contraindications to surgical release. CT should be performed if standard radiographs are inconclusive.

Posttraumatic DRUJ stiffness results from fibrosis and contracture of the capsule. The volar capsule normally has a redundant oblique fold that opens and forms a pocket to accept the ulnar head in supination.[78] Subsequent to trauma and immobilization in pronation, the capsular fold can become thickened, adherent, and shortened and can cause a restriction of supination. Contracture of the pronator quadratus from immobilization or injury can contribute to a pronation contracture. The dorsal capsule is normally much thinner and homogeneous, with transversely oriented fibers. It is much less likely to impede pronation after trauma or prolonged immobilization and is more likely to respond to therapy when contracted. Volar capsulectomy is performed for loss of supination, and dorsal capsulectomy is done for decreased pronation. Combined volar–dorsal capsulectomy is required for a severe bidirectional stiffness or fibrous ankylosis.

Operative Technique

Dorsal DRUJ Capsulectomy

A dorsal exposure of the DRUJ is made as described earlier for radioulnar ligament reconstruction. The entire dorsal capsule is excised to avoid damaging the dorsal radioulnar ligament or ECU sheath. The joint is inspected for injury or arthritis and carefully debrided if necessary. The forearm is gently manipulated into maximum allowable pronation. A long-arm or sugar tong plaster splint is applied with the forearm in full but not forced pronation and maintained for 2 to 3 weeks. A removable pronation splint is used at night and intermittently during the day for 1 month. Dynamic or static progressive splinting is used only if the original improvements in motion are not being sustained. Alternatively, if near full passive motion is easily achieved at surgery, immediate motion with night splinting is initiated.

Volar DRUJ Capsulectomy

A longitudinal incision is made radial to the FCU, extending proximal from the wrist crease. The pronator quadratus is exposed via the interval between the ulnar neurovascular bundle and the digital flexor tendons. The distal half of the pronator is raised subperiosteally from the ulna. The palmar radioulnar ligament is palpated, and an L-shaped capsulotomy is made, with the transverse limb parallel and just proximal to the palmar radioulnar ligament. The longitudinal limb is made parallel to the attachment of the capsule at the sigmoid notch. The entire volar capsule is excised with care so as not to damage the palmar radioulnar ligament. If the gain in supination is inadequate after gentle manipulation, the pronator quadratus is completely released or excised. A long-arm or sugar tong plaster splint is

http://e-surg.com

applied with the forearm in full but not forced supination and maintained for 2 weeks. A removable supination splint is used at night and intermittently during the day for 1 month. Dynamic or static progressive splinting is used only if the original gains in motion are lost.

Outcomes

In a report on a small series of patients, improvement in forearm motion was universal, with an average increase in supination of 51 degrees and in pronation of 28 degrees. There were no complications, including no iatrogenic cases of DRUJ instability.[78] In our experience, contracture release is a gratifying procedure for loss of supination after a distal radius fracture when the DRUJ is well aligned and not arthritic. A contracture release in the presence of a subluxated DRUJ or in the presence of DRUJ arthritis may result in a painful joint.

ECU TENOSYNOVITIS AND SUBLUXATION

The ECU tendon takes an angular path across the ulnar head to its insertion on the fifth metacarpal base when the forearm is supinated, which is accentuated further by ulnar deviation and flexion of the wrist (Figure 14.38). Normally, the ECU tendon is held within the groove of the ulnar head by a deep retinaculum, often referred to as the subsheath, which must resist the natural tendency for the tendon to subluxate.[119,153] The true extensor retinaculum passes over the subsheath without an attachment to the ulna and inserts on the pisiform, triquetrum, fifth metacarpal, and volar soft tissues. Repetitive stress on the subsheath can result in a stenosing tenosynovitis from fibrosis,[54,75] or the tendon can become unstable and dislocated from attenuation or tearing of its sheath.[19,36] Recurrent subluxation over the ulnar ridge of the groove can produce a partial tendon rupture. Variations in both the morphology of the ECU tendon and its groove and their relationship to one another have been described.[65] Such variation suggests that the diagnosis of ECU tenosynovitis and subluxation may be difficult to determine.[90]

Volar subluxation of the ECU is a common finding in rheumatoid arthritis and nearly always accompanies the caput ulna syndrome, which is characterized by dorsal subluxation of the ulna and volar subluxation of the carpus.[5] Although ECU subluxation is rarely symptomatic in these patients, repositioning the tendon to the dorsal aspect of the ulna reduces its deforming force on the wrist and may help to stabilize the distal ulna; it should be considered whenever performing an isolated ECU tenosynovectomy, a complete extensor tenosynovectomy, DRUJ synovectomy, or distal ulnar resection (see Case Study 14.1).

Although ECU stenosing tenosynovitis and instability would seem to be different, their clinical presentations and treatments are quite similar. Typically, the patient can reproduce the pain or snapping by combined supination and ulnar deviation against resistance (see Video 5.1). Treatment of acute conditions include rest, immobilization with the forearm in pronation and the wrist in neutral, and antiinflammatory modalities. Even though snapping may not resolve, often pain is relieved. Stenosing tenosynovitis can be treated by corticosteroid injection into the sheath. Surgery is reserved for recalcitrant symptoms (see Case Study 5.6).

There are three general surgical categories for the ECU sheath: (1) release, (2) repair, and (3) reconstruction. Typically, we consider sheath release only for patients with low activity demands or for patients whose previous surgeries resulted in failure.

Operative Technique

Sixth Dorsal Compartment Release

A longitudinal incision is made over the sixth compartment, and the retinaculum and subsheath are divided. The tendon is inspected and debrided, as necessary, if tendinosis is present. A tenosynovectomy is performed when indicated. The groove is inspected for spurs and prominent ridges, which also should be debrided. The retinaculum can be left open or repaired beneath the tendon when degenerative changes are present within the ulnar groove. Ligament reconstruction (see next subsection) to stabilize the tendon is done only if there is audible snapping during passive forearm rotation.[75] The patient is immobilized with a plaster wrist splint for 2 weeks followed by return to activities over several weeks.

Extensor Carpi Ulnaris Tendon Stabilization

A longitudinal incision is made between the fifth and sixth extensor compartments. A volar skin flap is raised while protecting the dorsal sensory branch of the ulnar nerve. The extensor retinaculum is incised at the extreme volar margin of the sixth extensor compartment. The ECU subsheath is opened longitudinally at its midline. The tendon and groove are inspected, and any osteophytes are debrided. At this point, a decision is made regarding a subsheath imbrication versus a ligament reconstruction.

The decision depends on the quality of subsheath tissue and condition of the groove. In more acute cases (<6 months), a primary subsheath repair is preferred if the tendon has minimal fraying and the groove is smooth. The sheath should not be overtightened; placing a pediatric feeding tube next to the tendon during sheath suture repair reduces this risk. The extensor retinaculum is repaired anatomically. Alternatively, if the groove is excessively shallow, it can be deepened with a bur to increase tendon stability and to avoid tendon constriction. Care must be taken to ensure that the groove is smooth.

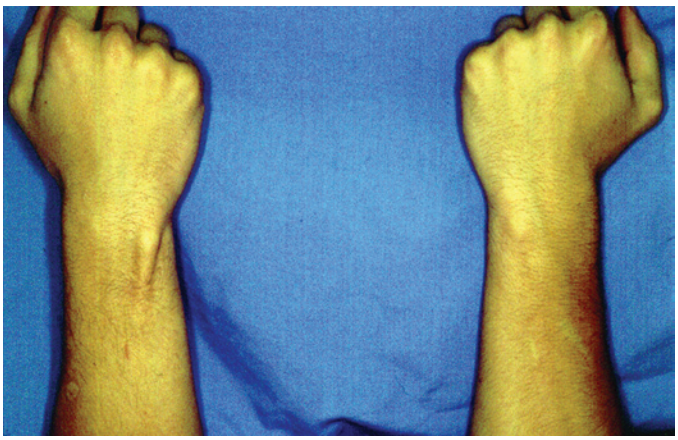

FIGURE 14.38 Subluxation of extensor carpi ulnaris tendon from groove in ulnar head is shown with wrist in supination.

http://e-surg.com

CASE STUDY 14.1 Tendinopathy

A 17-year-old female high school hockey star presents with painful dominant right wrist, ulnar side. She describes feeling a "snap" while making a slapshot 6 months previously. She attempted rest with splinting for several months and a 3-month course of therapy. She has been unable to return to playing, although she experiences minimal discomfort with daily, school, or other recreational activities. The patient declined cortisone injection and was referred for definitive treatment.

eFigure 14.1 displays the presenting radiographs. Physical examination revealed:

- Tenderness to ECU without snapping
- Lax, no gross instability of DRUJ
- Pain with resisted supination and ulnar deviation
- Ulnar impaction positive in full supination; otherwise negative

What is your working diagnosis?

a. Ulnar impaction syndrome
b. Kienböck disease
c. TFCC tear
d. ECU instability
e. Radioulnar instability

ANS: ECU instability

What additional workup should be ordered?

a. Bone scan
b. CT in three positions of rotation
c. MRI study
d. Bilateral pronated grip films
e. Dynamic ultrasound

ANS: Dynamic ultrasound

See Video 14.1, then review the following questions.

What is your diagnosis?

a. Ulnar impaction syndrome
b. Kienböck disease
c. TFCC tear
d. ECU instability
e. Radioulnar instability

ANS: ECU instability

What are your treatment recommendations?

a. Ulnar-shortening osteotomy
b. Radial-shortening osteotomy
c. Arthroscopic TFCC repair
d. ECU stabilization
e. Tendon graft ligament reconstruction of DRUJ

ANS: ECU stabilization

See eFigures 14.2 through 14.5 for a description of the surgical technique. The follow-up is shown in eFigure 14.6.

Scott W. Wolfe

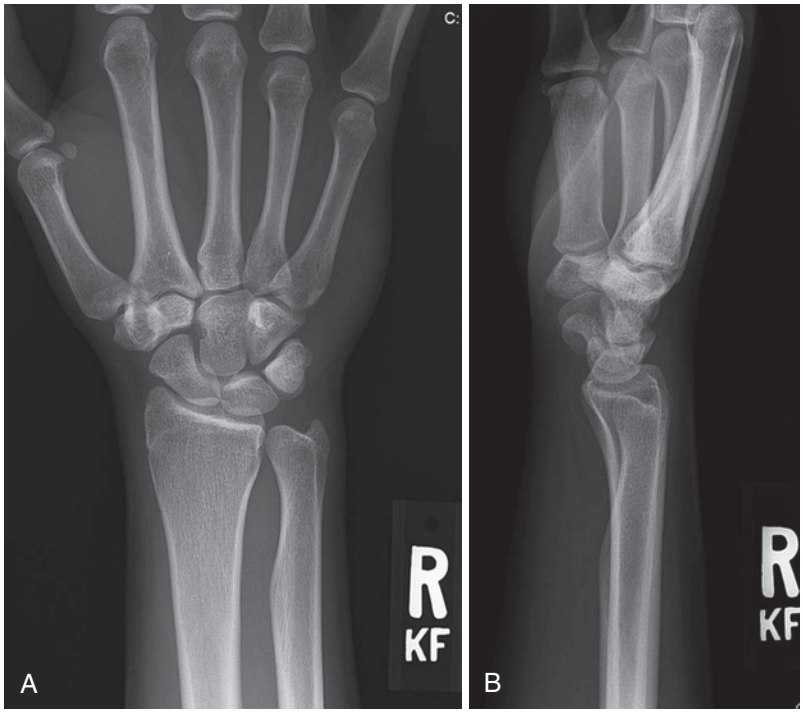

eFIGURE 14.1 **A, B,** Presenting radiographs. (Copyright © Scott W. Wolfe.)

http://e-surg.com

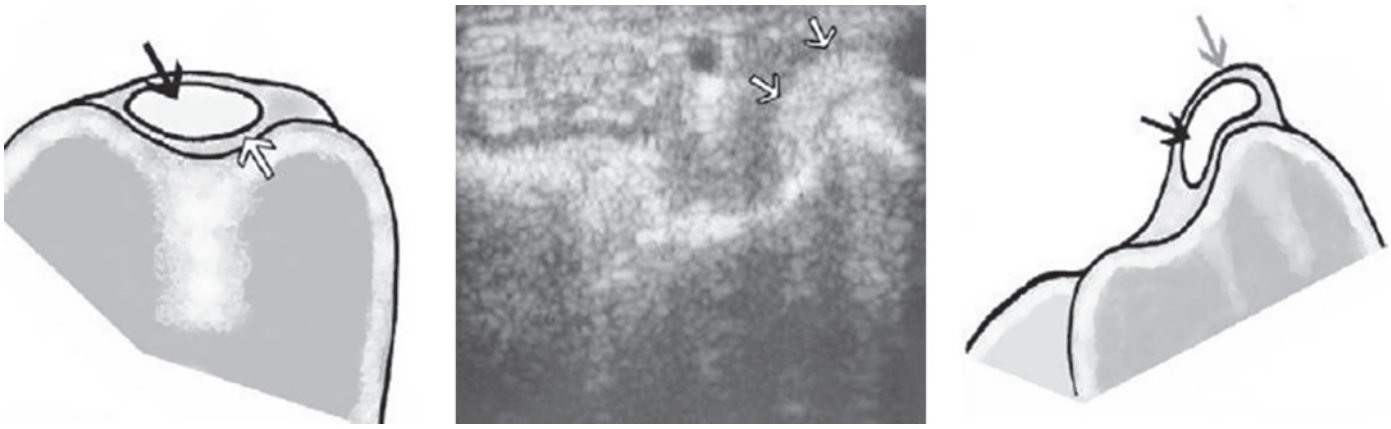

eFIGURE 14.2 Dynamic ultrasound of the wrist. With the wrist in supination, the extensor carpi ulnaris (ECU) tendon (*arrows*) subluxates out of the distal ulnar groove in an ulnar and volar direction. Illustration of ultrasound image: The ECU tendon (*black arrow*) subluxates out of the groove but remains within the sheath (*gray arrow*). (From MacLennan AJ, Nemecheck NM, Waitayawinyu T, et al: Diagnosis and anatomic reconstruction of extensor carpi ulnaris subluxation. *J Hand Surg Am* 33(1):59–64, 2008, with permission.)

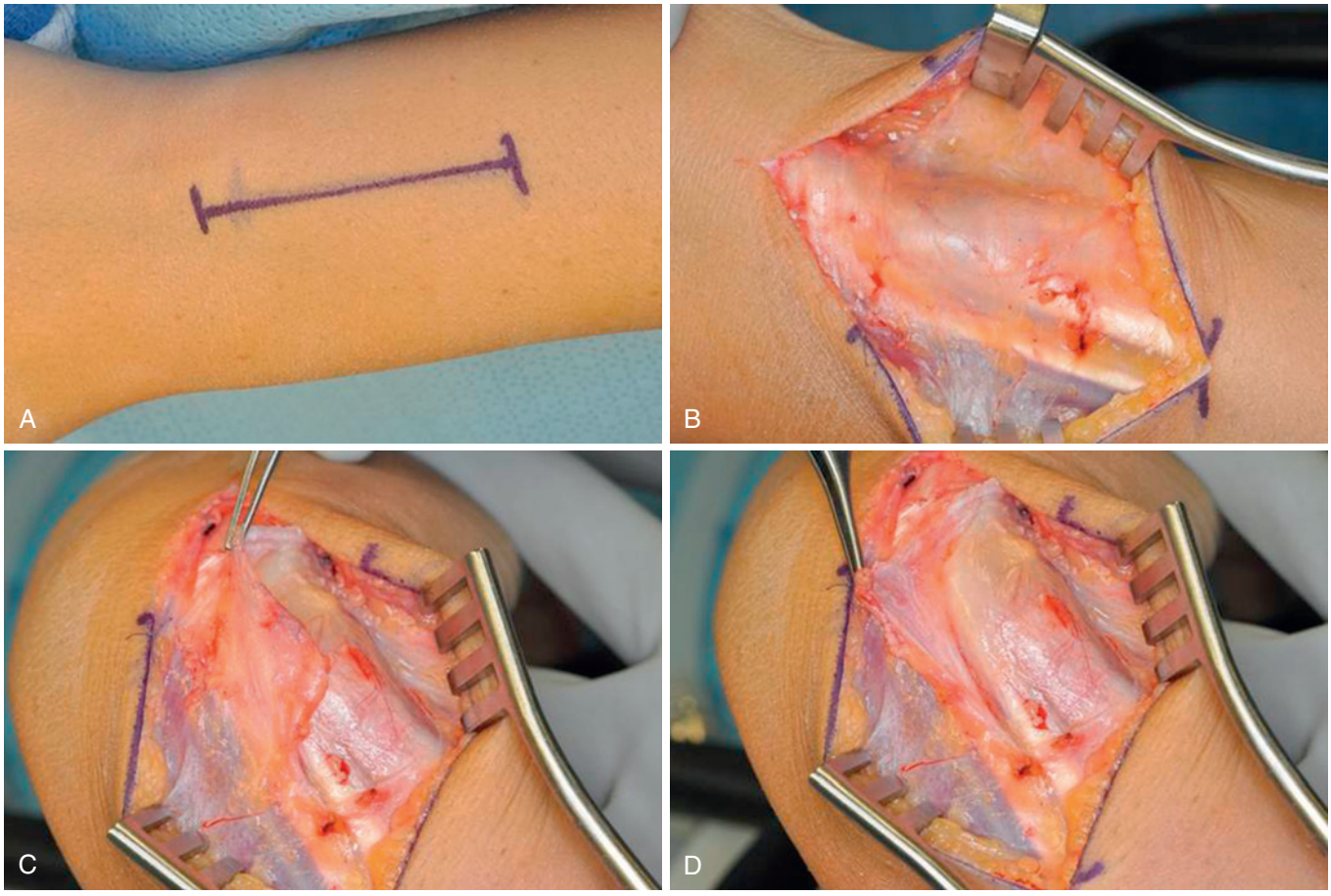

eFIGURE 14.3 **A-D,** 5-cm dorsoulnar incision; retinaculum incised and reflected radialwards to expose extensor carpi ulnaris subsheath and ulna. (Copyright © Scott W. Wolfe.)

http://e-surg.com

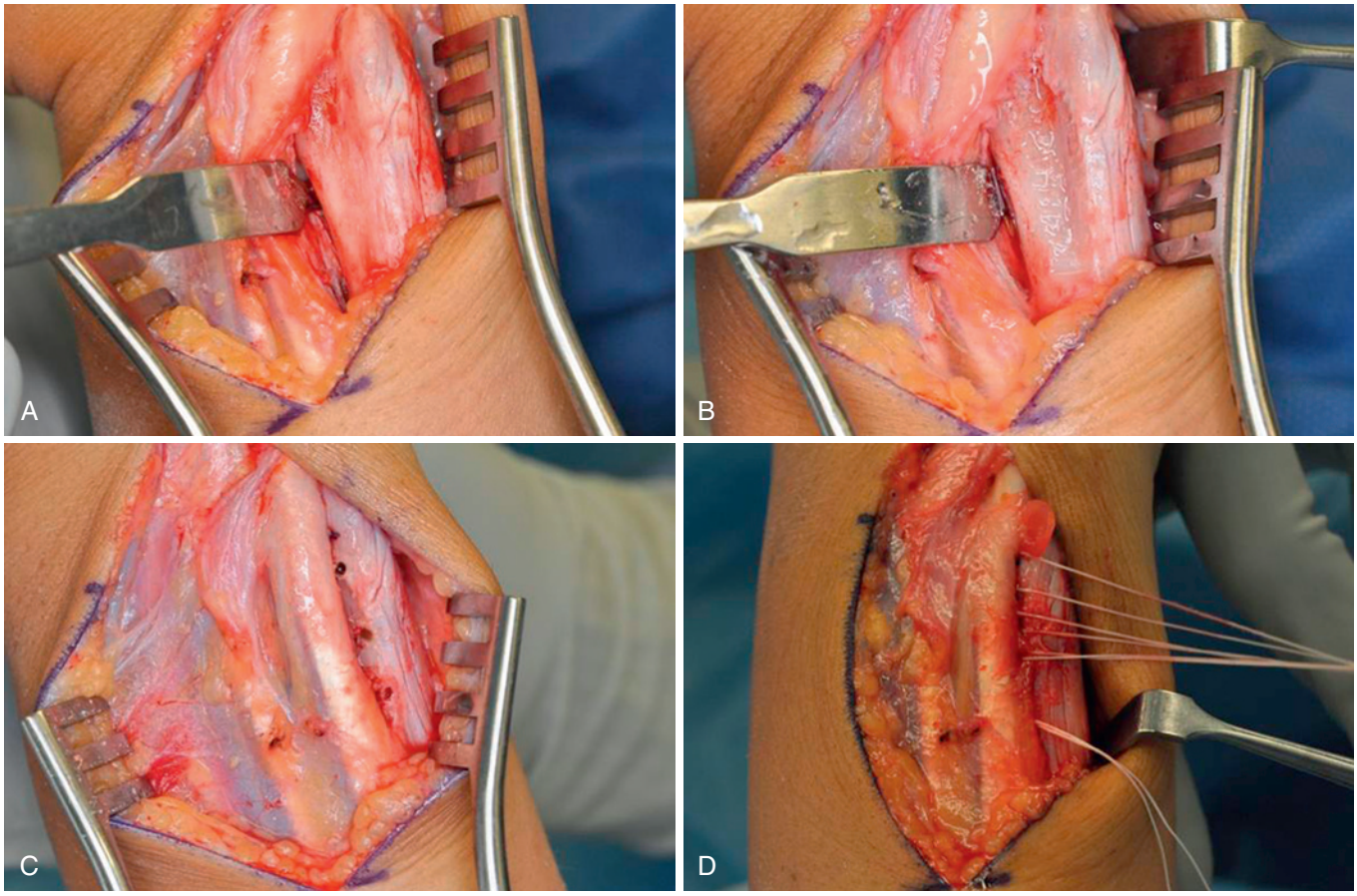

eFIGURE 14.4 **A,** Bennett retractor in interosseous space. **B,** Demonstrates extensor carpi ulnaris (ECU) groove (not deepened). **C,** Drill holes on ulnar side, multiple suture anchors placed. **D.** ECU subsheath imbricated and tied down. (Copyright © Scott W. Wolfe.)

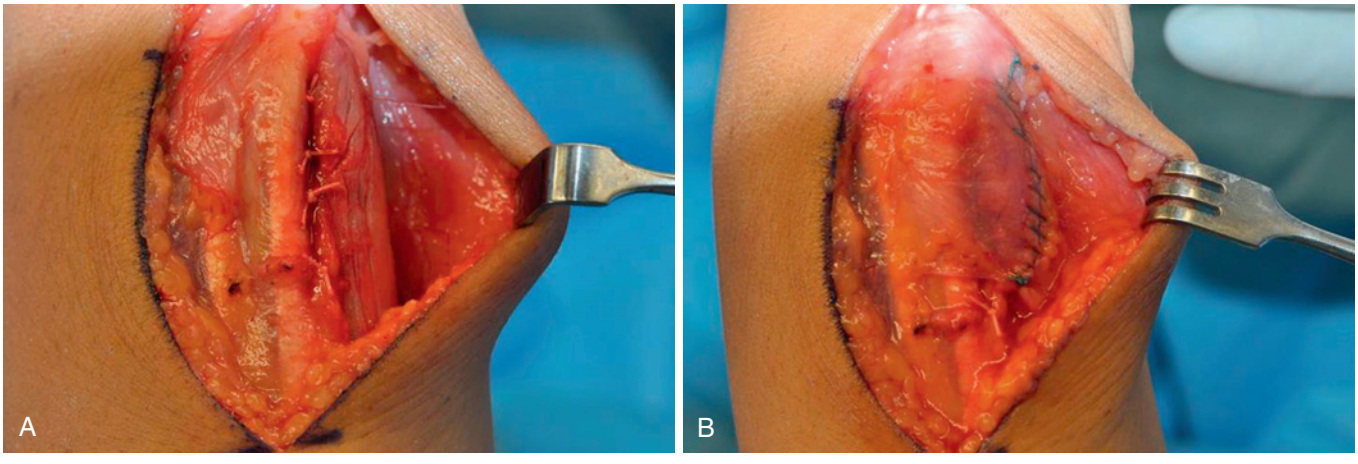

eFIGURE 14.5 **A, B,** Sheath successfully imbricated. Retinacular flap securely repaired. Follow up with 4 weeks in a long-arm cast, 4 weeks short-arm cast, and 4 weeks splint and range-of-motion exercises.

http://e-surg.com

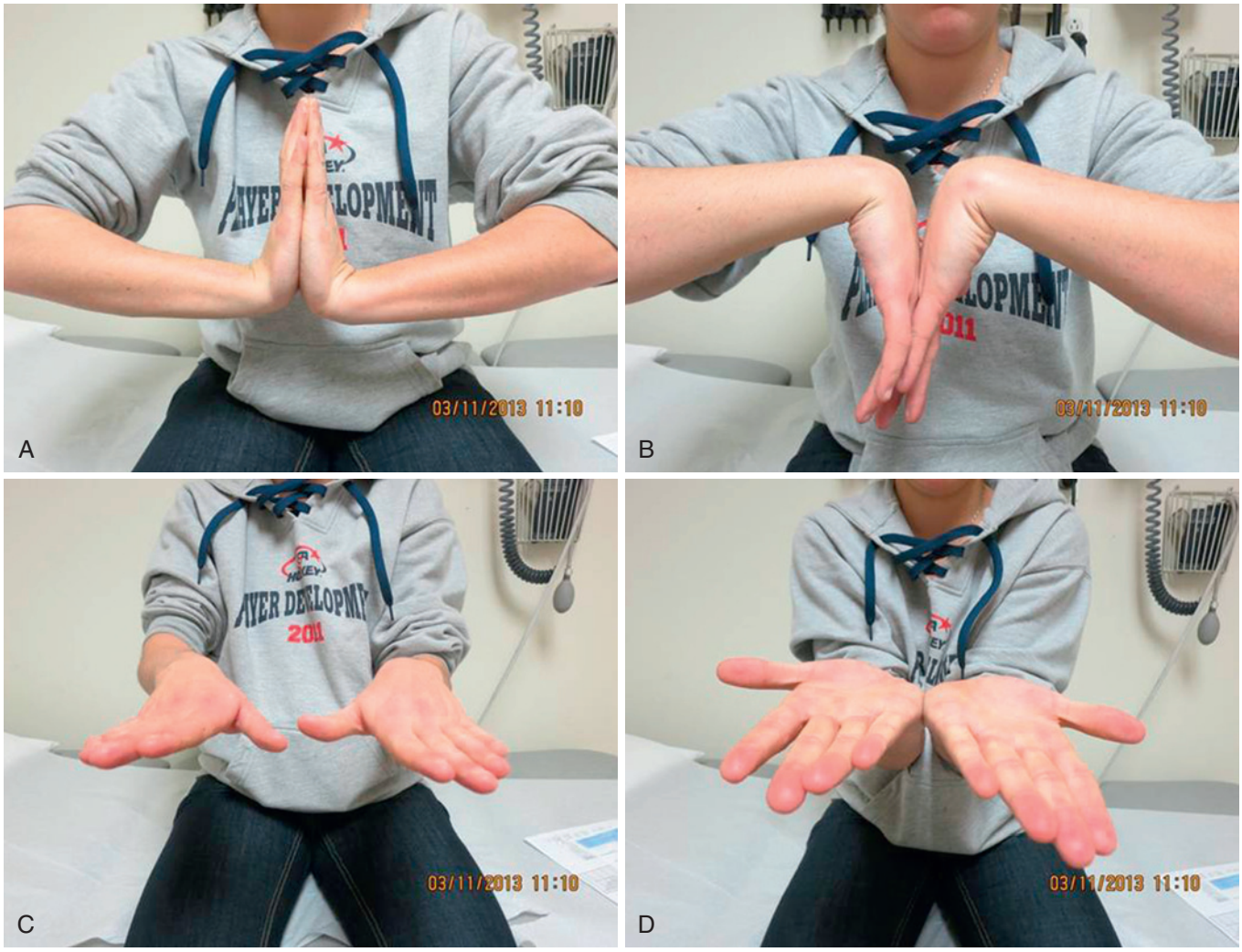

eFIGURE 14.6 **A-D,** Photos at 8-month follow-up. Patient successfully returned to playing hockey during senior year.

http://e-surg.com

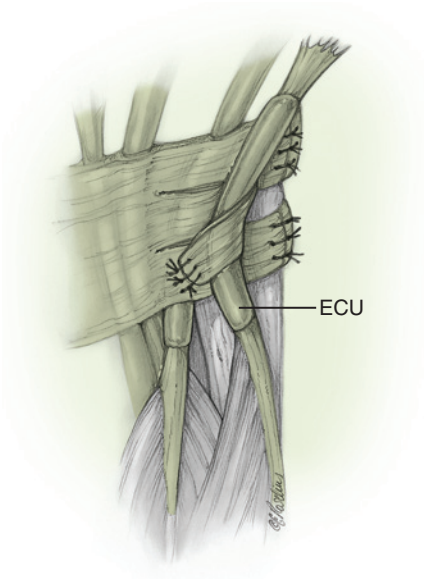

FIGURE 14.39 Extensor carpi ulnaris (ECU) stabilized by sling created from extensor retinaculum. (Copyright © Elizabeth Martin.)

When the groove is rough, when the subsheath is badly damaged, or in chronic cases, a ligament reconstruction to stabilize the tendon is preferred. Spinner and Kaplan employed a ½- to 1-in rectangular ulnar-based flap of retinaculum, using the septum between the fourth and fifth extensor compartments as its base.[153] The flap is raised to Lister's tubercle, folded back, and passed under the ECU tendon. The flap is brought back over the tendon and sutured to itself, which places the deep surface of the retinaculum against it. The previously released retinaculum over the sixth extensor compartment is repaired.

We prefer to create a flap from the retinaculum that had been raised previously for tendon exposure (Figure 14.39).[90] The central third of the retinaculum is raised using two parallel incisions extending from its divided ulnar edge to the septum between the fourth and fifth extensor compartments. The flap is passed under the ECU tendon and then is passed back over it. The flap is sutured to the more proximal portion of the retinaculum rather than to itself; this creates a loose sling rather than a tight noose. The remainder of the retinaculum is repaired anatomically. This method is easier and requires less exposure than that described by Spinner and Kaplan[153]; however, it places the superficial surface of the retinaculum against the tendon. The patient is immobilized for 3 weeks in a short-arm cast, followed by a wrist splint for 2 weeks. After this time, activities can be resumed as tolerated.

Outcomes

A few case reports and two larger series have reported good results for pain relief with conservative and surgical treatment for stenosing tenosynovitis.[54,75] These studies' authors reported no ECU instability by palpation or from passive or active wrist and forearm motion. Surgical failures were attributed to an incorrect diagnosis, with DRUJ arthritis being the most common. ECU tendon stabilization has been successful with good relief of pain and few recurrent subluxations.[19,32,56,60]

For Case Studies, Videos, and more, please visit ExpertConsult.com.

REFERENCES

1. Adams BD, Berger RA: An anatomic reconstruction of the distal radioulnar ligaments for posttraumatic distal radioulnar joint instability. *J Hand Surg [Am]* 27:243–251, 2002.
2. Adams BD, Holley KA: Strains in the articular disk of the triangular fibrocartilage complex: a biomechanical study. *J Hand Surg [Am]* 18:919–925, 1993.
3. af Ekenstam F, Hagert CG: Anatomical studies on the geometry and stability of the distal radioulnar joint. *Scand J Plast Reconstr Surg* 19:17–25, 1985.
4. Andersson JK, Lindau T, Karlsson J, et al: Distal radio-ulnar joint instability in children and adolescents after wrist trauma. *J Hand Surg Eur Vol* 39:653–661, 2014.
5. Backdahl M: The caput ulnae syndrome in rheumatoid arthritis: a study of the morphology, abnormal anatomy and clinical picture. *Acta Rheumatol Scand Suppl* 5:1–75, 1963.
6. Bae DS, Waters PM: Pediatric distal radius fractures and triangular fibrocartilage complex injuries. *Hand Clin* 22:43–53, 2006.
7. Bednar JM, Osterman AL: The role of arthroscopy in the treatment of traumatic triangular fibrocartilage injuries. *Hand Clin* 10:605–614, 1994.
8. Bednar MS, Arnoczky SP, et al: The microvasculature of the triangular fibrocartilage complex: its clinical significance. *J Hand Surg [Am]* 16:1101–1105, 1991.
9. Berger RA: The anatomy of the ligaments of the wrist and distal radioulnar joints. *Clin Orthop Relat Res* 383:32–40, 2001.
10. Bieber EJ, Linscheid RL, et al: Failed distal ulna resections. *J Hand Surg [Am]* 13(2):193–200, 1988.
11. Bilos ZJ, Chamberland D: Distal ulnar head shortening for treatment of triangular fibrocartilage complex tears with ulna positive variance. *J Hand Surg [Am]* 16:1116–1119, 1991.
12. Bizimungu RS, Dodds SD: Objective outcomes following semi-constrained total distal radioulnar joint arthroplasty. *J Wrist Surg* 2:319–323, 2013.
13. Blatt G, Ashworth C: Volar capsule transfer for stabilization following resection of the distal end of the ulna. *Orthop Trans* 3:13–14, 1979.
14. Bowers WH: Distal radioulnar joint arthroplasty: the hemiresection-interposition technique. *J Hand Surg [Am]* 10:169–178, 1985.
15. Boyes JH: Surgical repair of joints. In Bunnell S, editor: *Bunnell's surgery of the hand*, Philadelphia, 1970, Lippincott, pp 294–313.
16. Breen TF, Jupiter JB: Extensor carpi ulnaris and flexor carpi ulnaris tenodesis of the unstable distal ulna. *J Hand Surg [Am]* 14:612–617, 1989.
17. Bu J, Patterson RM, Morris R, et al: The effect of radial shortening on wrist joint mechanics in cadaver specimens with inherent differences in ulnar variance. *J Hand Surg [Am]* 31:1594–1600, 2006.
18. Buijze GA, Ring D: Clinical impact of united versus nonunited fractures of the proximal half of the ulnar styloid following volar plate fixation of the distal radius. *J Hand Surg [Am]* 35:223–227, 2010.
19. Burkhart SS, Wood MB, et al: Posttraumatic recurrent subluxation of the extensor carpi ulnaris tendon. *J Hand Surg [Am]* 7:1–3, 1982.
20. Chen NC, Wolfe SW: Ulna shortening osteotomy using a compression device. *J Hand Surg [Am]* 28:88–93, 2003.
21. Chidgey LK, Dell PC, et al: Histologic anatomy of the triangular fibrocartilage. *J Hand Surg [Am]* 16:1084–1100, 1991.
22. Cho CH, Lee YK, Sin HK: Arthroscopic direct repair for radial tear of the triangular fibrocartilage complex. *Hand Surg* 17:429–432, 2012.
23. Chun S, Palmer AK: The ulnar impaction syndrome: follow-up of ulnar shortening osteotomy. *J Hand Surg [Am]* 18:46–53, 1993.
24. Conaway DA, Kuhl TK, Adams BD: Comparison of the native ulnar head and a partial ulnar head resurfacing implant. *J Hand Surg [Am]* 34:1056–1062, 2009.
25. Constantine KJ, Tomaino MM, et al: Comparison of ulnar shortening osteotomy and the wafer resection procedure as treatment for ulnar impaction syndrome. *J Hand Surg [Am]* 25:55–60, 2000.
26. Cooney WP: Evaluation of chronic wrist pain by arthrography, arthroscopy, and arthrotomy. *J Hand Surg [Am]* 18:816–822, 1993.
27. Cooney WP, Damron TA, et al: En bloc resection of tumors of the distal end of the ulna. *J Bone Joint Surg Am* 79:406–412, 1997.
28. Crisco JJ, Moore DC, Marai GE, et al: Effects of distal radius malunion on distal radioulnar joint mechanics—an in vivo study. *J Orthop Res* 25:547–555, 2007.
29. Daneshvar P, Chan R, MacDermid J, et al: The effects of ulnar styloid fractures on patients sustaining distal radius fractures. *J Hand Surg [Am]* 39:1915–1920, 2014.
30. Darrow JC, Jr, Linscheid RL, et al: Distal ulnar recession for disorders of the distal radioulnar joint. *J Hand Surg [Am]* 10:482–491, 1985.
31. Das DS, Johnsen PH, Wolfe SW: Soft tissue complications of dorsal versus volar plating for ulnar shortening osteotomy. *J Hand Surg [Am]* 40(5):928–933, 2015.

http://e-surg.com

32. DiBenedetto MR, Lubbers LM, et al: Long-term results of the minimal resection Darrach procedure. *J Hand Surg [Am]* 16:445–450, 1991.
33. Dingman P: Resection of the distal end of the ulnar (Darrach operation). An end result study of twenty-four cases. *J Bone Joint Surg Am* 34A:893–900, 1952.
34. dos Reis FB, Katchburian MV, Faloppa F, et al: Osteotomy of the radius and ulna for the Madelung deformity. *J Bone Joint Surg Br* 80:817–824, 1998.
35. Dy CJ, Jang E, Taylor SA, et al: The impact of coronal alignment on distal radioulnar joint stability following distal radius fracture. *J Hand Surg [Am]* 39:1264–1272, 2014.
36. Eckhardt WA, Palmer AK: Recurrent dislocation of extensor carpi ulnaris tendon. *J Hand Surg [Am]* 6:629–631, 1981.
37. Ehman EC, Hayes ML, Berger RA, et al: Subluxation of the distal radioulnar joint as a predictor of foveal triangular fibrocartilage complex tears. *J Hand Surg [Am]* 36:1780–1784, 2011.
38. Epner RA, Bowers WH, et al: Ulnar variance—the effect of wrist positioning and roentgen filming technique. *J Hand Surg [Am]* 7:298–305, 1982.
39. Feldon P, Terrono AL, et al: Wafer distal ulna resection for triangular fibrocartilage tears and/or ulna impaction syndrome. *J Hand Surg [Am]* 17:731–737, 1992.
40. Fernandez DL: Radial osteotomy and Bowers arthroplasty for malunited fractures of the distal end of the radius. *J Bone Joint Surg Am* 70:1538–1551, 1988.
41. Friedman SL, Palmer AK: The ulnar impaction syndrome. *Hand Clin* 7:295–310, 1991.
42. Friedman SL, Palmer AK, et al: The change in ulnar variance with grip. *J Hand Surg [Am]* 18:713–716, 1993.
43. Frykman G: Fracture of the distal radius including sequelae—shoulder-hand-finger syndrome, disturbance in the distal radio-ulnar joint and impairment of nerve function. A clinical and experimental study. *Acta Orthop Scand* (Suppl 108):3, 1967.
44. Fujita S, Masada K, et al: Modified Sauvé-Kapandji procedure for disorders of the distal radioulnar joint in patients with rheumatoid arthritis. *J Bone Joint Surg Am* 87:134–139, 2005.
45. Galvis EJ, Pessa J, Scheker LR: Total joint arthroplasty of the distal radioulnar joint for rheumatoid arthritis. *J Hand Surg [Am]* 39(9):1699–1704, 2014.
46. Geissler WB, Fernandez DL, et al: Distal radioulnar joint injuries associated with fractures of the distal radius. *Clin Orthop Relat Res* (327):135–146, 1996.
47. George MS, Kiefhaber TR, Stern PJ: The Sauvé-Kapandji procedure and the Darrach procedure for distal radio-ulnar joint dysfunction after Colles' fracture. *J Hand Surg [Br]* 29:608–613, 2004.
48. Glowacki KA, Shin LA: Stabilization of the unstable distal ulna: the Linscheid-Hui procedure. *Tech Hand Up Extrem Surg* 3(4):229–236, 1999.
49. Goldner J, Hayes M: Stabilization of the remaining ulna using one-half of the extensor carpi ulnaris tendon after resection of the distal ulna. *Orthop Trans* 3:330–331, 1979.
50. Goncalves D: Correction of disorders of the distal radio-ulnar joint by artificial pseudarthrosis of the ulna. *J Bone Joint Surg Br* 56B(3):462–464, 1974.
51. Gordon L, Levinsohn DG, et al: The Sauvé-Kapandji procedure for the treatment of posttraumatic distal radioulnar joint problems. *Hand Clin* 7:397–403, 1991.
52. Grawe B, Heincelman C, Stern P: Functional results of the Darrach procedure: a long-term outcome study. *J Hand Surg [Am]* 37:2475–2480, 2012.
53. Greenberg JA, Werner FW, Smith JM: Biomechanical analysis of the distal metaphyseal ulnar shortening osteotomy. *J Hand Surg [Am]* 38:1919–1924, 2013.
54. Hajj AA, Wood MB: Stenosing tenosynovitis of the extensor carpi ulnaris. *J Hand Surg [Am]* 11:519–520, 1986.
55. Hammert WC, Williams RB, Greenberg JA: Distal metaphyseal ulnar-shortening osteotomy: surgical technique. *J Hand Surg [Am]* 37:1071–1077, 2012.
56. Hartz CR, Beckenbaugh RD: Long-term results of resection of the distal ulna for post-traumatic conditions. *J Trauma* 19:219–226, 1979.
57. Hauck RM, Skahen J, 3rd, et al: Classification and treatment of ulnar styloid nonunion. *J Hand Surg [Am]* 21:418–422, 1996.
58. Hermansdorfer JD, Kleinman WB: Management of chronic peripheral tears of the triangular fibrocartilage complex. *J Hand Surg [Am]* 16:340–346, 1991.
59. Hess F, Farshad M, Sutter R, et al: A novel technique for detecting instability of the distal radioulnar joint in complete triangular fibrocartilage complex lesions. *J Wrist Surg* 1(2):153–158, 2012.
60. Hui FC, Linscheid RL: Ulnotriquetral augmentation tenodesis: a reconstructive procedure for dorsal subluxation of the distal radioulnar joint. *J Hand Surg [Am]* 7:230–236, 1982.
61. Hulsizer D, Weiss APC, et al: Ulnar-shortening osteotomy after failed arthroscopic débridement of the triangular fibrocartilage complex. *J Hand Surg [Am]* 22:694–698, 1997.
62. Hunt TR, Hastings H, 2nd, Graham TJ: A systematic approach to handling the distal radio-ulnar joint in cases of malunited distal radius fractures. *Hand Clin* 14:239–249, 1998.
63. Hunter JM, Kirkpatrick WH: Dacron stabilization of the distal ulna. *Hand Clin* 7(2):365–371, 1991.
64. Iida A, Omokawa S, Akahane M, et al: Distal radioulnar joint stress radiography for detecting radioulnar ligament injury. *J Hand Surg* 37A:968–974, 2012.
65. Iorio ML, Bayomy AF, Huang JI: Morphology of the extensor carpi ulnaris groove and tendon. *J Hand Surg [Am]* 39:2412–2416, 2014.
66. Jang E, Dy CJ, Wolfe SW: Selection of tendon grafts for distal radioulnar ligament reconstruction and report of a modified technique. *J Hand Surg [Am]* 39(10):2027–2032, 2014.
67. Jansen JC, Adams BD: Long-term outcome of nonsurgically treated patients with wrist pain and a normal arthrogram. *J Hand Surg [Am]* 27:26–30, 2002.
68. Johnson RK: Stabilization of the distal ulna by transfer of the pronator quadratus origin. *Clin Orthop Relat Res* 275:130–132, 1992.
69. Johnson RK, Shrewsbury MM: The pronator quadratus in motions and in stabilization of the radius and ulna at the distal radioulnar joint. *J Hand Surg* 1:205, 1976.
70. Johnston Jones K, Sanders WE: Posttraumatic radioulnar instability: treatment by anatomic reconstruction of the volar and radioulnar ligaments. *Orthop Trans* 19:832, 1995–1996.
71. Kachooei AR, Chase SM, Jupiter JB: Outcome assessment after aptis distal radioulnar joint (DRUJ) implant arthroplasty. *Arch Bone Jt Surg* 2:180–184, 2014.
72. Kapandji IA: The Kapandji-Sauvé procedure. *J Hand Surg [Br]* 17:125–126, 1992.
73. Kessler I, Hecht O: Present application of the Darrach procedure. *Clin Orthop* 72:254–260, 1970.
74. Kim JK, Koh YD, Do NH: Should an ulnar styloid fracture be fixed following volar plate fixation of a distal radial fracture? *J Bone Joint Surg Am* 92:1–6, 2010.
75. Kip PC, Peimer CA: Release of the sixth dorsal compartment. *J Hand Surg [Am]* 19:599–601, 1994.
76. Kitamura T1, Moritomo H, Arimitsu S, et al: The biomechanical effect of the distal interosseous membrane on distal radioulnar joint stability: a preliminary anatomic study. *J Hand Surg [Am]* 36:1626–1630, 2011.
77. Kleinman WB, Graham TJ: Distal ulnar injury and dysfunction. In Peimer CA, editor: *Surgery of the hand and upper extremity*, New York, 1996, McGraw-Hill, p 670.
78. Kleinman WB, Graham TJ: The distal radioulnar joint capsule: clinical anatomy and role in posttraumatic limitation of forearm rotation. *J Hand Surg [Am]* 23:588–599, 1998.
79. Kleinman WB, Greenberg JA: Salvage of the failed Darrach procedure. *J Hand Surg [Am]* 20(6):951–958, 1995.
80. Korompilias AV, Lykissas MG, Kostas-Agnantis IP, et al: Distal radioulnar joint instability (Galeazzi type injury) after internal fixation in relation to the radius fracture pattern. *J Hand Surg [Am]* 36:847–852, 2011.
81. Krämer S, Meyer H, O'Loughlin PF, et al: The incidence of ulnocarpal complaints after distal radial fracture in relation to the fracture of the ulnar styloid. *J Hand Surg Eur Vol* 38:710–717, 2013.
82. LaPorte DM, Hashemi SS, Dellon AL: Sensory innervation of the triangular fibrocartilage complex: a cadaveric study. *J Hand Surg [Am]* 39:1122–1124, 2014.
83. Leslie BM, Carlson G, et al: Results of extensor carpi ulnaris tenodesis in the rheumatoid wrist undergoing a distal ulnar excision. *J Hand Surg [Am]* 15:547–551, 1990.
84. Lester B, Halbrecht J, et al: "Press-test" for office diagnosis of triangular fibrocartilage complex tears of the wrist. *Ann Plast Surg* 35:41–45, 1995.
85. Levis CM, Yang Z, et al: Validation of the extensor carpi ulnaris groove as a predictor for the recognition of standard posteroanterior radiographs of the wrist. *J Hand Surg [Am]* 27:252–257, 2002.
86. Lindau T, Adlercreutz C, et al: Peripheral tears of the triangular fibrocartilage complex cause distal radioulnar joint instability after distal radial fractures. *J Hand Surg [Am]* 25:464–468, 2000.
87. Lindau T, Runnquist K, et al: Patients with laxity of the distal radioulnar joint after distal radial fractures have impaired function, but no loss of strength. *Acta Orthop Scand* 73:151–156, 2002.
88. Linscheid RL: Biomechanics of the distal radioulnar joint. *Clin Orthop* 275:46, 1992.
89. Lo IK, MacDermid JC, et al: The radioulnar ratio: a new method of quantifying distal radioulnar joint subluxation. *J Hand Surg [Am]* 26:236–243, 2001.
90. MacLennan AJ, Nemechek NM, Waitayawinyu T, et al: Diagnosis and anatomic reconstruction of extensor carpi ulnaris subluxation. *J Hand Surg [Am]* 33:59–64, 2008.
91. Martin DE, Zlotolow DA, Russo SA, et al: Comparison of compression screw and perpendicular clamp in ulnar shortening osteotomy. *J Hand Surg [Am]* 39:1558–1564, 2014.
92. Masaoka S, Longsworth SH, et al: Biomechanical analysis of two ulnar head prostheses. *J Hand Surg [Am]* 27:845–853, 2002.
93. May MM, Lawton JN, et al: Ulnar styloid fractures associated with distal radius fractures: incidence and implications for distal radioulnar joint instability. *J Hand Surg [Am]* 27:965–971, 2002.
94. Melone CP, Jr, Nathan R: Traumatic disruption of the triangular fibrocartilage complex: pathoanatomy. *Clin Orthop Relat Res* 275:65–73, 1992.
95. Mikic ZD: Age changes in the triangular fibrocartilage of the wrist joint. *J Anat* 126:367–384, 1978.

http://e-surg.com

96. Milch H: Cuff resection of the ulna for malunited Colles fracture. *J Bone Joint Surg Am* 23:311–313, 1941.
97. Millard GM, Budoff JE, et al: Functional bracing for distal radioulnar joint instability. *J Hand Surg [Am]* 27:972–977, 2002.
98. Millroy P, Coleman S, et al: The Sauvé-Kapandji operation: technique and results. *J Hand Surg [Br]* 17:411–414, 1992.
99. Minami A, Kaneda K, et al: Hemiresection-interposition arthroplasty of the distal radioulnar joint associated with repair of triangular fibrocartilage complex lesions. *J Hand Surg [Am]* 16:1120–1125, 1991.
100. Minami A, Suzuki K, et al: The Sauvé-Kapandji procedure for osteoarthritis of the distal radioulnar joint. *J Hand Surg [Am]* 20:602–608, 1995.
101. Mino DE, Palmer AK, et al: Radiography and computerized tomography in the diagnosis of incongruity of the distal radio-ulnar joint: a prospective study. *J Bone Joint Surg Am* 67:247–252, 1985.
102. Morisawa Y, Nakamura T, Tazaki K: Dorsoradial avulsion of the triangular fibrocartilage complex with an avulsion fracture of the sigmoid notch of the radius. *J Hand Surg Eur Vol* 32:705–708, 2007.
103. Moritomo H: The distal interosseous membrane: current concepts in wrist anatomy and biomechanics. *J Hand Surg [Am]* 37:1501–1507, 2012.
104. Moritomo H: Anatomy and clinical relevance of the ulnocarpal ligament. *J Wrist Surg* 2:186–189, 2013.
105. Moriya T, Aoki M, Iba K, et al: Effect of triangular ligament tears on distal radioulnar joint instability and evaluation of three clinical tests: a biomechanical study. *J Hand Surg Eur* 34E:219–223, 2009.
106. Mrkonjic A, Geijer M, Lindau T, et al: The natural course of traumatic triangular fibrocartilage complex tears in distal radial fractures: a 13–15 year follow-up of arthroscopically diagnosed but untreated injuries. *J Hand Surg [Am]* 37:1555–1560, 2012.
107. Nakamura R, Horii E, et al: The ulnocarpal stress test in the diagnosis of ulnar-sided wrist pain. *J Hand Surg [Br]* 22:719–723, 1997.
108. Nakamura T, Iwamoto T, Matsumura N, et al: Radiographic and arthroscopic assessment of DRUJ instability due to foveal avulsion of the radioulnar ligament in distal radius fractures. *J Wrist Surg* 3:12–17, 2014.
109. Nakamura T, Sato K, Okazaki M, et al: Repair of foveal detachment of the triangular fibrocartilage complex: open and arthroscopic transosseous techniques. *Hand Clin* 27:281–290, 2011.
110. Nakamura T, Takayama S, Horiuchi Y, et al: Origins and insertions of the triangular fibrocartilage complex: a histological study. *J Hand Surg [Br]* 26(5):446–454, 2001.
111. Nishikawa S1, Toh S: Anatomical study of the carpal attachment of the triangular fibrocartilage complex. *J Bone Joint Surg Br* 84(7):1062–1065, 2002.
112. Noda K, Goto A, Murase T, et al: Interosseous membrane of the forearm: an anatomical study of ligament attachment locations. *J Hand Surg [Am]* 34:415–422, 2009.
113. Nolan WB, III, Eaton RG: A Darrach procedure for distal ulnar pathology derangements. *Clin Orthop* 275:85–89, 1992.
114. O'Donovan TM, Ruby LK: The distal radioulnar joint in rheumatoid arthritis. *Hand Clin* 5(2):249–256, 1989.
115. Ogawa T, Tanaka T, Yanai T, et al: Analysis of soft tissue injuries associated with distal radius fractures. *BMC Sports Sci Med Rehabil* 5:19, 2013.
116. Palmer AK: Triangular fibrocartilage complex lesions: a classification. *J Hand Surg [Am]* 14:594–606, 1989.
117. Palmer AK, Glisson RR, et al: Ulnar variance determination. *J Hand Surg [Am]* 7:376–379, 1982.
118. Palmer AK, Glisson RR, et al: Relationship between ulnar variance and triangular fibrocartilage complex thickness. *J Hand Surg [Am]* 9:681–682, 1984.
119. Palmer AK, Skahen FW, Glisson RR: The extensor retinaculum of the wrist: an anatomical and biomechanical study. *J Hand Surg [Br]* 10:11–16, 1985.
120. Palmer AK, Werner FW: The triangular fibrocartilage complex of the wrist—anatomy and function. *J Hand Surg [Am]* 6:153–162, 1981.
121. Palmer AK, Werner FW: Biomechanics of the distal radioulnar joint. *Clin Orthop Relat Res* (187):26–35, 1984.
122. Palmer AK, Werner FW, et al: Partial excision of the triangular fibrocartilage complex. *J Hand Surg [Am]* 13:391–394, 1988.
123. Papapetropoulos PA, Wartinbee DA, Richard MJ, et al: Management of peripheral triangular fibrocartilage complex tears in the ulnar positive patient: arthroscopic repair versus ulnar shortening osteotomy. *J Hand Surg [Am]* 35:1607–1613, 2010.
124. Petersen MS, Adams BD: Biomechanical evaluation of distal radioulnar reconstructions. *J Hand Surg [Am]* 18:328–334, 1993.
125. Peterson CA, 2nd, Maki S, et al: Clinical results of the one-bone forearm. *J Hand Surg [Am]* 20:609–618, 1995.
126. Pirela-Cruz MA, Goll SR, Klug M, et al: Stress computed tomography analysis of the distal radioulnar joint: a diagnostic tool for determining translational motion. *J Hand Surg [Am]* 16:75–82, 1991.
127. Pogue DJ, Viegas SF, Patterson RM, et al: Effects of distal radius fracture malunion on wrist joint mechanics. *J Hand Surg [Am]* 15:721–727, 1990.
128. Rayhack JM, Gasser SI, et al: Precision oblique osteotomy for shortening of the ulna. *J Hand Surg [Am]* 18:908–918, 1993.
129. Rettig ME, Raskin KB: Galeazzi fracture-dislocation: a new treatment-oriented classification. *J Hand Surg [Am]* 26:228–235, 2001.
130. Richards RS, Bennett JD, Roth JH, et al: Arthroscopic diagnosis of intra-articular soft tissue injuries associated with distal radial fractures. *J Hand Surg [Am]* 22:772–776, 1997.
131. Rozental TD, Bozentka DJ, et al: Evaluation of the sigmoid notch with computed tomography following intra-articular distal radius fracture. *J Hand Surg [Am]* 26:244–251, 2001.
132. Ruby LK, Ferenz CC, et al: The pronator quadratus interposition transfer: an adjunct to resection arthroplasty of the distal radioulnar joint. *J Hand Surg [Am]* 21:60–65, 1996.
133. Ruch DS, Lumsden BC, Papadonikolakis A: Distal radius fractures: a comparison of tension band wiring versus ulnar outrigger external fixation for the management of distal radioulnar instability. *J Hand Surg [Am]* 30(5):969–977, 2005.
134. Sabo MT, Talwalkar S, Hayton M, et al: Intermediate outcomes of ulnar head arthroplasty. *J Hand Surg [Am]* 39:2405–2411, 2014.
135. Sagerman SD, Zogby RG, et al: Relative articular inclination of the distal radioulnar joint: a radiographic study. *J Hand Surg [Am]* 20:597–601, 1995.
136. Savvidou C, Murphy E, Mailhot E, et al: Semiconstrained distal radioulnar joint prosthesis. *J Wrist Surg* 2:41–48, 2013.
137. Scheker LR, Babb BA, et al: Distal ulnar prosthetic replacement. *Orthop Clin North Am* 32:365–376, 2001.
138. Scheker LR, Belliappa PP, et al: Reconstruction of the dorsal ligament of the triangular fibrocartilage complex. *J Hand Surg [Br]* 19:310–318, 1994.
139. Scheker LR, Severo A: Ulnar shortening for the treatment of early post-traumatic osteoarthritis at the distal radioulnar joint. *J Hand Surg [Br]* 26:41–44, 2001.
140. Schuind F, An KN, Berglund L, et al: The distal radioulnar ligaments: a biomechanical study. *J Hand Surg [Am]* 16:1106–1114, 1991.
141. Schuind F, Linscheid RL, An KN, et al: Changes in wrist and forearm configuration with grasp and isometric contraction of elbow flexors. *J Hand Surg [Am]* 17:698–703, 1992.
142. Schuind FA, Linscheid RL, An KN, et al: A normal data base of posteroanterior roentgenographic measurements of the wrist. *J Bone Joint Surg Am* 74(9):1418–1429, 1992.
143. Schuurman AH, Bos KE: The ulno-carpal abutment syndrome: follow-up of the wafer procedure. *J Hand Surg [Br]* 20:171–177, 1995.
144. Shen J, Papadonikolakis A, Garrett JP, et al: Ulnar positive variance as a predictor of distal radioulnar joint ligament disruption. *J Hand Surg* 30A:1172–1177, 2005.
145. Shepard MF, Markolf KL, Dunbar AM: Effects of radial head excision and distal radial shortening on load-sharing in cadaver forearms. *J Bone Joint Surg Am* 83A:92–100, 2001.
146. Shigemitsu T, Tobe M, Mizutani K, et al: Innervation of the triangular fibrocartilage complex of the human wrist: quantitative immunohistochemical study. *Anat Sci Int* 82(3):127–132, 2007.
147. Shinohara T, Tatebe M, Okui N, et al: Arthroscopically assisted repair of triangular fibrocartilage complex foveal tears. *J Hand Surg [Am]* 38:271–277, 2013.
148. Slutsky DJ: Arthroscopic evaluation of the foveal attachment of the triangular fibrocartilage. *Hand Clin* 27:255–261, 2011.
149. Smet LD, Vandenberghe L, Degreef I: Ulnar impaction syndrome: ulnar shortening vs. arthroscopic wafer procedure. *J Wrist Surg* 3:98–100, 2014.
150. Smith AM, Urbanosky LR, Castle JA, et al: Radius pull test: predictor of longitudinal forearm instability. *J Bone Joint Surg* 84A:1970–1976, 2002.
151. Sotereanos DG, Gobel F, et al: An allograft salvage technique for failure of the Darrach procedure: a report of four cases. *J Hand Surg [Br]* 27:317–321, 2002.
152. Souer JS, Ring D, Matschke S, et al: AOCID Prospective ORIF Distal Radius Study Group. Effect of an unrepaired fracture of the ulnar styloid base on outcome after plate-and-screw fixation of a distal radial fracture. *J Bone Joint Surg Am* 91:830–838, 2009.
153. Spinner M, Kaplan EB: Extensor carpi ulnaris: its relationship to the stability of the distal radio-ulnar joint. *Clin Orthop Relat Res* 68:124–129, 1970.
154. Srinivasan RC, Jain D, Richard MJ, et al: Isolated ulnar shortening osteotomy for the treatment of extra-articular distal radius malunion. *J Hand Surg [Am]* 38:1106–1110, 2013.
155. Steyers CM, Blair WF: Measuring ulnar variance: a comparison of techniques. *J Hand Surg [Am]* 14:607–612, 1989.
156. Stuart PR, Berger RA, et al: The dorsopalmar stability of the distal radioulnar joint. *J Hand Surg [Am]* 25:689–699, 2000.
157. Swanson AB: Implant arthroplasty for disabilities of the distal radioulnar joint: use of a silicone rubber capping implant following resection of the ulnar head. *Orthop Clin North Am* 4:373–382, 1973.
158. Taleisnik J: The Sauvé-Kapandji procedure. *Clin Orthop* 275:110–123, 1992.
159. Tanabe K, Nakajima T, Sogo E, et al: Intra-articular fractures of the distal radius evaluated by computed tomography. *J Hand Surg [Am]* 36:1798–1803, 2011.

http://e-surg.com

160. Tay SC, Tomita K, Berger RA: The "ulnar fovea sign" for defining ulnar wrist pain: an analysis of sensitivity and specificity. *J Hand Surg [Am]* 32(4):438–444, 2007.
161. Tolat AR, Sanderson PL, et al: The gymnast's wrist: acquired positive ulnar variance following chronic epiphyseal injury. *J Hand Surg [Br]* 17:678–681, 1992.
162. Tolat AR, Stanley JK, Trail IA: A cadaveric study of the anatomy and stability of the distal radioulnar joint in the coronal and transverse planes. *J Hand Surg [Br]* 21:587–594, 1996.
163. Tomaino MM: The importance of the pronated grip x-ray view in evaluating ulnar variance. *J Hand Surg [Am]* 25:352–357, 2000.
164. Tomaino MM, Gainer M, Towers JD: Carpal impaction with the ulnar styloid process: treatment with partial styloid resection. *J Hand Surg [Br]* 26:252–255, 2001.
165. Trousdale R, Linscheid RL: Operative treatment of malunited fractures of the forearm. *J Bone Joint Surg Am* 77:894–902, 1995.
166. Trumble TE, Gilbert M, et al: Ulnar shortening combined with arthroscopic repairs in the delayed management of triangular fibrocartilage complex tears. *J Hand Surg [Am]* 22:807–813, 1997.
167. Tsai T, Shimizu H, et al: A modified extensor carpi ulnaris tenodesis with the Darrach procedure. *J Hand Surg [Am]* 18(4):697–702, 1993.
168. Tsai TM, Stilwell JH: Repair of chronic subluxation of the distal radioulnar joint (ulnar dorsal) using flexor carpi ulnaris tendon. *J Hand Surg [Br]* 9:289–294, 1984.
169. Tulipan DJ, Eaton RG, et al: The Darrach procedure defended: technique redefined and long-term follow-up. *J Hand Surg [Am]* 16:438–444, 1991.
170. van Schoonhoven J, Fernandez DL, et al: Salvage of failed resection arthroplasties of the distal radioulnar joint using a new ulnar head prosthesis. *J Hand Surg [Am]* 25:438–446, 2000.
171. Wallwork NA, Bain GI: Sigmoid notch osteoplasty for chronic volar instability of the distal radioulnar joint: a case report. *J Hand Surg [Am]* 26:454–459, 2001.
172. Ward LD, Ambrose CG, et al: The role of the distal radioulnar ligaments, interosseous membrane, and joint capsule in distal radioulnar joint stability. *J Hand Surg [Am]* 25:341–351, 2000.
173. Watson HK, Brown RE: Ulnar impingement syndrome after Darrach procedure: treatment by advancement lengthening osteotomy of the ulna. *J Hand Surg [Am]* 14(2 Pt 1):302–306, 1989.
174. Watson HK, Gabuzda GM: Matched distal ulna resection for posttraumatic disorders of the distal radioulnar joint. *J Hand Surg [Am]* 17:724–730, 1992.
175. Watson HK, Manzo RL: Modified arthroplasty of the distal radio-ulnar joint. *J Hand Surg [Br]* 27:322–325, 2002.
176. Webber JB, Maser SA: Stabilization of the distal ulna. *Hand Clin* 7:345–353, 1991.
177. Wechsler RJ, Wehbe MA, Rifkin MD, et al: Computed tomography diagnosis of distal radioulnar subluxation. *Skeletal Radiol* 16(1):1–5, 1987.
178. Wehbe MA, Cautilli DA: Ulnar shortening using the AO small distractor. *J Hand Surg [Am]* 20:959–964, 1995.
179. Werner FW, Murphy DJ, Palmer AK: Pressures in the distal radioulnar joint: effect of surgical procedures used for Kienböck's disease. *J Orthop Res* 7:445–450, 1989.
179a. Werner FW, Palmer AK, Fortino MD, et al: Force transmission through the distal ulna: effect of ulnar variance, lunate fossa angulation, and radial and palmar tilt of the distal radius. *J Hand Surg* 17A:423–428, 1992.
180. Wijffels MM, Keizer J, Buijze GA, et al: Ulnar styloid process nonunion and outcome in patients with a distal radius fracture: a meta-analysis of comparative clinical trials. *Injury* 45:1889–1895, 2014.
181. Willis AA, Berger RA, Cooney WP, 3rd.: Arthroplasty of the distal radioulnar joint using a new ulnar head endoprosthesis: preliminary report. *J Hand Surg [Am]* 32(2):177–189, 2007.
182. Wolf MB, Kroeber MW, Reiter A, et al: Ulnar shortening after TFCC suture repair of Palmer type 1B lesions. *Arch Orthop Trauma Surg* 130:301–306, 2010.
183. Wolfe SW, Mih AD, et al: Wide excision of the distal ulna: a multicenter case study. *J Hand Surg [Am]* 23:222–228, 1998.
184. Wysocki RW, Richard MJ, Crowe MM, et al: Arthroscopic treatment of peripheral triangular fibrocartilage complex tears with the deep fibers intact. *J Hand Surg [Am]* 37:509–516, 2012.
185. Wysocki RW, Ruch DS: Ulnar styloid fracture with distal radius fracture. *J Hand Surg [Am]* 37:568–569, 2012.
186. Yang Z, Mann FA, Gilula LA, et al: Scaphopisocapitate alignment: criterion to establish a neutral lateral view of the wrist. *Radiology* 205(3):865–869, 1997.
187. Yeh GL, Beredjiklian PK, et al: Effects of forearm rotation on the clinical evaluation of ulnar variance. *J Hand Surg [Am]* 26:1042–1046, 2001.
188. Zenke Y, Sakai A, Oshige T, et al: The effect of an associated ulnar styloid fracture on the outcome after fixation of a fracture of the distal radius. *J Bone Joint Surg Br* 91:102–107, 2009.

http://e-surg.com

15

Distal Radius Fractures

Scott W. Wolfe

Acknowledgments: I would like to acknowledge with sincere gratitude those giants who have written past editions of "Distal Radius Fractures," including Diego Fernandez and Andy Palmer. Their insightful perspectives, tricks, and techniques, as well as several of the original figures, tables, and parts of the text, have been an enormous asset to me in writing this chapter.

These videos may be found at *ExpertConsult.com:*

15.1 Insertion of a novel intramedullary device for locked fixation of articular fractures. (© Scott W. Wolfe, MD)

With the wide array of options available, this is an exciting era for the treatment of fractures of the distal radius. An improved understanding of kinematics, bone quality, and muscle forces acting across the wrist has led to an increased awareness of a fracture's relative stability, as well as the development of innovative devices to counteract these forces and restore anatomy. Innovations have occurred in closed treatment; percutaneous or spanning fixation; and, in particular, internal fixation devices. However, new implants and techniques require careful assessment of efficacy, risk, and benefit as they are applied in practice, especially because the incidence of fractures is rising in our aging population.

Distal radius fractures are the most common ones seen in the emergency department; they represent approximately 3% of all upper extremity injuries, with an incidence of greater than 640,000 annually in the United States alone.[27] There is a bimodal distribution of these injuries, with a peak in the 5- to 24-year-old, predominantly male population—athletic and high-energy injuries—and a second peak in the elderly, predominantly female population—lower-energy or "fragility" fractures. US Census data indicate that the percentage of people older than 65 in the United States is expected to increase to 16.5% of the population by 2020 (50 million citizens). Osteoporosis is a leading cause of fractures in the elderly, and therefore improved attention to care for this condition may reduce the incidence of such fractures.[138]

The goals of this chapter are to provide the surgeon with a detailed understanding of fracture types, better knowledge of wrist and fracture mechanics, improved recognition of individual fracture fragments, and an understanding of the expectations of fracture treatment. Using a case-based approach, it is hoped that the reader will go away with a better appreciation of the factors influencing treatment results and that the information here will enable the surgeon to develop an effective approach to fracture injuries.

THE RATIONALE FOR MODERN TREATMENT

Beginning with Pouteau (1783), Colles (1814), and Dupuytren (1847), early reports of fractures of the distal radius considered them to be a group of injuries with a relatively good prognosis irrespective of treatment. Until the mid-1900s, nearly all fractures of the distal radius were treated in a closed fashion, with or without reduction of alignment. Patients' expectations were in line with the treatment tools available at the time, and certainly other public health issues surpassed the wrist in importance to a patient's long-term productivity. Since then, tens of thousands of clinical and basic science publications have contributed to an improved understanding of fractures' complexity, stability, and prognosis and have, consequently, driven the development of modern techniques and technology to optimize patient outcomes. A brief summary of the evolution of modern fracture fixation is shown in Table 15.1, with the sentinel publications and techniques that fundamentally changed treatment of these challenging injuries. See ExpertConsult.com for more information about this topic.

What is clear from an analysis of the evolution of wrist fracture treatment is that (1) there is both general consensus and scientific evidence that restoration of the anatomy of the distal radius is linked to restoration of function; and (2) no single technique or method will yield results superior to those of other treatment methods given the wide divergence in fracture subtypes, energy associated with the injury, age, activity level, and related injuries. The indiscriminate use of one method to treat all fractures of the distal radius predictably can lead to cases of fixation failure, soft tissue injury, and inability to achieve the goals of intervention.

FRACTURE EVALUATION

PERTINENT ANATOMY

The distal radius functions as an articular plateau on which the carpus rests (Figures 15.1 and 15.2) and from which the radially based supporting ligaments of the wrist arise (Figure 15.3). The hand and radius, as a unit, articulate with and rotate about the ulnar head via the sigmoid notch of the radius (Figure 15.4). This latter relationship is maintained primarily by the ulnar-based supporting ligaments of the wrist—the TFCC.

The distal radius has three concave articular surfaces—the scaphoid fossa, the lunate fossa, and the sigmoid notch—for articulation with the scaphoid, lunate, and ulnar head, respectively (Figures 15.5 and 15.6). The sigmoid notch is concave, with a poorly defined proximal margin and well-defined dorsal, palmar, and distal margins (see Figure 15.6).

http://e-surg.com

Although closed reduction with a cast for treatment of distal radius fractures continues to be the mainstay for stable fractures, operative methods have evolved over the past century to treat fractures that defy management with a cast. Casting in acute wrist flexion and ulnar deviation, or the so-called Cotton-Loder position, even though thought to be beneficial for maintenance of reduction of unstable fractures, seemed to result in more stiffness in the digits and the potential for median nerve compression. The "pins-and-plaster" technique, attributed to Bohler in 1929,[16] was the predecessor of modern external fixation; it consists of the incorporation of percutaneous pins in the midradius and metacarpals into a circumferential plaster cast. Although the technique yielded initial improvements, it fell from favor because external-fixation devices were easier to apply and seemed to maintain the reduction with fewer complications. The use of external fixation began during the 1940s, and the principles were best summarized by Anderson and O'Neil[5]:

- Strong forearm muscular forces oppose fracture fixation.
- Loss of radial length is secondary to crushed metaphyseal bone.
- Distraction should be maintained for 8 to 12 weeks until the metaphysis is reconstituted.
- Open reduction of impacted articular fragments is necessary.
- Bone grafting is required to support the crushed articular surface.
- "Immediate use of the fingers and arm is the key to near perfect functional restoration."

Despite relative improvements in fracture fixation stability, there remained no hard data for surgeons to link patient function or outcome with treatment variables. Surgeons used a variety of techniques ranging from casting with or without Kirschner-wire (K-wire) fixation to pins and plaster or external fixation, without comparative studies or a means to judge results. In 1951, Gartland and Werley published a series of 60 patients treated by plaster immobilization; in it they devised a demerit point system to score subjective and objective function that continues to be used today.[50]

The authors defined the anatomic indices of normal volar tilt, radial length, and radial inclination and demonstrated that *60%* of treated fractures *assume their prereduction alignment* at final follow-up despite adequate cast treatment. In their series, all fractures lost some component of the initial reduction of dorsal tilt. For the first time, these authors showed that poor functional outcomes are associated with failure to restore and maintain bony alignment. In this and many subsequent series over the next several decades,[34,88,111,167] compelling evidence has been presented to link restoration of anatomy to restoration of function—a principle that is the basis of modern fracture treatment.

The popularity of external fixation for treatment of wrist fractures was catapulted forward in 1979 by Jacques Vidal's concept of "ligamentotaxis"; he advocated its use for comminuted articular fractures, including those of the hip, knee, ankle, spine, and wrist. The principle of ligamentotaxis involved the application of tension "by means of distraction forces working through capsule-ligamentous structures" to obtain reduction.[157] Even though not substantially different in concept from pins and plaster or the Roger Anderson frame, the spanning external fixator enabled the surgeon to adjust ligament tension using distraction and tensioning devices. Although the author described its use for highly comminuted fractures that were otherwise not suited for internal fixation, advocates of the technique championed it widely for virtually all distal radius fractures, and industry responded with a plethora of external-fixation devices during the 1980s and 1990s.

Within 10 years of Vidal's publication, multiple centers reported extensive complications related to overdistraction of articular injuries, including severe digital stiffness, reflex sympathetic dystrophy, and nerve dysfunction, as well as an inability to maintain reduction of articular fragments and radial length with traction alone.[29,82,113,165] Over the ensuing two decades, the technique of external fixation evolved to include "augmentation" of fixation with supplemental K-wires, mini-open or arthroscopic reduction (or both), and bone grafting, with a concomitant reduction in traction-related complications.

Frykman called attention to the importance of injuries on the ulnar side of the wrist to outcomes of distal radius fractures.[49] Pivotal work by Palmer and colleagues in the early 1980s unveiled the complex anatomy and the critical importance of the triangular fibrocartilage complex (TFCC) to the stability of the radioulnar joint and hand function after distal radial fractures.[128,146] Using mechanical loading experiments, the investigators provided fundamental scientific evidence to explain the relationship between dorsal malalignment of the radius and increased ulnar load transmission, as well as the compounding effect of increased ulnar variance as a result of radial settling.

Concurrently, Taleisnik and Watson demonstrated changes in resting carpal posture and aberrations in carpal kinematics caused by dorsal malunion of the radius and advocated realignment osteotomy to restore radiocarpal and midcarpal relationships.[152] Reports of excellent results after osteotomy and bone grafting of painful malunions by Fernandez and others provided further evidence to underscore the link between bony alignment and function.[46] These important clinical and "bench-top" advances helped surgeons understand how critical the articular relationships of displaced distal radial fragments are to upper extremity function; such advances solidified the tenet that these joints have a narrow tolerance for changes in radial angulation, tilt, and variance in young, active patients.

Although Scheck and others had drawn attention to the presence and importance of impacted articular fragments as a prognostic indicator,[141] Knirk and Jupiter focused attention on the need for longer-term functional studies, particularly in young adults with high-energy articular fractures.[92] Their long-term follow-up study documented a 91% rate of degenerative arthritis, as judged by plain radiographs, in patients with *any* degree of residual articular incongruity and a 100% rate in patients with 2 mm or greater incongruity. However, a multivariate analysis was not performed to eliminate the potential confounding effects of radial malalignment. The study did draw attention to the need for restoration of joint congruity and ignited a surge of interest in precision realignment of the articular surface. Subsequent studies supported their observation by linking residual articular incongruency directly with the early onset of degenerative changes.[36,97]

With the primary goal of restoration of joint congruity, several authors advocated meticulous restoration of the articular surface through an open dorsal or combined dorsal–volar

http://e-surg.com

approach, rigid internal fixation, and cancellous bone graft.[9,48] Although these techniques generally attained the goal of accurate reduction of the articular surface, a high rate of complications was reported, primarily extensor tendon irritation and rupture. This caused many to reconsider the use of dorsal plates. Surgeons and manufacturers teamed to design novel dorsal plate-fixation systems that combined improved material strength with low-profile plates and screws, which seemed to decrease the incidence of extensor tendonopathy.

Advances in the understanding of external fixation also led to improvements in clinical outcomes by using combined techniques of limited open reduction,[11,53] arthroscopic indirect reduction,[36,54,171] and percutaneous "augmented" external fixation. The complications of digital stiffness and overdistraction were reduced by using the external fixator as a neutralization device and percutaneous K-wires and bone graft to support impacted articular fragments.[142,143] Use of a bone graft was demonstrated to enable earlier removal of the fixator[103] while providing structural support for the articular surface and improvements in radial length and alignment. "Nonspanning" external fixation in selected patients was reported to lead to improvements in early and late functional and radiographic outcomes,[110] and the technique and indications for this procedure continue to be refined.

Despite the ability to improve articular congruity, a prospective assessment of displaced articular fractures with computed tomography (CT) documented progressive arthrosis of the radiocarpal joint in a high percentage of patients.[58] Interestingly, there was little correlation between patients' functional outcomes and the presence or severity of arthrosis. This finding suggests that despite the best effort to restore articular alignment, posttraumatic arthrosis (perhaps asymptomatic) may be unavoidable. In a randomized study, in which patients with unstable fractures were treated by either closed reduction, external fixation, or open reduction, improved functional results were directly related to restoration of carpal alignment in the sagittal plane (i.e., restoration of volar tilt); however, no technique proved superior in this regard.[112]

The last decade has witnessed an unprecedented interest in two internal-fixation techniques: (1) columnar fixation with miniature or "fragment-specific" fixation[102,133] and (2) fixation of a wide variety of fractures with fixed-angle devices through a single-volar approach.[125] Improvements in imaging and recognition of unstable fracture fragments have enabled surgeons to customize their approach and to identify and rigidly fix highly comminuted fractures with internal fixation, thereby enabling earlier resumption of wrist motion.

Enthusiasm for the new wave of implants and techniques has been tempered by reports of tendon rupture, hardware malposition, and loss of fixation, as well as by two prospective studies that demonstrated better patient outcomes with percutaneous techniques than with open reduction and plate fixation.[63,97] Yet, with each new technique comes an expansion of the understanding of fracture behavior and an improved ability to treat a multitude of fracture patterns in a widely diverse group of patients.

Progress in the treatment of wrist fractures over the last century suggests four principal tenets of intervention (i.e., ARMS) with the universal goal of restoration of pain-free hand and wrist function. Closed or operative management for young, active patients should seek to restore:

1. **A**rticular congruity (to reduce wear on articular cartilage and degenerative changes)
2. **R**adial alignment and length (to restore kinematics of the carpus and radioulnar joint)
3. **M**otion (to optimize return to functional activities for digits, wrist, and forearm)
4. **S**tability (to preserve length and alignment until healing of the fracture)

Surgeons can modify treatment based on the level of patient understanding, bone quality, compliance issues, and/or expectations. When they speak of "accepting" less-than-full attainment of these goals, it is generally done because of patient factors (i.e., systemic illness, age, activity level) rather than fracture pattern.

http://e-surg.com

TABLE 15.1 Contributions to Understanding Distal Radius Fracture Treatment

Author	Year	Area of Contribution	Significance
Colles	1814	Description of fracture and closed treatment	"[T]hat the limb will at some remote period again enjoy perfect freedom in all its motions."
Bohler	1929	Pins-and-plaster technique	Improvement over closed treatment for unstable fractures.
Anderson and O'Neil	1944	Principles and technique of external fixation	Reduction is easy to attain, maintenance is difficult. Advocated distraction by fixator, augmented with bone graft.
Gartland and Werley	1951	Outcome assessment	Of fractures treated with plaster, 60% collapse. A demerit point system is recommended; it has been in use for 7 decades.
DePalma et al.	1952	Closed-pin treatment	Outcomes linked to restoration of bony alignment.
Frykman	1967	Classification	Distinguished between radiocarpal and radioulnar articular involvement, and the importance of ulnar-sided injuries.
Vidal	1979	External fixation	Advanced the concept of "ligamentotaxis" to restore articular alignment in comminuted articular fractures.
Cooney et al.	1980s	Colles' fracture treatment	Treatment principles, complications of Colles' fractures, overdistraction, reflex sympathetic dystrophy, bone grafting.
Palmer et al.	1980s	Triangular fibrocartilage complex	Relationship of TFCC to radioulnar stability, malalignment to DRUJ dysfunction, and radial settling to ulnar impaction.
Fernandez	1982	Malunion	Established indications and technique for osteotomy of malunited distal radius fractures.
Taleisnik and Watson	1984	Carpal instability	Described relationship of dorsal malalignment to nondissociative carpal instability.
Knirk and Jupiter	1986	Articular congruency	Demonstrated relationship between articular incongruency and long-term arthritic change.
Axelrod and McMurty	1990	Internal-plate fixation	Recommended rigid internal fixation for comminuted articular fractures. Anatomically restored congruency, with higher complication rates.
Geissler	1990s	Percutaneous articular reduction	Percutaneous and arthroscopically assisted articular reduction.
Seitz	1991	Augmented external fixation	Advocated additional Kirschner wires and bone grafts to supplement external fixation so as to reduce dependency on traction.
Leung	1991	Bone graft external fixation	Bone graft reduces duration of external fixation, enables removal at 3-4 weeks postop.
Kaempffe et al.	1993	Complications of external fixation	Duration and degree of distraction related to RSD.
Gesensway et al.	1995	Dorsal fixed-angle plate fixation	Designed and demonstrated a fixed-angle blade plate that provided superior fixation strength to current ORIF designs.
Rikli and Regazzoni	1996	Columnar fixation	Defined radial, intermediate, and ulnar columns of wrist and advocated use of small implants with biplanar fixation.
Fitoussi et al.	1997	Dorsal and palmar plate fixation	Described ORIF with dual approaches for comminuted articular fractures.
Wolfe et al.	1998	External fixation	Fixation strength of augmented external fixation demonstrated to be comparable to ORIF.
Leslie and Medoff	2000	Fragment-specific fixation	Outlined principles and techniques of internal fixation using small "pin plate" and "wireform" implants.
Orbay	2000s	Palmar fixed-angle plate fixation	Proposed fixation and demonstrated outcomes of dorsally displaced fractures using palmar fixed-angle plates.
Kreder et al.	2005	Randomized trial ORIF vs. external fixation	Provided joint congruency can be attained; improved results demonstrated with percutaneous fixation vs. dorsal ORIF.
Goldfarb et al.	2006	Long-term evaluation of arthritis in ORIF patients	A 15-year follow-up with CT scans demonstrated arthrosis in 0.81% of ORIF patients. No correlation with upper extremity function.
Rozental and Blazar	2006	Complication of volar-plate fixation	Excellent functional outcomes with fixed-angle volar plate fixation, but high incidence of tendon and hardware complications.
Arora et al.	2011	Treatment of elderly	Unable to identify differences in outcomes of elderly patients with closed vs. ORIF of unstable radius fractures.
AAOS	2014	Appropriate use guidelines	Expert panels opine on appropriate treatment of 240 clinical scenarios of distal radius fracture fixation.

CT, Computed tomography; *DRUJ*, distal radioulnar joint; *ORIF*, open reduction internal fixation; *RSD*, reflex sympathetic dystrophy; *TFCC*, triangular fibrocartilage complex.

http://e-surg.com

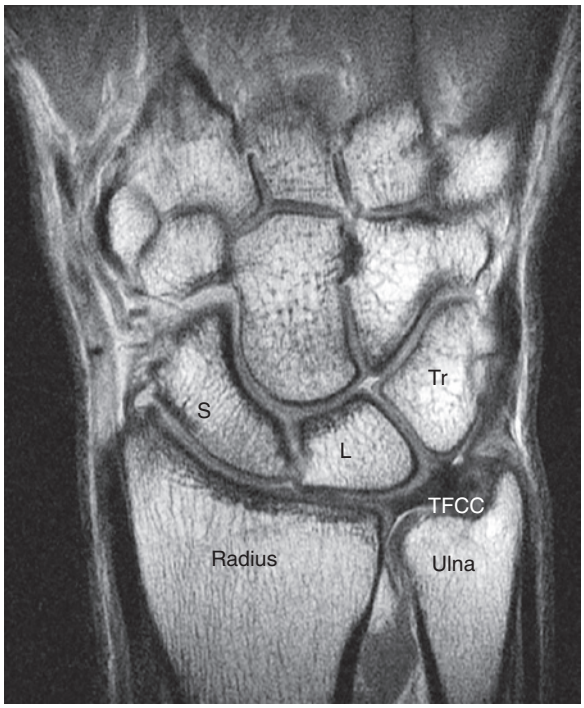

FIGURE 15.1 The scaphoid (S) and lunate (L) articulate with the distal articular surface of the radius, and the ulnar head articulates with the sigmoid notch. The triangular fibrocartilage complex (TFCC) is interposed between the ulnar carpus and the ulnar head. *Tq*, Triquetrum. (Magnetic resonance image, courtesy of Hollis Potter, MD, Department of Diagnostic Radiology, Hospital for Special Surgery.)



FIGURE 15.3 Dissection and illustration composite showing the dorsal ligaments of the wrist. *DIC*, Dorsal intercarpal ligament; *RS*, radioscaphoid; *RT*, radiotriquetral; *TFCC*, triangular fibrocartilage complex. (© Elizabeth Martin.)

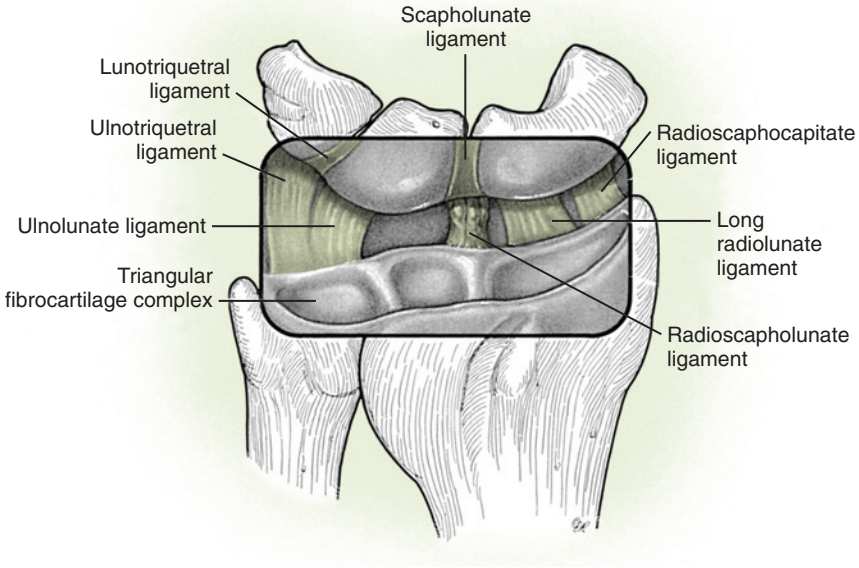

FIGURE 15.2 Arthroscopic anatomy of the radiocarpal joint. Pictured are the articular surfaces of the scaphoid, lunate, triquetrum, radius, and triangular fibrocartilage complex. The major extrinsic—radioscaphocapitate, long radiolunate, radioscapholunate, ulnolunate, and lunotriquetral—ligaments of the wrist are shown. The very important intrinsic ligaments of the wrist—the scapholunate ligament and lunotriquetral ligaments—are also shown. (© Elizabeth Martin.)

http://e-surg.com

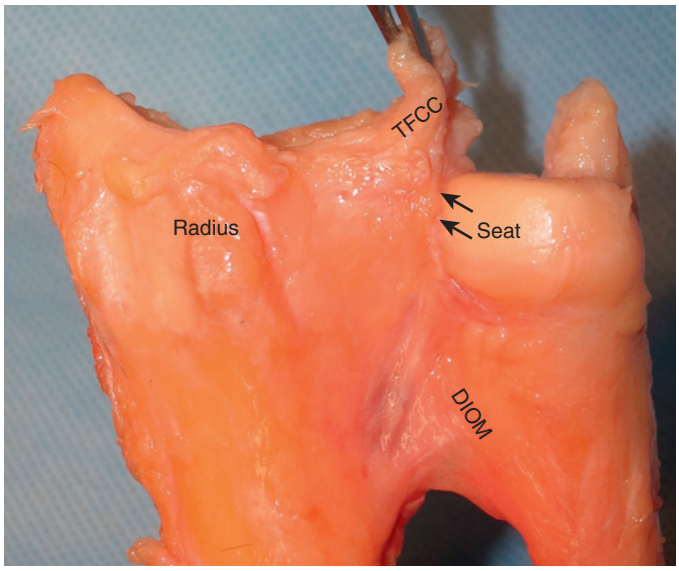

FIGURE 15.4 The ulnar head articulates with the sigmoid notch of the radius at the "seat" of the distal radioulnar joint (DRUJ). The triangular fibrocartilage complex (TFCC), detached to expose the ulnar head, is the primary restraint of the DRUJ, arising from the most ulnar border of the radius and inserts into the base and tip of the ulnar styloid process. The distal interosseous membrane (DIOM) is a secondary stabilizer, inserted on the radius at the base of the sigmoid notch.

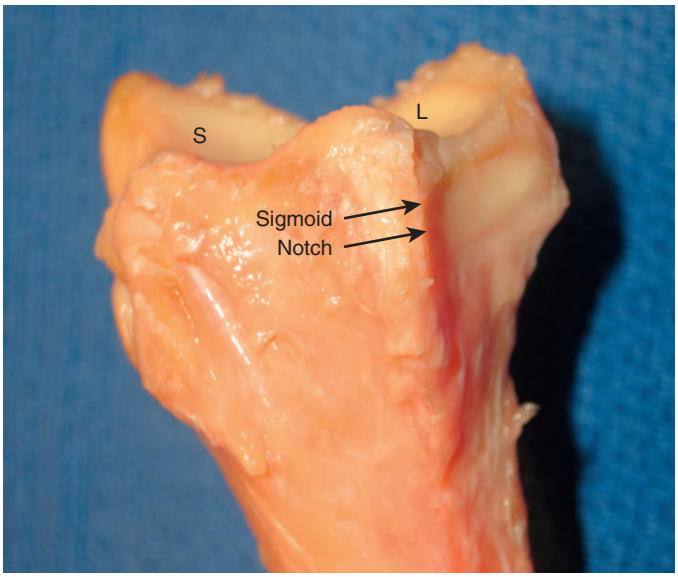

FIGURE 15.6 The sigmoid notch showing distinct dorsal, palmar, and distal borders and an indistinct proximal border. The scaphoid facet (S) and lunate facet (L) are also shown.

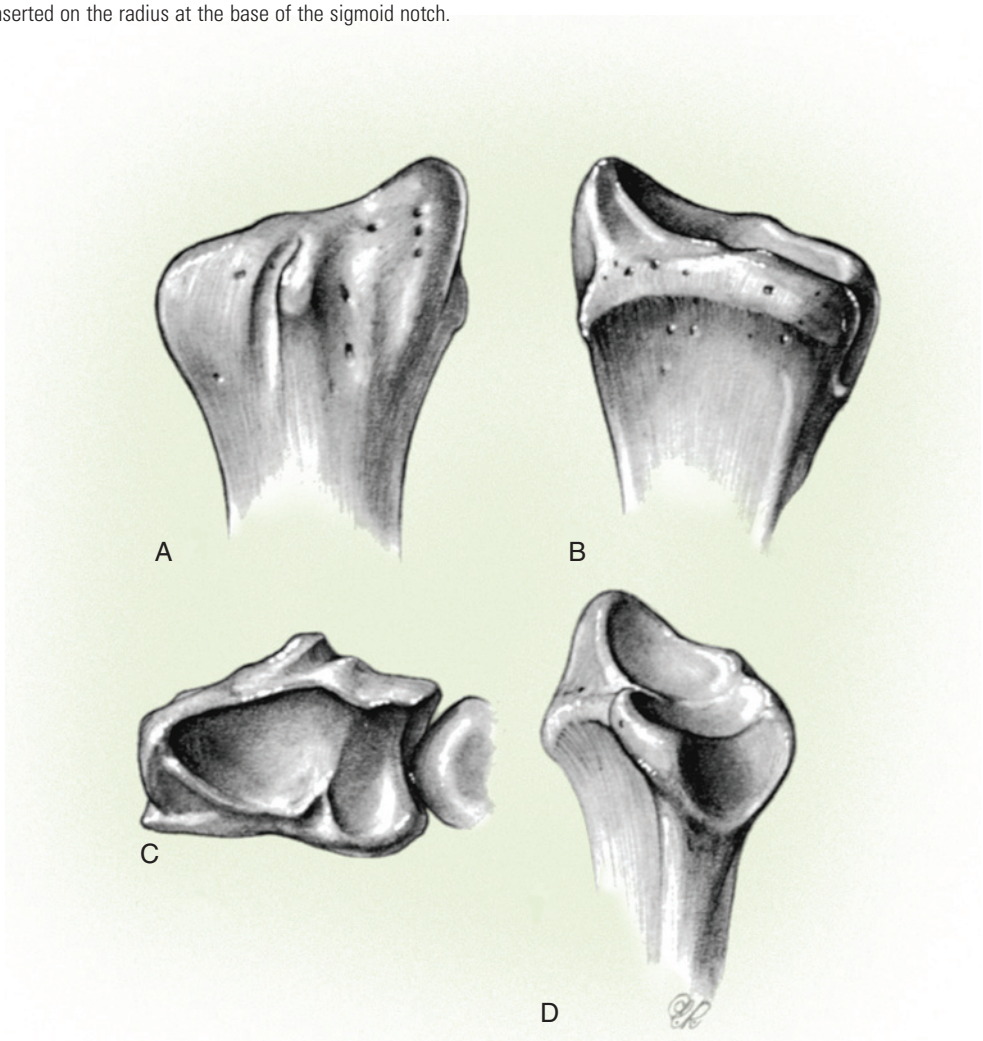

FIGURE 15.5 Artist's drawing of the distal radius. **A,** Dorsal view illustrating the Lister tubercle. **B,** Palmar view showing the scaphoid and lunate fossae distally, as well as the sigmoid notch ulnarly. Vascular foramina can be noted on the palmar and dorsal aspects of the distal radius. **C,** End-on view of the distal radius and radioulnar joint showing the scaphoid fossa, lunate fossa, and ulnar head resting in the sigmoid notch. **D,** View of the sigmoid notch from the ulnar aspect. (© Elizabeth Martin.)

http://e-surg.com

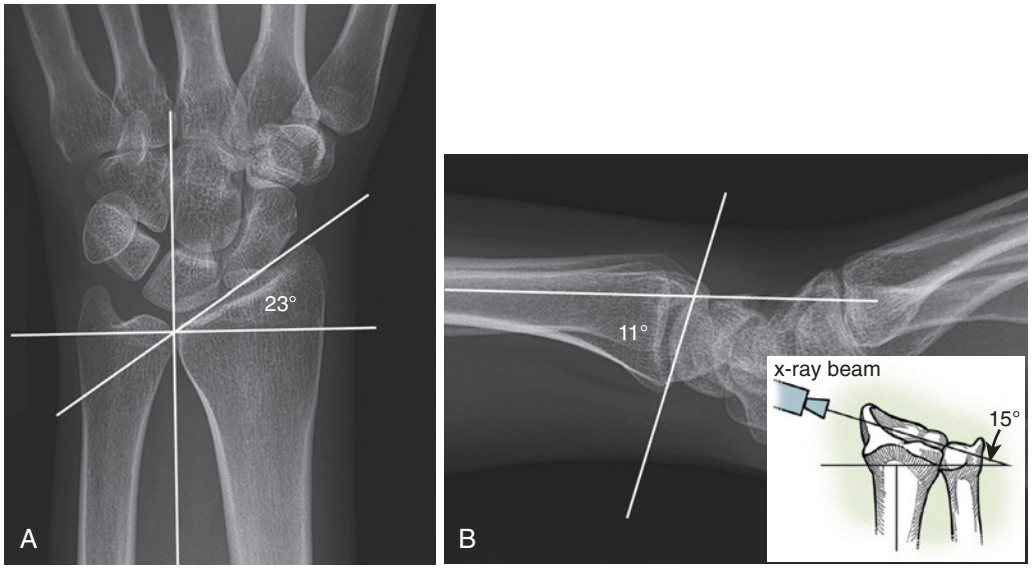

FIGURE 15.7 **A,** Posteroanterior radiograph of a wrist demonstrating radial inclination (23 degrees) and neutral ulnar variance. **B,** The "facet lateral" radiograph is performed by aligning the x-ray beam in a plane parallel to the lunate facet of the radius, approximately 15 degrees distal to proximal. (Drawing © Elizabeth Martin.)

The distal articular surface of the radius has a radial inclination, or slope, averaging 23 degrees and tilts palmarly an average of 11 degrees (Figure 15.7, *A*). Radial inclination is measured by the angle formed by a line drawn tangential to the distal radial articular surface on a posteroanterior (PA) radiograph and one perpendicular to the shaft of the radius. Palmar tilt is measured by the angle created by a line drawn between the dorsal and palmar lips of the lunate facet and the longitudinal axis of the radius. This angle is probably best appreciated on a *facet lateral* radiograph, performed with the beam inclined approximately 10 to 15 degrees distal-to-proximal, to profile the articular surface of the lunate facet and eliminate the bony overlap of the radial styloid (see Figure 15.7, *B*). Ulnar variance averages just under 1 mm negative[114] and ranges widely; variance is the axial difference between the subchondral bone of the lunate facet at the distal margin of the sigmoid notch and the most distal articular surface of the ulna, which is measured along the forearm's longitudinal axis (see Figure 15.7, *A*).

The dorsal aspect of the distal radius is convex and acts as a fulcrum for extensor tendon function (see Figure 15.5). The radial styloid area may have a groove for the tendon of the first dorsal compartment, and ulnar to this is a dorsal longitudinal prominence—the Lister tubercle, which acts as a fulcrum for the extensor pollicis longus (EPL) tendon.

RADIOGRAPHIC PATHOANATOMY

When evaluating fracture radiographs, it is important to understand several relationships and bony landmarks that may have subtle but important aberrations because of the malposition of fracture fragments. Perhaps the most important of these bony landmarks of the distal radius is the "teardrop,"[114] which represents the volar projection of the lunate facet of the distal radius and the mechanical buttress for subluxation of the lunate (see Figure 15.5, *D*). The teardrop projects 3-mm palmarward from the flat surface of the radial diaphysis, or 16% of the anterior-to-posterior height of the lunate facet.[3] A line drawn tangential to the subchondral bone of the articular surface through the tip of the teardrop normally subtends an angle of 70 degrees with the longitudinal axis of the radius (Figure 15.8, *A*)[114]; consequently, subtle dorsal rotation of an extraarticular fractured radius alters this relationship and decreases the teardrop's angle. Similarly, an impaction injury that splits the lunate facet may drive the lunate into the metaphysis of the radius and rotate the teardrop relationship (see Figure 15.8, *B, C*). The teardrop measures just 5 mm at its greatest width, thus making it difficult to gain stable fixation with traditional volar implants.[3]

Another useful measurement on the facet lateral film is the anteroposterior (AP) distance, and it is measured between the distal apex of the dorsal and volar rims of the lunate facet (Figure 15.9, *A, B*). The average AP distance is 20 mm in males and 18 mm in females; however, for improved accuracy, the AP distance on the injured side should be compared with that on the uninjured side. An appreciably widened (or narrowed) AP distance, in relation to the opposite side, represents an alteration in the contour of the lunate facet secondary to impaction or articular split of the lunate facet (see Figure 15.9, *B*). In a group of 81 patients followed for an average of 9 years, increases in AP distance were correlated with increased radiographic evidence of osteoarthritis.[43] See ExpertConsult.com for more information on this topic.

Another useful parameter with which to evaluate the adequacy of reduction is articular cavity depth, which is measured by the perpendicular distance from the line measuring the AP distance to the greatest depth of the articular cavity (Figure 15.10, *A, B*). The measurement is compared to the uninjured side. Increases in the articular cavity depth of greater than 2 mm have been correlated mechanically with increased radiocarpal contact pressures and decreased contact area, and clinically with decreased range of flexion–extension and increased radiographic grade of radiocarpal osteoarthritis.[44]

On the normal PA view, the dorsal rim of the radius projects 3 to 5 mm beyond the dense subchondral bone of the volar rim

http://e-surg.com

Because contralateral films are not always available and radiographs may be magnified, a useful comparative (and scalable) landmark on a lateral film of the injured side is the lunate itself. In a normal wrist, the curvature of the lunate facet of the radius and the curvature of the lunate are easily visualized on a facet lateral projection and are virtually concentric. In an uninjured wrist, the AP distance is essentially equal to the diameter of a circle that represents the best fit to the proximal articular surface of the lunate (1.04 ± 0.09) (eFigure 15.1, *A*). Fitting of a circle to the lunate articular contour is easily performed by using the digital toolbox on most modern picture-archiving and communication systems (PACSs). Nonconcentric articular contours or an altered AP–lunate diameter ratio suggests a sagittal split of the lunate facet, nonanatomic radiocarpal alignment, or both (see eFigure 15.1, *B*).

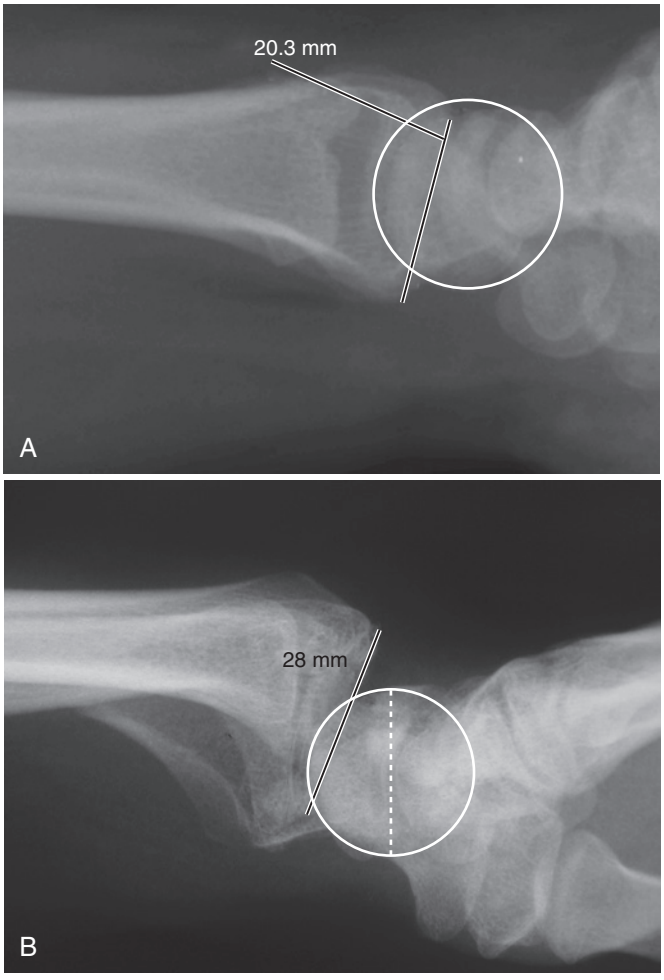

eFIGURE 15.1 Anteroposterior (AP) distance and AP–lunate diameter ratio. **A,** In an uninjured wrist, the AP distance (20.3 mm) is nearly equal to the diameter of a best-fit circle of the lunate contour (19.8 mm). **B,** In an injured wrist, the AP diameter is grossly widened (28 mm), and the AP–lunate diameter ratio is 1.3.

http://e-surg.com

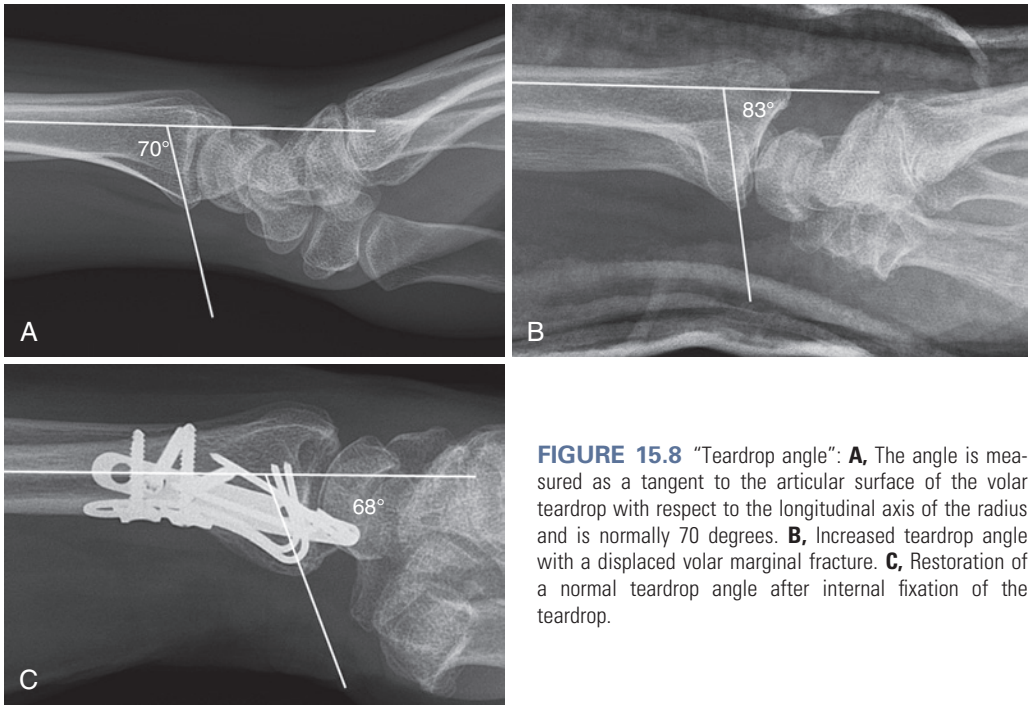

FIGURE 15.8 "Teardrop angle": **A,** The angle is measured as a tangent to the articular surface of the volar teardrop with respect to the longitudinal axis of the radius and is normally 70 degrees. **B,** Increased teardrop angle with a displaced volar marginal fracture. **C,** Restoration of a normal teardrop angle after internal fixation of the teardrop.

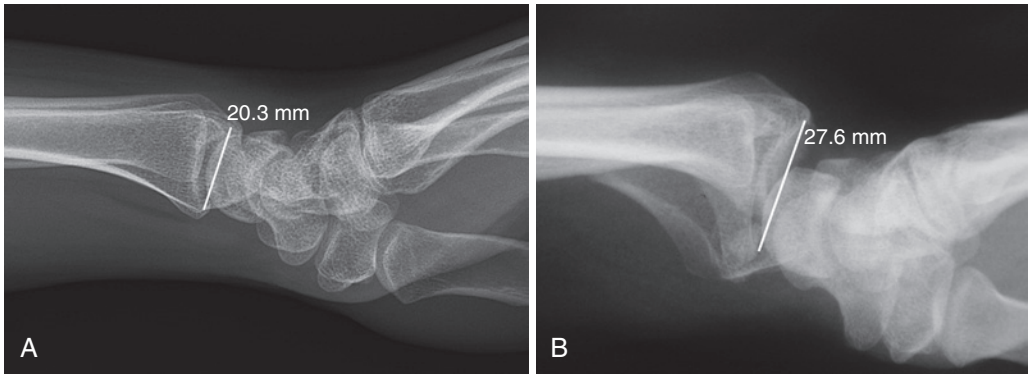

FIGURE 15.9 Anteroposterior (AP) distance: **A,** In an uninjured wrist, the AP distance is approximately 20 mm in males and 18 mm in females. **B,** In this lateral radiograph of an injured wrist, the AP diameter is grossly widened (~28 mm).

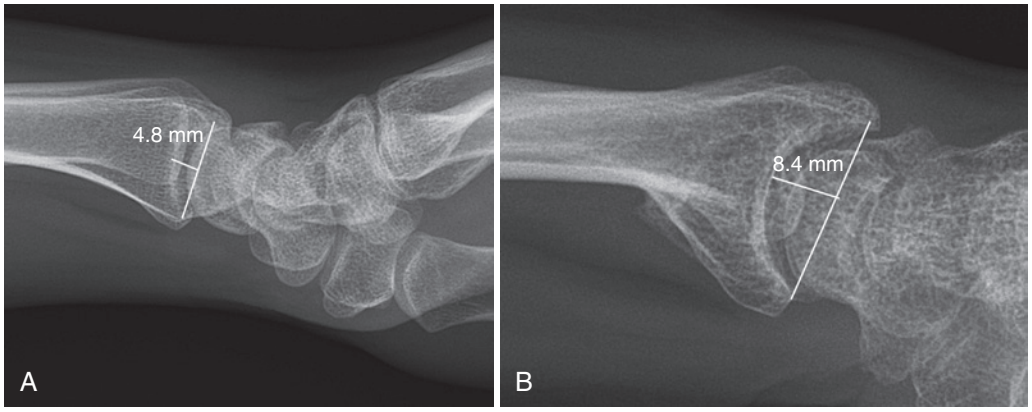

FIGURE 15.10 Articular cavity depth: **A,** Uninjured wrist's articular cavity depth as measured from anteroposterior distance is 4.8 mm. **B,** Healed comminuted impaction fracture with increased articular cavity depth of 8.4 mm. Increases in articular depth correlated with increased radiocarpal contact pressures, decreased range of motion and increased radiographic grade of arthritis.[44]

http://e-surg.com

of the radius (Figure 15.11). Displaced fractures may increase, reduce, or invert this relationship, depending on the degree of sagittal plane rotation of the distal fragment. Breaks in the dense subchondral bone on the PA view can be recognized as step-offs or articular gaps, and impacted articular fragments can be identified as linear densities within the metaphyseal bone on either the PA or the lateral view.

Radial translation[134] or *coronal shift* of the distal radius describes abnormal radial translation of the distal fragment of the distal radius fracture in the coronal (PA) plane and has been shown to cause radioulnar instability through its slackening effect on the distal oblique bundle (DOB) of the interosseous membrane[38] (Figure 15.12, *A, B*). Coronal alignment should be carefully assessed as a useful parameter of reduction, alongside the traditional parameters of volar tilt, radial inclination, and ulnar variance. Loss of the ulnar metaphyseal flare just proximal to the sigmoid notch, or an overhang of the radial styloid on the radial metaphyseal flare, should raise suspicion of a coronal shift.

Measurement of radial translation of the distal fragment is easily performed by extending a line along the ulnar diaphysis of the radius distally across the carpus on a PA radiograph.[134] A transverse line is drawn across the lunate at its widest point on the PA film. The percentage of the lunate radial to the intersection point of the lines averages 45%. Patients in whom less than half of the lunate remains ulnar to this intersection point following distal radius reduction or internal fixation should be scrutinized for residual coronal shift of the articular fragment (see Figure 15.12, *A*).

Careful analysis of fracture radiographs, a thorough understanding of common fracture patterns, and an appreciation of



FIGURE 15.11 The dorsal rim of the radius normally projects 3 to 5 mm distal to the dense subchondral bone of the articular surface, and this relationship may be altered by posttraumatic changes in volar tilt or die-punch injuries.

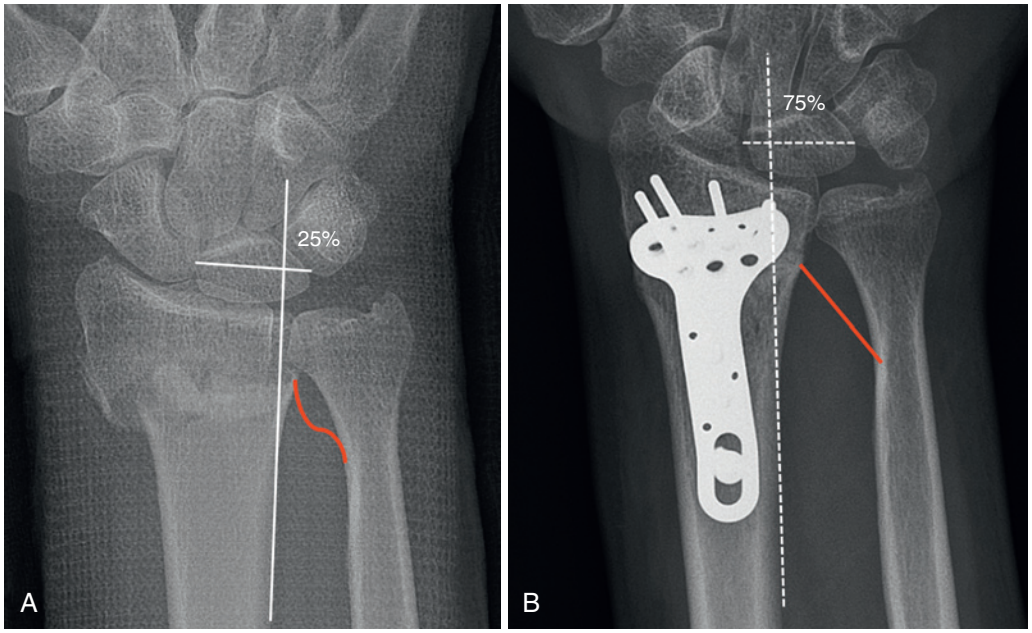

FIGURE 15.12 Coronal shift: **A,** Postreduction posteroanterior radiograph shows residual radial translation of the articular fragment and slackening the fibers of the distal interosseous membrane (DIOM). Less than 50% of the lunate (L) lies ulnar to a line drawn tangent to the ulnar diaphysis of the radius.[134] **B,** Following open reduction and internal fixation, the articular fragment is reduced, restoring the proper relationship of the L to the longitudinal line. Reduction restores tension to the DIOM, providing stability to the distal radioulnar joint by seating the ulnar head within the sigmoid notch.

http://e-surg.com

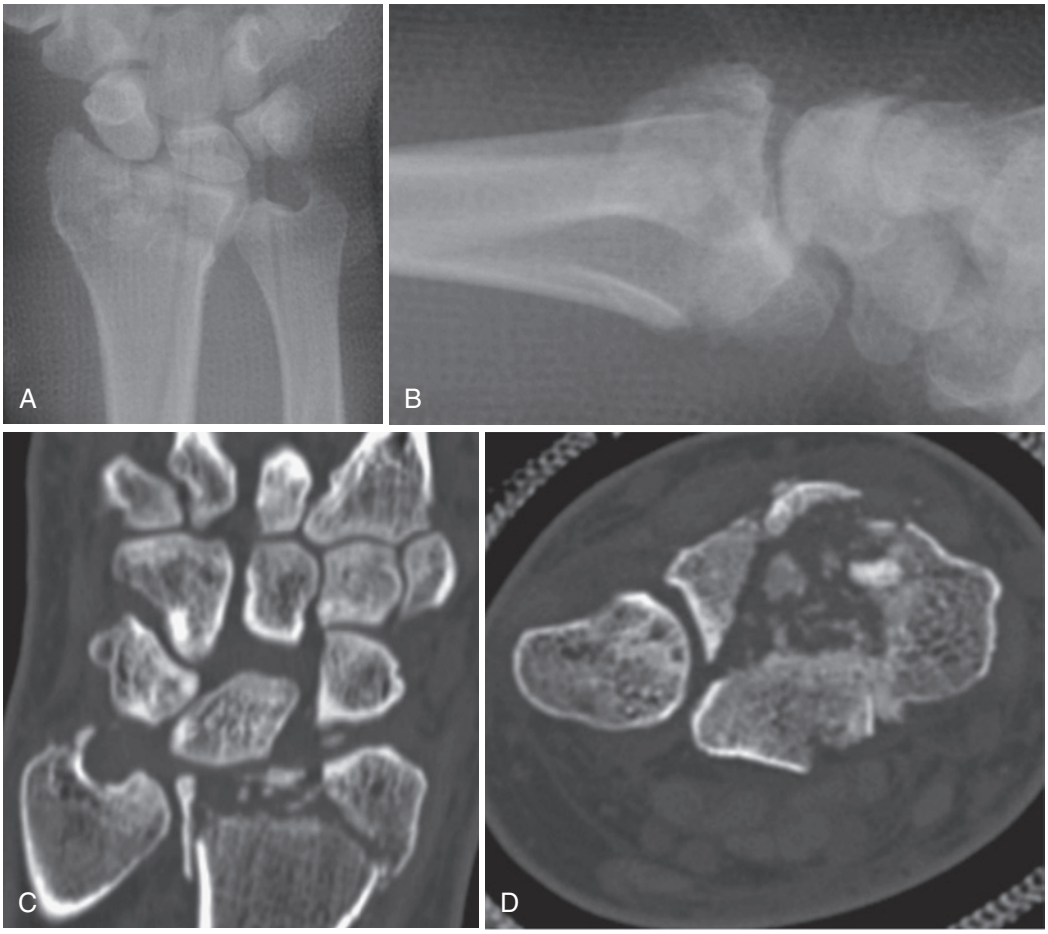

FIGURE 15.13 Use of computed tomography: **A, B,** Posteroanterior and lateral radiographs of a comminuted articular fracture after reduction that demonstrates what appears to be satisfactory reduction of the articular surface. **C, D,** Coronal and axial scans of the articular surface demonstrating multiple fragmentation, articular impaction, and incongruency. Note the separate volar lunate teardrop fragment that may not have been evident on the lateral radiograph.

the mechanism of the injury allows the examining physician to classify the fracture and begin to formulate a treatment plan. Generally, standard radiographic views (i.e., PA, facet lateral, oblique) are sufficient to understand a fracture's pathoanatomy. However, special imaging techniques (e.g., traction views after reduction, tomograms, CT scans) provide a more accurate diagnosis of the displacement pattern, the number of fragments, and the degree of joint involvement at both the radiocarpal and radioulnar levels (Figure 15.13, *A-D*). Three-dimensional reconstructions of CT scans of articular fractures more accurately define the number and presence of articular fragments and help guide the surgeon in the appropriate incision(s) and approach.[74] For unique injuries, modern software allows for the subtraction of the carpus with direct visualization of the articular surface of the radius in three dimensions.

RECOGNITION OF FRACTURE PATTERNS

There are few areas of skeletal trauma in which eponymic descriptions are so commonly used; contemporary authors have purposely avoided assigning their names to a particular fracture type and instead prefer to base newer classification systems on a variety of measurements, observations, and injury characteristics. As the common eponymous fractures are so deeply engrained in the orthopedic literature, a brief illustrated review with images follows (Figures 15.14 through 15.16).

Fracture Classifications

Distal radius fractures tend to cluster in recognizable patterns, and it is important that the treating physician be familiar with the multiple fracture variants to recognize a fracture's "personality," as determined by the energy of injury, articular involvement, relative stability, associated soft tissue injuries, and radioulnar joint involvement. The ideal fracture classification should provide reproducible anatomic, diagnostic, and prognostic considerations; assess the associated soft tissue lesions; and infer appropriate treatment. Physicians dealing with distal radius fractures should adopt a classification scheme that fulfills their needs for clinical and scientific purposes. When reporting outcomes or designing a multicenter study, however, it is important to choose a system with a satisfactory degree of intraobserver and interobserver reproducibility.

Intraobserver and interobserver reliability and reproducibility of many of the distal radius fracture classifications has been analyzed repeatedly.[4,98] Agreement was considered adequate for the three main groups of the AO classification, but was suboptimal when analyzing subgroups. Interobserver agreement was rated moderate for the Mayo and fair for the Frykman, Melone,

http://e-surg.com

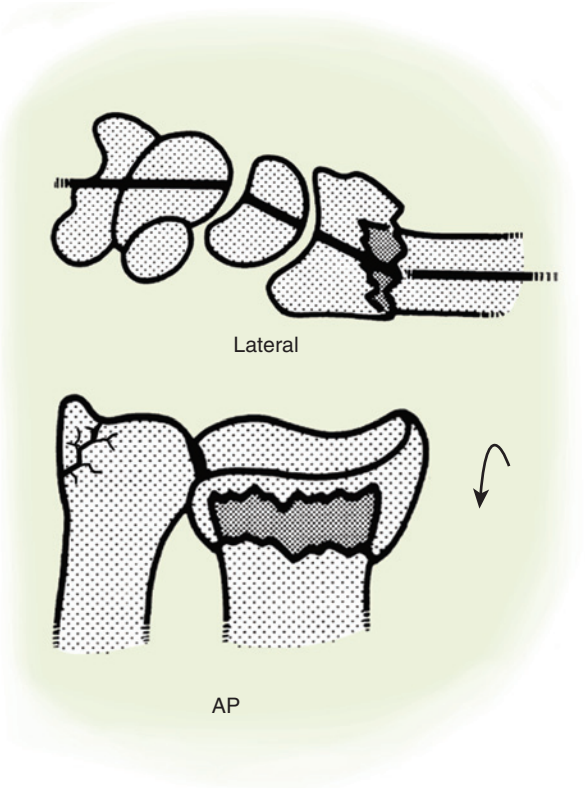

FIGURE 15.14 The typical features of a Colles' fracture, or a distal radius fracture with dorsal comminution, dorsal angulation, dorsal displacement, radial shortening, and an associated fracture of the ulnar styloid. (© Elizabeth Martin.)

and AO classifications. Most studies have concluded that these classifications lack the capacity for predicting outcome or comparing results among different studies. The AO system, while imperfect, is the most widely used when stratifying patients in a study protocol or registry. Three treatment-oriented classification systems are described as well.

Please see ExpertConsult.com for information on Frykman classification and Melone classification.

AO Classification

In 1986, the Swiss Association for the Study of Internal Fixation (ASIF) accepted a new classification of fractures that was further revised in 1990. In this system, applicable to all long bones, fractures are divided into three major types: type A (extraarticular), type B (partial articular), and type C (complete articular). This classification considers the severity of the fracture according to the extent of articular involvement and metaphyseal comminution. It is important to understand the distinction between type B fractures, in which some portion of the articular surface remains in continuity with the metaphysis, and type C fractures, in which no portion of the articular surface is in continuity with the metaphysis (Figure 15.17).

The three basic types are further subdivided into groups and subgroups to ultimately produce 27 different fracture patterns at the distal end of the forearm. Unfortunately, despite its ability to pigeonhole virtually every fracture variation, there is little interobserver agreement when the subdivisions are made; acceptable agreement is reached only when the three major subgroups have been chosen.[4]

Please see ExpertConsult.com for information on the Mayo Clinic classification.

"Fragment-Specific" Classification

Robert Medoff developed a simplified articular fracture classification by recognizing five major fragments—namely, the radial styloid, the dorsal wall, the impacted articular, the dorsal–ulnar corner (i.e., "die-punch"[115,141]), and the volar rim (Figure 15.18).[102] Articular fractures can be described by identifying their components, either alone or in combination. To more fully understand a fracture and to use this knowledge to plan treatment, the surgeon should also identify (1) the primary direction of the fracture angulation (dorsal–volar) and (2) the mechanism of the injury (see the Fernandez Classification later). The fragment-specific classification is treatment-oriented because fracture fixation is geared toward stabilization of each major fragment.

Columnar Classification

Daniel Rikli and Pietro Regazzoni introduced an important conceptual framework for the understanding and treatment of articular fractures by recognizing the three columns of the wrist (Figure 15.19).[133] The radial column, or *lateral* column, is composed of the radial styloid and scaphoid facet of the radius; restoration of this column reestablishes both length and alignment of the articular surface in the frontal and sagittal planes. The intermediate column includes the lunate facet and is the primary load-bearing column of the radius. Fractures of the intermediate column include the dorsal "die-punch" fragment, impacted articular fragments, and the volar–ulnar corner fragment. It is important to note that fractures of this column also disrupt the sigmoid notch of the radius and, consequently, the radioulnar joint.

The *medial* column constitutes the rotational column of the wrist and includes the distal ulna, the triangular fibrocartilage, and the radioulnar ligaments. To restore normal rotation of the forearm, it is critical that one assess and treat instability of this column when treating fractures of the radius. This, too, is a treatment-oriented classification system; Rikli and Regazzoni recommended orthogonally placed microplates to treat dual-column fractures of the radius and demonstrated the biomechanical and clinical efficacy of the concept.[132,133]

The Fernandez Classification

The author prefers the descriptive fracture classification developed by Diego Fernandez,[47] which is based on the *mechanism of injury* (Figure 15.20, *A*). In addition to the obvious bony injury to the radius, the associated ligamentous lesions, fractures of the neighboring carpal bones, and concomitant soft tissue damage are directly related to the direction and degree of trauma sustained. An understanding of the mechanism of the injury facilitates manual reduction through the application of a force opposite that produced by the injury and guides definitive treatment based on the direction and magnitude of impact, as well as the nature of associated soft tissue injuries (see Figure 15.20, *A*). Fractures of the distal radius can be divided into the following five types, recognizable on standard PA, facet lateral, and oblique radiographs:

Type I fractures are extraarticular *bending fractures of the metaphysis* in which one cortex fails with tensile stress and

http://e-surg.com

Frykman Classification

In 1967, Frykman proposed a classification that distinguished between extraarticular and articular fractures of the radiocarpal and radioulnar joints and the presence or absence of an associated distal ulnar fracture (eFigure 15.2).[49] This system is useful and is easy to learn and to communicate to colleagues; however, it does not readily translate into prognostic or treatment utility.

Melone Classification

In 1984, Melone introduced a classification of distal radial fractures in which he identified four major components: (1) the shaft, (2) the radial styloid area, (3) the dorsal medial facet, and (4) the volar medial facet (eFigure 15.3).[115] This classification focused much-needed attention on the important medial (lunate) facet of the distal radius (i.e., the "medial complex," the intermediate column, and the teardrop).

Mayo Clinic Classification

The classification system advocated by the Mayo Clinic group allows subclassification within types 1 to 4 based on whether the fracture is extraarticular or articular and whether the fracture is reducible or not reducible (eFigure 15.4).

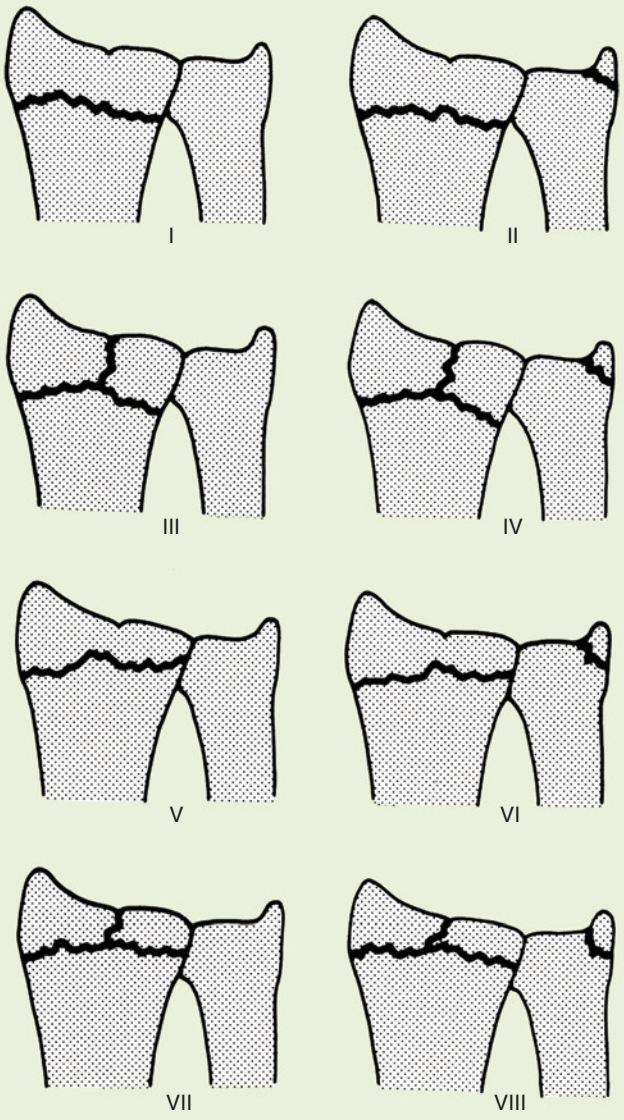

eFIGURE 15.2 The Frykman classification of distal radius fractures. Types I, III, V, and VII do not have an associated fracture of the distal ulna. Fractures III-VIII are articular fractures. Higher-classification fractures have worse prognoses. (© Elizabeth Martin.)

http://e-surg.com

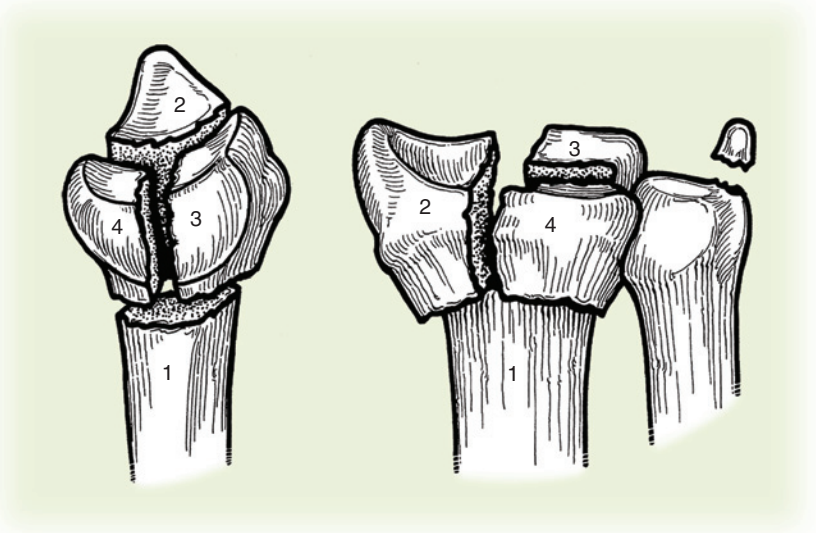

eFIGURE 15.3 The Melone classification of distal radial fractures. The four major fragments are (1) the radial shaft, (2) the radial styloid region, (3) the dorsal medial facet, and (4) the volar medial facet. The major fragment of this four-part fracture is the medial facet (i.e., fragments 3 and 4). (© Elizabeth Martin.)

Mayo Clinic classification

Extraarticular
- Nondisplaced
- Displaced
  - Stable
  - Unstable

Intraarticular
- Nondisplaced
- Displaced (reducible)
- Displaced (unreducible)
- Complex

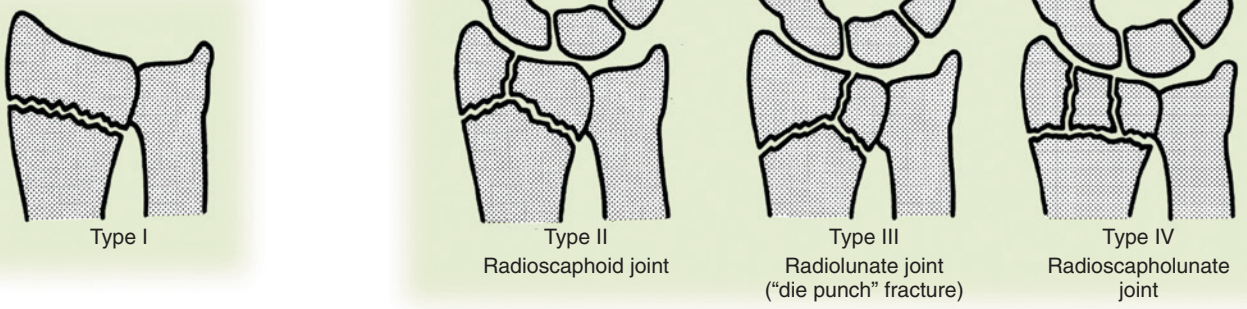

eFIGURE 15.4 The Mayo Clinic classification of distal radial fractures. Type 1 is an extraarticular one, and types 2 to 4 are intraarticular fractures. Emphasis is given to whether the fracture is displaced or nondisplaced and reducible or not reducible. (© Elizabeth Martin.)

http://e-surg.com

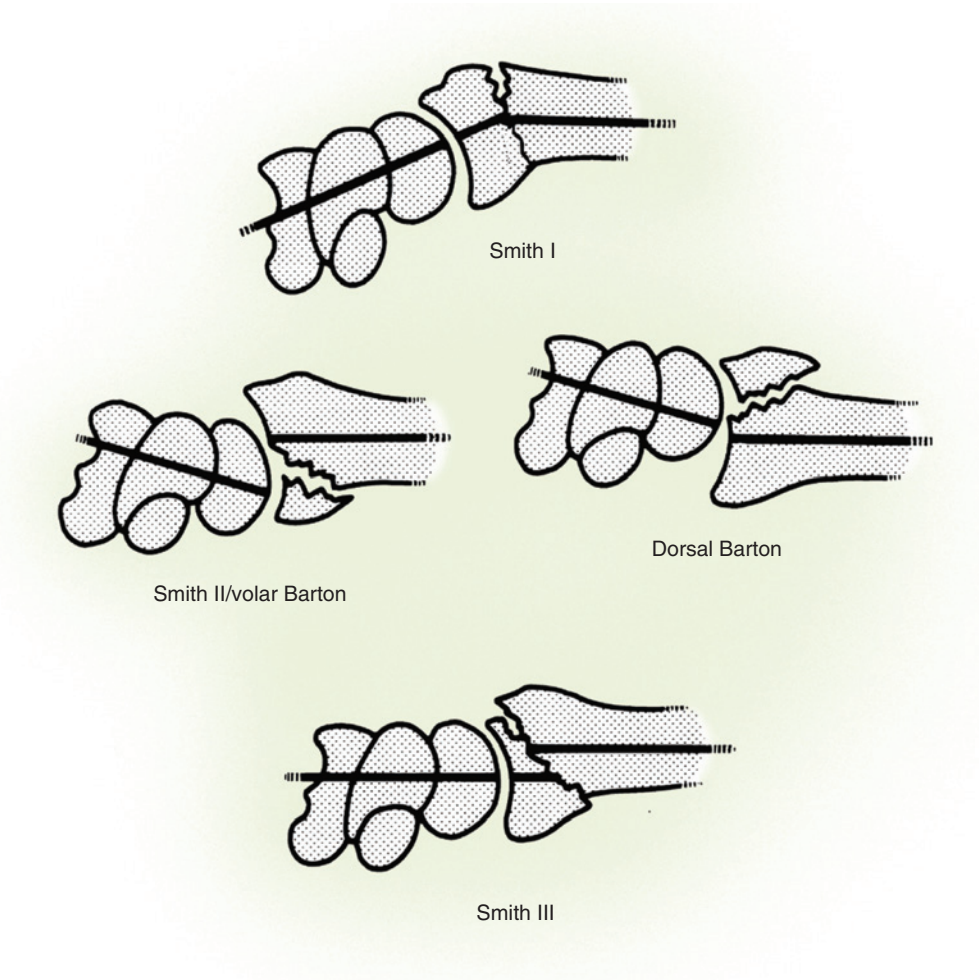

FIGURE 15.15 Thomas' classification (1957) of Smith fractures. A type I Smith fracture is an extraarticular one with palmar angulation and displacement of the distal fragment. A type II Smith fracture is an intraarticular one with volar and proximal displacement of the distal fragment along with the carpus. A Smith type II fracture is essentially a volar Barton fracture. A dorsal Barton fracture, illustrated for comparison, shows the dorsal and proximal displacement of the carpus and distal fragment on the radial shaft. A type III Smith fracture is an extraarticular one with volar displacement of the distal fragment and carpus. (In type III the fracture line is more oblique than in a type I fracture.) (© Elizabeth Martin.)

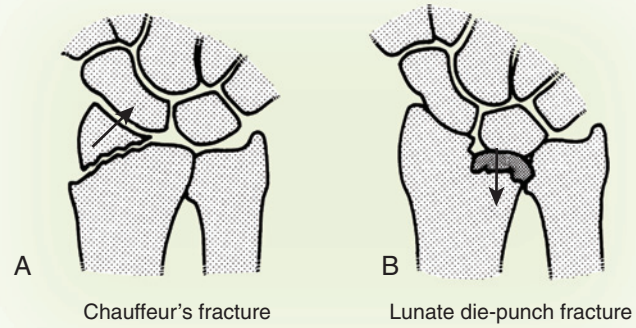

FIGURE 15.16 **A,** A "chauffeur's" fracture is illustrated with the carpus translated ulnarly by the radial styloid fracture. The fracture earned its now antiquated name because of the propensity for the chauffeur to be struck by the backfire recoil of a starter crank on an early 1900s automobile engine. Despite its seemingly innocuous name, this fracture is notorious for concomitant injuries to the intercarpal and extrinsic radiocarpal ligaments. **B,** A lunate die-punch fracture is shown with a depression of the lunate fossa of the radius that allows proximal migration of the lunate or proximal carpal row (or both). (© Elizabeth Martin.)

http://ebook.com

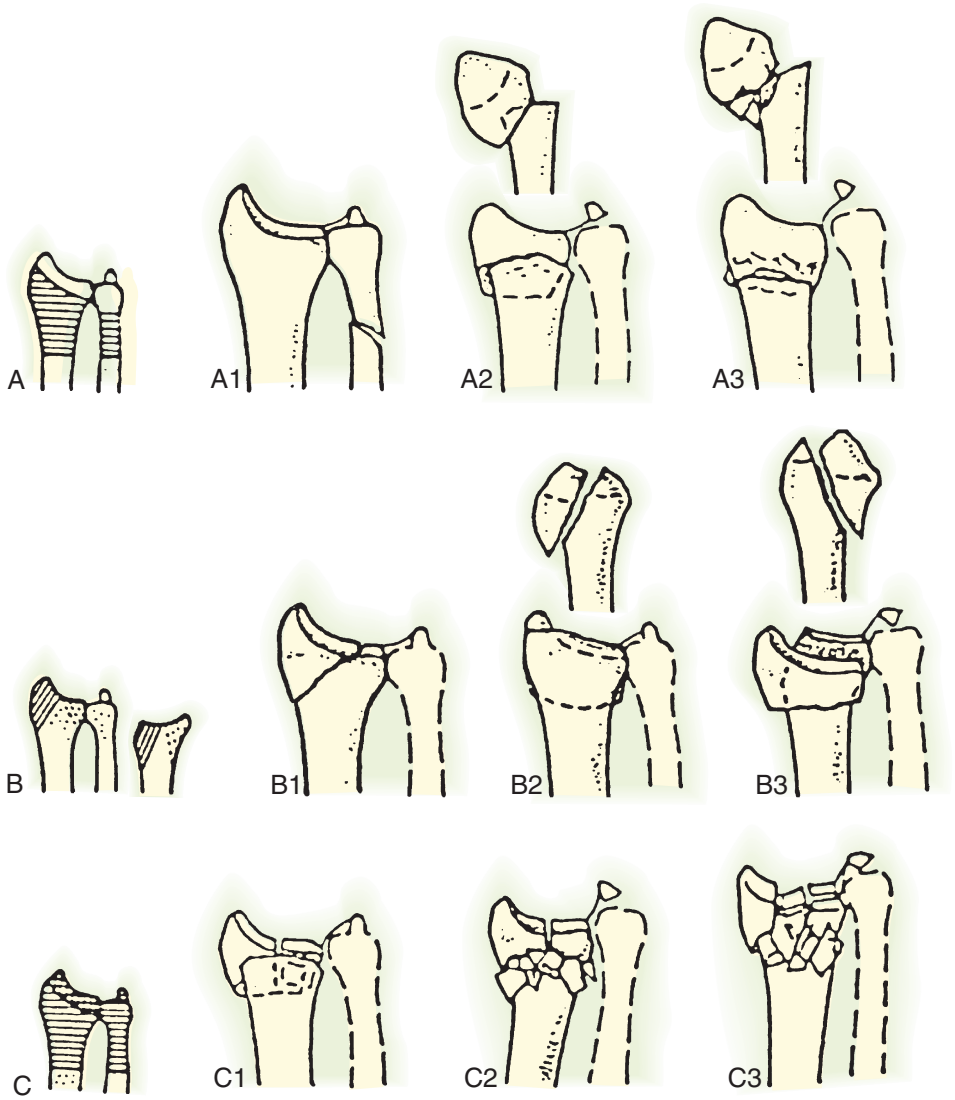

FIGURE 15.17 The comprehensive classification of fractures (AO): **A,** An extraarticular fracture affects neither the articular surface of the radiocarpal nor the radioulnar joints. **A1,** Extraarticular fracture of the ulna with the radius intact. **A2,** Extraarticular fracture of the radius, simple and impacted. **A3,** Extraarticular fracture of the radius, multifragmentary. **B,** A partial articular fracture affects a portion of the articular surface, but continuity of the metaphysis and epiphysis is intact. **B1,** Partial articular fracture of the radius, sagittal. **B2,** Partial articular fracture of the radius, dorsal rim (Barton). **B3,** Partial articular fracture of the radius, volar rim (reverse Barton; Goyrand-Smith II). **C,** A complete articular fracture affects the joint surfaces (i.e., radioulnar, radiocarpal, or both) and the metaphyseal area. **C1,** Complete articular fracture of the radius, articular simple and metaphyseal simple. **C2,** Complete articular fracture of the radius, articular simple and metaphyseal multifragmentary. **C3,** Complete articular fracture of the radius, multifragmentary.

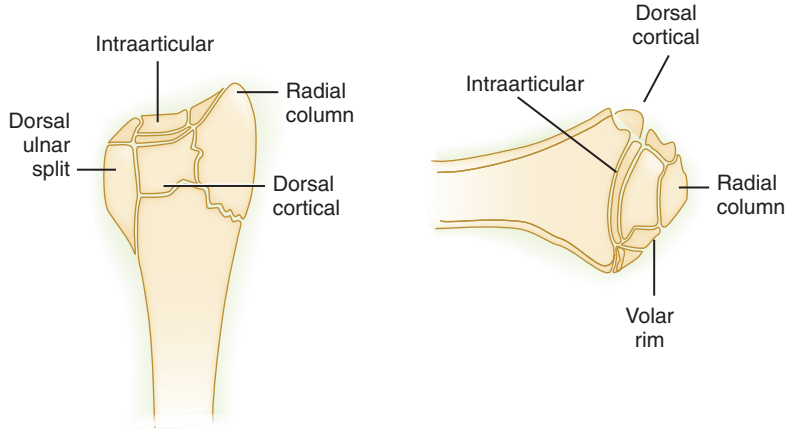

FIGURE 15.18 Fragment-specific classification.

http://e-surg.com

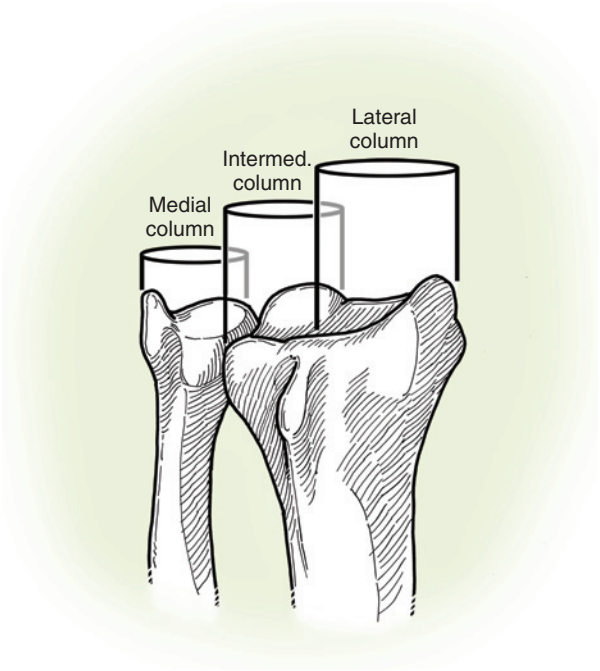

FIGURE 15.19 The columnar concept of the wrist. (© Elizabeth Martin.)

the opposite one undergoes a variable degree of comminution (Colles or Smith type I fractures; AO types A1–3).

Type II fractures are *shearing fractures of the joint surface* (the Barton, the reversed Barton, and chauffeur's fractures; AO types B1–3).

Type III fractures are *compression fractures of the joint surface* with impaction of subchondral and metaphyseal cancellous bone. These are generally high-energy injuries and usually involve disruption of both the radial and intermediate columns (Mayo type III, medial complex, die punch; AO types C1–2).

Type IV, or *avulsion fractures of ligament attachments*, includes dorsal rim and radial styloid fractures associated with radiocarpal fracture–dislocations.

Type V fractures are *high-velocity injuries* that involve combinations of bending, compression, shearing, and avulsion mechanisms or bone loss. Typically, there is diaphyseal as well as severe metaphyseal and articular disruption (AO type C3).

The treating physician should not lose sight of the purposes of fracture stratification when confronted by the multitude of eponyms and classifications that have been developed. The purpose of a classification should be to (1) catalog fracture types for subsequent reporting and comparison of outcomes and (2) understand fracture anatomy and guide treatment. The latter is perhaps best accomplished by describing the complexity, mechanism, and relative energy of the injury using the Fernandez system.

For extraarticular fractures, the primary determinant of treatment becomes the relative stability of the fracture. For articular fractures, in addition to an understanding of relative stability, the physician must obtain the necessary radiographs or advanced imaging studies (or both) to determine the location, number, and displacement of the articular fragments, as well as the integrity of the radial, intermediate, and ulnar columns. Careful consideration of these factors should enable one to develop an appropriate treatment plan and, when indicated, the optimal surgical approach and fixation strategy.

Associated Injuries to the Distal Radioulnar Joint

Outcomes of treatment of distal radius fractures can adversely and seriously be affected by residual incongruity or instability of the distal radioulnar joint (DRUJ). Figure 15.20, *B,* illustrates a useful classification of concomitant ulnar injuries and guidelines for treatment. After satisfactory realignment of the radioulnar relationship is attained by restoring radial length and sagittal and coronal tilt, stability of the radioulnar joint depends on two factors:

- Restoration of the mechanical integrity of the sigmoid notch
- Continuity of the dorsal and volar radioulnar ligament components of the TFCC, which attach at the ulnar fovea (see Chapter 14)

Type I consists of stable DRUJ lesions, which means that adequate reduction of the radius will render the joint clinically stable without disruption of the articular surface. Such lesions include: (1) avulsion of the tip of the ulnar styloid and (2) stable fracture of the neck of the ulna. In both, the primary stabilizers of the joint (i.e., TFCC foveal attachment) are intact.

Type II consists of unstable DRUJ lesions. Despite satisfactory reduction of the radius, the ulna is unstable as a result of (1) a massive tear of the TFCC and (2) an avulsion fracture of the ulnar styloid through or below the fovea. These injuries may require supination casting, repair of the TFCC, fixation of the avulsed ulnar styloid, or temporary cross-pinning of the radius and ulna to restore stability.

Type III includes comminuted articular injuries of either the sigmoid notch or the ulnar head, and these injuries require reduction and stabilization to restore articular congruency and prevent degenerative changes.

Fracture Stability

Certain fractures are unstable by definition or require surgical management in healthy, active adults, including:

- Open fractures
- Displaced shear fractures (type II)
- Comminuted and displaced articular fractures with articular impaction (type III)
- Fracture–dislocations (type IV)
- Combined injuries with metaphyseal–diaphyseal comminution (type V)
- Fractures complicated by nerve compression, compartment syndrome, or multiple injuries

The majority of fractures, including extraarticular and simple articular ones, are not easily sorted into operative and nonoperative treatment regimens, and determination of fracture stability becomes a critical crossroad for fracture treatment.

Treatment of inherently unstable fractures with casting will fail and result in loss of radial length, carpal alignment, or articular incongruity. Unnecessary casting in this scenario may prolong overall treatment time and cost, may lead to digital stiffness and trophic changes, and may require subacute surgical intervention or corrective osteotomy to restore alignment and function, depending on the particular patient's needs. What is not immediately intuitive is how to identify stable and unstable fractures early to optimize patient outcome and minimize unnecessary surgery or ineffective cast immobilization.

http://e-surg.com

Fracture type	Number of fragments	Associated injuries (nerve, tendon, ligament, skeletal trauma)	Recommended treatment
Type I Bending fracture of the metaphysis 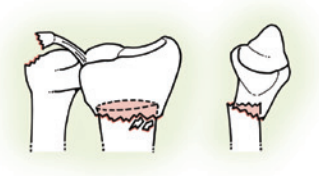	Two-part ± metaphyseal comminution	Rare	Stable: Nonoperative Unstable: Percutaneous pinning External fixation Volar locked plate Intramedullary fixation
Type II Shear fracture of the articular surface 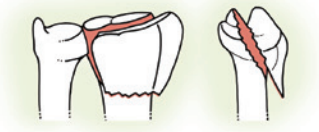	Two-part Three-part Comminuted	Infrequent chauffeur: Suspect scapholunate interosseus ligament injury	Dorsal plate Radial columnar fixation Volar buttress or locked plate Combination
Type III Compression fracture of the articular surface 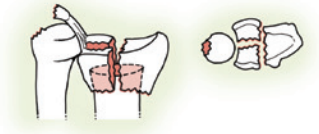	Two-part Three-part Four-part Comminuted	Common	Open or arthroscopic reduction of articular surface, and dorsal, volar, or fragment-specific fixation ± bone graft Augmented external fixation ± bone graft Spanning plate fixation
Type IV Avulsion fracture, radiocarpal fracture-dislocation 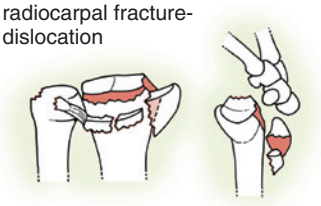	Two-part: Radial styloid Three-part: Styloid plus volar or dorsal margin Comminuted	Frequent	Closed or open reduction and K-wire or tension band fixation Columnar fixation Fragment-specific fixation Spanning plate fixation Assess carpal translation, treat accordingly
Type V Combined fracture (I-II-III-IV) High energy injury 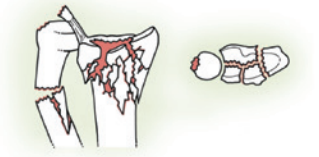	Comminuted ± bone loss. Open injuries not uncommon.	Always	Angular stable fixation Fragment-specific fixation Spanning plate fixation Augmented external fixation Combination

A

FIGURE 15.20 **A, B,** The Fernandez classification of distal radius fractures and associated distal radioulnar joint (DRUJ) lesions.

http://e-surg.com

	Pathoanatomy of the lesion	Joint surface involvement	Prognosis	Recommended treatment
Type I Stable (following reduction of the radius the distal radioulnar joint is congruous and stable)	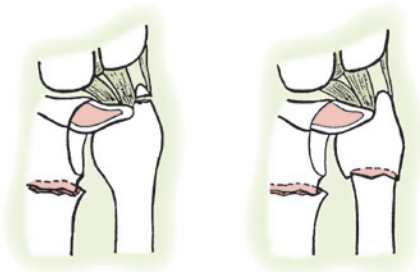 A Fracture of the tip of the ulnar styloid B Stable fracture of the ulnar neck	None	Good	Stable: Functional aftercare, early forearm rotation exercises Unstable: Assess and correct coronal shift. If still unstable, open reduction internal fixation ulnar neck or shaft.
Type II Unstable (subluxation or dislocation of the ulnar head present)	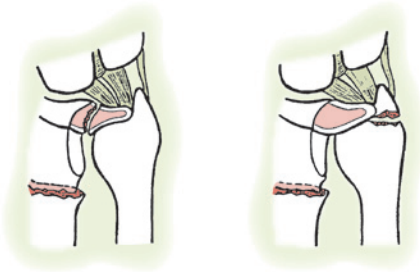 A Tear of the triangular fibrocartilage complex and/or palmar and dorsal capsular ligaments B Avulsion fracture of the base of the ulnar styloid	None	• Possible chronic instability • Painful limitation of supination if left unreduced • Possible late arthritic changes	Anatomic reduction of radius and sigmoid notch, and *reduced coronal shift*. If still unstable: LAC for four weeks in position of stability, or dual 0.062-in K-wire fixation of radius and ulna, or ulnar styloid fixation, or open or arthroscopic triangular fibrocartilage complex foveal repair
Type III Potentially unstable (subluxation possible)	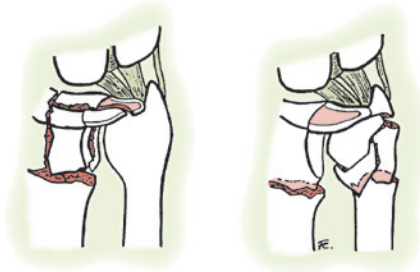 A Intraarticular fracture of the sigmoid notch B Intraarticular fracture of the ulnar head	Present	• Dorsal subluxation possible together with dorsally displaced die punch or dorsoulnar fragment • Risk of early degenerative changes and severe limitation of forearm rotation if left unreduced	Anatomic reduction of radius and sigmoid notch, and *reduced coronal shift*. Open reduction internal fixation of ulnar head, immediate Darrach (sedentary), or early forearm rotation to enhance remodeling, and late ulnar head resection, arthroplasty, or Sauve-Kapandji if painful Open or arthroscopic triangular fibrocartilage complex repair if still unstable after anatomic fixation.

B

FIGURE 15.20, cont'd B, DRUJ injury classification. (© Elizabeth Martin.)

In a cohort of 32 patients treated nonoperatively for unstable Colles' fractures, Bickerstaff and Bell demonstrated that the two best predictors of poor functional, subjective, and objective outcomes were residual dorsal tilt of the radial articular surface and the associated nondissociative dorsal lunate instability.[15] In a group of patients who required operative treatment of unstable fractures that failed closed reduction, McQueen and colleagues also demonstrated that failure to restore carpal alignment in the sagittal plane, as demonstrated on lateral radiographs at one year, was the single most predictive factor in deterioration of functional outcomes and objective measures of strength.[112] Failure to restore radial length was significantly associated with a reduction in grip and pinch strength. These authors delineated a useful parameter of carpal malalignment on neutral-positioned lateral radiographs by defining intersecting lines of the capitate axis and the longitudinal axis of the radius.

Carpal malalignment is defined when the two lines intersect outside the boundaries of the carpus (Figure 15.21). On a perfect lateral radiograph, however, these two lines may be parallel, thus this method may not be accurate. The author considers the carpus malaligned if the center of the capitate proximal pole does not lie within a "radial box" defined by the dorsal or volar cortical confines of the radius (Figure 15.22).

http://e-surg.com

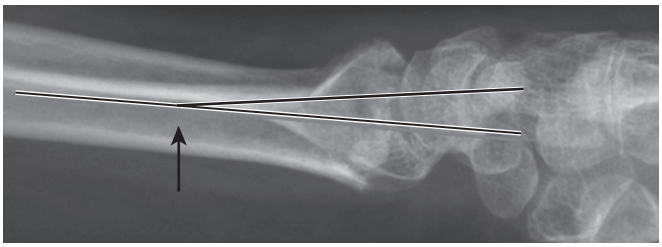

FIGURE 15.21 According to McQueen and colleagues,[112] carpal malalignment is defined when the longitudinal axis of the capitate and the radius intersect outside the boundaries of the carpus (*arrow*).

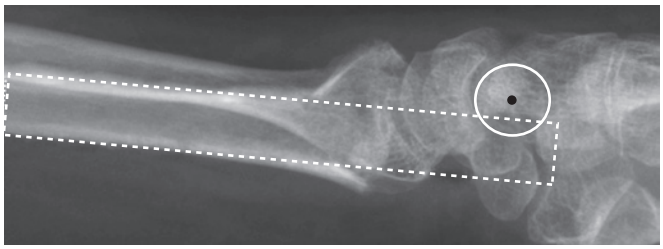

FIGURE 15.22 Alternative and rapid assessment of carpal malalignment using the "radial box" (*dashed lines*). The center of the capitate (*circle with black dot*) proximal pole should fall within a box generated along the dorsal and palmar cortical outlines of the radius on a true lateral radiograph.

Numerous authors have attempted to determine parameters that are predictive of radial instability in the acute setting. Lafontaine and colleagues defined five "instability parameters" and demonstrated a linear relationship between the number of instability parameters present on displaced fracture films and ultimate fracture collapse with closed treatment,[100] as follows:

- Dorsal angulation greater than 20 degrees
- Dorsal comminution
- Articular radiocarpal fracture
- Ulnar fracture
- Age of more than 60 years

Lafontaine et al recommended that patients with three or more of the five parameters be considered for surgical intervention at an early stage of management. Although inclusion of all the factors is the subject of some controversy, subsequent authors have confirmed that age, loss of radial length, and initial dorsal angulation are the most important predictors of collapse with cast treatment.

MacKenney and colleagues produced a quantitative, weighted formulaic approach for determination of fracture instability in a prospective study of 3559 patients with displaced and nondisplaced extraarticular fractures. They demonstrated a 60% malunion rate had all displaced fractures been treated by closed reduction.[107] Advanced age was the most predictive factor of instability, and the nature of the fracture on the initial films was also predictive of malalignment at healing. Specifically, in addition to a "relentless" association of instability and malalignment with *age, dorsal comminution*, and *increased ulnar variance* (≥3 mm) were important predictors of subsequent loss of reduction in plaster. Initial dorsal angulation was not predictive because it was confounded by the presence of dorsal comminution in the multivariate analysis. It is interesting to note from a historical perspective that 60 years ago Gartland and Werley also demonstrated that 60% of reduced and casted fractures returned to their original position in plaster.[50]

Taken together, though not infallible, evidence shows that patient age and the position and comminution of the fracture on initial trauma films can be vital predictive tools for assessment and formulation of treatment plans. Patients with a constellation of instability factors should be advised of the relative probability of loss of reduction, and physiologically young or active patients should be counseled concerning the option of early operative intervention. Patients with initial radial shortening and dorsal comminution, who elect to forego surgical stabilization, particularly if older than 60, should be observed weekly for radiographic evidence of fracture settling. Understanding that malunion[20,61] and carpal malalignment are important predictors of diminished strength and function in otherwise healthy adults should enable the physician to tailor the treatment expeditiously.

TREATMENT OPTIONS AND TECHNIQUES

Closed Reduction

The greatest challenge of closed treatment of a dorsally angulated fracture is to reduce the fracture and maintain the position without excessive flexion of the wrist joint. Inherently unstable fractures with initially acceptable closed-reduction alignment often become displaced again and shorten secondary to the resting muscular tension, occasional involuntary contraction, and the load transmitted from normal digital motion. Although *extreme* palmar flexion and ulnar deviation (the so-called Cotton-Loder position[30]) may be mechanically effective in restoring volar tilt, this position should not be maintained because a fully flexed wrist may cause compression of the median nerve and is a mechanical disadvantage to the digital flexor tendons.

Closed Reduction Technique

In preparation for closed reduction, the first step is gentle surgical preparation of the dorsal surface of the wrist. The hematoma associated with the fracture is then sterilely infiltrated with 1% lidocaine without epinephrine, and the anesthetic is allowed to diffuse around the fracture site for approximately 5 minutes. If the fracture is seen belatedly, and there is significant soft tissue swelling, a regional nerve block (axillary) or general anesthesia may be necessary. The arm is gently suspended with finger traps attached to the thumb and the index and long fingers (Figure 15.23) and 5 to 10 lb of countertraction across the upper part of the arm.

Once the patient is comfortable, the arm is allowed to hang from the finger traps for 5 to 10 minutes, pressure is applied by the treating physician's thumb to the distal fracture fragment in a direction that will reduce the displacement (see Figure 15.23, *D*). For a dorsally displaced fracture, the distal fragment is rotated with the physician's thumb into a slightly flexed position with a palmarly directed force. Care should be taken to avoid overpronation of the fracture fragment on the radial shaft. When the distal fragment is translated dorsally as well as angulated, it is helpful to simultaneously distract and hyperextend the fracture to decrease the impact of the fragments before subsequently reducing the deformity with a traction–flexion maneuver. A stable reduction generally holds its position with

http://e-surg.com

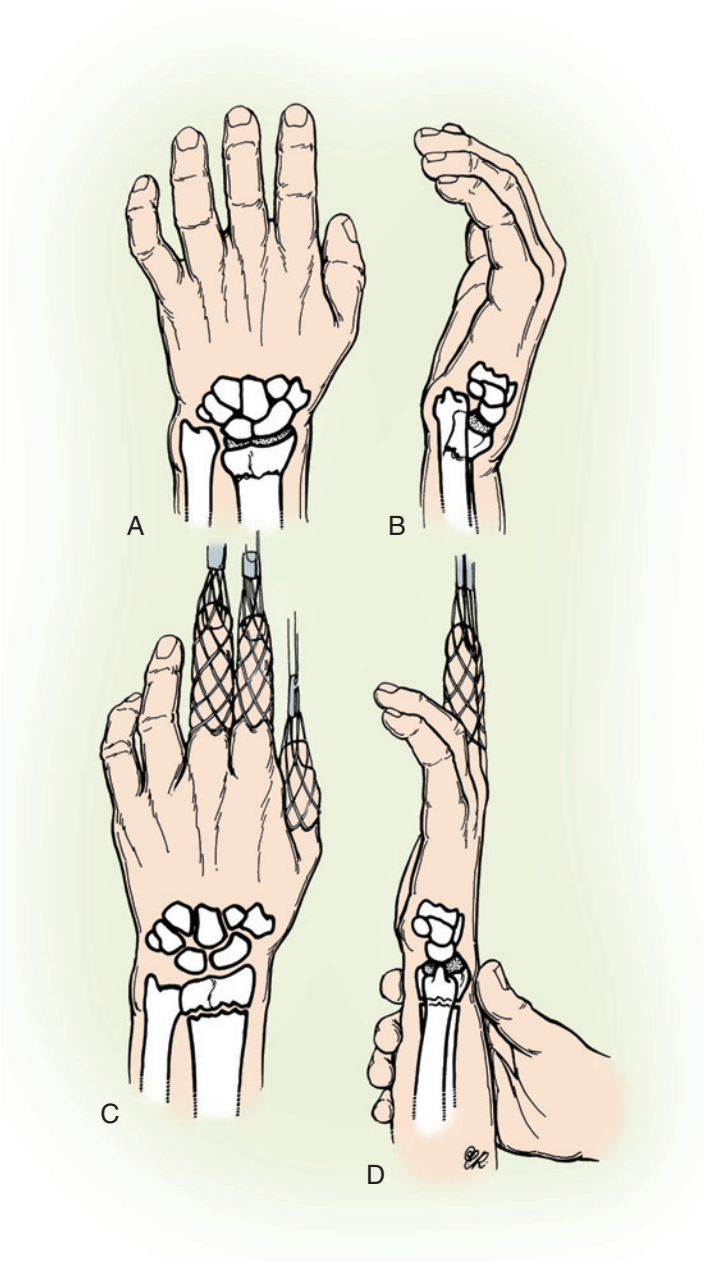

FIGURE 15.23 **A, B,** Distal radius (Colles') fracture. **C, D,** The author recommends reduction of this fracture. After suspending the arm from finger traps and allowing disimpaction of the fracture, apply pressure with the thumb over the distal fragment. (© Elizabeth Martin.)

the wrist only slightly flexed and ulnarly deviated. A sugar tong splint is applied to maintain the position (some prefer to apply it while still suspended in finger traps), and the fracture reduction can be fine-tuned as necessary with the splint in place (Figure 15.24).

Molding over the index metacarpal, with a countermold over the palmar apex of the fracture site, is helpful to maintain fracture position. The recommended position of immobilization for a dorsally angulated metaphyseal fracture is neutral to slight flexion, 20 to 30 degrees of ulnar deviation with neutral forearm rotation (Figure 15.25). Radiographs are obtained to confirm reduction. Although palmarly displaced, extraarticular Smith fractures are generally unstable, the flexion–pronation deformity of them can be reduced and occasionally stabilized effectively in extension and supination (45-60 degrees) with a sugar tong splint.

Depending on the fracture type and stability, patients should be examined weekly with cast checks and serial radiographs. Patients with stable fractures can be changed to a well-molded short-arm cast at 2 or 3 weeks. The principles of three-point bending should be used to help maintain reduction; dorsal molds are applied over the metacarpals and the mid-diaphysis of the radius, and a third palmar countermold is placed over the apex of the fracture. "Six-pack" digital exercises are begun immediately to reduce edema and prevent contractures and disuse atrophy (Figure 15.26). If displacement in the cast occurs, skeletal fixation should definitely be considered for young or physiologically active patients.

Percutaneous Pin Fixation

Percutaneous pinning, supplemented by an external fiberglass cast, is a relatively simple and effective fixation method that is applicable for reducible extraarticular fractures and simple articular fractures without metaphyseal comminution but with good bone quality.

A variety of techniques have been described; the most commonly used methods are shown in Figure 15.27. These include pins placed through the radial styloid alone, crossed radial styloid and dorsal–ulnar corner pins, intrafocal pinning *within* the fracture site, transulnar oblique pinning without transfixation of the DRUJ, one radial styloid pin and a second across the DRUJ, and multiple transulnar-to-radius pins, including the DRUJ.[131]

The procedure is done in the operating room, usually under regional block anesthesia with fluoroscopic guidance. The hand is prepared and suspended in finger traps with 5 to 10 lb of countertraction applied across the upper part of the arm. A closed reduction is performed and the adequacy of reduction confirmed fluoroscopically. Pinning of the fracture may be done while traction is maintained, or the hand may be removed for ease of manipulation, with 0.0625-in Kirschner wires (K-wires) being preferred. The pins can be inserted with a minidriver by using only one hand so that the surgeon's other hand is free to manipulate and stabilize the fracture.

Care must be taken to avoid injury to the dorsal sensory nerves, particularly when transfixing the radial styloid. The styloid pin is inserted first to simultaneously restore length and inclination of the distal fragment. At the tip of the styloid, the surgeon brackets the tendons of the first dorsal compartment with his fingers and identifies the starting point of the styloid pin immediately dorsal to the tendons. A 0.062-in K-wire is placed by hand through the skin to engage the tip of the styloid and the position is checked with fluoroscopy. The pin is directed obliquely to engage the stout diaphyseal bone of the opposing cortex at the metaphyseal flare. Position of the fracture is assessed, and a few additional degrees of volar tilt can be "dialed in" by rotating the fragment around the styloid wire. The second 0.062-in K-wire is placed at the dorsal–ulnar corner of the radius, just radial to the sigmoid notch and between the fourth and fifth extensor compartment tendons.

The easiest way is to place a free K-wire percutaneously and check its position before engaging the wire driver. The ideal

http://e-surg.com

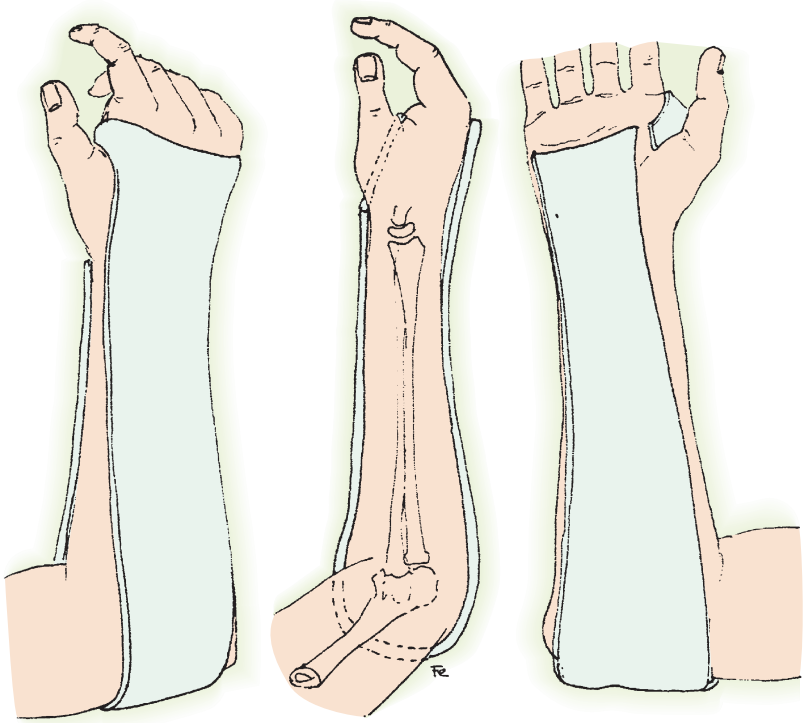

FIGURE 15.24 Sugar tong splint for a distal radius fracture. It controls forearm rotation while allowing some elbow flexion. The palmar crease should be free to allow full metacarpophalangeal flexion and the dorsal plaster should extend to the metacarpal heads.

starting position is just ulnar to the fourth dorsal compartment tendon in the "soft spot" of the 4-5 arthroscopy portal. The wire is gently navigated through subcutaneous tissues to engage the bone and its position is confirmed with fluoroscopy. The K-wire is then drilled at a 45- to 60-degree angle to the frontal and sagittal planes to engage the opposing stout volar bone well *proximal* to the fracture line. After confirmation of reduction, a second styloid wire increases the stability of the construct. For simple articular fractures, a fourth wire can be placed as necessary between the third and fourth dorsal compartments to stabilize the scaphoid facet fragment, but this is rarely necessary.

Before completion of the procedure, the extensor tendons are checked by passive flexion of the digits and wrist flexion tenodesis to be certain that they have not been tethered. Any skin tethering needs to be relieved with a No. 11 scalpel blade. The pins are bent and cut off 1 cm above the skin, and pin caps or petroleum gauze is applied. Alternatively, they can be cut beneath the skin. A well-padded sugar tong splint in supination is applied for 3 weeks, followed by a short-arm cast for an additional 3 weeks. Full forearm rotation is allowed after 2 weeks. The cast and pins are removed 5 to 6 weeks after reduction (Figure 15.28).

Kapandji popularized the technique of "double intrafocal wire fixation" to both reduce and maintain distal radial fractures (Figure 15.29).[85] This technique is best reserved for simple extraarticular fractures and is not without complications. Under fluoroscopic guidance, one K-wire is inserted into the fracture site in a radial-to-ulnar direction until the ulnar cortex of the radius is felt. The wire driver and wire are then moved distally to "lever" the distal radial fragment to regain normal radial inclination. The wire is then advanced through the ulnar cortex. Next, a second wire is inserted into the fracture 90 degrees to the first wire in a dorsal-to-palmar direction. The wire is advanced until the palmar cortex of the radius is reached. After that the wire and wire driver are moved distally to lever the fragment into its normal position of 12 to 15 degrees of palmar inclination. This second wire is then advanced through the palmar cortex of the radius.

External Fixation

Since the original idea of Roger Anderson of applying skeletal traction with a "portable" external-fixation device for the treatment of comminuted distal radial fractures,[5] there has been a constant evolution in both technique and design technology. One of the two most important developments has been the recognition that excessive distraction was harmful and associated with multiple complications and poor outcomes.[82] The second development was that distraction alone (i.e., ligamentotaxis) could not reduce displaced and impacted articular fragments.

Modern techniques include limited open or arthroscopic reduction of the articular surface, subchondral support with bone graft or a bone graft substitute, and "augmentation" with supplemental pin fixation. Augmentation of fixation allows the fixator to be placed in a neutralization mode with only minimal distraction, thereby enabling immediate use of the fingers for light activity. Early controlled motion of the wrist is sometimes possible between 4 and 6 weeks after the injury by removing the

http://e-surg.com



FIGURE 15.25 **A,** Typical radiographic appearance of a Colles' fracture in a young adult. **B,** The fracture was manually reduced and held in slight flexion, ulnar deviation, and slight pronation in a sugar tong splint for 3 weeks, followed by a short-arm cast for another 3 weeks. **C,** Follow-up radiographs at 1 year revealed loss of 2 mm of length but maintenance of normal volar and ulnar tilt. Notice the asymptomatic nonunion of the tip of the ulnar styloid.

fixator and leaving the pins in place for several additional weeks (Figure 15.30).

External-Fixation Technique

Under brachial block or general anesthesia, the anesthetized upper extremity is prepared and draped from the fingertips to the lower part of the arm, just below a pneumatic tourniquet. Sterile finger traps and a traction device can be used if preferred. Manual reduction is performed to grossly align the fracture fragments and approximate normal length, alignment, and tilt (see Figure 15.23).

A 2- to 3-cm-long incision is made over the dorsal radial aspect of the index metacarpal base. Blunt dissection with scissors exposes the metacarpal while carefully preserving and reflecting branches of the dorsal radial sensory nerve. A soft tissue protector is then placed on the metacarpal, and 3-mm self-tapping half-pins are inserted at a 30- to 45-degree angle dorsal to the frontal plane of the hand and forearm. Pin position and length are confirmed with portable fluoroscopy. Next, a 4-cm skin incision is made 8 to 10 cm proximal to the wrist joint and just dorsal to the midline.

Blunt dissection exposes superficial branches of the lateral antebrachial cutaneous nerve, the brachioradialis (BR), the two radial wrist extensors, and the radial sensory nerve, which exits in the mid-forearm from the investing fascia between the BR and the extensor carpi radialis longus (ECRL) (Figure 15.31). Two 3-mm half-pins (1.5 cm apart) are then introduced through a soft tissue protector between the radial wrist extensors at a 30-degree angle dorsal to the frontal plane of the forearm. The pins should just perforate the medial cortex of the radius and

http://e-surg.com

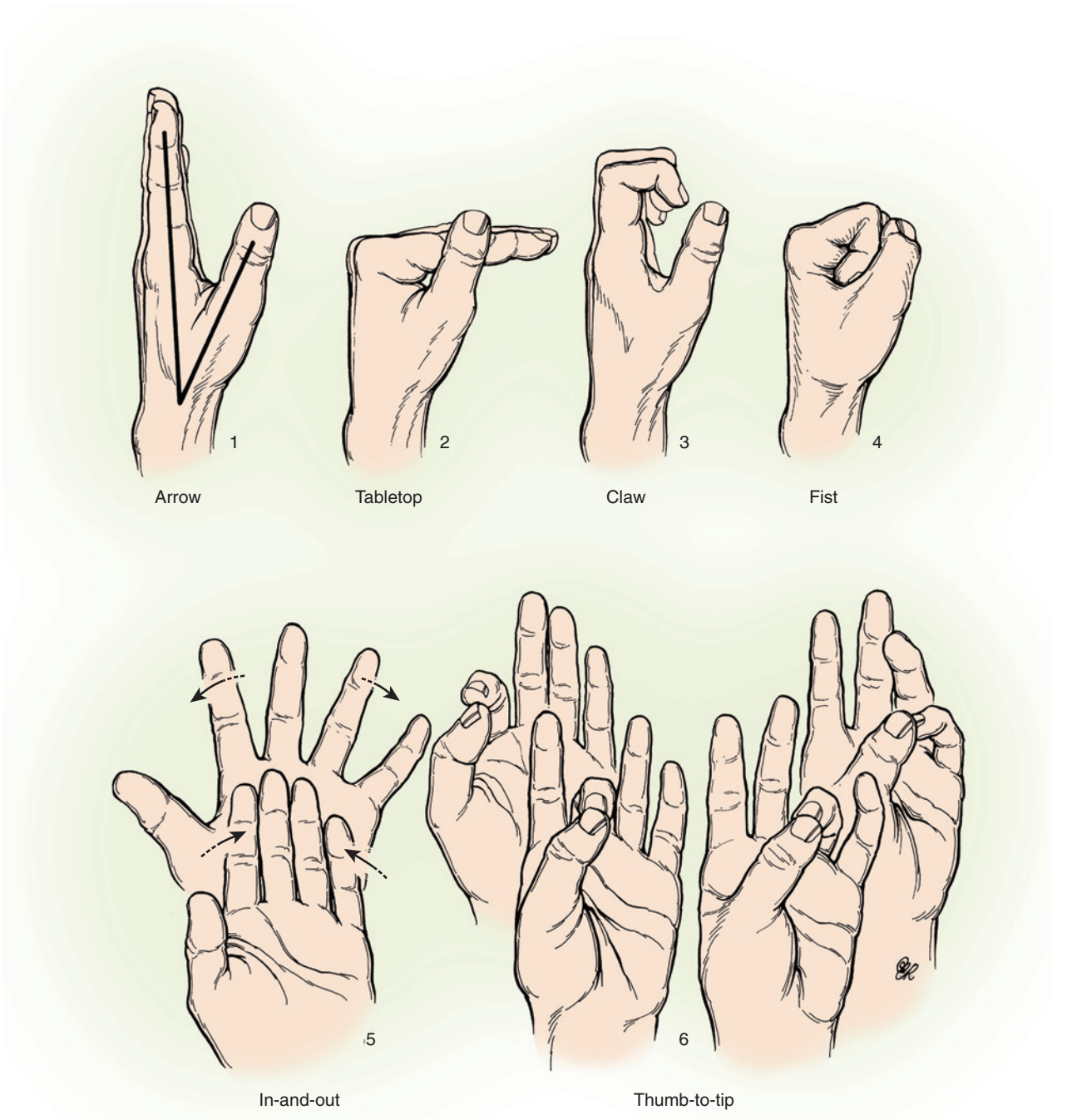

FIGURE 15.26 "Six-pack" exercises: Drawings 1 through 6 illustrate the position that the patient's hand should assume when performing these exercises. It is helpful to show the patient that full metacarpophalangeal (MP) extension makes the hand look like an arrow, full MP flexion makes the hand look like a tabletop; full MP extension combined with proximal and distal interphalangeal flexion, creates a claw; complete finger flexion creates a fist; and abduction and adduction of the fingers create an in-and-out motion. Finally, to complete the exercises, the individual touches the tip of the thumb to the tip of each finger. (© Elizabeth Martin.)

http://e-surg.com

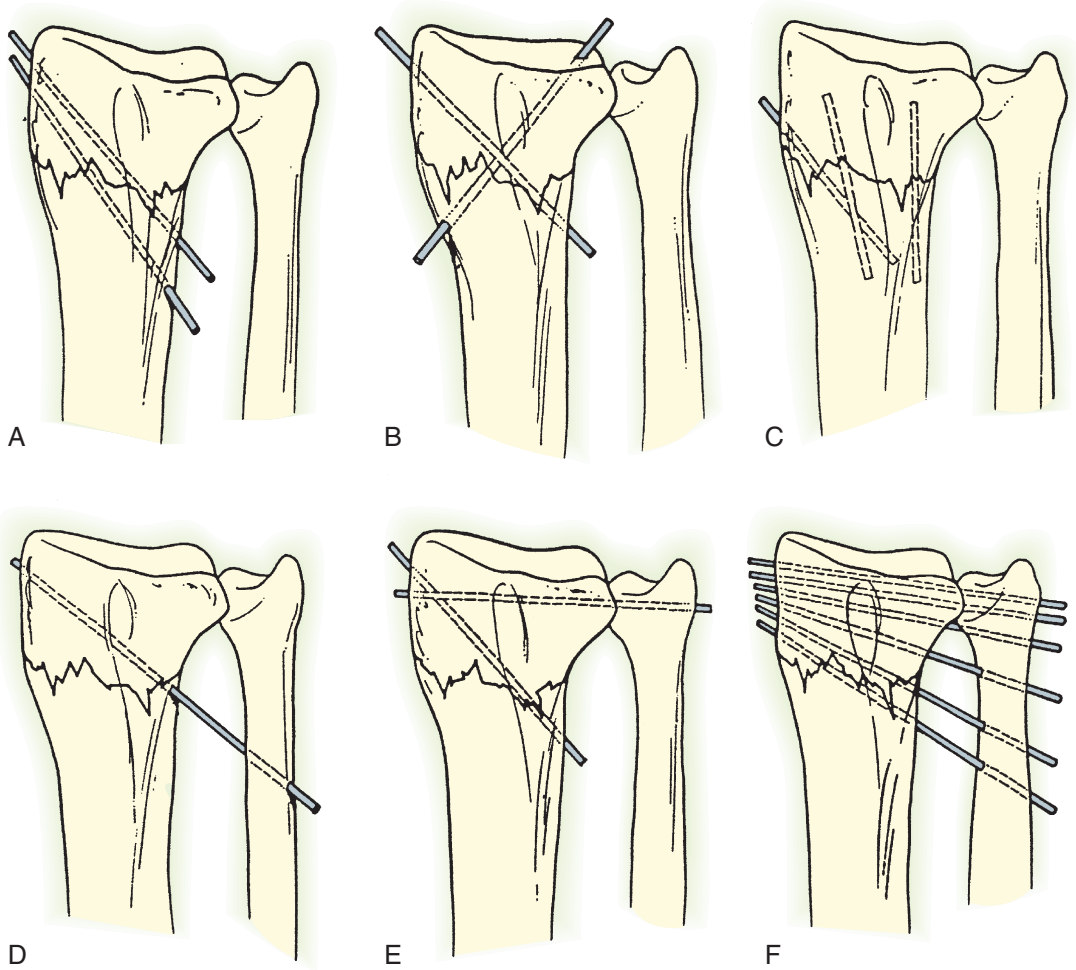

FIGURE 15.27 Several different techniques of percutaneous pinning of unstable bending fractures have been described. **A,** Pins placed primarily through the radial styloid. **B,** Crossing pins from the radial and ulnar sides of the distal fragment into the distal shaft. **C,** The intrafocal technique advocated by Kapandji. **D,** Ulnar-to-radius pinning without transfixation of the distal radioulnar joint (DRUJ). **E,** A radial styloid pin and one across the DRUJ. **F,** Multiple pins from the ulna to the radius, including transfixation of the DRUJ.

should be confirmed fluoroscopically. Both wounds are irrigated and closed with 4-0 nylon sutures before applying the frame.

For relatively stable fractures, and when performing augmented fixation with K-wires or a graft (or both), a simple single-bar external-fixation frame is ideal. The particular design or strength of the frame is less important from a mechanical perspective than the degree of stability attained by the supplemental K-wires (see Figure 15.30).[170]

If nonbridging external fixation is selected for a minimally comminuted extraarticular or simple articular fracture with good bone stock, proximal pin insertion is identical but the distal pins are introduced exclusively into the distal fragment. A radial-sided pin is placed through a small dorsal radial incision between the wrist extensors in the radial half of the distal fragment. Its direction is dorsal-to-palmar, parallel to the joint surface in the sagittal plane. A second pin is placed in the ulnar aspect of the distal fragment through a limited incision between the fourth and fifth extensor compartments. Its direction is also dorsal-to-palmar but aimed slightly obliquely from the ulnar-to-radial side to engage the palmar–ulnar cortex of the distal fragment.

Having securely fixed the distal pins, closed reduction is performed by using them as "joysticks" to restore volar tilt.[60,110] The pins are assembled with separate clamps and rods to create a triangular frame (Figure 15.32). An alternative design of nonbridging "crossed-pin" fixation is shown in Figure 15.33.

Augmented External Fixation

For all but minimally comminuted extraarticular fractures, augmented external fixation is recommended so as to provide additional support to individual fracture fragments and increase construct stability.[172] For unstable fractures without depressed articular fragments, 0.045- or 0.0625-in K-wires are introduced into the fragments in a crossed configuration according to the technique described earlier. One or two pins driven through the radial styloid fragment, and one through the dorsal–ulnar fragment into the radial shaft, combine to produce maximum additional stability.[172] The pins should pierce the ulnar cortex of the radius but not penetrate the ulnar shaft. The pins should be bent at an acute angle and cut off 1-cm external to the skin (eFigure 15.5).

Impacted and severely displaced fragments that do not respond to ligamentotaxis or external-reduction maneuvers

http://e-surg.com

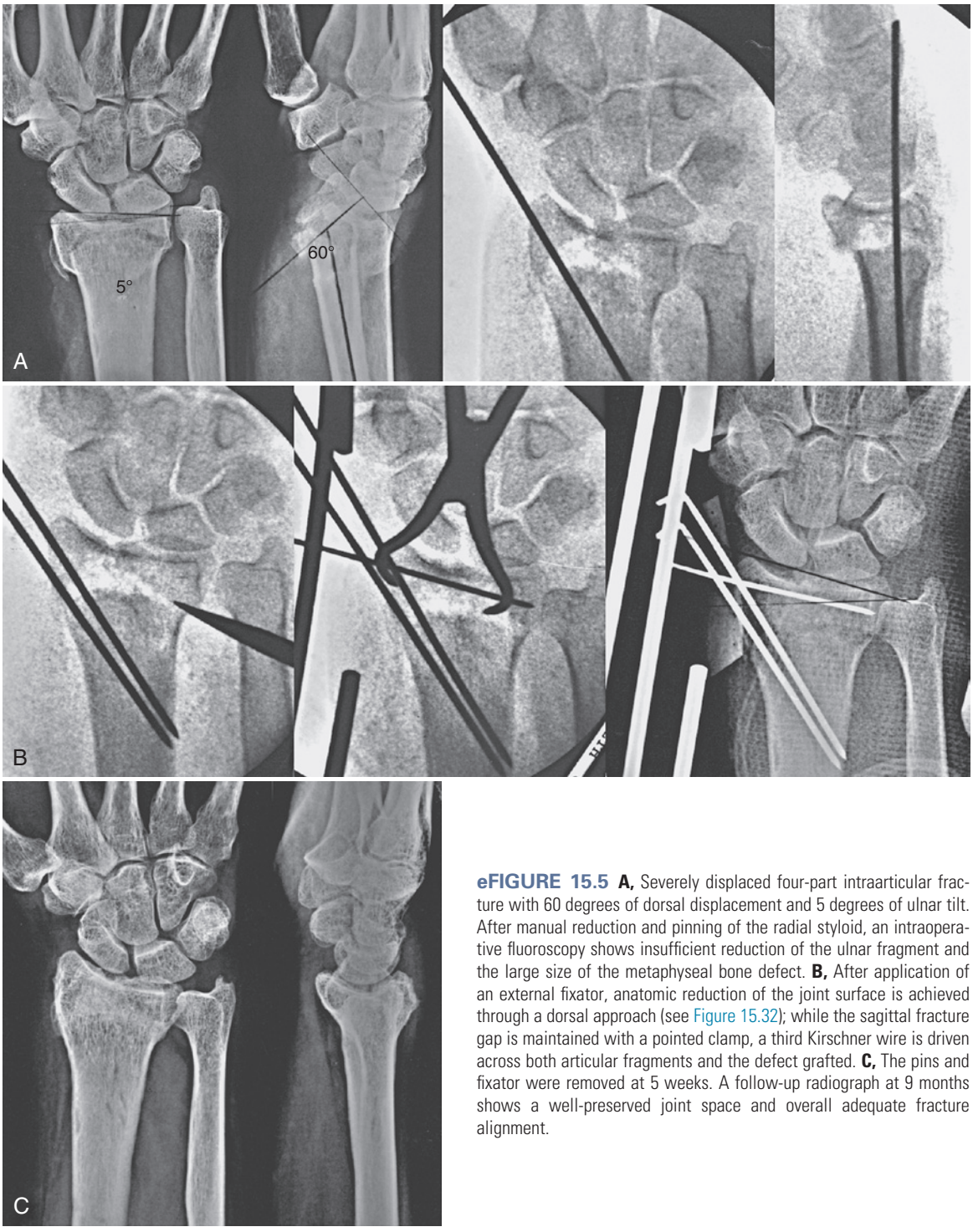

eFIGURE 15.5 **A,** Severely displaced four-part intraarticular fracture with 60 degrees of dorsal displacement and 5 degrees of ulnar tilt. After manual reduction and pinning of the radial styloid, an intraoperative fluoroscopy shows insufficient reduction of the ulnar fragment and the large size of the metaphyseal bone defect. **B,** After application of an external fixator, anatomic reduction of the joint surface is achieved through a dorsal approach (see Figure 15.32); while the sagittal fracture gap is maintained with a pointed clamp, a third Kirschner wire is driven across both articular fragments and the defect grafted. **C,** The pins and fixator were removed at 5 weeks. A follow-up radiograph at 9 months shows a well-preserved joint space and overall adequate fracture alignment.

http://e-surg.com

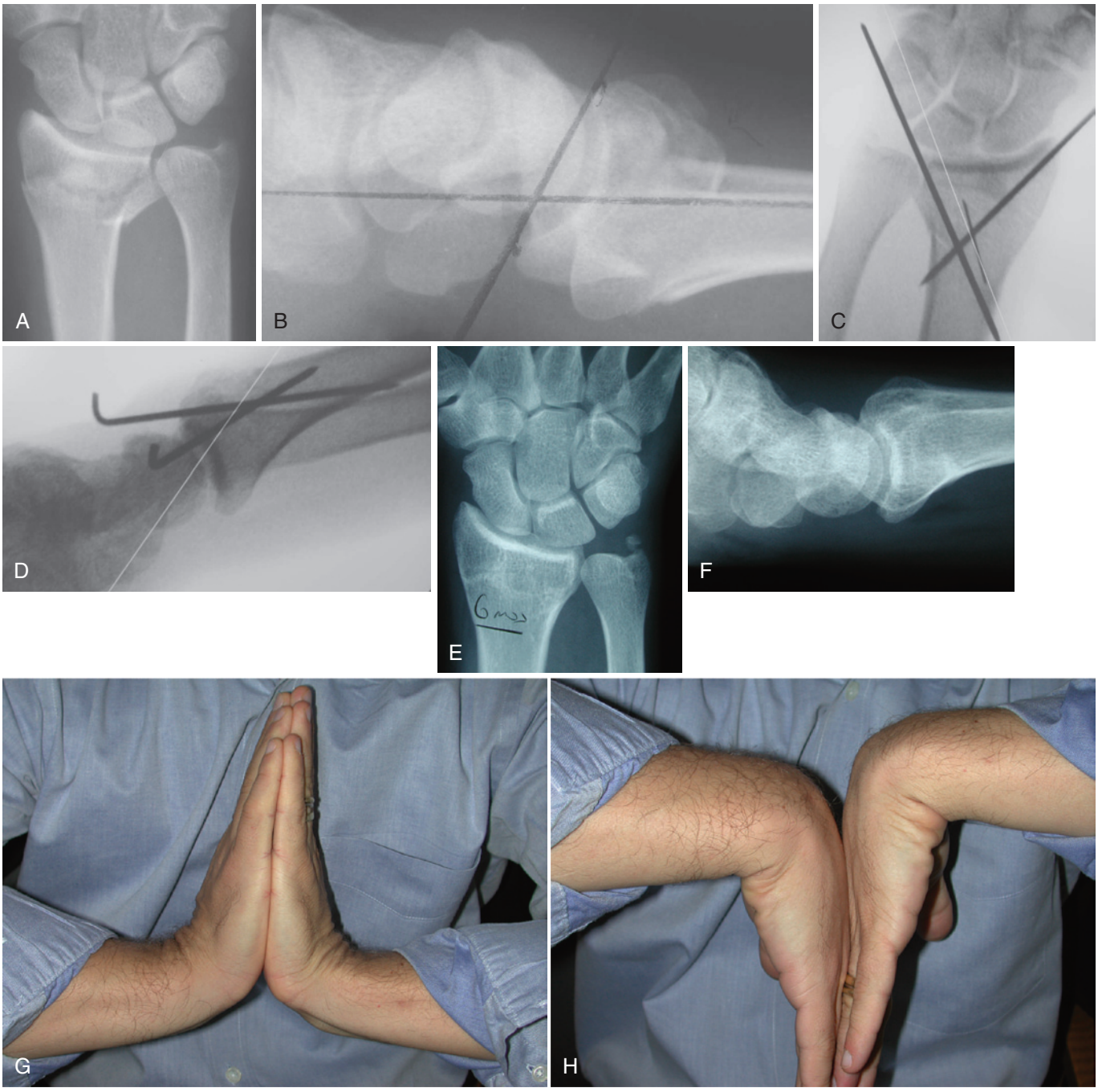

FIGURE 15.28 **A-H,** An unstable fracture in healthy but comminuted bone can be stabilized adequately with percutaneous pins and a cast for 6 weeks with the expectation of restoration of alignment and function.

require additional limited open reduction. This concept is defined as: selective surgical exposure of articular fragments that still remain displaced after the application of traction, closed manipulation, or percutaneous manipulation. The main objective of this technique is to achieve anatomic reduction with limited exposure and to minimize the use of implants in an effort to preserve ligament attachments, thereby minimizing iatrogenic soft tissue disruption and preserving the vascular supply of the fragments.

Limited open reduction is particularly useful for articular four-part fractures of the distal radius without metaphyseal comminution. Articular tilt, radial length, and reduction of the radial styloid fragments usually can be achieved with classic closed-reduction maneuvers alone or combined with longitudinal traction. However, the dorsal–ulnar and volar–ulnar fragments that disrupt the lunate fossa and the sigmoid notch may remain displaced because of either impaction or soft tissue interposition. The limited open reduction technique addresses the anatomic restoration of such fragments after percutaneous fixation of the radial styloid fragment.

After grossly aligning the fracture fragments, the external fixator is applied in slight distraction (see earlier), and the radial

http://e-surg.com

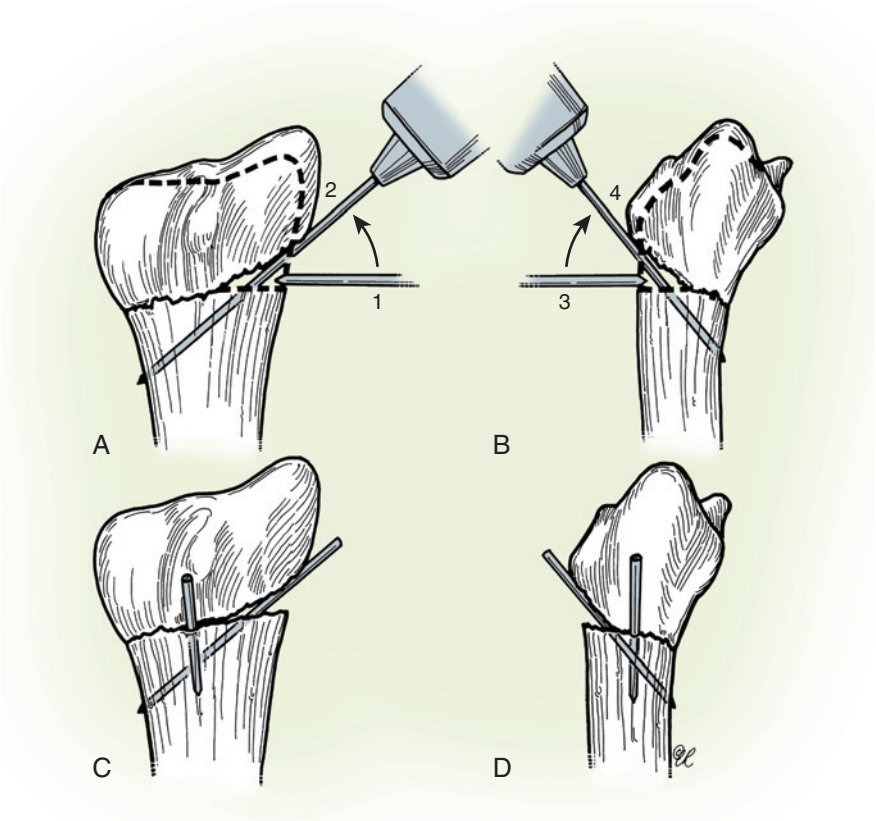

FIGURE 15.29 A-D, The Kapandji technique of "double intrafocal wire fixation" to reduce and maintain distal radial fractures. A 0.045- or 0.0625-in Kirschner wire is introduced into the fracture in a radial-to-ulnar direction. When the wire reaches the ulnar cortex of the radius, it is used to elevate the radial fragment and re-create the radial inclination. This wire is then introduced into the proximal ulnar cortex of the radius for stability. A second wire is introduced at 90 degrees to the first in a similar manner to restore and maintain volar tilt. (© Elizabeth Martin.)

articular surface is approached through a 3- to 4-cm dorsal longitudinal midline incision (Figure 15.34, *A, B*). The extensor retinaculum is opened over the Lister tubercle and the EPL transposed radially. The fourth compartment is opened, and a 2-cm section of the posterior interosseous nerve can be excised at the discretion of the surgeon. The EPL and wrist extensor tendons are retracted to the radial side and the finger extensors to the ulnar side. The wrist capsule is left intact; rarely is it necessary (or helpful) to perform an open inspection of the articular surface when using modern portable fluoroscopy.

If examination of the joint is deemed necessary, the surgeon is afforded a more complete view of all articular surfaces and associated soft tissues with the arthroscope (see next section). The radial styloid fragment is then reduced anatomically and stabilized with a single 0.062-in K-wire (or cannulated screw) as mentioned previously. Any traction that has been applied at this point is reduced, and the impacted articular fragments are elevated en bloc with a Freer elevator (Figure 15.35) or a pointed awl by using the opposing articular surfaces of the lunate and scaphoid as a template. The congruency of the reduction is checked with fluoroscopy, and the resultant metaphyseal void beneath the reduced subchondral bone is then packed with an autogenous bone graft or a structural bone graft substitute (see Figure 15.35, *B*).

Most advocates of augmented external fixation routinely graft all subchondral bone defects regardless of their size if the articular surface has been elevated. The bone graft provides mechanical buttressing of small cartilage-bearing fragments and may accelerate fracture healing by providing additional osteogenic potential. A second 0.045- or 0.062-in K-wire is then directed from the radial styloid transversely across the radius immediately beneath and tangent to the articular surface to engage the cortical bone of the sigmoid notch. Care should be taken to avoid protrusion of the wire into the DRUJ.

If there is joint incongruity involving the sigmoid notch of the radius, every attempt needs to be made to achieve an anatomic reduction. Usually, this can be accomplished with percutaneous manipulation of the fragment with a K-wire and K-wire fixation of the fragment to the stout volar metaphyseal bone (see earlier). If not reducible by percutaneous means, there may be soft tissue interposition; thus limited open reduction is required.

To gain access to the fragment, the fourth dorsal compartment tendons are retracted radially, and the extensor digiti minimi (EDM), which lies directly over the DRUJ, is exposed and retracted to the ulnar side. Great care needs to be taken to avoid disruption of the dorsal radioulnar ligament when exposing and realigning this fragment, and the periosteum is left intact to avoid vascular stripping. A 0.045-in K-wire can be passed at a 45-degree angle to the frontal and sagittal planes to engage the distal and ulnar margin of the dorsal–ulnar fragment and to secure it to the opposing palmar cortical bone. Reduction and fixation are confirmed with fluoroscopy.

http://e-surg.com

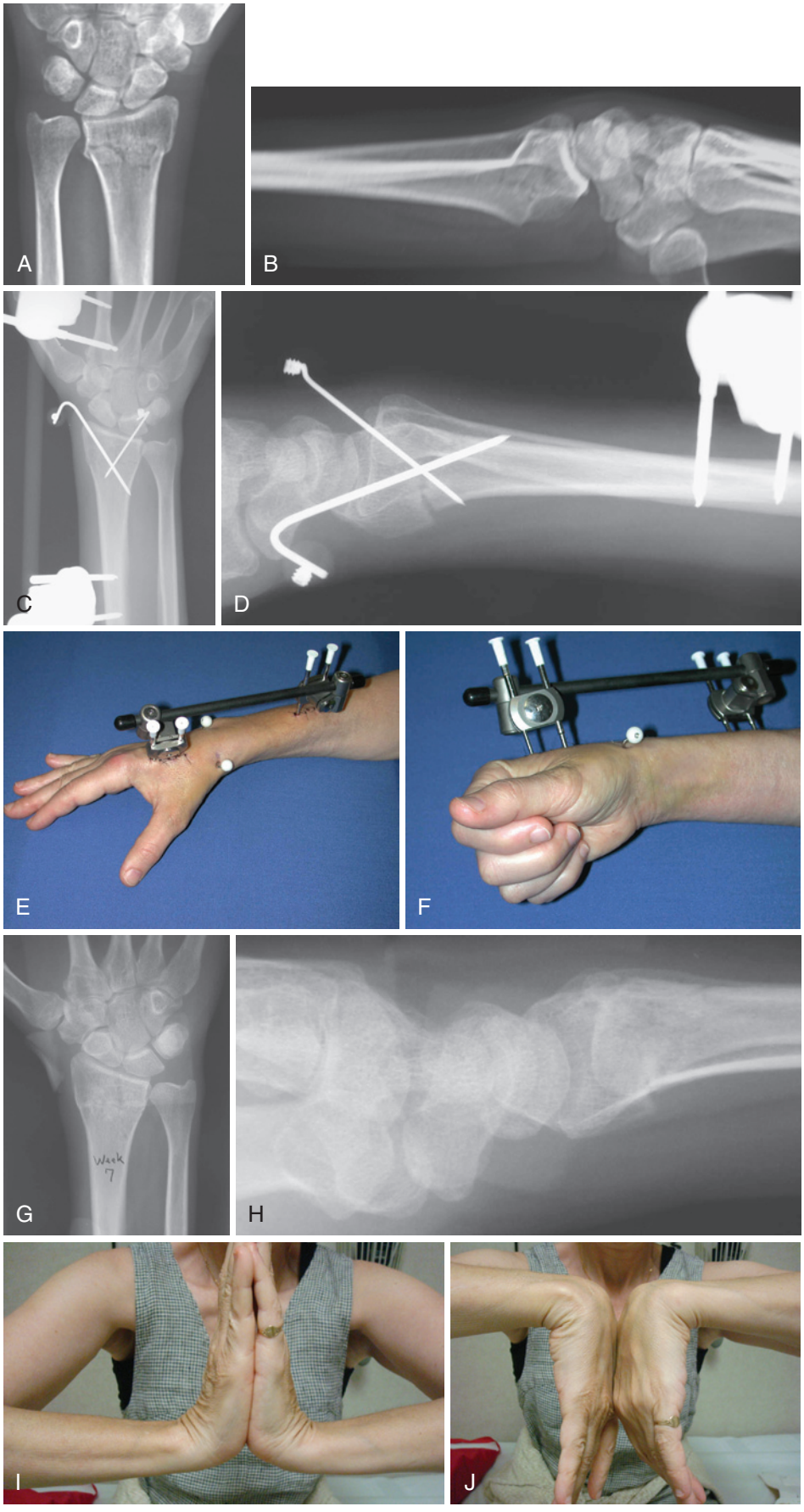

FIGURE 15.30 Augmented external fixation: **A, B,** Posteroanterior and lateral radiographs of an unstable extraarticular fracture. **C, D,** Crossed pin augmentation of external fixation yields optimal construct strength. **E, F,** Photos of the fixator shows it in a neutral position to allow full flexion and extension of the digits postoperatively. **G, H,** Healed fracture in satisfactory alignment. **I, J,** Photos showing symmetric range of motion postoperatively.

http://e-surg.com

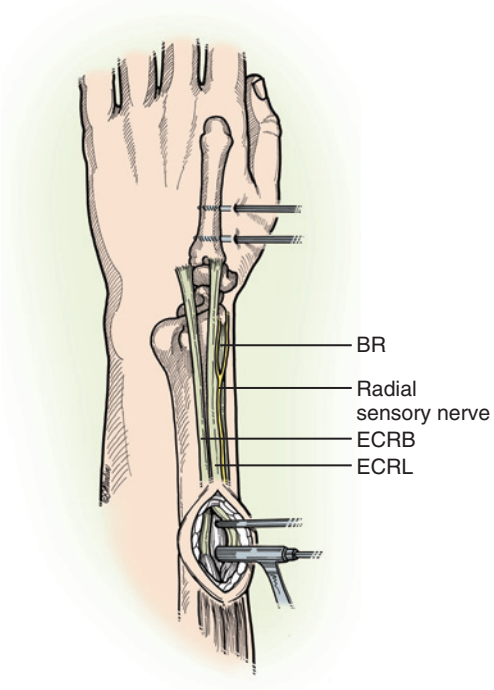

FIGURE 15.31 An external-fixation device being applied after two 3-mm half-pins have already been introduced into the base of the second metacarpal. Two 3-mm half-pins are then introduced into the distal radius via direct exposure of the radius between the extensor carpi radialis brevis (ECRB) and extensor carpi radialis longus (ECRL) at an angle 30 degrees dorsal to the coronal plane. The lateral antebrachial cutaneous and radial nerves are protected by directly identifying them and then inserting the half-pins through a tissue protector that is placed directly on the radius. *BR*, Brachioradialis. (© Elizabeth Martin.)

If an unstable volar–ulnar fragment is identified, reduction and hybrid fixation (see eFigure 15.6) through a limited volar approach must be performed to prevent subsequent volar displacement of the carpus. Percutaneous fixation of the volar–ulnar fragment is not recommended because of the density of neural, vascular, and tendinous structures overlying it. A variety of small internal-fixation devices are available, including fixed-angle 2.4-mm plates, tension bands, wireforms, and pin plates.

The fixator is then adjusted to a neutral position in the frontal and sagittal planes, and any excess traction is removed. Full passive flexion and extension of the digits and thumb are ensured at this time to be certain that there is neither residual distraction nor tethering. The wound is closed by reapproximating the extensor retinaculum while leaving the extensor pollicis transposed. DRUJ stability is assessed with a manual "shuck" test of the radioulnar joint. Gross instability must be treated to avoid long-term sequelae.

The external fixator pin clusters are dressed with a compressive wrap to prevent skin shear, the wounds are covered, and the wrist is immobilized in a light compression bandage with a supportive splint. It is preferable to immobilize the wrist in a supinated position with a sugar tong splint for 10 days until pain and swelling have subsided in order to promote DRUJ stability and facilitate resumption of full supination postoperatively. The frame is usually removed at 6 weeks and the supplemental pins may be kept in place for an additional 2 weeks.

To help prevent pin-track infection, it is recommended that the patient clean the skin–pin interface with saline once or twice daily until the wounds have sealed. Active- and passive-finger motion can be begun as soon as the anesthetic wears off and is encouraged for the entire time that the frame is in place. Supination–pronation of the forearm is started at the first postoperative visit and its importance is reemphasized throughout the postoperative period. Supervised hand therapy is begun for patients who are unwilling, uncomfortable, or unable to mobilize their fingers and forearms independently.

CRITICAL POINTS *Augmented External Fixation*

Indications
- Unstable extraarticular fractures of the distal radius (type I bending)
- Impacted articular fractures (type III compression)
- Comminuted unstable fractures with articular and metaphyseal involvement

Contraindications
- Severe osteoporosis
- Volar shear fractures (type II; Smith type II; volar Barton type)
- Patient preference, compliance concerns, or inability to care for the external fixation and pins

Technical Points
- Closed reduction with traction, finger traps, or both
- Mini-open placement of proximal- and distal-fixation pins to the index metacarpal and radius
- Placement of fixator pins in a plane 45 degrees oblique to the sagittal and frontal planes
- Closure of pin cluster incisions before assembly of the fixator
- Gross alignment of the fragments by fixation in moderate traction, flexion, and ulnar deviation
- Mini-open dorsal incision over the third dorsal compartment and transposition of the EPL
- Reduction of traction and elevation of impacted articular fragments with an elevator against the carpus
- Fluoroscopic check of reduction and support of fragments with graft or substitute
- Percutaneous 0.062- or 0.045-in K-wire or screw fixation through the radial styloid
- Percutaneous 0.045-in K-wire fixation transversely below the reduced subchondral bone
- Crossed percutaneous 0.062-in K-wire through the dorsal–ulnar corner
- Assessment of the volar ulnar fragment and performance of limited open reduction and fixation if needed
- Revision of the fixation posture to a neutral wrist angle to facilitate digital mobility and function
- Assessment of the DRUJ for stability and augmentation as needed

Postoperative Care
- Apply a sugar tong splint in supination for 5 to 10 days until suture removal.
- Begin digital range-of-motion exercises immediately.
- Use peroxide or dry pin care and apply compressive wraps until wounds are sealed.
- Begin forearm rotation and gentle active wrist motion exercises at the initial postoperative visit.
- Evaluate with radiographs at the initial postoperative visit and at 2 and 6 weeks postoperatively.
- Remove the fixator at 6 weeks while leaving the K-wires in place for 2 additional weeks.

http://e-surg.com

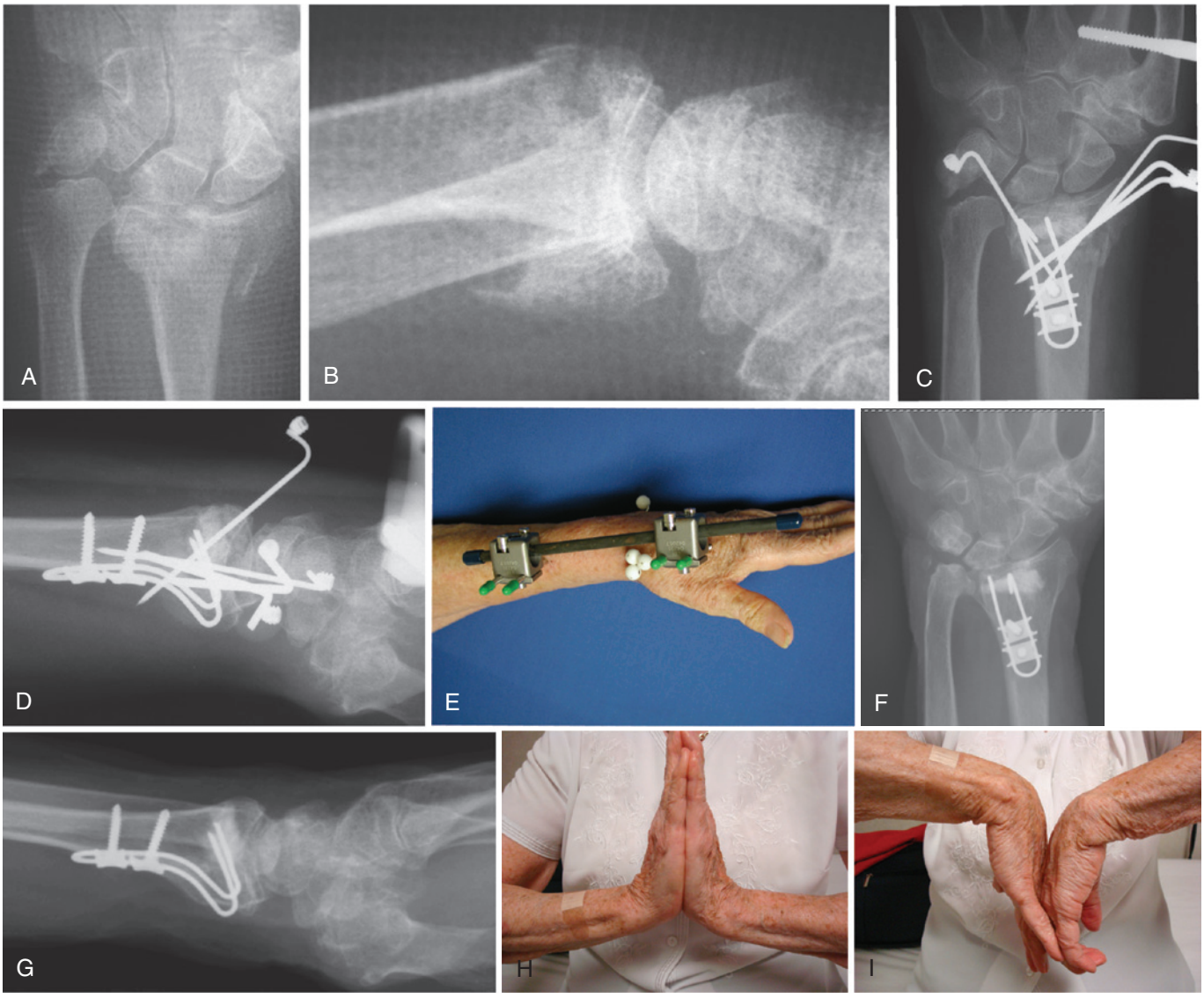

eFIGURE 15.6 Hybrid internal and external fixation in an elderly patient: **A, B,** Comminuted fracture with dorsal and volar marginal fractures of the lunate fossa. **C, D,** Augmented external fixation combined with a volar implant through a limited-incision approach to fix the volar ulnar corner fragment. **E,** Full motion of the digits is encouraged postop. **F, G,** Radiographs at 4 years postop. **H, I,** Nearly symmetric range of motion.

http://e-surg.com

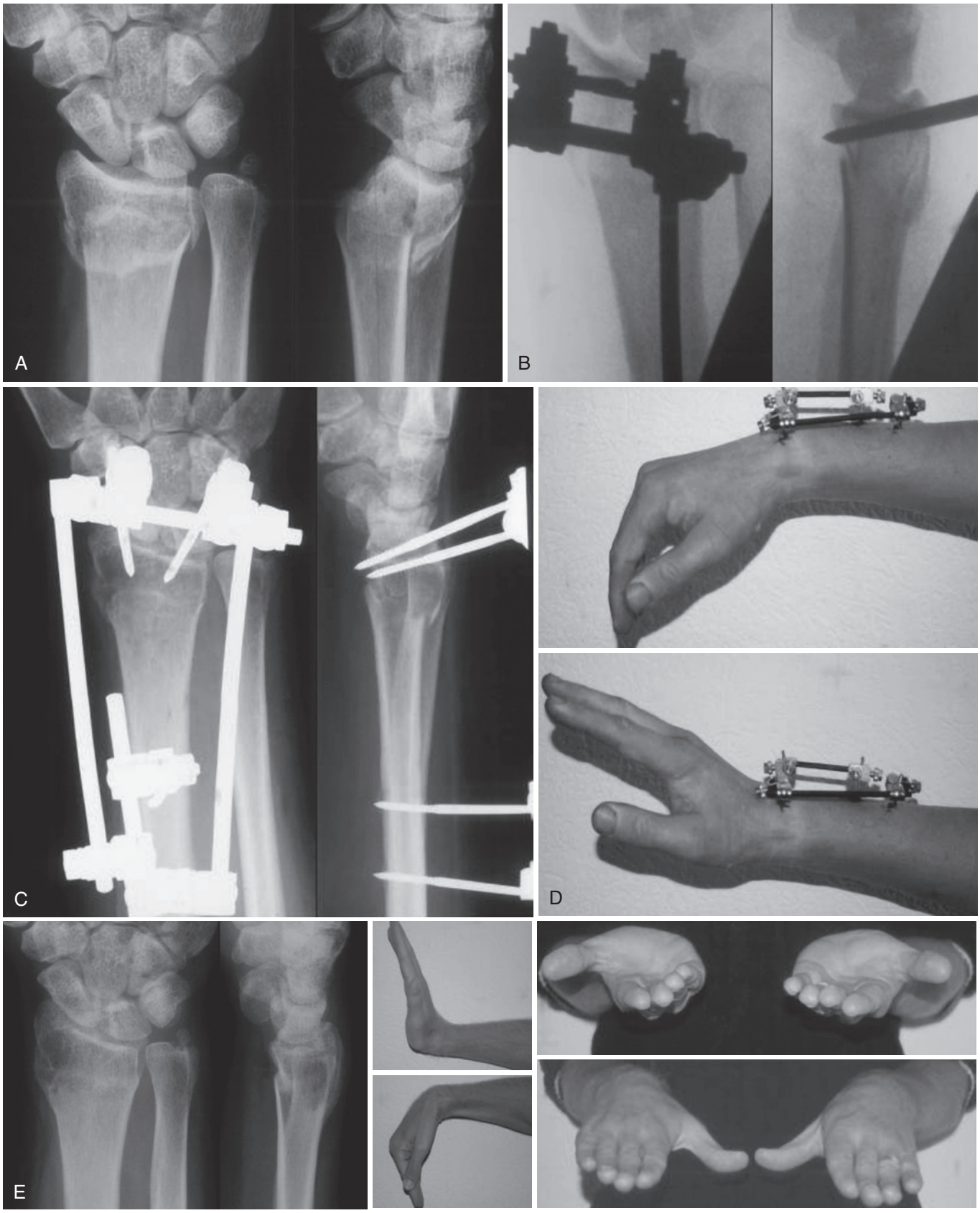

FIGURE 15.32 **A,** Radiographs of an unstable dorsally displaced extraarticular fracture of the distal radius. **B,** Fluoroscopic control of the nonbridging fixator. Notice the converging position of the distal pins in the frontal plane and parallel to the joint surface in the sagittal plane. **C,** Control radiographs 10 days after injury with well-maintained reduction. **D,** Early motion of the wrist is allowed as soon as the swelling has subsided. **E,** Radiographs at 3 months. The fracture has healed without displacement and correlates with free wrist motion and restoration of complete forearm rotation.

http://e-surg.com

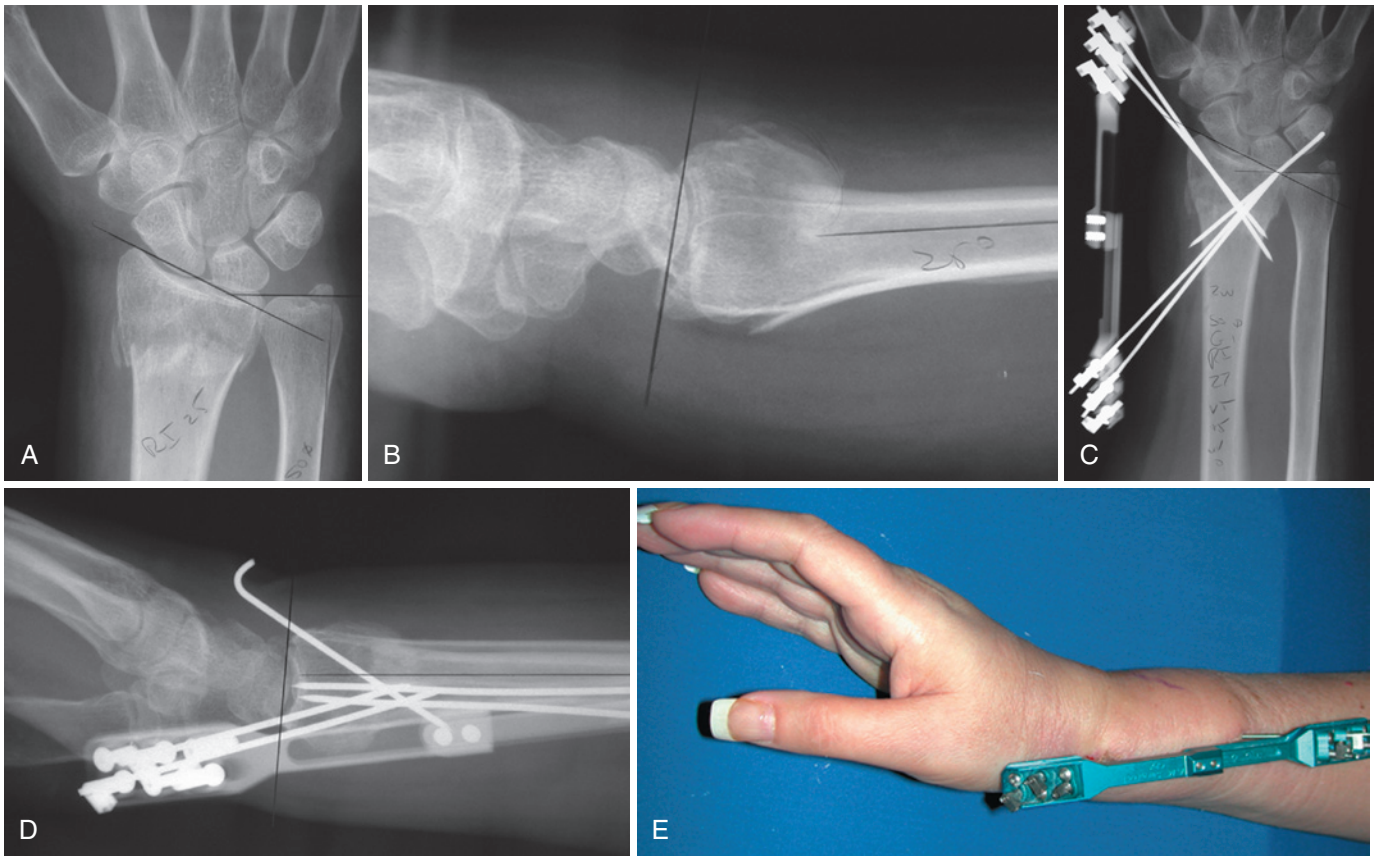

FIGURE 15.33 **A-E,** Cross-pinned nonbridging external fixation of the distal radius (CPX, AM Surgical, Smithtown, NY). For selected unstable fractures with large articular fragments and healthy bone, nonbridging fixation enables early wrist motion and compares favorably with bridging external fixation.

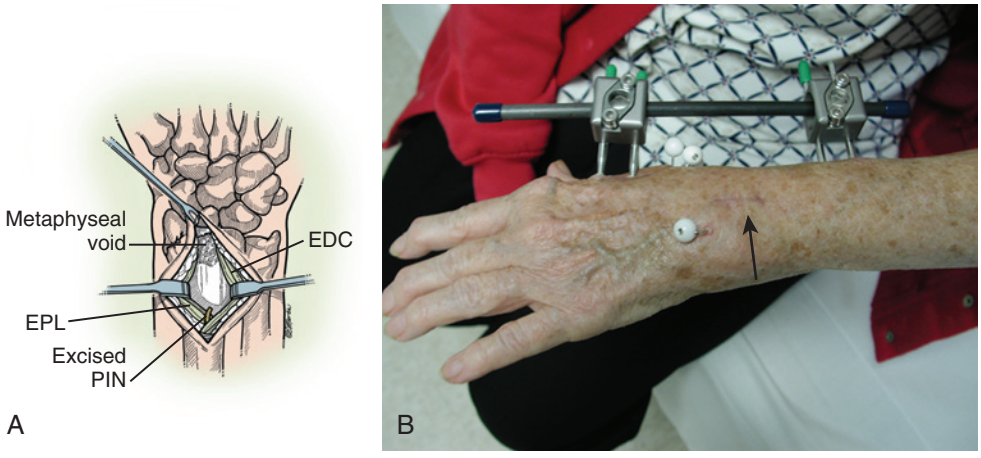

FIGURE 15.34 Limited open reduction: **A,** Limited exposure of the radial metaphyseal void between the third and fourth dorsal compartments enables percutaneous elevation of the articular surface and bone graft augmentation. **B,** Photo of healed 3-cm dorsal incision (*arrow*) for articular reduction and placement of bone graft. *EDC*, Extensor digitorum communis; *EPL*, extensor pollicis longus; *PIN*, posterior interosseous nerve. (**A,** © Elizabeth Martin.)

Arthroscopic Reduction and Percutaneous Fixation

Diagnostic and therapeutic wrist arthroscopy is widely used by many practicing hand surgeons. Its use in conjunction with a percutaneous means of fracture fixation offers several advantages in the management of articular fractures of the distal radius.[36,54] Arthroscopy is a minimally invasive means of monitoring articular reduction without the additional ligamentous and capsular damage that is inherent with open inspection of the articular surface. In addition, the arthroscope affords an unparalleled diagnostic view of the interosseous carpal ligaments, the carpal articular surfaces, and the TFCC. If indicated, arthroscopic or limited open management of concomitant soft

http://e-surg.com

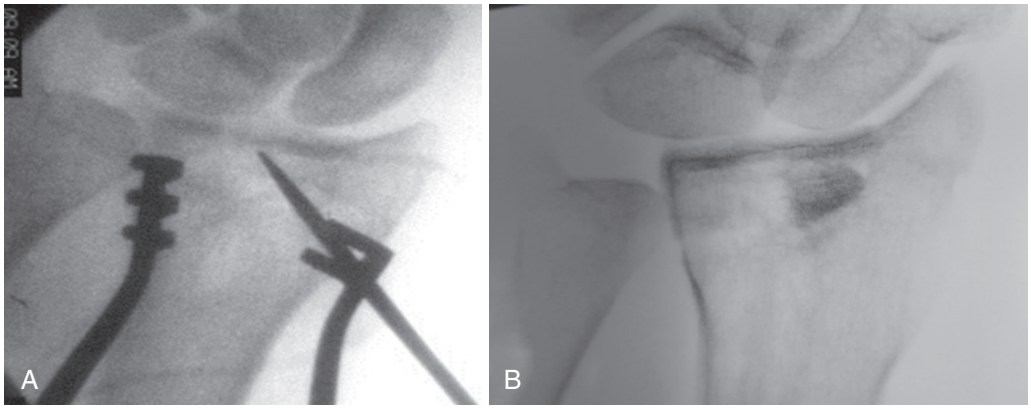

FIGURE 15.35 A, Limited open reduction of an impacted articular surface can be performed by inserting a Freer elevator into the metaphyseal defect through an area of comminution. Gentle pressure disimpacts and elevates articular fragments using the carpal bones as a template. **B,** Bone graft or graft substitute inserted into the metaphyseal defect supports the elevated articular surface.

tissue injuries of the carpus or DRUJ can be undertaken simultaneously.

Although the addition of arthroscopic inspection and reduction means additional operating room time and equipment, there is evidence to suggest that outcomes are improved. Doi and associates demonstrated improvements in range of motion and fracture reduction in a prospective cohort of patients treated by arthroscopically assisted percutaneous fixation when compared with a group treated by conventional open reduction and internal fixation (ORIF) for displaced articular fractures of the distal radius.[36]

Arthroscopic Reduction and Percutaneous Fixation Technique

When considering arthroscopically assisted reduction and fixation of an articular distal radius fracture, it is wise to reduce and stabilize the fracture in a splint for 3 to 7 days before surgery. Treatment of fractures acutely by arthroscopic means may limit visibility secondary to bleeding and may risk the development of compartment syndrome because of extravasation of fluid into the soft tissues. After 7 days, however, it becomes difficult to elevate impacted articular fragments without a formal open reduction.

The arm is prepared sterilely, draped in the usual manner, and suspended from sterile finger traps attached to the index and long fingers (Figure 15.36). The forearm may be exsanguinated with an Esmarch bandage that can be left in place from just proximal to the wrist up to the elbow to prevent fluid extravasation into the soft tissues. Alternatively, an elastic bandage can be wrapped around the hand and forearm to reduce soft tissue swelling. It is preferable to perform the arthroscopic portion of the procedure without a tourniquet, saving its use for any open reduction that may be required. The fracture is then evaluated under fluoroscopic guidance, and the fragments are manually manipulated into position. As an alternative to finger trap or tower traction, an external-fixation device can be applied before arthroscopy of the wrist to prevent the need for suspension traction.[171]

The arthroscope is inserted through the 3-4 portal, and an outflow portal is established in either the 4-5 or 6U position. Immediate and copious irrigation is critical to clear clot and debris and to improve visualization. Once this is done, continuous irrigation is maintained through the 6U portal, and working portals can be established in the 1-2 or 4-5 positions (or both). Doi and associates demonstrated the utility of an additional volar–radial portal created by means of a limited open incision over the flexor carpi radialis (FCR) tendon.[36] K-wires (0.0625 in) are useful as percutaneous joysticks when placed in the radial styloid and other large articular fragments.

Reduction of the fragment is then accomplished with the joysticks under fluoroscopic control, and it is stabilized as mentioned previously with either 0.045- or 0.0625-in K-wires (see Figure 15.36, *D, E*). Impacted articular fragments can be elevated through a mini-open dorsal approach (see earlier) and supported with a bone graft or substitute (see Figure 15.35, *B*). Pins can be replaced with cannulated screws at the discretion of the surgeon.[72,97] If pin fixation alone is used, the wrist must be supported in a cast until healed. If using augmented external fixation, the wrist posture is returned to neutral, and the forearm is immobilized in a supinated position for 7 to 10 days with a light sugar tong dressing. The cast or fixator is generally removed at 4 to 6 weeks, depending on the fracture and whether a bone graft is used; percutaneous pins are usually removed 2 to 3 weeks later.

Additional Soft Tissue Injuries

Concomitant complete tears of the scapholunate or lunotriquetral ligaments should be reduced anatomically and pinned or treated by limited open reduction, repair, and pin or screw fixation (see Chapter 13). A minimum of two divergent pins or a temporary compression screw should cross the affected intercarpal articulation, and one or two additional pins should be placed to temporarily stabilize the proximal row to the distal carpal row across the midcarpal joint. Intercarpal pins are left in place for at least 8 weeks and a graduated program of range-of-motion and resistive exercises is begun slowly thereafter. If using a temporary scapholunate screw, the device can be left in place while gentle midcarpal motion is begun with a dart-thrower's rehabilitation protocol[31] (see Chapter 13); the screw can be removed 4 to 6 months postoperatively. Complete peripheral detachment of the articular disk of the TFCC can also be treated by arthroscopically guided suture placement at the time of fracture reduction (see Chapter 14).

http://e-surg.com

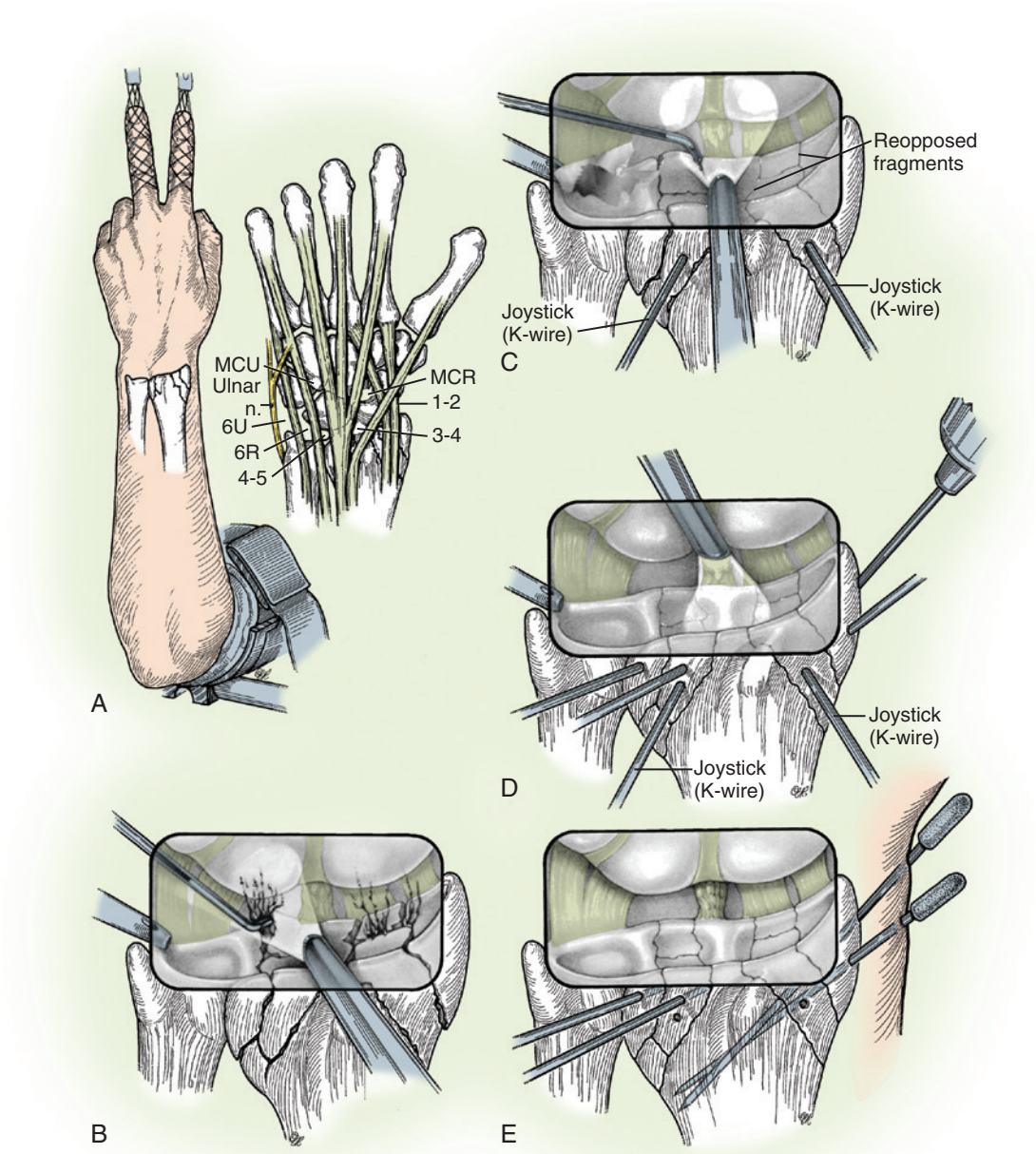

FIGURE 15.36 Operative technique for arthroscopic reduction and pinning of distal radial fractures: **A,** The arm is suspended from finger traps on the index and long fingers. The following anatomic landmarks are identified: arthroscopic portals 1-2, 3-4, 4-5, 6R (radial), 6U (ulnar), MCR (midcarpal radial), and MCU (midcarpal ulnar). The dorsal sensory branch of the ulnar nerve is noted. **B,** The arthroscope is introduced through the 3-4 or 4-5 portal, and with a probe through the 6R portal, the comminuted distal radial fracture is visualized. Clot and hemorrhage extrude from the fracture fragments. **C,** Joysticks (0.0625-in Kirschner wires [K-wires]) are introduced into the major fragments percutaneously to elevate the fracture fragments into an anatomic position. **D,** Additional K-wires are then introduced percutaneously into the fracture. **E,** The joysticks are then removed, the fixation pins are cut off outside the skin, and caps are applied. (© Elizabeth Martin.)

Bone Graft and Bone Graft Substitutes

A recent Cochrane systematic review of 10 trials involving 847 adult patients identified improvements in radiographic alignment among patients whose external or percutaneous fixation was supplemented by bone graft or bone graft substitutes; however, no differences in functional outcomes were identified.[70] The use of a bone graft to supplement internal or external fixation (see eFigure 15.7) has dramatically decreased during the last 5 years, in large part as a result of the seismic shift toward the use of angular stable implants[95,108] (Table 15.2). Supplemental bone graft is now most often used in subacute or *nascent malunions* requiring osteoclasis[81]; malunited fractures; and, less frequently, in the acute situation to buttress the reduction of small articular fragments (see Case Study 15.1).

Iliac Bone Graft Harvesting Technique

After a rolled towel has been placed under the ipsilateral sacroiliac joint, the iliac crest region is sterilely prepared and draped. A 5-cm-long incision is made over the iliac crest beginning 2-cm posterior to the anterior superior iliac spine and coursing

http://e-surg.com



eFIGURE 15.7 Augmented external fixation of an unstable intraarticular fracture with a bone graft substitute: **A, B,** Comminuted unstable fracture in an elderly woman. **C,** Packing of the metaphyseal void with coralline hydroxyapatite through a limited dorsal approach. **D, E,** Radiographs at 3 weeks postop demonstrating the crossed pin configuration and incorporation of the graft. **F,** Importance of neutral position and full digital motion. **G, H,** Radiographs at 3 years postoperative.

http://e-surg.com

CASE STUDY 15.1

A 71-year-old right-handed female suffers a fall while playing tennis; the injury was reduced and initially casted outside of the hospital (eFigure 15.11, *A–C*); a postfracture shift was evident at 2 weeks following the injury (eFigure 15.11, *D–F*). The patient presents at 5 weeks postinjury, and a nascent malunion is revealed (eFigure 15.12). Surgery with bone graft is recommended (eFigure 15.13).

Postoperative films and clinical photographs are displayed in eFigure 15.14.



eFIGURE 15.11 **A-C,** Radiographs of reduced and casted arm initially done outside the hospital. **D-F,** Postfracture shift at 2 weeks following injury.

http://e-surg.com



eFIGURE 15.12 **A-C,** Nascent malunion at 5 weeks postinjury. **D-F,** Preoperative computed tomography demonstrates marked articular comminution and gross shortening, radioulnar incongruency.

http://e-surg.com

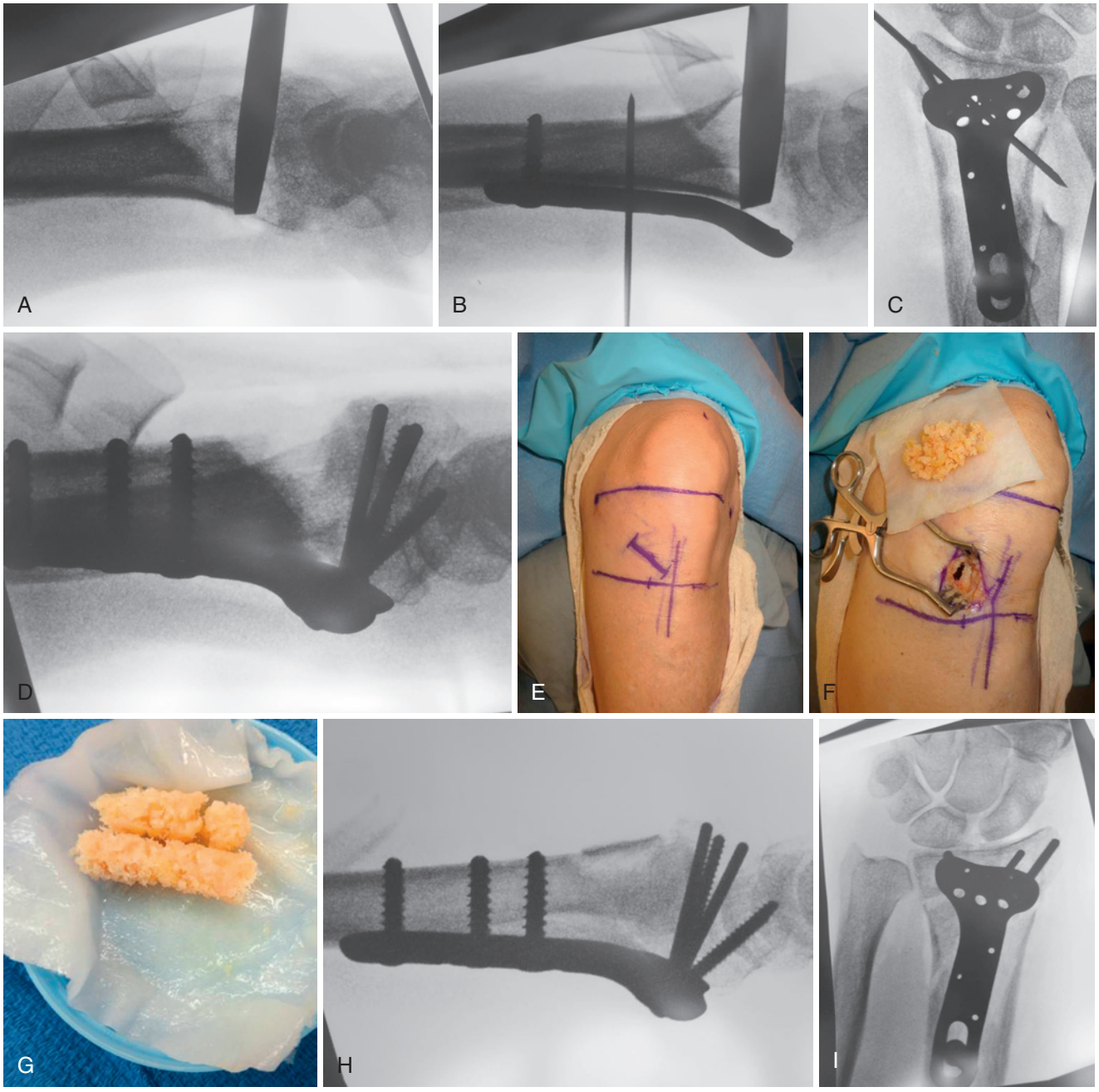

eFIGURE 15.13 **A,** Dorsal and volar approaches, articular fragments elevated en bloc with 12-mm osteotome. **B,** Volar plate applied provisionally to use as a buttress for articular realignment. **C,** Articular alignment maintained with provisional styloid 0.062-in pin-and-plate fixation. **D,** Large dorsal metaphyseal bone void created by elevating articular surface. **E-G,** Large amount of bone graft harvested from ipsilateral medial tibia with 2-cm incision. **H, I,** Bone void filled with graft; distal radioulnar joint and radiocarpal congruency restored with negative ulnar variance.

http://e-surg.com

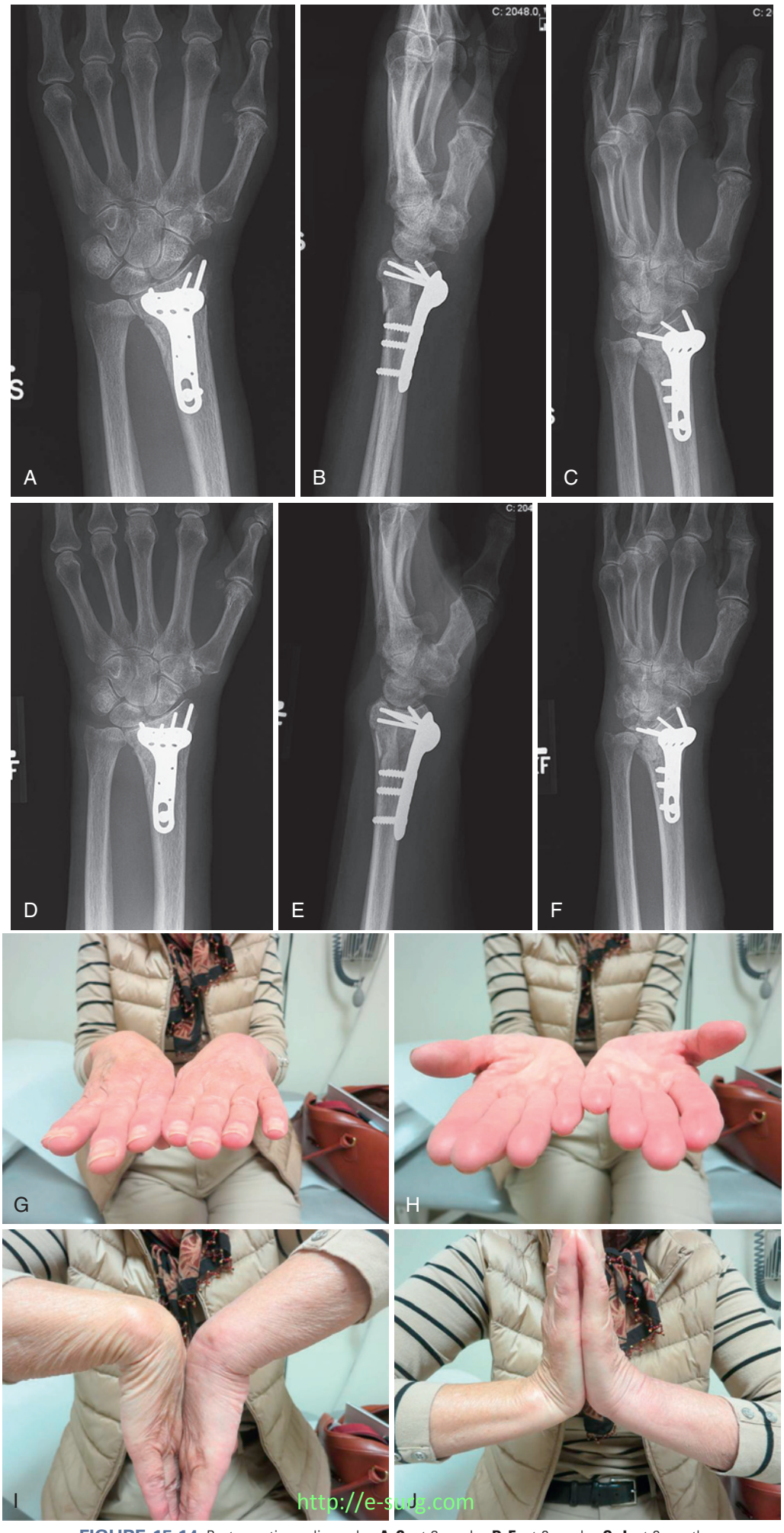

eFIGURE 15.14 Postoperative radiographs: **A-C,** at 2 weeks; **D-F,** at 6 weeks; **G-J,** at 3 months.

http://e-surg.com

TABLE 15.2 **Outcomes of Percutaneous and Single- and Multiple-Plate Fixation of Distal Radius Fractures**

Year	Author	Number of Patients	Age	Female	C Type	C3	Follow-up Time (Months)	Grafted	Compl	Loss Redux	GE	PRWE	DASH	F/E	Grip
Volar-plate fixation															
2002	Orbay	31	54	55%	45%	10%	12	10%	3%	0%	100%			82%	77%
2004	Orbay	24	79	71%	10%	4%	12	38%	17%	13%				82%	79%
2005	Musgrave	32	57	91%	66%	0%	13	0%	34%	0%				80%	
2005	Kamano	40	57	70%	15%	3%	12	10%	5%	0%	100%			85%	78%
2006	Ruch	14	46	50%	100%	71%	22	14%	29%	0%	86%			85%	78%
2006	Rozental	41	53	63%	46%	12%	17	7%	22%	10%	100%			70%	94%
2007	Rein	15	54	47%	100%	100%	48	0%	13%	7%	47%			80%	90%
2008	Egol	38	52	57%	38%		12	0%	21%	0%			13	85%	85%
2009	Wei	12	61	75%	75%		12	33%	17%	0%			4	91%	94%
2009	Rozental	23	51	70%	57%		12	0%	9%	0%			4	88%	85%
2011	Yu	47	56	62%	68%		38	0%	28%	2%					
2011	Wilcke	33	55	76%	21%		12	0%	21%	0%		11	7	92%	94%
2012	Jakubietz	22	68	86%	100%	23%	12	0%	41%	0%	94%		11	87%	95%
2013	Williksen	52	54	80%	69%	2%	12	0%	29%	2%			9	88%	86%
2014	Karantana	66			3%	0%	12	0%	27%	2%			9	91%	95%
AVERAGE		**33**	**57**	**68%**	**54%**	**23%**	**17**	**7%**	**21%**	**2%**	**88%**		**8**	**85%**	**87%**
Dorsal-plate fixation															
2005	Grewel	29	46	62%	100%	100%	18	86%	72%	0%				60%	86%
2006	Kamath	30	59	53%	70%	13%	18	33%	13%	3%	93%			85%	78%
2006	Ruch	20	49	55%	100%	75%	21	45%	20%	25%	75%			75%	74%
2006	Simic	51	55	59%	16%	0%	24	0%	12%	0%	78%			81%	92%
2007	Rein	14	45	71%	100%	100%	48	0%	50%	14%	36%			70%	85%
2011	Yu	57	51	62%	58%		49	0%	18%	2%					
2012	Jakubietz	20	68	85%	100%	30%	12	0%	55%	15%	64%		14	68%	75%
AVERAGE		**32**	**53**	**64%**	**78%**	**53%**	**27**	**23%**	**34%**	**8%**	**69%**		**14**	**73%**	**82%**

Fragment-specific fixation															
2000	Jakob	74	60	70%	66%	41%	12	51%	22%	6%	97%			84%	90%
2002	Konrath	25	53	44%	70%	33%	29	0%	28%	4%	92%			82%	83%
2006	Benson	85	50	68%	89%	21%	32	76%	20%	0%	100%		9	88%	92%
2009	Jupiter	150	51	59%	71%		24	12%	16%	3%	96%		7	86%	90%
2009	Abramo	26	48	67%	85%		12	8%	31%	4%			9	86%	90%
2012	Gavaskar	105	43	41%	100%	31%	12	4%	21%	5%		10	8	87%	78%
AVERAGE		**78**	**51**	**58%**	**80%**	**32%**	**20**	**25%**	**23%**	**4%**	**96%**	**10**	**8**	**86%**	**87%**
External fixation															
2001	Sakano	25	49	40%	76%	8%	30	100%	0%	0%	100%			88%	89%
2003	Werber	50	58	70%	60%	0%	6	0%	14%	0%	90%			65%	60%
2004	Harley	25	43	52%	80%	44%	12	12%	56%	0%	48%			81%	79%
2005	Grewal	33	45	36%	100%	85%	18	45%	24%					65%	97%
2005	Kreder	88	40	43%	83%		24	13%	11%	0%				94%	90%
2005	Gradl	25	60	12%	44%	20%	24	0%	16%	4%	96%			92%	
2008	Leung	74	42	38%	100%	39%	24	22%	13%	0%	94%				
2008	Egol	39	50	100%	59%		12	0%	18%				17	87%	100%
2009	Abramo	24	48	71%	83%		12	8%	58%	21%			14	86%	78%
2009	Wei	22	55	73%	55%		12	18%	17%	0%			18	90%	94%
2011	Grewel	24	54	75%	42%		12	0%	46%	4%		15		84%	86%
2011	Wilcke	30	56	77%	27%		12	0%	43%	10%		15	11	84%	85%
2013	Williksen	59	54	80%	76%	3%	12	0%	30%	5%			11	83%	81%
AVERAGE		**40**	**50**	**59%**	**68%**	**28%**	**16**	**17%**	**27%**	**4%**	**86%**	**15**	**14**	**83%**	**85%**

Compl, Complications; *DASH*, disabilities of the arm, shoulder and hand; *F/E*, flexion/extension; *GE*, good-to-excellent; *PRWE*, patient rated wrist evaluation.

http://e-surg.com

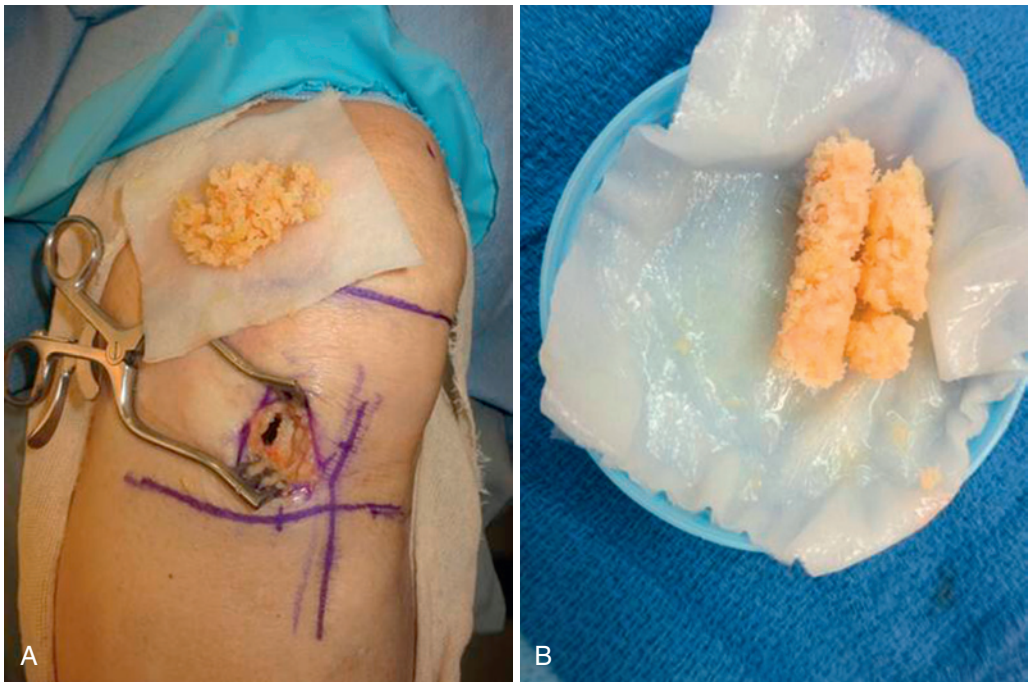

FIGURE 15.37 **A, B,** Approximately 25 cc of cancellous graft may be harvested rapidly with minimal morbidity from a small cortical window medial to the insertion of the patellar tendon on the tibia. The 2-cm oblique incision begins at a point 1 cm medial and 1 cm superior to the midpoint of the patellar tubercle.[76] (Redrawn with permission, Herford AS et al: Medial approach for tibial bone graft: anatomic study and clinical technique. *J Oral Maxillofac Surg* 61:358–363, 2003.)

posteriorly. With straight and curved 1-cm osteotomes, a section of the iliac crest 3 cm long and 1 cm thick is reflected cephalad on its medial periosteum and is still attached to the external oblique musculature. This exposes an abundant area of cancellous bone between the two cortical wings.

Cancellous bone is harvested and preserved in a moist saline-soaked sponge. The iliac crest flap is then turned back down into its bed and sutured in place. (This technique leaves virtually no cosmetic defect to either the eye or touch along the iliac crest.) The wound is then closed in layers over a suction catheter drain. Alternatively, a bone trephine set can be used to harvest one or more bicortical 10- to 12-mm plugs from the iliac wing through a 1- to 2-cm incision. Each harvest site is filled with thrombin-soaked Gelfoam® for hemostasis, and the area is infiltrated with a long-acting anesthetic. This procedure reduces the pain and local morbidity of iliac crest graft harvest, can be performed under local anesthesia with sedation, and generally obviates the need for an overnight stay or ambulatory assistance postoperatively.

Tibial Bone Graft Harvesting Technique

Up to 25 cc of cancellous graft can be harvested from the tibia, just medial to the tibial tubercle, without ambulatory aids or additional morbidity of an iliac crest graft.[76] The technique is rapid and straightforward and is adopted from work done by our maxilla-facial colleagues. The leg is prepared and draped from just below a sterile thigh tourniquet. A towel or sandbag is placed under the knee and the apex of the tibial tubercle is marked. Two perpendicular lines are marked, intersecting at this point: the first along the axis of the tibia and the second parallel to the joint line. The leg is exsanguinated and the tourniquet inflated.

A 2- to 3-cm oblique incision is made, centered on a point 1.5 cm proximal and 1.5 cm medial, at the tubercle apex (Figure 15.37) (see Case Study 15.1). Periosteum is incised and reflected, and a 15-mm oval or round defect is created with a K-wire driver and osteotomes. The cortical piece is lifted and saved for later replacement and an abundant cancellous graft is harvested. Thrombin-soaked Gelfoam is placed in the cavity, the cortical piece returned, and the periosteum and skin closed. A local compression dressing is applied, and the patient is allowed to bear weight immediately.

Bone graft substitutes may be used as an alternative to the harvesting of autogenous bone. With acute fractures, the need for structural support of the elevated articular surface generally outweighs the need for osteogenic stimulation of healing (see Figure 15.35, *B*). The intact radial metaphysis is normally an potent source of osteogenic cells, growth factors, and osteoinductive cancellous bone, and fractures through this area have a strikingly low rate of delayed union or nonunion.

The ability to expedite fracture healing by the addition of biologic products has not been demonstrated, except in situations in which healing potential has been compromised by disease or tobacco use.[99] Thus, bone graft substitutes that demonstrate compressive properties equal to or greater than cancellous bone are of greater utility in the management of comminuted articular fractures than are purely osteogenic or combined osteogenic-moldable putty formulations (see Case Study 15.2). The use of methyl methacrylate and other bone cements to support the articular surface has largely been abandoned because of their unfavorable mechanical properties.

The specific advantages and disadvantages of several common bone graft alternative categories are presented in eTable 15.1 (see ExpertConsult.com).

http://e-surg.com

CASE STUDY 15.2

A 57-year-old right-handed female presents after a fall onto an outstretched hand and 2 weeks of casting (eFigure 15.15). The operative technique using bone graft substitutes is displayed in eFigure 15.16.

Postoperative films and clinical photographs are displayed in eFigure 15.17.

http://e-surg.com

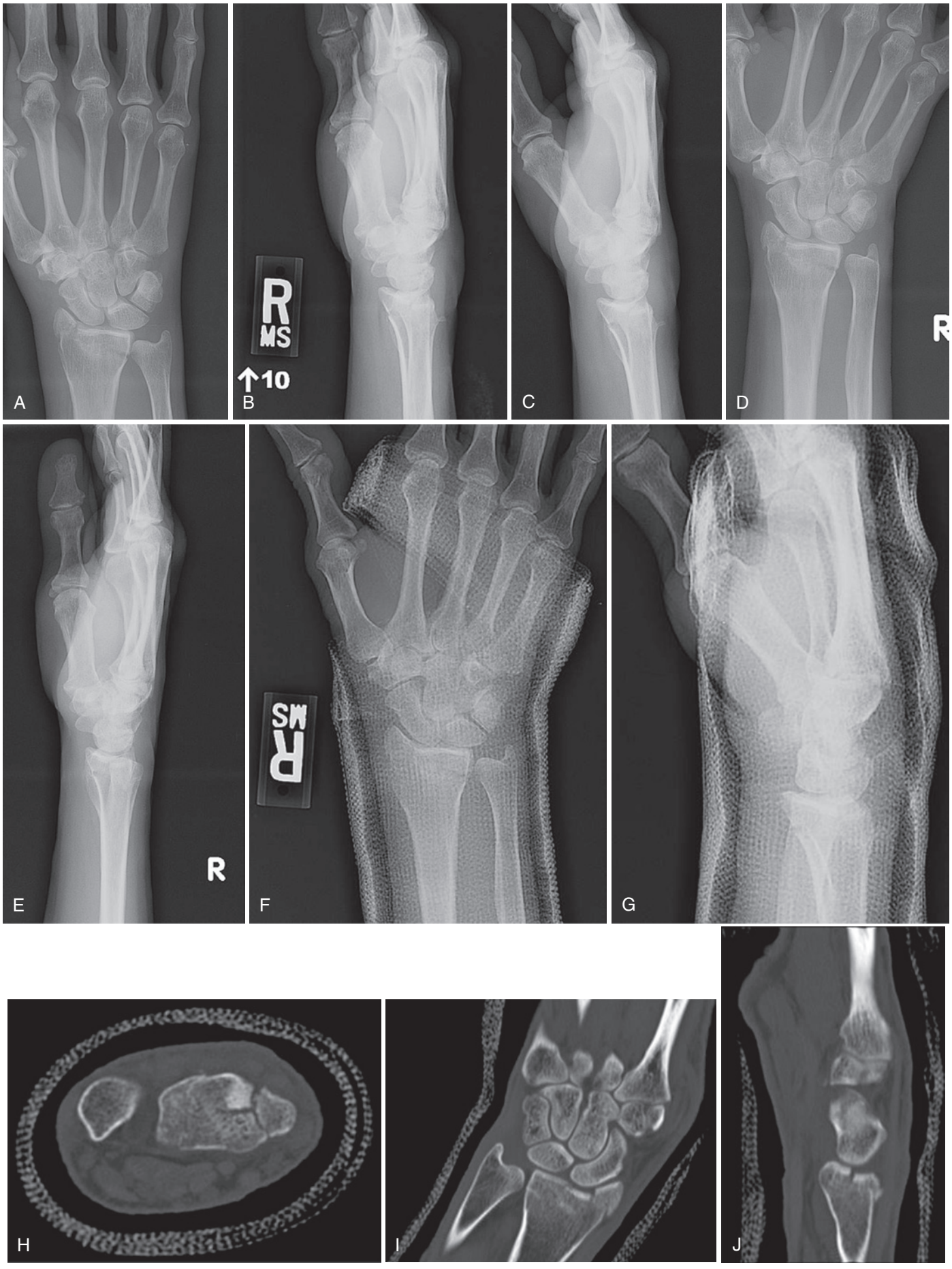

eFIGURE 15.15 **A-C,** Trauma films. **D, E,** Radiographs at 1 week postinjury. **F, G,** Preoperative radiographs at 2 weeks postinjury. **H,** Preoperative computed tomography (CT) axial view at 2 weeks postinjury. **I, J,** Preoperative CT coronal and sagittal view at 2 weeks postinjury.

http://e-surg.com

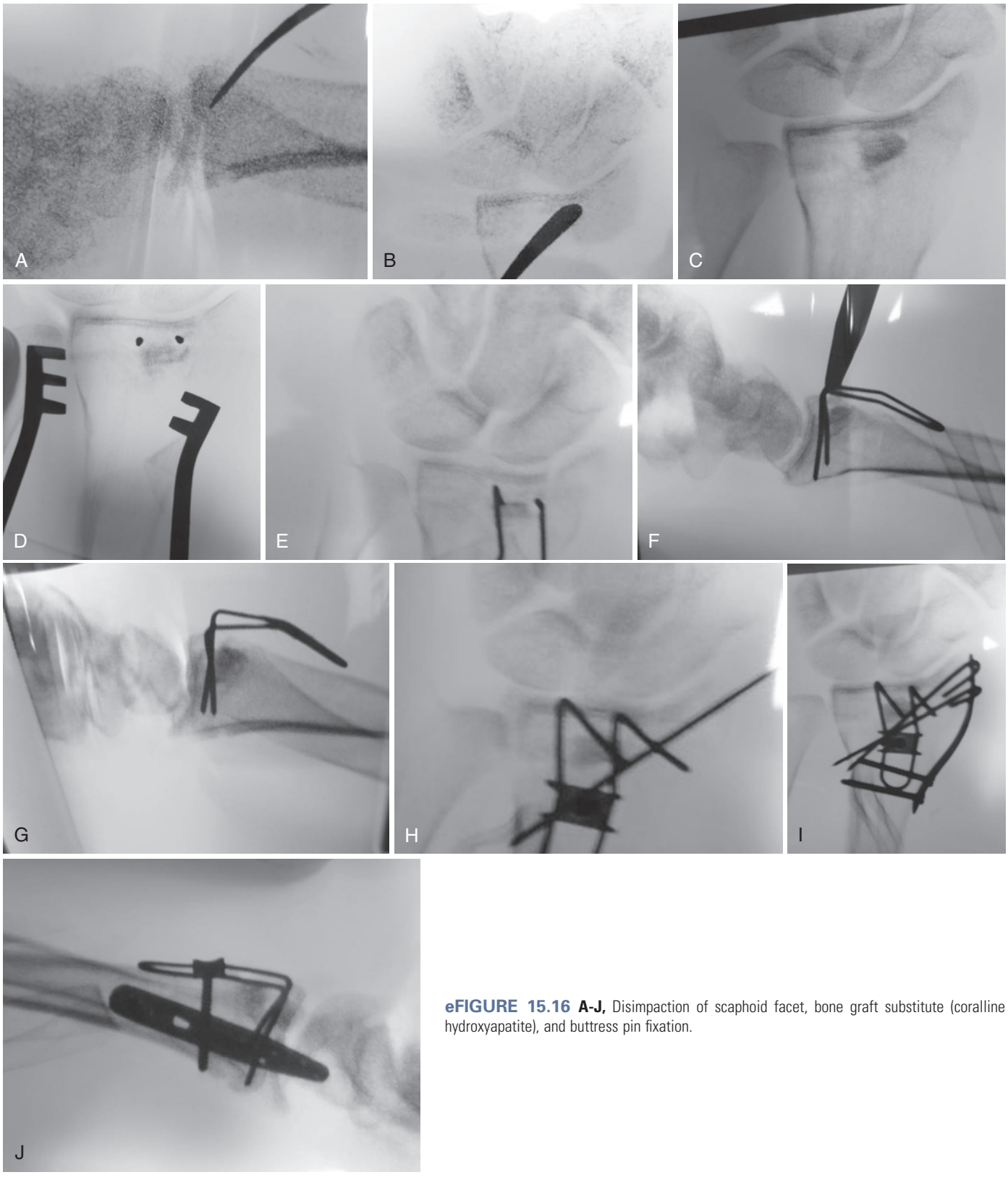

eFIGURE 15.16 A-J, Disimpaction of scaphoid facet, bone graft substitute (coralline hydroxyapatite), and buttress pin fixation.

http://e-surg.com

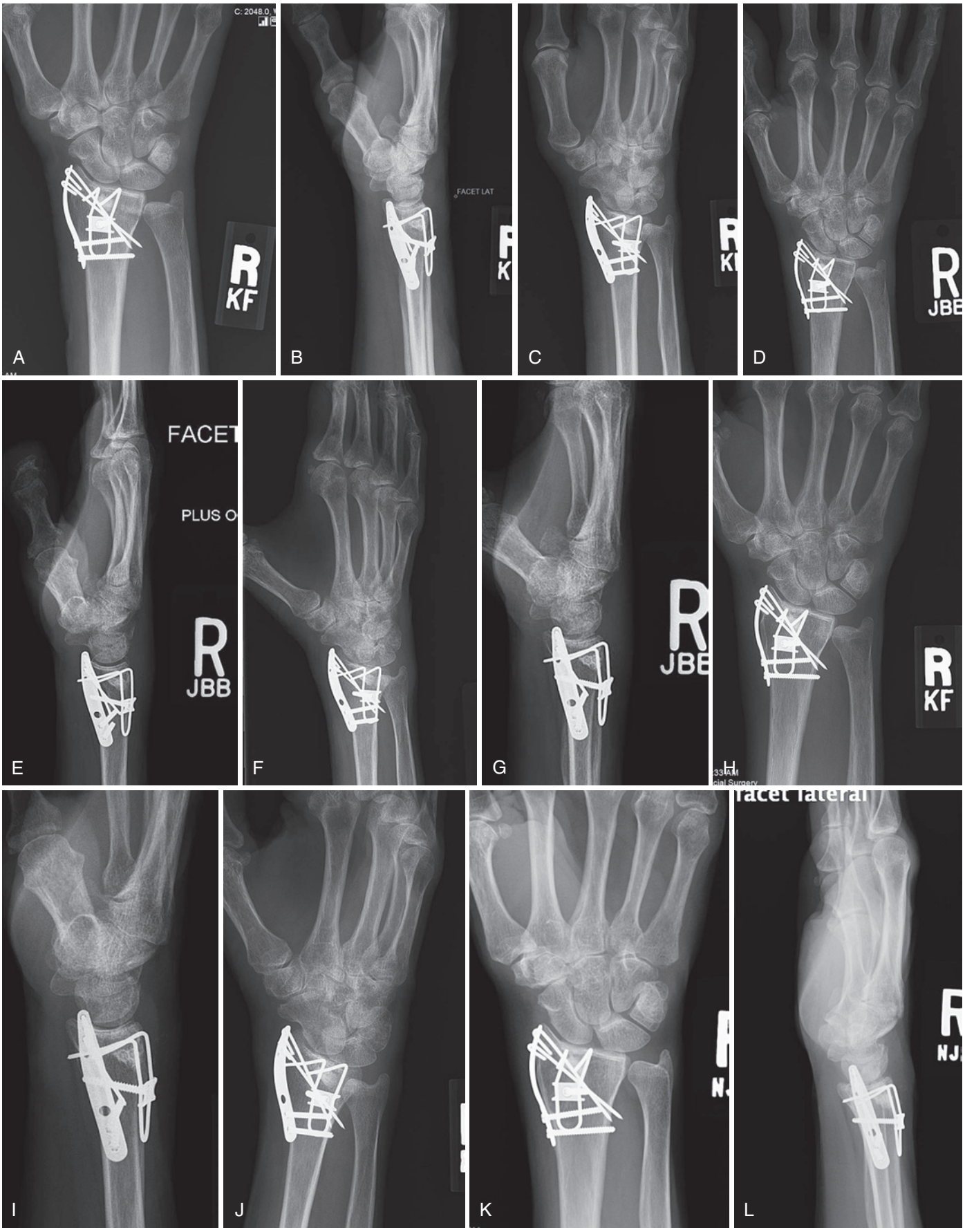

eFIGURE 15.17 Radiographs (**A-C**) at 9 days postoperative. Note coralline hydroxyapatite bone substitute (**B,** *arrow*). **D-G,** At 1 month postoperative. **H-J,** At 3 months postoperative. **K, L,** At 10 months postoperative.

http://e-surg.com

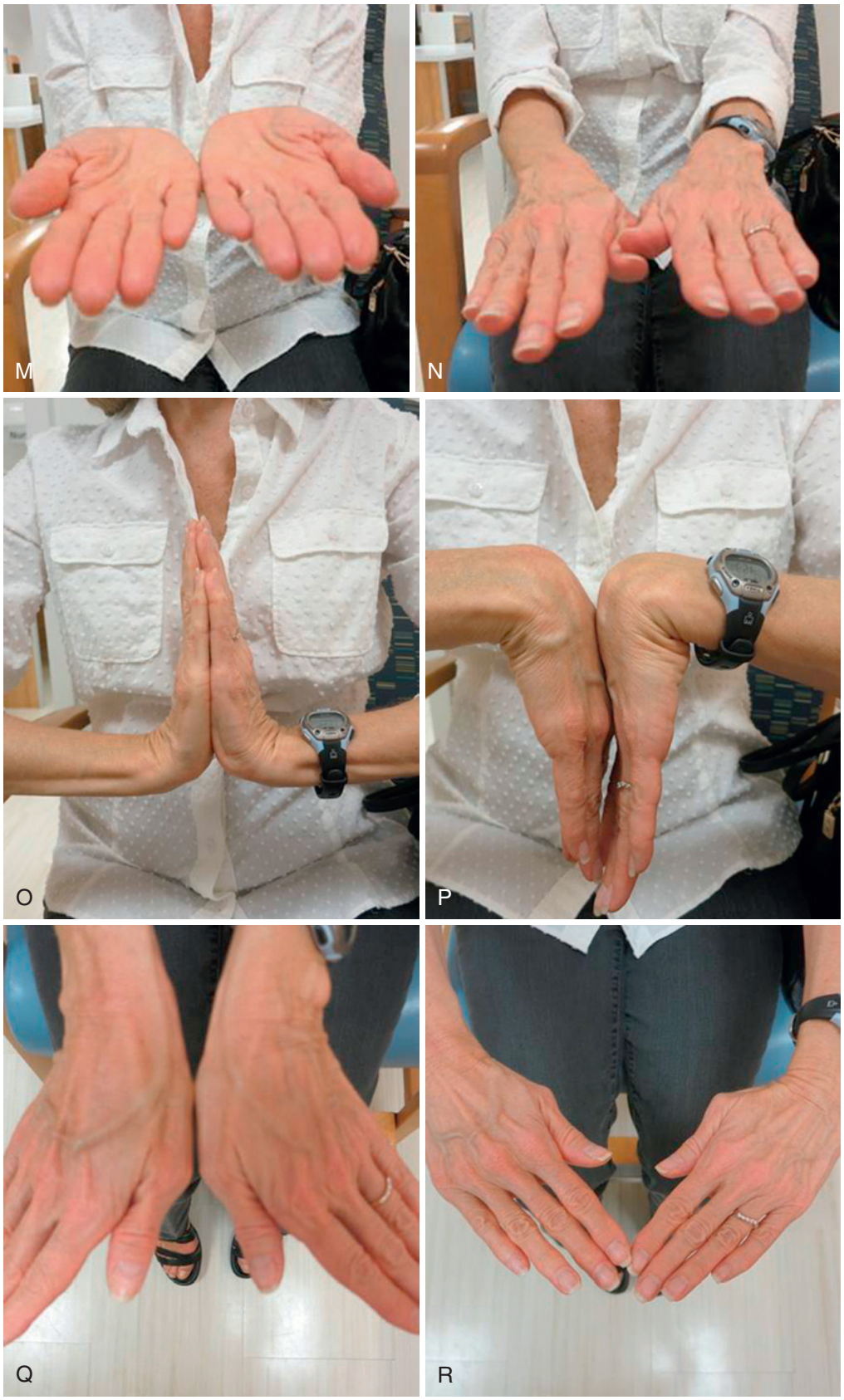

eFIGURE 15.17, cont'd **M-R,** Photos taken at 10 months postoperative.

http://e-surg.com

eTABLE 15.1 Alternatives to Autogenous Bone Graft for Management of Distal Radius Fractures

Type	Formulation	Application	Indications	Advantages	Disadvantages
Allograft					
Demineralized bone matrix	Amorphous, powder, gel, strips, putty, combinations	Manual insertion	Compromised host, impaired healing, nonunion	Osteoinductive and limited osteogenic potential	Variable osteogenic capability depending on composition and formulation; marginal to no structural support
Cancellous chips	5-7-mm freeze-dried cancellous chips	Manual packing	Metaphyseal void, elevated articular surface	Some structural support; osteoconductive and limited osteoinductive potential	Variable osteoinductive capability; limited structural support
Fresh frozen	Corticocancellous bone segments	Cut to shape, internal fixation	Segmental defect	Customized to defect, high structural support, osteoinductive	Rarely indicated for distal radius fractures, disease potential, immunogenicity, slow incorporation
Cancellous Substitutes					
Tricalcium phosphate combinations	Mixed with hydroxyapatite, collagen, marrow aspirate; available in strips, granules	Manual insertion	Metaphyseal void, elevated articular surface	Osteogenic and inductive when mixed with marrow aspirate	Minimal to no structural support, variable resorption rates
Calcium sulfate	Pellets, paste, putty	Manual or injectable; may harden to block form	Metaphyseal void, elevated articular surface	Resorbable defect filler, replaced by bone; injectable through minimal incision; may be combined with antibiotics	Minimal to no structural support, water soluble, rapidly resorbed
Nanoparticulate β-tricalcium phosphate (beta)	Blocks or granular, mixed with marrow	Manual or injectable	Metaphyseal void, elevated articular surface	Resorbable, injectable, porous; moderate compressive strength	Osteogenic and osteoinductive only if mixed with marrow
Coralline hydroxyapatite	Blocks, granules	Trimmed to shape defect	Metaphyseal void, elevated articular surface	Osteoconductive and porous; compressive strength equal to or exceeding that of cancellous bone; can shape to fit defect	Slow resorption; radiopacity may obscure healing
Bovine cancellous bone	Manual, trim to defect	Metaphyseal void, elevated articular surface	Osteoconductive, moderate structural support	Immunogenicity, variable osteoinductivity; not approved for use in United States	
Cements					
Calcium phosphate	Mixed components, hardens with time	Injectable, putty or block	Metaphyseal void, elevated articular surface	Can be injected percutaneously; animal models demonstrate resorption or remodeling; high compressive strength	Not osteoconductive or inductive; slow to remodel and reabsorb; lacks shear or tensile strength
PMMA	Mixed components, hardens in minutes	Injectable	Bone defect, metaphyseal void; augment ORIF in osteopenic bone	Can be injected percutaneously; high compressive strength	Not osteoconductive or inductive; exothermic; may cause thermal necrosis; brittle, poor shear or tensile strength; limited indications for distal radius
Biologics					
Recombinant BMP	Powder, strips, putty	Manual, injectable	Compromised host or tissue bed, nonunion or delayed union	Osteoinductive; may accelerate healing	Limited indications for distal radius application; dosage and timing not thoroughly studied

BMP, Bone morphogenetic protein; *ORIF*, open reduction and internal fixation; *PMMA*, polymethyl methacrylate.

http://e-surg.com

Open Reduction and Internal Fixation

Open reduction of distal radius fractures is indicated in active patients when satisfactory reduction cannot be achieved or maintained by closed manipulation and casting, and as an alternative to percutaneous fixation at the preference of the patient or surgeon. There is increasing evidence to support equivalent functional, clinical, and radiographic outcomes of fixed-angle internal fixation when compared with percutaneous and indirect fixation,[105,174] and it is an attractive alternative to the bulkiness and pin care issues of external fixation. Open reduction has also been demonstrated to yield improved radiographic alignment when compared with percutaneous pins and repeat closed reduction for fractures that have lost the original reduction after a trial of closed reduction and casting.[112]

Articular fractures in elderly, inactive patients, and in those with considerable osteoporosis, have traditionally been considered a contraindication to open reduction because in these patients there is a risk for complications, including fixation failure, nonunion, and reflex sympathetic dystrophy. However, since the introduction of fixed-angle internal-fixation devices, both unstable extraarticular and simple articular fractures in the elderly, active osteoporotic patients have had increasingly satisfactory outcomes with ORIF.[126] Subchondral buttressing with locking pins or screws secured to the plate greatly reduces the incidence of settling or secondary articular displacement, as well as the need for a supplemental bone graft (Figure 15.38).

The choice of surgical approach depends largely on the location and direction of displacement of the fracture fragments. Thus, dorsally or radially displaced fractures have been classically approached through dorsal incisions, whereas volarly displaced fractures (e.g., the Smith and reversed Barton) are classically approached through palmar exposures. There has been increased interest in the management of dorsally displaced nonarticular and articular fractures with volar fixed-angle plate fixation in an attempt to decrease the incidence of extensor tendon irritation associated with dorsal implants. When using multiple plates or fragment-specific fixation, dorsal, radial palmar, ulnar–volar, and ulnar incisions are used in combination, as dictated by the particular fracture's configuration.

General factors limiting surgical reconstruction of the articular surface include the number of fragments, their size, the amount of cancellous bone impaction, and associated traumatic lesions of the articular cartilage. Alternatives to open anatomic restoration, including percutaneous fixation and bridge plating, should be considered in cases of extreme articular comminution. In these cases, efforts should be directed at restoring the anatomic relationships of the radius and ulna and to ensuring normal alignment of the hand and carpus with the long axis of the forearm by percutaneous and indirect means. If radiocarpal arthritic changes subsequently occur, the restoration of normal length and alignment will greatly facilitate the performance of secondary reconstructive procedures.

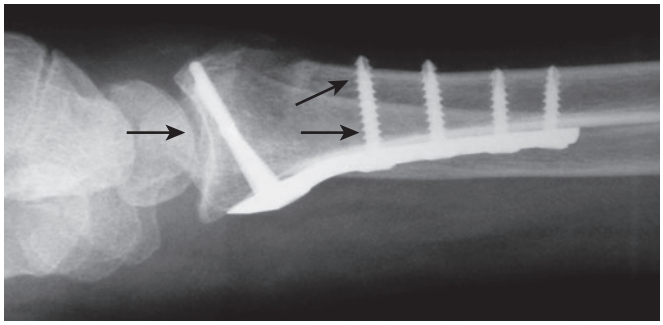

FIGURE 15.38 Ideal positioning of a volar fixed-angle plate. Notice the subchondral positioning of the distal fixed-angle pegs, by virtue of which axial loading is transmitted to the pegs and the volar plate and to the radial shaft. The dorsal comminuted area has not been grafted in this case.

Dorsal Plate Fixation

Although satisfactory outcomes have been reported with dorsal plating systems, the incidence of extensor tendon complications, including irritation, synovitis, attrition, and tendon rupture, is not negligible.[9,23,83] A dorsal approach is preferred by many surgeons in the more comminuted C3 type fractures because of improved visualization and ease of reduction of the impacted articular surface, or when the use of a bone graft is needed. Low-profile and stainless steel plates have a decreased incidence of dorsal tendinopathy when compared to traditional 3.5-mm implants[177]; however, with increased versatility, mechanical strength, and ease of application of fixed-angle volar devices, isolated dorsal-plate fixation for distal radius fractures is less commonly performed.

"Universal" Dorsal Approach to the Distal Radius. A 3- to 10-cm straight dorsal incision is made just ulnar to the Lister tubercle, centered over the radial metaphysis. Full-thickness skin flaps are raised at the retinacular level, including the dorsal sensory branches of the radial and ulnar nerves. An ulnar-based retinacular flap is begun just ulnar to the Lister tubercle and elevated to expose the EPL and the tendons of the fourth compartment. Some surgeons prefer to elevate the fourth dorsal compartment subperiosteally without exposing the tendons themselves. A 2-cm segment of the posterior interosseous nerve can be removed at the discretion of the surgeon. Subperiosteal exposure yields direct visualization of the fracture fragments, so rarely is it necessary to violate the wrist capsule. Additional exposure of the dorsal–radial styloid can be performed by undermining the second and first dorsal compartments.

Direct and indirect reduction of the fracture fragments is performed and confirmed with fluoroscopy, and temporary fixation is done with K-wires through the styloid and dorsal–ulnar corner of the radius. Articular reduction is facilitated by using a Freer elevator and subchondral elevation (see Figure 15.35), with the carpus being used as a template for reduction. Placement of the plate may be facilitated by removal of the Lister tubercle. The plate is contoured and fitted to the dorsal surface and conventional screws, or 2.4-mm fixed-angle pegs and screws, are inserted to support the subchondral bone. The tendons of the second and fourth compartments are put back over the plate, and a portion of the retinaculum can be used as an interposition flap between the tendons and the distal plate. The EPL tendon is primarily transposed to a subcutaneous position when closing the dorsal retinaculum (Figure 15.39).

If using older implants without angular stable fixation, the use of an autogenous iliac bone graft, or an appropriate structural bone graft substitute, to support comminuted or impacted articular fragments is important. If fixed-angle devices with subchondral buttressing are used, the need for bone grafting is reduced because the chance of secondary displacement of

http://e-surg.com



FIGURE 15.39 Comminuted articular fracture treated by dorsal plate fixation: **A, B,** Posteroanterior and lateral films demonstrate marked dorsal comminution. **C,** Subperiosteal exposure through a universal dorsal approach demonstrates dorsal fragmentation. **D,** A low-profile fixed-angle dorsal plate is applied after removal of the Lister tubercle. **E,** Retinacular closure. **F, G,** Healed postoperative radiographs demonstrate restoration of length and alignment. (Courtesy of Andrew J, Weiland MD, with permission.)

articular fragments is diminished by the increased structural properties of the fixed-angle plate. A compilation of published studies about internal fixation from 2000 to 2014 demonstrates that bone grafts were employed in 23% of cases in which single dorsal plates were used, in 25% of cases in which multiple fragment-specific plates were used, and in 7% of procedures that used volar fixed-angle plates (see Table 15.2). With the technologic improvements in angular stable plate design over the past 5 years, supplemental bone graft use has dropped to 8% or less for all types of internal fixations.

Volar Plate Fixation Technique. Regardless of the displacement of the distal fragment (i.e., dorsal, volar, radial), volar plating

http://e-surg.com

of both articular and nonarticular fractures is an effective fixation method that may reduce some of the soft tissue complications associated with dorsal plating. Advantages of palmar exposure and volar plating include the following:

- Minimal volar comminution facilitates reduction of dorsally displaced fractures.
- Anatomic reduction of the volar cortex facilitates restoration of radial length, inclination, and volar tilt.
- Avoidance of additional dorsal dissection helps preserve the vascular supply of comminuted dorsal fragments.
- Because the wrist's volar compartment has a larger cross-sectional space and the implant is separated from the flexor tendons by the pronator quadratus, the incidence of flexor tendon complications is minimized.
- The use of fixed-angle volar plate designs avoids screw "toggling" in the distal fragment and thus reduces the danger of secondary displacement.
- When stabilized with a fixed-angle, internal-fixation device that uses subchondral pegs or screws, control of shortening and late displacement of articular fragments are improved and the need for bone grafting is reduced (see Figure 15.38).

Fractures are exposed through the distal part of the Henry approach between the FCR and radial artery via an 8- to 9-cm longitudinal incision that courses proximally from the wrist crease. It is not generally necessary to cross the wrist crease, but an oblique "hockey-stick" extension can be made toward the scaphoid tubercle if additional exposure is required. The subsheath of the FCR is opened along its radial border to avoid inadvertent injury to the nearby palmar cutaneous branch of the median nerve. The virtual space beneath the flexor tendons is developed and the FCR and flexor tendons are retracted to the ulnar side, thus protecting the median nerve and its palmar branch.

The radial vascular bundle is retracted radially to expose the flexor pollicis longus (FPL) and the pronator quadratus, then transverse radial artery branches are cauterized. The distal fibers of the FPL muscle belly may require partial release from the radius for adequate radial shaft exposure. The brachioradialis tendon is sharply separated from overlying soft tissues and split longitudinally at the level of the pronator quadratus for 5 to 8 cm to its insertion on the radial styloid. It is not necessary to completely transect the BR tendon in most acute cases, though many surgeons do this routinely; there are no reported adverse consequences of BR release.

The first dorsal compartment is easily released to improve visualization of the radial styloid. Elevation of the pronator in continuity with the volar half of the split BR tendon facilitates anatomic suture repair and ensures plate coverage at the conclusion of the procedure (Figure 15.40; see also Figure 15.42 later). The distal border of the pronator is sharply incised at the volar lip of the radius and the muscle sharply reflected ulnarly from the radius and volar fragments. A manual reduction is performed, usually aided by traction and manipulation of the fragments against the surgeon's thumb that is held as a buttress on the metaphyseal flare of the radius. If anatomic reduction is confirmed clinically and with fluoroscopy, it is preferable to fix the fracture temporarily with an oblique 0.062-in K-wire inserted percutaneously through the radial styloid. Any degree of coronal shift of the articular fragment should be corrected at this juncture.[38,134]

I prefer to deliver a radial-directed moment via a small Bennett retractor, placed strategically on the ulnar metaphyseal flare of the radial shaft fragment. A clamp on the radial shaft proximal to the fracture is also useful in this regard. Counterpressure on the articular fragment in an ulnar direction is performed to reduce the fragment (Figure 15.41, *A, B*). Reduction

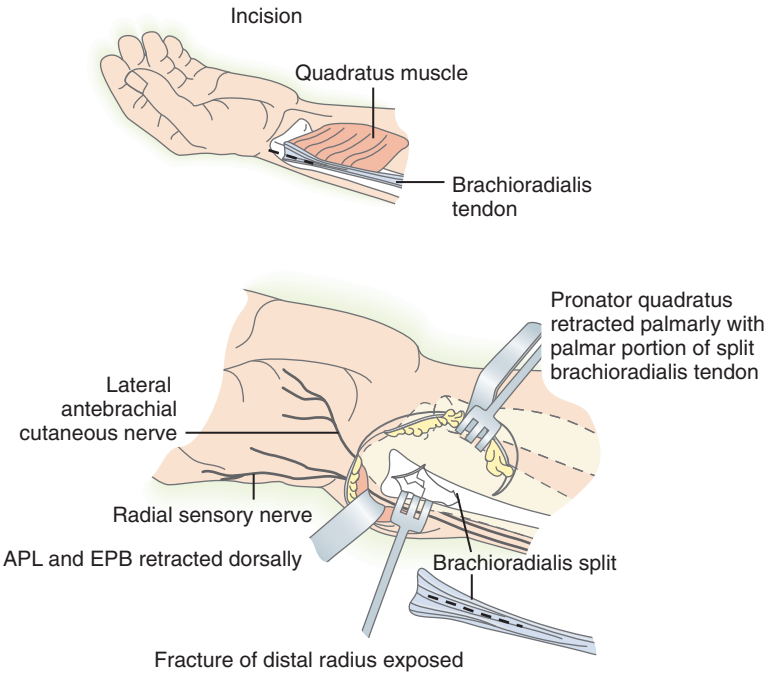

FIGURE 15.40 Volar–radial approach to the distal radius. The brachioradialis tendon may be split and elevated subperiosteally to expose the radial and intermediate columns and the volar aspect of the distal radius. *APL*, Abductor pollicis longus; *EPB*, extensor pollicis brevis. (© 2001, Virginia Ferrante.)

http://e-surg.com

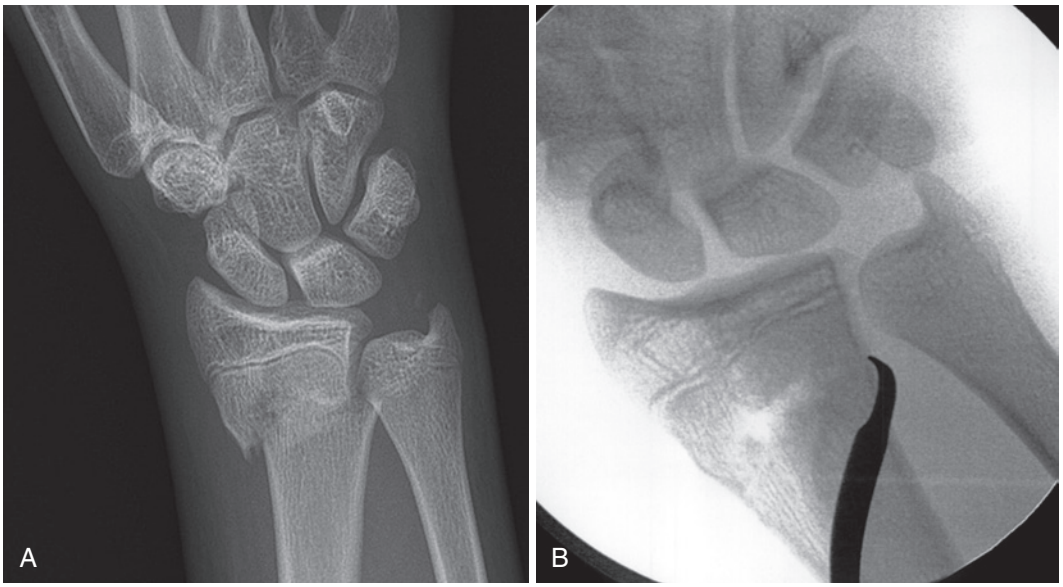

FIGURE 15.41 Reduction of radial translation (coronal shift): **A,** Prereduction fluoroscopy indicating a 4-mm radial coronal shift of the articular fragment in a 16-year-old golfer. **B,** A Hohmann retractor is placed on the ulnar border of the radial metaphyseal flare, proximal to the fracture line. Firm radial directed force is applied while the fracture fragment is pushed ulnarward to seat the ulna in the sigmoid notch.

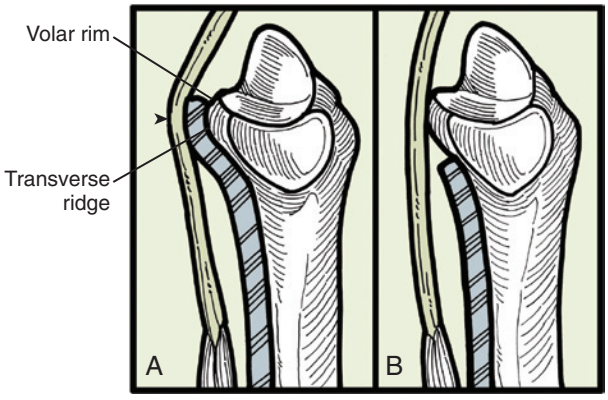

FIGURE 15.42 **A,** Incorrect placement of a volar fixed-angle device. A Soong grade 2 plate placement,[147] characterized by prominence of the hardware above the critical line, and within 2 mm of the tip of the volar rim. Without coverage by the pronator, the flexor tendons are in direct contact with the plate and may rupture. **B,** Correct placement of the implant, recessed proximally and with sufficient soft tissue coverage to prevent flexor irritation and rupture. (© Elizabeth Martin.)

of the coronal shift and anatomic seating of the distal ulna into the sigmoid notch of the radius is confirmed fluoroscopically on the frontal view.

A volar plate is chosen and contoured as necessary to fit the volar metaphyseal flare of the radius. Care needs to be taken to avoid placement of the plate distal to the transverse radial ridge (i.e., the so-called "watershed" line) because implants on the volar lip of the radius are in direct continuity with the flexor tendons, and there is a risk of tendon irritation and rupture (Figure 15.42).[33] Hardware placed 2 mm or more above the volar critical line (Soong Grade 1)[147] or within 3 mm of the distal edge of the volar rim (Soong Grade 2)[147] has been demonstrated to have a high rate of tendon rupture.[90] If fixation of the plate distal to this ridge is deemed necessary to stabilize small marginal or volar ulnar fragments, I recommend consideration of a tension-band fixation[25] or a low-profile miniplate or a wireform construct as alternative solutions to avoid the serious complication of flexor tendon rupture. If a decision is made to use a volar plate in this position, scheduled hardware removal should be discussed with the patient.

When optimal plate position is confirmed, the plate is provisionally fixed with K-wires or with a single screw in the oval hole of the plate at the diaphyseal level. Distal or proximal fine-tuning of plate position can be performed, as determined with fluoroscopy, to align the projected angles of the distal screws or pegs immediately beneath the subchondral bone on the facet lateral fluoroscopic image. It is important that volar tilt be restored before finalizing plate position to optimize peg placement beneath the subchondral bone and minimize articular penetration.

This is particularly important for patients with osteoporotic bone; subchondral buttressing with the locked pegs effectively controls fracture settling or dorsal displacement. It is also essential to contour the plate to match the patient's normal metaphyseal volar flare; undercontouring it can translate the articular surface dorsally or rotate the fragment into an unacceptable dorsal tilt position when associated with extensive dorsal comminution.

When optimal plate position is realized, the remainder of the proximal shaft screws are placed. It is important to have six cortices proximal to the fracture site for adequate fixation, although four may be adequate with locking screws. Longer metadiaphyseal plates are available in most sets to span comminuted or segmental fracture varieties. With the proximal plate fixed, fine-tuning of the reduction is performed and distal fixation is achieved by locking smooth pegs or screws into threaded holes in the distal plate.

Dozens of different plates are available, and several feature "multiaxial" screw projection to enable alteration of screw or peg angle to suit a particular fracture anatomy. Precise drilling with custom drill guides that are screwed or snapped into the

http://e-surg.com

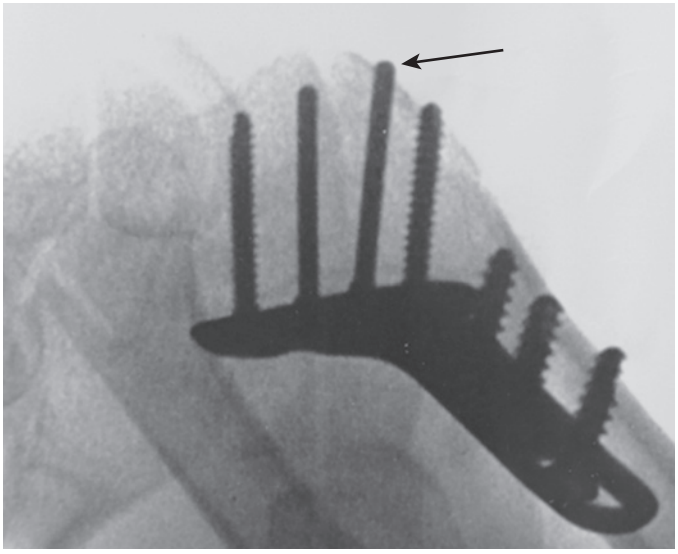

FIGURE 15.43 Tangential fluoroscopic or "horizon" views of the radius are essential to avoid protrusion of locking screws dorsally (*arrow*), risking delayed tendon rupture.

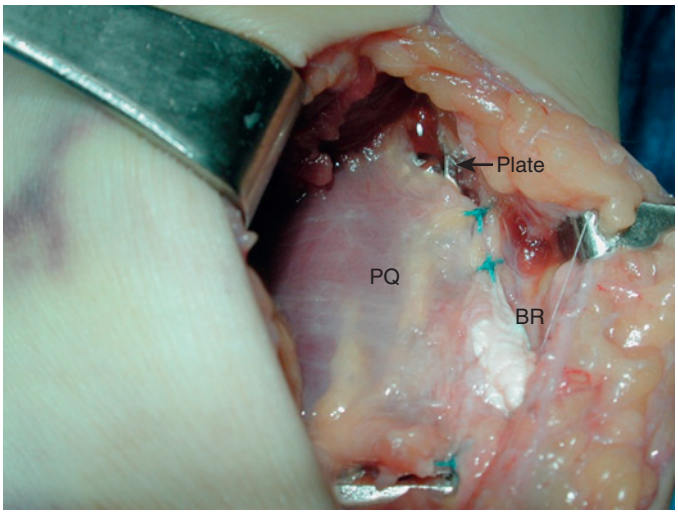

FIGURE 15.44 Splitting the brachioradialis (BR) longitudinally and leaving its volar tendinous portion attached to the pronator quadratus (PQ) allows a stout repair over the volar plate on closure.

distal holes is necessary when using fixed-angle devices to ensure engagement of the threaded heads on the plate. While most plates feature double rows of screw holes, inserting half of the pegs or screws achieves comparable mechanical strength,[120] especially if staggered between proximal and distal rows.[32] Use of screws or pegs is largely the surgeon's preference; there is no mechanical advantage to either, and the ease of insertion of smooth pegs may be offset by the increased difficulty of removal at a later date.[64]

Careful fluoroscopic assessment of screw length is mandatory to prevent its prominence dorsally and to detect articular protrusion. Several specialized views have been recommended to detect dorsal protrusion, and it is sensible to thoroughly evaluate final screw placement with a combination of lateral, supination, pronation, and dorsal tangential[127] or "horizon" views[78] (Figure 15.43). With locked screws or pegs, there is no mechanical advantage to penetration or purchase of the dorsal cortical bone; thus, it is recommended that screws 2 mm shorter than the measured length be routinely employed distally.

Although there is no demonstrated advantage to closure of the pronator quadratus, the implant can be easily covered with the pronator by restoring the split portion of the BR to the remaining tendon on the radius (Figure 15.44). The wound is closed in layers, and drainage is rarely necessary. The stability of the radioulnar joint is assessed and addressed as necessary. I routinely utilize a plaster sugar tong splint in full supination until suture removal 10 to 14 days postoperatively, followed by use of a removable wrist brace for comfort. Patients are encouraged to mobilize the digits immediately after surgery. Light functional use of the hand and wrist (e.g., eating, dressing, writing, typing) is permitted after suture removal (Figure 15.45). For elderly patients with an osteoporotic bone, the postoperative regimen can be modified as needed; if insufficient fixation is suspected, a light forearm cast is applied for 4 to 5 weeks after suture removal.

If anatomic reduction of the articular surface and dorsal marginal fragments cannot be achieved with manual reduction through the volar Henry incision, Orbay and Fernandez recommend an extended Henry approach to enable direct articular reduction.[125] To gain this degree of exposure, the entire proximal radius is pronated away from the fractured articular components by performing an extensive soft tissue release. It is theorized that complete subperiosteal elevation from the metaphyseal–diaphyseal portion of the radius is tolerated because of a rich endosteal blood supply.

The first step in the exposure is release of the radial septum (insertion of the BR and the palmar sheath of the first extensor compartment) to facilitate reduction of the radial styloid fragment. Next, the surgeon performs a subperiosteal exposure of the distal third of the radial diaphysis. Finally, to visualize the dorsal die-punch and centrally impacted fragments through the fracture plane, the proximal shaft fragment is fully pronated with a bone clamp. Using direct visualization, the fragments can be manipulated into a reduced position against the proximal carpal row (Figure 15.46). Thereafter, the proximal fragment is supinated back into place and a volar fixed-angle plate is applied. An attempt is made to fix large dorsal–ulnar fragments with locking screws through the plate. Orbay and Fernandez cite preservation of the extensor tendon sleeve and a reduced incidence of extensor tendinopathy as advantages of this exposure.

Alternatively, displaced fragments of the dorsal rim or intermediate column can be reduced and fixed by direct exposure through a limited dorsal incision with the application of additional 2.0- or 2.4-mm implants (or by reduction and stabilization with distal screws from the volar plate). Similarly, if complete capture of a large or comminuted radial styloid fragment cannot be attained with one or two of the locked pegs, the surgeon should definitely consider the addition of a radial column plate to complement volar fixation and prevent undesirable settling and consequent incongruity of the styloid and its scaphoid facet (Figure 15.47). Finally, volar fixed-angle plate fixation is not ideal for a small volar–ulnar corner or "teardrop" lunate facet fragments.[39] Failure to adequately capture this fragment with plate coverage and one or two locked pegs may

http://e-surg.com



FIGURE 15.45 Coronal split Smith type II fracture fixed with a volar locked-plate and immediate motion: **A, B,** Coronal split through the articular surface (*arrows*). **C, D,** Volar locked-plate fixation. **E, F,** Photos of range of flexion and extension 12 weeks postoperatively.

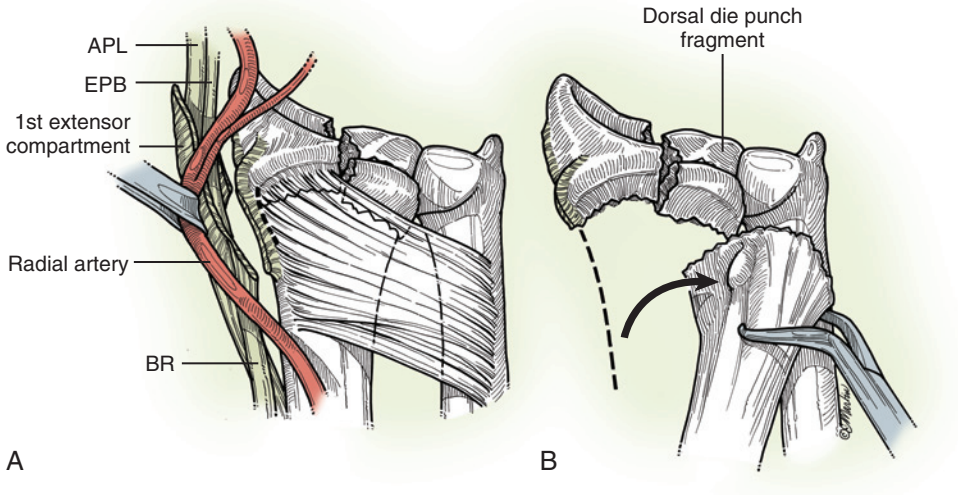

FIGURE 15.46 **A, B,** The extended volar approach enables direct disimpaction of articular fragments by subperiosteal exposure of the distal third of the radius and pronation of the proximal fragment. *APL*, Abductor pollicis longus; *BR*, brachioradialis; *EPB*, extensor pollicis brevis. (Adapted from Orbay JL, Fernandez DL: Volar fixation for dorsally displaced fractures of the distal radius: a preliminary report. *J Hand Surg [Am]* 27:205–215, 2002. Redrawn and © by Elizabeth Martin.)

result in loss of fixation[12] and palmar translation of the entire carpus during the postoperative period (Figure 15.48). Additional fixation of this fragment may be achieved with K-wires, a tension band, a 2.0-mm miniplate, a spring wire,[117] or a volar buttress pin.

Fragment-Specific Fixation

In an attempt to minimize the morbidity of extensive surgical dissections associated with conventional dorsal plate fixation of distal radius fractures, Robert Medoff devised a hybrid technique of percutaneous wire and plate fixation designed

http://e-surg.com



FIGURE 15.47 Hybrid fixation of the radial styloid: **A, B,** Posteroanterior (PA) and lateral radiographs demonstrating a comminuted articular fracture with palmar displacement and a large radial styloid fragment. **C,** PA radiograph 3 weeks postoperatively demonstrating incomplete fixation of the radial styloid. **D, E,** Computed tomography confirms insufficient styloid fixation with articular incongruency. **F,** Photo of revision stabilization of the radial column with a radial column plate and bone graft. **G, H,** PA and lateral radiographs of the healed construct.



FIGURE 15.48 **A, B,** Palmar subluxation of the carpus after volar plate fixation. Note the palmar and proximal translation of the carpus as a result of loss of fixation of the volar ulnar fragment on the lateral radiograph.

http://e-surg.com

CRITICAL POINTS *Volar Fixed-Angle Plate Fixation*

Indications
- Unstable nonarticular fractures of the distal radius (including osteoporotic bone)
- Nascent and established distal radius malunion
- Articular fractures

Contraindications
- Marginal shear fractures; very distal fracture–dislocations
- Small volar–ulnar corner fragment

Technical Points
- Make a longitudinal incision along the FCR tendon.
- Expose the pronator quadratus between the FCR and the radial artery.
- Release the first dorsal compartment tendons to expose the radial styloid.
- Detach the pronator quadratus with an "L"-shaped incision and leave a portion of the split BR attached to the pronator for subsequent closure.
- Reduce the fracture by restoring the volar cortex.
- Reduce any residual coronal shift of the distal fragment.
- Provide temporary fracture fixation with an oblique K-wire through the radial styloid.
- Apply the plate volarly and fix it to the shaft through an oval hole.
- Determine the ideal plate position with fluoroscopy, then place the remaining shaft screws.
- Avoid placement of plate on distal transverse ridge of the radius to prevent tendon rupture.
- Insert fixed-angle pegs or screws in a subchondral position.
- Insert screws 2 mm shorter than the measured length.
- Use a facet lateral fluoroscopic view to prevent articular protrusion.
- Use multiple fluoroscopic views, including a dorsal tangential one, to prevent dorsal screw prominence.
- Assess the adequacy of dorsal–ulnar fragment and radial styloid reduction and fixation and augment, as necessary, with columnar plates.
- Consider alternative or additional fixation of the volar lunate facet fragment if not adequately captured by the volar plate.
- Assess stability of the distal radioulnar joint, and treat as necessary.
- For articular fractures that are not reducible, an extended FCR approach is an option:
  - Perform a tenotomy of the BR tendon.
  - Release the first dorsal compartment.
  - Pronate the proximal fragment to expose the articular surface.

Postoperative Care
- Apply a sugar tong splint in supination for 10 to 12 days until suture removal.
- Begin digital range-of-motion exercises immediately.
- Begin forearm rotation and gentle active wrist motion exercises at the first postoperative visit.
- Evaluate with radiographs at the initial postoperative visit and at 6 weeks postoperatively.

to fix individual fracture fragments through several small incisions.[10,102] His "fragment-specific" classification (see Figure 15.18) defines articular fractures of the radius by recognition of five elemental fragments present alone or in combination in every fracture. The technique involves the use of ultrathin modular implants that can be shaped to customize fixation for various fragment configurations; the Medoff technique builds on the work of Rikli and Regazzoni[133] by placing these implants strategically along the radial and intermediate columns (see Figure 15.19) to maximize construct rigidity.[77]

The key component of the implant system is the so-called *pin plate* (TriMed, Inc., Valencia, CA), which combines the versatility of a K-wire with the rigidity of plate-and-screw fixation. The bending stiffness of conventional K-wire fixation is dramatically increased by passing the wire through the free end of a miniature 2.0-mm plate, secured proximally to the radial shaft, to create a pin plate hybrid with a three-point fixation. Mechanical studies using an unstable metaphyseal fracture model have demonstrated that dual 2.0-mm plates, when placed at 50- to 90-degree angles to each other in the axial plane, provide fixation that is statistically superior to that of either K-wire–augmented external fixation or to a traditional 3.5-mm dorsal "T"-plate.[35,129] Thus, the use of the term "fragment-specific fixation" in this text does not refer to a particular implant type but to the concept of the use of two or more low-profile implants placed strategically along the columns of the distal radius to fix individual fracture fragments.

Five recent single-cohort clinical series and one randomized trial totaling more than 450 patients, and using a variety of bicolumnar low-profile miniplate or wireform fixations, documented good-to-excellent results in 96% of patients at an average follow-up of 20 months (see Table 15.2).[13,77,94] The fractures were predominantly AO C-type (80%), and a supplemental bone graft was used for 25% of them. Grip strength was restored to 87% of the opposite side and flexion–extension to 86%. Average disabilities of arm, shoulder and hand (DASH) scores on 366 of the patients measured 8 on a 100-point scale. Fragment-specific fixation is indicated for most unstable and high-energy articular fractures of the distal radius and is generally contraindicated for fractures with substantial metaphyseal–diaphyseal extension or severe osteoporosis.

The radial styloid fragment is regarded as the cornerstone for reduction and stability of articular distal radius fractures and is therefore addressed first in the sequence of multifragment reduction and fixation. The other key fragments to be considered include the volar lip, the dorsal wall, the dorsal and volar components of the lunate facet, and the impacted articular (see Figure 15.18). Traction of 5 to 10 lb, applied via finger traps on the index and long fingers or through the use of a formal traction table, is helpful to grossly align fragments. Fluoroscopic images in traction are a valuable adjunct to assess the nature of the fracture and its key components.

The radial styloid is approached through a 4- to 5-cm incision on the volar–radial aspect of the metaphyseal flare, just radial to the radial artery and palmar to the tendons of the first dorsal compartment. Superficial branches of the radial sensory and antebrachial cutaneous nerves are retracted in the skin flaps, and the first dorsal compartment is opened to expose and retract its tendons. The BR tendon is split longitudinally and the tendon and periosteum are elevated in a dorsal and palmar plane to expose the radius (see Figure 15.40).

Complete palmar exposure of the radius is accomplished by elevating the pronator quadratus in continuity with the palmar margin of the BR. If necessary, the entire radial styloid can be exposed by dorsal elevation beneath the second dorsal compartment. The styloid fragment is reduced anatomically and fixed provisionally with a 0.045-in K-wire. At this time, attention is directed to the intermediate column of the radius for reduction

http://e-surg.com

and fixation of the lunate facet and impacted articular fragments.

Dorsal intermediate column fragments are most commonly approached through a 4- to 5-cm universal dorsal incision over the third dorsal compartment, where the dorsal wall, articular fragments, and the dorsal–ulnar corner can be simultaneously addressed. The EPL is isolated and primarily transposed out of its compartment, and the radial metaphysis can be widely exposed by elevating the second or fourth (or both) compartments in a subperiosteal fashion. The comminuted dorsal cortical wall can be lifted to expose the radial metaphysis and a Freer elevator used to disimpact the articular fragments and elevate the articular surface en bloc against the template of the proximal carpal row bones (see Figure 15.35).

It is not generally necessary to open the dorsal capsule to directly inspect the articular surface because fluoroscopy is used to document reduction of the fracture fragments and the articular surface. An autogenous bone graft or a suitable structural bone graft substitute can be utilized at the surgeon's discretion to augment the reduction of the impacted articular fragments (see Figure 15.35, *B*). The dorsal intermediate column fragments are then directly reduced and fixed in position with any of a series of modular wireform implants, 2.4-mm angular stable plates[80] that capture and hold the small periarticular fragments (Figure 15.49; see also Case Study 15.2).

An isolated dorsal–ulnar fragment may be accessed and reduced using a limited approach through the fifth dorsal compartment. It is important to note that this incision is not extensile and cannot be readily enlarged to gain access to larger metaphyseal and impacted articular fragments; thus, if multiple dorsal fragments require reduction and fixation, a standard dorsal approach is preferred. A 3- to 4-cm incision is made directly over the radioulnar joint. The EDM is identified and transposed out of its compartment after dividing the extensor retinaculum of the fifth dorsal compartment. Great care needs to be taken to avoid iatrogenic disruption of the dorsal radioulnar ligament as the dorsal–ulnar fragment is exposed and reduced. Reduction is facilitated by the use of a dental pick to anatomically align the fragment's proximal cortical margins.

A 0.045-in K-wire is placed obliquely from the dorsal and ulnar margin of the fragment into the stout volar metaphyseal bone. A three-hole ulnar pin plate or a 2.0- to 2.4-mm low-profile locked plate is contoured and applied so it fits over the fragment with care taken to not overlap the radioulnar joint. The pin plate is secured proximally with two bicortical screws. A second wire is driven through one of the distal holes and the two wires are sequentially measured, cut, and bent 180 degrees at their tips before being impacted back into a free hole in the plate (Figure 15.50).

A frequently overlooked, but critically destabilizing intermediate column fragment, is the volar–ulnar or teardrop fragment. It constitutes the volar half of the lunate facet and is thus the primary restraint to volar subluxation of the carpus. It also represents the volar rim of the sigmoid notch and contains the origin of the volar radioulnar ligament—a prime stabilizer of the distal radioulnar joint. Failure to recognize or adequately stabilize this fragment can result in dramatic palmar subluxation of the carpus, articular incongruency, radioulnar instability, and ulnocarpal impaction (see Figure 15.48). The fragment is often too small, too distal, and/or too ulnar to be adequately captured by the pegs or screws of a fixed-angle palmar plate and, consequently, can complicate volar-plate fixation by the delayed development of carpal subluxation.[73]

Surgical Approach to the Volar–Ulnar Fragment. Because only the volar aspect of the DRUJ and the ulnar corner of the radius need to be visualized, a limited incision that parallels the FCU tendon just proximal to the transverse wrist crease provides sufficient exposure. Surgical release of that ligament can be performed if necessary by extending the incision in a zigzag fashion across the wrist crease and into the palm (i.e., extended carpal tunnel incision). The interval between the flexor tendons and the ulnar artery and nerve is easily developed by blunt dissection, through which the pronator quadratus and volar wrist capsule are exposed. Usually, the distal border of the pronator quadratus has been disrupted by the fracture; this allows visualization of the metaphyseal fracture line and displaced volar–ulnar fragment with minimal soft tissue dissection. The pronator quadratus is partially released from its ulnar insertion and

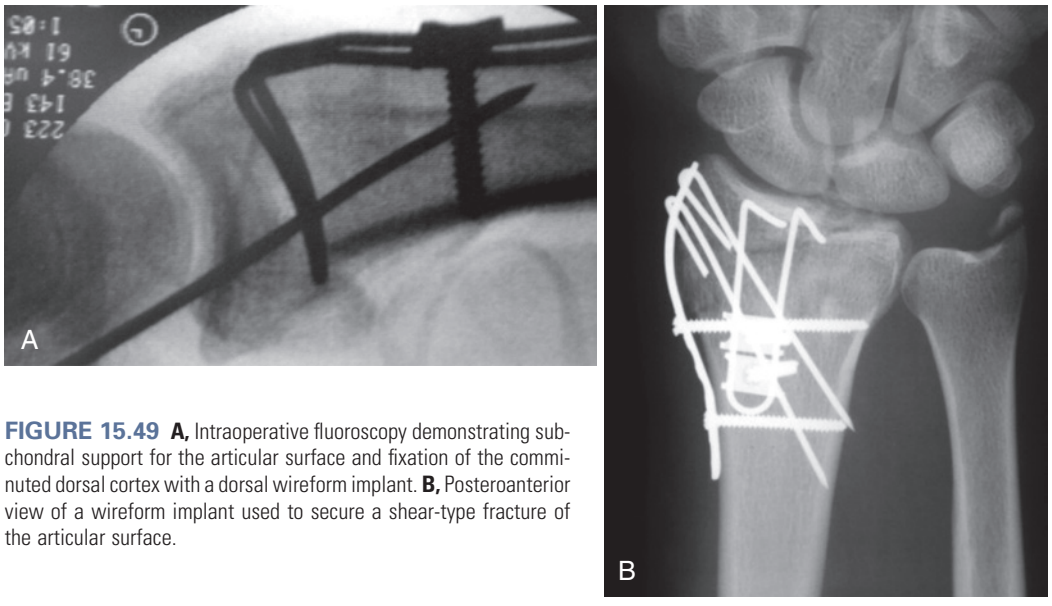

FIGURE 15.49 **A,** Intraoperative fluoroscopy demonstrating subchondral support for the articular surface and fixation of the comminuted dorsal cortex with a dorsal wireform implant. **B,** Posteroanterior view of a wireform implant used to secure a shear-type fracture of the articular surface.

http://e-surg.com

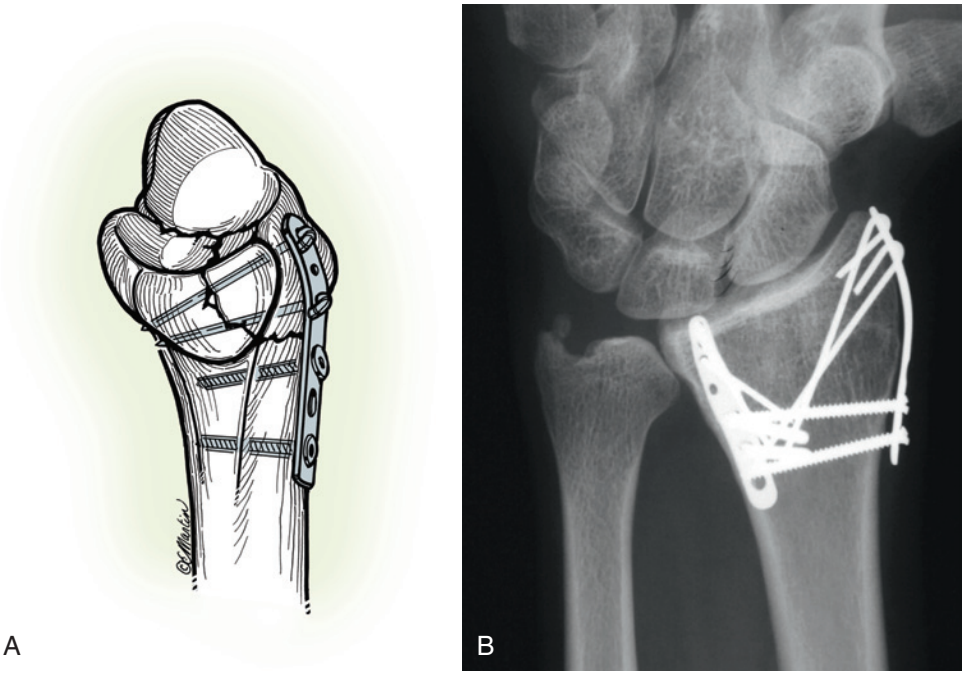

FIGURE 15.50 **A,** An ulnar "pin plate" or 2.0-mm miniplate can be used to fix unstable dorsal intermediate column fragments. **B,** The ulnar pin plate uses 0.045-in Kirschner wires and 2.0-mm screws and can be placed through a limited fifth dorsal compartment incision. It is important for most fractures that fixation of the intermediate column be supplemented with orthogonal (90–90) fixation of the radial column. (**A,** © Elizabeth Martin.)

retracted radially and proximally to expose the fracture site. Extreme care must be taken to avoid injury to the volar arm of the radioulnar ligamentous complex.

The volar–ulnar fracture fragment is then carefully reduced to restore continuity of the palmar cortex at the metaphyseal area by applying a dorsally directed force with an awl or periosteal elevator. Although not in rigid fixation, the fragment may be fixed by introducing a K-wire obliquely in a volar-to-dorsal direction. The wire is retrieved through the dorsal skin while making sure that its palmar end lies flush with the cortical level of the fragment to avoid impingement of the flexor tendons. For more stable fixation, the wire should be augmented with a suture or figure-of-eight wire placed through the proximal metaphyseal cortex in a tension band configuration.[25] Alternatively, if using a volar locked plate, the wire can be bent to match the curvature of the volar metaphyseal flare and captured beneath the volar plate as a "spring wire." Moore and Dennison reported maintenance of reduction in 9 of 9 patients treated in this fashion.[117]

I find that a volar buttress pin provides the most stable fixation for this fracture fragment and prevents carpal subluxation (Figure 15.51). The two prongs of the implant serve as a fixed-angle support for the subchondral bone, and the proximal implant is rigidly secured to the intact diaphyseal bone with washers and 2.3-mm screws. This restores the palmar stability of the fracture and provides a solid base on which the overlying dorsal–ulnar or die-punch fragment can be reduced. Additional volar rim fragments of the scaphoid facet can be stabilized with a volar buttress pin or a fixed-angle volar plate, at the surgeon's discretion.

The construct is completed by returning to the radial styloid to finish fixation with a radial columnar plate and screws (see Figure 15.51). To maximize stability of the fixation construct, it is important to place the radial styloid implant in a plane 50 to 90 degrees counter to the intermediate column's plane of fixation. The ideal position for a radial column implant lies directly beneath and oblique to the first dorsal compartment tendons, such that the distal tip of the plate is dorsal to the tendons and the plate's proximal end is palmar to them. If the previously placed provisional styloid K-wire is in an optimal position, a 3-, 5-, or 7-hole radial column pin plate is slid over the wire and positioned beneath the first dorsal compartment tendons. The plate is fixed to the intact metaphyseal–diaphyseal flare with two or more 2.3-mm bicortical screws proximally.

A second wire is passed through the plate distally and obliquely across the styloid to engage the opposing cortex. Each K-wire is sequentially measured, cut, and bent 180 degrees before being inserted into a neighboring hole in the pin plate. Final reduction and position of the implants are checked with fluoroscopy, and the BR tendon is closed over the radial column plate with a single running suture to interpose soft tissue between the implant and the overlying first dorsal compartment's tendons. By closing the BR tendon, the attached pronator quadratus simultaneously covers the volar implants. The dorsal wound is closed by transposing the EPL out of its compartment and closing the extensor retinaculum of the second and fourth extensor compartments beneath it. The DRUJ is then carefully assessed for stability, and appropriate treatment is rendered for residual instability. The wrist and forearm are temporarily immobilized in supination with a sugar tong splint for 5 to 10 days to allow soft tissue healing.

Rehabilitation is predicated on the strength of fracture fixation, but generally patients can be started on a program of active, unresisted motion exercises within a week of

http://e-surg.com

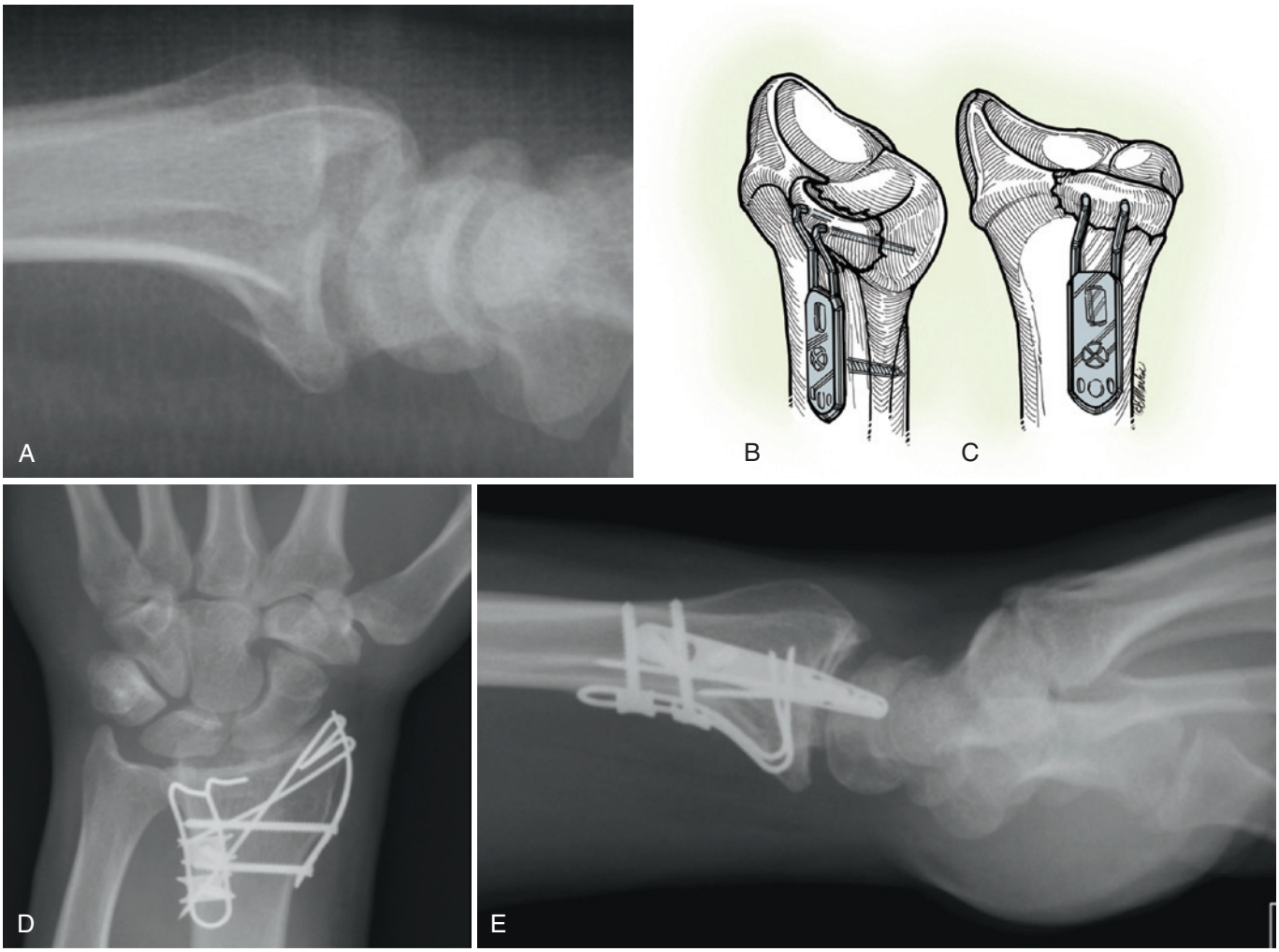

FIGURE 15.51 Fixation of the volar ulnar corner: **A,** Palmar subluxation of the carpus secondary to a volar ulnar teardrop fracture. **B, C,** A volar buttress pin is contoured to support the articular surface and can be placed immediately atop the palmar ridge of the radius and secured proximally beneath the pronator quadratus. **D, E,** Posteroanterior and lateral radiographs of the healed fracture at 1 year. (**B** and **C,** © Elizabeth Martin.)

surgery. Strengthening exercises are begun after radiographic evidence of fracture consolidation, generally at 6 to 8 weeks postoperatively.

Other Fixation Methods

Virtually all fractures of the distal radius can be managed with the previously detailed fixation strategies—namely, percutaneous/external, low-profile dorsal plate, angular stable volar plate, and fragment-specific. A surgeon versed in each of these techniques can apply them in isolation or in combination to effectively reduce a distal radius fracture and maintain fragment stability until healing. Conversely, failure to understand the indications and contraindications, or an inability to execute a difficult technique when necessary, can lead the surgeon to use an inappropriate application of a more familiar technique to a complicated fracture, with potential consequences of instability or loss of reduction.

On occasion, a highly comminuted distal radius fracture, if not amenable to complex periarticular reconstruction as detailed earlier or when associated with multiple extremity trauma, will need rapid, stable, and durable fixation to grossly restore radial alignment and length. In selected cases, the technique of distraction plating with an internal bridge plate, as initially described by Burke and Singer,[22] can provide highly satisfactory results. Hanel and colleagues recently published outcomes and complications of the treatment of 144 fractures in 140 patients treated with this technique over a 6-year period; the study demonstrated highly satisfactory results, with a 12.3% complication rate, for a very difficult injury cohort.[71]

Distraction Plating Technique. Incisions 4-cm long are centered over the long metacarpal and the dorsal–radial aspect of the radial midshaft, and a third 2-cm incision is done over the radiocarpal joint at the Lister tubercle.[56] A 3.5-mm low-contact compression plate that will span the fracture from the metacarpal shaft to a point at least three screw holes proximal to the most proximal fracture line is chosen. The plate is passed bluntly beneath the extensor tendons and across the fracture site to lie in the floor of the fourth dorsal compartment. To facilitate its passage, the EPL is freed from the retinaculum and an elevator is used to develop a plane below the fourth dorsal compartment tendons, through which the plate is tunneled proximally into the most proximal wound (Figure 15.52).

http://e-surg.com

CRITICAL POINTS *Fragment-Specific Fixation*

Indications

- Unstable extraarticular fractures of the distal radius (Fernandez' type I; AO type A)
- Articular fractures, simple-to-complex, multifragmentary fractures, shear fractures, fracture–dislocations (the Fernandez types II–IV; AO types B and C, all subtypes)
- Volar–ulnar teardrop fracture with carpal subluxation
- In combination with percutaneous fixation or volar fixed-angle plate fixation
- Nascent and established distal radius malunion

Contraindications

- Severe osteoporosis
- Extensive diaphyseal comminution (type V)

Technical Points

- Place multiple incisions directly over unstable fragments.
- Make a volar–radial incision to the radial column, and split the brachioradialis.
- Elevate the pronator quadratus with a portion of the split BR as needed to expose the volar surface.
- Reduce the fracture with traction and direct manipulation of the fragment.
- Provide temporary fracture fixation with an oblique K-wire through the radial styloid.
- Expose the intermediate column fracture via dorsal, volar, or both approaches and reduce it.
- Elevate impacted articular fragments through a dorsal 3- to 4-cm incision under fluoroscopic guidance.
- Support impacted articular fragments with a graft or substitute.
- Choose a dorsal wireform, 2.4-mm plate, or a pin plate to secure the intermediate column.
- Complete fixation of the volar rim or teardrop as needed with a 2.4-mm fixed-angle implant or a volar buttress pin.
- Apply a radial columnar plate or radial pin plate along the reduced styloid and fix proximally with a minimum of 2 to 3 screws.
- Assess distal radioulnar stability manually and repair or use internal fixation as needed.

Postoperative Care

- Apply a sugar tong splint in supination for 10 to 12 days until suture removal.
- Begin digital range-of-motion exercises immediately.
- Begin forearm rotation and gentle active wrist motion exercises at the initial postoperative visit.
- Evaluate with radiographs at the initial postoperative visit and at 2 and 6 weeks postoperatively.

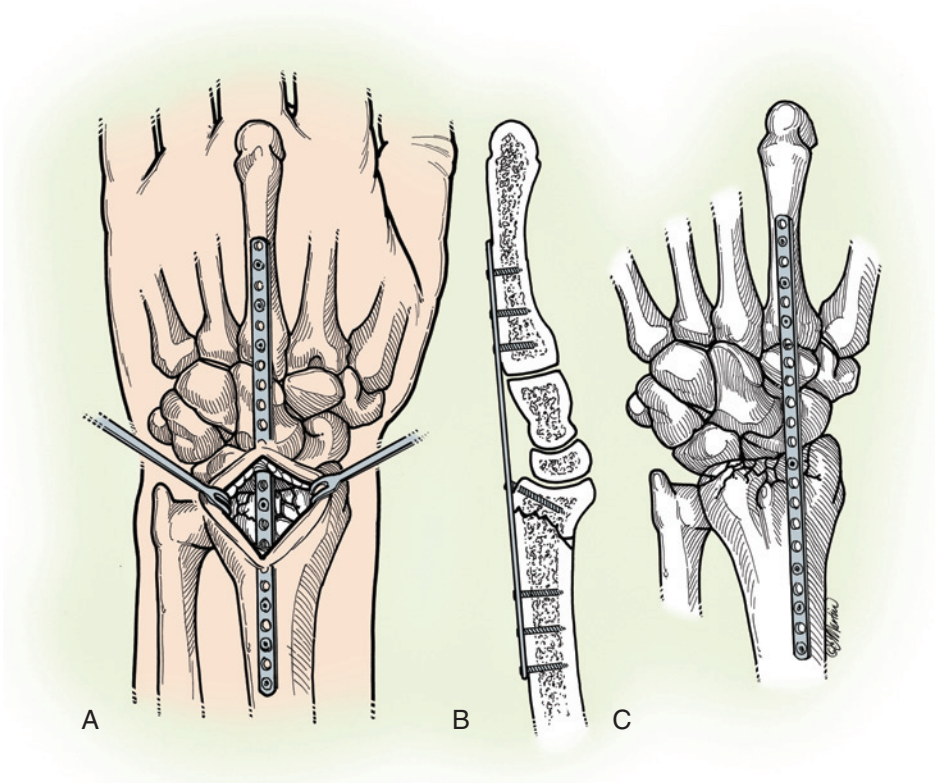

FIGURE 15.52 **A,** Distraction plating is performed through a limited dorsal incision with tunneling of the plate beneath the fourth dorsal compartment. Screws are placed proximally and distally to span the fracture site. **B,** Additional screw or wire fixation of the articular fragments may be performed through or outside the plate. **C,** Alternative positioning of a low-profile 2.4-mm plate below the second dorsal compartment and affixed to the index metacarpal. (© Elizabeth Martin.)

http://e-surg.com

The plate is fixed to the third metacarpal with a single screw, ideally in the midshaft of it to enable fine-tuning of fracture reduction. The hand and forearm are supinated approximately 60 degrees to avoid fixing the fracture in pronation, and a provisional fracture-reduction clamp is applied to hold the plate to the radius proximally. The forearm is taken through a full range of rotation and gross alignment is assessed with fluoroscopy. Care needs to be taken to prevent excess radiocarpal or midcarpal distraction when setting the final position, and the author recommends a maximum radiocarpal gap of 5 mm. Proximal and distal fixation is finalized with a minimum of three bicortical screws.

Attention is directed to the radiocarpal joint, where articular congruency is restored by subchondral elevation of the impacted fracture fragments, generous subchondral support with allograft, and percutaneous fixation of the periarticular fragments with K-wires or screws (see Mini-Open Fixation earlier). It is helpful to place one screw through the plate and immediately beneath the subchondral bone of the intermediate column.

Contraindications to bone grafting include grade III open fractures, prior contamination, or insufficient soft tissue coverage. After assessing the radioulnar joint for stability and treating as necessary (see earlier), the wounds are closed and splint immobilization is applied. Within 3 days of surgery, the splint is removed (except in cases of radioulnar instability), and patients can begin forearm supination–pronation and digital range-of-motion exercises. A 5-lb weightlifting limit is advised. The percutaneous wires are generally removed at 6 weeks and the plate at 4 to 6 months when healing should be complete.

Hanel and colleagues recommend placement of a smaller, 2.7-mm stainless steel custom locking plate on the index metacarpal, beneath the second dorsal compartment tendons at the radiocarpal level and fixed to the dorsal radial surface of the midshaft of the radius beneath the tendons of the two radial wrist extensors (see Figure 15.52, *C*). This is a rapid and simple approach that minimizes interference with extensor tendon function postoperatively, and the internal position of the low-profile device allows it to be used for an extended period if necessary[71] (Figure 15.53).

Intramedullary Implants. Recently, novel intramedullary (IM) methods have been developed to achieve rapid restoration of radial length, alignment, and tilt; they are designated low-profile, minimal-incision alternatives to locked volar–dorsal plate, fragment-specific, or bridging external fixation. These techniques are indicated primarily for unstable, nonarticular, or simple articular fractures and combine the stability and early mobility of internal fixation with minimal additional surgical intervention of percutaneous fixation. The techniques are deficient in long-term outcome or prospective comparative data and are offered as alternative fixation methods for predominantly lower-energy injuries.

The first is an IM device that uses locked, diverging screws distally to support the articular surface and interlocking screws proximally to provide stability across the fracture. The implant is inserted percutaneously in a retrograde manner at the radial styloid "bare spot" between the first and second dorsal compartments. Care must be taken to prevent injury to branches of the radial sensory nerve during the procedure. In the setting of acute fractures, indications for this IM implant include unstable extraarticular fractures, the reduction of which cannot be maintained by closed treatment (AO types A2 and A3), and simple articular fractures with large articular fragments that can be reduced percutaneously (AO types C1 and C2).

Other relative indications include AO type B fracture patterns (i.e., provided that the distal fragment can be captured with at least two screws), potentially unstable fractures in active patients who desire wrist motion during the healing period, and individuals requiring early return to work for whom cast immobilization is impractical. In a recent prospective study, 29 patients treated with IM fixation were followed for one year and were demonstrated to have excellent radiographic, clinical, and patient-rated outcomes; complications included two cases of lost reduction.[121] Complex articular fractures with multiple small articular fragments (AO type C3) are relative contraindications to fixation with this device (Figure 15.54).

A second IM device uses an expandable nitinol cage inserted into a prepared cavity within the metaphyseal flare of the radius, augmented by percutaneous fragment-specific cannulated screws that engage the rigid nitinol cage (Figure 15.55). The implant is inserted through a small diaphyseal incision proximal to the fracture, and the locking screws are inserted in a percutaneous or open approach through the radial styloid, dorsal, and volar–ulnar corner fragments (see Video 15.1). Biomechanical data support the stiffness of the device as being comparable to locked-plate fixation in axial bending and compression.[155] The device is novel in its low profile and high strength, intended for use in A-, B-, and C-type fractures, but there are no comparative clinical data at the time of this writing (see Case Study 15.3).

The Ulnar Column

The most frequent complaints of residual disability and functional loss following healed fractures of the distal radius emanate from the ulnar column. Therefore, it deserves as thorough an evaluation in the acute stage as the distal–radial fracture itself to address these injuries and prevent long-term dysfunction.

Some element of DRUJ involvement is present in every displaced distal radius fracture. The acute pathoanatomy of the ulnar column can be reduced to several discrete entities: articular incongruity (e.g., sigmoid notch, ulnar head), disruption of the TFCC, and changes in radioulnar alignment. Fernandez classified DRUJ injuries into a simple and useful three-group system that is helpful in defining treatment (see Figure 15.20, *B*). The key to a successful result depends on precise restoration of the anatomic relationships of the radius and the ulna; correction of articular incongruity at the sigmoid notch; identification of residual DRUJ instability through manual assessment; repair, or reconstruction as necessary; and maintenance of stability throughout the first 4 to 6 weeks after injury.

Ulnar Styloid Fixation

When fractured, realignment and fixation of the ulnar head, neck, or shaft may be necessary to restore the integrity and alignment of the ulnar column. There is considerable controversy, however, concerning the need to repair fractures of the ulnar styloid, including the so-called *basilar styloid (basistyloid) fracture*. It is of particular concern because of the attachment of the dorsal and volar radioulnar ligaments at its base (the fovea). A number of studies in the last decade have questioned

http://e-surg.com

CASE STUDY 15.3

A 30-year-old right-handed male presents 10 days after FOOSH with fractures of left distal radius and ipsilateral scaphoid distal pole (eFigure 15.18). Surgery using the closed reduction and intramedullary fixation technique is recommended (eFigure 15.19).

Postoperative films and clinical photographs are displayed in eFigure 15.20.



eFIGURE 15.18 **A-C,** Trauma films. **D, E,** Radiographs in traction. **F-H,** Postreduction.

Continued

http://e-surg.com

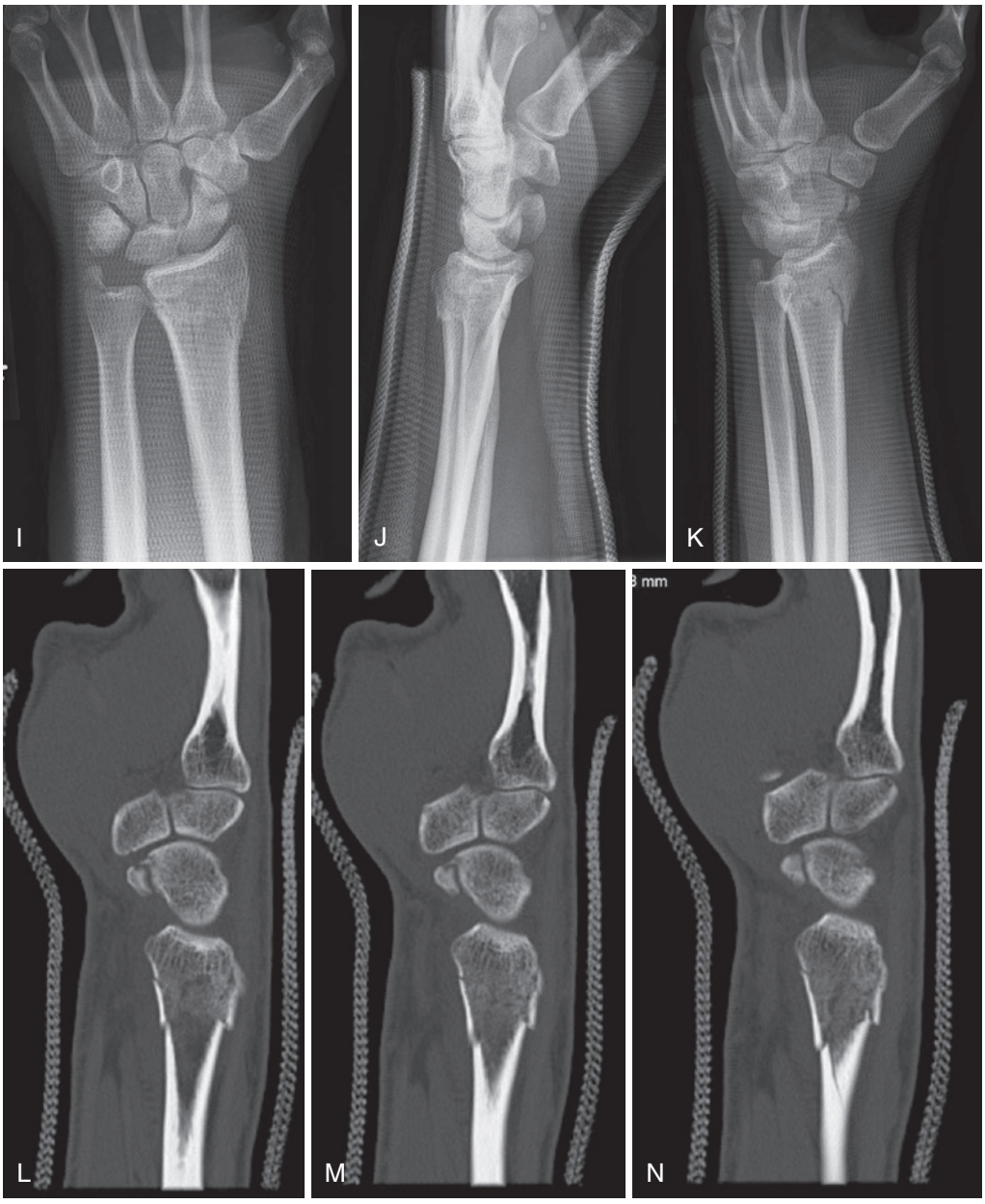

eFIGURE 15.18, cont'd **I-K,** Concomitant distal radius fracture and distal pole scaphoid, 2 mm coronal shift of articular fragment. **L-N,** Small distal pole fragment of scaphoid.

http://e-surg.com

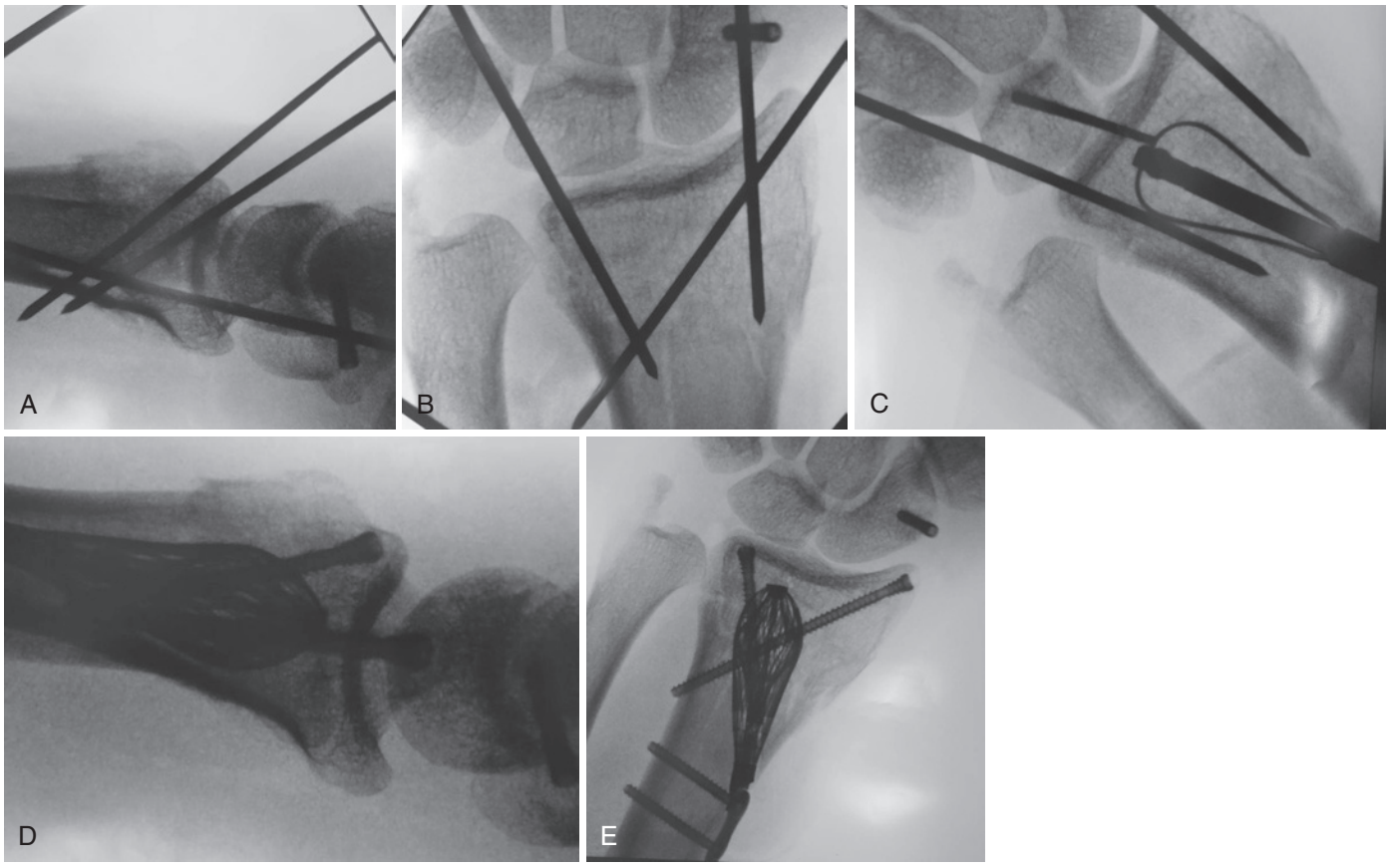

eFIGURE 15.19 Kapandji reduction technique: **A, B,** Percutaneous fixation and "cage" wires inserted dorsal to volar. **C,** Cavity preparation tool used through 3 cm radial incision. **D, E,** Distal pole scaphoid fixed with percutaneous miniature headless screw. Intramedullary expandable implant cage inserted with cross-screw locked fixation.

http://e-surg.com



eFIGURE 15.20 Views at: **A-C,** 9 days postoperative. **D-F,** 1 month postoperative. **G-I,** 2 months postoperative. **J-Q,** 2 months postoperative.

http://e-surg.com



eFIGURE 15.20, cont'd

http://e-surg.com



FIGURE 15.53 Bridge plate fixation: A 20-year-old man sustained life-threatening polytrauma in a fall from a height, including bilateral distal radius fractures **(A)** and a Monteggia fracture–dislocation on the left **(B)**. **C,** The ulnar fracture was stabilized with a plate, the volar rim of the left radius was reconstructed with volar 2.5-mm implants, the impacted subchondral bone was elevated and supported with allograft cancellous bone, and the severely comminuted dorsal metaphyseal bone was stabilized with a spanning plate in the second dorsal compartment. **D,** Healed fracture at the time of removal of the spanning plate at 4 months postoperatively. **E,** The volar plates were removed at 1 year. **F,** Radiographs at 1 year demonstrating active range of motion. (Courtesy of Douglas P. Hanel, MD, University of Washington, Seattle.)

https://e-surg.com

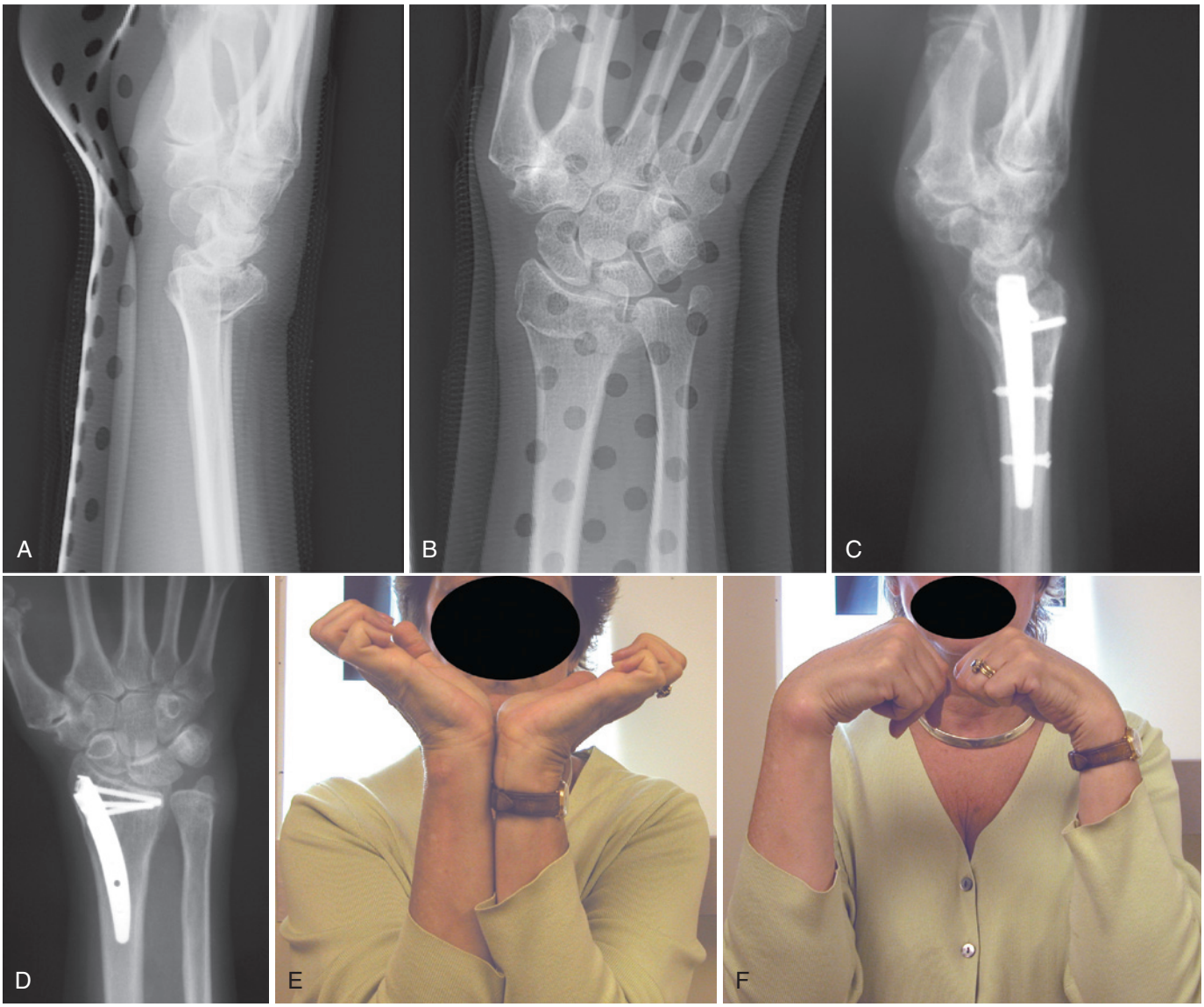

FIGURE 15.54 **A, B,** Posteroanterior and lateral radiograph of an intraarticular distal radius and ulnar styloid base fracture. **C, D,** A locked intramedullary nail (Micronail, Wright Medical, Arlington, TN) was used to stabilize the distal radius fracture, and suture fixation of the ulnar styloid was performed. **E, F,** Photos of range of motion 2 months postop; no immobilization was used postoperatively. (Courtesy of Virak Tan, MD, with permission.)

the importance of an ulnar styloid fracture to radioulnar stability. To summarize these findings, among operatively treated fractures without identifiable evidence of radioulnar instability, the presence or absence of an ulnar styloid fracture,[140] styloid fracture displacement,[148] or ulnar styloid nonunion[166] had no bearing on the radiographic or functional outcome of the distal radius fracture.

Even though underpowered, in the only prospective level II trial of nonrepaired ulnar styloid fractures, Kim et al demonstrated no influence of the size or displacement of ulnar styloid fractures on fracture outcome or on DRUJ stability as assessed manually.[89] However, it is important to note that all patients with intraoperative DRUJ stability in this study were treated with 4 weeks of long-arm casting. A study of the efficacy of internal fixation of the ulnar styloid for patients with manually identified DRUJ instability has not been performed.

The Coronal Shift (Radial Translation)

Anatomic reduction of the radius generally results in relocation of the ulnar head within the sigmoid notch, as occurs after reduction of Galeazzi-type fractures of the radial shaft. Recent attention has been given to the importance of anatomic reduction of the radius in the coronal plane to restore tension of the interosseous membrane and "seat" the ulna into the sigmoid notch (see Figures 15.12 and 15.41).[134,124] Investigators have identified the distal interosseous membrane (DIOM) and, in particular, the distal oblique bundle as the "major restraining structures" of dorsal and volar laxity of the distal radius relative to the ulnar head[161] when the TFCC is disrupted. The DIOM is tense in all positions of forearm rotation.[161] A recent anatomic study defined the ligament to insert distally and dorsally on the radius, coursing to insert palmar and proximal on the ulna, confirming its primary role in resisting dorsal translation of the

http://e-surg.com

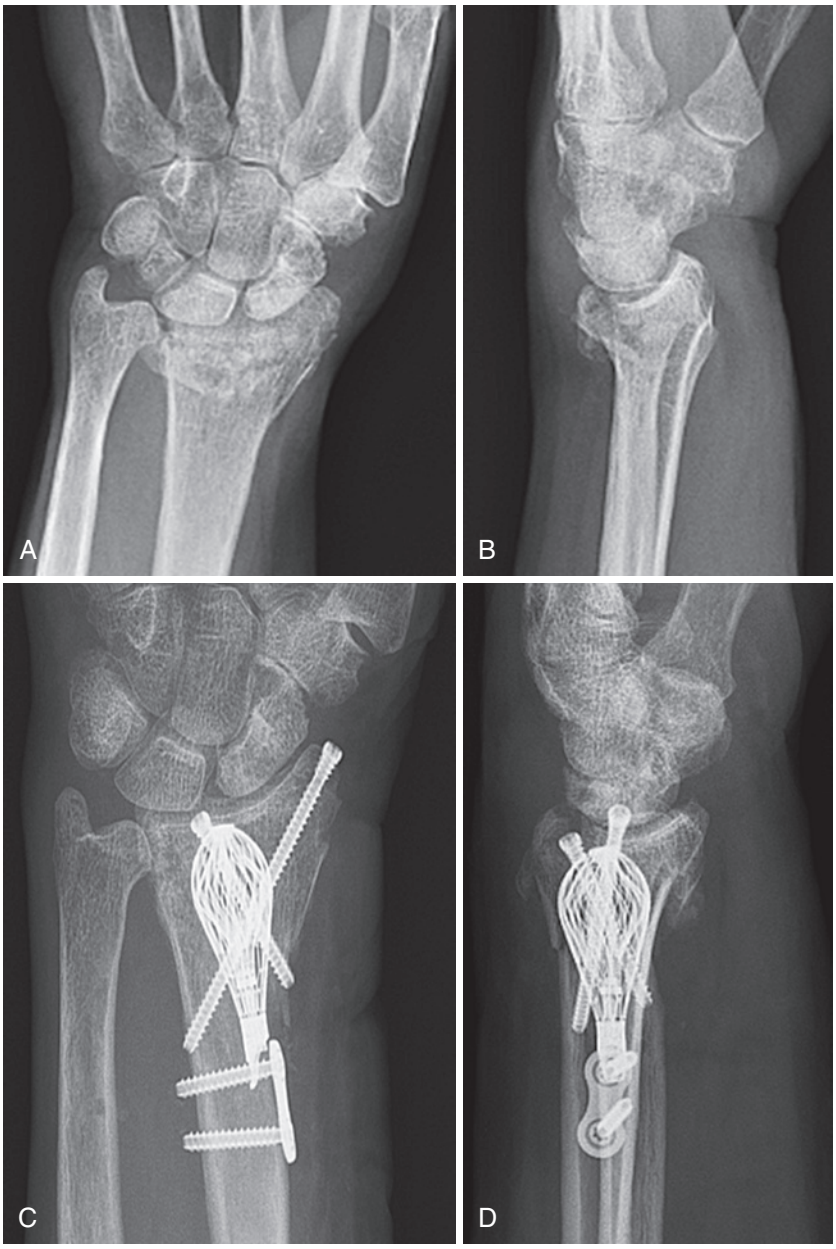

FIGURE 15.55 **A-D,** A novel intramedullary implant using an expandable nitinol cage and crossed locked screws (Conventus Orthopaedics, Maple Grove, MN) inserted percutaneously. Mechanical data demonstrate comparable rigidity to volar plate fixation.

radius on the ulna in supination.[118] As reviewed earlier, studies have demonstrated the lack of correlation between ununited or unrepaired basilar ulnar styloid fractures and DRUJ instability,[140,148] and this author and others[134] have noticed residual DRUJ instability despite isolated ulnar styloid repair when the anatomic spacing between the radius and ulna was not restored and the radius was translated radialward. Orbay noted that, when the DIOM is not torn, anatomic restoration of radial position in the coronal plane tensions the DIOM and stabilizes the radioulnar joint without need for TFCC reattachment.[124]

Nakamura and colleagues[119] demonstrated that radial translation, loss of radial inclination, ulnar shortening, and 4-mm radial translation of the ulnar styloid were all predictive of a foveal avulsion of the DRUJ ligaments; however, *radial translation was the only independent predictive variable*. Previously, this phenomenon had been referred to as ulnar translation of the proximal fragment[65,130]; by convention, it is probably more precise to describe position of the distal component of the fracture—that is, the articular fragment.[134] Failure to correct the coronal shift leads to laxity of the interosseous membrane, the pronator quadratus, and the distal interosseous membrane.[122,161]

Conversely, reduction of this deformity tensions the distal interosseous membrane and increases contact pressures by tensioning the surrounding soft tissue sleeve.[38,66,79,118,124] Dy et al, in a mechanical simulation of distal radius fractures in 10 cadaveric wrists, demonstrated that DRUJ instability was produced by a 2-mm coronal shift of the radius in forearms with an intact DOB.[38]

Reduction of the coronal shift is easily performed through any approach used for distal radius fracture fixation. Application of a radial reduction moment by a curved Hohmann

http://e-surg.com

retractor placed in the interosseous space on the ulnar metaphyseal flare, while counterpressure is applied on the radial styloid, will translate the fragment back to normal alignment (see Figure 15.41). Rapley et al described the insertion of an "Army-Navy" retractor in the interosseous space and rotating it 90 degrees until the radius and ulna were restored to their normal relationship.[130] Alternatively, a Gelpi retractor can be used to spread the radius and ulna apart until the proper tension is restored.

The deformity can also be corrected after preliminary application of a volar plate using the technique of Moritomo et al.[118] With the most proximal screw in place (but not fully tightened), several distal locked screws are applied to the distal fragment. A lion jaw clamp is applied between the ulnar cortex of the radius just proximal to the fracture site and the distal radial edge of the plate. Compression of the clamp reduces the distal fragment and seats it onto the ulnar head, restoring tension in the DIOM.

Distal Radioulnar Joint Injury Treatment Options

As outlined earlier in Figure 15.20, *B*, three treatment options are possible: (1) early mobilization, (2) closed treatment and cast immobilization with or without radioulnar pinning, and (3) operative management, including open and arthroscopic techniques.

To assess radioulnar stability following completion of radial fixation, a manual "shuck" test of the ulna is performed by grasping the ulnar head between the examiner's thumb and index finger and translating it dorsally and palmarly within the sigmoid notch. Gross instability is manifested by frank dislocation, but more subtle instability can be appreciated by the loss of a firm endpoint to translation and by increased subluxation of the ulna relative to the uninjured wrist. I find it helpful to have assessed the contralateral wrist's DRUJ stability before preparing and draping the injured wrist. It is important that the shuck test be performed in all rotation positions to specifically test both the palmar and the dorsal radioulnar ligaments (see DRUJ section).

For type I stable injuries, *functional aftercare* with early active forearm rotation exercises and minimal external support is recommended. Early motion is likewise recommended for patients with fractures of the distal ulna or ulnar styloid in which radioulnar stability has been restored with stable internal fixation, and for type III comminuted fractures of the ulnar head that are not amenable to internal fixation to allow fracture remodeling.

Type II subluxation can be treated successfully in a number of ways. Many prefer 4 weeks of cast immobilization with the forearm in the most stable rotation position; most often this is partial to complete supination.[153] Grossly unstable DRUJ dislocations may require percutaneous transfixion of the ulna to the radial shaft in the position of greatest stability with dual 0.062-in K-wires. The wires are placed just proximal to the joint, and it is helpful to leave their tips protruding through both the radial and ulnar cortices in the unlikely event that wire breakage occurs in the interosseous space. The wires may be removed at 4 weeks postoperatively and rotation exercises begun (Figure 15.56).

For type II *unstable* DRUJ lesions with a large ulnar basisty-loid fragment, fracture fixation should be considered. The styloid is exposed with a 3- to 4-cm incision midway between the extensor carpi ulnaris (ECU) and the flexor carpi ulnaris (FCU). Care is taken to identify and preserve the dorsal sensory branch of the ulnar nerve, which courses through the ulnar "snuffbox" just distal to the styloid tip. A 24-gauge wire or nonabsorbable suture can be passed either around or preferably through the styloid fragment and then through the ulna at the axilla of the shaft and the articular surface. The suture/wire is tensioned and tied with the forearm in neutral rotation. Alternatively, the fragment can be stabilized with two 0.035-in K-wires and a tension band wire passed proximally through the ulnar shaft. The forearm is immobilized in neutral rotation for 4 to 6 weeks, depending on the degree of stability attained.

Large fracture fragments also can be fixed with a compression screw or a cannulated headless screw. With the advent of ultrathin pin plates, basilar styloid fractures can be rigidly fixed with two K-wires and an ulnar pin plate contoured to the ulnar shaft (Figure 15.57). The stability of the DRUJ is then assessed manually again; if stable, gentle forearm rotation can be initiated within 7 to 10 days of surgery. Implants on the ulnar side of the wrist can, on occasion, cause irritation (of the ECU tendon) and discomfort when patients rest their hands on a tabletop; consequently, ulnar styloid hardware may need to be removed in 10 to 20% of patients.

For patients who have residual manual DRUJ instability in all rotation positions following anatomic reduction of the distal radius and without a basistyloid fracture, open or arthroscopic reattachment of the foveal attachment of the distal radioulnar ligaments may be considered (see Chapter 14). Repairs must be protected by cast immobilization in the position of maximum stability in an above-elbow cast for 4 to 8 weeks to allow the TFCC to heal.

When type III DRUJ instability is associated with a dorsally displaced dorsal–ulnar fragment of the sigmoid notch or a displaced ulnar head fracture, precise anatomic reduction and fixation are imperative to restore stability. Associated TFCC lesions should be addressed simultaneously as described previously.

❖ AUTHOR'S PREFERRED METHOD OF TREATMENT: Ulnar Column Instability

Anatomic restoration of length, inclination, tilt, and coronal alignment of the fractured radius is performed with internal or percutaneous fixation at the surgeon's discretion. Unstable fractures of the dorsal and volar margins of the sigmoid notch are rigidly stabilized because unstable fragments have been demonstrated to mechanically lead to radioulnar subluxation.[28] Neck or head fractures of the ulna are anatomically reduced and fixed with 2.4-mm or 2.7-mm plates, interfragmentary screws, cerclage wiring, or a tension band, depending on the nature of the fracture and the degree of comminution.

Residual instability of the DRUJ, as determined by a dorsal and volar shuck test in neutral, pronation, and supination, is treated aggressively. If a basilar styloid fracture is present, I prefer open reduction and fixation followed by early range of motion (see Figure 15.57). If no fracture is present and stability can be restored in full or partial supination, simple immobilization in a sugar tong splint is performed in the operating room and converted to a long-arm cast at 10 days. The cast is removed 4 weeks postoperatively and supination–pronation exercises begun. If stability cannot be restored with positioning,

http://e-surg.com



FIGURE 15.56 **A-F,** Gross instability of the radioulnar joint after anatomic realignment of a distal radius fracture can be treated satisfactorily with 4 weeks of cross-pinning of the ulnar and the radius. Dual 0.062-in Kirschner wires are recommended, and perforation of all four cortices is important.

augmentation with parallel 0.062-in transfixion wires is performed and maintained for 4 weeks (see Figure 15.56). I have not found open or arthroscopic repair of the TFCC to add appreciably to this algorithm.

EVIDENCE-BASED DECISION MAKING

Is there sufficient "evidence" in the literature in the form of randomized, prospective clinical trials to derive individual treatment decisions for distal radius fractures? Outcomes of treatment for such fractures have been the subject of several large Cochrane metaanalyses performed by Handoll and colleagues over the last decade.[67–69] Not surprisingly, the heterogeneity of the injuries, variations in reporting outcomes, and differences in operative techniques and patient populations have made the extrapolation of any firm conclusions difficult. These authors made a plea for future investigators to use a common classification system and standardized validated outcome measurements so that data for distal radius fractures can be compared and contrasted.

A plethora of randomized studies have been performed since the Handoll et al attempt to identify a "best" treatment for distal radius fractures based on 1- and 2-year outcomes. The 2008 Cochrane review demonstrated that there was insufficient evidence to support the use of one mode of treatment over another for distal radius fractures.[68] The American Academy of Orthopedic Surgeons (AAOS) subsequently convened three expert panels to examine the best-available evidence and to develop

http://e-surg.com



FIGURE 15.57 A 2.0-mm ulnar pin plate can be applied over a percutaneous Kirschner wire to rigidly fix unstable basilar ulnar styloid fractures with two proximal screws.

TABLE 15.3 Summary of Available Evidence

I. Nondisplaced fractures, no reduction required	• Dorsal splint leads to improved motion and strength vs. short-arm cast[123]
II. Nonoperative treatment, closed reduction, simple articular, healthy bone	• Sugar tong, short-arm cast, three-point brace: NMD[17,154]
III. Loss of reduction in cast	• Operative treatment leads to improved radiographic alignment vs. another reduction and cast[112]
IV. Simple bending (AO A) or simple articular (AO C1) fractures in healthy bone; anatomically reduced and maintained	• Casting, percutaneous fixation or ORIF: NMD[62,96,106,176]
V. *Unstable* bending and articular fractures in healthy bone	• External fixation improvement over cast treatment[86,96] • Augmented external fixation vs. percutaneous pin fixation: NMD[72] • Nonbridging external fixation improved radiographic parameters over bridging EF[8,75] • Subtle early[40,42,109,137] and sustained[45,159,168] improvements of volar locked-plate vs. percutaneous fixation
VI. Highly comminuted fractures	• No available evidence

EF, External fixation; *NMD*, no measureable difference; *ORIF*, open reduction internal fixation.

"appropriate use criteria" for treatment of distal radius fractures by voting on 240 different clinical scenarios.[164] Even though the panel was unable to identify "evidence-based conclusion[s] for the optimal operative treatment of distal radius fractures," the exhaustive report is a valuable resource that summarizes the conclusions of the many level II operative trials performed over the past two decades, along with consensus opinions of appropriate treatment.

A comparison of the randomized trials done during the past 8 years versus those done in the preceding decade reveals clear advances in the reporting of outcomes for distal radius fractures; specifically, the use of validated patient-rated functional outcome tools such as the DASH, quick-DASH, patient-rated wrist evaluation (PRWE), and Michigan Hand Outcomes Questionnaire (MHQ). By most modern functional outcome criteria, percutaneous fixation and open reduction with internal fixation led to similar outcomes for unstable distal radius fractures in several level II randomized trials,[62,87,137] calling into question the benefit of the increased cost of internal fixation.[40] Yet, several short studies in the literature argue against the immediate adoption of a treatment parity.

No standards for measurement of outcomes for distal radius fracture treatment have been universally adopted, making comparison of various series results difficult if not impossible.[59] Remarkably, pain is not consistently assessed as an outcome parameter in randomized trials of distal radius fracture treatment. In one study, only 37% of the variability of the patient assessments using the MHQ could be explained by measurable outcomes of wrist motion or grip strength.[144]

Another study demonstrated that it was only by inclusion of a pain-assessment visual analog scale (VAS), along with "objective" measurement of supination and grip strength, that the investigators could account for more than half of the variability of the DASH.[151] Perception of pain and, specifically, the *interference of pain on function* and activities, was the most significant predictor of patient-assessed arm disability as measured by quick-DASH scores in a third study.[116] Finally, no measures of activity level have been used to stratify distal radius fracture patients, despite the increasing use of activity level as an outcome measure in other orthopedic fields (e.g., hip, knee, shoulder, ankle).[21]

These data suggest that a battery of patient-rated and physician-rated outcome measures are critical to a complete assessment of outcomes. Comparisons across academic centers, states, countries, and continents could be facilitated by the use of accepted patient-rated functional scales, the VAS pain assessment, activity level and health stratification, physician-rated outcome parameters, complication analysis, and the return to activities or "life roles."[59]

With all its inherent limitations, what practical treatment recommendations can be assembled from the evidence? A concise summary of evidence-based recommendations is presented in Table 15.3, and the reader is referred to the complete AAOS report for an inclusive analysis of the available evidence.[164]

It is difficult to distill firm treatment recommendations from current "evidence" given the specific exclusion criteria of each study. All would agree that the restoration of pain-free hand and wrist function is the overarching goal of treatment for distal radius fractures. In studies where more patients are excluded

http://e-surg.com

than included,[42,137,169] and weighted heavily toward relatively noncomminuted dorsally displaced fractures,[87,109] the evidence supports intuition; for straightforward fractures, several fixation types are essentially interchangeable and will result in nearly equal outcomes at "some remote period [of time]."

Decisions must be made in part by the patient and in part by the surgeon's expertise and preference, and customized based on the patient's systemic factors and activity level. Patient preference for an internal implant rather than an external device because of the perceived benefit of early wrist motion and the avoidance of pin care and pin-tract infections may sway individual surgical decisions in favor of open reduction. However, bridging and nonbridging external-fixation techniques continue to demonstrate excellent outcomes in properly selected cases and should not be abandoned.

Treatment of the Elderly

Remarkable interest has been focused on the treatment of distal radius fractures in older individuals over the past 5 years, perhaps in part due to the recent focus on cost containment in medical care. Several prospective studies demonstrate a lack of significant functional outcome differences among elderly patients, and imply that treatment options for unstable distal radius fractures in this cohort are interchangeable.[1,6,41,57,173] However, several consistent findings of these studies, as well as notable shortcomings, should prompt considerable caution when interpreting the data.

The elderly cohort as a group takes longer to return of functional status,[26] has lower DASH functional scores, and has an inferior global health-related quality of life than their younger counterparts[2]; thus, the lack of differences within this group may be related to nonorthopedic factors. Conventional wisdom ascribes the lack of differences to the older cohort's "low functional demands."[1,175] In fact, up to 30% of US elderly patients describe themselves as "very active" and nearly 90% report no disability at all.[81] Notably, no study stratifies outcomes by activity level in the senior population; in actuality, only one validated elderly activity stratification exists.[160] To date, no prospective studies have utilized the physical activity scale for the elderly (PASE) to differentiate patients.

The AAOS appropriate use panel concluded that firm conclusions for distal radius fracture treatment in the elderly were confounded by the lack of studies that "distinguished patients based on infirmity, *functional demands*, bone quality, or energy of injury."[164] While Grewal et al identified no significant risk relationship between fracture alignment and outcome in their entire older cohort, their relative risk data suggest that their *active* elderly patients achieved better outcomes when the parameters of radial reduction were met.[61] It has been demonstrated that demented or infirm patients receive no benefit from anatomic reduction.[14]

Differences in perceived physiologic and actual age must be identified and considered when treating elderly patients.[2] Because malunion of the distal radius is associated with worse outcomes in women whose age is older than 55[18]; in all age cohorts,[51,61] patients with higher activity levels prior to injury will be disproportionately impaired. Second, in virtually all studies, early improvements in functional outcomes were noted in the operative cohorts; the importance of a 5-week earlier removal of immobilization and a 4-week earlier return to activities may be difficult to quantify; however, it is likely to be very important to a subset of active elderly individuals, especially those who live alone.

Shauver et al performed a cost–utility analysis with a group of seniors and identified a preference for internal fixation over other types of distal radius fracture treatments because of its more rapid return of function and a demonstrable improvement in quality-adjusted life years.[145] Although not consistently counted as a complication, the effect of a *100% loss of reduction* and deformity in the nonoperative cohort cannot be estimated using current functional scales.[6] Finally, the impact of a significant increase in arthritis[6,41] at *1 year* cannot be estimated for patients' future lifetime. Before we adopt a nihilistic approach to treatment of elderly patients and respond with more "cost-effective" solutions, further long-term studies need be performed.

❖ AUTHOR'S PREFERRED METHOD OF TREATMENT: The Elderly

Even though restoration of mobility, lack of pain, and return of function is the universal goal of treatment for the elderly, consideration must be given to the physiologic age and functional activity level so as to provide customized care. For the relatively inactive or sedentary patient, a treatment combining minimal morbidity with emphasis on maintenance of digital and forearm mobility is preferable; nonsurgical treatment is likely to result in very acceptable outcomes despite imperfect radiographic outcomes, and deficits in grip strength and range of motion are likely to be well tolerated.

For the highly active patients who place high functional demands on the wrist, deformity, pain, and loss of strength are not likely to be compatible with their lifestyle. In these individuals, efforts should be made to restore articular congruency, radial alignment, and a normal radioulnar relationship. Although several methods can achieve these goals, active elderly patients are quite conscious of quality of life and prefer a treatment that will return them to normal function earlier with minimal risk of complications.[145] Percutaneous methods have an increased risk of pin-tract infection and loss of reduction in osteopenic bone, while internal fixation has been noted to increase the risk of nerve or tendon complications.

My preference for the active elderly group is stable internal fixation with a fixed-angle volar plate, adding or substituting columnar fixation in the more comminuted or unstable fractures as needed. For those patients in the intermediate activity group, a customized decision is made after careful discussion with the patients, based on their needs, expectations, systemic issues, and fracture type. Those who prefer an earlier return to function may opt for internal fixation, with the assumption of additional risk and the knowledge that the long-term outcome may not be measurably different with any type of treatment.

❖ AUTHOR'S PREFERRED METHOD OF TREATMENT: A Case-Based Approach to Operative Management

…[It] is neither the fixation nor the implant [that] dictates the outcome but the ability of the surgeon to meet the goal of satisfactory reduction and vascular preservation with the least invasive procedure possible.

—Kreder et al, 2006

http://e-surg.com

It is no surprise that randomized trials fail to show convincing evidence of the superiority of one treatment technique over another for the entire spectrum of distal radius fractures. The variety and complexity of fracture patterns, associated injuries to the distal radioulnar and intercarpal ligaments, and widely divergent patient factors (e.g., osteoporosis, activity level, systemic illness) mitigate against a single treatment modality for all types of injuries. Instead, a treatment strategy must be developed to customize the treatment to the injury, with the overarching principle that the least additional surgical disruption of the soft tissue sleeve that is necessary to gain fracture stability and articular congruency will generally impart the best functional outcome.

To paraphrase Lee Trevino, "It's the archer, not the arrow." Although the literature is replete with a bewildering array of techniques and implants, it is important to understand that it is the judgment and skill of the surgeon in reaching the operative goals that will be the most important determinant of success. The goals of operative treatment (i.e., ARMS) are the following:

1. **A**rticular congruity (to prevent shear on articular cartilage and degenerative changes)
2. **R**adial alignment and length (to enable normal kinetics and kinematics of the carpus and radioulnar joint)
3. **M**otion (of digits, wrist, and forearm to optimize return to function and activities)
4. **S**tability (to preserve length, alignment, and congruency until the fracture heals)

My approach is built around three fundamentally different categories of fixation that, when matched to the particular fracture pattern, enable the surgeon to plan and execute successful wrist fracture repair for nearly all of its variations:

- Percutaneous/indirect fixation
- Fragment-specific fixation
- Volar or dorsal fixed-angle plating

For treatment purposes, I present an algorithm based on the Fernandez mechanism–based classification of distal radius fractures. Treatment recommendations are based on fractures in a physiologically young and active patient cohort; treatment can be tempered according to the patient's age, activity level, functional impairments, and general medical condition.

Treatment of Nondisplaced Distal Radius Fractures

For all injuries, the patient's history and physical examination should include age, handedness, occupation, aerobic activity level, sports and leisure activities, an extensive medical record, and a list of medications. Particular attention must be paid to conditions that might affect bone mass or bone quality, including endocrine disorders, inflammatory diseases, renal disease, steroid use, and other factors. The wrist should be inspected for wounds and tendon and nerve function, paying special attention to function of the median nerve.

Nondisplaced distal radius fractures in the physiologically young and active cohort can be treated with either a splint or short-arm cast at the surgeon's discretion while leaving the elbow, fingers, and thumb free to avoid stiffness. Patients should be advised of the possibility of an EPL rupture that, although rare, can complicate treatment of nondisplaced fractures. Interval radiographs are not generally necessary for truly nondisplaced fractures; a single follow-up examination with radiographs to determine union at 6 weeks is recommended.[136] Closer scrutiny should be given to elderly and osteoporotic patients as well as to any person's fracture that has an intraarticular component.

Type I—Bending Fractures

The prime determinant in dorsally displaced, nonarticular bending (Colles') fractures is the predicted stability of the fracture (see earlier). In younger patients with minimal comminution of the dorsal cortex and less than a 3-mm loss of radial length, an adequate closed reduction will be predictably quite stable. For active patients with a stable fracture type and excellent reduction, I prefer a sugar tong splint, which permits acute swelling for the first 2 to 3 weeks; then switch to a short-arm cast for 3 weeks until the fracture is healed both clinically and radiographically. Radiographs should be taken at 1, 2, or 3, and 6 weeks to ensure maintenance of the reduction.

A simple removable splint may be needed for comfort and support for an additional 2 weeks after cast removal. By providing patients with a removable splint that they can wean themselves from as they regain wrist motion and upper extremity confidence, much of their anxiety about possible reinjury is relieved and their rehabilitation process is shortened.

Minimizing Hand and Shoulder Stiffness

During the period of immobilization and weaning from the splint, all patients are instructed to keep their fingers, elbow, forearm, and shoulder mobile. The six-pack of hand exercises is illustrated earlier in Figure 15.26. Passive and active shoulder, elbow, and forearm motion should also be addressed as priorities as soon as the injury's pain subsides and specific immobilization requirements permit. In general, motion should be encouraged at least three times a day. Some patients benefit from supervised therapy, as well as a home program under the guidance of a hand therapist.

Unstable dorsal bending fractures are suspected in patients with comminution of greater than 50% of the lateral width of the radial diaphysis at the fracture site and initial radial shortening of greater than 3 mm. As MacKenney, Lafontaine, and others have demonstrated, advancing age is the most important predictor of instability, and a patient older than 60 years should be considered unstable when these two factors are present.[100,107]

Volar extraarticular bending fractures are decidedly less common than their dorsal counterparts and usually involve comminution of the important stout metaphyseal flare; consequently, these fractures are implicitly unstable and generally require operative stabilization. Patient education is extremely important for this group of injuries because she or he is likely to want to take an active role in the treatment decision. In healthy and active individuals, regardless of age, the patient should be counseled concerning the nature of the injury, its inherent instability, and the additional treatment time that may be required should the fracture demonstrate late instability and collapse in a cast.

If the patient elects nonoperative treatment, close observation of unstable fractures with weekly visits is necessary for the first 3 to 4 weeks, along with cast changes as necessary to maintain optimal three-point fixation. The surgeon should be vigilant for early signs of collapse and avoid the "slippery slope" of accepting a few degrees of additional dorsal tilt or loss of radial

http://e-surg.com

length on successive radiographs (see Case Study 15.4). The patient should be attuned to the potential need for relatively urgent operative intervention if the fracture collapses because a second attempt at closed reduction and casting is ineffective.[112] The author is not as aggressive in the treatment of unstable extraarticular fractures in elderly, sedentary patients because of the mitigating effect of advanced age (≥80 years) on hand dysfunction.[51]

Because the articular surface is intact, this group of injuries enjoys a high rate of functional return and patient satisfaction after several types of treatments, provided that anatomic indices of reduction are reasonably restored. Treatment possibilities include, but are not limited to, closed reduction and pinning, augmented bridging external fixation, nonbridging external fixation, low-profile columnar fixation, IM fixation, and volar locked plating (see Case Study 15.5). The surgeon should discuss the limitations and advantages of various techniques with the patient and tailor treatment to his or her preference and individual needs; each of these fixation techniques is used with some frequency. If a sizable metaphyseal bone void is anticipated because of the extremes of dorsal displacement or osteoporosis, the balance is tipped in favor of volar locked plating (see Case Study 15.6), augmented by bone graft or a substitute if necessary.

Similarly, if the fracture is several weeks old and a realignment of a "nascent" malunion is anticipated, volar locked plating is the preferred treatment (see Case Studies 15.7 and 15.8). For elderly and active patients who need or request operative fixation, especially those with decreased bone mass, the increased rigidity of volar locked-plate fixation is preferable. More and more frequently, active patients express the desire to avoid a 6-week period of casting when presented with a viable alternative; likewise, when given an option, most patients in the urban setting in which this author practices choose internal-fixation over external-fixation devices because of ease of care and avoidance of pin care. After surgery, immobilizing patients in a sugar tong splint in supination is necessary for 7 to 10 days and begin range of motion of the digits and shoulder immediately. Wrist and forearm motion is begun in a removable splint at the time of dressing change, and return to activity is initiated at 6 to 8 weeks, as permitted by radiographic evidence of healing.

Algorithm for Management of Articular Distal Radius Fractures

Type II—Shear Fractures

The basic feature common to *shearing marginal fractures of the joint surface* is that a portion of the metaphysis of the distal radius is intact and in continuity with the unaffected area of the joint surface. These fractures are inherently unstable because of the high deforming forces, and they fare poorly with nonoperative treatment. The ultimate prognosis of these fractures is generally good because the displaced articular fragment or fragments can be precisely reduced and solidly fixed to the intact radius. Furthermore, fractures with a distinct shearing component usually occur in young adults, whose firm cancellous bone offers ideal holding power for internal fixation.

Volarly displaced shear fractures (AO type C2) are not generally amenable to percutaneous fixation because of gross instability, the strong deforming forces of the flexor tendons, and the vulnerability of major nerves and vessels to percutaneous implant insertion. The obliquity of the fracture line and loss of palmar support of the carpus make these fractures inherently unstable. Shortening and palmar displacement of the fragment are always associated with volar subluxation of the carpus. This fracture may affect only the most radial aspect of the palmar articular surface, or it may extend ulnarly into the sigmoid notch. Depending on the quality of the bone and the severity of the impact, a variable amount of comminution of the volar fragment may be present.

Particular attention must be given to rule out the presence of a separate volar–ulnar or teardrop fragment (see earlier); its presence demands that the implant or implants rigidly capture and maintain reduction of this fragment to prevent postoperative carpal subluxation (see Figure 15.48 and Case Study 15.9). An increase in the AP distance on the lateral film (see earlier) suggests that a sagittal split in the articular surface is present and is of concern for a lunate facet or teardrop fragment. If there is any question about whether a separate lunate facet fragment is present, getting a CT scan is indicated.

For volarly displaced shear fractures with a single fragment, a volar fixed-angle plate is preferable, although a traditional 3.5-mm volar buttress plate or low-profile plate fixation is also appropriate (see Case Study 15.10). The standard FCR approach is performed, and provisional fixation of the fragment with one or more 0.062-in K-wires is helpful to maintain reduction before the application of a permanent fixation (see earlier). For injuries with a separate teardrop fragment, the author prefers fixing this lunate facet fragment with a volar buttress pin placed through a volar FCU approach (see earlier), followed by support of the radial column fragment with a 2.0-mm plate.

I am not impressed by the ability of most volar plates to adequately capture a small lunate facet teardrop fragment (see Figure 15.48), and advancement of the plate distally to cover the volar rim is not recommended because of concern for flexor tendon rupture (see Figure 15.42 and Figure 15.58).[33] In the event of primary median nerve signs and symptoms associated with a volar shear fracture, it is preferable to release the carpal tunnel through a separate 3-cm incision in the palm. Extension of the volar–radial approach into the palm risks injury to the palmar cutaneous branch of the median nerve.

A sugar tong splint in supination is worn for 7 to 10 days, followed by a removable wrist splint for 4 to 5 weeks until healing is complete. The patient is encouraged to use the hand for activities of daily living, but heavy manual work or sports are not allowed for 5 to 6 weeks after surgery, at which time the fracture should be healed.

Isolated dorsal shearing fractures (i.e., *dorsal Barton fractures*) are rare. As a group, dorsal marginal shear fractures represent less than 2% of all distal radius fractures and share the defining characteristic of (1) a fracture of the dorsal articular rim and (2) dorsal radiocarpal subluxation. This is a high-energy injury that occurs in a predominantly young male cohort. The injury is characterized by an intact volar metaphyseal rim in most cases.

Lozano-Calderón and colleagues identified four discrete subtypes of shearing fractures based on the degree of articular surface involvement (Figure 15.59).[104] The least common subtype is characterized by extension of the fracture line across the volar cortex with a relatively large and dorsally rotated volar

http://e-surg.com

CASE STUDY 15.4

A 61-year-old slipped on the driveway. The injury was treated and reduced elsewhere and placed in short-arm cast. Trauma films were not available. Consider whether the fracture shown in eFigure 15.21 is stable.

Lafontaine, criteria: trauma films

- Dorsal angulation >20 degrees
- Dorsal comminution
- Intraarticular fracture
- Ulnar fracture
- Age > 60

(Lafontaine M, Hardy D, Delince PH: Stability assessment of distal radius fractures. Injury 20(4):208–10, 1989.)

Predictors of malunion: Trauma films

- Age
- Comminution (dorsal)
- Ulnar variance

(Mackenney PJ et al., JBJS 2006;88:1944–1951)

Is the fracture shown in eFigure 15.21 stable?

ANS: No: See eFigure 15.22.

The recommendations for closed treatment include:

- Obtain trauma films.
- Identify instability factors and advise patient of relative probability of displacement.
- Weekly follow-up with radiographs.
- Establish parameters for loss of reduction and algorithm for intervention.

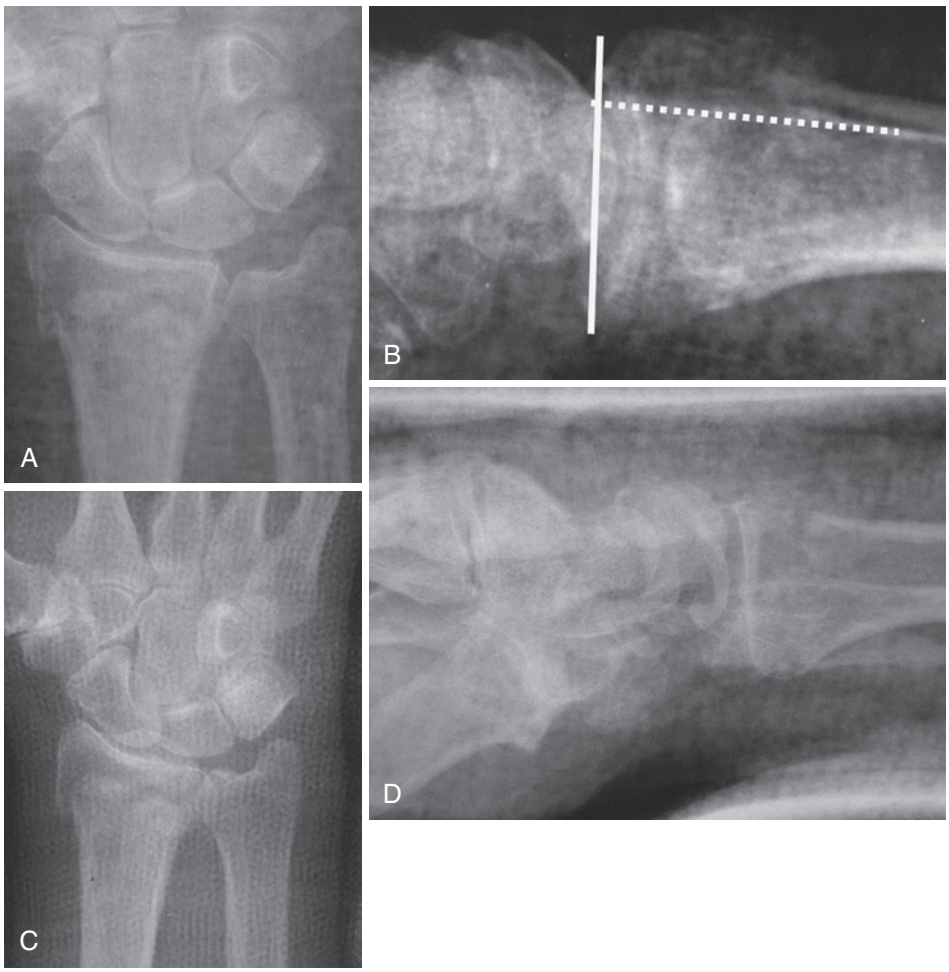

eFIGURE 15.21 Radiographs at: **A, B,** Presentation. **C, D,** Two weeks after presentation.

http://e-surg.com

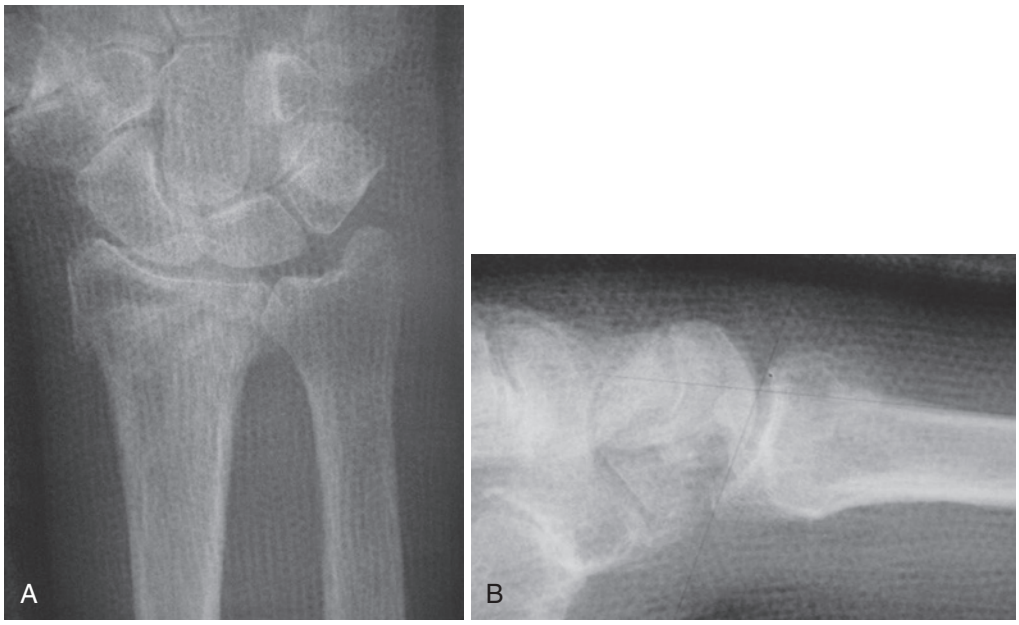

eFIGURE 15.22 **A, B,** At 6 weeks; fracture not stable.

http://e-surg.com

CASE STUDY 15.5

A 50-year-old female presents with bilateral unstable fractures (eFigure 15.23).

- Classify the fractures.
- Are these stable or unstable?
- Operative or nonoperative?

Operative options?

A. Percutaneous fixation
B. Fragment-specific fixation
C. Fixed-angle plating

ANS: Left wrist:

- Type I dorsal bending
- Minimal articular extension
- May be stable
- Operative treatment warranted for bilateral injury. Options:
  - Percutaneous fixation
  - Locked plate
  - Columnar fixation

Right wrist:

- Type II volar shear
- Unstable fracture
- Internal fixation

Several options:

- Buttress plate
- Volar locked plate
- Fragment-specific fixation

Augmented percutaneous fixation was performed on each (eFigures 15.24 and 15.25). Surgical results can be viewed in eFigure 15.26.

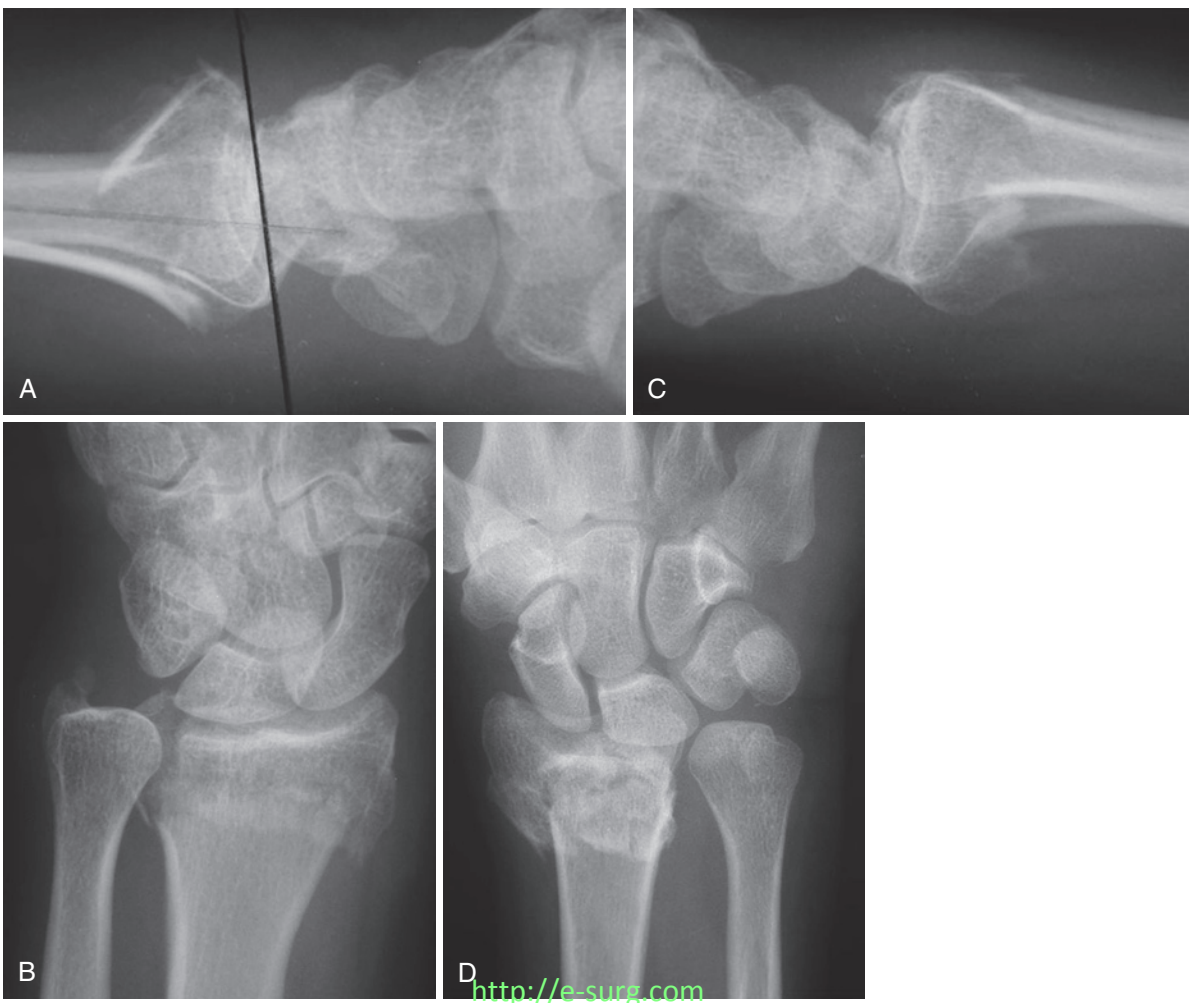

eFIGURE 15.23 Radiographs: **A, B,** Left. **C, D,** Right.

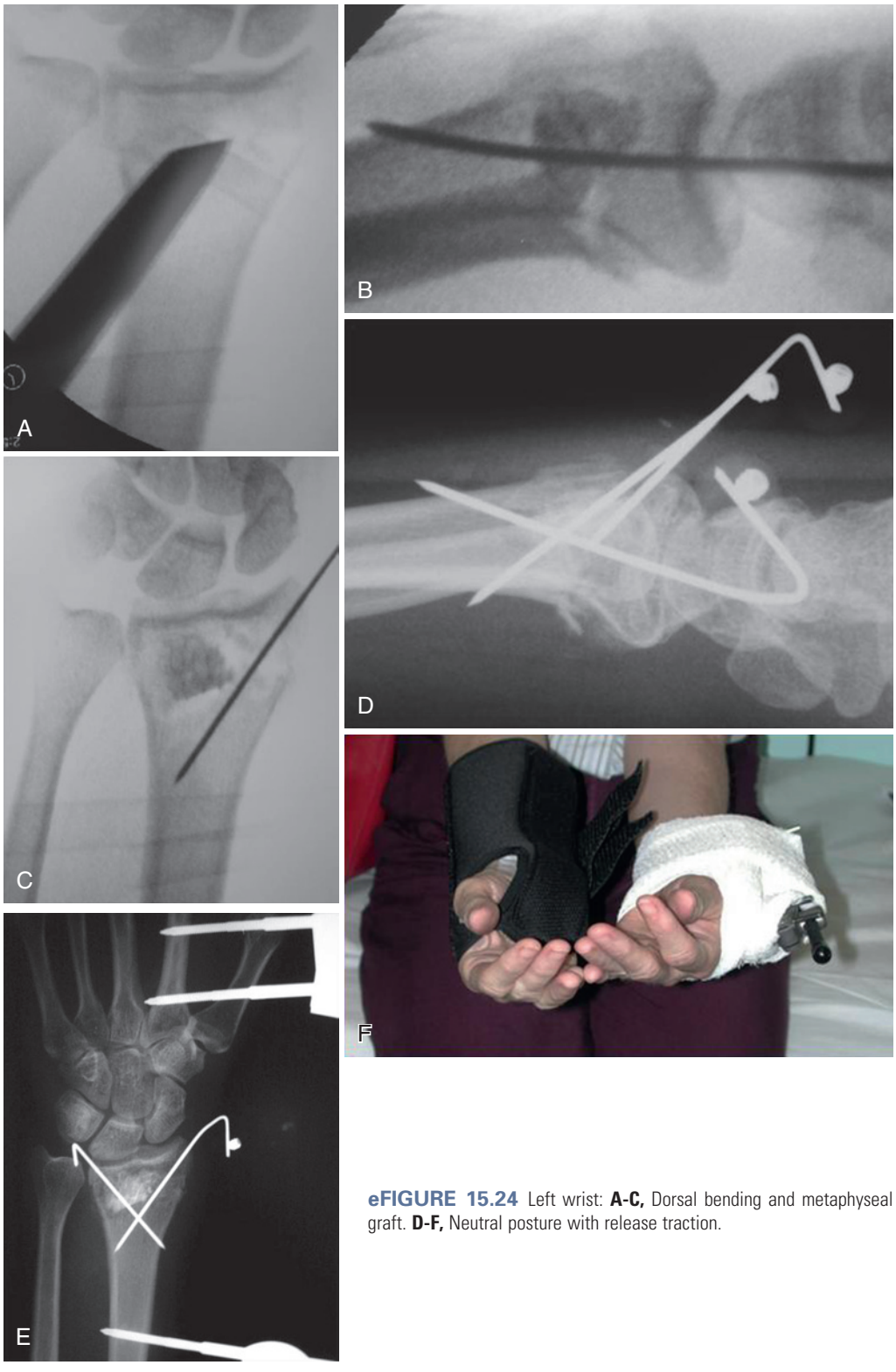

eFIGURE 15.24 Left wrist: **A-C,** Dorsal bending and metaphyseal graft. **D-F,** Neutral posture with release traction.

http://e-surg.com



eFIGURE 15.25 Right wrist: **A-D,** Volar shear fracture with fixed-angle plate.

http://e-surg.com

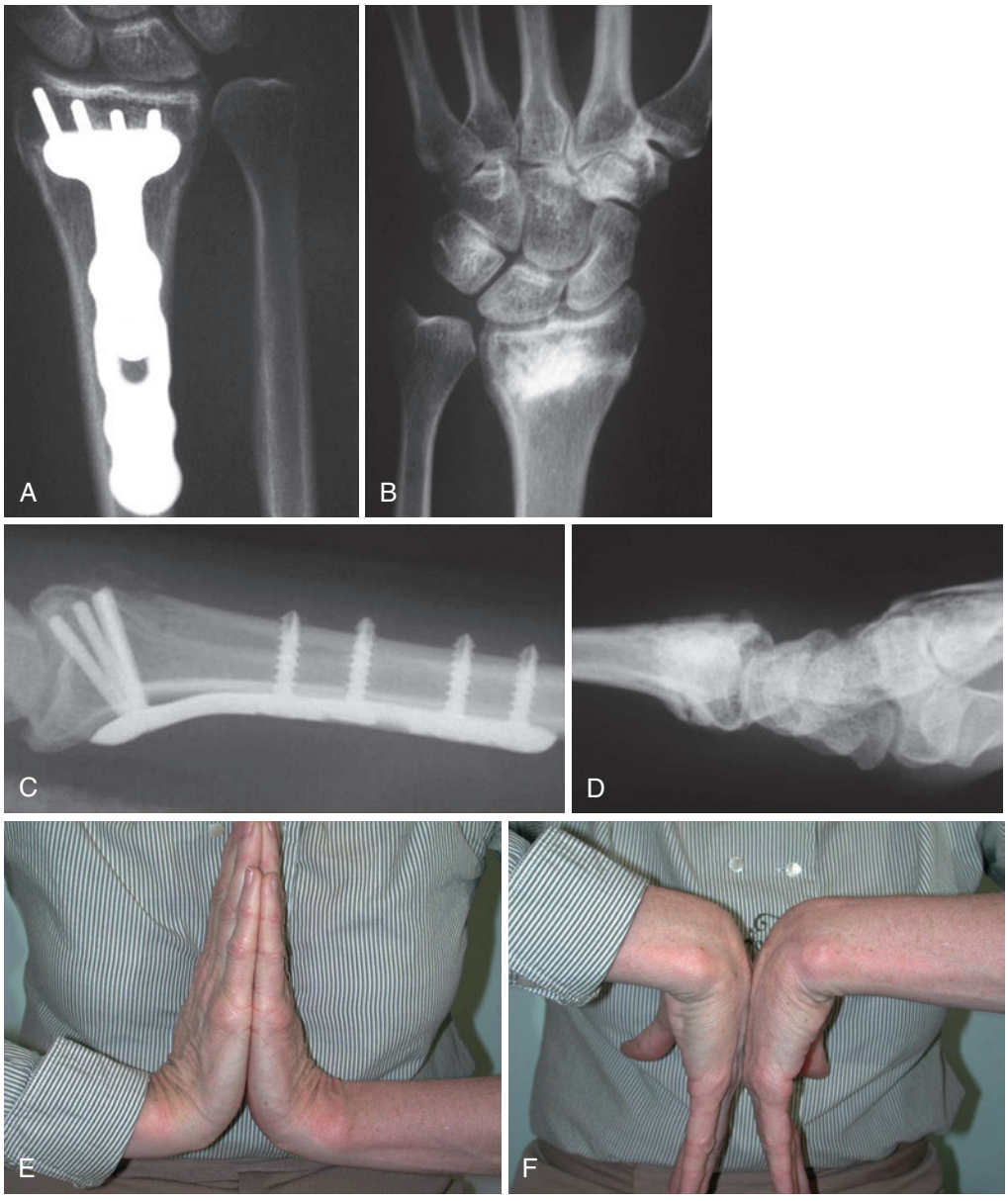

eFIGURE 15.26 The ulnar variance is equal in the right **(A)** and left **(B). C-F,** Radiographs at 6 months postoperative.

http://e-surg.com

CASE STUDY 15.6

A 36-year-old executive fell in an ice rink 5 days previously and presented in a splint, not reduced (eFigure 15.27).

What is the fracture type?

A. Bending
B. Shear
C. Compression
D. Fracture–dislocation
E. Combined

ANS: A. Bending

Which of these factors suggest that the injury is unstable?

A. Age
B. Dorsal comminution
C. Loss of ulnar variance

ANS: B. Dorsal comminution and C. Loss of ulnar variance

Which of the following are treatment options?

A. Closed reduction/cast
B. Closed reduction/percutaneous
C. ORIF (Several options)

ANS: C. ORIF, with fixed-angle volar plate

Procedural images for ORIF with fixed-angle volar plate are displayed in eFigure 15.28. Surgical results are shown in eFigure 15.29.

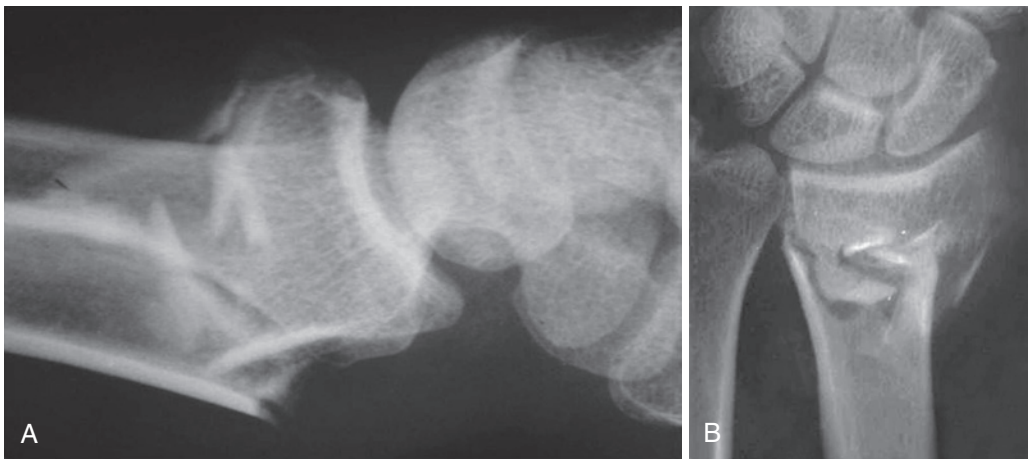

eFIGURE 15.27 **A, B,** Radiographs at presentation.

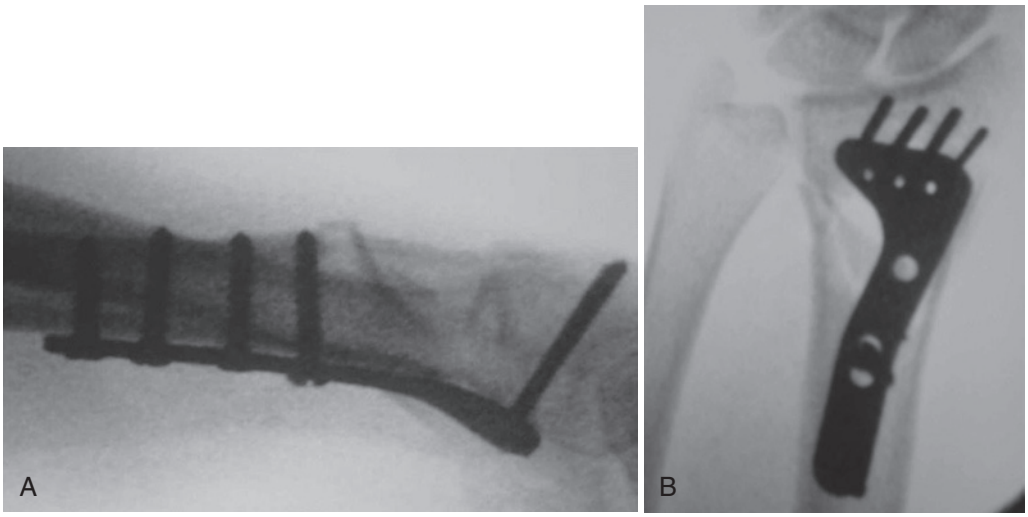

eFIGURE 15.28 **A, B,** Intraoperative radiographs.

http://e-surg.com



eFIGURE 15.29 **A, B,** Radiographs at 6 months postoperative. **C-F,** Photos at 6 months postoperative.

http://e-surg.com

CASE STUDY 15.7

Nascent Malunion

A 37-year-old office worker presents in a cast 6 weeks postinjury, lacking supination (eFigure 15.30). The patient is active and enjoys golf.

A nascent malunion:

- Digital motion good
- Minimal pain
- No other injuries, illnesses
- Options:
  - Continued cast
  - Splint, rehab
  - Early ORIF (eFigure 15.31)

Surgical outcome is displayed in eFigure 15.32.

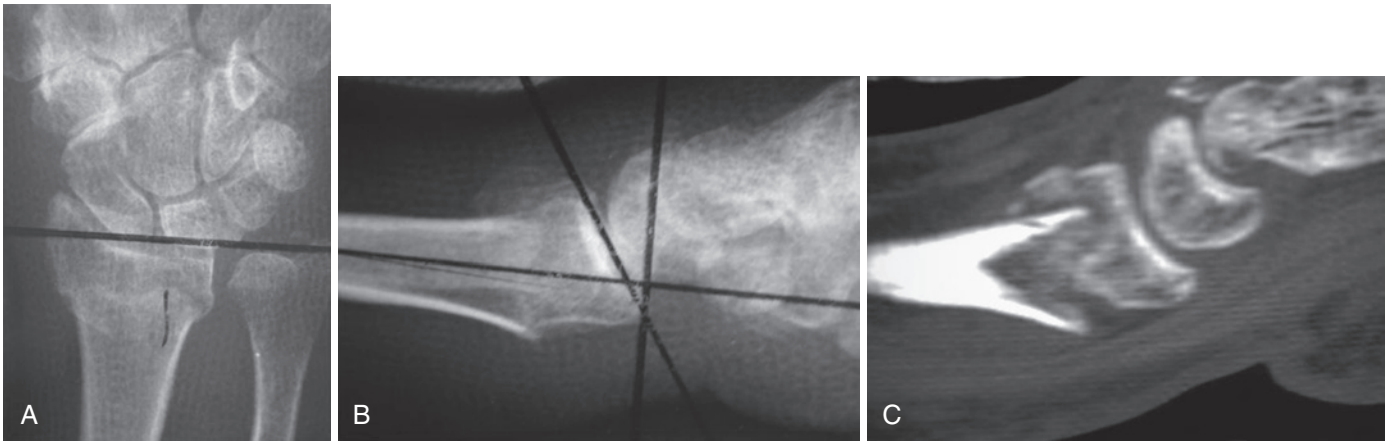

eFIGURE 15.30 **A, B,** Radiographs at presentation. **C,** Computed tomography obtained elsewhere that shows smooth articular surface; not united.

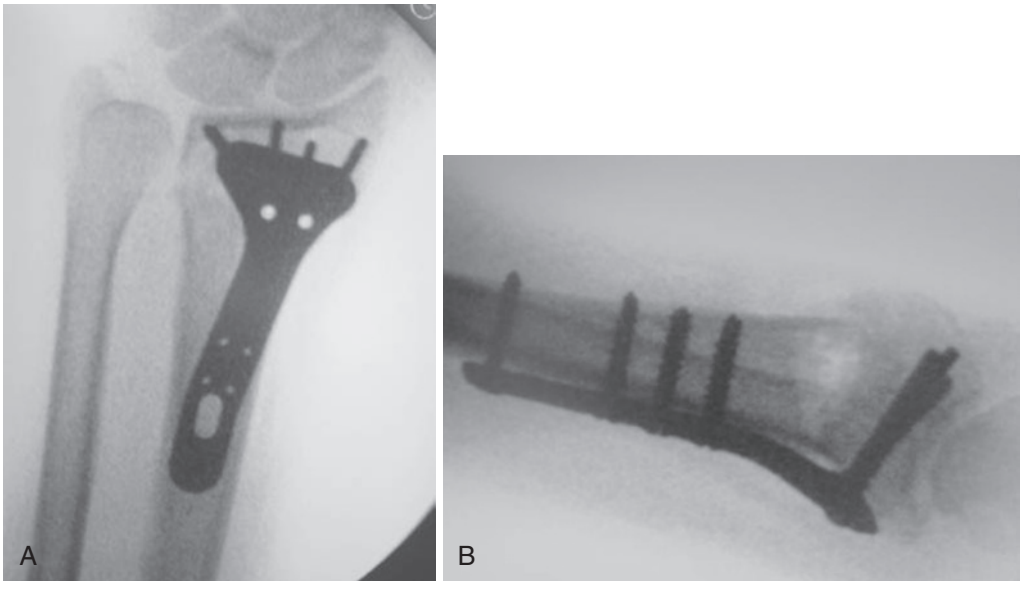

eFIGURE 15.31 **A, B,** Radiographs of early open reduction and internal fixation.

http://e-surg.com



eFIGURE 15.32 **A-D,** Photographs at 3 months postoperative.

http://e-surg.com

CASE STUDY 15.8

A 68-year-old right-handed female presents having undergone ORIF 4 weeks earlier in a remote village in Turkey (eFigure 15.33). Surgery was recommended to revise nascent malunion (eFigure 15.34).

Surgical results are shown in eFigure 15.35.

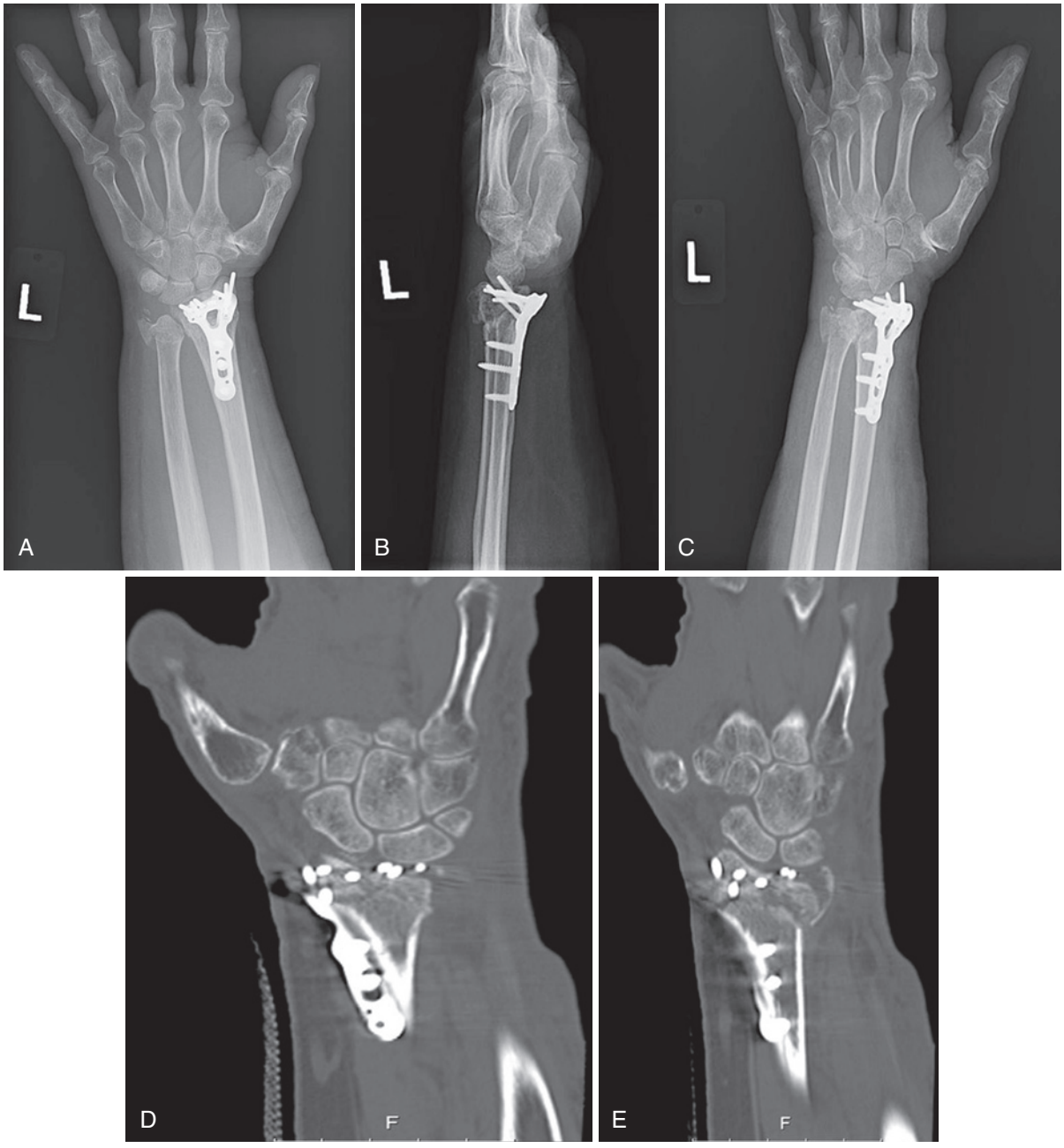

eFIGURE 15.33 **A-C,** Radiographs at presentation in United States at 4 weeks postoperative. **D, E,** Preoperative computed tomography demonstrates prominent hardware in radiocarpal joint.

http://e-surg.com

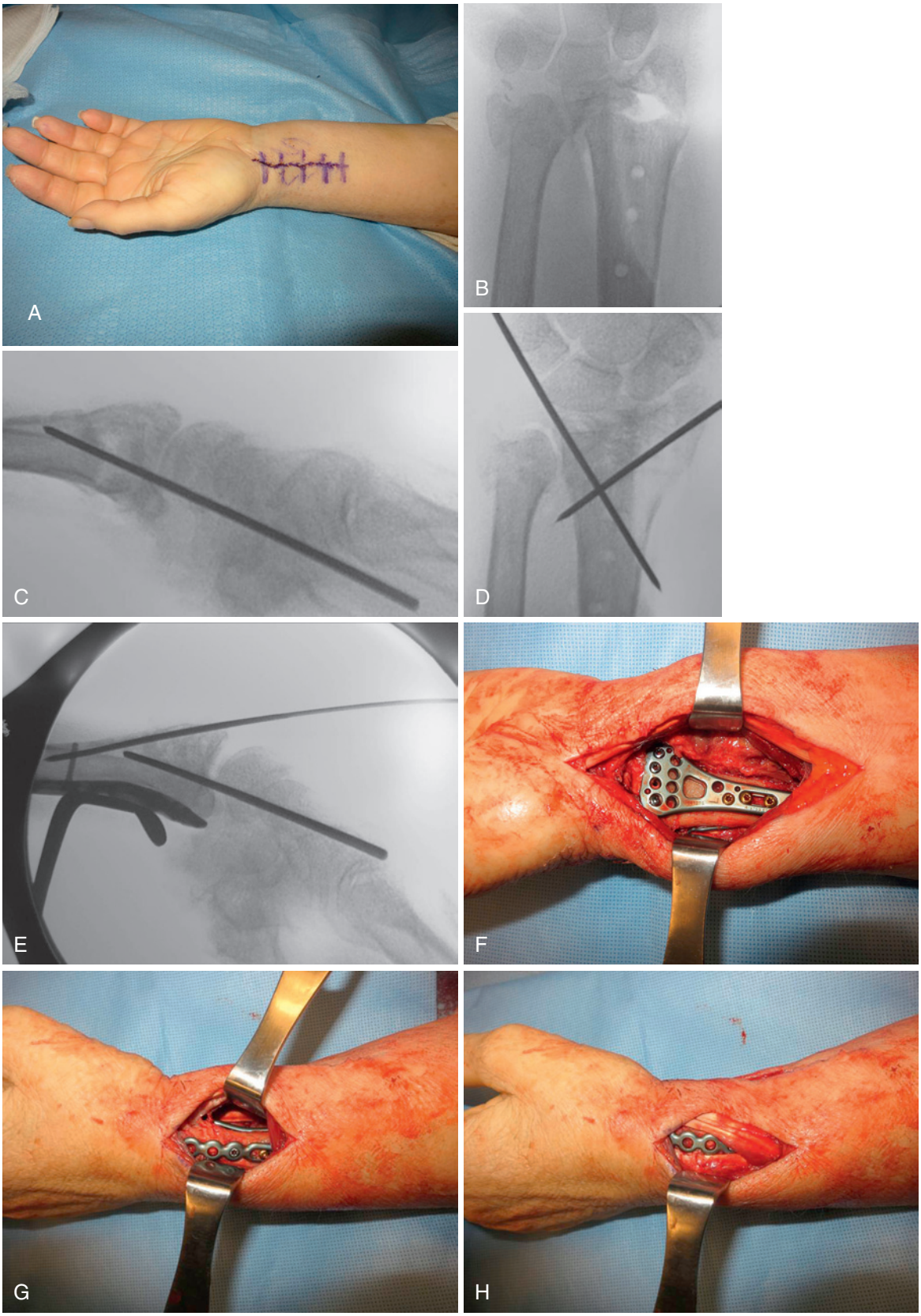

eFIGURE 15.34 **A,** Prior incision opened. **B,** Fluoroscopic posteroanterior demonstrates gross articular incongruency and coronal shift of articular fragments. **C, D,** Realignment and provisional percutaneous pin fixation performed. **E, F,** Volar plate applied as a buttress. **G,** Large unstable radial styloid fragment further stabilized with radial column plate. **H,** Note plate placement through second dorsoradial incision between first and second dorsal compartments. There is no concern for the skin bridge between incisions because the radial runs through the interval.

http://e-surg.com

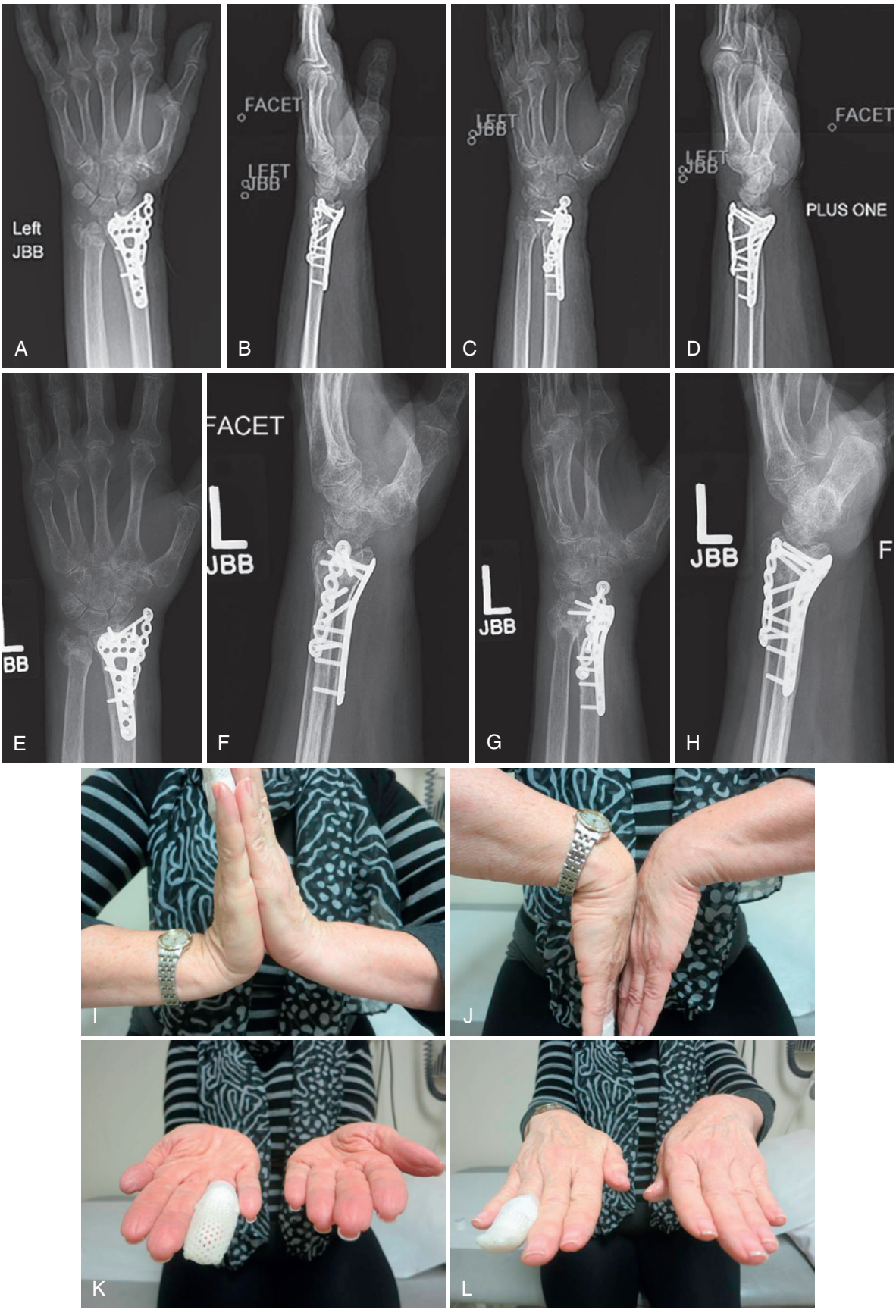

eFIGURE 15.35 Radiographs: **A-D,** at 10 days postoperative. **E-H,** At 6 weeks postoperative. **I-L,** At 3 months postoperative.

http://e-surg.com

CASE STUDY 15.9

Lunate Facet

A lunate facet is characterized by

- Palmar carpal subluxation
- Increased teardrop angle (eFigure 15.36)

eFigure 15.37 displays a small volar lunate facet fragment and styloid fragment.

Which is the best treatment option?

A. Percutaneous fixation
B. Fragment-specific fixation
C. Fixed-angle plate fixation

ANS: B. Fragment-specific fixation. It is difficult to percutaneously fix small volar fragments safely. Caution is advised with fixed-angle plate fixation: volar fragment may be too small for effective fixation. A backup plan must be available.

eFigure 15.38 displays intraoperative images. Surgical results are shown in eFigure 15.39.

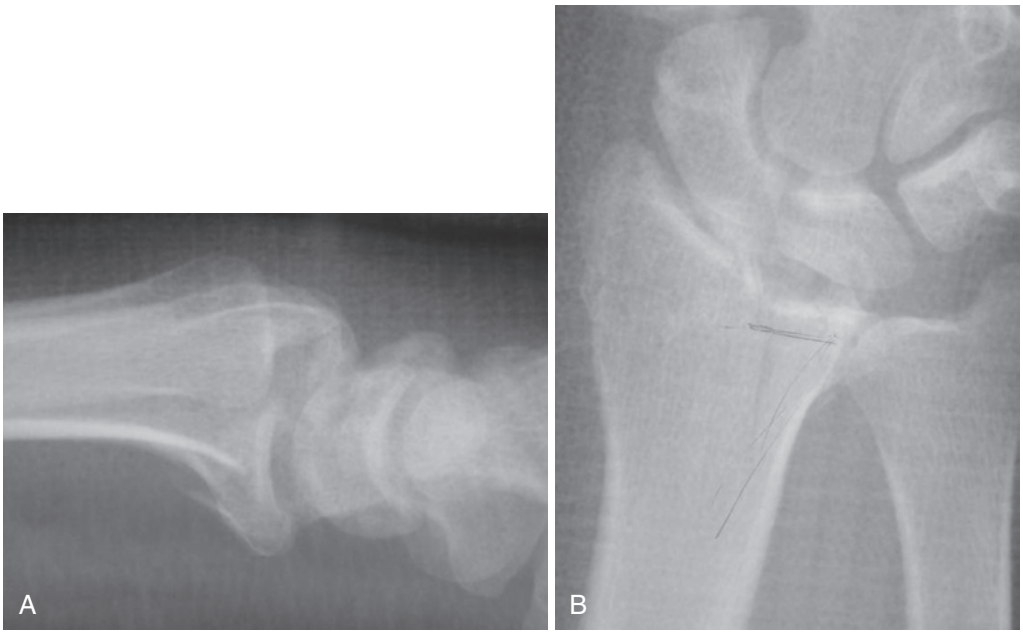

eFIGURE 15.36 **A, B,** Radiographs of lunate facet.

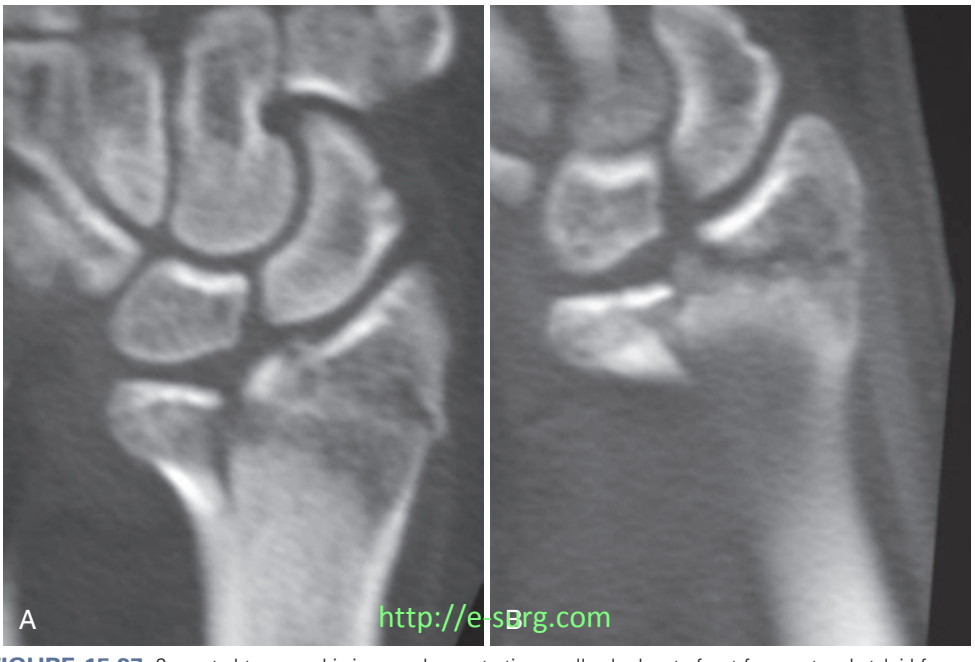

http://e-s rg.com

eFIGURE 15.37 Computed tomographic images demonstrating small volar lunate facet fragment and styloid fragment.

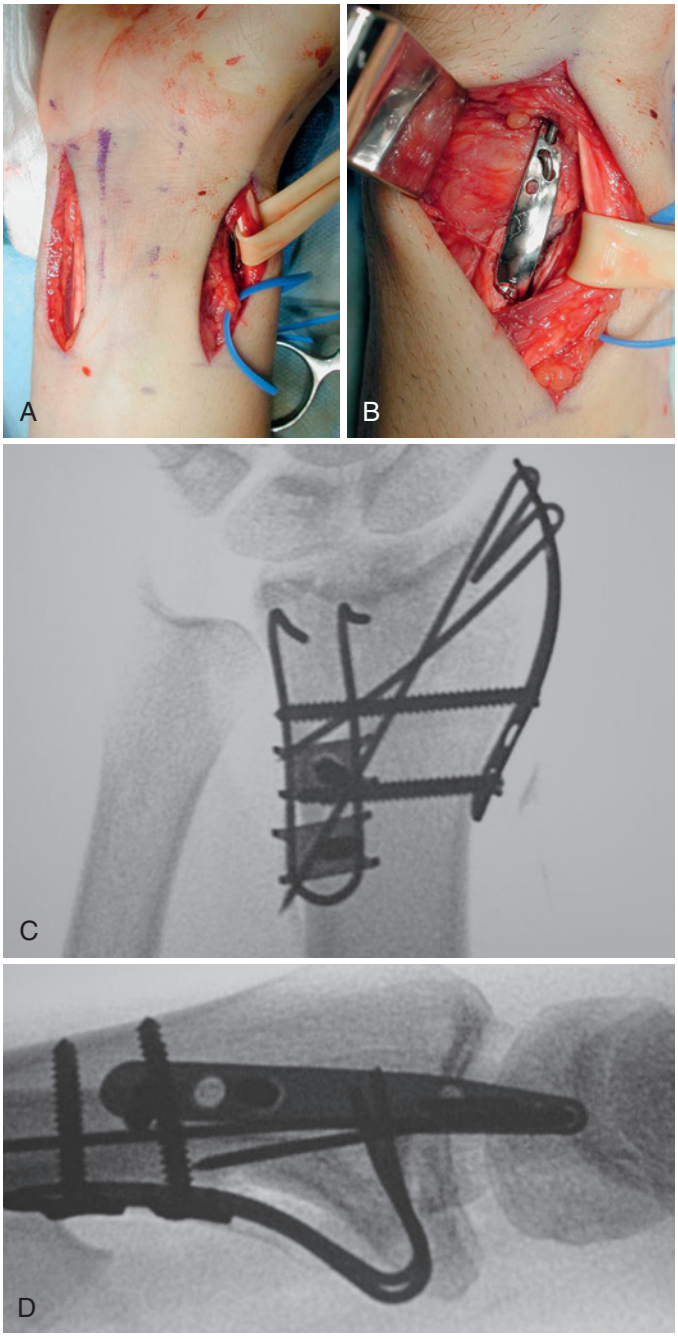

eFIGURE 15.38 Fragment-specific fixation: **A,** Limited incision approach to radial column and volar radius. **B,** Fluoroscopic images demonstrated reduction with radial column plate and volar buttress implant.

http://e-surg.com

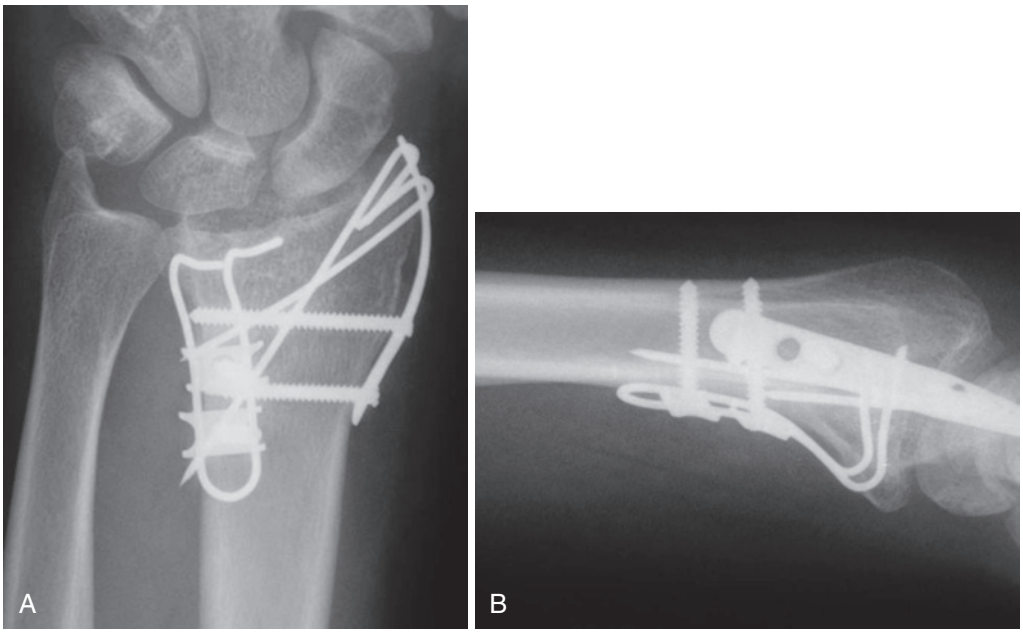

eFIGURE 15.39 **A, B,** Radiographs at 1 year postop.

http://e-surg.com

CASE STUDY 15.10

Volar Subluxation

A 34-year-old healthy male fell while skiing 4 days previously, injuring his dominant hand. Films revealed a multiple comminuted articular injury (eFigure 15.40).

What are the treatment options?

A. Percutaneous
B. Fragment-specific
C. Fixed-angle plate
   - Dorsal
   - Volar

ANS: C. Volar fixed-angle plate.

eFigure 15.41 displays intraoperative radiographs. The postsurgical results are shown in eFigure 15.42.

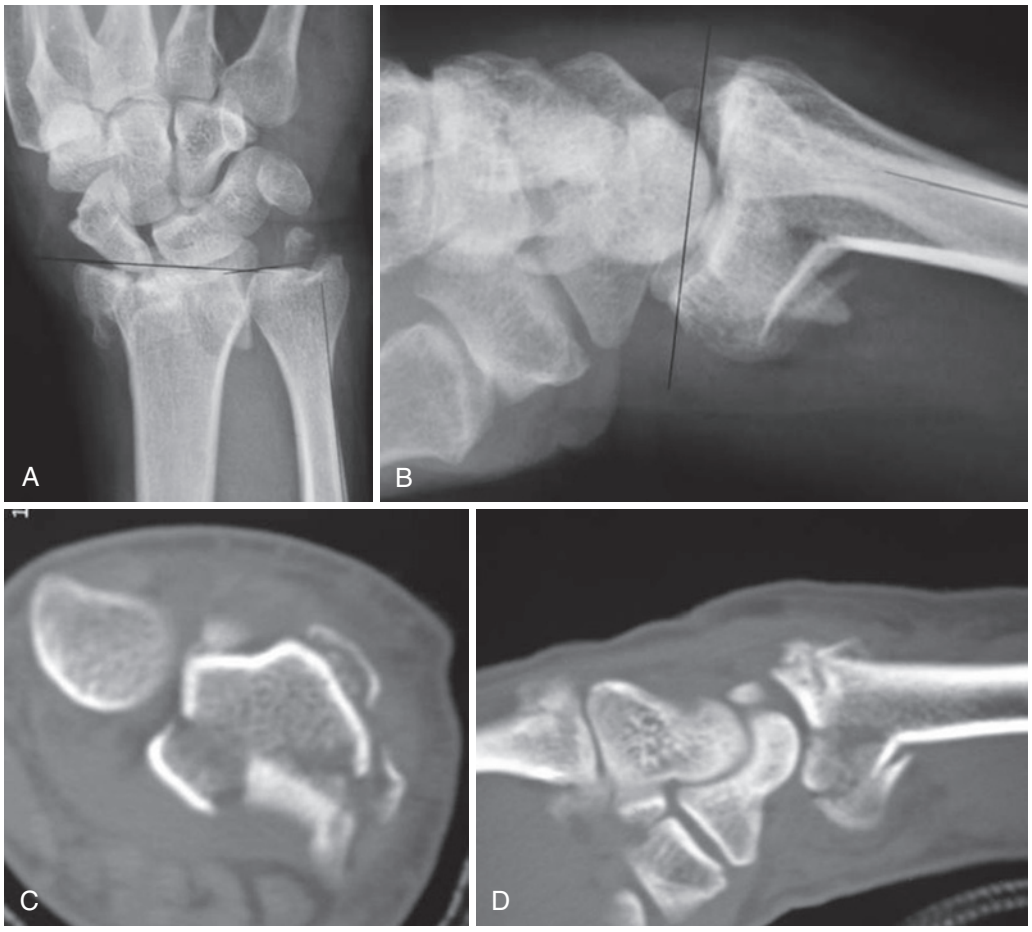

eFIGURE 15.40 **A, B,** Preoperative radiographs. **C, D,** Computed tomographic images demonstrating complex articular fracture with multiple fragments.

http://e-surg.com

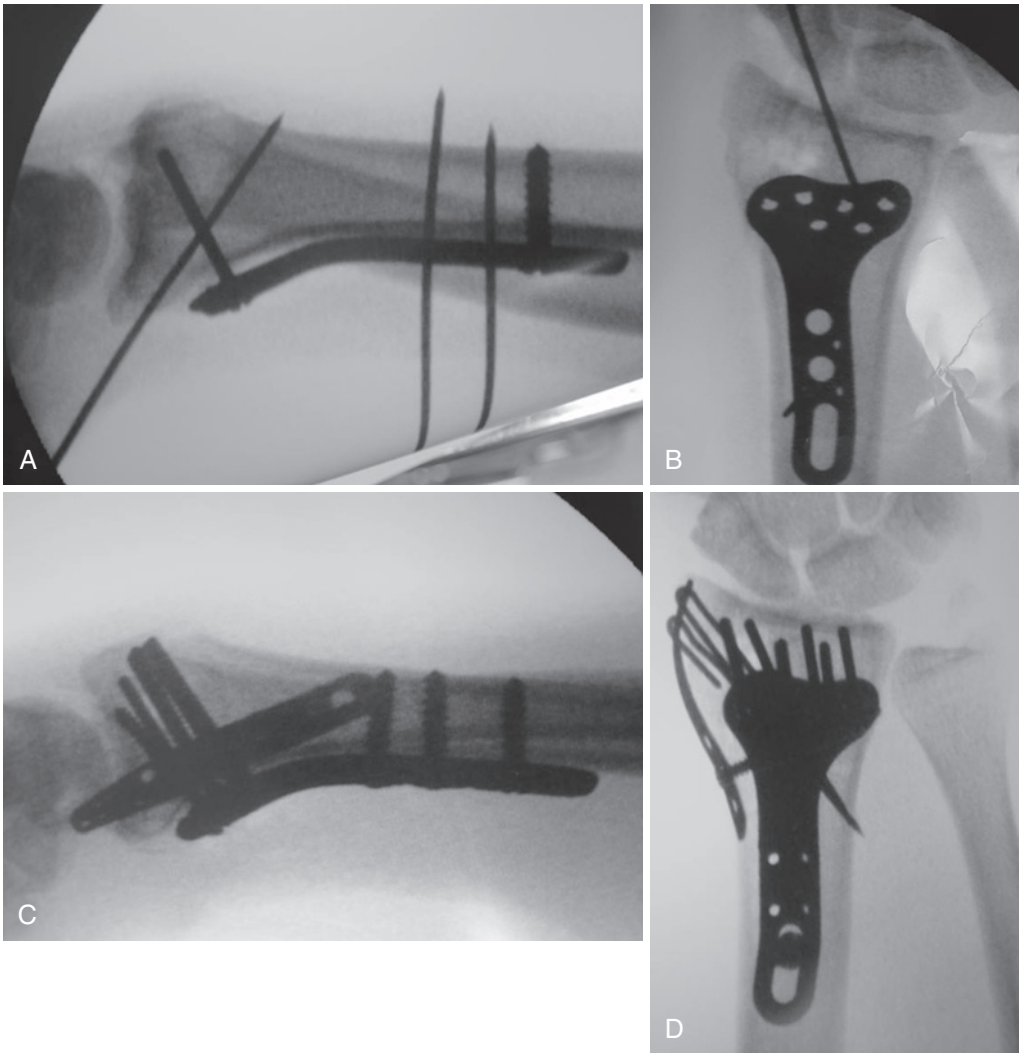

eFIGURE 15.41 Fixed-angle volar plate: **A, B,** Insufficient fixation of radial column identified. **C, D,** Augmented with radial column plate.

http://e-surg.com

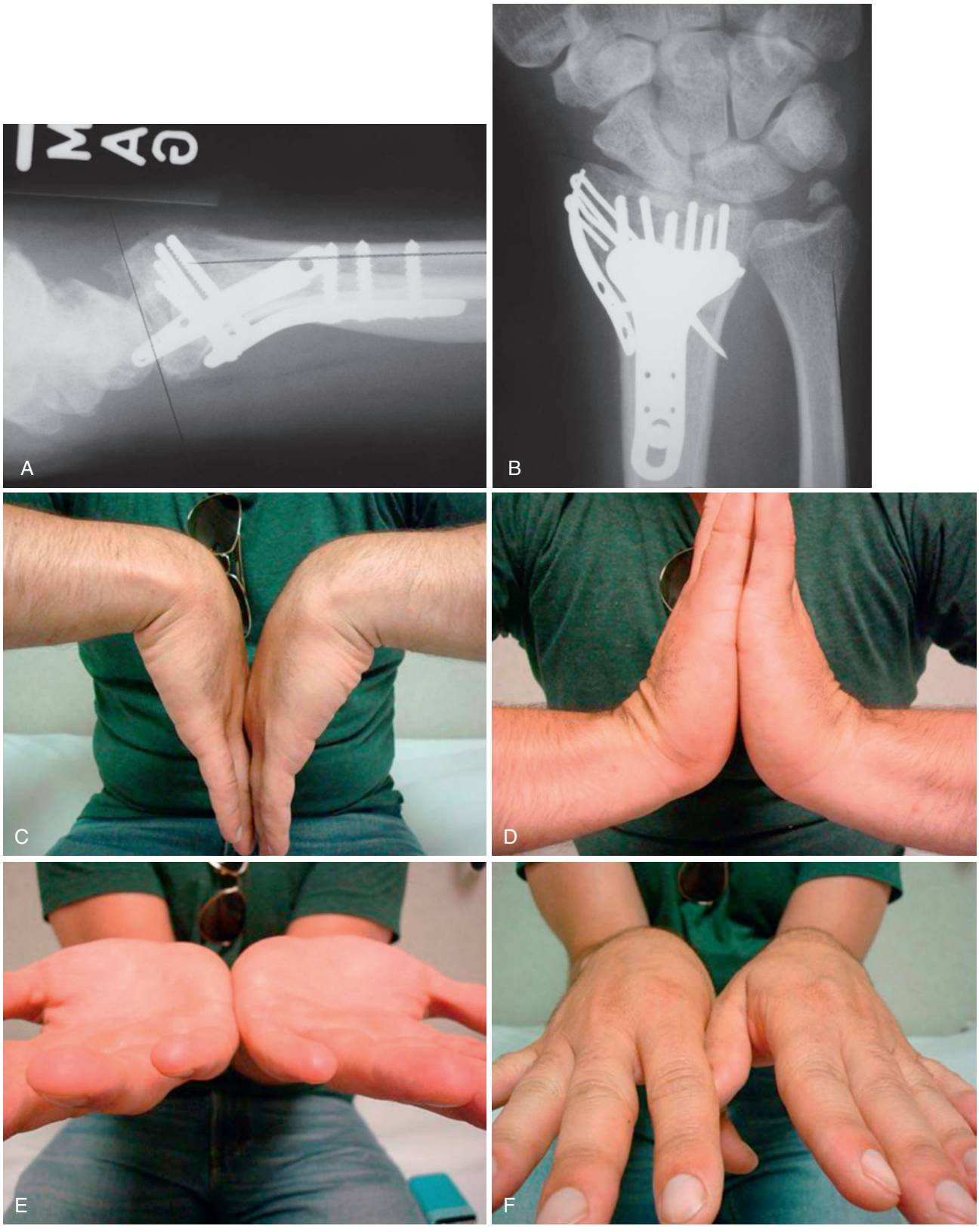

eFIGURE 15.42 **A, B,** Radiographs at 1 year postoperative. **C-F,** Clinical photos at 1 year postoperative.

http://e-surg.com

lip component and no appreciable articular impaction. Fractures of this subtype often can be indirectly reduced and stabilized using a volar approach and a fixed-angle plate. For the remainder of these fractures, however, adequate articular disimpaction and support cannot be achieved without direct visualization, carpal reduction, and stabilization through a dorsal or combined approach.

I prefer to approach these fractures through dual incisions: a volar–radial columnar approach and a universal dorsal approach through the third extensor compartment. First, the radial styloid fragment is carefully reduced through the radial column incision, checked for proper realignment at the metaphyseal level, and pinned provisionally to the proximal–radial shaft with an oblique 0.45-in K-wire. Then, the dorsal rim fragment is reduced against the scaphoid and lunate, and dorsal subluxation of the carpus is corrected. The fragments are provisionally pinned, and articular congruity is confirmed with fluoroscopy.



FIGURE 15.58 Advancement of a palmar plate onto the palmar rim of the radius should be avoided because there is no soft tissue buffer between the plate and the overlying flexor tendons.

Depending on the extent of metaphyseal comminution, an autogenous bone graft or a structural bone graft substitute (see earlier) may be required to support the reduced articular surface (see Figure 15.35, *B*). The dorsal rim fragment can then be secured to the intact radius with a dorsal wireform—typically a dorsal buttress pin or small-fragment buttress pin combination (Figure 15.60). As an alternative, use of 2.0- to 2.4-mm fixed-angle dorsal plates may provide sufficient stability to obviate the need for a structural bone graft.[104] A 3- or 5-hole radial column pin plate or a 2.4-mm fixed-angle radial column plate is then applied directly on the radial column to maintain reduction of the styloid fragment; this should also provide the increased mechanical stability of orthogonal fixation, with the implants placed in two planes at least 50 to 70 degrees apart (see Figure 15.60).[10,77] Fixation should be sufficiently stable to begin wrist and forearm range-of-motion exercises after removal of the sutures and the postoperative splint at 7 to 10 days.

Shear fractures of the radial styloid (chauffeur's fracture) are not uncommon and can be associated with intercarpal bony and soft tissue injuries. Scaphoid fractures and perilunate injuries, ranging from partial or complete scapholunate ligament disruption to lunate dislocation, on occasion may be associated with this injury (Figure 15.61, *A*). If the radial styloid fragment shows substantial proximal and radial displacement and the fracture line enters the joint at the level of the interfacet ridge between the scaphoid and lunate fossae, there is a distinct possibility of disruption of the scapholunate ligament. The scaphoid displaces proximally with the radial fragment, whereas the

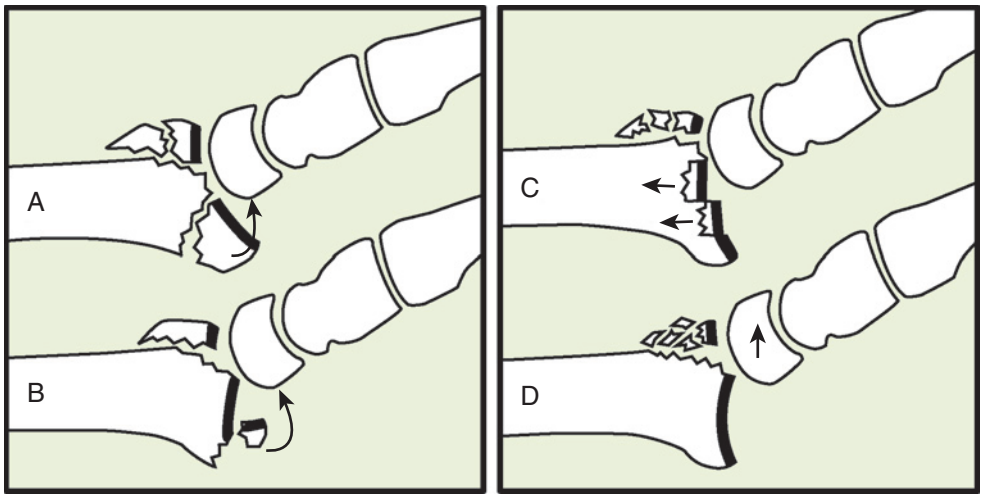

FIGURE 15.59 Four discrete types of dorsal shear fractures have been described by Lozano-Calderón and colleagues.[104] **A,** A relatively common variant has a large rotated volar fracture fragment that constitutes the majority of the articular surface. **B,** The most common subtype demonstrates a small volar lip (teardrop) fragment, from which the important short and long radiolunate ligaments originate. **C,** The central impaction pattern, associated with the shear fracture of the dorsal margin, is relatively uncommon, as is the true radiocarpal fracture–dislocation **(D),** which constitutes a serious combined ligamentous and bony injury. (© Elizabeth Martin.)

http://e-surg.com

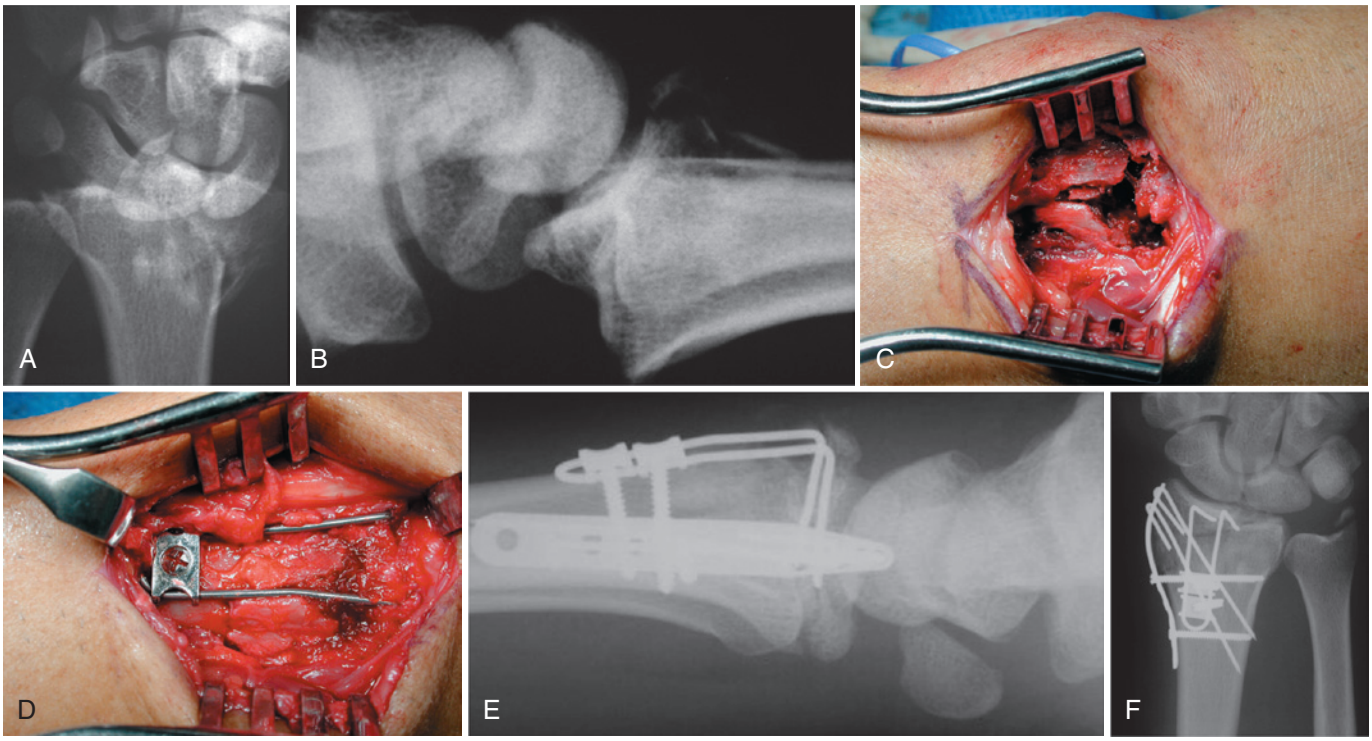

FIGURE 15.60 Type A dorsal shear fracture: **A, B,** Posteroanterior and lateral radiographs demonstrating shear of the entire articular surface with little attached subchondral bone. **C,** Dorsal view of the highly comminuted dorsal surface after closed reduction. **D,** Fixation of the thin dorsal rim and articular surface fragment with a dorsal wireform implant. **E, F,** Postoperative radiographs demonstrating restitution of articular alignment and length.

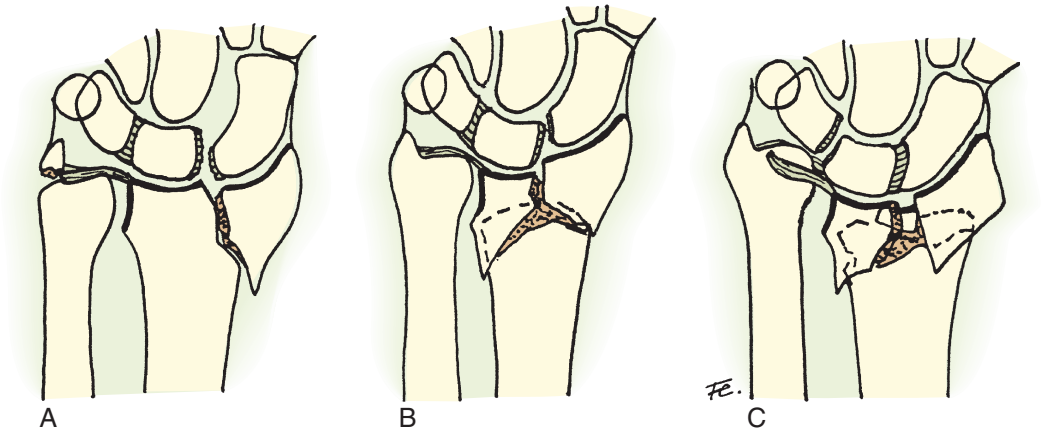

FIGURE 15.61 Mechanism of injury of intercarpal ligament disruption: **A,** Extension and radial deviation produce a proximally displaced shearing fracture of the radial styloid, scapholunate dissociation, and an avulsion fracture of the ulnar styloid. **B,** Axial compression with severe impaction of the lunate fossa accounts for shear loading of the scapholunate junction and tearing of the ligaments at this level. **C,** Axial compression and ulnar deviation with severe radial shortening produce acute ulnocarpal abutment and disruption of the lunotriquetral and triangular ligaments.

lunate remains in its anatomic position. Treatment should be directed at (1) diagnosis and management of associated soft tissue injuries and (2) stable fixation of the styloid fragment.

I recommend a low index of suspicion for concomitant scapholunate ligament disruption, and a large radial styloid fracture is a prime indication for arthroscopically assisted percutaneous reduction and fixation (see earlier).[52,171] In this procedure, irrigation of the articular hematoma, direct inspection of the scapholunate ligament from both the radiocarpal and midcarpal portals, and arthroscopic–fluoroscopic reduction of the articular surface is performed (see Figure 15.36). For incomplete disruptions of the scapholunate ligament, fluoroscopic and arthroscopic stress testing of the ligament is performed with a scaphoid shift maneuver to determine the degree of instability (see Chapter 13).

After assessment of the ligament, the cartilage-bearing fragment is manipulated with an awl or a periosteal elevator through a small skin incision under fluoroscopic and arthroscopic guidance, with a minimum of soft tissue dissection. Most of these cases can be stabilized with percutaneously inserted implants

http://e-surg.com

(e.g., cannulated screws, K-wires, external fixation, bridging or nonbridging, or any combination of these) provided there is good bone quality (Figure 15.62). Care should be taken to protect the superficial radial nerve, the radial artery, and the extensor tendons at the anatomic snuffbox level. For larger or more unstable fragments, I prefer the rigidity of a radial column plate applied through a 3- to 4-cm volar–radial approach (see earlier) (see Case Study 15.2). A bone graft or bone graft substitute may be required if there is a subchondral–metaphyseal void after fragment reduction.

I repair *complete* ruptures of the dorsal component of the scapholunate ligament through a limited dorsal approach that involves the use of a bone anchor in the scaphoid and a double row of sutures.[84] Although there are limited data available, it is best to immobilize the reduced scapholunate joint with a temporary cannulated screw inserted just distal to the radial styloid. The advantage of a temporary screw over wires is that it may be left in place while radiocarpal wrist motion is initiated.



FIGURE 15.62 Combined radial styloid and dorsal shearing fracture (dorsal Barton) in a 23-year-old woman. Notice the intact volar–ulnar portion of the joint surface in the lateral view. Both fragments were securely stabilized with lag screws, which permitted early wrist motion after suture removal.

For incomplete tears with fluoroscopic or arthroscopic evidence of scapholunate instability during a scaphoid shift examination (e.g., Geissler grade 2), I perform percutaneous temporary pin or screw fixation without open ligament repair. If radial styloid fixation alone is performed, wrist and forearm range-of-motion exercise is begun at the first postoperative dressing change. If the scapholunate ligament was repaired and fixed with pins or a temporary screw, gentle wrist range of motion is begun 6 to 8 weeks postoperatively, and the screw is removed 4 months after surgery.

Type III—Joint Surface Compression Fractures

Compression fractures have a variety of configurations, but all variants share comminution of the articular surface of the intermediate column,[77,133] the so-called die-punch fracture (see Figure 15.16, *B*).[115] These fractures occur most commonly in young and active individuals, so accurate reduction and maintenance of reduction are essential for an optimal outcome. Critical to their treatment is a thorough understanding of the fracture anatomy, and I recommend the fragment-specific classification (see Figure 15.18) to identify critical fracture components and guide treatment options. The surgeon should have a low threshold for advanced imaging studies (i.e., CT with or without three-dimensional reconstruction) of these challenging injuries to better understand the fracture anatomy and plan the operative approaches.

Intermediate Column Single-Fragment Fractures. If an intermediate column fracture is characterized by a simple nondisplaced or minimally displaced articular fragment (and is without significant metaphyseal comminution), closed reduction and cast application may be all that is necessary. In many cases, however, the higher energy of this fracture group displaces the intermediate column fragment, so operative reduction and stabilization are required. Joint distraction with horizontal finger-trap traction is not generally capable of disimpaction and realignment of small cartilage-bearing fragments, nor can it accomplish reduction of rotated volar lip and dorsal–ulnar corner fragments.

Isolated and displaced fractures of the dorsal or volar–ulnar corner are rare, but they are potentially serious injuries (see Case Study 15.11). It is important to recognize these fractures and treat them aggressively to avoid late subluxation of the carpus. More commonly, the combination of a *radial column or dorsal-bending fracture and a dorsal or volar intermediate column fragment* is seen. They may be misdiagnosed as Colles' fractures because the small (but critically important) ulnar corner fragment may be overlooked. An unreduced intermediate column fragment can lead to carpal subluxation, distal radioulnar incongruency, or both. If closed manipulation fails to provide anatomic congruity and stability of the joint surface, open reduction with direct fragment fixation is my preference (see Case Study 15.11), although mini-open reduction with percutaneous–external fixation is a suitable alternative for many fractures with a dorsal–ulnar corner component and good bone quality.

http://e-surg.com

I begin with closed reduction under fluoroscopy and use finger-trap traction as necessary to maintain the reduction during the surgical exposure. The radial column is approached first through the volar–radial column method (see Case Study 15.11), and after reflection of the first dorsal compartment tendons, fixed provisionally to the proximal–radial shaft with an oblique 0.045-in K-wire. I expose dorsal–ulnar corner fractures that are not associated with an impacted articular or dorsal wall component with a limited, nonextensile incision over the fifth dorsal compartment (see earlier). A provisional 0.045-in K-wire is directed across the fragment at a 45-degree angle to both the coronal and sagittal planes and secured to the proximal–radial shaft. A three-hole ulnar pin plate or a 2.0- to 2.4-mm fixed-angle plate is affixed to the proximal metaphysis to stabilize the fragment (see Figure 15.50).

A radial pin plate or a 2.4-mm radial column plate is used to stabilize the radial styloid fragment. The wrist is taken through a full range of motion under fluoroscopy to confirm a stable reduction. Stable fractures are mobilized with early hand therapy beginning 7 to 10 days postoperatively.

Volar intermediate column fractures (e.g., volar–ulnar corner, teardrop) are exposed through a limited volar–ulnar approach, as well as the radial column approach, and radial columnar fixation is performed as described previously. Fixation of the volar teardrop fragment is performed as described earlier, with a volar buttress pin or a tension band fixation, followed by fixation of the radial column plate. Alternatively, a volar-locked plate and spring wire combination can be employed.[117] Patients with stable fracture reductions are started on an early mobilization protocol (see Case Study 15.12).

Three- and Four-Part Injuries. Further fragmentation of the intermediate column produces more complex diagnostic and treatment challenges. Delineation of the location, relative stability, and number of fragments is essential in planning the operative approach and fixation strategy. A CT scan in such cases is vital and has been demonstrated to alter not only the decision to operate but also the surgical approach in nearly 50% of cases.[74]

In general, these fracture types will require a combination of (1) longitudinal traction or reduction of the metaphyseal fracture, (2) open reduction for restoration of joint congruity, (3) possible bone grafting of the metaphyseal defect, and (4) augmented external or internal fixation. Angular stable plates and miniplate–wireform techniques have enabled stable internal fixation of complex injuries and have reduced the need for combined internal and external fixation. Subchondral placement of pegs to buttress the small articular fragments and simultaneously control shortening and angular displacement are particularly helpful in osteoporotic bones.[126]

Although fixed-angle volar plating is straightforward and provides outstanding fixation strength for the less comminuted fracture variants, it may be difficult to adequately reduce and stabilize small or unstable dorsal rims, central articulars, and dorsal–ulnar corner fragments with a volar fixed-angle device unless an "extended Henry approach" is used (see Figure 15.46). I avoid this particular approach for the more comminuted fractures because of the extensive subperiosteal exposure required and the potential for fragment devascularization.

Management of complex articular fractures through a traditional dorsal approach and dorsal single- or double-plate fixation enables reduction of the dorsal–carpal subluxation, the radial styloid, a central articular impaction fragment, the dorsal rim, and the dorsal–ulnar fragment (see Figure 15.50). Although it may be used with a nondisplaced volar–ulnar fragment, the risk for iatrogenic displacement of this fragment is relatively high. The major disadvantage of dorsal exposure is its inability to permit direct control and manipulation of the volar–ulnar teardrop fragment, which is the *cornerstone* of the distal–radial articular surface. Failure to restore the anatomy of the volar–ulnar corner, the correct depth and concavity of the lunate fossa, and the corresponding area of the sigmoid notch gravely compromises both the radiocarpal joint and the DRUJ.

I prefer fragment-specific fixation for the more highly comminuted fracture patterns because it allows me the greatest latitude for multifragmentary fixation. A combination of radial, dorsal, and volar incisions is used, depending on the number and displacement of the fracture fragments, as determined by preoperative radiographs and the CT scan. Through a volar–radial approach, the radial column can be reduced anatomically and provisionally pinned in position. Elevation of the pronator gives access to the volar rim through the same incision (see Figure 15.40), and manual reduction can be readily performed. A large scaphoid facet or volar rim fragments can be stabilized with a buttress plate or volar fixed-angle device as needed.

If there is a separate volar–ulnar fragment, it is next reduced and stabilized with a volar buttress pin through a volar–ulnar incision parallel to the FCU. The forearm is pronated and a universal dorsal approach (see earlier) is used to gain access to the dorsal rim, dorsal–ulnar corner, and impacted articular fragments. It is often helpful to make all incisions before final fixation of any particular fracture fragment to ensure simultaneous and optimal reduction in all planes. Elevation of one of the larger dorsal metaphyseal fragments (i.e., the "trapdoor") enables access to the subchondral impaction zone, where the articular fragments are elevated en bloc against the template of the scaphoid and lunate. Bone graft or a structural graft substitute may be packed into the resultant defect as necessary (see Figure 15.35, *B*), and the dorsal rim and dorsal–ulnar corner fragments are reassembled (see Case Study 15.3).

Dorsal fixed-angle wireforms and pin plates are contoured to support the elevated articular surface and simultaneously secure the articular and metaphyseal cortical fragments to an intact volar bone. The articular surface reduction and fixation are checked with fluoroscopy. The radial styloid fragment is fixed with a 3-, 5-, or 7-hole radial pin plate along the radial column. Stability of the ulnar column is checked manually before closure and treated as necessary. The wrist is immobilized in neutral and the forearm in supination for 10 days in a sugar tong splint. Digital and shoulder motion exercises are initiated immediately, and the operative splint and sutures are removed when the edema and swelling have subsided, at which point wrist and forearm range-of-motion exercises are begun.

Type IV—Radiocarpal Fracture–Dislocation

These are high-energy injuries in a young patient cohort that combine bony and soft tissue components and have the potential for significant wrist dysfunction. Dumontier and colleagues describe two distinct variants of radiocarpal fracture–dislocation, with important treatment implications (see eFigure 15.8).[37] Even though distinctly uncommon, a radiocarpal

http://e-surg.com

CASE STUDY 15.11

Dorsoulnar Corner

A 55-year-old male banker suffered a biking injury 6 days previously. The injury was reduced at the ED. The patient presents with no other injuries.

The postreduction films (eFigure 15.43) demonstrate

- Dorsal bending fracture
- Separate articular dorsal–ulnar corner, including sigmoid notch
- Unstable fracture

What are the treatment options?

A. Percutaneous fixation
B. Volar fixed-angle device
C. Dorsal plate fixation
D. Multifragment fixation

ANS: D. Multifragment fixation

Rationale

- Dorsal approach: direct reduction and fixation of dorsal–ulnar corner
  - Volar fixed-angle fixation of large dorsal corner fragments less predictable
  - Secure fixation of sigmoid notch
- Minimal soft tissue disruption
- Biplanar stability when used in conjunction with radial column fixation
- Alternatives: Dorsal single plate or percutaneous fixation

Intraoperative photos are displayed in eFigure 15.44.



eFIGURE 15.43 **A-C,** Postreduction radiographs.

http://e-surg.com

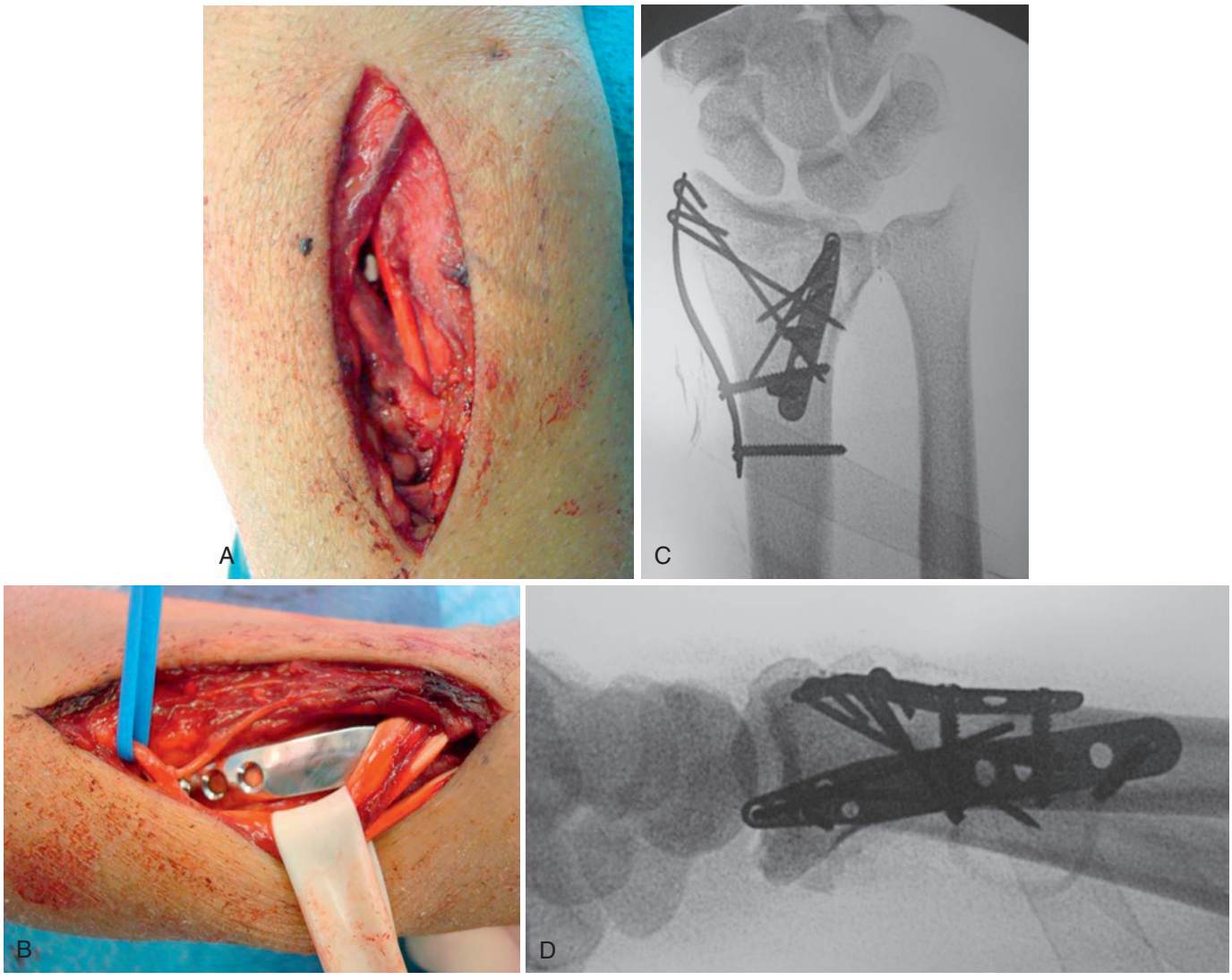

eFIGURE 15.44 Multifragment fixation: **A,** Fifth dorsal compartment approach. **B,** Radial column approach. **C, D,** Intraoperative fluoroscopic images.

http://e-surg.com

CASE STUDY 15.12

Intermediate Column Injury

A 40-year-old suffers a farm tractor accident when after hitting a stump the steering wheel cranked sharply to the right. The immediate deformity was splinted in the local ED. The films (eFigure 15.45) revealed an intermediate column injury.

Intermediate Column Injury

- Fracture components
  - Radial column
  - Volar–ulnar (teardrop) fragment
- Classification: Fracture–dislocation
- Unstable fracture

What are the treatment options?

A. Closed treatment
B. Percutaneous fixation
C. Volar fixed angle
D. Dorsal plate
E. Fragment-specific fixation

ANS: E. Fragment-specific fixation

Rationale

- Volar ulnar approach: rapid exposure of small teardrop fragment
  - Too small for capture with volar fixed-angle plate
  - Distal plate fixation risks tendon irritation or rupture
  - Not accessible by percutaneous fixation
  - Too unstable for closed treatment
- Alternatives: tension band, 2.4 mm

Intraoperative images are displayed in eFigure 15.46. One-year follow-up is shown in eFigure 15.47.

http://e-surg.com

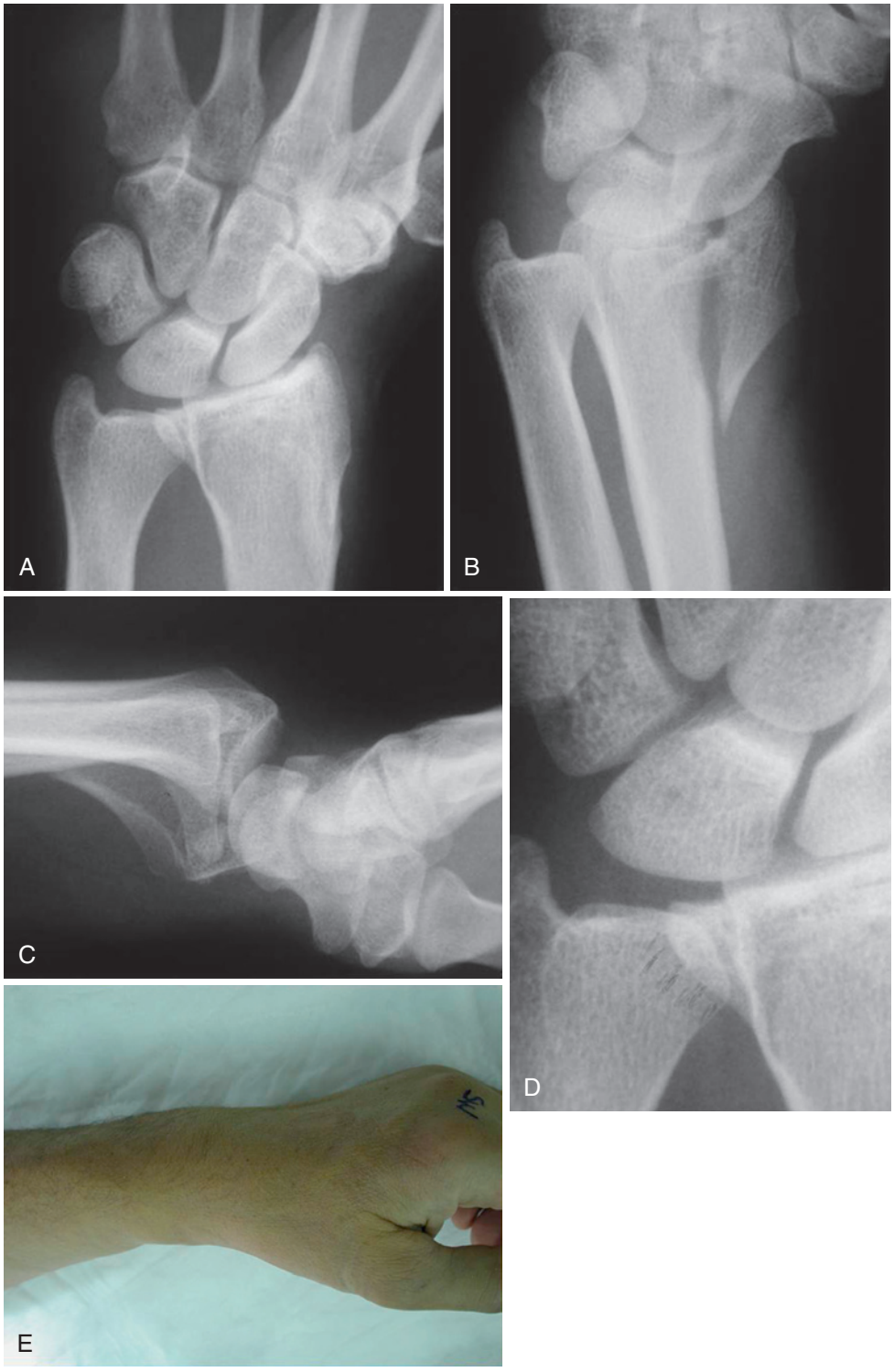

eFIGURE 15.45 **A-E,** Intermediate column injury

http://e-surg.com

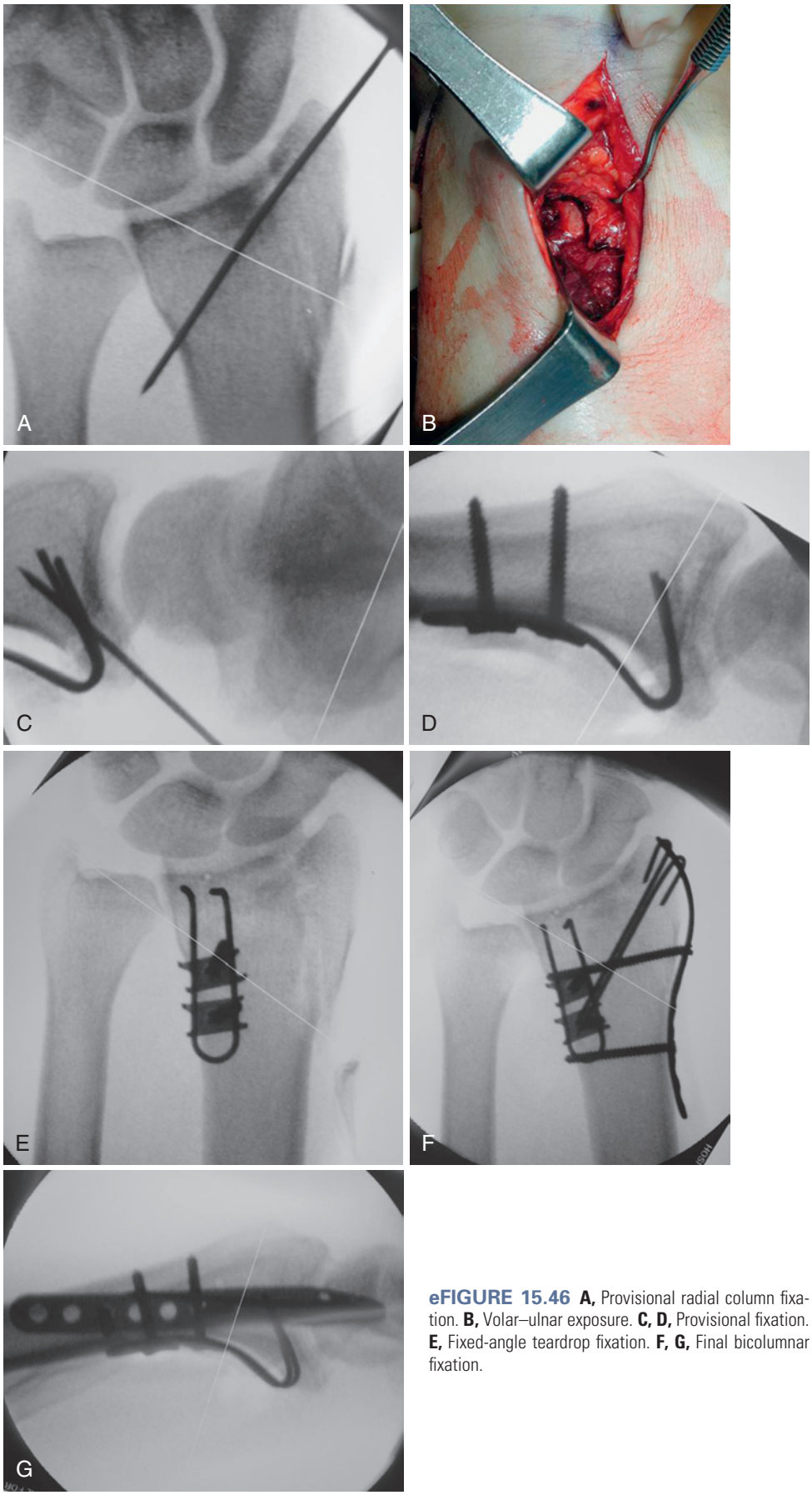

eFIGURE 15.46 **A,** Provisional radial column fixation. **B,** Volar–ulnar exposure. **C, D,** Provisional fixation. **E,** Fixed-angle teardrop fixation. **F, G,** Final bicolumnar fixation.

http://e-surg.com

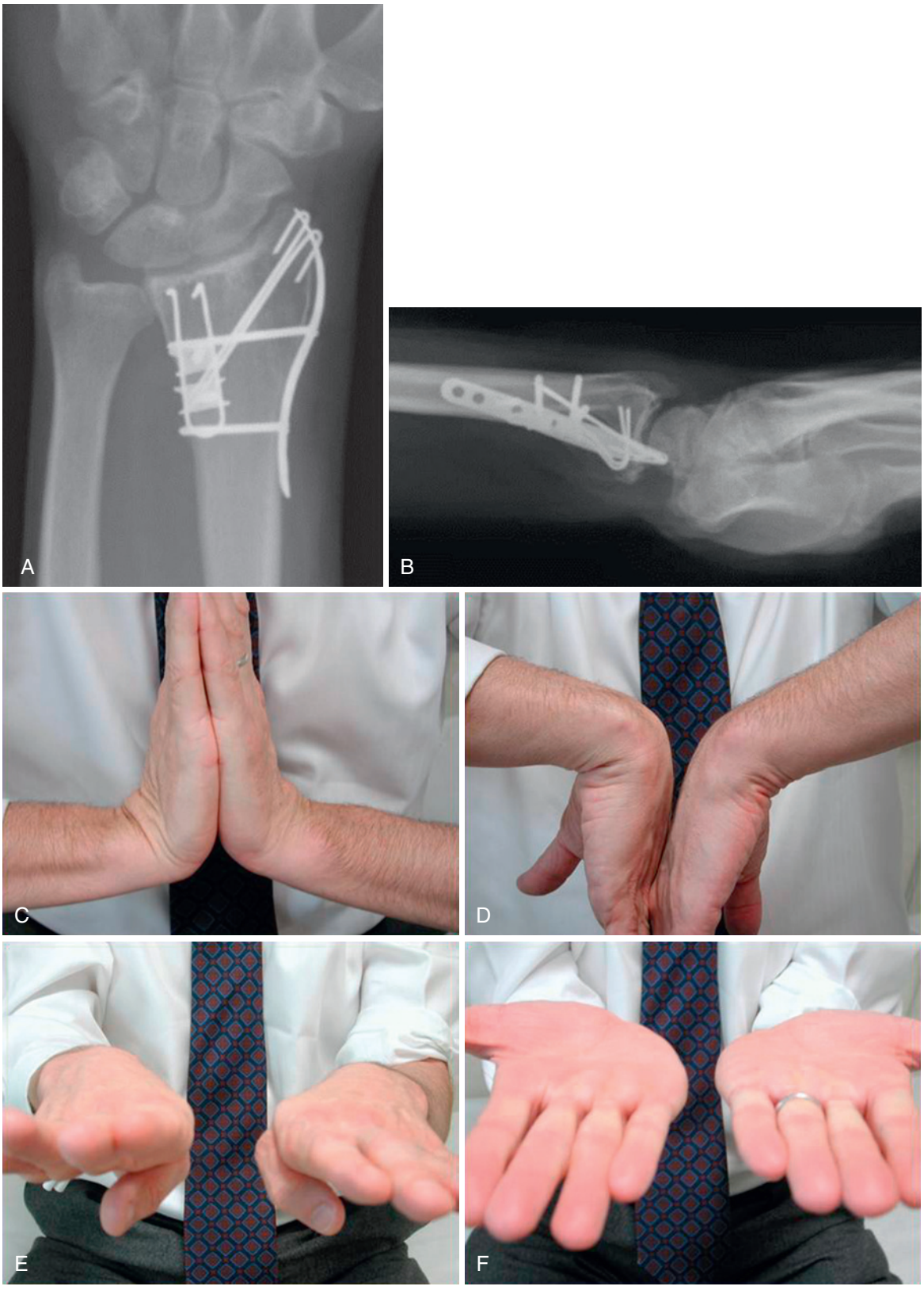

eFIGURE 15.47 One year postoperative: **A, B,** Radiographs. **C-F,** Clinical photographs.

http://e-surg.com

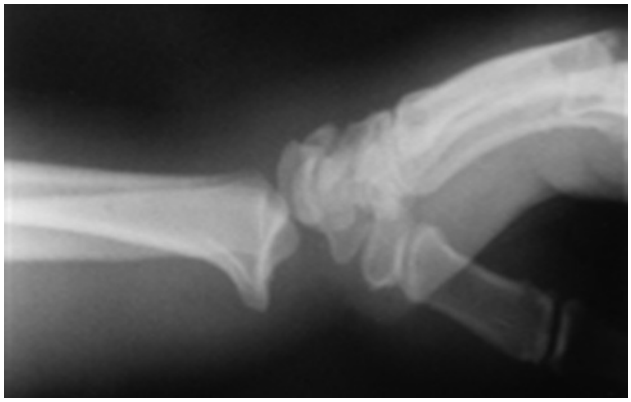

FIGURE 15.63 Radiocarpal fracture–dislocation with minimal bony avulsion. Treatment must be directed at the necessary subtotal ligamentous disruption with the use of multiple Kirschner wires. Alternatively, a temporary bridge plate could be considered. (Reprinted with permission from Dumontier C, Meyer zu Reckendorf G, Sautet A, et al: Radiocarpal dislocations: classification and proposal for treatment. A review of twenty-seven cases. *J Bone Joint Surg [Am]* 83:212–218, 2001.)

dislocation with only a small fleck of attached bone has by necessity disrupted each of the volar and dorsal extrinsic ligamentous stabilizers of the carpus and will predictably progress to an ulnar translational deformity unless meticulous repair of the volar ligaments is performed through an extended volar–carpal tunnel incision (Figure 15.63). Multiple K-wire or temporary dorsal distraction plating placement (see Figures 15.52 and 15.53) should be done to stabilize this injury during ligament healing.

More commonly, a large fragment of the radial styloid, with or without a portion of the articular surface and its attached dorsal–radial rim, is avulsed at the time of injury. Treatment consists of anatomic reduction and stable fixation of the styloid and dorsal rim fragments. Fragments that comprise at least a third of the scaphoid facet of the radius preserve the radioscaphocapitate and long radiolunate ligaments in continuity with the carpus such that anatomic reduction and healing restore stability to the carpus.[37] It is preferable to use a rigid columnar fixation of the styloid piece with a radial pin plate or a 2.4-mm radial column plate through a volar–radial incision (see earlier), combined with dorsal rim fixation using a dorsal wireform (see Case Study 15.13) or a 2.4-mm dorsal plate.[80] Fixation stability is tested in the operating room under fluoroscopy, and postoperative immobilization is customized. Cannulated screw fixation, isolated K-wires, or a tension band can also be used, depending on the size of the styloid fragment and surgeon's preference.

Type V—Combined/Complex Injury

Finally, for more *complex fracture patterns*, such as type V or C3-3 high-energy fractures (e.g., combined articular, metaphyseal, diaphyseal), no single implant or treatment paradigm is appropriate to solve all components of the fracture and the soft tissue injuries. If the fracture has a relatively simple articular component and extensive metaphyseal–diaphyseal comminution with large butterfly fragments, internal fixation with interfragmentary screws and a metadiaphyseal fixed-angle device is the method of choice to simultaneously restore radial alignment and length and to bridge the bony comminution. Initial application of a bridging external fixator to gain length and alignment may be helpful, and it may be left in place at the surgeon's discretion for additional stability (see Case Study 15.14). For more comminuted articular fractures, a combined dorsal–volar exposure with compartment and median nerve release, autologous cancellous bone grafting of the metaphyseal defect, and a combination of external, internal, or fragment-specific fixation may be required (Figure 15.64).

For cases with extensive articular and metaphyseal–diaphyseal disruption, particularly for patients who present with multiple traumas, or those who require load bearing on their injured wrist in the immediate postoperative period, bridge (distraction) plating is a comparably rapid and effective solution that preserves radial length during the healing process. I prefer the use of the smaller 2.7-mm stainless steel bridge plate that spans the second extensor compartment and can be affixed to the index metacarpal distally (see Figures 15.52 and 15.53).

ASSOCIATED INJURIES

Distal radius fractures may be the result of significant trauma to the entire upper extremity. Whether evaluating a patient with an acute or chronic distal radius fracture, a complete examination of the entire upper extremity should always be undertaken to identify and treat associated musculoskeletal and neurovascular injuries. Conversely, on occasion, serious associated injuries (e.g., shoulder dislocation or scapulothoracic dissociation, elbow fracture–dislocation, plexus injury, or vascular injury) can overshadow a concomitant distal radius fracture. The associated injuries, particularly those to a peripheral nerve, often lead to more problems than the distal radius fracture itself.

Open Fractures

Most fractures of the distal radius are closed injuries, but I consider any fracture that communicates with the external environment to be an open fracture. The associated skin injury may be massive, or it may be a pinpoint, with the only real indication that it communicates to the fracture being a small amount of fatty fluid that exudes from the wound. All open fractures should be treated as surgical emergencies. My treatment plan for open distal radius fractures calls for clinical and radiologic evaluation in the emergency department followed by local cleansing, wound irrigation, and temporary stabilization in a splint. Specimens should be obtained from the wound for culture after initial cleansing, and intravenous broad-spectrum cephalosporin antibiotics need to be initiated before transport to the operating room.

Injuries that occur on a farm, or grossly contaminated wounds, should receive additional anaerobic and aminoglycoside coverage. The patient should be transported to the operating room expeditiously, where the wound is enlarged, the skin and fracture margins are debrided, and the wound is irrigated with abundant quantities of saline. Restoration of stability is paramount to control infection; thus, if the fracture is unstable, there is adequate soft tissue coverage, and the wound has been suitably cleaned, I prefer to stabilize the fracture with internal or percutaneous fixation, depending on the fracture's particular characteristics. If the fracture is stable, the wound extensions can be closed primarily, while leaving the traumatic wound open, and the fracture immobilized in a cast. If the wound

http://e-surg.com

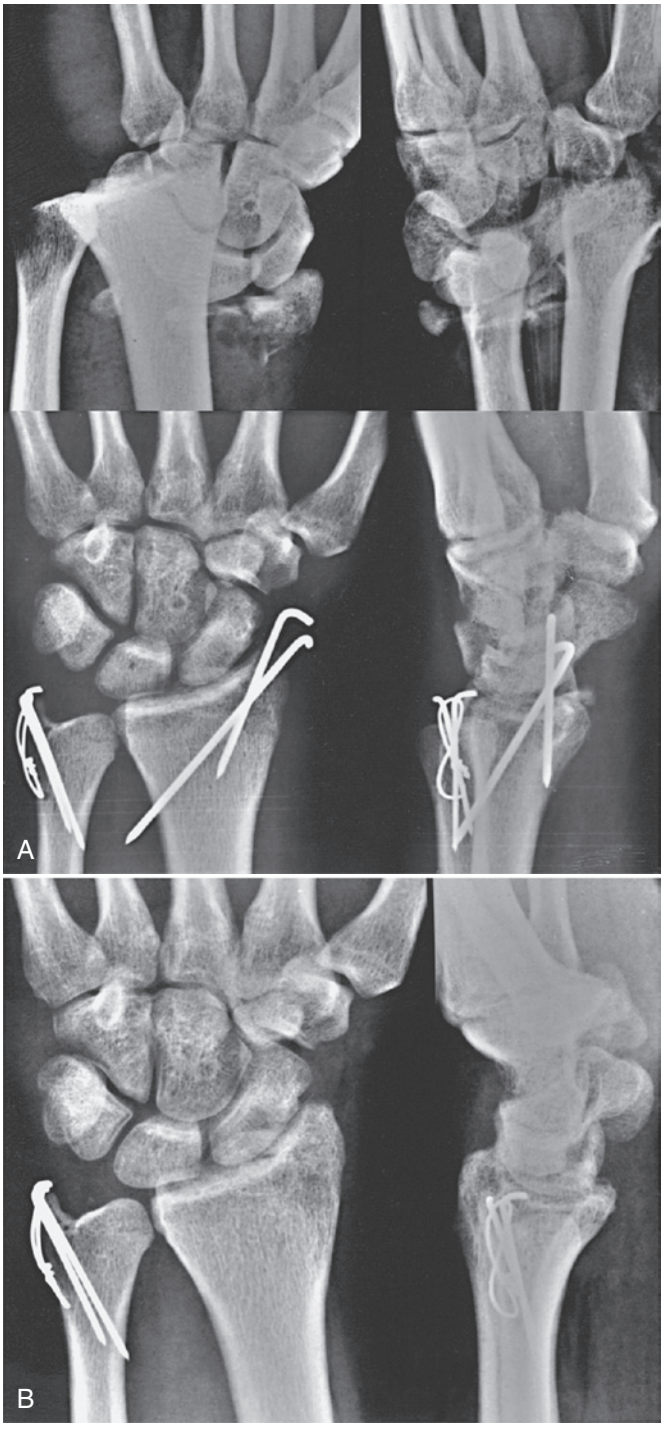

eFIGURE 15.8 **A,** Severely displaced radiocarpal fracture–dislocation. After open reduction and Kirschner wire fixation of the radial styloid, the distal radioulnar joint (DRUJ) was grossly unstable. Bony avulsion of the triangular fibrocartilage complex was treated by tension band wiring. **B,** Follow-up radiographs at 2 years show a congruent DRUJ.

http://e-surg.com

CASE STUDY 15.13

A 37-year-old school teacher slipped and fell on ice, resulting in a gross deformity with numbness in thumb, index, and middle fingers on her dominant hand (Figure 15.48).

What is the fracture type?

A. Bending
B. Shear
C. Compression
D. Fracture–dislocation
E. Combined

ANS: D. Fracture–dislocation (eFigure 15.49)

What additional workup is recommended?

A. New radiographs
B. EMG
C. MRI
D. CT scan
E. Traction films

ANS: D. CT scan (eFigure 15.50)

What is the best treatment option, given the following considerations?

- Fragments are small
- Volar rim too small for fixed-angle plate
- Gross dorsal instability
- Central articular impaction

Options:

A. Percutaneous fixation
B. Volar fixed-angle plate
C. Dorsal fixed-angle plate
D. Bridge plate
E. Fragment-specific fixation

ANS: See eFigure 15.51

- Radial and dorsal intermediate column fixation to provide most rigid orthogonal fixation of small fragments
- Bone graft behind reduced articular fragment
- Reduction of rim fragments should enable ligament healing
- Carpal tunnel release for persistent median paresthesias

Alternatives include the following:

- Percutaneous external fixation
  - Mini-open reduction
  - K-wire augmentation with graft
  - Minimizes articular distraction
- Bridge plate fixation
  - Reduces sagittal and coronal plane instability



eFIGURE 15.48 Preoperative radiograph.



eFIGURE 15.49 Best reduction.

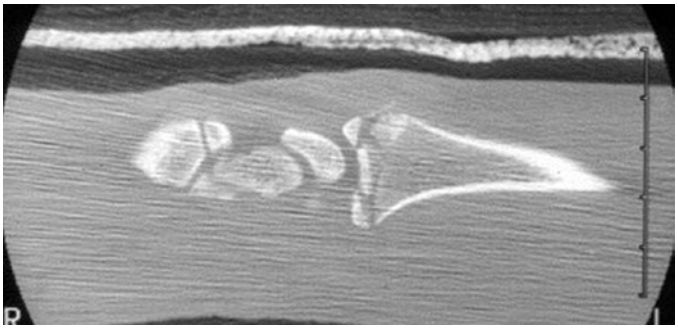

eFIGURE 15.50 Computed tomographic scan.

http://e-surg.com

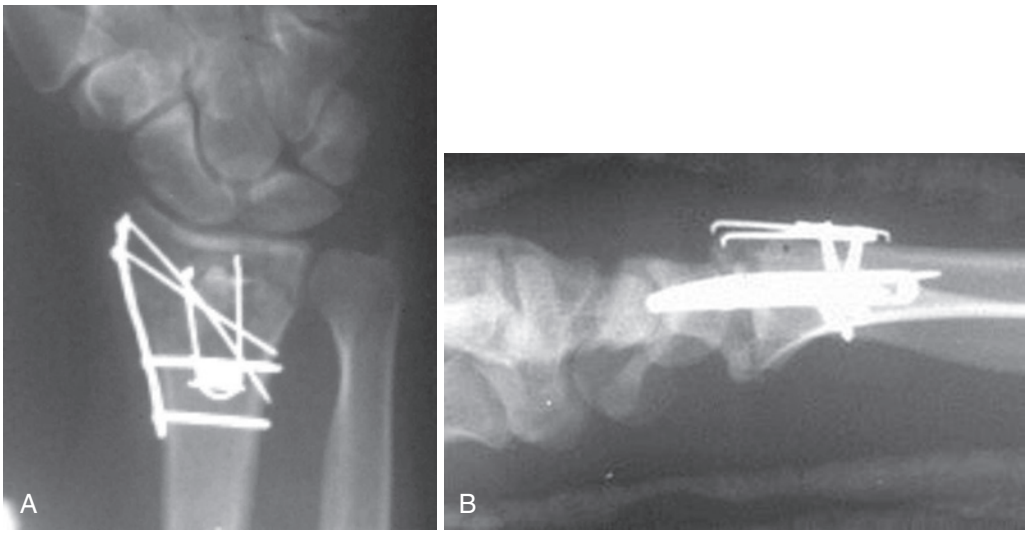

eFIGURE 15.51 **A, B,** Fragment specific fixation with radial column implant; bone graft and dorsal wireform fixation of impacted articular surface provides sufficient fixation for early ROM.

http://e-surg.com

CASE STUDY 15.14

Combined Injury

A 45-year-old longshoreman suffered an open left wrist fracture, 48 h previously. The injury was washed out in ED and casted elsewhere. He presented with a closed right wrist fracture (eFigure 15.52) and mild head injury.

The issues to consider include:

- Open wound, 48 h old (eFigure 15.53)
  - Appropriate for internal fixation?
  - Span metaphysis with external fix?
- Bilateral fixation?
- ORIF ulna?
- Bone graft?

ANS: See eFigure 15.54

Surgical results can be viewed in eFigures 15.55 and 15.56. The patient returned to work as a longshoreman.

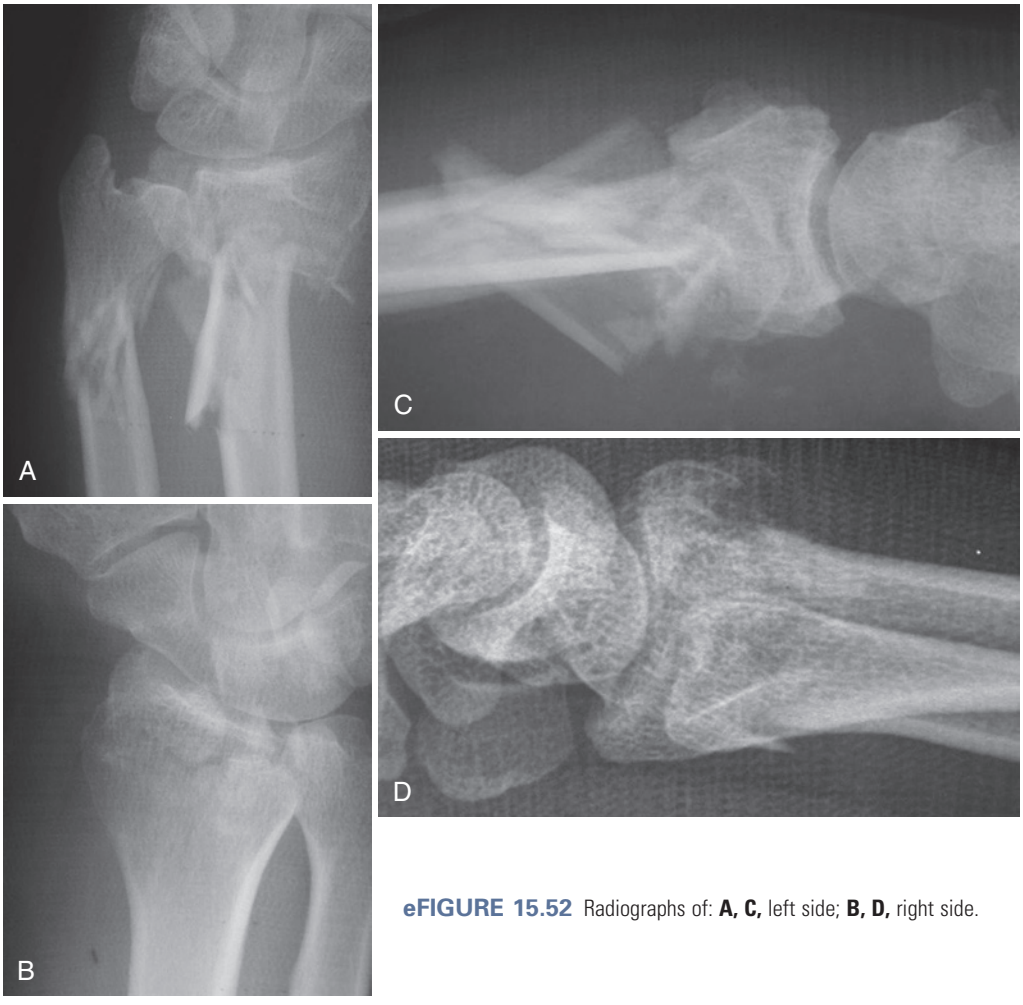

eFIGURE 15.52 Radiographs of: **A, C,** left side; **B, D,** right side.

http://e-surg.com

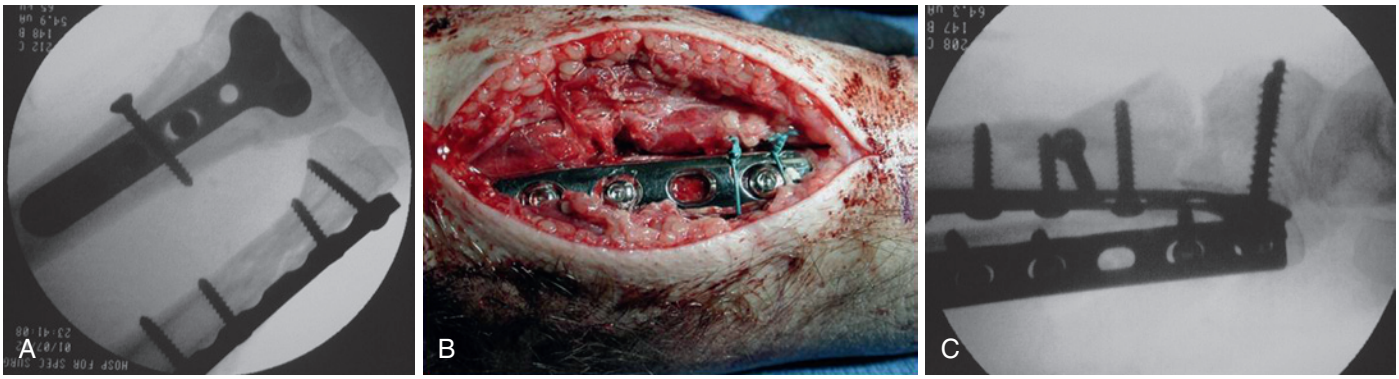

eFIGURE 15.53 Left side.

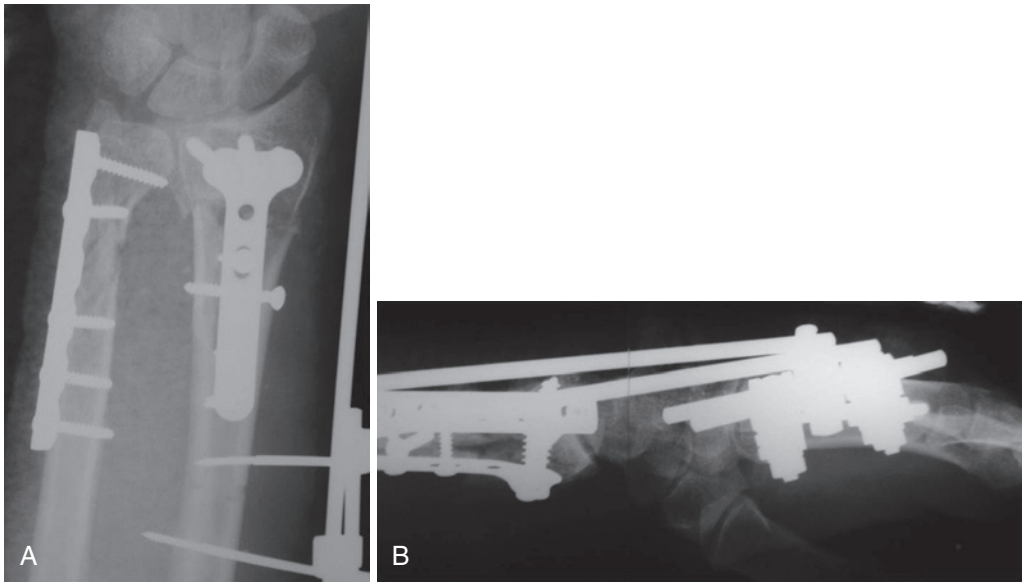

eFIGURE 15.54 Nonlocked fixation of left side predates fixed-angle plates **(A)**. Temporary external fixation used to neutralize forces and span metaphysical bone loss **(B)**.

http://e-surg.com



eFIGURE 15.55 Radiographs and photos at 4 weeks postoperative: **A-E,** Left side. **F-K,** right side.

http://e-surg.com

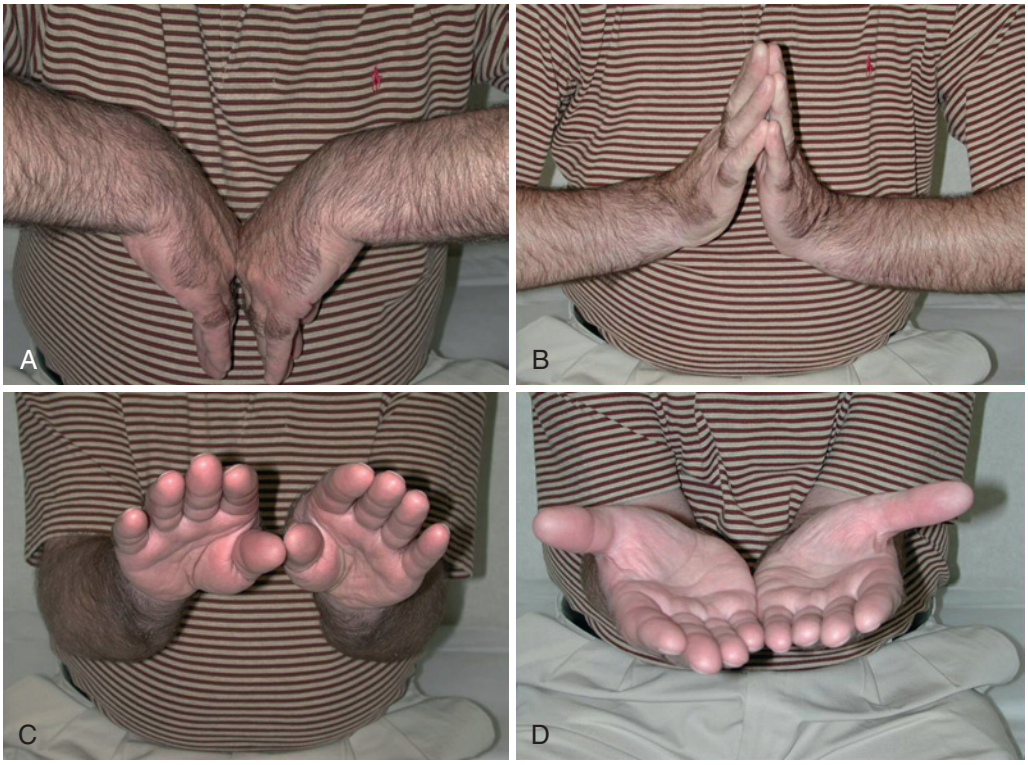

eFIGURE 15.56 **A-D,** Photos at 3 months postoperative.

http://e-surg.com

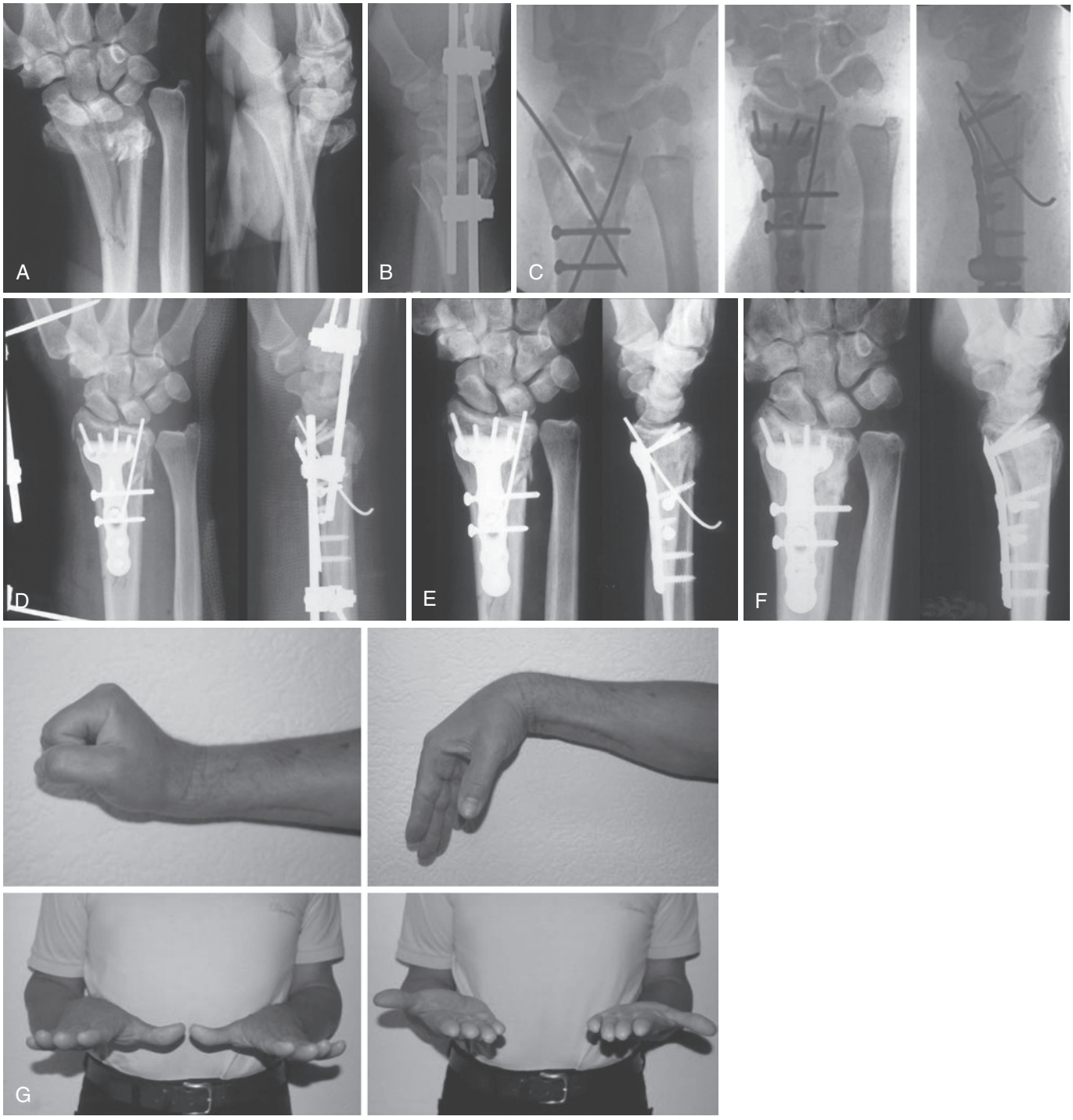

FIGURE 15.64 **A,** Radiographs of a severely displaced type V complex distal radial fracture with intraarticular and metaphyseal comminution. **B,** Partial insufficient reduction obtained with the application of an external fixator. **C,** Intraoperative fluoroscopic views showing reconstruction of the metaphyseal fracture with two transverse lag screws, provisional fixation of the radial and ulnar fragments with Kirschner wires (K-wires), and application of a volar fixed-angle device. An oblique K-wire inserted palmarly to dorsally has been applied to the volar–ulnar fragment. **D,** Postoperative radiographs showing acceptable reduction and restoration of radial length. The fixator was maintained for 3 weeks. **E,** Fracture was healed 6 weeks after surgery. Notice healing of the dorsal and ulnar comminuted area. At this time the additional K-wire was removed. **F,** Radiographs at 1 year show good restoration of the joint surface and a well-remodeled distal radius. **G,** Photos of adequate arc of flexion and with extension and free forearm rotation restored.

http://e-surg.com

cannot be suitably cleaned or if it has been open for more than 12 h, the fracture should be stabilized with an external fixator, the wound left open, and the patient returned to the operating room at 48 h for definitive treatment and wound closure as possible.

Associated Median Nerve Injury

Varying levels of median nerve compromise, usually caused by blunt contusion or stretching of the nerve over the angulated distal radius, commonly accompany acute distal radius fractures. A fracture hematoma also can compromise the nerve within the carpal tunnel, particularly in patients who may have mild or nocturnal symptoms preceding the injury. It is essential to record the degree of nerve involvement with careful measurements of two-point discrimination and, if possible, thenar motor function before treatment. Closed reduction is performed under adequate local or regional anesthesia, and, if satisfactory reduction is obtained, observation plus careful follow-up is all that is necessary in most instances. If the reduction can be maintained, the nerve compression syndrome generally improves substantially over the subsequent 24 to 48 h. If neurologic symptoms get worse or show no improvement during that period, or if the reduction cannot be obtained or maintained in the presence of median nerve compression, early closed reduction under anesthesia, carpal tunnel release, and operative stabilization of the fracture is preferable. There are no data to support routine release of the carpal tunnel at the time of operative fixation in patients without preoperative evidence of median nerve compromise.

Associated Carpal Ligament Injuries

Carpal ligament disruption can occur with both intraarticular and extraarticular fractures of the distal radius and exacerbate the fracture's prognosis. Certain fracture patterns (e.g., radiocarpal fracture–dislocations and severely displaced radial styloid fractures entering the ridge between the scaphoid and lunate fossae) are particularly at risk for associated carpal ligament injury (see earlier). The incidence of associated carpal ligament disruption with fractures of the distal radius has been documented with arthroscopy by several authors, and an approximate incidence of 30% for partial or complete scapholunate tears and 15% for lunotriquetral tears has been demonstrated.[55] There is no clear association between fracture type and location or the extent of interosseous ligament injury.

Arthroscopic assessment is recommended when injury to the interosseous scapholunate or lunotriquetral ligament is suspected. Complete interosseous ligament injuries in young and active individuals require aggressive operative treatment. Open repair of scapholunate disruptions is recommended after reduction and fixation of the distal radial fracture (see Chapter 13). Arthroscopic pinning or cannulated screw fixation is appropriate for partial scapholunate lesions with instability and for unstable or complete lunotriquetral injuries.

OUTCOME AND PATIENT EXPECTATIONS

Table 15.2 summarizes a compilation of data from single-cohort studies published since 2000, broken down into broad fixation categories. One can generalize from these data that the use of modern fixation techniques generates highly successful *physician-rated* outcomes in the vast majority of patients, with restoration of grip strength to 80 to 90% of preinjury values, restoration of range of wrist flexion–extension to 80 to 85%, and nonvalidated outcome measures indicating 85 to 95% good to excellent results. The more recent use of patient-rated validated functional outcome tools enables somewhat easier comparisons between series studies. The patient cohorts are largely comparable, with a trend toward less comminuted fractures in the fixed-angle volar plate group and lower use of bone graft in the fixed-angle plate cohorts.

It is difficult to draw definitive outcome inferences from the combined data considering differences in fracture types, patient age, and surgeon expertise, in particular because of the convergence of outcomes toward excellent anatomic and functional restoration in all cohorts. Whether improvement in outcomes is because of an intense concentration on the principles and techniques of operative indications, fracture fixation, technologic improvements, or some combination can only be speculated.

Factors that lead to a patient's perception of a successful outcome after any surgical intervention are inadequately understood and abundantly illustrated by the lack of consensus on primary outcome measures for management of distal radius fractures (see above). After an exhaustive review of 3371 comparisons in 48 randomized trials for treatment of distal radius fractures, Handoll and colleagues were unable to definitively identify particular surgical interventions that produced consistently improved long-term patient outcomes when compared with nonsurgical treatment. Their 2003 review was hampered by inconsistencies in reporting and the paucity of validated outcome tools in most publications. These authors made a plea for a validated "standard core dataset" for classification and uniform reporting of *objective* and *patient-derived* outcomes.[68]

More recently, Goldhahn et al presented a consensus document calling for the establishment of a core set of specific modules addressing both symptoms and function as separate domains.[59] Going forward, it will be increasingly important for wrist investigators to use common classification and outcome parameters if we are to successfully collect data with which to compare and contrast treatment interventions for wrist injuries. At a minimum, it would seem prudent to collect a standard core dataset that includes the following:

- AO classification of wrist fracture type
- Activity level stratification pre- and postop (PASE)
- Functional assessment (PRWE)
- Pain assessment (VAS)
- ROM of the digits, wrist, and forearm
- Grip strength (bilateral)
- Radiographic parameters
  - Congruence
  - Tilt
  - Variance
  - Inclination
  - Radial translation

COMPLICATIONS

Although it was once believed that all patients with distal radius fractures did relatively well regardless of treatment, it is now well recognized that treatment of these fractures is associated

http://e-surg.com

with a high complication rate. As can be seen earlier in Table 15.2, surgical complications with modern fixation techniques, particularly after articular or high-energy injuries (or both), are still reported for nearly 25% of patients and as many as 72% of them in some series.

The complications that continue to plague treatment of distal radius fractures include persistent neuropathy, tendinopathy or tendon rupture, radiocarpal or radioulnar arthrosis, malunion, nonunion, chronic regional pain syndrome (CRPS), ulnar impaction, loss of rotation, finger stiffness, and compartment syndrome, though rarely. An understanding of these complications should lead us to be more aggressive in the original care of such fractures.

Chronic Regional Pain Syndrome

Although full-blown reflex sympathetic dystrophy is a relatively infrequent problem, milder variants are surprisingly common in conjunction with distal radius fractures. Early recognition and attention to patients with an inordinate amount of pain, finger stiffness, swelling, allodynia, or paresthesias may prevent many of the problems of this serious complication. Removal or splitting of a dressing or cast to relieve pressure, elevation of an edematous hand, and intensive hand therapy are frequently very helpful in preventing the development of full-blown CRPS.

A short course of tapered prednisone is often a valuable means of intervention and may allow a patient to turn the corner and avoid escalation of symptoms. More often than not, an irritated or entrapped peripheral nerve underlies most cases of early dystrophy, and the surgeon should have a low threshold for performing electrodiagnostic studies or surgical decompression (or both) for suspected nerve entrapment. For patients who do not respond to early local measures, sympathetic blocks, even with a cast in place, should be considered (see Chapter 53).

Zollinger et al, in a well-controlled randomized trial, confirmed that a daily dose of 500 mg of vitamin C for 50 days reduced the incidence of symptoms associated with CRPS (e.g., swelling, pain, digital stiffness, elevated skin temperature, color changes) in patients treated for distal radius fractures.[178] Although independent confirmation of these findings is pending, the practice is endorsed by the AAOS guidelines and the risks and cost of treatment are decidedly low. For patients who have a previous history of CRPS, there may be value in preemptive treatment with a long-acting sympathetic block or indwelling catheter for a regional nerve blockade for any proposed surgical procedure.

Tendon Rupture

Cast treatment of nondisplaced or minimally displaced distal radius fractures is complicated by rupture of the extensor pollicis brevis (EPB) in up to 5% of cases, a number higher than previously reported in the literature.[135] Patients with painful thumb extension, especially if radiographs demonstrate an irregularity in the region of the Lister tubercle, should be examined by dynamic ultrasound for signs of tendon irritation or fraying. On occasion, decompression and/or internal fixation is warranted to prevent this complication; however, so far strict clinical guidelines are lacking.

The incidence of EPL tendinopathy and rupture appears to have risen following the introduction of locked fixed-angle volar plating. The best treatment of this complication is prevention whenever possible. As mentioned earlier, precise placement of locked screws or pegs, deliberate downsizing of screw length to avoid dorsal protrusion, and careful assessment of screw placement through the use of specialized radiographic views is necessary to prevent this serious complication.[78]

Similarly, flexor tendon rupture complications following volar plating have been reported with increasing frequency. A systematic review of 21 studies that report flexor tendon ruptures documented the highest incidence in the FPL (57% of reported cases), followed by the index of flexor digitorum profundus (FDP) (15%).[7] The average time to rupture was 9 months postoperatively, but ruptures have been reported as late as 10 years following surgery. Guidelines for prevention of this complication is (1) careful placement of the implant proximal to the transverse ridge of the radial metaphyseal flare (i.e., the watershed line) and (2) avoiding plate prominence either above the volar critical line or within 3 mm of the articular rim of the radius[90] (see Soong guidelines).

Patients may present with volar swelling, tenderness, crepitus, or pain with finger or thumb motion months or years following surgery. I find ultrasound useful to identify flexor tendon proximity to the plate, tendinopathy, fraying, or tenosynovitis. If radiographs demonstrate Soong grade 1 or 2 positioning, I recommend plate removal if the fracture is fully healed to prevent rupture. Ruptured tendons require hardware removal and reconstruction with direct repair, a tendon graft, or a tendon transfer, as indicated by patient impairment (see Chapter 31).

Nonunion

Nonunion of distal radius fractures is rare but presents unique treatment challenges because of the associated pain, joint contractures, tendon imbalance or rupture, and occasional severe bone deformity. Treatment must be individualized, but generally involves workup for subclinical infection, removal of existing hardware, anatomic realignment of the radiocarpal and radioulnar joints, and stable fixation with a bone graft. In contrast, nonunion of ulnar styloid process fractures in conjunction with distal radius fractures is quite common and yet is rarely symptomatic.[166] Treatment of ulnar styloid nonunion must be individualized and based on the patient's symptoms and functional deficits.

Symptomatic nonunion of the ulnar styloid is best treated by excision of the styloid unless the ulnar styloid fragment is large enough for rigid internal fixation. It is essential, however, for the examiner to distinguish between radioulnar instability secondary to foveal avulsion of the TFCC and ulnar styloid nonunion or impingement. If DRUJ instability is suspected clinically, magnetic resonance imaging (MRI) of the radioulnar ligaments, or CT of both wrists in full supination and pronation (or both) can help differentiate between the various conditions (see Chapter 14). If a styloid nonunion is accompanied by distal–ulnar instability, the TFCC should be reattached to the fovea at the time of fragment excision or fixation.

Malunion

Malunion of distal radius fractures may result in wrist pain, decreased range of motion, midcarpal instability, or any combination of these complications. Two studies that examined threshold criteria for an acceptable reduction demonstrated a

http://e-surg.com

significant correlation between outcome and adverse radiographic parameters across all age groups, but mitigated to a great deal in patients older than 65.[20,61] Factors most closely correlated with outcome included ulnar variance,[19,61,93] radial inclination,[61] and volar tilt.[19,93] Greater disability was identified when two factors were present in combination,[19] and this effect was sustained at 2 years' follow-up.[20] In general, ulnar-sided wrist pain is the factor that leads most patients with malunited distal radius fractures to seek treatment because of the effect of changes in variance, congruency, or alignment of the sigmoid notch.

Recognition of associated carpal malalignment and DRUJ derangement is mandatory to decide whether additional procedures, together with radial osteotomy, are necessary to help ensure a good result. Assessment of carpal malalignment with malunited distal radius fractures includes determination of the presence of (1) dorsal subluxation of the carpus, (2) a type I (*adaptive*) dorsal intercalated segment instability (DISI) that is *reducible* by radial osteotomy, or (3) a type II (*fixed*) DISI pattern that does not improve after radial osteotomy. A reducible deformity is usually characterized by a mobile lunate on flexion and extension lateral radiographs. A fixed DISI is generally associated with a more chronic deformity and may be associated with an unrecognized disruption of the scapholunate or radiocarpal ligaments.

Correction of posttraumatic wrist deformity must be tailored to the specific site of the deformity and depends on whether the malunion is extraarticular, involves the radiocarpal or radioulnar joints (or both), or is complex (i.e., metaphyseal and articular deformity). The decision to perform a simultaneous procedure at the DRUJ depends on the amount of radial shortening and the presence of osteoarthritic changes or instability of the joint. Instability or ulnocarpal impingement that results from radial shortening, angulation, or malrotation without associated degenerative changes can generally be corrected by restoration of radial anatomy alone.

My indications for corrective osteotomy in a young, symptomatic, and active individual include articular step-off with or without carpal subluxation, 15 degrees or more of dorsal tilt, ulnar-positive variance with impaction, or marked loss of radial inclination. Less commonly, increased volar tilt results in carpal subluxation and manifests as a painful deformity and loss of extension, supination, or both. If an impending malunion is recognized in the subacute stage (i.e., before complete bony healing) and the patient is medically stable, early intervention provides easier realignment because of the absence of soft tissue and capsular contractures, and shortens the overall recovery–disability time. In patients with swollen and dystrophic changes, it may be prudent to wait until the soft tissues have stabilized and the patient has plateaued in wrist, digital, and forearm motion before osteotomy and fixation.

Extraarticular Radial Osteotomy Technique

The aims of radial osteotomy are to restore function and improve the appearance of the wrist by correcting the deformity at the level of the fracture site. The osteotomy should reorient the joint surface to restore normal load distribution, reestablish the mechanical balance of the midcarpal joint, and improve the anatomic relationships of the DRUJ. Because radial shortening is a constant component of the deformity in both volar and dorsal malunions, an opening wedge osteotomy that is transverse in the frontal plane and oblique (i.e., parallel to the joint surface) in the sagittal plane is used to permit radial lengthening. Such an osteotomy allows for the following:

- Radial lengthening of up to 10 to 12 mm
- Correction of volar tilt in the sagittal plane
- Correction of radial inclination in the frontal plane
- Correction of rotational deformity in the axial plane

A 2011 comparative study showed improved correction of ulnar variance and better Mayo scores with closing wedge osteotomy and a simultaneous ulnar-shortening osteotomy.[158] Regardless of technique, it is important that the osteotomy be parallel to the articular surface, as close as possible to the site of the original fracture, so as to restore the relationship between the center of rotation of the carpus and the long axis of the radius (Figure 15.65).

With large defects created by an opening wedge osteotomy, a cancellous or corticocancellous bone graft (see earlier) can be used to fill the bone defect and to induce more rapid consolidation. Angular–stable plate fixation is ideal for corrective osteotomies in osteopenic bone and nascent malunions and when using nonstructural bone grafts. If partial or complete resection of the distal end of the ulna is performed simultaneously, the resected ulnar head can be sculpted and used to fill the radial defect. Preoperative planning and the use of K-wires to mark the angle of deformity help to facilitate accurate angular correction, simplify the procedure, and reduce the degree of exposure to fluoroscopy.[46] Radiographs of the uninjured wrist should be performed to determine the physiologic ulnar variance and calculate restoration of radial length (Figure 15.66).

Dorsal Approach for Osteotomy of Malunited Distal Radius Fractures

Dorsal malunions may be exposed through a universal dorsal incision between the third and fourth extensor compartments (see earlier). For severe deformities, this has the benefit of a single approach through which soft tissue release, bone grafting, and internal fixation can be performed. The healed fracture site is identified with fluoroscopy. If dorsal plate fixation of the osteotomy is planned, the Lister tubercle should be removed with a rongeur to provide a flat surface on which to apply the plate. If K-wire or low-profile columnar fixation of the osteotomy is planned, the Lister tubercle may be left undisturbed.

To be sure that the osteotomy, as seen in the sagittal plane, is parallel to the joint surface, a 25-gauge needle is introduced through the dorsal part of the capsule into the radiocarpal joint and along the articular surface of the radius. In accordance with the preoperative plan,[46] two 2.5-mm K-wires with threaded tips are inserted so that the angle of correction in the sagittal plane is subtended on both sides of the future osteotomy (see Figure 15.66). These wires not only control intraoperative angular correction but also help manipulate and maintain the distal fragment in the corrected position with a small external fixator bar until the graft is inserted in the defect.

The osteotomy is performed with an oscillating saw, with care taken to not osteotomize the volar cortex completely. It is then opened dorsally and radially by manipulating the wrist into flexion, by applying a laminar spreader dorsally, or by using 2.5-mm Schanz screws as joysticks. The osteotomy is opened until both wires are parallel in the sagittal plane. Opening up

http://e-surg.com

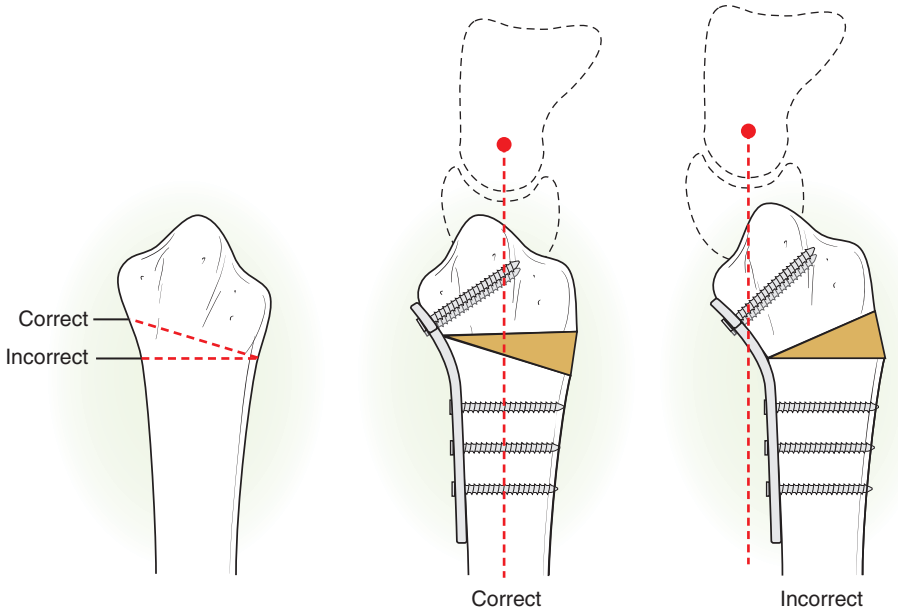

FIGURE 15.65 It is imperative that the osteotomy be parallel to the articular surface to avoid creating a secondary deformity. (© Elizabeth Martin.)

the osteotomy on the radial side can be difficult, and complete tenotomy of the BR tendon is recommended to facilitate realignment.

A small external fixator bar with two clamps can be attached between both Schanz screws to maintain reduction of the distal fragment. With the elbow in 90 degrees of flexion, intraoperative forearm rotation and wrist motion are checked. Radiographic control with the image intensifier may be advisable at this point to assess the quality of correction and radial lengthening before definitive internal fixation of the osteotomy is undertaken.

Depending on the rigidity of fixation planned, corticocancellous or cancellous bone graft can be inserted into the defect. At this point, a 1.6- or 2.0-mm K-wire is driven obliquely from the radial styloid across the graft and into the proximal fragment, after which the threaded screws and the external fixator bar can be removed. The osteotomy can be stabilized by a variety of methods. In young adults with good bone quality and, especially when the volar cortex is not disrupted, simple K-wire fixation (one through the radial styloid and one through the Lister tubercle in an oblique dorsal–palmar direction) offers adequate stability. However, this method requires casting and prolonged immobilization.

As an alternative, stable plate fixation can be used with the advantage of early wrist rehabilitation. The use of low-profile fixed-angle implants (2.4-mm condylar plates or any of a number of dorsal fixed-angle devices) has helped diminish extensor tendon irritation. For dorsal fixation, I prefer to use a radial column plate and a fixed-angle wireform implant that spans the opening wedge osteotomy and provides rigid fixation when combined with a corticocancellous graft (Figure 15.67).

Volar Approach for Osteotomy of a Malunited Distal Radius Fracture

Alternatively, malunited dorsally angulated fractures can be corrected through a volar approach to avoid extensor tendon

CRITICAL POINTS *Radial Osteotomy for Malunited Extraarticular Fracture*

Indications

- Symptomatic malunion (e.g., pain, weakness, cosmetic disturbance)
- Limited palmar flexion
- DRUJ incongruency, limited forearm rotation
- Adaptive carpal instability

Technical Points

- Use a 6- to 7-cm dorsal approach with the incision centered on the Lister tubercle.
- Expose the distal radius between the third and fourth compartments.
- Mobilize the EPL tendon.
- Mark the osteotomy at the previous fracture line.
- Use 2.5-mm K-wires (also can be used as joysticks) to determine the angle of correction.
- Perform an osteotomy parallel to the joint surface in the sagittal plane and transverse in the frontal plane.
- Open the osteotomy dorsally until the K-wires are parallel (use a laminar spreader or temporary external fixator).
- Fill the defect with corticocancellous bone graft.
- Use temporary K-wire fixation and fluoroscopic control (i.e., for position of the distal fragment and DRUJ congruency).
- Perform internal fixation of the osteotomy (low-profile fixed-angle plates).
- Morcellized cancellous grafts or bone substitutes can alternatively be used depending on rigidity of fixation.

Postoperative Care

- Apply a dorsal and palmar splint until suture removal. Use a sugar tong cast in supination for 2 weeks when concomitant distal–ulna excision is performed.
- Apply a short-arm cast for 4 to 6 weeks, when using pin fixation, until radiograph shows healing.
- Apply a palmar splint and initiate gentle range-of-motion exercises if fixed-angle fixation is used.

http://e-surg.com

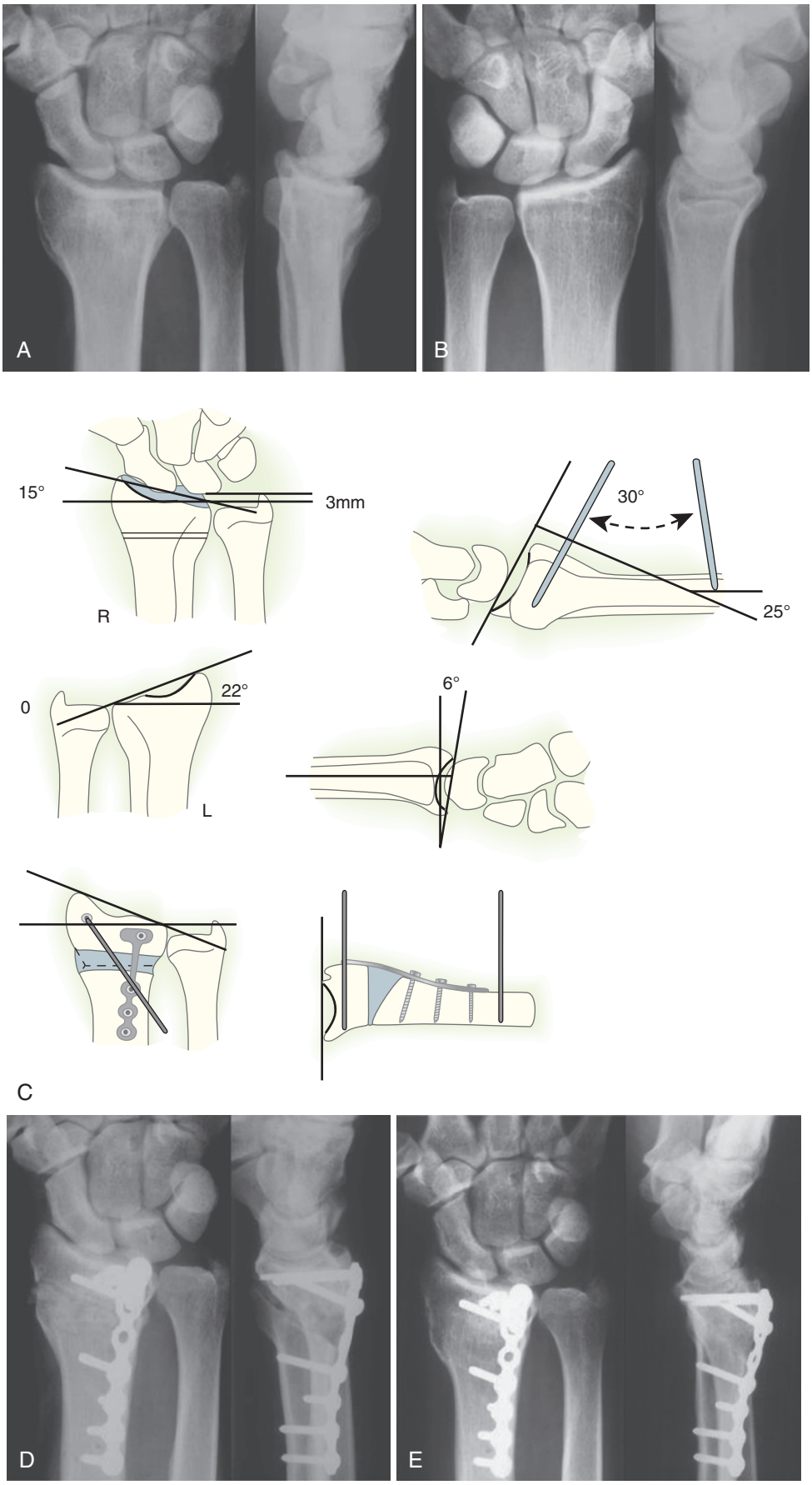

FIGURE 15.66 **A,** Radiographs of a malunited Colles' fracture with 30 degrees of dorsal tilt, 15 degrees of ulnar inclination, and an ulnar-plus variance of 3 mm. **B,** Comparative radiographs for preoperative planning. **C,** Preoperative planning for the opening wedge dorsal osteotomy and fixation with the minicondylar plate. **D,** Immediate postoperative radiographs. **E,** Radiographs 1.5 years after osteotomy with anatomic restoration of wrist anatomy and carpal alignment.

http://e-surg.com

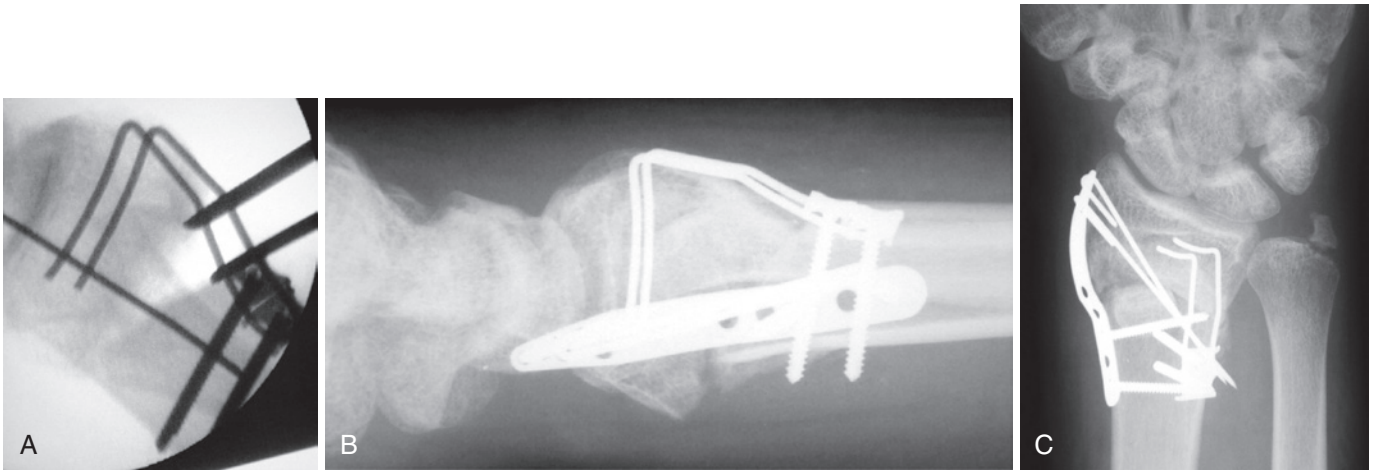

FIGURE 15.67 **A,** A dorsally malunited distal radius fracture is corrected with a dorsal opening wedge osteotomy and the use of a laminar spreader to correct volar tilt. A prebent dorsal wireform implant is in place, but final screw tightening has not yet been performed. **B,** Radiograph 2 weeks postoperatively demonstrates correction of volar tilt and biplane fixation. **C,** Posteroanterior radiograph at 2 weeks demonstrating an iliac crest graft and reduction of the radial inclination and length.

irritation that may be associated with dorsal plate fixation. A fixed-angle volar device anatomically designed to match the normal anatomic contours of the palmar–radial surface can be used as a guide for precision restoration of palmar tilt (Figure 15.68). The author prefers to calculate the degree of correction in the sagittal and coronal planes, apply the volar plate to the distal fragment with parallel smooth pegs before osteotomy, then remove the plate to cut the osteotomy (see Case Study 15.15). Care should be taken to finish the ostetotomy of the dorsal cortex with an osteotome to decrease the possibility of an injury to the extensor tendons.

The EPL and wrist extensor tendons are particularly at risk, and a small counterincision to isolate and protect these tendons may be considered. The plate is then reapplied distally by inserting the parallel smooth pegs into the predrilled holes and rotating into position on the proximal–radial shaft to simultaneously realign the articular surface in both planes. Fixation is completed both proximally and distally with additional screws and pegs. Large deformities may require a concomitant dorsal incision, periosteal division, and the use of a laminar spreader to gain length. If making a separate incision, I generally fill the resultant defect with a cancellous bone graft to expedite healing, although some surgeons rely on the rigidity of locked-plate fixation alone.

If the length discrepancy between the ulna and the radius is more than 10 mm, or if performing a closing wedge osteotomy, a combined radial osteotomy and simultaneous ulnar shortening can be performed.[158] Stable fixation of both the radius and the ulna is necessary. The presence of severe degenerative changes in the DRUJ mandates resection of the distal ulna or prosthetic replacement of the joint. If the radial shortening is greater than 2 to 3 cm, progressive lengthening with the distraction osteogenesis technique may be necessary to prevent nerve or tendon dysfunction, or both.

Ulnar-Shortening Osteotomy

Ruch and colleagues advocate isolated ulnar shortening osteotomy for patients with up to 20 degrees of symptomatic dorsal extraarticular radial malunion and simultaneous ulnar-positive variance.[149] These authors demonstrated marked improvements in wrist and forearm range of motion, VAS scores, and DASH scores in 18 patients with isolated ulnar-shortening osteotomy (USO) and recommend it as a simpler treatment for a uniplanar radius deformity (see Chapter 14).

Please see ExpertConsult.com for information about Watson's trapezoidal osteotomy.

Malunited Smith Fractures

The classic symptoms of volar malunion include decreased wrist extension and supination because of the tendency for Smith fractures to heal with a pronation deformity. Symptomatic malunions can be exposed through a standard FCR incision, with radial detachment of the pronator quadratus muscle and partial elevation of the FPL from the radial shaft. Two K-wires or a two-pin external fixator are inserted on the volar aspect to mark the angle of correction and manually hold reduction during plate application. A palmar opening wedge osteotomy, grafting, and plating are then carried out as in the preceding (eFigure 15.10).

Care must be taken to not translate the entire distal radius fragment dorsally and, in so doing, shift the center of rotation of the carpus dorsally. Temporary K-wire fixation through the radial styloid and a second wire placed volar-to-dorsal from the radial rim helps stabilize the correction, which is verified with fluoroscopy. Application of a fixed-angle volar plate automatically derotates the pronation deformity of the distal fragment by virtue of the contoured surface of the plate. Dorsiflexion of the distal fragment and derotation, as well as lengthening, reorient the sigmoid notch of the radius with respect to the ulnar head. Degenerative arthritis of the DRUJ may necessitate simultaneous distal–ulnar excision or ulnar head replacement.

Articular Osteotomies

The role of an osteotomy in correcting an articular malunion of the radiocarpal joint after a distal–radius fracture is limited

http://e-surg.com

CASE STUDY 15.15

Malunion

A 52-year-old homemaker is 2 years post–closed reduction/casting for extraarticular fracture. She is experiencing ulnar-sided pain with mild loss of supination and no instability (eFigure 15.57). Physical therapy, splint, and injection have failed. The patient wishes to return to golfing.

What is the best treatment option?

A. Nonoperative care
B. Darrach
C. Ulnar-shortening osteotomy
D. Distal ulnar arthroplasty
E. Radial osteotomy

ANS: E. Radial osteotomy

See eFigure 15.58 for operative procedure.

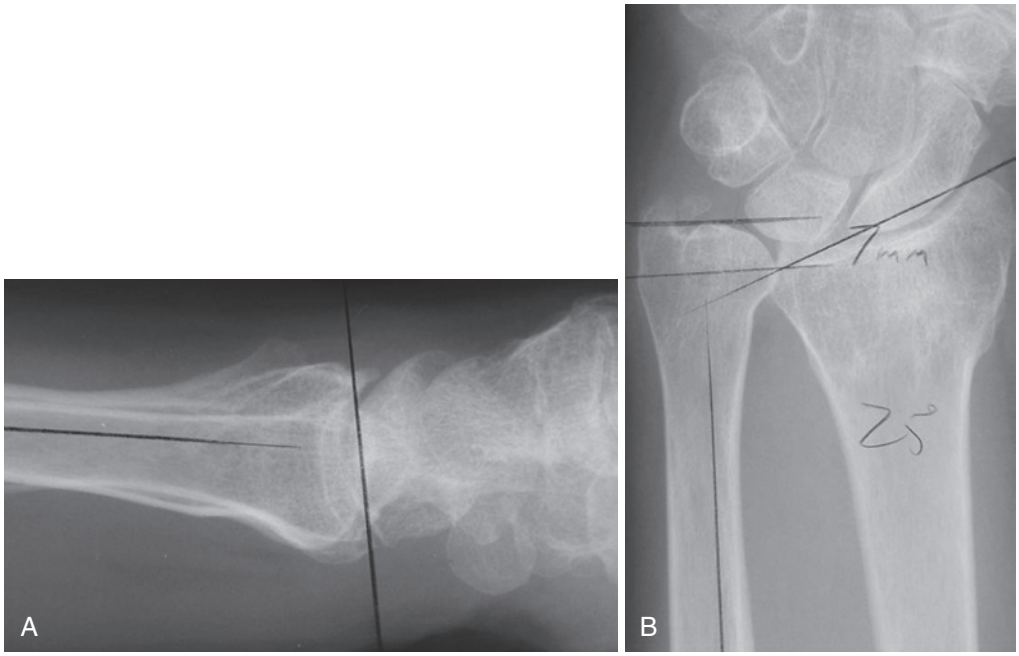

eFIGURE 15.57 Radiographs show a 7-mm ulnar-positive variance **(A)** and a 25-degree dorsal tilt **(B).**

http://e-surg.com

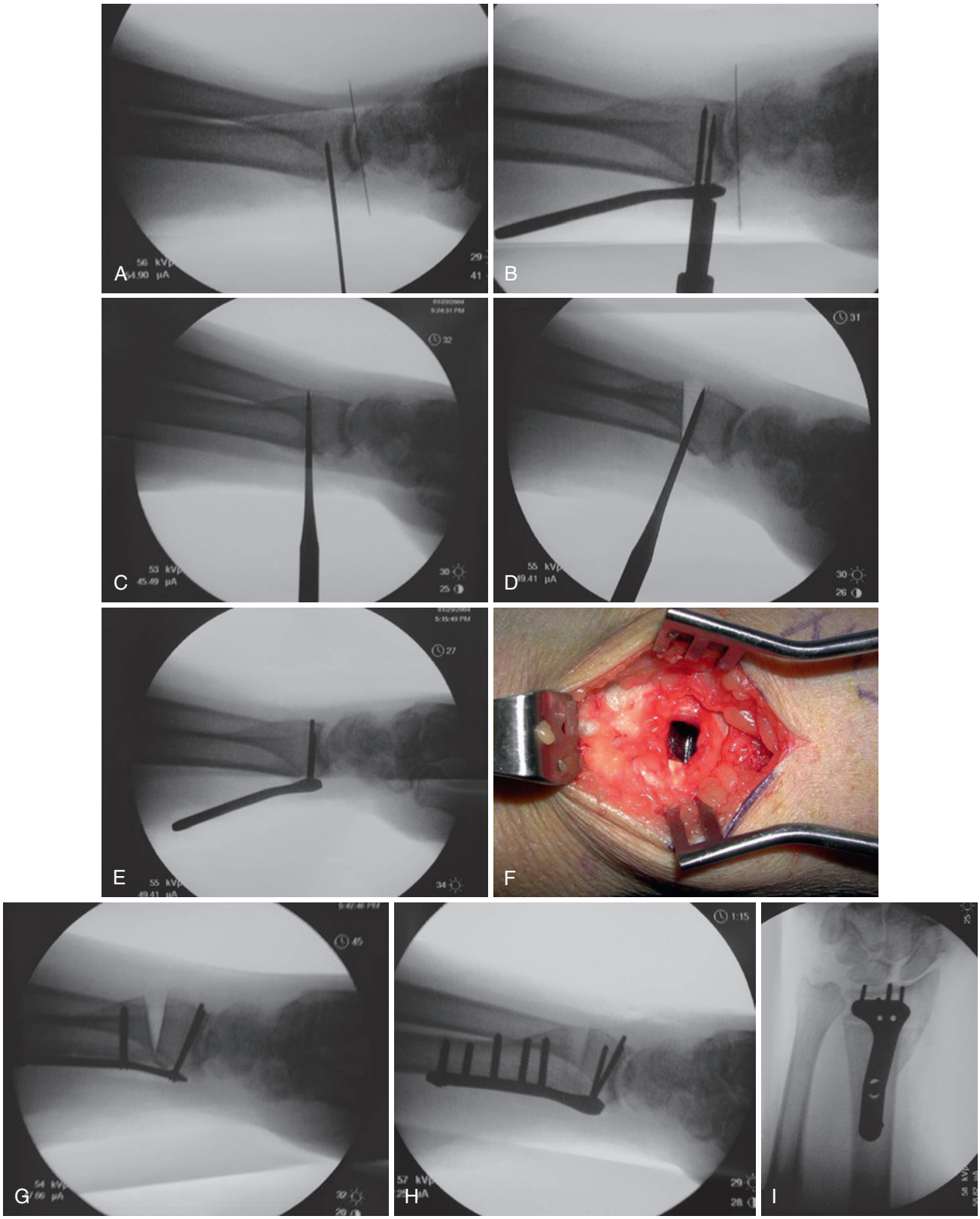

eFIGURE 15.58 **A,** A 25-g needle localizes articular surface and guides initial Kirschner wire insertion. **B,** Fixed-angle device positioned distally with two parallel smooth pegs. The corrective angle between plate and radius is defined. **C,** Plate and parallel pegs withdrawn, osteotomy performed with saw, osteotomes. **D,** Distal fragment rotated into position. **E,** Plate slid back into position into distal fragment; remainder of distal pegs are applied. **F,** Small dorsal exposure done, if necessary, to divide dorsal periosteum; insert bone graft if desired. A small laminar spreader can be helpful to open osteotomy. **G,** Plate levered into position and fixed with proximal screws. **H,** Note that chronic dorsal intercalated segmental instability deformity may not be corrected completely. **I,** Posteroanterior radiograph showing restoration of alignment and length.

http://e-surg.com

Watson's Trapezoidal Osteotomy

In 1988, Watson and Castle described the biplanar osteotomy technique plus a trapezoidal distal–radial local autogenous bone graft for the treatment of malunion of the distal radius (eFigure 15.9).[162] These authors recommended exposure of the distal radius through a transverse dorsal incision, although a universal dorsal approach also may be used. The articular surface of the radius is visualized, and the osteotomy is made parallel with the articular surface and approximately 1 cm proximal to it. In a biplanar mode, to correct the loss of radial tilt and volar inclination, the osteotomy is opened and held in position with a laminar spreader while a radiograph is obtained. If the correct amount of tilt has been produced to restore normal radial inclination and volar tilt, a trapezoidal corticocancellous graft is obtained from the radius just proximal to the osteotomy site dorsally.

The bone graft is removed from the radius, rotated 90 degrees, then reinserted into the osteotomy site. If correction of the volar tilt is insufficient, it is increased by flexing the wrist while the graft is wedged deeper into the osteotomy space. The osteotomy and graft are secured with two crossed 0.0625-in K-wires to "cage" the corticocancellous graft, and the wrist is protected in a cast for 4 to 6 weeks. This technique has the advantage of using a local graft, so it can be performed with the use of regional anesthesia. I would, however, not recommend it for severe radial malunion or when substantial length discrepancy is present.

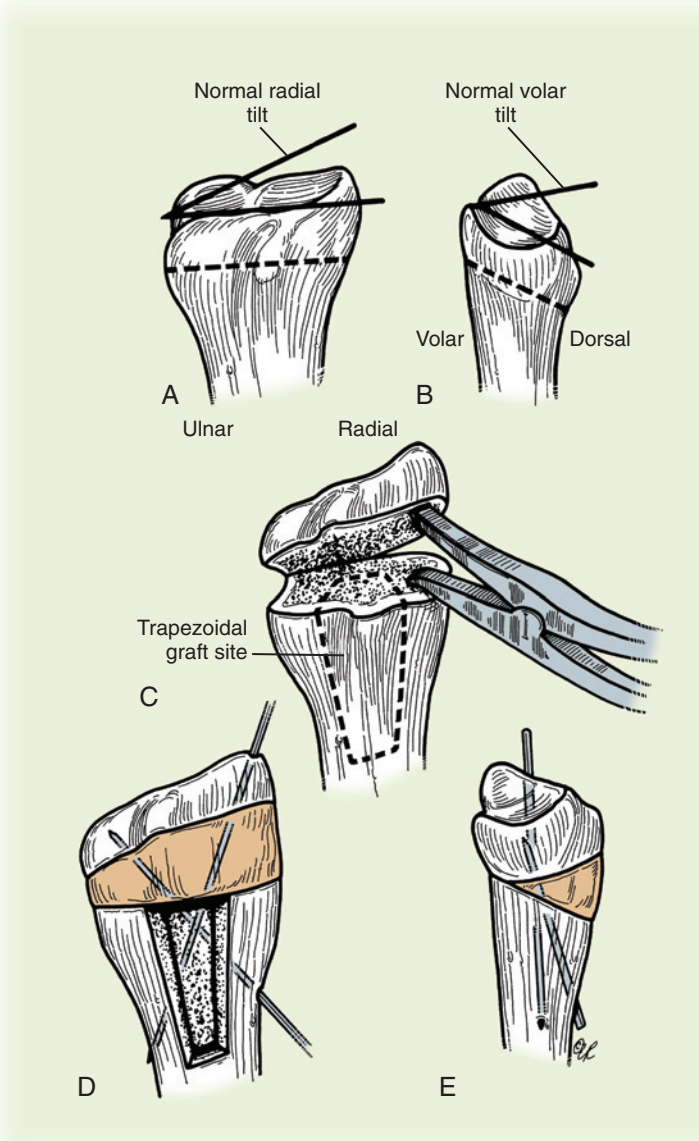

eFIGURE 15.9 The operative technique of trapezoidal osteotomy for the treatment of malunion of the distal radius, as described by Watson and Castle,[162] uses distal radial bone. **A, B,** The osteotomy is made 1 cm proximal to the articular surface and parallel to the articular surface. **C,** With a lamina spreader, the distal fragment is elevated and displaced to produce a biplanar osteotomy. An appropriate section of distal radial bone is then outlined on the dorsal aspect of the distal radius. **D, E,** The bone graft is harvested, rotated 90 degrees, packed into the biplanar osteotomy site, and fixed with two Kirschner wires. (© Elizabeth Martin.)

http://e-surg.com

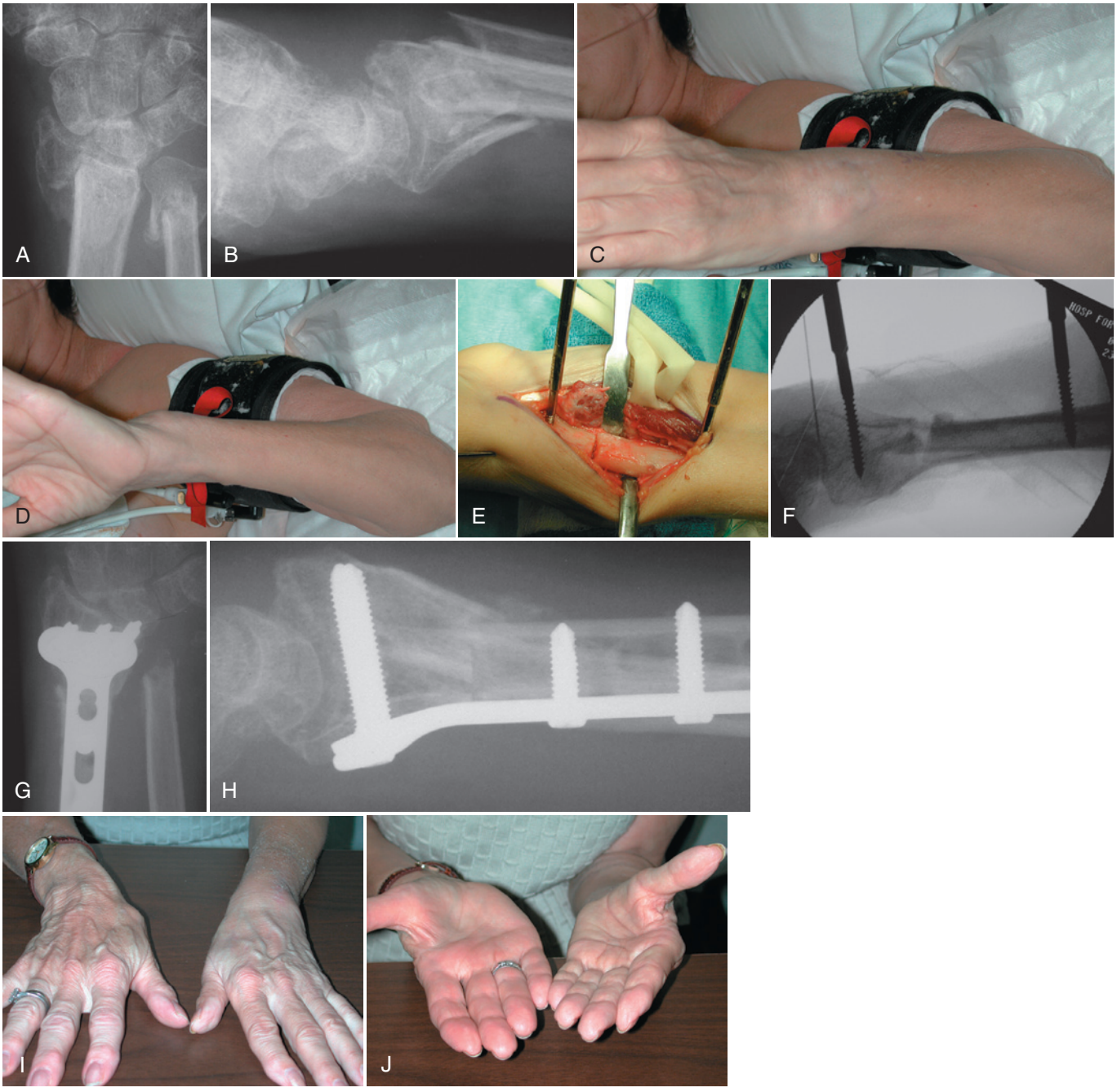

eFIGURE 15.10 **A, B,** A malunited Smith fracture with palmar translation and a pronation deformity of the distal fragment resulting in marked loss of supination **(C, D). E, F,** Intraoperative photograph and fluoroscopy demonstrating the use of a two-pin external fixator to simultaneously gain length, rotation, and sagittal alignment of the distal fragment with an opening wedge osteotomy. Preoperative degenerative disease of the distal radioulnar joint in this 70-year-old necessitated matched excision of the distal ulna. **G-J,** Radiographic and clinical results at 3 months postoperatively demonstrating marked improvement in rotation and wrist alignment.

http://e-surg.com

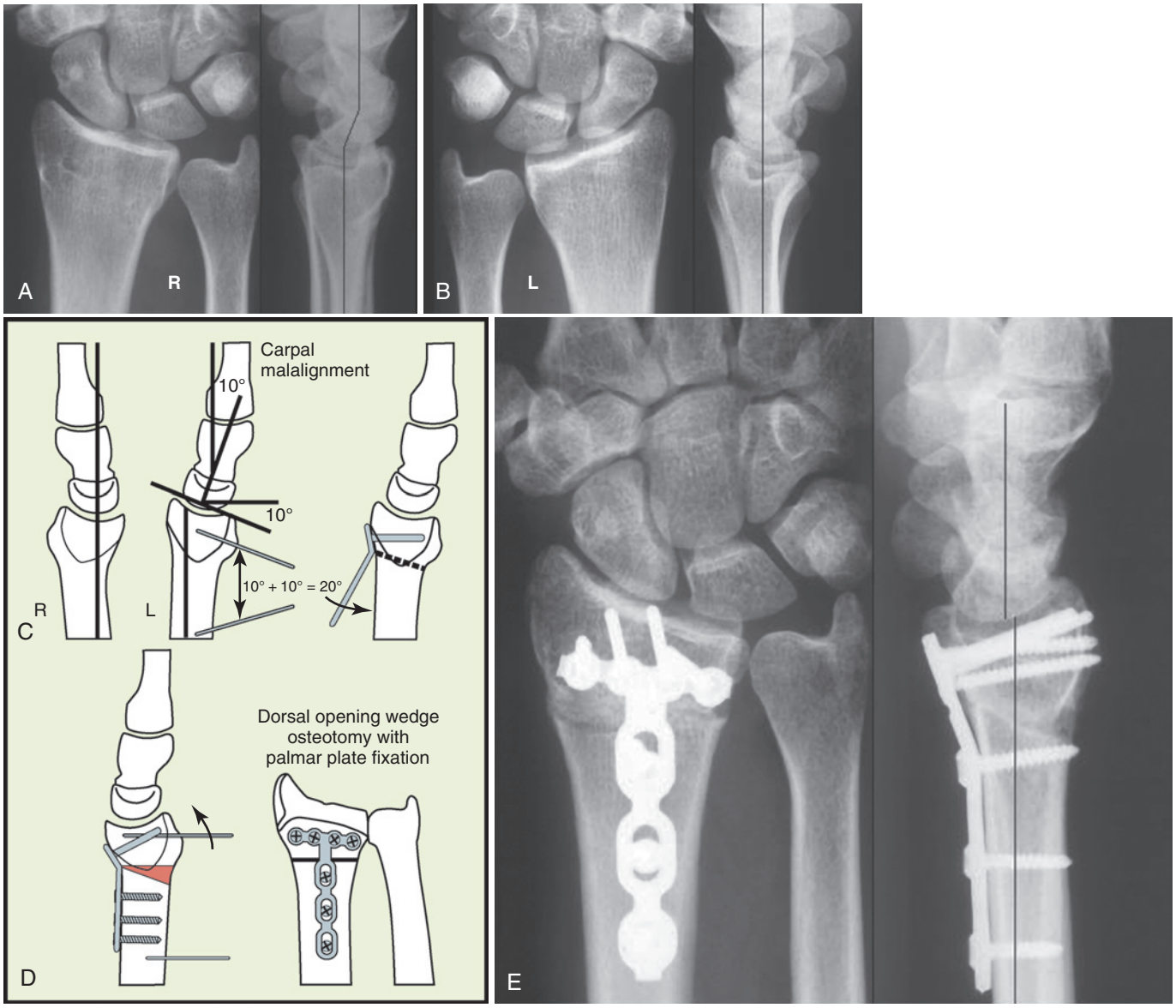

FIGURE 15.68 **A,** Dynamic midcarpal instability in a malunited Colles' fracture with 10 degrees of dorsal tilt. The patient has painful clicking on ulnar deviation of right wrist. **B,** Comparative radiographs of the left wrist showing normal carpal alignment. **C, D,** Preoperative radiographs and planning: An opening wedge osteotomy was performed through a volar approach and fixed with a fixed-angle plate and morcellized cancellous bone. Preapplication of the fixed-angle plate to the distal fragment at the anticipated angle of correction with two parallel pegs allows the surgeon to subsequently remove the plate, make the osteotomy, and then reattach the plate to precisely rotate the distal fragment into position. **E,** Realignment of the distal radius with restoration of a 10-degree volar tilt, improved carpal alignment, and controlled instability. Notice the subchondral positioning of the central fixed-angle pegs. (**D,** © Elizabeth Martin.)

by both chronology and the type of injury. The osteotomy should be done as early as possible after fracture, and the fracture plane can be readily identified upward of 8 to 12 weeks after injury (see Case Study 15.16). A high-resolution CT with multiplanar reformatting is particularly helpful in identifying the fracture plane and planning the osteotomy (see Case Study 15.1). Custom sterile cutting guides can be created to ensure precision correction of articular and combined defects[150] (see Case Study 15.16). MRI with cartilage-sensitive sequences or concomitant wrist arthroscopy may play a useful role in evaluating the amount of cartilage damage and articular incongruence. The presence of areas that lack subchondral bone represents a formal contraindication to osteotomy.

It is preferable to reserve such a procedure for malunited fractures that have a relatively simple articular component (Figure 15.69). Such fractures include malunited radial styloid, volar or dorsal shearing (i.e., a Barton fracture), dorsal die-punch, and palmar carpal subluxation due to a displaced palmar–lunate facet fragment.[139] The choice of surgical approach is as indicated for the fracture scenario in the acute stage. Stable fixation of the osteotomized fragment enables early rehabilitation of the radiocarpal and radioulnar joints.

Distal Radioulnar Joint Procedures

The most common cause of residual wrist disability after fracture of the distal radius involves the wrist's ulnar side. The three

http://e-surg.com

CASE STUDY 15.16

Distal Radius Osteotomy for Malunion Using CT-Modeled Custom Cutting Guides

A 42-year-old right-handed female falls after slipping on an icy driveway onto her right hand (eFigure 15.59). A closed reduction is performed (eFigures 15.60 and 15.61). The patient presents 10 months later with incapacitating painful malunion and lack of forearm rotation (eFigures 15.62, 15.63, and 15.64).

Complex intraarticular deformity may require combined intra- and extraarticular osteotomy. A plan is made for CT-modeled osteotomy using software by Materialise (Leuven, Belgium). See eFigure 15.65.

The operative procedure is shown in eFigure 15.66. Surgical results are displayed in eFigure 15.67.

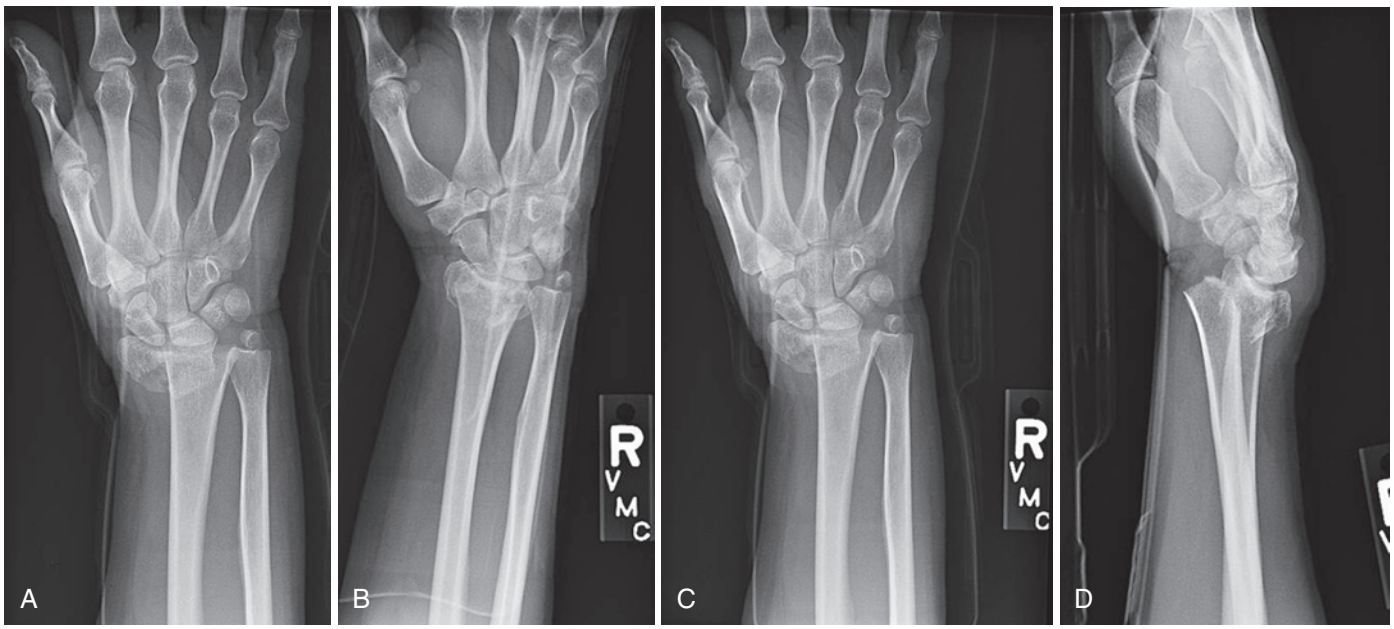

eFIGURE 15.59 **A-D,** Trauma films.

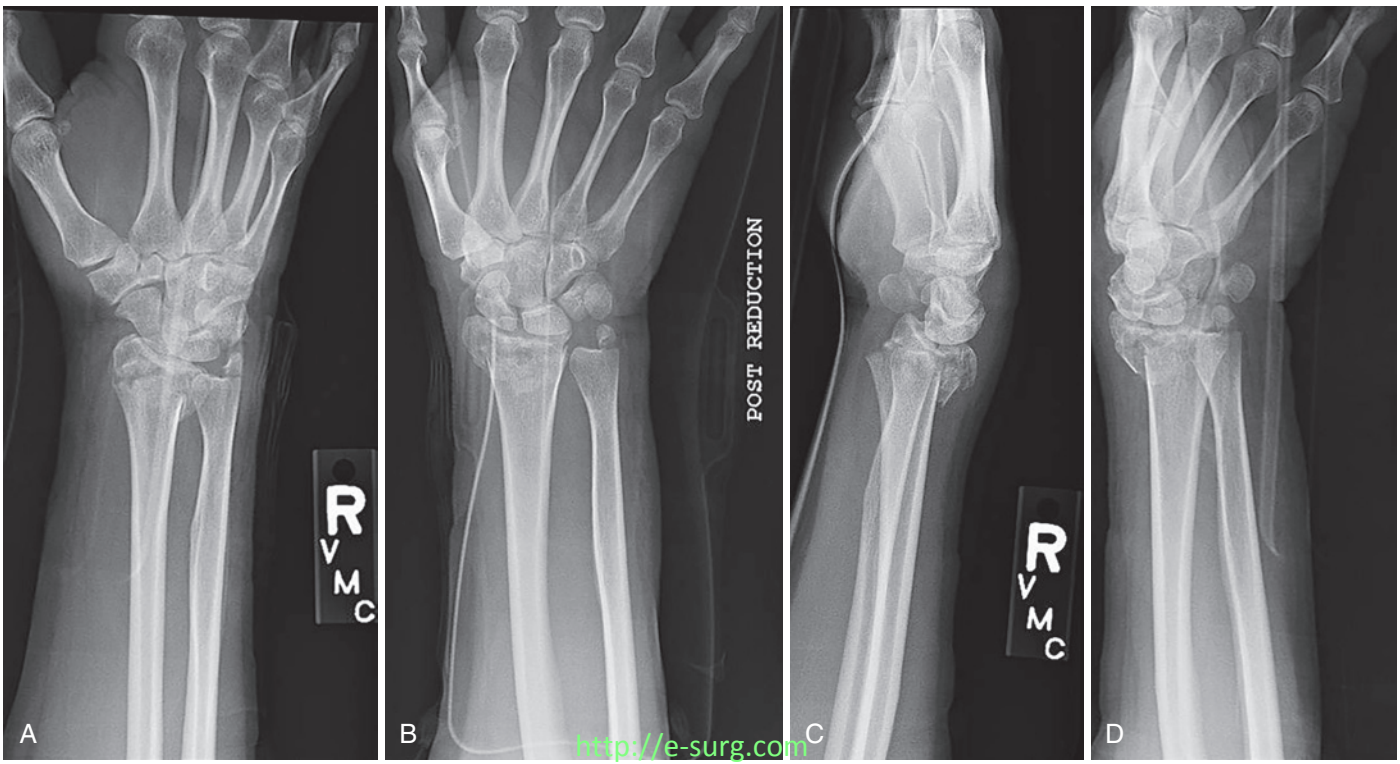

http://e-surg.com

eFIGURE 15.60 **A-D,** Postreduction.

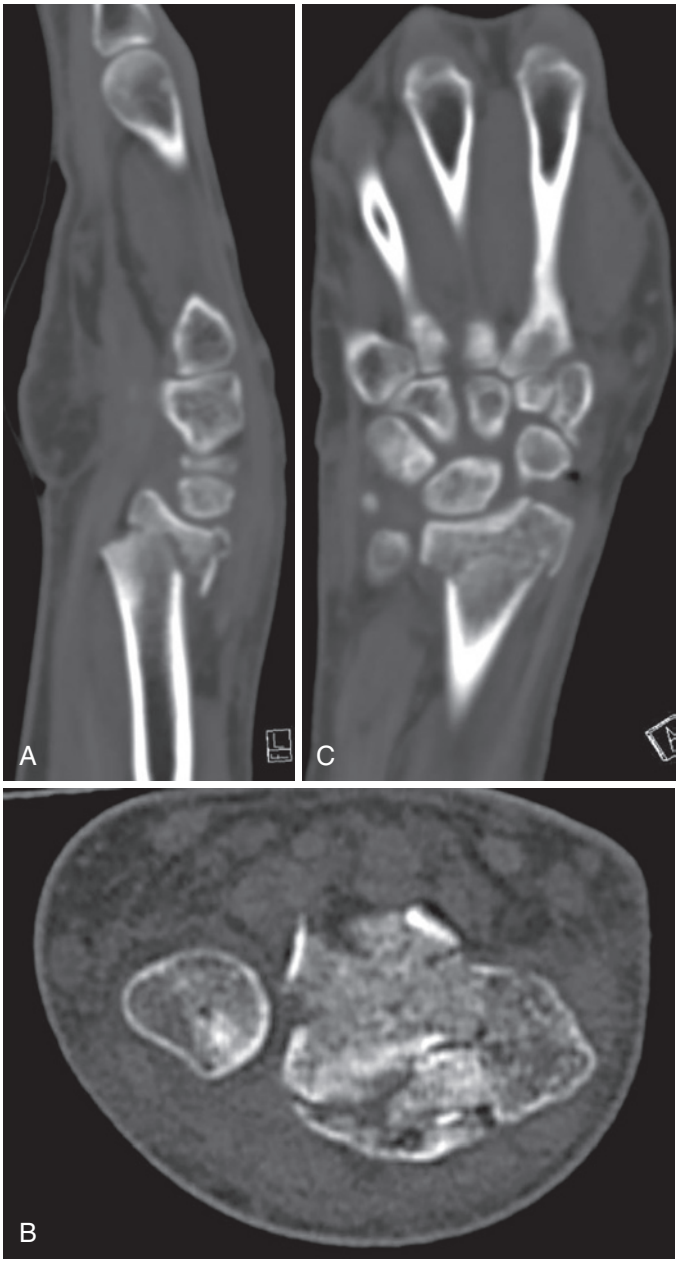

eFIGURE 15.61 A-C, Computed tomographic image cuts on day of fracture.

http://e-surg.com

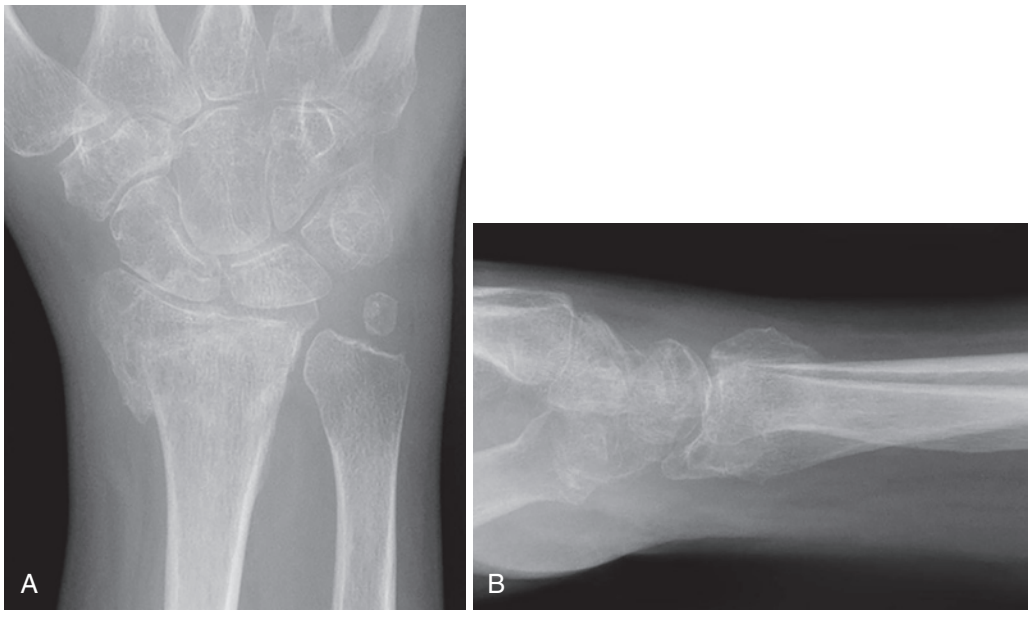

eFIGURE 15.62 **A, B,** Healed fracture.

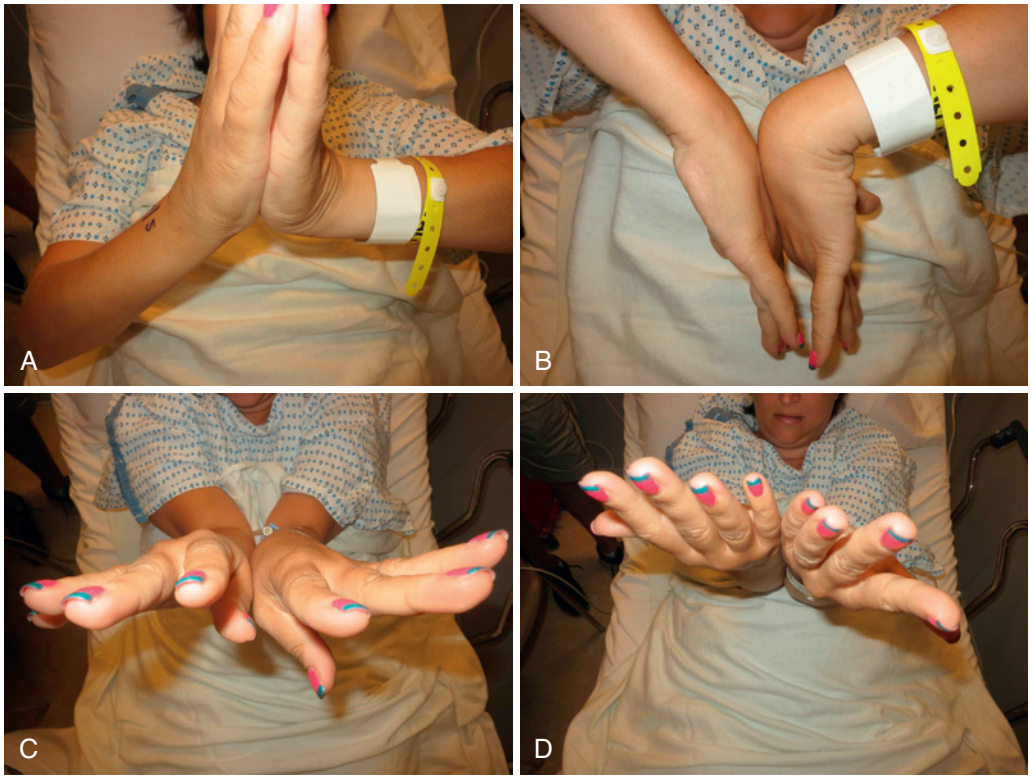

eFIGURE 15.63 **A-D,** Clinical photos at presentation.

http://e-surg.com

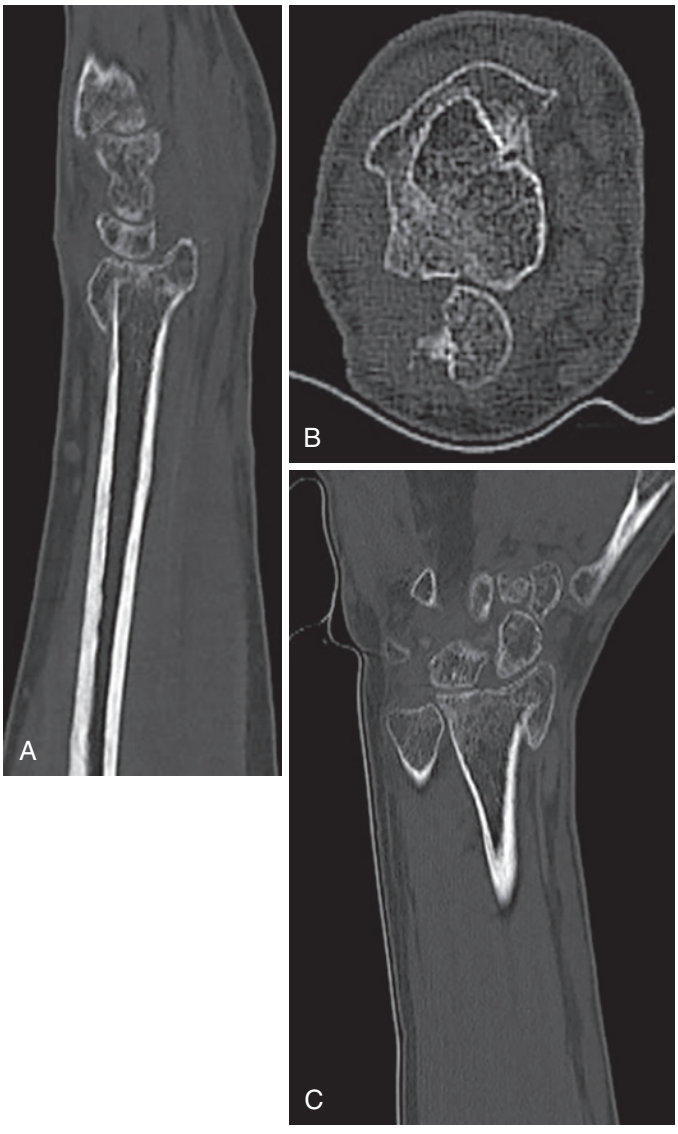

eFIGURE 15.64 Preoperative computed tomographic image cuts 3.5 months after fracture.

http://e-surg.com

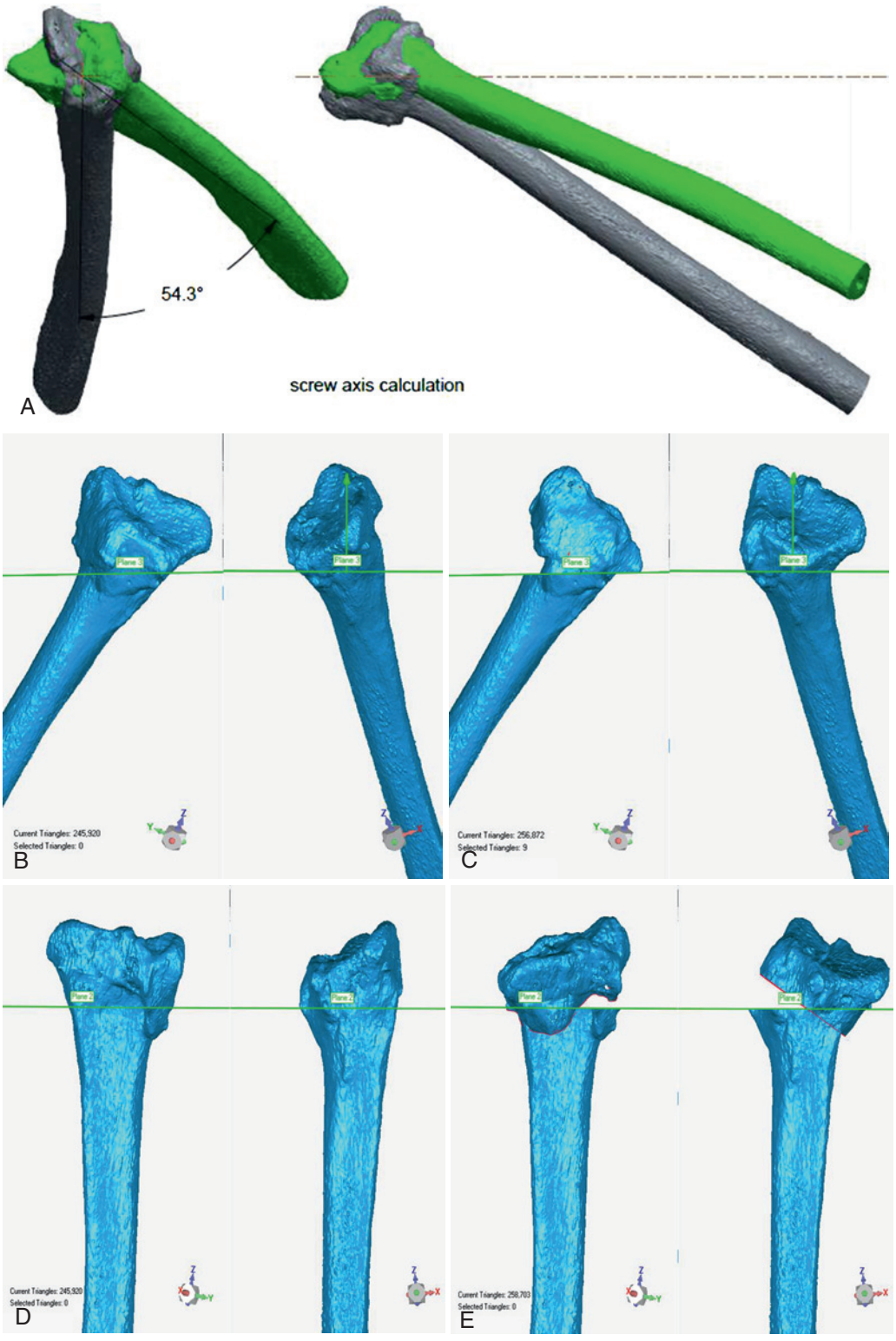

eFIGURE 15.65 Modeling plan: **A,** Screw axis calculation (54.3-degree rotation about axis). **B, C,** Osteotomy plan #1—cut perpendicular to screw axis. **D-F,** Osteotomy plan #2—osteotomy transverses to bone axis. Note interference, marked with *red arrow* on **F. G, H,** Completed plan.

Continued

http://e-surg.com

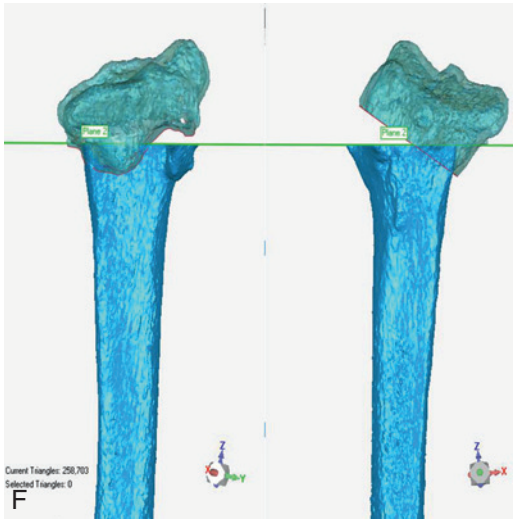

F

CaseID:
Patient Name:
Date of birth:
PO number:
Surgeon:
Surgery type: Corrective osteotomy of the distal radius
Side: Right
Surgery date:

Two guides have to be used during surgery.

Pre- operative situation

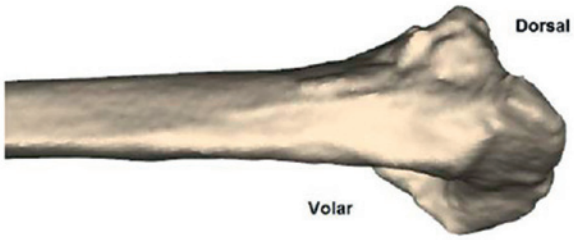

Planned correction



G

The planned osteotomy is an opening wedge osteotomy.



Bone model B, the planned outcome model, can be used in bone graft preparation. The gap in the model is the planned gap between the fragments.

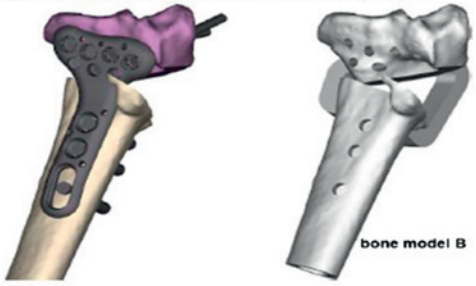

The volume of the graft area is approximately 2 cubic centimeters.

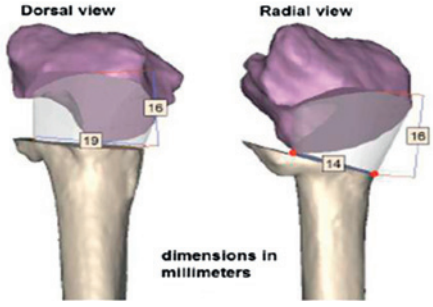

H

eFIGURE 15.65, cont'd

http://e-surg.com

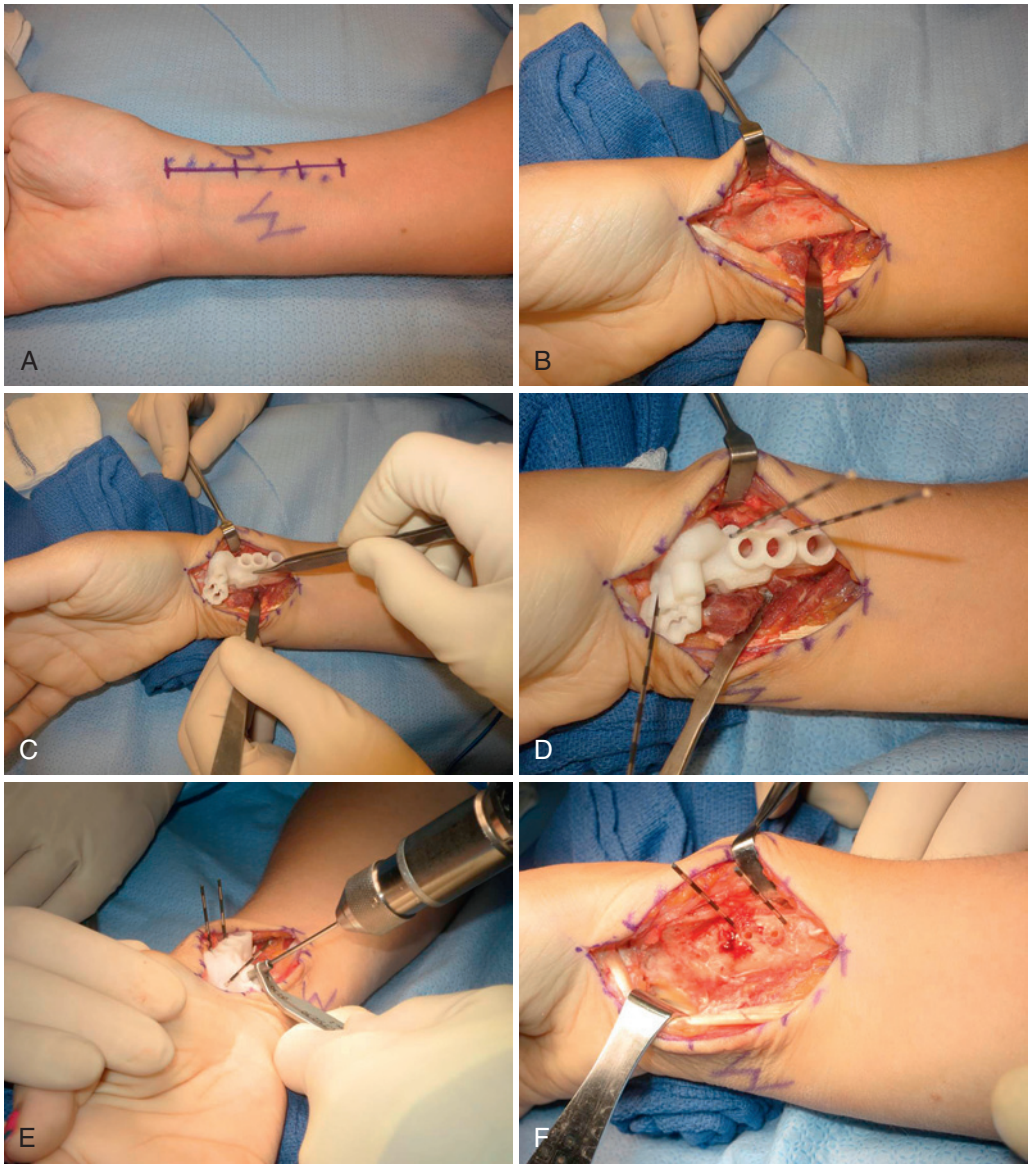

eFIGURE 15.66 **A-L,** Photos of right distal radius extraarticular osteotomy with autogenous tibial bone graft using custom computed tomographic-modeled guides.

Continued

http://e-surg.com

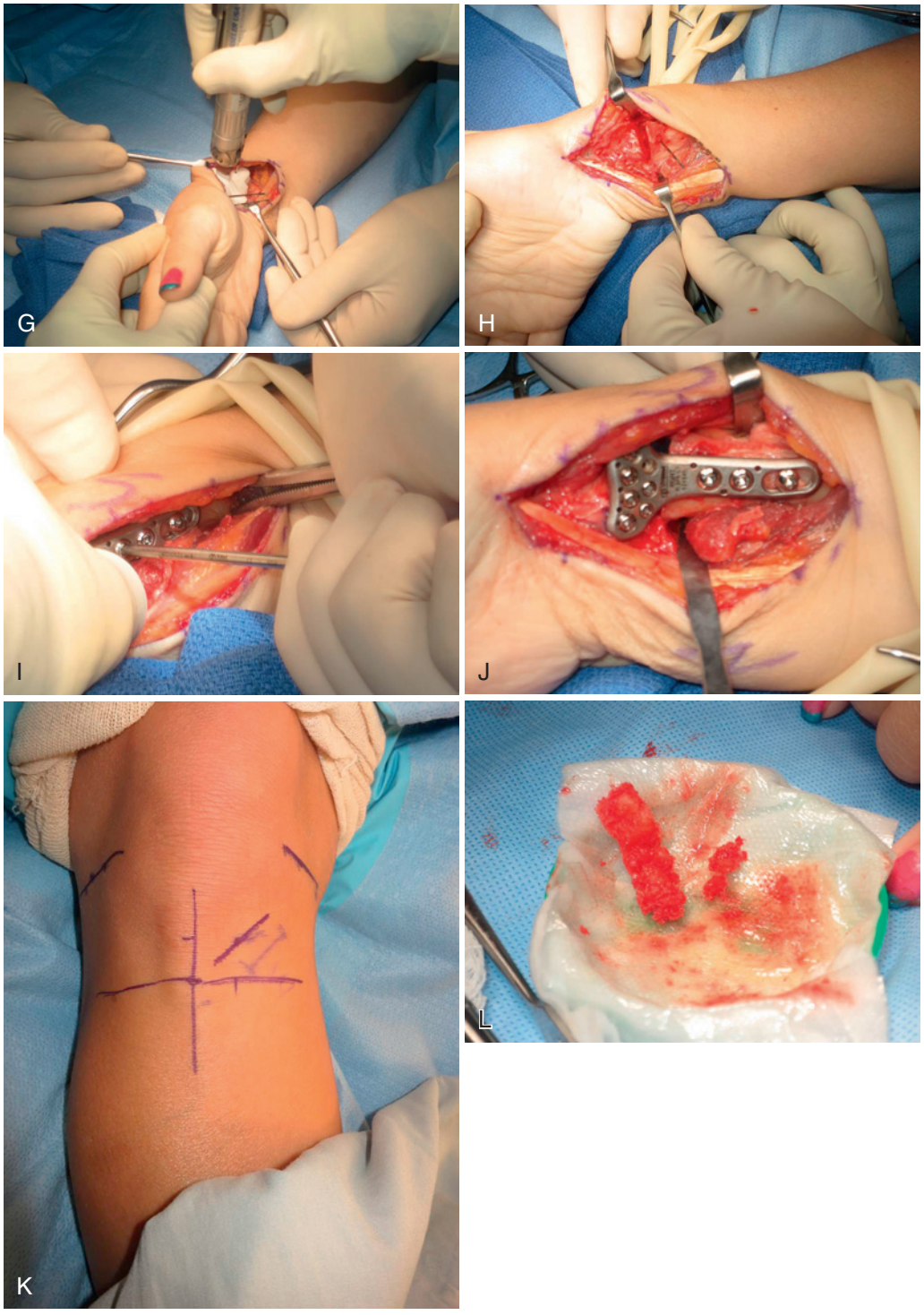

eFIGURE 15.66, cont'd

http://e-surg.com



eFIGURE 15.67 **A-C,** Radiographs at 11 days postoperative. **D-H,** Radiographs at 4 weeks postoperative. **I, J,** Clinical photos at 4 weeks postoperative.

Continued

http://e-surg.com

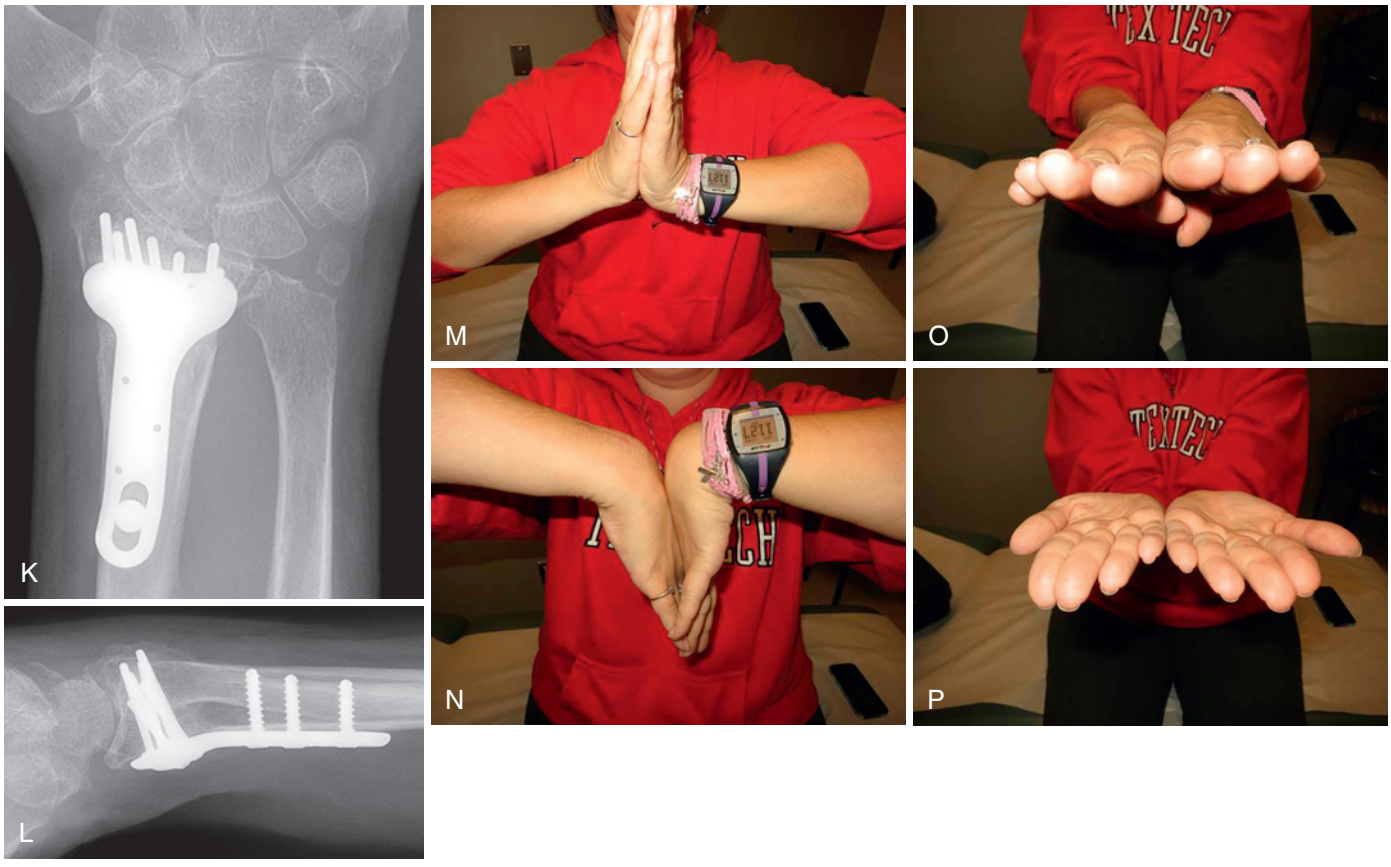

eFIGURE 15.67, cont'd **K, L,** Radiographs at 3 months postoperative. **M-P,** Clinical photos at 3 months postoperative.

http://e-surg.com



FIGURE 15.69 Relatively simple articular malunion involving articular depression of the scaphoid facet.

basic conditions responsible for pain associated with limited forearm rotation are sigmoid notch incongruency, positive ulnar variance, and instability of the joint. Less frequent (or concomitant) findings are painful nonunion of the ulnar styloid, capsular contracture of the joint, and radioulnar impingement (i.e., after distal ulnar resections or Sauvé-Kapandji procedures). Incongruency of the DRUJ may be due to (1) extraarticular deformity of the radius or ulna, which leads to an abnormal orientation of joint surfaces (sigmoid notch and ulnar head) in space; (2) disruption of the articular joint surface by a fracture line affecting the sigmoid notch or the ulnar head, or both; and (3) extraarticular and articular factors combined.

Ulnar impaction syndrome occurs at the ulnocarpal joint as a result of posttraumatic radial shortening and is synonymous with ulnocarpal abutment. With continuing impaction of the ulnar head against the carpus, progressive traumatic changes follow in a predictable sequence, including attenuation and tears of the TFCC; chondromalacia of the ulnar head, lunate, and triquetrum (Tq); attenuation and tears of the triquetrolunate ligament; and finally, ulnocarpal degenerative changes. Instability is the result of loss of ligament support, generally due to avulsion of the palmar and dorsal radioulnar ligaments from their foveal insertion. Additional injuries to the secondary joint stabilizers (e.g., capsular ligaments, sheath of the ECU, interosseous membrane, pronator quadratus) or disruption of the joint surface may aggravate the degree of laxity.

If the patient's main complaints are localized to the DRUJ (i.e., pain associated with limited forearm rotation) and the angulation of the radial articular surface in the sagittal and frontal planes is less than 20 degrees,[149] a reconstructive procedure at the distal radioulnar level is indicated, without a corrective radial osteotomy. However, if significant radial deformity is clearly associated with identifiable DRUJ problems, radial osteotomy and the appropriate DRUJ procedure can be performed simultaneously.

For radial shortening and ulnocarpal impaction with acceptable congruency of the sigmoid notch and ulna, as demonstrated by CT, a shortening osteotomy of the ulna is the procedure of choice. Ulnar shortening decompresses the wrist's ulnar compartment, reestablishes DRUJ congruity, and tightens the TFCC, which exerts a stabilizing effect on the distal ulna. An oblique osteotomy with resection of a bony segment and rigid fixation with a compression plate is recommended (see Chapter 14).[24]

If associated instability of the DRUJ is present and persists following correction of the radial malunion, transosseous reattachment of the dorsal and palmar radioulnar ligaments may be required. If the DRUJ is unstable and the dorsal and palmar radioulnar ligaments are in continuity with a large ulnar styloid fragment, bony reattachment with a screw, ulnar pin plate, or tension band construct is preferred.

If plain radiographs or CT demonstrates posttraumatic incongruity or degenerative changes of the radioulnar joint, either a resection arthroplasty, an ulnar head prosthetic replacement (Figure 15.70), or a Sauvé-Kapandji arthrodesis is required to alleviate pain. A partial ulnar head or "matched ulna" resection[163] with periosteal and capsular imbrication preserves the ulnocarpal ligaments and the TFCC in continuity with the distal ulnar stump. Partial ulnar resection does not alter the ulnar variance, and therefore additional ulnar shortening, either at the styloid level or at the ulnar shaft, may be required to prevent stylocarpal impingement. The disadvantages of the Darrach procedure (e.g., loss of grip strength, loss of ulnar support of the carpus, and instability of the distal ulnar stump) are thoroughly described, but the two most common causes of failure are the result of excessive resection of the distal ulna and failure to correct a concomitant distal radius malunion.

Radioulnar impingement, or convergence and scalloping of the resected ulna on the radial metaphysis, can be treated with an ulnar head prosthesis, and acceptable midterm results have been reported with this procedure.[156] Table 15.4 shows an algorithm for ulnar-sided disorders that may accompany fractures and malunions of the distal radius. The Darrach procedure still has a place in the treatment of distal ulnar derangement or osteoarthritis after a Colles' fracture in elderly patients, or it can be used as a salvage procedure for failed reconstructive procedures of the radioulnar joint (see Chapter 14).

DRUJ arthrodesis with the creation of a proximal pseudarthrosis (i.e., Sauvé-Kapandji procedure) preserves both the ulnocarpal ligaments and the bony support of the carpus. This operation is useful for younger, active patients because it improves forearm rotation in those with fixed DRUJ subluxation after articular fractures of the distal radius and severe destruction of the joint (Figure 15.71). The author recommends primary stabilization of the remaining distal ulna with distally based tendon weaves using slips of both the FCU and the ECU, as described by Lamey and Fernandez.[101]

Distal Radioulnar Joint Contracture

Capsular contraction of the DRUJ may be responsible for limitation of forearm rotation after distal radius fractures. Having ruled out joint incongruity, subluxation, radioulnar synchondrosis, interosseous membrane contracture, or derangement of the proximal radioulnar joint as other possible causes of limited forearm rotation, surgical release is helpful if the condition does not improve after a trial of physiotherapy.

http://e-surg.com

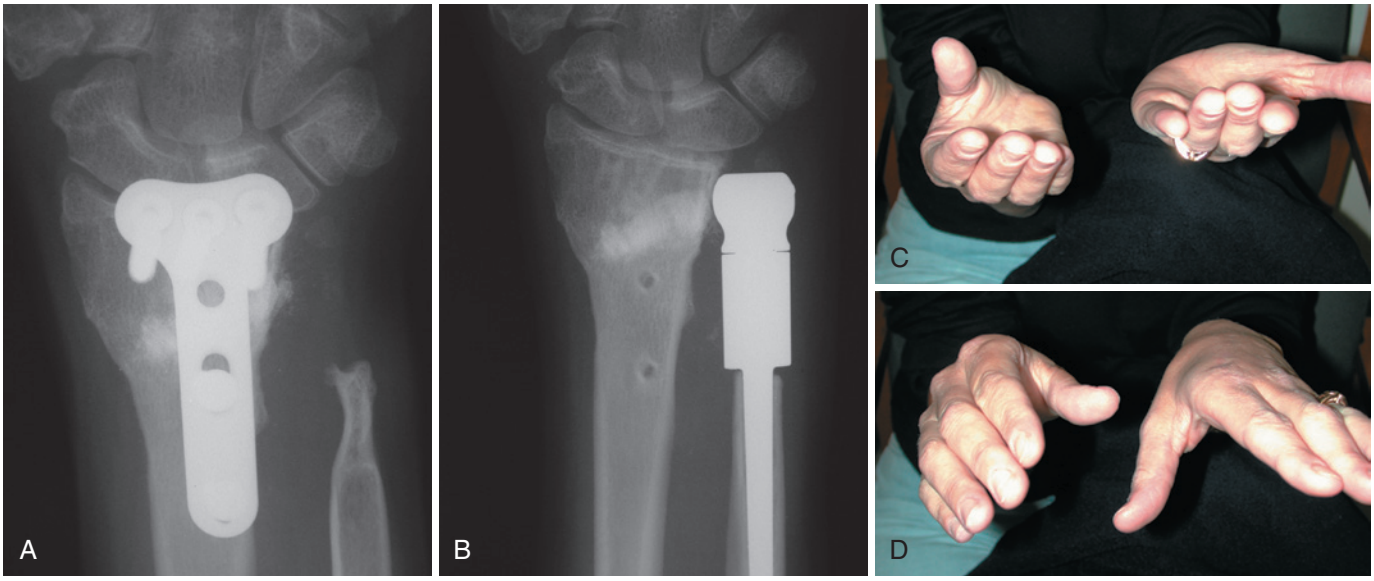

FIGURE 15.70 A 42-year-old with a chronically painful and unstable ulna after multiple procedures for distal radial malunion. **A,** Radically shortened ulna. **B,** Stability of the distal radioulnar joint was restored with a custom ulnar head replacement. **C, D,** Photos of functional and pain-free supination and pronation at 2 years postoperatively.

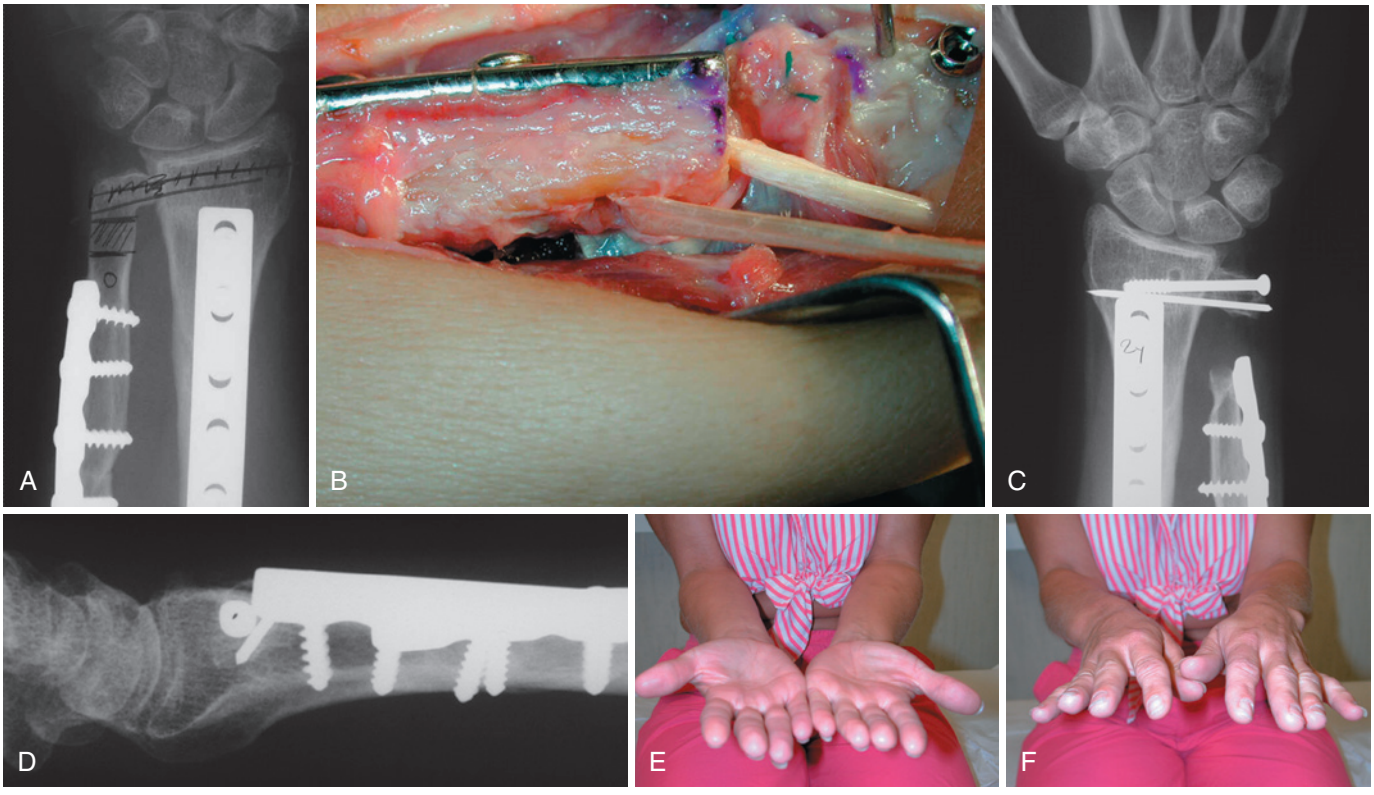

FIGURE 15.71 Suavé-Kapandji procedure: **A,** A 28-year-old emergency medical technician with a chronically unstable and degenerative distal radioulnar joint after multiple procedures for a malunited distal both-bones fracture. **B,** Intraoperative photograph of the flexor carpi ulnaris tendon woven through the proximal stump of the Sauvé-Kapandji reconstruction. **C, D,** Radiographs at 4 years postoperatively. **E, F,** Photos of pain-free functional rotation enabled return to all activities.

The volar aspect of the joint is exposed through a longitudinal incision just ulnar to the FCU tendon. Having exposed and protected the dorsal cutaneous branch of the ulnar nerve, the tendon and the ulnar neurovascular bundle are retracted radially. Next, the pronator quadratus is sectioned longitudinally 5 mm radial to its ulnar insertion. The contracted palmar capsule is exposed to retract the pronator quadratus radially. It is useful to place a 25-gauge needle between the TFCC and the ulnar head and confirm placement under fluoroscopy before resection of the palmar capsule. A longitudinal capsulotomy

http://e-surg.com

TABLE 15.4 Algorithm for Management of DRUJ Disorders After Distal Radius Fracture

Disorder	Management
DRUJ incongruity	
Extraarticular	Reorient the sigmoid notch with a radial osteotomy
Articular	Depending on the severity of degenerative changes, age, dominance, and occupation, resection arthroplasty, Sauvé-Kapandji procedure, or prosthetic replacement
Combined	Radial osteotomy and DRUJ procedure as for an articular disorder
DRUJ instability	Reattachment of the dorsal and palmar radioulnar ligaments ORIF of an ulnar styloid nonunion Shortening osteotomy of the ulna
Ulnocarpal impaction	Restore the radioulnar index or ulnar variance to normal Ulna-shortening osteotomy Wafer procedure Combined radius–ulna osteotomies
Symptomatic (painful) nonunion of the ulnar styloid	Excision
Capsular contracture	Dorsal and/or palmar capsulotomy[91]
Radioulnar impingement	Ulnar head prosthesis

Note: If these conditions occur in association, two or more procedures may need to be combined. A classic example is a malunited Colles fracture and degenerative changes in the DRUJ.
DRUJ, Distal radioulnar joint; *ORIF,* open reduction internal fixation.

just proximal to the volar radioulnar ligament close to the sigmoid notch is performed and then continued proximally to the neck of the ulna. The entire palmar capsule is excised to expose the articular surface of the ulnar head.

A more radial approach between the ulnar neurovascular bundle and the digital flexor tendons can also be used for this purpose. A "silhouette" capsulotomy[91] of the dorsal capsule is then performed with a counterincision through the fifth dorsal compartment. Postoperatively, it is important to begin immediate mobilization of the forearm and use dynamic supination bracing if necessary.

For Case Studies, Videos, and more, please visit ExpertConsult.com.

REFERENCES

1. Aktekin CN, Altay M, Gursoy Z, et al: Comparison between external fixation and cast treatment in the management of distal radius fractures in patients aged 65 years and older. *J Hand Surg [Am]* 35(5):736–742, 2010.
2. Amorosa LF, Vitale MA, Brown S, et al: A functional outcomes survey of elderly patients who sustained distal radius fractures. *Hand (NY)* 6(3):260–267, 2011.
3. Andermahr J, Lozano-Calderón S, Trafton T, et al: The volar extension of the lunate facet of the distal radius: a quantitative anatomic study. *J Hand Surg [Am]* 31(6):892–895, 2006.
4. Andersen DJ, Blair WF, Steyers CM, Jr, et al: Classification of distal radius fractures: an analysis of interobserver reliability and intraobserver reproducibility. *J Hand Surg [Am]* 21(4):574–582, 1996.
5. Anderson R, O'Neil G: Comminuted fractures of the distal end of the radius. *Surg Gyn Obstet* 78:434–442, 1944.
6. Arora R, Lutz M, Deml C, et al: A prospective randomized trial comparing nonoperative treatment with volar locking plate fixation for displaced and unstable distal radial fractures in patients sixty-five years of age and older. *J Bone Joint Surg Am* 93(23):2146–2153, 2011.
7. Asadollahi S, Keith PP: Flexor tendon injuries following plate fixation of distal radius fractures: a systematic review of the literature. *J Orthop Traumatol* 14(4): 227–234, 2013.
8. Atroshi I, Brogren E, Larsson GU, et al: Wrist-bridging versus non-bridging external fixation for displaced distal radius fractures: a randomized assessor-blind clinical trial of 38 patients followed for 1 year. *Acta Orthop* 77(3):445–453, 2006.
9. Axelrod TS, McMurtry RY: Open reduction and internal fixation of comminuted, intraarticular fractures of the distal radius. *J Hand Surg [Am]* 15(1):1–11, 1990.
10. Barrie KA, Wolfe SW: Internal fixation for intraarticular distal radius fractures. *Tech Hand Up Extrem Surg* 6(1):10–20, 2002.
11. Bass RL, Blair WF, Hubbard PP: Results of combined internal and external fixation for the treatment of severe AO-C3 fractures of the distal radius. *J Hand Surg [Am]* 20(3):373–381, 1995.
12. Beck JD, Harness NG, Spencer HT: Volar plate fixation failure for volar shearing distal radius fractures with small lunate facet fragments. *J Hand Surg [Am]* 39(4):670–678, 2014.
13. Benson LS, Minihame KP, Stern LD, et al: The outcome of intra-articular distal radius fractures treated with fragment-specific fixation. *J Hand Surg [Am]* 31A:1333–1339, 2006.
14. Beumer A, McQueen MM: Fractures of the distal radius in low-demand elderly patients: closed reduction of no value in 53 of 60 wrists. *Acta Orthop Scand* 74(1):98–100, 2003.
15. Bickerstaff DR, Bell MJ: Carpal malalignment in Colles' fractures. *J Hand Surg [Br]* 14(2):155–160, 1989.
16. Bohler L: *The treatment of fractures*, New York, 1929, Grune and Stratton, p 420.
17. Bong MR, Egol KA, Leibman M, et al: A comparison of immediate postreduction splinting constructs for controlling initial displacement of fractures of the distal radius: a prospective randomized study of long-arm versus short-arm splinting. *J Hand Surg [Am]* 31(5):766–770, 2006.
18. Brogren E, Hofer M, Petranek M, et al: Fractures of the distal radius in women aged 50 to 75 years: natural course of patient-reported outcome, wrist motion and grip strength between 1 year and 2 to 4 years after fracture. *J Hand Surg Eur Vol* 36(7):568–576, 2011.
19. Brogren E, Hofer M, Petranek M, et al: Relationship between distal radius fracture malunion and arm-related disability: a prospective population-based cohort study with 1-year follow-up. *BMC Musculoskelet Disord* 12:9, 2011.
20. Brogren E, Wagner P, Petranek M, et al: Distal radius malunion increases risk of persistent disability 2 years after fracture: a prospective cohort study. *Clin Orthop Relat Res* 471(5):1691–1697, 2013.
21. Brophy RH, Lin K, Smith MV: The role of activity level in orthopaedics: an important prognostic and outcome variable. *J Am Acad Orthop Surg* 22(7):430–436, 2014.
22. Burke EF, Singer RM: Treatment of comminuted distal radius with the use of an internal distraction plate. *Tech Hand Up Extrem Surg* 2(4):248–252, 1998.
23. Carter PR, Frederick HA, Laseter GF: Open reduction and internal fixation of unstable distal radius fractures with a low-profile plate: a multicenter study of 73 fractures. *J Hand Surg [Am]* 23(2):300–307, 1998.
24. Chen NC, Wolfe SW: Ulna shortening osteotomy using a compression device. *J Hand Surg [Am]* 28(1):88–93, 2003.
25. Chin KR, Jupiter JB: Wireloop fixation of volar displaced osteochondral fractures of the distal radius. *J Hand Surg [Am]* 24(3):523–533, 1999.
26. Chung KC, Kotsis SV, Kim HM: Predictors of functional outcomes after surgical treatment of distal radius fractures. *J Hand Surg [Am]* 32(1):76–83, 2007.
27. Chung KC, Spilson SV: The frequency and epidemiology of hand and forearm fractures in the United States. *J Hand Surg [Am]* 26(5):908–915, 2001.
28. Cole DW, Elsaidi GA, Kuzma KR, et al: Distal radioulnar joint instability in distal radius fractures: the role of sigmoid notch and triangular fibrocartilage complex revisited. *Injury* 37(3):252–258, 2006.
29. Cooney WP, III, Dobyns JH, Linscheid RL: Complications of Colles' fractures. *J Bone Joint Surg* 62A:613–619, 1980.
30. Cotton FJ: *Dislocations and joint fractures.* 1-1-0024. Philadelphia, 1924, W.B. Saunders, pp 348–358.
31. Crisco JJ, Coburn JC, Moore DC, et al: In vivo radiocarpal kinematics and the dart thrower's motion. *J Bone Joint Surg Am* 87(12):2729–2740, 2005.
32. Crosby SN, Fletcher ND, Yap ER, et al: The mechanical stability of extra-articular distal radius fractures with respect to the number of screws securing the distal fragment. *J Hand Surg [Am]* 38(6):1097–1105, 2013.
33. Cross AW, Schmidt CC: Flexor tendon injuries following locked volar plating of distal radius fractures. *J Hand Surg [Am]* 33(2):164–167, 2008.
34. DePalma AF: Comminuted fractures of the distal end of the radius treated by ulnar pinning. *J Bone Joint Surg* 34A(3):651–662, 1952.

http://e-surg.com

35. Dodds SD, Cornelissen S, Jossan S, et al: A biomechanical comparison of fragment-specific fixation and augmented external fixation for intra-articular distal radius fractures. *J Hand Surg [Am]* 27(6):953–964, 2002.
36. Doi K, Hattori Y, Otsuka K, et al: Intra-articular fractures of the distal aspect of the radius: arthroscopically assisted reduction compared with open reduction and internal fixation. *J Bone Joint Surg Am* 81(8):1093–1110, 1999.
37. Dumontier C, Meyer ZU, Reckendorf G, et al: Radiocarpal dislocations: classification and proposal for treatment. A review of twenty-seven cases. *J Bone Joint Surg Am* 83-A(2):212–218, 2001.
38. Dy CJ, Jang E, Taylor SA, et al: The impact of coronal alignment on distal radioulnar stability following distal radius fracture. *J Hand Surg Am* 39:1045–1052, 2014.
39. Dy CJ, Wolfe SW, Jupiter JB, et al: Distal radius fractures: strategic alternatives to volar plate fixation. *Instr Course Lect* 63:27–37, 2014.
40. Dzaja I, MacDermid JC, Roth J, et al: Functional outcomes and cost estimation for extra-articular and simple intra-articular distal radius fractures treated with open reduction and internal fixation versus closed reduction and percutaneous Kirschner wire fixation. *Can J Surg* 56(6):378–384, 2013.
41. Egol KA, Walsh M, Romo-Cardoso S, et al: Distal radial fractures in the elderly: operative compared with nonoperative treatment. *J Bone Joint Surg Am* 92(9): 1851–1857, 2010.
42. Egol K, Walsh M, Tejwani N, et al: Bridging external fixation and supplementary Kirschner-wire fixation versus volar locked plating for unstable fractures of the distal radius: a randomised, prospective trial. *J Bone Joint Surg Br* 90(9):1214–1221, 2008.
43. Erhart S, Schmoelz W, Arora R, et al: The biomechanical effects of a deepened articular cavity during dynamic motion of the wrist joint. *Clin Biomech (Bristol, Avon)* 27(6):557–561, 2012.
44. Erhart S, Schmoelz W, Lutz M: Clinical and biomechanical investigation of an increased articular cavity depth after distal radius fractures: effect on range of motion, osteoarthrosis and loading patterns. *Arch Orthop Trauma Surg* 133(9): 1249–1255, 2013.
45. Esposito J, Schemitsch EH, Saccone M, et al: External fixation versus open reduction with plate fixation for distal radius fractures: a meta-analysis of randomised controlled trials. *Injury* 44(4):409–416, 2013.
46. Fernandez DL: Correction of post-traumatic wrist deformity in adults by osteotomy, bone-grafting, and internal fixation. *J Bone Joint Surg Am* 64(8):1164–1178, 1982.
47. Fernandez DL: Fractures of the distal radius: operative treatment. *Instr Course Lect* 42:73–88, 1993.
48. Fitoussi F, Ip WY, Chow SP: Treatment of displaced intra-articular fractures of the distal end of the radius with plates. *J Bone Joint Surg Am* 79(9):1303–1312, 1997.
49. Frykman GK: Fracture of the distal radius including sequelae-shoulder-hand-finger syndrome, disturbance in the distal radioulnar joint and impairment of nerve function. A clinical and experimental study. *Acta Orthop Scand* 108:1–25, 1967.
50. Gartland JJ, Werley CW: Evaluation of healed Colles' fractures. *J Bone Joint Surg Am* 33A(4):895–907, 1951.
51. Gehrmann SV, Windolf J, Kaufmann RA: Distal radius fracture management in elderly patients: a literature review. *J Hand Surg [Am]* 33(3):421–429, 2008.
52. Geissler WB: Arthroscopically assisted reduction of intra-articular fractures of the distal radius. *Hand Clin* 11(1):19–29, 1995.
53. Geissler WB, Fernandez DL: Percutaneous and limited open reduction of the articular surface of the distal radius. *J Orthop Trauma* 5(3):255–264, 1991.
54. Geissler WB, Freeland AE: Arthroscopic management of intra-articular distal radius fractures. *Hand Clin* 15(3):455–465, viii, 1999.
55. Geissler WB, Freeland AE, Savoie FH, et al: Intracarpal soft-tissue lesions associated with an intra-articular fracture of the distal end of the radius. *J Bone Joint Surg Am* 78(3):357–365, 1996.
56. Ginn TA, Ruch DS, Yang CC, et al: Use of a distraction plate for distal radial fractures with metaphyseal and diaphyseal comminution. Surgical technique. *J Bone Joint Surg Am* 88(Suppl 1 Pt 1):29–36, 2006.
57. Goehre F, Otto W, Schwan S, et al: Comparison of palmar fixed-angle plate fixation with K-wire fixation of distal radius fractures (AO A2, A3, C1) in elderly patients. *J Hand Surg Eur Vol* 39(3):249–257, 2014.
58. Goldfarb CA, Rudzki JR, Catalano LW, et al: Fifteen-year outcome of displaced intra-articular fractures of the distal radius. *J Hand Surg [Am]* 31(4):633–639, 2006.
59. Goldhahn J, Beaton D, Ladd A, et al: Recommendation for measuring clinical outcome in distal radius fractures: a core set of domains for standardized reporting in clinical practice and research. *Arch Orthop Trauma Surg* 134(2):197–205, 2014.
60. Gradl G, Jupiter JB, Gierer P, et al: Fractures of the distal radius treated with a nonbridging external fixation technique using multiplanar k-wires. *J Hand Surg [Am]* 30(5):960–968, 2005.
61. Grewal R, MacDermid JC: The risk of adverse outcomes in extra-articular distal radius fractures is increased with malalignment in patients of all ages but mitigated in older patients. *J Hand Surg [Am]* 32(7):962–970, 2007.
62. Grewal R, MacDermid JC, King GJ, et al: Open reduction internal fixation versus percutaneous pinning with external fixation of distal radius fractures: a prospective, randomized clinical trial. *J Hand Surg [Am]* 36(12):1899–1906, 2011.
63. Grewel R, Perey B, Wilmink M, et al: A randomized trial on the treatment of intra-articular distal radius fractures: open reduction internal fixation with dorsal plating versus mini open reduction, percutaneous pinning and external fixation. *J Hand Surg [Am]* 30A:764–772, 2005.
64. Gyuricza C, Carlson MG, Weiland AJ, et al: Removal of locked volar plates after distal radius fractures. *J Hand Surg [Am]* 36(6):982–985, 2011.
65. Hagert CG: Distal radius fracture and the distal radioulnar joint—anatomical considerations. *Handchir Mikrochir Plast Chir* 26(1):22–26, 1994.
66. Hagert E, Hagert CG: Understanding stability of the distal radioulnar joint by understanding its anatomy. *Hand Clin* 26:459–466, 2010.
67. Handoll HH, Huntley JS, Madhok R: External fixation versus conservative treatment for distal radial fractures in adults. *Cochrane Database Syst Rev* (3): CD006194, 2007.
68. Handoll HH, Madhok R: Surgical interventions for treating distal radial fractures in adults. *Cochrane Database Syst Rev* (3):CD003209, 2003.
69. Handoll HH, Vaghela MV, Madhok R: Percutaneous pinning for treating distal radial fractures in adults. *Cochrane Database Syst Rev* (3):CD006080, 2007.
70. Handoll HH, Watts AC: Bone grafts and bone substitutes for treating distal radial fractures in adults. *Cochrane Database Syst Rev* (2):CD006836, 2008.
71. Hanel DP, Ruhlman SD, Katolik LI, et al: Complications associated with distraction plate fixation of wrist fractures. *Hand Clin* 26(2):237–243, 2010.
72. Harley BJ, Scharfenberger A, Beaupre LA, et al: Augmented external fixation versus percutaneous pinning and casting for unstable fractures of the distal radius—a prospective randomized trial. *J Hand Surg [Am]* 29(5):815–824, 2004.
73. Harness N, Ring D, Jupiter JB: Volar Barton's fractures with concomitant dorsal fracture in older patients. *J Hand Surg [Am]* 29(3):439–445, 2004.
74. Harness NG, Ring D, Zurakowski D, et al: The influence of three-dimensional computed tomography reconstructions on the characterization and treatment of distal radial fractures. *J Bone Joint Surg Am* 88(6):1315–1323, 2006.
75. Hayes AJ, Duffy PJ, McQueen MM: Bridging and non-bridging external fixation in the treatment of unstable fractures of the distal radius: a retrospective study of 588 patients. *Acta Orthop* 79(4):540–547, 2008.
76. Herford AS, King BJ, Audia F, et al: Medial approach for tibial bone graft: anatomic study and clinical technique. *J Oral Maxillofac Surg* 61(3):358–363, 2003.
77. Jakob M, Rikli DA, Regazzoni P: Fractures of the distal radius treated by internal fixation and early function. A prospective study of 73 consecutive patients. *J Bone Joint Surg Br* 82B(3):340–344, 2000.
78. Joseph SJ, Harvey JN: The dorsal horizon view: detecting screw protrusion at the distal radius. *J Hand Surg [Am]* 36(10):1691–1693, 2011.
79. Jupiter JB: Commentary: the effect of ulnar styloid fractures on patient-rated outcomes after volar locking plating of distal radius fractures. *J Hand Surg [Am]* 34(9):1603–1604, 2009.
80. Jupiter JB, Marent-Huber M: Operative management of distal radial fractures with 2.4-millimeter locking plates. A multicenter prospective case series. *J Bone Joint Surg Am* 91(1):55–65, 2009.
81. Jupiter JB, Ring D, Weitzel PP: Surgical treatment of redisplaced fractures of the distal radius in patients older than 60 years. *J Hand Surg [Am]* 27(4):714–723, 2002.
82. Kaempffe FA, Wheeler DR, Peimer CA, et al: Severe fractures of the distal radius: effect of amount and duration of external fixator distraction on outcome. *J Hand Surg [Am]* 18(1):33–41, 1993.
83. Kambouroglou GK, Axelrod TS: Complications of the AO/ASIF titanium distal radius plate system (pin plate) in internal fixation of the distal radius: a brief report. *J Hand Surg [Am]* 23(4):737–741, 1998.
84. Kang L, Ek E, et al: Biomechanical analysis of scapholunate ligament repair techniques. *JHS* 2015 epub ahead of print.
85. Kapandji AI, Epinette JA: Colles' fractures: Treatment by double intrafocal wire fixation. In Razemon JP, Fisk GR, editors: *The wrist*, New York, 1988, Churchill Livingstone, pp 65–73.
86. Kapoor H, Agarwal A, Dhaon BK: Displaced intra-articular fractures of distal radius: a comparative evaluation of results following closed reduction, external fixation and open reduction with internal fixation. *Injury* 31(2):75–79, 2000.
87. Karantana A, Downing ND, Forward DP, et al: Surgical treatment of distal radial fractures with a volar locking plate versus conventional percutaneous methods: a randomized controlled trial. *J Bone Joint Surg Am* 95(19):1737–1744, 2013.
88. Karnezis IA, Panagiotopoulos E, Tyllianakis M, et al: Correlation between radiological parameters and patient-rated wrist dysfunction following fractures of the distal radius. *Injury* 36(12):1435–1439, 2005.
89. Kim JK, Koh YD, Do NH: Should an ulnar styloid fracture be fixed following volar plate fixation of a distal radial fracture? *J Bone Joint Surg Am* 92(1):1–6, 2010.
90. Kitay A, Swanstrom M, Schreiber JJ, et al: Volar plate position and flexor tendon rupture following distal radius fracture fixation. *J Hand Surg [Am]* 38(6):1091–1096, 2013.

http://e-surg.com

91. Kleinman WB, Graham TJ: The distal radioulnar joint capsule: clinical anatomy and role in posttraumatic limitation of forearm rotation. *J Hand Surg [Am]* 23(4):588–599, 1998.
92. Knirk JL, Jupiter JB: Intra-articular fractures of the distal end of the radius in young adults. *J Bone Joint Surg Am* 68(5):647–659, 1986.
93. Kodama N, Takemura Y, Ueba H, et al: Acceptable parameters for alignment of distal radius fracture with conservative treatment in elderly patients. *J Orthop Sci* 19(2):292–297, 2014.
94. Konrath GA, Bahler S: Open reduction and internal fixation of unstable distal radius fractures: results using the trimed fixation system. *J Orthop Trauma* 16(8): 578–585, 2002.
95. Koval KJ, Harrast JJ, Anglen JO, et al: Fractures of the distal part of the radius. The evolution of practice over time. Where's the evidence? *J Bone Joint Surg Am* 90(9):1855–1861, 2008.
96. Kreder HJ, Agel J, McKee MD, et al: A randomized, controlled trial of distal radius fractures with metaphyseal displacement but without joint incongruity: closed reduction and casting versus closed reduction, spanning external fixation, and optional percutaneous K-wires. *J Orthop Trauma* 20(2):115–121, 2006.
97. Kreder HJ, Hanel DP, Agel J, et al: Indirect reduction and percutaneous fixation versus open reduction and internal fixation for displaced intra-articular fractures of the distal radius. *J Bone Joint Surg Br* 87-B:829–836, 2005.
98. Kreder HJ, Hanel DP, McKee M, et al: Consistency of AO fracture classification for the distal radius. *J Bone Joint Surg Br* 78(5):726–731, 1996.
99. Ladd AL, Pliam NB: The role of bone graft and alternatives in unstable distal radius fracture treatment. *Orthop Clin North Am* 30(2):337–351, 2001.
100. Lafontaine M, Hardy D, Delince PH: Stability assessment of distal radius fractures. *Injury* 20(4):208–210, 1989.
101. Lamey DM, Fernandez DL: Results of the modified Sauvé-Kapandji procedure in the treatment of chronic posttraumatic derangement of the distal radioulnar joint. *J Bone Joint Surg Am* 80(12):1758–1769, 1998.
102. Leslie BM, Medoff RJ: Fracture specific fixation of distal radius fractures. *Tech Orthop* 15(4):336–352, 2000.
103. Leung KS, So WS, Chiu VD, et al: Ligamentotaxis for comminuted distal radial fractures modified by primary cancellous grafting and functional bracing: long-term results. *J Orthop Trauma* 5(3):265–271, 1991.
104. Lozano-Calderón SA, Doornberg J, Ring D: Fractures of the dorsal articular margin of the distal part of the radius with dorsal radiocarpal subluxation. *J Bone Joint Surg Am* 88(7):1486–1493, 2006.
105. Lozano-Calderón SA, Doornberg JN, Ring D: Retrospective comparison of percutaneous fixation and volar internal fixation of distal radius fractures. *Hand (NY)* 3(2):102–110, 2008.
106. Ludvigsen TC, Johansen S, Svenningsen S, et al: External fixation versus percutaneous pinning for unstable Colles' fracture. Equal outcome in a randomized study of 60 patients. *Acta Orthop Scand* 68(3):255–258, 1997.
107. MacKenney PJ, McQueen MM, Elton R: Prediction of instability in distal radius fractures. *J Bone Joint Surg Am* 88:1944–1951, 2006.
108. Mattila VM, Huttunen TT, Sillanpaa P, et al: Significant change in the surgical treatment of distal radius fractures: a nationwide study between 1998 and 2008 in Finland. *J Trauma* 71(4):939–942, 2011.
109. McFadyen I, Field J, McCann P, et al: Should unstable extra-articular distal radial fractures be treated with fixed-angle volar-locked plates or percutaneous Kirschner wires? A prospective randomised controlled trial. *Injury* 42(2):162–166, 2011.
110. McQueen MM: Redisplaced unstable fractures of the distal radius. A randomised, prospective study of bridging versus non-bridging external fixation. *J Bone Joint Surg Br* 80(4):665–669, 1998.
111. McQueen MM, Caspers J: Colles' fracture: does the anatomical result affect the final function? *J Bone Joint Surg Am* 34A(3):649–651, 1988.
112. McQueen MM, Hajducka C, Court-Brown CM: Redisplaced unstable fractures of the distal radius: a prospective randomised comparison of four methods of treatment. *J Bone Joint Surg Br* 78(3):404–409, 1996.
113. McQueen MM, Michie M, Court-Brown CM: Hand and wrist function after external fixation of unstable distal radial fractures. *Clin Orthop* 285:200–204, 1992.
114. Medoff RJ: Essential radiographic evaluation for distal radius fractures. *Hand Clin* 21:279–288, 2005.
115. Melone CP, Jr: Articular fractures of the distal radius. *Orthop Clin North Am* 15(2):217–236, 1984.
116. Menendez ME, Bot AG, Hageman MG, et al: Computerized adaptive testing of psychological factors: relation to upper-extremity disability. *J Bone Joint Surg Am* 95(20):e149, 2013.
117. Moore AM, Dennison DG: Distal radius fractures and the volar lunate facet fragment: Kirschner wire fixation in addition to volar-locked plating. *Hand (NY)* 9(2): 230–236, 2014.
118. Moritomo H, Omori S: Influence of ulnar translation of the radial shaft in distal radius fracture on distal radioulnar joint instability. *J Wrist Surg* 3(1):18–21, 2014.
119. Nakamura T, Iwamoto T, Matsumura N, et al: Radiographic and arthroscopic assessment of DRUJ instability due to foveal avulsion of the radioulnar ligament in distal radius fractures. *J Wrist Surg* 3(1):12–17, 2014.
120. Neuhaus V, Badri O, Ferree S, et al: Radiographic alignment of unstable distal radius fractures fixed with 1 or 2 rows of screws in volar locking plates. *J Hand Surg [Am]* 38(2):297–301, 2013.
121. Nishiwaki M, Tazaki K, Shimizu H, et al: Prospective study of distal radial fractures treated with an intramedullary nail. *J Bone Joint Surg Am* 93(15):1436–1441, 2011.
122. Noda K, Goto A, Murase T, et al: Interosseous membrane of the forearm: an anatomical study of ligament attachment locations. *J Hand Surg [Am]* 34(3):415–422, 2009.
123. O'Connor D, Mullett H, Doyle M, et al: Minimally displaced Colles' fractures: a prospective randomized trial of treatment with a wrist splint or a plaster cast. *J Hand Surg [Br]* 28(1):50–53, 2003.
124. Orbay JL: Ulnar head and styloid fractures. In Slutsky DJ, editor: *Principles and practice of wrist surgery*, Philadelphia, 2010, WB Saunders, pp 198–204.
125. Orbay JL, Fernandez DL: Volar fixation for dorsally displaced fractures of the distal radius: a preliminary report. *J Hand Surg [Am]* 27(2):205–215, 2002.
126. Orbay JL, Fernandez DL: Volar fixed-angle plate fixation for unstable distal radius fractures in the elderly patient. *J Hand Surg [Am]* 29(1):96–102, 2004.
127. Ozer K, Wolf JM, Watkins B, et al: Comparison of 4 fluoroscopic views for dorsal cortex screw penetration after volar plating of the distal radius. *J Hand Surg [Am]* 37(5):963–967, 2012.
128. Palmer AK, Werner FW: Biomechanics of the distal radioulnar joint. *Clin Orthop* 187:26–35, 1984.
129. Peine R, Rikli DA, Hoffmann R, et al: Comparison of three different plating techniques for the dorsum of the distal radius: A biomechanical study. *J Hand Surg [Am]* 25A(1):29–33, 2000.
130. Rapley JH, Kearny JP, Schrayer A, et al: Ulnar translation, a commonly overlooked, unrecognized deformity of distal radius fractures: techniques to correct the malalignment. *Tech Hand Up Extrem Surg* 12(3):166–169, 2008.
131. Rayhack JM, Langworthy JN, Belsole RJ: Transulnar percutaneous pinning of displaced distal radial fractures: a preliminary report. *J Orthop Trauma* 3(2):107–114, 1989.
132. Rikli DA, Kupfer K, Bodoky A: Long-term results of the external fixation of distal radius fractures. *J Trauma* 44(6):970–976, 1998.
133. Rikli DA, Regazzoni P: Fractures of the distal end of the radius treated by internal fixation and early function. A preliminary report of 20 cases. *J Bone Joint Surg Br* 78(4):588–592, 1996.
134. Ross M, Di ML, Peters S, et al: Defining residual radial translation of distal radius fractures: a potential cause of distal radioulnar joint instability. *J Wrist Surg* 3(1):22–29, 2014.
135. Roth KM, Blazar PE, Earp BE, et al: Incidence of extensor pollicis longus tendon rupture after nondisplaced distal radius fractures. *J Hand Surg [Am]* 37(5):942–947, 2012.
136. Roth KM, Blazar PE, Earp BE, et al: Incidence of displacement after nondisplaced distal radial fractures in adults. *J Bone Joint Surg Am* 95(15):1398–1402, 2013.
137. Rozental TD, Blazar PE, Franko OI, et al: Functional outcomes for unstable distal radial fractures treated with open reduction and internal fixation or closed reduction and percutaneous fixation. A prospective randomized trial. *J Bone Joint Surg Am* 91(8):1837–1846, 2009.
138. Rozental TD, Makhni EC, Day CS, et al: Improving evaluation and treatment for osteoporosis following distal radial fractures. A prospective randomized intervention. *J Bone Joint Surg Am* 90(5):953–961, 2008.
139. Ruch DS, Wray WH, III, Papadonikolakis A, et al: Corrective osteotomy for isolated malunion of the palmar lunate facet in distal radius fractures. *J Hand Surg [Am]* 35(11):1779–1786, 2010.
140. Sammer DM, Shah HM, Shauver MJ, et al: The effect of ulnar styloid fractures on patient-rated outcomes after volar locking plating of distal radius fractures. *J Hand Surg [Am]* 34(9):1595–1602, 2009.
141. Scheck M: Long-term follow-up of treatment of comminuted fractures of the distal end of the radius by transfixation with Kirshner wires and cast. *J Bone Joint Surg* 44A:337–351, 1962.
142. Seitz WH, Jr, Froimson AI, Leb R, et al: Augmented external fixation of unstable distal radius fractures. *J Hand Surg [Am]* 16(6):1010–1016, 1991.
143. Seitz WH, Jr, Putnam MD, Dick HM: Limited open surgical approach for external fixation of distal radius fractures. *J Hand Surg Am* 15A:288–293, 1990.
144. Shauver MJ, Chang KW, Chung KC: Contribution of functional parameters to patient-rated outcomes after surgical treatment of distal radius fractures. *J Hand Surg [Am]* 39(3):436–442, 2014.
145. Shauver MJ, Clapham PJ, Chung KC: An economic analysis of outcomes and complications of treating distal radius fractures in the elderly. *J Hand Surg [Am]* 36(12):1912–1918, 2011.
146. Short WH, Palmer AK, Werner FW, et al: A biomechanical study of distal radial fractures. *J Hand Surg [Am]* 12(4):529–534, 1987.

http://e-surg.com

147. Soong M, Earp BE, Bishop G, et al: Volar locking plate implant prominence and flexor tendon rupture. *J Bone Joint Surg Am* 93(4):328–335, 2011.
148. Souer JS, Ring D, Matschke S, et al: Effect of an unrepaired fracture of the ulnar styloid base on outcome after plate-and-screw fixation of a distal radial fracture. *J Bone Joint Surg Am* 91(4):830–838, 2009.
149. Srinivasan RC, Jain D, Richard MJ, et al: Isolated ulnar shortening osteotomy for the treatment of extra-articular distal radius malunion. *J Hand Surg [Am]* 38(6): 1106–1110, 2013.
150. Stockmans F, Dezillie M, Vanhaecke J: Accuracy of 3D virtual planning of corrective osteotomies of the distal radius. *J Wrist Surg* 2(4):306–314, 2013.
151. Swart E, Nellans K, Rosenwasser M: The effects of pain, supination, and grip strength on patient-rated disability after operatively treated distal radius fractures. *J Hand Surg [Am]* 37(5):957–962, 2012.
152. Taleisnik J, Watson HK: Midcarpal instability caused by malunited fractures of the distal radius. *J Hand Surg [Am]* 9(3):350–357, 1984.
153. Trousdale RT, Amadio PC, Cooney WP, et al: Radio-ulnar dissociation. A review of twenty cases. *J Bone Joint Surg Am* 74(10):1486–1497, 1992.
154. Tumia N, Wardlaw D, Hallett J, et al: Aberdeen Colles' fracture brace as a treatment for Colles' fracture. A multicentre, prospective, randomised, controlled trial. *J Bone Joint Surg Br* 85(1):78–82, 2003.
155. van Kampen RJ, Thoreson AR, Knutson NJ, et al: Comparison of a new intramedullary scaffold to volar plating for treatment of distal radius fractures. *J Orthop Trauma* 27(9):535–541, 2013.
156. van Schoonhoven J, Fernandez DL, Bowers WH, et al: Salvage of failed resection arthroplasties of the distal radioulnar joint using a new ulnar head prosthesis. *J Hand Surg [Am]* 25(3):438–446, 2000.
157. Vidal J, Adrey J, Connes H, et al: A biomechanical study and clinical application of the use of Hoffman's external fixator. In Brooker AF, Edwards CC, editors: *External fixation: current state of the art*, Baltimore, 1979, Williams & Wilkins, pp 327–343.
158. Wada T, Tatebe M, Ozasa Y, et al: Clinical outcomes of corrective osteotomy for distal radial malunion: a review of opening and closing-wedge techniques. *J Bone Joint Surg Am* 93(17):1619–1626, 2011.
159. Wang J, Yang Y, Ma J, et al: Open reduction and internal fixation versus external fixation for unstable distal radial fractures: a meta-analysis. *Orthop Traumatol Surg Res* 99(3):321–331, 2013.
160. Washburn RA, Smith KW, Jette AM, et al: The physical activity scale for the elderly (PASE): development and evaluation. *J Clin Epidemiol* 46(2):153–162, 1993.
161. Watanabe H, Berger RA, Berglund LJ, et al: Contribution of the interosseous membrane to distal radioulnar joint constraint. *J Hand Surg [Am]* 30(6):1164–1171, 2005.
162. Watson HK, Castle TH, Jr: Trapezoidal osteotomy of the distal radius for unacceptable articular angulation after Colles' fracture [see comments]. *J Hand Surg [Am]* 13(6):837–843, 1988.
163. Watson HK, Gabuzda GM: Matched distal ulna resection for posttraumatic disorders of the distal radioulnar joint. *J Hand Surg [Am]* 17(4):724–730, 1992.
164. Watters WC, Sanders JO, Murray J, et al: The American Academy of Orthopaedic Surgeons Appropriate Use Criteria on the treatment of distal radius fractures. *J Bone Joint Surg Am* 96(2):160–161, 2014.
165. Weber SC, Szabo RM: Severely comminuted distal radial fracture as an unsolved problem: complications associated with external fixation and pins and plaster techniques. *J Hand Surg [Am]* 11(2):157–165, 1986.
166. Wijffels M, Ring D: The influence of non-union of the ulnar styloid on pain, wrist function and instability after distal radius fracture. *J Hand Microsurg* 3(1):11–14, 2011.
167. Wilcke MK, Abbaszadegan H, Adolphson PY: Patient-perceived outcome after displaced distal radius fractures. A comparison between radiological parameters, objective physical variables, and the DASH score. *J Hand Ther* 20(4):290–298, 2007.
168. Wilcke MK, Abbaszadegan H, Adolphson PY: Wrist function recovers more rapidly after volar locked plating than after external fixation but the outcomes are similar after 1 year. *Acta Orthop* 82(1):76–81, 2011.
169. Williksen JH, Frihagen F, Hellund JC, et al: Volar locking plates versus external fixation and adjuvant pin fixation in unstable distal radius fractures: a randomized, controlled study. *J Hand Surg [Am]* 38(8):1469–1476, 2013.
170. Wolfe SW, Austin G, Lorenze MD, et al: Comparative stability of external fixation: a biomechanical study. *J Hand Surg [Am]* 24A:516–524, 1999.
171. Wolfe SW, Easterling KE, Yoo H: Arthroscopic-assisted reduction of distal radius fractures. *Arthroscopy* 11(6):706–714, 1995.
172. Wolfe SW, Swigart CR, Grauer J, et al: Augmented external fixation of distal radius fractures: A biomechanical analysis. *J Hand Surg [Am]* 23A(1):127–134, 1998.
173. Wong TC, Chiu Y, Tsang WL, et al: Casting versus percutaneous pinning for extra-articular fractures of the distal radius in an elderly Chinese population: a prospective randomised controlled trial. *J Hand Surg Eur Vol* 35(3):202–208, 2010.
174. Wright TW, Horodyski M, Smith DW: Functional outcome of unstable distal radius fractures: ORIF with a volar fixed-angle tine plate versus external fixation. *J Hand Surg [Am]* 30(2):289–299, 2005.
175. Young BT, Rayan GM: Outcome following nonoperative treatment of displaced distal radius fractures in low-demand patients older than 60 years. *J Hand Surg [Am]* 25(1):19–28, 2000.
176. Young CF, Nanu AM, Checketts RG: Seven-year outcome following Colles' type distal radial fracture. A comparison of two treatment methods. *J Hand Surg [Br]* 28(5):422–426, 2003.
177. Yu YR, Makhni MC, Tabrizi S, et al: Complications of low-profile dorsal versus volar locking plates in the distal radius: a comparative study. *J Hand Surg [Am]* 36(7):1135–1141, 2011.
178. Zollinger PE, Tuinebreijer WE, Breederveld RS, et al: Can vitamin C prevent complex regional pain syndrome in patients with wrist fractures? A randomized, controlled, multicenter dose-response study. *J Bone Joint Surg Am* 89(7):1424–1431, 2007.

http://e-surg.com

16

Fractures of the Carpal Bones

Steve K. Lee

Acknowledgments: I would like to give full acknowledgment to the authors of the previous version of this chapter, Dr. William B. Geissler and the late Dr. Joseph F. Slade. Their chapter was the foundation of the current chapter; I have maintained many of their principles but have updated the chapter with my own thoughts, influenced by prime mentors of mine, Drs. Martin Posner, Scott Wolfe, and Michael Hausman. Dr. Slade was one of my mentors and teachers from residency. Most know of his contributions to hand and upper extremity surgery and his continual willingness to teach and instruct worldwide. His dedication and enthusiasm for hand surgery are legendary and are an inspiration to us all. Thank you also to Dr. Geissler, who continues to be a pioneer in our specialty. Acknowledgments to Dr. Dean G. Sotereanos and Dr. James P. Higgins, who authored two of the Case Studies for this chapter available on ExpertConsult.com. I also wish to acknowledge Zina Model, BA, for editorial assistance.

These videos may be found at *ExpertConsult.com*:
16.1 Arthroscopic fixation scaphoid of nonunion

SCAPHOID FRACTURES AND NONUNION

The treatment of scaphoid fractures requires knowledge of the blood supply, surgical approaches, and effects that fractures and nonunions of the scaphoid have on carpal kinematics, stability, and arthritis.[211] Vigilant care of these fractures can usually lead to a functional result for the patient. However, incorrect fracture healing can potentially lead to a relentless downward spiral of wear and cartilage damage. Chronic pain and dysfunction of the wrist results, which affects both hand function and the entire upper extremity.

Within the past two decades, methods of scaphoid repair have been developed to minimize additional surgical trauma and optimize stabilization until healing. Minimally invasive fixation has been demonstrated to have a higher union rate than cast treatment and has relatively few complications. This approach allows the patient or athlete to return to work or sports within weeks or months, whereas a failed attempt at healing with cast immobilization can result in months of lost time, compounded by the increased complexity, cost, and complications of nonunion repair. This chapter will explore the mechanics, biologic factors, and modern treatment regimens for fractures of the scaphoid and neighboring carpal bones.

General Considerations in Fractures and Nonunion of the Scaphoid

Incidence and Cause of Scaphoid Fractures

The scaphoid bone garners more interest in upper extremity surgery for its weight and size than any other bone because it is the "keystone" of the carpus. In architecture, the keystone is the central stone at the summit of an arch, locking the whole together. Likewise, the scaphoid links the carpus together. Pathologic conditions of the scaphoid can affect the entire wrist.

The scaphoid is not only important but it is the most commonly fractured carpal bone. Scaphoid fractures account for 60% to 70% of all carpal fractures and are second in frequency of wrist fractures only to distal radius fractures. The majority of injuries are low-energy injuries, either from a sporting event (59%) or from a fall onto an outstretched wrist (35%); the remainder result from high-energy trauma such as a fall from a height or a motor vehicle injury. Howe documented that 82% of the scaphoid fractures in Norway occur in males, with an average age of 25 years (range, 11 to 79 years).[100] The age-specific incidence in males remained significantly higher than that in females until age 60 years, at which point the incidences were similar. The annual incidence was 43 per 100,000 people.[2] The statistics were similar in Larsen's series; the mechanism for scaphoid fracture was a fall in 69% of cases and a blow to the wrist in 28% of cases.[126]

More recently, Wolf studied a large U.S. military population and found a greater incidence of scaphoid fracture than the previous data had shown, 121 per 100,000 person-years.[224] Males and the 20- to 24-year-old age group were associated with higher rates of scaphoid injury.[224] The more active nature of the occupations of this population may explain this higher incidence. Van Tassel and colleagues[209a] showed a peak incidence in scaphoid fractures in the second decade, and few after age 50 years (Figure 16.1).

PERTINENT ANATOMY OF THE SCAPHOID

Bony and Ligamentous Anatomy. The shape of the scaphoid bone has been described with several terms: as a boat ("skaphos" in Greek), as a twisted peanut, and as bean shaped. The complex shape of the bone can present challenges to reconstruction and fixation. Approximately 80% of the scaphoid is covered by cartilage, limiting ligamentous attachment and vascular supply (Figure 16.2).[7,17] The scaphoid is divided into three regions: proximal pole, waist, and distal pole (tubercle). The proximal pole articulates with the scaphoid fossa of the distal radius and

http://e-surg.com

the lunate. The scaphoid is oriented in the carpus with an intrascaphoid angle averaging 40 ± 3 degrees in the coronal plane and 32 ± 5 degrees in the sagittal plane.[7,17]

The scaphoid is the only carpal bone that bridges the proximal and distal carpal rows and acts as a tie-rod. The carpal rows are supported by stout intrinsic ligaments and reinforced by a complex system of volar and dorsal extrinsic ligaments (Figure 16.3). The scapholunate interosseous ligament (SLIL) is a stout ligament connecting the scaphoid to the lunate and is the primary stabilizer. The dorsal aspect of this ligament is composed of transverse collagen fibers, whereas the palmar ligament is composed of oblique collagen fibers inserting to the volar capsular ligaments. The dorsal portion is twice as strong as the anterior portion. Only 20 to 30 degrees of motion is possible at an intact scapholunate interval.[2] The dorsal and palmar regions are critical in maintaining normal carpal kinematics and function of the scapholunate interval. The dorsal region resists palmar-dorsal translation and gap, whereas the volar portion resists rotation. The proximal fibrocartilaginous region is the weakest mechanically and is well suited to accept the compression and shear loads at the radiocarpal joint. The radioscaphocapitate (RSC) ligament originates from the volar radial aspect of the radius, crosses the volar concavity of the scaphoid waist, and proceeds ulnarly toward the capitate, acting as a fulcrum around which the scaphoid rotates. The scaphoid can also fracture around this fulcrum at the waist. The scaphocapitate ligament originates from the distal scaphoid at the border between the trapezoid facet and the capitate facet. It inserts into the volar

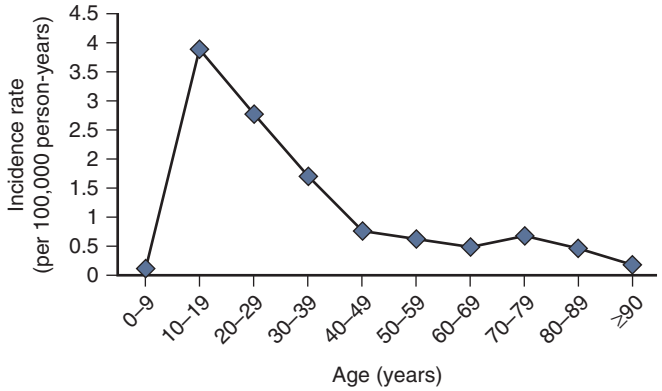

FIGURE 16.1 Incidence of scaphoid fracture by age decade. (See Van Tassel Reprinted, with permission, from Elsevier.)

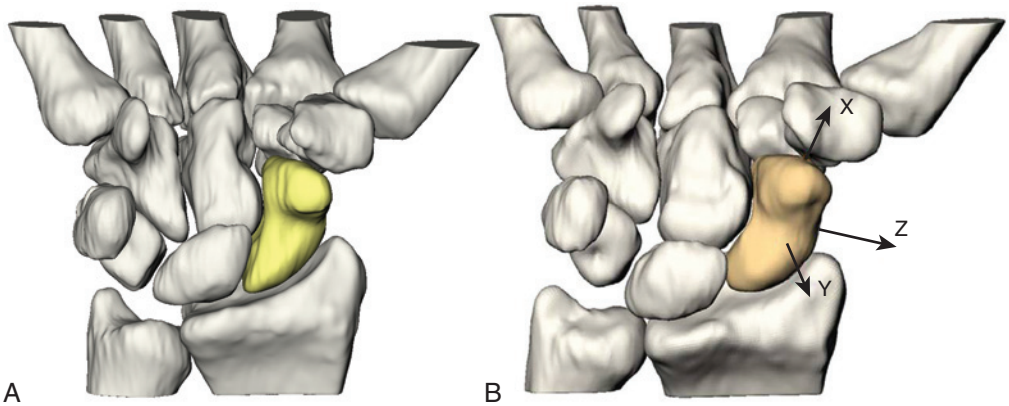

FIGURE 16.2 **A,** A three-dimensional reconstruction of the scaphoid from CT images of 25 normal wrists. Note the scaphoid's position spanning the proximal and distal carpal rows and acting as a "tie-rod" to coordinate smooth carpal motion. **B,** Eighty percent of the normal scaphoid surface is covered by articular cartilage. The scaphoid derives its name from its peculiar boat- or skiff-shaped contour. *X,* rotation (pronation/supination); *Y,* sagittal (flexion/extension); *Z,* coronal (radial/ulnar). (**A,** From Joseph J. Crisco, PhD, Department of Orthopaedics, The Alpert Medical School of Brown University and Rhode Island Hospital.)

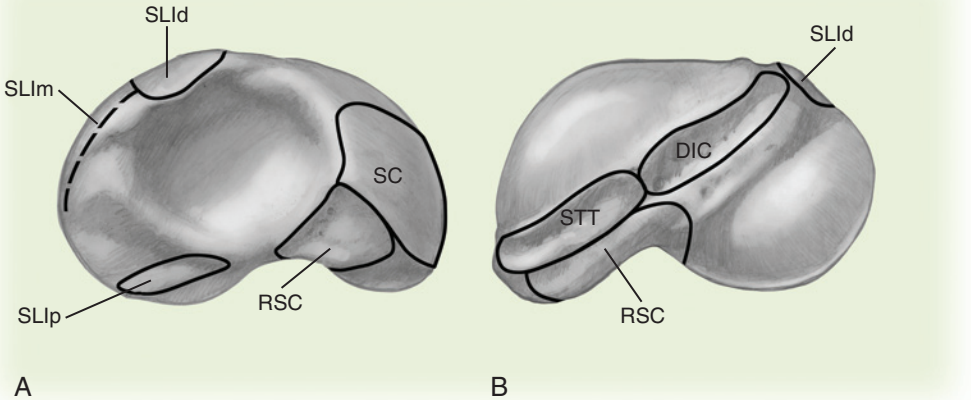

FIGURE 16.3 Ligamentous attachments to the radial and ulnar aspects of the scaphoid. **A,** Medial surface of a right scaphoid demonstrating the attachment zones of the scaphocapitate ligament (*SC*), the radioscaphocapitate ligament (*RSC*), and the dorsal (*SLId*), membranous (*SLIm*), and palmar (*SLIp*) regions of the scapholunate interosseous ligament. **B,** Right scaphoid from a dorsal radial perspective demonstrating the attachment zones of the scaphotrapeziotrapezoidal ligament (*STT*), RSC, dorsal intercarpal ligament (*DIC*), and SLId. (Copyright Elizabeth Martin.)

http://e-surg.com

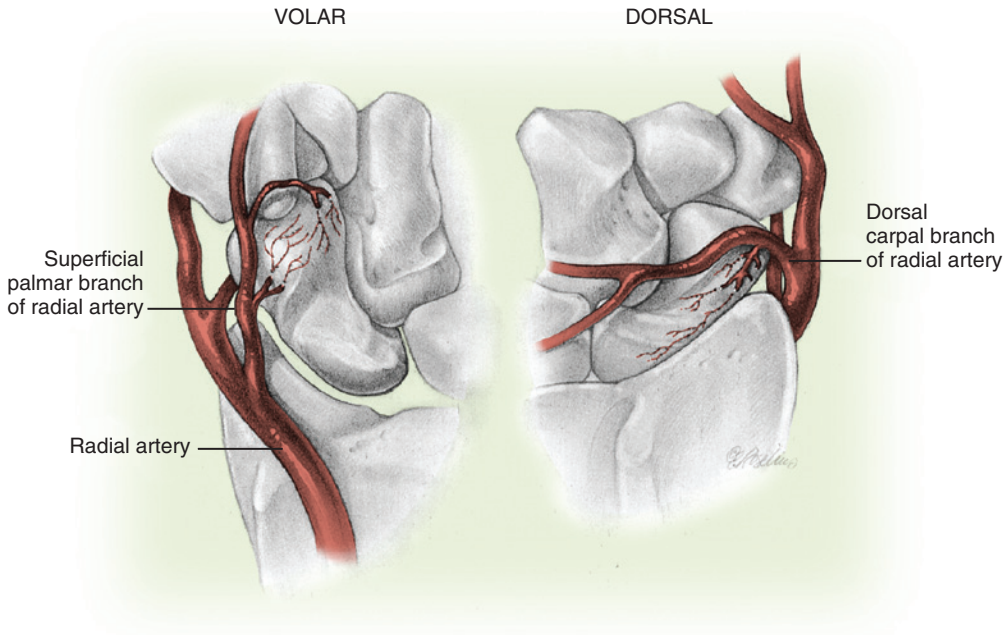

FIGURE 16.4 Schematic representation of the blood supply of the scaphoid. (Copyright Elizabeth Martin.)

waist of the capitate distal to the RSC ligament. This ligament, along with the scaphotrapezial ligament, functions as a primary restraint of the distal pole.

Vascular Anatomy. The blood supply of the scaphoid bone is not robust, because it is predominantly retrograde. The major blood supply to the scaphoid is via the radial artery: Seventy percent to 80% of the intraosseous and proximal pole vascular supply is from branches of the radial artery entering distally through the dorsal ridge of the scaphoid between the proximal and distal articular surfaces. The radial artery or the superficial palmar arch also give volar branches that enter in the region of the tubercle and provide the blood supply to 20% to 30% of the bone in the region of the distal pole (Figure 16.4).[73] The proximal pole also gets blood supply from the radioscapholunate ligament (ligament of Testut, a neurovascular conduit) and directs scapholunate branches from the palmar and dorsal transverse carpal arches.[29] Handley and colleagues found that the venous drainage from the proximal pole of the scaphoid was via the dorsal ridge into the venae comitantes of the radial artery.[86]

The more proximal the fracture, the more likely the bone is to be dysvascular and the higher the risk of nonunion. Proximal pole fractures have been reported to have an incidence of avascular necrosis (AVN) of 13% to 50%.[194] Knowledge of the vascular anatomy has implications for sensible approaches to the scaphoid. Combined palmar and dorsal approaches taking off the soft tissue at the tubercle *and* the dorsal ridge would not be advisable. During the dorsal approach to the scaphoid, the majority of the dorsal ridge tissue and vessels can and should be left intact.

Biomechanics of Scaphoid Fractures and Implications of Nonunion

Although the exact mechanism of fracture is not completely understood, hyperextension past 95 degrees[219] is the usual position of injury, but other mechanisms such as axial loading have also been postulated to produce scaphoid fractures,[99] as has hyperflexion of the wrist. With the hyperextension mechanism, a fracture of the scaphoid usually begins at the volar waist with a tensile failure; the forces propagate to the dorsal surface with compression loading, until failure occurs. In a cadaveric study, wrists placed in extreme dorsiflexion and ulnar deviation produced fractures through the scaphoid waist as the scaphoid impinged on the dorsal rim of the radius. Proximal scaphoid fractures resulted from dorsal subluxation during forced hyperextension. Carpal dislocations and scapholunate ligament tears were reproduced with wrist extension and ulnar deviation, combined with intercarpal supination.[138]

As with any fracture, the potential for healing relies on the fracture's location, vascularity, and stability. Nonunion occurs in 10% to 15% of all scaphoid fractures. The risk of nonunion increases with:

1. Delay of treatment for more than 4 weeks
2. Proximal pole fractures
3. Fracture displacement greater than 1 mm
4. Osteonecrosis
5. Tobacco use
6. Associated carpal instability (DISI = dorsal intercalated segmental instability with a scapholunate angle > 60 degrees and a capitolunate angle > 15 degrees) secondary to humpback (flexed with intrascaphoid angle > 45 degrees; the normal intrascaphoid angle is 24 degrees) scaphoid positioning (Figure 16.5).[40,125,199]

For nondisplaced waist fractures treated with casting, nonunion rates are 5% to 12%.[39] Nonunion rates for displaced scaphoid fractures treated nonoperatively are higher, reaching 50%.[199]

Untreated displaced fractures of the waist are subject to varying degrees of these forces and will usually angulate as the volar bone is reabsorbed, yielding a "humpback" of flexion

http://e-surg.com

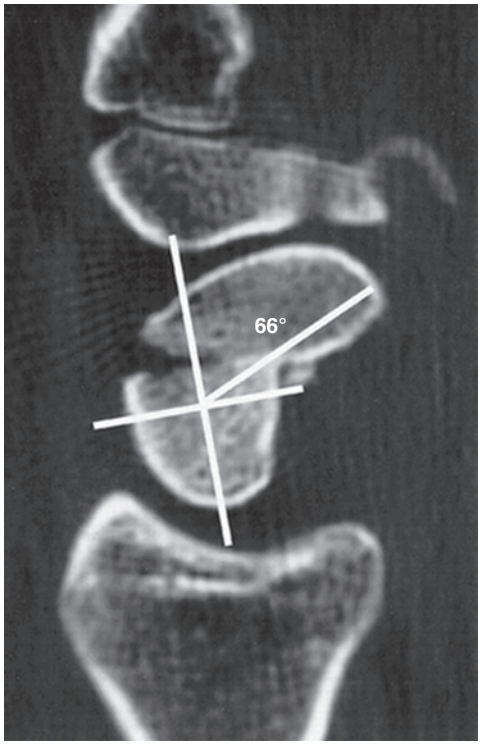

FIGURE 16.5 Example of intrascaphoid angle of 66 degrees. (From Trumble TE, Gilbert M, Murray LW, et al: Displaced scaphoid fractures treated with open reduction and internal fixation with a cannulated screw. *J Bone Joint Surg Am* 82(5):633–641, 2000.)

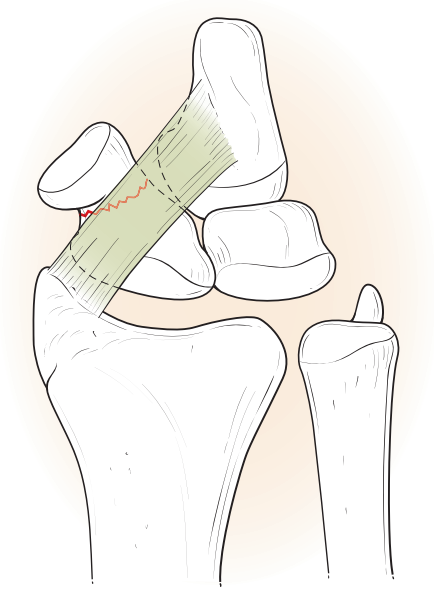

FIGURE 16.6 The radioscaphocapitate ligament crosses the scaphoid waist and acts as a fulcrum over which the scaphoid fractures.

deformity of the scaphoid. Simultaneous extension of the lunate through its attachment to the triquetrum results in a DISI deformity. Ultimate treatment of a humpback scaphoid nonunion with DISI requires both restitution of scaphoid anatomy and reversal of the secondary changes in carpal kinematics.

Untreated scaphoid nonunion will predictably progress to arthritic change, in what has been termed scaphoid nonunion advanced collapse (SNAC).[211] Arthritic change arises at the radial styloid articulation with the distal scaphoid pole and is followed by degeneration of the midcarpal joint and ultimately by pancarpal arthritis. Arthritic changes have been found in 97% of the patients assessed at least 5 years after injury, with the degree of arthritic changes being proportionate to the duration of nonunion.[133] Patients generally present with escalating mechanical pain, with limitations in range of motion. Duppe[55] reviewed 30-year follow-up results of scaphoid fractures treated with thumb spica short-arm casts. Ten percent of the patients developed nonunion; 60% of these demonstrated radiographic evidence of radiocarpal osteoarthrosis, while only 2% of the healed group demonstrated degenerative change.

Examination and Imaging of the Scaphoid

Clinical Presentation

The patient usually presents with pain on the radial side of the wrist. There may be swelling on the radial side, as well. There is usually a history of trauma, such as falling on an outstretched hand, collision of the wrist against a person or heavy obstacle, or possibly a direct blow against an object. There may be limited range of motion and pain when applying extended wrist loading or positioning the wrist in extreme positions of flexion or extension.

Physical Examination

Physical examination starts with visual inspection. Wrists with acute fractures may have swelling and bruising in the radial aspect of the wrist. There may be limited range of motion. Wrists with chronic injury may have swelling in the dorsoradial wrist. "Snuffbox tenderness" has become synonymous with scaphoid fracture, but this applies predominantly to waist fractures, which represent 70% of scaphoid fractures. The second most common type of scaphoid fracture is proximal pole fracture, at 20%. The least common is distal pole fracture, at 10%.[122] Fractures tend to occur at the waist partly because the RSC ligament acts as a fulcrum over which the scaphoid waist fractures (Figure 16.6).[35]

The full physical examination of the scaphoid bone should include all of its parts: the waist, distal pole, and proximal pole. To palpate the anatomic snuffbox for the waist examination, palpate just distal to the radial styloid in the "soft spot." The distal pole should be palpated at the scaphoid tubercle on the palmar aspect of the wrist. To do this, place the index finger in the anatomic snuffbox and place the thumb on the palmar aspect just distal to the anatomic snuffbox. The prominent bone palpated is the distal pole of the scaphoid. With radial deviation of the wrist, this prominence should move palmarly toward the examiner's thumb. This distal pole should be checked for tenderness. The proximal pole is palpated dorsally in line with the second ray just distal to the dorsal radius lip. The scapholunate ligament is in line between the second and third rays just distal to the dorsal radius lip and corresponds to the 3-4 wrist arthroscopy portal. The proximal pole is just radial to this scapholunate ligament/3-4 portal area. In diagnosing scaphoid fracture, physical examination is sensitive but its specificity is low, ranging from 74% to 80%.[82,158]

http://e-surg.com

Diagnostic Imaging of Scaphoid Fractures and Nonunion

Computed Tomography. Computed tomography (CT) scanning helps elucidate scaphoid fracture displacement, bony morphologic findings, gapping, sclerosis, cysts, and evidence of healing. CT is particularly helpful in addressing nonunions. It is important that CT scans are taken with overlapping 1-mm cuts along the long axis of the scaphoid and with coronal and sagittal reconstructions. CT scans have particular utility in evaluating for healing after scaphoid surgery, especially because radiographs are often indeterminate.[94] CT scanning has also demonstrated some utility in evaluating the vascularity of the proximal pole of the scaphoid. Increased radiodensity of the proximal pole is a sign of dysvascularity.[186]

Magnetic Resonance Imaging. Magnetic resonance imaging (MRI) is best to determine whether there is occult scaphoid fracture. Specificity is 90% and sensitivity is between 90% and 100%,[164] as opposed to bone scintigraphy, which is 92% to 95% sensitive and 60% to 95% specific.[16]

Use of MRI to assess bony vascularity is controversial. Some authors advocate its use,[8] whereas others present cogent arguments questioning its efficacy and utility.[84,149,223] MRI findings of hypointense areas of bone on both T1-weighted and T2-weighted sequences have been suggested to be correlated with AVN.[8] However, subsequent studies have shown poor correlation,[54] and almost no data exist correlating MRI findings with operative or nonoperative healing rates.

In a study of 88 patients for which imaging results were compared with findings of intraoperative bleeding, Schmitt and colleagues[176] concluded that viability of the proximal fragment in scaphoid nonunion can be significantly better assessed with contrast-enhanced MRI than with nonenhanced MRI. Contrast-enhanced MRI has demonstrated significantly improved sensitivity (77% vs. 6%; $p < .001$) in detecting scaphoid AVN compared with nonenhanced MRI. However, this study suggests that, even with contrast enhancement, MRI might fail to detect proximal pole AVN in nearly a quarter of cases. This might be due to ingrowth of nonspecific inflammatory tissue into the proximal pole from the nonunion site, resulting in contrast enhancement despite the necrotic bone. Additional techniques for improving the sensitivity of MRI, such as dynamic gadolinium enhancement, are being developed and investigated,[153] but they are still currently inferior to standard gadolinium-enhanced MRI.[54] Therefore, MRI with or without contrast enhancement might be helpful in assessing the vascularity of the bone, but the entire picture must be taken into account using the patient history and CT imaging. Even though MRI with gadolinium was thought to have a better correlation with intraoperative scaphoid bleeding assessment,[33] MRI with gadolinium still could not predict fracture healing in a paper by Dawson and colleagues.[44]

One of the strongest arguments against MRI was presented by Willems and colleagues,[223] who studied vascularized bone grafting in a canine carpal AVN model. AVN was induced in carpal bones by excising bones, deep freezing, and coating in cyanoacrylate and then reimplanting them. A vascularized bone graft from the radius was implanted in the avascular carpal bone. The contralateral side served as an untreated ischemic control. Bone blood flow, bone volume, radiography, histomorphometry, histology, and MRI were analyzed at 4 weeks. T1 and T2 signals on MRI did not correlate with quantitative bone blood flow measurements. Necrotic bones with no blood flow had normal T1 and T2 signals, whereas revascularized bones had signal changes when compared with adjacent carpal bones. A major point of this work is that MRI did not necessarily correlate with known blood flow to the carpal bone in an animal model.[84]

Controversy about MRI is complicated by differences in techniques and image quality, which depend on programming of the image acquisition parameters and reading of the images and on the MRI machines, magnet power, and specialized wrist coils used; all of these factors influence the quality of information presented.

Preferred Modes of Diagnostic Imaging. I prefer to take five radiographic views for the assessment of scaphoid fractures: wrist posteroanterior (PA), lateral, and oblique views; scaphoid view; and clenched pencil view.[128] It is important to take a true scaphoid pisiform capitate (SPC) lateral radiograph of the wrist, wherein the palmar cortex of the pisiform bone overlays the interval between the palmar cortex of the distal scaphoid pole and the palmar cortex of the capitate. This allows true assessment of the carpal alignment.

A predictable scaphoid view is taken where a fist is made, with the thumb covering the dorsum of the middle phalanges of the index and middle fingers. The pronated forearm and hand are placed on the radiography table. The wrist is placed in ulnar deviation (Figure 16.7). The rationale behind this position is to take the scaphoid out of its usual position of flexion and pronation. With the thumb in the above position, the wrist is extended and supinated slightly. Ulnar deviation and wrist extension extend the proximal carpal row. This view allows a full view of the scaphoid bone with minimal overlap from neighboring bones.

A clenched pencil view is also taken.[127,128] This is the best view to assess associated dynamic scapholunate widening[128] (Figure 16.8, *A* and *B*) and in my experience also shows SNAC and SLAC (scapholunate advanced collapse) wrist changes better than standard PA views.

For better detail of bony anatomy, especially in patients with small proximal poles, comminution, or nonunion, I obtain a CT scan without contrast at 1-mm cuts, along the long axis of the scaphoid with coronal and sagittal reconstructions. If the status of the cartilage is in question, I obtain an MRI without contrast with cartilage-sensitive sequencing.

Scaphoid healing cannot be reliably determined by standard radiographs at 3 months;[49] consequently, CT provides enhanced resolution and definitive information regarding healing. Most acutely treated scaphoid fractures require approximately 10 to 12 weeks to heal. I obtain a CT scan at 3 months to determine healing and before allowing full return to heavy occupational demands, sports, or recreational pursuits.

Scaphoid Fracture Classification and Implications for Treatment

Scaphoid fractures have been classified by fracture location (proximal, waist, or distal), plane (transverse or oblique), and stability (stable or unstable). The goal of a fracture classification is to guide management of injuries, in order to enable rapid healing with minimal complications and allow return to activities of daily living, work, and sports or hobbies. The consequences of failed healing include wrist pain, loss of wrist

http://e-surg.com



FIGURE 16.7 Scaphoid view. The subject makes a fist and places the forearm and fist pronated palm side down with the wrist in ulnar deviation. (Courtesy of Steve K. Lee, MD.)

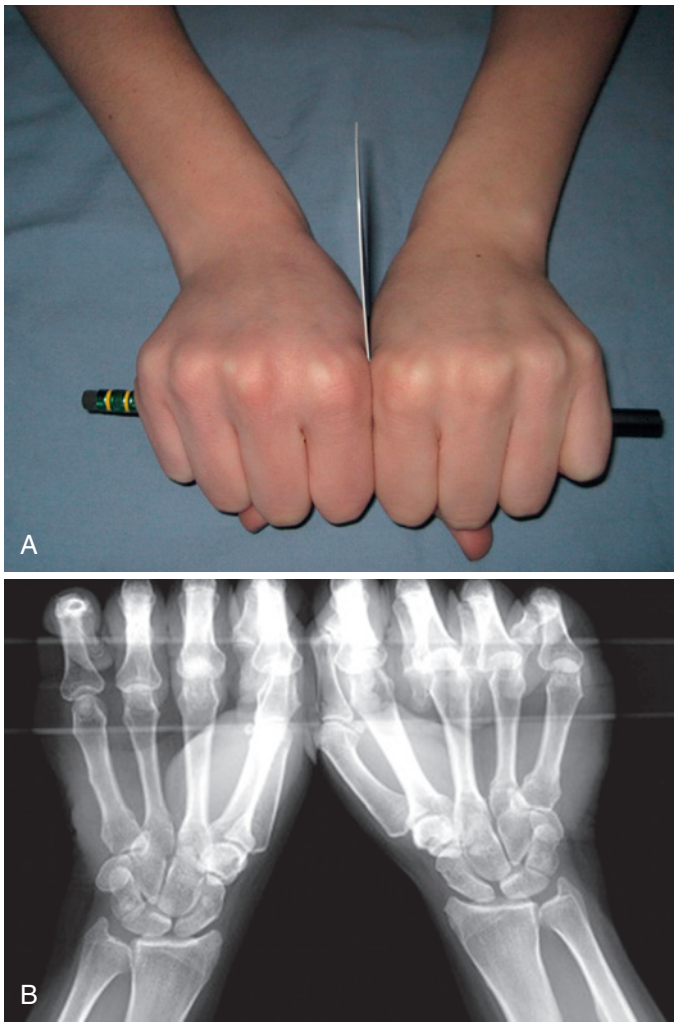

FIGURE 16.8 Clenched pencil views. **A,** The subject gently presses a card between the first dorsal interosseous muscles while gripping a pencil. **B,** Posteroanterior radiograph showing asymmetric scapholunate widening. (**A** and **B,** From Lee SK, Desai H, Silver B, et al: Comparison of radiographic stress views for scapholunate dynamic instability in a cadaver model. *J Hand Surg [Am]* 36:1149–1157, 2011.)

motion, loss of grip strength, loss of productivity, and premature articular degeneration. Of particular importance is identifying which scaphoid fractures require surgical intervention to heal. A failure to identify an unstable scaphoid fracture and treat it accordingly will predictably result in 6 months or more of additional treatment and restricted activities.

One of the earliest efforts to identify unstable fractures was to examine the scaphoid fracture plane. Russe recognized that oblique fractures were unstable and difficult to control with immobilization and that they resulted in an increased rate of nonunion.[172] Herbert and Fisher classified scaphoid fractures according to their stability.[91] Stable fractures, classified as type A, included incomplete fractures or fractures of the scaphoid tubercle. The authors stated that these fractures could be safely treated with immobilization with expectation of a high rate of union. All other fractures were considered potentially unstable and merited rigid fixation, a point of some controversy. Despite the assertions of these authors, however, Desai and colleagues were unable to predict fracture union with closed treatment using either the Russe or the Herbert classification system.[46]

Cooney and colleagues attempted to further define unstable injuries.[39] These included fractures with more than 1 mm of displacement, a lateral intrascaphoid angle of more than 35 degrees, bone loss or comminution, perilunate fracture-dislocation, DISI alignment, and proximal pole fractures. He advocated open surgical fixation for all unstable injuries.

Preferred Method of Classification

I prefer to use a classification method that mimics actual cases that present to the surgeon. It borrows from some elements of the Herbert and Fisher classification and from Cooney's definition of an unstable injury. It also includes a classification of scaphoid nonunions.

Stable Acute Fractures
- Distal pole fracture, nondisplaced
- Incomplete fracture through waist
- Negative radiographs, positive MRI

Unstable Acute Fractures
- Waist fracture, visible on radiographs
- Proximal pole fracture
- Displaced fracture
- (displacement is defined as DISI malalignment of 1 mm [DISI = dorsal intercalated instability with scapholunate angle > 60 degrees and capitolunate angle >15 degrees])
- Scaphoid fracture as part of perilunate fracture-dislocation

Nonunion
- Nonunion of waist fracture, no arthritis, acceptable alignment, stable
- Nonunion of waist fracture, no to minimal (only SNAC I) arthritis, humpback deformity
- Nonunion of proximal pole fracture, no arthritis
- Nonunion of waist fracture, arthritis, SNAC II to III, nonreconstructable, distal pole grossly deformed
- Nonunion of proximal pole fracture, no arthritis, not salvageable (proximal pole <5 mm)

For completeness, two other classification schemes of scaphoid nonunion are shown in Tables 16.1 and 16.2.

http://e-surg.com

TABLE 16.1 Slade and Geissler Classification of Scaphoid Fracture Nonunion

Type	Description
Type 1	Delayed presentation for 4 to 12 weeks
Type 2	Fibrous union, minimal fracture line
Type 3	Minimal sclerosis of less than 1 mm
Type 4	Cystic formation of 1 to 5 mm
Type 5	Humpback deformity with cystic change of more than 5 mm
Type 6	Wrist arthrosis

From Geissler WB: Arthroscopic management of scaphoid fractures in athletes. *Hand Clin* 25(3):359–369, 2009.

TABLE 16.2 Alnot Classification of Scaphoid Fracture Nonunion

Grade	Description
I	Linear nonunion without altered scaphoid form, instability, or intracarpal malalignment
IIA	Stable nonunion with incipient bone resorption at fracture line, without instability or malalignment
IIB	More or less mobile nonunion with anterior defect and proximal pole flexion on distal tubercle inducing DISI
III	More or less mobile displacement nonunion with instability or reducible malalignment with IIIA: isolated styloscaphoid arthritis IIIB: radial and/or intracarpal arthritis
IV	Proximal fragment necrosis with IVA: malalignment IVB: radioscaphoid and/or intracarpal arthritis

DISI, Dorsal intercalated segmental instability.
From Gras M, Mathoulin C: Vascularized bone graft pedicled on the volar carpal artery from the volar distal radius as primary procedure for scaphoid non-union. *Orthop Traumatol Surg Res* 97(8):800–806, 2011.

Management of Scaphoid Fractures

Up to 25% of scaphoid fractures are not visible on initial radiographs (see Preferred Modes of Diagnostic Imaging, above). Unless the x-ray beam lies in the same plane as the fracture, the fracture line may be missed. Because failure to treat a stable scaphoid fracture within 4 weeks increases the nonunion rate, all clinically suspected scaphoid fractures are treated as fractures with short-arm thumb spica cast immobilization until the cause of the symptoms is clarified (Table 16.3). Follow-up radiographs and clinical examination without the cast are performed at 10 to 14 days. If a fracture is clinically suspected in the presence of negative follow-up radiographs, we prefer MRI. At our institution, MRI is the most reliable imaging modality for the diagnosis of acute and occult fractures and is generally diagnostic within 24 hours of injury.

The obvious goal is to attain healing of the scaphoid fracture in an anatomic position while maintaining carpal alignment. Patients with union have better functional results.[40,109,165,192] Table 16.3 summarizes treatment options.

TABLE 16.3 Algorithm for Acute Scaphoid Fracture Management

Type of Fracture	Treatment
Stable Fractures, Nondisplaced (Obtain CT Scan to Ensure the Fracture Is Completely Nondisplaced, Especially on Sagittal View)	
Tubercle fracture	Short-arm cast for 6 to 8 weeks
Distal third fracture or incomplete fracture	Short-arm cast for 6 to 8 weeks
Waist fracture	Short-arm thumb spica cast until healed, especially for pediatric patients and sedentary or low-demand patients, preference for nonoperative treatment Mini-open internal fixation (APM: dorsal approach), especially for active, young, manual worker, athlete, or worker in high-demand occupation, preference for early range of motion
Proximal pole fracture, nondisplaced	Mini-open internal fixation, dorsal approach
Unstable Fractures	
Displacement of more than 1 mm Lateral intrascaphoid angle of more than 35 degrees Bone loss or comminution Perilunate fracture-dislocation Dorsal intercalated segmental instability alignment (DISI = dorsal intercalated instability with scapholunate angle > 60 degrees and capitolunate angle > 15 degrees)	Mini-open internal fixation (APM: dorsal approach)

APM, Author's preferred method.

Stable Acute Fractures

Distal Pole Fractures. Distal pole and tubercle fractures of the scaphoid are generally treated nonoperatively. The distal pole of the scaphoid is well vascularized, and distal scaphoid pole fractures have a high rate of union after 6 to 8 weeks of plaster immobilization in a short-arm cast. The two predominant distal fracture types treated in plaster immobilization are (1) avulsion fractures from the radiopalmar lip of the scaphoid tuberosity and (2) impaction fractures of the radial half of the distal scaphoid articular surface. However, malunion of impacted radial-sided compression fractures may result in symptomatic degenerative arthritis. When in doubt, CT can delineate the articular surface, and operative fixation can be implemented if deemed necessary to try to reduce the risk of late degenerative arthritis of the scaphotrapezial joint.

Incomplete Fracture Through the Waist, Negative Radiographs, Positive MRI Studies. Incomplete fractures through the waist and injuries that have negative radiographs but positive MRI views for signal change probably need even less strict immobilization. Depending on the patient, a short-arm thumb spica cast or, in particularly compliant patients, a thumb spica splint has been used. Other authors recommend internal percutaneous fixation for these fractures (see the following).

http://e-surg.com

Unstable Acute Fractures

Waist Fracture, "Nondisplaced." Even if a scaphoid fracture is visible but is "nondisplaced" on radiographs, it is arguably displaced and may be seen as a flexion deformity in the sagittal plane via CT scan. Therefore, an argument can be made for fixing all scaphoid fractures where a fracture line is seen on plain radiographs. In addition, there is evidence that fixing nondisplaced fractures allows for faster healing and earlier return to work. Bond and colleagues demonstrated that in a prospective study of 25 patients randomized to cast or screw treatment, union rates (time to healing) were significantly faster for the group who had surgery (7 vs. 12 weeks) and the return to work time was also significantly faster for this group (8 vs. 15 weeks).[23]

The choice of operative or nonoperative treatment must be individualized based on the discussion of pros and cons of treatment with the patient. If a cast is chosen, there are controversies about what type of cast to use. There is no agreement in the literature as to the optimum position of immobilization (extension, ulnar deviation, neutral) or type of cast (thumb spica, interphalangeal [IP] free, IP included, long arm, short arm), suggesting that many waist fractures can be treated in a variety of positions and casts.

Controversies include short-arm versus long-arm casting and whether to include the thumb. In a prospective, randomized trial of long-arm versus short-arm thumb spica casting, there was significantly faster healing with long-arm casting (9.5 vs. 12.7 weeks). The nonunion rate was not different, with numbers tested at 0 with long-arm casting and 2 with short-arm casting. The authors recommended long-arm thumb spica casting for the first 6 weeks, followed by short-arm casting until healing.[75] Immobilization of the elbow produced no long-term disability. Displaced fractures were excluded from this study, and the minimum follow-up was 6 months. This carefully conducted study is probably the best evidence in favor of the long-arm cast for the initial immobilization period.

In a cadaveric study, there was motion of 1 to 4 mm in simulated scaphoid fractures treated with a short-arm thumb spica cast. Therefore, the authors recommended a long-arm thumb spica cast.[116] Other indirect evidence that short-arm cast immobilization with the thumb free is inadequate is that in a series by Dias and colleagues; with this method of immobilization, 23% did not unite at 12 weeks.[50]

In the most recent literature, Symes and Stothard[198] performed a systematic review of cast versus surgery for acute scaphoid fractures. The rate of nonunion was three times less for surgery, and recovery was quicker. However, there were more complications with surgery. In the end, there was no difference in pain, cost, functional outcome, or patient satisfaction, though the secondary costs and morbidity of nonunion treatment were not taken into account. In two trials that compared long-arm casts versus short-arm casts and thumb spica casts versus short-arm cast, there was no difference in outcome.[198] Alshryda and associates performed a metaanalysis of 13 level I studies (randomized controlled trial [RCT]) and concluded that for closed treatment there is no difference between short-arm and long-arm casting or between thumb spica and short-arm casting. Union rates are the same for surgical and nonoperative treatment for undisplaced fractures. Surgery is recommended for displaced fractures.[6]

Taking all the above factors into account, I obtain a CT scan to ensure that a "nondisplaced" fracture on a radiograph is truly nondisplaced. I not uncommonly see fractures that seem to be nondisplaced on radiographs but are shown as displaced on CT scans, especially on sagittal views where the fracture is flexed at the waist. If the fracture is truly nondisplaced, I discuss with the patient the pros and cons of operative and nonoperative care. If the patient opts for nonoperative care, I prefer to treat with short-arm thumb spica casting until the fracture is healed. If healing has not occurred by 3 months and/or there are no longer interval changes, I consider operative intervention. If the fracture is displaced on CT scanning, I recommend operative intervention.

Proximal Pole Fracture. Proximal pole nonunion may be attributed to impaired vascularity or instability of the proximal fragment. Proximal pole fractures are considered unstable, whether or not they are displaced, because of their small size, their tenuous blood supply, their interarticular location, and the relatively large moment arms across the fracture site. Rettig and Raskin reported 100% healing of 17 proximal pole fractures treated acutely with operative screw fixation through a dorsal approach.[167] There is consensus that proximal pole fractures cannot be reliably treated nonoperatively. Consequently, I believe that any proximal pole fracture, whether nondisplaced or displaced, should be fixed operatively. The nonunion rate is higher for proximal pole fractures if treated closed. Because of the position of the fracture in that the proximal pole is dorsal, proximal pole fractures are best fixed from the dorsal approach.

Mechanics of Fracture Fixation

Bone healing requires viable bone cells, an adequate blood supply, and stabilization of the fracture site. For a fixation device to be successful in providing rigid fixation of scaphoid fractures, it must be able to resist complex bending, shearing, and translational forces during normal functional loading. Because the majority of the scaphoid is covered with cartilage, fracture callus is not produced, so primary bone healing is entirely dependent on rigid stabilization of the fracture fragments until healing.

The mechanical effectiveness of internal fixation is determined by the bone quality, fracture geometry, fracture reduction, choice of implant, and implant placement. While all five of these independent variables are important, bone quality and fracture geometry are intrinsic to the patient. Fracture reduction, choice of implant, and implant placement are all under the surgeon's control. Fracture reduction and placement of the implant in the biomechanically ideal position are the most important of the five variables. Trumble and colleagues observed that screws placed in the central third of the scaphoid were associated with significantly shorter healing times than screws placed outside of the central third axis ($p < .05$).[205] To explain this observation, McAdams and colleagues simulated scaphoid waist fractures and compared screws placed in the central axis with screws placed eccentrically.[140] This study demonstrated that screws centrally placed in the proximal fragment of the scaphoid had superior results compared with screws placed in an eccentric position. Fixation with central placement of the screw demonstrated 43% greater stiffness, 113% greater load at 2 mm of displacement, and 39% greater load at failure.[140]

http://e-surg.com

Biomechanically, the longer the screw, the more rigid the fixation, because longer screws reduce forces at the fracture site and bending forces are spread along the screws.[51] In a cadaveric study by Slade and colleagues, short or long screws were placed along the central scaphoid axis after an osteotomy was simulated at the waist.[51] Scaphoids that were repaired with longer screws were significantly stiffer than those repaired with short screws. When rigid fixation cannot be provided by a central screw placement alone (as in extreme proximal pole fractures and nonunions), augmentation may be necessary to prevent micromotion at the fracture site. Supplemental fixation can be applied from the distal scaphoid to the capitate using a 0.045-inch or 0.062-inch Kirschner wire or a mini–headless screw. If a Kirschner wire is placed, it should be buried, because it usually has to stay in place for 3 months until the bone is healed.

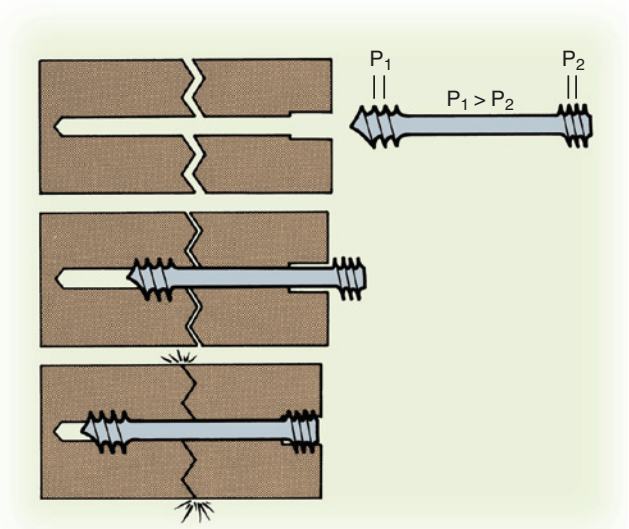

FIGURE 16.9 The difference in pitch between the leading thread (P_1) and the trailing thread (P_2) of the Herbert screw governs the rate of "take-up," or drawing together, of the two bone fragments to produce compression. (Redrawn, by Elizabeth Martin, from Herbert TJ, Fisher WE: Management of the fractured scaphoid using a new bone screw. *J Bone Joint Surg Br* 66:114–123, 1984.)

Techniques for Rigid Fixation

Implants for Rigid Fixation of Scaphoid Fractures

Implants used included Kirschner wires, AO compression screws, headless compression screws, plates, and bioabsorbable implants. Solid and cannulated screws are available from several manufacturers. Any implant used must reduce bending, shearing, and translational forces acting at a fracture site.

Kirschner Wires

Although Kirschner wires are easy to insert, they have a narrow role for scaphoid fixation today, given the relatively insecure fixation and minimal compression afforded by these implants.[35] Kirschner wire fixation must be supplemented with a cast until healing, and a separate procedure for Kirschner wire removal is required. In multitrauma situations or open fractures, rapid stabilization of an unstable scaphoid fracture may be expedient.

Screws

In 1954, McLaughlin described fractures of the scaphoid as "an unsolved problem."[143] His main interest was returning a "breadwinner" to work with a treatment that would "hold bone fragments in apposition" until healing. He reported on the fixation of scaphoid fractures using solid lag screws. The operative procedure was technically challenging, the optimal screw position was not always achieved, and the incidence of nonunion in unstable fractures was not substantially reduced over that obtained by casting alone.

Herbert and Fisher in 1984 presented the results of the first headless screw used to treat 158 patients from 1977 to 1981. The rate of union was 100% for acute fractures and 83% overall.[91] This screw revolutionized bone fixation because it permitted compression of a fracture with two heads of differential pitches (Figure 16.9). The embedded threaded heads of headless screws are placed in the densest bone of both poles for maximum bony purchase. This paper also demonstrated that screws placed perpendicular to an acute fracture plane using compression and rigid fixation could successfully heal an acute fracture. The implant, however, is not technically easy to insert, and other centers reported lower rates of union with screw fixation of acute scaphoid fractures secondary to technical problems.[1]

The next major development in headless screw design was the cannulated compression screw. This device greatly simplified accurate placement of the screw within the scaphoid bone by using a thin guidewire placed under fluoroscopic control. A fully threaded, variable-pitch implant, the Acutrak screw (AcuMed, Hillsboro, OR), demonstrated compression comparable to that of a standard 4-mm compression screw and greater compression when compared with the Herbert screw in biomechanical testing.[222] Several manufacturers have developed cannulated compression screws with unique advantages and disadvantages. There have been a number of recent biomechanical studies comparing headless compression screws.[13,81,83,88,159] Most second-generation headless compression screws achieve adequate compression, the compression decreases by 50% 12 hours after placement, and the compression does not necessarily correlate with the feel of torque on the screwdriver.

What is unknown is how much compression is necessary for bone healing. Few clinical studies exist with which to compare implants, and which screw to use is still largely a matter of surgeon preference.

Other Implants. Bailey reported on the mechanics of a bioresorbable cannulated screw composed of poly-L-lactic acid and hydroxyapatite that was developed for small bone fracture fixation.[14] The bioresorbable screw has been shown to have good compressive properties compared with commonly used small bone fragment compression screws, but no clinical data have been presented.

Staple Fixation. The use of staples has had its proponents as a means of achieving stable fixation. Early studies demonstrated simple application and satisfactory healing rates among patients with scaphoid nonunions and acute fractures but long-term degenerative changes secondary to hardware impingement.[120] New staples with memory achieve compression after insertion as they warm to body temperature. These staples might be indicated for fractures or nonunions requiring open reduction through a palmar approach, and clinical data are lacking at this time.

http://e-surg.com

Plate Fixation. Plate fixation has also been used to stabilize scaphoid fractures.[27] Huene and Huene reported their experience in 1991.[101] The Ender blade plate is suitable for adding stability in scaphoid nonunions with AVN, cystic degeneration, and osseous size discrepancy or compromise. Plate fixation can be used with scaphoid nonunion humpback deformity. Dodds and colleagues presented a combination of volar buttress plating and a vascularized volar distal radius wedge autograft pedicled on the volar carpal artery for salvage treatment of chronic scaphoid nonunion.[52] Ghoneim reported on healing of 13 of 14 scaphoid nonunions with an iliac crest wedge graft and a volar miniplate of 1.5 or 2 mm.[77]

Surgical Treatment Methods

❖ AUTHOR'S PREFERRED TREATMENT METHOD: Dorsal Approach (Figure 16.10)

Scaphoid Open Reduction and Internal Fixation From the Dorsal Approach/Mini-Open Approach. The tourniquet is placed proximally on the arm and draped to allow full motion of the extremity. A small (≈2-3 cm) longitudinal or transverse incision should be made over the proximal pole at the position of the scapholunate ligament. A miniincision is safer than the purely percutaneous method when approaching from the dorsal wrist.



FIGURE 16.10 Acute scaphoid fracture at waist showing open reduction and internal fixation with a dorsally placed headless compression screw. Preoperative radiograph of scaphoid **(A)** and preoperative lateral radiograph **(B)** of wrist. **C,** Preoperative sagittal magnetic resonance imaging of wrist. **D,** Dorsal incision for drilling and screw placement. **E,** Measuring screw length. **F,** Countersinking to avoid hoop stresses. **G,** Screw placement. **H,** Intraoperative fluoroscopic view of scaphoid showing optimal screw position. **I,** Intraoperative fluoroscopic oblique view of wrist. **J,** Intraoperative fluoroscopic lateral view of wrist.

http://e-surg.com

Weinberg and colleagues have shown that there is a 13% chance of tendon injury with a purely percutaneous technique.[220]

The incision is just radial to the area that corresponds with the 3-4 arthroscopic portal. This area is also in line between the second and third metacarpal interspaces, and just distal to the dorsal lip of the radius. The extensor pollicis longus (EPL) is carefully identified and the second and third dorsal compartment tendons are retracted radially. For the mini-open approach, the capsule is opened with a mini inverted-"T" incision. If more exposure is necessary, a ligament-sparing approach can be used[18] (see Chapter 13).

Extreme care is taken to avoid disruption of the dorsal fibers of the SLIL when reflecting the capsular flap. Dissection in a plane tangential to the dorsal surfaces of the scaphoid and the lunate can be performed with a scalpel or Beaver blade. The distal boundaries of dissection of the scaphoid are determined by the vascular supply along the dorsal ridge. Care is taken not to disrupt the blood vessels entering the waist of the scaphoid. Retractors are placed deeper to retract the capsule. If the scaphoid is displaced, the hematoma should be evacuated and the scaphoid reduced, possibly with the aid of smooth Kirschner-wire joysticks, if necessary. The wrist is flexed and the entrance point on the scaphoid is identified 1 to 2 mm radial to the membranous portion of the scapholunate ligament and in the midportion of the scaphoid in the sagittal plane. The guidewire for the headless compression screw is started there; the surgeon should aim the wire for the articular base of the thumb metacarpal (because the scaphoid distal pole, trapezium, and metacarpal base are collinear). Once this wire is placed, the surgeon must not extend the wrist, because this will bend the wire at the radiocarpal joint and not allow overdrilling and screw placement. Fluoroscopic images are taken to assess the fracture and wire position. Posteroanterior (PA), lateral, and oblique images are taken. It is important to take several oblique views to ensure that there is no screw penetration out of the scaphoid in any view. In order to obtain the PA images while keeping the wrist flexed, it is imperative to flex the elbow. A center-center position of the guidewire in all views (PA, lateral, and oblique) should be obtained. Although a screw that is shorter and perpendicular to the fracture is as effective as a long-axis screw,[58] I generally prefer a screw in the most central portion of the bone. In a retrospective review of 34 patients, time to union is shorter when the screw is placed in the central third.[205]

Once the wire position is determined to be optimal, the wire is advanced to the subchondral bone on the distal end of the scaphoid bone. This distance is then measured. The appropriate screw length is shorter than this distance by at least 4 mm; I often use a screw even shorter than this. For an adult man, 20 mm is often an appropriate length. The screw should be relatively long but should *definitely* not be too long. If the screw is too long, it can distract the fracture if it hits the unyielding distal subchondral bone or protrude out of the bone distally or proximally. Once this length is determined, the guidewire is driven into the trapezium bone and out of the thenar skin, so that wire retrieval can be easily accomplished should the wire break during drilling or screw insertion. A second, antirotation wire may be placed. The wire is overdrilled with a cannulated drill. Although some of the systems tout a "self-drilling" screw, my preference is to overdrill to the subchondral bone on the far end of the scaphoid bone as determined by fluoroscopy. After drilling, I believe it to be imperative to countersink the proximal hole. Most systems come with a countersink. This is to decrease the hoop stresses placed on the proximal bone which can cause a fracture in the proximal bone. After countersinking, a screw of the appropriate size is placed, making sure that it is well seated below the cartilage and into the proximal subchondral bone. A study by Hart and colleagues showed that the torque of the screw turns felt by the surgeon does not correlate with fracture compression.[88] After the screw is placed, it is important to remove the guidewire and check all fluoroscopic views (PA, lateral, supinated and pronated oblique views) to ensure an excellent position of fracture reduction and hardware placement. If unsure about screw position, live fluoroscopy should be used, rotating the scaphoid dynamically. The capsule is closed with absorbable braided suture. The tourniquet is released and hemostasis achieved. The skin is closed and a well-padded short-arm splint is placed. Depending on fracture stability and patient compliance, a postoperative short-arm thermoplastic splint or short-arm cast may be placed at 2 weeks until the bone is healed; this may take 6 to 10 weeks following operation. Fracture healing is determined clinically by lack of tenderness and by imaging with radiographs and with CT scanning if there is any radiographic ambiguity.

Dorsal Percutaneous Slade Technique

The main difference in the Slade technique[76] is that it is a percutaneous technique; as such the entrance point is identified by flexing the wrist and identifying the superimposed rings on fluoroscopy of the proximal and distal poles. The guidewire is placed down the center of the superimposed rings. The wire is advanced out of the radial aspect of the thumb so the wrist can be extended for standard wrist radiographs. When satisfactory wire placement is confirmed, the wrist is again flexed and the wire driven dorsally for the remainder of the procedure, which is identical to the author's preferred method above.

Unstable Acute Fractures: Waist Fracture, Displaced

Acute waist fractures can be approached dorsally or palmarly. There are advantages and disadvantages to both approaches. The main advantage of the dorsal approach is that the fixation can get down the true axis better than the palmar approach. Many surgeons prefer dorsal percutaneous screw fixation because of the ease of access and the ability to place a screw closer to the central axis.[28,127] The disadvantages of the dorsal approach are that it either (1) requires a miniopen approach to retract extensor tendons or (2) risks injury or rupture of the extensor tendons with a percutaneous approach. The dorsal approach also requires flexion of the wrist, which may theoretically displace an unstable fracture. The dorsal miniopen and Slade percutaneous approaches are described above.

The palmar approach may be used for waist fractures and the infrequent distal pole fracture that may require surgical fixation. An advantage of the palmar approach is that the entrance of the scaphoid tubercle is subcutaneous; thus there are no tendons in the path of the approach. A small (1-cm) incision may be used if needed to allow overdrilling of the guidewire and placement of the screw. Another advantage of the palmar approach is that the wrist is extended, theoretically helping to reduce the fracture. A disadvantage is that it is not possible to place the screw down the true axis of the bone because the trapezium blocks the entrance of the center of the distal scaphoid (Figure 16.11, *A*).

http://e-surg.com

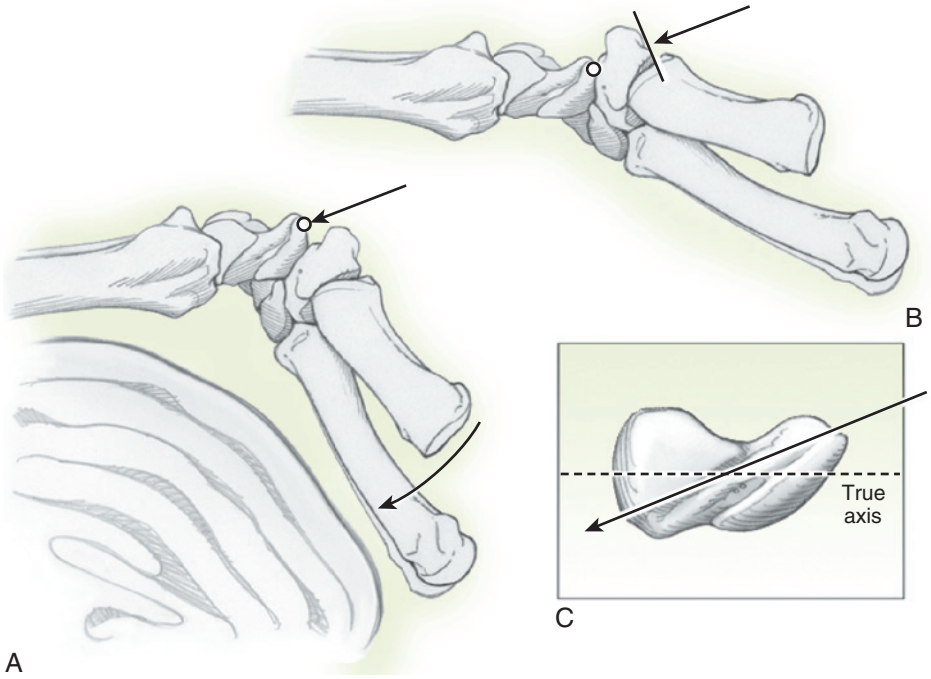

FIGURE 16.11 **A,** With the wrist in neutral position, the trapezium blocks the scaphoid bone. **B,** With the wrist in the hyperextended position, the trapezium moves dorsally out of the way for access to the starting point on the scaphoid bone. **C,** Even with the wrist extended, it is not possible to get down the true axis from the volar approach, because the trapezium is in the way.

The placement of the screw is always oblique; the more proximal the fracture, the higher the chance of not engaging enough screw threads in the proximal fragment. Another concern is penetration of the dorsal surface of the bone by the screw. The optimal radiographic views for determining screw prominence are the oblique views as reported by Kim and colleagues (Figure 16.12).[119]

Like the dorsal approach, the percutaneous approach can be extended if necessary to openly reduce the fracture or treat a nonunion.

Scaphoid Open Reduction and Internal Fixation From the Palmar Approach

In the open volar approach, a hockey-stick incision is made beginning between the flexor carpi radialis (FCR) tendon and the radial artery in the distal forearm and angled across the distal wrist crease toward the base of the thumb. The FCR tendon is retracted ulnarly and the radial artery radially. The wrist capsule is entered through a longitudinal incision from the volar lip of the radius to the proximal tubercle of the trapezium. The capsule and intracapsular ligaments are carefully divided and reflected sharply off of the scaphoid with a scalpel. The capsule needs to be preserved, as it contains the RSC ligament and will be repaired at the close of the procedure. Some surgeons prefer to tag the ligaments at this stage with nonabsorbable sutures for later repair. The entire volar scaphoid is exposed. Reduction is performed by manipulation or with joysticks, and Kirschner wires are used to provide provisional fixation. Bone grafting can be performed as required for volar comminution or in subacute fractures, with the grafts harvested from the volar radius beneath the pronator quadratus by extending the incision an additional 2 to 3 cm. The scaphotrapezial joint is opened to place a central guidewire in preparation for final fixation. If necessary, a small amount of the proximal trapezium can be excised with a rongeur to clear an unobstructed path for the implant. Rigid internal fixation can be performed with the implant of choice.



FIGURE 16.12 Supinated oblique view for assessment of proximal scaphoid articular cannulated screw penetration. (From Kim RY, Lijten EC, Strauch RJ: Pronated oblique view in assessing proximal scaphoid articular cannulated screw penetration. *J Hand Surg [Am]* 33(8):1274–1277, 2008.)

With the volar approach, it is important to know that it is impossible to put the screw down the long axis of the scaphoid

http://e-surg.com

without violating the trapezium. Verstreken and colleagues have popularized a transtrapezial approach that enables more central screw position.[76,144] Leventhal and associates performed a computational analysis to identify the ideal starting point (1.7 mm dorsal and 0.2 mm radial to the tip of the scaphoid tubercle) to enable the longest possible screw trajectory in the scaphoid without violating the trapezium.[129]

Palmar Percutaneous Method

Streli[81] was the first to describe volar percutaneous screw fixation of the scaphoid fracture in 1970 using traction applied through the thumb and a standard ASIF screw. In 1991, Wozasek and Moser reported on an adaptation of Streli's technique using cannulated 2.9-mm screws via a volar percutaneous approach.[225] Later, Bond and colleagues demonstrated faster healing and return to work with percutaneous screw fixation from the palmar approach compared with cast immobilization. They used modern cannulated headless compression screws.[23]

Fractures suitable for treatment with the volar percutaneous (distal to proximal) approach are fractures at the waist and distal pole. Humpback deformities or scaphoid collapse with a DISI deformity usually require open reduction, bone grafting, and fixation. Unsuitable fractures include proximal pole fractures, which are best treated via a dorsal (proximal to distal) approach.

❖ AUTHOR'S PREFERRED METHOD: Scaphoid Mini-Open Screw From the Palmar Approach

The tourniquet is placed proximally on the arm and the upper extremity draped to allow for full motion of the extremity and enable adequate visualization with fluoroscopy. A tourniquet is used at the surgeon's discretion. A small longitudinal incision (≈1 cm, or just long enough to accommodate the drill bit/screw) is made over and just distal to the scaphoid tubercle. The wrist is hyperextended and ulnarly deviated over a bump. This moves the trapezium dorsally away from the entrance point on the scaphoid bone (see Figure 16.11, *B*).

If the trapezium has a particularly palmar location, a rongeur may be needed to remove a small amount of bone to gain access to the entrance point. The guidewire is started as dorsally as possible on the scaphoid in the sagittal plane without impinging on the trapezium. On the coronal plane, a good landmark for the starting point is a third of the distance from the radial side of the distal pole of the scaphoid (Figure 16.13). The surgeon should attempt to drop the hand to get as close as possible to the axis of the scaphoid (Figure 16.14). Fluoroscopy is used to optimize guidewire placement.

Once the guidewire is placed, multiple minifluoroscopic views are taken, including anteroposterior (AP), lateral, and oblique views. It is imperative to take 45-degree oblique views in supination and pronation to ensure that the wire is within the bone in all planes.[119] The wire should be advanced to the subchondral bone on the proximal side and measured.

The appropriate screw length is shorter than this distance by at least 4 mm; I often use a screw even shorter; a 20-mm screw is often an appropriate length for an adult male. The screw should be relatively long but should *definitely* not be too long. If it is too long, it can distract the fracture or protrude out of the bone distally or proximally. Once this length is determined, the guidewire is driven into the radius or out of the dorsal skin

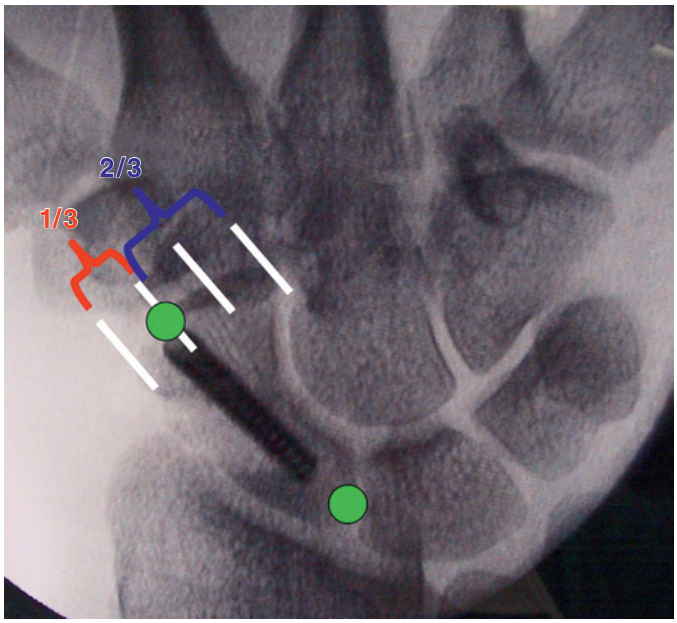

FIGURE 16.13 On the coronal plane, a good landmark for the starting point of the guidewire is one third of the distance from the radial side of the distal pole of the scaphoid. (Courtesy of Steve K. Lee, MD.)

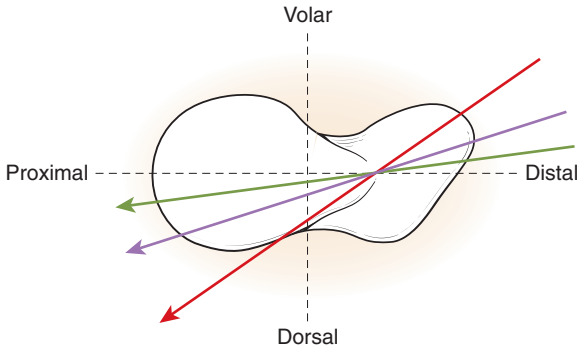

FIGURE 16.14 The surgeon should attempt to be closer to the *green line* and not the *red line* for wire placement from the volar approach. If the fracture is at the proximal waist, using the *red line* trajectory risks having minimal proximal bone purchase.

and clamped so that the wire will not come out during drilling. A second antirotation wire may be placed. The wire is overdrilled with a cannulated drill that is common to most headless compression screw systems. Although some of the systems tout a "self-drilling" screw, my preference is to overdrill up to the subchondral bone on the far end of the scaphoid as determined by fluoroscopy. After drilling, I believe it to be imperative to countersink the entrance hole. This is to decrease hoop stresses when tightening the screw, which can crack the distal fragment. After countersinking, a screw of appropriate size is placed, making sure that it is seated below the cartilage and flush with the subchondral bone. After the screw is placed and the guidewire removed, it is important to check all fluoroscopic views (AP, lateral, supinated and pronated oblique views) to ensure an excellent position of fracture reduction and hardware placement. If a tourniquet is used, it is deflated at this time. If an incision is used, it is closed with sutures or Steri-Strips. A well-padded short-arm splint is placed. Depending on fracture stability and patient compliance, a thermoplastic splint or short-arm cast is placed at 2 weeks until the bone is healed.

http://e-surg.com

Some surgeons allow light activities as tolerated and early range-of-motion exercises to restore wrist mobility prior to complete healing. Fracture healing at 6 to 10 weeks postoperatively is assessed clinically by lack of tenderness and by imaging with radiographs and/or CT scans.

CRITICAL POINTS *Pearls and Pitfalls for Surgical Treatment*

- Place the guidewire as centrally as possible in the scaphoid.
- Consider using an antirotation wire.
- Common error is using a screw that is too long.
- Subtract at least 4 mm from the measured distance.
- A common screw length for an adult male is 20 mm.
- Do not ream past the far cortex.
- If feeling a lot of resistance (especially when reaming over wire), *stop* and look. The wire may be bent and break or the drill bit may break (Figure 16.15).[121]
- Beware of hoop stresses. Use countersinking to avoid excessive hoop stresses that can fracture the near fragment.
- Consider the use of joysticks to gain reduction.
- If needed, reduce and pin the lunate in neutral (out of DISI) (Figure 16.16, *A* to *C*).
- Consider supplemental fixation for more stability (Figure 16.17).

Palmar Percutaneous Method of Scaphoid Fixation (Alternate Method)

In the palmar percutaneous method of scaphoid fixation,[76] the patient is placed supine on an operating table and the hand is suspended vertically by the thumb using a finger trap (Figure 16.18).[85] This position extends the scaphoid and ulnarly deviates the wrist to improve access to the distal pole of the scaphoid. A fluoroscopic imaging unit is rotated parallel to the floor and positioned so that the wrist is in its central axis. Traction from a tower permits full rotation of the scaphoid in the imaging beam. In the majority of cases, longitudinal traction is enough to reduce the scaphoid fracture. If the fracture is not reduced, Kirschner wires can be inserted and used as joysticks to manipulate the fragments into position. The quality of the reduction can then be checked radiographically.

Having achieved an acceptable reduction, the most important step is to establish the entry point of the guidewire. The ulnar deviation of the wrist extends the scaphoid to make the tubercle more accessible. The entry point, the scaphoid tuberosity, is located using a 12- or 14-gauge intravenous needle introduced on the anteroradial aspect of the wrist, just radial and

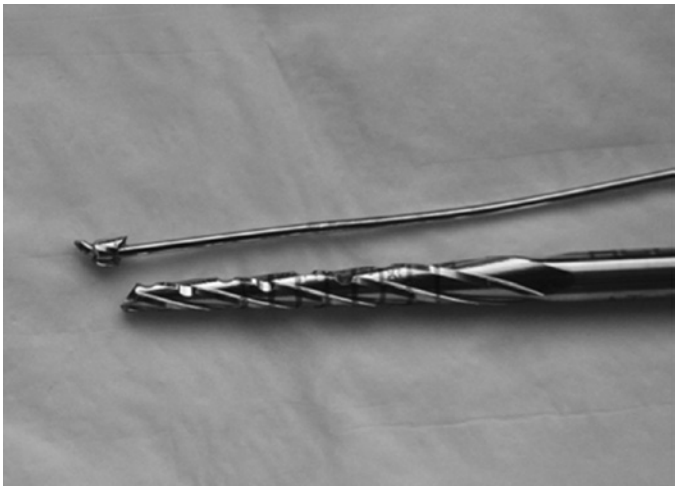

FIGURE 16.15 Broken drill bit from attempting to drill over a bent guidewire. (From Kosy JD, Standley DM: Retrieval of broken Acutrak drill bit. *J Hand Surg Eur* 35(8):683, 2010.)

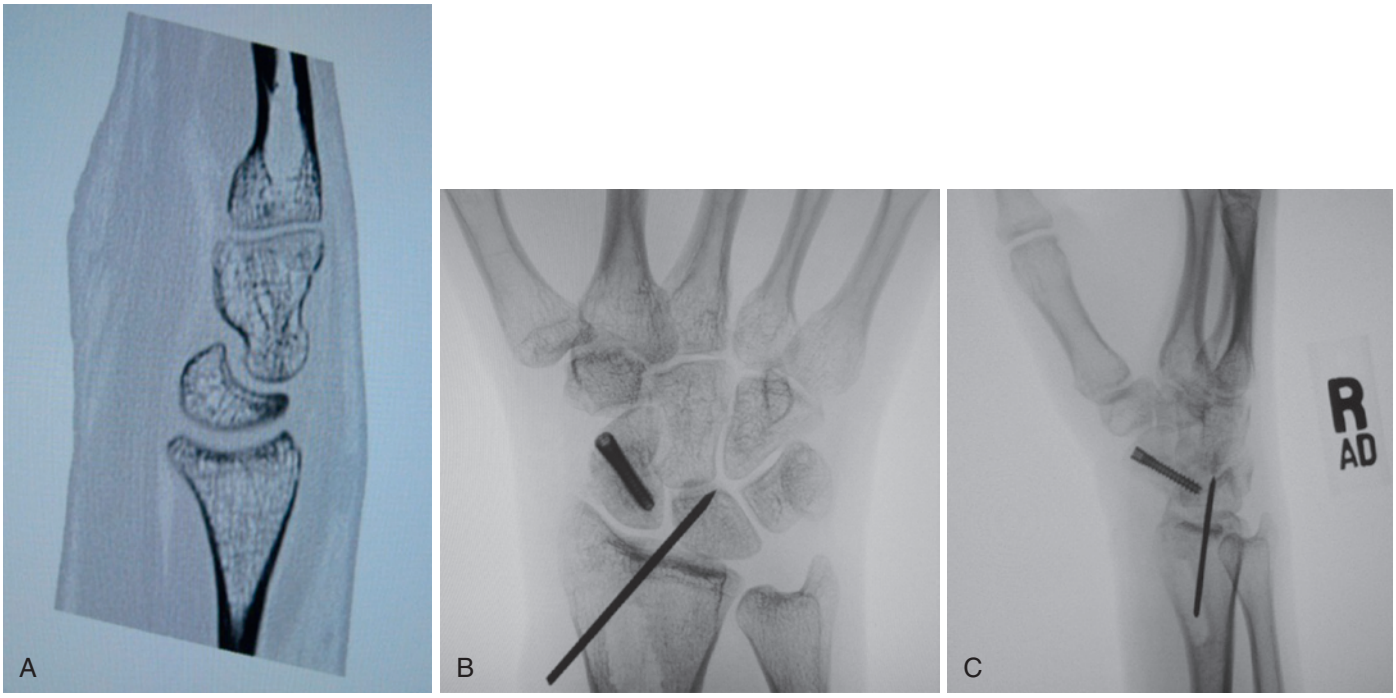

FIGURE 16.16 **A,** Preoperative computed tomographic scan showing dorsal intercalated segmental instability (DISI). Postoperative posteroanterior view **(B)** and lateral view **(C)** after reduction of DISI and Kirschner wire placement from radius to lunate. (Courtesy of Scott W. Wolfe, MD.)

http://e-surg.com

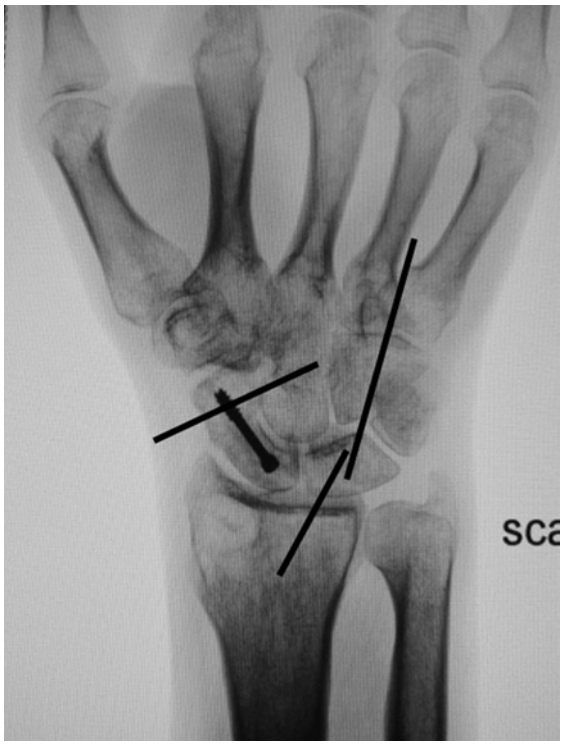

FIGURE 16.17 Example of supplemental fixation for stability. (Courtesy of Steve K. Lee, MD.)

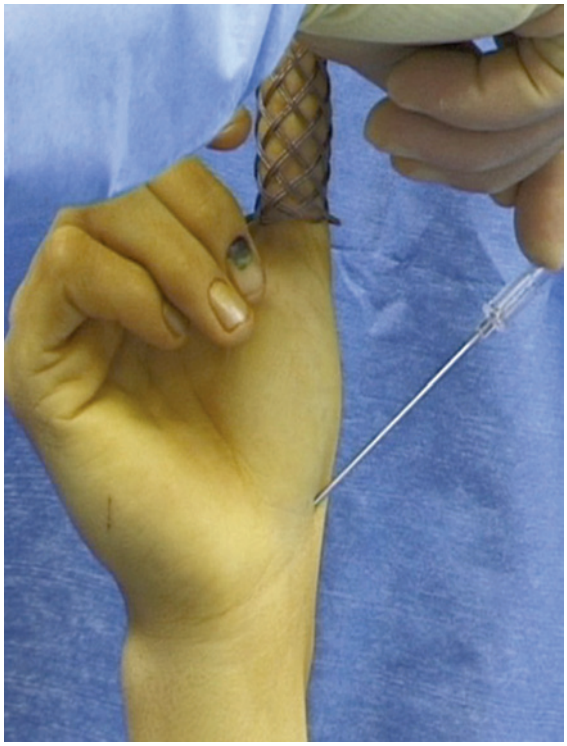

FIGURE 16.18 In 1998, Haddad and Goddard reported on a simplified volar percutaneous technique using traction and a cannulated screw to stabilize waist fractures. The thumb is suspended by a single finger trap. It permits free rotation of the hand throughout the operation, and the scaphoid remains in the center of an imaging unit. The C-arm is turned to a horizontal position surrounding the wrist. The most important step is to establish the entry point of the guidewire and the position of the screw. The ulnar deviation of the wrist is provided by thumb traction and allows the distal half of the scaphoid to slide out from under the radial styloid. The scaphoid tuberosity is easily palpable and is the key to the insertion point. The entry point is located using a 12- or 14-gauge intravenous needle, which is introduced radial and distal to the scaphoid tuberosity. (Haddad FS, Goddard NJ: Acute percutaneous scaphoid fixation: a pilot study. *J Bone Joint Surg Br* 80(1):95–99, 1998.)

distal to the scaphoid tuberosity. The needle serves as a trocar to guide the wire and establish a central path along the scaphoid. The needle is inserted into the scaphotrapezial joint and tilted into a vertical position. The needle is levered on the trapezium, which brings the distal pole of the scaphoid more radially and facilitates screw insertion. The wrist is rotated in the fluoroscopic beam to confirm that the needle is aligned along the axis of the scaphoid in all planes, with the intent of directing the guidewire into the proximal pole to a point just radial to the scapholunate ligament. Leventhal and colleagues identified the ideal starting point to be approximately 2 mm dorsal and just radial to the apex of the scaphoid tubercle, in order to achieve maximum guidewire length within the scaphoid.[129]

Once the entry point and the direction of the guidewire are confirmed, the needle is impacted into the soft articular cartilage over the distal pole of the scaphoid so that the tip does not slip during insertion of the guidewire. The guidewire is passed down through the needle and drilled across the fracture; its direction is continually checked on the image intensifier and adjusted as necessary, with the goal of entering the radial aspect of the proximal pole. The position is checked in multiple fluoroscopy planes, and, if satisfactory, a longitudinal incision of 0.5 cm is made at the entry point of the wire and deepened down to the distal pole of the scaphoid using a small hemostat and blunt dissection. This is a relatively safe zone, with minimal risk to the adjacent neurovascular structures.

The length of the screw is determined using a depth gauge or by advancing a second guidewire of the same length up the distal cortex of the scaphoid and subtracting the difference between the two. The correct screw size is 4 to 5 mm shorter than the measured length, which will ensure that the screw head is fully buried below the cartilage and the subchondral bone on each end. In rare cases a second antirotation wire may be inserted parallel to the first prior to drilling and reaming. The wire is advanced into the radius or out of the dorsal skin and clamped, so as to avoid loss of wire position with drilling. The 12-gauge needle is removed and the cannulated drill is passed over the wire and advanced under imaging guidance, stopping 1 to 2 mm short of the far articular surface. At this point the hand is taken out of traction so that the screw will adequately compress the scaphoid. A countersink or a trailing drill is used, depending on the particular set. A self-tapping screw is advanced over the guidewire. The final position is checked with multiple fluoroscopic views to confirm complete containment within the scaphoid. A hyperpronated PA view profiles the dorsal-radial cortical margin of the scaphoid, where a perforation of the proximal cortical bone can occur. Compression of the fracture site is confirmed radiographically on the image intensifier. The wire is removed, the skin closed with a suture or Steri-Strips, and the wound covered with a sterile compressive dressing.

Postoperative Care. A volar plaster splint is removed at 10 to 14 days postoperatively. The sutures are removed at this stage, and wrist radiographs are taken to confirm that screw position is satisfactory. Depending on the bone quality, fixation, and

http://e-surg.com

assumed patient compliance, a short-arm thumb spica cast or well-molded Orthoplast short-arm thumb spica splint is used for 4 additional weeks or until the wrist has healed. Hand therapy may be useful to regain hand motion; no heavy carrying or weight-bearing activity is permitted. A return to sedentary work is allowed as soon as the patient feels ready or when 75% of the contralateral range of movement is achieved. When radiographic and clinical union have been achieved, the splint is discontinued and all previous activities are resumed as tolerated. CT is used to confirm healing before return to heavy lifting or competitive athletics.

Potential complications include malposition of the screw, violation of the cortical surface, and hardware protrusion within the radioscaphoid or scaphocapitate joint proximally, breakage of a guidewire, and fracture of the scaphoid during screw placement. Another potential problem is a failure to completely bury the head of the screw within the scaphoid, which can lead to scaphotrapeziotrapezoidal (STT) arthrosis. This problem is avoided by selecting a screw length approximately 4 to 5 mm shorter than measured with the depth gauge. Fracture displacement can occur with guidewire malposition or in proximal pole or oblique fractures. Other risks include transient dysesthesia just distal to the scar. This is secondary to a neurapraxia of a sensory branch of the median nerve and usually resolves within 4 to 6 weeks. Volar fixation of a small proximal scaphoid fragment is contraindicated because of tenuous fixation and minimal compression. Nonunions or delayed unions using the volar approach have occurred with proximal pole fractures, and small proximal pole fractures should be treated using a dorsal approach.

Arthroscopy-Assisted Percutaneous Scaphoid Fixation

The goals of arthroscopy-assisted stabilization of scaphoid fractures[76] are to reduce displaced fractures without an open incision and provide secure fixation that will permit early motion until solid union has been achieved.[71] The early results of arthroscopy-assisted percutaneous screw fixation of displaced fractures of the scaphoid suggest that minimally invasive reduction and fracture union can be predictably obtained with good to excellent functional results in the correctly selected patient.[184] Avoidance of open exposure limits the potential for wrist ligament injury, may help to preserve the blood supply, and minimizes postoperative stiffness. However, many scaphoid fractures are now treated with percutaneous or mini-open techniques that create little scarring and do not adversely affect postoperative motion.

Slade reviewed his results in arthroscopy-assisted fixation from a dorsal approach in 27 consecutive patients.[182] There were 18 waist fractures and 9 fractures of the proximal pole. Seventeen patients were treated within 1 month of injury, and 10 patients were treated late. All fractures healed, as documented by CT.

Arthroscopy-assisted fixation of scaphoid fractures also allows for simultaneous detection of associated intracarpal soft tissue injuries. Braithwaite originally reported on four patients with a fracture of the scaphoid with complete scapholunate dissociation.[26] As in fractures of the distal radius, associated soft tissue lesions may occur with scaphoid fractures, and arthroscopic evaluation allows detection and management. It is not known whether early arthroscopic detection and management of the associated injuries improve the final outcome. For operative details of arthroscopic-assisted percutaneous treatment of scaphoid fractures and scaphoid nonunions, the reader is referred to Chapter 17.

Delayed (Subacute) Presentation of Waist Fracture

Surgery is generally indicated for delayed presentation of a scaphoid fracture 4 to 6 weeks or more following injury. Patients with delayed presentation of scaphoid fractures have a higher likelihood of nonunion with closed treatment and require 4 to 6 months to heal in plaster.[134]

Managing Scaphoid Fractures in Athletes

Scaphoid fractures are common in competitive and recreational athletes, and such patients are reluctant to submit to the long period of immobilization and restricted activity that plaster requires. These factors may influence our treatment decisions. The treating physician may permit participation in athletic activity with a playing cast. Some organizations permit casts that are protected with foam padding. Whether the forces generated by firm gripping are detrimental to healing probably depends on the fracture's inherent stability. One study reported a faster return to play with internal fixation compared with a playing cast alone.[166] A potential problem with plaster immobilization is compliance. Young people often will modify or remove the cast and are increasingly noncompliant with follow-up over time. The pressure to return to sports may lead the patient and coach to seek ways of shortening the period off of the field. The player's ability to return to sports before the fracture is healed depends on the sport and its requirements. Options to be weighed will be surgery, a playing cast, and playing restrictions. The goal will be the successful union of the scaphoid fracture regardless of the patient's athletic responsibilities. Clearly, educating the patient, family, trainer, and coach is essential.

Complex Scaphoid Injuries

Combined Fractures of the Scaphoid and Distal Radius

Combined fractures of the distal radius and scaphoid are uncommon but present a challenging treatment dilemma. Scaphoid fractures may not be recognized when associated with a comminuted distal radius fracture and when untreated can result in carpal collapse, cystic degeneration, and eventual carpal degenerative arthritis. Although an isolated stable scaphoid fracture might be safely managed with plaster immobilization, the 12 to 16 weeks of immobilization required for healing are not appropriate for the treatment of the distal radius fracture. Prolonged immobilization may result in arthrofibrosis and atrophy of the forearm and hand, making the recovery of full hand function difficult.

A review of the published reports on combined scaphoid and distal radius fractures demonstrates that treatments have evolved over the past decade. Trumble and colleagues reported on six patients treated with internal fixation for ipsilateral combined fractures of the scaphoid and radius.[204] All patients sustained a high-energy injury from a fall from a substantial height. All of the fractures united, with the radial fractures healing in an average of 6 weeks and the scaphoid fractures healing in an

http://e-surg.com

average of 13 weeks. Internal fixation of the scaphoid in these combined injuries allowed for earlier and more aggressive therapy to maximize wrist and forearm motion. Treatment in my hands is usually open reduction and internal fixation (ORIF) of the distal radius fracture and the mini-open approach and fixation of the scaphoid fracture.

Transscaphoid Perilunate Fracture-Dislocations

Open and Arthroscopic Treatment. Acute fracture-dislocations of the carpus are uncommon. Perilunate fracture-dislocations represent approximately 5% of wrist fractures and are about twice as common as pure ligamentous dislocations. Transscaphoid perilunate fracture-dislocation is the most common type of complex carpal dislocation.

Treatment of these injuries can be challenging owing to the extensive soft tissue, cartilaginous, and bony damage. Furthermore, obtaining universally excellent long-term results can be elusive.[92] Various operative treatment options have been recommended, including dorsal, volar, percutaneous, and arthroscopic approaches.[189]

These injuries are usually due to a high-energy impact, as may occur in motor vehicle accidents, a fall from a height, or contact sports. The mechanism of injury characteristically involves forceful wrist extension, ulnar deviation, and intercarpal supination. The injuries have been classified as greater and lesser arc injuries. Greater arc injuries have associated fractures and lesser arc injuries do not; lesser arc injuries are purely ligamentous. Bone or ligament failure usually begins with the radial styloid and or scaphoid fracture or palmar capsuloligamentous disruption starting radially and propagating ulnarly. In the greater arc injury, the energy takes a transosseous route through the scaphoid, with usual disruption of the lunotriquetral interosseous (LTIO) ligament and fracture of the ulnar styloid. The proximal fragment of the scaphoid and the lunate remain with the radius, while the distal fragment of the scaphoid dislocates dorsal to the lunate with the attached distal carpal row. In 10% of dislocations, the distal scaphoid fragment and the distal carpal row dislocate palmarly to the lunate. Variations of perilunate fracture-dislocations include fractures of the capitate, triquetrum, radial styloid, and ulnar styloid. A specific variation of the perilunate fracture-dislocation is *scaphocapitate syndrome*. In this injury, the injury force passes through the neck of the capitate, fracturing both the scaphoid and the capitate. The proximal portion of the capitate may rotate 90 to 180 degrees, with the articular surface of the head of the capitate directed distally. The injury to the capitate can be missed on plain radiographs. If scaphocapitate syndrome is suspected, a CT scan will better elucidate the pathoanatomic situation. ORIF is indicated in scaphocapitate syndrome through a dorsal approach. Both the capitate and scaphoid should be reduced and fixed with proximal to distal headless compression screws. Briseno and Yao reported on a lunate fracture along with perilunate injury and stressed the importance of looking for this injury and treating it appropriately. Even with treatment, the simultaneous lunate fracture portends a worse prognosis.[28]

Herzberg and Forissier investigated the medium-term results (mean follow-up, 8 years) of a series of 14 transscaphoid dorsal perilunate fracture-dislocations treated operatively at an average of 6 days following injury.[92] Eleven underwent ORIF through a dorsal approach. Combined palmar and dorsal approaches were used in three cases: in two cases, ORIF, and in one case, proximal row carpectomy. All internally fixed scaphoids healed, and no carpal AVN or collapse was observed. Carpal alignment was satisfactory in most cases. Posttraumatic radiologic midcarpal arthritis or radiocarpal arthritis, or both, was almost always observed.

Nearly every combination of radiocarpal and intercarpal dislocation has been described, but few fit neatly into a particular pattern or classification scheme. These injuries may be subtle, and diagnosis is still frequently delayed; the dislocation is missed by primary providers in up to 25% of cases.[117] Prompt recognition, accurate reduction, and stable internal fixation all contribute to improved outcomes. Internal fixation techniques depend on the pathologic condition of the carpus. Although arthroscopic techniques and fluoroscopically aided percutaneous techniques have been described,[68] my preference for treatment is an open procedure. The wrist is approached dorsally primarily for treatment of the scaphoid fracture or the scapholunate tear if it is a lesser arc injury. In 3% of cases, a complete SLIL tear accompanies a scaphoid fracture-dislocation.[92] An extended carpal tunnel approach is added if one of two situations is present: (1) The preoperative history and examination are consistent with acute carpal tunnel syndrome. If left untreated, median nerve compression can lead to long-term nerve deficits, hand stiffness, and, potentially, a complex regional pain syndrome. (2) A perilunate fracture-dislocation is irreducible from the dorsal approach. The lunate is visualized in the space of Poirier between the RSC ligament and long radiolunate ligament. Using a Freer elevator or similar instrument from the volar approach and manual wrist manipulation, the lunate can be negotiated into reduction.

For associated lunotriquetral ligament injury, the lunotriquetral joint is reduced and held with two Kirschner wires. One technique that is very valuable and surgically efficient is to place one or two double-ended Kirschner wires from within the lunotriquetral joint out the ulnar side of the wrist through the triquetrum before the lunate is reduced. A similar technique can be used in the scaphoid when the SLIL is torn. It is important to protect the soft tissues (radial artery, superficial radial nerve, tendons, veins) on the radial side of the wrist. The lunate is reduced and the wires are driven back into the lunate from inside the triquetrum and scaphoid, respectively. If extended carpal tunnel release has been performed, the stronger palmar component of the lunotriquetral ligament can be sutured with nonabsorbable braided suture from the palmar side.

Occasionally the dorsal radioulnar ligament origin is avulsed off of the dorsal ulnar corner of the radius. The distal radioulnar joint will be unstable and the dorsal ulnar corner of the radius will be devoid of soft tissue during the exposure. It is

CRITICAL POINTS *Perilunate Dislocation*

1. It is imperative during reduction to restore Gilula's lines in coronal plane and attain neutral radiolunate and capitolunate alignment in the sagittal plane.
2. Consider starting K wires from within the scapholunate joint and going out radially and ulnarly. Reduce the joint, then drive wires back in to fix the scapholunate joint and lunotriquetral joints, respectively.
3. Bury K wires because they should stay for approximately 10 to 12 weeks.
4. Beware of concomitant wrist injuries, such as dorsal radioulnar ligament injury.

http://e-surg.com

important to repair the ligament with bone suture anchor. Repairs are generally protected with cast immobilization for 8 to 12 weeks, followed by removal of Kirschner wires and then gentle active mobilization of the wrist over the next 4 to 8 weeks (Figure 16.19, *A* to *H*).

Complications of Scaphoid Fracture Treatment

The most common complications reported in the literature are delayed union, nonunion, arthritis, reduced wrist motion, and loss of strength. Prolonged cast immobilization leads to muscle atrophy, possible joint contracture, disuse osteopenia, and potential financial hardship. Closed treatment of scaphoid waist fractures may require cast immobilization for 3 months or longer, and fractures of the proximal third of the scaphoid in particular may take 6 months or longer to heal. Surgical repair of scaphoid nonunion is successful in 50% to 95% of patients, depending on the vascular status and presence of arthritis or carpal collapse; successfully repaired scaphoid nonunions may require up to 6 additional months for healing and rehabilitation.

Other complications are reported. Filan and Herbert in 1996 reported on 431 patients treated with ORIF using the Herbert bone screw.[63] They reported that 56 patients had hypertrophic scarring and 20 patients complained of postoperative pain and swelling at the donor site of a bone graft. Four superficial infections and one deep wound infection resolved satisfactorily with conservative treatment. Four patients had early signs of reflex sympathetic dystrophy after surgery. In two patients these signs resolved spontaneously, but two patients developed carpal tunnel syndrome, which required surgical decompression. Only two wrists showed instability of the scaphoid after surgery. One had sustained a tear of the scapholunate ligament at the time of injury; the other appeared to have a late rupture of this ligament. AVN developed after surgery in 20 scaphoids, all of which required further operations. In one case, a very small necrotic fragment of the proximal pole was excised and the scaphoid stabilized by dorsal capsulorrhaphy. Five wrists had a midcarpal fusion. The necrotic proximal pole was excised in 14 cases and was replaced with a stabilized silicone implant in 13 and an osteochondral autograft in one.

In another early report of headless screw fixation, Dias and colleagues investigated 88 patients with minimally displaced or nondisplaced bicortical fractures of the waist of the scaphoid in a prospective, randomized controlled study comparing plaster immobilization in a below-elbow plaster cast with early internal fixation with use of a Herbert or Herbert-Whipple screw.[50] Complications occurred in 13 patients (30%) who had been managed operatively, and nonunion occurred in 10 of 44 patients (23%) of those treated in a cast. Most operative complications were minor, and included superficial wound infection (in one patient), sensitive scar (in three patients), hypertrophic scar (in four patients), sensitive and hypertrophic scar (in three patients), hypoesthesia in the region of the palmar cutaneous branch of the median nerve (in one patient), and mild early complex regional pain syndrome (in one patient). Technical difficulty was experienced in seven patients (16%) during surgery. In four of them, there was initial misplacement of either the drill or the screw. In one patient, the scaphoid tuberosity split during screw insertion.

Bushnell reported his complications with repair of scaphoid fractures using a dorsal percutaneous approach and cannulated headless screw fixation in 24 cases performed over 5 years.[30] All cases involved nondisplaced (<1 mm) fractures of the scaphoid waist. The overall complication rate was 29%; there were five major complications (21%) and two minor complications (8%). Major complications consisted of one case of nonunion, three cases of hardware problems, and one case of postoperative fracture of the proximal pole of the scaphoid. Minor complications included intraoperative equipment breakage, with one case involving a screw and one case involving a guidewire.

Complications of internal fixation are usually due to screw placement and length.[146] Controversy exists as to whether the screw should be placed centrally in the scaphoid[141] or perpendicular to the fracture.[108,140] Eccentric screws decrease fixation strength and risk penetration out of the scaphoid.[141]

Use of Fluoroscopy and Surgical Navigation to Reduce Screw Malposition

The development of small cannulated screws has permitted minimally invasive percutaneous fixation of acute scaphoid fractures. There are known mechanical advantages to increased screw length and central screw placement. As cited above, there are potential deleterious effects of eccentric screw placement, including articular protrusion, proximal pole fracture, and nonunion. Tumilty and Squire reported that the curvilinear surface of the proximal pole of the scaphoid may lead to errors in calculation of screw length and penetration into the joint.[207] In this cadaveric study of six specimens, two screws were found to be penetrating subchondral bone. The plain x-ray films were accurate in only five of the six specimens, while 360-degree fluoroscopic views were accurate in all six. Fluoroscopy during placement of a scaphoid screw may decrease the rate of subchondral penetration.

Recently, investigators have evaluated CT-generated models to assist in the development of a targeting system for implantation of screws into a reduced scaphoid fracture. Several investigative teams have demonstrated that a computer-assisted navigation of volar percutaneous scaphoid screw placement improved accuracy and required less time, less use of fluoroscopy, and diminished radiation exposure when compared with traditional percutaneous techniques.[70,96,115,129,214] Hoffman and colleagues showed in a cadaveric model that compared with the standard fluoroscopic technique, an electromagnetic navigation technique had a higher accuracy rate and lower rates of complications and required less operative time and radiation exposure time.[96]

Cost of Surgical or Nonsurgical Treatment

The treatment of stable scaphoid waist fractures by surgery has raised the issue of cost. Would the health care system be better served by plaster immobilization of these stable fractures, not considering the costs of re-treating fractures that failed to heal (6% to 23% nonunion rate)? Arora and colleagues compared two groups of stable scaphoid fractures, one treated with plaster immobilization and the other with internal screw fixation.[11] They concluded that internal screw fixation of nondisplaced scaphoid fractures had a shorter time to bony union and that the patients returned to work an average of 7 weeks earlier than patients with cast immobilization. Although it is assumed that operative treatment is more expensive, in this study the overall cost was not found to be higher.[11]

http://e-surg.com

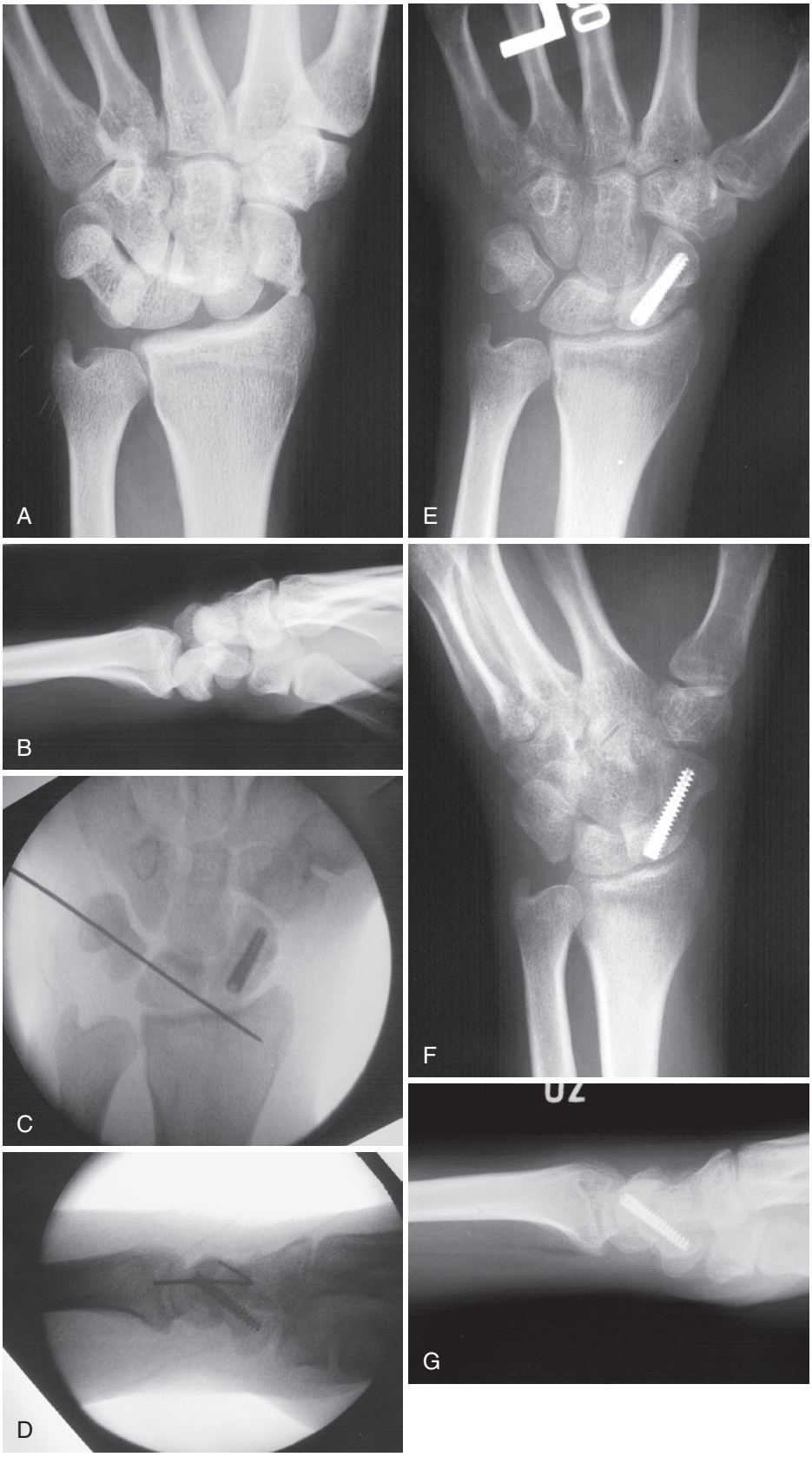

FIGURE 16.19 Transscaphoid perilunate fracture-dislocation. Preoperative posteroanterior (PA) **(A)** and lateral **(B)** radiographs of wrist. Intraoperative PA **(C)** and lateral **(D)** fluoroscopic images of wrist. At 3 months following operation, PA **(E)**, oblique **(F)**, and lateral **(G)** radiographs of wrist.

http://e-surg.com



FIGURE 16.19, cont'd **H,** Postoperative range of motion at 6 months following operation.

Davis and colleagues conducted a cost/utility analysis to weigh ORIF against cast immobilization in the treatment of acute nondisplaced midwaist scaphoid fractures.[43] The authors used a model to calculate the outcomes and costs of ORIF and of cast immobilization, assuming the societal perspective. Medical costs were estimated using Medicare reimbursement rates, and costs of lost productivity were estimated by average wages obtained from the U.S. Bureau of Labor Statistics. ORIF offered greater quality-adjusted life-years than casting. ORIF was less costly than casting ($7940 versus $13,851 per patient) because of a longer period of lost productivity with casting. When considering only direct costs, the incremental cost/utility ratio for ORIF ranged from $5438 per quality-adjusted life-year for the 25- to 34-year-old age group to $11,420 for the 55- to 64-year-old age group, and $29,850 for the age group 65 years and older. They concluded that, unlike casting, ORIF is more cost-effective relative to other widely accepted interventions.[43]

Bone Growth Stimulators

The currently used bone stimulators that have been discussed in the context of scaphoid fractures fall into two major categories: external stimulation of ultrasound or pulsed electromagnetic field (PEMF) therapy. The external stimulators mimic stress to the bones, augmenting bone formation. Ultrasound (Exogen, Bioventus, Durham, NC) is used for only 20 minutes per day and PEMF for 8 to 12 hours per day; understandably, patient compliance with PEMF use is difficult to achieve. Randomized controlled data for ultrasound treatment in acute scaphoid fractures support its use. Mayr reported on 30 patients in a randomized study who had a cast with or without ultrasound for 20 minutes per day.[139] His results showed that fractures that underwent ultrasound treatment healed in 43.2 ± 10.9 days, versus 62 ± 19.2 days in the control group ($p < .01$). Using criteria of trabecular bridging as evidence of healing, 81.2% ± 10.4% of the ultrasound-stimulated fractures were healed at 6 weeks, versus 54.6% ± 29% in the control group ($p < .05$).[139] PEMF has been used to attempt to accelerate scaphoid healing. However, there are no reliable randomized controlled data for PEMF in scaphoid fractures. My preference is to use ultrasound for difficult scaphoid fractures.

Biologic Stimulation of Scaphoid Nonunions

Bone morphogenetic proteins play critical roles in both bone development and fracture healing. Urist first showed that extracts from demineralized bone matrix were capable of inducing new bone formation when implanted in an intramuscular site.[208] The osteoinductive properties of bone morphogenetic proteins for inducing bone formation in ectopic sites and producing healing of critical-sized segmental bone defects in experimental animal studies are attributable to their ability to stimulate the chemotaxis and differentiation of mesenchymal stem cells into chondroblasts or osteoblasts, or both. With the difficulty in treating proximal pole scaphoid nonunions, it is natural that these biologic enhancements would be investigated.

In a case reported by Jones and colleagues, a chronic nonunion of a proximal pole fracture of the scaphoid was treated by curettage of the nonunion, single Kirschner wire fixation, and implantation of 50 mg of human bone morphogenetic protein followed by 12 weeks of cast immobilization without any conventional corticocancellous bone grafting or rigid screw fixation.[111] Radiographs showed signs of bony healing by 12 weeks, and an MRI 6 years after surgery showed no signs of AVN. The authors discussed the potential future applications of human bone morphogenetic protein in hand surgery.[111]

Bilic and colleagues reported on 17 patients with scaphoid nonunion at the proximal pole treated with and without bone graft osteogenic protein-1 (OP-1) or bone morphogenetic protein 7 (BMP-7).[21] OP-1 improved the performance of both autologous and allograft bone implants and reduced radiographic healing time to 4 weeks compared with 9 weeks without OP-1. CT scans and scintigraphy showed that in patients treated with OP-1, sclerotic bone was replaced by well-vascularized bone. Allograft and autologous grafts treated with OP-1 healed at a similar rate.[21] At present, there is insufficient evidence to derive recommendations concerning the role of biologics in scaphoid fracture or nonunion treatment, and their use is not common.

Scaphoid Fracture in Children

Fractures of the immature scaphoid are uncommon and can be challenging to diagnose. These fractures most commonly involve the distal scaphoid and are effectively treated with cast immobilization. Fortunately most acute pediatric scaphoid fractures heal with nonoperative treatment, and surgery in children is indicated only if there is nonunion.[10]

The diagnosis of acute scaphoid fracture may be missed or delayed because of minimal symptoms. This is particularly true in athletic adolescents, who may return to sports prematurely after a seemingly minor injury to the wrist. The presentation of scaphoid fractures in adolescents has changed over the years and today more closely resembles the adult pattern. Malunion or nonunion may occur in patients with a missed diagnosis or delayed presentation and occasionally in patients treated promptly with immobilization. Surgical intervention should be considered for fracture nonunions in patients who are at or near skeletal maturity or in those in whom nonsurgical treatment has failed. Mintzer and Waters presented the outcome of 13 pediatric scaphoid fracture nonunions in 12 children treated over an 18-year period.[148] The average elapsed time between fracture and surgery was 16.7 months. Four of the nonunions were treated with inlay bone graft from a palmar approach, and

http://e-surg.com

nine were treated with Herbert screw fixation and iliac crest bone grafting. The average time of follow-up was 6.9 years (range, 2 to 19 years). All cases went on to clinical and radiographic union. Patients had no statistically significant difference in range of motion or strength between the operative and nonoperative wrists. The length of time for postoperative immobilization in the Herbert screw group was significantly less than that in the inlay bone graft group. Though scaphoid nonunions in children can heal with prolonged cast immobilization, the authors recommended that the treatment of scaphoid fracture nonunions in the skeletally immature patient be rigid fixation with a compression screw and iliac crest bone graft.

Masquijo and Willis presented their series of 23 pediatric (average age, 15 years) scaphoid nonunions fixed with iliac crest bone graft and screws, with a 95.6% union rate.[136]

Weber reported on six children with nonunited scaphoid fractures treated conservatively.[218] The mean age was 12.8 years (range, 9.7 to 16.3 years), and the mean follow-up time was 67 months. Five had no previous treatment, and the time to diagnosis averaged 4.6 months (range, 3 to 7 months) after injury. Treatment consisted of cast immobilization until clinical and radiologic union. Fractures united in all six children after a mean period of immobilization of 5 months (range, 3 to 7 months). All patients returned to regular activities. Although prolonged treatment with cast immobilization resulted in union of the fracture and an excellent subjective wrist score in all patients, this delay may not be well tolerated by the child or family.

Management of Scaphoid Nonunion

The ability to successfully treat scaphoid nonunions in part defines the abilities of a hand/upper extremity surgeon. Unfortunately, missed scaphoid fractures are relatively common, because oftentimes the patient, trainer, or urgent care personnel will dismiss a wrist injury as a "sprain." The traditional definition of scaphoid nonunion is failure of union following cast immobilization or surgical treatment of 6 months' duration. When most patients with scaphoid nonunion present, however, they have not had any form of treatment, months to years have elapsed since the injury, and secondary deformities and carpal collapse have occurred. If scaphoid nonunion is left untreated, the natural history is carpal collapse and degenerative arthritis.[133] In a long-term follow-up study of more than 30 years of scaphoid fractures treated with short-arm thumb spica casts, 10% had nonunion. Osteoarthritis with associated pain and weakness was present in 56% of patients. Only 2% of the healed group had osteoarthritis.[55]

To minimize the incidence of arthritis, the goal of treatment is to attain a healed scaphoid with anatomic alignment. Advanced imaging, including CT and MRI, aids in the evaluation of scaphoid alignment, bone loss, scaphoid humpback deformity, carpal collapse, and osteonecrosis. Generally, scaphoid nonunions from waist fractures with severe collapse and humpback deformity must be approached volarly with interposition of bone graft and internal fixation. For proximal pole nonunions, a dorsal approach allows access for curetting the nonunion site, bone grafting, and internal fixation of headless compression screw(s) from proximal to distal. The indications and best method of vascularized bone grafting are controversial.

Evaluation of Scaphoid Nonunion

When evaluating patients with scaphoid nonunion, the following issues regarding the fracture must be considered:

1. Where is the nonunion? At the waist or at the proximal pole?
2. Is the nonunion displaced?
3. Is there a humpback deformity?
4. Is there comminution, cyst formation, or cavitation?
5. Is DISI present?
6. Was there previous surgery?
7. Does the proximal pole look dysvascular?
8. Is there arthritis (SNAC wrist)? If so, at what stage?
9. Is the scaphoid deformed or salvageable?

Fracture Site. The more proximal the fracture, the more likely the proximal bone will be dysvascular. This may have implications for the choice of bone graft or other treatment.

Amount of Scaphoid Deformity and Carpal Malalignment. If there is humpback deformity and carpal malalignment, they may have to be corrected at the time of bone grafting and fixation.

Stability of Nonunion; Amount of Bone Loss. If the nonunion is stable and well aligned and bone loss is minimal, limited opening in the nonunion site, curetting as necessary, and cancellous bone grafting may be appropriate, followed by internal fixation by a headless compression screw. Slade and colleagues had previously reported on successful percutaneous bone grafting and fixation for nonunions.[182,183] I have not performed this and prefer an open technique, which also allows for confirmation of stability of the fracture and an intact cartilaginous envelope. Imaging, even CT scanning, does not necessarily predict the stability well (Mark Cohen, MD, personal communication).

Previous Treatment. Any previous surgical or other treatments should be taken into account because they would make further treatment more complex. We have had success with removal of the screw from the original surgery (usually, a volarly placed screw), cavitation of sclerotic or dysvascular bone, hybrid corticocancellous Russe autogenous bone grafting, and placement of a new screw from the opposite pole, usually from proximal to distal because the distal fragment has a hole from the previous screw.

Vascularity of Fragments. There is general agreement that vascularity is important. Green showed that 92% of scaphoid fractures with good vascularity healed when treated by Russe bone grafting. Union took place in 71% of patients when there was diminished vascularity in the scaphoid, but healing did not take place in any patients when the proximal pole was avascular.[80]

There is a lack of agreement on how to best determine vascularity. X-rays are not adequate to assess AVN,[177] and MRI and intraoperative punctate bleeding do not always correlate[84,112] (see previous section on Magnetic Resonance Imaging).

According to Green, vascularity was best determined by punctate bleeding. The use of punctate bleeding intraoperatively to determine AVN has recently been challenged. Even if the fragment is deemed to be dysvascular, there is lack of agreement about the optimal and necessary treatment, as will be discussed.

Possibly to better determine vascularity, curettings of the proximal and distal poles of the scaphoid should be evaluated by a pathologist who is experienced in bone histologic findings.

http://e-surg.com

Salvageability of the Fragment. The fragment must not be collapsed or deformed beyond repair. In some cases the proximal pole has fragmented and collapsed and is not usable; this may occasionally happen with the distal pole, as well.

Presence and Location of Arthritis. If there is arthritis of the radiocarpal, midcarpal, or distal radioulnar joint, the treatment may have to be tailored accordingly For instance, if early arthritis (SNAC I) is confined to the radial styloid, radial styloidectomy and scaphoid bone grafting could be considered. With advanced arthritis, nonoperative management is considered if symptoms are not severe. With increasing pain, other options may include partial denervation or salvage procedures such as scaphoid excision and four-bone fusion, proximal row carpectomy, total wrist fusion, hemiwrist arthroplasty, and total wrist arthroplasty.

Patient parameters to consider when evaluating scaphoid nonunions include:

1. Length of time nonunion has been present
2. Age of patient
3. Amount of pain or dysfunction
4. Activity level
5. Systemic comorbidities present

Length of Time Nonunion Has Been Present. The longer the nonunion has been present, the more likely it is that there will be secondary issues such as arthritis, scaphoid deformity, and carpal instability. In a study by Mack and colleagues, older nonunion was associated with more severe arthritis.[133]

Age of the Patient. Although scaphoid fractures are usually a problem of young males, in the case of nonunion in an older patient, treatment might be tailored depending on individual needs and activity levels.

Amount of Pain or Dysfunction. In the case of nonunion with arthritis where a salvage procedure of scaphoid excision and four-bone fusion or proximal carpectomy might be an option, if the level of pain and dysfunction is tolerable, nonoperative treatment might be employed; the patient should be told that a salvage procedure may be needed later.

Activity Level. Elderly, inactive, or infirm patients may choose to accept the pain and limited range of motion of a scaphoid nonunion. There is no mandate for operative repair because salvage operations may always be considered if escalating arthritic pain causes increasing impairment.

Presence of Comorbidities. Scaphoid nonunion surgery can be complex and complicated, and the best efforts may be thwarted by heavy tobacco use, poor compliance, uncontrolled diabetes or inflammatory arthritis, steroid dependency, or other factors.

Operative Treatment of Scaphoid Nonunion (Table 16.4)

Type I: Delayed or Fibrous Union, No Deformity. Scaphoid nonunions without substantial bone loss require only rigid fixation to heal if there is adequate perfusion. These include fractures with a delayed presentation, fibrous unions, and nonunions with minimal sclerosis (<1 mm). Stable scaphoid fractures presenting for treatment after 1 month have already developed bone resorption at the fracture site from shearing. Early bony resorption is not typically detected by standard radiographs. Scaphoid fractures with delayed presentation (>4 weeks) have a poorer union rate with casting alone. Selected stable scaphoid delayed unions without deformity or substantial bone loss can be successfully treated with reduction and internal rigid fixation without bone grafting using techniques described for acute fractures above.

TABLE 16.4 Algorithm for Scaphoid Nonunion Management

Type of Fracture	Treatment
I. Delayed union	Mini-open rigid fixation with headless compression screw
II. Established waist nonunion, no deformity Fibrous nonunion, waist Sclerotic nonunion, waist	Open repair and autogenous bone grafting Dorsal or volar
Humpback nonunion	Volar approach Russe or Matti-Russe corticocancellous autograft Intercalated wedge autograft Hybrid Russe autograft
III. Proximal pole nonunion, viable	Dorsal approach Open bone grafting and fixation with headless screw Percutaneous bone grafting with headless screw Lock midcarpal joint with Kirscher wire(s) or miniscrew(s)
IV. Dysvascular nonunion, waist or proximal pole	Nonvascularized vs. vascularized bone graft: dorsal or palmar approach Osteoarticular graft

Similarly, established fibrous nonunions stabilized with a compression screw and without a bone graft typically heal. Shah and Jones examined 50 scaphoid nonunions treated with open Herbert screw fixation and noted that the scaphoid nonunions that had an intact cartilaginous envelope or a stable fibrous union healed with screw fixation alone without bone grafting.[178]

Scaphoid nonunions that have minimal bone resorption of the anterior cortical bone and minimal fracture sclerosis (<2 mm confirmed by CT scan) still have the potential for healing in the early stages with screw fixation alone. Slade and coworkers successfully treated aligned nonunions without bone loss using headless screw fixation alone. All 15 patients in this case series healed at an average of 14 weeks and showed bridging cortical bone on CT scans.[182]

Type II: Scaphoid Waist Nonunion, Without Arthritis. The most common type of nonunion faced by the surgeon will be a midwaist fracture nonunion with fracture site resorption and varying degrees of deformity and bone loss. For this type, nonvascularized bone grafting either from the distal radius or iliac crest will generally suffice for healing of the bone as long as certain technical aspects are followed. A point of controversy is whether deformity must be corrected to provide an optimal outcome. In a long-term follow-up study of healed scaphoid nonunions, Jiranek and colleagues identified a higher percentage of arthritic changes in malunited scaphoid fractures.[109] The degree of arthritis did not correlate with the activity level, satisfaction, or return to work, however. Although anatomic alignment is intuitively preferable for restoration of normal

http://e-surg.com

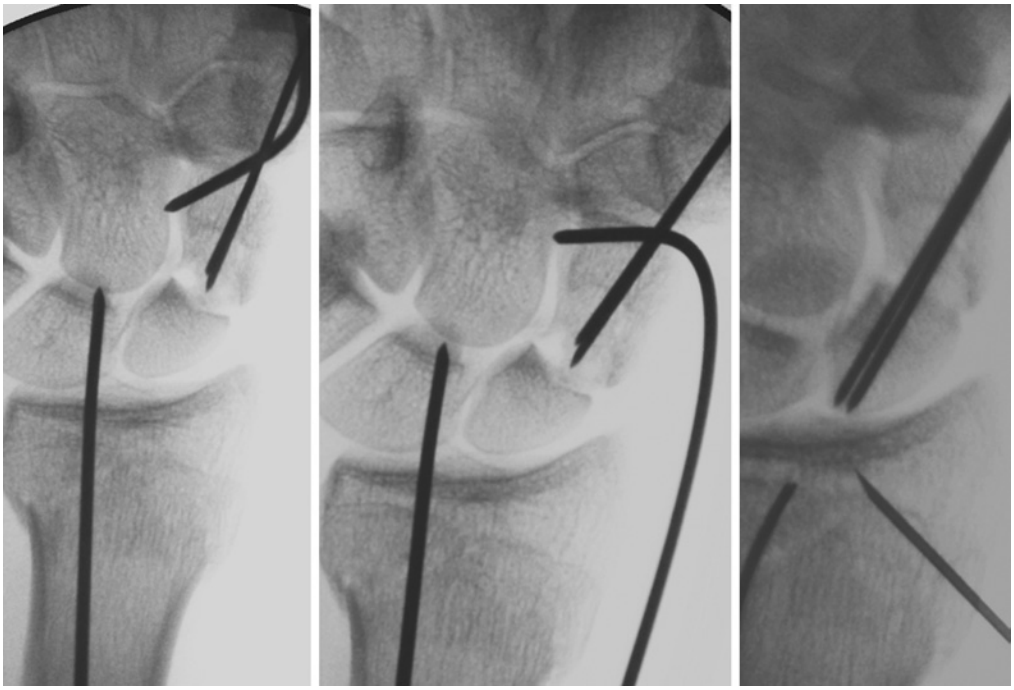

FIGURE 16.20 Once fracture reduction has been accomplished using the joysticks, the central axis guidewire in the distal scaphoid fragment is driven from volar to dorsal, capturing and holding the fracture reduction. Very unstable fractures may require two central axis wires to resist bending and fracture rotation.

kinematics, some degree of malunion seems to be tolerable.[37,50,64] I make every attempt to correct intercarpal malalignment and DISI at the time of nonunion surgery, especially in young and active patients, to avoid the otherwise inevitable progression of arthritis.

Surgical Fixation With Nonvascularized Bone Graft (Local). The procedure can be done from a volar or dorsal approach. Adequate preparation of the bone surfaces with care taken not to cause thermal necrosis with a bur or saw is imperative. Curetting to bleeding bone is necessary on both proximal and distal poles. The scaphoid is reduced and abundant autogenous bone graft packed into the proximal and distal poles. Fixation with a headless compression screw is optimal and is generally performed from distal to proximal in waist nonunions, as detailed in the section, Hybrid Russe Procedure. If the lunate is malrotated into dorsiflexion, reduction and temporary fixation of the lunate with a 0.062-inch radiolunate Kirschner wire will facilitate accurate alignment of the scaphoid proximal pole prior to scaphoid grafting and fixation (Figure 16.20). Supplemental fixation across the scaphocapitate joint may further stabilize the construct, especially if there is concern about the rigidity of fixation.

For nonvascularized bone graft, there is no difference in outcomes between distal radius and iliac crest bone grafts.[35,145] A systematic review of the literature showed the superiority of screw over Kirschner wires for fixation of the scaphoid.[145] Cohen and colleagues reported on 12 patients who all healed with cancellous bone graft from the distal radius and a distal to proximal headless compression screw. The average lateral intrascaphoid angles were improved from 49 degrees to 32 degrees.[37]

Matti Technique, Matti-Russe Technique, and Green's Modification of the Russe Technique. In the original Matti technique, only cancellous bone was used, and this is optimum for scaphoid waist nonunions without humpback deformity and carpal collapse. The Matti-Russe technique and Green's modification of the Russe technique have a high percentage of cortical to cancellous bone (Figure 16.21). In the current author's preferred method of the hybrid Russe technique, the cortical strut volume is much smaller yet still "props open" the scaphoid, and it can be performed for both well-aligned and humpback scaphoid nonunions. The rest of the scaphoid is filled with cancellous bone, and a headless compression screw is used for both axial and centripetal compression.

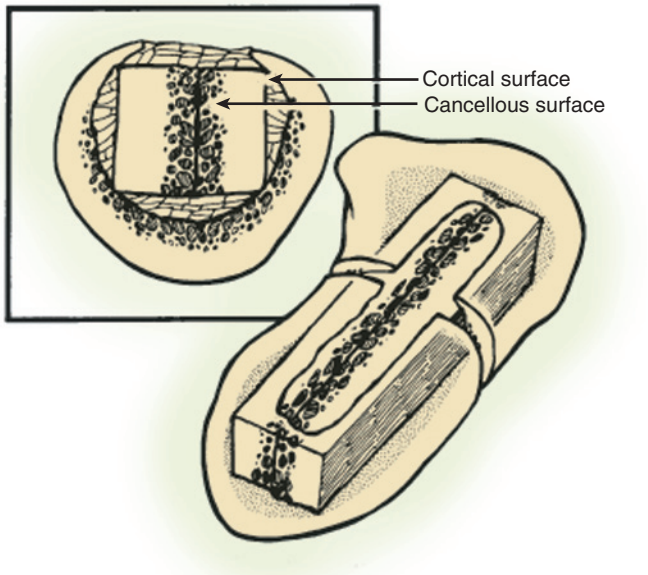

FIGURE 16.21 Russe technique using two corticocancellous bone grafts. (From Green DP: The effect of a vascular necrosis on Russe bone grafting for scaphoid nonunion. *J Hand Surg [Am]* 10:597–605, 1985.)

http://e-surg.com

Barton had less success in long-term evaluation of Russe bone grafting, especially in proximal pole nonunions, which demonstrated a success rate of only 54%.[15]

❖ AUTHOR'S PREFERRED METHOD: Hybrid Russe Procedure

The hybrid Russe procedure is advantageous because it is effective for humpback scaphoid nonunions with DISI. The procedure exposes healthy bleeding cancellous bone in both scaphoid poles, uses a strut to maintain reduction of the humpback deformity, and resists collapse during screw compression. The technique incorporates abundant cancellous bone with optimal healing potential, which provides earlier healing than the standard Russe procedure.[80] It also avoids graft extrusion and uses local bone grafts.

In a series of hybrid Russe corticocancellous grafting procedures for scaphoid nonunion, we reported union in 16 of 16 patients at an average of 13 weeks. Compared with the contralateral side, the mean ipsilateral grip strength was 91% (p = .029). The mean postoperative scapholunate angle was significantly reduced when compared with the preoperative angle (47 degrees postoperatively from 70 degrees preoperatively, p < .001). The mean postoperative intrascaphoid angle was also reduced with surgery (32 degrees vs. 62 degrees, p < .001). Similarly, the mean radiolunate angle was reduced postoperatively by 30 degrees (−4 degrees vs. 26 degrees, p = .031). The median visual analog pain scale score postoperatively was 1, with a highest frequency of 0. There were no reported complications.[170]

Hybrid Russe Procedure. The patient is placed in the supine position under general or regional anesthesia with a pneumatic tourniquet on the injured extremity. The arm is cleansed with antimicrobial solution and draped using sterile technique. Exsanguination is performed with an Esmarch bandage, and an arm tourniquet is inflated to 250 mm Hg. A volar incision is made along the course of the FCR tendon and extended distally along the border of the glabrous skin of the thenar eminence. The distal incision is limited to the level of the scaphotrapezial joint in preparation for screw fixation starting in the distal pole of the scaphoid. Splitting the sheath of the FCR allows the FCR to be retracted ulnarly. The floor of the FCR sheath is incised longitudinally to expose the distal and proximal poles of the scaphoid. The superficial branch of the radial artery to the superficial arch is retracted radially or divided between sutures. The nonunion is exposed with the aid of skin hooks (Figure 16.22). All fibrous tissue at the nonunion site is removed and bone is curetted to remove sclerotic bone and fibrous tissue down to bleeding cancellous bone. In cases of humpback deformity and DISI, the lunate is reduced with a wrist flexion maneuver and a percutaneous radiolunate 0.062-inch Kirschner wire is placed dorsally or radially for temporary fixation and to correct proximal scaphoid pole alignment. Proximal dissection is carried out, incising and reflecting the pronator quadratus off the metaphysis of the radius toward the ulnar side. A cortical window of 20 × 5 mm is made on the volar cortex of the distal radius, and the cortical fragment is set aside for later use (Figure 16.23). Abundant cancellous bone graft is harvested from the radius. A "matchstick" is fabricated from the volar cortical window of the radius and sized to act as a cortical strut (to extend and reduce the humpback deformity and restore the length of the scaphoid) (Figure 16.24). Using bone hooks to extend the prepared proximal and distal poles, the cortical strut is inserted in intramedullary fashion and tamped into position. Cancellous bone graft is packed into the remainder of the nonunion site (Figure 16.25), and this is followed with fixation with a headless screw (Figures 16.26 and 16.27). Intraoperative fluoroscopy is used as needed to confirm adequate reduction and fixation. The volar capsule and radiocarpal ligaments are repaired with interrupted nonabsorbable sutures, and the subcutaneous layer and skin are closed in layers. A splint is kept in place for 2 weeks following the operation. For patients with a radiolunate wire, above-elbow immobilization is critical to prevent wire breakage. The wire is removed in the office at 4 weeks, and a short-arm cast is applied until healing occurs. A CT scan is performed to confirm union at 10 to 14 weeks following operation, and immobilization is converted to a custom-molded removable splint.

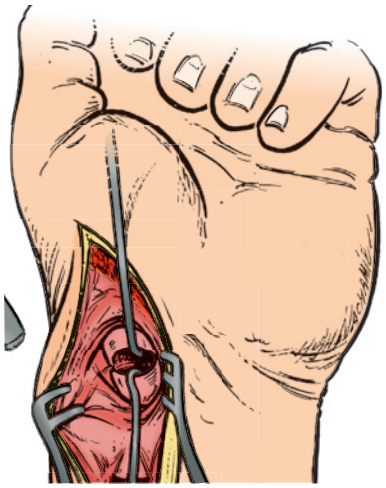

FIGURE 16.22 Volar incision over flexor carpi radialis. Nonunion site is exposed with aid of skin hooks, and fibrous tissue is resected. (Courtesy of Steve K. Lee, MD.)



FIGURE 16.23 A cortical window is made on the volar cortex of the distal radius. Cancellous bone graft is harvested. (Courtesy of Steve K. Lee, MD.)

http://e-surg.com

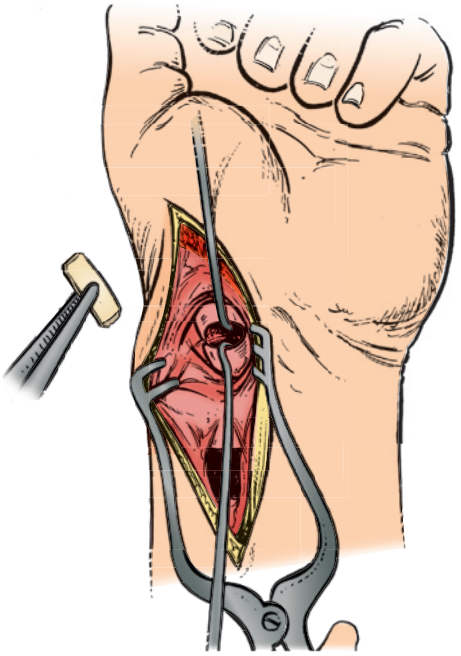

FIGURE 16.24 A "matchstick" is made from the volar cortex of the distal radius and placed in the nonunion site in intramedullary fashion as a strut. (Courtesy of Steve K. Lee, MD.)

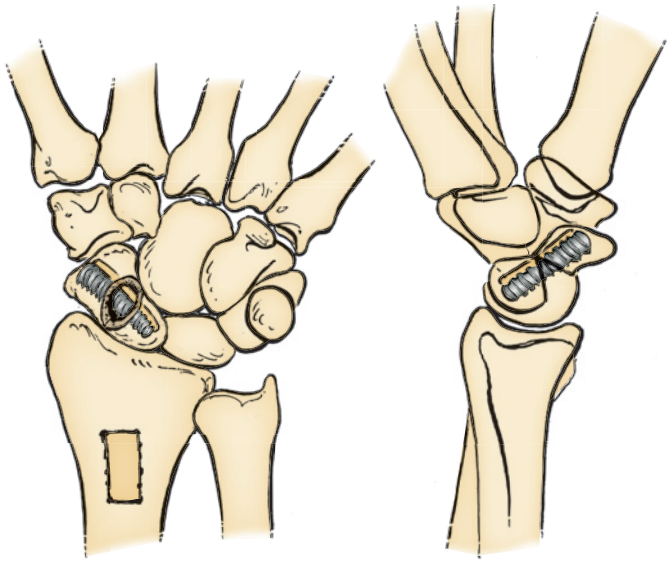

FIGURE 16.26 Posteroanterior (*PA*) and lateral line drawings showing the scaphoid after hybrid Russe procedure. The humpback deformity has been corrected and the length of the scaphoid has been restored. Headless screw provides additional fixation to the construct. (Courtesy of Steve K. Lee, MD.)

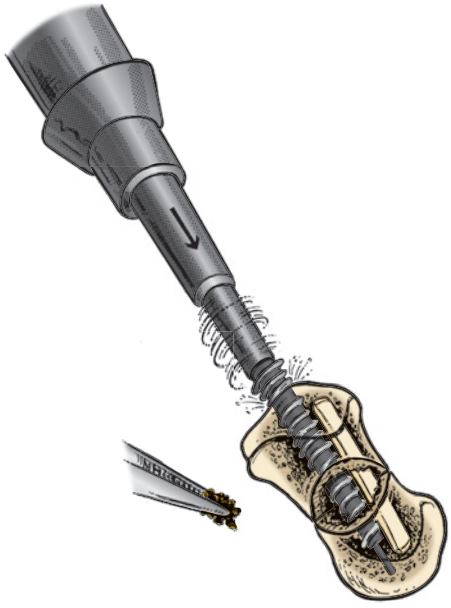

FIGURE 16.25 Cancellous bone graft is packed in the remainder of the nonunion site, followed by fixation with a headless compression screw. (Courtesy of Steve K. Lee, MD.)

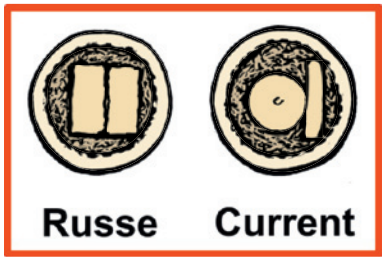

FIGURE 16.27 Drawing showing axial cut through the scaphoid comparing the Green's modified Russe procedure *(left)* and the hybrid procedure *(right),* showing the position of the screw as well as the graft.

If surgery has been performed previously, this technique may still be used, but the new screw should be placed from the opposite direction (Figure 16.28, *A* to *F*). The cortical strut may be inserted down the previous screw tract.

Surgical Fixation of Scaphoid Nonunion With Nonvascularized Bone Graft (Distant) Wedge Graft

Fernandez-Fisk wedge graft. In 1984, Fernandez presented his modification of the Fisk procedure to treat scaphoid nonunions associated with carpal instability.[60] His article described the following modifications: (1) preoperative calculation of the exact scaphoid length and form based on comparative radiographs of the opposite wrist, (2) the use of a palmar approach, (3) the insertion of a wedge-shaped corticocancellous graft from the iliac crest after resection of the pseudarthrosis, and (4) the use of internal fixation (Figure 16.29, *A* to *D*).

Preoperative planning is considered essential to restore the anatomic length, analyze the angular deformity, evaluate the pathologic scapholunate angle, and calculate the resection and size of the graft needed. The palmar approach reduces the danger of iatrogenic damage of the vascular supply of the scaphoid and accidental lesions of the superficial branches of the radial nerve. Iliac bone is preferred to the radial styloid graft, as proposed by Fisk, because of its better ability to resist compression forces. Internal fixation adds rotational stability so that continued postoperative plaster immobilization can be reduced to a minimum of 8 weeks.

In 1990, Fernandez reported union of 19 of 20 established nonunions repaired with this technique, with an average time off work of 8.9 weeks.[61] In a review of the pertinent literature, he determined that the most common reasons for recalcitrant

http://e-surg.com

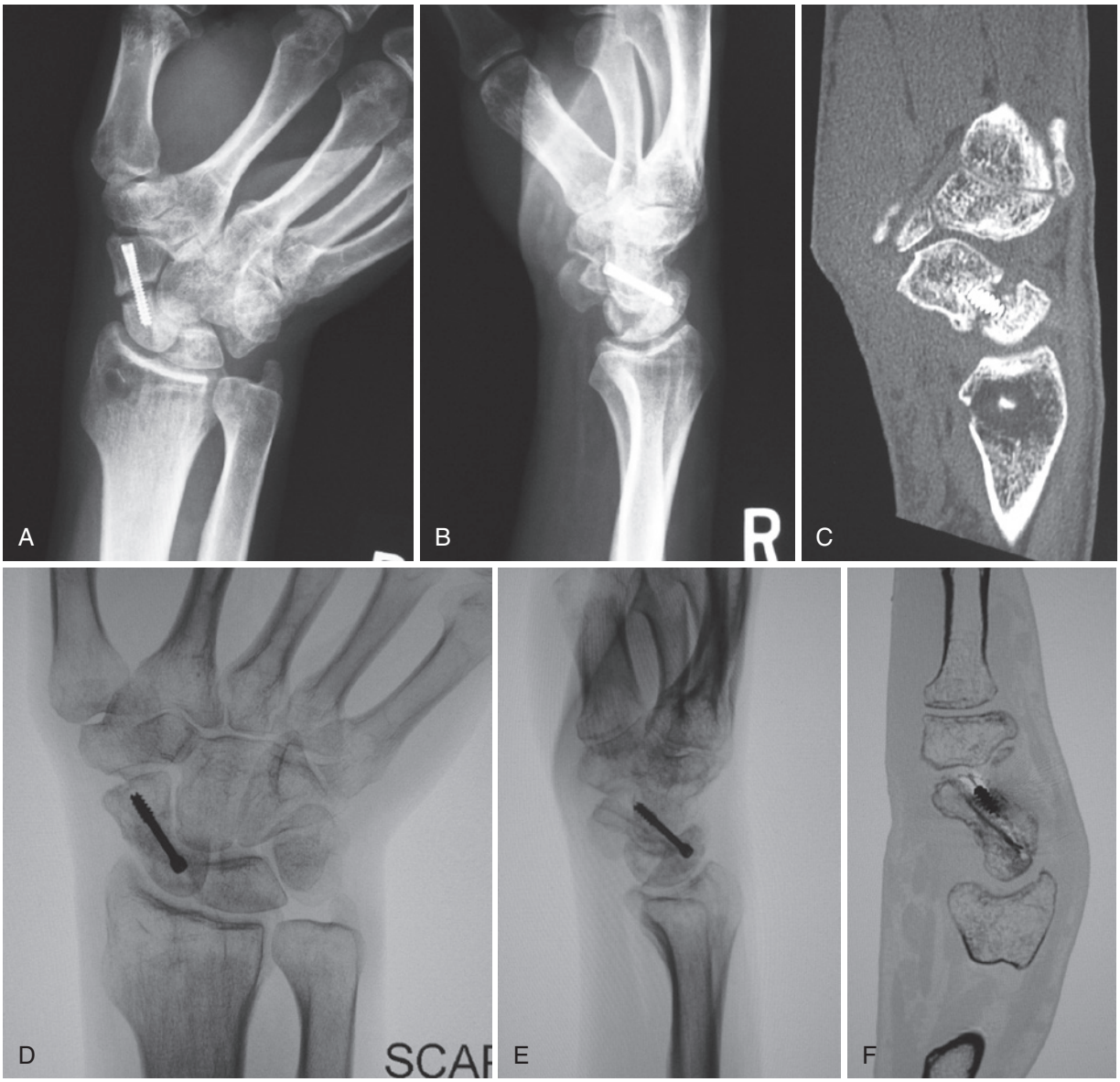

FIGURE 16.28 **A,** Oblique radiograph of wrist showing scaphoid nonunion after attempted open reduction and internal fixation. **B,** Lateral wrist radiograph. **C,** Computed tomography (CT) scan, sagittal view. At 12 weeks following operation, healing is evident on scaphoid **(D)** and lateral **(E)** radiographs and sagittal CT scan **(F)**. (Courtesy of Scott W. Wolfe, MD.)

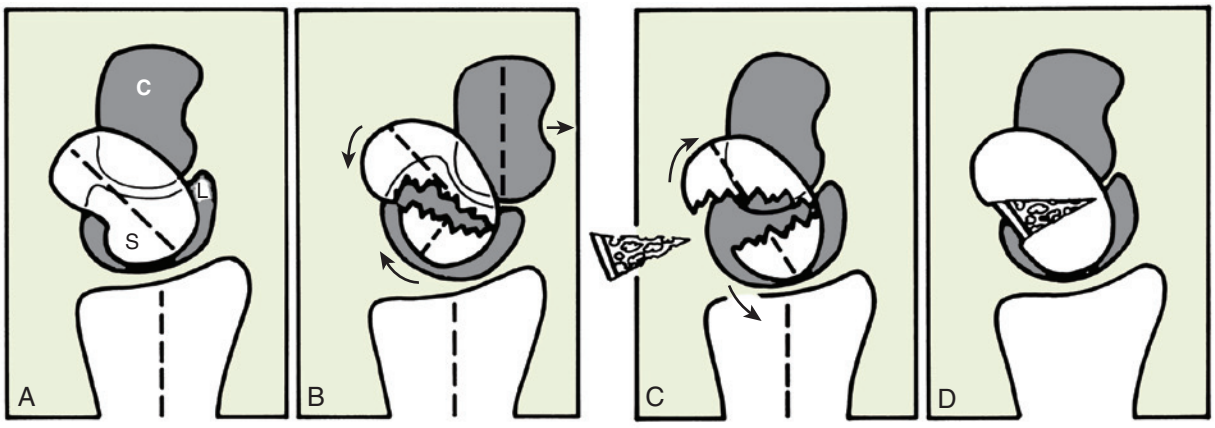

FIGURE 16.29 **A,** Schematic representation of normal alignment of the scaphoid (*S*), lunate (*L*), and capitate (*C*). **B,** Nonunion of a fracture of the scaphoid with palmar flexion of the distal fragment and a dorsal intercalated segmental instability pattern. **C,** The scaphoid alignment is corrected. **D,** It is maintained by the insertion of a palmar wedge-shaped bone graft. (From Taleisnik J: *The Wrist*, New York, 1985, Churchill Livingstone. Redrawn by Elizabeth Martin.)

http://e-surg.com

nonunion were improper internal fixation techniques or the absence of bone grafting, or both.

Eggli reported on a retrospective review of 37 patients with scaphoid fracture nonunions treated by interpositional bone grafting and internal fixation at an average follow-up of 5.7 years.[56] Solid radiographic union was achieved in 35 cases. Preexisting AVN was a major adverse factor for achievement of union and satisfactory outcome. Patients with preexisting degenerative changes had a significantly worse clinical outcome. The vast majority of the patients had satisfactory correction of scaphoid length and the associated DISI. Although 30 patients showed radiographic evidence of mild or moderate degenerative changes at their latest follow-up, there was no significant progression of arthrosis, and carpal collapse deformity did not progress after healing of the fracture nonunion.[56]

Arguments against the wedge graft. The wedge graft technique as described does not routinely incorporate curettage of the proximal and distal poles to bleeding cancellous bone. I would advise removing sclerotic, fibrotic, or cystic bone in the proximal and distal poles prior to insertion of the wedge graft and packing with additional cancellous graft. Volar wedge bone grafting may require 3 to 6 months to heal and may result in reduced wrist motion.[68] In documented avascular cases without punctate bleeding, volar wedge grafting with an autologous iliac crest graft is associated with union rates of only 30%.[168] Finally, the technique is exacting, and it may be challenging to simultaneously attain excellent compression, anatomic restitution of normal scaphoid anatomy, and rigid fixation.

Technique of anterior wedge grafting. Preoperative PA, lateral, and ulnar deviation PA radiographs of the injured wrist and the opposite normal wrist are used to determine the amount of resection and size of the graft needed. The surgeon must determine the amount of scaphoid flexion deformity, the extent of carpal collapse, and the scapholunate and lunocapitate angles (Figure 16.30, *A* to *C*). The humpback deformity can be evaluated more exactly using CT scans taken along the long axis of the scaphoid.

Nonunions of the distal third and waist are approached through a palmar hockey-stick incision along the FCR, extended obliquely toward the thenar eminence. The anterior capsule is incised from the distal radius to the scaphotrapezoidal joint to expose the most palmar-radial corner of the scaphoid. The capsular flaps contain the RSC ligament. Sclerotic or irregular borders of the nonunion site are resected with an oscillating saw to obtain flat bony surfaces. Cystic defects are curetted and filled with cancellous bone chips. The extended lunate is corrected by flexing the wrist until the lunate assumes a neutral position under fluoroscopy, and a 0.062-inch Kirschner wire is placed through the diaphyseal-metaphyseal junction of the radial styloid into the lunate under fluoroscopic control. The flexion deformity and shortening of the scaphoid are then corrected by distracting the osteotomy with small bone hooks or large skin hooks while hyperextending the wrist over a rolled towel. A bicortical or tricortical graft is harvested from the iliac crest, along with additional curetting of cancellous bone. The graft is kept in aspirated blood from the iliac wound until ready for use. Osteotomes of various sizes can be used to measure the depth, width, and length of the trapezoidal defect of the scaphoid,[168] and the graft is sculpted to the correct dimensions using a saw and osteotomes. The bone graft is impacted into the defect, and

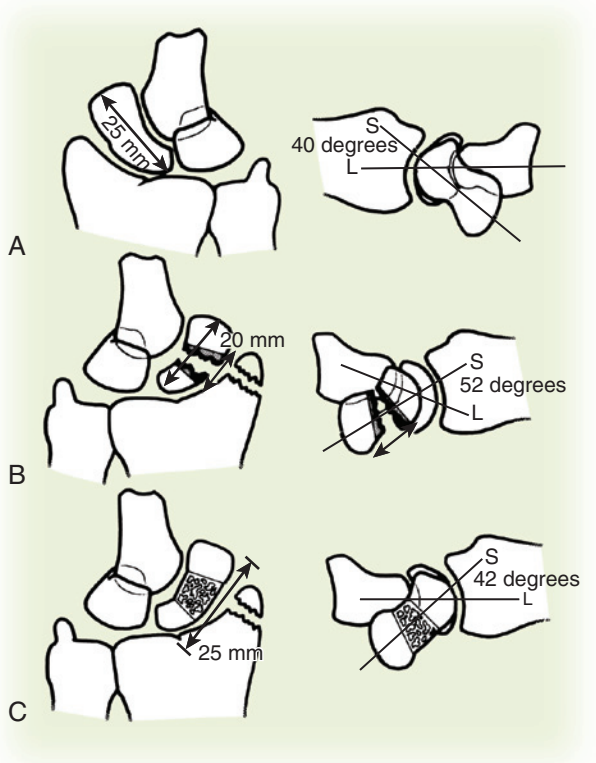

FIGURE 16.30 **A,** Preoperative planning for insertion of a wedge-shaped graft. Tracing of the opposite uninjured wrist and measurement of scaphoid length and scapholunate angle. **B,** Calculation of size, resection area, and form of graft. **C,** Definitive diagram of the operation. *L,* Lunate; *S,* scaphoid. (Redrawn from Fernandez DL: A technique for anterior wedge-shaped grafts for scaphoid nonunions with carpal instability. *J Hand Surg [Am]* 9:733–737, 1984. Redrawn by Elizabeth Martin.)

scaphoid alignment and posture are checked with fluoroscopy. A guidewire is advanced from distal to proximal across the scaphoid and intercalated graft. Finally, compression screw fixation of the scaphoid is performed. Careful closure of the palmar capsule and repair of the RSC ligament is done. A long-arm thumb spica postoperative splint is applied. Sutures are removed at 10 to 12 days, and the above-elbow immobilization is continued until the radiolunate pin is removed.

For long-standing DISI deformity that presents with a radiolunate angle greater than 20 degrees, the radiolunate transfixion wire is left in place for 4 to 6 weeks to reduce forces on the healing scaphoid. Short-arm casting is preferred until radiographic or CT evidence of trabecular healing has occurred. Fernandez's criteria for establishing healing include the absence of pain, radiographic evidence of bridging bony trabeculae on both sides of the interposed graft, a disappearance of the osteotomy lines in conventional x-rays, and no signs of screw loosening.[60] CT is advised to confirm union prior to return to athletic activities.

Type III: Proximal Pole Nonunion, No Arthritis

Open Dorsal Technique for Scaphoid Nonunions. This technique is particularly applicable for proximal third fractures with minimal displacement and cystic cavitation without humpback deformity. The technique is similar to that described above in the acute treatment of scaphoid fractures from the dorsal approach.

http://e-surg.com

The tourniquet is placed proximally on the arm and draped to allow full motion of the extremity. A small (≈2-3 cm) longitudinal incision is made just radial to the 3-4 arthroscopic portal. This area is also in line between the second and third metacarpal interspaces and extends proximally just radial to the Lister tubercle, crossing the dorsal lip of the radius. The EPL is carefully identified by opening the third dorsal compartment and may be transposed external to the retinaculum at the conclusion of the case. The second and fourth dorsal compartments are retracted and protected with Penrose drains. The capsule is incised along the dorsal rim of the radius, splitting the dorsal radiotriquetral ligament in the line of its fibers. If more exposure is necessary, a full ligament-sparing approach can be used (see Chapter 13), reflecting a radially based capsular flap by splitting the dorsal intercarpal ligament in line with its fibers.[18]

Extreme care is taken to avoid disruption of the dorsal fibers of the SLIL when reflecting the capsular flap. Dissection in a plane tangential to the dorsal surfaces of the scaphoid and the lunate can be performed with a scalpel or Beaver blade. The distal boundaries of dissection of the scaphoid are determined by the vascular supply along the dorsal ridge. Care is taken not to disrupt the blood vessels entering the waist of the scaphoid. Retractors may be placed deeper to retract the capsule. The proximal pole nonunion site may not be immediately evident, and a 25-g needle can be inserted under fluoroscopy to confirm the location. A small dorsal window is created to expose the nonunion site, and curets are used to excavate cystic areas. The proximal and distal poles are débrided to bleeding cancellous bone, and if the nonunion is adherent and has a smooth cartilaginous shell, no attempt is made to disrupt the two poles. If displaced, the scaphoid is aligned using Kirschner wire joysticks.

The Lister tubercle is removed with an osteotome and saved for re-placement in the graft cavity. A large amount of cancellous bone can be harvested. The harvested cancellous bone graft can be compacted using a 3-mL syringe and its plunger and cut to size for impaction into the nonunion. Thrombin-soaked Gelfoam may be inserted into the radial defect, and the tubercle can be replaced or inverted as a lid. The nonunion site is packed with cancellous bone graft. Screw fixation is performed as is described in the section on Author's Preferred Treatment Method: Dorsal Approach. Use of two microheaded screws (1.2-1.7 mm) can also be considered, but it is important to countersink and bury these small noncannulated headed screws. The capsule is closed with a running suture, and the retinaculum is closed with 2-0 absorbable suture.

Additional maneuvers to augment stability of the construct are to place a 0.045- or 0.062-inch Kirschner wire or headless compression screw from the distal scaphoid to the capitate[68] and to reduce the lunate to be collinear with the radius and pin from the radius to the lunate. If used, the radiolunate pin is stabilized with an above-elbow cast and the pin removed after 4 weeks. Scaphocapitate fixation is retained until healing, which may take 10 to 12 weeks. Inoue reported a successful union rate of 80% with cancellous bone grafting and Herbert screw placement through a dorsal approach.[105]

Percutaneous Bone Graft or Bone Graft Substitute, Arthroscopic Technique (Video 16.1)**.** Geissler and Slade are proponents of percutaneous bone grafting of proximal pole nonunions.[68] Slade and Gillon reviewed their experience with percutaneous bone grafting in a series of 234 scaphoid fractures.[183] Successful percutaneous treatment of scaphoid nonunions requires careful planning and the use of a number of imaging tools, including standard radiography, minifluoroscopy, CT or MRI, and arthroscopy. Chu and Shih reported that 14 of 15 (93%) scaphoid nonunions healed with arthroscopic-assisted use of injected bone graft substitute (Genex, Biocomposites, Keele, England). Herbert Whipple screw fixation was used.[36]

Percutaneous Bone Grafting of Scaphoid Nonunions. Selected minimally displaced or nondisplaced scaphoid fracture nonunions can be treated with percutaneous bone grafting and internal fixation. This may be particularly helpful for the small proximal pole fragment with cystic resorption at the fracture site but an intact cartilage shell. The technique for dorsal wire placement is the same as for acute fractures. The starting position for the guidewire is the proximal pole of the scaphoid. The wire is introduced into the proximal scaphoid pole using fluoroscopic imaging and is guided down the scaphoid central axis toward the thumb. The wrist is moderately flexed to avoid bending the guidewire. The wire is advanced toward the thumb base from a dorsal to volar position until the dorsal trailing end of the wire clears the radiocarpal joint, permitting full extension of the wrist. Once the dorsal trailing end of the guidewire has been buried into the proximal scaphoid pole, the wrist can be extended for imaging to confirm scaphoid alignment and correct positioning of the guidewire. If percutaneous wire placement is not possible, a mini-incision can be made over the 3-4 portal. The EPL tendon is located and retracted radially and the capsule is incised, exposing the proximal scaphoid pole. A drill guide is placed on the scaphoid proximal pole and a 0.045-inch double-cut guidewire is driven in a radial and distal direction toward the thumb base. Fluoroscopic imaging is used to confirm the correct course of the wire in the scaphoid.

Displaced nonunions may be percutaneously manipulated and reduced with the use of dorsally placed 0.062-inch joystick Kirschner wires in each fragment and a percutaneously placed hemostat, using the previously described techniques for acute fractures. Following accurate fracture reduction, placement of the guidewire, and measurement of the screw length, the wire is driven distally and out of the skin of the thenar eminence and clamped.

The scaphoid is reamed from the proximal scaphoid pole, crossing the nonunion site to the distal scaphoid 2 mm from the far cortex. The reaming of the distal scaphoid reestablishes a fresh blood supply and removes the devitalized bone at the nonunion site. The scaphoid wire is withdrawn distally across the nonunion site and into the distal fragment. A curet is placed through the proximal scaphoid portal to the nonunion site. This is done using real-time imaging. The outer cortex, which often has fibrous tissue, must not be violated, because this tissue acts as a net holding the percutaneously introduced bone graft. The wire is reintroduced across the fracture and out of the dorsal wound.

Percutaneous harvesting of bone graft. Bone graft can be percutaneously harvested from the distal radius or iliac crest using one of several bone-coring devices that are commercially available. We prefer a 4-inch 8-gauge bone biopsy needle (Baxter Jamshidi, Deerfield, IL) to percutaneously harvest cancellous bone graft. A guidewire is percutaneously inserted into the

http://e-surg.com

dorsal distal radius near or at the Lister tubercle. A small incision and blunt dissection expose the bone cortex. A hand reamer is used to penetrate the cortex. The bone biopsy cannula is introduced over the Kirschner wire, the Kirschner wire is removed, and cancellous bone plugs are harvested.

Attention is directed back to the scaphoid, and the biopsy cannula is inserted over the guidewire into the prepared nonunion site. The guidewire is withdrawn into the distal scaphoid pole. Guided by imaging, autogenous bone plugs are implanted through the cannula into the nonunion site using the plunger, and the graft is impacted. The guidewire is driven back across the proximal pole and out of the dorsal wound. Rigid fixation is obtained with percutaneous cannulated headless screw fixation along the guidewire axis. Additional implants may be inserted to further stabilize the fracture site and prevent bone shearing until bone healing has occurred as needed, including a screw or wire to temporarily lock the midcarpal joint and a radiolunate wire as needed. In some cases, extreme proximal scaphoid pole nonunions have been treated with bone grafting and compression by sandwiching a compression screw from the midscaphoid to the lunate in addition to the midcarpal locking screw.

Postoperative care. Immediate postoperative care includes a bulky compressive hand dressing and a volar splint. The patient is encouraged to initiate early finger exercises to reduce swelling. The therapist fashions a removable volar splint that holds the wrist and hand in a functional position at the first postoperative visit, and the patient is started on an immediate gentle strengthening program the purpose of which is to axially load the fracture site now secured with an intramedullary screw to stimulate healing. This early digital motion program decreases swelling and permits an early return of hand function. Patients with eccentric fractures, particularly proximal pole fractures, are restricted from wrist motion until CT scan confirms bridging bone at the fracture site at 6 weeks following operation. Although postoperative radiographs are obtained at the first postoperative visit and at 6-week intervals, a CT scan is used to confirm trabecular bridging.

Dysvascular Nonunion, Waist or Proximal Pole Fracture. When vascularized bone grafting was first introduced, the healing rate was reported to be 100%.[195,228] With time, the original enthusiasm has waned because more reports have shown much lower healing percentages. Hirche and colleagues reported a healing rate of only 75% with the 1,2 intercompartmental supraretinacular artery bone graft.[94] Chang and associates reported a union rate of 50% with the same graft if AVN was present,[34] and Straw and coworkers reported a union rate of only 12% if AVN was present.[196] No distinct guidelines exist as to which cases would most benefit from vascularized bone grafting.

Previous papers reported low healing rates with the Russe technique[80] (0% union) or volar iliac crest wedge grafting[168] (30% union) when ischemic bone was diagnosed by the absence of punctate bleeding. Many of these patients were treated with Kirschner wire fixation, before the advent of headless screw fixation. Modern methods of rigid internal fixation have called into question the relative importance of ischemia versus fixation strength as the key parameter influencing healing of scaphoid nonunions. Whether removal of necrotic or dysvascular bone and replacement with healthy autogenous bone and rigid fixation is preferable to retention of ischemic bone and implantation of a vascular graft to encourage creeping substitution has not been answered by the current scientific evidence. In fact, few papers report the histologic findings of surgically treated nonunions, making comparative studies impossible. There is controversy as to how to best assess vascularity of the proximal pole, whether by preoperative MRI with or without contrast or by the presence or absence of bleeding bone intraoperatively. Given all of these unanswered questions, the role of vascular grafting for scaphoid nonunion cannot be stated with certainty; the various options available and current best evidence will be reviewed.

In 1979, Hori and colleagues performed elegant canine studies to demonstrate the efficacy of an implanted arteriovenous pedicle to treat osteonecrosis.[97] Sunagawa and colleagues, in a subsequent canine study, compared nonvascularized (conventional) grafts with arteriovenous pedicle graft implantation and quantitatively assessed bone blood flow, fracture healing, and bone remodeling.[197] They found that 73% of the vascularized grafts and none of the conventional grafts healed. At 6 weeks, bone blood flow in the proximal pole was significantly higher on the side of the vascularized graft. Quantitative histomorphometry of the avascular proximal segment demonstrated significantly higher levels of fluorochrome-labeled osteoid- and osteoblast-covered trabecular surfaces on the vascularized graft side. These data supported the clinical application of pedicled vascularized bundle implantation in the treatment of carpal osteonecrosis including proximal pole scaphoid nonunions (Figure 16.31).[62]

Vascularized Bone Grafting. Since 1986 there has been great interest in vascularized bone grafting to treat bony nonunion

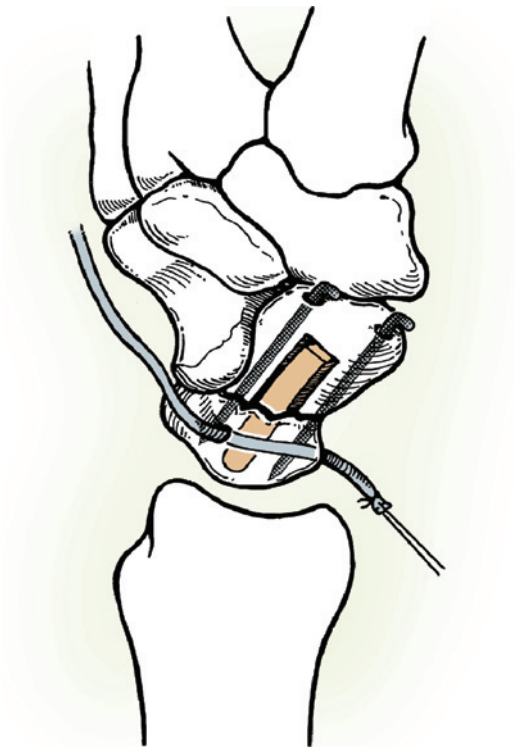

FIGURE 16.31 Second intermetacarpal vascular bundle implantation. (From Fernandez DL, Eggli S: Nonunion of the scaphoid: revascularization of the proximal pole with implantation of a vascular bundle and bone grafting. *J Bone Joint Surg [Am]* 6:883–893, 1995. Redrawn by Elizabeth Martin.)

http://e-surg.com

including the scaphoid. Shi reported on an experimental study and clinical uses of the fasciosteal flap for bone healing.[180] In 1991, Zaidemberg and colleagues demonstrated a consistent vascularized bone graft source from the distal dorsal radial radius for the treatment of scaphoid nonunions using latex injection techniques.[228] In a preliminary series of 11 patients, these authors reported 100% success.[228]

Although when to use vascularized bone grafting is controversial, many authors discuss using it for AVN when there is lack of punctate bleeding witnessed intraoperatively. Another indication may be persistent nonunion following previously attempted surgical treatment. Some of the more common vascularized bone graft choices are:

1. 1,2 intercompartmental supraretinacular artery (ICSRA) pedicle (Zaidemberg)
2. Pedicled on the volar carpal artery (Mathoulin)
3. Dorsal capsular pedicle (Sotereanos)
4. Free medial femoral condyle graft (Doi, Bishop and Shin, Higgins)

1,2 Intercompartmental Supraretinacular Artery Pedicle

Vascular anatomy of dorsal radius grafts. The vessels supplying the nutrient arteries to the dorsal radius are best described by their relationship to the extensor compartments of the wrist and the extensor retinaculum. The 1,2 intercompartmental supraretinacular artery (1,2 ICSRA) is superficial to the extensor retinaculum and lies between the first and second compartments. The 2,3 intercompartmental supraretinacular artery (2,3 ICSRA) lies superficial between the second and third compartments. Both arteries are at areas where the extensor retinaculum is firmly attached to bone, allowing nutrient arteries to penetrate the cortex. In addition to the superficial vessels, two vessels are deep to the extensor tendons on the floor of the fourth and fifth dorsal compartments. These are the fourth and fifth extensor compartment arteries (ECAs). The 1,2 ICSRA branches from the radial artery 5 cm proximal to the radiocarpal joint and rises dorsally to lie on the extensor retinaculum between the first and second compartments.

Technique for surgical preparation of the 1,2 ICSRA graft. The 1,2 ICSRA graft for scaphoid nonunion described by Zaidemberg and colleagues[228] (Figure 16.32) is most useful for scaphoid nonunion, but it has a relatively short pedicle. A dorsal radial incision is centered over the radiocarpal joint between the first and second compartments. This allows good exposure of the dorsal radial scaphoid. Branches of the superficial radial

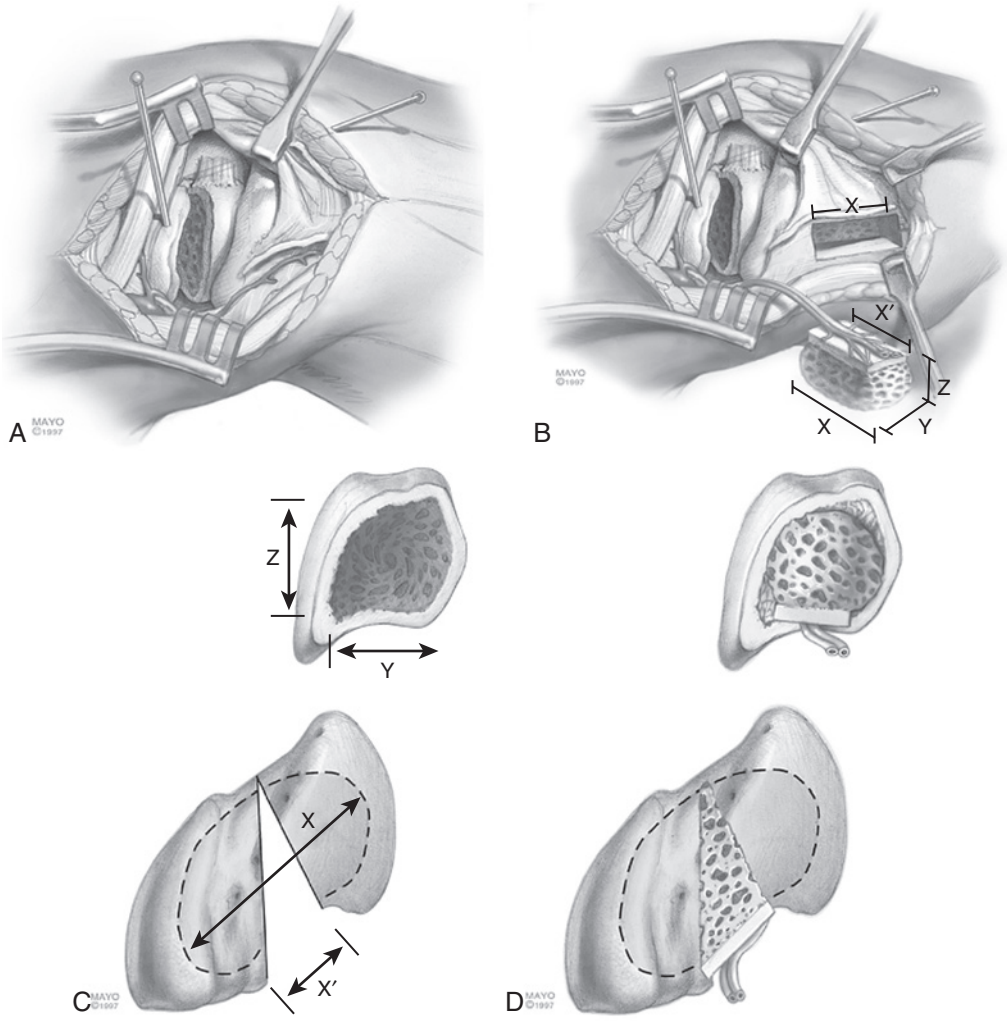

FIGURE 16.32 Use of a dorsal radius vascularized graft in cases of malunion or humpback deformity. **A,** The scaphoid is prepared before graft elevation. **B,** A large graft is harvested that can be shaped into a wedge. **C** and **D,** The graft is trimmed to fit the defect dimensions and used as a volar strut. *X,* length of intramedullary defect; *X′,* length of cortical gap; *Y,* width; *Z,* height. (By permission of Mayo Foundation for Medical Education and Research. All rights reserved.)

http://e-surg.com

nerve need to be identified and protected. The 1,2 ICSRA is found coursing up dorsally from the radial artery to lie superficially on the surface of the extensor retinaculum between the first and second compartments (Figure 16.33). The first and second compartments are incised at their attachments to bone near the 1,2 ICSRA. The 1,2 ICSRA is carefully mobilized as a pedicle (Figure 16.34). Care is taken not to elevate the pedicle off the bone more than 10 to 15 mm proximal to the joint line, because this is the area where the nutrient vessels begin to penetrate the cortex. The pedicle is freed almost to the radial artery at the level of the first compartment.

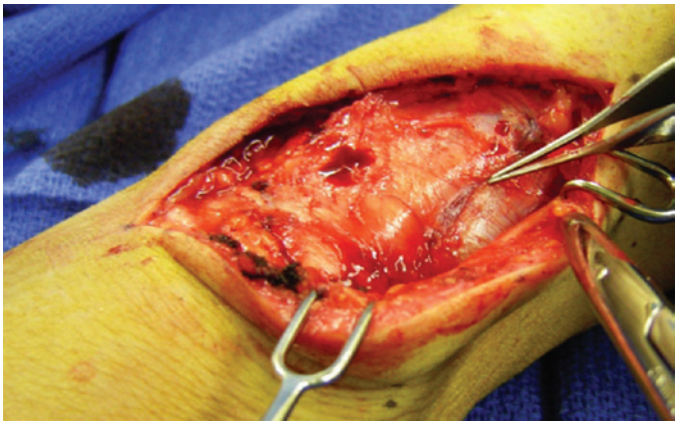

FIGURE 16.33 1,2 intercompartmental supraretinacular artery (1,2 ICSRA) is found coursing dorsally from the radial artery to lie superficially on the surface of the extensor retinaculum between the first and second extensor tendon compartments. The vascularized bone graft is harvested on a pedicle from the 1,2 ICSRA. Branches of the superficial radial nerve need to be identified and protected during the isolation of this pedicle. (Figure used with permission from Seth D. Dodds, MD.)

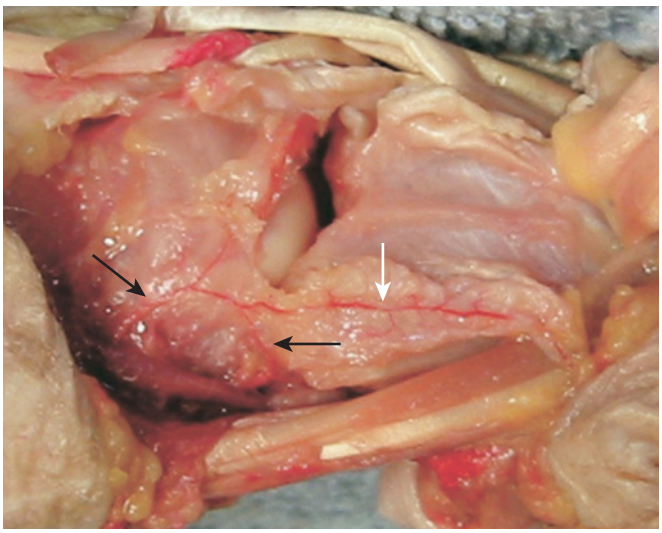

FIGURE 16.34 The first and second compartments are incised at their attachments to bone near the 1,2 intercompartmental supraretinacular artery (IC)SRA. The 1,2 ICSRA is mobilized as a pedicle. The pedicle is not elevated off of the bone more than 10 to 15 mm proximal to the joint line, because this is the area where the nutrient vessels begin to penetrate the cortex (*arrows*). The pedicle is freed up almost to the radial artery at the level of the first compartment. (Figure used with permission from Seth D. Dodds, MD.)

After elevation of the pedicle, the scaphoid nonunion is approached through a radial longitudinal incision at the capsule. The nonunion site is identified and exposed. Ideally, a rectangular slot is created, bridging the fracture site in the scaphoid that will receive the bone graft. If the fracture is in the proximal pole, a slot can be created in the distal fragment, and the proximal pole can be curetted or burred out of avascular bone. In such a case, the graft would slide into the concavity of the proximal pole and fit into the slot in the distal fragment. A small, limited radiostyloidectomy can improve visualization but is often not needed. If the scaphoid is foreshortened with a humpback deformity, a vascularized graft may be placed as a volar wedge graft. This requires a wider exposure, which is accomplished by radial styloidectomy.

Once the nonunion site is prepared, the pedicled graft is carefully lifted from the radial metaphysis using small osteotomes. The 1,2 ICSRA is ligated proximal to the graft, and the graft is checked for flow by deflating the tourniquet. The graft is passed under the radial wrist extensors and impacted gently into place. If a significant concavity exists in either the proximal or distal fragment, additional cancellous bone is harvested from the distal radius to fill out the deep area of concavity in the scaphoid. Once the graft is in place, a screw is placed down the scaphoid and supplemental internal fixation may be used. Alternatively, if the scaphoid fragments are loose and grossly unstable with respect to each other, internal fixation can be placed first to stabilize the scaphoid as a single unit, and the vascularized graft can be impacted into place. The screw should be placed in the volar third of the scaphoid to reduce the chance of dislodging the graft.

Outcomes. Outcomes of the 1,2 ICSRA vascularized bone graft have had an interesting and evolving history. Initial reports were incredible, with some authors reporting union rates of 100%.[195,228] Later investigations were more critical, with healing rates of only 71%, and, if AVN was present, only 50%. Moreover, failures occurred in 64% if humpback deformity and DISI were present. The conclusion was that 1,2 ICSRA grafting is not suitable for scaphoid nonunion with AVN and carpal collapse.[34] Straw and colleagues[196] reported on Zaidemberg's technique, which they used to treat 22 established scaphoid fracture nonunions, 16 of which were found to have avascular proximal poles at surgery. The union rate was a dismal 27%. If AVN was present, the union rate was a mere 12.5%. A confounding element of this study was poor fixation of a single Kirschner wire. Boyer and colleagues showed poor healing with the 1,2 ICSRA when there was AVN, with 6 of 10 (60%) achieving union.[25] In a recent study, a union rate of only 75% was achieved.[94]

For a humpback deformity and AVN, Henry[90] showed good results; this is in contrast to a level I study by the Mayo group[110] in which a distal radial pedicle graft was compared with a medial femoral condyle graft (see the following). Henry reported a union rate of 100% in 15 patients with a scaphoid nonunion and proximal pole AVN with humpback deformity at a mean of 11.5 weeks after surgery with a volarly inserted, wedge-shaped, 1,2-ICSRA vascularized bone graft and headless compression screw fixation.[90]

Vascularized Bone Graft Pedicled on the Volar Carpal Artery. Kuhlmann and colleagues were the first to describe the vascularized bone graft pedicled on the volar carpal artery,[124] which lies between the palmar periosteum of the radius and the

http://e-surg.com

distal part of the superficial aponeurosis of the pronator quadratus. It is harvested from the distal radius along with a 5-mm-wide strip of fascia and periosteum, using a volar approach. A trapezoidal graft can be harvested and placed palmarly in the case of humpback deformity.

Dailiana reported its use in nine patients with scaphoid nonunion; union was achieved in 100% of cases. However, there was no preoperative carpal collapse and only one patient had AVN.[42] Gras and Mathoulin reported on the use of this vascularized bone graft in 111 patients, 47 of whom had DISI. None had AVN. The union rate was 96% for primary nonunions and 90% for secondary nonunions (Figure 16.35).[79]

Other Pedicled Bone Grafts

Surgical fixation of scaphoid nonunion with vascularized bone graft; dorsal capsular pedicle. Sotereanos and colleagues[188] described a dorsal capsular-based vascularized distal radius graft. This graft is harvested from the dorsal distal radius, just ulnar and distal to the Lister tubercle, and is based on a wide distally based strip of the dorsal wrist capsule, which is supplied by the artery of the fourth extensor compartment. The graft is placed as a dorsal inlay graft. Their series had 13 patients, 10 of whom had AVN and two of whom had DISI (Case Study 16.1). The rate of union was 10 of 13 (77%).[188]

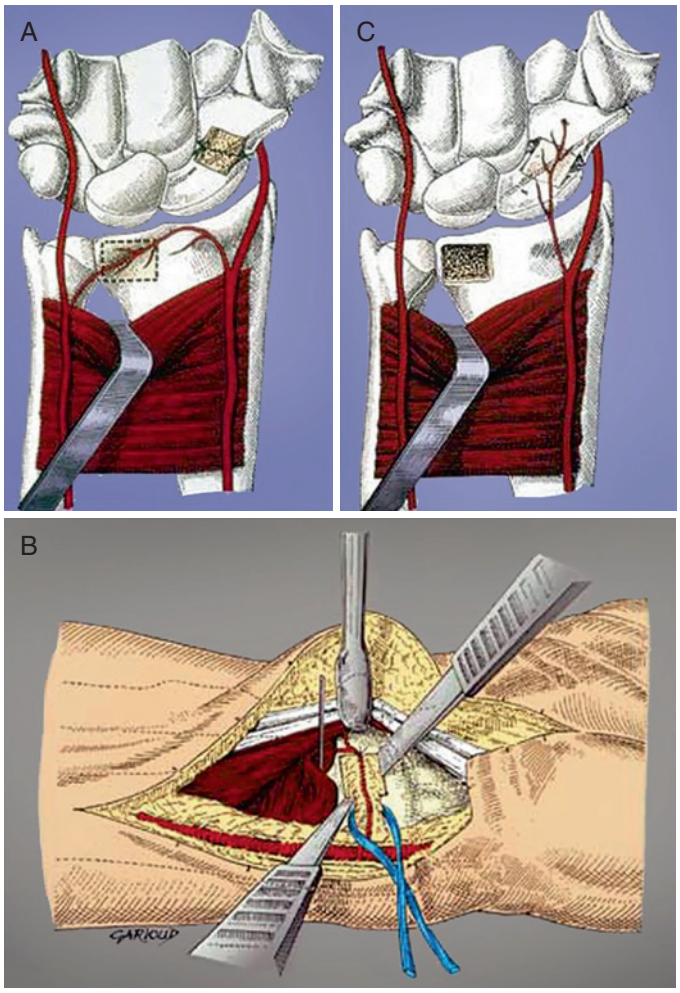

FIGURE 16.35 Harvest and inset of the volar distal radius vascularized bone graft based on the radial contribution to the volar carpal artery. Donor site **(A)**, graft elevation with small osteotomes **(B)**, and inset **(C)** are noted. A small pyramid-shaped graft is harvested, and a small rim of fascia is taken around the pedicle during its subperiosteal dissection from the distal radius. (Adapted, with permission, from Mathoulin C: Treatment of scaphoid nonunion with a vascularized bone graft harvested from the volar aspect of the radius, Maîtrise Orthopédique no. 105, June 2001. Reprint is in Derby BM, Murray PM, Shin AY, Bueno RA, Mathoulin CL, Ade T, Neumeister MW: Vascularized bone grafts for the treatment of carpal bone pathology. *Hand* 8(1):27-40, 2013.)

Surgical fixation of scaphoid nonunion with vascularized bone graft; thumb metacarpal based on first dorsal metacarpal artery. Bertelli and colleagues[20] reported on the use of a bone graft from the thumb metacarpal pedicle on the first dorsal metacarpal artery used as a volar interposition graft to treat persistent scaphoid nonunions. They achieved a 90% union rate in 10 patients. Mathoulin and Brunelli presented the transfer of the index metacarpal pedicle (based on the dorsal intermetacarpal artery) for failed scaphoid surgery. Healing occurred in 14 of 15 patients, but only 10 patients had good function; previously unrecognized arthritis prevented good function in the other patients.[137]

Free Vascularized Bone Grafts

Iliac crest vascularized bone graft. The iliac crest vascularized bone graft is based on the deep circumflex iliac vascular pedicle. The vascular anastomosis is performed end-to-side to the radial artery and end-to-end to the venae comitantes. Gabl reported on its use in 15 patients with AVN and achieved union in 12 of 15 cases (80%).[65] Arora and colleagues reported on 21 patients in whom this technique was used for failed previous surgery with AVN; 76% achieved union.[12]

Surgical fixation of scaphoid nonunion with vascularized bone graft; free medial femoral condyle graft. In 1991 Doi and colleagues described the medial femoral condyle as a vascularized bone graft based on the articular branch of the descending genicular artery and vein or the superomedial genicular vessels.[173] Doi subsequently reported achieving union in 100% of 10 patients with scaphoid nonunion.[53]

Jones and colleagues[110] compared the medial femoral condyle vascularized bone graft with the 1,2 ICSRA graft. Twenty-two patients with scaphoid waist nonunions associated with an avascular proximal pole and carpal collapse were treated. Four of the 10 nonunions treated with the distal radial pedicle graft healed (40%) at a median of 19 weeks, and all 12 nonunions treated with the free medial femoral condyle graft healed (100%) at a median of 13 weeks. The rate of union was higher ($p = .005$) and the median time to healing was significantly shorter ($p < .001$) for the nonunions treated with the medial femoral condyle graft (Figure 16.36, *A* to *F* and Case Study 46.1).

Clinical use has spurred anatomic studies to further define the vascular anatomy. The descending genicular artery was present in 89% of specimens, originating at an average distance proximal to the articular surface of 13.7 cm, and the superior medial genicular artery was present in 100%, at 5.2 cm from the joint line. The average number of perforating vessels was greatest in the posterior distal quadrant condyle.[226]

Vascularized medial femoral trochlea osteocartilaginous flap reconstruction. Higgins and Burger published their series of vascularized medial femoral trochlea osteocartilaginous flap reconstruction of proximal pole nonunion and had healing in 15 of 16 patients. Similar to the rib osteochondral autograft, indications are unreconstructable or completely necrotic proximal poles without arthritis[93] (Case Study 16.2).

http://e-surg.com

CASE STUDY 16.1 Scaphoid Proximal Pole Nonunion

A 32-year-old man had a history of pain for 6 months in the radial side of the right wrist after he had fallen onto the outstretched hand. The hand had been treated with a cock-up splint.

1. What is the diagnosis?
   a. Scaphoid humpback nonunion
   b. Dysvascular scaphoid proximal pole nonunion
   c. Scaphoid nonunion advanced collapse
   d. Partially healed scaphoid fracture
   e. Scaphoid malunion
   ANS: b. Dysvascular scaphoid proximal pole nonunion
2. Which of the following treatment options is most likely to result in union?
   a. Proximal pole excision
   b. Percutaneous screw fixation retrograde
   c. Percutaneous screw fixation antegrade
   d. Autogenous graft with Kirschner wire fixation
   e. Vascularized bone graft
   ANS: e. Capsular-based vascularized bone graft from the dorsal distal radius
   The outcome at 5 months following operation is shown in eFigures 16.8 and 16.9.
3. Which of the following is the best indication for vascularized bone grafting to the scaphoid?
   a. Symptomatic scaphoid nonunion
   b. Humpback scaphoid nonunion with dorsal intercalated segmental instability (DISI)
   c. Preiser disease with scaphoid collapse
   d. Avascular necrosis of the proximal pole
   e. Scaphoid nonunion advanced collapse
   ANS: d. Avascular necrosis of the proximal pole

Dean G. Sotereanos, MD
Clinical Professor of Orthopaedic Surgery
University of Pittsburgh School of Medicine
Orthopaedic Specialists–UPMC
Pittsburgh, Pennsylvania



http://e-surg.com

eFIGURE 16.1



eFIGURE 16.2



eFIGURE 16.3

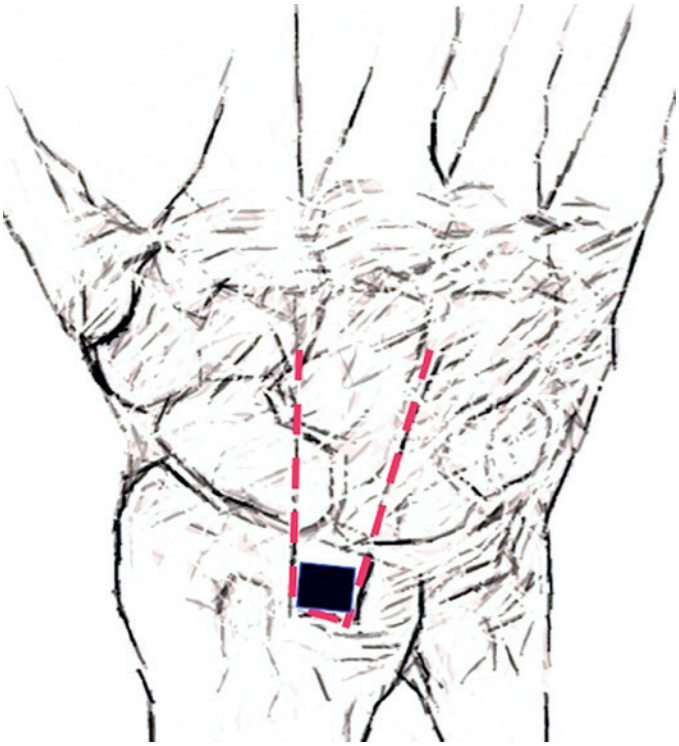

eFIGURE 16.4 (From Sotereanos D: The capsular-based vascularized bone graft from the dorsal distal radius. In Slutsky DJ, editor: *The art of microsurgical hand reconstruction,* New York, 2013, Theme, pp 234–241, Figure 28.1a.)

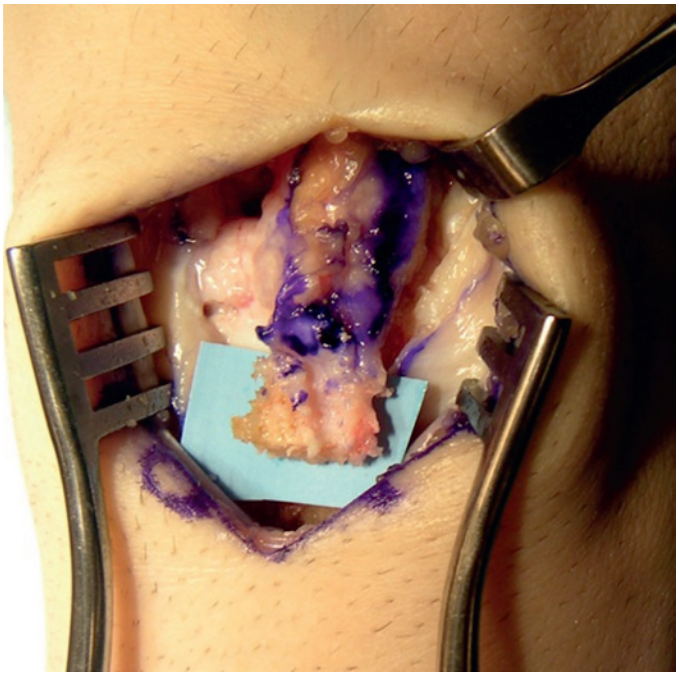

eFIGURE 16.5



eFIGURE 16.6 (From Sotereanos D: The capsular-based vascularized bone graft from the dorsal distal radius. In Slutsky DJ, editor: *The art of microsurgical hand reconstruction,* New York, 2013, Theme, pp 234–241, Figure 28.2a.)



eFIGURE 16-7 (From Sotereanos D: The capsular-based vascularized bone graft from the dorsal distal radius. In Slutsky DJ, editor: *The art of microsurgical hand reconstruction,* New York, 2013, Theme, pp 234–241, Figure 28.2b.)

http://e-surg.com



eFIGURE 16.8



eFIGURE 16.9

http://e-surg.com

CASE STUDY 16.2 Scaphoid Nonunion

A 27-year-old right-hand–dominant man had sustained a proximal pole scaphoid fracture 2 years prior to presentation. He was initially casted, but the scaphoid failed to heal. One year later he had undergone grafting with the 1,2 intercompartmental vascularized bone flap. Again the bone failed to unite. He presents now with a very small proximal pole scaphoid nonunion (eFigures 16.10 and 16.11) that has caused pain with grasping.

In order to preserve his scaphoid, he underwent free medial femoral trochlear osteochondral flap reconstruction. The screw as well as a subtotal proximal scaphoid excision was performed to the level of the scaphoid waist (eFigure 16.12).

The convex cartilage of the proximalmost portion of the medial femoral trochlea was harvested in continuity with the periosteal transverse branch of the descending geniculate artery (eFigures 16.13 and 16.14).

The cartilage surface was used to recreate the greater curvature of the proximal scaphoid. The flap was secured to the distal pole via cannulated screw fixation. The vascular pedicle was anastomosed to the radial artery in the snuffbox in an end-to-side fashion. X-rays at 4 weeks demonstrated good alignment and preservation of normal scapholunate alignment (eFigures 16.15 and 16.16). X-rays 1 year following operation reveal excellent recapitulation of the scaphoid form (eFigure 16.17).

James P. Higgins, MD
Chief, Curtis National Hand Center
Union Memorial Hospital
Baltimore, Maryland



eFIGURE 16.11



eFIGURE 16.10



eFIGURE 16.12

http://e-surg.com

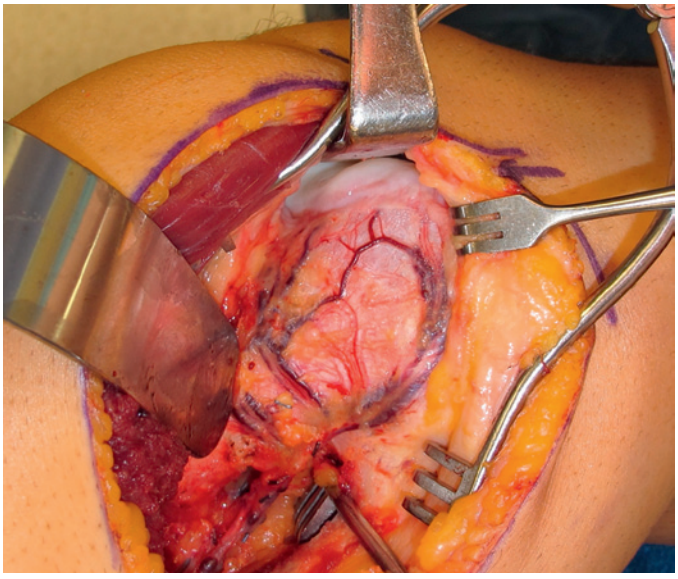

eFIGURE 16.13

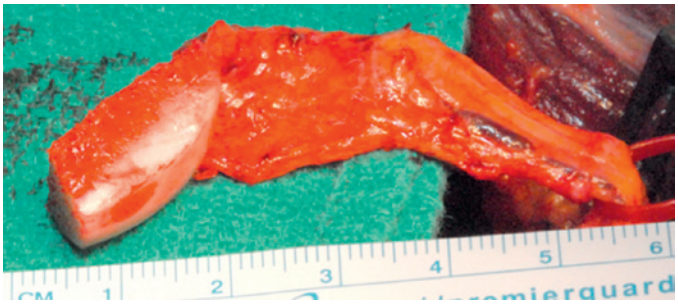

eFIGURE 16.14



eFIGURE 16.15



eFIGURE 16.16



eFIGURE 16.17

http://e-surg.com

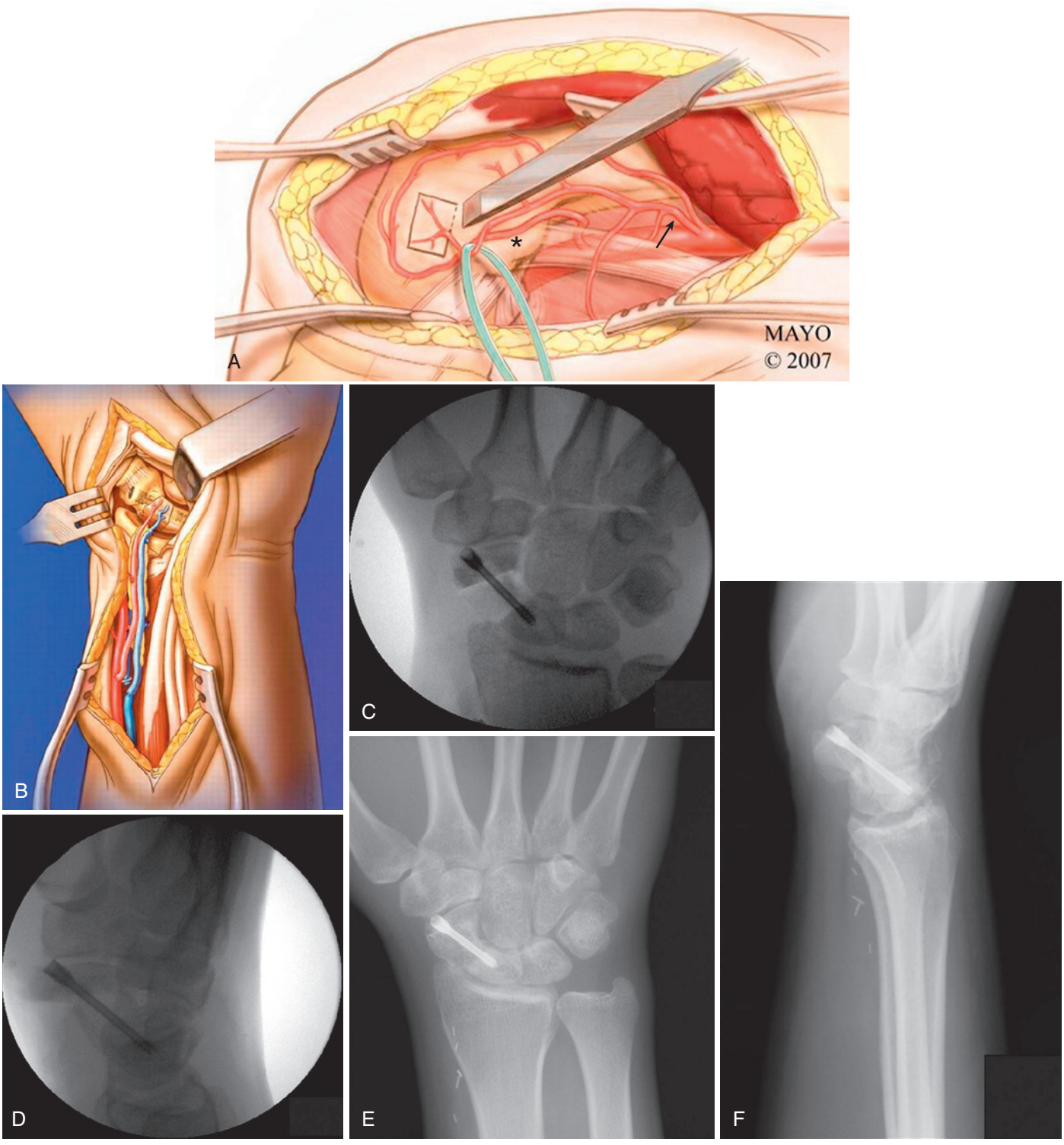

FIGURE 16.36 **A,** Raising the medial femoral condyle graft. **B,** The graft transferred to the scaphoid nonunion. **C** and **D,** Posteroanterior and lateral fluoroscopic intraoperative views after graft and screw placement. **E** and **F,** Posteroanterior and lateral radiographic views after healing. (From Jones DB Jr, Burger H, Bishop AT, et al: Treatment of scaphoid waist nonunions with an avascular proximal pole and carpal collapse: a comparison of 2 vascularized bone grafts. *J Bone Joint Surg Am* 90:2616–2625, 2008.)

Prognosis for Healing of Scaphoid Nonunion

Merrell and colleagues performed a systematic quantitative metareview of the literature to provide evidenced-based suggestions for the treatment of scaphoid nonunion.[145] This search identified 1121 articles, of which 36 met eligibility requirements. In unstable nonunions, screw fixation with corticocancellous wedge grafting, which resulted in union in 94% of cases, was superior to Kirschner wires and wedge grafting, which resulted in union in 77% of cases. Immediate mobilization was compared with 6 weeks or more of casting, and they

http://e-surg.com

demonstrated comparable healing rates of 74%. For patients with reported AVN of the proximal fragment, union was achieved in 88% of patients with a vascularized graft versus 47% with screw and intercalated corticocancellous graft.

Shah and Jones reported on 50 scaphoid nonunions treated with Herbert screw fixation.[178] Success rates fell off as the duration of nonunion increased. The authors felt that this may have been related to the increased incidence of AVN with time. In their series, the major adverse determinants for outcome were AVN and a history of previous surgery for nonunion.

Inoue and colleagues retrospectively reviewed 160 cases of scaphoid nonunion treated by internal fixation using a Herbert screw with bone grafting at an average follow-up of 24 months.[104] Radiographic union was achieved in 90% of cases. Failure of union was related to the existence of avascular changes of the proximal fragment, instability of the fracture fragment, the prolonged delay in surgery, and the location of the fracture site. Persistent flexion deformity of the scaphoid adversely affected outcomes.

Schuind and colleagues reported on a multicenter study of 138 patients following scaphoid nonunion surgery.[177] Definitive healing occurred in only 74% of cases. Duration of nonunion longer than 5 years was associated with nonunion following the operation.

❖ AUTHOR'S PREFERRED METHOD: Scaphoid Nonunion (Table 16.5)

Unsalvageable Scaphoid Proximal Pole Nonunion

Rib osteochondral autograft reconstruction of the proximal pole. Yao and colleagues[227] reported success in three cases with more than 2 years of follow-up of rib osteochondral autograft reconstruction of the proximal pole of the scaphoid. Indications are unreconstructable or completely necrotic proximal poles in the absence of arthritis. They all healed and had good function. Sandow reported on 47 cases, none going to revision surgery.[174] Veitch reported on success on 13 of 14 cases.[210]

1. For delayed union, use rigid fixation with headless compression screw. Nonvascularized bone graft should be used if CT shows bone loss. Dorsal versus palmar approach is dependent on the location of the fracture. For waist or proximal, use the dorsal approach. The palmar approach should be used if the fracture is distal to the waist.
2. For waist nonunion with humpback, use the Hybrid Russe procedure.
3. For proximal pole nonunion, dorsal approach, use nonvascularized bone graft and screw fixation. Consider supplemental K wire fixation of distal scaphoid to capitate to neutralize long lever arm.
4. If nonsalvageable proximal pole (fragmented), then use osteochondral medial femoral condyle free flap.

TABLE 16.5 Author's Preferred Treatment: Scaphoid Nonunion

Nonunion waist, no arthritis to minimal arthritis, with humpback deformity
- Hybrid Russe bone graft technique
- Headless compression screw
- Possible radial styloidectomy if SNAC I
- If surgery had been performed previously, the screw is removed and a new screw is placed from the opposite pole
- Consider radiolunate wire after lunate reduction if DISI is present

Nonunion proximal pole, no arthritis, with or without ischemia
- Nonvascularized bone graft, headless compression screw from dorsal approach
- Controversial to use vascularized bone graft during first surgery
- Consider scaphocapitate and, possibly, radiolunate temporary Kirschner wire or screw

Nonunion waist, no arthritis, acceptable alignment, stable
- In situ nonvascularized cancellous bone graft
- Headless compression screw

Nonunion waist, arthritis, SNAC II. nonreconstructable, distal pole grossly deformed
- Scaphoid excision with four-bone fusion
- Proximal row carpectomy
- Consider distal scaphoid pole excision if proximal scaphoid fossa is preserved and capitolunate arthritis is not present

Nonunion proximal pole, no arthritis, not salvageable (proximal pole < 5 mm)
- Scaphoid excision with four-corner fusion
- Proximal row carpectomy
- Osteoarticular autograft vascularized[93] or nonvascularized[227]

CRITICAL POINTS *Scaphoid Nonunion*

1. Preoperative CT is imperative to understand three dimensional pathoanatomy and plan surgical approach and appropriate hardware placement.
2. Carpal alignment should be corrected; use of joysticks (K wires in two poles) may be necessary.
3. Scaphoid nonunion site must be prepared adequately; use curettes to remove all nonunion fibrous tissue and callus to cancellous bone.
4. If the scaphoid has deformity, use cortical bone graft to strut open scaphoid and use cancellous bone to pack nonunion site tightly.
5. A central headless compression screw should be placed.
6. Supplemental K wire fixation, such as radiolunate wire and scaphocapitate wire, should be considered for unstable nonunions.
7. CT scan should be used postoperatively to confirm healing.

Treatment of Scaphoid Malunion

There are insufficient data to justify routine corrective osteotomy in patients with malunited scaphoids. The literature is mixed as to whether scaphoid deformity and associated lunate dorsal rotation influence the long-term outcome, provided the scaphoid is healed. In a recent study, Forward, Davis, and colleagues studied 42 patients with malunion and found no correlation between malunion measurements and functional outcome. They concluded that the goal of scaphoid treatment is to heal the scaphoid.[64]

Similarly, Jiranek and colleagues studied the effect of malunion on patients who had bone grafting for scaphoid nonunion.[109] Although there were significant objective differences and increased degenerative changes when patients with malunited and normally aligned scaphoids were compared, there were no subjective differences in satisfaction, pain relief, and return to work or sporting activities.

Amadio and colleagues reported on 45 patients with 46 scaphoid fractures that were studied more than 6 months after union by clinical examination and trispiral tomography.[7] Twenty fractures healed with normal scaphoid alignment as defined by lateral intrascaphoid angles of less than 35 degrees. There were satisfactory clinical outcomes in 83% and posttraumatic arthritis in only 22% of those with normal scaphoid

http://e-surg.com

anatomy. Worsening results were associated with increasing lateral scaphoid angulation and humpback deformity. In patients with more than 45 degrees of lateral intrascaphoid angulation present at the time of union, there was a satisfactory clinical outcome in 27% and posttraumatic arthritis in 54%. The authors felt that union alone is an insufficient criterion for measuring success in treating scaphoid fractures.

Similarly, Nakamura reported on 10 patients with symptomatic malunion of a carpal scaphoid fracture. All had displacement with DISI and suffered from pain, restricted range of movement at the wrist, and decreased grip strength. The restriction of flexion-extension and the decreased grip strength correlated with the severity of the DISI deformity. Seven patients had a corrective osteotomy using an anterior wedge-shaped bone graft with internal fixation by Herbert screw, and all had satisfactory results.[154]

Fernandez and colleagues presented a small series of three patients with painful rotational malalignment of the scaphoid and significant loss of active wrist extension who were treated with an opening wedge multiplanar osteotomy that corrected flexion, ulnar deviation, and pronation rotational malalignment of the distal fragment.[62] After a minimum follow-up of 4 years, all three patients were satisfied with the procedure and were pain free. The preoperative range of wrist motion had improved, and they had returned to their preoperative occupations.

Lynch and Linscheid reported on a long-term follow-up of five patients with DISI who underwent corrective osteotomy for symptomatic scaphoid malunion.[132] At an average of 9 years after the procedure (range, 1.5 to 19 years), all patients had healed and demonstrated an improvement in range of motion and grip strength. The preoperative intrascaphoid and carpal malalignments were reduced as demonstrated by trispiral tomography.

While firm evidence cannot be cited to justify routine osteotomy and correction of scaphoid malunion, clinical and laboratory studies support an attempt to restore correct alignment and length of the scaphoid and carpus when addressing scaphoid nonunion, particularly in active patients without degenerative change.

Nonunion of Distal Pole Scaphoid Fractures

Nonunion of distal pole scaphoid fractures is decidedly uncommon. Oron and colleagues[156] reported an incidence of 4.1% of 193 scaphoid nonunions at their institution. All were type IIC fractures of Prosser,[163] which are comminuted with a "Y"-split configuration at the scaphotrapeziotrapezoidal (STT) joint, and all had DISI deformity.[156]

Salvage Procedures for Scaphoid Nonunion Advanced Collapse

Radial Styloidectomy. Radial styloidectomy may be performed subperiosteally through the anatomic snuffbox. Care must be taken to avoid injury to the superficial radial nerve and potentially lateral antebrachial cutaneous nerves. It is important to preserve the important volar RSC ligament attachments; if more than 1 cm of styloid is removed, the RSC ligament origin will be significantly compromised, which could lead to instability.[181] Styloidectomies have been unsatisfactory as isolated procedures for SNAC arthritis, but they have enjoyed success for stage I SNAC arthritis when combined with procedures to heal scaphoid nonunions. Although some surgeons have not considered styloidectomy to be an essential part of the treatment of nonunions, the procedure does consistently improve on the results of bone grafting alone.

Distal Scaphoid Resection Arthroplasty. Malerich, Eaton, Littler, and colleagues reported on 19 patients with chronic scaphoid nonunion and stage I (radioscaphoid) SNAC arthritis who were treated with distal scaphoid fragment excision.[135] The original series of 19 patients has been followed for 25 years. Grip improved from 36% of the unaffected side to 83% (range, 45% to 111%, $p < .001$). The range-of-motion arc improved from 72 degrees preoperatively to 139 degrees postoperatively ($p < .0001$). There has been minimal change in the radiolunate angle (from −28 to −33 degrees). There were two failures requiring revision surgery to proximal row carpectomy and scaphoid excision and four-bone fusion. Only one patient, other than the two failures, had pain that required nonsteroidal antiinflammatory drugs. More than half of the patients developed asymptomatic midcarpal arthritis. The authors recommended the procedure in selected cases because of its technical simplicity and high satisfaction rate and stated that it does not preclude later salvage procedures. Ruch and colleagues reported satisfactory results in a cohort of 13 patients treated for SNAC arthritis with scaphoid distal pole excision at 4 years postoperatively.[171] They documented significant increases in wrist range of motion but noted significant increases in DISI posture in six patients.

Current indications for the Malerich procedure are a waist fracture nonunion with SNAC I styloscaphoid arthritis with significant loss of wrist dorsiflexion and radial deviation and pain on wrist loading, gripping, and range of motion. Chronicity is a favorable indication. Contraindications are DISI of 60 degrees or greater, midcarpal subluxation, or scapholunate ligament incompetence with gapping (personal communication, Matthew Malerich, MD).

Surgical Technique for Distal Scaphoid Resection. A dorsal midline incision is made in line with the third ray. The sensory branches of the radial nerve are identified and protected. The third extensor compartment is released and the EPL tendon retracted radially. The second and fourth compartment tendons are mobilized and an inverted-"T" capsulotomy is made. The radial artery is identified and protected. The dorsal branch of the radial artery is vulnerable at the distal pole area. A 2-cm segment of the posterior interosseous nerve is resected. There are occasionally dorsal osteophytes around the dorsal radiocarpal joint that should be excised with a rongeur. The distal scaphoid fragment is excised while protecting the RSC ligament. To remove the distal fragment, negotiate a key elevator in the STT joint and use the trapezium and trapezoid as a fulcrum to elevate and remove the fragment. Some surgeons prefer to remove the distal scaphoid from a palmar approach.

When the distal scaphoid has been removed, it is essential to test the stability of the distal row relative to the proximal scapholunate socket. Should the capitate subluxate, a salvage procedure, such as scaphoid excision and four-bone fusion or proximal row carpectomy, should be considered instead. If stable, the capsule is closed and a bulky dressing applied. The wrist is splinted until suture removal and wrist motion exercises are initiated with therapy. Aggressive strengthening exercises are

http://e-surg.com

postponed until 3 months after surgery; heavy wrist loading in flexion would promote an excessive compressive load of the capitate against the dorsal lip of the lunate, thus inducing the appearance of further DISI malalignment and dorsal midcarpal subluxation. These patients are advised to avoid contact sports for the first 6 months after surgery.

Proximal Row Carpectomy. Proximal row carpectomy for advanced SNAC arthritis is a motion-preserving salvage operation. Compared with intercarpal arthrodesis, it is simple to perform, avoids the risk of nonunion, requires a short period of immobilization, and requires little rehabilitation. Several long-term studies have shown it to be a durable procedure with predictable results.[41,103] Patients can expect to achieve grip strength of 70% to 80% and a wrist arc range of motion of 50% to 60% of their contralateral extremity. Although the majority of patients develop radiographic degenerative change at the radiocapitate articulation, most are asymptomatic. In a recent review of patients with a minimum of 20 years of follow-up, Wall and colleagues[187] found that proximal row carpectomy provides satisfaction, with a survival rate of 65%; the 35% with failure went on to radiocarpal arthrodesis at an average time of 11 years after proximal row carpectomy. The majority of the 65% were satisfied, with a total arc of motion of 68 degrees and grip strength of 72% of the contralateral side. There was no correlation between radiographs and satisfaction. Patients who were younger than 40 years had a higher probability of failure; such patients should be counseled about this possibility.

Indications and Contraindications. The ideal candidate is a relatively low-demand patient older than 40 years with stage II or III SNAC with no to minimal capitolunate degenerative disease (may have scaphocapitate changes). Heavy laborers are usually excluded.

Surgical Technique. A dorsal incision about 8 cm long is centered over the Lister tubercle. The EPL tendon is identified distal to the extensor retinaculum. The third dorsal compartment is opened and the EPL is retracted radially. The second and fourth compartments are opened and the tendons retracted. A posterior interosseous neurectomy may be performed. An inverted-"T" capsulotomy is performed. The longitudinal portion is made in line with the third ray and the transverse limb is made off of the dorsal lip of the distal radius. The wrist is flexed to expose the proximal carpal row, and the capitate and the lunate fossa of the distal radius are inspected for degenerative change. If there is full-thickness cartilage loss, an intracarpal fusion or total wrist arthrodesis should be considered.

The removal of the proximal row begins with the resection of the scaphoid. Care must be taken to avoid injury to the RSC ligament that lies at the volar midportion of the scaphoid extending from the volar radial styloid to the volar capitate. The RSC ligament prevents postoperative ulnar translocation of the carpus because the other major palmar extrinsic wrist ligament will be taken during the proximal row carpectomy (the long radiolunate = radiolunotriquetral). The lunate and triquetrum are removed next, with care taken not to damage the articular surface of the head of the capitate. It may be helpful to use a threaded Steinmann pin or 3.5-mm threaded Schanz screw to drill into the carpal bones for assistance with manipulation and excision. If there is minimal wear in the capitate head, capsular interposition may be performed. A distally based flap of the capsule is sutured to the volar capsule. The wrist capsule is closed. The EPL tendon is left transposed out of its compartment, and the extensor retinaculum is also closed. A short-arm wrist splint is applied and a PA fluoroscopic image is taken to confirm the location of the capitate within the lunate fossa of the radius while the splint is drying. Axial compression and slight ulnar deviation are often necessary to seat the capitate head in the lunate fossa. I do not place temporary fixation across the new radiocarpal articulation. A thermoplastic splint is applied at 2 weeks following operation to be worn full time. Gradual increased motion is permitted 6 weeks postoperatively. Patients are counseled that it can take 4 to 6 months or more to realize the benefit of surgery.

Intercarpal Fusion. The purpose of intercarpal fusion is to stabilize the midcarpal joint after the scaphoid is resected. Four-bone (capitate-lunate-hamate-triquetrum) fusion with scaphoid excision satisfactorily treats degenerative SNAC arthritis affecting the radioscaphoid and midcarpal joints while preserving an anatomically congruous radiolunate joint.

The priorities in properly executing four-bone fusion and scaphoid excision include (1) adequate decortication of joints, (2) correction of DISI deformity, (3) bone apposition, (4) rigid internal fixation, with options including headless compression screws, Kirschner wires, plates, or staples, and (5) appropriate postoperative immobilization. If the lunate is not derotated into neutral from its extended position and the capitate is fused in a dorsally subluxated position, as is often present in the SNAC wrist, radiocapitate abutment will prevent necessary wrist extension and cause pain.

Technique. A dorsal incision about 8 cm long is centered over the Lister tubercle. The EPL tendon is identified distal to the extensor retinaculum. The third dorsal compartment is opened and the EPL is retracted radially. The second and fourth compartments are opened and the tendons retracted. A posterior interosseous neurectomy may be performed. An inverted-"T" capsulotomy is performed. The longitudinal portion is made in line with the third ray and the transverse limb is made off of the dorsal lip of the distal radius. If more exposure is necessary to expose the proximal triquetrum for screw placement, the fifth compartment with the extensor digitorum quinti may need to be opened as well and the extensor digitorum quinti tendon retracted. The wrist is flexed to expose the proximal and midcarpal rows and scaphoid and lunate fossae of the distal radius to confirm degenerative changes.

The scaphoid is excised, with care taken to preserve the critical volar carpal ligaments (RSC and long radiolunate [LRL] ligaments). A threaded Steinmann pin or 3.5-mm Schanz screw may be inserted down the axis of the scaphoid as a joystick to manipulate and excise the bone. The midcarpal joint surfaces of the distal lunate and triquetrum and proximal capitate and hamate are decorticated to spongy cancellous bone. A combination of a rongeur, curets, and a 3-mm round bur may be used. Constant irrigation of the bur is important to avoid thermal necrosis of the bone, which may impede healing and bony fusion. I prefer to use a bur to create two to three channels, or "oil wells," in the articulation between the bones that will later be filled with bone graft. The primary joints to be fused are between the proximal row of the lunotriquetral complex and the capitohamate complex. The lunotriquetral and capitohamate joints are inherently very stable and are not formally taken

http://e-surg.com

down (two-column, or "bicolumnar," fusion). This method is much more surgically efficient than taking down all joints; in the latter situation, the presence of four independent and unstable bones makes the remainder of the procedure more difficult without appreciable clinical gain.

Bone graft is harvested from the excised scaphoid and/or a small window at the Lister tubercle and packed tightly into all intercarpal spaces. The lunate is derotated out of DISI to a neutral position. If there is difficulty in rotating the lunate out of DISI, the attachments of the dorsal radiocarpal ligament on the triquetrum may be released in the coronal plane, which will release both the lunate and triquetrum to allow them to palmarly flex back to anatomic position. The capitate is reduced to its anatomic position on the lunate. In the coronal plane, the lunate should be restored to its anatomic position, covering approximately two thirds of the capitate rather than the entire bone. The carpal bones are held reduced and axially compressed while one to three temporary 0.062-inch Kirschner wires are placed from distal to proximal (capitate to lunate and hamate to triquetrum).

My preference for fixation is staples, but Kirschner wires, plates, staples, or other techniques may be used. The wrist is placed in a volar/dorsal splint, and the splint is converted to a short-arm cast until union, which generally occurs 6 weeks postoperatively. Digital motion exercises are encouraged immediately following surgery, and wrist motion rehabilitation and strengthening are initiated at healing.

CRITICAL POINTS *Scaphoid Excision, Partial (Midcarpal) Wrist Fusion*

1. The joints to be fused need to prepared adequately to cancellous bone and packed with bone graft.
2. The midcarpal joint should reduced out of DISI. The dorsal radiocarpal ligament may need to be released in the coronal plane off of the lunate and triquetral bones.
3. The capitolunate joint should be fused in the anatomic position (the lunate usually covers approximately two thirds of the capitate).
4. Stable fixation must be achieved.

FRACTURES OF CARPAL BONES OTHER THAN THE SCAPHOID

Whereas fractures of the scaphoid are relatively common, fractures of the remaining carpal bones are relatively rare.[24] Larsen and colleagues reported that the relative incidence of carpal fractures excluding the scaphoid was 1.1% of all fractures.[126] They estimated the annual incidence to be 36 fractures per 100,000 people. In a review of 1000 consecutive hand injuries, only 18% involved fractures of the carpus, with the scaphoid being the most commonly injured carpal bone (58%).[126] Fractures of the carpus occur in three general groups: perilunate pattern injuries, axial pattern injuries, and local avulsion/impaction injuries.

Most carpal fractures are the consequence of a fall onto an outstretched hand. The energy from the fall may be focused on the distal carpal row. If the mechanism of injury continues, it produces an extension moment across the proximal carpal row transmitted through the volar carpal ligaments. These ligaments may be disrupted or result in shear stress around the area of the lunate. This results in perilunate-pattern or "lesser arc" injuries. Carpal fractures or ligamentous injuries may occur in an arc around the lunate. Carpal fractures may occur on the volar aspect of the wrist from tensile stress, or dorsal cortical comminution may occur from compression shear stress. Fractures of the scaphoid, capitate, triquetrum, or radial styloid, or all four, in conjunction with perilunate instability, are known as "greater arc" injuries.

Strong anterior to posterior compression injuries may result in axial-pattern disruption of the carpus. The forced injury propagates both radially and ulnarly, separating the carpus on both sides of the capitate. Frequently, this may result in an open fracture associated with variable soft tissue injury. These injuries are usually unstable and require surgical stabilization.

Lastly, avulsions may occur owing to localized forced concentration. These forces commonly cause avulsion injuries at the volar/dorsal aspect of the triquetrum secondary to ligament insertions, but trapezial ridge, hamate hook, and pisiform fractures may occur as well.

Garcia-Elias noted several characteristics common to carpal fractures.[67] First, these injuries generally occur in young individuals with high functional demands; second, these injuries are frequently missed at initial presentation; third, the small size of the fractured carpal bone complicates surgical reduction and potentially compromises its vascular supply; fourth, the displaced carpal fracture may significantly affect the congruency of the articular surface to the wrist, resulting in posttraumatic degenerative changes; fifth, unstable carpal fractures frequently are associated with adjacent ligamentous injury, as previously described; and sixth, because of the close relationship of the carpus to the tendon and neurovascular structures, secondary entrapment neuropathies or tendon ruptures can occur by friction of nonreduced bone fragments.

The relative frequency of each carpal bone fracture is controversial (Table 16.6).[67] Many authors report that the triquetrum is second only to the scaphoid as the most commonly fractured carpal bone, with 3% to 5% of all carpal fractures.[3] Garcia-Elias reviewed 10,400 consecutive wrist injuries over a 10-year period and reported on 249 carpal fractures.[67] In his series, there were 153 scaphoid fractures, 64 triquetrum fractures, 15 trapezoid fractures, 5 capitate fractures, 5 hamate fractures, and 2 lunate fractures.

Fractures of the Triquetrum

In most authors' series, fractures of the triquetrum are reported to represent the second or third most common carpal bone fracture.[67,130] Three primary patterns are usually observed: dorsal cortical fracture, triquetral body fracture, and palmar cortical fracture (Box 16.1).

Triquetral Fracture Patterns

Dorsal Cortical Fracture. The dorsal cortical fracture is by far the most common (Figure 16.37).[66,95,130] Its frequency is often reported to be as high as 93% of all triquetral fractures.[130] Different mechanisms of injury have been proposed for dorsal triquetral fractures.[66,95,130] These include avulsion, shear forces, or impaction. Extreme palmar flexion with radial deviation would be a primary cause for a dorsal avulsion fracture due to

http://e-surg.com

TABLE 16.6 Relative Incidence of Carpal Bone Fractures

Source	Total Number of Fractures	BONE FRACTURED							
		Scaphoid	Lunate	Triquetrum	Pisiform	Trapezium	Trapezoid	Capitate	Hamate
Garcia-Elias	249	153	2	64	5	15	1	5	4
Auffray	245	144	10	72	1	10	—	4	4
Snodgrass	170	144	11	7	1	3	1	2	1
Borgeskov	143	102	2	29	1	5	1	2	1
Franz	122	81	13	6	4	8	1	6	3
Dunn	72	59	1	5	1	2	—	—	4

Data from Garcia-Elias M: Carpal bone fractures (excluding scaphoid fractures). In Watson H, Weinberg J, editors: *The wrist,* Philadelphia, 2001, Lippincott Williams & Wilkins, pp 174–181.

BOX 16.1 Fractures of the Triquetrum

Incidence
Second most common carpal bone fracture; approximately 15% of all carpal fractures

Classification
Type 1 Dorsal cortical fracture (Figure 16.41), most common
Type 2 Triquetral body fracture
- Medial tuberosity fracture
- Sagittal plane fracture
- Transverse proximal pole fracture
- Transverse body fracture
- Comminuted fracture

Type 3 Palmar cortical fracture

Mechanisms
Type 1 Dorsal cortical fracture
Mechanism 1: Extreme palmar flexion/twist with avulsion by dorsal ligaments: radiotriquetral (dorsal radiocarpal) and triquetroscaphoid (dorsal intercarpal) ligaments
Mechanism 2: Hyperextension and ulnar deviation during fall with impaction by ulnar styloid or hamate
Type 2 Triquetral body fracture
Medial tuberosity fracture (caused by direct blow)
Sagittal plane fracture (anterior-posterior crush injury or axial dislocation)
Transverse proximal pole fracture (perilunate injury)
Transverse body fracture (perilunate injury)
Comminuted fracture (due to high-energy trauma)
Type 3 Palmar cortical fracture
Avulsion of palmar ligaments (palmar ulnar triquetral or lunotriquetral ligament)
Shear from pisiform

Special Imaging
CT scanning still often necessary
Oblique, 45-degree pronated view for dorsal cortical fracture
Palmar cortical fracture may be a harbinger of carpal instability, and MRI may be helpful in further assessment

Treatment
Type 1 Dorsal cortical fracture
Small fragment, no instability: short-arm cast for 3 to 4 weeks; then wrist splint for comfort. Progressive range of motion and strengthening. Excision if symptomatic after 6 to 9 months
Signs of carpal instability: ORIF
Type 2 Triquetral body fracture
Nondisplaced body fracture: short-arm cast for 4 to 6 weeks
Displaced body fracture: CRIF vs. ORIF with compression screws and/or Kirschner wires
Beware of associated lunotriquetral ligament injury. If lunotriquetral ligament is disrupted, pin across the joint
Type 3 palmar cortical fracture
Small fragment, no instability: Wrist splint vs. short-arm cast for 4 to 6 weeks
Ligamentous avulsion with carpal instability: ORIF
Shear from pisiform: short-arm cast for 4 to 6 weeks; excision of fragment and pisiform if injury remains symptomatic

Associated Injury
Perilunate fracture-dislocation
Axial pattern fracture-dislocations
Radius or ulna fractures

Complications
Nonunion
Persistent carpal instability
Pisotriquetral arthritis

CRIF, Closed reduction and internal fixation; *ORIF*, open reduction and internal fixation.

the attachment of the dorsal radiotriquetral and triquetroscaphoid ligaments. The most common mechanism is a fall onto a wrist in dorsiflexion and ulnar deviation. The ulnar styloid may act as a chisel and is driven into the dorsal cortex of the triquetrum. Garcia-Elias, in a study of 76 patients with triquetral fractures as compared with 100 uninjured patients, noted that the mean size of the ulnar styloid was significantly ($p = .001$) longer in the fracture patients.[66] Lastly, the shear force applied by the proximal edge of the hamate against the distal dorsal triquetrum during wrist extension has also been shown as a potential mechanism of injury for dorsal triquetrum chip fractures.[95]

Triquetral Body Fracture. Triquetral body fractures are the second most common type of triquetral fractures. These

http://e-surg.com

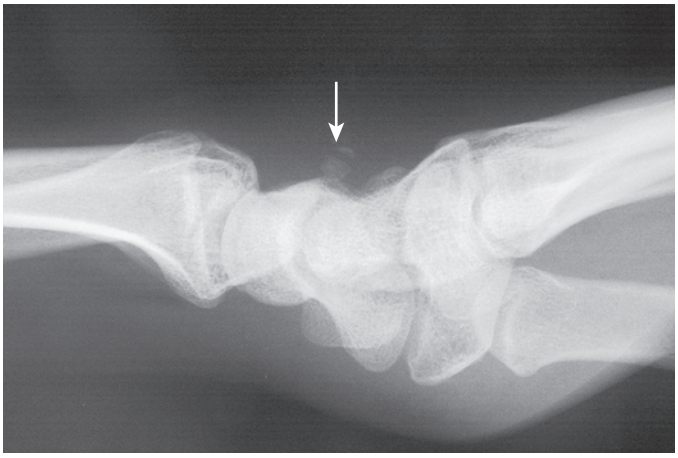

FIGURE 16.37 Wrist radiograph, lateral view. Dorsal cortical fracture of the triquetrum. (Courtesy of Steve K. Lee, MD.)

fractures generally require a high amount of injury to the wrist. Fractures of the body of the triquetrum are occasionally seen with perilunate fracture-dislocations. Perilunate fracture-dislocations are seen in 12% to 25% of triquetral injuries. A fracture of the body of the triquetrum should alert the physician to look for associated ligamentous injuries.

Fractures of the body of the triquetrum may be divided into five categories. These include sagittal fractures, fractures in the medial tuberosity, transverse fractures of the proximal pole, transverse fractures of the body, and comminuted fractures. A direct blow to the ulnar border of the wrist may cause a medial tuberosity fracture and occasionally involves the palmar articular surface of the triquetrum. Sagittal fractures are commonly associated with axial dislocations, with flattening of the transverse carpal arch. Small fractures of the proximal pole are frequently associated with perilunate dislocations. Small avulsion fractures to the volar aspect of the triquetrum may be the result of avulsion of the palmar LTIO ligaments and carry a much worse prognosis than isolated dorsal tip fractures, as noted by Smith and Murray.[185]

Palmar Cortical Fracture. Lastly, palmar cortical fractures have been described in the triquetrum. These fractures usually represent an avulsion of the palmar ulnar triquetral ligament and the LTIO ligament.

Clinical and Radiographic Features

Patients with a fracture of the triquetrum complain of point tenderness to palpation directly over the triquetrum. A patient who has a dorsal avulsion fracture is usually symptomatic with wrist flexion and extension.

Most triquetral fractures can be identified with anteroposterior (AP), lateral, and 45-degree pronated oblique radiographs of the wrist. The lateral and oblique views most often reveal the dorsal cortical fragments. Radial deviation views are helpful to diagnose a palmar cortical fragment that may be hidden behind the hamate or remaining triquetrum. Occasionally, CT scans are helpful in identifying occult triquetral fractures.

Treatment

Management of triquetral fractures depends on the fracture pattern. Most fractures are dorsal cortical fractures and are treated nonoperatively with immobilization for approximately 4 to 6 weeks. Immobilization is generally used in treating the underlying soft tissue injury. MRI is occasionally obtained to identify extrinsic intercarpal ligament injuries or occult fractures. It is important for the patient to understand that despite immobilization, fibrous nonunion of the fracture may occur. Patients generally complain of mild discomfort over the dorsum of the wrist for several months. Hocker reviewed his results in these injuries and showed excellent return of motion and function of the wrist.[95] In symptomatic nonunions, excision of the painful dorsal fragment may be performed.

Guidelines for treatment of triquetral body fractures are less clear. Isolated triquetral body fractures can generally be treated successfully by casting and immobilization for 4 to 6 weeks. Nonunion of a triquetral body fracture is very rare. Most fractures of the body of the triquetrum are associated with severe trauma and may be associated with a perilunate fracture-dislocation. Usually, treatment is directed toward managing the LTIO ligament by pinning the joint, ignoring the fracture of the body of the triquetrum. However, in cases of displaced triquetral body fractures, ORIF has been described (Figure 16.38).[162] A patient with an isolated triquetral body fracture in which the proximal row initially looks intact should receive close follow-up with radiographs looking for instability, particularly of the scapholunate interval, or further MRI. Fractures of the body of the triquetrum associated with scapholunate instability are best managed by early primary repair of the ligamentous disruption and fixation of the triquetral fracture with a compression screw.

Palmar cortical fractures of the triquetrum are rare. MRI to evaluate the fracture pattern and involvement of potential carpal instability is recommended. Treatment should be directed toward restoring carpal stability rather than treating the small avulsion fragment.

Fractures of the Trapezium

The trapezium forms a set articulation for the base of the thumb metacarpal. Fractures of the trapezium constitute approximately 1% to 5% of all carpal bone fractures, making the trapezium the third most commonly fractured carpal bone in most authors' series (Box 16.2).[161,209] The largest series of fractures of the trapezium was described by Pointu and colleagues, who reviewed 34 cases.[161] Fractures of the trapezium are usually associated with fractures of other bones, usually the distal radius or metacarpal. Isolated fractures occur rarely. Fractures of the trapezium typically involve the body or the ridge. The palmar ridge of the trapezium projects in a palmar direction and serves as an attachment for the transverse carpal ligament. The tendon of the FCR passes along a groove formed by the trapezial ridge. Fractures of the body are more common. Walker and colleagues described five different fracture patterns of the trapezium (Figure 16.39).[213] A vertical intraarticular fracture pattern is the most common, followed by fractures of the dorsoradial tuberosity.

Mechanism of Injury

The position of the trapezium below the thumb metacarpal generally protects it from a direct blow, making this an uncommon cause of trapezial fracture. Several mechanisms of injury have been described for fractures of the trapezium. These fractures are incurred from a fall onto an outstretched thumb,

http://e-surg.com



FIGURE 16.38 Posterioranterior radiograph of a patient following stabilization of multiple carpal fractures and instability, including stabilization of the fracture of the body of the triquetrum.

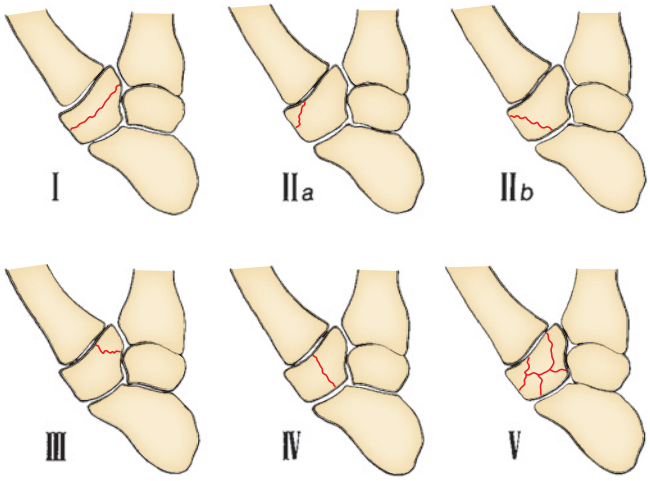

FIGURE 16.39 Classification of trapezial body fractures by Walker and colleagues: I, horizontal fractures; IIA, fractures of the radial tuberosity through the carpometacarpal joint; IIB, fractures of the radial tuberosity through the scaphotrapezial joint; III, fractures of the ulnar tuberosity; IV, fractures of the carpometacarpal joint (two-part); and V, fractures of the scaphotrapezial joint (comminuted). (From Walker JL, Greene TL, Lunseth PA: Fractures of the body of the trapezium. *J Orthop Trauma* 2:22–28, 1988.)

BOX 16.2 Fractures of the Trapezium

Incidence

Third most commonly fractured carpal bone; 1% to 5% of all carpal fractures

Classification (see Figure 16.40)

Type 1 Vertical intraarticular fracture, most common, frequently accompanies Bennett fracture
Type 2 Horizontal fracture (rare)
Type 3 Dorsoradial tuberosity fracture
Type 4 Palmar trapezial ridge fracture
- 4A Fracture of base
- 4B Fracture of tip

Type 5 Comminuted fracture

Mechanism

Type 1 Axial compression from first metacarpal
Type 2 Horizontal shear
Type 3 Vertical shear between radial styloid and first metacarpal
Type 4 Direct blow or avulsion of transverse carpal ligament
Type 5 High-energy injuries

Special Radiographs

CT scanning still often necessary
Bett view (see Imaging section)
Pronated AP view
Carpal tunnel view (for palmar trapezial ridge fractures)

Treatment

Fracture of body
- Nondisplaced: Short-arm thumb spica cast for 4 to 6 weeks
- Displaced: ORIF (palmar Wagner approach, headless compression screws and/or Kirschner wires)
- Comminuted: ORIF combined with traction pin (first to second metacarpal) or external fixator

Palmar trapezial ridge fracture
- Type 4A (base of ridge): Short-arm thumb spica cast for 4 to 6 weeks (usually heals)
- Type 4B (tip avulsion): Short-arm thumb spica cast for 4 to 6 weeks (often does not heal; excise if symptomatic)

Associated Injury

Bennett fracture
Fracture-dislocations with fractures of scaphoid, trapezoid, capitate, metacarpals, distal radius

Complications

Basal joint posttraumatic arthritis
Contracture of first web space
Nonunion
Carpal tunnel syndrome
FCR tendinopathy and late rupture

ORIF, Open reduction and internal fixation.

causing the base of the thumb metacarpal to be driven axially into the trapezium. This results in a vertical intraarticular shear fracture on the radial aspect of the trapezial body (Figure 16.40). The body of the trapezium is split and displaced proximally with the attached metacarpal, resulting in subluxation or dislocation of the joint. Depending on the angle of compression, a fracture of the trapezium or a Bennett fracture of the thumb metacarpal, or occasionally both, may occur. Dorsoradial trapezial fractures may be the result of vertical shear when the trapezium is being trapped between the metacarpal and the tip of the radial styloid. Most fractures of the trapezium have a vertical orientation consistent with a vertical shear force.

The ridge of the trapezium is superficial. It can be palpated just distal to the scaphoid tubercle at the base of the thenar

http://e-surg.com



FIGURE 16.40 Posteroanterior radiograph demonstrating a fracture of the body of the trapezium that is split into volar and dorsal fragments. This was secondary to the thumb metacarpal being driven proximally into the body of the trapezium.



FIGURE 16.42 The fracture from Figure 16.41 was approached volarly, elevating the thenar musculature. The fracture was anatomically reduced and provisionally stabilized with Kirschner wire fixation.

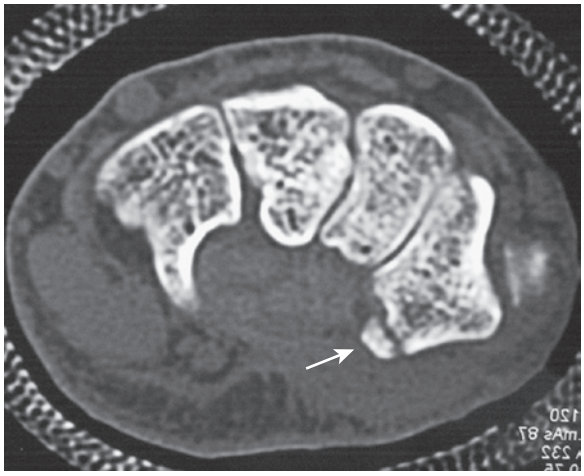

FIGURE 16.41 Computed tomography showing avulsion of the transverse carpal ligament produced by an anteroposterior crush. (Courtesy of Steve K. Lee, MD.)

eminence. Because the ridge is superficial, fractures of this structure are generally caused by direct trauma such as a fall onto an outstretched hand or being struck by a pitched ball. Other mechanisms include avulsion of the transverse carpal ligament produced by an AP crush (Figure 16.41).

Imaging

Fractures of the body of the trapezium can usually be identified on standard PA and lateral radiographic wrist views. A pronated AP view further defines the articular surface and is helpful for detecting any displacement. The Bett view is obtained with the elbow raised from the cassette, the thumb extended and abducted, and the hand partially pronated. Fractures of the trapezial ridge are not readily seen on standard PA and lateral radiographs. A carpal tunnel view is best for identifying a fracture of the ridge of the trapezium when it is suspected. CT scan will best define the fracture.

Treatment

Nondisplaced fractures of the trapezium are relatively rare; treatment would be with a short-arm thumb spica cast for 4 to 6 weeks. Patients do require close follow-up, as these injuries result from a fairly high-energy impact, are unstable, and are prone to displacement. Displaced fractures of the body of the trapezium are best managed by closed versus open reduction and internal fixation.[178] Fractures of the trapezium are best addressed through a volar approach. The thenar muscle is elevated, exposing the fracture site. The radial artery is at risk during the exposure and should be identified and protected during the procedure. The fracture may be stabilized by compression screws or Kirschner wires, or a combination of both (Figures 16.42 and 16.43). Frequently, because of the compressive forces involved in producing the fracture, bone grafts may be needed to support the articular surface. Allograft cancellous bone may be used because it has structural integrity or autologous cancellous bone graft may be obtained from the volar aspect of the distal radius or from the olecranon. Various bone substitutes may also be used.

Fractures of the ridge of the trapezium may be easily missed. Patients present with pain at the base of the thumb and pain

http://e-surg.com



FIGURE 16.43 Following anatomic reduction of the fracture from Figure 16.41, a cannulated screw was placed over the guidewire, anatomically reducing the intraarticular fracture to the trapezium.

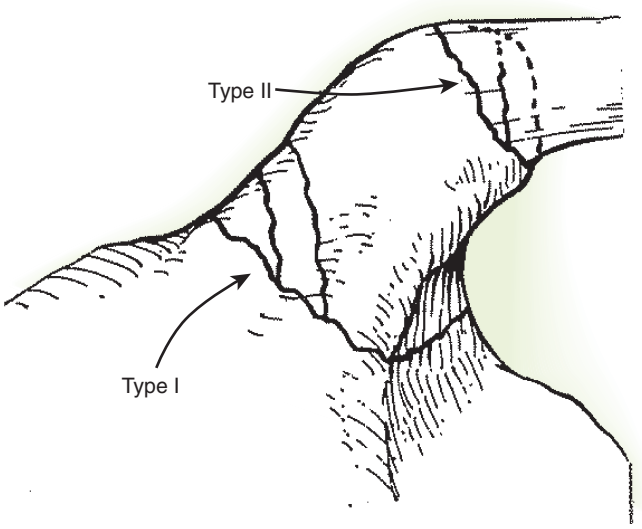

FIGURE 16.44 The fractures of the trapezial ridge were classified by Palmer. Type I fractures involve the base, and type II fractures involve the tip.

with wrist flexion. According to Palmer, two types of trapezial ridge fractures exist (Figure 16.44).[157] Type I fractures occur at the base of the ridge, and type II fractures are avulsion fractures at the tip of the ridge. The main aspect of these fractures is recognizing them by clinical suspicion via the patient's area of pain and tenderness, but CT scanning is frequently required for confirmation. Types I and II fractures may be treated in a short-arm thumb spica cast for 4 to 6 weeks. If the fracture does not heal and ends up in painful nonunion, excision of the fracture fragments may be required. Padded gloves are used to help the patient return to activities as the scar may be tender for several months.

Fracture of the trapezium may result in chronic conditions such as carpal tunnel syndrome, tendinitis, or potential rupture of the FCR tendon as it passes by the trapezium. Excision of fracture fragments and bony osteophytes is recommended in chronic injuries that are symptomatic. The fragment is removed through a volar approach and the thenar musculature is elevated off of the capsule. The FCR tendon must be identified and carefully protected as it is easily injured during excision of fragments.

BOX 16.3 Fractures of the Capitate

Incidence
Fourth most common carpal fracture; 1% to 2%

Classification
Type 1 Transverse body fracture; most common, associated with perilunate injuries, with or without fracture of scaphoid and/or radial styloid
Type 2 Transverse proximal pole (waist) fracture
Type 3 Coronal oblique fracture
Type 4 Parasagittal fracture

Blood Supply
Retrograde

Special Imaging
CT scan may be needed to confirm

Mechanisms
Most commonly, fall on outstretched hand; hyperextension with capitate striking distal radius
Axial load down the third metacarpal
Direct blow

Treatment
Nondisplaced fracture: Short-arm thumb spica cast for 6 to 8 weeks
Displaced fracture: ORIF (headless compression screws)
Beware of scaphocapitate syndrome (proximal capitate fragment rotates 180 degrees; ORIF is necessary for treatment)

Associated Injury
Perilunate injury

Complications
Most common is nonunion, which is often related to delay in diagnosis
Avascular necrosis of capitate
Posttraumatic arthritis
Malunion of capitate

ORIF, Open reduction and internal fixation.

Fractures of the Capitate

Similar to the trapezoid, the capitate is centered within the carpus and is well protected from injury. Fractures of the capitate account for 1% to 2% of all carpal fractures (Box 16.3). Adler and Shaftan found 72 previously published cases in their review of the literature and published 12 additional cases of their own.[2] However, isolated fractures of the capitate are being diagnosed with increased frequency, and a heightened awareness of these injuries is important. The capitate articulates with

http://e-surg.com

the scaphoid and lunate proximally and is well attached along the metacarpal distally to form the central column of the hand and wrist. Fractures of the capitate are incurred as an isolated injury or more frequently are part of a transscaphoid perilunate fracture-dislocation. This was described by Fenton as a scaphocapitate fracture syndrome.[59]

Four major patterns of fractures have been observed in the capitate. These include transverse fracture of the body of the capitate, transverse fracture of the proximal pole of the capitate, coronal oblique fracture, and a parasagittal fracture pattern. Transverse fractures of the capitate occur most frequently and are usually associated with a transscaphoid, transcapitate perilunate fracture-dislocation.[59]

Mechanism of Injury

Stein and Siegel investigated the mechanism of injury for fractures of the capitate that can result from up to 180 degrees of rotation of the proximal fragment (Figure 16.45, *A* to *C*).[193] In the scaphocapitate perilunate fracture-dislocation, the mechanism of injury is a high-energy fall with the wrist hyperextended. The force is initially transmitted through the scaphoid, which fractures at the waist. As the wrist continues to extend, the neck of the capitate impacts on the dorsal ridge of the radius and fractures as a result of tensile forces on the palmar aspect.

When the wrist returns to neutral, shortening of the carpus prevents reduction of the proximal fragment. As the wrist continues to go into flexion, the fractured distal portion of the capitate exerts a flexion moment to the proximal pole, which may result in complete rotation, causing the articular surface of the capitate proximal pole to face distally into the capitate fracture site. Other possible mechanisms of capitate fracture include an axial load down the third metacarpal or a direct blow.

Radiographic Features

Routine PA, lateral, and oblique radiographs are usually sufficient to diagnose a capitate fracture (Figure 16.46, *A* and *B*). Occasionally, however, initial radiographs of a nondisplaced capitate fracture may appear normal. Close evaluation of the radiographs is important. A patient may present with a typical transscaphoid perilunate fracture-dislocation, and the capitate fracture may be overlooked. A patient's continued wrist pain following trauma may require serial radiographs and temporary immobilization until the pain resolves or a diagnosis is made. The fracture is subsequently recognized when resorption of the fracture site is noted.

Treatment

The head of the capitate is nearly completely covered with articular cartilage, similar to the proximal pole of the scaphoid. Like proximal pole scaphoid fractures, fractures of the head and neck of the capitate are subject to major vascular disruption and, hence, prolonged healing and poor outcome because the blood supply is retrograde. These fractures are inherently unstable and frequently lead to delayed union or nonunion. These factors need to be considered if casting and immobilization are recommended, because the several months of cast immobilization required for healing may result in additional morbidity. MRI has helped to evaluate the vascular supply of the proximal pole of the capitate and the healing capacity of the capitate head.

Displaced fractures of the capitate, delayed diagnosis of nondisplaced capitate fractures, and transscaphoid, transcapitate perilunate fracture-dislocations are best managed by ORIF. The capitate is repaired through a dorsal incision between the third and fourth dorsal compartments. The incision is in line with the radial border of the long finger. Palmar flexion of the wrist provides access to the head of the capitate, which may be rotated

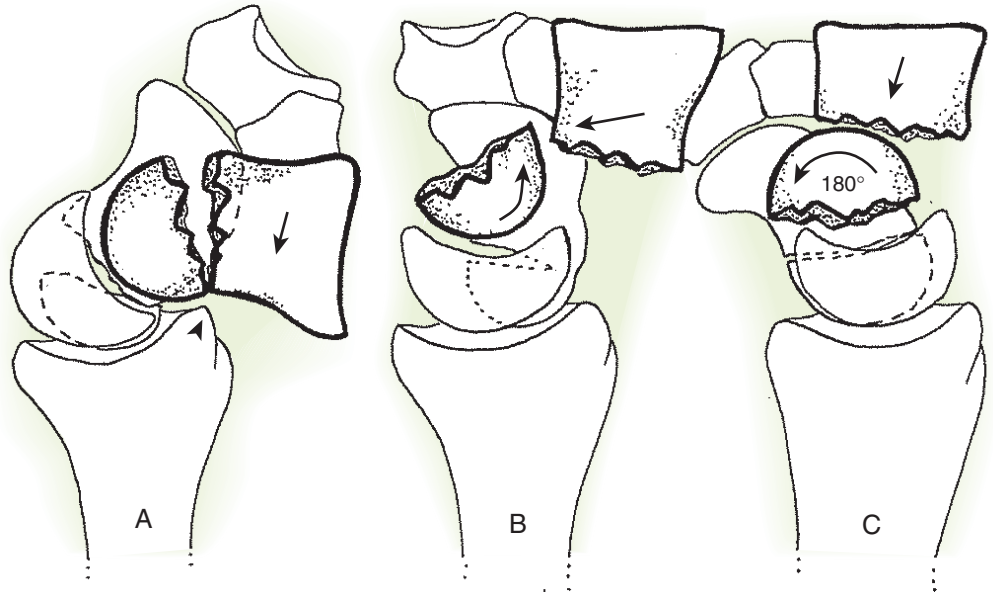

FIGURE 16.45 The mechanism of injury to fractures of the capitate. **A,** The neck of the capitate may impact on the dorsal ridge of the radius once the scaphoid has fractured. **B,** As the wrist recovers to its neutral position, shortening of the carpus prevents reduction of the proximal fragment. **C,** As the capitate regains its normal alignment in relation to the radius, it exerts a flexion moment to the proximal fragment that may result in a 180-degree rotation, with the fracture site facing the distal aspect of the lunate.

http://e-surg.com

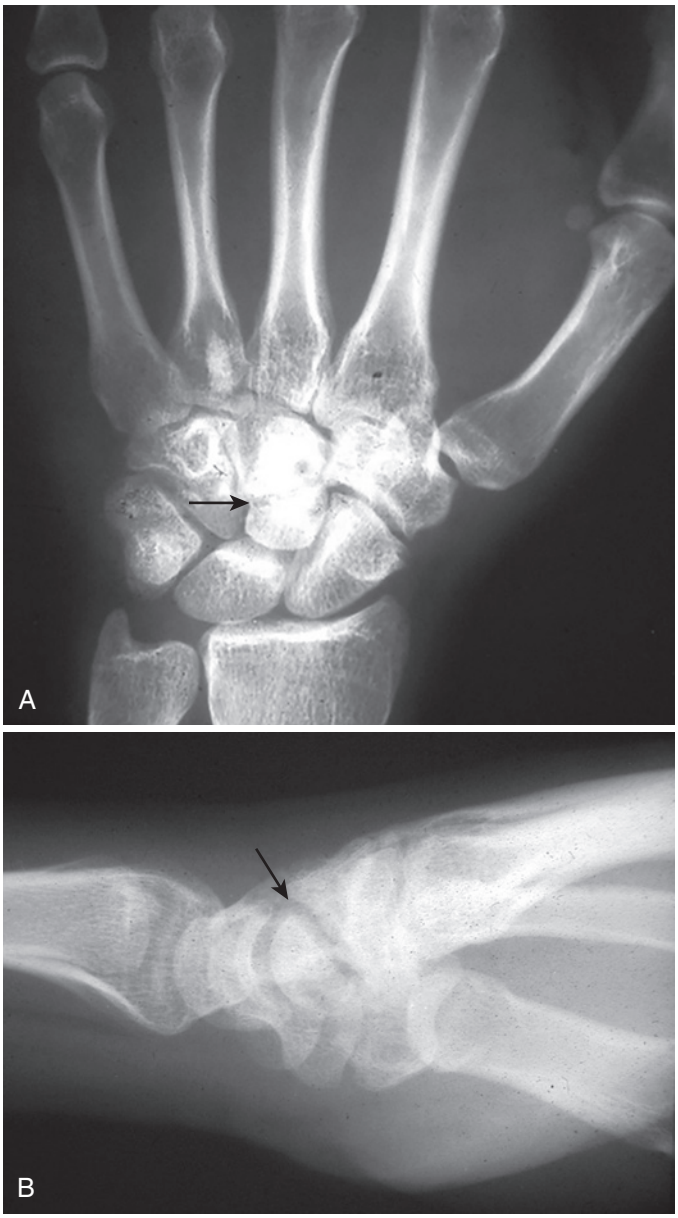

FIGURE 16.46 Capitate neck fracture. **A,** Posteroanterior radiographic view of the wrist. **B,** Lateral radiographic view of the wrist. (Courtesy of Martin A. Posner, MD.)

180 degrees. One or two headless compression screws may be placed from proximal to distal in the capitate to provide adequate stability (Figure 16.47, *A* and *B*).[69] The scaphoid may be stabilized from the same dorsal approach or through a separate volar approach if it is fractured.

It is important to reestablish the carpal height of the capitate when managing an established capitate nonunion. Corticocancellous interposition bone grafts are usually necessary to reestablish the carpal height to prevent carpal collapse and overloading to the scaphotrapezialtrapezoidal and triquetral hamate joints.

A coronal fracture is caused by transmission of an axial load along the shaft of the third metacarpal, resulting in a joint compressive force on the dorsal aspect of the capitate articular surface. This fracture is not well seen in typical AP radiographs but is seen on a lateral view. These fractures are managed by ORIF if displaced.

Fractures of the Hamate

It has been reported that hamate fractures make up approximately 2% of all carpal fractures (Box 16.4).[1,147] These fractures are probably underreported if carpometacarpal fracture-dislocations are taken into account where there are dorsal avulsion fractures related to the metacarpal bases. Also, hook fractures may be more common but may not be symptomatic enough for treatment by a hand surgeon. The unique anatomy of the hamate hook places it at risk: It protrudes from the base of the hamate into the hypothenar eminence. The hook of the hamate is the site of origin for the flexor digiti minimi muscles, opponens digiti minimi muscles, hypothenar muscles, pisohamate ligaments, and distal attachment of the transverse carpal ligament. Fractures of the hamate may be divided into two groups: those affecting the hook of the hamate and those involving the body.

Fractures of the Hook of the Hamate

Fractures of the hook of the hamate are relatively rare in the general population but more common in athletes.[69] The hook of the hamate is at risk for a fracture in any athlete who swings a racket, club, or bat (Figure 16.48).

Direct compression of the handle of the club against the protruding hook is the primary cause of fracture. In addition, shear forces from the adjacent flexor tendons or contraction of the attached hypothenar muscles may contribute to the fracture or displacement. The wrist nearest the handle is at risk for fracture. The nondominant hand is usually involved in golfers and baseball players, whereas the dominant hand is more likely involved in tennis and racketball players.

Clinical and Radiographic Presentation. Fractures of the hook of the hamate frequently present late as chronic pain at the base of the hypothenar eminence. Patients may complain of ulnar nerve paresthesia into the ring and small fingers and weakened grip strength. Tenderness to palpation is felt over the hamate hook approximately 2 cm distal and radial to the pisiform. Patients complain of pain aggravated by active grasping. Pain with resistance of ring- and small-finger flexion that is worst with the wrist in ulnar deviation and lessened by radial deviation can help further document a fracture of the hook of the hamate, which irritates the flexor tendons at the ring and small fingers. A chronic unrecognized hamate hook fracture may present with a rupture of the small or ring finger deep or superficial flexor tendon.

Fractures of the hamate hook are difficult to recognize on standard anterior, posterior, and lateral radiographs. Clues on the PA radiograph include absence of the hook or cortical ring or sclerosis in the region of the hook. The hamate hook can be visualized with radiographs taken with the wrist in 45 degrees of supination or with the carpal tunnel view. The carpal tunnel view is typically used to profile the hook of the hamate but may be difficult to obtain in patients with acute pain from a fracture precluding sufficient extension (Figure 16.49). A CT scan may be used to define the fracture. The superiority of CT scan over conventional radiographs was demonstrated by Andresen and colleagues.[9] CT was found to have a sensitivity of 100%, a speci-

http://e-surg.com

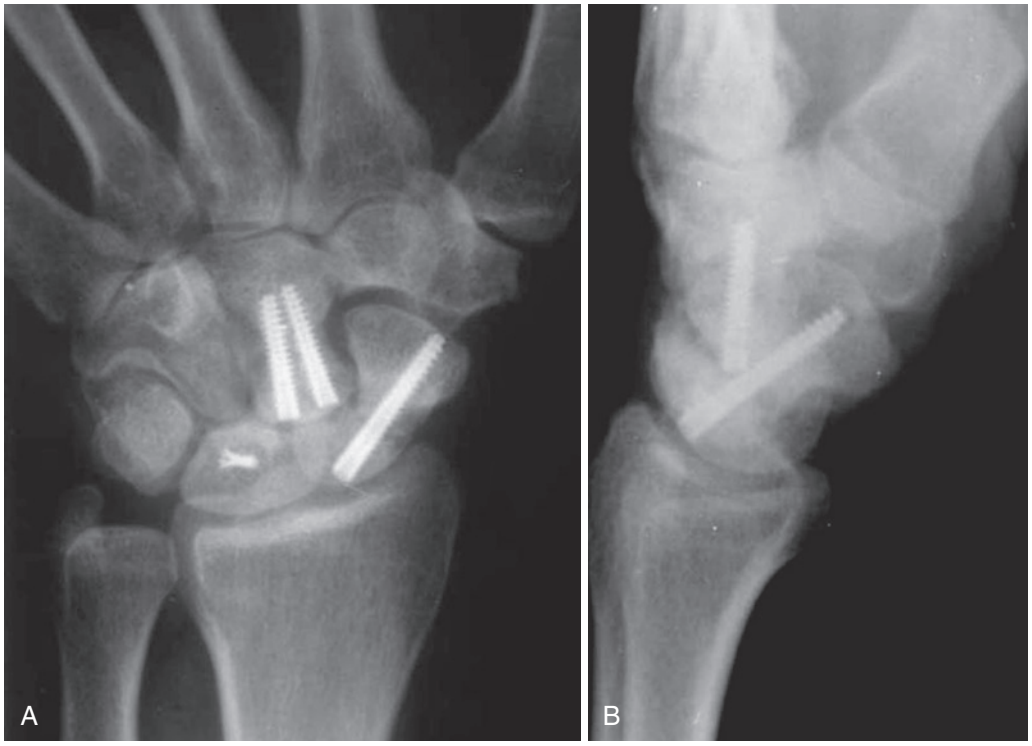

FIGURE 16.47 **A,** Transscaphoid, transcapitate perilunate fracture-dislocations are best stabilized through a dorsal approach. The capitate was stabilized with two headless cannulated screws, and the fracture of the scaphoid was stabilized with a single screw inserted in a proximal-distal direction. The patient had a complete tear of the lunotriquetral interosseous ligament; it was primarily repaired and provisionally stabilized with Kirschner wires, which were eventually removed. **B,** Lateral radiograph following open reduction and internal fixation of a transscaphoid, transcapitate perilunate fracture-dislocation. The radiograph confirms normal restoration of the scapholunate angle.



FIGURE 16.48 Mechanism of hook of hamate fracture. (From Sennwald GR: Carpal bone fractures other than the scaphoid. In Berger RA, Weiss AP, editors: *Hand Surgery,* Philadelphia, 2004, Lippincott Williams & Wilkins, p 418; with permission.)

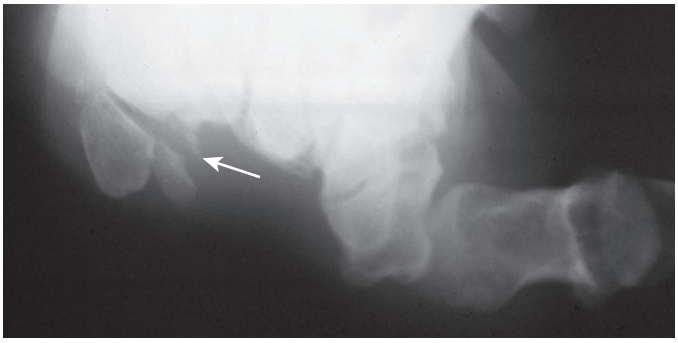

FIGURE 16.49 Hook of hamate fracture *(arrow).* Carpal tunnel radiograph view. (Courtesy of Martin A. Posner, MD.)

ficity of 94%, and an accuracy of 97.2% in defining hook fractures, as compared with radiographs, which had a 72% sensitivity, an 88% specificity, and an 80.5% accuracy.

Blood Supply. The blood supply to the hamate has been studied extensively.[57] The hamate has three vascular pedicles. Palmar and dorsal vascular pedicles enter the hamate along the midcarpal capsular attachments and from the interosseous network that supplies the body of the hamate in a retrograde fashion. One group of small and nutrient arteries arising from the ulnar artery at the level of the Guyon canal supplies the hook of the hamate. Few anastomoses exist between the two systems. Failla described a vascular supply of the hamate as a variable pattern.[57] He described all hamates as having a nutrient vessel that enters the radial base of the hamate. However, only 71% have a nutrient vessel entering at its tip. Therefore, approximately 29% of the population is at risk for osteonecrosis of the hamate hook with a fracture distal to the basal nutrient artery. This poorly vascularized area adjacent to the base of the hook (watershed area) has a greater risk of nonunion if the fracture is not acutely immobilized.

Treatment. According to Milch, there are three different types of fractures of the hook of the hamate.[147] These have been classified as avulsion fractures of the tip of the hook, fractures through the base of the hamate hook, and fractures through the waist.

http://e-surg.com

BOX 16.4 Fracture of the Hamate

Incidence
2%, probably more due to underreporting

Classification
Type 1 Hook fracture
- Fracture of tip (avulsion)
- Fracture of waist
- Fracture of base

Type 2 Body fracture
- Proximal pole fracture
- Medial tuberosity fracture
- Sagittal oblique fracture (usually radial to hook)
- Dorsal coronal fracture (usually with 4,5 carpometacarpal fracture-dislocation)

Blood Supply
Hook: Watershed region at waist
Body: Retrograde; distal hamate with volar and dorsal blood supply

Mechanisms
Type 1 Hook fracture
- Repeated trauma (golf, tennis, baseball) or direct blow

Type 2 Body fracture
- Wrist fracture-dislocation, shear
- Direct blow
- AP crush, high-energy trauma
- Axial load of fourth and fifth metacarpals

Special Radiographs
CT scanning still often necessary
Carpal tunnel view
Oblique (45-degree supinated) view

Treatment
Type 1 Hook fracture
- Acute nondisplaced fracture: Ulnar gutter cast (IPs free) for 3 weeks, short-arm cast for 3 weeks (counsel that healing rate is 50% and future surgery is possible if symptomatic)
- Acute displaced fracture: Early excision of bony fragment vs treatment as in acute nondisplaced hook of hamate fractures
- Chronic, symptomatic nonunion: excision of bony fragment
- Ulnar nerve/artery or tendon symptoms with displaced hook: decompression, excision. (This is controversial; some authors recommend ORIF; the author prefers excision because studies show no adverse sequelae of wrist range of motion or grip strength with hook of hamate excision.*)
- It is important to identify and protect the ulnar nerve [especially the ulnar motor branch] and artery prior to hook of hamate excision).

Type 2 Body fracture
- Nondisplaced body fracture: Ulnar gutter cast (IPs free) for 3 weeks, short-arm cast for 3 weeks
- Displaced body fracture: ORIF with headless compression screws or low-profile plates and/or Kirschner wires

Associated Injuries
Ulnar artery/nerve injury in hook fractures
Fourth and fifth metacarpal fracture-dislocations in coronal body fractures
Greater arc perilunate fracture-dislocations in oblique body fractures
Axial carpal instability

Complications
Avascular necrosis in proximal wedge (pole) body fractures
Ulnar nerve compression in Guyon canal
Carpal tunnel syndrome
Flexor digitorum profundus tendon rupture
Ulnar artery thrombosis (hypothenar hammer syndrome)
Nonunion
Carpometacarpal posttraumatic arthritis

*See Devers BN, Douglas KC, Naik RD, et al: Outcomes of hook of hamate fracture excision in high-level amateur athletes. *J Hand Surg [Am]* 38(1):72–76, 2013; Stark HH, Chao EK, Zemel NP, et al: Fracture of the hook of the hamate. *J Bone Joint Surg Am* 71(8):1202–1207, 1989.

Acute nondisplaced fractures of the hook of the hamate may heal with casting and immobilization. With displaced hamate hook fractures or chronic injuries, most authors advise excision of the hook of the hamate fragment. One study noted less favorable results if hamate hook fractures are treated after the first week.[32] The unrecognized or untreated hamate hook fracture may lead to partial or complete rupture of the ring and small finger deep or superficial flexor tendons.

The reported results of hook of the hamate excision have generally been favorable.[187] Some pain and weakness may persist, but most patients will be able to return to full athletic and occupational activities. Occasionally, padded gloves are useful to allow the athlete to return to competition earlier following hook of the hamate excision. Watson and Rogers, however, noted that the hook of the hamate constitutes the medial wall of the carpal concavity, acting as an important pulley that enhances the action of the flexor tendons of the small finger by increasing its moment arm.[216] Excising the hamate may affect the function of the small finger. Because of this, some authors have recommended ORIF for hamate hook fractures.[216] There is little available literature reporting the results of ORIF.[216]

Most authors recommend excision of symptomatic fractures of the hook of the hamate,[187] and this is my preference. Studies show no adverse sequelae on wrist range of motion or grip strength with hook of hamate excision.[47,191] Excision is accomplished through a curvilinear incision centered over the hook of the hamate. If exposure requires crossing the flexor wrist crease, it is important to zigzag across the crease to avoid a flexion contracture. The ulnar nerve and artery are identified proximally in the incision and traced out distally through the Guyon canal past the hook of the hamate and protected. The distal portion of the transverse carpal ligament surrounding the tip of the hook of the hamate is released. The ulnar nerve and artery are traced along the ulnar border of the hook of the hamate. The motor branch exits from the ulnar nerve along the dorsal ulnar aspect of the nerve, passes deep to the remaining ulnar nerve, and dives beneath the flexor digiti minimi. This motor branch almost always lies at the fracture site at the base of the hamate (Figure 16.50). This nerve must be clearly identified and mobilized and retracted before the hook of the hamate fracture is excised. The hook of the hamate is a fairly long bone in the palmar-dorsal dimension. Close subperiosteal dissection is performed from palmar to dorsal to expose the base of the

http://e-surg.com

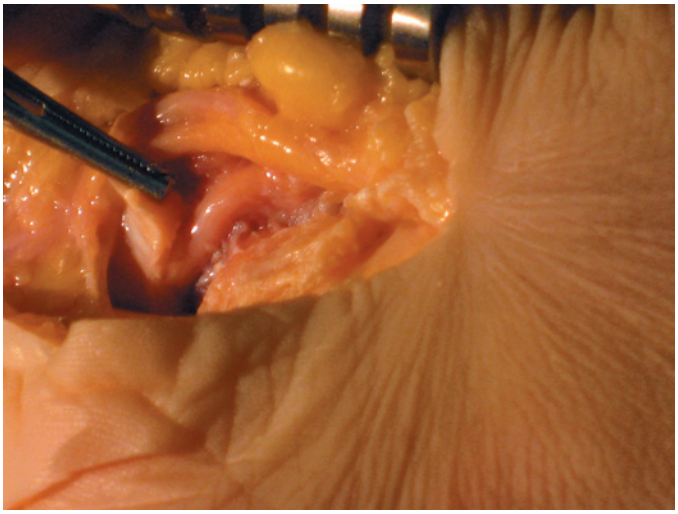

FIGURE 16.50 The motor branch of the ulnar nerve runs very near the base of the hook of the hamate. It should be identified prior to excision of the hook.

hamate at the fracture site clearly while protecting the motor branch of the ulnar nerve. Once the fracture site has been clearly dissected and protected, the hook of the hamate fragment is removed. Any sharp bony edges are smoothed with a rongeur and/or rasp. The remaining periosteum is then closed over the base of the hamate body to decrease irritation from the remaining fracture surfaces to the ulnar nerve and flexor tendons.

Postoperative Care. Following removal of the hook of the hamate, patients can return to sports relatively quickly. Scar sensitivity is the primary factor limiting a return to sports. Physical therapy modalities, including scar massage, a silicone patch, and padded gloves, help with early return to activities. A 3% complication rate has been reported in association with excision of hamate hook fractures. Injury to the motor branch of the ulnar nerve was the most common complication.[188]

Fractures of the Body of the Hamate

Body of the hamate fractures have been divided into four major groups: proximal pole fractures, fractures of the medial tuberosity, sagittal oblique fractures, and dorsal coronal fractures. Proximal pole fractures usually are the result of shear forces in fracture-dislocations of the wrist. They are usually small intraarticular osteochondral fractures. Fractures of the medial tuberosity are usually the result of a direct blow to the ulnar side of the wrist. Sagittal oblique fractures are the result of high-energy trauma causing severe flattening of the transverse carpal arch. The ulnar nerve is at risk with this mechanism of injury. Dorsal coronal fractures are often the result of axial forces transmitted through the metacarpal. These fractures are best identified in lateral and 45-degree pronated oblique radiographs, and can be further defined with CT scan (Figure 16.51, *A* and *B*).

The small- and ring-finger hamate carpometacarpal joints are important for gripping and normally allow for approximately 30 degrees of motion. Isolated nondisplaced fractures of the body are generally stable and may be treated with casting and immobilization. Displaced fractures of the hamate that involve the carpometacarpal joint are best managed by ORIF. The fracture is exposed through a dorsal approach between the fourth and fifth extensor digitorum communis tendons. The

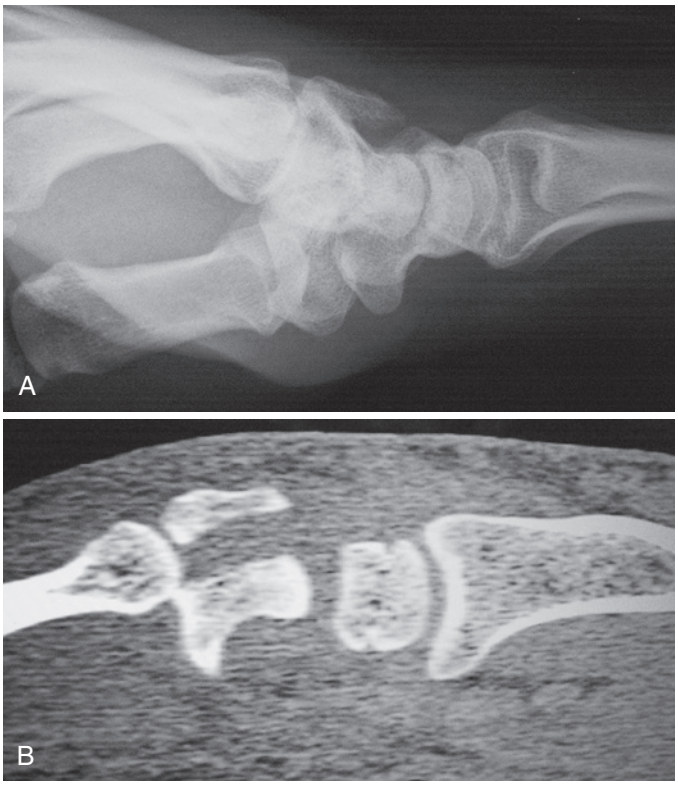

FIGURE 16.51 A lateral wrist radiograph **(A)** and computed tomography scan **(B)** to identify dorsal coronal hamate fractures. (Courtesy of Steve K. Lee, MD.)

carpometacarpal joints are usually unstable and require reduction and fixation with Kirschner wires that are driven from involved metacarpals to carpal bones. The hamate fracture may be stabilized by small compression screws or by a small "H"-plate (Figure 16.52, *A* and *B*). Care must be taken when drilling dorsal to the palmar aspect of the hamate because of the close association of the motor branch of the ulnar nerve.

Injuries associated with fractures of the hamate body include ulnar artery or nerve injury in hook fractures, fourth and fifth metacarpal fracture-dislocations in coronal body fractures, greater arc perilunate fracture-dislocations in oblique body fractures, and axial carpal instability.

Fractures of the Pisiform

The pisiform is a sesamoid contained within the flexor carpi ulnaris (FCU) tendon. It articulates with a concave facet of the triquetrum. The pisiform serves as an attachment of the origin of the pisohamate and pisotriquetral ligaments, transcarpal ligament, and abductor digiti minimi muscle. Fracture of the pisiform accounts for approximately 2% of all fractures of the carpal bones (Box 16.5).[142] Approximately 200 reports of fractures of the pisiform have been published in the literature.[142]

Pisiform fractures occur in sports secondary to a direct blow, such as being struck by a baseball or a fall onto an outstretched hand. Occasionally, pisiform fractures are seen in marksmen from the force transmitted through a handgun, similar to the fracture of the hook of the hamate seen in players using a racket, club, or bat. Because of the pisiform's multiple soft tissue attachments, a fracture of the pisiform can also result from an avulsion mechanism. Fracture of the pisiform is frequently associated

http://e-surg.com

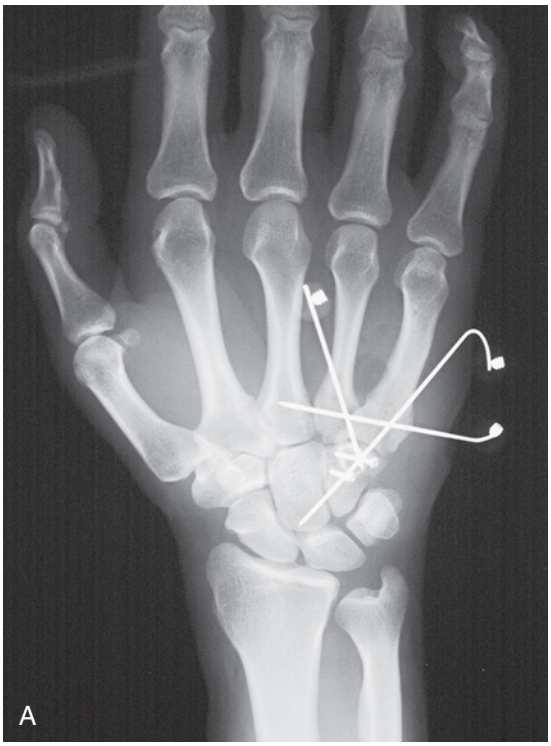



FIGURE 16.52 Postoperative radiographs after open reduction and internal fixation of hamate body fracture. Posteroanterior view **(A)** and lateral view **(B)** of wrist. (Courtesy of Steve K. Lee, MD.)

BOX 16.5 Fractures of the Pisiform

Incidence
2%

Classification
Type 1 Transverse fracture (most common)
Type 2 Parasagittal fracture
Type 3 Comminuted fracture
Type 4 Pisotriquetral impaction

Blood Supply
Robust (however, avascular necrosis has been reported)

Mechanisms
Direct blow, commonly in sports
Eccentric load of the FCU tendon
Repetitive trauma

Special Radiographs
CT scanning still often necessary
Reverse oblique view (45-degree supination with wrist extended)
Carpal tunnel view

Treatment
Acute treatment
- Nondisplaced to minimally displaced parasagittal fracture (in line with FCU) or transverse fracture: short-arm cast for 4 to 6 weeks
- Widely displaced fracture with loss of FCU continuity: comminuted: pisiform excision and FCU repair

Chronic, symptomatic nonunion or arthritic pisotriquetral joint: pisiform excision (it is important to identify and protect the ulnar nerve and artery prior to pisiform excision)

Associated Injury
50% with other upper extremity injury
Ulnar nerve injury

Complications
Posttraumatic pisotriquetral arthritis
- Nonunion

with digital, carpal, or ligamentous injuries. A high index of suspicion is warranted, as there is a high chance of an associated injury to the distal radius or carpus when a fracture of the pisiform is identified. With pisiform fractures involving the body of the triquetrum, there is a high incidence of additional injuries, and close follow-up is needed.

Four different types of pisiform fractures have been described: transverse fractures, parasagittal fractures, comminuted fractures, and pisiform-triquetral impaction fractures. Transverse fractures are most commonly associated with a sudden contracture of the FCU while the pisiform is locked between the triquetrum and the floor during a fall onto an outstretched palm. These fractures may represent discontinuity of the FCU tendon when they are severely displaced. Parasagittal fractures usually involve the ulnar rim of the pisiform and do not involve disruption of the FCU tendon. These fractures have a better prognosis. Comminuted fractures usually result from a direct blow of the base in the hypothenar area and are associated with additional soft tissue injuries, particularly of the ulnar neurovascular bundle.

The pisiform is difficult to visualize on standard PA and lateral radiographs. It is best visualized on oblique radiographs taken with the wrist supinated 45 degrees from the lateral position in slight extension. A carpal tunnel view can be helpful (Figure 16.53). CT scan is usually obtained to clarify the injury.

Acute nondisplaced pisiform fractures are managed by casting and immobilization for 4 to 6 weeks. Most heal by bony or fibrous union. Comminuted fractures, widely displaced transverse fractures, and symptomatic nonunions are best managed with excision of the pisiform. Incongruence of the pisotriquetral joint can cause persistent pain, particularly with gripping and radioulnar motion. Athletes will continue to complain of pain while swinging a bat or golf club.

The pisiform is approached through a volar zigzag approach. The point of a zig or transverse limb is centered over the distal

http://e-surg.com

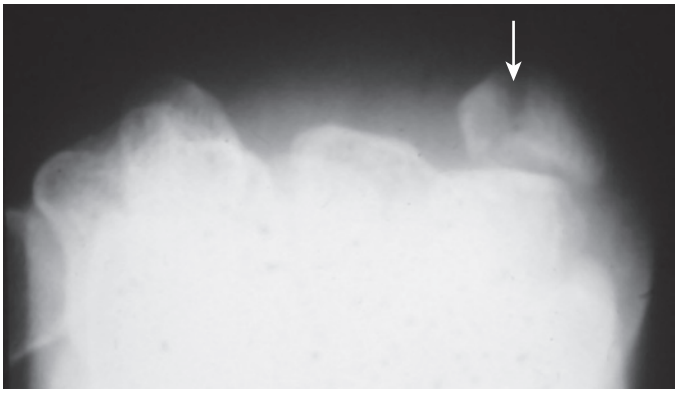

FIGURE 16.53 A radiograph with a carpal tunnel view indicating a pisiform fracture *(arrow)*. (Courtesy of Martin A. Posner, MD.)

palmar crease. The ulnar neurovascular bundle is identified throughout the field and protected prior to excision of the pisiform. The pisiform is then carefully shelled out from the FCU tendon. The tendon fibers must be left intact to preserve function of the FCU. The FCU is repaired side-to-side with nonabsorbable braided suture.

Carroll and Coyle reviewed their results with excision of the pisiform.[31] They found little or no functional impairment with pisiform excision. Pisiform excision appears to have little effect on wrist flexion strength. Patients are returned to activities as tolerated.

Ulnar nerve injuries that occur at the same time as the pisiform fracture are usually neurapraxias. These usually resolve with observation. Nerve exploration is recommended with excision of the pisiform if symptoms persist or worsen after 12 weeks of observation. Immediate exploration of the ulnar nerve is recommended if ulnar nerve dysfunction occurs following pisiformectomy during which the nerve was not identified.

Fractures of the Trapezoid

The trapezoid is a wedge-shaped bone widest at its dorsal surface with strong ligament attachments that bind it to the adjacent bones. The dorsal surface is twice as wide as the volar surface. The trapezoid is well positioned between the trapezium, scaphoid, capitate, and index metacarpal. In its well-protected position, the trapezoid is the least commonly fractured carpal bone (<1% of all carpal fractures) (Box 16.6). Isolated fractures of the trapezoid are very rare. When the trapezoid is fractured, the mechanism of injury is usually a high-energy axial or bending mechanism transmitted through the index metacarpal proximally. This can result in a shear fracture, dorsal avulsion of the trapezoid, and dorsal dislocation of the index metacarpal or trapezoid.

Palmar dislocations and fracture-dislocations have also been reported. Fewer than 20 isolated fractures of the trapezoid have been reported.[67]

A fracture-dislocation of the trapezoid is usually evident on standard PA, lateral, and oblique radiographic views. Fracture-dislocations of the trapezoid–index metacarpal joint are usually better visualized on the PA view than on the lateral view. A dislocated trapezoid allows proximal migration and overlap of the index metacarpal. Patients present with tenderness at the base of the index metacarpal. Pain can be elicited with motion of the index metacarpal. CT scans may help clarify the injury, and MRI may be helpful for occult fractures.

BOX 16.6 Fractures of the Trapezoid

Incidence
Trapezoidal fractures are the rarest carpal fractures, at less than 1%

Classification
Type 1 Dorsal rim fracture
Type 2 Fracture of the body, often with proximal dorsal subluxation of the second metacarpal

Blood Supply
70% dorsal, 30% palmar

Mechanism
Axial load of index metacarpal
Extreme index metacarpal palmar flexion
High-energy trauma

Special Radiographs
CT scanning still often necessary
Standard radiographs; CT particularly helpful
MRI may be helpful for occult fractures

Treatment
Nondisplaced fracture: Short-arm thumb spica cast for 4 to 6 weeks
Displaced: ORIF with headless compression screws or Kirschner wires; excision of fragments is contraindicated because of risk of second metacarpal subluxation
Severe comminution with unreconstructable trapezoid: Primary carpometacarpal arthrodesis with possible bone grafting
Chronic fracture with arthritic changes: Carpometacarpal arthrodesis

Associated Injury
Dorsal or palmar dislocation of trapezoid or index metacarpal
Multiple injuries of carpal and metacarpal bones, other extremities, and systems due to high-energy trauma

Complications
Delayed union or nonunion
Posttraumatic arthritis
Possible avascular necrosis if dorsal fracture-dislocation has occurred

Isolated fractures of the trapezoid without displacement are usually treated nonoperatively. Displaced fractures are managed by ORIF. If the fragment is small, occasionally closed reduction with cast protection may provide satisfactory results. However, if the fragments are larger, ORIF is recommended. Fractures are stabilized with pin or screw fixation. Excision of the trapezoid is contraindicated secondary to potential proximal migration of the index metacarpal. The trapezoid receives approximately 70% of its interosseous blood supply through dorsal branches.[143] Dorsal dislocations have been complicated by AVN. Severe comminution with unreconstructable trapezoid and chronic injuries with arthritis are best managed by carpometacarpal arthrodesis owing to the minimal motion that occurs at the index carpometacarpal joint.

Fractures of the Lunate

The lunate is well enclosed within the large lunate fossa of the distal radius. Hence, isolated fractures of the lunate body are

http://e-surg.com

BOX 16.7 Fractures of the Lunate

Incidence
1%
Controversy exists regarding relative frequency because Kienböck disease and congenital bipartite lunates confound diagnosis

Classification
Type I Palmar pole fracture
Type II Osteochondral chip
Type III Dorsal pole fracture
Type IV Sagittal body fracture
Type V Transverse body fracture
Type VI Comminuted fracture

Blood Supply
Most lunates have palmar and dorsal blood supply; 20% have palmar supply only

Mechanism
Usually, axial compression from capitate being driven into lunate with wrist in dorsiflexion and ulnar deviation; slight differences in position may lead to different fracture patterns
Type I Hyperextension, possible ligamentous avulsion fracture
Type II Shear
Type III Shear from capitate or ligamentous (scapholunate) avulsion fracture
Type IV Shear during radiocarpal fracture-dislocation
Type V
- Hyperextension with capitate forcing dorsal half of lunate into extension and short radiolunate ligament forcing palmar half into flexion; fracture in midsection results
- Shear with palmar displacement of capitate in palmar perilunate injury

Type VI Axial compression between radius and capitate

Special Radiographs
CT scanning still often necessary
Oblique wrist views

Treatment
First step is to determine if the pathologic process is Kienböck disease, congenital bipartite lunate, or acute traumatic fracture
If fracture fragments are too small but there is concern about instability, Kirschner wire to adjacent carpal bones may be needed
Carefully assess scapholunate and lunotriquetral ligaments for injury, and evaluate for carpal instability if small avulsion fractures appear benign on radiographs or CT scans because there may be extensive ligamentous disruption
Type I
- Nondisplaced and small, no instability: Short-arm cast for 4 to 6 weeks
- Large and/or displaced, or signs of carpal instability (usually VISI as lunate is unlinked from triquetrum): ORIF with headless compression screws or Kirschner wires; may need carpal reduction and Kirschner wire stabilization to adjacent bones if signs of carpal instability

Type II Short-arm cast for 4 to 6 weeks; arthroscopic débridement or excision if remains symptomatic
Type III
- Nondisplaced and small, no instability: Short-arm cast for 4 to 6 weeks
- Large and/or displaced, or signs of carpal instability (usually DISI as lunate is unlinked from scaphoid): ORIF with headless compression screws or Kirschner wires; may need carpal reduction and Kirschner wire stabilization to adjacent bones if signs of carpal instability

Type IV ORIF with headless compression screws or Kirschner wires *if displaced*
Type V ORIF with headless compression screws or Kirschner wires *if displaced or carpal instability*
Type VI Severe comminution or chronic (without capitate/lunate fossa arthrosis): Proximal row carpectomy

Associated Injury
Distal radius
Carpus
Metacarpals

Complications
Nonunion
Avascular necrosis
Carpal instability
Posttraumatic arthritis

DISI, Dorsal intercalated segmental instability; *ORIF*, open reduction and internal fixation; *VISI*, volar intercalated segmental instability.

rare (Box 16.7). Acute traumatic fractures of the lunate account for 1% of all carpal fractures.[202] However, fractures of the lunate are controversial. It is difficult to determine whether a fracture of the lunate is acute or whether the fracture is pathologic and the result of repetitive trauma on a weakened osteonecrotic bone resulting from Kienböck disease.[202]

Mechanism of Injury and Radiographic Presentation

Fractures of the body of the lunate usually occur from direct axial compression as the head of the capitate is driven proximally into the lunate. Differences in wrist position may lead to different fracture patterns. The dorsal lip of the lunate may be fractured as the head of the capitate impacts on it and on the dorsal distal edge of the radius in a severe hyperextension and ulnar deviation injury. If the capitate appears volarly subluxated on a lateral radiograph, a fracture of the volar lip of the lunate is suspected.

Teisen and Hjarbaek proposed a classification of fresh lunate fractures into five groups based on a review of 17 cases collected over 31 years.[202] These groups are palmar pole fractures with involvement of the palmar nutrient arteries, osteochondral chip fractures of the proximal articular surface without substantial damage to the nutrient vessels, dorsal pole fractures, sagittal fracture through the body of the lunate, and transverse fractures of the body (Figure 16.54). Fractures may also be comminuted.

Patients present with pain on the dorsum of the wrist and generalized swelling. Fractures of the lunate may be difficult to visualize on standard radiographs because of the overlapping adjacent carpal bones. CT is extremely helpful to visualize the fracture fragments and particularly to evaluate for any displacement. MRI may be helpful to evaluate for associated ligamentous injury. Signs of carpal instability should be evaluated, such as DISI, volar intercalated segmental instability (VISI), loss of Gilula lines, and asymmetric carpal bone gapping.

http://e-surg.com

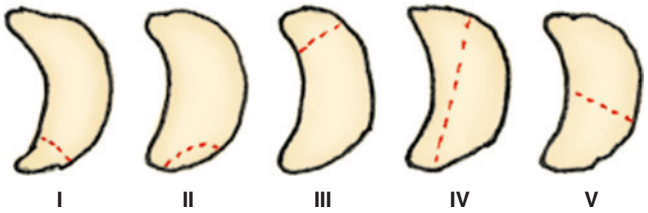

FIGURE 16.54 Lateral view line drawings of the five patterns of lunate fractures: palmar pole (I), osteochondral chip (II), dorsal pole (III), sagittal (IV), and transverse (V). (Courtesy of Steve K. Lee, MD.)

Fractures involving separation of the proximal articular surface from the body of the lunate are usually the result of Kienböck disease. A crescent line parallel to the proximal outline of the lunate is usually seen. Distinguishing fracture of a normal lunate from pathologic fracture of a lunate with AVN (as in Kienböck disease) must be done.

Treatment

Fractures of the lunate must be diagnosed and managed promptly. Careful assessment for carpal instability is imperative because a finding of small lunate fragments either dorsally or palmarly may seem benign by their size but may actually be a sign of major ligamentous disruptions. Imaging should be scrutinized for DISI or VISI deformity, loss of Gilula lines, and carpal gapping. Nondisplaced fractures of the lunate with no signs of carpal instability are treated by casting and immobilization, with close follow-up for any displacement.

Displaced fractures of the lunate require ORIF, particularly if there are signs of carpal instability. The carpus should be reduced and pinned. Lunate fragments are fixed. If open reduction is required, dorsal and body fractures are approached dorsally, palmar fragments palmarly, and osteochondral fragments either arthroscopically or dorsally.

Dorsal ridge fractures occur by shear force transmitted by the capitate. Most dorsal pole fractures are relatively benign. Treatment is determined according to the clinical findings (pain and swelling) and radiographic findings. Small dorsal chip fractures are treated with a short course of immobilization with close imaging follow-up.

Avulsions of the dorsal portion of the SLIL need to be repaired primarily. Malalignment of the capitate over the lunate (DISI) or scapholunate diastasis is consistent with carpal instability. This portion of the SLIL contains the stout transverse fibers important for stability across the scapholunate interval. The carpus needs to be reduced and pinned and the scapholunate ligament needs to be repaired primarily to the lunate with one or two micro-bone suture anchors.

Fractures of the body of the lunate and dorsal chip fractures are approached through a standard dorsal approach via the third dorsal compartments. The EPL is released, the second and fourth dorsal compartments are elevated, and the capsule is opened by the ligament-sparing technique of Berger and colleagues, exposing the carpus.[19] When the joint surface in a fracture of the body is involved, it is best seen through the dorsal approach. Body fractures may be fixed with headless compression screws and/or Kirschner wires. Comminuted fractures may require a cancellous bone graft harvested from the distal radius. Scaphocapitate pinning during slight distraction of the wrist may take pressure off the healing lunate when internal fixation is performed. If there is severe comminution with an unreconstructable lunate or chronic injury with arthritis, proximal row carpectomy or scaphocapitate fusion may be indicated.

VISI deformity may be seen with palmar chip fractures. Palmar lunate fractures are probably the result of a wrist extension injury, with the proximal pole being avulsed by the short radiolunate ligament. The hyperextended capitate continues to load the dorsal portion of the lunate. The dorsal portion of the lunate shifts dorsally as it is no longer constrained by the palmar ligaments, and the capitate acts as a proximal wedge. This causes a separation and a high rate of nonunion, and there is a chance of palmar subluxation of the capitate and eventual degenerative disease.

Volar fragments are reduced through an extended carpal tunnel approach exposing the volar lunate. Because the incision crosses the palmar wrist crease, it is important that the incision be made in a zigzag fashion to avoid flexion contracture from the scar. The incision crosses ulnar to the palmaris longus tendon proximally so as not to affect the palmar cutaneous branch of the median nerve. Volar pole fractures are often small and may not tolerate screw fixation. In these cases, the fragment may be secured with a bone suture anchor that captures bone and palmar ligaments. Carpal reduction and stabilization by pinning the scapholunate and lunotriquetral ligaments may be needed. A pin from the scaphoid into the capitate is placed to hold the capitate reduced and to decrease compressive loads across the lunate (Figures 16.55, *A* to *C* and 16.56).

Blood Supply

The vascular supply of the lunate has been studied extensively (Figure 16.57).[57,72,74] Both a palmar and a dorsal blood supply are present in 74% to 100% of bones.[57,72,74] These studies have demonstrated a single vascular blood supply in approximately 7% of lunates. Of those lunates with a dual blood supply, 33% have a single palmar and dorsal vessel for anastomosis, 66% have a three-vessel anastomosis, and 10% have a four-vessel anastomosis.[57,72,74] In those lunates with a single nutrient vessel, interruption may lead to necrosis of the entire bone; similarly, a coronal fracture in these lunates can lead to avascularity of the opposite pole.

Injection studies of the anterior interosseous vascular lunate have demonstrated a consistent palmar blood supply but frequently an inconsistent dorsal blood supply. On the palmar aspect, the radial, ulnar, and palmar branches of the anterior interosseous artery combine to form three transverse arches to supply the lunate. Dorsally, the radial, ulnar, and dorsal branches of the anterior interosseous artery combine to form three arches. The dorsal blood supply to the lunate is drawn from the proximal two transverse arches over the radiocarpal and intercarpal joints.

Because of internal anastomoses, both dorsal and palmar flow must be interrupted for the lunate to lose circulation. Fractures that split the lunate into dorsal and palmar halves or dislocations that leave a dorsal hinge should not be expected to result in AVN. However, 20% of lunates have only a palmar nutrient artery supply in the bone. Displaced volar fragments left untreated may place predisposed lunates at risk for AVN. These fractures may be anatomically reduced and fixed.

http://e-surg.com

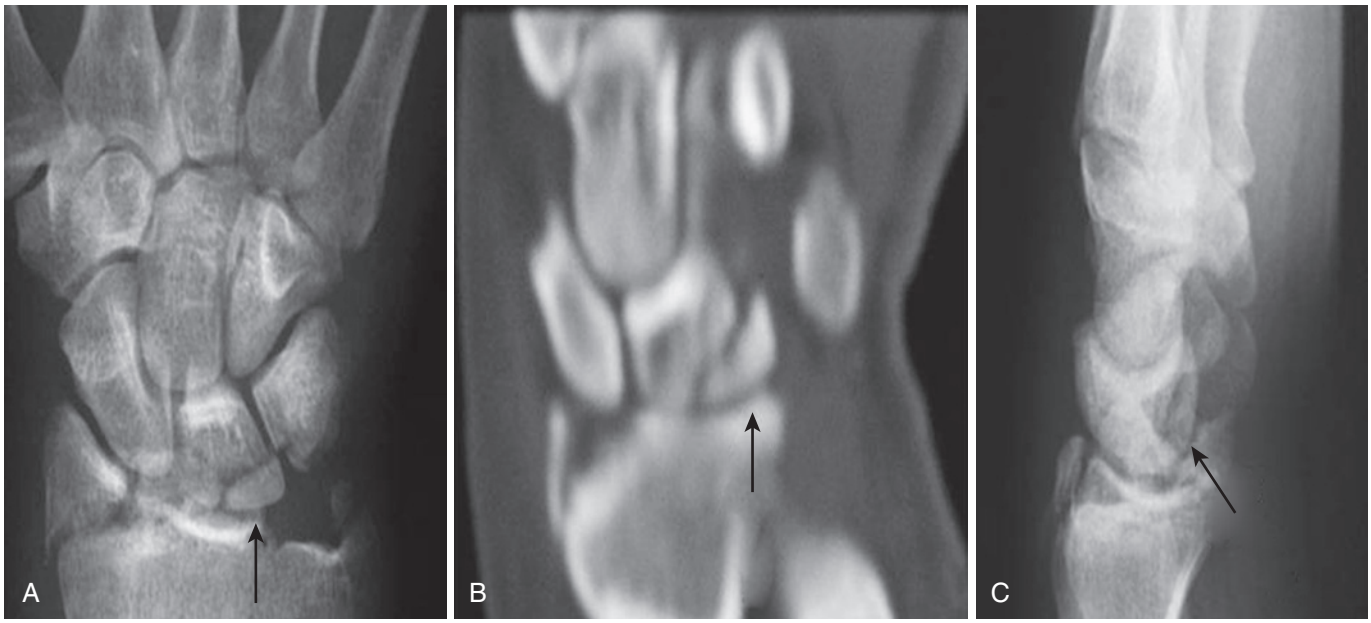

FIGURE 16.55 Lunate fracture *(arrows)*. Plain radiographic **(A)** and tomographic (**B** and **C**) evaluations demonstrating a fracture to the body and volar lip of the lunate. Radial styloid fracture is also present.



FIGURE 16.56 The lunate fracture in Figure 16.55 was approached through an extended carpal tunnel incision crossing in oblique fashion across the superficial wrist crease between the wrist flexor tendons and the ulnar nerve vascular bundle. The fracture was stabilized with a headless screw.

Osteonecrosis

Kienböck Disease

AVN of the lunate was first described in 1843 by Peste, who noted a collapsed lunate in certain cadaver dissections.[160] Robert Kienböck, a radiologist, described the x-ray changes associated with lunatomalacia that is now associated with his name.

Etiologic Findings

There is no consensus about the relationship between acute lunate fractures and Kienböck disease. Uncertainty exists as to whether some lunate fractures are actually pathologic fractures in patients with preexisting Kienböck disease. Teisen and Hjarbaek noted in a long-term follow-up series that lunate fractures had failed to show AVN even though half of the patients studied had ulnar-negative variance.[202] Persistent pain following a lunate fracture can be evaluated by MRI to see whether Kienböck disease is present.[202] However, radiographic findings of AVN in a patient with a fracture can be difficult to define. AVN of the lunate should be considered when there is homogeneous signal loss of the entire lunate rather than signal loss of a portion secondary to fracture.

http://e-surg.com

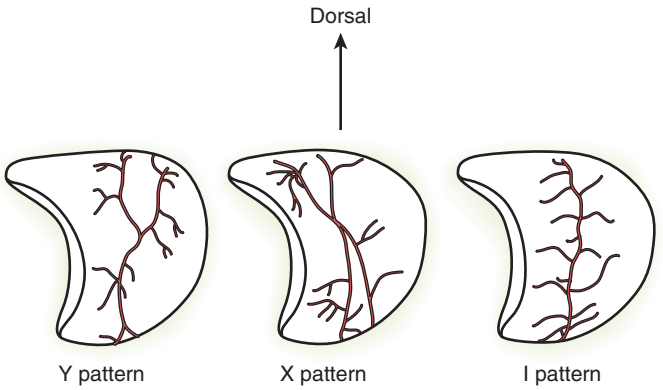

FIGURE 16.57 The vascular supply of the lunate has been thoroughly studied, and three major vascular patterns have been identified. These have been previously described as the Y, X, and I patterns. The I pattern is the only one with a single vessel to the lunate and is considered to be most at risk for development of avascular necrosis.

Despite years of clinical experience, the origin and natural history of Kienböck disease remain unclear. The loss of blood supply to the lunate has been attributed to primary circulatory problems, traumatic interference, poor circulation, ligament injury with collapse, and single or multiple fractures resulting in secondary vascular impairment. Although fracture-dislocation of the carpus may result in transient radial density of the lunate, the avascular changes of Kienböck disease are progressive. Kienböck disease has been associated with various medical conditions, including scleroderma, sickle cell anemia, systemic lupus erythematosus, and corticosteroid use. However, no consistent correlation with any specific disease process has been demonstrated. Most likely, the cause of Kienböck disease is multifactorial.

The relationship of ulnar variance and Kienböck disease is controversial. Gelberman and colleagues described a significant relationship between ulnar-negative variance and Kienböck disease.[72] However, D'Hoore and colleagues reviewed 125 normal wrists in 52 patients with Kienböck disease and found no significant statistical relationship between ulnar variance and Kienböck disease.[48] It was also noted that if Kienböck disease were related to ulnar-negative variance, the incidence of Kienböck disease would be higher, particularly in patients who had undergone Darrach procedures or ulnar shortenings. Nakamura and colleagues reviewed Kienböck disease in the Japanese population.[155] They found that ulnar-negative variance occurs with equal frequency in the general population and in the population with Kienböck disease.

Schiltenwolf and colleagues studied the interosseous pressure of the lunate with wrist motion.[175] In their study, they found that the interosseous pressure of the lunate is greater than its axial neighboring capitate by 40 mm Hg in wrist extension than in neutral. This rise in interosseous pressure may explain the lunate's predisposition to osteonecrosis.

The slope of the distal radius has been studied as a potential cause of Kienböck disease. Tsuge and Nakamura found that the radial inclination was lower in patients with Kienböck disease.[206] Other investigators found that the radial slope in the AP projection has a significant effect on both the forces transmitted to the lunate and the patient's age at the onset of Kienböck disease.

Clinical and Radiographic Presentation. The diagnosis of Kienböck disease is suspected particularly in young males with pain and stiffness in the dominant wrist. Tenderness is centered over the dorsal lunate, and patients experience decreased grip strength. The lunate lies just distal to the distal radius dorsal lip in line with the third ray. Patients frequently describe an insidious onset of dull pain centered over the radiolunate joint; however, some will provide a history of recent hyperextension injury. Patients complain of pain aggravated by activity and relieved with rest and immobilization.

On physical examination, patients may demonstrate a radiocarpal effusion with boggy synovitis of the radiocarpal joint. Range of motion of the wrist is limited, and grip strength is decreased compared with the opposite side.

Standard PA and lateral radiographs of the wrist are obtained with the wrist in neutral rotation. Increased bone density of the lunate is the early sign of avascularity on plain radiographs. MRI is the most sensitive imaging study for Kienböck disease. It is important not to confuse Kienböck disease with findings limited to the ulnar side of the lunate consistent with ulnar impaction (=abutment). Frequently, radiologists will diagnose ulnar impaction changes as Kienböck disease; the entire lunate must show signal loss on MRI to warrant the diagnosis of Kienböck disease, however.

Bone scintigraphy may also show increased uptake in the early stage of Kienböck disease. This technique is less commonly used today and has mostly been supplanted by MRI. Radiographic findings depend on the stage of the disease. Typical radiographic findings include lunate sclerosis, progressive loss of lunate height, fragmentation of the lunate, especially in the sagittal plane, progressive loss of carpal height as the capitate migrates proximally, and eventual degenerative joint changes related to rotation of the scaphoid and carpal collapse.

MRI will demonstrate a uniform decrease in signal intensity on T1 radial images due to the decreased vascularity. To make the diagnosis of Kienböck disease, a signal change must be seen throughout the entire lunate (*black lunate sign*). Ulnar impaction syndrome, fractures, interosseous ganglions, and enchondromas will cause MRI changes within the lunate, but these conditions will cause a focal change rather than a magnetic imaging change in the entire bone.

Staging. The most common method for staging Kienböck disease was first described by Stahl in 1947.[190] Lichtman and colleagues' 1977 modification of the system is widely used.[131] This classification system is based on plain radiographs and MRI findings. Treatment is based on the stage of disease (Table 16.7).

In stage I disease, plain radiographs may be normal or may show a linear compression fracture. Lunate collapse has not occurred. Diagnosis at this stage is usually made by MRI evaluation. A decreased signal on both T1- and T2-weighted images suggests AVN. Patients have intermittent dorsal wrist pain.

In stage II disease, there is sclerosis and fracture of the lunate but no change in the size or shape of the bone. There may also be multiple fracture lines, but the lunate is not collapsed. I find CT scan with sagittal and coronal reconstructions very helpful to assess for collapse and reconstructability of the lunate bone. Clinically, affected patients complain of pain, persistent swelling, and stiffness of the wrist.

http://e-surg.com

TABLE 16.7 Lichtman Classification for Kienböck Disease

Stage	Description
I	Plain radiographs are generally normal, but a linear fracture through the lunate may be noted. MRI demonstrates diffuse T1 signal decrease in lunate. Bone scan is positive.
II	Sclerosis of the lunate is seen on plain radiographs. Multiple fracture lines may be seen, though collapse of the lunate has not occurred.
IIIA	Lunate collapse has occurred, but the carpal height alignments have been maintained.
IIIB	Lunate collapse has occurred, and the capitate has migrated proximally. The scaphoid assumes a hyperflexed position.
IV	This is a continuation of stage IIIB disease, with the addition of carpal (radiocarpal and/or midcarpal) arthritis.

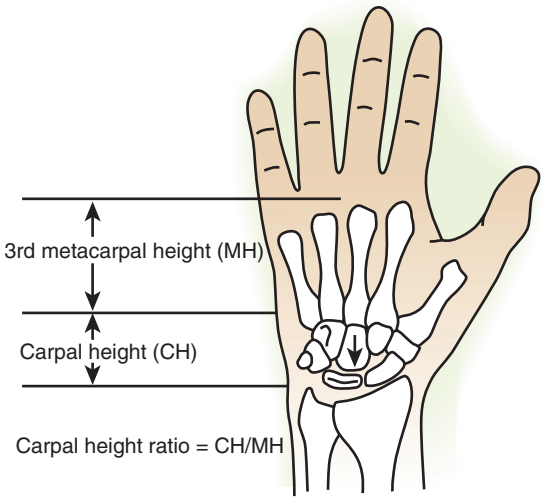

FIGURE 16.58 The carpal height index is measured on the posteroanterior radiograph. The carpal height ratio is defined as the carpal height divided by the height of the third metacarpal.

From the Lichtman-Stahl classification, stage III disease is divided into stages A and B. In stage IIIA, the lunate has collapsed but the carpus remains unchanged, with normal alignment and height. Lateral radiographs show that the lunate is wider in its AP dimension. In stage IIIB, the capitate has migrated proximally and the scaphoid has assumed a flexed position. As the carpal height ratio decreases, the lunate collapses and the capitate migrates proximally (Figure 16.58). Scaphoid rotation produces a DISI pattern of carpal instability. Patients complain of progressive stiffness with diminished grip strength. Clunking with radial and ulnar deviation of the wrist may be found.

Using radiographs, Goldfarb and colleagues found that interobserver reliability for differentiating between stages IIIA and IIIB of the Lichtman classification was poor. With the additional criterion that the radioscaphoid angle must be greater than 60 degrees to qualify for stage IIIB, interobserver reliability increased to a Kappa value of 0.75.[78] Using radiographs, Jensen and colleagues reported a reliability Kappa value of between 0.45 and 0.52 and a reproducible Kappa coefficient of between 0.26 and 0.63, which is fair to moderate.[107] Jafarnia and colleagues reported an average paired weighted Kappa coefficient of 0.71 for interobserver reliability of the Lichtman classification among four observers who reviewed radiographs from 64 patients and 10 control subjects.[106] The coefficient for interobserver reliability was noted to be 0.77. Condit and colleagues found that the preoperative radioscaphoid angle correlated best with clinical outcomes.[38] Specifically, wrists with preoperative radioscaphoid angles of greater than 60 degrees tend to do poorly with any procedure aimed at salvaging the lunate.

In stage IV disease, continued carpal collapse is related to arthritic changes in the radiocarpal and midcarpal joints. Radiographs show subchondral sclerosis with joint space narrowing, osteophyte formation, and degenerative cysts. Patients complain of decreased range of motion of the wrist with constant pain and swelling.

Imaging. I currently use radiographs, MRI, and CT scans to assess Kienböck disease. MRI is best for the assessment of vascularity of the lunate, specifically documenting the absence of vascularity on *all* imaging sequences. On occasion, an abnormal signal in a portion of the lunate will be interpreted on MRI to represent Kienböck disease, when in fact clinical and radiographic signs point more toward ulnar impaction syndrome. MRI with cartilage-sensitive sequencing also aids in knowledge of the state of cartilage and arthritic change. I believe that the usefulness of staging classic IIIA and IIIB disease in guiding treatment is uncertain. I use CT scans to determine the morphologic condition of the lunate and the probability that it can be salvaged.

Treatment. Treatment algorithms for Kienböck disease have primarily been determined by the stage of the disease according to the Lichtman classification. There are many treatment options, but they basically fall into three main groups: procedures to unload the lunate, procedures to promote revascularization of the necrotic lunate, and salvage procedures used when the lunate is not reconstructable or arthritic conditions exist.

Stahl recommended prolonged immobilization for Kienböck disease.[190] Tajima reviewed 80 patients with Kienböck disease with a follow-up of 42 years and found no appreciable difference in the end results of nonoperative or surgical treatment.[200]

Kristensen and colleagues followed 46 patients with Kienböck disease treated nonoperatively for a minimum of 5 years, with a mean of 20 years.[123] Although 66% of the patients had arthritic changes of the wrist at follow-up, only 25% had significant pain. Taniguchi and colleagues found that although radiographic findings worsened in 70% of 20 patients followed for 35 years, only 20% had significant symptoms limiting their activities.[201] However, a recent study by Keith and colleagues reviewed 33 patients treated nonoperatively for Kienböck disease.[118] They found a predictable pattern of deterioration of motion, grip strength, and Disabilities of the Arm, Shoulder, and Hand (DASH) scores.

Stage I, II, or IIIA Kienböck Disease with Ulnar-Negative Variance. In stage I, II, or IIA Kienböck disease with ulnar-negative variance, carpal collapse into an instability pattern has not occurred (radioscaphoid angle < 60 degrees). Salvage of the lunate may be possible to maintain normal carpal kinematics. In a symptomatic patient with stage I, II, or IIIA disease with

http://e-surg.com

ulnar-negative variance, a joint-leveling procedure should be considered. Some authors have found that unloading the joint can be useful even in patients with stage IIIB pathologic changes.[5,221] The most common procedure for unloading the lunate in patients with ulnar-negative variance is radial-shortening osteotomy. This can be done through either a volar or dorsal approach, although the volar approach is more commonly performed. Specialized jigs and forearm-shortening plates have been designed to simplify the procedure. The goal is to leave the patient with ulnar-neutral or slightly ulnar-positive variance. Some authors have described lengthening of the ulna; however, this technique requires two osteotomy sites and a bone graft, unlike radial shortening, and is not commonly performed.

Joint-leveling procedures. Radial-shortening osteotomy is considered for patients with Kienböck disease who have an ulnar-negative variance, a salvageable lunate, no carpal collapse (radioscaphoid angle < 60 degrees), and no arthritic changes around the adjacent intercarpal or radiocarpal joints. Patients who are ulnar neutral or ulnar positive are at risk for developing ulnar impaction syndrome after ulnar shortening. Several biomechanical studies have compared the changes of force distribution across the carpus. Trumble and colleagues reviewed the force distribution across the carpus with various procedures for Kienböck disease.[203] In this study, capitate-hamate fusion did not significantly decrease lunate strain. However, ulnar lengthening, radial shortening, and STT fusion all produced a 70% decrease in lunate strain. The advantage of joint-leveling procedures such as radial shortening is that it does not affect the final range of motion of the wrist, unlike intraarticular procedures such as STT fusion, which limits wrist radial deviation and extension. Trumble and colleagues noted that 90% of the reduction in lunate strain following radial shortening or ulnar lengthening occurred in the first 2 mm of length alteration, although strain reduction increased in both procedures with up to 3 mm of length alteration.[203] Length alteration of more than 4 mm produced no further changes in the lunate load; in addition, shortening of more than 4 mm runs the risk of incongruence to the distal radioulnar joint. Based on the biomechanical studies, the object of radial shortening is to shorten the radius approximately 2 to 3 mm and not merely to obtain ulnar-neutral variance.

Similarly, Horii and colleagues used a mathematical model to evaluate joint-leveling procedures.[98] Ulnar lengthening and radial shortening were equivalent in this mathematical model, leading to a 45% decrease in the force transmitted through the radiolunate joint. This decrease was mostly borne by the ulnar lunate and ulnar triquetral joints, where force increased by 50% and 78%, respectively. The force transmitted to the radioscaphoid joint increased by 6%, and in the midcarpal region there was an increase in the lunatocapitate joint force of 13%. Scaphocapitate fusion led to a decrease in the radiolunate joint force of 12%, capitate hamate fusion had no change, and capitate shortening combined with carpal hamate fusion led to a 66% force decrease.

Radial-shortening osteotomy. Radial shortening may be performed through either a volar or a dorsal approach. In the volar approach, an incision is centered over the radial border of the FCR tendon. The tendon sheath is released, and the FCR is retracted ulnarly to protect the median nerve. The pronator quadratus is released from the radial border of the radius and retracted ulnarly. There are a few radial shortening plate systems on the market, or a freehand technique may be used with a dynamic compression plate and dynamic compression/distraction device using a screw placed outside of the plate.

A plate is placed on the volar aspect of the radius. It may be slightly prebent distally to fit the volar curvature to the distal radius. A locking screw is placed in the most distal screw hole, and a 3.5-mm nonlocking screw is placed in the oval reduction slot. The osteotomy will be performed over the oblique lag screw hole. This area is marked on the radius with the plate in place. The plate is removed. A transverse or oblique osteotomy to the distal radius is performed. If an oblique cut is made, a 2-mm wafer is removed because of the geometry of compression. If a transverse cut is made, a wafer of bone of approximately 3 mm is removed. The forearm osteotomy plate is replaced and fixed to the radius. An articulated distraction-compression device with which to gain increased compression at the osteotomy site may be used at the discretion of the surgeon. The most distal 3.5-mm locking screw is placed first. The radius is shortened, and the 3.5-mm nonlocking screw in the reduction slot is tightened (Figure 16.59. *A* and *B*). Additional compression is gained by a second oblique screw hole proximally in the plate. An oblique lag screw may be used if an oblique osteotomy is performed. The remaining 3.5-mm locking screws are placed in neutral mode. Patients generally wear a cast until healing occurs, usually at approximately 6 weeks.

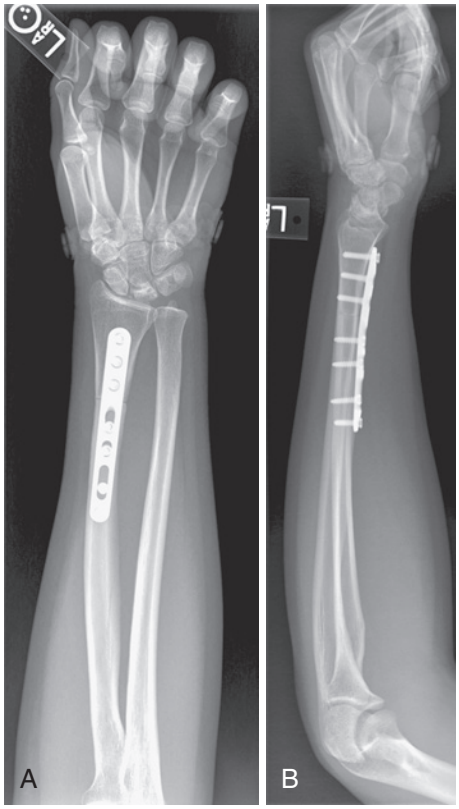

FIGURE 16.59 A, PA radiograph following radial-shortening osteotomy. A forearm-shortening osteotomy plate (AcuMed, Hillsboro, OR) was placed on the volar surface of the radius. The patient now is ulnar neutral. **B,** Lateral radiograph showing the anatomically contoured plate along the volar aspect of the radius following radial-shortening osteotomy.

http://e-surg.com

Alternatively, an osteotomy can be performed more distally in the metaphyseal bone. In this incidence, a long distal radius plate may be used. The plate is initially placed with distal screws, and a proximal screw is inserted. The plate is removed, a transverse osteotomy is performed in the metaphysis of the distal radius, the radius is shortened, the distal plate is replaced, and the radius is compressed. This technique has a potentially better incidence of healing because the osteotomy is made in the metaphyseal bone. However, compression is more difficult to obtain at the osteotomy site as compared with a formal forearm osteotomy plate.

Alternatively, a plate may be placed dorsally. However, a dorsal plate may be symptomatic because of its more superficial location and may need to be removed in the future.

Most authors report good results after a radial-shortening osteotomy.[5,169,221] Weiss and colleagues reviewed the results of 29 patients who underwent the procedure for stages I through IIIB disease.[221] At a minimum follow-up of 2 years, they reported that 87% of the patients had decreased pain and that the wrist range of motion had increased by an average of 32%. There was no progressive evidence of carpal collapse. It is important to note there was no improvement in the radiographic appearance of the lunate. Rock and colleagues reviewed 16 patients who underwent radial-shortening osteotomy.[169] Six patients were classified as stage III and four were classified as stage IV. At an average follow-up of 4.5 years, 13 of 16 patients were pain free, and the range of motion improved in the AP plane by 15 degrees. Grip strength increased by 20% to 30%. Almquist and Burns reported pain relief in 11 of 12 patients, although no patient was pain free in their series at 5 to 10 years' follow-up.[5] Wrist range of motion increased by an average of 40 degrees, and grip strength improved.

Vascularized bone grafting. Vascularized bone grafting is another useful technique for patients with stage I, II, or IIIA disease; however, precise indications are not clear. The dorsal distal radius vascular anatomy is constant and demonstrates a consistent special relationship to anatomic landmarks. An anatomic network for the intercompartmental and compartmental arteries is provided by a series of arterial arches across the dorsum of the hand and wrist. These include the dorsum of the carpal arch, the dorsal radiocarpal arch, and the dorsal supraretinacular arch. Dorsal arterial arches are the source of the vascularized bone graft from the base of the second and third metacarpals. The vessels supplying nutrient branches directly to the dorsal radius and ulna are described at those locations with respect to the extensor compartments of the wrist and extensor retinaculum. *Intercompartmental vessels* are located between compartments, and *compartmental vessels* lie within an extensor compartment. Vessels lying superficial to the retinaculum are further described as *supraretinacular.*

Technique based on the fourth and fifth extensor compartment arteries. The most useful vessels for vascularized bone grafting for the treatment of Kienböck disease are the fourth and fifth ECAs. A vascularized bone graft using the fifth ECA's connection to the fourth ECA by way of their common origin is preferred because of the large diameter of the fifth ECA. The ECA pedicle provides an ideal pedicle length that can reach anywhere in the carpus.

A longitudinal incision is made to expose the lunate and distal radius. The fifth ECA is exposed by opening the fifth dorsal extensor compartment. The fifth ECA is visualized on the radial floor of the compartment adjacent to or partially in the septum separating the fourth and fifth extensor compartments. The fifth ECA is traced proximally to its origin at the anterior osseous artery while the fourth ECA is identified and distally traced, opening the fourth compartment (Figure 16.60). A bone graft centered 11 mm proximal to the radiocarpal joint and overlying the fourth ECA to include the nutrient vessels is outlined (Figure 16.61). Ligation of the anterior osseous artery proximally to the fourth and fifth ECA is

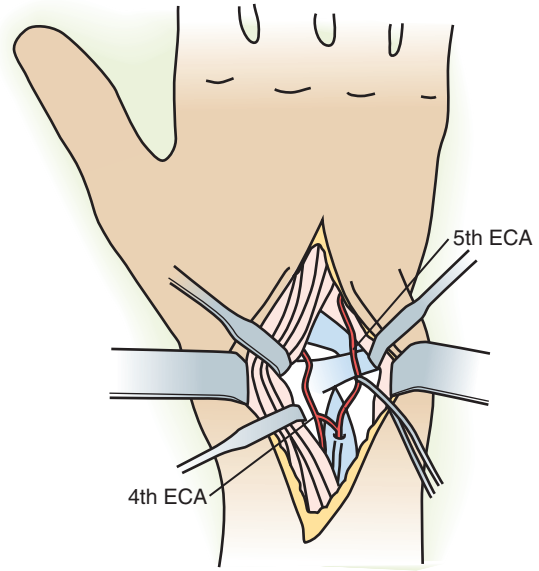

FIGURE 16.60 The fifth extensor compartment artery is identified by incising the fifth dorsal extensor compartment. It is visualized on the radial aspect of the compartment by an adjacent septum separating the fourth and fifth dorsal compartments. (By permission of Mayo Foundation for Medical Education and Research. All rights reserved.)

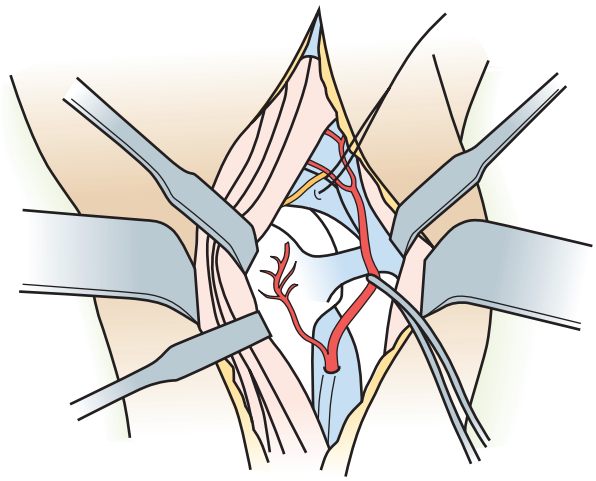

FIGURE 16.61 The fifth extensor compartment artery is identified and traced proximally to its origin from the anterior interosseous artery. The fourth extensor compartment artery is identified and traced distally to the distal radius. A bone graft is centered approximately 11 mm from the radiocarpal joint overlying the fourth extensor compartment artery. (By permission of Mayo Foundation for Medical Education and Research. All rights reserved.)

http://e-surg.com

performed. Graft elevation is completed with the use of osteotomes (Figure 16.62). The tourniquet is deflated to verify blood flow to the graft. Cancellous bone graft can be additionally obtained from the donor site. While protecting the bone graft and its pedicle, the lunate is exposed via a dorsal ligament–sparing capsulotomy. A dorsal cortical window is made in the lunate, and the necrotic bone is removed (Figure 16.63). With the wrist distracted, a scaphocapitate Kirschner wire is placed to unload the lunate. If partially collapsed, the lunate is reduced by a hemostat so that the morphologic condition is uncompressed. Cancellous bone graft is packed in the defect, leaving room for the vascularized bone graft. The 4,5 ECA vascularized bone graft is rotated and transferred into the lunate (Figure 16.64). Moran and colleagues reported on 26 patients with Kienböck disease who had the 4,5 ECA graft. Although they had a short follow-up of 3 months, 92% of patients had significant improvement in their pain. Grip strength improved from 50% to 89% of the unaffected side. Satisfactory results were seen in 85% of patients based on the Lichtman outcome score. Of patients who had a postoperative MRI, 71% showed evidence of revascularization.[151]

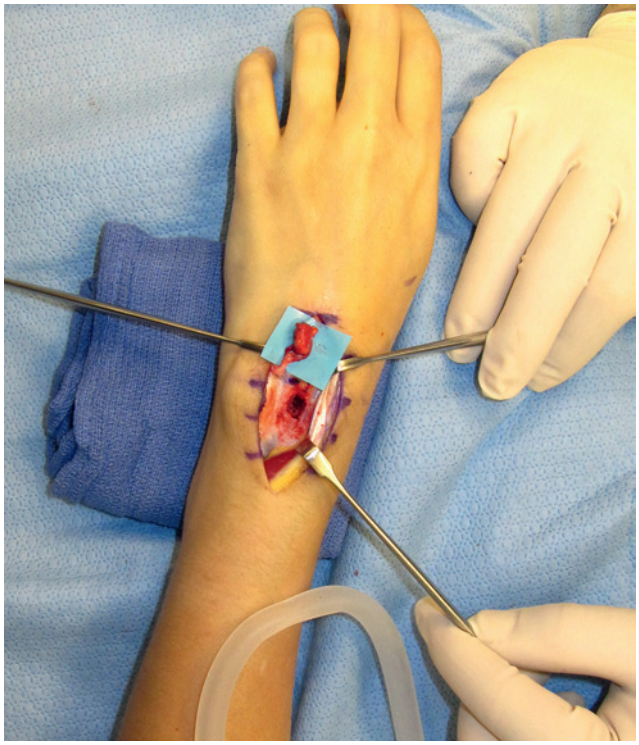

FIGURE 16.62 Graft elevation is completed with the use of osteotomes. (Courtesy of Steve K. Lee, MD.)

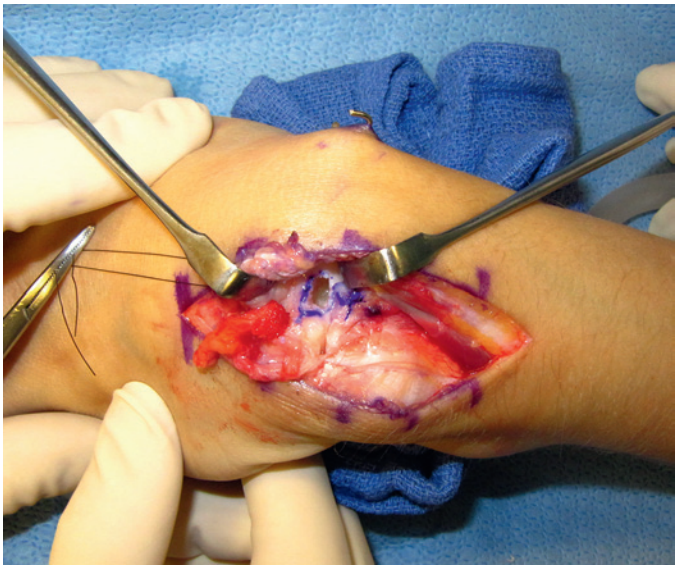

FIGURE 16.63 While protecting the bone graft and its pedicle, the lunate is exposed via a dorsal ligament–sparing capsulotomy. A dorsal cortical window is made in the lunate, and the necrotic bone is removed. (Courtesy of Steve K. Lee, MD.)

Other graft options include the 2,3 ICSRA graft based on antegrade flow through the fifth ECA. The 2,3 ICSRA has a proximal origin from the anterior interosseous artery or its posterior division. It lies superficial to the extensor retinaculum directly over the Lister tubercle and anastomoses with the dorsal intercarpal arch, the dorsal radiocarpal arch, and occasionally the fourth ECA. It is easily harvested and has an arc of rotation that reaches the entire proximal row.[179]

Technique based on the second or third metacarpal. This technique takes advantage of the distal vascular arcade to use the vascularized bone graft through a single midline incision. Releasing the distal portion of the fourth dorsal compartment exposes the distal vascular arcade. The pedicle may be mobilized in either an ulnar or a radial direction to a length sufficient to reach the lunate. The bone graft is harvested from the base of the second or third metacarpal, depending on where the artery has the greatest area of contact. The vascularized bone graft is harvested and is inserted into the lunate, as in the previously described technique using the fourth and fifth ECAs (Figure 16.65).

Technique for vascularized bundle implantation. Hori and colleagues described a technique for vascular bundle implantation using the second dorsal intermetacarpal artery.[97] Indications for this technique include patients who maintain a

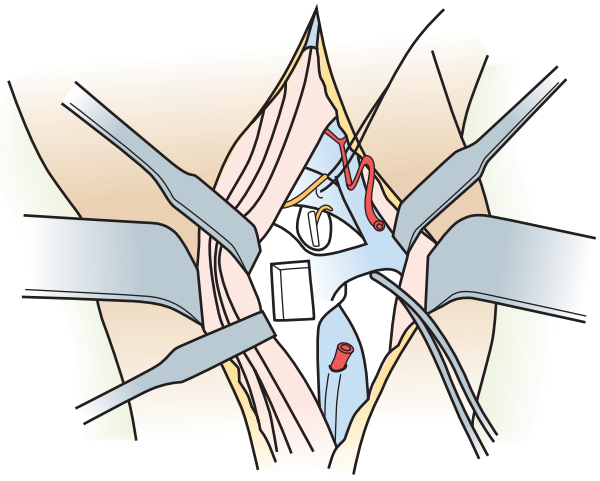

FIGURE 16.64 The vascularized bone graft is inserted into the lunate. The pedicle is oriented vertically with the cortical surface and arranged in proximal-distal orientation to maintain lunate height. (By permission of Mayo Foundation for Medical Education and Research. All rights reserved.)

http://e-surg.com

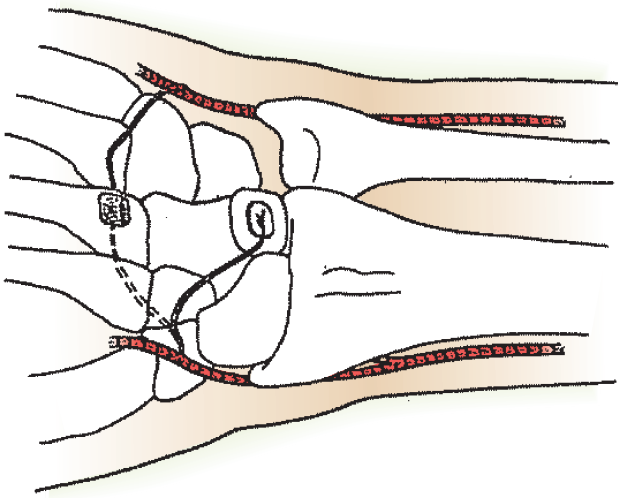

FIGURE 16.65 An optional source of vascularized bone graft may be obtained from the base of the second or third metacarpal based on the dorsal metacarpal arcade.

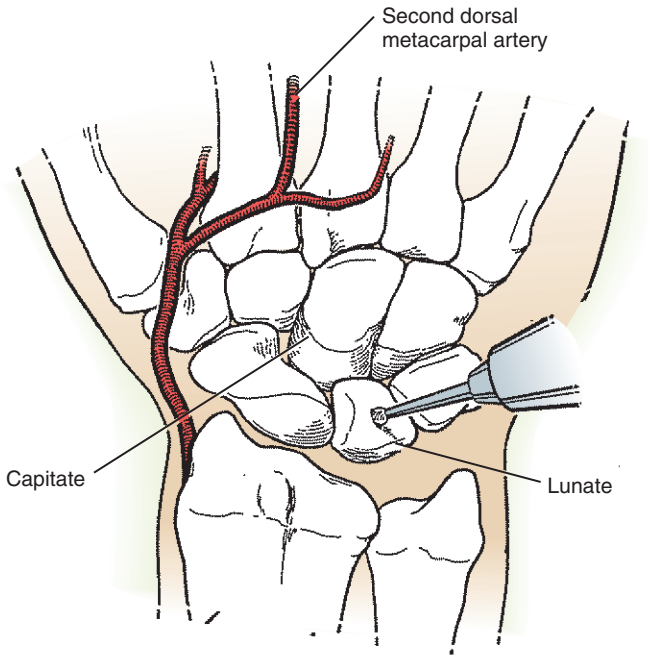

FIGURE 16.66 The dorsal second intermittent carpal artery lies just beneath the aponeurosis and covers the interosseous muscles. The fascia is divided to expose the intermittent carpal artery.

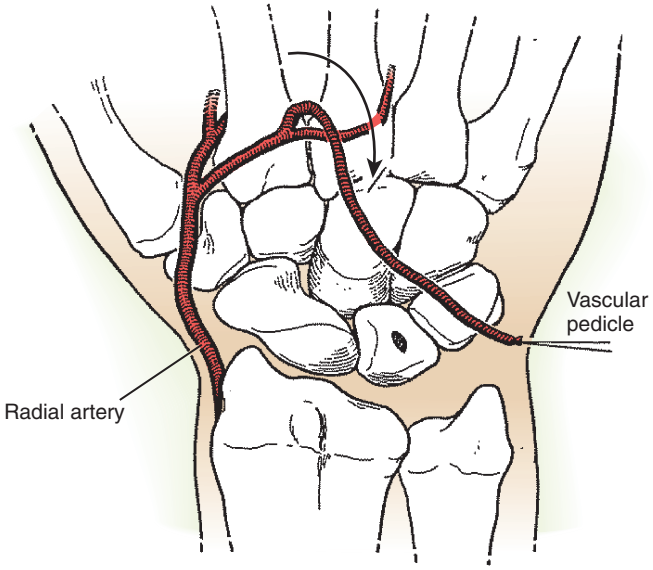

FIGURE 16.67 The distalmost extent of the artery is ligated with a 5-0 monofilament suture. This provides a 5- to 6-cm length of vessel.

relatively normal arch of the carpus. The second dorsal metacarpal artery is a branch of the dorsal metacarpal artery to the index and long fingers. It travels between the index and long metacarpals. If this vessel is damaged or cannot be found, the third dorsal metacarpal artery may be used. A dorsal incision is made starting proximal to the second metacarpophalangeal joint; it is continued proximally and curves around the Lister tubercle. Dissection is continued between the second and third extensor compartments, which are released, and the extensor carpi radialis longus and brevis are retracted radially. The extensor digiti communis tendon is retracted ulnarly so that the capsule of the carpus is visualized. A proximally based flap is made to visualize the lunate. In the nonarticular portion of the lunate a dorsal window is made in the bone using 0.035-inch Kirschner wires and a sharp osteotome to remove the outer layer of bone. Sclerotic bone is removed. The second dorsal intermetacarpal artery lies underneath the aponeurosis that covers the interosseous muscles (Figure 16.66). This fascial layer is divided from proximal to distal to the level of the second web space. The artery and venae comitantes are elevated with a thin layer of surrounding perivascular tissue. At the distalmost extent of the artery, the vessels are ligated with a 5-0 monofilament suture (Figure 16.67). This should provide a 5- to 6-cm length of vessel. The lunate should be unloaded by any number of procedures (such as external fixation, capitate shortening, or temporary scaphocapitate pinning). Devascularized and necrotic bone is removed from the lunate. Cancellous bone chips are packed into the defect. A 2.7-mm drill is used to create a hole in the proximal avascular portion of the lunate. The vascular bundle is passed through this hole in a dorsal to volar direction (Figure 16.68). This may be performed by attaching a fine resorbable suture on a straight needle to the 5-0 monofilament suture. The needle exits through the palmar skin just ulnar to the FCR tendon. A small skin incision is made, and the suture is tied over the palmar antebrachial fascia.

Hori and colleagues reported their experience with implantation of the dorsal metacarpal arteriovenous pedicle.[97] Nine cases of Kienböck disease were reviewed, with improvement described in eight patients. Several authors have described their experience with transfer of the vascularized pisiform into the necrotic lunate. Bochud and Buchler reported on 32 patients with a follow-up of 2 years.[22] Initial restoration of the lunate anatomy was observed in 95% of the patients. However, only 33% retained a correction, and nearly half of the long-term results were only fair or poor. Moran and colleagues reviewed the results of vascularized bone grafting in 48 patients with follow-up over a 10-year period.[150] Ninety-eight percent of patients experienced significant pain relief. Grip strength

http://e-surg.com

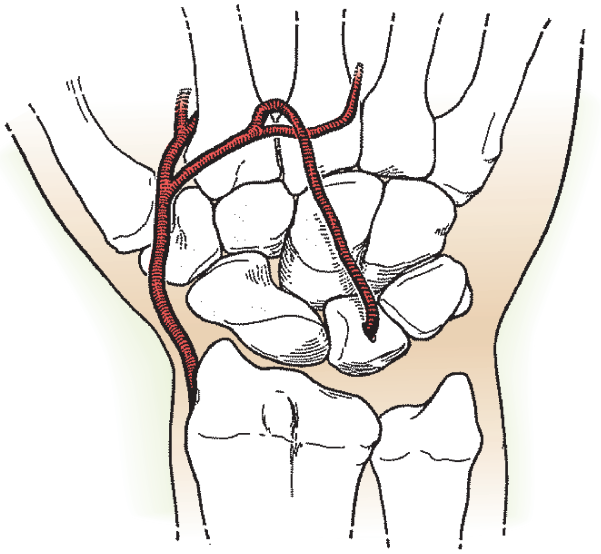

FIGURE 16.68 The vascular bundle is passed through a 2.7-mm drill hole in a dorsal-volar direction.

improved, although range of motion did not. Postoperative MRI showed evidence of vascularization in 60% of the patients in their series.

Stage I, II, or IIIA Kienböck Disease With Ulnar-Positive or Ulnar-Neutral Variance. In this situation, the radius is as short as the ulna, and further shortening is not likely to decrease the load on the lunate. The lunate has not collapsed, so salvage procedures are not warranted.

Capitate shortening alone or combined with capitate-hamate fusion has been reported in the literature.[5] This technique was first described by Almquist in 1993, and he reported lunate revascularization rates as high as 83%.[4] Stage IV Kienböck disease would be a contraindication to this surgical technique.

Technique for capitate shortening with capitate-hamate fusion. A dorsal incision is made from the base of the third metacarpal to the Lister tubercle. The fifth dorsal compartment is released, and the extensor digiti quinti tendon is retracted. The fourth dorsal compartment tendons are retracted radially, and the dorsal capsule is opened. Care is taken not to elevate the fourth compartment and disrupt the vascular supply. The capitate-hamate joint is incised from proximal to distal, and the waist of the capitate is identified for the proposed osteotomy. This level should correspond to the distal pole of the scaphoid. Almquist, in his technique, described using a sharp, thin osteotome to make the bone cut to avoid disruption of the volar capsule blood supply. A small curved elevator is inserted carefully into the capitolunate joint, avoiding injury into the articular surface. The elevator is used to compress the capitate head against the distal segment, and two crossed 0.062-inch Kirschner wires are used to stabilize the osteotomy site. Alternatively, headless compression screws can be used. If a capitate-hamate fusion is performed, all cartilage and subchondral bone at the capitate-hamate interface is removed, and bone harvested from the osteotomy or from a separate distal radius graft site is packed into the space. Kirschner wires or headless cannulated screws are placed percutaneously from the hamate into each of the capitate fragments. Viola noted that when performing this procedure, the tip of the hamate becomes prominent proximally, preventing the unloading effect of the capitate shortening.[212] The tip of the hamate may be removed to correct this problem.

Alternatively, the surgeon can perform the osteotomy across both the capitate and the hamate. The composite osteotomy is then reduced and secured with Kirschner wires or buried headless screws inserted from proximal to distal.

Hanel and Hunt noted in the review of their patients that the initial results in 1 year were remarkable with this technique.[87] Range of motion and strength plateaued between 8 and 12 months. Almquist noted grip strength of the affected hand to be 80% of the opposite side, and he reported an 83% satisfaction rate in his series.[4]

Technique for closing wedge radial osteotomy. Radial-closing radial osteotomy with reduction in the angle of radial inclination has been described.[215] Watanabe and colleagues' rigid body spring model showed that the axial load through the radiolunate joint is redistributed to the radioscaphoid joint without increasing the ulnar carpal load.[215] Radial osteotomy does not violate the intraarticular space of the wrist, so the range of motion is maintained. The technique is technically demanding. Radial osteotomy is not indicated in advanced Kienböck disease with collapse.

In this technique, a standard volar approach is made to the distal radius. The FCR is released and retracted ulnarly to protect the median nerve. The pronator quadratus is released along the radial surface. A trapezoidal wedge-shaped segment of bone may be removed from the distal quarter of the radius or metaphysis. The osteotomy would be wider radially than ulnarly to decrease the radial inclination (Figure 16.69, *A* to *C*).

Core decompression. Illarramendi and colleagues described their technique of coring out the metaphyseal region of the distal radius and ulna for treating Kienböck disease.[102] The idea for this technique arose from the authors' observation that complete resolution of Kienböck disease occurred in patients who sustained a distal radius fracture. By coring out the distal radius, they felt they would be able to create a scenario similar to that of a distal radius fracture. Twenty-two patients were followed for an average of 10 years. Sixteen patients were pain free and four patients had occasional pain. No patient required further surgery. This technique is used mainly to increase venous outflow, which is similar to cord decompression, and to decrease interosseous congestion.

Stage IIIB Kienböck Disease. If the disease has progressed to stage IIIB, the various salvage procedures should be considered.[155] Various intercarpal fusions have been described, including STT and scaphocapitate arthrodesis. Proximal row carpectomy has also been reported for stage IIIB disease. Watson and colleagues reported their results in 69 patients who underwent 71 triscaphe scaphotrapezial arthrodesis procedures for Kienböck disease.[217] (Two patients in the series had bilateral disease.) Initially, in the authors' series, the lunate was excised and Silastic lunate arthroplasty was performed. The prevalence of Silastic particulate synovitis led to the discontinuation of the Silastic prosthesis. In their series, 46% of the patients had excellent subjective results and 32% had good results. The carpal height index remained essentially unchanged in 35 of 36 patients. Eighty-two percent returned to their preoperative

http://e-surg.com

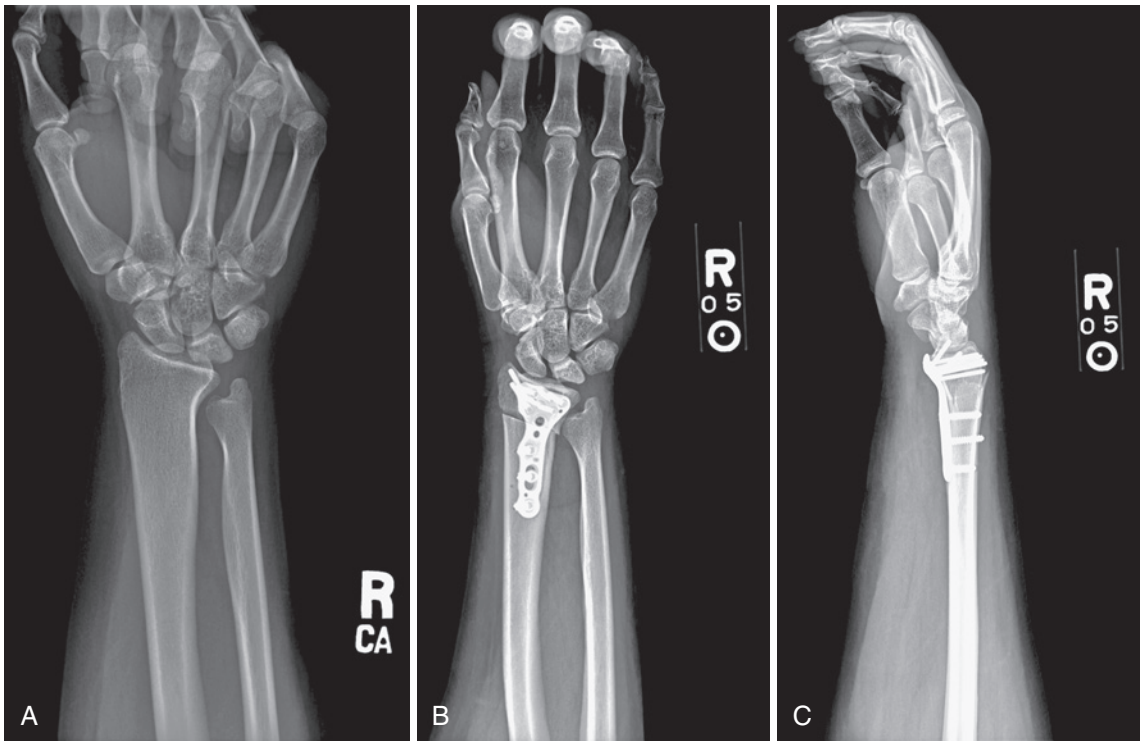

FIGURE 16.69 Closing wedge osteotomy. **A,** Posteroanterior wrist radiograph of a 23-year-old female with a congenital abnormality with increased radial tilt and Kienböck disease. **B,** Because of the increased tilt, a trapezoidal wedge osteotomy was performed. The osteotomy is stabilized by an AcuLoc (AcuMed, Hillsboro, OR) volar distal radial plate. **C,** Lateral wrist radiograph following trapezial wedge osteotomy.

work or avocational activities. Further wrist salvage procedures were needed in 5.6% of patients, including proximal carpectomy in two patients and total wrist arthrodesis in two patients. Scaphocapitate fusion is thought to be technically easier to perform than STT fusion. It is important to maintain the normal distance between the scaphoid and capitate.

De Smet and colleagues reported on their results for 21 patients who underwent proximal row carpectomy for advanced lunate AVN.[45] In their series, 13 patients had no pain to mild pain, 3 patients reported moderate pain, and 5 patients had severe pain. Nakamura and colleagues reported better results with proximal row carpectomy than with limited wrist arthrodesis for advanced Kienböck disease.[155] Based on their experience, they recommended proximal carpectomy over STT fusion, although the difference was not statistically significant (Figure 16.70, *A* to *F*).

Recently, pyrocarbon arthroplasty has become an option in patients with late-stage Kienböck disease. The pyrocarbon lunate may be stabilized by either suture or tendon. There are no long-term studies with this technique.

Stage IV Disease. In stage IV disease, there is significant collapse of the lunate in addition to perilunate arthritis. Generalized degenerative changes are noted at the radiocarpal and midcarpal joints. Proximal row carpectomy may be a possibility, but it is important to determine that the head of the capitate and the lunate fossa are relatively well preserved. Potentially, a dorsal capsule interposition or soft tissue graft may be placed on the lunate fossa.

In most instances with end-stage Kienböck disease and arthritic radiocarpal and midcarpal joints, total wrist fusion is recommended. Patients frequently achieve pain relief, but wrist fusion is not without potential complications and residual symptoms.

❖ AUTHOR'S PREFERRED METHOD

I prefer to think of Kienböck disease in two stages: (1) the lunate is salvageable and (2) the lunate is not salvageable. I base this decision on radiographs, MRIs, and CT scans and believe all three add to the decision-making process. MRI is best for specific evaluation of complete avascularity of the lunate on all sequences. MRI with cartilage-sensitive sequencing also provides knowledge of cartilage and arthritic changes. CT scans are used to assess the lunate morphologic conditions of collapse and carpal alignment. If the lunate is salvageable and there is ulnar-negative variance, I shorten the radius to 2 to 3 mm and perform a posterior interosseous nerve neurectomy. If the lunate is salvageable and there is ulnar-neutral or ulnar-positive variance, I perform vascularized bone grafting from the 4,5 ECA and posterior interosseous nerve neurectomy. If the lunate is not salvageable and the lunate fossa and capitate head cartilage are preserved, I perform proximal row carpectomy and posterior interosseous nerve neurectomy. If the lunate is not salvageable and the lunate fossa and capitate head cartilage are not preserved, I perform proximal row carpectomy and capsular interposition versus total wrist fusion, depending on a preoperative discussion with the patient regarding the possibility

http://e-surg.com

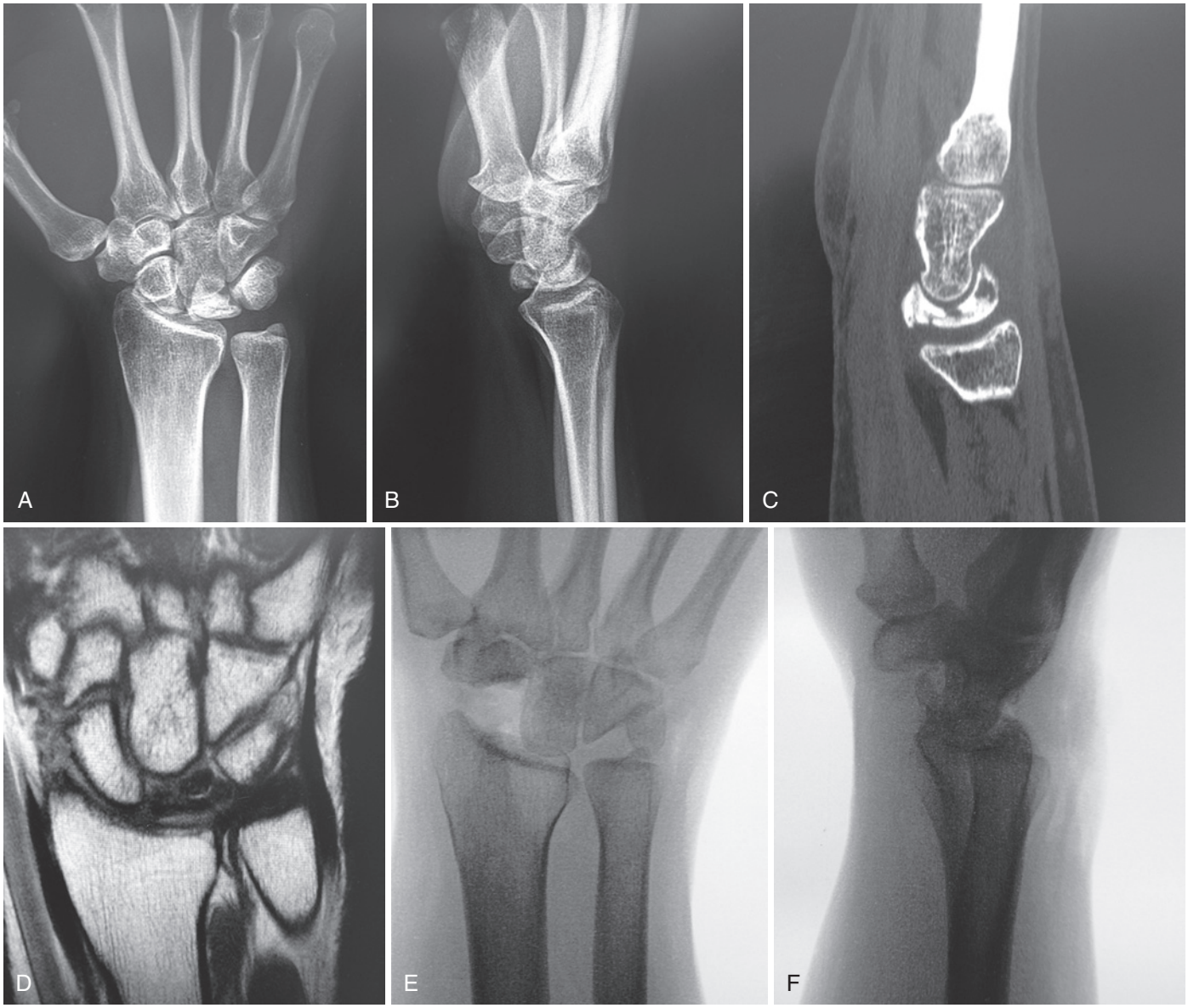

FIGURE 16.70 Proximal row carpectomy for stage IIIB Kienböck disease. Posteroanterior (PA) radiograph **(A)** and lateral radiograph **(B)** of the wrist. **C,** Computed tomography scan, sagittal view. **D,** Magnetic resonance image, coronal view. PA fluoroscopic image **(E)** and and lateral fluoroscopic image **(F)** of wrist following proximal row carpectomy. (Courtesy of Steve K. Lee, MD.)

that total wrist fusion may be needed later if proximal row carpectomy is first attempted.

Preiser Disease

In 1910, Preiser described a rarefying osteitis of the scaphoid that he distinguished from a scaphoid fracture. He compared the condition with Kienböck disease and thought that the causes were similar. However, recently Kallen and Strackee[114] have called into question Georg Preiser's original observations. They recovered the images of the five cases he described and showed that they all had fractures but did not have AVN. Kalainov and colleagues[113] described type 1, whole bone, and type 2, partial bone, patterns of Preiser disease. Type I has the propensity to fragmentation and collapse, no matter the treatment. Type 2 patterns usually maintain their architecture, with the same types of treatment. The cause has been related to collagen vascular disease, steroid therapy, repetitive trauma, or idiopathic conditions. Clinical findings are related to local pain and tenderness. Radiographically, involved areas are typically sclerotic, and there is often fragmentation of the proximal articular surfaces. CT and MRI may be helpful to define the changes. This condition can present in children.

Treatment of Preiser disease has not been standardized. Nonoperative symptomatic management, joint débridement, silicone replacement arthroplasty, and electrical stimulation have all been tried, with mixed results. Reversed-flow vascularized bundle implantation has been performed in a limited number of cases with variable success. Vascularized bone grafting may also be considered, but results have been variable and revascularization has been incomplete.[152] Hayashi and associates reported on decreased but continued pain after closing wedge radial osteotomy.[89] The success of scaphoid-preserving

http://e-surg.com

procedures may be compromised by chronic degenerative changes that are often present in the carpus at the time of reconstruction, particularly at the radial styloid and radioscaphoid articulation; this makes pain-free motion following successful salvage difficult. Furthermore, there is often insufficient satisfactory cortical bone into which a graft can be inserted, as the surface is too fragmented. Therefore, if revascularization is to be considered, the patient should also consent to scaphoid excision and midcarpal arthrodesis or proximal row carpectomy should vascularized grafting prove technically impossible. If revascularization is attempted and proves unsuccessful, scaphoid excision combined with either midcarpal arthrodesis or proximal row carpectomy may be appropriate for persistently symptomatic cases. Given the lack of reliable treatment options, in the absence of severe pain and disability a conservative approach is probably warranted and should be discussed with the patient.

Avascular Necrosis of the Capitate

The capitate is at risk for AVN because the proximal pole is essentially an intraarticular structure. The retrograde intraosseous blood flow to the capitate is similar to that in the scaphoid, which makes the proximal pole of the capitate prone to AVN at its waist.[171] Dorsal and palmar vessels are present but vary considerably. Additional causes of AVN include vibration exposure, steroid use, repetitive wrist extension, and ligamentous laxity.[209]

Attempts to promote revascularization with bone grafting have had mixed results.[209] There are no long-term follow-up reports on AVN. AVN has been reported infrequently in isolated capitate fractures but is more common in higher-energy fractures, particularly when the capitate is rotated.

For Case Studies, Videos, and more, please visit ExpertConsult.com.

REFERENCES

1. Adams BD, Blair WF, Reagan DS, et al: Technical factors related to Herbert screw fixation. *J Hand Surg [Am]* 13(6):893–899, 1988.
2. Adler JB, Shaftan GW: Fractures of the capitate. *J Bone Joint Surg Am* 44:1537–1547, 1962.
3. Adolfsson L, Lindau T, Arner M: Acutrak screw fixation versus cast immobilisation for undisplaced scaphoid waist fractures. *J Hand Surg [Br]* 26(3):192–195, 2001.
4. Almquist EE: Capitate shortening in the treatment of Kienbock's disease. *Hand Clin* 9(3):505–512, 1993.
5. Almquist EE, Burns JF, Jr: Radial shortening for the treatment of Kienbock's disease: a 5- to 10-year follow-up. *J Hand Surg [Am]* 7(4):348–352, 1982.
6. Alshryda S, Shah A, Odak S, et al: Acute fractures of the scaphoid bone: systematic review and meta-analysis. *Surgeon* 10(4):218–229, 2012.
7. Amadio PC, Berquist TH, Smith DK, et al: Scaphoid malunion. *J Hand Surg [Am]* 14(4):679–687, 1989.
8. Anderson SE, Steinbach LS, Tschering-Vogel D, et al: MR imaging of avascular scaphoid nonunion before and after vascularized bone grafting. *Skeletal Radiol* 34(6):314–320, 2005.
9. Andresen R, Radmer S, Sparmann M, et al: Imaging of hamate bone fractures in conventional X-rays and high-resolution computed tomography: an in vitro study. *Invest Radiol* 34(1):46–50, 1999.
10. Anz AW, Bushnell BD, Bynum DK, et al: Pediatric scaphoid fractures. *J Am Acad Orthop Surg* 17(2):77–87, 2009.
11. Arora R, Gschwentner M, Krappinger D, et al: Fixation of nondisplaced scaphoid fractures: making treatment cost-effective: prospective controlled trial. *Arch Orthop Trauma Surg* 127(1):39–46, 2007.
12. Arora R, Lutz M, Zimmermann R, et al: Free vascularised iliac bone graft for recalcitrant avascular nonunion of the scaphoid. *J Bone Joint Surg Br* 92(2):224–229, 2010.
13. Assari S, Darvish K, Ilyas AM: Biomechanical analysis of second-generation headless compression screws. *Injury* 43(7):1159–1165, 2012.
14. Bailey CA, Kuiper JH, Kelly CP: Biomechanical evaluation of a new composite bioresorbable screw. *J Hand Surg [Br]* 31(2):208–212, 2006.
15. Barton NJ: Experience with scaphoid grafting. *J Hand Surg [Br]* 22(2):153–160, 1997.
16. Beeres FJ, Hogervorst M, Rhemrev SJ, et al: A prospective comparison for suspected scaphoid fractures: bone scintigraphy versus clinical outcome. *Injury* 38(7):769–774, 2007.
17. Berger RA: The anatomy of the scaphoid. *Hand Clin* 17(4):525–532, 2001.
18. Berger RA: A method of defining palpable landmarks for the ligament-splitting dorsal wrist capsulotomy. *J Hand Surg [Am]* 32(8):1291–1295, 2007.
19. Berger RA, Bishop AT, Bettinger PC: New dorsal capsulotomy for the surgical exposure of the wrist. *Ann Plast Surg* 35(1):54–59, 1995.
20. Bertelli JA, Peruchi FM, Rost JR, et al: Treatment of scaphoid non-unions by a palmar approach with vascularised bone graft harvested from the thumb. *J Hand Surg Eur Vol* 32(2):217–223, 2007.
21. Bilic R, Simic P, Jelic M, et al: Osteogenic protein-1 (BMP-7) accelerates healing of scaphoid non-union with proximal pole sclerosis. *Int Orthop* 30(2):128–134, 2006.
22. Bochud RC, Buchler U: Kienbock's disease, early stage 3: height reconstruction and core revascularization of the lunate. *J Hand Surg [Br]* 19(4):466–478, 1994.
23. Bond CD, Shin AY, McBride MT, et al: Percutaneous screw fixation or cast immobilization for nondisplaced scaphoid fractures. *J Bone Joint Surg Am* 83(4):483–488, 2001.
24. Botte MJ, Gelberman RH: Fractures of the carpus, excluding the scaphoid. *Hand Clin* 3(1):149–161, 1987.
25. Boyer MI, von Schroeder HP, Axelrod TS: Scaphoid nonunion with avascular necrosis of the proximal pole: treatment with a vascularized bone graft from the dorsum of the distal radius. *J Hand Surg [Br]* 23(5):686–690, 1998.
26. Braithwaite IJ, Jones WA: Scapho-lunate dissociation occurring with scaphoid fracture. *J Hand Surg [Br]* 17(3):286–288, 1992.
27. Braun C, Gross G, Buhren V: Osteosynthesis using a buttress plate: a new principle for stabilizing scaphoid pseudarthroses. *Unfallchirurg* 96(1):9–11, 1993.
28. Briseno MR, Yao J: Lunate fractures in the face of a perilunate injury: an uncommon and easily missed injury pattern. *J Hand Surg [Am]* 37(1):63–67, 2012.
29. Buchler U, Nagy L: The issue of vascularity in fractures and non-union of the scaphoid. *J Hand Surg [Br]* 20(6):726–735, 1995.
30. Bushnell BD, McWilliams AD, Messer TM: Complications in dorsal percutaneous cannulated screw fixation of nondisplaced scaphoid waist fractures. *J Hand Surg [Am]* 32(6):827–833, 2007.
31. Carroll RE, Coyle MP, Jr: Dysfunction of the pisotriquetral joint: treatment by excision of the pisiform. *J Hand Surg [Am]* 10(5):703–707, 1985.
32. Carroll RE, Lakin JF: Fracture of the hook of the hamate: acute treatment. *J Trauma* 34(6):803–805, 1993.
33. Cerezal L, Abascal F, Canga A, et al: Usefulness of gadolinium-enhanced MR imaging in the evaluation of the vascularity of scaphoid nonunions. *AJR Am J Roentgenol* 174(1):141–149, 2000.
34. Chang MA, Bishop AT, Moran SL, et al: The outcomes and complications of 1,2-intercompartmental supraretinacular artery pedicled vascularized bone grafting of scaphoid nonunions. *J Hand Surg [Am]* 31(3):387–396, 2006.
35. Christodoulou LS, Kitsis CK, Chamberlain ST: Internal fixation of scaphoid nonunion: a comparative study of three methods. *Injury* 32(8):625–630, 2001.
36. Chu PJ, Shih JT: Arthroscopically assisted use of injectable bone graft substitutes for management of scaphoid nonunions. *Arthroscopy* 27(1):31–37, 2011.
37. Cohen MS, Jupiter JB, Fallahi K, et al: Scaphoid waist nonunion with humpback deformity treated without structural bone graft. *J Hand Surg [Am]* 38(4):701–705, 2013.
38. Condit DP, Idler RS, Fischer TJ, et al: Preoperative factors and outcome after lunate decompression for Kienbock's disease. *J Hand Surg [Am]* 18(4):691–696, 1993.
39. Cooney WP, Dobyns JH, Linscheid RL: Fractures of the scaphoid: a rational approach to management. *Clin Orthop Relat Res* 149:90–97, 1980.
40. Cooney WP, 3rd, Dobyns JH, Linscheid RL: Nonunion of the scaphoid: analysis of the results from bone grafting. *J Hand Surg [Am]* 5(4):343–354, 1980.
41. Croog AS, Stern PJ: Proximal row carpectomy for advanced Kienbock's disease: average 10-year follow-up. *J Hand Surg [Am]* 33(7):1122–1130, 2008.
42. Dailiana ZH, Malizos KN, Zachos V, et al: Vascularized bone grafts from the palmar radius for the treatment of waist nonunions of the scaphoid. *J Hand Surg [Am]* 31(3):397–404, 2006.
43. Davis EN, Chung KC, Kotsis SV, et al: A cost/utility analysis of open reduction and internal fixation versus cast immobilization for acute nondisplaced mid-waist scaphoid fractures. *Plast Reconstr Surg* 117(4):1223–1235, discussion 1236–1238, 2006.

http://e-surg.com

44. Dawson JS, Martel AL, Davis TR: Scaphoid blood flow and acute fracture healing. A dynamic MRI study with enhancement with gadolinium. *J Bone Joint Surg Br* 83(6):809–814, 2001.
45. De Smet L, Robijns P, Degreef I: Proximal row carpectomy in advanced Kienbock's disease. *J Hand Surg [Br]* 30(6):585–587, 2005.
46. Desai VV, Davis TR, Barton NJ: The prognostic value and reproducibility of the radiological features of the fractured scaphoid. *J Hand Surg [Br]* 24(5):586–590, 1999.
47. Devers BN, Douglas KC, Naik RD, et al: Outcomes of hook of hamate fracture excision in high-level amateur athletes. *J Hand Surg [Am]* 38(1):72–76, 2013.
48. D'Hoore K, De Smet L, Verellen K, et al: Negative ulnar variance is not a risk factor for Kienbock's disease. *J Hand Surg [Am]* 19(2):229–231, 1994.
49. Dias JJ, Taylor M, Thompson J, et al: Radiographic signs of union of scaphoid fractures: an analysis of inter-observer agreement and reproducibility. *J Bone Joint Surg Br* 70(2):299–301, 1988.
50. Dias JJ, Wildin CJ, Bhowal B, et al: Should acute scaphoid fractures be fixed? A randomized controlled trial. *J Bone Joint Surg Am* 87(10):2160–2168, 2005.
51. Dodds SD, Panjabi MM, Slade JF, 3rd: Screw fixation of scaphoid fractures: a biomechanical assessment of screw length and screw augmentation. *J Hand Surg [Am]* 31(3):405–413, 2006.
52. Dodds SD, Patterson JT, Halim A: Volar plate fixation of recalcitrant scaphoid nonunions with volar carpal artery vascularized bone graft. *Tech Hand Up Extrem Surg* 18(1):2–7, 2014.
53. Doi K, Oda T, Soo-Heong T, et al: Free vascularized bone graft for nonunion of the scaphoid. *J Hand Surg [Am]* 25(3):507–519, 2000.
54. Donati OF, Zanetti M, Nagy L, et al: Is dynamic gadolinium enhancement needed in MR imaging for the preoperative assessment of scaphoidal viability in patients with scaphoid nonunion? *Radiology* 260(3):808–816, 2011.
55. Duppe H, Johnell O, Lundborg G, et al: Long-term results of fracture of the scaphoid. A follow-up study of more than thirty years. *J Bone Joint Surg Am* 76(2):249–252, 1994.
56. Eggli S, Fernandez DL, Beck T: Unstable scaphoid fracture nonunion: a medium-term study of anterior wedge grafting procedures. *J Hand Surg [Br]* 27(1):36–41, 2002.
57. Failla JM: Hook of hamate vascularity: vulnerability to osteonecrosis and nonunion. *J Hand Surg [Am]* 18(6):1075–1079, 1993.
58. Faucher GK, Golden ML, 3rd, Sweeney KR, et al: Comparison of screw trajectory on stability of oblique scaphoid fractures: a mechanical study. *J Hand Surg [Am]* 39(3):430–435, 2014.
59. Fenton RL: The naviculo-capitate fracture syndrome. *J Bone Joint Surg Am* 38(3):681–684, 1956.
60. Fernandez DL: A technique for anterior wedge-shaped grafts for scaphoid nonunions with carpal instability. *J Hand Surg [Am]* 9(5):733–737, 1984.
61. Fernandez DL: Anterior bone grafting and conventional lag screw fixation to treat scaphoid nonunions. *J Hand Surg [Am]* 15(1):140–147, 1990.
62. Fernandez DL, Eggli S: Non-union of the scaphoid: revascularization of the proximal pole with implantation of a vascular bundle and bone-grafting. *J Bone Joint Surg Am* 77(6):883–893, 1995.
63. Filan SL, Herbert TJ: Herbert screw fixation of scaphoid fractures. *J Bone Joint Surg Br* 78(4):519–529, 1996.
64. Forward DP, Singh HP, Dawson S, et al: The clinical outcome of scaphoid fracture malunion at 1 year. *J Hand Surg Eur Vol* 34(1):40–46, 2009.
65. Gabl M, Reinhart C, Lutz M, et al: Vascularized bone graft from the iliac crest for the treatment of nonunion of the proximal part of the scaphoid with an avascular fragment. *J Bone Joint Surg Am* 81(10):1414–1428, 1999.
66. Garcia-Elias M: Dorsal fractures of the triquetrum: avulsion or compression fractures? *J Hand Surg [Am]* 12(2):266–268, 1987.
67. Garcia-Elias M: Carpal bone fractures (excluding scaphoid fractures). In Watson H, Weinberg J, editors: *The wrist*, Philadelphia, 2001, Lippincott Williams & Wilkins, pp 174–181.
68. Geissler W, Slade JF: Fractures of the carpal bones. In Wolfe SW, Hotchkiss RN, Pederson WC, et al, editors: *Green's operative hand surgery*, ed 6, Philadelphia, 2011, Elsevier/Churchill Livingstone.
69. Geissler WB: Carpal fractures in athletes. *Clin Sports Med* 20(1):167–188, 2001.
70. Geissler WB: Arthroscopic management of scaphoid fractures in athletes. *Hand Clin* 25(3):359–369, 2009.
71. Geissler WB, Hammit MD: Arthroscopic aided fixation of scaphoid fractures. *Hand Clin* 17(4):575–588, viii, 2001.
72. Gelberman RH, Bauman TD, Menon J, et al: The vascularity of the lunate bone and Kienbock's disease. *J Hand Surg [Am]* 5(3):272–278, 1980.
73. Gelberman RH, Menon J: The vascularity of the scaphoid bone. *J Hand Surg [Am]* 5(5):508–513, 1980.
74. Gelberman RH, Panagis JS, Taleisnik J, et al: The arterial anatomy of the human carpus. Part I: The extraosseous vascularity. *J Hand Surg [Am]* 8(4):367–375, 1983.
75. Gellman H, Caputo RJ, Carter V, et al: Comparison of short and long thumb-spica casts for non-displaced fractures of the carpal scaphoid. *J Bone Joint Surg Am* 71(3):354–357, 1989.
76. Geurts GF, Van Riet RP, Meermans G, et al: Volar percutaneous transtrapezial fixation of scaphoid waist fractures: surgical technique. *Acta Orthop Belg* 78(1): 121–125, 2012.
77. Ghoneim A: The unstable nonunited scaphoid waist fracture: results of treatment by open reduction, anterior wedge grafting, and internal fixation by volar buttress plate. *J Hand Surg [Am]* 36(1):17–24, 2011.
78. Goldfarb CA, Hsu J, Gelberman RH, et al: The Lichtman classification for Kienbock's disease: an assessment of reliability. *J Hand Surg [Am]* 28(1):74–80, 2003.
79. Gras M, Mathoulin C: Vascularized bone graft pedicled on the volar carpal artery from the volar distal radius as primary procedure for scaphoid non-union. *Orthop Traumatol Surg Res* 97(8):800–806, 2011.
80. Green DP: The effect of avascular necrosis on Russe bone grafting for scaphoid nonunion. *J Hand Surg [Am]* 10(5):597–605, 1985.
81. Grewal R, Assini J, Sauder D, et al: A comparison of two headless compression screws for operative treatment of scaphoid fractures. *J Orthop Surg Res* 6:27, 2011.
82. Grover R: Clinical assessment of scaphoid injuries and the detection of fractures. *J Hand Surg [Br]* 21(3):341–343, 1996.
83. Gruszka DS, Burkhart KJ, Nowak TE, et al: The durability of the intrascaphoid compression of headless compression screws: in vitro study. *J Hand Surg [Am]* 37(6):1142–1150, 2012.
84. Gunal I, Ozcelik A, Gokturk E, et al: Correlation of magnetic resonance imaging and intraoperative punctate bleeding to assess the vascularity of scaphoid nonunion. *Arch Orthop Trauma Surg* 119(5–6):285–287, 1999.
85. Haddad FS, Goddard NJ: Acute percutaneous scaphoid fixation. A pilot study. *J Bone Joint Surg Br* 80(1):95–99, 1998.
86. Handley RC, Pooley J: The venous anatomy of the scaphoid. *J Anat* 178:115–118, 1991.
87. Hanel DP, Hunt TR: Capitate shortening osteotomy: Kienbock's disease. *Atlas Hand Clin* 4:45–58, 1999.
88. Hart A, Harvey EJ, Lefebvre LP, et al: Insertion profiles of 4 headless compression screws. *J Hand Surg [Am]* 38(9):1728–1734, 2013.
89. Hayashi O, Sawaizumi T, Ito H: Closed radial wedge osteotomy for Preiser's disease: a report of four cases. *Hand Surg* 16(3):347–352, 2011.
90. Henry M: Collapsed scaphoid non-union with dorsal intercalated segment instability and avascular necrosis treated by vascularised wedge-shaped bone graft and fixation. *J Hand Surg Eur Vol* 32(2):148–154, 2007.
91. Herbert TJ, Fisher WE: Management of the fractured scaphoid using a new bone screw. *J Bone Joint Surg Br* 66(1):114–123, 1984.
92. Herzberg G, Forissier D: Acute dorsal trans-scaphoid perilunate fracture-dislocations: medium-term results. *J Hand Surg [Br]* 27(6):498–502, 2002.
93. Higgins JP, Burger HK: Proximal scaphoid arthroplasty using the medial femoral trochlea flap. *J Wrist Surg* 2(3):228–233, 2013.
94. Hirche C, Heffinger C, Xiong L, et al: The 1,2-intercompartmental supraretinacular artery vascularized bone graft for scaphoid nonunion: management and clinical outcome. *J Hand Surg [Am]* 39(3):423–429, 2014.
95. Hocker K, Menschik A: Chip fractures of the triquetrum: mechanism, classification and results. *J Hand Surg [Br]* 19(5):584–588, 1994.
96. Hoffmann M, Reinsch OD, Petersen JP, et al: Percutaneous antegrade scaphoid screw placement: a feasibility and accuracy analysis of a novel electromagnetic navigation technique versus a standard fluoroscopic method. *Int J Med Robot* 11(1):52–57, 2015.
97. Hori Y, Tamai S, Okuda H, et al: Blood vessel transplantation to bone. *J Hand Surg [Am]* 4(1):23–33, 1979.
98. Horii E, Garcia-Elias M, Bishop AT, et al: Effect on force transmission across the carpus in procedures used to treat Kienbock's disease. *J Hand Surg [Am]* 15(3): 393–400, 1990.
99. Horii E, Nakamura R, Watanabe K, et al: Scaphoid fracture as a "puncher's fracture." *J Orthop Trauma* 8(2):107–110, 1994.
100. Howe LM: Epidemiology of scaphoid fractures in Bergen, Norway. *Scand J Plast Reconstr Surg Hand Surg* 33:423–426, 1999.
101. Huene DR, Huene DS: Treatment of nonunions of the scaphoid with the Ender compression blade plate system. *J Hand Surg [Am]* 16(5):913–922, 1991.
102. Illarramendi AA, Schulz C, De Carli P: The surgical treatment of Kienbock's disease by radius and ulna metaphyseal core decompression. *J Hand Surg [Am]* 26(2):252–260, 2001.
103. Imbriglia JE, Broudy AS, Hagberg WC, et al: Proximal row carpectomy: clinical evaluation. *J Hand Surg [Am]* 15(3):426–430, 1990.
104. Inoue G, Shionoya K: Herbert screw fixation by limited access for acute fractures of the scaphoid. *J Bone Joint Surg Br* 79(3):418–421, 1997.
105. Inoue G, Shionoya K, Kuwahata Y: Ununited proximal pole scaphoid fractures: treatment with a Herbert screw in 16 cases followed for 0.5-8 years. *Acta Orthop Scand* 68(2):124–127, 1997.

http://e-surg.com

106. Jafarnia K, Collins ED, Kohl HW, 3rd, et al: Reliability of the Lichtman classification of Kienbock's disease. *J Hand Surg [Am]* 25(3):529–534, 2000.
107. Jensen CH, Thomsen K, Holst-Nielsen F: Radiographic staging of Kienbock's disease: poor reproducibility of Stahl's and Lichtman's staging systems. *Acta Orthop Scand* 67(3):274–276, 1996.
108. Jeon IH, Micic ID, Oh CW, et al: Percutaneous screw fixation for scaphoid fracture: a comparison between the dorsal and the volar approaches. *J Hand Surg [Am]* 34(2):228–236, e1, 2009.
109. Jiranek WA, Ruby LK, Millender LB, et al: Long-term results after Russe bone-grafting: the effect of malunion of the scaphoid. *J Bone Joint Surg Am* 74(8):1217–1228, 1992.
110. Jones DB, Jr, Burger H, Bishop AT, et al: Treatment of scaphoid waist nonunions with an avascular proximal pole and carpal collapse. A comparison of two vascularized bone grafts. *J Bone Joint Surg Am* 90(12):2616–2625, 2008.
111. Jones NF, Brown EE, Mostofi A, et al: Healing of a scaphoid nonunion using human bone morphogenetic protein. *J Hand Surg [Am]* 30(3):528–533, 2005.
112. Kakar S, Bishop AT, Shin AY: Role of vascularized bone grafts in the treatment of scaphoid nonunions associated with proximal pole avascular necrosis and carpal collapse. *J Hand Surg [Am]* 36(4):722–725, quiz 725, 2011.
113. Kalainov DM, Cohen MS, Hendrix RW, et al: Preiser's disease: identification of two patterns. *J Hand Surg [Am]* 28(5):767–778, 2003.
114. Kallen AM, Strackee SD: On the history and definition of Preiser's disease. *J Hand Surg Eur Vol* 39(7):770–776, 2014.
115. Kam CC, Greenberg JA: Computer-assisted navigation for dorsal percutaneous scaphoid screw placement: a cadaveric study. *J Hand Surg [Am]* 39(4):613–620, 2014.
116. Kaneshiro SA, Failla JM, Tashman S: Scaphoid fracture displacement with forearm rotation in a short-arm thumb spica cast. *J Hand Surg [Am]* 24(5):984–991, 1999.
117. Kardashian G, Christoforou DC, Lee SK: Perilunate dislocations. *Bull NYU Hosp Jt Dis* 69(1):87–96, 2011.
118. Keith PP, Nuttall D, Trail I: Long-term outcome of nonsurgically managed Kienbock's disease. *J Hand Surg [Am]* 29(1):63–67, 2004.
119. Kim RY, Lijten EC, Strauch RJ: Pronated oblique view in assessing proximal scaphoid articular cannulated screw penetration. *J Hand Surg [Am]* 33(8):1274–1277, 2008.
120. Korkala OL, Kuokkanen HO, Eerola MS: Compression-staple fixation for fractures, non-unions, and delayed unions of the carpal scaphoid. *J Bone Joint Surg Am* 74(3):423–426, 1992.
121. Kosy JD, Standley DM: Retrieval of broken Acutrak drill bit. *J Hand Surg Eur Vol* 35(8):683, 2010.
122. Kozin SH: Incidence, mechanism, and natural history of scaphoid fractures. *Hand Clin* 17(4):515–524, 2001.
123. Kristensen SS, Thomassen E, Christensen F: Ulnar variance in Kienbock's disease. *J Hand Surg [Br]* 11(2):258–260, 1986.
124. Kuhlmann JN, Mimoun M, Boabighi A, et al: Vascularized bone graft pedicled on the volar carpal artery for non-union of the scaphoid. *J Hand Surg [Br]* 12(2):203–210, 1987.
125. Langhoff O, Andersen JL: Consequences of late immobilization of scaphoid fractures. *J Hand Surg [Br]* 13(1):77–79, 1988.
126. Larsen CF, Brondum V, Skov O: Epidemiology of scaphoid fractures in Odense, Denmark. *Acta Orthop Scand* 63(2):216–218, 1992.
127. Lawand A, Foulkes GD: The "clenched pencil" view: a modified clenched fist scapholunate stress view. *J Hand Surg [Am]* 28(3):414–418, discussion 419–420, 2003.
128. Lee SK, Desai H, Silver B, et al: Comparison of radiographic stress views for scapholunate dynamic instability in a cadaver model. *J Hand Surg [Am]* 36(7): 1149–1157, 2011.
129. Leventhal EL, Wolfe SW, Walsh EF, et al: A computational approach to the "optimal" screw axis location and orientation in the scaphoid bone. *J Hand Surg [Am]* 34(4):677–684, 2009.
130. Levy M, Fischel RE, Stern GM, et al: Chip fractures of the os triquetrum: the mechanism of injury. *J Bone Joint Surg Br* 61(3):355–357, 1979.
131. Lichtman DM, Mack GR, MacDonald RI, et al: Kienbock's disease: the role of silicone replacement arthroplasty. *J Bone Joint Surg Am* 59(7):899–908, 1977.
132. Lynch NM, Linscheid RL: Corrective osteotomy for scaphoid malunion: technique and long-term follow-up evaluation. *J Hand Surg [Am]* 22(1):35–43, 1997.
133. Mack GR, Bosse MJ, Gelberman RH, et al: The natural history of scaphoid nonunion. *J Bone Joint Surg Am* 66(4):504–509, 1984.
134. Mack GR, Wilckens JH, McPherson SA: Subacute scaphoid fractures. A closer look at closed treatment. *Am J Sports Med* 26(1):56–58, 1998.
135. Malerich MM, Clifford J, Eaton B, et al: Distal scaphoid resection arthroplasty for the treatment of degenerative arthritis secondary to scaphoid nonunion. *J Hand Surg [Am]* 24(6):1196–1205, 1999.
136. Masquijo JJ, Willis BR: Scaphoid nonunions in children and adolescents: surgical treatment with bone grafting and internal fixation. *J Pediatr Orthop* 30(2):119–124, 2010.
137. Mathoulin C, Brunelli F: Further experience with the index metacarpal vascularized bone graft. *J Hand Surg [Br]* 23(3):311–317, 1998.
138. Mayfield JK, Johnson RP, Kilcoyne RK: Carpal dislocations: pathomechanics and progressive perilunar instability. *J Hand Surg [Am]* 5(3):226–241, 1980.
139. Mayr E, Rudzki MM, Rudzki M, et al: Does low intensity, pulsed ultrasound speed healing of scaphoid fractures? *Handchir Mikrochir Plast Chir* 32(2):115–122, 2000.
140. McAdams TR, Spisak S, Beaulieu CF, et al: The effect of pronation and supination on the minimally displaced scaphoid fracture. *Clin Orthop Relat Res* 411:255–259, 2003.
141. McCallister WV, Knight J, Kaliappan R, et al: Central placement of the screw in simulated fractures of the scaphoid waist: a biomechanical study. *J Bone Joint Surg Am* 85(1):72–77, 2003.
142. McCarty V, Farber H: Isolated fracture of the pisiform bone. *J Bone Joint Surg Am* 28:390, 1946.
143. McLaughlin HL: Fracture of the carpal navicular (scaphoid) bone: some observations based on treatment by open reduction and internal fixation. *J Bone Joint Surg Am* 36(4):765–774, 1954.
144. Meermans G, Verstreken F: Percutaneous transtrapezial fixation of acute scaphoid fractures. *J Hand Surg Eur Vol* 33(6):791–796, 2008.
145. Merrell GA, Wolfe SW, Slade JF, 3rd: Treatment of scaphoid nonunions: quantitative meta-analysis of the literature. *J Hand Surg [Am]* 27(4):685–691, 2002.
146. Meyer C, Chang J, Stern P, et al: Complications of distal radial and scaphoid fracture treatment. *J Bone Joint Surg Am* 95(16):1517–1526, 2013.
147. Milch H: Fracture of the hamate bone. *J Bone Joint Surg Am* 16:459–462, 1934.
148. Mintzer CM, Waters PM: Surgical treatment of pediatric scaphoid fracture nonunions. *J Pediatr Orthop* 19(2):236–239, 1999.
149. Moon ES, Dy CJ, Derman P, et al: Management of nonunion following surgical management of scaphoid fractures: current concepts. *J Am Acad Orthop Surg* 21(9):548–557, 2013.
150. Deleted in review.
151. Moran SL, Cooney WP, Berger RA, et al: The use of the 4 + 5 extensor compartmental vascularized bone graft for the treatment of Kienbock's disease. *J Hand Surg [Am]* 30(1):50–58, 2005.
152. Moran SL, Cooney WP, Shin AY: The use of vascularized grafts from the distal radius for the treatment of Preiser's disease. *J Hand Surg [Am]* 31(5):705–710, 2006.
153. Muller GM, Mansson S, Muller MF, et al: Assessment of perfusion in normal carpal bones with dynamic gadolinium-enhanced MRI at 3 tesla. *J Magn Reson Imaging* 38(1):168–172, 2013.
154. Nakamura P, Imaeda T, Miura T: Scaphoid malunion. *J Bone Joint Surg Br* 73(1):134–137, 1991.
155. Nakamura R, Horii E, Watanabe K, et al: Proximal row carpectomy versus limited wrist arthrodesis for advanced Kienbock's disease. *J Hand Surg [Br]* 23(6):741–745, 1998.
156. Oron A, Gupta A, Thirkannad S: Nonunion of the scaphoid distal pole. *Hand Surg* 18(1):35–39, 2013.
157. Palmer AK: Trapezial ridge fractures. *J Hand Surg [Am]* 6(6):561–564, 1981.
158. Parvizi J, Wayman J, Kelly P, et al: Combining the clinical signs improves diagnosis of scaphoid fractures. A prospective study with follow-up. *J Hand Surg [Br]* 23(3):324–327, 1998.
159. Pensy RA, Richards AM, Belkoff SM, et al: Biomechanical comparison of two headless compression screws for scaphoid fixation. *J Surg Orthop Adv* 18(4):182–188, 2009.
160. Peste JL: Discussion. *Bull Soc Anat* 18:169, 1843.
161. Pointu J, Schwenck JP, Destree G, et al: Fractures of the trapezium: Mechanisms: anatomo-pathology and therapeutic indications. *Rev Chir Orthop Reparatrice Appar Mot* 74(5):454–465, 1988.
162. Porter ML, Seehra K: Fracture-dislocation of the triquetrum treated with a Herbert screw. *J Bone Joint Surg Br* 73(2):347–348, 1991.
163. Prosser AJ, Brenkel IJ, Irvine GB: Articular fractures of the distal scaphoid. *J Hand Surg [Br]* 13(1):87–91, 1988.
164. Raby N: Magnetic resonance imaging of suspected scaphoid fractures using a low field dedicated extremity MR system. *Clin Radiol* 56(4):316–320, 2001.
165. Reigstad O, Grimsgaard C, Thorkildsen R, et al: Long-term results of scaphoid nonunion surgery: 50 patients reviewed after 8 to 18 years. *J Orthop Trauma* 26(4):241–245, 2012.
166. Rettig AC, Weidenbener EJ: Gloyeske R. Alternative management of midthird scaphoid fractures in the athlete. *Am J Sports Med* 22(5):711–714, 1994.
167. Rettig ME, Raskin KB: Retrograde compression screw fixation of acute proximal pole scaphoid fractures. *J Hand Surg [Am]* 24(6):1206–1210, 1999.
168. Robbins RR, Ridge O, Carter PR: Iliac crest bone grafting and Herbert screw fixation of nonunions of the scaphoid with avascular proximal poles. *J Hand Surg [Am]* 20(5):818–831, 1995.
169. Rock MG, Roth JH, Martin L: Radial shortening osteotomy for treatment of Kienbock's disease. *J Hand Surg [Am]* 16(3):454–460, 1991.

http://e-surg.com

170. Roman J, Lockyer P, Paksima N, et al: *The modified Russe procedure for scaphoid waist fracture non-union with deformity*. Feb 7, 2012, AAOS.
171. Ruch DS, Papadonikolakis A: Resection of the scaphoid distal pole for symptomatic scaphoid nonunion after failed previous surgical treatment. *J Hand Surg [Am]* 31(4):588–593, 2006.
172. Russe O: Fracture of the carpal navicular: diagnosis, non-operative treatment, and operative treatment. *J Bone Joint Surg Am* 42:759–768, 1960.
173. Sakai K, Doi K, Kawai S: Free vascularized thin corticoperiosteal graft. *Plast Reconstr Surg* 87(2):290–298, 1991.
174. Sandow MJ: Costo-osteochondral grafts in the wrist. *Tech Hand Up Extrem Surg* 5(3):165–172, 2001.
175. Schiltenwolf M, Martini AK, Mau HC, et al: Further investigations of the intraosseous pressure characteristics in necrotic lunates (Kienbock's disease). *J Hand Surg [Am]* 21(5):754–758, 1996.
176. Schmitt R, Christopoulos G, Wagner M, et al: Avascular necrosis (AVN) of the proximal fragment in scaphoid nonunion: is intravenous contrast agent necessary in MRI? *Eur J Radiol* 77(2):222–227, 2011.
177. Schuind F, Haentjens P, Van Innis F, et al: Prognostic factors in the treatment of carpal scaphoid nonunions. *J Hand Surg [Am]* 24(4):761–776, 1999.
178. Shah J, Jones WA: Factors affecting the outcome in 50 cases of scaphoid nonunion treated with Herbert screw fixation. *J Hand Surg [Br]* 23(5):680–685, 1998.
179. Sheetz KK, Bishop AT, Berger RA: The arterial blood supply of the distal radius and ulna and its potential use in vascularized pedicled bone grafts. *J Hand Surg [Am]* 20(6):902–914, 1995.
180. Shi ZM, Xu ZG: Experimental study and clinical use of the fasciosteal flap. *Plast Reconstr Surg* 78(2):201–210, 1986.
181. Siegel DB, Gelberman RH: Radial styloidectomy: an anatomical study with special reference to radiocarpal intracapsular ligamentous morphology. *J Hand Surg [Am]* 16(1):40–44, 1991.
182. Slade JF, 3rd, Geissler WB, Gutow AP, et al: Percutaneous internal fixation of selected scaphoid nonunions with an arthroscopically assisted dorsal approach. *J Bone Joint Surg Am* 85(Suppl 4):20–32, 2003.
183. Slade JF, 3rd, Gillon T: Retrospective review of 234 scaphoid fractures and nonunions treated with arthroscopy for union and complications. *Scand J Surg* 97(4):280–289, 2008.
184. Slade JF, 3rd, Grauer JN, Mahoney JD: Arthroscopic reduction and percutaneous fixation of scaphoid fractures with a novel dorsal technique. *Orthop Clin North Am* 32(2):247–261, 2001.
185. Smith DK, Murray PM: Avulsion fractures of the volar aspect of triquetral bone of the wrist: a subtle sign of carpal ligament injury. *AJR Am J Roentgenol* 166(3):609–614, 1996.
186. Smith ML, Bain GI, Chabrel N, et al: Using computed tomography to assist with diagnosis of avascular necrosis complicating chronic scaphoid nonunion. *J Hand Surg [Am]* 34(6):1037–1043, 2009.
187. Smith P, 3rd, Wright TW, Wallace PF, et al: Excision of the hook of the hamate: a retrospective survey and review of the literature. *J Hand Surg [Am]* 13(4):612–615, 1988.
188. Sotereanos DG, Darlis NA, Dailiana ZH, et al: A capsular-based vascularized distal radius graft for proximal pole scaphoid pseudarthrosis. *J Hand Surg [Am]* 31(4):580–587, 2006.
189. Sotereanos DG, Mitsionis GJ, Giannakopoulos PN, et al: Perilunate dislocation and fracture dislocation: a critical analysis of the volar-dorsal approach. *J Hand Surg [Am]* 22(1):49–56, 1997.
190. Stahl F: On lunatomalacia (Kienbock's disease): a clinical and roentgenological study, especially on its pathogenesis and the late results of immobilization treatment. *Acta Chir Scand* 126(Suppl):1–133, 1947.
191. Stark HH, Chao EK, Zemel NP, et al: Fracture of the hook of the hamate. *J Bone Joint Surg Am* 71(8):1202–1207, 1989.
192. Stark HH, Rickard TA, Zemel NP, et al: Treatment of ununited fractures of the scaphoid by iliac bone grafts and Kirschner-wire fixation. *J Bone Joint Surg Am* 70(7):982–991, 1988.
193. Stein F, Siegel MW: Naviculocapitate fracture syndrome: a case report: new thoughts on the mechanism of injury. *J Bone Joint Surg Am* 51(2):391–395, 1969.
194. Steinmann SP, Adams JE: Scaphoid fractures and nonunions: diagnosis and treatment. *J Orthop Sci* 11(4):424–431, 2006.
195. Steinmann SP, Bishop AT, Berger RA: Use of the 1,2 intercompartmental supraretinacular artery as a vascularized pedicle bone graft for difficult scaphoid nonunion. *J Hand Surg [Am]* 27(3):391–401, 2002.
196. Straw RG, Davis TR, Dias JJ: Scaphoid nonunion: treatment with a pedicled vascularized bone graft based on the 1,2 intercompartmental supraretinacular branch of the radial artery. *J Hand Surg [Br]* 27(5):413, 2002.
197. Sunagawa T, Bishop AT, Muramatsu K: Role of conventional and vascularized bone grafts in scaphoid nonunion with avascular necrosis: a canine experimental study. *J Hand Surg [Am]* 25(5):849–859, 2000.
198. Symes TH, Stothard J: A systematic review of the treatment of acute fractures of the scaphoid. *J Hand Surg Eur Vol* 36(9):802–810, 2011.
199. Szabo RM, Manske D: Displaced fractures of the scaphoid. *Clin Orthop Relat Res* 230:30–38, 1988.
200. Tajima T: An investigation of the treatment of Kienbock's disease (abstract). *J Bone Joint Surg Am* 48:1649, 1966.
201. Taniguchi Y, Tamaki T, Nakatan N: Long-term results of non-surgical treatment in Kienbock's disease. *J Jpn Soc Surg Hand* (9):962–968, 1993.
202. Teisen H, Hjarbaek J: Classification of fresh fractures of the lunate. *J Hand Surg [Br]* 13(4):458–462, 1988.
203. Trumble T, Glisson RR, Seaber AV, et al: A biomechanical comparison of the methods for treating Kienbock's disease. *J Hand Surg [Am]* 11(1):88–93, 1986.
204. Trumble TE, Benirschke SK, Vedder NB: Ipsilateral fractures of the scaphoid and radius. *J Hand Surg [Am]* 18(1):8–14, 1993.
205. Trumble TE, Clarke T, Kreder HJ: Non-union of the scaphoid: treatment with cannulated screws compared with treatment with Herbert screws. *J Bone Joint Surg Am* 78(12):1829–1837, 1996.
206. Tsuge S, Nakamura R: Anatomical risk factors for Kienbock's disease. *J Hand Surg [Br]* 18(1):70–75, 1993.
207. Tumilty JA, Squire DS: Unrecognized chondral penetration by a Herbert screw in the scaphoid. *J Hand Surg [Am]* 21(1):66–68, 1996.
208. Urist MR, Strates BS: Bone formation in implants of partially and wholly demineralized bone matrix. including observations on acetone-fixed intra and extracellular proteins. *Clin Orthop Relat Res* 71:271–278, 1970.
209. Vander Grend R, Dell PC, Glowczewskie F, et al: Intraosseous blood supply of the capitate and its correlation with aseptic necrosis. *J Hand Surg [Am]* 9(5):677–683, 1984.
209a. Van Tassel DC, Owens BD, Wolf JM: Incidence estimates and demographics of scaphoid fracture in the U.S. population. *J Hand Surg [Am]* 35(8):1242–1245, 2010.
210. Veitch S, Blake SM, David H: Proximal scaphoid rib graft arthroplasty. *J Bone Joint Surg Br* 89(2):196–201, 2007.
211. Vender MI, Watson HK, Wiener BD, et al: Degenerative change in symptomatic scaphoid nonunion. *J Hand Surg [Am]* 12(4):514–519, 1987.
212. Viola RW, Kiser PK, Bach AW, et al: Biomechanical analysis of capitate shortening with capitate hamate fusion in the treatment of Kienbock's disease. *J Hand Surg [Am]* 23(3):395–401, 1998.
213. Walker JL, Greene TL, Lunseth PA: Fractures of the body of the trapezium. *J Orthop Trauma* 2(1):22–28, 1988.
214. Walsh E, Crisco JJ, Wolfe SW: Computer-assisted navigation of volar percutaneous scaphoid placement. *J Hand Surg [Am]* 34(9):1722–1728, 2009.
215. Watanabe K, Nakamura R, Horii E, et al: Biomechanical analysis of radial wedge osteotomy for the treatment of Kienbock's disease. *J Hand Surg [Am]* 18(4):686–690, 1993.
216. Watson HK, Rogers WD: Nonunion of the hook of the hamate: an argument for bone grafting the nonunion. *J Hand Surg [Am]* 14(3):486–490, 1989.
217. Watson HK, Ryu J, DiBella A: An approach to Kienbock's disease: triscaphe arthrodesis. *J Hand Surg [Am]* 10(2):179–187, 1985.
218. Weber DM, Fricker R, Ramseier LE: Conservative treatment of scaphoid nonunion in children and adolescents. *J Bone Joint Surg Br* 91(9):1213–1216, 2009.
219. Weber ER, Chao EY: An experimental approach to the mechanism of scaphoid waist fractures. *J Hand Surg [Am]* 3(2):142–148, 1978.
220. Weinberg AM, Pichler W, Grechenig S, et al: The percutaneous antegrade scaphoid fracture fixation: a safe method? *Injury* 40(6):642–644, 2009.
221. Weiss AP, Weiland AJ, Moore JR, et al: Radial shortening for Kienbock disease. *J Bone Joint Surg Am* 73(3):384–391, 1991.
222. Wheeler DL, McLoughlin SW: Biomechanical assessment of compression screws. *Clin Orthop Relat Res* 350:237–245, 1998.
223. Willems WF, Alberton GM, Bishop AT, et al: Vascularized bone grafting in a canine carpal avascular necrosis model. *Clin Orthop Relat Res* 469(10):2831–2837, 2011.
224. Wolf JM, Dawson L, Mountcastle SB, et al: The incidence of scaphoid fracture in a military population. *Injury* 40(12):1316–1319, 2009.
225. Wozasek GE, Moser KD: Percutaneous screw fixation for fractures of the scaphoid. *J Bone Joint Surg Br* 73(1):138–142, 1991.
226. Yamamoto H, Jones DB, Jr, Moran SL, et al: The arterial anatomy of the medial femoral condyle and its clinical implications. *J Hand Surg Eur Vol* 35(7):569–574, 2010.
227. Yao J, Read B, Hentz VR: The fragmented proximal pole scaphoid nonunion treated with rib autograft: case series and review of the literature. *J Hand Surg [Am]* 38(11):2188–2192, 2013.
228. Zaidemberg C, Siebert JW, Angrigiani C: A new vascularized bone graft for scaphoid nonunion. *J Hand Surg [Am]* 16(3):474–478, 1991.

http://e-surg.com

Wrist Arthroscopy

William B. Geissler

These videos may be found at *ExpertConsult.com*:
17.1 Diagnostic arthroscopy. *(Copyright © 2015, Scott W. Wolfe.)*

INTRODUCTION

Arthroscopy has revolutionized the practice of orthopedics by providing the technical capacity to examine and treat intraarticular abnormalities under magnified and bright conditions. The development of wrist arthroscopy was a natural progression in the successful application of it to larger joints. The wrist itself is a labyrinth of eight carpal bones, multiple articular surfaces with intrinsic and extrinsic ligaments, and a triangular fibrocartilage complex all within a 5-cm interval. Wrist arthroscopy has continued to see considerable growth since Whipple et al. reported on the original description of the techniques they developed.[130] The complex wrist joint continues to challenge clinicians with an array of potential diagnoses, pathology, and treatment options.

Indications for wrist arthroscopy continue to expand as new techniques and instrumentation are developed and improved. Diagnostic indications include assessment of the spectrum of interosseous ligament injuries, and an array of pathology that can occur on the ulnar side of the wrist, including injuries of the triangular fibrocartilage complex.[48,71,89,92,97] The use of wrist arthroscopy in fracture evaluation continues to grow with management of both radius and scaphoid fractures.[19,25] Wrist arthroscopy is extremely sensitive for detecting chondral defects of both the radial carpal and midcarpal joint, which frequently are difficult to evaluate by imaging studies alone.[25,27,67,70,87,93,96,126] These can be a source of chronic wrist pain of unknown etiology.[1] Arthroscopy of the thumb carpometacarpal joint (and the other small joints) continues to grow in popularity. Finally, the advantage of dry wrist arthroscopy and its indications are expanding.[69]

The purpose of this chapter is to present the indications for, techniques, and expected outcomes of wrist arthroscopy and how the techniques can be applied to an array of wrist pathology.

GENERAL SETUP FOR WRIST ARTHROSCOPY

Small joint instrumentation is absolutely essential for wrist arthroscopy.[129] Large joint instrumentation is not appropriate for the small joint of the wrist. In general, a small joint arthroscope (2.7 mm or less) is used with either a 30- or 70-degree visualization angle. Small joint punches and graspers are utilized particularly for management of tears to the articular disk of the triangular fibrocartilage complex. A small joint shaver of 3.5 mm or less with varied tips is available for joint débridement.

Traction is essential for visualization.[39] This can be accomplished with the use of a commercial traction tower that stabilizes the forearm while traction is applied to two or more of the digits with finger traps. The amount of traction can be adjusted by means of a gear mechanism. Recent traction towers are now made with the traction bar at the side of the forearm rather than the middle, which makes the tower much more fluoroscopy friendly and expands the indication of wrist arthroscopy for management of carpal instability and fracture management (Figures 17.1 and 17.2). The traction tower has the advantage of applying constant traction to the wrist while it is slightly flexed; this wrist position makes it easier to insert the arthroscope and instruments. The improved visualization and increased ability to equip the wrist with newer traction towers continue to expand the possibility for treating various wrist pathologies.

If a traction tower is not available, a shoulder holder can be used to provide overhead support of the wrist. A countertraction band is placed around the arm. The wrist can be aligned in a horizontal manner on a hand table, which allows it to be stabilized by a pulley attached to the table, with weights hanging over the end (see Figure 17.2). Some surgeons prefer the horizontal position for wrist arthroscopy. In general, approximately 7 to 10 pounds (4.5 kilograms) is used for traction, depending on the intrinsic laxity of the individual.

PORTAL PLACEMENT

Radiocarpal Portals

Accurate portal placement in wrist arthroscopy is vital because of the small space available in the wrist joint.[19,21] eTable 17.1 reviews most of the common wrist arthroscopy portals and the articular structures that can be identified in their field of view. Appropriate portal placement begins with palpation and marking the base of the index, long, and ring metacarpals. Next the radial and ulnar borders of the extensor carpi ulnaris tendon are identified and marked (Figure 17.3). The radiocarpal space can be palpated and marked by rolling the surgeon's thumb over the dorsal rim of the distal radius and making an impression with the fingernail. The tendons of the extensor pollicis longus and extensor digitorum communis tendons can be palpated and marked unless obscured by swelling from an acute injury.

All portals should be drawn on the skin prior to making the incision, and after traction has been applied (Figure 17.4). The

http://e-surg.com

eTABLE 17.1 Field of View

Portal	Radial	Central	Volar	Dorsal/Distal	Ulnar
1-2	Scaphoid and lunate fossa, dorsal rim of radius	Proximal and radial scaphoid, proximal lunate	Oblique views of RSC, LRL, SRL	Oblique views of DRCL	TFCC poorly visualized
3-4	Scaphoid and lunate fossa, volar rim of radius	Proximal scaphoid and lunate, dorsal and membranous SLIL	RSC, RSL, LRL, ULL	Oblique views of the DRCL insertion onto the dorsal SLIL	TFCC radial insertion, central disk, ulnar attachment, PRUL, DRUL, PSO, PSR
4-5	Lunate fossa, volar rim of radius	Proximal lunate, triquetrum, dorsal and membranous LTIL	RSL, LRL, ULL	Poorly seen	TFCC radial insertion, central disk, ulnar attachment, PRUL, DRUL, PSO, PSR
6-R	Poorly seen	Proximal lunate, triquetrum, dorsal and membranous LTIL	ULL, ULT	Poorly seen	TFCC radial insertion, central disk, ulnar attachment, PRUL, DRUL, PSO, PSR
6-U	Sigmoid notch	Proximal triquetrum, membranous LTIL	Oblique views of ULL, ULT	Oblique views of DRCL	TFCC oblique views of the radial insertion, central disk, ulnar attachment, PRUL, DRUL
VR	Scaphoid and lunate fossa, dorsal rim of radius	Scaphoid and lunate fossa, dorsal rim of radius	Palmar scaphoid and lunate, palmar SLIL	Oblique views of RSL, LRL ULL	Oblique views of the radial insertion, central disk, ulnar attachment, PRUL DRUL
Midcarpal radial	STT joint, distal scaphoid pole	SLIL joint, distal scaphoid, distal lunate	Radial limb of arcuate ligament (i.e., continuation of the RSC ligament)	Proximal capitate, CHIL, oblique views of proximal hamate	LTIL joint, partial triquetrum
Midcarpal ulnar	Distal articular surface of the lunate and triquetrum and partial scaphoid	SLIL joint	Volar limb of arcuate ligament (i.e., continuation of the triquetro-capitolunate)	Oblique views of proximal capitate, CHIL, proximal hamate	LTIL joint, triquetrum
Dorsal DRUJ	Sigmoid notch, radial attachment of TFCC	Ulnar head	Palmar radioulnar ligament	Proximal surface of articular disk	Limited view of deep DRUL
Volar DRUJ	Sigmoid notch, radial attachment of TFCC	Ulnar head	Dorsal radioulnar ligament	Proximal surface of articular disk	Foveal attachment of deep fibers of TFCC (i.e., DRUL, PRUL)

CHIL, Capitohamate ligament; *DRUL*, dorsal radioulnar ligament; *LRL*, long radiolunate ligament; *LTIL*, lunotriquetral interosseous ligament; *PRUL*, palmar radioulnar ligament; *PSR*, prestyloid recess; *PTO*, pisotriquetral orifice; *RCL*, radiocarpal ligament; *RSC*, radioscaphocapitate ligament; *RSL*, radioscapholunate ligament; *SLIL*, scapholunate interosseous ligament; *SRL*, short radiolunate ligament; *TFCC*, triangular fibrocartilage; *ULL*, ulnolunate ligament; *ULT*, ulnotriquetral ligament.

Adapted from Slutsky DJ: Wrist arthroscopy portals. In Slutsky DJ, Nagle DJ, editors: *Techniques in hand and wrist arthroscopy*, Philadelphia, 2006, Elsevier, Inc.

http://e-surg.com

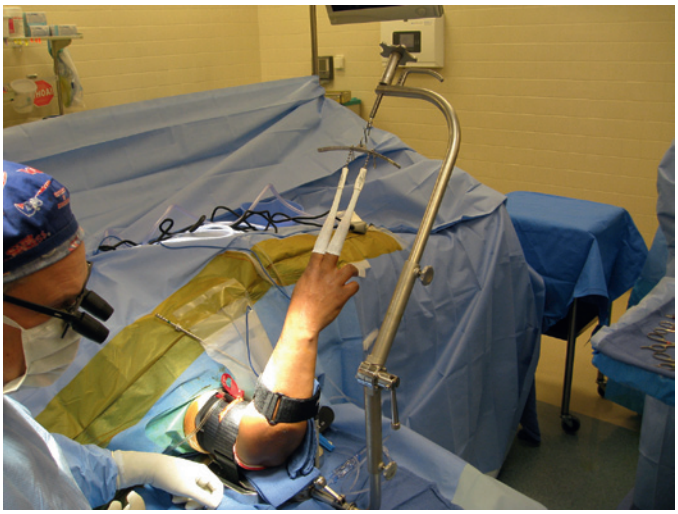

FIGURE 17.1 A traction tower is very helpful to support and distract the wrist during arthroscopic evaluation. They provide support of the forearm and allow the wrist to be slightly flexed to make it easier to initially insert the arthroscope, compared to overhead traction to keep the wrist straight.

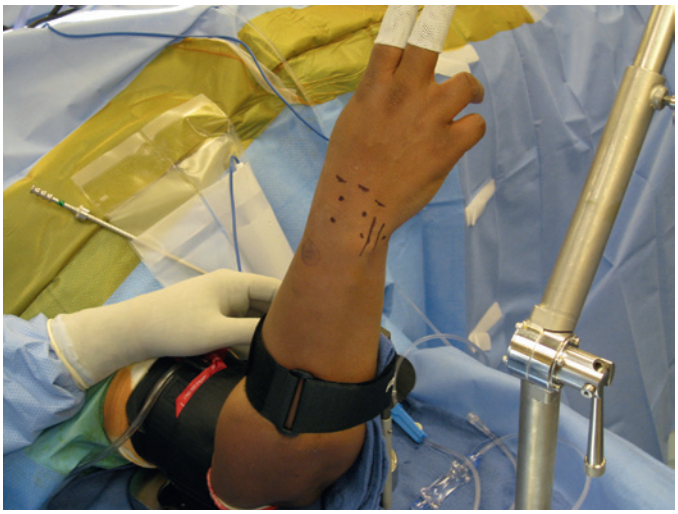

FIGURE 17.3 The bony landmarks can always be palpable even in swollen wrists. The base of the metacarpals and the tendon sheath of the extensor carpi ulnaris are identified. The standard 3-4 portal, 6-R portal, radial and ulnar midcarpal portals, and 6-U portal are marked.



FIGURE 17.2 Some surgeons prefer to use the arthroscope with the wrist in a horizontal position. This may be more helpful particularly in addressing arthroscopic management of wrist fractures. Another option is to employ finger traps connected to weights that hang over the edge of the table with towels underneath the wrist so it is in a slightly flexed position.

portals are named by the position relative to the dorsal extensor tendons. The 3-4 portal is the most common viewing portal and is located between the third and fourth compartments on the dorsal aspect of the wrist. The 3-4 portal is identified by palpating Lister's tubercle and moving the finger approximately 1 cm distally until a soft spot is reached between the third and fourth compartments. The 3-4 portal also is in line with the radial border of the long finger. The 4-5 portal, which is located between the fourth and fifth dorsal compartments, is the primary working portal. It is made by having the surgeon roll his or her finger ulnarward over the palpable fourth compartment and identifying a second soft spot immediately ulnar to the fourth compartment tendons. As a general rule, the 4-5 portal lies slightly more proximal than the 3-4 portal because of the normal radial inclination of the distal radius. The 4-5 portal also is in line with the midaxis of the ring finger.

The 1-2 portal is situated between the first extensor compartment containing the abductor pollicis longus (APL) tendon and the extensor pollicis brevis (EPB) tendon and the second dorsal compartment. It is important to remember that branches of the dorsal sensory branch of the radial nerve travel through the portal zone, as does the radial artery. One study showed that the radial artery is located at an average of 3 mm radial to the portal and the branches of the dorsal sensory branch of the radial nerve were within 3 mm radial and 5 mm ulnar to the portal. A separate study noted the mean distance of the superficial branch of the radial nerve was only 1.8 mm. It is generally recommended that, if this portal is utilized, it be as close as possible to the extensor pollicis longus (EPL) tendon (on its radial border) and just distal to the radial styloid to avoid injury to the radial artery. This portal is helpful for arthroscopic radial styloidectomy, as well as for peripheral triangular fibrocartilage (TFC) repair, using the Tuohy needle technique.[98]

The 6-R and 6-U portals are named according to their position relative to the extensor carpi ulnaris tendon, with the 6-R portal being radial and 6-U portal being ulnar to it. The 6-R portal is generally a working portal while the 6-U portal is frequently used for inflow of fluid. Normally, 3 to 5 mm of irrigation fluid is injected into the wrist at the radial carpal space through the inflow cannula at the 6-U portal. As the wrist joint is inflated with irrigation fluid, the dorsal aspect of the 3-4 portal bulges. This further helps to localize the proper position of the 3-4 portal. A pressurized pump can provide a feedback mechanism to maintain a constant pressure flow of irrigation into the joint.

http://e-surg.com

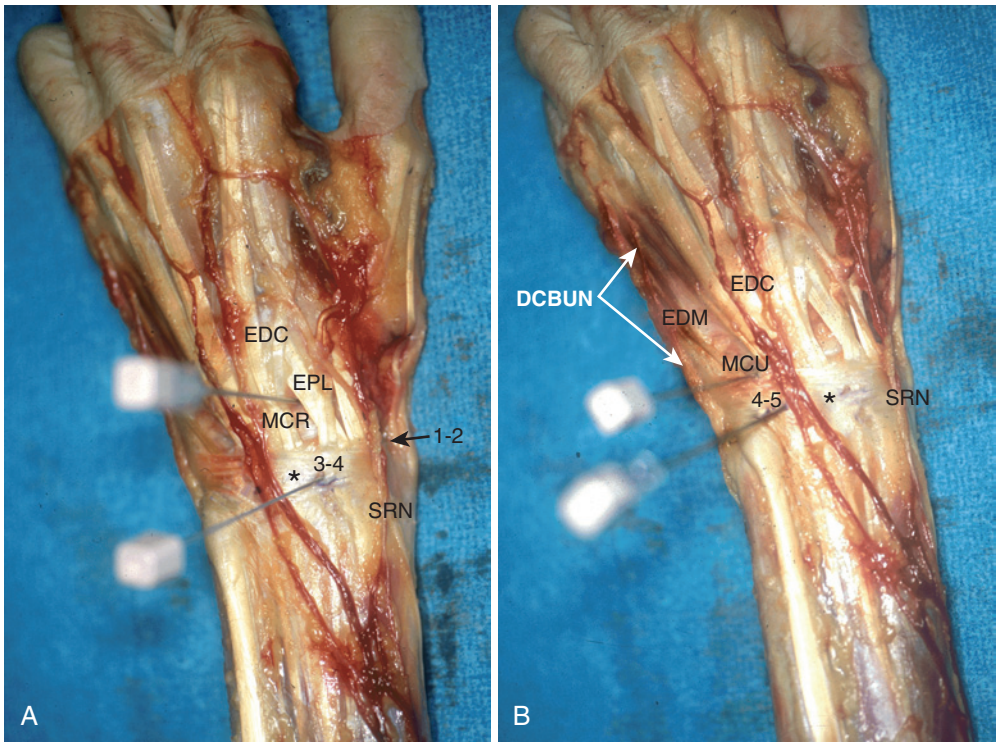

FIGURE 17.4 Dorsal portal anatomy. **A,** Cadaver dissection of the dorsal aspect of a left wrist demonstrating the relative positions of the dorsoradial portals. **B,** Relative positions of the dorsoulnar portals. *DCBUN*, Dorsal cutaneous branch of the ulnar nerve; *EDC*, extensor digitorum communis; *EDM*, extensor digiti minimi; *EPL*, extensor pollicis longus; *MCR*, midcarpal radial; *MCU*, midcarpal ulnar; *SRN*, superficial radial nerve; *, the Lister tubercle.

The wrist is suspended in the traction tower in slight flexion, which makes it easier to insert the arthroscope and instrumentation. Prior to committing to a portal, a needle is placed in the proposed location to ensure that it passes easily into the joint without injuring the distal radius, ulna, or carpus. Portal incisions may be longitudinal or transverse. Transverse portals may be more cosmetic but potentially pose a slightly higher risk of injury to the underlying sensory branches of the radial and ulnar nerves. To avoid injury to the underlying sensory branches and extensor tendons, the surgeon uses his or her thumb to pull the skin against the tip of a number 11 scalpel blade, avoiding a deep plunge (Figures 17.5 and 17.6). Blunt dissection is continued down with the hemostat to the level of the joint capsule. The arthroscopic cannula with a blunt or semiblunt trocar is placed at approximately a 10-degree angle relative to the forearm to allow the cannula to enter the joint in line with the normal volar slope of the distal radius (Figures 17.7 and 17.8).

Two volar portals have been described to view the dorsal structures and the volar aspect of the radiocarpal interosseous ligaments.[109,110] The volar radial (VR) portal is made between the interval of the radioscaphocapitate ligament and the long radial lunate ligament. This portal is most easily made by placing the arthroscope directly through that interligamentous interval with the scope in the 3-4 portal. The scope is removed from the cannula, and a blunt trocar or switching stick is then inserted into the cannula and gently passed through the volar capsule, tenting the skin on the volar aspect of the wrist near the radial artery. A small incision is then made in the skin, and the switching stick is bluntly eased through the skin incision.



FIGURE 17.5 An 18-gauge needle is used to identify the precise location of the 3-4 portal prior to committing the skin incision. If the portal is located too far proximal or distal, it can damage the articular cartilage of the distal radius or carpus.

http://e-surg.com

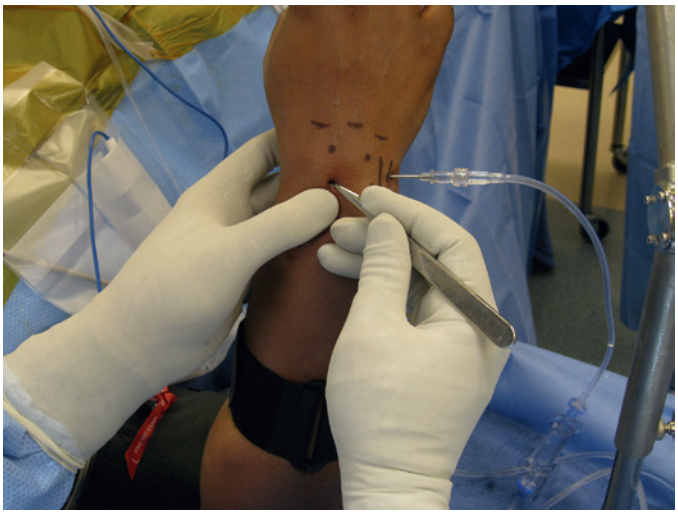

FIGURE 17.6 The skin is pulled with the thumb against the tip of the 11 blade to incise it to create the portal. In this manner, it decreases the risk of injury to the cutaneous nerves and tendons about the wrist.



FIGURE 17.7 The arthroscope with a blunt trocar is introduced initially into the 3-4 portal. It is important to use a blunt trocar rather than a sharp one to avoid injury to the articular cartilage of the wrist.

The cannula is removed from the dorsal portal and reinserted around the switching stick into the joint through the volar portal.

The volar ulna (VU) portal has been described by Slutsky.[109] The VU portal is established via a 2-cm longitudinal or zigzag incision centered just proximal to the wrist crease along the ulnar edge of the finger flexor tendons. Those tendons are retracted to the radial side and the flexor carpi ulnaris (FCU) and ulnar neurovascular bundle is retracted to the ulnar side.



FIGURE 17.8 View of the arthroscope in the 3-4 portal. Note the approximately 10-degree tilt of the arthroscope to match the slope of the distal radius. It is the author's preference to have a separate inflow through the 6-U portal and outflow through the arthroscopic sheath, which drains into a basin. Because of the small diameter of the sheath, it is difficult to get much flow with the inflow attached directly to the arthroscopic sheath.

Just distal to the pronator quadratus, the radiocarpal joint space is identified and pierced with a 22-gauge needle. Blunt tenotomy scissors are used to pierce the volar capsule, followed by insertion of the trocar/cannula, then the arthroscope. The ulnar nerve is protected by use of the cannula. The median nerve is protected by the adjacent flexor tendons. This portal penetrates between the ulnolunate and ulnotriquetral ligaments adjacent to the radial insertion of the TFC complex. The palmar region of the lunotriquetral interosseous ligament can usually be seen slightly distal and radial to the portal.

Alternatively, the VU portal can be made by an inside-out technique with the arthroscope in the 3-4 portal. A blunt trocar is inserted through the 6-U portal and pushed anteriorly through the ulnar carpal joint complex between the ulnolunate and triquetrum ligaments exiting the floor of the flexor tendons. It is important to remember that the ulnar artery and nerve have generally been found approximately 5 mm ulnar to the trocar, and the median nerve is protected by the flexor tendons. This portal provides a view of the dorsal articular surface of the radius and the dorsal extrinsic ligaments.

MIDCARPAL PORTALS

The midcarpal portals are made approximately 1 cm distal to the 3-4 and 4-5 portals.[46] The radial midcarpal portal is in line with the radial margin of the long metacarpal. Radially, the extensor carpi radialis brevis tendon will pass and ulnarly the

http://e-surg.com

fourth dorsal extensor tendons. The midcarpal space is somewhat tighter than the radial carpal space, and care should be taken when entering with a blunt trocar. A needle is always used first to identify the precise position of the midcarpal portals prior to cutting the skin. The radial midcarpal portal has slightly less room compared to the ulnar midcarpal portal.

If the surgeon has difficulty entering the radial midcarpal portal, it is suggested that the arthroscope be placed in the ulnar midcarpal space first where there is more room to enter the joint. The ulnar midcarpal portal is situated in the soft depression of the four-corner intersection of the lunate, triquetrum, capitate, and hamate. It is in line with the midaxis of the ring metacarpal. This portal is situated approximately 1 to 1.5 cm distal to the 4-5 portal. It is bound radially by the extensor digitorum communis tendons, and ulnarly by the extensor digiti minimi tendon. Inflow is provided through the arthroscopic cannula, and a needle is used to provide outflow in the radial midcarpal space to improve visualization.

Four other midcarpal portals are described: the volar midcarpal (VM),[106] the scaphotrapeziotrapezoid (STT), the radial STT (STT-R), and the triquetral-hamate (TH).[22,106,120] To make the VM portal, a skin incision is made similar to the outside-in technique for the VR portal. The volar aspect of the midcarpal joint is identified with a needle at an average of 11 mm distal to the entry of the volar radial portal. The joint is enlarged with a hemostat and blunt trocar. This portal may be useful for assessing the palmar aspect of the capitate and hamate.

The scaphotrapezoid portal is found at the level of the STT joint in line with the radial margin of the index metacarpal just ulnar to the EPL tendon. The portal is bordered on its ulnar aspect by the extensor carpi radialis longus tendon and proximally by the distal pole of the scaphoid. The proposed portal site is located with an 18-gauge needle piercing the joint as viewed with the arthroscope in the radiomidcarpal space. This portal is used primarily for arthroscopic resection of the distal pole of the scaphoid in STT arthritis. Branches of the radial sensory nerve are in close proximity to this portal. The STT-R portal is located at the same level as the STT joint but radial to the APL tendon. This portal may be made in conjunction with the standard STT portal for resection of the distal portion of the scaphoid.

The TH portal is an infrequently used midcarpal portal, but it can help to define the ulnar aspect of the midcarpal joint. It is located between the extensor carpi ulnaris and FCU tendons and is bordered proximally by the triquetrum and distally by the base of the fifth metacarpal and hamate. This portal is more frequently used for instrumentation rather than viewing and can also be used for inflow or outflow. The dorsal ulnar sensory nerve crosses the midline just proximal to the portal site.

DISTAL RADIOULNAR JOINT PORTALS

Four portals for the distal radioulnar joint (DRUJ) have been described, including two dorsal, one volar, and a direct fovea.[8,20,107] The two standard portals are the distal DRUJ (D-DRUJ) and the proximal (P-DRUJ) portals for evaluation of the foveal insertion of the deep fibers of the radioulnar ligaments. A 1.9-mm small joint arthroscope is generally used at the outset since access to the DRUJ can be difficult; however, a standard 2.7-mm scope provides a better field of view.

The D-DRUJ portal is located in line with the 6-R portal approximately 5 to 8 mm proximal and just under the triangular fibrocartilage. This portal is bordered radially by the extensor digitorum minimi tendon and ulnarly by the ECU tendon. Proximal to the portal is the ulnar head and distal is the articular disk. The portal is located with a needle prior to making a skin incision. For patients who are ulnar positive, this portal is of limited use. The proximal DRUJ (P-DRUJ) portal is useful for evaluating the articular surface of the ulnar head proximally and the undersurface of the articular disk distally. The P-DRUJ portal is situated approximately 1 cm proximal to the D-DRUJ portal. This portal is located in the axilla of the joint just proximal to the sigmoid notch of the radius in the flare of the ulnar metaphysis. This portal is useful to evaluate the articular cartilage of the sigmoid notch of the radius and the articular surface of the neck of the ulna.

The volar distal radial ulnar joint (V-DRUJ) uses the same landmarks as previously described for the VU portal. After a skin incision has been made, the flexor tendons are retracted radially and the flexor carpi ulnaris tendon and ulnar neurovascular bundle are retracted ulnarly to expose the joint capsule. The portal is located with a needle and then enlarged.

Finally, the direct fovea (DF) portal, as described by Atzei et al, is located 1 cm proximal to the standard 6-U portal.[8] To make the portal, the forearm is held in full supination. This portal is bound by the ECU tendon volarly and the FCU tendon volarly. Care should be taken to dissect and protect the dorsal sensory branch of the ulnar nerve. It may be helpful to encircle it with a vessiloop for additional protection. This portal is generally used as a working portal for possible repair of the articular disk to the ulnar fovea or débridement.

Trapeziometacarpal Arthroscopy

The portals for thumb basal joint arthroscopy are defined as the 1-R and 1-U portals.[15] The 1-R portal is just radial to the APL tendon. The 1-U portal is located just ulnar to the EPB tendon. The 1-R portal is best for viewing the dorsoradial ligament (DRL), posterior oblique ligament (POL), and the ulnar collateral ligament (UCL). The 1-U portal provides views of the anterior oblique ligament (AOL) and the ulnar collateral ligament. There is no true internervous plane because branches of the superficial radial nerve surround the field and are at risk for injury. The radial artery courses immediately posterior and ulnar to the arthroscopic field.

Accessory Thumb Carpometacarpal Portals

Accessory portals have been described by Orellana and Chow.[88] They discuss a modified radial portal (RP) for improving the radial view of the trapeziometacarpal joint. This portal is established by placing the scope in the 1-U portal and directed just radial to the AOL. A percutaneous 22-gauge needle is placed just distal to the ridge of the trapezium and visualized arthroscopically before finalizing the portal. Walsh et al. described a thenar portal, which is made by illuminating the thenar eminence with the arthroscope in the 1-U portal and inserting a 18-gauge needle through the bulk of the thenar muscles at the level of the carpometacarpal (CMC) joint.[125] This portal is approximately 90 degrees from the 1-U portal.

Slutsky developed a distal dorsal (D-2) accessory portal that allows one to look down the trapezium as opposed to across it,

http://e-surg.com

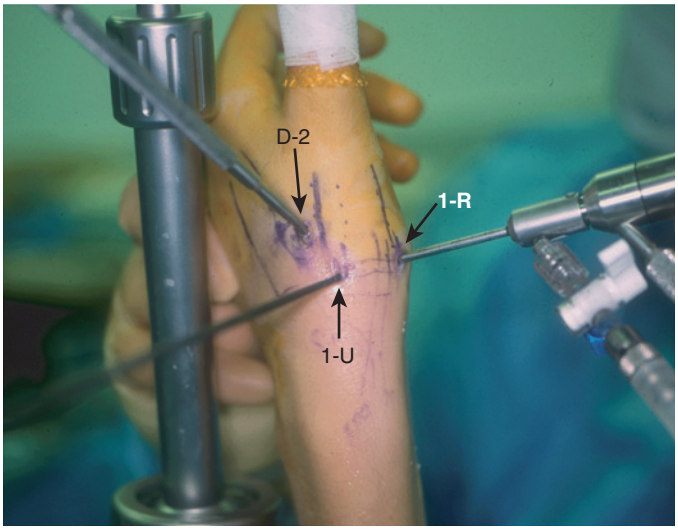

FIGURE 17.9 Trapeziometacarpal arthroscopy with use of the D-2 portal. The scope is in the 1-R portal, with a probe in the 1-U portal and a Freer elevator in the D-2 portal.

which he feels is safer for resection of medial osteophytes.[108] This portal is situated in the dorsal aspect of the first web space ulnar to the EPL tendon and 1 cm distal to the V-shaped soft spot at the junction of the index and thumb metacarpal bases. A 22-gauge needle is inserted 1 cm distal to the index–thumb metacarpal junction and angulated in a proximal, radial, and palmar direction while hugging the thumb metacarpal. Confirmation of joint access is performed from either the 1-R or 1-U portal. A small skin incision is made, and tenotomy scissors are used to spread the soft tissue and pierce the joint capsule followed by the arthroscope or instrumentation. There is no true safe zone for the D-2 portal, so a careful wound-spread technique is of paramount importance (Figure 17.9).

DRY ARTHROSCOPY

Dry arthroscopy has recently been increasing in popularity because of improved visualization, avoidance of normal tissue plane disruption by pressurized fluid, and the ability to use larger portals.[35,68] Dry arthroscopy avoids potential complications of extravasation of irrigation fluid into the soft tissues and the potential risk of compartment syndrome. An initial washing of the joint with 10 to 20 mm of fluid through a syringe attached to the side valve of the arthroscope sheath may be useful for evacuating hematoma or debris, especially if the procedure is indicated for the evaluation and reduction of articular fractures. The wrist arthroscope can be dried with small surgical padding inserted through a separate portal. *Tip:* To improve visualization immerse the tip of the arthroscope in warm water to prevent condensation. It is important to keep the side valve on the cannula open to air so that suction does not collapse the joint capsule. Suction should be used sparingly.

ARTHROSCOPIC ANATOMY

Arthroscopic evaluation of the radiocarpal space is started with the arthroscope in the 3-4 portal and progresses from a radial-to-ulnar direction. The radial styloid process articulates with

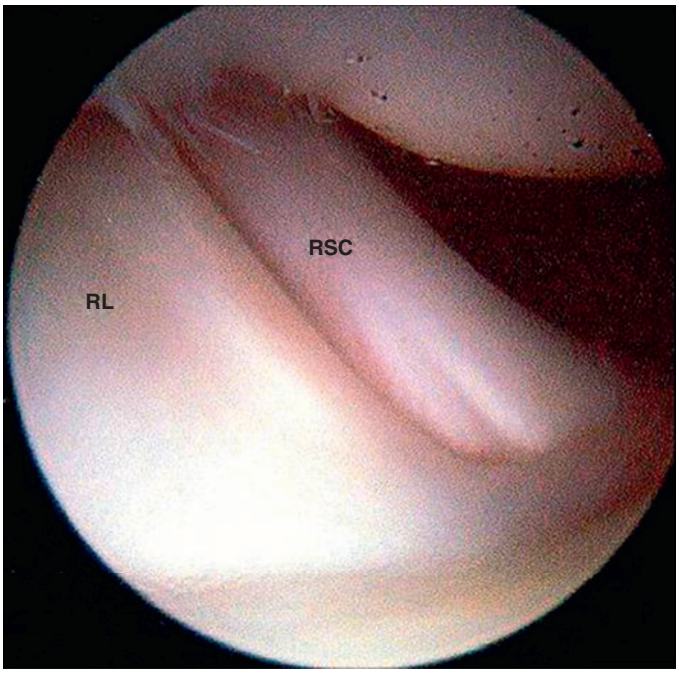

FIGURE 17.10 Arthroscopic view of the radioscaphocapitate (RSC) and long radial lunate (RL) ligaments with the arthroscope in the 3-4 portal. The RSC ligament is the most radial ligament and the long RL ligament is wider and lies just ulnar.

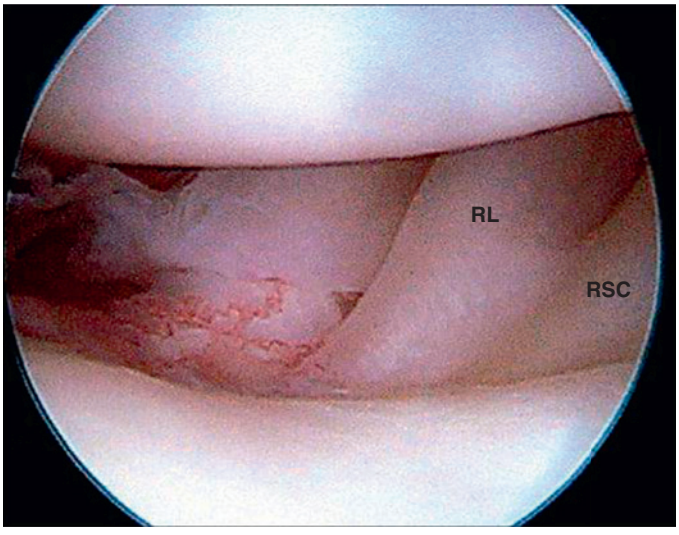

FIGURE 17.11 Arthroscopic view of the short radial lunate (RL) ligament and the well-vascularized ligament of Testut from the 3-4 portal. *RSC,* Radioscaphocapitate.

the proximal pole of the scaphoid and is examined for any signs of chondromalacia or synovitis, which can be seen in SLAC wrists. The volar extrinsic ligaments are then evaluated. The radial scaphocapitate ligament is the most radial extrinsic ligament that can be easily viewed.[18] The long radial lunate ligament is just ulnar to the radial scaphocapitate ligament and may be 2 to 3 times the width of the radial scaphocapitate ligament (Figure 17.10).[19,86]

Ulnar to the long radial lunate ligament is the short radial lunate ligament, which is a vascularized structure immediately volar to the scapholunate interval (Figure 17.11). The

http://e-surg.com

scapholunate interosseous ligament is then identified between the scaphoid and the lunate (Figure 17.12). It should have a normal concave appearance between the two carpal bones. As one continues to move ulnarward, the lunate facet of the distal radius is seen and the origin of the articular disk of the TFC complex is identified on the ulnar aspect of the radius.

The normal thickening of the volar and dorsal radial ulnar ligaments is also easily viewed. A probe may be inserted in either the 4-5 or 6-R portal to palpate the articular disk, which should be taut similar to a trampoline and can be balloted. The prestyloid recess is located dorsal to the ulnar carpal ligaments (Figure 17.13). This is a normal anatomic finding not to be confused with a peripheral tear of the articular disk of the TFC complex (Figure 17.14). The 6-U inflow cannula is traditionally placed in this recess (Figure 17.15). The lunotriquetral interosseous and the ulnar carpal ligaments are best visualized with the arthroscope in either the 4-5 or 6-R portal. The ulnolunate and ulnotriquetral ligaments are capsular thickenings on the volar aspect of the ulnar capsule. The lunotriquetral interosseous ligament should have a normal concave appearance between the lunate and triquetrum that is very similar to the scapholunate interosseous ligament (Figure 17.16)

The midcarpal space is then examined after appropriate evaluation of the radial carpal space.[118] All six midcarpal portals can be used as needed for the particular pathology suspected.

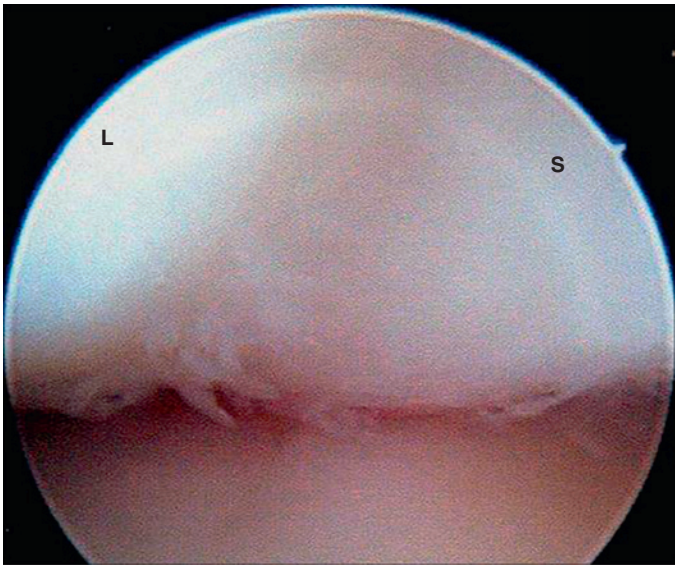

FIGURE 17.12 Arthroscopic view of the normal concave appearance of the scapholunate interosseous ligament between the scaphoid (S) and the lunate (L).

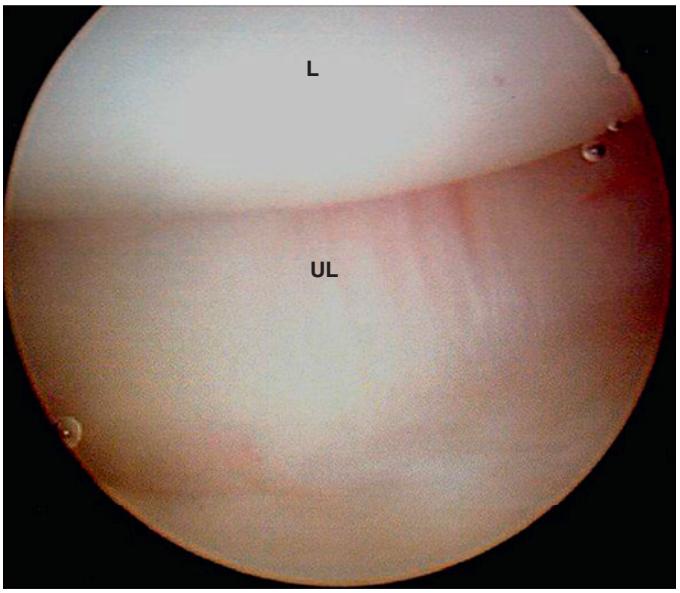

FIGURE 17.13 Arthroscopic view of the ulnolunate (UL) ligament with the arthroscope in the 3-4 portal. The lunate (L) is seen superiorly.

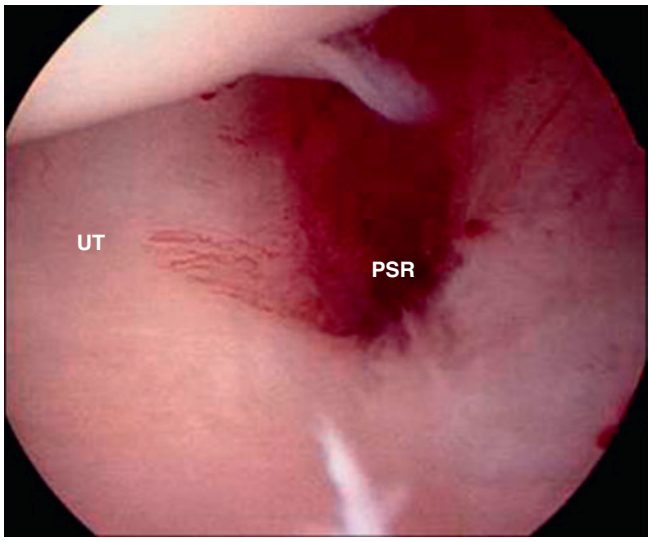

FIGURE 17.14 Arthroscopic view of the ulnotriquetral (UT) ligament with the arthroscope in the 6-R portal. Note the prestyloid recess (PSR) just dorsal and ulnar to this structure. It is important to note that this is a normal open space and not to mistake it for a peripheral tear of the articular disk, which is usually seen dorsal to the prestyloid recess.

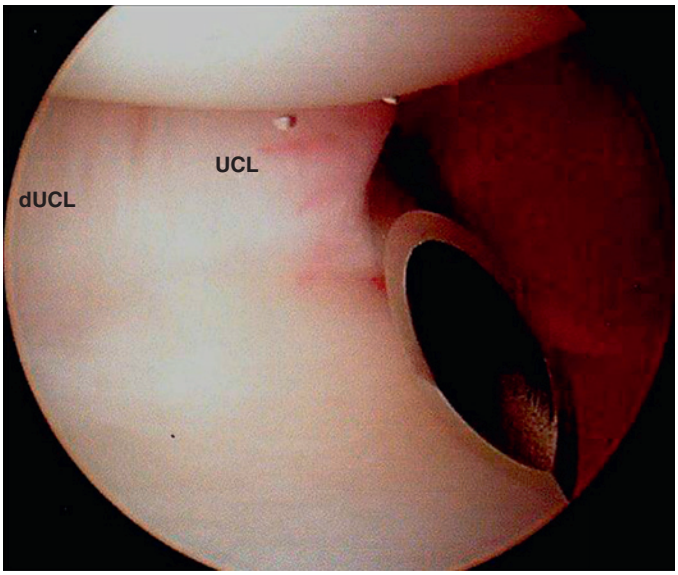

FIGURE 17.15 Arthroscopic view of the inflow needle being placed through the prestyloid recess. It is important to place the inflow distal to the articular disk so as not to injure this structure. *dUCL*, Distal ulnar collateral ligament; *UCL*, ulnar collateral ligament.

http://e-surg.com

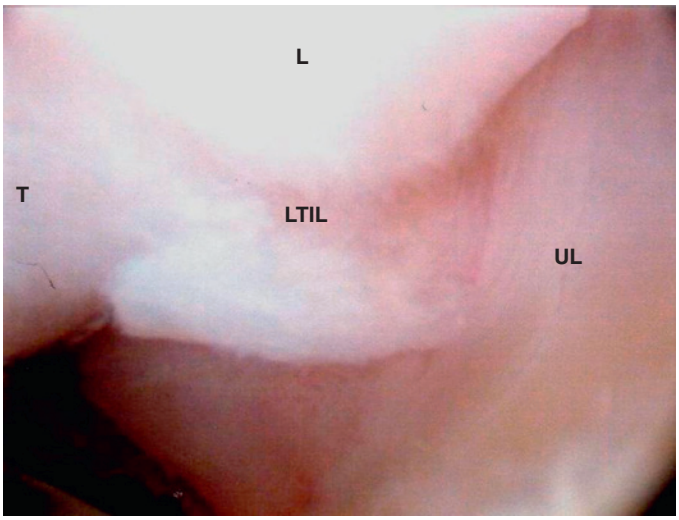

FIGURE 17.16 Arthroscopic view of a partial tear of the lunotriquetral interosseous ligament (LTIL) as seen with the arthroscope in the 6-R portal. It is important to note that this cannot be seen very well with the arthroscope in the 3-4 portal due to the more distal position of the triquetrum (T) in relation to the lunate (L). To thoroughly evaluate the lunotriquetral interval, the arthroscope needs to be placed on the ulnar side of the wrist, either in the 4-5 or 6-R portal. *UL,* Ulnar lunate.

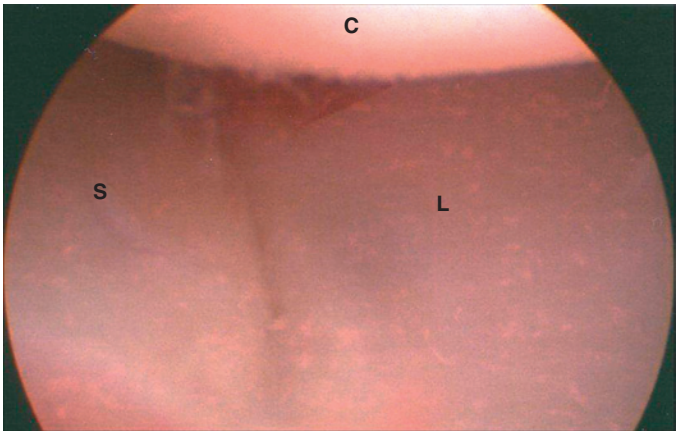

FIGURE 17.17 Arthroscopic view of the normal tight congruent articulation of the scaphoid (S) and lunate (L) as seen from the radial midcarpal portal. Note there is no step-off or gap between the scaphoid and lunate. The capitate (C) is seen distally.

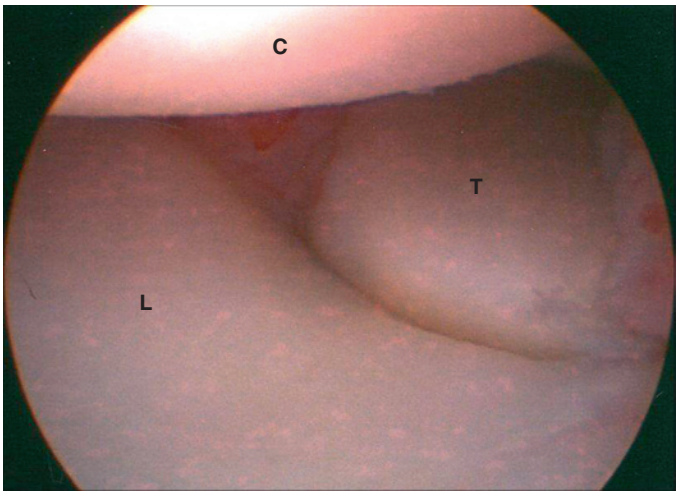

FIGURE 17.18 Arthroscopic view of the lunate (L) and triquetrum (T) as seen with the arthroscope in the radial midcarpal portal. Note that the triquetrum has about 1 mm of play or is positioned slightly distal to the lunate. This is a normal arthroscopic finding. *C,* Capitate.

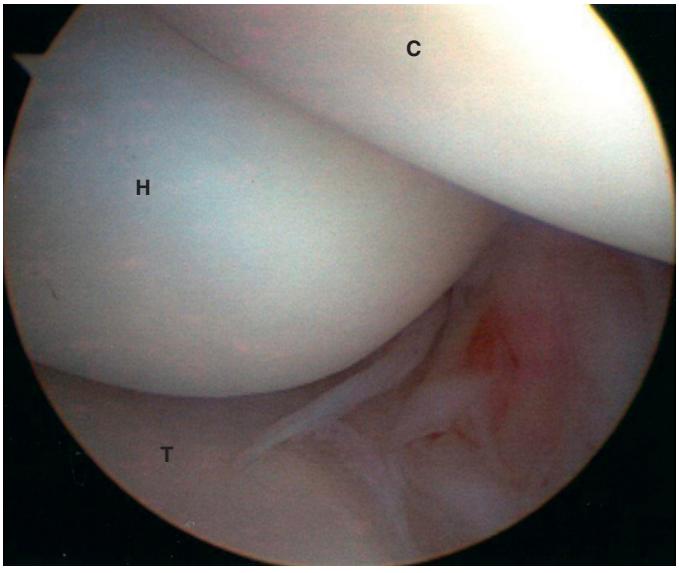

FIGURE 17.19 Arthroscopic view of the capitate (C), hamate (H), and triquetrum (T) as seen with the arthroscope in the ulnar midcarpal portal. This articulation can be a common location for symptomatic focal chondral defects, especially the proximal hamate, that can be difficult to image accurately.

The arthroscope is usually placed in the radial midcarpal portal, although in smaller wrists, it may be easier to start the examination with the arthroscope in the ulnar midcarpal portal.

The scapholunate interval proximally and the head of the capitate distally are initially identified as the arthroscope is placed in the radial midcarpal portal (Figure 17.17). This portal is useful for evaluating carpal instability, scaphoid fractures, articular cartilage defects to the midcarpal space, and the pathology of the STT joint. The lunotriquetral interval was seen as well as the proximal aspect of the hamate as the arthroscope is translated ulnarly (Figures 17.18 and 17.19). The arthroscope can then be translated radially and distally between the scaphoid and the capitate to visualize the STT joint. The trapezoid would be the carpal bone in the foreground and the trapezium in the background (Figure 17.20).

Two additional STT portals are established as in the preceding for arthroscopic treatment of the STT joint. The ulnar midcarpal portal is established, and the arthroscope can be moved back and forth between the two portals to evaluate and treat the appropriate conditions. Ulnar midcarpal viewing is helpful for suspected lunotriquetral tears, midcarpal instability, and to evaluate the type II lunate and any associated hamate impaction or degenerative disease.

DRUJ ARTHROSCOPY

The DRUJ is a very small space to arthroscopically evaluate and into which to insert instrumentation. Distal radioulnar joint

http://e-surg.com

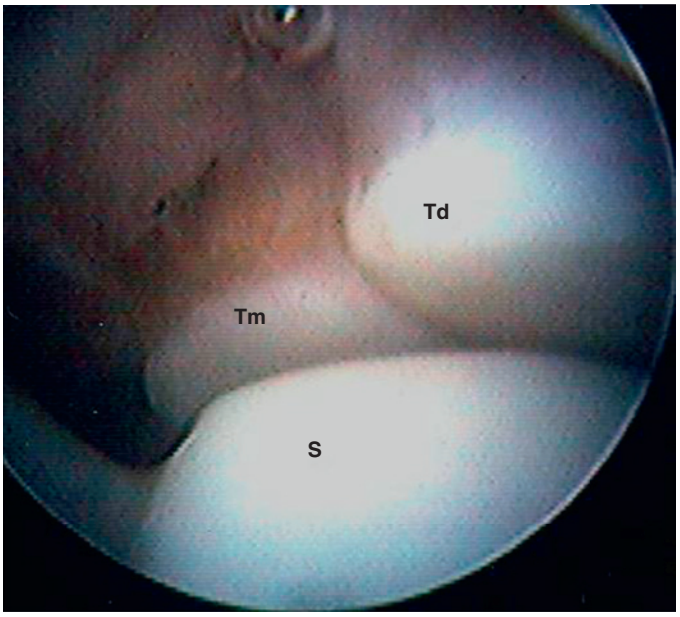

FIGURE 17.20 Arthroscopic view of the scaphotrapeziotrapezoid joint with the arthroscope in the radial midcarpal portal. The trapezium (Tm) is seen volar in relation to the trapezoid (Td). The scaphoid (S) is seen inferiorly.

TABLE 17.1 Carpal Instability Chart

Grade	Description	Management
I	Attenuation or hemorrhage of interosseous ligament as seen from the radiocarpal space. No incongruency of carpal alignment in midcarpal space.	Cast immobilization
II	Attenuation or hemorrhage of interosseous ligament as seen from radiocarpal space. Incongruency or step-off seen in midcarpal space. There may be a slight gap (less than width of probe) between carpal bones.	Arthroscopic pinning
III	Incongruency or step-off of carpal alignment as seen from both radiocarpal and midcarpal space. Probe may be passed through gap between carpal bones.	Arthroscopic pinning/open repair
IV	Incongruency or step-off of carpal alignments as seen from both radiocarpal and midcarpal space. There is gross instability with manipulation. A 2.7-mm arthroscope may be passed through gap between carpal bones.	Open repair

arthroscopy is useful for evaluation of the articular cartilage of the ulnar head or sigmoid notch and assessment of soft tissue disorders that cannot be seen from the radiocarpal space. Indications include débridement of undersurface flap tears of the articular disk, removal of loose bodies, diagnosis and evaluation of sigmoid notch arthritis, capsulorraphy for arthrofibrosis, and débridement/resection of the ulnar head for class II degenerative lesions of the triangular fibrocartilage complex (TFCC). Four portals have been described: two dorsal, one volar, and one foveal. It is generally recommended that a 1.9-mm arthroscope be used and traction decreased to help reduce tension on the capsule so as to improve visualization. As the view improves with débridement and, particularly in larger joints, ultimately a 2.9-mm arthroscope can be inserted to improve visualization.

CARPAL INSTABILITY

The radiocarpal and midcarpal space both should be evaluated arthroscopically when carpal instability is suspected. The key to arthroscopic management of carpal instability is the recognition of what is normal and what is pathologic when viewing the interosseous ligaments and the alignment of the carpal bones. Wrist arthroscopy is not complete until the midcarpal space is examined when carpal instability is suspected. The interosseous ligaments are unusual in that they can stretch and attenuate substantially before they avulse. This can allow bulging of the interosseous ligament and rotation of the carpal bones even without complete tearing.

The mechanics of carpal instability are quite complex involving not only the interosseous ligaments but also the extrinsic ligaments.[16] This combination of both intrinsic and extrinsic pathology allows for malrotation of the carpal bones and clinical instability. As the interosseous ligament tears, it hangs down, blocking visualization with the arthroscope in the radial carpal space. Rotation of the carpal bones is best accomplished with the unobstructed view available with the arthroscope in the midcarpal space.

The scapholunate and lunotriquetral interosseous ligaments should have a normal concave appearance as seen from the radial carpal space. The scapholunate interosseous ligament is best seen with the arthroscope in the 3-4 portal and the lunotriquetral interosseous ligament is best seen with the arthroscope in either the 4-5 or 6-R portal because of its oblique distal relationship to the proximal carpal row. In the midcarpal space, the scapholunate interval should be tightly congruent without any step-off. The lunotriquetral interval should be congruent, but frequently a 1 mm distal step-off of the triquetrum to the lunate is seen; this is normal. When the triquetrum is palpated, there is generally slight motion between the lunate and the triquetrum.

A limited type of intraoperative arthrogram (poor person's arthrogram) may be performed for the evaluation of carpal instability. A needle is placed in either the radial or ulnar midcarpal portal, and a tear of the interosseous ligament is strongly suspected when there is free flow of irrigation fluid from one carpal space to the other.

A spectrum of injury can be seen in both the scapholunate and lunotriquetral interosseous ligaments when they are injured. The interosseous ligament appears to attenuate and then tear from a volar-to-dorsal direction. Geissler et al. devised an arthroscopic classification of carpal instability based on observations of injury to the scapholunate and lunotriquetral interosseous ligaments when associated with fractures of the distal radius (Table 17.1).[48]

In grade I injuries, there is loss of the normal concave appearance between the carpal bones. The interosseous ligament bulges with a convex appearance as seen with the arthroscope in the radial carpal space (Figure 17.21). Evaluation of the midcarpal space shows the carpal bones to be congruent

http://e-surg.com

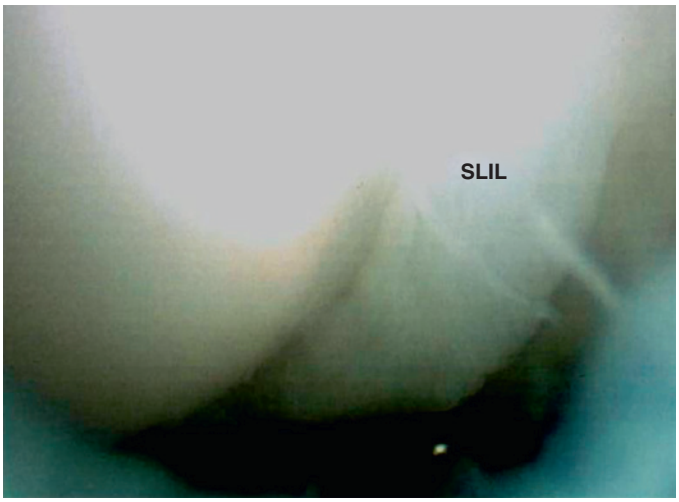

FIGURE 17.21 Arthroscopic view of a Geissler grade I injury to the scapholunate interosseous ligament (SLIL) as seen with the arthroscope in the 3-4 portal. Note the loss of the normal concave appearance of the interosseous ligament. The convex and stretched ligament bulges into the radiocarpal joint. In the midcarpal space, arthroscopic evaluation will show no step-off or congruency of the scapholunate interval in a grade I injury.

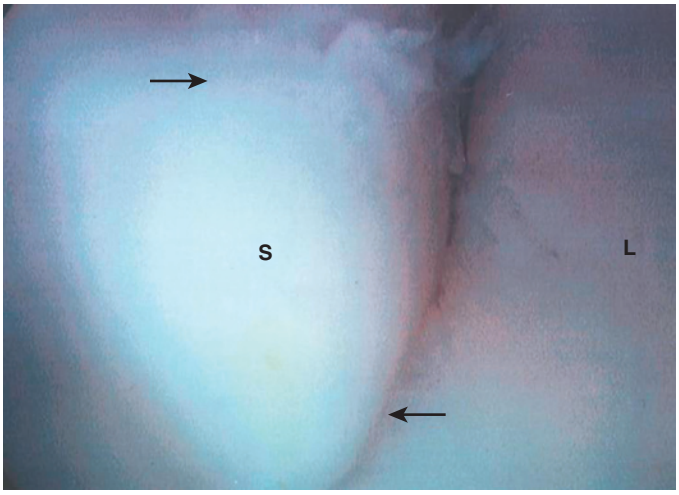

FIGURE 17.22 Arthroscopic view from the midcarpal joint of a Geissler grade II injury to the scapholunate interosseous ligament. Similar to a grade I injury, there is bulging of the ligament as seen in the radiocarpal space. In the midcarpal space as seen here, now there is joint incongruency and palmar flexion of the scaphoid in relation to the lunate as demonstrated by the *arrows*. *L*, Lunate; *S*, scaphoid.



FIGURE 17.23 Arthroscopic view of a Geissler grade III injury to the scapholunate ligament as seen with the arthroscope in the radiocarpal space. Note a gap is seen between the scaphoid on the left and the lunate on the right. Normally, the ligament tears in a volar-to-dorsal direction.

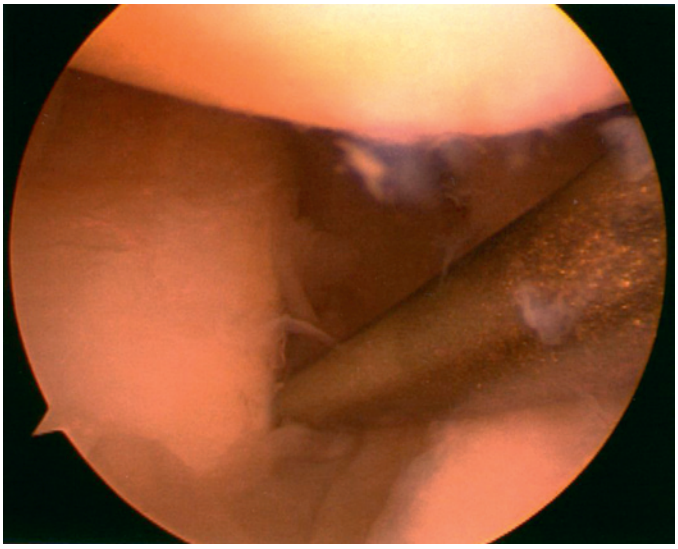

FIGURE 17.24 Arthroscopic view of a Geissler grade III injury as seen with the arthroscope in the radial midcarpal space. Note the separation between the scaphoid and lunate when palpated with a probe.

with no step-off. In grade II injuries, the interosseous ligament is again convex as seen with the arthroscope in the radial carpal space. In the midcarpal space, the carpal bones are no longer congruent (Figure 17.22). With scapholunate instability, the scaphoid is observed with a slight palmar flexion because the dorsal edge is distal compared to the lunate. However, there is no gap between the scaphoid and the lunate. In injuries to the lunotriquetral interosseous ligament, there is increased motion as seen in the lunate and triquetrum when palpated with a probe inserted through the ulnar midcarpal portal.

With grade III injuries, the interosseous ligament begins to tear and a gap is seen from the carpal bones of both the radial carpal and midcarpal spaces. A probe may be inserted between the scaphoid and lunate and gapping can be observed from the radiocarpal and midcarpal space (Figures 17.23 and 17.24). In grade IV injuries, the interosseous ligament is completely detached and the arthroscope can be passed freely from the radial carpal to the midcarpal space to the interval of the carpal bones. This is a so-called "drive-through sign." This corresponds to a widening scapholunate gap as seen on the radiographs of patients with a complete scapholunate disassociation (Figure 17.25).

Acute tears of the scapholunate or lunotriquetral interosseous ligaments that result in incongruency from the midcarpal space may be arthroscopically reduced and temporarily pinned. It is felt that in patients who have a grade I injury, typically the wrist sprain will resolve with immobilization alone as there is no incongruency.

http://e-surg.com

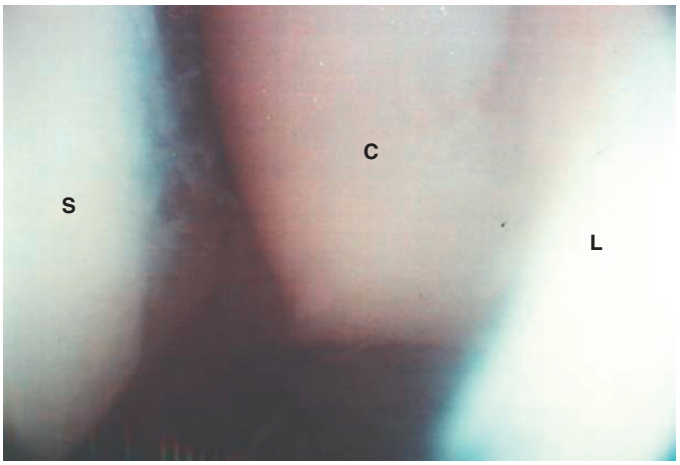

FIGURE 17.25 Arthroscopic view of a Geissler grade IV injury with the so-called "drive through sign." The arthroscope can freely be passed through the gap between the scaphoid (S) and lunate (L) and between the radiocarpal and midcarpal spaces. The capitate (C) is easily seen distally.



FIGURE 17.26 The scapholunate-intercarpal-carpal screw (Acumed, Hillsboro, OR). This screw rotates between the threaded portions on either end to allow rotation between the scaphoid and the lunate. It also has approximately 20 degrees of toggle at the two ends. This screw is designed to remain in place for a prolonged period of time while the repair of the interosseous ligament heals and matures.

Two or three guidewires are placed just distal to the radial styloid into the scaphoid under fluoroscopy. It is important to place the guidewire either through a cannula or in oscillation mode to avoid injury to the dorsal sensory branch of the radial nerve. The Kirschner wires are placed into the scaphoid aiming toward the lunate under fluoroscopic control. The wrist is suspended in the traction tower. The arthroscope is placed in the ulnar midcarpal portal. It is most effective arthroscopically to look across the wrist. A joystick may be placed into the lunate to help control rotation as well. The scapholunate interval is anatomically reduced as viewed from the midcarpal space. The Kirschner wires have been driven across the scapholunate interval.

Frequently, droplets of fat are seen exiting the interval between the scapholunate as Kirschner wires are being driven across the carpal bones. Three or four wires are placed and left in position for approximately 8 weeks. The Kirschner wires can be buried or left exposed for easier removal based on the surgeon's preference. The wrist is immobilized in a below-elbow cast and the wire tracks are evaluated every 2 to 3 weeks. Digital range of motion is encouraged. The wires are removed at 8 weeks and the wrist is immobilized an additional 4 weeks. Physical therapy for wrist range of motion and grip strength is initiated after a 3-month interval.

Management of acute tears to the lunotriquetral interosseous ligament is essentially the same except the arthroscope is placed in the radial midcarpal space as the pins are driven across the lunotriquetral interval. The Kirschner wires are placed through a catheter or in oscillation mode to avoid injury to the dorsal sensory branch of the ulnar nerve. Frequently, reduction of the lunotriquetral interval is not as difficult compared to the scapholunate interval.

There is a complete tear of the interosseous ligament in grade IV injuries to the wrist. It is felt that direct primary repair of a complete tear of the interosseous ligament is the best option; it is performed through a small arthrotomy rather than pinning alone. While Kirschner wires are effective for stabilization, they can only be left in for a short period of time (6-8 weeks). These wires have been associated with pin tract infections and potentially can limit rehabilitation. The concern is that the interosseous ligaments may take a long time to heal, and a period of 6 to 8 weeks may not be enough for them to heal when the pins are pulled.

An alternative is placement of a screw specially designed by Acumed (Hillsboro, OR) for carpal instability—the scapholunate-intercarpal-carpal (SLIC). A SLIC screw rotates in its midsection and has approximately 20 degrees of toggle (Figure 17.26). The theory with an SLIC screw is that it can be left in for a prolonged period of time (6-9 months) and allows rotation of the scaphoid and lunate in the sagittal plane while the ligament heals. The cannulated screw can be removed in the future. Using a screw to temporarily augment scapholunate repair has advantages over Kirschner wires, which are mechanically less secure and have problems of pin irritation and pin tract infection.

Whipple reviewed the results of arthroscopic treatment of scapholunate instability in patients who were followed for a duration of 1 to 3 years.[132] Patients were classified in two distinct groups of 40 patients each according to the duration of symptoms and the side-to-side scapholunate gap. Eighty-three percent of patients who had scapholunate instability of 3 months or less, and a gap of 3 mm or less, had symptomatic relief compared to only 21 patients (63%) who had symptoms greater than 3 months and more than a 3-mm side-to-side difference. The conclusion from the study was that arthroscopic pinning should be reserved for patients with an acute injury rather than a chronic, complete tear.

Osterman and Seidman reviewed their study's results of arthroscopic treatment of acute lunotriquetral instability in 20 patients who did not have volar intercalated segment instability.[91] Follow-up was done at an average of 32 months, and 16 patients had good-to-excellent relief of pain. Grip strength improved in 18 patients.

Weiss et al. reviewed results of arthroscopic débridement of interosseous ligament tears alone at an average of 27 months following the procedure.[127] In the study, 31 of 36 patients who had a partial tear of the scapholunate interosseous ligament had complete resolution or a decrease in their symptoms compared

http://e-surg.com

to 19 to 21 patients who had a complete tear of the scapholunate interosseous ligament. All 42 patients who had a partial tear of the lunotriquetral interosseous ligament and 26 of 33 patients who had a complete tear of the lunotriquetral interosseous ligament had complete resolution or a decrease in their symptoms. Grip strength improved in an average of 23% in study participants. Weiss et al. concluded that débridement of lunotriquetral interosseous ligament tears had a better result compared to injury to the scapholunate interosseous ligament. In addition, débridement of partial tears to the interosseous ligament had better results compared to complete tears.

Although electrothermal shrinkage of ligaments in other joints of the body, primarily the shoulder, has not been shown to be effective, electrothermal shrinkage may play a role in the management of chronic partial tears of the interosseous ligaments. This is because the wrist may be immobilized for a prolonged period of time, allowing the contracted collagen to mature. Electrothermal shrinkage is based on heating and denaturing of collagen, which results in shrinkage. This technique is best indicated for chronic grade I or grade II partial tears of the interosseous ligament. The monopolar or bipolar probe can be used. The monopolar probe is shown to lead to deeper penetration of heat to contract the interosseous ligament compared to a bipolar probe. In addition, a bipolar probe yields higher surface temperatures that can further increase the temperature of the irrigation fluid in the wrist due to its small volume.

An electrothermal probe is used to shrink the remaining portion of the interosseous ligament following mechanical débridement of the tear. It is important not to paint the tissue but to spot weld and to leave viable tissue in between the contracted areas (Figure 17.27). The probe addresses primarily the membranous portion of the interosseous ligament but also the dorsal and volar capsule may be shrunk. In addition, the probe can be placed in the midcarpal space to shrink the volar capsule. It is extremely important to increase the flow of irrigation fluid into the wrist joint during thermal shrinkage. Increasing the fluid's flow helps to disseminate the heat from the wrist probe. The volume of flow to the wrist joint is quite small and can be rapidly heated up with a thermal probe. The temperature of the irrigation fluid as it leaves the wrist should be monitored as well to help prevent burns to the patient. It is recommended that a separate inflow through the 6-U portal be used to maintain a high volume of fluid in and out of the joint.

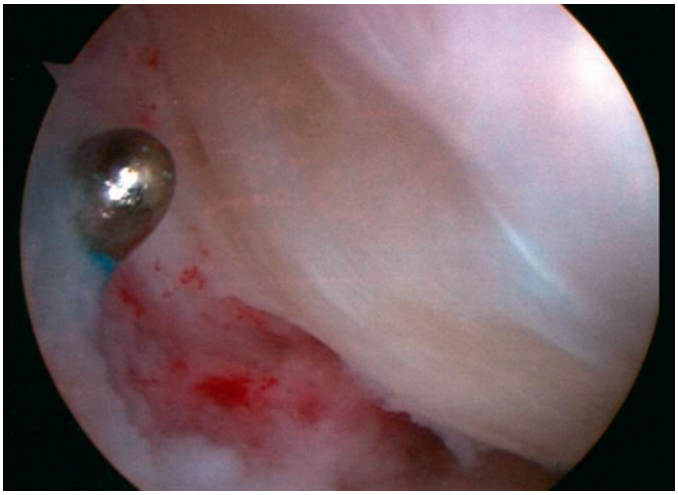

FIGURE 17.27 View with the arthroscope in the 6-R portal following electrothermal shrinkage of the scapholunate interosseous ligament. The thermal probe is inserted through the 3-4 portal. Note the caramel colorization following shrinkage of the scapholunate interosseous ligament and restoration of the normal concave appearance to the ligament.

Postoperative management of thermal shrinkage for chronic partial tears of the interosseous ligament is controversial as minimal protocols are available. Some authors believe that immobilization alone is sufficient while others recommend temporary Kirschner wire stabilization. Patients' wrists are immobilized for approximately 8 weeks then for an additional 4 weeks in a removable brace after physical therapy exercises are initiated.

Geissler reviewed the results of 19 patients with chronic isolated interosseous ligament tears.[46] A chronic injury was defined as symptoms greater than 6 months. Geissler noted that grade II tears of the scapholunate and lunotriquetral interosseous ligaments had significantly better results compared to grade III tears. There is no real difference in the study between scapholunate and lunotriquetral interosseous ligament tears. The lunate was neutral in those patients with partial interosseous ligament injuries.

Darlis et al. performed arthroscopic débridement and capsular shrinkage on 16 patients with 14 reporting good-to-excellent results. In their series, eight of those patients were pain-free; there were two failures.[33] In a similar study, Hirsh et al. performed his study with 10 patients who were 90% pain-free on an average follow-up of 10 months.[61]

Mathoulin et al. described a unique arthroscopic dorsal capsule ligament repair for chronic reducible scapholunate interosseous ligament tears.[77,124] Their hypothesis is that the dorsal intercarpal ligament is avulsed from the intact dorsal scapholunate interosseous ligament (dSLI). In this technique, a 3.0 PDS suture is placed through a needle as visualized arthroscopically and passed through the dorsal intercarpal ligament (DICL) and the dorsal scapholunate ligament, tied to form a capsuloplasty. No pins are used. In their study series of 36 patients with a 13-month follow-up, results were generally excellent. Patients regained 96% of grip strength compared to the contralateral side and reported that seven of the patients involved in sports were able to return to the same level of activity postoperatively. The advantage of this technique is in the reduction of postoperative stiffness by minimizing the dorsal capsule dissection compared to traditional open surgery.

del Pinal et al. described an all-inside technique for arthroscopic suturing of the volar scapholunate interosseous ligament.[36] With this technique, sutures are placed volarly through a Tuohy needle to plicate the volar ligament remnants and the long radial lunate ligament. He described using this technique in four patients.

Van Kampen and Moran reported on a new technique for capsulodesis based on cadaver study.[118] With this technique, a volar capsulodesis is used to reconstruct the volar scapholunate interosseous ligament using a portion of the long radial lunate ligament; they included a detailed description.

As can be seen, more and more investigative work is being performed to address the difficult problem of scapholunate instability. More attention is being placed, in particular, on addressing the volar aspect of instability instead of concentrating on the dorsal aspects. Chronic isolated lunotriquetral

http://e-surg.com

interosseous ligament injuries have been treated with various techniques including ligament repair, ligament reconstruction, and lunotriquetral fusion.

Moskal and Savoie described a ligament plication of the ulnotriquetral-ulnolunate ligaments.[82] Contraindication to this technique would be a VISI deformity. In this technique, the standard 3-4, 6-R, and 6-U arthroscopic portals are made. A volar 6-U (v6-U) portal is established. The v6-U portal, similar to the normal 6-U portal, is placed just dorsal to the disk carpal ligaments. Through the v6-U portal an 18-gauge needle is passed just volar to the disk triquetral, ulnar capitate, and disk lunate in the radial carpal joint at the radial edge of the ulnolunate ligament just distal to the articular surface of the radius. A 2.0-PDS suture is placed through the needle into the joint. The suture is retrieved either sequentially through the 6-R and through the v6-U or directly through v6-U using a wire loop suture retriever. The suture is then tagged as the first plicating suture.

In a likewise fashion, a second plicating suture is placed approximately 5 mm distal to the first suture parallel to the lunate and triquetrum. Finally, through the v6-U a spinal needle is passed through the volar aspect of the capsule at the prestyloid recess and then through the periphery of the articular disk of the TFCC. The retriever is introduced through the ulnar capsule, and the suture is brought out of the v6-U portal through the ulnar capsule. The three sutures are then tied after the lunotriquetral joint has been congruently reduced and stabilized with Kirschner wires. In their study series, 19 out of 21 patients had an excellent or good result with two fair.

Various authors have cast light on the importance of the dorsal radiocarpal ligament pertaining to carpal instability.[79,99,103,122] It is felt that tears of the dorsal radiocarpal ligament (DRCL) have been linked to the development of both volar and dorsal intercalated segmental instabilities. It also has been implicated as a cause of midcarpal instability.[66,81,121] It is generally felt that DRCL is commonly overlooked with the general arthroscopic examination of the wrist. The dorsal radiocarpal ligament may be seen through either the 1-2 or 6-R portals. Visualization may be difficult in a smaller, tight wrist. Wrist arthroscopy through a volar radial portal is the most ideal way to access the DRCL due to straight access of the site.

Slutsky described his technique for arthroscopic repair of a lesion to DRCL.[106] Using his technique, the VR portal is made as previously described. He feels that while the procedure may be done dry, it is easier to see the torn edges of the DRCL with fluid irrigation. The DRCL is seen just radial to the standard 3-4 portal underneath the lunate. He notes that the dorsal capsule may often appear redundant and can protrude into the joint; however, when a DRCL tear is present, the frayed ligamentous fibers can be seen. It is often helpful to insert a 3-mm hook probe through the 3-4 portal for orientation. The torn DRCL then may be pulled into the joint with a probe that differentiates it from the redundant dorsal capsule.

A repair of a DRCL is performed by inserting a 22-gauge spinal needle through the 3-4 or 4-5 portals (Figure 17.28). A 2.0 absorbable suture is threaded through the spinal needle and retrieved with a grasper or suture retriever and passed through the opposite portal. A curved hemostat is then used to pull either end of the suture underneath the dorsal extensor tendons. A suture knot is tied either at the 3-4 or 4-5 portal. Slutsky notes that usually one suture is sufficient but additional ones may be added. In this technique, the patient is placed in a cast for approximately 4 weeks followed by wrist mobilization.

Slutsky reviewed a retrospective series of 22 patients. There were 6 men and 16 women in his study.[105] A dorsal capsulodesis was performed with 7 patients as a primary treatment and 13 underwent DRCL repair with thermal shrinkage. It was noted that 5 patients who underwent an isolated DRCL repair were satisfied with the surgery's outcome and would repeat it because of the improvement. All 5 described their pain as none or mild, and all returned to their previous occupations without restrictions.

Wrist arthroscopy also can serve as a valuable adjunct in the management of chronic injuries to the interosseous ligaments beyond thermal shrinkage. Wrist arthroscopy can be used to evaluate the degree and extent of articular cartilage degeneration in patients with chronic scapholunate advanced collapsed (SLAC) wrist. Arthroscopic evaluation of the status of the articular cartilage to the head of the capitate is extremely useful to help determine the indications for four-corner fusion versus proximal row carpectomy, and it may be used as an alternative or an adjunct to magnetic resonance imaging.

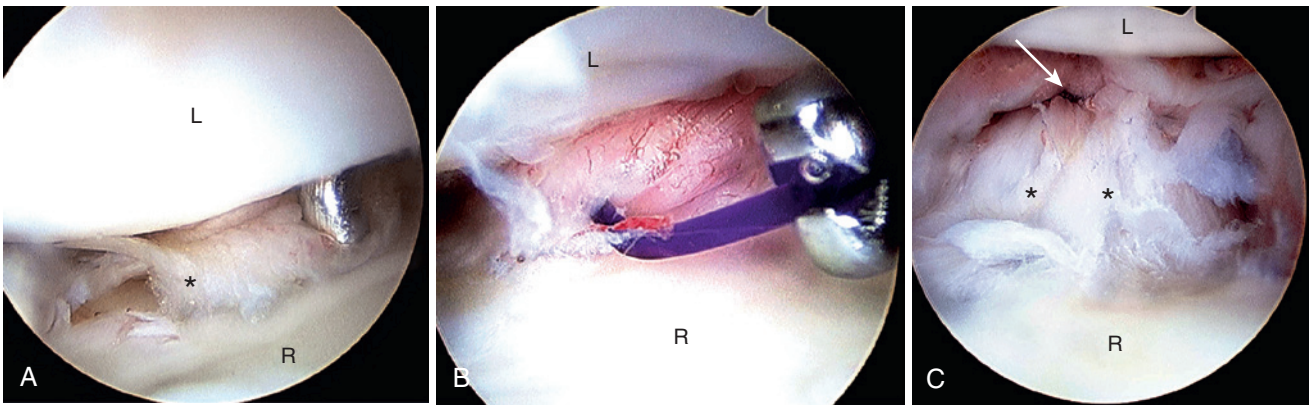

FIGURE 17.28 Dorsal radiocarpal ligament repair. **A,** View from the volar radial portal demonstrating the torn edge of the dorsal radiocarpal ligament (DRCL) (*) protruding into the joint space. **B,** The suture is entering from the 4-5 portal and being retrieved by a grasper in the 3-4 portal. **C,** Note how the suture (*arrow*) pulls the DRCL (*) up against the dorsal capsule. *L*, Lunate; *R*, radius.

http://e-surg.com

FRACTURE MANAGEMENT

Scaphoid Fractures

Cast immobilization has shown a successful healing rate of 85 to 95% of acute nondisplaced scaphoid fractures.[54] While cast immobilization may be successful, it comes with a price: muscle atrophy, osteopenia, and potential wrist stiffness. An athlete may lose his scholarship, and an employee his job, should a prolonged period of immobilization and ultimately surgery for scaphoid nonunion be required. Arora et al. compared cast and operative fixation for stable scaphoid fractures.[7] They noted the operative group had a shorter time to union, decreased overall costs, and a 7-week earlier return to sports and/or work. Several minimal incision techniques have been developed, including a volar percutaneous approach, a percutaneous dorsal approach, mini-open, and all-arthroscopic fixation. The reader is referred to Chapter 16 for a complete description of operative techniques.

❖ AUTHOR'S PREFERRED TREATMENT: Arthroscopic Reduction and Internal Fixation of Scaphoid Fractures

Geissler Technique

This technique can be used for both acute fractures and selected scaphoid fracture nonunions.[53] The advantage of this technique is that the starting point is viewed directly arthroscopically and there is no guesswork concerning the insertion point of the guidewire and the headless cannulated screw. It is also felt that this technique may have a technical advantage over the dorsal percutaneous approach because the wrist is not hyperflexed during wire insertion, which could create a flexion/humpback deformity in the scaphoid. It is important to note that this technique is indicated for patients with acute fractures of the scaphoid and for nonunions without a humpback deformity or dorsal intercalated segment instability (DISI).

The wrist is placed in the traction tower and the arthroscope is inserted in the 3-4 portal to evaluate any associated soft tissue injuries that may be associated with the fracture. It is helpful to place the forearm baseplate on the dorsal aspect of the forearm to make it easier to flex the wrist (Figures 17.29 and 17.30). The arthroscope is then transferred into the 6-R portal and the wrist is flexed approximately 30 degrees. A 14-gauge needle is inserted through the 3-4 portal to align the ideal starting point for the guidewire in the scaphoid proximal pole. The needle should pass easily and care be taken to avoid puncture or injury to an extensor tendon.

Viewing from the 6-R portal, the needle is pushed by hand into the scaphoid proximal pole at its junction with the membranous portion of the scapholunate interosseous ligament at the approximate volar-dorsal midpoint (Figure 17.31). The flexed wrist is then evaluated under fluoroscopy in the PA plane and the starting point of the needle is confirmed and adjusted as necessary (Figure 17.32). The needle is next aimed toward the thumb and a guidewire is advanced under fluoroscopy down the central axis of the scaphoid to abut the distal pole (Figure 17.33). The position of the guidewire is then evaluated in the PA plane, oblique, and lateral views under fluoroscopy by rotating the forearm in the traction tower (Figure 17.34). A second guidewire is then inserted percutaneously to abut the proximal pole of the scaphoid, and the length of the screw is determined by the difference in the length of the two wires. It is very important that a screw at least 4 mm shorter than measured be used to avoid screw prominence or distraction of the fracture site.

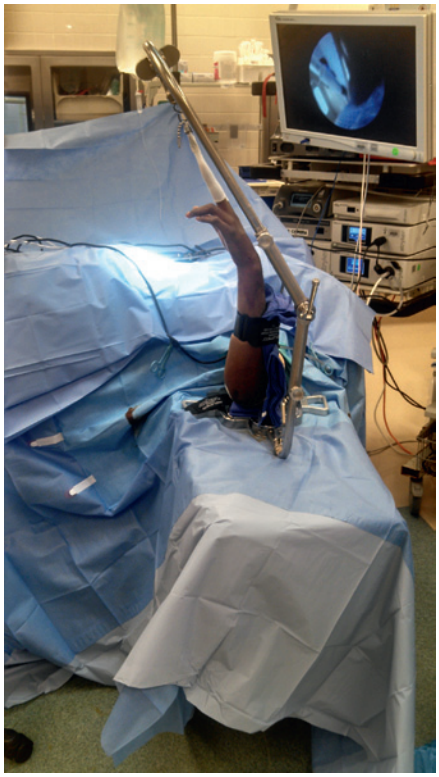

FIGURE 17.29 It is helpful with arthroscopic fixation of the scaphoid to place the forearm base plate of the traction tower on the dorsal aspect of the forearm. In this manner, it is easier to flex the forearm when evaluating the position of the needle and guidewire under fluoroscopy.

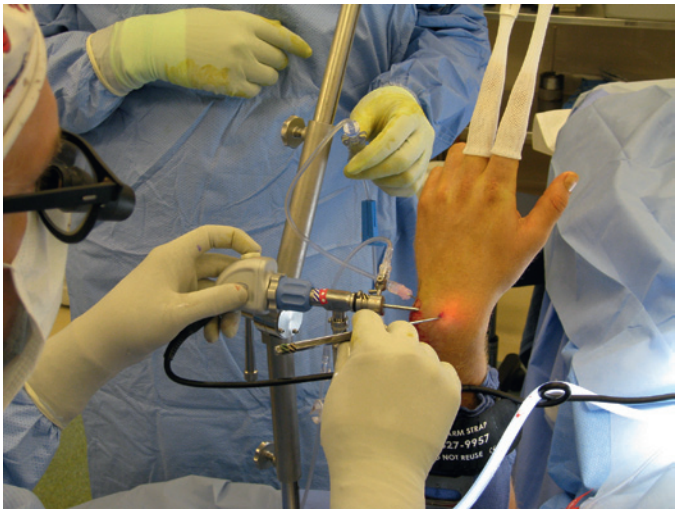

FIGURE 17.30 The arthroscope is placed in the 6-R portal and the ideal starting position for the scaphoid guidewire is palpated with a probe in the 3-4 portal.

The arthroscope is then placed in the midcarpal space to evaluate the fracture reduction. Fractures of the proximal pole are best seen with the arthroscope in the ulnar midcarpal portal, and fractures of the waist are best visualized with the arthroscope in the radial midcarpal portal. The guidewire is then

http://e-surg.com

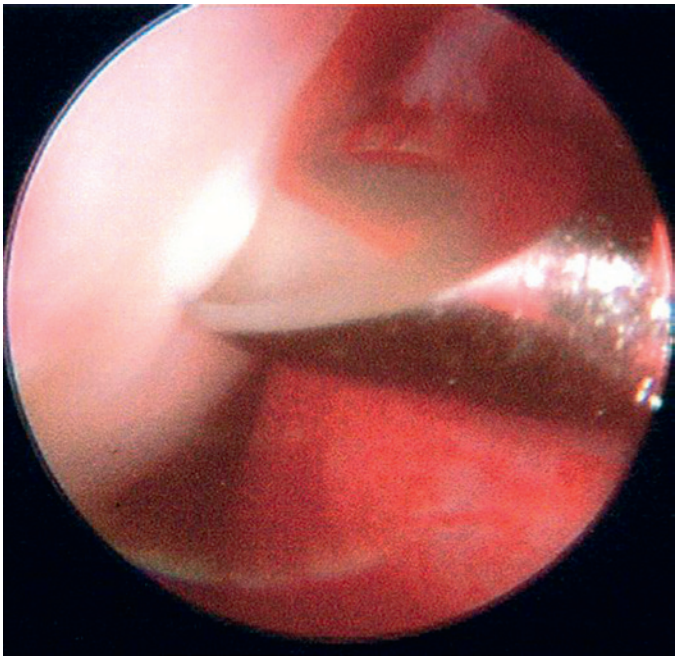

FIGURE 17.31 A 14-gauge needle is then brought in through the 3-4 portal and the proximal pole of the scaphoid is impaled just radial to the junction of the interosseous ligament. It is important as one passes the needle through the 3-4 portal that it easily goes through the portal so as not to injure an extensor tendon.



FIGURE 17.33 Fluoroscopic view showing ideal position of the 14-gauge needle on the proximal pole of the scaphoid so that the guidewire will pass perpendicular to the scaphoid fracture.

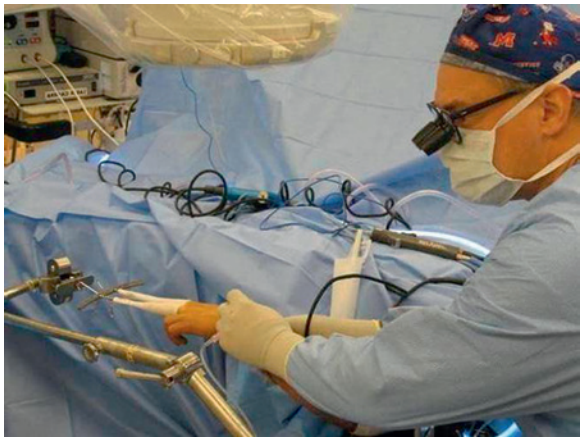

FIGURE 17.32 The traction tower is then flexed to horizontal to check position of the needle under fluoroscopy to be exactly at the proximal pole of the scaphoid.



FIGURE 17.34 Fluoroscopic view showing the guidewire inserted through the 14-gauge needle and down the central axis of the scaphoid.

advanced out the volar aspect of the wrist, generally through the thenar eminence. This is an important step because if the guidewire breaks at any point during the procedure, the two ends can be retrieved from dorsal and palmar. If the reduction is not considered satisfactory, the wire is further withdrawn distally until it is in the distal fragment alone, and a joystick is inserted into the proximal pole to help manipulate the fracture to an anatomic reduction. Frequently, flexion and extension and radial and ulnar deviation of the wrist in the traction tower help facilitate the reduction. Once the fracture is felt to be anatomic, as viewed directly with the arthroscope in the midcarpal space, the guidewire is advanced proximally into the proximal pole of the scaphoid and out the initial 3-4 portal.

At this point, the guidewire should be exiting the volar and dorsal aspects of the wrist. The scaphoid is then reamed through a trocar to protect the extensor tendons and cutaneous nerves. A cannulated screw is then placed over the guidewire (Figure 17.35). The position of the screw is evaluated under fluoroscopy in the PA, oblique, and lateral planes (Figure 17.36). The wrist

http://e-surg.com



FIGURE 17.35 Fluoroscopic view showing the headless cannulated screw placed over the guidewire down the axis of the scaphoid. Note the wire exits the volar aspect of the wrist so it is easily accessible if there is any breakage or bending of the guide wire.



FIGURE 17.36 Fluoroscopic view showing ideal placement of the headless cannulated screw across the scaphoid fracture.

is then evaluated arthroscopically both from the midcarpal and radial carpal spaces. From the midcarpal space, the reduction and compression of the scaphoid are evaluated.

In the radiocarpal space, it is imperative to evaluate that the headless cannulated screw has been advanced below the articular cartilage (Figure 17.37). Occasionally, the screw may look to



FIGURE 17.37 Arthroscopic view showing the headless cannulated screw buried beneath the articular cartilage to the level of the subchondral bone.



FIGURE 17.38 Fluoroscopic view of the guidewire in place using the Slade technique. The proximal and distal poles of the scaphoid have been aligned by hyperflexion to form the "ring sign." The guidewire is passed parallel to the fluoroscopic beam.

be buried under fluoroscopy, but arthroscopic evaluation shows the screw remains slightly prominent, which could injure the articular cartilage of the distal radius. If this is the case, the screw is further advanced into the scaphoid.

Slade Technique

Slade et al. described the dorsal arthroscopic assisted technique.[104] In this technique, the wrist is flexed and pronated until the proximal and distal poles of the scaphoid are aligned into a cylinder. This forms a ring sign (Figure 17.38). Once the ring sign is achieved, a guidewire is placed down the center of the ring in line with the axis of the x-ray beam. The wire is advanced out the volar aspect of the wrist until it is flush with the dorsal pole of the scaphoid. In this manner, now the wrist can be

http://e-surg.com

extended to verify the precise position of the guidewire and the posterior, anterior, oblique, and lateral planes. The position of the guidewire in the proximal pole of the scaphoid can be verified with the arthroscope in the radiocarpal space. The arthroscope can be placed in the midcarpal space to evaluate reduction of the scaphoid fracture.

Fractures of the waist of the scaphoid are best seen with the arthroscope in the radial midcarpal portal, and proximal pole fractures are best seen with the arthroscope in the ulnar midcarpal portal. If reduction is not satisfactory, the guidewire can be advanced out the thenar eminence and withdrawn until it is only within the distal pole. Separate joysticks are placed in the proximal and distal poles to manipulate the fracture fragments; extension and radial deviation of the wrist in the traction tower also help to align the fracture anatomically. The wire can then be advanced back proximally across the fracture site. Once ideal reduction of the scaphoid is confirmed arthroscopically, the wrist is flexed and the guidewire is brought out dorsally through the 3-4 portal until it abuts the subchondral bone of the distal pole and is measured. It is imperative that a screw at least 4 mm shorter than the measured length be used to avoid prominence or fracture distraction. The scaphoid is then reamed and a headless cannulated screw is placed.

Herbert–Whipple Technique

Another arthroscopic-assisted technique using the Herbert-Whipple jig (Zimmer, Warsaw, IN) has been described. With the arthroscope in the 6-R portal, the jig is inserted into the 1-2 portal and the spike of the jig is placed at the junction of the scapholunate interosseous ligament and the proximal pole of the scaphoid, identical to the starting point of the Geissler technique (Figure 17.39). An incision is then made over the distal pole of the scaphoid and the barrel of the jig is advanced to the scaphoid tubercle to provide provisional compression of the fracture. The reduction of the scaphoid may be arthroscopically assessed by placing the arthroscope in the radial midcarpal portal (Figure 17.40).

If the fracture is not anatomically reduced, the barrel of the jig is released and with manipulation or joysticks, the scaphoid fracture is anatomically reduced (Figure 17.41). Once anatomic reduction of the scaphoid fracture is confirmed arthroscopically, the barrel of the jig is then compressed to provide provisional fixation (Figure 17.42). A guidewire is then



FIGURE 17.39 Arthroscopic view of the Herbert–Whipple jig being inserted through the 1-2 portal. The spike of the guide is placed at the junction of the scapholunate interosseous ligament and the proximal pole of the scaphoid.



FIGURE 17.40 Arthroscopic view of the scaphoid fracture from the radial midcarpal space with the Herbert–Whipple jig applied but not tensioned. The fracture gap remains open.

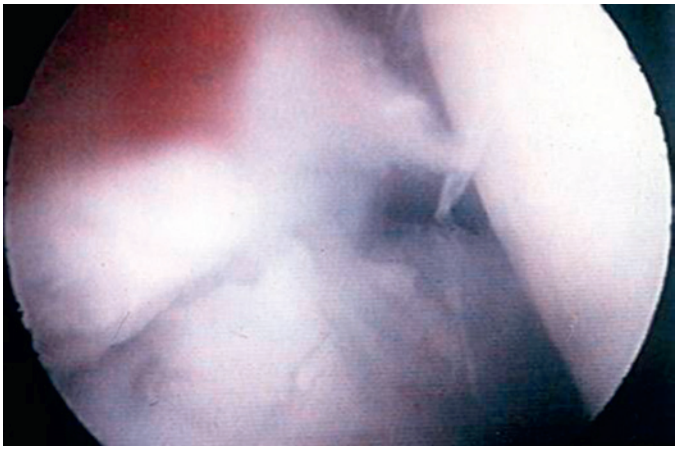

FIGURE 17.41 Arthroscopic view of the reduced fracture gap. In most incidences, with extension and radial deviation, the fracture can be manipulated in the tower to be anatomically reduced, and the jig is compressed to provide provisional stabilization.

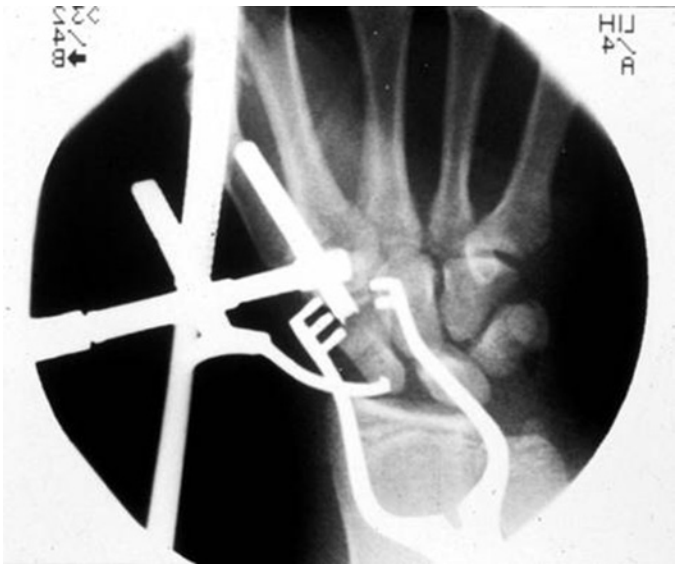

FIGURE 17.42 Fluoroscopic view showing ideal alignment of the scaphoid fracture with the Herbert–Whipple jig (Zimmer, Warsaw, IN) in place.

http://e-surg.com



FIGURE 17.43 Fluoroscopic view showing the Herbert–Whipple screw (Zimmer, Warsaw, IN) placed across the fracture site.

TABLE 17.2 Scaphoid Nonunion Classifications of Slade and Geissler

Type	Description
I	Delayed presentation at 4-12 weeks
II	Fibrous union, minimal fracture line
III	Minimal sclerosis <1 mm
IV	Cystic formation, 1-5 mm
V	Humpback deformity, >5 mm cystic change
VI	Wrist arthrosis

From Geissler WB, Slade JF: Fractures of the carpal bones. In Wolfe SW, Hotchkiss RN, Peterson WC, et al, editors: *Green's operative hand surgery,* vol 1, ed 6, Philadelphia, 2010, Elsevier, pp 639–707.

placed down the jig into the long axis of the scaphoid. It is then drilled from distal to proximal, measured, and the appropriate length Herbert–Whipple headless compression screw is placed (Zimmer, Warsaw, IN) (Figure 17.43).

Arthroscopic Reduction of Selected Scaphoid Nonunions

Geissler and Slade developed a classification of scaphoid nonunions based on the chronicity, degree of fracture sclerosis, and deformity (Table 17.2).[54] Utilizing this classification, the percutaneous arthroscopic-assisted dorsal fixation techniques developed for acute scaphoid fractures were effective in types I to III.[52] In addition, 15 patients with stable fibrous nonunions were treated with Slade et al's dorsal percutaneous technique[104] using a headless cannulated screw and no accessory bone graft. All patients' fractures healed in an average time of 3 months. Eight of the 15 patients had confirmed healing with CT evaluation. This technique avoided the morbidity of bone graft harvest from the iliac crest or distal radius.

In patients who have a type IV cystic scaphoid nonunion, Geissler described a technique for arthroscopic fixation with percutaneous demineralized bone matrix (DBM) putty insertion at the nonunion site. Utilizing this technique, the guidewire is placed arthroscopically as previously described. The scaphoid is then reamed with a cannulated reamer. A bone biopsy needle



FIGURE 17.44 In cases of scaphoid nonunion without a humpback deformity, the nonunion can be addressed either with percutaneous bone grafting or injection of putty (DBM) into the nonunion site. Here a bone biopsy needle is filled with putty and inserted over a guidewire directly into the scaphoid nonunion site.

is filled with DBM putty and placed directly over the wire into the cystic nonunion site of the scaphoid (Figure 17.44). The guidewire is then retracted distally but still remains in the distal pole of the scaphoid. The DBM putty is then injected through the bone biopsy needle directly into the central aspect of the scaphoid at the nonunion site that has been previously reamed. The guidewire is then advanced back through the bone biopsy needle from a volar-to-dorsal direction out the dorsum of the wrist following putty injection. In this manner, the guidewire passes through the original path of the proximal pole of the scaphoid and out the soft tissues. A headless cannulated screw is inserted over the wire across the scaphoid nonunion site. As before, both the radial carpal and midcarpal spaces are reevaluated arthroscopically to confirm position of the screw and reduction of the scaphoid nonunion.

Geissler reported his technique for 15 patients with cystic scaphoid nonunions without a humpback deformity.[53] Utilizing the technique, 14 of the 15 patients had their cystic scaphoid nonunions healed.

Transscaphoid Perilunate Fracture-Dislocations

Geissler recently described an all-arthroscopic technique for management of seven patients with transscaphoid perilunate dislocations (unpublished data) (Figure 17.45). With this technique, the wrist is initially arthroscopically evaluated to confirm a tear to the lunotriquetral interosseous ligament. Once confirmed, a SLIC screw (Acumed, Hillsboro, OR) is percutaneously inserted over a guidewire and stabilized across the lunotriquetral interval (Figure 17.46). The wrist is then suspended in a traction tower. The scaphoid is arthroscopically stabilized as previously described (Figures 17.47 through 17.50).

http://e-surg.com



FIGURE 17.45 Radiographic view of a transscaphoid perilunate dislocation.



FIGURE 17.46 The dislocation has been anatomically reduced. Following arthroscopic confirmation of a complete tear to the lunotriquetral interosseous ligament, a scapholunate-intercarpal-carpal screw (Acumed, Hillsboro, OR) is percutaneously placed across the lunotriquetral interval.



FIGURE 17.47 Fluoroscopic view following stabilization of the lunotriquetral interval. The wrist is arthroscopically evaluated and the exact location of the guidewire needle in the proximal pole of the scaphoid has been identified.

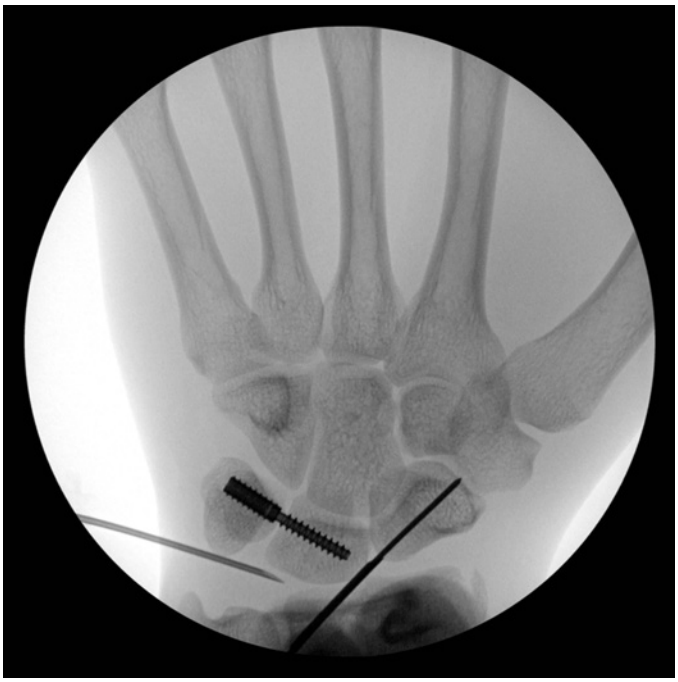

FIGURE 17.48 Fluoroscopic view showing ideal placement of the guidewire down the axis of the scaphoid.

At 3 months, all fractures had healed and the wrist flexion–extension arc ranged from 70 to 120 degrees. Five of the seven patients had no pain. Stabilization of perilunate dislocations without Kirschner wires allowed patients to participate in physical therapy at an earlier stage and resulted in a very functional range of motion at 3 months postoperatively.[55]

Fractures of the Distal Radius

Articular fractures of the distal radius are a unique subset of distal fractures.[70] The prognosis for these injuries depends on restoration of original length, articular inclination, and articular reduction both of the radial carpal and distal radial ulnar joint.[4,12,45,70,72,75,114,117,123] Arthroscopic-assisted fixation of intra-articular fractures allows for reduction of the joint surface under bright light and magnified conditions.[74,131] It allows for lavage of hematoma and multiple-joint debris and management of associated soft tissue injuries that may occur with these fractures.[43,83,97]

Arthroscopic-assisted fixation can be used for simple articular fractures that have large, well-defined fragments, including the radial styloid, volar and dorsal die punch, volar and dorsal

http://e-surg.com



FIGURE 17.49 Fluoroscopic view showing screw stabilization of the lunotriquetral interval and the scaphoid fracture with a headless cannulated screw. The transscaphoid perilunate dislocation has been completely stabilized by percutaneous and arthroscopic fixation. Without a buried or protruding Kirschner wire earlier range of motion can be initiated.



FIGURE 17.50 Lateral fluoroscopic view following arthroscopic stabilization of the transscaphoid perilunate dislocation.

Barton, and as an adjunct in the management of three- and four-part articular fractures with metaphyseal comminution.[49,134] It is well known that a fracture of the distal radius is a true wrist injury rather than a fracture alone and is associated with additional soft tissue injuries.[56,62,65,80,89] Both articular and nonarticular fractures of the distal radius have a high prevalence of associated soft tissue injuries of the triangular fibrocartilage complex as well as scapholunate and lunotriquetral interosseous ligaments.[50] These associated soft tissue injuries are easily seen arthroscopically and can be managed at the same sitting.



FIGURE 17.51 Fluoroscopic view of a displaced fracture of the radial styloid.

Operative Technique

Arthroscopic-assisted reduction and fixation of displaced unstable articular fractures of the distal radius should generally have surgery within 2 to 10 days from injury. A delay of at least 48 h helps to minimize bleeding from the fracture during the arthroscopy.[47] For fractures that are 10 days or older, it may sometimes be difficult to manipulate the fragments due to early healing. The operating room is set up so that both fluoroscopy and arthroscopy can be used simultaneously. The wrist is suspended with 10 lb of traction in a standard traction tower. The standard 3-4, 6-R, and 6-U portals are made. It is helpful to lavage the joint of fracture debris and hematoma prior to introduction of the arthroscope. This is done by placing the inflow through the 6-U portal and the arthroscopic cannula in the 3-4 portal. A shaver is brought in through the 6-R portal to remove any further fracture debris. A traditional diagnostic wrist arthroscopy is then performed (see Video 17.1).

Fractures of the radial styloid are ideal for arthroscopic management. Rotation is best judged by looking across the wrist from an ulnar portal. Under fluoroscopy, one or two guidewires are placed using oscillation mode into the tip of the radial styloid but not across the fracture site (Figures 17.51 and 17.52). Using the guidewires in the radial styloid fragment and a trocar placed in the 3-4 portal, the radial styloid fragment can be manipulated and anatomically reduced back to the radius (Figures 17.53 and 17.54). The guidewire is then advanced across the fracture site for provisional stabilization. Once the

http://e-surg.com

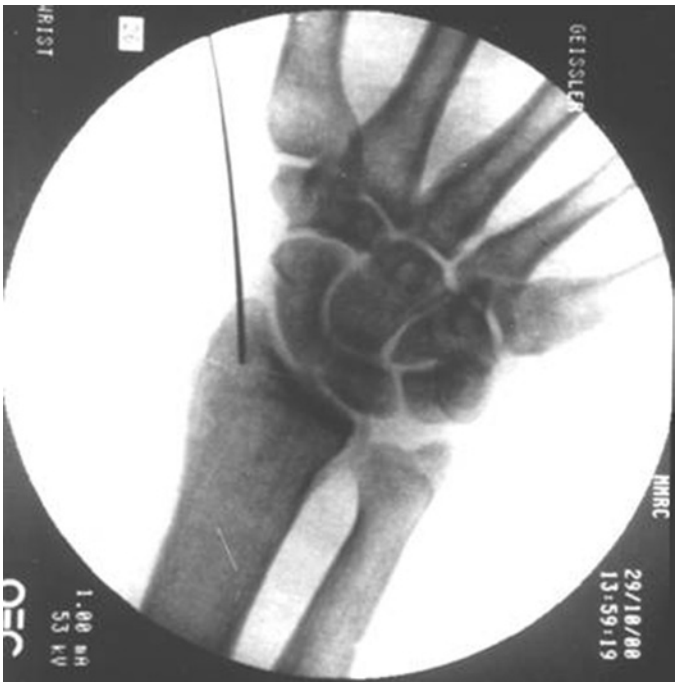

FIGURE 17.52 Fluoroscopic view of a guidewire placed into the radial styloid fragment. This can be used as a joystick to help reduce the fracture; it is not placed across the fracture site.

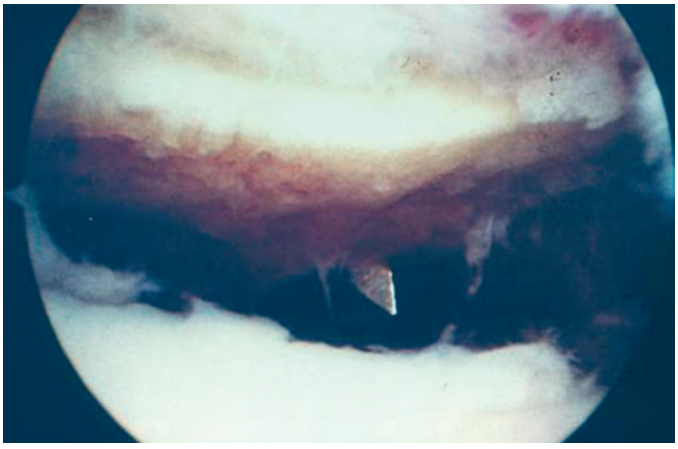

FIGURE 17.53 Arthroscopic view showing the guidewire in the radial styloid fragment. It is best to place the arthroscope in the 6-R portal to look across the wrist to judge rotation of the radial styloid fragment.

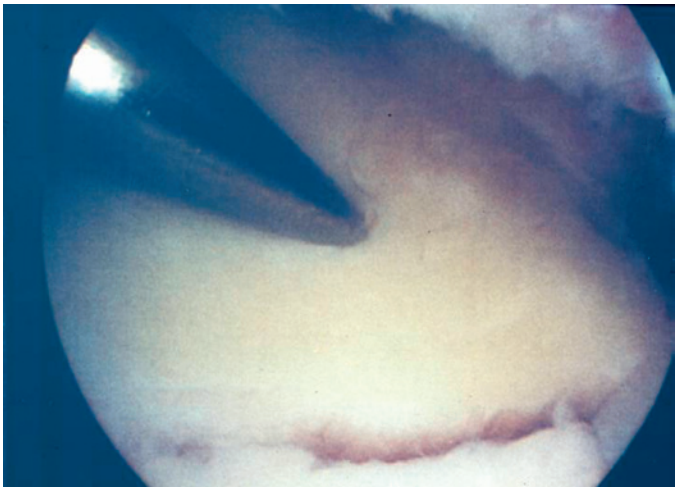

FIGURE 17.54 Arthroscopic view showing reduction of the radial styloid fragment with a combination of the guidewire joystick and a trocar inserted through the 3-4 portal to help control rotation and position of the fracture fragment.



FIGURE 17.55 Radiographic view showing anatomic restoration of the joint surface with stabilization of the radial styloid fracture with two headless cannulated screws.

fracture is judged to be anatomically reduced by arthroscopic and fluoroscopic confirmation, additional wires are placed across the fracture site. One or two headless cannulated screws are then placed into the radial styloid fragment (Figure 17.55). By utilizing headless screws, the implant is contained within the bone, which decreases soft tissue irritation and enables early mobilization.

In three-part articular fractures without metaphyseal comminution, the radial styloid fragment may be closed, reduced, and provisionally pinned under fluoroscopy (Figure 17.56). This will serve as a landmark to elevate the lunate facet. The wrist is then suspended in a traction tower and the articular surface is evaluated. A headless cannulated screw is placed in the radial styloid fragment as previously described. The lunate facet fragment is identified and a needle is placed over the fragment percutaneously. This is used as a fluoroscopic landmark. A Steinmann pin is placed approximately 2 cm proximal to the needle to percutaneously elevate the die punch fragment (Figure 17.57). The previously reduced radial styloid fragment is used as an arthroscopic landmark to ensure the lunate facet fragment is correctly reduced (Figure 17.58).

Once the fragment is elevated and judged to be anatomic, a guidewire is placed subchondrally transversely beneath the bone surface to stabilize the fragment, which is usually best seen

http://e-surg.com



FIGURE 17.56 In three-part fractures, the radial styloid is provisionally pinned and reduced. This can then be used as a landmark to help reduce the impacted lunate facet fragment.



FIGURE 17.57 Outside view demonstrating elevation of the impacted lunate facet with a large Steinmann pin as viewed with the arthroscope in the 3-4 portal.

with the arthroscope in the 3-4 portal (Figure 17.59). It is important to pronate and supinate the wrist to ensure the transverse guide pin does not violate the distal radial ulnar joint. An additional headless cannulated screw is then placed transversely over the guidewire to support the lunate facet fragment (Figure 17.60).

Usually the guidewire is aimed slightly dorsally because the fragment is generally a dorsal fragment. Following placement of the headless cannulated screw, the wrist is again pronated and supinated to make sure there is no violation of any hardware into the distal radial ulnar joint. Arthroscopic management of transradial perilunate fractures may be performed.

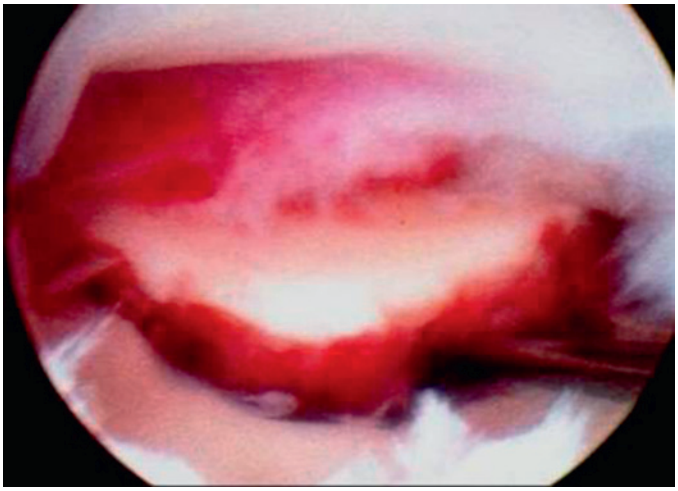

FIGURE 17.58 Arthroscopic view of a displaced three-part fracture to the distal radius.

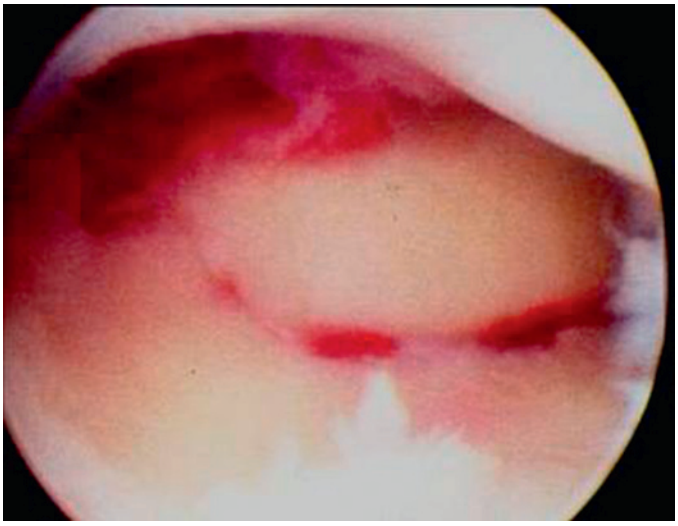

FIGURE 17.59 Arthroscopic view following reduction of the impacted lunate facet fragment with the arthroscope in the 3-4 portal.

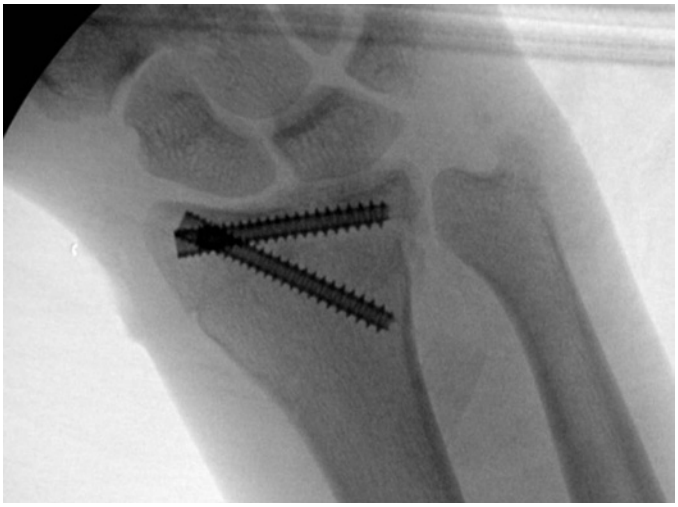

FIGURE 17.60 Fluoroscopic view showing anatomic restoration of the joint surface with two headless cannulated screws. One screw is placed perpendicular to the radial styloid fragment, and the second is placed transversely beneath the subchondral bone. Following placement of the screw, rotation of the forearm is performed to evaluate for any potential crepitus from a prominent screw.

http://e-surg.com



FIGURE 17.61 Fluoroscopic view demonstrating arthroscopic and percutaneous fixation of a greater arc transscaphoid perilunate dislocation. The displaced fracture of the distal radius and scaphoid are arthroscopically reduced. The fracture of the capitate was percutaneously reduced and stabilized with a headless cannulated screw, and a scapholunate-intercarpal-carpal screw (Acumed, Hillsboro, OR) was placed percutaneously across the lunotriquetral interval to stabilize a complete tear of the lunotriquetral interosseous ligament.



FIGURE 17.62 Radiographic view of a displaced articular fracture of the distal radius with metaphyseal comminution.

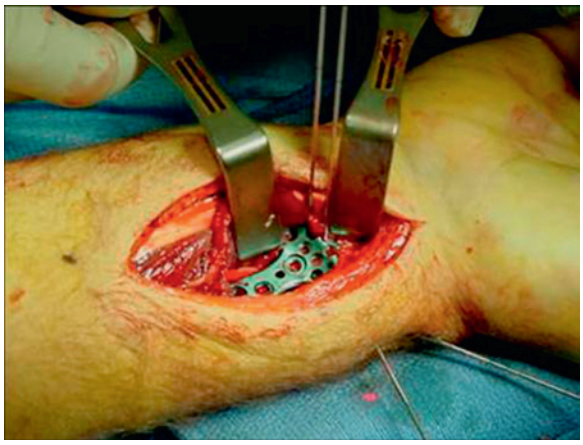

FIGURE 17.63 An Acu-loc (Acumed, Hillsboro, OR) is placed through a standard volar incision to stabilize the displaced fracture. Under fluoroscopic visualization, the articular reduction is provisionally stabilized.



FIGURE 17.64 Fluoroscopic view following volar placement of the distal radius plate with reduction to the articular surface. Under fluoroscopy, the articular reduction looks satisfactory.

In this example, all fractures were treated percutaneously or arthroscopically, thereby enabling early range of motion (Figure 17.61).

For patients who have metaphyseal comminution, simple cannulated screw fixation alone may not sufficiently stabilize the fracture (Figure 17.62). Wrist arthroscopy is used as an adjunct in the management of such fractures. A standard volar approach is made over the flexor carpi radialis tendon to the wrist if a volar plate is being used. The flexor carpi radialis tendon is retracted radially, the flexor pollicis longus is retracted ulnarly, and the pronator quadratus is released to expose the fracture site. The fracture is reduced under fluoroscopy and a volar plate is placed and attached proximally to the shaft. The plate is provisionally pinned distally to the fracture site (Figures 17.63 and 17.64). Following this, the wrist is suspended in a traction tower and the arthroscope is placed in the 3-4 portal. The joint is lavaged as before with inflow through the 6-U portal.

The fracture line is identified, and the distal screws are then placed in the plate if the fracture is anatomically reduced as

http://e-surg.com

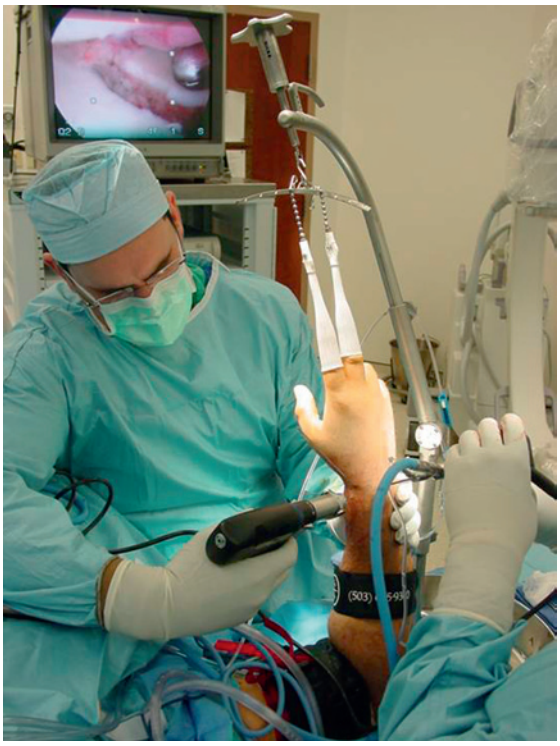

FIGURE 17.65 The wrist is then arthroscopically evaluated. Note at the monitor that despite the fracture looking anatomically reduced under fluoroscopy, there is still significant articular step-off. The pins are then backed off the fracture and the articular surface is anatomically reduced as viewed arthroscopically.

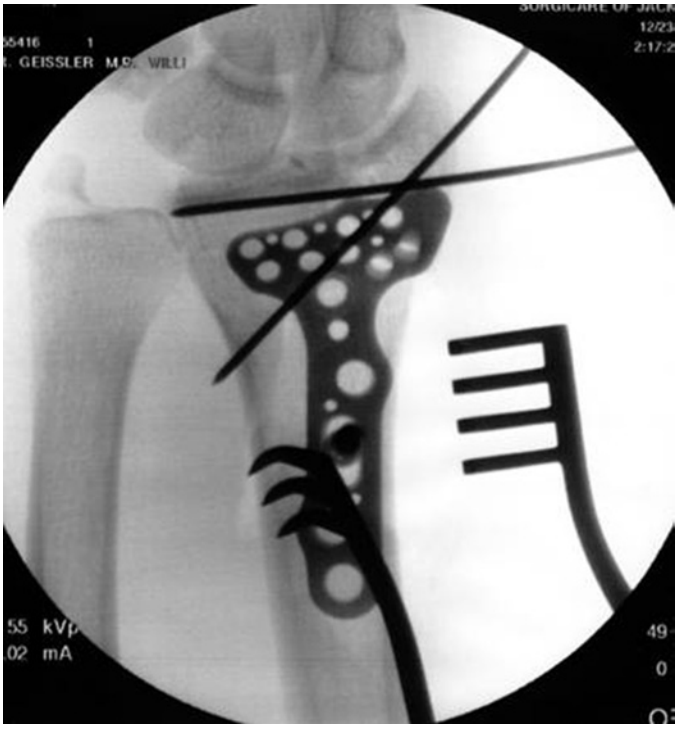

FIGURE 17.66 Fluoroscopic view showing anatomic restoration of the joint surface after being anatomically reduced as viewed arthroscopically.



FIGURE 17.67 Fluoroscopic view showing anatomic restoration of the joint surface with the volar plate in place.

viewed with the arthroscope. The provisional Kirschner wires are backed out of the plate if the fracture is not reduced and the fracture fragments are manipulated percutaneously (Figure 17.65). When the fracture is reduced, the Kirschner wires are replaced through the plate and then the distal locking screws are added (Figure 17.66). In this manner, arthroscopy is used as an adjunct to fine-tune the anatomic reduction and further define any associated soft tissue injuries that occur in these areas (Figure 17.67).

This technique is particularly helpful in four-part fractures, where the volar ulnar fragments are first reduced with the radial styloid to the radial shaft and provisionally stabilized by the plate. The wrist is then suspended in the traction tower and the dorsal ulnar fracture fragments can be percutaneously elevated and reduced to the volar fragment. Once anatomic reduction has been achieved, the distal locking screws are placed.

del Pinal et al. have recently advocated the advantages of dry arthroscopy in the management of distal radius fractures. They described the technique that was used for seven patients.[35]

TREATMENT OF TRIANGULAR FIBROCARTILAGE COMPLEX INJURIES

Injuries to the triangular fibrocartilage complex (TFCC) typically occur with extension and pronation of the axial loaded wrist. The most common mechanism of injury is a fall on an outstretched hand. Peripheral tears of the articular disk are common athletic injuries that involve racket sports or golf that requires rapid twisting and loading to the ulnar side of the wrist. Peripheral ulnar-sided tears of the articular disk are also common work injuries. Patients often describe a mechanism of traction or torqueing of the forearm that occurred when a motorized drill bit suddenly binds. The reader is referred to Chapter 14 for a complete discussion of the anatomy, kinematics, and classification of injuries of the TFCC.

http://e-surg.com

Patients with peripheral tears of the TFCC complain of deep diffuse pain across the ulnar side of the wrist. Frequently, they complain of weakness when gripping as well as a clicking sensation with rotation of the forearm. They complain particularly of pain with twisting of the wrist such as turning a doorknob or twisting the lid off a jar. Patients with a peripheral tear are point tender in the prestyloid recess. Patients who have a central tear of the articular disk frequently complain of pain over the distal aspect of the ulna. This pain can be accentuated by hyperpronation and supination of the wrist. Dorsal subluxation of the ulnar head in relation to the radius can be seen in foveal detachments.

Indications for surgical intervention include specific ulnar-sided wrist pain not relieved by conservative management for 3 months. An additional indication is for patients with symptomatic instability of the distal radial ulnar joint that is not relieved by immobilization.[60]

ARTHROSCOPIC MANAGEMENT OF TRAUMATIC INJURIES

Palmer Class IA tears (see Chapter 14) are perforations of the articular disk that are usually 1 to 2 mm wide and located approximately 2 to 3 mm just ulnar to its radial attachment to the sigmoid notch (Figure 17.68).[92] Arthroscopic débridement of the unstable flap of the tear is a preferred treatment in those patients whose symptoms do not resolve with temporary splinting and are ulnar neutral or minus. The arthroscope is placed in the 3-4 portal and a small banana blade is inserted through the 6-R portal. The unstable flap is outlined with a banana blade and a grasper is used to remove the fragment. The arthroscope is then transferred to the 6-R portal and a small punch is inserted through the 3-4 portal to débride the most ulnar aspect of the tear (Figure 17.69). A small joint shaver is then used to smooth the remaining portion of the articular disk. Approximately two-thirds of the articular disk can be excised without causing instability. An approximately 2-mm rim should be left intact to protect the volar and dorsal radial ulnar ligaments, which are important stabilizers of the distal radial ulnar joint (Figure 17.70).



FIGURE 17.69 View with the arthroscope in the 3-4 portal and a wrist arthroscopic punch in the 6-R portal débriding the unstable tear back to a stable surface.

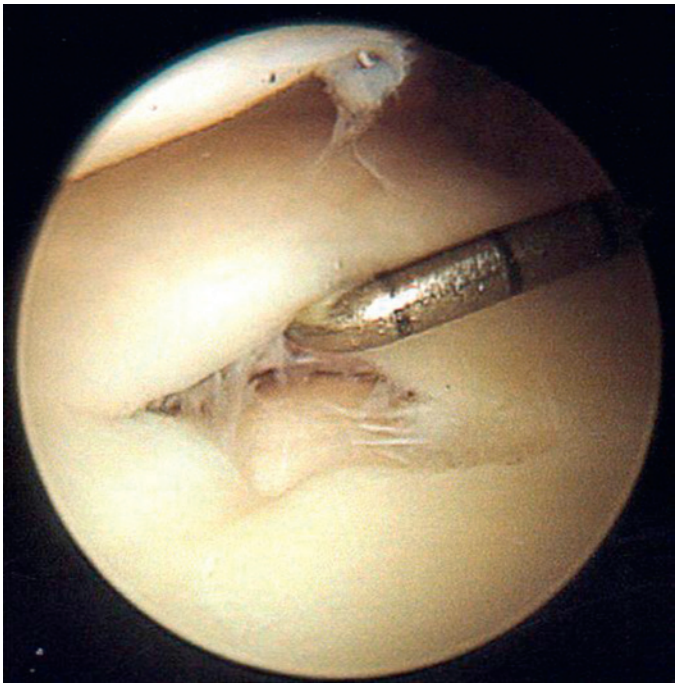

FIGURE 17.68 View with the arthroscope in the 3-4 portal demonstrating a Palmer type IA tear of the articular disk of the triangular fibrocartilage complex.

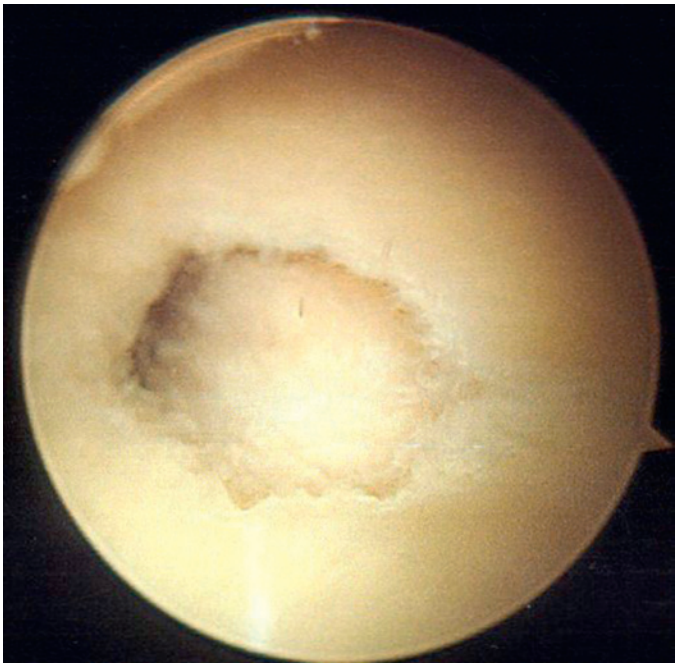

FIGURE 17.70 Arthroscopic view following débridement of the tear of the articular disk back to a stable surface. The ulnar head can be seen through the defect of the articular disk.

http://e-surg.com

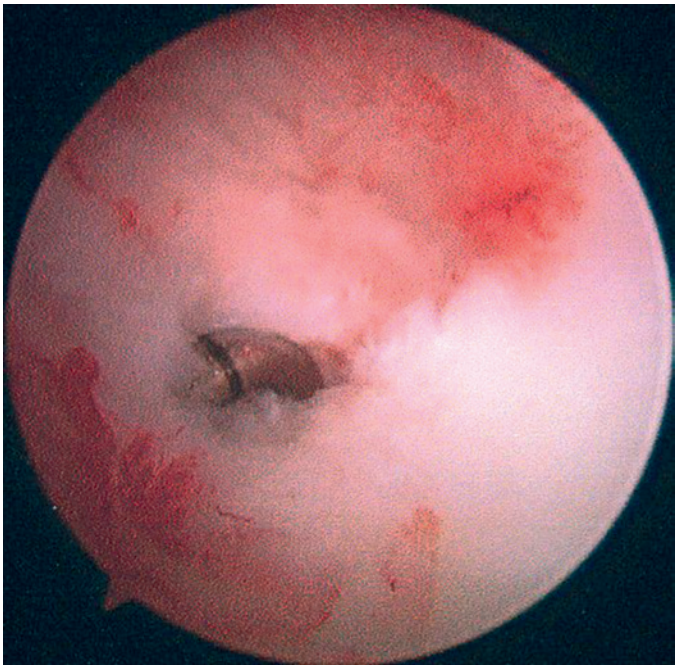

FIGURE 17.71 View with the arthroscope in the 3-4 portal demonstrating a peripheral tear of the articular disk (Palmer type IB).

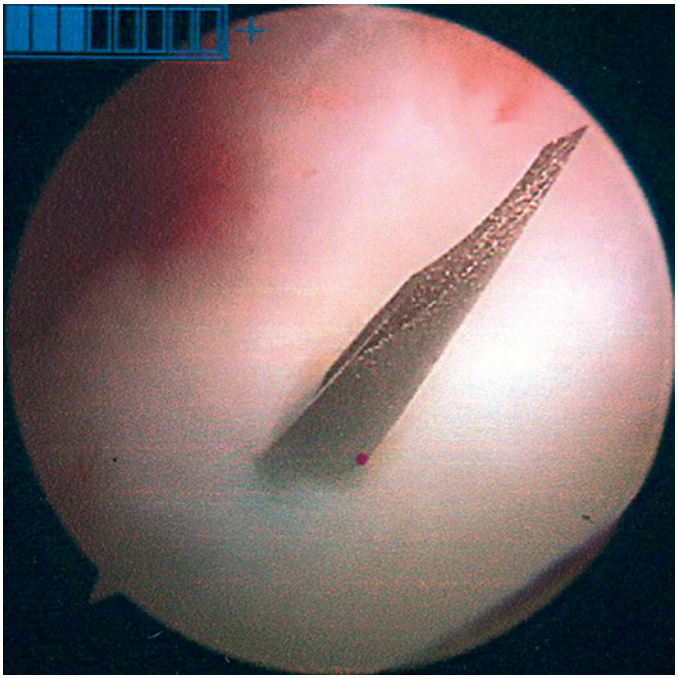

FIGURE 17.72 Arthroscopic view showing an 18-gauge needle being inserted through the floor of the extensor carpi ulnaris tendon sheath and perpendicular to the articular disk. It is imperative that the needle be placed as vertically as possible so that, as the suture is being inserted and tensioned, it will not shred through the articular disk.

Class IB injuries are traumatic avulsions of the triangular fibrocartilage complex from its insertion onto the distal ulna. These injuries usually are associated to some degree with instability to the distal radial ulnar joint. Several techniques for repair have been described in the literature.[3] These injuries are potentially reparable due to the blood supply.[13,112]

Whipple described an outside-in technique, wherein sutures are placed longitudinally to reattach the articular disk back to the floor of the tendon sheath of the extensor carpi ulnaris.[130] In this technique, the arthroscope is placed in the 3-4 portal and a peripheral tear is débrided with a small motorized shaver through the 6-R portal to help delineate the site of the tear and to facilitate revascularization (Figure 17.71). The 6-R portal is then elongated for approximately 1.5 cm and the retinaculum of the extensor carpi ulnaris tendon sheath is opened. The tendon is retracted ulnarly to expose the floor of the sheath of the ECU. An 18-gauge needle is then placed as vertically as possible to the floor of the sheath of the extensor carpi ulnaris to perforate the articular disk as viewed arthroscopically (Figure 17.72).

A 2.0-PDS suture is advanced through the needle into the radial carpal space (Figure 17.73). A suture retriever is then passed through the floor of the sheath of the extensor carpi ulnaris distal to the articular disk to retrieve the suture (Figures 17.74 and 17.75). Usually three sutures are placed, as described in the preceding, to close the tear (Figures 17.76 and 17.77). The wrist is taken out of traction and placed in slight supination and the sutures are tied. A sliding knot is very useful to tension the repair of the disk through such a small incision. It is vital to close the retinaculum of the ECU following the procedure. Corso et al. reported a high percentage of good-to-excellent results with this technique in a multicenter study.[29]

Ekman and Poehling described a Tuohy needle technique for repair of peripheral ulnar-sided tears to the articular disk.[39]

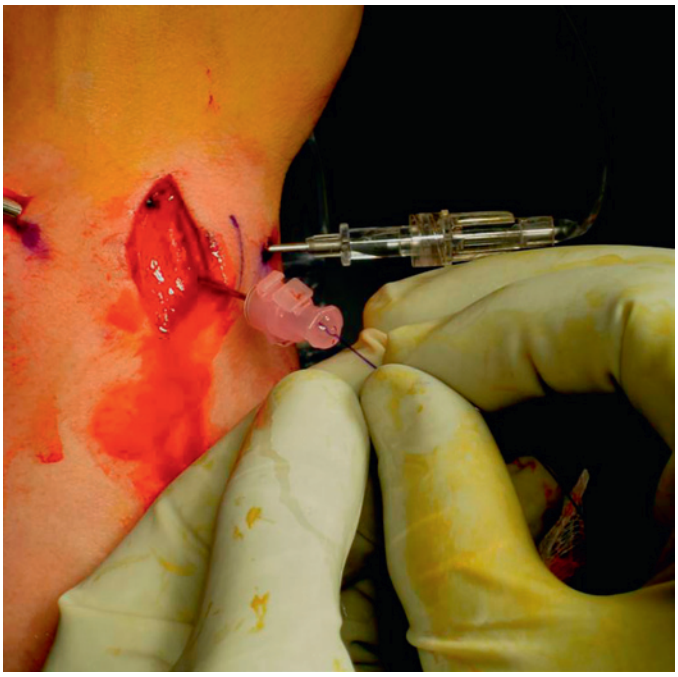

FIGURE 17.73 Outside view showing a monofilament suture being inserted through the needle.

With this technique, a 20-gauge anesthetic Tuohy needle is placed into the radial carpal space through either the 1-2 or 3-4 portal. The arthroscope is placed in the 4-5 portal. The Tuohy needle is passed across the wrist to the torn edge of the articular disk above the ulnar styloid process and advanced out of the

http://e-surg.com

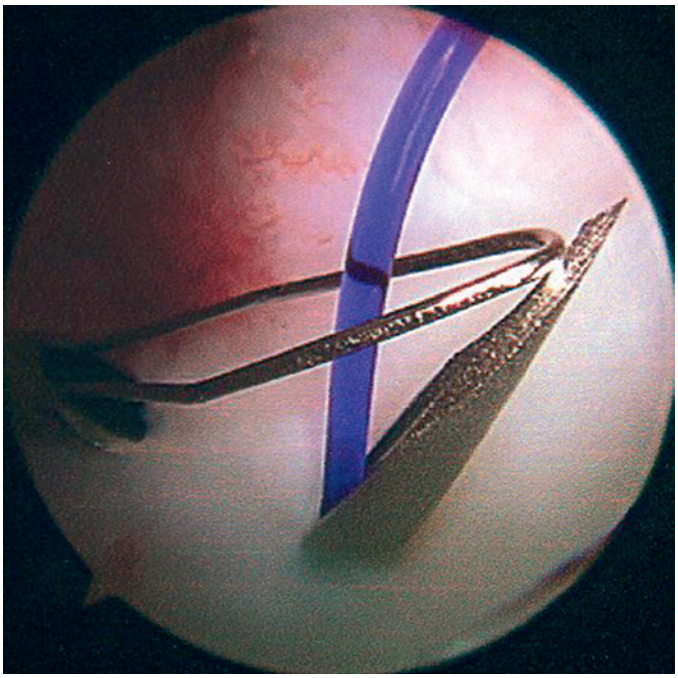

FIGURE 17.74 Arthroscopic view showing a suture grasper being inserted distal to the articular disk to grasp the monofilament suture as it is being inserted through the 18-gauge needle.

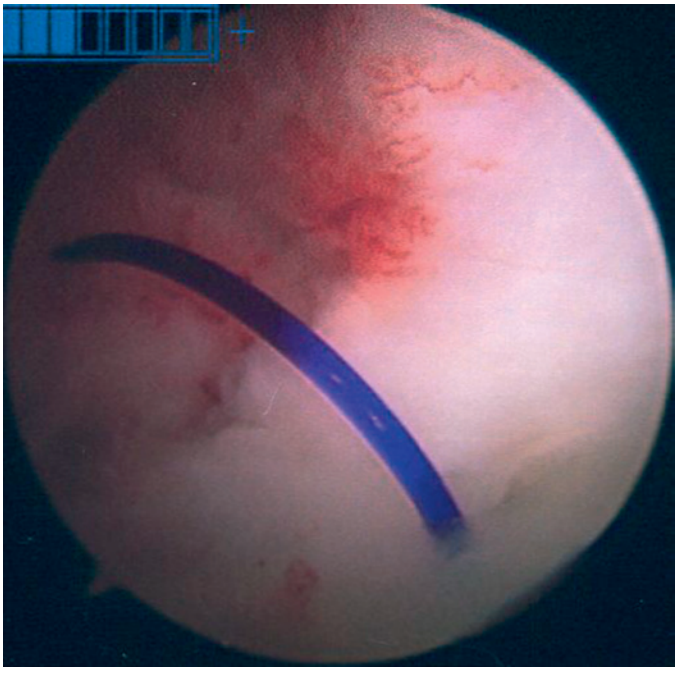

FIGURE 17.76 Arthroscopic view showing a monofilament suture placed across the peripheral tear in a vertical mattress suture.



FIGURE 17.75 Outside view demonstrating the suture grasper pulling the suture out of the joint to be tied on the floor of the sheath of the extensor carpi ulnaris tendon.

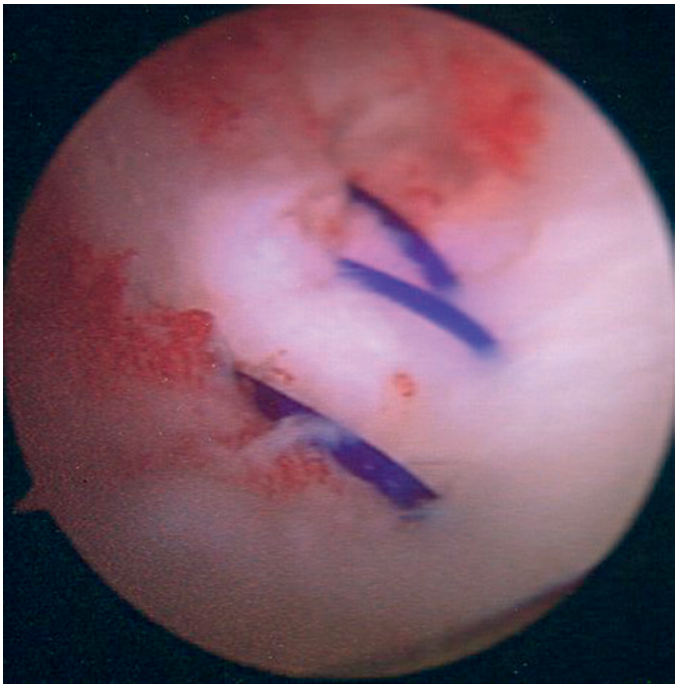

FIGURE 17.77 Arthroscopic view following placement of three monofilament sutures across the peripheral tear after being tied. Note the tensioning of the articular disk.

skin. A grasper may be helpful to direct the needle across the wrist and help perforate the articular disk.

A 2.0 absorbable suture is threaded through the entire needle and exits the skin. A hemostat is placed on the suture exiting the skin. The needle is retrieved back into the radial carpal space and repassed through the edge of the articular disk and advanced out the skin so a whole mattress suture is placed. The loop of suture that is exiting the needle is then pulled out the ulnar side of the wrist. This process may be repeated two or three times to form a horizontal mattress suture. Blunt dissection is then carried out where the sutures are tied onto the joint capsule. It is very important to ensure that branches of the dorsal sensory branch of the ulnar nerve are not entrapped beneath the sutures as they are tied down to the capsule.

http://e-surg.com

Geissler described an all-arthroscopic knotless technique for repair of peripheral ulnar-sided tears back to the ulna.[52] In this technique, the standard 3-4 and 6-R portals are made. An accessory 6-R portal is made approximately 1.5 cm distal to and in line with the 6-R portal. The accessory 6-R portal is made by using an 18-gauge needle inserted through the skin into the fovea at the base of the ulnar styloid (Figure 17.78). It is helpful if the wrist is flexed 20 to 30 degrees for easier access to the fovea. The accessory 6-R portal is enlarged with an 11 blade and blunt dissection is carried down with a hemostat to the capsule. A suture lasso is then inserted through the accessory 6-R portal into the radial carpal space. The curved suture lasso is then passed through the articular disk in a proximal-to-distal direction (Figures 17.79 and 17.80). It is helpful to gently twist the lasso with the thumb and index finger as it passes through the tough fibers of the articular disk.

The suture wire is then inserted through the lasso and retrieved through the 6-R portal with a crochet hook (Figure 17.81). A 2.0-fiber wire suture is then passed through the wire retriever and pulled out of the suture lasso distally through the handle (Figures 17.82 and 17.83). The suture lasso is then backed out of the articular disk and reinserted either anterior or posterior to the original perforation so that a horizontal mattress suture results (Figures 17.84 and 17.85). As the suture lasso passes through the articular disk for the second time, a loop of suture is formed; it will be retrieved through the 6-R portal with a suture retriever. At this stage, neither suture limb is exiting the 6-R portal (Figure 17.86).



FIGURE 17.78 Outside view demonstrating the accessory 6-R portal. Note that this portal is approximately 1.5 cm distal and in line with the standard 6-R portal.

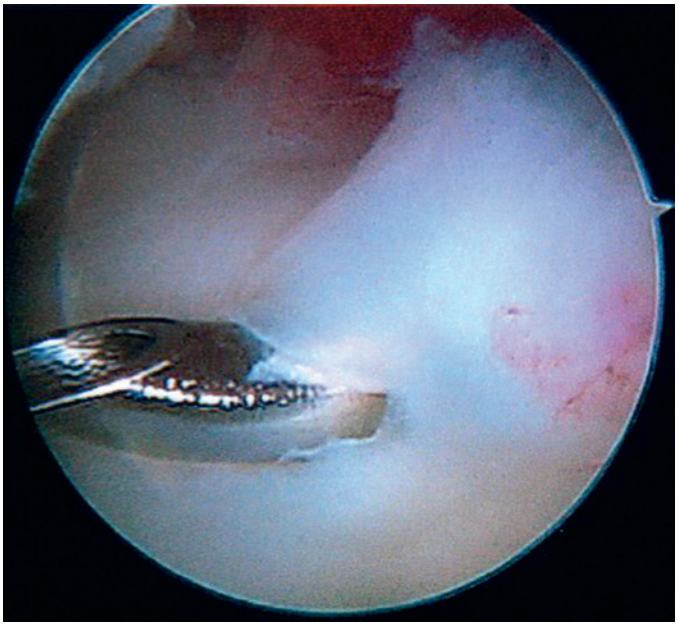

FIGURE 17.80 The suture lasso is then passed through the articular disk. It is helpful to gently twist the lasso between the thumb and index finger to allow it to penetrate through the articular disk.

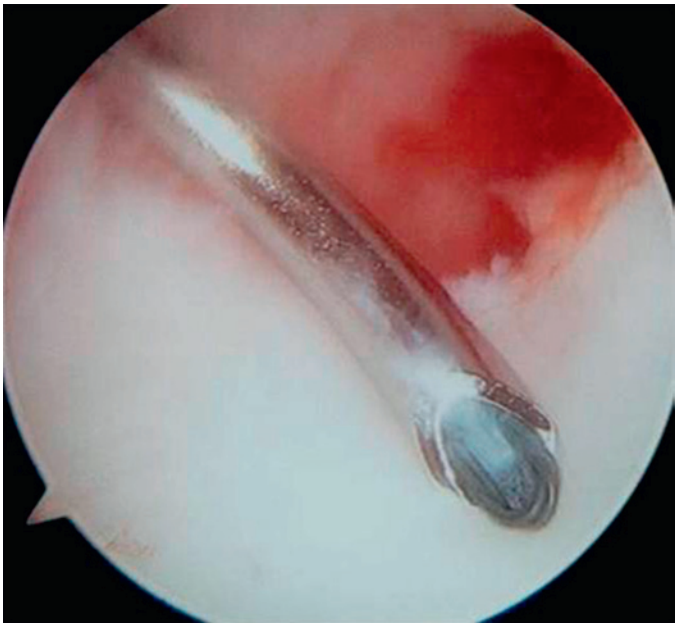

FIGURE 17.79 A suture lasso (Arthrex, Naples, FL) is inserted through the accessory 6-R portal.



FIGURE 17.81 A crochet hook (Arthrex, Naples, FL) is inserted through the standard 6-R portal to grab the lasso suture wire.

http://e-surg.com

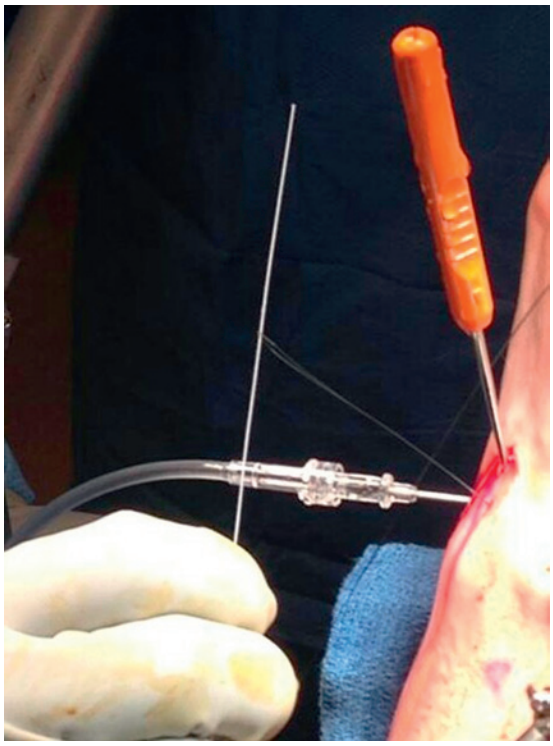

FIGURE 17.82 The suture wire is then pulled out of the standard 6-R portal. A 2.0-fiber wire suture (Arthrex, Naples, FL) is passed through the suture wire.



FIGURE 17.83 The suture wire is then used to pull the fiber wire suture out distally through the handle of the suture lasso.

A slotted cannula is then inserted through the accessory 6-R portal into the radial carpal space. Then a crochet hook is used to retrieve both sutures distally through the cannula in the accessory 6-R portal (Figure 17.87). The cannula is then advanced down directly onto the bone at the ulnar fovea and

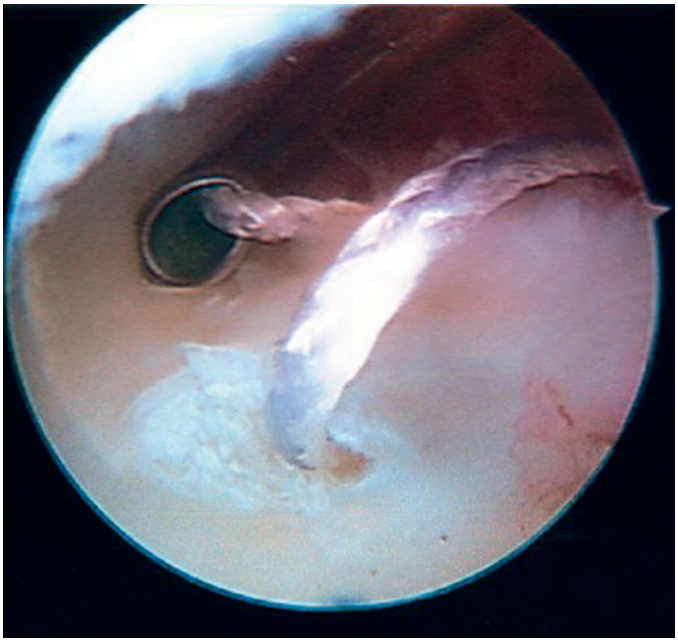

FIGURE 17.84 Arthroscopic view showing the suture lasso as it is about to be passed for the second time through the articular disk. It is important not to pull the suture lasso out of the joint following placement of the first suture to help eliminate any soft tissue bridge on the fiber wire suture.



FIGURE 17.85 Arthroscopic view showing the suture lasso (Arthrex, Naples, FL) piercing through the articular disk for the second time.

held in position. The two suture limbs are pulled out of the slot in the cannula so that they will not be twisted as the ulna is drilled (Figure 17.88). The drill is inserted through the cannula and the base of the ulna is drilled as the cannula is held firmly against the ulna bone (Figure 17.89). The two suture limbs are threaded through a suture anchor, and they are inserted down the cannula into the drill hole (Figure 17.90). The sutures are tensioned as the PushLock® is advanced into the ulnar head (Figures 17.91 and 17.92).

http://e-surg.com

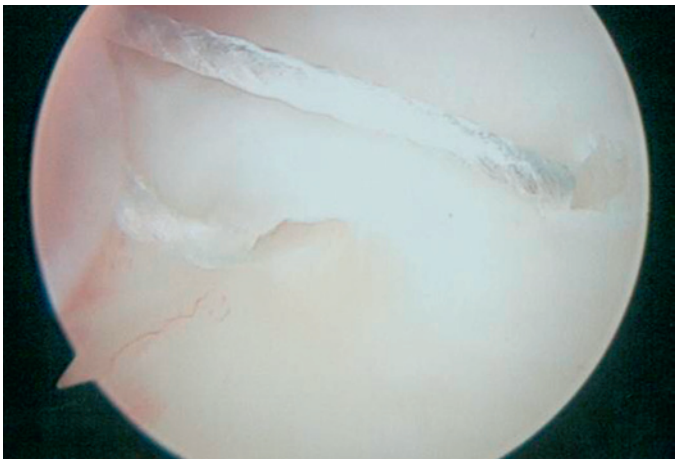

FIGURE 17.86 Arthroscopic view from the 3-4 portal showing a horizontal mattress suture of 2.0-fiber wire (Arthrex, Naples, FL) through the articular disk.

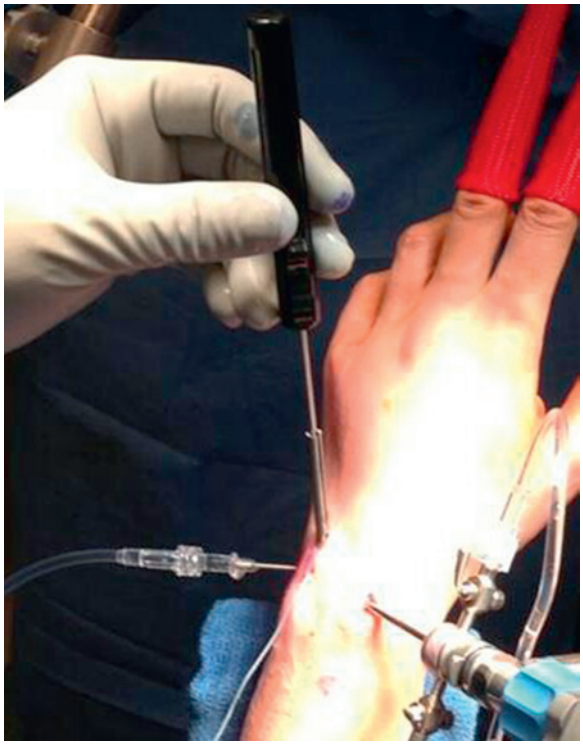

FIGURE 17.87 An outside view of a slotted cannula being passed through the accessory 6-R portal. A crochet hook is then used to pull the 2.0-fiber wire suture out through the cannula.



FIGURE 17.88 Outside view showing the 2.0-fiber wire being passed out distally through the slot of the cannula. The sutures are passed out of the slot so as the distal ulna is being drilled, they will not become twisted in the drill.



FIGURE 17.89 The cannula is now being held firmly against the ulnar fovea as it is being drilled. The drill is cannulated so that a guidewire can be placed and its position evaluated under fluoroscopy to confirm its location in the ulna fovea prior to drilling, based on the surgeon's preference.

After the anchor has been seated, moderate tension is applied to the handle to make sure the anchor and sutures cannot be pulled out. If there is resistance, the anchor has been inserted correctly into the bone. The tendency is for the anchor to slide off the volar aspect of the ulnar. If this occurs, the anchor will easily pull out with minimal tension on the handle and may be simply reinserted. When the correct anchor tension is confirmed, the suture ends are cut with a small up-biter and removed through the 6-R portal.

Postoperatively, the patient is immobilized in an above-elbow splint for approximately 4 weeks and then at week 3 a removable wrist brace is used. General wrist flexion–extension range-of-motion exercises start immediately. General pronation and supination exercises are initiated at week 4. At 7 weeks postoperatively, the patient is referred for a physical therapy program for grip strengthening and improved range of motion.

Class IC tears are rare and involve the distal attachment of the articular disk to the lunate and lunotriquetral ligaments (Figure 17.93). Complete tears of the ulnocarpal ligaments can result in ulnar carpal instability and/or translocation of the

http://e-surg.com

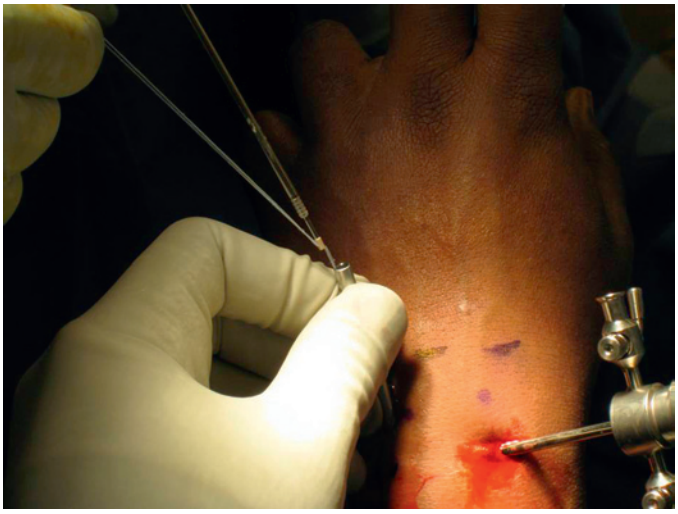

FIGURE 17.90 The suture is now being loaded into the mini-PushLock® anchor (Arthrex, Naples, FL) and then passed down the cannula.

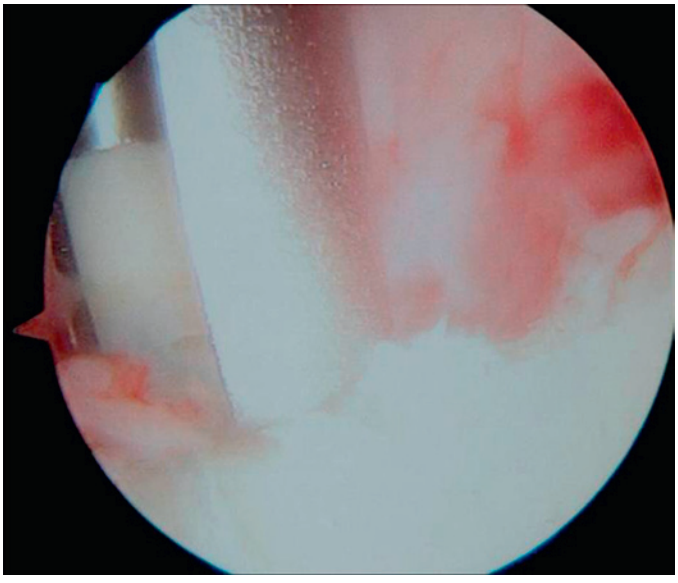

FIGURE 17.91 Arthroscopic view with the arthroscope in the 3-4 portal showing placement of the anchor down the cannula into the drilled hole.

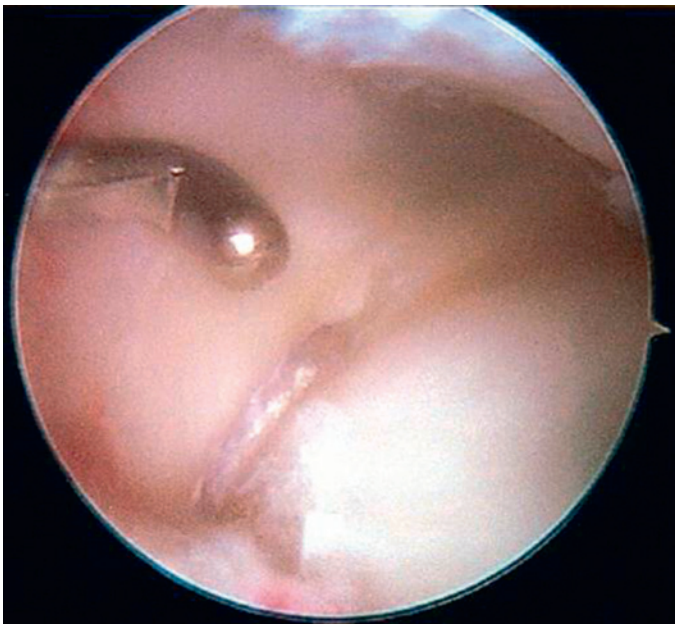

FIGURE 17.92 Arthroscopic view with the arthroscope in the 6-R portal showing repair of the peripheral tear of the articular disk back down to bone in an all arthroscopic knotless technique.

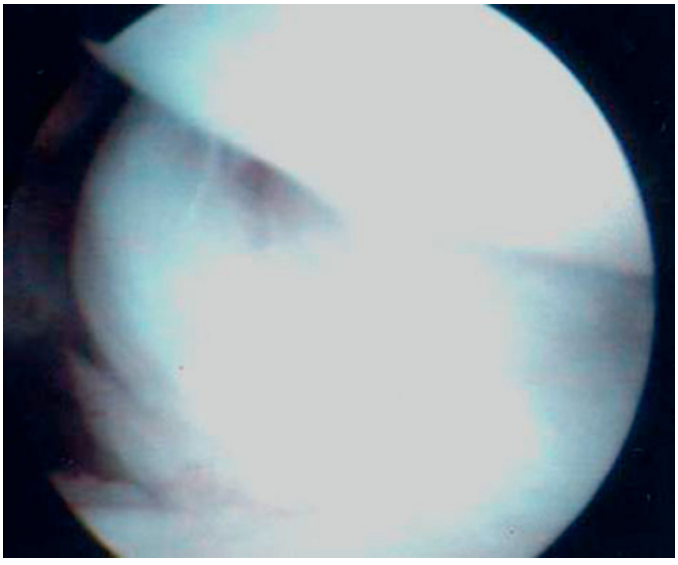

FIGURE 17.93 Arthroscopic view with the arthroscope in the 6-R portal demonstrating a distal tear of the ulnocarpal ligaments (Palmer type 1C).

ulnar carpus in relation to the radius. Patients complain of tenderness over the pisiform bone with locking and pain with grip exercises. Treatment recommendations include arthroscopic suture placement, as noted by Trumble, with good results (Figure 17.94).[115] Other options include simple débridement or electrothermal shrinkage which may restore tension back to the ulnar carpal ligaments (Figures 17.95 through 17.99).

Class ID lesions of the TFCC involve a traumatic avulsion of the articular disk from the attachment of the sigmoid notch of the distal radius and the volar and/or dorsal radial ulnar ligaments (see Figure 17-99). An ID tear may or may not be associated with a fracture of the distal radius involving the sigmoid notch. Patients may complain of diffuse tenderness along the ulnar side of the wrist.

In patients who have a traumatic avulsion, these fragments can be arthroscopically reduced and pinned.[41] Sagerman and Short suggested suture repair if the patient does not have an avulsion.[101] In this technique, a cannula is placed in the 6-U portal and the arthroscope is placed in the 3-4 portal (Figures 17.100 and 17.101). A 0.062 Kirschner wire is put through the cannula in the 6-U portal and pushed from the sigmoid notch across the radius to exit the midaxial radial border near the diaphyseal–metaphyseal flare. Care must be taken to avoid injury to the radial sensory nerve; it is advisable to make a counterincision at the exit point of the K-wire and retract/protect the nerve. Three parallel drill holes are created. Long meniscus repair needles are then inserted at the 6-U portal through the articular disk and into the drill holes

http://e-surg.com

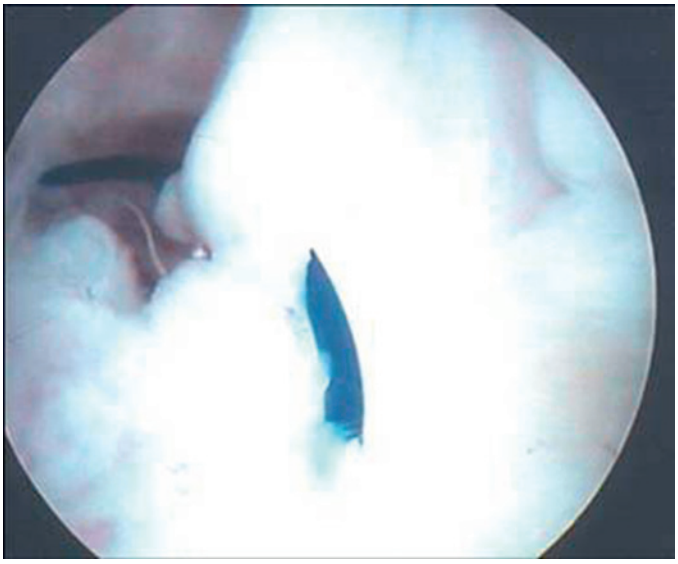

FIGURE 17.94 Arthroscopic view with the arthroscope in the 6-R portal showing placement of a suture through the articular disk and distally through the ulnocarpal ligament repairing the tear and restoring tension.

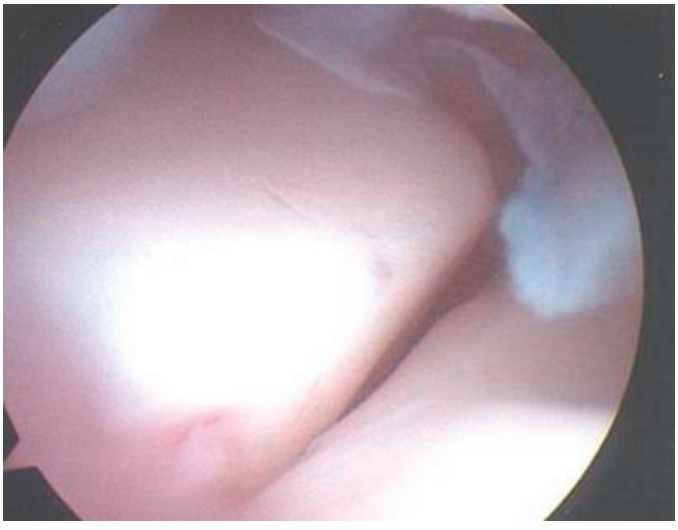

FIGURE 17.96 Arthroscopic view with the arthroscope in the ulnar midcarpal portal demonstrating instability to the lunotriquetral interval.

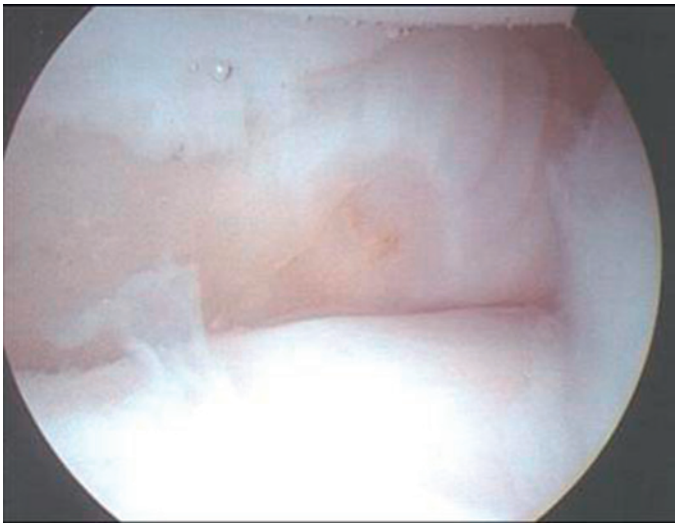

FIGURE 17.98 Arthroscopic view with the arthroscope in the 6-R portal following shrinkage of the ulnocarpal ligaments. Note the change in the apparent tension of the ligaments.

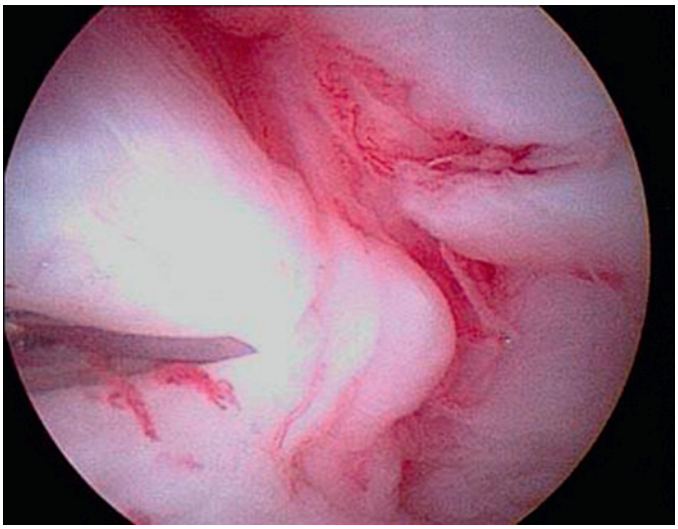

FIGURE 17.95 Arthroscopic view with the arthroscope in the 6-R portal demonstrating a tear and lack of tension to the ulnocarpal ligaments in a chronic Palmer type IC injury.

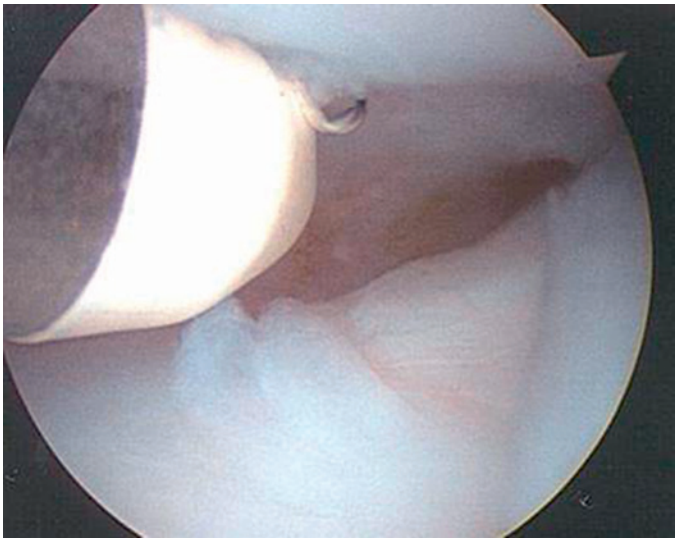

FIGURE 17.97 Arthroscopic view with the arthroscope in the 3-4 portal during thermal shrinkage to the ulnocarpal ligament.

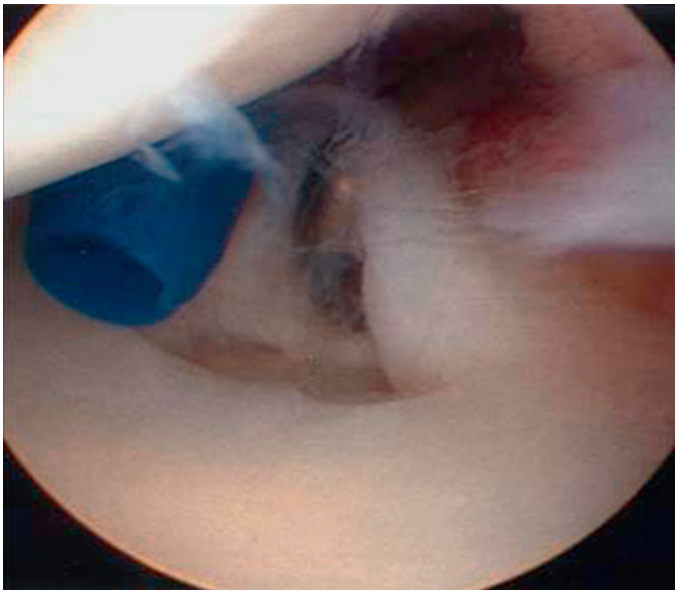

FIGURE 17.99 Arthroscopic view with the arthroscope in the 3-4 portal demonstrating a Palmer type 1D tear of the articular disk. This tear involved the volar radioulnar ligament.

http://e-surg.com

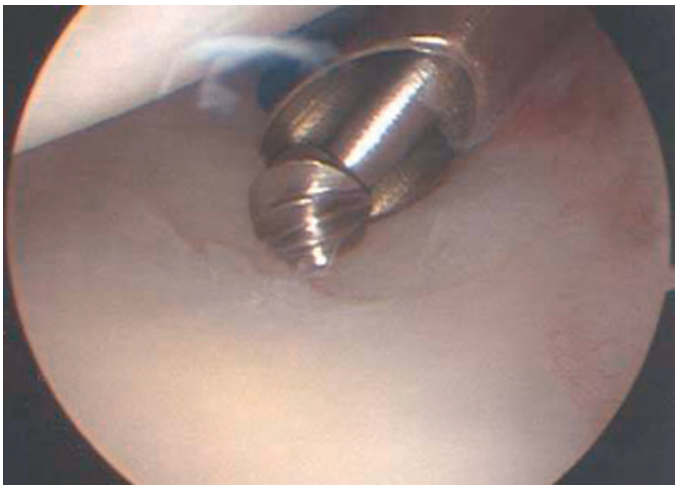

FIGURE 17.100 Arthroscopic burring of the sigmoid notch of the distal radius. Similar to a rotator cuff tear, the distal radius is lightly burred to subchondral bone to facilitate revascularization for the articular disk repair.



FIGURE 17.101 Arthroscopic view with the arthroscope in the 6-R portal following burring of the S notch. Note that just a minimal amount of bone is removed with this technique. If too much bone is taken, then the articular disk will not stretch to bone.

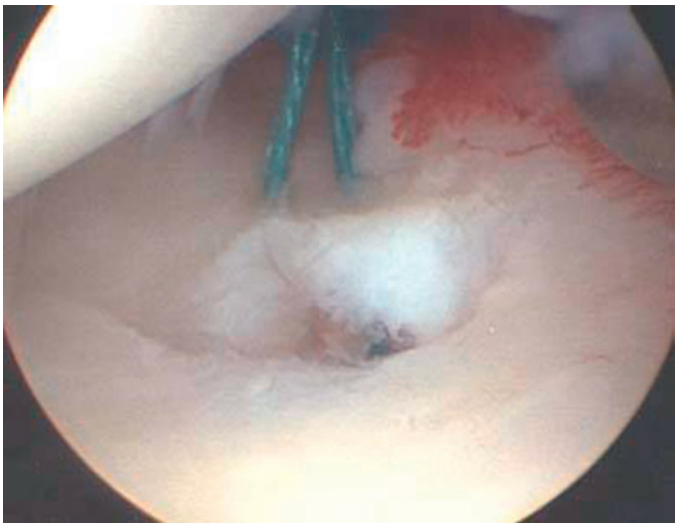

FIGURE 17.102 Arthroscopic view with the arthroscope in the 3-4 portal showing placement of a braided horizontal mattress suture through the articular disk for repair to the radius. Long meniscus needles have been placed through the articular disk and through transradial drill holes.

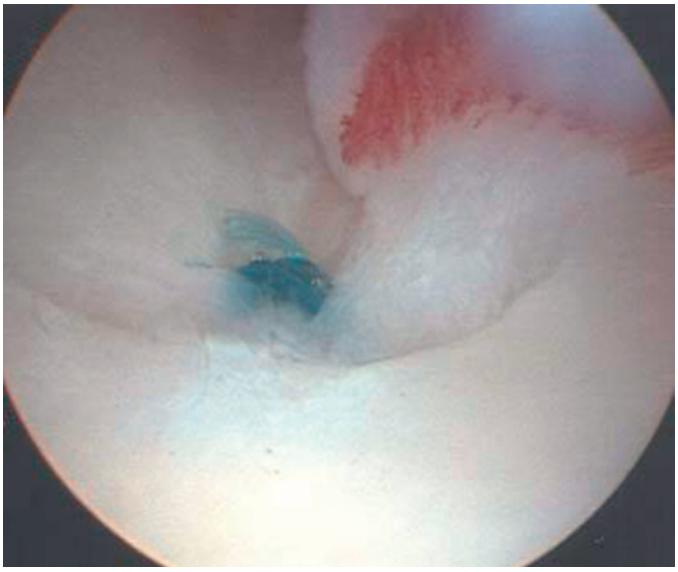

FIGURE 17.103 Arthroscopic view following placement of the meniscus needles through the distal radius as the suture is being tied. Note restoration of the tension of the volar radioulnar ligament.

(Figure 17.102). A grasper is helpful in terms of the 6-R portal to invert the disk to help with passage of the meniscus repair needle. Two stitches of a 2.0 Ethibond suture are placed horizontally in mattress fashion (Figures 17.103 and 17.104). Sutures are retrieved and tied to bone through the radial incision.

Recently, Corrella et al described a technique for all-arthroscopic knotless repair of radial-sided TFCC tears (Figure 17.105).[28] It requires use of the 3-4, 4-5, and 6-R portals. This technique requires one visualization portal (3-4) and two working portals (4-5 and 6-R). The 70-degree TFC suture lasso (Arthrex, Naples, FL) is inserted through the 6-R portal (Figure 17.106). The tip is situated just above the articular disk, and it penetrates from distally to proximally, coming out underneath the tear. It is sometimes helpful to insert a probe through the 3-4 portal to make counterpressure from the inferior side. The suture lasso is then loaded with a fiber stick suture (Arthrex, Naples, FL), which is a 2.0-fiber wire suture with a more rigid end to facilitate insertion in the passer. It is recovered with a minisuture hook (Arthrex, Naples, FL) or with a grasper through the 4-5 portal (Figure 17.107). The suture is retrieved through the 4-5 portal.

Following this, the suture lasso is withdrawn and is reinserted a few millimeters from the first point in a distal-to-proximal direction. The loop of the suture from the suture lasso is then retrieved through the 4-5 portal, leaving a vertical mattress-type suture (Figure 17.108). The suture lasso is withdrawn and a slotted cannula with an operator (TFC instrument kit, Arthrex, Naples, FL) is inserted through the 6-R portal (Figure 17.109). The operator is withdrawn from the cannula

http://e-surg.com

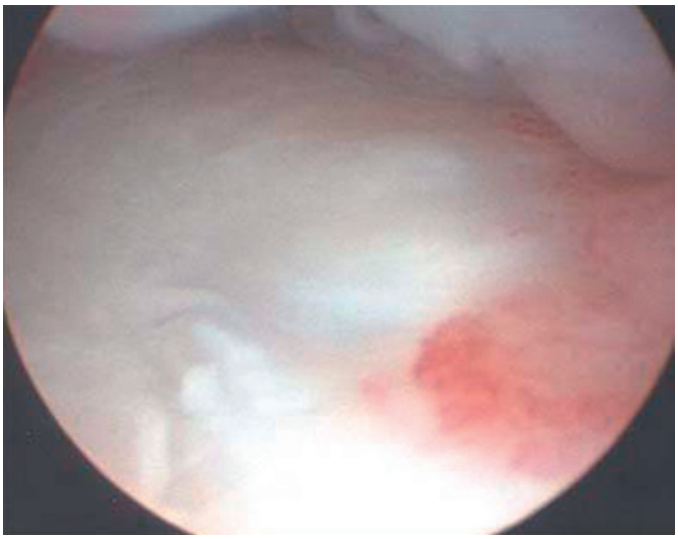

FIGURE 17.104 Arthroscopic view 2 years following repair of the articular disk. This demonstrates healing of the articular disk back to bone. In this case, the patient complained of pain over the screw where the suture was tied, so the screw was removed. This gave the opportunity to arthroscopically review the repair.

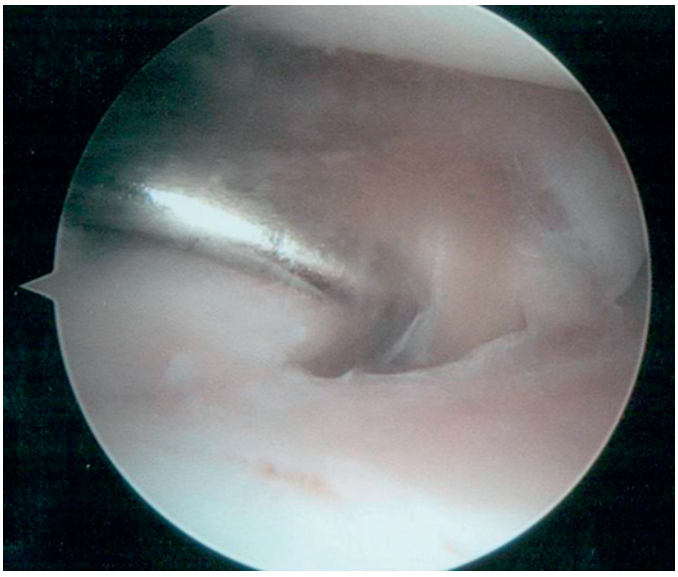

FIGURE 17.105 Arthroscopic view demonstrating a Palmer type 1D tear with instability of the distal radioulnar joint.

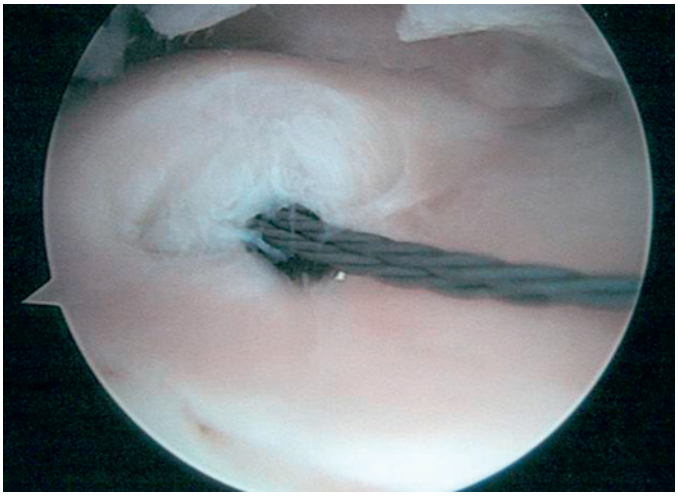

FIGURE 17.106 Arthroscopic view with the arthroscope in the 3-4 portal showing passage of the suture lasso through the 6-R portal.

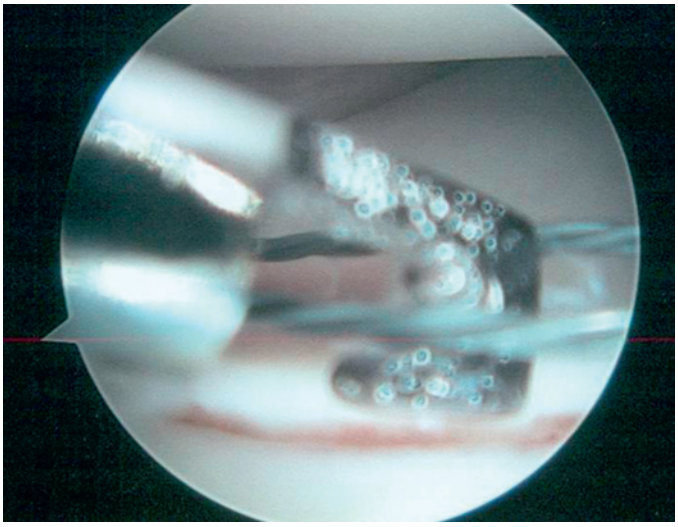

FIGURE 17.107 Arthroscopic view with the arthroscope in the 3-4 portal showing grasping of the suture wire with a crochet hook in the 4-5 portal.

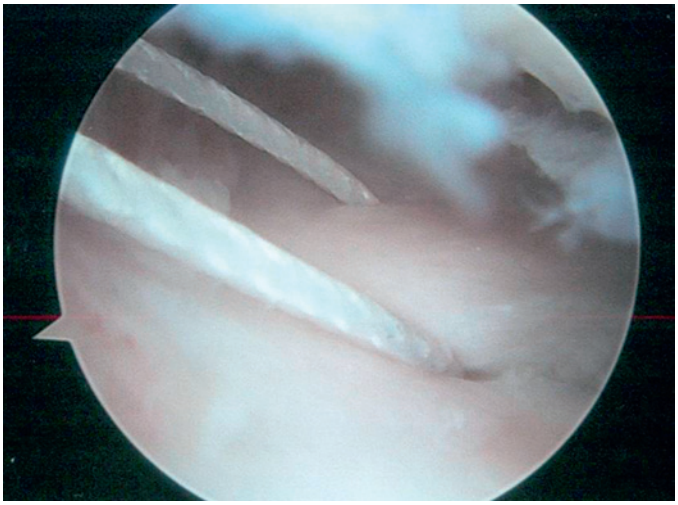

FIGURE 17.108 Arthroscopic view following placement of a 2.0-fiber wire (Arthrex, Naples, FL) stitch passed through the articular disk.

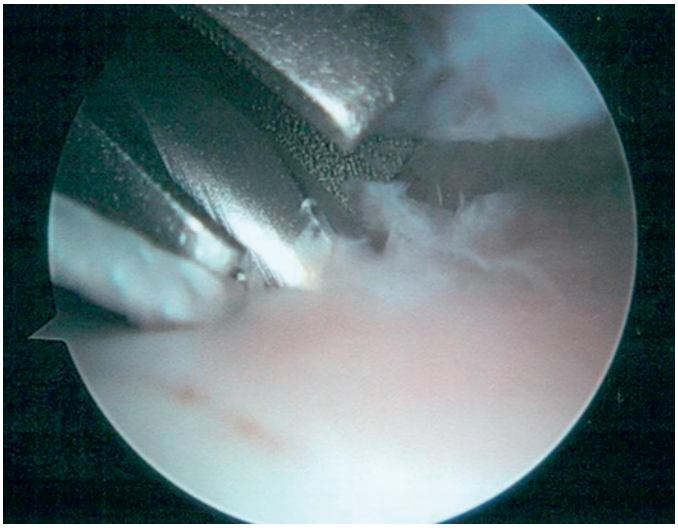

FIGURE 17.109 Arthroscopic view with the arthroscope in the 3-4 portal showing drilling of the distal radius with the cannula inserted through the 6-R portal.

http://e-surg.com

and a minisuture hook is used to transfer the two sutures from the 4-5 portal to the 6-R portal. The sutures are passed outside the cannula through the slot so that drilling will not affect the sutures.

Through the obturator in the cannula, a guidewire can be placed to help confirm the ideal position of the eventual anchor. A cannulated drill is then used over the guidewire to drill the hole for the suture anchor (Figure 17.110). The 2.0-fiber wire suture is then inserted into a 2.5-mm PushLock anchor (Arthrex, Naples, FL), and the anchor is then inserted through the drill hole. Tension on the sutures can be performed by pulling the suture and holding the PushLock anchor in place. The anchor should be advanced until flush with the bone, locking the anchor and suture into the predrilled hole. The suture is cut and tension on repair of the articular disk is verified with a probe (Figure 17.111).

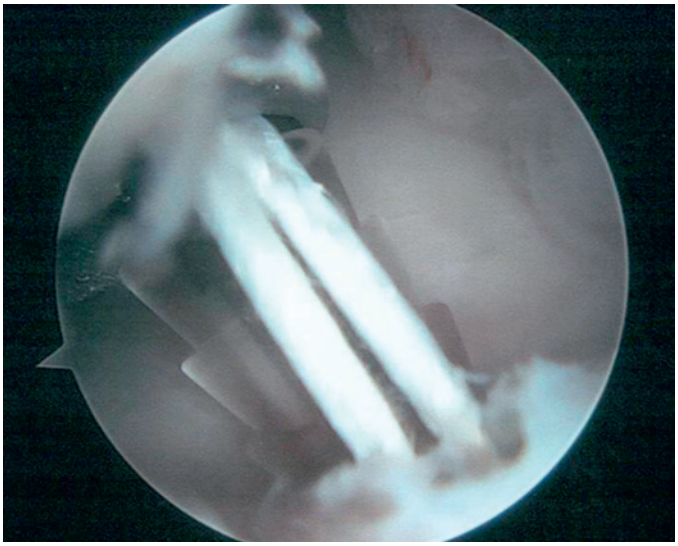

FIGURE 17.110 Arthroscopic view showing the mini-PushLock anchor (Arthrex, Naples, FL) being inserted through the 6-R portal repairing the articular disk back to the distal radius.

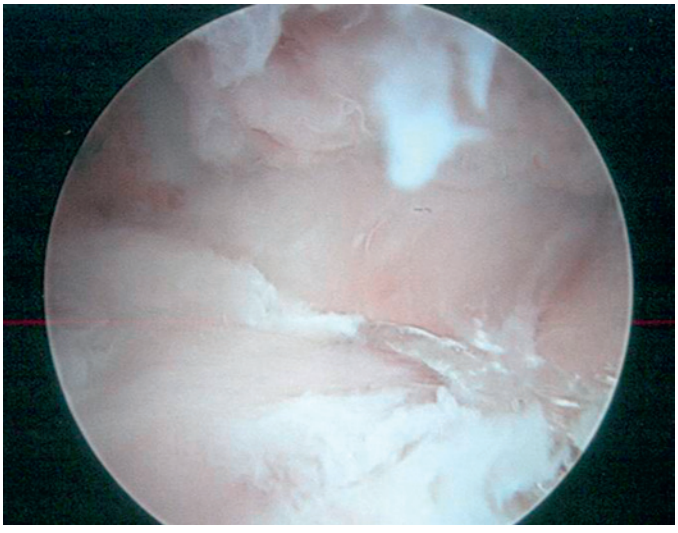

FIGURE 17.111 Arthroscopic view with the arthroscope in the 3-4 portal demonstrating repair of the Palmer type 1D tear back to the distal radius with an all-arthroscopic knotless technique.

DEGENERATIVE LESIONS CLASS II

Palmer class II lesions are degenerative lesions on the ulnar side of the wrist involving the TFCC (see Chapter 14). If a tear of the articular disk is present, it is usually circular as opposed to the typical traumatic longitudinal tear of an acute injury. The patient may also have chondromalacia of both the lunate and the ulna. The final stage includes disruption of the lunotriquetral interosseous ligaments. It is important to remember that in class II lesions, the prominent pathology is not the articular disk but the relatively long ulna, and ulna-shortening osteotomy is usually recommended. For patients who have a class IIA or IIB lesion when there is no perforation of the articular disk, an ulnar-shortening osteotomy is performed.[67,89,116] For patients who have a class IIC lesion, a perforation of the articular disk is present. In this instance, the surgeon has the option of an arthroscopic débridement of the ulnar head by working through the central tear of the articular disk.

Arthroscopic Wafer Resection of the Ulnar Head

The arthroscope is inserted in the 3-4 portal and a bur is placed in the 6-R portal. The head of the ulna is resected through the defect in the articular disk (Figure 17.112). The wrist is pronated and supinated to gain access to the peripheral margins of the ulnar head. In addition, the bur can be placed in a separate portal proximal to the articular disk to improve access to the ulnar head. Under normal conditions, approximately 3 to 4 mm of bone is resected. Fluoroscopy is strongly encouraged to monitor the amount of resection because arthroscopic magnification makes it difficult to judge the amount of bone that has been removed. Care should be taken not to take too much articular cartilage from the distal radial ulnar joint. When this happens, patients may have prolonged pain with forearm rotation.

The wafer procedure was first presented as an alternative to ulnar-shortening osteotomy by Feldon et al.[40] The wafer procedure was intended to resect the distalmost aspect of the ulnar head, while still preserving the attachments of the ulnar carpal

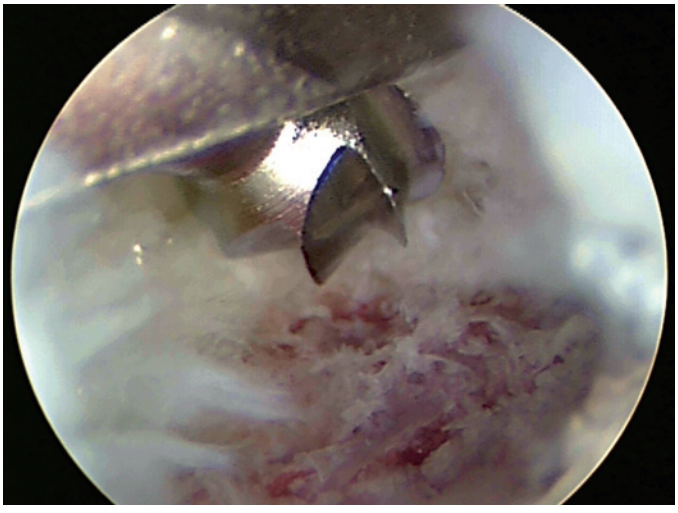

FIGURE 17.112 Arthroscopic wafer resection. The adequacy of the wafer resection of the ulnar head is viewed from the 6-U portal with the bur in the 4-5 portal.

http://e-surg.com

ligaments in the TFCC's horizontal portion. By limiting the resection to 2 to 4 mm, the DRUJ is left relatively undisturbed. It has been shown that by shortening the ulnar head by 3 mm, the force transmitted across the ulna is decreased by 50%.[34,133]

Bernstein et al., in a retrospective comparative study, found that combined arthroscopic TFCC débridement and the arthroscopic wafer procedure provided similar pain relief and restorative function with fewer procedures compared to arthroscopic débridement of a torn TFC and ulnar-shortening osteotomy.[17] However, in this author's opinion, patients who have an arthroscopic wafer procedure have lingering discomfort with pronation and supination compared to open ulnar-shortening osteotomy.

In class IID lesions, there is instability to the lunotriquetral interval. An open ulnar-shortening osteotomy is recommended because traction on the ulnar carpal ligaments helps reduce instability to the lunotriquetral interval. In class IIE lesions, there are frank arthritic changes involving the distal radial ulnar joint, and treatment must address the arthritis in addition to any component of ulnar impaction.

ARTHROSCOPIC GANGLIONECTOMY

Arthroscopic excision of dorsal ganglions was popularized by Osterman and Rafael, who reported excellent initial results.[90] Open excision of dorsal ganglions is not a benign procedure, and patients occasionally complain of wrist stiffness during flexion. The arthroscopic procedure can be performed with less scarring and more rapid return of wrist flexion, compared to an open procedure.[51] Rate of recurrence is low and comparable to open procedures.[5]

Surgical Technique: Arthroscopic Ganglion Excision

The arthroscope is initially placed in the 4-5 or 6-R portal with inflow provided through a needle in the 6-U portal. A needle is then placed through the sac of the ganglion, usually located distal to the site of the 3-4 portal, into the radial carpal space. Because of this, the needle must be placed more obliquely into the joint to pass through the ganglion and into the radial carpal space. The needle typically enters the joint over the dorsal capsule at the level of the scapholunate interosseous ligament. A skin portal is made once ideal placement of the needle has been confirmed arthroscopically. A small joint shaver is then placed through the portal and into the joint (Figure 17.113). An approximately 1-cm full thickness defect in the capsule is then made. The capsular defect is typically at the junction of the dorsal capsule with the scapholunate interosseous ligament. Sometimes the stalk of the ganglion cyst can be identified and removed with débridement. A dorsal extensor tendon must be seen following removal of the capsule to ensure a full thickness defect and débridement of the capsule has been performed (Figure 17.114).

Palpation of the ganglion cyst as the capsule is being resected usually demonstrates a sudden blush because the cyst and stock have been débrided. A small joint punch can also be used to further débride the joint capsule. It is difficult but not impossible to injure the extensor tendons; small joint shavers and punches are minimally aggressive. The technique is particularly useful when a single-lobed ganglion is centered in the typical location on the dorsum of the wrist. Usually minimal formal therapy is required. The patient is encouraged to begin range-of-motion exercises the following day.

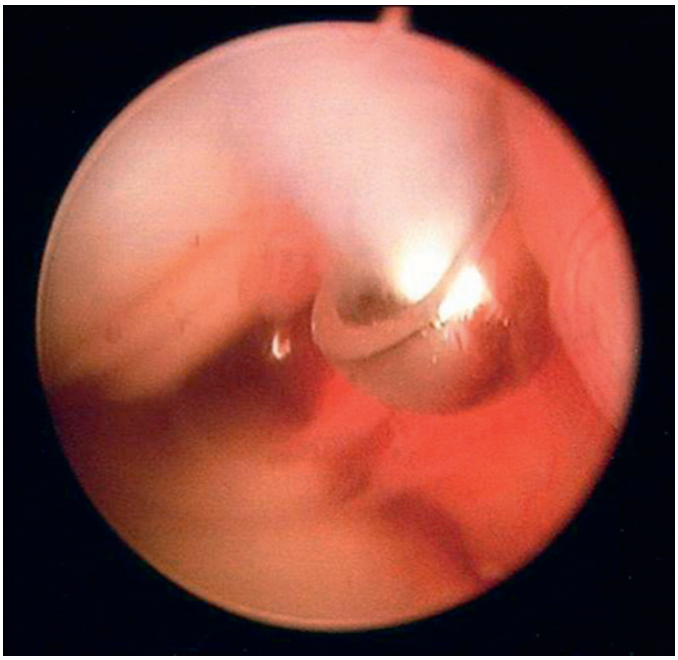

FIGURE 17.113 Arthroscopic view with the arthroscope in the 6-R portal demonstrating the shaver inserted through the sac of the ganglion with resection of the dorsal capsule.

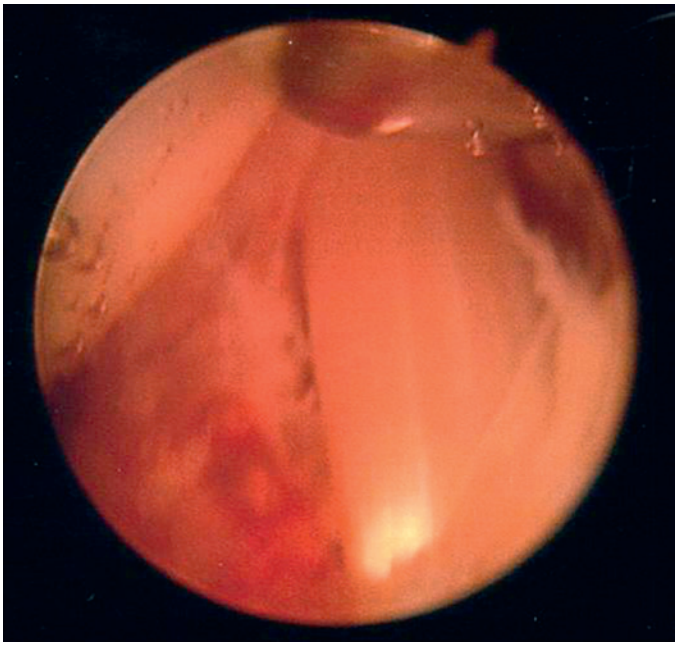

FIGURE 17.114 Arthroscopic view with the arthroscope in the 6-R portal demonstrating a full thickness defect of the capsule and exposure of the extensor tendons.

Volar wrist ganglions are the second most common mass in the wrist and arise from a pedicle that originates in either the volar scapholunate joint, the scaphotrapezial joint, or the trapeziometacarpal joint. They usually appear between the flexor

http://e-surg.com

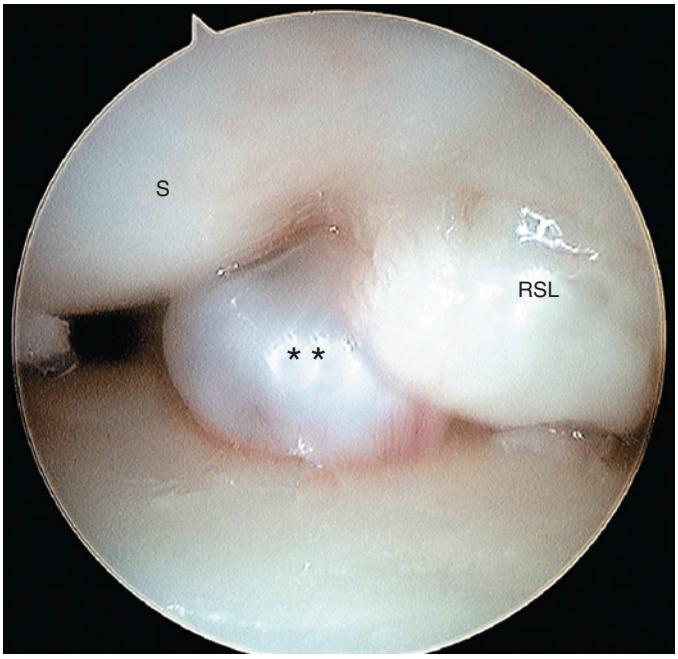

FIGURE 17.115 View of a volar ganglion (*asterisks*) from the 3-4 portal. *RSL*, Radioscapholunate ligament; *S*, scaphoid.

carpi radialis tendon and the flexor pollicis longus tendon. Arthroscopic excision of a volar ganglion has the advantage of avoiding extensive dissection, scarring, and potential damage to the surrounding structures. With this technique, the 3-4, 4-5, and 1-2 portals are used. The arthroscope is initially placed in the 3-4 portal. Synovial capsular abnormalities may be seen between the interval of the radioscaphocapitate (RSC) and long radiolunate ligament (LRL) or between the LRL and short radiolunate ligament (SRL) (Figure 17.115).

It is helpful to manually compress the ganglion externally so that capsular bulging can be seen arthroscopically at the involved volar capsular sites. A 2.0–2.9 arthroscopic shaver is then introduced into the 1-2 portal to débride the region. Care needs to be taken to avoid injury to dorsal radial sensory nerves during establishment of this portal. Shaving is performed until a capsular defect of approximately 1 cm is created. It is important not to advance the shaver too far anteriorly to avoid injury to the volar structures. No attempt should be made to remove the ganglion wall as a separate structure.

Fernandez et al described their experience with 31 arthroscopic volar ganglionectomies.[42] It was their experience that the 4-5 portal is the ideal one for visualization, while instrumentation is best placed through the 1-2 portal. The authors noted one case of superficial radial neuritis, two hematomas, and one recurrence.

For those ganglions that arise from the scaphotrapeziotrapezoidal (STT) joint or another component of the midcarpal joint, a different approach is used. In these situations, finger-trap traction is applied to the thumb. A standard radial midcarpal portal is made, and an STT portal is established as previously described. A third portal is then made in the volar aspect of the trapeziometacarpal joint. The excision of a ganglion arising from the STT interval is more difficult compared to the standard volar ganglion.

WRIST ARTHRITIS

The arthroscope can play an important role in diagnosis and treatment of a wide array of arthritic conditions in the wrist. From palliative procedures, such as débridement of osteophytes or radial styloidectomy in an early SLAC wrist, to wrist synovectomy in inflammatory arthritis, to the more advanced procedures of carpectomy and partial arthrodesis, arthroscopic techniques have evolved to play a vital role in management of these common and disabling conditions.

Wrist Synovectomy

Adolfsson established the protocol for arthroscopic synovectomy in patients with rheumatoid arthritis.[2] Indications include persistent joint symptoms following a 6-month course of pharmacological treatment and only early radiographic degeneration or erosions as defined by Larsen et al.[73] The arthroscopic technique for synovectomy is straightforward. The standard 3-4, 4-5, and/or 6-R portals are established. A relatively rapid and efficient procedure is important to minimize wrist swelling and preserve visualization. With the arthroscope in the 3-4 portal, a synovectomy is performed in an ulnar-to-radial direction using instruments in the 4-5 and 6-R portals. The portals are then switched and with the arthroscope in the 6-R portal, the remaining synovitis on the radial side of the wrist is resected. Adolfsson et al. reported improved wrist arc of motion from 70 to 90 degrees and an 87% increase in grip strength in 18 patients 6 months following synovectomy.[3] In their longer-term follow-up study, the authors demonstrated continued improvements in pain for the majority of patients at 3.8 years after surgery.[2]

Chung et al. reviewed their series of 21 patients with rheumatoid arthritis following arthroscopic synovectomy.[24] At 3 months' follow-up, the authors noted arthroscopic synovectomy resulted in decreased pain, improved joint motion, and lower disability scores. It was felt that arthroscopic synovectomy should be considered an option for patients with mild-to-moderate stages of inflammatory arthritis.

Focal chondral defects are a common source of wrist pain. Proximal pole hamate arthrosis has been associated with the (bifacet) type II lunate morphology, and it can be a common cause of ulnar-sided wrist pain, particularly when sports or occupational demands require extremes of ulnar deviation (Figure 17.116). It has been noted that type II lunate can lead to chondral defects in approximately 44% of specimens but only 2% in type I lunates.[57,85,135] Arthroscopic or open resection of the proximal pole of the hamate has yielded good results, as noted by Yao et al.[136]

Patients with early SLAC disease and focal radioscaphoid arthritis may be candidates for arthroscopic radial styloidectomy. Patients with point tenderness directly over the tip of the radial styloid may attain improved function with a palliative procedure to remove the degenerated areas, provided they understand that the procedure will not restore normal joint kinematics and will not reverse the underlying condition. Arthroscopic radial styloidectomy ensures preservation of the critical RSC ligament, thus preventing iatrogenic ulnar translation of the wrist. In this technique, the arthroscope is placed in the standard 3-4 portal, and a 3.5-mm bur is inserted through the 1-2 portal. The chondromalacia noted on the scaphoid facet

http://e-surg.com

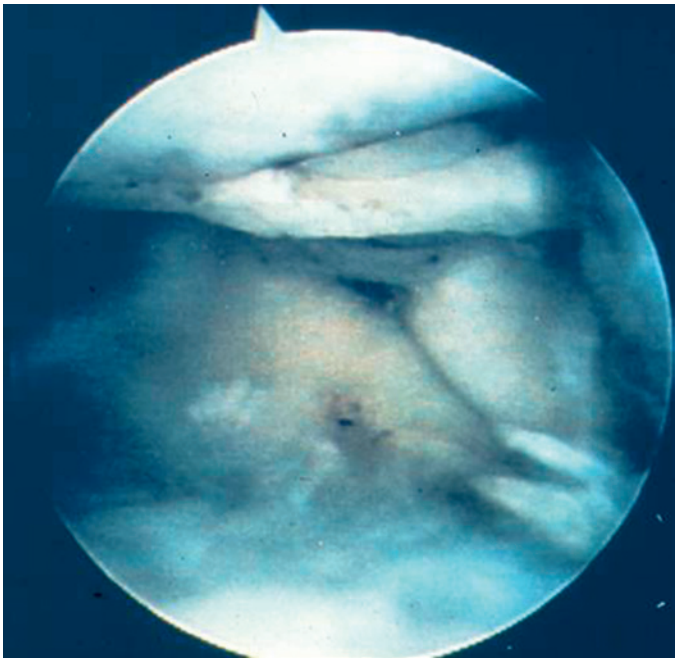

FIGURE 17.116 Arthroscopic view of a chondral defect of the hamate with the arthroscope in the radial midcarpal portal. This defect was débrided to relieve pain.

of the distal radius marks the area of resection. Approximately 4 mm of bone may be arthroscopically removed. Fluoroscopy is strongly encouraged to monitor the amount of resection.

Arthroscopic proximal carpectomy is a reproducible and effective arthroscopic technique that compares favorably to the established open technique.[30,32,128] Although there is a steep learning curve, arthroscopic proximal carpectomy can be accomplished in a reasonable amount of surgical time with routine small- and large-joint instrumentation. Arthroscopic proximal row carpectomy avoids disruption of the dorsal capsule allowing for immediate postoperative range of motion and improved wrist stability. Indications for arthroscopic proximal carpectomy are identical to the open procedure. The procedure is reserved for those patients with debilitating wrist pain and intact articular cartilage of the lunate fossa and capitate head.

To perform the procedure, the routine radiocarpal portals (i.e., 3-4, 4-5, 6-R, and 6-U) and midcarpal portals (i.e., midcarpal radial, midcarpal ulnar, and STT) are established. In the technique as described by Weiss et al, the arthroscope is placed in the ulnar midcarpal portal and a small joint arthroscopic bur is introduced through the radial midcarpal portal.[128] It is important at all times to avoid any injury to the articular cartilage of the capitate head. The hood of the shaver should always face the head of the capitate to avoid cartilage injury. Utilizing the small joint bur, the distal ulnar corner of the scaphoid is resected.

Once adequate resection of the ulnar corner of the scaphoid has been performed, a large joint shaver and, subsequently, a 4.0-mm bur can be introduced into the radial midcarpal portal. The larger bur obviously facilitates more rapid removal of bone. The scaphoid is then excised with the bur moving from ulnar-to-radial and distal-to-proximal. To complete resection of the most distal pole of the scaphoid, the bur can be placed through the STT portal. A small joint rongeur is helpful to remove small fragments that wind up in the joint capsule.

Following excision of the scaphoid, the arthroscope is moved to the STT portal. With the 4.0-mm bur in the radial midcarpal portal, the lunate is excised in a radial-to-ulnar and distal-to-proximal direction. Great care should be taken to avoid injury to the capitate head as well as the lunate facet of the distal radius. Wrist traction and adequate fluid flow are essential to create a safe space above the distal radius and protect the articular cartilage. A rongeur can be used to remove the final fragments of bone that adhere to the capsule. The arthroscope is then moved to the radial midcarpal portal and the bur is placed in the ulnar midcarpal portal to remove the triquetrum. Fluoroscopic views are made to confirm complete excision of the proximal row of the carpus.

Weiss and coauthors reviewed their series of 35 patients with an average of 33-months' follow-up.[128] The authors noted no major complications and no patients required conversion to an open procedure. Specifically, there were no complications of radiocarpal subluxation despite immediate mobilization. What is impressive is that the average length of surgery was 61 minutes. Patients retained an average 78% of the flexion–extension arc of the wrist and 70% of radial and ulnar deviation. Grip strength averaged 83% compared to the opposite wrist. The authors reported a 94% rate of patient satisfaction with the arthroscopic procedure.

Partial wrist fusion is a widely accepted technique for a patient with an arthritic wrist who still desires preservation of some motion and additional pain relief. Conventionally, these procedures are performed through an open approach. Ho described his case series of arthroscopic partial wrist fusion.[63] He notes an arthroscopic approach provides an excellent view of the wrist and is a viable adjunct for various techniques of partial wrist fusion. Ho combines an arthroscopic débridement of the cartilaginous surfaces with strong percutaneous fixation and feels that he can generate better functional outcomes by avoiding wrist arthrotomy.

Ho reported outcomes of 23 partial wrist fusions for patients with an average age of 42,[63] as follows: STT fusion in 3, scaphoidectomy and four-corner fusion in 5, scaphoidectomy and lunocapitate fusion in 4, lunate excision and scaphocapitate fusion in 3, radioscapholunate fusion in 4, radial lunate fusion in 2, and lunotriquetral fusion in 2. Surgical complications included superficial pin tract infections and a skin burn.[63] Radiographic fusion was completed in 19 cases, 3 cases were reported as having stable and asymptomatic fibrous union, and 1 case required revision of a nonunion.

Intercarpal Arthrodesis

Through the radial midcarpal portal, the corresponding articular surfaces are removed with an arthroscopic bur and curet. Carpal bones are provisionally transfixed with Kirschner wires and alignment confirmed under fluoroscopic control. A cancellous bone graft or bone substitute is inserted at the fusion site through a cannula under arthroscopic and fluoroscopic visualization. Final fixation was achieved with multiple Kirschner wire fixation or cannulated screws. Rigid fixation enabled early mobilization in most patients.

http://e-surg.com

Arthroscopic Arthrolysis

Wrist stiffness is a debilitating condition that may be secondary to trauma or prolonged immobilization and may have intraarticular and extraarticular etiologies. Arthrofibrosis may involve the radiocarpal, radioulnar, and ulnocarpal joints. Arthroscopic arthrolysis is an effective treatment for restoring range of motion and reducing pain.

Contraindications

Carpal instability is a contraindication for capsular release, since release of the volar and/or dorsal extrinsic ligaments would likely exacerbate the condition. Similarly, the presence of posttraumatic arthritis or osteoarthritis would limit any potential gains. Patients who cannot comply with postoperative dynamic–static progressive splinting are not appropriate candidates.

Technique

The traditional radiocarpal portals are used for arthroscopic arthrolysis, and the volar radioulnar portals may be utilized as necessary. Although less common, if the midcarpal joint is involved, traditional midcarpal portals may be used. In a technique by Luchetti et al, dry arthroscopy is used more frequently and avoids fluid extravasation into the soft tissues.[76] Luchetti notes that arthroscopic arthrolysis always starts from the radial side of the radiocarpal joint. The traditional 3-4 viewing portal is used and 1-2 is a working portal. The portals are used interchangeably under triangulation. Once fibrosis is completely removed from the radial side of the wrist, the arthroscope is transferred to the 3-4 portal and the shaver through the 6-R portal.

It is noted that, frequently, a fibrotic band is identified between the scapholunate ligament and the interfacet ridge of the distal radius.[58] This fibrotic band can be partial or complete and is incised using a small dissector through the 6-R portal. Depending on the range of motion obtained from arthroscopic débridement of intraarticular adhesions, the volar and/or dorsal capsule may need to be released. Volar capsulectomy is usually easier than dorsal because the structures are immediately in the field of vision when viewing from the standard dorsal arthroscopy portals. A mini-banana blade can be inserted through the 1-2 portal with the arthroscope in the standard 3-4 portal. The radioscaphocapitate ligament is incised at its base and the procedure continues to the ulnar aspect of the wrist. The ulnar side of the volar capsule is released with a banana blade in the 6-R portal using the arthroscope in the 3-4 portal. The LRL should be preserved to minimize the risk of ulnocarpal translation. Following release of the volar capsule, manipulation can be performed.

To release the dorsal capsule, the arthroscope is placed through the 1-2 portal and the banana blade through the 6-R portal. The dorsal central portion of the capsule is resected first. The arthroscope is then transferred to the 6-R portal and the remaining radial side of the dorsal capsule is released with a banana blade inserted through the 1-2 portal. Small open incisions can be used as needed to protect the extensor tendons. Resection of a portion of the dorsal rim of the distal radius may be helpful when wrist extension is restricted secondary to a malunion of the distal radius. After dorsal capsule release has been performed, the dorsal rim is resected with a bur alternating between the 6-R and 1-2 portals. Following capsular release the wrist is taken out of traction and gently manipulated. The procedure is complete when a functional passive range of motion has been achieved as previously described. Postoperatively the patient is placed in a bulky splint for 2 to 3 days to reduce hematoma formation, followed by aggressive wrist mobilization.

Luchetti et al. published their results of five cases with a 10-month follow-up.[76] The patients' average flexion improved from 44 degrees to 54 degrees postoperatively. Similarly, wrist extension improved from 40 degrees preoperatively to 60 degrees postoperatively. Hattori et al. reported an improvement of 20 degrees in the flexion–extension arc of nine males and two females after arthroscopic capsular release for a variety of posttraumatic arthrofibrotic conditions.[2]

KIENBÖCK'S DISEASE

In 1999, Menth-Chiari et al first described the use of wrist arthroscopy in the treatment of Kienböck's disease.[78] The authors used arthroscopy in seven patients with late-stage disease (Lichtman stage IIIA or IIIB) to assess the articular surfaces, to débride the lunate, and to perform a synovectomy. At 19 months' follow-up all patients experienced relief of pain and improvement in mechanical symptoms; three of the seven experienced radiographic progression of the disease.

Bain and Begg described their arthroscopic classification in 2006 (Table 17.3).[10] The classification system is based on the number of nonfunctional articular surfaces. A normal articular surface was defined as having a glistening appearance or minor fibrillation with normal hard subchondral bone with probing. A nonfunctional articular surface is defined as having extensive fibrillation, fissuring, localized or extensive articular loss, floating articular surface, or fracture (Figures 17.117 and 17.118).

The number of nonfunctional articular surfaces determines the grade. In the Bain and Begg study series, they found a consistent pattern of changes within the lunate and that the changes always occurred initially on the proximal articular surface of the lunate. The more severe cases would develop a subchondral fracture and subsequently secondary chondral changes in the apposing lunate facet of the radius. They noted

TABLE 17.3 Bain and Begg Arthroscopic Classification

Grade	Description
0	All functional surfaces are working
I	One nonfunctional articular surface—usually the proximal articular surface of the lunate
II	Two nonfunctional articular surfaces divided into types A and B
IIa	Proximal lunate facet of the radius
IIb	Proximal surface of the lunate and distal articular surface of the lunate
III	Three nonfunctional articular surfaces—lunate facet of the radius, proximal and distal articular surfaces of the lunate with a preserved head of the capitate
IV	All functional surfaces are nonfunctional

http://e-surg.com

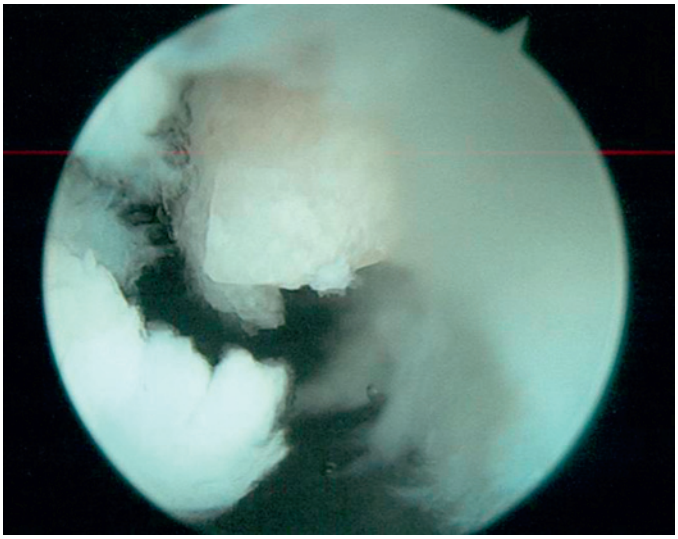

FIGURE 17.117 Arthroscopic view from the 3-4 portal demonstrating a necrotic lunate in Kienböck's disease.

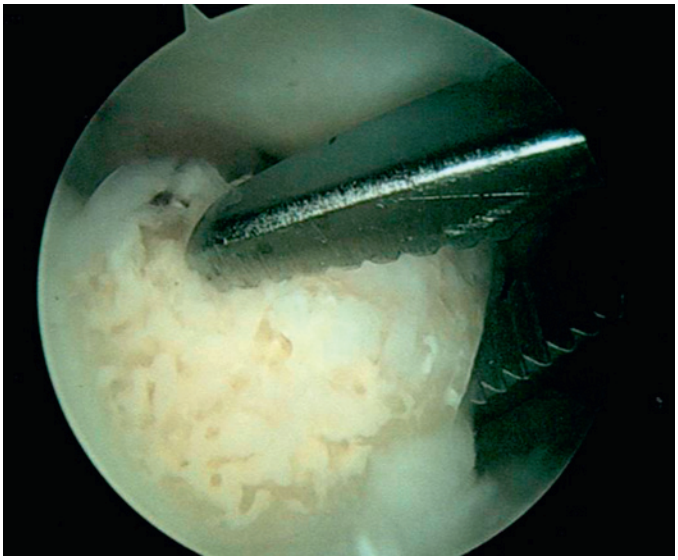

FIGURE 17.118 Arthroscopic view showing débridement and the removal of the necrotic fragments of the lunate.

that involvement of the distal articular surface of the lunate was rare; exceptions included a coronal fracture extending to the distal articular surface for chronic cases.

The authors found that the degree of synovitis correlated with the degree of articular damage. The severity of articular cartilage as seen on plain radiographs was underestimated when seen arthroscopically. They found that findings of arthroscopy commonly changed the initial treatment plan. More important, Bain and Begg identified cases where the articular cartilage envelope remained intact while the underlying subchondral bone had collapsed. The authors postulated that this subgroup may have undergone spontaneous lunate revascularization.

Bain and Durrant developed a treatment algorithm based on their arthroscopic grading.[11] The principles of the algorithm were to remove only the nonfunctional surfaces while maintaining range of motion. In grade 0, all the articular surfaces are functional. Arthroscopic synovectomy is performed. Further treatment may include an unloading procedure, revascularization, arthroscopic or open core decompression, or bone grafting. Arthroscopic core decompression is recommended only for patients with a neutral or positive ulnar variance.[11]

Pegoli et al. described arthroscopic bone grafting for the necrotic lunate; it is drilled at a site near the dorsal insertion of the lunotriquetral interosseous ligament. The necrotic lunate is then débrided with a motorized shaver and osteoscopy is then performed by inserting a scope into the lunate to confirm adequate débridement. Cancellous bone graft is then harvested from the volar aspect of the distal radius and inserted into the lunate through a trocar.[94]

Grade I Kienböck's disease is defined by a nonfunctioning proximal lunate articular surface. Treatment options include proximal row carpectomy or radioscapholunate fusion. In grade IIa, both the proximal articular surface of the lunate and the lunate fossa are nonfunctional. In this case, radioscapholunate fusion removes the nonfunctional articular surface while maintaining normal midcarpal kinematics. In grade IIb, the proximal and distal articular surfaces of the lunate are nonfunctional. Bain and Begg feel a proximal carpectomy is the treatment of choice, provided the lunate articular facet of the radius is intact.

In grade III Kienböck's, three articular surfaces are nonfunctional although the capitate articular surface usually remains functional. In this instance, Bain and Begg recommend a salvage procedure such as a total wrist fusion or arthroplasty. A third option is a resurfacing hemiarthroplasty of the distal radius that articulates with the head of the capitate. In grade IV Kienböck's, all four articular surfaces are nonfunctional and a total wrist fusion or arthroplasty is recommended.

Tatebe et al. performed arthroscopic inspection of 57 patients who underwent radial osteotomy for Kienböck's disease.[111] All patients were classified using the Bain and Begg classification. They noted the number of articular surfaces involved did not correlate with the Lichtman radiographic stage or the duration from onset to surgery. The authors noted that all but two patients had cartilage lesions in the proximal articular surface of the lunate and that loss of additional articular surfaces correlated with patient age. For workup, staging, and a complete review of treatment options for Kienböck's disease, the reader is referred to Chapter 16.

THUMB CARPOMETACARPAL ARTHROSCOPY

The thumb carpometacarpal joint is the most common one in the hand to develop degenerative arthritis. While there has been considerable attention paid to the treatment of advanced disease, much less attention has focused on early intervention to prevent or delay the need for a salvage procedure.[37] Recent advances in small joint arthroscopy allow for treatment of symptomatic basal joint laxity in a minimally invasive fashion without joint destabilization.

Badia defined an arthroscopic classification of thumb carpometacarpal arthritis.[9] In stage 1, there is diffuse synovitis but the articular cartilage is intact and volar capsule laxity is demonstrated. In stage 2, there is central fovea articular cartilage loss of the trapezium, deep metacarpal base loss, and resulting synovitis. In stage 3, there is widespread articular cartilage loss and deep osteophyte on trapezium. The staging system was

http://e-surg.com

gradually developed as a result of more than 20 years performing arthroscopic assessment of recalcitrant basal joint arthritis, which did not improve after conservative management.

Thermal stabilization of the capsule ligamentous structures has been used with some success in hand and wrist surgery compared to its use in other joints. It is thought that prolonged immobilization allows for capsular shrinkage to mature.[6,59,84] Thermal stabilization exploits the heat liable intramolecular bonds that maintain the triple helix structure in type I collagen. Ideal temperatures for thermal stabilization have been described as between 60°C to 67°C. Thermal shrinkage occurs until a plateau is reached beyond which thermal shrinkage will not occur. As the tissue cools, it has been shown that up to 10% of initial shrinkage may be lost and some of the bonds renature. This technology has been most recently applied to the thumb carpometacarpal joint.

Indications

As a general rule, any patient who has isolated and refractory degenerative disease of the trapeziometacarpal joint is a candidate for an arthroscopic treatment. This form of treatment does not preclude an open trapeziectomy and/or ligament reconstruction at a later date as a salvage procedure.

Contraindications

This would include any general contraindication to thumb arthroscopy including distortion of the anatomy due to swelling, unstable or friable skin that would preclude the use of traction, and recent infection. The presence of pantrapezial degenerative disease is a relative contraindication, although simultaneous arthroscopic TM and STT arthroplasty has been reported. Because of excessive ligamentous laxity, patients with Ehlers-Danlos syndrome or lupus arthritis are not ideal candidates for this procedure although a successful arthroscopic tendon arthroplasty has been reported.[108] If present, MP joint hyperextension must be carefully considered and addressed separately (see Chapter 11).

Technique: Arthroscopic Capsular Shrinkage

Five to ten pounds of sterile finger trap traction is applied to the thumb so that the wrist is in slight ulnar deviation. The elbow is flexed 90 degrees, nearly parallel to the long axis of the traction tower. It is helpful to wrap Coban™ around the forearm and the tower itself to help stabilize the wrist. It is often helpful to have fluoroscopy in the room to verify correct placement of the portals for the thumb's carpometacarpal joint.

It is important to confirm each portal location using a 22-gauge needle inserted under fluoroscopy before committing to a skin incision. The 1-R and 1-U portals may be used interchangeably to inspect the joint, and visualization is markedly improved by the use of a synovial resector. Some authors prefer a standard 2.7-mm arthroscope for the thumb carpometacarpal joint. Others prefer a 1.9-mm scope.

For thermal capsular shrinkage, the arthroscope is initially placed in the 1-U portal and a thermal probe is introduced into the 1-R portal.[31] The probe is passed repeatedly over the capsule ligamentous structures in a controlled, systemic manner. It is important not to pass the probe too rapidly, which will result in insufficient shrinkage. Remember that the CMC joint is a very small space, and the fluid can heat up rapidly. If the probe is passed too slowly, this may result in excessive thermal damage. It is also important not to paint the capsular structures but rather to make precise stripes. The anterior oblique ligament is initially shrunk and progress is made toward the ulnar collateral ligament.

At this point, the portals are switched and the remaining ulnar collateral ligament and posterior oblique ligament, as well as the dorsal radial ligament, can be treated with the thermal probe. A pin should be placed across the thumb CMC joint or between the thumb and index metacarpals following the procedure to stabilize the joint. The pin is removed in 3 to 4 weeks and range-of-motion exercises begun. Strengthening exercises are started 6 weeks postoperatively.

With more severe degenerative disease of the thumb carpometacarpal joint, either arthroscopic hemitrapeziectomy or complete trapeziectomy are indicated.

Technique: Arthroscopic Hemitrapeziectomy

The arthroscope is inserted in the standard 1-U portal. A full-radius resector is placed through a thenar working portal to débride the synovitis and degenerative articular cartilage. The advantage of a thenar portal is that it is located further from the dorsal sensory branch of the radial nerve and is perpendicular to the 1-U portal to allow for easier triangulation. A 2.9-mm arthroscopic bur is then placed through the thenar portal to complete the hemitrapeziectomy. Approximately 3 to 5 mm of the distal aspect of the trapezium should be removed. The shaver and arthroscope are switched between the two portals for optimal visualization and débridement. It is vital to confirm the degree of trapezial resection under fluoroscopy.

A ballottement test can be performed by alternately applying traction and compression to the thumb metacarpal while visualizing the amount of translation. The thumb metacarpal should temporarily be pinned for 3 to 4 weeks to maintain the resection space. Alternatively, to decrease the amount of postoperative immobilization while still maintaining support to the thumb metacarpal, a mini-tightrope suture device (Arthrex, Naples, FL) can be placed between the thumb and the index metacarpal (see Chapter 11). A short explanation of the tight-rope device can be found in this chapter online at ExpertConsult.com.

Arthroscopic trapeziectomy has been described by Cobb et al.[26] In this technique, the standard 1-R and 1-U portals are made for thumb carpometacarpal arthroscopy. STT arthroscopy portals are made by using 1-R and 1-U portals placed approximately 1 cm proximal to the standard 1-R and 1-U portals as described earlier. These portals are ideally localized using fluoroscopy with 22-gauge needles. Initially, a 3.5-mm full resector is used to clean out debris within the joint. Cobb and coauthors recommend electrothermal shrinkage to tighten the capsule and create an articular denervation. It is critical to maintain high fluid flow to minimize overheating and potential burns with the use of radio frequency probes. A 3.0- or 4-mm bur is then used to resect 2 to 3 mm of bone from the distal aspect of the trapezium and the proximal aspect of the thumb metacarpal.

The STT resection arthroplasty is performed by removing 2 to 3 mm of bone from the distal aspect of the scaphoid and from the proximal aspect of the trapezium and trapezoid. Once space is more readily available, a 4-mm barrel bur can be used.

http://e-surg.com

The tightrope device consists of a braided suture that is looped between two steel buttons with one button affixed to the thumb metacarpal and the other to the index metacarpal. This eliminates the need for K-wire stabilization. Following hemitrapeziectomy, an incision is made at the 1-R portal site. The position of the suture button through the 1-R portal minimizes the hardware prominence as the suture button may be placed under part of the APL tendon and promotes pronation of the thumb. A guidewire is then drilled from the thumb metacarpal base obliquely to the proximal diaphysis of the second metacarpal. A second incision is made ulnar to the index metacarpal and retractors are placed to protect the dorsal sensory branch of the radial nerve. A guidewire is placed bicortically through the thumb metacarpal into the index metacarpal and used to pass the sutures. The second button is then fitted over the sutures and placed against the dorsal aspect of the index metacarpal.

The key is not to tie the sutures too tightly so that the thumb metacarpal impinges on the base of the index metacarpal. A ballottement test is performed under fluoroscopy to confirm proper positioning. Yao reviewed the results of more than 40 patients after using this technique for some with follow-up >3 years.[136] Two complications occurred in the same patient: one was chronic radial pain syndrome, which occurred 6 weeks postoperatively; the second was a fracture of the index metacarpal. Yao feels that use of the button suspensionplasty allows the patient to start thumb range-of-motion exercises earlier; K-wire fixation prevents potential complications such as pin tract infections, pin migration, and skin irritation.

http://e-surg.com

When an interposition material is to be utilized, Cobb et al recommend the graft jacket (Wright Medical Technology, Inc., Memphis, TN). They feel that this material tends to adhere effectively and has a decreased inflammatory response.[26] In Cobb and coauthors' earlier experience, no fixation methods were used to secure the interposition material.

To prevent extrusion, the interposition material is now secured with sutures tied over buttons external to the skin on the volar and dorsal aspect of the joint. Fixation is performed by passing absorbable sutures into the volar portal, across the joint and out the dorsum of the hand. The suture can be used to pull the graft into the prepared joint. A second suture is placed on the opposite side of the interposition material so that the interposition material can be manipulated to lie in the center of the joint as viewed arthroscopically. The sutures are then tied over buttons on the dorsal and volar sides of the joint. Postoperatively, the patients are immobilized in a thumb spica splint that is converted to a thermoplastic splint after 5 to 7 days. The pull-out suture is removed at approximately 2 weeks. It is felt that early range of motion provides for a better overall outcome.

Cobb et al reviewed their results in 35 patients with arthroscopic resection arthroplasty of the thumb carpometacarpal joint performed in 35 patients for thumb arthrosis.[26] The average pain level improved from 7 preoperatively to 1 postoperatively at 1-year follow-up. DASH scores improved from 46 preoperatively to 19 at 1-year follow-up. Grip strength improved 4.3 kg and key pinch improved 1.3 kg. There were four reoperations in his series. As Cobb et al noted, the indications for interposition are not well established. Good results have been reported with resection arthroplasty without interposition.[38,64]

SMALL JOINT ARTHROSCOPY

Please see www.expertconsult.com.

COMPLICATIONS

Complications of wrist arthroscopy are relatively rare.[44] Beredjiklian et al. reported 11 complications in 211 patients who underwent wrist arthroscopy.[14] There were two major complications in his studies: one case of severe arthrofibrosis and one case of a ganglion that developed at the 3-4 portal. Nine patients developed minor complications including transient ulnar neurapraxia, transient wrist and finger stiffness, skin burn, portal site infection, and extensor carpi ulnaris tendonitis. All complications had resolved at the last follow-up visit.[14] Pell and Uhl noted three tendon ruptures in their series of 47 patients treated with thermal ablation during wrist arthroscopy.[95] One patient had a full-thickness skin burn after the use of thermal shrinkage.

To prevent complications of wrist arthroscopy, careful portal planning is essential. A few millimeters difference with regard to placement of the portals can make a big difference in proximity to vital structures and ease of joint access. A needle should always be used, prior to cutting the skin, to determine precise portal placement. The needle should pass easily into the joint without impaling tendons, carpal bones, or the distal radius.

It is important to always use blunt trocars to prevent iatrogenic damage of the articular cartilage during introduction of the arthroscopic cannulae. Separate inflow and outflow portals limit fluid extravasation into the soft tissues. Use of physiological solutions (e.g., lactated Ringer) allows reabsorption of extravasated fluid and minimizes the risk of compartment syndrome. Kirschner wires should always be inserted with the use of a soft tissue protector or the oscillation mode to limit any potential damage to the numerous sensory branches surrounding the wrist.

CONCLUSION

In summary, arthroscopy continues to grow in popularity as a valuable diagnostic and therapeutic adjunct for complex disorders of the wrist. It allows for the evaluation of articular structures under bright light and magnified conditions with minimal morbidity. Continued improvement in the techniques will occur as more surgeons are exposed to wrist arthroscopy and better instrumentation is developed.

For Case Studies, Videos, and more, please visit ExpertConsult.com.

REFERENCES

1. Adolfsson L: Arthroscopic diagnosis of ligament lesions of the wrist. *J Hand Surg* 19B:505–512, 1994.
2. Adolfsson L: Arthroscopic synovectomy in wrist arthritis. *Hand Clin* 21:527–530, 2005.
3. Adolfsson L, Nylander G: Arthroscopic synovectomy of the rheumatoid wrist. *J Hand Surg [Br]* 18:92–96, 1993.
4. Anderson DD, Bell AL, Gaffney MB, et al: Contact stress distributions in malreduced intraarticular distal radius fractures. *J Orthop Trauma* 10:331–337, 1996.
5. Angelides AC, Wallace F: The dorsal ganglion of the wrist: its pathogenesis, gross and microscopic anatomy, and surgical treatment. *J Hand Surg* 1:228–235, 1976.
6. Arnoczky SP, Aksan A: Thermal modification of connective tissues: basic science consideration and clinical implications. *J Am Acad Orthop Surg* 8:305–313, 2000.
7. Arora R, Gschwentner M, Krappinger D, et al: Fixation of nondisplaced scaphoid fractures: making treatment cost effective. Prospective controlled trial. *Arch Orthop Trauma Surg* 127:39–46, 2007.
8. Atzei A, Rizzo A, Luchetti R, et al: Arthroscopic foveal repair of triangular fibrocartilage complex peripheral lesion with distal radioulnar joint instability. *Tech Hand Up Extrem Surg* 12:226–235, 2008.
9. Badia A: Trapeziometacarpal arthroscopy: A classification and treatment algorithm. *Hand Clin* 22:153–163, 2006.
10. Bain GI, Begg M: Arthroscopic assessment and classification of Kienbock's disease. *Tech Hand Up Extrem Surg* 10:8–13, 2006.
11. Bain GI, Durrant A: An articular-based approach to Kienbock avascular necrosis of the lunate. *Tech Hand Up Extrem Surg* 15(1):41–47, 2011.
12. Baratz ME, Des Jardins JD, Anderson DD, et al: Displaced intra-articular fractures of the distal radius: the effect of fracture displacement on contact stresses in a cadaver model. *J Hand Surg* 21A:183–188, 1996.
13. Bednar MS, Arnoczky SP, Weiland AJ: The microvasculature of the triangular fibrocartilage complex: its clinical significance. *J Hand Surg [Am]* 16(6):1101–1105, 1991.
14. Beredjiklian PK, Bozentka DJ, Leung L, et al: Complications of wrist arthroscopy. *J Hand Surg [Am]* 29:406–411, 2004.
15. Berger RA: A technique for arthroscopic evaluation of the first carpometacarpal joint. *J Hand Surg [Am]* 22:1077–1080, 1997.
16. Berger RA, Landsmeer JMF: The palmar radiocarpal ligaments: a study of adult and fetal human wrist joints. *J Hand Surg* 15A:847–854, 1990.
17. Bernstein MA, Nagel DJ, Martinez A, et al: A comparison of combined arthroscopic triangular fibrocartilage complex debridement and arthroscopic wafer distal ulna resection versus arthroscopic triangular fibrocartilage complex debridement and ulnar shortening osteotomy for ulnocarpal abutment syndrome. *Arthroscopy* 20(4):392–401, 2004.
18. Bettinger PC, Cooney WP, III, Berger RA: Arthroscopic anatomy of the wrist. *Orthop Clin North Am* 26:707–719, 1995.
19. Botte MJ, Cooney WP, Linscheid RL: Arthroscopy of the wrist: anatomy and technique. *J Hand Surg* 14A:313–316, 1989.

http://e-surg.com

SMALL JOINT ARTHROSCOPY

The progression and development of small and microarthroscopes have continued to push the development of small joint arthroscopy. Arthroscopy of the metacarpal phalangeal joint, proximal interphalangeal joint, and even the distal phalangeal joints has been described. These arthroscopic techniques include synovectomy, chondroplasty, capsulorrhaphy, joint resurfacing, and all arthroscopic-assisted fixation of intraarticular fractures.

Chen first described arthroscopy of the metacarpal phalangeal joints among other small joints of the hand.[23] His paper described the use of the Watanabe number 25 arthroscope within the wrist, metacarpal phalangeal joints, and interphalangeal joints of the hand. Vaupel and Andrews first described using arthroscopic treatment in metacarpal phalangeal joints after Chen's initial report on a professional golfer with a 1-year history of chronic synovitis within the thumb metacarpal phalangeal joint.[119] In this report, the golfer was able to return to his sport within a 6-month period. Ryu and Fagan presented a small series on treating Stener lesions involving the ulnar collateral ligament.[100] They described arthroscopic reduction of the lesions in eight thumbs with a follow-up period of more than 3 years. Once reduction of the Stener lesion was performed, it was pinned to stabilize the joint to allow healing.

Metacarpal phalangeal joint arthroscopy requires the use of a 1.9-mm arthroscope or less due to the small dimension of these relatively constrained joints. Chinese finger traps are applied to the involved digit, as well as approximately 5 to 8 lb of traction. A 2.0-mm shaver is usually used for synovectomy in most joint débridement while a small radio frequency probe also may be utilized. Frequently, small joint arthroscopy requires only the use of local anesthesia. The use of lidocaine with epinephrine may alleviate the need for a tourniquet as these are generally short-lasting procedures. The portals are made radial and ulnar to the extensor mechanism. The portal is localized with an 18-gauge needle, and frequently fluoroscopy is helpful to further confirm the ideal location of the portal site. Radial and ulnar portals are made on either side of the visible palpable extensor tendon.

Thomsen et al. described their experience with PIP joint arthroscopy.[113] This paper focuses on the anatomic findings and anatomy of eight cadaver PIP joints followed by two clinical examples. They noted the technique was demanding and, at the time, limited by instrumentation. Sekiya et al reported their results in PIP arthroscopy for 21 rheumatoid patients.[102] They described the results with 27 PIP joints that underwent rheumatoid synovectomy. It was noted that the technique was promising following synovectomy, and the authors felt there was early clinical improvement to range of motion.

In PIP joint arthroscopy, the joint is infiltrated with 1 to 2 ccs of lidocaine, which is an adequate digital block. The standard radioulnar portals are made on either side of the central slip between the lateral bands. This technique requires a joint arthroscope of 1.9 mm or smaller and 2-mm suction shavers.

http://e-surg.com

20. Bowers WHWT: Arthroscopic anatomy of the wrist. In McGinty J, editor: *Operative arthroscopy*, New York, 1991, Raven Press, pp 613–623.
21. Buterbaugh GA: Radiocarpal arthroscopy portals and normal anatomy. *Hand Clin* 10:567–576, 1994.
22. Carro LP, Golano P, Farinas O, et al: The radial portal for scaphotrapeziotrapezoid arthroscopy. *Arthroscopy* 19:547–553, 2003.
23. Chen YC: Arthroscopy of the wrist and finger joints. *Orthop Clin North Am* 10(3): 723–733, 1979.
24. Chung CY, Yen CH, Yip ML, et al: Arthroscopic synovectomy for rheumatoid wrists and elbows. *J Orthop Surg (Hong Kong)* 20:219–223, 2012.
25. Chung KC, Zimmerman NB, Travis MT: Wrist arthrography versus arthroscopy: a comparative study of 150 cases. *J Hand Surg* 21A:591–594, 1996.
26. Cobb T, Sterbank P, Lemke J: Arthroscopic resection arthroplasty for the treatment of combined carpometacarpal and scaphotrapeziotrapezoid (pantrapezial) arthritis. *J Hand Surg [Am]* 36:413–419, 2011.
27. Cooney WP: Evaluation of chronic wrist pain by arthrography, arthroscopy, and arthrotomy. *J Hand Surg* 18A:815–822, 1993.
28. Corella F, Ocampos M, Del Cerro M: Are extensor tendons safe on your first wrist arthroscopy? *J Hand Surg Eur* 36(9):817–818, 2011.
29. Corso SJ, Savoie FH, Geissler WB, et al: Arthroscopic repair of peripheral avulsions of the triangular fibrocartilage complex of the wrist: a multicenter study. *Arthroscopy* 13:78–84, 1997.
30. Culp RW, McGuigan FX, Turner MA, et al: Proximal row carpectomy: a multicenter study. *J Hand Surg* 18A:19–25, 1993.
31. Culp RW, Rekant MS: The role of arthroscopy in evaluating and treating trapeziometacarpal disease. *Hand Clin* 17(2):315–319, 2001.
32. Culp RW, Osterman AL, Kaufmann RA: Wrist arthroscopy: operative procedures. In Green DP, Hotchkiss RN, Pederson WC, et al, editors: *Green's operative hand surgery*, ed 5, Philadelphia, 2005, Elsevier, pp 781–803.
33. Darlis NA, Weiser RW, Sotereanos DG: Partial scapholunate ligament injuries treated with arthroscopic debridement and thermal shrinkage. *J Hand Surg [Am]* 30:908–914, 2005.
34. Deitch MA, Stern SJ: Ulnocarpal abutment: treatment options. *Hand Clin* 14(2): 251–263, 1998.
35. del Pinal F, Garcia-Gernal FJ, Pisani D, et al: Dry arthroscopy of the wrist: surgical technique. *J Hand Surg [Am]* 32:119–123, 2007.
36. del Pinal F, Studer A, Thams C, et al: An all-inside technique for arthroscopic suturing of the volar scapholunate ligament. *J Hand Surg [Am]* 36:2044–2046, 2011.
37. Eaton RG, Lane LB, Littler JW, et al: Ligament reconstruction for the painful thumb carpometacarpal joint: a long-term assessment. *J Hand Surg [Am]* 9:692–699, 1984.
38. Edwards SG, Ramsey PN: Prospective outcomes of stage 3 thumb CMC arthritis. *J Hand Surg [Am]* 35:566–571, 2010.
39. Ekman EF, Poehling GG: Principles of arthroscopy and wrist arthroscopy equipment. *Hand Clin* 10:557–566, 1994.
40. Feldon P, Terrono AL, Belsky MR: Wafer distal ulna resection for triangular fibrocartilage tears and/or ulna impaction syndrome. *J Hand Surg [Am]* 17:731–737, 1992.
41. Fellinger M, Peicha G, Seibert FJ, et al: Radial avulsion of the triangular fibrocartilage complex in acute wrist trauma: a new technique for arthroscopic repair. *Arthroscopy* 13:370–374, 1997.
42. Fernandes CH, Meirelles LM, Raduan Neto J, et al: Characteristics of global publications about wrist arthroscopy: a bibliometric analysis. *Hand Surg* 17(3): 311–315, 2012.
43. Fontes D, Lenoble E, De Somer B, et al: Lesions ligamentaires associees aux fractures distales du radius. A propos de cinquante-huit athrographies peroperatories. *Ann Chair Main* 11:119–125, 1992.
44. Fortems Y, Mawhinney I, Lawrence T, et al: Late rupture of extensor pollicis longus after wrist arthroscopy. *Arthroscopy* 11:322–323, 1995.
45. Geissler WB, Fernandez DL: Percutaneous and limited open reductions of the articular surface of the distal radius. *J Orthop Trauma* 5:255–264, 1991.
46. Geissler WB, Savoie FH: Arthroscopic techniques of the wrist. *Medi-guide Orthop* 11:1–8, 1992.
47. Geissler WB: Arthroscopically assisted reduction of intra-articular fractures of the distal radius. *Hand Clin* 11:19–29, 1995.
48. Geissler WB, Freeland AE, Savoie FH, et al: Intercarpal soft-tissue lesions associated with an intra-articular fracture of the distal end of the radius. *J Bone Joint Surg* 78A:357–365, 1996.
49. Geissler WB, Freeland AE: Arthroscopically assisted reduction of intraarticular distal radial fractures. *Clin Orthop* 327:125–134, 1996.
50. Geissler WB, Fernandez DL, Lamey DM: Distal radioulnar joint injuries associated with fractures of the distal radius. *Clin Orthop* 327:135–146, 1996.
51. Geissler WB: Arthroscopic excision of dorsal wrist ganglia. *Tech Upper Extrem Surg* 2:196–201, 1998.
52. Geissler WB: Arthroscopic knotless peripheral ulnar-sided TFCC repair. *Hand Clin* 27(3):273–279, 2011.
53. Geissler WB, Hammit MD: Arthroscopic aided fixation of scaphoid fractures. *Hand Clin* 17:575–588, viii, 2001.
54. Geissler WB, Slade JF: Fractures of the carpal bones. In Wolfe SW, Hotchkiss RN, Peterson WC, et al, editors: *Green's operative hand surgery*, vol 1, ed 6, Philadelphia, 2010, Elsevier, pp 639–707.
55. Geissler WB: *AANA Fall Course*, Palm Springs, CA, 2014.
56. Hanker GJ: *Wrist arthroscopy in distal radius fractures*. Read at the Annual Meeting of the Arthroscopy Association of North America, Albuquerque, NM, Oct. 9, 1993.
57. Harley BJ, Werner FW, Boles SD, et al: Arthroscopic resection of arthrosis of the proximal hamate: a clinical and biomechanical study. *J Hand Surg [Am]* 29:661–667, 2004.
58. Hattori T, Tsunoda K, Watanabe K, et al: Arthroscopic mobilization for contracture of the wrist. *Arthroscopy* 22(8):850–854, 2006.
59. Hayashi K, Markel M: Thermal modification of joint capsule and ligamentous tissues. *Tech Sports Med* 6:120–125, 1998.
60. Hermansdorfer JD, Kleinman WB: Management of chronic peripheral tears of the triangular fibrocartilage complex. *J Hand Surg* 16A:340–346, 1991.
61. Hirsh L, Sodha S, Bozentka D, et al: Arthroscopic electrothermal collagen shrinkage for symptomatic laxity of the scapholunate interosseous ligament. *J Hand Surg [Br]* 30:643–647, 2005.
62. Hixon ML, Walker CW, Fitzrandolph RL, et al: Acute ligament tears of the wrist associated with Colles' fractures. *Orthop Trans* 14:164–165, 1990.
63. Ho PC: Arthroscopic partial wrist fusion. *Tech Hand Up Extrem Surg* 12:242–265, 2008.
64. Hofmeister EP, Leak RS, Culp RW, et al: Arthroscopic hemitrapeziectomy for the first metacarpal arthritis: results at seven-year follow-up. *Hand* 4(1):24–28, 2009.
65. Hollingsworth R, Morris J: The importance of the ulnar side of the wrist in fractures of the distal end of the radius. *Injury* 7:263–266, 1976.
66. Horii E, Garcia-Elias M, An KN, et al: A kinematic study of lunotriquetral dissociations. *J Hand Surg [Am]* 16:355–362, 1991.
67. Hulsizer D, Weiss AP: Akeiman E. Ulna-shortening osteotomy after failed arthroscopic debridement of the triangular fibrocartilage complex. *J Hand Surg* 22A:694–698, 1997.
68. Johnstone DJ, Thorogood S, Smith WH, et al: A comparison of magnetic resonance imaging and arthroscopy in the investigation of chronic wrist pain. *J Hand Surg* 22-B:714–718, 1997.
69. Jones CM, Grasu BL, Murphy MS: Dry wrist arthroscopy. *J Hand Surg [Am]* 40(2):388–390, 2015.
70. Knirk JL, Jupiter JB: Intra-articular fractures of the distal end of the radius in young adults. *J Bone and Joint Surg* 68A:647–659, 1986.
71. Kolkin L: *Wrist arthroscopy*. Presented at the Annual Meeting of the American Academy of Orthopaedic Surgeons, Washington, DC, Feb. 22, 1992.
72. Kreder HJ, Hanel DP, McGee M, et al: *Limited open versus standard open reduction and internal fixation of intra-articular fractures of the radius: a prospective randomized trial*. Read at the Annual Meeting of the Canadian Orthopaedic Association, Auckland, NZ, Feb. 5, 1998.
73. Larsen A, Dale K, Eek M: Radiographic evaluation of rheumatoid arthritis and related conditions by standard reference films. *Acta Radiol Diagn (Stockholm)* 18:481–491, 1977.
74. Levy HJ, Glickel SZ: Arthroscopic assisted internal fixation of volar intraarticular wrist fractures. *Arthroscopy* 9:122–124, 1993.
75. Llinas A, McKellop HA, Marshall GJ, et al: Healing and remodeling of articular incongruities in a rabbit fracture model. *J Bone Joint Surg* 75A:1508–1523, 1993.
76. Luchetti R, Atzei A, Papini-Zorli I: Arthroscopic wrist arthrolysis. *Chir Main* 25:S244–S253, 2006.
77. Mathoulin CL, Dauphin N, Wahegaonkar AL: Arthroscopic dorsal capsuloplasty in chronic scapho-lunate ligament tears: a new procedure. *Hand Clin* 27:563–572, 2011.
78. Menth-Chiari WA, Poehling GG, Wiesler ER, et al: Arthroscopic debridement for the treatment of Kienbock's disease. *Arthroscopy* 15:12–19, 1999.
79. Mitsuyasu H, Patterson RM, Shah MA, et al: The role of the dorsal intercarpal ligament in dynamic and static scapholunate instability. *J Hand Surg [Am]* 29:279–288, 2004.
80. Mohanti RC, Kar N: Study of triangular fibrocartilage of the wrist in Colles' fracture. *Injury* 11:321–324, 1980.
81. Moritomo H, Viegas SF, Elder KW, et al: Scaphoid nonunions: a 3-dimensional analysis of patterns of deformity. *J Hand Surg [Am]* 25A:520–528, 2000.
82. Moskal MJ, Savoie FH, 3rd, Field LD: Arthroscopic capsulodesis of the lunotriquetral joint. *Clin Sports Med* 20:141–153, ix–x, 2001.
83. Mudgal CS, Jones WA: Scapholunate diastasis: a component of fractures of the distal radius. *J Hand Surg* 15B:503–505, 1990.
84. Nagle DJ: *The use of lasers in wrist arthroscopy*. Read at the Annual Meeting of the Arthroscopy Association of North America, Rosemont, IL, Nov. 4, 1997.
85. Nakamura K, Patterson RM, Moritomo H, et al: Type I versus type II lunates: ligament anatomy and presence of arthrosis. *J Hand Surg [Am]* 26:428–436, 2001.

http://e-surg.com

86. North ER, Thomas S: An anatomic guide for arthroscopic visualization of the wrist capsular ligaments. *J Hand Surg* 13A:815–822, 1988.
87. Oneson SR, Timins ME, Scales LM, et al: MR imaging diagnosis of triangular fibrocartilage pathology with arthroscopic correlation. *Am J Roentengol* 168:1513–1518, 1997.
88. Orellana MA, Chow JC: Arthroscopic visualization of the thumb carpometacarpal joint: introduction and evaluation of a new radial portal. *Arthroscopy* 19:583–591, 2003.
89. Osterman AL: Arthroscopic debridement of triangular fibrocartilage complex tears. *Arthroscopy* 6:120–124, 1990.
90. Osterman AL, Raphael J: Arthroscopic resection of dorsal ganglion of the wrist. *Hand Clin* 11:7–12, 1995.
91. Osterman AL, Seidman GD: The role of arthroscopy in the treatment of lunatotriquetral ligament injuries. *Hand Clin* 11:41–50, 1995.
92. Palmer AK: Triangular fibrocartilage complex lesions: a classification. *J Hand Surg* 14A:594–606, 1989.
93. Pederzini L, Luchetti R, Soragni O, et al: Evaluation of the triangular fibrocartilage complex tears by arthroscopy, arthrography, and magnetic resonance imaging. *Arthroscopy* 8:191–197, 1992.
94. Pegoli L, Ghezzi A, Cavalli E, et al: Arthroscopic assisted bone grafting for early stages of Kienbock's disease. *Hand Surg* 16(2):127–131, 2011.
95. Pell RFT, Uhl RL: Complications of thermal ablation in wrist arthroscopy. *Arthroscopy* 20(2):84–86, 2004.
96. Potter HG, Asnis-Erngerg L, Weiland AJ, et al: The utility of high-resolution magnetic imaging in the evaluation of the triangular fibrocartilage complex of the wrist. *J Bone Joint Surg* 79A:1675–1684, 1997.
97. Richards RS, Bennett JD, Roth JH, et al: Arthroscopic diagnosis of intra-articular distal radius fractures. *J Hand Surg* 22A:57–65, 1997.
98. Roth JH, Poehling GG, Whipple TL: Hand instrumentation for small joint arthroscopy. *Arthroscopy* 4:126–128, 1988.
99. Ruch DS, Smith BP: Arthroscopic and open management of dynamic scaphoid instability. *Orthop Clin North Am* 32:233–240, vii, 2001.
100. Ryu J, Fagan R: Arthroscopic treatment of acute complete thumb metacarpophalangeal ulnar collateral ligament tears. *J Hand Surg [Am]* 20:1037–1042, 1995.
101. Sagerman SD, Short W: Arthroscopic repair of radial-sided triangular fibrocartilage complex tears. *Arthroscopy* 12:339–342, 1996.
102. Sekiya I, Kobayashi M, Taneda Y, et al: Arthroscopy of the proximal interphalangeal and metacarpophalangeal joints in rheumatoid hands. *Arthroscopy* 18:292–297, 2002.
103. Short WH, Werner FW, Green JK, et al: The effect of sectioning the dorsal radiocarpal ligament and insertion of a pressure sensor into the radiocarpal joint on scaphoid and lunate kinematics. *J Hand Surg [Am]* 27:68–76, 2002.
104. Slade JF, 3rd, Geissler WB, Gutow AP, et al: Percutaneous internal fixation of selected scaphoid nonunions with an arthroscopically assisted dorsal approach. *J Bone Joint Surg Am* 85(4):20–32, 2003.
105. Slutsky DJ: Arthroscopic repair of dorsal radiocarpal ligament tears. *Arthroscopy* 18:E49, 2002.
106. Slutsky DJ: Clinical applications of volar portals in wrist arthroscopy. *Tech Hand Up Extrem Surg* 8:229–238, 2004.
107. Slutsky DJ: Distal radioulnar joint arthroscopy and the volar ulnar portal. *Tech Hand Up Extrem Surg* 11:38–44, 2007.
108. Slutsky DJ: The use of a dorsal-distal portal in trapeziometacarpal arthroscopy. *Arthroscopy* 23:1244 e1–1244 e4, 2007.
109. Slutsky DJ: The use of a volar ulnar portal in wrist arthroscopy. *Arthroscopy* 20:158–163, 2004.
110. Slutsky DJ: Wrist arthroscopy through a volar radial portal. *Arthroscopy* 18:624–630, 2002.
111. Tatebe M, Hirata H, Shinohara T, et al: Arthroscopic findings of Kienbock's disease. *J Orthop Sci* 16(6):745–748, 2011.
112. Thiru RG, Ferlic DC, Clayton ML, et al: Arterial anatomy of the triangular fibrocartilage complex of the wrist and its surgical significance. *J Hand Surg [Am]* 11(2): 258–263, 1986.
113. Thomsen N, Nielsen N, Jorgensen N, et al: Arthroscopy of the proximal interphalangeal joints of the finger. *J Hand Surg [Br]* 27(3):253–255, 2002.
114. Trumble TE, Schmitt SR, Vedder NB: Factors affecting functional outcome of displaced intra-articular distal radius fractures. *J Hand Surg* 19A:325–340, 1994.
115. Trumble TE, Gilbert M, Vedder N: Isolated tears of the triangular fibrocartilage: management by early arthroscopic repair. *J Hand Surg* 22A:57–65, 1997.
116. Trumble TE, Gilbert M, Vedder N: Ulnar shortening combined with arthroscopic repairs in the delayed management of triangular fibrocartilage complex tears. *J Hand Surg* 22A:807–813, 1997.
117. Trumble TE, Culp R, Hanel DP, et al: Intra-articular fractures of the distal aspect of the radius. *J Bone Joint Surg* 80A:582–600, 1998.
118. Van Kampen RJ, Moran SL: A new volar capsulodesis for scapholunate dissociation. *J Wrist Surg* 1(2):s16–s17, 2013.
119. Vaupel GL, Andrews JR: Diagnostic and operative arthroscopy of the thumb metacarpophalangeal joint. A case report. *Am J Sports Med* 13(2):139–141, 1985.
120. Viegas SF: Midcarpal arthroscopy: anatomy and portals. *Hand Clin* 10:577–587, 1994.
121. Viegas SF, Patterson RM, Peterson PD, et al: Ulnar-sided perilunate instability: an anatomic and biomechanic study. *J Hand Surg [Am]* 15:268–278, 1990.
122. Viegas SF, Yamaguchi S, Boyd NL, et al: The dorsal ligaments of the wrist: anatomy, mechanical properties, and function. *J Hand Surg [Am]* 24:456–468, 1999.
123. Wagner WF, Jr, Tencer AF, Kiser P, et al: Effects of intra-articular distal radial depression on wrist joint contact characteristics. *J Hand Surg* 21A:554–560, 1996.
124. Wahegaonkar AL, Mathoulin CL: Arthroscopic dorsal capsule ligamentous repair in the treatment of chronic scapho-lunate ligament tears. *J Wrist Surg* 2:141–148, 2013.
125. Walsh EF, Akelman E, Fleming BC, et al: Thumb carpometacarpal arthroscopy: a topographic, anatomic study of the thenar portal. *J Hand Surg [Am]* 30:373–379, 2005.
126. Weiss APC, Akelman E, Lambiase R: Comparison of the findings of triple-injection cinearthrography of the wrist with those of arthroscopy. *J Bone Joint Surg* 78A:348–356, 1996.
127. Weiss AP, Sachar K, Glowacki KA: Arthroscopic debridement alone for intercarpal ligament tears. *J Hand Surg* 22A:344–349, 1997.
128. Weiss ND, Molina RA, Gwin S: Arthroscopic proximal row carpectomy. *J Hand Surg* 36A:577–582, 2011.
129. Whipple TL, Marotta JJ, Powell JH III: Techniques of wrist arthroscopy. *Arthroscopy* 2:244–252, 1986.
130. Whipple TL: *Arthroscopic surgery. The wrist*, Philadelphia, 1992, J. B. Lippincott, pp 103–105.
131. Whipple TL: The role of arthroscopy in the treatment of intra-articular wrist fractures. *Hand Clin* 11:13–18, 1995.
132. Whipple TL: The role of arthroscopy in the treatment of scapholunate instability. *Hand Clin* 11:37–40, 1995.
133. Wnorowki DC, Palmer AK, Werner FW, et al: Anatomic and biomechanical analysis of the arthroscopic wafer procedure. *Arthroscopy* 8:204–212, 1992.
134. Wolfe SW, Easterling KJ, Yoo HH: Arthroscopic-assisted reduction of distal radius fractures. *Arthroscopy* 11:706–714, 1995.
135. Yao J, Osterman AL: Arthroscopic techniques for wrist arthritis (radial styloidectomy and proximal pole hamate excisions). *Hand Clin* 21:519–526, 2005.
136. Yao J, Zlotolow DA, Murdock R, et al: Suture button compared with K-wire fixation for maintenance of posttrapeziectomy space height in a cadaver model of lateral pinch. *J Hand Surg [Am]* 35(12):2061–2065, 2010.

http://e-surg.com

18

Fractures of the Distal Humerus

David P. Barei and Douglas P. Hanel

Fracture of the distal humerus is one of the most challenging injuries that confront the orthopedic traumatologist. Given the relative rarity of these fractures, most surgeons have only limited experience in their management.[102] Because of the complex regional anatomy, fracture comminution, and limited points for secure fixation, even experienced surgeons find it challenging to achieve stable fixation leading to early return of range of motion. Injuries of the distal humerus include extracapsular fractures in the supracondylar region, extraarticular intracapsular (transcondylar) fractures, isolated unicondylar fractures, partial or complete articular fractures, and, most commonly, combined supracondylar-intercondylar fractures. We also address infrequent patterns, which have different demands.

GENERAL CONSIDERATIONS IN DISTAL HUMERUS FRACTURES

Preoperative Evaluation

Fractures of the distal humerus occur in a bimodal age distribution, with distinct patient characteristics. Fractures that occur in physiologically young patients are typically the result of high-energy mechanisms, such as motor vehicle collisions or falls from a significant height.[39] Open wounds, other ipsilateral upper extremity injuries, and general systemic injuries frequently coexist because of the higher-energy mechanism.[39] As the elderly population increases, there is a concomitantly increasing incidence of low-energy falls resulting in fractures of the distal humerus. This distinctive version of the fracture is characterized by poor bone quality and may be associated with poor general health or preexisting arthritic changes. There is an increasing incidence of higher-energy injuries in active, higher-demand elderly patients with poor bone quality; therapeutic decisions are more difficult for the surgeon to make with these patients.

History and Physical Examination

The history should focus on the mechanism and time of injury and the identification of other sites of injury. It is also necessary to recognize prior elbow injuries or surgical procedures or preexisting medical conditions that may have affected the entire upper extremity. In addition, assessment of preexisting medical comorbidities, medication use, and function is necessary to determine optimal management. An understanding of the patient's type of employment and physical demands at work will assist in planning the goals and duration of rehabilitation, subsequently facilitating the timing and implementation of modifications at the workplace.

In addition to a complete physical examination, particularly in the setting of a high-energy mechanism, a detailed and focused examination of the injured extremity should be performed. Inspection of the limb may reveal swelling, bruising, and deformity, particularly angulation and shortening. A complete circumferential inspection of the elbow is done to avoid missing open wounds that occur most commonly on the posterior aspect.[73] Patients are typically unable to perform any significant elbow range-of-motion movements because of pain.

The distal vascular status is evaluated by inspecting the color of the distal extremity and by palpation of the radial and ulnar pulses. Poorly palpable pulses are checked using noninvasive Doppler ultrasound or pulse oximetry. If there is a questionable pulse and gross malalignment of the arm, gentle traction can often realign the limb and restore the distal pulse. Angiography or urgent operative vascular exploration is necessary in patients who continue to show an abnormal vascular examination. Any concern for vascular injury should also prompt a careful assessment for compartment syndrome and the necessary surveillance prior to and following surgery. A detailed neurologic examination of the hand and digits, including motor function, sensation, and two-point discrimination, should be performed and recorded to identify injury to the median, radial, ulnar, anterior interosseous, or posterior interosseous nerves. Gofton and coworkers[33] noted that approximately one quarter of the patients in their series exhibited incomplete ulnar neuropathy at the time of injury. These findings, particularly with two-point discrimination, are recorded for later reference in case there is a change before or after surgery. At the conclusion of the physical examination, a sterile dressing is placed over any open wounds and a lightweight above-elbow splint is applied.

Radiographic Examination

Standard anteroposterior and lateral radiographs are generally sufficient to make the diagnosis of a fracture of the distal humerus and to provide a reasonable assessment of the fracture

http://e-surg.com

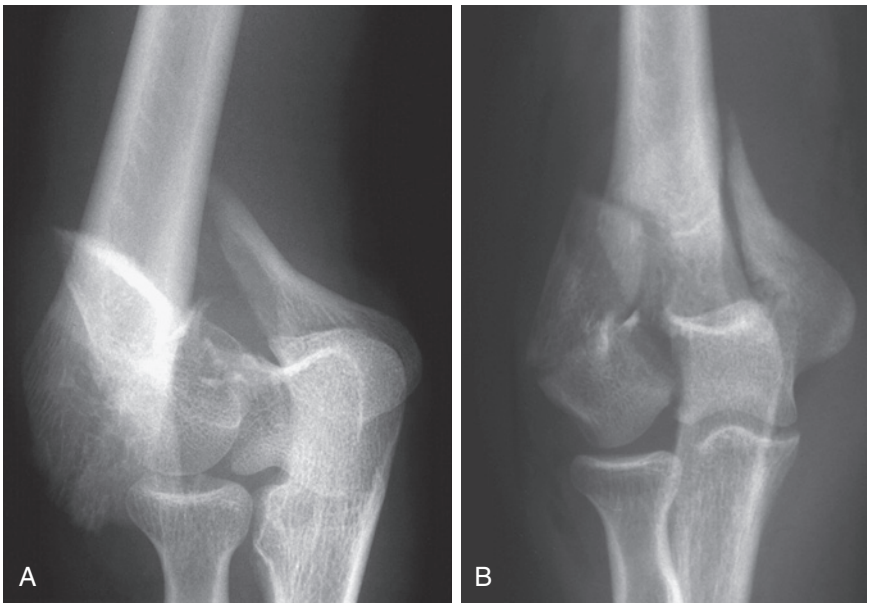

FIGURE 18.1 Resting **(A)** and traction **(B)** anteroposterior radiographs of severely displaced fracture of distal humerus. Note improved fracture comprehension obtained with traction radiograph.

pattern. Radiographs of significantly displaced fractures may be incomprehensible, however, because the normal radiographic landmarks become distorted. Gentle traction can substantially improve alignment to provide more understandable anteroposterior and lateral images. Some sedation may be needed if traction images are performed in the emergency department. Alternatively, traction images in the operating room can be obtained when complete anesthesia has been achieved. Invariably, the previously bizarre appearance of the distal humerus becomes much more understandable (Figure 18.1). Computed tomography (CT) is helpful for fractures distal to the olecranon fossa or fractures primarily occurring in the coronal plane (Figure 18.2).[53,71,101] In particular, fracture comprehension and preoperative planning seem to be improved when the CT scan is obtained with three-dimensional reconstruction.[17] CT may also be useful in older patients to assess the degree of comminution and to aid in deciding whether internal fixation or total elbow arthroplasty (TEA) should be attempted. The complexity of these fractures is underscored in a recent article that describes the number of articular fracture fragments related to fracture type as defined by three-dimensional CT. Bicolumnar patterns were associated with 19 fracture fragments; isolated capitellar and trochlear fractures were associated with 6.5 fracture fragments.[5]

ANATOMY

When viewed from an anterior or posterior position, the distal humerus appears to be shaped like a triangle. The humeral diaphysis diverges into medial and lateral bony columns in the metaphyseal portion of the distal humerus (Figure 18.3). The trochlea (a word derived from a Greek term meaning "pulley") is covered anteriorly, inferiorly, and posteriorly with articular cartilage, creating an arc of approximately 270 degrees.[70] The spatial relationships of the medial column, lateral column, and trochlea are conceptually similar to a spool of thread being held between the thumb and index finger.[55]

The blood supply to the distal humeral diaphysis is entirely dependent on a single nutrient vessel that terminates in the distal humeral metaphysis approximately 3 to 4 cm proximal to the olecranon fossa.[59,124] Vascular watersheds are areas of poor blood flow that occur between the lateral trochlea and capitellum and in the supracondylar area, specifically the olecranon, coronoid, and radial head fossa (Figure 18.4).[59] This latter finding may partially explain why this area is relatively more prone to nonunion than other regions of the distal humerus.

The posterior aspect of the lateral column is covered by the distal origin of the medial head of the triceps muscle and, distally, by the origin of the anconeus. The brachioradialis and extensor carpi radialis longus originate from the lateral supracondylar ridge. The common extensor mass, consisting of the extensor carpi radialis brevis, extensor digitorum communis, and extensor carpi ulnaris, and the cephalad portion of the anconeus muscle originate from the lateral epicondyle, immediately posterior to the origin of the lateral collateral ligament complex. The lateral ligament complex and the common extensor origin blend together and do not have discrete origins.

Most surgical exposures of the distal humerus are performed using a posterior approach; an understanding of the anatomic relationships and paths taken by the ulnar and radial nerves is essential to the safe management of these injuries (Figure 18.5). In the intact humerus, the radial nerve can be found crossing the posterior aspect of the humeral shaft approximately 20 cm proximal to the medial epicondyle (74% of the length of the humerus) to 14 cm proximal to the lateral epicondyle (51% of the length of the humerus). At the lateral aspect of the humeral shaft, the radial nerve trifurcates into a branch to the medial head of the triceps, the lower lateral brachial cutaneous nerve, and the continuation of the radial nerve into the forearm (the posterior interosseous nerve and the superficial cutaneous nerve). After the trifurcation, the posterior interosseous continuation of the radial nerve pierces the lateral intermuscular

http://e-surg.com

septum approximately 10 cm proximal to the lateral epicondyle (the distal 36% of the humerus) (Figure 18.6).[30]

At the level of the distal attachment of the coracobrachialis to the humerus, approximately 10 cm proximal to the medial epicondyle, the ulnar nerve courses from the anterior compartment to the posterior compartment of the arm by piercing the medial intermuscular septum. The nerve travels along the anteromedial border of the medial head of the triceps along the medial intermuscular septum, ultimately traveling posterior to the medial epicondyle of the distal humerus (Figure 18.7). In approximately 70% of the population, a thick fascial band (arcade of Struthers) connects the medial head of the triceps to the intermuscular septum crossing the ulnar nerve approximately 8 cm proximal to the medial epicondyle.[113] An anatomic clue to the presence of this fascial band is to identify muscle fibers of the medial head of the triceps crossing superficial to the ulnar nerve.[113] As the nerve passes posterior to the medial epicondyle, it becomes enclosed in a fibrous sheath, the roof of the cubital tunnel. As the nerve exits the cubital tunnel, it courses between the two heads of the flexor carpi ulnaris, passes beneath the fibrous origin of the flexor digitorum superficialis, and travels distally through the anterior compartment of the forearm on the anterior surface of the flexor digitorum profundus. The first branch of the ulnar nerve provides sensory innervation to the elbow capsule.[113] After exiting the cubital tunnel, motor branches to the flexor carpi ulnaris can be identified. The remaining branches of the ulnar nerve are encountered in the distal forearm and hand.

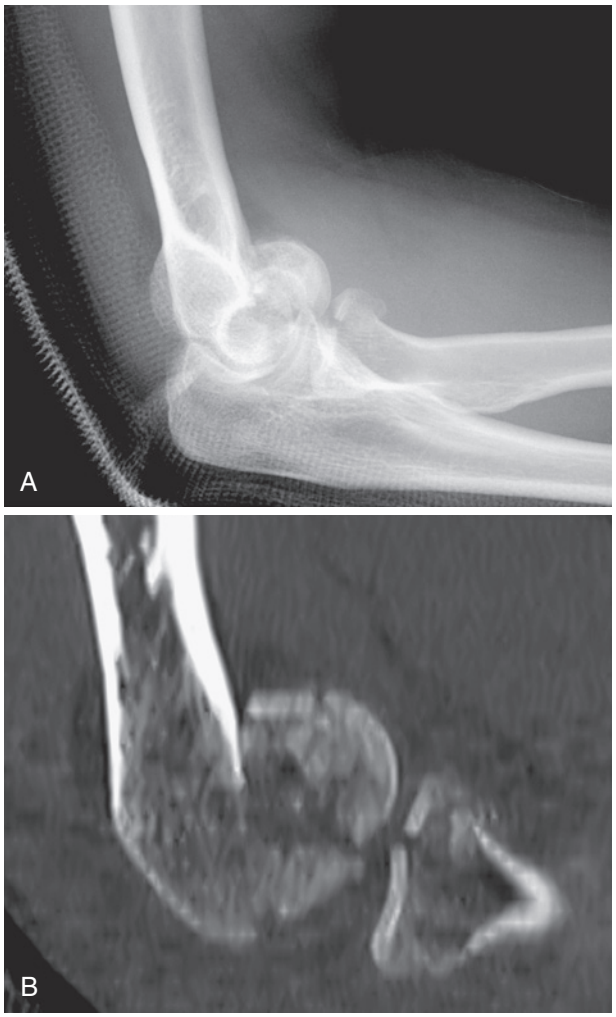

FIGURE 18.2 **A,** Lateral radiograph of coronal shear variant capitellar fracture. **B,** Sagittal reformation of same image more clearly identifies posterior comminution of distal portion of capitellum. The preoperative plan may now require use of bone graft, changing the anticipated exposure, or use of supplemental posterolateral plating techniques.

Classification of Distal Humerus Fractures

For decades, fractures of the distal humerus were collectively referred to as "T" or "Y" fractures, when they involved both columns, or as unicondylar fractures, when they involved only one column. With improvements and refinements in operative management over the past 30 years, a greater understanding of the complexity and variability of fracture patterns affecting the distal humerus has occurred. Ideally, a classification system should provide a basis for reporting results and permitting comparisons among surgeons and cohorts of patients. In addition, the classification should guide decision making and enable some degree of prognostication for each patient. Finally, the classification system should be easy to use, widely accepted, and reproducible.

At the present time, there is no fracture classification system for the distal humerus that fulfills these objectives adequately. The problem of intraobserver and interobserver variability has been found in classification systems for many types of fractures; this problem does not seem to be unique to classification

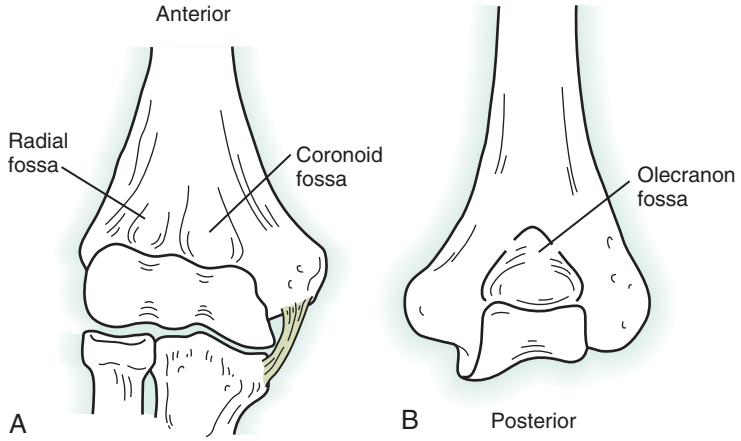

FIGURE 18.3 **A** and **B,** Anterior and posterior views of osseous distal humerus and important bony landmarks.

http://e-surg.com

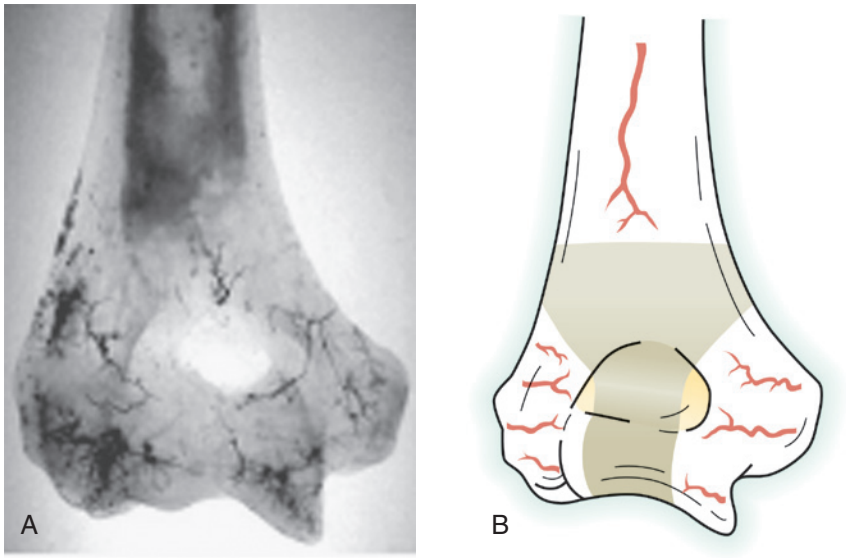

FIGURE 18.4 Actual injection study **(A)** and schematic representation **(B)** showing intraosseous blood supply of dorsal aspect of left distal humerus. Predominant blood supply to the lateral condyle is posterior; also note relative vascular watershed between medial condyle, lateral condyle, and humeral shaft. (**A,** From Kimball JP, Glowczewskie F, Wright TW: Intraosseous blood supply to the distal humerus, *J Hand Surg [Am]* 32:644, 2007.)

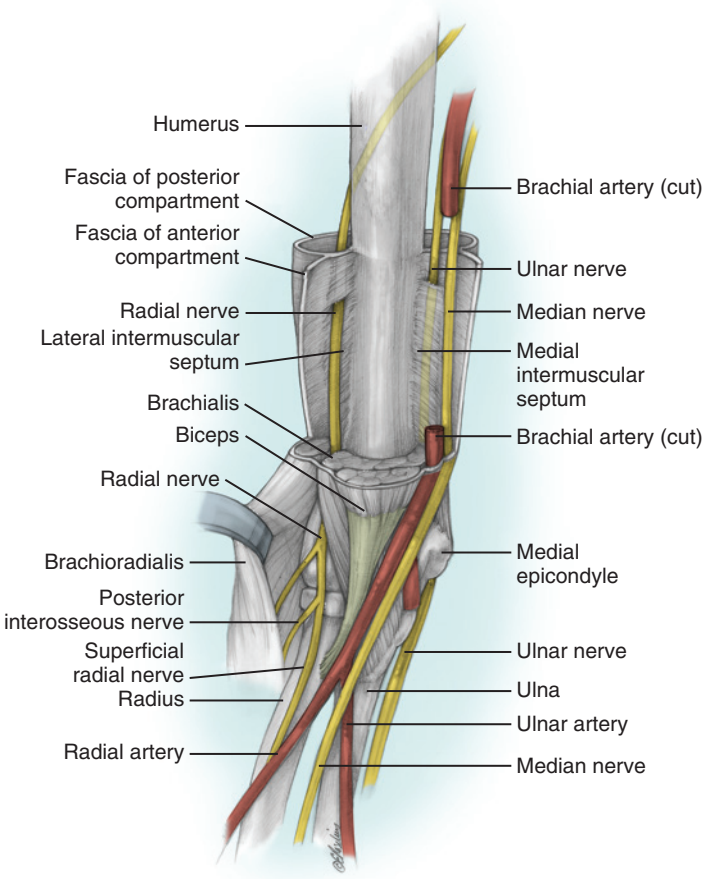

FIGURE 18.5 Relationships of major anatomic structures within upper extremity. Ulnar nerve travels from anterior compartment to posterior compartment, radial nerve passes from posterior compartment to anterior compartment through lateral intermuscular septum, and median nerve stays in anterior compartment between biceps and brachialis. (Copyright © Elizabeth Martin.)

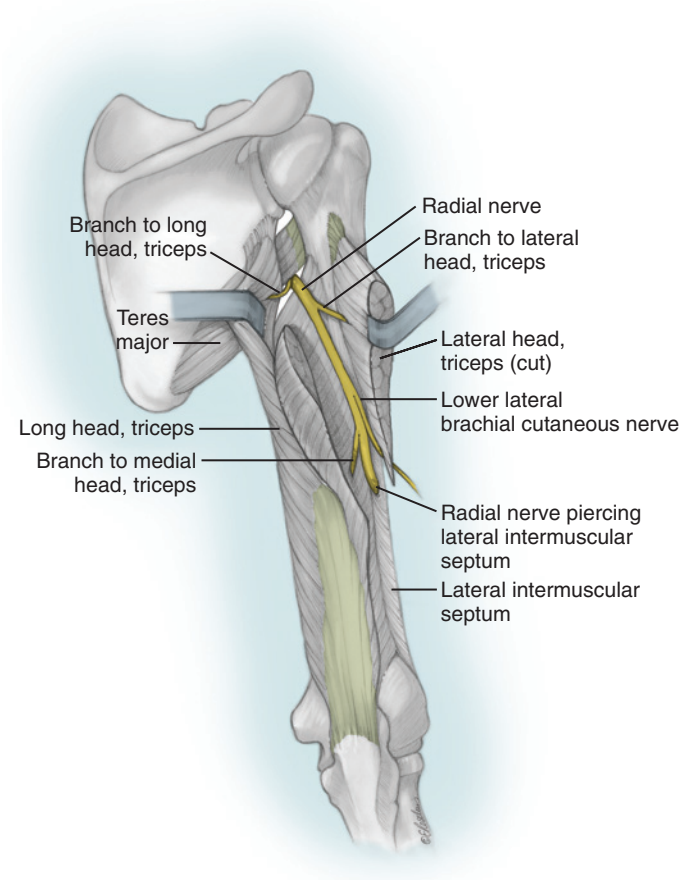

FIGURE 18.6 Posterior view of humerus focusing on midshaft to elbow joint. (Copyright © Elizabeth Martin.)

http://e-surg.com

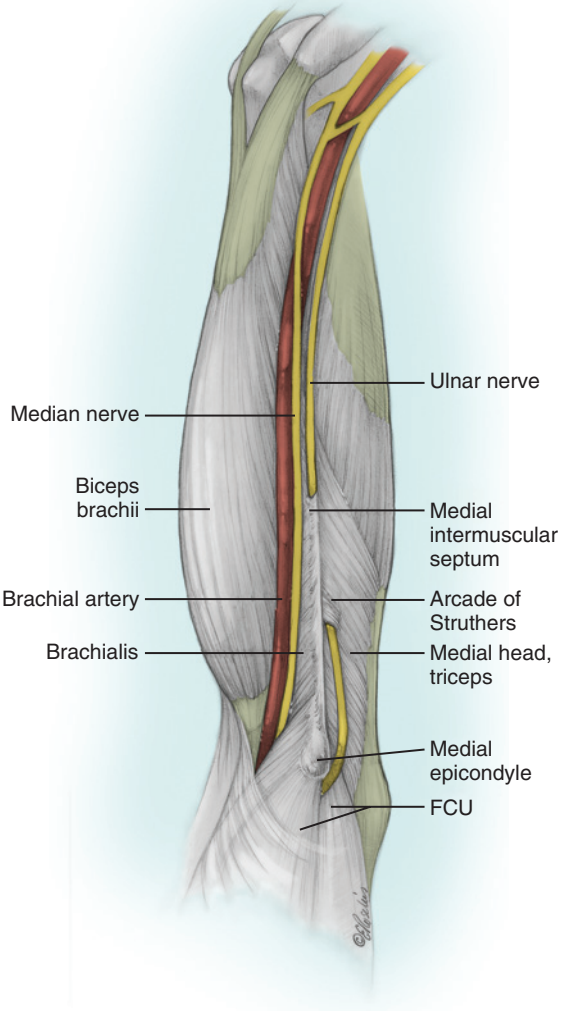

FIGURE 18.7 Course of ulnar nerve as it proceeds through medial intermuscular septum of upper extremity as it travels toward elbow. Note relationship of brachial artery to median nerve. *FCU,* Flexor carpi ulnaris. (Copyright © Elizabeth Martin.)

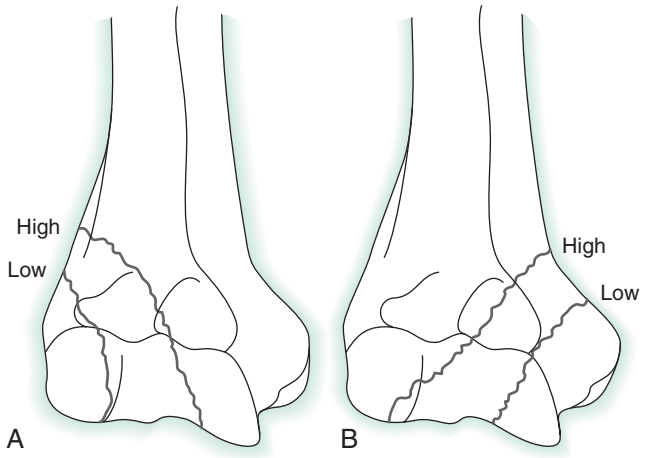

FIGURE 18.8 **A,** Lateral column fracture of distal humerus. **B,** Medial column fracture of distal humerus.

systems for fractures of the distal humerus. In addition, some patterns of fractures are more common in persons of a certain age than in others. Older patients often exhibit extensive comminution of the articular surface without the same pattern of column fracture described in the classification schemes (see section on fractures in elderly adults). The use of three-dimensional CT scanning may improve observer variability in the currently used distal humerus fracture classification systems.[17]

Comprehensive Classification Systems

Column Concept of Classification. Jupiter and Mehne[55] recommended that the distal humerus be described as two diverging columns supporting an intercalary articular surface, the trochlea, rather than as rounded projections known as condyles. Conceptualizing the distal humerus as medial and lateral columns more accurately describes the injury patterns and allows consistency in the general fracture categories. The Mehne and Matta classification[55,77] is based on surgical anatomic findings and the columnar concept and helps in formulating effective preoperative surgical tactics. The basic surgical aim is to restore all three elements of the distal humerus triangle (medial column, lateral column, and intervening trochlea) with enough stability to allow early functional movement. Using this classification system, there are three basic fracture categories: intraarticular, extraarticular intracapsular, and extracapsular. Intraarticular fractures are subclassified as single-columnar or bicolumnar injuries, capitellar fractures, or trochlear fractures. Extraarticular intracapsular fractures traverse both columns of the distal humerus without involving the articular surface and are uncommon fractures more likely to be seen in pediatric patients. Extracapsular fractures include injuries to the medial or lateral epicondyles.

Intraarticular Fractures

Single-column fractures. Single-column injuries are uncommon (Figure 18.8). These injuries are divided into medial or lateral *column* fractures, rather than medial or lateral *condyle* fractures as previously described by Milch.[79] Lateral column fractures are reportedly more common than medial column fractures.[79] Rather than emphasizing the involvement of the lateral trochlear ridge, as Milch suggests,[79] this classification system differentiates two types of single-column fractures: "high" fractures and "low" fractures. High fractures have the following characteristics:

- The fractured column contains the bulk of the trochlea.
- The ulna and radius follow the displacement of the fractured column.
- Internal fixation is predictable because of the size of the fragment.

Low single-column fractures have the opposite characteristics for each of the above-mentioned items. Originally, these injuries were thought to be the result of abduction or adduction forces, with involvement of the lateral trochlear ridge being a major determinant of elbow stability.[79] Conversely, Jupiter and Mehne[55] suggested that extensive capsular injury and collateral ligament rupture are more likely to be responsible for the ultimate displacement of the fragment than involvement of the lateral trochlear ridge.

http://e-surg.com

Bicolumnar fractures. Fractures that involve both columns are seen in most injuries to the distal humerus and, by definition, affect all three "sides" of the distal humerus triangle. In this classification system, bicolumnar fractures are classified in a descriptive fashion, with comminution being a variant superimposed on the basic fracture pattern (Figure 18.9).[55,77] The main patterns include the following:

1. "T" pattern, which may be high or low, depending on whether the transverse component of the fracture is above or below the superior limit of the olecranon fossa
2. "Y" pattern
3. "H" pattern
4. Lambda pattern, described as medial if the obliquely oriented supracondylar fracture line travels from proximal medial to distal lateral or as lateral if the fracture line travels from proximal lateral to distal medial

The value of this classification system is in differentiating fracture patterns that occur at or below the level of the olecranon and coronoid fossae.[100] More distal fractures produce small articular fragments that challenge secure fixation. The "H"-type injury produces a small trochlear fragment that may be completely devoid of soft tissue attachments. This fragment is frequently difficult to secure, and the potential for avascular necrosis exists.[100]

Extraarticular Intracapsular Fractures. In contrast to supracondylar fractures, transcolumnar fractures lie partially or entirely within the joint capsule of the distal humerus. Transcolumnar fractures display a main fracture line that crosses the distal humerus without involving the distal humeral articular surface. The lack of articular involvement differentiates these fractures from the more common bicolumnar (intraarticular) patterns. Transcolumnar fractures are distinguished from one another on the basis of the location and orientation of the major fracture line; this gives rise to four basic transcolumnar fracture patterns: high, low, abduction, and adduction (Figure 18.10). The high and low patterns can be subdivided further into flexion and extension subgroups. These fractures are uncommon in adults, and the literature specifically discussing this injury type is limited.[55] Several authors have suggested that this fracture, when encountered, is usually more common in elderly adults with osteopenic bone.[46] Important surgical

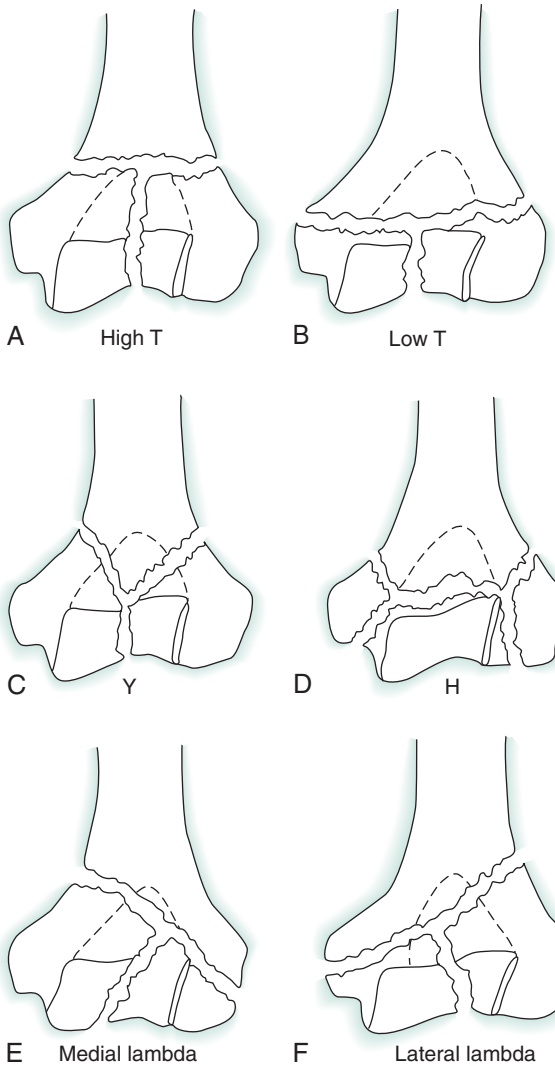

FIGURE 18.9 **A to F,** Bicolumnar classification of fractures of distal humerus.

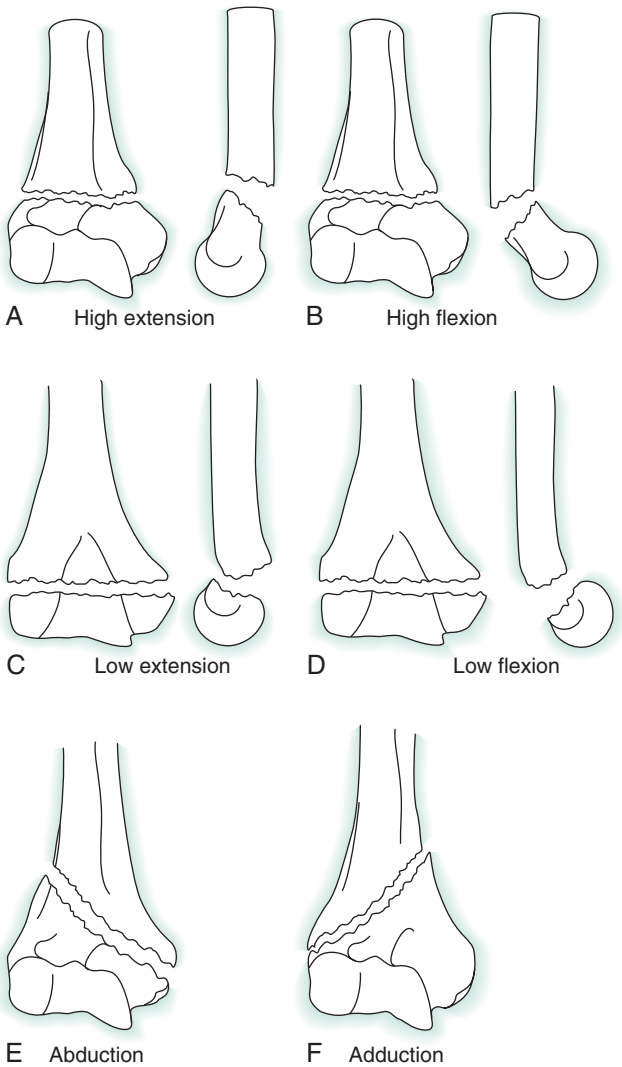

FIGURE 18.10 **A to F,** Transcolumnar classification system.

http://e-surg.com

considerations for management of this fracture type include the following:

1. The more distal the fracture is (low types), the more difficult neutralization of the articular fragment becomes. This situation is worsened in the presence of osteopenic bone.[46]
2. Fractures that are managed nonoperatively or with nonrigid fixation may develop excessive callus formation that obliterates the olecranon, coronoid, and radial fossae, resulting in a loss of motion.[46]

AO/ASIF Classification. The AO/ASIF classification is a comprehensive alphanumeric fracture classification system that distinguishes extraarticular injuries, partial articular injuries (where continuity is maintained between the shaft and a portion of the articular surface), and complete articular injuries.[90] In the three main categories, types A, B, and C, injuries are grouped according to increasing severity, intuitively suggesting that a partial articular injury is more severe than an extraarticular injury, and that a complete articular injury is more severe than a partial articular injury. Within each type, emphasis is placed on the comminution of the supracondylar metaphysis or the articular surface, or both. All three types are extensively subdivided to include most fracture patterns. Type C3 fractures are the most severe, with significant comminution of the articular surface and supracondylar area.

Classification of Fracture Patterns Unique to the Articular Surface

Although involvement of the articular surface is an integral component of most injuries of the distal humerus and a component of the classification systems already described, identification of fracture patterns unique to the articular surface continues to evolve. Conceptually, injuries of the articular surface of the distal humerus may be considered as a spectrum, rather than as discrete entities, because the components of the articular injury may be found in isolation (pure articular injury) or in association with supracondylar injury.

Fractures of the Capitellum. Fractures of the capitellum have been recognized since the mid-19th century. Despite their rarity, two types of fractures have traditionally been described.[22,76] Type I, or *Hahn-Steinthal fracture*, is a fracture of the capitellum that involves a large portion of the osseous structure of the capitellum. The fragment varies in size and usually contains a part of the adjacent ridge of the trochlea. Type II, or *Kocher-Lorenz fracture*, is superficial and mainly involves the chondral surface of the capitellum with very little bone attached. This fracture type essentially results in a shell of capitellar articular cartilage with minimal subchondral bone.[22,76] Subsequently, capitellar fractures have been classified into three types. Type I fractures are complete fractures of the capitellum (similar to the Hahn-Steinthal fracture), type II fractures are superficial (corresponding to the Kocher-Lorenz fracture), and type III fractures are comminuted. A fourth type of capitellar fracture, described by McKee and associates,[71] is termed the *coronal shear fracture*. This fracture involves the capitellum but also extends beyond the lateral trochlear ridge to include a variable, but significant, portion of the trochlea (Figure 18.11). The radiographic hallmark of the coronal shear fracture pattern is the *double-arc sign* on the lateral radiograph, which represents the subchondral bone of the capitellum and lateral trochlear ridge.[71]

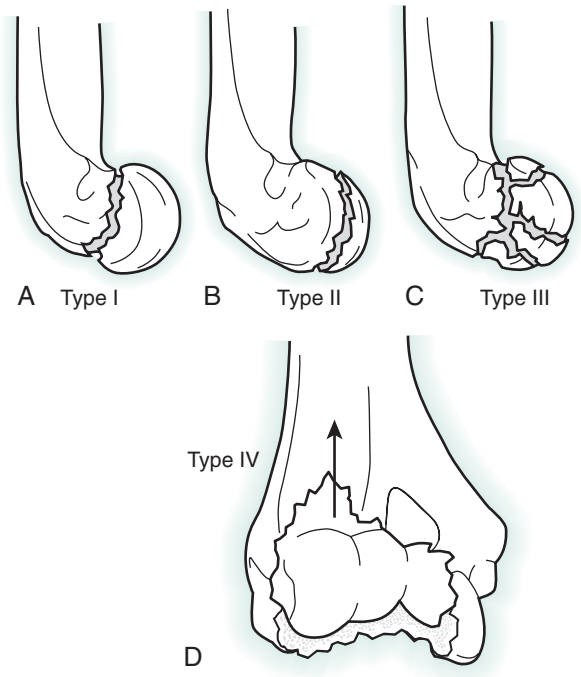

FIGURE 18.11 Four types of capitellum fractures. **A,** Type I fracture is a single fracture line of capitellum that involves a fair-sized piece of bone and anterior aspect of joint. **B,** Type II is a thin fragment, with very little bone attached to anterior cartilage. Type II fractures have much less bone attached to cartilage than seen in type I fractures. **C,** Type III is fracture of capitellum that is in multiple fragments. **D,** Type IV fracture includes capitellum but also extends medially to take off the lateral trochlear lip.

Dubberley and colleagues[21] proposed a classification system that aids with preoperative planning and the formulation of a surgical plan. Type 1 fractures primarily involve the capitellum with or without the lateral trochlear ridge, type 2 fractures involve the capitellum and trochlea as one piece, and type 3 fractures consist of fractures of the capitellum and the trochlea as separate fragments. Within each fracture type, the presence or absence of posterior condylar comminution is noted (Figure 18.12). Medial visualization and exposure are increasingly required with increasing fracture type, and the potential need for bone graft and plate fixation increases with posterior condylar comminution.

Despite the different fracture patterns and variations that exist, fractures of the capitellum are essentially shearing coronal plane injuries.[70] The mechanism of these fractures seems to be an axial load, with the final fracture configuration determined by the degree of elbow flexion at the time of loading.[71]

Fractures of the Trochlea. Isolated trochlear fractures are exceedingly rare injuries.[46,53] Although a formal classification system has not been developed, the two main patterns are fractures of the entire trochlear process and osteochondral fractures.[46,76] Jupiter and other authors[46,53] have suggested that the rarity of these injuries may be due to the trochlea lying protected within the depth of the semilunar notch of the olecranon, without capsular, muscular, or ligamentous attachments. The mechanism of injury remains speculative because of the rarity of the injury, but may involve the coronoid acting as a fulcrum when a force is applied to the flexed elbow.[53] The osteochondral

http://e-surg.com

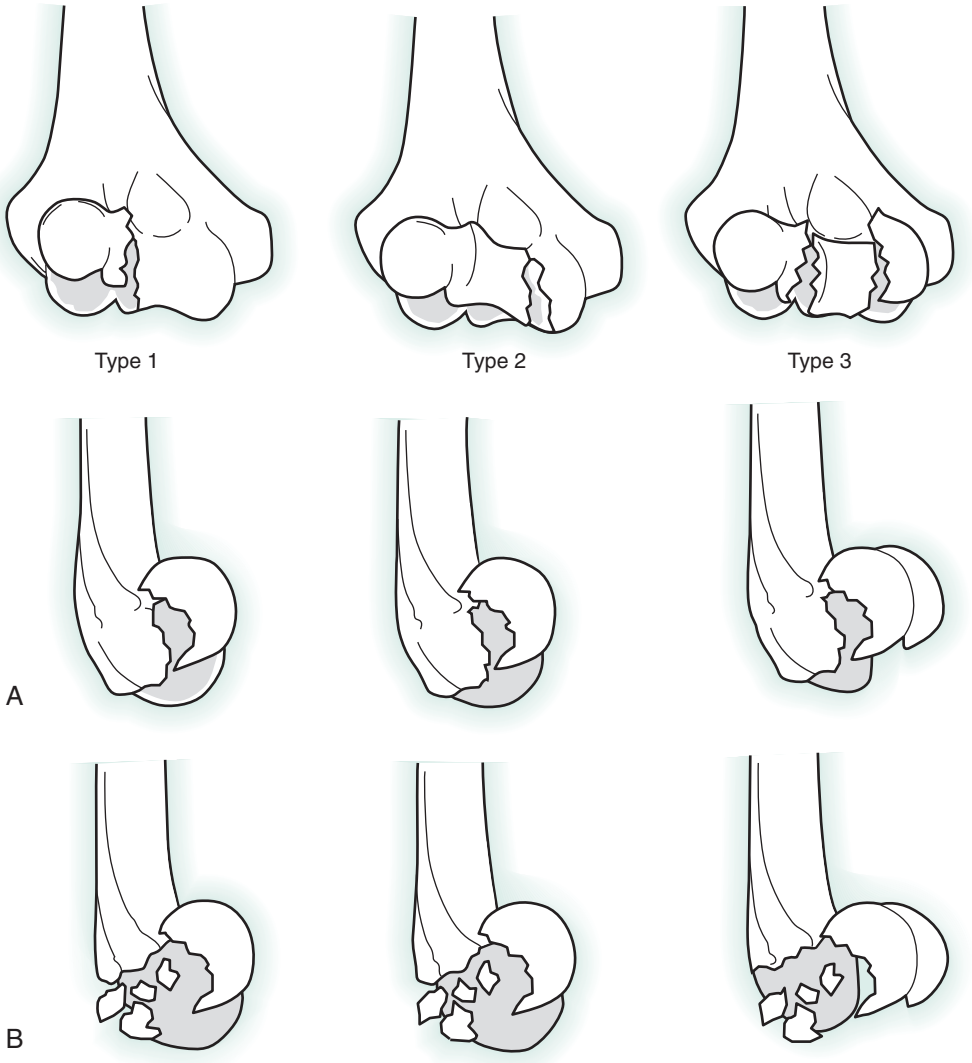

FIGURE 18.12 Type 1 fractures involve primarily capitellum with or without lateral trochlear ridge. Type 2 fractures involve capitellum and trochlea as one piece. Type 3 fractures consist of fractures of capitellum and trochlea as separate fragments. Further characterizations include absence **(A)** or presence **(B)** of posterior condylar comminution.

patterns may be associated with elbow dislocations, however, implying the involvement of a shearing force.

Other Articular Fracture Patterns. Emphasizing the fact that articular fractures of the distal humerus may represent a continuum of injury, Ring and associates[101] evaluated 21 patients with pure articular fractures of the distal humerus. The fracture fragments included and extended beyond the capitellum but did not extend above the base of the olecranon fossa. Five different patterns of injury were identified with increasing involvement of the posterolateral articular surface and medial articular surface (Figure 18.13), as follows:

Type 1 injuries are the coronal shear fractures previously described by McKee and colleagues.[71]

Type 2 fractures are type 1 fractures with involvement of the lateral epicondyle.

Type 3 fractures have associated impaction of the metaphyseal bone posterior to the capitellum.

Type 4 fractures have the additional feature of a fracture of the posterior aspect of the trochlea.

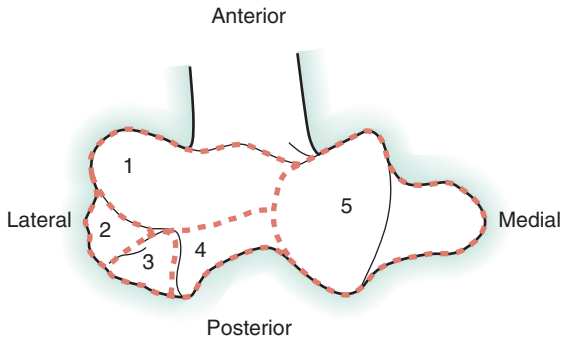

FIGURE 18.13 Classification of pure articular injuries of distal humerus.

Type 5 fractures are type 4 fractures with a fracture of the medial epicondyle.

These specific fracture types represent a progression of injury severity extending from an isolated articular component displaced in the frontal plane to combinations of shearing and

http://e-surg.com

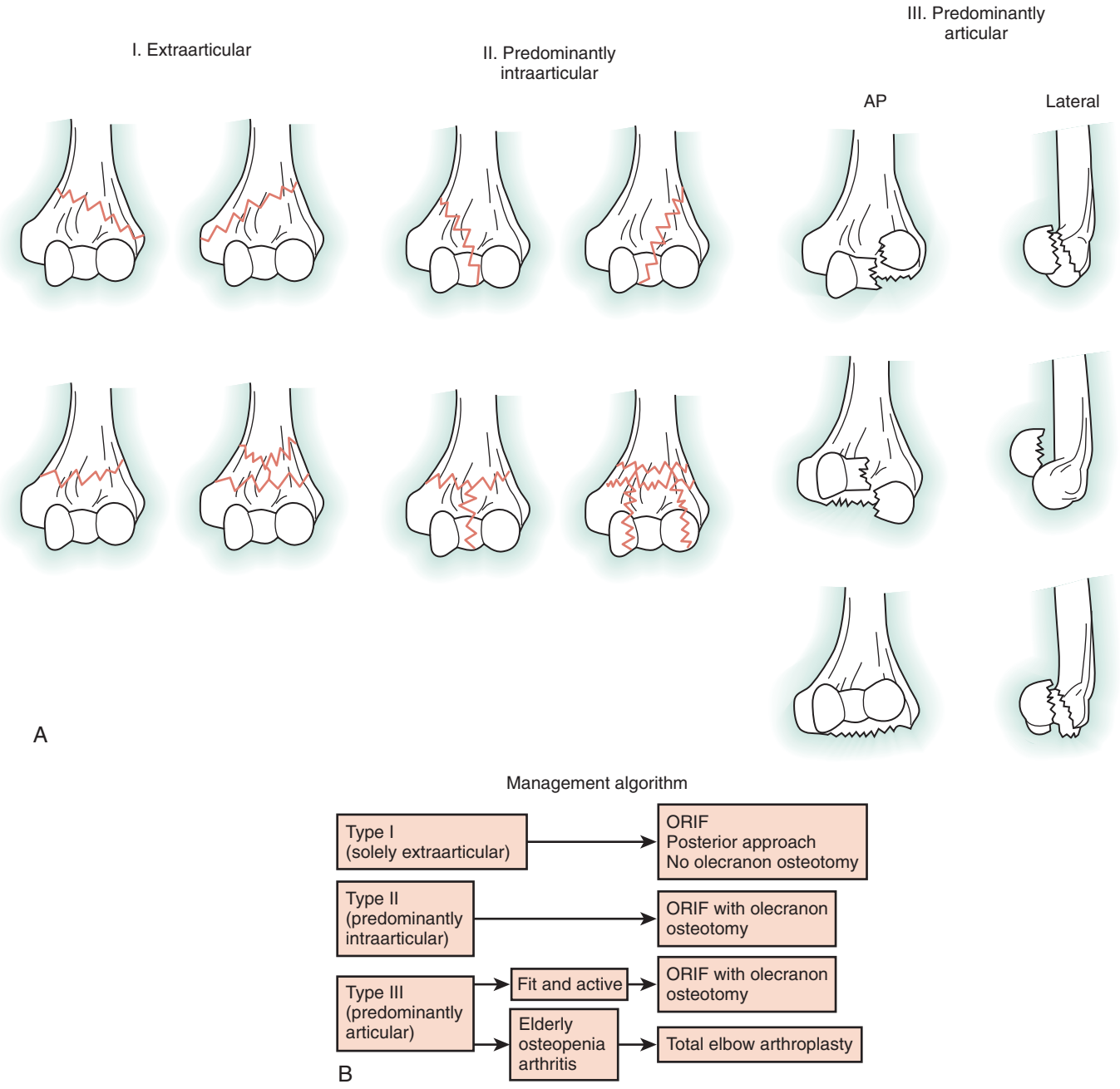

FIGURE 18.14 **A,** Clinically applicable classification system for fractures of distal humerus. **B,** Subsequent management algorithm using this classification as a functional tool. *AP,* Anteroposterior; *ORIF,* open reduction and internal fixation.

impaction injuries of the capitellum and trochlea with a limited zone of metaphyseal bone support. Because of the difficulty in appreciating some of the potential fracture fragments with standard radiographs, CT scanning with three-dimensional reconstructions may enhance comprehension and preoperative planning.[17,71,101]

Davies and Stanley[15] proposed a unifying classification system emphasizing clinical applicability and a management algorithm. Type I fractures are extraarticular and are analogous to AO/ASIF type A injuries. Type II injuries are single-columnar and bicolumnar fractures where the fracture lines begin in the distal humerus metaphysis and propagate into the trochlea or capitellum, or both. Type III fractures are fractures in which the fracture lines lie predominantly within the articular surface of the distal humerus but may extend proximally into the distal metaphysis below or at the level of the olecranon fossa (Figure 18.14, *A*). This classification system was noted to be reliable and reproducible and the observer variability was superior to that of either the AO/ASIF or the Mehne classification system. Although simplistic, the proposed management algorithm when used in conjunction with the proposed classification system may be useful for determining basic therapeutic options (see Figure 18.14, *B*).

Historical Review

The history of fracture care was marked by a significant change in management philosophy during the 1960s. The group responsible for the change is known as the Arbeitsgemeinschaft

http://e-surg.com

TABLE 18.1 Closed and Indirect Methods for Treatment of Distal Humerus Fractures

Author	Year	Description
Hitzrot[42]	1932	Described 25 patients treated with traction. Based on his results, Hitzrot strongly advised against open reduction, stating that anatomic reduction was of secondary importance. Eastwood would later agree, stating that perfect anatomic reduction is unnecessary to obtain a good result. Few agree with this view today.
Reich[97]	1936	Described reduction technique using ice tongs to compress condylar displacement, with portable traction to allow the patient to be ambulatory. In six patients, the results were noted to be good in three, fair in two, and poor in one. These outcomes were believed to be better than complications and results shown by ORIF.
Eastwood[23]	1937	Reviewed 14 patients treated with a collar-and-cuff support followed by early elbow mobilization (credited to Thomas). The results were so satisfactory that Eastwood believed it was unwise to use any other technique. Eastwood concluded by stating that function was more important than radiographic appearance.
Watson-Jones[121]	1944	Classic fracture textbook concluded that, "Operative reduction and internal fixation is not justified by the results." Surgical dissection, avascularity of fragments, and use of metallic implants were believed to result in dense adhesions and stiffness. Manipulative reduction, brief casting, and motion were recommended.
Riseborough and Radin[102]	1969	Unveiled Riseborough-Radin classification system. The authors suggested that this classification allowed therapeutic decision making based on amount of rotatory deformity and comminution. Despite this therapeutic classification system, Riseborough and Radin believed that ORIF was rarely indicated. This classification system was used for approximately 2 decades. The best results were obtained in 22 of 29 patients treated with casting or traction.
Brown and Morgan[6]	1971	Described "bag of bones" technique for closed management of intercondylar "T"-shaped fractures of the distal humerus. Flexion-extension arc in 6 of 10 patients was >105 degrees. Better motion seemed to be obtained in elderly patients, with younger adult patients having restricted arcs <85 degrees. These results continued to challenge the results obtained by proponents of ORIF. The role of the "bag of bones" technique in elderly patients was strengthened.
Horne[44]	1980	Review of 50 patients with supracondylar, condylar, and supracondylar/intercondylar fracture patterns. Of 29 patients treated surgically, 16 had poor results compared with 6 of 21 patients treated with casting. Inadequate internal fixation and prolonged postoperative immobilization were responsible for the poor results. Horne recommended conservative treatment for supracondylar/intercondylar distal humerus fractures, particularly when comminuted.

ORIF, Open reduction and internal fixation.

für Osteosynthesefragen (AO), or Association for the Study of Internal Fixation (ASIF) in English-speaking regions. The general fracture principles developed during the early AO days remain true today and are particularly applicable to fractures of the distal humerus. These principles include the following:

1. Fracture reduction and fixation to restore anatomic relationships, particularly of the articular surface
2. Stability by fixation or splintage, as the type of fracture and injury requires
3. Preservation of the blood supply to soft tissues and bone by careful handling and gentle reduction techniques
4. Early and safe mobilization of the part and the patient

Before the development of the AO and before their principles were widely accepted, strong opposition to operative management of distal humerus fractures existed. Reich[97] recognized, however, that open reduction was the only procedure that offered any hope of complete functional restoration. He also recognized that the unsatisfactory results seen with open treatment were due to the "frank exposure" and the difficulty in reducing and then maintaining reduction.[97] In the decades preceding the AO advances, numerous publications debated the superiority of results in patients treated with open versus conservative methods.[11,12,23,42,79,97,117] Numerous closed techniques were described, including manipulation and casting, olecranon traction, cast traction, and condylar reductions using ice tongs or clamps.[42,97,102] Influential authors such as Watson-Jones[121] and the contradictory views of the 1964 and 1966 Instructional Course Lectures from the American Academy of Orthopaedic Surgeons on these fractures continued the controversy.[80] Although known for their classification system, Riseborough and Radin[102] concluded their article by noting that open reduction and adequate internal fixation are not easy and would seem to offer little chance of a good outcome. These authors believed that open reduction was very rarely indicated. Advocates of either closed or open management recognized that the inability to obtain and maintain a reduction and the subsequent need for rigid immobilization ultimately resulted in poor outcomes (Table 18.1).[7,23,44,50]

During the late 1960s and early 1970s, an increasing number of publications reported satisfactory results with operative reduction and fixation of distal humerus fractures.[7,11,39,53,57,74,115,119,125] A review of the operative techniques contained in these reports shows an increasing use of plate and screw fixation, rather than Kirschner wire fixation, and recommendations of early postoperative mobilization. The importance of proper technique was illustrated by Johansson and Olerud,[50] who suggested that "The osteosynthesis demands as stable fixation as possible, and in our experience this is best obtained by screws, but at the same time exact apposition of the fracture surfaces is required." They further noted that stable osteosynthesis eliminated the need for postoperative immobilization.[50]

The 1980 report by Horne[44] underscored the poor results that are obtained when the goals of open reduction and internal fixation (ORIF) are not met. Horne[44] wrote, "The availability of excellent equipment for the internal fixation of fractures is

http://e-surg.com

not an indication for its use," ultimately concluding that except for simple fractures and unicondylar fractures, conservative management is the recommended treatment. Shortly thereafter, Jupiter and colleagues[56] published the results of 34 intercondylar fractures of the humerus managed operatively using the techniques advanced by AO/ASIF. The high proportion of good or excellent results, using a score incorporating range of motion and pain, finally solidified the advantages of ORIF for these fractures.

The last 3 decades of the 20th century have shown tremendous advances in understanding of the various fracture patterns, the techniques used to obtain anatomic reduction and fixation, and the evaluation of these results. Improved appreciation of fracture patterns and techniques combined with substantial progress in understanding the surgical anatomy of the elbow has allowed dramatic advances in posttraumatic management of stiff or arthritic elbows. Advances in arthroplasty and newer fixation techniques are options for the management of comminuted fractures of physiologically sound but elderly patients. The optimal implant remains unknown, however. The use of tensioned-wire fixators, allograft materials, and vascularized autografts has permitted salvage of the most challenging acute high-energy injuries in younger patients. Last, outcome-scoring instruments may further assist in the assessment of treatment (Table 18.2).

OPERATIVE MANAGEMENT OF DISTAL HUMERUS FRACTURES

Operative management of specific fractures of the distal humerus requires identification of fracture and soft tissue injury and patient characteristics, including age, associated injuries, comorbidities, and functional level before injury. These considerations are used to determine the reconstructive tactics, including patient positioning, operative approach, and choice of fixation implants. Important preoperative decisions include the following:

1. Determination of whether the fracture is reconstructible or if the patient is better served by elbow arthroplasty
2. Estimation of the need for visualization of the articular surface to determine the surgical approach and handling of the extensor mechanism
3. Identification of a stable fixation construct that would allow early unrestricted range-of-motion movement

Timing of Operative Intervention

Fractures of the distal humerus are best managed early, but as with most complex intraarticular fractures, definitive treatment should be delayed until optimal surgical resources and personnel and the necessary implants are available. Preoperative planning is essential and should include imaging studies necessary to request the resources mentioned earlier. Patients with isolated injuries are managed at the discretion of the surgeon and based on readiness of the operating suite and the availability of implants. Elderly patients or patients with associated comorbidities must be stabilized before fracture reconstruction. Patients who are managed within 24 hours seem to have fewer complications associated with heterotopic ossification and elbow stiffness and may be more likely to return to work.[65]

Polytrauma Patients

Patients with trauma of multiple bones or associated multisystem trauma are managed according to their overall status and prioritization of their other injuries. This situation may result in a significant delay in definitive management ranging from days to weeks. Such delays ultimately make fracture reduction and fixation more difficult and jeopardize the long-term outcome. Close collaboration with the trauma team leader, general surgeon, or intensivist allows these team members to appreciate the importance and benefits of early fracture fixation. Similarly, the treating orthopedist should be available to proceed with fixation when the patient has been stabilized and cleared for surgery.

Open Fractures

Open fractures are managed urgently with irrigation and débridement. Definitive internal fixation should be applied when the wound is free of contamination and the general condition of the patient permits the procedure.[88] McKee and coworkers[73] reviewed the results of 26 open intraarticular supracondylar fractures managed with a posterior exposure and medial and lateral column plating. The overall infection rate in this series was 11% (3 of 26); however, only one patient developed a deep infection requiring surgical débridement.[73] Other authors have noted a deep infection rate of 28% in high-energy fractures.[34] A much larger proportion of Gustilo type III fractures was noted in the latter study compared with McKee's report (45% vs. 15.4%) and may account for the apparent discrepancy in infection rates. Not surprisingly, open fractures have been shown to have worse functional outcomes than their closed counterparts.[81]

Fractures in Elderly Adults

Successful execution of the principles of ORIF becomes increasingly more difficult in elderly patients because of fracture comminution, poor bone quality, inadequate fracture stability, and a relative intolerance of joint immobilization. Although good results have been shown in many series, complication rates approaching 30% have also been documented.[47,51,63,95,114] In response to these poor outcomes, some authors have advocated TEA as a primary treatment method.[13,58,83,89,96] Although early results of TEA for distal humerus fractures are encouraging, long-term data regarding loosening rates, periprosthetic fracture, and functional outcomes are scant. It is nearly impossible to carry out successfully a truly randomized clinical trial because often the reason for abandoning internal fixation is the practical limitation imposed by the bone quality and degree of comminution. In addition, a failed total elbow replacement in an otherwise active patient can be devastating.

Open Reduction and Internal Fixation in Elderly Adults. The ideal of stable ORIF followed by early joint mobilization and rehabilitation is usually achievable in younger patients, but elderly patients with fracture of the distal humerus may require different strategies to obtain a satisfactory result. In response to the difficulties in achieving adequate fixation in osteopenic elderly patients with distal humerus fracture, modifications to the traditional dual-plate fixation techniques have evolved, including the use of a supplemental third plate,[52,54,55] locking plates,[62,64,109] Kirschner wire augmentation,[82] and parallel plating techniques.[116] A review of ORIF in elderly patients has revealed

http://e-surg.com

TABLE 18.2 Open Methods for Treatment of Distal Humerus Fractures

Author	Year	Description
Van Gorder[117]	1940	Reported eight patients with fractures of distal humerus operatively managed using posterior "triceps-turndown" approach (credited to Campbell) where an inverted "V" of the triceps aponeurosis is incised and reflected distally to gain exposure. Subsequent authors used it for open reduction of similar fractures.
Cassebaum[12]	1952	Used olecranon osteotomy for management of nine "T" and "Y" fractures of distal humerus. This is apparently the first report of the transolecranon approach for management of distal humerus fractures. The original description was credited to MacAusland[67] in 1915.
Milch[79]	1964	Classic early work on isolated fractures of humeral condyles, their injury mechanism, and their relationship with elbow dislocation. It was hypothesized that involvement of the lateral wall of the trochlea was associated with injuries that also led to elbow dislocation. In elbows with dislocations, Milch recommended open treatment.
Miller[80]	1964	This Instructional Course Lecture reviewed a 3-year experience of distal humerus fractures treated with closed means versus ORIF. In one of the first comparative series of distal humerus fractures, Miller noted that the operative group had a substantially greater elbow range of motion than the closed treatment group (111 degrees vs. 47 degrees). Miller was convinced that ORIF was the procedure of choice, but recognized the following limitation: "If the arm requires immobilization after open reduction and fixation, then the advantage of surgery is lost."
Cassebaum[11]	1969	Reported 36 distal humerus "T" and "Y" fractures treated with internal fixation using transolecranon approach. Recognized elbow arc of 50 to 165 degrees as excellent because most tasks could be completed within this range. Cassebaum's range-of-motion criteria for excellent, good, and fair were used extensively in subsequent reports.
Bryan and Bickel[7]	1971	Reviewed 25 operatively managed distal humerus fractures treated through posterior approach. Bryan and Bickel preferred screw fixation rather than Kirschner wires and recommended early mobilization after secure internal fixation. They suggested that their patients would not have done as well with closed methods but that the open technique should be done by an experienced surgeon. They also warned that occasionally the difficulties encountered during ORIF of comminuted distal humerus fractures "may be mortifying." This article was presented during a period when there was no consensus in the literature regarding the best method of treatment for these fractures.
Scharplatz and Allgower[105]	1975	Review of 105 fracture-dislocations of elbow. Principles of AO operative treatment of the distal humerus were outlined: reconstruction of the joint surface first, the trochlea being the most important part, and then connection to the shaft of the humerus.
Jupiter et al[56]	1985	Results of 34 intercondylar fractures of distal humerus treated with operative fixation using AO techniques; 27 of 34 patients obtained good to excellent results at a mean of 5.8 years. Jupiter and colleagues confirmed the ability to achieve improved and more predictable results with operative treatment even in a comminuted fracture.
Zagorski et al[125]	1986	Compared results of 42 intraarticular fractures of the distal humerus; 29 were treated operatively with screws or plate and screw constructs, and 13 were treated nonoperatively. Of patients, 76% treated with open techniques had a good to excellent result compared with 8% in the conservatively treated group. Zagorski and associates believed that final fracture reduction was related to functional end results.
Jupiter et al[57]	1988	Jupiter and coworkers managed 22 unicondylar fractures operatively; 18 had good to excellent results. This article illustrated AO principles applied to unicondylar fractures.
Helfet and Hotchkiss[36]	1990	Biomechanical study evaluated implant configurations and distal humerus fracture stability. The 90-degree orthogonal plate construct was identified and proven to be mechanically superior. Helfet and Hotchkiss could not find a difference between tubular plates, 3.5-mm reconstruction plates, or mixed plates.
John et al[51]	1994	First large series evaluating contemporary ORIF techniques in distal humerus fractures in elderly patients. Average age was 80 years (range 75 to 90 years); 85% were thought to have a functional arc of motion (>90 degrees); 66% had no pain. Implant failures were related to use of tubular plates.
Garcia et al[28]	2002	Consecutive series of 19 patients all >60 years old treated with primary TEA for nonreconstructible fracture of distal humerus. There was no associated inflammatory illness; 3-year follow-up showed 68% with no pain and a mean Mayo score of 93 (excellent). This article shows early advantages of TEA in this patient population. Long-term data are lacking, however. ORIF versus TEA in elderly patients continues to be debated.

ORIF, Open reduction and internal fixation; *TEA*, total elbow arthroplasty.

satisfactory results for the most part. Pereles and colleagues[95] showed an average arc of motion of 112 degrees, a functional Mayo Elbow Performance Score, and no difference in the SF-36 score compared with normal data in 14 patients with distal humerus fractures treated with ORIF. Good or excellent results were achieved in 12 patients, but only 25% of patients reported no pain. The mean age in this group was 70 years.

John and associates[51] evaluated 49 older patients (mean age 80 years) an average of 18 months after ORIF. Good or very good results were achieved in 85%, with 85% having a range of motion of 90 degrees or greater; 66% of these patients reported no pain. This group included extraarticular fractures (16%), unicolumnar fractures (27%), and bicolumnar fractures (57%). Huang and coworkers[47] retrospectively reviewed 19 patients older than 65 years with distal humerus fractures treated with ORIF. In this series, all fractures united with a mean time to union of 14.6 weeks, and all patients showed a good-to-excellent result based on the Mayo Elbow Performance Score.

http://e-surg.com

Other more recent studies have shown far less satisfactory results, however, with higher complication rates and additional surgeries (Table 18.3).

Total Elbow Replacement in Elderly Adults. Early clinical experiences with elbow arthroplasty for various degenerative conditions showed variable results, with high rates of unsatisfactory outcomes related to loosening and instability. Advances in implant technology and surgical technique have led to predictably good outcomes in properly selected patients. The available literature evaluating elbow arthroplasty in older patients with acute distal humerus fractures shows excellent early results, with a satisfactory flexion-extension arc of approximately 110 degrees and excellent relief of pain.[13,26-28,93,96] The length of follow-up in these studies is 2 to 4 years and does not address the long-term concerns of implant loosening, mechanical failure, revision requirements, and functional implications.

More recently, Kamineni and Morrey[58] evaluated the results of 49 distal humerus fractures in 48 elderly patients treated with TEA after an average of 7 years. The authors showed high functional outcome scores, but with a relatively higher rate of postoperative complications than seen in other studies. They noted a regression of the initial flexion-extension arc by 25 degrees, ultimately still averaging a functional arc of 24 to 131 degrees. Although long-term results in patients with TEA for inflammatory arthritis do seem durable,[32,41,108,123] the results of TEA in patients with posttraumatic arthritis show lower patient satisfaction and possibly greater mechanical failure rates than in patients with inflammatory arthritis.[41,108] A patient seeking to engage in high-demand activities is a poor choice for TEA (Table 18.4).

In one of the few comparative studies, Frankle and associates[26] compared the results of TEA with ORIF in women older

TABLE 18.3 Clinical Outcomes After Open Reduction and Internal Fixation of Distal Humerus Fractures in Elderly Patients

Reference	No. Patients (Mean Age)	No. Good-to-Excellent Results	Mean Postoperative Flexion-Extension Arc	No./Type of Complications	No. Secondary Procedures
John et al[51]	49 (80 yr)	31/39 complete follow-up (79%)	85% with minimum of 30 to 120 degrees	10 (20%)/1 wound infection, 1 nonunion, 2 broken plates, 6 transient ulnar neurapraxias	2: 1 wound débridement for infection, 1 broken implant removal
Pereles et al[95]	18 (71 yr)	12/12 complete follow-up (100%)	18 to 130 degrees	2 (11%)/2 loose implants	1: revision for loosened implants
Huang et al[47]	19 (72 yr)	19 (100%)	17 to 128 degrees	2 (10.5%)/1 superficial wound infection, 1 ulnar nerve injury	None
Srinivasan et al[114]	21 (85 yr)	12 (57%)	22 to 100 degrees	7 (25%)/4 wound infections, 2 nonunions, 1 heterotopic ossification	1: removal of implants secondary to infection
Korner et al[63]	45 patients (73 yr)	58%	Median arc 100 degrees	13 (29%)/12 implant failure and screw loosening, 1 persistent ulnar neuropathy	7: all secondary to implant failure or loosening

Adapted from Strauss EJ, Alaia M, Egol KA: Management of distal humeral fractures in the elderly. *Injury* 38(Suppl 3):S10–S16, 2007.

TABLE 18.4 Clinical Outcomes of Primary Total Elbow Arthroplasty for Treatment of Distal Humerus Fractures in Elderly Patients

Reference	No. Patients (Mean Age)	No. Good-to-Excellent Results; Mean Mayo Elbow Score	Mean Postoperative Flexion-Extension Arc	No./Type of Complications	No. Secondary Procedures
Cobb and Morrey[13]	20 (72 yr)	20 (100%); 95	25 to 130 degrees	5 (25%)/1 ulnar component fracture, 3 ulnar neurapraxias, 1 reflex sympathetic dystrophy	1: revision fractured ulnar component
Ray et al[96]	7 (82 yr)	7 (100%); 92	20 to 130 degrees	1 (14%)/1 superficial wound infection	None
Gambirasio et al[27]	10 (85 yr)	10 (100%); 94	23.5 to 125 degrees	1 (10%)/1 heterotopic ossification	None
Garcia et al[28]	19 (73 yr)	16/16 complete follow-up (100%); 93	24 to 125 degrees	1 (5%)/1 superficial wound infection	None
Kamineni and Morrey[58]	49 (67 yr)	40/43 complete follow-up (93%); 93	24 to 131 degrees	17 with at least 1 complication (35%)/11 wound infections, 3 neurologic symptoms, 3 periprosthetic fractures, 3 loose implants	10: 5 wound débridements, 2 revisions for periprosthetic fracture, 3 revisions for loose components

Adapted from Strauss EJ, Alaia M, Egol KA: Management of distal humeral fractures in the elderly. *Injury* 38(Suppl 3):S10–S16, 2007.

http://e-surg.com

than 65 years with distal humerus fractures. Patients treated with TEA showed significantly better results using the Mayo Elbow Performance Score than patients treated with ORIF. The authors suggested that women older than 65 years with significant associated comorbidities (e.g., rheumatoid arthritis, osteoporosis, and conditions requiring systemic steroids) and the presence of articular comminution be managed with TEA. Provided that the articular fracture components are large, however, these authors recommended ORIF as long as the patient's physiologic age is less than 90 years.

McKee and colleagues, in a prospective randomized controlled trial of ORIF versus TEA for displaced intraarticular distal humerus fractures in elderly patients, concluded that in patients who are not amenable to stable fixation with ORIF, TEA is the preferred alternative treatment modality.[75]

We agree with the previously mentioned studies of Frankle and associates[26] that successful management of these patients must take into account the patient's physiologic age, functionality, associated comorbidities, and fracture characteristics. Specific fracture characteristics in this patient population that are unreliably stabilized with internal fixation include the following:

- Significant comminution of the trochlea
- Associated coronal plane fracture patterns
- Fractures that occur almost entirely below the olecranon fossa

In these injuries, the small fragments combined with frequently coexisting osteoporosis make TEA an attractive alternative (Case Study 18.1). CT is particularly useful in assessing the presence of coronal plane fracture fragments. Patients who are unable or unwilling to refrain from strenuous physical activity must be extensively counseled regarding the risks of implant loosening and periprosthetic fracture and the potential for a poor outcome. In these patients, ORIF with techniques to obtain union of the distal humerus, including postoperative immobilization, should be strongly considered, rather than TEA.[35]

Patient Position and Anesthesia

Fractures of the distal humerus can be managed with the patient in the supine, lateral, or prone position, with the choice based on the anticipated exposure, the presence of other injuries, and surgeon preference.[38,74,92,105] The lateral and prone positions (Figure 18.15) are most commonly employed when proceeding

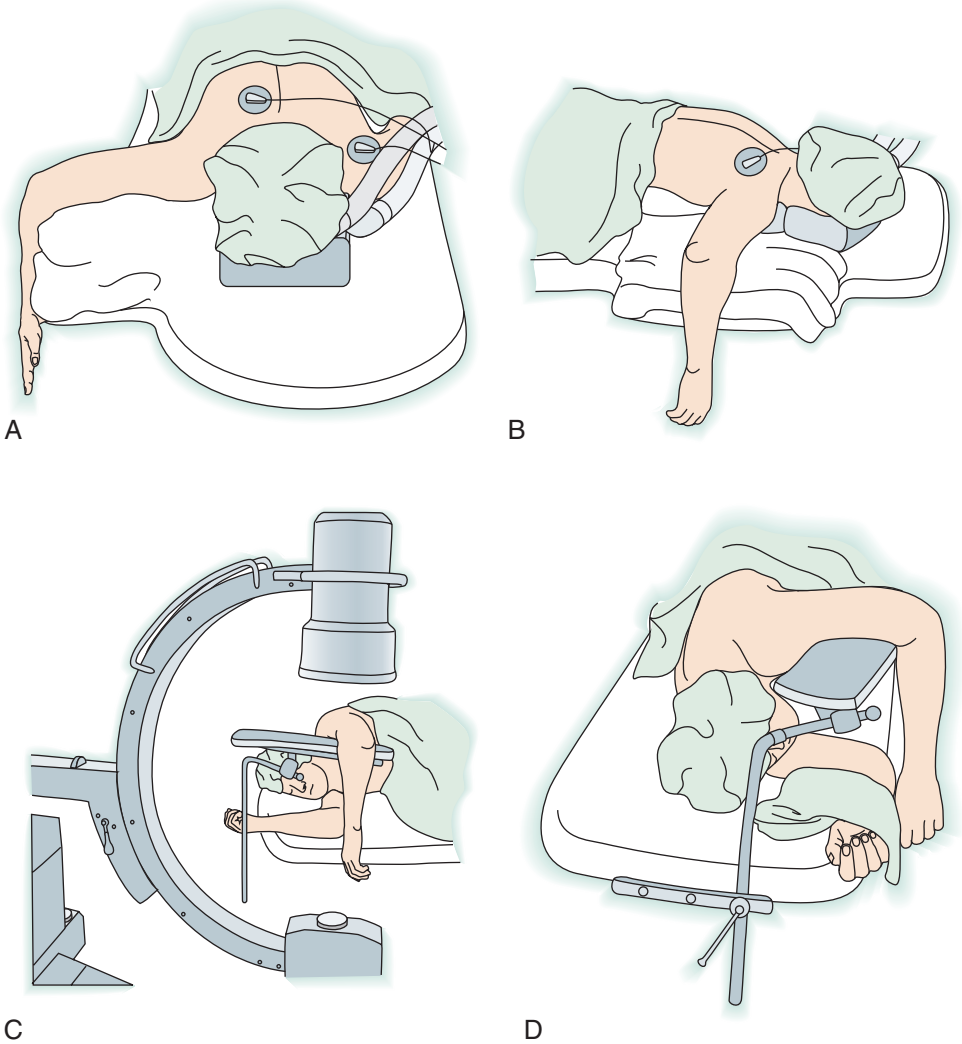

FIGURE 18.15 **A** and **B,** Surgical patient in prone position before open reduction and internal fixation. **C** and **D,** Same patient in lateral position. Note "C"-arm used for anteroposterior radiographs **(C)**.

http://e-surg.com

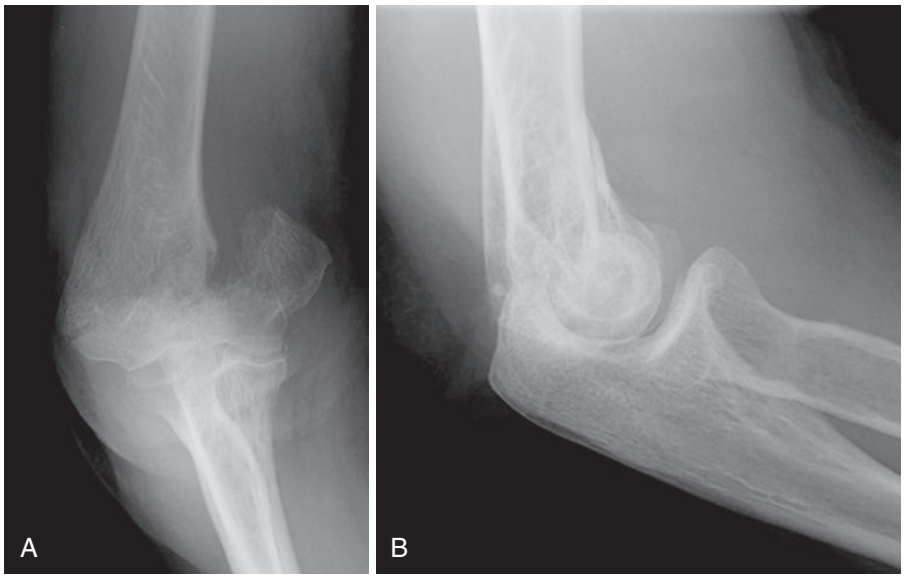

eFIGURE 18.1

CASE STUDY 18.1 Geriatric Total Elbow Arthroplasty

A 74-year-old woman has a low-energy distal humerus fracture that occurred when she fell from a standing position (eFigure 18.1). She has no significant associated comorbidities.

Your preferred treatment method is:

A. Open reduction and external fixation (ORIF) via olecranon osteotomy
B. ORIF via a triceps-sparing exposure
C. Total elbow arthroplasty
D. Cannot determine without CT scanning

Correct answer:

C. Total elbow arthroplasty

The injury pattern is that of a very low, comminuted distal humerus fracture with significant osteopenia. CT scanning is likely to confirm the comminution but is not essential. ORIF is extremely challenging and if performed should be done using a triceps-mobilizing exposure rather than an osteotomy because of the difficulty in switching to an arthroplasty in the setting of an osteotomy.

The degree of comminution is displayed in eFigure 18.2.

A cemented total elbow arthroplasty procedure was performed using the Bryan-Morrey triceps-sparing approach to the elbow (eFigure 18.3).

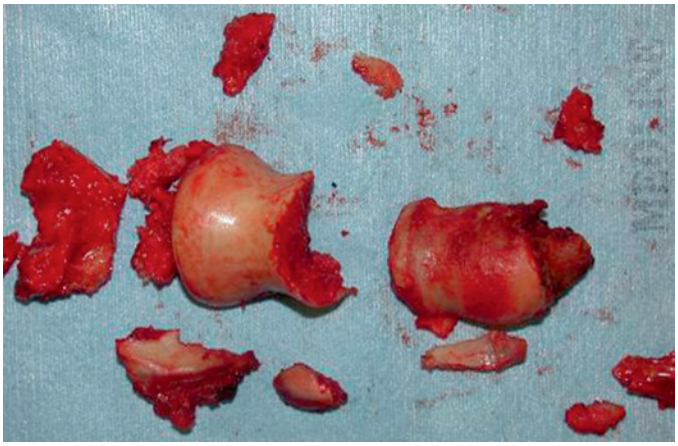

eFIGURE 18.2 Intraoperative photograph.

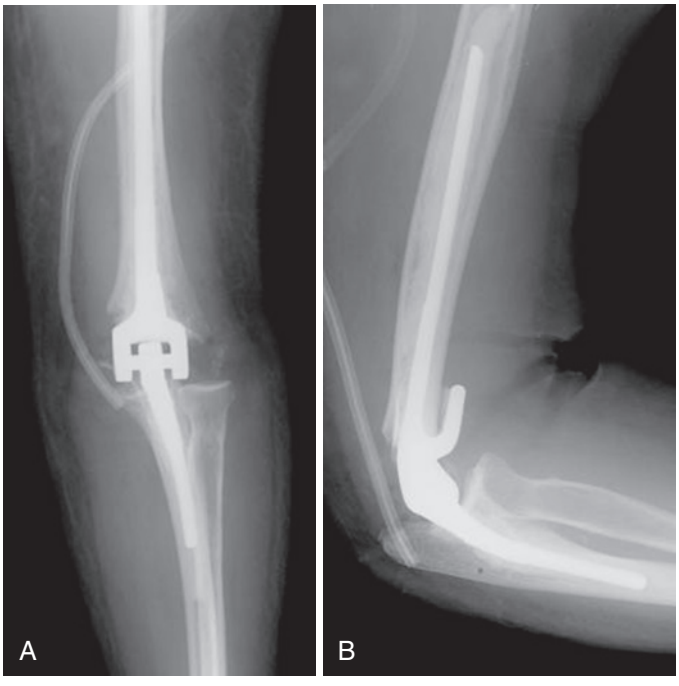

eFIGURE 18.3 Postoperative radiographs.

http://e-surg.com

with posterior exposures of the elbow. The supine position is typically reserved for lateral elbow exposures or for patients with multisystem trauma that precludes lateral or prone positions.

ORIF of fractures of the distal humerus is typically a lengthy procedure requiring a general anesthetic. Postoperative pain control may include the use of selective upper extremity nerve blockades; however, the postoperative neurologic examination of the hand would be impaired for the duration of the block. Consideration should be given to postoperative block placement, which allows for examination of nerve function after completion of the case. A sterile tourniquet may be employed but is used infrequently, only if it can be placed proximal enough on the arm to avoid interference with fracture reduction and fixation.

Operative Exposures

Virtually all fractures of the distal humerus treated operatively can be approached through a midline posterior skin incision (Figure 18.16). An effort should be made to deviate the incision a full 2 cm away from the tip of the olecranon. The lateromedial plane of dissection is directed between the triceps muscle and its investing fascia. The next step in any exposure of the medial column is identification and protection of the ulnar nerve. The nerve is mobilized and protected throughout the procedure. Instruments are not attached to any loop or Penrose drain around the nerve to prevent accidental traction on the nerve. A Penrose drain is looped about the nerve and sutured to itself. No instruments should be attached to the drain to avoid accidental traction injury to the nerve. The medial intermuscular septum is incised if fracture management requires exposure of the anteromedial elbow. Similarly, the laterally directed dissection leads to the lateral intermuscular septum.

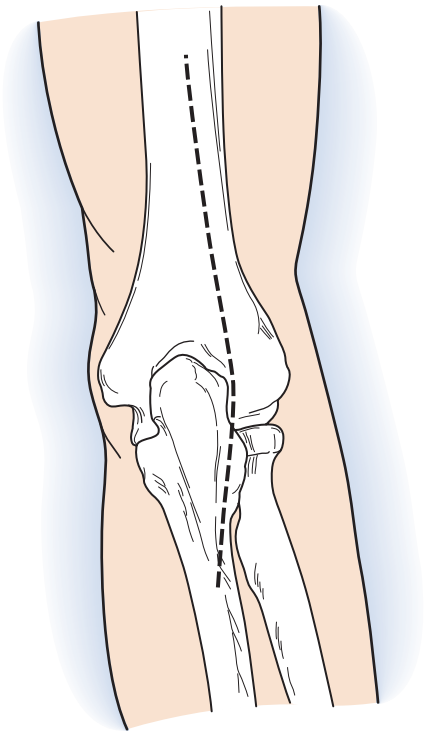

FIGURE 18.16 Posterior view of upper arm and elbow area showing location of skin incision. The ideal surgical incision is a generally straight line that gently curves laterally (or radially) to avoid tip of olecranon.

The course of the radial nerve is less obvious than its medial counterpart but can still be reliably identified. First, the nerve crosses through the lateral intermuscular septum approximately halfway along the length of the humerus, or half the distance between the tip of the acromion and the tip of the olecranon. Second, if the dissection is directed from the lateral epicondyle proximally, the cutaneous branches to the posterior lateral arm and forearm are encountered in the dissection of the lateral intermuscular septum. These cutaneous nerves are branches of the radial nerve, and they can be followed proximally to their origin. In most distal humerus fractures treated with open reduction, the radial nerve does not need to be exposed. The lateral intermuscular septum is divided, however, for exposure to the anterolateral elbow region. This approach provides near-circumferential access to the medial and lateral columns. This posterior midline approach can be used for later reconstructive procedures, obviating the need for multiple skin incisions.

How the extensor mechanism of the elbow is subsequently managed is the key differentiating feature among the potential approaches used to expose the distal humerus and is dictated by the fracture characteristics and surgeon preference. For significant intraarticular fractures of the distal humerus requiring direct visualization of the articular surface, there are two options for management of the extensor mechanism: an olecranon osteotomy or soft tissue mobilization around the olecranon.

Paratricipital Approach

The least disruptive posterior approach is the paratricipital exposure.[1,107] This dissection entails mobilization of the triceps off the posterior aspect of the medial and lateral intermuscular septa and the posterior aspect of the humerus. Medially, the ulnar nerve is identified and protected. Laterally, the radial nerve is identified and mobilized, allowing surgical manipulation of approximately 95% of the posterior aspect of the humeral shaft.[30] At the elbow joint, the triceps can be retracted posteriorly and distally, enabling visualization of the posterior aspect of the lateral column and limited visualization of the posterior aspect of the trochlea (Figure 18.17). Supracondylar fractures, transcondylar fractures, and simple intraarticular fractures (unicolumnar or bicolumnar) without articular comminution are the main injuries that can be managed with this exposure. It is exceedingly difficult to appreciate, let alone secure, comminuted intraarticular fractures of the distal humerus through this exposure. Currently, the paratricipital approach is the authors' preferred exposure for total elbow replacement in a nonreconstructible intraarticular distal humerus fracture in an elderly patient (Case Study 18.2).

Olecranon Osteotomy

Olecranon osteotomy is the classic exposure for reduction and fixation of intraarticular fractures of the distal humerus.[11,12,67] As in the paratricipital approach, the triceps muscle is mobilized from the medial and lateral septa and followed distally. The osteotomy is performed at the deepest portion of the trochlear notch of the olecranon process and is coincident with an area devoid of articular cartilage, termed the "bare area." We favor a chevron-shaped osteotomy because of its increased

http://e-surg.com

CASE STUDY 18.2 Paratricipital Exposure for Total Elbow Arthroplasty

An 87-year-old frail female sustained a low-energy fall, injuring her left elbow. She is ambulatory and lives at home, has low functional demands, and is otherwise healthy (eFigure 18.4).

Total arthroplasty is performed (eFigure 18.5).

Note in eFigure 18.6 the cerclage wire that was inserted to avoid iatrogenic fracture of the proximal ulna during reaming and implantation of the ulnar component. Postoperative active range of motion was facilitated by the intact extensor mechanism.

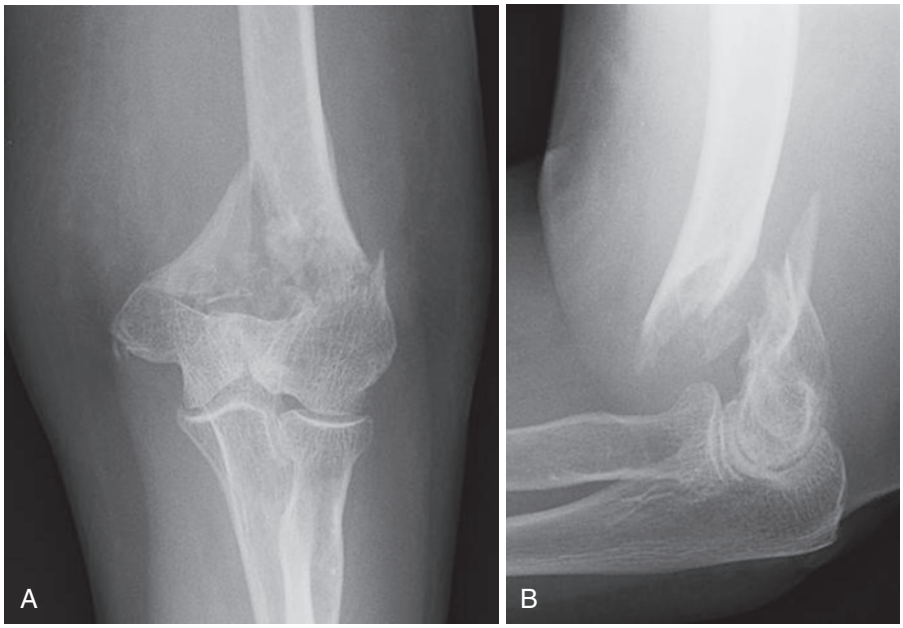

eFIGURE 18.4 Preoperative radiographs.

http://e-surg.com

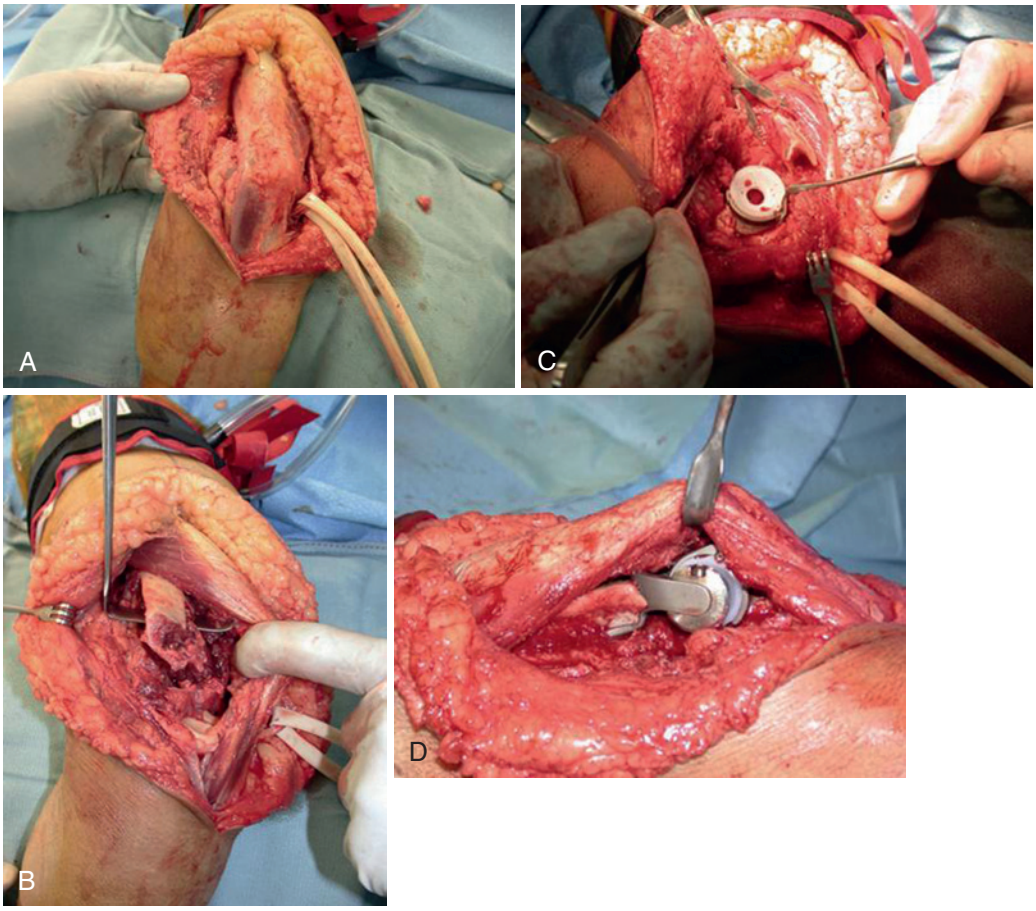

eFIGURE 18.5 Paratricipital exposure for total arthroplasty. **A,** The left distal humerus has been exposed using a posterior longitudinal incision, and the ulnar nerve has been mobilized. **B,** The extensor mechanism, including the anconeus, has been retracted medially. The fractured distal humeral condyles have been excised, and the humeral shaft has been delivered into view. **C,** The ulnar component has been trialed and fitted with a bushing. **D,** The humeral and ulnar components have been inserted. The extensor mechanism remains attached to the proximal ulna.

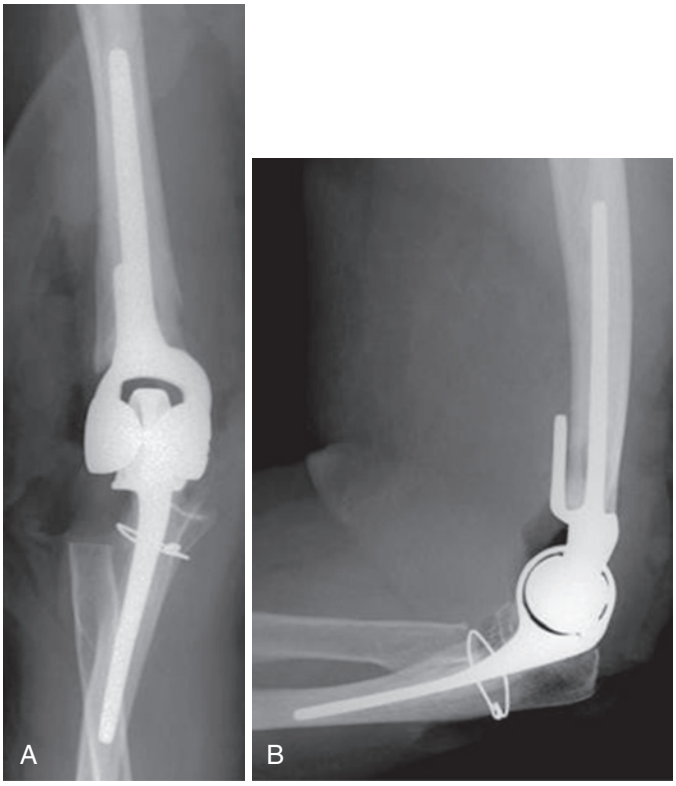

eFIGURE 18.6 Final intraoperative radiographs.

http://e-surgeon.com

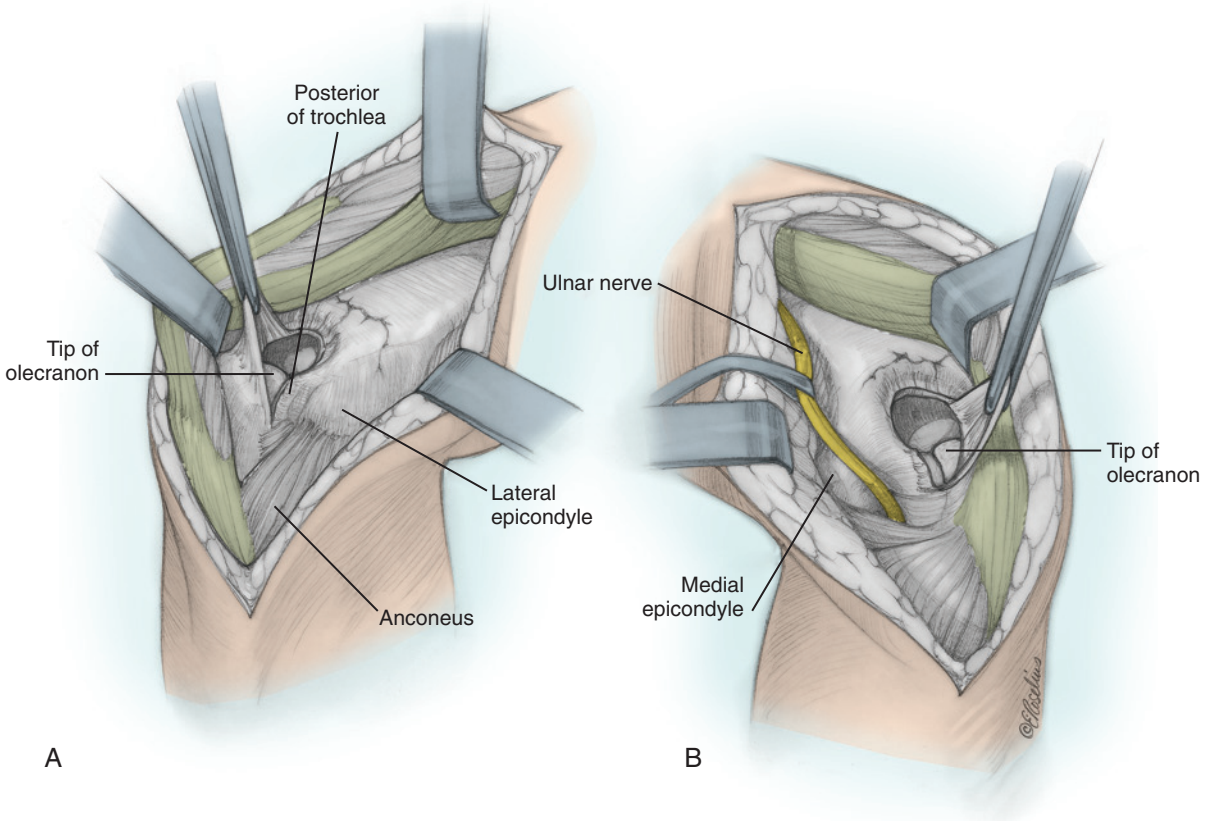

FIGURE 18.17 Paratricipital approach. **A,** Starting at lateral epicondyle, triceps is elevated from posterior aspect of humerus. More proximal dissection reveals radial nerve crossing lateral margin of humerus to enter anterior compartment of arm. Lateral column is readily identified through this dissection. Lateral aspect of trochlea is appreciated, but visualizing articular surface is difficult. **B,** Medial column and medial aspect of trochlea are exposed after mobilizing and protecting ulnar nerve. (Copyright © Elizabeth Martin.)

postfixation stability.[56] To avoid splitting the proximal olecranon fragment, the apex of the chevron points distally.[70] It is typically initiated with a fine oscillating saw and completed with a thin osteotome. The triceps muscle and the osteotomized proximal half of the olecranon are then reflected superiorly (Figure 18.18).

Techniques of olecranon osteotomy fixation include Kirschner wire and tension band constructs, screw and tension band constructs, and plate fixation.[11,12,38,39,56,57] The advantage of the olecranon osteotomy is the excellent and direct visualization of the distal humeral articular surface,[122] enabling anatomic reduction. Increased operative exposure time is a potential drawback of the olecranon osteotomy, but it may be offset by the visualization afforded for direct articular reduction. Olecranon osteotomy is most commonly used in the management of bicolumnar fractures with articular displacement. Any articular injury of the distal humerus, including unicondylar fractures, and pure articular fractures extending posterior to the capitellum or the posterior aspect of the trochlea, or both, are indications for this exposure.[56,101]

Cited complications or disadvantages of olecranon osteotomy include osteotomy nonunion, delayed union, and hardware prominence.[39] More recent evidence has suggested that these drawbacks are quite infrequent compared with previous reports. Coles and colleagues[14] reported on 70 distal humerus fractures exposed using a chevron-shaped olecranon osteotomy exposure. Osteotomies were secured with either medullary screw and dorsal tension band wire fixation or plate fixation. In this study, despite more than half of the injuries being open fractures, the authors noted that all osteotomies united, and only 8% of patients required implant removal for local symptoms. Ring and associates[98] reviewed 45 consecutive patients with acute fractures of the distal humerus or distal humerus nonunions treated using an olecranon osteotomy exposure. The authors noted a 98% union rate within 6 months using a Kirschner wire and modified tension band wiring technique. Of these patients, 13% had olecranon implants removed for relief of local symptoms. Hewins and colleagues[40] similarly noted a 100% osteotomy union rate in 17 consecutive patients with distal humerus fracture treated with a chevron-shaped olecranon osteotomy. Repair consisted of a contoured 3.5-mm reconstruction plate; only one of these required later removal for relief of local symptoms.

Triceps-Splitting Approach

The triceps-splitting approach described by Campbell[9] splits the triceps aponeurosis and medial head in the midline.[73,126] Subperiosteal dissection of the distal humerus and proximal ulna is performed medially and laterally. This dissection does not cease at the tip of the olecranon but continues along the proximal one quarter of the ulna with dissection of the triceps insertion off the proximal ulna medially and laterally (Figure 18.19). The joint capsule is divided to allow visualization of the articular surface. At the conclusion of the procedure, the triceps

http://e-surg.com

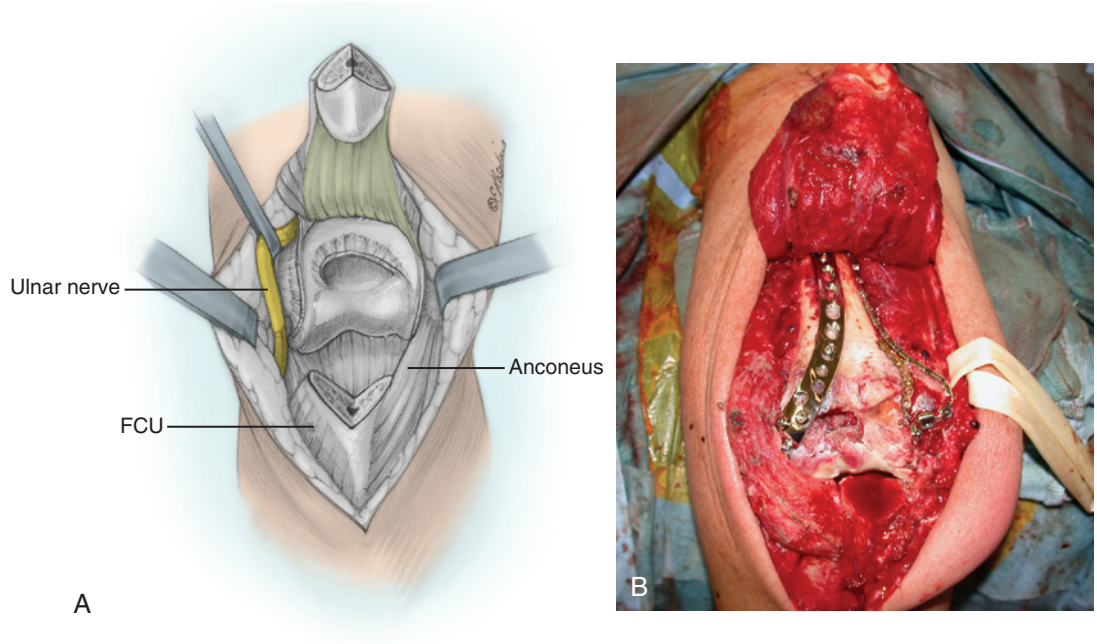

FIGURE 18.18 Olecranon osteotomy. **A,** Entire posterior aspect of humerus is exposed, and articular surface is visualized after performing olecranon osteotomy. **B,** Intraoperative photograph after open reduction and internal fixation of comminuted open intraarticular distal humerus fracture. A portion of lateral column and posterolateral trochlea were absent at the time of ORIF. *FCU,* Flexor carpi ulnaris. (**A,** Copyright © Elizabeth Martin.)

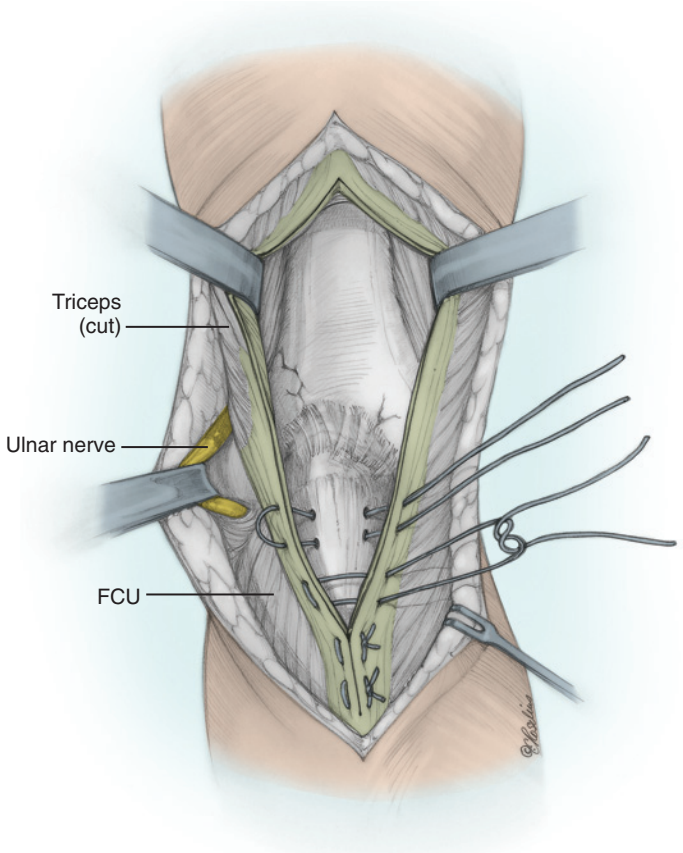

FIGURE 18.19 Triceps-splitting approach. Distal one third of triceps is simply split longitudinally to olecranon process. At olecranon process, split continues longitudinally, with elevation of triceps insertion sharply off bone medially and laterally. Triceps is essentially split into medial and lateral halves and retracted peripherally, allowing visualization of underlying distal humerus. *FCU,* Flexor carpi ulnaris. (Copyright © Elizabeth Martin.)

is repaired back to the proximal ulna with interrupted, nonabsorbable suture through osseous drill holes. Cited advantages of this exposure are its technical ease, the ability to use the trochlear notch as a template against which the distal humerus can be reduced, and the avoidance of hardware around the proximal ulna.[70] A potential complication of this exposure is the loss of strength of elbow extension. McKee and colleagues[74] were unable to show a difference in elbow extension strength, however, in patients treated with the triceps-splitting approach compared with patients treated with an olecranon osteotomy, making it a satisfactory alternative to olecranon osteotomy.

Although the main disadvantage of this exposure is the inability to visualize directly a significant portion of the articular surface compared with olecranon osteotomy, hyperflexion of the elbow substantially improves this limitation.[126] The main indications for this exposure have included bicolumnar intraarticular fractures of the distal humerus and extraarticular supracondylar fractures. This exposure is also indicated when the triceps aponeurosis has been transected by the distal aspect of the humeral diaphysis (Case Study 18.3); when this occurs, the fracture is typically open posteriorly.[73] In this situation, olecranon osteotomy further disrupts the integrity of the extensor mechanism, and this situation is a relative contraindication for olecranon osteotomy. McKee and colleagues[73] were able to show improved results with the triceps-splitting approach in these open injuries compared with using an olecranon osteotomy. A modification of the exposure is typically required to incorporate nonmidline traumatic disruptions of the extensor mechanism.[73,126]

Bryan-Morrey "Triceps-Sparing" Approach

The Bryan-Morrey triceps-sparing approach is commonly used for performing TEA procedures[8] but may also be used for

http://e-surg.com

CASE STUDY 18.3 Triceps-Splitting Open Reduction and Internal Fixation

A 37-year-old healthy male sustained an isolated open, comminuted, bicolumnar distal humerus fracture after falling on a fishing boat (eFigure 18.7). He is healthy. An open wound was noted to be directly posterior.

At operation, approximately 80% of his triceps aponeurosis was found to be disrupted (eFigure 18.8).

Your preferred surgical exposure for this injury is:

A. Olecranon osteotomy
B. Triceps-splitting exposure
C. Triceps-reflecting anconeus pedicle (TRAP) procedure
D. Bryan-Morrey procedure

Correct answer:

B. Triceps-splitting exposure

The posterior extensor mechanism disruption was incorporated into a triceps-splitting exposure (eFigure 18.9).

The intraoperative fluoroscopic images in eFigure 18.10 demonstrate the sequence of fixation.

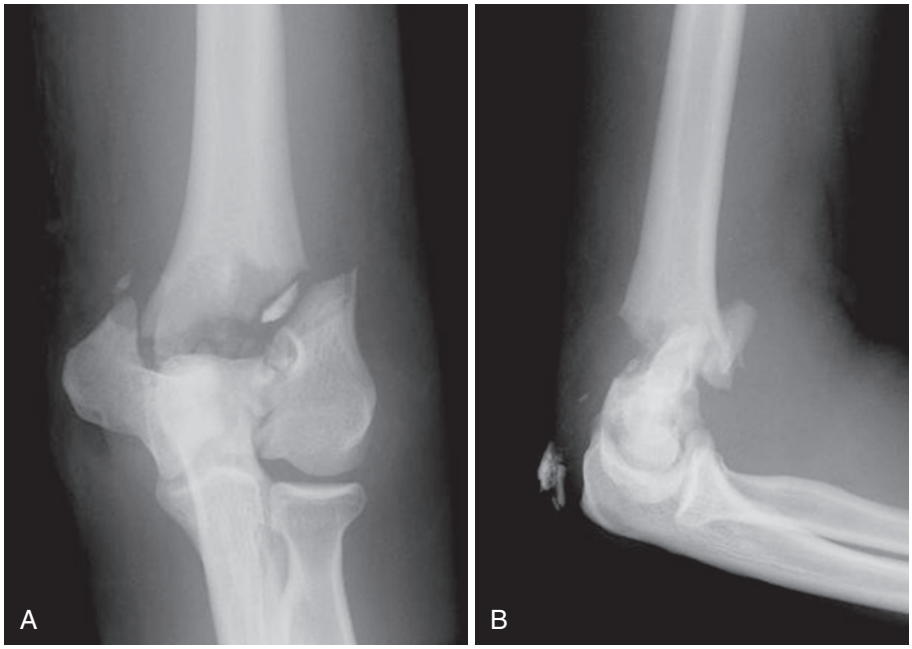

eFIGURE 18.7 **A,** Anteroposterior injury radiograph. **B,** Lateral injury radiograph.

http://e-surg.com

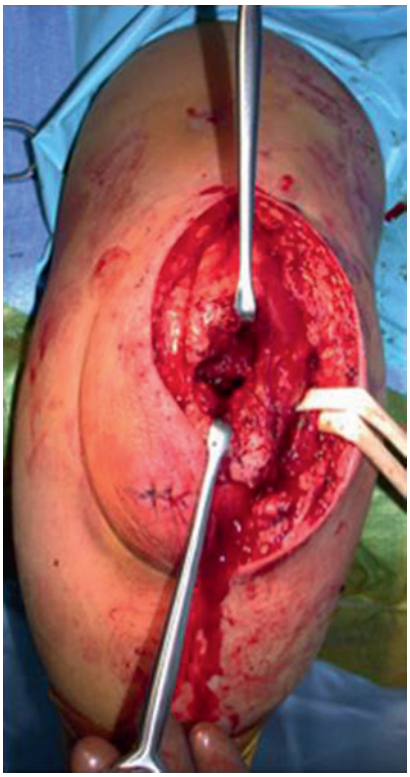

eFIGURE 18.8

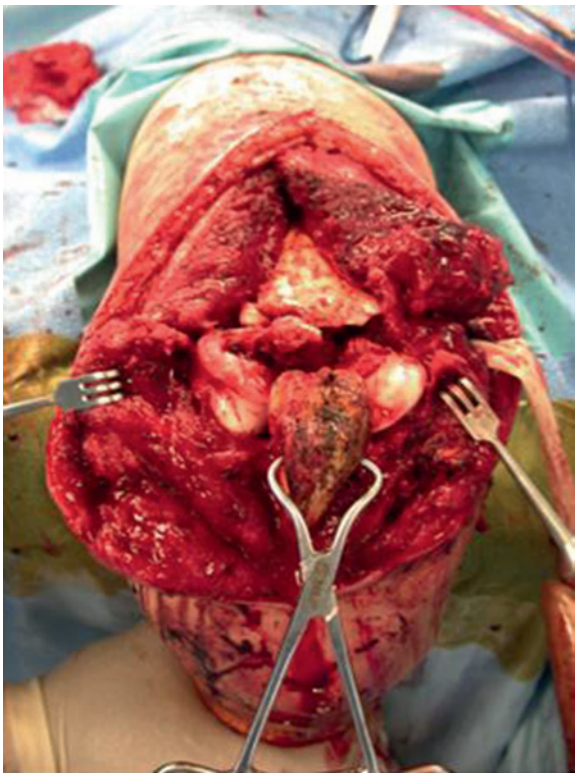

eFIGURE 18.9

http://e-surg.com

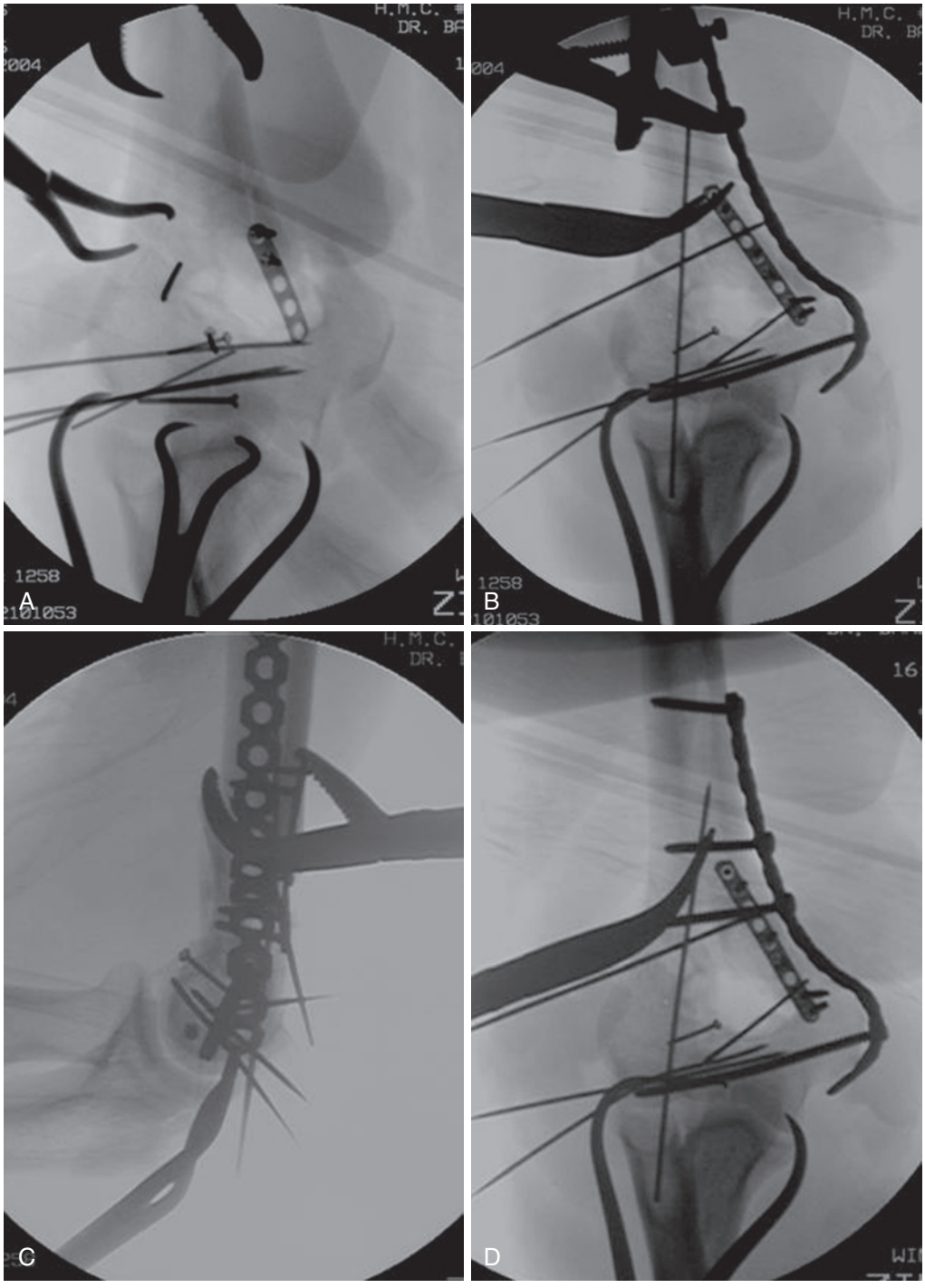

eFIGURE 18.10 Intraoperative fluoroscopic images demonstrating the sequence of fixation. **A** and **B,** Minifragment screws are used to initially stabilize multiplanar articular comminution. **C** and **D,** A 2-mm plate is used to provisionally stabilize the comminuted medial column.

Continued

http://e-surg.com

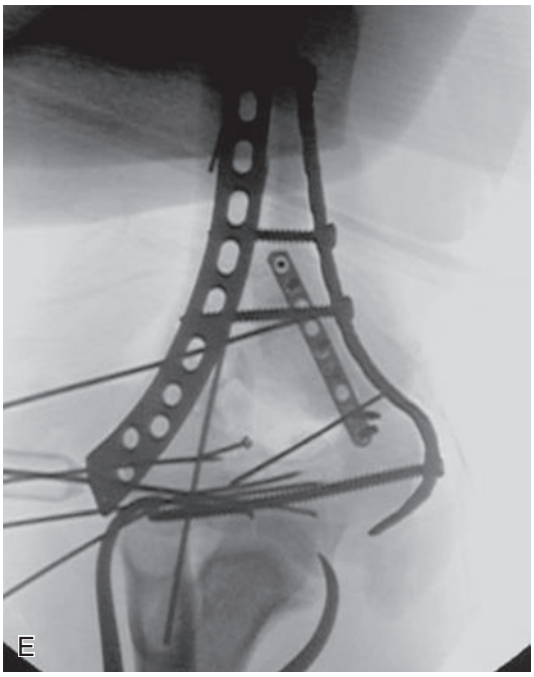





eFIGURE 18.10, cont'd E, Multiple Kirschner wires and clamps temporarily secure the articular reduction. Plate fixation begins medially, followed by lateral column plating. **F** and **G,** Final fluoroscopic views of the fracture reduction and fixation. Repair of the triceps insertion was performed with nonabsorbable transosseous suture.

http://e-surg.com

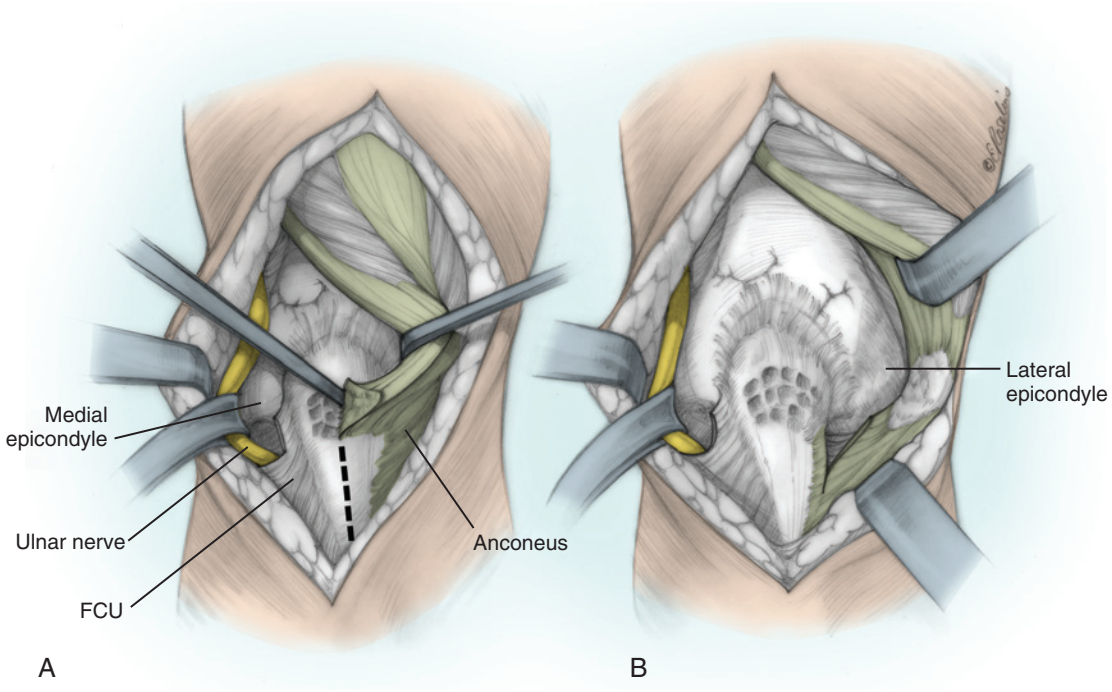

FIGURE 18.20 Bryan-Morrey "triceps-sparing" approach. **A,** Initiation of dissection on medial aspect. **B,** Entire triceps insertion taken off proximal ulna. Note view of posterior aspect of distal humerus. *FCU,* Flexor carpi ulnaris. (Copyright © Elizabeth Martin.)

fixation of fractures of the distal humerus.[24] After a midline posterior skin incision is made, the ulnar nerve is identified along the medial aspect of the triceps and is elevated from its bed. Dissection carries through the cubital tunnel and fascia over the flexor carpi ulnaris muscle until the first motor branch is identified. When the ulnar nerve is freed and protected, dissection continues with the elevation of the medial aspect of the triceps off the posterior aspect of the medial intermuscular septum and posterior aspect of the distal humerus. Distally, the fascia over the flexor carpi ulnaris is incised toward the ulna. The triceps insertion is sharply reflected directly off bone (Figure 18.20). This medial-to-lateral dissection is continued until the anconeus and triceps can be retracted over the lateral humeral condyle. Because the fascia over the proximal ulna is thin and prone to perforations during its elevation, some authors have described elevation as an osteoperiosteal flap.[94] A small osteotome can be used to elevate the fascia with small petals of bone, which aids in repositioning the triceps insertion at the conclusion of the procedure (restoring the normal length-tension relationship) and in healing of the extensor mechanism back to the proximal ulna. The triceps insertion is repaired back to the proximal ulna with nonabsorbable transosseous suture. Advantages and disadvantages of this approach are similar to the triceps-splitting procedure. This exposure is indicated in older patients undergoing ORIF of a distal humerus fracture that may require intraoperative conversion to TEA.

Triceps-Reflecting Anconeus Pedicle Approach

The triceps-reflecting anconeus pedicle (TRAP) approach, as described by O'Driscoll,[92] offers an extensile option for surgical exposure of the distal humerus without the need for olecranon osteotomy, while preserving the neurovascular supply to the anconeus muscle. After an adequate midline posterior skin incision, the ulnar nerve is identified and protected as in all the previously described procedures. The interval between the anconeus and extensor carpi ulnaris is identified and followed to the lateral border of the ulna. Beginning distally, the anconeus is dissected subperiosteally off the lateral aspect of the ulna, and the dissection is carried proximally toward the lateral epicondyle and along the lateral supracondylar ridge. Medially, the triceps is mobilized as described in the Bryan-Morrey approach.[8] The dissection medially along the proximal ulna ends 10 cm distal to the olecranon, joining with the distal extent of the lateral exposure. The triceps insertion is sharply removed from the olecranon and carried laterally to become confluent with the previous lateral dissection. Ultimately, the distal humerus and proximal ulna are exposed subperiosteally, and a triceps and anconeus flap is created and mobilized proximally to allow visualization of the distal humerus (Figure 18.21).

As with all procedures that sharply detach the triceps insertion from the olecranon, heavy nonabsorbable transosseous suture repair is mandatory to restore extensor mechanism integrity. Similar to the Bryan-Morrey exposure, the exact insertion of the triceps into the olecranon may be identified with the incorporation of a small wafer of bone or a suture to aid in anatomic repair.[8,94] Advantages of this approach include the avoidance of complications of olecranon osteotomy; preservation of the anconeus as a dynamic stabilizer of the lateral aspect of the elbow and vascular muscle bed for the proximal ulna and lateral elbow; and, similar to the Bryan-Morrey approach, the ability to convert to TEA should fracture reduction and fixation prove to be unattainable.

Anconeus Flap Transolecranon Approach

The anconeus flap transolecranon approach, described by Athwal and colleagues,[3] combines the anconeus preservation of

http://e-surg.com

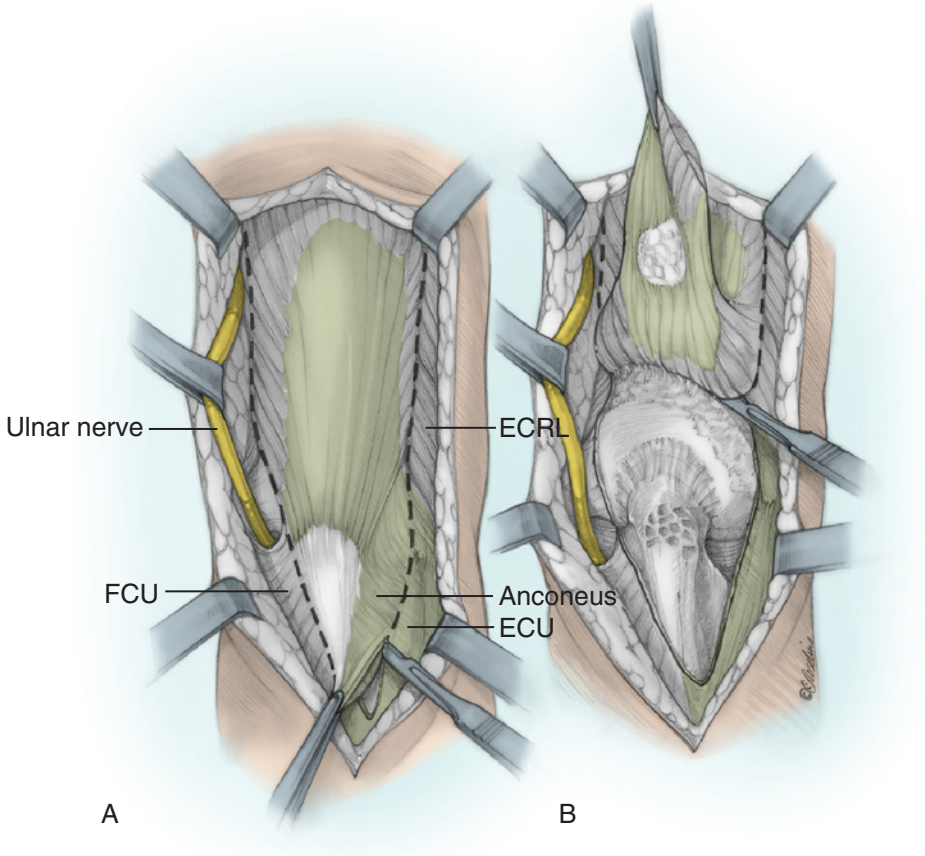

FIGURE 18.21 Triceps-reflecting anconeus pedicle (TRAP) approach. **A,** Posterior view of distal humerus after skin incision. Important features are ulnar nerve and *dotted lines* that indicate where deep dissections begin. **B,** Illustration of how triceps insertion and anconeus are taken off as single structure from proximal ulna. Extensor mechanism is reflected cephalad. *ECRL,* Extensor carpi radialis longus; *ECU,* extensor carpi ulnaris; *FCU,* flexor carpi ulnaris. (Copyright © Elizabeth Martin.)

the TRAP[92] approach with the exposure obtained from olecranon osteotomy. Using an adequate midline posterior skin incision and mobilization of the ulnar nerve, the interval between the anconeus and extensor carpi ulnaris is identified and followed to the lateral border of the ulna. The anconeus muscle is elevated from distal to proximal off the ulna to the level of the planned osteotomy, typically at the deepest portion of the trochlear notch. An apex distal chevron-shaped olecranon osteotomy is created as described earlier. The anconeus muscle flap and the olecranon fragment are elevated off the posterior aspect of the humerus, in continuity with the triceps muscle, allowing exposure of the articular surface.[3] At the conclusion of the procedure, the osteotomy is rigidly stabilized, and the anconeus flap is anatomically repaired to the extensor carpi ulnaris fascia laterally and the ulnar periosteum medially. The purported advantage of the anconeus flap transolecranon approach is the maximal articular visualization afforded by olecranon osteotomy, while preserving an innervated vascularized anconeus through the use of internervous planes (Figure 18.22).

Lateral Approach

The lateral approach may be initiated with either a lateral or a posterior skin incision.[20,94] The choice of a posterior skin incision requires the elevation of a full-thickness lateral cutaneous flap, but this may be preferred should alternative deep dissection be required, such as conversion to an olecranon osteotomy, or if future reconstructive procedures are anticipated. The main indication for this approach and its extensile variations is in the management of significant fractures of the capitellum and other articular fracture variants.

In Kocher's lateral approach, the dissection is directed through the substance of the anconeus and the lateral capsule and then carried proximally from the exposed radial head. Hotchkiss[45] noted that this exposure disrupts a significant portion of the posterolateral capsular complex. He advocated that a better lateral approach is one that preserves this vital structure by starting proximally at the lateral condyle and proceeding distally. Using the skin incisions described earlier, the lateral epicondyle is palpated, and the muscles originating from the anterior surface of this ridge are elevated with sharp dissection. The anterior joint capsule is raised, and the capitellum is exposed. Attached to the lateral condyle are the fibers of the lateral ligament complex. Hotchkiss[45] suggested that "the articular surface of the capitellum should be bisected as one looks from the vantage point of the lateral aspect of the capitellum," and that all of the capsular structures that run anterior to this imaginary line can be elevated, whereas all of those posterior should be preserved (Figure 18.23).[45]

The anterior capsule is elevated as a single layer to the level of the radiocapitellar joint. Further distal joint exposure requires dividing the annular ligament. Still further distal dissection requires entering the common extensor compartment. The

http://e-surg.com

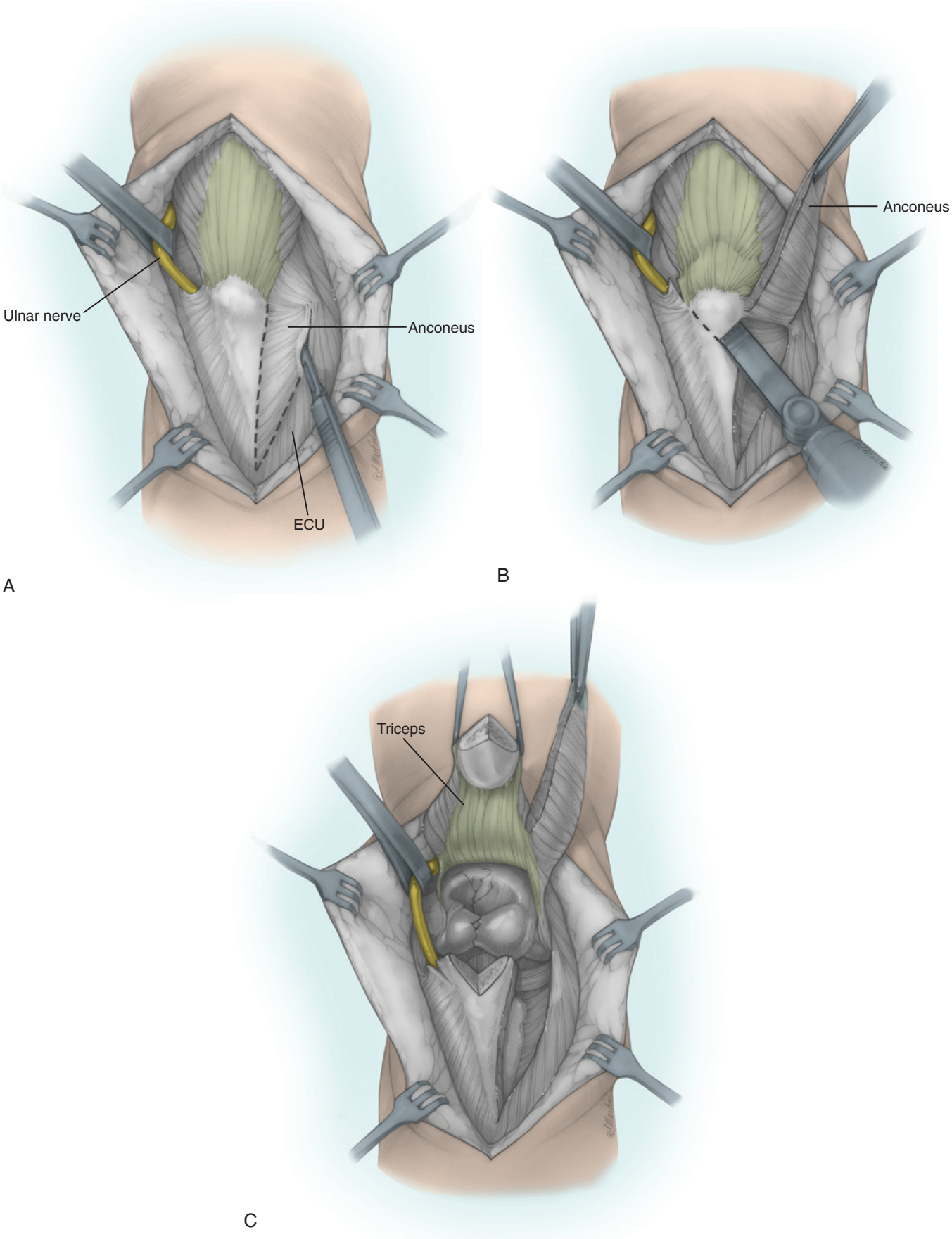

FIGURE 18.22 Anconeus flap transolecranon approach to distal humerus. **A,** The anconeus musculature is identified and elevated from the lateral aspect of the proximal ulna, preserving its neurovascular supply. **B,** With the anconeus retracted proximally, the olecranon is osteotomized. **C,** The extensor mechanism, the olecranon process, and the anconeus muscle are reflected cephalad, revealing distal humerus. *ECU,* Extensor carpi ulnaris. (Copyright © Elizabeth Martin.)

http://e-surg.com

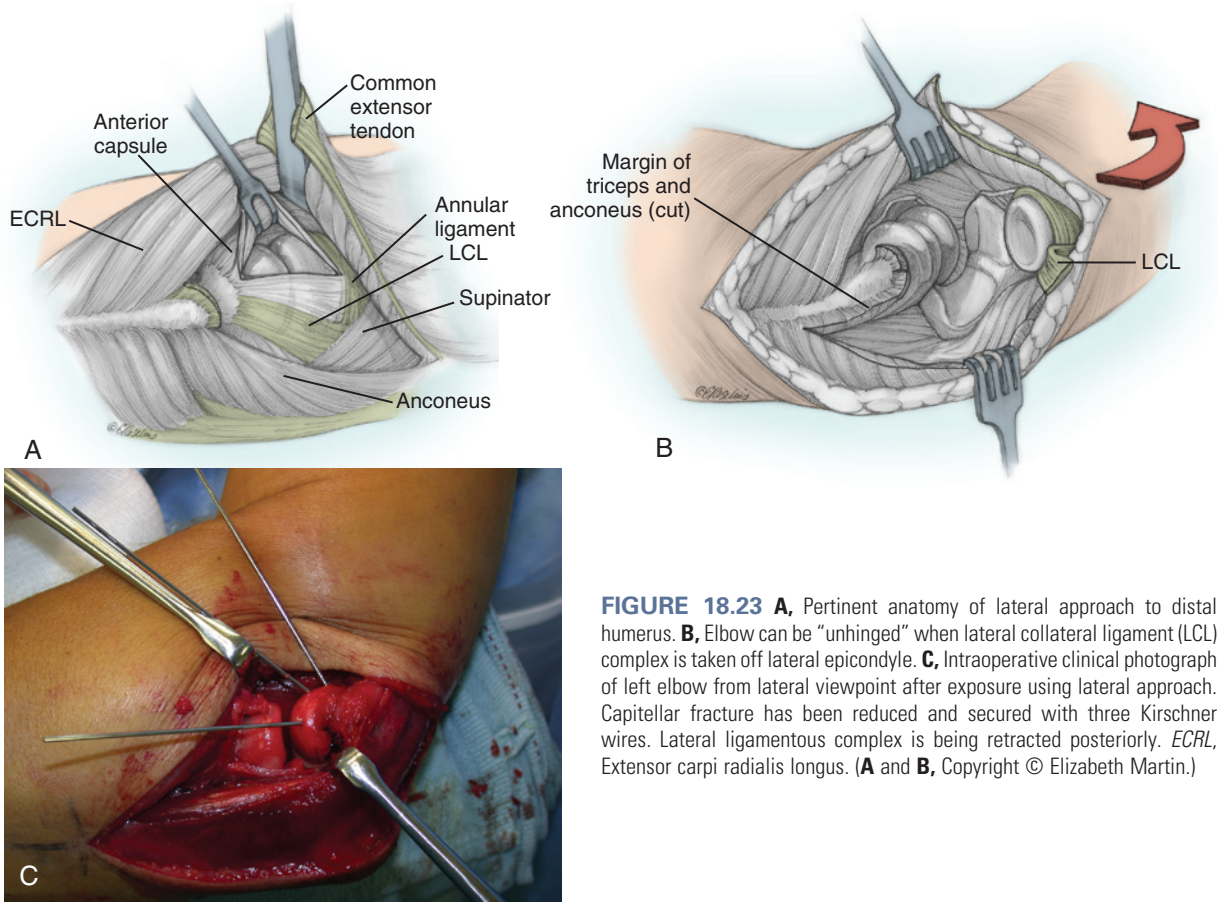

FIGURE 18.23 **A,** Pertinent anatomy of lateral approach to distal humerus. **B,** Elbow can be "unhinged" when lateral collateral ligament (LCL) complex is taken off lateral epicondyle. **C,** Intraoperative clinical photograph of left elbow from lateral viewpoint after exposure using lateral approach. Capitellar fracture has been reduced and secured with three Kirschner wires. Lateral ligamentous complex is being retracted posteriorly. *ECRL,* Extensor carpi radialis longus. (**A** and **B,** Copyright © Elizabeth Martin.)

posteriormost portion of this muscle mass is elevated from the septum separating it from the anconeus. As the common extensor mass is elevated, the intermuscular septum, the anconeus, and the posterior lateral ligamentous complex are left intact; this exposes the muscle fibers of the supinator muscle. The supinator muscle can be elevated from the posterior lateral margin on the ulna while holding the forearm in full pronation. This approach protects the posterior interosseous nerve while exposing the head and neck of the radius. Fractures of the lateral column and shearing fractures of the capitellum can be identified and reduced with this approach.

If the posterior aspect of the lateral column needs to be exposed, the triceps muscle is lifted from the posterior face of the lateral column and the medial edge of the triceps followed into the anconeus muscle. The posterior joint capsule can be elevated off the dorsal aspect of the lateral column, but the joint fibers that are found emanating from the distal lateral aspect of the lateral column should be left intact. They are the posterior lateral ligaments of the elbow.

In cases in which visualization of the posterior and inferior aspects of the lateral column is still inadequate, the origin of the lateral collateral ligament and the lateral margin of the triceps and anconeus can be elevated from the lateral epicondyle. At this point, the elbow can be hinged open on the intact medial collateral ligament complex.[101] At the conclusion of the procedure, the lateral collateral ligament is returned to its origin and secured to the lateral epicondyle with transosseous nonabsorbable suture or suture anchors.

Fixation Principles

The goals of operative fixation of fractures of the distal humerus are to restore articular congruity; reestablish anatomic mechanical axes; and obtain enough fracture stability to allow early, unrestricted elbow range of motion. Numerous factors contribute to making these goals difficult to reach, including the following:

1. Relatively small, cancellous distal fragments offer poor fixation potential.
2. The complex osseous anatomy makes plate contouring difficult.
3. Screws that violate the articular surfaces and the olecranon, coronoid, and radial fossae hamper motion.
4. Osteopenic bone compromises construct stability.

Despite the numerous fracture patterns possible, several fixation principles are applicable to all fracture patterns (Case Study 18.4), as follows:

1. Kirschner wires are used to provide provisional fixation before definitive plate fixation and should be placed strategically to avoid interference with the application of definitive implants. Common Kirschner wire sizes are 0.045-inch (1.14-mm), 0.054-inch (1.37-mm), and 0.062-inch (1.57-mm) wires. When Kirschner wires cannot be placed to maintain a provisional reduction reliably, small 2-mm plates secured with 2-mm screws may be used to secure a critical reduction zone. As with the placement of Kirschner wires, these small temporary plates should not interfere with definitive fixation.

http://e-surg.com

CASE STUDY 18.4 Fixation Principles and Multiplanar Involvement

A 56-year-old male sustained a bicolumnar distal humerus fracture after falling from a truck (eFigure 18.11).

A number of fixation principles are demonstrated in the olecranon osteotomy illustrated in eFigure 18.12.

Satisfactory articular reduction with medial lateral plate fixation was achieved (eFigure 18.13).

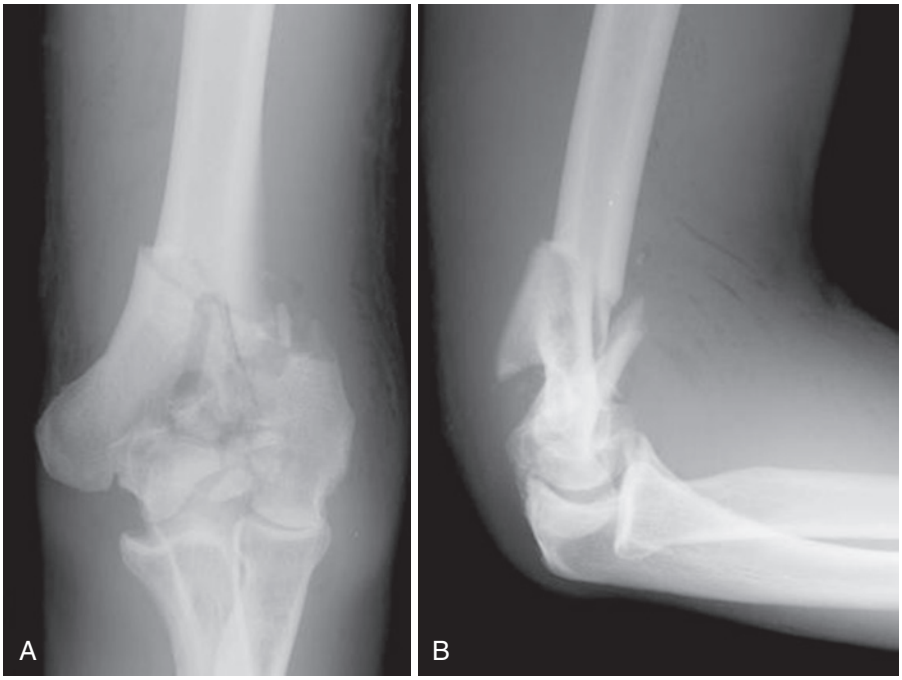

eFIGURE 18.11 **A,** Anteroposterior injury radiograph. **B,** Lateral injury radiograph.

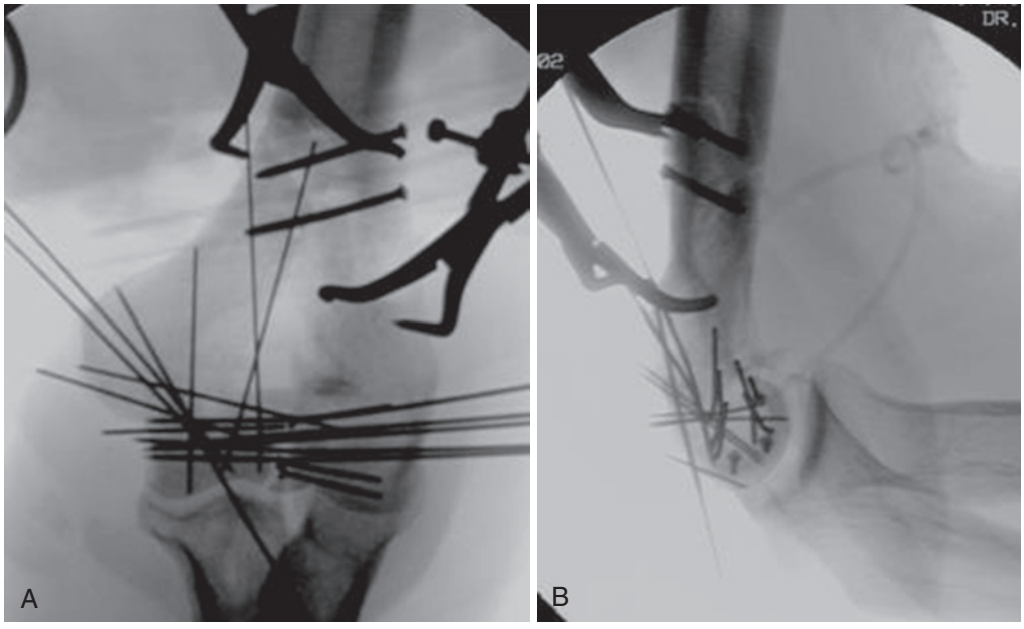

eFIGURE 18.12 **A** and **B,** Intraoperative fluoroscopy of olecranon osteotomy. Provisional Kirschner wire fixation and intraosseous minifragment screw fixation of the articular surface. Metaphyseal reduction is maintained with clamps and supplemental screws. An olecranon osteotomy has been performed.

http://e-surg.com

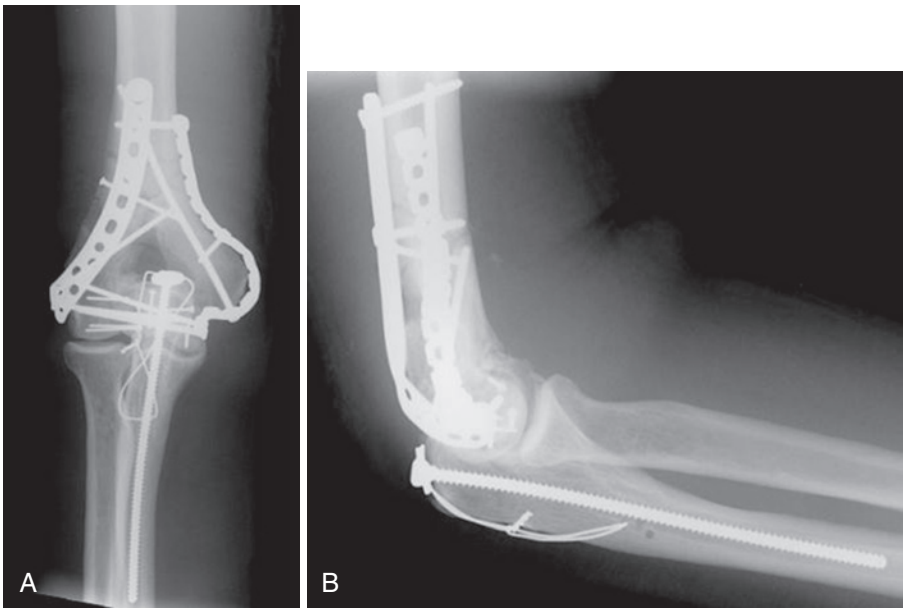

eFIGURE 18.13 **A** and **B,** Note that the medial plate extends to the medial aspect of the trochlea, allowing secure fixation of this important articular fragment. A medial column screw has been placed to enhance fixation of the medial column. The osteotomy is secured with a 4.5-mm screw and tension band wire.

http://e-surg.com

CRITICAL POINTS *Operative Exposures in Distal Humerus Fractures*

Paratricipital Approach
- It elevates the triceps from posterior aspects of distal humerus and medial and lateral intermuscular septa.
- It can be converted to an olecranon osteotomy if needed.
- Laterally, it can be developed into an extensile posterior exposure.
- It offers the least visualization of the articular surface compared with other exposures.
- It is the exposure least disruptive to the extensor mechanism.

Indications
- Supracondylar and transcondylar fractures
- Bicolumnar fractures with simple articular involvement
- Medial or lateral column only can be developed for treatment of unicolumnar fractures with simple articular involvement
- Authors' preferred exposure for TEA in nonreconstructible distal humerus fracture in an elderly patient

Olecranon Osteotomy
- It provides maximal articular surface visualization.
- Historic osteotomy nonunion rates approximated 10%; current studies show markedly lower nonunion rates of 0 to 2%.
- Symptoms may develop because of the prominence of the osteotomy fixation implants.

Indications
- Unicolumnar or bicolumnar fractures with articular comminution
- Articular fracture variants with significant posterior or medial involvement, or both
- Authors' preferred exposure for fractures of distal humerus with significant articular displacement or comminution

Triceps-Splitting Approach
- Familiar exposure of the distal third of the humeral metadiaphysis is provided.
- For adequate articular visualization, the triceps insertion is dissected off the proximal one fourth of the ulna medially and laterally.

Indications
- Supracondylar and transcondylar fractures
- Bicolumnar fractures with significant disruption of the triceps aponeurosis (i.e., open fractures)
- Fractures in elderly patients that may require conversion to TEA

Bryan-Morrey "Triceps-Sparing" Approach
- Extensor mechanism is reflected off the posterior aspect of the humerus and olecranon from medial to lateral

Indication
- Classic exposure for ORIF of fractures in elderly patients that may require conversion to TEA

Triceps-Reflecting Anconeus Pedicle (TRAP) Procedure
- It preserves the neurovascular supply to the anconeus.
- It allows conversion to TEA if required.
- Articular visualization is similar to that of triceps-splitting and triceps-sparing approaches.

Indications
- Similar to indications for triceps-splitting and triceps-sparing approaches

Anconeus Flap Transolecranon Approach
- It combines the preservation of the neurovascular supply to the anconeus with the articular visualization obtained with transolecranon osteotomy.

Indications
- Similar to indications for olecranon osteotomy

Lateral Approach
- Initial dissection should be anterior to the lateral epicondyle, along a line bisecting the capitellum.
- Medial column articular injuries are not well visualized.
- Visualization is enhanced by (1) elevating the musculature and joint capsule from the anterior aspect of the supracondylar ridge of the distal humerus or (2) detaching the lateral ligamentous complex from the lateral epicondylar region.

Indication
- Isolated lateral column articular injuries (capitellar fractures and variants)

2. Fixation of the trochlea should achieve interfragmentary compression but avoid stenosis.[52,56] This latter situation may be encountered in patients with central sulcus comminution and functional or overt articular bone loss (Figure 18.24). Stenosis results in joint incongruity and altered cartilage loading, leading to decreased range of motion and posttraumatic arthritis. Although its use is exceedingly rare, structural corticocancellous bone graft has been recommended to bridge the defect, with satisfactory results noted.[31]
3. Whenever possible, screws placed into the distal articular segment should be placed through a plate that is subsequently attached to the diaphysis. Because of the limited space available for fixation devices within the trochlea, placement of screws through the plate allows two functions to be performed with a single implant: (1) neutralization of sagittal fracture lines within the trochlea and (2) attachment of the trochlea to the humeral diaphysis.
4. Smaller articular fragments can be secured with Herbert screws or independent 1.5-mm, 2-mm, or 2.4-mm screws that are countersunk below the articular surface.[71,101,115] These implants are typically placed to neutralize coronal plane articular fragments before fixation of the more common sagittally oriented trochlear fragments. These implants need to be strategically placed so as not to interfere with the trochlear fixation coming from the medial and lateral plates.
5. Medial column fractures that result in the separation of the trochlea from the medial epicondyle ("H" pattern) are particularly challenging because the trochlea has no attachment to the medial or lateral column and may be devoid of soft tissue attachments. In this situation, the medial plate can be contoured around the medial

http://e-surg.com

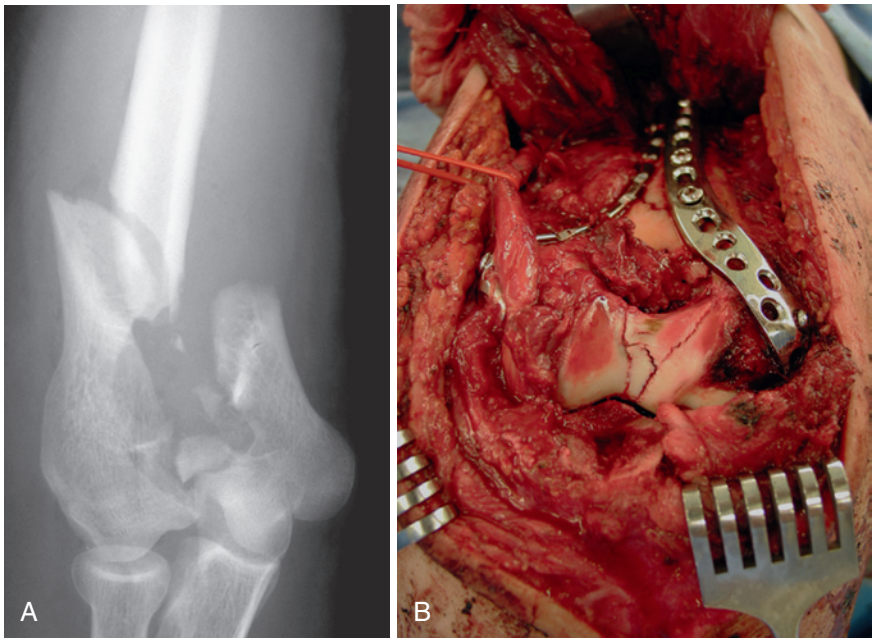

FIGURE 18.24 A, Anteroposterior injury radiograph of bicolumnar distal humerus fracture. Note central trochlear comminution. **B,** Intraoperative photograph of same injury after reduction and definitive stabilization using olecranon osteotomy exposure. Note that central trochlear comminution has been reduced and stabilized. Failure to reduce this fragment may result in overcompression of trochlea and ultimately ulnar-trochlear incongruity.

epicondyle and then distally along the medial wall of the trochlea. The most distal hole of the plate can be used additionally to secure the trochlea. Plate contouring of this area is quite difficult but can be performed on an anatomic model preoperatively to decrease operative time, or, alternatively, a precontoured periarticular distal humerus plating system that features this contour can be used. Because of the metallic bulk in this region of the cubital tunnel, the ulnar nerve is commonly transposed.

6. Secure fixation of the reconstructed articular segment to the distal humerus metadiaphysis can be enhanced with the placement of a screw that begins at the distal portion of either the medial or the lateral column plate and travels retrograde within the distal medial or lateral column, engaging the distal humerus diaphyseal cortex. These "column screws" improve the construct rigidity across the distal humerus metaphysis, but they should not jeopardize fixation of the distal articular surface to the medial or lateral plates.
7. Unicondylar fractures may be managed with single-column screw and plate implants or screw fixation alone, with both options showing satisfactory results.[57] With single-column plating techniques, the plate typically functions as an antiglide device. In unicondylar fractures with columnar comminution in the supracondylar region, the plate acts as a buttress.

Implant Biomechanics

The orthopedic community generally agrees that surgical reduction and internal fixation of distal humerus fractures show improved outcomes compared with nonoperative treatment. There is also agreement that unstable internal fixation commonly results in a poor outcome. What remains controversial is the question of which implant design and placement would be ideal and provide optimal stability for fractures of the distal humerus. The guidelines proposed by the AO group are considered by most orthopedists to represent the standard technique for fixation of bicolumnar distal humerus fractures. Their recommended technique consists of screw fixation of the articular fragments and column stabilization with two plates at a 90-degree angle to one another. The specific recommendations for plate types have included tubular, 3.5-mm reconstruction, or combinations thereof. Subsequent to the guidelines proposed by the AO group, Helfet and Hotchkiss[36] published an influential study that confirmed that orthogonally oriented plates were much stiffer in the sagittal plane than either crossed malleolar screws or a posterior "Y"-plate. Their orthogonal plate groups consisted of medial and posterolateral 3.5-mm reconstruction plates, medial and posterolateral tubular plates, and a medial tubular plate and a posterolateral 3.5-mm reconstruction plate. No significant differences in stiffness could be detected among the orthogonal plating groups, and the authors concluded that two-plate fixation at right angles was the optimal construct for the stabilization of fractures of the distal humerus. The biomechanical properties of parallel plating constructs were not examined in this study, however, and implants were not stiffer than the 3.5-mm reconstruction plates used because these were the implants available at the time.

Jacobson and colleagues[49] examined five different distal humerus plating constructs in cadaveric specimens. They concluded that a medially applied 3.5-mm pelvic reconstruction plate and a 3.5-mm posterolateral dynamic compression plate provided the greatest sagittal plane stiffness and equivalent frontal plane and torsional stiffness compared with other constructs, including parallel-plated and triple-plated specimens. In that series, the parallel-plated specimens consisted of 3.5-mm reconstruction plates. Schemitsch and colleagues[106] evaluated the construct rigidity of distal humerus fixation with plates

http://e-surg.com

placed in five different configurations. These authors concluded that if maximum rigidity is required, in the absence of cortical contact between fragments, two plates applied opposite to each other are biomechanically superior in providing rigidity of fixation. Specifically, that model consisted of a medial 3.5-mm pelvic reconstruction plate and a rigid lateral, precontoured, anatomically shaped "J"-plate. They further concluded that two-plate constructs do not require placement at 90 degrees to obtain sufficient rigidity, but do require placement on separate columns and different surfaces. Schemitsch and colleagues[106] also noted that a further advantage of the lateral plate was the ability to insert long screws transversely from lateral to medial into the medial trochlea, allowing increased screw purchase.

Self and associates[110] similarly noted that a parallel plate construct consisting of a lateral "J"-plate with a medial 3.5-mm reconstruction plate showed significantly more rigidity to axial loading than orthogonal 3.5-mm reconstruction plates. Linking the parallel plates with a cross-bolt was found to stiffen and strengthen this construct further, suggesting that linking of the distal portion of the medial and lateral plates improves fixation into the distal articular segment. In a distal humerus fracture model, Arnander and coworkers[2] showed that parallel 3.5-mm reconstruction plates were significantly stronger and stiffer than perpendicular 3.5-mm reconstruction plates when they were subjected to sagittal bending forces. The strength of this study is that the only variables that changed were the plate position (from a posterolateral location to the straight lateral aspect of the lateral column) and the subsequent screw lengths that secured the lateral plate.

Despite the theoretical benefits associated with locked plate fixation in osteopenic bone, support for locking plate fixation of the distal humerus remains limited. Korner and colleagues[62] reported that locking compression plates placed in an orthogonal position showed significant improvement in sagittal bending and torsional stiffness compared with plates placed in a dorsal position. The utility of this conclusion is minimized because the use of purely dorsal plating in the management of distal humerus fractures has been abandoned. The authors further concluded, however, that the plating technique is more important for obtaining stable fracture fixation than the type of plate used because there was no significant mechanical difference between orthogonally placed conventional reconstruction plates and locking compression plates. Schuster and colleagues[109] showed improved mechanical stability of distal humerus fracture fixation with locking orthogonal plate constructs over conventional fixation in specimens with poor bone mineral density, but noted no difference in specimens with high bone mineral density. Similarly, Stoffel and colleagues[116] compared two distal humerus locking plate systems in paired cadaveric bone fracture models. These authors concluded that the parallel locking plate system provided significantly higher mechanical stability than the orthogonal system. More recently, studies comparing precontoured anatomic plates with and without locking fixation show that locking constructs provide greater fixation stiffness, with the inference that they may be more beneficial in the setting of severe comminution or poor bone quality.[48]

Despite the array of plate types, constructs, and fracture models that have been examined, some conclusions can be made regarding the mechanical stabilization of bicolumnar distal humerus fractures. First, the literature strongly continues to support two-column plating, rigid fixation, and anatomic reconstruction of the articular surface, and when properly applied, less expensive and more readily available implants can be expected to provide similar results.[10,61]

When examining plates of the same type, two parallel plates seem to offer improved mechanical stability compared with strictly orthogonal plates, particularly in the sagittal plane. As long as both columns are secured rigidly, the columnar component of the fracture is likely to heal. Limited-contact dynamic compression plates, 3.5-mm reconstruction plates, and precontoured periarticular plates all are sufficiently rigid to provide satisfactory stable fixation. Thinner one-third tubular plates used as primary column support should be avoided.[39,43]

❖ AUTHORS' PREFERRED METHOD OF TREATMENT

Fracture management requires the surgeon to be prepared with a thorough preoperative plan yet remain amenable and versatile enough to modify the initial plan as the operation proceeds. Because every fracture is unique, principles, rather than a strict series of steps, should be understood and followed. Common pitfalls should be anticipated before the patient enters the operating room. Conceptually, pitfalls may be organized as related to the fracture pattern or related to fixation problems.

General Considerations and Potential Pitfalls

Unanticipated fracture lines or comminution can pose significant problems in the execution of a preoperative plan and may require intraoperative modifications, including changing from one anticipated operative exposure to another or modifying the fracture construct, or both. Fracture patterns that are particularly troublesome are (1) coronal plane fractures of the capitellum or trochlea, or both, (2) separation of the medial aspect of the trochlea from the medial column, and (3) "low" (very distal) fracture patterns.

These fracture characteristics can be identified on plain radiographs, particularly on quality traction films. When the presence of these fractures is suspected, CT may aid in the diagnosis[71,101] and comprehension, particularly when combined with three-dimensional reconstructions.[17] When associated coronal fractures exist, they are reduced and managed before reduction of the remainder of the articular surface. Fracture of the trochlea from the medial column frequently requires distal modification of the medial column plate to ensure rigid fixation of the articular segment to the humeral shaft. Low fracture patterns result in a small distal articular segment that jeopardizes distal fixation. We believe olecranon osteotomy is required to manage these fracture patterns adequately.

Achieving adequate fixation to allow early range of motion is often crucial for successful management of fractures of the distal humerus. If the quality of fixation would not tolerate aggressive rehabilitation and motion of the elbow, preservation of the joint takes priority. Accepting some loss of motion is preferable to losing the entire articular surface of the trochlea. The articular segment is usually where fixation is most tenuous. There are techniques that may improve fixation. By placing several screws through the distal portions of medial and lateral plates across the distal articular segment, empowered fixation can be achieved through the "interference" of the screws within the segment.[91,104] The risk in this technique is the loss of

http://e-surg.com

reduction as the screws are forced to engage one another. A second option, particularly useful in elderly patients, is to shorten the humerus in the metaphyseal fracture area, creating enhanced bone contact and a more stable supracondylar construct. Additionally, three or more plates can be used distally to obtain orthogonal fixation within each column. These supplementary plates can provide surprisingly good stability and have been shown to be clinically effective in this setting.[33,52]

Supracondylar and Transcondylar Fractures: Proximal Patterns

Displaced extraarticular fractures of the distal humerus are managed operatively to avoid prolonged immobilization of the elbow joint and resultant stiffness. Patients may be positioned in the lateral or prone position, depending on the presence of other injuries. Because of the distal location of the fracture, stabilization generally requires the application of medial and lateral column plates, and a paratricipital approach using a posterior skin incision is used. Given the extraarticular nature of these fractures, olecranon osteotomy is rarely indicated. Occasionally, the fracture pattern results in the lateral column extending proximally to a point that sufficient distal fixation may be obtained with a single plate fixed proximally along the posterior aspect of the humeral diaphysis and, distally, along the posterior aspect of the lateral column (e.g., abduction transcondylar variant). In this situation, the extensile exposure described by Gerwin and associates[30] is used, without the need for dissection of the medial column. If at any point the stability of the fracture is in question, this approach is easily expanded to the paratricipital exposure, allowing manipulation and stabilization of the medial column.

Bicolumnar Fractures in an Active Patient With Healthy Bone

Bicolumnar fractures of the distal humerus are managed operatively with ORIF techniques using a posterior universal midline skin incision. Patients are usually placed lateral on a well-padded radiolucent table with a radiolucent arm board to support the injured upper extremity. The prone position is particularly useful for fractures that extend into the humeral diaphysis, allowing easier fluoroscopic imaging. We use the lateral position for patients who are otherwise unable to be placed prone. Definitive fixation is with medial and lateral plate and screw implants. Multiple plate constructs should be considered for significantly comminuted fractures on a case-by-case basis.

Minimally Comminuted Fractures. Preoperatively, the degree of articular comminution and displacement is assessed. Fractures with simple articular splits, with large condylar fragments, and without major displacement are exposed using the paratricipital approach. If a satisfactory reduction can be obtained along the medial or lateral column in the supracondylar region, this reduction is performed first, allowing indirect approximate reduction of the articular surface. Supracondylar reductions are provisionally stabilized with Kirschner wires. The adequacy of articular reduction is mainly confirmed fluoroscopically; with retraction of the triceps aponeurosis posteriorly and flexion of the elbow, the posterior aspect of the trochlea is also directly visualized and palpated with a small periosteal elevator, confirming or disproving fluoroscopic images. Adjustment of the articular surface reduction is performed with larger-diameter Kirschner wires placed into the condyles to act as joysticks. When the articular surface is realigned, a large pointed reduction clamp is placed across the condyles, and the articular surface is compressed. The articular reduction is provisionally maintained with Kirschner wires (Case Study 18.5).

CRITICAL POINTS *Bicolumnar Fractures*

Preoperative Evaluation
- Obtain anteroposterior, lateral, and traction view radiographs.
- Consider CT for extreme distal (or "low") fracture patterns in elderly patients or articular fractures of variant patterns.

Pitfalls
- Unrecognized articular comminution, particularly in the coronal plane
- Fracture lines that separate the medial trochlea from the medial column
- Unanticipated poor bone quality (osteoporosis)

Operative Exposure
- Choose the exposure that best allows reduction and stabilization of the articular surface.
- With increased patient age, choose an exposure that does not compromise a TEA.
- We prefer olecranon osteotomy for managing displaced, comminuted fractures involving the articular surface. The paratricipital approach is our preferred exposure for patients who may require conversion to TEA.

Technical Points
- Medial and lateral column fixation provides the best fracture stability.
- A medial plate is usually a reconstruction-type implant and is applied directly medially; a lateral implant is frequently stiffer (dynamic compression plate) and is applied to the posterior aspect of the lateral column.
- Medial fixation is typically applied first because it is less likely to be obstructed by temporary Kirschner wires.
- Precontoured periarticular plates are available, but they may still need minor contour adjustments.
- Secure articular fragments with screws that are placed through a plate, whenever possible.
- Consider ulnar nerve transposition.
- Before wound closure, the elbow is placed through a range of motion to ensure fracture stability.

Postoperative Care
- The elbow is splinted in extension at the conclusion of the procedure.
- Range-of-motion exercises are begun within 24 to 48 hours postoperatively. The patient must understand that the initial goal of rehabilitation is to obtain motion.
- Active flexion and passive extension are performed for all exposures except for lateral and paratricipital exposures, which are allowed active extension.
- Gentle stretching and active range-of-motion exercises for extension and flexion are initiated at 6 weeks.
- Resistive and strengthening exercises begin at week 12 and should be commensurate with radiographic consolidation.
- Static progressive splinting is considered between weeks 6 and 12 if the active range of motion plateaus below a functional arc.

Athletic Participation and Manual Labor
- Consolidation of fracture lines radiographically is required.
- Strength should be approaching 75% of the contralateral uninjured extremity.

http://e-surg.com

CASE STUDY 18.5

A 21-year-old woman was involved in a high-speed motor vehicle accident. She sustained an isolated injury to the right upper extremity (eFigure 18.14). The neurovascular examination is normal and the soft tissues are intact.

Your preferred exposure is:

A. Olecranon osteotomy
B. Paratricipital exposure
C. Triceps-reflecting anconeus pedicle (TRAP) procedure
D. Triceps turndown procedure
E. Triceps-splitting exposure

Correct answer:

B. Paratricipital exposure

Injury radiographs demonstrate a comminuted distal humerus fracture with marked displacement of the shaft fragment anteriorly. The articular surface demonstrates a simple split. Cortical fracture line interdigitation is available in the metaphyseal region, enabling satisfactory indirect reduction of the articular surface. A paratricipital approach was used for this fracture.

Uneventful union and a satisfactory functional result ensued (eFigure 18.15).

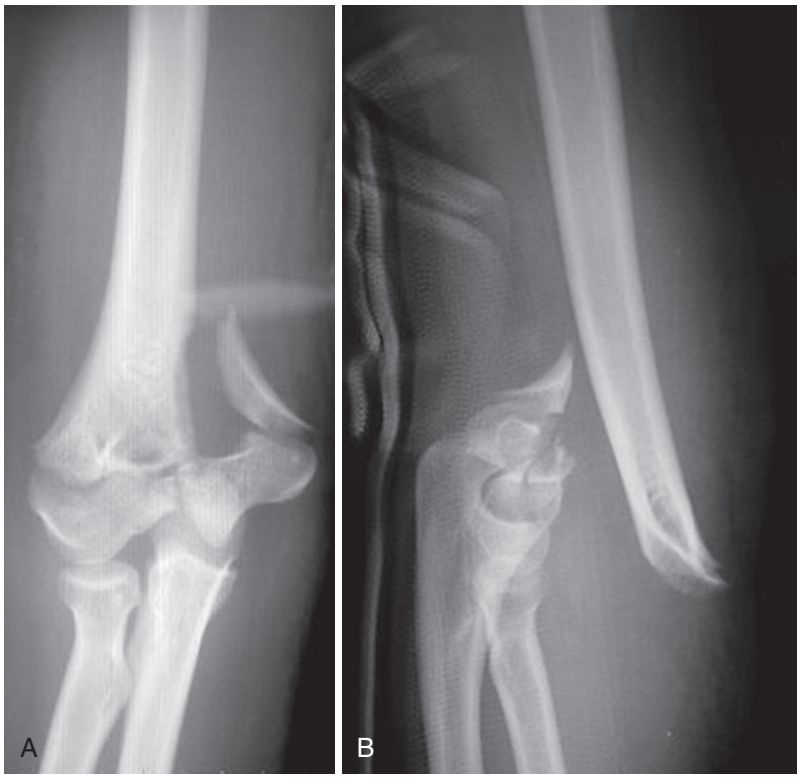

eFIGURE 18.14 Preoperative radiographs.

http://e-surg.com

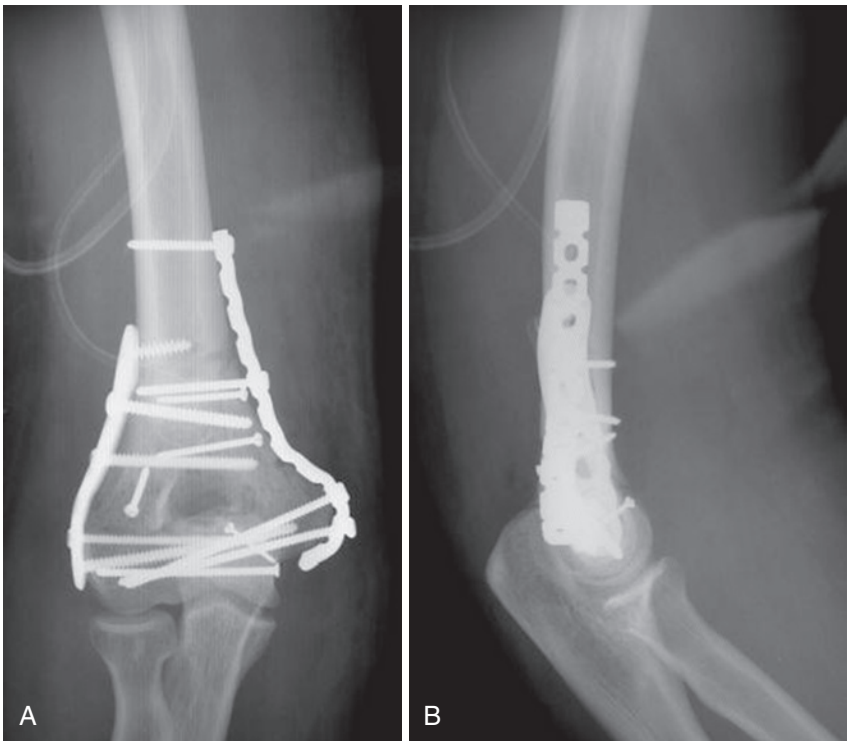

eFIGURE 18.15 Postoperative radiographs.

http://e-surg.com

Fractures with significant comminution of the articular surface are treated using olecranon osteotomy. The reduction sequence varies, depending on the particular fracture patterns.

Multiplanar Articular Involvement. Fractures that display multiplanar involvement of the articular surface (coronal plane fragmentation) are managed first with reduction and stabilization of the anterior articular components (see Case Study 18.3). This is usually accomplished by displacing the sagittal fracture line, allowing access to the medial aspect of the capitellum and the lateral aspect of the trochlea. By allowing the metaphysis to shorten through the supracondylar fracture, visualization of the anterior components of the articular surface is facilitated. The anterior articular surface is typically definitively stabilized at this point with posterior-to-anterior minifragment screws while direct visual confirmation of secure anatomic reduction is still possible. When the anterior articular surface is secured, the sagittally oriented fracture (separating the distal articular surface into medial and lateral components) is reduced and provisionally stabilized. The metaphyseal fracture is reduced, essentially orienting the distal humerus articular segment appropriately beneath the metadiaphysis. This segment is provisionally stabilized, and intraoperative fluoroscopy is used to confirm the adequacy of reduction.

Simple Supracondylar Involvement. Intraarticular fractures that show minimal comminution in the supracondylar region have long fracture planes that are amenable to anatomic reduction (medial and lateral lambda patterns). When these features are present, we prefer to begin the reduction and temporary stabilization sequence in this supracondylar area first. The goal is to restore reliably a segment of the articular surface to the metadiaphysis and then build the remaining articular surface to this restored column. This sequence is effective, provided that the supracondylar area can be reduced and provisionally stabilized reliably.

Combined Articular and Supracondylar Comminution. Fractures with combined articular and supracondylar comminution are a significant challenge and must be individualized (Case Study 18.6). In fracture patterns where metaphyseal comminution is extensive, we initially focus on the reduction and temporary stabilization of the articular surface. The distal humerus articular surface is oriented and provisionally stabilized in the proper transverse, sagittal, and coronal planes relative to the metadiaphyseal region. In situations with marked metaphyseal comminution, this area is indirectly reduced and secured with the aid of appropriately contoured or precontoured periarticular plates; this maintains viability of the metaphyseal fragments, allowing predictable union. In an older patient undergoing ORIF, the humerus can be shortened through the comminuted metaphysis to allow intrinsic bone contact and stability of the entire construct. Shortening provides minimal functional deficits, provided that the olecranon and coronoid fossae are not obliterated, and offers improved fracture stability and union in older patients.

Technique for Olecranon Osteotomy. For maximum visualization of the articular surface of the distal humerus, we prefer to perform an olecranon osteotomy. At the conclusion of the procedure, the osteotomy is secured with a medullary screw and tension band technique. The screw is placed in a unicortical fashion with distal purchase obtained from the screw threads interacting with the endosteal ulnar surface. In many patients, a partially threaded 4.5-mm screw and washer are used; however, in older patients or patients with larger stature, a 6.5-mm lag screw is occasionally used. The technique for a 4.5-mm screw is described.

Creation of Osteotomy. Visualization of the "bare area" of the olecranon is performed by division and elevation of the medial and lateral capsular attachments along the olecranon process and corresponds to the deepest portion of the semilunar notch. Using the lateral fluoroscopic image, the olecranon is predrilled, first with a 4.5-mm glide hole to the level of the anticipated osteotomy. This is followed with a 3.2-mm drill bit. It is imperative to begin the drill hole in the center of the proximal aspect of the olecranon process relative to its medial and lateral surfaces. When the glide hole in the metaphyseal area of the olecranon is passed, the 3.2-mm drill bit is inserted to the limit of the glide hole and subsequently oscillated distally within the ulnar medullary canal. The purpose for oscillating the drill is to avoid exiting the ulnar diaphysis inadvertently. Approximately at the junction of the middle and proximal thirds, the ulna curves, presenting a convexity laterally. Drilling is stopped at this curved area, approximately 90 to 120 mm distal to the tip of the olecranon. The length of the anticipated screw is measured, and the drill hole is tapped with a 4.5-mm tap. This last step is eliminated if self-tapping screws are used.

A small sponge is placed between the articular surface of the semilunar notch and the fractured articular surface of the distal humerus. Placement of a sponge allows an assistant to provide counterpressure on the proximal ulna and avoids inadvertent injury to the distal humerus articular surface. With the aid of the lateral fluoroscopic image, a 2.5-mm drill is placed in the midline dorsal surface of the olecranon process immediately across from the "bare area." The drill is advanced to the subchondral surface, but not through it (Figure 18.25, *A*). A fine oscillating saw is used to create the osteotomy into, but not through, the subchondral bone (see Figure 18.25, *B*). The osteotomy is created in a chevron pattern, with the apex of the chevron pointing distally (see Figure 18.25, *A*). The 2.5-mm drill hole on the dorsal surface orients the operator and avoids creating an "X" at the apex of the osteotomy. A thin osteotome is inserted into the saw tract, and the osteotomy is completed by cracking the remaining osteochondral surface (see Figure 18.25, *C*). The tip of the olecranon and triceps is reflected proximally. A suture is used to hold the extensor mechanism to the skin of the proximal arm as a retraction aid. A moistened sponge is draped over the exposed triceps musculature and olecranon. Figure 18.26 provides a clinical example.

Fixation of Osteotomy. The previously placed proximal retraction suture is removed, allowing the extensor mechanism to return to its normal orientation. A 2.5-mm drill bit is used to create a bicortical drill hole from medial to lateral in the ulnar shaft approximately 3 to 4 cm distal to the osteotomy site, in anticipation of the tension band wire. A long 3.2-mm drill bit is placed by hand through the previously created drill hole in the tip of the olecranon process and delivered down the medullary canal of the ulna. This drill bit acts as a guide rail along which the olecranon process can be steered, helping to eliminate translational deformities. Medial and lateral large point-to-point reduction forceps are placed across the osteotomy and are used to fine-tune the reduction and ultimately to compress the osteotomy. Two 0.062-inch Kirschner wires are placed from the

http://e-surg.com

CASE STUDY 18.6 Comminuted Complex Articular and Metaphyseal Involvement

A 54-year-old man sustained an open bicolumnar distal humerus fracture after falling from a ladder. The open wound was located posteromedially (eFigure 18.16). An associated intracranial hemorrhage precluded operative management of the elbow for 3 days.

Your management consists of:

A. Open reduction and internal fixation (ORIF) via olecranon osteotomy
B. Acute total elbow replacement
C. Delayed total elbow replacement (after 6 weeks) because of the 3-day-old open wound
D. ORIF using a triceps-splitting exposure
E. Allograft distal humeral replacement

Correct answer:

A. ORIF via olecranon osteotomy

Injury radiographs demonstrate significant displacement and comminution of the distal humerus. Note that the trochlea has been fractured from the medial column. An associated comminuted fracture of the radial head is also identified. The preoperative plan consisted of ORIF, with medial and lateral plating using an olecranon osteotomy, and radial head replacement (eFigure 18.17).

Recovery was complicated by significant elbow stiffness resulting from heterotopic ossification and soft tissue contracture. This was successfully managed with elbow release.

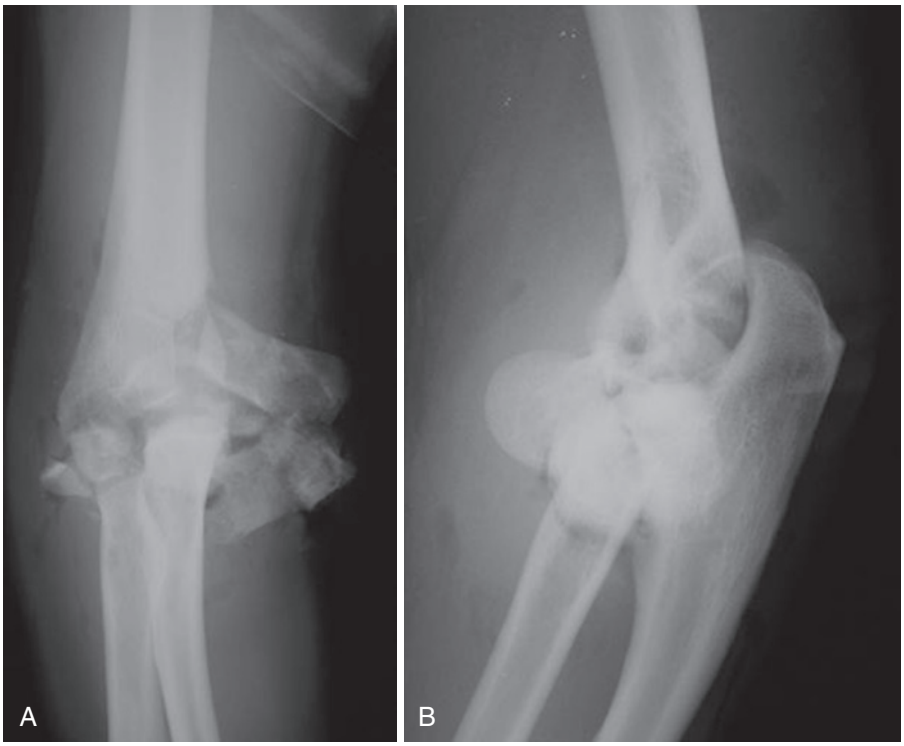

eFIGURE 18.16 Preoperative radiographs.

http://e-surg.com

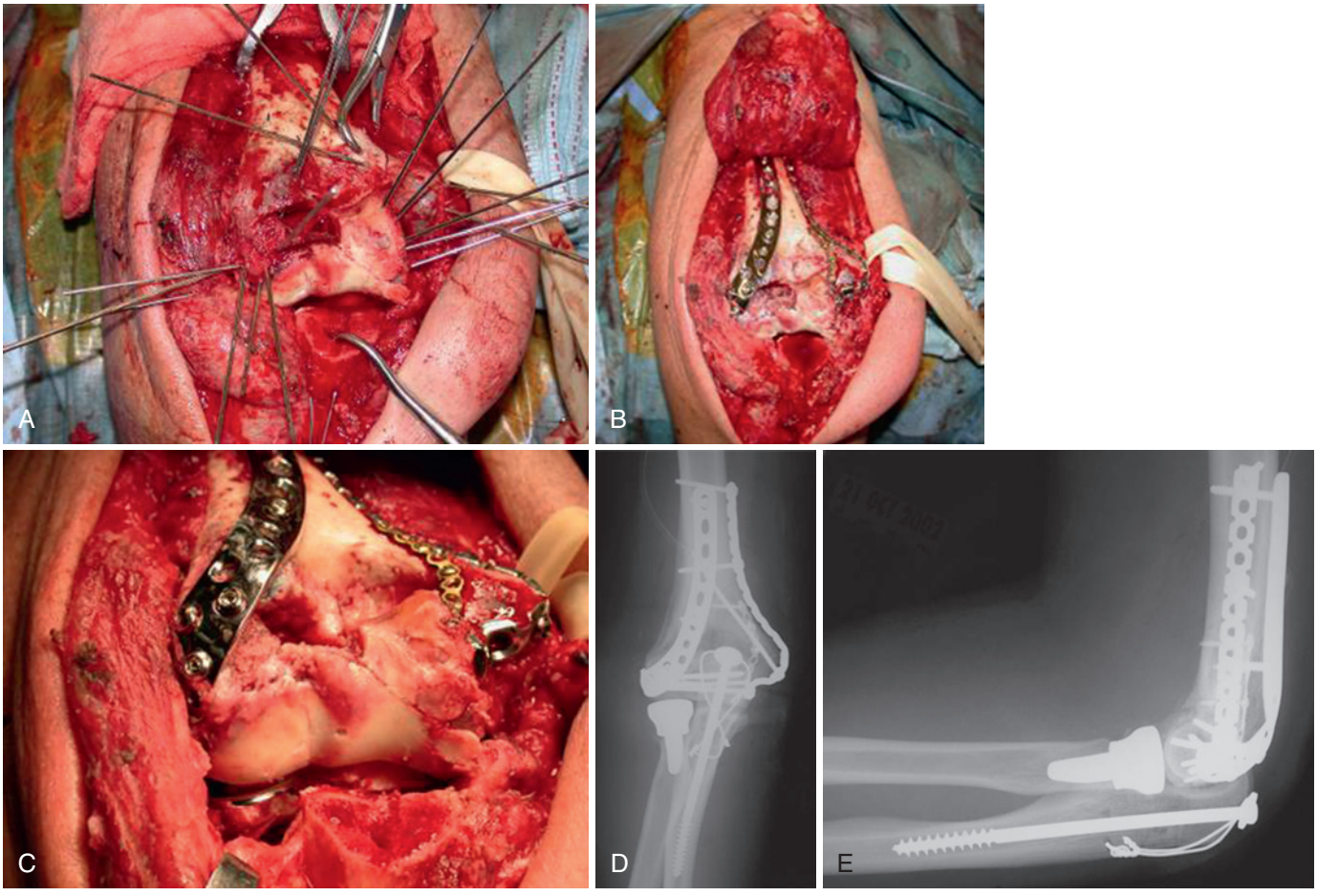

eFIGURE 18.17 Open reduction and internal fixation via olecranon osteotomy. **A,** Intraoperative photograph demonstrates provisional reduction and Kirschner wire fixation. Kirschner wires are placed to first allow application of a direct medial plate. Once the medial column is secured, extraneous Kirschner wires can be removed to allow placement of the lateral plate. **B** and **C,** Intraoperative photographs demonstrating final reduction and fixation. The medial plate is contoured to accommodate the medial aspect of the trochlea. A supplemental 2-mm plate is contoured along the posteromedial distal humerus to supplement fixation of the trochlea. The radial head has been replaced. A portion of the distal posterior lateral column was lost at the accident. **D** and **E,** Final radiographs demonstrate satisfactory reduction. The osteotomy is secured with a partially threaded 6.5-mm screw and tension band wire.

http://e-surg.com

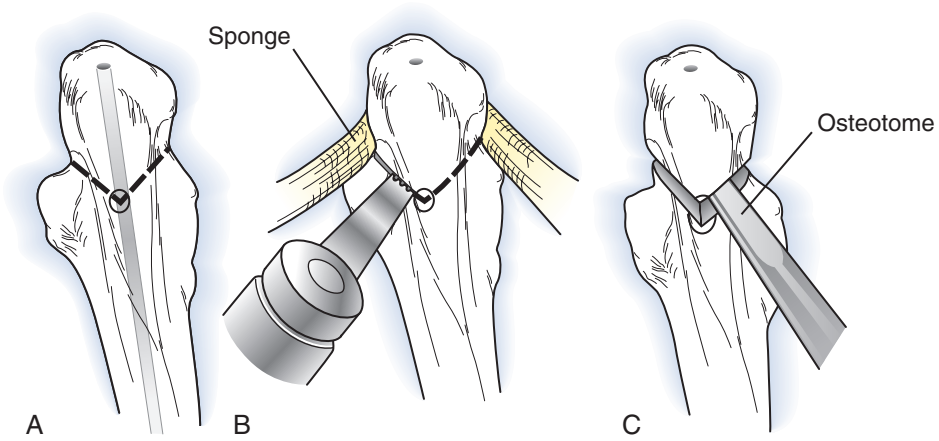

FIGURE 18.25 **A,** Shape of chevron osteotomy with apex pointing distally. Note drill hole at apex. **B,** Sponge protecting articular surface of distal humerus. **C,** Osteotomy with osteotome.

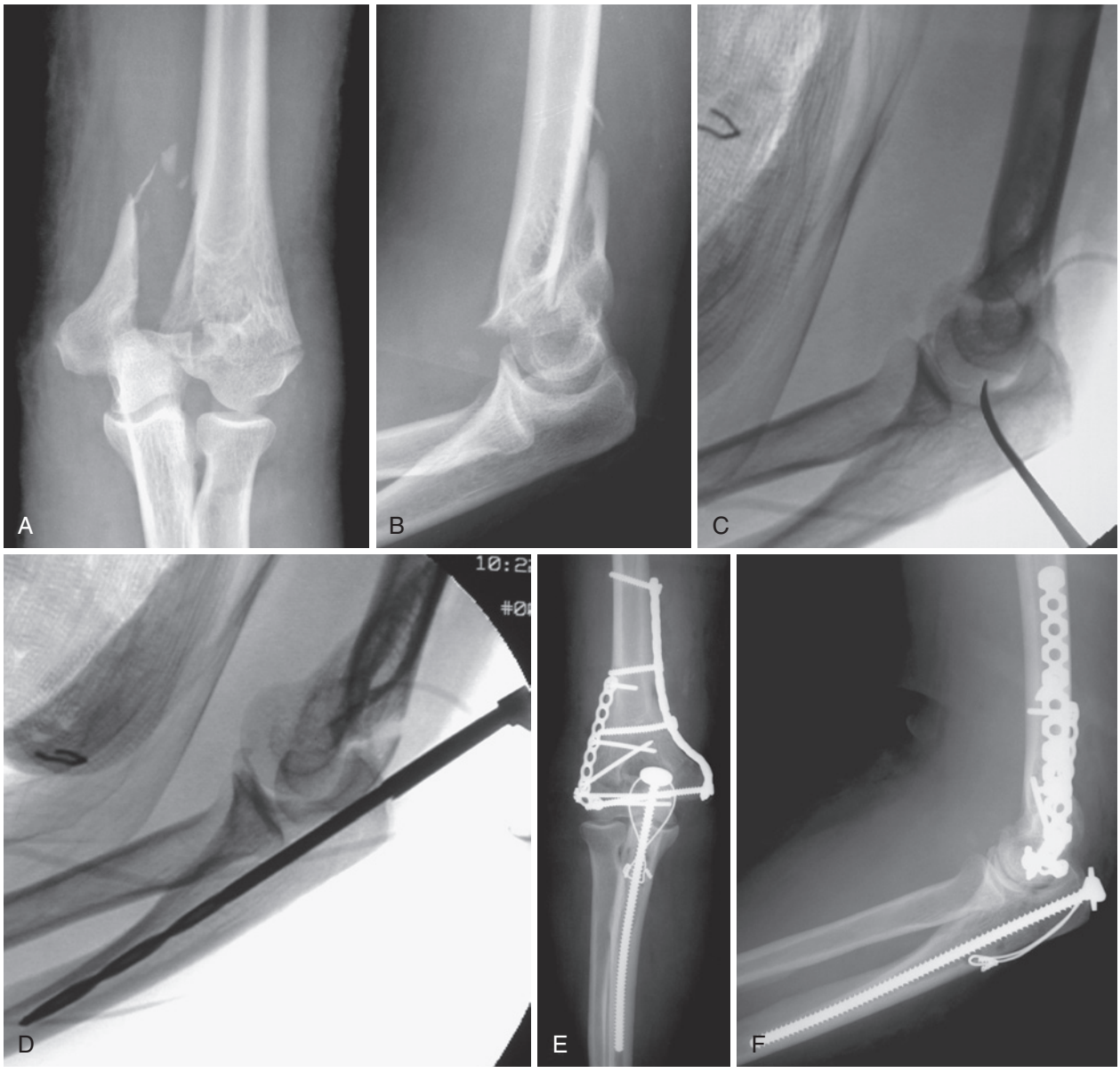

FIGURE 18.26 Anteroposterior **(A)** and lateral **(B)** injury radiographs show supracondylar/intercondylar distal humerus fracture with displacement of articular surface and very low injury of lateral column. To improve visualization of articular surface, olecranon osteotomy was chosen as preferred surgical approach. **C** and **D,** On intraoperative fluoroscopic images, a small elevator is used to show "bare area" of semilunar notch, and proximal ulna is predrilled before creation of osteotomy. **E** and **F,** Final radiographs show reduction and stabilization of distal humerus fracture and fixation of osteotomy using a 4.5-mm screw with washer and tension band wiring.

http://e-surg.com

olecranon process, across the reduced osteotomy, and into the dense bone of the coronoid process, providing provisional stability. The 3.2-mm drill bit is removed, and a 4.5-mm screw of appropriate length and its washer are placed into the proximal ulna but not fully tightened.

A tension band wire, usually of 18 gauge, is subsequently cut into two segments. One segment is placed through the medial-to-lateral drill hole created distal to the osteotomy site. The second is placed from medial to lateral at the tip of the olecranon process. This second wire is placed deep to the triceps insertion and washer, at the proximal aspect of the screw. The screw is tightened enough to trap the wire beneath the washer but still allow the wire to be manipulated. A figure-of-eight pattern is created with the wire, and the proximal ends are twisted to the corresponding ends of the distal wire in a double-knot technique. The knots are placed medially and laterally, avoiding the tip of the olecranon, helping to decrease implant prominence. When the tension band wire has been fully tightened, the screw is finally fully seated and tightened. Temporary clamps and Kirschner wires are removed. The elbow is placed through a range of motion, and a secure osteotomy is ensured. Infrequently, because of inadvertent osteotomy obliquity, comminution, or olecranon fracture, stability of the osteotomy cannot be ensured with the screw and tension band technique. In these situations, we proceed with plate osteosynthesis of the osteotomy. Since the first edition of this chapter was published, various devices tailored specifically to the olecranon have been manufactured and touted for their anatomic specificity and ease of application. None to date has been demonstrated to be any more beneficial than the techniques described above.

Fixation Sequence. The fixation sequence varies depending on the individual fracture characteristics. Because most of the Kirschner wires are placed in a posterior-to-anterior direction, the medial surface of the distal humerus is usually unobstructed and free of temporary implants, allowing the medial plate to be placed first. This plate is typically a more malleable plate, such as a reconstruction plate, and is applied directly medially with attention paid to ensuring that it is accurately contoured around the medial epicondyle. The first screw inserted is usually at a point immediately proximal to the most proximal fracture line on the medial column. Slight undercontouring of the plate along the medial supracondylar ridge allows a buttressing effect distally as the screw is tightened. The orientation of the plate on the medial column is confirmed on anteroposterior and lateral intraoperative fluoroscopic studies.

Screw fixation proceeds distally with placement of screws across the distal humerus articular surface. Finally, screws are placed in the proximal portion of the plate. Because the medial implant is a malleable reconstruction plate, it tends to be contoured to the bone rather than the provisionally reduced fracture being displaced to the plate. When the medial column plate is secured to the medial column, several redundant Kirschner wires may be removed to decrease interference when the lateral column is subsequently secured. We typically use a stiff precontoured posterolateral periarticular plate to provide rigid lateral column stability while allowing screws to be placed from lateral to medial across the distal humerus articular surface. The distal lateral portion of the plate is confirmed to be in a satisfactory position clinically and fluoroscopically and is applied closely to the lateral epicondylar region to avoid plate prominence in this area. The plate is maintained in the appropriate position with several Kirschner wires, and screws are strategically inserted beginning proximally and working distally.

CRITICAL POINTS *Olecranon Osteotomy*

Creation

- Preoperatively determine whether a 4.5-mm cortical screw or a 6.5-mm partially threaded screw will be used to secure the osteotomy.
- The choice of screw is based on the diameter of the medullary canal.
- Identify the bare area and confirm this with fluoroscopy.
- Predrill the proximal ulna using a 3.2-mm drill bit. This serves as the thread hole for 4.5-mm and 6.5-mm screws. If a 4.5-mm screw is anticipated, a 4.5-mm glide hole is created initially.
- A 2.5-mm drill hole is placed through the dorsal surface of the proximal ulna at the anticipated position of the osteotomy apex.
- An oscillating saw initiates the chevron osteotomy (apex pointing distally) at the bare area. The previously placed 2.5-mm drill hole helps orient the operator.
- A fine osteotome is used to "fracture" the articular surface, completing the osteotomy.

Fixation

- Place a 3.2-mm drill bit antegrade into the drill hole of the osteotomized fragment. Continue passing the drill bit into the medullary canal of the ulna.
- Medial and lateral pointed bone reduction clamps are placed across the osteotomy. The intramedullary drill bit helps to eliminate translational deformities during this maneuver.
- Kirschner wires are used to secure the osteotomy.
- A transverse drill hole is created in the proximal ulna, distal to the osteotomy.
- Remove the drill bit, and insert the intramedullary screw and washer.
- Before final tightening of the screw, cerclage wire is passed beneath the washer and through the transverse hole in the proximal ulna. A figure-of-eight pattern is used.
- The cerclage wire is tightened, and the screw is secured.
- Remove Kirschner wires and clamps.
- Place the elbow through a range of motion, and ensure stability of the osteotomy.

Pitfalls

- Before performing the osteotomy, the drill bit must be placed at the center of the olecranon and pass smoothly down the medullary canal of the ulna. Eccentric placement of the drill hole in the olecranon may result in translational forces and malreduction of the osteotomy during fixation.
- Osteotomies that are not perpendicular to the intramedullary screw displace with tightening.
- Long 6.5-mm screws that significantly engage the bow of the ulna may displace the osteotomy. This is less likely to occur with less stiff 4.5-mm screws.

Pearls

- If poor purchase is obtained with a 4.5-mm screw, the screw length can be increased to engage more of the curved portion of the ulna. Improved distal purchase is obtained as the screw bends to accommodate the medullary canal. If this still fails to give satisfactory purchase, a 6.5-mm screw should be used.
- Osteotomies that remain unstable or that continually displace with final tightening of the intramedullary screw are managed with plate stabilization.

Unicolumnar Fractures

The surgical tactic for management of single-column fractures of the distal humerus begins with an assessment of the degree

http://e-surg.com

of comminution of the articular surface and a close inspection of the opposite column to rule out subtle fracture lines that change the diagnosis to a bicolumnar injury (Case Study 18.7). Invariably, significantly displaced fractures of the lateral or medial column are approached through a universal posterior skin incision with the patient in the prone or lateral position. Depending on the involved column, the corresponding paratricipital interval is developed. Regardless of which column is fractured, the ulnar nerve is routinely mobilized and protected. If significant articular surface comminution exists, both paratricipital intervals are exposed and an olecranon osteotomy is performed. If the articular surface is not comminuted, the fractured column is mobilized, and the triceps is elevated off the posterior aspect of the distal humerus. The fracture is reduced using cortical metaphyseal fracture interdigitations, indirectly reducing the articular surface. The olecranon is gently distracted from the distal humerus articular surface, and the articular reduction is assessed under direct vision and with palpation with a blunt periosteal elevator.

If a satisfactory reduction cannot be obtained, or the articular surface is significantly comminuted, we proceed with olecranon osteotomy. In significantly displaced, or "high," unicolumnar fractures, the radius and ulna frequently follow the displaced trochlear fragment. In this situation, reduction of the fractured column is quite difficult without the aid of osteotomy because the weight of the arm continues to act as a displacing force. Lag screw fixation alone is infrequently used for these injuries; we prefer plate stabilization of the injured column.

Capitellar and Articular Variant Fractures

The elucidation of the injury spectrum that occurs in capitellar injuries of the distal humerus continues to evolve, with the realization that many of these fractures are much more complicated than originally described.[103] Associated medial collateral ligament tears, disruption of the lateral ligamentous complex, and other periarticular fractures are common. More liberal use of CT has resulted in increased identification of several additional fracture features, including (1) involvement of the adjacent trochlea, (2) comminution of the posterior aspect of the capitellum or trochlea, or both, and (3) epicondylar fractures that may destabilize the ulnohumeral articulation further.[21,71,101]

These features are important because the surgical tactic may need to include an approach that allows access to the medial aspect of the elbow, visualization of the articular surface through the use of an olecranon osteotomy, and bone graft material. For these reasons, we recommend thin-cut preoperative CT evaluation in patients whose fracture patterns show any potential involvement of the posterior aspect of the capitellum or trochlea on plain radiographs. Isolated capitellar fractures and other articular fracture variants are managed operatively in physiologically active patients. In physiologically older patients, a fracture with significant articular comminution and displacement that cannot be reconstructed with standard ORIF techniques is treated with elbow arthroplasty.

Simple Fractures of the Capitellum

Simple capitellar fractures, including those with a coronal shear pattern, are managed with the patient in the supine position. The common feature of these fractures is that they are mainly confined to the anterolateral aspect of the distal humerus and are accessible using a lateral approach.

The patient is placed supine on the operating table, and a radiolucent arm board is used to support the injured extremity. A posterior universal skin incision is made, and the anconeus and extensor carpi ulnaris interval is developed. The joint capsule is incised, and the fracture is identified, cleansed of hematoma, and assessed. Simple fractures may be reduced at this point; however, comminuted capitellar fragments or fragments that extend beyond the lateral trochlear ridge require improved visualization. To improve visualization, detaching the origins of the extensor carpi ulnaris, common extensor tendon, and a portion of the extensor carpi radialis longus from the lateral supracondylar ridge extends the proximal interval. The origin of the lateral collateral ligament is detached sharply from its origin at the lateral epicondyle, and the elbow joint capsule is incised at its origin on the distal humerus. The capitellar fracture fragments are reduced with dental picks to the intact distal humerus. Temporary fixation is performed with small Kirschner wires, and the reduction is confirmed under direct visualization and with biplanar fluorographic imaging.

There is no consensus regarding the optimal fixation method for these fractures. Early reports in the literature recommended 4-mm cancellous lag screws or Herbert screws placed in an anterior-to-posterior direction.[71,76] In a cadaveric model, Elkowitz and associates[25] showed that posterior-to-anterior cancellous screw fixation was biomechanically superior, however, suggesting that the countersinking of the anterior-to-posterior screws removed dense subchondral bone, resulting in less rigid fixation. In the same study, headless anterior-to-posterior screws showed the strongest fixation, perhaps because of the preservation of the subchondral bone. The potential detrimental effects of removing a portion of the articular surface of the capitellum to insert anterior-to-posterior screws have not been determined, however. Posterolateral plate fixations have also been described and are most useful for providing a buttress effect to support the fractures with posterolateral comminution.[21,78] In our experience, definitive fixation is individualized based on the fracture pattern. Typically, fixation is achieved with 1.5-mm, 2-mm, or 2.4-mm countersunk screws. Posterolateral minifragment plate fixation is used to buttress complex capitellar fractures with posterolateral comminution. The lateral collateral ligament is repaired to its origin using suture anchors, and the extensor origins are repaired along the lateral supracondylar ridge.

Complex Capitellar Fractures and Articular Fracture Variants

Complex capitellar fractures and articular fracture variants are considered separately from simple capitellar fractures because of the potential involvement of the posterior aspect of the capitellum, lateral epicondyle, trochlea, and medial epicondylar region (Case Study 18.8).[21,101] With increasing involvement of the posterior and medial articular surfaces, visualization, reduction, and stabilization become increasingly difficult. As described by Ring and associates,[101] the inability to reduce the anterior capitellar fragments, or a capitellar fracture involving the lateral epicondyle, suggests the presence of this associated posterior injury. As noted earlier, preoperative CT evaluation identifies these important fracture features.

In patterns that involve the capitellum and the posterior aspect of the lateral column, the posterolateral aspect of the

http://e-surg.com

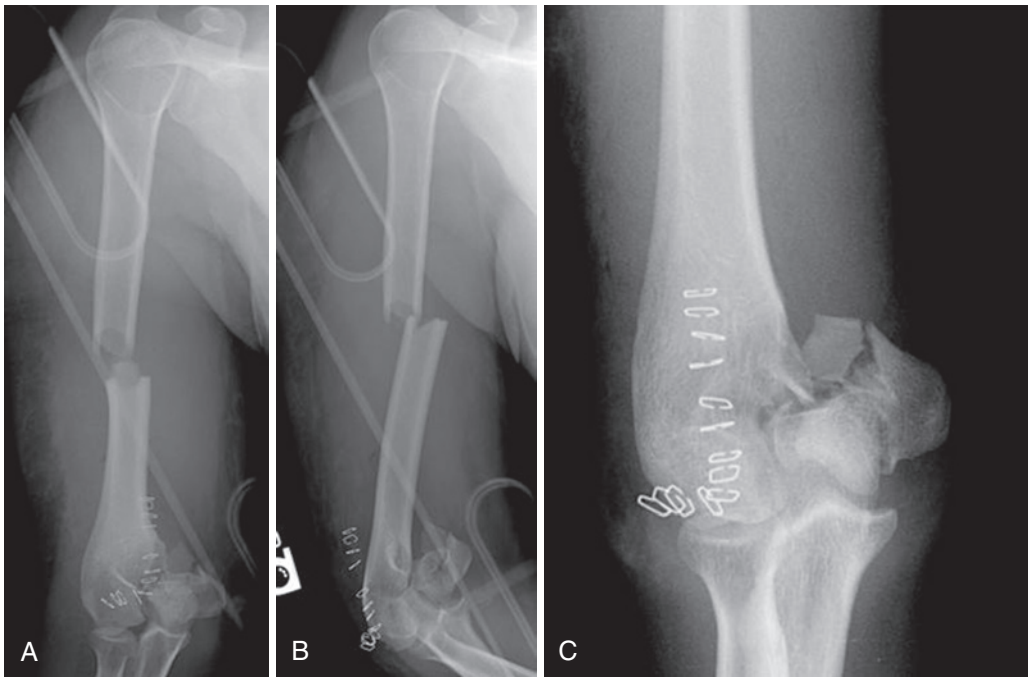

eFIGURE 18.18 Injury radiographs demonstrate a low medial column fracture with comminution of the medial supracondylar ridge and probable separation of the trochlea from the medial condylar fragment. Note that the ulna appears to displace with the medial fragment. An associated midshaft humerus fracture is also present. Surgical skin clips are present from the patient's initial operative débridement.

CASE STUDY 18.7 Unicolumnar Injury

A 27-year-old female was involved in a motor vehicle collision. She sustained an isolated injury to the right upper extremity. She was initially assessed at an outside facility and diagnosed with an open fracture of the distal humerus. Prior to transfer to our facility, she was managed with urgent irrigation and débridement, and the limb was placed into a long-arm plaster splint.

Upon arrival at our institution, the patient was fully examined, and the distal neurovascular structures were found to be intact. An "L"-shaped wound was noted at the posterolateral aspect of the elbow (eFigure 18.18).

Your preferred treatment strategy includes:

A. Olecranon osteotomy and extensile modified posterior exposure and plating of both the humeral shaft and medial condyle
B. Olecranon osteotomy and closed humeral nailing
C. Triceps-splitting exposure with plate fixation of the medial condyle and humeral shaft
D. Operative treatment of the medial condyle fracture and functional bracing of the humeral shaft

Correct answer:

A. Olecranon osteotomy and extensile modified posterior exposure and plating of both the humeral shaft and medial condyle

Postoperative radiographs demonstrate an uneventful union. The functional result is excellent months after injury (eFigures 18.19 and 18.20).

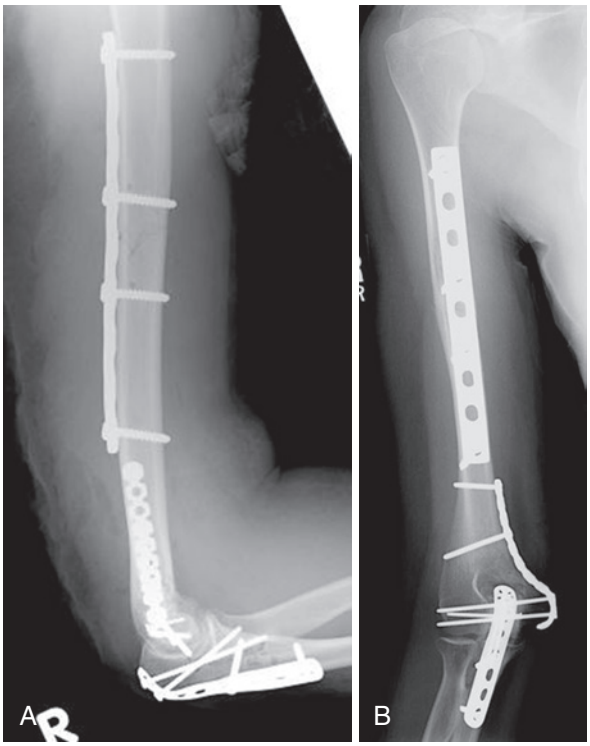

eFIGURE 18.19 Postoperative radiographs.

http://e-surg.com

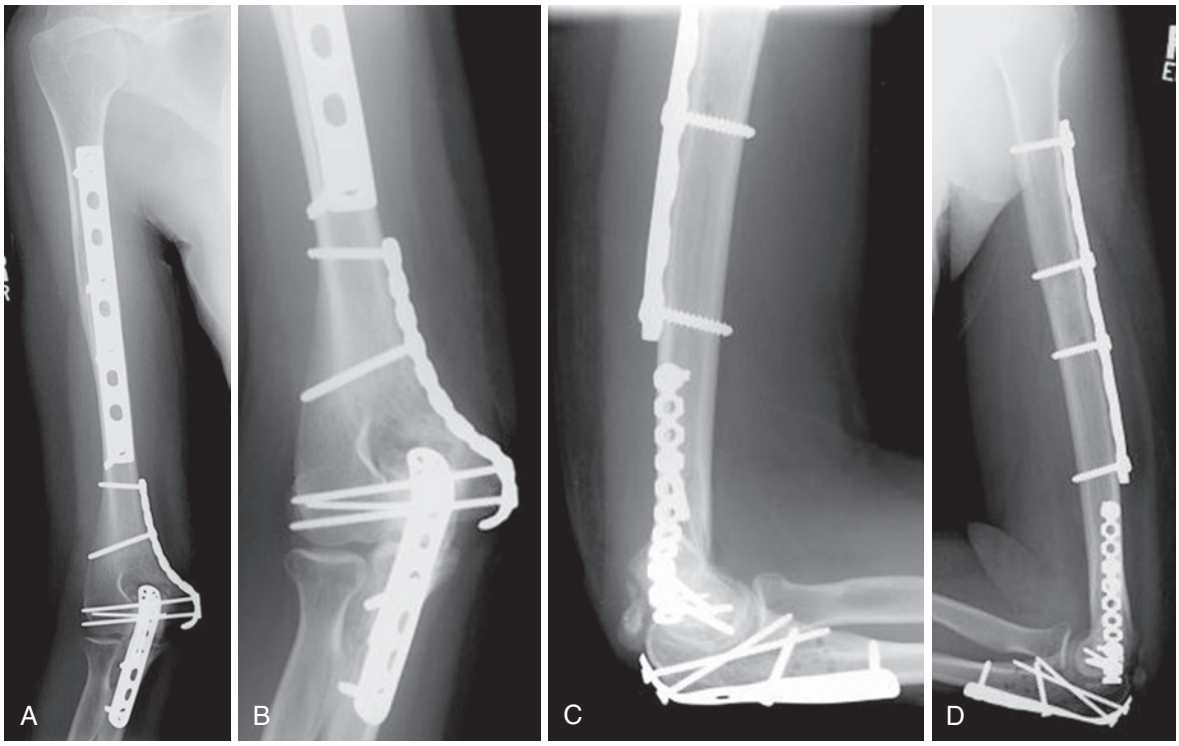

eFIGURE 18.20 Eight-month follow-up.

http://e-surg.com

CASE STUDY 18.8 Complex Lateral Column Fracture

A 33-year-old female sustained a complex comminuted fracture of the capitellum and anterior aspect of the trochlea after a fall from a bicycle. An associated displaced fracture of the radial head is also present (eFigures 18.21 and 18.22).

The operative tactic may include all of the following except:

A. Olecranon osteotomy
B. Bone graft material
C. Minifragment and small-fragment plates
D. Ligamentous repair
E. Elbow arthroplasty

Correct answer:

E. Elbow arthroplasty

Using an extensile lateral approach, the fracture was reduced and stabilized with multiple screw fixations. The postoperative course was complicated by significant loss of elbow motion resulting from soft tissue contracture and heterotopic ossification (eFigure 18.23). Successful elbow release was performed 10 months later.

Surgeons managing complex lateral column injuries such as these should be prepared to perform an olecranon osteotomy to maximize visualization and access to the articular surface. Bone graft, minifragment plates, and methods to deal with epicondylar avulsions or ligamentous disruption, particularly of the lateral column, are often needed.

Elbow arthroplasty would be strongly considered in a low-demand elderly patient but not in the young, active patient in the current example.

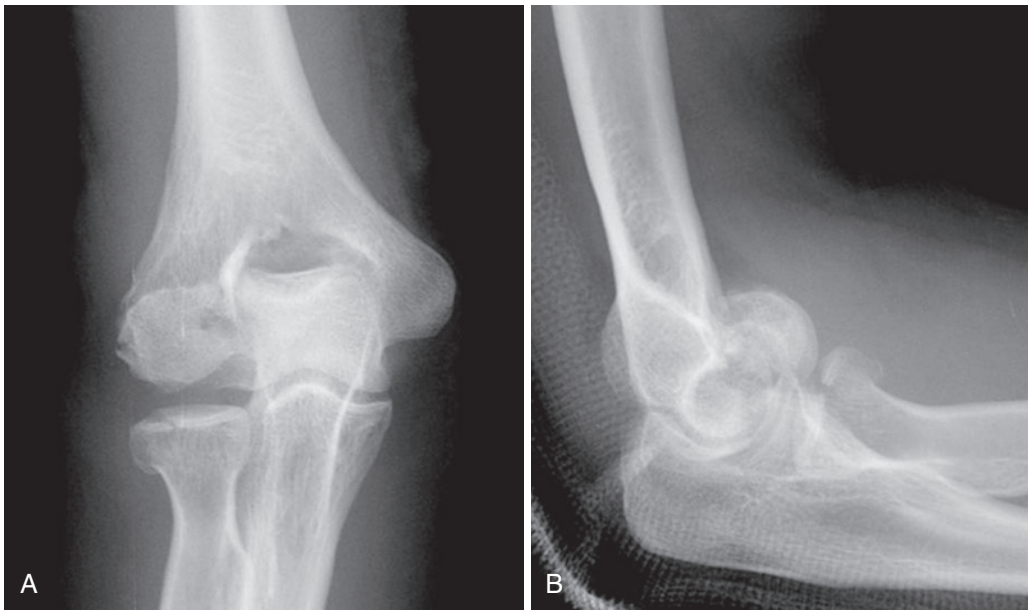

eFIGURE 18.21 **A** and **B,** Preoperative radiographs.

http://e-surg.com

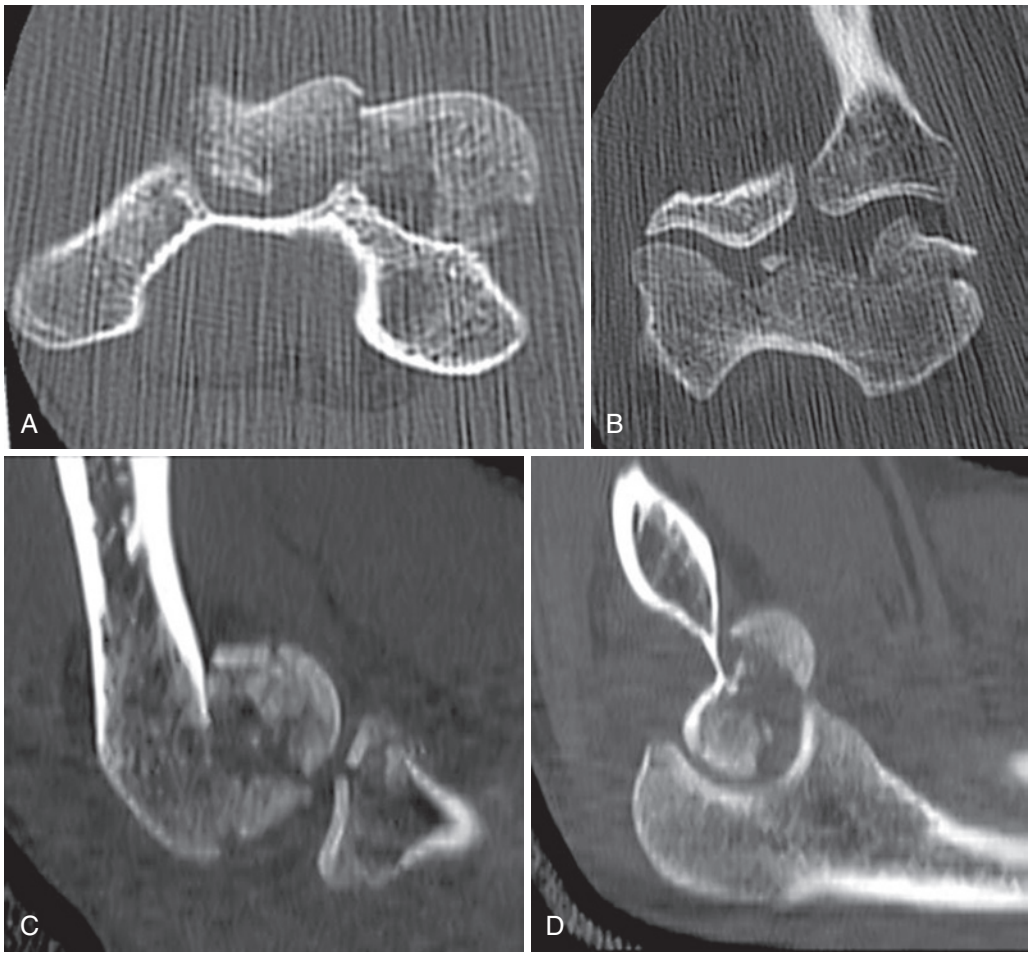

eFIGURE 18.22 Computed tomographic (CT) scans. **A** and **B,** Two axial CT scans demonstrate the extent of the injury to the articular surface. At the level of the radial head, note the absence of articular surface along the anterior aspect of the trochlea and capitellum. At the level of the coronoid and olecranon fossae, the displaced anterior trochlea and capitellar fragments are identified. Note that the trochlear fragment includes the medial trochlear lip. The capitellar and trochlear fragments are separated by a sagittal fracture line. **C** and **D,** Sagittal reformation demonstrates comminution of the capitellar fragment. The displaced anterior half of the trochlea is identified on the medial sagittal reformation. The posterointerior aspect of the capitellum is comminuted.

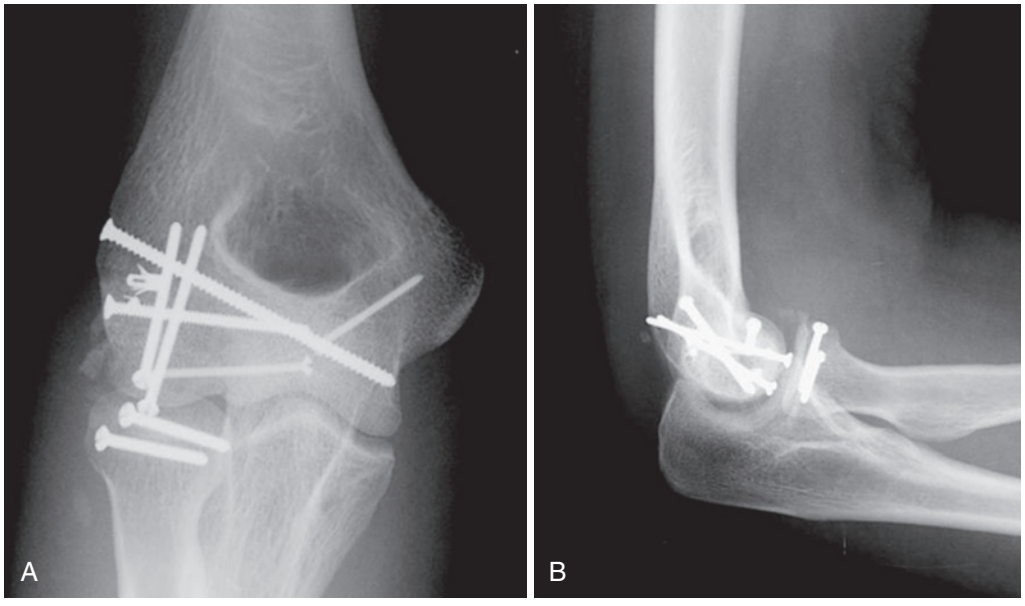

eFIGURE 18.23 Postoperative radiographs.

http://e-surg.com

medial head of triceps and the anconeus are elevated. The elbow is hinged open posterolaterally, allowing access to the posterior aspect of the lateral column. If the fracture begins to involve the posterior aspect of the trochlea or medial epicondyle, we prefer to use olecranon osteotomy to access the components of these challenging fractures more reliably. Stabilization is with small or minifragment screws. Fractures with significant comminution or impaction may require bone grafting or plating, or both, to help support articular segments.[21]

Distal Humerus Fractures With Extensive Related Injuries

Massive Bone Loss. Patients sustaining open injuries with massive bone loss are rarely encountered. The initial focus is on determining if the limb is viable or salvageable. A detailed vascular examination of the ipsilateral hand and digits is crucial. In situations with a salvageable injury, the open wound is thoroughly irrigated and débrided in the operating room. An intraoperative assessment of the amount of bone loss is performed and correlated with the radiographic assessment. Because of the high energy involved in the creation of these injuries, patients frequently have associated polytrauma or markedly contaminated wounds around the elbow, or both, and temporary spanning external fixation is performed acutely. This temporary fixation allows the skeleton and soft tissues to be stabilized rapidly and allows other serious injuries to be managed. A simple uniplanar external fixator is applied, with Schanz pins placed into the humeral diaphysis under direct vision (to avoid injury to the radial nerve) and into the ulna. Repeated débridements are performed until all nonviable tissue is excised. Definitive management depends on the type and amount of bone lost.

Nonarticular Bone Loss. Patients with a reconstructible articular surface and supracondylar bone loss are managed with ORIF, shortening of the humerus through the area of bone loss, and placement of antibiotic beads in the region of any residual bone defect. Delayed bone grafting is performed when the soft tissue envelope has stabilized, typically at 6 to 8 weeks. Patients are at high risk for elbow stiffness or ankylosis that may be improved with elbow mobilization procedures after fracture union is confirmed.

Articular Bone Loss. Options for patients presenting with significant articular bone loss include procedures that allow the development of a pseudarthrosis in the region of the distal humerus, elbow fusion, and allograft elbow replacements. In severely contaminated wounds or selected patients, some of these injuries are managed with a brief period of immobilization to allow soft tissue recovery, followed by active range-of-motion exercises. These patients develop a mobile pseudoarticulation that provides some mobility and function. Elbow fusions are typically reserved for patients with articular loss; overt infection; and painful, mobile residual articulations not amenable to elbow arthroplasty.[68]

In physiologically young patients with partial articular bone loss, salvage of the patient's native distal humerus should remain the goal. Giannoudis and colleagues[31] described the use of tricortical iliac crest bone graft for the primary reconstruction of the trochlea. Similarly, Spang and coworkers[112] described reconstruction of severe fractures of the lateral trochlea and capitellum using structural ipsilateral radial head autograft with excellent results (Case Study 18.9). In these situations, we have acceptable functional results with satisfactory flexion-extension and pronation-supination arcs of motion. In situations with dramatic articular bone loss, we prefer allograft replacement.[16] This option offers the ability to maintain a mobile, comfortable elbow articulation in the short term and to restore bone stock for later elbow arthroplasty if needed (Case Study 18.10).

Ballistic Injuries. Low-energy ballistic injuries usually have minor to moderate contamination and soft tissue injury and minor to moderate bone comminution. The fracture is managed according to the principles outlined earlier.

Conversely, high-energy ballistic injuries are associated with neurovascular injury, large contaminated wounds, and significant skeletal comminution with or without functional bone loss. The management of these injuries is with repeated débridements until a healthy, viable soft tissue envelope is created. Fixation is performed using the principles outlined earlier. The surgeon should anticipate some amount of bone loss (articular or nonarticular, or both) when managing these fractures. Some of these injuries have been salvaged with circular tensioned-wire fixators[60] or uniplanar external fixation as definitive treatment,[88] but we have little experience with this in the acute setting.

Postoperative Care

At the conclusion of the procedure, the surgical incisions and traumatic wounds are covered with sterile gauze bandages, and the extremity is placed into a long-arm plaster splint with the elbow in extension. Patients are managed with 24 hours of postoperative antibiotic administration. A suction drain, if used, is removed after 24 hours. Approximately 48 hours postoperatively, the splint is removed, and the surgical incision is inspected. Provided that the surgical incision is sealed, range-of-motion exercises are begun. Therapy is performed several times per day and consists of active range of motion of the shoulder, forearm, wrist, and fingers. Exercises are initially performed under the supervision of a physical therapist before discharge.

Active and active-assisted elbow flexion is permitted for all situations. Patients managed via a paratricipital approach or olecranon osteotomy are allowed active elbow extension. Patients treated with an approach that mobilizes the extensor insertion from the proximal ulna, such as the Bryan-Morrey approach, perform passive, gravity-assisted elbow extension movements for 6 weeks. Strengthening exercises, particularly resisted elbow extension, are deferred until radiographic union occurs. In situations where patients fail to make progress toward a functional arc of motion (30 to 130 degrees at the ulnohumeral joint) despite a supervised physical therapy program, the use of static progressive splinting is strongly considered. More recent reports have shown sustained improvements in the overall arc of motion, with several patients avoiding operative contracture release.[18,29] Although the optimal timing for the institution of static progressive splinting is unknown, we prefer to initiate this treatment when conventional active and active-assisted methods plateau below a functional arc of motion, typically 6 to 12 weeks after the injury.

Patients are examined in the outpatient clinic at the following intervals:

- Postoperative day 7 to 10 for examination of the surgical incision, suture removal, edema control, and reinforcement of the physical therapy regimen; patients who are

http://e-surg.com

CASE STUDY 18.9 Partial Articular Loss

A 42-year-old female was involved in a rollover motor vehicle collision; her left arm was caught outside the vehicle. In addition to sustaining a severe soft tissue injury and segmental loss of the radial nerve, the lateral aspect of the distal humerus was lost, including the capitellum, the lateral aspect of the trochlea, and the distal aspect of the entire lateral column (eFigure 18.24).

Her median and ulnar nerves are intact. She has a strong radial pulse and a well-perfused hand.

Initial treatment consisted of aggressive débridement, irrigation, and transarticular elbow-spanning external fixation (eFigure 18.25).

After repeated débridements, skeletal reconstruction was performed by means of reconstruction of the distal humeral lateral column using a radial head allograft. The soft tissue defect was covered with an early latissimus free flap and split-thickness skin grafting, and immediate tendon transfers were done to manage the permanent radial nerve injury (eFigure 18.26).

Her fracture was secured with an anteromedial 2.4-mm locking plate and a direct lateral distal radius locking "T"-plate. The nonconventional plate placements and types were to minimize further soft tissue disruption and dissection and to provide durable fixation. After definitive soft tissue coverage, a transarticular elbow external fixator was used to maintain a reduced ulnotrochlear articulation for 8 weeks (eFigures 18.27 and 18.28).

Passively, the patient demonstrates a pronation-supination arc of 120 degrees and a flexion-extension arc of 45 to 115 degrees (eFigure 18.29). The elbow is stable throughout this range. The goal of this patient's care is to provide a stable, functional elbow to support a sensate, functional hand.

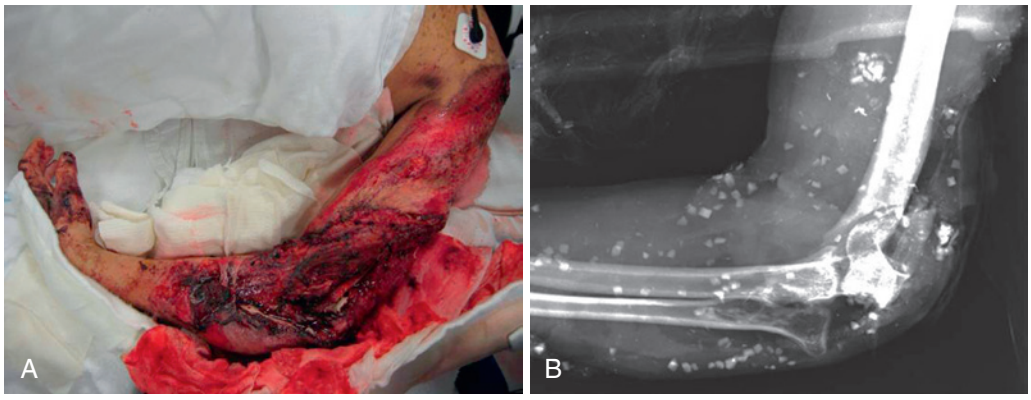

eFIGURE 18.24 **A,** Clinical photograph demonstrating exposed and dislocated ulnohumeral and radiocapitellar articulations, along with marked contamination and soft tissue loss. **B,** Plain anteroposterior radiograph demonstrates gross dislocation of the ulnar humeral articulation, foreign debris, and an intraarticular distal humerus fracture with osteoarticular bone loss of the lateral column.

http://e-surg.com

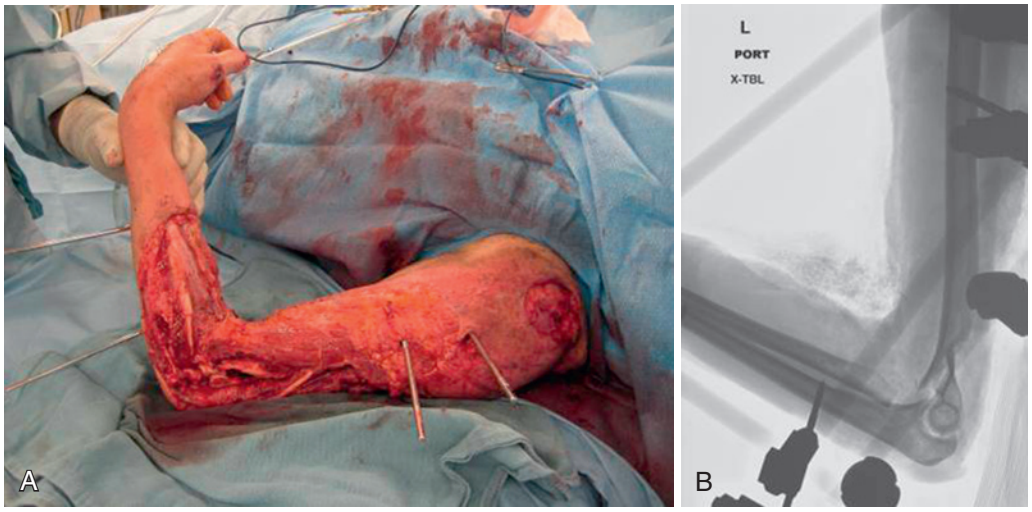

eFIGURE 18.25 **A, B,** The left arm is viewed from the lateral vantage point. A radial head allograft is shaped and sized to the remaining bone of the fractured distal humerus. The intent of the allograft is to reconstruct the lateral trochlear ridge to help maintain ulnohumeral stability.

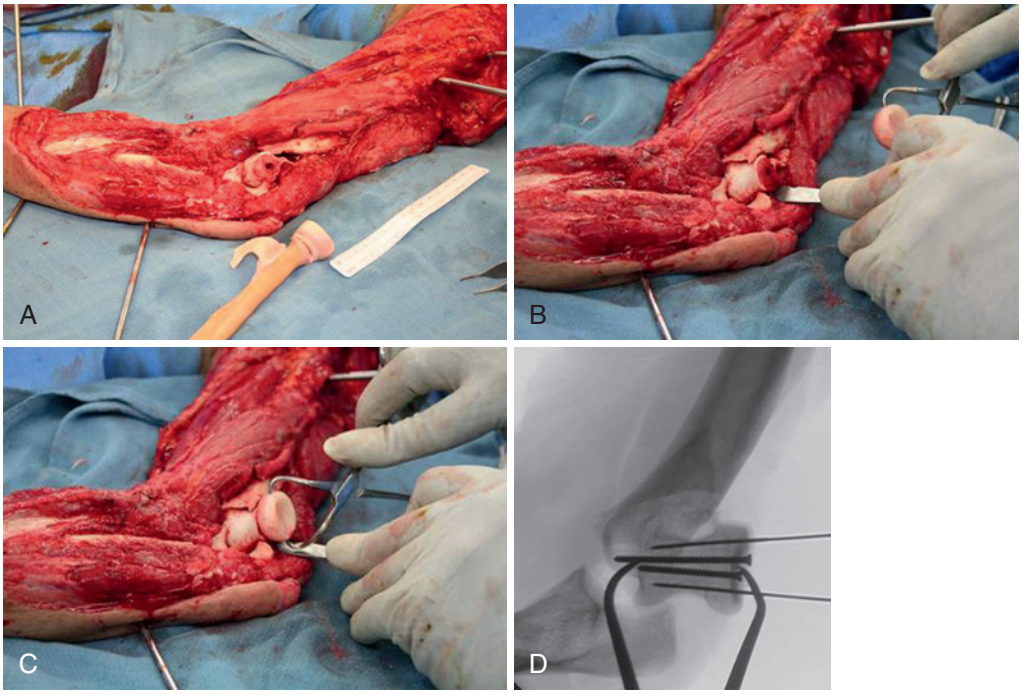

eFIGURE 18.26 **A** through **C,** The intent of the allograft is to reconstruct the lateral trochlear ridge to help maintain ulnohumeral stability. **D,** Intraoperative anteroposterior fluorograph demonstrating fixation of the articular segment.

http://e-surg.com

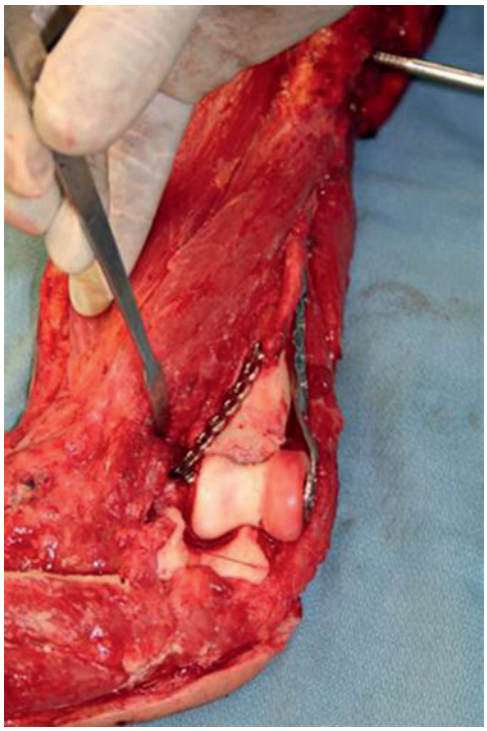

eFIGURE 18.27

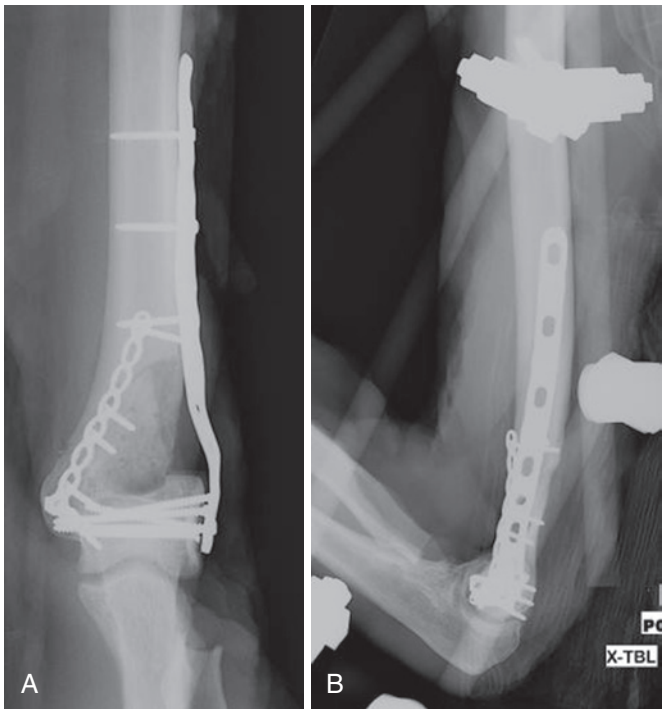

eFIGURE 18.28 Immediate postoperative anteroposterior and lateral radiographs.



eFIGURE 18.29 Anteroposterior radiograph immediately after external fixation removal.

http://e-surg.com

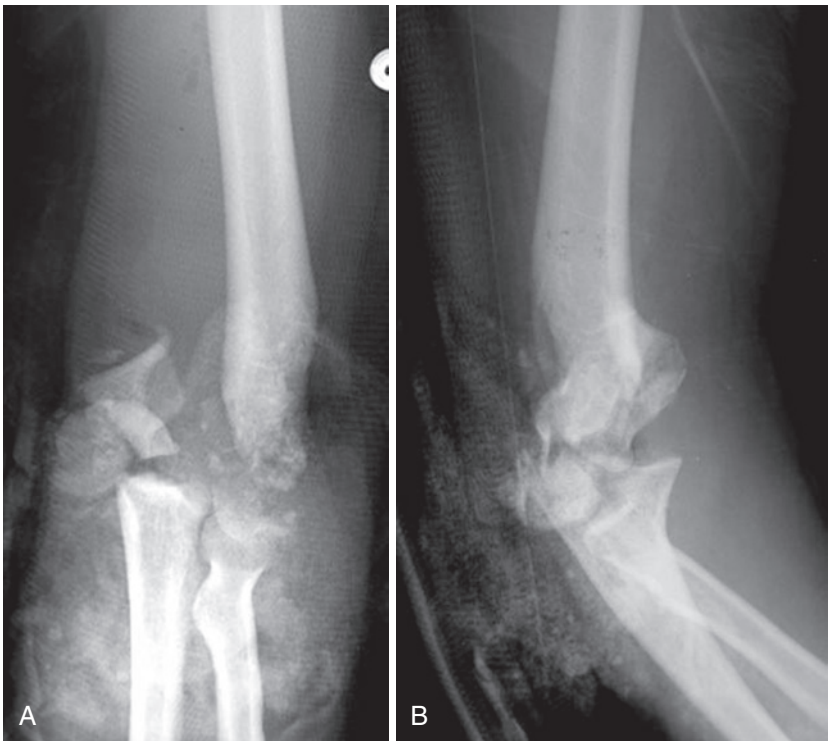

eFIGURE 18.30 Anteroposterior **(A)** and lateral **(B)** radiographs of injury.

CASE STUDY 18.10 Complete Articular Loss

A 30-year-old female was seriously injured in a high-speed motor vehicle collision (eFigure 18.30). The physical examination demonstrated a large transverse wound along the posterior aspect of the elbow. The neurologic examination revealed absent ulnar nerve function and weakened radial nerve function.

Management consisted of débridement of nonviable tissue, insertion of antibiotic beads, and application of a spanning external fixator. The ulnar nerve was found to be transected. Nine days later the patient underwent primary ulnar nerve repair. The extensor mechanism is reparable (eFigure 18.31).

Your preferred management now is:

A. Total elbow arthroplasty
B. Resection arthroplasty
C. Elbow fusion
D. Allograft elbow replacement
E. Amputation

Correct answer:

D. Allograft elbow replacement.

Because of the patient's age and amount of bone loss, allograft elbow replacement was chosen as the definitive procedure (eFigure 18.32).

Approximately 18 months later, the allograft elbow has been incorporated into the host bone, but joint destruction and instability are identified (eFigure 18.33). Early failure was probably due to the presence of the neuropathic joint combined with excessive use of the joint.

A second allograft replacement was performed, with satisfactory union at the allograft-host junction and preservation of the articulation (eFigures 18.34 and 18.35).

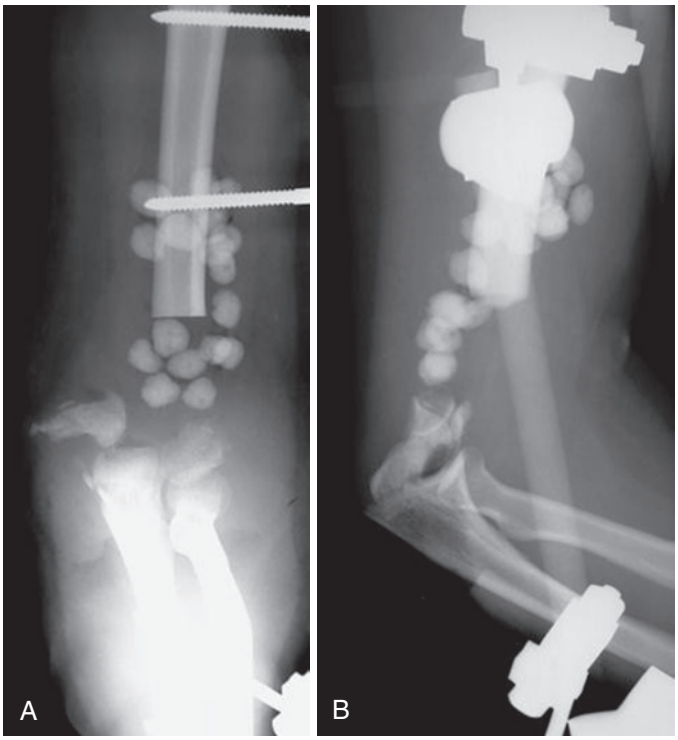

eFIGURE 18.31

http://e-surg.com

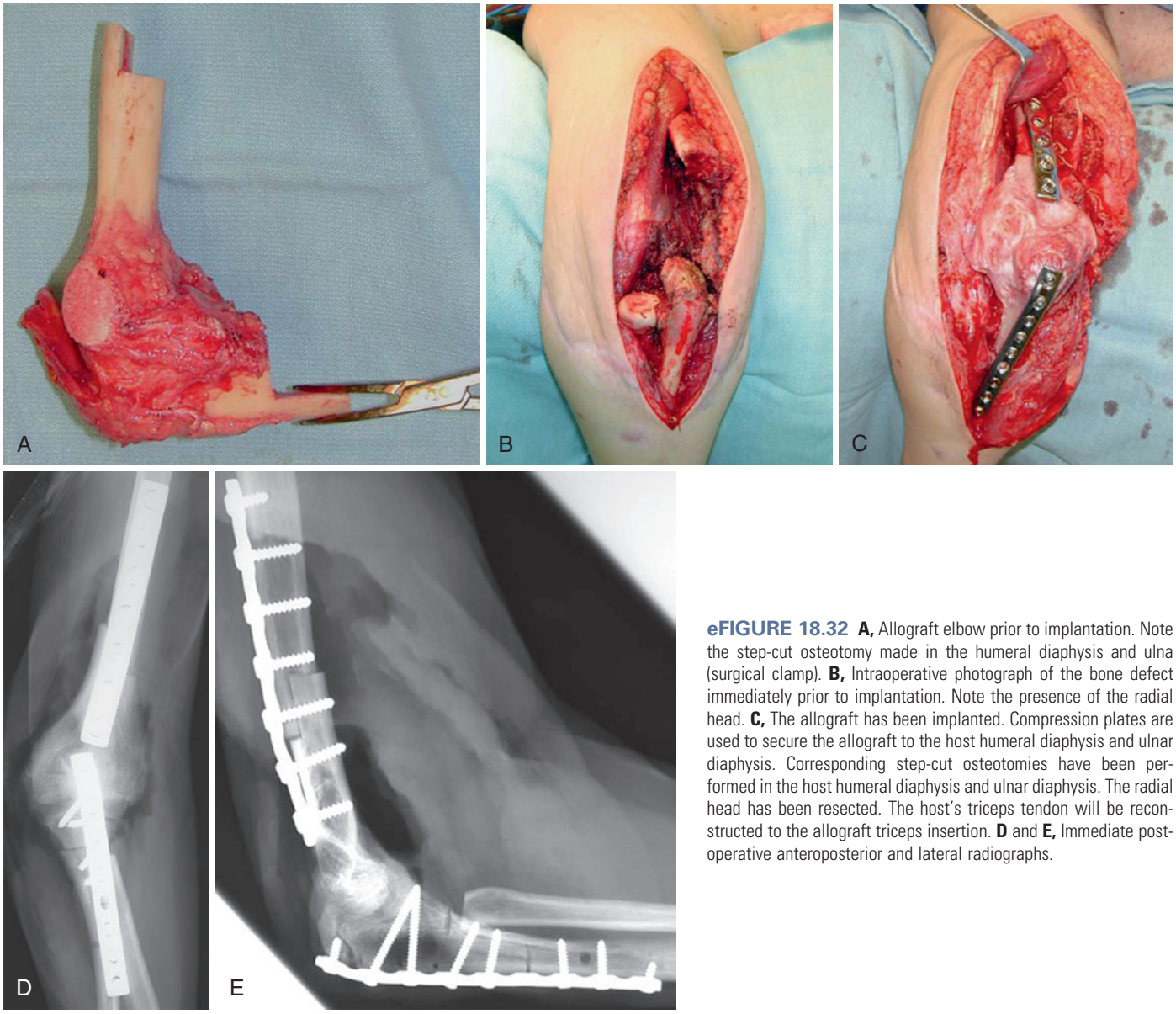

eFIGURE 18.32 **A,** Allograft elbow prior to implantation. Note the step-cut osteotomy made in the humeral diaphysis and ulna (surgical clamp). **B,** Intraoperative photograph of the bone defect immediately prior to implantation. Note the presence of the radial head. **C,** The allograft has been implanted. Compression plates are used to secure the allograft to the host humeral diaphysis and ulnar diaphysis. Corresponding step-cut osteotomies have been performed in the host humeral diaphysis and ulnar diaphysis. The radial head has been resected. The host's triceps tendon will be reconstructed to the allograft triceps insertion. **D** and **E,** Immediate postoperative anteroposterior and lateral radiographs.

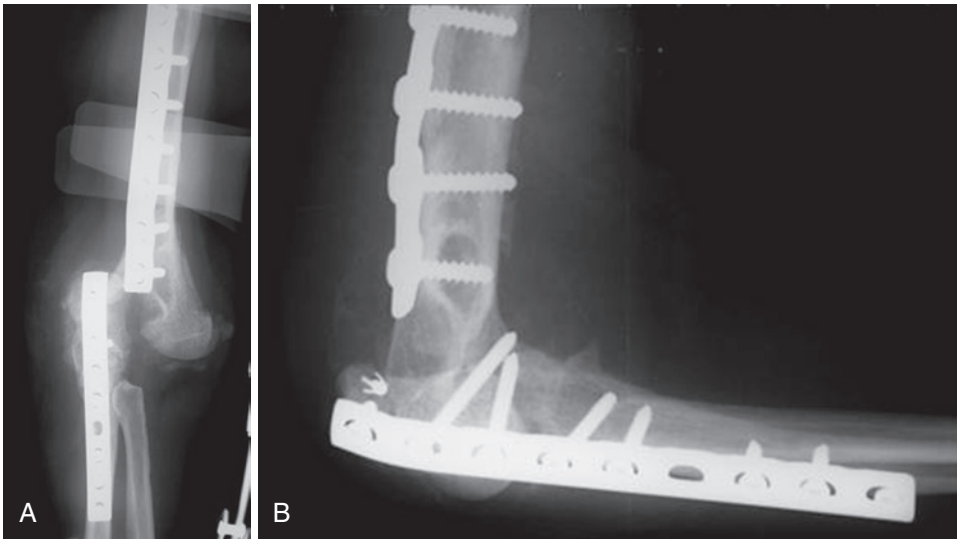

eFIGURE 18.33 Radiographs 18 months following operation. Joint destruction and instability are identified.

http://e-surg.com

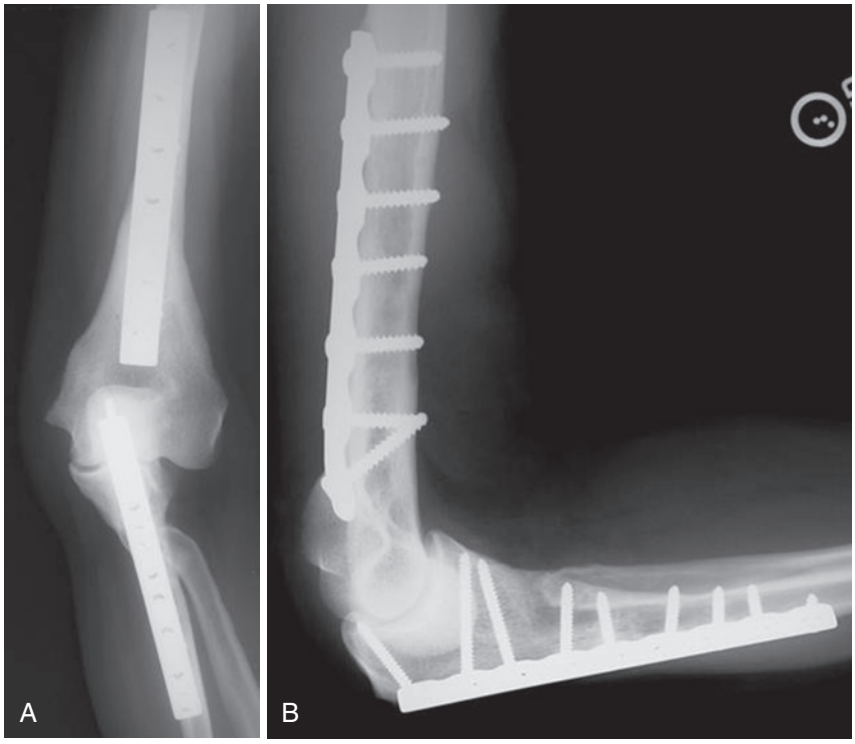

eFIGURE 18.34



eFIGURE 18.35 Clinical photographs of this patient after the second allograft implantation. Note the functional range of motion.

http://e-surg.com

unclear regarding the importance, frequency, or timing of physical therapy are seen by a therapist in the outpatient clinic area to review exercises and to arrange outpatient therapy at a convenient location
- Week 6 for motion evaluation and radiographs
- Week 12 for motion evaluation, radiographic assessment, and initiation of strengthening and stretching exercises
- Weeks 20 to 26 for motion evaluation, radiographic assessment, identification of patient concerns, and discussion of return to athletics or heavy labor
- Week 52 and as needed for final radiographic assessment and identification of any patient concerns

Expectations

Several parameters are used to assess the outcome of fractures of the distal humerus. Elbow range of motion, forearm rotation, occurrence of and time to union, and complication rates all have been reported in the literature. It is recognized, however, that these parameters may not accurately reflect the patient's perception of satisfaction. For this reason, limb-specific and disease-specific validated outcome scoring measures have been created in an attempt to assess more accurately outcomes of numerous conditions.

All fractures of the distal humerus are associated with some degree of measurable loss of range of motion, particularly extension. Despite this absolute loss of "normal" motion, most patients can expect functional results. Patients with significant associated polytrauma, high-energy injuries, or significant soft tissue injury can be expected to have worse outcomes.

Most activities of daily living require a flexion-extension arc at the elbow of approximately 100 degrees (30 to 130 degrees) and an arc of forearm rotation from 50 degrees of supination to 50 degrees of pronation.[87] In bicolumnar fractures of the distal humerus treated with bicolumnar plating, McKee and colleagues[74] showed a flexion-extension arc of approximately 108 degrees with a mean flexion contracture of approximately 25 degrees. This represents approximately 74% of the motion on the contralateral, uninjured side. Similarly, flexion and extension strength were approximately 75% that of the uninjured side.[74] Using an orthogonal plating and olecranon osteotomy approach, Gofton and associates[33] reported on 23 patients with "C"-type distal humerus fractures. At a mean follow-up of 45 months, the authors showed an average flexion-extension arc of approximately 122 degrees, but noted a reduction in flexion-extension strength of approximately 20% and a similar 20% loss of pronation-supination strength. Despite the limitations in motion and strength, most patients had minimal functional loss and low pain scores, and 93% were satisfied with their outcome.

Sanchez-Sotelo and coworkers[104] reported the results of 32 distal humerus fractures at a mean follow-up of 2 years. These fractures were treated with a parallel plating technique using various surgical approaches, most of which were soft tissue mobilizations of the extensor mechanism from the proximal ulna. Of 32 fractures, 31 united primarily, with no elbow showing failure of internal fixation. Despite the high proportion of open fractures and fractures with intraarticular comminution, the authors showed an average flexion-extension arc of 99 degrees, with an average arc of motion of 26 to 125 degrees. Using the Mayo Elbow Performance Score, 27 patients were graded as having a good-to-excellent result. Other authors have shown similar functional motion arcs and losses of flexion and extension strength in studies done over the short term.[56]

The best long-term data examining the results of distal humerus fractures were provided by Doornberg and colleagues,[19] who evaluated 30 patients at an average of 19 years after ORIF of a distal humerus fracture. Most patients were treated with plates and screws via olecranon osteotomy, and no patient was treated with ulnar nerve transposition. The authors noted an average flexion arc of 106 degrees, with minimal disability and excellent outcome scores when measured with numerous validated functional outcome measurement systems. The findings of these studies are similar to those of shorter-term studies, suggesting that the initial results are durable over the long term. Despite most patients showing the radiographic presence of arthrosis, this variable was not predictive of disability or elbow function. A unique factor in this study was the finding that most variations in the physician-based elbow rating scores were attributable to pain, limb dominance, and flexion arc. Additionally, only one patient had signs and symptoms of ulnar nerve dysfunction at the time of follow-up; this finding makes one question the need for routine anterior subcutaneous ulnar nerve transposition, a step that is recommended by some authorities.

Expectations must be tailored to the individual patient, and the data obtained by McKee and colleagues[73,74] and Gofton and associates[33] provide a useful framework for discussion with patients and their families. In patients with isolated, closed fractures of the distal humerus or open fractures without significant contamination or soft tissue destruction, the expected results are similar to those described previously. Patients with sedentary employment are encouraged to return to part-time work when they are feeling systemically stable. Ideally, the workplace should allow for slower completion of tasks, with frequent breaks for rest or periods of physical therapy. Patients who are engaged in labor that requires more physical exertion are also encouraged to return to the workplace, but in a modified role. Patients who are active in heavy labor are assessed individually. Frequently, an independent medical examination or physical capacities review is performed to obtain an objective measure of the patient's ability to return to the same job or a similar one. These employment issues frequently are foremost on patients' minds, and discussion of the plan to return to work is initiated early in the management phase.

At our institution, a high percentage of distal humerus fractures are secondary to high-energy injuries and have associated polytrauma. Patients who sustain significant associated injuries are expected to have a worse outcome in terms of range of motion and strength.[100] In patients with polytrauma where the operative delay approaches 7 days, significant stiffness has been noted. In these patients, we still strive for anatomic reduction of the articular surface and axial realignment, planning on delayed excision of heterotopic ossification or capsular release, or both. This "staged" approach to an ultimately functional elbow is explained to the family and patient during the early phase of care. In these situations, the ultimate outcome is satisfactory, provided that the distal humerus articular anatomy is restored at the time of the initial procedure and the patient is able to participate fully in the postsurgical rehabilitation program.[118]

http://e-surg.com

The functional outcome after ORIF of capitellar fractures and the coronal shear variant seems to be very satisfactory,[71,115] with several authors describing near-normal flexion-extension and pronation-supination arcs.[71,115] Most patients in these series were managed with screw fixation, with comparatively poorer results noted with Kirschner wire fixation. Because of the absence of significant soft tissue attachments to the capitellar fragment, avascular necrosis is a commonly discussed potential complication of this fracture pattern. Avascular necrosis changes noted with plain radiography seem to be relatively infrequent, however, with an incidence ranging from 0% to 20% in larger series.[66,71,115] The clinical sequelae of avascular necrosis seem to be even less frequent than sequelae seen on radiographic studies.[115]

With more of the articular surface involved, a decrease in the flexion-extension arc and lower functional outcome scores have been shown.[101] Dubberley and colleagues[21] evaluated 28 patients with capitellar and trochlear fractures managed with operative fixation. These authors noted an average flexion-extension motion arc of 119 degrees (range 19 to 138 degrees), with a high proportion of patients reporting excellent function and minimal disability. It was noted, however, that patients with isolated noncomminuted capitellar or trochlear fractures have better results than patients with more complex fractures.

Complications

Nonunion of the Distal Humerus

Nonunion of fractures of the distal humerus has been reported in 2 to 10% of cases, invariably occurring in the metadiaphyseal region.[56,111,119,125] Nonunion is primarily the consequence of inadequate fixation[39,111] that may be the result of other predisposing factors, such as high-energy injuries, extensive comminution, and poor bone quality. Patients are typically significantly disabled because of pain and loss of function. The frequent presentation is of a painful, mobile nonunion with significant motion restriction at the ulnar-humeral articulation. Associated ulnar neuropathy is common.[37]

A few of these nonunions can be treated satisfactorily in a brace; however, most require operative management to achieve a stable, comfortable, functional elbow. Surgical reconstruction is technically demanding because of the distorted local anatomy, scarring, retained or broken implants, poor bone quality of the articular component, and capsular contracture.[37,69] Despite these difficulties, operative reconstruction is the procedure of choice in active individuals.

The surgical plan involves a wide posterior surgical exposure incorporating previous skin incisions if possible. The use of olecranon osteotomy depends on the presence of significant articular malunion or nonunion and the location of the supracondylar nonunion. If osteotomy is not required, a paratricipital exposure is performed. The ulnar nerve is identified and freed from scar tissue well above and below the medial epicondyle. Substantial perineural fibrosis is often encountered. Posterior capsular adhesions and fibrosis are resected, particularly those crowding the olecranon fossa. Anterior capsular adhesions are released by working through the nonunion site or by elevating the structures from the lateral supracondylar ridge. The lateral collateral ligament origin should be preserved during this exposure, but it may be elevated and subsequently repaired if needed. The nonunion site is cleared of its fibrous material, and the bone ends are resected to healthy, bleeding margins. Intraoperative cultures are routinely obtained. Secure fixation typically entails medial and lateral plate fixation, and bone grafting is invariably required. The elbow is placed through a range of motion, and the stability of the construct is tested. The ulnar nerve is transposed anteriorly.[37,99] Early motion is initiated when the wound is sealed.

Results of nonunion repair have been satisfactory. Helfet and coworkers[37] showed satisfactory union in 51 of 52 patients after a single procedure. The average motion arc improved from 71 degrees preoperatively to 94 degrees postoperatively; however, it is likely that the preoperative motion was a combination of ulnar-humeral and nonunion motion, giving an overestimation of the preoperative motion arc. Similarly, McKee and colleagues[69] showed an average postoperative arc of motion of 97 degrees, with ulnar nerve function improving in all cases. Excellent improvement in pain can be expected, but associated injuries can influence the ultimate functional outcome, and significant long-term disability may persist despite bony union.[37,54,69]

Total elbow replacement in nonunited fractures in elderly patients has also been described.[85,99] This procedure is particularly effective in low-demand patients with poor bone stock. Satisfactory results can be expected, provided that septic complications are minimized.[85,86] In a series of complex distal humerus nonunions, Brinker and coworkers[4] showed the effectiveness of Ilizarov treatment for infected distal humerus nonunions after failure of internal fixation. The authors noted a 100% union rate with substantial improvements in levels of disability, pain, and quality-of-life measurements. The average arc of motion was documented at 81 degrees, with all patients having at least 95 degrees of elbow flexion.

Nonunion of the Olecranon Osteotomy

Nonunion or delayed union of an olecranon osteotomy has been reported in the literature with rates of 10%.[33,38,39,43,56] Henley and associates[39] described 3 of 29 (10%) osteotomies that developed delayed unions or nonunions. More recently, Gofton and associates[33] reported 2 of 22 (9%) olecranon osteotomies with nonunions. Several factors, such as lack of inherent fracture interdigitation and suboptimal osteotomy fixation, are believed to be responsible for the development of this complication.[38,39] Olecranon osteotomy nonunions have been described with Kirschner wire and screw fixations.[39,56] The use of a chevron osteotomy, rather than a transverse osteotomy, creates increased surface area for bone union and improved rotational stability of the osteotomy and would be expected to improve union rates.

To prevent the occurrence of olecranon osteotomy nonunion, we prefer to create a chevron osteotomy. Compressive apposition of the osteotomy surfaces is performed with the application of medial and lateral clamps that are removed after the osteotomy is temporarily secured with Kirschner wires. Medullary screw fixation, rather than Kirschner wire fixation, is used for a secure definitive construct. At the conclusion of the osteotomy fixation, the elbow is placed through a range of motion to assess the stability of the osteotomy. Any significant gapping or instability should be recognized and managed. In the unusual situations where this occurs, we prefer immediate plate fixation to improve osteotomy stability and healing.

http://e-surg.com

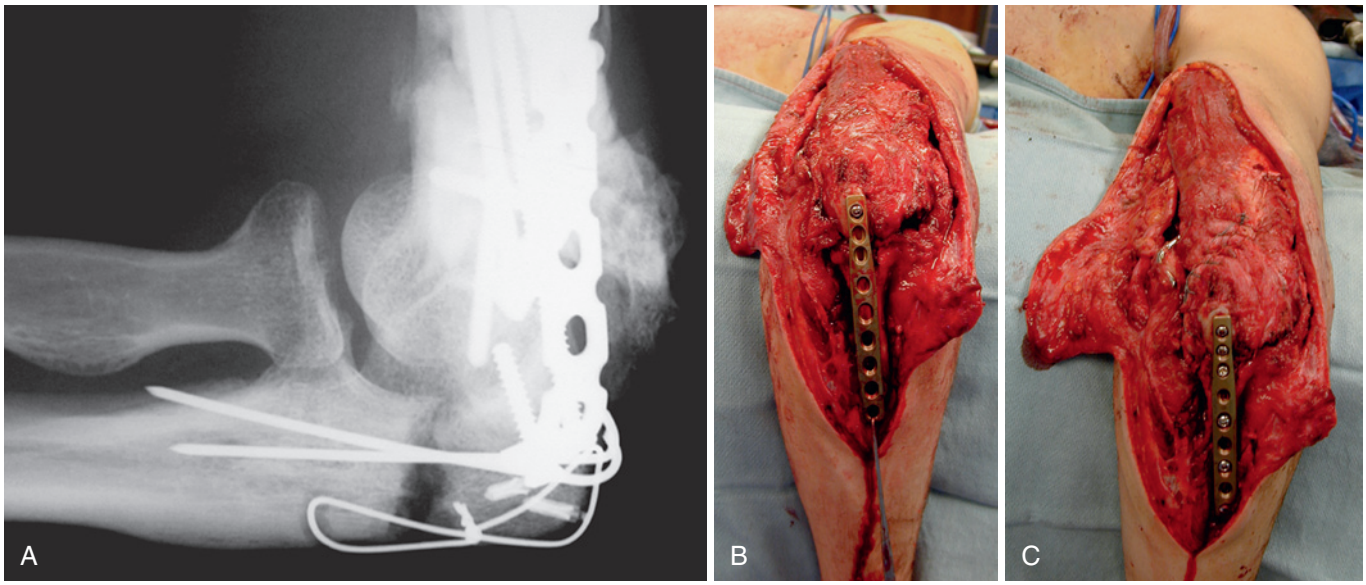

FIGURE 18.27 **A,** Lateral radiograph of bicolumnar distal humerus fracture managed using olecranon osteotomy. Osteotomy was secured with Kirschner wires and figure-of-eight tension band technique. Note obvious nonunion at site of osteotomy. **B,** Intraoperative photograph of posterior aspect of right elbow. The hand is located at the bottom of the image. Olecranon nonunion has been débrided to viable bone margins, and autogenous bone graft has been applied. Dynamic compression plate has been applied to dorsal surface and secured to proximal fragment. Proximal portion of this plate is narrowed and has tighter hole spacing to accommodate multiple 2.7-mm screws into smaller proximal olecranon fragment; distal aspect of plate is composed of standard 3.5-mm plate and hole specifications. Bone hook located at distal aspect of plate is used to tension plate and compress nonunion. **C,** Intraoperative photograph of posterior aspect of right elbow showing final screw placement and secure fixation of nonunion.

Current literature supports the use of multiple fixation techniques, all of which show exceptionally high union rates.[14,40,98]

Management of olecranon osteotomy nonunion is with repeat osteosynthesis using plate fixation and autogenous bone grafting (Figure 18.27). In situations where the proximal fragment is of insufficient size or quality, the fragment is excised and the triceps tendon is advanced.[70]

Infection

The deep infection rate of surgically managed fractures of the distal humerus is low despite the soft tissue dissection, prolonged operative time, and frequency of open injuries. Most deep infection rates reported range from 0 to 9%.[33,39,57,73,74] Management of acute postoperative wound infections requires débridement of nonviable tissue and an assessment of fracture stability. If the implants continue to stabilize the fracture, management is with suppressive culture-specific antibiotics until union occurs. In the setting of sepsis with fracture instability, treatment requires débridement and antibiotics with repeat osteosynthesis when the infection is controlled. Late presentations after union respond well to removal of internal fixation and antibiotic therapy. Severe deep infections with articular destruction may require salvage procedures, such as resection arthroplasty or elbow fusion.

Ulnar Neuropathy

Symptoms attributable to dysfunction of the ulnar nerve are common after fractures of the distal humerus.[56,100] Patients presenting with reconstructive issues almost invariably have ulnar nerve symptoms or signs. Factors responsible for postoperative ulnar neuropathy include injury from displaced bone fragments, excessive manipulation and retraction during the surgical procedure, and fibrosis and scarring of the tissues around the nerve in the region of the medial epicondyle and cubital tunnel.[70,100]

We use several techniques to minimize complications attributed to the ulnar nerve. When the posterior approach is used, adequate liberation of the nerve proximally and distally is performed at the beginning of the procedure, with care taken not to devascularize the nerve during mobilization. A broad Penrose drain is used for retraction purposes. To minimize traction injury to the nerve, the ends of the Penrose drain are sutured rather than clamped. At the conclusion of the procedure, anterior subcutaneous transposition of the nerve is performed for most fractures of the distal humerus. Isolated capitellar fractures and variants, lateral condyle fractures, and fractures managed using the Kocher interval do not require transposition.

Routine subcutaneous transposition of the ulnar nerve after operative fixation of a bicolumnar distal humerus fracture is very controversial. Because ulnar neuropathy is a common associated component of the complaints that may occur after distal humerus fractures, routine anterior subcutaneous transposition has evolved as a logical "preventive" measure in decreasing their incidence. Using routine transposition, Wang and colleagues[120] were unable to identify any postoperative ulnar neuropathy in 20 patients treated with dual plating. Other authors have shown similar results with routine anterior subcutaneous ulnar nerve transposition.[33,104] Although these results seem encouraging, Doornberg and associates[19] noted the rarity of ulnar nerve problems in long-term follow-up in patients after ORIF of distal humerus fractures, in whom no ulnar nerve

http://e-surg.com

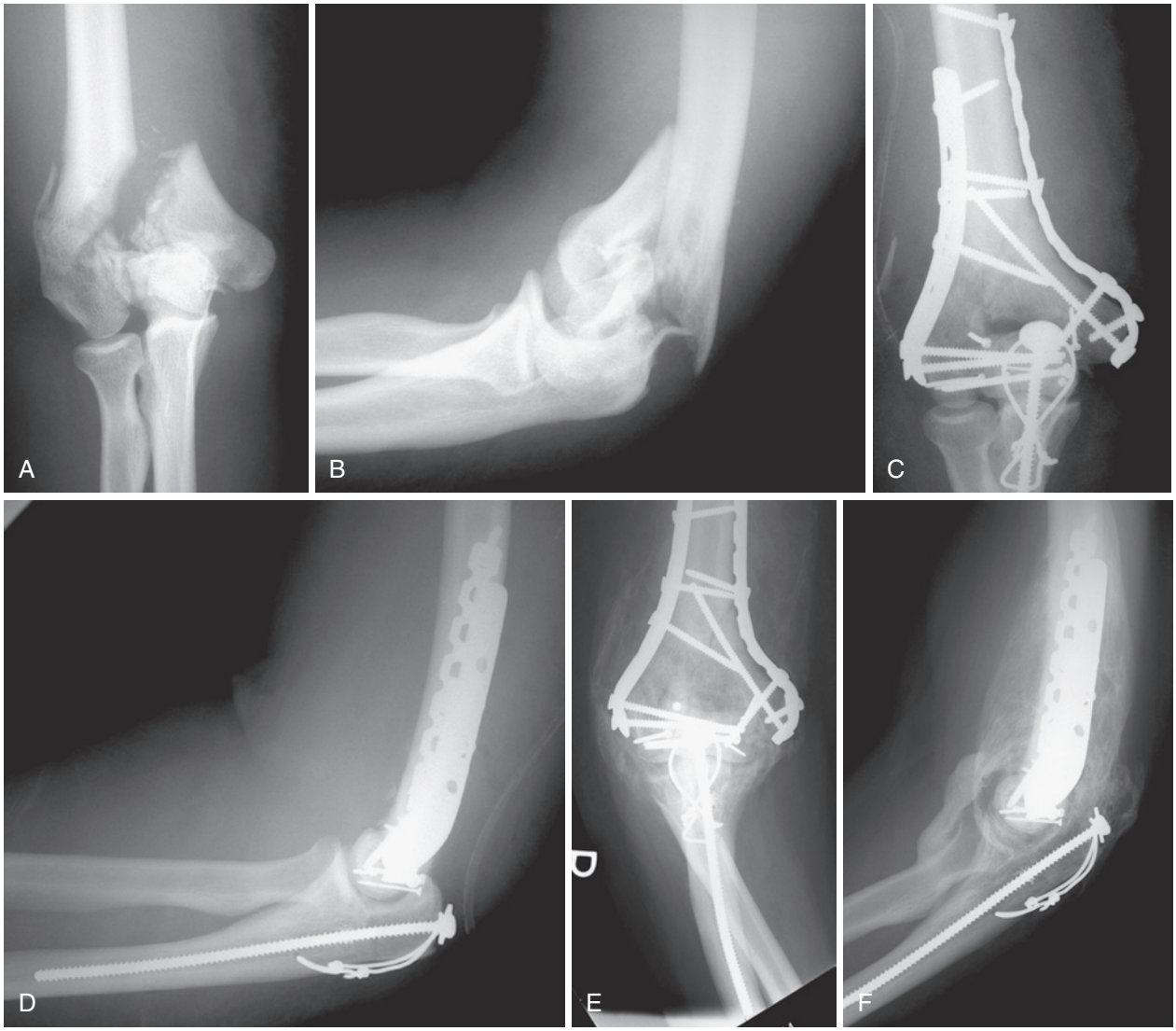

FIGURE 18.28 A 24-year-old man was involved in a high-speed motor vehicle collision. He sustained serious injuries, including severe bilateral pulmonary contusions, a closed head injury, and multiple fractures. **A** and **B,** Anteroposterior and lateral radiographs of right distal humerus show significant displacement and comminution of articular surface. Because of the patient's other injuries, operative fixation of distal humerus fracture was performed 8 days after the accident. **C** and **D,** Operative treatment consisted of medial and lateral plate fixation via olecranon osteotomy. **E** and **F,** Follow-up radiographs show maintenance of reduction and union of fracture, but also development of massive periarticular elbow heterotopic ossification resulting in complete ankylosis of elbow joint.

transposition occurred, calling into question whether routine transposition is necessary.

The successful management of ulnar neuropathy has been shown with ulnar neurolysis and anterior transposition.[69,72,118] Despite high patient satisfaction and improved objective measures, ulnar nerve function does not seem to normalize, and all efforts at minimizing complications of the ulnar nerve should be taken.[70,72]

Stiffness and Heterotopic Ossification

Most patients who undergo operative management with appropriate internal fixation usually obtain functional flexion-extension arcs. Significant contractures may be encountered in polytrauma patients, patients who undergo a significant delay before definitive management, patients who sustain high-energy injury, or patients with open fractures (Figure 18.28).[65,101,118] Kundel and coworkers[65] showed significant differences in time to return to work, ultimate range of motion, and incidence of significant heterotopic ossification in patients treated beyond 24 hours compared with patients managed within 24 hours of injury. In this same study, cases of ankylosing heterotopic ossification occurred exclusively in the delayed group. Provided that the fracture proceeds to union with satisfactory restoration of the articular surface and mechanical axes, a good result can still be obtained after capsular release and heterotopic ossification excision.

To prevent significant ankylosis, we prefer to manage fractures of the distal humerus as soon as possible, achieving secure fixation that allows early and unrestricted motion. We rarely use heterotopic ossification prophylaxis because we have found patient compliance with medical prophylaxis to be exceedingly low.

http://e-surg.com

Management of a stiff elbow after operative fixation of a distal humerus fracture entails removal of internal fixation; capsulectomy; débridement of the olecranon, coronoid, and radial fossae; and excision of ectopic bone if necessary.[84,118] Management is performed after fracture union, typically 6 to 12 months after injury, and depends on complete fracture union and recovery from any other injuries that the patient may have incurred.[118] For a successful outcome after contracture release, it is vital that the patient be able to devote full attention to postoperative rehabilitation.

For Case Studies, Videos, and more, please visit ExpertConsult.com.

REFERENCES

1. Alonso-Llames M: Bilaterotricipital approach to the elbow: its application in the osteosynthesis of supracondylar fractures of the humerus in children. *Acta Orthop Scand* 43:479–490, 1972.
2. Arnander MW, Reeves A, MacLeod IA, et al: A biomechanical comparison of plate configuration in distal humerus fractures. *J Orthop Trauma* 22:332–336, 2008.
3. Athwal GS, Rispoli DM, Steinmann SP: The anconeus flap transolecranon approach to the distal humerus. *J Orthop Trauma* 20:282–285, 2006.
4. Brinker MR, O'Connor DP, Crouch CC, et al: Ilizarov treatment of infected nonunions of the distal humerus after failure of internal fixation: an outcomes study. *J Orthop Trauma* 21:178–184, 2007.
5. Brouwer KM, Bolmers A, Ring D: Quantitative 3-dimensional computed tomography measurement of distal humerus fractures. *J Shoulder Elbow Surg* 21(7):977–982, 2012.
6. Brown RF, Morgan RG: Intercondylar T-shaped fracture of the humerus: results in ten cases treated by early mobilisation. *J Bone Joint Surg Br* 53:425–428, 1971.
7. Bryan RS, Bickel WH: "T" condylar fractures of distal humerus. *J Trauma* 11:830–835, 1971.
8. Bryan RS, Morrey BF: Extensive posterior exposure of the elbow: a triceps-sparing approach. *Clin Orthop Relat Res* 166:188–192, 1982.
9. Campbell WC: Incision for exposure of the elbow joint. *Am J Surg* 15:65–67, 1932.
10. Caravaggi P, Laratta JL, Yoon RS, et al: Internal fixation of the distal humerus: a comprehensive biomechanical study evaluating current fixation techniques. *J Orthop Trauma* 28(4):222–226, 2014.
11. Cassebaum WH: Open reduction of T and Y fractures of the lower end of the humerus. *J Trauma* 9:915–925, 1969.
12. Cassebaum WH: Operative treatment of T and Y fractures of the lower end of the humerus. *Am J Surg* 83:265–270, 1952.
13. Cobb TK, Morrey BF: Total elbow arthroplasty as primary treatment for distal humeral fractures in elderly patients. *J Bone Joint Surg Am* 79:826–832, 1997.
14. Coles CP, Barei DP, Nork SE, et al: The olecranon osteotomy: a six-year experience in the treatment of intraarticular fractures of the distal humerus. *J Orthop Trauma* 20:164–171, 2006.
15. Davies MB, Stanley D: A clinically applicable fracture classification for distal humeral fractures. *J Shoulder Elbow Surg* 15:602–608, 2006.
16. Dean GS, Holliger EHT, Urbaniak JR: Elbow allograft for reconstruction of the elbow with massive bone loss: long term results. *Clin Orthop Relat Res* 341:12–22, 1997.
17. Doornberg J, Lindenhovius A, Kloen P, et al: Two- and three-dimensional computed tomography for the classification and management of distal humeral fractures: evaluation of reliability and diagnostic accuracy. *J Bone Joint Surg Am* 88:1795–1801, 2006.
18. Doornberg JN, Ring D, Jupiter JB: Static progressive splinting for posttraumatic elbow stiffness. *J Orthop Trauma* 20:400–404, 2006.
19. Doornberg JN, van Duijn PJ, Linzel D, et al: Surgical treatment of intra-articular fractures of the distal part of the humerus: functional outcome after twelve to thirty years. *J Bone Joint Surg Am* 89:524–532, 2007.
20. Dowdy PA, Bain GI, King GJ, et al: The midline posterior elbow incision: an anatomical appraisal. *J Bone Joint Surg Br* 77:696–699, 1995.
21. Dubberley JH, Faber KJ, Macdermid JC, et al: Outcome after open reduction and internal fixation of capitellar and trochlear fractures. *J Bone Joint Surg Am* 88:46–54, 2006.
22. Dushuttle RP, Coyle MP, Zawadsky JP, et al: Fractures of the capitellum. *J Trauma* 25:317–321, 1985.
23. Eastwood WJ: The T-shaped fracture of the lower end of the humerus. *J Bone Joint Surg Am* 19:364–369, 1937.
24. Ek ET, Goldwasser M, Bonomo AL: Functional outcome of complex intercondylar fractures of the distal humerus treated through a triceps-sparing approach. *J Shoulder Elbow Surg* 17:441–446, 2008.
25. Elkowitz SJ, Polatsch DB, Egol KA, et al: Capitellum fractures: a biomechanical evaluation of three fixation methods. *J Orthop Trauma* 16:503–506, 2002.
26. Frankle MA, Herscovici D, Jr, DiPasquale TG, et al: A comparison of open reduction and internal fixation and primary total elbow arthroplasty in the treatment of intraarticular distal humerus fractures in women older than age 65. *J Orthop Trauma* 17:473–480, 2003.
27. Gambirasio R, Riand N, Stern R, et al: Total elbow replacement for complex fractures of the distal humerus: an option for the elderly patient. *J Bone Joint Surg Br* 83:974–978, 2001.
28. Garcia JA, Mykula R, Stanley D: Complex fractures of the distal humerus in the elderly: the role of total elbow replacement as primary treatment. *J Bone Joint Surg Br* 84:812–816, 2002.
29. Gelinas JJ, Faber KJ, Patterson SD, et al: The effectiveness of turnbuckle splinting for elbow contractures. *J Bone Joint Surg Br* 82:74–78, 2000.
30. Gerwin M, Hotchkiss RN, Weiland AJ: Alternative operative exposures of the posterior aspect of the humeral diaphysis with reference to the radial nerve. *J Bone Joint Surg Am* 78:1690–1695, 1996.
31. Giannoudis PV, Al-Lami MK, Tzioupis C, et al: Tricortical bone graft for primary reconstruction of comminuted distal humerus fractures. *J Orthop Trauma* 19:741–743, 2005.
32. Gill DR, Morrey BF: The Coonrad-Morrey total elbow arthroplasty in patients who have rheumatoid arthritis: a ten- to fifteen-year follow-up study. *J Bone Joint Surg Am* 80:1327–1335, 1998.
33. Gofton WT, Macdermid JC, Patterson SD, et al: Functional outcome of AO type C distal humeral fractures. *J Hand Surg [Am]* 28:294–308, 2003.
34. Grant SD, Gorczyca JT, Pugh KJ: *Open distal humerus fractures*, Boston, Orthopaedic Trauma Association 12th Annual Meeting, 1996.
35. Hausman M, Panozzo A: Treatment of distal humerus fractures in the elderly. *Clin Orthop Relat Res* (425):55–63, 2004.
36. Helfet DL, Hotchkiss RN: Internal fixation of the distal humerus: a biomechanical comparison of methods. *J Orthop Trauma* 4:260–264, 1990.
37. Helfet DL, Kloen P, Anand N, et al: Open reduction and internal fixation of delayed unions and nonunions of fractures of the distal part of the humerus. *J Bone Joint Surg Am* 85:33–40, 2003.
38. Henley MB: Intra-articular distal humeral fractures in adults. *Orthop Clin North Am* 18:11–23, 1987.
39. Henley MB, Bone LB, Parker B: Operative management of intra-articular fractures of the distal humerus. *J Orthop Trauma* 1:24–35, 1987.
40. Hewins EA, Gofton WT, Dubberly J, et al: Plate fixation of olecranon osteotomies. *J Orthop Trauma* 21:58–62, 2007.
41. Hildebrand KA, Patterson SD, Regan WD, et al: Functional outcome of semiconstrained total elbow arthroplasty. *J Bone Joint Surg Am* 82:1379–1386, 2000.
42. Hitzrot JM: Fractures at the lower end of the humerus in adults. *Surg Clin North Am* 12:291–304, 1932.
43. Holdsworth BJ, Mossad MM: Fractures of the adult distal humerus: elbow function after internal fixation. *J Bone Joint Surg Br* 72:362–365, 1990.
44. Horne G: Supracondylar fractures of the humerus in adults. *J Trauma* 20:71–74, 1980.
45. Hotchkiss RN: Displaced fractures of the radial head: internal fixation or excision? *J Am Acad Orthop Surg* 5:1–10, 1997.
46. Hotchkiss RN: Fractures and dislocations of the elbow. In Rockwood CA, Jr, Green DP, Bucholz RW, et al, editors: *Rockwood and Green's fractures in adults* (vol 1), ed 4, Philadelphia, 1996, Lippincott-Raven, pp 929–1024.
47. Huang TL, Chiu FY, Chuang TY, et al: The results of open reduction and internal fixation in elderly patients with severe fractures of the distal humerus: a critical analysis of the results. *J Trauma* 58:62–69, 2005.
48. Hungerer S, Wipf F, von Oldenburg G, et al: Complex distal humerus fractures: comparison of polyaxial locking and nonlocking screw configurations: a preliminary biomechanical study. *J Orthop Trauma* 28(3):130–136, 2014.
49. Jacobson SR, Glisson RR, Urbaniak JR: Comparison of distal humerus fracture fixation: a biomechanical study. *J South Orthop Assoc* 6:241–249, 1997.
50. Johansson H, Olerud S: Operative treatment of intercondylar fractures of the humerus. *J Trauma* 11:836–843, 1971.
51. John H, Rosso R, Neff U, et al: Operative treatment of distal humeral fractures in the elderly. *J Bone Joint Surg Br* 76:793–796, 1994.
52. Jupiter JB: The surgical management of intraarticular fractures of the distal humerus. In Morrey BF, editor: *The elbow*, ed 2, Philadelphia, 2002, Lippincott Williams & Wilkins, pp 65–81.
53. Jupiter JB, Barnes KA, Goodman LJ, et al: Multiplane fracture of the distal humerus. *J Orthop Trauma* 7:216–220, 1993.
54. Jupiter JB, Goodman LF: The management of complex distal humerus nonunions in the elderly by elbow capsulectomy, triple plating, and ulnar nerve neurolysis. *J Shoulder Elbow Surg* 1:37–46, 1992.

http://e-surg.com

55. Jupiter JB, Mehne DK: Fractures of the distal humerus. *Orthopedics* 15:825–833, 1992.
56. Jupiter JB, Neff U, Holzach P, et al: Intercondylar fractures of the humerus: an operative approach. *J Bone Joint Surg Am* 67:226–239, 1985.
57. Jupiter JB, Neff U, Regazzoni P, et al: Unicondylar fractures of the distal humerus: an operative approach. *J Orthop Trauma* 2:102–109, 1988.
58. Kamineni S, Morrey BF: Distal humeral fractures treated with noncustom total elbow replacement. *J Bone Joint Surg Am* 86:940–947, 2004.
59. Kimball JP, Glowczewskie F, Wright TW: Intraosseous blood supply to the distal humerus. *J Hand Surg [Am]* 32:642–646, 2007.
60. Komurcu M, Yanmis I, Atesalp AS, et al: Treatment results for open comminuted distal humerus intra-articular fractures with Ilizarov circular external fixator. *Mil Med* 168:694–697, 2003.
61. Koonce RC, Baldini TH, Morgan SJ: Are conventional reconstruction plates equivalent to precontoured locking plates for distal humerus fracture fixation? A biomechanics cadaver study. *Clin Biomech (Bristol, Avon)* 27(7):697–701, 2012.
62. Korner J, Diederichs G, Arzdorf M, et al: A biomechanical evaluation of methods of distal humerus fracture fixation using locking compression plates versus conventional reconstruction plates. *J Orthop Trauma* 18:286–293, 2004.
63. Korner J, Lill H, Muller LP, et al: Distal humerus fractures in elderly patients: results after open reduction and internal fixation. *Osteoporos Int* 16(Suppl 2):S73–S79, 2005.
64. Korner J, Lill H, Muller LP, et al: The LCP-concept in the operative treatment of distal humerus fractures: biological, biomechanical and surgical aspects. *Injury* 34(Suppl 2):B20–B30, 2003.
65. Kundel K, Braun W, Wieberneit J, et al: Intraarticular distal humerus fractures: factors affecting functional outcome. *Clin Orthop Relat Res* 332:200–208, 1996.
66. Liberman N, Katz T, Howard CB, et al: Fixation of capitellar fractures with the Herbert screw. *Arch Orthop Trauma Surg* 110:155–157, 1991.
67. MacAusland WR: Ankylosis of the elbow: with report of 4 cases treated by arthroplasty. *JAMA* 64:312–318, 1915.
68. McAuliffe JA: Surgical alternatives for elbow arthritis in the young adult. *Hand Clin* 18:99–111, 2002.
69. McKee M, Jupiter J, Toh CL, et al: Reconstruction after malunion and nonunion of intra-articular fractures of the distal humerus: methods and results in 13 adults. *J Bone Joint Surg Br* 76:614–621, 1994.
70. McKee M, Jupiter JB: Fractures of the distal humerus. In Browner BD, Jupiter JB, Levine AM, et al, editors: *Skeletal trauma: basic science, management, and reconstruction* (vol 2), ed 3, Philadelphia, 2003, WB Saunders, pp 1436–1480.
71. McKee MD, Jupiter JB, Bamberger HB: Coronal shear fractures of the distal end of the humerus. *J Bone Joint Surg Am* 78:49–54, 1996.
72. McKee MD, Jupiter JB, Bosse G, et al: Outcome of ulnar neurolysis during posttraumatic reconstruction of the elbow. *J Bone Joint Surg Br* 80:100–105, 1998.
73. McKee MD, Kim J, Kebaish K, et al: Functional outcome after open supracondylar fractures of the humerus: the effect of the surgical approach. *J Bone Joint Surg Br* 82:646–651, 2000.
74. McKee MD, Wilson TL, Winston L, et al: Functional outcome following surgical treatment of intra-articular distal humeral fractures through a posterior approach. *J Bone Joint Surg Am* 82:1701–1707, 2000.
75. McKee MD, Veillette CJ, Hall JA, et al: A multicenter, prospective, randomized, controlled trial of open reduction–internal fixation versus total elbow arthroplasty for displaced intra-articular distal humeral fractures in elderly patients. *J Shoulder Elbow Surg* 18(1):3–12, 2009.
76. Mehdian H, McKee MD: Fractures of capitellum and trochlea. *Orthop Clin North Am* 31:115–127, 2000.
77. Mehne DK, Matta J: *Bicolumn fractures of the adult humerus*, New Orleans, Fifty-third Annual Meeting of the American Academy of Orthopaedic Surgeons, 1986.
78. Mighell MA, Harkins D, Klein D, et al: Technique for internal fixation of capitellum and lateral trochlea fractures. *J Orthop Trauma* 20:699–704, 2006.
79. Milch H: Fractures and fracture dislocations of the humeral condyles. *J Trauma* 15:592–607, 1964.
80. Miller WE: Comminuted fractures of the distal end of the humerus in the adult. *J Bone Joint Surg Am* 46:644–657, 1964.
81. Min W, Ding BC, Tejwani NC: Comparative functional outcome of AO/OTA type C distal humerus fractures: open injuries do worse than closed fractures. *J Trauma Acute Care Surg* 72(2):E27–E32, 2012.
82. Molloy S, Jasper LE, Burkhart BG, et al: Interference Kirschner wires augment distal humeral fracture fixation in the elderly. *J Orthop Trauma* 19:377–379, 2005.
83. Morrey BF: Fractures of the distal humerus: role of elbow replacement. *Orthop Clin North Am* 31:145–154, 2000.
84. Morrey BF: Surgical treatment of extraarticular elbow contracture. *Clin Orthop Relat Res* 370:57–64, 2000.
85. Morrey BF, Adams RA: Semiconstrained elbow replacement for distal humeral nonunion. *J Bone Joint Surg Br* 77:67–72, 1995.
86. Morrey BF, Adams RA, Bryan RS: Total replacement for post-traumatic arthritis of the elbow. *J Bone Joint Surg Br* 73:607–612, 1991.
87. Morrey BF, Askew LJ, Chao EY: A biomechanical study of normal functional elbow motion. *J Bone Joint Surg Am* 63:872–877, 1981.
88. Mostafavi HR, Tornetta P, 3rd: Open fractures of the humerus treated with external fixation. *Clin Orthop Relat Res* 337:187–197, 1997.
89. Muller LP, Kamineni S, Rommens PM, et al: Primary total elbow replacement for fractures of the distal humerus. *Oper Orthop Traumatol* 17:119–142, 2005.
90. Muller ME, Nazarian S, Koch P, et al: *The comprehensive classification of fractures of long bones*, Berlin, 1990, Springer-Verlag.
91. O'Driscoll SW: Optimizing stability in distal humeral fracture fixation. *J Shoulder Elbow Surg* 14(1 Suppl S):186S–194S, 2005.
92. O'Driscoll SW: The triceps-reflecting anconeus pedicle (TRAP) approach for distal humeral fractures and nonunions. *Orthop Clin North Am* 31:91–101, 2000.
93. Obremskey WT, Bhandari M, Dirschl DR, et al: Internal fixation versus arthroplasty of comminuted fractures of the distal humerus. *J Orthop Trauma* 17:463–465, 2003.
94. Patterson SD, Bain GI, Mehta JA: Surgical approaches to the elbow. *Clin Orthop Relat Res* 370:19–33, 2000.
95. Pereles TR, Koval KJ, Gallagher M, et al: Open reduction and internal fixation of the distal humerus: functional outcome in the elderly. *J Trauma* 43:578–584, 1997.
96. Ray PS, Kakarlapudi K, Rajsekhar C, et al: Total elbow arthroplasty as primary treatment for distal humeral fractures in elderly patients. *Injury* 31:687–692, 2000.
97. Reich RS: Treatment of intercondylar fractures of the elbow by means of traction. *J Bone Joint Surg Am* 18:997–1004, 1936.
98. Ring D, Gulotta L, Chin K, et al: Olecranon osteotomy for exposure of fractures and nonunions of the distal humerus. *J Orthop Trauma* 18:446–449, 2004.
99. Ring D, Gulotta L, Jupiter JB: Unstable nonunions of the distal part of the humerus. *J Bone Joint Surg Am* 85:1040–1046, 2003.
100. Ring D, Jupiter JB: Complex fractures of the distal humerus and their complications. *J Shoulder Elbow Surg* 8:85–97, 1999.
101. Ring D, Jupiter JB, Gulotta L: Articular fractures of the distal part of the humerus. *J Bone Joint Surg Am* 85:232–238, 2003.
102. Riseborough EJ, Radin EL: Intercondylar T fractures of the humerus in the adult: a comparison of operative and non-operative treatment in twenty-nine cases. *J Bone Joint Surg Am* 51:130–141, 1969.
103. Root CG, Meyers K, Wright T, et al: Capitellum excision: mechanical implications and clinical consequences. *J Orthop Res* 32(2):346–350, 2014.
104. Sanchez-Sotelo J, Torchia ME, O'Driscoll SW: Complex distal humeral fractures: internal fixation with a principle-based parallel-plate technique. *J Bone Joint Surg Am* 89:961–969, 2007.
105. Scharplatz D, Allgower M: Fracture-dislocations of the elbow. *Injury* 7:143–159, 1975.
106. Schemitsch EH, Tencer AF, Henley MB: Biomechanical evaluation of methods of internal fixation of the distal humerus. *J Orthop Trauma* 8:468–475, 1994.
107. Schildhauer TA, Nork SE, Mills WJ, et al: Extensor mechanism-sparing paratricipital posterior approach to the distal humerus. *J Orthop Trauma* 17:374–378, 2003.
108. Schneeberger AG, Adams R, Morrey BF: Semiconstrained total elbow replacement for the treatment of post-traumatic osteoarthrosis. *J Bone Joint Surg Am* 79:1211–1222, 1997.
109. Schuster I, Korner J, Arzdorf M, et al: Mechanical comparison in cadaver specimens of three different 90-degree double-plate osteosyntheses for simulated C2-type distal humerus fractures with varying bone densities. *J Orthop Trauma* 22:113–120, 2008.
110. Self J, Viegas SF, Buford WL, Jr, et al: A comparison of double-plate fixation methods for complex distal humerus fractures. *J Shoulder Elbow Surg* 4(1 Pt 1): 10–16, 1995.
111. Sodergard J, Sandelin J, Bostman O: Mechanical failures of internal fixation in T and Y fractures of the distal humerus. *J Trauma* 33:687–690, 1992.
112. Spang JT, Del Gaizo DJ, Dahners LE: Reconstruction of lateral trochlear defect with radial head autograft. *J Orthop Trauma* 22:351–356, 2008.
113. Spinner M, Spinner RJ: Nerve decompression. In Morrey BF, editor: *The elbow*, ed 2, Philadelphia, 2002, Lippincott Williams & Wilkins, pp 265–289.
114. Srinivasan K, Agarwal M, Matthews SJ, et al: Fractures of the distal humerus in the elderly: is internal fixation the treatment of choice? *Clin Orthop Relat Res* 434:222–230, 2005.
115. Stamatis E, Paxinos O: The treatment and functional outcome of type IV coronal shear fractures of the distal humerus: a retrospective review of five cases. *J Orthop Trauma* 17:279–284, 2003.
116. Stoffel K, Cunneen S, Morgan R, et al: Comparative stability of perpendicular versus parallel double-locking plating systems in osteoporotic comminuted distal humerus fractures. *J Orthop Res* 26:778–784, 2008.
117. Van Gorder GW: Surgical approach in supracondylar "T" fractures of the humerus requiring open reduction. *J Bone Joint Surg Am* 22:278–292, 1940.

http://e-surg.com

118. Viola RW, Hanel DP: Early "simple" release of posttraumatic elbow contracture associated with heterotopic ossification. *J Hand Surg [Am]* 24:370–380, 1999.
119. Waddell JP, Hatch J, Richards R: Supracondylar fractures of the humerus: results of surgical treatment. *J Trauma* 28:1615–1621, 1988.
120. Wang KC, Shih HN, Hsu KY, et al: Intercondylar fractures of the distal humerus: routine anterior subcutaneous transposition of the ulnar nerve in a posterior operative approach. *J Trauma* 36:770–773, 1994.
121. Watson-Jones R: *Fractures and joint injuries* (vol 2), ed 3, Baltimore, 1944, Williams & Wilkins.
122. Wilkinson JM, Stanley D: Posterior surgical approaches to the elbow: a comparative anatomic study. *J Shoulder Elbow Surg* 10:380–382, 2001.
123. Wright TW, Wong AM, Jaffe R: Functional outcome comparison of semiconstrained and unconstrained total elbow arthroplasties. *J Shoulder Elbow Surg* 9:524–531, 2000.
124. Yamaguchi K, Sweet FA, Bindra R, et al: The extraosseous and intraosseous arterial anatomy of the adult elbow. *J Bone Joint Surg Am* 79:1653–1662, 1997.
125. Zagorski JB, Jennings JJ, Burkhalter WE, et al: Comminuted intraarticular fractures of the distal humeral condyles: surgical vs. nonsurgical treatment. *Clin Orthop Relat Res* 202:197–204, 1986.
126. Ziran BH, Smith WR, Balk ML, et al: A true triceps-splitting approach for treatment of distal humerus fractures: a preliminary report. *J Trauma* 58:70–75, 2005.

http://e-surg.com

19

Fractures of the Radial Head

Graham J.W. King

These videos may be found at *ExpertConsult.com*:
19.1 Open reduction and internal fixation of the radial head.
19.2 Radial head replacement. *(Copyright © Wright Medical Technology. Used by permission.)*

Fractures of the head of the radius are the most common fractures of the elbow. The majority occur between the ages of 20 and 60, with the incidence in females being twice that of males. Although fractures that are not displaced typically occur in isolation, displaced fractures are frequently associated with ligament injuries of the medial and lateral collateral ligaments and/or of the interosseous membrane. In more severe injuries, dislocations of the elbow and forearm may be associated with fractures of the radial head. Fractures of the coronoid, olecranon, and capitellum are commonly seen with fractures of the radial head and further impair elbow stability. The radial head is an important stabilizer for the elbow in the setting of these associated bony and ligamentous injuries.

Although undisplaced and minimally displaced fractures of the radial head usually have a favorable functional outcome with nonoperative management, there is little information demonstrating the optimal treatment of patients with displaced and/or comminuted fractures. In 1935, Jones stated: "Fracture of the head or neck of the radius with displacement is a serious injury. While the prognosis is good for recovery of a useful elbow, rarely is it a normal elbow."[105] This statement remains true today. A mechanical block to motion is an absolute indication for surgery. Concomitant injuries requiring surgical treatment, such as a large displaced coronoid fracture or elbow instability, frequently dictate the management of the radial head. Good results have been reported following open reduction and internal fixation for selected noncomminuted displaced radial head fractures. Excision of fragments, early or delayed radial head excision, and arthroplasty all have a role in the management of more comminuted displaced fractures.

EVALUATION

Clinical Assessment

A patient's history usually indicates that there was a fall onto the outstretched hand. High-energy injuries, such as a motor vehicle crash, typically have more comminuted fracture patterns and a higher incidence of associated injuries. Inspection may reveal ecchymosis along the forearm and/or medial aspect of the elbow. Tenderness over the radial head is expected and typically the most notable is anteriorly. Pain over the lateral epicondyle may represent a concomitant injury of the lateral collateral ligament. Careful palpation of the medial epicondyle and the sublime tubercle of the ulna should be performed to look for an associated medial collateral ligament injury. The interosseous membrane of the forearm and the distal radioulnar joint should be evaluated for tenderness; however, these injuries are often subtle and may not be evident even with a careful physical examination. Because associated injuries of the shoulder, forearm, wrist, and hand are common, these areas should also be examined. A careful neurologic and vascular examination of the extremity needs to be performed; however, concomitant nerve and arterial injuries are rare and usually associated with severe injuries.

Range of motion, including forearm rotation and elbow flexion–extension, should be evaluated. Palpable and auditory crepitus should be noted during movement. Forearm rotation is generally preserved but may sometimes be limited by pain or a mechanical block. In these circumstances, reevaluation a few days later may be prudent. Alternatively, aspiration of the hemarthrosis and injection of local anesthetic should be considered.[47,92,168,214] With a sterile technique and with the forearm in pronation to protect the radial nerve, a needle is introduced into the lateral soft spot located at the center of a triangle formed by the lateral epicondyle, olecranon, and radial head (Figure 19.1). After the hemarthrosis is aspirated, 10 mL of 1% lidocaine (Xylocaine) is injected. Persistent loss of rotation after pain relief suggests a mechanical block, whereas palpable grating suggests articular incongruity, both require surgical management. A mild loss of terminal elbow flexion and extension is expected as a consequence of an elbow hemarthrosis and does not necessarily indicate a mechanical block that needs surgical treatment.

Imaging

Anteroposterior, lateral, and oblique elbow radiographs usually provide sufficient information for the diagnosis and treatment of fractures of the head of the radius. The x-ray beam must be centered on the radiocapitellar joint to ensure a tangential view of the radial head. Because a hemarthrosis prevents elbow extension, two anteroposterior radiographs may be required if there is significant loss of extension: anteroposterior views of the distal humerus and the forearm. An oblique radiocapitellar view can be useful as it places the radial head in profile.[75] The elbow is positioned for a lateral radiograph but the x-ray tube is angled 45 degrees cephalad (Figure 19.2). In patients with undisplaced fractures of the radial head or neck, plain radiographs may only demonstrate elevation of the anterior or

http://e-surg.com

posterior fat pads (sail sign) as a consequence of a hemarthrosis (Figure 19.3). Bilateral posteroanterior radiographs of both wrists in neutral rotation should be performed to evaluate ulnar variance in patients with wrist discomfort and in those who have a comminuted fracture of the radial head as there is a higher incidence of an associated interosseous membrane injury in these patients.[44,99,209] A magnetic resonance image (MRI) or ultrasound may be considered to evaluate the presence of associated collateral ligament or interosseous membrane injuries but these investigations are uncommonly required.[56,99] Because of the cylindrical shape of the radial head, conventional elbow radiographs often underestimate the extent of articular surface involvement and magnitude of displacement.[104,115] Computed tomography (CT) is useful to quantify fracture size, location, displacement, and comminution in cases in which the indications for surgery are less clear. CT may also assist with preoperative planning with respect to the need

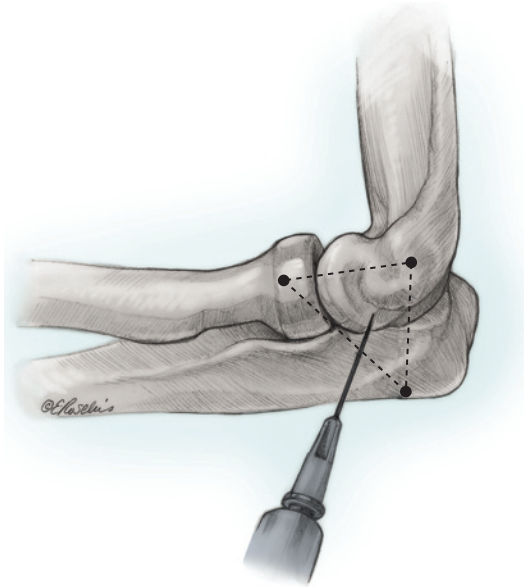

FIGURE 19.1 Aspiration of the elbow. Under a sterile technique with the forearm maintained in pronation, a needle is introduced into the center of a triangle formed by the lateral epicondyle, radial head, and tip of the olecranon. The hemarthrosis is aspirated, and local anesthetic is injected. An improvement in rotation is suggestive of pain-limiting motion, whereas a persistent restriction of rotation is suggestive of a mechanical block requiring surgical management.

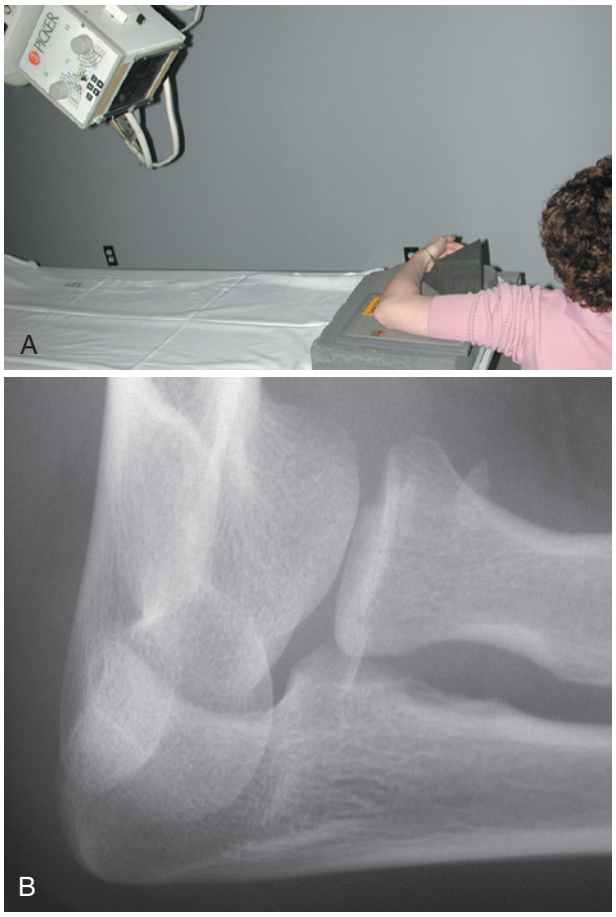

FIGURE 19.2 The radiocapitellar view can be useful because it places the radial head in profile. **A**, **B**, The elbow is positioned for a lateral radiograph, but the x-ray tube is angled 45 degrees cephalad.

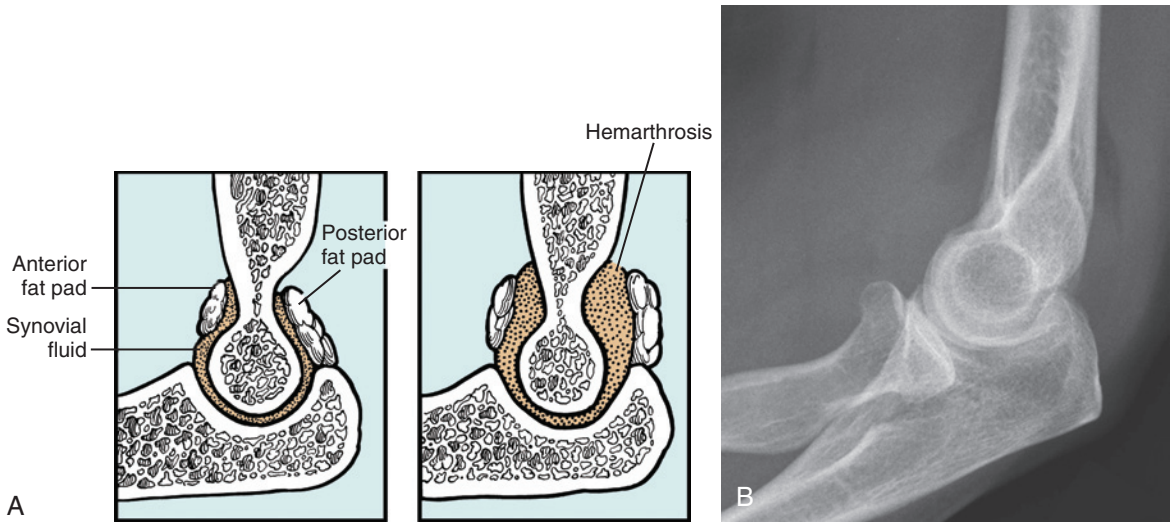

FIGURE 19.3 Fat pad sign. **A**, Normal position of fat pads in the elbow and displacement of fat pads induced by an intraarticular effusion. **B**, Lateral radiograph demonstrating anterior and posterior fat pad signs in patient with an undisplaced fracture of the radial head.

http://e-surg.com

for specialized equipment for fracture fixation or prosthetic replacement.

Mason classified fractures of the radial head into three types: type I, fissure or marginal sector fractures without displacement; type II, marginal sector fractures with displacement; and type III, comminuted fractures involving the whole head (Figure 19.4).[135] One study demonstrated moderate to poor intra- and interobserver reproducibility of this classification based on plain radiographs.[146] Other authors have reported that many Mason II fractures are reclassified to type III during surgery owing to additional fracture segments being found that are not revealed on plain radiographs.[115] Johnston added a fourth type: fracture of the radial head associated with an elbow dislocation.[104] This additional category does little to direct treatment other than to emphasize that radial head excision without replacement is contraindicated in the setting of an associated elbow dislocation. Morrey has suggested that isolated fractures of the radial head be referred to as "simple or uncomplicated," while those associated with other soft tissue or bony injuries be referred to as "complex or complicated."[148]

More recently Hotchkiss developed a management-based classification with three types[93] (Table 19.1):

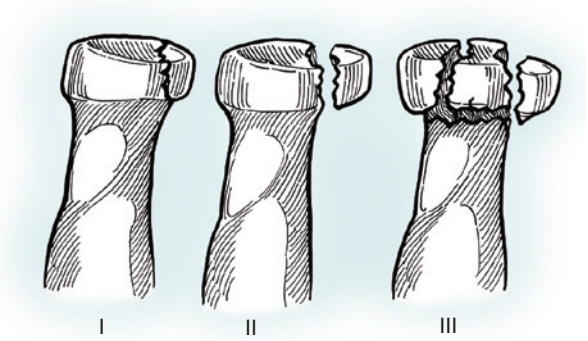

FIGURE 19.4 Mason classification. Mason described three types of fractures of the radial head: *I*, undisplaced; *II*, displaced wedge fragment(s); and *III*, comminuted.

TABLE 19.1 Hotchkiss Classification of Proximal Radial Fractures*

Type I	Nondisplaced or minimally displaced fracture of head or neck No mechanical block to rotation Displacement > 2 mm or a marginal lip fracture
Type II	Displaced (usually >2 mm) fracture of head or neck (angulated) May have mechanical block to motion or be incongruous Without severe comminution (technically possible to repair using open reduction and internal fixation) More than a marginal lip fracture of the radial head
Type III	Severely comminuted fracture of the radial head or neck Judged not reconstructable on basis of radiographic or intraoperative appearance Usually requires excision for movement

*All of these fractures may have associated injuries (e.g., a coronoid fracture, elbow dislocation, medial collateral or lateral collateral ligaments) or interosseous membrane tears.
From Hotchkiss RN: Displaced fractures of the radial head: Internal fixation or excision. *J Am Acad Orthop Surg* 5:1–10, 1997.

Type I: undisplaced or minimally displaced (<2 mm) small marginal fracture of the head or neck with no mechanical block to motion

Type II: displaced (>2 mm) fracture of the head or neck that is reconstructable with open reduction and internal fixation (ORIF). It may have a mechanical block or be incongruous; more than a marginal lip fracture

Type III: comminuted fracture of the head or neck that is unreconstructable as judged by radiographs or at surgery; usually requires excision for movement

While the Hotchkiss classification helps to direct treatment, the type of operation needed is less clear because the distinction between types II and III fractures remains problematic. The decision as to which fracture is reconstructable depends on surgeon factors (e.g., experience and implants available), patient factors (e.g., osteoporosis), and fracture factors (e.g., fragment size, comminution, and associated soft tissue injuries). The final decision as to whether a fracture is reconstructable or whether it requires radial head excision and/or replacement often can only be decided during surgery. Therefore, this classification, to some extent, may be of more use retrospectively and is less helpful in deciding which type of surgery should be performed.

Associated Injuries

Fractures of the radial head and neck commonly occur following a fall on the outstretched hand. A comminuted fracture of the radial head or neck is likely the result of failure in compression due to axial or valgus loads (Figure 19.5). In one cadaveric study, an isolated fracture of the radial head was most likely to occur when an axial load between 35 and 80 degrees of flexion is applied.[6] In 1924, Odelberg-Johnson reported that elbow subluxation was an important mechanism of wedge fractures in a series of cadaveric experiments.[157] In the author's experience posterolateral rotatory subluxation of the elbow, the first stage of an elbow dislocation, likely causes many of these anterolateral wedge fractures. This segment of the radial head shears off as the rim of the radial head dish subluxates off the capitellum with the forearm in neutral to supination.

Displaced fractures of the radial head are commonly associated with disruption of the ligaments of the elbow or forearm.[44,99,102,109,210] In one study, no patient with a minimally or undisplaced fracture had an associated disruption of the medial collateral ligament when stress radiographs were performed.[44] However, 71% of patients with a displaced shear fracture of the radial head or an impacted fracture of the radial neck had a medial collateral ligament injury. All of the patients with a comminuted fracture had disruption of the medial collateral ligament of the elbow or of the interosseous membrane of the forearm (91% and 9%, respectively).

Johansson, using arthrography, reported medial collateral ligament or capsular disruptions in 4%, 21%, and 85% of Mason types I, II, and III fractures, respectively.[102] Itamura and colleagues performed MR scans on 24 patients with displaced Mason types II and III fractures of the radial head. They reported that the medial collateral ligament was disrupted in 54%, the lateral ulnar collateral ligament was disrupted in 80%, both collateral ligaments were disrupted in 50%, capitellar osteochondral defects were present in 29%, capitellar bone bruises were evident in 96%, and loose bodies were noted in

http://e-surg.com

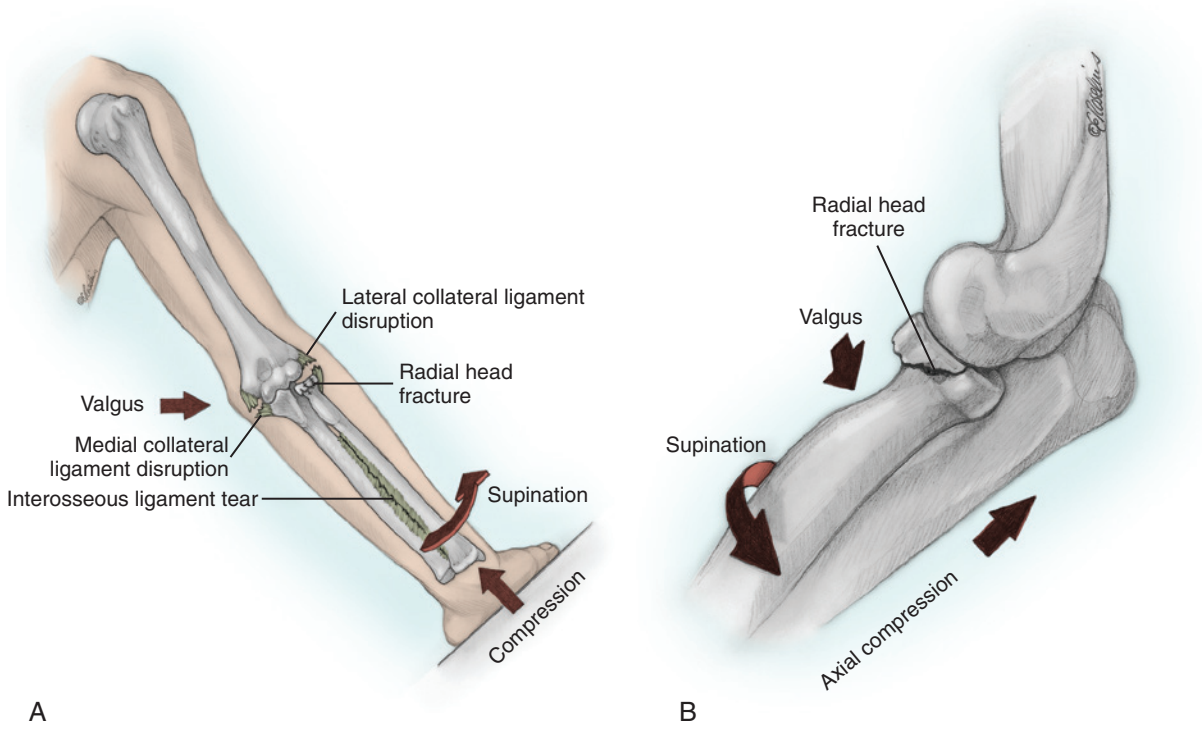

FIGURE 19.5 Mechanism of fracture of the radial head. **A**, Valgus and/or axial loading of the elbow causes failure of the radial head in compression and possible medial collateral ligament or interosseous membrane disruption. **B**, Posterolateral rotatory subluxation of the elbow causes disruption of the lateral ulnar collateral ligament and the anterolateral aspect of the radial head to shear off as it slides posterior to the capitellum with the forearm in supination. This mechanism likely explains the commonly associated lateral ligamentous injuries and chondral damage of the capitellum seen with this fracture pattern. Continued subluxation of the elbow may result in a fracture of the coronoid, disruption of the medial collateral ligament, and a complete dislocation.

92%.[99] In one series of patients with Essex-Lopresti injuries presenting for reconstruction, 15 of 20 had undergone a radial head resection without knowledge of the forearm ligamentous injury, suggesting that this uncommon injury may be easily missed in clinical practice.[206] Collectively, these data suggest that minimally displaced fractures have a low incidence of associated soft tissue disruption. More displaced and comminuted fractures are likely with higher energy, and therefore have a greater incidence of associated ligamentous injuries. Careful physical examination and intraoperative evaluation of the elbow are needed to detect these associated ligamentous injuries.

Fractures of the capitellum may be appear as chondral injuries[89] or displaced osteochondral fractures. Ward and Nunley reported that 50% of patients with fractures of the capitellum had an associated fracture of the radial head, whereas only 1% of the fractures of the radial head had a capitellar fracture.[217] For displaced fractures of the radial head treated operatively, the incidence of an associated capitellar fracture was 24%. These injuries may or may not be visible with plain radiographs or CT scans and are often only diagnosed during surgery.[31] Capitellar fractures may be responsible for a mechanical block of elbow or forearm motion in the absence of significant displacement of a fracture of the radial head seen radiographically (Figure 19.6).

Dislocations of the elbow are seen in 3 to 10% of patients with fractures of the radial head.[104,106,172] Patients with an associated elbow subluxation or dislocation may have a fracture of the coronoid as part of a "terrible triad" injury with disruption of one or both collateral ligaments of the elbow.[171] Small coronoid fragments typically present as triangular fragments situated anteriorly in the coronoid fossa and are often mistaken as a fragment of the radial head. Larger coronoid fragments are associated with greater instability of the elbow and require specific treatment as outlined in Chapter 22. Elbow fracture–dislocations should be managed by immediate closed reduction followed by treatment of the radial head, the same as for isolated fractures.[27,61,104,106] Whereas some authors recommend urgent operative management of the radial head if needed (within 24 h) to reduce the incidence of heterotopic ossification, this practice remains controversial.[67,104] Early motion seems to improve outcome; therefore urgent, not emergent, management of the fracture is appropriate. Excision of the radial head without replacement should be avoided for patients with associated dislocations due to a high risk of another dislocation and instability.[61,106,178] Fractures of the olecranon or proximal ulna may also be seen in association with fractures of the radial head as a variant of the Monteggia fracture.[147]

ANATOMY AND BIOMECHANICS

The anatomy of the radial head and neck is complex and highly variable.[117,211] The head of the radius consists of a circular concave dish that articulates with the spherical capitellum (Figure 19.7). The dish has a greater radius of curvature than the capitellum making this articulation only moderately constrained. The articular dish is variably offset from the axis of the radial neck. The margin of the radial head that articulates with the radial notch of the ulna is slightly elliptical[14] producing a cam effect during forearm rotation that displaces the shaft

http://e-surg.com

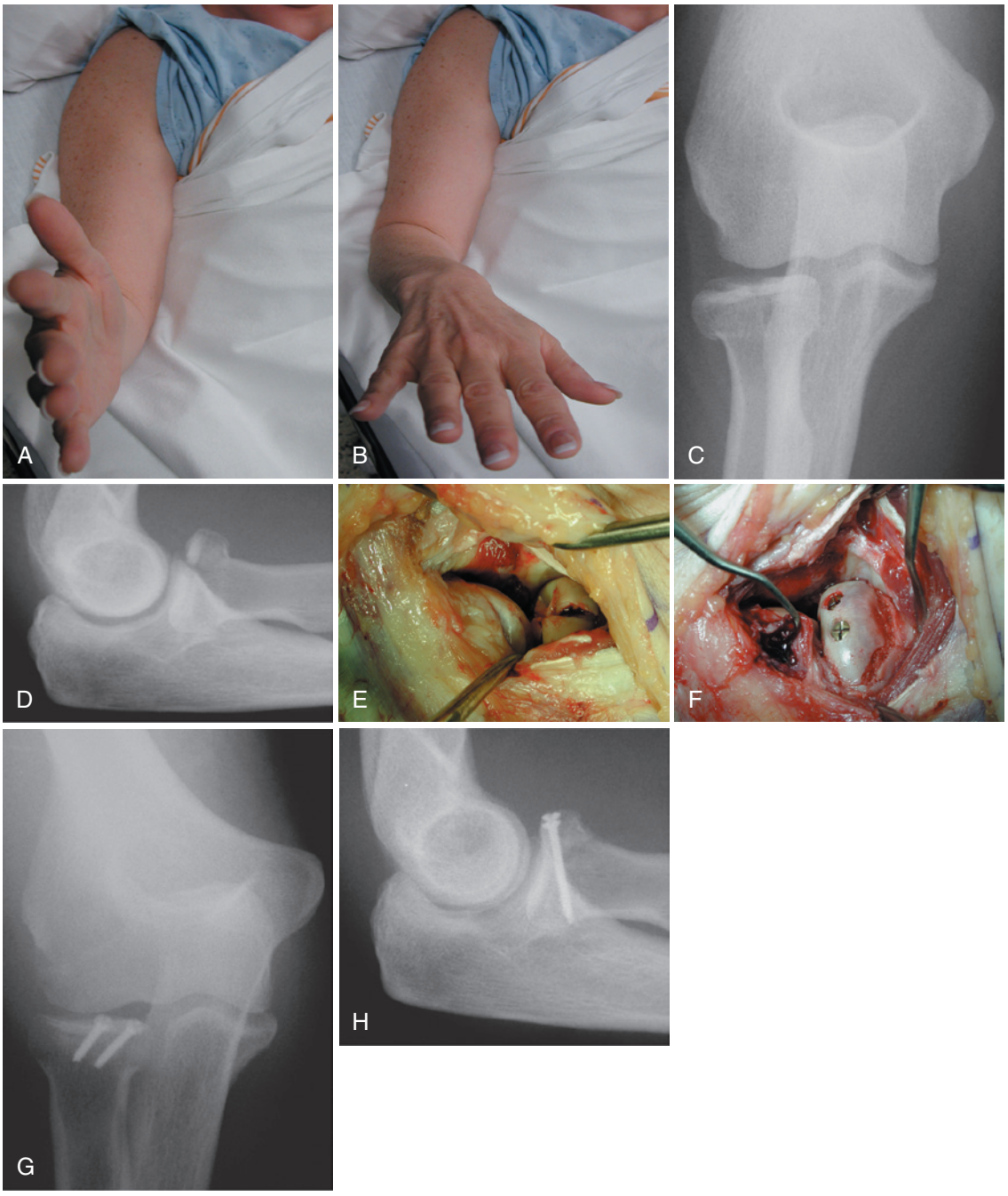

FIGURE 19.6 Capitellar cartilage shear fracture. **A**, **B**, Clinical photos of a 49-year-old woman with a persistent block to supination 2 weeks after a minimally displaced fracture of the radial head. **C**, **D**, Preoperative anteroposterior and lateral radiographs demonstrating a displaced fracture of the radial head. **E**, Intraoperative photograph of cartilage shear fracture. **F**, Intraoperative photograph demonstrating reduction of the fracture with two 2.0-mm screws and cancellous bone grafting of the radial neck from the lateral epicondyle. **G**, **H**, Postoperative anteroposterior and lateral radiographs after open reduction and internal fixation of the radial head and débridement of the capitellum.

somewhat radially during pronation.[58] The radial notch of the proximal ulna comprises an arc of 60 to 70 degrees and forms a relatively congruous articulation with the radial head, allowing for only modest radioulnar translation during forearm rotation. The anterolateral one-third of the articular margin of the radial head is devoid of cartilage allowing placement of internal fixation without impingement with the radial notch during forearm rotation.

A "safe zone" for internal fixation has been described as a 110-degree arc centered on a point 10 degrees anterior to the midpoint of the lateral side of the radial head as judged with the forearm in neutral rotation (Figure 19.8).[32,58,192,194] This nonarticular portion can also be identified by the rounded shape of its margin relative to the flatter surface that articulates with the proximal radioulnar joint. The rotational interval between the Lister tubercle and the radial styloid of the distal radius is

http://e-surg.com

another useful anatomic landmark for the nonarticular portion of the radial head.[32] Placement of plates on the nonarticular margin may be required when managing fractures involving the radial neck. The radial head is surrounded by the annular ligament; therefore, bulky internal fixation is poorly tolerated. Implants should be low profile to minimize soft tissue adherence that may impede forearm rotation.

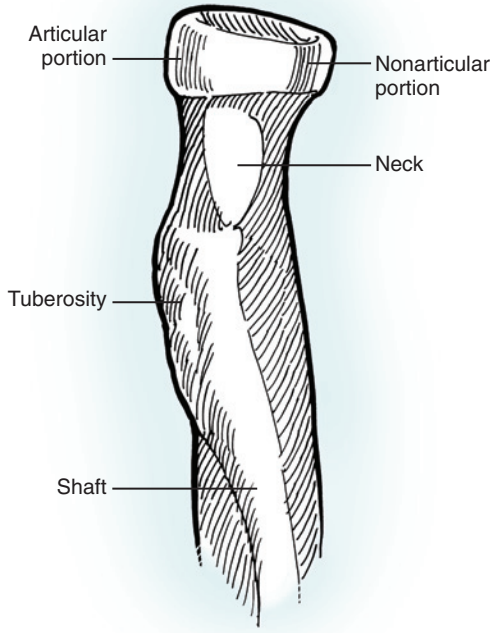

FIGURE 19.7 Anatomy of the proximal radius. The radial head is somewhat elliptical. The concave surface of the radial head that articulates with the capitellum is variably offset in a radial direction from the axis of the radial neck. The portion of the radial head that does not articulate with the radial notch of the ulna is more rounded, whereas the articulating portion is more flattened.

The cancellous trabeculae are oriented perpendicular to the surface of the radial head confirming the load-bearing function of the radial head. It has been suggested that the subchondral bone is weaker in the anterolateral portion of the radial head; this was confirmed by a recent CT imaging study which demonstrated that the cancellous bone volume was lowest in the anterolateral quadrant of the radial head.[86]

The blood supply of the radial head is composed of both intra- and extraosseous sources.[72] Vessels penetrate the radial neck from the periosteum at the head–neck junction; the dorsolateral periosteum is a key area for these branches. Preservation of the periosteal attachment of displaced fragments is important during open reduction and internal fixation of fractures of the radial head and neck. Proximal radius plate fixation further compromises the vascularity of the radial head.[121]

A better understanding of the lateral ligamentous anatomy of the elbow has resulted in improvements in surgical techniques for fractures of the head of the radius. The annular ligament wraps around the radial head, attaching to the anterior and posterior margins of the radial notch, of the ulna and stabilizes the radial head in the proximal radioulnar joint. The radial collateral ligament arises from the lateral epicondyle and attaches to the annular ligament. The lateral ulnar collateral ligament arises from the lateral epicondyle and is inserted on the crista supinatoris of the proximal ulna. The lateral ulnar collateral and radial collateral ligaments are important restraints against varus and posterolateral rotational instability of the elbow (Figure 19.9).[51,155,156]

Conventional surgical approaches to the radial head through the Kocher interval (between the extensor carpi ulnaris and the anconeus) often cause iatrogenic injury to the lateral ulnar collateral ligament unless the dissection is brought more anterior such that the radial collateral and annular ligaments are divided at the midaxis of the radial head.[120] Additionally, this approach tends to expose the radial head too posteriorly to permit internal fixation of the commonly involved anterolateral portion of

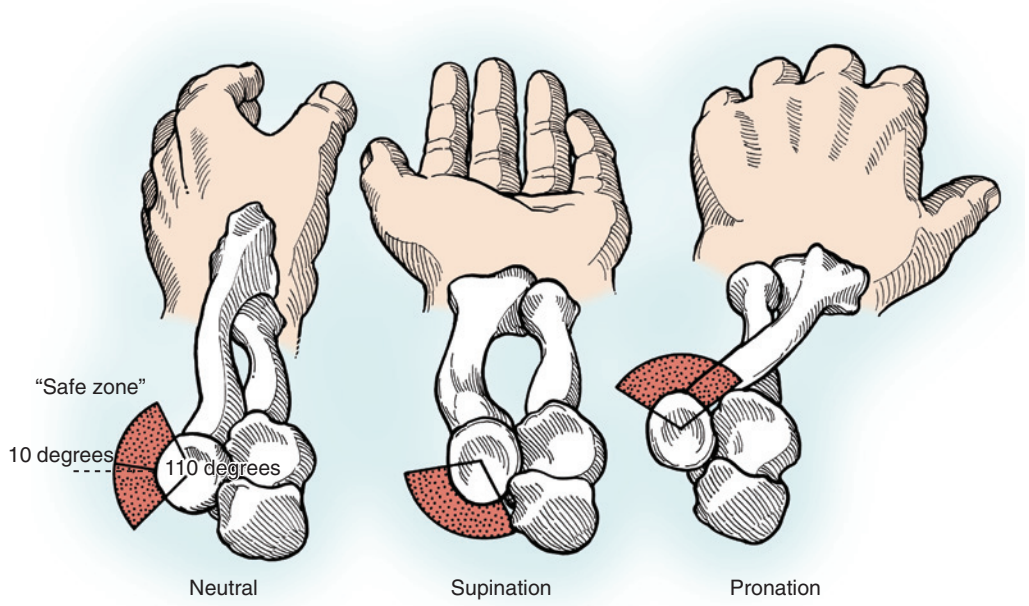

FIGURE 19.8 Nonarticular portion of the radial head. The nonarticular portion "safe zone" of the radial head can be identified as a 110-degree arc centered on a point 10 degrees anterior to the midpoint of the lateral side of the radial head with the forearm in neutral rotation.

http://e-surg.com

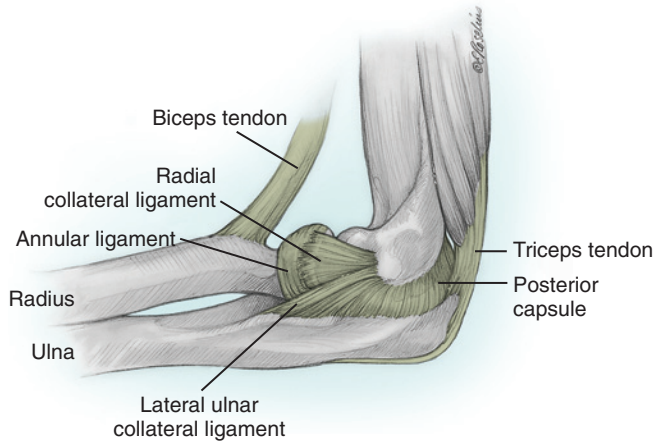

FIGURE 19.9 Lateral ligaments of the elbow. The lateral ligaments of the elbow include the radial collateral, lateral ulnar collateral, and annular ligaments. The lateral ulnar collateral ligament is an important stabilizer against posterolateral rotational and varus instability of the elbow. The annular ligament stabilizes the proximal radioulnar joint and contributes to varus and posterolateral rotatory elbow instability by virtue of its attachment to the radial collateral ligament.

the radial head. Maintaining the integrity of the lateral ulnar collateral ligament or performing a strong repair to bone is essential to prevent instability, which may be an important cause of failure of internal fixation, late pain, and arthritis.

Repair of the fascial interval between the anconeus and extensor carpi ulnaris has also been shown to further augment elbow stability.[39] For isolated fractures of the radial head without associated ligamentous or osseous injuries, a more anterior muscle–tendon splitting approach through the common extensor tendon at the midportion of the radial head should be considered. This approach allows for good visualization of the radial head and avoids detachment of the lateral ulnar collateral ligament. However, it is less extensile distally, limited by the proximity of the posterior interosseous nerve, which lies on average 33 mm (minimum 22 mm) from the capitellum in supination and 52 mm (minimum 38 mm) in pronation.[46]

Resisted isometric elbow flexion has been estimated to generate forces up to four times body weight across the joint.[4,5] The radiocapitellar articulation may account for up to 60% of the load transfer across the elbow.[79] Contact forces across this articulation are greatest with the forearm in pronation.[150] Displaced fractures of the radial head result in a decreased residual surface area available for load transfer and therefore increased cartilage contact pressures, which may predispose to arthritis. Excision of the radial head increases the tension in the medial collateral ligament and concentrates the forces acting across the elbow on the lateral aspect of the ulnohumeral joint; it has been calculated that the force can reach as high as nine times body weight.[4] Posterolateral rotational instability of the elbow is aggravated by excision of fragments or the entire radial head as a consequence of both the loss of "capture" of the articulating dish of the radial head by the capitellum and a diminished tensioning effect on the lateral collateral ligament.[16,155] Repair or replacement of displaced radial head fractures improves load transfer and elbow stability.[17,103]

The head of the radius is an important valgus stabilizer of the elbow, particularly in the setting of an incompetent medial collateral ligament.[118,149,153,165,181] In vitro biomechanical studies have shown that the kinematics and stability of the elbow are altered by radial head excision, even in the setting of intact collateral ligaments.[17,101] Replacement of the radial head with metallic prostheses has been demonstrated to improve the stability of elbows with intact and deficient medial and/or lateral collateral ligaments.[17,118] Axial forearm stability is also improved by metallic radial head prostheses in the setting of an interosseous ligament disruption.[183] Silicone radial head replacements are inferior to metallic implants for restoring both axial and valgus stability.[94,95,118,167,183]

HISTORICAL REVIEW

Paul of Aegina (CE 625-690) was likely the first to report an injury to the proximal radius, as documented by Schwartz and Young in an excellent review of the early history of radial head fractures.[182] Desault, in 1811, suggested that fractures of the proximal radius were uncommon relative to the middle or distal end and that diagnosis was difficult because of the surrounding thick muscular covering. In 1897, Helserich described a fracture of the radial head and suggested that resection of it was helpful for late deformity. In 1910, Hammond stressed the utility of radiology in making the diagnosis of a fracture of the radial head, which he noted to be difficult based on patient history and physical examination alone.[82] He also found that marked fracture displacement was a poor prognostic sign for outcome with nonoperative management and recommended excision of the fragments or radial head. In 1926, Cutler described three types of fractures of the radial head and recommended closed treatment for fractures that were not displaced.[43] He recommended surgery if a displaced fragment interfered with full motion, prevented reduction of an elbow dislocation, and in cases of malunion, ankylosis, or forearm stiffness.

Watson-Jones reported in 1930 that only a 50% good result could be obtained in the management of displaced fractures of the radial head.[218] He avoided excision of it as a result of the "inevitable" radial shortening with subluxation or dislocation of the lower end of the ulna. Angulated fractures of the radial neck were stabilized with a sling of kangaroo tendon because he felt that angulation interfered with forearm rotation. In 1935, Jones reported good results could be achieved by excising fragments that involve less than one-third of the radial head.[105] He reported better results with early-versus-late radial head excision.

In 1950, Carstam reported that generally fractures of the radial head were not isolated injuries; most had an elbow subluxation that had spontaneously reduced.[35] He suggested that open reduction and internal fixation should be considered for marginal fractures with moderate displacement and reported good outcomes. The results of fragment and whole-head excision were not appreciably different. He noted changes, such as cubitus valgus and proximal migration of the radius, were frequent but did not commonly cause symptoms, except in children.

In 1954, Mason reviewed 100 patients who had sustained a fracture of the radial head and described a classification system.[135] He recommended nonoperative treatment for undisplaced type I fractures and reported good results. Type II fractures, which he described as "marginal sector fractures with

http://e-surg.com

displacement," had more variable results. He recommended that conservative treatment should be pursued if the fracture fragment did not involve more than one-quarter of the articular circumference and was reasonably well aligned. In all other cases, "no matter how minimal the tilting and comminution of the fracture segment," he recommended excision of the radial head. He described the axiom of radial head fracture treatment as: "If in doubt—resect." Type III fractures were comminuted, and he advised primary radial head excision and reported good early results. In 1962, Johnston added a fourth subtype to the Mason classification: a radial head fracture associated with an elbow dislocation.[104] He considered that radial head excision was not a benign procedure and stated: "If in doubt, treat conservatively."

Subsequent to these papers, there has been an explosion of interest in radial head anatomy,[21,32,74,117] biomechanics,[5,6,14,79,101,118,149,150,152,153,165,167,183,184] and fracture management.[93] The importance of the radial head to the kinematics and load transfer of the elbow is now better understood, and there is an increasing interest in salvaging the radial head whenever possible.[8,25,54,57,64,68,69,89,93,113,115,138,161,174,179,185] Advances in screw-and-plate designs have resulted in increasing utilization of open reduction and internal fixation for displaced fractures of the radial head with excellent results for simple fracture configurations. Even though long-term follow-up studies suggest that radial head excision is generally well tolerated clinically in the absence of associated ligament injuries, the incidence of osteoarthritis has been high.[25,41,61,63,73,97,100,114,144,178,216] Implant arthroplasty has become popular for the treatment of comminuted displaced fractures of the radial head where open reduction and internal fixation is less predictable.

Speed reported the use of a metallic radial head arthroplasty in 1941.[195] Subsequently, acrylic was employed with some early success.[37] Silicone implants gained widespread use in the 1970s and early 1980s.[25,33,131,151,196,199,213] More recently there has been a resurgence of interest in metallic radial head implant arthroplasty as a result of problems with wear and failure of silicone when placed under compressive load.[34,84,85,107,108,119,147,147,189,195] The success of first-generation metallic radial head implants has led to newer modular designs to allow easier implantation and improved sizing options to provide a closer match to patients' anatomy.[21,76,78,117,127,186]

TREATMENT OPTIONS

Fractures of the head of the radius should be managed based on patient factors such as age, bone quality, associated injuries, and activity level.[81] Fracture factors that influence decision making include size, displacement and location, and the presence of a mechanical block to elbow or forearm motion. For example, an older patient with osteoporosis and a comminuted fracture of the radial head is a poor candidate for internal fixation. Arthroplasty of the radial head is the preferred option for displaced nonreconstructable fractures in the setting of an associated injury to the medial or lateral collateral ligaments or the interosseous membrane because excision further compromises instability.[94,95,118,134,165,167,183]

The influence of radial head fracture size and displacement on patient outcome is unknown due to a lack of scientific data directing clinical practice. In vitro biomechanical studies revealed a progressive loss in radiocapitellar joint stability with increasing size of wedge defects in the radial head.[18,19] Wedge defects greater than one-third of the radial head did not contribute to stability in this model. These data suggest that, particularly in the setting of elbow instability, fixation of fragments smaller than one-third of the radial head may be advantageous. Whereas, it seems that most displaced intraarticular fractures in other joints benefit from anatomic reduction, stable fixation, and early motion; displaced fractures of the radial head historically have often been managed nonoperatively if they do not impede joint motion.

Good long-term clinical results have been reported in the majority of patients with the nonoperative treatment of isolated displaced partial articular fractures of the proximal radius.[2] Articular displacement causes abnormal joint contact pressures and may predispose one to the development of arthritis or persistent pain at either early or late follow-up. While delayed excision of the radial head is typically helpful under these circumstances, complete relief of symptoms is not assured.[26,63,216] Randomized clinical trials are needed to compare the outcomes of operative and nonoperative treatment of displaced radial head fractures without a block to motion or associated injuries requiring treatment. Fractures with a mechanical block to motion have a clear indication for surgical treatment regardless of their size. These are typically fractures that involve the articular portion of the radius or fragments that extrude into the proximal radioulnar joint.

The degree of displacement of a fracture of the neck of the radius that requires surgery in adults is unknown; a mechanical block to rotation remains the primary indication for surgical management.[10] Although most undisplaced fractures of the radial neck heal when treated with early motion, nonunions do occur.[38,57,173] Nonoperative treatment is recommended except in the setting of associated injuries requiring surgical management such as fractures of the coronoid or olecranon. Translation of the radial head on the neck produces a cam effect and often impedes forearm rotation if it is greater than 2 to 3 mm. Neck angulation of more than 20 degrees in adults commonly interferes with forearm rotation as a result of altered kinematics with the capitellum and radial notch of the ulna and should be considered for surgical management.[10]

The initial management of a fracture of the radial head associated with an elbow dislocation is a gentle closed reduction of the elbow under intravenous sedation. Repeat radiographs taken after the reduction should be obtained to better evaluate the radial head fracture for further management, either nonoperative or operative. A careful assessment for an associated fracture of the coronoid and/or capitellum is needed for patients with a fracture of the radial head, particularly those with a history of an elbow dislocation. The presence of a coronoid fracture suggests an unstable elbow for which operative management may be required to achieve an optimal outcome. The author's recommended management is the algorithm shown in Figure 19.10.

Nonoperative Management

Undisplaced or isolated displaced fractures of the radial head and neck, which do not cause a block to elbow or forearm motion, are offered nonoperative management. Depressed fractures generally do not impede forearm rotation, whereas

http://e-surg.com

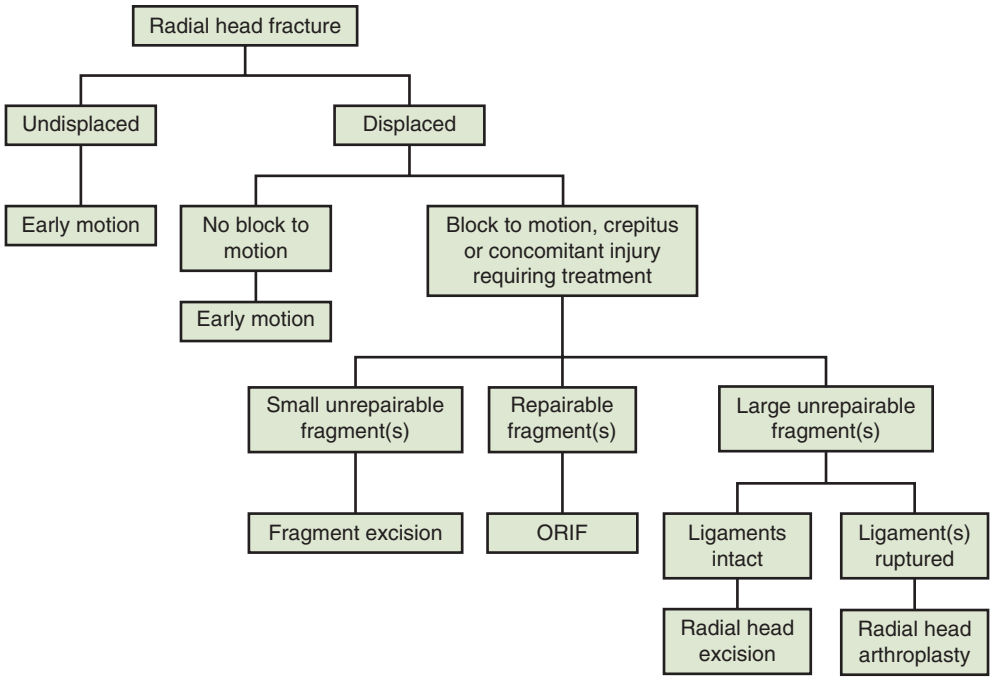

FIGURE 19.10 Author's recommended management algorithm for fracture of the head of the radius. Note the indications for surgery for isolated displaced fractures without a block to motion are controversial. Radial head excision is avoided in the setting of acute injuries due to the high incidence of associated damage to the collateral ligaments and/or interosseous membrane. *ORIF,* Open reduction and internal fixation.



FIGURE 19.11 Undisplaced fracture. Anteroposterior (**A**) and lateral (**B**) radiographs of a 28-year-old woman with an undisplaced fracture of the radial neck. **C**, Management with a collar and cuff sling. The patient had a complete return of motion and no residual pain.

extruded fragments do, often by virtue of their impingement with the proximal radioulnar joint and annular ligament. Whereas some authors have recommended cast immobilization,[77,137] most studies have supported the concept of early motion.[36,129,136,204,207,219] Aspiration of the elbow hemarthrosis and injection of local anesthetic, as previously described, should be considered only if there is sufficient pain to prevent evaluation of forearm rotation.[47,168] In a prospective randomized clinical trial, aspiration and injection of anesthetic in the absence of a mechanical block to motion demonstrated that the final outcome was not altered.

Active motion should be initiated within one week, owing to the frequent development of elbow stiffness with longer periods of immobilization. A collar and cuff, or sling, is used for comfort between periods of active motion and should be discontinued by 4 weeks (Figure 19.11). The use of a static progressive extension splint should be considered at night if elbow extension does not progressively improve in the first 4 to 6 weeks following the injury. Although subsequent displacement is uncommon, careful clinical and radiographic follow-up is required. Late displacement may be more common with fractures involving more than one-third of the radial head.[135]

http://e-surg.com

Operative Management

Open Reduction and Internal Fixation

Patients with isolated noncomminuted displaced fractures of the radial head with a mechanical block to forearm or elbow motion and those with concomitant injuries requiring surgical management (e.g., coronoid, olecranon, or capitellum fractures or complex elbow instability) are managed with ORIF if stable fracture repair is possible. Based on a lack of scientific evidence to direct management, the option of ORIF is explained to healthy active patients if they have an isolated noncomminuted fracture of the radial head that is displaced more than 2 mm and involves greater than one-third of the diameter without a mechanical block to rotation. I also explain that many patients with these fractures can do well with nonsurgical treatment, and that we are not sure what the optimal management is.[221] Mason suggested that displaced fractures greater than one-fourth of the diameter of the radial head should be treated by radial head excision.[135]

Geel and colleagues recommended ORIF of displaced (>2 mm) fractures involving more than one-fourth of the radial head.[69] Radin and Riseborough[170] suggested that displaced fractures greater than one-third of the radial head should be managed operatively. Miller and others reported that fragment size had no effect on the outcome of type II fractures.[145] Ultimately, it is best to try to help the patient make an informed decision between operative and nonoperative management.

The ability to reliably repair the radial head often can only be determined intraoperatively. ORIF of multifragmented radial head fractures can be successful if stable internal fixation is achieved so that early motion can be initiated.[25,54,69,89,93,113,115,138,158,161,164,174,179,185] One study has reported a high incidence of complications following ORIF of greater than three fragments, suggesting an alternative treatment method should be considered for more comminuted fractures.[174] Failure to achieve a congruous reduction and rigid fixation owing to comminution or osteoporosis should prompt the surgeon to intraoperatively consider excision of the radial head or replacement. Tenuous fixation in the setting of associated ligamentous injuries should be avoided because minimal residual instability following ligament repair will likely lead to fixation failure.[115,172,174] Failed surgical reconstruction usually leads to articular injury of the capitellum and the radial notch of the ulna. Stiffness and pain frequently require further surgery, often with less than satisfactory results. The outcome for patients with failed internal fixation is typically not as successful as those managed initially with excision of the radial head or replacement, suggesting that intraoperative decision making is critical to optimize treatment result.[186]

Reduction and internal fixation of displaced fractures of the radial head using arthroscopy are difficult owing to the inability to distract the radiocapitellar joint to properly evaluate the articular reduction. Furthermore, bleeding often compromises the view such that a 3- to 5-day delay before surgery is recommended. Standard elbow arthroscopic techniques and equipment are employed; however, a 70-degree arthroscope may be helpful to better visualize the joint's surface. The efficacy and indications for arthroscopic reduction of fractures of the radial head are evolving. Open surgical approaches remain the current standard of care.

Although most authors prefer a Kocher approach,[120] some have employed a lateral epicondyle osteotomy.[88] Splitting the common extensor tendon allows better access to the anterior radial head where most marginal fractures occur and avoids injuring the lateral ulnar collateral ligament which is at risk with the Kocher approach.[45]

Fixation is performed using bioabsorbable pins, headless screws, 1.5- or 2.0-mm screws, and 2.5- or 3.0-mm cannulated screws. Plate options include standard small-fixation systems or purpose-designed proximal radius precontoured locking systems. Smooth Kirschner wires are useful to reduce fragments and provide provisional fixation; however, they should not be employed for definitive fixation because of the tendency for these to migrate during the postoperative period. Screws should be countersunk to prevent impingement with the radial notch and annular ligament even if placed on the nonarticular margin.

The use of crossed cannulated 2.5- or 3.0-mm screws has been found to be effective for stabilizing the radial head on the neck in the absence of comminution.[71,190] Intramedullary fixation also has been reported.[111] Plate fixation is employed for comminuted radial neck fractures in an effort to stabilize the radial head onto the neck and achieve union. Precontoured locking plates are biomechanically superior to the standard T-plates and may yield improved clinical results.[71,160] Plates should be placed on the nonarticular portion of the radial head as previously described.[194] If bone grafting is required following elevation of a depressed fragment(s), the lateral epicondyle or proximal ulna is a convenient source. Caution should be exercised when performing ORIF of comminuted displaced fractures of the radial neck in adults as even with optimal reduction and rigid fixation, avascular necrosis and nonunion may occur due to the disruption of both the interosseous and periosteal blood supply to the head.

Excision of Fragments of the Radial Head

Fragment excision is infrequently indicated with the advent of improved fixation systems with small diameter screws. Cartilage flaps and small displaced fragments (less than one-third of the radial head) that block forearm rotation due to extrusion into the proximal radioulnar joint or loose fragments that prevent elbow flexion or extension are treated with open or arthroscopic fragment excision if ORIF is not technically feasible because of small fragment size, comminution, or osteoporosis.[36,105,154,220] Fragments that articulate with the proximal radioulnar joint should not be excised because of interference with forearm rotation.

Delayed Excision of the Radial Head

Early motion with delayed excision of the radial head may be considered for patients with displaced fractures who have no mechanical block to forearm or elbow motion. This approach may be useful in elderly low-demand patients with concomitant injuries to the medial collateral or interosseous ligaments and for patients with a delayed presentation. The radial head can be excised either open or arthroscopically if the patient remains symptomatic after healing of the fracture and any associated ligamentous injury.[1,26,63] The radial head is excised just distal to

http://e-surg.com

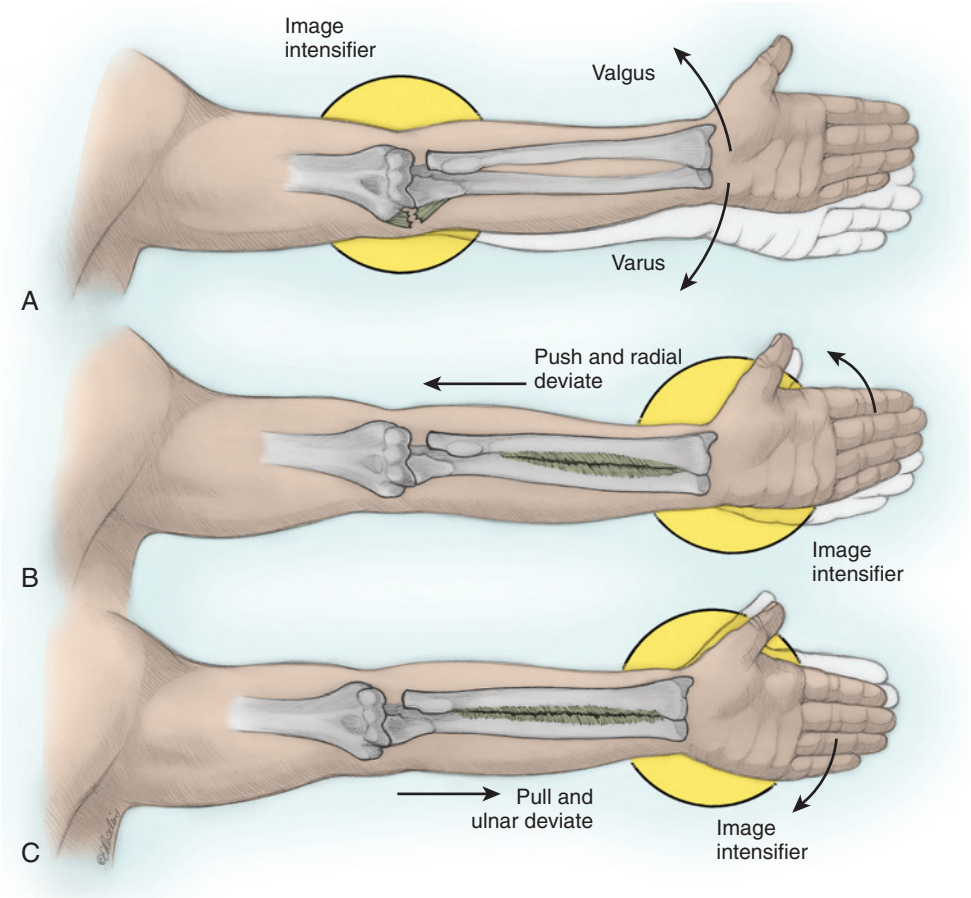

FIGURE 19.12 **A**, A valgus and varus stress test of the elbow should be performed to evaluate the integrity of the medial and lateral collateral ligaments using an image intensifier before excision of the radial head. **B**, **C**, Similarly, the axial stability of the forearm should be evaluated by alternatively applying axial traction/ulnar deviation and compression/radial deviation to the forearm and wrist while monitoring ulnar variance at the wrist with an image intensifier.

the radial notch with careful preservation of the lateral ulnar collateral ligament and repair of the annular ligament if done through an arthrotomy. To ensure replacement arthroplasty is not required; intraoperative valgus and a varus stress fluoroscopy should be obtained after radial head excision to ensure competency of the medial and lateral collateral ligaments of the elbow.[44] To evaluate for an interosseous ligament tear, perform axial loading with radial deviation of the wrist and forearm distraction with ulnar deviation of the wrist while monitoring ulnar variance with fluoroscopy (Figure 19.12). Using a serrated reduction clamp on the radial neck and applying a proximal–distal pull may be a more sensitive technique to identify axial instability after radial head excision.[191]

Excision of the Radial Head

Prior to the development of more reliable methods of internal fixation and durable prostheses, displaced fractures of the radial head, both simple and comminuted, were commonly treated by open excision of the radial head.[1,24,36,41,43,90,105,114,135,144,154,170,214,216] Although less frequently performed currently, excision of the radial head is preferable to an unstable or incongruous ORIF.[174] Should radial head reconstruction be technically impossible, associated soft tissue injuries and concomitant fractures should be evaluated because acute radial head excision is contraindicated in the setting of concomitant disruption of the medial or lateral collateral ligaments, interosseous membrane, or an elbow dislocation.[1,104]

The radial head can be excised either through an arthrotomy or arthroscopically[130,143] as previously noted. If the intraoperative stress tests for varus, valgus, and axial instability described are negative, there was no associated elbow dislocation and no clinical suspicion of a ligamentous injury, acute radial head excision without implant replacement may be considered. Given the high incidence of associated ligamentous injuries with comminuted radial head fractures, and the difficulty in diagnosing these associated conditions, the author currently does not perform this procedure unless there is gross wound contamination, a nonreconstructable extension of the fracture into the radial neck, or a concomitant severe articular injury to the capitellum that precludes the use of a metallic radial head arthroplasty. Careful preservation of the lateral ulnar collateral ligament and repair of the annular ligament should be performed if the radial head is excised open. The timing of radial head excision is controversial as a result of concerns regarding the potential development of heterotopic ossification, with some authors recommending early excision (<24 h)[1,67,104,203] and others excision within 10 days.[35,135] The presence of an associated dislocation and head injury appears to be the risk factor

http://e-surg.com

most associated with the development of heterotopic ossification following elbow surgery.[1,66,203]

Arthroplasty of the Radial Head

Replacement arthroplasty is indicated for displaced comminuted fractures of the radial head and neck when an anatomic reduction and stable internal fixation is not achievable and there are, or are likely to be, associated soft tissue or bony injuries. These include soft tissue injuries to the medial or lateral collateral ligaments, the interosseous membrane, and/or triangular fibrocartilage and bony injuries of the coronoid or olecranon.

Silicone implants have been employed in the past.[25,33,131,151,196,199] However, they are no longer recommended as they are biomechanically inferior to metal and have a high incidence of fracture and fragmentation, sometimes with the development of silicone synovitis.[118,167,183] Recent clinical series of studies using metallic implants noted good results relative to earlier reports using silicone.[11,49,59,76,84,85,108,119,147,189,222] Earlier metallic radial head implants employed a monoblock design making size-matching suboptimal and implant insertion often difficult owing to the need to subluxate the elbow to allow for insertion of these devices.[78] Modular metallic radial head prostheses, with separate heads and stems, are now employed, allowing improved sizing options and easier implantation. The implantation techniques for the currently available implants vary somewhat; however, most employ a Kocher or common extensor tendon-splitting approach and divide the radial collateral and annular ligaments while preserving the integrity of the lateral ulnar collateral ligament when it is intact.[120] Available prostheses include smooth stem spacer implants, press-fit, or ingrowth stems, as well as cemented devices. Metallic and pyrolytic carbon articulations are also available. Most implants have a fixed head-stem but bipolar devices are available too. Although most designs are axisymmetric, there is one currently available system with a more elliptical articulation. There are no reported studies comparing the clinical outcome of the various radial head implant designs.

Even with intact ligaments, biomechanical studies have demonstrated an alteration in the kinematics and stability of the elbow following radial head excision.[17,101] These in vitro studies have also shown that metallic radial head replacement restores the kinematics and stability of the elbow similar to that with a native radial head.[15,17] Furthermore, the clinical results of radial head excision at long-term follow up have been variable[26,28,30,41,63,68,73,90,97,100,114,144,152,202] while the medium-term results of metallic radial head arthroplasty have been encouraging.[11,49,59,76,84,85,119,147,189,222] On the basis of these biomechanical and clinical studies and the known high incidence of concomitant ligamentous injuries with comminuted fractures, this author routinely replaces the radial head in the setting of a nonreconstructable fracture.

❖ AUTHOR'S PREFERRED TREATMENT

Surgical Approach. Place the patient in the supine position on the operating table and use a sandbag beneath the ipsilateral scapula to assist in positioning the arm across the chest. Alternatively, an arm table can be used with the surgeon sitting. Use a lateral decubitus position in the setting of a concomitant proximal ulna or olecranon requiring fixation. Administer prophylactic intravenous antibiotics. General or regional anesthesia should be employed. I perform a fluoroscopic evaluation of the elbow prior to prepping and draping to look for associated ligament injuries and instability of it and/or forearm.

Use a sterile tourniquet. While many surgeons use a lateral incision, I prefer a midline posterior elbow incision just lateral to the tip of the olecranon and elevate a full-thickness lateral flap on the deep fascia (Figure 19.13). This extensile incision decreases the risk of cutaneous nerve injury and provides access to the radial head, coronoid, medial, and lateral collateral ligaments if needed for the management of more complex injuries.[50,159] A posterior incision is also more cosmetically acceptable than standard laterally placed incisions. Maintain the forearm in pronation to move the posterior interosseous nerve more distal and anterior during the surgical approach.[197]

In patients with known injuries to the lateral collateral ligament, such as following a dislocation or as identified using fluoroscopy, my preference is a Kocher approach to access the radial head and to facilitate ligament repair.[120] Identify the fascial interval between the anconeus and extensor carpi ulnaris by noting the diverging direction of the muscle fibers and small vascular perforators that exit at this interval (Figure 19.14). Humeral avulsion of the lateral collateral ligament and common extensor muscles from the lateral epicondyle are commonly noted in patients following fractures of the radial head; this is a consistent finding in patients with a concomitant elbow dislocation, simplifying surgical exposure of the radial head. In these circumstances the radial head is easily visualized after opening the fascia of the Kocher interval at which point a bald lateral epicondyle is evident and the deep dissection exploits this disruption to approach the radial head.[141]

If the lateral ligament is intact, elevate the extensor carpi ulnaris anteriorly off the underlying lateral ulnar collateral ligament and incise the radial collateral and annular ligaments longitudinally at the midaxis of the radial head. Elevate the humeral origin of the radial collateral ligament and the overlying extensor muscles anteriorly off the lateral epicondyle to better expose the anterior half of the radial head if required. Avoid posterior dissection in the setting of intact ligaments to preserve the integrity of the lateral ulnar collateral ligament and thereby maintain the varus and posterolateral rotatory stability of the elbow.[52,155] Release the posterior component of the lateral collateral ligament if further exposure is needed, and carefully repair the ligament at the end of the procedure. Elevate the supinator, and identify the posterior interosseous nerve if dissection is required distal to the radial tuberosity to allow fixation of a proximal radius fracture.

For patients with an intact lateral collateral ligament, I prefer a common extensor tendon-splitting approach (Figure 19.15).[45] Divide the common extensor tendon and the underlying radial collateral and annular ligaments longitudinally at the midaspect of the radial head. Keep the forearm in pronation and avoid dissection distal to the radial tuberosity to protect the posterior interosseous nerve. Elevate the radial collateral ligament and common extensor muscles anteriorly off the lateral epicondyle if needed to further improve exposure. Division of the posterior component of the lateral collateral ligament can be considered if further exposure of the radial head is needed, but a meticulous ligament repair is required. Similarly, extension distal to

http://e-surg.com

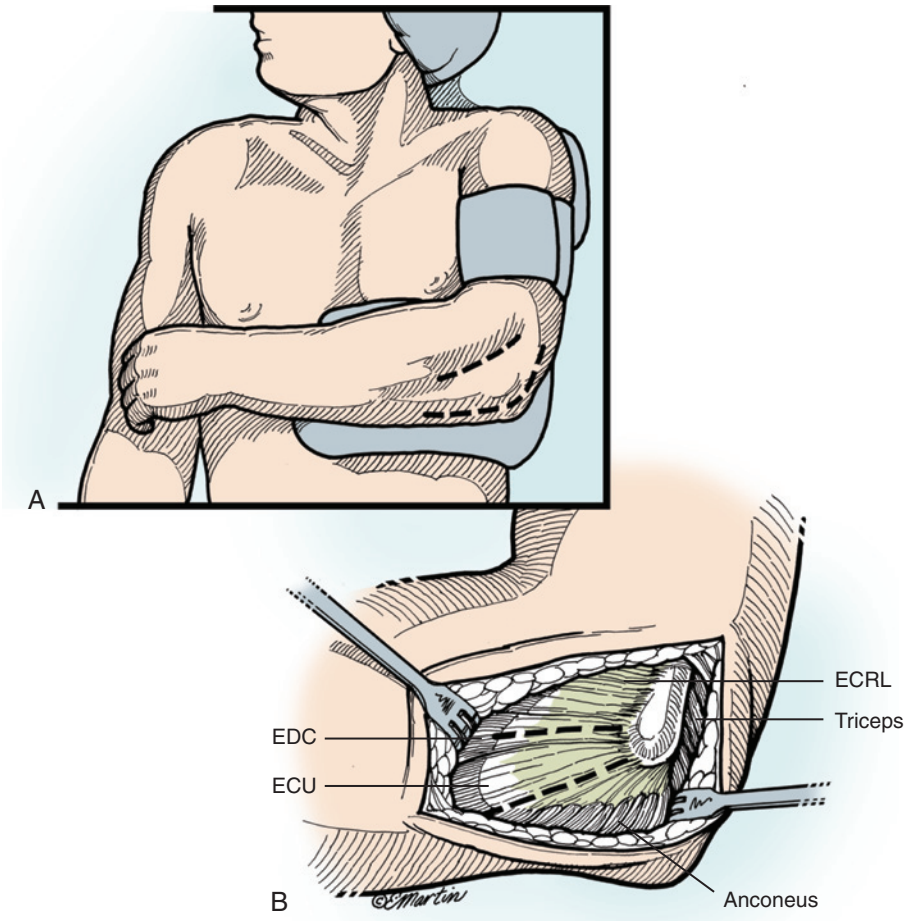

FIGURE 19.13 Superficial surgical approaches. **A**, Posterior midline skin incision is employed just lateral to the tip of the olecranon. **B**, A full-thickness lateral flap is elevated. The use of this incision allows access to the medial aspect of the elbow (if necessary) to manage associated injuries to the medial collateral ligament or coronoid, is less obvious due to its location, and has a low incidence of cutaneous nerve injury. Alternatively, lateral incision can be employed at the surgeon's discretion. Lateral extensor musculature. Exposure of the radial head can be obtained using either a Kocher approach between the anconeus and extensor carpi ulnaris or a more anterior common extensor tendon split. *ECU*, Extensor carpi ulnaris; *EDC*, extensor digitorum communis; *ECRL*, extensor carpi radialis longus.

the proximal aspect of the radial tuberosity requires identification of the posterior interosseous nerve.

Fragment Excision. If a decision can be made preoperatively that a small, displaced fragment(s) cannot be reliably fixed with ORIF, I use arthroscopy to remove the fragments. Localization of the fragment(s) is superior to what can be achieved with a limited arthrotomy, and the morbidity is low. Standard arthroscopic techniques, as described in Chapter 26, are employed. Surgery is performed 3 to 5 days after injury to avoid problematic bleeding that may occur with early surgery.

The decision that a fracture cannot be reliably fixed is most commonly made intraoperatively during an attempted open reduction (Figure 19.16). I use an image intensifier, a pituitary rongeur, and copious irrigation to extract small, displaced, unreconstructable fragments.[105,220] Avoid inadvertent removal of a coronoid fragment by noting its triangular shape and attaching it to the anterior capsule. Evaluate the remaining radial head to ensure that the deficient portion does not articulate with the radial notch in any position of forearm rotation. Ensure congruent tracking of the residual radial head with the capitellum before repairing the annular, radial, and lateral ulnar collateral ligaments as described later. Because removal of the anterior rim of the radial head in the setting of a lateral collateral ligament injury may contribute to residual posterolateral rotatory instability,[18,19] careful lateral collateral ligament repair and rehabilitation with the forearm in pronation is essential to achieve a successful outcome.[52]

Open Reduction and Internal Fixation. In my experience, arthroscopic reduction and internal fixation of fractures of the radial head has not been rewarding because of the difficulty of obtaining a good view of the articular dish, which is obscured by the curvature of the capitellum. The inability to distract the radiocapitellar joint makes visualization of the reduction much more difficult than similar approaches at the wrist or knee. Further complicating arthroscopic reduction and internal fixation is the small working space in which the fragments can be manipulated and limited safe-approach angles for fixation devices.

One of the two open surgical approaches is used, as previously described. For displaced partial articular fractures I carefully reduce the fragments to avoid the loss of any residual periosteal attachments with its concomitant blood supply

http://e-surg.com

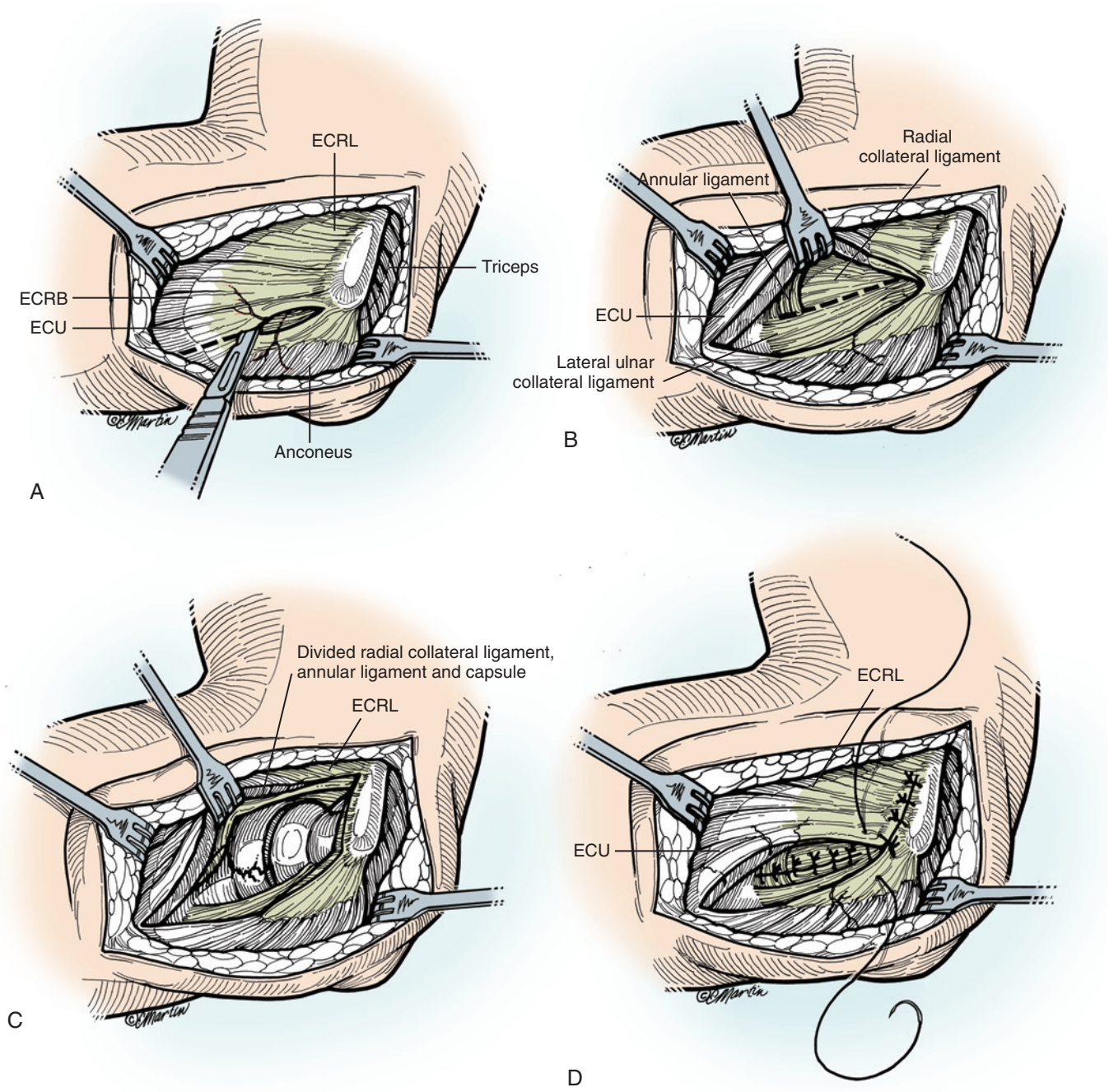

FIGURE 19.14 The Kocher approach to the radial head. **A**, The interval between the anconeus and extensor carpi ulnaris (ECU) is opened as evident by the divergent muscle fibers and vascular perforators that exit this interval. **B**, The ECU is elevated anteriorly off the lateral collateral ligament and an arthrotomy is performed at the midportion of the radial head, thereby avoiding detachment of the lateral ulnar collateral ligament. The radial collateral and annular ligaments are divided to give adequate exposure of the fracture. The radial collateral ligament and extensor muscles commonly need to be detached off the lateral epicondyle to achieve visualization of the anterior portion of the radial head (*dotted line*). **C**, The radial collateral ligament and extensor muscles are detached from the lateral epicondyle to achieve visualization of the anterior portion of the radial head. **D**, Closure of the arthrotomy is accomplished by reattaching the radial collateral ligament to the intact lateral ulnar collateral ligament. The fascia of the Kocher interval is then repaired. If the lateral ligaments are incompetent, either as a result of injury or surgical release, a careful repair is required as outlined in Figure 19.21. *ECRB,* Extensor carpi radialis brevis; *ECRL*, extensor carpi radialis longus.

http://e-surg.com

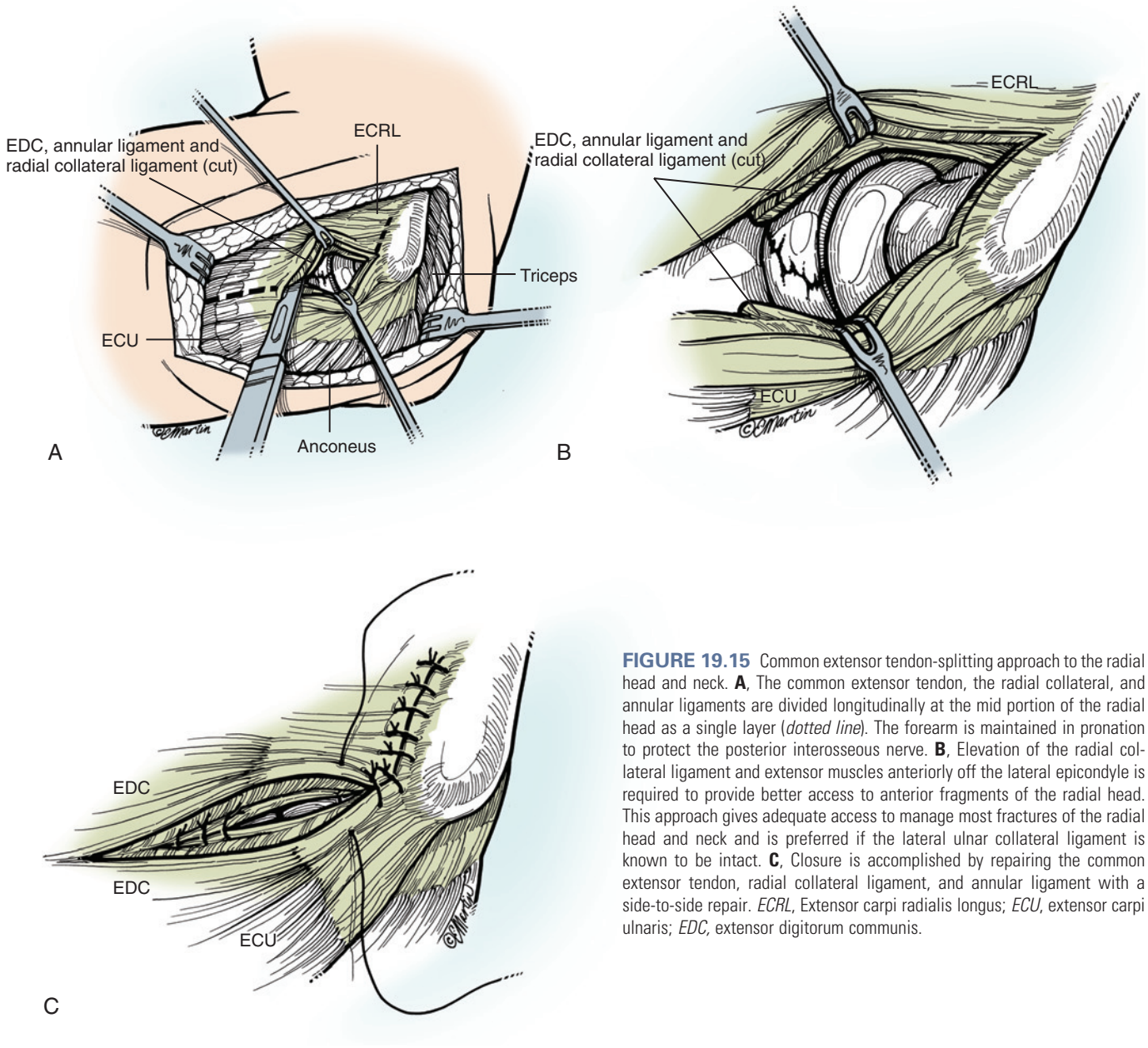

FIGURE 19.15 Common extensor tendon-splitting approach to the radial head and neck. **A**, The common extensor tendon, the radial collateral, and annular ligaments are divided longitudinally at the mid portion of the radial head as a single layer (*dotted line*). The forearm is maintained in pronation to protect the posterior interosseous nerve. **B**, Elevation of the radial collateral ligament and extensor muscles anteriorly off the lateral epicondyle is required to provide better access to anterior fragments of the radial head. This approach gives adequate access to manage most fractures of the radial head and neck and is preferred if the lateral ulnar collateral ligament is known to be intact. **C**, Closure is accomplished by repairing the common extensor tendon, radial collateral ligament, and annular ligament with a side-to-side repair. *ECRL*, Extensor carpi radialis longus; *ECU*, extensor carpi ulnaris; *EDC*, extensor digitorum communis.

CRITICAL POINTS *Fragment Excision*

Indication
- Displaced unreconstructable fragment(s) less than one-third radial head diameter that is blocking forearm or elbow motion or is interposed within the articulation.

Pearls
- Localize fragments with CT preoperatively and an image intensifier intraoperatively.
- Compare size of missing section of radial head to removed fragment(s) to ensure all fragments have been found.

Pitfalls
- Displaced medial fragments may be missed if a lateral surgical approach is used.
- Elbow instability due to deficiency of collateral ligaments is exacerbated by partial excision of the radial head.

Technical Points
- Arthroscopic fragment removal allows complete joint inspection.
- Use an open approach through a common extensor tendon split or Kocher interval.
- Consider fragment fixation if it is technically possible.
- Use pituitary rongeur and copious irrigation to remove loose unreconstructable fragments.

Postoperative Care
- Begin early range of motion exercises to avoid restricted forearm rotation as a consequence of annular ligament adherence to deficient portion of the radial head.

http://e-surg.com



FIGURE 19.16 Excision of a fragment of the radial head. Anteroposterior (**A**) and lateral (**B**) radiographs of a 32-year-old man who fell while rollerblading; he had limited prosupination. **C**, **D**, CT scan demonstrated an undisplaced coronoid fracture, a posterior capitellum impression fracture, and a fragment of the radial head anterior to the radial neck. **E**, Attempts to retrieve the fragment arthroscopically failed due to its location distal to the radial head, and an arthrotomy was needed to excise the small fragment. **F**, **G**, After a lateral ligament repair and early range-of-motion exercises the patient recovered a full arc of forearm rotation and a functional arc of elbow motion.

(Figure 19.17).[72] Use smooth Kirschner wires as joysticks to elevate depressed fragments and to achieve provisional fixation. Fix fragments using appropriate screws, typically 1.5 or 2.0 mm. Countersink all screws to avoid impingement with the annular ligament and radial notch. Avoid perforation of the far cortex while drilling to allow for more accurate length measurements with a depth gauge. Screws that are too long should be avoided as they may interfere with forearm rotation (Video 19.1).

For complete articular fractures, in which the radial head has separated from the neck, I assemble the radial head on a back table if there are no soft tissue attachments to the fragments. After rigid fixation of the radial head has been achieved, secure the radial head to the neck using divergent cannulated 2.5-mm screws if the neck is not comminuted (Figure 19.18). The cannulated feature of the screws prevents the tips from glancing off the cortex when placed at an oblique angle. I treat most comminuted radial neck fractures with implant arthroplasty due to the high risk of nonunion, avascular necrosis, hardware failure, and stiffness. However, if the bone quality is good and the patient is young, I perform ORIF with a fixed-angle precontoured locking plate. Secondary hardware removal is often needed to manage rotational stiffness (Figure 19.19). I no longer use small plates because, in my experience and that of others, they provide less rigid fixation than fixed-angle devices and have had a high risk of nonunion.[160] Place plates on the nonarticular portion "safe zone" of the radial head to prevent interference with the proximal radioulnar joint.[32,192] Use cancellous bone from the lateral epicondyle, the proximal ulna, or the distal radius to graft bone defects if necessary.

Check hardware placement with an image intensifier at completion of the internal fixation to ensure that screw lengths are appropriate. Plain radiographs are insufficient; imaging in multiple positions of forearm rotation is needed to confirm appropriate placement of the hardware. If an anatomic reduction and stable fixation cannot be achieved, I perform radial head

http://e-surg.com



FIGURE 19.17 Partial articular fracture of the radial head: open reduction and internal fixation (ORIF). Anteroposterior (**A**), lateral (**B**), and oblique (**C**) radiographs of a 38-year-old woman who fell while ice-skating. **D**, **E**, CT confirmed significant fracture displacement. **F**, **G**, The patient underwent ORIF of the radial head with 2.0- and 1.5-mm screws. **H**-**K**, The patient recovered a full arc of elbow and forearm motion and had no pain 6 months following the injury.

replacement because of the high incidence of failure of ORIF under these circumstances.[115,174]

Excision of the Radial Head. I no longer perform radial head excision without replacement for acute fractures except in the setting of gross wound contamination or extensive fractures of the radial neck or capitellum that cannot be reconstructed. I use either of the two open surgical approaches described earlier depending on the integrity of the lateral collateral ligament (Figure 19.20). The excised fragments are reassembled outside of the elbow to ensure that all of the radial head has been retrieved. Use a microsaggital saw to complete the resection until it is just distal to the radial notch. Avoid excessive removal of the radial neck to prevent proximal radioulnar impingement. Evaluate the valgus, axial, and rotational stability of the elbow, and check for residual fragments using an image intensifier.[44] If there is any suggestion or suspicion of an associated ligamentous injury (and there usually is as previously described), I perform a radial head arthroplasty. Revise the surgical approach to reduce the residual laxity induced by the loss of collateral ligament tension resulting from excision of the radial head.

http://e-surg.com

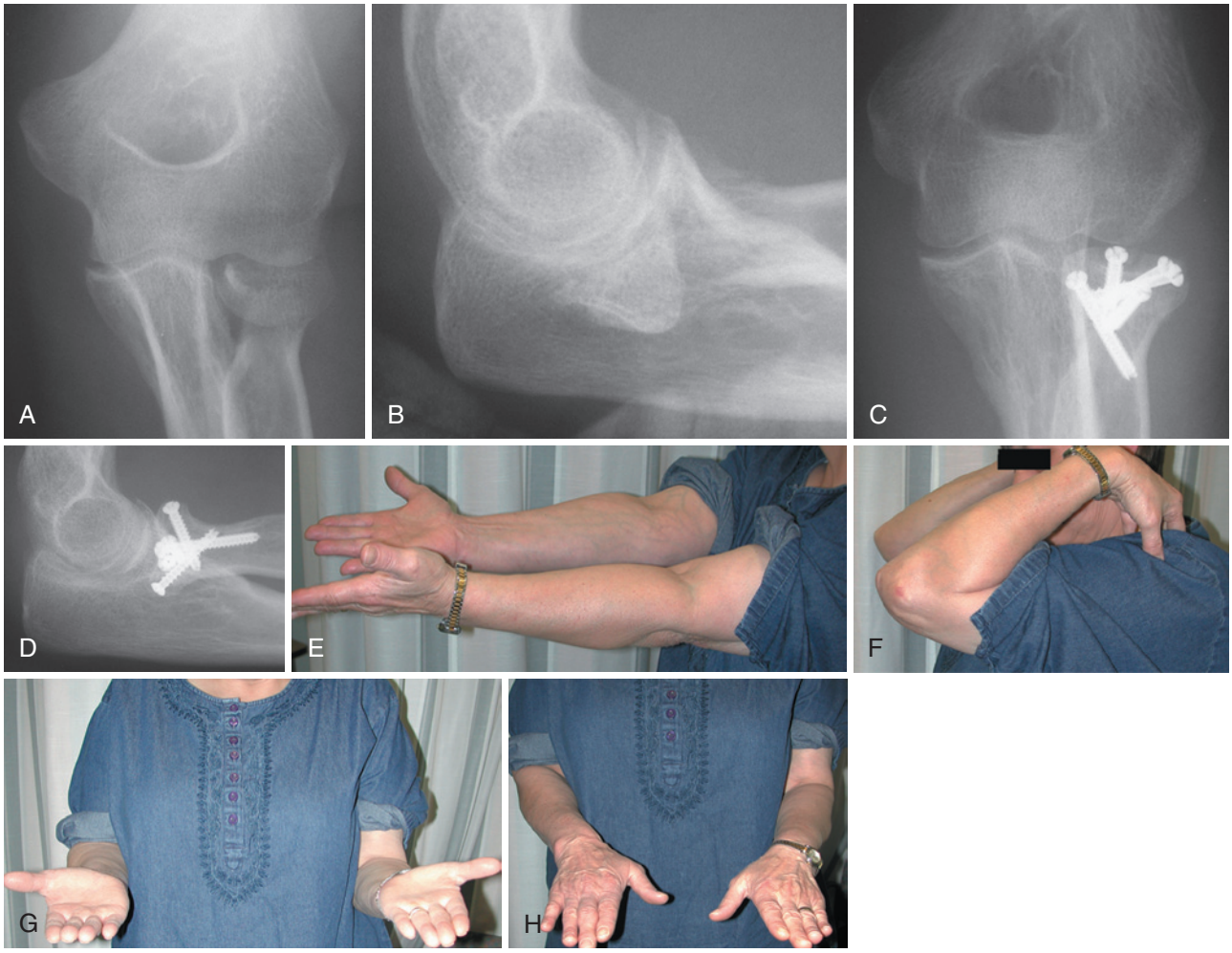

FIGURE 19.18 Complete articular fracture of the radial neck: ORIF. Anteroposterior (**A**) and lateral (**B**) radiographs of a 52-year-old woman who slipped and fell and sustained a displaced fracture of the radial neck. **C**, **D**, The fracture was fixed using cannulated 3.0 mm screws. **E**-**H**, An excellent clinical result was achieved with no evidence of avascular necrosis at 6 months.

CRITICAL POINTS *Open Reduction and Internal Fixation*

Indication
- Displaced reconstructable fragments(s) interfering with forearm or elbow motion or concomitant fractures or ligament injuries of the elbow requiring treatment

Pearls
- CT scan may be helpful in planning surgery.
- Avoid screw penetration through opposite cortex.
- Fragments are typically quite anterior; avoid posterior dissection with damage to lateral ulnar collateral ligament.

Pitfalls
- Hardware impingement with annular ligament
- Nonrigid fixation
- Fixation of comminuted fractures involving more than three fragments

Technical Points
- Use an open approach through common extensor tendon split or Kocher's interval.
- Use cross-cannulated screws for noncomminuted fractures of the radial neck.
- Use fixed-angle precontoured plates for selected comminuted fractures of the radial neck; arthroplasty preferred for most patients.
- Place plate on the nonarticular portion of radial head which presents laterally with forearm in neutral rotation.
- Perform careful ligament repair to avoid radiocapitellar subluxation with failure of fixation.

Postoperative Care
- Early range-of-motion exercises are required to avoid annular ligament adherence to hardware or fracture lines.

http://e-surg.com



FIGURE 19.19 Comminuted fracture of the radial head and neck: open reduction and internal fixation (ORIF). Anteroposterior (**A**) and lateral (**B**) radiographs of a 35-year-old man who fell off a ladder, sustaining a comminuted fracture of the proximal ulna and radius. **C**, **D**, CT scans define the nature of the fractures more clearly. **E**, **F**, Radiographs two years postop: ORIF. A precontoured locking plate was used for fixation of the proximal radius (Wright Medical Technology, Arlington, TN). **G**-**J**, At 2 years the patient had no pain and near complete range of motion.

I perform arthroscopic excision of the radial head for nonunions, malunions, and posttraumatic arthritis using standard portals and instruments.[130,143] Use a high-speed bur, resectors, and pituitary rongeurs to remove the cartilaginous and osseous fragments. A tourniquet is essential to control bleeding. Use imaging to ensure that the elbow and forearm are stable, all of the fragments have been removed, and an adequate resection has been accomplished.

Implant Arthroplasty of the Radial Head. I use a common extensor tendon-splitting approach if the lateral collateral ligament is intact and a Kocher's approach if the lateral collateral ligament is deficient as described earlier. Collect the fragments of the radial head, and reconstruct it for sizing purposes and to ensure all of the radial head is excised. The implantation technique will vary slightly depending on the arthroplasty design selected. Over the last 25 years, I have employed an uncemented

http://e-surg.com

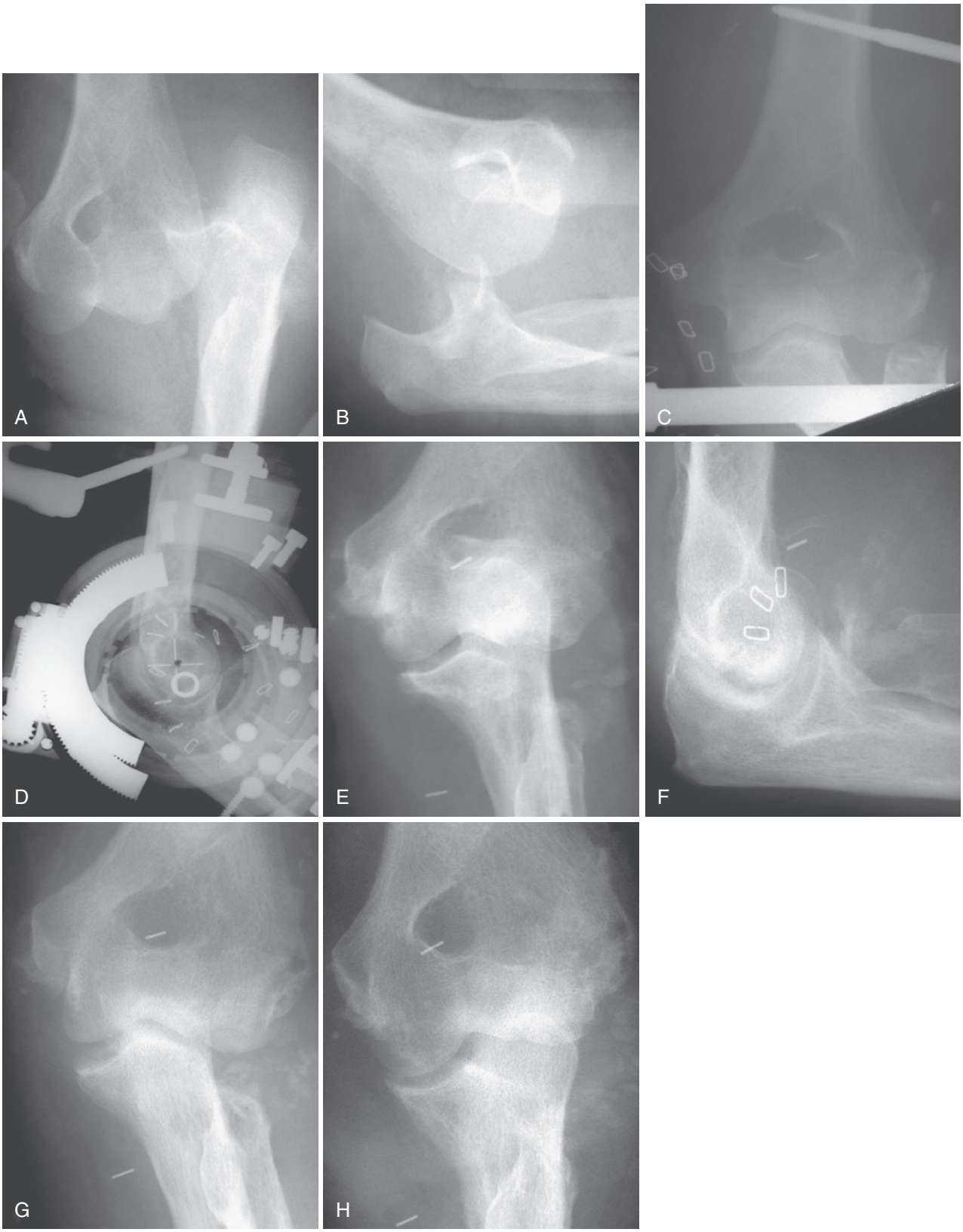

FIGURE 19.20 Comminuted fracture of the radial head and neck: excision. **A**, **B**, Radiographs of a 69-year-old man with a compound fracture-dislocation of the elbow and renal insufficiency. Owing to extensive contamination of the wound, delayed treatment, and chronic immunosuppression he was managed by excision of the radial head without replacement. **C**, **D**, An articulated external fixator (Compass Hinge, Smith and Nephew Richards) was employed to maintain a concentric reduction of the elbow. **E**, **F**, After fixator removal the patient had mild pain and a functional arc of motion. Stress testing disclosed significant residual valgus instability (**G**) and varus instability (**H**).

http://e-surg.com

CRITICAL POINTS *Excision of the Radial Head*

Indications
- Rarely employed for acute fractures; typically for nonunions, malunions and posttraumatic arthritis
- Displaced unreconstructable fragments(s) interfering with forearm or elbow motion without a known associated or probable medial or lateral collateral ligaments or an interosseous membrane injury

Pearls
- Assemble excised fragments to ensure all are removed; intraoperative fluoroscopy is helpful.

Pitfalls
- Avoid excision with unrecognized ligamentous injuries.
- Excessive excision of the radial neck may cause proximal radioulnar impingement.

Critical Technical Points
- Use an open approach through a common extensor tendon split or the Kocher interval.
- Excise the radial head just distal to the proximal radioulnar joint.
- Use intraoperative fluoroscopy to perform varus, valgus, and axial stress tests.

Postop Management
- Early range-of-motion exercises are critical to avoid soft tissue adherence to radial neck.

metallic smooth stem implant, which functions as a spacer while healing of the soft tissue occurs[49,76,84,85,147,186] (Figure 19.21 and Video 19.2). Most implants are now modular to facilitate improved size-matching of the native radial head and neck and to allow easier placement in the setting where the lateral ligaments of the elbow are competent.[117]

Excise a minimal amount of the radial neck at a right angle to the medullary canal to make a smooth surface for seating of the implant. Select the diameter and thickness of the radial head arthroplasty from the reconstructed excised radial head (Figure 19.22). Choose an implant with a diameter that is equal to the minor diameter of the elliptical native radial head. The minor diameter typically is 2 mm smaller than the major diameter of the native radial head.[117] Select the thickness of the prosthesis using the height of the reconstructed excised radial head as a template. Avoid overlengthening of the radius by placement of a radial head implant that is too thick because this may cause capitellar wear and pain.[208,212] The lack of a gap between the radial head and capitellum is not a useful method of determining the correct thickness of the prosthesis since the lateral ligaments are often incompetent for patients undergoing radial head arthroplasty. Check to ensure that the arthroplasty articulates at the height of the proximal radioulnar joint, about 2-mm distal to the coronoid.[48] This is a valid landmark except in cases of disruption of the interosseous membrane where proximal migration of the radius may be present. Check the ulnar variance at the wrist to rule out an Essex-Lopresti injury. If the radius is overlengthened, the lateral ulnohumeral joint will be gapped open laterally; however, this is difficult to visualize intraoperatively without using a dental mirror. Using fluoroscopy, check the alignment of the distal radioulnar joint to ensure that the ulnar variance is equivalent to the opposite wrist. The medial ulnohumeral joint space should be parallel on an anteroposterior fluoroscopic view, confirming that the prosthesis is neither too thick nor too thin, resulting in a varus or valgus alignment of the elbow, respectively.

The lateral ulnohumeral joint space is often wider than the medial ulnohumeral joint radiographically so it cannot be used to evaluate prosthesis thickness unless a contralateral radiograph is available.[176,12,13] Postoperative radiographs are unreliable when evaluating the length of the radius; therefore, the most accurate technique to ensure the correct implant thickness is employed is to use an implant constructed with the same overall thickness as that of the excised radial head.[48,176,187] I use preoperative radiographic templating of the contralateral normal radial head in the setting of a secondary radial head replacement, such as a previous excision or a malunion, but not for a primary replacement for an acute fracture where the radial head is available for sizing. The capitellum diameter is also a useful parameter in the setting of a prior radial head excision.[3,123]

Deliver the radial neck laterally by placing a Hohmann retractor around the posterior aspect of the proximal radial neck and prying against the ulna. Do not use anteriorly placed Hohmann retractors owing to the risk of injury from pressure on the posterior interosseous nerve. Ream the medullary canal of the radial neck using hand reamers until cortical contact is encountered. Insert a trial stem 1 mm smaller than the size of the final reamer to achieve a nontight fit of the smooth stem. Attach a trial head of the appropriate diameter and thickness to the stem, and evaluate the congruency of the prosthesis both visually and with an image intensifier as previously described. If the prosthesis is not tracking properly on the capitellum with forearm rotation, a smaller stem size should be placed to ensure that the articulation of the radial head with the capitellum is optimal. With this spacer design, motion pathways of the radial head are controlled by the annular ligament and the articular congruency of the implant with the capitellum and radial notch. The motions of the radial head prosthesis with respect to the capitellum are not dictated by the motions of the proximal radius because the stem is smooth and able to move within the medullary canal. The spacer concept of this implant allows the use of an axisymmetric prosthesis when replacing the native radial head, which has a complex shape that is difficult to replicate with an off-the-shelf prosthesis.[117] Movement of the stem is well tolerated and lucencies around the stem are expected and have not been correlated with residual symptoms.[49,76,147,186] The concept is similar to a bipolar design without the need for a polyethylene articulation and potential concerns about wear debris and durability.[166]

Place a Hohmann retractor behind the radial neck, and pull the radius laterally by prying against the ulna to insert the assembled modular radial head prosthesis. In some patients insufficient translation of the proximal radius prevents the insertion of a preassembled modular implant, typically in the setting of reconstruction rather than acute fractures. If it is not possible to place an assembled prosthesis, insert the stem first, place the head onto the stem, and couple the implant in situ using the locking tool. Repair the annular ligament to ensure congruent tracking of the radial head implant on the capitellum. Close the lateral deep surgical approach as previously described.

http://e-surg.com

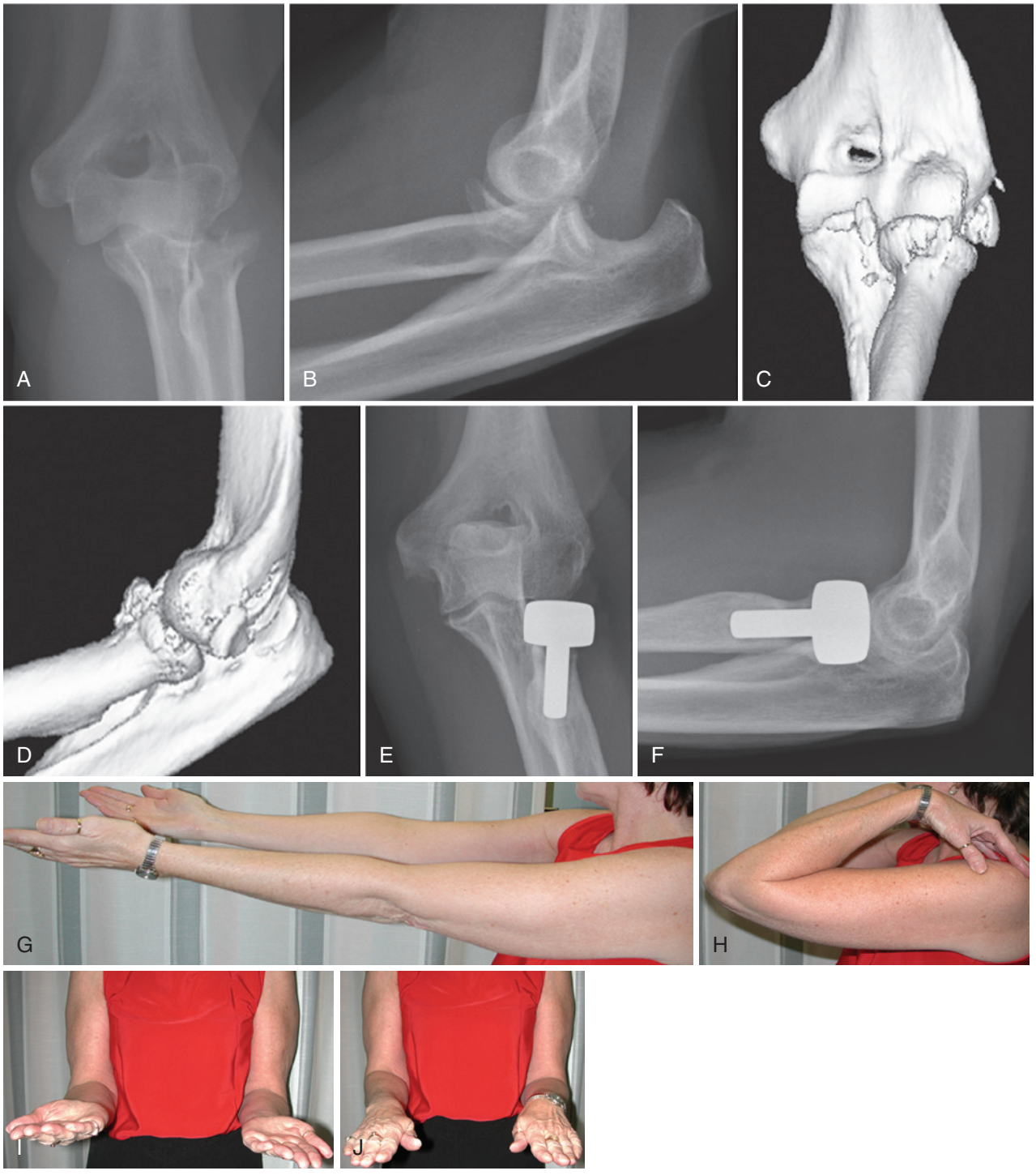

FIGURE 19.21 Comminuted fracture of the radial head and neck: replacement. Anteroposterior (**A**) and lateral radiographs (**B**) of a 55-year-old woman who slipped on the ice sustaining a posterolateral elbow dislocation and a comminuted fracture of the radial head. **C**, **D**, Computed tomography following a closed reduction demonstrated the extent of injury to the radial head and an associated comminuted fracture of the tip of the coronoid. **E**, **F**, A modular radial head arthroplasty was employed (Evolve, Wright Medical Technology, Arlington, TN), and the lateral ligaments were repaired using drill holes in the lateral epicondyle. The coronoid fracture was not fixed. Although the medial collateral ligament repair was disrupted, repair was not required to allow early motion. At 2 years postoperatively dystrophic calcification is seen in the medial collateral ligament and some typical nonprogressive lucencies are noted around the implant stem in the proximal radius. **G**-**J**, An excellent range of motion was achieved, and the patient was asymptomatic at 2 years.

http://e-surg.com

CRITICAL POINTS *Implant Arthroplasty of the Radial Head*

Indications
- Displaced unreconstructable fracture larger than one-third of the diameter of the radial head with known or probable medial or lateral collateral ligament or interosseous membrane injury
- Nonunion, malunion, and posttraumatic arthritis of the radial head

Pearls
- Choose the diameter and thickness of radial head implant on the basis of the reconstructed excised radial head if available.
- The diameter of the radial head arthroplasty is determined from the minor diameter of the elliptical reconstructed excised radial head. This is typically 2 mm smaller than the major diameter of the native radial head.
- The radial head prosthesis should articulate at the level of proximal radioulnar joint, 2-mm distal to the coronoid.
- If radial head does not articulate well with the capitellum, downsize the stem.
- Translate the radial neck laterally to facilitate implant placement.

Pitfalls
- Choosing the size of prosthesis by evaluating the gap between the radial head and capitellum will result in overlengthening of the radius since the lateral ligaments are often incompetent in patients undergoing radial head arthroplasty.
- Avoid placing Hohmann retractors anteriorly on the radial neck because of pressure on the posterior interosseous nerve.
- Avoid excessive thickness and diameter of the radial head.

Critical Technical Points
- Open approach through common extensor tendon split or the Kocher interval
- Excise the radial head perpendicular to the radial neck.
- Using the reconstructed excised radial head as a template, select an implant thickness to restore radial length and an implant diameter similar to the minor diameter of the native radial head.
- Use intraoperative fluoroscopy to check implant thickness by evaluating whether the medial ulnohumeral joint space is parallel, the implant is at the level of proximal radioulnar joint, 2-mm distal to coronoid and that ulnar variance is corrected.
- Careful lateral ligament repair is required if damaged by the injury or surgical approach.

Postop Management
- Early range-of-motion exercises are critical to avoid soft tissue adherence to radial neck.

Closure. After fragment excision, ORIF, or excision or replacement of the radial head, repair the lateral collateral ligament and common extensor muscle origins. If the anterior half of the lateral collateral ligament and extensor origin was detached from the lateral epicondyle, repair the anterior half of the lateral collateral ligament (the annular and radial collateral ligaments) to the posterior half using interrupted absorbable sutures. If the lateral collateral ligament and extensor origin have been completely detached either by the injury or surgical exposure, repair these using drill holes through bone and nonabsorbable sutures. I use transosseous tunnels as opposed to suture anchors because the soft tissues can be drawn toward the attachment site, better tensioning the repair (Figure 19.23). Drill a single hole at the axis of motion (the center of the arc of curvature of the capitellum), and connect this to a hole placed anterior and posterior to the lateral supracondylar ridge. Alternatively, if bone quality is good, I use two drill holes posterior to the supracondylar ridge because passing the sutures posteriorly is technically easier. Use a locking suture technique to obtain a secure hold of both the lateral collateral ligament and the common extensor muscle fascia. Pull the ligament sutures and extensor origin sutures into the holes drilled in the distal humerus using suture retrievers. Pronate the forearm, and avoid varus forces to close the lateral side of the elbow while tensioning the sutures prior to tying them. Avoid overtensioning the repair as this can pull the elbow into varus, particularly if the medial collateral ligament is deficient.[62] Place the knots anterior or posterior to the lateral supracondylar ridge to avoid prominence.

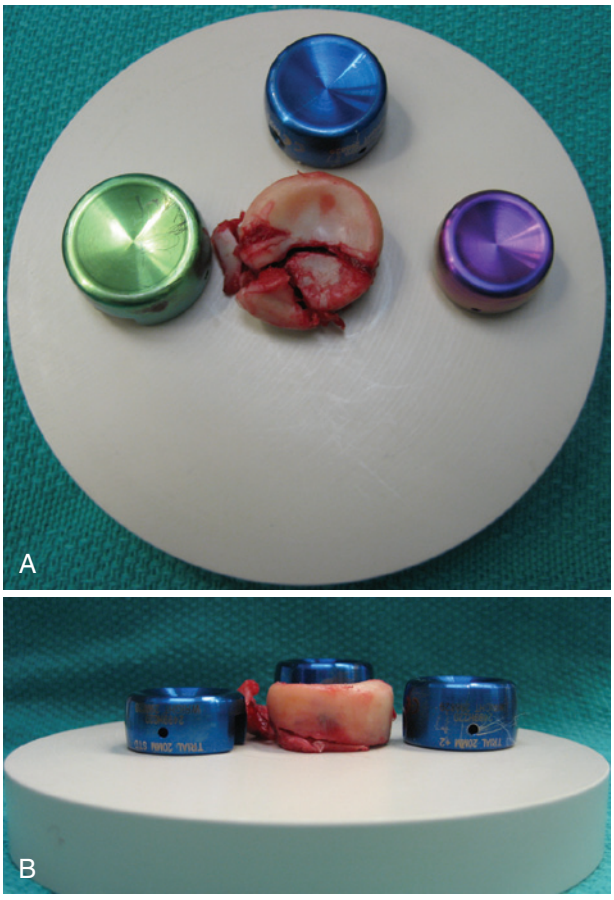

FIGURE 19.22 Sizing of the radial head prosthesis. The diameter and thickness of the prosthesis are best determined using the reconstructed excised radial head as a template. **A**, The articular dish diameter is typically 2 mm smaller than the outer diameter of the radial head and is selected as the diameter of the implant head. **B**, The overall thickness of the prosthesis should be the same as the excised radial head with care taken to avoid placing a prosthesis that is too thick.

POSTOPERATIVE MANAGEMENT AND EXPECTATIONS

Outcome Data

Nonoperative Management

The outcome of undisplaced fractures of the radial head is generally favorable, with return of function within 6 to 12

http://e-surg.com

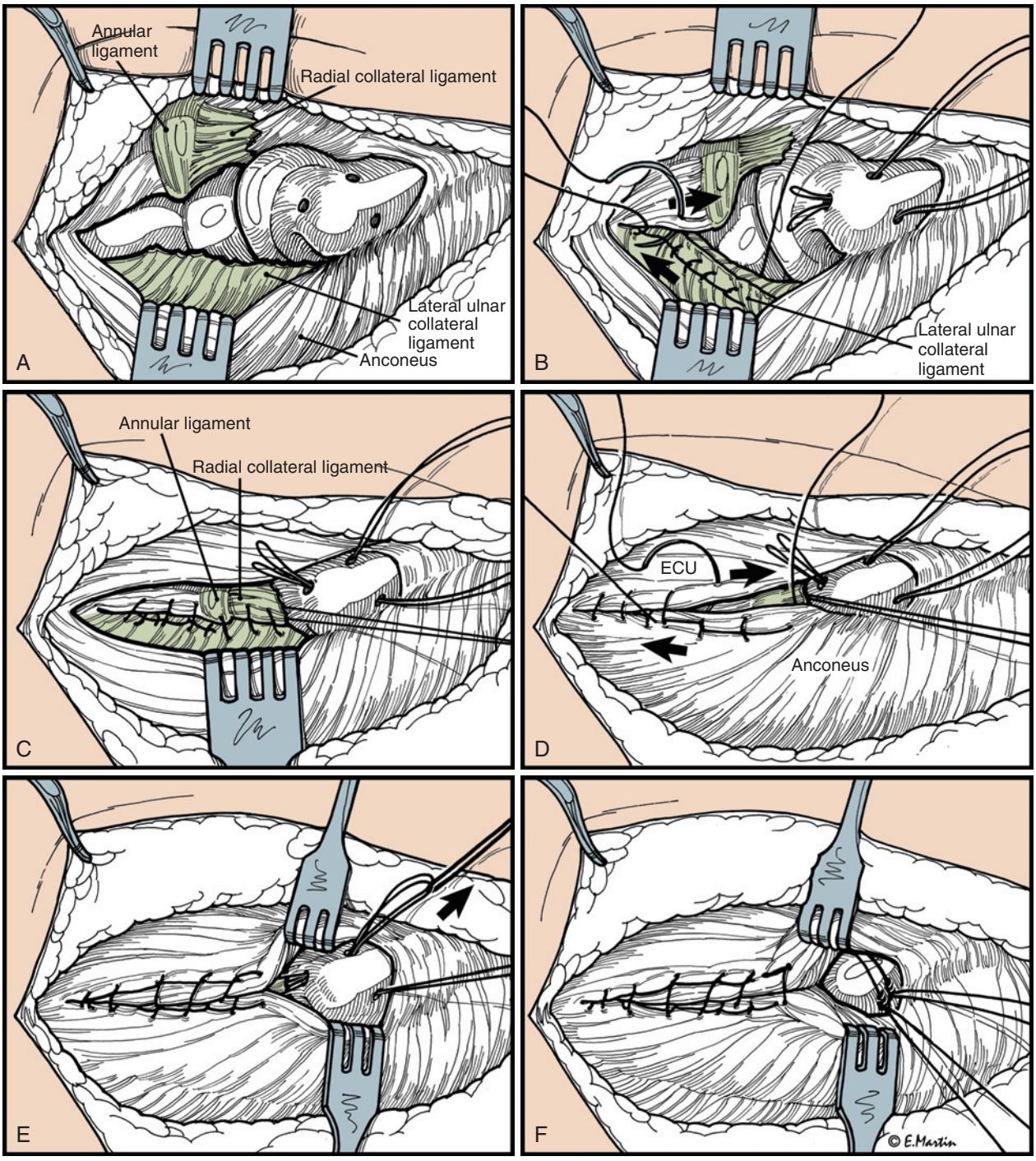

FIGURE 19.23 Lateral collateral ligament repair technique. Method of suture repair of torn or detached lateral collateral ligament using transosseous sutures in the lateral epicondyle. **A**, A single hole is drilled at the axis of motion (the center of the arc of curvature of the capitellum) and connected to a hole placed anterior and posterior to the lateral supracondylar ridge. Suture passers are placed to facilitate the repair. **B**, **C**, A locking suture technique is employed to gain a secure hold of the lateral ulnar collateral ligament. The interval between the radial collateral and lateral ulnar collateral ligaments and the annular ligament are closed as this suture is brought back to the lateral epicondyle. **D**, **E**, The common extensor muscles and fascia of the Kocher interval is closed as a separate layer in a similar fashion. **F**, The ligament and fascial sutures are pulled into the holes drilled in the distal humerus while maintaining the forearm in pronation and avoiding varus forces while tying the sutures. *ECU,* extensor carpi ulnaris.

weeks. Late displacement is uncommon but has been reported, particularly with fracture fragments that are greater than one-third of the diameter of the radial head.[135,170] Careful clinical and radiographic follow-up of these injuries is mandatory. Residual pain is uncommon. Mild residual flexion contractures of 10 to 15 degrees are not infrequent sequelae.[129,135,136,204,207,219] Some patients develop arthrofibrosis and a more severe capsular contracture unresponsive to therapy and splinting requiring arthroscopic or open capsular release (see Chapter 24). Stiffness is more common in patients with associated injuries such as an

http://e-surg.com

elbow dislocation, ligamentous injury, or coronoid fracture. Overall, most study series report 85 to 95% good results for undisplaced fractures managed with early motion. An initial period of cast immobilization does not appear to be necessary, nor is it advisable, as demonstrated in one prospective randomized trial.[207] Aspiration of the elbow in the absence of a block to forearm rotation does not appear to influence ultimate outcome.[47,92]

Although successful nonoperative management has been reported for displaced fractures of the radial head, the outcome seems to be less reliable.[1,2,29,113,135,145,170] Mason reported that 9 of 15 patients had some pain at an average of 11 years following nonoperative treatment for fractures involving greater than 25% of the joint surface.[135] He advocated excision of the radial head. Radin and Riseborough reported better motion in patients with displaced radial head fractures managed with radial head excision than that achieved with nonoperative treatment.[170] Burton reported that only 2 of 9 patients with displaced radial head fractures managed nonoperatively had good results; he recommended radial head excision in such cases.[29] Khalfayan and coworkers reported on 26 patients with Mason type II radial head fractures at an average of 18 months following either open reduction and internal fixation or nonoperative treatment with early motion.[113] The operatively treated group had 90% good or excellent results while the nonoperatively treated group had 44% good or excellent results. Pain, functional limitations, and osteoarthritis were more frequent in the nonoperatively treated group. Akesson and coworkers reported on the outcome of 49 patients with moderately displaced Mason type II partial articular two-fragment fractures at an average of 19 years.[2]

At final follow up the incidence of osteoarthritis was high at 82%; however, only 6 patients had an unsatisfactory result requiring a subsequent radial head excision and only 9 of the 49 patients had subjective complaints. Collectively these studies indicate that the outcome of nonoperative treatment of isolated displaced radial head fractures can be successful for many patients provided there is no block to motion and early motion is initiated. Randomized clinical trials are needed to determine which subgroup of patients with displaced fractures of the radial head should be offered operative treatment.

Open Reduction and Internal Fixation

The clinical outcome of ORIF of the radial head has been good when an anatomic reduction and rigid internal fixation has been achieved and early motion is initiated in the postoperative period.[10,25,35,54,61,69,88,89,93,97,98,113,115,128,138,158,161,163,174,179,185,221] There has been a low incidence of nonunion, avascular necrosis or stiffness requiring further surgery. For simple partial articular fractures, success rates generally exceed 90%; however, the outcome has been worse and the complication rate has been higher in patients with more comminuted fractures, particularly fractures that completely separate the radial head and neck.

King et al reviewed the elbows of 14 patients treated with open reduction and internal fixation at an average follow up of 32 months.[115] Mason type II fractures had 100% good or excellent results. Only 33% of Mason type III fractures treated with open reduction and internal fixation had a good or excellent result. An associated elbow dislocation did not affect the results significantly but was associated with an increased fixed-flexion deformity. Fractures were often more comminuted than suggested by plain radiographs. Excellent results were obtained provided an anatomic reduction with stable fixation and early range of motion were achieved. However, if a stable anatomic reduction cannot be obtained, alternative treatment methods should be considered.

More recently Ikeda and coworkers reported 90% good to excellent results using ORIF of comminuted Mason type III fractures treated with low-profile miniplates, suggesting that with recent advances in techniques and implants successful ORIF is possible in selected patients with comminuted fractures.[98] Ring and coworkers reviewed the results of open reduction and internal fixation of fractures of the radial head in 56 patients.[174] These authors recommended open reduction and internal fixation for partial articular fractures consisting of a single fragment and for complete articular fractures with three or less fragments. They recommended that comminuted fractures were best managed by radial head excision or replacement arthroplasty. Concomitant injuries, such as dislocations and other fractures, increased the failure rate of ORIF of the radial head.

There are no prospective randomized studies comparing ORIF with nonoperative management. The clinical and radiographic results of nonoperatively treated displaced radial head fractures were inferior for a similar group of patients treated with open reduction and internal fixation as reported by Khalfayan et al.[113] Boulas and Morrey compared the outcome of 36 patients managed with open reduction and internal fixation, excision, silastic replacement, and nonoperative management.[25] The best outcome was achieved with ORIF of displaced radial head fractures. Lindenhovius and coworkers compared the results of ORIF versus excision for unstable displaced fractures of the radial head in 28 patients at an average of 17 years' follow-up.[128] They reported that ORIF reduced the incidence of subsequent elbow dislocation and reduced the frequency and severity of osteoarthritis when compared to patients who had a primary radial head excision. Ikeda and coworkers also reported better outcomes with ORIF when compared to a matched cohort of patients who had radial head excision for comminuted Mason type III fractures.[96] In a nonrandomized comparison of partial articular radial head fractures displaced 5 mm or less performed by Yoon et al, comparing 30 patients treated with ORIF to 27 patients managed nonoperatively, the functional outcomes were similar; however, the complications were higher with surgical care.[133]

Collectively these studies demonstrate that ORIF of displaced radial head fractures leads to a successful outcome for the majority of patients and is superior to radial head excision. The indication for ORIF versus nonoperative management remains unclear and requires further study.

Fragment Excision

Although fragment excision is infrequently indicated with the advent of improved small diameter screws and surgical techniques, the outcome can be favorable in carefully selected patients. Fragment excision should be limited to small marginal fragments that are not amenable to ORIF because of comminution or osteopenia. Some authors have reported good results in more than 80% of patients, but others have reported less

http://e-surg.com

satisfactory results.[105,154,220] Carstam reported that only 17 of 33 patients (52%) managed with fragment excision had good or excellent results.[35] Fragment excision should be performed with caution when concomitant elbow instability is present because the loss of the stabilizing effect of the fragment may further compromise elbow stability.

Delayed Radial Head Excision

Reports in the literature are conflicting as to the success of delayed radial head excision.[1,26,35,63,170] Delayed radial head excision was often employed in the past because of a lack of sophisticated internal fixation devices and prostheses and concerns about stiffness and heterotopic ossification with early surgery.[1,26,35,67] Current thinking is that the extent of the initial trauma and presence of concomitant associated injuries are more important variables in the development of stiffness. Surgical timing is now thought to be less critical, so definitive early management of fractures of the radial head is preferred.[27,63] Delayed radial head excision is currently employed for residual symptoms from malunions and arthritis. Considerable improvement in pain and motion can be expected; however, the pain relief is variable, primarily dependent on whether arthritis has developed in the ulnohumeral joint.[1,26,63,112]

Adler and Shaftan reported good results with delayed excision (8 weeks) and recommended against early excision except in the setting of a block to motion.[1] Broberg and Morrey reported that delayed excision (1 month to 20 years after fracture) improved motion and decreased pain in 81% of the 21 patients reviewed.[26] In 77% of patients there was a good or excellent result. Osteoarthritis was common at follow-up, being mild to moderate in 77%. Fuchs and Chylarecki reported a better outcome following early (<2 weeks) versus delayed excision.[63] Sixty-nine percent of patients who underwent early excision were satisfied as compared with 44% who had a delayed excision.

Primary Resection of the Radial Head

The outcome after primary resection of the radial head without replacement is controversial in the literature with some authors reporting good clinical and radiographic results and others reporting a high incidence of pain, valgus and/or axial instability, elbow dislocation, weakness and degenerative elbow, and/or wrist arthritis, particularly at long-term follow-up.[1,41,63,73,96,97,100,105,106,128,144,145,152,202,214,216] Morrey et al reported 80% satisfactory results after resection for displaced fractures of the radial head at an average of 20 years' follow-up.[152] Mild ulnohumeral arthritis was common radiographically, but residual symptoms were uncommon and mild. Wrist pain occurred in 15% of patients but was usually mild. Proximal migration averaged 2 mm. Fuchs and Chylarecki assessed the outcome of 108 patients after radial head resection at an average of 6 years; 64% had an isolated fracture and 26% had an associated elbow dislocation.[63] Clinical outcome and strength were better for patients treated with a primary versus a secondary radial head excision.

Ikeda and Oka reviewed 15 patients treated with early radial head resection for a fracture of the radial head at an average of 10 years.[97] All of the patients had reduced elbow power and only 5 of them were pain free. Janssen and Vetger reported on a follow-up of 21 patients with a Mason type III fracture treated by excision of the radial head at between 16 and 30 years.[100] Only 4 of their patients had elbow pain. Of the 16 patients who had radiographic follow-up, 11 had degenerative arthritis of the elbow. Berger and coworkers reported good or excellent results in 10 of 30 patients at an average of 5 years.[22] Valgus deformity of the elbow was common.

Josefsson et al reported on 23 patients with an elbow dislocation associated with a displaced fracture of the radial head.[106] Nineteen patients had the radial head excised at an average of 2 days after injury. In 4 patients' elbows with an associated displaced fracture of the coronoid process, redislocation occurred. A follow-up examination performed in 19 patients between 3 and 34 years after the injury demonstrated severe osteoarthritis in 12 elbows. Reduced range of motion was the most common complaint, and reduced extension was the most common finding. To lower the risk and prevent severe instability, the authors recommended that the radial head should be preserved if possible in the setting of an associated elbow dislocation. Mikic and Vukadinovic reported on 58 patients who had been treated with excision of a radial head and who were reviewed at an average of 6.5 years.[144] Osteoarthritis was present in 52% and residual symptoms were found in 43%. Forearm rotation was limited in 58%, and 25% had symptomatic proximal migration of the radius with distal radioulnar joint symptoms. Given their 50% fair or poor results, the authors suggested that the indications for radial head excision should be relatively limited.

More recently, Antuna and coworkers reviewed 26 patients at an average follow-up of 25 years following a primary radial head excision for a displaced radial head fracture without associated elbow instability. The functional outcome was good or excellent in 92% of the patients, an increased carrying angle and osteoarthritis were present in all; however, wrist pain was only significant in 3 patients.[7]

Arthroplasty of the Radial Head

Silicone arthroplasty of the radial head, although initially successful in many patients,[22,25,33,125,131,151,196,199] has fallen out of favor due to problems with residual instability and late arthritis. Reports of implant fracture and silicone synovitis as a result of particulate debris have provided further evidence to support the use of alternative materials.[196,213] While the short- and medium-term results of metallic radial head implants are encouraging, the long-term outcome with respect to loosening, capitellar wear, and arthritis has not been reported.[11,34,49,59,76,84,85,108,119,147,166,186,189,195,222] Knight et al reported on 31 patients with comminuted fractures of the radial head treated by primary replacement with a Vitallium prosthesis at mean follow-up of 4.5 years.[119] There was reliable restoration of stability and prevention of proximal radial migration. There were no dislocations or prosthetic failures, but two implants were removed for symptomatic loosening.

Moro and coworkers reported the functional outcome of 25 patients managed with a monoblock titanium smooth stem arthroplasty of the radial head for unreconstructable fractures at an average follow-up of 3.5 years.[147] The results were rated as 7 excellent, 10 good, 5 fair, and 3 poor. The radial head prosthesis restored elbow stability when the fractured radial head occurred in combination with a dislocation of the elbow, rupture of the medial collateral ligament, fracture of the

http://e-surg.com

coronoid, or fracture of the proximal ulna. No patients required removal of the implant. Harrington et al reported their experience with monoblock titanium smooth stem arthroplasty of the radial head in 20 patients at an average follow-up of 12 years.[106] The results were excellent in 12, good in 4, fair in 2, and poor in 2; 4 patients had the implant removed.

Doornberg and coworkers evaluated the outcome of 27 patients treated with a modular cobalt-chrome smooth stem radial head prosthesis at an average of 3.5 years.[49] Stability was restored to all elbows and 22 patients displayed good or excellent results. Although stem lucencies were common, they did not correlate with residual elbow symptoms. Popovic and coworkers reviewed the results of 51 bipolar cemented prostheses at an average of 8 years. They reported 14 excellent, 24 good, 9 fair, and 3 poor results. They observed a high prevalence of periprosthetic osteolysis possibly due to polyethylene wear and suggested that bipolar implants should be used cautiously in young active patients. Zunkiewicz et al reported a mean Mayo elbow performance index (MEPI) of 92 at an average of 3 years following a smooth stem bipolar implant.[222] Osteolysis was not noted as an issue with this device at this early follow-up. Flinkkila et al reviewed 37 patients who had metallic press-fit prostheses at an average of 4 years.[59] Early stem loosening occurred in 12 patients and of these, 9 required removal due to pain and progressive osteolysis; the average MEPI was 86. Sarris et al reported the early results of a pyrocarbon implant, an alternative bearing surface to metal. At a mean of 27 months postoperatively they reported good clinical outcomes in 97% of patients despite two catastrophic failures at the head–neck junction and six patients with osteolysis.[180] Comparative clinical trials are needed to evaluate the outcome of the different prosthesis design concepts.

Postoperative Protocol

Following fragment excision, ORIF, excision of the radial head, or replacement arthroplasty and lateral soft tissue closure as previously described, the elbow should be placed through an arc of flexion–extension intraoperatively while carefully evaluating for elbow stability in pronation, neutral, and supination.[91] Pronation is generally beneficial if the lateral ligaments are still deficient,[52] supination is helpful if the medial ligaments are deficient,[9] and the neutral position is used if both sides have been damaged. For patients who have an associated elbow dislocation, repair of the medial collateral ligament and flexor pronator origin should be considered if the elbow subluxates at 30 degrees or more of flexion following appropriate management of the radial head, coronoid, and lateral ligament, as previously described.[60]

The elbow, with a stable osseous and ligamentous repair, should be splinted in extension and elevated for 24 to 48 h to diminish swelling, decrease tension on the posterior wound, and minimize the tendency to develop a flexion contracture. In the setting of a more tenuous ligamentous repair or the presence of some residual instability at the end of the operative procedure, the elbow should initially be splinted in 60 to 90 degrees of flexion in the optimal position of forearm rotation to maintain stability as outlined earlier.

The efficacy of indomethacin in the prevention of heterotopic ossification of the elbow remains unproven. Indomethacin 25 mg three times daily for three weeks may be considered for patients undergoing surgery on the radial head to decrease postoperative pain, reduce swelling, and potentially lower the incidence of heterotopic ossification. In patients with a concomitant dislocation, those undergoing delayed or repeat surgery and those with an associated head injury, the incidence of heterotopic ossification may be increased.[1,203] This medication should be avoided in elderly patients, those with a history of peptic ulcer disease, or those with a known allergy to the medication. Radiation should be avoided in acute injuries because it retards bone and soft tissue healing.[80]

For an isolated fracture of the radial head treated with a lateral ulnar collateral ligament-sparing approach, active range of motion should be initiated within a few days of surgery. A sling or collar and cuff with the elbow maintained at 90 degrees is employed for comfort between exercises. A static progressive extension splint is fabricated for nighttime use (Figure 19.24). This splint is adjusted weekly as extension improves and is discontinued when full extension is achieved. Strengthening commences once fracture union is secure, typically 8 weeks postoperatively.

Patients with associated fractures and ligamentous injuries should begin active range-of-motion exercises within a few days postoperatively.[201] Elbow extension is limited to a safe arc as defined by the stability of the elbow during surgery. Elbows with significant instability should begin with a rehabilitation protocol with the elbow overhead.[124] The patient is supine and the humerus is oriented 90 degrees to the bed; active motion is encouraged. Hinged braces are to be avoided. A resting splint with the elbow maintained at 90 degrees and the forearm in the appropriate rotation position is employed for 3 to 6 weeks. Active forearm rotation is performed with the elbow in flexion to minimize stress on the medial and/or lateral ligamentous injuries or repairs. A static progressive night extension splinting program is initiated as ligamentous healing progresses and stability improves, usually at 4 to 6 weeks postoperatively. Passive stretching is not permitted for 6 weeks to reduce the incidence

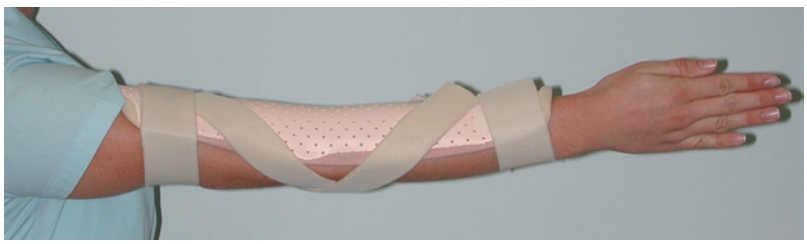

FIGURE 19.24 Static progressive extension splint. An orthosis is molded to the anterior surface of the elbow and forearm to maintain the elbow in comfortable extension. The splint is worn at night and adjusted weekly by a therapist as motion improves.

http://e-surg.com

of heterotopic ossification. Strengthening exercises are initiated once the fracture and ligament injuries have adequately healed, usually at 8 weeks postoperatively.

Complications

Nerve Injury

Posterior interosseous nerve injuries are uncommon but may occur after management of fractures of the radial head. Risk factors include dissection distal to the radial tuberosity and placement of retractors anterior to the radial neck.[142,197,198,205] Prevention of these injuries can be achieved by maintaining the forearm in pronation while performing the surgical approach.[46] Placement of retractors around the radial neck should be done cautiously. Isolation and protection of the posterior interosseous nerve are recommended if dissection is required greater than 2 cm distal to the radial head with the forearm in supination and 4 cm in pronation.[46]

Avascular Necrosis

Avascular necrosis is likely to be common after fractures of the radial head because displaced fragments typically have an absent or precarious blood supply.[72] Fortunately, it is usually asymptomatic; the fragments usually heal if stably fixed, revascularize uneventfully, and late collapse is uncommon. A temporizing approach should be taken. Avascular necrosis of the entire radial head in association with fractures of the radial neck is more problematic because this is often associated with the development of a nonunion and failure of hardware requiring radial head excision or revision to a radial head arthroplasty (Figure 19.25).

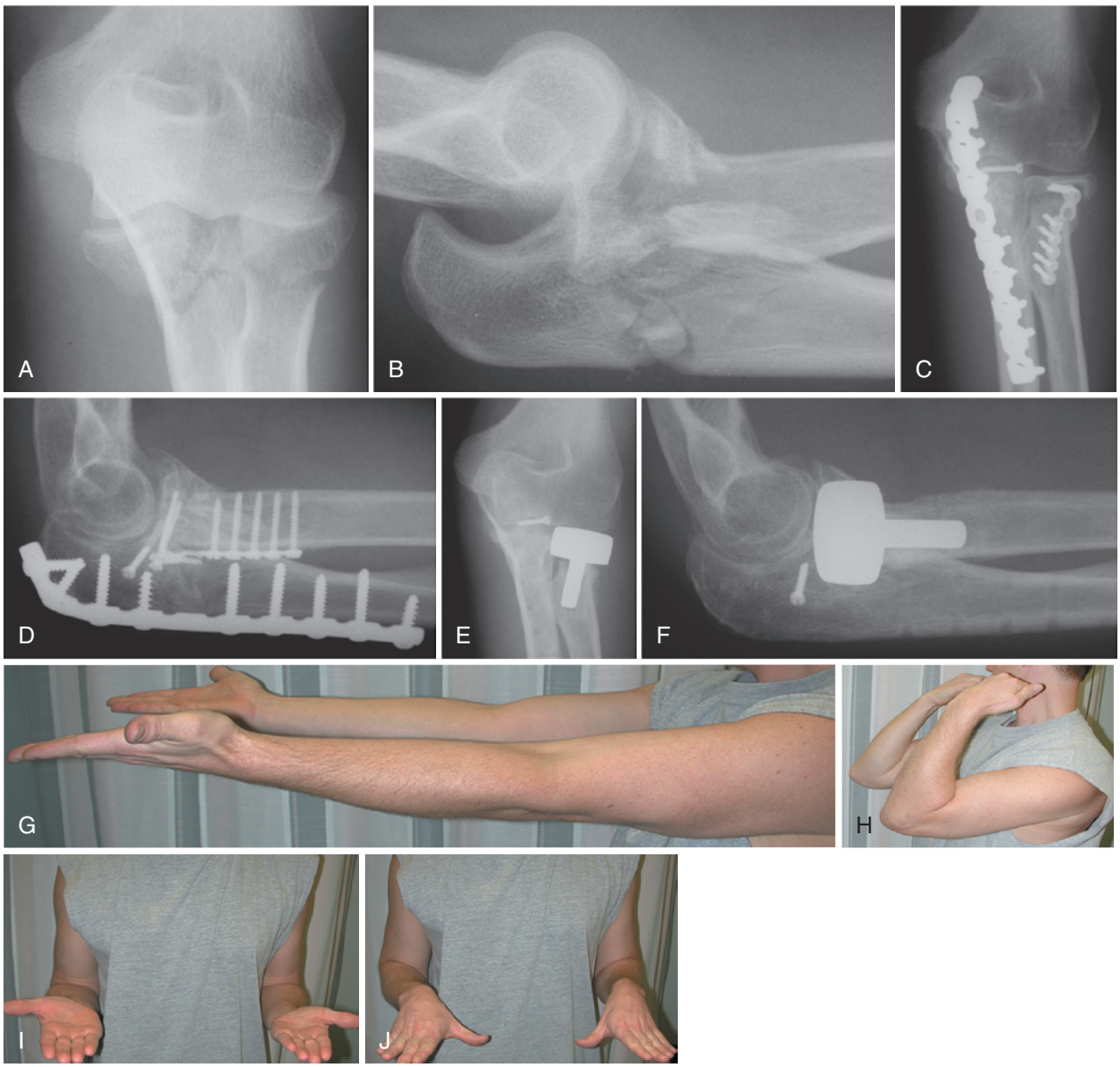

FIGURE 19.25 Avascular necrosis/nonunion of fracture of the radial neck. Anteroposterior (**A**) and lateral (**B**) radiographs demonstrating a comminuted radial head and a proximal ulnar fracture treated with ORIF of the radial head/neck and ulna. **C**, **D**, The patient developed a nonunion of the radial neck with associated avascular necrosis and a stiff elbow with limited forearm rotation. **E**, **F**, An elbow contracture release, removal of hardware, and an arthroplasty of the radial head was performed. **G**-**J**, An excellent range of motion was achieved postoperatively.

http://e-surg.com



FIGURE 19.26 Malunion of fracture of the radial head. Anteroposterior (**A**) and lateral radiographs (**B**) of a 40-year-old woman who sustained a fracture of the radial head managed with early motion. One year after injury she presented with persistent lateral elbow pain and clicking. **C**, **D**, Computed tomography demonstrates residual incongruity of the radial head. **E**, **F**, Intraoperative appearance before and after osteotomy. **G**, **H**, Radiographs 3 years after intraarticular radial head osteotomy demonstrate restoration of proximal radial anatomy. The patient had resolution of her pain and clicking.

Nonunion

Nonunions are often associated with avascular necrosis and seem to be more common in patients with displaced fractures of the radial neck, particularly if the internal fixation is not secure.[38,57,115,173,174] Nonunions should be managed without surgery if they are not symptomatic.[38,173] Revision ORIF with bone grafting, radial head excision, or replacement may be employed if the nonunion is symptomatic. This author's experience with attempts to achieve union in this setting have been meager, likely owing to compromised blood supply, so revision to a radial head arthroplasty is preferred.

Malunion

Malunions are usually seen as a consequence of nonoperative treatment, unstable fracture fixation, or collapse due to avascular necrosis. Restricted motion, pain, clicking, or crepitus are typical clinical features. Extraarticular or intraarticular osteotomies (Figure 19.26) may be helpful in younger patients, whereas excision or replacement of the radial head should be considered in those who are older and of lower demand.[175] Careful preoperative planning is required if an intraarticular osteotomy is being considered. If there is significant osteoarthritis of the capitellum, excision of the radial head may be preferable.

http://e-surg.com

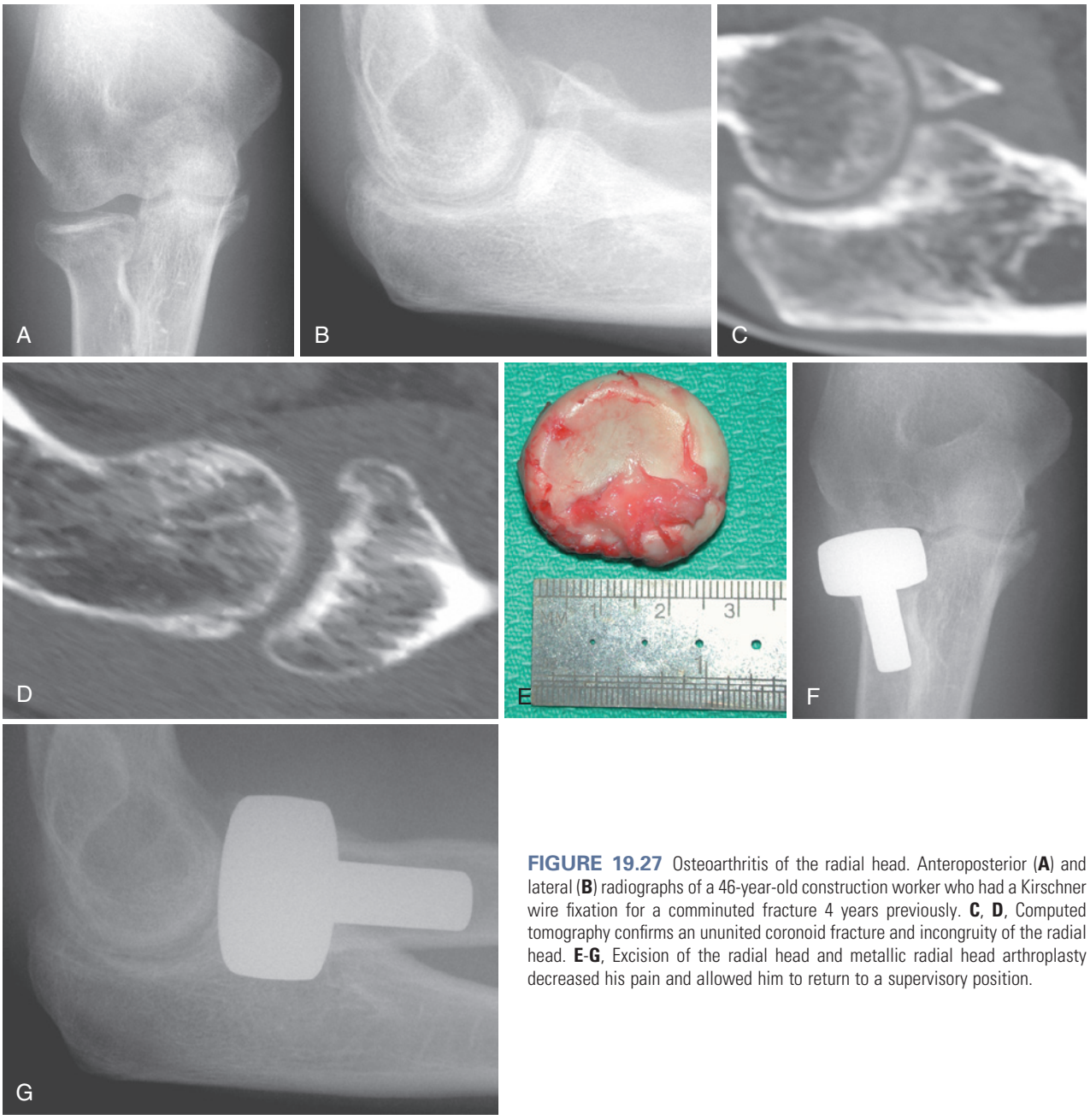

FIGURE 19.27 Osteoarthritis of the radial head. Anteroposterior (**A**) and lateral (**B**) radiographs of a 46-year-old construction worker who had a Kirschner wire fixation for a comminuted fracture 4 years previously. **C**, **D**, Computed tomography confirms an ununited coronoid fracture and incongruity of the radial head. **E**-**G**, Excision of the radial head and metallic radial head arthroplasty decreased his pain and allowed him to return to a supervisory position.

Preservation of a periosteal sleeve of the osteotomized fragment should be attempted to avoid problems with avascular necrosis and/or healing. Rigid fixation and bone grafting should be performed to promote union and early postoperative range-of-motion exercises initiated.

Osteoarthritis

Osteoarthritis is seen as a consequence of articular cartilage damage from the initial injury, articular incongruity, or persistent instability. Pain and stiffness develop as the arthritis progresses. Although typically beginning in the radiocapitellar joint, it usually progresses to involve the ulnohumeral articulation. Débridement, either open or arthroscopic, can be helpful to manage mechanical symptoms from loose bodies or osteophytes. Radial head arthroplasty can be employed in the early stages when the capitellum is not too severely arthritic (Figure 19.27).[186] Excision of the radial head, either open or arthroscopically, can be helpful if the ulnohumeral joint is not too involved and there is no residual elbow or forearm instability. In my experience, ulnohumeral arthritis tends to progress more rapidly following radial head excision, so débridement or replacement is preferred over excision. Unicompartmental radiocapitellar arthroplasty may have a role in the management of radiocapitellar arthritis when radial head replacement is contraindicated; however, the clinical outcome and durability of these new devices have not been established yet.[177] Total elbow arthroplasty may be required for more generalized posttraumatic elbow arthritis.

http://e-surg.com

Stiffness and Heterotopic Bone

Stiffness is a common sequelae of fractures of the radial head and may be the result of capsular contracture, heterotopic ossification, impinging hardware, or retained cartilaginous or osseous fragments.[67,115,135,174] Loss of terminal extension is most frequent. Capsular contractures identified at 6 to 8 weeks usually respond to passive stretching under the supervision of a physical therapist.[116] Static progressive splinting using a flexion cuff and/or a resting extension splint also may be helpful in regaining terminal range. A static progressive or dynamic pronation splint is employed for patients with loss of forearm rotation. Turnbuckle splinting initiated 12 to 16 weeks postoperatively can be useful to regain flexion or extension in patients refractory to standard therapy.[70]

Patients who fail nonoperative management and who are symptomatic due to residual stiffness can be reliably managed by open or arthroscopic capsular release, which restores a functional arc of motion in most patients.[40,132] Loss of forearm rotation tends to be less successfully treated on a delayed basis than loss of flexion–extension which can be improved even years later. I have had much better results when operating early for loss of rotation, which does not respond to therapy, typically at 6 months postoperatively (Figure 19.28).[20] This may be due to secondary contractures of the interosseous membrane or the capsule of the distal radioulnar joint.

Heterotopic bone can be excised as soon as the cortical margins are well defined and the elbow is no longer inflamed.[139] Bone scans are not useful in directing surgical timing. Patients treated with early (<6 months) excision of heterotopic bone are managed by a single dose of radiation postoperatively to prevent recurrence, typically 500 cGy. Late excision is usually managed using indomethacin, with radiation reserved for those with a contraindication or known intolerance to nonsteroidal antiinflammatory agents. Patients with residual cognitive deficits after head injuries should also be considered for radiation owing to a higher risk of recurrent heterotopic bone.[65]

Valgus Instability

Late symptomatic valgus instability is uncommon unless the radial head has been excised and not replaced. Prevention is key because late reconstruction often leads to less than satisfactory results. Medial collateral ligament reconstruction has not been reliable in restoring stability in the absence of a radial head replacement, likely owing to attenuation of the soft tissue repair. Metallic arthroplasty of the radial head may have a role to play in the resolution of these difficult clinical problems provided the capitellar cartilage is not excessively damaged and the proximal radius has not subluxated too far posteriorly such that the radial neck cannot be realigned with the capitellum. Valgus instability can be managed with metallic replacement of the radial head and reconstruction of the medial collateral ligament at the same time.[42]

Axial Instability

Morrey and Coleman and their colleagues reported that proximal radial migration averaged 2 mm in patients who had a

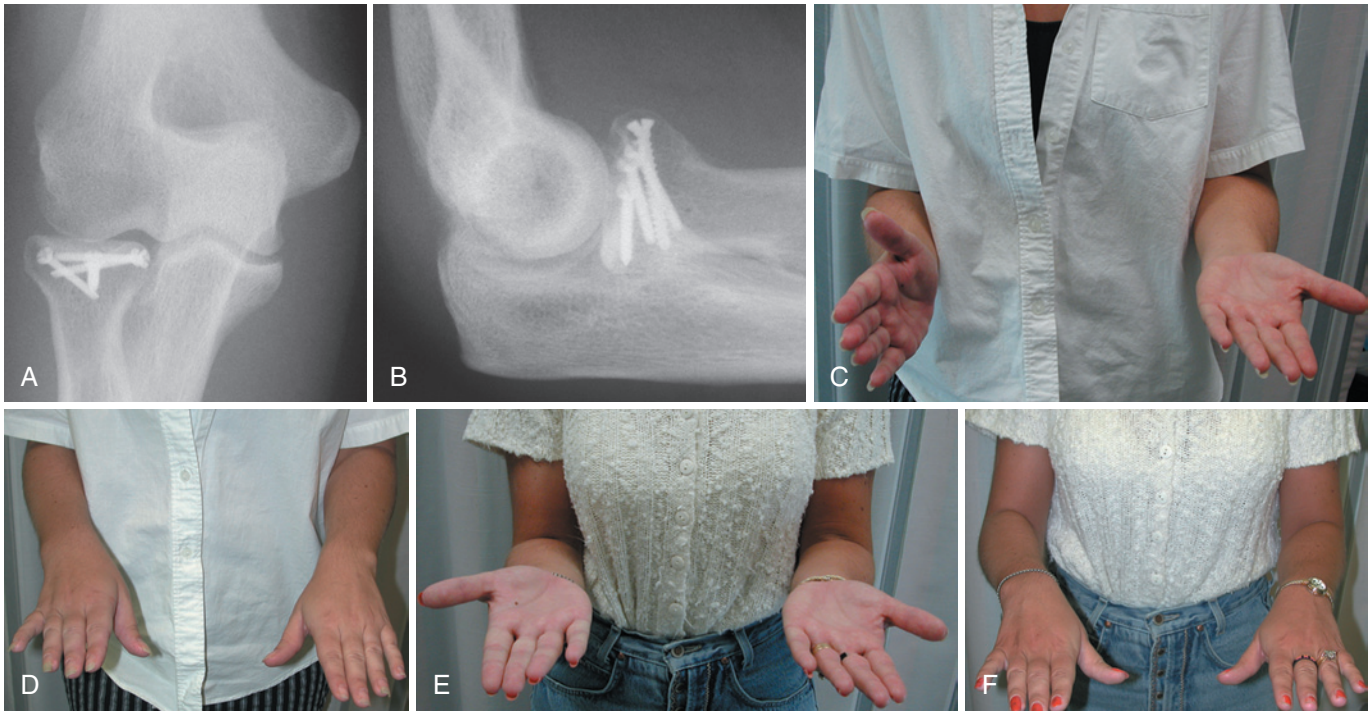

FIGURE 19.28 Arthroscopic release for rotation loss. **A**, **B**, Radiographs of a 36-year-old woman 4 months status-post open reduction and internal fixation of a displaced fracture of the radial head. **C**, **D**, Clinical appearance with loss of rotation that had persisted in spite of physiotherapy and splinting. **E**, **F**, At 6 weeks after arthroscopic release of arthrofibrosis there was a marked improvement in forearm supination.

http://e-surg.com

radial head resection, and most were asymptomatic.[41,152] The incidence and magnitude and symptoms of proximal migration vary considerably between studies.[140,202] Lewis and Thibodeau reported this phenomenon in 7 of 8 patients who had a radial head excision; 2 of their patients were symptomatic.[126] Some patients have greater migration and may develop impingement of the proximal radial stump on the capitellum or the distal ulna on the carpus. True Essex-Lopresti injuries are uncommon[23,53,55,83,114,125]; however, they often go unrecognized[56,206] and present as a late problem.[28,30,140,193] If detected early, preservation of the radial head with ORIF or metallic radial head arthroplasty is indicated.[183] Late reconstruction of axial forearm instability remains a difficult surgical problem without a definitive solution.[30,94,169,184,193] Whereas a one bone forearm can solve the instability problem, nonunions and other complications are common.[162]

Salvage using allografts of the radial head has been reported; however, increasing experience and longer follow-up suggests a higher incidence of complications (e.g., nonunion, collapse, and resorption) such that they can no longer be recommended.[110,200] Reconstruction of the interosseous membrane combined with a metallic arthroplasty of the radial head has been proposed in biomechanical studies; however, no clinical outcome studies are available.[94,122,133,183,188,215] Ulnar shortening alone is ineffective because the correction in ulnar variance is commonly not maintained.[193] This author's preference is to reconstruct late axial instability in a staged manner using a metallic implant of the radial head. Prerequisites are a proximal radial stump that can be reduced to the capitellum and the absence of significant capitellar arthritis. The metallic arthroplasty of the radial head is performed first, avoiding overlengthening of the radius. Six months later, an ulnar shortening osteotomy is performed to restore the normal relationship of the distal radial ulnar joint. This staged reconstruction seems to allow the cartilage and bone of the capitellum to respond to reloading in a more graduated manner and avoids capitellar erosion and pain that has been seen when completing a single-stage reconstruction (Figure 19.29).[87]

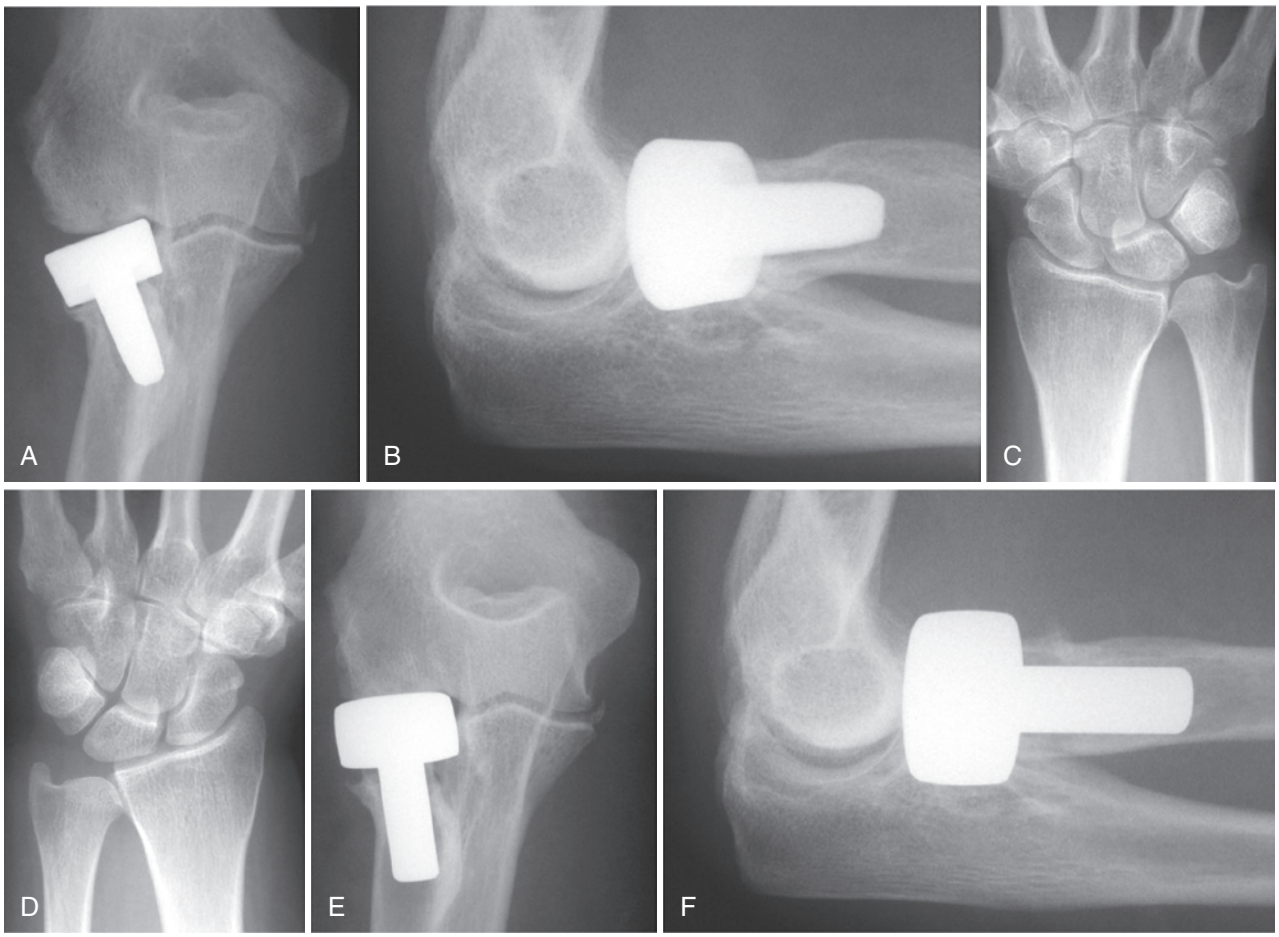

FIGURE 19.29 Essex-Lopresti prosthetic reconstruction. Anteroposterior (**A**) and lateral (**B**) radiographs of the right elbow and bilateral posteroanterior wrist radiographs (**C**, **D**) of a 47-year-old woman who had previously had two Silastic and one metallic arthroplasty for a missed Essex-Lopresti injury initially managed with excision of the radial head. She had persistent pain in both her elbow and wrist. **E**, **F**, Following revision of the malarticulated arthroplasty of the radial head to a modular design (Evolve, Wright Medical Technology, Arlington, TN).

Continued

http://e-surg.com

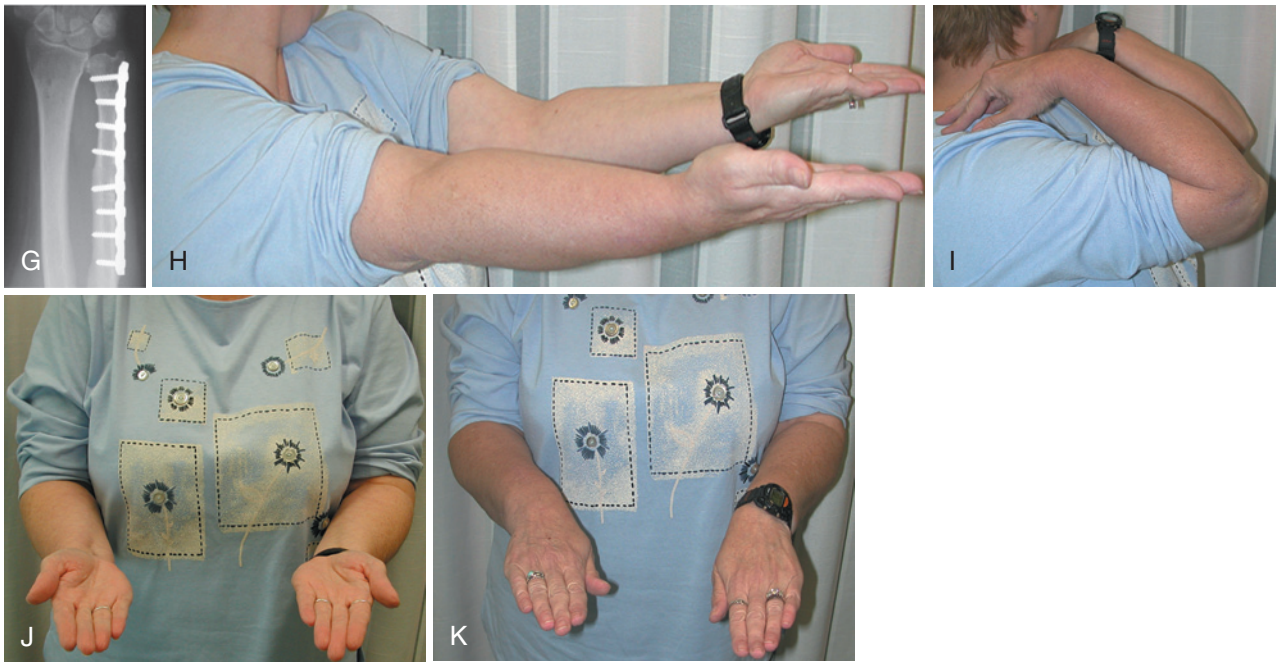

FIGURE 19.29, cont'd **G**, An ulnar shortening osteotomy was done 6 months later. **H**-**K**, Her wrist and elbow pain has resolved.

For Case Studies, Videos, and more, please visit ExpertConsult.com.

REFERENCES

1. Adler JB, Shaftan GW: Radial head fractures, is excision necessary? *J Trauma* 4:115–136, 1962.
2. Akesson T, Herbertsson P, Josefsson PO, et al: Primary nonoperative treatment of moderately displaced two-part fractures of the radial head. *J Bone Joint Surg Am* 88(9):1909–1914, 2006.
3. Alolabi B, Studer A, Gray A, et al: Selecting the diameter of a radial head implant: an assessment of local landmarks. *J Shoulder Elbow Surg* 22(10):1395–1399, 2013.
4. Amis AA, Miller JH, Dowson D, et al: Biomechanical aspects of the elbow: joint forces related to prosthesis design. *Eng Med* 10(2):65–68, 1981.
5. Amis AA, Dowson D, Wright V: Elbow joint force predictions for some strenuous isometric actions. *J Biomech* 13(9):765–775, 1980.
6. Amis AA, Miller JH: The mechanisms of elbow fractures: an investigation using impact tests in vitro. *Injury* 26(3):163–168, 1995.
7. Antuna SA, Sanchez-Marquez JM, Barco R: Long-term results of radial head resection following isolated radial head fractures in patients younger than forty years old. *J Bone Joint Surg Am* 92(3):558–566, 2010.
8. Arce AA, Garin DM, Garcia MV, et al: Treatment of radial head fractures using a fibrin adhesive seal. A review of 15 cases. *J Bone Joint Surg Br* 77(3):422–424, 1995.
9. Armstrong AD, Dunning CE, Faber KJ, et al: Rehabilitation of the medial collateral ligament-deficient elbow: an in vitro biomechanical study. *J Hand Surg [Am]* 25(6):1051–1057, 2000.
10. Arner O, Ekengren K, Von Schreeb T: Fractures of the head and neck of the radius: a clinical and roentgenographic stduy of 310 cases. *Acta Chir Scand* 112:115, 1957.
11. Ashwood N, Bain GI, Unni R: Management of Mason type-III radial head fractures with a titanium prosthesis, ligament repair, and early mobilization. *J Bone Joint Surg Am* 86A(2):274–280, 2004.
12. Athwal GS, Frank SG, Grewal R, et al: Determination of correct implant size in radial head arthroplasty to avoid overlengthening: surgical technique. *J Bone Joint Surg Am* 92(Suppl 1 Pt 2):250–257, 2010.
13. Athwal GS, Rouleau DM, MacDermid JC, et al: Contralateral elbow radiographs can reliably diagnose radial head implant overlengthening. *J Bone Joint Surg Am* 93(14):1339–1346, 2011.
14. Bartz B, Tillmann B, Schleicher A: Stress in the human elbow joint. II. Proximal radio-ulnar joint. *Anat Embryol (Berl)* 169(3):309–318, 1984.
15. Beingessner DM, Bennett JD, King GJ: Intraarticular radial head osteotomy. *J Shoulder Elbow Surg* 8(2):172–174, 1999.
16. Beingessner DM, Dunning CE, Beingessner CJ, et al: The effect of radial head fracture size on radiocapitellar joint stability. *Clin Biomech (Bristol, Avon)* 18(7): 677–681, 2003.
17. Beingessner DM, Dunning CE, Gordon KD, et al: The effect of radial head excision and arthroplasty on elbow kinematics and stability. *J Bone Joint Surg Am* 86A(8):1730–1739, 2004.
18. Beingessner DM, Dunning CE, Beingessner CJ, et al: The effect of radial head fracture size on radiocapitellar joint stability. *Clin Biomech (Bristol, Avon)* 18(7): 677–681, 2003.
19. Beingessner DM, Dunning CE, Gordon KD, et al: The effect of radial head fracture size on elbow kinematics and stability. *J Orthop Res* 23(1):210–217, 2005.
20. Beingessner DM, Patterson SD, King GJ: Early excision of heterotopic bone in the forearm. *J Hand Surg [Am]* 25(3):483–488, 2000.
21. Beredjiklian PK, Nalbantoglu U, Potter HG, et al: Prosthetic radial head components and proximal radial morphology: a mismatch. *J Shoulder Elbow Surg* 8(5):471–475, 1999.
22. Berger M, Urvoy P, Mestdagh H: [Comparative study of the treatment of fractures of the head of the radius by resection or by Swanson's silastic implant]. *Ann Chir* 45(5):418–425, 1991 [in French].
23. Bock GW, Cohen MS, Resnick D: Fracture-dislocation of the elbow with inferior radioulnar dislocation: a variant of the Essex-Lopresti injury. *Skeletal Radiol* 21(5):315–317, 1992.
24. Bohrer JV: Fractures of the head and neck of the radius. *Ann Surg* 97:204–208, 1933.
25. Boulas HJ, Morrey BF: Biomechanical evaluation of the elbow following radial head fracture. Comparison of open reduction and internal fixation vs. excision, silastic replacement, and non-operative management. *Chir Main* 17(4):314–320, 1998.
26. Broberg MA, Morrey BF: Results of delayed excision of the radial head after fracture. *J Bone Joint Surg Am* 68(5):669–674, 1986.
27. Broberg MA, Morrey BF: Results of treatment of fracture-dislocations of the elbow. *Clin Orthop* (216):109–119, 1987.
28. Brockman EP: Two cases of disability at the wrist joint following excision of the head of the radius. *Proc R Soc Med* 24:904, 1930.
29. Burton AE: Fractures of the head of the radius. *Proc R Soc Med* 35:764–765, 1942.
30. Capuano L, Craig N, Ashcroft GP, et al: Distraction lengthening of the radius for radial longitudinal instability after distal radio-ulnar subluxation and excision of the radial head: a case report. *Scand J Plast Reconstr Surg Hand Surg* 35(3):331–335, 2001.
31. Caputo AE, Burton KJ, Cohen MS, et al: Articular cartilage injuries of the capitellum interposed in radial head fractures: a report of ten cases. *J Shoulder Elbow Surg* 15(6):716–720, 2006.

http://e-surg.com

32. Caputo AE, Mazzocca AD, Santoro VM: The nonarticulating portion of the radial head: anatomic and clinical correlations for internal fixation. *J Hand Surg [Am]* 23(6):1082–1090, 1998.
33. Carn RM, Medige J, Curtain D, et al: Silicone rubber replacement of the severely fractured radial head. *Clin Orthop* (209):259–269, 1986.
34. Carr CR, Howard JW: Metallic cap replacement of radial head following fracture. *West J Surg* 59:539–546, 1951.
35. Carstam N: Operative treatment of fractures of the upper end of the radius. *Acta Orthop Scand* 59:502–523, 1950.
36. Castberg T, Thing E: Treatment of fractures of the upper end of the radius. *Acta Chir Scand* 1051:62–69, 1953.
37. Cherry JC: Use of acrylic prothesis in the treatment of fracture of the head of the radius. *J Bone Joint Surg Br* 35B:70–71, 1953.
38. Cobb TK, Beckenbaugh RD: Nonunion of the radial neck following fracture of the radial head and neck: case reports and a review of the literature. *Orthopedics* 21(3):364–368, 1998.
39. Cohen MS, Hastings H: Rotatory instability of the elbow. The anatomy and role of the lateral stabilizers. *J Bone Joint Surg Am* 79(2):225–233, 1997.
40. Cohen MS, Hastings H: Operative release for elbow contracture: the lateral collateral ligament sparing technique. *Orthop Clin North Am* 30(1):133–139, 1999.
41. Coleman DA, Blair WF, Shurr D: Resection of the radial head for fracture of the radial head. Long-term follow-up of seventeen cases. *J Bone Joint Surg Am* 69(3):385–392, 1987.
42. Conway JE, Jobe FW, Glousman RE, et al: Medial instability of the elbow in throwing athletes. Treatment by repair or reconstruction of the ulnar collateral ligament. *J Bone Joint Surg Am* 74(1):67–83, 1992.
43. Cutler CW: Fractures of the head and neck of the radius. *Ann Surg* 8:267–278, 1926.
44. Davidson PA, Moseley JB, Jr, Tullos HS: Radial head fracture. A potentially complex injury. *Clin Orthop* (297):224–230, 1993.
45. Desloges W, Louati H, Papp SR, et al: Objective analysis of lateral elbow exposure with the extensor digitorum communis split compared with the Kocher interval. *J Bone Joint Surg Am* 96(5):387–393, 2014.
46. Diliberti T, Botte MJ, Abrams RA: Anatomical considerations regarding the posterior interosseous nerve during posterolateral approaches to the proximal part of the radius. *J Bone Joint Surg Am* 82(6):809–813, 2000.
47. Dooley JF, Angus PD: The importance of elbow aspiration when treating radial head fractures. *Arch Emerg Med* 8(2):117–121, 1991.
48. Doornberg JN, Linzel DS, Zurakowski D, et al: Reference points for radial head prosthesis size. *J Hand Surg [Am]* 31(1):53–57, 2006.
49. Doornberg JN, Parisien R, van Duijn PJ, et al: Radial head arthroplasty with a modular metal spacer to treat acute traumatic elbow instability. *J Bone Joint Surg Am* 89(5):1075–1080, 2007.
50. Dowdy PA, Bain GI, King GJ, et al: The midline posterior elbow incision. An anatomical appraisal. *J Bone Joint Surg Br* 77(5):696–699, 1995.
51. Dunning CE, Zarzour ZD, Patterson SD, et al: Ligamentous stabilizers against posterolateral rotatory instability of the elbow. *J Bone Joint Surg Am* 83-A(12):1823–1828, 2001.
52. Dunning CE, Zarzour ZD, Patterson SD, et al: Muscle forces and pronation stabilize the lateral ligament deficient elbow. *Clin Orthop* 388:118–124, 2001.
53. Edwards GS, Jr, Jupiter JB: Radial head fractures with acute distal radioulnar dislocation. Essex-Lopresti revisited. *Clin Orthop* 234:61–69, 1988.
54. Esser RD, Davis S, Taavao T: Fractures of the radial head treated by internal fixation: late results in 26 cases. *J Orthop Trauma* 9(4):318–323, 1995.
55. Essex-Lopresti P: Fractures of the radial head with distal radio-ulnar dislocation. *J Bone Joint Surg Br* 33B:244–247, 1951.
56. Failla JM, Jacobson J, van Holsbeeck M: Ultrasound diagnosis and surgical pathology of the torn interosseous membrane in forearm fractures/dislocations. *J Hand Surg [Am]* 24(2):257–266, 1999.
57. Faraj AA, Livesly P, Branfoot T: Nonunion of fracture of the neck of the radius: a report of three cases. *J Orthop Trauma* 13(7):513–515, 1999.
58. Fischer LP, Gonon GP, Carret JP, et al: [Possibility of screwing in various simple fractures of the radial head (with anatomo-physiologic considerations of the radio-cubital joint)]. *Rev Chir Orthop Reparatrice Appar Mot* 62(2 Suppl):89–96, 1976.
59. Flinkkila T, Kaisto T, Sirnio K, et al: Short- to mid-term results of metallic press-fit radial head arthroplasty in unstable injuries of the elbow. *J Bone Joint Surg Br* 94(6):805–810, 2012.
60. Forthman C, Henket M, Ring DC: Elbow dislocation with intra-articular fracture: the results of operative treatment without repair of the medial collateral ligament. *J Hand Surg [Am]* 32(8):1200–1209, 2007.
61. Frankle MA, Koval KJ, Sanders RW, et al: Radial head fractures associated with elbow dislocations treated by immediate stabilization and early motion. *J Shoulder Elbow Surg* 8(4):355–360, 1999.
62. Fraser GS, Pichora JE, Ferreira LM, et al: Lateral collateral ligament repair restores the initial varus stability of the elbow: an in vitro biomechanical study. *J Orthop Trauma* 22(9):615–623, 2008.
63. Fuchs S, Chylarecki C: Do functional deficits result from radial head resection? *J Shoulder Elbow Surg* 8(3):247–251, 1999.
64. Furry KL, Clinkscales CM: Comminuted fractures of the radial head. Arthroplasty versus internal fixation. *Clin Orthop* (353):40–52, 1998.
65. Garland DE, Hanscom DA, Keenan MA, et al: Resection of heterotopic ossification in the adult with head trauma. *J Bone Joint Surg Am* 67(8):1261–1269, 1985.
66. Garland DE, O'Hollaren RM: Fractures and dislocations about the elbow in the head-injured adult. *Clin Orthop* 49(168):38–41, 1982.
67. Gaston SR, Smith FM, Baab OD: Adult injuries of the radial head and neck: importance of time element in treatment. *Am J Surg* 78:631–635, 1949.
68. Geel CW, Palmer AK: Radial head fractures and their effect on the distal radioulnar joint. A rationale for treatment. *Clin Orthop* (275):79–84, 1992.
69. Geel CW, Palmer AK, Ruedi T, et al: Internal fixation of proximal radial head fractures. *J Orthop Trauma* 4(3):270–274, 1990.
70. Gelinas JJ, Faber KJ, Patterson SD, et al: The effectiveness of turnbuckle splinting for elbow contractures. *J Bone Joint Surg Br* 82(1):74–78, 2000.
71. Giffin JR, King GJ, Patterson SD, et al: Internal fixation of radial neck fractures: an in vitro biomechanical analysis. *Clin Biomech (Bristol, Avon)* 19(4):358–361, 2004.
72. Girard JY, Rogez JM, Robert R, et al: Vascularisation of the head of the radius in the adult. *Surg Radiol Anat* 17(1):41–45, 1995.
73. Goldberg I, Peylan J, Yosipovitch Z: Late results of excision of the radial head for an isolated closed fracture. *J Bone Joint Surg Am* 68(5):675–679, 1986.
74. Gordon KD, Duck TR, King GJ, et al: Mechanical properties of subchondral cancellous bone of the radial head. *J Orthop Trauma* 17(4):285–289, 2003.
75. Greenspan A, Norman A, Rosen H: Radial head-capitellum view in elbow trauma: clinical application and radiographic-anatomic correlation. *AJR Am J Roentgenol* 143(2):355–359, 1984.
76. Grewal R, MacDermid JC, Faber KJ, et al: Comminuted radial head fractures treated with a modular metallic radial head arthroplasty. Study of outcomes. *J Bone Joint Surg Am* 88(10):2192–2200, 2006.
77. Grossman J: Fracture of the head and neck of the radius. *New York Medical Journal* 117:472–475, 1923.
78. Gupta GG, Lucas G, Hahn DL: Biomechanical and computer analysis of radial head prostheses. *J Shoulder Elbow Surg* 6(1):37–48, 1997.
79. Halls AA, Travill A: Transmission of pressures across the elbow joint. *Anat Rec* 150:243–248, 1964.
80. Hamid N, Ashraf N, Bosse MJ, et al: Radiation therapy for heterotopic ossification prophylaxis acutely after elbow trauma: a prospective randomized study. *J Bone Joint Surg Am* 92(11):2032–2038, 2010.
81. Hammacher ER, van der Werken C: Radial head fractures: operative or conservative treatment? The Greek temple model. *Acta Orthop Belg* 62(Suppl 1):112–115, 1996.
82. Hammond R: Fracture of the head and neck of the radius. *Ann Surg* 53:207–214, 1910.
83. Hargadon EJ, Porter ML: The Essex-Lopresti injury: a variation. *J Hand Surg [Br]* 13(4):450–452, 1988.
84. Harrington IJ, Sekyi-Otu A, Barrington TW, et al: The functional outcome with metallic radial head implants in the treatment of unstable elbow fractures: a long-term review. *J Trauma* 50(1):46–52, 2001.
85. Harrington IJ, Tountas AA: Replacement of the radial head in the treatment of unstable elbow fractures. *Injury* 12(5):405–412, 1981.
86. Haverstock JP, Katchky RN, Lalone EA, et al: Regional variations in radial head bone volume and density: implications for fracture patterns and fixation. *J Shoulder Elbow Surg* 21(12):1669–1673, 2012.
87. Heijink A, Morrey BF, van Riet RP, et al: Delayed treatment of elbow pain and dysfunction following Essex-Lopresti injury with metallic radial head replacement: a case series. *J Shoulder Elbow Surg* 19(6):929–936, 2010.
88. Heim U: [Surgical treatment of radial head fracture]. *Z Unfallchir Versicherungsmed* 85(1):3–11, 1992.
89. Heim U, Trub HJ: [Experiences with primary osteosynthesis in radial head fractures]. *Helv Chir Acta* 45(1–2):63–69, 1978.
90. Hergenroeder PT, Gelberman R: Distal radioulnar joint subluxation secondary to excision of the radial head. *Orthopedics* 3:649–650, 1980.
91. Hildebrand KA, Patterson SD, King GJ: Acute elbow dislocations: simple and complex. *Orthop Clin North Am* 30(1):63–79, 1999.
92. Holdsworth BJ, Clement DA, Rothwell PN: Fractures of the radial head—the benefit of aspiration: a prospective controlled trial. *Injury* 18(1):44–47, 1987.
93. Hotchkiss RN: Displaced fractures of the radial head: internal fixation or excision? *J Am Acad Orthop Surg* 5(1):1–10, 1997.
94. Hotchkiss RN, An KN, Sowa DT, et al: An anatomic and mechanical study of the interosseous membrane of the forearm: pathomechanics of proximal migration of the radius. *J Hand Surg [Am]* 14(2 Pt 1):256–261, 1989.
95. Hotchkiss R, Weiland A: Valgus stability of the elbow. *J Orthop Res* 5(3):372–377, 1987.

http://e-surg.com

96. Ikeda M, Sugiyama K, Kang C, et al: Comminuted fractures of the radial head. Comparison of resection and internal fixation. *J Bone Joint Surg Am* 87A:76–84, 2005.
97. Ikeda M, Oka Y: Function after early radial head resection for fracture: a retrospective evaluation of 15 patients followed for 3-18 years. *Acta Orthop Scand* 71(2): 191–194, 2000.
98. Ikeda M, Yamashina Y, Kamimoto M, et al: Open reduction and internal fixation of comminuted fractures of the radial head using low-profile mini-plates. *J Bone Joint Surg Br* 85(7):1040–1044, 2003.
99. Itamura J, Roidis N, Mirzayan R, et al: Radial head fractures: MRI evaluation of associated injuries. *J Shoulder Elbow Surg* 14(4):421–424, 2005.
100. Janssen RP, Vegter J: Resection of the radial head after Mason type-III fractures of the elbow: follow-up at 16 to 30 years. *J Bone Joint Surg Br* 80(2):231–233, 1998.
101. Jensen SL, Olsen BS, Sojbjerg JO: Elbow joint kinematics after excision of the radial head. *J Shoulder Elbow Surg* 8(3):238–241, 1999.
102. Johansson O: Capsular and ligament injuries of the elbow joint. A clinical and arthrographic study. *Acta Chir Scand* 287(Suppl):5–71, 1962.
103. Johnson JA, Beingessner DM, Gordon KD, et al: Kinematics and stability of the fractured and implant reconstructed radial head. *J Shoulder Elbow Surg* 14(Suppl 1):195S–201S, 2005.
104. Johnston GW: A follow-up of one hundred cases of fracture of the head of the radius with a review of the literature. *Ulster Med J* 31:51–56, 1962.
105. Jones SG: Fractures of the head and neck of the radius—separation of upper radial epiphysis. *N Engl J Med* 212:914–917, 1935.
106. Josefsson PO, Gentz CF, Johnell O, et al: Dislocations of the elbow and intraarticular fractures. *Clin Orthop* (246):126–130, 1989.
107. Judet T: Results of acute excision of the radial head in elbow radial head fracture-dislocations. *J Orthop Trauma* 15(4):308–309, 2001.
108. Judet T, Garreau DL, Piriou P, et al: A floating prosthesis for radial-head fractures. *J Bone Joint Surg Br* 78(2):244–249, 1996.
109. Kaas L, van Riet RP, Vroemen JP, et al: The incidence of associated fractures of the upper limb in fractures of the radial head. *Strategies Trauma Limb Reconstr* 3(2):71–74, 2008.
110. Karlstad R, Morrey BF, Cooney WP: Failure of fresh-frozen radial head allografts in the treatment of Essex-Lopresti injury. A report of four cases. *J Bone Joint Surg Am* 87(8):1828–1833, 2005.
111. Keller HW, Rehm KE, Helling J: Intramedullary reduction and stabilisation of adult radial neck fractures. *J Bone Joint Surg Br* 76(3):406–408, 1994.
112. Key J: Treatment of fractures of the head and neck of the radius. *JAMA* 96:101–104, 1930.
113. Khalfayan EE, Culp RW, Alexander AH: Mason type II radial head fractures: operative versus nonoperative treatment. *J Orthop Trauma* 6(3):283–289, 1992.
114. King B: Resection of the radial head and neck: An end-result study of thirteen cases. *J Bone Joint Surg Br* 21:839–857, 1939.
115. King GJ, Evans DC, Kellam JF: Open reduction and internal fixation of radial head fractures. *J Orthop Trauma* 5(1):21–28, 1991.
116. King GJ, Faber KJ: Posttraumatic elbow stiffness. *Orthop Clin North Am* 31(1):129–143, 2000.
117. King GJ, Zarzour ZD, Patterson SD, et al: An anthropometric study of the radial head: implications in the design of a prosthesis. *J Arthroplasty* 16(1):112–116, 2001.
118. King GJ, Zarzour ZD, Rath DA, et al: Metallic radial head arthroplasty improves valgus stability of the elbow. *Clin Orthop* (368):114–125, 1999.
119. Knight DJ, Rymaszewski LA, Amis AA, et al: Primary replacement of the fractured radial head with a metal prosthesis. *J Bone Joint Surg Br* 75(4):572–576, 1993.
120. Kocher T: *Textbook of operative surgery*, ed 3, London, 1911, Adam and Charles Black.
121. Koslowsky TC, Schliwa S, Koebke J: Presentation of the microscopic vascular architecture of the radial head using a sequential plastination technique. *Clin Anat* 24(6):721–732, 2011.
122. Lanting BA, Ferreira LM, Johnson JA, et al: The effect of excision of the radial head and metallic radial head replacement on the tension in the interosseous membrane. *Bone Joint J* 95B(10):1383–1387, 2013.
123. Leclerc AE, Deluce S, Ferreira L, et al: Measurements of the ispilateral capitellum can reliably predict the diameter of the radial head. *J Shoulder Elbow Surg* 22(12):1724–1728, 2013.
124. Lee AT, Schrumpf MA, Choi D, et al: The influence of gravity on the unstable elbow. *J Shoulder Elbow Surg* 22(1):81–87, 2013.
125. Levin PD: Fracture of the radial head with dislocation of the distal radio-ulnar joint: case report. Treatment by prosthetic replacement of the radial head. *J Bone Joint Surg Am* 55(4):837–840, 1973.
126. Lewis RW, Thibodeau AA: Deformity of the wrist following resection of the radial head. *Surg Gynecol Obstet* 64:1079–1085, 1937.
127. Liew VS, Cooper IC, Ferreira LM, et al: The effect of metallic radial head arthroplasty on radiocapitellar joint contact area. *Clin Biomech (Bristol, Avon)* 18(2):115–118, 2003.
128. Lindenhovius AL, Felsch Q, Doornberg JN, et al: Open reduction and internal fixation compared with excision for unstable displaced fractures of the radial head. *J Hand Surg [Am]* 32(5):630–636, 2007.
129. Liow RY, Cregan A, Nanda R, et al: Early mobilisation for minimally displaced radial head fractures is desirable. A prospective randomised study of two protocols. *Injury* 33(9):801–806, 2002.
130. Lo IK, King GJ: Arthroscopic radial head excision. *Arthroscopy* 10(6):689–692, 1994.
131. Mackay I, FitzGerald B, Miller JH: Silastic replacement of the head of the radius in trauma. *J Bone Joint Surg Br* 61B(4):494–497, 1979.
132. Mansat P, Morrey BF: The column procedure: a limited lateral approach for extrinsic contracture of the elbow. *J Bone Joint Surg Am* 80(11):1603–1615, 1998.
133. Marcotte AL, Osterman AL: Longitudinal radioulnar dissociation: identification and treatment of acute and chronic injuries. *Hand Clin* 23(2):195–208, vi, 2007.
134. Markolf KL, Lamey D, Yang S, et al: Radioulnar load-sharing in the forearm. A study in cadavera. *J Bone Joint Surg Am* 80(6):879–888, 1998.
135. Mason ML: Some observations on fracture of the head of the radius with a review of one hundred cases. *Br J Surg* 42:123–132, 1954.
136. Mason JA, Shutkin NM: Immediate active motion in the treatment of fractures of the head and neck of the radius. *Surg Gynecol Obstet* 76:731–737, 1943.
137. Mathur N, Sharma CS: Fracture of the head of the radius treated by elbow cast. *Acta Orthop Scand* 55(5):567–568, 1984.
138. McArthur RA: Herbert screw fixation of fracture of the head of the radius. *Clin Orthop* (224):79–87, 1987.
139. McAuliffe JA, Wolfson AH: Early excision of heterotopic ossification about the elbow followed by radiation therapy [see comments]. *J Bone Joint Surg Am* 79(5):749–755, 1997.
140. McDougall A, White J: Subluxation of the inferior radio-ulnar joint complicating fracture of the radial head. *J Bone Joint Surg Br* 39B:278–287, 1957.
141. McKee MD, Schemitsch EH, Sala MJ, et al: The pathoanatomy of lateral ligamentous disruption in complex elbow instability. *J Shoulder Elbow Surg* 12(4):391–396, 2003.
142. Mekhail AO, Ebraheim NA, Jackson WT, et al: Vulnerability of the posterior interosseous nerve during proximal radius exposures. *Clin Orthop* (315):199–208, 1995 Jun.
143. Menth-Chiari WA, Ruch DS, Poehling GG: Arthroscopic excision of the radial head: Clinical outcome in 12 patients with post-traumatic arthritis after fracture of the radial head or rheumatoid arthritis. *Arthroscopy* 17(9):918–923, 2001.
144. Mikic ZD, Vukadinovic SM: Late results in fractures of the radial head treated by excision. *Clin Orthop* (181):220–228, 1983.
145. Miller GK, Drennan DB, Maylahn DJ: Treatment of displaced segmental radial-head fractures. Long-term follow-up. *J Bone Joint Surg Am* 63(5):712–717, 1981.
146. Morgan SJ, Groshen SL, Itamura JM, et al: Reliability evaluation of classifying radial head fractures by the system of Mason. *Bull Hosp Jt Dis* 56(2):95–98, 1997.
147. Moro JK, Werier J, MacDermid JC, et al: Arthroplasty with a metal radial head for unreconstructible fractures of the radial head. *J Bone Joint Surg Am* 83A(8): 1201–1211, 2001.
148. Morrey BF: Radial head fracture. In Morrey BF, editor: *The elbow and its disorders*, ed 3, Philadelphia, 2000, W.B. Saunders, pp 341–364.
149. Morrey BF, An KN: Articular and ligamentous contributions to the stability of the elbow joint. *Am J Sports Med* 11(5):315–319, 1983.
150. Morrey BF, An KN, Stormont TJ: Force transmission through the radial head. *J Bone Joint Surg Am* 70(2):250–256, 1988.
151. Morrey BF, Askew L, Chao EY: Silastic prosthetic replacement for the radial head. *J Bone Joint Surg Am* 63(3):454–458, 1981.
152. Morrey BF, Chao EY, Hui FC: Biomechanical study of the elbow following excision of the radial head. *J Bone Joint Surg Am* 61(1):63–68, 1979.
153. Morrey BF, Tanaka S, An KN: Valgus stability of the elbow. A definition of primary and secondary constraints. *Clin Orthop* (265):187–195, 1991.
154. Murray RC: Fractures of the head and neck of the radius. *Br J Surg* 27:106–118, 1940.
155. O'Driscoll SW, Bell DF, Morrey BF: Posterolateral rotatory instability of the elbow. *J Bone Joint Surg Am* 73(3):440–446, 1991.
156. O'Driscoll SW, Morrey BF, Korinek S, et al: Elbow subluxation and dislocation. A spectrum of instability. *Clin Orthop* 74(280):186–197, 1992.
157. Odelberg-Johnsson G: On fractures of the proximal portion of the radius and their causes. *Acta Radiol* 3:45–53, 1924.
158. Odenheimer K, Harvey JP, Jr: Internal fixation of fracture of the head of the radius. Two case reports. *J Bone Joint Surg Am* 61(5):785–787, 1979.
159. Patterson SD, Bain GI, Mehta JA: Surgical approaches to the elbow. *Clin Orthop* 370:19–33, 2000.
160. Patterson JD, Jones CK, Glisson RR, et al: Stiffness of simulated radial neck fractures fixed with 4 different devices. *J Shoulder Elbow Surg* 10(1):57–61, 2001.

http://e-surg.com

161. Pelto K, Hirvensalo E, Bostman O, et al: Treatment of radial head fractures with absorbable polyglycolide pins: a study on the security of the fixation in 38 cases. *J Orthop Trauma* 8(2):94–98, 1994.
162. Peterson CA, Maki S, Wood MB: Clinical results of the one-bone forearm. *J Hand Surg [Am]* 20(4):609–618, 1995.
163. Pike JM, Athwal GS, Faber KJ, et al: Radial head fractures—an update. *J Hand Surg [Am]* 34(3):557–565, 2009.
164. Pike JM, Grewal R, Athwal GS, et al: Open reduction and internal fixation of radial head fractures: do outcomes differ between simple and complex injuries? *Clin Orthop Relat Res* 471(7):2120–2127, 2014.
165. Pomianowski S, Morrey BF, Neale PG, et al: Contribution of monoblock and bipolar radial head prostheses to valgus stability of the elbow. *J Bone Joint Surg Am* 83A(12):1829–1834, 2001.
166. Popovic N, Lemaire R, Georis P, et al: Midterm results with a bipolar radial head prosthesis: radiographic evidence of loosening at the bone-cement interface. *J Bone Joint Surg Am* 89(11):2469–2476, 2007.
167. Pribyl CR, Kester MA, Cook SD, et al: The effect of the radial head excision and prosthetic radial head replacement on resisting valgus stress at the elbow. *Orthopedics* 9(5):723–726, 1986.
168. Quigley TB: Aspiration of the elbow joint in the treatment of fractures of the head of the radius. *N Engl J Med* 240:915–916, 1949.
169. Rabinowitz RS, Light TR, Havey RM, et al: The role of the interosseous membrane and triangular fibrocartilage complex in forearm stability. *J Hand Surg [Am]* 19A:385–393, 1994.
170. Radin EL, Riseborough EJ: Fractures of the radial head. A review of eighty-eight cases and analysis of the indications for excision of the radial head and nonoperative treatment. *J Bone Joint Surg Am* 48(6):1055–1064, 1966.
171. Regan W, Morrey B: Fractures of the coronoid process of the ulna. *J Bone Joint Surg Am* 71(9):1348–1354, 1989.
172. Ring D, Jupiter JB, Zilberfarb J: Posterior dislocation of the elbow with fractures of the radial head and coronoid. *J Bone Joint Surg Am* 84-A(4):547–551, 2002.
173. Ring D, Psychoyios VN, Chin KR, et al: Nonunion of nonoperatively treated fractures of the radial head. *Clin Orthop* 398:235–238, 2002.
174. Ring D, Quintero J, Jupiter JB: Open reduction and internal fixation of fractures of the radial head. *J Bone Joint Surg Am* 84A(10):1811–1815, 2002.
175. Rosenblatt Y, Young C, MacDermid JC, et al: Osteotomy of the head of the radius for partial articular malunion. *J Bone Joint Surg Br* 91(10):1341–1346, 2009.
176. Rowland AS, Athwal GS, MacDermid JC, et al: Lateral ulnohumeral joint space widening is not diagnostic of radial head arthroplasty overstuffing. *J Hand Surg [Am]* 32(5):637–641, 2007.
177. Sabo MT, Shannon HL, Deluce S, et al: Capitellar excision and hemiarthroplasty affects elbow kinematics and stability. *J Shoulder Elbow Surg* 21(8):1024–1031, 2012.
178. Sanchez-Sotelo J, Romanillos O, Garay EG: Results of acute excision of the radial head in elbow radial head fracture-dislocations. *J Orthop Trauma* 14(5):354–358, 2000.
179. Sanders RA, French HG: Open reduction and internal fixation of comminuted radial head fractures. *Am J Sports Med* 14(2):130–135, 1986.
180. Sarris IK, Kyrkos MJ, Galanis NN, et al: Radial head replacement with the MoPyC pyrocarbon prosthesis. *J Shoulder Elbow Surg* 21(9):1222–1228, 2012.
181. Schwab GH, Bennett JB, Woods GW, et al: Biomechanics of elbow instability. The role of the medial collateral ligament. *Clin Orthop* 146:42–52, 1980.
182. Schwartz RP, Young F: Treatment of fractures of the head and neck of the radius and slipped radial epiphysis in children. *Surg Gynecol Obstet* 528–537, 1933.
183. Sellman DC, Seitz WH, Jr, Postak PD, et al: Reconstructive strategies for radioulnar dissociation: a biomechanical study. *J Orthop Trauma* 9(6):516–522, 1995.
184. Shepard MF, Markolf KL, Dunbar AM: Effects of radial head excision and distal radial shortening on load sharing in cadaver forearms. *J Bone Joint Surg Am* 83A(1):92–100, 2001.
185. Shmueli G, Herold HZ: Compression screwing of displaced fractures of the head of the radius. *J Bone Joint Surg Br* 63B(4):535–538, 1981.
186. Shore BJ, Mozzon JB, MacDermid JC, et al: Chronic posttraumatic elbow disorders treated with metallic radial head arthroplasty. *J Bone Joint Surg Am* 90(2): 271–280, 2008.
187. Shors HC, Gannon C, Miller MC, et al: Plain radiographs are inadequate to identify overlengthening with a radial head prosthesis. *J Hand Surg [Am]* 33(3):335–339, 2008.
188. Skahen JR, III, Palmer AK, Werner FW, et al: Reconstruction of the interosseous membrane of the forearm in cadavers. *J Hand Surg [Am]* 22(6):986–994, 1997.
189. Smets S, Govaers K, Jansen N, et al: The floating radial head prosthesis for comminuted radial head fractures: a multicentric study. *Acta Orthop Belg* 66(4):353–358, 2000.
190. Smith AM, Morrey BF, Steinmann SP: Low profile fixation of radial head and neck fractures: surgical technique and clinical experience. *J Orthop Trauma* 21(10):718–724, 2007.
191. Smith AM, Urbanosky LR, Castle JA, et al: Radius pull test: predictor of longitudinal forearm instability. *J Bone Joint Surg Am* 84A(11):1970–1976, 2002.
192. Smith GR, Hotchkiss RN: Radial head and neck fractures: anatomic guidelines for proper placement of internal fixation. *J Shoulder Elbow Surg* 5(2 Pt 1):113–117, 1996.
193. Sowa DT, Hotchkiss RN, Weiland AJ: Symptomatic proximal translation of the radius following radial head resection. *Clin Orthop* (317):106–113, 1995.
194. Soyer AD, Nowotarski PJ, Kelso TB, et al: Optimal position for plate fixation of complex fractures of the proximal radius: a cadaver study. *J Orthop Trauma* 12(4):291–293, 1998.
195. Speed K: Ferrule caps for the head of the radius. *Surg Gynecol Obstet* 73:845–850, 1941.
196. Stoffelen DV, Holdsworth BJ: Excision or silastic replacement for comminuted radial head fractures. A long-term follow-up. *Acta Orthop Belg* 60(4):402–407, 1994.
197. Strachan JC, Ellis BW: Vulnerability of the posterior interosseous nerve during radial head resection. *J Bone Joint Surg Br* 53(2):320–323, 1971.
198. Strauch RJ, Rosenwasser MP, Glazer PA: Surgical exposure of the dorsal proximal third of the radius: how vulnerable is the posterior interosseous nerve? *J Shoulder Elbow Surg* 5(5):342–346, 1996.
199. Swanson AB, Jaeger SH, La Rochelle D: Comminuted fractures of the radial head. The role of silicone-implant replacement arthroplasty. *J Bone Joint Surg Am* 63(7):1039–1049, 1981.
200. Szabo RM, Hotchkiss RN, Slater RR, Jr: The use of frozen-allograft radial head replacement for treatment of established symptomatic proximal translation of the radius: preliminary experience in five cases. *J Hand Surg [Am]* 22(2):269–278, 1997.
201. Szekeres M, Chinchalkar SJ, King GJ: Optimizing elbow rehabilitation after instability. *Hand Clin* 24(1):27–38, 2008.
202. Taylor TKF, O'Connor BT: The effect upon the inferior radioulnar joint of excision of the head of the radius in adults. *J Bone Joint Surg Br* 46B:83–88, 1964.
203. Thompson HC, III, Garcia A: Myositis ossificans: aftermath of elbow injuries. *Clin Orthop* 50:129–134, 1967.
204. Thompson JD: Comparison of flexion versus extension splinting in the treatment of Mason type I radial head and neck fractures. *J Orthop Trauma* 2(2):117–119, 1988.
205. Tornetta P, III, Hochwald N, Bono C, et al: Anatomy of the posterior interosseous nerve in relation to fixation of the radial head. *Clin Orthop* (345):215–218, 1997.
206. Trousdale RT, Amadio PC, Cooney WP, et al: Radio-ulnar dissociation. A review of twenty cases. *J Bone Joint Surg Am* 74(10):1486–1497, 1992.
207. Unsworth-White J, Koka R, Churchill M, et al: The non-operative management of radial head fractures: a randomized trial of three treatments. *Injury* 25(3):165–167, 1994.
208. Van Glabbeek F, van Riet RP, Baumfeld JA, et al: Detrimental effects of overstuffing or understuffing with a radial head replacement in the medial collateral-ligament deficient elbow. *J Bone Joint Surg Am* 86A(12):2629–2635, 2004.
209. van Riet RP, Morrey BF: Documentation of associated injuries occurring with radial head fracture. *Clin Orthop Relat Res* 466(1):130–134, 2008.
210. van Riet RP, Morrey BF, O'Driscoll SW, et al: Associated injuries complicating radial head fractures: a demographic study. *Clin Orthop Relat Res* 441:351–355, 2005.
211. van Riet RP, Van Glabbeek F, Neale PG, et al: The noncircular shape of the radial head. *J Hand Surg [Am]* 28(6):972–978, 2003.
212. van Riet RP, Van Glabbeek F, Verborgt O, et al: Capitellar erosion caused by a metal radial head prosthesis. A case report. *J Bone Joint Surg Am* 86A(5):1061–1064, 2004.
213. Vanderwilde RS, Morrey BF, Melberg MW, et al: Inflammatory arthritis after failure of silicone rubber replacement of the radial head. *J Bone Joint Surg Br* 76(1):78–81, 1994.
214. Wagner CJ: Fractures of the head of the radius. *Am J Surg* 89:911–913, 1955.
215. Wallace AL, Walsh WR, Rooijen M, et al: The interosseous membrane in radioulnar dissociation. *J Bone Joint Surg Br* 79B:422–427, 1997.
216. Wallenbock E, Potsch F: Resection of the radial head: an alternative to use of a prosthesis? *J Trauma* 43(6):959–961, 1997.
217. Ward WG, Nunley JA: Concomitant fractures of the capitellum and radial head. *J Orthop Trauma* 2(2):110–116, 1988.
218. Watson-Jones R: Discussion of minor injuries of the elbow joint. *Proc R Soc Med* 23:323–327, 1930.
219. Weseley MS, Barenfeld PA, Eisenstein AL: Closed treatment of isolated radial head fractures. *J Trauma* 23(1):36–39, 1983.
220. Wexner SD, Goodwin C, Parkes JC, et al: Treatment of fractures of the radial head by partial excision. *Orthop Rev* 14:83–86, 1985.
221. Yoon A, King GJ, Grewal R: Is ORIF superior to nonoperative treatment in isolated displaced partial articular fractures of the radial head? *Clin Orthop Relat Res* 427(7):2105–2112, 2014.
222. Zunkiewicz MR, Clemente JS, Miller MC, et al: Radial head replacement with a bipolar system: a minimum 2-year follow-up. *J Shoulder Elbow Surg* 21(1):98–104, 2011.

http://e-surg.com

20

Fractures of the Proximal Ulna

George S.M. Dyer and David Ring

Acknowledgment: The authors would like to acknowledge the contributions of Jesse Jupiter, an author of this chapter in the previous edition.

Fractures of the proximal ulna include olecranon fractures, olecranon fracture-dislocations, Monteggia fractures, and fractures of the coronoid process. Fractures of the proximal ulna may compromise the function of both the elbow and forearm articulations. Recognition of patterns and common injury characteristics is improving, and this, in turn, may improve the results of treatment.

PREOPERATIVE EVALUATION

As with other traumatic injuries, the first step in management is to perform a thorough evaluation according to the Advanced Trauma Life Support guidelines. Most fractures of the proximal ulna are associated with low-energy falls in older patients.[64] Such patients should be evaluated for medical conditions that may have contributed to the fall, for injuries related to older age (e.g., other osteoporosis-related fractures, subdural hematoma), and for the effect the injury may have on their social situation (i.e., whether they will be able to live independently while recovering).

The elbow should be checked for wounds and neurovascular injury. Anterior and lateral Monteggia fractures can be associated with injury to the posterior interosseous nerve. Fracture-dislocations can injure the ulnar nerve. High-energy complex fractures of the proximal ulna are occasionally associated with forearm compartment syndrome, especially when there is another fracture within the forearm.[27]

The initial radiographs obtained after the injury are often of low quality due to the deformity and pain in the limb. Nevertheless, it is usually possible to discern the overall pattern of the injury, which may lead one to suspect other injury components that may not be immediately obvious. For example, a posterior olecranon fracture-dislocation is often associated with fractures of the radial head and coronoid process as well as injury to the lateral collateral ligament complex,[64] whereas an anterior fracture-dislocation rarely involves injury to the radial head or collateral ligaments.[63]

Radiographs obtained after manipulative reduction and splint immobilization of the limb (when appropriate) may provide better views of the elbow and additional information about the injury (Figure 20.1, *A* and *B*). When additional information about fractures of the radial head or coronoid may influence decision making, computed tomography (CT) is useful (see Figure 20.1, *C*).[14] In particular, three-dimensional reconstructions with the distal humerus removed can provide a very accurate characterization of the injury (see Figure 20.1, *D* and *E*). Use of such images makes the preoperative planning more accurate.[32]

Additional information regarding the character of the injury can be obtained by viewing the elbow under the image intensifier once the patient is anesthetized. For some complex injuries, complete characterization of the injury pattern—and, therefore, a final treatment plan—can only be made after the injury is exposed operatively. The surgeon must therefore be comfortable with extensile exposures providing adequate access to the injury components.

ANATOMY

Trochlear Notch of the Ulna

The trochlear notch of the ulna has a circumference of nearly 180 degrees, making it one of the most inherently constrained human articulations. Further enhancements of stability include (1) a central longitudinal ridge that interdigitates with a groove in the trochlear articular surface of the distal humerus and (2) a posterior tilt of the articular surface, with the angle between the tip of the coronoid and olecranon processes subtending approximately 30 degrees with a line parallel to the ulnar shaft (Figure 20.2).[37] There is a complementary anterior offset of the trochlea of the humerus from the shaft. This combination is what permits the ulnohumeral joint to flex to 140 degrees, and to extend not at all.

The articular surface has separate coronoid and olecranon areas separated by a small nonarticular transverse groove (see Figure 20.2, *B*).[36,71] Consequently, the treatment of articular fractures of the trochlear notch should focus primarily on restoring the proper relationship between the coronoid and olecranon processes; injury to the region between their articular facets has less impact than similar injuries at other articulations.[63,64]

Coronoid Process

It is useful to consider the following areas of the coronoid articular surface: the anteromedial facet, the lesser sigmoid notch region, the tip, and the base. The anteromedial facet, in particular, is now recognized as a critical stabilizer of the elbow under varus and rotational stress.[13-15]

The soft tissue attachments to the coronoid also figure prominently in the understanding of proximal ulnar fractures (Figure 20.3). The anterior band of the medial collateral ligament

http://e-surg.com

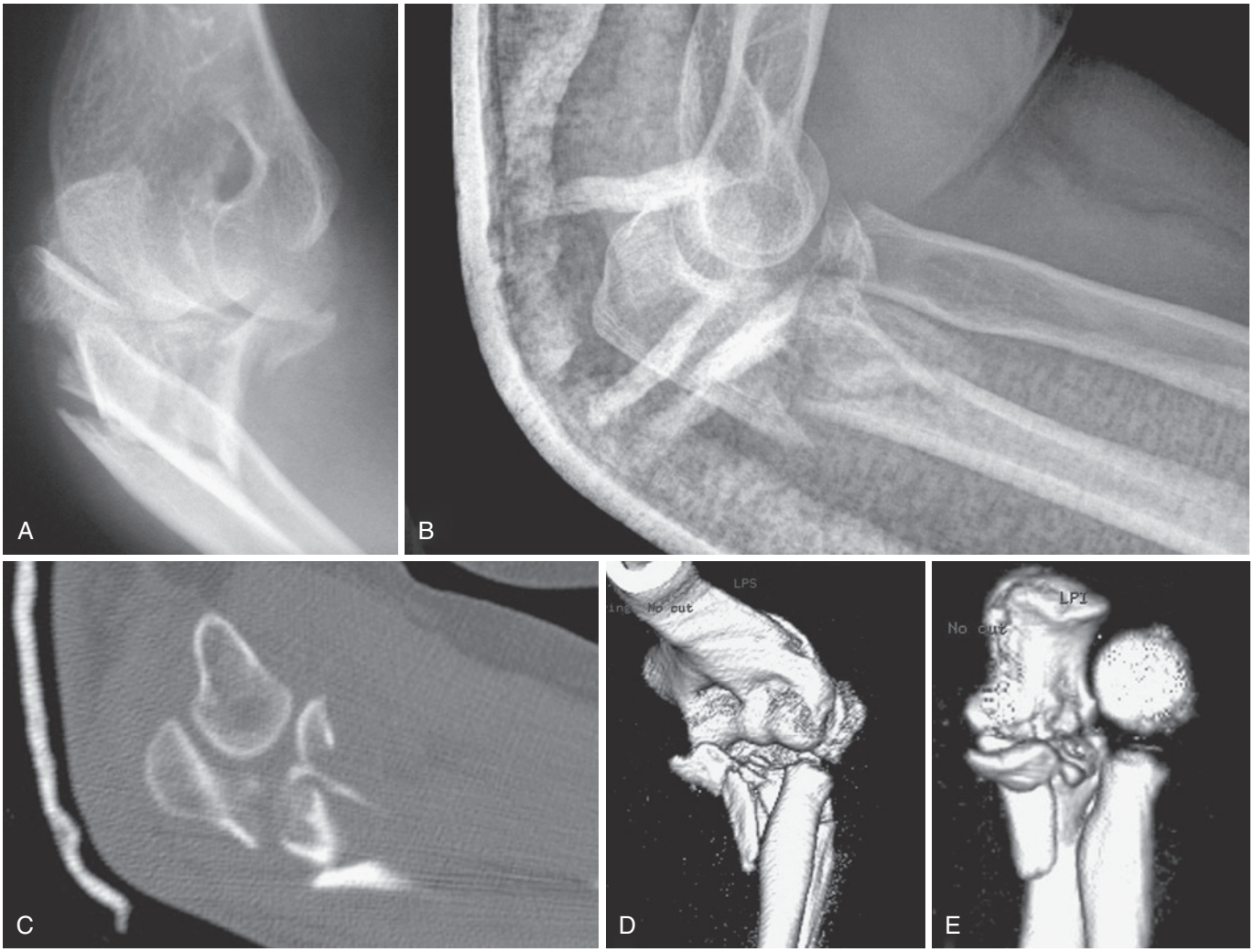

FIGURE 20.1 Imaging of complex proximal ulnar fractures. **A,** A radiograph taken immediately after the injury, before manipulative reduction, gives important information about the injury pattern and displacement. **B,** After manipulative reduction and splinting, the characteristics of the fractures may be more apparent. **C,** Two-dimensional CT scanning can show greater detail, but it can be difficult to follow specific fracture fragments between images. **D,** Three-dimensional reconstructions of CT images can be easier to interpret, particularly after the distal humerus has been removed from the image **(E).** (Copyright © David Ring, MD.)

inserts on the base of the coronoid process.[5] Consequently, the anterior band of the medial collateral ligament is likely to be intact in complex fractures associated with large fractures of the coronoid base or anteromedial coronoid fractures, although its function will be disrupted by the bony injury and restored with stable internal fixation. Surgically, the fragment is a useful landmark for identifying the location of the medial collateral ligament.[14,17]

The brachialis has a broad insertion that extends distal to the coronoid process.[5] Even with large coronoid fractures, a substantial portion of the brachialis insertion remains on the ulnar shaft.

The lateral collateral ligament complex has a broad insertion on the lateral ulna below the radial head and neck and below the level of most coronoid fractures.[8] Traumatic failure of this complex occurs almost without exception as an avulsion of its origin from the lateral epicondyle and not as an intrasubstance tear or avulsion from the ulna.

The anterior capsule inserts a few millimeters below the tip of the olecranon process.[5] This has been interpreted to mean that very small coronoid fractures (a simple fleck, according to Regan and Morrey[53]) may represent intraarticular free fragments; however, operative treatment of these injuries discloses that coronoid tip fractures are much larger than might be guessed based on radiographs and that they always include the capsular insertion.[18,59,60]

Olecranon Process

The junction of the olecranon process with the proximal ulnar metaphysis occurs at the transverse groove of the olecranon, which is a nonarticular area with consequently less subchondral bone and which is also a relatively narrow area in the sagittal plane. These factors may increase the susceptibility to fracture at this site.[36]

The triceps has a very broad and thick insertion onto the posterior and proximal aspects of the olecranon. This is notable

http://e-surg.com

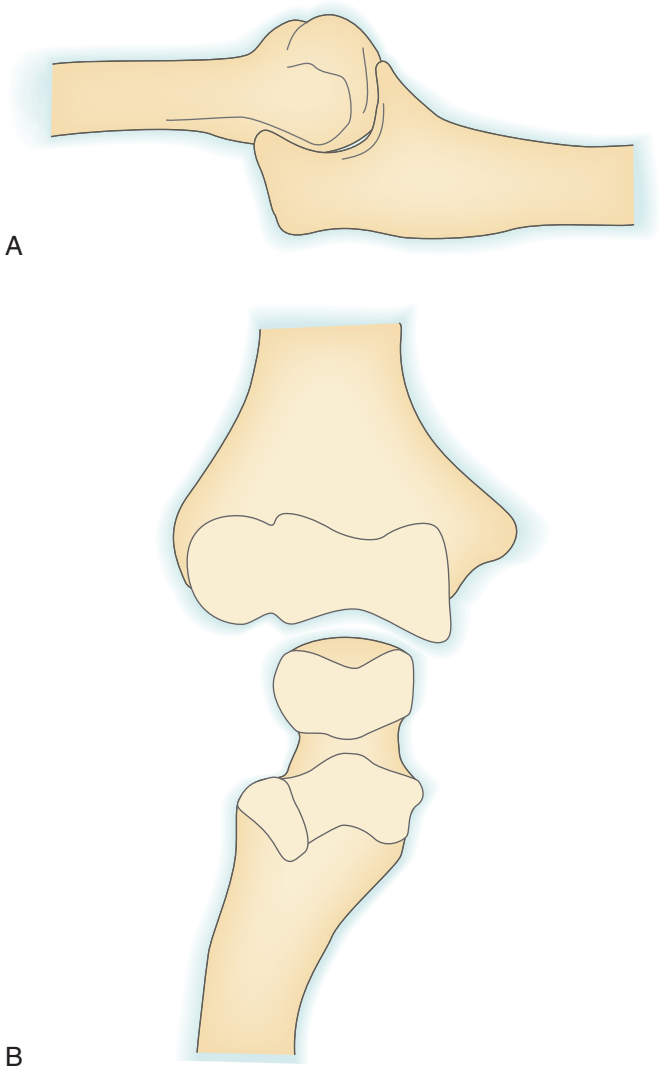

FIGURE 20.2 Anatomy of the trochlear notch. **A,** The trochlear notch of the ulna has a circumference of nearly 180 degrees that tilts somewhat posteriorly. A line drawn between the tips of the olecranon and coronoid processes should create a 30-degree angle with a line parallel to the ulnar shaft. **B,** The stability of the ulnotrochlear articulation is enhanced by interdigitation of a central ridge in the trochlear notch with a groove in the trochlea. The trochlear notch has separate coronoid and olecranon articular facets with an intervening nonarticular area.

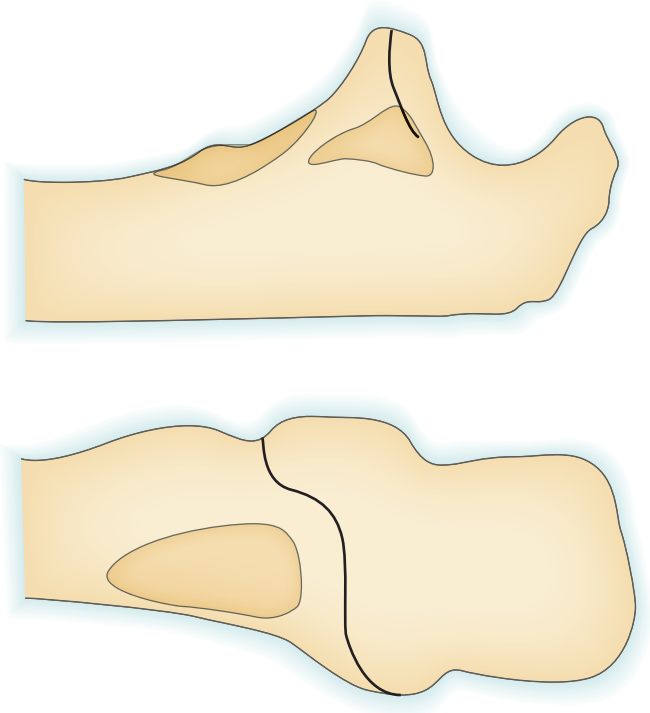

FIGURE 20.3 Soft tissue attachments to the coronoid. The brachialis has a broad and very distal insertion that goes beyond the coronoid and is therefore not disrupted by coronoid fractures. The anterior band of the medial collateral ligament inserts at the base of the coronoid process so that only a very large or medial-sided coronoid fracture will involve the medial collateral ligament insertion. The anterior elbow capsule inserts a few millimeters below the tip of the coronoid process; however, even coronoid fractures that are very small on radiographs nearly always remain attached to the capsule. (Adapted from Cage DJN, Abrams RA, Callahan JJ, Botte MJ: Soft tissue attachments of the ulnar coronoid process. *Clin Orthop Relat Res* 320:154–158, 1995.)

during the application of a plate that contours around this portion of the bone: if the center of the triceps insertion is not split and elevated from the bone, the proximal aspect of the plate will rest well off the bone. For complex olecranon fractures this situation may sometimes be preferable to additional dissection of the soft tissue attachments. Removal of the plate is often needed after healing.

Radial Head

The anatomy of the radial head is difficult to replicate with a prosthesis. It has a slightly elliptic cross section and interdigitates precisely with both the lesser sigmoid notch and the lateral lip of the trochlea, not to mention the capitellar articular surface.[11,12,31] The slight angulation of the proximal radius with respect to the shaft further complicates attempts to reconstruct or replace the radius.

When plates are used to repair the radial head, several anatomic features are important. First, the posterior interosseous nerve runs deep to the supinator along the lateral aspect of the radial neck and is therefore at risk during operative dissection and implant application. Full pronation provides an average of approximately 5 cm of safe area for dissection and internal fixation,[9] but this is not the usual position for internal fixation, and it may be safest to routinely expose the nerve when very distal dissection is needed.[25]

Second, the radial head has a relatively small nonarticular surface, so implants placed on the articular surface must be countersunk. This is possible with plates as well as screws.[21] The nonarticular area can be determined as an arc of roughly 90 degrees with its midpoint directly lateral with the arm in neutral position, with a slightly greater margin anteriorly.[70] As a rough guide to this area, the area between the Lister tubercle and the radial styloid on the distal radius has been suggested.[6]

Finally, the vascular supply to the radial head is limited and tenuous.[72] This may be one reason for the nonunions observed after both operative and nonoperative treatment.[67]

Anatomy of Elbow Stability

The foundation of elbow stability has been increasingly well understood in recent years. The large bony notch formed by the coronoid and olecranon is an obvious source of stability in the

http://e-surg.com

sagittal plane, but the coronal plane anatomy of the coronoid has been elucidated as essential for varus-valgus stability as well.[10,13] Considering ligaments, attempts to quantify the contributions of various anatomic structures to elbow stability have suggested that the anterior band of the medial collateral ligament is the most important stabilizer of the elbow under valgus stress[39] and that the radial head is a secondary stabilizer under valgus stress.[40] It may be more useful to consider the roles of the medial collateral ligament and radial head as overlapping and synergistic rather than hierarchic. Throwing a baseball or javelin probably requires all of these structures.

Observations of valgus stability have had a strong influence on considerations of elbow stability overall: however, if global elbow stability or the ability to maintain a concentric reduction is considered, the complexity increases. Either subluxation or dislocation of the elbow is more directly related to injury to the lateral collateral ligament complex than to the medial collateral ligament.[46,59] Complete dislocation of the elbow can occur with the anterior band of the medial collateral ligament intact. Furthermore, most cases of recurrent elbow instability are related to lateral collateral ligament insufficiency.[44] Loss of the radial head, coronoid, or olecranon will exacerbate this posterolateral rotatory instability.[51,57]

Mechanical studies in cadavers have demonstrated a progressive loss of ulnohumeral stability with greater amounts of olecranon excision, even when all of the ligaments and the radial head are preserved.[1]

Clinical and radiograph-based studies have found that even small coronoid fractures are associated with a substantial effect on elbow stability.[13-15] Clinical experience corroborates these predictions; coronoid fracture is associated with patterns of injury that are notoriously unstable and probably reflect greater capsuloligamentous and musculotendinous injury in addition to the loss of bony buttress.[66]

The contribution of the radial head to stability may not be apparent in the laboratory until several soft tissue structures have also been divided, but in the clinical setting, when managing complex trauma of the elbow and forearm, contact between the radial head and capitellum provides substantial stability. Furthermore, some have suggested that the ulnohumeral joint is more susceptible to arthritis in the absence of radiocapitellar contact,[68] although this will be difficult to prove or disprove.

CLASSIFICATION AND PATTERNS OF INJURY

Monteggia Fractures

Fractures of the proximal ulna that do not involve the trochlear notch often have associated dislocation of the proximal radioulnar joint, the so-called Monteggia lesion.[37,64] The most commonly used classification of these injuries is that of Bado, who distinguished four lesions based on the direction of dislocation of the radial head: type 1, anterior; type 2, posterior; type 3, lateral; and type 4, any direction, associated with a diaphyseal fracture of the radius.[2] In practice, the most useful distinction is between fractures with anterior or lateral displacement of the radial head and those with posterior displacement. The management of injuries with anterior or lateral displacement centers on stable restoration of the ulnar alignment, which nearly always restores alignment and function of the proximal radioulnar joint.[52,64,65]

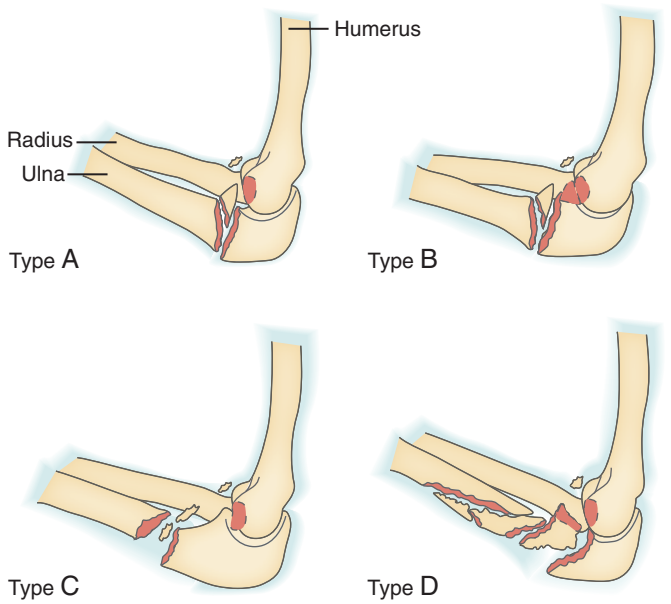

FIGURE 20.4 Illustration of a spectrum of posterior Monteggia injuries. Type A, injury at the ulnohumeral joint with fractures of the olecranon and coronoid; type B, injury at the most common location, the proximal ulnar metaphysis; type C, injury at the diaphyseal level; type D, complex fractures that involve multiple levels. (Copyright © Massachusetts General Hospital Department of Orthopaedic Surgery.)

The Bado type 2, or posterior Monteggia, lesion has long been recognized as a distinct injury that is usually associated with fracture of the radial head and often occurs in the setting of osteoporosis.[29,48,49] There is a spectrum of posterior Monteggia injuries with similar features that vary according to the location of the ulnar fracture.[29] These have been subclassified as type A when the fracture is at the level of the trochlear notch (involving the olecranon and often the coronoid processes); type B when the fracture is in the metaphysis just distal to the trochlear notch; and type C when the fracture is in the diaphysis. Type D fractures are multifragmented fractures that involve more than one region (Figure 20.4).[29] Type D fractures are inherently unstable by virtue of the associated capsuloligamentous damage, fracture and dislocation of the radial head, and morphologic situation of the ulnar fracture, which often involves a triangular or quadrangular fragment of the ulna that includes the anterior ulnar cortex and, sometimes, the coronoid process.

Olecranon Fractures

The Mayo classification of olecranon fractures distinguishes three factors that have a direct influence on treatment: (1) fracture displacement, (2) comminution, and (3) ulnohumeral instability (Figure 20.5).[37] Type 1 fractures that are nondisplaced or minimally displaced are either noncomminuted (type 1A) or comminuted (type 1B) and are treated nonoperatively. Type II fractures feature displacement of the proximal fragment without elbow instability; these fractures require operative treatment. Type IIA fractures (without comminution) are usually treated with tension band wire fixation. When the fracture is oblique, an ancillary interfragmentary compression screw can be added. Type IIB fractures are comminuted and

http://e-surg.com

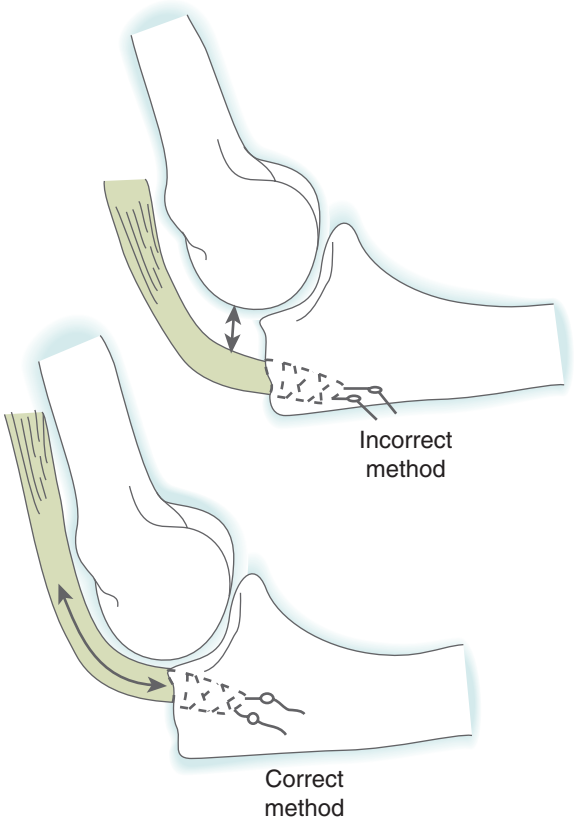

FIGURE 20.5 When the triceps is advanced and reattached to the proximal ulna after olecranon excision, it is better to insert it close to the articular margin.



FIGURE 20.6 The posteromedial varus rotational instability–pattern injury has only recently been recognized. It is characterized by a fracture of the anteromedial coronoid facet and rupture of the origin of the lateral collateral ligament complex from the lateral epicondyle. (Copyright © David Ring, MD.)

require plate fixation. Type III fractures feature instability of the ulnohumeral joint.

Olecranon Fracture-Dislocations

Fractures of the proximal ulna can appear extremely complex. The identification of basic injury patterns can facilitate management. Even a simple fracture pattern of the olecranon can have associated injuries, which the surgeon must be careful not to miss.

Posteromedial varus rotational instability–pattern injuries (Figure 20.6) arise from fracture of the anteromedial facet of the coronoid process, resulting in varus instability.[51] There is an associated injury of either an avulsion of the lateral collateral ligament complex from the lateral epicondyle or a fracture of the olecranon, but rarely both. The radial head is rarely fractured.

On rare occasion, a simple elbow dislocation is associated with a fracture of the olecranon (Figure 20.7). The pattern of olecranon fracture may represent a bony alternative to rupture of the medial collateral ligament complex.

The majority of olecranon fracture-dislocations occur in either an anterior or a posterior direction.[4,63,64]

Anterior (transolecranon) olecranon fracture-dislocations are less common and are often caused by a high-energy direct blow to the forearm.[63] The injury is defined by a complex olecranon or proximal ulna facture, dislocation of the forearm, and *maintenance of the proximal radioulnar relationship* (see Figure 20.8).[41,42,63] This injury pattern was first referred to as a



FIGURE 20.7 In this unusual case, a patient has sustained a posterior dislocation of the elbow associated with a fracture of the olecranon process on the medial aspect, essentially avulsing the posterior aspect of the medial collateral ligament complex. (Copyright © David Ring, MD.)

http://e-surg.com

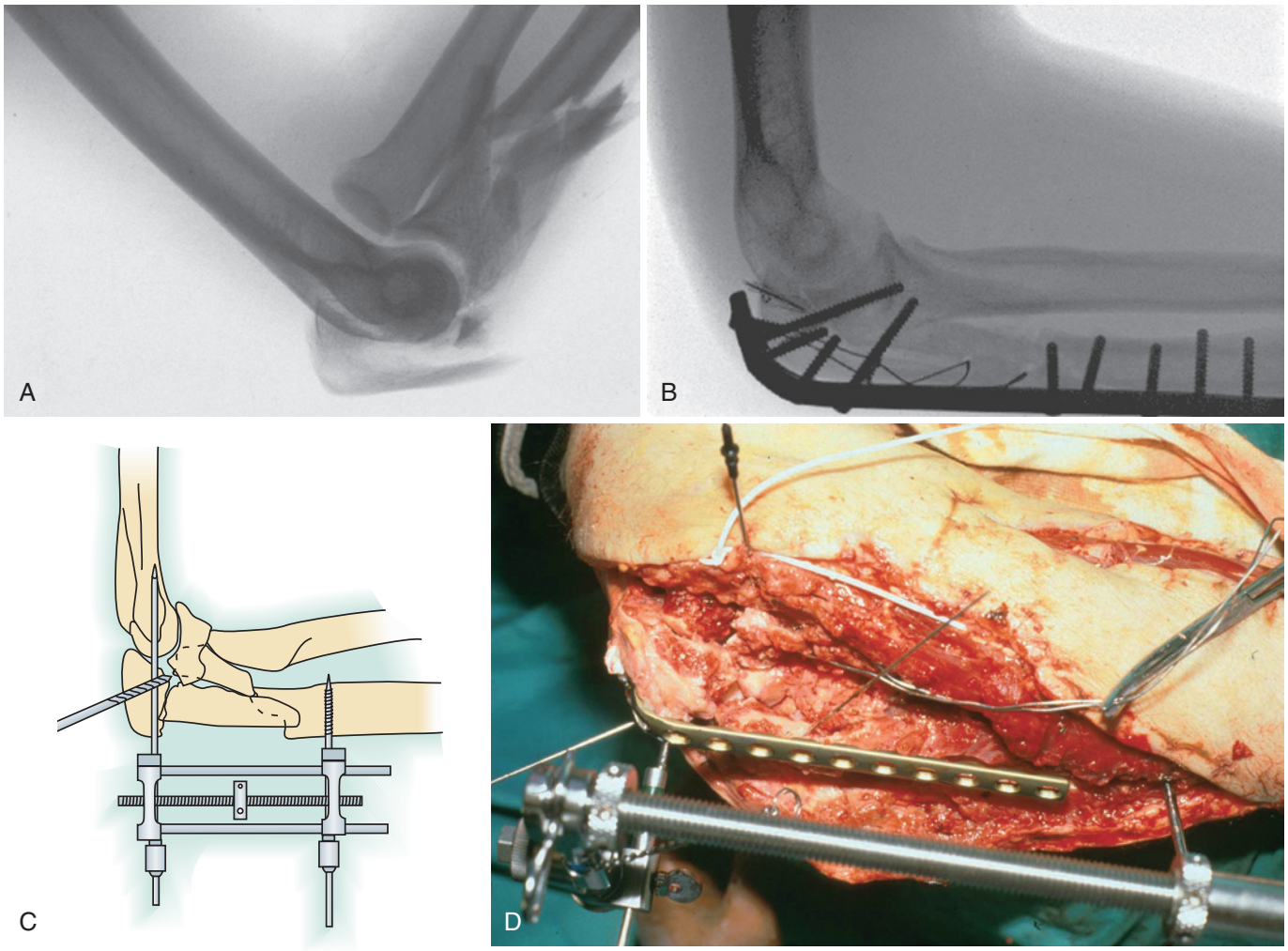

FIGURE 20.8 Anterior (transolecranon) fracture-dislocation of the elbow. **A,** The forearm is displaced anteriorly with the radioulnar relationship relatively spared. The trochlea has imploded through the proximal ulna, creating a very complex fracture with a large coronoid fracture and comminution extending into the diaphysis. The collateral ligaments are usually not injured. **B,** A long contoured dorsal plate secures the relationship between the coronoid and olecranon processes (the contour and dimensions of the trochlear notch) and bridges the comminution. A tension wire engages the fragmented olecranon process. **C,** As described by Mast, an external fixator can assist with reduction and provisional fixation. **D,** The olecranon fragment is held to the trochlea with a stout smooth Kirschner wire. Distraction between this wire and a second distal wire helps realign the intervening fragments. (Copyright © David Ring, MD.)

"trans-olecranon fracture dislocation" in 1974 by Biga and Thomine.[4] This and subsequent studies emphasized the distinction from Monteggia injuries, in which the radioulnar relationship is dissociated.[42,63] When the capsuloligamentous structures are maintained, the elbow is typically rendered stable once the proximal ulnar anatomy is reduced and secured. Associated collateral ligament injury is unusual,[4,63] and the outcomes are generally favorable.[41]

It is useful to consider posterior fracture-dislocations of the olecranon as the most proximal type of posterior Monteggia injuries.[9] Common features of posterior Monteggia injuries include an apex-posterior fracture of the ulna, posterior translation of the radial head with respect to the capitellum, fracture of the radial head, and frequent injury to the lateral collateral ligament complex. With posterior olecranon fracture-dislocations (or type A posterior Monteggia fractures, according to Jupiter and colleagues[29]), the fracture of the ulna occurs at the level of the olecranon and is nearly always associated with a fracture of the coronoid process (Figure 20.9). When a complex olecranon fracture-dislocation is identified as being posterior, fractures of the radial head and coronoid and injury to the lateral collateral ligament should be suspected.

HISTORICAL REVIEW

Lister selected fracture of the olecranon as the first fracture to undergo internal fixation (with a silver wire) using his antiseptic surgical techniques in 1873.[22] Screws may have been used even earlier.[3] Since that time, attempts to repair fractures of the olecranon with simple wiring techniques or long screws have been associated with problems with loosening and migration (or at least prominence) of implants, leading to secondary surgeries to address symptoms and complications such as infection, malunion, and nonunion.[33] This led to a debate regarding whether to repair these fractures or simply excise them and advance the triceps.[20] With careful consideration of technical

http://e-surg.com

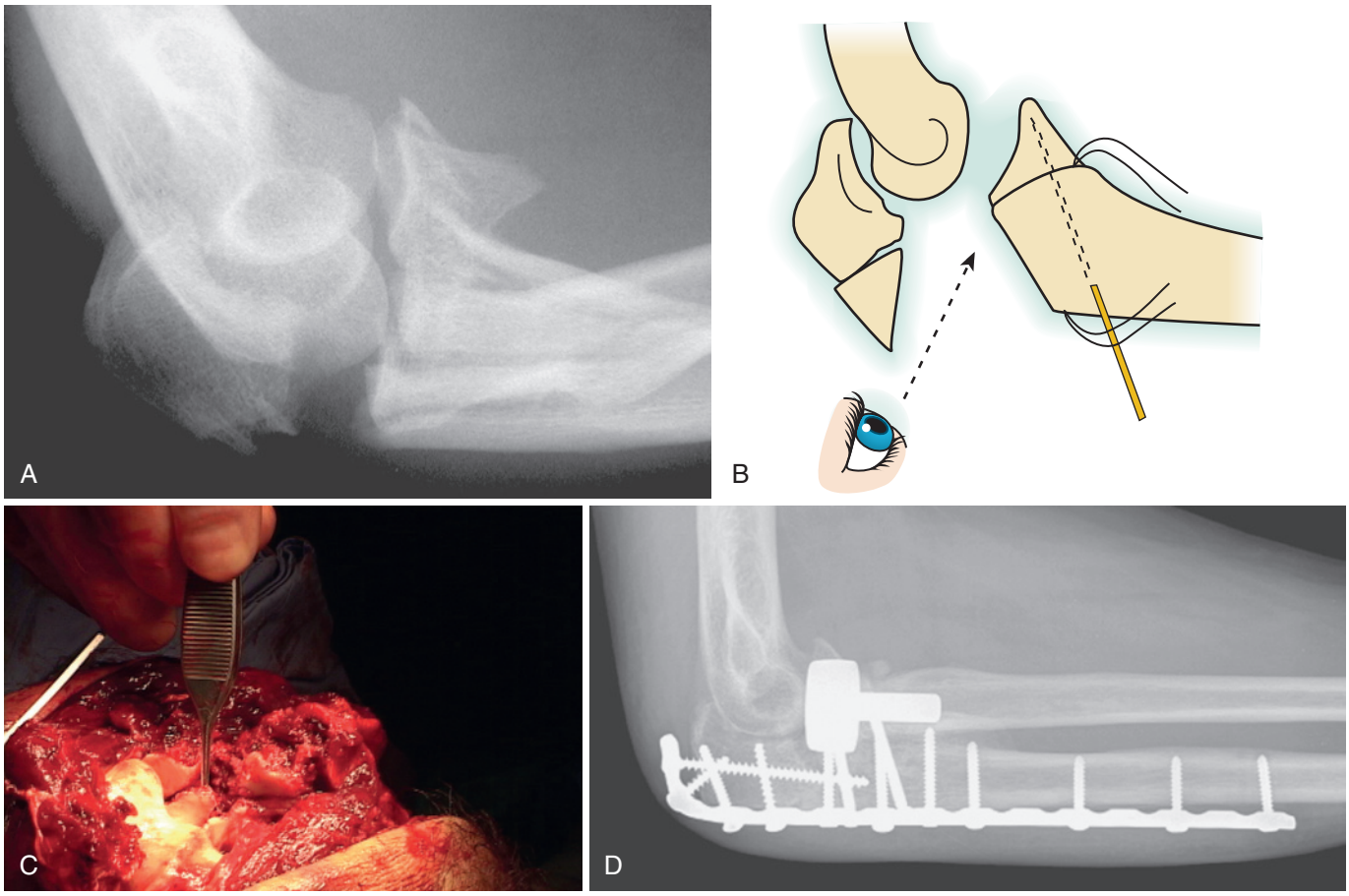

FIGURE 20.9 Posterior olecranon fracture-dislocation (posterior Monteggia fracture type A). **A,** Posterior olecranon fracture-dislocations feature fractures of the coronoid and radial head and frequent injury to the lateral collateral ligament complex. **B,** The coronoid fracture can be visualized and manipulated through the olecranon fracture. **C,** In this patient the coronoid was fractured into three major fragments: anteromedial, central, and lesser sigmoid notch. **D,** A contoured dorsal plate is applied with additional screws repairing the coronoid, and the radial head is replaced with a prosthesis. (Copyright © David Ring, MD.)

aspects of olecranon fixation, the complications have been diminished to the point that excision of the olecranon is used very rarely, and usually only in a very infirm patient.

The major advances in understanding proximal ulnar fractures have related to the recognition of the more complex injury patterns described. An elbow injury that includes a fracture of the ulna is no longer seen as just an "olecranon fracture." Bony injury to the ulna is increasingly seen as one element along a continuum of ligamentous and bony injury that may destabilize the elbow joint. O'Driscoll, Morrey, and others have better defined the mechanism of dislocation and the fracture-related anatomy of the medial collateral ligament.[45,46] Schneeberger and others elucidated the relationship between the bone and ligament stabilizers and the mechanisms of disclocation.[43,69] It is now recognized that both simple olecranon fractures associated with other fractures or ligament injuries and comminuted olecranon fractures are better treated with a plate and screws than with simpler techniques intended for simple olecranon fractures. The characterization of anterior and posterior patterns of olecranon fracture-dislocations is not new but is better recognized, and the value of these distinctions in patient management is better understood.

Our understanding of fractures of the coronoid continues to expand. The importance of a separate fracture of the anteromedial facet is evidence that the Regan and Morrey classification[53] may no longer be adequate to describe these injuries. Using detailed analysis of imaging, Ring, Jupiter, and Doornberg have improved our understanding of the osseous anatomy of the coronoid and called particular attention to its anteromedial facet.[13,14,55] Whereas Regan and Morrey cited large coronoid fractures as more troublesome,[54] recent work has shown that operative fixation of these fractures can be associated with good results[63,64] and that smaller fractures are often associated with more troublesome injury patterns such as the "terrible triad."[66] Many surgeons now believe that most coronoid fractures associated with complex injury patterns merit internal fixation; however, the exposures and fixation techniques are still in evolution.[61]

OPERATIVE PROCEDURE

Skin Incision

A midline posterior skin incision is used for all complex fractures of the proximal ulna. Traumatic wounds are incorporated. Some surgeons prefer that the incision not pass directly over the olecranon and so curve it slightly.[36] A direct midline incision may cut fewer cutaneous nerves.[16]

http://e-surg.com

Excision and Triceps Advancement

The olecranon process is rarely so fragmented that it cannot be repaired. Tension wire techniques can gain fixation of the soft tissue attachments until healing occurs. Hence, excision of the olecranon and triceps advancement is used sparingly for primary treatment of fractures of the olecranon and occasionally for treatment of secondary complications. As primary treatment, excision of the olecranon is best suited to infirm older patients with limited functional demands. The surgeon must be certain that the collateral ligaments, radial head, and coronoid process are intact.

The fragments of the olecranon are excised. Holes are drilled starting from immediately adjacent to the articular margin of the remaining olecranon and exiting the dorsal surface of the ulna. Stout sutures are placed in the triceps using one of a variety of techniques designed to gain hold over a broad portion of the tendon. These are then passed through the drill holes in the ulna, put under tension, and tied.

The elbow is immobilized for 4 weeks, and active motion is allowed thereafter. In low-demand individuals, formal therapy is not necessary.

CRITICAL POINTS *Olecranon Excision and Advancement of the Triceps*

Indications
- Comminuted, osteoporotic fracture
- Older, infirm, inactive patient
- No instability or associated fractures
- Salvage of complex cases
- Rarely used today

Preoperative Evaluation
- Anteroposterior and lateral radiographs of the elbow
- Evaluation of elbow stability under anesthesia

Pearls and Pitfalls
- If the triceps is not advanced to the articular margin of the ulna, this margin may be prominent and grind against the trochlea of the distal humerus.
- Suture anchors cannot be relied on in osteoporotic metaphyseal bone, and the sutures should be passed through drill holes and tied over the dorsum of the ulna.

Postoperative Care
- Provide cast immobilization for 4 to 6 weeks.
- Allow unrestricted active use of the arm thereafter with selective use of therapy.

Athletic Participation
- Not applicable

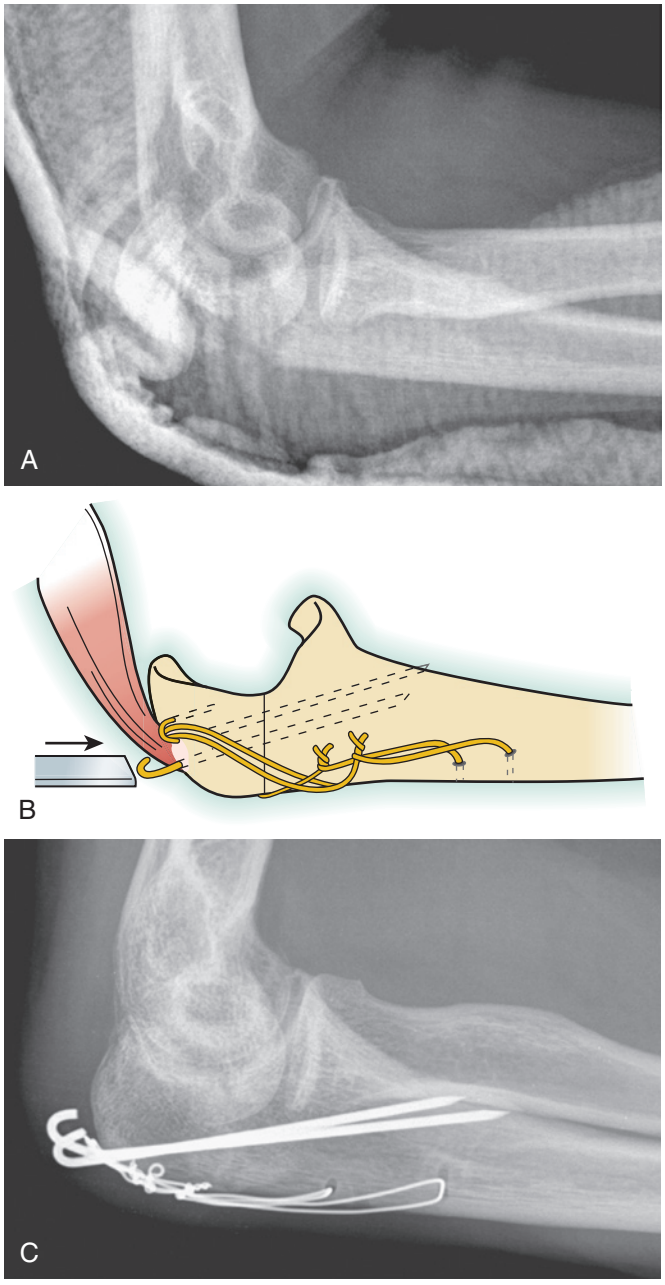

FIGURE 20.10 Tension band wiring. **A,** Tension band wiring is suitable for simple fractures without fracture of the radial head or coronoid or dislocation/subluxation of the ulnohumeral joint. **B,** A technique using anteriorly oriented Kirschner wires, impaction of the proximal ends into the olecranon beneath the triceps insertion, and two small-gauge tension wires can limit hardware-related problems. **C,** Active motion is initiated the morning after surgery. (Copyright © David Ring, MD.)

Tension Band Wiring

Tension band wiring is appropriate for relatively simple fractures at the level of the transverse groove of the trochlear notch, without associated ligament injuries or fracture of the coronoid or radial head (Figure 20.10, *A*). Tension band wire techniques have been described using screws or Kirschner wires. The most common mistake is the failure to distinguish a simple fracture at the transverse groove from a fracture more distal, comminuted, or complex, where a tension band technique will likely fail.

The fracture is opened and hematoma removed to be sure that comminution and articular involvement are limited. The periosteum and muscular attachments are elevated minimally, just enough to ensure accurate reduction of the fragment. A large tenaculum clamp can be used to maintain reduction of the olecranon. A hole drilled in the dorsal surface of the ulna can provide a good anchor point for the distal tine of the clamp.

http://e-surg.com

CRITICAL POINTS *Tension Band Wiring*

Indications
- Simple, noncomminuted fracture
- No instability or associated fractures
- Location of the fracture must be at or proximal to the midpoint of the olecranon fossa

Preoperative Evaluation
- Anteroposterior and lateral radiographs of the elbow

Pearls
- The use of two smaller-gauge wires can limit the prominence of the knots.
- Kirschner wire engagement of the anterior ulnar cortex and olecranon can limit migration.
- Small implants placed appropriately provide adequate fixation for active motion.

Technical Points
- Open the fracture site to evaluate the articular surface.
- Use a dorsoulnar drill hole as an anchor point for the reduction clamp.
- Two 0.045-inch Kirschner wires exit the anterior ulnar cortex distal to the coronoid process.
- Retract the Kirschner wires 5 to 10 mm for later impaction.
- Place two 22-gauge stainless steel wires through separate drill holes in the ulnar diaphysis.
- Pass wires underneath the triceps insertion using a large-bore needle.
- Tension figure-of-eight wires both medially and laterally.
- Bend the Kirschner wires 180 degrees using wire-bending pliers.
- Perform impaction of the cut proximal ends of the Kirschner wires into the olecranon.
- Test the security of the fixation through full flexion.

Pitfalls
- Small (22-gauge) wires are easy to break; use tension but do not tighten.
- Wires left above the triceps insertion are prominent when swelling resolves.

Postoperative Care
- Active elbow motion initiated the morning after surgery
- Arm used for light functional activity
- Resistive exercises when early healing has been established (about 6 weeks)

Athletic Participation
- Allowed after fracture has healed and motion and strength are normal or near-normal (4 to 6 months)

Kirschner Wire Technique

Two parallel Kirschner wires are drilled across the osteotomy site. The majority of surgeons use 0.062-inch wires, but we use 0.045-inch wires with few problems. The wires are often drilled parallel to the ulnar diaphysis, but we and others favor drilling the wires obliquely so that they pass through the anterior ulnar cortex, just distal to the coronoid process.[50,56] This is intended to limit the potential for wire migration; the wires are anchored in the anterior ulnar cortex. After exiting the anterior cortex, the wires are retracted from 5 to 10 mm, anticipating subsequent impaction of the wires into the olecranon process proximally.

The extensor carpi ulnaris and flexor carpi ulnaris muscles are partly elevated from the apex of the ulna distal to the osteotomy site to expose the cortex. The appropriate distance between the fracture and this drill hole has been based on mechanical calculations, but the placement of these holes is determined more practically by transition from the flat proximal ulna to the apex posterior triangular shape of the diaphysis. Likewise, the placement of the drill holes in the anteroposterior plane is not critical, except that they should not be so dorsal as to risk breaking out of the ulna. Large drill holes (2.5 mm) facilitate wire passage.

Many surgeons use a single 18-gauge stainless steel wire for the tension wire, but we prefer to use two 22-gauge stainless steel wires, each passed through its own drill hole distally. The smaller wires are less prominent. An alternative is a size 5 metric sternal wire of the type used in cardiac surgery, which is approximately the same gauge as a 23-gauge wire and comes swedged to a large cutting needle. This facilitates passage through bone tunnels and through the triceps tendon.

The tension wires are placed in a figure-of-eight arrangement over the dorsal ulna. The proximal end of the wire is passed dorsal to the Kirschner wires through the insertion of the triceps using a large-gauge needle. The tension wires are tensioned on both the medial and lateral sides of the ulna until the wires rest flush with the ulna. Some surgeons prefer to twist the wires until they are very tight, but this cannot be done with smaller-gauge wires because they will break. The wires do not need to be tight, only free of slack. This tension is achieved by twisting the wire until it starts to bend over itself. The twisted ends are trimmed and bent into adjacent soft tissues to limit prominence.

The proximal ends of the Kirschner wires are bent 180 degrees and trimmed. The triceps insertion is incised, and impaction of the bent ends into the proximal olecranon is achieved with a bone tamp (see Figure 20.10, *B* and *C*). The strength of the fixation can be tested by completely flexing the elbow; the fracture should not separate.

Screw Technique

Some surgeons prefer to use screws instead of Kirschner wires. Some recommend using a very long screw that engages the intramedullary canal of the ulnar diaphysis distally.[26] Others recommend aiming the screw anteriorly to engage the anterior ulnar cortex. An oblique screw is particularly well suited to an oblique fracture. The remaining portion of the technique is as described for the Kirschner wire technique.

A large (6.5-mm) screw, meant to capture the distal canal of the ulna, may cause a fracture of the distal ulna on insertion. If this occurs, the tension band technique must be abandoned for the plate fixation described next.

Plate and Screws

A plate and screws are used for comminuted olecranon fractures (Figure 20.11), Monteggia fractures (Figure 20.12), and olecranon fracture-dislocations (see Figures 20.8 and 20.9).

Standard Techniques

When a plate is applied to the proximal ulna, it should be contoured to wrap around the proximal aspect of the ulna. A straight plate will have only two or three screws in the

http://e-surg.com

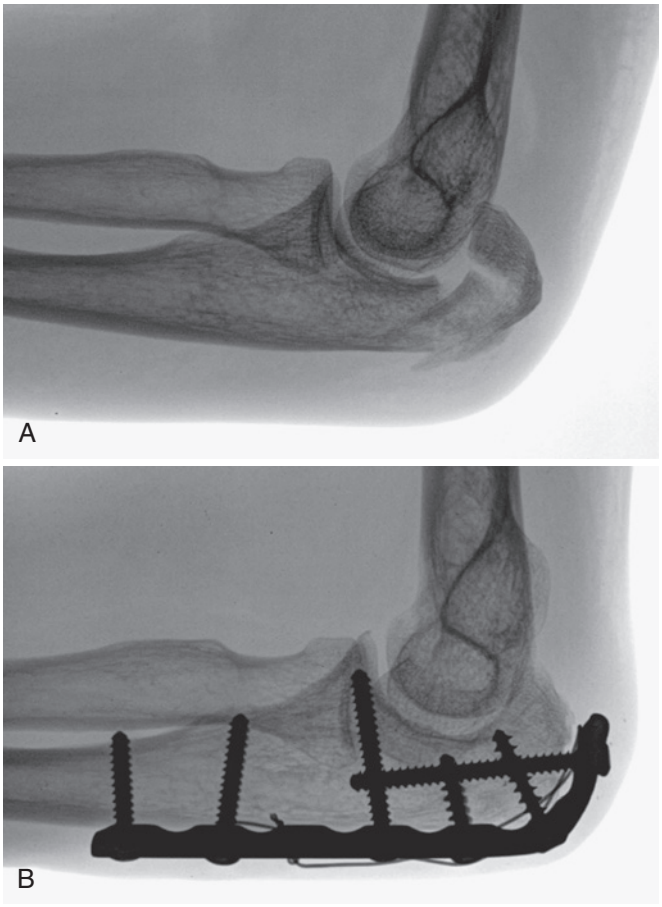

FIGURE 20.11 Plate fixation. **A,** Plate fixation is used for comminuted fractures and fracture-dislocations. **B,** The plate is applied to the dorsal surface of the ulna and contoured around the proximal olecranon. A tension wire engaging the triceps insertion can enhance fixation. (Copyright © David Ring, MD.)

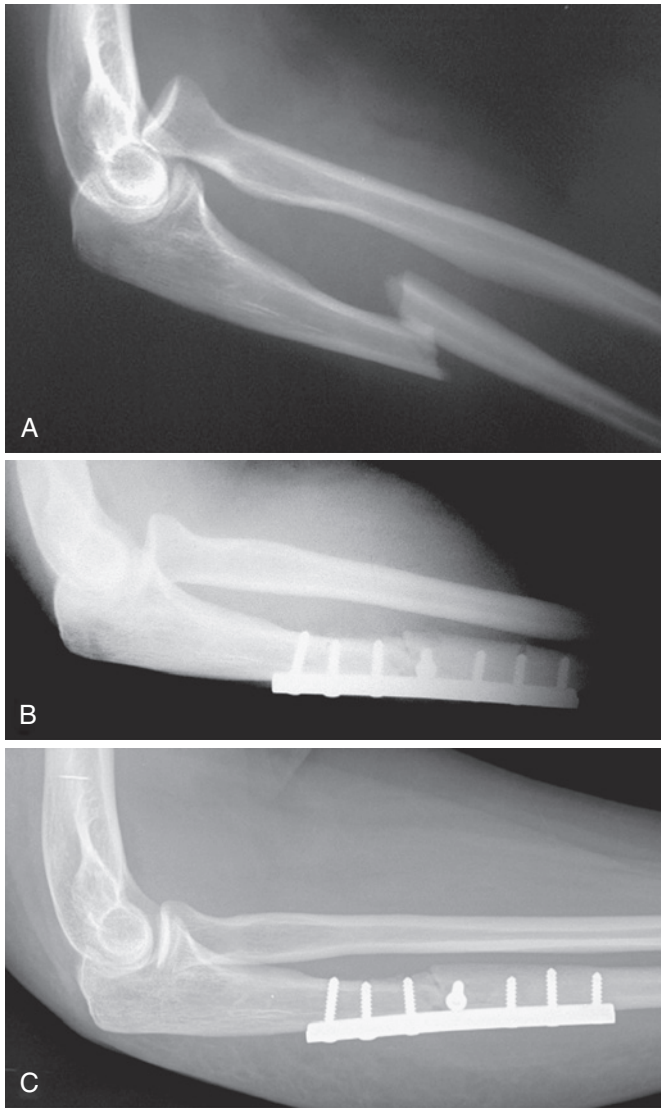

FIGURE 20.12 Anterior (Bado I) Monteggia fracture. **A,** The anterior Monteggia fracture (fracture of the ulnar diaphysis with anterior dislocation of the proximal radioulnar joint) is uncommon in adult patients. **B,** Persistent subluxation of the proximal radioulnar (and radiocapitellar) joints nearly always reflects residual malalignment of the ulna. **C,** Revision of the ulnar fixation achieved better alignment of the forearm. (Copyright © David Ring, MD.)

metaphyseal bone proximal to the fracture. Many patients with complex proximal ulnar fractures have osteopenic bone, which further compromises the strength of plate and screw fixation. Bending the plate around the proximal aspect of the olecranon provides additional screws in the proximal fragment. In addition, the most proximal screws are oriented so that they are orthogonal to more distal screws. Finally, the most proximal screws can be very long screws crossing the fracture line into the distal fragment. In some cases, these screws can be directed to engage one of the cortices of the distal fragment, such as the anterior ulnar cortex. There are now many plating systems that are precontoured to apply to the proximal ulna and may offer a technical advantage and ease of use. These systems also offer locking screws, which improve stability in osteopenic or comminuted bone.

A plate applied to the dorsal surface of the proximal ulna also has several advantages over plates applied to the medial or lateral aspect of the ulna. Placing the plate along the flat dorsal surface can assist with obtaining and monitoring reduction. The dorsal surface is in the plane of the forces generated by active elbow motion, so that the plate functions to a certain extent as a tension band. Finally, dorsal plate placement requires very limited soft tissue stripping.

Exposure of the ulna should preserve periosteal and muscle attachments. A plate contoured to wrap around the proximal ulna can be placed on top of the triceps insertion with few problems. This is particularly useful when the olecranon fragment is small or fragmented. Alternatively, the triceps insertion can be incised longitudinally and partially elevated medially and laterally enough to allow direct plate contact with bone.

Distally, a dorsal plate will lie directly on the apex of the ulnar diaphysis. This might seem unsettling to some surgeons but has not been a problem. One advantage of this situation is that the muscle needs be split only enough to gain access to this apex; there is no need to elevate the muscle or periosteum off either the medial or lateral flat aspect of the ulna. No attempt is made to precisely realign intervening fragmentation. Once the relationship of the coronoid and olecranon facets is restored and the overall alignment is regained, the remaining fragments are bridged, leaving their soft tissue attachments intact. In spite of extensive fragmentation, bone grafts[28] are rarely necessary if the soft tissue attachments are preserved.[63,64]

http://e-surg.com

CRITICAL POINTS *Plate Fixation*

Indications
- Comminuted fractures of the olecranon
- Fracture-dislocations of the elbow

Preoperative Evaluation
- Anteroposterior and lateral radiographs of the elbow
- CT scan and three-dimensional reconstructions to evaluate coronoid and radial head

Pearls
- The pattern of injury can indicate the injury components and prognosis.
- Medial facet coronoid fractures may need direct medial fixation.
- Use of ancillary tension wire can enhance fixation of small, comminuted, or osteoporotic olecranon fragments.
- Restoration of the coronoid and olecranon processes is critical.
- If stripping is limited and fixation is secure, the metaphyseal bone will heal without grafting in most cases.

Technical Points
- Use a dorsal skin incision.
- Use full-thickness skin flaps.
- Access the coronoid through the olecranon fracture or a medial or lateral fascial exposure, within the same single dorsal skin incision.
- Perform provisional fixation of articular fragments to the distal humerus as needed.
- Use contoured dorsal plate fixation.

Pitfalls
- A third tubular plate may be inadequate; fixation may require a dynamic compression plate or its equivalent.
- Comminuted coronoid fractures may need to be protected with hinged fixation.

Postoperative Care
- Active elbow motion is initiated the morning after surgery when fixation is secure.
- Avoid stressing the lateral collateral ligament repair; advise the patient not to abduct the shoulder.
- The arm can be used for light functional activity.
- The arm should be protected in a splint or in hinged external fixation for complex or tenuous repairs.
- Resistive exercises can begin when early healing is established (about 6 weeks).

Athletic Participation
- Allowed after fracture has healed, and motion and strength are normal or near-normal (4 to 6 months)

Monteggia Fractures

The majority of anterior and lateral Monteggia lesions feature diaphyseal fractures of the ulna. Standard compression plate techniques with the plate applied to one of the flat surfaces of the ulna should restore forearm alignment.[64] If the radial head does not align with the capitellum after the ulna is reduced, misalignment of the ulna is the cause until proved otherwise (see Figure 20.12). Only on rare occasions is a separate open reduction of the radial head necessary. If a soft tissue block to reduction is present, the posterior interosseous nerve may be entrapped. Therefore, one should not simply divide the tissue without adequate exposure.

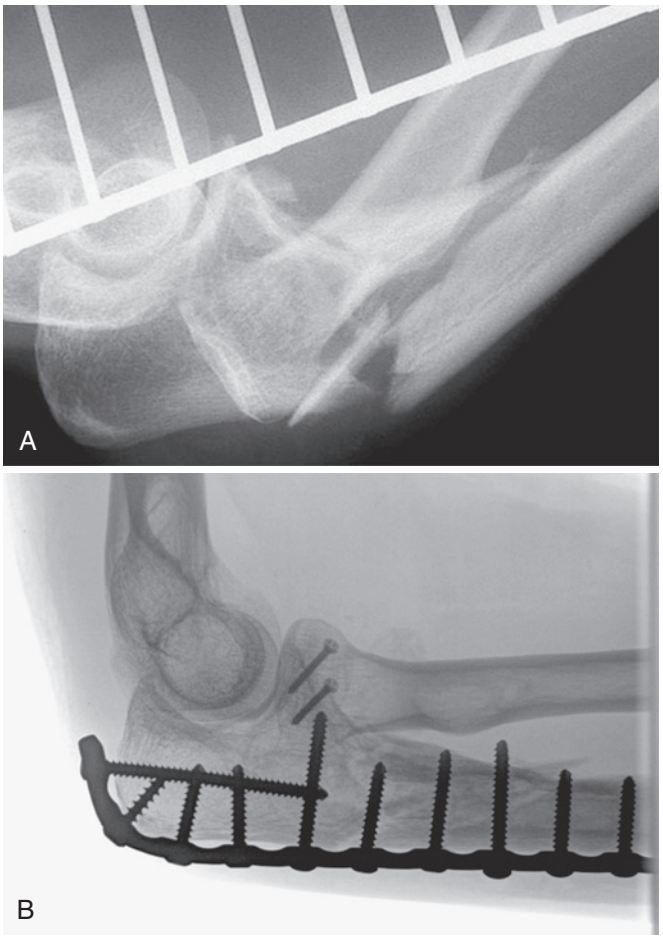

FIGURE 20.13 Metaphyseal posterior Monteggia fracture. **A,** Fractures at the level of the metaphysis often feature a triangular or quadrangular anterior fragment. **B,** Contoured dorsal plate fixation can provide adequate stability to bridge this comminuted area and prevent recurrent apex posterior deformity. (Copyright © David Ring, MD.)

Posterior Monteggia injuries that do not involve the ulnohumeral joint most frequently occur at the level of the proximal ulnar metaphysis. In this location a dorsally applied plate is preferred (Figure 20.13).[65] Posterior Monteggia injuries are also associated with radial head fractures and lateral collateral ligament injuries that may need to be addressed.

Fracture-Dislocations

Fractures of the radial head and coronoid process can be evaluated and often definitively treated through the exposure provided by the fracture of the olecranon process. With little additional dissection, the olecranon fragment can be mobilized proximally, providing exposure of the coronoid through the ulnohumeral joint. If the exposure of the radial head through the posterior injury is inadequate, a separate muscle interval (e.g., Kocher or Kaplan interval[36]) can be used and approached by the elevation of a broad lateral skin flap.

If the exposure of the coronoid is inadequate through the straight dorsal skin incision, a separate deep medial or lateral fascial exposure can be developed. Posterior olecranon fracture-dislocations often require a lateral exposure to address a fracture of the radial head or coronoid or to repair the lateral

http://e-surg.com

CRITICAL POINTS *Extraarticular Monteggia Fractures*

Indications
- Anterior or lateral Monteggia fractures
- Extraarticular Monteggia fractures

Preoperative Evaluation
- Anteroposterior and lateral radiographs of the elbow

Pearls
- Residual radiocapitellar malalignment nearly always reflects ulnar malalignment.
- Posterior Monteggia fractures are often associated with radial head fractures and lateral collateral ligament injury (and therefore elbow instability).

Technical Points
- Perform open reduction of the ulnar fracture.
- Perform closed reduction of the proximal radioulnar joint/radiocapitellar relationship.
- Use plate fixation of the ulna.
- Use a long plate for comminuted fractures.
- Use a contoured dorsal plate for proximal, osteoporotic fractures.
- Check forearm and elbow relationships through full motion.
- Open reduction and stabilization of the radial head is rarely necessary.

Pitfalls
- Residual malalignment of the ulna
- Ulnohumeral instability after posterior Monteggia fracture owing to inadequate treatment of the radial head and lateral collateral ligament
- Early loss of alignment of the ulna owing to an inadequate plate (often a plate placed on the medial or lateral surface of the ulna and with too few proximal screws)

Postoperative Care
- Active motion the morning after surgery
- Functional use of the arm for light tasks
- Resistive exercises when early healing is established (about 6 weeks)

Athletic Participation
- Allowed after fracture has healed, and motion and strength are normal or near-normal (4 to 6 months)

collateral ligament. When the lateral collateral ligament is injured, it is usually avulsed from the lateral epicondyle. This facilitates both exposure and repair. The lateral collateral ligament origin and common extensor musculature can be included in an anterior or posterior flap or mobilized distally.

Exposure of the coronoid can be improved by releasing the origins of the radial wrist extensors from the lateral supracondylar ridge and elevating the brachialis from the anterior humerus and by excising the fractured radial head.[18] A medial exposure, obtained between the two heads of the flexor carpi ulnaris or by splitting the flexor-pronator mass more anteriorly, may be needed to address a complex fracture of the coronoid, particularly one that involves the anteromedial facet of the coronoid process (see Figure 20.6).

The fracture of the coronoid can often be reduced directly through the elbow joint using the limited access provided by the olecranon fracture[18,24] (see Figure 20.9). Provisional fixation can be obtained using Kirschner wires to attach the fragments either to the metaphyseal or diaphyseal fragments of the ulna or to the trochlea of the distal humerus when there is extensive fragmentation of the proximal ulna.[23,34] An alternative to keep in mind when there is extensive fragmentation of the proximal ulna is the use of a skeletal distractor (a temporary external fixator)[34,63] (see Figure 20.16).

External fixation applied between a wire driven through the olecranon fragment and up into the trochlea and a second wire in the distal ulnar diaphysis can often obtain reduction indirectly when distraction is applied between the pins. Definitive fixation can usually be obtained with screws applied under the guidance of an image intensifier. The screws are placed through the plate when there is extensive fragmentation of the proximal ulna. If the coronoid fracture is very comminuted and cannot be securely repaired, the ulnohumeral joint should be protected with temporary hinged or static external fixation or with temporary pin fixation of the ulnohumeral joint, depending on the equipment and expertise available.

A long plate is contoured to wrap around the proximal olecranon. A very long plate (between 12 and 16 holes) should be considered, particularly when there is extensive fragmentation or the bone quality is poor. When the olecranon is fragmented or osteoporotic, a plate and screws alone may not provide reliable fixation. In this situation, it has proved useful to use ancillary tension wire fixation to control the olecranon fragments through the triceps insertion.

❖ AUTHORS' PREFERRED METHOD OF TREATMENT

Nondisplaced, Stable Fractures (Type I)

We use cast immobilization for stable, nondisplaced fractures of the olecranon. The elbow is immobilized at 90 degrees of flexion and neutral forearm rotation. The cast is discontinued after 3 or 4 weeks, and active-assisted elbow range-of-motion exercises are initiated. These injuries are rare, and careful surveillance for displacement must be employed.

Displaced Fractures Without Comminution and Proximal to the Midpoint of the Olecranon (Type IIA)

For simple, noncomminuted fractures without associated ligament injuries, we use tension band wiring. We use 0.045-inch Kirschner wires directed to engage the anterior ulnar cortex distal to the coronoid and bent 180 degrees and impacted into the olecranon proximally. We use two 22-gauge stainless steel tension wires, or size 5 metric sternal suture wires, each passed through its own hole to limit the prominence of the implants.[56]

Displaced Fractures With Comminution and/or Dislocation of the Elbow

For comminuted fractures and fracture-dislocations, we use a dorsal plate and screws contoured to wrap around the proximal ulna.[59,63,64] For some complex fractures, we place the proximal aspect of the plate over the triceps insertion, and otherwise we elevate the triceps insertion and place the plate directly on bone. When the proximal olecranon fragment is small, fragmented, or osteopenic, we also use a tension wire that engages the triceps insertion (see Figures 20.8 and 20.10). In our experience, plates with numerous small screws for the olecranon fragment have not been reliable in this situation. For fracture-dislocations, we use the methods described earlier.

http://e-surg.com

Coronoid Fractures

For fractures of the coronoid that involve the anteromedial facet we use a medial plate unless the fragments are large enough to reliably repair with screws.[18] For nonreconstructible or very complex fractures of the coronoid, we allow 4 to 8 weeks of hinged external fixation to maintain a concentric ulnohumeral reduction and protect the healing coronoid.[7]

POSTOPERATIVE MANAGEMENT AND EXPECTATIONS

Postoperative Protocol

The goal of internal fixation of the proximal ulna is secure fixation allowing active-assisted elbow motion the day after surgery. In the unusual circumstance with more tenuous fixation (usually in an older patient with a complex, osteoporotic fracture), the elbow can be immobilized in a removable elbow splint for 4 weeks before initiating active-assisted elbow motion.

Hand exercises are critical to eliminating hand swelling and preventing hand stiffness. Passive elbow manipulation and joint mobilization are never used. Gravity-assisted and splint-assisted exercises under the control of the patient are very useful. Static progressive splints have been more useful than dynamic splints in our experience.

Resistive exercises and strengthening of the limb are delayed until early healing is established. Full activity is allowed when solid healing is apparent, usually between 3 and 4 months after injury. Plate removal is elective and should be delayed at least 12 to 18 months after injury to avoid the risk of refracture.

Expected Outcome

Intraarticular elbow injuries are commonly associated with some loss of elbow flexion. With very complex injuries, the flexion contracture may be as much as 30 to 40 degrees. Nearly full flexion should be possible in the absence of heterotopic bone or ulnar neuropathy but is also commonly restricted after complex injuries. Forearm rotation is rarely restricted with injury to the olecranon, but posterior fracture-dislocations associated with fracture of the radial head can be associated with diminished forearm rotation.

There is a moderate chance of additional surgery related to prominent or loose implants, elbow contracture with or without heterotopic ossification,[2] or ulnar neuropathy.[19]

Arthrosis is uncommon except after fracture-dislocations, particularly those that involve a coronoid fracture. In spite of arthrosis, the elbow is usually durable if the trochlear notch is restored.

COMPLICATIONS

Early Failure of Fixation

Tension band wire constructs can fail when used for complex fractures or fracture-dislocations (Figure 20.14), but they rarely fail when used for simple fractures unless the patient returns to forceful activity too soon. Plate loosening is most common in older patients with fracture-dislocations when a noncontoured plate has been placed on either the medial or the lateral side of the proximal ulna (Figure 20.15).

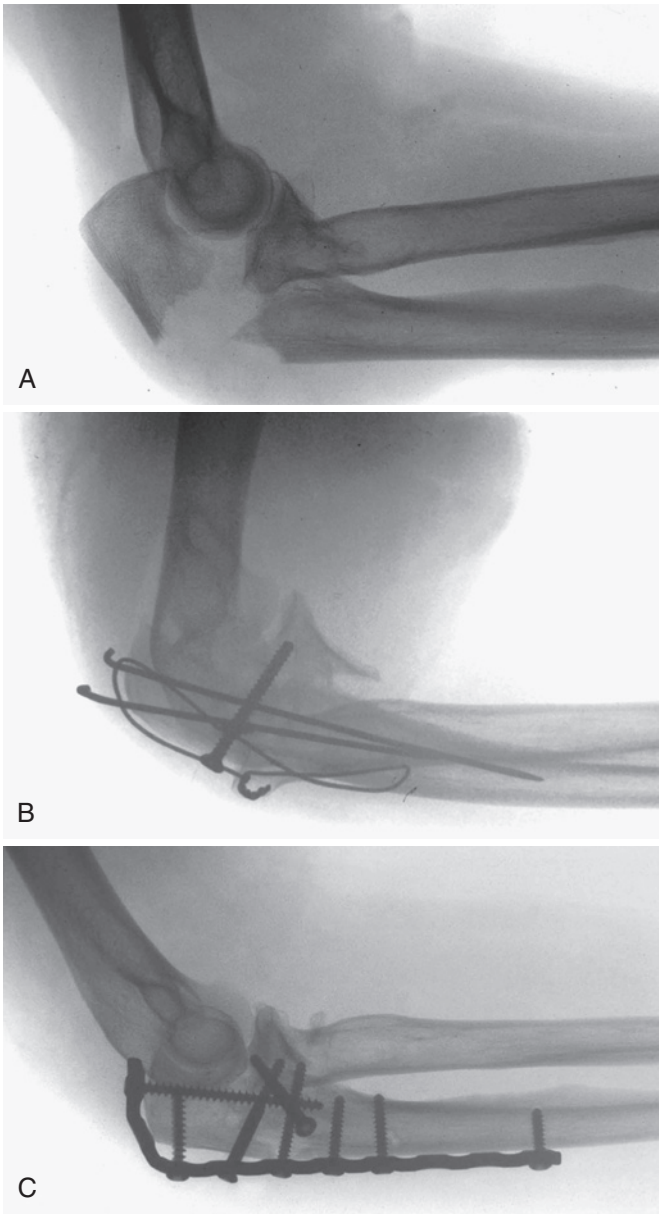

FIGURE 20.14 Failed operative fixation of a posterior olecranon fracture-dislocation. **A,** Type A posterior Monteggia fracture with fractures of the olecranon, coronoid, and radial head. **B,** Internal fixation with a tension band wire construct and a screw proved insufficient. **C,** Revision to a dorsal contoured plate achieved better alignment and more secure fixation. (Copyright © David Ring, MD.)

Failed internal fixation can be salvaged with realignment and repeat internal fixation using a dorsal contoured plate and screws (see Figures 20.14 and 20.15). If there is a bone defect or delayed union, autogenous cancellous bone graft can be applied to the fracture site.

Infection

Infection is unusual after operative treatment of a closed injury and is most often encountered after a complex open injury. In either case, if stable fixation is retained the infection can be treated without implant removal. Adequate soft tissue coverage, serial débridements, and parenteral antibiotics can often eradicate an infection and at a minimum can allow healing to become established before implant removal. For this to be successful, no

http://e-surg.com

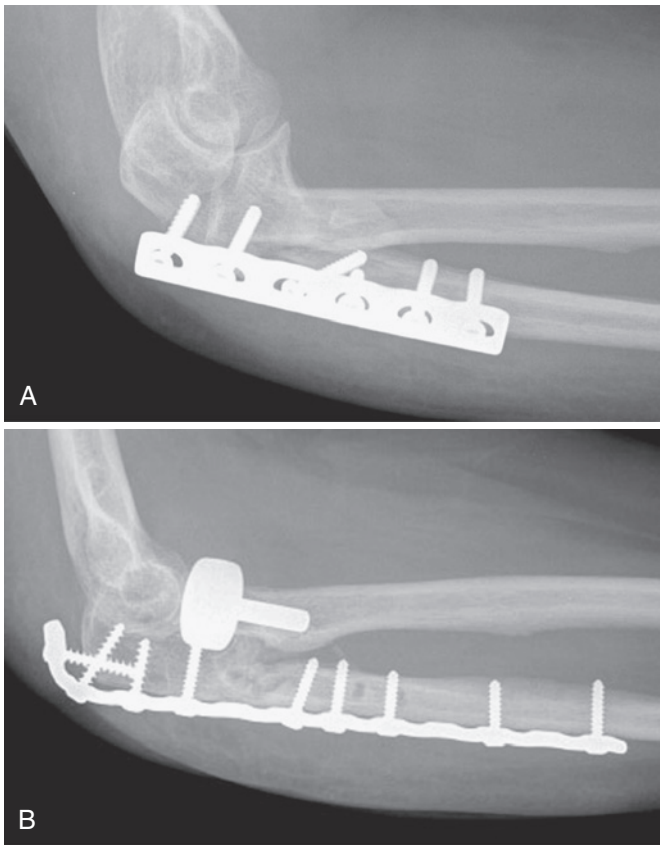

FIGURE 20.15 Plate loosening after operative treatment of a posterior Monteggia fracture. **A,** Posterior Monteggia fractures are common in older, osteoporotic patients. A plate applied to the medial or lateral surface and not contoured around the proximal ulna may have an inadequate hold on the proximal metaphyseal segment. **B,** Revision to a long contoured dorsal plate can achieve better fixation and improve elbow and forearm function. (Copyright © David Ring, MD.)

devitalized tissue can remain in the wound. If there is extensive devitalized tissue, a more thorough débridement and removal of implants may be necessary.

Instability

Elbow instability can occur after posterior olecranon fracture-dislocations and posterior Monteggia fractures.[50] It can result from one or more features, including residual posterior angulation of the proximal ulna with posterior subluxation of the radial head with respect to the capitellum; inadequate restoration of the coronoid or radial head; or lateral collateral ligament injury. Restoration of these factors along with temporary hinged external fixation can usually restore stability. The procedure is addressed more completely in Chapter 23 (Figure 20.16).

Nonunion

Nonunion after simple olecranon fractures is very unusual.[40] Proximal ulna nonunion usually occurs after a fracture-dislocation of the proximal ulna. Union can usually be achieved with contoured dorsal plate fixation and autogenous bone grafting[47,62] (Figure 20.17).

Ulnar Neuropathy

Ulnar neuropathy is an important and increasingly recognized sequel of complex elbow trauma. Patients who struggle with flexion during the postoperative period and have hypersensitivity or complaints of pain greater than expected should be carefully evaluated for symptoms and signs of ulnar neuropathy.

On occasion, a patient who initially is recovering well will lose motion and have increased pain between 4 and 6 weeks after injury concomitant with signs and symptoms of ulnar neuropathy. Patients with this type of subacute ulnar neuropathy might benefit from ulnar nerve release.[19]

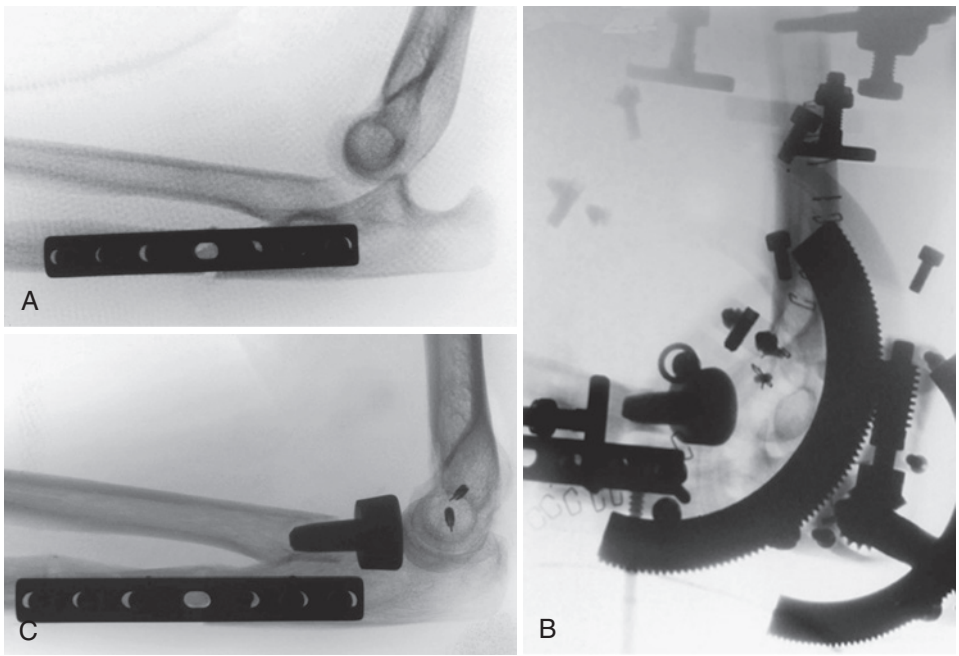

FIGURE 20.16 Ulnohumeral instability after posterior Monteggia fracture. **A,** Surgeons are occasionally surprised by ulnohumeral instability after what was perceived to be a forearm injury; however, posterior Monteggia injuries can include fracture of the radial head and injury to the lateral collateral ligament complex. **B,** Open relocation of the ulnohumeral joint, restoration of radiocapitellar contact with a radial head prosthesis, repair of the lateral collateral ligament complex, and temporary hinged fixation were used to restore stability. **C,** A stable, well-aligned elbow and forearm with good function was achieved. (Copyright © David Ring, MD.)

http://e-surg.com

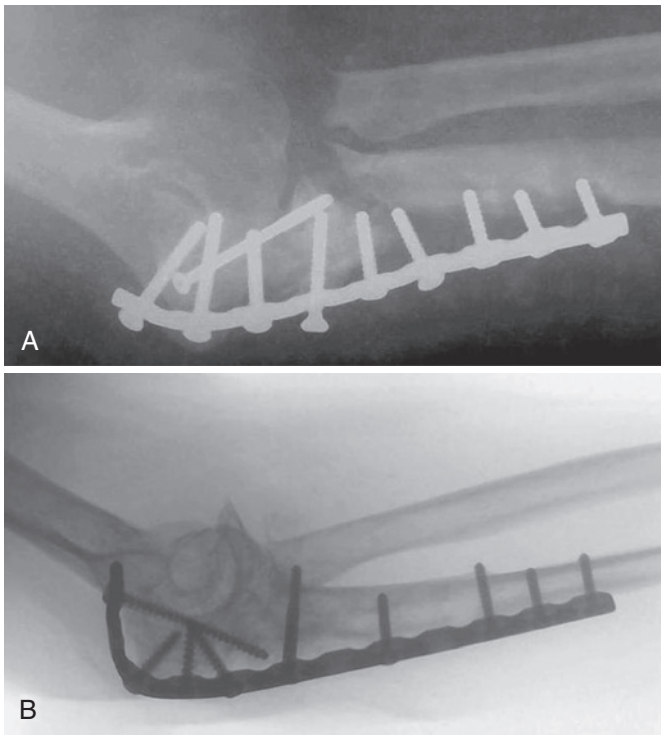

FIGURE 20.17 Nonunion of the proximal ulna. **A,** Nonunion of the proximal ulna is most common after a complex fracture and is uncommon after simple olecranon fracture. This patient has loose internal fixation and a synovial nonunion. **B,** Contoured dorsal plate fixation and autogenous cancellous bone grafting achieved union and improved elbow and forearm function. (Copyright © David Ring, MD.)

Chronic ulnar neuropathy can respond to ulnar nerve release. Even weakness and atrophy can sometimes improve after release, although it may take many years.[35]

Stiffness of Heterotopic Ossification

Stiffness is a very common complication of fractures of the proximal ulna.[2] The ulnar nerve should be carefully evaluated and addressed as just described. If heterotopic ossification is restricting motion, this can be resected as soon as radiographically mature (within 3 to 4 months) as long as the soft tissue envelope is stable and mobile.[30,58] Postoperative irradiation can serve as useful prophylaxis against recurrent heterotopic bone (see Chapter 24).

In the absence of ulnar neuropathy or heterotopic bone, capsular contracture will usually respond to active-assisted elbow mobility exercises. Dynamic or static progressive splints are also very useful in this situation. If nonoperative treatment is unsuccessful, operative capsular excision will restore motion in most patients.

Arthrosis

Severe arthrosis is uncommon after proximal ulnar fractures. With lesser grades of arthrosis, the native elbow will function better than a prosthetic or interpositional arthroplasty and should be maintained as long as possible. Older, infirm patients with severe arthrosis can be treated with semiconstrained total elbow arthroplasty.[32] Healthy active patients with stiffness and pain from arthrosis may be better treated by interpositional arthroplasty.[38]

For Case Studies, Videos, and more, please visit ExpertConsult.com.

REFERENCES

1. An KN, Morrey BF, Chao EY: The effect of partial removal of proximal ulna on elbow constraint. *Clin Orthop Relat Res* 209:270–279, 1986.
2. Bauer AS, Lawson BK, Bliss RL, et al: Risk factors for posttraumatic heterotopic ossification of the elbow: case-control study. *J Hand Surg [Am]* 37(7):1422–1429, 2012.
3. Berenger-Feraud L, editor: *Des Fractures en V au point de vue de leur gravite et de leur traitement*, Paris, Impr, 1864, Hennuyer.
4. Biga N, Thomine JM: [Trans-olecranal dislocations of the elbow]. *Rev Chir Orthop Reparatrice Appar Mot* 60(7):557–567, 1974.
5. Cage DJ, Abrams RA, Callahan JJ, et al: Soft tissue attachments of the ulnar coronoid process. An anatomic study with radiographic correlation. *Clin Orthop Relat Res* 320:154–158, 1995.
6. Caputo AE, Mazzocca AD, Santoro VM: The nonarticulating portion of the radial head: anatomic and clinical correlations for internal fixation. *J Hand Surg [Am]* 23(6):1082–1090, 1998.
7. Cobb TK, Morrey BF: Use of distraction arthroplasty in unstable fracture dislocations of the elbow. *Clin Orthop Relat Res* 312:201–210, 1995.
8. Cohen MS, Hastings H, 2nd: Rotatory instability of the elbow. The anatomy and role of the lateral stabilizers. *J Bone Joint Surg Am* 79(2):225–233, 1997.
9. Diliberti T, Botte MJ, Abrams RA: Anatomical considerations regarding the posterior interosseous nerve during posterolateral approaches to the proximal part of the radius. *J Bone Joint Surg Am* 82(6):809–813, 2000.
10. Doornberg JN, de Jong IM, Lindenhovius AL, et al: The anteromedial facet of the coronoid process of the ulna. *J Shoulder Elbow Surg* 16(5):667–670, 2007.
11. Doornberg JN, Linzel DS, Zurakowski D, et al: Reference points for radial head prosthesis size. *J Hand Surg [Am]* 31(1):53–57, 2006.
12. Doornberg JN, Parisien R, van Duijn PJ, et al: Radial head arthroplasty with a modular metal spacer to treat acute traumatic elbow instability. *J Bone Joint Surg Am* 89(5):1075–1080, 2007.
13. Doornberg JN, Ring D: Coronoid fracture patterns. *J Hand Surg [Am]* 31(1):45–52, 2006.
14. Doornberg JN, Ring DC: Fracture of the anteromedial facet of the coronoid process. *J Bone Joint Surg Am* 88(10):2216–2224, 2006.
15. Doornberg JN, van Duijn J, Ring D: Coronoid fracture height in terrible-triad injuries. *J Hand Surg [Am]* 31(5):794–797, 2006.
16. Dowdy PA, Bain GI, King GJ, et al: The midline posterior elbow incision. An anatomical appraisal. *J Bone Joint Surg Br* 77(5):696–699, 1995.
17. Duckworth AD, Ring D, Kulijdian A, et al: Unstable elbow dislocations. *J Shoulder Elbow Surg* 17(2):281–286, 2008.
18. Dyer GSM, Ring D: Open treatment of complex traumatic elbow instability. In Lee DH, Neviaser RJ, editors: *Shoulder and elbow surgery: operative techniques*, Philadelphia, 2011, Elsevier.
19. Faierman E, Wang J, Jupiter JB: Secondary ulnar nerve palsy in adults after elbow trauma: a report of two cases. *J Hand Surg [Am]* 26(4):675–678, 2001.
20. Gartsman GM, Sculco TP, Otis JC: Operative treatment of olecranon fractures. Excision or open reduction with internal fixation. *J Bone Joint Surg Am* 63(5):718–721, 1981.
21. Geel CW, Palmer AK, Ruedi T, et al: Internal fixation of proximal radial head fractures. *J Orthop Trauma* 4(3):270–274, 1990.
22. Godlee RJ: *Lord Lister*, London, 1918, Macmillan.
23. Hastings H, 2nd, Engles DR: Fixation of complex elbow fractures. Part II: Proximal ulna and radius fractures. *Hand Clin* 13(4):721–735, 1997.
24. Heim U: [Combined fractures of the radius and the ulna at the elbow level in the adult. Analysis of 120 cases after more than 1 year]. *Rev Chir Orthop Reparatrice Appar Mot* 84(2):142–153, 1998.
25. Hotchkiss RN: Displaced fractures of the radial head: internal fixation or excision? *J Am Acad Orthop Surg* 5(1):1–10, 1997.
26. Hutchinson DT, Horwitz DS, Ha G, et al: Cyclic loading of olecranon fracture fixation constructs. *J Bone Joint Surg Am* 85(5):831–837, 2003.
27. Hwang RW, de Witte PB, Ring D: Compartment syndrome associated with distal radial fracture and ipsilateral elbow injury. *J Bone Joint Surg Am* 91(3):642–645, 2009.
28. Ikeda M, Fukushima Y, Kobayashi Y, et al: Comminuted fractures of the olecranon. Management by bone graft from the iliac crest and multiple tension-band wiring. *J Bone Joint Surg Br* 83(6):805–808, 2001.
29. Jupiter JB, Leibovic SJ, Ribbans W, et al: The posterior Monteggia lesion. *J Orthop Trauma* 5(4):395–402, 1991.
30. Jupiter JB, Ring D: Operative treatment of post-traumatic proximal radioulnar synostosis. *J Bone Joint Surg Am* 80(2):248–257, 1998.

http://e-surg.com

CASE STUDY 20.1 Complex Posterior Olecranon Fracture-Dislocation of the Elbow (Type A Posterior Monteggia Fracture)

A 45-year-old woman fell down stairs, fracturing her elbow (eFigure 20.1).

The coronoid was realigned and provisionally secured through the olecranon fracture. Definitive fixation was achieved with a precontoured plate (Acumed, Hillsboro, Oregon). The radial head was replaced with a prosthesis, and the lateral collateral ligament was reattached to the lateral epicondyle (eFigure 20.2).

http://e-surg.com

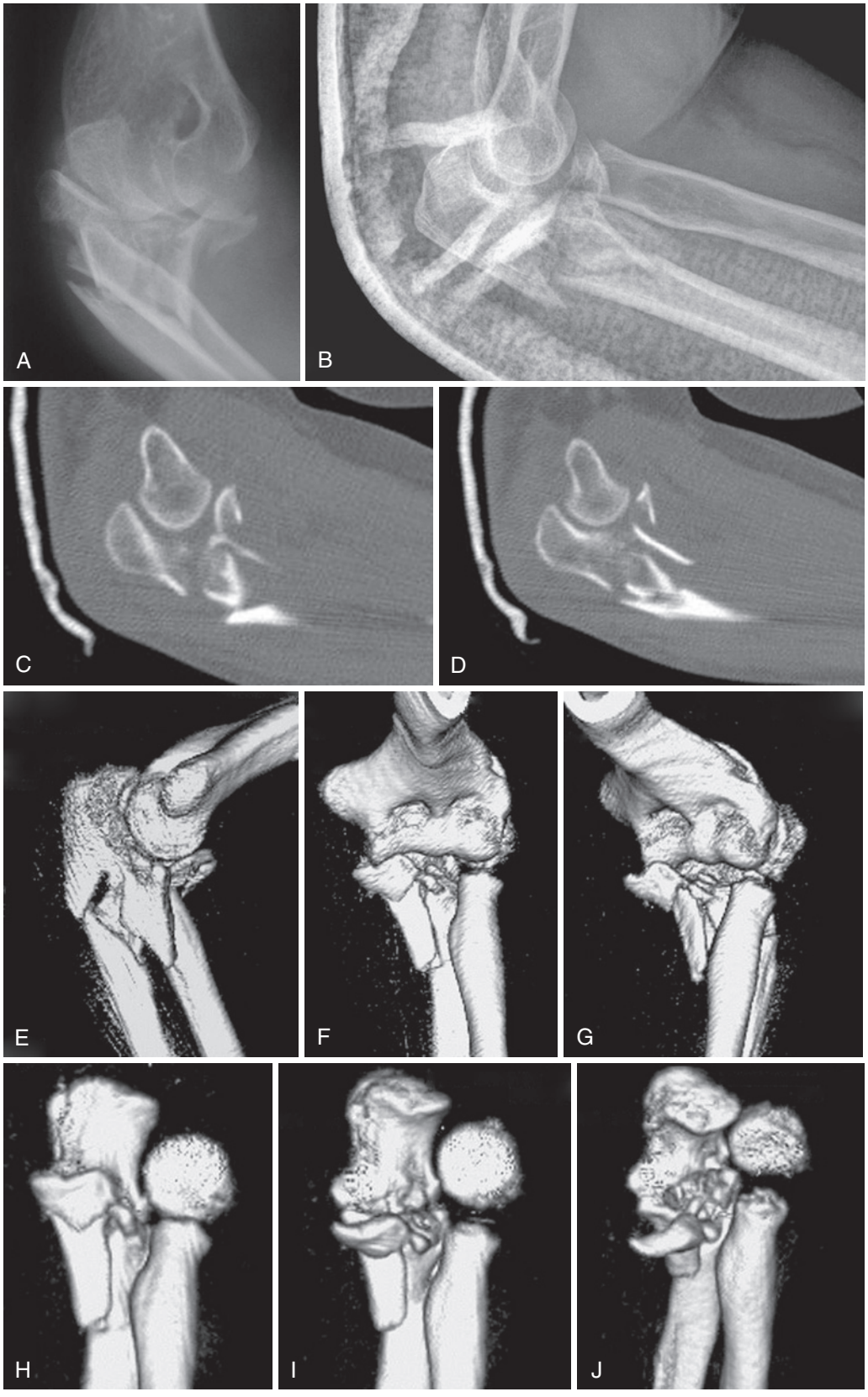

eFIGURE 20.1 **A,** The radiographs taken prior to reduction of the injury showed an apex posterior fracture of the proximal ulna with posterior dislocation of the radial head with respect to the capitellum. **B,** After manipulative reduction and splinting, it is apparent that there are comminuted fractures of the coronoid and radial head. **C** and **D,** Two-dimensional computed tomography (CT) images depict the coronoid fracture, but it can be difficult to follow the fragments and remain oriented from image to image. **E** to **J,** Three-dimensional CT reconstructions with and without the distal humerus show the fracture and injury pattern in easily interpreted images. There is a large anteromedial and tip coronoid fragment, comminution of the lesser sigmoid notch, and comminution of the base of the coronoid. The radial head is fractured into one large fragment and several small fragments.

http://e-surg.com

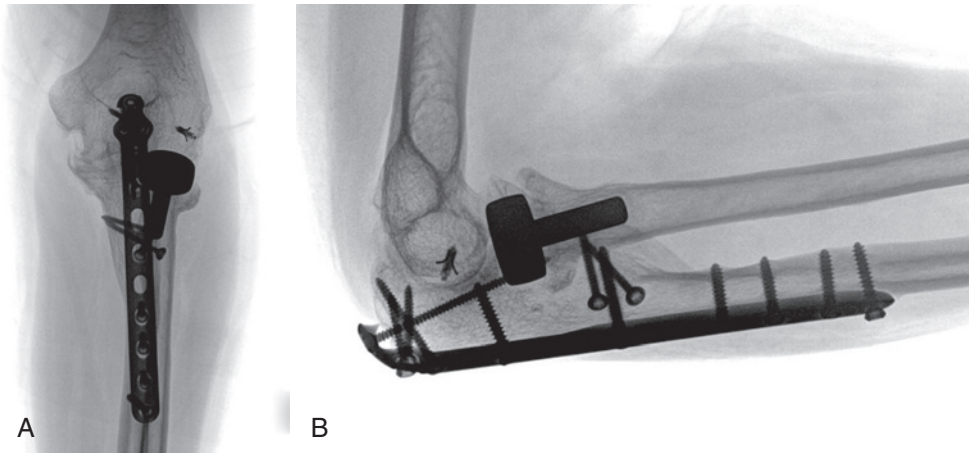

eFIGURE 20.2 **A** and **B,** Postsurgical radiographs.

http://e-surg.com

CASE STUDY 20.2 Posterior Olecranon Fracture-Dislocation

A 40-year-old man fell from a height (eFigure 20.3). The coronoid was manipulated and reduced through the olecranon fracture; the proximal ulna was secured with a dorsal contoured plate and screws; the radial head was replaced with a prosthesis; and the lateral collateral ligament complex was reattached to the lateral epicondyle with a suture anchor (eFigure 20.4).

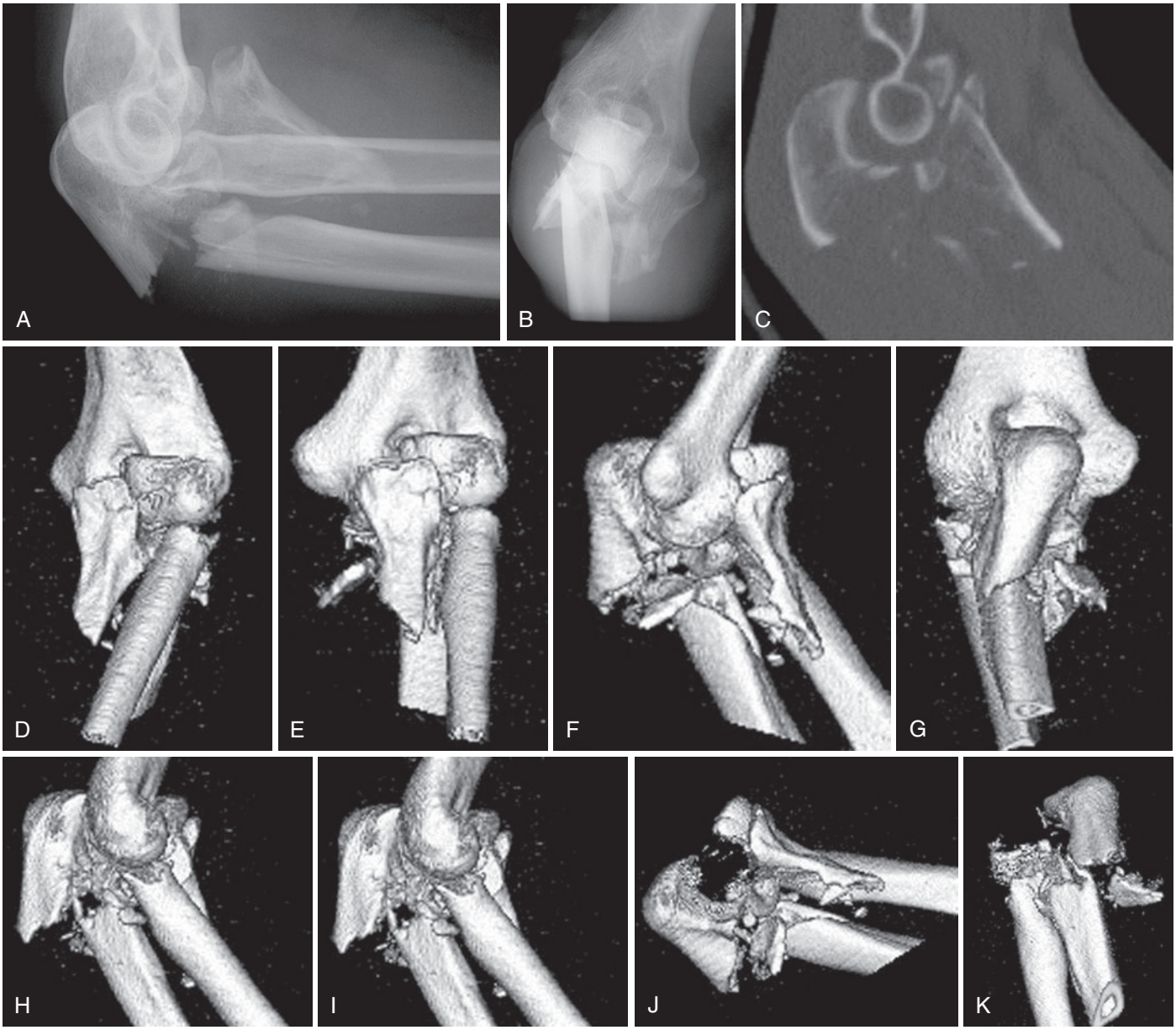

eFIGURE 20.3 **A** and **B,** Lateral and anteroposterior radiographs after injury show an apex posterior ulna fracture, a large coronoid fracture, and posterior dislocation of the radial head with fracture. **C,** Two-dimensional CT scanning is helpful but difficult to interpret. **D** to **K,** Three-dimensional CT images with and without the distal humerus are much more easily interpreted. The fractures of the coronoid and radial head are comminuted, but there is a large coronoid facet fragment that can be useful.

http://e-surg.com

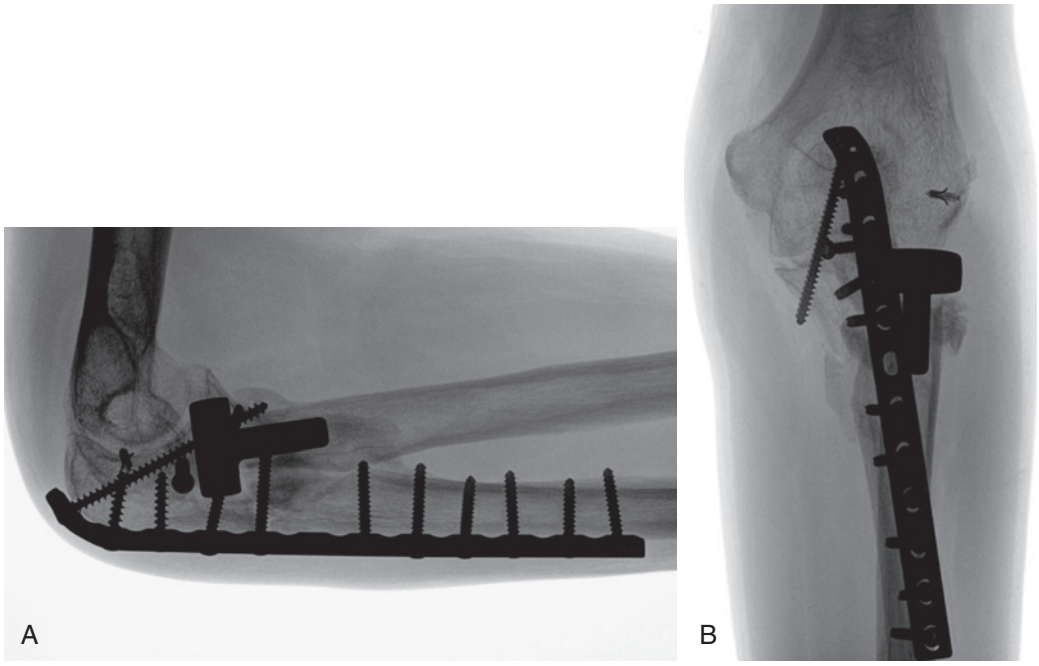

eFIGURE 20.4 **A** and **B,** Postsurgical radiographs.

http://e-surg.com

CASE STUDY 20.3 Posterior Olecranon Fracture-Dislocation

A 49-year-old woman fell down stairs, sustaining a complex fracture-dislocation of the proximal ulna (eFigure 20.5).

The surgical procedure is shown in eFigure 20.6, and the fixation and results in eFigure 20.7.

http://e-surg.com

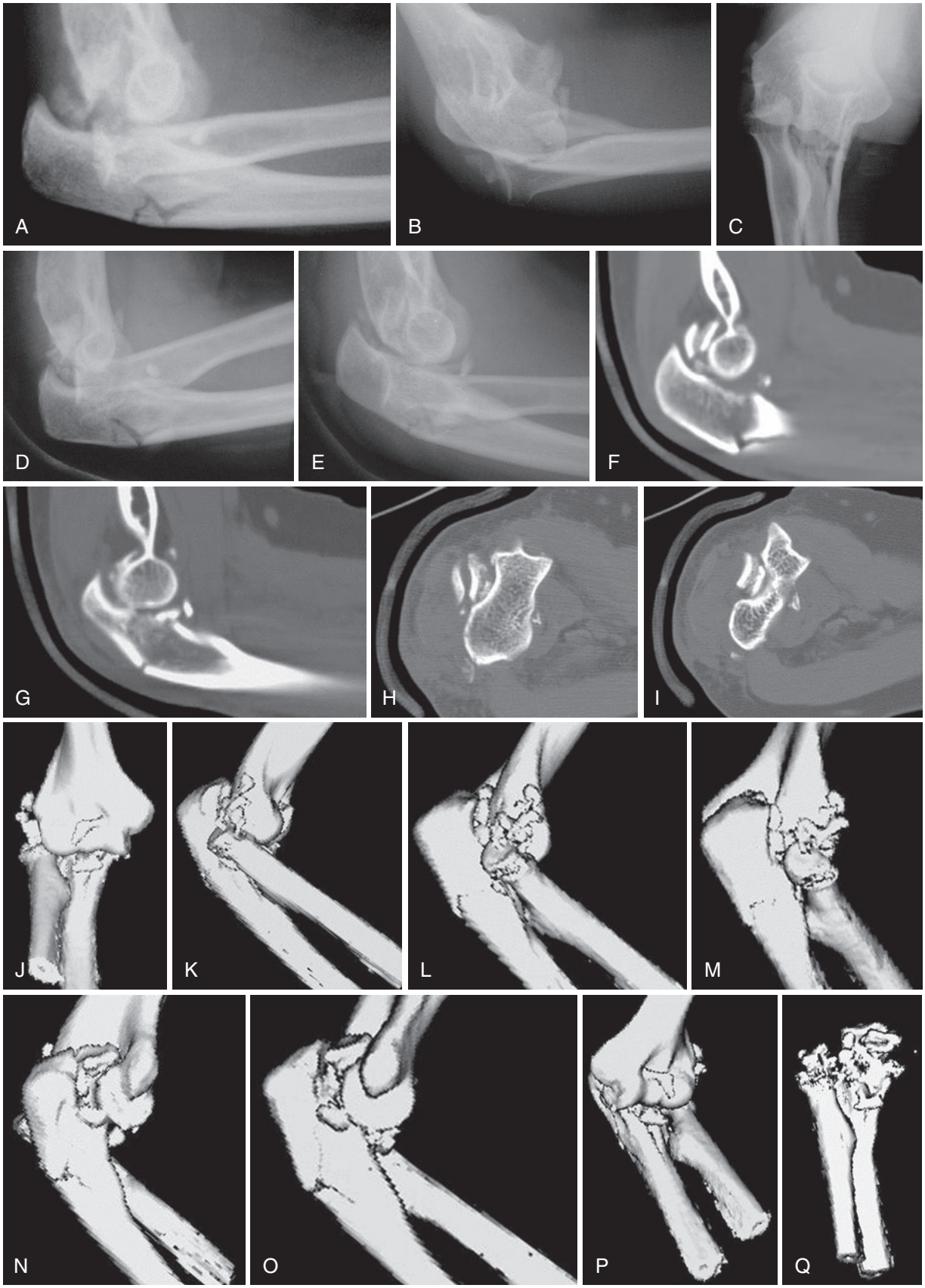

eFIGURE 20.5 **A** to **C,** In this case, the ulna is fractured at the metaphyseal rather than the olecranon level, and the coronoid is fractured at its base. **D** and **E,** The coronoid is extremely comminuted, with a major fragment displaced to the posterior aspect of the joint. The ulna fracture cannot be opened up to expose the coronoid in this case; the fracture is so distal that the lateral collateral ligament attachment and many of the muscle attachments remain intact. **F** to **I,** The two-dimensional CT images show these features in greater detail. In particular, one can see the comminuted fracture of the olecranon with large intraarticular fragments posterior to the trochlea. **J** to **Q,** The three-dimensional reconstructions are not as clear for this patient, partly due to the technique of the scan and partly to the complexity of the injury. Nonetheless, they are more straightforward to interpret and provide useful information.

http://e-sug.com

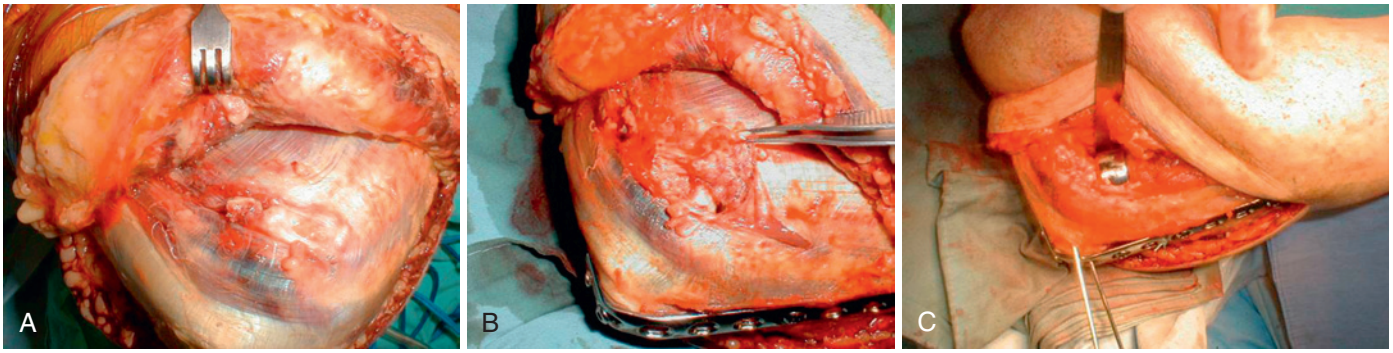

eFIGURE 20.6 **A,** Although the lateral collateral ligament and common extensor muscles were avulsed from the lateral epicondyle, there was only a small tear in the common extensor muscles visible after the lateral skin flap was elevated. A piece of the radial head was extruded through this rent. **B,** The minimally displaced fracture of the proximal ulnar metaphysis was realigned and secured with a dorsal plate and screws. In this case, the plate was applied directly over the triceps insertion without incising it. After additional incision of the deep fascia, the underlying injury to the lateral collateral ligament and common extensor origin (the so-called bald or bare lateral epicondyle) is apparent (forceps). **C,** The origins of radial wrist extensors (extensor carpi radialis brevis and longus) have been incised to improve exposure of the coronoid. With the radial head removed and the common extensors and supinator split distally, a good view of the coronoid can be obtained. The coronoid could not be repaired. A fragment of the radial head was used to reconstruct the coronoid process, and the radial head was replaced with a metal prosthesis.

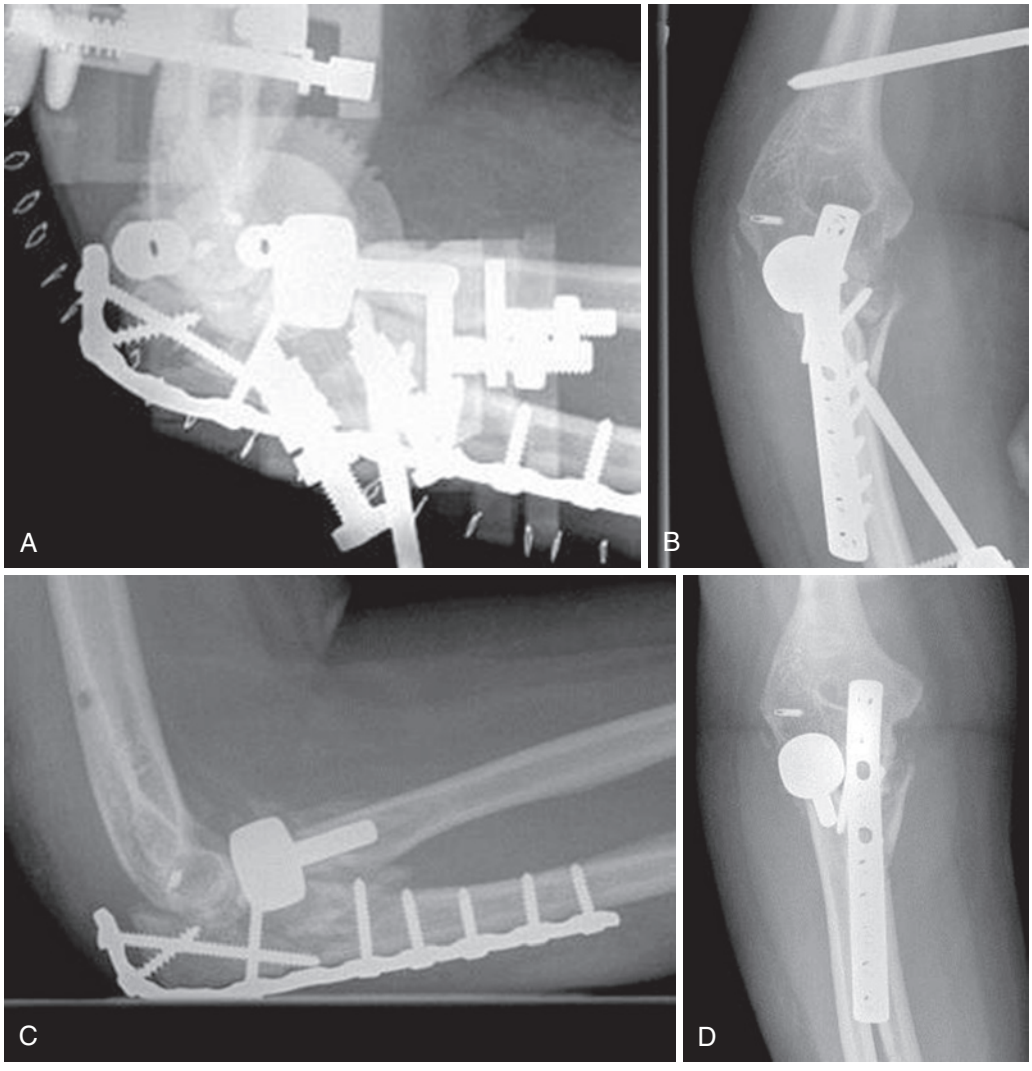

eFIGURE 20.7 **A** and **B,** The reconstructed coronoid was protected with 6 weeks of hinged external fixation. **C** and **D,** Initially a good alignment was obtained, but the coronoid reconstruction proved insufficient and the humerus rotated externally, translating forward into the relative defect of the coronoid.

http://e-surg.com

CASE STUDY 20.4 Posteromedial Varus Rotational Instability Pattern

See eFigure 20.8 for the exploration of diagnostic films, eFigure 20.9 for the operative procedure, and eFigure 20.10 for the surgical results.

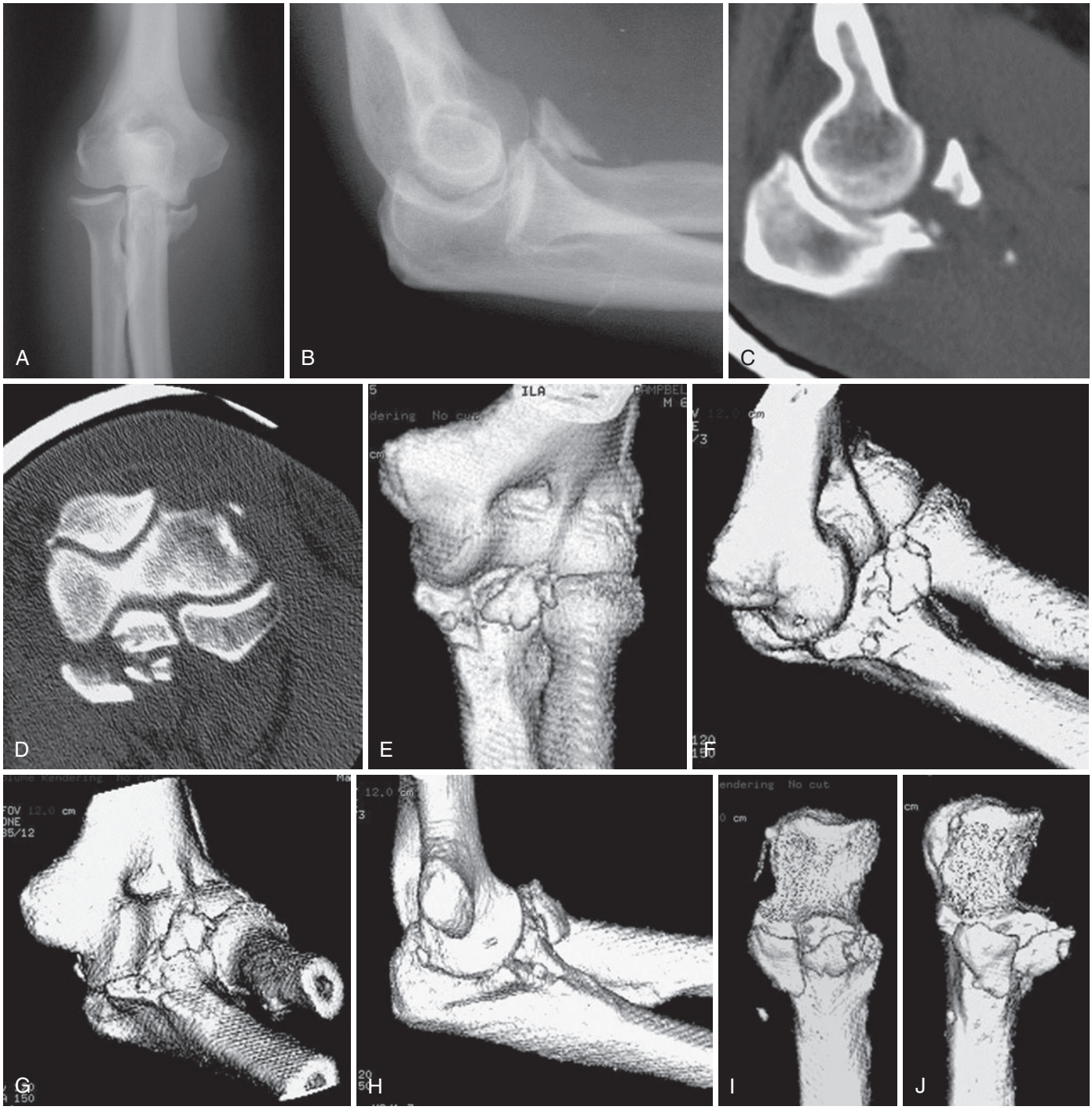

eFIGURE 20.8 **A,** The posteromedial varus rotational instability–pattern injury is characterized by a fracture of the anteromedial coronoid facet and rupture of the origin of the lateral collateral ligament complex from the lateral epicondyle. **B,** The pitfall of this injury is that the lateral view can look relatively innocuous with a Regan and Morrey type 2 fracture. **C** and **D,** Two-dimensional CT shows more detail, but the pattern of the injury is not apparent. **E** to **J,** Three-dimensional reconstructions show the separate tip and anteromedial facet fractures. What is not apparent is that the sublime tubercle (insertion point of the anterior band of the medial collateral ligament) was also fractured.

http://e-surg.com

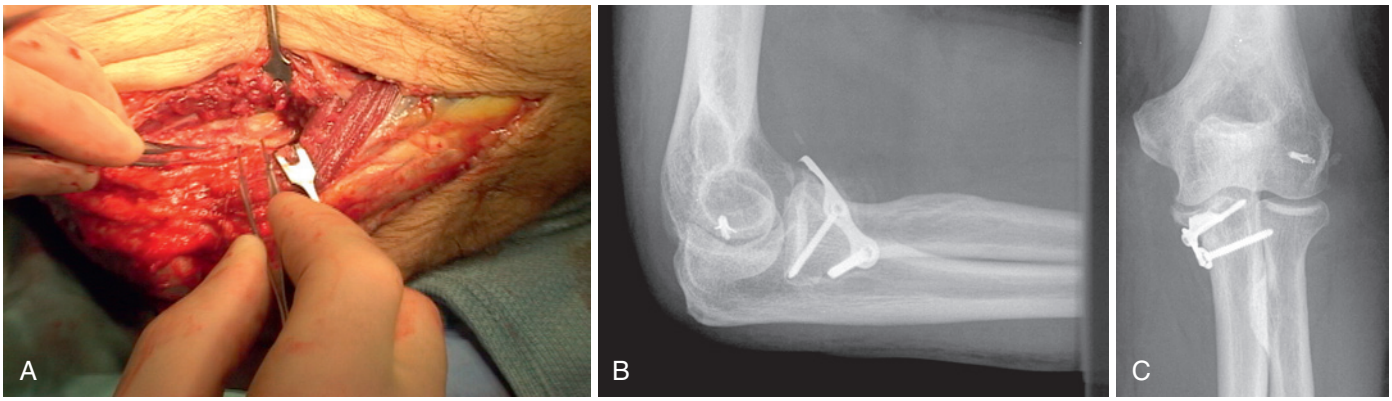

eFIGURE 20.9 **A,** The interval between the ulnar and humeral origins of the flexor pronator mass was used for exposure of the coronoid after anterior subcutaneous transposition of the ulnar nerve. The attachment of the medial collateral ligament to the sublime tubercle is preserved. **B** and **C,** The coronoid was repaired with a precontoured plate and the lateral collateral ligament was reattached to the lateral epicondyle with suture anchors.



eFIGURE 20.10 **A** to **D,** Functional motion was achieved.

http://e-surg.com

CASE STUDY 20.5 Posterior Dislocation of the Elbow Associated With Fracture of the Olecranon Process

In this unusual case, a patient has sustained a posterior dislocation of the elbow associated with a fracture of the olecranon process on the medial aspect, essentially avulsing the posterior aspect of the medial collateral ligament complex (eFigure 20.11).

The surgical procedure is displayed in eFigure 20.12, and the results are shown in eFigure 20.13.

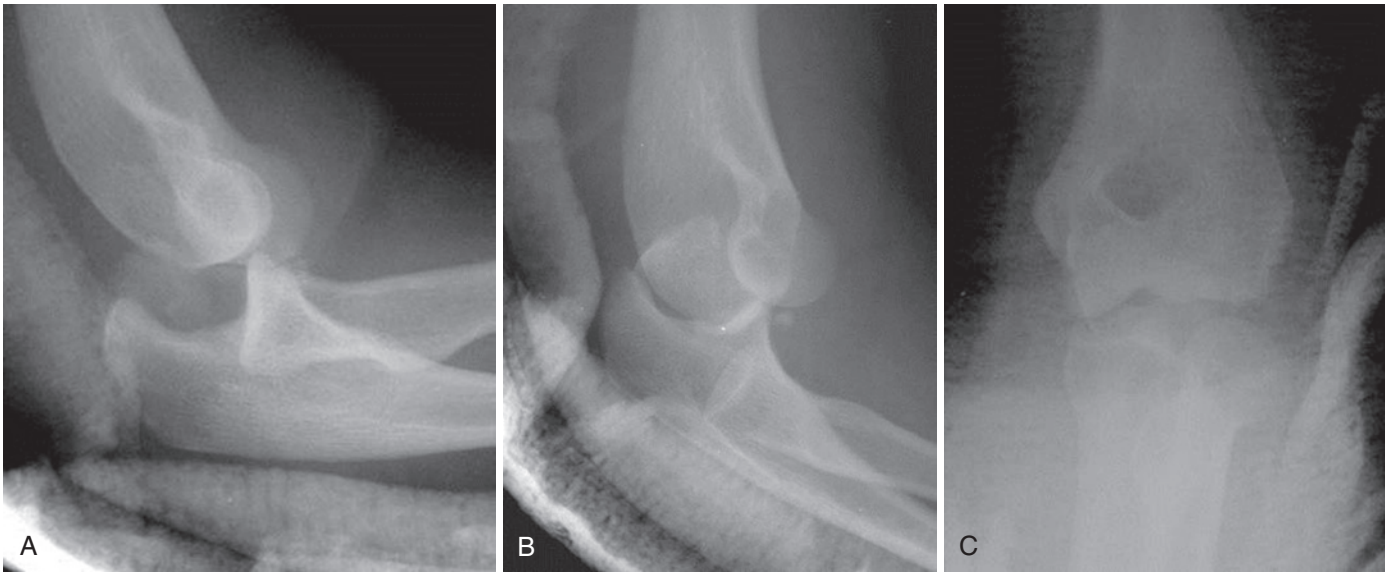

eFIGURE 20.11 **A** to **C,** This posterior dislocation of the elbow is associated with a fracture of the olecranon process on the medial aspect, essentially avulsing the posterior aspect of the medial collateral ligament complex.

http://e-surg.com

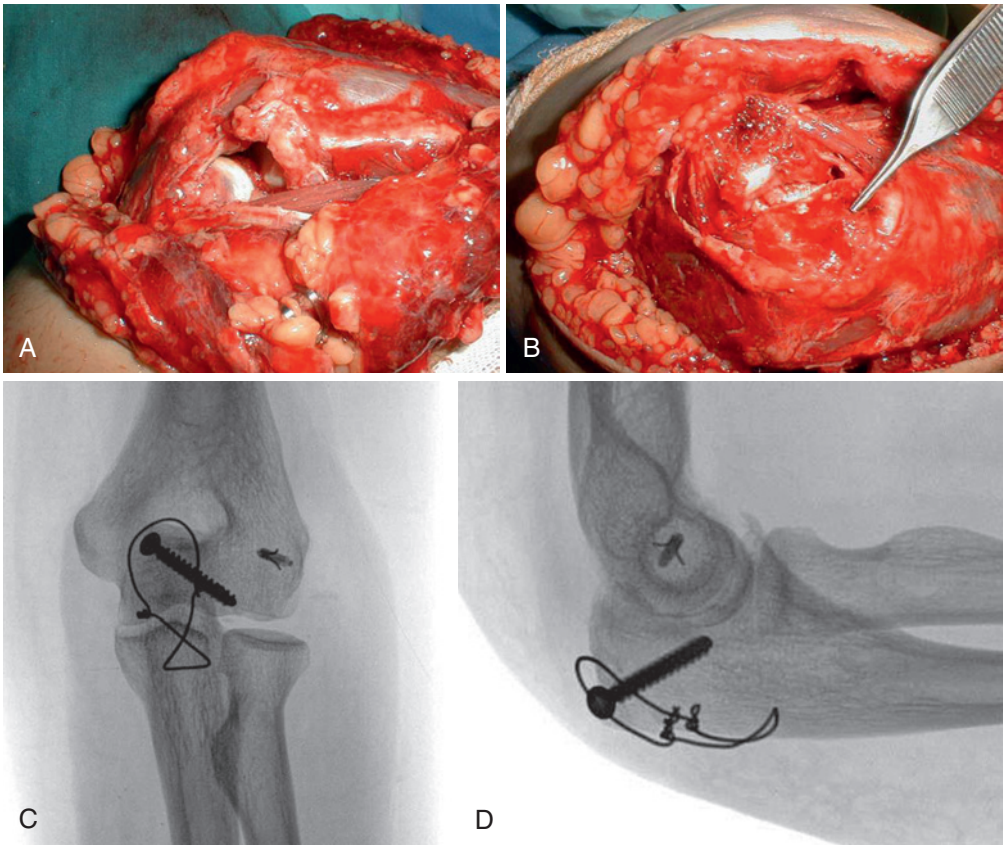

eFIGURE 20.12 **A** to **D,** The olecranon fracture was repaired with a screw and tension wire, and the lateral collateral ligament was reattached to the lateral epicondyle with a suture anchor.



eFIGURE 20.13 **A** to **D,** Functional motion was obtained.

http://e-surg.com

CASE STUDY 20.6 Anterior (Transolecranon) Fracture-Dislocation of the Elbow

The patient presented with an anterior fracture-dislocation of the elbow (eFigure 20.14).

The surgical procedure is displayed in eFigure 20.15, and the results are shown in eFigure 20.16.

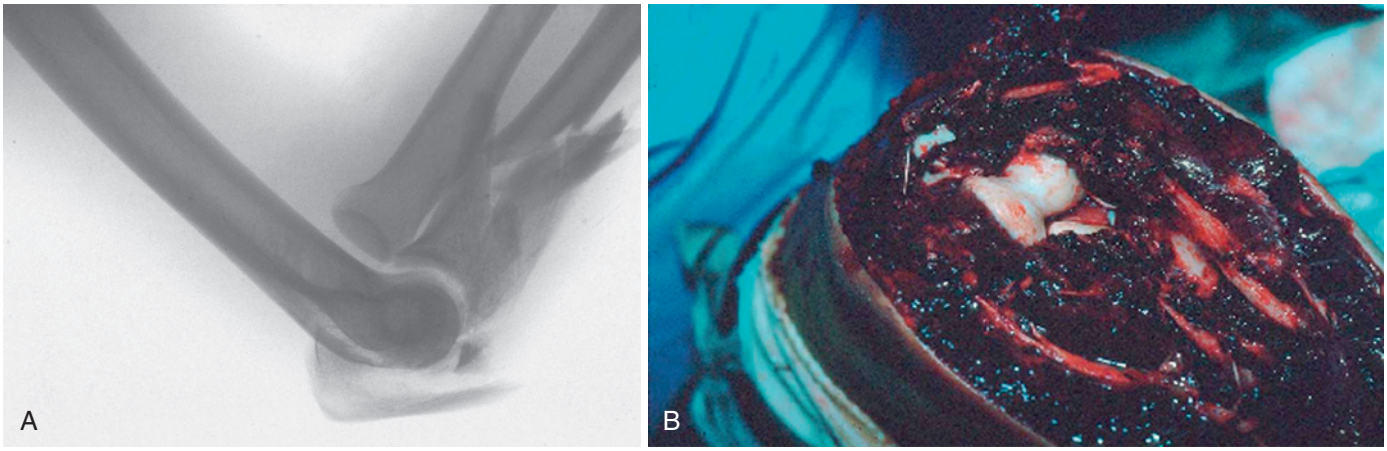

eFIGURE 20.14 **A,** The forearm is displaced anteriorly, with the radioulnar relationship relatively spared. **B,** The trochlea has imploded through the proximal ulna, creating a very complex fracture with a large coronoid fracture and comminution extending into the diaphysis. The collateral ligaments are usually not injured.

http://e-surg.com

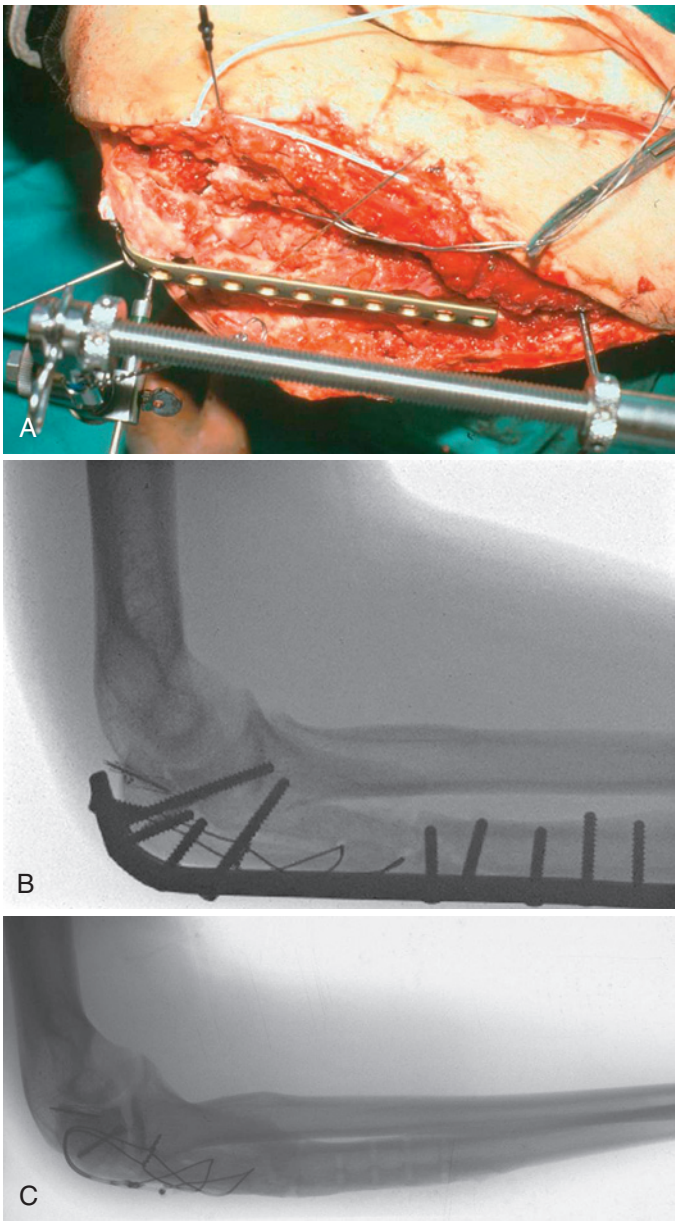

eFIGURE 20.15 **A,** As described by Dr. Jeff Mast, an external fixator can assist with reduction and provisional fixation. **B,** A long contoured dorsal plate secures the relationship between the coronoid and olecranon processes (the contour and dimensions of the trochlear notch) and bridges the comminution. A tension wire engages the fragmented olecranon process. **C,** Radiograph after plate removal.

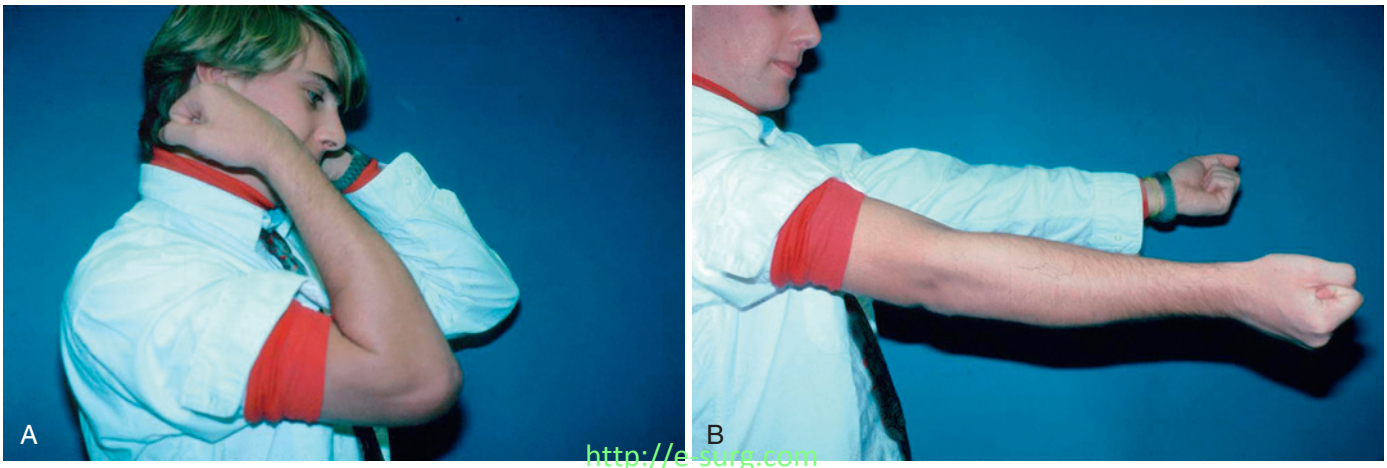

http://e-surg.com

eFIGURE 20.16 **A** and **B,** Functional motion was achieved.

CASE STUDY 20.7 Posterior Olecranon Fracture-Dislocation (Posterior Monteggia Fracture Type A)

Radiographs of this injury are presented in eFigure 20.17.

The surgical procedure is displayed in eFigure 20.18, and the results are shown in eFigure 20.19.

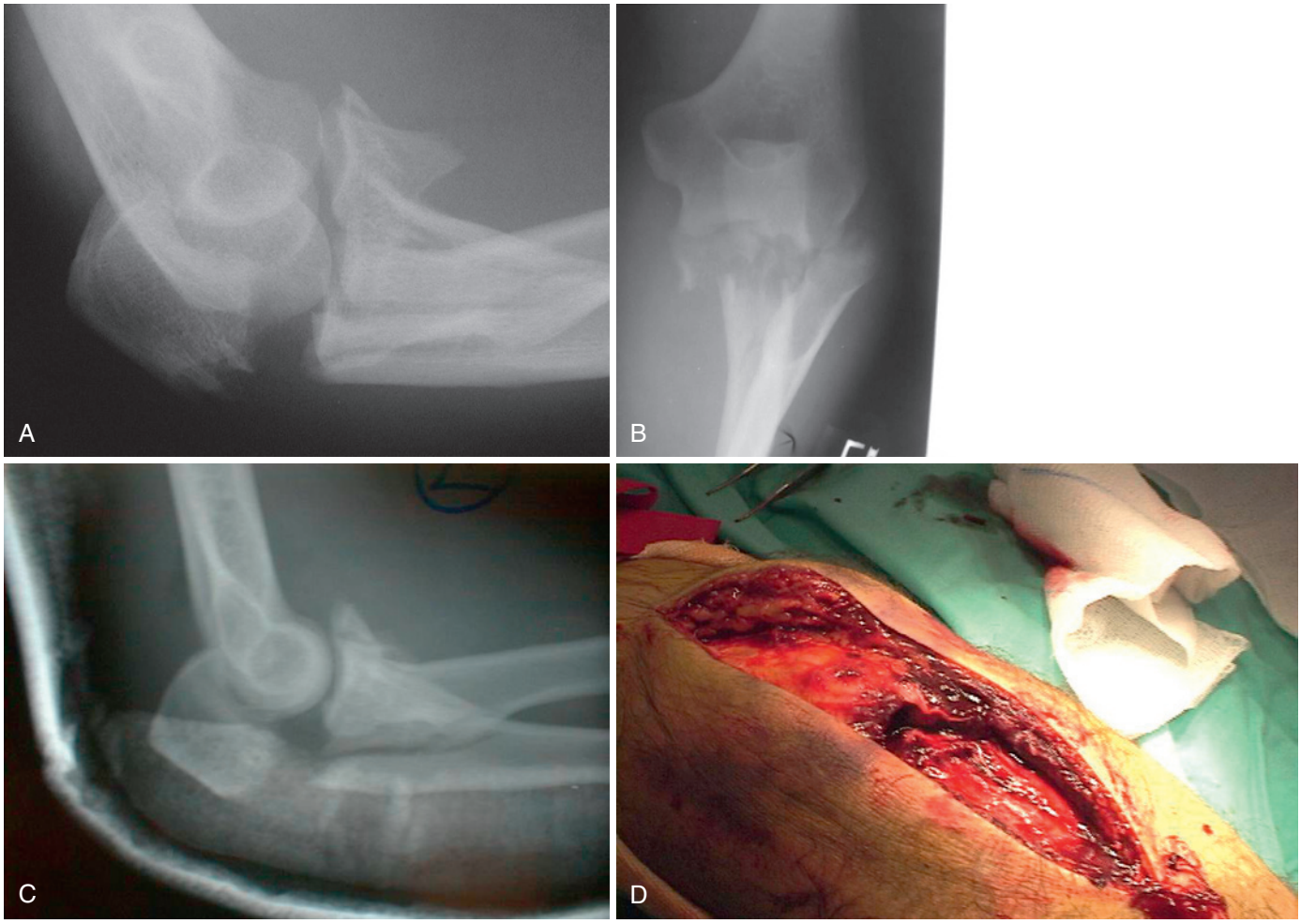

eFIGURE 20.17 **A,** Posterior olecranon fracture-dislocations feature fractures of the coronoid and radial head and frequent injury to the lateral collateral ligament complex. **B,** The anteroposterior radiograph shows that the coronoid is comminuted with a separate anteromedial facet fragment. **C,** Postreduction radiographs show the injury somewhat better. **D,** The posterior muscles have been torn by the injury.

http://e-surg.com

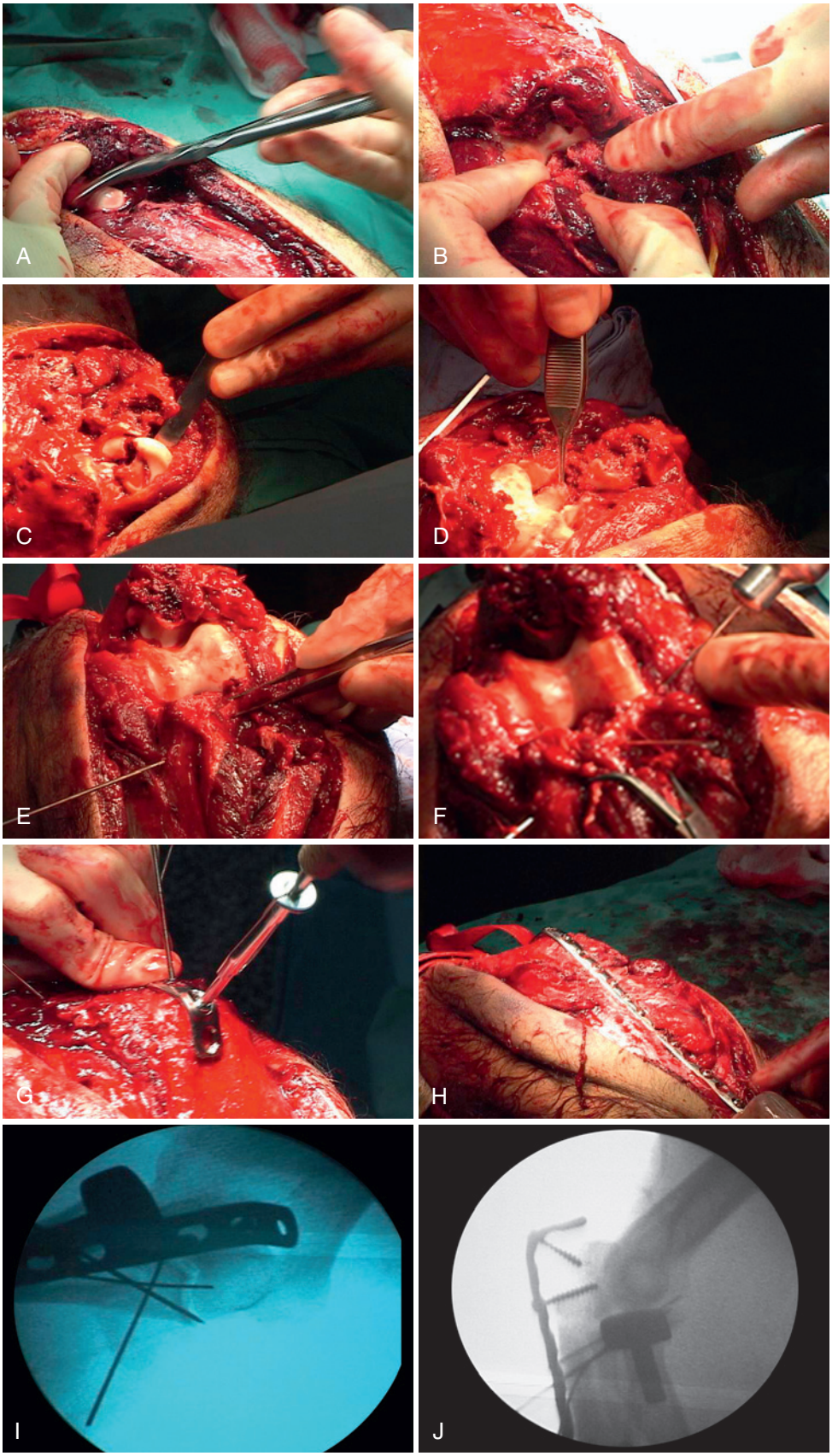

eFIGURE 20.18 **A,** This traumatic interval is used to gain access to the coronoid fracture. The olecranon fragment is mobilized proximally. **B,** The coronoid fragments can be directly manipulated through the olecranon fracture. **C,** The fractured radial head was excised through the posterior traumatic interval and replaced with a metal prosthesis. **D,** The coronoid fracture had three major fragments, anteromedial facet, central, and lesser sigmoid notch. **E** and **F,** Provisional fixation with Kirschner wires. **G,** A dorsal contoured plate was placed over the triceps insertion. **H,** A long plate was used to bridge the comminution. **I** and **J,** The anteromedial facet was held reduced with provisional wires.

http://e-surg.com

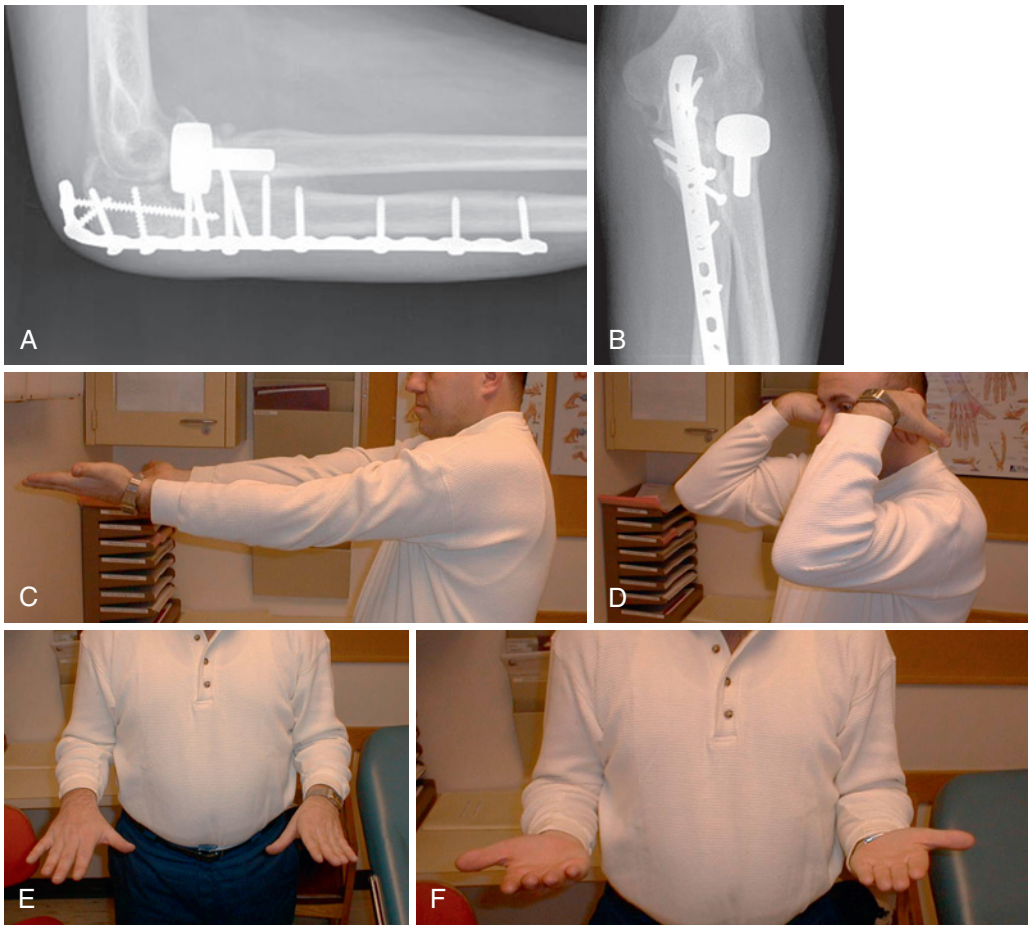

eFIGURE 20.19 **A** and **B,** The fracture healed with good alignment. **C** to **F,** Functional motion was obtained.

http://e-surg.com

CASE STUDY 20.8 Tension Band Wiring

Tension band wiring is suitable for simple fractures without fracture of the radial head or coronoid or dislocation/subluxation of the ulnohumeral joint (eFigure 20.20).

The surgical procedure is displayed in eFigure 20.21, and the results are shown in eFigure 20.22.

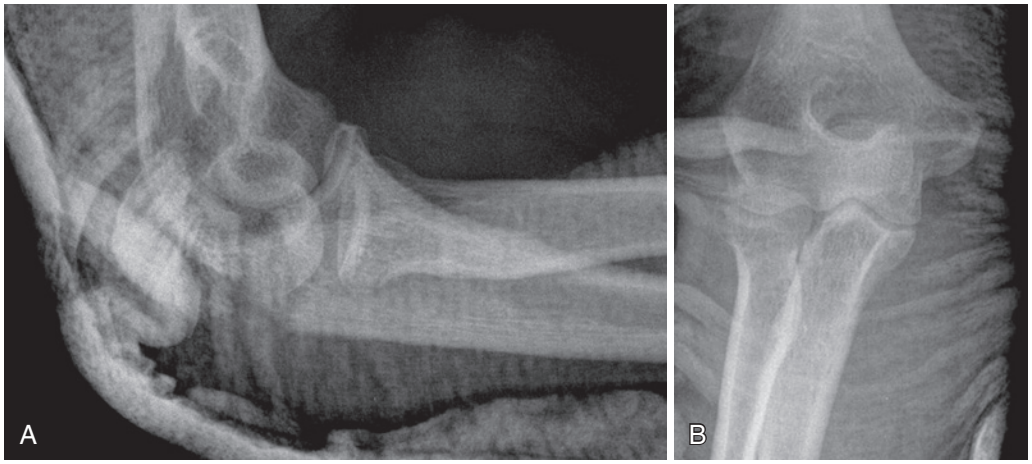

eFIGURE 20.20 **A** and **B,** A simple fracture of the olecranon after splinting.

http://e-surg.com

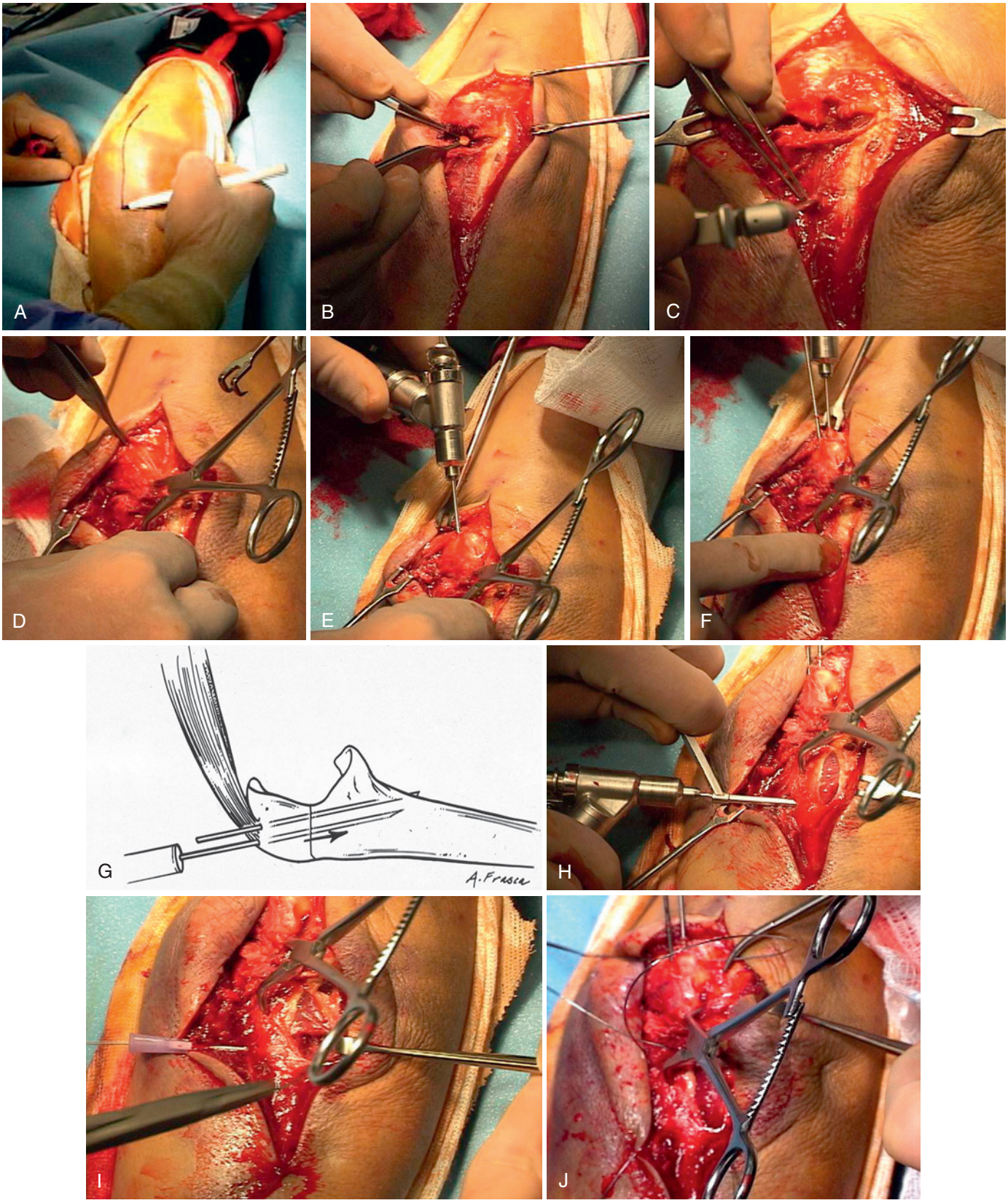

eFIGURE 20.21 Tension band wiring. **A,** A straight dorsal skin incision is used. **B,** The fracture site was opened and a loose articular fragment was removed and discarded. **C,** A dorsal drill hole was made in the ulna distal to the fracture site as an anchor point for a reduction forceps. **D,** Fracture reduction is maintained with a reduction clamp. **E** and **F,** Kirschner wires are drilled across the olecranon obliquely. **G,** The Kirschner wires engage the anterior ulnar cortex distal to the coronoid process. **H,** Two drill holes are made in the ulna distal to the fracture site. **I,** A large-gauge needle is used to pass 22-gauge wires through the drill holes. **J,** A needle is also used to pass the wires beneath the triceps insertion proximal to the Kirschner wires. The tension wires are placed in a figure-of-eight pattern over the dorsal ulna.

Continued

http://e-surg.com

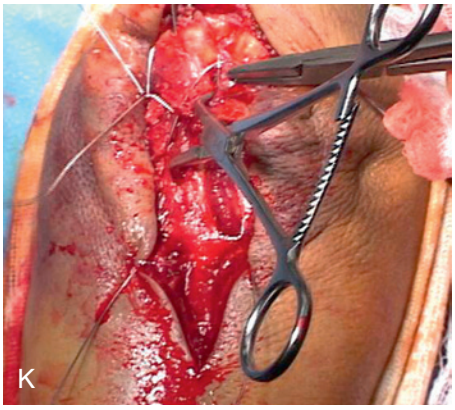

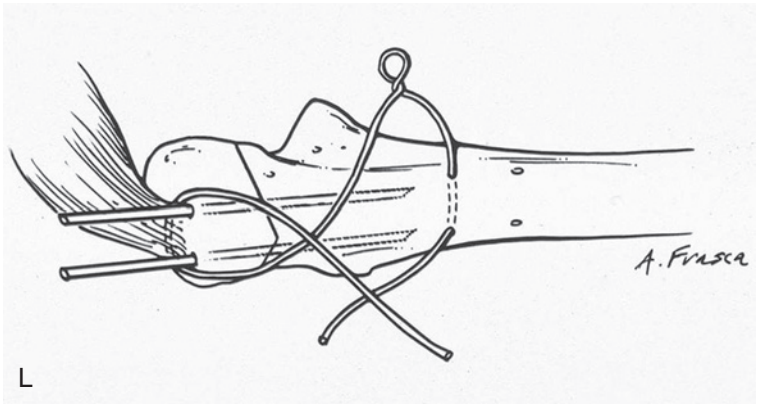

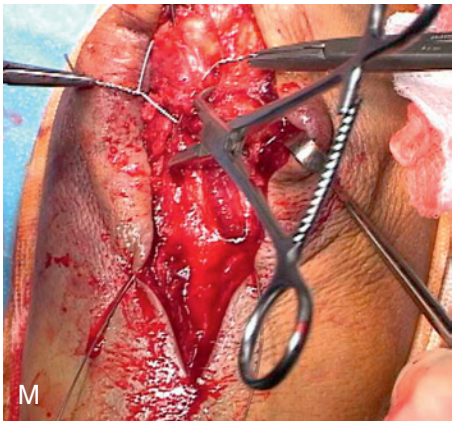

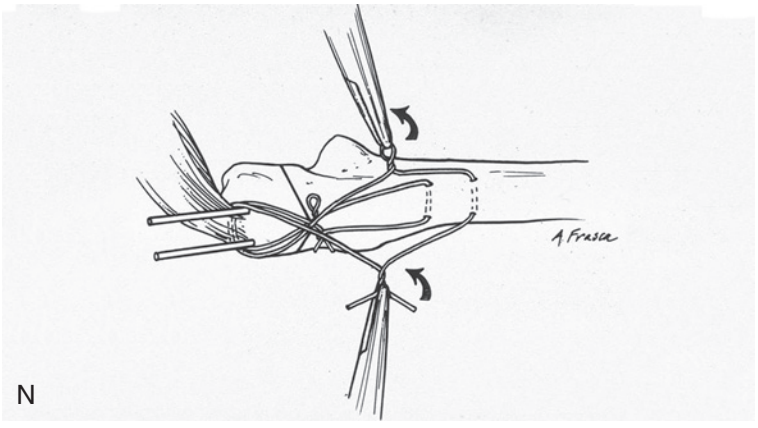

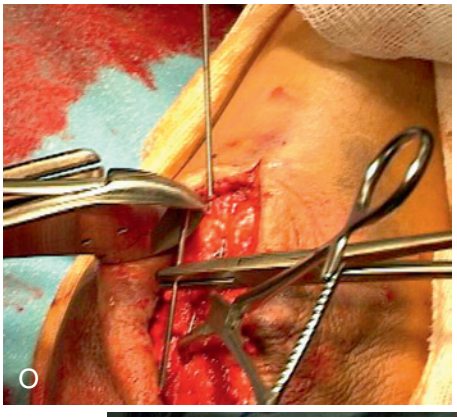

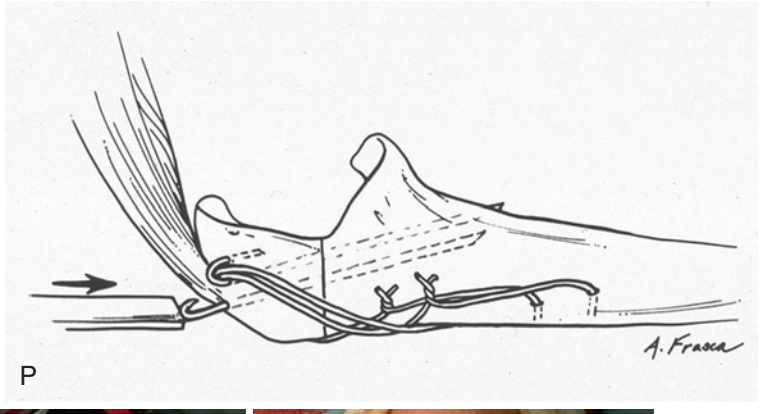





eFIGURE 20.21, cont'd **K** to **N,** The wires were tensioned both medially and laterally. **O** and **P,** The proximal ends of the wires were bent 180 degrees and trimmed, and impaction into the proximal olecranon was achieved. **Q,** The security of the fixation is tested in flexion. **R,** Wound closure.

http://e-surg.com

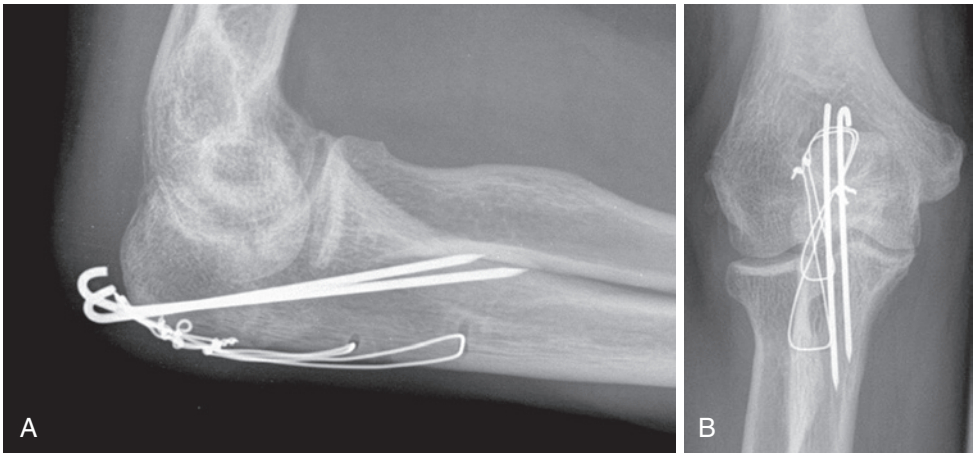

eFIGURE 20.22 **A** and **B,** Final radiographs.

http://e-surg.com

CASE STUDY 20.9 Plate Fixation

A 35-year-old woman suffers a comminuted fracture of the olecranon without associated fractures or dislocations (eFigure 20.23).

The fracture was treated with plate fixation (eFigure 20.24).

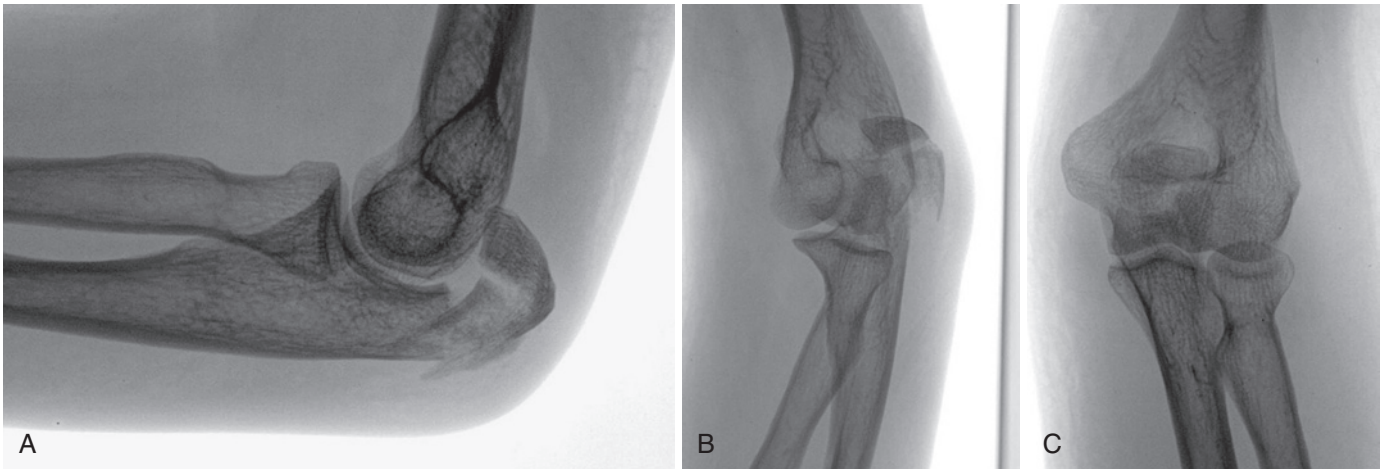

eFIGURE 20.23 **A** to **C,** Radiographs of comminuted fracture of the olecranon without associated fractures or dislocations in a 35-year-old woman.

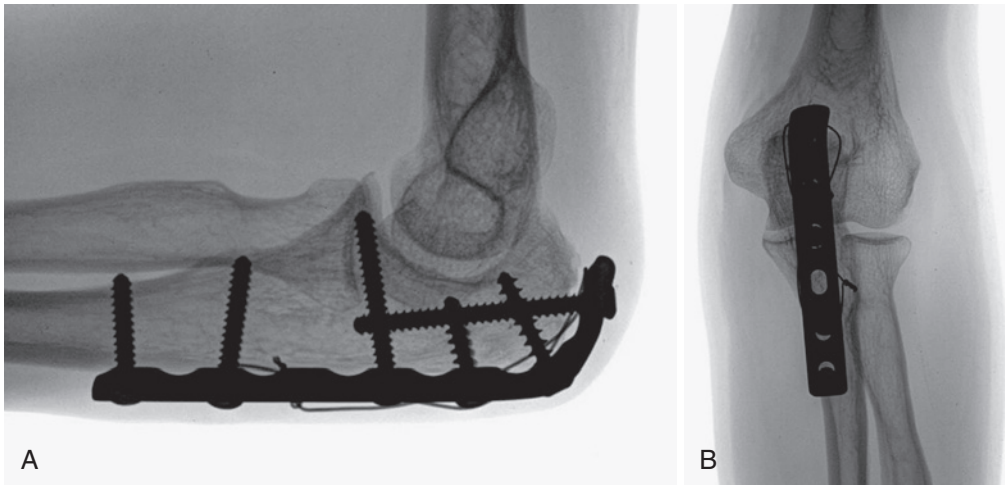

eFIGURE 20.24 **A** and **B,** The plate is applied to the dorsal surface of the ulna and contoured around the proximal olecranon. A tension wire engaging the triceps insertion can enhance fixation. Functional motion was obtained.

http://e-surg.com

CASE STUDY 20.10 Metaphyseal Posterior Monteggia Fracture

A metaphyseal posterior Monteggia fracture is shown in eFigure 20.25. Fixation is displayed in eFigure 20.26, and patient results are shown in eFigure 20.27.

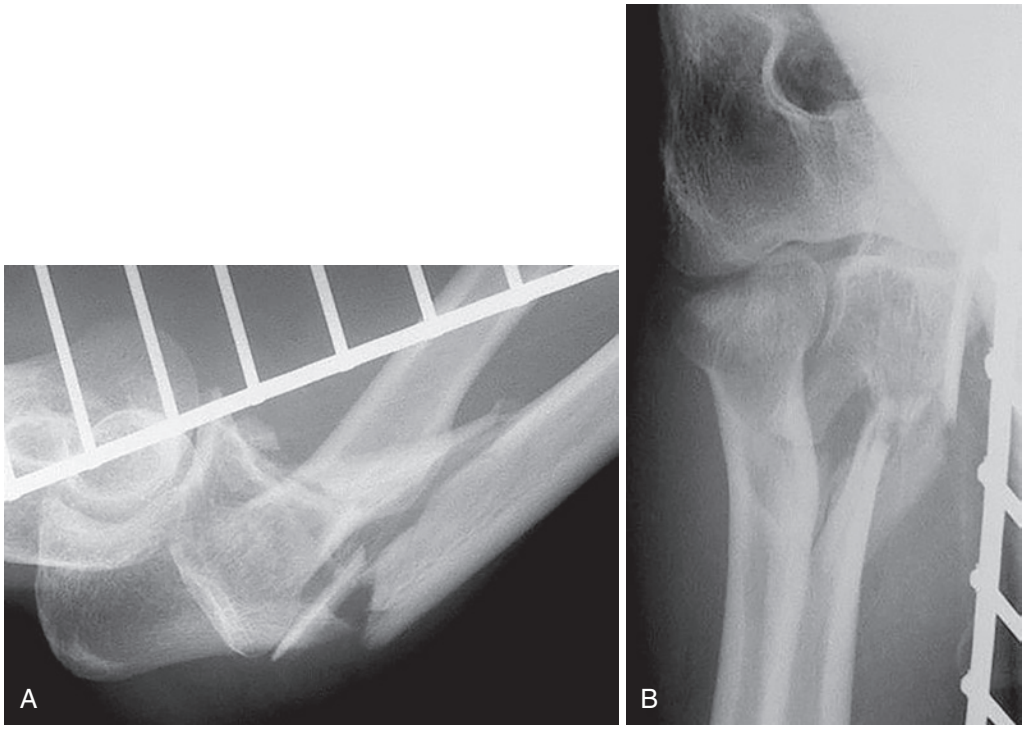

eFIGURE 20.25 **A** and **B,** Fractures at the level of the metaphysis often feature a triangular or quadrangular anterior fragment.

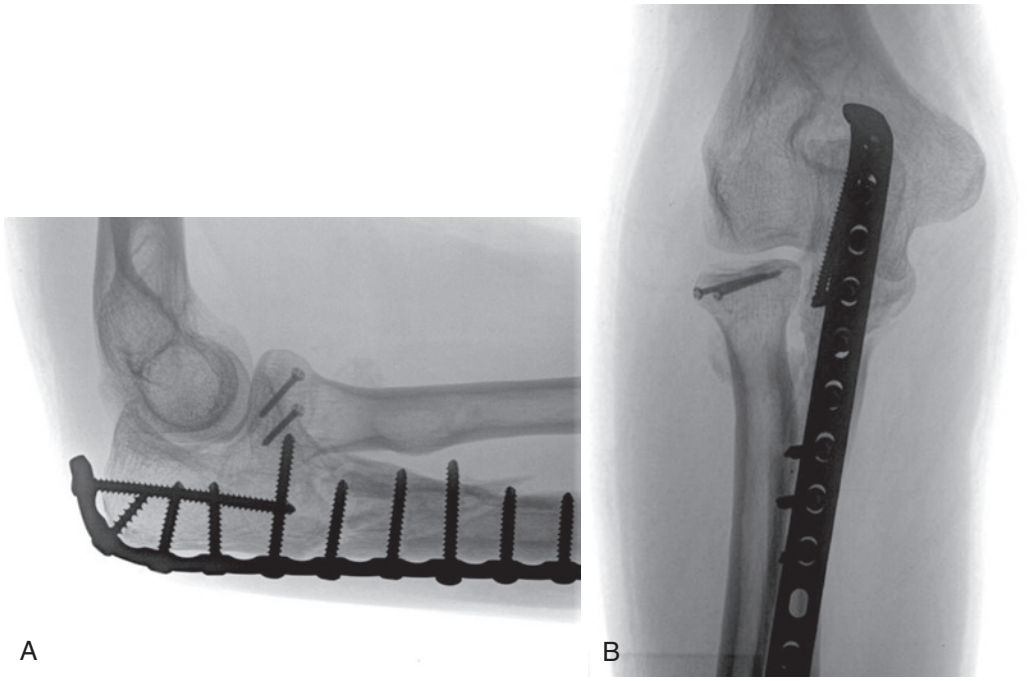

eFIGURE 20.26 **A** and **B,** Contoured dorsal plate fixation can provide adequate stability to bridge this comminuted area and prevent recurrent apex posterior deformity.

http://e-surg.com



eFIGURE 20.27 **A** to **D,** Full motion was achieved.

http://e-surg.com

CASE STUDY 20.11 Failed Operative Fixation of a Posterior Olecranon Fracture-Dislocation

eFigure 20.28 shows a failed operative fixation of a posterior olecranon fracture-dislocation. Surgical repair is shown in eFigure 20.29, and patient results are shown in eFigure 20.30.

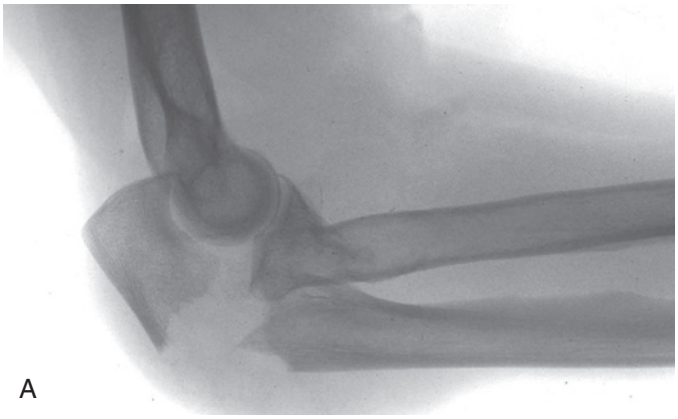

A

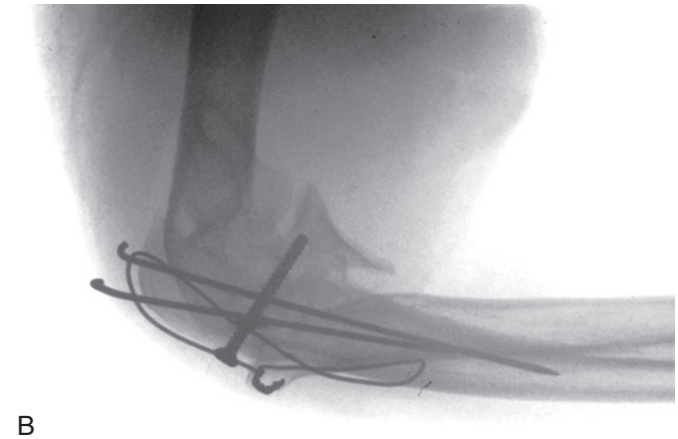

B

eFIGURE 20.28 **A,** Type A posterior Monteggia fracture with fractures of the olecranon, coronoid, and radial head. **B,** Internal fixation with a tension band wire construct and a screw proved insufficient.

http://e-surg.com

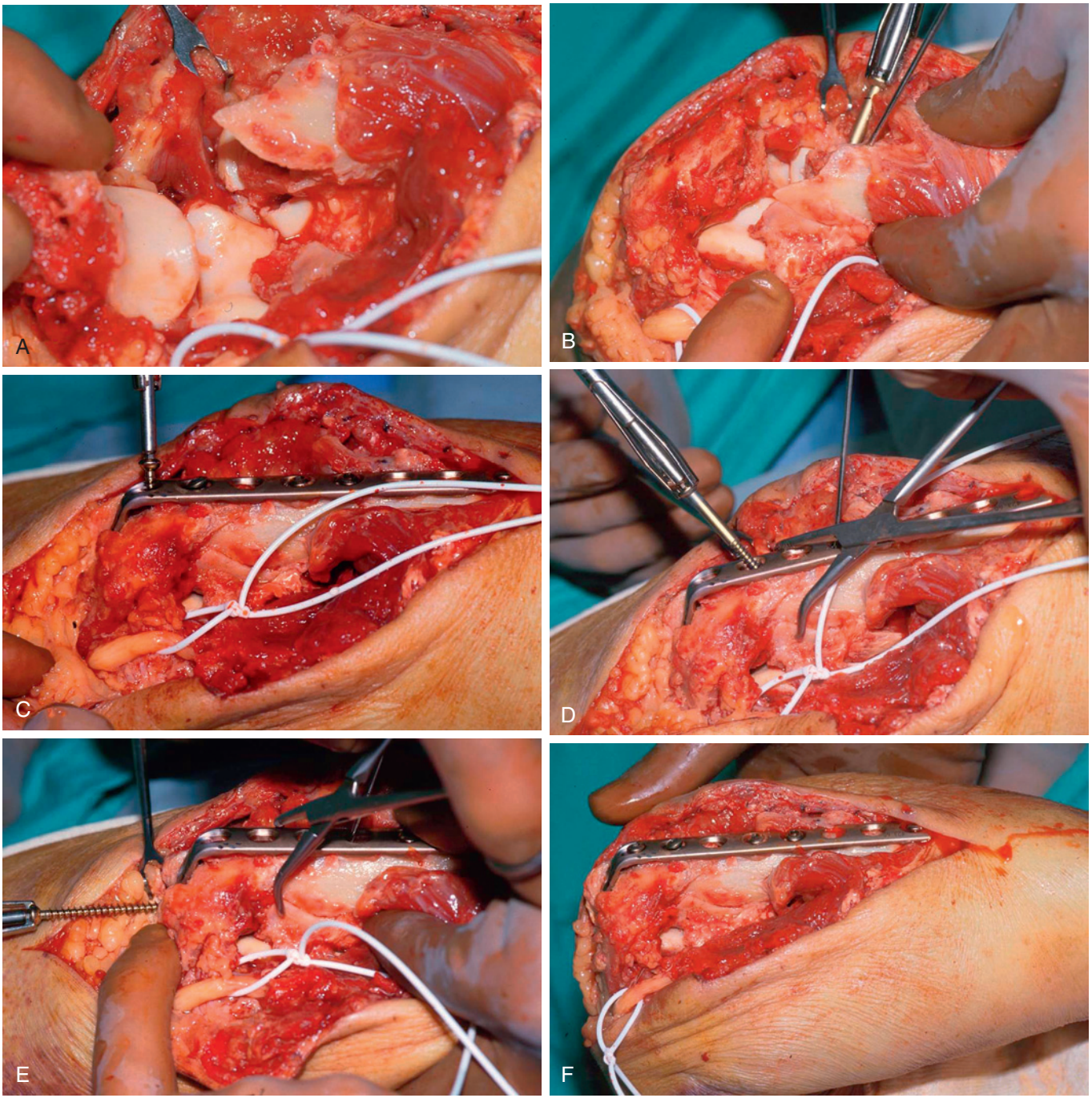

eFIGURE 20.29 **A,** Access to the coronoid fracture was obtained both though the olecranon fracture and by transposing the ulnar nerve and exposing the medial surface of the ulna and coronoid. **B,** The coronoid was secured with a screw entering separately from the plate. **C** to **F,** A dorsal contoured plate was used to secure the ulna.

http://e-surg.com

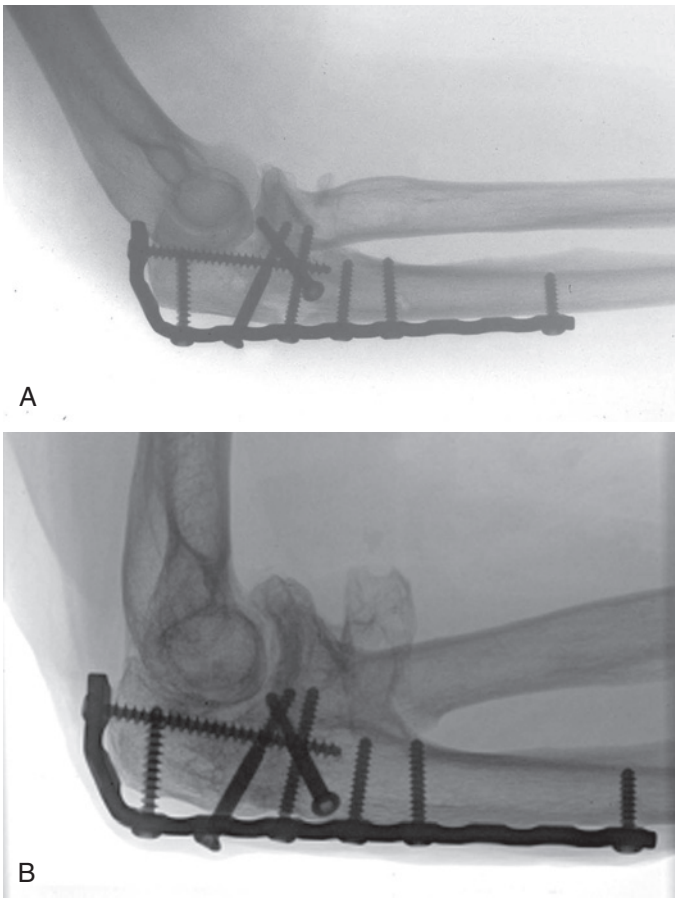

eFIGURE 20.30 **A,** The initial postoperative views show much improved alignment. **B,** Although the coronoid fixation loosened, the fracture healed solidly and a good functional result was obtained.

http://e-surg.com

CASE STUDY 20.12 Plate Loosening After Operative Treatment of a Posterior Monteggia Fracture

Posterior Monteggia fractures are common in older, osteoporotic patients. A plate applied to the medial or lateral surface and not contoured around the proximal ulna may have inadequate hold on the proximal metaphyseal segment (eFigure 20.31).

Surgical treatment is shown in eFigure 20.32; patient results are in eFigure 20.33.

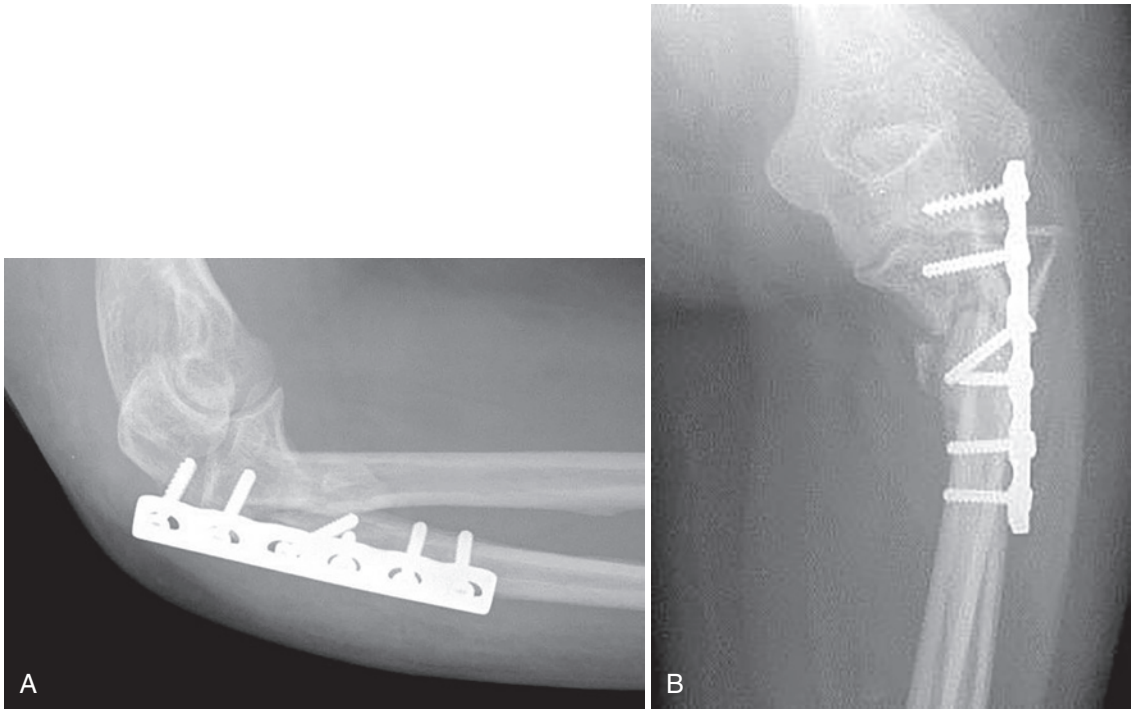

eFIGURE 20.31 **A** and **B,** Radiographs of loosened plate, installed for treatment of posterior Monteggia fracture.

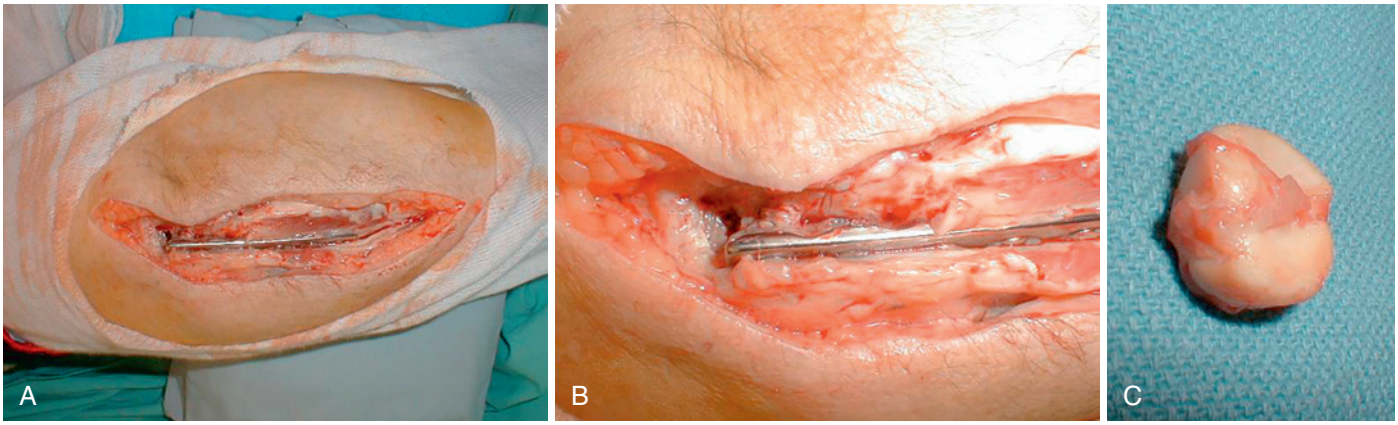

eFIGURE 20.32 **A** and **B,** The loose plate was removed. **C,** The fractured radial head was deformed and was restricting forearm rotation; it was removed and replaced with a prosthesis.

http://e-surg.com

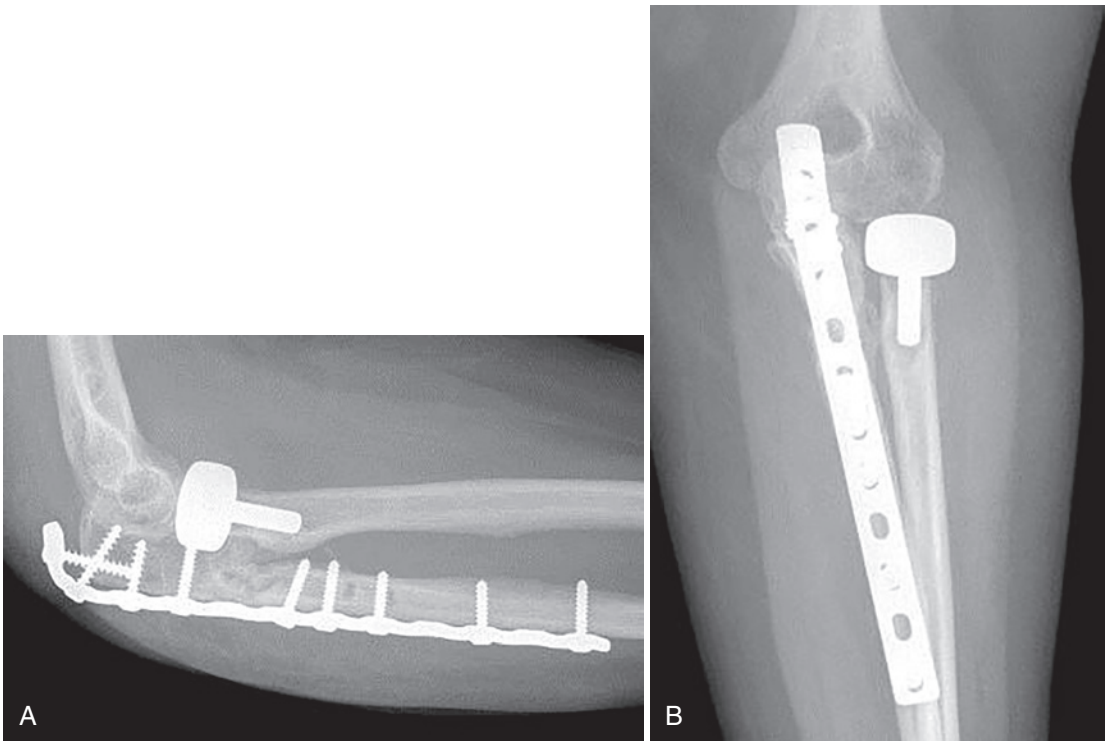

eFIGURE 20.33 **A** and **B,** A long dorsal contoured plate achieved healing with good alignment.

http://e-surg.com

CASE STUDY 20.13 Ulnohumeral Instability After Posterior Monteggia Fracture

Surgeons are occasionally surprised by ulnohumeral instability after what was perceived to be a forearm injury; however, posterior Monteggia injuries can include fracture of the radial head and injury to the lateral collateral ligament complex (eFigure 20.34).

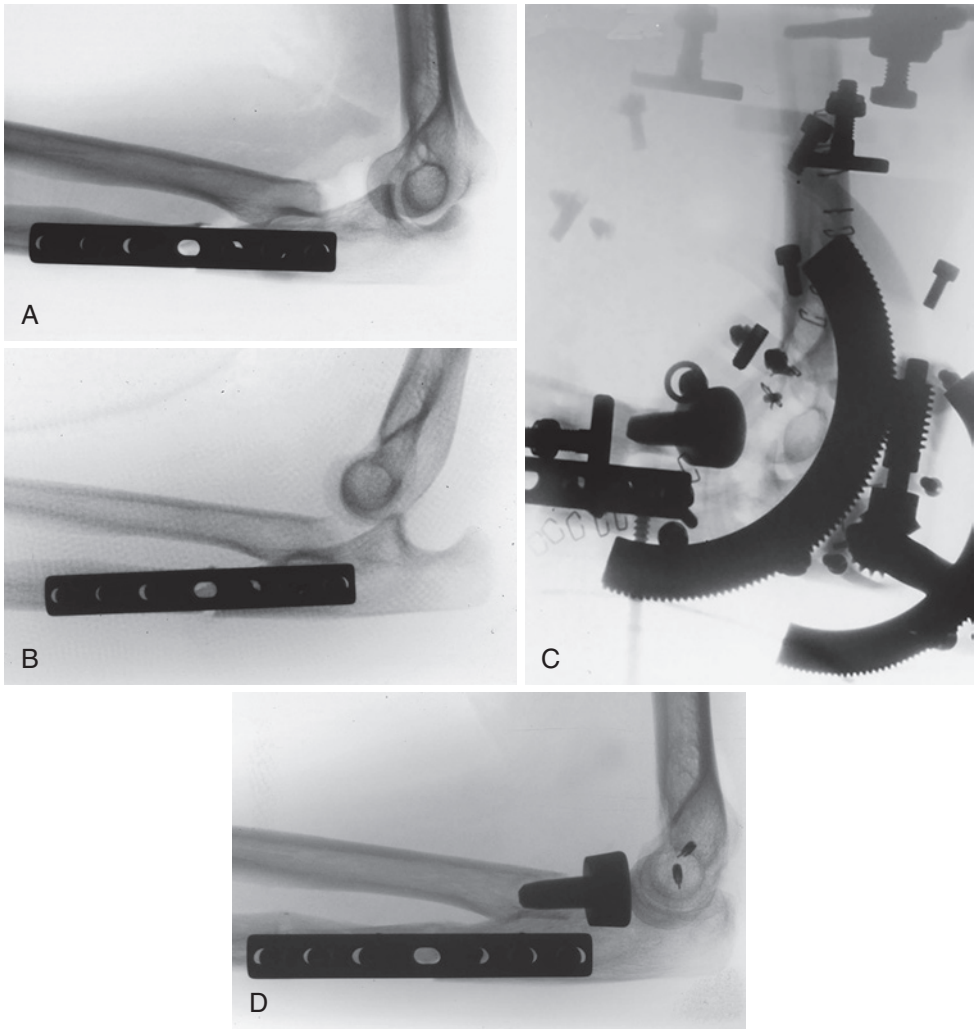

eFIGURE 20.34 **A** and **B,** Monteggia injuries can include fracture of the radial head and injury to the lateral collateral ligament complex, causing ulnohumeral instability. **C,** Open relocation of the ulnohumeral joint, restoration of radiocapitellar contact with a radial head prosthesis, repair of the lateral collateral ligament complex, and temporary hinged fixation were used to restore stability. **D,** A stable, well-aligned elbow and forearm with good function was achieved.

http://e-surg.com

CASE STUDY 20.14 Nonunion of the Proximal Ulna

Nonunion of the proximal ulna is most common after a complex fracture and is uncommon after a simple olecranon fracture (eFigure 20.35).

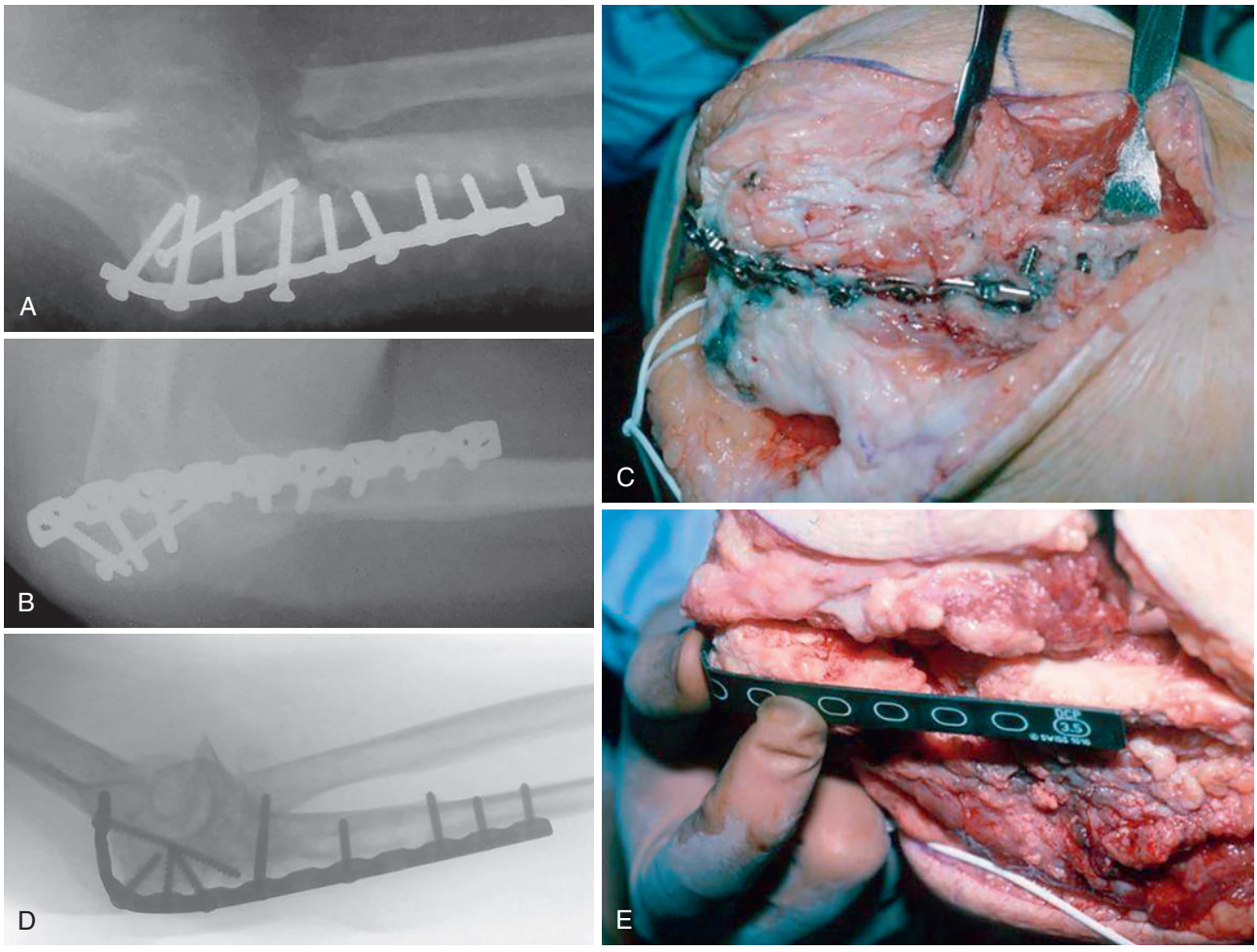

eFIGURE 20.35 **A** and **B,** Nonunion of the proximal ulna. **C,** This patient has loose internal fixation and a synovial nonunion. **D** and **E,** Contoured dorsal plate fixation and autogenous cancellous bone grafting achieved union and improved elbow and forearm function.

http://e-surg.com

31. Kapandji AI: *The physiology of the joints*, vol I, upper limb, ed 6, St. Louis, 2007, Churchill Livingstone–Elsevier.
32. Lindenhovius A, Karanicolas PJ, Bhandari M, et al: Interobserver reliability of coronoid fracture classification: two-dimensional versus three-dimensional computed tomography. *J Hand Surg [Am]* 34(9):1640–1646, 2009.
33. Macko D, Szabo RM: Complications of tension-band wiring of olecranon fractures. *J Bone Joint Surg Am* 67(9):1396–1401, 1985.
34. Mast J, Jakob R, Ganz R, editors: *Planning and reduction technique in fracture surgery*, Heidelberg, 1989, Springer.
35. McKee MD, Jupiter JB, Bosse G, et al: Outcome of ulnar neurolysis during posttraumatic reconstruction of the elbow. *J Bone Joint Surg Br* 80(1):100–105, 1998.
36. Morrey B, editor: Surgical exposures of the elbow. In *The elbow and its disorders*, Philadelphia, 1995, WB Saunders, pp 16–52.
37. Morrey BF: Current concepts in the treatment of fractures of the radial head, the olecranon, and the coronoid. *Instr Course Lect* 44:175–185, 1995.
38. Morrey BF, Adams RA, Bryan RS: Total replacement for post-traumatic arthritis of the elbow. *J Bone Joint Surg Br* 73(4):607–612, 1991.
39. Morrey BF, An KN: Articular and ligamentous contributions to the stability of the elbow joint. *Am J Sports Med* 11(5):315–319, 1983.
40. Morrey BF, Tanaka S, An KN: Valgus stability of the elbow. A definition of primary and secondary constraints. *Clin Orthop Relat Res* 265:187–195, 1991.
41. Mortazavi SM, Asadollahi S, Tahririan MA: Functional outcome following treatment of transolecranon fracture-dislocation of the elbow. *Injury* 37(3):284–288, 2006.
42. Mouhsine E, Akiki A, Castagna A, et al: Transolecranon anterior fracture dislocation. *J Shoulder Elbow Surg* 16(3):352–357, 2007.
43. O'Driscoll SW: Elbow instability. *Hand Clin* 0(3):405–415, 1994.
44. O'Driscoll SW, Bell DF, Morrey BF: Posterolateral rotatory instability of the elbow. *J Bone Joint Surg Am* 73(3):440–446, 1991.
45. O'Driscoll SW, Jaloszynski R, Morrey BF, et al: Origin of the medial ulnar collateral ligament. *J Hand Surg [Am]* 17(1):164–168, 1992.
46. O'Driscoll SW, Morrey BF, Korinek S, et al: Elbow subluxation and dislocation. A spectrum of instability. *Clin Orthop Relat Res* 280:186–197, 1992.
47. Papagelopoulos PJ, Morrey BF: Treatment of nonunion of olecranon fractures. *J Bone Joint Surg Br* 76(4):627–635, 1994.
48. Pavel A, Pitman JM, Lance EM, et al: The posterior Monteggia fracture: a clinical study. *J Trauma* 5:185–199, 1965.
49. Penrose JH: The Monteggia fracture with posterior dislocation of the radial head. *J Bone Joint Surg Br* 33(1):65–73, 1951.
50. Prayson MJ, Williams JL, Marshall MP, et al: Biomechanical comparison of fixation methods in transverse olecranon fractures: a cadaveric study. *J Orthop Trauma* 11(8):565–572, 1997.
51. Pribyl CR, Kester MA, Cook SD, et al: The effect of the radial head and prosthetic radial head replacement on resisting valgus stress at the elbow. *Orthopedics* 9(5):723–726, 1986.
52. Radin EL, Riseborough EJ: Fractures of the radial head. A review of eighty-eight cases and analysis of the indications for excision of the radial head and nonoperative treatment. *J Bone Joint Surg Am* 48(6):1055–1064, 1966.
53. Regan W, Morrey B: Fractures of the coronoid process of the ulna. *J Bone Joint Surg Am* 71(9):1348–1354, 1989.
54. Regan W, Morrey BF: Classification and treatment of coronoid process fractures. *Orthopedics* 15(7):845–848, 1992.
55. Ring D, Doornberg JN: Fracture of the anteromedial facet of the coronoid process. Surgical technique. *J Bone Joint Surg Am* 89(Suppl 2 Pt 2):267–283, 2007.
56. Ring D, Gulotta L, Chin K, et al: Olecranon osteotomy for exposure of fractures and nonunions of the distal humerus. *J Orthop Trauma* 18(7):446–449, 2004.
57. Ring D, Hannouche D, Jupiter JB: Surgical treatment of persistent dislocation or subluxation of the ulnohumeral joint after fracture-dislocation of the elbow. *J Hand Surg [Am]* 29(3):470–480, 2004.
58. Ring D, Jupiter JB: Excision of heterotopic bone around the elbow. *Tech Hand Up Extrem Surg* 8(1):25–33, 2004.
59. Ring D, Jupiter JB: Fracture-dislocation of the elbow. *J Bone Joint Surg Am* 80(4):566–580, 1998.
60. Ring D, Jupiter JB: Operative exposure of fractures of the distal radius. *Tech Hand Up Extrem Surg* 3(4):259–264, 1999.
61. Ring D, Jupiter JB: Reconstruction of posttraumatic elbow instability. *Clin Orthop Relat Res* 370:44–56, 2000.
62. Ring D, Jupiter JB, Gulotta L: Atrophic nonunions of the proximal ulna. *Clin Orthop Relat Res* 409:268–274, 2003.
63. Ring D, Jupiter JB, Sanders RW, et al: Transolecranon fracture-dislocation of the elbow. *J Orthop Trauma* 11(8):545–550, 1997.
64. Ring D, Jupiter JB, Simpson NS: Monteggia fractures in adults. *J Bone Joint Surg Am* 80(12):1733–1744, 1998.
65. Ring D, Jupiter JB, Waters PM: Monteggia fractures in children and adults. *J Am Acad Orthop Surg* 6(4):215–224, 1998.
66. Ring D, Jupiter JB, Zilberfarb J: Posterior dislocation of the elbow with fractures of the radial head and coronoid. *J Bone Joint Surg Am* 84(4):547–551, 2002.
67. Ring D, Quintero J, Jupiter JB: Open reduction and internal fixation of fractures of the radial head. *J Bone Joint Surg Am* 84(10):1811–1815, 2002.
68. Sanchez-Sotelo J, Morrey BF, O'Driscoll SW: Ligamentous repair and reconstruction for posterolateral rotatory instability of the elbow. *J Bone Joint Surg Br* 87(1):54–61, 2005.
69. Schneeberger AG, Sadowski MM, Jacob HA: Coronoid process and radial head as posterolateral rotatory stabilizers of the elbow. *J Bone Joint Surg Am* 86(5):975–982, 2004.
70. Smith GR, Hotchkiss RN: Radial head and neck fractures: anatomic guidelines for proper placement of internal fixation. *J Shoulder Elbow Surg* 5(2 Pt 1):113–117, 1996.
71. Tillmann B: *A contribution to the functional morphology of articular surfaces*, Stuttgart, 1978, PSG.
72. Yamaguchi K, Sweet FA, Bindra R, et al: The extraosseous and intraosseous arterial anatomy of the adult elbow. *J Bone Joint Surg Am* 79(11):1653–1662, 1997.

http://e-surg.com

21

Disorders of the Forearm Axis

Mark E. Baratz

Acknowledgments: I would like to acknowledge Kenneth R. Means, Jr., and Thomas J. Graham for their sixth edition version of this chapter. A special thank you goes to Alexandra Andoga, BS, for her help in the preparation of the seventh edition of this chapter.

FOREARM FUNCTIONAL ANATOMY

The elbow, forearm, and wrist act as a unified structure to provide a stable, strong, and highly mobile unit for positioning the hand in space and for performing load-bearing tasks. Understanding the relevant anatomy and biomechanics is essential for the surgeon who treats disorders of the forearm axis.[135]

The ulna is the primary "load-bearing" bone of the forearm and supports the radius as it rotates during pronation and supination. The ulna is essentially straight and suspends the radius through stabilizing ligaments at the wrist, at the elbow (proximal radioulnar joint [PRUJ]), and in the midshaft. The radius has an anterior bow allowing it to rotate around the ulna. Just proximal to the tuberosity of the radius, the bone is oriented exactly parallel to the axis of rotation of the forearm and lies at a 15-degree angle to the shaft of the radius. This configuration allows the radius to line up and articulate in a congruent fashion at the PRUJ. It is worth noting that malalignment of the PRUJ is relatively well tolerated and does not have much effect on forearm rotation. Conversely, malalignment of the distal radioulnar joint (DRUJ) has a major effect on pronation and supination. This is due to the fact that the distal radius has to swing in three planes to rotate about the ulnar head. The longitudinal axis of forearm rotation passes through the center of the radial head at the elbow and through the fovea of the ulnar head at wrist level (Figure 21.1).[135] This axis is not constant but changes slightly as the radial and ulnar heads shift on their respective articular surfaces during pronation and supination. With pronation the radial head moves into a position that is anterior and medial on the capitellum. With supination the head moves into a position that is lateral and posterior.[44]

Forearm rotation occurs between the radial head and the radial notch of the ulna proximally (PRUJ) and between the ulnar head and the sigmoid notch of the radius distally (DRUJ). These joints act as hemijoints in facilitating forearm rotation. In addition, the component parts of the interosseous membrane (IOM) act to stabilize the radius on the ulna during forearm rotation and loading (as well as presenting an expanded surface from which certain muscles take origin). The IOM has distal, middle, and proximal portions, together constituting an integrated mechanism constraining the relative movements of the radius and ulna. The condensations within the membrane that appear to have the greatest mechanical strength are the distal oblique band, the central and accessory bands, the dorsal oblique accessory cord, and the proximal oblique cord (Figure 21.2).[91] Forearm rotation is a complex motion with rotational and translational elements. Injuries and inflammatory conditions can disrupt the seamless relationship between the forearm structures.[70]

This chapter focuses on pertinent anatomy and biomechanics, as well as operative techniques for adult disorders, including radial shaft fractures, middle and distal ulnar shaft fractures, both-bone fractures of the forearm, removal of radial and ulnar shaft plates, nonunion and malunion of the radius and ulna, radioulnar synostosis, and longitudinal instability of the forearm.

RADIAL SHAFT FRACTURES

General Evaluation and Preoperative Considerations

Fractures of the radial shaft may be isolated or may be more extensive and have significant associated soft tissue involvement, as seen on radiographic views. The unique "bowed" osseous anatomy of the radius, supported between the stable PRUJ and DRUJ, makes it vulnerable to direct trauma through its diaphysis. Transmission of forces created by a fall on the outstretched hand may lead to a global forearm injury. Because of the unique anatomy, any deviation in the spatial orientation of the radius can decrease forearm rotation. Restoration of motion requires acceptable axial and rotational alignment in addition to the maintenance of the radial bow.

The concept of the forearm as a ring helps direct the evaluation and treatment of all forearm fractures. High-energy injuries can disrupt the ligaments supporting the DRUJ or PRUJ. As such, it is judicious to examine the entire extremity. This includes the neurologic and vascular systems.

Imaging should begin with frontal and lateral radiographs of the entire forearm with a low threshold to obtain views of the wrist and elbow.[8,81,122] Computed tomography (CT) or magnetic resonance imaging (MRI) is not typically necessary in the initial assessment of acute forearm shaft fractures. However, imaging with CT can be useful in evaluating the extent of healing following open reduction and plate fixation.

PERTINENT ANATOMY

Neurovascular structures are vulnerable to trauma and to surgical treatment of forearm fractures and dislocations (Figure

http://e-surg.com

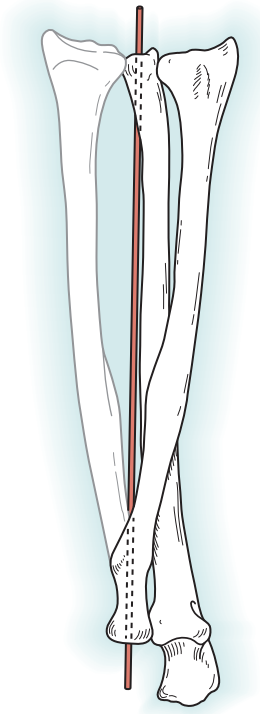

FIGURE 21.1 The axis of rotation for the forearm passes through the center of the radial head proximally and through the ulnar fovea at the base of the ulnar styloid distally.

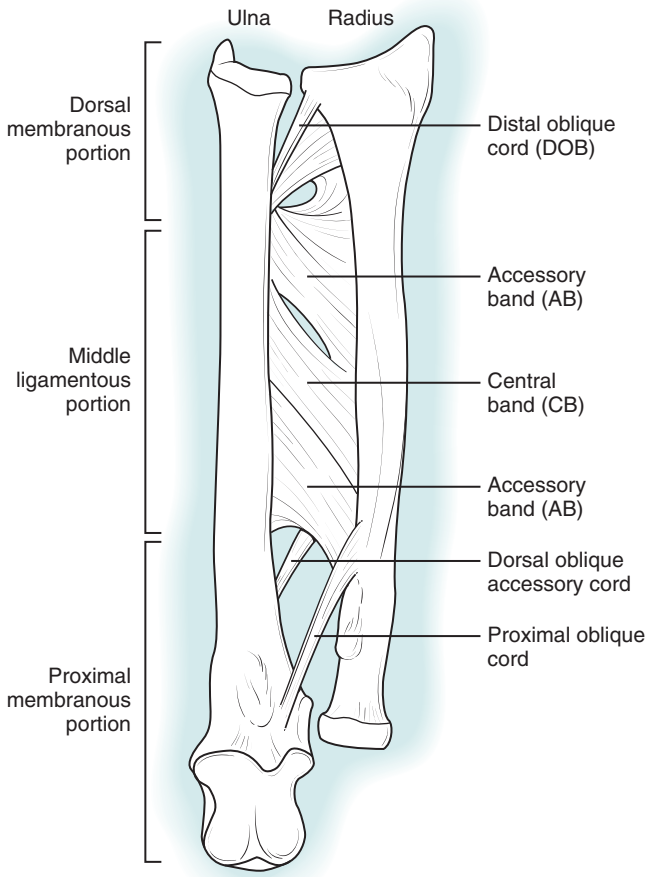

FIGURE 21.2 Diagram of the interosseous membrane (right forearm, anterior aspect). Key features include the distal oblique cord (DOB) that lies within the distal membranous portion and the proximal oblique cord that lies on the anterior surface proximally. The middle ligamentous complex contains the central band (CB) and accessory bands (AB). (Reproduced with permission of Elsevier from Noda K, Goro A, Murase T, et al: Interosseous membrane of the forearm: an anatomical study of ligament. *J Hand Surg [Am]* 34:415–422, 2009.)

21.3). As the radial nerve enters the forearm, it divides into the deep posterior interosseous nerve and the superficial sensory, or dorsal radial sensory, nerve. The posterior interosseous nerve (PIN) passes anterior to the elbow capsule and enters the supinator. The PIN crosses the proximal radius 5 to 6 cm distal to the radiocapitellar joint before exiting the supinator (Figures 21.4 and 21.5). This nerve is particularly vulnerable to injury in this region from trauma or in the course of the surgical exposure of the proximal radius (Figure 21.6). The PIN provides motor fibers, in succession, to the extensor carpi radialis brevis (ECRB), supinator, extensor digitorum communis (EDC), extensor digiti minimi, extensor carpi ulnaris, abductor pollicis longus, extensor pollicis longus (EPL), extensor pollicis brevis (EPB), and extensor indicis proprius. The nerve terminates as a proprioceptive sensory nerve to the wrist. The superficial sensory branch of the radial nerve travels beneath the brachioradialis and emerges between the brachioradialis and extensor carpi radialis longus (ECRL) tendons approximately 8 cm proximal to the radial styloid.[84,108]

After entering the forearm beneath the bicipital aponeurosis, the median nerve travels between the two heads of the pronator teres. The anterior interosseous nerve is a branch that emanates just proximal to the flexor digitorum superficialis (FDS) and then passes between the two heads of this muscle. The median nerve proper continues distally in the forearm between the FDS and flexor digitorum profundus (FDP) until it enters the carpal tunnel, passing beneath the palmaris longus. The palmar cutaneous nerve branches from the median nerve in the distal part of the forearm, approximately 8.5 cm proximal to the distal volar wrist crease. It runs between the flexor carpi radialis and palmaris longus, deep to the forearm fascia. It pierces the fascia approximately 4.5 cm proximal to the volar wrist crease.

The radial and ulnar arteries branch from the brachial artery after it exits beneath the bicipital aponeurosis. The radial artery continues into the forearm beneath the brachioradialis until it reaches the distal end of the forearm, where it immediately becomes a subfascial structure.

Understanding of the osseous morphology of the radius, especially the anterior bow in the diaphysis, helps the surgeon when treating radius fractures or malunions. This is especially true with comminuted fractures and injuries with segmental bone loss. As discussed, the radial bow is crucial to pronation and supination because it allows the radius to rotate about the ulna. The radial bow is assessed on a frontal radiograph with the forearm in neutral rotation, the shoulder abducted 90 degrees, and the elbow flexed 90 degrees. The radial bow can be defined by drawing a line between the radial tuberosity proximally and the most ulnar edge of the radius distally. A perpendicular line is drawn at the point of maximal radial bow, and the length of this line is measured (Figure 21.7).[116]

http://e-surg.com

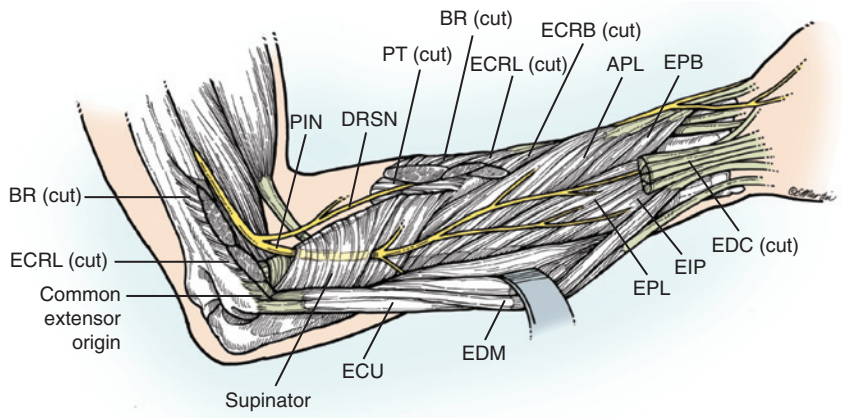

FIGURE 21.3 Anatomic relationships of the posterior interosseous and superficial sensory branches of the radial nerve in the forearm. *APL*, Abductor pollicis longus; *BR*, brachioradialis; *DRSN*, dorsal radial sensory nerve; *ECRB*, extensor carpi radialis brevis; *ECRL*, extensor carpi radialis longus; *ECU*, extensor carpi ulnaris; *EDC*, extensor digitorum communis; *EDM*, extensor digiti minimi; *EIP*, extensor indicis proprius; *EPB*, extensor pollicis brevis; *EPL*, extensor pollicis longus; *PIN*, posterior interosseous nerve; *PT*, pronator teres. (Copyright Elizabeth Martin.)

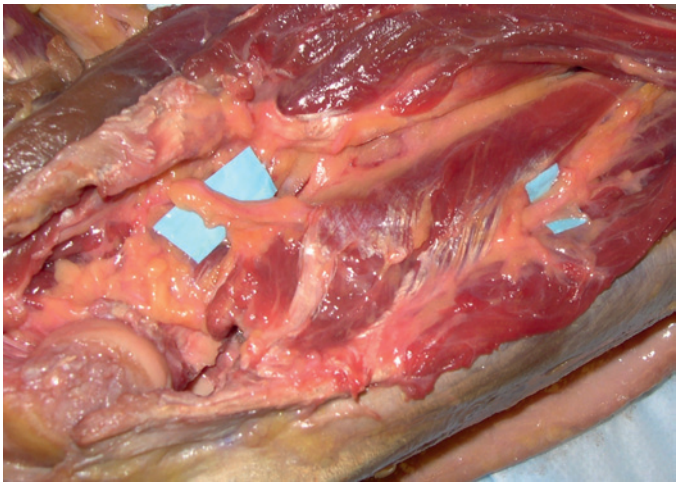

FIGURE 21.4 The posterior interosseous nerve of a right forearm is highlighted with a *light blue background* as it passes through the supinator.

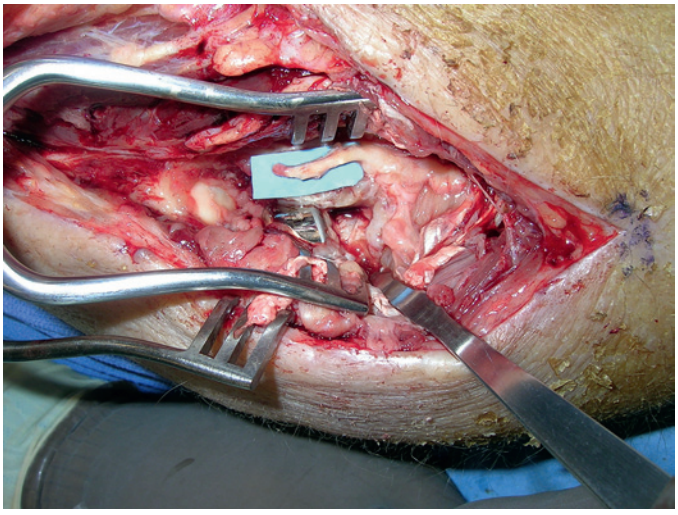

FIGURE 21.6 The posterior interosseous nerve (lying on a *light blue background*) was found to be transected following surgery to treat an elbow fracture-dislocation with a radial head fracture.

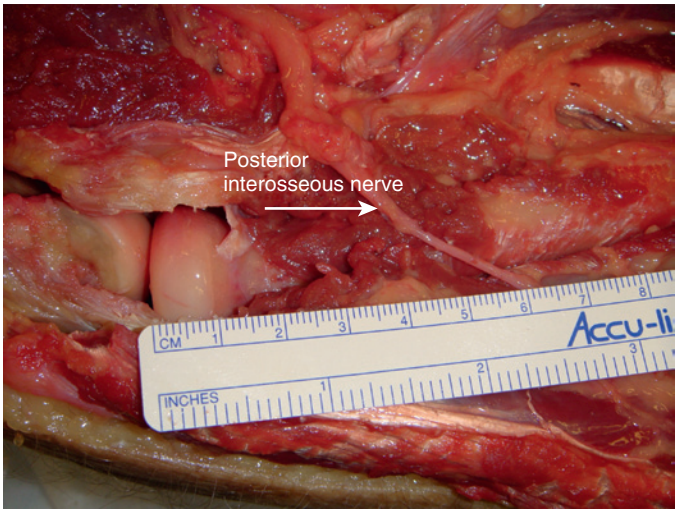

FIGURE 21.5 The posterior interosseous nerve crosses the radius approximately 5 to 6 cm from the radiocapitellar joint.

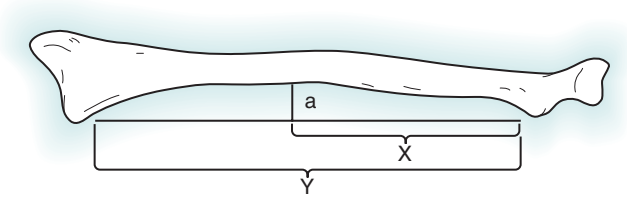

Maximum radial bow
a (mm)
Location of maximum radial bow
X/Y × 100

FIGURE 21.7 Measuring radial bow.

http://e-surg.com

Surgical Approaches for Fractures of the Radial Shaft

Anterior Approach

There are several advantages to the anterior approach to the radial shaft, also known as the "volar approach of Henry." The entire radius may be exposed with this approach, from the radial head proximally to the radial styloid distally. The anterior approach to the radial shaft is indicated for practically any fracture involving the radius. There are well-defined intervals for the exposure that permit hardware to be placed on the anterior surface of the radius while still providing excellent muscle and soft tissue coverage. During the anterior approach, "blind" placement of curved retractors around the proximal radial shaft should be performed, with care taken to avoid injury to the PIN.

The patient is placed supine on the operating room table. A radiolucent arm board is placed under the injured extremity. All potential pressure areas are well padded. General or regional anesthesia is appropriate. Prophylactic intravenous antibiotics are administered when surgical implants are anticipated.[107] A nonsterile tourniquet padded with a cotton roll is applied to the upper part of the operative extremity.

An incision of varying length, determined by the longitudinal extent of the fracture, is made on the anterior and radial aspect of the forearm by using a line extending from the lateral aspect of the distal biceps tendon to the radial styloid (Figure 21.8). The incision is centered on the site of the fracture and extended proximally and distally to allow reduction and fixation without undue retraction on the skin edges or underlying structures. The fascia of the anterior forearm musculature is incised longitudinally, just ulnar to the brachioradialis, which may be seen just deep to the fascia. Once the fascia is opened, the radial artery can be identified ulnar to the brachioradialis. The interval between the radial artery and the brachioradialis is developed (Figure 21.9), and arterial branches to the brachioradialis are ligated or cauterized. In the distal third of the forearm, the radial artery will be clearly distinct and ulnar to the brachioradialis. More proximally, the radial artery lies deep to the brachioradialis. When mobilizing the brachioradialis radially, the superficial sensory branch of the radial nerve should be identified deep to the brachioradialis and protected. It is mobilized radially with the brachioradialis (Figure 21.10).

Deep dissection differs proximally and distally. In the proximal third of the forearm, the lateral antebrachial cutaneous nerve should be identified and protected as it exits between the brachioradialis and the distal biceps muscle. One should then find the insertion of the biceps tendon. Just lateral to it, there is a small bursa. An incision is made in the bursa (the radial artery at that level is medial and superficial to the biceps tendon, so that dissection is safe lateral to the tendon). It is more difficult to mobilize the brachioradialis radially as it travels obliquely across the forearm. By staying lateral to the distal biceps tendon, the brachioradialis and radial artery are separated. The recurrent branch of the radial artery is usually seen at this level and may need to be divided to allow for adequate exposure. Supination of the forearm reveals the supinator muscle, which is elevated in a subperiosteal plane in an ulnar

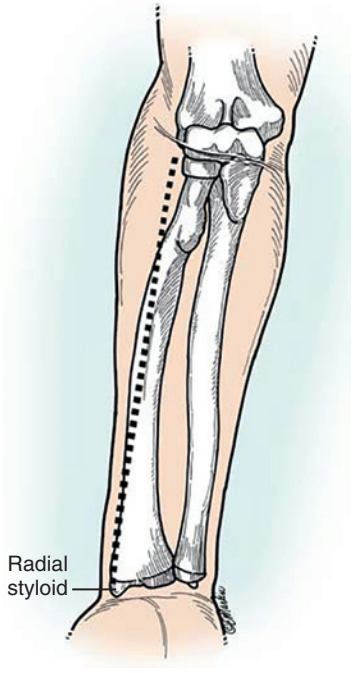

FIGURE 21.8 Incision for the anterior approach to the radial shaft. The length of the incision varies depending on exposure requirements. (Copyright Elizabeth Martin.)

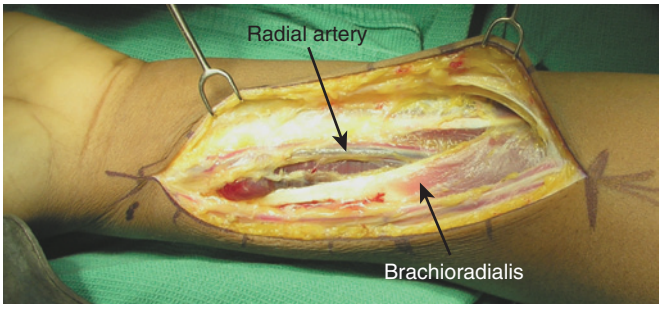

FIGURE 21.9 Clinical photograph demonstrating superficial exposure of the anterior approach to the radius and the anatomic relationships of the radial artery.

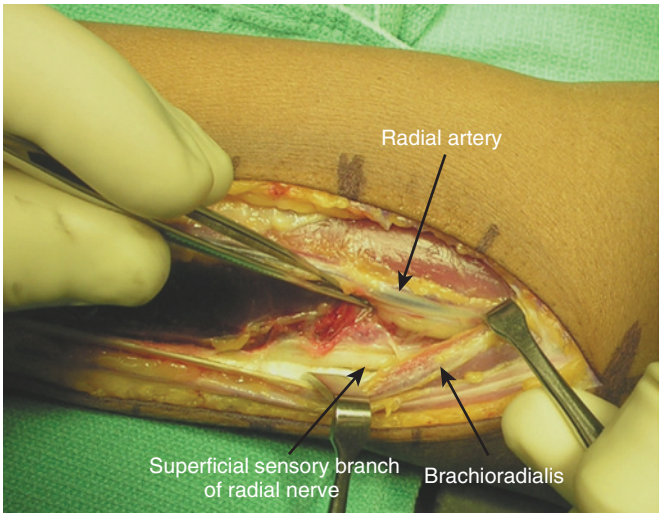

FIGURE 21.10 Clinical photograph demonstrating anatomic relationships of the radial artery, brachioradialis, and superficial sensory branch of the radial nerve.

http://e-surg.com

to radial direction (Figure 21.11). Because the PIN may lie directly on the posterior aspect of the radial shaft at this level, subperiosteal dissection does not necessarily ensure that the nerve has been elevated and is protected. For this reason, the anterior portion of the radius is exposed only in a supinated position. Curved retractors or other tools should not be placed around the posterior aspect of the radial shaft at this level. Once the interval between the brachioradialis and the radial artery is developed, the pronator teres is visualized and divided at its radial insertion. The pronator is elevated in a radial to ulnar direction to expose the radial shaft. In the distal third of the forearm, the interval between the radial artery and the flexor carpi radialis may be used. The flexor pollicis longus and pronator quadratus muscles are dissected off of the radial shaft in a radial to ulnar direction to expose the shaft.

Posterior Approach for Radial Shaft Fixation

The posterior approach to the radial shaft (*Thompson approach*) is used primarily for proximal fractures. This approach requires that the surgeon identify the PIN. The entire radius can be exposed when working between muscle intervals.

The patient is placed supine on the operating table. The arm may be placed on an arm board or across the patient's chest. With the forearm pronated, an incision is made starting just anterior to the lateral epicondyle and proceeding distally toward the middle of the wrist (Figure 21.12). The incision is carried

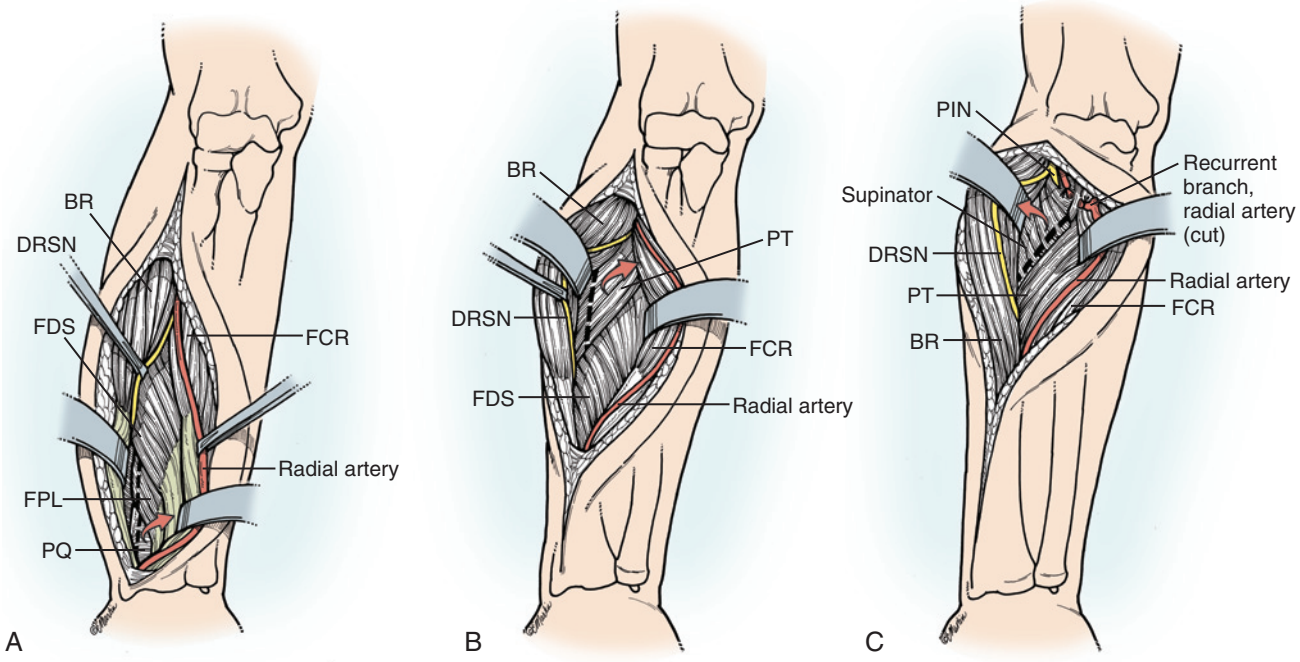

FIGURE 21.11 **A** to **C,** Deep dissection for the anterior approach to the radial shaft. *BR*, Brachioradialis; *DRSN*, dorsal radial sensory nerve; *FCR*, flexor carpi radialis; *FDS*, flexor digitorum superficialis; *FPL*, flexor pollicis longus; *PIN*, posterior interosseous nerve; *PQ*, pronator quadratus; *PT*, pronator teres. (Copyright Elizabeth Martin.)

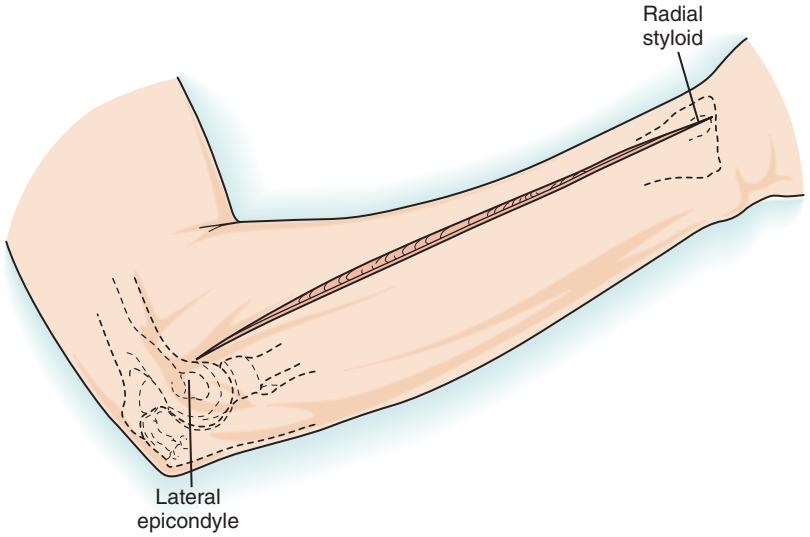

FIGURE 21.12 Incision for the posterior approach to the radial shaft. The length of incision is varied according to exposure needs.

http://e-surg.com

through the subcutaneous tissue. The interval between the ECRB and the EDC is identified and developed (Figure 21.13). Once the incision is deep to those muscles, the supinator is immediately apparent. The radial nerve is within the substance of the muscle and should be dissected, mobilized, and protected. Distally, the abductor pollicis longus and EPB (first extensor compartment muscles) emerge from between the EDC and the ECRB, making the interval more identifiable at this level (Figure 21.14). Immediately deep to the EDC-ECRB interval proximally is the supinator muscle belly. The PIN is identified as it enters the supinator muscle proximally. The nerve is dissected through the length of the supinator by dividing its superficial head. Once the nerve has been identified and protected, the supinator is elevated off of the radial shaft in an anterior to posterior direction. The shaft is now exposed, and reduction and stabilization can proceed. The abductor pollicis longus and EPB cover the radius near the junction of the middle and distal third of the shaft and may be elevated proximally or distally as needed. Distal to this level, the interval is between the ECRB and the EPL, or it can be shifted between the EPL and EDC if exposure is required more distally.

Fracture Stabilization

Conventional wisdom has suggested that optimal fixation of radial shaft fractures consists of compression plating with a 3.5-mm plate and screws engaging five or six cortices proximal and distal to the fracture ends.[18,124] Recent studies have demonstrated a high union rate (90%) with only four cortices of fixation proximal and distal to the fracture site, but often with supplemental lag screw fixation. In addition, the screws are placed in a near-far/near-far orientation relative to both sides of the fracture site.[24,75] Plates larger than 3.5 mm are not typically used, because of concern for fracture through the screw holes, cross-union of the radius and ulna, or fracture after plate removal.[11]

With regard to locking versus nonlocking plates, the evidence suggests that there is no difference in union rates or clinical outcome between these two implants for most forearm

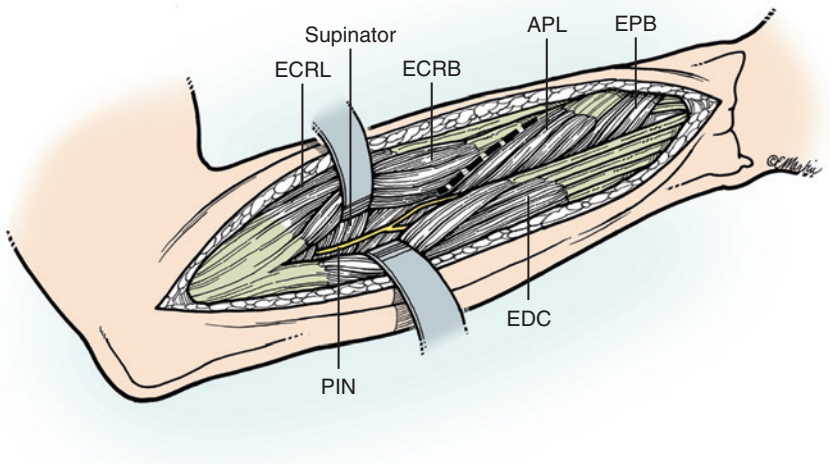

FIGURE 21.13 Superficial muscular intervals for the Thompson posterior approach to the radial shaft. *APL*, Abductor pollicis longus; *ECRB*, extensor carpi radialis brevis; *ECRL*, extensor carpi radialis longus; *EDC*, extensor digitorum communis; *EPB*, extensor pollicis brevis; *PIN*, posterior interosseous nerve. (Copyright Elizabeth Martin.)

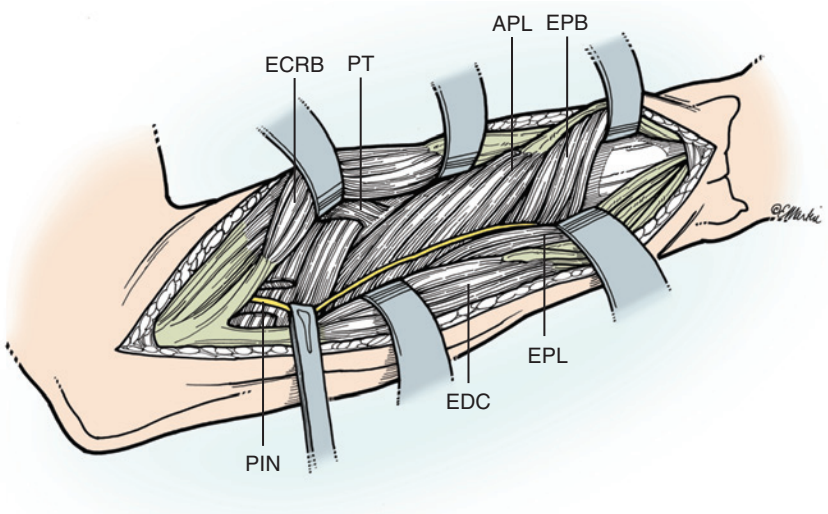

FIGURE 21.14 Distal interval. *APL*, Abductor pollicis longus; *ECRB*, extensor carpi radialis brevis; *EDC*, extensor digitorum communis; *EPB*, extensor pollicis brevis; *EPL*, extensor pollicis longus; *PIN*, posterior interosseous nerve; *PT*, pronator teres. (Copyright Elizabeth Martin.)

http://e-surg.com

fractures.[7] Locking plates may help for fractures with significant comminution when the implant functions as a bridge plate and for fixation of osteoporotic bone.[43,121]

Segmental fractures require longer plates, and their use will necessitate contouring of the plate to maintain an acceptable radial bow. If significant contouring is required, reconstruction-type plates (with scallops along the sides of the plate) may be considered, but these plates are substantially weaker than compression plates. Newer prebent plates with a radial bow contour that do not have this disadvantage are available for long radial shaft fractures. Fractures with significant comminution but without proximal-distal cortical contact may need to be bridged by a plate without compression of the fracture site. In this situation, comparison radiographs from the uninjured forearm may help determine the appropriate length and radial bow.

Bone Grafting

The indications for bone grafting are somewhat controversial. Some studies suggest that grafting of comminuted fractures confers no significant benefit.[4,105,138,140] Application of bone graft should not be indiscriminate. The chance of radioulnar synostosis is increased with undue dissection. Likewise, bone graft in the interosseous space may promote unwanted bone formation that can lead to limited forearm rotation. Generally, bone graft is recommended when there is significant comminution and bone loss at the fracture site of approximately 50% of the bony diameter.

Fixation of Galeazzi-Type Fracture-Dislocations

The Galeazzi fracture-dislocation is part of the family of forearm axis injuries where both bone and soft tissue trauma compromise forearm stability. This pattern consists of a fracture at the junction of the middle and distal thirds of the radial shaft and DRUJ dislocation or injury (Figure 21.15, *A* and *B*). Any fracture of the radial shaft about the junction of the middle and distal thirds should raise suspicion of a DRUJ injury, although isolated shaft fractures remain statistically more common.[106] In one study, radial shaft fractures within 7.5 cm of the distal radial articular surface had a significantly higher likelihood of associated DRUJ instability than did those that were more than 7.5 cm away from the distal articular surface.[103] It can be helpful to examine the uninjured wrist to assess the inherent laxity of the patient's DRUJ. It may also be useful to get radiographs of the uninjured wrist to estimate that patient's native ulnar variance.

Galeazzi fractures are typically fixed with a 3.5-mm plate placed on the anterior aspect of the radius. The plate needs to be bent distally to accommodate the anterior concavity of the radius at the metadiaphyseal level (Figure 21.16). Fixation in this region may be more difficult if the fracture is more distal. In this case, it is helpful to use a precontoured volar plate designed for distal radius fractures that is sufficiently long to span the fracture proximally.

Anatomic reduction of the radius should restore alignment to the DRUJ. If the DRUJ remains incongruent, the reduction of the radius should be reassessed. If the DRUJ does not reduce, in spite of anatomic reduction of the radius, in rare instances the reduction can be blocked by soft tissue interposition. The extensor carpi ulnaris is a common culprit in this setting.[13,16,56] During the operation, one can examine the DRUJ. A "clunk"

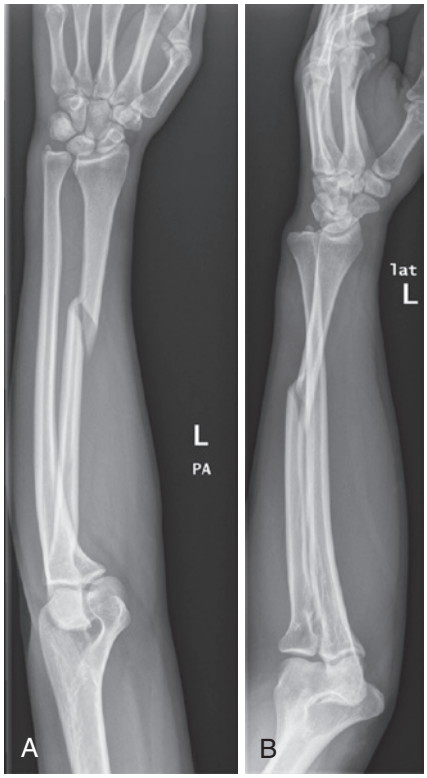

FIGURE 21.15 **A** and **B,** Radiographs of a Galeazzi fracture-dislocation.

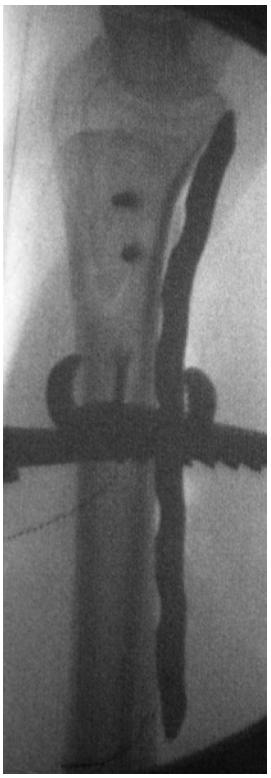

FIGURE 21.16 Lateral radiograph of proposed fixation for a Galeazzi fracture-dislocation.

http://e-surg.com

with passive rotation is evidence of gross instability. Translation of the ulnar head with the forearm in full pronation, neutral rotation, and supination can also be assessed.

If the reduced DRUJ is not stable throughout a full arc of rotation, there are several options. Typically the DRUJ will be more stable in supination and can be immobilized in that position for 3 to 4 weeks. Gross laxity of the DRUJ can be managed with two 0.062-inch smooth Kirschner wires placed proximal to the DRUJ across all four cortices. Having the pin tips exit the radial aspect of the radius and the ulnar aspect of the ulna ensures that all pins can be extracted if the pins break in the interosseous space.

Some surgeons have advocated open or arthroscopic repair of the triangular fibrocartilage complex or open repair of an associated ulnar styloid fracture. In one study, van Duijvenbode and colleagues[130] reviewed the outcome of isolated diaphyseal radius fractures with and without dislocation of the DRUJ. They concluded that anatomic fixation of the radius seemed sufficient without concomitant pinning of the radius to the ulna or repair of the triangular fibrocartilage complex.

Alternative Fixation Methods for Fractures of the Radial Shaft: Intramedullary Rods and External Fixation

The forearm remains the only major diaphyseal segment in which intramedullary fixation is rarely used. Obvious advantages of intramedullary implants in the forearm include minimizing soft tissue stripping, facilitating load sharing, having a low profile design, and reducing the risk of refracture with implant removal.[64] This is particularly true in segmental injuries (Figure 21.17) and instances where the soft tissues have been compromised by severe contusion or burns. Unfortunately, this technique has been plagued by high rates of nonunion and malunion. There is also a risk of injury to neurovascular structures, especially with proximal locking screws.[125] Locked nails provide increased stability and have union rates that approach or match those of compression plating.[45,137]

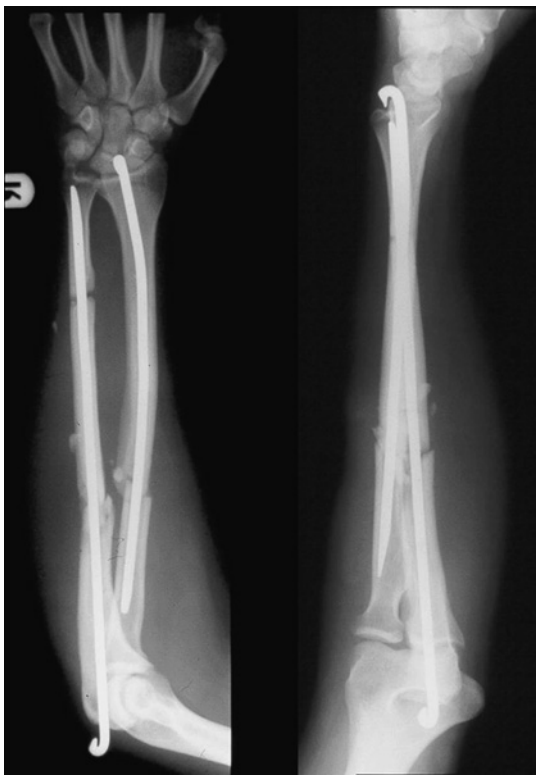

FIGURE 21.17 Intramedullary fixation of radial shaft and segmental ulnar shaft fractures associated with significant blunt soft tissue injury.

One attractive indication for intramedullary nailing is the management of pathologic fractures. This is particularly true for lesions where the diagnosis is known and treatment consists of bone stabilization followed by irradiation.[77]

The contraindications for nailing of forearm fractures include active infection, previous malunion, canal diameter smaller than that of the available implant,[101] and fracture extension to the metaphysis or articular surface.[71]

The evidence for plate versus nail fixation of adult forearm fractures consists mostly of retrospective reviews of closed radius or ulna fractures and those in which bone grafting is deemed unnecessary. Lee and associates[73] reported their experience in 27 patients with 38 fractures using a contoured, locking intramedullary nail (Acumed, Hillsboro, OR). The nail has a proximal interlocking screw and a "paddle tip" to provide rotational stability. In their series, which included seven open fractures, there was one superficial infection and one nonunion. Five nails (13%) were removed, with no refractures. The average Disabilities of the Arm, Shoulder, and Hand (DASH) score was 15 (range, 5 to 61), with 92% of patients obtaining good or excellent results.

Ozkaya and coworkers[95] retrospectively compared results of treatment in 42 patients with diaphyseal forearm fractures. Twenty-two of the fractures were treated with open reduction and plate fixation, and 20 were treated with closed reduction and locked intramedullary nailing. There was no difference in fracture severity between the groups. Three fractures in the plate group were bone grafted; none was grafted in the nail group. All of the fractures healed. The plates were removed in 12 patients (55%), and the nails were removed in 5 patients (25%). There were no significant differences in outcome.

Visna and colleagues[134] reported the results of a prospective study evaluating 80 patients with 115 forearm fractures treated with either plate or nail fixation. There was one refracture following plate removal. There were two cases of incomplete synostosis and two cases of partial migration of the interlocking screw in the nail group. No significant differences in functional outcome were detected.

Finally, external fixation of fractures of the forearm is limited to temporary stabilization of complex forearm injuries and management of segmental defects associated with infection (Figure 21.18, *A* to *C*).

❖ AUTHOR'S PREFERRED METHOD OF TREATMENT: Radial Shaft Fractures

Nonoperative treatment is limited to nondisplaced or minimally displaced or angulated shaft fractures and to patients who are too sick to undergo surgical treatment.

The forearm shaft fracture "tool kit" includes 3.5-mm plates with fracture instrumentation, intraoperative fluoroscopy, and a plan for bone graft if necessary (autograft, allograft, or a bone graft substitute). The anterior approach is used for all fractures of the radius except for proximal fractures involving the radial head and/or neck that extend to the radial tuberosity. In those instances we prefer the Thompson approach. Periosteal

http://e-surg.com

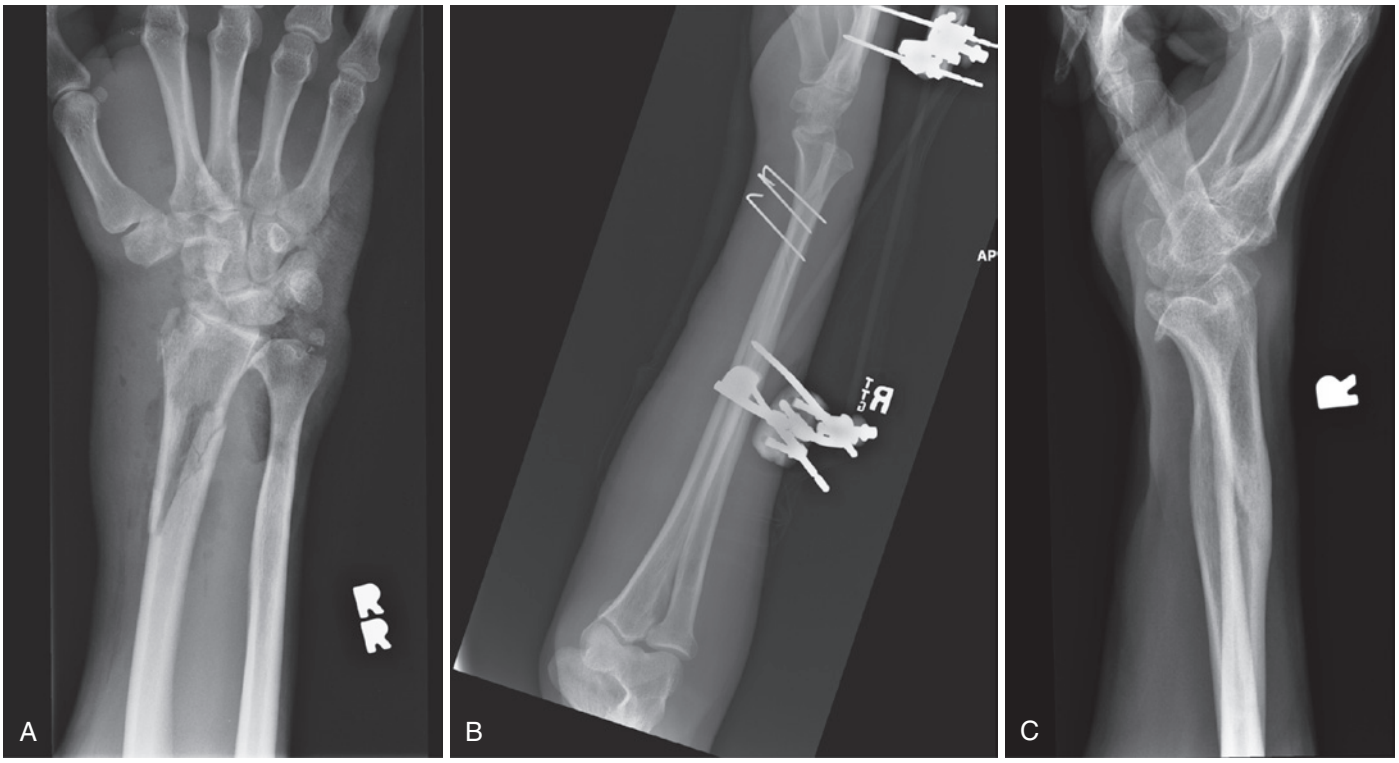

FIGURE 21.18 **A** to **C,** Radiographs of a patient seen in delayed fashion with a grossly contaminated distal forearm and wrist crush injury with open fractures. External fixation plus limited internal fixation was used to provide adequate initial stability to allow soft tissue and radial shaft fracture healing.

elevation is limited to the fracture site. Reduction clamps are used to grasp the shaft of the radius and raise the bone ends sufficiently to clean the fractured surfaces. Spiral and long oblique components of the fracture can be fixed with 2.7-mm lag screws and neutralized with a 3.5-mm compression plate. Transverse fractures will often interdigitate and simplify the reduction and stabilization. Short oblique fractures can be "slippery" and therefore more challenging. One can gain control of one end of the fracture by first contouring the plate replicating the radial bow and then securing this to either the proximal or the distal fragment with a single screw. Fluoroscopy is used to confirm reduction, restoration of the radial bow, and hardware position. We still strive to secure six cortices on either side of the fracture (Figure 21.19, *A* and *B*).

In instances where there is severe comminution, a "bridge plate" can be precontoured to span the defect. It is as important to re-create the correct location of maximal bow as it is to re-create the amount of maximal bow.[116] Transverse or short oblique fractures can usually be fixed with straight plates while maintaining the radial bow. It is considered safe to use a straight plate even if the radial or ulnar edge of the plate is slightly off the bone proximally or distally (as long as the screw purchase is not compromised). Plates used for longer fractures will need to be contoured. In these cases, it may be helpful to have a radiograph of the contralateral, uninjured forearm. Rotational alignment of the radius can be checked by comparing the proximal bicipital tuberosity with the distal radial styloid on a fully supinated radiograph. With an anatomic reduction, the tuberosity and styloid should be seen in profile and facing in opposite directions, that is, ulnarly and radially, respectively. With more distal shaft fractures, an anterior bend may need to be placed in the plate to match the anterior flare of the radius in the metadiaphyseal region (see Figure 21.16). The best way to ensure re-creation of an adequate radial bow and restoration of appropriate rotational and angular alignment is to check passive rotation after provisional fixation. With full forearm rotation, it is likely that near-normal relationships have been restored.

As mentioned above, the role of bone grafting is somewhat controversial. We use bone grafting in fractures in which contact at the fracture site is 50% or less. Most commonly, cancellous autograft is harvested from either the iliac crest or the proximal tibia. The olecranon process of the ulna and the distal radius (in proximal fractures) are other options. Compressed cancellous autograft is also used for significant gaps with stable fixation. If fracture fixation is tenuous, intercalary corticocancellous grafting using the iliac crest can be considered to augment stability. Locking plates are useful in this setting and may obviate the need for structural bone graft.

Postoperative Management and Expectations

Hand stiffness and loss of forearm supination are among the most common complications of forearm trauma. A nonconstrictive dressing will help facilitate free finger motion. Immediate forearm rotation should be possible in most cases after fixation. Immobilization is typically limited to short-arm immobilization in a lightweight splint for comfort and support. Weight bearing, strengthening, and static progressive splinting are deferred until there is radiographic evidence of union. Long-arm immobilization for approximately 4 weeks is typical for patients with a Galeazzi fracture when there was instability

http://e-surg.com



FIGURE 21.19 **A** and **B,** Posteroanterior and lateral radiographs of the DRUJ after anatomic reduction and fixation of the radial shaft in a Galeazzi fracture-dislocation.

CRITICAL POINTS *Anterior Approach for Plate Fixation of the Radial Shaft*

- Maintain a superficial interval between the brachioradialis and radial artery/flexor carpi radialis.
- Protect the dorsal radial sensory nerve beneath the brachioradialis.
- The deep interval is dependent on the proximal-distal level of the fracture.
- Use interfragmentary compression techniques (lag screws or compression plating, or both) when possible.
- Use intraoperative fluoroscopy to confirm adequate reduction and hardware placement.
- Ensure adequate passive pronation-supination after reduction and provisional fixation.

of the DRUJ. These patients are given a short-arm splint for 2 weeks thereafter and closely monitored for residual instability.

Union rates for uncomplicated radial shaft fractures are in excess of 95%.[30,32,48,52,121] Morrey and associates[87] defined the functional arc of forearm rotation as 50 degrees of supination and 50 degrees of pronation. This should be easily achievable in most shaft fractures. Ultimate forearm rotation will vary with the severity of the associated soft tissue injury and the time to union. Droll and coworkers[32] noted a "moderate reduction" in the strength of the forearm, wrist, and hand.

EXPECTED OUTCOMES *Anterior Approach for Plate Fixation of the Radial Shaft*

- Near-anatomic reduction with stable fixation
- Greater than 95% union rates
- Excellent hand motion and a functional arc of forearm rotation
- Mild to moderate loss of forearm strength

Complications

Most of the untoward consequences of forearm shaft fractures are the result of soft tissue damage from the energy dissipated by the injury. In its wake lie damaged muscle, bruised or cut tendons, damaged nerves, and a swollen limb. Appropriate treatment can minimize but not eliminate the effects of this initial insult to the arm. Higher-energy injuries carry higher risks of nonunion, malunion, and residual stiffness.

DISTAL AND MIDSHAFT ULNAR FRACTURES

Preoperative Evaluation

Isolated distal and midshaft ulnar fractures are most often a result of direct trauma. One should always be wary of possible associated injuries to the wrist, forearm, and elbow. In isolation, the so-called *nightstick fracture* follows a blow to the subcutaneous border of the ulna. Closed distal and midshaft ulnar fractures can be treated successfully with nonoperative methods, such as functional bracing or short-arm casting, when the displacement or angulation is minimal.[3,6,23,46,115] A recent Cochrane review[54] included three trials comparing various methods of nonoperative treatment for isolated diaphyseal fractures of the middle and distal thirds of the ulna in adults. The review concluded that there was no evidence that immobilization of the elbow provided short-term benefit in terms of pain relief or fracture union compared with casts or braces that immobilized only the forearm. Van Leemput and colleagues[132] reviewed a total of 102 patients who were treated with a compression bandage (n = 34), a short-arm cast for 6 weeks (n = 36), or a long-arm cast for 3 weeks followed by a short-arm cast for 3 additional weeks (n = 32). At 12 weeks of follow-up, there was no significant difference in the incidence of delayed union, time to fracture union, mean pain scores, or range of motion among the three groups.

The ideal treatment of these fractures, regardless of the degree of displacement, has yet to be determined.[53] Displaced fractures with more than 10 degrees of angulation or 50% displacement are considered candidates for operative treatment.[15,100] It has been suggested that displacement of more than 50% indicates that at least partial disruption of the IOM is present.[35,94]

PERTINENT ANATOMY

The ulna is the stable post of the forearm. The radius rotates about the ulna to allow a functional arc of forearm rotation.[100] In the distal and midshaft portions, the ulna is essentially straight. The midshaft region has a narrow apex adjacent to the

http://e-surg.com

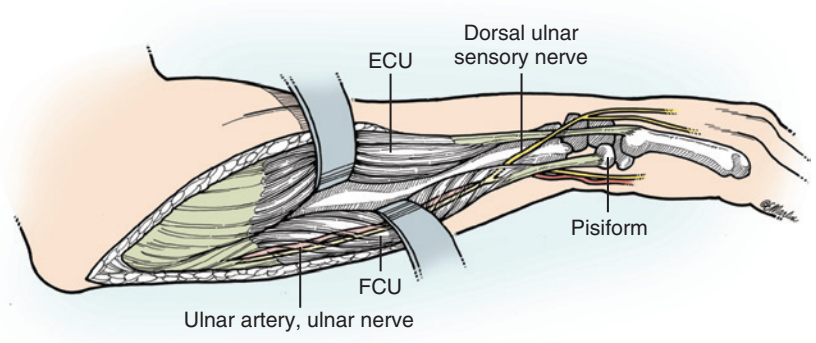

FIGURE 21.20 Pertinent anatomy relative to the surgical approach to the ulna. Note the proximity of the ulnar neurovascular structures to the incision and deep dissection and, in particular, the course of the ulnar sensory nerve through the "ulnar snuffbox." *ECU,* Extensor carpi ulnaris; *FCU,* flexor carpi ulnaris. (Copyright Elizabeth Martin.)

subcutaneous border, which makes direct ulnar placement of a plate more difficult. The ulna is triangular through most of the diaphysis, with a sharp radial border serving as the origin of the interosseous ligament. This morphologic picture affords a relatively flat volar surface where the ulna is also relatively wide, making it well suited for longitudinal implants. Volar placement also provides better soft tissue coverage, better matching of the undersurface plate structure with the underlying bone structure, and, theoretically, minimization of the need for future plate removal due to plate prominence.

The ulnar nerve and artery lie deep to the flexor carpi ulnaris muscle belly in the proximal part of the forearm and are radial and deep to its tendon. The dorsal ulnar sensory nerve may exit the deep forearm fascia anywhere from 1 to 4 cm proximal to the ulnar styloid. It courses though the "ulnar snuffbox" in a proximal volar to distal dorsal direction[84] (Figure 21.20).

Surgical Alternatives for Fractures of the Ulnar Shaft

Direct Ulnar Approach for Distal and Midshaft Ulnar Fixation

The main advantage of this approach is the ease of exposing the entirety of the ulna. Disadvantages are a potential difficulty with soft tissue coverage of the bone and implants along the subcutaneous border of the ulna.

Plate Fixation for Ulnar Shaft Fractures

The principles of plate fixation for ulnar shaft fractures are identical to those of radial shaft fractures, as outlined above. Locking plates have not been shown to improve clinical or biomechanical results for isolated, uncomplicated fractures of the ulna.[4,140] Segmental fractures and those with extensive comminution may require "bridge" plating and the use of supplemental autogenous bone grafting or bone graft substitutes. In these situations, locked plating systems may be useful.[4,105] Plates are ideally placed anterior to the subcutaneous border of the ulna to minimize plate prominence.

Intramedullary Rods for Ulnar Shaft Fractures

There has been renewed interest in intramedullary nail fixation of displaced forearm fractures. Early reports were disappointing, with high rates of nonunion.[112] It is easier to use intramedullary devices for the ulna than for the radius because of the significant bow in the radius that must be re-created when stabilizing fractures.[27] Nails may be helpful, especially for segmental fractures.[45] Further comparative studies are needed to define the risk-benefit ratio of intramedullary fixation.

Preoperative Planning

Because isolated ulnar shaft fractures do not typically require contouring of the plate, special instrument sets and substantial preoperative planning to include contralateral imaging are not generally necessary. The ulna is primarily a cortical bone and small in caliber, so the use of supplemental bone graft is a key consideration, especially for comminuted fractures or those with bone loss.

❖ AUTHOR'S PREFERRED METHOD OF TREATMENT: Direct Ulnar Approach for Plate Fixation of Distal and Midshaft Ulnar Fractures

Operating on the ulna can be facilitated by suspending the hand in a wrist arthroscopy traction tower. An incision of appropriate length is made along the subcutaneous border of the ulna. If the incision is over the distal third of the ulna, the dorsal cutaneous branches of the ulnar nerve should be protected. This superficial sensory nerve is typically distal enough to be considered out of the operative field for the majority of forearm injuries; it may exit the deep forearm fascia anywhere from approximately 1 to 4 cm proximal to the ulnar styloid. The nerve courses in a proximal volar to distal dorsal direction and crosses the midaxis of the hand-forearm unit between the ulnar styloid and the base of the fifth metacarpal.[84] In the rare case when ulnar styloid fixation is required, the nerve must be identified and protected.

The interval between the ulnar-innervated flexor carpi ulnaris and the PIN-innervated extensor carpi ulnaris is developed. Distally, it is easier to identify this interval and rapidly expose the periosteum surrounding the ulna. As dissection proceeds proximally, the extensor carpi ulnaris is elevated dorsally. The periosteum is opened only near the fracture site, and the fracture is cleaned. Standard fixation principles are applied, depending on the orientation of the fracture (e.g., transverse, short oblique, long oblique, comminuted). Transverse and short oblique fractures are fixed with compression plating, typically with five or six cortices of fixation proximal and distal to the fracture.

http://e-surg.com

We prefer placing the plate on the anterior surface of the ulna. Long oblique fractures may be amenable to interfragmentary lag screw fixation using the plate for neutralization. For fractures with comminution, if the fragments are large enough, they may first be fixed with small lag screws and then the comminution can be spanned with a neutralization plate. If the comminution is more severe, the fragments may be left with their periosteal sleeve intact and bridged with a plate. Alternatively, if the fragments have significant soft tissue stripping and are unlikely to heal, they may be removed and the fracture gap bone-grafted and bridged with a plate. The bone graft may be cancellous bone or a corticocancellous structural supporting graft when segmental bone loss compromises the stability of the fracture-plate construct. With locking plates as previously noted, structural bone graft may not be needed. After provisional fracture fixation, clinical and radiographic alignments are checked. It is important to visualize the fracture, the length of the ulna (usually best judged at the DRUJ), and the elbow and wrist to ensure that anatomic relationships have been restored.

CRITICAL POINTS *Plate Fixation of Distal and Midshaft Ulnar Fractures*

- Maintain the interval between the extensor carpi ulnaris and flexor carpi ulnaris.
- Protect the dorsal ulnar sensory nerve up to 4 cm proximal to the ulnar styloid.
- Use interfragmentary compression techniques (lag screws or compression plating, or both).
- Ensure adequate passive wrist and elbow range of motion after provisional fixation.
- Check the ulnar length relative to the radius at the wrist.

Postoperative Management and Expectations

If stable fixation is achieved in the operating room, early motion is instituted. In 7 to 10 days the surgical dressing and splint are removed and replaced with a long-wrist splint or clamshell brace. Union is expected in at least 95% of cases, and a nearly normal range of motion is typically achieved in all but complex injuries.[23] Patients are typically protected from sports and heavy use until there is evidence of radiographic consolidation.

EXPECTED OUTCOMES *Ulnar Approach for Plate Fixation of the Ulnar Shaft*

- Nearly anatomic reduction is achieved with stable fixation.
- High union rates are seen (>90% to 95% for uncomplicated fractures).
- Nearly normal pronation-supination and flexion-extension of the wrist and elbow are achieved.
- There is minor loss of strength without functional deficit.

Complications

Infection may occur after surgical treatment. This is more common in open injuries. Failure to achieve anatomic or nearly anatomic alignment of the ulna may cause incongruity and instability of the PRUJ or DRUJ, or both. This may be more frequent when considerable bone defects are encountered. Malunion and nonunion may be a result of the severity of the injury, unstable fixation, or excessive load in the postoperative period.

FRACTURES OF BOTH BONES OF THE FOREARM

Preoperative Evaluation

Preoperative evaluation of patients with both-bone forearm fractures begins with understanding that higher-energy trauma is typically required to produce this injury. The workup should be tailored to the mechanism of injury. For example, an isolated blow to the forearm does not require a general trauma evaluation. However, a fall from a height or a motor vehicle collision does require a more comprehensive evaluation. The skin envelope must be examined for skin breaks, particularly on the anterior and ulnar aspects of the forearm. The elbow and wrist are examined for tenderness and joint stability.[16] Pulses, nerve function, and compartment turgor are documented.[2,96]

Radiographs of the wrist, full forearm, and elbow are helpful in these injuries. In highly comminuted or segmental fractures, radiographs of the contralateral forearm can aid in preoperative planning and intraoperative confirmation of appropriate fracture reduction.

❖ AUTHOR'S PREFERRED METHOD OF TREATMENT: Anterior Approach for Radial Shaft Fixation and Direct Ulnar Approach for Ulnar Shaft Fixation

An anterior approach to the radius and exposure along the subcutaneous border of the ulna are the workhorses for the majority of both-bone fractures. Open fractures, even Gustilo and Anderson grade IIIA fractures, can be treated with immediate internal fixation.[52,65,83,84] Grades IIIB and IIIC open fractures are associated with worse outcomes when treated with immediate plating, although optimal treatment has not been determined for these most difficult injuries.[34] Open fractures of the radial and ulnar shafts require irrigation and débridement of contaminated or devitalized tissue, including bone. Significant soft tissue injuries may require repeat operative débridement prior to bone grafting. Only in rare instances is immediate plate fixation not advisable.

For both closed and open fractures, separate approaches to the radius and ulna help decrease the chance of a synostosis.[9,55] We typically expose both bones first and then reduce and fix the radius, followed by reduction and fixation of the ulna. If one bone is comminuted, the fracture with less comminution is reduced first. The IOM and DRUJ/PRUJ may then help with indirect reduction of the other more severely comminuted bone.[102,113,116] Fractures that are transverse and at different levels can be challenging to reduce once one of the fractures is plated. In these cases, it may be easier to reduce both prior to plating either one.

Intraoperative fluoroscopy is particularly helpful when there is comminution of both the radius and ulna. With the forearm in full supination, a frontal view should show the bicipital tuberosity and the radial styloid pointing in opposite directions



FIGURE 21.21 Radiograph of a both-bone forearm fracture with significant bone loss associated with the radial fracture. (Courtesy of Leon Nesti, MD, and Walter Reed Army Medical Center.)

(in an ulnar direction and a radial direction, respectively). The ulnar styloid should be seen in the center of the ulnar head. With the forearm in full supination, the bicipital tuberosity should not be visible on a true lateral view of the forearm. With forearm supination, the ulnar styloid should appear dorsal to the dorsal cortex of the distal radius on a lateral view of the wrist. Once clinical and radiographic assessment confirms appropriate reduction, definitive fixation of both bones is completed.

The ulnar wound is usually closed to ensure coverage of the fracture and hardware. The radial wound may be closed if there is no undue tension. When the forearm is swollen and the anterior wound cannot be closed, it can be managed with a wound vacuum. A less expensive option is the use of staples along the skin edges and a vessel loop threaded through the staples like a shoelace. The vessel loop can be subsequently tightened as the swelling subsides until the wound is narrow enough for healing by secondary intention or a return to the operating room for delayed primary closure. Fractures with significant bone loss may require bone grafting as part of the index procedure (Figure 21.21). See the Author's Preferred Methods for Radial Shaft Fractures.

Postoperative Management and Expectations

With anatomic reduction and rigid fixation of both-bone forearm fractures, patients can expect a union rate of 95% or greater and functional forearm rotation.[30,32,48,52,121] A moderate amount of objective strength loss is expected, although it is not necessarily perceived as functionally limiting by patient-rated outcome measures such as the DASH questionnaire and the short-form health survey, 36 items (SF-36).[32,47]

EXPECTED OUTCOMES *Plate Fixation of Both-Bone Forearm Fractures*

- Anatomic reduction with stable fixation if minimal comminution exists
- High union rates (>95% for uncomplicated fractures)
- Nearly normal pronation-supination and flexion-extension of the wrist and elbow
- Minor loss of strength without functional deficit

If stable fixation is achieved intraoperatively, early range of motion may be implemented. This usually consists of flexion-extension and pronation-supination of the elbow and wrist once pain and soft tissue swelling have eased enough to allow these motions. After sufficient range of motion has been achieved and clinical and radiographic evidence has confirmed continued fracture stability, strengthening is initiated. This typically occurs at 6 to 8 weeks postoperatively. Once strength is more than 50% to 75% of the uninvolved side, resumption of normal activities is permitted. We allow patients to resume noncontact athletic activities after they have achieved this milestone and at least 3 months has elapsed since the surgery date. Contact sports are allowed in the 3- to 6-month range with use of a playing splint or brace, if feasible, and patients are permitted to play without a brace after 6 months.

Potential complications specific to these injuries include malunion, nonunion, synostosis, and compartment syndrome. Specific treatment of nonunion, malunion, and synostosis is detailed later.

REMOVAL OF HARDWARE FROM THE RADIUS AND ULNA

There is little evidence to support routine removal of forearm hardware in an asymptomatic patient. It was initially thought that plates should be removed because of concern for later insufficiency fractures as a result of stress shielding by stainless steel plates with their high modulus of elasticity.[24,88,90] Studies have shown a higher-than-expected rate of fracture after plate removal.[24,29,60,111] Some evidence suggests that the decrease in bone density beneath stiff plates resolves in approximately 2 years after insertion.[110] There is also a lower fracture rate after the removal of smaller, less stiff plates such as one-third tubular plates.[10] However, the higher incidence of nonunion and malunion associated with such plates outweighs the benefits of a decreased fracture rate after removal.[52] There is evidence to show that the use of plates of 4.5 mm or larger is associated with an unacceptably higher rate of fracture but does not confer a significant improvement in the union rate when compared with systems of 3.5 mm.[24,116]

The major concern with hardware removal remains refracture at the original fracture site or occasionally through one of the vacated screw holes.[74,82] It would be rare for a fracture to occur at a site either proximal or distal to the previously applied plate, but off-center screw application (i.e., a transcortical screw) may cause enough increased stress to precipitate refracture.

Infection and nerve complications are possible consequences of plate and screw removal.[24,72] If a patient is complaining of pain as a reason to consider hardware removal, the surgeon must determine whether there are other causes, including infection, nonunion, or malunion. CT scanning or fluoroscopic examination may assist in determining whether union has truly been achieved. Inspecting the screw holes carefully for evidence of lucency may indicate whether there is micromotion or infection.

The subcutaneous positioning of an ulnar plate and screws has a higher potential for causing skin and soft tissue irritation. It is rare for the radial shaft hardware itself to cause direct tissue irritation unless the screws are too long. Some authors believe that hardware should be removed if the patient is resuming contact or high-energy sports or other activities, whereas others do not.[116] Military service or other specialized vocations may require removal of metallic implants.

The ideal time for removal of hardware, as well as the duration of restrictions after hardware removal, is also controversial because refracture occurs most often 6 months or longer after plate removal.[59] From our experience and a review of the literature, we typically recommend that hardware remain in place unless there are specific requirements for removal. If removal is necessary, we prefer to wait 1 year or longer after implantation.[10]

Preoperative radiographs for hardware removal should include frontal, lateral, and oblique views to look for radiolucency at the initial fracture site.[82,117] If there is a question regarding fracture consolidation, a CT scan may be helpful. After plate removal, any hypertrophic bone around the plate or screw margins is removed until it is smooth, without violating the native cortex. Immediate range of motion is permitted while wearing a protective splint for sleep and activities for 6 weeks. If at 6 weeks patients have no pain or tenderness and radiographs confirm complete healing at the fracture site, patients are allowed to return to activities as tolerated.[121] Patients are counselled that there is always a chance for refracture or a new fracture in the area where hardware had been placed previously.

NONUNION AND MALUNION OF THE RADIAL AND ULNAR SHAFTS

Preoperative Evaluation

Loss of forearm rotation and the presence of wrist pain from malalignment are common presenting complaints of a patient with malunion of the radius or ulna (Figure 21.22).[20,78,89,92,114,126] The individual with an ununited fracture will have the added issue of pain at the nonunion site. Surgical treatment is dictated on the basis of clinical and radiographic findings. Pain, tenderness, and radiolucency at the fracture site are concerning for delayed union or nonunion. Screw loosening and plate fracture are obvious signs and nearly always require operative intervention. Isolated nonunion of the ulna occurs most commonly in the middle third.[46,94] Most forearm nonunions are atrophic or oligotrophic.[104] Hypertrophic nonunion is more common in fractures treated nonoperatively or with intramedullary devices. Hypertrophic nonunion of the radius or ulna may be treated with compression plating alone. Although some recommend that autogenous bone graft should be applied at the nonunion site, it is typically not necessary in the hypertrophic setting.[109]



FIGURE 21.22 Malunion of a both-bone forearm fracture.

Preoperative evaluation includes an assessment of the soft tissue envelope of the forearm with an eye toward scar contractures and signs of chronic infection. Motion and stability of the elbow, forearm, and wrist are documented. Although bone alignment can typically be corrected, extensive soft tissue contractures may preclude a favorable outcome. Several studies have suggested that the length of time from the initial injury is inversely correlated with the chance of successful correction of malunion and directly correlated with the complication rate.[129,131]

Preoperative radiographs should include views of the elbow and forearm and a true PA view of the wrist to establish ulnar variance. The PA view is obtained with the shoulder abducted 90 degrees, the elbow flexed 90 degrees, and the forearm in neutral rotation (the so-called *zero rotation series*).[38] Contralateral images of an uninvolved forearm may be helpful. CT scans can be helpful to confirm union at the fracture site, document infection, or help characterize angular and rotational malunion.[12,69]

A recent study using fluoroscopy and cross-sectional MRI to assess forearm mechanics in healthy volunteers found a normal side-to-side variation in torsion profile of 20 degrees for the ulna and 35 degrees for the radius. The authors recommend considering derotational osteotomy only if the difference in the contralateral forearm exceeds these parameters.[33]

The possibility of chronic infection as a cause of nonunion is best considered prior to surgery, particularly when the initial injury was open. The preoperative workup can include a complete blood count, erythrocyte sedimentation rate, and

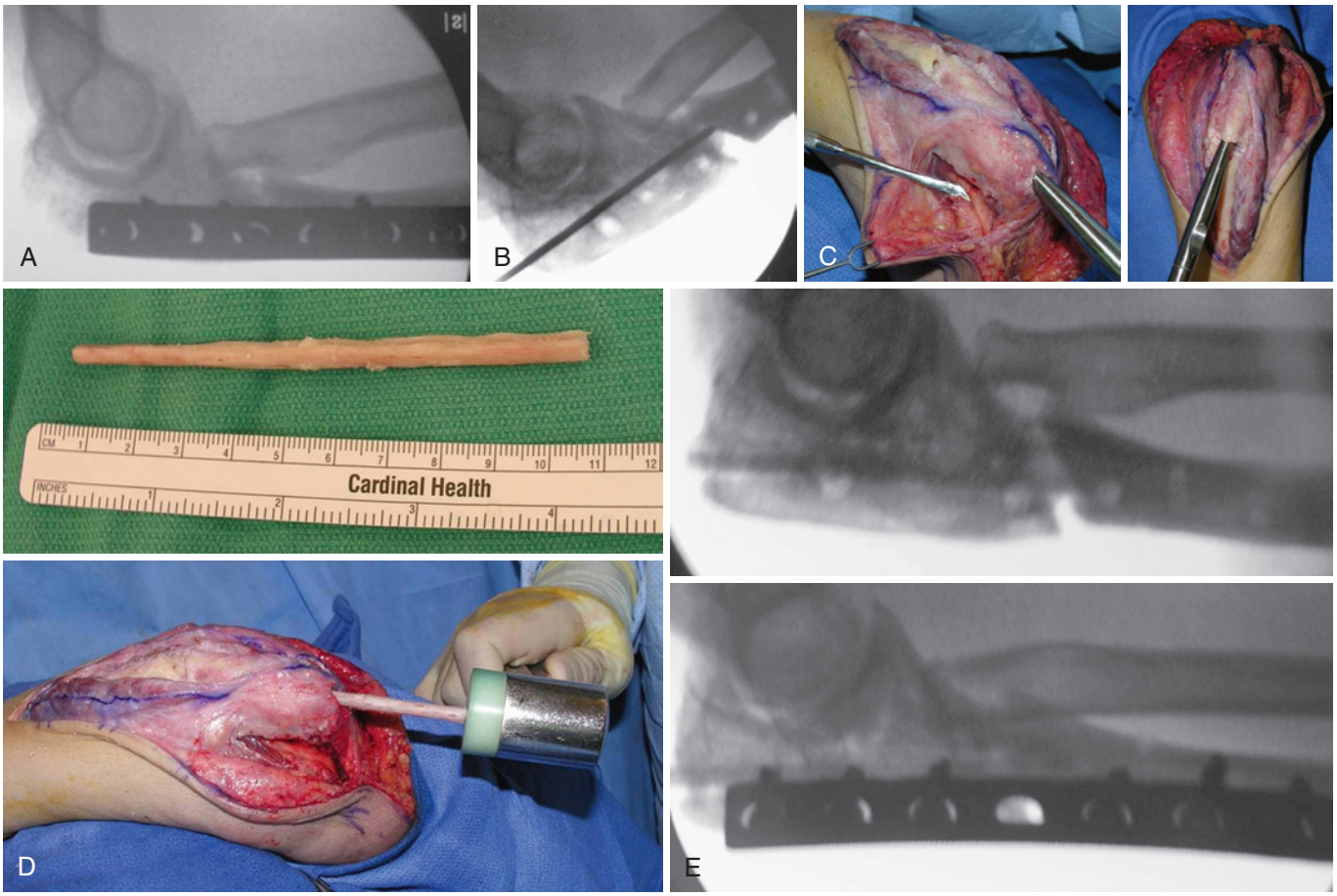

FIGURE 21.23 **A,** Initial radiographs of recalcitrant proximal ulna nonunion. **B,** Intraoperative fluoroscopic study of intramedullary preparation of the proximal ulnar shaft. **C,** Intraoperative photographs demonstrating preparation of the ulnar canal. **D,** Intraoperative photograph of a fibular allograft strut fashioned and being driven proximally to distally down the ulnar canal. **E,** Initial radiograph showing intramedullary fibular allograft peg fixation followed by manual compression of the proximal and distal ulnar fragments along the allograft peg, plate and screw fixation, and cancellous bone grafting.

quantitative C-reactive protein levels. MRI and a triple-phase bone scan with indium-tagged white blood cells may be useful. Unfortunately, the results of imaging studies are unlikely to change the surgical algorithm. What is most important is preparing a strategy in the event that osteomyelitis is encountered at the time of surgery. This includes a frank discussion with the patient and family that the procedure may need to be staged. On the day of surgery, preoperative antibiotics should be held until cultures are obtained, along with gram-stained smears for bacteria and fungal elements and tissue for assessment of white blood cells per high-power field. The laboratory may be unable to verify to the surgeon's satisfaction that an infection is present. In some cases, if the fracture site does not look healthy, one can débride all necrotic tissue and bone, provide temporary stabilization of the bone, and place an antibiotic-impregnated cement spacer. Empirical treatment with intravenous antibiotics should be initiated. Reconstruction of the defect can proceed if available cultures are negative or after a course of intravenous antibiotics if an infection is confirmed.

In a setting of nonunion, compression of the bone ends is the goal, but this must be balanced with the need to maintain appropriate bone length. As with acute fractures, sufficient radial bow and a straight ulna must be restored to maximize stability and the arc of pronation-supination. The nonunion is most commonly stabilized with 3.5-mm compression plates.

The range of choices for bridging gaps in forearm nonunions includes compressed cancellous autograft, corticocancellous autograft, vascularized bone transfer, and allograft.[22,28,39,67,85,86,88,100,109,120,139] (Figures 21.23 and 21.24).

❖ AUTHOR'S PREFERRED METHOD OF TREATMENT: Open Reduction and Internal Fixation of Nonunion of the Radius or Ulna

There is a spectrum of nonunions of the forearm, ranging from hypertrophic nonunion in a young, healthy patient to failure of fixation following an open, high-energy injury with the possibility of osteomyelitis. For the more complex injuries, treatment begins with an earnest discussion with the patient and family regarding the challenges they face. As discussed, the procedure may have to be staged, achieving union may be difficult, and there is a high likelihood of residual forearm dysfunction. Patients have to quit smoking or chewing tobacco. Their nutritional status is optimized. Consent is obtained for autogenous graft from either the iliac crest, the proximal tibia, or a free-vascularized fibula in rare cases. The CT scan is the single best preoperative imaging tool; it can define the location of the

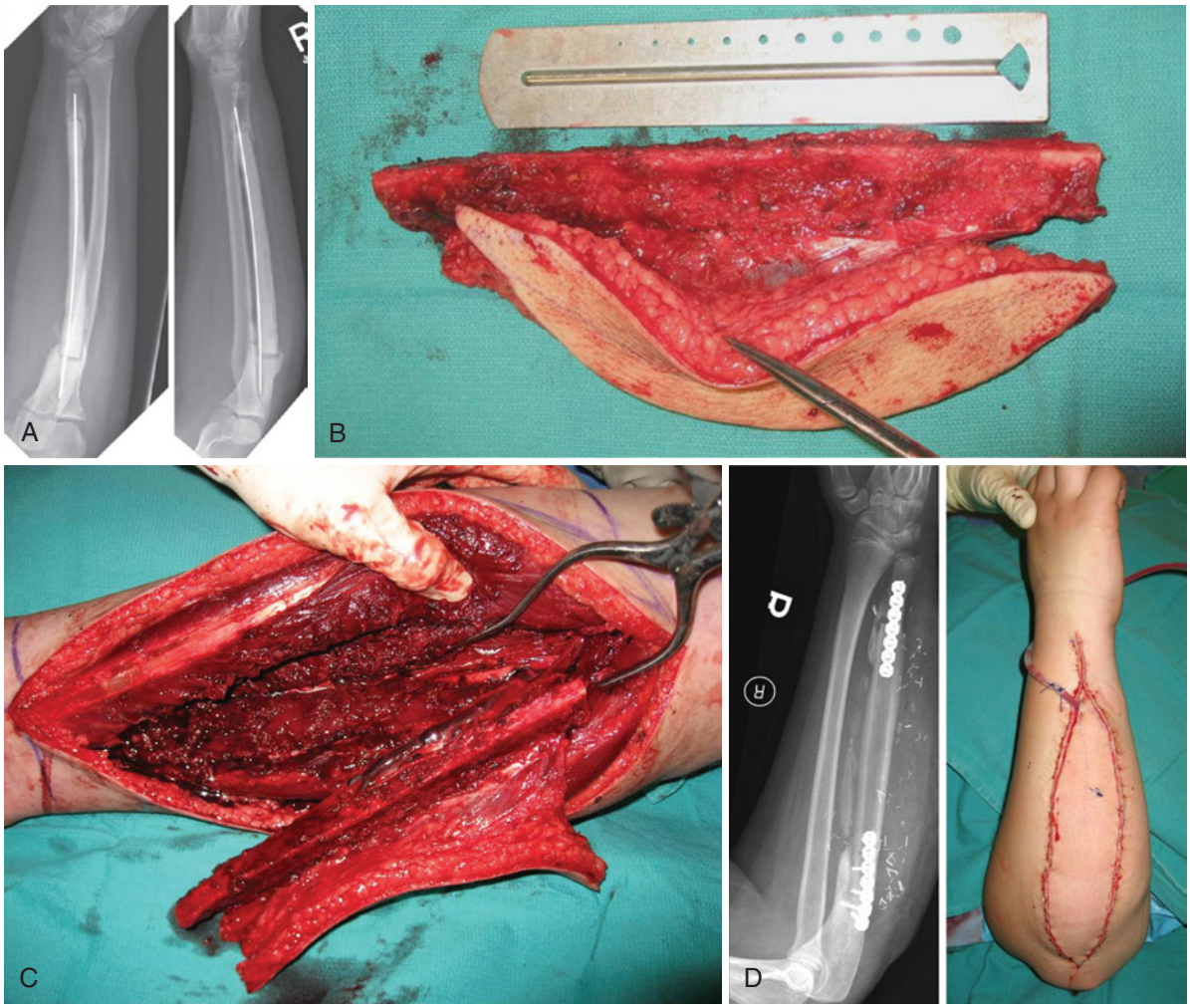

FIGURE 21.24 **A,** Initial radiographs of a long ulnar shaft defect secondary to osteomyelitis previously treated by resection and insertion of the antibiotic-impregnated cement spacer seen here. **B,** Clinical photograph of an osseoseptocutaneous free fibula flap. **C,** Clinical photograph of inset of the free fibular flap. **D,** Radiograph and clinical photograph after internal fixation and wound closure.

nonunion and the quality of the adjacent bone, and it may show reactive bone consistent with osteomyelitis.

The nonunion tool kit includes a 3.5-mm compression plating system, an external fixator, Steinmann pins, antibiotic-impregnated cement, and osteotomes and curets for obtaining bone graft. After exposing the fracture site, loose hardware, devitalized bone, and tissue are débrided. Multiple cultures are taken, and tissue is sent for quantification of the white blood cells per high-power field. If infection is suspected, the bone is stabilized with an external fixator or, more simply, with a Steinmann pin cut slightly longer than the defect. The pin is wrapped in antibiotic-impregnated cement, and a tip of the pin on either end is left free. Once the cement is hard, the pin-cement construct is keyed into either end of the proximal and distal bone. The wound is closed and a splint is applied. While awaiting cultures, empirical treatment with intravenous antibiotics is initiated. Treatment thereafter is based on the results of culture.

Once it is deemed safe to proceed with reconstruction, the site is again débrided and multiple specimens are sent for culture a second time. Most cases are managed with bridge plating using a 3.5-mm compression plate with eight cortices distally and eight cortices proximally. Locking implants are useful in this setting. If the construct is stable, the gap is filled with cancellous autograft that is compressed in a syringe and laid into the defect. Using this technique, Ring and coworkers[104] reported a 100% union rate in 35 patients with atrophic nonunion of the forearm diaphysis. If the construct is not stable after using the bridge plate, stability may be enhanced by placing an intercalary corticocancellous iliac crest graft. For recalcitrant nonunions, a free-vascularized fibula may be required to span the defect and obtain union.

Rotational or Angular Osteotomies for Malunion of the Radius or Ulna

Templating of the malunion from normal contralateral forearm radiographs is helpful for preoperative planning. If rotational malunion is suspected, a CT scan with both forearms in maximal pronation and supination may aid in determining the degree of correction required.[57] Three-dimensional reconstructions of these scans can aid in visualization of the true plane of deformity. Plastic bone models derived from CT scans of malunited forearm fractures have been used to design a prebent plate and guide the corrective osteotomy. Using this technique, with a three-dimensional corrective osteotomy,

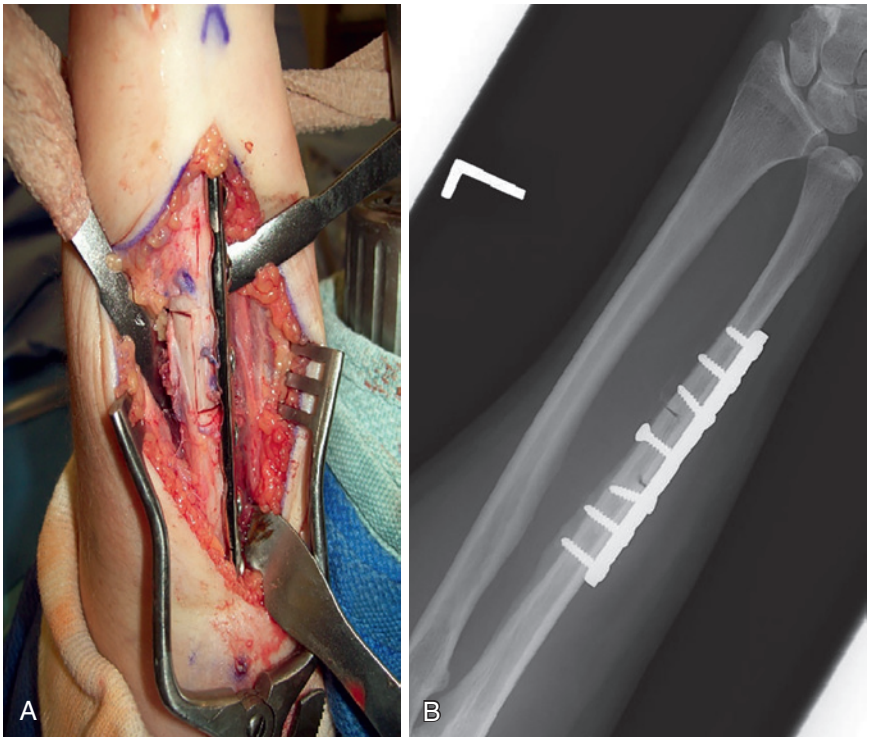

FIGURE 21.25 **A,** Step-cut osteotomy of the ulna. **B,** Radiograph showing step-cut osteotomy of the ulna with lag screw across the osteotomy site.

Kataoka and colleagues were able to precisely correct four forearm malunions.[69]

An anterior approach is used for the radius and an incision along the subcutaneous border for the ulna. If both bones are malunited, the more severe malunion is addressed first. Any hardware that is already in place is removed. The site of the previous fracture is localized with fluoroscopy. An 18-gauge wire can be twisted into the site if the fracture is not mature. Callous is removed from the surrounding region down to native cortical bone. Again, this is more easily performed if the fracture has not remodeled. The malunion is taken down, when possible, with osteotomes and a narrow rongeur along the course of the previous fracture. As previously discussed, it is possible to obtain a CT-generated plastic model of the malunion and prebent plates to optimize correction of the deformity. The ideal situation for this approach is a deformity in three planes, in which remodeling obliterates the path of the original fracture. If this technique is not an option, long oblique osteotomies will facilitate multiplanar correction, as well as provide a larger surface area for healing. Provisional fixation is established proximal and distal to the malunion. Passive pronation-supination is checked. Intraoperative fluoroscopy of the provisional fixation is used to determine rotational alignment of the wrist, forearm bones, and elbow by using anatomic landmarks as described previously. Once the alignment is acceptable, plate fixation with eight cortices is performed proximal and distal to the malunion. Cancellous autograft is harvested from the proximal tibia or iliac crest and placed around the osteotomy site.

If correction of the more severe malunion produces sufficiently increased intraoperative motion, the other bone may not require surgical treatment.[57] If both bones will require correction, the ulna is fixed first to re-create the stable and straight unit of the forearm. If length discrepancy is the only correction required, a long step-cut osteotomy of the ulna allows fine-tuning of the length during fixation (Figure 21.25).

There are few studies examining corrective osteotomies of forearm fracture malunion. Matthews and associates[78] did combined osteotomies of the middle thirds of the radius and ulna in cadavers and found that there was minimal loss of pronation-supination with 10 degrees of angulation but a functional loss of motion with 20 degrees of angulation. In another cadaveric study by Tarr and coworkers,[126] a 10-degree angular deformity in both bones of the forearm resulted in an average loss of pronation-supination of 13% when the fracture was in the distal third of the forearm and an average loss of 16% when it was in the middle third. The researchers also observed that rotatory deformities produced a loss of pronation and supination that was equal to the degree of deformity. Trousdale and Linscheid[129] did a retrospective review of 27 corrective osteotomies for malunited fractures of the forearm. They obtained a mean improvement of 79 degrees in forearm rotation when an osteotomy was done within 12 months of injury, compared with a gain of only 30 degrees if the corrective osteotomy was done more than 12 months after the injury. They proposed that soft tissue contractures involving the IOM may contribute to this difference and recommended that corrective osteotomies be done within 12 months of injury.[129] In contrast, Chia and colleagues[20] performed corrective osteotomies for six symptomatic adults with malunited forearm shaft fractures. The average interval between the original fracture and the corrective osteotomy was 42 months. They reported improved function

despite a long delay between the injury and subsequent osteotomy.

CRITICAL POINTS *Plate Fixation of Nonunion or Malunion of the Radius or Ulna*

- Determine with plain radiographs if it is possible to follow the line of the previous fracture when taking down the malunion.
- If the fracture has completely remodeled, consider using a CT-generated model and a prebent plate.
- Preoperative templating with the contralateral forearm can serve as a guide.
- Use interfragmentary compression techniques (lag screws or compression plating, or both) when possible.
- Confirm adequate passive wrist and elbow range of motion, including pronation-supination, after provisional fixation.
- Intraoperative fluoroscopic studies can document restoration of near-normal relationship of bony landmarks.
- Graft the site with autogenous cancellous graft.

Treatment of Nonunion of Forearm Bones Using Distraction-Compression Osteogenesis

Use of a circular external frame with fine wires is effective in nonunions and malunions with deformities in multiple planes.[93] The treatment may be monofocal or bifocal. Monofocal treatment, developed by Ilizarov, involves compression (first phase) followed by distraction at the nonunion site. Bifocal treatment involves simultaneous compression at the nonunion site and lengthening at a different location within the same bone. Orzechowski and colleagues[93] presented six patients with pseudarthroses of the forearm bones with limb shortening and axis deformity, which were treated with a circular frame. Union was achieved in all patients. Normal radial length was restored in four patients, while a residual shortening of 1 cm persisted in two patients. Significant improvements in limb function and appearance were achieved in all patients.

Postoperative Management and Expectations

Union rates for malunion and nonunion of the radius and ulna are lower than those for primary fracture treatment but are still 90% or greater.[14,94] Restoration of normal motion and strength is rarely possible.[61,99,109]

The optimal time to begin postoperative motion is defined by the stability of the plate-bone construct and by the environment in which the procedure took place. A single-plane osteotomy with excellent fixation in a young, healthy patient can begin immediately. Forearm rotation is begun more cautiously following revision surgery for a recalcitrant nonunion.[50] Though the available evidence suggests that electromagnetic field stimulation may offer some benefit in the treatment of delayed union and nonunion of long bone fractures, the literature is inconclusive and cannot, by itself, guide current practice. Ultrasound has also been used to stimulate bone growth. The evidence regarding ultrasound for this application is, similarly, inconclusive.[51] When healing is in question at 3 to 4 months following operation, a CT scan may be performed.

The complications associated with treatment of forearm nonunion and malunion are similar to those associated with treatment of acute radial and ulnar shaft fractures. In the patients with nonunion or malunion, the rate of complications is higher and may be as much as 50% in some series.[25,57,109]

RADIOULNAR SYNOSTOSIS

Posttraumatic radioulnar synostosis is a relatively rare complication, estimated to occur in 1.2% to 6.6% of patients with a fracture of one or both bones of the forearm following treatment with compression plating.[47,99] The rate of synostosis is higher in persons with head injury, occurring in as many as 18%.[31] The literature consists mostly of level IV retrospective case studies and case reports. The synostosis may be located anywhere from the ulnohumeral articulation to the DRUJ. The formation of ectopic bone is not easily accommodated in the forearm, where "tolerances" are small (Figure 21.26). Risk factors include Monteggia fracture, fracture of both bones at the same level, high-energy injuries, burns, open fractures, comminuted fractures, bone fragments on the IOM, and head injury.[47,107,133] Iatrogenic risk is lessened by the use of separate incisions to approach the radius and ulna for fracture fixation.[47] In complete synostosis, the patient is free of pain, with forearm rotation completely blocked. The patient with an incomplete synostosis may have a painful block to forearm rotation.

A classification system was established to describe heterotopic ossification about the elbow and forearm (Table 21.1).[57] This system took into account the fact that any amount of ectopic bone may limit both the elbow flexion-extension arc and forearm rotation, with limitations ranging from a partial block to frank ankylosis.

Preoperative evaluation of forearm heterotopic ossification or cross-union should include plain radiographs of the forearm,



FIGURE 21.26 Posttraumatic radioulnar synostosis.

TABLE 21.1 Classification of Heterotopic Ossification

Class	Description
Class I	HO that does not cause functional limitation
Class II	HO that causes subtotal limitation of motion
Class IIA	Partial loss of elbow flexion-extension
Class IIB	Partial loss of forearm supination-pronation
Class IIC	Partial loss of both flexion-extension and supination-pronation
Class III	Complete ankylosis of the elbow or forearm, or both

From Hastings H 2nd, Graham TJ: The classification and treatment of heterotopic ossification about the elbow and forearm. *Hand Clin* 10:417–437, 1994.

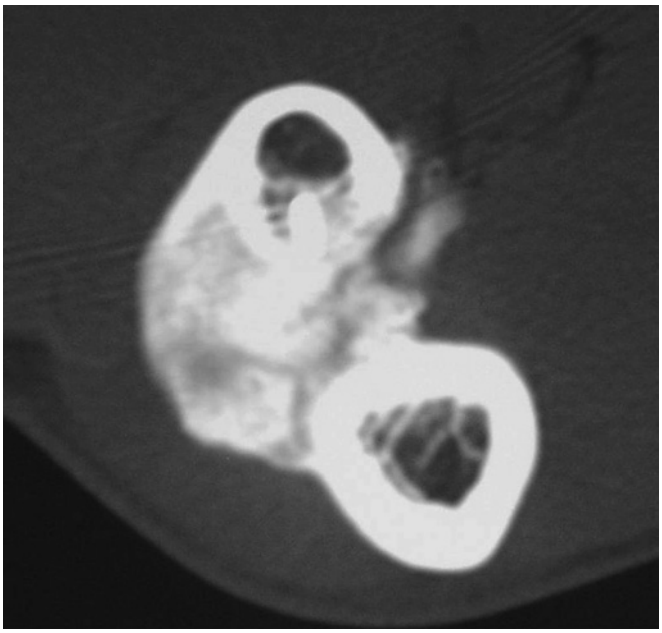

FIGURE 21.27 CT scan demonstrating the location and extent of radioulnar synostosis.

with frontal, lateral, and oblique views. A CT scan with or without three-dimensional reconstruction is invaluable in defining the site of cross-union and in planning the surgical approach (Figure 21.27). The synostosis can occur at a single site or multiple sites. Nonsurgical management is reserved for low-demand patients, those with recurrence following multiple attempts at resection, and those who are unable to tolerate additional procedures.

The optimal timing for the takedown of a synostosis is unknown. In the past, it was recommended that the bone mass "mature" prior to resection. There is no current consensus or evidence regarding timing. However, resection is typically considered after approximately 3 to 4 months.

❖ AUTHOR'S PREFERRED METHOD OF TREATMENT: Radioulnar Synostosis

Several factors help indicate whether the takedown of a synostosis will be successful:

1. Localization of the bone mass
2. Healed fracture(s) in acceptable alignment
3. Normal PRUJ and DRUJ
4. A compliant IOM and soft tissue envelope

A preoperative CT scan of the forearm, including the PRUJ and DRUJ, will show whether the first three factors are present. The presence of factor four is more difficult to assess, but skin contractures from burns or crushing and degloving injuries may hinder efforts to restore motion.

The location of the synostosis as defined by a CT scan will determine the surgical approach. Proximal synostoses may be accessible by elevating the anconeus and common extensor muscle mass. In cases where the bone extends anteriorly, it may be prudent to use an anterior approach in which the median and radial nerves can be identified and protected. Access to middiaphyseal synostoses is typically via an anterior Henry approach. Exposure along the subcutaneous border of the ulna is also an option. Distal synostoses can be reached through an anterior or dorsal approach. There may be an associated soft tissue contracture that will limit motion after bone resection (e.g., release of the anterior capsule of the DRUJ often helps recover forearm supination).

Surgical hardware may be left in place unless it is specifically limiting exposure or range of motion. Intraoperative fluoroscopy is used to localize the borders between normal cortical bone and heterotopic bone. The borders can be marked with Kirschner wires. The bone is removed with osteotomes, a bur, and/or rongeurs. Postresection fluoroscopy helps confirm the resection margins.

Various strategies have been employed to prevent reformation of the synostosis, including use of medications, irradiation, and interposed barriers.[10,11,23,56,59,82,106] There are no prospective controlled studies to suggest which, if any, intervention is best to prevent recurrence.[31,102] Our practice has been to simply cover the exposed bone with bone wax and begin early motion. There is little evidence to support the use of preoperative or postoperative irradiation.[68] The one situation in which irradiation may be indicated is the unusual case involving recurrent heterotopic bone; the patient is given a perioperative dose of 350 to 700 Gy.

Lastly, there are instances where taking down the synostosis is not feasible. One example is recurrent synostosis involving most of the proximal third of the forearm. In these instances, one can consider creating a resection arthroplasty distal to the synostosis (Figure 21.28).

Postoperative Management and Expectations

Active, active-assisted, and passive motion are begun immediately after surgery. Patients are reevaluated frequently to assess their progress. Once the wounds are healed, static progressive splinting can be added. Significant gains in rotation are expected assuming that the resection was adequate, the bones are aligned, the PRUJ and DRUJ are congruent, and the skin is supple.[41] The reported chance of recurrence is 5% to 10%, especially at the proximal and distal ends of the forearm axis.[55,58]

LONGITUDINAL INSTABILITY OF THE FOREARM AXIS

Essex-Lopresti is credited with the concept of dissociation of the forearm axis, although the actual disorder had been previously described.[26,40] It is a rare injury. Longitudinal forearm

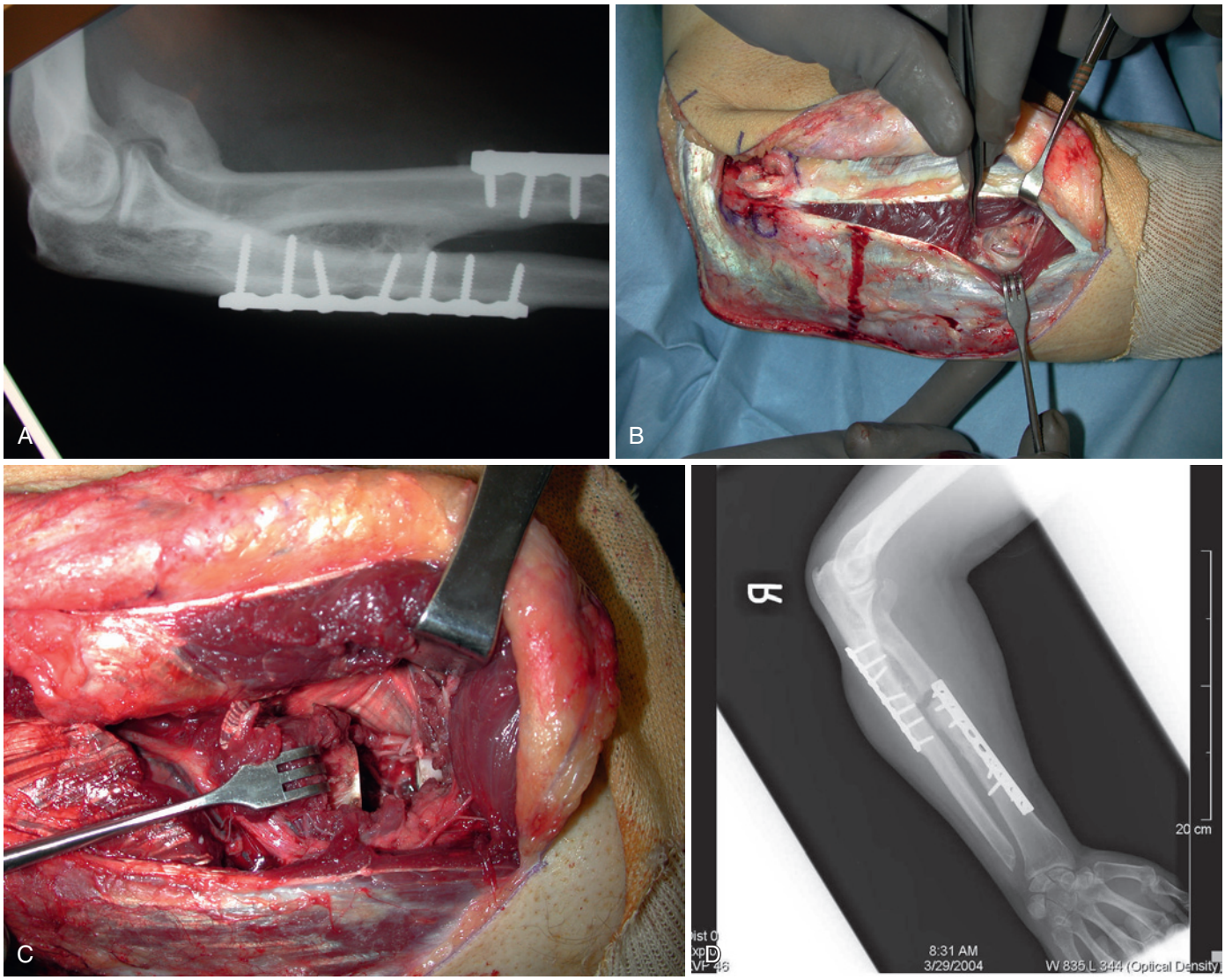

FIGURE 21.28 **A,** Extensive proximal radioulnar synostosis. **B,** Dorsolateral approach with the exposure of the posterior interosseous nerve. **C,** Resection of 2 cm of the radial shaft. **D,** Lateral radiograph of the forearm 2 years later. Patient had 10 degrees of supination and full pronation.

instability results from an axial load leading to fracture of the radial head and disruption of the IOM and triangular fibrocartilage complex.[80] The radiographic and clinical findings may not be immediately apparent at the time of initial evaluation.[66,49] In a series of 106 referred Essex-Lopresti injuries, the diagnosis was made only 38% of the time.[76]

Appreciation of the extent of injury often follows surgical resection of a radial head or neck fracture. Proximal migration of the radial shaft occurs, and the distal ulna abuts the carpus.[128] Longitudinal instability of the forearm axis has been seen in combination with other forearm fractures, but loss of radiocapitellar support, which uncovers the incompetence of the DRUJ stabilizers and disrupted IOM, is the classic scenario.[37]

The initial physical examination helps direct the diagnosis. Wrist pain in conjunction with a radial head fracture should raise one's suspicion. Instability of the DRUJ should further raise suspicion regarding a forearm axis injury. Radiographs of the elbow and a neutral rotation view of the wrist are useful in evaluating the relative ulnar variance.[38] It is worthwhile to get comparison views of the contralateral wrist.

MRI can be helpful in confirming the diagnosis of an IOM disruption. It has been shown to have nearly 90% or greater sensitivity, specificity, and positive and negative predictive values.[79] Fester and colleagues[42] used a cadaver model to establish the sensitivity and specificity of MRI to diagnose central band transections of the IOM. The mean sensitivity was 93%, specificity 100%, and overall accuracy in diagnosing an IOM central third disruption 96%.[42] Ultrasound is another effective method to evaluate the integrity of the IOM; it is less expensive than MRI, can be performed quickly, and allows for a dynamic evaluation of the soft tissues. In the same model, Fester and associates evaluated the effectiveness of ultrasound to diagnose IOM disruptions. The sensitivity was 100%, specificity 89%, and overall accuracy 94%. In their comparison between

ultrasound and MRI, they found no significant difference between the accuracy of the two methods.[42] CT scanning is useful in assessing concurrent articular fractures of the wrist or elbow or to help determine whether reconstructive or salvage options are appropriate in the subacute or chronic setting. Axial CT scans of both radioulnar joints in supination, pronation, and neutral position can confirm suspected DRUJ instability.

PERTINENT ANATOMY

The primary structure that prevents proximal radius migration is the radial head. Secondary structures include the central band of the IOM and the structures about the triangular fibrocartilage complex and DRUJ. The IOM is a complex structure composed of five distinct bands.[91] The most mechanically stout is the central band, sometimes referred to as the interosseous ligament. The central band suspends the radius by virtue of fibers that originate on the distal ulna and insert on the proximal radius.[62,98] The radial insertion is located at the junction of the proximal and middle thirds of the radius. The origin is at the junction of the middle and distal thirds of the ulna. The central band rests at an angle of approximately 20 to 25 degrees (Figure 21.29).[17,119]

When axial forces are experienced at the wrist, most of the force (as much as 75% to 80%) is transmitted through the radius. Axial compression of the radius is converted to tension in the interosseous ligament, amplifying the magnitude of compressive forces in the ulnar column. Because of the conversion of lateral or radial compression to tension through the interosseous ligament and ultimately to ulnar compression, the normal forces recorded at the elbow demonstrate a rough equalization of the joint reactive forces between the radial and ulnar columns, slightly weighted toward the ulnotrochlear joint. Thus, excision of the radial head, in combination with rupture of the IOM and interosseous ligament, removes any mechanical block to proximal radial migration under axial loads. This is the key pathoanatomic finding in Essex-Lopresti injuries (Figure 21.30).

The triangular fibrocartilage complex is an important stabilizer of the radius and ulna at the DRUJ, preventing longitudinal instability. It is responsible for 8% of the forearm's resistance to axial load.

Types of Operations

Prevention of Longitudinal Instability of the Forearm

Preventing the downward spiral of events that result from radial head excision is the preferred approach to handling this complex problem. By recognizing the global extent of the injury and addressing each component in the acute period, it may be possible to avoid further instability. Treatment of acute injuries is associated with improved outcomes when compared with treatment of chronic instability.[97]

In the acute setting, the ideal option is to repair the radial head. When this is not possible, the integrity of the IOM is

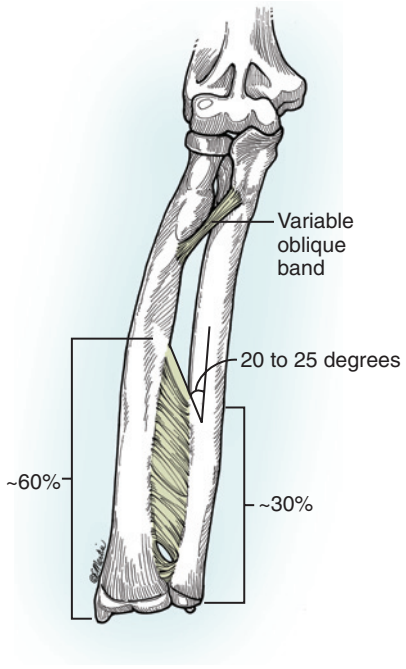

FIGURE 21.29 Illustration of the interosseous ligament and its anatomic relationships. (Copyright Elizabeth Martin.)

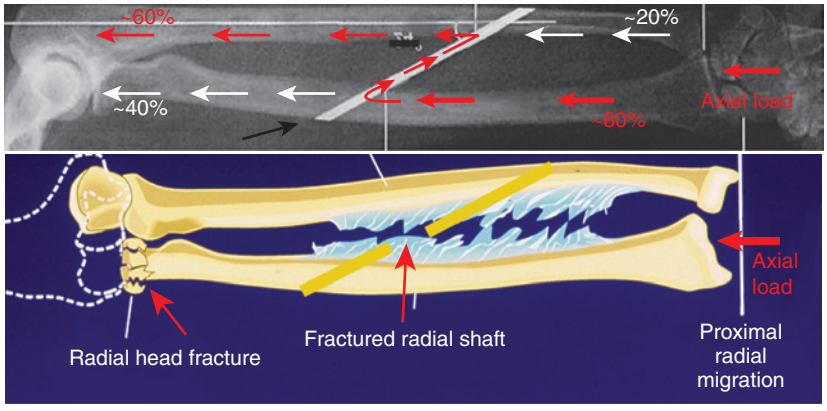

FIGURE 21.30 Illustration of biomechanics of a normal forearm and a forearm with longitudinal instability of the forearm axis.

evaluated by the pull test. The cut end of the proximal radius is secured with a towel clip. As one pulls on the radius, ulnar variance is evaluated using fluoroscopy. Two millimeters of radial excursion is within the range of normal. Three millimeters or more suggests longitudinal instability in cadaver studies. If there is evidence of longitudinal stability in the face of an unrepairable radial head, a metal radial head implant should be used. In the normal forearm, the central band shares the load with the radial head. Radial head replacement should thus, theoretically, allow the central band and the triangular fibrocartilage complex to heal.[36,38,66,76] However, there is suspicion that the ruptured IOM may not be capable of healing. This raises two issues:

1. Should an attempt be made to repair or reconstruct the central band acutely to reduce loads across the articulation of the prosthesis and capitellum?
2. Subsequent procedures should be performed with caution and with assessment of longitudinal stability of the forearm axis.[123]

After the radial head is addressed, the stability of the DRUJ is evaluated. Instability can be managed with immobilization in a position of stability, repair of the triangular fibrocartilage complex, or simple pinning of the DRUJ, as described above. There is no evidence to guide selection among these three options.

Restoration of the Length of the Radius and Ulna With Reduction of the Distal and Proximal Radioulnar Joints

Replacing the radial head and reducing and pinning the DRUJ are possible in the acute setting. In a subacute setting, this procedure can be combined with an ulnar-shortening osteotomy. Unfortunately, this approach places tremendous loads across the radiocapitellar joint.

Reconstruction of the Central Band of the Interosseous Membrane

Reconstruction of the central band of the IOM has the advantage of also attempting to restore the normal relationships between the radius and ulna, DRUJ, and PRUJ. Reconstruction of the IOM has been described using the palmaris longus, flexor carpi radialis tendon, Achilles allograft, pronator teres, synthetic materials, and bone–patellar tendon–bone graft (Figure 21.31,

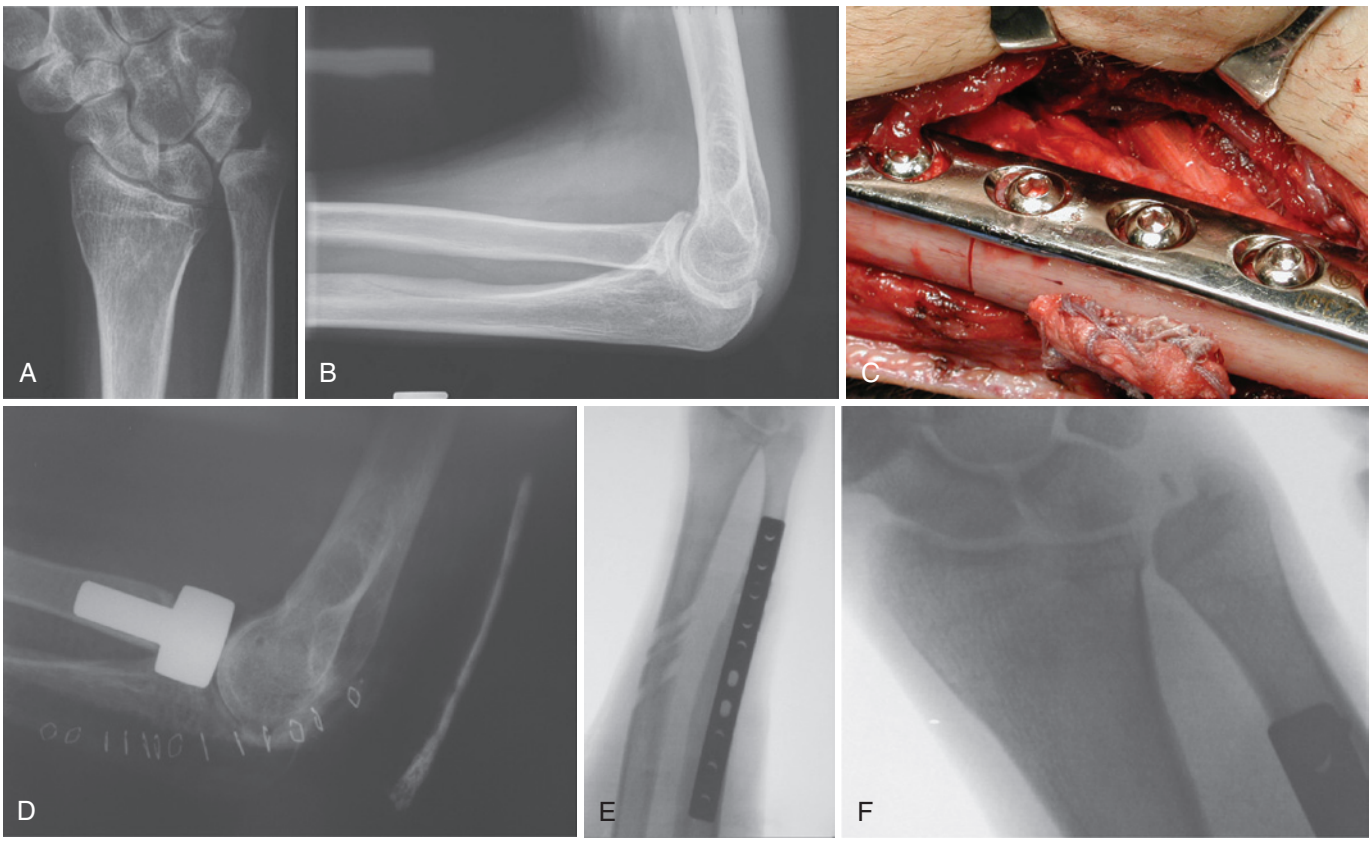

FIGURE 21.31 **A** and **B,** Initial radiographs showing severe proximal radial migration after radial head excision in the setting of disruption of the forearm axis. **C,** Intraoperative photograph demonstrating plate and screw fixation of the ulnar-shortening osteotomy and ulnar docking of the semitendinosus allograft. **D,** Radiograph after replacement of the radial head with a prosthesis. **E,** Anteroposterior radiograph of the forearm after ulnar-shortening osteotomy and fixation, radial head replacement, and reconstruction of the interosseous ligament with a semitendinosus allograft. **F,** Restoration of the normal relationships of the radius and ulna length. (Courtesy of Andrew Stein, MD, Anthony Deluise, MD, and Seth Levitz, MD.)

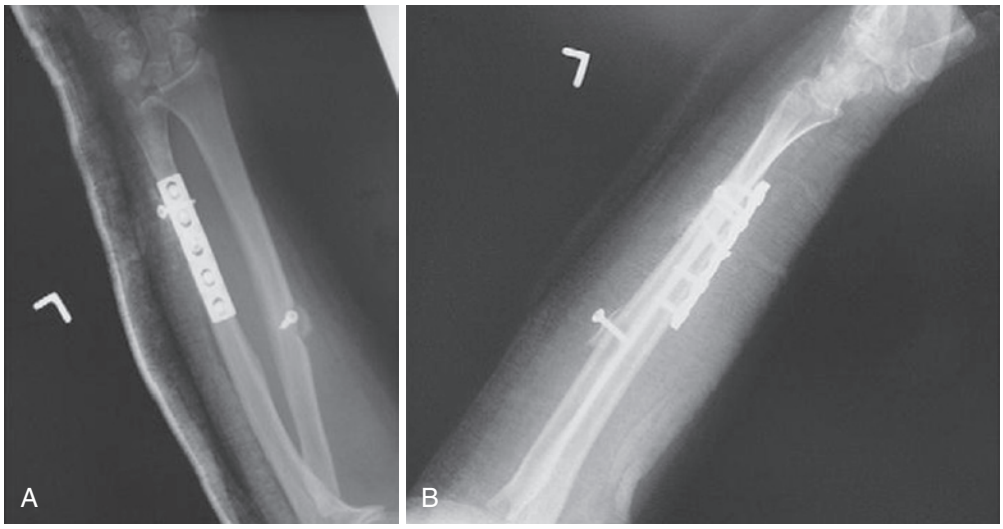

FIGURE 21.32 **A** and **B,** Anteroposterior and lateral radiographs after ulnar-shortening osteotomy and bone–patellar tendon–bone reconstruction of the interosseous ligament.

A to *F*).[21,76,118,123,127] The bone-ligament-bone reconstruction described by Marcotte and Osterman involves an ulnar-shortening osteotomy that is combined with a bone–patellar tendon–bone allograft (Figure 21.32).[76]

One-Bone Forearm Technique

Creating a one-bone forearm is considered the definitive salvage technique for the multiply operated, painful, and unstable forearm. The advantage of this procedure is that it provides a stable platform for the hand so that the shoulder and elbow may position the hand in space. The ulnohumeral joint is maintained to allow elbow flexion and extension, and wrist motion should be minimally affected. The disadvantages include complete loss of pronation-supination and the risk of nonunion, infection, and compartment syndrome.[136]

The two main techniques are transferring the radius to the ulna and creating a bridging synostosis between the radius and ulna. Typically the forearm is positioned in slight pronation. The patient can "test drive" different positions by immobilizing the forearm with a Munster-style splint or cast.[5] If supination is lacking in the contralateral forearm, the one-bone forearm can be placed in slight supination because the shoulder can abduct to compensate for a deficit in pronation.

Allende and Allende[1] reported that seven of seven patients in their series who underwent a one-bone forearm procedure for posttraumatic instability had a stable and pain-free forearm at an average follow-up of 9 years. All patients were satisfied with the position, function, and cosmesis of the reconstructed forearm. Jacoby and colleagues[63] studied 10 patients who had undergone one-bone forearm procedures but found that they experienced poor functional outcomes. The largest case series to date was reported by Peterson and associates,[97] who presented the outcomes of 19 patients. The authors categorized their patients into two groups based on the cause of injury: those who underwent one-bone forearm surgery because of posttraumatic instability and those who underwent the surgery because of instability after oncologic resection or a congenital deformity. The authors noted that nearly all of the major complications after surgery occurred in patients with acquired posttraumatic instability and concluded that the higher-energy injuries had worse results regardless of the reconstruction technique.

❖ AUTHOR'S PREFERRED METHODS OF TREATMENT

Acute Injuries

The initial evaluation begins with a history of a high-energy axial load to the forearm with complaints of elbow and wrist pain. The physical examination includes palpation and stress testing of the DRUJ for tenderness or instability. If an IOM injury is suspected, the forearm is studied with ultrasound or MRI. A neutral-rotation PA of the contralateral wrist is obtained with and without grip.

The surgical procedure begins with a lateral approach to the elbow. The radial head is repaired if the construct appears stable enough to support axial loads. If not, the radial head is resected and a pull test is performed as described previously. If the radius translates 3 mm or more or if there is a high suspicion of an IOM injury, a radial head arthroplasty is inserted. The lateral ligament complex of the elbow must be repaired to prevent posterolateral rotatory instability. If the DRUJ is unstable, our preference is to place two 0.062-inch pins across the distal ulna and radius proximal to the DRUJ. The pins should exit the far cortex of the radius. This facilitates retrieval if the pins break.

Interosseous Ligament Reconstruction

We have modified the technique using a bone-ligament-bone graft as described by Marcotte and Osterman.[76] The distal ulna is exposed along its subcutaneous border. The origin of the central band is estimated at the junction of the distal and middle thirds of the ulna. A 2.5-mm drill hole is created on an angle of around 25 degrees in a medial to lateral direction. The

extensor carpi ulnaris is elevated, and two No. 5 braided, nonabsorbable sutures are passed through the hole from lateral to medial. This is facilitated by first passing a bent 24-gauge dental wire through the hole from medial to lateral and using it as a suture retriever. A counterincision is made on the dorsoradial aspect of the forearm at the approximate junction of the middle and proximal thirds of the radius. The proximal radius is accessed between the ECRB and ECRL, with care taken to protect the radial sensory nerve. A 2.5-mm drill hole is made at the insertion of the central band and angled 25 degrees toward the ulna. Wrist extension and elbow flexion will help relax the extensor mass. Starting from the radial incision, a large, curved Kelly hemostat is used to gently create a path along the dorsal surface of the radius and ulna, aiming for the drill holes in the ulna. The two No. 5 sutures are retrieved and passed through the drill hole in the proximal radius. The bone-ligament-bone allograft is fashioned so that it spans the radius and ulna along the course of the native IOM. The bone is trimmed so that the bone blocks do not sit directly over the drill holes. This is intended to protect the suture when a screw is used to secure the block. A shallow notch for the bone block is created on the dorsal surface of the radius and ulna with a barrel bur. The bone-ligament-bone graft is passed beneath the extensors.

Once the reconstruction is "teed-up," the elbow is accessed by a lateral approach. The integrity of the lateral collateral ligament complex is confirmed by extending the elbow and retracting the common extensors. The status of the articular cartilage of the capitellum is evaluated and documented. A gauze pad is placed on the capitellum, and a lamina spreader is used to distract the proximal radius. Intraoperative fluoroscopy is used to confirm reduction of the DRUJ. The distal ulna is pinned to the radius with two 0.062-inch wires placed proximal to the DRUJ. With the length of the radius restored, a radial head prosthesis is placed in the proximal radius. This implant is intended to prevent convergence of the proximal radius and ulna. It need not and should not have a tight fit against the capitellum.

The reconstruction is completed by tying the two ends of the suture over a button on the proximal radius. The sutures are tensioned at the distal ulna and tied over a button. The bone block is fixed to the radius proximally using a single lag screw. The graft is tensioned and fixed to the ulna with a single lag screw distally.

The arm is immobilized in a long-arm splint. This can be converted to a Munster splint in 2 weeks. The pins are removed at 6 weeks following operation. At that time, active forearm rotation is allowed. At 3 months, the patient can begin light resistance exercises and, if necessary, participate in passive forearm rotation and static progressive splinting.

One-Bone Forearm Technique

We have no personal experience creating a one-bone forearm. The previous authors of this chapter recommended a bridging synostosis technique as opposed to the actual transfer of the radius to the ulna. Unless previous incisions or specific posttraumatic soft tissue concerns dictate otherwise, the radius is approached anteriorly. An osteotomy of the radius is made near the midshaft level. The distal radial shaft is pushed proximally or distally as needed to correct any length mismatch of the distal radius and ulna. The opposing cortices of the radius and ulna at the sites of planned cross-union are prepared by decortication with a bur. The radius is pinned to the ulna proximally and distally with temporary Kirschner wires, and intraoperative fluoroscopy is used to confirm anatomic positioning of the radius and ulna at the wrist and elbow. At least three quadricortical screws are placed proximal *and* distal to the radial shaft osteotomy. The screws are directed from the radius, across the interosseous space, and into the ulna. Cancellous autograft is placed in the interosseous space. Only the subcutaneous tissues and skin are closed. The fascia is left open, and a drain is used. Patients are monitored overnight. Elbow and wrist motion is allowed while bracing the forearm to prevent pronation-supination. Resistive exercises and weight bearing are restricted until clinical and radiographic healing is present.

A one-bone forearm can also be created with the aid of a vascularized free fibula graft if additional length or stability is needed.[5,22]

Postoperative Expectations

Following reconstruction of the IOM, the goal is a stable forearm with minimal pain and a functional arc of forearm rotation. Marcotte and Osterman reviewed a series of 16 patients who had been treated by bone-ligament-bone reconstruction and ulnar-shortening osteotomy since 1992 with an average follow-up of 78 months.[76] They reported that 15 of these patients had improvement in wrist pain and required no further surgery for longitudinal instability. Grip strength improved from 59% preoperatively to 86% postoperatively relative to the contralateral limb.

Following creation of a one-bone forearm, patients can expect little to no pain, a stable forearm, and no forearm rotation. Patients must understand the severity of their injury, realize the complexity of the reconstruction involved, and have reasonable expectations of being "functional" but not "normal."

Complications

Complications resulting from the initial injury include arthrosis at the wrist or elbow, or both, pain, lost range of motion, and lost function. Complications as a result of the IOM reconstruction also include persistent pain, recurrent instability, and progressive arthritis. The one-bone forearm technique carries with it a concern for compartment syndrome. Malunion and nonunion are also potential complications. Because the procedure is done infrequently, the true incidence of nonunion is unknown, but it has been reported to be up to 30%.[19,97]

REFERENCES

1. Allende C, Allende B: Posttraumatic one-bone forearm reconstruction: a report of seven cases. *J Bone Joint Surg Am* 86:364–369, 2004.
2. al-Qattan MM, Clarke HM, Zimmer P: Radiological signs of entrapment of the median nerve in forearm shaft fractures. *J Hand Surg [Br]* 19:713–719, 1994.
3. Altner PC, Hartmann JT: Isolated fractures of the ulnar shaft in the adult. *Surg Clin North Am* 52:155–170, 1972.
4. Anderson LD, Sisk TD, Tooms RE, et al: Compression-plate fixation in acute diaphyseal fractures of the radius and ulna. *J Bone Joint Surg Am* 57:287–297, 1975.
5. Arai K, Toh S, Yasumura M, et al: One-bone forearm formation using vascularized fibula graft for massive bone defect of the forearm with infection: case report. *J Reconstr Microsurg* 17:151–155, 2001.
6. Atkin DM, Bohay DR, Slabaugh P, et al: Treatment of ulnar shaft fractures: a prospective, randomized study. *Orthopedics* 18:543–547, 1995.

7. Azboy I, Demirtas A, Uçar BY, et al: Effectiveness of locking versus dynamic compression plates for diaphyseal forearm fractures. *Orthopedics* 36(7):e917–e922, 2013.
8. Barquet A: Posterior dislocation of the ulna at the elbow with associated fracture of the radial shaft. *Injury* 15:390–392, 1984.
9. Bauer G, Arand M, Mutschler W: Post-traumatic radio-ulnar synostosis after forearm fracture osteosynthesis. *Arch Orthop Trauma Surg* 110:142–145, 1991.
10. Beaupre GS, Csongradi JJ: Refracture risk after plate removal in the forearm. *J Orthop Trauma* 10:87–92, 1996.
11. Bednar DA, Grandwilewski W: Complications of forearm-plate removal. *Can J Surg* 35:428–431, 1992.
12. Bindra RR, Cole RJ, Yamaguchi K, et al: Quantification of the radial torsion angle with computerized tomography in cadaver specimens. *J Bone Joint Surg Am* 79:833–837, 1997.
13. Borens O, Chehab EL, Roberts MM, et al: Bilateral Galeazzi fracture-dislocations. *Am J Orthop* 35:369–372, 2006.
14. Boyd HB, Lipinski SW: Causes and treatment of non-union of the shafts of the long bones with a review of 741 patients. *Instr Course Lect* 17:165–183, 1960.
15. Brakenbury PH, Corea JR, Blakemore ME: Non-union of the isolated fracture of the ulnar shaft in adults. *Injury* 12:371–375, 1981.
16. Bruckner JD, Lichtman DM, Alexander AH: Complex dislocations of the distal radio-ulnar joint. Recognition and management. *Clin Orthop Relat Res* 275:90–103, 1992.
17. Chandler JW, Stabile KJ, Pfaeffle HJ, et al: Anatomic parameters for planning of interosseous ligament reconstruction using computer-assisted techniques. *J Hand Surg [Am]* 28:111–116, 2003.
18. Chapman MW, Gordon JE, Zissimos AG: Compression-plate fixation of acute fractures of the diaphyses of the radius and ulna. *J Bone Joint Surg Am* 71:159–169, 1989.
19. Chen F, Culp RW, Schneider LH, et al: Revision of the ununited one-bone forearm. *J Hand Surg [Am]* 23:1091–1096, 1998.
20. Chia DS, Lim YJ, Chew WY: Corrective osteotomy in forearm fracture malunion improves functional outcome in adults. *J Hand Surg Eur Vol* 36(2):102–106, 2011.
21. Chloros GD, Wiesler ER, Stabile KJ, et al: Reconstruction of Essex-Lopresti injury of the forearm: technical note. *J Hand Surg [Am]* 33(1):124–130, 2008.
22. Choudry UH, Bakri K, Moran SL, et al: The vascularized medial femoral condyle periosteal bone flap for the treatment of recalcitrant bony nonunions. *Ann Plast Surg* 60:174–180, 2008.
23. Corea JR, Brakenbury PH, Blakemore ME: The treatment of isolated fractures of the ulnar shaft in adults. *Injury* 12:365–370, 1981.
24. Crow BD, Mundis G, Anglen JO: Clinical results of minimal screw plate fixation of forearm fractures. *Am J Orthop* 36:477–480, 2007.
25. Cullen JP, Pellegrini VD, Jr, Miller RJ, et al: Treatment of traumatic radio-ulnar synostosis by excision and postoperative low-dose irradiation. *J Hand Surg [Am]* 19:394–401, 1994.
26. Curr JF, Moe WA: Dislocation of the inferior radio-ulnar joint. *Br J Surg* 34:74–77, 1946.
27. De Pedro JA, Garcia-Navarrete F, Garcia De Lucas F, et al: Internal fixation of ulnar fractures by locking nail. *Clin Orthop Relat Res* 283:81–85, 1992.
28. Dell PC, Sheppard JE: Vascularized bone grafts in the treatment of infected forearm nonunions. *J Hand Surg [Am]* 9:653–658, 1984.
29. Deluca PA, Lindsey RW, Ruwe PA: Refracture of bones of the forearm after the removal of compression plates. *J Bone Joint Surg Am* 70:1372–1376, 1988.
30. Dodge HS, Cady GW: Treatment of fractures of the radius and ulna with compression plates. *J Bone Joint Surg Am* 54:1167–1176, 1972.
31. Dohn P, Khiami F, Rolland E, et al: Adult post-traumatic radioulnar synostosis. *Orthop Traumatol Surg Res* 98(6):709–714, 2012.
32. Droll KP, Perna P, Potter J, et al: Outcomes following plate fixation of fractures of both bones of the forearm in adults. *J Bone Joint Surg Am* 89:2619–2624, 2007.
33. Dumont CE, Nagy L, Ziegler D, et al: Fluoroscopic and magnetic resonance cross-sectional imaging assessments of radial and ulnar torsion profiles in volunteers. *J Hand Surg [Am]* 32:501–509, 2007.
34. Duncan R, Geissler W, Freeland AE, et al: Immediate internal fixation of open fractures of the diaphysis of the forearm. *J Orthop Trauma* 6:25–31, 1992.
35. Dymond IW: The treatment of isolated fractures of the distal ulna. *J Bone Joint Surg Br* 66:408–410, 1984.
36. Edwards GS, Jr, Jupiter JB: Radial head fractures with acute distal radioulnar dislocation. Essex-Lopresti revisited. *Clin Orthop Relat Res* 234:61–69, 1988.
37. Eglseder WA, Hay M: Combined Essex-Lopresti and radial shaft fractures: case report. *J Trauma* 34:310–312, 1993.
38. Epner RA, Bowers WH, Guilford WB: Ulnar variance: the effect of wrist positioning and roentgen filming technique. *J Hand Surg [Am]* 7:298–305, 1982.
39. Esser RD: Treatment of a bone defect of the forearm by bone transport. A case report. *Clin Orthop Relat Res* 326:221–224, 1996.
40. Essex-Lopresti P: Fractures of the radial head with distal radio-ulnar dislocation: report of two cases. *J Bone Joint Surg Br* 33:244–247, 1951.
41. Failla JM, Amadio PC, Morrey BF: Post-traumatic proximal radio-ulnar synostosis. Results of surgical treatment. *J Bone Joint Surg Am* 71:1208–1213, 1989.
42. Fester E, Murray P, Sanders T, et al: The efficacy of magnetic resonance imaging and ultrasound in detecting disruptions of the forearm interosseous membrane: a cadaver study. *J Hand Surg [Am]* 27:418–424, 2002.
43. Fulkerson E, Egol KA, Kubiak EN, et al: Fixation of diaphyseal fractures with a segmental defect: a biomechanical comparison of locked and conventional plating techniques. *J Trauma* 60:830–835, 2006.
44. Galik K, Baratz ME, Butler AL, et al: The effect of the annular ligament on kinematics of the radial head. *J Hand Surg [Am]* 32(8):1218–1224, 2007.
45. Gao H, Luo CF, Zhang CQ, et al: Internal fixation of diaphyseal fractures of the forearm by interlocking intramedullary nail: short-term results in eighteen patients. *J Orthop Trauma* 19:384–391, 2005.
46. Gebuhr P, Hölmich P, Orsnes T, et al: Isolated ulnar shaft fractures. Comparison of treatment by a functional brace and long-arm cast. *J Bone Joint Surg Br* 74:757–759, 1992.
47. Goldfarb CA, Ricci WM, Tull F, et al: Functional outcome after fracture of both bones of the forearm. *J Bone Joint Surg Br* 87:374–379, 2005.
48. Grace TG: Eversmann WW, Jr: Forearm fractures: treatment by rigid fixation with early motion. *J Bone Joint Surg Am* 62:433–438, 1980.
49. Green JB, Zelouf DS: Forearm instability. *J Hand Surg [Am]* 34(5):953–961, 2009.
50. Griffin XL, Costa ML, Parsons N, et al: Electromagnetic field stimulation for treating delayed union or non-union of long bone fractures in adults. *Cochrane Database Syst Rev* (4):CD008471, 2011.
51. Griffin XL, Smith N, Parsons N, et al: Ultrasound and shockwave therapy for acute fractures in adults. *Cochrane Database Syst Rev* (2):CD008579, 2012.
52. Hadden WA, Reschauer R, Seggl W: Results of AO plate fixation of forearm shaft fractures in adults. *Injury* 15:44–52, 1983.
53. Handoll HH, Pearce PK: Interventions for isolated diaphyseal fractures of the ulna in adults. *Cochrane Database Syst Rev* (2):CD000523, 2004.
54. Handoll HHG, Pearce P: Interventions for treating isolated diaphyseal fractures of the ulna in adults. *Cochrane Database Syst Rev* (6):CD000523, 2012.
55. Hanel DP, Pfaeffle HJ, Ayalla A: Management of posttraumatic metadiaphyseal radio-ulnar synostosis. *Hand Clin* 23:227–234, vi-vii, 2007.
56. Hanel DP, Scheid DK: Irreducible fracture-dislocation of the distal radio-ulnar joint secondary to entrapment of the extensor carpi ulnaris tendon. *Clin Orthop Relat Res* 234:56–60, 1988.
57. Hastings H, 2nd, Graham TJ: The classification and treatment of heterotopic ossification about the elbow and forearm. *Hand Clin* 10:417–437, 1994.
58. Henket M, van Duijn PJ, Doornberg JN, et al: A comparison of proximal radioulnar synostosis excision after trauma and distal biceps reattachment. *J Shoulder Elbow Surg* 16:626–630, 2007.
59. Hertel R, Pisan M, Lambert S, et al: Plate osteosynthesis of diaphyseal fractures of the radius and ulna. *Injury* 27:545–548, 1996.
60. Hidaka S, Gustilo RB: Refracture of bones of the forearm after plate removal. *J Bone Joint Surg Am* 66:1241–1243, 1984.
61. Hong G, Cong-Feng L, Hui-Peng S, et al: Treatment of diaphyseal forearm nonunions with interlocking intramedullary nails. *Clin Orthop Relat Res* 450:186–192, 2006.
62. Hotchkiss RN, An KN, Sowa DT, et al: An anatomic and mechanical study of the interosseous membrane of the forearm: pathomechanics of proximal migration of the radius. *J Hand Surg [Am]* 14:256–261, 1989.
63. Jacoby SM, Bachoura A, Diprinzio EV, et al: Complications following one-bone forearm surgery for posttraumatic forearm and distal radioulnar joint instability. *J Hand Surg [Am]* 38(5):976–982, 2013.
64. Jones DB, Jr, Kakar SJ: Adult diaphyseal forearm fractures: intramedullary nail versus plate fixation. *J Hand Surg [Am]* 36(7):1216–1219, 2011.
65. Jones JA: Immediate internal fixation of high-energy open forearm fractures. *J Orthop Trauma* 5:272–279, 1991.
66. Jungbluth P, Frangen TM, Muhr G, et al: A primarily overlooked and incorrectly treated Essex-Lopresti injury: what can this lead to? *Arch Orthop Trauma Surg* 128:89–95, 2008.
67. Jupiter JB, Gerhard HJ, Guerrero J, et al: Treatment of segmental defects of the radius with use of the vascularized osteoseptocutaneous fibular autogenous graft. *J Bone Joint Surg Am* 79:542–550, 1997.
68. Jupiter JB, Ring D: Operative treatment of post-traumatic proximal radioulnar synostosis. *J Bone Joint Surg Am* 80(2):248–257, 1998.
69. Kataoka T, Oka K, Miyake J, et al: Three-dimensional prebent plate fixation in corrective osteotomy of malunited upper extremity fractures using a real-sized plastic bone model prepared by preoperative computer simulation. *J Hand Surg [Am]* 38(5):909–919, 2013.
70. Kei O, Matsuki KM, Shang M, et al: In vivo 3D kinematics of normal forearms: analysis of dynamic forearm rotation. *Clin Biomech* 25:979–983, 2010.

71. Knight RA, Purvis GD: Fractures of both bones of the forearm in adults. *J Bone Joint Surg Am* 31(4):755–764, 1949.
72. Langkamer VG, Ackroyd CE: Removal of forearm plates. A review of the complications. *J Bone Joint Surg Br* 72:601–604, 1990.
73. Lee YH, Lee SK, Chung MS, et al: Interlocking contoured intramedullary nail fixation for selected diaphyseal fractures of the forearm in adults. *J Bone Joint Surg Am* 90:1891–1898, 2008.
74. Leung F, Chow SP: A prospective, randomized trial comparing the limited contact dynamic compression plate with the point contact fixator for forearm fractures. *J Bone Joint Surg Am* 85:2343–2348, 2003.
75. Lindvall EM, Sagi HC: Selective screw placement in forearm compression plating: results of 75 consecutive fractures stabilized with 4 cortices of screw fixation on either side of the fracture. *J Orthop Trauma* 20:157–162, discussion 162–163, 2006.
76. Marcotte AL, Osterman AL: Longitudinal radioulnar dissociation: identification and treatment of acute and chronic injuries. *Hand Clin* 23:195–208, vi, 2007.
77. Martin W, Field J, Kulkarni M: Intramedullary nailing of pathological forearm fractures. *Injury* 33(6):530–532, 2002.
78. Matthews LS, Kaufer H, Garver DF, et al: The effect on supination-pronation of angular malalignment of fractures of both bones of the forearm. *J Bone Joint Surg Am* 64:14–17, 1982.
79. McGinley JC, Roach N, Hopgood BC, et al: Forearm interosseous membrane trauma: MRI diagnostic criteria and injury patterns. *Skeletal Radiol* 35:275–281, 2006.
80. McGlinn EP, Sebastin SJ, Chung KC: A historical perspective on the Essex-Lopresti injury. *J Hand Surg [Am]* 38(8):1599–1606, 2013.
81. Mehara AK, Bhan S: Ipsilateral radial head dislocation with radial shaft fracture: case report. *J Trauma* 35:958–959, 1993.
82. Mih AD, Cooney WP, Idler RS, et al: Long-term follow-up of forearm bone diaphyseal plating. *Clin Orthop Relat Res* 299:256–258, 1994.
83. Moed BR, Kellam JF, Foster RJ, et al: Immediate internal fixation of open fractures of the diaphysis of the forearm. *J Bone Joint Surg Am* 68:1008–1017, 1986.
84. Mok D, Nikolis A, Harris PG: The cutaneous innervation of the dorsal hand: detailed anatomy with clinical implications. *J Hand Surg [Am]* 31:565–574, 2006.
85. Moroni A, Caja VL, Sabato C, et al: Composite bone grafting and plate fixation for the treatment of nonunions of the forearm with segmental bone loss: a report of eight cases. *J Orthop Trauma* 9:419–426, 1995.
86. Moroni A, Rollo G, Guzzardella M, et al: Surgical treatment of isolated forearm non-union with segmental bone loss. *Injury* 28:497–504, 1997.
87. Morrey BF, Askew LJ, Chao EY: A biomechanical study of normal functional elbow motion. *J Bone Joint Surg Am* 63:872–877, 1981.
88. Muller ME, Allgower M, Willenegger H: *Technique of internal fixation of fractures*, Berlin, 1963, Springer-Verlag.
89. Nagy L, Jankauskas L, Dumont CE: Correction of forearm malunion guided by the preoperative complaint. *Clin Orthop Relat Res* 466(6):1419–1428, 2008.
90. Naiman PT, Schein AJ, Siffert RS: Use of ASIF compression plates in selected shaft fractures of the upper extremity: a preliminary report. *Clin Orthop Relat Res* 71:208–216, 1970.
91. Noda K, Goro A, Murase T, et al: Interosseous membrane of the forearm: an anatomical study of ligament. *J Hand Surg [Am]* 34:415–422, 2009.
92. Oda T, Wada T, Isogai S, et al: Corrective osteotomy for volar instability of the distal radio-ulnar joint associated with radial shaft malunion. *J Hand Surg Eur Vol* 32:573–577, 2007.
93. Orzechowski W, Morasiewicz L, Dragan S, et al: Treatment of non-union of the forearm using distraction-compression osteogenesis. *Orthop Traumatol Rehabil* 9(4):357–365, 2007.
94. Ostermann PA, Ekkernkamp A, Henry SL, et al: Bracing of stable shaft fractures of the ulna. *J Orthop Trauma* 8:245–248, 1994.
95. Ozkaya U, Kiliç A, Ozdoan U, et al: Comparison between locked intramedullary nailing and plate osteosynthesis in the management of adult forearm fractures [in Turkish]. *Acta Orthop Traumatol Turc* 43:14–20, 2009.
96. Pai VS: Unusual arterial injury following a fracture of the forearm bones: a case report. *J Orthop Surg (Hong Kong)* 8:15–17, 2000.
97. Peterson CA, 2nd, Maki S, Wood MB: Clinical results of the one-bone forearm. *J Hand Surg [Am]* 20:609–618, 1995.
98. Poitevin LA: Anatomy and biomechanics of the interosseous membrane: its importance in the longitudinal stability of the forearm. *Hand Clin* 17:97–110, vii, 2001.
99. Posman CL, Little RE: Radio-ulnar synostosis following an isolated fracture of the ulnar shaft. A case report. *Clin Orthop Relat Res* 213:207–210, 1986.
100. Ray RD, Johnson RJ, Jameson RM: Rotation of the forearm: an experimental study of pronation and supination. *J Bone Joint Surg Am* 33:993–996, 1951.
101. Rehman S, Sokunbi G: Intramedullary fixation of forearm fractures. *Hand Clin* 26(3):391–401, 2010.
102. Reilly TJ: Isolated and combined fractures of the diaphysis of the radius and ulna. *Hand Clin* 18:179–194, 2002.
103. Rettig ME, Raskin KB: Galeazzi fracture-dislocation: a new treatment-oriented classification. *J Hand Surg [Am]* 26:228–235, 2001.
104. Ring D, Allende C, Jafarnia K, et al: Ununited diaphyseal forearm fractures with segmental defects: plate fixation and autogenous cancellous bone-grafting. *J Bone Joint Surg Am* 86:2440–2445, 2004.
105. Ring D, Rhim R, Carpenter C, et al: Comminuted diaphyseal fractures of the radius and ulna: does bone grafting affect nonunion rate? *J Trauma* 59:438–441, discussion 442, 2005.
106. Ring D, Rhim R, Carpenter C, et al: Isolated radial shaft fractures are more common than Galeazzi fractures. *J Hand Surg [Am]* 31:17–21, 2006.
107. Rizvi M, Bille B, Holtom P, et al: The role of prophylactic antibiotics in elective hand surgery. *J Hand Surg [Am]* 33:413–420, 2008.
108. Robson AJ, See MS, Ellis H: Applied anatomy of the superficial branch of the radial nerve. *Clin Anat* 21:38–45, 2008.
109. Rosen H: Compression treatment of long bone pseudarthroses. *Clin Orthop Relat Res* 138:154–166, 1979.
110. Rosson JW, Petley GW, Shearer JR: Bone structure after removal of internal fixation plates. *J Bone Joint Surg Br* 73:65–67, 1991.
111. Rosson JW, Shearer JR: Refracture after the removal of plates from the forearm. An avoidable complication. *J Bone Joint Surg Br* 73:415–417, 1991.
112. Sage FP, Smith H: Medullary fixation of forearm fractures. *J Bone Joint Surg Am* 39:91–98, 1957.
113. Salvi AE: Forearm diaphyseal fractures: which bone to synthesize first? *Orthopedics* 29:669–671, discussion 671, 2006.
114. Sarmiento A, Ebramzadeh E, Brys D, et al: Angular deformities and forearm function. *J Orthop Res* 10:121–133, 1992.
115. Sarmiento A, Kinman PB, Murphy RB, et al: Treatment of ulnar fractures by functional bracing. *J Bone Joint Surg Am* 58:1104–1107, 1976.
116. Schemitsch EH, Richards RR: The effect of malunion on functional outcome after plate fixation of fractures of both bones of the forearm in adults. *J Bone Joint Surg Am* 74:1068–1078, 1992.
117. Schweitzer G: Refracture of bones of the forearm after the removal of compression plates. *J Bone Joint Surg Am* 72:152, 1990.
118. Sellman DC, Seitz WH, Jr, Postak PD, et al: Reconstructive strategies for radioulnar dissociation: a biomechanical study. *J Orthop Trauma* 9:516–522, 1995.
119. Skahen JR, 3rd, Palmer AK, Werner FW, et al: Reconstruction of the interosseous membrane of the forearm in cadavers. *J Hand Surg [Am]* 22:986–994, 1997.
120. Smith WR, Elbatrawy YA, Andreassen GS, et al: Treatment of traumatic forearm bone loss with Ilizarov ring fixation and bone transport. *Int Orthop* 31:165–170, 2007.
121. Snow M, Thompson G, Turner PG: A mechanical comparison of the locking compression plate (LCP) and the low contact-dynamic compression plate (DCP) in an osteoporotic bone model. *J Orthop Trauma* 22:121–125, 2008.
122. Soon JC, Kumar VP, Satkunanartham K: Elbow dislocation with ipsilateral radial shaft fracture. An unusual outcome. *Clin Orthop Relat Res* 329:212–215, 1996.
123. Sowa DT, Hotchkiss RN, Weiland AJ: Symptomatic proximal translation of the radius following radial head resection. *Clin Orthop Relat Res* 317:106–113, 1995.
124. Stern PJ, Drury WJ: Complications of plate fixation of forearm fractures. *Clin Orthop Relat Res* 175:25–29, 1983.
125. Tabor OB, Jr, Bosse MJ, Sims SH, et al: Iatrogenic posterior interosseous nerve injury: is transosseous static locked nailing of the radius feasible? *J Orthop Trauma* 9:427–429, 1995.
126. Tarr RR, Garfinkel AI, Sarmiento A: The effects of angular and rotational deformities of both bones of the forearm. An in vitro study. *J Bone Joint Surg Am* 66:65–70, 1984.
127. Tomaino MM, Pfaeffle J, Stabile K, et al: Reconstruction of the interosseous ligament of the forearm reduces load on the radial head in cadavers. *J Hand Surg [Br]* 28:267–270, 2003.
128. Trousdale RT, Amadio PC, Cooney WP, et al: Radio-ulnar dissociation. A review of twenty cases. *J Bone Joint Surg Am* 74:1486–1497, 1992.
129. Trousdale RT, Linscheid RL: Operative treatment of malunited fractures of the forearm. *J Bone Joint Surg Am* 77:894–902, 1995.
130. van Duijvenbode DC, Guitton TG, Raaymakers EL, et al: Long-term outcome of isolated diaphyseal radius fractures with and without dislocation of the distal radioulnar joint. *J Hand Surg [Am]* 37(3):523–527, 2012.
131. van Geenen RC, Besselaar PP: Outcome after corrective osteotomy for malunited fractures of the forearm sustained in childhood. *J Bone Joint Surg Br* 89:236–239, 2007.
132. Van Leemput T, Mahieu G: Conservative management of minimally displaced isolated fractures of the ulnar shaft. *Acta Orthop Belg* 73:710–713, 2007.
133. Vince KG, Miller JE: Cross-union complicating fracture of the forearm. Part I: adults. *J Bone Joint Surg Am* 69:640–653, 1987.

134. Visna P, Vicek M, Valcha M, et al: Management of diaphyseal forearm fractures using LCP angle stable fixation devices and intramedullary nailing. *Rozhl Chir* 88:708–715, 2009.
135. Lees VC: The functional anatomy of forearm rotation. *J Hand Microsurg* 1(2):92–99, 2009.
136. Wang AA, Jacobson-Petrov J, Stubin-Amelio L, et al: Selection of fusion position during forearm arthrodesis. *J Hand Surg [Am]* 25:842–848, 2000.
137. Weckbach A, Blattert TR, Weisser CH: Interlocking nailing of forearm fractures. *Arch Orthop Trauma Surg* 126:309–315, 2006.
138. Wei SY, Born CT, Abene A, et al: Diaphyseal forearm fractures treated with and without bone graft. *J Trauma* 46:1045–1048, 1999.
139. Wood MB: Upper extremity reconstruction by vascularized bone transfers: results and complications. *J Hand Surg [Am]* 12:422–427, 1987.
140. Wright RR, Schmeling GJ, Schwab JP: The necessity of acute bone grafting in diaphyseal forearm fractures: a retrospective review. *J Orthop Trauma* 11:288–294, 1997.

Complex Traumatic Elbow Dislocation

George S.M. Dyer and Jesse B. Jupiter

Acknowledgment: We wish to thank Dr. Jawa and Dr. Hotchkiss for their excellent chapter in the last edition of Green's Operative Hand Surgery *and their generosity in permitting much of their text and many of their illustrations to be reused.*

The elbow is one of the most constrained and inherently stable joints in the body, owing to numerous bony and soft tissue structures.[66,68] Therefore even simple elbow dislocation, where there is no fracture, indicates substantial soft tissue injury with disruption of the capsule and ligaments.[45,48] It is unusual, however, to observe chronic elbow instability or arthrosis after a stable reduction of a simple dislocation.[47,65,83]

In contrast, complex elbow dislocations are defined by capsuloligamentous disruption in association with fracture of one or more of the major bony stabilizers: the radial head, coronoid, or olecranon.[8,94] These fractures make the dislocation inherently unstable and almost always necessitate operative intervention to restore anatomic alignment and elbow stability.[46,108] The risk of recurrent instability and late arthrosis increases with the complexity of the injury and the number of stabilizers that are injured.[38,94,98] Understanding of the pathoanatomy of these injuries is still developing, and many questions exist about the best treatment algorithm. Successful evaluation and treatment require an understanding of the importance, function, and relationship of each major element of bony and soft tissue anatomy and its contribution to elbow stability.

FUNCTIONAL ANATOMY

Ulnar-Humeral Joint

The primary contributor to elbow stability is the ulnar-humeral joint. It is highly constrained: 180 degrees of the trochlea articulates with the proximal ulna.[1,66,68] The distal humerus tilts 30 degrees anteriorly, and the semilunar notch tilts posteriorly.[105,118] This reciprocal relationship increases the prominence of the coronoid and makes it a key stabilizer of the ulnar-humeral joint. The intact coronoid resists the posteriorly directed moments of the biceps and the triceps (Figure 22.1).[4,19,68] The coronoid is also important because the anterior band of the medial collateral ligament (MCL) inserts at its base. The MCL is the primary stabilizer to valgus moments.[9] More recently, the anteromedial facet of coronoid has been recognized as important for resisting varus moments as well[15,19,89,108] (Figure 22.2).

The olecranon is less important as a bony stabilizer. In cadaveric studies, resistance to posterior translation decreases linearly with olecranon excision, although 50% of the olecranon can be resected without affecting elbow stability.[1] The intact olecranon is important, however, in resistance to valgus moments.[67]

Radiocapitellar Joint

The radial head, along with the coronoid, resists posterior subluxation of the ulna.[103] With other osseous and ligamentous components of the elbow intact, the radiocapitellar articulation contributes minimally to valgus stability.[44,68] With MCL or coronoid injury, the radial head becomes the primary stabilizer to valgus stress and prevents subluxation or dislocation of the elbow.[69]

Capsuloligamentous Components

The MCL and the lateral collateral ligament (LCL) are the main capsuloligamentous stabilizers of the elbow.[74,75] The MCL is composed of anterior, posterior, and transverse bundles. The posterior and transverse bundles are subtle thickenings of the capsule, whereas the anterior bundle is a robust, identifiable structure that is crucial to resist valgus moments.[29,67,107] The anterior bundle originates from the medial epicondyle and inserts on the sublime tubercle at the base of the coronoid process.[27,77] Medial epicondyle fracture, large coronoid fracture, and MCL tear all are injury variants that can cause valgus elbow instability.[75]

The LCL complex comprises the radial collateral ligament, annular ligament, and posterior band, or lateral ulnar collateral ligament (LUCL).[104] The LUCL originates from the lateral epicondyle and inserts on the supinator crest of the proximal ulna where it is confluent with the annular ligament. The LUCL is the prime restraint to posterolateral rotatory instability.[23,72,76,79] Additional lateral soft tissues, including the extensor origin and the annular ligament, contribute to resisting posterolateral instability.[13,24,78]

Musculotendinous Components

The osseous and ligamentous structures all provide static stability for the elbow, whereas the muscles crossing the elbow joint provide dynamic stability.[94] The biceps, brachialis, and triceps muscles help maintain the trochlea in the semilunar notch with posteriorly directed forces.[29] The flexor and extensor masses are secondary stabilizers of the medial and lateral sides.[13,23]

PREOPERATIVE EVALUATION

Clinical Assessment

Acute Injury

As in all acute fractures, especially high-energy elbow fracture-dislocations, the patient should be evaluated first according to the Advanced Trauma Life Support guidelines. Associated head trauma has an effect on management and outcome of the elbow



FIGURE 22.1 The elbow is highly constrained; 180 degrees of the articulating surface of trochlea is in contact with proximal ulna. The distal humerus tilts approximately 30 degrees anteriorly, and semilunar notch tilts posteriorly in a reciprocal relationship.

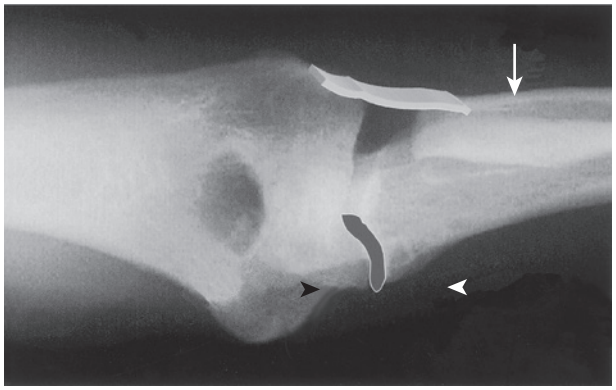

FIGURE 22.2 The elbow joint experiences varus stress *(arrow)* when shoulder abduction occurs. Resistance to varus load comes from tension in posterior lateral collateral ligament and load across medial facet of coronoid and distal humerus *(arrowheads).* (Copyright Robert N. Hotchkiss.)

because of increased incidence of heterotopic bone formation.[30,32] Additionally, concomitant fractures, dislocations, and injuries in the ipsilateral upper extremity occur in 10% to 20% of cases.[108] Distal radioulnar joint tenderness may represent an interosseous ligament disruption and should alert the examiner to the possibility of an Essex-Lopresti injury.[34,108,111]

Fracture-dislocations are notable for significant swelling, pain, and visible deformity. A thorough neurovascular examination before and after any reduction or manipulation is mandatory because of the high-energy nature of these injuries. Most nerve injuries are secondary to traction. The ulnar nerve is the most vulnerable and commonly injured because of its positioning directly medial to the joint.[60,106] Median nerve and radial nerve injuries are rare but have been reported, including entrapment of both nerves in the joint.[58,115] Stretching and tearing of other anterior structures, including the brachial artery, have been reported and rarely can lead to ischemia and compartment syndrome.[109] These injuries are seen more often in pediatric patients.[39]

Monitoring of the soft tissue swelling is essential because forearm compartment syndrome must always be suspected in high-energy injuries. A "floating forearm" injury, where a more distal radius fracture occurs together with an elbow fracture, is particularly associated with forearm compartment syndrome.[43]

Delayed Treatment or Previous Surgery

For patients who present for delayed treatment or who may have had previous surgery, a careful assessment of their range of motion, pain, and nerve function should be recorded. Ulnar nerve function may be already diminished without the patient being aware, overshadowed by the pain and overall impact of the elbow injury.[26] Flexion and extension and forearm rotation should be checked.

Imaging

Acute Injury

Anteroposterior and lateral radiographs of the elbow are necessary; however, it is often difficult to evaluate these complex injuries fully with the initial radiographs. Trauma films may be inadequate because of pain, deformity, bandages, and splinting material. Radiographs of the shoulder, wrist, and hand should also be included to rule out ipsilateral injuries. Two-dimensional and three-dimensional reformatted computed tomography (CT) scans of the elbow after closed reduction are extremely helpful for understanding the injury pattern and for preoperative planning. CT scans identify and help quantify injuries of the coronoid, radial head, or olecranon that may have been missed on plain radiographs. Lastly, fluoroscopic examination under anesthesia is useful while making operative decisions for treatment.[55]

Delayed Treatment or Previous Surgery

In cases in which the patient has undergone previous treatment but has an elbow that remains either dislocated or unstable, imaging must be tailored to the individual circumstances. Plain radiographs are mandatory, but because the joint is often stiff and the patient is unable to change its position, this situation requires some creativity and collaboration with the radiology staff for nonstandard views. The goal of plain radiographs is to document the integrity and alignment of the articulating surfaces of the distal humerus, radial head, and proximal ulna. Displaced articular fragments may be difficult to see. Internal fixation and radial head implants can obscure the joint surfaces and alignment. In these cases, magnetic resonance imaging (MRI) can be more valuable than CT because the scatter from the metal can be effectively reduced.

CLASSIFICATION AND PATTERNS OF INJURY

Posterolateral Rotational Injury

Most complex dislocations occur from a high-energy injury, such as a fall on an outstretched hand or motor vehicle accident. In 90% of dislocations, the injury is a combination of valgus, supination, and axial directed moments that combine to cause

a posterior or posterolateral displacement of the proximal ulna from the trochlea.[14,75,76,108] Sequential and predictable injury starts from the lateral side and moves anteriorly and posteriorly to the medial side. This pattern of disruption is commonly referred to as the Horii circle.[40,78] The LCL complex is one of the first injured structures and is usually avulsed from the lateral epicondyle. The anterior band of the MCL is the last structure injured, and experimentally the elbow may dislocate with it intact. The flexor and extensor origins have a variable degree of injury.[25,45] Depending on how the energy is dissipated, the injury may result in pure capsuloligamentous disruption and a simple elbow dislocation or a complex dislocation with fractures of the radial head or coronoid or both.[25,46,94]

Dislocation With Radial Head Fracture

Ulnar-humeral dislocation is seen in less than 10% of radial head fractures[46] (Figure 22.3). These are higher-energy injuries than simple dislocations and involve greater instability and a higher risk of arthrosis. Hotchkiss' modification of the Mason classification (see Chapter 19) provides a useful scheme for evaluation. In the context of a fracture-dislocation, type I fractures do not require operative intervention, type II fractures require fixation, and type III fractures require replacement arthroplasty.[41] The LCL is typically avulsed from its origin at the lateral epicondyle and must be addressed surgically; conversely, although the MCL is sometimes disrupted, it rarely causes persistent instability.[28]

Dislocation With Radial Head and Coronoid Fracture ("Terrible Triad")

These injuries have an increasing threat of persistent instability and posttraumatic arthrosis[12,84,98] (Figure 22.4). Coronoid fractures may be classified by their location and size into tip fractures, anteromedial fractures, and basal fractures (Figure 22.5). Subtype I tip fractures are 2 mm or smaller in size. Subtype II fractures are greater than 2 mm in size, but do not extend into the sublime tubercle.[18,108] The distinction between the two subtypes is arbitrary, however, and does not seem to affect treatment. The anterior capsule is usually still attached to the coronoid piece and must be considered when treating this fracture.[18] Anteromedial and basal fractures are typically seen with varus posteromedial rotational injuries and olecranon fracture-dislocations and are discussed in the next sections. The LCL and MCL are disrupted, although sometimes the anterior bundle of the MCL may remain intact. Ultimately, elbow stability is proportional to the size and location of the coronoid fracture, the extent of radial head comminution, and the severity of ligamentous disruption.[20,87]

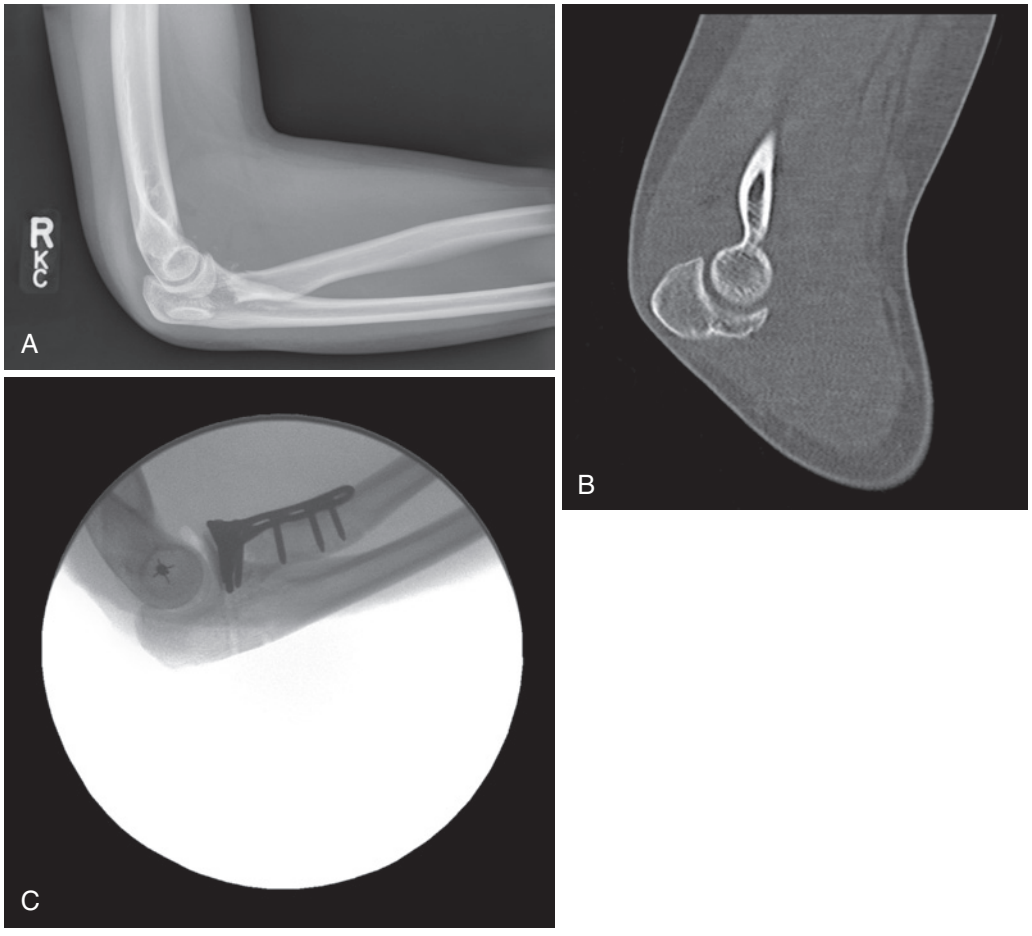

FIGURE 22.3 **A,** Lateral radiograph in a 16-year-old girl with a radial head fracture associated with elbow dislocation. The elbow is shown here reduced, but the incarcerated radial head fragment, the malalignment of the radial neck and capitellum, and the fleck from the coronoid are clues to instability. **B,** Sagittal CT showing telltale coronoid fracture. **C,** Reconstructed elbow. The anterior instability has been repaired with transosseous suture, the radial head has been repaired, and the LCL repaired with a suture anchor.

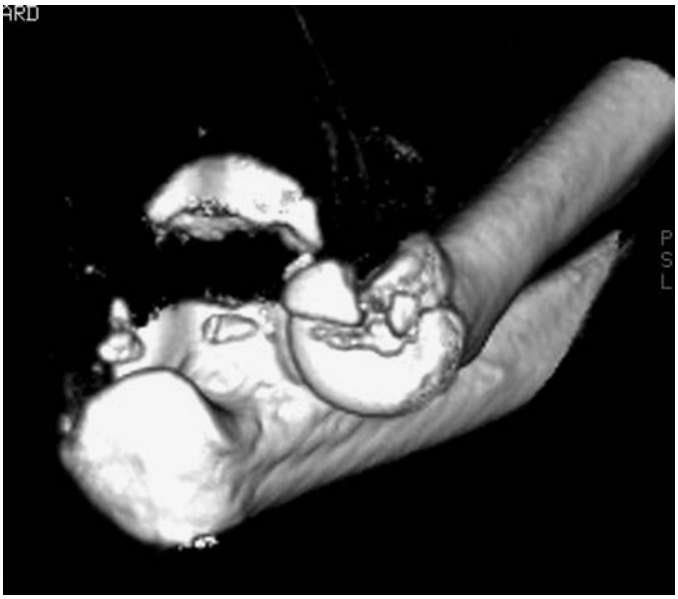

FIGURE 22.4 A 3D CT scan shows a coronoid fracture that is typical for a terrible triad injury: a single transverse fragment that includes the insertion of the anterior capsule. Notice that the radial head fracture involves only 40% of the articular surface but is too complex to repair. (Courtesy David Ring, MD, PhD)

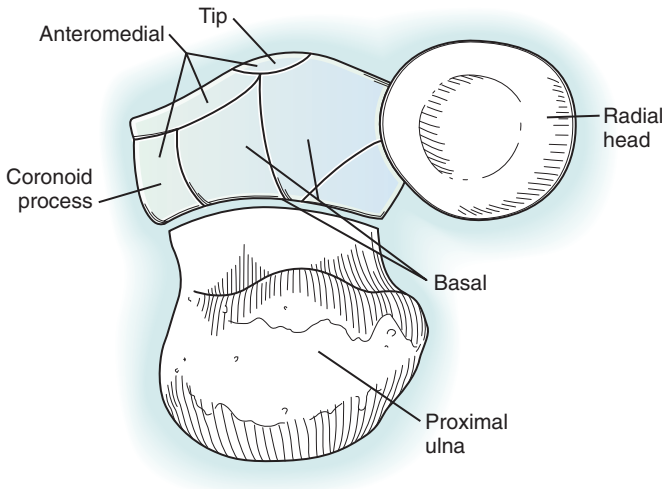

FIGURE 22.5 Coronoid fracture classification as described in O'Driscoll and colleagues.[78] Tip fractures have two subtypes: Subtype I involves <2 mm of coronoid height, and subtype II involves >2 mm of coronoid height. Anteromedial fractures have three subtypes: Subtype I involves the anteromedial rim, subtype II involves the anteromedial rim and tip, and subtype III involves the anteromedial rim and sublime tubercle. Basal fractures have two subtypes: Subtype I involves the coronoid body, indicated by at least 50% of the height of the coronoid, and subtype II is associated with olecranon fractures.

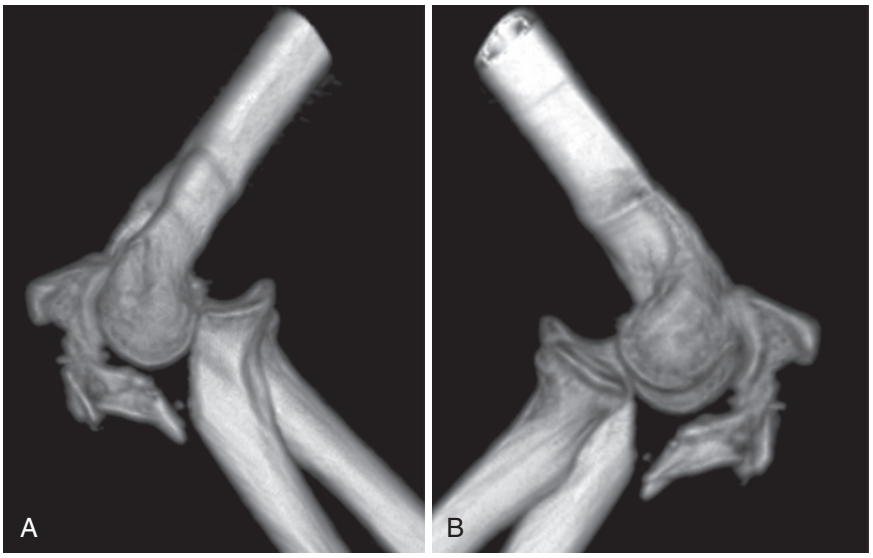

FIGURE 22.6 **A,** Three-dimensional reconstructions of anterior transolecranon fracture-dislocation. **B,** Proximal radioulnar joint relationship is not disrupted in this injury.

Olecranon Fracture-Dislocations

Olecranon fracture-dislocations typically represent the next stage in the continuum of instability and complexity and include disruption of the semilunar notch, dislocation or fracture or both of the radial head, and fracture of the coronoid process.[49,94,96,113] There may be complete disruption of all osseous stabilizers of the elbow. These injuries may not be true dislocations, however, because the apposition of the articular surfaces may be maintained. The coronoid fractures are typically one large piece (>50% height), but may also be comminuted; the basal subtype II fractures are most commonly associated with olecranon fractures[18,89] (see Figure 22.5). These fracture-dislocations can be divided into anterior and posterior injuries, which have different mechanisms and injury patterns.

Transolecranon Fracture-Dislocation

Transolecranon fracture-dislocations are less common and are caused by a high-energy direct blow to the forearm.[96] Depending on the mechanism and direction of the blow, the forearm may be dislocated either anteriorly or posteriorly, but the injury is defined by a complex olecranon or proximal ulna facture, dislocation of the forearm, and maintenance of the proximal radioulnar relationship[70,71,96] (Figure 22.6). This injury pattern was first described and named "trans-olecranal fracture

dislocation" in 1974 by Biga and Thomine.[6] This and subsequent studies emphasized the distinction from Monteggia fractures, in which the radioulnar relationship is dissociated.[71,97] When the capsuloligamentous structures are maintained, the elbow is typically rendered stable once the proximal ulna anatomy is reduced and fixed. Even when ligamentous repair is required, outcomes are often favorable. This is because the forearm is not disrupted, so good recovery of forearm rotation can be expected.[70]

Posterior Monteggia Lesion

Chapter 21 explores the Monteggia lesion in detail, so that injury is covered here only briefly. Penrose[81a] proposed that the posterior Monteggia lesion is a type of fracture-dislocation of the elbow[49,81,97,100] (Figure 22.7). The injury is usually seen in older osteopenic women after a low-energy fall onto the elbow. The injury is characterized by a posterior radial head dislocation, a proximal ulna fracture, a coronoid fracture (basal subtype II), and ulnar-humeral instability.[73,93,108] The coronoid fracture is more variable than with anterior injuries, may involve the tip or the anteromedial facet, and may be comminuted. The radial head is fractured in two-thirds of injuries. The LCL may be injured, but the MCL is typically spared. In contrast to anterior olecranon fracture-dislocations, instability may persist after restoration of the bony stabilizers.[98] Posterior Monteggia injuries can be classified as follows[49,117]:

Type A: Fractures including the coronoid process
Type B: Fractures of the ulnar metaphysis
Type C: Fractures of the ulnar diaphysis
Type D: Complex, comminuted fractures of the entire proximal ulna

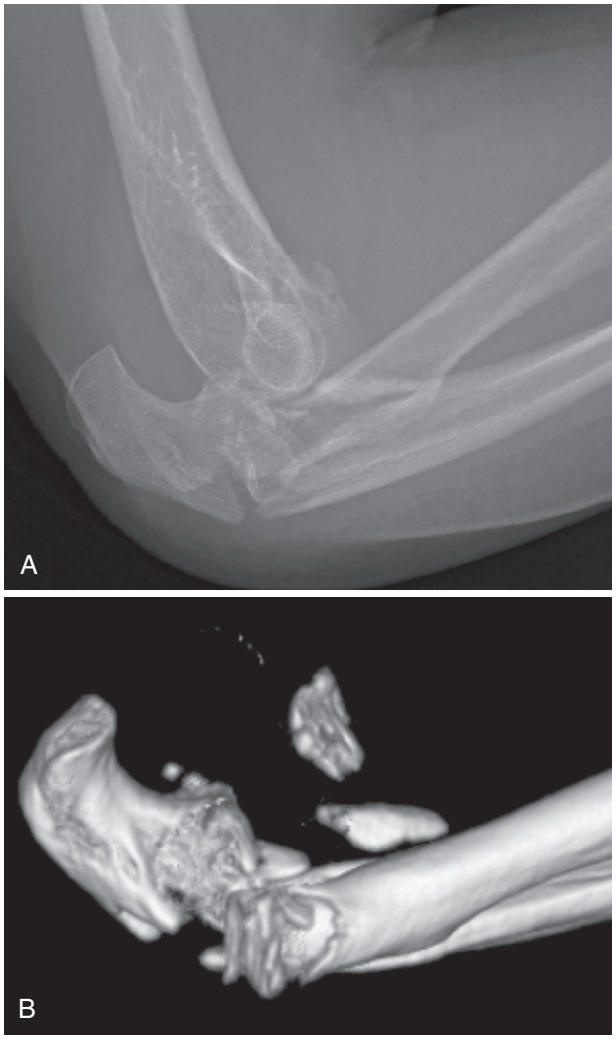

FIGURE 22.7 **A,** Lateral radiograph of posterior Monteggia fracture-dislocation. **B,** Three-dimensional reconstruction of posterior Monteggia injury. Note posterior position of radial head and loss of normal proximal radioulnar relationship. Also note coronoid fracture that is typically seen with these injuries.

Varus Posteromedial Rotational Injury

Varus posteromedial rotational injury is a less common variant.[18,19] Similar to olecranon fracture-dislocations, these injuries may not be true dislocations in that the relationship of the articular surfaces is maintained[89] (Figure 22.8). In these injuries, a fall on an outstretched arm with the shoulder in flexion and abduction creates a varus posteromedial rotational force on the forearm. This force causes the LCL complex to tear from the lateral epicondyle in tension. Simultaneously, the medial coronoid process is forced against the medial trochlea and sometimes results in an anteromedial facet fracture of the coronoid. The coronoid fracture can just involve the anteromedial rim (subtype I), extend to involve the tip with comminution (subtype II), or involve the sublime tubercle and the attachment of the anterior band of the MCL (subtype III) (see Figure 22.5). Anteromedial facet fractures are seen in combination with elbow dislocation, sometimes with an olecranon fracture, but rarely with an associated radial head fracture.[19] This fracture pattern of instability may show only subtle joint incongruity and may be missed, leading to rapid development of arthrosis.[4,5,15,28]

HISTORICAL REVIEW

In 1927, McWhorter[64] reported on his indications and techniques for treatment of olecranon and coronoid fractures. His technique of exposure to the coronoid and proposed fixation with suture or a screw is very similar to what we do today. He recognized almost 90 years ago that coronoid fractures associated with dislocations and radial head fractures had poor outcomes. He encouraged operative fixation of displaced fractures and early motion—concepts that we are currently rediscovering.

After McWhorter's work, the diagnosis and treatment of elbow fracture-dislocations progressed slowly for several decades. Poor outcomes were acknowledged, but the critical components of elbow instability were not recognized. It was not until the 1980s that Josefsson and colleagues[46,47] made the clear distinction between the excellent long-term outcomes of simple elbow dislocations and the poor outcomes of fracture-dislocations.

Subsequently, understanding of the patterns of injury and treatment of complex elbow dislocations continued to expand rapidly. Regan and Morrey[86,87] classified and recognized the importance of the coronoid fracture to stability, whereas Hotchkiss[41] formally recognized the terrible triad injury pattern, which McWhorter described 80 years earlier.

Since 2000 there has been steady improvement in understanding of the pathoanatomy of elbow fracture-dislocations



FIGURE 22.8 Posteroanterior (**A**) and lateral (**B**) radiographs of acute, isolated anteromedial facet coronoid fracture. Note ulnar-humeral instability in this fracture pattern. **C** and **D,** Three-dimensional reconstructions of fracture.

and the development of standard ways of approaching them surgically. O'Driscoll, Morrey and others have better defined the mechanism of dislocation and the fracture-related anatomy of the MCL.[77,78] Schneeberger and others elucidated the relationship between the bone and ligament stabilizers and the mechanisms of dislocation.[74,103] Using detailed analysis of imaging, Ring, Jupiter, and Doornberg have improved our understanding of the osseous anatomy of the coronoid and called particular attention to its anteromedial facet.[15,92,94] McKee and colleagues published what they called a "standard protocol" for addressing the terrible triad injury, with systematic management of coronoid and anterior capsule injury, radial head fracture, and LCL injury, in that order.[62] These advances have led to substantially better outcomes for patients with these injuries. Yet problems remain including stiffness,[91] associated nerve injury,[26,106] and heterotopic ossification.[3]

TREATMENT OPTIONS

Acute Injuries (Less Than 2 Weeks)

Treatment of acute injuries is done with the intention of establishing sufficient stability to allow for early active motion. The first step is to restore osseous stability by anatomically aligning and stabilizing the articular surface of the semilunar notch.[95] Next, the radial head and the radiocapitellar contact need to be restored. Finally, the ligaments need to be repaired. The LCL complex is more important to stability in the setting of complex traumatic dislocations than the MCL. The MCL rarely needs to be repaired and heals with restoration of bony anatomy and with active motion.[28]

Dislocation

Simple dislocations should be managed by immediate closed reduction. Reduction requires adequate relaxation and analgesia, but can be readily performed in the emergency department with conscious sedation and intravenous medication. The reduction maneuver requires placing firm pressure on the olecranon tip to push the ulna distal to allow the trochlea to fall into the semilunar notch. Successful reduction is accompanied by a clunking sensation. The elbow should be tested for stability at this point by taking it through a range of motion. Most elbows are stable after reduction, but may have a tendency for redislocation in extension or with valgus stress. Radiographs should confirm a concentric reduction, and the elbow should be splinted in approximately 90 degrees of flexion for 1 week, at which time repeat radiographs should confirm reduction.

Splinting can help reduce swelling and pain, but should not be prolonged. Motion should be started in the first week, although splinting for 2 weeks does not seem to affect long-term outcomes. Splinting beyond 3 weeks increases the risk of persistent flexion contracture and pain and may predispose to heterotopic ossification.[65,102]

Sometimes, slight postreduction subluxation of the elbow is identified on radiographs and is known as the "drop sign." This is analogous to pseudosubluxation of the shoulder after closed reduction and can be treated with exercises and avoidance of varus stress.[22] Infrequently, simple elbow dislocations are unstable after reduction and require operative intervention with ligamentous repairs or skeletal fixation. This topic is discussed further in Chapter 23.

Fracture-Dislocation (Radial Head)

Closed reduction of the elbow dislocation is performed as described earlier. Fracture of the radial head with an associated ulnar-humeral dislocation creates an additional potential cause of elbow instability. CT scan is useful to rule out a subtle, but important, coronoid fracture that may necessitate operative intervention. The radial head generally should not be resected (without replacement) in the setting of dislocation because the injured ligaments must heal at the correct length and tension. Maintenance of radiocapitellar contact is important in the early postinjury period.

Nonoperative Management. In the absence of a coronoid fracture, a radial head fracture with an elbow dislocation can be treated nonoperatively. Josefsson and colleagues[45] and Broberg and Morrey[8] reported good results in patients treated with closed reduction with or without radial head excision and cast immobilization. The best results were obtained in patients with Mason type II fractures treated with closed reduction and Mason type III fractures treated with excision.[83] None of these patients had an associated coronoid fracture and many of the patients treated nonoperatively required delayed radial excisions for pain or stiffness.[7] Additionally, there is some risk of instability if fractures are treated nonoperatively. Motivated patients who understand the risks who choose nonoperative treatment should be seen within 1 week after injury for radiographs to show maintenance of reduction. Although Broberg and Morrey[8] treated patients in a cast for 1 month, it is reasonable to treat patients in a splint with early range of motion and close follow-up. The reader is referred to Chapter 19 for a more detailed discussion of radial head fractures.

Operative Treatment: Repair, Arthroplasty, and Lateral Collateral Ligament Complex Repair. Restoration of the native anatomy of the lateral column contributes to elbow stability and prevention of late arthrosis, so the radial head should be fixed when possible and the LCL complex repaired.[34,51,85] One- or two-part partial articular fractures and fractures that separate the entire head in one piece with a clean break are generally amenable to repair. It is advisable to replace the head when struggling to reconstruct it in situations that would either greatly extend the length of the operation, when the resulting construct would be too delicate to withstand early motion, or when the complexity and deformity portend a poor prognosis in terms of union or forearm rotation.[88,90] For fractures that have three or more articular fragments or cannot be repaired with confidence, resection and replacement with a metal radial head arthroplasty are appropriate (see Chapter 20).[37,99,119] Silicone replacements should not be used.[10,82,116] Short-term results appear similar whether the radial head is replaced or repaired.[54] Oversizing the radial head should be avoided because it may cause capitellar arthrosis and pain.[1] The reconstructed articular surface should end up no more than 1 mm proud of the corner of the lesser sigmoid notch[16] (Figure 22.9).

After radial head repair or replacement, the LCL and extensor musculature origin commonly require repair (especially if there is disruption or persistent instability).[13,63] This can be done with suture anchors or transosseous drill holes placed through the lateral epicondyle. MCL repair is rarely required, but needs to be evaluated if instability remains after radial head and LCL repair and reconstruction.[28]

Technique of Lateral Collateral Ligament Repair. If the LCL is avulsed off the epicondyle, it is repaired with suture anchors or heavy suture (usually No. 2 nonabsorbable suture) passed through drilled bone tunnels or by simply driving a stout suture needle through the bone in the desired direction. A locking weave using a Krackow-type loop is used to secure the LCL complex. The suture anchor or the bone tunnels should be placed at the isometric point of the lateral ligamentous complex. This point is located at the central axis of the capitellar circumference and is surprisingly distal and anterior to the lateral epicondyle, typically 2 or 3 mm anterior and distal. The two tunnels should exit posteriorly and should be separated by a sufficient bony bridge over which the suture is tied. The sutures are passed and tied over bone after bony fixation is completed with the joint reduced.

Fracture-Dislocation (Coronoid)

The understanding of elbow dislocations with isolated coronoid fractures has been rapidly developing. Despite the often small size of the fracture, the injury may be unstable and require operative intervention.[4,19] The initiation of active range of motion, without coronoid fixation, may result in chronic subluxation and the rapid development of arthrosis.[18,20,80,89,92,108]

Examination Under Anesthesia. Stress radiographs have been suggested, but in the setting of an acute trauma this may be impractical. Examining these patients under anesthesia with image intensification is often useful to reveal subtle ulnar-humeral subluxation as the elbow is taken through a range of motion. Varus stress may elucidate LCL injury with opening of the radiocapitellar joint. In the unusual circumstance that no instability exists under anesthesia, nonoperative treatment may be appropriate, but this should be done with great caution and frequent clinical and radiographic follow-up.

Technique: Open Reduction and Internal Fixation. The patient is placed in a supine position with an arm table. The arm can be draped free with either a sterile or a nonsterile tourniquet. Either a posterior midline incision with elevation of a medial skin flap or a direct medial approach can be used. If a medial approach is used, the medial antebrachial cutaneous nerve should be protected. The ulnar nerve should always be found and protected. The ulnar nerve can be held and protected anteriorly by suturing the skin flap to the forearm fascia. At the end of the procedure, the ulnar nerve may be transposed subcutaneously but some authors have found that moving the nerve increases the incidence of palsy.[106] The coronoid fracture is exposed between the two heads of flexor carpi ulnaris, where

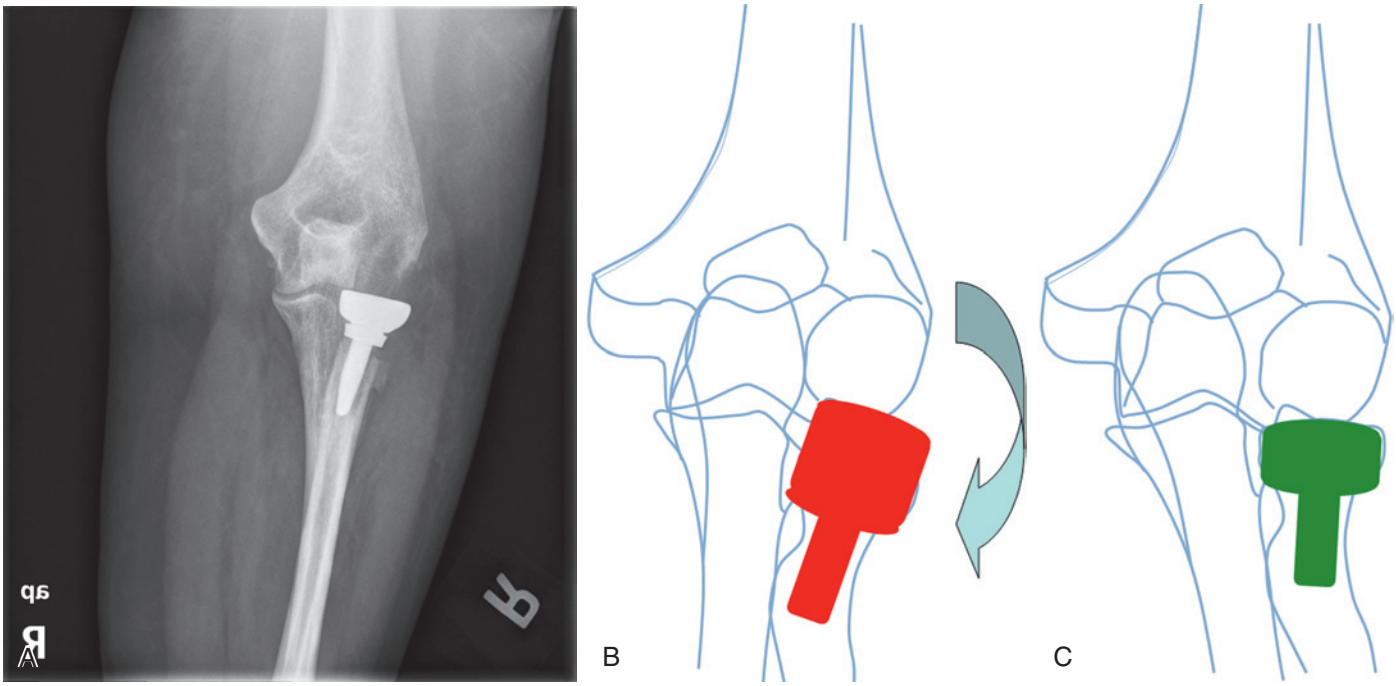

FIGURE 22.9 Oversizing the radial head may "stabilize" the elbow by placing the entire lateral soft tissue complex on tension, but this is an error. **A,** Anteroposterior radiograph showing excessive lateral ulnohumeral joint space and medial ulnohumeral translation due to overstuffing of the radial head prosthesis. **B,** The anatomical relationships with a radial head prosthesis that is too large. **C,** A sketch showing the appropriate anatomical relationships.

the ulnar nerve lies; through elevation of the entire flexor pronator mass; or through the over-the-top approach described by Hotchkiss.[41] Details of this description can be found in Chapter 24.

The anterior band of the MCL, which lies below the flexor pronator mass, should be protected to prevent injury and further instability. After the fracture is exposed and reduced, various options for fixation exist, including transosseous sutures, Kirschner wires, lag screws, and plate fixation. Isolated coronoid fractures with elbow dislocation and without a radial head fracture are typically anteromedial facet fractures and require stable, anatomic fixation. Threaded 0.062-inch Kirschner wires may be passed through the ulna into the coronoid fragment, or lag screws, small T-plates, or special coronoid buttress plates can be used for fixation. Generally, large anteromedial coronoid fragments are best stabilized with lag screws or buttress plates, whereas small tip fragments may be best treated with Kirschner wire fixation or transosseous sutures. If LCL complex injury is present, the lateral skin flap should be elevated or a separate lateral incision should be made and the ligament repaired as detailed earlier. Failure to repair the LCL may result in persistent instability. The elbow should be taken through a range of motion under image intensification to assess stability.

❖ AUTHORS' PREFERRED TECHNIQUE

We prefer a posterior skin incision, then isolating and protecting the ulnar nerve. The coronoid fracture is exposed directly through the heads of the flexor carpi ulnaris, where the nerve lies before transposition. The MCL is protected, and the fracture is fixed with a T-plate or a specially designed buttress plate. Stability of the elbow is tested after fixation with gravity extension. If instability persists, a separate lateral exposure is used through the same skin incision to repair the LCL with suture anchors. The LCL typically needs to be repaired with this fracture pattern. Postoperatively, active and active-assisted motion may begin 1 to 2 days after surgery.

Dislocation With Radial Head and Coronoid Fractures (Terrible Triad Injuries)

The addition of a coronoid fracture, regardless of size, to an elbow dislocation with a radial head fracture substantially increases the chances of acute and chronic instability and posttraumatic elbow arthrosis.[98] CT scans are helpful for preoperative planning, specifically for evaluating coronoid fractures. The coronoid fragment should be fixed by suture repair of the anterior capsule, screw fixation, or plate and screws to restore elbow stability.

Nonoperative Management. A small subset of terrible triad injuries with small coronoid and radial head fractures that remain concentrically reduced can be treated effectively without surgery. Patients must be able to avoid shoulder abduction and must be willing to flex their elbow actively with confidence. The patients we have treated nonoperatively were seen a few days or a week after injury and were either out of the splint moving well or were very motivated to avoid surgery. As a rule, however, virtually all terrible triad injuries should be considered to require surgery.

Operative Management. The patient is placed in a supine position with an arm table. The arm should be draped free with either a sterile or a nonsterile tourniquet. The injury can be repaired with a lateral approach to the elbow if the radial head is going to be excised and replaced. A posterior midline approach, elevating a lateral skin flap, can be used, however, if

CRITICAL POINTS *Coronoid Repair*

Indications
- Coronoid fracture with elbow instability

Preoperative Evaluation
- Posteroanterior and lateral radiographs of elbow
- CT scan with three-dimensional reconstructions

Pearls
- The LCL typically needs to be repaired.
- The ulnar nerve can be held and protected anteriorly by suturing the skin flap to the forearm fascia.

Technical Points
- Release and protect the ulnar nerve.
- Expose the fracture through the flexor carpi ulnaris heads.
- Remain superficial to the MCL.
- A small T-plate or a specially designed buttress plate is preferred for fixation.
- Test elbow stability with image intensification.
- If instability persists, a separate lateral deep exposure should be made to repair the LCL.
- If instability persists after LCL repair, a hinged external fixator (see Chapter 24) should be used.

Pitfalls
- Ulnar neuropathy can occur because of excessive retraction on the nerve.
- Excision of a seemingly small coronoid piece can lead to persistent instability and arthrosis.
- Anteromedial facet fractures require anatomic, stable reduction; otherwise, instability may persist.

Postoperative Care
- Active range of motion is begun 1 to 2 days after surgery.
- Avoid shoulder abduction, which stresses the LCL repair.
- Check the elbow frequently in the early postoperative period for maintenance of reduction.

a medial approach is contemplated. A traumatic rent in the fascia is almost always present and may be developed for exposure. Otherwise, the supracondylar ridge is identified, and the extensor origins are elevated anteriorly. At this point, it is often noted that the LCL and the extensor musculature are traumatized or pulled off of the ridge and epicondyle.

Distally, an incision is made that extends from the tip of the lateral epicondyle and bisects the radial head and neck. The traumatic rent in the extensor musculature can usually be exploited to gain exposure to the radial head. The dissection should stay anterior to the midline of the capitellum to preserve residual soft tissue attachments. Distally, dissection should be unnecessary beyond the radial neck, and caution should be used because the posterior interosseous nerve is at risk. Keeping the forearm in pronation minimizes risk to the nerve.

At this point, a decision to repair or replace the radial head is made. If the radial head is to be repaired, the coronoid tip fracture can be fixed after resection of the radial head because this greatly improves exposure. To further improve access to the coronoid, the elbow can be hinged open on the intact medial structures. Deep retractors, such as Z-knee retractors, are helpful to gain exposure to the coronoid. If access is still difficult, a medial skin flap can be raised from the posterior incision, or a separate medial incision can be made to expose the coronoid fracture. Medial exposure should also be used when the coronoid fracture includes a portion or all of the medial facet. In these cases, screw or plate and screw fixation should be used as detailed above.

After identifying the coronoid tip fracture fragment, two tunnels for suture can be made with a small drill bit or a 0.062-inch Kirschner wire from the subcutaneous border of the ulna into the base of the coronoid fracture. One tunnel should be medial and one lateral in the fracture base. The dorsal exit points should be positioned 1 cm apart to create a bone bridge to tie over and may be placed slightly off the very ridge of the ulna to reduce knot prominence. The transtibial guide used in cruciate ligament reconstruction of the knee is helpful for this step. The tip fragment itself may be resected if it is tiny, or it may be included in the suture repair to reduce and fix it. Heavy nonabsorbable suture (No. 2 or No. 5) is passed through the anterior capsule or brachialis insertion. The suture is passed through the drill holes with a suture passer or a Keith needle from the dorsal ulna. Exact anatomic reduction is unnecessary; instead, the goal is to restore the anterior capsular attachment to the proximal ulna. The suture should not be tied until after the radial head replacement has been completed to avoid disrupting the coronoid fixation.

If the LCL complex is avulsed off the epicondyle, it must be repaired with suture anchors or heavy suture (usually No. 2) passed through transosseous drilled bone tunnels (as previously described). After the repair is complete, stability should be checked visually and under image intensification through an arc of motion. If instability persists, thought should be given to repair of the MCL, application of a hinged external fixator (see Chapter 24), or both (Figure 22.10).

The MCL is repaired through a separate deep medial exposure. The ulnar nerve is found and released from the intermuscular septum to the Osborne fascia. The nerve is protected and transposed into the subcutaneous tissue anteriorly. The avulsed MCL origin and common flexor origin are identified and repaired using suture anchors or sutures passed through bone tunnels (as described for the LCL complex repair in Chapter 20).

If the elbow continues to be unstable despite the surgeon's best efforts, an external fixator can be applied. Alternatively, the joint can be cross pinned. After manipulation under fluoroscopy, two large Kirschner wires (0.078 in) are drilled through the ulnar-humeral joint. The wires are directed posteriorly through the posterior humeral cortex to prevent pin migration. After reduction is confirmed, the wires are cut and bent at the skin, and a well-padded cast is applied. The wires are removed at 3 or 4 weeks, and active motion is initiated.

❖ AUTHORS' PREFERRED TECHNIQUE

We treat the injury from inside out, first fixing the coronoid, then the radial head, and then the LCL. The LCL typically needs to be repaired back to the lateral epicondyle with a suture anchor or through bone tunnels. The elbow is tested with gravity extension with the forearm in neutral. If the ulnar-humeral joint remains reduced from full flexion to 45 degrees of flexion, MCL repair is unnecessary. Otherwise, the MCL should be repaired or extension should be limited postoperatively for up to 4 weeks by a splint or hinged elbow brace while

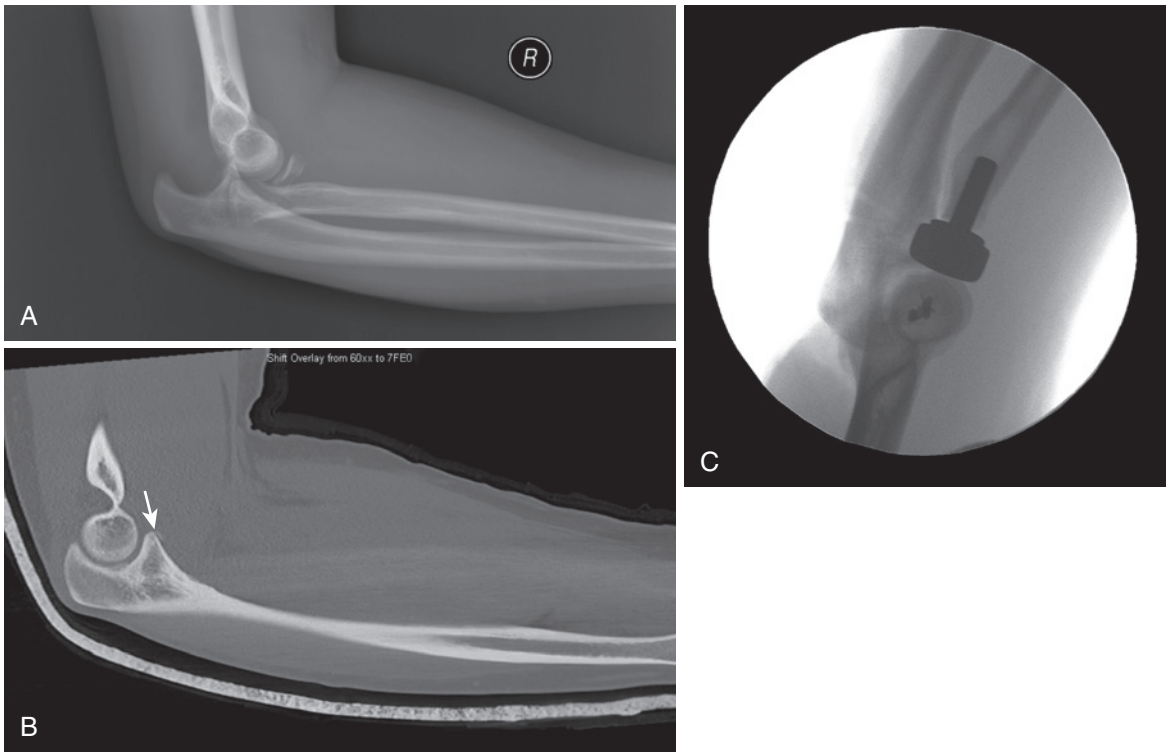

FIGURE 22.10 **A,** Lateral radiograph of an acute terrible triad injury in a 32-year-old man. **B,** Postreduction, preoperative CT scan showing fleck from coronoid is the only clue to anterior instability. **C,** Reconstructed elbow. The anterior instability was repaired with transosseous suture, the radial head has been replaced, and the LCL repaired with a suture anchor. The elbow was still unstable so the medial collateral ligament was also repaired.

CRITICAL POINTS *Terrible Triad Repair*

Indications
- Virtually all terrible triad injuries require operative repair.

Preoperative Evaluation
- Posteroanterior and lateral radiographs of elbow
- CT scan with three-dimensional reconstructions

Pearls
- Most repairs can be done from the lateral side.
- Z-knee or deep retractors help with exposure medially from the lateral side.

Technical Points
- Elevate the extensors off the supracondylar ridge.
- Expose the radial head, preserving the LCL posteriorly.
- Excise the radial head if it is not repairable for better exposure of the coronoid.
- Fix the coronoid with the suture technique, replace the radial head, and repair the LCL.
- Make a separate medial approach if exposure to the coronoid is difficult because of a largely intact, repairable radial head.
- Test elbow stability with image intensification.

Pitfalls
- Instability may result from failure to fix a small coronoid fracture.
- Failure to use an external fixator if instability persists.
- Resection of the radial head without replacement leads to persistent instability.

Postoperative Care
- Active range of motion is begun 1 to 2 days after surgery.
- Avoid shoulder abduction, which stresses the LCL repair.
- Check the elbow frequently in the early postoperative period for maintenance of reduction.
- Strengthening begins after evidence of bony healing at 6 to 8 weeks.

the MCL heals. Stability is usually obtained, however, without the need for MCL repair, hinged external fixation, or cross pinning of the elbow. If the MCL requires repair, a separate medial exposure is used. Postoperatively, active and active-assisted motion should begin 1 to 2 days after surgery.

Olecranon Fracture-Dislocations

The critical element in the treatment of proximal ulna fractures is the restoration of the semilunar notch with anatomic alignment of the coronoid and olecranon. Anterior fracture-dislocations rarely involve the radial head and LCL, whereas posterior injuries often do. For this reason, instability may persist after restoration of bony stabilizers for posterior fracture-dislocations. A distractor may be helpful in reducing the fracture. The details of surgical repair and technique are provided in Chapter 21, although we briefly review our experience here.

Operative Technique. In our experience, these fractures can usually be treated entirely through the olecranon fracture,

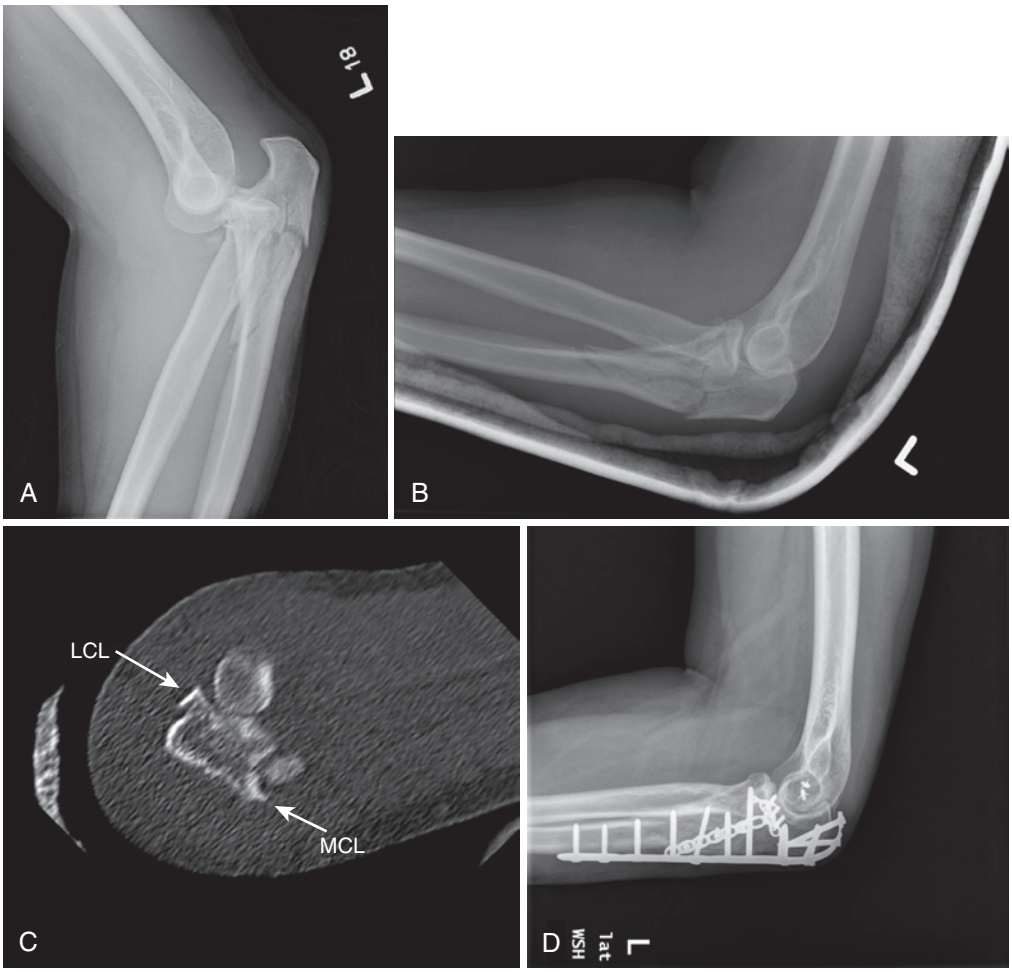

FIGURE 22.11 **A,** Lateral radiograph of an unstable transolecranon fracture-dislocation in a 24-year-old man. **B,** The same injury after reduction. **C,** Axial CT showing characteristic bony fragments corresponding to the attachments of the medial collateral ligament (*MCL*) and lateral collateral ligament (*LCL*). **D,** Postoperative construct. The proximal ulna was reconstructed with a medial buttress plate and a dorsal bridging plate. Anterior stability was restored using sutures passed through an empty screw hole that lined up with the coronoid. The LCL and MCL were repaired with suture anchors.

which is exposed through a midline posterior skin incision. The radial head is typically replaced because of comminution, and the LCL needs to be exposed and repaired. The coronoid fractures can be quite comminuted and difficult to repair. There are usually large fragments associated with the attachment points of the LCL (the crista supinatoris) and the MCL (the sublime tubercle). This consistent pattern is useful for orienting and understanding the jumbled fragments (Figure 22.11). A distractor may be helpful to attain reduction, and a hinged external fixator may be needed to maintain the reduction. The addition of a tension band to plate fixation may help in stabilizing a comminuted olecranon fracture. The keys to maintaining stability are repair of the torn LCL and stable coronoid fixation.

Hinged External Fixation

After reconstruction of the bony and ligamentous structures, the elbow should be tested with image intensification for stability. The elbow is tested by gravity extension with the forearm in neutral position from full flexion until reaching 45 to 60 degrees of flexion. Some authors recommend testing the elbow in pronation because it enhances elbow stability. Slight subluxation may be seen radiographically and may be acceptable.[21] If the elbow seems unstable and vulnerable to redislocation after fixation, we also recommend the use of an external fixator that stabilizes the joint and allows immediate mobilization.[50,84,112] The goal of the hinged external fixator is to allow concentric ulnar-humeral motion, while protecting the bony and ligamentous repairs.[110,114] With external fixation, the patient starts moving the elbow from the first postoperative day, gradually increasing the range of motion and preventing stiffness. If a hinged external fixator is not available, it is acceptable to use a static frame or pin the ulnohumeral joint with a large K-wire or Steinmann pin.

The external fixator is removed 6 to 8 weeks later, and the patient starts strengthening exercises. The patient returns to his or her previous activities approximately 4 to 6 months after the repair when full strength of the arm is regained.

Successful treatment of complex elbow fracture-dislocations demands facility with the indications and application of the hinged external fixator. The extra operative time and technical difficulties may make surgeons reluctant to use the device. A

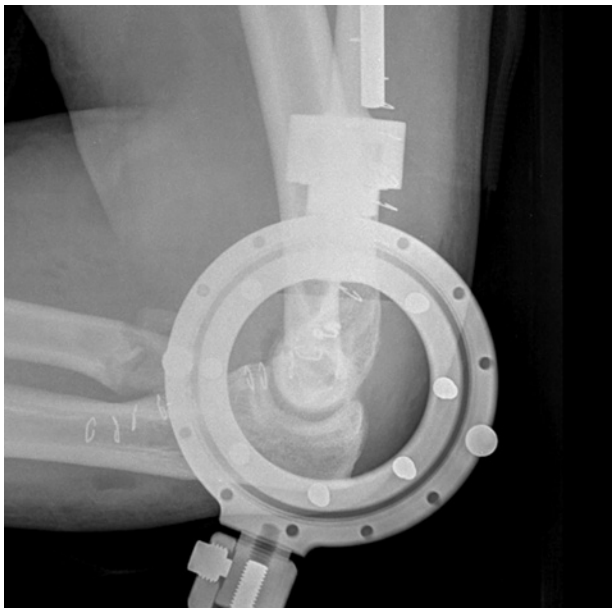

FIGURE 22.12 Lateral radiograph showing that the hinged external fixator is built around a temporary axis pin placed through the trochlea and capitellum at the center of ulnar-humeral rotation. The center of the external fixator ring corresponds with the center of the trochlea.

stiff, unstable elbow is an even larger problem to manage, however.

Operative Technique. Surgical application of a hinged fixator is demanding and requires knowledge and experience with one of the commercially available devices. There are two types of devices used: unilateral, which are generally easier to place, or multiplanar, which provide more rigid fixation. The placement of an axis pin around which the frame is built (Figure 22.12) is crucial to each device. Slight misalignment of the pin can increase the energy of motion significantly.[59,110]

The temporary axis pin is placed under fluoroscopic guidance and must be colinear with axis of rotation at the center of trochlea and capitellum. This line is slightly distal to the lateral epicondyle and slightly distal and anterior to the medial epicondyle. Care should be taken not to disrupt bony fixation or collateral ligament repair while placing the pin, although this can be technically challenging. If a multiplanar frame is used, the pin penetrates the medial cortex and the ulnar nerve needs to be protected. Based on the axis pin, half pins are placed on the humerus and ulna, although typically the humeral pins are placed first. The radial nerve should be identified and retracted through an open incision before placement of the lateral humeral pins. It is equally important to identify and protect the ulnar nerve while placing the medial humeral pins. The most distal humeral pin should be placed proximal to the metaphyseal flare. When the humeral pins are fixed, the joint can be reduced and the ulnar pins can be placed. Joint reduction can be facilitated by the use of gravity to align the joint and, if needed, by temporary cross wire fixation of the joint. The ulnar pins are placed lateral to medial or dorsal to volar. After the frame is placed, concentric elbow motion should be checked with image intensification. The axis pin is removed to prevent septic arthritis. Active mobilization should be initiated the day after surgery, and the fixator should be removed at 6 to 8 weeks.

CRITICAL POINTS *Hinged External Fixation*

Indications
- Persistent instability after attempted bony and ligamentous repair in the acute setting
- Chronic elbow instability in delayed treatment or failed previous treatment

Evaluation
- Intraoperative gravity extension with image intensification

Technical Points
- Different commercial external fixators are available that are either unilateral or multiplanar.
- A joint axis pin must be placed colinear with the axis of rotation.
- The line of rotation is slightly distal to the lateral epicondyle and slightly anterior and distal to the medial epicondyle.
- Find the radial nerve before placing the lateral humeral pins and the ulnar nerve if placing medial humeral pin.
- Reduce the joint and temporarily hold it reduced with smooth 0.078-inch wires.
- Place the distal pins with direct visualization.

Pearls and Pitfalls
- The work of elbow motion is increased fourfold with 5 degrees of misalignment of the axis pin.
- Ligamentous repair failure or loss of fracture reduction can occur with placement of the fixator.
- Avoid impaling muscle or tendon because this limits motion.
- All pins should be placed with direct visualization to prevent nerve injury.

Postoperative Care
- Active range of motion is begun soon after surgery.
- The fixator is removed at 6 to 8 weeks.
- Therapy with dynamic or static splinting is begun to improve range of motion after removal.

Delayed Treatment

The challenges of precise restoration of bony alignment and soft tissue stability for elbow fracture-dislocations are compounded by a delay in treatment. Additional difficulties may include extensive scar, partially or nonunited bone fragments, poor skin cover, and a subluxated or dislocated joint. For patients who present for treatment several weeks or months after the original injury, the difficulty of the case is often intensified by damage to the articular surfaces.

❖ AUTHORS' PREFERRED TECHNIQUE

Positioning and Incision. The best position for delayed operative treatment may be either the lateral or the prone position. These positions permit a simple posterior incision and a wide exposure of the joint. This position also makes application of the hinged fixator simpler because there is a tendency for the joint to rest in a position of reduction rather than dislocation.

The skin incisions are dictated by previous incisions and the particular problem. Generally, previous incisions should be used to avoid loss of skin coverage in the postoperative period. We prefer either a single posterior or separate medial or lateral incisions to permit access to the lateral and medial joint surfaces, the ulnar nerve, and the posterior ulna. The first structure that must be identified and protected is the ulnar nerve.

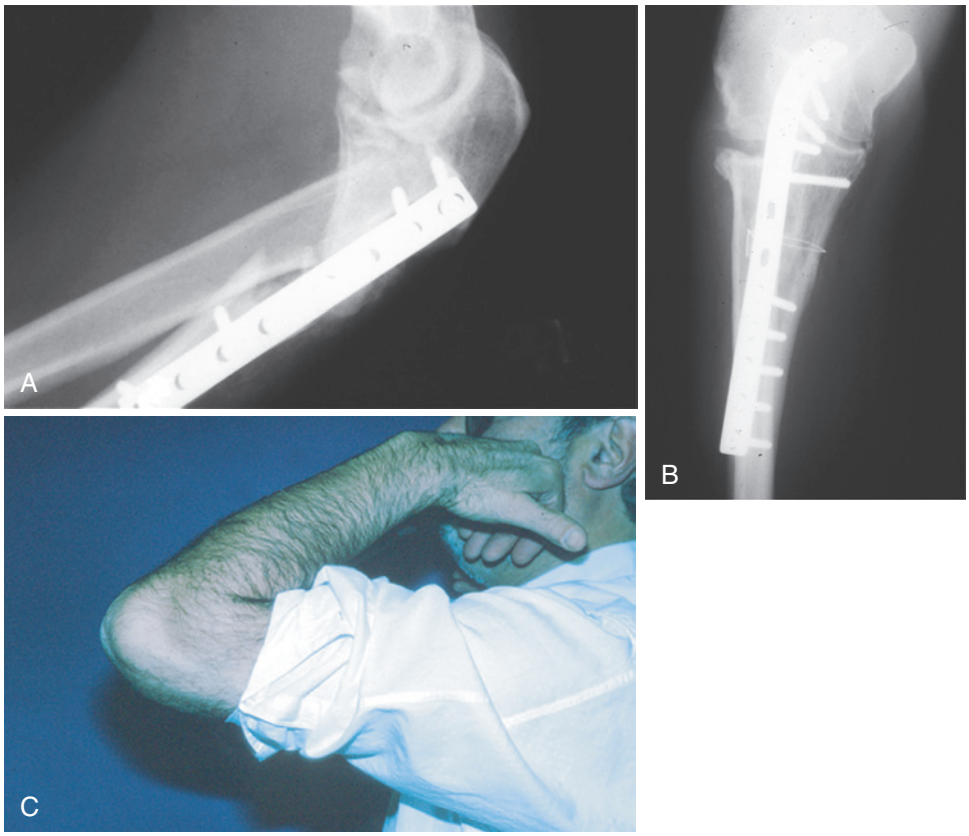

FIGURE 22.13 **A,** Lateral radiograph of a 64-year-old patient 3 weeks after initial open treatment of posterior Monteggia fracture-dislocation. The radial head is dislocated posteriorly and the proximal ulna is malaligned. **B,** Postoperative radiograph after replating ulna. **C,** Postoperative motion showing loss of extension and adequate flexion.

Dissection of the nerve must be done carefully, usually starting proximal to the previous dissection. We free the nerve gently and transpose it to an anterior subcutaneous location with adequate mobilization to perform the open reduction.

Reconstruction. When the nerve is free, the next task is to reduce the joint and expose the fracture fragments for fixation. The thickened capsule on the anterior and posterior surfaces must be completely excised to permit the joint to be reduced. The posterior olecranon fossa and the coronoid fossa are also gently excavated down to the original surfaces so that the ulna can track properly. The articular surfaces on both sides of the joint are usually covered with thickened scar tissue, and this layer must be carefully lifted away without damaging the underlying remaining articular cartilage. A small blunt elevator is often useful at this point in the case. The condition of these surfaces is unpredictable, and it is common to find extensive delamination and damage.

During the exposure, the lateral collateral ligament complex should be identified and isolated for later reattachment and repair. We do not routinely repair or reconstruct the medial ligaments; however, if there is tissue that can be approximated on the medial side after reduction of the joint, it should be prepared for repair.

When the joint has been completely dissected free of restraining scar and it can be held in a reduced position through an acceptable range of motion, the bone work can be done. Occasionally, malalignment of the ulna must also be addressed before the joint is stable, and the surgeon should be prepared for these situations (Figure 22.13). Nonetheless, with the joint now reduced, the radial head can be prepared for replacement. In cases of delayed treatment, we have not found repair to be likely or possible.

The lateral ligament complex is reattached as in the acute situation. It is important not to tie the ligament repairs if a hinged fixator is to be used. At this stage, the joint is grossly unstable, and we prefer to secure the joint into position with hinged fixation and with the sutures in place but not tied. After the fixator is in place, we tie them securely, without fear of dislodging the repair while applying the fixator. Additional bone anchors can be used to secure the posterior tissues to the anterior lateral capsule, further improving varus stability.

We often use a hinged external fixator in these complex and delayed reconstructions.[10,16,40,116] There is often only one more chance to achieve stable and useful elbow function; if persistent painful dislocation recurs, the only remaining options are to accept the situation or consider a distraction-interposition arthroplasty, total elbow replacement, or arthrodesis.

POSTOPERATIVE MANAGEMENT AND OUTCOME

Postoperative Management

For all elbow fracture-dislocations, postoperative management is based on the same principles. Gentle active and active-assisted range of motion exercises are started several days after surgery.

CRITICAL POINTS *Delayed Treatment or Previous Repair*

Indications
- Instability more than 2 weeks after injury or after previous repair

Preoperative Evaluation
- Posteroanterior and lateral radiographs of elbow
- CT scan with three-dimensional reconstructions
- Other imaging tailored to the individual circumstances and previous surgery
- Assessment of ulnar, median, and radial nerve function

Pearls
- Prone positioning can help with the placement of a hinged external fixator.
- An osteotomy may be required to obtain fixation.
- Tie down the ligamentous repairs after placement of the external fixator.

Technical Points
- Incisions are determined by previous surgery.
- Elevate large skin flaps.
- Identify the ulnar nerve.
- Excise thickened capsule and scar tissue anteriorly and posteriorly.
- Clear the articular surface and fracture fragments.
- Identify, preserve, and tag the remnants of the LCL complex.
- Reduce the fracture fragments and replace the radial head.
- If ulnar-humeral reduction is impossible, ulna osteotomy may be necessary.
- Test elbow stability with image intensification and determine the need for external fixation.
- Place a hinged external fixator or tie ligament repairs.

Pitfalls
- Instability may result from failure to place an external fixator.

Postoperative Care
- Active range of motion is begun soon after surgery.
- The hinged fixator is removed in 6 to 8 weeks.

For anteromedial facet fractures of the coronoid, a hinged brace may be helpful in resisting gravitational varus stresses that may stress the fracture fixation. If the fixation is tenuous, especially in osteoporotic bone, immobilization in 90 degrees of flexion may be advisable until the first postoperative visit at 1 to 2 weeks, before movement is started. Stiffness occurs if motion is not initiated soon after fixation. If a choice needs to be made between joint stability and early mobility, stability takes precedence. It is easier to correct a stiff congruent joint than a chronically unstable one.

Expected Outcomes

Outcomes after elbow fracture-dislocations are directly related to the degree of soft tissue and bony injury. Because understanding and treatment of these injuries are still evolving, there are few data to know the long-term outcomes for many treatments. Some degree of stiffness and arthrosis often results.

The outcomes for simple radial head fractures treated with open reduction and internal fixation or comminuted fractures treated with radial head replacement have been favorable.[2,17,28,51,52] Some decreased forearm rotation and elbow extension can be expected. Less favorable outcomes have been reported after open reduction and internal fixation of radial head fractures that have more than three articular fragments.[88] Ring and colleagues[99] showed that 13 of 14 patients with Mason type III fractures characterized by more than three articular fragments had unsatisfactory results. In contrast, of the 12 patients with Mason type III fractures with two or three simple fragments, none had early failure, one had a nonunion, and all had greater than 100 degrees of forearm motion.

Historically, outcomes for treatment of coronoid fractures are difficult to interpret because the pathoanatomy was not fully understood and the fractures were often combined with other injuries.[86] As fracture patterns have been more clearly appreciated and appropriately stabilized, outcomes are generally favorable and residual instability is rare. Some degree of arthrosis and stiffness is expected.

Terrible triad injuries have historically done poorly because of recurrent instability and the development of arthrosis.[8,46,98] With improved understanding and standardization of operative protocols as described in this chapter,[62] postoperative results are significantly improved, however. Few well-documented large series of these injuries have been reported. McKee and associates[62] used a standardized algorithm for terrible triad injuries in 36 patients and showed an average flexion-extension arc of 112 ± 11 degrees, an average forearm rotation of 136 ± 16 degrees, and an average Mayo elbow performance score of 88 (range 45-100) out of 100 at an average follow-up of nearly 3 years.

Olecranon fracture-dislocations, although high-energy injuries, have better results than terrible triad injuries with decreased incidence of postoperative instability and arthrosis.[71,96] As a rule, treatment of posterior dislocations is much less predictable than anterior dislocations. Posterior Monteggia injuries have higher rates of recurrent instability and poor outcomes.[49,97,100] The crucial factor for success of these injuries seems to be anatomic reduction of the ulna and the greater semilunar notch.

Delayed treatment and failed previous treatment have less predictable outcomes and depend on the individual fracture patterns and the skill and experience of the surgeon. Some reports incorporating a protocol of hinged external fixation have had success in maintaining stability and gaining satisfactory results.[50,61,93,101] In four studies that used hinged external fixation, the average flexion arc ranged from 84 to 123 degrees of motion. Functional forearm rotation was maintained in all studies. Three studies used the Mayo elbow performance index and showed an average score greater than 84 points, indicating a "good" outcome.[50,61,93,101]

COMPLICATIONS

Recurrent Instability

Failure to recognize or treat a fracture or ligament injury is the most common cause of recurrent instability. As described earlier, salvage may involve reconstruction of disrupted or attenuated ligamentous structures, osteotomies or grafting for osseous malunions or bone loss, and hinged external fixation.

Heterotopic Ossification

Heterotopic ossification increases with higher levels of injury and soft tissue damage, brain injury, infection, delay to surgery, and burns.[3,30,32,35,113] It is most often seen anteriorly between the

capsule and brachialis and posteriorly between the capsule and triceps. There is no consensus on the ideal timing for resection, but many surgeons resect the heterotopic bone when trabeculae are seen on plain radiographs. This typically occurs 3 to 4 months after the initial insult. Prophylaxis with indomethacin (Indocin) or radiation is unproven for traumatic elbow injuries and may impair fracture healing.[30] A prospective randomized study suggests radiation therapy should not be used acutely for prophylaxis after elbow trauma because of the increased rate of fracture or olecranon osteotomy nonunion.[36]

Stiffness

Some loss of motion after elbow fracture-dislocation is expected. Typically, patients lose more extension than flexion. The amount of stiffness increases with the energy of the initial injury, the amount of heterotopic bone formed, and delay of motion after repair.[83,87] Treatment includes static or dynamic splinting, heterotopic bone excision, and capsular release.[33,35,42,56,91]

Posttraumatic Arthritis

Arthritis is common after high-energy injuries and is likely attributable to a combination of the initial chondral impact and the degree of recurrent instability. Fascial arthroplasty is an option for younger patients, whereas total elbow replacement is an option for older, less active patients.[11,53]

REFERENCES

1. An KN, Morrey BF, Chao EY: The effect of partial removal of proximal ulna on elbow constraint. *Clin Orthop Relat Res* (209):270–279, 1986.
2. Bain GI, Ashwood N, Baird R, et al: Management of Mason type-III radial head fractures with a titanium prosthesis, ligament repair, and early mobilization. Surgical technique. *J Bone Joint Surg Am* 87(Suppl 1 Pt 1):136–147, 2005.
3. Bauer AS, Lawson BK, Bliss RL, et al: Risk factors for posttraumatic heterotopic ossification of the elbow: case-control study. *J Hand Surg [Am]* 37(7):1422–1429, e1–6, 2012.
4. Beingessner DM, Dunning CE, Stacpoole RA, et al: The effect of coronoid fractures on elbow kinematics and stability. *Clin Biomech (Bristol, UK)* 22(2):183–190, 2007.
5. Beingessner DM, Stacpoole RA, Dunning CE, et al: The effect of suture fixation of type I coronoid fractures on the kinematics and stability of the elbow with and without medial collateral ligament repair. *J Shoulder Elbow Surg* 16(2):213–217, 2007.
6. Biga N, Thomine JM: [Trans-olecranal dislocations of the elbow]. *Rev Chir Orthop Reparatrice Appar Mot* 60(7):557–567, 1974.
7. Broberg MA, Morrey BF: Results of delayed excision of the radial head after fracture. *J Bone Joint Surg Am* 68(5):669–674, 1986.
8. Broberg MA, Morrey BF: Results of treatment of fracture-dislocations of the elbow. *Clin Orthop Relat Res* 216:109–119, 1987.
9. Cage DJ, Abrams RA, Callahan JJ, et al: Soft tissue attachments of the ulnar coronoid process. An anatomic study with radiographic correlation. *Clin Orthop Relat Res* 320:154–158, 1995.
10. Carn RM, Medige J, Curtain D, et al: Silicone rubber replacement of the severely fractured radial head. *Clin Orthop Relat Res* 209:259–269, 1986.
11. Cheng SL, Morrey BF: Treatment of the mobile, painful arthritic elbow by distraction interposition arthroplasty. *J Bone Joint Surg Br* 82(2):233–238, 2000.
12. Cobb TK, Morrey BF: Use of distraction arthroplasty in unstable fracture dislocations of the elbow. *Clin Orthop Relat Res* 312:201–210, 1995.
13. Cohen MS, Hastings H, 2nd: Rotatory instability of the elbow. The anatomy and role of the lateral stabilizers. *J Bone Joint Surg Am* 79(2):225–233, 1997.
14. Deutch SR, Jensen SL, Olsen BS, et al: Elbow joint stability in relation to forced external rotation: An experimental study of the osseous constraint. *J Shoulder Elbow Surg* 12(3):287–292, 2003.
15. Doornberg JN, de Jong IM, Lindenhovius AL, et al: The anteromedial facet of the coronoid process of the ulna. *J Shoulder Elbow Surg* 16(5):667–670, 2007.
16. Doornberg JN, Linzel DS, Zurakowski D, et al: Reference points for radial head prosthesis size. *J Hand Surg [Am]* 31(1):53–57, 2006.
17. Doornberg JN, Parisien R, van Duijn PJ, et al: Radial head arthroplasty with a modular metal spacer to treat acute traumatic elbow instability. *J Bone Joint Surg Am* 89(5):1075–1080, 2007.
18. Doornberg JN, Ring D: Coronoid fracture patterns. *J Hand Surg [Am]* 31(1):45–52, 2006.
19. Doornberg JN, Ring DC: Fracture of the anteromedial facet of the coronoid process. *J Bone Joint Surg Am* 88(10):2216–2224, 2006.
20. Doornberg JN, van Duijn J, Ring D: Coronoid fracture height in terrible-triad injuries. *J Hand Surg [Am]* 31(5):794–797, 2006.
21. Duckworth AD, Kulijdian A, McKee MD, et al: Residual subluxation of the elbow after dislocation or fracture-dislocation: treatment with active elbow exercises and avoidance of varus stress. *J Shoulder Elbow Surg* 17(2):276–280, 2008.
22. Duckworth AD, Ring D, Kulijdian A, et al: Unstable elbow dislocations. *J Shoulder Elbow Surg* 17(2):281–286, 2008.
23. Dunning CE, Zarzour ZD, Patterson SD, et al: Ligamentous stabilizers against posterolateral rotatory instability of the elbow. *J Bone Joint Surg Am* 83-A(12):1823–1828, 2001.
24. Dunning CE, Zarzour ZD, Patterson SD, et al: Muscle forces and pronation stabilize the lateral ligament deficient elbow. *Clin Orthop Relat Res* 388:118–124, 2001.
25. Durig M, Muller W, Ruedi TP, et al: The operative treatment of elbow dislocation in the adult. *J Bone Joint Surg Am* 61(2):239–244, 1979.
26. Faierman E, Wang J, Jupiter JB: Secondary ulnar nerve palsy in adults after elbow trauma: a report of two cases. *J Hand Surg [Am]* 26(4):675–678, 2001.
27. Floris S, Olsen BS, Dalstra M, et al: The medial collateral ligament of the elbow joint: anatomy and kinematics. *J Shoulder Elbow Surg* 7(4):345–351, 1998.
28. Forthman C, Henket M, Ring DC: Elbow dislocation with intra-articular fracture: the results of operative treatment without repair of the medial collateral ligament. *J Hand Surg [Am]* 32(8):1200–1209, 2007.
29. Fuss FK: The ulnar collateral ligament of the human elbow joint. Anatomy, function and biomechanics. *J Anat* 175:203–212, 1991.
30. Garland DE: Clinical observations on fractures and heterotopic ossification in the spinal cord and traumatic brain injured populations. *Clin Orthop Relat Res* 233:86–101, 1988.
31. Garland DE, Blum CE, Waters RL: Periarticular heterotopic ossification in head-injured adults. Incidence and location. *J Bone Joint Surg Am* 62(7):1143–1146, 1980.
32. Garland DE, O'Hollaren RM: Fractures and dislocations about the elbow in the head-injured adult. *Clin Orthop Relat Res* 168:38–41, 1982.
33. Gates HS, 3rd, Sullivan FL, Urbaniak JR: Anterior capsulotomy and continuous passive motion in the treatment of post-traumatic flexion contracture of the elbow. A prospective study. *J Bone Joint Surg Am* 74(8):1229–1234, 1992.
34. Geel CW, Palmer AK, Ruedi T, et al: Internal fixation of proximal radial head fractures. *J Orthop Trauma* 4(3):270–274, 1990.
35. Green DP, McCoy H: Turnbuckle orthotic correction of elbow-flexion contractures after acute injuries. *J Bone Joint Surg Am* 61(7):1092–1095, 1979.
36. Hamid N, Ashraf N, Bosse MJ, et al: Radiation therapy for heterotopic ossification prophylaxis acutely after elbow trauma: a prospective randomized study. *J Bone Joint Surg Am* 92(11):2032–2038, 2010.
37. Harrington IJ, Sekyi-Otu A, Barrington TW, et al: The functional outcome with metallic radial head implants in the treatment of unstable elbow fractures: a long-term review. *J Trauma* 50(1):46–52, 2001.
38. Heim U: [Combined fractures of the radius and the ulna at the elbow level in the adult. Analysis of 120 cases after more than 1 year]. *Rev Chir Orthop Reparatrice Appar Mot* 84(2):142–153, 1998.
39. Hofammann KE, 3rd, Moneim MS, Omer GE, et al: Brachial artery disruption following closed posterior elbow dislocation in a child: assessment with intravenous digital angiography. A case report with review of the literature. *Clin Orthop Relat Res* 184:145–149, 1984.
40. Horii E, Nakamura R, Watanabe K, et al: [Posterolateral rotatory instability of the elbow—a case report and anatomical study of the lateral collateral ligament]. *Nihon Seikeigeka Gakkai Zasshi* 67(1):34–39, 1993.
41. Hotchkiss RN: Displaced fractures of the radial head: internal fixation or excision? *J Am Acad Orthop Surg* 5(1):1–10, 1997.
42. Husband JB, Hastings H, 2nd: The lateral approach for operative release of post-traumatic contracture of the elbow. *J Bone Joint Surg Am* 72(9):1353–1358, 1990.
43. Hwang RW, de Witte PB, Ring D: Compartment syndrome associated with distal radial fracture and ipsilateral elbow injury. *J Bone Joint Surg Am* 91(3):642–645, 2009.
44. Jensen SL, Deutch SR, Olsen BS, et al: Laxity of the elbow after experimental excision of the radial head and division of the medial collateral ligament. Efficacy of ligament repair and radial head prosthetic replacement: a cadaver study. *J Bone Joint Surg Br* 85(7):1006–1010, 2003.
45. Josefsson PO, Gentz CF, Johnell O, et al: Surgical versus non-surgical treatment of ligamentous injuries following dislocation of the elbow joint. A prospective randomized study. *J Bone Joint Surg Am* 69(4):605–608, 1987.

46. Josefsson PO, Gentz CF, Johnell O, et al: Dislocations of the elbow and intraarticular fractures. *Clin Orthop Relat Res* 246:126–130, 1989.
47. Josefsson PO, Johnell O, Gentz CF: Long-term sequelae of simple dislocation of the elbow. *J Bone Joint Surg Am* 66(6):927–930, 1984.
48. Josefsson PO, Johnell O, Wendeberg B: Ligamentous injuries in dislocations of the elbow joint. *Clin Orthop Relat Res* 221:221–225, 1987.
49. Jupiter JB, Leibovic SJ, Ribbans W, et al: The posterior Monteggia lesion. *J Orthop Trauma* 5(4):395–402, 1991.
50. Jupiter JB, Ring D: Treatment of unreduced elbow dislocations with hinged external fixation. *J Bone Joint Surg Am* 84-A(9):1630–1635, 2002.
51. King GJ, Evans DC, Kellam JF: Open reduction and internal fixation of radial head fractures. *J Orthop Trauma* 5(1):21–28, 1991.
52. Knight DJ, Rymaszewski LA, Amis AA, et al: Primary replacement of the fractured radial head with a metal prosthesis. *J Bone Joint Surg Br* 75(4):572–576, 1993.
53. Lee DH: Posttraumatic elbow arthritis and arthroplasty. *Orthop Clin North Am* 30(1):141–162, 1999.
54. Leigh WB, Ball CM: Radial head reconstruction versus replacement in the treatment of terrible triad injuries of the elbow. *J Shoulder Elbow Surg* 21(10):1336–1341, 2012.
55. Lindenhovius A, Karanicolas PJ, Bhandari M, et al: Interobserver reliability of coronoid fracture classification: two-dimensional versus three-dimensional computed tomography. *J Hand Surg [Am]* 34(9):1640–1646, 2009.
56. Lindenhovius AL, Doornberg JN, Brouwer KM, et al: A prospective randomized controlled trial of dynamic versus static progressive elbow splinting for posttraumatic elbow stiffness. *J Bone Joint Surg Am* 94(8):694–700, 2012.
57. Lindenhovius AL, Jupiter JB: The posttraumatic stiff elbow: a review of the literature. *J Hand Surg [Am]* 32(10):1605–1623, 2007.
58. Liu GS, Jupiter JB: Posterolateral rotatory elbow subluxation with intra-articular entrapment of the radial nerve. A case report. *J Bone Joint Surg Am* 86-A(3):603–606, 2004.
59. Madey SM, Bottlang M, Steyers CM, et al: Hinged external fixation of the elbow: optimal axis alignment to minimize motion resistance. *J Orthop Trauma* 14(1):41–47, 2000.
60. Malkawi H: Recurrent dislocation of the elbow accompanied by ulnar neuropathy: a case report and review of the literature. *Clin Orthop Relat Res* 161:270–274, 1981.
61. McKee MD, Bowden SH, King GJ, et al: Management of recurrent, complex instability of the elbow with a hinged external fixator. *J Bone Joint Surg Br* 80(6):1031–1036, 1998.
62. McKee MD, Pugh DM, Wild LM, et al: Standard surgical protocol to treat elbow dislocations with radial head and coronoid fractures. Surgical technique. *J Bone Joint Surg Am* 87(Suppl 1 Pt 1):22–32, 2005.
63. McKee MD, Schemitsch EH, Sala MJ, et al: The pathoanatomy of lateral ligamentous disruption in complex elbow instability. *J Shoulder Elbow Surg* 12(4):391–396, 2003.
64. McWhorter G: Fracture of both the coronoid and the olecranon process of the ulna: indications for operation and treatment. *J Bone Joint Surg Am* 9:767–777, 1965.
65. Mehlhoff TL, Noble PC, Bennett JB, et al: Simple dislocation of the elbow in the adult. Results after closed treatment. *J Bone Joint Surg Am* 70(2):244–249, 1988.
66. Morrey BF, An KN: Articular and ligamentous contributions to the stability of the elbow joint. *Am J Sports Med* 11(5):315–319, 1983.
67. Morrey BF, An KN: Functional anatomy of the ligaments of the elbow. *Clin Orthop Relat Res* 201:84–90, 1985.
68. Morrey BF, An KN: Stability of the elbow: osseous constraints. *J Shoulder Elbow Surg* 14(1 Suppl S):174S–178S, 2005.
69. Morrey BF, Tanaka S, An KN: Valgus stability of the elbow. A definition of primary and secondary constraints. *Clin Orthop Relat Res* 265:187–195, 1991.
70. Mortazavi SM, Asadollahi S, Tahririan MA: Functional outcome following treatment of transolecranon fracture-dislocation of the elbow. *Injury* 37(3):284–288, 2006.
71. Mouhsine E, Akiki A, Castagna A, et al: Transolecranon anterior fracture dislocation. *J Shoulder Elbow Surg* 16(3):352–357, 2007.
72. Nestor BJ, O'Driscoll SW, Morrey BF: Ligamentous reconstruction for posterolateral rotatory instability of the elbow. *J Bone Joint Surg Am* 74(8):1235–1241, 1992.
73. Nsouli AZ, Makarem RR, Nsouli TA: Fracture-dislocation of the coronoid and olecranon processes of the ulna with posterolateral dislocation of the head of the radius: case report. *J Trauma* 37(5):855–857, 1994.
74. O'Driscoll SW: Elbow instability. *Hand Clin* 10(3):405–415, 1994.
75. O'Driscoll SW: Elbow instability. *Acta Orthop Belg* 65(4):404–415, 1999.
76. O'Driscoll SW, Bell DF, Morrey BF: Posterolateral rotatory instability of the elbow. *J Bone Joint Surg Am* 73(3):440–446, 1991.
77. O'Driscoll SW, Jaloszynski R, Morrey BF, et al: Origin of the medial ulnar collateral ligament. *J Hand Surg [Am]* 17(1):164–168, 1992.
78. O'Driscoll SW, Morrey BF, Korinek S, et al: Elbow subluxation and dislocation. A spectrum of instability. *Clin Orthop Relat Res* 280:186–197, 1992.
79. Olsen BS, Vaesel MT, Sojbjerg JO, et al: Lateral collateral ligament of the elbow joint: anatomy and kinematics. *J Shoulder Elbow Surg* 5(2 Pt 1):103–112, 1996.
80. Papandrea RF, Morrey BF, O'Driscoll SW: Reconstruction for persistent instability of the elbow after coronoid fracture-dislocation. *J Shoulder Elbow Surg* 16(1):68–77, 2007.
81. Pavel A, Pitman JM, Lance EM, et al: The posterior Monteggia fracture: a clinical study. *J Trauma* 5:185–199, 1965.

81a. Penrose JH: The Monteggia fracture with posterior dislocation of the radial head. *J Bone Joint Surg [Br]* 33(1):65–73, 1951.

82. Pribyl CR, Kester MA, Cook SD, et al: The effect of the radial head and prosthetic radial head replacement on resisting valgus stress at the elbow. *Orthopedics* 9(5):723–726, 1986.
83. Protzman RR: Dislocation of the elbow joint. *J Bone Joint Surg Am* 60(4):539–541, 1978.
84. Pugh DM, Wild LM, Schemitsch EH, et al: Standard surgical protocol to treat elbow dislocations with radial head and coronoid fractures. *J Bone Joint Surg Am* 86-A(6):1122–1130, 2004.
85. Ramon Soler R, Paz Tarela J, Soler Minores JM: Internal fixation of fractures of the proximal end of the radius in adults. *Injury* 10(4):268–272, 1979.
86. Regan W, Morrey B: Fractures of the coronoid process of the ulna. *J Bone Joint Surg Am* 71(9):1348–1354, 1989.
87. Regan W, Morrey BF: Classification and treatment of coronoid process fractures. *Orthopedics* 15(7):845–848, 1992.
88. Ring D: Open reduction and internal fixation of fractures of the radial head. *Hand Clin* 20(4):415–427, vi, 2004.
89. Ring D: Fractures of the coronoid process of the ulna. *J Hand Surg [Am]* 31(10):1679–1689, 2006.
90. Ring D: Radial head fracture: open reduction-internal fixation or prosthetic replacement. *J Shoulder Elbow Surg* 20(2 Suppl):S107–S112, 2011.
91. Ring D, Adey L, Zurakowski D, et al: Elbow capsulectomy for posttraumatic elbow stiffness. *J Hand Surg [Am]* 31(8):1264–1271, 2006.
92. Ring D, Doornberg JN: Fracture of the anteromedial facet of the coronoid process. Surgical technique. *J Bone Joint Surg Am* 89(Suppl 2 Pt 2):267–283, 2007.
93. Ring D, Hannouche D, Jupiter JB: Surgical treatment of persistent dislocation or subluxation of the ulnohumeral joint after fracture-dislocation of the elbow. *J Hand Surg [Am]* 29(3):470–480, 2004.
94. Ring D, Jupiter JB: Fracture-dislocation of the elbow. *J Bone Joint Surg Am* 80(4):566–580, 1998.
95. Ring D, Jupiter JB: Reconstruction of posttraumatic elbow instability. *Clin Orthop Relat Res* 370:44–56, 2000.
96. Ring D, Jupiter JB, Sanders RW, et al: Transolecranon fracture-dislocation of the elbow. *J Orthop Trauma* 11(8):545–550, 1997.
97. Ring D, Jupiter JB, Simpson NS: Monteggia fractures in adults. *J Bone Joint Surg Am* 80(12):1733–1744, 1998.
98. Ring D, Jupiter JB, Zilberfarb J: Posterior dislocation of the elbow with fractures of the radial head and coronoid. *J Bone Joint Surg Am* 84-A(4):547–551, 2002.
99. Ring D, Quintero J, Jupiter JB: Open reduction and internal fixation of fractures of the radial head. *J Bone Joint Surg Am* 84-A(10):1811–1815, 2002.
100. Ring D, Tavakolian J, Kloen P, et al: Loss of alignment after surgical treatment of posterior Monteggia fractures: salvage with dorsal contoured plating. *J Hand Surg [Am]* 29(4):694–702, 2004.
101. Ruch DS, Triepel CR: Hinged elbow fixation for recurrent instability following fracture dislocation. *Injury* 32(Suppl 4):SD70–SD78, 2001.
102. Schippinger G, Seibert FJ, Steinbock J, et al: Management of simple elbow dislocations. Does the period of immobilization affect the eventual results? *Langenbecks Arch Surg* 384(3):294–297, 1999.
103. Schneeberger AG, Sadowski MM, Jacob HA: Coronoid process and radial head as posterolateral rotatory stabilizers of the elbow. *J Bone Joint Surg Am* 86-A(5):975–982, 2004.
104. Seki A, Olsen BS, Jensen SL, et al: Functional anatomy of the lateral collateral ligament complex of the elbow: configuration of Y and its role. *J Shoulder Elbow Surg* 11(1):53–59, 2002.
105. Shiba R, Sorbie C, Siu DW, et al: Geometry of the humeroulnar joint. *J Orthop Res* 6(6):897–906, 1988.
106. Shin R, Ring D: The ulnar nerve in elbow trauma. *J Bone Joint Surg Am* 89(5):1108–1116, 2007.
107. Sojbjerg JO, Ovesen J, Nielsen S: Experimental elbow instability after transection of the medial collateral ligament. *Clin Orthop Relat Res* 218:186–190, 1987.
108. Sotereanos DG, Darlis NA, Wright TW, et al: Unstable fracture-dislocations of the elbow. *Instr Course Lect* 56:369–376, 2007.
109. Squires NA, Tomaino MM: Brachial artery rupture without median nerve dysfunction after closed elbow dislocation. *Am J Orthop (Belle Mead NJ)* 32(6):298–300, 2003.
110. Stavlas P, Jensen SL, Sojbjerg JO: Kinematics of the ligamentous unstable elbow joint after application of a hinged external fixation device: a cadaveric study. *J Shoulder Elbow Surg* 16(4):491–496, 2007.

111. Szabo RM, Hotchkiss RN, Slater RR, Jr: The use of frozen-allograft radial head replacement for treatment of established symptomatic proximal translation of the radius: preliminary experience in five cases. *J Hand Surg [Am]* 22(2):269–278, 1997.
112. Tan V, Daluiski A, Capo J, et al: Hinged elbow external fixators: indications and uses. *J Am Acad Orthop Surg* 13(8):503–514, 2005.
113. Teasdall R, Savoie FH, Hughes JL: Comminuted fractures of the proximal radius and ulna. *Clin Orthop Relat Res* 292:37–47, 1993.
114. Tomaino MM, Sotereanos DG, Plakseychuk A: Technique for ensuring ulnohumeral reduction during application of the Richards compass elbow hinge. *Am J Orthop (Belle Mead NJ)* 26(9):646–647, 1997.
115. Tropet Y, Menez D, Brientini JM, et al: [Entrapment of the median nerve after dislocation of the elbow]. *Acta Orthop Belg* 55(2):217–221, 1989.
116. Vanderwilde RS, Morrey BF, Melberg MW, et al: Inflammatory arthritis after failure of silicone rubber replacement of the radial head. *J Bone Joint Surg Br* 76(1):78–81, 1994.
117. Vichard P, Tropet Y, Dreyfus-Schmidt G, et al: Fractures of the proximal end of the radius associated with other traumatic lesions of the upper limb. A report of seventy-three cases. *Ann Chir Main* 7(1):45–53, 1988.
118. Wadstrom J, Kinast C, Pfeiffer K: Anatomical variations of the semilunar notch in elbow dislocations. *Arch Orthop Trauma Surg* 105(5):313–315, 1986.
119. Watters TS, Garrigues GE, Ring D, et al: Fixation versus replacement of radial head in terrible triad: is there a difference in elbow stability and prognosis? *Clin Orthop Relat Res* 472(7):2128–2135, 2014.

23

Chronic Elbow Instability
Ligament Reconstruction

Mark S. Cohen

The elbow is one of the most congruous joints in the body. Joint stability is provided by a combination of the bony architecture and the collateral ligaments and muscles. The lateral collateral ligament (LCL) complex plays a key role in elbow stability, preventing the proximal ulna and radius from subluxating as the supinated forearm is axially loaded.[14] Trauma, usually dislocation, is the most frequent cause of disruption of the LCL complex.[54,56] However, chronic varus load and steroid injections for epicondylitis have been described as possible causes of LCL insufficiency.[44,52] After trauma has occurred, restoration of lateral soft tissue support can usually be accomplished by a direct repair of the lateral ligament and extensor tendon origins to the humeral epicondyle. In instances of recurrent dislocation or subluxation, temporally remote from the initial injury, a tendon graft may be needed.

The medial collateral ligament (MCL) resists valgus force and supports the ulnohumeral joint. Medial collateral instability is most commonly due to chronic attenuation of the medial ligament complex resulting from overhead throwing motions. It can also occur in javelin throwers, gymnasts, quarterbacks, and other athletes who use overhead throwing motions and exert a repetitive valgus stress across the elbow.[23,24,33,41] When medial instability limits athletic participation and conservative care fails, a free tendon graft reconstruction is typically required.

CHRONIC LATERAL INSTABILITY

Preoperative Evaluation

Chronic LCL insufficiency varies in its presentation. A patient may report a painful clunking and/or snapping of the elbow.[3] Others will describe apprehension or weakness when reaching for an object with an outstretched hand, in varus load. Some may have episodes of frank giving way or apprehension, especially when the elbow is axially loaded in extension and supination. This can occur, for example, when one is pushing up from a chair. In this setting, the supinated radius and proximal ulna rotate laterally off of the distal humerus in a pattern termed *posterolateral rotatory instability (PLRI)*. Occasionally, unremitting lateral elbow pain is the patient's chief complaint.

Physical Examination

Physical examination in patients with chronic PLRI is characteristically benign. Grip strength and range of motion are usually unaffected, although some extension deficit may be present. In the setting of chronic instability, minor discomfort may be present on palpation of the lateral elbow. Occasionally, a synovial fistula can be observed as a fluid collection about the lateral elbow.[44]

Due to apprehension and guarding in a patient who is awake, it is often difficult to elicit frank posterolateral instability in the office, especially in muscular individuals. Subluxation of the elbow can be appreciated, however, with the appropriate provocative maneuvers. The elbow may be examined with a patient sitting or lying supine on a table. In the sitting position, one hand stabilizes the adducted humerus, with the fingers placed along the lateral ulnohumeral joint. While the elbow is partially flexed 40 to 45 degrees, the examiner's contralateral hand loads the proximal forearm in supination with slight axial and valgus force applied. Instability is appreciated as gapping at the ulnohumeral articulation as the radius and ulna subluxate. This results in a posterolateral prominence as the radial head subluxates away from the capitellum. The ulnohumeral articulation can be reduced by pronation of the forearm and slight flexion of the joint. Reduction is occasionally accompanied by a palpable clunk.

Alternatively, the *posterolateral rotatory apprehension (pivot shift)* and *drawer tests* are performed with the patient in the supine position. The patient's arm is brought overhead while the examiner stands at the head of the patient. By maximally flexing and externally rotating the shoulder, the humerus is "locked" into a fixed position. For the *pivot shift test*, the forearm is held in maximal supination while a valgus moment and axial compression is applied through the elbow at 40 to 70 degrees of flexion. In the relaxed patient with PLRI, this maneuver will lead to dimpling of the skin overlying the radiocapitellar joint, which occurs when the ulna and radius rotate off of the distal humerus. The subluxated elbow is reduced with flexion, frequently causing a palpable and visible (and sometimes audible) clunk.[54] The *posterolateral rotatory drawer test* is performed in the same position. A posteriorly directed force is applied onto the proximal radius while holding the forearm and elbow in the same position as for the apprehension test. Dimpling of the skin around the radiocapitellar joint at 40 to 70 degrees of flexion confirms PLRI. The amount of instability should decrease with greater elbow flexion.

In addition, in our practice, we routinely examine patients with suspected PLRI under image intensification. The clinical suspicion can in many cases be confirmed radiographically, aiding in establishing an appropriate treatment plan. In addition to the aforementioned rotatory tests, the extended elbow

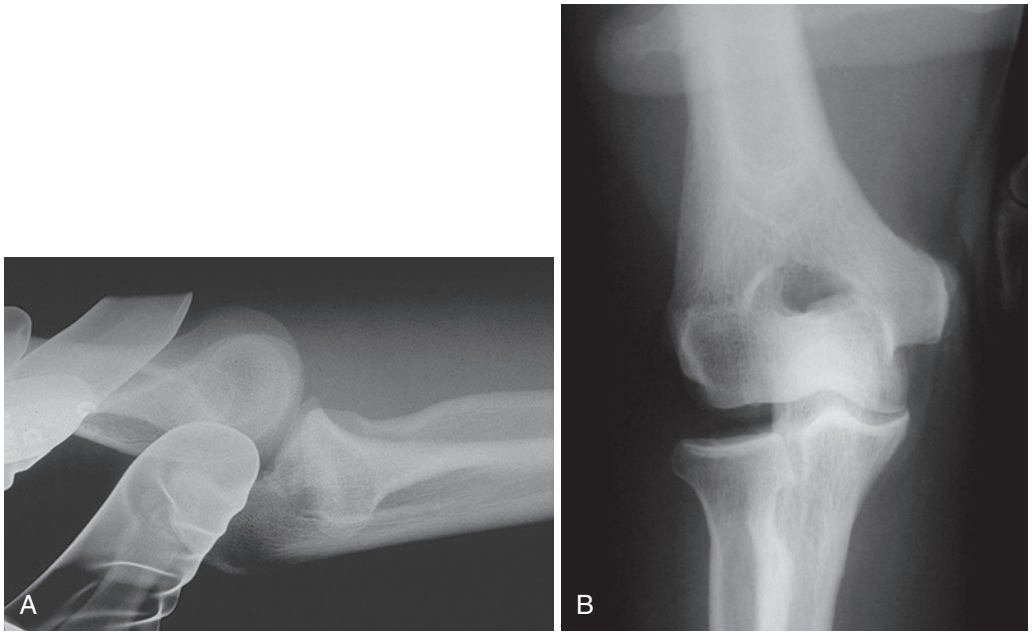

FIGURE 23.1 **A,** Lateral stress radiograph taken in a patient with lateral collateral instability of the elbow. This is taken with provocative stress applied using the rotatory instability test (supination with axial and valgus force applied). Note the gapping at the ulnohumeral articulation and posterior translation of the radial head now projecting posterior to the center of the capitellum. **B,** Anteroposterior stress radiograph in a patient with lateral collateral instability of the elbow. This is taken with varus stress applied to the joint. Note the gross gapping of the lateral joint between the radial head and the capitellum, confirming the diagnosis. (Copyright © Mark S. Cohen, Chicago.)

can be simply loaded in varus. Pathologic gapping at the radiocapitellar joint confirms instability laterally. This can be readily compared with the contralateral, unaffected side (see the following).

Patients with PLRI characteristically actively resist provocative maneuvers that stress the joint, which in and of itself can be interpreted as a "positive apprehension sign." However, in the cooperative patient, a successful examination can be performed with careful manipulation. As one would expect, the most reliable examination is performed under anesthesia. The recommendation is to always perform these maneuvers as the first step in evaluation of a patient for surgical reconstruction. It is also advisable to include these examination maneuvers prior to elective surgery for lateral epicondylitis.

Diagnostic Imaging

Plain radiographs of the elbow are frequently negative in patients with PLRI. However, small avulsion fragments or ossification at the humeral origin of the LCL can frequently be visualized. If PLRI is suspected, a lateral stress or varus stress view of the elbow can be obtained in the office using image intensification. The elbow is maximally supinated and axially loaded. Instability is confirmed by widening of the ulnohumeral joint and posterior subluxation of the radial head (Figure 23.1). Anteroposterior radiographs or fluoroscopy under varus load can often reveal pathologic gapping of the radiocapitellar joint (see Figure 23.1). As noted, imaging of the contralateral elbow is recommended to help confirm asymmetric gapping or displacement. Magnetic resonance imaging can aid in confirming the diagnosis. Signal changes are commonly seen at the epicondyle, revealing disruption of the lateral collateral and tendinous origins at the humeral epicondyle (Figure 23.2).



FIGURE 23.2 Magnetic resonance image of the elbow in a patient with chronic lateral collateral ligament insufficiency. Fluid is seen between the collateral ligament and extensor tendon origins and the lateral epicondyle. Magnetic resonance scanning can help confirm the diagnosis and rule out other pathologic processes about the lateral elbow. (Copyright © Mark S. Cohen, Chicago.)

PERTINENT ANATOMY

The LCL complex originates at the base of the lateral epicondyle and lateral aspect of the capitellum. The isometric origin of the LCL is located at the geometric center of the capitellum.[50] In the reduced elbow, the isometric origin is located at the intersection of a distal projection of the anterior cortex of the humerus and the longitudinal axis of the radial head.[16] Distally, the LCL blends with the annular ligament to form a broad common insertion onto the proximal ulna (Figure 23.3).[16,18]

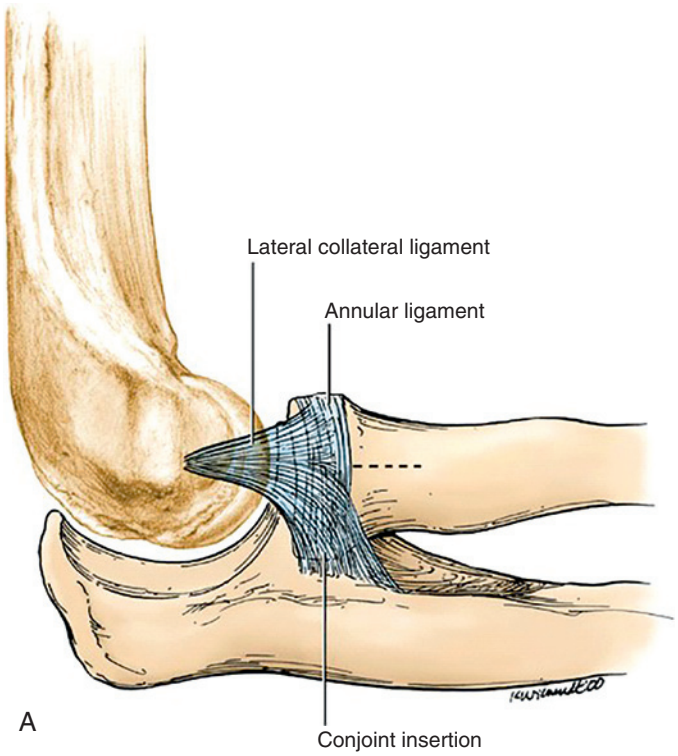

FIGURE 23.3 Schematic drawing **(A)** and cadaveric specimen **(B)** depicting anatomy of the lateral collateral and annular ligament complex. The overlying extensor muscles and supinator fibers have been removed. The collateral ligament originates at the base of the lateral epicondyle and fans out, blending with the annular ligament. These form a broad conjoined insertion onto the proximal ulna along the supinator crest just posterior to the proximal radioulnar joint. (Copyright © Mark S. Cohen, Chicago.)

The posterior fibers, which extend over 2 cm along the supinator crest from the proximal border of the radial head distally, have been termed the "lateral ulnar collateral ligament."[52] The LCL complex is covered anteriorly by the supinator muscle, which originates off the lateral epicondyle, supinator crest, and annular ligament. Posteriorly, the anconeus muscle is in close proximity to the LCL complex as it originates off the lateral epicondyle and inserts onto the lateral aspect of the proximal ulna.[38]

Both ligamentous and musculotendinous restraints provide stability to the elbow. The LCL complex, along with the anterior bundle of the MCL and the ulnohumeral joint, has been shown to act as a primary stabilizer of the elbow. Clinically, lateral elbow instability requires insufficiency of both ligamentous and musculotendinous stabilizers. The most common mechanism involves proximal attenuation or avulsion of these structures from their humeral original.[17,18,43,70] Occasionally, the distal insertion of the LCL may become compromised either as an avulsion injury or as a fracture of the supinator crest.[7,68]

The contribution of the LCL complex and overlying extensor tendon origins to lateral elbow joint stability have been well described in ex vivo studies.[18,27] The LCL complex represents the primary lateral stabilizer of the elbow, maintaining the ulnohumeral and radiocapitellar joints in a reduced position when the elbow is axially loaded with the forearm in supination. The extensor muscles, along with their fascial bands and intermuscular septae, assume a role as secondary restraints.[18] The extensor muscles serve to independently support the forearm unit from laterally rotating away from the humerus. In supination, these muscles provide a static and dynamic force supporting the lateral joint. The extensor carpi ulnaris is the most proximal of the extensor muscles and thus has the best mechanical advantage in supporting the proximal forearm. This muscle has a consistent fascial band on its undersurface, which originates at the inferior aspect of the lateral epicondyle and inserts onto the ulna approximately 5 cm distal to the radial head. The fascial band of the extensor carpi ulnaris becomes taut in supination and, along with the extensor tendon origins and septae, provides secondary resistance to lateral rotatory instability.[18]

Disruption of the LCL complex occurs in most instances as a consequence of an acute elbow dislocation mechanism. Although more than one pattern exists, dislocations frequently occur as the elbow is loaded with a combination of axial compressive, external rotatory, and valgus forces, in which the body internally rotates with respect to the affected extremity.[54,56] In this setting, disruption of elbow stabilizers proceeds in a circular path from lateral to medial.[58] Less frequently, instability may result as a consequence of a varus-deforming force applied to the extended elbow.[52] LCL insufficiency should be kept in mind as a differential diagnosis in patients with nonremitting lateral epicondylitis, with or without a history of previous local steroid injections.[44] Patients with chronic cubitus varus deformity, a prior history of failed surgery for lateral epicondylitis, or prior surgery of the radial head may have underlying iatrogenic lateral elbow instability.[48,59]

Indications

Primary repair of the LCL is required in the setting of fracture-dislocations of the elbow. The so-called *terrible triad of the elbow*

indicates a fracture of the coronoid process and radial head with an associated injury to the LCL. In this setting, LCL repair is an integral part of the treatment algorithm. In chronic PLRI of the elbow, some authors have shown favorable outcomes with simple repair of the LCL complex, but reconstruction is typically required to restore lateral joint stability.

Contraindications

LCL repair or reconstruction requires an intact buttress at the proximal radius. In cases of radial head insufficiency, operative reduction and fixation of the radial head or prosthetic replacement should accompany the reconstruction. Patient compliance with postoperative rehabilitation plays a key role in achieving adequate outcomes. Patients who are unable or unwilling to follow rehabilitation guidelines should not undergo reconstruction, especially as an elective procedure.

Technique

❖ AUTHOR'S PREFERRED TECHNIQUE

In the setting of chronic PLRI of the elbow, reconstruction is typically performed with tendon graft augmentation. Allograft hamstring and ipsilateral palmaris longus tendon grafts are most commonly used. If autograft is chosen for reconstruction, patients should be examined for the presence of a palmaris longus tendon. Frequently, the palmaris autograft is found to be suboptimal (too small or too short) to use for reconstruction. Alternative autograft options include the contralateral palmaris, flexor carpi radialis, and gracilis tendons. We favor hamstring allografts when the palmaris is not of sufficient quality, and the gracilis seems to be most optimal in terms of diameter and length.

Surgical equipment required for ligament reconstruction includes standard retractors and elevators for the elbow, drill bits and drill sleeves for the bone tunnels (typically 3.2 mm and 4.5 mm in diameter), a cannulated 4.5-mm drill, and strong braided nonabsorbable suture material. Optional equipment includes a tendon stripper for autograft harvest, ligature passers and/or fine monofilament wire (e.g., 26-gauge) to aid graft passage through the bone tunnels, and a cortical button.

The procedure is commonly performed under regional anesthesia with a long-acting block. Examination under anesthesia is recommended to confirm the diagnosis of PLRI. An extended Kocher incision is used beginning along the supracondylar humeral ridge and passing distally over the lateral epicondyle toward the ulna.[34] Deep dissection is continued along the lateral supracondylar ridge, beneath the epicondyle and distally between the anconeus and the extensor carpi ulnaris. The anconeus is reflected posteriorly with the triceps and the extensor carpi ulnaris is retracted anteriorly, revealing the deep collateral and annular ligament layer overlying the radial head. The capsule over the so-called soft spot of the elbow is maintained to provide a layer between the joint and the graft.

In preparation for the humeral tunnel, a separate arthrotomy at the midline of the radiocapitellar joint exposes the epicondyle and the radiocapitellar joint. To reach this, the extensor carpi ulnaris and part of the extensor digitorum tendons are carefully elevated tangentially from posterior to anterior off of the deep ligament layer to the midline of the radiocapitellar joint. A transverse arthrotomy allows for direct inspection of the joint to visualize the curvature of the capitellum and identify its geometric center where the isometric origin of the LCL will be located (Figure 23.4). Additionally, localization of the radiocapitellar joint will allow accurate placement of the ulnar tunnels. Not uncommonly, one will visualize wear and flattening on the rim of the radial head due to chronic subluxation.

It is important to have a clear understanding of the insertion of the lateral collateral and annular ligament complex when fashioning the ulnar tunnels. An entry hole is made in the lateral cortex of the ulna at the proximal margin of the radial head and just several millimeters posterior to the joint using sequential drill bits. Typically, a 3.2-mm drill bit is used followed by a 4.5-mm drill bit. An exit hole is created approximately 2 cm distally along the supinator crest (see Figure 23.4). Theoretically, more distally placed tunnels provide a graft that better resists varus stress and more proximal tunnels provide greater resistance to joint subluxation in supination. Curets are used to create a path within the ulna between the drill holes.

For the humeral graft attachment, we favor a single tunnel. This is easiest to create with a cannulated drill because the angle is quite "flat." A 0.062-inch guide pin is started for a 4.5-mm drill bit so that the posterior and distal periphery of the hole will be located at the isometric origin of the LCL (see Figure 23.4). It is important to avoid placing the tunnel posterior to the isometric point, as this will lead to laxity of the graft in extension where it is needed most. Once adequate placement of this pin into the posterior aspect of the lateral humeral column has been confirmed, the 4.5-mm cannulated drill is advanced from distal to proximal without penetrating the far cortex. The far cortex is perforated using a 3.2-mm drill. This will allow for ideal fixation using the cortical button.

The tendon graft is obtained either by harvesting an autograft or by thawing an allograft. The graft is prepared by placing a running, locking nonabsorbable suture on one end (typically, the distal tendon.) A double-armed suture attached to a Keith needle (#2 FiberLoop, Arthrex, Naples, FL) can be used to facilitate this. The suture ends are shuttled through the ulnar tunnel using a bent suture passer or fine monofilament wire. Care must be taken to clear the tunnel adequately to allow passage of the graft. Prior to securing the tendon in the humerus, the lateral capsulotomy that had been made at the midline of the radiocapitellar joint is repaired. In addition, we have found it useful to reattach the origin of the native collateral ligament and extensor tendon origins to reinforce the reconstruction. To this end, a stout nonabsorbable running, locking suture is placed starting at the tendon and ligament origin on the humerus, run distally into the common extensor tendon down toward the ulna, and run back to the entry point. These sutures are passed into the humeral tunnel prior to the graft with the help of a straight suture retriever or wire. A hemostat helps maintain these proximally.

The prepared end of the graft is placed into the humeral entry hole with the sutures exiting posteriorly. Although the original description of the technique suggested the use of a four-ply graft,[52] most surgeons now use a "docking" technique popularized on the medial side of the elbow for ligament reconstruction in the throwing athlete (see Figure 23.4). The goal of this method is for both arms of the free graft to be "docked" within the humeral tunnel, with only the two sets of sutures

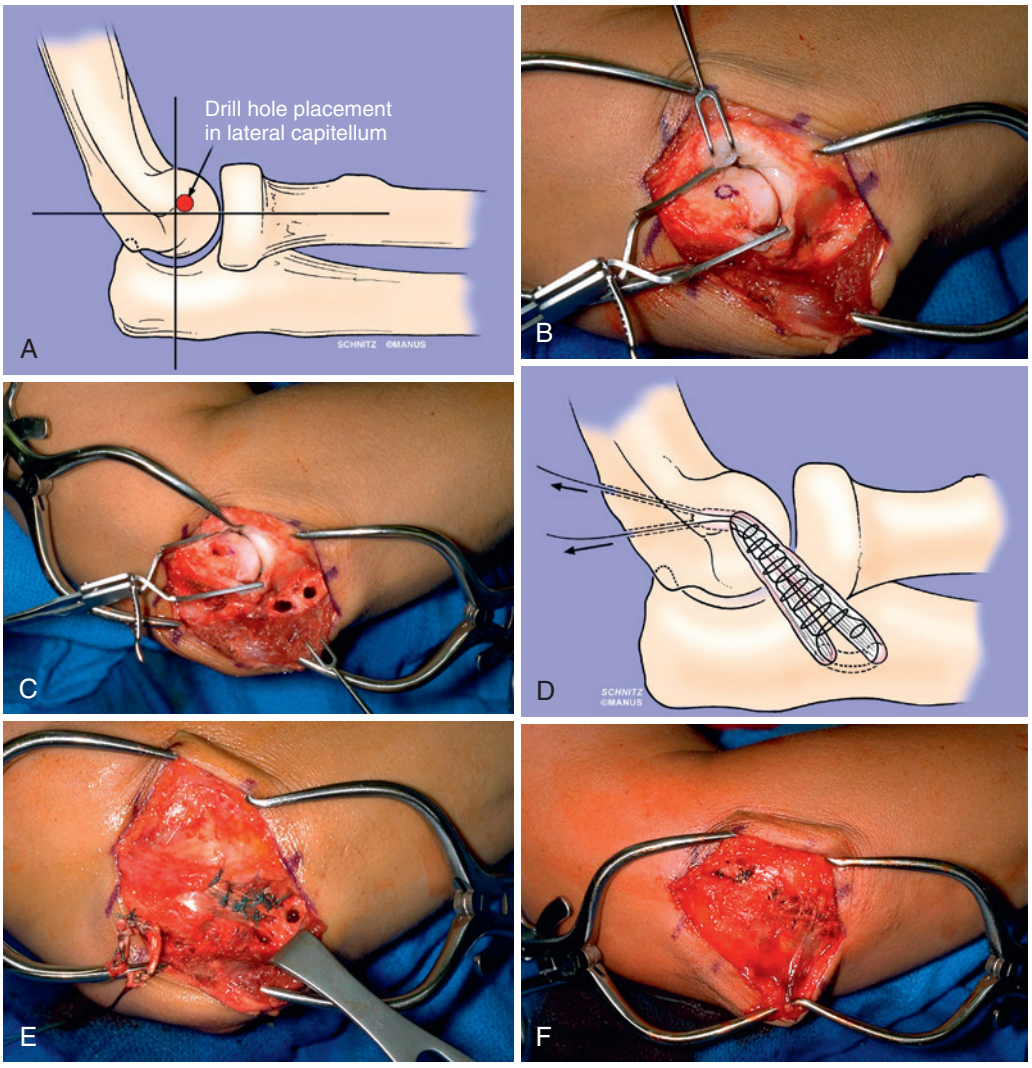

FIGURE 23.4 **A,** Schematic drawing depicting appropriate position for the humeral tunnel origin. Note how the tunnel begins anterior to the center of the capitellum (isometric point). In this way, the posteriormost margin of the tunnel will define isometry. **B,** Intraoperative photograph depicting the starting point for the humeral tunnel. **C,** Intraoperative photograph after the humeral and ulnar tunnels have been created. Note that the proximal ulnar tunnel is drilled just posterior to the proximal aspect of the radial head to re-create normal ligament anatomy. **D,** Schematic drawing depicting "docking" technique used to secure the free tendon graft. A triangular graft configuration is created by cutting the graft length so that both tendon arms end in a single humeral tunnel. In this diagram, the sutures alone are passed through separate bone tunnels posteriorly. Tension is provided, and the graft is secured by tying the sutures over a humeral bone bridge. Alternatively, a cortical button can be used. **E,** Intraoperative photograph depicting final graft position after being passed through the humeral tunnels. Note how the arms of the graft have been sutured to one another and the underlying native soft tissue to reinforce the reconstruction. **F,** The anconeus and extensor carpi ulnaris fascia have been closed over this free tendon graft, completing the procedure. (**A** and **D,** Courtesy of Hill Hastings II, MD, and The Indiana Hand Center. **B, C, E,** and **F,** Copyright © Mark S. Cohen, Chicago.)

exiting out of the posterior humerus. Once approximately 10 to 15 mm of the graft is within the humeral tunnel, the second arm of the graft is cut at the appropriate length that will allow it to end within the humerus. Care is taken not to cut the graft too short. The second end of the graft is prepared with a separate running, locking suture. Tails of this suture are passed out of the humeral tunnel. Traction on the two sets of graft sutures should allow the two-ply graft to become taut as it advances within the humerus. When using this technique with one humeral tunnel, the suture ends are threaded through the eyelets of an endobutton behind the lateral humeral column.

The forearm is flexed to approximately 45 to 60 degrees and fully pronated, reducing any residual posterolateral subluxation. The forearm is lifted off of the table to remove any varus stress. First, the two ends of the suture that have been placed in the native tissue are tied over the posterior humeral bone bridge or endobutton. The tendon graft is pulled taut, and the four suture strands are tied, completing the reconstruction. The arms of the free tendon graft spanning the elbow joint can be sutured to one another and to the underlying collateral and annular complex to reinforce and tension the reconstruction if necessary. The elbow can be taken through a range of motion once the graft is secured. One will now appreciate the function of the graft, which acts as a reinforcement to the radial collateral and annular ligament complex. It holds up the proximal ulna to the humeral trochlea and, in addition, provides a lateral

restraint to the radial head, not allowing it to subluxate laterally from the capitellum in supination.

For closure, the split in the anconeus and extensor fascia is repaired, sealing the reconstruction, and the skin is sutured in layers (see Figure 23.4). A compressive dressing is applied, with a splint maintaining the elbow in at least 90 degrees of flexion and the forearm in neutral rotation or slight pronation.

Postoperative Management and Expectations

Motion may be started at 7 to 10 days after surgery. However, motion may be delayed for 2 to 3 weeks without significant morbidity, as stiffness is not typically a problem in this patient population.[15] A progressive range-of-motion program is subsequently started, with interval splinting for protection and support. Initially, all motion is performed with the arm at the patient's side, avoiding shoulder abduction. Supination is allowed only with the elbow maximally flexed, which helps lock the ulnohumeral joint, thereby protecting the lateral soft tissue structures. Patients gradually gain elbow extension over the first 6 to 8 weeks. At that time, the protective splint is weaned and full extension should be safely achieved. Isometric strengthening can begin at 8 to 10 weeks. More vigorous strengthening or loading of the elbow is not started until closer to 4 to 6 months after surgery. Unrestricted use of the extremity is delayed until at least 6 months postoperatively, to allow time for the graft to incorporate and mature.

Expected Outcomes

Several surgical techniques have been described for management of PLRI. Most recently, Daluiski and colleagues[20] reported on primary repair of the LCL complex in patients undergoing surgery within 30 days of injury versus more than 30 days after dislocation; the results were similar. In their cohort of 34 patients, only 2 had recurrent instability; both had undergone operation in the early postoperative period.[20] Lee and associates reported excellent or good results in 8 of 10 patients who underwent either tendon graft reconstruction (6 patients) or humeral reattachment (4 patients). All patients treated with graft reconstruction had an excellent result.[46] Nestor and coworkers reported on 11 patients who underwent either advancement or reconstruction of the lateral elbow. Of the five patients who underwent reconstruction with a palmaris longus graft, three were graded as having an excellent result and two as having a fair result, based on a scale that evaluates stability, range of motion, and pain.[52] Lin and colleagues reported on 14 patients who underwent ligament reconstruction using either a palmaris or gracilis autograft. Reconstruction was performed in 11 patients with only lateral instability and 3 with concomitant medial instability. Excellent and good results based on the scale of Nestor and associates was reported in patients with lateral instability only, whereas of the patients with associated medial instability 2 had a good result and 1 a fair result.[47] Using a docking technique for reconstruction of eight purely ligamentous PLRIs, Jones and coworkers reported a mean Mayo Elbow Performance Score of 88 (range, 75 to 100) at a mean follow-up of 7 years. Complete resolution of instability was achieved in six patients, while two had occasional instability.[42] In a previous article, the senior author reported the results of reconstruction on 16 patients with documented chronic PRLI using the technique described in this paper. Symptoms of instability resolved in all patients, with elbow range of motion returning to baseline at 3 months after surgery. Loss of range of motion consisted of 5 to 10 degrees of terminal extension in 7 patients, but it did not affect final elbow function.

In a recent systematic review of the literature, Anakwenze and colleagues analyzed eight studies that included a total of 130 patients who underwent LCL reconstruction for PLRI. Ninety-one percent of patients had good or excellent results. However, complications occurred in 11% of patients, with recurrent instability occurring in 8%.[4]

Complications

Recurrent instability is the most frequent complication after LCL reconstruction. This is reported to occur in up to 25% of cases.[42] Revision surgery poses special challenges because of bone loss from a prior attempted reconstruction. Baghdadi and associates assessed 11 patients who underwent revision surgery for PLRI over an 11-year period. Although instability was corrected in 8 patients, only 6 patients achieved good or excellent outcomes according to the Mayo Elbow Performance Score.[9]

CHRONIC MEDIAL INSTABILITY

Preoperative Evaluation

Physical Examination

Physical examination of an individual with presumed medial joint insufficiency should focus on palpation of the course of the MCL. The patient may have pain at its origin (humeral epicondyle) or insertion site (sublime tubercle of the ulna). Irritation of the ulnar nerve, with symptoms of ulnar neuritis, may be present secondary to inflammation of the ligamentous complex.[13] Valgus stress testing of the elbow should be performed with the examiner stabilizing the forearm and supporting the proximal arm at the axilla. The elbow is flexed past 30 degrees and a valgus stress is applied across the elbow joint. Provocative maneuvers have been described to help confirm the diagnosis of medial ligamentous insufficiency. The "milking" maneuver consists of static traction placed on the thumb with the elbow flexed beyond 90 degrees and the shoulder externally rotated. The moving valgus stress test involves a similar load applied to the elbow while the joint is taken through a range of motion. Pain at approximately 70 to 120 degrees (the position of late cocking and early acceleration of throwing) characteristically occurs in patients with symptomatic medial ligament insufficiency.[57,69]

Diagnostic Imaging

Plain films are commonly negative in these individuals, although a small fragment of bone can occasionally be seen along the medial joint line. Stress anteroposterior radiographs can be used with a valgus load applied to the joint, but especially in the awake patient, these are often normal. Magnetic resonance imaging can be used to confirm pathologic conditions of the ligament.[73] Most commonly, the medial ligament fails distally at its ulnar insertion, but proximal ligament failure and midsubstance attenuation can also occur (Figure 23.5). The use of magnetic resonance arthrography has been suggested to be more sensitive, allowing the identification of undersurface tears

in the ligament.[36] However, it is now clear that in a subset of patients with symptomatic medial ligament pathologic conditions, MRI scans are relatively normal. In these cases, the diagnosis is confirmed by the history and physical examination findings.



FIGURE 23.5 Magnetic resonance image of the elbow in a patient with chronic medial collateral ligament insufficiency. Fluid is seen between the collateral ligament and its insertion point on the ulna. Magnetic resonance scanning can help confirm the diagnosis of ligament disruption and identify any associated intraarticular pathologic conditions. (Copyright © Mark S. Cohen, Chicago.)

PERTINENT ANATOMY

The MCL of the elbow can be divided into three components, the anterior, posterior, and transverse bundles (Figure 23.6).[12,30,32,50] The anterior bundle originates on the central 65% of the anteroinferior surface of the medial epicondyle, just posterior to the axis of the elbow joint,[50,53,55] with a footprint that is approximately 10 mm wide. Previously it was believed that the ulnar collateral ligament inserted on a small area of the sublime tubercle (a protuberance off of the medial coronoid) of the proximal ulna, but recent evidence demonstrates that the ulnar collateral ligament inserts in a broad fashion over a span of 25 mm.[29] The anterior bundle is composed of two functional components.[12,30,66] The anterior band of the anterior bundle is taut from full extension to 60 degrees of flexion, while the posterior component is taut from 60 to 120 degrees of flexion.[12,61,66] There is a distinct ridge on the sublime tubercle that separates the anterior and posterior band attachments.[26,29]

The anterior bundle of the MCL is the strongest and stiffest of the elbow collateral ligaments, with an average load to failure of 260 Newtons.[61] Certain activities such as throwing have been estimated to generate up to 290 Newtons of tensile force on the medial elbow, highlighting the importance of dynamic stability provided by the flexor-pronator muscle group.[76] Ochi and colleagues determined that the deep middle portion of the anterior band is isometric during elbow flexion.[53] They further demonstrated that this deep middle bundle is positioned along the ulnohumeral joint axis.

The posterior bundle of the MCL is a less well-defined thickening of the posterior elbow joint capsule.[10,43] The transverse bundle, also known as the Cooper ligament, is variably present.[30,45,50] It is composed of fibers running along the medial joint capsule from the tip of the olecranon to the medial ulna, just distal to the coronoid.[10,50] The transverse fibers have little role in elbow joint stability because they originate and insert on the ulna (see Figure 23.6).

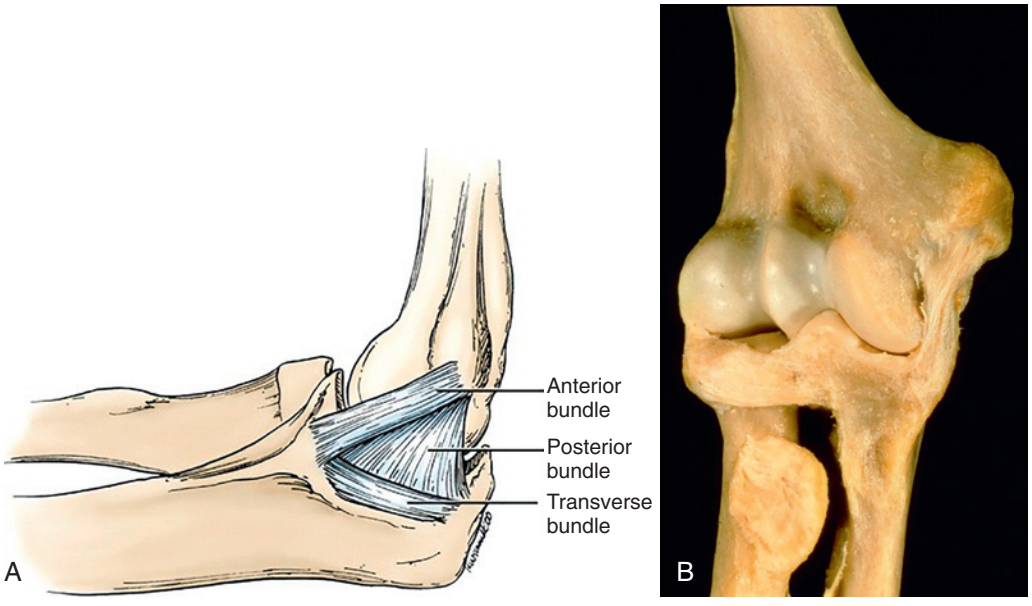

FIGURE 23.6 Schematic diagram **(A)** and cadaveric specimen **(B)** depicting the anatomy of the medial collateral ligament complex of the elbow, including the three bundles. The stout anterior bundle is the main stabilizer of the elbow to valgus stress. (Copyright © Mark S. Cohen, Chicago.)

The principal function of the MCL complex is to maintain medial joint stability with applied valgus stress. As noted, the anterior band of the anterior bundle is the most important component of the ligamentous complex, as it primarily stabilizes the elbow from 30 to 120 degrees of flexion.[12,30,37,49-51,71] The posterior band of the anterior bundle functions equally as a corestraint with the anterior band at terminal elbow flexion. The radial head functions as a secondary ulnohumeral joint stabilizer to valgus loads.[37,51] The flexor-pronator muscles originate at the medial epicondyle and provide additional static and dynamic support to the medial elbow.[2] The flexor carpi ulnaris and flexor digitorum superficialis are the most effective in this regard.[21]

A subset of patients with MCL injury present with ulnar nerve symptoms or positive cubital tunnel findings on physical examination. The ulnar nerve lies along the medial joint line just posterior to the anterior bundle of the MCL. As such, the nerve is predisposed to local trauma and inflammation when ligament attenuation has occurred. Aoki and associates measured the strain on the ulnar nerve during overhead throwing. They found that the strain recorded during the acceleration phase of throwing approximated the elastic limit of the ulnar nerve.[6] This suggests that the repetitive strain of throwing can lead to intraneural ischemia and deformation and ulnar nerve symptoms, especially when the ligament is incompetent.

The most common mechanism of MCL insufficiency is chronic attenuation, as seen in athletes who perform overhead throwing. Patients typically report a single episode of severe pain with throwing, although on careful questioning most report that low-grade symptoms had been present earlier. Following the development of pain, vigorous throwing is typically not possible and reproduces medial joint symptoms. Although not as common, the medial elbow ligament can also fail in a posttraumatic setting, usually following a fall on an outstretched arm. A combination of valgus and external rotation force has been proposed.[8,19,40,45,66] Associated injuries following trauma may include fractures of the radial head, olecranon, or medial humeral epicondyle.[45,66] Finally, MCL injury can be iatrogenic, secondary to excessive medial epicondylectomy for cubital tunnel syndrome.[31,35]

Indications

The indication for operative reconstruction of the medial elbow ligament is failure of conservative measures; a subset of patients with these injuries will heal without reconstruction.[24,62] Treatment for early symptoms of MCL injury includes rest with cessation of throwing or valgus loading for 8 to 12 weeks, physical therapy modalities, and nonsteroidal antiinflammatory medication. Strengthening of the flexor-pronator mass (the flexor carpi ulnaris and flexor digitorum superficialis in particular) may facilitate rehabilitation.[21] These muscles provide a secondary restraint to valgus stress and protect the underlying ligamentous complex. Because the medial ligament's function is important mainly in throwing motions, elbow reconstruction is warranted only in patients who want to play sports that involve throwing. In some patients, activity modification is a reasonable alternative to surgery. Valgus laxity has been shown to cause minimal functional impairment with normal activities of daily living.[45] In addition, unlike chronic lateral ligament insufficiency, there is little long-term detrimental effect of medial ligament pathology on elbow motion or function.

Contraindications

Patients must be compliant and willing to undergo the rehabilitation necessary for a proper surgical outcome. Because throwing is delayed for many months, patients must be willing to wait for the lengthy recovery needed.

Technique

Dr. Frank Jobe first published his initial ulnar collateral ligament reconstruction technique in 1986, which involved elevation of the flexor pronator mass, a figure-of-eight graft configuration, and tunnels on both the ulnar and humerus.[40] Over the years there have been several modifications of this technique, including the "modified Jobe technique" (a flexor-pronator muscle-splitting approach with a figure-of-eight graft configuration), the "docking technique" (the use of a triangular graft configuration through a single humeral tunnel), the "DANE-TJ technique" (the use of an interference screw for ulnar graft fixation), and the "ASMI technique" (a more posterior approach to the sublime tubercle working through the cubital tunnel).[5,22,63,72] These surgical modifications include differences in relation to graft configuration, fixation, and management of the flexor pronator mass. At present, no consensus has been reached in the literature regarding the optimal technique for reconstruction.[1,60,67]

❖ AUTHOR'S PREFERRED TECHNIQUE

In chronic cases, operative treatment typically involves a reconstruction with a free tendon graft. Several options exist for the graft, including a palmaris longus or hamstring autograft or a hamstring or Achilles allograft. No study to date has demonstrated the superiority of any one graft.[11,65] Because the palmaris tendon is often of insufficient width or length, a back-up tendon is necessary even when the palmaris is present. We favor the semitendinosis, either as autograft or allograft, which is the largest hamstring tendon.

The surgical equipment required for ligament reconstruction includes standard elbow instruments, drill bits and sleeves of 3.2 mm and 4.5 mm in diameter for the bone tunnels, a 4.5-mm cannulated drill, and a strong braided nonabsorbable suture. Optional equipment includes a tendon stripper for autograft harvest, ligature passers and/or fine monofilament wire (e.g., 26-gauge) to aid graft passage through the bone tunnels, and a cortical button.

Some authors elect to perform routine elbow arthroscopy prior to ulnar collateral ligament reconstruction to remove posteromedial osteophytes and to assess the overall status of the elbow joint. We do not routinely perform elbow arthroscopy unless concomitant pathologic change exists that is most amenable to arthroscopic treatment.

The procedure is commonly performed under regional anesthesia. A medial approach to the elbow is used, and the medial antebrachial cutaneous sensory branches are dissected out and protected. For this procedure, the entire flexor-pronator musculotendinous origin needs to be exposed. The ulnar nerve is identified and released proximally to expose the medial humeral column beneath the triceps muscle. This nerve dissection can be carried down to the proximal aspect of the cubital tunnel.

The nerve can be simply left in situ or formally transposed into a subcutaneous position after the reconstruction has been completed. We tend to only transpose the ulnar nerve in patients with preoperative ulnar nerve symptoms or signs of nerve involvement (a positive Tinel sign or elbow flexion test). Occasionally, patients with MCL insufficiency have a symptomatic posteromedial osteophyte. Simple elevation of the triceps allows direct access to the posteromedial olecranon tip if spur débridement is necessary.

As noted above, although the original description of the technique involved elevation of the flexor-pronator muscle mass from the humerus (Figure 23.7),[39,40] we prefer a muscle-splitting approach. This allows identification of the anterior band of the medial ligament with less morbidity. The posterior aspect of the flexor-pronator fascia is opened along the line of its fibers, usually through a white fibrous raphe along the anterior margin of the humeral head of the flexor carpi ulnaris. The flexor-pronator muscle is bluntly split down to the ligament. The ligament is defined as a stout, white structure coursing from the epicondyle to the sublime tubercle of the ulna. The tubercle can often be palpated distally, and it guides the plane of the muscle split. Of note, the sublime tubercle is always more distal than one would think. Deep retractors are placed, and an Army-Navy retractor placed distally is especially useful for exposure. The ligament is split longitudinally. This allows visualization of the medial ulnohumeral joint. Forced supination and valgus load commonly demonstrate insufficiency of the ligament, which manifests as gapping of the medial ulnohumeral joint. Distally, limited subperiosteal dissection allows identification of the sublime tubercle, which is palpable as a prominence with a central ridge. This has a triangular configuration tapering distally.

In the past, we used anterior and posterior bone tunnels in the ulna analogous to the lateral side. However, this does require significant stripping to expose the anterior and posterior slopes of the sublime tubercle. In addition, in this area an adequate bone bridge can be challenging to preserve. Furthermore, posteriorly it must be appreciated that the ulnar nerve lies very near to the ligament edge. As such, for safety and simplicity, we now use a single tunnel in the ulna similar to the humerus (a double-docking technique). Without a bone bridge in the ulna, a single-strand graft may be used. For the ulna, a 4.5-mm drill hole is made in the center of the sublime tubercle perpendicular to its surface beginning approximately 3 mm distal to the joint (Figure 23.8). It may be easiest to start this with a 3.2-mm drill and enlarge the hole with the bigger drill. A curet can be used to create a cavity in which to seat the graft. Through this tunnel, divergent holes can be made exiting the posterolateral cortex of the ulna for the tendon sutures. A 0.062-inch Kirschner wire with a drill sleeve to protect the soft tissues is useful for this purpose. Care is taken to leave at least a 1-cm separation between the two exit points. These can usually be exposed through the same incision by elevating a full-thickness skin flap posteriorly and dissecting in a subperiosteal fashion along the ulna posteriorly and laterally. A ligature passer that has the tendon loop proximally (nitinol wire) allows easiest passage of the ultimate sutures (see Figure 23.8).

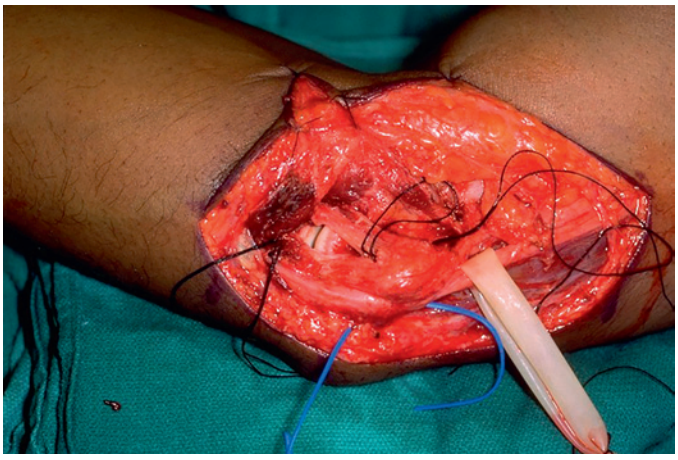

FIGURE 23.7 Intraoperative photograph in a patient undergoing a medial ligament reconstruction. In this case, the origin of the flexor-pronator muscles has been elevated and retracted distally to allow exposure of the ligament. Note the protection of the ulnar nerve posteriorly (Penrose drain) and the longitudinal split in the ligament, revealing the medial aspect of the ulnohumeral joint. This approach has been replaced by the more popular technique in which the muscle is split in line with its fibers to expose the underlying ligament. (Copyright © Mark S. Cohen, Chicago.)

The isometric point for the humerus is important and is defined by the midpoint of the medial epicondyle height (from base to tip) on the face of the anteroinferior epicondyle.[26,30,55] Enough epicondyle is exposed to allow for identification of this origin (Figure 23.9). Typically, the tunnel is started just superficial to this point to allow for closure of the native ligament beneath the tendon graft. As was the case laterally, it is easiest to create the medial humeral tunnel with a cannulated 4.5-mm drill. A 0.062-inch guide pin is placed at the tunnel starting point, exiting the posteromedial column of the humerus. Care is taken to leave an adequate medial cortical bone bridge without aiming too far laterally toward the posterior ulnohumeral joint. Once the pin is properly placed, the tunnel is created with the cannulated drill, with care taken to retract and protect the ulnar nerve posteriorly at the tunnel's exit.

The tendon graft is prepared in a fashion similar to that described laterally. Because this technique uses a single-strand graft, if the palmaris longus is chosen it is folded upon itself (two-ply). For the semitendinosis, a running, locking stitch is simply placed into one end. If there is any concern that the tendon graft may not fit within the tunnels, the graft can be passed through the 4.5-mm drill sleeve to confirm proper sizing (and trimmed accordingly).

The graft is now seated in the ulna. Both suture ends are pulled through the transosseous tunnels using the nitinol wire ligature passer. Traction placed on the sutures brings the tendon edge to the tunnel entry. Manual placement of the graft end into the tunnel can be helpful to aid in seating of the graft. The sutures are tied over the cortical bone bridge of the ulna. The knot can be pushed laterally, beneath the extensor carpi ulnaris, and the fascia can be repaired posteriorly over the ulna to complete the closure.

Next the graft is reflected distally and the native medial ligament is repaired, closing the longitudinal split (see Figure 23.8). Care is taken to carefully suture the ligament distally to cover the medial ulnohumeral joint. It may be easiest to place the most distal sutures in the native ligament (without tightening them) before the graft is seated to allow free access to both the

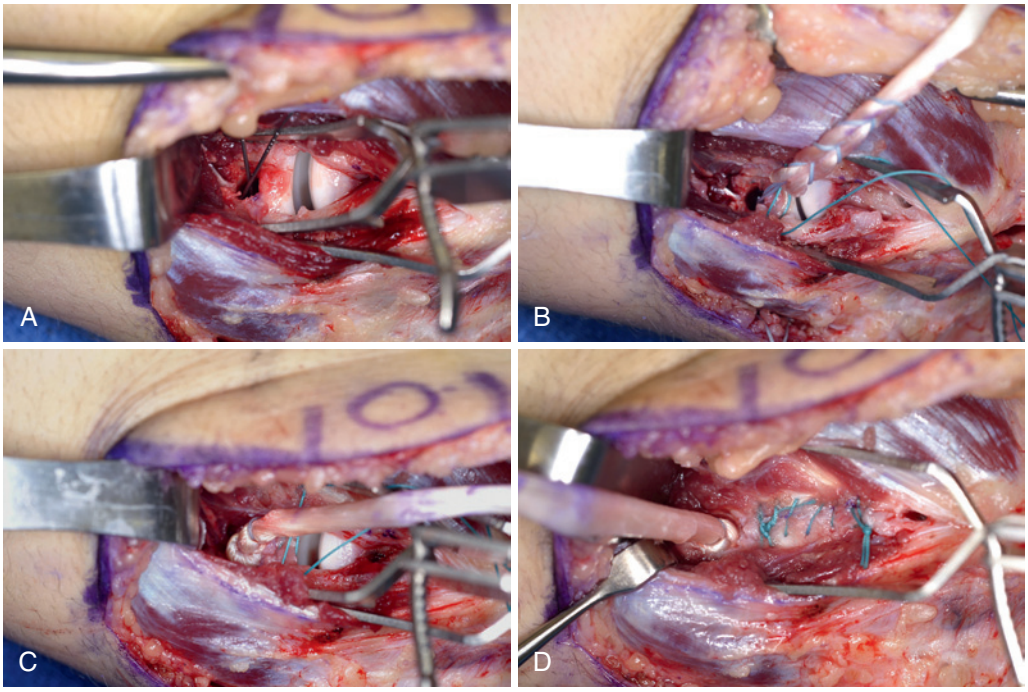

FIGURE 23.8 **A,** Intraoperative photograph depicting a single ulnar tunnel in the center of the sublime tubercule. Note the two ligature passers which are positioned to thread the tendon sutures through the ulna. **B,** A single semitendinosis hamstring autograft is now being advanced into the tunnel. **C,** Final graft seating with the sutures tied over bone bridge on the posterolateral cortex of the ulna. **D,** The tendon has been reflected distally, revealing the repair of the native ligament. Note how this completely covers the ulnohumeral joint. (Copyright © Mark S. Cohen, Chicago, IL.)

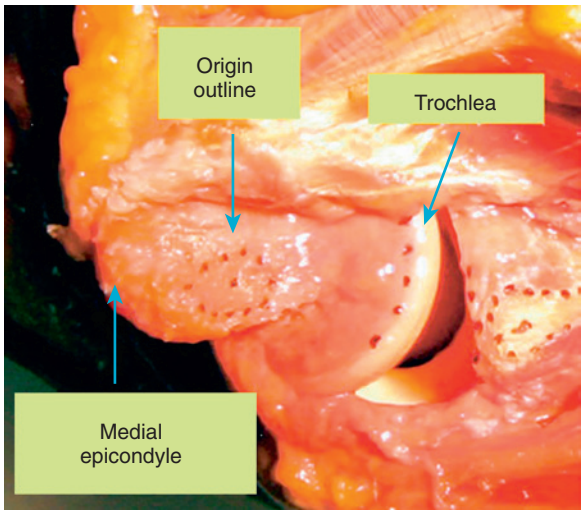

FIGURE 23.9 Cadaveric specimen depicting the origin of the anterior bundle of the medial collateral ligament on the medial epicondyle. Note how the ligament originates on the inferior face of the epicondyle at the center of its height (base to tip). One can also see the outline of the distal ligament attachment on the sublime tubercle of the ulna *(outlined with dots)*. (Dugas JR, Ostrander RV, Cain EL, et al: Anatomy of the anterior bundle of the ulnar collateral ligament. *J Shoulder Elbow Surg* 16:657–660, 2007. Reproduced with permission from Elsevier.)

ligament edge and the tunnel. Proximally, the ligament is repaired up to the humerus without completely blocking the tunnel entry point.

For the humerus, a docking technique is used as it was for the lateral reconstruction. Care is taken not to make the graft too short. Once the proximal running, locking suture is placed, the suture is guided through the humerus and threaded through an endobutton (Figure 23.10). During graft tightening, care is taken to lift the elbow off of the table to remove any valgus stress. In addition, the elbow is placed in maximum supination, which closes down the medial ulnohumeral joint. The elbow can be moved from 30 to 90 degrees of its range of motion several times to pretension the graft, at which time the sutures are tied over the endobutton. The suture knot is pushed laterally, and the medial triceps fascia can typically be closed, protecting the ulnar nerve from the endobutton and suture knot if it is not to be transposed.

Once secured, the arms of the graft can be sutured down to the underlying native ligament to reinforce the reconstruction. This is often unnecessary, and again it must be appreciated that the ulnar nerve rests just posterior to the native ligament and graft. The flexor-pronator muscle split is repaired, and the ulnar nerve is either maintained or transposed anteriorly into a subcutaneous position. A compressive dressing is applied, with a splint maintaining the elbow in approximately 90 degrees of flexion.

Postoperative Management and Expectations

The elbow is immobilized in a splint for the first week after operation. Following this, rehabilitation begins, initially concentrating on the recovery of elbow motion. A long-arm splint is used between exercises for comfort and support. Gentle isometric strengthening is initiated at 6 to 8 weeks. A light underhand medicine ball toss and light bench press exercises are begun at 12 to 20 weeks. At 20 weeks (5 months), light throwing on a flat ground is allowed at 45 feet every other day and can

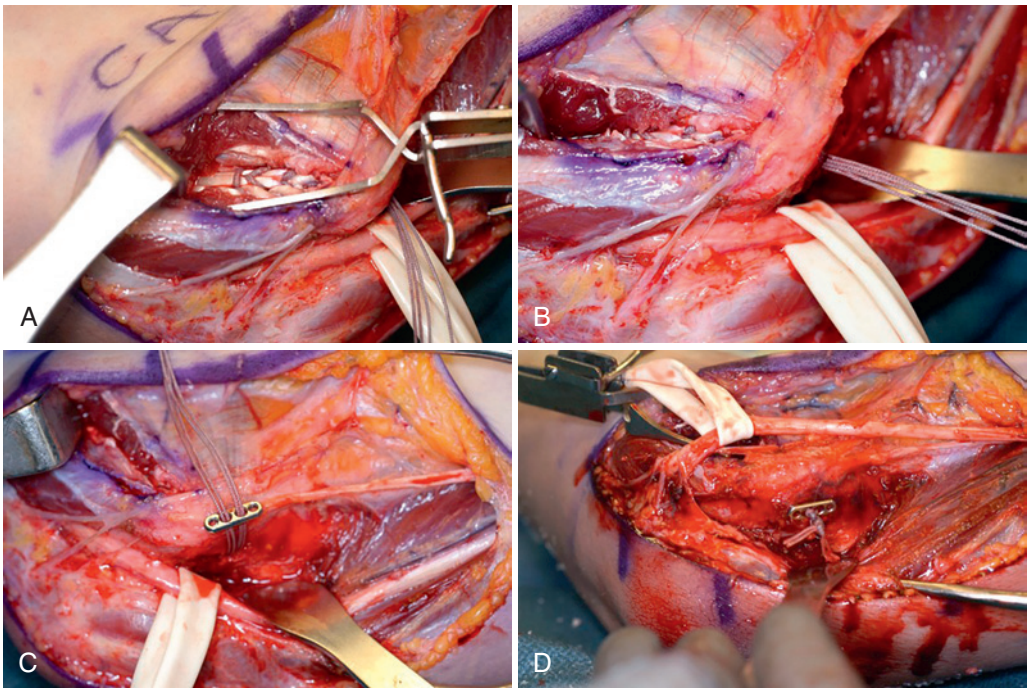

FIGURE 23.10 **A,** Intraoperative view of a patient undergoing medial ligament reconstruction. The graft has been seated distally, and the sutures have been passed through the humeral tunnel. Note the ulnar nerve (Penrose drain) and the medial antebrachial cutaneous sensory nerve branch beneath and distal to the epicondyle, respectively. These have been identified and protected. **B,** The sutures that have been placed in a running, locking fashion in the tendon ends have been passed through the humeral tunnel, exiting the posterior humeral column. **C,** With the ulnar nerve retracted, the sutures are passed through an endobutton, which functions as a washer for the suture knot. This simplifies the humeral tunnel configuration. **D,** Final tightening and seating of the sutures and the endobutton, completing the tendon graft reconstruction. In this case, the ulnar nerve has been completely dissected out in preparation for anterior transposition. (Copyright © Mark S. Cohen, Chicago.)

be slowly increased to 60 feet by the 6-month mark. Proper pitching mechanics have to be monitored, and strengthening is focused on the flexor-pronator muscle mass. Athletes who use overhead throwing can begin to throw off of a mound at 50% speed and effort at 7 to 8 months with no special pitches. Intensity is gradually increased, and lower-extremity weight training (including squats and lunges with weight) may be initiated. Playing in a game, including batting, is allowed at 8 to 10 months postoperatively; however, a full return to effective play may not be successful for several additional months.

Expected Outcomes

Several series have documented the success of reconstruction in returning athletes to competitive throwing. One of the earliest series reported a return to a high level of throwing of 68%.[19] More recent series quote a higher percentage of success of between 82% and 93%.[8,11,25,28,64,72,74] The further along the athlete is in the level of play (e.g., a high school athlete versus a professional athlete), the higher the percentage of success.

Complications

Complications of the procedure most commonly include ulnar nerve embarrassment, fracture of the ulnar bone bridge, or fracture of the medial epicondyle.[75] Identification and protection of the ulnar nerve is paramount during this procedure. The nerve is always dissected out and protected proximally during exposure of the posterior aspect of the medial humeral column. It must be retracted when drilling the humeral tunnel. In addition, in early cases, it may be prudent to first identify the ulnar nerve distally between the two heads of the flexor carpi ulnaris. The muscle split for ligament exposure will then be just anterior to this level. It cannot be overemphasized how close the nerve lies relative to the medial ligament. Even retractors placed during the flexor-pronator muscle split can compromise the nerve. To avoid postoperative humeral fracture, we have found the described cannulated drill technique to be helpful. It allows precise planning for the tunnel path. Distally, a single tunnel also minimizes the potential for a fracture of the sublime tubercle bone bridge.

REFERENCES

1. Ahmad CS, Lee TQ, El Attrache NS: Biomechanical evaluation of a new ulnar collateral ligament reconstruction technique with interference screw fixation. *Am J Sports Med* 31(3):332–337, 2003.
2. An KN, Zobitz ME, Morrey BF: Biomechanics of the elbow. In Morrey BF, editor: *The elbow and its disorders*, ed 4, St. Louis, 2009, WB Saunders, pp 39–63.
3. Anakwenze OA, Kancherla VK, Iyengar J, et al: Posterolateral rotatory instability of the elbow. *Am J Sports Med* 42(2):485–491, 2014.
4. Anakwenze OA, Kwon D, O'Donnell E, et al: Surgical treatment of posterolateral rotatory instability of the elbow. *Arthroscopy* 30(7):866–871, 2014.
5. Andrews JR, Timmerman LA: Outcome of elbow surgery in professional baseball players. *Am J Sports Med* 23(4):407–413, 1995.
6. Aoki M, Takasaki H, Muraki T, et al: Strain on the ulnar nerve at the elbow and wrist during throwing motion. *J Bone Joint Surg Am* 87:2508–2514, 2005.
7. Athwal GS, Faber KJ, King GJ, et al: Crista supinatoris fractures of the proximal part of the ulna. *J Bone Joint Surg Am* 96(4):326–331, 2014.

8. Azar FM, Andrews JR, Wilk KE, et al: Operative treatment of ulnar collateral ligament injuries of the elbow in athletes. *Am J Sports Med* 28:16–23, 2000.
9. Baghdadi YM, Morrey BF, O'Driscoll SW, et al: Revision allograft reconstruction of the lateral collateral ligament complex in elbows with previous failed reconstruction and persistent posterolateral rotatory instability. *Clin Orthop Relat Res* 472(7):2061–2067, 2014.
10. Berg EE, DeHoll D: Radiography of the medial elbow ligaments. *J Shoulder Elbow Surg* 6:528–533, 1997.
11. Cain EL, Jr, Andrews JR, Dugas JR, et al: Outcome of ulnar collateral ligament reconstruction of the elbow in 1281 athletes: results in 743 athletes with minimum 2-year follow-up. *Am J Sports Med* 38(12):2426–2434, 2010.
12. Callaway GH, Field LD, Deng XH, et al: Biomechanical evaluation of the medial collateral ligament of the elbow. *J Bone Joint Surg Am* 79:1223–1231, 1997.
13. Ciccotti MG, Jobe FW: Medial collateral ligament instability and ulnar neuritis in the athlete's elbow. *Instr Course Lect* 48:383–391, 1999.
14. Cohen MS: Lateral collateral ligament instability of the elbow. *Hand Clin* 24(1):69–77, 2008.
15. Cohen MS: Lateral collateral ligament reconstruction. In Baker CL, Plancher KD, editors: *Operative Treatment of Elbow Injuries*, New York, 2002, Springer-Verlag, pp 101–108.
16. Cohen MS, Bruno RJ: The collateral ligaments of the elbow: anatomy and clinical correlation. *Clin Orthop Relat Res* 383:123–130, 2001.
17. Cohen MS, Hastings H: Acute elbow dislocation: evaluation and management. *J Am Acad Orthop Surg* 6(1):15–23, 1998.
18. Cohen MS, Hastings H: Rotatory instability of the elbow: the role of the lateral stabilizers. *J Bone Joint Surg Am* 79:225–233, 1997.
19. Conway JE, Jobe FW, Glousman RE, et al: Medial instability of the elbow in throwing athletes: treatment by repair or reconstruction of the ulnar collateral ligament. *J Bone Joint Surg Am* 74:67–83, 1992.
20. Daluiski A, Schrumpf MA, Schreiber JJ, et al: Direct repair for managing acute and chronic lateral ulnar collateral ligament disruptions. *J Hand Surg [Am]* 39(6): 1125–1129, 2014.
21. Davidson PA, Pink M, Perry J, et al: Functional anatomy of the flexor pronator muscle group in relation to the medial collateral ligament of the elbow. *Am J Sports Med* 23:245–250, 1995.
22. Dines JS, El Attrache NS, Conway JE, et al: Clinical outcomes of the DANE TJ technique to treat ulnar collateral ligament insufficiency of the elbow. *Am J Sports Med* 35(12):2039–2044, 2007.
23. Dines JS, Jones KJ, Kahlenberg C, et al: Elbow ulnar collateral ligament reconstruction in javelin throwers at a minimum 2-year follow-up. *Am J Sports Med* 40(1):148–151, 2012.
24. Dodson CC, Slenker N, Cohen SB, et al: Ulnar collateral ligament injuries of the elbow in professional football quarterbacks. *J Shoulder Elbow Surg* 19(8):1276–1280, 2010.
25. Dodson CC, Thomas A, Dines JS, et al: Medial ulnar collateral ligament reconstruction of the elbow in throwing athletes. *Am J Sports Med* 34(12):1926–1932, 2006.
26. Dugas JR, Ostrander RV, Cain EL, et al: Anatomy of the anterior bundle of the ulnar collateral ligament. *J Shoulder Elbow Surg* 16:657–660, 2007.
27. Dunning CE, Zarzour ZDS, Patterson SD, et al: Ligamentous stabilizers against posterolateral rotatory instability of the elbow. *J Bone Joint Surg Am* 83:1823–1828, 2001.
28. El Attrache NS, Bast SC, David T: Medial collateral ligament reconstruction. *Tech Shoulder Elbow Surg* 2:38–49, 2001.
29. Farrow LD, Mahoney AJ, Stefancin JJ, et al: Quantitative analysis of the medial ulnar collateral ligament footprint and its relationship to the ulnar sublime tubercle. *Am J Sports Med* 39(9):1936–1941, 2011.
30. Floris S, Olsen BS, Dalstra M, et al: The medial collateral ligament of the elbow joint: anatomy and kinematics. *J Shoulder Elbow Surg* 7:345–351, 1998.
31. Froimson AI, Anouchi YS, Seitz WH, et al: Ulnar nerve decompression with medial epicondylectomy for neuropathy at the elbow. *Clin Orthop Relat Res* 265:200–206, 1991.
32. Fuss FK: The ulnar collateral ligament of the human elbow joint: anatomy, function and biomechanics. *J Anat* 175:203–212, 1991.
33. Grumet RC, Friel NA, Cole BJ: Bony avulsion of the medial ulnar collateral ligament in a gymnast: a case report. *J Shoulder Elbow Surg* 19(7):e1–e6, 2010.
34. Hastings HH, Cohen MS: General deep approaches to the elbow: lateral approaches. *Tech Shoulder Elbow Surg* 3(1):10–15, 2002.
35. Heithoff SJ, Millender LH, Nalebuff EA, et al: Medial epicondylectomy for the treatment of ulnar nerve compression at the elbow. *J Hand Surg [Am]* 15:22–29, 1990.
36. Hill NB, Bucchieri JS, Shon F, et al: Magnetic resonance imaging of injury to the medial collateral ligament of the elbow: a cadaveric model. *J Shoulder Elbow Surg* 9:18–22, 2000.
37. Hotchkiss RN, Weiland AJ: Valgus stability of the elbow. *J Orthop Res* 5:372–377, 1987.
38. Imatani J, Ogura T, Morito Y, et al: Anatomic and histologic studies of lateral collateral ligament complex of the elbow joint. *J Shoulder Elbow Surg* 8(6):625–627, 1999.
39. Jobe FW, Kvitne RS: Reconstruction of the ulnar collateral ligament of the elbow. *Tech Orthop* 6:39–42, 1991.
40. Jobe FW, Stark H, Lombardo SJ: Reconstruction of the ulnar collateral ligament in athletes. *J Bone Joint Surg Am* 68:1158–1163, 1986.
41. Jones KJ, Conte S, Patterson N, et al: Functional outcomes following revision ulnar collateral ligament reconstruction in major league baseball pitchers. *J Shoulder Elbow Surg* 22(5):642–646, 2013.
42. Jones KJ, Dodson CC, Osbahr DC, et al: The docking technique for lateral ulnar collateral ligament reconstruction: surgical technique and clinical outcomes. *J Shoulder Elbow Surg* 21(3):389–395, 2012.
43. Josefsson PO, Johnell O, Wendeberg B: Ligamentous injuries in dislocations of the elbow joint. *Clin Orthop Relat Res* 221:221–225, 1987.
44. Kalainov DM, Cohen MS: Posterolateral rotatory instability of the elbow in association with lateral epicondylitis. *J Bone Joint Surg Am* 87:1120–1125, 2005.
45. Kuroda S, Sakamaki K: Ulnar collateral ligament tears of the elbow joint. *Clin Orthop Relat Res* 208:266–271, 1986.
46. Lee BP, Teo LH: Surgical reconstruction for posterolateral rotatory instability of the elbow. *J Shoulder Elbow Surg* 12(5):476–479, 2003.
47. Lin KY, Shen PH, Lee CH, et al: Functional outcomes of surgical reconstruction for posterolateral rotatory instability of the elbow. *Injury* 43(10):1657–1661, 2012.
48. Morrey BF: Re-operation for failed tennis elbow surgery. *J Shoulder Elbow Surg* 1:47–49, 1992.
49. Morrey BF, An KN: Articular and ligamentous contributions to the stability of the elbow joint. *Am J Sports Med* 11:315–319, 1983.
50. Morrey BF, An KN: Functional anatomy of the ligaments of the elbow. *Clin Orthop Relat Res* 201:84–90, 1985.
51. Morrey BF, Tanaka S, An KN: Valgus stability of the elbow: a definition of primary and secondary constraints. *Clin Orthop Relat Res* 265:187–195, 1991.
52. Nestor BJ, O'Driscoll SW, Morrey BF: Ligamentous reconstruction for posterolateral rotatory instability of the elbow. *J Bone Joint Surg Am* 4:1235–1241, 1992.
53. Ochi N, Ogura T, Hashizume H, et al: Anatomic relation between the medial collateral ligament of the elbow and the humero-ulnar joint axis. *J Shoulder Elbow Surg* 8:6–10, 1999.
54. O'Driscoll SW, Bell DF, Morrey BF: Posterolateral rotatory instability of the elbow. *J Bone Joint Surg Am* 73:440–446, 1991.
55. O'Driscoll SW, Jaloszynski R, Morrey BF, et al: Origin of the medial ulnar collateral ligament. *J Hand Surg [Am]* 17:164–168, 1992.
56. O'Driscoll SW, Jupiter JB, Cohen MS, et al: Difficult elbow fractures: pearls and pitfalls. *Instr Course Lect* 52:113–136, 2003.
57. O'Driscoll SW, Lawton RL, Smith AM: The ''moving valgus stress test'' for medial collateral ligament tears of the elbow. *Am J Sports Med* 33:231–239, 2005.
58. O'Driscoll SW, Morrey BF, Korinek S, et al: Elbow subluxation and dislocation. A spectrum of instability. *Clin Orthop Relat Res* 280:186–197, 1992.
59. O'Driscoll SW, Spinner RJ, McKee MD, et al: Tardy posterolateral rotatory instability of the elbow due to cubitus varus. *J Bone Joint Surg Am* 83:1358–1369, 2001.
60. Paletta GA, Jr, Klepps SJ, Difelice GS, et al: Biomechanical evaluation of 2 techniques for ulnar collateral ligament reconstruction of the elbow. *Am J Sports Med* 34(10):1599–1603, 2006.
61. Regan WD, Korinek SL, Morrey BF, et al: Biomechanical study of ligaments around the elbow joint. *Clin Orthop Relat Res* 271:170–179, 1991.
62. Rettig AC, Sherrill C, Snead DS, et al: Nonoperative treatment of ulnar collateral ligament injuries in throwing athletes. *Am J Sports Med* 29:15–17, 2001.
63. Rohrbough JT, Altchek DW, Hyman J, et al: Medial collateral ligament reconstruction of the elbow using the docking technique. *Am J Sports Med* 30(4):541–548, 2002.
64. Deleted in review.
65. Savoie FH, 3rd, Morgan C, Yaste J, et al: Medial ulnar collateral ligament reconstruction using hamstring allograft in overhead throwing athletes. *J Bone Joint Surg Am* 95(12):1062–1066, 2013.
66. Schwab GH, Bennett JB, Woods GW, et al: Biomechanics of elbow instability: the role of the medial collateral ligament. *Clin Orthop Relat Res* 146:42–52, 1980.
67. Shah RP, Lindsey DP, Sungar GW, et al: An analysis of four ulnar collateral ligament reconstruction procedures with cyclic valgus loading. *J Shoulder Elbow Surg* 18(1):58–63, 2009.
68. Shukla DR, O'Driscoll S: Atypical etiology of lateral collateral ligament disruption and instability. *J Orthop Trauma* 27(6):e144–e146, 2013.
69. Smith AM, O'Driscoll SW: Diagnosing medial elbow pain in throwers. *J Musculoskeletal Med* 22:305–316, 2005.
70. Sojbjerg JO, Helmig P, Kjaersgaard-Anderson P: Dislocation of the elbow: an experimental study of the ligamentous injuries. *Orthopedics* 12:461–463, 1989.
71. Sojbjerg JO, Ovesen J, Nielsen S: Experimental elbow instability after transection of the medial collateral ligament. *Clin Orthop Relat Res* 218:186–190, 1987.

72. Thompson WH, Jobe FW, Yocum LA, et al: Ulnar collateral ligament reconstruction in athletes: muscle-splitting approach without transposition of the ulnar nerve. *J Shoulder Elbow Surg* 10:152–157, 2001.
73. Timmerman LA, Schwartz ML, Andrews JR: Preoperative evaluation of the ulnar collateral ligament by magnetic resonance imaging and computed tomography arthrography. Evaluation in 25 baseball players with surgical confirmation. *Am J Sports Med* 22(1):26–31, 1994.
74. Vitale MA, Ahmad CS: The outcome of elbow ulnar collateral ligament reconstruction in overhead athletes: a systematic review. *Am J Sports Med* 36:1193–1205, 2008.
75. Watson JN, McQueen P, Hutchinson MR: A systematic review of ulnar collateral ligament reconstruction techniques. *Am J Sports Med* 42(10):2510–2516, 2014.
76. Werner SL, Fleisig GS, Dillman CJ, et al: biomechanics of the elbow during baseball pitching. *J Orthop Sports Phys Ther* 1:274–278, 1993.

24

Treatment of the Stiff Elbow

Robert N. Hotchkiss

Although this text carries the title *Operative Hand Surgery* and was originally conceived as a compilation of techniques for surgery of the hand, attention to the problem of the stiff elbow is warranted for three reasons. First, loss of motion of the elbow directly restricts the ability to place the hand in space to and from the body, thereby disabling the function of the entire upper limb. Second, surgeons skilled in operations on the hand are increasingly called on to evaluate and treat stiff elbows following trauma or caused by arthritis and other conditions. Surgical release of a contracted elbow often requires meticulous dissection of neurovascular structures at the elbow, an area of anatomy that usually falls most comfortably under the purview of the hand surgeon. Finally, in the past 20 years, development of more dependable methods and techniques has made contracture release more reliable and clinically possible.

Before the 1990s, the published literature, including textbooks on orthopedics, reflected a general reluctance to treat the stiff elbow surgically. The condition was seldom discussed in textbooks; Wilson[78] was one of the few who wrote about the subject in the 1940s. The terms that were applied in the literature, such as *contracture*, *stiff elbow, posttraumatic elbow*, and *arthrolysis,* were not precise enough for comparative purposes. Since then, operative treatment has become more common and results more predictable, although the lack of uniformity in reporting for evidence-based comparison persists. In general, reported results reflect a consensus that open capsulectomy, carefully performed on a willing patient, using a medial, lateral, or mediolateral approach to the elbow joint, results in a consistent and notable improvement in motion with only a small risk of serious complications.* The use of arthroscopy alone remains controversial,[21,32,57,64] and the need for hinged external fixation seems more limited.[60,71] For further reading, I recommend the well-written summaries of King,[33] Modabber and Jupiter,[44] and Sojbjerg.[68]

CAUSES AND PREVENTION OF THE STIFF AND CONTRACTED ELBOW

Our understanding of what creates a stiff joint is limited. We do know that an intraarticular effusion causes the joint to assume a position of flexion to maximize the volume of the capsule and minimize pressure. This may explain the position of flexion assumed for comfort immediately after injury.[7] In addition, there are biologic factors that help explain this process.[25] Once in a flexed position, the flexors and extensors tend to contract together, perhaps to minimize pain, leading to a cycle of increasing stiffness. More research is needed to understand the neuromuscular response to pain and trauma.[3,5,55] Before injury and capsular scarring has occurred, the elbow has adequate clearance for full extension and flexion, and the capsule is thin and usually transparent. After trauma, the capsule thickens, limiting flexion and extension as a "block" and a "tether," respectively. The thickness of the capsule that requires excision, even after minimal trauma, may exceed 5 mm (Figure 24.1).

It is important to institute active motion with gentle passive assistance as soon as is practical after injury, although there are times when rehabilitation must be tempered owing to tenuous fixation of intraarticular fractures. Often, unfortunately, motion is not started until 6 weeks or longer after a simple fracture or dislocation, and by that time it is often too late.[66] Even with attentive, supervised therapy that is initiated early, however, many patients will not regain optimal motion after trauma.

Our tools for minimizing contracture after injury are generally limited to physical therapy and splinting. Manipulation has been reported as useful but should be approached with caution after fracture or in the presence of internal fixation. Undoubtedly, as we begin to understand more about protective or overactive muscle reflexes and pain, as well as the molecular biology of scar formation, we will have better tools to minimize pathologic contractures.

It is helpful to remember a few guidelines when discussing a stiff elbow with a patient and the family, especially after trauma:

1. Unless evidence of gross malpractice exists, the contracture is seldom caused by the method of internal fixation or technical performance of the surgeon.
2. The therapist usually has not *failed to improve* the patient's motion. Many therapists have minimal experience with stiff elbows following trauma and are appropriately timid. However, blaming a therapist for using a dynamic splint for 9 months with little success (which is not uncommon) serves no purpose. The therapist is often caught between the frustration of the patient and the hidden worry of the surgeon, both of whom see the failure to regain motion as a defeat.
3. The patient is usually not at fault, either. It is not uncommon for a patient to state that both the surgeon and the therapist have told the patient "You didn't work hard enough." Patients respond to treatment differently, and those with a traumatized elbow demonstrate a wide range of responses. It is helpful to listen carefully to the patient and family. Most will tell of weeks and months of visits

*See references 22, 29, 41, 49, 67, 74, and 76.

to the therapist, painful dynamic splints, and, finally, frustration. Any patient on whom one is considering operative treatment must be brought into the team and made to feel an integral part of the solution.

In summary, there is usually little value in spending time laying blame for a stiff or contracted elbow. A more productive use of time can be discussing your evaluation and plans to improve the situation and your rationale for treatment.

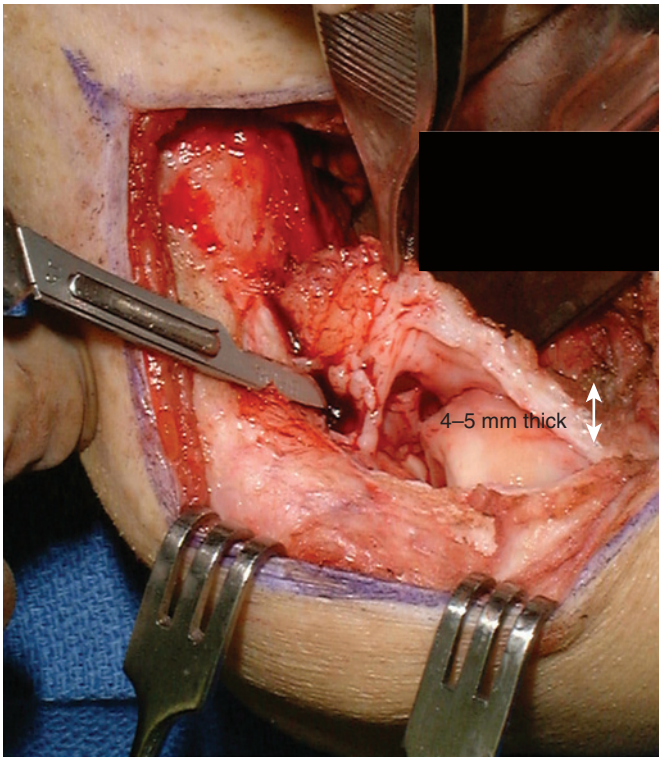

FIGURE 24.1 The anterior capsule is being elevated, viewed from the lateral exposure. The capsule is approximately 5 mm thick.

PREOPERATIVE ASSESSMENT

It is helpful to categorize the contracture as severe, moderate, or minimal (Table 24.1). This classification permits a starting point for assessment, operative planning, postoperative management, and expectations. As the surgeon gains experience, the arbitrary categories become a continuum and consequently less valuable.

Operative treatment of a stiff elbow begins with an understanding of the probable cause of the patient's contracture and the patient's functional requirements, both vocationally and recreationally. Other factors such as the patient's age and the time since injury must be considered (discussed in more detail later). These factors, taken together, determine not only the indications for surgery but also which surgical approach and type of postoperative treatment are likely to produce a successful result. The checklist in Table 24.1 is intended to help guide patient selection, operative approach, and regimen of postoperative rehabilitation. However, the need for midcourse corrections in the operating room and during the postoperative period is a constant and fundamental feature of operative treatment for a stiff elbow. To make these adjustments, the surgeon and therapist must have all of the resources for assessment and treatment available.

Patient History

Age of the Patient

The group of patients with the highest success rate in my practice is from 18 to 50 years old. These are generally people with high motivation who are capable of understanding their disability and seek to change it. The results reported in the

TABLE 24.1 Categories of Posttraumatic Stiffness

Category	Range of Motion	Associated Findings and Characteristics	Likely Treatment	Likely Outcome
Minimal	Less than 30 degrees of motion loss (usually extension)	Single isolated injury Single previous surgery Near-normal joint Identifiable cause of motion loss	Open release with limited exposure Possible arthroscopic release Outpatient PT	Nearly complete recovery of motion
Moderate	40 to 100 degrees of total motion	Moderately severe injury More than one previous operation Ulnar nerve at risk Moderate HO present, both anteriorly and posteriorly Minor joint surface injury	Ulnar nerve release (transposition) Open release with medial and lateral exposure Coordinated PT Inpatient CPM with indwelling catheter	Seldom regain full extension
Severe	Less than 30 degrees total motion	Severe injury Several previous operative procedures "Enveloping fibrosis" Joint surface injury may be present Nerve entrapment or risk Often, all three of above findings Massive HO Potential joint surface incongruity Triceps may be adherent to midhumerus	Complete dissection/protection of all nerves Resection of HO from all blocking locations Triceps tenolysis Possible hinged external fixation Protection of posterolateral ligament Comprehensive-coordinated PT (indwelling catheter)	30° to 130° of motion achieved Prolonged rehabilitation Strength and power often limited

CPM, Continuous passive motion; *HO*, heterotopic ossification; *PT*, physical therapy.

pediatric population are more varied.[2,41,43,69] Despite this, my success rate has improved with careful selection and better management. I have reviewed 30 patients with open elbow contracture release at a mean age of 13.9 years (range, 5 to 18 years). In a somewhat arbitrary fashion, I separated the patients into three groups. Seven patients were younger than 10 years of age, 9 were between 10 and 14 years, and 14 were between 15 and 18 years at the time of surgery. The net improvement in the total arc of elbow motion ranged from approximately 70 degrees to 125 degrees and did not vary significantly between groups. A child with joint injury and cartilage damage is still very challenging, and surgery should be contemplated with caution. This is especially true in adolescents who are in a rebellious phase or who lack the maturity for cooperation.[2] Occasionally, parents will bring an unwilling and uncooperative teenager for consideration of operative contracture release. Such patients will generally not participate in the postoperative therapy program and fail to regain motion. Some may even worsen after operative treatment. However, some individuals in this age group can also be quite rewarding to treat, especially those injured during participation in organized sports (such as gymnastics and wrestling), who are anxious to return to the team. They are usually highly motivated and will follow instructions to the letter.

Lower rates of success are generally achieved with the elderly.[41] Elderly patients with a stiff elbow may have significant associated swelling of the hand and stiffness of the shoulder, both of which limit the possibility of success and the impact of improved elbow mobility. In addition, the quality of the joint may be so poor that the only reasonable option is total elbow replacement. In these cases, the long-standing dysfunction, usually caused by protracted immobilization of the entire limb, makes for prolonged and often incomplete restoration of function.

Duration of Contracture and Timing of Operative Release

There has been much speculation about the timing of contracture release, especially when considering excision of heterotopic ossification (HO)[75] (Figure 24.2). Although the use of technetium bone scans was touted in the past for predicting the "activity" and, therefore, the probability of recurrence of HO, this test should be completely discarded as irrelevant because the scan sometimes remains "hot" for many years.

The optimal timing of intervention depends on the source of the contracture. If the loss of motion is due to a fracture that has fallen apart because of failed internal fixation or a persistently dislocated elbow, waiting serves no purpose.[39] These patients should have the joint surfaces and congruity restored as soon as is practical in the hope of preserving some function. These cases are the most difficult and require both contracture release and restoration of the architecture, followed by immediate motion. Often, external fixation, hinged or fixed, is required (see Chapter 22).

For patients who have normal or nearly normal articulation, the timing of intervention should be based on documented failure of physical therapy and progressive splinting to improve motion. Although there is increased interest in earlier operative intervention, it is important to be certain that all nonoperative methods have been exhausted. In general, most patients do not improve beyond 4 to 6 months after injury (except children with supracondylar fractures). At the 6-month mark, unless there is significant brain injury, intervention can be considered. In cases with HO, the process has usually matured and can safely be removed at this time as well without fear of recurrence (see Fig. 24.2). Some have reported that contracture release after more than 1 year after injury has been associated with a lesser gain in motion.[22] For patients who have had a significant loss of motion for more than 10 years, regaining substantial motion may be impossible without humeral shortening and ulnohumeral arthroplasty because of changes in length of the median nerve and brachial artery.

Pain and the Stiff Elbow

Most uncomplicated posttraumatic contractures are not very painful. There may be some discomfort at the end range of motion, but within the zone of limited motion, the patient is generally comfortable. If this is not the case, one should suspect posttraumatic arthrosis or joint incongruity. Patients who have had excessively forceful manipulations or passive mobilization in a misguided attempt to restore motion at a late date may have reactive pain and swelling. However, as the scar matures and tissue equilibrium is regained, this inflammatory response usually abates.

Ipsilateral shoulder pain is common with flexion contractures over 40 degrees as the patient attempts to position the hand at the side while walking or carrying, causing the shoulder to extend. In the patient with long-standing stiffness, an examination of the shoulder is helpful, because limited rotation or abduction may decrease access during surgery of the elbow.

Another source of pain may be ulnar nerve entrapment.[13] Patients with a sensitive or trapped ulnar nerve after trauma may not exhibit the usual symptoms and signs of cubital tunnel syndrome. Instead of a definitive loss of sensibility in the distribution of the ulnar nerve, these patients may only exhibit resistance and reluctance to flexion in the first 2 months and tenderness along the medial elbow. They may describe "tightness" or "soreness" in the ulnar digits without frank sensory changes or weakness. As the contracture matures, the ulnar nerve is not under tension and therefore may not exhibit dysfunction.

In primary arthritis of the elbow associated with anterior and posterior osteophyte formation, pain is usually present at the end range of flexion and extension. That is where the osteophytes impinge. The middle range is usually comfortable and without crepitation. However, as the condition progresses and further deterioration of the trochlear surface of the humerus and other cartilage loss occurs, the pain may be more constant, severe, and present in all positions.

Assessment of Motion Loss and the Effect on Function

What Degree of Motion Is Necessary?

Morrey and colleagues studied normal subjects by electrogoniometry and determined that most tasks of daily living could be performed in a range of 30 to 130 degrees of flexion and extension.[50] This study was helpful in defining what most normal people use throughout the course of daily activity, but it did not ask the question, *what is required for these tasks*.

With the assistance of our therapy department, my colleagues and I studied 52 patients with decreased elbow motion and recorded the tasks that they could perform with and

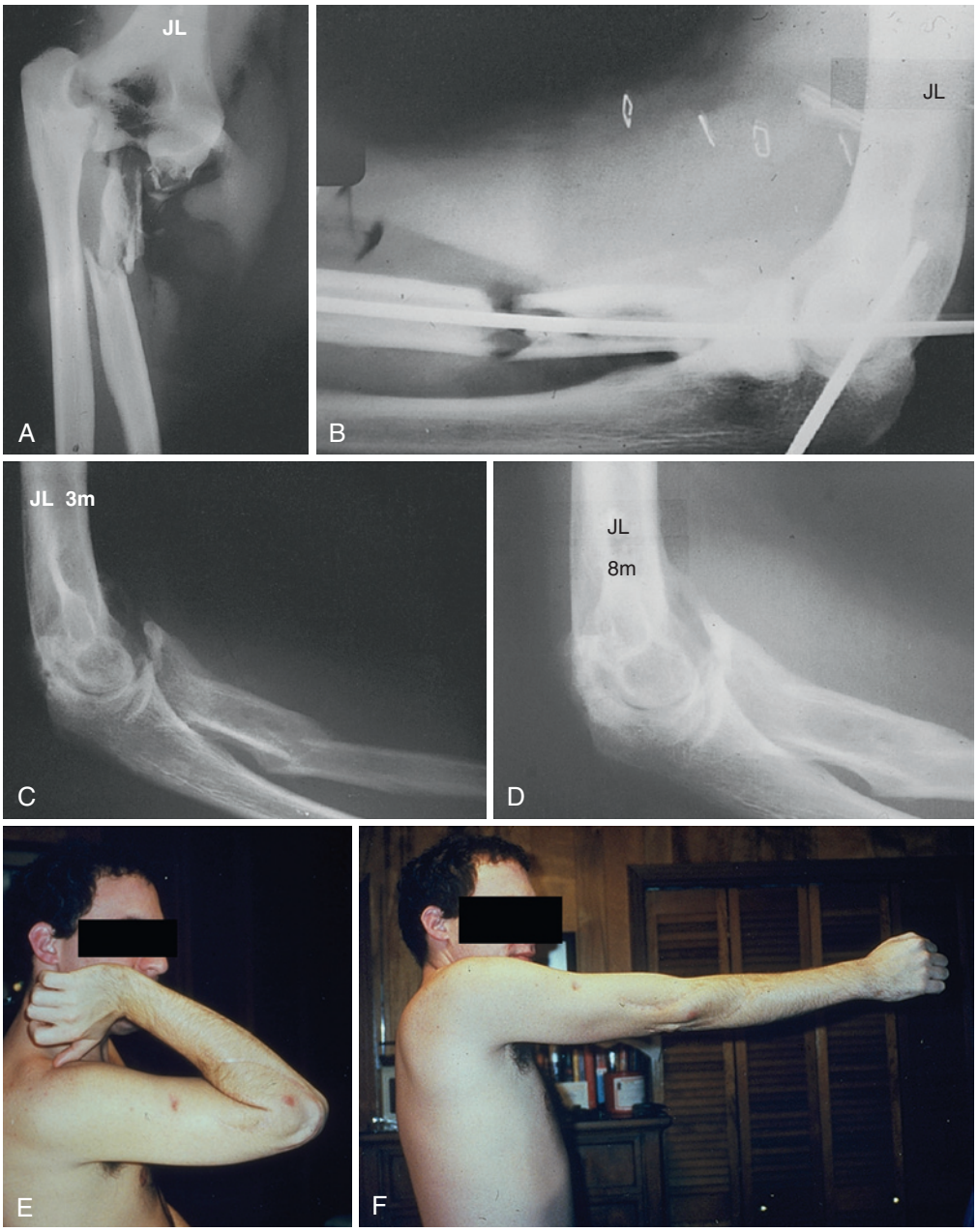

FIGURE 24.2 **A,** Severe open injury caused by a motorboat propeller in a lake. **B,** The joint was pinned and immobilized in a reduced position. Plates were not used for fear of infection and soft tissue stripping. **C,** Three months after the injury, wispy immature heterotopic ossification can be seen forming along the anterior surface of the joint. **D,** At 8 months, both sides of the joint are enveloped by bone. The patient has no motion in the elbow. **E** and **F,** Two years after open release and hinged external fixation with a Compass Hinge, the patient has nearly full extension and flexion without pain or deterioration of the joint. This excellent result was possible because the initial treating surgeon kept the joint reduced. Despite the ensuing stiffness, the reduced joint protected cartilage and ligaments. (Copyright © Robert N. Hotchkiss.)

without specified adaptations. Twenty elbow-dependent tasks ranging from buttoning a collar to reaching for a lower drawer were evaluated. The goal was to examine which tasks could be performed and, of those performed, which required a significant postural or spatial adaptation. The study found that patients lacking flexion of more than 110 degrees were unlikely to be able to button a collar, shave the face, place an earring, or tie a scarf or necktie. Loss of elbow flexion limits using eating utensils and self-care of the hair, face, and neck. In our study, patients could not compensate for loss of flexion; the neck and wrist are limited in their capacity to flex to assist the hand in reaching the neck, face, head, or ears. Although loss of flexion is generally ignored in the published literature, every effort should be made to improve flexion, especially when there is less than 105 degrees present.

Patients with lack of extension, however, can much more easily accommodate for the loss. In our study, flexion contracture of greater than 40 degrees required positional adaptation, but the tasks could still be accomplished. Reaching the feet or toes was possible with increased knee, hip, and trunk flexion.

For opening low drawers, the patient could kneel to pull them open bimanually. In other words, positioning the hand in space, away from the body or to the feet, is limited with loss of extension, but the patient can accommodate for this by moving the trunk (and hand) closer to the object of interest.

An important conclusion from our study was that if improved extension is sought, it should not be obtained at the expense of flexion. This is not a "trade" that patients will want to make.

In the preoperative assessment it is helpful for patients to detail what tasks they have difficulty performing because of limitation of motion. Patients may be functional with a 40-degree flexion contracture but simply not like the appearance. Given the complexity of the surgery and the postoperative effort usually required, I generally do not recommend contracture release for the improvement of appearance only.

Elbow motion must be carefully documented by goniometry and a standardized technique. I have found the interobserver error in trained personnel to be about ±10 degrees. My own intraobserver error is about 5 degrees when using a large goniometer. Given these numbers, I doubt the value of reporting elbow measurements in increments of less than 5 degrees. It is important for the surgeon to measure the angles personally and not merely rely on measurements recorded by others.

Indications for Contracture Release

It is impossible to set absolute indications for operative contracture release. Generally, any patient with a 40-degree loss of extension or with less than 105 degrees of flexion will benefit from improved motion and should be considered for contracture release. It is seldom possible to guarantee full extension, irrespective of the operative approach or postoperative management. This point is especially important to discuss with patients such as gymnasts, who require full extension, or even hyperextension, to "lock out" the arms during handstands or floor exercises. Occasionally, patients with posttraumatic contractures of 30 degrees or less, despite being very functional, seek nearly full extension for sports, especially for the throwing arm. If the contracture is simple and uncomplicated by joint incongruity, these patients can often be improved by either arthroscopic release or a release from the lateral approach alone.

Physical Examination of the Ulnar Nerve

The ulnar nerve is vulnerable to injury, scarring, and dysfunction after trauma, distal humeral internal fixation, and complex dislocations.[6] Hence, careful preoperative assessment of the nerve is mandatory. In many cases it is not possible to be certain whether the nerve has been transposed. Even if the previous operative note is available and states that a transposition was performed, the nerve may have slipped back into a more posterior position.

If the ulnar nerve is entrapped or shows signs of significant dysfunction, neurolysis and transposition at the time of contracture release can restore sensibility and strength in the proximal muscles innervated by the ulnar nerve. The more distal intrinsic muscles of the hand are less likely to recover, although occasionally in younger patients dramatic improvement may be seen.

Most patients with loss of flexion require ulnar nerve transposition at the time of surgery, and this point should be discussed with the patient. Patients with primary osteoarthritis of the elbow often demonstrate osteophytes extending into the cubital tunnel. These patients, usually middle-aged men, may have a subclinical, indolent course. When carefully examined, the intrinsic weakness may be subtle and the loss of sensibility discovered only with threshold measurements or two-point discrimination. If there is doubt, preoperative electrophysiologic testing, with special attention to electromyography, should be performed.

Patients may have temporary postoperative ulnar nerve dysfunction, especially if the nerve is already symptomatic. Most improve with neurolysis and transposition, but recovery is often slow if the dysfunction has been present for a long time.

When dissecting the ulnar nerve, there is seldom any reason to perform an internal neurolysis or intrafascicular or even epineural dissection. Instead, the goal is to free the nerve from the entrapment posterior to the axis of the joint and allow it to be transposed to the anterior position. Leaving a cuff of soft tissue, especially in a setting of reoperation, poses less threat to nerve function than trying to strip all soft tissue from the nerve.

Assessment of the Ulnohumeral Joint Surface After Trauma

The most challenging reconstructive problem is elbow stiffness with concomitant cartilage loss in the ulnohumeral joint. Hence, assessment of this surface either by computed tomography (CT) or magnetic resonance imaging (MRI) is paramount if the joint surface is suspected to be of poor quality. Ultimately, however, the articular surface must be inspected at the time of surgery to determine whether there is adequate cartilage in the functional zone of motion. The radiocapitellar surface can be sacrificed with radial head resection or excision of the capitellum. In some cases, the end-bearing surface of the radial head is devoid of cartilage, but patients are not symptomatic during forearm rotation. In these patients, typically middle-aged men with osteoarthritis, the radial head does not need to be addressed. However, if incongruity or poor cartilage surfaces in the ulnohumeral joint are present, a contracture release alone is not likely to be beneficial. I have made the mistake of improving motion but inducing pain by performing a contracture release in degenerated joints.

In the older patient with limited demand, total elbow replacement may be the optimal choice (see Chapter 27). In the younger patient with severe incongruity, interposition arthroplasty is sufficiently unpredictable that I seldom perform this procedure following trauma.

Imaging the Stiff Elbow

Many radiologic features need to be assessed before surgery is considered:

- What is the quality of the joint and relative health of the cartilage?
- Where is the hardware, and is it impeding motion? (Is removal necessary?)
- Where is the HO or impingement located?
- Are the fractures healed?

A significant flexion contracture may preclude visualization of the distal humeral articular surface with standard radiographic techniques. Typically, the technician places the film plate perpendicular to the joint at midrange. An anteroposterior view with the distal humerus lying flat on the cassette is a

helpful additional view. A true lateral view is also mandatory. In some cases I also obtain true lateral views in maximal active flexion and maximal active extension. Technicians find these difficult at first because the humerus tends to internally or externally rotate at the extremes of position and the "true lateral" view is lost.[37] These additional views may show subtle shifts of the joint, as well as previously unseen projections of heterotopic bone.

As noted previously, the quality of the articular surfaces in a stiff posttraumatic elbow is of paramount importance. The ulnohumeral joint is probably more important than the radiocapitellar joint, although having both intact and functional is optimal. Assessing this joint and the quality of the cartilage is best done with plain radiographs. If this is insufficient, CT scans with thin slices in the sagittal and coronal planes may be needed. I recommend 0.8-mm–thick contiguous slices with overlap. This acquisition method permits multiplanar reconstruction and other manipulations. Three-dimensional surface reconstructions can be helpful in preoperative planning.

For fracture cases, it is sometimes difficult to determine whether union has been achieved, especially when plates and screws overlie the area in question. CT is problematic because of "noise" from the metal; however, CT radiologists continue to improve their ability to suppress this effect, especially with titanium implants. MRI techniques are improving to better assess fragment healing, viability, and perfusion, even in the presence of metallic hardware.[15,36]

At no time have I used bone scans to assess a contracted elbow, finding them of no use in patients with posttraumatic contracture with or without heterotopic bone.

The Preoperative Discussion

Once you have determined that a surgical release *could* be performed, it is important to discuss expectations, the surgery, and the potential complications with the patient. From this discussion alone, the patient may shy away and appropriately conclude that it is possible to live quite well with the limitation of motion.

Much like rehabilitation after flexor tendon repair, without the full cooperation and dedication of the patient, surgery may not succeed. In fact, given the complexity of some cases, the attempted release may worsen motion.

As detailed later, each contracture requires at least two operative plans. If the first approach does not succeed in achieving the expected goal during surgery, the second option should be employed. If you believed that a medial approach to the joint would permit a complete capsulectomy but at surgery find the lateral structures both limiting and out of safe reach, then a concomitant lateral approach should be considered. Likewise, postoperative management varies greatly, depending on each patient's individual response. It is important to explain the variability in response to operative release. Fortunately, most patients with contractures understand this because they have already been told that this was in some way their fault or the fault of their "muscles." Some require very little supervised therapy, even little continuous passive motion (CPM); others need serial static progressive bracing (flexion and extension) and occasionally a carefully administered manipulation. For massive HO with long-standing contractures, I also explain the use of dynamic hinged external fixation. As a matter of disclosure, I helped design and patent the Compass Elbow Hinge (manufactured by Smith and Nephew, UK). However, for 15 years I have received no compensation in any form.

If during any of the discussion with the patient you detect unwillingness or wariness, waiting may be warranted. I also encourage patients to discuss their questions with other patients, and I keep a list of former patients willing to discuss their operative experience.

Patients should also be informed about the possibility of transient increased ulnar nerve symptoms.

Classifying the Contracture and Matching the Operative Plan

After deciding to proceed with contracture release, it is helpful to classify the contracture as minimal, moderate, or severe (see Table 24.1). This general guide may help in planning what is needed to succeed. The most common reason for a failed contracture release, in my opinion, is a failure on the part of the surgeon to abandon an orthodox method in favor of a less assured technique (arthroscopy) or to use a single anatomic approach to the joint when the potential gain in motion is not achieved at the time of surgery. The operative contracture release requires a progressive, adaptive surgical approach, and the surgeon must safely increase the exposure in order to excise the offending fibrosis on nearly all aspects of the joint, anteroposterior and mediolateral.[41,72] If an uncomplicated, simple dislocation has caused a 30-degree flexion contracture, arthroscopic capsular excision might be sufficient; however, this technique has little role in moderate stiffness and none in severe cases.

The operative tools needed for successful contracture release range from arthroscopy to hinged external fixation to total elbow arthroplasty. Deciding which one you need depends on the patient's age, the cause of the stiffness, the quality of the joint, and, in some ways, the patient's personality. As we have gained experience with both the different causes of contracture and different types of patients, we have also had access to new tools and methods of treatment. The best care for a given patient with a contracture is the most minimal necessary surgery, including minimal anatomic exposure, and rehabilitation to achieve the desired result. For instance, a patient with a range of 40 to 105 degrees and HO will usually require exposure of the capsule for complete excision from both the medial and lateral approaches but not necessarily hinged fixation. Although in this situation the use of hinged fixation may potentially improve extension (from 20 degrees achieved with capsulectomy alone to perhaps 5 additional degrees with hinged fixation), I do not believe that this is worth the cost, potential complications, or aggravation to the patient.

In a different circumstance with more massive HO, hinged external fixation may be necessary to stabilize the elbow postoperatively and permit immediate motion with intermittent passive stretch.

I set out to perform the operation most likely to achieve the goal, but I am always prepared to change methods, extend the exposure, or approach the joint from an additional direction, and I explain this to the patient preoperatively. In other words, if I think that an arthroscopic release is likely to be sufficient, I also plan for the possibility of an open release if full passive motion is not achieved on the operating table. In cases in which I am reasonably certain that a dual-approach, anteroposterior

release will suffice, I may plan for hinged fixation in case there is unexpected muscle-tendon tightness and failure to regain extension or flexion on the table or the joint is surprisingly or excessively worn and requires interposition. Having now performed more than 400 contracture releases, I have found the need for hinged fixation to be less likely.[60,71] In older patients with suspected cartilage damage or avascular bone, total elbow replacement should be available and discussed before surgery.

Predicting what you need and what will succeed is an iterative process that comes from your own experience and the seasoned opinions of others. It is important to be prepared to change and not be wedded to any single approach.[33] Orthodoxy here should only be a dedication to optimizing your patient's motion and not to a single exposure, approach, or device.

ANESTHESIA FOR CONTRACTURE RELEASE

Regional blocks are preferred[39] and are in fact the only method I have used for contracture release over the past 20 years. At my institution, ultrasound-guided infraclavicular blocks have become standard for contracture release; an indwelling catheter is often used so that additional dosing can occur 24 to 72 hours postoperatively.[52] Long-acting agents are the norm. Bupivacaine may leave the patient blocked for 24 to 48 hours. Although this may cause the surgeon concern, especially regarding the inability to check the status of the nerve, the pain relief and slow return of sensation are helpful as the patient begins motion the next day.

If the infraclavicular (or supraclavicular) technique or catheter is not available, axillary blocks may be used, but these may leave the upper end of the medial incision with sensibility. A small amount of local anesthetic in this area is usually all that is needed.

General anesthesia with endotracheal intubation may be used if regional blocks are unsuccessful or the anesthesia staff is unwilling to do regional blocks. More narcotics may be needed in the immediate postoperative period.

In children, I use infraclavicular indwelling catheters combined with general anesthesia. This is the "best of both worlds" for this challenging age group.

OPERATIVE TECHNIQUES AND APPROACHES

Arthroscopic Release

Arthroscopic elbow release is becoming more applicable as the techniques and instruments are improved and experience is gained.[28] This method works best in a young athlete with loose bodies or a history of a hyperextended elbow and a resultant minimal but annoying contracture. The anterior capsule can safely be released under direct arthroscopic visualization.

Two groups should be approached with great caution. The first group includes patients with a posttraumatic stiff elbow, in whom the capsule may be quite thick, sometimes 0.5 to 1 cm thick, and adherent to the anterior humerus. Because of this envelope of fibrotic tissue, arthroscopic release fails to excise the restraining tissue and puts the ulnar, median, and radial nerves at risk.[21,31,56]

The other group "at risk" is typified by a 45- to 55-year-old with primary osteoarthritis and simple osteophytes projecting from the coronoid and the tip of the olecranon.[37] In my opinion, arthroscopic release *should not* be performed if the patient requires ulnar nerve transposition or if there are large osteophytes in the posteromedial corner, which is the floor of the cubital tunnel.[4] I have treated two patients in whom the ulnar nerve had accidentally been débrided with an arthroscopic shaver. Other injuries have also been reported.[21] The surgeon should resist the temptation to use the shaver in this region unless the ulnar nerve is mobilized. Open techniques are safe and relatively simple, permitting visualization of the relevant neurovascular structures as needed. It is my firm belief that one should understand and be able to perform an open capsulectomy (described in the following) using both medial and lateral approaches before using the arthroscope as the primary tool of visualization and capsulectomy. Furthermore, adequate experience and skill in elbow arthroscopy is required because this is technically a difficult arthroscopic operation.

Open Release

When an open release is planned, the location of the potential pathologic condition and the nature of the contracture should determine the approach to the joint. One should not feel constrained to use one approach over another because of an unfounded allegiance to a given method. If the patient has a simple flexion contracture related to a radial head fracture, the lateral approach is usually sufficient and is relatively simple to perform.[7,8,27,35,40] In more complex cases in which the ulnar nerve requires exposure, I usually begin with the medial "over-the-top" exposure.[30,45,76] I am always prepared to use a supplementary lateral approach in these cases if there is HO located on the lateral side, if I am concerned about the position and safety of the radial nerve, or if there is an impinging osteophyte behind the capitellum. It is therefore important to understand both the medial and lateral approaches and be able to use them as needed in the operating room. Both a transhumeral and a transolecranon approach have been described, but I have not used either.[23,79] I also no longer use the Outerbridge-Kashiwagi procedure[48] (transhumeral trephination), which is designed to treat patients with primary arthritis of the elbow. If there is a significant lack of flexion (limited to <90 degrees), evidence of ulnar nerve dysfunction, or osteophytes in the posteromedial joint line, I prefer the medial "over-the-top" approach. As described in the next section, this approach permits exposure of the ulnar nerve and access to the anterior and posterior osteophytes. If flexion is minimally limited and the ulnar nerve is palpable and mobile, I prefer arthroscopic débridement and contracture release.

Only rarely can contracture be treated with anterior capsulectomy alone. Of the more than 400 contractures that I have treated operatively over the past 10 years, only a handful were adequately freed by incising the anterior capsule alone. In most instances, you should always plan to have access to the posterior joint surface, whether from the medial or lateral side of the joint. The olecranon fossa must be free of bone and soft tissue for full terminal extension to be achieved.

The advantage of knowing and using both the medial and lateral approaches is that you can protect the anterior medial ligament on the medial side by using the medial "over-the-top" approach. From the lateral exposure, the lateral ligaments described as noted by Husband and Hastings[27] and others[7,40] can be protected.

Medial "Over-the-Top" Approach

The principal advantages of this approach are as follows:

- Allows exposure, protection, and transposition of the ulnar nerve
- Preserves the anterior medial collateral ligament
- Preserves the posterolateral ulnohumeral ligament complex
- Permits both anterior and posterior access to the joint
- Allows access to the coronoid and anterior osteophytes with an intact radial head
- Can be easily converted to the triceps-sparing exposure of Bryan-Morrey, which permits complete dislocation of the joint and a more extensile approach (for total elbow replacement)

The disadvantages are as follows:

- Difficult to remove heterotopic bone or osteophytes on the lateral side of the joint
- Poor access to the radial head

Patient Position and Preparation. The patient is usually supine with the arm supported by a hand table (Figure 24.3, *A*). It is helpful to bring as much of the patient as possible onto the hand table. The patient's head may require support with a small foam ring because a standard pillow projects too far toward the shoulder and impedes the skin preparation. Two folded towels should be placed under the ipsilateral scapula to lift the shoulder away from the surgical table. The preparation should include the axilla to allow a sterile tourniquet to be applied. For the surgeon to visualize the anterior and posterior surfaces of the distal humerus, the patient should have fairly free external rotation of the shoulder.

Skin Incision and Superficial Exposure. The skin incision for this exposure can vary between the boundaries of a pure posterior skin incision and a midline medial incision (see Figure 24.3, *B*). The key to this exposure is identification of the medial supracondylar ridge of the humerus (see Figure 24.3, *C*). At this level one can locate the medial intermuscular septum, the origin of the flexor-pronator muscle mass, and the ulnar nerve. This location also serves as the point to begin the subperiosteal extracapsular dissection of the joint for both the anterior and posterior surfaces.

Once the subcutaneous skin is elevated, the first structure to identify is the medial intermuscular septum. If the skin incision is more posterior, the medial intermuscular septum can be found by locating the aponeurosis of the triceps tendon 2 to 3 cm proximal to the medial epicondyle and gently spreading with scissors anteriorly. Anterior to the septum and running immediately on top of the fascia (and not in the subdermal tissue) is the medial antebrachial cutaneous nerve, which usually has several branches. Generally this nerve can be traced distally and protected in this approach, but the branching pattern varies. It is occasionally necessary to divide this nerve to gain full exposure and adequately mobilize the ulnar nerve, especially in revision surgery. If nerve excision is required, the nerve should be divided as far proximally as the skin incision will allow while ensuring that the cut nerve end lies in the subcutaneous fat. If the patient has had previous surgery, the ulnar

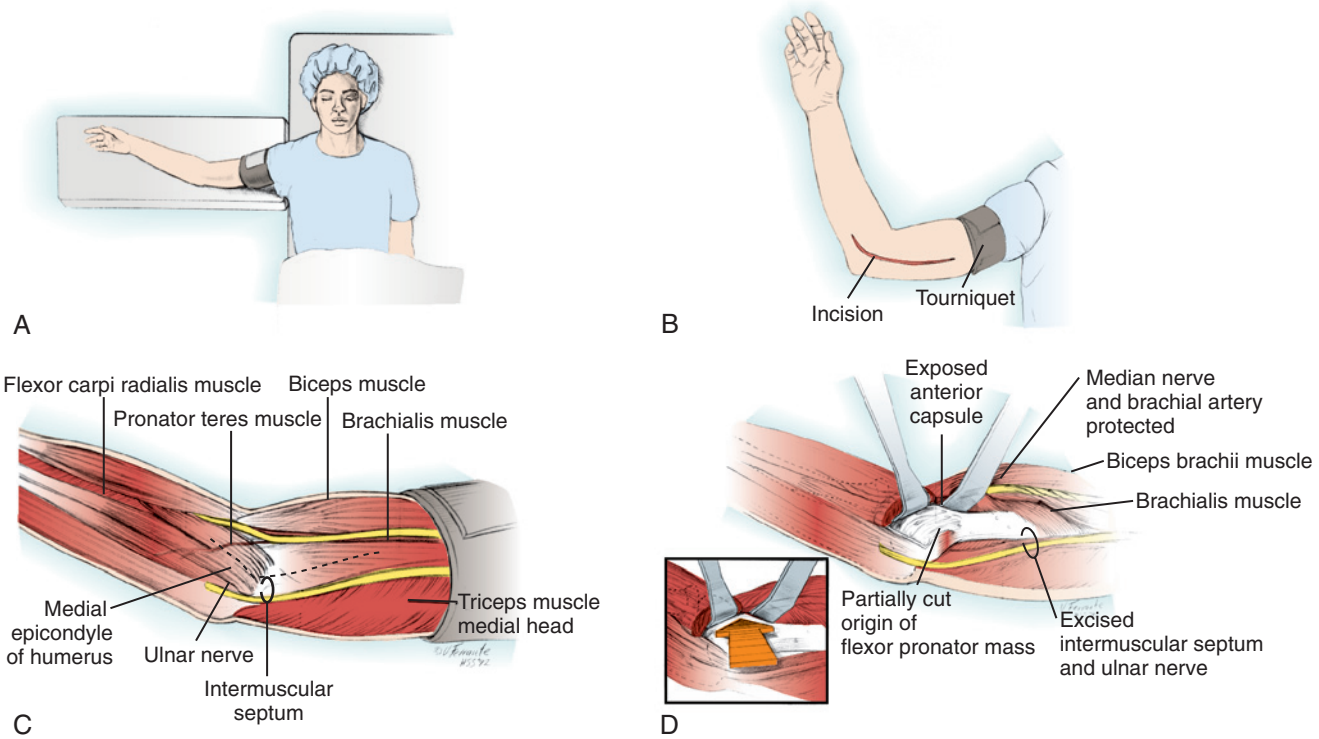

FIGURE 24.3 Medial "over-the-top" approach. **A,** The supine position is the most useful. Two folded towels should be placed under the ipsilateral scapula. **B,** The skin incision may vary according to previous incisions. If the incision is made along the posterior surface, larger flaps are needed. **C,** The intermuscular septum should be recognized as a landmark and excised for adequate mobilization of the ulnar nerve. **D,** The anterior capsule is first exposed by splitting fibers between the flexor carpi ulnaris and the pronator. The anterior portion of the medial collateral ligament is protected.

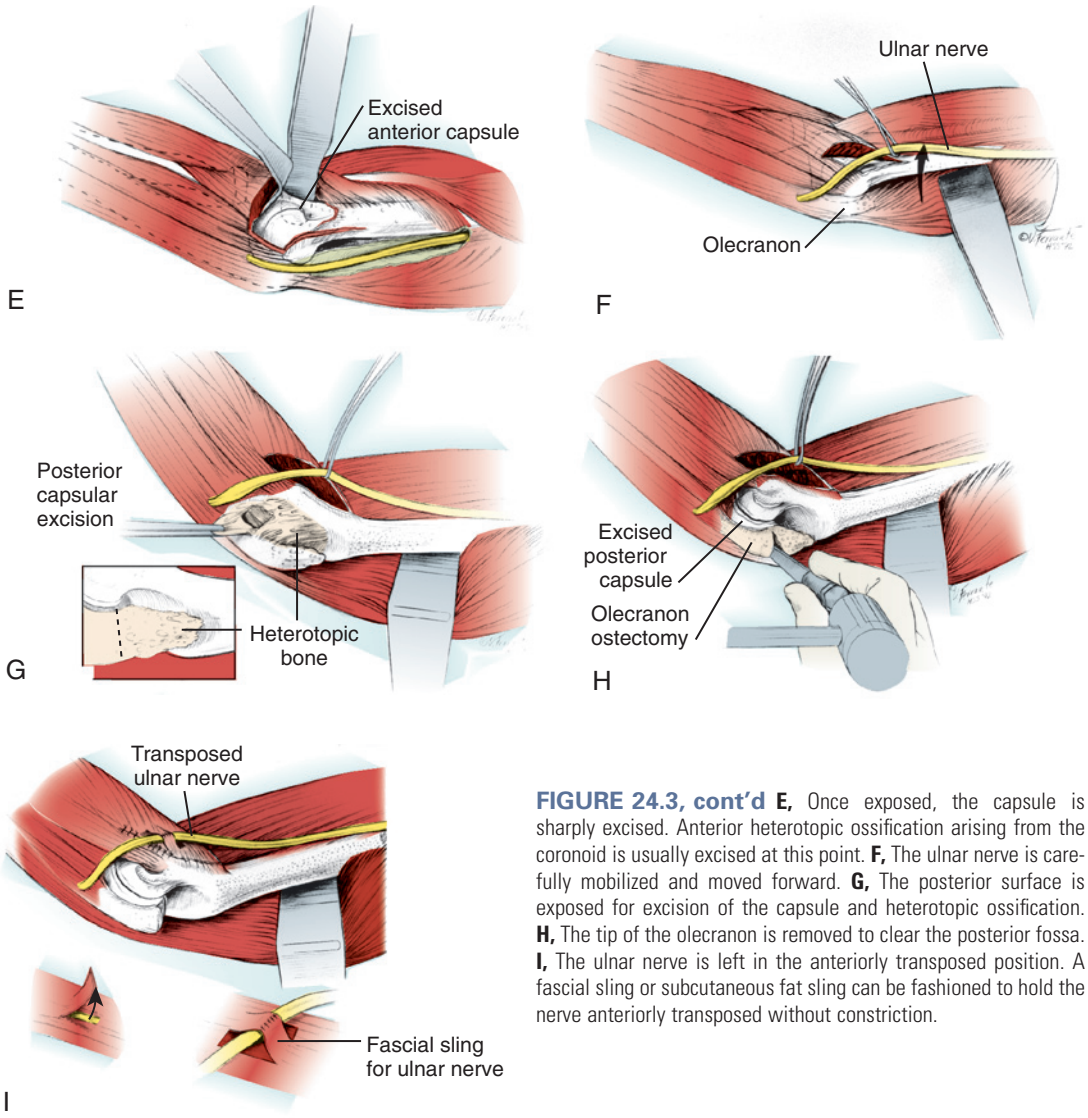

FIGURE 24.3, cont'd **E,** Once exposed, the capsule is sharply excised. Anterior heterotopic ossification arising from the coronoid is usually excised at this point. **F,** The ulnar nerve is carefully mobilized and moved forward. **G,** The posterior surface is exposed for excision of the capsule and heterotopic ossification. **H,** The tip of the olecranon is removed to clear the posterior fossa. **I,** The ulnar nerve is left in the anteriorly transposed position. A fascial sling or subcutaneous fat sling can be fashioned to hold the nerve anteriorly transposed without constriction.

nerve should be identified proximally before proceeding distally. If a previous anterior transposition has been performed, the nerve should be fully identified and mobilized before proceeding. In this setting, the nerve is flattened over the medial flexor-pronator muscle mass. Great care is needed to dissect the nerve in this location.

Once the medial intermuscular septum has been identified proximally, the surface of the origin of the flexor-pronator muscle mass can be found by dissecting at this same level and sweeping the subcutaneous tissue laterally. In most cases the medial antebrachial cutaneous nerve will be in this flap of subcutaneous tissue. The nerve will generally cross to the posterior aspect of the elbow distal to the epicondyle and can be elevated with the flap and retracted out of harm's way.

The medial intermuscular septum can now be excised from its insertion on the supracondylar ridge to the proximal extent of the wound, usually about 5 cm. There are many veins and perforating arteries at the most distal portion that require cautery. The septum can be cleared of muscle by using a small Cobb elevator along the posterior surface above the ulnar nerve.

Anterior Capsular Exposure. The supracondylar ridge is located, and the anterior muscle is elevated with a wide Cobb elevator (see Figure 24.3, *D*). All the anterior structures in the distal humeral region are elevated sufficiently subperiosteally to allow placement of a wide Bennett retractor. The median nerve, brachial vein, and brachial artery are superficial to the brachialis muscle. Once the septum is excised, the flexor-pronator muscle mass is divided parallel to its fibers, with a span of approximately 1.5 cm of flexor carpi ulnaris tendon left attached to the epicondyle. A tag stitch can be used to help align the tissues at closure. A small cuff of fibrous tissue of the origin can be left on the supracondylar ridge as the muscle is elevated. This facilitates reattachment when closing. A proximal transverse incision in the lacertus fibrosus may also be needed to adequately mobilize this layer of muscle. The flexor-pronator origin should be dissected down to the level of bone but superficial to the joint capsule. As this plane is developed, the brachialis muscle will be encountered from the underside. This muscle should be kept anterior and elevated from the capsule and anterior surface of the distal humerus.

It is often helpful at this point to return to the supracondylar ridge by sharply dissecting down to bone on the medial surface of the humerus. The ulnar nerve should be lying posteriorly. Dissection of the capsule to separate it from the brachialis muscle can proceed both laterally and distally.

At this point it is helpful to feel for the coronoid process by gently flexing and extending the elbow. For the first few times using this approach the coronoid will seem quite deep and distal. A deep, narrow retractor may facilitate exposure of the coronoid. From this vantage and after capsular excision, the radial head and capitellum can be visualized and freed of scar as needed.

In the case of contracture, the capsule, once separated from the overlying brachialis and brachioradialis, can be sharply excised (see Figure 24.3, *E*). The radial nerve lies between the brachialis and brachioradialis. Care should be taken when elevating over to the lateral side to stay deep to these two muscles. If heterotopic bone or previous surgery has potentially displaced the nerve, it is safer to make a lateral incision at this point and either identify the nerve or make certain that you are deep to the nerve with the plane of dissection.

The far anteromedial corner of the exposure deserves special comment. In a contracture release, the anteromedial portion often requires release. To see this area, a small narrow retractor can be inserted to pull the attached flexor carpi ulnaris medially. This will allow visualization of the far anteromedial capsule and also affords protection of the anterior medial collateral ligament.

Posterior Capsular Exposure. The ulnar nerve should now be fully mobilized to permit anterior transposition (see Figure 24.3, *F*). Because the intermuscular septum has been excised, only the vascular attachments and perineural investments confine the nerve proximally. The ulnar nerve is carefully elevated using a vessel loop for retraction. The dissection needs to be carried distally enough to allow the nerve to sit in the anterior position without kinking distal to the epicondyle.

The posterior capsule of the joint is exposed in a fashion analogous to that for the anterior capsule. The supracondylar ridge is again identified. With a Cobb elevator the triceps is elevated from the posterior distal surface of the humerus. The exposure should be proximal enough to permit the use of a Bennett retractor.

The posterior capsule can be separated from the triceps as the elevator sweeps in a proximal-to-distal direction. The medial joint line should also be identified (see Figure 24.3, *G*). In contracture release, the posterior capsule and posteromedial ligaments should be excised. The medial joint line, up to the anterior medial ligament, should also be exposed and the capsule excised. Along this line there is usually heterotopic bone on the olecranon or posterior medial osteophytes. More olecranon needs to be excised than one would expect (see Figure 24.3, *H*). The posterior fossa must be completely clear of impinging soft tissue or bone. If not, maximal extension will be limited.

Structures That Require Repair

Flexor-Pronator Muscle Origin. The flexor-pronator mass should be reattached to the supracondylar ridge with nonabsorbable braided 1-0 or 0 suture. If enough fibrous tissue was left behind, no holes in bone are needed. If not, holes can be drilled in the edge of the supracondylar ridge to secure the flexor-pronator muscle mass. The lacertus fibrosus often requires release to permit full medial reattachment.

Ulnar Nerve Transposition. After reattachment to the medial supracondylar region, the ulnar nerve should be transposed and left in the anterior position. I no longer routinely use a fascial sling, but I will occasionally raise a small fat flap to prevent posterior subluxation (see Figure 24.3, *I*). The sling can be fashioned by elevating two overlapping rectangular flaps of fascia. The nerve is placed under the flaps, and these are approximated with adequate room so that nerve is not compressed, only stabilized. Superficial fat flaps can also be used to maintain the nerve in the anterior position. I use whatever keeps the nerve in an anterior position without tension, compression, or kinks. The joint should be flexed and extended to ensure that the nerve is free to move.

CRITICAL POINTS *Medial "Over-the-Top" Approach*

Anterior Joint

- Center the skin incision posterior to the medial epicondyle (may be directly posterior).
- Identify and protect all branches of the medial antebrachial cutaneous nerve.
- Identify and dissect the ulnar nerve to permit anterior subcutaneous transposition.
- Lift the flexor-pronator off the medial supracondylar ridge with a Cobb elevator.
- Divide the flexor carpi ulnaris, leaving 1 cm of the posterior portion attached to the epicondyle.
- Bluntly separate the anterior muscle, leaving the capsule behind.
- Excise the capsule from the distal humerus to the proximal ulna (coronoid process).
- Continue the dissection to the lateral edge of the joint line.
- Check for areas of remaining taut capsule by gently manipulating the elbow into extension and flexion.

Posterior Joint

- Complete mobilization of the ulnar nerve for anterior transposition.
- Starting at the medial supracondylar ridge, lift the triceps off with a Cobb elevator.
- Continue the dissection distally, lifting the triceps tendon, leaving the posterior capsule behind.
- Excise the posterior capsule, including the posteromedial corner.
- Remove the posterior olecranon, usually about 1 cm (depends on the size of the osteophytes).
- Check for posterior impingement and deepen the olecranon fossa as necessary.
- Check for areas of remaining taut capsule by gently manipulating the elbow into extension and flexion.
- If there are still soft tissue limitations along the lateral joint line, these can be incised, but beware of the radial nerve; if uncertain, approach it from the lateral column.

Lateral Approach

Patient Position, Preparation, and Skin Incision. In the lateral approach,[7,27,40] the patient is usually in the supine position and the arm supported by a hand table. A sterile tourniquet for the upper arm is useful because it permits proximal exposure if needed. The skin incision is centered over the lateral epicondyle.

The proximal extent of the skin incision depends on the needs of the case. For contracture release or treatment of fractures of the distal humerus, the skin incision may extend from 4 to 8 cm proximal to the lateral epicondyle, as needed. For simple contracture release, the incision may need to be extended only to the supracondylar ridge. For exposure of the radial head, the proximal extension may need to be only 5 cm. Extension of the exposure to 10 cm proximal to the lateral epicondyle may risk injury to the radial nerve. If proximal extension to 10 cm or more above the lateral epicondyle is planned, the radial nerve should be identified in the interval between the brachioradialis and brachialis.

The skin incision does not need to be over the lateral epicondyle but may also begin in the posterior midline. If this incision is used, a longer skin incision will be needed and larger flaps developed to gain access to the lateral joint.

The anterolateral approach to the elbow remains anterior to the anconeus. Once full-thickness skin flaps have been elevated, the key to this exposure is identification of the lateral supracondylar ridge of the distal humerus and the posterior border of the wrist extensor muscle mass. The flare of the ridge is palpated just superior to the lateral epicondyle, anterior to the triceps and posterior to the brachioradialis. The plane of the anterior dissection will continue anterior to the midline of the epicondyle, especially distally. The posterior dissection will continue between the anconeus and the extensor carpi ulnaris. In this way, the central origin of the extensor mass and the collateral ligament are preserved.

Anterior Capsular Exposure. After subperiosteal dissection of the distal humerus, a Bennett retractor can be inserted beneath the brachioradialis to retract the anterior tissues. When this exposure is used for contracture release, an elevator is used to bluntly separate the brachioradialis and the capsule as the dissection proceeds distally. In this interval the radial nerve is more vulnerable because the plane of dissection is more superficial. However, if the elevator is carefully advanced on top of the capsule and the muscle fibers pushed anteriorly, the radial nerve will be protected by muscle. If in doubt, find the nerve between the brachioradialis and brachialis proximally. With the Bennett retractor in place, sharp division of the more distal capsule, down to bone, will expose the articular portion of the distal humerus. The capsule should be excised at the level of the joint, across to the medial side.

The joint should be gently manipulated to test whether sufficient release has been achieved. If not, a decision needs to be made about whether to switch to the medial joint exposure or to expose the posterior joint from the lateral side while protecting the posterolateral ligament complex.

Posterior Capsular Exposure From the Lateral Side. As described by Husband and Hastings[27] and others,[7,40] the posterior capsule can be safely excised from the lateral side, and even HO can be removed from the posterior surface. If the ulnar nerve has not been exposed, remember that it is vulnerable, trapped in scar tissue, and located at the very edge of the posteromedial extent of the exposure, so that it will be difficult to see.

The posterolateral ligament complex is identified distally between the anconeus and extensor carpi ulnaris and is *not* incised. An elevator is introduced near the supracondylar flare of the distal humerus and swept distally along the posterior surface. It is helpful to leave the capsule attached before excising it. The tip of the olecranon usually requires excision to clear the posterior fossa for adequate extension.

Immediate Postoperative Care

Closed Suction Drainage. Although I have heard surgeons remark that they do not routinely use closed suction drainage, I believe that this is vital in almost all cases after open release. Occasionally, a simple lateral approach with anterior-only release is associated with minimal postoperative bleeding and drains are not required. However, as the complexity of the surgery and the severity move up the scale, postoperative hematoma must be avoided. Retained blood and hematoma cause pain, inflammation, and occasional temporary nerve dysfunction, all of which retard progress toward improved motion. If hinged fixation or CPM is planned for the immediate postoperative period, I secure the drains with sutures. Because these drains are left in place for 2 to 3 days after surgery, they can easily be dislodged either during placement of the hinged external fixator or during CPM. The elbow is usually splinted in maximal extension following surgery. These splints are left in place until CPM begins the following day.

The First 24 Hours. Many surgeons prefer to begin CPM immediately after surgery. However, I now use the first 12 to 18 hours for rest, application of ice, and elevation of the extremity. If a hinge fixator is used, the device is set in maximal tolerable extension and ice bags are placed around the elbow.

CRITICAL POINTS *Contracture Release: Technical Tips and Suggestions*

- Wait to remove hardware until the end of the procedure and after any manipulation that may be required.
- Secure the suction drains with sutures and plan to leave them in place as the postoperative CPM is under way.
- Seldom, if ever, does the range of motion improve from what is gained in the operating room.
- Honestly measure and dictate in the operative note the degree of motion achieved with light pressure applied in both flexion/extension and supination/pronation.
- Splint the patient in the position of greatest "challenge" before beginning CPM. In general, this is in extension.
- If splinting in flexion, inspect the posterior skin over the olecranon. Occasionally this will blanch and lead to skin breakdown if not progressively flexed.

Special Circumstances

Fracture of the Distal Humerus After Open Reduction and Internal Fixation

After fracture of the distal humerus, the stiffness of the joint can come from intraarticular malunion, HO, or capsular contracture. CT is helpful for visualizing the distal humerus and specifically the ulnohumeral joint. In thin patients, the plates on the medial and lateral columns of the distal humerus may feel superficial, and the patient often requests their removal. The fracture must be solidly healed if the hardware is to be removed. If there is uncertainty, the surgeon must be prepared to replate and bone graft a nonunion while performing the contracture release. If the fracture is healed and the hardware is to be removed, the contracture release is done first, followed

by hardware removal. If the hardware is removed first, refracture may occur even with gentle manipulation during the contracture release. This complication can be avoided by releasing the contracture, performing the intraoperative manipulation, and then removing the hardware if indicated.

In elderly patients, if there is a nonunion or if avascular necrosis of the articular surface is suspected, total elbow replacement with a semiconstrained linked implant is the best option (see Chapter 27).

Nonunion of the Distal Humerus

Most nonunions of the distal humerus are associated with joint contracture. This finding is especially true in patients with failed attempts at internal fixation, in whom the elbow is often immobilized in the slim hope that union may occur despite the presence of mechanical failure. To treat the nonunion, the contracture of the joint must be completely relieved. If not, the newly plated nonunion site will experience continued excessive torque and be prone to repeated failure. If the joint contracture is released, stress is minimized at the distal humeral fixation.

Head Trauma and Brain Injury

Patients with head trauma and associated residual spasticity have two strikes against them (Figure 24.4).[1,16,54,62] First, they tend to have exuberant HO and are often prevented from seeking care for excision in the first year. Therefore, the ankylosis is usually complete and the surrounding tissue thickened and unyielding. Second, voluntary control of the elbow is difficult to judge. After the brain injury has stabilized, I have tried to assess effective volitional control in these patients by both physical examination and surface electromyography. At a minimum, patients must be able to fire the biceps and triceps on command before contracture release is considered. Unfortunately, the capacity to contract these muscles volitionally while the joint is ankylosed does not guarantee the ability to flex and extend with strength once passive motion is achieved. I have unfortunately seen patients regain remarkable passive motion after the excision of massive HO only to watch them gradually lose mobility over a period of months because of a lack of active strength and effective control over the entire arc of motion. In addition, the hand, wrist, and forearm may also be spastic and of little use beyond simple positioning. The goals and expectations of the patient (and the family) must be carefully weighed before proceeding with contracture release. Nonetheless, this is also a group of patients who are extremely grateful if they can regain some motion for positioning their hands for transfer, the use of motorized devices, and self-care.

It is important to allow the patient with brain injury to recover. This may mean waiting 12 to 24 months. Recovery of volitional muscle control and strength will occur in adjacent muscles and should be viewed as a positive prognosis. During this time, the family and patient will become more realistic about the goals of contracture release. In addition, the patient's capacity for rehabilitation and social setting will generally improve, permitting a more reasoned assessment of the patient's and family's capacity for postoperative care and rehabilitation.

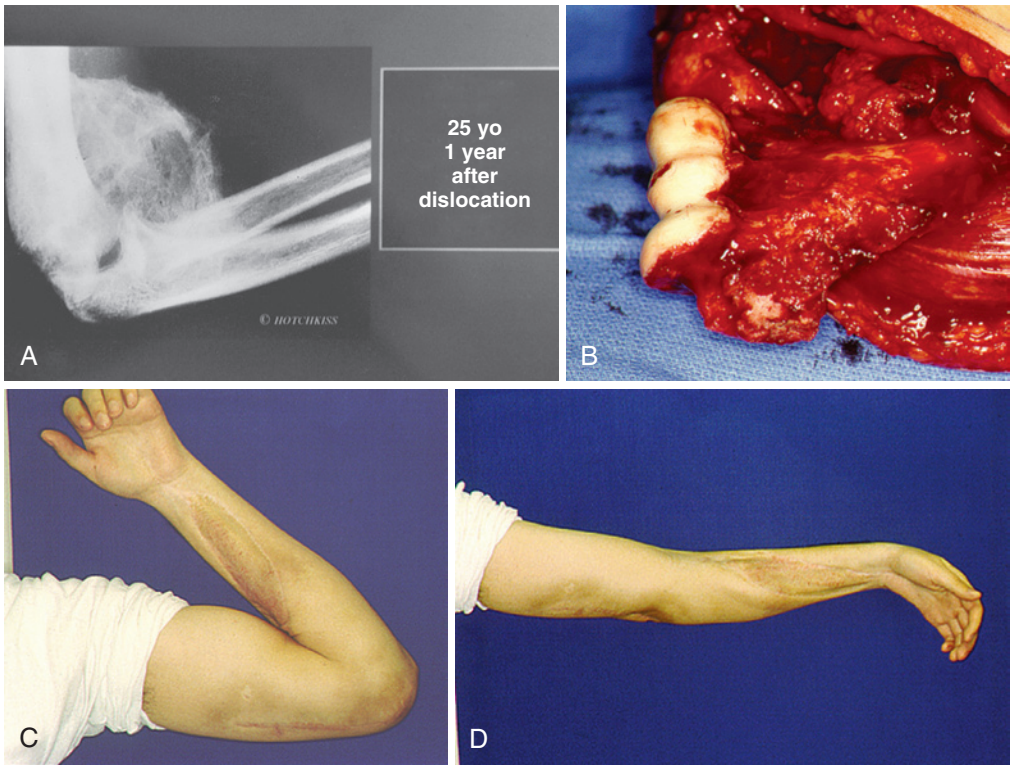

FIGURE 24.4 **A,** A 25-year-old man presented with previous head trauma and open elbow dislocation. He had no permanent spasticity and had complete volitional control. **B,** Because of extensive heterotopic ossification 1 year after dislocation, the distal humerus required complete exposure and excision of ligaments. This degree of intraoperative instability required hinged external fixation. This patient wore the hinge for 10 weeks. **C** and **D,** Three years after surgery he retained excellent motion and strength. (Copyright © Robert N. Hotchkiss.)

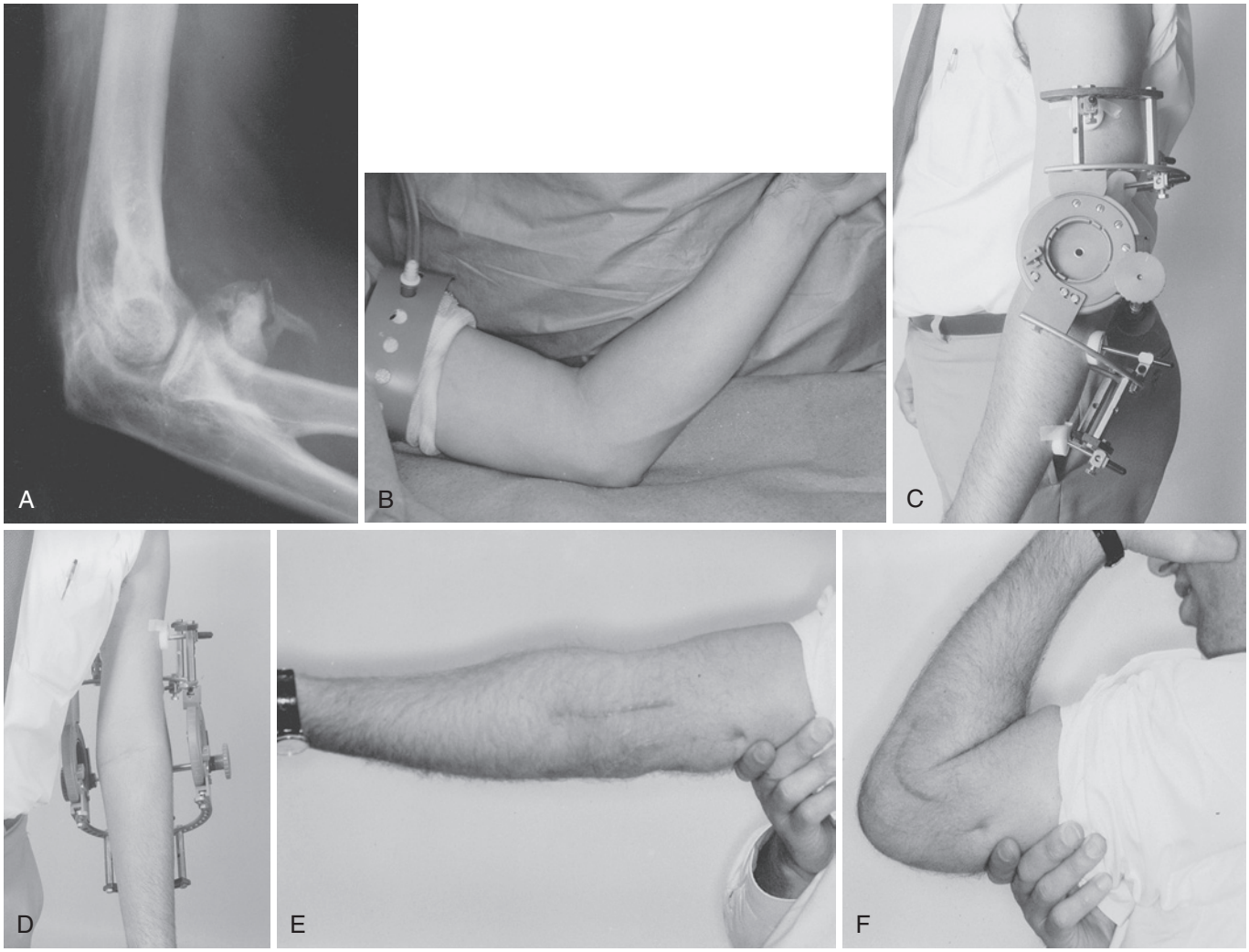

FIGURE 24.5 **A,** Heterotopic bone is seen on both the front and the back of the joint in this radiograph following treatment for a fracture-dislocation. A previous attempt at contracture release was unsuccessful. **B,** Maximal extension under anesthesia. **C** and **D,** Patient wearing the hinged external fixator. **E** and **F,** Range of motion approximately 2 years after treatment. No degenerative changes developed in the joint. (Copyright © Robert N. Hotchkiss.)

Hinged Fixation After Contracture Release

Indications for the use of hinged external fixation* are (1) instability after contracture release, (2) excessive muscle-tendon tightness noted at the time of complete capsular release (Figure 24.5), and (3) distraction arthroplasty (with or without interposition).†

Each type of hinged fixator requires a detailed understanding of the principles of use, method of application, and problems that may be encountered. I believe that the primary surgeon must be familiar with one type of fixator and the specific techniques required for successful application. Each of the companies that manufacture these devices provides instructional materials and courses. It may be useful to visit someone with experience. The assisting surgeon should also be familiar with the device and its application. During placement, one set of eyes is often needed to place a half-pin properly while the primary surgeon makes certain that the overall alignment of the device is maintained.

In addition to the technical challenges, these cases can be of long duration, exceeding 4 hours. For inexperienced operators, a difficult contracture release, requiring extensive dissection with careful protection of all nerves, can be tiring. The application of the hinged fixator cannot be viewed as an afterthought. If the pins are misaligned or care is not taken to ensure that the joint is completely reduced, all the work is for naught.

Instability After Release

Instability after release is common and has been noted by many authors, especially in patients with severe joint involvement or those with more massive HO.[16] In these cases, the stabilizing ligaments are often trapped in the HO and cannot be protected during release. Even if the ligaments are not completely released, a wide area of capsular excision and stripping is often needed

*See references 14, 18, 30, 53, 59, 61, and 63.
†See references 14, 18, 30, 34, 46, 53, and 73.

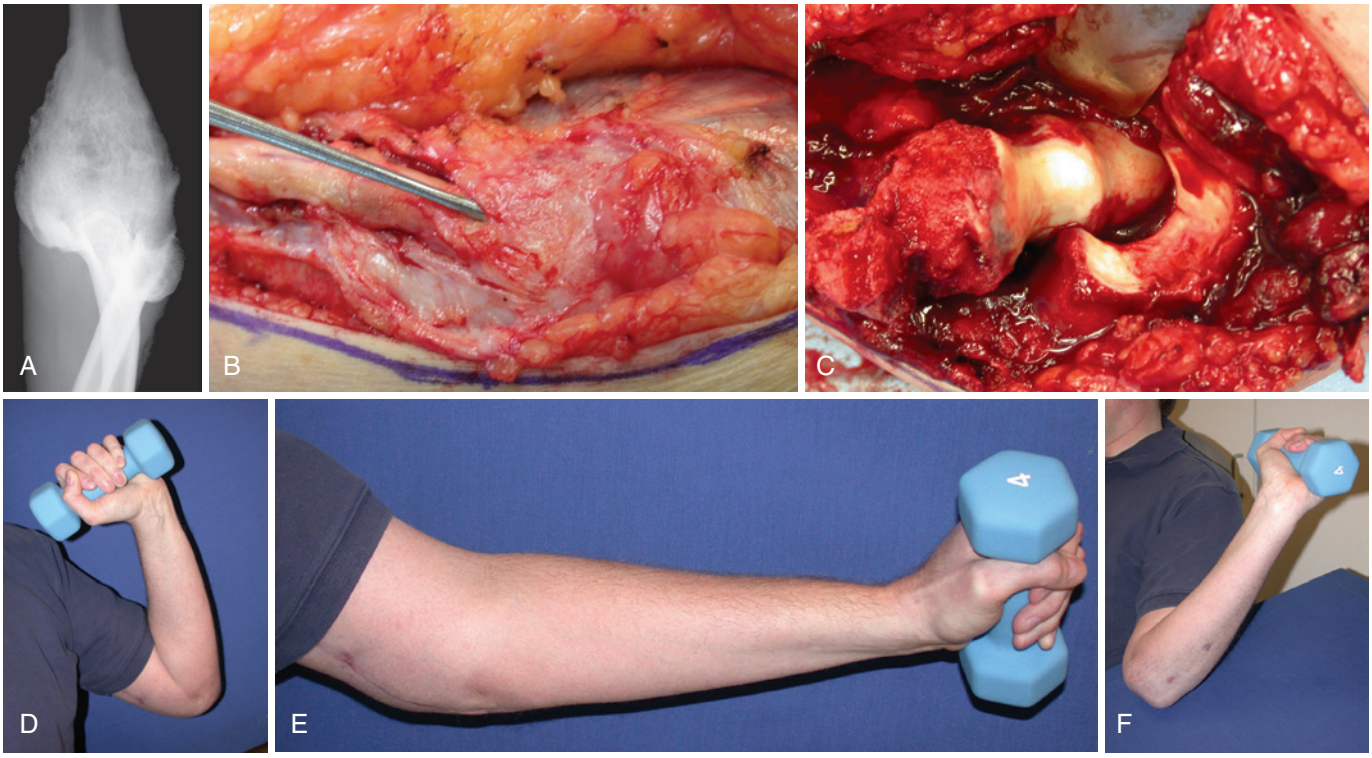

FIGURE 24.6 **A,** An ankylosed elbow after combined head and elbow trauma in a 45-year-old man confined to a wheelchair. Note the faint hint of a joint line in the ulnohumeral joint. **B,** The ulnar nerve is covered by bone during neurolysis. (A Freer elevator is under a shelf of bone.) **C,** Intraoperative instability from radical resection of medial heterotopic ossification that included medial ligaments, requiring the use of hinged fixation. **D** and **E,** At 6 months there is good mobility and he is able to transfer using his left arm. **F,** Even without reconstruction of the medial collateral ligament, there is no valgus instability. (Copyright © Robert N. Hotchkiss.)

to free the joint. In this circumstance, especially if there has been a long-standing limitation (>18 months), the patient has a very difficult time regaining motion and maintaining that motion in the first 8 weeks after surgery. Hinged fixation is used in those settings where acute and gross instability is created after contracture release (Figure 24.6). In general, as one gains experience, there is less need for the use of hinged fixation after contracture release.

Excessive Muscle Tightness

In a long-standing contracture with excessive muscle tightness, some have recommended lengthening of the biceps, brachialis, or triceps tendons.[10] In my opinion this should be avoided if at all possible. The muscle-tendon unit is undoubtedly shortened in the case of a long-standing contracture, but lengthening these structures in a nonspastic patient risks loss of strength and requires some protection of the repair during rehabilitation.

Distraction (Interposition) Arthroplasty

For interposition arthroplasty, there are several devices that provide stability and distraction of the joint. A fixator is used to temporarily stabilize the joint after resurfacing of the joint with fascia or cutis (skin with the epidermal layer removed). The fixator replicates the flexion/extension axis of the elbow, permitting motion. One device uses hinged fixators with a passive drive mechanism, and another device uses hinged fixators without a passive drive mechanism. The axis of rotation, centered at the distal humerus, is located by several methods, depending on which device is used. External fixation pins, usually two in the humerus and two in the ulna, are applied. The axis pin is then removed so that there is less chance of infection during the postoperative period. The passive drive mechanism in the Compass Elbow Hinge (Smith and Nephew, Memphis, TN) allows passive mobilization, but most surgeons consider it to be more complicated to apply. All devices require an understanding of the anatomy and kinematics of the elbow in addition to the use of the particular device. For most commercially available devices, technique manuals are available online.

If hinged fixation is used, the device must be left on for at least 6 to 8 weeks while maximizing motion and allowing the soft tissues to regain stability. Further information about both of these devices is available from the manufacturers. Familiarity with one or both devices is essential for complex reconstructive surgery on the elbow.

The clinical results from distraction arthroplasty for posttraumatic contracture are not stellar. Often the patient feels instability. The distal humerus may also undergo bony dissolution over months, resulting in more laxity and instability. I use interposition arthroplasty with hinged fixation very sparingly in the posttraumatic patient. The goals should be limited to some pain relief and a notable gain in motion (especially flexion). Few if any patients achieve a high-performance elbow with heavy lifting capacity and full mobility.

POSTOPERATIVE MANAGEMENT

Use of Intravenous Dexamethasone for Postoperative Swelling

Intravenous dexamethasone has been quite helpful in reducing the associated swelling in the perioperative period. We routinely give adult patients 8 mg intravenously before the incision is made and continue with a dose of 8 mg intravenously every 8 hours while the patient is in the hospital, usually for 48 hours. The impact of this strategy was first noted by maxillofacial surgeons, who realized that it avoided the untoward effects of infection or other problems associated with long-term steroid use.[77] In patients with diabetes, caution and judgment must be used.

Adjuvant Therapy for Heterotopic Ossification

The efficacy of nonsteroidal medication or irradiation for the prevention of HO has *not* been studied using randomized double-blind trials. Nonetheless, there are numerous reports that support the use of indomethacin or low-dose irradiation for the prevention of recurrent growth of HO.* Jupiter and colleagues reported abandoning the use of any nonsteroidal agents and reported no pathologic recurrence of HO.[29] I no longer prescribe antiinflammatory agents for this purpose and have noted no increase in the recurrence of HO. Patients who have undergone major organ transplantation are especially vulnerable to HO formation and usually are not permitted to take oral antiinflammatory agents.[51] In adults who have widespread HO and tend to form osteophytes with only minor trauma, I use radiation therapy at a single dose of 700 cGy within 72 hours of surgery. The use of gentle CPM, passive turnbuckle splinting, or dynamic external hinged fixation has undoubtedly diminished the incidence of HO, irrespective of adjuvant therapy.*

In the aforementioned last 450 cases, I have employed irradiation on six occasions.

Physical Therapy and Splinting

A knowledgeable therapy department is a valuable and perhaps crucial asset for success in treatment of stiff elbows. Once the contracture is released, patients may benefit from therapy to overcome the spasm and pain associated with immediate motion. As with many conditions, the frequency of visits to the therapist varies from patient to patient. However, the need for splints is nearly universal. Several texts and articles describe the fabrication and use of these devices.[20,26,38,80] There will undoubtedly be continued improvement in the design, comfort, and effectiveness as materials and technology improve. I do not use any dynamic splints for elbow contractures; I have found that patients do not tolerate these splints and compliance is very low. The constant torque applied by the dynamic splints is painful and poorly tolerated, which often lowers compliance. The splints described here rely instead on intermittent passive and static progressive positioning. These splints apply an incremental displacement to the joint, followed by stress relaxation of the muscle and soft tissue. For reasons that are unclear, this approach, much like an Ilizarov lengthening, is more effective with my patients.

The splints I use regularly are designed to maintain the gains made in the operating room. Seldom if ever can a surface splint (as opposed to hinged external fixation) increase the motion that was achieved on the operating table.[19]

Static Splints

Resting Extension Splint. After 24 to 48 hours following operation, we employ resting extension splints when not using CPM. At 24 to 48 hours after surgery, in conjunction with CPM, we use static extension splints to maintain maximal tolerated extension. After swelling decreases days later, a static flexion splint is also added, again, to maintain maximal flexion at end range. The splints are worn usually at night to maintain position after removal of the CPM device. A slight extension moment applied by tightening the splint's strap is most effective at maintaining the position of the elbow at or near full extension.

Turnbuckle Splint (for Extension or Flexion). If the elbow is tending toward a flexion contracture of 30 degrees or more, a turnbuckle splint should be considered (Figure 24.7). The turnbuckle splint, as first reported by Green and McCoy,[20] is invaluable in static progressive splinting. In my view, this splint is most helpful for patients with a 25- to 40-degree flexion contracture that requires mechanical assistance to increase extension. We have used the Aircast Mayo Clinic Elbow Brace (DonJoy Orthopedics, Vista, CA) with modifications and success.[36] There are many commercially fabricated splinting systems available to provide a "serial static" mode of patient-controlled displacement. There is no single manufacturer or design that fits all.

These splints are generally required for 8 to 12 weeks after surgery, following the period of acute postoperative swelling and pain. The duration of wear must be tailored to the individual. Most patients cannot wear them all the time, especially when a significant displacement force is applied. However, even if these splints only help maintain the position gained in the operating room during the early phase, they are worth using. Later, the splint will help regain the motion that has been temporarily lost during the acute postoperative period.

"Come-Along" Flexion Splint. Patients highly value improvement in flexion, more so than gains of extension. I have found that a static progressive splint, fabricated from D-rings and straps, is well tolerated and not as limiting or as complicated to construct as a turnbuckle device. The patient simply pulls the straps on each side in a sequential fashion, pulling the elbow into more flexion, as tolerated (Figure 24.8).

Continuous Passive Motion (or Slow Intermittent Passive Positioning) Device

CPM devices have been used by many authors and are reported to assist in maintaining the motion gained after surgical release.[17,34] I use CPM in all patients who have undergone open release but were not fitted with a dynamic hinged fixator. After arthroscopic release, a supervised outpatient program usually suffices with end-range splinting.

CPM is helpful when used according to a different principle than continuous motion. Rather than having the device flexing and extending the elbow on a continuous basis, I use the

*See references 12, 24, 29, 42, 61, and 65.

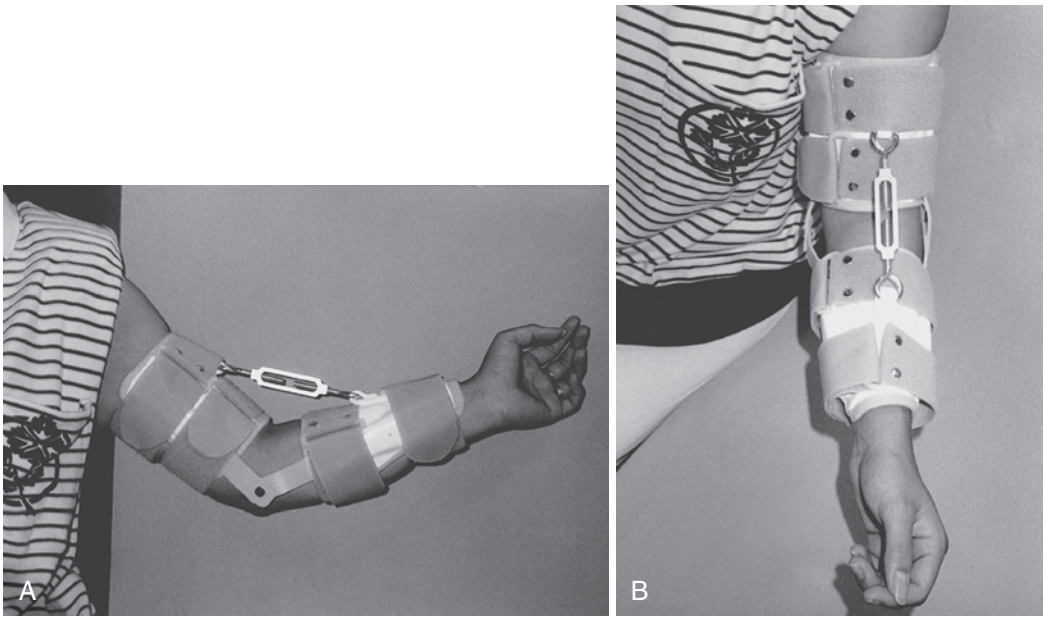

FIGURE 24.7 **A** and **B,** The turnbuckle splint is especially effective with flexion contractures of more than 40 degrees. Once the patient achieves more extension, other splinting devices may be more effective. (Courtesy of S. Davila, San Antonio, Texas.)

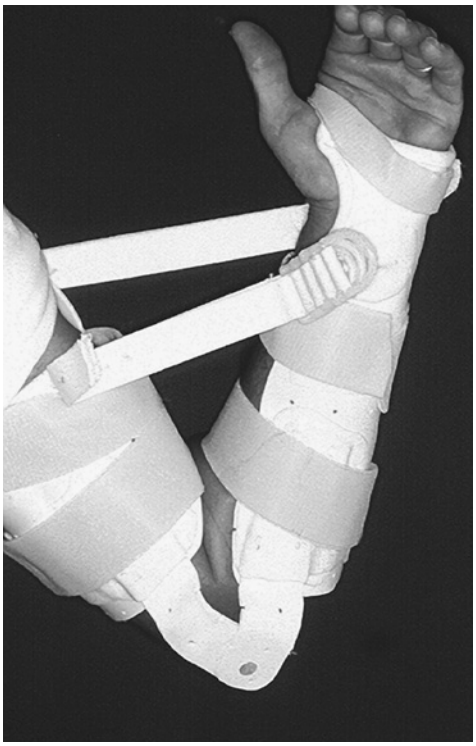

FIGURE 24.8 A "come-along" splint designed to increase flexion of the elbow. The patient advances each successive ring onto a hook placed on both the dorsal and palmar surfaces of the distal portion of the forearm section. Once the soft tissues have relaxed, the next ring is hooked into place. (Copyright © Robert N. Hotchkiss.)

device as *slow intermittent passive positioning*. My patients begin slow intermittent passive positioning the day after release, the first 12 to 24 hours being used for rest and elevation. The machine is initially set at the maximal tolerable positions of extension and flexion. It is important to remove the bandages in the antecubital fossa because they will block flexion. The patient (or parent) is taught to use the button that stops the machine. The rate of displacement is set at the absolute minimum. The patient is instructed to allow the device to move the elbow to maximal extension and then stop and hold it at that position for 20 to 30 minutes. The button is clicked to resume motion to the point of maximally tolerated flexion. Again, the position is held for 20 to 30 minutes. In this way the joint is held at the extremes of position from the beginning of rehabilitation, which is the goal. Cycling the joint faster and more frequently has no advantage and may increase the amount of swelling. If the CPM evokes significant guarding, the indwelling catheter (see anesthesia section previously) can be used to administer anesthesia to relieve pain and relax the muscular guarding.

EXPECTATIONS AND RESULTS

The results of most reports and my personal experience are gratifying, with significant improvement in over 90% of patients. The published literature, as mentioned in the first section of this chapter, is filled with inconsistent inclusion criteria, different methods of operative exposure, and variance in postoperative management. This lack of standardization reflects the varied nature of the condition; differences among patients; and continued enhancements in surgical technique, postoperative devices, and management. As with all complex surgical procedures, there are complications, disappointments, and failures.

For a minimal uncomplicated flexion contracture (<30 to 40 degrees), extension will usually improve to 5 to 10 degrees of residual contracture without loss of flexion.

For more moderate contractures with localized HO and motion limited in both flexion and extension (50 to 105 degrees), a final range of motion of 20 to 130 degrees is a reasonable expectation.

For patients with less than 30 degrees of total motion, a reasonable goal is 25 to 130 degrees. However, the results of this group of patients are variable. Some patients do surprisingly well and can achieve even better results despite starting with a completely ankylosed joint (see Figure 24.6).[61]

COMPLICATIONS AND OBSTACLES

Acute Recurrent Stiffness: "Gelling"

The primary reason to carefully follow patients in the first 2 to 3 weeks after surgery is to assess their range of motion. In my experience with the last 400 contracture releases, nearly 25% of patients experience a temporary setback in their progress, many commonly losing the gains in flexion made in the operating room. It is critical to record their motion in the operating room and immediately after surgery while in the hospital. A critical parameter is *failure to achieve 105 to 110 degrees* of flexion between the second and third week after surgery. The usual source seems to be pain in the distal triceps against the surface of the posterior humerus. In these cases with stalled progress, the patient undergoes a *gentle* closed manipulation under regional anesthesia. The procedure is done in a procedure room or a monitored setting using an infraclavicular block and as little sedation as possible to allow the patient to witness and visualize the amount of motion achieved. Often the elbow will be splinted in the flexed position for 4 to 6 hours followed by immediate resumption of therapy and splinting.

It is less common to lose extension in the early recovery phase, but the same level of scrutiny should be applied.

Nerve Palsy

The ulnar nerve, as noted earlier, is particularly vulnerable because of entrapment, previous injury, and intraoperative surgical manipulation. Care must be taken to painstakingly mobilize and protect the nerve during contracture release, especially if hinged fixation is used. Even with these precautions, I have found that about 10% of patients will have dysfunction of the nerve after release. Most of these resolve over a period of days, weeks, or months. Often there is preoperative ulnar nerve dysfunction that may not be evident. It is therefore important to document ulnar nerve function preoperatively and warn patients that nerve function may temporarily worsen and may not necessarily improve to normal after release. As mentioned earlier, arthroscopic release may pose an even greater risk of permanent damage.[21]

The radial and posterior interosseous nerves are also vulnerable, especially if excessive retraction is applied through the lateral approach. If there is abundant HO at the lateral joint, the posterior interosseous nerve should be carefully exposed and protected during excision of the HO. In most cases the HO lifts the nerve and muscle away from the joint. In nonreduced dislocations with HO or in more proximal fractures, the radial nerve may be entrapped in bone and require meticulous, painstaking dissection from the surrounding bone. I have had two patients with temporary radial nerve palsies after contracture release. Both palsies resolved completely.

Heterotopic Ossification

Recurrent pathologic HO (i.e., ossification that blocks motion) after contracture release has become rare since the advent of better methods of restoration of motion in the early postoperative period. It is not uncommon to see HO along the ligamentous structures or edge of the capsule. As a reflection of the benignity of these flecks of bone, this condition is sometimes referred to as "ectopic calcification" as opposed to true HO. This bone usually does not restrict motion. In the more dramatic cases of ankylosis, the use of hinged external fixation has eliminated the need for temporary casting or splinting in a flexed position for instability, thus minimizing the risk of recurrent HO.

Pin Tract Infections

The risk of pin tract infection is significant with the use of hinged external fixation. There is a 50-50 chance that the patient will need to take oral antibiotics for the duration of treatment. The actual incidence of pin redness and erythema is 60% for the elbow. I treat each of these patients with a 5- to 7-day course of an oral cephalosporin. In no patient has pin tract–related osteomyelitis developed.

Joint Infection

A far more worrisome and potentially devastating infection may occur in the joint itself. The most vulnerable patient is one with poor soft tissue coverage and a history of previous infection. Another risk factor is distraction interposition arthroplasty in a patient with poorly vascularized bone. (The majority of infections in my practice have come after this procedure.) In these cases, the distal humerus often has a poor blood supply, and the material inserted as interposition is avascular and a foreign body. Additionally, external pins either at the joint or nearby may act as a nidus for spread into the joint. If these pins become infected, the joint should be débrided of all foreign material and stabilized by using different pin sites. Although my experience with these patients is fortunately limited, the joint often performs surprisingly well despite the travail.

Soft Tissue Deficiencies or Wound Necrosis

Patients with burns or long-standing contractures may lack sufficient soft tissue to permit mobilization or may develop skin necrosis over the tip of the olecranon, especially as they attempt to regain flexion.[9,11,58,61,70] If one predicts the need for additional soft tissue, it is usually better to perform the soft tissue reconstruction as a separate procedure before contracture release. Depending on the amount of tissue needed, the flaps I most commonly use are either a gracilis free flap with a split-thickness skin graft or, for smaller defects over the olecranon, a radial forearm flap as an island pedicle. The radial forearm flap, using the distal skin and fascia at the distal forearm, causes a donor defect that bothers some patients. Nonetheless, the coverage over the olecranon is ideal in thickness and mobility. A flexor carpi ulnaris pedicle flap has also been described for this region. The delayed recognition of skin loss after contracture release may temporarily stall progress, but acting quickly to cover the wound with sufficient soft tissue will usually rescue the contracture release and permit the flexion gained in the primary contracture release. In other words, one should not simply wait and hope that the posterior ulceration will simply get better, especially if there is exposed bone (Figure 24.9). (See Chapter 44 for a more detailed discussion of coverage of elbow defects.)



FIGURE 24.9 **A,** Two weeks after initial contracture release, the wound shows signs of breakdown and necrosis. **B,** Débridement reveals a larger wound than was initially thought. **C,** Intraoperative photo of a radial forearm flap. Note the distal harvest site. **D** and **E,** Postoperative flap of a different patient with a similar defect approximately 2 weeks after surgery. **E,** Note the degree of flexion permitted. (Copyright © Robert N. Hotchkiss.)

Failure to Achieve Improved Motion

Three percent to 8% of patients will completely fail to achieve the goals of improved motion, sustained painless function, and stability. The usual cause of failure is articular surface destruction that is either underappreciated or progressive. Morrey refers to this as "intrinsic contracture."[47] The only option in these cases is to resurface the elbow. In older patients, a total elbow arthroplasty is the optimal choice. Distraction interposition arthroplasty may be an option in younger patients but must be carefully considered, and in my hands it remains unpredictable.

Finally, approximately 1% to 2% of patients seem to experience a pathologic arthrofibrosis. Despite careful dissection, relatively routine operative release, and attentive rehabilitation, these patients develop recurrent contracture without any notable HO. In these rare cases,[2] I have returned to excise the contracted capsule and used hinged fixation with the passive drive (i.e., Compass Elbow Hinge) with success.

REFERENCES

1. Ada L, Canning CG, Low SL: Stroke patients have selective muscle weakness in shortened range. *Brain* 126:724–731, 2003.
2. Bae DS, Waters PM: Surgical treatment of posttraumatic elbow contracture in adolescents. *J Pediatr Orthop* 21:580–584, 2001.
3. Bankov S: A test for differentiation between contracture and spasm of the biceps muscle in post-traumatic rigiditis of the elbow joint. *Hand* 7:262–265, 1975.

4. Blonna D, Wolf JM, Fitzsimmons JS, et al: Prevention of nerve injury during arthroscopic capsulectomy of the elbow utilizing a safety-driven strategy. *J Bone Joint Surg Am* 95(15):1373–1381, 2013.
5. Chantelot C, Fontaine C, Migaud H, et al: [Retrospective study of 23 arthrolyses of the elbow for post-traumatic stiffness: result predicting factors]. *Rev Chir Orthop Reparatrice Appar Mot* 85:823–827, 1999.
6. Chen NC, Liu A: The role of prophylactic ulnar nerve release during elbow contracture release. *J Hand Surg [Am]* 39(9):1837–1839, 2014.
7. Cohen MS, Hastings H: Post-traumatic contracture of the elbow: operative release using a lateral collateral ligament sparing approach. *J Bone Joint Surg Br* 80:805–812, 1998.
8. Cohen MS, Hastings H: Operative release for elbow contracture: the lateral collateral ligament sparing technique. *Orthop Clin North Am* 30:133–139, 1999.
9. Dias DA: Heterotopic para-articular ossification of the elbow with soft tissue contracture in burns. *Burns Incl Therm Inj* 9:128–134, 1982.
10. Duke JB, Tessler RH, Dell PC: Manipulation of the stiff elbow with patient under anesthesia. *J Hand Surg [Am]* 16:19–24, 1991.
11. El Khatib HA, Mahboub TA, Ali TA: Use of an adipofascial flap based on the proximal perforators of the ulnar artery to correct contracture of elbow burn scars: an anatomic and clinical approach. *Plast Reconstr Surg* 109:130–136, 2002.
12. Ellerin BE, Helfet D, Parikh S, et al: Current therapy in the management of heterotopic ossification of the elbow: a review with case studies. *Am J Phys Med Rehabil* 78:259–271, 1999.
13. Faierman E, Wang J, Jupiter JB: Secondary ulnar nerve palsy in adults after elbow trauma: a report of two cases. *J Hand Surg [Am]* 26:675–678, 2001.
14. Fox RJ, Varitimidis SE, Plakseychuk A, et al: The Compass Elbow Hinge: indications and initial results. *J Hand Surg [Br]* 25:568–572, 2000.
15. Ganapathi M, Savage R, Jones AR: MRI assessment of the proximal pole of the scaphoid after internal fixation with a titanium alloy Herbert screw. *J Hand Surg [Br]* 26:326–329, 2001.
16. Garland DE: Surgical approaches for resection of heterotopic ossification in traumatic brain-injured adults. *Clin Orthop Relat Res* 263:59–70, 1991.
17. Gates HS, III, Sullivan FL, Urbaniak JR: Anterior capsulotomy and continuous passive motion in the treatment of post-traumatic flexion contracture of the elbow: a prospective study. *J Bone Joint Surg Am* 74:1229–1234, 1992.
18. Gilbert MS, Radomisli TE: Management of fixed flexion contracture of the elbow in haemophilia. *Haemophilia* 5(Suppl 1):39–42, 1999.
19. Glynn JJ, Niebauer JJ: Flexion and extension contracture of the elbow: surgical management. *Clin Orthop Relat Res* 117:289–291, 1976.
20. Green DP, McCoy H: Turnbuckle orthotic correction of elbow-flexion contractures after acute injuries. *J Bone Joint Surg Am* 61:1092–1095, 1979.
21. Haapaniemi T, Berggren M, Adolfsson L: Complete transection of the median and radial nerves during arthroscopic release of post-traumatic elbow contracture. *Arthroscopy* 15:784–787, 1999.
22. Heirweg S, De Smet L: Operative treatment of elbow stiffness: evaluation and outcome. *Acta Orthop Belg* 69:18–22, 2003.
23. Hertel R, Pisan M, Lambert S, et al: Operative management of the stiff elbow: sequential arthrolysis based on a transhumeral approach. *J Shoulder Elbow Surg* 6:82–88, 1997.
24. Heyd R, Strassmann G, Schopohl B, et al: Radiation therapy for the prevention of heterotopic ossification at the elbow. *J Bone Joint Surg Br* 83:332–334, 2001.
25. Hildebrand KA, Zhang M, Salo PT, et al: Joint capsule mast cells and neuropeptides are increased within four weeks of injury and remain elevated in chronic stages of posttraumatic contractures. *J Orthop Res* 26:1313–1319, 2008.
26. Hotchkiss RN, Davila S: Rehabilitation of the elbow contracture. In Nickel VL, editor: *Orthopaedic rehabilitation*, New York, 1992, Churchill Livingstone, pp 746–773.
27. Husband JB, Hastings H: The lateral approach for operative release of posttraumatic contracture of the elbow. *J Bone Joint Surg Am* 72:1353–1358, 1990.
28. Jones GS, Savoie FH, III: Arthroscopic capsular release of flexion contractures (arthrofibrosis) of the elbow. *Arthroscopy* 9:277–283, 1993.
29. Jupiter JB, O'Driscoll SW, Cohen MS: The assessment and management of the stiff elbow. *Instr Course Lect* 52:93–111, 2003.
30. Kasparyan NG, Hotchkiss RN: Dynamic skeletal fixation in the upper extremity. *Hand Clin* 13:643–663, 1997.
31. Katolik LI, Cohen MS: Anterior interosseous nerve palsy after open capsular release for elbow stiffness: report of 2 cases. *J Hand Surg [Am]* 34:288–291, 2009.
32. Kim SJ, Kim HK, Lee JW: Arthroscopy for limitation of motion of the elbow. *Arthroscopy* 11:680–683, 1995.
33. King GJ: Stiffness and ankylosis of the elbow. In Norris TR, editor: *Orthopedic knowledge update: shoulder and elbow*, Rosemont, IL, 1997, American Academy of Orthopaedic Surgeons, pp 325–336.
34. King GJ, Faber KJ: Posttraumatic elbow stiffness. *Orthop Clin North Am* 31:129–143, 2000.
35. Kraushaar BS, Nirschl RP, Cox W: A modified lateral approach for release of posttraumatic elbow flexion contracture. *J Shoulder Elbow Surg* 8:476–480, 1999.
36. Libicher M, Freyschmidt J: [Radiological diagnosis in contracted elbow joint: value of CT and MRI]. *Orthopade* 30:593–601, 2001.
37. London JT: Kinematics of the elbow. *J Bone Joint Surg Am* 63:529–535, 1981.
38. MacKay-Lyons M: Low-load, prolonged stretch in treatment of elbow flexion contractures secondary to head trauma: a case report. *Phys Ther* 69:292–296, 1989.
39. Mahaisavariya B, Laupattarakasem W, Supachutikul A, et al: Late reduction of dislocated elbow: need triceps be lengthened? *J Bone Joint Surg Br* 75:426–428, 1993.
40. Mansat P, Morrey BF: The column procedure: a limited lateral approach for extrinsic contracture of the elbow. *J Bone Joint Surg Am* 80:1603–1615, 1998.
41. Marti RK, Kerkhoffs GM, Maas M: Progressive surgical release of a posttraumatic stiff elbow: technique and outcome after 2-18 years in 46 patients. *Acta Orthop Scand* 73:144–150, 2002.
42. McAuliffe JA, Wolfson AH: Early excision of heterotopic ossification about the elbow followed by radiation therapy. *J Bone Joint Surg Am* 79:749–755, 1997.
43. Mih AD, Wolf FG: Surgical release of elbow-capsular contracture in pediatric patients. *J Pediatr Orthop* 14:458–461, 1994.
44. Modabber MR, Jupiter JB: Reconstruction for post-traumatic conditions of the elbow joint. *J Bone Joint Surg Am* 77:1431–1446, 1995.
45. Moritomo H, Tada K, Yoshida T: Early, wide excision of heterotopic ossification in the medial elbow. *J Shoulder Elbow Surg* 10:164–168, 2001.
46. Morrey BF: Post-traumatic contracture of the elbow: operative treatment, including distraction arthroplasty. *J Bone Joint Surg Am* 72:601–618, 1990.
47. Morrey BF: Posttraumatic stiffness: distraction arthroplasty. *Orthopedics* 15:863–869, 1992.
48. Morrey BF: Primary degenerative arthritis of the elbow: treatment by ulnohumeral arthroplasty. *J Bone Joint Surg Br* 74:409–413, 1992.
49. Morrey BF: Surgical treatment of extraarticular elbow contracture. *Clin Orthop Relat Res* 370:57–64, 2000.
50. Morrey BF, Askew LJ, Chao EY: A biomechanical study of normal functional elbow motion. *J Bone Joint Surg Am* 63:872–877, 1981.
51. Munin MC, Balu G, Sotereanos DG: Elbow complications after organ transplantation: case reports. *Am J Phys Med Rehabil* 74:67–72, 1995.
52. Neidhardt A, Neidhardt-Audion M, Mourand JL, et al: [Subclavicular brachial plexus anesthesia: Apropos of 200 cases. Anatomical and clinical justification]. *Cah Anesthesiol* 32:651–655, 1984.
53. Nielsen D, Nowinski RJ, Bamberger HB: Indications, alternatives, and complications of external fixation about the elbow. *Hand Clin* 18:87–97, 2002.
54. O'Dwyer NJ, Ada L, Neilson PD: Spasticity and muscle contracture following stroke. *Brain* 119(Pt 5):1737–1749, 1996.
55. Page C, Backus SI, Lenhoff MW: Electromyographic activity in stiff and normal elbows during elbow flexion and extension. *J Hand Ther* 16:5–11, 2003.
56. Park JY, Cho CH, Choi JH, et al: Radial nerve palsy after arthroscopic anterior capsular release for degenerative elbow contracture. *Arthroscopy* 23:1360.e1–1360.e3, 2007.
57. Phillips BB, Strasburger S: Arthroscopic treatment of arthrofibrosis of the elbow joint. *Arthroscopy* 14:38–44, 1998.
58. Prakash V, Bajaj SP: A new concept for the treatment of postburn contracture of the elbow. *Ann Plast Surg* 45:339, 2000.
59. Regan WD, Reilly CD: Distraction arthroplasty of the elbow. *Hand Clin* 9:719–728, 1993.
60. Ring D, Hotchkiss RN, Guss D, et al: Hinged elbow external fixation for severe elbow contracture. *J Bone Joint Surg Am* 87:1293–1296, 2005.
61. Ring D, Jupiter JB: Operative release of complete ankylosis of the elbow due to heterotopic bone in patients without severe injury of the central nervous system. *J Bone Joint Surg Am* 85:849–857, 2003.
62. Roberts JB, Pankratz DG: The surgical treatment of heterotopic ossification at the elbow following long-term coma. *J Bone Joint Surg Am* 61:760–763, 1979.
63. Rodriguez-Merchan EC: Therapeutic options in the management of articular contractures in haemophiliacs. *Haemophilia* 5(Suppl 1):5–9, 1999.
64. Sahajpal D, Choi T, Wright TW: Arthroscopic release of the stiff elbow. *J Hand Surg [Am]* 34:540–544, 2009.
65. Schaeffer MA, Sosner J: Heterotopic ossification: treatment of established bone with radiation therapy. *Arch Phys Med Rehabil* 76:284–286, 1995.
66. Schippinger G, Seibert FJ, Steinbock J: Management of simple elbow dislocations. Does the period of immobilization affect the eventual results? *Langenbecks Arch Surg* 384:294–297, 1999.
67. Schrumpf MA, Lyman S, Do H, et al: Incidence of postoperative elbow contracture release in New York State. *J Hand Surg [Am]* 38(9):1746–1752.e1-3, 2013.
68. Sojbjerg JO: The stiff elbow. *Acta Orthop Scand* 67:626–631, 1996.
69. Stans AA, Maritz NG, O'Driscoll SW: Operative treatment of elbow contracture in patients twenty-one years of age or younger. *J Bone Joint Surg Am* 84:382–387, 2002.
70. Stern PJ, Law EJ, Benedict FE: Surgical treatment of elbow contractures in postburn children. *Plast Reconstr Surg* 76:441–446, 1985.

71. Tan V, Daluiski A, Capo J: Hinged elbow external fixators: indications and uses. *J Am Acad Orthop Surg* 13:503–514, 2005.
72. Tan V, Daluiski A, Simic P: Outcome of open release for post-traumatic elbow stiffness. *J Trauma* 61:673–678, 2006.
73. Tomaino MM, Sotereanos DG, Plakseychuk A: Technique for ensuring ulnohumeral reduction during application of the Richards compass elbow hinge. *Am J Orthop* 26:646–647, 1997.
74. Vardakas DG, Varitimidis SE, Goebel F, et al: Evaluating and treating the stiff elbow. *Hand Clin* 18:77–85, 2002.
75. Viola RW, Hanel DP: Early "simple" release of posttraumatic elbow contracture associated with heterotopic ossification. *J Hand Surg [Am]* 24:370–380, 1999.
76. Wada T, Ishii S, Usui M, et al: The medial approach for operative release of post-traumatic contracture of the elbow. *J Bone Joint Surg Br* 82:68–73, 2000.
77. Weber CR, Griffin JM: Evaluation of dexamethasone for reducing postoperative edema and inflammatory response after orthognathic surgery. *J Oral Maxillofac Surg* 52(1):35–39, 1994.
78. Wilson PD: Capsulectomy for the relief of flexion contractures of the elbow following fracture. *Clin Orthop Relat Res* 370:3–8, 2000.
79. Wu CC: Posttraumatic contracture of elbow treated with intraarticular technique. *Arch Orthop Trauma Surg* 123:494–500, 2003.
80. Zander CL, Healy NL: Elbow flexion contractures treated with serial casts and conservative therapy. *J Hand Surg [Am]* 17:694–697, 1992.

Elbow Tendinopathies and Tendon Ruptures

Julie E. Adams and Scott P. Steinmann

These videos may be found at *ExpertConsult.com:*
25.1 Endobutton single-incision repair of the distal biceps tendon.

LATERAL EPICONDYLITIS

History

In 1873, Runge described a condition associated with lateral humeral condylar tenderness and difficulty writing; Morris referred to it in 1882 as "lawn tennis arm." Eventually, this entity became known as "tennis elbow" or lateral epicondylitis.[45]

Multiple treatments have been proposed for epicondylitis affecting the elbow, ranging from benign neglect to physiotherapy, bracing modalities, injection of various substances, and surgery; the optimal treatment remains controversial. Boyer and Hastings[28] suggested that "there is much witchcraft and pseudoscience involved in the treatment of patients with lateral tennis elbow." In 1936, Cyriax[46] suggested "that the condition usually clears up in eight to twelve months without any treatment except perhaps avoidance of the painful movements for a time," although cases ". . . lasting much longer . . . are encountered." Few conditions elicit as much frustration and controversy regarding cause, treatment, and outcomes among patients and physicians.

Etiology, Associations, and Pathophysiology

Boyer and Hastings[28] reported that "lateral tennis elbow is most commonly an idiopathic or a work-related condition. A distinct pathoetiology has not been definitively identified." Lateral epicondylitis likely represents a multifactorial condition with elements of repetitive microtrauma in a physiologically susceptible individual.

The pathology associated with lateral epicondylitis is believed to involve the attachment of the extensor carpi radialis brevis (ECRB) at the lateral epicondyle. It is suggested that the extensor digitorum communis (EDC) is involved in approximately one third of cases, and rarely the extensor carpi radialis longus (ECRL) or extensor carpi ulnaris (ECU) is involved.[29,118] The ECRB and EDC origins are indistinguishable at the level of the lateral epicondyle. They only visibly become separate muscle-tendon units several centimeters distal at the elbow.

Lateral epicondylitis has been associated with forceful repetitive activities and smoking.[96,134,143] The peak prevalence is at age 45 years, with most patients 35 to 54 years old[75,143] and the dominant arm usually affected.[75] There is an equal distribution between the genders.[75] Of patients followed for 18 months after initial presentation to a general practitioner with the diagnosis of lateral epicondylitis, more than half exhibited a recurrence of symptoms.[75]

It is now recognized that lateral epicondylitis is a degenerative tendinopathy or tendinosis, rather than an inflammatory tendinitis.[3,4,29,64,88,99,112,118,130,133,158] Nirschl[118] described the histologic findings as an angiofibroblastic tendinosis, with a gross appearance of a gray friable edematous tendon structure.[29,118,120] The first three stages of epicondylitis include an inflammatory stage that is restricted to the early course of the disease, followed by angiofibroblastic degeneration in stage II and structural failure in stage III. The fourth stage has a hallmark of fibrosis or calcification in the setting of components of stage II or III.[36,119]

Repetitive contraction of the extensors is believed to cause microtrauma to the tendons, eventually resulting in lateral epicondylitis.[4,42,91,135] Other authors have suggested that impingement of the ECRB tendon against the lateral edge of the capitellum causes abrasion and wear of the tendon during elbow motion, which eventually results in the condition.[30]

In the diseased state, the normally avascular tendon attempts to repair itself with fibroblastic elaboration of collagen and fibrovascular proliferation.[3,4,29,99] Continued mechanical trauma in the setting of an inadequate healing response leads to tendinosis.

Histopathologic findings include fibrocartilaginous formation[64,88,158] or mucoid or hyaline degeneration,[64,88,130,133] fibrovascular proliferation,[64,88,130,133,158] and focal calcifications.[64,88,112,130,158] Milz and colleagues[112] investigated the gross and histologic and molecular features of the common flexor and extensor origins in cadaveric specimens to attempt to describe the ranges of normal and pathologic findings at these locations. The tendon insertions medially and laterally showed confluence with the underlying collateral ligaments, resulting in a complex integrated structure. Fibrocartilage, which had previously been thought to represent a pathologic condition, was found frequently in all age groups, suggesting that it may be present under normal conditions. In addition, degeneration of tendon structure at the epicondylar insertions was present in elderly specimens, indicating that the presence of degenerative changes at the epicondyle may be associated with age.

Presentation

In lateral epicondylitis, patients typically complain of pain localized to the lateral epicondyle and at the ECRB origin, just slightly distal and anterior to the lateral epicondyle; the pain is exacerbated by wrist extension. On clinical examination, pain

is elicited with resisted wrist extension with the forearm pronated and elbow fully extended. Additionally, resisted supination with the wrist flexed can precipitate the pain of lateral epicondylitis. The "chair test," in which the patient is asked to lift a chair with the arm in forearm pronation and wrist flexion, typically causes pain.[66] There is an overlap with radial tunnel syndrome in patient complaints and physical findings with use of provocative tests.[155] Pain occurs with resisted finger extension and resisted forearm supination in both processes, so these are not definitive tests for either diagnosis.

If the history is vague and pain is poorly localized or unrelated to activity, other conditions should be considered. This is especially true if the physical examination fails to localize the area of tenderness as described previously. Chondromalacia, periarticular tumors, loose bodies, plica, osteochondral defects, cervical radiculopathy, or ligamentous instability should be considered. Radial tunnel syndrome (supinator syndrome) may also be present (with an estimated incidence of 5%).[63,155]

Diagnosis

The diagnosis of lateral epicondylitis is based on the clinical history and examination findings of pain centered over the origin of the common extensor mechanism, particularly the area of the ECRB and EDC. Radiographic evaluation of the elbow is typically not helpful in lateral epicondylitis but may exclude other disease entities. There might occasionally be some ossification of the soft tissues, but whether this is a result of treatment from multiple injections or is a natural process of the disease is uncertain.

Frequently, magnetic resonance imaging (MRI) studies are obtained in patients with elbow pain, often ordered by the referring physician or requested by the patient. MRI findings consistent with lateral epicondylitis include increased signal on T1 and T2 sequences.[108,130] MRI can show frank tearing and separation of muscle from the bone,[130,158] and it has been suggested that there is good correlation between MRI findings and intraoperative findings.[130]

Frequently, asymptomatic patients have false-positive findings with signal enhancement,[108,139] however, and enhancement may persist even after clinical resolution of symptoms.[139]

In practice, just about every patient with mild pain over the lateral aspect of the elbow seems to have positive changes on MRI, particularly if the patient has had a series of injections. MRI is not significantly helpful in making the diagnosis or dictating treatment but can be used as an adjunct to look for other causes of potential pain around the elbow.

MEDIAL EPICONDYLITIS

Presentation

Medial epicondylitis is much less common than lateral epicondylitis, with a prevalence of 0.4% compared with 1.3% in one study.[143] Other studies have found an estimated prevalence of 3.2% to 8.2% in patients employed in repetitive labor tasks.[51,105,134] Medial epicondylitis is suggested to constitute 10% to 20% of all epicondylitis cases.[35,98,153]

Risk factors are similar to those in lateral epicondylitis and seem to include obesity, physical loads, and smoking; some studies suggest a female preponderance, whereas others do not.[51,74,96,143]

There seems to be an association of medial epicondylitis with other work-related or overuse musculoskeletal disorders.[51,124] As in lateral epicondylitis, patients are typically middle-aged (fourth to fifth decades) and the dominant arm is usually involved.[35,124] An exception is young throwing athletes who may experience medial-sided elbow pain.[111]

The history typically involves an insidious onset of pain at the medial aspect of the elbow. Tenderness exists at the medial epicondyle and distally over the pronator teres (PT) and flexor carpi radialis (FCR). Pain is worsened with resisted pronation and resisted wrist flexion.[35]

Etiology and Pathogenesis

It has been suggested that the cause is related to overuse or repetitive motions leading to microtrauma to the muscular origins at the medial epicondyle; most commonly, to the PT and FCR, but also occasionally to the palmaris longus, flexor digitorum superficialis, and flexor carpi ulnaris origins.[23,29,36,98,110,118,124] As implied by the layperson's term *golfer's elbow*, repetitive use and microtrauma can precipitate the condition, and it has been associated with repetitive valgus loads in golf, racquet sports, football, baseball, weight lifting, and archery, in addition to occupational exposures requiring repetitive motions of the hand, wrist, elbow, or forearm.[35,65,89,98,124,168] One of the oldest references is that of Morris,[116] who described a condition in rowers occurring after "long and vigorous sculling," with pain at the "inner part of the elbow," which resolved with rest and avoidance of pronosupination. Although usually associated with a chronic overuse type of phenomenon, occasionally a single sudden traumatic episode can cause avulsion of the flexor pronator origin and lead to this condition.[36]

As in lateral epicondylitis, pathologic findings include a degenerative tendinosis rather than an inflammatory tendinitis, and it has been suggested that this is due to the repetitive microtears in the setting of an inadequate healing response and, eventually, altered biomechanics of the elbow joint.[110] In pitchers, the stresses are conferred to the medial structures of the elbow, including the flexor pronator muscles and medial collateral ligament (MCL).[110]

Acceleration and valgus forces may exceed the tensile strength of the medial constraints of the elbow, leading to tears with a spectrum of pathologic findings ranging from epicondylitis to MCL insufficiency.[35,124]

The pathologic change found in medial epicondylitis is indistinguishable from that found in lateral epicondylitis with angiofibroblastic tendinosis.[124]

In 23 to 60% of patients, ulnar neuritis is present.[62,97,110,124,168] The pathophysiologic mechanism has been suggested to be a combination of traction injury with entrapment and compression.[35]

Diagnosis

The differential diagnosis includes neurologic conditions (ulnar nerve neuritis, cervical radiculopathy, pronator syndrome); intraarticular pathologic conditions such as elbow synovitis, arthritis, or osteochondral defects; and ligamentous deficiency (MCL insufficiency).[110] Typically, the diagnosis is made on clinical grounds. Radiographs may reveal calcification adjacent to the medial epicondyle or traction spurs or calcifications, particularly in throwing athletes.[36,110] As in lateral epicondylitis,

radiographs are not typically necessary for the diagnosis, but they may exclude alternative causes of elbow pain. Some authors have investigated use of other imaging modalities, and ultrasonography has been noted to be highly specific and sensitive. Typically, a focal hypoechogenic or anechogenic area is shown,[127] although ultrasound is usually not necessary to make the diagnosis.

MRI may be useful to rule out other conditions, such as MCL insufficiency or intraarticular pathologic conditions such as osteochondral defects. In the setting of medial epicondylitis, MRI may show increased signal intensity on T1 and T2 series,[89] but it is again typically not required to make the diagnosis and it is not specific, because signal changes can be seen in asymptomatic individuals.[89] It has been suggested that these signal changes in asymptomatic patients may represent senescent changes or prior epicondylitis that has become quiescent.[89]

Because of a high rate of concomitant ulnar neuritis, the clinical examination should include evaluation of the ulnar nerve, including provocative maneuvers such as a cubital tunnel Tinel sign, a cubital tunnel compression test, and an elbow flexion test.[35,110] Electromyography is of limited utility because it is normal in 90% of patients with ulnar nerve symptoms.[110]

The status of the MCL should be assessed to rule out insufficiency. Valgus stress should be applied to the elbow in a position of 30 degrees short of full extension. Potential compensatory action of the flexor pronator group can be eliminated by placing the pronated forearm in a position of wrist flexion and 30 degrees of elbow extension before stress is applied. The *milking maneuver*, in which the examiner pulls on the patient's thumb, generating a valgus stress when the forearm is supinated in a position of elbow flexion, also tests for MCL insufficiency. In both tests, pain and instability are typically absent in pure medial epicondylitis, and their presence may represent MCL injury.[35,110]

TREATMENT OF MEDIAL AND LATERAL EPICONDYLITIS

Treatment considerations for medial and lateral epicondylitis are similar and are considered together. The treatment of epicondylitis is controversial. There are multiple reports advocating different techniques for treatment, but many are flawed studies.[43]

Nonoperative Treatment

Nonoperative therapy is the main treatment option for medial and lateral epicondylitis.[36] It has been suggested that more than 85 to 90% of patients respond to nonoperative treatment,[42,73,124] but some series suggest more modest results, with 40% of patients with lateral epicondylitis having some residual discomfort.[25]

Activity modification is one of the mainstays of treatment, with avoidance of precipitating activities. Several studies have noted that tennis players who use a two-handed backstroke are less likely to develop tennis elbow, perhaps because of altered biomechanics and dissipation of the forces experienced at ball contact.[68,98,135] Likewise, other modifications of equipment and action can help symptoms resolve.

Three phases of treatment have been proposed for epicondylitis. Phase one involves activity modification to avoid precipitating activities and use of icing several times daily. Nonsteroidal antiinflammatory drugs may be used to diminish any accompanying elbow synovitis. Night splinting and corticosteroid injections may be considered,[35,124] and counterforce bracing may be considered during phase one to limit contraction of the muscles, although use of these treatment options has been questioned and efficacy of injections, bracing, therapy, and oral or topical medications remains uncertain.[35,128]

Phase two involves starting a rehabilitation program after the acute symptoms are diminished with restoration of full painless wrist and elbow motion. A program of isometric exercises and stretching is initiated, followed by resistive exercises and sports or work hardening.[35]

The third phase is a maintenance phase involving equipment and technique modification for sports or work and continued conditioning to prevent recurrence.[35] Injection of various substances has been suggested as a treatment for lateral and medial epicondylitis. Nevertheless, review of the literature demonstrates conflicting and inconclusive evidence upon which to base recommendations for injections as treatment of lateral epicondylitis.[93]

Botulinum toxin injection has been suggested for lateral epicondylitis, with some benefit shown in some but not all series, although muscle weakness may be seen as an expected side effect.[82,174] Injection of autologous blood has been suggested to be beneficial for epicondylitis.[40,54,83] One series showed a beneficial effect of dry needling and injection of autologous blood in medial epicondylitis,[160] and another showed a beneficial effect in lateral epicondylitis.[54] Platelet-rich plasma injections have also been reported, with mixed results.[70,94,113,163]

Corticosteroid injection has historically been suggested to decrease pain and early inflammation or joint synovitis and in some series has been found to be beneficial, particularly in the short term.[7,164] Despite short-term improvement, corticosteroid injection does not seem to influence the outcome at 3 or 12 months.[131,146,148,154,169] A more recent study suggests that there is no difference between injection with corticosteroid and local anesthetic versus local anesthetic alone at 1 or 6 months; the presence of concomitant depression or poor coping skills was a better predictor of outcome than treatment modality.[102]

Finally, a recent study and subsequent metaanalysis should provoke caution in the use of corticosteroid injections. Coombes and colleagues found that injection of corticosteroid resulted in poorer outcomes relative to placebo at 1 year.[41] A metaanalysis suggests that despite short-term beneficial effects of corticosteroid injection, the intermediate-term results show a negative effect and the long-term effects are uncertain, with conflicting data.[123] Other studies have suggested that the technique of injection plays a larger role than the substance injected. These theories center on the ability to induce a vascular healing response by a "peppering" technique in which the needle is redirected multiple times to puncture the epicondylar region at multiple sites. This idea is supported by studies in which lateral epicondylitis was injected with either corticosteroid, autologous blood, or lidocaine, with equivalent good results at follow-up.[6,94,173]

Corticosteroid injection is better than physiotherapy and modalities in most,[25,131,154,169] but not all, series.[90,117,148]

Physiotherapy has equivocal long-term results.[117,148] Modalities such as ultrasound or iontophoresis have been suggested to provide benefit, but their efficacy and role in treatment remain controversial. One study showed that ultrasound therapy for lateral epicondylitis has no benefit.[48] Pulsed electromagnetic field therapy is suggested to be more beneficial than placebo for treatment of lateral epicondylitis; however, results across series are conflicting.[167] In addition, extracorporeal shock-wave therapy has shown some benefit in medial and lateral epicondylits,[60,136,142,151,171] but most studies have failed to find any advantage for it over control groups and it is not routinely recommended.[26,34,78,92,100,142,152,156,157,170]

Surgical Treatment

Surgical indications for medial or lateral epicondylitis include failure of a nonoperative treatment course of 6 or more months and, in medial epicondylitis, tendon disruption in a throwing athlete or progressive ulnar neuritis.[35,110,120,124]

Surgical treatment typically involves excision of the area of tendinosis, débridement of the local tissue bed, and reattachment of the tendon origin as indicated. Reported success rates are 97% in primary lateral epicondylitis, 83% in revision cases, and 87 to 100% in primary medial epicondylitis.[52,61,111,120,124,125]

The area of pathologic change may extend beyond the visibly abnormal area, and concern exists regarding the need to débride all affected tissue while preserving normal structures. This concern is particularly relevant because gross appearance of the tendon and patients' symptoms do not always correlate with the degree of histopathology, with grossly degenerative tissue having minimal histologic findings in some cases.[29] Some authors have proposed the "scratch test" to differentiate between normal and abnormal tissue, suggesting that normal tendon would not be removed by scraping with a No. 10 knife blade.[29]

In the setting of medial epicondylitis, it is important to query the patient about symptoms and examine the patient specifically for ulnar nerve pathologic conditions, as failure to address this at the time of surgery may lead to persistent discomfort.

Lateral Epicondylitis Surgery

Choices in lateral epicondylitis surgery include open or percutaneous procedures that release the extensor origin from the lateral epicondyle, procedures in which tendinosis is removed from the lateral epicondyle and the ECRB origin is released or repaired, denervation of the lateral epicondyle, intraarticular procedures, and arthroscopic débridement or release of the ECRB origin. Outcomes after open release or débridement are generally good to excellent in 70 to 97% of patients; however, a prolonged recovery and unsatisfactory results can be seen in 15 to 20% of cases.[39,52] Percutaneous release of the common extensor origin from the lateral epicondyle has been described using a small incision. Reported success rates are 70 to 91%.[20,73,175,176]

Several cadaver and clinical studies have evaluated the safety and efficacy of arthroscopic lateral epicondylitis surgery and have suggested it is a safe and reliably reproducible procedure.[16,17,95,126,149] A classification system based on arthroscopic findings has shown three types, although outcomes do not correlate with classification type.[17] Arthroscopic treatment has been suggested to have benefits over open treatments, including easier and faster recovery, earlier return to work, and provision of a surgical means for evaluating and treating intraarticular pathologic conditions, which in some series are present in 69% of cases.[16,17,72,81,126,129] Likewise, selective release of the involved ECRB with preservation of the uninvolved common extensor origin can be achieved.[17]

Cohen and colleagues[39] described the anatomic relationships of the extensor tendon origins and made specific recommendations from their cadaveric study for arthroscopic ECRB release. The bony origin of the ECRB was reliably found just anterior to the distalmost tip of the lateral supracondylar ridge, with a diamond-shaped footprint. Proximally, the ECRB arose from a longitudinal line paralleling the long axis of the humerus, and the superior margin was at the superior capitellum, whereas the inferior margin was at the midpoint of the radiocapitellar joint or capitellum. The ECRB was intimate but easily distinguishable from the joint capsule deep to it. Based on these dissections, the authors performed arthroscopic release of the ECRB. A standard anteromedial portal was established first, and a modified lateral portal was made from an inside-out technique 2 to 3 cm proximal and anterior to the lateral epicondyle. A monopolar thermal device was used to expose the ECRB by ablation of the capsule, and then release of the ECRB was performed.

Cohen and colleagues[39] noted that the capsule must be resected to gain access to the ECRB, which can be identified and released from the top of the capitellum to the midportion of the radiocapitellar joint; care is taken not to release it posterior to the midline of the joint so as to protect the ligament, and care is also taken to preserve the extensor aponeurosis lying superficial to the ECRB tendon.

Smith and coworkers[149] noted that inadvertent injury to the lateral ulnar collateral ligament could be avoided by using the anterior half of the radial head as a landmark for the safe region for débridement of the extensor tendon origin.

With regard to outcomes, results comparable to those of open procedures have been seen with maintained success at a mean follow-up of 130 months.[16] Superiority over open procedures has not been shown,[129] however, and some authors have suggested that arthroscopic procedures can be associated with residual tendinopathy and symptoms because of the inability to visualize and treat the area of pathologic change fully.[28,44] Likewise, elbow arthroscopy generally has a high learning curve and has been associated with neurovascular injuries, with the potential to destabilize the lateral ligamentous structures even in the most experienced of hands.[1,17,159,165]

One study comparing effectiveness and a Cochrane Database review concluded that there is no evidence to suggest one procedure over another and recommended surgeon experience and preference in deciding which procedure, open versus arthroscopic versus percutaneous, to perform.[103,161]

Surgery for Recurrent Lateral Epicondylitis

Revision surgery for failed tennis elbow surgery has been reported to have a greater than 80% success rate.[5,104,125,140] Common findings include inadequate or incomplete resection of tendinosis in 97% of cases.[125] More thorough resection of tissue and repair of the extensor aponeurosis resulted in an 83% success rate.[125] In addition, for recurrent or primary lateral epicondylitis in which a wide degenerative tendon has been seen intraoperatively, anconeus muscle flap transposition has been used with good results and a patient satisfaction rate of 94% in one series.[5,104,140]

Surgical Treatment for Medial Epicondylitis

Surgical treatment of medial epicondylitis is performed in a manner similar to that for surgery on the lateral side. The interval between the PT and FCR is developed, revealing the deep tissues that are diseased, and they are sharply excised.[62,110,124]

Caution is needed to avoid injury to the ulnar nerve and the anterior bundle of the MCL. Injury to the medial antebrachial cutaneous nerve may result in a bothersome numb patch or a painful neuroma.[124]

Expected Outcomes

Good to excellent results have been achieved in 83 to 96% of patients using variations in technique,[20,62,124,168] with poorer outcomes reported in patients with ulnar nerve symptoms.[62] Little information is available in the literature regarding optimal treatment for recurrent medial epicondylitis or failed prior surgery.

❖ AUTHORS' PREFERRED METHOD OF TREATMENT: Elbow Epicondylitis

Variable opinions exist regarding the cause and natural history of epicondylitis. Even more controversial is the subject of the optimal treatment of this condition, including the role of benign neglect, therapy, injections, modalities, and surgery.[43]

When patients present for evaluation and treatment of epicondylitis, they often expect some active intervention. Based on the available evidence, most cases resolve with patience and minimal intervention within 18 months; the probable best recommendation for treatment is oral analgesics for symptom relief, activity modification (at work and at play), and an overall plan of "waiting things out" for up to18 months. It may be unrealistic, however, to expect most patients to accept the intellectual explanation that "lateral elbow pain is a harmless rite of passage into middle age"[102] that often resolves on its own, and that "leaving things be" and allowing significant time for healing is sufficient treatment.

Based on available evidence in the literature, corticosteroid injection, although commonly used by physicians and frequently requested by patients, has little, if any, benefit over placebo. Likewise, such injections usually do not change the natural history of the disease, although recent data suggest that poorer results are seen in the intermediate and long term following corticosteroid injections relative to placebo. With respect to corticosteroid injection and short-term relief of symptoms, there is some evidence to suggest improvement, although injection with local anesthetic or saline may fulfill the same role.[102,131,146,148,154,169]

In our practice, we attempt to have a frank, complete discussion with the patient about the pathologic conditions and explain the available evidence suggesting that with a significant amount of time (≤2 years), the process tends to be self-limiting and dissipates.[147] Some patients will find this reassuring, but many do not. There is evidence in the literature to suggest that poorer outcomes are seen in patients who complain of severe pain, have concomitant neck pain, are involved in workers' compensation claims, have concomitant depression, or have poor coping skills.[102,147] Patients who are inclined to reject the notion that this is a benign, albeit frustrating, self-limited process and want "something done" may request and be offered an injection with local anesthetic or corticosteroid, although the recent data again suggest that long-term outcomes are poorer with corticosteroid injection. We encourage patients to modify activity to avoid sports and work-related extension of the elbow with wrist extension and flexion.

If a patient continues to have symptoms beyond 6 to 9 months despite activity modification, surgical intervention is offered if the patient desires further treatment. Surgical treatment of lateral epicondylitis can be performed either by open procedures or arthroscopically. The literature confirms that outcomes between the two procedures are comparable. We discuss with the patient the minimally invasive nature of arthroscopic treatment; however, we also explain that arthroscopy is accompanied by an increased risk of neurovascular injury and instability compared with open release of the elbow.[1,17] Surgical treatment of medial epicondylitis is by open procedures only; there is no arthroscopic option.

Open release of lateral epicondylitis is performed under tourniquet control for visualization or "wide-awake" anesthesia with local anesthesia combined with epinephrine. A lateral incision of approximately 4 cm is made overlying the epicondyle or just anterior to it (Figure 25.1). The ECRL-EDC interface is identified and incised, and the ECRL is retracted anteriorly (Figure 25.2). The degenerated tissue at the ECRB origin is identified, usually appearing as a white-gray friable abnormal tissue. This tissue is sharply excised (Figure 25.3). Typically, the joint is not opened. It is also important to protect the lateral ulnar collateral ligament by restricting the excision of the degenerated tissue to the anterolateral epicondyle. As discussed in Chapter 23, some surgeons have inadvertently excised the

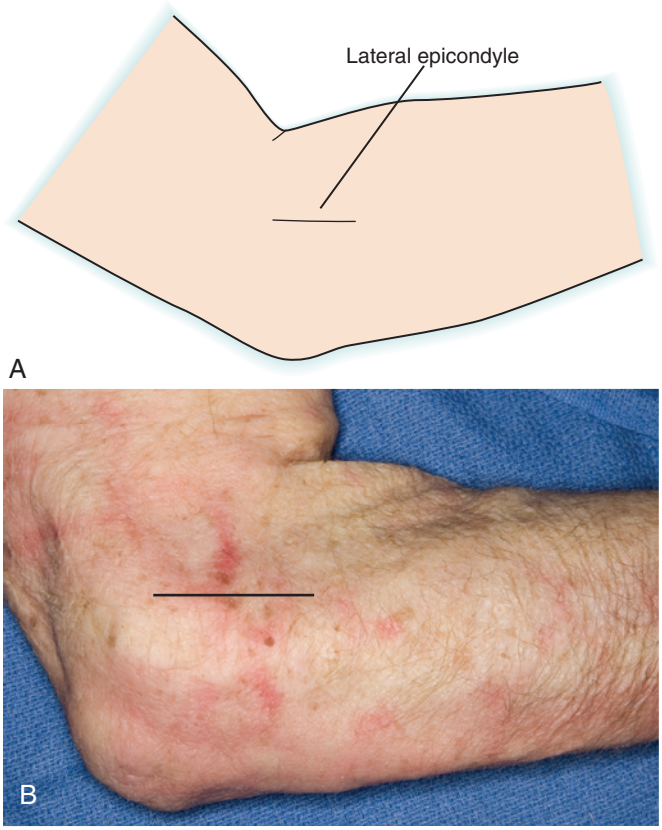

FIGURE 25.1 Skin incision is based just distal to lateral epicondyle.

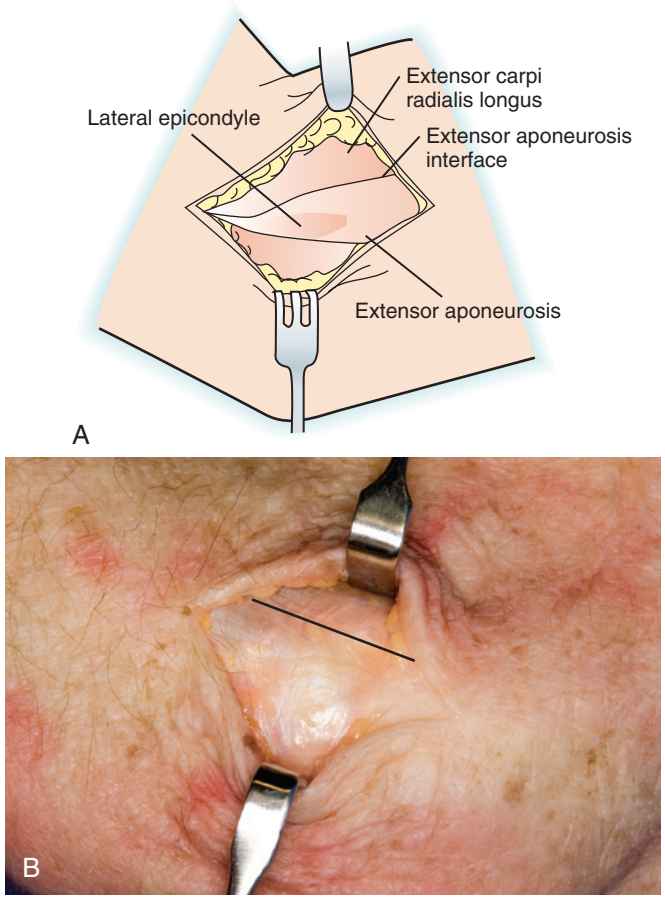

FIGURE 25.2 Extensor carpi radialis longus–extensor digitorum communis interface is identified.

ligament, leading to chronic instability requiring repair or reconstruction. The epicondyle itself may be rongeured to remove the diseased and degenerative tendon, and a small bur may be used to decorticate the epicondyle; alternatively, a Kirschner wire or drill may be used to drill into the bone (Figure 25.4).

The ECRL origin is repaired as needed, hemostasis is obtained after the tourniquet is released, and the wound is closed. A sterile soft dressing is applied. The patient is asked to use a sling for 2 to 3 days and then is allowed normal use of the elbow as tolerated. A cock-up removable wrist splint may be placed at the time of surgery to take pressure off the common extensor origins and can be worn for 1 to 2 weeks until the wound is healed and elbow motion has returned to normal.

Arthroscopic Technique

The patient is positioned in the lateral position, and the arm is secured in a dedicated arm holder. Regional anesthesia is generally avoided, so that an accurate neurovascular examination can be performed after completion of the procedure. The elbow is examined to rule out a subluxating ulnar nerve, and all portal sites and bony landmarks are marked before joint insufflation. The joint is distended with 30 mL of saline introduced via an 18-gauge needle into the anterolateral portal. Arthroscopic treatment of lateral epicondylitis is achieved through two portals, with viewing from the anteromedial portal and working through the anterolateral portal. We prefer to start the arthroscopy from the anterolateral portal, with a subsequent anteromedial portal made under direct visualization and using a switching stick to swap viewing portals; however, establishing the anteromedial portal first is acceptable as well. The anterolateral portal should be placed slightly more distally and anteriorly than the standard anterolateral portal, just distal to the radiocapitellar joint. If the portal is placed directly over the radiocapitellar joint, it can be difficult to address the area of the ECRB.

Diagnostic arthroscopy is performed to rule out any other articular pathologic findings, such as loose bodies, plicae, or thickening of the annular ligament. A shaver or radiofrequency probe is used to débride the capsule through the anterolateral portal.[17] This débridement exposes the undersurface of the white tendinous ECRB-EDC conjoined tendon origins, which have a clearly visible demarcation from the muscular, more anterior ECRL. The ECRB (and part of the EDC) is released from its origin with a shaver or a radiofrequency probe. A radiofrequency probe is useful to elevate the ECRB, which may then be released from the lateral epicondyle. Release posterior to the midline of the radiocapitellar joint should be avoided to prevent instability. A shaver or bur may be used to decorticate the lateral epicondyle, especially in chronic cases, to promote vascularity and healing.[17]

The instruments are withdrawn, and no suturing or closure, other than of the skin portals, is required. A sterile dressing is applied, and the arm is placed into a sling. Within 24 to 48 hours, the patient is allowed to use the arm for gentle activities. A removable cock-up wrist splint, as used with the open procedure, is helpful.

Surgical Technique for Treatment of Medial Epicondylitis

Surgical treatment for medial epicondylitis is rarely required; most patients respond to nonoperative treatment. Failure to respond to activity modifications and other nonoperative means for more than 6 to 9 months may represent an indication for surgical management, however. A procedure similar to what is done on the lateral side is performed. There is no current arthroscopic treatment for this condition.

A tourniquet is used on the upper arm to facilitate visualization. The incision is made from 2 cm proximal to the medial epicondyle and extends distally parallel to the epicondyle for 4 to 5 cm (Figure 25.5). The medial antebrachial cutaneous nerve and its branches are preserved; inadvertent injury may lead to a bothersome numbness or a painful neuroma. The interval between the PT and FCR is developed (Figure 25.6).[62,124] The PT is retracted anteriorly and the FCR is retracted posteriorly to reveal the deep tissues that are diseased in this condition; these are sharply excised (Figure 25.7).[110] Care is taken to preserve the anterior bundle of the MCL; otherwise, iatrogenic instability may ensue. Abnormal tissue is removed, and the medial epicondyle is prepared by cutting away fibrous tissue with a rongeur and placing small drill holes through the cortex to improve vascularity (Figure 25.8).

The PT-FCR interval is closed with running 2-0 braided suture (Figure 25.9); this is adequate in simple cases of medial epicondylitis without concomitant MCL injury. For the latter condition, the PT-FCR interval is developed further, and the common flexor origin is split along its fibers. The MCL is

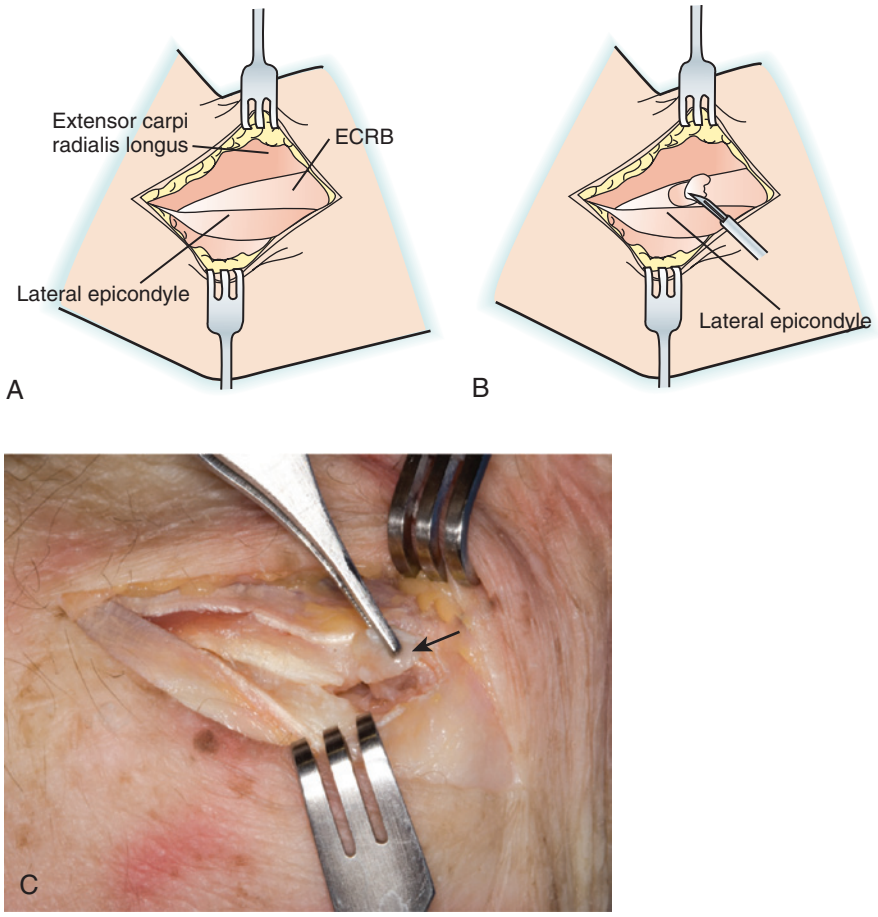

FIGURE 25.3 **A** to **C,** Degenerated tissue at extensor carpi radialis brevis (ECRB) is identified and incised.

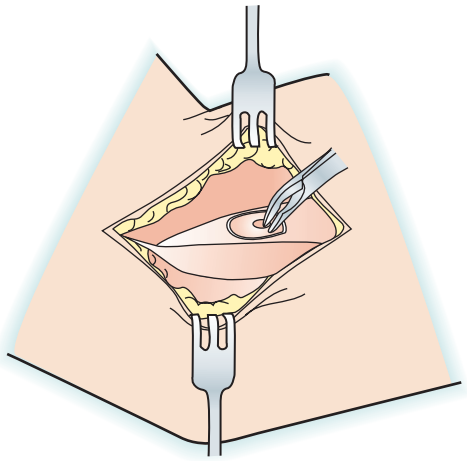

FIGURE 25.4 A bur is used to decorticate bone.

exposed, the anterior bundle of the MCL is reconstructed as indicated, and drilling and reattachment of the origin are performed as described earlier. If ulnar nerve symptoms are present preoperatively, the ulnar nerve should be decompressed in situ or transposed.

Postoperatively, the arm is placed in a sling for comfort for 1 to 2 weeks until sutures are removed. Range of motion and gentle use of the arm are allowed. Resisted wrist flexion or pronation is avoided for 4 to 6 weeks for simple medial epicondylitis; more restrictions are required if reconstruction of the MCL has been performed.

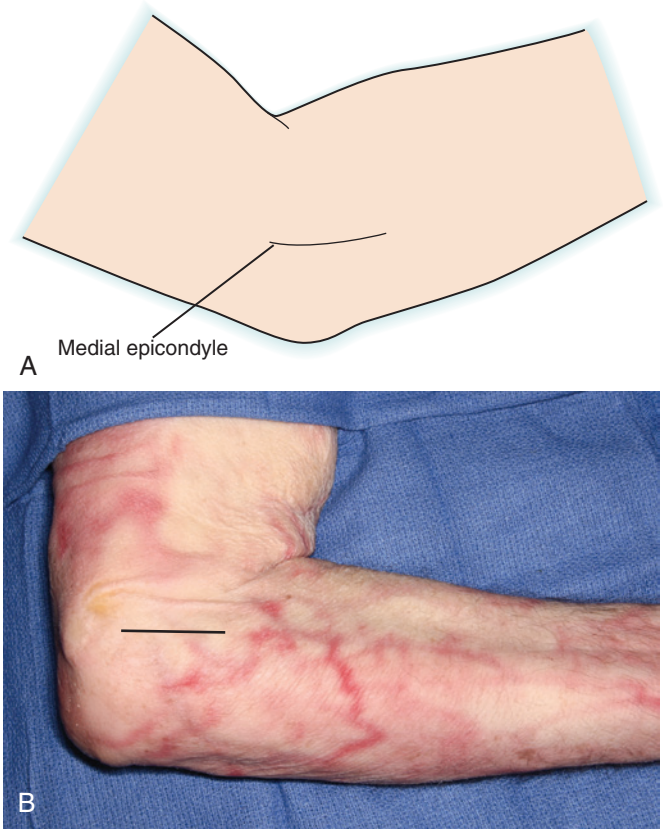

FIGURE 25.5 Medial incision posterior to medial epicondyle is made.

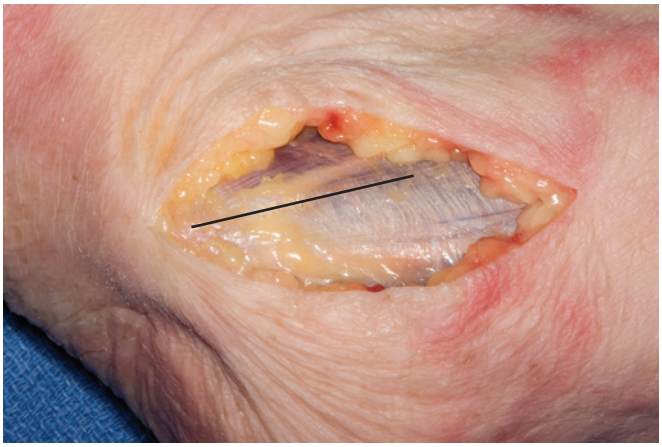

FIGURE 25.6 Interval between pronator teres and flexor carpi radialis is identified and developed.

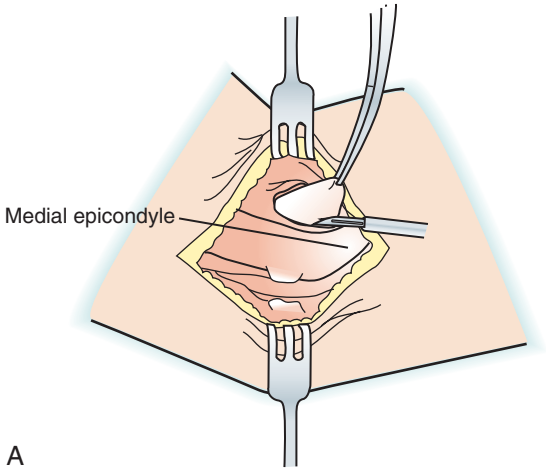

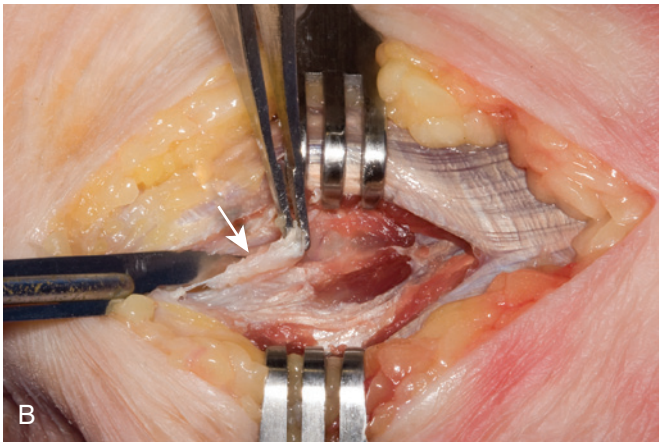

FIGURE 25.7 **A** and **B,** Area of tendinosis is identified and excised.

Avulsion of the flexor pronator origin is important to rule out in the evaluation of medial elbow pain. This condition can commonly occur in golfers who hit the ground instead of the ball or in individuals after a fall, conferring a sudden injury to the medial elbow. In this instance, this is not medial epicondylitis but rather true avulsion of the flexor pronator origin. This avulsion can often be mistaken for medial epicondylitis; however, flexor pronator avulsion does not tend to improve with conservative treatment. It is surprising how trivial injuries,

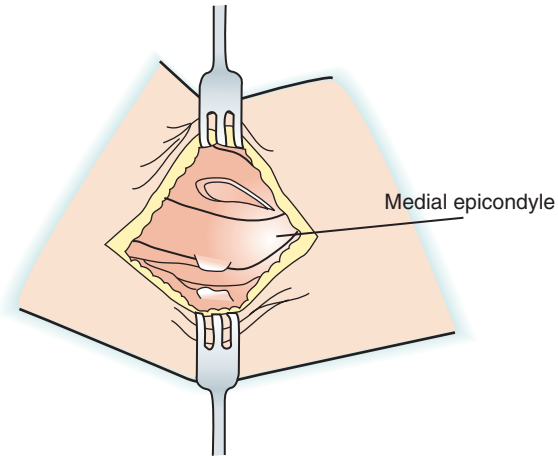

FIGURE 25.8 Medial epicondyle is prepared by removing fibrous tissue with rongeur.

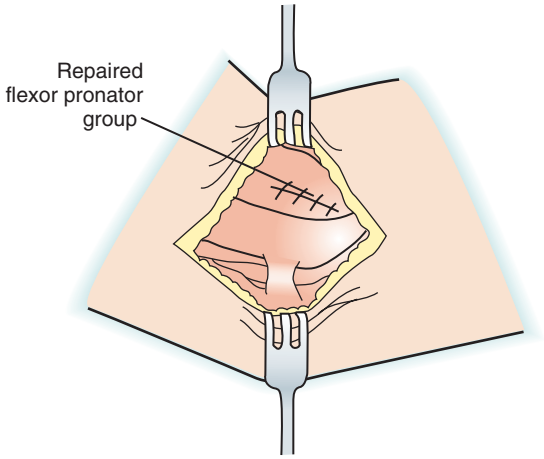

FIGURE 25.9 Pronator teres–flexor carpi radialis interval is closed with 2-0 suture.

such as hitting the ground with a golf club or falling while playing sports, can avulse the flexor pronator group; however, MRI shows avulsion of a significant portion of the flexor pronator group with interposed scar tissue.

If the patient is seen acutely, operative fixation of the flexor pronator group may be indicated. Patients with late presentations should be given the option of conservative treatment for 3 to 6 months, however. Although most patients do not improve with conservative management, they should be given a chance.

Operative treatment of a flexor pronator avulsion involves a posterior incision with full-thickness flaps developed to expose the medial side or a direct medial approach. Often chronic cases have interposed scar at the edge of the flexor pronator group; this must be débrided to a healthy muscular origin. The origin is repaired with No. 0 braided nonabsorbable suture to the medial epicondyle through drill holes (or, alternatively, suture anchors may be used). The wound is closed in the usual fashion. The patient is placed in a long-arm splint in neutral rotation and neutral wrist position until he or she returns for suture removal at 7 to 14 days. Subsequently, the patient is protected from forced extension of the wrist or powerful active flexion of the wrist for 4 to 6 weeks with a removable splint.

CRITICAL POINTS *Lateral and Medial Epicondylitis*

- In lateral and medial epicondylitis, most patients respond to nonoperative therapy (activity modifications with or without adjunctive measures) within 18 months.
- Little evidence exists regarding the efficacy of adjunctive nonoperative therapies over placebo; however, they are widely used and may give the patient satisfaction and some subjective benefit in pursuing an "active" treatment.
- Operative treatment may be considered after more than 6 to 9 months of recalcitrant symptoms; in medial epicondylitis, the presence of acute avulsion of the flexor pronator origin, worsening ulnar neuritis, or MCL insufficiency in a throwing athlete are also indications for surgery.
- In open lateral epicondylitis surgery and medial epicondylitis surgery, the abnormal tissue is identified as a gray, friable, edematous tendon and is excised.
- The origins are repaired as indicated, and resisted wrist motion is avoided postoperatively.
- Arthroscopic lateral epicondylitis surgery requires familiarity and competency with arthroscopic elbow procedures and anatomy.

DISTAL BICEPS RUPTURE

Ruptures of the distal biceps tendon are readily diagnosed by the history in most cases. The patient is typically a middle-aged man (fifth or sixth decade) who relates a history of lifting an object or a forced extension of a flexed and loaded forearm.[114] It is exceedingly unusual for distal biceps pathologic conditions to occur in women. There have been anecdotal reports of distal biceps rupture in women[19,172]; however, our personal experience involves only two female patients who had partial tearing and tendinopathy involving the distal biceps that was unresolved and responded well to operative treatment of débridement and reinsertion of the biceps tendon. Commonly, a middle-aged man experiences a sudden "pop" or giving way in the antecubital fossa after flexing and supinating the elbow against a form of resistance. If the patient is seen a few days after this episode, there is ecchymosis present over the elbow and proximal forearm, and the patient often points out the asymmetry and the "Popeye" deformity in the biceps muscle belly. This makes the diagnosis quite easy to make, and with this classic history, the diagnosis can also be made over the telephone. Partial biceps tendon tears may result from an acute event or tearing in conjunction with chronic degeneration.[14,50] Clinical complaints and findings are similar to those of complete rupture, with pain in the antecubital fossa and weakness of supination. In contrast, the biceps may still be palpable, and MRI findings suggest a partial tear.[14]

In some patients, the diagnosis is less clear. These patients frequently have a partial tear of a chronic and slowly degenerative nature and complain of nonspecific elbow pain that is worsened with daily activities. They may not complain specifically of pain while supinating the forearm. On physical examination, patients often point to the anterior middle aspect of the antecubital fossa but do not specifically point to the posterolateral aspect of the elbow or the area of the radial tuberosity. This presentation can make the diagnosis less obvious, and other pathologic changes around the elbow, such as lateral epicondylitis, plica, or elbow arthritis, may be considered. On examination, full range of motion is present, but frequently there is exacerbation of symptoms with resisted elbow flexion and supination and with deep palpation of the biceps and antecubital fossa. In addition, deep palpation of the radial tuberosity from the posterolateral aspect while passively pronating the forearm sometimes elicits pain. This finding of pain noted with palpation over the radial tuberosity is a very good indication of tendinopathy involving the insertion of the distal biceps.

The pathologic changes that occur with distal biceps tendinopathy may be similar to those of tendinopathies elsewhere in the body, such as in the shoulder or wrist. The insertion site of the tendon on the radial tuberosity undergoes degenerative changes that are visible and begin with partial tearing of the tendon. This process can be painful, but it also clearly can be asymptomatic. We have treated many patients with distal biceps ruptures that showed, in addition to the acute rupture for which they were undergoing surgical treatment, signs of significant chronic degeneration with partial tearing before rupture. Many of these patients deny having any symptoms referable to their distal biceps insertion before the acute event (rupture) that caused them to present for treatment.

Diagnosis

On clinical examination, a patient with biceps pathologic conditions exhibits pain and weakness in flexion and supination and sometimes ecchymoses in the antecubital fossa or an abnormal muscle contour of the biceps. Also, with the elbow at 90 degrees of flexion, one may ask the patient to rotate the pronated forearm into supination; normally, the examiner can hook the tip of his or her thumb around the biceps tendon in the cubital fossa (Figure 25.10).[122] With distal avulsion of the tendon, this may be impossible.

Occasionally, some fibers or a fascial sleeve may remain intact, giving an appearance of an intact tendon. The examiner must discriminate between the normal lacertus fibrosus, which often remains intact even with biceps rupture, and the biceps tendon.

Imaging studies are of mixed benefit in the workup of a patient with suspected distal biceps pathologic findings. Plain film radiographs should be obtained, but are most commonly normal and do not show pathologic changes. Biceps ruptures typically do not involve bony ruptures, and minimal changes are seen on standard radiographs of the elbow.

MRI may show rupture, but it is unnecessary in most cases and occasionally may be read as falsely negative, although some authors suggest a 100% correlation with intraoperative findings.[58] MRI may be useful to exclude alternative diagnoses and to evaluate the extent of suspected partial rupture; it also may be useful in cases in which the history suggests a biceps rupture but the clinical examination is unclear.[56,58] MRI findings suggestive of complete rupture include absence of the tendon insertion or a fluid-filled sheath, whereas partial ruptures are typically seen as high signal intensity, fluid within the tendon sheath, or thinning or thickening of the tendon distally.[56,69] Positioning of the prone patient with the shoulder abducted over the head and the elbow in 90 degrees of flexion and the forearm in supination (the so-called FABS view) (Figure 25.11)[32] has been suggested to improve visualization of the distal biceps insertion into the radial tuberosity.[69] Ultrasound is a lower-cost diagnostic tool that is also usually unnecessary but has been

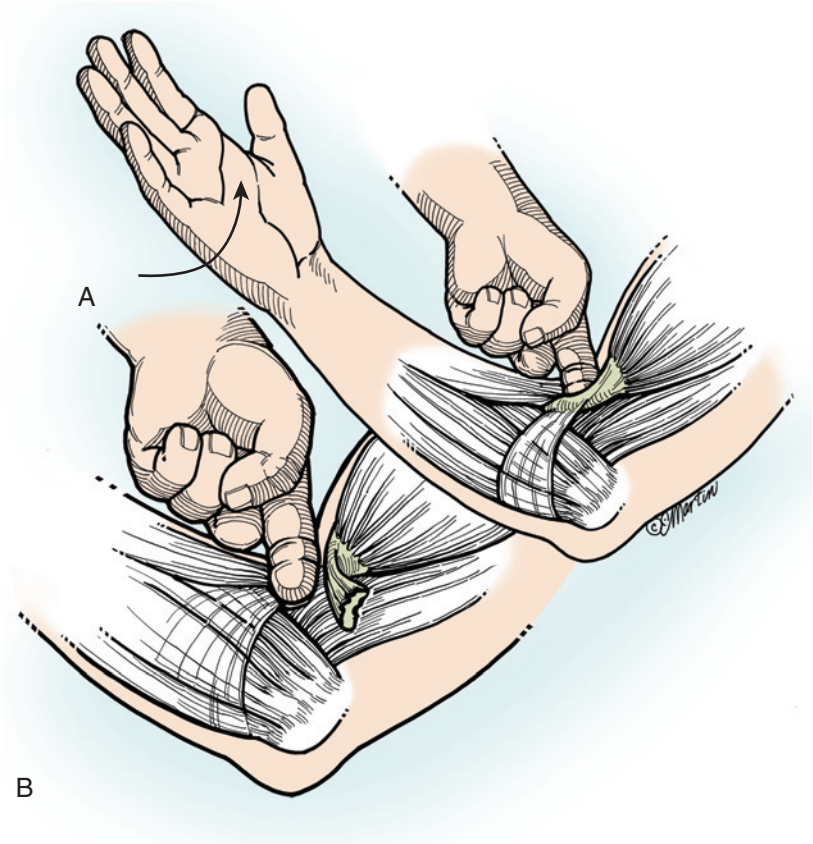

FIGURE 25.10 **A** and **B,** Hook test described by O'Driscoll and colleagues involves assessment for intact biceps tendon by "hooking" examiner's finger around biceps with elbow at 90 degrees and in supination. (From O'Driscoll SW, Goncalves LB, Dietz P: The hook test for distal biceps tendon avulsion, *Am J Sports Med* 35:1865-1869, 2007. Redrawn by Elizabeth Martin.)

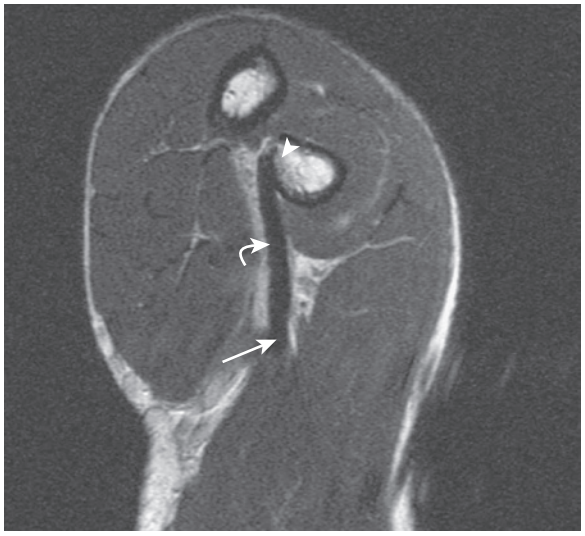

FIGURE 25.11 Forearm in supination view by magnetic resonance imaging shows insertion of biceps tendon into radial tuberosity (*arrows,* biceps tendon; *arrowhead,* biceps insertion into radial tuberosity). (From Giuffrè BM, Moss MJ: Optimal positioning for MRI of the distal biceps brachii tendon: flexed abducted supinated view, *AJR Am J Roentgenol* 182:944-946, 2004.)

shown to be accurate in the diagnosis of complete or partial tears.[22] Findings suggestive of complete rupture include tendon absence, fluid, and mass in the antecubital fossa; incomplete rupture may be represented by a focal hypoechogenic area or thinning of the tendon.[22]

Treatment

Treatment of partial or complete biceps ruptures may be nonoperative; however, an estimated loss of 40% to 60% of supination power and 30% of flexion power can be anticipated in the setting of untreated complete distal biceps ruptures. Despite this, some patients may compensate well and even regain substantial supination strength over time.[21,33,59,115,141] Although functional difficulties may persist and one series has suggested that a high rate of residual pain and weakness may persist at 4.5 years of follow-up after nonoperative treatment,[15,33,67] other series have suggested that many patients compensate well, with a high rate of satisfactory outcomes scores and only a modest loss of supination strength at a median follow-up of 38 months.[59] If operative treatment is elected, it should ideally proceed within 7 to 10 days of injury, before tissue can become retracted and scarred. In addition, complications of early repairs are less likely, although a recent series challenges this thought, with no higher complication rate seen in patients up to 4 weeks following rupture.[8,27,38,84]

Primary repair is almost certainly possible 4 weeks after injury and as late as 9 months in our experience. Commonly, the lacertus fibrosus is partially intact, which serves to anchor the biceps distally and prevent proximal retraction to some extent. The biceps can be mobilized and repaired to the tuberosity even with the elbow in some flexion, which universally stretches out over time, yielding nearly full extension at final follow-up. Rarely, augmentation, as with Achilles tendon allograft, is required.[138] Using a graft extension does not restore

the proper muscle tendon length, just as adding a tendon graft to a profundus tendon rupture does not restore finger flexion. Although it is tempting to add a graft to restore continuity of the muscle-tendon unit, it does little to restore elbow active function. A better alternative to repair with graft in chronic cases is tenodesis of the distal biceps to the brachialis, although results in postoperative strength may be less satisfactory.[21] Good results can be seen with operative treatment of partial tears.[50,84] In surgical treatment, issues that remain unclear include optimal fixation technique of the tendon to bone and whether a two-incision versus one-incision surgical approach has fewer complications or better outcome.[24,31]

PERTINENT ANATOMY

Anatomic studies have shown that the insertion site of the tendon onto the radial tuberosity occurs through a long, thin, ribbon-like insertion. The advantage of this long, thin insertion, primarily on the medial aspect of the tuberosity, is that the tendon can wrap around the tuberosity, which acts as a cam, giving mechanical advantage to rotation of the radius (Figure 25.12). In addition, it has become apparent that the distal biceps tendon represents continuations of the short and long heads of the muscle distally. The short head, which is more significant, inserts distal to the radial tuberosity and functions as a flexor of the elbow, whereas the long head inserts away from the axis of rotation, to function in supination (Figure 25.13).[12,53,80,109] Restoring the correct anatomic alignment is crucial for optimal function of the biceps.[12,53,80,109]

The anatomy of the radial tuberosity varies widely; it is similar to retroversion of the humeral head. This can range from 30 degrees off of the radial tuberosity to almost 90 degrees. Repair techniques using a single anterior incision may be unable to accurately restore the correct insertion point of the tendon if the medially oriented angle of insertion is closer to 90 degrees. Detailed anatomic studies of the footprint of the biceps insertion have revealed that the biceps inserts on the posterior ulnar portion of the radial tuberosity, suggesting that an anatomic repair through a single anterior approach may be difficult, particularly if forearm supination is limited preoperatively.[12,80]

Two-incision techniques offer the ability to limit the size of the anterior exposure and decrease the risk of neurovascular injury, and if a muscle-splitting approach is used, there is no higher risk of radioulnar synostosis (Figure 25.14). El-Hawary and associates[55] compared complications after a single-incision technique and after a modified Boyd-Anderson two-incision technique. Complication rates were 44% versus 10% in the single-incision and two-incision techniques, respectively; patients undergoing the two-incision technique had a slightly more rapid recovery of flexion strength. At final follow-up, differences between the two groups were minimal. Other series have suggested a 7% synostosis rate with a two-incision technique.[27] Although a two-incision technique is said to be associated with heterotopic ossification, a single-incision technique may also be complicated by this problem.[87]

Grewal and colleagues[71] evaluated patients who were prospectively randomized to either a single-incision repair with suture anchors or a two-incision technique with bony tunnels. Outcomes were similar, with two exceptions: there was a significantly increased risk of complications (mostly related to neurapraxia of the lateral antebrachial cutaneous nerve) associated with the single-incision technique, and there was a significant increase of 10% in flexion strength in the two-incision group over the single-incision group. Technique of repair to bone is also variable. Options include direct repair to bone through bony tunnels and use of interference screws, suture anchors, or other devices. Although fixation with a button device is strongest in biomechanical testing in vitro, it seems from clinical series and biomechanical testing that fixation with transosseous sutures and suture anchors is sufficient to withstand forces in vivo exerted during rehabilitation.[27,31,77,85,86] Transosseous sutures are also less costly and biologically provide a bone-to-tendon interface for robust healing. Comparison of transosseous fixation two-incision techniques with suture anchor techniques or tie-on button techniques shows satisfactory

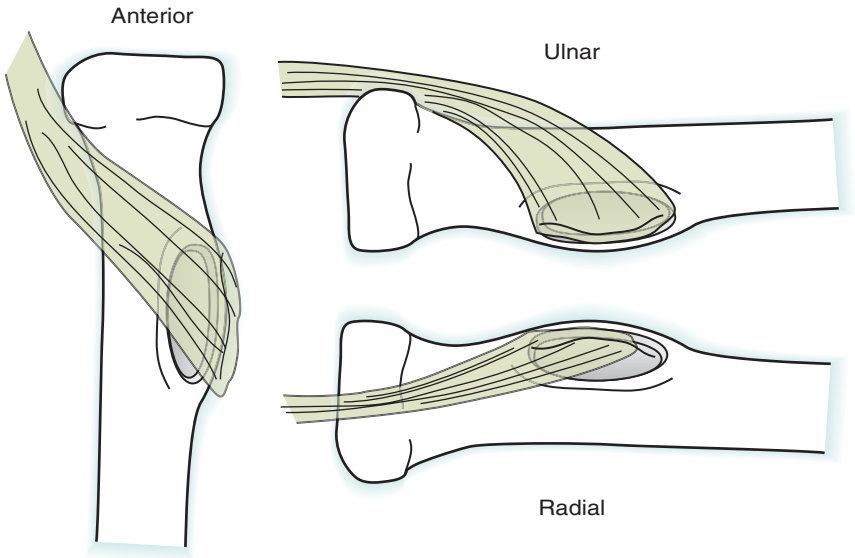

FIGURE 25.12 Biceps insertion occurs in long, ribbon-like fashion onto ulnar aspect of radial tuberosity. (From Mazzocca AD, Cohen M, Berkson E, et al: The anatomy of the bicipital tuberosity and distal biceps tendon, *J Shoulder Elbow Surg* 16:122-127, 2007.)

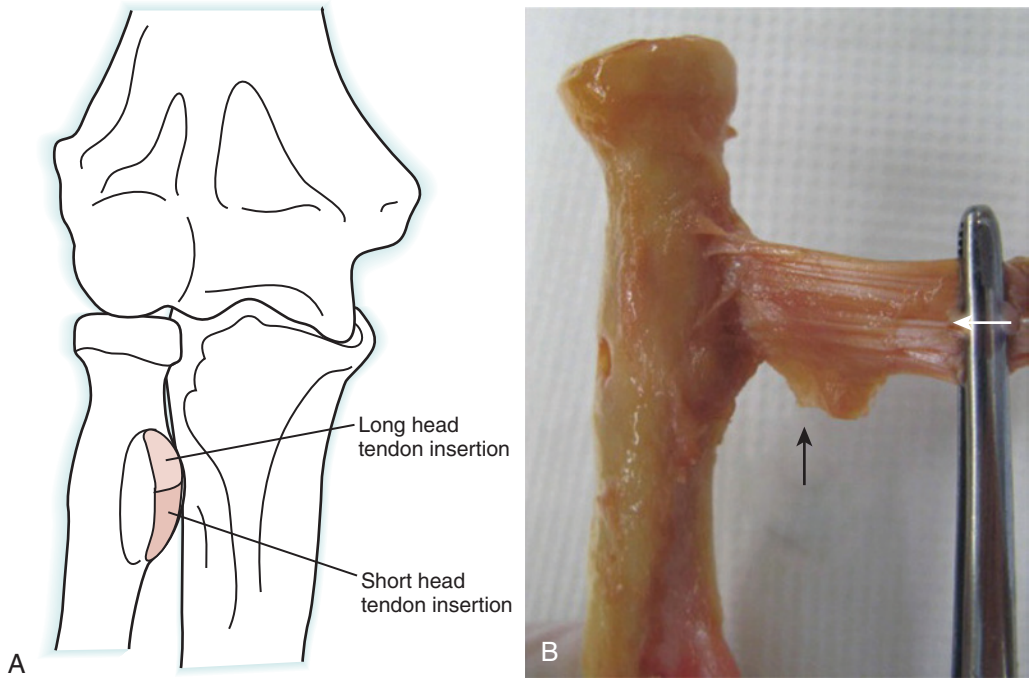

FIGURE 25.13 **A** and **B,** Long and short heads of biceps have distinct anatomic insertions at radial tuberosity. (From Athwal GS, Steinmann SP, Rispoli DM: The distal biceps tendon: footprint and relevant clinical anatomy, *J Hand Surg [Am]* 32:1225-1229, 2007.)

outcomes in all groups. Practically speaking, all techniques in common practice today have an acceptable complication risk and nearly comparable results.

Complications

Risks of surgery include recurrence of rupture; heterotopic ossification; injury to neurovascular structures, especially the lateral antebrachial cutaneous nerve and the posterior interosseous nerve; and persistent anterior elbow pain. Recurrence of rupture is exceedingly rare, with most series reporting a rate of 0 to 4%.

Heterotopic ossification is uncommon and likely depends on patient-related and injury-related factors rather than surgical technique. Heterotopic ossification around the elbow remains poorly understood, and the role of possible prophylaxis with nonsteroidal antiinflammatory drugs remains unclear. It has been suggested that heterotopic ossification is more common with a two-incision technique; however, this finding seems variable across series.[31,55] Nonetheless, biceps repair surgery seems particularly prone to this complication.

Injury to vascular structures around the elbow, including the lateral antebrachial cutaneous nerve and the posterior interosseous nerve, have been described. A single anterior exposure may be associated with a higher risk of neurovascular injury compared with a two-incision approach; however, injury to the posterior interosseous nerve can occur in a two-incision approach if excessive traction is placed for a prolonged period, as with a self-retaining retractor or Hohmann retractor placed over the neck of the radius. When the radial tuberosity is exposed through the posterolateral approach of the two-incision technique, the forearm should be placed in a position of pronation to allow the posterior interosseous nerve to fall further away from the surgical field.[1]

Expected Outcomes

Postoperatively, most patients are satisfied and experience a full return to flexion-extension motion. Rotation motion may be limited in some, but not all, cases, and strength and endurance in flexion can be expected to return to nearly normal. Supination strength and endurance in most series returns to normal or nearly normal, although it may be less than normal in some cases, particularly in the nondominant arm.[2,15,18,47,49]

❖ AUTHORS' PREFERRED METHOD OF TREATMENT: Partial Biceps Tears

Patients who present with a classic history of a "pop" in the arm with resisted motion and sudden onset of pain should be treated as having complete biceps tears regardless of MRI findings suggestive of "partial tear." In these cases, some strands of the distal biceps may be intact; however, they are not functional, and this lesion should be regarded as and treated as an acute complete distal biceps rupture.

Partial biceps tears are described as a chronic tendinopathy in which the patient complains of a chronic aching in the antecubital fossa, rather than a sudden onset of pain. When the diagnosis of a partial distal biceps tear is made through clinical examination and imaging modalities, treatment should be nonoperative for the first 3 to 6 months. Patients are encouraged to avoid heavy lifting and to use the arm primarily for activities of daily living only. Patients typically do not lose motion with a partial biceps tendon rupture, and strengthening exercises and physical therapy are unnecessary for these individuals. In some instances, several months of conservative management may result in symptom abatement.

In our experience, significant partial distal biceps tears commonly do not improve after even 6 months of nonoperative treatment. In this situation, operative treatment, which involves

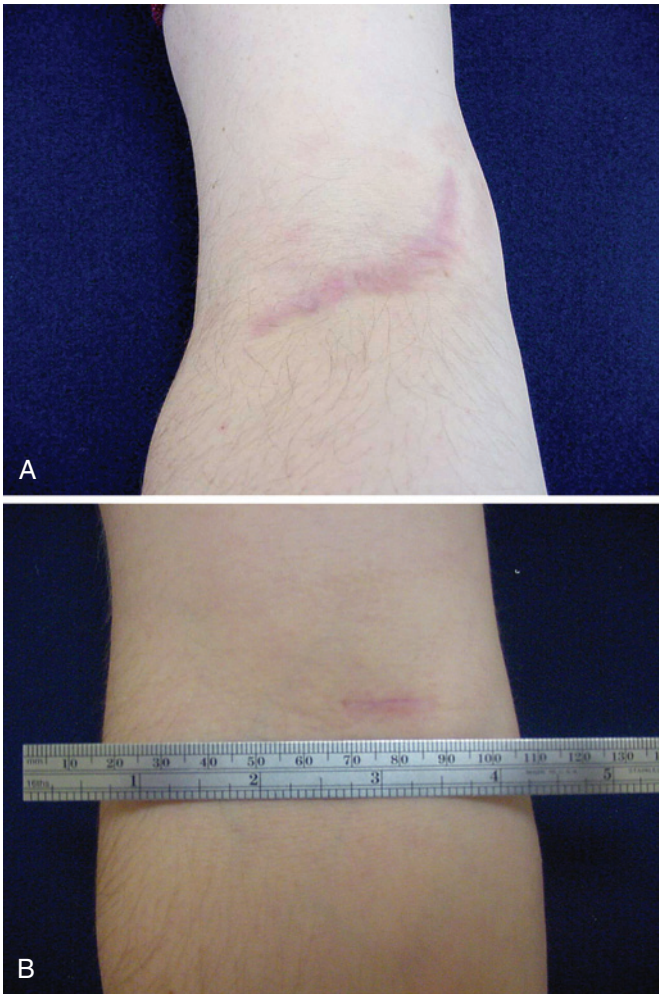

FIGURE 25.14 **A,** Large incision is required to perform repair safely via single anterior approach. **B,** Two-incision approach allows use of smaller cosmetic anterior incision. (From Hartman MW, Merten SM, Steinmann SP: Mini-open 2-incision technique for repair of distal biceps tendon ruptures, *J Shoulder Elbow Surg* 16:616-620, 2007.)

taking down the remaining fibers of the distal biceps and repair to the insertion site, has been found to be satisfactory with restoration of function and resolution of symptoms through a single posterior incision.

Treatment of Acute Complete Biceps Ruptures

Acute distal biceps ruptures are commonly seen in middle-aged men, and operative and nonoperative treatments have been advocated for these individuals. Proponents of nonoperative treatment point out the fact that patients have full flexion and extension of the elbow and are able to pronate and supinate even when seen shortly after an acute injury. Long-term studies of nonoperative treatment of biceps tendon ruptures show that with time, patients experience resolution of pain and continue to have full flexion and extension and good pronation and supination, but may continue to have functional deficits. Studies performed at the Mayo Clinic on chronic tears showed a loss of supination strength of 40% and loss of flexion strength of 30%.[21,33,115]

In our experience, many patients are told that they should be treated nonoperatively, often by a primary care provider or family member. Quite often, these patients come to orthopedic attention because they find nonoperative care to be unsatisfactory, with functional difficulties, cosmetic complaints owing to the "Popeye muscle," and a sense of achiness and cramping in the biceps muscle itself. Although studies after nonoperative treatment show a small loss of flexion and supination strength, they cannot put a "number" on the achiness and cramping that patients often experience because the muscle-tendon unit (the biceps) has been detached and is nonfunctional. It is common to have a patient complain of a cramping and aching in the biceps that takes several hours to resolve after a vigorous day of work or play.

Operative treatment of acute distal biceps ruptures is preferred in most cases. Operative treatment tends to involve either a single anterior incision or dual incisions, one in an anterior location and one in a posterolateral location. Essentially, the literature supports use of either approach, and the individual surgeon should use the one that he or she is most comfortable with and yields the best results in his or her hands.

Single-Incision Technique

The single-incision approach typically involves either a large longitudinal (see Figure 25.14) or a boat-race type of incision that mirrors the River Thames from Putney to Mortlake as it makes an "S" shape up the arm. It is important when doing a single anterior approach to have good visualization of the radial tuberosity, which is deep in the forearm, and this involves a significant operative exposure to visualize the radial tuberosity safely. The surgery is performed under tourniquet control for this purpose.

During the exposure, the lateral antebrachial cutaneous nerve is at risk as it enters the antecubital area between the biceps and the brachialis laterally. There are multiple veins in this area that must be ligated as needed, and the radial nerve, although not directly in the area of dissection, is within a few centimeters. The significant neurovascular structures on the medial aspect of the elbow, the median nerve, and the brachial artery can be palpated and are located more medially than the biceps itself. The stump of the tendon is identified in the antecubital fossa wound or retrieved proximally if it has retracted. Dissection proceeds distally to identify the bicipital tuberosity on the radius, which can be palpated by pronating and supinating the forearm. It is cleared of tendon debris and fibrous tissue and prepared for reinsertion of the biceps tendon.

Multiple techniques have been proposed for securing the tendon to bone; essentially all have been shown to provide sufficient in vivo strength of repair. Through an anterior incision, suture anchors or endobutton devices typically are used according to the manufacturer's instructions (Video 25.1). The postoperative regimen is described subsequently in the two-incision technique. Because of the large and noncosmetic incision needed to perform this procedure safely and the difficulty in restoring the anatomic insertion site via anterior incision techniques, we prefer the two-incision technique.

Two-Incision Repair

In our hands, advantages of a two-incision technique include a more cosmetic and smaller (<2 cm) scar anteriorly (Figure 25.15; see also Figure 25.14) and the ability to restore the biceps insertion site more anatomically through the second

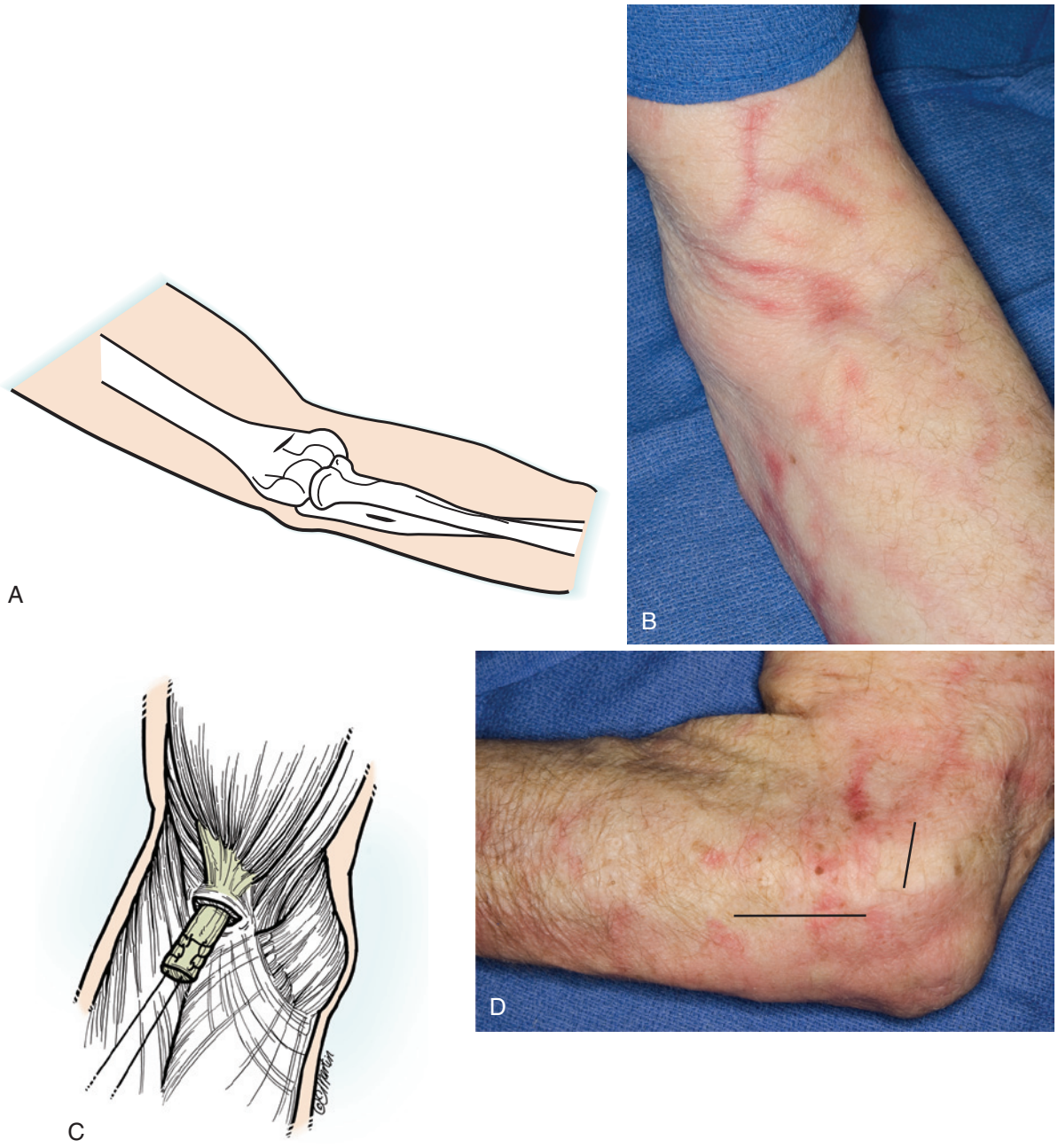

FIGURE 25.15 **A** to **D,** Two-incision approach involves short anterior transverse incision and posterolateral incision. (**C,** Copyright © Elizabeth Martin.)

posterolateral incision. The surgery is performed with the patient in the supine position, with an arm board. A sterile tourniquet is applied, and just distal to the cubital crease, a transverse incision of 2 to 3 cm is made centered over the cubital fossa (Figure 25.16; see also Figure 25.15, *B*, *D*). Dissection proceeds, with care taken to identify and preserve the lateral antebrachial cutaneous nerve, which lies lateral to the biceps tendon (Figure 25.17). The unwary surgeon may mistake the brachialis for an untorn biceps tendon.

The biceps tendon often retracts proximally, and blunt exploration with the surgeon's finger can retrieve the stump into the surgical wound. The end of the tendon is typically bulbous and thickened. This is débrided, and the end is freshened up to healthy tissue and trimmed so that it fits into the tuberosity. A Krackow stitch is used with No. 2 nonabsorbable braided suture, with the tails exiting through the center of the tendon distally (Figure 25.18).

After the tendon is prepared, attention is turned to the insertion site. Multiple techniques have been proposed for securing the tendon to bone; essentially, all have been shown to provide sufficient in vivo strength of repair. We prefer a bony tunnel technique. By pronating and supinating the forearm, the biceps tuberosity can be palpated in all but the most muscular or obese patients. Intraoperative fluoroscopy can be useful in larger individuals for this purpose. An incision is made over this region (see Figure 25.15, *D*), with dissection proceeding down to the



FIGURE 25.16 A 2-cm incision is made in antecubital fossa.

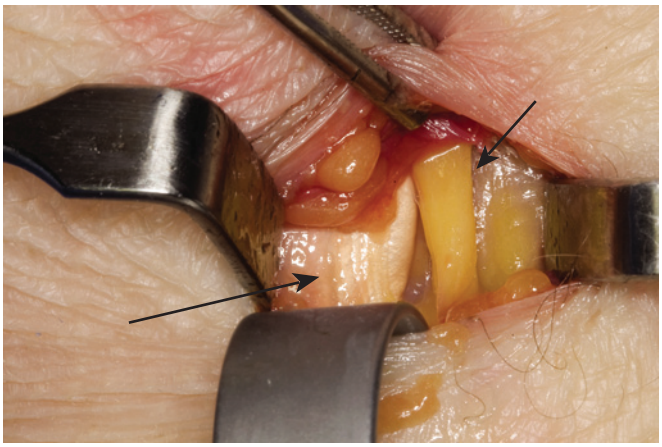

FIGURE 25.17 Lateral antebrachial cutaneous nerve *(short arrow)* lies in close proximity to biceps tendon *(long arrow).*

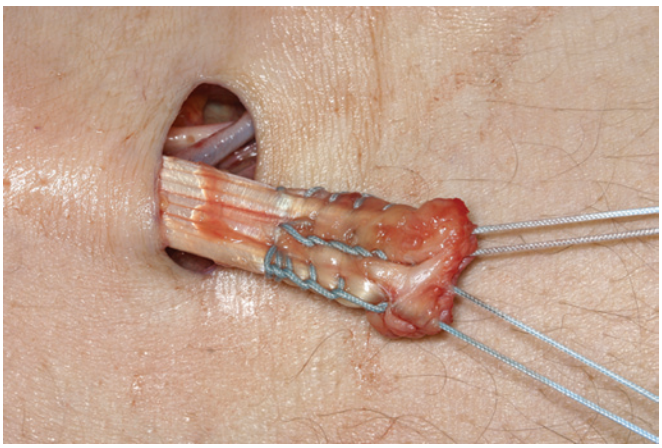

FIGURE 25.18 Krackow stitch is placed in preparation for fixation to bone. (From Hartman MW, Merten SM, Steinmann SP: Mini-open 2-incision technique for repair of distal biceps tendon ruptures, *J Shoulder Elbow Surg* 16:616-620, 2007.)

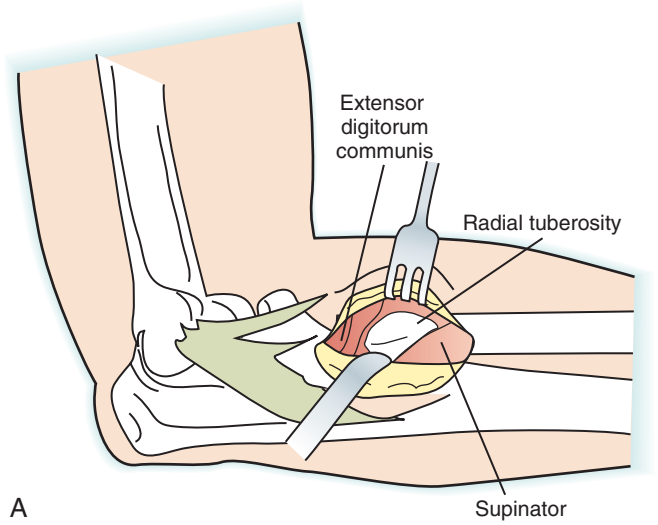

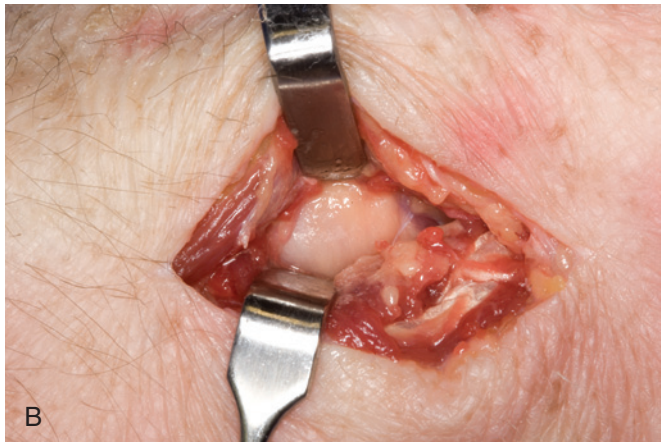

FIGURE 25.19 **A** and **B,** Incision is made over tuberosity, and muscle-splitting approach is made to expose tuberosity.

tuberosity, splitting the common extensors and supinator (Figure 25.19). The forearm is placed in a position of full pronation, and the tuberosity is prepared. Usually, there is retained soft tissue and tendon debris on the tuberosity; this is excised, and a bur is used to create a cancellous trough for the tendon (Figure 25.20). The forearm is supinated slightly, bringing the radial edge of the trough into view, and two small drill holes are placed exiting into the trough. Care should be taken to allow for a sufficient bony bridge.

The suture tails of the prepared biceps stump are passed distally into the posterolateral wound (Figure 25.21). Care should be taken to exit through the muscle-splitting approach rather than exposing the ulna. The sutures are passed through the bony tunnels such that the biceps tendon is delivered into the tuberosity trough; this is facilitated by supinating the forearm slightly and may be done with the Hewson suture passer, 26-gauge wire, or a free needle. The sutures are drawn taut, and the forearm is gently supinated and pronated to seat the tendon into the tuberosity trough (Figure 25.22). Finally, the sutures are tied over the bony bridge with the forearm slightly supinated (Figure 25.23). The elbow is gently ranged in pronation-supination and flexion-extension. One can fully pronate to document seating of the tendon end into the bony cavity. The wounds are closed in layers, with a running subcuticular stitch for the skin.

Postoperative Treatment Protocol

Historically, patients have been immobilized in a cast or splint for 2 to 4 weeks before initiation of motion. More recently, early

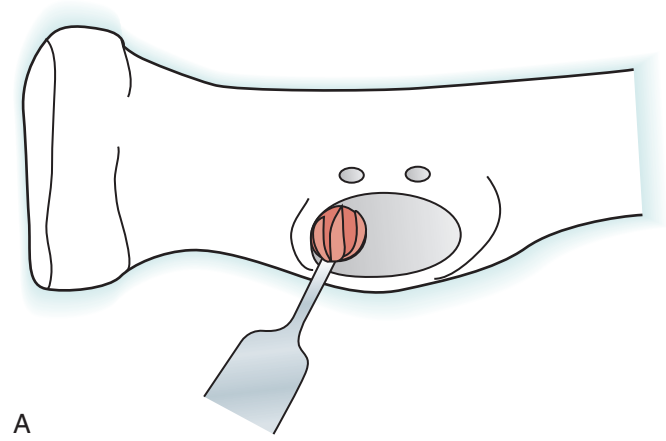

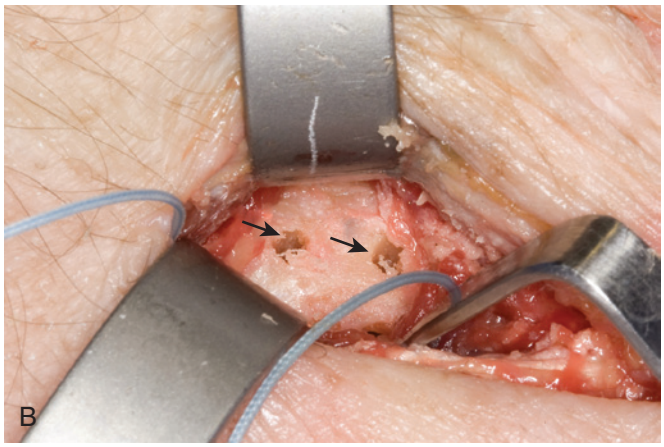

FIGURE 25.20 **A** and **B,** Tuberosity is exposed, and bur is used to create trough.

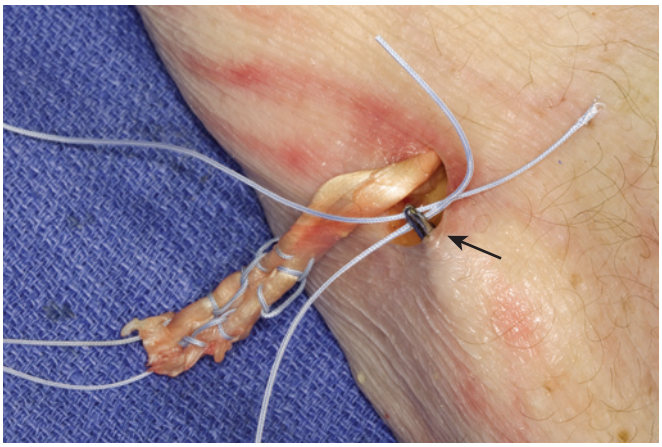

FIGURE 25.21 Tails of sutures are passed into posterolateral wound.

mobilization has become more widespread, and in our experience, after a standard repair, patients can be allowed full active motion of the elbow with no resistance at 2 days postoperatively with no splinting.[77] Patients are allowed to use the arm for activities of daily living with no "lifting heavier than a telephone receiver." Passive supination and pronation with the elbow at 90 degrees of flexion are initiated within days of surgery.

With this motion protocol, at 2 to 3 weeks patients typically have a full range of motion in flexion-extension and by the end

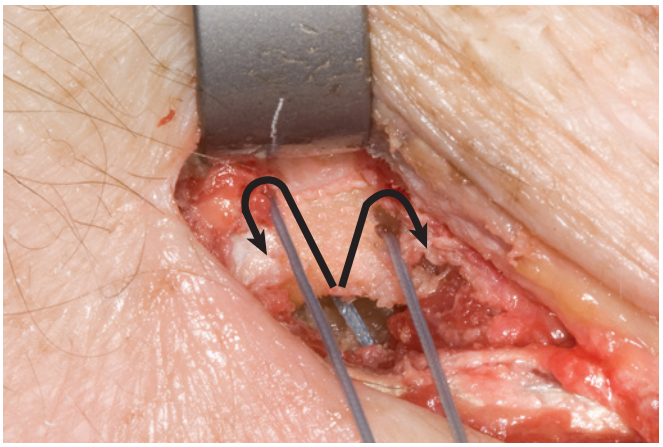

FIGURE 25.22 Sutures are drawn taut, and forearm is gently supinated and pronated to seat tendon into tuberosity.

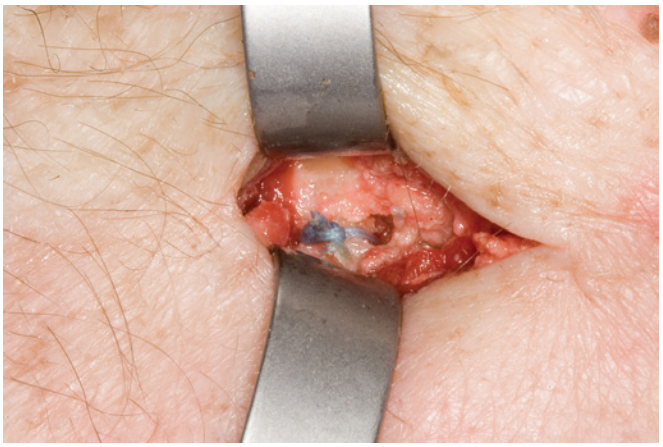

FIGURE 25.23 Sutures are tied over bony bridge.

of 1 month have full pronation and supination of the elbow. Although good results in general and a high percentage of intact repairs have been reported in series where patients have been immobilized for 4 weeks or more, it has been shown that earlier mobilization of the elbow allows for high patient satisfaction and, most importantly, continuity of the repaired tendon.[77]

CRITICAL POINTS *Distal Biceps Rupture*

- Patients with the classic history of a "pop" while lifting objects and pain in the antecubital fossa almost inevitably have an acute complete distal biceps rupture.
- In most cases, acute complete distal biceps ruptures are treated operatively in younger, more active individuals.
- Chronic tendinopathy may ultimately require surgical management.
- The available literature supports either a single anterior incision or a two-incision technique.
- Most techniques have sufficient strength at the time of repair to permit early gentle active motion during the initial postoperative period.

TRICEPS AVULSIONS AND RUPTURE

Injury to the triceps may occur at the osseous insertion, at the musculotendinous junction, or as an intrasubstance muscle

rupture. Avulsion from the osseous insertion is the most common pattern of injury, whereas intrasubstance rupture is the least common.[144,145,162]

Although the terms *rupture* and *avulsion* are often used interchangeably, Tarsne[162] suggested that *avulsion* be used for disruption at the osseous insertion and *rupture* be used for intrasubstance or musculotendinous disruption. It must be noted that "complete" rupture typically involves both the long and lateral tendinous heads of the triceps, with some of the deeper muscular insertion of the medial head remaining intact.

Spontaneous injury of the triceps tendon other than that associated with prior total elbow arthroplasty is rare.* At the Mayo Clinic, over a 25-year period, only 14 patients were seen with 16 triceps avulsions.[144] Of 1014 tendon injuries in one review, less than 0.8% were triceps injuries, and half of those represented open lacerations.[10]

The pathogenesis usually involves direct or indirect trauma in association with forced eccentric contraction.[10,57,79,144,145] Typically, the defect occurs at the osseous insertion. Diagnosis is usually clinical, with a palpable defect and lack of forceful active extension function. Partial ruptures may occur and are marked by decreased extension strength against resistance. Radiographs are indicated and are useful to rule out olecranon fracture or bony avulsion.[57,79,144] In addition, radial head fracture has been reported in association with this lesion.[101] MRI or ultrasound may be useful to show the pathologic changes and help differentiate between partial and complete lesions (Figure 25.24).[76,106,107,144]

Much has been speculated about predisposing factors, including enthesiopathies, medication associations, renal failure with or without hyperparathyroidism, and anabolic steroid usage.[13,57,144,150,166] It seems that intrasubstance rupture is not associated with steroid use or chronic medical conditions, in contrast to avulsion or musculotendinous rupture.[11,107,121,145]

Early surgical repair is indicated for acute complete avulsions. This involves repair with locking nonabsorbable sutures attaching the tendon to the olecranon through drill holes. If a large bony fragment is present, use of hardware to fix bone to bone may facilitate earlier rehabilitation, but prominent hardware sometimes mandates later reoperation for hardware removal.[9,57,76,79,107,132,144] The arm is immobilized for approximately 3 to 4 weeks in 30 to 45 degrees of flexion, followed by gentle mobilization and, finally, active extension beginning at 6 weeks. Weight bearing or lifting should be avoided for 4 to 6 months.[9,57,144]

The treating physician should differentiate between complete avulsions and partial avulsions by assessing active elbow extension. It has been suggested that incomplete avulsions may be treated nonoperatively with close follow-up to ensure that they do not become complete.[57] In addition, some patients with partial triceps avulsions treated nonoperatively have residual weakness or functional defects, or both, and come to surgical management.[106] Chronic lesions in which local tissue is inadequate or in which retraction of the muscle tendon makes primary repair difficult may require augmentation using allograft or reconstruction with triceps aponeurosis or fascia or a local rotational anconeus flap.[37,137,140]

Intramuscular ruptures of the triceps or ruptures at the musculotendinous junction are even more rare, and the literature is mixed regarding the need for operative therapy. It has been suggested that nonoperative treatment is effective, particularly in patients who have only partial rupture and do not require full elbow extension strength.[121,145] This lesion is more likely to be seen in young patients without significant comorbidities and may be associated with sports injury.[11,121,145]

*References 9, 10, 13, 79, 132, 144, 145, 162, 166.

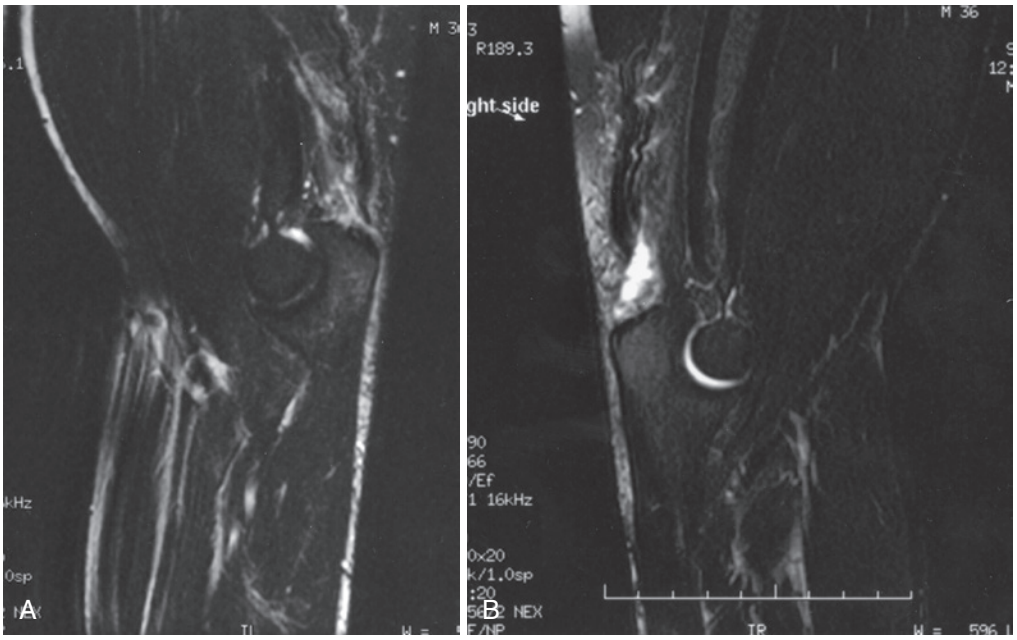

FIGURE 25.24 **A** and **B,** Magnetic resonance images showing avulsion of triceps with proximal retraction of musculotendinous units. (From Sierra RJ, Weiss NG, Shrader MW, et al: Acute triceps ruptures: case report and retrospective chart review, *J Shoulder Elbow Surg* 15:130-134, 2006.)

❖ AUTHORS' PREFERRED METHOD OF TREATMENT: Repair of Complete Avulsion Injuries

The surgery is performed with the patient in the supine position with the arm across the chest. A midline posterior incision is used to expose the triceps tendon (Figure 25.25). Commonly, there is a significant partial tear with a portion of the deep muscular fibers of the triceps still attached to the olecranon. Sometimes this is a delaminating tear in which the triceps splits along superficial and deep planes; similar to the situation in rotator cuff tears, the dorsal portion may have a superficially benign appearance. MRI and surgical exposure show a deeper injury to the tendon, however, than had been initially apparent.

After the tear has been exposed (Figure 25.26), any fibrous tissue or scar tissue is excised to "freshen up" the tendon edges.



FIGURE 25.25 Posterior midline incision is used to expose triceps.

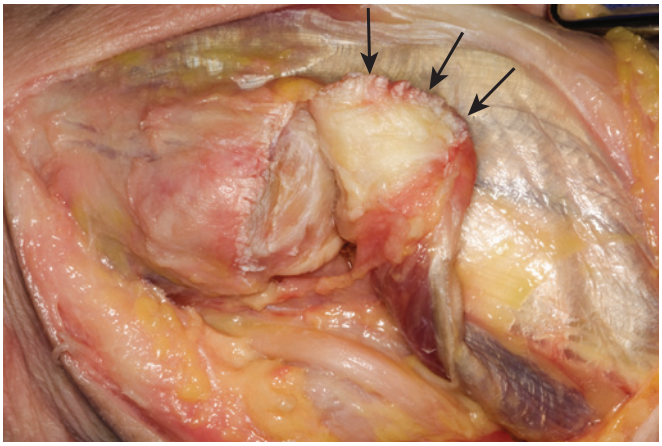

FIGURE 25.26 Triceps is exposed and prepared for reattachment to bone. *Arrows* indicate the triceps tendon.

A heavy nonabsorbable braided No. 5 suture is placed with a Krackow stitch through the triceps to prepare for reattachment to bone (Figure 25.27). The tip of the olecranon is decorticated to bleeding bone, and a 2-mm drill or Keith needle is used to create bony tunnels to pass the sutures. The sutures are passed and tied over a bony bridge (Figure 25.28). The patient is placed in a sling, and gentle motion is initiated in 1 to 2 weeks. If the repair occurs late or if myotendinous contracture has occurred, the arm should be splinted in extension for the initial 2 weeks after surgery and then slowly allowed to regain motion over the ensuing 4 to 6 weeks.

Partial tears of the triceps may sometimes present a diagnostic and therapeutic dilemma. The typical history is one in which the patient sustains an eccentric load to the elbow and presents with point tenderness over the posterior humerus and elbow. There is often tenderness at the triceps insertion. Active elbow extension is intact, however, and MRI reveals a partial triceps tear. In our experience, many patients do poorly with nonoperative therapy; however, some respond. Patients should be given a trial of conservative treatment and followed for 3 to 6 months; they may be offered surgical intervention if improvement is not seen. Of note, it is important to differentiate what can be read as a "partial triceps rupture." As discussed, in a partial rupture, no tendon has been torn and retracted proximally. A complete rupture of the long and lateral heads with some deep triceps muscle remaining intact is not a "partial" injury.

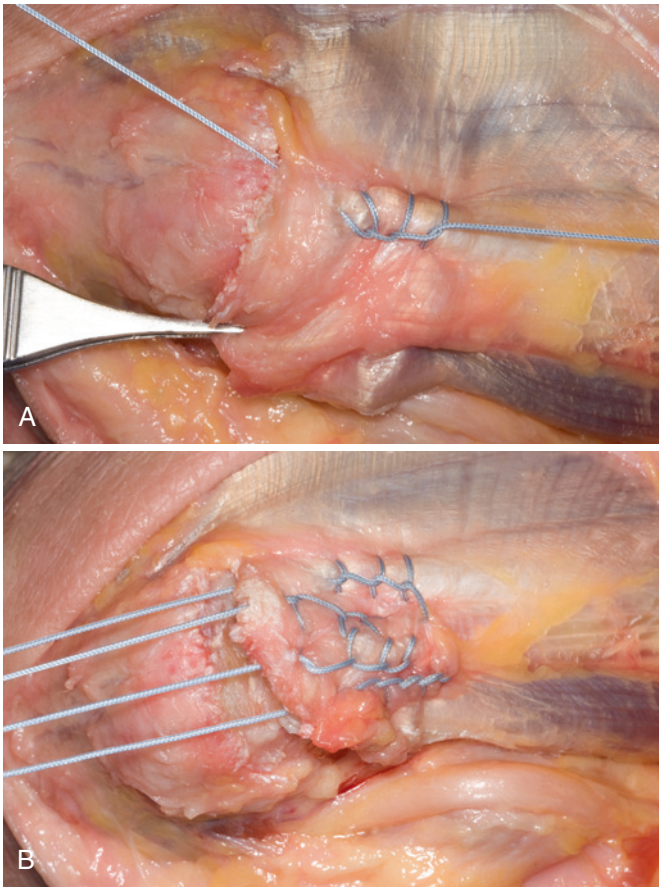

FIGURE 25.27 **A** and **B,** Krackow stitches are placed to secure triceps to bone.

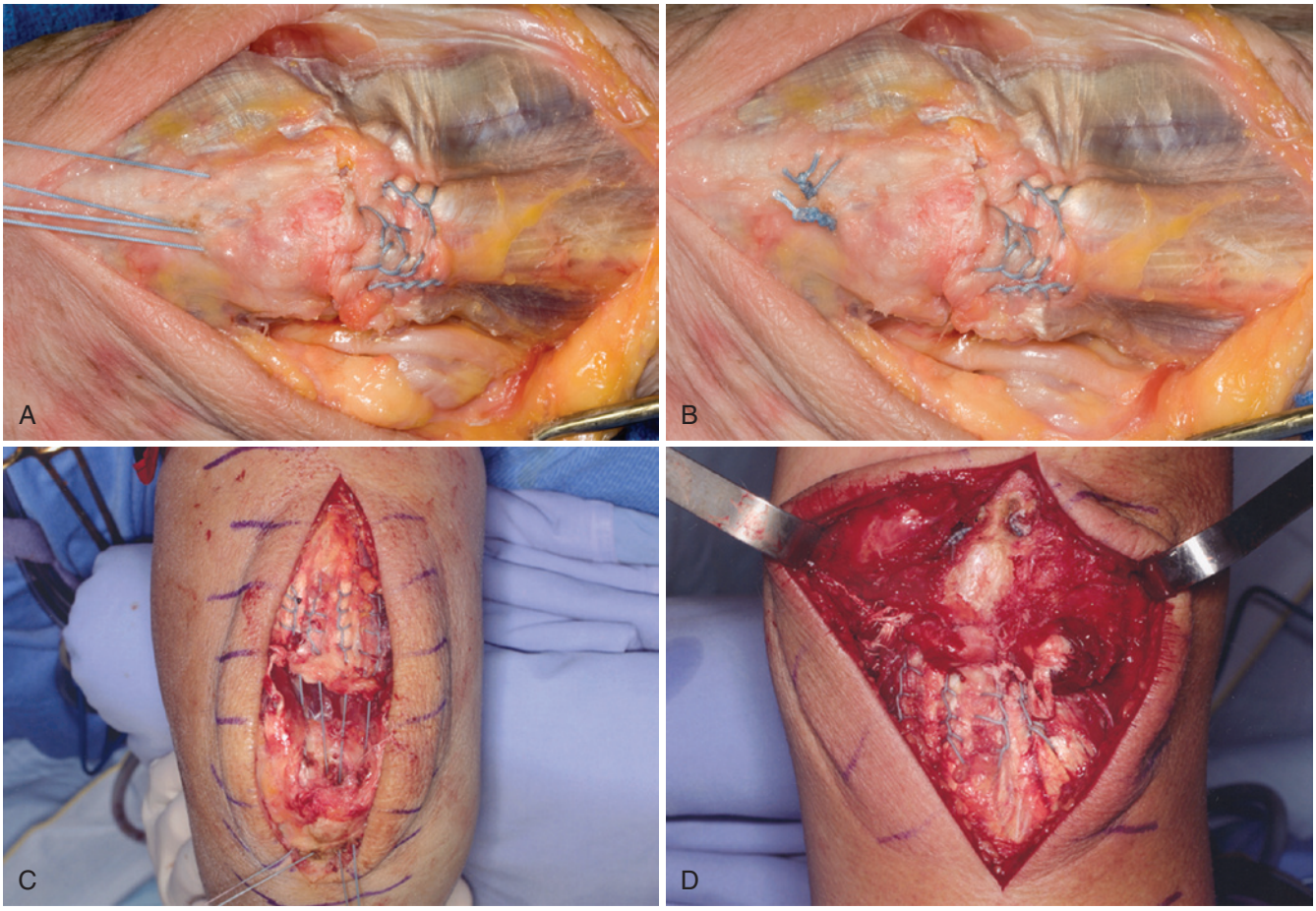

FIGURE 25.28 **A** to **D,** Sutures are passed through bony tunnels and tied. (**C** and **D,** From Sierra RJ, Weiss NG, Shrader MW, et al: Acute triceps ruptures: case report and retrospective chart review, *J Shoulder Elbow Surg* 15:130-134, 2006.)

CRITICAL POINTS *Triceps Avulsions and Ruptures*

- Triceps injuries are rare.
- Injuries may occur at the tendinous insertion (avulsion), as a rupture at the musculotendinous junction, or as an intramuscular rupture.
- Early repair of avulsions is generally preferred.

For Case Studies, Videos, and more, please visit ExpertConsult.com.

REFERENCES

1. Adams JE, Steinmann SP: Nerve injuries about the elbow. *J Hand Surg [Am]* 31:303–313, 2006.
2. Agins HJ, Chess JL, Hoekstra DV, et al: Rupture of the distal insertion of the biceps brachii tendon. *Clin Orthop Relat Res* 234:34–38, 1988.
3. Almekinders LC: Tendinitis and other chronic tendinopathies. *J Am Acad Orthop Surg* 6:157–164, 1998.
4. Almekinders LC, Temple JD: Etiology, diagnosis, and treatment of tendonitis: an analysis of the literature. *Med Sci Sports Exerc* 30:1183–1190, 1998.
5. Almquist EE, Necking L, Bach AW: Epicondylar resection with anconeus muscle transfer for chronic lateral epicondylitis. *J Hand Surg [Am]* 23:723–731, 1998.
6. Altay T, Gunal I, Ozturk H: Local injection treatment for lateral epicondylitis. *Clin Orthop Relat Res* 398:127–130, 2002.
7. Alvarez-Nemegyei J, Canoso JJ: Evidence-based soft tissue rheumatology: epicondylitis and hand stenosing tendinopathy. *J Clin Rheumatol* 10:33–40, 2004.
8. Anakwenze OA, Baldwin K, Abboud JA: Distal biceps tendon repair: an analysis of timing of surgery on outcomes. *J Athl Train* 48(1):9–11, 2013.
9. Anderson KJ, Lecocq JF: Rupture of the triceps tendon. *J Bone Joint Surg Am* 39:444–446, 1957.
10. Anzel SH, Covey KW, Weiner AD, et al: Disruption of muscles and tendons: an analysis of 1,014 cases. *Surgery* 45:406–414, 1959.
11. Aso K, Torisu T: Muscle belly tear of the triceps. *Am J Sports Med* 12:485–487, 1984.
12. Athwal GS, Steinmann SP, Rispoli DM: The distal biceps tendon: footprint and relevant clinical anatomy. *J Hand Surg [Am]* 32:1225–1229, 2007.
13. Bach BR, Jr, Warren RF, Wickiewicz TL: Triceps rupture: a case report and literature review. *Am J Sports Med* 15:285–289, 1987.
14. Bain GI, Johnson LJ, Turner PC: Treatment of partial distal biceps tendon tears. *Sports Med Arthrosc* 16:154–161, 2008.
15. Baker BE, Bierwagen D: Rupture of the distal tendon of the biceps brachii: operative versus non-operative treatment. *J Bone Joint Surg Am* 67:414–417, 1985.
16. Baker CL, Jr, Baker CL, 3rd: Long-term follow-up of arthroscopic treatment of lateral epicondylitis. *Am J Sports Med* 36:254–260, 2008.
17. Baker CL, Jr, Murphy KP, Gottlob CA, et al: Arthroscopic classification and treatment of lateral epicondylitis: two-year clinical results. *J Shoulder Elbow Surg* 9:475–482, 2000.
18. Balabaud L, Ruiz C, Nonnenmacher J, et al: Repair of distal biceps tendon ruptures using a suture anchor and an anterior approach. *J Hand Surg [Br]* 29:178–182, 2004.
19. Bauman JT, Sotereanos DG, Weiser RW: Complete rupture of the distal biceps tendon in a woman: case report. *J Hand Surg [Am]* 31:798–800, 2006.
20. Baumgard SH, Schwartz DR: Percutaneous release of the epicondylar muscles for humeral epicondylitis. *Am J Sports Med* 10:233–236, 1982.
21. Bell RH, Wiley WB, Noble JS, et al: Repair of distal biceps brachii tendon ruptures. *J Shoulder Elbow Surg* 9:223–226, 2000.
22. Belli P, Costantini M, Mirk P, et al: Sonographic diagnosis of distal biceps tendon rupture: a prospective study of 25 cases. *J Ultrasound Med* 20:587–595, 2001.
23. Bennett JB: Lateral and medial epicondylitis. *Hand Clin* 10:157–163, 1994.
24. Berlet GC, Johnson JA, Milne AD, et al: Distal biceps brachii tendon repair: an in vitro biomechanical study of tendon reattachment. *Am J Sports Med* 26:428–432, 1998.

25. Binder AI, Hazleman BL: Lateral humeral epicondylitis—a study of natural history and the effect of conservative therapy. *Br J Rheumatol* 22:73–76, 1983.
26. Bisset L, Paungmali A, Vicenzino B, et al: A systematic review and meta-analysis of clinical trials on physical interventions for lateral epicondylalgia. *Br J Sports Med* 39:411–422, discussion 411–422, 2005.
27. Bisson L, Moyer M, Lanighan K, et al: Complications associated with repair of a distal biceps rupture using the modified two- incision technique. *J Shoulder Elbow Surg* 17(1 Suppl):67S–71S, 2008.
28. Boyer MI, Hastings H, 2nd: Lateral tennis elbow. "Is there any science out there?" *J Shoulder Elbow Surg* 8:481–491, 1999.
29. Budoff JE, Hicks JM, Ayala G, et al: The reliability of the "scratch test." *J Hand Surg Eur Vol* 33:166–169, 2008.
30. Bunata RE, Brown DS, Capelo R: Anatomic factors related to the cause of tennis elbow. *J Bone Joint Surg Am* 89:1955–1963, 2007.
31. Chavan PR, Duquin TR, Bisson LJ: Repair of the ruptured distal biceps tendon: a systematic review. *Am J Sports Med* 36:1618–1624, 2008.
32. Chew ML, Giuffre BM: Disorders of the distal biceps brachii tendon. *Radiographics* 25:1227–1237, 2005.
33. Chillemi C, Marinelli M, De Cupis V: Rupture of the distal biceps brachii tendon: conservative treatment versus anatomic reinsertion—clinical and radiological evaluation after 2 years. *Arch Orthop Trauma Surg* 127:705–708, 2007.
34. Chung B, Wiley JP: Effectiveness of extracorporeal shock wave therapy in the treatment of previously untreated lateral epicondylitis: a randomized controlled trial. *Am J Sports Med* 32:1660–1667, 2004.
35. Ciccotti MC, Schwartz MA, Ciccotti MG: Diagnosis and treatment of medial epicondylitis of the elbow. *Clin Sports Med* 23:693–705, xi, 2004.
36. Ciccotti MG, Ramani MN: Medial epicondylitis. *Tech Hand Up Extrem Surg* 7:190–196, 2003.
37. Clayton ML, Thirupathi RG: Rupture of the triceps tendon with olecranon bursitis: a case report with a new method of repair. *Clin Orthop Relat Res* 184:183–185, 1984.
38. Cohen MS: Complications of distal biceps tendon repairs. *Sports Med Arthrosc* 16:148–153, 2008.
39. Cohen MS, Romeo AA, Hennigan SP, et al: Lateral epicondylitis: anatomic relationships of the extensor tendon origins and implications for arthroscopic treatment. *J Shoulder Elbow Surg* 17:954–960, 2008.
40. Connell DA, Ali KE, Ahmad M, et al: Ultrasound-guided autologous blood injection for tennis elbow. *Skeletal Radiol* 35:371–377, 2006.
41. Coombes BK, Bisset L, Brooks P, et al: Effect of corticosteroid injection, physiotherapy, or both on clinical outcomes in patients with unilateral lateral epicondylalgia: a randomized controlled trial. *JAMA* 309(5):461, 2013.
42. Coonrad RW, Hooper WR: Tennis elbow: its course, natural history, conservative and surgical management. *J Bone Joint Surg Am* 55:1177–1182, 1973.
43. Cowan J, Lozano-Calderon S, Ring D: Quality of prospective controlled randomized trials: analysis of trials of treatment for lateral epicondylitis as an example. *J Bone Joint Surg Am* 89:1693–1699, 2007.
44. Cummins CA: Lateral epicondylitis: in vivo assessment of arthroscopic debridement and correlation with patient outcomes. *Am J Sports Med* 34:1486–1491, 2006.
45. Cyriax JH: Tennis elbow. *BMJ* 559:1937.
46. Cyriax JH: The pathology and treatment of tennis elbow. *J Bone Joint Surg Br* 18:921–940, 1936.
47. D'Alessandro DF, Shields CL, Jr, Tibone JE, et al: Repair of distal biceps tendon ruptures in athletes. *Am J Sports Med* 21:114–119, 1993.
48. D'Vaz AP, Ostor AJ, Speed CA, et al: Pulsed low-intensity ultrasound therapy for chronic lateral epicondylitis: a randomized controlled trial. *Rheumatology (Oxf)* 45:566–570, 2006.
49. Davison BL, Engber WD, Tigert LJ: Long term evaluation of repaired distal biceps brachii tendon ruptures. *Clin Orthop Relat Res* 333:186–191, 1996.
50. Dellaero DT, Mallon WJ: Surgical treatment of partial biceps tendon ruptures at the elbow. *J Shoulder Elbow Surg* 15:215–217, 2006.
51. Descatha A, Leclerc A, Chastang JF, et al: Medial epicondylitis in occupational settings: prevalence, incidence and associated risk factors. *J Occup Environ Med* 45:993–1001, 2003.
52. Dunn JH, Kim JJ, Davis L, et al: Ten- to 14-year follow-up of the Nirschl surgical technique for lateral epicondylitis. *Am J Sports Med* 36:261–266, 2008.
53. Eames MH, Bain GI, Fogg QA, et al: Distal biceps tendon anatomy: a cadaveric study. *J Bone Joint Surg Am* 89:1044–1049, 2007.
54. Edwards SG, Calandruccio JH: Autologous blood injections for refractory lateral epicondylitis. *J Hand Surg [Am]* 28:272–278, 2003.
55. El-Hawary R, Macdermid JC, Faber KJ, et al: Distal biceps tendon repair: comparison of surgical techniques. *J Hand Surg [Am]* 28:496–502, 2003.
56. Falchook FS, Zlatkin MB, Erbacher GE, et al: Rupture of the distal biceps tendon: evaluation with MR imaging. *Radiology* 190:659–663, 1994.
57. Farrar EL, 3rd, Lippert FG, 3rd: Avulsion of the triceps tendon. *Clin Orthop Relat Res* 161:242–246, 1981.
58. Fitzgerald SW, Curry DR, Erickson SJ, et al: Distal biceps tendon injury: MR imaging diagnosis. *Radiology* 191:203–206, 1994.
59. Freeman CR, McCormick KR, Mahoney D, et al: Nonoperative treatment of distal biceps tendon ruptures compared with a historical control group. *J Bone Joint Surg Am* 91(10):2329, 2009.
60. Furia JP: Safety and efficacy of extracorporeal shock wave therapy for chronic lateral epicondylitis. *Am J Orthop* 34:13–19, discussion 19, 2005.
61. Gabel GT: Acute and chronic tendinopathies at the elbow. *Curr Opin Rheumatol* 11:138–143, 1999.
62. Gabel GT, Morrey BF: Operative treatment of medical epicondylitis: influence of concomitant ulnar neuropathy at the elbow. *J Bone Joint Surg Am* 77:1065–1069, 1995.
63. Gabel GT, Morrey BF: Tennis elbow. *Instr Course Lect* 47:165–172, 1998.
64. Galliani I, Burattini S, Mariani AR, et al: Morpho-functional changes in human tendon tissue. *Eur J Histochem* 46:3–12, 2002.
65. Galloway M, DeMaio M, Mangine R: Rehabilitative techniques in the treatment of medial and lateral epicondylitis. *Orthopedics* 15:1089–1096, 1992.
66. Gardner RC: Tennis elbow: diagnosis, pathology and treatment. Nine severe cases treated by a new reconstructive operation. *Clin Orthop Relat Res* 72:248–253, 1970.
67. Geaney LE, Brenneman DJ, Cote MP, et al: Outcomes and practical information for patients choosing nonoperative treatment for distal biceps ruptures. *Orthopedics* 33(6):391, 2010.
68. Giangarra CE, Conroy B, Jobe FW, et al: Electromyographic and cinematographic analysis of elbow function in tennis players using single- and double-handed backhand strokes. *Am J Sports Med* 21:394–399, 1993.
69. Giuffre BM, Moss MJ: Optimal positioning for MRI of the distal biceps brachii tendon: flexed abducted supinated view. *AJR Am J Roentgenol* 182:944–946, 2004.
70. Gosens T, Peerbooms JC, van Laar W, et al: Ongoing positive effect of platelet-rich plasma versus corticosteroid injection in lateral epicondylitis: a double-blind randomized controlled trial with 2-year follow-up. *Am J Sports Med* 39(6):1200, 2011.
71. Grewal R, Athwal GS, MacDermid JC, et al: Single vs double incision technique for the repair of acute distal biceps ruptures: a randomized clinical trial. *J Bone Joint Surg Am* 94(13):1166–1174, 2012.
72. Grifka J, Boenke S, Kramer J: Endoscopic therapy in epicondylitis radialis humeri. *Arthroscopy* 11:743–748, 1995.
73. Grundberg AB, Dobson JF: Percutaneous release of the common extensor origin for tennis elbow. *Clin Orthop Relat Res* 376:137–140, 2000.
74. Hales TR, Bernard BP: Epidemiology of work-related musculoskeletal disorders. *Orthop Clin North Am* 27:679–709, 1996.
75. Hamilton PG: The prevalence of humeral epicondylitis: a survey in general practice. *J R Coll Gen Pract* 36:464–465, 1986.
76. Harris PC, Atkinson D, Moorehead JD: Bilateral partial rupture of triceps tendon: case report and quantitative assessment of recovery. *Am J Sports Med* 32:787–792, 2004.
77. Hartman MW, Merten SM, Steinmann SP: Mini-open 2-incision technique for repair of distal biceps tendon ruptures. *J Shoulder Elbow Surg* 16:616–620, 2007.
78. Ho C: Extracorporeal shock wave treatment for chronic lateral epicondylitis (tennis elbow). *Issues Emerg Health Technol* 96(Pt 2):1–4, 2007.
79. Holleb PD, Bach BR, Jr: Triceps brachii injuries. *Sports Med* 10:273–276, 1990.
80. Hutchinson HL, Gloystein D, Gillespie M: Distal biceps tendon insertion: an anatomic study. *J Shoulder Elbow Surg* 17:342–346, 2008.
81. Jerosch J, Schunck J: Arthroscopic treatment of lateral epicondylitis: indication, technique and early results. *Knee Surg Sports Traumatol Arthrosc* 14:379–382, 2006.
82. Kalichman L, Bannuru RR, Severin M, et al: Injection of botulinum toxin for treatment of chronic lateral epicondylitis: systematic review and meta-analysis. *Semin Arthritis Rheum* 40(6):532, 2011.
83. Kazemi M, Azma K, Tavana B, et al: Autologous blood vs corticosteroid local injection in the short term treatment of lateral elbow tendinopathy: a randomized clinical trial of efficacy. *Am J Phys Med Rehabil* 89(8):660–667, 2010.
84. Kelly EW, Steinmann S, O'Driscoll SW: Surgical treatment of partial distal biceps tendon ruptures through a single posterior incision. *J Shoulder Elbow Surg* 12:456–461, 2003.
85. Kettler M, Lunger J, Kuhn V, et al: Failure strengths in distal biceps tendon repair. *Am J Sports Med* 35:1544–1548, 2007.
86. Kettler M, Tingart MJ, Lunger J, et al: Reattachment of the distal tendon of biceps: factors affecting the failure strength of the repair. *J Bone Joint Surg Br* 90:103–106, 2008.
87. Khan AD, Penna S, Yin Q, et al: Repair of distal biceps tendon ruptures using suture anchors through a single anterior incision. *Arthroscopy* 24:39–45, 2008.
88. Khan KM, Cook JL, Bonar F, et al: Histopathology of common tendinopathies: update and implications for clinical management. *Sports Med* 27:393–408, 1999.
89. Kijowski R, De Smet AA: Magnetic resonance imaging findings in patients with medial epicondylitis. *Skeletal Radiol* 34:196–202, 2005.

90. Korthals-de Bos IB, Smidt N, van Tulder MW, et al: Cost effectiveness of interventions for lateral epicondylitis: results from a randomised controlled trial in primary care. *Pharmacoeconomics* 22:185–195, 2004.
91. Kraushaar BS, Nirschl RP: Tendinosis of the elbow (tennis elbow): clinical features and findings of histological, immunohistochemical, and electron microscopy studies. *J Bone Joint Surg Am* 81:259–278, 1999.
92. Krischek O, Hopf C, Nafe B, et al: Shock-wave therapy for tennis and golfer's elbow—1 year follow-up. *Arch Orthop Trauma Surg* 119(1–2):62–66, 1999.
93. Krogh TP, Bartels EM, Ellingsen T, et al: Comparative effectiveness of injection therapies in lateral epicondylitis: a systematic review and network meta-analysis of randomized controlled trials. *Am J Sports Med* 41(6):1435, 2013.
94. Krogh TP, Fredberg U, Stengaard-Pedersen K, et al: Treatment of lateral epicondylitis with platelet rich plasma, glucocorticoid, or saline: a randomized, double-blind, placebo controlled trial. *Am J Sports Med* 41(3):625, 2013.
95. Kuklo TR, Taylor KF, Murphy KP, et al: Arthroscopic release for lateral epicondylitis: a cadaveric model. *Arthroscopy* 15:259–264, 1999.
96. Kurppa K, Viikari-Juntura E, Kuosma E, et al: Incidence of tenosynovitis or peritendinitis and epicondylitis in a meat-processing factory. *Scand J Work Environ Health* 17:32–37, 1991.
97. Kurvers H, Verhaar J: The results of operative treatment of medial epicondylitis. *J Bone Joint Surg Am* 77:1374–1379, 1995.
98. Leach RE, Miller JK: Lateral and medial epicondylitis of the elbow. *Clin Sports Med* 6:259–272, 1987.
99. Leadbetter WB: Cell-matrix response in tendon injury. *Clin Sports Med* 11:533–578, 1992.
100. Lebrun CM: Low-dose extracorporeal shock wave therapy for previously untreated lateral epicondylitis. *Clin J Sport Med* 15:401–402, 2005.
101. Levy M, Fishel RE, Stern GM: Triceps tendon avulsion with or without fracture of the radial head—a rare injury? *J Trauma* 18:677–679, 1978.
102. Lindenhovius A, Henket M, Gilligan BP, et al: Injection of dexamethasone versus placebo for lateral elbow pain: a prospective, double-blind, randomized clinical trial. *J Hand Surg [Am]* 33:909–919, 2008.
103. Lo MY, Safran MR: Surgical treatment of lateral epicondylitis: a systematic review. *Clin Orthop Relat Res* 463:98–106, 2007.
104. Luchetti R, Atzei A, Brunelli F, et al: Anconeus muscle transposition for chronic lateral epicondylitis, recurrences, and complications. *Tech Hand Up Extrem Surg* 9:105–112, 2005.
105. Luopajarvi T, Kuorinka I, Virolainen M, et al: Prevalence of tenosynovitis and other injuries of the upper extremities in repetitive work. *Scand J Work Environ Health* 5(Suppl 3):48–55, 1979.
106. Madsen M, Marx RG, Millett PJ, et al: Surgical anatomy of the triceps brachii tendon: anatomical study and clinical correlation. *Am J Sports Med* 34:1839–1843, 2006.
107. Mair SD, Isbell WM, Gill TJ, et al: Triceps tendon ruptures in professional football players. *Am J Sports Med* 32:431–434, 2004.
108. Martin CE, Schweitzer ME: MR imaging of epicondylitis. *Skeletal Radiol* 27:133–138, 1998.
109. Mazzocca AD, Cohen M, Berkson E, et al: The anatomy of the bicipital tuberosity and distal biceps tendon. *J Shoulder Elbow Surg* 16:122–127, 2007.
110. McCluskey GM: Open treatment of medial epicondylitis. In Yamaguchi K, King GW, McKee MD, et al, editors: *Advanced reconstruction elbow*, Chicago, 2007, American Academy of Orthopaedic Surgeons, pp 137–142.
111. McCluskey GM, Merkley MS: Lateral and medial epicondylitis. In Baker CL, Jr, Plancher KD, editors: *Operative treatment of elbow injuries*, New York, 2002, Springer.
112. Milz S, Tischer T, Buettner A, et al: Molecular composition and pathology of entheses on the medial and lateral epicondyles of the humerus: a structural basis for epicondylitis. *Ann Rheum Dis* 63:1015–1021, 2004.
113. Mishra AK, Skrepnik NV, Edwards SG, et al: Efficacy of platelet-rich plasma for chronic tennis elbow: a double-blind prospective, multi center, randomized controlled trial of 230 patients. *Am J Sports Med* 42(2):463–471, 2014.
114. Morrey BF: Tendon injuries about the elbow. In Morrey BF, editor: *The elbow and its disorders*, Philadelphia, 1993, WB Saunders, pp 492–504.
115. Morrey BF, Askew LJ, An KN, et al: Rupture of the distal tendon of the biceps brachii: a biomechanical study. *J Bone Joint Surg Am* 67:418–421, 1985.
116. Morris H: Lawn tennis elbow. *BMJ* 2:557, 1883.
117. Newcomer KL, Laskowski ER, Idank DM, et al: Corticosteroid injection in early treatment of lateral epicondylitis. *Clin J Sport Med* 11:214–222, 2001.
118. Nirschl RP: Elbow tendinosis/tennis elbow. *Clin Sports Med* 11:851–870, 1992.
119. Nirschl RP: Prevention and treatment of elbow and shoulder injuries in the tennis player. *Clin Sports Med* 7:289–308, 1988.
120. Nirschl RP, Pettrone FA: Tennis elbow: The surgical treatment of lateral epicondylitis. *J Bone Joint Surg Am* 61:832–839, 1979.
121. O'Driscoll SW: Intramuscular triceps rupture. *Can J Surg* 35:203–207, 1992.
122. O'Driscoll SW, Goncalves LB, Dietz P: The hook test for distal biceps tendon avulsion. *Am J Sports Med* 35:1865–1869, 2007.
123. Olaussen M, Holmedal O, Lindbaek M, et al: Treating lateral epicondylitis with corticosteroid injections or non-electrotherapeutical physiotherapy: a systematic review. *BMJ Open* 3(10):29, 2013.
124. Ollivierre CO, Nirschl RP, Pettrone FA: Resection and repair for medial tennis elbow: a prospective analysis. *Am J Sports Med* 23:214–221, 1995.
125. Organ SW, Nirschl RP, Kraushaar BS, et al: Salvage surgery for lateral tennis elbow. *Am J Sports Med* 25:746–750, 1997.
126. Owens BD, Murphy KP, Kuklo TR: Arthroscopic release for lateral epicondylitis. *Arthroscopy* 17:582–587, 2001.
127. Park GY, Lee SM, Lee MY: Diagnostic value of ultrasonography for clinical medial epicondylitis. *Arch Phys Med Rehabil* 89:738–742, 2008.
128. Pattanittum P, Turner T, Green S, et al: Non-steroidal anti-inflammatory drugs (NSAIDs) for treating lateral elbow pain in adults. *Cochrane Database Syst Rev* 5:CD003686, 2013.
129. Peart RE, Strickler SS, Schweitzer KM, Jr: Lateral epicondylitis: a comparative study of open and arthroscopic lateral release. *Am J Orthop* 33:565–567, 2004.
130. Potter HG, Hannafin JA, Morwessel RM, et al: Lateral epicondylitis: correlation of MR imaging, surgical, and histopathologic findings. *Radiology* 196:43–46, 1995.
131. Price R, Sinclair H, Heinrich I, et al: Local injection treatment of tennis elbow—hydrocortisone, triamcinolone and lignocaine compared. *Br J Rheumatol* 30:39–44, 1991.
132. Rajasekhar C, Kakarlapudi TK, Bhamra MS: Avulsion of the triceps tendon. *Emerg Med J* 19:271–272, 2002.
133. Regan W, Wold LE, Coonrad R, et al: Microscopic histopathology of chronic refractory lateral epicondylitis. *Am J Sports Med* 20:746–749, 1992.
134. Ritz BR: Humeral epicondylitis among gas- and waterworks employees. *Scand J Work Environ Health* 21:478–486, 1995.
135. Roetert EP, Brody H, Dillman CJ, et al: The biomechanics of tennis elbow: an integrated approach. *Clin Sports Med* 14:47–57, 1995.
136. Rompe JD, Decking J, Schoellner C, et al: Repetitive low-energy shock wave treatment for chronic lateral epicondylitis in tennis players. *Am J Sports Med* 32:734–743, 2004.
137. Sanchez-Sotelo J, Morrey BF: Surgical techniques for reconstruction of chronic insufficiency of the triceps: Rotation flap using anconeus and tendon Achilles allograft. *J Bone Joint Surg Br* 84:1116–1120, 2002.
138. Sanchez-Sotelo J, Morrey BF, Adams RA, et al: Reconstruction of chronic ruptures of the distal biceps tendon with use of an Achilles tendon allograft. *J Bone Joint Surg Am* 84:999–1005, 2002.
139. Savnik A, Jensen B, Norregaard J, et al: Magnetic resonance imaging in the evaluation of treatment response of lateral epicondylitis of the elbow. *Eur Radiol* 14:964–969, 2004.
140. Schmidt CC, Kohut GN, Greenberg JA, et al: The anconeus muscle flap: its anatomy and clinical application. *J Hand Surg [Am]* 24:359–369, 1999.
141. Schmidt CC, Brown BT, Sawardeker PJ, et al: Factors affecting supination strength after a distal biceps rupture. *J Shoulder Elbow Surg* 23(1):68, 2014.
142. Sems A, Dimeff R, Iannotti JP: Extracorporeal shock wave therapy in the treatment of chronic tendinopathies. *J Am Acad Orthop Surg* 14:195–204, 2006.
143. Shiri R, Viikari-Juntura E, Varonen H, et al: Prevalence and determinants of lateral and medial epicondylitis: a population study. *Am J Epidemiol* 164:1065–1074, 2006.
144. Sierra RJ, Weiss NG, Shrader MW, et al: Acute triceps ruptures: case report and retrospective chart review. *J Shoulder Elbow Surg* 15:130–134, 2006.
145. Singh RK, Pooley J: Complete rupture of the triceps brachii muscle. *Br J Sports Med* 36:467–469, 2002.
146. Smidt N, Assendelft WJ, van der Windt DA, et al: Corticosteroid injections for lateral epicondylitis: a systematic review. *Pain* 96(1–2):23–40, 2002.
147. Smidt N, Lewis M, van der Windt DA, et al: Lateral epicondylitis in general practice: course and prognostic indicators of outcome. *J Rheumatol* 33:2053–2059, 2006.
148. Smidt N, van der Windt DA, Assendelft WJ, et al: Corticosteroid injections, physiotherapy, or a wait-and-see policy for lateral epicondylitis: a randomised controlled trial. *Lancet* 359:657–662, 2002.
149. Smith AM, Castle JA, Ruch DS: Arthroscopic resection of the common extensor origin: anatomic considerations. *J Shoulder Elbow Surg* 12:375–379, 2003.
150. Sollender JL, Rayan GM, Barden GA: Triceps tendon rupture in weight lifters. *J Shoulder Elbow Surg* 7:151–153, 1998.
151. Spacca G, Necozione S, Cacchio A: Radial shock wave therapy for lateral epicondylitis: a prospective randomised controlled single-blind study. *Eura Medicophys* 41:17–25, 2005.
152. Speed CA, Nichols D, Richards C, et al: Extracorporeal shock wave therapy for lateral epicondylitis—a double blind randomised controlled trial. *J Orthop Res* 20:895–898, 2002.
153. Spencer GE, Jr, Herndon CH: Surgical treatment of epicondylitis. *J Bone Joint Surg Am* 35:421–424, 1953.
154. Stahl S, Kaufman T: The efficacy of an injection of steroids for medial epicondylitis: a prospective study of sixty elbows. *J Bone Joint Surg Am* 79:1648–1652, 1997.

155. Stanley J: Radial tunnel syndrome: a surgeon's perspective. *J Hand Ther* 19:180–184, 2006.
156. Staples MP, Forbes A, Ptasznik R, et al: A randomized controlled trial of extracorporeal shock wave therapy for lateral epicondylitis (tennis elbow). *J Rheumatol* 35:2038–2046, 2008.
157. Stasinopoulos D, Johnson MI: Effectiveness of extracorporeal shock wave therapy for tennis elbow (lateral epicondylitis). *Br J Sports Med* 39:132–136, 2005.
158. Steinborn M, Heuck A, Jessel C, et al: Magnetic resonance imaging of lateral epicondylitis of the elbow with a 0.2-T dedicated system. *Eur Radiol* 9:1376–1380, 1999.
159. Steinmann SP: Elbow arthroscopy: where are we now? *Arthroscopy* 23:1231–1236, 2007.
160. Suresh SP, Ali KE, Jones H, et al: Medial epicondylitis: is ultrasound guided autologous blood injection an effective treatment? *Br J Sports Med* 40:935–939, discussion 939, 2006.
161. Szabo SJ, Savoie FH, 3rd, Field LD, et al: Tendinosis of the extensor carpi radialis brevis: an evaluation of three methods of operative treatment. *J Shoulder Elbow Surg* 15:721–727, 2006.
162. Tarsney FF: Rupture and avulsion of the triceps. *Clin Orthop Relat Res* 83:177–183, 1972.
163. Thanasas C, Papadimitriou G, Charalambidis C, et al: Platelet-rich plasma vs autologous whole blood for the treatment of chronic lateral elbow epicondylitis: a randomized controlled clinical trial. *Am J Sports Med* 39(10):2130–2134, 2011.
164. Tonks JH, Pai SK, Murali SR: Steroid injection therapy is the best conservative treatment for lateral epicondylitis: a prospective randomised controlled trial. *Int J Clin Pract* 61:240–246, 2007.
165. Tseng V: Arthroscopic lateral release for treatment of tennis elbow. *Arthroscopy* 10:335–336, 1994.
166. Tsourvakas S, Gouvalas K, Gimtsas C, et al: Bilateral and simultaneous rupture of the triceps tendons in chronic renal failure and secondary hyperparathyroidism. *Arch Orthop Trauma Surg* 124:278–280, 2004.
167. Uzunca K, Birtane M, Tastekin N: Effectiveness of pulsed electromagnetic field therapy in lateral epicondylitis. *Clin Rheumatol* 26:69–74, 2007.
168. Vangsness CT, Jr, Jobe FW: Surgical treatment of medial epicondylitis: results in 35 elbows. *J Bone Joint Surg Br* 73:409–411, 1991.
169. Verhaar JA, Walenkamp GH, van Mameren H, et al: Local corticosteroid injection versus Cyriax-type physiotherapy for tennis elbow. *J Bone Joint Surg Br* 78:128–132, 1996.
170. Wang CJ: An overview of shock wave therapy in musculoskeletal disorders. *Chang Gung Med J* 26:220–232, 2003.
171. Wang CJ, Chen HS: Shock wave therapy for patients with lateral epicondylitis of the elbow: a one- to two-year follow-up study. *Am J Sports Med* 30:422–425, 2002.
172. Wilson BP, Kocheta AA, Forgacs B: Two-level complete rupture of the distal biceps tendon in a woman: a case report. *J Shoulder Elbow Surg* 17:e1–e3, 2008.
173. Wolf JM, Ozer K, Scott F, et al: Comparison of autologous blood, corticosteroid, and saline injection in the treatment of lateral epicondylitis: a prospective, randomized, controlled, multi center trial. *J Hand Surg [Am]* 36(8):1269, 2011.
174. Wong SM, Hui AC, Tong PY, et al: Treatment of lateral epicondylitis with botulinum toxin: a randomized, double-blind, placebo-controlled trial. *Ann Intern Med* 143:793–797, 2005.
175. Yerger B, Turner T: Percutaneous extensor tenotomy for chronic tennis elbow: an office procedure. *Orthopedics* 8:1261–1263, 1985.
176. Zhu J, Hu B, Xing C, et al: Ultrasound-guided, minimally invasive, percutaneous needle puncture treatment for tennis elbow. *Adv Ther* 25:1031–1036, 2008.

Elbow Arthroscopy

George S. Athwal

Acknowledgment: The author would like to acknowledge Dr. Laura Kember for her assistance with the preparation of this manuscript.

Arthroscopy of the elbow, as with arthroscopy of other joints, has undergone a transition from simple diagnostic procedures to complex advanced procedures for the management of stiffness, fractures, and arthritis. The technical advances in elbow arthroscopy have been possible because of an improved understanding of anatomy, the use of safe portals, and the development of improved instruments and motorized tools specific to arthroscopy. In addition, transitional techniques have been developed, such as miniopen procedures and the use of arthroscopic retractors to improve visualization and protect adjacent neurovascular structures. Presently, the accepted indications[46] for elbow arthroscopy include the treatment of rheumatoid arthritis, degenerative arthritis, lateral epicondylitis, synovitis, osteochondritis dissecans, loose bodies, symptomatic plica, infection, contracture, instability, and fractures of the coronoid, capitellum, trochlea, and radial head. Unfortunately, as the complexity of elbow arthroscopy procedures increases, so does the risk of complications. Complications encountered with elbow arthroscopy include nerve injury, vascular injury, infection, instability, and stiffness. The purpose of this chapter is to describe the various techniques of elbow arthroscopy for the management of the aforementioned disorders. Specifically, débridement of an osteoarthritic elbow with hypertrophic osteophytes requiring a capsulectomy will be used as a representative example.

PREOPERATIVE EVALUATION

The detailed disease-specific evaluation of the patient who may benefit from elbow arthroscopy is beyond the scope of this chapter. A comprehensive history is mandatory, detailing the location of injury or disease; the hand dominance; the symptoms, such as pain or numbness, and situations that exacerbate symptoms; the mechanism of injury; the patient's medical history, including medications taken and prior nonoperative and operative treatments; the patient's occupation; and the presence of allergies. Signs and symptoms specific to the disease process should be sought. For example, with rheumatoid arthritis, the history would include questions about pain and swelling affecting multiple joints, cervical spine involvement, and the use of biologic agents.

Symptoms specifically of the elbow should be documented, such as impingement pain at the extremes of flexion and extension, joint locking or snapping, instability, numbness, and the location of pain (in the anterior, medial, lateral, or posterior elbow).

Physical Examination

Examination of the elbow should take a general approach consisting of inspection, palpation, and evaluation of active and passive range of motion and the neurovascular status. Tests for specific diseases should be conducted as indicated.

Inspection of the elbow should include an assessment of deformities, muscle bulk, swelling, masses, and scarring from past surgical incisions. The elbow has several discrete bony and soft tissue landmarks that should be palpated for tenderness, such as the epicondyles, biceps and triceps tendons, ulnar nerve, collateral ligaments, and joint lines. Active and passive range of motion of the elbow, including flexion, extension, supination, and pronation, should be measured with a long-arm goniometer and documented. Patients with a limited range of motion should have the end range assessed for bony or soft tissue end points. Anterior and posterior bony impingement tests[12] for symptomatic impinging osteophytes should be conducted.

A standard neurovascular examination is appropriate. The ulnar nerve, however, does require special attention. Ulnar neuritis or neuropathy is commonly associated with elbow disorders. Also, the location of the ulnar nerve is important when considering arthroscopic portals, especially the anteromedial portals. In situ release or transposition of the ulnar nerve may be indicated as an associated procedure in the arthroscopic management of the stiff elbow, especially in patients with limited flexion or those who have preoperative symptoms related to ulnar nerve disorders.

A prior ulnar nerve transposition or a subluxating nerve is not an absolute contraindication to elbow arthroscopy; however, particular attention must be directed to identifying the location of the nerve via palpation, ultrasound studies, or a miniopen procedure. Alternatively, if the elbow disorder allows, anterior joint arthroscopy may be conducted via two laterally based portals, avoiding the anteromedial portals altogether.

The elbow arthroscopist should be familiar with several tests for specific diseases of the elbow. Common elbow disorders for which special tests may be performed are posterolateral rotatory instability, medial collateral ligament insufficiency, lateral epicondylitis, and radiocapitellar plica syndrome.[12] Examination of the elbow should conclude with an examination of the hand, shoulder, and cervical spine. In many cases, ipsilateral joint involvement may have an effect on the elbow. For example, patients with rheumatoid arthritis may have profound shoulder stiffness, which may influence ideal positioning during the surgical setup for elbow arthroscopy.

Diagnostic Imaging

In preparation for elbow arthroscopy, standard anteroposterior, oblique, and lateral elbow radiographs are indicated. The radiographs should be scrutinized for alignment, deformity, arthritic changes, osteophytes, heterotopic ossification, loose bodies, and fractures. In patients with osteoarthritis, rheumatoid arthritis, posttraumatic arthritis, bony deformity, posteromedial impingement, osteochondritis dissecans, or loose bodies, computed tomography (CT) is recommended. Three-dimensional reconstructions are particularly helpful in preoperative planning. These predictably allow for a much more rapid assessment of bony architecture. For osteoarthritis, three-dimensional CT reconstructions allow for visualization of the orientation, size, and location of impinging osteophytes. Typically, with osteoarthritis of the elbow (Figure 26.1), posterior osteophytes are identified within the olecranon fossa and along the medial and lateral aspects of the olecranon process.[28] Anteriorly, osteophytes are usually located on the coronoid tip and within the radial fossa and coronoid fossae. Additionally, occult osteophytes may be found along the posterior aspect of the capitellum that may impinge against the radial head in extension (see Figure 26.1, *E*).

CT scanning is useful for characterizing fractures that are amenable to arthroscopic fixation, such as fractures of the coronoid, capitellum, distal humerus, and radial head. Additionally, the size, orientation, and depth of osteochondritis dissecans lesions can be appreciated, along with characterization of the osteochondritis dissecans fragment to determine its size and reparability. If loose bodies are present, many may be cartilaginous, and therefore a CT arthrogram or magnetic resonance imaging (MRI) study may be beneficial if standard imaging techniques are normal.

MRI is useful if required to assist with the diagnosis of disorders of soft tissue. Many soft tissue disorders can be diagnosed on clinical examination, such as tears of the medial collateral ligament, lateral epicondylitis, medial epicondylitis, triceps tears, and distal biceps tears. MRI is also helpful in intraarticular disorders, such as radiocapitellar plica (Figure 26.2), osteochondritis dissecans lesions, or cartilaginous loose bodies.

ANESTHESIA AND POSITIONING

Elbow arthroscopy may be performed under a general anesthetic or a regional anesthetic. A general anesthetic has the advantage of muscle relaxation and ease of patient positioning. For arthroscopy, patients may be positioned in either the lateral decubitus or prone position, either of which is poorly tolerated in a patient who is awake. Regional anesthetic techniques, such as supraclavicular and interscalene blocks, are commonly used; patients should be educated about the length of the procedure and the requirement to remain still, however. In addition to regional blocks, intravenous sedation may be beneficial for patient relaxation.

After appropriate anesthesia, patient positioning and the arthroscopy setup are important early steps in a successful procedure. If a patient is poorly positioned, portal identification and creation and joint instrumentation may be challenging and visualization may be limited. Patients are typically placed in the prone or lateral position. Supine positioning is a less common option. Positioning typically depends on surgeon preference; certain disorders may lend themselves to one form of positioning over another, however.

The supine position was first reported by Andrews and Carson[4] and involves abducting the extremity to 90 degrees and flexing the elbow to 90 degrees. The wrist and/or forearm are secured to an overhead traction device. The advantage of this arrangement is that it is well known to anesthesiologists and nurses, airway access is routine, and there is a lower risk of complications related to positioning, such as compressive neuropathies. Another advantage of supine positioning is that the arthroscopic procedure can be easily converted to an open procedure. Disadvantages of supine positioning include the need for overhead traction and the increased difficulties in obtaining access to the posterior elbow compartment.

Prone positioning was described by Poehling and colleagues.[34] It involves placing the patient flat on chest bolsters. The arm is abducted to 90 degrees and the elbow is flexed over an elbow positioner. An advantage of prone positioning is that the posterior compartment of the elbow and the ulnar nerve are easily accessible and a traction device or holder is not required. Disadvantages typically include a longer setup time, limited airway access, and susceptibility to compression-related complications. Prone positioning is poorly tolerated with regional anesthetic techniques.

The author prefers lateral positioning, in which the patient is placed operative side up on a beanbag. The nonoperative arm is placed in 90 degrees of forward elevation and 90 degrees of elbow flexion and rested on an arm board. A well-padded axillary roll is placed slightly distal in the nonoperative axilla to decrease pressure on the contralateral brachial plexus. Additionally, pillows and pads are placed between the legs and beneath the malleoli and fibular head of the lower leg. The operative arm is elevated forward to 90 degrees and internally rotated at the shoulder, and the elbow is flexed over an arm positioner (Figure 26.3). Advantages of lateral positioning over prone positioning include better access to the posterior compartment, better access to the airway, and, generally, better positioning of the patient. Additionally, when regional anesthesia is used and the patient is awake, the patient tolerates the lateral position better than the prone position. Disadvantages include a longer time to set up lateral positioning than supine positioning, a risk of compression-related complications, and the possible need for repositioning if conversion to open débridement is required.

PERTINENT ANATOMY AND PORTALS

The elbow, fortunately, has several subcutaneous bony landmarks that can be used to orient the surgeon, locate neurovascular structures, and create safe portals. The neurovascular structures are of special importance due to their close proximity to arthroscopic portals and the joint capsule (Figure 26.4). The median nerve and brachial artery are located just superficial to the anteromedial joint capsule and brachialis muscle. On the anterolateral side of the elbow, the radial nerve splits into the superficial sensory branch and the posterior interosseous nerve. The posterior interosseous nerve is just superficial to the anterior joint capsule, and at the level of the radiocapitellar joint, it courses longitudinally along the medial side of the capitellum.[32] At the level of the joint, a thin layer of brachialis lies between

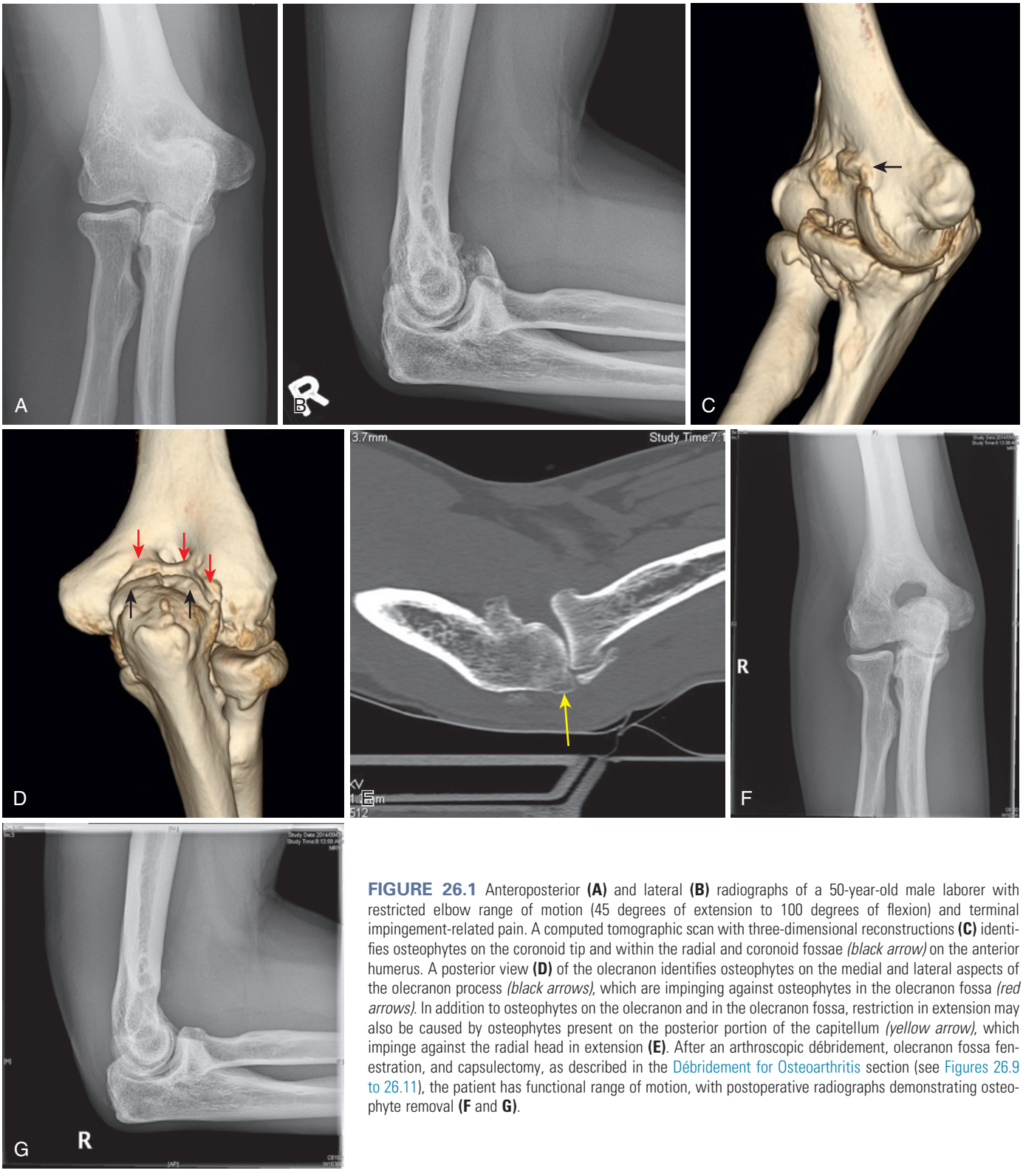

FIGURE 26.1 Anteroposterior **(A)** and lateral **(B)** radiographs of a 50-year-old male laborer with restricted elbow range of motion (45 degrees of extension to 100 degrees of flexion) and terminal impingement-related pain. A computed tomographic scan with three-dimensional reconstructions **(C)** identifies osteophytes on the coronoid tip and within the radial and coronoid fossae *(black arrow)* on the anterior humerus. A posterior view **(D)** of the olecranon identifies osteophytes on the medial and lateral aspects of the olecranon process *(black arrows)*, which are impinging against osteophytes in the olecranon fossa *(red arrows)*. In addition to osteophytes on the olecranon and in the olecranon fossa, restriction in extension may also be caused by osteophytes present on the posterior portion of the capitellum *(yellow arrow)*, which impinge against the radial head in extension **(E)**. After an arthroscopic débridement, olecranon fossa fenestration, and capsulectomy, as described in the Débridement for Osteoarthritis section (see Figures 26.9 to 26.11), the patient has functional range of motion, with postoperative radiographs demonstrating osteophyte removal **(F** and **G)**.

the posterior interosseous nerve and the capsule; distally, at the level of the radial neck, the nerve may come into direct contact with the capsule, however. Capsular resection at the level of the radial neck should be avoided or conducted with extreme caution because the nerve may be adhering to the joint capsule.[32] The ulnar nerve is located just superficial to the posteromedial joint capsule and should be identified and assessed for anterior subluxation with palpation. Alternatively, if any concerns exist with respect to the ulnar nerve, it can be identified via arthroscopic exposure or by a miniopen incision.

The locations of the above nerves can be predicted based on an assessment of surface anatomy. Typically, landmarks that are

marked on the elbow prior to starting arthroscopy are the medial epicondyle, ulnar nerve, olecranon, lateral epicondyle, and radial head. Special care is taken to draw out the path of the ulnar nerve.

Three compartments are used in arthroscopy of the elbow joint, the anterior, posterior, and posterolateral (posterior radiocapitellar) compartments. Several portals may be used to address pathologic findings within a compartment. It is not unusual to use four to six portals for a simple elbow arthroscopy and up to seven or eight for more complex cases.



FIGURE 26.2 A sagittal magnetic resonance image depicting a symptomatic posterior radiocapitellar plica *(yellow arrow)*.

Anterior Compartment Portals

There are five commonly described anterior joint arthroscopy portals. On the medial side of the elbow, two portals are commonly used, the anteromedial and proximal anteromedial portals. On the lateral side, three portals are described, the proximal anterolateral, midanterolateral, and distal anterolateral portals. All portals are typically created with the elbow flexed to 90 degrees. Before the portals are created, a sterile tourniquet is inflated to 250 mm Hg and 20 to 40 mL of saline is injected into the joint for distention. The saline is injected with a syringe through either the soft spot (triangle between the lateral epicondyle, radial head, and olecranon) or percutaneously through the triceps tendon into the olecranon fossa.

Anteromedial Portals

Proximal Anteromedial Portal. The proximal anteromedial portal is likely the most frequently used anteromedial portal (Figure 26.5). It was described by Poehling and associates[34] to be located approximately 2 cm proximal to the medial epicondyle and just anterior to the medial intermuscular septum. To create this portal, the medial intermuscular septum is palpated and a surgical marker is used to mark a location approximately 2 cm proximal to the medial epicondyle. The location of this portal in the proximal-distal direction will vary according to patient size. The purpose of this portal is to allow entry into the joint just proximal to the level of the superior aspect of the medial trochlea. Before the skin is incised, the location of the ulnar nerve, posterior to the medial epicondyle, is confirmed. After the skin is incised, a portal can be created by using a blunt trocar or by carrying dissection down to the capsule with a hemostat. It is the author's preference to use a dull switching stick to enter the joint, aiming toward the capitellum while staying in contact

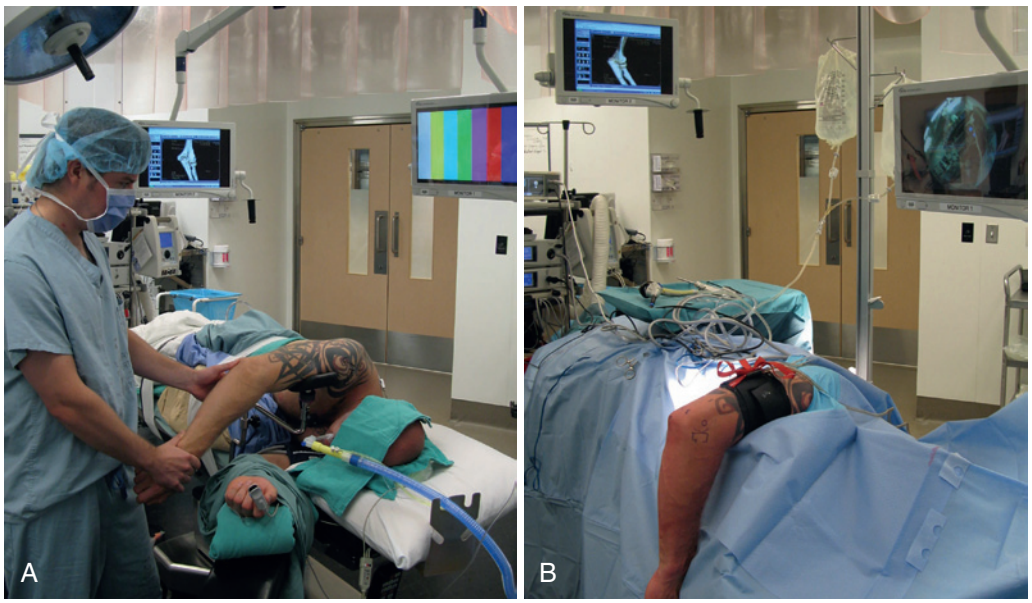

FIGURE 26.3 Lateral positioning on a beanbag with use of an elbow-positioning device prior to surgical preparation **(A)** and after preparation and draping **(B)**.

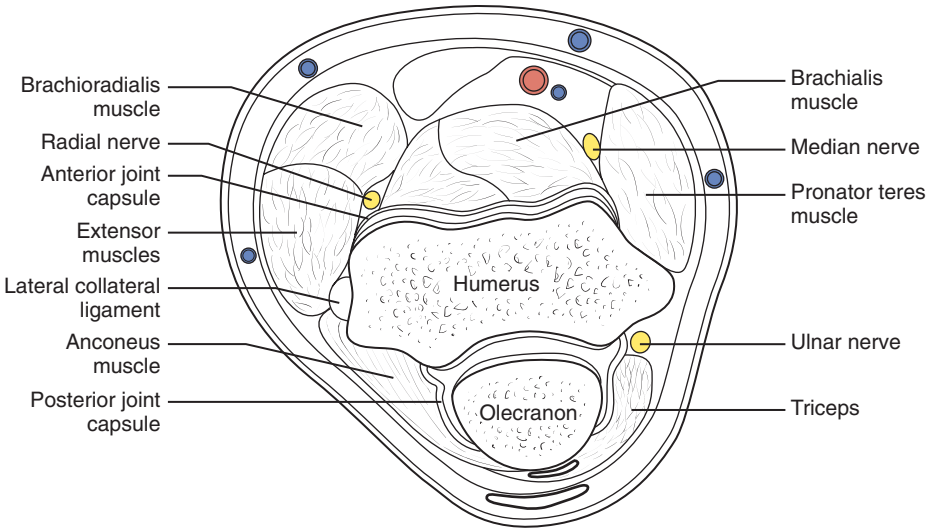

FIGURE 26.4 The three major nerves to the hand all cross the elbow and are in close proximity to arthroscopic portals and the joint capsule.

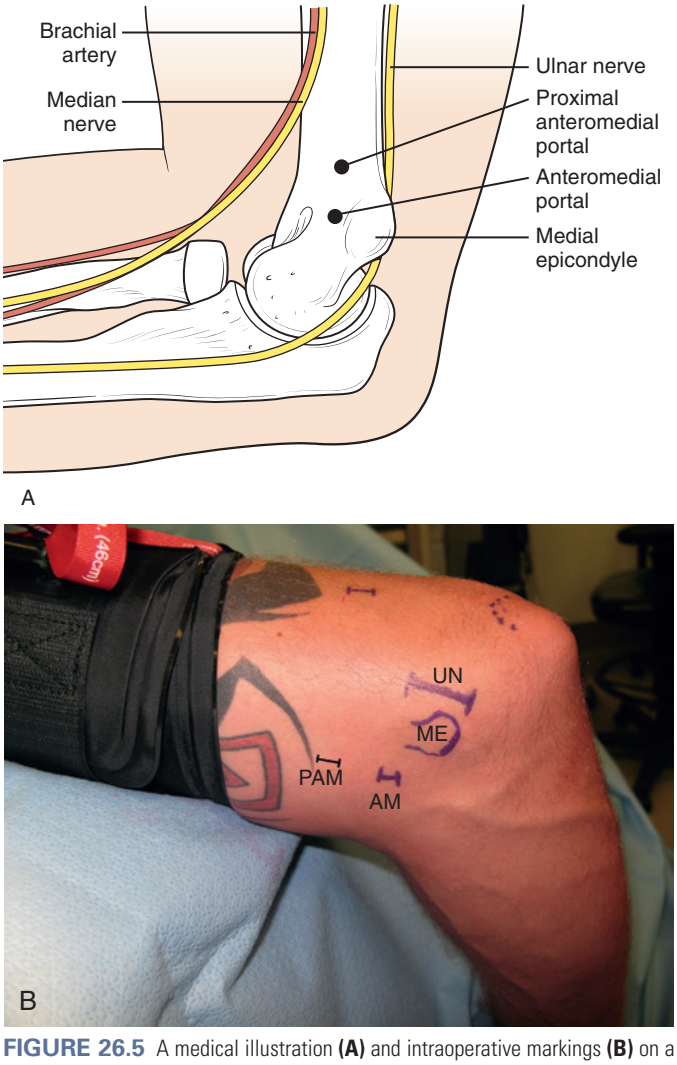

FIGURE 26.5 A medical illustration **(A)** and intraoperative markings **(B)** on a right elbow in the lateral position depicting medial portals. *AM*, Anteromedial portal; *ME*, medial epicondyle; *PAM*, proximal anteromedial portal; *UN*, ulnar nerve.

with the anterior humerus. Inserting a standard 30-degree arthroscope through this portal will allow visualization of the entire anterior joint compartment, including the radial head, capitellum, trochlea, and coronoid.

Anteromedial Portal. The standard anteromedial portal is described as 2 cm distal and 2 cm anterior to the medial epicondyle. This portal enters the elbow at the level of the anteromedial joint line. The portal is created by directing the trocar laterally, which places the portal in close proximity to the median and medial antebrachial cutaneous nerves. The standard anteromedial portal, although described in the literature, is not recommended by the author because the proximal anteromedial portal affords better visualization and is farther away from local nerves.

Anterolateral Portals

There are three commonly described anterolateral portals for anterior compartment arthroscopy, the proximal anterolateral, midanterolateral, and distal anterolateral portals (Figure 26.6).

Proximal Anterolateral Portal. The proximal anterolateral portal has been described by several authors.[11,40] It is templated 2 cm proximal to and 1 to 2 cm anterior to the lateral epicondyle. The portal is directed toward the center of the joint, with the tip of the trocar maintaining contact with the anterolateral humerus (see Figure 26.6). This portal has been described as the safest of the anterolateral portals.[11] Through this portal, the entire anterior compartment can be visualized, and especially good visualization can be obtained of the anteromedial joint structures, such as the medial trochlea and anteromedial coronoid. When working through this portal, there is good access to the capitellum, radial head, radial fossa, anterolateral joint capsule, and extensor tendon origin. When one is looking from the medial side, this portal can be made using a spinal needle for localization and an outside-in technique.

Midanterolateral Portal. The midanterolateral portal is also known as the anterosuperior lateral portal. This portal is landmarked 1 cm anterior to the lateral epicondyle (see Figure 26.6). The portal can be made via an outside-in or inside-out

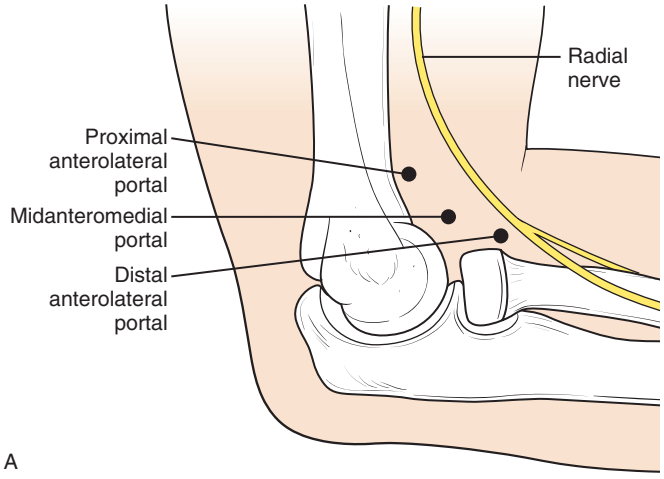

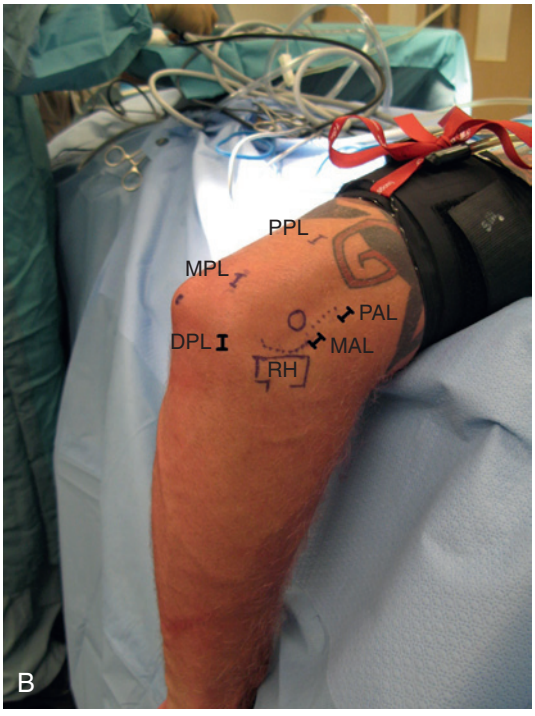

FIGURE 26.6 A medial illustration **(A)** and intraoperative markings **(B)** on a right elbow in the lateral position depicting the lateral portals. *DPL*, Distal posterolateral portal; *MAL*, midanterolateral portal; *MPL*, midposterolateral portal; *PAL*, proximal anterolateral portal; *PPL*, proximal posterolateral portal; *RH*, radial head.

technique. The portal enters the elbow joint at the superior aspect of the radiocapitellar joint. It has several purposes; it can be used as a viewing portal, an instrumentation portal, or an accessory portal.

Distal Anterolateral Portal. The distal anterolateral portal is also known as the original anterolateral portal. This portal was described by Andrews and Carson[4] and is located 3 cm distal to and 1 cm anterior to the lateral epicondyle. This portal is quite close to the radial nerve and the posterior antebrachial cutaneous nerve.[23] Because of the proximity of this portal to neurologic structures and because the midanterolateral and proximal anterolateral portals offer similar capabilities, most surgeons do not recommend using the distal anterolateral portal.



FIGURE 26.7 A posterior view of a right elbow in the lateral position depicting the posterior and posterolateral portals. *DPL*, Distal posterolateral; *MPL*, midposterolateral portal; *O*, olecranon tip; *PC*, posterior central portal; *PPL*, proximal posterolateral portal; *UN*, ulnar nerve.

Posterior Compartment Portals

There are typically three posterior compartment portals, the posterior central, proximal posterolateral, and midposterolateral portals (Figure 26.7).

Posterior Central Portal

The posterior central portal is also referred to as the straight posterior portal or the direct posterior portal. This portal is located midline approximately 3 cm proximal to the tip of the olecranon (see Figure 26.7). The orientation of the portal is obliquely directed through the musculotendinous junction of the triceps mechanism to the olecranon fossa. This portal functions as both a working portal and a viewing portal.

Proximal Posterolateral Portal

The proximal posterolateral portal is located adjacent to the posterior central portal along the lateral margin of the triceps (see Figure 26.7). The portal is typically made with an outside-in technique using a spinal needle or trocar. It typically functions as a viewing portal because it provides good visualization of the olecranon process, olecranon fossa, and medial gutter of the elbow joint. When conducting a medial gutter débridement with the camera in the proximal posterolateral portal, a retractor may be introduced through the posterior central portal to protect the medial gutter capsule and the immediately adjacent ulnar nerve.

Midposterolateral Portal

The midposterolateral portal is usually used for viewing at the beginning of posterior joint arthroscopy. This portal is located

in the proximal aspect of the lateral gutter as it enters the olecranon fossa. The landmarks for this portal require drawing a line from the subcutaneous olecranon tip to the lateral epicondyle. The midpoint of this line is typically located over the posterolateral ulnohumeral joint (lateral gutter). The midposterolateral portal is made approximately 1 cm farther proximal, and the portal trajectory is to the olecranon fossa (see Figure 26.7). By placing the portal 1 cm proximal to the lateral gutter, a 30-degree scope can be used to visualize the area past the olecranon tip and down the medial gutter. Any instruments inserted through this portal can be used in the medial gutter.

Posterolateral Compartment Portals

The posterolateral compartment is composed of the posterior aspect of the radiocapitellar joint and the distal lateral aspect of the ulnohumeral joint. The posterolateral compartment can be visualized and instrumented by several portals, the midposterolateral, distal posterolateral, and distal ulnar portals (see Figure 26.7).

Midposterolateral Portal

The midposterolateral portal is described above as a posterior compartment portal. This portal can be used to visualize the posterolateral elbow compartment. By advancing the scope distally along the lateral margin of the ulnohumeral joint, the posterolateral compartment can be reached.

Distal Posterolateral Portal

The distal posterolateral portal is also referred to as the midlateral, direct lateral, or soft spot portal. This portal is formed at the center of a triangle created by the olecranon tip, radial head, and lateral epicondyle. This portal traverses through the anconeus muscle. This portal can be used as a working portal with visualization obtained from the midposterolateral portal. In larger individuals and in some conditions such as osteochondritis of the capitellum, a second distal posterolateral portal can be made adjacent to the first one. This allows direct visualization of the inferior hemisphere of the capitellum and the radial head. With side-by-side distal posterolateral portals, one portal is used for visualization and the other for instrumentation (see Figure 26.7).

Distal Ulnar Portal

The distal ulnar portal is described as located 3 to 4 cm distal to the posterior aspect of the radiocapitellar joint and just lateral to the palpable subcutaneous border of the ulna.[43] The trajectory of the portal is directed deep and obliquely toward the posterior radiocapitellar joint. This portal is usually used as a viewing portal, which leaves the standard distal posterolateral portal available for a working portal.

INSTRUMENTATION

Fluid management techniques for elbow arthroscopy include gravity inflow versus commercially available arthroscopic pumps. In general, it is the author's preference to use gravity inflow with two 3-L bags of normal saline placed to a height of approximately 5 feet. The gravity method is cheap and easy to use, but vigilance is required to monitor the elbow for swelling.



FIGURE 26.8 Standard arthroscopy instruments that may be useful when conducting elbow arthroscopy. From left to right, a large pituitary grasper, two angled curets, straight and curved osteotomes, a Howarth retractor, a standard metal cannula, a dull pointed switching stick, and a standard switching stick.

It is the author's preference to use a sterile tourniquet; however, a nonsterile tourniquet may also be used.

In general, a standard 4-mm, 30-degree arthroscope is used; however, smaller scopes may be required for smaller elbows or to visualize tight areas. Cannulas may or may not be used, depending on surgeon preference. Standard arthroscopic instruments include a dull switching stick, a pointed switching stick, an arthroscopic grasper (or a pituitary grasper), a motorized arthroscopic shaver, and a motorized arthroscopic bur (Figure 26.8). Other instruments that may be beneficial during elbow arthroscopy include a Howarth retractor, which is used to retract tissues such as the joint capsule or to protect neurovascular structures. Curved and/or straight osteotomes of 5 to 8 mm may be useful for removing osteophytes. Additionally, curved curets may be useful to clear out spaces, such as the coronoid fossa and the radial fossa along the anterior aspect of humerus.

Specialized instrumentation may be required depending on the case being conducted. For example, arthroscopic fixation of fractures may require cannulated screws, fracture reduction clamps, and intraoperative fluoroscopy. The treatment of osteochondritis dissecans with osteochondral grafts will require specialized arthroscopic harvest and insertion instruments.

HISTORICAL REVIEW

In 1931, the elbow was described as a joint that was not suitable for arthroscopic examination. Only 1 year later, the elbow was described as arthroscopically appropriate. Table 26.1 lists the historically important advancements in elbow arthroscopy.

TABLE 26.1 Contributions to Elbow Arthroscopy

Author	Publication Date	Main Area of Contribution	Significance
Burman	1932	Technique	Reported that elbow arthroscopy was technically feasible
Andrews and Carson	1985	Technique	Described the initial technique of diagnostic arthroscopy and loose body removal
Guhl	1985	Technique and indications	Described the technique; established indications for inflammatory synovectomy, débridement of osteochondritis dissecans, excision of osteophytes, and treatment of fractures
Lynch et al	1986	Neurovascular anatomy	Described the proximity of neurovascular structures to portals
Clarke	1988	Plica	Described the arthroscopic features of a radiocapitellar plica
O'Driscoll et al	1990	Anatomy	Reported the intraarticular volume of the elbow joint
O'Driscoll et al	1992	Risks	Reported on the complications associated with elbow arthroscopy
Jones et al	1993	Contractures	Described the arthroscopic release of elbow flexion contractures
Lo and King	1994	Indications	Reported on arthroscopic excision of the radial head
Ogilvie-Harris et al	1995	Indications	Described posterior joint débridement for osteoarthritis
Baker et al	2000	Anatomy	Reported the arthroscopic appearance and classification of lateral epicondylitis
Hardy et al	2002	Indications	First report of arthroscopic management of capitellar fractures
Smith et al	2003	Anatomy	Defined the safe zone for arthroscopic tennis elbow release to be anterior to an intraarticular line bisecting the radial head
Adams et al	2007	Fractures	Arthroscopic fixation of coronoid fractures is described
Athwal et al	2009	Triceps tendon	Described the technique of arthroscopic triceps tendon repair
Yeoh et al	2012	Indications	Reported the evidence-based indications for elbow arthroscopy
O'Brien et al	2014	Ligament repair	An arthroscopic repair of the lateral collateral ligament is described

TYPES OF OPERATIONS

Loose Body Removal

Loose bodies frequently are found in the elbow, causing symptoms such as joint locking, clicking, pain, and limited range of motion. The arthroscopic removal of loose bodies is an established procedure that is safe and effective. There are several advantages to removing elbow loose bodies arthroscopically, such as a reduced surgical insult compared with open arthrotomy, the ability to better visualize all compartments of the elbow, and possible reduction of postoperative scarring and stiffness as compared with open techniques. The only disadvantage of arthroscopic loose body removal is related to the inherent risks of elbow arthroscopy. The surgeon planning to conduct elbow arthroscopy should be experienced and familiar with the anatomy, location of neurovascular structures, and described safe portals.

In patients presenting with symptoms of loose bodies, imaging studies should be examined to confirm the presence of loose bodies and the potential underlying cause that resulted in the loose bodies. Standard radiographs may be able to visualize bony loose bodies, but loose bodies may be cartilaginous and also hidden in the elbow gutters. MRI or CT arthrogram studies are better able to visualize the numbers and locations of loose bodies. These imaging studies should also be examined to identify the potential cause, such as osteoarthritis, fractured osteophytes, osteochondritis dissecans, or synovial chondromatosis.

Indications and Contraindications

The primary indication for arthroscopic removal of loose bodies is a symptomatic patient who has failed nonoperative management. Symptoms may include joint locking, crepitus, pain, catching, and stiffness. The contraindications to arthroscopic removal include elbow conditions that preclude arthroscopy, such as extensive postoperative scarring, altered anatomy, and deformity. When an elbow condition does not allow accurate assessment of the local anatomy to determine predictably safe portal locations, this is a contraindication to arthroscopy unless miniopen portals are created to ensure that neurovascular structures are not at risk. A prior ulnar nerve transposition or nerve subluxation is a relative contraindication; unless arthroscopy is conducted via lateral portals only, a miniopen technique is used for the medial portals, or intraoperative ultrasound is used to confirm the location of the ulnar nerve.

Preoperative Planning

Imaging studies should be scrutinized to assess the location and approximate number of loose bodies. No specific special instruments are required, other than a large pituitary grasper or an arthroscopic grasper. Hemostats of various sizes are also helpful. For larger loose bodies, the surgeon should be prepared to expand the working portal to ensure complete removal.

Technique

For isolated loose body removal, standard arthroscopic techniques are used. The bone and soft tissue landmarks are marked on the skin, antibiotics are administered, the tourniquet is inflated, the joint is insufflated with saline via a syringe, and the standard portals are used. Surgeon preference and the location of the loose bodies on preoperative imaging will determine which elbow compartment is examined first. However, it is essential that all three compartments be visualized, including

the medial and lateral gutters, to ensure complete removal of loose bodies and for diagnostic purposes.

For anterior compartment loose body removal, the arthroscope is introduced via the proximal anteromedial portal, and the proximal or midanterolateral portals are used for loose body removal. The camera is switched to an anterolateral portal to ensure that there are no loose bodies in the anteromedial gutter adjacent to the anteromedial facet of the coronoid. For posterior compartment arthroscopy, the posterior central and midposterolateral portals are typically used. The posteromedial gutter must be visualized, and this can usually be accomplished with the camera in the midposterolateral portal; if visualization is incomplete, however, the camera should be switched to the posterior central portal. The posterolateral compartment can be accessed with the camera in the midposterolateral portal, and work can proceed through the distal posterolateral portal (soft spot portal).

When loose bodies are encountered, they can be removed with pituitary or arthroscopic grasping instruments. Larger loose bodies can be removed by crushing them into fragments or via a dilated portal. If loose bodies are difficult to grasp because they are swirling in eddies of fluid, the arthroscopic fluid inflow can be temporarily turned off to decrease turbulence, making it easier to capture moving loose bodies.

Postoperative Management

Arthroscopy is usually conducted as an outpatient procedure. Patients are discharged to go home with a light surgical bandage that does not restrict range of motion and a sling for comfort. Patients are encouraged to start elbow range-of-motion exercises immediately following surgery. Formal physiotherapy may be started within the first week following operation if required. If range-of-motion recovery is incomplete at 3 to 4 weeks following operation, flexion and extension splinting is recommended.

Outcomes

Arthroscopic loose body removal has been reported as safe and effective.[29,31,46] However, when patients have other concomitant pathologic conditions such as osteoarthritis, removal of loose bodies in isolation is ineffective in resolving symptoms.

Débridement for Osteoarthritis

Elbow osteoarthritis can present with pain and restricted range of motion. Typically, nonoperative management is initially recommended to address symptoms. In patients with symptoms that are refractory to nonoperative treatment modalities, surgery is offered. The type of surgery depends on the patient's symptoms, age, activity level, degree of joint degeneration, and bony deformity. Depending on the above factors, surgical options include arthroscopic débridement, open débridement, interposition arthroplasty, elbow arthroplasty, and fusion.

Arthroscopic débridement of the osteoarthritic elbow, which is also termed *arthroscopic osteocapsular arthroplasty*, has gained increasing acceptance as arthroscopic techniques have advanced. However, arthroscopic débridement has not demonstrated any clinical superiority over traditional open débridement procedures. Arthroscopic débridement is best suited to patients with a relatively well-preserved joint space and symptoms stemming from peripheral osteophytes and capsular contracture that restrict range of motion and cause terminal motion impingement pain. The primary goal of arthroscopic management of the osteoarthritic elbow is to remove osteophytes, remove loose bodies, improve the impingement-free range of motion, and possibly release the capsule if it is restricting motion.

Indications and Contraindications

The indications for proceeding to arthroscopic débridement are failure of nonoperative management, the presence of a relatively well-preserved ulnohumeral joint space, and a compliant patient. The relative contraindications include bone loss, joint deformity, instability, and ankylosis. A patient who has undergone multiple prior open procedures may also be a relatively poor candidate. If an open operation has already been performed in an elbow, arthroscopic procedures for the elbow should be approached with caution because structures such as the ulnar nerve may have been transposed, resulting in altered anatomy.

Preoperative Planning

Standard elbow radiographs are required to make the diagnosis of elbow arthritis. When planning a complete arthroscopic débridement, however, a CT scan is helpful in identifying the sizes and locations of impinging osteophytes (see Figure 26.1). Additionally, a three-dimensional reconstruction of the joint can greatly enhance preoperative planning because osteophyte locations, orientations, and sizes are easier to visualize.

Disposable arthroscopic instruments typically used when conducting an osteocapsular arthroplasty include a 5.5-mm soft tissue motorized shaver, a 5- to 6-mm motorized bur, and possibly a radiofrequency ablation device. Additional instruments that are helpful include a No. 11 scalpel blade, a switching stick, a dull pointed switching stick, and an arthroscopic grasper (or a pituitary grasper). A Howarth retractor, which is used to retract tissues such as the joint capsule, may also be helpful (see Figure 26.8). Curved and/or straight 5- to 8-mm osteotomes may be convenient for removing osteophytes. Curved curets may be helpful in débriding bony spaces such as the coronoid fossa and the radial fossa along the anterior aspect of the humerus. Because some osteocapsular arthroplasties are conducted with a limited in situ ulnar nerve decompression, tenotomy scissors, small angled retractors, and a bipolar cautery unit may be useful.

Technique

Patients are typically placed in the lateral decubitus position on a beanbag, and the affected elbow is flexed over an elbow-positioning stand (see Figure 26.3). A viewing monitor is placed at eye level across from the elbow, and another monitor is used to display the three-dimensional CT scan. To prevent instruments and motorized devices from falling on the floor, a Mayo stand is brought over the patient to serve as a flat surface on which to place instruments when they are not being used (see Figure 26.3, *B*). A sterile tourniquet is used with gravity inflow for the arthroscopy fluid.

In patients undergoing osteocapsular arthroplasty who will be starting continuous passive motion postoperatively, it is the author's practice to conduct a limited in situ ulnar nerve decompression to decrease the potential for delayed onset of ulnar neuritis.[6,7]

In preparation for arthroscopy, the relevant arthroscopy portals are marked and fluid is injected into the elbow joint, as described earlier. It is the author's preference to create the standard anteromedial portal first, to function as a fluid drainage portal. A No. 11 scalpel blade is used to incise the skin only. Following skin incision, a dull-tipped switching stick is pushed through the soft tissues from the anteromedial portal and directed into the anterior elbow joint, aiming toward the capitellum. Once the anterior elbow joint is entered from the anteromedial portal, a small-diameter metal cannula is inserted over the switching stick to allow fluid drainage. Once a drainage portal is established in patients with tricompartmental osteoarthritis, it is the author's preference to conduct the posterior compartment débridement first, followed by débridement of the posterolateral radiocapitellar compartment and then the anterior joint compartment.

Arthroscopic débridement of the posterior compartment is started by placing the camera through the midposterolateral portal and the shaver and radiofrequency ablation device through the posterior central portal (Figure 26.9, *A*). The olecranon fossa fat pad is débrided to allow visualization of the arthritic olecranon fossa and olecranon tip (see Figure 26.9, *B*). Typically, the olecranon fossa contains a transverse ridge of osteophytes, which function as a mechanical block to extension. The ridge of osteophytes is removed with a bur (see Figure 26.9, *C* and *D*), which can also be used to remove osteophytes present on the lateral and central portions of the olecranon tip in extension. Once the central portion of the posterior compartment is débrided, attention is directed to the posteromedial gutter.

The posteromedial gutter is safely viewed by placing the camera into the proximal posterolateral portal (see Figure 26.9, *E*). A Howarth retractor can be inserted from the posterior central portal and used to safely retract the posteromedial joint capsule to protect the ulnar nerve. With the posteromedial capsule retracted, the shaver, bur, or osteotome can be used to remove osteophytes from the medial aspect of the olecranon and the posteromedial trochlea (see Figure 26.9, *F* and *G*). At the completion of osteophyte removal from the medial gutter, the posterior bundle of the medial collateral ligament may rarely require release to obtain further flexion. If necessary (rarely), a duckbill tissue resector can be used to carefully release the posteromedial capsule and the ligament. This should be done with extreme caution because the ulnar nerve is in close proximity. Alternatively, if a miniopen ulnar nerve release is being done, the posteromedial capsule can be released through the open incision with gentle retraction of the ulnar nerve.

A direct central view of the olecranon tip can be obtained by inserting the camera into the posterior central portal for viewing in a distal direction (see Figure 26.9, *H*). With the camera in the posterior central portal, a bur can be brought into the posterior compartment via the proximal posterolateral portal or the midposterolateral portal. The bur is used to complete osteophyte removal from the olecranon fossa and the central and lateral aspects of the olecranon. If needed, the olecranon fossa can be arthroscopically fenestrated, as is done during the *Outerbridge-Kashiwagi procedure*. An advantage of fenestration of the olecranon fossa is that it provides an additional portal option for viewing the anterior compartment (see Figure 26.9, *I* and *J*).

The posterolateral radiocapitellar compartment is viewed by inserting the camera through the midposterolateral portal and sliding it distally along the lateral gutter. The lateral gutter terminates at the posterior aspect of the radiocapitellar joint. A working portal is typically established through the soft spot (distal posterolateral portal), and the motorized instruments are used to resect soft tissues and débride osteophytes (Figure 26.10). At times, an osteophyte may be present along the posterior aspect of the capitellum and should be removed if it is functioning to block full extension by impinging on the radial head.

Anterior compartment arthroscopy requires switching the camera and instruments between the medial and lateral portals to allow ideal visualization and instrument trajectory for débriding and resecting impinging bone. It is the author's preference to insert the camera through the anteromedial drainage portal that has already been created. With the camera view directed toward the anterolateral capsule, a standard midanterolateral portal is created using an outside-in technique. Using a combination of burs, shavers, radiofrequency ablation devices, osteotomes, and angled curets, the radial fossa on the anterolateral distal humerus and the coronoid fossa on the anteromedial distal humerus are re-created; soft tissue, osteophytes, and loose bodies are removed. In most cases, the coronoid tip can be débrided or osteotomized with the camera remaining in the anteromedial portal (Figure 26.11). The osteotome is typically brought in from the lateral portal to osteotomize the coronoid tip. To excise osteophytes on the anteromedial coronoid facet, the camera is switched to a lateral portal and the bur is brought in through the anteromedial portal. Once the bony débridement is done in the anterior compartment, the elbow is placed through a range of motion. If an extension deficit related to the soft tissue exists, because of an anterior capsular tether, the anterior capsule is released or excised. It is the author's preference to use a duckbill resector to begin the capsulotomy and develop a plane between the anterior capsule and the overlying brachialis muscle. The capsulotomy is done with great care because the radial nerve is adjacent to the anterolateral capsule[32] at the level of the medial capitellum. Additionally, on the anteromedial side of the elbow, the median nerve is at risk. The more proximal the capsulotomy, the safer it is. Once the capsulotomy has been conducted, the residual capsule is resected using a soft tissue shaver. Alternatively, the anterior capsular tether can be bluntly released from its attachment on the humerus using a Howarth retractor or elevator-type instrument.

Upon completion of the tricompartmental débridement, the elbow is placed through a gentle range of motion. If substantial blocks to motion exist, the arthroscope is reintroduced to the various compartments to assess for any areas of impingement or soft tissue contracture. When complete, the tourniquet is deflated and a drain is typically placed into the posterior compartment. The portals are closed with a nonabsorbable monofilament suture, and the elbow is placed into nearly full extension.

Postoperative Management

Once the patient has recovered from the anesthetic and has been transferred to a hospital room, continuous passive motion is typically initiated within a few hours. Patients are monitored

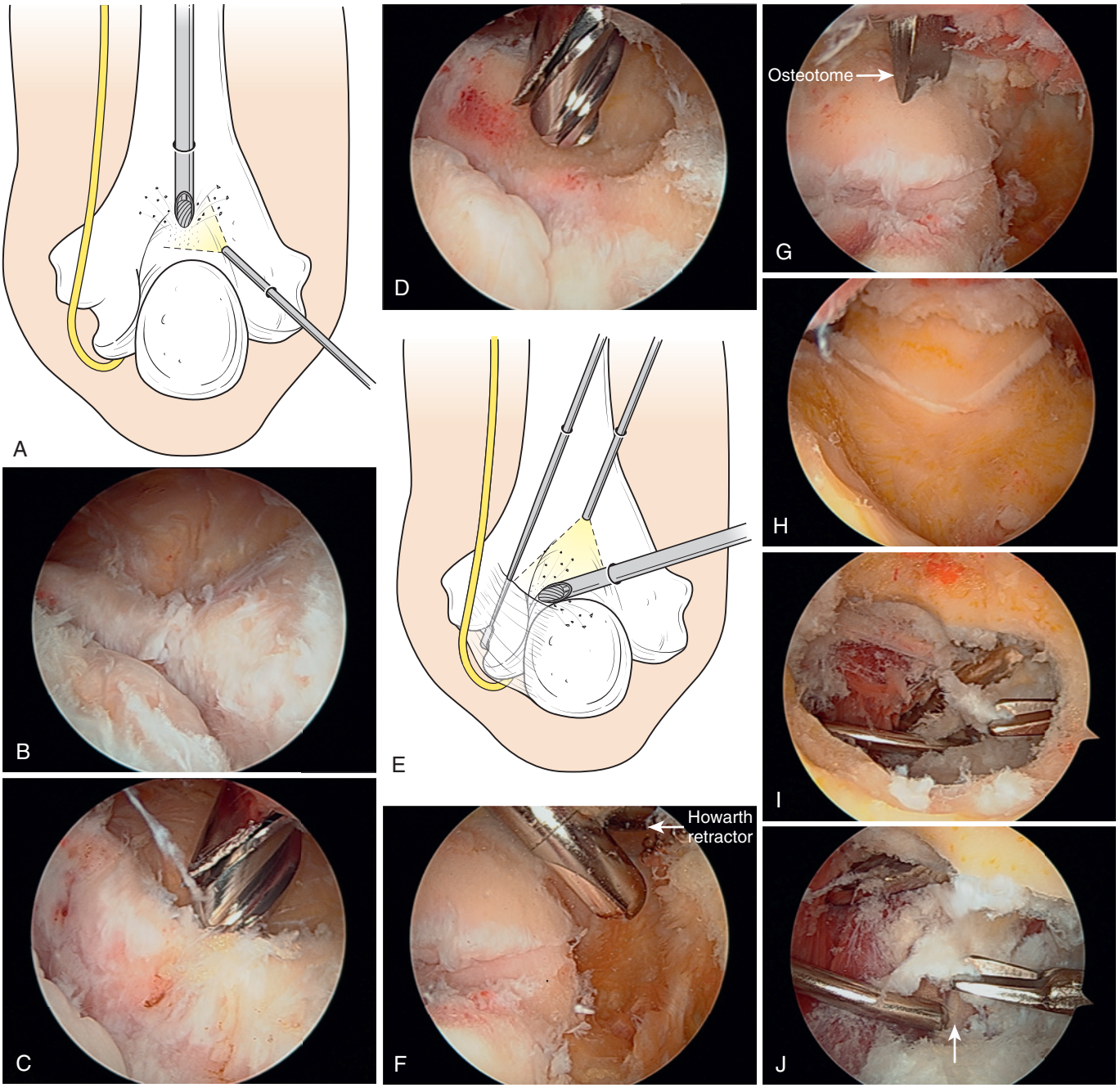

FIGURE 26.9 Arthroscopic débridement for osteoarthritis of the posterior compartment is started with the camera in the midposterolateral portal and the shaver/bur in the posterior central portal **(A)**. The osteophytes in the olecranon fossa and olecranon tip are removed with a bur **(B** to **D)**. The posteromedial gutter is safely viewed by placing the camera into the proximal posterolateral portal **(E)**; a Howarth retractor can be inserted from the posterior central portal to retract the posteromedial joint capsule and protect the ulnar nerve. The posteromedial gutter is cleared of osteophytes using a bur and/or osteotomes **(F** and **G)**. By placing the camera into the posterior central portal **(H)**, a direct view of the olecranon process and the medial and lateral gutters can be obtained. To resect remaining osteophytes in the olecranon fossa and on the olecranon process, the bur is used via the midposterolateral portal. If needed, the olecranon fossa can be arthroscopically fenestrated to prevent impingement and to function as an accessory-view portal. The camera can be placed through the posterior central portal and driven through the fenestrated olecranon fossa to view the anterior joint **(I)**. If the camera is held by the assistant, the surgeon can dissect anterior structures bimanually with instruments inserted via both the anteromedial and anterolateral portals **(J)**. **J** depicts the view from the arthroscope when it is inserted from the posterior central portal and directed through the olecranon fenestration. The switching stick is used to retract the posterior interosseous nerve *(arrow)* as the duckbill punch is used to remove the anterior capsule.

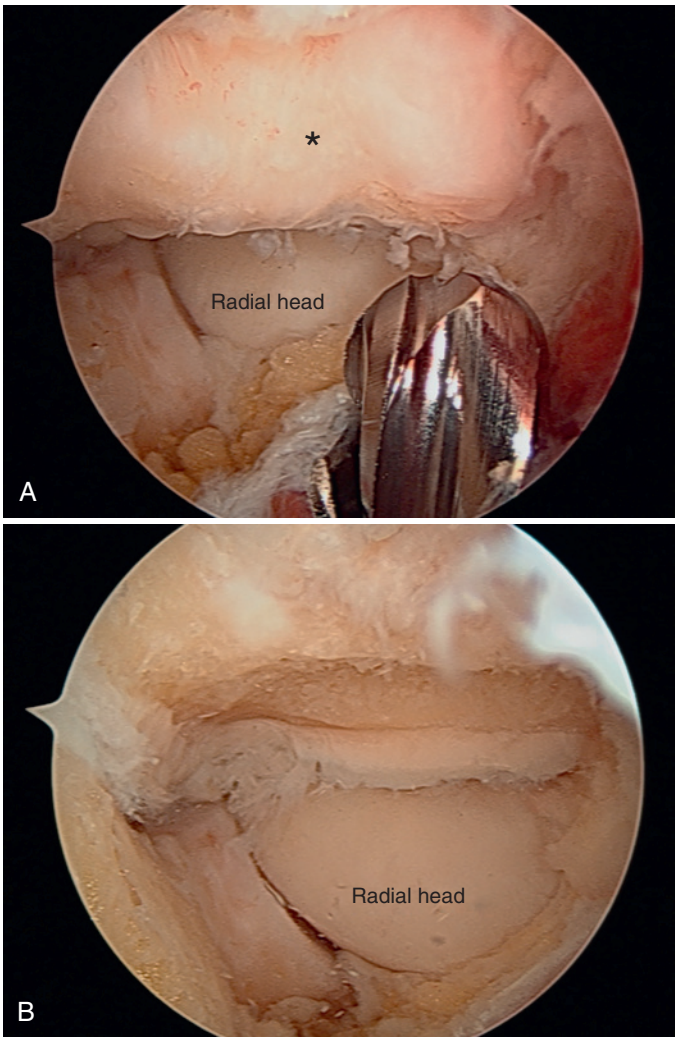

FIGURE 26.10 Posterolateral radiocapitellar joint débridement is conducted with the camera in the midposterolateral portal **(A)** and the radiofrequency/bur inserted through the distal posterolateral (soft spot) portal. Osteophytes present along the posterior aspect of the capitellum *(star)* are resected **(B)**.

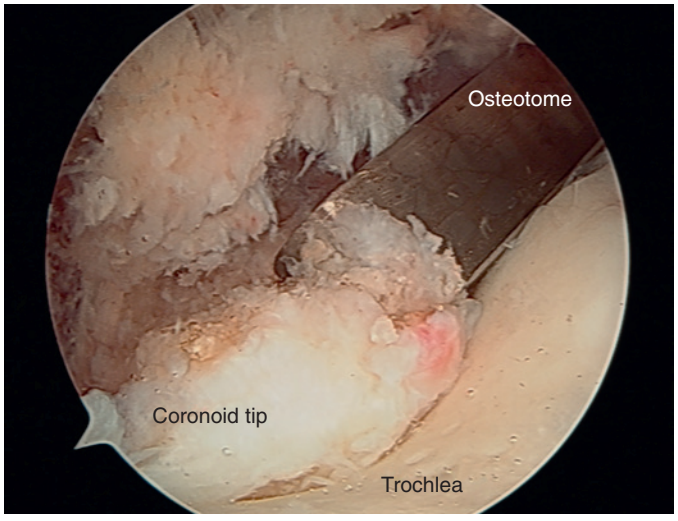

FIGURE 26.11 An osteotome is used to osteotomize the coronoid tip osteophyte. Additionally, a bur can be used to resect any remaining osteophytes present on the coronoid or in the radial or coronoid fossae.

closely to ensure there are no signs of iatrogenic nerve injury or delayed onset of ulnar neuritis. The patient is usually discharged within 24 to 36 hours without continuous passive motion but with flexion and extension splints as well as a range-of-motion home exercise program and a referral for outpatient physiotherapy. Additionally, patients are placed on heterotopic ossification prophylaxis with indomethacin 25 mg three times daily for 3 weeks and a gastroprotective agent. Patients typically return to the clinic for their first postoperative visit within a week. Sutures are removed at 2 weeks.

CRITICAL POINTS *Arthroscopic Elbow Débridement*

- Examine the elbow with three-dimensional CT scanning.
- Place the patient in the lateral or prone position.
- Be prepared for ulnar nerve release or transposition (typically, in situ ulnar nerve decompression).
- On the skin, mark the position of the portals and the location of the ulnar nerve.
- Use gravity or a pump to manage joint distention by fluid.
- Débridement of the posterior joint is performed first in the olecranon fossa and then in the medial gutter, olecranon tip, and lateral gutter; fenestration of the olecranon fossa is performed if needed.
- During posterolateral radiocapitellar joint débridement, remove the posterior capitellar osteophytes and assess for plicae.
- Débridement of the anterior joint focuses on the radial and coronoid fossae; the coronoid tip is excised; capsulotomy is done if needed; radial head excision is rarely done.

Outcomes

The outcomes of arthroscopic débridement for elbow osteoarthritis are generally good.[46] Adams and colleagues[3] reported on 42 elbows with osteoarthritis that underwent arthroscopic débridement, which consisted of removal of loose bodies, resection of osteophytes, and release of contracted capsular tissues. At a minimum of 24 months of follow-up, there were statistically significant improvements in range of motion and Mayo Elbow Performance scores, with 81% of patients reporting good to excellent outcomes. The complications were acceptable and included heterotopic ossification and ulnar nerve dysesthesias.

Cohen and associates[9] conducted a comparative study between open and arthroscopic débridement in a heterogeneous cohort, which consisted mostly of patients with osteoarthritis. In most of these patients, even though they were treated before some of the newer, more advanced arthroscopic techniques were available, the outcomes were good. The authors found that the group who had undergone open procedures had better flexion range of motion and the group who had undergone arthroscopy had better pain control. Savoie and coworkers[39] reported on 24 patients undergoing arthroscopic débridement and found substantial improvements in pain and range of motion. The complication rate was similar to that reported with open débridement.

In summary, there is a robust amount of literature supporting the effectiveness of arthroscopic débridement for elbow osteoarthritis. In their systematic review, Yeoh and colleagues[46] stated that there is poor-quality evidence for, rather than against,

the arthroscopic treatment of degenerative arthritis. In their review of the literature, they found the most common complications were transient neurologic injuries and heterotopic ossification.

Synovectomy for Rheumatoid Arthritis

Arthroscopic techniques are well suited for conducting débridement of a synovitic elbow. The arthroscope and resection instruments are able to view all compartments of the elbow to allow for a thorough synovectomy. Overall, the incidence of surgical intervention for recalcitrant rheumatoid disease is on the decline because of the widespread use of disease-modifying agents and biologics. However, in patients with synovitis recalcitrant to rheumatologic medications, arthroscopic synovectomy of the elbow is effective and safe. It does, however, often require advanced arthroscopic skill.

Indications and Contraindications

The indications for arthroscopic synovectomy are a painful, stiff, inflamed elbow due to synovitis that has failed medical management. Typically, the elbow is described as boggy and swollen. Patients with limited joint destruction (Larsen grade 2 or less) have better outcomes than those with altered bony architecture. The goals of surgery are to decrease pain, improve the range of motion, and potentially provide joint preservation by removal of the aggressive inflammatory panus. Contraindications to arthroscopic synovectomy are severe bone loss with instability, a "dry" rheumatoid elbow without synovitis, and bony ankylosis.

Preoperative Planning

Radiographs of the involved elbow are examined for joint space abnormalities, bone loss, erosions, and instability. An MRI may be helpful to visualize the degree and location of the synovitis. In preparation for surgical intervention, patients with inflammatory arthritis typically undergo a cervical spine examination to rule out instability. Consultation with an anesthesiologist for airway assessment can be considered as well. In patients with gross cervical instability, cervical stabilization surgery may supersede elective elbow surgery.

Technique

The patient is positioned as previously described. In patients with cervical spine disease, supine positioning may be preferable. The technical aspects and viewing portals are similar to those described in the section on débridement for osteoarthritis. In patients with active rheumatoid arthritis, however, synovitis may obscure the typical landmarks inside of the joint. In addition, the capsular tissue in these individuals is typically much thinner and more friable than in patients with osteoarthritis. Therefore, when conducting the synovectomy with a motorized soft tissue resector, great care must be taken to avoid perforating the capsule and injuring adjacent critical neurovascular structures. Two areas in the rheumatoid elbow where specific caution should be observed are the anterolateral capsule above the radial head and neck (radial nerve) and the posteromedial gutter (ulnar nerve). Methods that may be used to minimize damage to the capsule in high-risk areas include limiting the use of suction, directing the aperture of the resecting instruments away from the capsule, and using soft tissue retractors.

Ideally, a complete synovectomy should be conducted, resecting inflamed synovium from the anterior joint, posterior joint, posterolateral radiocapitellar compartment, and medial and lateral gutters. Resection of bone is not usually required in rheumatoid arthritis. If some bone removal is required, the surgeon should remember that rheumatoid bone is typically softer than osteoarthritic bone and, therefore, burs should be used cautiously. Finally, if one of the goals of surgery is to restore the range of motion, manipulation of the elbow after synovectomy and arthroscopic release should be minimized or done very gently, because there is a greater risk of iatrogenic fracture in individuals with this disorder.

Postoperative Management

Patients typically start range-of-motion movements in the immediate postoperative period. Flexion and extension splints may be used under the guidance of a physiotherapist. Continuous passive motion protocols may also be used. However, there is no high-level evidence to support the additional costs.

Outcomes

The outcomes of arthroscopic elbow synovectomy for rheumatoid arthritis are generally good. Tanaka and associates[41] conducted a prospective cohort study comparing arthroscopic synovectomy with open synovectomy in patients with rheumatoid arthritis of Larsen grade 2 or less. Overall, all patients benefited from the synovectomy procedure, with improved pain control and function. There were no statistically significant differences between groups. The authors observed better pain relief in the arthroscopic group and better function in the open group, however.

Nemoto and coworkers[27] reported on 11 elbows that were treated with arthroscopic synovectomy. The authors divided the cohort into group A, patients with Larsen grade 1 to 3 disease, and group B, patients with Larsen grade 4 disease. Overall, the authors reported substantial improvement in pain relief and function. When comparing groups, pain relief occurred in both, but range of motion improved more in group A. The authors concluded that arthroscopic synovectomy of the elbow is a beneficial procedure, even in patients with Larsen grade 4 changes.

Yeoh and colleagues,[46] in their systematic review, concluded that arthroscopic synovectomy should be given a "B" recommendation. The authors stated that consistent findings across multiple studies showed that arthroscopic synovectomy for rheumatoid arthritis is beneficial.

Arthroscopy for Lateral Epicondylitis

Lateral epicondylitis, or *tennis elbow*, is one of the most common conditions involving the elbow. The cause is debatable; most believe it is a degenerative condition of the origin of the extensor tendons, specifically the extensor carpi radialis brevis tendon. Traditionally, treatment is nonsurgical, with rest, activity modification, splints, physiotherapy, and steroid injections. In cases recalcitrant to nonoperative management, surgery may be considered, consisting of release and débridement of the extensor carpi radialis brevis tendon origin. Historically, surgery has consisted of an open procedure; over the past 2 decades, however, arthroscopic techniques have gained popularity.

Cohen and colleagues[10] conducted an anatomic study that outlined the insertional footprint of the extensor carpi radialis

brevis tendon on the lateral epicondyle. The authors reported a discrete origin site of the extensor carpi radialis brevis that was approximately 13 mm in length and 7 mm in width, located at the distalmost extent of the supracondylar ridge between the midline of the radiocapitellar joint and the top of the capitellum. The tendon footprint was described as diamond shaped. The authors concluded that this footprint could be effectively released and débrided using arthroscopic techniques.[10]

Indications and Contraindications

Arthroscopic tennis elbow release is indicated in patients who have failed nonoperative management. The precise duration of nonoperative management that should be instituted before surgical treatment is offered is controversial. Most believe a patient should have recalcitrant symptoms for a minimum of 6 to 12 months before surgery is considered. Lateral elbow pain, unfortunately, is common and may be due to other pathologic conditions, such as a synovial plica, osteochondritis dissecans, radiocapitellar arthritis, or posterolateral rotatory instability.

Preoperative Planning

Preoperative planning for lateral elbow pain includes a detailed history, physical examination, and imaging that corroborates the diagnosis of lateral epicondylitis. Typically, if the history and physical examination are clear without any red flags, the only imaging studies required are plain radiographs. Elbow films are usually normal in patients with lateral epicondylitis, although some may show signs of lateral calcific deposits at the epicondyle (Figure 26.12). In patients with atypical findings, advanced imaging may be helpful.

Technique

The patient is positioned in the lateral decubitus position, as described earlier. An examination under anesthesia is conducted to ensure that the elbow has a full range of motion and is stable. Kalainov and Cohen[18] have reported on the association of posterolateral rotatory instability with lateral epicondylitis treatment.

It is the author's practice to examine the posterior compartment and the medial and lateral gutters first with a scope to identify any loose bodies or other pathologic conditions. Following posterior compartment arthroscopy, the camera is driven into the posterior radiocapitellar joint. The radiocapitellar joint is viewed to rule out a posterolateral radiocapitellar plica, which is excised if identified.

Following posterior compartment diagnostic arthroscopy, the camera is introduced through the anteromedial portal. At times, disruption of the extensor origin can be visualized (see Figure 26.12, *B*). For the midanterolateral portal, it is the author's preference to create this portal higher than normal. Creating this portal slightly more anterior and proximal will allow a better trajectory for the arthroscopic instruments in approaching the extensor carpi radialis brevis origin. Initially, an arthroscopic shaver or ablation device is used to detach the capsule. The ablation device (preferred) or shaver is then used to detach the extensor carpi radialis brevis tendon origin on the distal aspect of the lateral supracondylar ridge, as described by Cohen and associates.[10] During release of the tendon origin, dissection remains above the midequator of the capitellum to avoid disruption of the lateral collateral ligament origin.

Postoperative Management

Following operation, patients are placed into a light dressing and immobilized in a sling for less than 1 week. Early range of motion is encouraged. It is the author's preference to place patients into a removable wrist splint to limit forced wrist extension. As pain subsides, patients are encouraged to use the arm as tolerated.

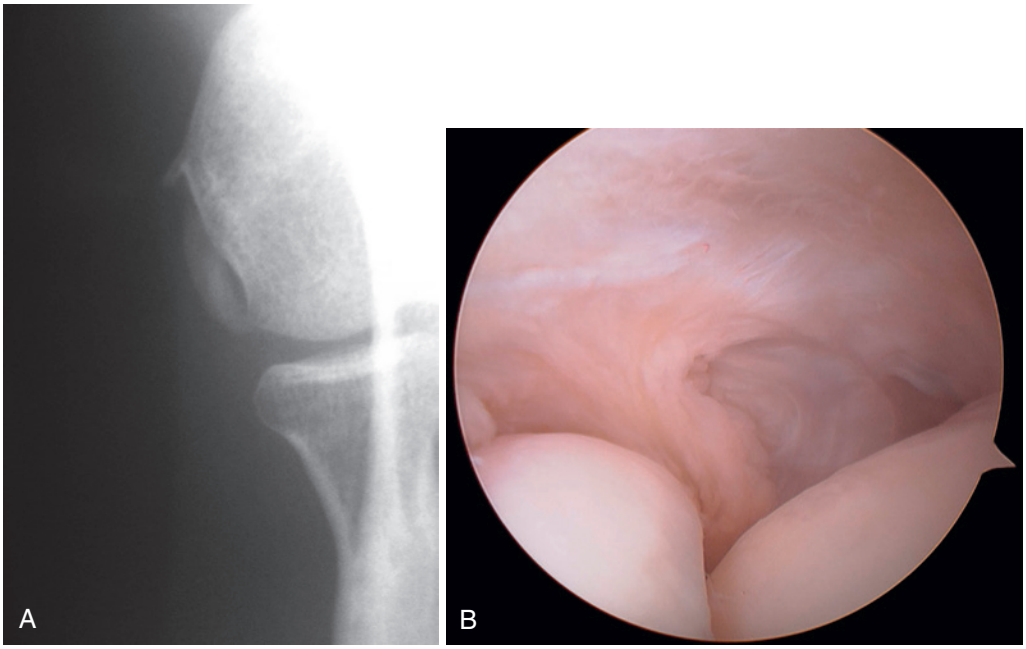

FIGURE 26.12 Calcific tendonitis within the extensor carpi radialis brevis tendon in a patient with lateral epicondylitis symptoms **(A)**. An intraoperative view of a right elbow demonstrating an avulsion of the extensor origin **(B)**.

Outcomes

The literature on arthroscopic management of lateral epicondylitis demonstrates outcomes similar to those of open techniques.[46] Peart and colleagues[33] conducted a comparative cohort study between open and arthroscopic techniques. At follow-up, all patients had relief of pain and improvement of function; however, there was an earlier return to work in the arthroscopic group. Rubenthaler and associates,[36] in a similar study, found no difference between arthroscopic and open techniques with respect to pain, functional scores, surgical time, and range of motion.

Lattermann and coworkers[22] conducted a retrospective review of 36 patients treated for recalcitrant lateral epicondylitis with arthroscopic débridement. At a mean of 3.5 years of follow-up, patient-rated pain and elbow scores were significantly improved from the preoperative scores. Interestingly, approximately 30% of patients still described mild pain with strenuous activities. Overall, the authors concluded that arthroscopic techniques were safe and effective and allowed for identification and treatment of other associated intraarticular pathologic conditions. Preoperative education is essential, however. As with all procedures for epicondylitis, there is a subset of patients who will fail and others who still have symptoms during loading.

Fracture Management by Arthroscopic Fixation

Articular fracture of the distal humerus, radial head, or coronoid can be managed with arthroscopic techniques. The advantage of arthroscopically assisted fracture fixation is that it allows visualization of the intraarticular anatomy without an extensive open surgical approach. Fractures that are amenable to arthroscopic reduction and internal fixation are those of the capitellum-trochlea, coronoid, and radial head and a limited subset of distal humerus injuries.[14,16,25,35,44] The suitability of fractures for arthroscopic techniques should be individualized based on the degree of comminution, associated injuries, timing of the fracture, fracture characteristics, and patient factors. The literature on arthroscopic techniques for elbow fracture fixation is limited to case reports and small case series. For the purposes of this chapter, we will discuss arthroscopic techniques for the management of capitellar fractures, coronoid fractures, and radial head fractures.

Indications and Contraindications

It is beyond the focus of this chapter to discuss the various fracture-specific indications for reduction and internal fixation. Fractures should meet the operative indications for arthroscopic techniques and should have characteristics amenable to screw fixation. Plate fixation, for example, for a bicolumnar distal humerus fracture, is likely best managed with open techniques.

Preoperative Planning

It is the author's preference to obtain three-dimensional CT scans for most patients undergoing arthroscopically assisted fracture reduction and fixation. The scans can provide good characterization of fracture patterns and identify fracture comminution. Typically, fracture comminutions or multiple fracture fragments are much more difficult to manage arthroscopically than with open techniques. It is the author's preference to place patients in the lateral decubitus position on a beanbag using an elbow positioner. Intraoperative fluoroscopy is also essential.

Technique for Arthroscopic Fixation of Capitellar Fractures

Simple displaced capitellar fractures can be effectively managed arthroscopically (Figure 26.13). The presence of comminution or impaction of the lateral column increases the complexity of the procedure, however, and therefore these patterns are better suited to more experienced arthroscopists.

For capitellar shear fractures, it is the author's preference to start the arthroscopy in the posterior compartment. The hematoma is evacuated and the arthroscope is directed into the posterolateral radiocapitellar compartment via the midposterolateral portal. A distal posterolateral portal is used to débride and clear the fracture bed of hematoma and debris. An angled curet may be useful in débriding the fracture bed and also in elevating any depressed bony fragments of the lateral column. Typically, displaced capitellar fractures are hinged open anteriorly by the radial head. Following preparation of the fracture bed, a reduction maneuver is conducted by extending the elbow with the forearm in supination and applying a gentle varus force. If this is unsuccessful, the surgeon can apply external manual pressure on the displaced capitellum. If this fails, a midanterolateral portal can be used to introduce a dental pick or a Howarth retractor to manipulate the capitellum inferiorly and posteriorly for reduction.

Once a reduction is obtained, it is examined from the posterolateral compartment and the anterior compartment. The arthroscope may now be introduced into the anterior compartment through the anteromedial portal. If the reduction is anatomic, the elbow is maintained in 90 degrees of flexion to allow the radial head to engage and compress the fractured capitellum. Fluoroscopy may also be used to assess the reduction. Once deemed appropriate, guidewires from a cannulated screw system are introduced from the posterior aspect of the lateral column into the capitellum. The guidewires can be passed into the radiocapitellar joint to assist with ideal screw position and length. It is the author's preference to place a hemostat clamp on the guidewire tip through the midanterolateral portal to prevent it from backing out during drilling. Two, or preferably three, posterior-to-anterior partially threaded cannulated screws are typically inserted into the capitellum for internal fixation. Direct arthroscopic visualization and fluoroscopy are used to confirm the reduction and appropriate screw lengths.

Postoperatively, if stable fixation has been attained, a splint is applied at 90 degrees of elbow flexion for 2 to 5 days. At the patient's first follow-up visit, the splint is removed and elbow radiographs are obtained. If the radiographs demonstrate appropriate reduction and stability, early active range of motion may be initiated.

Technique for Arthroscopic Fixation of Coronoid Fractures

Coronoid fractures rarely occur in isolation and are typically associated with complex elbow fracture-dislocations. In many cases, coronoid fractures are associated with severe triad-type injuries, Monteggia fractures, and transolecranon fracture-dislocations. In these sorts of injuries, open approaches are required to appropriately address the associated injuries, such as radial head arthroplasty for comminuted radial head

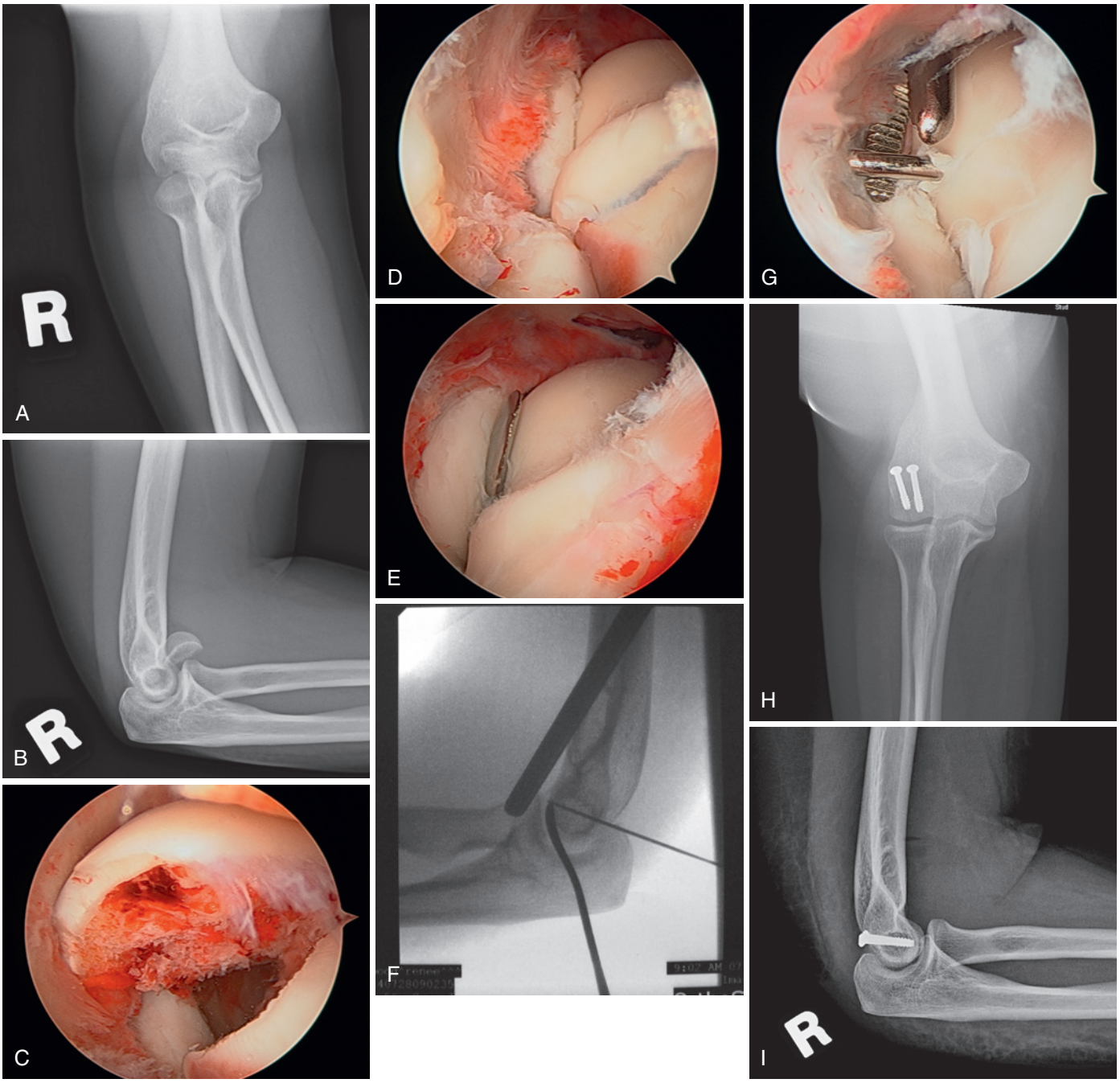

FIGURE 26.13 A 43-year-old woman with radiographs demonstrating an acute right displaced capitellar fracture **(A** and **B)**. The patient was managed with arthroscopic reduction and internal fixation with cannulated screws. An arthroscopic view from the anteromedial portal demonstrates the displaced fracture **(C)**. After provisional reduction **(D)**, an anatomic reduction is obtained by inserting a Howarth retractor through the soft spot portal to compress the capitellum **(E)**. Guide pins from a cannulated screw system are inserted in a retrograde manner with fluoroscopic assistance **(F** and **G)**. Radiographs at 6 months after cannulated screw fixation demonstrate anatomic healing **(H** and **I)**.

fractures and plate fixation for proximal ulnar fractures. Arthroscopically assisted techniques for the coronoid in these circumstances provide little added benefit and may actually increase the complexity of treatment. At present, our indications for arthroscopic fixation of coronoid fractures are isolated displaced basilar coronoid fractures, displaced Regan-Morrey type 2 fractures with Mason type 1 or 2 radial head fractures where the radial head fracture is amenable to nonoperative management or arthroscopic fixation, and larger anteromedial coronoid fractures that are not comminuted.

For coronoid fractures, the patient is placed in the lateral decubitus position and fluoroscopy is used. It is the author's preference to use a scope in the posterior and posterolateral compartments of the elbow initially to evacuate hematomas and assess for any associated injuries or osteochondral loose fragments. Following posterior compartment arthroscopy, the

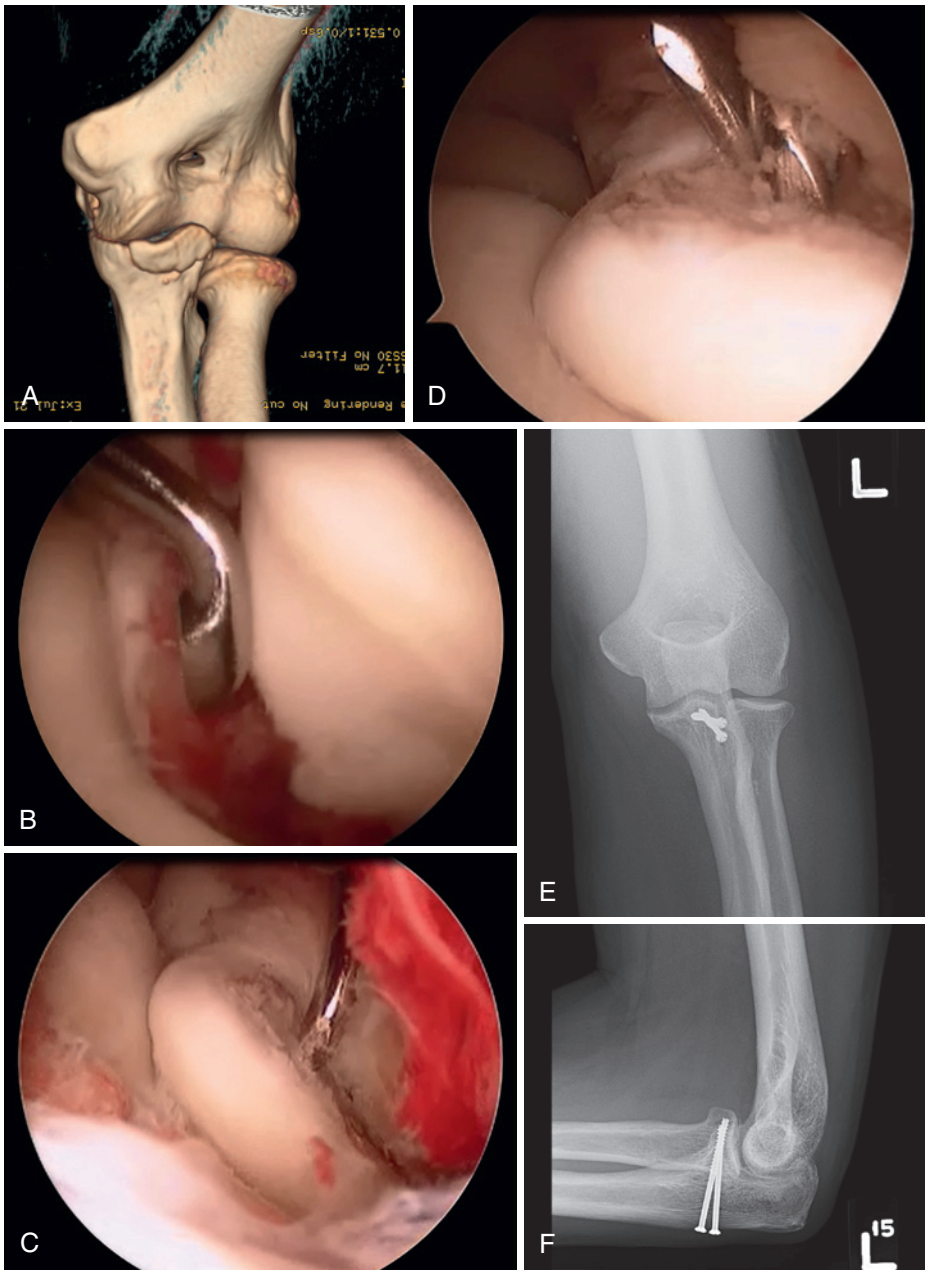

FIGURE 26.14 A 19-year-old male wrestler sustained a left displaced coronoid fracture **(A)**. The patient underwent arthroscopic reduction and internal fixation with two cannulated screws. An angled curet **(B)** and an arthroscopic shaver were used to débride the fracture site of hematoma. Once débridement had been done, an AO reduction forceps was used to provisionally reduce the fracture **(C)** until a guide pin was inserted in a retrograde manner **(D)**. Radiographs after 6 months demonstrate healing of the fracture **(E** and **F)**.

camera is introduced into the anterior compartment (Figure 26.14). Reduction of the coronoid fragment is obtained by use of a dental pick. To provisionally maintain the reduction, one tine of a pointed AO large reduction forceps can be brought in through a portal and used to clamp down on the fracture, with the other tine percutaneously placed on the subcutaneous border of the ulna. It is the author's preference to insert two or three guidewires with fluoroscopic guidance from the subcutaneous border of the ulna directed into the coronoid tip. Alternatively, an anterior cruciate ligament (ACL)-type targeting device can be used to direct the guidewires into the coronoid tip. Ideally, two partially threaded 2.7- to 3.5-mm cannulated screws are inserted from posterior to anterior. In smaller coronoid factures, however, it may be possible to insert only a single screw. After arthroscopic reduction and internal fixation of the coronoid fracture, other associated injuries are addressed, such as radial head fixation or lateral collateral ligament repair. Although lateral collateral ligaments can be repaired arthroscopically, it is the author's preference to repair them via a miniopen incision placed directly over the isometric point of the lateral epicondyle. Prior to completion of the surgical procedure, fluoroscopy is used to ensure an anatomic reduction and appropriate screw lengths and to assess elbow stability. Postoperative immobilization and rehabilitation are conducted based on an assessment of the stability of the fixation and also based on the associated injuries.

Technique for Arthroscopic Fixation of Radial Head Fractures

Arthroscopic techniques can be used for fixation of displaced radial head fractures. The advantages of arthroscopic techniques are better visualization of the entire joint, with less soft tissue disruption than in an open approach. The indications for arthroscopically assisted fixation are few, because in most patients with displaced radial head fractures, associated injuries are present that may preclude arthroscopy. Additionally, displaced and separated radial head fragments are typically difficult to reduce arthroscopically, and therefore it is my preference to use an open approach. For simple isolated displaced radial head fractures, arthroscopic techniques can be effective. At the present time, my preference is to use open procedures for most radial head fractures that require surgery.

It is my preference to start the arthroscopy in the posterior compartment. The hematoma is evacuated and the arthroscope is directed into the lateral gutter and posterior radiocapitellar joint. If the radial head fracture was associated with a dislocation, an impression fracture caused by the once dislocated radial head may be visible on the posterior aspect of the capitellum. The radial head is viewed from the midposterolateral portal. The radial head is placed through a full arc of prosupination to determine the best viewing and working portals for reduction and internal fixation. If the radial head fracture fragment is accessible from the posterior approach, a dental pick or elevator is placed through the distal posterolateral portal and used to elevate the depressed fragment. It is our experience that elevation of impacted radial head fracture fragments is difficult and typically requires more force than expected. Once a reduction is obtained, percutaneous guide pins are inserted into the fracture fragment. If fracture visualization or mobilization is poor through the posterior portals, the arthroscope can be introduced through the midanteromedial portal, with the midanterolateral portal functioning as a working portal. Cannulated screws of 2.7, 3, or 3.5 mm are typically used for internal fixation. Fluoroscopy is used to ensure an anatomic reduction and appropriate screw lengths.

Prior to closure, the elbow is placed through a range of motion to ensure there are no blocks to motion and stability is maintained. Postoperatively, range-of-motion movements can be initiated immediately because internal fixation typically results in stable radial head fixation.

Outcomes

The peer-reviewed outcome literature on the arthroscopic management of elbow fractures is limited. Kuriyama and colleagues[21] reported on two patients undergoing arthroscopic fixation of capitellar-trochlear fractures with good outcomes. Adams and associates[1a] reported on seven patients with coronoid fractures treated with arthroscopic techniques. The authors state that all patients had good function and a pain-free result after arthroscopic treatment. Hausman and coworkers[15] also reported on patients with coronoid fractures treated with arthroscopic techniques. In their series, four patients underwent arthroscopic reduction and fixation and were evaluated at a minimum of 1 year following surgery. All patients achieved a functional range of motion, and the authors concluded that arthroscopic techniques allow for excellent fracture visualization that enables anatomic repair without extensive open soft tissue dissection. For the radial head, Michels and colleagues[25] reported on 14 patients who underwent arthroscopic management for displaced partial articular head fractures. The authors reported that all patients had good to excellent outcomes. They caution, however, that the technique is technically demanding.

Arthroscopic Release of Elbow Stiffness Caused by Trauma or Developing Following Surgery

Arthroscopic management of elbow stiffness caused by subacute trauma or developing following surgery should be reserved for the highly experienced elbow arthroscopist. Stiffness may be due to intrinsic or extrinsic causes. Intrinsic causes include articular damage or malunion, intraarticular hardware, and loose bodies; extrinsic causes include a contracted joint capsule and ligaments, heterotopic ossification, prominent hardware, and skin contracture.

Although in theory the technical steps for arthroscopic release may be similar to those for osteoarthritis, there are actually several important differences. A posttraumatic or postsurgical contracture is typically associated with a damaged, abnormally thickened joint capsule and the potential for altered anatomy. The joint space is usually contracted, and the capsule is scarred down to the bones, making it difficult to even enter the elbow joint. The anatomy can be visually confusing once the joint is entered because adhesions and scarring may be present. Because the anterior soft tissues are usually contracted, the locations of the median and radial nerves may be altered. In some cases, endoscopic nerve identification may be required to safely conduct an arthroscopic contracture release. For this reason, the major disadvantage of arthroscopic release of postsurgical or posttraumatic stiffness is damage to the adjacent neurologic structures (and/or the articular cartilage). The major advantage of the procedure, if it is conducted safely by an experienced arthroscopist, is effective contracture release without the possible complications associated with an open approach, such as hematoma, seroma, and skin flap issues.

Indications and Contraindications

The indications and contraindications for arthroscopic release of nonarthritic stiffness of the elbow are individualized to each patient, the associated pathologic findings, and the experience of the arthroscopist. Relative contraindications are an inability to identify neurovascular structures safely, the presence of extensive heterotopic ossification or myositis ossificans, or the presence of a large amount of hardware, removal of which would require an extensive open approach.

Preoperative Planning

Preoperative planning is individualized to the patient's particular pathologic condition. Along with radiographs, CT scans are typically helpful to identify heterotopic ossification, locate hardware or screws, and define the articular pathologic findings. Ultrasound or MRI may also be helpful if the locations of nerves are unknown, for example, to identify an ulnar nerve transposition.

Technique

The major technical steps of contracture release of a stiff elbow are similar to those for release in osteoarthritis. However, the execution of the steps is technically much more challenging and should be reserved for the highly experienced arthroscopist.

The surgery progresses through all of the elbow compartments in a systematic fashion, with pathologic structures being excised or released as required. It is beyond the scope of this chapter to outline the techniques for endoscopic nerve neurolysis or extracapsular arthroscopic releases (outside-in arthroscopic release).[19] It is the author's recommendation that posttraumatic or postsurgical stiffness of the elbow be cautiously approached with arthroscopy.

Outcomes

Cefo and Eygendaal[8] reported on 27 patients undergoing arthroscopic release for posttraumatic stiffness. At follow-up, the patients' range of motion was significantly better, with the mean total arc of motion improving from 99 degrees preoperatively to 125 degrees postoperatively. The elbow function assessment scores improved significantly from 69 preoperatively to 91 postoperatively. The authors concluded that arthroscopic release is safe and reliable. However, it is a technically challenging procedure.

Timmerman and Andrews[42] reported on 19 cases of posttraumatic stiffness from elbow fracture or fracture-dislocation. In their series, good to excellent results were obtained in 79% of patients. The extension range of motion improved from 29 to 11 degrees, and flexion improved from 123 to 134 degrees. The authors stated that although good outcomes can be expected in most patients, recovery of full range of motion is unlikely.

Although the literature cited previously demonstrates good outcomes with arthroscopic techniques for posttraumatic stiffness, results should be interpreted with caution because the cohorts are likely biased. The papers are authored by expert arthroscopists who also conduct open procedures for cases deemed too risky for arthroscopy. The patients in the two series cited did not have high-grade contractures or ankylosis as evidenced by the preoperative range-of-motion values. Each patient with posttraumatic or postsurgical stiffness should be evaluated individually for suitability for an arthroscopic release. Furthermore, if arthroscopic release is attempted, one must be ready to convert to an open approach if necessary.

Advanced Arthroscopic Procedures

In addition to the previously mentioned procedures, several other pathologic conditions may be managed arthroscopically. Unfortunately, it is beyond the scope of this chapter to specifically address all of the conditions that can be managed with elbow arthroscopy. O'Brien and colleagues[28a] have described an arthroscopic technique for repair of the lateral collateral ligament after acute and subacute elbow dislocations in high-demand patients. Fourteen patients were reviewed at a mean of 30 months following surgery. All patients were described as satisfied with their outcome, and the authors concluded that the procedure is safe and effective at restoring elbow stability and allowing patients to return to activities.

Arthroscopic techniques can also be used to repair partial and complete triceps tendon injuries. Athwal and associates[5] described arthroscopic repair of isolated avulsions of the medial head of the triceps insertion in two patients with good outcomes. Heikenfeld and coworkers[17] described the endoscopic repair of partial triceps tendon insertional tears in 14 patients. The authors described the endoscopic repair of superficial triceps tears as leading to excellent outcomes at 1 year of follow-up.

Zonno and colleagues[47] conducted a cadaveric study to examine the technique of arthroscopic medial epicondylitis surgery. The authors concluded that arthroscopic medial epicondylar débridement can be performed with minimal risk of injury to the ulnar nerve or medial collateral ligament. In their cadaveric study, the mean distance between the débridement site and the ulnar nerve or medial collateral ligament was 21 mm and 8 mm, respectively.

COMPLICATIONS

As with any surgical procedure, complications do occur with elbow arthroscopy. The greatest concern is injury to the adjacent nerves. The literature has demonstrated that all major nerves around the elbow are at risk for injury.[1,2,20,24,26,37,38,45] The overall incidence of nerve injury after elbow arthroscopy is likely underestimated; however, the literature reports a rate of between 1 and 14%. Nerve injuries are most frequently reported as neurapraxias; with elbow arthroscopy, however, the risk of nerve transection is higher than normal. Nerve transection can occur with the insertion of sharp trocars through portals and inadvertently with motorized soft tissue resectors. Factors that may be associated with an increased risk of nerve injury include rheumatoid arthritis, severe contractures, ankylosis, postsurgical contractures, and posttraumatic stiffness. Any condition that results in altered anatomy may place the nerves at risk. With rheumatoid arthritis, the risk is believed to be higher due to the thin capsular tissue that is easily resected, with resultant injury to the adjacent nerves.

Superficial portal site infection or localized stitch abscesses are common following arthroscopy and can be managed with local wound care and oral antibiotics. Deep infection following arthroscopy is rare and typically should be managed with surgical débridement and intravenous antibiotics. Other complications that are reported to occur after elbow arthroscopy are compartment syndrome, heterotopic ossification, thromboembolism, arthrofibrosis, and fracture[1,9,13,38-40,44-47]

REFERENCES

1. Adams JE, King GJ, Steinmann SP, et al: Elbow arthroscopy: indications, techniques, outcomes, and complications. *J Am Acad Orthop Surg* 22(12):810–818, 2014.

1a. Adams JE, Merten SM, Steinmann SP: Arthroscopic-assisted treatment of coronoid fractures. *Arthroscopy* 23(10):1060–1065, 2007.

2. Adams JE, Steinmann SP: Nerve injuries about the elbow. *J Hand Surg [Am]* 31(2):303–313, 2006.

3. Adams JE, Wolff LH, 3rd, Merten SM, et al: Osteoarthritis of the elbow: results of arthroscopic osteophyte resection and capsulectomy. *J Shoulder Elbow Surg* 17(1):126–131, 2008.

4. Andrews JR, Carson WG: Arthroscopy of the elbow. *Arthroscopy* 1(2):97–107, 1985.

5. Athwal GS, McGill RJ, Rispoli DM: Isolated avulsion of the medial head of the triceps tendon: an anatomic study and arthroscopic repair in 2 cases. *Arthroscopy* 25(9):983–988, 2009.

6. Blonna D, Huffmann GR, O'Driscoll SW: Delayed-onset ulnar neuritis after release of elbow contractures: clinical presentation, pathological findings, and treatment. *Am J Sports Med* 42(9):2113–2121, 2014.

7. Blonna D, O'Driscoll SW: Delayed-onset ulnar neuritis after release of elbow contracture: preventive strategies derived from a study of 563 cases. *Arthroscopy* 30(8):947–956, 2014.

8. Cefo I, Eygendaal D: Arthroscopic arthrolysis for posttraumatic elbow stiffness. *J Shoulder Elbow Surg* 20(3):434–439, 2011.

9. Cohen AP, Redden JF, Stanley D: Treatment of osteoarthritis of the elbow: a comparison of open and arthroscopic debridement. *Arthroscopy* 16(7):701–706, 2000.
10. Cohen MS, Romeo AA, Hennigan SP, et al: Lateral epicondylitis: anatomic relationships of the extensor tendon origins and implications for arthroscopic treatment. *J Shoulder Elbow Surg* 17(6):954–960, 2008.
11. Field LD, Altchek DW, Warren RF, et al: Arthroscopic anatomy of the lateral elbow: a comparison of three portals. *Arthroscopy* 10(6):602–607, 1994.
12. Gammon B, Bicknell RT, Athwal GS: Physical examination of the shoulder and elbow. In Boyer MI, editor: *AAOS comprehensive orthopaedic review 2*, ed 2, Rosemont, IL, 2014, American Academy of Orthpaedic Surgeons, pp 899–912.
13. Gofton WT, King GJ: Heterotopic ossification following elbow arthroscopy. *Arthroscopy* 17(1):E2, 2001.
14. Hardy P, Menguy F, Guillot S: Arthroscopic treatment of capitellum fracture of the humerus. *Arthroscopy* 18(4):422–426, 2002.
15. Hausman MR, Klug RA, Qureshi S, et al: Arthroscopically assisted coronoid fracture fixation: a preliminary report. *Clin Orthop Relat Res* 466(12):3147–3152, 2008.
16. Hausman MR, Qureshi S, Goldstein R, et al: Arthroscopically-assisted treatment of pediatric lateral humeral condyle fractures. *J Pediatr Orthop* 27(7):739–742, 2007.
17. Heikenfeld R, Listringhaus R, Godolias G: Endoscopic repair of tears of the superficial layer of the distal triceps tendon. *Arthroscopy* 30(7):785–789, 2014.
18. Kalainov DM, Cohen MS: Posterolateral rotatory instability of the elbow in association with lateral epicondylitis. A report of three cases. *J Bone Joint Surg Am* 87(5): 1120–1125, 2005.
19. Kamineni S, Savoie FH, 3rd, ElAttrache N: Endoscopic extracapsular capsulectomy of the elbow: a neurovascularly safe technique for high-grade contractures. *Arthroscopy* 23(7):789–792, 2007.
20. Kelly EW, Morrey BF, O'Driscoll SW: Complications of elbow arthroscopy. *J Bone Joint Surg Am* 83(1):25–34, 2001.
21. Kuriyama K, Kawanishi Y, Yamamoto K: Arthroscopic-assisted reduction and percutaneous fixation for coronal shear fractures of the distal humerus: report of two cases. *J Hand Surg [Am]* 35(9):1506–1509, 2010.
22. Lattermann C, Romeo AA, Anbari A, et al: Arthroscopic debridement of the extensor carpi radialis brevis for recalcitrant lateral epicondylitis. *J Shoulder Elbow Surg* 19(5):651–656, 2010.
23. Lynch GJ, Meyers JF, Whipple TL, et al: Neurovascular anatomy and elbow arthroscopy: inherent risks. *Arthroscopy* 2(3):190–197, 1986.
24. Marti D, Spross C, Jost B: The first 100 elbow arthroscopies of one surgeon: analysis of complications. *J Shoulder Elbow Surg* 22(4):567–573, 2013.
25. Michels F, Pouliart N, Handelberg F: Arthroscopic management of Mason type 2 radial head fractures. *Knee Surg Sports Traumatol Arthrosc* 15(10):1244–1250, 2007.
26. Nelson GN, Wu T, Galatz LM, et al: Elbow arthroscopy: early complications and associated risk factors. *J Shoulder Elbow Surg* 23(2):273–278, 2014.
27. Nemoto K, Arino H, Yoshihara Y, et al: Arthroscopic synovectomy for the rheumatoid elbow: a short-term outcome. *J Shoulder Elbow Surg* 13(6):652–655, 2004.
28. Nishiwaki M, Willing R, Johnson JA, et al: Identifying the location and volume of bony impingement in elbow osteoarthritis by 3-dimensional computational modeling. *J Hand Surg [Am]* 38(7):1370–1376, 2013.
28a. O'Brien MJ, Lee Murphy R, Savoie FH, 3rd: A preliminary report of acute and subacute arthroscopic repair of the radial ulnohumeral ligament after elbow dislocation in the high-demand patient. *Arthroscopy* 30(6):679–687, 2014.
29. O'Driscoll SW: Elbow arthroscopy for loose bodies. *Orthopedics* 15(7):855–859, 1992.
30. O'Driscoll SW, Morrey BF: Arthroscopy of the elbow. Diagnostic and therapeutic benefits and hazards. *J Bone Joint Surg Am* 74(1):84–94, 1992.
31. Ogilvie-Harris DJ, Schemitsch E: Arthroscopy of the elbow for removal of loose bodies. *Arthroscopy* 9(1):5–8, 1993.
32. Omid R, Hamid N, Keener JD, et al: Relation of the radial nerve to the anterior capsule of the elbow: anatomy with correlation to arthroscopy. *Arthroscopy* 28(12):1800–1804, 2012.
33. Peart RE, Strickler SS, Schweitzer KM, Jr: Lateral epicondylitis: a comparative study of open and arthroscopic lateral release. *Am J Orthop (Belle Mead NJ)* 33(11):565–567, 2004.
34. Poehling GG, Whipple TL, Sisco L, et al: Elbow arthroscopy: a new technique. *Arthroscopy* 5(3):222–224, 1989.
35. Rolla PR, Surace MF, Bini A, et al: Arthroscopic treatment of fractures of the radial head. *Arthroscopy* 22(2):233 e1–233 e6, 2006.
36. Rubenthaler F, Wiese M, Senge A, et al: Long-term follow-up of open and endoscopic Hohmann procedures for lateral epicondylitis. *Arthroscopy* 21(6):684–690, 2005.
37. Ruch DS, Poehling GG: Anterior interosseus nerve injury following elbow arthroscopy. *Arthroscopy* 13(6):756–758, 1997.
38. Savoie FH, 3rd, Field LD: Arthrofibrosis and complications in arthroscopy of the elbow. *Clin Sports Med* 20(1):123–129, ix, 2001.
39. Savoie FH, 3rd, Nunley PD, Field LD: Arthroscopic management of the arthritic elbow: indications, technique, and results. *J Shoulder Elbow Surg* 8(3):214–219, 1999.
40. Stothers K, Day B, Regan WR: Arthroscopy of the elbow: anatomy, portal sites, and a description of the proximal lateral portal. *Arthroscopy* 11(4):449–457, 1995.
41. Tanaka N, Sakahashi H, Hirose K, et al: Arthroscopic and open synovectomy of the elbow in rheumatoid arthritis. *J Bone Joint Surg Am* 88(3):521–525, 2006.
42. Timmerman LA, Andrews JR: Arthroscopic treatment of posttraumatic elbow pain and stiffness. *Am J Sports Med* 22(2):230–235, 1994.
43. van den Ende KI, McIntosh AL, Adams JE, et al: Osteochondritis dissecans of the capitellum: a review of the literature and a distal ulnar portal. *Arthroscopy* 27(1): 122–128, 2011.
44. Van Tongel A, Macdonald P, Van Riet R, et al: Elbow arthroscopy in acute injuries. *Knee Surg Sports Traumatol Arthrosc* 20(12):2542–2548, 2012.
45. Verhaar J, van Mameren H, Brandsma A: Risks of neurovascular injury in elbow arthroscopy: starting anteromedially or anterolaterally? *Arthroscopy* 7(3):287–290, 1991.
46. Yeoh KM, King GJ, Faber KJ, et al: Evidence-based indications for elbow arthroscopy. *Arthroscopy* 28(2):272–282, 2012.
47. Zonno A, Manuel J, Merrell G, et al: Arthroscopic technique for medial epicondylitis: technique and safety analysis. *Arthroscopy* 26(5):610–616, 2010.

Total Elbow Arthroplasty

Mark S. Cohen and Neal C. Chen

Acknowledgments: We would like to acknowledge the contributions of prior author Leonid Katolik, MD, for his contributions to earlier editions and his insights in developing the current text.

Total elbow arthroplasty (TEA) is increasingly used for the treatment of debilitating elbow arthropathies. Although clinical outcomes following TEA were initially disappointing, modifications in surgical technique and implant design have improved reliability; however, durability with normal loading (>10 pounds) is uncertain. Prosthetic replacement of the elbow relieves pain and typically provides a functional arc of motion, thereby permitting patients to better perform low-load activities of daily living. The longevity of implants in younger patients (those younger than 70 years) is often short, and revision options are limited. Long-term follow-up studies report high rates of revision relative to arthroplasties of the hip, knee, and shoulder.[15,30] Because of the high potential for mechanical failure and loosening, this procedure should be limited to low-demand elderly patients or those terribly debilitated by pain and instability. It is hoped that improvements in materials, implant design, and surgical technique will one day extend the suitability of TEA to a wider array of pathologic conditions and a broader demographic spectrum.

RHEUMATOID ARTHRITIS

Twenty percent of patients with rheumatoid arthritis have arthritic changes in the elbow.[45] As with other major joints affected by rheumatoid arthritis, the elbow undergoes a predictable pattern of intraarticular degeneration of the ulnohumeral and radiocapitellar surfaces, ultimately leading to functional loss in advanced cases. Rheumatoid arthritis has been divided into four stages, based on the physical examination and plain radiographs.[21] Stage I reveals osteoporosis and active synovitis with normal radiographs. Stage II demonstrates chronic synovitis with mild arthritic changes and some loss of joint space. In these early stages, arthroscopic synovectomy can be effective and seems to be more long-lasting in combination with the newer systemic agents. However, regardless of treatment, some patients proceed to complete loss of cartilage with associated pain and loss of strength (stage III). The most severe form (stage IV) demonstrates extensive loss of bone and gross instability (Figure 27.1). It is this last group of patients that derives the greatest benefit from TEA.

Preoperative Evaluation

Multiple Joint Involvement

Before considering TEA in a rheumatoid patient, the patient's overall status must be considered. If lower extremity joint replacements are planned, use of the affected limb may be needed for assisted ambulation. If shoulder replacement is being considered, this should generally be performed before TEA; surgical access to the elbow will be simpler, and the elbow replacement will not be stressed during shoulder replacement surgery. The cervical spine should be evaluated preoperatively, with special attention placed on atlantoaxial instability.

Physical Examination

Nerve Status. The status of the radial, ulnar, and median nerves should be assessed and documented before surgery. Rheumatoid arthritis of the elbow can lead to secondary compressive neuropathies of the upper extremity. Antecubital cysts and proliferative synovitis may extend through the joint, compressing the posterior interosseous nerve in the region of the proximal radioulnar joint. Similarly, the ulnar nerve lies along the medial ulnohumeral joint and may be compromised by bony deformity, instability, and direct soft tissue compression from synovitis. A careful neurologic evaluation is thus required in all patients before elbow replacement surgery.

If unconstrained arthroplasty is being considered, it is important to evaluate the integrity of the collateral ligaments. Ligamentous laxity or insufficiency may lead one to consider using a convertible or semiconstrained arthroplasty instead.

Medications. Patients with rheumatoid arthritis are now being treated with a variety of medications that require management in the perioperative period. It is wise to consult with the patient's rheumatologist before surgery. Methotrexate can generally be continued during the perioperative period, in the hope of avoiding a flare of inflammation. In contrast, the biologic drugs (anti–tumor necrosis factor agents) are withheld for at least one cycle before surgery and resumed after suture or staple removal. Patients who have been receiving long-term corticosteroid treatment may require stress dosing in the perioperative period. Further study is needed to determine the relative risk of infection and poor wound healing versus stimulating an inflammatory flare by withholding these valuable medications.

Preoperative Planning

Preoperative radiographs should include multiple views of the elbow as well as long-length humerus and forearm films. Views of the contralateral elbow may be helpful for templating if there

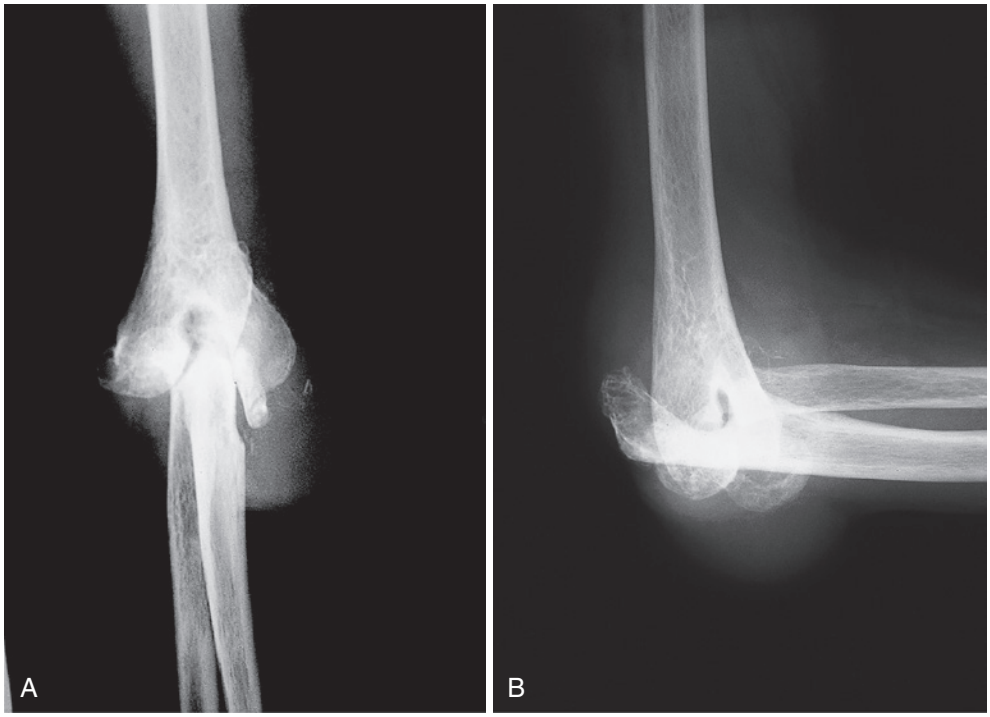

FIGURE 27.1 Anteroposterior **(A)** and lateral **(B)** radiographs of a severe stage IV rheumatoid elbow. The loss of bone support and ligamentous integrity leads to gross joint instability.

are large areas of bony destruction in the affected joint. Any arthroplasties of adjacent joints are evaluated for stem length, mode of fixation, and any cement defects. Any areas of cortical thinning should also be noted. For all elbow arthroplasties, preoperative templating should be performed to anticipate stem length and size.

POSTTRAUMATIC ARTHRITIS

Posttraumatic arthritis is an increasingly common indication for replacement arthroplasty.[39] The treatment of posttraumatic arthritis must take into account the age and activity level of the patient, degree of impairment, and joint pathologic findings involved. Given the lack of durability of TEA and the propensity for implant failure, techniques such as internal fixation for nonunion and malunion, joint release and débridement, and interposition arthroplasty should be considered in younger, more active adults. Evaluation of the deformity and the quality of the articular surface may require additional radiographic studies in these patients, such as computed tomography. Replacement arthroplasty should be considered when the ulnohumeral joint is no longer salvageable (Figure 27.2). This option is typically limited to individuals older than approximately 60 to 65 years with lower physical demands. However, there may be circumstances in which the impairment and pain warrant the consideration of TEA. Any history of infection after fracture treatment requires careful consideration and may require a staged approach.

Preoperative Assessment

Soft Tissue Envelope

Some patients have had multiple surgeries or flap coverage and incisions should be evaluated carefully. In general, attempts are made to incorporate prior incisions into the approach. If a flap is present, Doppler identification of the flap pedicle may be considered and incisions can be designed to preserve it.

Preoperative Planning

Prior hardware should be noted and preparations for hardware removal should be made, taking into account the hardware manufacturer and the possibility that screws may be difficult to remove, especially if they are made of titanium. Preoperative templating should be used in order to bypass the most proximal humeral or distal ulnar screw hole by two diaphyseal widths if possible.

FRACTURES OF THE DISTAL HUMERUS

TEA may be indicated for elderly patients with displaced and comminuted fractures of the distal humerus.[5,11,34] In the past, the so-called bag-of-bones treatment was recommended because the fracture fragments were too small and the bone too osteoporotic to permit rigid internal fixation. However, this treatment of hopeful neglect frequently resulted in significant pain, stiffness, and decreased function of the hand. TEA after a fracture beyond repair may permit a more rapid return to function. TEA should also be considered in patients with fracture when there is preexisting joint destruction (Figure 27.3). Again, elbow arthroplasty should be limited to older, lower-demand individuals.

Preoperative Assessment

Radiographs

Radiographs of the shoulder and wrist should be performed to screen for other fractures. Radiographs of the elbow should be scrutinized for any extension into the humeral diaphysis that

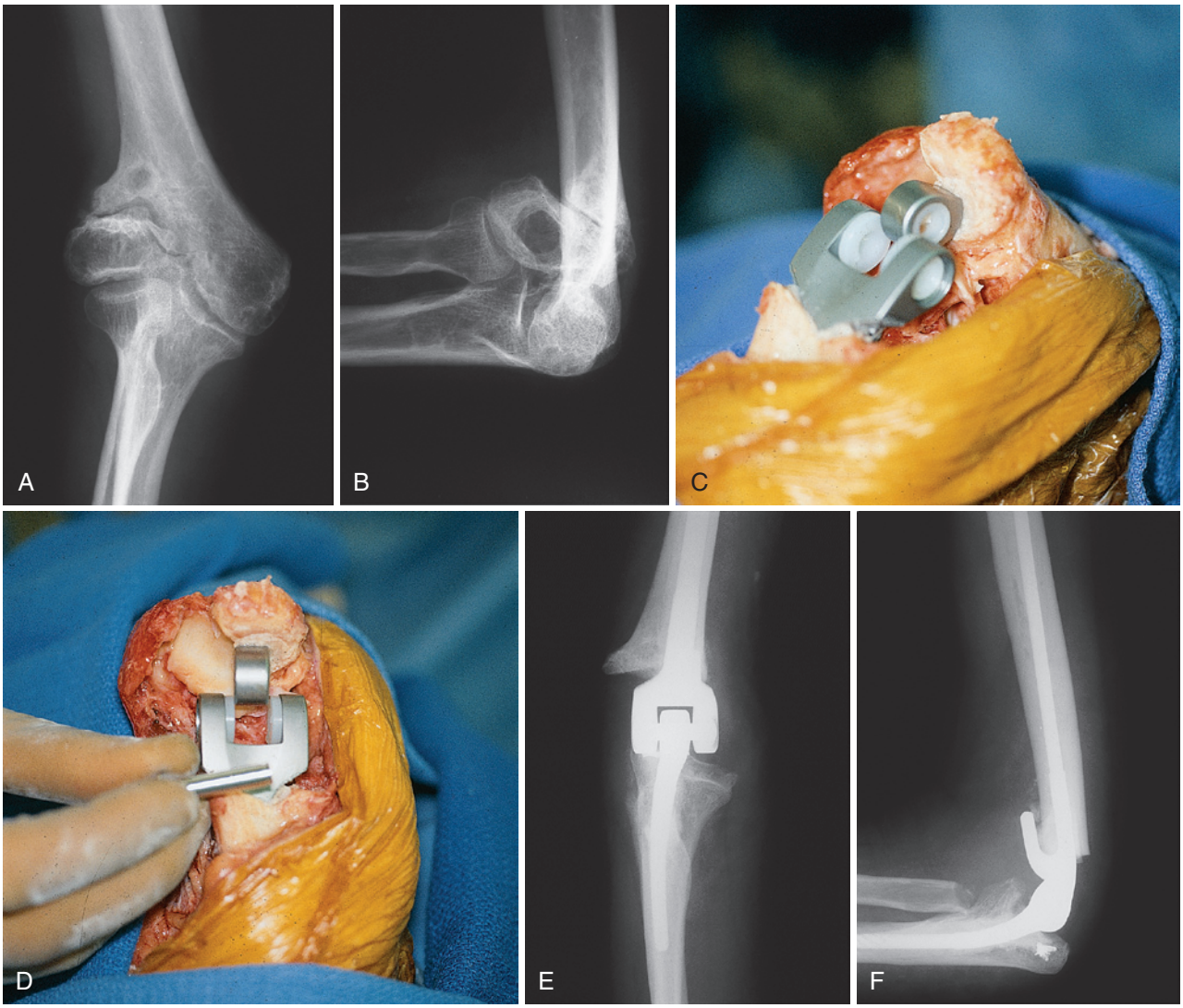

FIGURE 27.2 Anterior **(A)** and lateral **(B)** radiographs depicting posttraumatic arthritis of the elbow in a 66-year-old man with severe deformity and loss of function. **C,** Intraoperative view with the triceps reflected, showing humeral and ulnar components cemented in place. The remaining humeral condyles have been resected. **D,** Semiconstrained arthroplasty uses an axis pin to unite the components. Final anteroposterior **(E)** and lateral **(F)** radiographs of total elbow arthroplasty.

may affect arthroplasty placement. Advanced imaging (computerized tomography) may be used in this regard. It is important to understand the morphologic status of the distal humerus fracture. Injuries with low supracondylar involvement and osteoporotic bone with comminution may be amenable to TEA. Internal fixation is preferred for more proximal fractures, for example, when the transverse limb is proximal to the olecranon fossa.

PRIMARY OSTEOARTHRITIS

Primary osteoarthritis of the elbow affects middle-aged and older individuals, primarily men in the fifth decade of life or later; it is rare in women. Most cases involve the dominant side, and many patients report a lifetime of heavy loading. The most common presenting complaint in this population is pain at the extremes of motion, with loss of terminal flexion and extension. Loss of forearm rotation is less common. Intermittent "locking" and pain may be due to loose bodies within the joint.

Individuals with primary arthritis of the elbow typically have bony overgrowth and osteophytes at the coronoid and olecranon processes. Fluffy densities may be observed filling the olecranon and coronoid fossae, and loose bodies can be seen. Narrowing at the radiocapitellar joint is a common finding, although it is not typically symptomatic. The central aspect of the ulnohumeral joint is characteristically spared in this patient population. Pain throughout the entire arc of elbow motion usually signifies synovitis or articular cartilage degeneration in the central ulnohumeral articulation. This is rare and is seen only in late disease.

It must be emphasized that up to 20% of patients with primary osteoarthritis of the elbow have some degree of ulnar neuropathy. The signs and symptoms can be quite insidious and may go unnoticed by the patient until there is substantial nerve

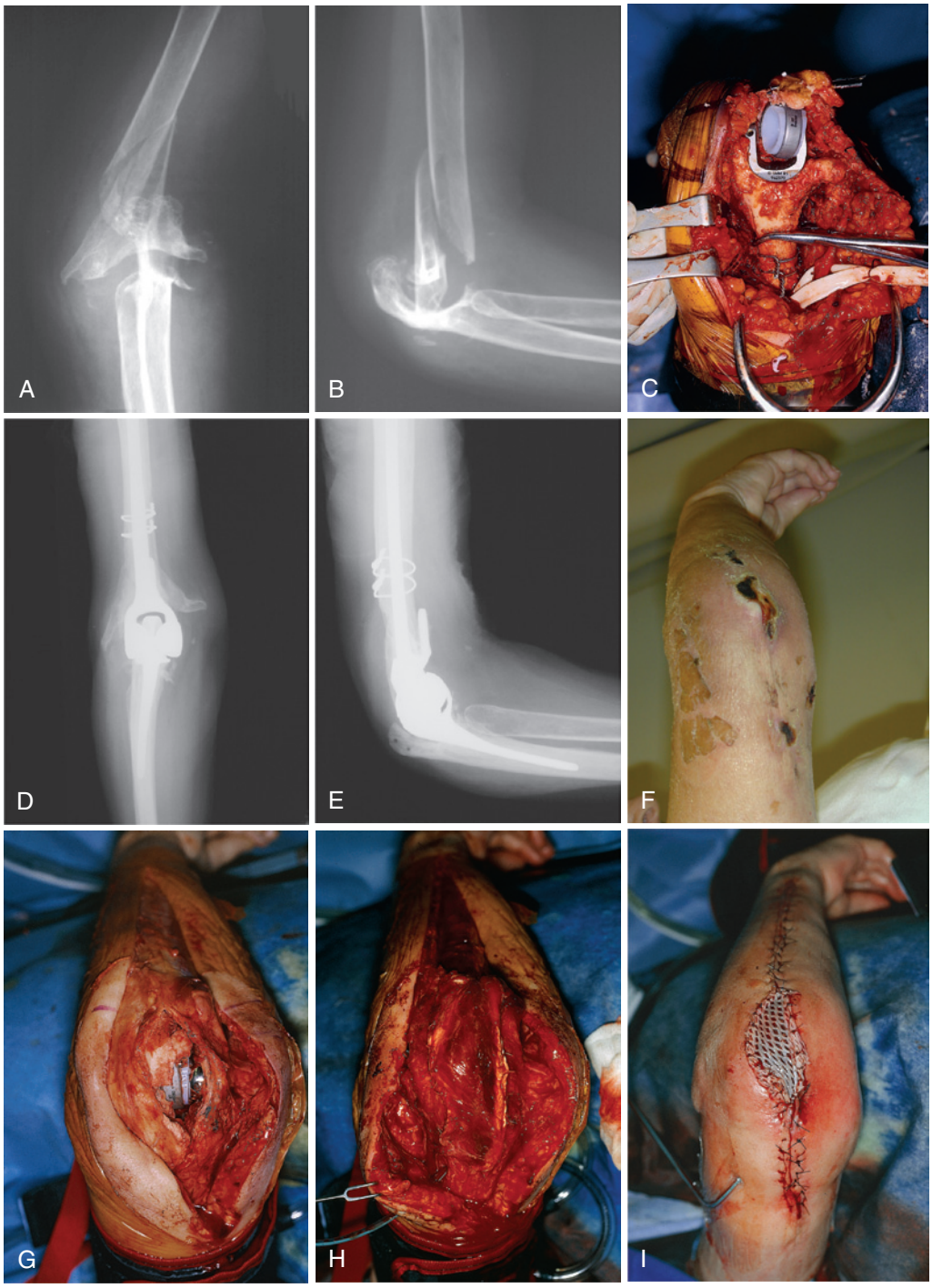

FIGURE 27.3 Anteroposterior **(A)** and lateral **(B)** radiographs of a 64-year-old woman with rheumatoid arthritis and an unstable distal humerus fracture above a severely arthritic joint. Note the presence of osteopenia. **C,** Intraoperative photograph depicts open reduction and internal fixation of the fracture with cerclage wires and cemented arthroplasty components. Postoperative anteroposterior **(D)** and lateral **(E)** radiographs. Note reduction of the humerus fracture. **F,** Unfortunately, the patient exhibited wound dehiscence, which failed to heal with local wound care. She was taking several immunosuppressive agents. **G,** Intraoperative view once the skin has been opened. The component is visible and communicates with the wound owing to partial triceps subluxation laterally. **H,** Joint and component coverage is obtained with a flexor carpi ulnaris muscle pedicle flap. **I,** Final coverage with a split-thickness skin graft over muscle. The joint cultures grew several organisms. The patient received 6 weeks of intravenous antibiotics and is taking chronic oral suppression therapy. At 3 years' follow-up, she has not had a recurrent infection.

dysfunction. The close association of the nerve to the posteromedial joint capsule leaves it susceptible to impingement from osteophytes or from medial joint synovitis expanding the capsule. Early cubital tunnel syndrome in these patients often manifests as pain at the medial elbow. It is thus important to examine these individuals for ulnar nerve irritability and traction signs.

Initial management of primary elbow arthritis consists of activity modification, antiinflammatory medication, intraarticular injection, and, occasionally, therapy. When these modalities prove unsuccessful and symptoms are troublesome, surgical intervention may be warranted. Given the generally young age and high functional demand of patients with primary osteoarthritis at the elbow, prosthetic replacement is usually not recommended. Arthroscopic or open joint débridement and release have traditionally been the primary surgical options because the central ulnohumeral joint space is typically maintained. TEA is reserved for individuals with more advanced arthrosis and lower functional demands who are older than 60 to 65 years. The mechanical failure of TEA in this group of patients has been well documented, so this treatment should be reserved for patients who are willing to reduce their level of activity.

HEMOPHILIC ARTHROPATHY

Patients with hemophilia may present with severe joint destruction as a result of hemophilic arthropathy. Involvement is commonly multiarticular, affecting the shoulders, elbows, hips, knees, and ankles. Potentially severe functional deficits may result. Surgical intervention for hemophilic arthropathy requires a coordinated, multidisciplinary approach. Factor VIII must be supplemented during the perioperative period. Furthermore, the prevalence of human immunodeficiency virus (HIV) in this population predisposes patients to considerable risks, including an increased incidence of secondary infection and a more rapid progression to acquired immunodeficiency syndrome (AIDS) in those with low CD4 counts.[18] Further investigation is needed to define the role of total elbow replacement in treating hemophilic arthropathy.

Preoperative Considerations

Perioperative Management of Blood Clotting

Perioperative management of hemophilia depends on the cause of the clotting disorder. It is important to have the patient's hematologist involved in blood product management and factor replacement throughout the preoperative and postoperative periods. In classic hemophilia, factor VIII must be supplemented during the perioperative period. In patients with von Willebrand disease, DDAVP or cryoprecipitate may be needed. Preparations with the inpatient blood bank are crucial to ensure adequate blood products are available at the time of surgery. At surgery, careful attention to hemostasis is important to avoid postoperative hematoma. Postoperative drain placement may be considered.

CONTRAINDICATIONS TO TOTAL ELBOW ARTHROPLASTY

There are several absolute and relative contraindications to TEA.

Presence of Infection at the Elbow

Any suspicion of infection in the skin, soft tissue, or bone should cause a postponement of the surgery.[53] Patients with rheumatoid arthritis and poor skin quality who are taking immunosuppressive drugs are especially prone to catastrophic postoperative infections. Other sources of bacteria, such as urinary tract infections, should also be screened. If an attempt at internal fixation for fracture has failed, deep infection at the site should be considered, and cultures should be obtained while the patient is free of any antibiotic treatment. The organisms can be quite indolent, especially *Staphylococcus epidermidis* species.

If active infection is present or even suspected, full débridement of all infected or compromised tissue is required, including all hardware. Trustworthy cultures must be obtained and the proper antibiotics administered through a peripherally inserted central catheter (PICC) line typically for a minimum of 6 weeks. Often a follow-up culture and biopsy of the elbow are obtained after the patient has stopped taking all antibiotics for 6 or more weeks. TEA is considered only after these studies confirm the absence of infection and acute inflammation.

Complete Ankylosis of the Neuropathic Joint

In patients with complete and painless ankylosis of the elbow, implant arthroplasty may not improve overall function. Although a considerable improvement in functional arc of motion has been reported following the conversion of elbow arthrodesis to prosthetic replacement,[24] the nature of the underlying pathologic condition leads to frequent postoperative complications and a less predictable outcome. Total elbow replacement is contraindicated in patients with neuropathic joint destruction owing to their inherent inability to comply with postoperative restrictions.

Poor-Quality Soft Tissue at the Elbow

Severely contracted, scarred, or burned skin needs to be assessed before considering total elbow replacement. For the implant to function properly, the skin and soft tissue need to be pliable enough to permit manipulation for placement of the implant. If there is inadequate soft tissue, a muscle flap should be considered before arthroplasty (see Chapter 44 on soft tissue coverage about the elbow).

HISTORICAL REVIEW OF TOTAL ELBOW ARTHROPLASTY

Elbow arthroplasty has evolved from attempts at resurfacing of the distal humerus or ulna with various materials. Constrained TEA, using a rigid hinge, led to rapid failures. Attempts at distal humeral and proximal ulna resurfacing were commonly complicated by component failure. These prototypes have evolved into the designs used currently (Table 27.1).

TYPES OF IMPLANTS

There are two general types of implants for the arthritic elbow: linked and unlinked. An unlinked or nonconstrained prosthesis relies on adequate bony support and collateral ligaments for stability. This theoretically decreases loosening at the

TABLE 27.1 Historical Review of Elbow Arthroplasty

Device and Era	Year of Notable Development	Author	Significance
Hemiarthroplasty, 1920 to 2000s	1952	Venable[48]	Metal distal humerus replacement
	1965	Barr and Eaton[2]	Vitallium replacement of distal humerus
	1970	Johnson and Schlein[16]	Vitallium replacement of proximal ulna
	1971	Peterson and Janes[31]	Vitallium ulnar "saddle" interposition; limited arc of motion; acceptable longevity
	2011	Burkhart et al[3]	Convertible hemiarthroplasty for distal humerus fracture
Constrained Arthroplasty, 1970 to 1980s	1972	Dee[7]	Hinged total elbow arthroplasty
	1982	Dee[8]	Recognition that rigid hinge has high rate of implant loosening
Surface Replacement Arthroplasty, 1970 to 1990s	1984	Rydholm et al[35]	Wadsworth prosthesis had high rates of humeral component loosening
	1990	Kudo and Iwano[19]	70% of surface replacements had humeral subsidence
Stemmed Unconstrained Arthroplasty, 1970s to 1990s	1983	Pritchard[32]	Early experience with stemmed resurfacing arthroplasty of ulna, radius, and distal humerus
	1994	Kudo et al[20]	Titanium-stemmed unconstrained arthroplasty: failures observed at humeral stem junction
	1999	Trail et al[47]	Souter-Strathclyde unconstrained arthroplasty: flanges into medial and lateral columns for added stability
Stemmed Semiconstrained Arthroplasty, 1970 to Present	1977	Schlein[38]	Introduction of semiconstrained prosthesis
	1982	Morrey and Bryan[26]	Recognition that semiconstrained prosthesis has better survivorship than tightly constrained hinge
	1992	O'Driscoll et al[28]	Anterior flange limits stress on cement interface

bone-cement interface but carries a greater risk of instability, especially in the rheumatoid population. Many unlinked designs have been discontinued but may be encountered in the revision setting. These include the Kudo/Instrumented Bone Preserving (Biomet Europe), Souter-Strathclyde (Wright, Arlington, TN; Figure 27.4), and Pritchard ERS (Depuy, Warsaw, IN).

Currently, linked designs involve stemmed implants with a semiconstrained articulation. Semiconstrained devices have the advantage over unlinked devices with respect to stability. However, even with several degrees of varus-valgus laxity, the most popular sloppy hinge mechanisms allow only a small area of contact between the humeral and ulnar components, leading to high contact stresses. Polyethylene wear of the bushings, osteolysis, and subsequent failure remain clinical problems.[21] Commonly used semiconstrained designs include the Coonrad-Morrey (Zimmer, Warsaw, IN) and Solar (Stryker, Mahwah, NJ).

In practice, reports of pain relief and functional gains appear to be similar for linked and unlinked designs. In an effort to improve on polyethylene wear; several new implants have been introduced. Some do not depend on a true hinge for stability and theoretically lead to decreased wear, as seen in prior hinge designs (Discovery, Biomet, Warsaw, IN). Other prostheses have the capacity to be inserted in either a linked or an unlinked fashion (Latitude, Tornier, Saint-Ismier, France). No long-term data exist on these newer designs. It is hoped that continued advances in biomaterials and better anatomic designs will lead to improved and more durable implant options in the future.

❖ AUTHORS' PREFERRED METHOD OF TREATMENT

We currently use a semiconstrained linked prosthesis with either a loose hinge or a spherical articulation for the majority of elbow replacement surgeries. Although the unlinked designs should theoretically have lower loosening rates, this has not been proven clinically. The procedure is typically performed in a laminar flow room. The patient is positioned in a semilateral decubitus position on a beanbag, and the affected arm is rested across the chest on a bolster. A sterile tourniquet is applied. A posterior skin incision is made and taken down to the fascia, raising full-thickness fasciocutaneous flaps medially and laterally. The ulnar nerve is carefully dissected, transposed anteriorly into a subcutaneous pocket, and protected throughout the procedure.

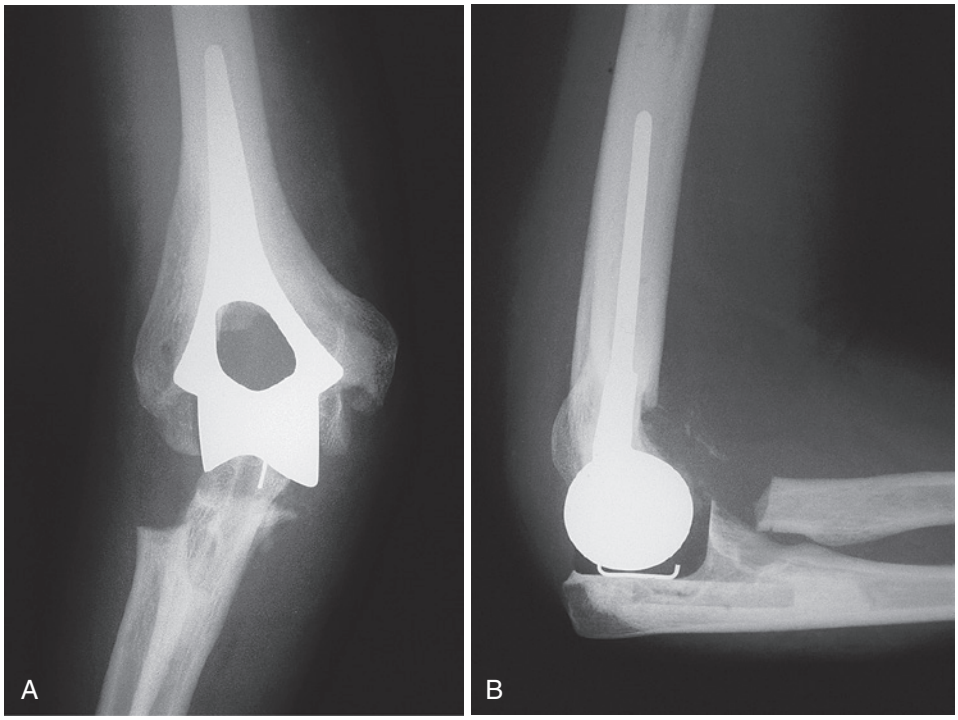

FIGURE 27.4 Anteroposterior **(A)** and lateral **(B)** radiographs of a Souter-Strathclyde unconstrained implant. The ulnar component consists of polyethylene, which is radiolucent.

Several options exist for reflecting the triceps mechanism to expose the joint. In the traditional approach, described by Bryan and Morrey, the triceps is elevated from medial to lateral in continuity with the anconeus to expose the distal humerus and elbow. One problem with this approach is postoperative triceps insufficiency, presumed to be related to failure of the repair. One of us (MSC) uses a straight triceps-splitting approach as described by Gschwend, in which the triceps muscle and tendon are split longitudinally and sharply elevated off the proximal ulna down the midline (Figure 27.5).[4,14] This may allow for a more secure repair of the triceps muscle and tendon at the completion of the procedure, with less theoretical tendency for the triceps to slide back off the olecranon process laterally. It is yet to be determined whether the rate of triceps insufficiency is reduced with this method.

Another option is a triceps-preserving approach.[33] The entirety of the triceps insertion is left intact while bone preparation, provisional assembly, and final prosthesis implantation are performed through medial and lateral windows. This approach allows immediate active triceps rehabilitation. However, it limits exposure and makes broaching of the ulnar canal and prosthesis assembly somewhat more challenging in situ. Furthermore, exposure of the humerus requires complete release of both collateral ligaments. It is unclear whether this soft tissue release adds morbidity with respect to implant longevity, such as by increasing stress on the polyethylene owing to a loss of ligamentous support.

Whichever approach is chosen to reflect the triceps mechanism, it is important to carefully dissect the Sharpey fibers off the olecranon process in a subperiosteal fashion. This can be very tedious, especially in the rheumatoid population. A knife should be used for this purpose, not a monopolar cautery. The latter can lead to tissue necrosis and may inhibit tendon healing following repair. The insertion point of the triceps on the tip of the olecranon should be tagged to allow a more anatomic repair following implantation. This may help decrease triceps dysfunction postoperatively.

In cases with deficient distal humeral columns, including fractures and nonunions, one can use a true triceps-sparing approach. In this technique, the distal humerus is excised, and one can work through either side of the triceps insertion while preserving its attachment to the olecranon (Figure 27.6). As noted, this does compromise visualization, especially for the ulna. Because triceps insufficiency is not uncommon following arthroplasty, and because humeral condyle resection does not affect the ultimate strength or functional outcome when using semiconstrained devices,[25] one may consider resecting the distal humerus at the proximal aspect of the trochlea in selected cases (e.g., elderly patients with rheumatoid arthritis). This approach necessitates complete release of the collateral ligaments and flexor-pronator and extensor muscle origins from the humerus. Rehabilitation is simplified, and this may improve elbow extension power and control. The amount of distal humerus resected also depends on the type of articulation of the implant arthroplasty.

Once the joint surfaces are exposed, including the trochlea, humeral columns, and olecranon process, the bony work is initiated. Exposure is facilitated by hyperflexion and subluxation of the elbow with external rotation of the shoulder. The tip of the olecranon and the tip of the coronoid process are resected to decrease the potential for impingement. Bony impingement of the olecranon or coronoid should be checked

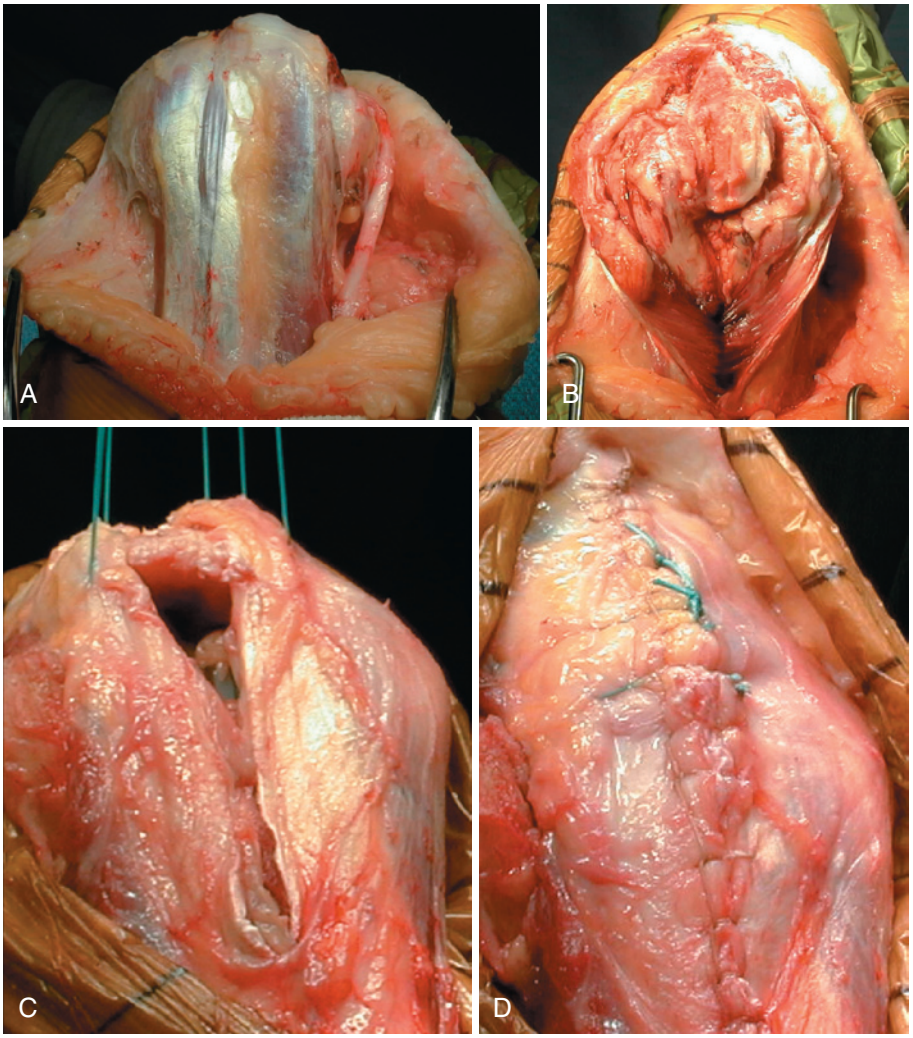

FIGURE 27.5 **A,** Intraoperative view of the Gschwend triceps-splitting approach to the elbow. Note that the ulnar nerve has been dissected out and protected. The split occurs in the tendinous portion of the triceps. **B,** Joint exposure is obtained with full-thickness medial and lateral flaps. **C,** Sutures are in place for repair and closure of the split. **D,** Final repair, with several sutures placed through drill holes in the olecranon.

both during trial implant insertion and after the permanent implant is placed. Unless the arthritis is limited to the ulnohumeral articulation, the radial head is commonly excised. Care should be taken to place retractors around the neck of the radius to protect the posterior interosseous nerve, which lies just anterior to the radial head outside the elbow capsule. Next, the central aspect of the trochlea is resected, and the humeral canal is entered with a bur. The entry point is typically more posterior than initially appreciated. Once the canal is defined, cutting guides are typically used to prepare the distal humerus and trial implants can be evaluated. Complete seating of the prosthesis can be blocked by the anterior cortex, which occasionally has to be deepened to accept the anterior flange of the implant.

The ulna is more difficult to prepare than the humerus. The ulnar canal is commonly entered with a bur, and the opening is enlarged with a bur and rasps. It is important to open the proximal ulna widely. A common technical error is to make an ulnar aperture that is too small. This makes seating of the rasps difficult. A second technical error is to seat the ulnar component too distally into the ulna, causing impingement of the coronoid against the remaining distal humerus in flexion. Care must be taken not to perforate the thin cortices of the proximal ulna, especially in patients with rheumatoid arthritis. If the alignment is in question, intraoperative fluoroscopy may be helpful to confirm the direction of the rasp, bur, and stem. One must appreciate the 4- to 5-degree valgus angulation of the shaft of the ulna relative to the greater sigmoid notch. When there is difficulty seating a rasp, bone at the canal entry is most commonly the limiting factor. In addition, a trough is commonly required in the posterior olecranon to avoid placing the ulnar component in flexion. Once component sizes are chosen, one should insert trial implants to ensure an adequate arc of motion without impingement.

During insertion of the trial components, the range of motion should be carefully examined. Elbow joints that were quite stiff before surgery may require an extensive release of the anterior capsule from the humerus and a more generous

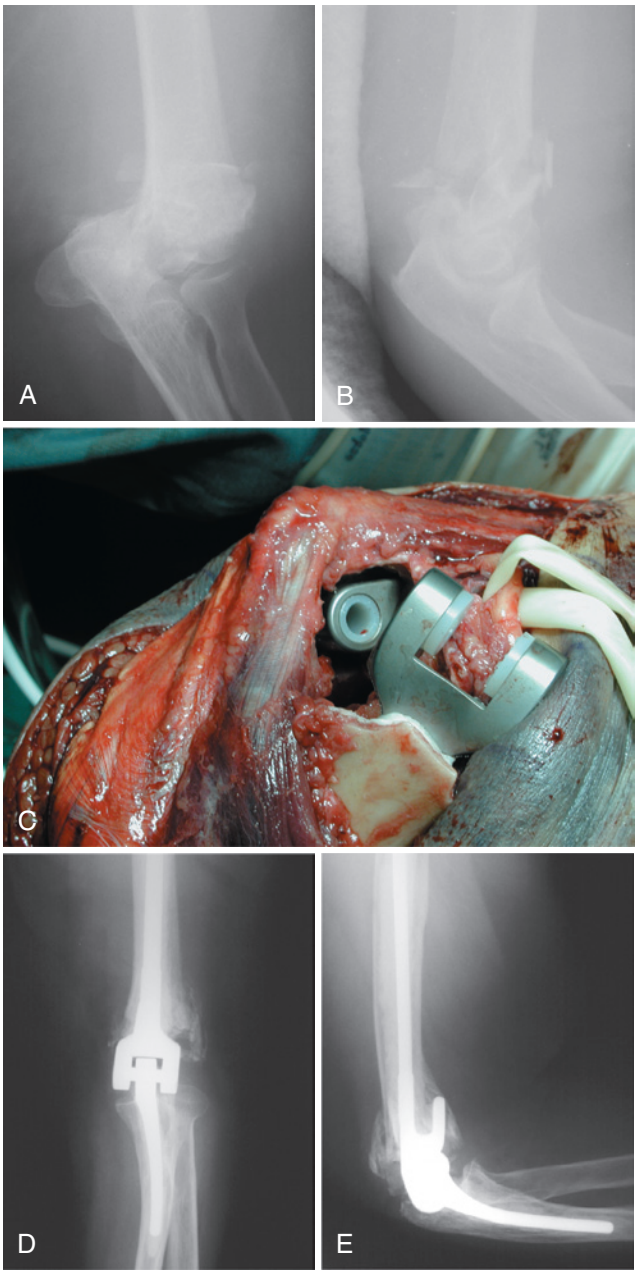

FIGURE 27.6 Anteroposterior **(A)** and lateral **(B)** radiographs of a severe distal humerus fracture in an 89-year-old woman with osteopenia. Note the high degree of comminution and osteopenia. **C,** Intraoperative view shows the triceps-preserving approach, with exposure of the humerus by working on each side of the triceps mechanism without distal detachment. This approach is possible in fractures or nonunions when the distal humerus is resected. Postoperative anteroposterior **(D)** and lateral **(E)** films, with the cemented semiconstrained arthroplasty in place. Note the condylar resection. (**C,** Courtesy of Graham King, MD.)

resection of the distal humerus, shortening the bone and permitting greater extension of the joint.

We currently use polyethylene cement restrictors in both the humeral and ulnar canals. As the humeral canal gets larger proximally, standard restrictors often do not allow a seal; umbrella designs are more effective (e.g., Tornier, Saint-Ismier, France). Alternatively, a small piece of cancellous bone can be used in the ulna. The canals are lavaged, dried, and injected with antibiotic-laden cement in a retrograde fashion using a cement gun with thin tubing. It is helpful to cool the cement and inject it in a more liquid state because it may be difficult to deliver viscous cement down the long, thin tube. Once placing the components, if the design allows, the joint may be cycled to theoretically help with component alignment. The elbow is then held in extension until the polymerization is complete. If the triceps is intact, cementing both components simultaneously may be more challenging. Excess cement is removed during this process.

Hemostasis is obtained once the tourniquet is deflated and the triceps mechanism is meticulously repaired. We use a running, locking, Kevlar-reinforced suture passed through drill holes in the olecranon tip for reattachment. This aspect of the procedure is very important, and care must be taken to complete a secure and anatomic repair. Tension after reattachment of the triceps needs to be checked so that full flexion can be achieved without detachment. If the Gschwend splitting approach is chosen, the running, locking stitch can be placed several millimeters away from the tendon edge, and additional side-to-side sutures can be placed centrally. More than one transosseous suture is commonly used with either method. The soft tissues are closed in a routine fashion, and the ulnar nerve is maintained in a subcutaneous position anterior to the epicondyle. A suction drain may be used depending on surgeon preference.

POSTOPERATIVE MANAGEMENT AND EXPECTATIONS

In rheumatoid patients with thin and friable skin, we immobilize the elbow for 10 to 14 days to allow soft tissue healing before motion is instituted. If the triceps was released from the ulna during exposure, the repair must be protected by restricting active extension for 6 to 8 weeks postoperatively. Initially, we often prescribe a sling during the day and a nighttime elbow orthosis in maximal extension to decrease the potential for flexion contracture. A removable long-arm orthosis for comfort and support between exercises may also be considered. At follow-up, patients are counseled on the importance of protecting the joint from excessive loads. Empirically, a 5-pound limit when lifting with the operated arm is recommended. Yearly clinical and radiographic evaluations are arranged, regardless of clinical symptoms.

At follow-up, frontal and lateral radiographs should be evaluated carefully, paying particular attention to the cement mantle and any signs of osteolysis. The ulnar component is at greatest risk for loosening. The bearing should be evaluated carefully for signs of wear on a true anteroposterior film with the elbow in full extension. In a Coonrad-Morrey semiconstrained prosthesis, partial wear is defined as greater than 7 degrees of ulnar component angulation relative to the humeral yoke.[12] Complete wear is defined as greater than 10 degrees of ulnar component angulation relative to the humeral yoke.[12] In cases of advanced osteolysis, lucencies may be seen at either the bone-cement or prosthetic-cement interface. The expected outcome following uncomplicated surgery is a nearly painless and functional arc of elbow motion. Patients commonly do not recover terminal elbow extension but ultimately regain full flexion within several months. Overall functional scores and satisfaction are generally

higher and long-term complications are lower in rheumatoid patients than in those with posttraumatic arthritis.[12] This likely relates to the lower demands of the rheumatoid population. Although pain relief is almost uniformly excellent in rheumatoid individuals, range of motion often improves only modestly. This is especially true in patients with very limited elbow function preoperatively, such as that seen in juvenile rheumatoid disease. These individuals often remain quite stiff even after successful arthroplasty.

For posttraumatic arthritis, results are less uniform. One study reported that 69 of 85 joints were functional at a mean follow-up of 9 years with the use of a semiconstrained prosthesis for posttraumatic dysfunction. Sixty-eight percent of patients had a good to excellent Mayo Elbow Performance Score. However, 29 elbows had complications, including infection, component fracture, and bushing wear.[46]

When arthroplasty is used for acute trauma following distal humerus fracture, successful results can be obtained in selected patients. The largest study reviewed 49 cases with an average follow-up of 7 years. Many of the patients (62%) had coexistent conditions, with nearly 40% suffering from rheumatoid arthritis.[17] It was therefore difficult to generalize to patients with only fractures. Although 93% of patients had a satisfactory outcome, 29% reported complications. These included wound problems, transient nerve dysfunction, component fracture, and component loosening. The authors stressed the need for strict inclusion criteria when using arthroplasty in this setting.

Prosthesis Longevity

The national registries of Scotland and Finland report 10-year survivorship rates of TEA at 90% and 83%, respectively.[15] Other studies have reported an overall 5-year survivorship rate as low as 72%.[41] TEA in patients with rheumatoid arthritis has superior longevity, with a survival rate of 92% at 10 years.[12] TEA performed for posttraumatic arthritis has a 70% 15-year implant survival rate, with a significant association between earlier age at time of arthroplasty and implant failure.[46]

Complications of Total Elbow Arthroplasty

When the world literature is reviewed, the complication rate of TEA varies between 20% and 45%.[14] Intraoperatively, fracture of a humeral condyle can be treated with simple excision. Alternatively, if the fragment is large, reduction and internal fixation can be considered (Figure 27.7). The risk of intraoperative complications due to bone loss is significantly increased in individuals with advanced rheumatoid arthritis.[23] Late humeral condyle fracture can occur, most commonly along the medial column. This typically heals uneventfully with a short period of joint protection.

Regardless of the care taken during dissection and transposition of the ulnar nerve, sensory dysfunction is not uncommon following arthroplasty. Ulnar motor weakness is less common. Postoperative ulnar neuropathy has been reported in up to 25% of patients.[14,27] Excessive traction on the nerve perioperatively, hematoma, constricting dressings, thermal damage due to polymerization of methylmethacrylate, and devitalization of the nerve during translocation have all been implicated as causative factors. Incomplete sensory deficits typically improve with time, but normal subjective sensation does not return in all cases, especially in an elderly person with multiple comorbidities.

Elbow extension weakness following arthroplasty is more common than is typically appreciated, especially if the triceps insertion was detached using the traditional Bryan-Morrey approach. Although the cause of triceps insufficiency is unclear, possible explanations include alteration of the joint level, affecting triceps tension, and failure of reattachment, with tendon retraction or subluxation. We believe the latter to be more

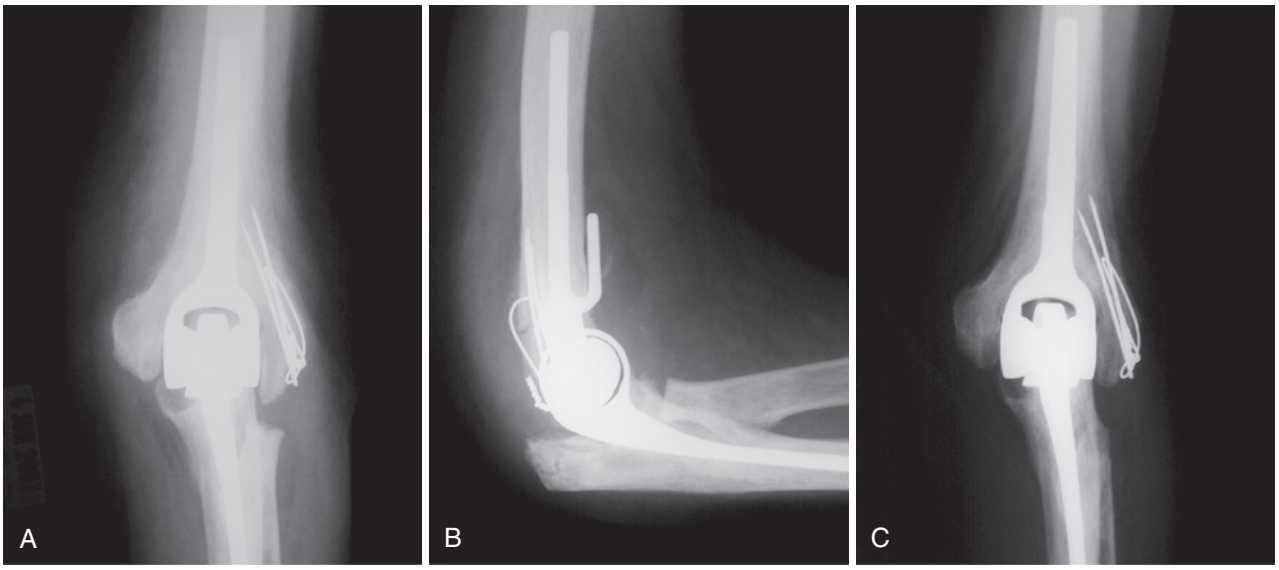

FIGURE 27.7 Anteroposterior **(A)** and lateral **(B)** radiographs depicting the tension band wire technique used to repair a fracture of the lateral column that occurred intraoperatively. Most commonly, these fragments are excised. Internal fixation was chosen in this case because of the patient's young age and the proximal extent of the fracture. This preserves bone stock as well as the extensor muscle origin at the epicondyle. **C,** Healing of the fracture at 3 months' follow-up.

probable and have observed this mode of tendon failure during revision surgery for loosening. Fortunately, even with detachment of the triceps from its insertion on the olecranon tip, some extensor function typically remains. Because elbow extension weakness is reasonably well tolerated using gravity assistance, there is usually little indication for triceps repair or reconstruction owing to insufficiency following arthroplasty.

Instability following TEA is largely limited to unlinked designs. Prevention of instability with a nonlinked prosthesis depends on meticulous technique, with restoration of proper tension to the soft tissues following implantation. Ligamentous insufficiency is a relative contraindication for these designs. Furthermore, implants that sacrifice the radial head decrease lateral joint support and impart a greater load to the collateral ligaments. Finally, axial malalignment of either component may compromise stability.[44] Limiting elbow extension in the immediate postoperative period may minimize the incidence of dislocation.[43,44] If a dislocation occurs, immobilization of the elbow at 90 degrees for 3 to 6 weeks is recommended. Recurrent symptomatic instability is addressed with soft tissue reconstruction when possible or revision to a linked design.

Disassembly of a linked prosthesis may occur. This was a particular problem with the earlier designs, such as the GSB III.[17] It was thought that an overly extensive soft tissue release, as well as component malposition, might lead to gradual overload of the linkage mechanism until disassembly ultimately occurred.

Mechanical Failure

Mechanical failure, loosening, and osteolysis underscore the fact that arthroplasty is relatively contraindicated in patients who anticipate strenuous physical activity or are not expected to comply with the postoperative protocol. Arthroplasty candidates must be willing to adhere to postoperative limitations of not lifting anything heavier than approximately 5 to 10 pounds and no repetitive lifting of any object heavier than 2 to 3 pounds. Optimal cementing technique may help minimize loosening. This includes careful canal preparation, use of a cement restrictor, and application of low-viscosity cement with pressurization. These methods are thought to improve the initial fixation of the humeral component and perhaps decrease the incidence of aseptic loosening.[6,9]

Unfortunately, wear debris and osteolysis can be seen relatively early, even in lower-demand individuals (Figure 27.8). This may be secondary to stress concentration and mechanical wear of the bushings in the current semiconstrained designs. Suboptimal positioning of the prosthesis may affect its longevity. For example, it has been shown that if the humeral component of the Coonrad-Morrey prosthesis is inserted in more than 10 degrees of malrotation, the varus and valgus laxity during the flexion and extension arc follow the structural limits of the hinge.[40] This neutralizes the advantages of the sloppy hinge mechanism and leads to increased stresses on the polyethylene and the bone-cement interface. Excessively tight soft tissues, such as those following inadequate release, may also contribute to wear.

If progressive osteolysis is noted on serial radiographs, even in the absence of symptoms, consideration must be given to revision surgery. If the components are stable and positioned appropriately, débridement, bone grafting, and replacement of the polyethylene bushings may be all that are indicated. Consideration can also be given to oral diphosphonates, which slow osteolytic progression. If the components are found to be loose intraoperatively, implant revision is required.

Osteolysis and aseptic loosening are increasingly recognized complications of TEA. This is likely due to multiple modes of wear, including asymmetric thinning of the humeral bushings and unintended metal-on-metal wear between bearing and nonbearing surfaces or between two nonbearing surfaces. Wear between the stem and cement mantle is typically observed in most ulnar components at the time of revision. The histopathologic status of the periprosthetic tissues at the time of revision surgery has been found to be similar in character to that observed in association with osteolysis and loosening of total hip and knee replacements.[13,22,50]

The potential for component fracture is inherent to any implantable device. For the elbow, a resultant force vector of up to three times body weight is directed anteriorly in flexion and posteriorly in extension. Approximately 1 million compression-distraction loading cycles are generated per year. In spite of these tremendous stresses, advanced metallurgy and modifications in prosthetic design make ulnar or humeral stem fracture an uncommon event, cited in 0.6 to 12% of cases.[14,39] The most common cause of implant fracture is periarticular osteolysis, leading to cantilever bending and fatigue fracture of the prosthetic stem (see Figure 27.8). Notch sensitivity and component design are postulated to further contribute to component fracture. When implant fracture occurs, revision is indicated. This can be accomplished by techniques such as cement-within-cement reimplantation. These techniques have been shown to be reliable for relieving pain and restoring function in revision surgery.[1]

Periprosthetic fractures of the humerus and ulna following TEA can be very challenging to treat. They can be related to significant trauma to the upper extremity or represent pathologic fractures from osteolysis and bone loss at the tip of the stem (Figures 27.9 and 27.10). The cited incidence is between 3% and 5%.[29] These fractures are managed based on their location, the quality of prosthetic fixation, and the quality of the remaining bone stock. Experience with periprosthetic fractures in the lower extremity has been extrapolated and applied to the upper extremity.[29,36] Periprosthetic humeral fractures have been classified as H1-fractures around the condyles or column, H2-fractures around the stem, and H3-fractures proximal to the implant.[36] Periprosthetic ulna fractures have been classified as U1-fractures of the olecranon, U2-fractures around the stem, and U3-fractures distal to the implant. Fractures around the stem are subclassified as 1-well fixed, 2-loose with acceptable bone stock, or 3-loose with severe bone loss.[10]

Unfortunately, uncemented stems, which account for the bulk of revision fixation options in the lower extremity, are not available in revision TEAs. When the components are stable, standard fracture treatment is typically indicated, including internal fixation with or without the incorporation of allograft struts. Periprosthetic fractures around a loose humeral component can be treated with revision cemented arthroplasty using strut allograft augmentation to improve bone stock, with predictable union rates.[10,36] Large cavitary defects have been treated with impaction grafting and massive defects have been treated

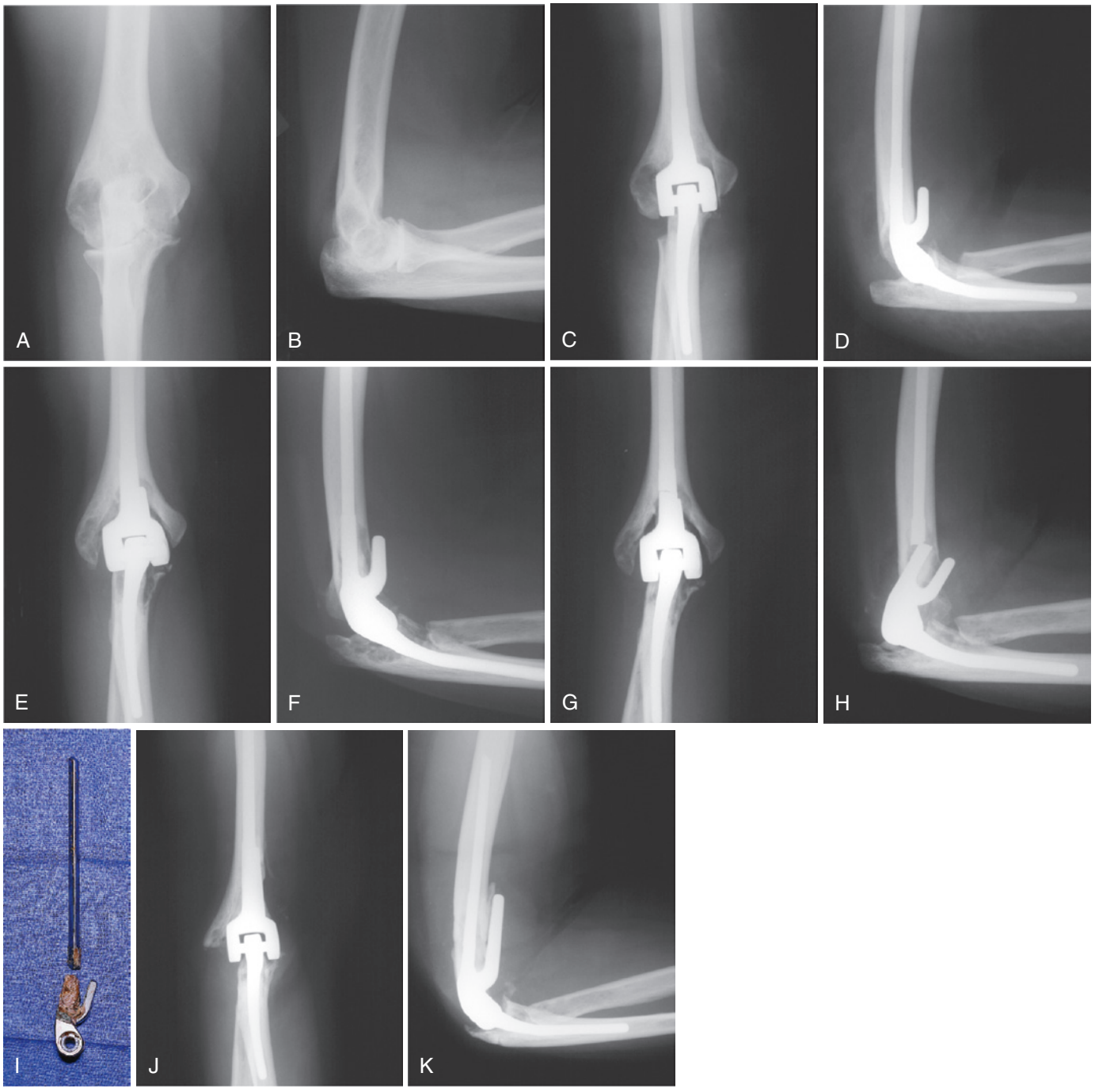

FIGURE 27.8 Anteroposterior **(A)** and lateral **(B)** radiographs of 57-year-old woman with rheumatoid arthritis and advanced elbow arthritis who failed conservative measures. Immediate postoperative anteroposterior **(C)** and lateral **(D)** radiographs depict the semiconstrained device. On the 3-year follow-up anteroposterior **(E)** and lateral **(F)** films, note osteolysis involving the distal humerus and proximal ulna adjacent to the hinge. Anteroposterior **(G)** and lateral **(H)** views 2 years later when the patient presented with acute pain after lifting a box of detergent at home. Progressive osteolysis has placed excessive stress on the component, leading to implant fracture. Intraoperative photograph **(I)** of the broken implant at revision surgery. Anteroposterior **(J)** and lateral **(K)** radiographs after revision surgery. Note the humeral component's long anterior flange. The ulnar component was well fixed, so the proximal ulnar canal was débrided and bone-grafted.

with allograft prosthetic composites. When exposure of the humeral diaphysis is necessary, it is important to identify and protect the radial nerve. In certain cases, for example, when large humeral allografts are necessary, the radial nerve can be transposed anterior to the humeral shaft to facilitate future revision surgery.

Infection

Finally, infection is a potentially devastating complication of TEA.[49] The reported rate of infection is between 1% and 11%, with approximately half being superficial infections and half deep infections.[14,49,52] Risk factors include immunosuppressive therapy or immune compromise, diabetes mellitus, poor

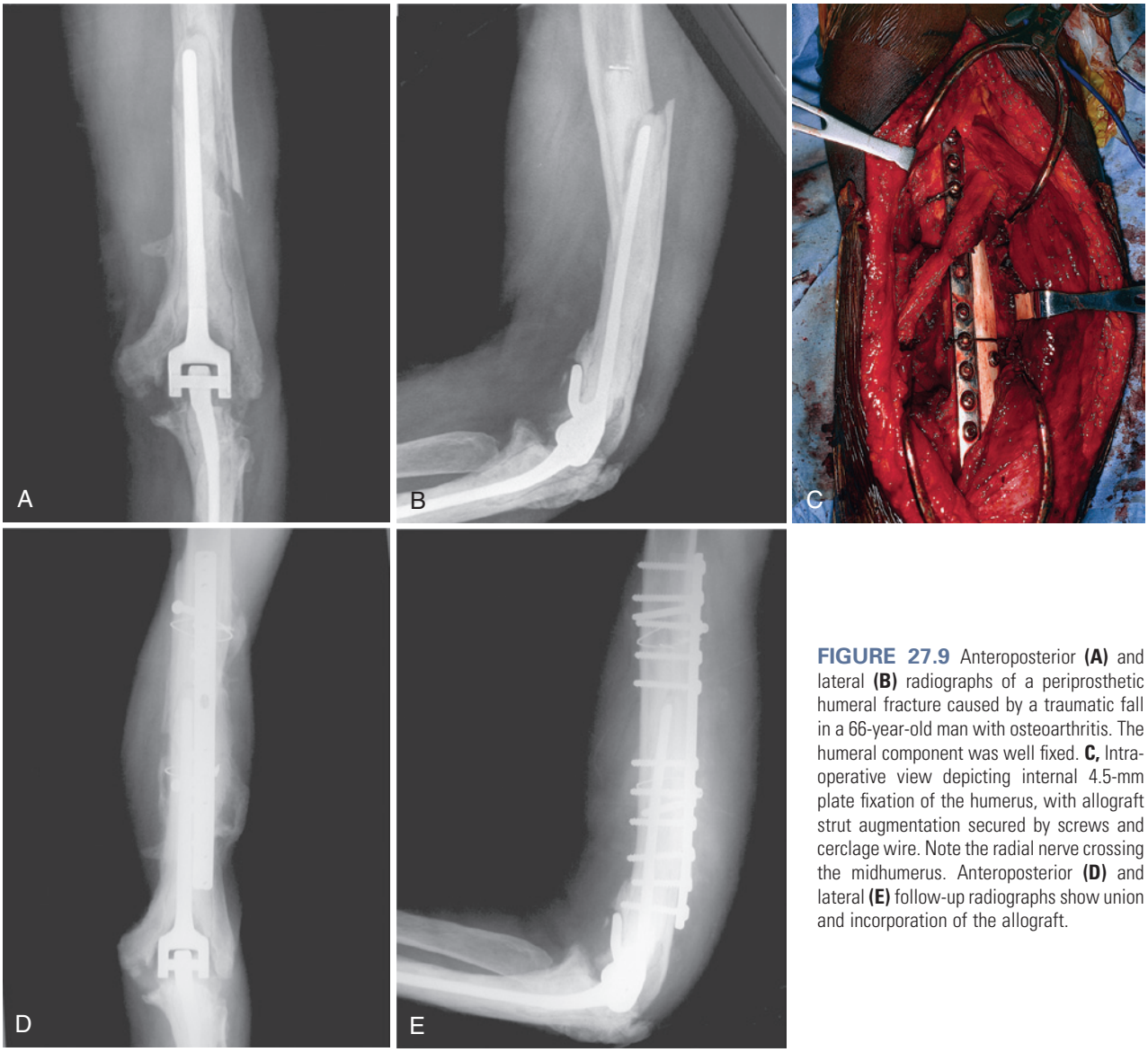

FIGURE 27.9 Anteroposterior **(A)** and lateral **(B)** radiographs of a periprosthetic humeral fracture caused by a traumatic fall in a 66-year-old man with osteoarthritis. The humeral component was well fixed. **C,** Intraoperative view depicting internal 4.5-mm plate fixation of the humerus, with allograft strut augmentation secured by screws and cerclage wire. Note the radial nerve crossing the midhumerus. Anteroposterior **(D)** and lateral **(E)** follow-up radiographs show union and incorporation of the allograft.

nutrition, obesity, multiple prior surgical interventions, prior infection, and prolonged wound drainage. Infection rates may be reduced with proper prophylactic measures, such as the use of intravenous antibiotics, antibiotic-impregnated cement, care and preservation of a robust soft tissue envelope, laminar flow operating rooms, and exhaust suits.[52]

When a deep infection occurs, a decision must be made regarding implant preservation. Patient factors, the duration of symptoms, bacteriologic factors, the quality of component fixation, the presence of a sinus, and a history of preceding bacteremia are important considerations in treatment planning. Options include surgical débridement (with or without polyethylene exchange) combined with chronic suppressive antibiotic therapy versus implant removal with or without a second-stage reimplantation. *Staphylococcus aureus* infections may be more amenable to repeat débridement and component retention.[27,52] Although less virulent, *S. epidermidis* has an increased propensity for adherence and biofilm formation and has been associated with a higher failure rate with attempted prosthetic retention.[52] Early irrigation and débridements with component retention may be possible for well-fixed components, symptom duration of less than 30 days, infection with a low-virulence organism, and medically fit patients.[49] The overall success of irrigation and débridement ranges from 22 to 70%.[49,52]

Staged exchange is another treatment alternative for an infected TEA. Much of the experience with staged exchange is derived from its successful use in the lower extremities. In a medically fit patient with a loose component and a duration of infection longer than 21 days, this may be a viable option for TEA salvage. It requires meticulous cement removal, which may involve extended osteotomies of the ulna and humerus. This is followed by placement of an antibiotic-laden cement spacer and intravenous antibiotics used typically for 6 weeks; clearance of infection is demonstrated by negative tissue biopsy prior to reimplantation.

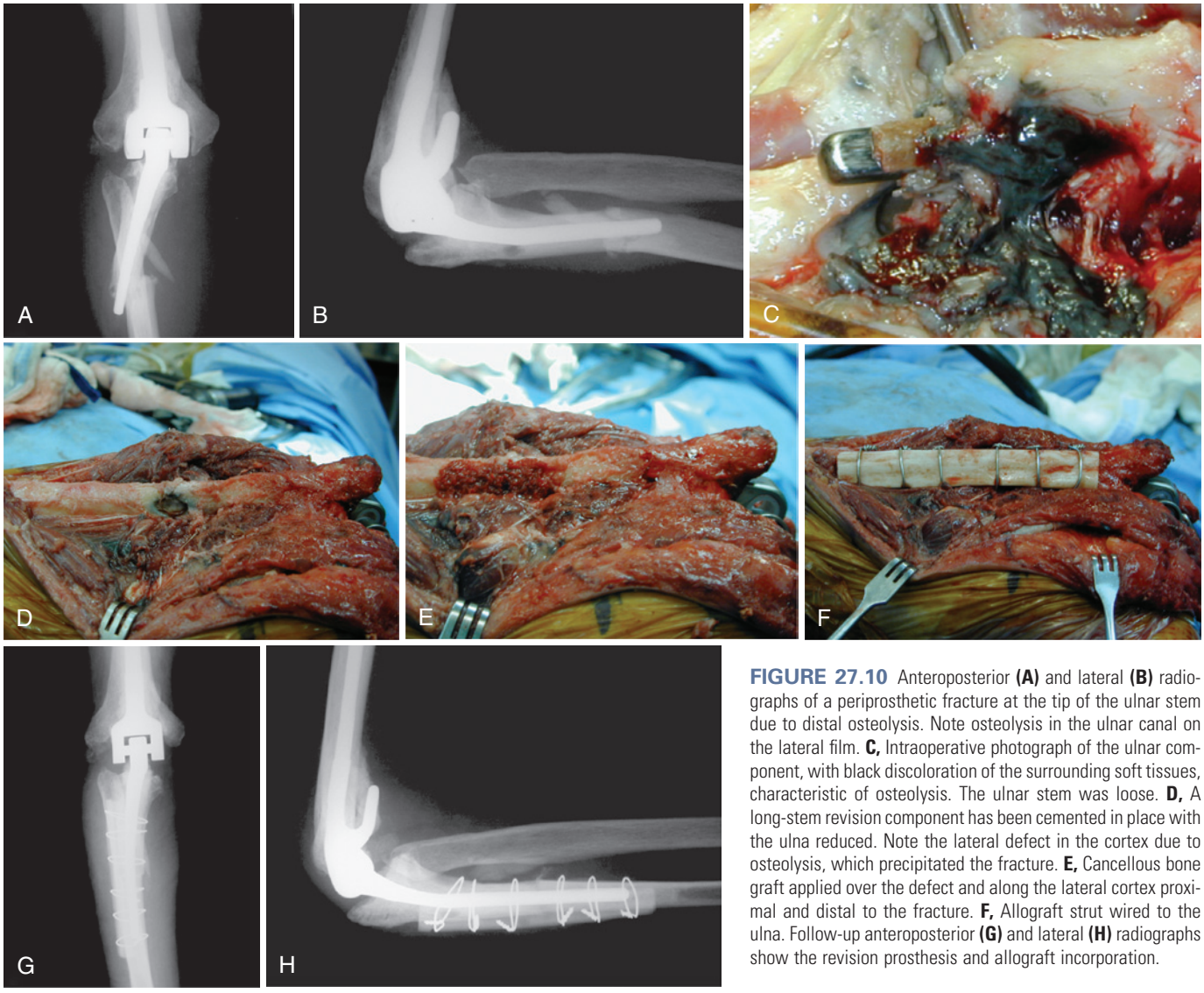

FIGURE 27.10 Anteroposterior **(A)** and lateral **(B)** radiographs of a periprosthetic fracture at the tip of the ulnar stem due to distal osteolysis. Note osteolysis in the ulnar canal on the lateral film. **C,** Intraoperative photograph of the ulnar component, with black discoloration of the surrounding soft tissues, characteristic of osteolysis. The ulnar stem was loose. **D,** A long-stem revision component has been cemented in place with the ulna reduced. Note the lateral defect in the cortex due to osteolysis, which precipitated the fracture. **E,** Cancellous bone graft applied over the defect and along the lateral cortex proximal and distal to the fracture. **F,** Allograft strut wired to the ulna. Follow-up anteroposterior **(G)** and lateral **(H)** radiographs show the revision prosthesis and allograft incorporation.

In the setting of infected TEA, soft tissue coverage in the face of ongoing disease and multiple surgeries may pose additional treatment challenges. Regional or free tissue transfer may be required to provide a stable soft tissue envelope and maximize the potential for preserving elbow function. We have found the flexor carpi ulnaris pedicle flap to be effective in providing vascularized coverage for the posterior elbow (see Figure 27.3).[51] Larger defects can be treated with a scapular flap, periscapular flap, or pedicled latissimus flap. It is important to educate the patient about protecting the flap as it is insensate and susceptible to pressure injuries.

For chronic deep infections following TEA, resection arthroplasty is probably the only viable option. It is clearly the treatment of choice for severely debilitated or medically compromised patients, including those who are severely immunocompromised. If the medial and lateral humeral columns are left intact and contoured to encircle the remaining ulna, the patient will likely be left with reasonable stability and a limited pain-free range of motion. An exception to this approach may be elderly, debilitated patients with multiple medical problems and well-fixed components who are asymptomatic and have no systemic signs of infection. These individuals often develop draining sinuses, which decompress the joint. When it is decided to leave an infected prosthesis in place in this specific clinical setting, chronic oral suppressive antibiotics and local wound care are continued indefinitely.

Mortality Rates

Perioperative mortality has been extensively explored with regard to lower extremity arthroplasty but has not been well researched in TEA. With advancements in prosthetic design and a broadening of operative indications for arthroplasty, such information is vital to the process of informed consent for all arthroplasty patients. The 90-day mortality rate following TEA has been estimated at approximately 0.64%.[37] Risk factors include age older than 60 years, multiple comorbidities, and arthroplasty for the treatment of trauma or nonunion.

CRITICAL POINTS *Total Elbow Arthroplasty*

Indications

Pain, stiffness, and loss of function associated with:

- Rheumatoid arthritis
- Posttraumatic arthritis
- Primary osteoarthritis
- Hemophilic arthropathy
- Comminuted fracture of the distal humerus in an elderly person when osteosynthesis is not possible

Contraindications

- Neuropathic joint
- Poor soft tissue coverage
- Presence of infection at the elbow

Technical Points

Exposure Through Full-Thickness Fasciocutaneous Flaps Posteriorly

- Transpose ulnar nerve
- Reflect triceps
- Carefully dissect the Sharpey fibers off the olecranon in a subperiosteal fashion
- Bryan-Morrey approach: elevate triceps from medial to lateral in continuity with anconeus
- Gschwend approach: split triceps muscle and tendon longitudinally and elevate them off of the proximal ulna in the midline
- Triceps-sparing approach (insertion left intact): useful in patients with deficient distal humeral columns (fractures, nonunions)

Humeral Preparation

- Resect the central aspect of the trochlea
- Enter the humeral canal with a bur
- Use cutting guides to prepare the distal humerus
- Evaluate trial implants
- Anterior cortex may need to be deepened to accept the anterior flange of the implant and allow complete seating of the prosthesis

Ulnar Preparation

- Resect tips of olecranon and coronoid process
- Enter canal with a bur, and enlarge it with rasps
- Must appreciate 5 degrees of valgus of the ulnar shaft relative to the sigmoid notch
- Bone at canal entry often limits complete component seating

Trial Components

- Evaluate range of motion
- Use capsular release if needed

Cement

- Thoroughly lavage and dry canals
- Use restrictors in humerus and ulna
- Use thin flexible tubing for retrograde filling
- Use low-viscosity cement (consider antibiotic-laden cement)
- Use cement early in the polymerization process

Repair of Extensor Mechanism

- Use multiple transosseous sutures distally

Closure

- Wound is closed in layers after hemostasis is achieved
- Ulnar nerve is transposed anteriorly
- Drains are optional with adequate hemostasis
- Compressive dressing is applied, and arm is splinted in partial extension

Postoperative Care

- Elevate the elbow and begin intravenous antibiotic therapy
- Begin active and gentle passive range-of-motion exercises at 7 to 10 days (in immunosuppressed or rheumatoid patients with thin, friable skin, the elbow can be immobilized for a longer period to allow soft tissue healing before motion is initiated)
- Protect triceps (if detached) for 6 to 8 weeks
- Use nighttime elbow extension splint in maximal extension to limit potential flexion contracture
- Limit lifting to 5 pounds with operated extremity, indefinitely[23,42]

REFERENCES

1. Athwal GS, Morrey BF: Revision total elbow arthroplasty for prosthetic fractures. *J Bone Joint Surg Am* 88:2017–2026, 2006.
2. Barr JS, Eaton RG: Elbow reconstruction with a new prosthesis to replace the distal end of the humerus. A case report. *J Bone Joint Surg Am* 47:1408–1413, 1965.
3. Burkhart KJ, Nijs S, Mattyasovszky SG, et al: Distal humerus hemiarthroplasty of the elbow for comminuted distal humeral fractures in the elderly patient. *J Trauma* 71:635–642, 2011.
4. Cheung EV, Steinmann SP: Surgical approaches to the elbow. *J Am Acad Orthop Surg* 17:325–333, 2009.
5. Cobb TK, Morrey BF: Total elbow arthroplasty as primary treatment for distal humeral fractures in elderly patients. *J Bone Joint Surg Am* 79:826–832, 1997.
6. Danter MR, King GJ, Chess DG, et al: The effect of cement restrictors on the occlusion of the humeral canal: an in vitro comparative study of 2 devices. *J Arthroplasty* 15:113–119, 2000.
7. Dee R: Total replacement arthroplasty of the elbow for rheumatoid arthritis. *J Bone Joint Surg Br* 54:88–95, 1972.
8. Dee R: Reconstructive surgery following total elbow endoprosthesis. *Clin Orthop Relat Res* 196–203, 1982.
9. Faber KJ, Cordy ME, Milne AD, et al: Advanced cement technique improves fixation in elbow arthroplasty. *Clin Orthop Relat Res* 334:150–156, 1997.
10. Foruria AM, Sanchez-Sotelo J, Oh LS, et al: The surgical treatment of periprosthetic elbow fractures around the ulnar stem following semiconstrained total elbow arthroplasty. *J Bone Joint Surg Am* 93:1399–1407, 2011.
11. Gambirasio R, Riand N, Stern R, et al: Total elbow replacement for complex fractures of the distal humerus. An option for the elderly patient. *J Bone Joint Surg Br* 83:974–978, 2001.
12. Gill DR, Morrey BF: The Coonrad-Morrey total elbow arthroplasty in patients who have rheumatoid arthritis. A ten- to fifteen-year follow-up study. *J Bone Joint Surg Am* 80:1327–1335, 1998.
13. Goldberg SH, Urban RM, Jacobs JJ, et al: Modes of wear after semiconstrained total elbow arthroplasty. *J Bone Joint Surg Am* 90:609–619, 2008.
14. Gschwend N, Simmen BR, Matejovsky Z: Late complications in elbow arthroplasty. *J Shoulder Elbow Surg* 5:86–96, 1996.
15. Jenkins PJ, Watts AC, Norwood T, et al: Total elbow replacement: outcome of 1,146 arthroplasties from the Scottish Arthroplasty Project. *Acta Orthop* 84:119–123, 2013.
16. Johnson EW, Jr, Schlein AP: Vitallium prosthesis for the olecranon and proximal part of the ulna. Case report with thirteen-year follow-up. *J Bone Joint Surg Am* 52:721–724, 1970.
17. Kamineni S, Morrey BF: Distal humeral fractures treated with noncustom total elbow replacement. *J Bone Joint Surg Am* 86:940–947, 2004.
18. Kjaersgaard-Andersen P, Christiansen SE, Ingerslev J, et al: Total knee arthroplasty in classic hemophilia. *Clin Orthop Relat Res* 256:137–146, 1990.
19. Kudo H, Iwano K: Total elbow arthroplasty with a non-constrained surface-replacement prosthesis in patients who have rheumatoid arthritis. A long-term follow-up study. *J Bone Joint Surg Am* 72:355–362, 1990.
20. Kudo H, Iwano K, Nishino J: Cementless or hybrid total elbow arthroplasty with titanium-alloy implants. A study of interim clinical results and specific complications. *J Arthroplasty* 9:269–278, 1994.

21. Larsen A, Dale K, Eek M: Radiographic evaluation of rheumatoid arthritis and related conditions by standard reference films. *Acta Radiol Diagn (Stockh)* 18:481–491, 1977.
22. Lee BP, Adams RA, Morrey BF: Polyethylene wear after total elbow arthroplasty. *J Bone Joint Surg Am* 87:1080–1087, 2005.
23. Lehtinen JT, Kaarela K, Kauppi MJ, et al: Bone destruction patterns of the rheumatoid elbow: a radiographic assessment of 148 elbows at 15 years. *J Shoulder Elbow Surg* 11:253–258, 2002.
24. Mansat P, Morrey BF: Semiconstrained total elbow arthroplasty for ankylosed and stiff elbows. *J Bone Joint Surg Am* 82:1260–1268, 2000.
25. McKee MD, Pugh DM, Richards RR, et al: Effect of humeral condylar resection on strength and functional outcome after semiconstrained total elbow arthroplasty. *J Bone Joint Surg Am* 85:802–807, 2003.
26. Morrey BF, Bryan RS: Complications of total elbow arthroplasty. *Clin Orthop Relat Res* 170:204–212, 1982.
27. Morrey BF, Bryan RS: Revision total elbow arthroplasty. *J Bone Joint Surg Am* 69:523–532, 1987.
28. O'Driscoll SW, An KN, Korinek S, et al: Kinematics of semi-constrained total elbow arthroplasty. *J Bone Joint Surg Br* 74:297–299, 1992.
29. O'Driscoll SW, Morrey BF: Periprosthetic fractures about the elbow. *Orthop Clin North Am* 30:319–325, 1999.
30. Park SE, Kim JY, Cho SW, et al: Complications and revision rate compared by type of total elbow arthroplasty. *J Shoulder Elbow Surg* 22:1121–1127, 2013.
31. Peterson LF, Janes JM: Surgery of the rheumatoid elbow. *Orthop Clin North Am* 2:667–677, 1971.
32. Pritchard RW: Anatomic surface elbow arthroplasty. A preliminary report. *Clin Orthop Relat Res* 179:223–230, 1983.
33. Prokopis PM, Weiland AJ: The triceps-preserving approach for semiconstrained total elbow arthroplasty. *J Shoulder Elbow Surg* 17:454–458, 2008.
34. Ray PS, Kakarlapudi K, Rajsekhar C, et al: Total elbow arthroplasty as primary treatment for distal humeral fractures in elderly patients. *Injury* 31:687–692, 2000.
35. Rydholm U, Tjornstrand B, Pettersson H, et al: Surface replacement of the elbow in rheumatoid arthritis. Early results with the Wadsworth prosthesis. *J Bone Joint Surg Br* 66:737–741, 1984.
36. Sanchez-Sotelo J, O'Driscoll S, Morrey BF: Periprosthetic humeral fractures after total elbow arthroplasty: treatment with implant revision and strut allograft augmentation. *J Bone Joint Surg Am* 84:1642–1650, 2002.
37. Sanchez-Sotelo J, Sperling JW, Morrey BF: Ninety-day mortality after total elbow arthroplasty. *J Bone Joint Surg Am* 89:1449–1451, 2007.
38. Schlein AP: Semiconstrained total elbow arthroplasty. *Clin Orthop Relat Res* 121:222–229, 1976.
39. Schneeberger AG, Adams R, Morrey BF: Semiconstrained total elbow replacement for the treatment of post-traumatic osteoarthrosis. *J Bone Joint Surg Am* 79:1211–1222, 1997.
40. Schuind F, O'Driscoll S, Korinek S, et al: Loose-hinge total elbow arthroplasty. An experimental study of the effects of implant alignment on three-dimensional elbow kinematics. *J Arthroplasty* 10:670–678, 1995.
41. Shi LL, Zurakowski D, Jones DG, et al: Semiconstrained primary and revision total elbow arthroplasty with use of the Coonrad-Morrey prosthesis. *J Bone Joint Surg Am* 89:1467–1475, 2007.
42. Sneppen O, Fredensborg N, Karle A, et al: Lateral dislocation of the patella following Marmor and Guepar arthroplasty of the knee. *Acta Orthop Scand* 49:291–294, 1978.
43. Soni RK, Cavendish ME: A review of the Liverpool elbow prosthesis from 1974 to 1982. *J Bone Joint Surg Br* 66:248–253, 1984.
44. Stokdijk M, Nagels J, Garling EH, et al: The kinematic elbow axis as a parameter to evaluate total elbow replacement: A cadaver study of the iBP elbow system. *J Shoulder Elbow Surg* 12:63–68, 2003.
45. Tanaka E, Saito A, Kamitsuji S, et al: Impact of shoulder, elbow, and knee joint involvement on assessment of rheumatoid arthritis using the American College of Rheumatology Core Data Set. *Arthritis Rheum* 53:864–871, 2005.
46. Throckmorton T, Zarkadas P, Sanchez-Sotelo J, et al: Failure patterns after linked semiconstrained total elbow arthroplasty for posttraumatic arthritis. *J Bone Joint Surg Am* 92:1432–1441, 2010.
47. Trail IA, Nuttall D, Stanley JK: Survivorship and radiological analysis of the standard Souter-Strathclyde total elbow arthroplasty. *J Bone Joint Surg Br* 81:80–84, 1999.
48. Venable CS: An elbow and an elbow prosthesis; case of complete loss of the lower third of the humerus. *Am J Surg* 83:271–275, 1952.
49. Wolfe SW, Figgie MP, Inglis AE, et al: Management of infection about total elbow prostheses. *J Bone Joint Surg Am* 72:198–212, 1990.
50. Wright TW, Hastings H: Total elbow arthroplasty failure due to overuse, C-ring failure, and/or bushing wear. *J Shoulder Elbow Surg* 14:65–72, 2005.
51. Wysocki RW, Gray RL, Fernandez JJ, et al: Posterior elbow coverage using whole and split flexor carpi ulnaris flaps: a cadaveric study. *J Hand Surg [Am]* 33:1807–1812, 2008.
52. Yamaguchi K, Adams RA, Morrey BF: Infection after total elbow arthroplasty. *J Bone Joint Surg Am* 80:481–491, 1998.
53. Yamaguchi K, Adams RA, Morrey BF: Semiconstrained total elbow arthroplasty in the context of treated previous infection. *J Shoulder Elbow Surg* 8:461–465, 1999.

28

Compression Neuropathies

Susan E. Mackinnon and Christine B. Novak

Acknowledgment: We would like to acknowledge Robert M. Szabo, MD, and William W. Eversmann, Jr., MD, for their contributions to the chapter on this subject in previous editions of this textbook.

These videos may be found at *ExpertConsult.com*:

28.1 Carpal tunnel release—standard *(Courtesy Washington University of St. Louis, School of Medicine.)*
28.2 Carpal tunnel release—extended *(Courtesy Washington University of St. Louis, School of Medicine.)*
28.3 Median nerve forearm decompression—standard *(Courtesy Washington University of St. Louis, School of Medicine.)*
28.4 Median nerve release in the forearm *(Courtesy Washington University of St. Louis, School of Medicine.)*
28.5 Guyon canal and carpal tunnel release—standard *(Courtesy Washington University of St. Louis, School of Medicine.)*
28.6 Submuscular ulnar nerve transposition—standard *(Courtesy Washington University of St. Louis, School of Medicine.)*
28.7 Transmuscular ulnar nerve transposition *(Courtesy Washington University of St. Louis, School of Medicine.)*
28.8 Posterior interosseous nerve release *(Courtesy Washington University of St. Louis, School of Medicine.)*
28.9 Revision carpal tunnel release *(Courtesy Washington University of St. Louis, School of Medicine.)*
28.10 Revision carpal tunnel release, part I *(Courtesy Washington University of St. Louis, School of Medicine.)*

Compression neuropathies in the upper extremity are common and are being recognized with increasing frequency. The rising prevalence of obesity in North America coupled with an aging population suggests that the problems of upper extremity compression neuropathy will likely increase in the next decade. The etiologic relationship between nerve compression disorders and occupation was extremely controversial in the 1990s.[31,68] The existence of multiple levels of nerve compression is now generally recognized, although the contributions of work-related issues of these problems is still debated.[90] Except for significant exposure to vibration and some specific occupations with a high prevalence of carpal tunnel syndrome, it is generally accepted that work is just one component of many factors that contribute to and aggravate compression neuropathy.[6,90] When compared with other compression neuropathies in the upper extremity, carpal tunnel syndrome is, in general, managed less successfully with nonoperative treatment.

Surgeons treating nerve compression in the upper extremity must be aware of other neurologic problems, such as brachial plexus neuritis, Parsonage-Turner syndrome, mononeuritis, and motor neuropathies that can mimic entrapment neuropathies and will not respond to surgical intervention. Similarly, there exists a group of individuals who are genetically sensitive to the development of nerve compression. The prevalence of genetic predisposition is unknown but may help to explain some clinical manifestations of entrapment neuropathy, as do systemic factors such as obesity, diabetes, and thyroid disease.

PATHOPHYSIOLOGY OF CHRONIC NERVE COMPRESSION

The clinical findings in patients with chronic nerve compression are variable and reflect the broad spectrum of histopathologic changes that occur in the nerve. Because of associated morbidity, biopsy of neural tissue is not performed, and much of the information known about the histopathology of human nerve compression has been extrapolated from animal models. Some studies have suggested neural ischemia as contributing to compression neuropathies.[26,54] Many of these studies, however, reflect acute changes that occur with compression. Several animal models have been described in which different techniques are used to induce chronic nerve compression.[62,87] Although there is some concern about the potential for silicone tubes to induce reactive effects on a nerve, the histologic changes seen in the silicone tube cuff model are essentially identical to those noted in the few histologic studies of chronic nerve compression that have been published. Studies have shown limited tissue reaction around the tubes 1 year after human nerve repair.

The continuum of neural changes that will take place depends on the force and duration of the compression. The histopathologic changes that occur with chronic nerve compression begin with breakdown of the blood-nerve barrier, followed by endoneurial edema and, subsequently, perineurial thickening (Figure 28.1).[62,87] Increased endoneurial pressure will result in changes in the microneural circulation and render

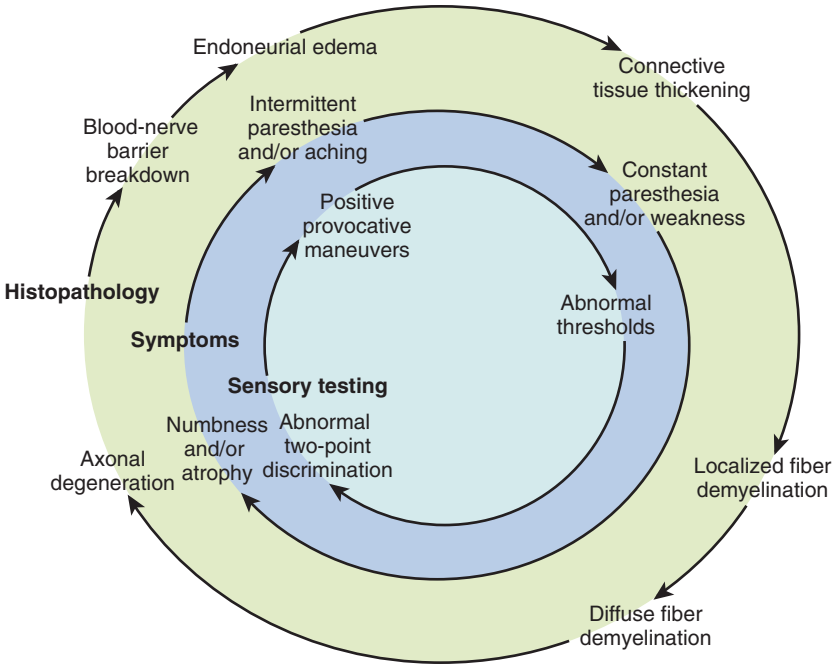

FIGURE 28.1 The histopathologic findings of chronic nerve compression span a spectrum of changes that begins with breakdown of the blood-nerve barrier and, with continued compression, progression to axonal degeneration. The patient's signs and symptoms and sensory testing will parallel the histopathologic changes occurring in the nerve.

the nerve susceptible to dynamic ischemia. With increased compression, there will be localized demyelination, followed by more diffuse demyelination and finally axonal degeneration. Neural changes may not occur uniformly across the nerve and may vary depending on the distribution of compressive forces across the nerve. Superficial fascicles will undergo changes sooner and may result in varying patient symptoms within a single nerve distribution.[52] For example, in early carpal tunnel syndrome the superficial fascicles to the long finger and ring finger are usually affected before the fascicles to the thumb and radial side of the index finger.

Patient sensory complaints will generally parallel the histopathologic neural changes and will progress from intermittent paresthesia to persistent numbness (see Figure 28.1). Sensory testing will also vary with the degree of nerve compression. Initially, patients will have altered threshold measures, and with more severe nerve compression, they will progress to deficits in two-point discrimination.

Double-Crush Mechanism

First introduced by Upton and McComas,[111] the double-crush mechanism is an important concept in nerve compression. In their clinical review of 115 patients with median or ulnar nerve compression, 81 had evidence of a cervical root lesion, and they concluded that compression of a nerve at one level will make the nerve more susceptible to damage at another level. The authors hypothesized that axoplasmic flow would be compromised by proximal compression on the nerve and then be further compromised by the distal compression site. The reverse double-crush syndrome was described by Lundborg.[52] He hypothesized that a distal site of compression would decrease the flow of neurotrophic substances back to the neuron and thus decrease the production of substances to be transported distally. Other clinical studies have supported the double-crush mechanism with associations between the cervical spine, thoracic outlet, and distal sites of compression, including the carpal and cubital tunnels. Hurst and associates reported on 1000 cases of carpal tunnel syndrome in 888 patients and noted a significant relationship between bilateral carpal tunnel syndrome and patients with cervical arthritis and diabetes.[37] Other studies have reported similar findings with cervical radiculopathy, thoracic outlet syndrome, and distal nerve entrapment in the arm.

Animal models demonstrating the double-crush mechanism have been described.[20,79] Using a canine model, Nemoto and colleagues placed compression clamps on the sciatic nerve and evaluated conduction velocity.[79] Placement of a second clamp at a proximal site reduced motor conduction velocity to a value less than that in both the normal state and the clamped state. This study also evaluated the effect of removing the sequential compression clamps 3 weeks later. Removal of both clamps improved motor conduction velocity to 65% of the original value, whereas removal of only one clamp improved conduction velocity to a lesser amount. Dellon and Mackinnon developed a rodent model that simulated sciatic nerve compression with silicone tubes.[20] In one of three groups of animals the silicone tube was placed proximal to the sciatic nerve trifurcation (group 1), in the second group the tube was placed on the tibial nerve distal to the trifurcation (group 2), and in the third group, tubes were placed simultaneously on the sciatic nerve and the peroneal nerve. In groups 1 and 2 after 7 months, a second tube was placed on the nerve (on the tibial nerve in group 1 and proximal to the sciatic nerve trifurcation in group 2) and no surgery was performed on the double-banded group. After 5

more months, the final electrodiagnostic studies were performed. The addition of a second band either proximally or distally resulted in a decrease in conduction velocity equal to that in the group that received the double bands initially. Because both the proximal and distal second band compromised conduction velocity equally, this study supports the double-crush and the reverse double-crush mechanisms of nerve compression.

Systemic Conditions and Personal Factors

Other medical conditions and personal factors have been associated with carpal tunnel syndrome, including diabetes mellitus, hypothyroidism, excessive alcohol use, obesity, and tobacco use.[39,77,78] When compared with a control group without symptoms of carpal tunnel syndrome, patients with carpal tunnel syndrome demonstrated a higher prevalence of hypothyroidism, diabetes, and obesity.[39] These findings supported previous reports of an increased prevalence of these conditions in patients with carpal tunnel syndrome. In a retrospective case-control study, smoking history did not result in an increased incidence of carpal tunnel syndrome.[39]

Hereditary motor-sensory neuropathy consists of a group of inherited disorders that affect the motor and sensory nerves of the peripheral nervous system, including Charcot-Marie-Tooth disease and hereditary neuropathy with liability to pressure palsies (HNPP). HNPP is an autosomal dominant demyelinating motor-sensory neuropathy. It is characterized by underexpression of the peripheral myelin protein-22 gene on chromosome 17 and is manifested as recurrent, multifocal nerve compression. Patients may have rapid-onset neuropathies after minor trauma with decreased nerve conduction (motor and sensory) in the affected and unaffected nerves. In most cases, recovery is complete without surgery. In the upper extremity, the ulnar nerve is most commonly affected, and in the lower extremity the peroneal nerve is affected. The presence of HNPP should be considered in patients with multiple recurrent neuropathies.

Longitudinal Nerve Mobility

Longitudinal nerve mobility is important for normal nerve function. Although some longitudinal movement is permitted via the plexus formation within a nerve and via the loose attachment of its mesoneurium, damage may occur with excessive or prolonged traction. Venous obstruction has been shown with acute stretching of 8% of a nerve's resting length, and ischemia occurred when it was stretched 15% of its resting length.[55] Watanabe and colleagues investigated nerve strain in a rat model.[114] The authors used the same amount of strain in the continuous and the repetitive strain groups and reported abnormalities in the repetitive strain group as determined by histologic, electrophysiologic, and functional evaluation. They concluded that a small amount of repetitive strain on neural tissue may result in neural dysfunction, particularly in cases with underlying subclinical nerve pathologic findings.

Studies have shown evidence of strain on the median and ulnar nerves during median and ulnar nerve tension tests and reported restriction of median nerve excursion in patients with carpal tunnel syndrome. Nerve compression may induce connective tissue and synovial thickening that may secondarily result in restriction of neural mobility with joint motion.[76,105]

Authors' Opinion

Much of the controversy associated with nerve compression is related to patients with diffuse symptoms and to the relationship of occupation to nerve compression disorders. Certain postures and positions may contribute to nerve compression. It is well accepted that wrist positions of moderate flexion and extension will increase pressure within the carpal canal, and this is hypothesized to contribute to carpal tunnel syndrome.[25,117] Similarly, elbow flexion will increase pressure within the cubital tunnel and thereby compromise the ulnar nerve.[26,93] However, these postures and positions will not only have an impact on the nerve but may also affect the surrounding musculature (Figure 28.2).[67] We believe that prolonged or extreme postures

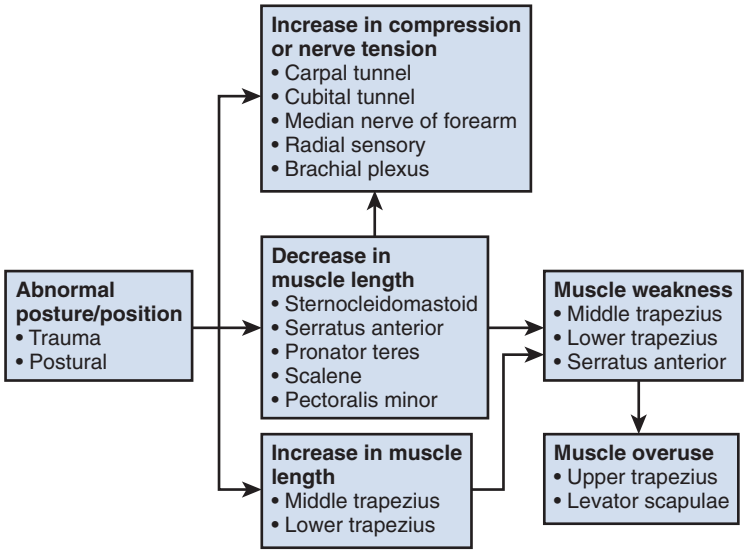

FIGURE 28.2 Abnormal postures or positions will have three main effects: (1) nerves may be compressed or placed on tension and progress to chronic nerve compression, (2) muscles may be placed in shortened positions and then secondarily compress nerves, or (3) muscles in elongated or shortened positions will be weakened and thus underused. Other muscles will compensate for the weakness and be overused, thereby establishing a pattern of muscle imbalance.

or positions will affect the nerves and soft tissues in the upper extremity and cervicoscapular region and that multifocal nerve compression and muscle imbalance can contribute to diffuse upper quadrant patient symptoms.

EVALUATION OF COMPRESSION NEUROPATHIES

To develop an effective treatment plan, it is necessary to identify all sites of nerve compression and the musculoskeletal disorders that are contributing to a patient's symptoms. Different diagnostic tests will yield important information at different stages of nerve compression (see Figure 28.1). Not all tests will be positive at all stages; therefore, it is important to use the assessment tools that will give the most accurate information for identifying a pathologic change or determining the grade severity. A complete sensory and motor evaluation, including electrodiagnostic studies, can determine the severity of nerve compression. In patients with work-related symptoms, detailed consideration should be given to determine the involvement of work as a contributing factor. Use of a subjective pain evaluation questionnaire is helpful to identify all symptomatic areas and other factors that may contribute to a patient's symptoms.[40,47,74] We have found the use of a pain evaluation questionnaire that includes a body diagram, a subjective questionnaire, and visual analog scales to be very useful in the evaluation of patients with nerve compression or diffuse symptoms, or with both (Figure 28.3).

Self-report questionnaires are useful to capture the patient's perception of physical impairment, impact of the condition, and level of disability. A number of validated questionnaires to assess both global upper extremity and specific nerve-related symptoms and disability have been used in the assessment of nerve compression. The carpal tunnel syndrome questionnaire is a disease-specific measure that allows specific items related to carpal tunnel syndrome to be assessed from the patient's perspective and has been shown to be reliable, valid, and sensitive to change.[2,23,30,34,45,47] The carpal tunnel syndrome questionnaire assesses symptom severity (11 items) and functional status (8 items). Each item is ranked on a Likert scale (1 is the low level and 5 is the high level of symptoms or difficulty), and the higher mean values indicate decreased status. The most commonly used generic upper extremity measure for disability is the Disabilities of the Arm, Shoulder, and Hand (DASH) score; using a standardized 30 items allows for comparison of upper extremity conditions.[35] Upper extremity disability is assessed based upon physical symptoms and functional status; each item is ranked from 1 to 5. Scores are calculated, and higher scores indicate higher levels of disability. The Michigan Hand Outcomes Questionnaire (MHQ) is a longer questionnaire (67 items) and has the capability of addressing specific domains of overall hand function, physical function, cosmesis, and satisfaction.[15] Similar to the DASH, each item is scored on a Likert scale (1 to 5), but in contrast to the DASH, the MHQ assesses function of each upper extremity (independent use, hand dominance, and bilateral involvement). Although standardized item questionnaires provide the opportunity to compare scores and answers between patients and conditions, these generic questionnaires may not reflect specific changes in each patient or the items that are most important to each patient. Questionnaires such as the Patient-Specific Functional Scale (PSFS) assesses items that are identified by each patient. In this assessment each patient identifies three activities or tasks that the patient finds difficult or impossible to perform.[102] Each item is ranked on a scale from 0 to 10 and anchored based on perceived ability to perform these separate activities. Good validity, reliability, and responsiveness have been shown in patients with upper extremity disorders.[33,73] Although the PSFS allows patients to select items that are specifically relevant, comparison between patients is more challenging. Combined use of generic questionnaires such as the DASH, MHQ, and our pain evaluation questionnaire in combination with the PSFS may provide a more comprehensive self-report evaluation.

For successful management, evaluation and treatment should be directed at all levels of nerve compression and any soft tissue disorders that are present.

Use of Provocation Tests

Many signs and provocation tests have been described for clinical evaluation of carpal tunnel syndrome.[57,94,95] The concept of increasing tension or compression on a nerve to assess for nerve compression at the carpal tunnel may be extrapolated to other sites of nerve compression in the upper extremity. The concept of the double-crush mechanism is important in the assessment of patients with suspected upper extremity nerve compression. Because one site of nerve compression may affect other sites of nerve compression, all potential entrapment sites of nerve compression should be evaluated.

Provocation tests involving direct pressure or joint movement to increase compression on the nerve can be performed (Table 28.1). Beginning at the more distal sites and advancing proximally, a *Tinel sign* or a *nerve percussion test* is performed by applying repeated digital percussion at each potential entrapment site (carpal tunnel, median nerve in the forearm, cubital tunnel, radial sensory nerve, brachial plexus). The test is considered positive with radiation of a tingling sensation into the affected nerve's sensory neural distribution. In patients who are hyperresponsive to stimuli or have positive nerve percussion test results at multiple entrapment sites, it is helpful to perform a nerve percussion test at points where nerves are not anatomically located as a negative control. Similarly, all provocative tests are done in both upper extremities in all patients, even in those with symptoms in only one upper extremity.

The *Phalen test* uses wrist flexion to increase pressure on the median nerve and is a common provocation test for assessment of carpal tunnel syndrome.[94,95] Since first described in 1966, a number of provocation tests using position or pressure, or both, to increase compression on the nerve have been reported.[18,57,120] Provocation tests should be maintained for 1 minute and are considered positive when symptoms are reproduced in the appropriate neural distribution. To correctly identify a site of chronic nerve compression, it is important to compress only one nerve entrapment site with each test. Pressure provocation can be performed to assess the median nerve at the carpal tunnel by placing the wrist in either flexion or extension and then applying digital pressure just proximal to the carpal tunnel. In patients with restricted wrist movement, the pressure provocative test can be done with the wrist in a neutral position. Because the median nerve and the ulnar nerve can be compressed in this position, sensory alteration in the median and

Pain Questionnaire

Name:_____ Date:_____

Age:___Sex: Male_ Female_ Dominant hand: Right_ Left_ Diagnosis:_____

1. Pain is difficult to describe. Circle the words that best describe your symptoms.

Burning	Throbbing	Aching	Stabbing	Tingling	Twisting	Squeezing
Cramping	Cutting	Shooting	Numbing	Vague	Stinging	Indescribable
Pulling	Smarting	Pressure	Coldness	Dull	Other: _____	

Level of symptoms: place a mark through the line to indicate the level of your pain, if zero is no pain and the end of the line is the most severe pain you can imagine having.

For Example: No pain — Most severe pain

2. Mark your average level of pain in the last month

No pain — Most severe pain

3. Mark your worst level of pain in the last week

Right: No pain — Most severe pain

Left: No pain — Most severe pain

4. Where is your pain? (draw on diagram)

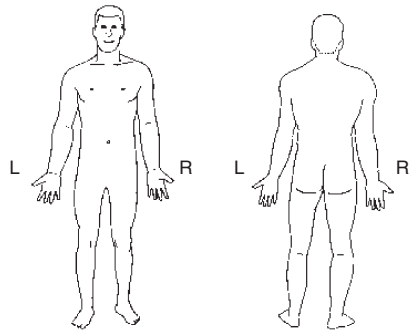

5. Mark your average level of stress in the last month.

at home: 0 — 10

at work: 0 — 10

6. How well are you able to cope with that stress?

at home: Very well — Not at all

at work: Very well — Not at all

7. How did the pain that you are now experiencing occur?
   a. Sudden onset with accident or definable event
   b. Slow progressive onset
   c. Slow progressive onset with acute exacerbation without an accident or definable event
   d. A sudden onset without an accident or definable event

8. How many surgical procedures have you had **in order to eliminate the cause of your pain**?
   a. None or one
   b. Two surgical procedures
   c. Three or four surgical procedures
   d. Greater than four surgical procedures

9. Does movement have any effect on your pain?
   a. The pain is always worsened by use or movement
   b. The pain is usually worsened by use and movement
   c. The pain is not altered by use and movement

10. Does weather have any effect on your pain?
    a. The pain is usually worse with damp or cold weather.
    b. The pain is occasionally worse with damp or cold weather.
    c. Damp or cold weather has no effect on the pain.

11. Do you ever have trouble falling asleep or awaken from sleep?
    a. No - Proceed to Question 12 b. Yes - Proceed to 11A & 11B

    11A. How often do you have trouble falling asleep?
    a. Trouble falling asleep every night due to pain
    b. Trouble falling asleep due to pain most nights of the week
    c. Occasionally having difficulty falling asleep due to pain
    d. No trouble falling asleep due to pain
    e. Trouble falling asleep which is not related to pain

    11B. How often do you awaken from sleep?
    a. Awakened by pain every night
    b. Awakened from sleep by pain more than 3 times per week
    c. Not usually awakened from sleep by pain
    d. Restless sleep or early morning awakening with or without being able to return to sleep, both unrelated to pain

12. Has your pain affected your intimate personal relationships?
    a. No b. Yes

13. Are you involved in any legal action regarding your physical complaint?
    a. No b. Yes

14. Is this a Workers' Compensation case?
    a. No b. Yes

15. Are you presently receiving psychiatric treatment?
    a. No b. Yes c. Previous psychiatric treatment

16. Have you ever thought of suicide?
    a. No b. Yes c. Previous suicide attempts

17. Are you a victim of emotional abuse?
    a. No b. Yes c. No comment

18. Are you a victim of physical abuse?
    a. No b. Yes c. No comment

19. Are you a victim of sexual abuse?
    a. No b. Yes c. No comment

20. Are you presently a victim of abuse?
    a. No b. Yes c. No comment

21. If you are retired, a student, or a homemaker, proceed to Question 21B.
    21A. Are you still working?
    a. Working every day at the same job I had before pain developed
    b. Working every day but the job is not the same as the job I had before pain developed; I now have reduced responsibility and physical activity
    c. Working occasionally
    d. Not presently working
    21B. Are you able to do your household chores?
    a. Do same level of household activities without discomfort
    b. Do same level of household chores with discomfort
    c. Do a reduced amount of household chores
    d. Most household chores are now performed by others

22. What medications have you used in the past month?
    a. No medications
    b. List medications:_____

23. If you had three wishes for anything in the world, what would you wish for?
    1. _____
    2. _____
    3. _____

0% — 100%

FIGURE 28.3 The pain evaluation questionnaire consists of pain adjectives, a body diagram, a questionnaire, and visual analog scales scored from 0 to 10 for pain, stress, and coping. Patients who select more than three adjectives, draw a pain pattern that does not follow a known anatomic pattern, or score more than 20 on the questionnaire are considered positive for that component. Patients who score positive in more than two components are considered for psychological or psychiatric evaluation before any surgical intervention. (Modified from Hendler N, Viernstein M, Gucer P, et al: A preoperative screening test for chronic back pain patients, *Psychosomatics* 20:801–808, 1979; Mackinnon SE, Dellon AL: *Surgery of the peripheral nerve,* New York, Thieme Medical, 1988; and Melzack R: The McGill pain questionnaire: major properties and scoring methods, *Pain* 1:277–299, 1975.)

Continued

PAIN EVALUATION SCORE SHEET

Name: _____ Date: _____

DOB: _____ Age: ____ Sex: M __ F __ Dominant Hand: R __ L __

Diagnosis: _____

1. Number of Descriptors: ___

2. Pain Level: on average ___ 3. Pain level: worst right ___ left ___

4. Body Diagram: _____

5. Stress Level: home ___ work ___ 6. Coping Level: home ___ work ___

7. a. 0 b. 0 c. 3 d. 4	8. a. 0 b. 2 c. 3 d. 4	9. a. 0 b. 2 c. 3	10. a. 0 b. 2 c. 3	11. a. 3 b. 0	11A. a. 0 b. 1 c. 2 d. 3 e. 4	11B. a. 0 b. 1 c. 3 d. 4
12. a. 0 b. 2	13. a. 0 b. 3	14. a. 0 b. 2	15. a. 0 b. 4 c. 2	16. a. 0 b. 2 c. 5	17. a. 0 b. 5 c. 3	18. a. 0 b. 5 c. 3
19. a. 0 b. 5 c. 3	20. a. 0 b. 5 c. 3	21A. a. 0 b. 0 c. 2 d. 3	21B. a. 0 b. 0 c. 2 d. 3	22. a. 0 b. 1 Valium c. 2 Narcotic d. 3 Psychotropic or antidepressant drugs	23. a. 0 No pain only wish b. 1 No pain one of wishes c. 2 Wishes only of personal nature d. 3 Wishes of nonpersonal nature (i.e., world peace)	

Total: _____

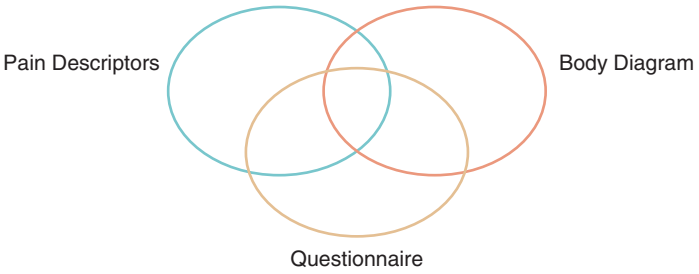

FIGURE 28.3, cont'd

TABLE 28.1 Provocative Tests for Nerve Compression

Nerve	Entrapment Site	Provocative Test	Conservative Management
Median	Carpal tunnel	Pressure proximal to the carpal tunnel Phalen test Reverse Phalen test (hyperextension of the wrist)	Splint the wrist in neutral position at night
	Proximal forearm	Pressure over the proximal forearm in the region of the pronator teres with the forearm in supination Resisted elbow flexion, pronation, and finger flexion	Use stretching exercises for the pronator teres
Ulnar	Guyon canal	Pressure proximal to Guyon canal Reverse Phalen test	Splint the wrist in neutral position at night
	Cubital tunnel	Elbow flexion and pressure proximal to the cubital tunnel	Educate about the elbow pad, positioning in elbow extension, and decreasing direct pressure on the nerve
Radial (posterior interosseous)	Arcade of Fröhse	Pressure over the supinator Resisted supination Resisted long-finger and wrist extension	Position in supination and avoid repetitive pronation and supination activities
Radial (sensory)	Forearm	Pressure over the junction of the brachioradialis/extensor carpi radialis tendon Forearm pronation with wrist ulnar flexion	Avoid repetitive pronation and supination activities
Brachial plexus	Supraclavicular	Elevation of arms above the head Pressure over the brachial plexus in the interscalene region	Avoid provocative positions Stretch shortened muscles and strengthen weakened scapular stabilizers

ulnar nerve distribution may be reported and should be documented. To evaluate the median nerve in the forearm, the patient's forearm is placed in full supination with full elbow extension, and digital pressure is applied to the median nerve in the region of the pronator teres muscle. A positive response is noted with sensory alteration in the median nerve distribution. To evaluate the cubital tunnel, the elbow is placed in full flexion with neutral forearm rotation and the wrist in neutral. Digital pressure is placed on the ulnar nerve just proximal to the cubital tunnel.[80] The position of the ulnar nerve should also be evaluated because subluxation of the ulnar nerve over the medial epicondyle may occur in some patients. The radial sensory nerve is evaluated by placing the wrist in flexion and ulnar deviation and the forearm in a pronated position. Compression of the brachial plexus at the thoracic outlet should also be screened by having the patient raise both arms overhead and noting reproduction of the patient's symptoms in the hands.[83] Pain in the shoulder region is not considered predictive of brachial plexus nerve compression, and further evaluation of the shoulder is indicated.

Cervical nerve root impingement is assessed clinically with the *Spurling test*.[108] This foraminal nerve root encroachment test is performed by placing the patient's cervical spine in slight extension and lateral flexion. Axial compression is then applied to the patient's head, and if a "spray" of symptoms into the arm is reported, it is considered positive for nerve root compression. The test is repeated with lateral flexion to the contralateral side. Tong and colleagues evaluated 255 patients and found the Spurling test to have a sensitivity of 30% and a specificity of 93%.[108] This study would suggest that the test correctly identifies patients with no cervical radiculopathy but is not an effective screening test to identify patients with cervical radiculopathy. Therefore, in a patient with symptoms suggesting involvement of the cervical spine and a negative response to the Spurling test, further cervical spine radiologic investigation may be indicated.

The *scratch collapse test* is another clinical test that may be used to identify a site of nerve compression and has been shown to have good psychometric properties.[9,13,28] This test is unique in that it uses a response independent of the sites of compression in the upper extremity. A positive response relies on the loss of muscle strength (shoulder external rotation) and therefore provides an outcome unrelated to the site of nerve compression. This test has been shown to have good positive and negative predictive value in the assessment of patients with carpal and cubital tunnel syndrome with abnormal nerve conduction studies.[13] However, this test is particularly useful in patients with diffuse symptoms, multiple levels of nerve compression, and normal nerve conduction studies. For examination with the scratch collapse test, the examiner is positioned in front of the patient with arms in neutral shoulder rotation, 90 degrees of elbow flexion, wrists in neutral position, and fingers extended. The examiner assesses isometric shoulder external rotation strength by applying a force to both forearms, and the patient applies an equal resisted force of external shoulder rotation to maintain the arms in a static position. The skin over the site of nerve compression to be assessed is lightly scratched and a similar force is applied to the forearms to resist isometric shoulder external rotation. A loss of shoulder external rotation strength will result in "collapse" of the arm toward the abdomen. This is a positive response and indicative of nerve compression at the site of provocation. Each site of nerve compression may be assessed independently.

Shoulder and Scapular Movement Examination

Examination of the shoulder and evaluation of scapular movement patterns are important components of the physical examination of patients complaining of upper extremity pain.[41,67,99] Abnormal postures of the neck, shoulder, and scapular region are frequently associated with muscle imbalance, especially weakness of the serratus anterior and middle/lower trapezius muscles. To evaluate the strength of the serratus anterior muscles, the patient is asked to flex the shoulders forward while raising the arms above the head. Scapular position and movement are noted with the movement and at end range of motion. As the arms are slowly lowered, the examiner looks for any winging of the scapula to evaluate for serratus anterior strength. Similarly, to evaluate trapezius muscle strength, the patient is asked to abduct the shoulders and raise the arms above the head and then slowly lower the arms (in the coronal plane) as the examiner looks for winging of the scapula.

Compression of the mixed motor/sensory nerves in the upper extremity will produce symptoms of paresthesia and numbness. By contrast, aching pain and arm fatigue symptoms are associated more with muscle imbalance. Pure motor nerve compression (e.g., long thoracic, suprascapular, dorsal scapular, spinoaccessory nerve) can present with the above symptoms and atrophy. In patients with these symptoms, if examination of the scapular position and movement indicates weakness of the serratus anterior and middle/lower trapezius muscles, this should be further evaluated and treated. Similarly, if the patient has associated rotator cuff tendinitis or shoulder impingement, the symptoms will also be reflected in upper extremity discomfort. Examination of the shoulder for these problems is likewise important.

Sensory Evaluation

Even though provocation of the nerve can help identify sites of nerve compression, it does not quantify sensory function. Many instruments and assessment devices have been described for evaluation of sensibility, but no single test has been accepted as the gold standard. This in part relates to the varying capacities of the sensory tests to evaluate different parameters of nerve function.

The four sensory receptors that are found in the glabrous skin of the hand are categorized by differing receptive field size and response qualities. The slowly adapting receptors (Merkel cell neurite complex and Ruffini end-organs) respond to static touch, whereas the quickly adapting receptors (Meissner and Pacinian corpuscles) respond to moving touch. The threshold and tactile discrimination of the quickly and slowly adapting receptors can be evaluated. Threshold is the minimum stimulus required to elicit a response and is assessed with vibration thresholds (quickly adapting receptors) and with cutaneous pressure thresholds (slowly adapting receptors). Tactile discrimination reflects the number of innervated sensory receptors and is assessed with moving and static two-point discrimination. Vibration and cutaneous pressure thresholds will permit quantification of the early changes that occur with chronic nerve compression. Changes in sensory receptor innervation

density will occur in the later stages of chronic nerve compression, and therefore two-point discrimination measures will become abnormal only in the more severe stages of nerve compression.

Light Moving Touch

Quick screening of the large A-beta fibers can be performed with the *ten test*.[103] Introduced by Strauch and coworkers, the ten test allows patients to rank their sensation of light moving touch on a scale from 0 to 10 in comparison with the normal contralateral area.[103] Good reliability and validity were reported when compared with Semmes-Weinstein monofilament testing. In patients with carpal tunnel syndrome, Patel and Bassini reported the ten test to be more sensitive than the Weinstein Enhanced Sensory Test and two-point discrimination.[92] For assessment with the ten test, the examiner applies a light touch and moves the stimulus with a finger to an area of normal sensation on the contralateral digit. A similar stimulus is applied simultaneously to the affected area, and the patient is asked to rank the sensation on a scale from 0 to 10, with 10 being perfect sensation and 0 being no sensation. Although this has proved to be an excellent screening test, it has limited use in patients with systemic sensory neuropathy and bilateral upper extremity nerve compression.

Vibration Thresholds

Vibration can be used to assess the thresholds of quickly adapting receptors. Qualitatively, vibration thresholds may be evaluated with a tuning fork. The tuning fork is applied to the affected and contralateral digit pulp, and the patient is asked to compare the stimuli. Limitations of this test include patient subjective assessment in recalling the applied stimuli and lack of consistent application of the tuning fork by the examiner.

A number of fixed-frequency and variable-frequency vibrometers have been described that permit quantification of vibration thresholds. Although good reliability has been reported with single-frequency vibrometers, the greatest limitation is that only one frequency is assessed. In a study of 130 factory workers, Werner and colleagues did not find single-frequency vibrometry useful as a screening tool for median nerve pathologic conditions.[118] In those with nerve compression, it is hypothesized that perception of the higher frequencies is affected earlier; therefore, evaluation at multiple frequencies may permit earlier identification of sensory loss.[53] However, in a study of patients with brachial plexus nerve compression, vibration thresholds measured at multiple frequencies were not useful in identifying these patients.[17]

Cutaneous Pressure Thresholds

Pressure thresholds of the slowly adapting receptors are commonly evaluated with Semmes-Weinstein monofilaments. These nylon monofilaments vary in diameter and thus differ in application force and produce different pressure thresholds. The set of Semmes-Weinstein monofilaments increases in diameter on a logarithmic scale ($\log_{10}$ force of 0.1 mg). The examiner applies pressure with each successive nylon filament until the filament just begins to bend. The smallest monofilament that the patient can perceive is documented as the pressure threshold. Each monofilament size is associated with a grading of sensory impairment (e.g., normal, diminished light touch, diminished protective sensation). Consistency in monofilament diameter and the testing procedure is necessary to ensure reliability.[46,112] Pressure thresholds have been shown to be sensitive in testing for carpal tunnel syndrome.

Two-Point Discrimination

Two-point discrimination reflects the number of innervated sensory receptors. Initially measured with a paper clip, other instruments such as the Disk-Criminator (Patterson Medical/Sammons Preston, Bolingbrook, IL) have been described for the measurement of static and moving two-point discrimination. Although good reliability has been shown with the Disk-Criminator,[85] alterations in two-point discrimination occur only with advanced nerve compression. Therefore, this is not a very sensitive test for patients with mild chronic nerve compression and may be more appropriate for assessment of recovery after nerve repair. In our clinical experience, two-point discrimination of greater than 8 mm is essentially nonfunctional, and we therefore classify this as "no two-point discrimination." Consequently, in the upper extremity, we have standardized our measurement of moving and static two-point discrimination to include two-point discrimination up to 8 mm.

Electrodiagnostic Studies

Electrodiagnostic studies include electromyography and nerve conduction studies. The tests are not a substitute for a detailed clinical examination by an experienced clinician. Unfortunately, some physicians rely on these studies without recognizing the major limitations of electrodiagnostic examination.[119] A well-performed electromyogram (EMG) and nerve conduction study can complement the clinical evaluation by helping to localize the level and severity of the injury and predict the likelihood of spontaneous regeneration and recovery.

A major limitation of the nerve conduction portion of the electrodiagnostic study is that it evaluates only the large myelinated fibers. This includes the motor axons and sensory axons relaying vibration and light touch but not the smaller axons conveying pain or temperature sensation. The determination of nerve latency reflects the conduction of the best myelinated fibers rather than the most severely affected axons, and normal latency may still be present even when many nerve fibers are affected. In chronic nerve compression, the first alterations that occur in the nerve fiber population are changes in unmyelinated nerve fibers, which cannot be evaluated with electrodiagnostic studies.[63] For example, early symptoms of pain and paresthesia cannot be assessed objectively with electrodiagnostic studies. Another limitation of nerve conduction studies relates to the location of the nerve injury in the extremity. Nerve problems occurring very distally or very proximally in the extremity are difficult to assess. Dynamic changes in blood flow that may produce intermittent alterations in peripheral nerve function may not be detected with electrodiagnostic studies. The timing of nerve conduction studies also influences their utility because even complete nerve transection will not become apparent for 2 to 6 weeks after injury. In situations with more than one level of injury or when a systemic polyneuropathy is present, nerve conduction studies may be less reliable. Although electrodiagnostic studies provide the surgeon with quantifiable values, they are extremely dependent on the expertise of the examiner who performs them.

Electromyography

For the EMG component of the study, needle recording electrodes are inserted into the muscles to evaluate either spontaneous or volitional electrical activity. Muscle response with needle insertion at rest and during activation is noted. A normal muscle will respond with a brief burst of electrical activity on needle insertion (insertional activity). Abnormal insertional activity can include insertional positive sharp waves, as seen with early denervation, or electrical silence, which is associated with chronic muscle degeneration without reinnervation. In the rest phase there will normally be electrical silence, but after nerve injury, spontaneous activity with fibrillation potentials is noted. Fibrillation potentials are the earliest sign of muscle denervation and are generated by muscles after denervation of at least 2 weeks' duration. A single motor axon innervates hundreds to thousands of muscle fibers; thus, fibrillation potentials are the most sensitive indicator of motor axon loss and can be seen in nerve compression syndromes long before there is any clinical evidence of muscle weakness. During the muscle activation portion of the EMG, the patient is instructed to contract the muscle to elicit voluntary motor unit potentials (MUPs). In a normal muscle, because numerous MUPs are activated, individual MUPs cannot be seen and a full interference pattern is noted. With nerve injury, incomplete MUP activation and reduced MUP recruitment are seen. Patients responding with pain or decreased effort can show incomplete MUP activation, but the rate will be slow to moderate. With reduced MUP recruitment because of a peripheral nerve problem, the firing rate will be faster and the configuration will be of increased duration and amplitude. The neurologist doing the EMG will be able to determine chronic neurogenic MUP changes from incomplete MUP activation as seen with upper motor neuron disease or decreased patient effort. MUPs associated with reinnervation will initially be of very low amplitude and extremely polyphasic, and they will fire at a slow to moderate rate. Eventually, they will remodel so that the duration and number of phases decrease and the amplitude increases.

Nerve Conduction Studies

Nerve conduction studies can be used to study motor, sensory, and mixed nerves. Surface electrodes are used to stimulate and record from the nerve. During motor nerve conduction studies, electrodes are placed over the muscle and the motor axons are stimulated proximal to the surface electrode. Motor axons are *indirectly* assessed by the size and configuration of the compound muscle action potentials (CMAPs) that are generated in response to nerve stimulation. Motor nerve conduction studies are characterized by a large-amplitude response, in contrast to sensory nerve conduction studies, in which the sensory axons themselves are directly assessed and the sensory nerve action potential (SNAP) is very small. Sensory nerve function can be assessed in antegrade (orthodromic) or retrograde (antidromic) fashion by placing the recording electrode either proximal or distal to the stimulating electrode, respectively. Because of their small size and low amplitude, SNAPs may be adversely affected by technical problems or by factors such as skin or room temperature. The parameters of nerve conduction studies include wave amplitude, duration, latency, the area of the recorded response, and conduction velocity. Laboratories have their own set of normal values based on age. It is customary for individuals with unilateral neurologic problems to have a drop in amplitude of 50% or more on the symptomatic side as compared with the normal extremity.

Latency is an indirect measure of the speed of impulse conduction along the fastest conducting fibers and is expressed in milliseconds. Sensory nerves are stimulated at one point and recorded at a surface electrode, and the recorded latency is defined as the time elapsed until onset of the peak deflection. Motor latency is defined as the time elapsed between a supramaximal stimulus over the involved nerve and the onset of deflection at the motor point of the innervated muscle.

Amplitude is the height of the action potential expressed in millivolts for motor nerve conduction studies and in microvolts for sensory nerve conduction studies. The amplitude provides an assessment of the number of conducting axons. Amplitudes are more difficult to assess, but because they reflect the number of functioning axons, they may give more information about muscle weakness and paresthesia than latency measurements, which reflect only the fastest conducting fibers. Conduction velocity is calculated by stimulating the nerve at two measured distances and determining the rate of conduction in meters per second between the two points. It is useful when comparing results between subjects with different limb lengths. Diffusely slowed conduction velocity across several nerves may also indicate a systemic peripheral neuropathy. However, conduction velocity reflects the speed of the fastest conducting fibers and, unlike amplitude, does not give any information regarding the number of conducting axons. Area beneath the curve is a function of amplitude and duration of response and more accurately reflects the number of axons, but like amplitude, it is technically more difficult to assess.

Electrodiagnostic Studies and Nerve Compression

Nerve conduction studies give information about axon and myelin pathologic conditions, and each component is important to properly identify such conditions of nerves. Latency and conduction velocity should not be viewed in isolation, because the speed of conduction relates only to the "healthiest surviving" myelinated nerve fibers. Similarly, even though amplitude is a reflection of the number of functioning axons, amplitude may also be affected by other pathologic situations, such as myopathy. In moderate cases of nerve compression, EMG studies may demonstrate scarce fibrillation potentials, and if the axonal problem is more severe, reduced MUP recruitment will be present. In rare cases, the examiner may identify fibrillation potentials on the EMG with maintenance of normal nerve latencies. With progression, the number of fibrillation potentials will increase and action potential amplitudes will decrease. SNAP amplitudes are affected before CMAP amplitudes. Eventually, MUP recruitment will decrease. With a complete injury, nerve conduction motor and sensory responses will be absent, fibrillation potentials will be marked, and no MUPs will be identified.

The early stage of nerve compression is associated with dynamic ischemic events involving the nerve. Thus, the results of electrodiagnostic studies for the most part are normal. As the nerve compression progresses, demyelination will occur and conduction velocity will slow across the site of compression. Axonal loss does not usually take place until late in the course of the neuropathy. With carpal tunnel syndrome, nerve

conduction study latencies may be prolonged, but the EMG is generally normal until late in the disease. Demyelination and focal conduction slowing are typical of most patients with carpal tunnel syndrome and at least half of those with cubital tunnel syndrome, with axonal changes being found much later in the course of the disease.

Electrodiagnostic studies are useful in ruling out other associated problems such as cervical disk disease, motor neuron problems, myopathy, or superimposed polyneuropathies. They are particularly useful in the investigation of symptoms related to the ulnar nerve, which can sometimes herald the presence of other, more sinister diagnoses. Patients with isolated motor deficits and spared sensory function must have a motor neuropathy ruled out before an entrapment neuropathy can be diagnosed. Electrodiagnostic studies can also help rule out problems that are "functional." Muscles that are weak or atrophic because of disuse will show no EMG abnormalities other than poor voluntary MUP generation, in keeping with submaximal effort by the patient. If the muscle is weak or atrophic because of a peripheral nerve problem, the CMAP will be of low amplitude, MUP recruitment will be reduced, and fibrillation potentials will be noted, unless the process is extremely chronic. Electrodiagnostic studies are not generally helpful in confirming a diagnosis of thoracic outlet syndrome because of its proximal location at the brachial plexus and the often dynamic nature of the compression.

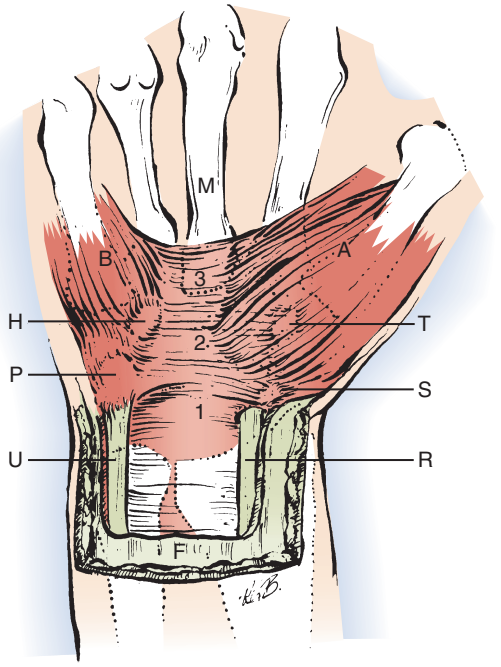

FIGURE 28.4 Anatomy of the three portions of the flexor retinaculum. The distal portion of the flexor retinaculum (3) consists of a thick aponeurosis between the thenar (A) and hypothenar (B) muscles. The thenar muscles attach to the radial half of the classic flexor retinaculum, which is composed of the distal portion of the flexor retinaculum (3) and the transverse carpal ligament (2). Bony attachments of the transverse carpal ligament—pisiform (P), hamate (H), tubercle of the trapezium (T), and tubercle of the scaphoid (S)—are also shown. The proximal portion of the flexor retinaculum (1) courses deep to the flexor carpi ulnaris (U) and flexor carpi radialis (R). The flexor carpi radialis tendon is shown as it pierces the flexor retinaculum at the junction of the proximal and middle portions to enter its fibroosseous canal. F, Antebrachial fascia; M, third metacarpal. (From Cobb TK, Dalley BK, Posteraro RH, et al: Anatomy of flexor retinaculum, *J Hand Surg [Am]* 18:91–99, 1993. Redrawn by Elizabeth Martin.)

COMPRESSION OF THE MEDIAN NERVE

Median Nerve Compression at the Wrist: Carpal Tunnel Syndrome

Carpal tunnel syndrome refers to compression of the median nerve at the wrist and is the most commonly diagnosed site of nerve compression in the upper extremity. Symptoms include paresthesia or numbness (or both) in the median nerve distribution (thumb, index finger, middle finger, and radial side of the ring finger). Nocturnal paresthesias in the radial three digits of the hand are nearly pathognomonic for carpal tunnel syndrome. Paresthesias also occur characteristically in "fixed wrist activities" such as reading a book or a newspaper, driving, or use of a keyboard or mouse. Patients may describe aching in the thenar eminence and, with advanced nerve compression, weakness and atrophy of the abductor pollicis brevis and opponens pollicis. Carpal tunnel syndrome is a clinical diagnosis based on a combination of symptoms and characteristic physical findings; its presence may be subsequently confirmed with electrodiagnostic studies.[38,96] Electrodiagnostic studies are useful to stage the degree of nerve compression and may therefore assist the surgeon and patient in anticipating the time needed for recovery of nerve function. Patients with long-standing symptoms, severe atrophy of the thenar musculature, and dense sensory loss should be cautioned that release can only arrest the progression of the disorder and will not lead to complete recovery of sensation or thenar strength.

ANATOMY

The roof of the carpal canal is the flexor retinaculum, which extends from the hamate and triquetrum on the ulnar side to the scaphoid and trapezium on the radial side. The median nerve and flexor tendons (flexor pollicis longus tendon, four flexor digitorum superficialis tendons, and four flexor digitorum profundus tendons) pass through this tunnel. Although the carpal tunnel is open at its proximal and distal ends, it maintains distinct tissue fluid pressure levels. The diameter of the carpal tunnel is narrowest at a point approximately 2 cm from its leading edge (Figure 28.4), and this corresponds to the site of morphologic changes in the nerve in patients with carpal tunnel syndrome. The median nerve lies just beneath the flexor retinaculum. At the distal end of the flexor retinaculum, the median nerve gives off the recurrent motor branch to innervate the abductor pollicis brevis muscle, superficial head of the flexor pollicis brevis muscle, and opponens pollicis muscles and then divides into the digital nerves that provide sensation to the thumb and index finger, middle finger, and radial half of the ring finger.

Knowledge of variations in the branching pattern of the median nerve is important, particularly during surgical decompression.[61] Lanz has classified variations of the recurrent motor branch into four subgroups (Figures 28.5 to 28.7).[43] In most cases, the motor branch divides from the median nerve distal to the flexor retinaculum in an extraligamentous pattern (46-90%). Less common variations include the subligamentous pattern (31%) and transligamentous pattern (23%). There have

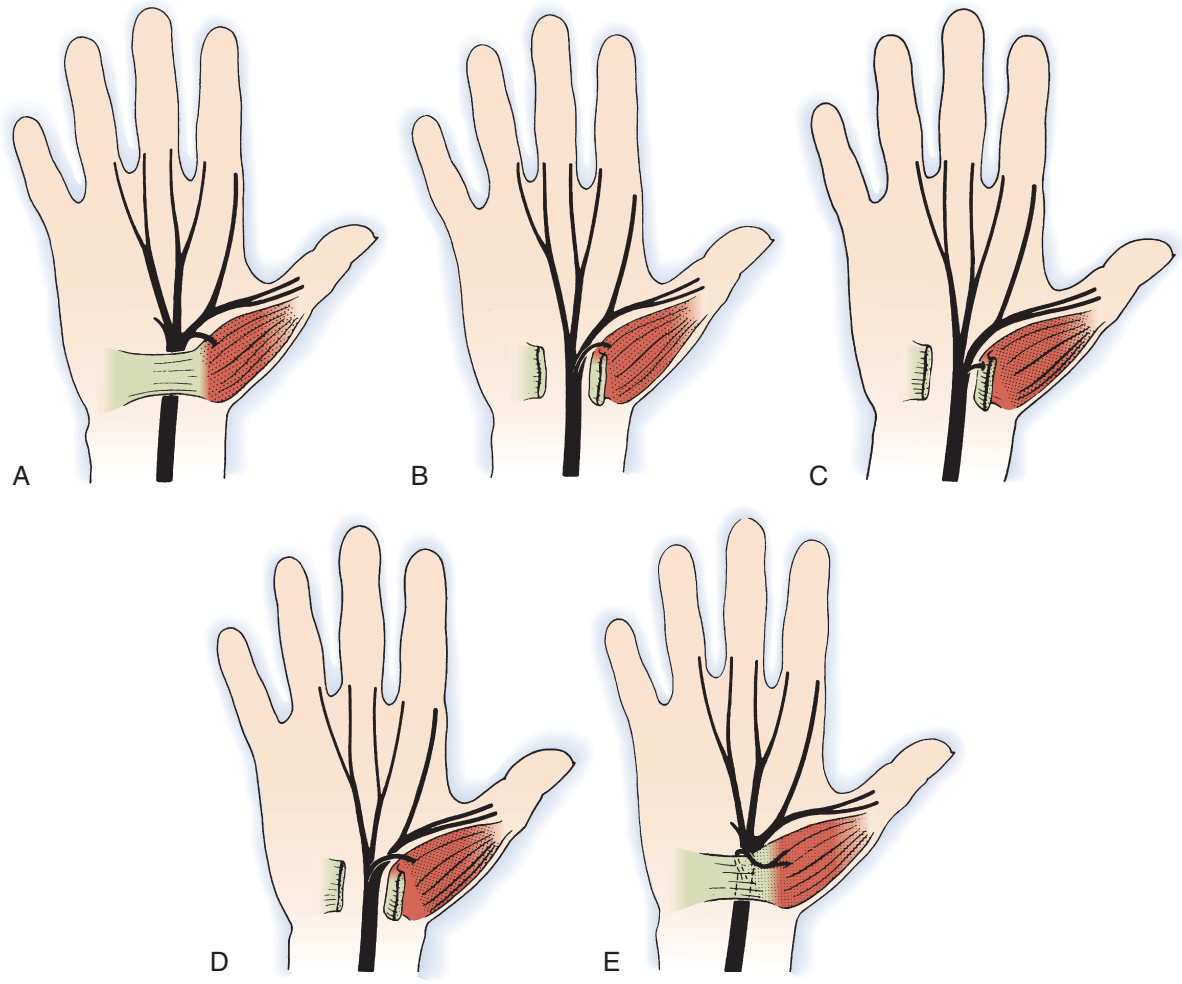

FIGURE 28.5 Variations in median nerve anatomy in the carpal tunnel. **A,** The most common pattern of the motor branch is extraligamentous and recurrent. **B,** Subligamentous branching of a recurrent median nerve. **C,** Transligamentous course of the recurrent branch of the median nerve. **D,** The motor branch can uncommonly originate from the ulnar border of the median nerve. **E,** The motor branch can lie on top of the transverse carpal ligament. (From Lanz U: Anatomical variations of the median nerve in the carpal tunnel, *J Hand Surg [Am]* 2:44–53, 1977.)

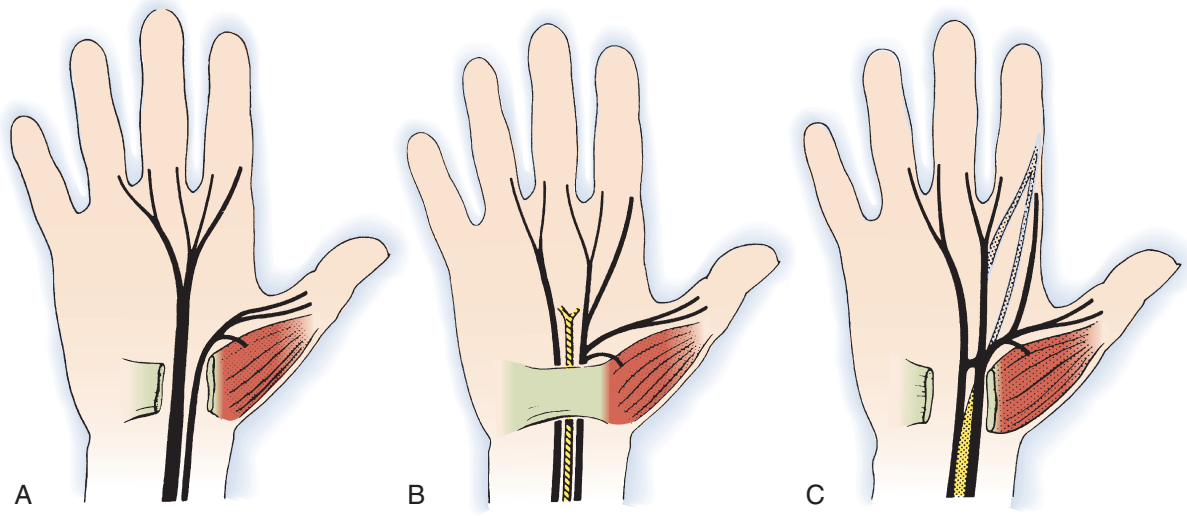

FIGURE 28.6 Variations in median nerve anatomy in the carpal tunnel. Group III variations include high divisions of the median nerve **(A)** that may be separated by a persistent median artery **(B)** or an aberrant muscle **(C)**. (From Lanz U: Anatomical variations of the median nerve in the carpal tunnel, *J Hand Surg [Am]* 2:44–53, 1977.)

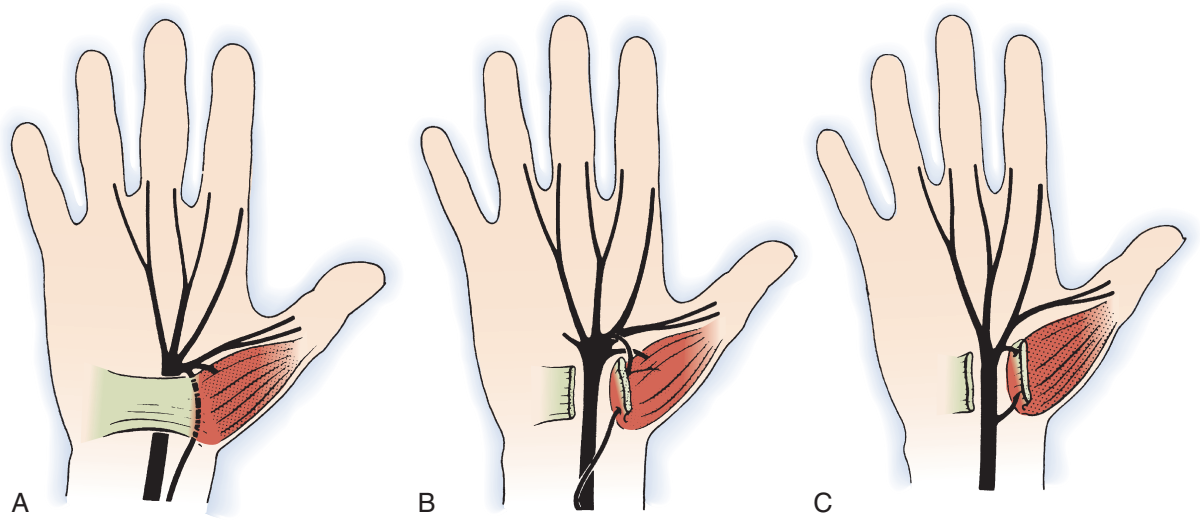

FIGURE 28.7 Variations in median nerve anatomy in the carpal tunnel. Group IV variations include rare instances in which the thenar branch leaves the median nerve proximal to the carpal tunnel: **A,** accessory branch; **B,** accessory branch from the ulnar aspect of the median nerve; **C,** accessory branch running directly into the thenar musculature. (From Lanz U: Anatomical variations of the median nerve in the carpal tunnel, *J Hand Surg [Am]* 2:44–53, 1977.)

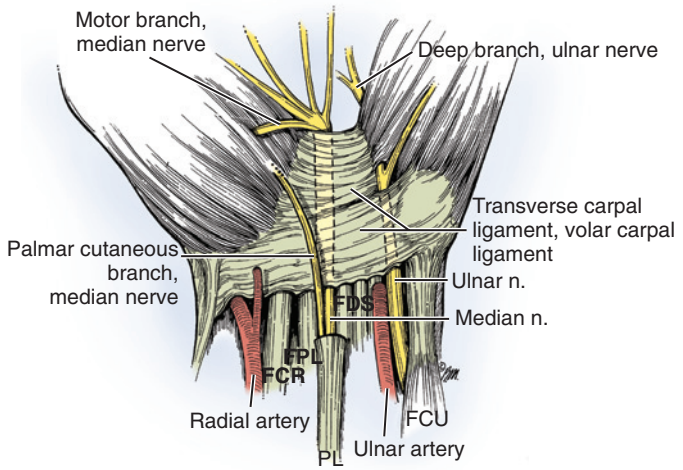

FIGURE 28.8 The palmar cutaneous branch of the median nerve lies radial to the median nerve and ulnar to the flexor carpi radialis (FCR) tendon. It may pierce either the volar carpal or transverse carpal ligament or the antebrachial fascia before it becomes subcutaneous. *FCU*, Flexor carpi ulnaris; *FDS*, flexor digitorum superficialis; *FPL*, flexor pollicis longus; *PL*, palmaris longus. (Copyright © Elizabeth Martin.)

been reports of the recurrent motor branch dividing from the medial side of the median nerve and other unusual variations in which a separate compartment within the carpal tunnel contained half of a bifid median nerve. Variation in the branching pattern of the palmar cutaneous branch of the median nerve has also been described. The palmar cutaneous nerve has been reported to branch through the palmaris tendon proximal to the palmar fascia and also through the antebrachial fascia proximal to the wrist crease (Figure 28.8). To avoid injury to these anomalous branching patterns during the surgical approach to the median nerve, Taleisnik recommended an incision ulnar to the axis of the flexed ring finger.[106] Although considerable variation in the length and location of the surgical incision used for carpal tunnel release exists among hand surgeons,[48] consideration of the anatomy of the palmar cutaneous and recurrent motor nerves is essential to avoid inadvertent nerve injury.

Nonoperative Management

A number of nonoperative treatments of carpal tunnel syndrome have been described that vary from wrist splinting to corticosteroid injection.

Wrist splinting is frequently recommended for nonoperative treatment.[12,116] Prefabricated wrist splints are often used and can present a unique problem if they are placed in a functional position of 30 degrees of extension. Carpal canal pressures have been shown to be elevated in patients with carpal tunnel syndrome, and pressure is further elevated when the wrist is in a position of extension.[25] To control symptoms related to nerve compression at the wrist, wrist splints are most effective in a neutral position.[8] Maintaining the wrist in a neutral position will minimize carpal canal pressure, but the functional position of the wrist is 30 degrees of extension. Because of the limitation of wrist movement in a nonfunctional position, we do not recommend wrist splints during normal daily activity. We recommend splinting only at night to maintain the wrist in a neutral position.

Oral antiinflammatory medications and corticosteroid injections have been used for the treatment of carpal tunnel syndrome with varying reports of success.[4,12,24,116] Using a randomized placebo-controlled trial to investigate the efficacy of steroid injection, Atroshi and coauthors reported good temporary symptom improvement but little difference in likelihood of surgery within 1 year.[4] Celiker and coauthors reported a randomized controlled trial conducted to evaluate the efficacy of corticosteroid injection versus nonsteroidal antiinflammatory drugs and splinting.[12] They reported significant improvement with both methods of treatment; however, the brief follow-up time of just 8 weeks limited the applicability of the study. Green[29] reported that temporary relief after carpal tunnel injection was an excellent prognostic factor for successful carpal tunnel surgery. Complications with steroid injection have been

reported, including injury to the median nerve. In a study evaluating the effects of steroid nerve injection in a rodent model, dexamethasone was found to have no deleterious effects on the nerve, even when injected directly into the nerve.[65] All other corticosteroids caused varying degrees of nerve injury when directly injected into the rodent sciatic nerve. However, given its temporary relief of symptoms and finite risk for nerve injury, in our practice corticosteroid injection is not indicated routinely.

More recently, nerve gliding exercises have been used to alleviate symptoms of nerve compression.[10,98,100] Rozmaryn and associates used nerve and tendon gliding exercises to treat a group of patients with carpal tunnel syndrome and noted less surgical intervention in this group than in a historical control group.[98] Seradge and coauthors reported good symptomatic relief and avoidance of surgery in up to 80% of patients with mild or moderate compression treated with nerve gliding and stretching exercises who were monitored for 18 months.[100]

Operative Treatment

When a regimen of conservative treatment fails to relieve the patient's symptoms, surgical decompression of the median nerve is usually recommended. The first carpal tunnel release was reportedly performed by Herbert Galloway in 1924. Numerous approaches for carpal tunnel release have been described that range from an open technique to a small incision to endoscopic release. The controversy regarding open versus endoscopic carpal tunnel release continues and the decision is largely dependent on surgeon preference and patient selection. A meta-analysis was published in 2008 to evaluate outcomes related to endoscopic and open carpal tunnel release. The authors concluded that the data related to symptom relief and return to work are inconclusive and there is increased likelihood of reversible nerve injury with endoscopic release.[107] A study using a randomized controlled design evaluated one compared to two incisions and found no long-term differences between these surgical techniques.[11] Although release of the median nerve is the goal of treatment, injury to even a few fascicles of the nerve can have devastating consequences for the patient. Therefore, the surgeon should choose the surgical method that offers the best visualization of the median nerve to avoid nerve injury.

Minimal incision and endoscopic techniques were introduced to decrease the length of the incision and thus potentially decrease postoperative incisional discomfort. A number of endoscopic systems have been described, but the risk for complications, including iatrogenic nerve injury, poor visualization, inability to identify anatomic variations, incomplete release, and apparent beneficial cost savings, is still debated. Those who support endoscopic carpal tunnel release also advocate specialized training in cadaveric courses before performance of endoscopic carpal tunnel release. Others have introduced surgical releases with smaller incisions termed "minimally invasive" to decrease postoperative incisional pain and thus minimize postoperative morbidity. In this chapter, we have reviewed the original endoscopic techniques as introduced by Chow and Agee, but others have also introduced variations of endoscopic approaches.[32]

Chow Two-Portal Endoscopic Technique. A two-portal endoscopic technique was introduced by Chow.[14] A tourniquet is placed but not inflated. Local anesthesia with 1% lidocaine without epinephrine is used, with or without intravenous sedation. The entry portal is located by drawing a line 1 to 1.5 cm radially from the proximal pole of the pisiform and a second line 0.5 cm proximally from the first line. A 1-cm transverse incision is made through the skin radially from the end of the second line. A longitudinal incision is made through the fascia. A curved dissector-obturator slotted cannula assembly is inserted through the distal edge of the entry portal incision along the long axis of the forearm. It is used to free synovial tissue from the inferior surface of the flexor retinaculum. The assembly tip touches the hook of the hamate, the hand is lifted off the table, and the wrist and fingers are hyperextended. At 1 cm proximal to a line drawn that bisects the angle formed by the distal border of the fully abducted thumb and the third web space, a 0.5-cm exit portal incision is made. The slotted cannula assembly is advanced distally and the tip palpated at the exit portal in the palm. The assembly is passed through, and the hand is stabilized in a custom hand-holding device. The endoscope is inserted into the proximal tube opening, and a probe is inserted distally to identify the distal edge of the flexor retinaculum. The probe knife is used to release the distal edge of the flexor retinaculum in a distal to proximal direction. The triangle knife is then used to release the midsection of the flexor retinaculum, and the retrograde knife is positioned in the second cut and drawn distally to join the first cut to release the distal part of the flexor retinaculum. The endoscope is withdrawn and replaced in the distal tube opening, and the probe knife is used to release the proximal edge of the flexor retinaculum. The retrograde knife is inserted into the midsection and drawn proximally to complete release of the flexor retinaculum. The trocar is reinserted and the cannula removed. The antebrachial fascia is released through the proximal incision with tenotomy scissors, and the skin is sutured.

Agee Single-Portal Endoscopic Technique. A single-incision technique was described by Agee and associates.[1] A tourniquet is used for this procedure. The authors recommend that initially a general or regional anesthetic be used, and with more surgeon experience, they recommend local anesthesia. A 2- to 3-cm transverse skin incision is made in the distal wrist flexion crease between the flexor carpi radialis and flexor carpi ulnaris tendons. With the use of spreading longitudinal dissection, the cutaneous nerves are protected and the forearm fascia is identified. A "U"-shaped, distally based flap of forearm fascia is incised and elevated in a palmar direction. A probe is passed down the ulnar side of the carpal tunnel, radial to the hook of the hamate. The wrist is placed in slight extension, and the blade assembly is inserted with the viewing window toward the inner aspect of the flexor retinaculum. The tip of the blade assembly is palpated with the surgeon's contralateral hand. The distal edge of the flexor retinaculum is located by video, ballottement, and light touch through the skin. When the correct position is ensured, the blade is deployed upward from within the device, the device is withdrawn, and the distal aspect of the flexor retinaculum is incised. The blade is retracted, the assembly is reinserted, the flexor retinaculum division is inspected, and additional cuts are made to release the remaining flexor retinaculum. Using tenotomy scissors, the antebrachial forearm fascia is released proximal to the skin incision. The skin incision is closed, and splinting is performed at the discretion of the surgeon. Agee and colleagues strongly recommend that if complete visualization is

not obtained, the endoscopic technique should be abandoned and the carpal tunnel released with an open technique.

❖ AUTHORS' PREFERRED METHOD OF TREATMENT: Open Carpal Tunnel Release

We prefer the classic open carpal tunnel release with intravenous regional anesthesia (Bier block) for the treatment of carpal tunnel syndrome (Videos 28.1 and 28.2). General anesthesia is rarely indicated; more recently there has been a trend toward increased use of local and regional anesthesia. Axillary blocks have been associated with nerve injection injuries, and although this complication is exceedingly rare, when it does occur, it may be devastating for the patient. Many surgeons use local anesthesia, but we believe that patients are more comfortable with some sedation and tolerate the tourniquet better with an intravenous regional block (250 mm Hg). In the rare cases in which use of a tourniquet is contraindicated, anesthetic nerve blocks of the median, radial, and ulnar nerves at the elbow can be used as an alternative to general anesthesia or brachial plexus blocks. As a preemptive action against the sympathetic nervous system, dexmedetomidine hydrochloride is usually included with the intravenous regional anesthetic. A double tourniquet on the upper part of the arm is used, and the tourniquets are changed at 10 minutes so that patients do not experience tourniquet pain. A forearm tourniquet is used for obese patients because the upper arm tourniquet can sometimes be less reliable and result in a venous tourniquet. In thin patients with small hands when the tourniquet time is going to be exceedingly short, a forearm tourniquet is used. Less volume of anesthetic is needed and no dexmedetomidine hydrochloride is used, and the tourniquet can be released earlier.

The incision is marked about 6 mm ulnar to the thenar crease to ensure that any scarring is away from the median nerve and that the incision is well ulnar to the palmar cutaneous branch of the median nerve, which is located in the thenar crease (Figure 28.9). A curvilinear incision is made that parallels the thenar crease, 2 or 3 cm in length, and ends just distal to the transverse wrist crease. If more exposure is necessary to release the antebrachial fascia, the incision is extended proximally in a zigzag fashion across the wrist in an ulnar direction. With the increased prevalence of obesity, use of a longer incision should be considered in these patients to provide adequate visualization. Two double hooks are used for retraction, and dissection is carried out through the soft tissue. About 15% of the time, a crossing cutaneous branch from the ulnar nerve will be identified in the distal portion of the incision and protected. Senn retractors are used to retract through the fatty tissue to expose the proximal portion of the flexor retinaculum and the distal portion of the antebrachial fascia. A No. 15 blade is used, and very carefully, slowly, and with control, the proximal portion of the flexor retinaculum and distal portion of the antebrachial fascia are opened. A different color of the darker synovium around the flexor tendons will be seen once the ligament has been cut. The blunt end of a Freer retractor can be placed gently into the carpal canal if desired. The rake portions of the two Senn retractors are used to retract the soft tissue above the flexor retinaculum, and tenotomy scissors are used to spread the fatty tissue for identification of the flexor retinaculum. The carpal ligament is carefully released along the ulnar side. The flexor retinaculum is released as far distally as the fat around the superficial arch. With observation of the fat, one knows that the distal ligament has been released completely. In obese individuals or people with very large hands, the incision may need to be extended more distally to ensure that the entire ligament has been released and to identify the fatty tissue signaling the end of the ligament. Proximally, using the down-curved portion of two Senn retractors, the fatty tissue is retracted above the antebrachial fascia. The surgeon is positioned at the end of the hand table to ensure excellent visualization. With the use of pick-ups, one edge of the antebrachial fascia is pulled distally. With slight volar wrist flexion, the median nerve will drop away from the antebrachial fascia. Under direct vision, the antebrachial fascia is released with the tenotomy scissors or a No. 15 blade. If difficulty releasing this antebrachial fascia under direct vision is encountered, the incision must be extended proximally above the wrist to ensure that the antebrachial fascia has been adequately released and that there is no injury to the median nerve. The rake end of the Senn retractor is used to retract the radial side of the divided flexor retinaculum up or anteriorly. The median nerve is visualized. Rarely, before operation, some patients will describe a deep, aching thenar pain or present with significant thenar wasting with minimal sensory complaints, findings indicating that specific exploration of the recurrent motor branch of the median nerve is warranted. The rake end of the Senn retractor is used to pull up on the radial side of the divided ligament, and the median nerve is carefully retracted toward the surgeon. This will cause the recurrent motor branch of the median nerve to tent up as it enters the thenar muscle mass and allow identification of the recurrent motor branch as it curves toward the thenar muscle. In patients with deep, aching

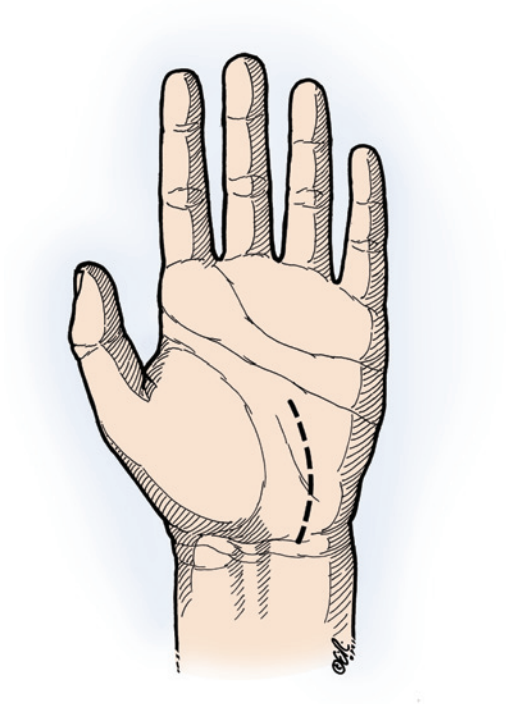

FIGURE 28.9 Authors' preferred carpal tunnel incision. A curved longitudinal incision is made so that it parallels the thenar crease and crosses the wrist crease obliquely in an ulnar direction at a point in line with the long axis of the flexed ring finger or just on the ulnar side of the palmaris longus tendon. (Copyright © Elizabeth Martin.)

thenar pain or thenar muscle wasting (or both), the recurrent motor branch will often enter the thenar musculature through its own tendinous tunnel. (Similarly, in these patients, the thenar motor branch may come off of the ulnar side of the median nerve, exposing it to more compression as it travels across the top of the nerve and directly under the ligament.) This maneuver of pulling up on the flexor retinaculum and pulling the median nerve medially toward the surgeon will help with easy identification of the recurrent motor branch. The floor of the carpal canal can be visualized by retracting the flexor tendons to evaluate for any pathologic conditions such as ganglions. We believe that neurolysis of the median nerve during primary carpal tunnel release is not indicated.[66] Studies have also reported no benefit with epineurotomy.[7] Similarly, synovectomy is not indicated during primary carpal tunnel decompression. The tourniquet is deflated, and bupivacaine (Marcaine) is injected into the incision under careful direct vision for postoperative comfort. Microbipolar cautery is used for hemostasis. The incision is closed with interrupted 4-0 nylon suture, and a bulky dressing is applied while keeping the wrist in neutral, with fiberglass casting incorporated into the dressing. A sling may be used for the early postoperative period, but the patient is cautioned against unnecessary elbow flexion, which may result in flare-up of an associated cubital tunnel syndrome, and against shoulder immobilization, which may result in shoulder stiffness.

In cases of severe carpal tunnel syndrome with thenar muscle atrophy, opponensplasty may be considered. In this patient population, a palmaris longus (Camitz) transfer is the ideal transfer for improved thenar abduction because of its minimal donor deficit and immediate availability in the same surgical incision. In the authors' opinion, it is rarely required, as patients have adapted to the slow progressive loss associated with the chronic neuropathy. Because this is an in-continuity nerve lesion, there is also the potential for muscle reinnervation and motor recovery, as is the case with sensory recovery. Finally, the older population that presents with severe thenar atrophy may not desire or tolerate the requisite cast immobilization after tendon transfer.

Expected Outcome After Carpal Tunnel Decompression

Following carpal tunnel decompression for mild or moderate compression, there will be return of "painless" sensation to the digits innervated by the median nerve in mild or moderate compression. Reinnervation of the thenar muscles will also occur, and there will be full range of motion at the wrist.

Postoperative Care

Immobilization after decompression of the carpal tunnel was historically used to protect the wound and immobilize the wrist to prevent the flexor tendons from bowstringing. However, because of advancing knowledge in the importance of postoperative tendon and nerve gliding, such postoperative immobilization has been dramatically decreased.[36,44] After carpal tunnel decompression, a bulky dressing is used to restrict wrist range of motion during the first 2 postoperative days for patient comfort and is then removed. The patient is instructed in range-of-motion exercises for the fingers, wrist, and arm. A splint in a wrist neutral position is used at night for 2 to 3 weeks for patient comfort or until the patient has regained comfortable full range of motion of the wrist. The sutures are removed 12 to 14 days postoperatively. At 1 month after surgery patients are allowed to return to work with a 2-pound weight restriction, and at 6 to 8 weeks after surgery they are allowed full activity without restrictions.

CRITICAL POINTS *Carpal Tunnel Release*

Indications
- Failed night splinting with the wrist in neutral position

Preoperative Evaluation
- Electrodiagnostic studies to "stage" the degree of nerve compression for helping to predict the anticipated rate and degree of recovery

Pearls
- Document preoperative pain distribution.
- Document preoperative examination of the entire upper extremity.
- Use dexmedetomidine hydrochloride in a Bier block.
- Postoperatively, begin early movement.

Technical Points
- Make an incision ulnar to the thenar crease and extend it proximally in obese patients.
- Avoid the ulnar cutaneous branch (15%) in the distal portion of the incision.
- Release the flexor retinaculum in a proximal to distal direction.
- Release the ligament distally to the fat pad.
- Release the antebrachial fascia under direct vision.
- Provide hemostasis after release of the tourniquet.
- Use bupivacaine in the incision.

Pitfalls
- In obese patients, use a forearm tourniquet to avoid a "venous" tourniquet.
- Failure to adequately release the distal ligament or the proximal antebrachial fascia may occur.

Postoperative Care
- Remove the dressing on day 2 or 3.
- Use night splinting in a wrist neutral position for 2 to 3 weeks for patient comfort.
- Begin range-of-movement exercises on day 2 or 3.
- Avoid unnecessary elbow flexion because it may result in irritation of the ulnar nerve.
- Begin strengthening exercises after 4 weeks.
- There are no restrictions after the second month.

Median Nerve Compression at the Elbow and Forearm

A rare and very proximal site of median nerve compression in the upper extremity occurs under the ligament of Struthers in patients who have a supracondylar process (Figure 28.10). An accessory bicipital aponeurosis that can cause an anterior interosseous nerve palsy has also been identified. Sensory disturbance in the median nerve by a snapping brachialis tendon has been reported. Fibrous bands between the deep and superficial heads of the pronator teres are frequently cited as the cause of compression in cases of anterior interosseous nerve palsy and pronator teres syndrome. Compression may result from a fibrous arch between the two heads of the pronator teres, from

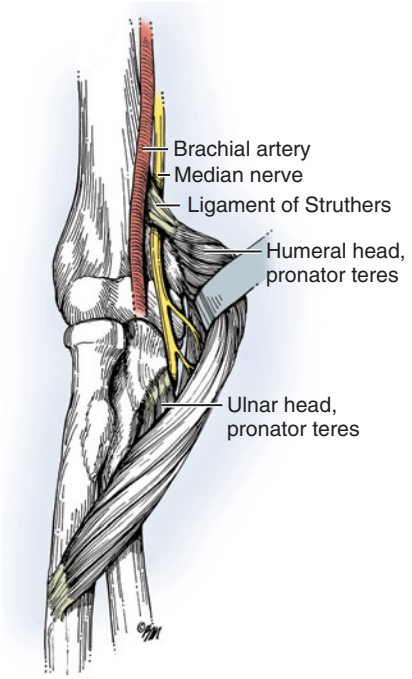

FIGURE 28.10 The median nerve lies deep and the brachial artery lies superficial to the ligament of Struthers, which forms an accessory origin for the pronator teres. (Copyright © Elizabeth Martin.)

a tendinous deep head of the pronator teres, from the flexor digitorum superficialis arch, or from other bands in the distal part of the forearm. Other accessory and anomalous muscles, including the accessory head of the flexor pollicis longus (Gantzer muscle), the palmaris profundus, and the flexor carpi radialis brevis, have been identified as compressive structures. The Gantzer muscle was found to be present in 45% in one cadaveric study. Cadaveric dissections to identify the anatomic variations and fibrous arches that may contribute to compression in the forearm revealed that the superficial head of the pronator teres was always present, the flexor digitorum superficialis varied in origin size, and the median nerve may be crossed by one or two fibrous aponeurotic arches. The fibrous arch of the pronator teres has been found to be located 3 to 7.5 cm distal to the humeral epicondylar line and the fibrous arch of the flexor digitorum superficialis to be 6.5 cm distal to the humeral epicondylar line in its most proximal position.

Compression of the median nerve in the forearm is less common than carpal tunnel syndrome. Compression in the forearm can produce sensory disturbance in the median nerve distribution or motor dysfunction of the muscles innervated by the anterior interosseous nerve and median nerve, or both sensory and motor dysfunction. Parsonage and Turner described spontaneous paralysis of the flexor pollicis longus and flexor digitorum profundus to the index finger, which they termed "neuralgic amyotrophy."[91,110] The pathologic findings of this mononeuritis is related to the anterior horn cell and most commonly occurs after a viral illness. Parsonage-Turner neuritis is not confined to the anterior interosseous nerve; the periscapular and shoulder muscles may be affected as well. Anterior interosseous nerve palsy can also occur after a surgical procedure in the ipsilateral upper extremity, which makes the etiologic picture more confusing. There is almost always complete recovery without surgical intervention, although this recovery may take many months.

ANATOMY

The median nerve is formed from branches of the medial and lateral cords of the brachial plexus. It receives its sensory contribution predominantly from the lateral cord and its motor fibers predominantly from the medial cord. The median nerve crosses over the brachial artery to lie on the medial side in contact with the brachialis muscle. It continues distally between the brachialis muscle and the medial intermuscular septum and then passes through the antecubital fossa and under the lacertus fibrosus (bicipital aponeurosis). The nerve travels between the deep and superficial heads of the pronator teres and in some cases posterior to the pronator teres. Before the nerve divides into the main median nerve and the anterior interosseous nerve, the fascicles remain separate within the median nerve.[104] Before passing through the pronator teres, there are branches exiting to the palmaris longus, flexor carpi radialis, flexor digitorum superficialis, and, rarely, flexor digitorum profundus. In a cadaveric anatomic study by Tung and Mackinnon, the pronator teres muscle received more than one branch in 73% of cases and the flexor digitorum superficialis received two or more branches in 94% of cases.[109] After exiting the pronator teres, the median nerve courses deep to the fibrous arch of the flexor digitorum superficialis and becomes more superficial in the distal part of the forearm.

The anterior interosseous nerve provides innervation to the flexor digitorum profundus of the index and middle fingers, the flexor pollicis longus, and the pronator quadratus. The nerve provides sensory fibers to the radiocarpal, intercarpal, carpometacarpal, and radioulnar joints. The anterior interosseous nerve is relatively tethered as it separates from the main median nerve, which makes it relatively more susceptible to traction injuries. A Martin-Gruber anastomosis (connection between the median and ulnar nerves in the forearm) is found in 15% of the population, and in half of the cases the communicating branch originates from the anterior interosseous nerve.

The palmar cutaneous nerve branches from the median nerve approximately 5 cm proximal to the proximal wrist crease. It separates from the median nerve and enters a tunnel immediately medial to the flexor carpi radialis tendon and then innervates the skin of the thenar eminence. Evaluation of thenar sensation is helpful in differentiating median nerve compression in the carpal canal from more proximal sites of compression.

Pronator Syndrome

Pronator syndrome is defined as compression of the median nerve in the forearm that results in isolated sensory alteration in the median nerve distribution in the digits and thenar eminence. This syndrome is much less common than carpal tunnel syndrome and has been reported in individuals who do repetitive upper extremity activity. Provocation tests should reproduce symptoms in affected patients. These tests include resisted forearm pronation, with the forearm in full supination and elbow extended, and also in some cases resisted elbow flexion or flexion of the middle finger flexor digitorum superficialis. If the forearm is placed in maximum supination with the wrist in

a neutral position, pressure over the leading edge of the pronator teres will produce paresthesias in the median sensory distribution. Also in patients with median nerve compression at the pronator teres, the scratch collapse test is positive with deep digital pressure over the leading edge of pronator teres and not with scratching the skin over this region. In the majority of patients, electrodiagnostic testing is negative. Radiographs of the distal end of the humerus can identify the rare supracondylar process and alert the physician to the probability of the presence of a ligament of Struthers.

Anterior Interosseous Nerve Syndrome

Anterior interosseous nerve syndrome is manifested as weakness or motor loss of the flexor pollicis longus, the flexor digitorum profundus to the index finger, the pronator quadratus, and, occasionally, the flexor digitorum profundus to the middle finger. In a true anterior interosseous nerve syndrome, the weakness or loss of motor function usually occurs spontaneously. Patients may describe clumsiness with fine motor skills, such as writing and pinching. Because the anterior interosseous nerve does not innervate the skin, the syndrome is not associated with sensory loss.

Parsonage-Turner mononeuritis should be considered in the differential diagnosis in patients with an anterior interosseous nerve palsy. These patients typically have a history of severe pain for several days or weeks. The pain may follow a viral illness. High doses of corticosteroids and antiviral medications such as acyclovir are recommended if the neuritis is diagnosed early. In a neuritis involving the anterior interosseous nerve, spontaneous recovery usually occurs, although up to 1 year may be needed for full recovery. In patients with a spontaneous anterior interosseous nerve palsy and no electrodiagnostic evidence of reinnervation, consideration should be given to nerve exploration or nerve transfer (or both) at 7 to 10 months.[69] In patients with concomitant nerve compression, local decompression in those with Parsonage-Turner syndrome may accelerate recovery.

Operative Technique

The operative technique for decompression of the median nerve in the forearm is the same for pronator syndrome and compression of the anterior interosseous nerve; all potential compressive sites should be released.

❖ AUTHORS' PREFERRED METHOD OF TREATMENT

Preoperatively, significant compression points on the median nerve are determined by physical examination, either with stress on a particular tendon or muscle unit or with elicitation of pain by direct palpation. A padded tourniquet is applied to the arm several centimeters above the cubital crease and inflated after exsanguination. The incision begins at the antecubital fossa and continues distally in a lazy-"S" direction for about 10 cm (Figure 28.11 and Videos 28.3 and 28.4). The dissection is carried down through soft tissue to identify and preserve any cutaneous sensory branches. The bicipital aponeurosis (lacertus fibrosus) is identified and divided (Figure 28.12). The tendon of the superficial head of the pronator teres is identified, which is best done in the distal portion of the surgical exposure just radial to the radial vessels. A step-lengthening incision is made in the tendon by performing the "up" cut distally where visualization

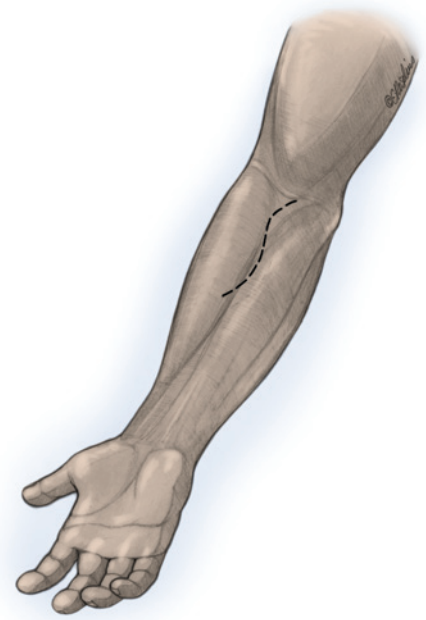

FIGURE 28.11 The incision to explore the median nerve and anterior interosseous nerve in the proximal part of the forearm begins at least 5 cm above the elbow crease. (Copyright © Elizabeth Martin.)

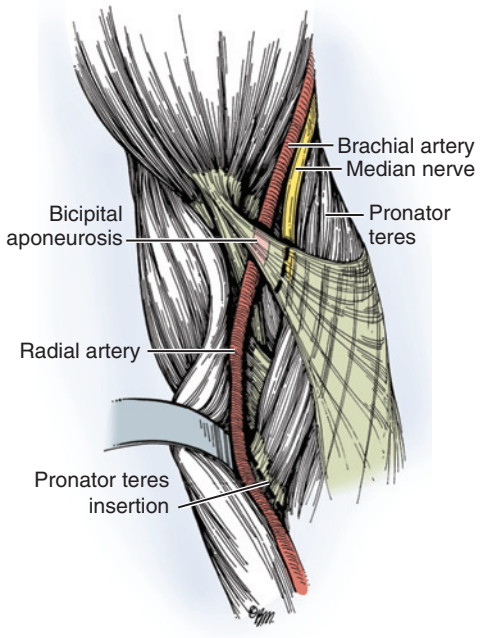

FIGURE 28.12 The bicipital aponeurosis may act as a compressive band across the flexor muscle in pronation; it should be divided during any exploration of the median nerve. A step-lengthening tenotomy of the tendon of the superficial head of the pronator teres is necessary to allow exposure of the median nerve. (Copyright © Elizabeth Martin.)

is more difficult. The "down" cut is done proximally (Figure 28.13). Lengthening will take tension off the superficial (radial) head of the pronator teres muscle and allow better visualization of the median nerve. The median nerve is identified proximally, just medial to the brachial artery and vein. The nerve is intimate with the pronator muscle and can be found just distal to the

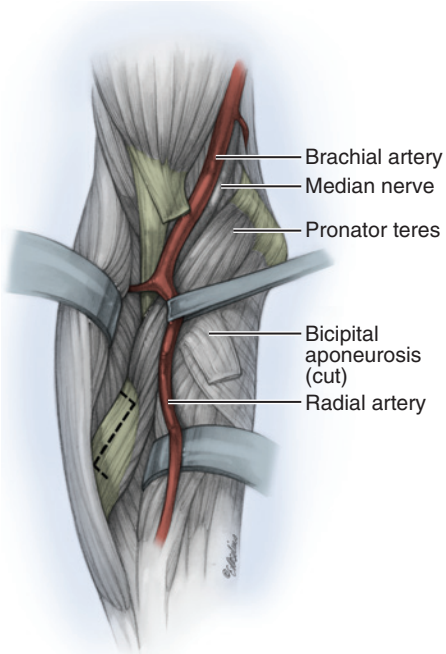

FIGURE 28.13 Exposure of the median nerve and anterior interosseous nerve by reflection of the humeral (the superficial head of the pronator teres also exposes the arch of the superficialis) and the deep head of the pronator teres (ulnar head). The step-lengthening tenotomy facilitates the exposure. (Copyright © Elizabeth Martin.)

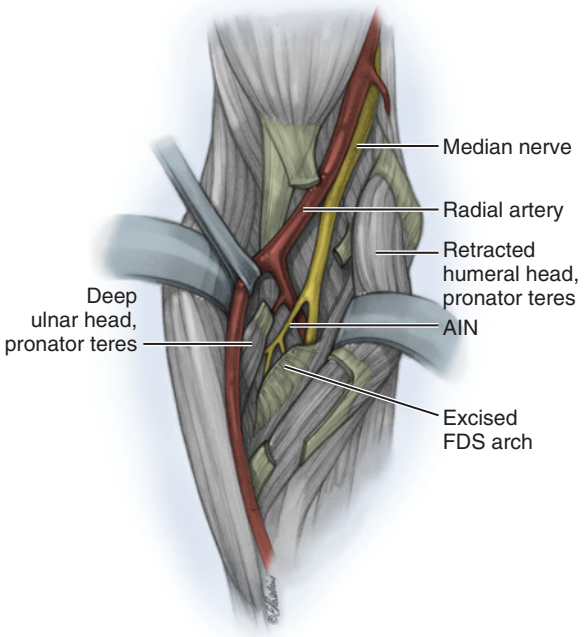

FIGURE 28.14 The proximal tendinous attachment of the deep head (ulnar) of the pronator teres and the proximal tendinous arch of the superficialis are excised to completely release the median nerve. *AIN,* Anterior interosseous nerve; *FDS,* flexor digitorum superficialis. (Copyright © Elizabeth Martin.)

cubital crease, adjacent to if not just within the flexor pronator muscle mass (Figure 28.14). The median nerve is followed distally to identify the deep head of the pronator teres where it blends with the leading tendinous edge of the flexor digitorum superficialis. The proximal tendinous attachment of the deep head is about 2 cm in length. It arches around the median nerve and attaches at the deep ulnar head of the pronator teres onto the ulna. There is muscle attached to the tendinous tissue, and the tendinous portion is excised. The tendinous portion of the arch from the leading edge of the flexor digitorum superficialis tendons is divided to completely release the median nerve. The surgeon can run a finger proximally along the median nerve, and if a ligament of Struthers is identified, the incision is extended above the elbow crease. During dissection, care is taken to obtain complete hemostasis. The vessels in this area are very thin walled and will "stain" the tissues if good hemostasis is not achieved with microbipolar cautery or ligature ties as necessary. Internal neurolysis or epineurotomy techniques are not indicated. There is no need to reconstruct the tendon lengthening of the superficial head of the pronator teres because the deep head has been left intact. The incision is closed with 3-0 absorbable suture in the subcutaneous tissue and 4-0 subcuticular suture with adhesive strips. Bupivacaine is placed in the incision for postoperative comfort. In rare cases in which the patient had extreme pain preoperatively, a bupivacaine infusion pump can be used. Fiberglass casting is incorporated into the dressing to keep the elbow slightly flexed and the wrist in a neutral position.

Postoperative Care

The bulky dressing is removed 2 days after surgery. The patient is instructed in range-of-motion exercises for the fingers, wrist, and arm. A sling may be used at night for patient comfort to prevent full elbow extension. However, the patient is encouraged to begin exercises to regain full elbow extension with forearm supination. Patients are allowed full activity and can return to work without restrictions 6 to 8 weeks after surgery.

COMPRESSION OF THE ULNAR NERVE

The ulnar nerve is most commonly compressed at the elbow in the region of the cubital tunnel and less frequently at the wrist in the Guyon canal. With compression of the ulnar nerve, patient complaints will include paresthesia or numbness, or both, in the small or the ring finger, or in both. In more severe cases, ulnar nerve motor dysfunction will lead to weakness, atrophy, and hand clumsiness.[72]

Compression of the Guyon Canal

Guyon in 1861 first described the space in the hypothenar region of the wrist where the ulnar nerve divides and suggested that ulnar nerve compression could occur in this region. Compression in the Guyon canal may result from a number of causes, including acute or repetitive trauma, hamate hook nonunion, anomalous muscles, or space-occupying lesions, including ganglions, thrombosis, and pseudoaneurysms.

The unique anatomy of the Guyon canal will influence the symptoms. The nerve can be compressed proximal to its bifurcation (zone I), thereby yielding a mix of both motor and sensory deficits; along the course of the deep motor branch (zone II), characterized by pure motor loss; or along its superficial sensory branch (zone III), which is associated with pure sensory changes. If the compression produces intrinsic weakness, the functional motor loss in the hand can be profound, manifested by a strongly positive Froment sign, clawing of the ring and small digits, and severe interosseous atrophy. Because

CRITICAL POINTS *Median Nerve Release in the Proximal Forearm*

Indications
- Rare as a pain syndrome
- Anterior interosseous nerve palsy localizing to the forearm
- De novo anterior interosseous nerve palsy is most likely a neuritis and not caused by mechanical compression.
- Patients with median nerve sensory complaints localizing to the level of the pronator teres are usually treated successfully with forearm flexor muscle stretching exercises.
- Patients with associated carpal tunnel syndrome generally require only carpal tunnel release.

Preoperative Evaluation
- Without motor symptoms, electrodiagnostic studies are usually normal.
- Persistent median nerve symptoms are reproduced by provocation at the forearm.

Pearls
- The tendon of the superficial head of the pronator teres is located just lateral to the radial vessels in the distal part of the surgical exposure.
- The median nerve is located just medial to the vessels in the proximal portion of the surgical field and is intimate with the flexor pronator muscle mass.

Technical Points
- Use a lazy "S" incision in the proximal part of the forearm.
- Release the lacertus fibrosus.
- Identify the superficial tendon of the pronator teres lateral to vessels.
- Use a step-lengthening tenotomy of the superficial tendon of the pronator teres.
- Identify the median nerve in the proximal part of the forearm medial to vessels.
- Identify and excise the deep head of the pronator teres.
- Release the superficial tendinous arch of the flexor digitorum superficialis.
- Ensure that no compressive bands are located proximally over the median nerve.
- Use bupivacaine in the incision and consider suction drainage.
- Immobilize the elbow and wrist in a bulky dressing.

Pitfall
- Beware of inadequate release of the median nerve compression points of the arch of the pronator teres muscles and the flexor digitorum superficialis.

Postoperative Care
- Remove the dressing on day 2 or 3.
- Begin early range-of-motion exercises on day 2 or 3.
- Begin strengthening exercises in the second month.

of the propensity for space-occupying lesions within the Guyon canal, the preoperative workup should include appropriate imaging studies in addition to electrodiagnostic studies, particularly when an isolated motor palsy is identified.

It is critical that the examiner differentiate ulnar nerve compression at the wrist from more proximal sites in the upper limb. The localization of numbness and paresthesias to the arm or forearm should alert the examiner to more proximal sites, including the plexus and thoracic outlet. Similarly, paresthesias

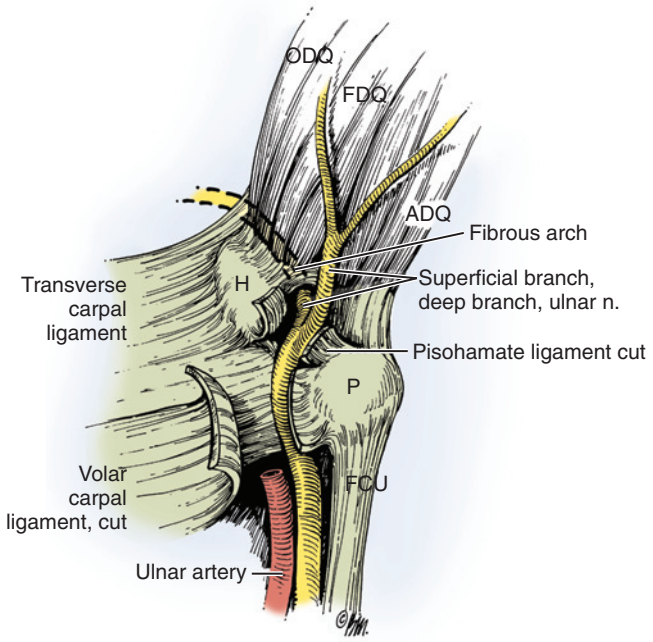

FIGURE 28.15 The ulnar nerve courses through the Guyon canal between the volar carpal ligament and the transverse carpal ligament. *ADQ,* Abductor digiti quinti; *FCU,* flexor carpi ulnaris; *FDQ,* flexor digiti quinti; *H,* hamate; *ODQ,* opponens digiti quinti; *P,* pisiform. (Copyright © Elizabeth Martin.)

on the dorsal and volar sides of the fifth digit can only occur in compression proximal to the wrist, as the dorsal sensory branch exits the ulnar nerve several centimeters proximal to the wrist crease. Motor weakness confined to the intrinsic muscles, particularly when unassociated with sensory symptoms, focuses any compressive cause on zone II of the Guyon canal. Because of the unopposed force of the normal flexor digitorum profundus, clawing from distal entrapment is paradoxically worse than compression at more proximal sites, which weaken the ulnar flexor digitorum profundus symmetrically.

ANATOMY

After passing anterior to the flexor retinaculum, the ulnar nerve divides into superficial and deep branches. The superficial branch innervates the palmaris brevis muscle and then supplies sensory innervation to the small finger and the medial side of the ring finger. The deep branch of the ulnar nerve innervates the hypothenar muscle, the medial two lumbricales, the interosseous muscles, the adductor pollicis muscle, and half of the flexor pollicis brevis (Figure 28.15).

Nonoperative Management

Nonoperative treatment is recommended with acute cases of localized closed trauma (i.e., long-distance cycling). A wrist splint in neutral position for a few weeks may be helpful. Electrodiagnostic studies may be used to monitor improvement.

Operative Technique

❖ AUTHORS' PREFERRED METHOD OF TREATMENT

The incision used for carpal tunnel release is appropriate for release of the ulnar nerve in the Guyon canal, except that it will need to be extended slightly more proximally and

distally. Similar anesthetic and tourniquet techniques are used (Video 28.5).

The incision is marked 6 mm ulnar to the thenar crease. A curvilinear incision (3 to 4 cm in length) is made parallel to the thenar crease. Two double hooks are used for retraction, and the dissection is carried down through soft tissue. A crossing cutaneous branch in the distal portion of the incision that runs from the ulnar nerve up to the overlying skin can be seen in about 15% of patients and needs to be identified and protected. The Guyon canal is opened, and the hook of the hamate is palpated. The ulnar nerve lies deep and medial to the ulnar vascular bundle. The neurovascular bundle is retracted medially to identify the deep motor branch of the ulnar nerve. The technique for identifying the motor branch of the ulnar nerve is to note the oblique fascial pattern along the surface of the hypothenar muscles. At the proximal leading edge of the hypothenar muscles, the surgeon will see just 1 or 2 mm of the deep motor branch of the ulnar nerve as it curves around the hook of the hamate. Tenotomy scissors are placed underneath the leading edge of the hypothenar muscles, and the muscle is divided to identify the motor branch. It is released completely around the hook of the hamate to ensure division of any tendinous bands within the hypothenar muscles distally that can compress the ulnar nerve. There are also small, thin-walled vessels running with the motor branch that should be protected so that the surgeon does not need to subsequently obtain hemostasis with cautery deep in the wound in proximity to the nerve. The ulnar nerve proper is released through the Guyon canal, and the incision is usually extended in a zigzag fashion proximal to the wrist to release the distal extent of the antebrachial fascia. The tourniquet is deflated, and microbipolar cautery is used for hemostasis. Bupivacaine is infiltrated into the incision for postoperative comfort. The incision is closed with interrupted 4-0 nylon suture and a bulky dressing is applied while keeping the wrist in a neutral position, with fiberglass casting being incorporated into the dressing. If a carpal tunnel release has also been done, night splinting with the wrist in neutral is maintained for 3 weeks; otherwise, night splinting is continued for patient comfort.

CRITICAL POINTS *Guyon Canal Release*

Indications
- Uncommon
- Ulnar nerve symptoms and signs localizing to Guyon canal on physical examination

Preoperative Evaluation
- Electrodiagnostic studies are often helpful in localizing the compression point to Guyon canal.
- Preoperative imaging studies are needed if a space-occupying lesion is suspected.

Pearls
- Only 1 or 2 mm of the deep motor branch can be seen diving beneath the hypothenar muscles.
- Look for the deep motor branch at the free edge of the hypothenar muscles.

Technical Points
- Same incision as for a carpal tunnel release, but extend it both proximally and distally.
- Avoid the ulnar cutaneous communicating branch in the distal portion of the incision.
- Open the Guyon canal.
- Palpate the hook of the hamate.
- Dissect the neurovascular bundle ulnarward along its length through the Guyon canal.
- Visualize the leading tendinous edge of the hypothenar muscles.
- Release the deep motor branch of the ulnar nerve, which is located just below the leading tendinous edge of the hypothenar muscle origin.

Pitfall
- Failure to identify and release the deep motor branch of the ulnar nerve

Postoperative Care
- Remove the dressing on day 2 or 3.
- Splint the wrist in neutral for 2 weeks at night.
- Begin range-of-motion exercises on day 2 or 3.
- Begin strengthening exercises after 4 weeks.
- If the carpal tunnel has also been released, use a night splint in a wrist neutral position for 3 weeks.

Postoperative Care

A bulky dressing is applied to maintain a wrist neutral position, and this dressing is removed 2 days after surgery. The patient is instructed in range-of-motion exercises for the fingers, wrist, and arm. A splint in a wrist neutral position is used at night for patient comfort. The sutures are removed 12 to 14 days postoperatively. Patients are allowed full activity and return to work without restrictions 6 to 8 weeks after surgery.

Cubital Tunnel Syndrome

Chronic compression of the ulnar nerve at the cubital tunnel may occur as a result of ischemia or mechanical compression by repeated elbow flexion, posttraumatic scarring, anomalous musculature, or direct compression, although the exact cause may be difficult to identify. Acute trauma to the ulnar nerve from periarticular elbow fractures or subsequent surgery may compromise ulnar nerve function. Ulnar nerve subluxation may also contribute to cubital tunnel syndrome, in addition to the slack region and restricted mobility of the ulnar nerve.[86] The area within the cubital tunnel is decreased with elbow flexion, and this can increase pressure on the cubital tunnel. Apfelberg and Larson reported a 55% decrease in cubital tunnel area with elbow flexion.[3] Pechan and Julis reported increased pressure within the cubital tunnel with elbow flexion, and this pressure was further compromised with wrist extension or shoulder abduction (or with both).[93] Gelberman and colleagues reported increased intraneural ulnar nerve pressure and decreased cubital tunnel volume with elbow flexion.[26]

Compression of the ulnar nerve at the cubital tunnel is extremely common and second in incidence only to carpal tunnel syndrome. The diagnosis is a clinical one because electrodiagnostic testing is frequently negative. Complaints often include paresthesia and numbness in the small and ring fingers with aching in the medial aspect of the elbow and forearm. The Tinel sign is usually positive over the nerve at or proximal to the cubital tunnel, but the test is overly sensitive and usually bilaterally positive. Provocative testing for cubital tunnel syndrome consisting of combined elbow flexion with digital pressure placed on the ulnar nerve proximal to the cubital tunnel

has good sensitivity and specificity.[80] With severe ulnar nerve compression, patients may exhibit clawing of the small and ring fingers, atrophy of the ulnar nerve–innervated intrinsic muscles, and positive Froment and Wartenberg signs. These motor changes will not identify the level of ulnar nerve compression. However, many patients are initially seen in the early stages of nerve compression and will have no obvious motor deficit. Careful sensory testing as outlined previously can help quantify changes in sensibility. In the early stages of nerve compression, provocation testing may be the only positive sign, followed by alteration of threshold testing (vibration and Semmes-Weinstein monofilaments). In the later stages, two-point discrimination will become abnormal.[51,80] McGowan described a classification system for ulnar neuropathy at the elbow that is based predominantly on the loss of ulnar nerve motor function and does not include sensory changes.[72] This classification system is widely quoted in the literature, although it is limited in clinical applicability. In the McGowan classification, grade I neuropathies have no muscle weakness, grade II neuropathies have muscle weakness with no atrophy, and grade III neuropathies have muscle atrophy.

Although clinical diagnosis of cubital tunnel syndrome remains the gold standard, electrodiagnostic studies may be used to confirm the diagnosis. Nerve conduction studies and EMG are useful in localizing the level of nerve compression, in addition to identifying other sites of nerve compression or other disease processes that may be present (i.e., upper motor neuron disease, peripheral neuropathy). To confirm the diagnosis of cubital tunnel syndrome with nerve conduction studies, many reports support the use of a decreased motor conduction velocity across the elbow.[51] Ulnar nerve motor conduction velocity across the elbow of less than 50 m/sec is considered confirmatory of cubital tunnel syndrome.

Unlike carpal tunnel syndrome, there are other sinister diagnoses that can mimic cubital tunnel syndrome, such as motor neuron disease or Guillain-Barré syndrome. The surgeon must be alert for the common problem of cervical disk disease and the rare but devastating problem of amyotrophic lateral sclerosis when evaluating patients with ulnar motor complaints, particularly if the motor findings exceed the sensory findings (severe motor loss with minimal sensory changes).

ANATOMY

The ulnar nerve is derived from the C8 and T1 nerve roots and is a terminal branch of the medial cord. In the upper part of the arm, the ulnar nerve is posteromedial to the brachial artery, posterior to the intermuscular septum, and anterior to the medial head of the triceps muscle (Figure 28.16). The intermuscular septum is continuous from the humeral medial epicondyle to the coracobrachialis muscle. The arcade of Struthers is a band of deep brachial fascia that attaches to the intermuscular septum and covers the ulnar nerve approximately 8 cm proximal to the medial epicondyle (Figure 28.17). The medial antebrachial cutaneous nerve passes posterior to the ulnar nerve at or proximal to the epicondyle in 90% of cases.[71] The proximal branch of the medial antebrachial cutaneous nerve often runs with the medial intramuscular septum.[50] The ulnar nerve passes posterior to the medial epicondyle and medial to the olecranon. The ulnar nerve then enters the cubital tunnel, which is defined by a taut fascial layer extending from the flexor carpi ulnaris

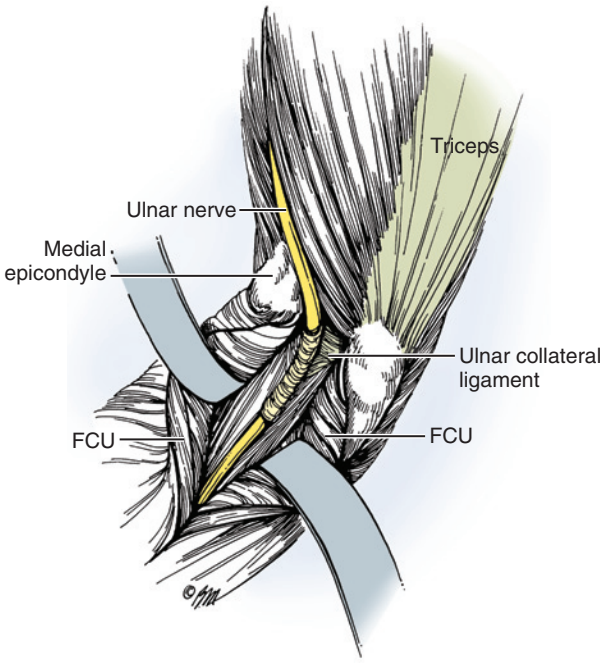

FIGURE 28.16 The ulnar nerve lies on the medial head of the triceps muscle, enters the cubital tunnel behind the medial epicondyle, and continues distally beneath the arcade of fascia, where it joins the heads of the flexor carpi ulnaris (FCU). (Copyright © Elizabeth Martin.)

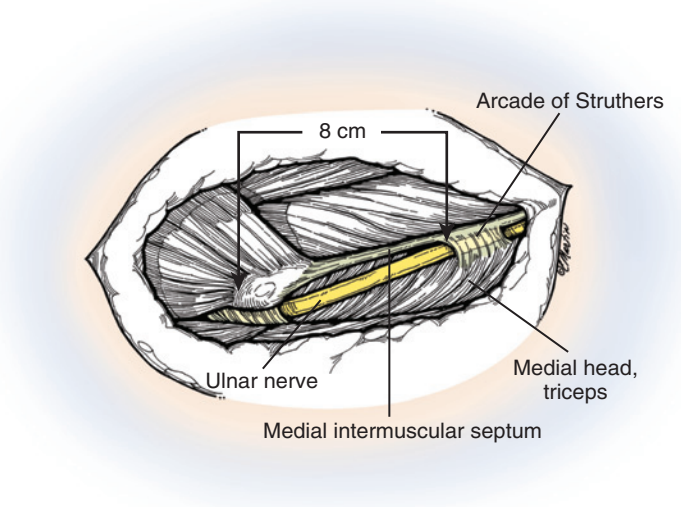

FIGURE 28.17 The arcade of Struthers arises 8 cm proximal to the medial humeral epicondyle. (From Spinner M: Nerve decompression. In Morrey BF, editor: *The elbow,* New York, Raven Press, 1994, and by permission of Mayo Foundation. Redrawn by Elizabeth Martin.)

muscle and the arcuate ligament of Osborne. After passing through the cubital tunnel, the ulnar nerve travels deep into the forearm between the ulnar and humeral heads of the flexor carpi ulnaris muscle.

A number of sites within the region of the cubital tunnel can contribute to ulnar nerve compression, including the arcade of Struthers, the intermuscular septum, the flexor carpi ulnaris fascia, the anconeus epitrochlearis, the Osborne ligament, and fascial bands within the flexor carpi ulnaris distally. The cause is variable among affected individuals. The superficial position

of the ulnar nerve at the cubital tunnel and the increase in tension and traction that it experiences with elbow flexion probably combine to make it susceptible to compression neuropathy.

Nonoperative Management

Cubital tunnel syndrome can often be managed conservatively, with education of the patient to avoid positions and activities that combine elbow flexion with pressure over the ulnar nerve, such as while driving or speaking on the telephone or during sleep. Postural modifications may be necessary for several months before the symptoms resolve, and occasionally surgery will be needed to relieve the symptoms. Unfortunately, the incidence of poor outcomes after surgical management of cubital tunnel syndrome far exceeds that of carpal tunnel syndrome, and when surgery fails, the consequences for patients can be devastating.

Demonstration of the changes in skin tension can be useful in explaining the tightness that occurs in the ulnar nerve with elbow flexion (Figure 28.18). Decreasing elbow flexion and direct pressure on the nerve may help alleviate symptoms in patients with a mild or moderate degree of nerve compression. Recommendations for nonoperative treatment have included static night splinting of the elbow in extension. Rigid night splints are often ineffective because of patient discomfort and noncompliance. Soft elbow pads can be used to protect the ulnar nerve from direct compression. We recommend wearing these pads up to 24 hours per day; both to protect the ulnar nerve from direct compression and also to remind the patient about positions that may be eliciting symptoms. Because the ulnar nerve can be compressed between the two heads of the flexor carpi ulnaris muscle during hand and wrist activities, patients are instructed in specific stretching and nerve gliding exercises.

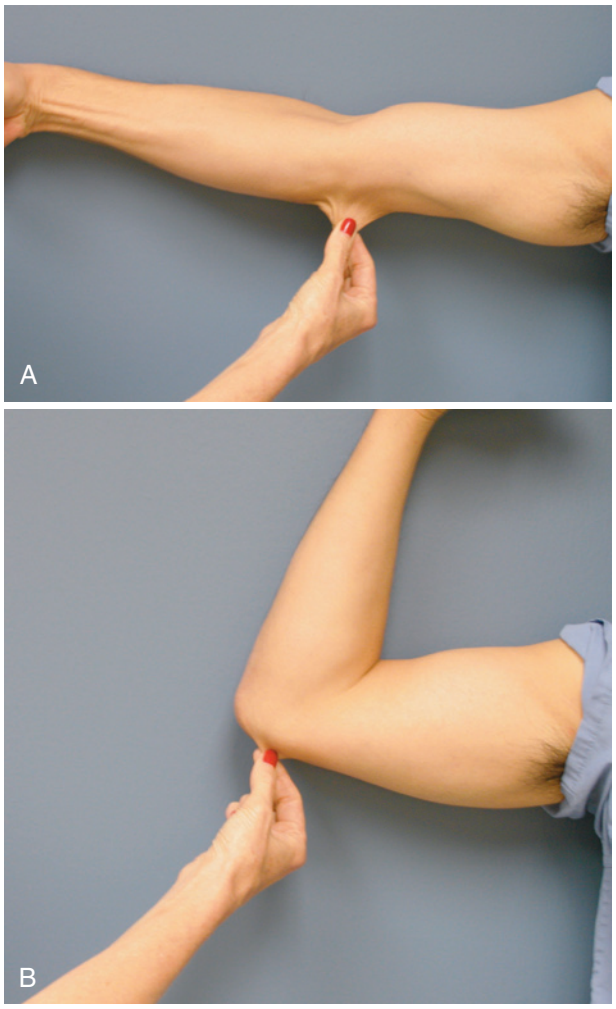

FIGURE 28.18 **A,** The effect of elbow flexion in increasing tension on the ulnar nerve is illustrated to the patient by noting that when the elbow is extended, just as when the skin is loose, the ulnar nerve is loose. **B,** By contrast, when the elbow is flexed, just as when the skin is tight, the nerve is stretched and tight.

In our experience, many patients with mild cubital tunnel syndrome can be managed successfully with 2 to 4 months of nonoperative treatment. We use motor conduction velocity across the elbow as a guide to management and treat all patients with a conduction velocity of 40 m/sec or greater with a minimum of 2 to 3 months of nonoperative treatment. If this approach is unsuccessful or if the initial conduction velocity is less than 40 m/sec, the patient will likely require surgical intervention. A number of surgical approaches have been described for the treatment of cubital tunnel syndrome and include simple decompression, medial epicondylectomy, and anterior transposition of the ulnar nerve in a subcutaneous, submuscular, intramuscular, or transmuscular position. More recently, minimally invasive and endoscopic approaches have been introduced as a surgical option for decompression of the ulnar nerve at the cubital tunnel.[16]

Operative Treatment

The fact that there are several techniques currently recommended by experienced hand surgeons for the surgical management of cubital tunnel syndrome speaks to the ongoing controversy regarding its treatment. Surgical options range from simple decompression to medial epicondylectomy to various anterior transposition techniques.[82] The ideal operative technique should address the mechanism of cubital tunnel syndrome. The superficial position of the nerve at the elbow renders it susceptible to mechanical compression, and its position behind the medial epicondyle causes it to undergo increased tension with elbow flexion. In theory, only a transposition procedure would substantially change the tension on the nerve as the elbow is flexed. A comprehensive review concluded that with more advanced cubital tunnel syndrome, simple decompression was unlikely to be successful.[19] In a metaanalysis of the treatment of cubital tunnel syndrome that included 30 studies over a period of 5 decades, Mowlavi and colleagues concluded that the recurrence rate was highest in nonoperated patients.[75] In patients with moderate nerve compression, relief was achieved most often with a submuscular transposition, and in severely affected patients, all treatments produced similarly poor results.[75] In contrast, a review by Bartels and coworkers determined that patients with severe compression had the best outcome with subcutaneous transposition.[5] These authors recommended simple decompression for the surgical treatment of mild to moderate cubital tunnel syndrome unless ulnar nerve subluxation or severe compression is present, in which case anterior subcutaneous transposition is performed. To investigate the outcome predictors following anterior ulnar nerve

transposition, a systematic review was conducted and found conflicting results across the 26 studies included in the review. The authors concluded that higher-quality studies needed to be performed to identify the predictors of surgical outcome.[101] A metaanalysis was performed to compare outcomes following simple decompression and submuscular transposition of the ulnar nerve. Combining data from 10 studies (published from 1979 to 2006), the authors found no statistical differences between procedures.[56]

In our opinion, the indications for in situ decompression of the ulnar nerve are limited because mild cases of cubital tunnel syndrome in patients with a short duration of symptoms can usually be managed conservatively. Furthermore, if simple decompression fails to relieve the symptoms, any secondary surgery needed to transpose the nerve will be significantly more difficult because of scar tissue formation in the previously operated region.

Technique of in Situ Decompression. An intravenous or regional anesthetic technique is used, and a 6- to 10-cm incision is made along the course of the ulnar nerve midway between the medial epicondyle and the olecranon. Care is taken to avoid injury to the medial antebrachial cutaneous nerve. The intramuscular septum is palpated proximally, and the ulnar nerve is identified just below this septum. The ulnar nerve is decompressed from well above the medial epicondyle distally through the cubital tunnel. The nerve is exposed between the two heads of the flexor carpi ulnaris muscle, and the leading tendinous edge of the flexor carpi ulnaris muscle is released. The ulnar nerve need not be disturbed in its bed, and neurolysis is not performed. Care is taken to ensure that good distal and proximal release of the ulnar nerve has been achieved. The elbow is moved through a range of movement, and any points that might compress the ulnar nerve either proximally or distally are evaluated. The intramuscular septum and the brachial fascia where it might compress the ulnar nerve proximally are excised. If the ulnar nerve subluxates over the medial epicondyle when the elbow moves into flexion, consideration should be given to medial epicondylectomy or anterior transposition to avoid postoperative discomfort. At the conclusion of the procedure, the tourniquet is deflated and hemostasis is obtained. Bupivacaine may be placed in the incision and the subcutaneous layer closed with a subcuticular skin closure. A bulky dressing with or without fiberglass support is applied. The postoperative dressing is removed 2 to 3 days after surgery, and active range of motion is started at that time. A sling may be used at night during sleep for patient comfort until full elbow range of motion is achieved.

Medial Epicondylectomy for Ulnar Neuritis. In 1950, King and Morgan described removal of the medial epicondyle in 16 patients with ulnar neuritis and reported their long-term outcomes in 1959. Most patients in the series had posttraumatic injuries and were not typical of those with idiopathic cubital tunnel syndrome. Other surgeons have expanded this technique to treat nontraumatic causes of cubital tunnel syndrome and believe that it allows some degree of anterior transposition with less dissection. A potential complication of this technique is medial elbow instability, which can occur with "overzealous resection" of the epicondyle. O'Driscoll and associates demonstrated that only approximately 20% of the overall depth of the epicondyle can be removed without violating a portion of the anterior medial collateral ligament and described a safer plane for removal that would avoid the anteroinferior origin of the ligament from the epicondyle.[88]

An intravenous or regional anesthetic is used and the ulnar nerve is decompressed as for a simple decompression. The ulnar nerve is not disturbed in its bed. It is not necessary to perform internal or external neurolysis. The medial epicondyle is exposed subperiosteally, with the flexor-pronator origin being left in continuity with the periosteal sleeve (Figure 28.19). A 2.5-cm osteotome is used to score the leading edge of the epicondyle. To avoid detachment of the anterior medial band of the ulnar collateral ligament, a plane is chosen between the sagittal and coronal planes of the humerus, not along the medial margin of the trochlea as traditionally described. A portion of the epicondyle along with the attached medial intramuscular septum is removed (Figure 28.20). Care should be taken not to enter the

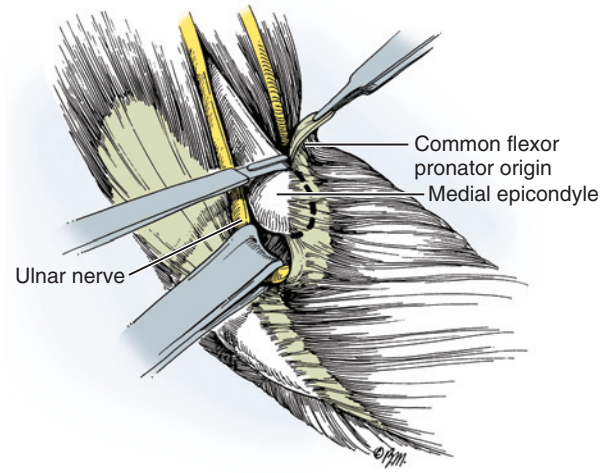

FIGURE 28.19 Medial epicondylectomy is begun by protecting the ulnar nerve and elevating the common flexor pronator origin from the medial epicondyle. The arcade of the flexor carpi ulnaris must be incised to the midportion of the proximal third of the forearm (not shown in the drawing). (Copyright © Elizabeth Martin.)

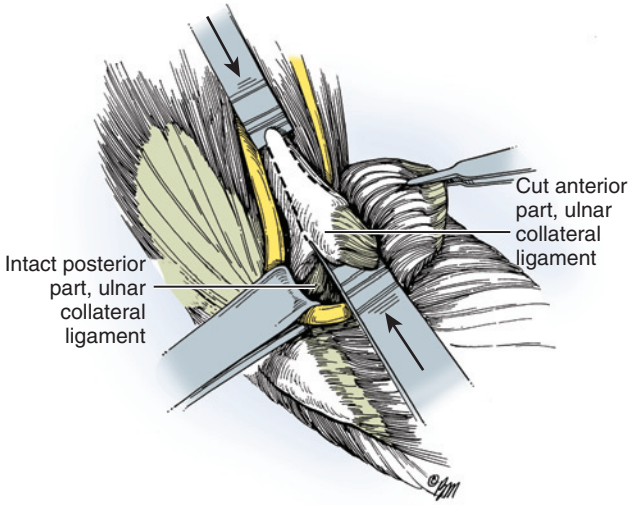

FIGURE 28.20 The guide for the proper plane of osteotomy for the medial epicondyle is the plane between the sagittal and coronal planes. The sharp posterior edge of the osteotomy must be smoothed and rounded. (Copyright © Elizabeth Martin.)

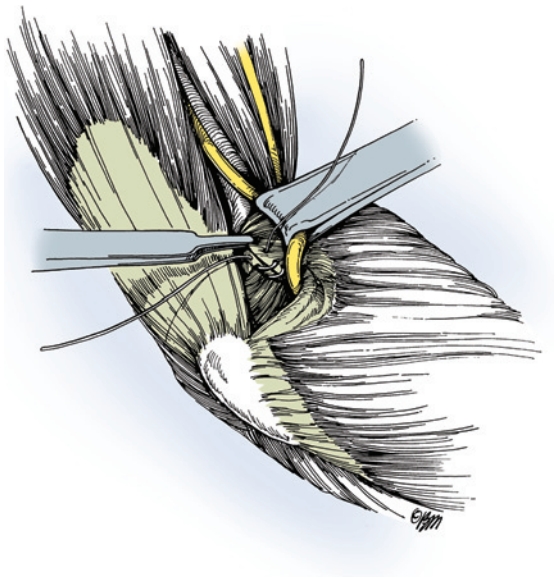

FIGURE 28.21 Repair of the flexor-pronator origin to the humerus. After repair of the muscles, the ulnar nerve is allowed to seek its own position. The arcade of the flexor carpi ulnaris must be opened sufficiently to prevent impingement on the nerve (not shown in the drawing). (Copyright © Elizabeth Martin.)

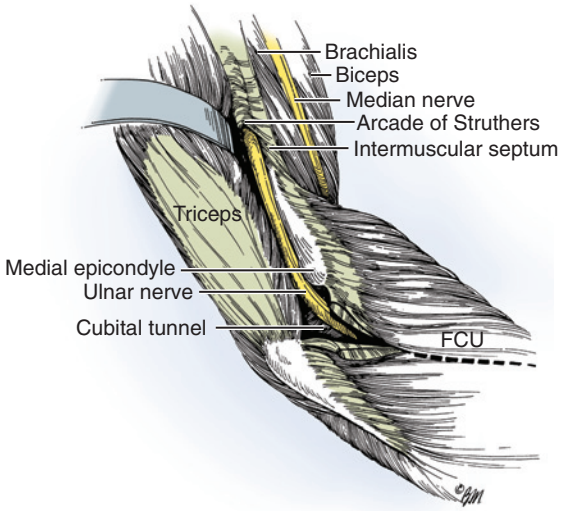

FIGURE 28.22 Mobilization of the ulnar nerve and any associated vessels necessitates decompression of the cubital tunnel, fasciotomy of the flexor carpi ulnaris (FCU), and dissection along the ulnar nerve, at least 8 cm proximal to the medial epicondyle. (Copyright © Elizabeth Martin.)

elbow joint or detach the ulnar collateral ligament. After removal of a portion of the epicondyle, the raw bone edges are rasped smooth and the periosteal flaps with attached flexor-pronator origin are imbricated with buried 3-0 nonabsorbable suture (Figure 28.21). The elbow is moved through a full range of movement to ensure that there is good gliding of the ulnar nerve and no compression of the nerve proximally or distally. The skin is closed routinely and a bulky dressing applied. The dressing is removed 2 to 3 days postoperatively, and range of motion is started.

Subcutaneous Anterior Transposition of the Ulnar Nerve. Proponents of the anterior transposition of the ulnar nerve believe that the procedure further reduces tension on the ulnar nerve during elbow flexion. Some advocates of subcutaneous transposition are concerned about compromise of flexor-pronator muscle strength and the increased scarring that may occur when performing an intramuscular or submuscular transposition. Ogata and associates, in an experimental primate model, demonstrated that anterior transposition of the ulnar nerve was associated with a significant decrease in regional blood flow that was not noted with simple decompression or medial epicondylectomy. Intraneural circulation was restored by the fourth to seventh postoperative day.[89]

Theoretically, anterior transposition should adequately correct symptoms associated with cubital tunnel syndrome as long as care is taken to ensure that new compression points are not created proximally and distally. Given the ulnar nerve's submuscular position above and below the cubital tunnel, extensive proximal and distal exposure is needed to leave the nerve in the subcutaneous location and not produce kinking proximally or distally.

Intravenous or regional anesthesia is used and the procedure begins as a simple decompression. A longer incision is necessary (≈15 cm in length) to accommodate the transposition. The distal medial antebrachial cutaneous nerve crosses the incision about 3.5 cm distal to the medial epicondyle. The proximal branch of this nerve crosses the incision 1.5 cm proximal to the medial epicondyle and often runs with the medial intramuscular septum. These sensory nerves are protected throughout the procedure. The ulnar nerve is identified posterior to the medial intramuscular septum. After removal of the medial intramuscular septum, the ulnar nerve is released through the cubital tunnel and followed between the two heads of the flexor carpi ulnaris muscle. The motor branches to the flexor carpi ulnaris and the flexor digitorum profundus are preserved. The nerve is then carefully lifted from its bed with its accompanying longitudinal vascular supply intact by using a small Penrose drain to prevent constriction. Segmental feeding vessels are identified and ligated to prevent tethering. Neurolysis can be performed as necessary to separate the posterior motor branches from the main ulnar nerve to allow adequate anterior transposition without tension.[115] These motor branches can also be followed into the flexor carpi ulnaris muscle to allow mobilization of the ulnar nerve and protection of these posterior motor branches. The ulnar nerve is moved anteriorly to a subcutaneous position (Figure 28.22). The ulnar nerve should be examined proximally and especially distally to ensure that it lies loosely with no proximal or distal compression points (Figure 28.23). Even very thin fascial bands distally will compress the nerve and lead to a suboptimal result. To keep the ulnar nerve in its anterior position and prevent it from returning to its original position, some of the soft tissue of the anterior skin flap can be sutured to the fascia over the medial epicondyle. Care is taken to exclude any branches of the medial antebrachial cutaneous nerve. One recommendation has been to elevate a 1- to 1.5-cm^2 flap of flexor pronator fascia based on the medial epicondyle and then sew it to the overlying dermis to create a barrier that maintains the nerve in its anterior transposed position. Care must be taken to ensure that the fascial flap does not compress the ulnar nerve and cause a new compression point. Closure, dressing, and postoperative care are as previously described for the other cubital tunnel surgeries.

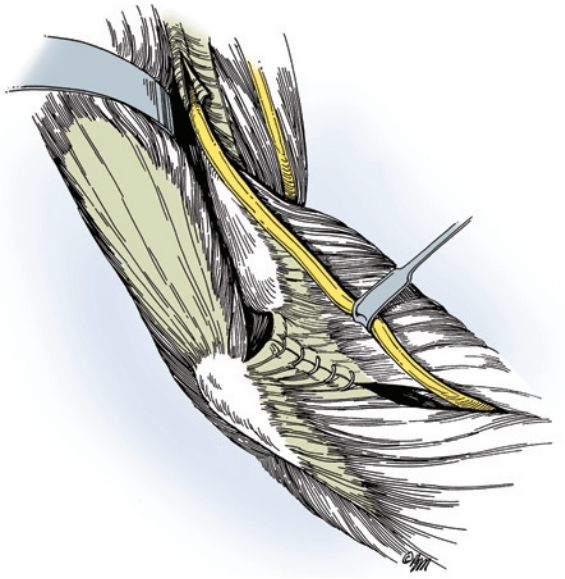

FIGURE 28.23 At the completion of a subcutaneous transposition, the arcade of Struthers does not bind the ulnar nerve and there is adequate release of the flexor carpi ulnaris for the ulnar nerve to reenter the forearm. (Copyright © Elizabeth Martin.)

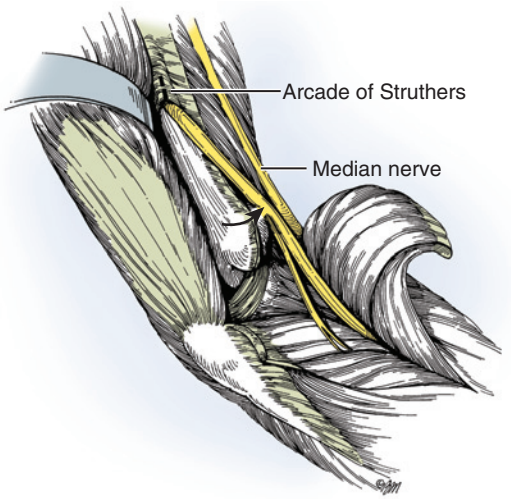

FIGURE 28.24 After submuscular transposition, care must be taken to prevent angulation of the ulnar nerve at the arcade of Struthers. The branches to the flexor carpi ulnaris should be preserved. (Copyright © Elizabeth Martin.)

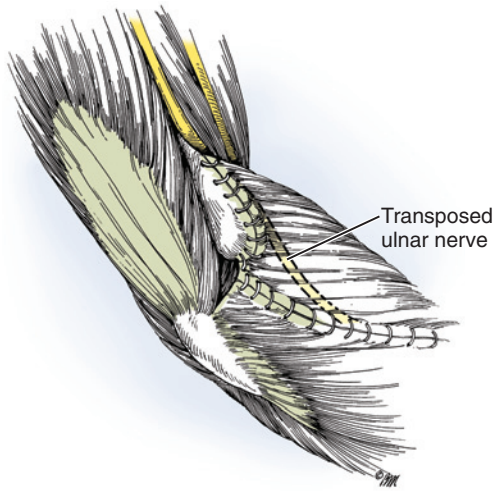

FIGURE 28.25 Completion of the submuscular transposition by repair of the flexor muscles to the medial epicondyle. (Copyright © Elizabeth Martin.)

Intramuscular Transposition of the Ulnar Nerve. In 1918, Adson described intramuscular transposition of the ulnar nerve, and this is the technique also used by Kleinman and Bishop.[42] Proponents of this method believe that it is an improvement over subcutaneous transposition because the nerve lies in a straighter position as it moves from the arm to the forearm and in a more protected position than with the subcutaneous location. Critics suggest that dissection into the muscle will cause more scarring.

The procedure is the same as for subcutaneous transposition except that a groove is dissected in the muscle in line with the location of the ulnar nerve in its transposed position. Fibrous septa within the pronator teres muscle are removed to provide a soft vascularized muscle bed. A fascial flap or a subcutaneous flap is created as for a subcutaneous transposition to keep the nerve in its anterior location. Proponents of this procedure recommend 3 weeks of immobilization and do not allow unrestricted activity until 10 weeks after this procedure.

Submuscular Transposition of the Ulnar Nerve. In 1942, Learmonth described his classic submuscular transposition (Video 28.6). Proponents advocate submuscular transposition as being the "definitive" procedure and the technique of choice in throwing athletes and after previously failed cubital tunnel surgery. Critics cite the extensive dissection and concern for the longitudinal blood supply of the ulnar nerve, as well as the potential for new compression or heterotopic bone under the incised flexor-pronator muscle mass.

The ulnar nerve is exposed and transposed as described earlier for subcutaneous anterior transposition. The incision, however, will be longer (15 to 20 cm). The extent of the flexor-pronator muscle mass is identified. A plane is developed distal to the medial epicondyle and beneath the flexor-pronator muscle mass. The flexor-pronator muscle mass is then incised 1 to 2 cm distal to the medial epicondyle, and a periosteal elevator is used to reflect the muscle distally. Care is taken not to disrupt the ulnar collateral ligament. The median nerve is exposed at the point where it lies on the brachialis muscle by dividing the lacertus fibrosus and dissecting lateral to the elevated flexor-pronator muscle mass. The ulnar nerve is transposed anteriorly, adjacent and parallel to the median nerve (Figure 28.24). The flexor-pronator muscle mass is anatomically reattached with nonabsorbable suture (Figure 28.25). Alternatively, the flexor-pronator mass can be divided in a step-cut fashion and lengthened by 1 to 2 cm during closure to decrease compression on the transposed nerve. The elbow is maintained at 90 degrees with a plaster-reinforced bulky dressing. Range of movement is started 5 to 10 days after surgery.

❖ AUTHORS' PREFERRED METHOD OF TREATMENT

Optimal surgical management of cubital tunnel syndrome is controversial. Because the mechanism of cubital tunnel syndrome is related to the position of the nerve behind the axis of the elbow joint and because elbow flexion increases tension on the nerve, procedures that do not transpose the nerve may not consistently correct the condition. A medial epicondylectomy

goes partway toward decreasing the range through which the nerve must course with elbow flexion. Subcutaneous transposition should be effective as long as there is no kinking of the nerve in either the proximal or the distal transposition site, especially where the nerve moves from the subcutaneous to the intramuscular position distally. Any associated epicondylitis cannot be addressed adequately with a subcutaneous transposition. The classic Learmonth submuscular transposition can result in compression of the nerve by any remaining tendinous bands within the flexor-pronator muscle mass or at its distal transposition site. Associated medial epicondylitis is not addressed because the tension on the flexor-pronator muscle origin is actually increased as it is reset tighter when the flexor origin is reattached. Our preferred method is anterior transposition of the nerve with release of the flexor-pronator muscle origin and positioning of the nerve in a transmuscular location (Figure 28.26 and Video 28.7).[51,59] Transposition through the muscle places no tension on the nerve in any direction and

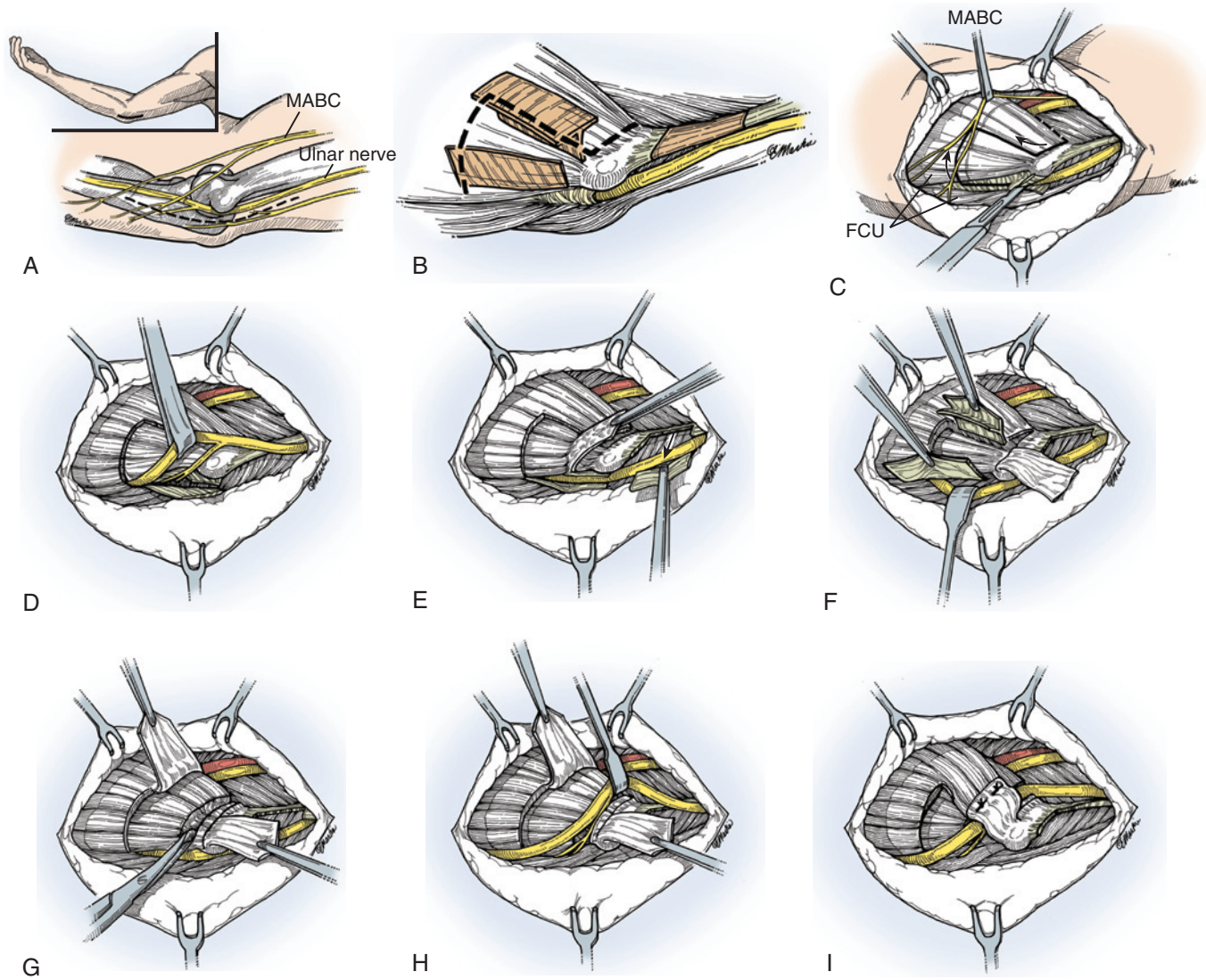

FIGURE 28.26 Authors' preferred technique of transmuscular transposition of the ulnar nerve. **A,** Avoid injury to the branches of the medial antebrachial cutaneous nerve (MABC). **B,** A series of three-dimensional fascial planes underlie the skin and subcutaneous tissues at the elbow: the intermuscular septum above the elbow, the cubital tunnel fascia overlying the ulnar nerve, the "T"-shaped fascia within the pronator teres muscle, the septum separating the pronator teres from the flexor carpi ulnaris muscle, and the leading edge of the flexor carpi ulnaris musculature. These structures must be released or excised to allow mobilization and transposition of the ulnar nerve. **C,** The flexor-pronator origin is identified, and the fascia overlying the muscle is incised in half along its obliquity. A perpendicular incision connects the fascia-splitting incision, with the incision dividing the leading edge of the flexor carpi ulnaris (FCU) to create a distal fascial flap. A second perpendicular incision connects the initial fascia-splitting incision with the free proximal border of the flexor-pronator muscle origin to create a proximal flap. **D,** The posterior motor branch is neurolyzed proximally. **E,** The intermuscular septum is removed. **F,** With elevation of the distal pronator fascia flap, a "T"-shaped fascial structure composed of a horizontal plate overlying a vertical plate is exposed. The flexor-pronator muscle is dissected from these fascial edges. This fascial structure is sharply excised. The fascial septum separating the pronator teres from the FCU is excised. **G,** The proximal flap is elevated from the flexor-pronator muscle origin. The muscle is dissected to the level of the brachialis muscle proximally, but distally some flexor-pronator muscle is left intact. **H,** The ulnar nerve is transposed with no tension either proximally or distally. **I,** The fascia flaps are sutured very loosely. After adequate hemostasis, a Jackson-Pratt drain and a bupivacaine (Marcaine) infusion pump are placed in the wound. The wound is closed in dermal and subcuticular layers. (Copyright © Elizabeth Martin.)

shortens the distance that the ulnar nerve must traverse in all ranges of elbow movement. Identification and removal of all potential tendons, bands, and fascial septum ensure that no new compression points on the nerve will occur. Release of the flexor-pronator muscle origin treats any associated medial epicondylitis. Leaving some flexor-pronator muscle intact facilitates earlier return of strength. The results of this procedure have been extremely satisfactory.[21,84]

The procedure is performed with the patient under general anesthesia and a single tourniquet, augmented by a Bier block with dexmedetomidine hydrochloride and lidocaine. The incision is placed behind the medial epicondyle (10 to 12 cm). Complete release of all points of ulnar nerve compression is performed as described earlier, and care is taken to identify and protect branches of the medial antebrachial cutaneous nerve.[50] The soft tissue above the flexor-pronator muscle origin is elevated, and then the fascial flaps are marked for elevation and transposition (see Figure 28.26, *B* and *C*). The flexor-pronator muscle origin is marked in half, and the first incision is made along this line. Distally, the flap is connected to the incision that was made in the fascia of the flexor carpi ulnaris overlying the ulnar nerve. The proximal edge of the proximal flap is the free border of the flexor-pronator muscle fascia. The distal fascial flap is elevated by sharp dissection. The proximal flap elevates easily with some muscle attached. The fascial bands are identified within the flexor-pronator muscle origin. The muscle attachments are released in a proximal to distal direction to preserve muscle innervation. The "T"-shaped tendinous fascia (about 4 cm in length) is removed. The ulnar nerve is identified as it courses through the proximal portion of the flexor carpi ulnaris muscle. There is another fascial septum here that needs to be removed. This septum is located between the median nerve–innervated flexor-pronator muscle and the ulnar nerve–innervated flexor carpi ulnaris muscle and curves around distally and over the ulnar nerve (see Figure 28.26, *B*). Just like the proximal medial intramuscular septum, if left intact, it will kink the ulnar nerve at the distal location of the transposition. Proximally, the flexor-pronator muscle is released for a short distance down to the level of the brachialis. Distally, the flexor-pronator muscle is released only as necessary to transpose the ulnar nerve anteriorly without tension. It is important to ensure that the ulnar nerve, when transposed, lies in a straight line with no compression proximally or distally. If necessary, the proximal motor branch of the ulnar nerve (branches to the flexor carpi ulnaris) can be neurolyzed from the main trunk with loupe magnification and microinstrumentation so that the branch does not tether the ulnar nerve when it is moved anteriorly. The fascial flaps are closed loosely over the ulnar nerve with two nonabsorbable sutures. It should be possible to put at least a finger between the fascial flaps and the nerve below so that there is no pressure on the ulnar nerve from these flaps. The nerve should be evaluated again to ensure that no kinking of the nerve is present either proximally or distally. The more anterior the nerve is transposed, the more distal in the forearm that possible "kinking" sites will be located. If inadvertently a branch of the medial antebrachial cutaneous nerve has been injured, the distal end should be cauterized and transposed well above the elbow and away from the scar. To assist in pain control, bupivacaine is placed in the incision and a continuous infusion pump can also be used.

A 2-mL infusion pump is used, and the catheter is placed anteriorly over the ulnar nerve. A Jackson-Pratt drain is placed in the ulnar groove. The incision is closed with 3-0 absorbable subcutaneous and 4-0 monofilament intradermal suture with Steri-Strips. The arm is immobilized with 4-inch light casting material in a padded dressing while keeping the wrist in neutral, the forearm pronated, and the elbow flexed.

Expected Outcome After Anterior Transposition of the Ulnar Nerve With Release of the Flexor-Pronator Muscle Origin for Cubital Tunnel Syndrome

In mild to moderate cases, there is return of "painless" functional sensation to the digits innervated by the ulnar nerve. There is also reinnervation of the muscles innervated by the ulnar nerve distal to the cubital tunnel. The elbow and forearm have full range of motion.

Postoperative Care

The bulky dressing, bupivacaine infusion pump, and Jackson-Pratt drain are removed 2 days after surgery. The patient is instructed in range-of-motion exercises for the fingers, wrist, forearm, elbow, and shoulder. For patient comfort, a sling is used at night to limit elbow extension until full elbow extension with forearm supination is achieved. The patient is restricted from heavy lifting for 1 month after surgery. Patients who do not regain full active range of motion within the first 2 to 3 weeks after surgery are referred for therapy. Most patients, however, begin therapy for strengthening exercises 4 weeks after surgery. Patients are allowed full activity and return to work without restrictions 8 weeks after surgery.

In a follow-up study of 119 operated cases at least 2 years after anterior transmuscular transposition of the ulnar nerve, 75% of patients who underwent unilateral procedures reported improvement and 68% of patients with bilateral surgery reported improvement.[84] There were no significant differences in patients with workers' compensation/litigation, obesity, concomitant carpal tunnel syndrome, or abnormal preoperative nerve conduction studies. However, nonsmokers had significantly better outcomes than smokers. Patients with severe and chronic compression, atrophy and dense sensory loss should be cautioned that surgery will arrest the progression and improve their symptoms but will not return normal strength or sensation.

COMPRESSION OF THE RADIAL NERVE

Superficial Radial Nerve Compression

In 1932, Wartenberg described five cases of compression neuropathy of the radial sensory nerve in the forearm and coined the term *cheiralgia paresthetica*. The superficial location of the radial sensory nerve in the forearm renders it susceptible to external compression. Tight wristwatch bands or handcuffs have been described in this compression neuropathy. Work-related repetitive activity requiring significant pronation or supination of the forearm or ulnar wrist flexion has also been associated with compression of the radial sensory nerve. It has been suggested that anatomically the radial sensory nerve is relatively susceptible to increased compression and traction. In pronation, the tendons of the brachioradialis and extensor carpi radialis longus approximate, and as the wrist moves from radial

CRITICAL POINTS *Cubital Tunnel Surgery*

Indications
- Failure to relieve symptoms with the use of an elbow pad and avoidance of elbow flexion and activity modification
- Ulnar intrinsic muscle atrophy

Preoperative Evaluation
- Electrodiagnostic studies to "stage" the degree of nerve compression to help predict the anticipated rate of recovery

Pearls
- Document the preoperative pain distribution.
- Document preoperative examination of the entire upper extremity.
- Use dexmedetomidine hydrochloride and a Bier block.
- Use a bupivacaine infusion pump.
- Begin early movement (postoperative day 2 or 3).

Technical Points
- Avoid injury to all branches of the medial antebrachial cutaneous nerve.
- Remove the intramuscular septum.
- Elevate fascial flaps.
- Remove tendinous bands in the flexor-pronator muscle mass.
- Remove the distal intermuscular septum between the flexor carpi ulnaris and the flexor-pronator muscles.
- Dissect enough flexor-pronator muscle to allow the ulnar nerve to run in a straight line anterior to the medial epicondyle.
- Close the fascial flaps above the ulnar nerve extremely loosely.
- Most importantly, ensure that the ulnar nerve is not kinked at the distal transposition site.
- Place bupivacaine in the incision.
- Use a suction drain and an infusion bupivacaine pump.
- Begin early range of motion postoperatively.

Pitfalls
- Kinking of the ulnar nerve may occur distally as it moves from its position within the flexor carpi ulnaris to its position anterior to the medial epicondyle.
- Do not immobilize the arm for more than 2 or 3 days postoperatively.

Postoperative Care
- Remove the dressing on postoperative day 2 or 3.
- Begin range-of-motion exercises within the patient's comfort level starting on postoperative day 2 or 3.
- Use a sling at night for 3 weeks.
- Begin strengthening exercises in the second month.
- Restrict weight lifting to 5 pounds at 1 month.
- There are no restrictions after the second month.

extension to ulnar flexion, the nerve becomes stretched, and these tendons may compress the nerve. Over time, edema and fibrosis can cause chronic nerve compression. This compression neuropathy has been described histopathologically to range from subperineurial edema or fibrosis to segmental demyelination to Wallerian degeneration.[63,64]

ANATOMY

The radial sensory nerve branches from the main radial nerve at the lateral humeral epicondyle below the brachioradialis and enters the subcutaneous tissue between the tendons of the brachioradialis and the extensor carpi radialis longus in the mid-

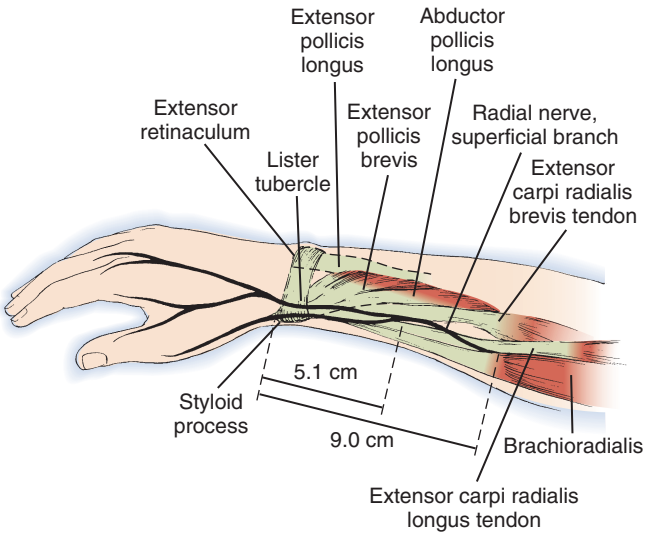

FIGURE 28.27 The most common pattern of the superficial branch of the radial nerve. (From Abrams RA, Brown RA, Botte MJ: The superficial branch of the radial nerve: an anatomic study with surgical implications, *J Hand Surg [Am]* 17:1037–1041, 1992.)

forearm. In 3 to 10% of individuals, the superficial branch of the radial nerve will become subcutaneous by actually piercing the tendon of the brachioradialis. It bifurcates into two main branches 5 cm proximal to the radial styloid, and the major palmar branch continues to innervate the dorsal radial aspect of the thumb. The major dorsal branch continues to innervate the dorsal ulnar aspect of the thumb and the dorsal radial aspect of the index finger. A third branch continues to become the dorsoulnar and dorsoradial digital nerves of the index and long fingers (Figure 28.27). The lateral antebrachial cutaneous nerve has a significant overlap pattern with the radial sensory nerve.[60]

Patients with radial sensory nerve compression typically describe paresthesia, pain, or numbness in the radial sensory nerve distribution. The diagnosis of radial sensory nerve entrapment is suspected when symptoms are reproduced by forearm pronation and ulnar wrist flexion. A positive nerve percussion sign is identified over the radial sensory nerve at the point where it exits the deep fascia in the forearm. The differential diagnosis of radial sensory nerve entrapment should include de Quervain disease; conversely, the Finkelstein sign can also be positive in patients with Wartenberg syndrome. It has been reported that both conditions can coexist because entrapment of the first dorsal compartment tendons can cause scarring or neuritis of the distal branch of the superficial radial nerve. Patients with de Quervain disease should demonstrate normal sensory testing in the dorsal radial aspect of the hand, in contrast to patients with radial sensory nerve compression, in whom sensation may be decreased. Patients with de Quervain disease tend to have pain with percussion over the first extensor compartment and do not have a typical Tinel sign that reproduces symptoms in the radial sensory nerve distribution. Electrodiagnostic studies are rarely if ever useful in diagnosing this condition.

Rarely, the lateral antebrachial cutaneous nerve, which partially or completely overlaps the sensory territory of the radial

sensory nerve, may be entrapped.[60] Differential nerve blocks and positive nerve percussion testing will help distinguish these two nerve entrapments, but in our experience it is relatively rare. Patients who describe paresthesia, numbness, or pain in the radial sensory nerve distribution should be examined to rule out cervical disk disease. If findings localize to the forearm and the cervical spine is excluded as a source of pathologic findings, the patient is instructed to modify inciting activities and to maintain the forearm in a more supinated position whenever possible. Modification of activities to avoid excessive pronation and supination and a local corticosteroid injection at the entrapment site between the tendons of the extensor carpi radialis longus and brachioradialis are generally successful, and surgical release is rarely necessary. Splinting is not usually successful because of the difficulty of splinting in forearm supination.

❖ AUTHORS' PREFERRED METHOD OF TREATMENT: Radial Sensory Nerve Decompression

The radial sensory nerve is released at its point of compression between the tendons of the extensor carpi radialis longus and brachioradialis (Figure 28.28). Preoperatively, the most intense site of the Tinel sign is determined. An intravenous regional block is used with dexmedetomidine hydrochloride and lidocaine, and a padded above-elbow tourniquet is inflated after exsanguination of the limb. A longitudinal incision (2 to 3 cm) is marked just volar to the musculotendinous junction of the brachioradialis muscle. Loupe magnification is used to identify and protect the crossing branches of the lateral antebrachial cutaneous nerve. The musculotendinous junction of the brachioradialis is identified, and the fascia between the tendons of the brachioradialis and the extensor carpi radialis longus is opened. The fascia above the radial sensory nerve is released to identify the radial sensory nerve. The nerve is followed proximally and distally for a distance of about 10 cm. A portion of the tendon of the brachioradialis can be resected to completely decompress the radial sensory nerve. With proximal and distal retraction, the radial sensory nerve can be released over a long distance. Neurolysis is not performed. The tourniquet is deflated, and good hemostasis is obtained. Bupivacaine is placed in the incision. The incision is closed over a plastic angiocatheter, and 2 mL of dexamethasone is injected along the course of the radial sensory nerve through the angiocatheter, with removal of the angiocatheter when the wound is closed. A bulky dressing is applied while keeping the wrist in neutral.

Postoperative Care

The dressing is removed on the second postoperative day, and early movement of the upper extremity is encouraged. Desensitization of the radial sensory distribution on the dorsum of the hand is also started. Patients should avoid heavy lifting for the first month and then start strengthening exercises at the end of the first month.

POSTERIOR INTEROSSEOUS NERVE SYNDROME AND RADIAL TUNNEL SYNDROME

Compression of the radial nerve in the proximal forearm region can result in the posterior interosseous nerve palsy or radial tunnel syndrome. In posterior interosseous nerve palsy, the muscles innervated by the nerve are affected, including the extensor carpi radialis brevis, supinator, extensor carpi ulnaris, extensor digitorum communis, extensor digiti quinti, extensor indicis proprius, abductor pollicis longus, and extensor pollicis longus and brevis. The onset of symptoms may occur after trauma, or an insidious onset may be reported. Other causes can include proliferative rheumatoid synovitis and mononeuritis or Parsonage-Turner syndrome. Rarely, iatrogenic injury

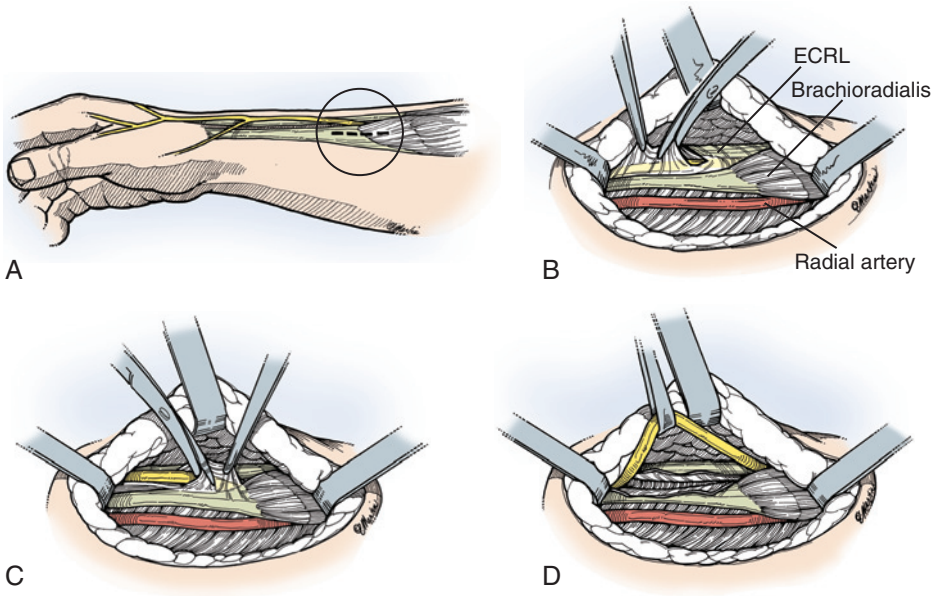

FIGURE 28.28 Radial sensory nerve decompression. **A,** The incision is made on the flexor aspect of the forearm and centered on the radial sensory nerve. The fascia between the brachioradialis and extensor carpi radialis longus tendons is divided distally **(B)** and then proximally **(C). D,** The nerve is freed from its underlying bed. *ECRL,* Extensor carpi radialis longus. (From Dellon AL, Mackinnon SE: Radial sensory nerve entrapment in the forearm, *J Hand Surg [Am]* 11:199–205, 1986. Redrawn by Elizabeth Martin.)

CRITICAL POINTS *Radial Sensory Nerve Release*

Indications
- Rare
- Failure of supination posture to relieve radial sensory symptoms

Preoperative Evaluation
- Tinel sign over the entrapment point in the forearm
- Electrodiagnostic studies

Pearls
- Encouragement of a palm-up position or corticosteroid injection (or both) usually relieves the symptoms without surgery.
- Rule out C7 cervical disk disease and thoracic outlet syndrome.

Technical Points
- Preoperatively identify the muscle-tendon junction of the brachioradialis.
- Make a longitudinal lazy-"S" incision just volar to the muscle-tendon junction of the brachioradialis.
- Take care to avoid injury to the lateral antebrachial cutaneous nerve.
- Open the fascia between the brachioradialis and extensor carpi radialis longus.
- Remove a portion of the tendon of the brachioradialis to adequately release the radial sensory nerve.
- Release the radial sensory nerve proximally and distally to ensure the absence of compressive fascial bands.
- Instill corticosteroid around the nerve and place Seprafilm over it.
- Place bupivacaine in the incision.

Pitfalls
- Confusion with cervical disk disease
- Injury to the lateral antebrachial cutaneous nerve
- Failure to diagnose associated de Quervain disease

Postoperative Care
- Remove the dressing on day 2 or 3.
- Begin range-of-motion exercises on day 2 or 3.
- Begin strengthening exercises in the second month.

can occur during elbow surgery for biceps reattachment, elbow arthroscopy, or radial head reconstruction. Tendon rupture or masses at the elbow may also result in loss of posterior interosseous nerve function. Because the extensor carpi radialis longus is innervated by the radial nerve proximal to the injury, the wrist tends to deviate radially during active wrist extension.

Radial tunnel syndrome is a more controversial diagnosis. Symptoms of pain and weakness may be reported by patients after activities of forceful elbow extension or forearm rotation. The forearm pain typically localizes to the lateral aspect of the forearm, and weakness is often secondary to the pain. Lateral epicondylitis must be considered in the differential diagnosis. Both lateral epicondylitis and radial tunnel syndrome can occur simultaneously. The tendinous origin of the extensor carpi radialis brevis can be implicated in both conditions.

The radial tunnel begins anterior to the radiocapitellar joint and is approximately 5 cm in length. The tunnel is formed laterally by the extensor carpi radialis longus and brevis and the brachioradialis muscles, medially by the biceps tendon and brachialis, and posteriorly by the radiocapitellar joint capsule. The brachioradialis muscle passes over the nerve in a lateral to anterior direction to form the roof of the tunnel. Although the tunnel was originally described as ending at the arcade of Fröhse, compressive tendinous bands have been described that extend to the distal end of the supinator muscle.

Radial tunnel syndrome is a clinical diagnosis based on tenderness over the radial tunnel, pain at the origin of the extensor carpi radialis brevis with resistance of middle finger extension, and pain with resisted forearm supination. Electrodiagnostic studies are not particularly useful in this condition. Because reproduction of pain with deep palpation is important in making this diagnosis, it is important to test the contralateral asymptomatic arm for comparison. Pressure is placed over the posterior interosseous nerve in the interval between the brachioradialis and extensor carpi radialis brevis muscles, and the patient's response is compared between the two forearms. Pressure over the supinator may be quite painful. To determine whether a concomitant problem exists over the radial nerve, pressure is exerted between the brachioradialis and brachialis muscles just above the elbow. Because this is a subjective diagnosis, it is important to check the patient's pain response at nonentrapment sites and to reexamine the patient on a few occasions. The scratch collapse test is also useful in the physical examination to identify radial tunnel compression. Some physicians find it helpful to use sequential diagnostic injections of lidocaine into the lateral epicondyle and then the supinator (to effect a posterior interosseous nerve block) to help differentiate nerve entrapment from lateral epicondylitis.

There is no specific nonoperative treatment of radial tunnel syndrome. However, nerve gliding exercises may be useful. In patients with concomitant lateral epicondylitis, therapy may ameliorate the symptoms associated with lateral epicondylitis. Tennis elbow straps are not recommended for patients with radial tunnel syndrome because of the increased pressure that may be placed on the radial nerve.

ANATOMY

The radial nerve is one of two terminal branches of the posterior cord of the brachial plexus, and it splits away from the axillary nerve just proximal to the quadrangular space. It lies behind the axillary artery and brachial artery anterior to the long head of the triceps muscle. The radial nerve courses laterally and posteriorly deep to the long head of the triceps and lies deep to the lateral head and superficial to the medial head of the triceps near the spiral groove. After innervating the triceps, the nerve pierces the lateral intermuscular septum and enters the anterior compartment of the arm approximately 10 cm proximal to the lateral epicondyle (Figure 28.29). The radial nerve sends one to three accessory branches to the brachialis muscle 3 to 9 cm proximal to the epicondyle and a larger branch to the brachioradialis muscle. Occasionally, this branch can arise from the superficial branch of the radial nerve distal to the epicondyle. The anconeus muscle is innervated proximal to the joint, followed by the extensor carpi radialis longus. The radial nerve enters the forearm anterior to the lateral epicondyle and then divides into the superficial and deep branches (posterior interosseous nerve). The extensor carpi radialis brevis is generally innervated distal to the elbow joint from either the posterior interosseous nerve or the superficial radial nerve. The posterior interosseous nerve passes under the arcade of Fröhse before passing between the two heads of the supinator. The

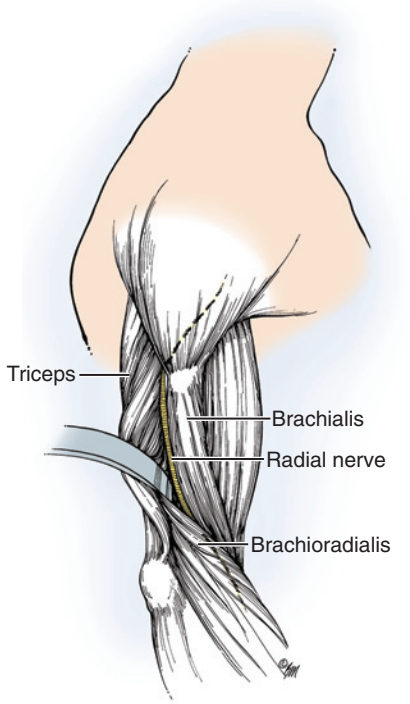

FIGURE 28.29 The radial nerve pierces the lateral intermuscular septum 10 cm above the lateral humeral condyle and courses in a groove between the brachialis and brachioradialis muscles. (Copyright © Elizabeth Martin.)

arcade of Fröhse is a fibrous arch that originates from the lateral epicondyle and in a number of cases has a tendinous consistency. Fibrous bands within the supinator muscle or hypertrophy of the superficial head may cause compression in this location. After exiting the supinator muscle, the posterior interosseous nerve divides into deep and superficial branches. The superficial branch innervates the extensor carpi ulnaris, extensor digitorum communis, and extensor digiti quinti muscles. The deep branch innervates the abductor pollicis longus, extensor pollicis longus, extensor pollicis brevis, and, finally, the extensor indicis proprius muscle.

Operative Techniques

Several approaches (anterior, posterior, and transmuscular brachioradialis splitting) have been described for release of the posterior interosseous nerve based on the relationship of the incision to the brachioradialis muscle (Video 28.8).

Transmuscular Brachioradialis-Splitting Approach

With the use of regional or intravenous block anesthesia, a longitudinal or "S"-shaped incision is made beginning proximal to the radial head and 3 cm lateral to the biceps tendon (Figure 28.30). The fascia over the brachioradialis muscle is incised and the muscle belly is split bluntly while aiming for the radial head until the fat overlying the radial nerve is seen. The brachioradialis muscle split is lengthened over the radial tunnel. Transverse vessels are coagulated, and the fibrous bands overlying the posterior interosseous nerve and the fibrous edge of the extensor carpi radialis brevis are divided. Recurrent radial vessels are ligated and the superficial head of the supinator muscle is divided completely.

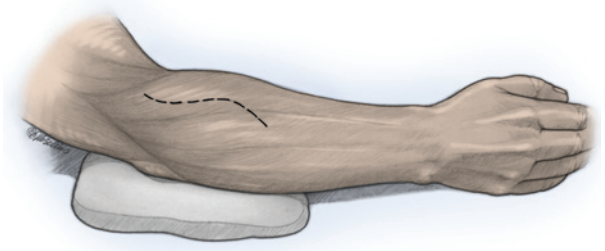

FIGURE 28.30 Extended approach to the posterior interosseous nerve through the brachioradialis-splitting approach. (Copyright © Elizabeth Martin.)

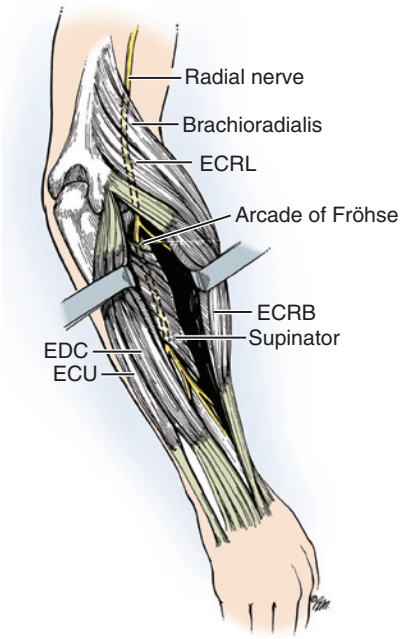

FIGURE 28.31 Extension of the posterior Thompson approach to the radial tunnel. *ECRB*, Extensor carpi radialis brevis; *ECRL*, extensor carpi radialis longus; *ECU*, extensor carpi ulnaris; *EDC*, extensor digitorum communis. (Copyright © Elizabeth Martin.)

Posterior (Henry or Thompson) Approach

The forearm is pronated and a 10-cm straight skin incision is made along an imaginary line extending from the lateral epicondyle to the Lister tubercle. The incision can be extended proximally onto the lateral ridge of the epicondyle as necessary (Figure 28.31). The posterior cutaneous nerve of the forearm is identified and protected. The forearm fascia is incised in the interval between the extensor digitorum communis and the extensor carpi radialis longus. Dissection begins at a point where the two tendons can be identified distally and is extended proximally to the lateral epicondyle. The extensor carpi radialis brevis lies deep to the extensor carpi radialis longus, and its tendon of origin can safely be detached from the lateral epicondyle as needed for exposure. The extensor digitorum communis muscle can be partially detached from the lateral epicondyle anteriorly. The supinator is identified deep to the extensor muscles in the proximal third of the incision. The posterior interosseous nerve can then be found at the proximal edge of the supinator, and the fibrous leading edge of the extensor carpi radialis brevis and the tendinous leading edge of the supinator

are released. The recurrent leash of the vessels of Henry is ligated. The superficial head of the supinator muscle should be released to its distal border.

Anterior (Modified Henry) Approach

A curvilinear incision is made starting above the lateral humeral epicondyle and continuing distally between the biceps and brachioradialis muscles and then curving laterally 2 cm above the elbow flexion crease, back over the mobile wad, and medial to the ulnar border of the brachioradialis muscle. The cutaneous nerves are identified and protected and the fascia divided along the brachioradialis muscle, which is retracted laterally while the biceps and pronator teres in the distal wound are retracted medially. The radial nerve is identified in the interval between the brachialis and brachioradialis and followed distally. Fibrous bands overlying the posterior interosseous nerve and the fibrous leading edge of the extensor carpi radialis brevis muscles are divided. The recurrent radial vessels of Henry are ligated and the arcade of Fröhse is released. The mobile wad is elevated and retracted to visualize the entire length of the supinator. The superficial head of the supinator is divided to expose the nerve to its terminal branches.

❖ AUTHORS' PREFERRED METHOD OF TREATMENT

Decompression of the posterior interosseous nerve is done through the bloodless interval between the brachioradialis and the extensor carpi radialis longus. This approach can easily be extended proximally to release the radial nerve in the interval between the brachialis and the brachioradialis and distally to decompress the posterior interosseous nerve through the supinator.

Preoperatively, it is important to identify the interval between the extensor carpi radialis longus and the brachioradialis muscles. The patient is instructed to resist elbow flexion, and the planned incision is marked along the posterior border of the brachioradialis muscle. Intravenous regional or general anesthesia is used, as are loupe magnification and microbipolar cautery. A straight 10-cm incision is made along the posterior border of the brachioradialis muscle. The posterior cutaneous nerve of the forearm is small, but it is always located exactly at the junction between the fascia of the brachioradialis muscle and the extensor carpi radialis longus muscle. There is a color distinction between the fascia of these two muscles. The brachioradialis muscle is a more intense red color because the fascia is thinner. By contrast, the fascia of the extensor carpi radialis longus is thicker and appears lighter. This fascial interval is sharply divided with a No. 15 blade, and the dissection is deepened by blunt finger dissection down to the region of the arcade of Fröhse (Figure 28.32, *A*). If the dissection is not an easy finger dissection, the surgeon is not in the correct plane. Deep retractors are used to retract the brachioradialis muscle and the extensor carpi radialis longus muscle. The crossing vessels are identified and carefully ligated and divided. The surgeon can then easily identify the radial sensory nerve, the small nerve to the extensor carpi radialis brevis, and the posterior interosseous nerve (see Figure 28-32, *B*). The tendon of the extensor carpi radialis brevis is divided from its origin on the lateral epicondyle. This effectively treats any component of the symptoms that may be attributed to lateral epicondylitis. Both the tendinous part and the underlying muscle of the

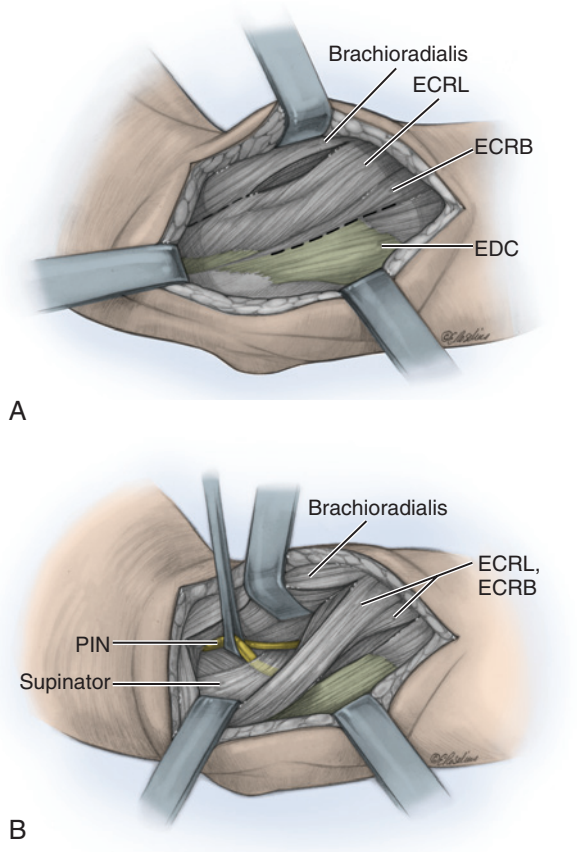

FIGURE 28.32 Extended approach to the posterior interosseous nerve (PIN) through the brachioradialis/extensor carpi radialis longus (ECRL) interval. **A,** Superficial exposure. **B,** Deep exposure. *ECRB,* Extensor carpi radialis brevis; *EDC,* extensor digitorum communis. (Copyright © Elizabeth Martin.)

superficial head of the supinator are divided to release the posterior interosseous nerve completely. Occasionally, there will be tendinous bands compressing the posterior interosseous nerve distally within the supinator, and thus the division should proceed to its distal edge. The surgeon should run a finger along the proximal portion of the radial nerve above the elbow; if any bands are encountered, a second incision may be needed above the elbow along the anterior border of the brachioradialis muscle. Deep dissection is performed bluntly between the brachioradialis muscle and the brachialis muscles. If the dissection is difficult or through muscle fibers, the surgeon is in the wrong plane. The radial nerve proper is easily identified and followed proximally to release any tendinous bands up to the level of the lateral intermuscular septum. Bupivacaine is placed in the incision or incisions. The tourniquet is deflated, and hemostasis is achieved with bipolar electrocautery. A drain is rarely needed. The incisions are closed in layers with absorbable suture. A bulky dressing immobilizes the arm with the wrist in neutral and the elbow flexed.

Postoperative Care

The dressing is removed 2 to 3 days postoperatively, and the patient is encouraged to begin full range-of-motion exercises. The sutures are removed 10 to 14 days after surgery. In the second month, strengthening exercises are begun. The patient is returned to light duty work at the end of the first month and released to full and unrestricted duty after 2 months.

CRITICAL POINTS ***Posterior Interosseous and Radial Tunnel Nerve Release***

Indications
- Localized pain over the posterior interosseous nerve in the region of the arcade of Fröhse
- Failure to respond to physical therapy and treatment of possible concomitant lateral epicondylitis

Preoperative Evaluation
- Document discrete significant pain at the junction of the brachioradialis and extensor carpi radialis longus.

Pearls
- Preoperatively mark the incision just dorsal to the brachioradialis muscle.
- Use dexmedetomidine hydrochloride and a Bier block.
- Note that the fascia of the brachioradialis is redder than the lighter fascia of the extensor carpi radialis longus.
- Release the tendon of the extensor carpi radialis brevis across the forearm to treat for any potential associated lateral epicondylitis.
- Ensure complete hemostasis.
- Begin early movement.
- If the patient preoperatively had localized pain over the radial nerve above the elbow, a second incision is made to decompress the main radial nerve above the elbow.

Technical Points
- Make an incision along the junction between the brachioradialis and extensor carpi radialis longus.
- Identify and protect the posterior cutaneous nerve of the forearm.
- Use blunt dissection in the interval between the brachioradialis and the extensor carpi radialis longus down to the arcade of Fröhse.
- Preserve the nerve to the extensor carpi radialis brevis.
- Ligate the crossing vessels.
- Release the tendon of the extensor carpi radialis brevis over the posterior interosseous nerve and across the forearm.
- Release the superficial head of the supinator to completely decompress the posterior interosseous nerve.
- Use finger palpation proximally to feel for any fibrous bands over the radial head.
- Make a proximal incision above the elbow between the brachioradialis and brachialis if any fibrous bands are palpated from the distal incision.
- Place bupivacaine in the incision.

Pitfalls
- Failure to identify and protect the posterior cutaneous nerve of the forearm and the radial sensory nerve
- Failure to adequately excise the extensor carpi radialis brevis tendon and the entire superficial head of the supinator
- Failure to achieve meticulous hemostasis

Postoperative Care
- Remove the dressing on postoperative day 2 or 3.
- Begin range-of-motion exercises on day 2 or 3.
- Continue range-of-motion exercises throughout the first month.
- Start strengthening exercises in the second month.
- If patient has undergone an associated procedure on the lateral epicondyle, use a soft sling for 1 or 2 weeks.

PROXIMAL RADIAL NERVE COMPRESSION

Compression of the radial nerve proximal to the elbow is uncommon. A fibrous arch from the lateral head of the triceps has been associated with radial nerve compression, and cases have been reported after strenuous muscular activity. A bony exostosis of the humerus has also been associated with this problem. Patients will have variable degrees of radial nerve dysfunction. Typically it is not painful, and spontaneous recovery usually occurs. Patients may provide a history of alcohol or drug abuse that suggests prolonged positioning with pressure over the radial nerve in the spiral groove. If there is no clinical evidence of recovery in 3 months, electrodiagnostic studies should be done. If these do not show evidence of reinnervation, surgical release of the radial nerve can be considered. In chronic, recurrent, or painful cases of radial nerve compression related to sports or exertion, decompression is occasionally indicated despite normal electrodiagnostic studies.

Operative Technique

With the patient under general anesthesia, the entire arm is prepared and draped. Although distal dissection can be performed with the use of a sterile tourniquet, the procedure cannot be completed under tourniquet control because of the proximal exposure required. A long lateral incision is made between the deltoid and the lateral head of the triceps muscle, extends distally along the lateral margin of the biceps, and ends in the interval between the brachioradialis and brachialis muscles just proximal to the cubital crease. The radial nerve is first identified by blunt dissection in the interval between the brachioradialis and brachialis muscles. The nerve is then followed proximally and the lateral intermuscular septum divided to follow the nerve proximally under the lateral head of the triceps. Care is taken to protect the cutaneous radial branches. If necessary, intraoperative electrodiagnostic studies can be done to confirm the area of conduction block. If the long head of the triceps and the tendons of the teres major and latissimus dorsi are divided, these tendons must be reattached at the conclusion of the procedure. The incision is closed in layers, and a bulky dressing is applied along with an arm sling.

If the surgeon believes that proximal decompression will be likely, the modified posterior approach of Gerwin and colleagues enables exposure of the radial nerve along 94% of the humerus by elevating the medial and lateral heads of the triceps without detachment after dividing the entire intermuscular septum.[27]

Postoperative Care

The dressing is removed 2 to 3 days after surgery, and general range-of-motion exercises are started. The sling can be used at night for comfort for 3 weeks after surgery. If a triceps, teres major, and latissimus dorsi release and repair have been performed, active shoulder exercises are delayed 3 to 4 weeks.

SURGERY FOR PREVIOUSLY FAILED PROCEDURES

In carefully selected patients, well-performed surgery with good postoperative patient compliance should adequately decompress or take tension off a nerve such that symptoms from the

compression neuropathy resolve and further surgery is not needed. As extremity surgeons become experienced in the management of patients with compression neuropathies, they are likely to be referred patients who have undergone previous decompression surgeries with less than favorable results. Management of this patient population is much more challenging than that of patients with primary compressive neuropathies.[58,121] These patients often have a very significant pain component. Our pain evaluation form (see Figure 28.3) is critical in helping to identify ongoing symptoms and to determine potential surgical candidates. The assistance of a pain management physician may also be required. Pregabalin or nortriptyline, or both, can be recommended. If surgery is suggested, informed consent will emphasize the possibility of incomplete relief of pain and even decreased neurologic function. In general, if the patient has undergone more than two surgical attempts to correct a nerve compression problem, it is less likely that a third operation to relieve symptoms and improve function will be helpful. In patients with a motor deficit, nerve graft, nerve transfer, or tendon transfers are considered. If pain is the primary problem, a peripheral nerve stimulator or dorsal column stimulator should be considered.[81]

In general, after a failed procedure to treat nerve compression, patients can be classified into three groups: (1) patients may describe the same symptoms postoperatively as they had preoperatively with no relief of symptoms; (2) they may describe a period of relief of compression symptoms, followed at 6 months or later by recurrence of the same symptoms; or (3) they may describe an entirely new symptom complex after the decompression surgery. This last group is the most challenging to manage because it typically includes patients with substantial pain and nerve injury, either to the affected nerve and/or to a nearby cutaneous nerve.

Recurrent Carpal Tunnel Syndrome

The most common reasons for persistent symptoms are failure to adequately decompress the carpal tunnel. In our recent review, the most common intraoperative findings were incomplete release of the flexor retinaculum and median nerve adherence to surrounding tissue.[121] In obese patients, failure to make an incision of adequate length may have led to insufficient decompression of the median nerve, especially at the proximal and distal sites of the surgical exposure. The Phalen test will be positive in these patients, and no other significant sites of compression neuropathy along the course of the median nerve will be noted. Electrodiagnostic studies to evaluate recurrent carpal tunnel syndrome may not be particularly helpful given that patients with successful carpal tunnel surgery will frequently have persistent electrical changes.[22] A second common cause of persistent symptoms after primary carpal tunnel release is the likelihood that carpal tunnel syndrome was not the correct diagnosis or that it was causing an insignificant component of the patient's symptom complex. These patients may demonstrate compression on the median nerve in the forearm or cervical disk disease or may have a sensory neuropathy resistant to surgical decompression. Similarly, patients with sensory complaints on the dorsal aspect of the thumb and the index and long fingers will obviously not respond to carpal tunnel release.

In patients who have definite relief of symptoms for 6 months or longer and then have a recurrence of the same symptoms, a secondary traction neuritis of the median nerve has probably developed as a result of scar formation. Incisions that are placed directly over the median nerve are susceptible to the development of scar between the median nerve and the overlying flexor retinaculum at a later period. In these patients, the Phalen test is positive and there are no other sites of significant proximal median nerve compression.

The most challenging patient management group consists of patients in whom completely new symptoms develop after carpal tunnel release, and this development is usually accompanied by very significant pain dysfunction. Although reflex sympathetic dystrophy or complex regional pain syndrome is uncommon after carpal tunnel release, minor injuries to the median nerve or the palmar cutaneous branch of the median nerve are unfortunately well-recognized complications of carpal tunnel release. A patient's history and physical examination will allow the surgeon to determine which component or components of the median nerve or nearby cutaneous nerves have been injured. A proximal percussion test may help determine this; beginning 2 to 3 inches proximal to the surgical incision, gentle digital percussion is made along the course of the median nerve and its palmar cutaneous branch. At this level, the patient may describe painful paresthesia in the distribution of the involved nerve or nerve branches. By contrast, if digital percussion is done exactly over the area of nerve injury, it may be so painful that the patient cannot be specific about what components (fascicles) of the median nerve have been injured. Typically, the more superficial branch to the third web space (radial side of the ring finger and ulnar side of the long finger) is injured or entrapped in scar tissue. In cases of nerve injury, nonoperative treatment will be unsuccessful.

Patients are referred for therapy to decrease pain, increase range of motion, and increase strength. Medications such as pregabalin or nortriptyline may be helpful in decreasing neuropathic pain. After an appropriate trial of nonoperative treatment, revision surgery is recommended for patients with continued or recurrent symptoms in the median nerve distribution that localize with provocation to the level of the carpal tunnel or with identification of a partial median nerve injury or one to the palmar cutaneous branch of the median nerve.

Revision Surgery

The surgical management of persistent and recurrent carpal tunnel syndrome requires an incision well ulnar to the thenar crease regardless of the first incision and extends this proximal and distal to the area of the previous surgery. Dissection begins proximally to identify the median nerve and is then followed distally through the surgical site. The median nerve is usually found to be densely adherent to the underside of the flexor retinaculum. Micro-internal neurolysis is almost always necessary in recurrent cases but is never indicated for primary carpal tunnel syndrome. Microsurgical instruments are used to perform a longitudinal epineurotomy. Frequently, however, there will be tension on the nerve both transversely and longitudinally, and thus a second epineurotomy going circumferentially around the nerve is also performed. The external epineurium is reflected and neurolysis performed until bands of Fontana are noted in the fascicles. These bands represent redundancy in the peripheral nerves and are thus an "endpoint" for the neurolysis technique. Rarely, an abductor digiti minimi

flap is used to provide soft tissue coverage over the nerve. Alternatively, the nerve can be covered with fat transposed from the neighboring Guyon canal. If the patient has a neuroma of the palmar cutaneous branch of the median nerve, neurolysis of the injured fascicle is performed well proximal to its branching point, and the transected nerve is transposed proximally to lie in the muscle interface between the deep and superficial flexors of the forearm. Injuries to the median nerve itself are treated as for the management of a neuroma in continuity; that is, injuries to the fascicles of the median nerve innervating the third web space can be reconstructed with a short nerve graft, or this fascicular group can be easily separated from the main median nerve for a very long distance and transposed proximally into the forearm between the two flexor masses.[97] The distal end of the common digital nerve to the third web space can be transferred in an end-to-side fashion to the second common digital nerve to recover some sensibility in the third web space.[113] With motor branch deficits and no thumb opposition, local tendon transfers are recommended (Videos 28.9 and 28.10).

Recurrent Cubital Tunnel Syndrome

A review of 100 patients after repeat cubital tunnel surgery and a survey of the operative procedures have led us to a hypothesis regarding the operative management of cubital tunnel syndrome.[70,82] Discussion and debates on the "best" operative procedure have resulted in numerous publications that support various procedures with claims of "excellent results." It is our hypothesis that an understanding of the etiologic factors inherent in the development of cubital tunnel syndrome and an understanding of the potential for surgery to create *new* problems will yield optimal outcomes. Therefore, any of the operative procedures described for cubital tunnel syndrome can result in an excellent outcome if the basic principles related to cubital tunnel syndrome are followed. However, without adherence to these principles, a poor result can occur with any of the standard cubital tunnel procedures. An understanding of the etiologic factors that result in cubital tunnel syndrome is necessary, and, most importantly, it is essential that the surgical procedure does not create any new areas of compression on the ulnar nerve.

Surgical failures are more frequent in cases of cubital tunnel syndrome than in cases of carpal tunnel syndrome, and management of such failures is made exceedingly difficult by the previous surgical procedure and resultant scarring of the nerve. The classification of failed cubital tunnel syndrome is similar to that for carpal tunnel syndrome. Patients may have persistence of the same preoperative symptoms with no change at all in their clinical status. They may have relief of symptoms for several months to years and then have recurrent problems. Finally, they may exhibit new symptoms of neurologic loss or pain (or both) after the cubital tunnel surgery.

Many conditions can mimic cubital tunnel syndrome, and the surgeon needs to be well aware of these. Amyotrophic lateral sclerosis or Pancoast tumors can be accompanied by ulnar nerve symptoms. It is important to be alert for a situation in which the sensory loss and motor loss are decidedly different. If the sensory loss far exceeds the motor complaints, a sensory neuropathy should be considered. By contrast, if the motor complaints exceed the sensory complaints, compression in the Guyon canal should be considered, especially if the proximal extrinsic hand muscles are normal and there is no thenar atrophy. If there is additional thenar atrophy, compression in the thoracic outlet with the very rare Gilliatt "true" neurogenic thoracic outlet syndrome should be considered. If the extrinsic motors are equally involved, brachial plexus neuritis can be considered or upper motor neuron disease if the deep tendon reflexes are increased. Electrodiagnostic studies by an experienced examiner are critical in the differential diagnosis and localization of the level of compression.

Failure to relieve symptoms may imply an incomplete decompression with the primary surgical procedure or an incorrect diagnosis. Recurrence of symptoms after a period of 6 months or more after initial relief of the symptoms usually implies a new site of ulnar nerve compression in the previous surgical field. Severe causalgia-type pain at the elbow radiating into the medial aspect of the forearm suggests a neuroma of the medial antebrachial cutaneous nerve. Severe causalgia-type pain in the ulnar nerve distribution suggests an injury to the ulnar nerve itself. A proximal percussion test above the area of the previous surgical site along the course of the basilic vein will result in pain and/or paresthesia, in the distribution of the medial antebrachial cutaneous nerve if there is a neuroma of this nerve. Similarly, percussion along the course of the ulnar nerve above the area of the previous surgery will result in paresthesia and pain in the ulnar nerve distribution if there is a problem with the ulnar nerve itself. Palpation along the course of the ulnar nerve in the distal forearm progressing to the region of the surgical site will result in deep pain distal to the previous surgical site if a new compression point has developed at the site of the distal surgical exposure. This finding is common if great care has not been taken to ensure smooth transposition of the ulnar nerve from its position in the forearm underneath the flexor carpi ulnaris to the transposition site at the elbow.

Revision Surgery

Surgical management of secondary cubital tunnel syndrome has been reviewed.[49] In a recent review of the operative findings during reoperation for cubital tunnel syndrome, the most common patient complaints after the primary surgery included new symptoms in the ulnar nerve distribution and pain in the medial antebrachial cutaneous nerve distribution.[70] Operative findings included a medial antebrachial cutaneous neuroma and distal kinking of the ulnar nerve as it was moved into the transposed position anterior to the medial epicondyle.[70]

If the patient previously underwent simple decompression, the finding is usually scar around the ulnar nerve in the surgical site or a tendency for the ulnar nerve to sublux over the medial epicondyle (or both). In both cases the ulnar nerve must be mobilized, and a transmuscular transposition is performed as described previously. Similar findings and management are used if the patient has previously had an unsuccessful medial epicondylectomy. If the patient has previously undergone a subcutaneous transposition, the nerve is usually found to be scarred along its course within the surgical site, either to the anterior surface of the medial epicondyle or distally where the ulnar nerve moves from its transposition site to the flexor carpi ulnaris muscle mass. Occasionally, a retained medial intermuscular septum will cause compression on the nerve proximally. In all cases, the ulnar nerve is mobilized, the distal and proximal

compression sites are released, and a transmuscular procedure is performed.

If the patient has previously undergone an intramuscular procedure, the nerve is generally scarred along its entire surgical course, or a tight fascial or suture band can be identified at the medial epicondyle, where the surgeon has created a sling to prevent subluxation. Typically, there is also compression of the ulnar nerve at the distal transposition site by fascia of the flexor carpi ulnaris muscle and the tendinous fascia between the pronator muscle and the flexor carpi ulnaris muscle. The ulnar nerve is mobilized, and fascial flaps are marked on the flexor-pronator muscle origin as described for a primary transmuscular transposition, except in this situation the flaps are based more anteriorly and just in front of the previous surgical intramuscular trough.

If the patient has undergone the classic Learmonth submuscular transposition, the ulnar nerve may be found to be compressed by the tendinous "T" fascia septum within the flexor-pronator muscle origin. The nerve typically takes a right-angled turn when it goes from its submuscular position in front of the medial epicondyle near the median nerve to its posterior location within the flexor carpi ulnaris muscle. The distal fascial septum between the pronator and the flexor carpi ulnaris is also usually intact and may compress the nerve. In these situations, the dissection starts proximally out of the area of the previous surgical site. The dissection carefully follows the ulnar nerve into the area of the previous surgery. The ulnar nerve is found distal to the previous surgical site and followed proximally along its course into the region of the previous surgery. Because a Learmonth submuscular transposition has previously been performed, it is usually possible to leave some overlying muscle intact and remove the tendinous fascial septa that are compressing the ulnar nerve. Thus, no fascial flaps are needed to prevent the ulnar nerve from relocating posteriorly because the overlying flexor-pronator muscle accomplishes this. All tendinous bands and septa that are compressing the nerve are released under the muscle and proximally and distally.

When operating for recurrent cubital tunnel syndrome and particularly in patients who have undergone multiple procedures, extreme care must be taken to preserve the vascular supply to the nerve. The profound intrinsic blood supply of the normal ulnar nerve may become more dependent on the extrinsic blood supply, and ischemia of the nerve can occur if excessive neurolysis is performed. An external epineurotomy and cautious external neurolysis are preferred only to ensure that the ulnar nerve fascicles and bands of Fontana are visualized. In all situations of secondary cubital tunnel surgery, care must be taken to identify the medial antebrachial cutaneous nerve and follow the two main branches distally to make sure that they have been protected. If the branches have been injured, the neuromas are excised and these nerves are transposed proximally to lie well away from the elbow and overlying scar. The distal end of the transposed nerve is cauterized to "cap" the nerve endings with connective tissue and placed either in a muscular bed or in subcutaneous tissue, depending on the patient's body habitus.

Recurrent Guyon Canal Compression

Patients who have persistent ulnar intrinsic atrophy after the release of Guyon canal need to be evaluated to ensure that there is not another cause of the ulnar intrinsic atrophy, as described previously. If not, reexploration can be considered. In our experience, the majority of surgeons do not adequately release the deep motor branch of the ulnar nerve as it curves around the hook of the hamate below the hypothenar muscles. Review of the previous operative notes should provide insight about whether that portion of the procedure had been performed.

For Case Studies, Videos, and more, please visit ExpertConsult.com.

REFERENCES

1. Agee JM, Peimer CA, Pyrek JD, et al: Endoscopic carpal tunnel release: A prospective study of complications and surgical experience. *J Hand Surg Am* 20A:165–172, 1995.
2. Amadio PC, Silverstein MD, Ilstrup DM, et al: Outcome assessment for carpal tunnel surgery: The relative responsiveness of generic, arthritis-specific, disease-specific and physical examination measures. *J Hand Surg Am* 21A:338–346, 1996.
3. Apefelberg DB, Larson SJ: Dynamic anatomy of the ulnar nerve at the elbow. *Plast Reconstr Surg* 51(1):76–81, 1973.
4. Atroshi I, Flondell M, Hofer M, et al: Methylprednisolone injections for the carpal tunnel syndrome: a randomized, placebo-controlled trial. *Ann Intern Med* 159(5):309–317, 2013.
5. Bartels RHMA, Menovsky T, Van Overbeeke JJ, et al: Surgical management of ulnar nerve compression at the elbow: an analysis of the literature. *J Neurosurg* 89:722–727, 1998.
6. Bernard BP: *Musculoskeletal disorders and workplace factors. DHHS(NIOSH) Publication No. 97-141*, Cincinnati, 1997, U.S. Department of Health and Human Services.
7. Blair WF, Goetz DD, Ross MA, et al: Carpal tunnel release with and without epineurotomy: A comparative prospective trial. *J Hand Surg Am* 21A:655–661, 1996.
8. Brininger TL, Rogers JC, Holm MB, et al: Efficacy of a fabricated customized splint and tendon and nerve gliding exercises for the treatment of carpal tunnel syndrome: A randomized controlled trial. *Arch Phys Med Rehabil* 88:1429–1435, 2007.
9. Brown JM, Mohktee D, Evangelista MS, et al: Scratch collapse test localizes Osborne's band as the point of maximal nerve compression in cubital tunnel syndrome. *Hand* 4:50–54, 2009.
10. Butler DS: *Mobilisation of the nervous system*, Melbourne, 1991, Churchill Livingstone.
11. Castillo TN, Yao J: Prospective randomized comparison of single-incision and two-inciison carpal tunnel release outcomes. *Hand* 9:36–42, 2014.
12. Celiker R, Arslan S, Inanici F: Corticosteroid injection vs nonsteroidal antiinflammatory drug and splinting in carpal tunnel syndrome. *Am J Phys Med Rehabil* 81(3):182–186, 2002.
13. Cheng CJ, Mackinnon-Patterson B, Beck JL, et al: The scratch collapse test for evaluation of carpal and cubital tunnel syndrome. *J Hand Surg Am* 33A:1518–1524, 2008.
14. Chow JC: Endoscopic carpal tunnel release: Two-portal technique. *Hand Clin* 10: 637–646, 1994.
15. Chung KC, Pillsbury MS, Walters MR, et al: Reliability and validity testing of the Michigan Hand Outcomes Questionnaire. *J Hand Surg Am* 23A(4):575–587, 1998.
16. Cobb TK: Endoscopic cubital tunnel release. *J Hand Surg Am* 35A:1690–1697, 2010.
17. Dale A, Novak CB, Mackinnon SE: Utility of vibration thresholds in patients with brachial plexus nerve compression. *Ann Plast Surg* 42(6):613–618, 1999.
18. de Krom MCTFM, Knipschild PG, Kester ADM, et al: Efficacy of provocative tests for diagnosis of carpal tunnel syndrome. *Lancet* 335:393–395, 1990.
19. Dellon AL: Review of treatment results for ulnar nerve entrapment at the elbow. *J Hand Surg Am* 14A(4):688–700, 1989.
20. Dellon AL, Mackinnon SE: Chronic nerve compression model for the double crush hypothesis. *Ann Plast Surg* 26(3):259–264, 1991.
21. Ebersole GC, Davidge K, Damiano M, et al: Validity and responsiveness of the DASH questionnaire as an outcome measure following ulnar nerve transposition for cubital tunnel syndrome. *Plast Reconstr Surg* 132:81e–90e, 2013.
22. Faour-Martin O, Martin-Ferrero MA, Almaraz-Gomez A, et al: The long-term postoperative electromyographic evaluation of patients who have undergone carpal tunnel decompression. *J Bone Joint Surg* 94B(7):941–945, 2012.
23. Gay RE, Amadio PC, Johnson JC: Comparative responsiveness of the Disabilities of the Arm, Shoulder and Hand, the Carpal Tunnel Questionnaire, and the SF-36

to clinical change after carpal tunnel release. *J Hand Surg Am* 28A(2):250–254, 2003.
24. Gelberman RH, Aronson D, Weisman MH: Carpal tunnel syndrome. Results of a prospective trial of steroid injection and splinting. *J Bone Joint Surg* 62A:1181–1184, 1980.
25. Gelberman RH, Hergenroeder PT, Hargens AR, et al: The carpal tunnel syndrome: A study of carpal canal pressures. *J Bone Joint Surg* 63A:380–383, 1981.
26. Gelberman RH, Yamaguchi K, Hollstien SB, et al: Changes in interstitial pressure and cross-sectional area of the cubital tunnel and of the ulnar nerve with flexion of the elbow. *J Bone Joint Surg* 80A(4):492–501, 1998.
27. Gerwin M, Hotchkiss RN, Weiland AJ: Alternative operative exposures of the posterior aspect of the humeral diaphysis with reference to the radial nerve. *J Bone Joint Surg* 78A(11):1690–1695, 1996.
28. Gillenwater J, Cheng J, Mackinnon SE: Evaluation of the scratch collapse test in peroneal nerve compression. *Plast Reconstr Surg* 128(4):933–939, 2011.
29. Green DP: Diagnostic and therapeutic value of carpal tunnel injection. *J Hand Surg Am* 9A:850–854, 1984.
30. Greenslade JR, Mehta RL, Belward P, et al: Dash and Boston questionnaire assessment of carpal tunnel syndrome outcome: what is the responsiveness of an outcome questionnaire? *J Hand Surg Am* 29B(2):159–164, 2004.
31. Hadler NM: Repetitive upper extremity motions in the workplace are not hazardous. *J Hand Surg Am* 22A(1):19–29, 1997.
32. Hansen TB, Majeed HG: Endoscopic carpal tunnel release. *Hand Clin* 30:47–53, 2014.
33. Hefford C, Abbot JH, Arnold R, et al: The patient-specific functional scale: validity, reliability, and responsiveness in patients with upper extremity musculoskeletal problems. *J Orthop Sports Phys Ther* 42:56–65, 2012.
34. Heybeli N, Kutluhan S, Demirci S, et al: Assessment of outcome of carpal tunnel syndrome: a comparison of electrophysiological findings and a self-administered Boston Questionnaire. *J Hand Surg Am* 27B(3):259–264, 2002.
35. Hudak PL, Amadio PC, Bombardier C: Development of an upper extremity outcome measure: The DASH (Disabilities of the Arm, Shoulder and Hand). *Am J Ind Med* 29(6):602–608, 1996.
36. Huemer GM, Koller M, Pachinger T, et al: Postoperative splinting after open carpal tunnel release does not improve functional and neurological outcome. *Muscle Nerve* 36:528–531, 2007.
37. Hurst LC, Weissberg D, Carroll RE: The relationship of the double crush to carpal tunnel syndrome. *J Hand Surg Am* 10B(2):202–204, 1985.
38. Jablecki CK, Andary MT, So YT, et al: Literature review of the usefulness of nerve conduction studies and electromyography for the evaluation of patients with carpal tunnel syndrome. *Muscle Nerve* 16(12):1392–1414, 1993.
39. Karpitskaya Y, Novak CB, Mackinnon SE: Prevalence of smoking, obesity, diabetes mellitus and thyroid disease in patients with carpal tunnel syndrome. *Ann Plast Surg* 48:269–273, 2002.
40. Katz JN, Stirrat CR, Larson MG, et al: A self-administered hand symptom diagram for the diagnosis and epidemiologic study of carpal tunnel syndrome. *J Rheumatol* 17(11):1495–1498, 1990.
41. Kendall FP, McCreary EK, Provance PG: *Muscles: testing and function*, Baltimore, 1993, Williams & Wilkins.
42. Kleinman WB, Bishop AT: Anterior intramuscular transposition of the ulnar nerve. *J Hand Surg Am* 14A(6):972–979, 1989.
43. Lanz U: Anatomic variations of the median nerve in the carpal tunnel. *J Hand Surg Am* 2A:44–53, 1977.
44. Leinberry CF, Rivlin M, Maltenfort M, et al: Treatment of carpal tunnel syndrome by members of the American Society for Surgery of the Hand: A 25-year perspective. *J Hand Surg Am* 37A:1997–2003, 2012.
45. Leite JC, Jerosch-Herold C, Song F: A systematic review of the psychometric properties of the Boston Carpal Tunnel Questionnaire. *BMC Musculoskelet Disord* 7(78):1–9, 2006.
46. Levin S, Pearsall G, Ruderman RJ: Von Frey's methods of measuring pressure sensibility in the hand: An engineering analysis of the Weinstein-Semmes pressure aesthesiometer. *J Hand Surg Am* 3A:211–216, 1978.
47. Levine DW, Simmons BP, Koris MJ, et al: A self-administered questionnaire for the assessment of severity of symptoms and functional status in carpal tunnel syndrome. *J Bone Joint Surg* 75A(11):1585–1592, 1993.
48. Levis CM, Tung TH, Mackinnon SE: Variations in incisions and postoperative management in carpal tunnel surgery. *Can J Plast Surg* 10:63–67, 2002.
49. Lowe JB, Mackinnon SE: Management of secondary cubital tunnel syndrome. *Plast Reconstr Surg* 113:1e–16e, 2004.
50. Lowe JB, Maggi S, Mackinnon SE: The position of crossing branches of the medial antebrachial cutaneous nerve during cubital tunnel surgery in humans. *Plast Reconstr Surg* 114:692–696, 2004.
51. Lowe JB, Novak CB, Mackinnon SE: Current approach to cubital tunnel syndrome. *Neurosurg Clin N Am* 12(2):267–284, 2001.
52. Lundborg G: *Nerve injury and repair: regeneration, reconstruction, and cortical remodeling*, ed 2, New York, 2004, Elsevier.
53. Lundborg G, Lie-Stenstrom A, Stromberg T, et al: Digital vibrogram: A new diagnostic tool for sensory testing in compression neuropathy. *J Hand Surg Am* 11A: 693–699, 1986.
54. Lundborg G, Myers R, Powell H: Nerve compression injury and increased endoneurial fluid pressure: A miniature compartment syndrome. *J Neurol Neurosurg Psychiatry* 46:1119–1124, 1983.
55. Lundborg G, Rydevik BL: Effects of stretching the tibial nerve of the rabbit: Preliminary study of the intraneural circulation of the barrier function of the perineurium. *J Bone Joint Surg* 55B:390–401, 1973.
56. Macadam SA, Gandhi R, Bezuhly M, et al: Simple decompression versus anterior subcutaneous and submuscular transposition of the ulnar nerve for cubital tunnel syndrome: a meta-analysis. *J Hand Surg Am* 33A:1314–1324, 2014.
57. MacDermid J: Accuracy of clinical tests used in the detection of carpal tunnel syndrome: A literature review. *J Hand Ther* 4:169–176, 1991.
58. Mackinnon SE: Secondary carpal tunnel syndrome. *Neurosurg Clin N Am* 2:75–91, 1991.
59. Mackinnon SE: Submuscular transposition of the ulnar nerve at the elbow. In Rengachary SS, Wilkins RH, editors: *Neurosurgical operative atlas*, Park Ridge, IL, 1995, American Association of Neurological Surgeons, pp 225–233.
60. Mackinnon SE, Dellon AL: The overlap pattern of the lateral antebrachial cutaneous nerve and the superficial branch of the radial nerve. *J Hand Surg Am* 10A:522–526, 1985.
61. Mackinnon SE, Dellon AL: Anatomic investigations of nerves at the wrist: I. Orientation of the motor fascicle of the median nerve in the carpal tunnel. *Ann Plast Surg* 21:32–35, 1988.
62. Mackinnon SE, Dellon AL, Hudson AR, et al: A primate model for chronic nerve compression. *J Reconstr Microsurg* 1:185–195, 1985.
63. Mackinnon SE, Dellon AL, Hudson AR, et al: Chronic human nerve compression: a histological assessment. *Neuropathol Appl Neurobiol* 12:547–565, 1986.
64. Mackinnon SE, Dellon AL, Hudson AR, et al: Histopathology of chronic nerve compression of the superficial radial nerve in the forearm. *J Hand Surg Am* 11A: 206–210, 1986.
65. Mackinnon SE, Hudson AR, Gentili F, et al: Peripheral nerve injection injury with steroid agents. *Plast Reconstr Surg* 69:482–489, 1982.
66. Mackinnon SE, McCabe S, Murray JF: Internal neurolysis fails to improve the results of primary carpal tunnel decompression. *J Hand Surg Am* 16A:211–218, 1991.
67. Mackinnon SE, Novak CB: Clinical commentary: Pathogenesis of cumulative trauma disorder. *J Hand Surg Am* 19A(5):873–883, 1994.
68. Mackinnon SE, Novak CB: Repetitive strain in the workplace. *J Hand Surg Am* 22A:2–18, 1997.
69. Mackinnon SE, Novak CB: Nerve Transfers. *Hand Clin* 15(4):643–666, 1999.
70. Mackinnon SE, Novak CB: Operative findings in reoperation of patients with cubital tunnel syndrome. *Hand* 2(3):137–142, 2007.
71. Masear VR, Meyer RD, Pichora DR: Surgical anatomy of the medial antebrachial cutaneous nerves. *J Hand Surg Am* 14A:267–271, 1989.
72. McGowan AJ: The results of transposition of the ulnar nerve for traumatic ulnar neuritis. *J Bone Joint Surg* 32B(3):293–301, 1950.
73. McMillan CR, Binhammer PA: Which outcome measure is the best? Evaluating responsiveness of the Disabilities of the Arm, Shoulder and Hand questionnaire, the Michigan Hand Questionnaire and the Patient-Specific Functional Scale following hand and wrist surgery. *Hand* 4(3):311–318, 2009.
74. Melzack R: The McGill pain questionnaire: Major properties and scoring methods. *Pain* 1(3):277–299, 1975.
75. Mowlavi A, Andrews K, Lille S, et al: The management of cubital tunnel syndrome: A meta-analysis of clinical studies. *Plast Reconstr Surg* 106(2):327–334, 2000.
76. Nakamichi K, Tachibana S: Restricted motion of the median nerve in carpal tunnel syndrome. *J Hand Surg Am* 20B(4):460–464, 1995.
77. Nathan PA, Keniston RC, Lockwood RS, et al: Tobacco, caffeine, alcohol and carpal tunnel syndrome in American industry. A cross-sectional study of 1464 workers. *J Occup Environ Med* 38(3):290–298, 1996.
78. Nathan PA, Keniston RC, Myers LD, et al: Obesity as a risk factor for slowing of sensory conduction of the median nerve in industry. *J Occup Med* 34:379–383, 1992.
79. Nemoto K, Matsumoto N, Tazaki K, et al: An experimental study on the "double crush" hypothesis. *J Hand Surg Am* 12A(4):552–559, 1987.
80. Novak CB, Lee GW, Mackinnon SE, et al: Provocative testing for cubital tunnel syndrome. *J Hand Surg Am* 19A(5):817–820, 1994.
81. Novak CB, Mackinnon SE: Outcome following implantation of a peripheral nerve stimulator in patients with chronic nerve pain. *Plast Reconstr Surg* 105(6):1967–1972, 2000.
82. Novak CB, Mackinnon SE: Selection of operative procedures for cubital tunnel syndrome. *Hand* 4(1):50–54, 2009.
83. Novak CB, Mackinnon SE, Patterson GA: Evaluation of patients with thoracic outlet syndrome. *J Hand Surg Am* 18A(2):292–299, 1993.

84. Novak CB, Mackinnon SE, Stuebe AM: Patient self-reported outcome after ulnar nerve transposition. *Ann Plast Surg* 48(3):274–280, 2002.
85. Novak CB, Mackinnon SE, Williams JI, et al: Establishment of reliability in the evaluation of hand sensibility. *Plast Reconstr Surg* 92(2):311–322, 1993.
86. Novak CB, Mehdian H, von Schroeder HP: Laxity of the ulnar nerve during elbow flexion and extension. *J Hand Surg Am* 37A:1163–1167, 2012.
87. O'Brien JP, Mackinnon SE, MacLean AR, et al: A model of chronic nerve compression in the rat. *Ann Plast Surg* 19(5):430–435, 1987.
88. O'Driscoll SW, Jaloszynski R, Morrey BF, et al: Origin of the medial ulnar collateral ligament. *J Hand Surg Am* 17A:164–168, 1992.
89. Ogata K, Manske PR, Lesker PA: The effects of surgical dissection on regional blood flow to the ulnar nerve in the cubital tunnel. *Clin Orthop Relat Res* 193:195–198, 1985.
90. Panel on Musculoskeletal Disorders and the Workplace: *Musculoskeletal disorders and the workplace*, Washington, D.C., 2001, National Academy Press.
91. Parsonage MJ, Turner JW: Neuralgic amyotrophy: The shoulder-girdle syndrome. *Lancet* 254:974–978, 1948.
92. Patel MR, Bassini L: A comparison of five tests for determining hand sensibility. *J Reconstr Microsurg* 15(7):523–526, 1999.
93. Pechan J, Julis I: The pressure measurement in the ulnar nerve. A contribution to the pathophysiology of the cubital tunnel syndrome. *J Biomech* 8:75–79, 1975.
94. Phalen GS: The carpal tunnel syndrome: Seventeen years experience in diagnosis and treatment of six hundred and fifty four hands. *J Bone Joint Surg* 48A(2):211–228, 1966.
95. Phalen GS: The carpal tunnel syndrome. Clinical evaluation of 598 hands. *Clin Orthop Relat Res* 83:29–40, 1972.
96. Rempel D, Evanoff BA, Amadio PC, et al: Consensus criteria for the classification of carpal tunnel syndrome in epidemiologic studies. *Am J Public Health* 88(10): 1447–1451, 1998.
97. Ross DC, Mackinnon SE, Chang YL: Intraneural anatomy of the median nerve provides "third web space" donor nerve graft. *J Reconstr Microsurg* 8:225–232, 1992.
98. Rozmaryn LM, Dovelle S, Rothman ER, et al: Nerve and tendon gliding exercises and the conservative management of carpal tunnel syndrome. *J Hand Ther* 11: 171–179, 1998.
99. Sahrmann SA: *Diagnosis and treatment of movement impairment syndromes*, St. Louis, 2002, Mosby.
100. Seradge H, Parker W, Baer C, et al: Conservative treatment of carpal tunnel syndrome: an outcome study of adjunct exercises. *J Okla State Med Assoc* 95:7–14, 2002.
101. Shi Q, MacDermid JC, Santaguida PL, et al: Predictors of surgical outcomes following anterior transpostion of ulnar nerve for cubital tunnel syndrome: a systematic review. *J Hand Surg Am* 36A(12):e1–e6, 2011.
102. Stratford P, Gill C, Westaway M, et al: Assessing disability and change on individual patients: A report of a patient specific measure. *Physiotherapy Canada* 47(4):258–262, 1995.
103. Strauch B, Lang A, Ferder M, et al: The Ten Test. *Plast Reconstr Surg* 99(4):1074–1078, 1997.
104. Sunderland S: *Nerve and nerve injuries*, ed 2, Edinburgh, 1978, Churchill Livingstone.
105. Szabo RM, Bay BK, Sharkey NA: Median nerve displacement through the carpal tunnel. *J Hand Surg Am* 19A:901–906, 1994.
106. Taleisnik J: The palmar cutaneous branch of the median nerve and the apporach to the carpal tunnel: An anatomical study. *J Bone Joint Surg* 55A:1212–1217, 1973.
107. Thoma A, Veltri K, Haines T, et al: A meta-analysis of randomized controlled trials comparing endoscopic and open carpal tunnel decompression. *Plast Reconstr Surg* 114(5):1137–1146, 2008.
108. Tong HC, Haig AJ, Yamakawa K: The Spurling test and cervical radiculopathy. *Spine* 27:156–159, 2002.
109. Tung TH, Mackinnon SE: Flexor digitorum superficialis nerve transfer to restore pronation: Two case reports and anatomic study. *J Hand Surg Am* 26A:1065–1072, 2001.
110. Turner JW, Parsonage MJ: Neuralgic anyotrophy (paralytic brachial neuritis) with special reference to prognosis. *Lancet* 273:209–211, 1957.
111. Upton ARM, McComas AJ: The double crush in nerve-entrapment syndromes. *Lancet* 2:359–362, 1973.
112. van Vliet D, Novak CB, Mackinnon SE: Duration of contact time alters cutaneous pressure threshold measurements. *Ann Plast Surg* 31(4):335–339, 1993.
113. Vernadakis AJ, Koch H, Mackinnon SE: Management of neuromas. *Clin Plast Surg* 30:247–268, 2003.
114. Watanabe M, Yamaga M, Kato T, et al: The implication of repeated versus continuous strain on nerve function in a rat forelimb model. *J Hand Surg Am* 26A:663–669, 2001.
115. Watchmaker GP, Lee GW, Mackinnon SE: Intraneural topography of the ulnar nerve in the cubital tunnel facilitates anterior transposition. *J Hand Surg Am* 19A(6):915–922, 1994.
116. Weiss AP, Sachar K, Gendreau M: Conservative management of carpal tunnel syndrome: A reexamination of steroid injection and splinting. *J Hand Surg Am* 19A:410–415, 1994.
117. Weiss ND, Gordon L, Bloom T, et al: Position of the wrist associated with the lowest carpal-tunnel pressures: Implications for splint design. *J Bone Joint Surg* 77A(11):1695–1699, 1995.
118. Werner R, Franzblau A, Johnston E: Comparison of multiple frequency vibrometry testing and sensory nerve conduction measures in screening for carpal tunnel syndrome in an industrial setting. *Am J Phys Med Rehabil* 74(2):101–106, 1995.
119. Wilbourn AJ: The electrodiagnostic examination with peripheral nerve injuries. *Clin Plast Surg* 30:139–154, 2003.
120. Williams TM, Mackinnon SE, Novak CB, et al: Verification of the pressure provocative test in carpal tunnel syndrome. *Ann Plast Surg* 29(1):8–11, 1992.
121. Zieske L, Ebersole GC, Davidge K, et al: Revision carpal tunnel surgery: a 10-year review of intraoperative findings and outcomes. *J Hand Surg Am* 38A(8):1530–1539, 2013.

29

Thoracic Outlet Compression Syndrome

Richard Meyer

Acknowledgment: The author would like to thank and acknowledge the work of Dr. Karen Johnson Jones in previous versions of this chapter.

These videos may be found at *ExpertConsult.com:*

29.1 Resection with improved pulse: Complete mobilization of the subclavian artery is required to visualize the lower trunk, and this includes ligation of the deep transverse cervical artery when present. Note the presence of sutures. Complete decompression also requires excision of anterior and medial scalene muscles; note the pleura and lung deep to the vessel. *© Scott W. Wolfe, MD.*

Treatment of peripheral nerve compression in the upper extremity is one of the main components of a hand surgeon's practice; however, most of them shy away from treatment of thoracic outlet syndrome (TOS). Seeing that objective electrodiagnostic studies of TOS can confirm clinical suspicions, refute them, or determine the stage of disease, there is little controversy about treatment regimens for carpal tunnel, cubital tunnel, and other entrapment neuropathies. Because TOS is a compressive neuropathy that may include all of the nerves to the upper extremity, neck, shoulder, upper back, and chest, it may share the characteristics of or mimic the other compressive neuropathies. For most surgeons who do not regularly operate on the upper extremity, and for many who do, there are few disorders as difficult to diagnose or as frustrating to treat as TOS. Diagnosis of it is by exclusion and suspicion, which often are based on clinical diagnostic criteria alone, because there is no definitive electrodiagnostic test that can verify the surgeon's opinion. Most TOS patients have seen an average of 4.7 doctors before a diagnosis is established.[40]

Although hand surgeons see many patients with vague upper-extremity pain, few have received training in recognition and treatment of TOS. In major texts that describe TOS, there are no chapters by hand surgeons. Because the area of compression lies in "expensive real estate," even fewer treat TOS surgically, and still fewer operate without collaborating with a vascular or thoracic surgeon. In an email survey of the American Society for Surgery of the Hand (ASSH) membership regarding TOS, 60% of respondents reported that they treat patients, but only 19% perform surgery for TOS, and only 10 of the 255 hand surgeons who responded treat more than 10 cases per year. A third of respondents operate with a vascular or thoracic surgeon present; this may be appropriate because the typical fellowship-trained hand surgeon may not be prepared to handle the potential risks. Interestingly, almost 20% of the respondents did not believe TOS exists as a legitimate diagnosis.[110]

HISTORY

Historically significant events in the early recognition of TOS as a clinical entity are detailed in the text by Sanders and Haug, *Thoracic Outlet Syndrome: A Common Sequela of Neck lnjuries*.[91] These authors note three important historical periods, and the reader is referred to that text for a comprehensive discussion of the individual historical events. A second excellent source of historical information and state-of-the-art treatment is available as a monograph published as an edition of *Hand Clinics*.[109]

CLASSIFICATION

The two basic types of TOS are vascular and neurogenic. The vascular type is further divided into arterial and venous subtypes, and the neurogenic type has been subdivided into "true" and "disputed" neurogenic. The subclassification and distinction of true versus disputed neurogenic TOS are attributed to Wilbourn.[111]

Patients with the arterial, venous, and electrically positive neurogenic TOS present with an obvious mechanical obstruction to blood flow, or have positive nerve conduction study results, rarely have secondary concerns (e.g., workers' compensation issues, litigation) that cloud the issue. Diagnosis by physical examination, routine diagnostic imaging, or testing for neurogenic TOS is straightforward, and surgical treatment, when indicated, is relatively successful.

The fourth subtype (i.e., disputed neurogenic), however, has been more difficult for some patients to accept. Although the classification was described first in 1984, it is time to drop this nomenclature and adopt the term *electrically negative neurogenic TOS*. This is because patients with it account for up to 97% of all those diagnosed and treated for TOS. It is only a disputed entity for those clinicians who must do objective diagnostic studies or imaging. So far there have been no definitive studies or means by which one can make the diagnosis; therein lies the problem.

Arterial Thoracic Outlet Syndrome

Arterial TOS is uncommon, accounting for only 1 to 2% of all cases of TOS. There is almost always an osseous anomaly such as a cervical rib, an anomalous first rib, or a history of fracture



FIGURE 29.1 An oblique radiograph of the cervical spine of a patient with a complete right cervical rib and true thoracic outlet syndrome ("button marks" on the rib). (From the Christine M. Kleinert Institute for Hand and Microsurgery, Inc., with permission).



FIGURE 29.2 Photograph of venous collaterals in a patient's left anterior chest with subclavian thrombosis (i.e., Paget-Schroetter syndrome).

(Figure 29.1). Arterial TOS may present as a limb-threatening condition. The subclavian artery can become stenotic or develop an aneurysm because of compression between the rib and the clavicle or because of traction over the cervical rib. In addition, it can ulcerate, become occluded, or become thrombotic.[26,42] There can be fingertip ulcerations, Raynaud's symptoms, pain, and claudication. The arterial type is more commonly indolent and has a history that suggests intermittent complete or partial arterial occlusion. Symptoms may be brought on by sports activities that place the upper extremity in an extended and hyperabducted position. Clavicle nonunion, malunion, post-traumatic subluxation of the sternoclavicular joint, and rib fractures also have been identified as causes.[26]

Venous Thoracic Outlet Syndrome

Venous TOS is slightly more common than the arterial type and represents 2 to 3% of all cases. These patients may have a sudden, effort-induced thrombosis (i.e., Paget-Schroetter syndrome) or, less commonly, a thrombosis that occurs at rest with the extremity in a compromised position for a prolonged time. There may be intermittent venous compression alone or intermittent compression that precedes a sudden event. With time, large venous collaterals around the shoulder, chest, or breast may develop (Figure 29.2).

In acute thrombosis, pain, edema, and cyanosis are dramatic. In contrast, in patients who have a history of intermittent compression, collateral venous drainage minimizes the signs of distal swelling and cyanosis. In the intermittent compression group, however, fullness in the supraclavicular and infraclavicular areas may make the clavicle difficult to discern. Most acute venous TOS is seen in muscular young males with symptoms that develop after vigorous exercise or physical exertion. Throwing athletes and swimmers have been recognized as "at risk" owing to repetitive extremity positioning in postures that occlude the subclavian vein.[19] Hypercoagulable states put these people at risk as well.

Neurogenic Thoracic Outlet Syndrome

True or electrically positive neurogenic TOS is also rare, occurring in 1 out of 1 million patients with TOS.[27] These patients have objective physical evidence of chronic nerve compression



FIGURE 29.3 Photograph of a patient with true thoracic outlet syndrome; it demonstrates intrinsic atrophy of the right hand.

(e.g., hypothenar atrophy, decreased grip, and sensory deficits), usually in the C8-T1 distribution (Figure 29.3). The pain and paresthesias seen in the other subtypes also may occur. In true neurogenic TOS there may be a bony anomaly causing the compression, such as a rudimentary or fully developed cervical rib[76] (Figures 29.4 and 29.5), although most patients I have seen with this just have compressive bands.

Electrically Negative Neurogenic Thoracic Outlet Syndrome

This type of TOS is by far the most commonly encountered (>95% of cases). These patients have a wide variety of upper extremity complaints, and usually no objective findings are found on electrodiagnostic testing, Doppler imaging, pulse volume recordings, or radiographs. Even though there may be some ambiguity of symptoms, most patients have numbness in the hand and pain in the arm, hand, and especially the shoulder and neck. Frequently there is activity-related or positional exacerbation. Most TOS surgeons would agree that physical complaints reproduced by provocative testing alone, in the absence

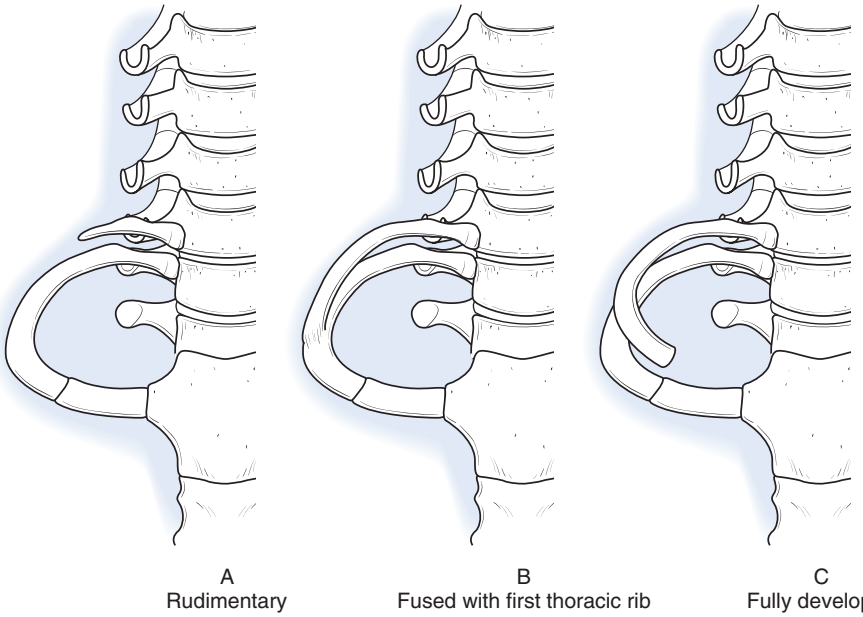

FIGURE 29.4 Three common variants of cervical ribs: **A,** rudimentary; **B,** fused with first thoracic rib; **C,** fully developed. (Redrawn from the Christine M. Kleinert Institute for Hand and Microsurgery, Inc., with permission).

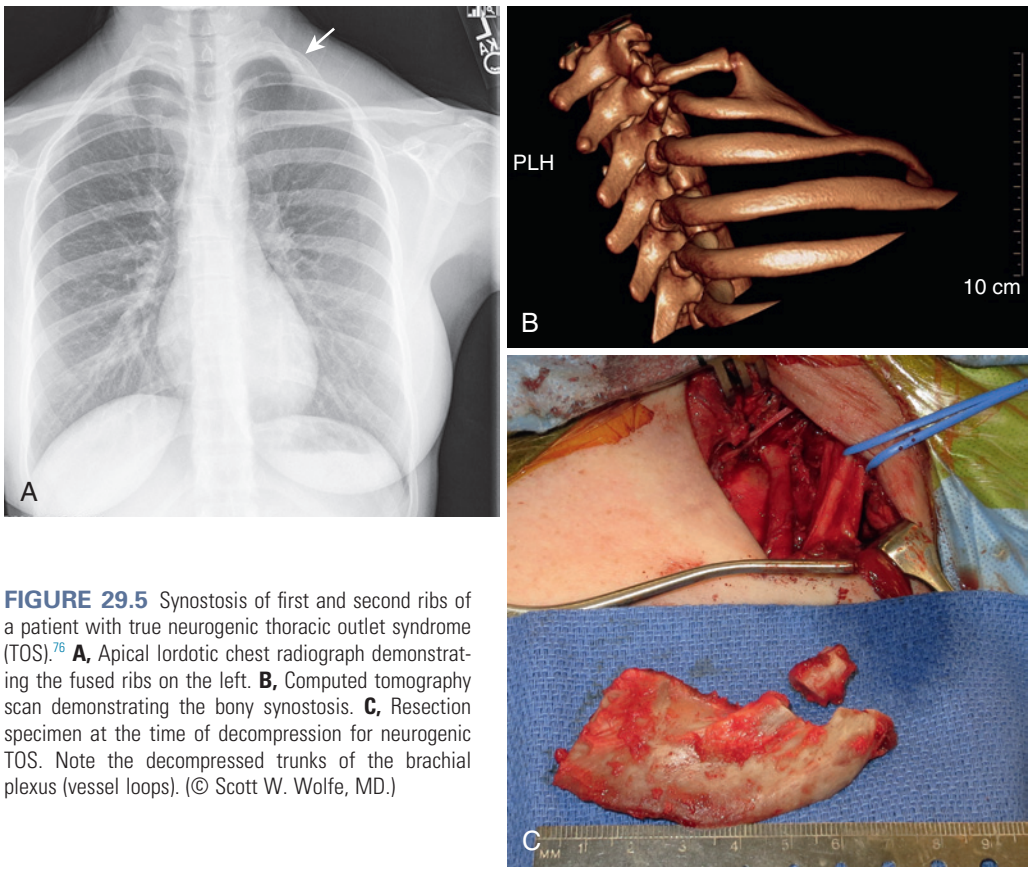

FIGURE 29.5 Synostosis of first and second ribs of a patient with true neurogenic thoracic outlet syndrome (TOS).[76] **A,** Apical lordotic chest radiograph demonstrating the fused ribs on the left. **B,** Computed tomography scan demonstrating the bony synostosis. **C,** Resection specimen at the time of decompression for neurogenic TOS. Note the decompressed trunks of the brachial plexus (vessel loops). (© Scott W. Wolfe, MD.)

of another explanation for the patient's complaints, are sufficient to justify a working diagnosis of neurogenic TOS. In our practice, numbness in the ulnar nerve distribution of a patient with clinical symptoms suggestive of TOS, but with negative electrodiagnostic studies, is indicative of TOS until proven otherwise.

In 1982, Roos classified TOS according to the segment of the brachial plexus involved.[82] Categories of compression include upper trunk, lower trunk, and combined. Symptoms attributable to the lower- and combined-compression groups are found in 85 to 90% of all patients with TOS. Electrical studies are of no value for this classification scheme.

EPIDEMIOLOGY

Although there are few firm epidemiologic data, the five most frequently cited predisposing factors for TOS are gender, age, occupation, geographic location, and insurance status.

Thoracic outlet syndrome is diagnosed in women 3.5 to 4 times as often as in men and most frequently in adults of working age. Occupational risk factors for TOS have been suggested. From 1987 to 1989, according to the Bureau of Labor Statistics, there was a 100% increase in the reported number of cases of cumulative trauma disorder (reporting requirements also changed dramatically during that time).[9] Diagnoses reported in the shoulder region, including TOS, ranked second in frequency only to lower back and neck complaints.[96] Awkward or static upper-extremity positioning, including holding the arm in 45 degrees of abduction, has been found to increase the prevalence of TOS symptoms. Hairdressers, painters, heavy construction workers, grocery clerks, switchboard operators, nurses, and clerical workers have more complaints of TOS symptoms when compared with the general population. These occupations have in common repetitive lifting or repetitive, uninterrupted arm movements with the hand at or above the shoulder level, and awkward or static extremity posture.[41,78,96]

The reported incidence of TOS in the general population is 1% or 2%, and it may be this low because TOS is underdiagnosed and undertreated.[3,83] In my series of several hundred patients with TOS, 25% of them had previously had shoulder surgery on the same side. Also, in the same group of patients with rotator cuff and shoulder injuries, a significant number had numbness and tingling, dysesthesias, and neurogenic symptoms at the time of initial presentation. The same forces that can cause a cuff or labral tear are certainly sufficient to cause an injury to the scalenes or brachial plexus. We are now seeing an increased number of adolescent TOS patients as a result of intense sports–related activities.

PERTINENT ANATOMY

The general anatomy of the thoracic outlet and brachial plexus is familiar to upper-extremity and vascular surgeons. However, the specific neuroanatomy of the brachial plexus, the vascular components of the thoracic outlet, and the bony and muscular anatomy are highly variable among patients. Fibrous or fascial bands, as well as developmental or acquired variations, are not uncommon, and movement or positioning of the neck, thorax, and shoulder girdle can cause dynamic compression against normal or anomalous structures (see Figure 29.4). In one series of 200 consecutive transaxillary surgical approaches for TOS, cervical ribs were encountered in 8.5%, scalenus minimus in 10%, subclavius tendon anomalies in 19.5%, and anomalies of scalene muscle development or insertion in 43%.[53] The limited exposure of the plexus afforded by the transaxillary approach may have obscured additional anomalies. In another study of 250 cadavers (i.e., 500 thoracic outlets), anatomic anomalies were noted in 46%.[75] In a study of 40 aborted fetuses, anomalies were found in 60%.[24,74]

The anatomic corridor in the thoracic outlet has been partitioned into three sections: the interscalene triangle, the costoclavicular triangle, and the subcoracoid or pectoralis minor space (Figure 29.6).

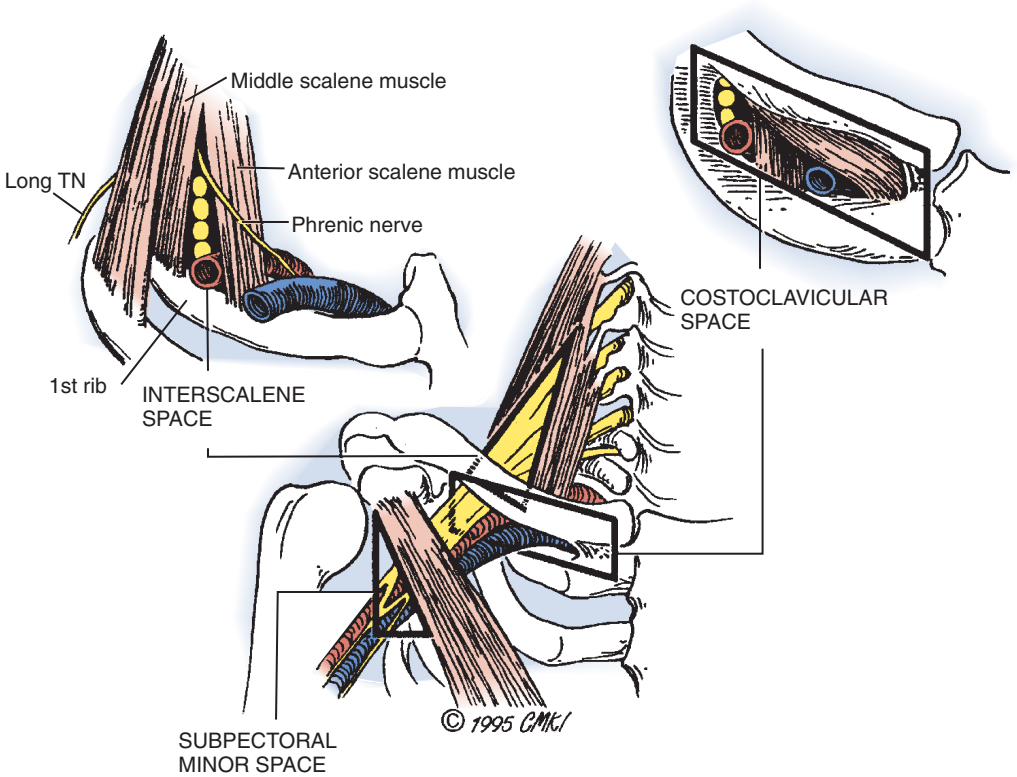

FIGURE 29.6 The three anatomic triangles of the thoracic outlet. *TN*, Thoracic nerve. (From the Christine M. Kleinert Institute for Hand and Microsurgery, Inc., with permission.)

Interscalene Triangle

The interscalene triangle (the most common site for compression) is defined anteriorly by the anterior scalene muscle, posteriorly by the middle scalene muscle, and inferiorly by the first rib. The subclavian vein passes anterior to the anterior scalene and just inferior and lateral to the costocoracoid or costoclavicular ligament.[53] The subclavian artery passes with the plexus between the anterior and middle scalenes. The anterior scalene originates from the anterior tubercles of the transverse processes of C3 to C6. The middle scalene originates from the posterior tubercles of the transverse processes of C2 to C7.[67]

A wide range of anatomic variation can predispose to pathology. Actual crossing, or "intercostalization," of the scalene insertions has been found in 15% of cadaver dissections. It is not uncommon to find slips of the middle scalene penetrating between the upper and middle, or middle and lower, trunks causing direct compression with every contracture. This also may produce a "V"-shaped deformity at the base that can have a scissoring effect on the neural and vascular structures. Alternatively, a "U"-shaped formation can create a sling effect that places pressure on the structures from below.[3]

The scalenus minimus muscle comes up from C6 to C7 and inserts on the deep fascia between the subclavian artery and lower trunk, where it can produce a wedge effect on the lower trunk.[3] It also may wrap around the subclavian artery and pull it against pleural bands, causing positional changes in flow. The downward slope of the first rib, when increased (more commonly seen in women), may drive the neurovascular structures into the angle formed by the lateral edge of the anterior scalene tendon and the first rib (see Figure 29.6, *A*).[67]

Cervical ribs, a commonly cited etiology for TOS, have been identified in 0.5 to 0.6% of the population and are bilateral in 50 to 80% of those affected. Because cervical rib growth is developmentally suppressed by a full contribution of the lower spinal nerve root (T1) to the plexus, there is an association between cervical ribs and a prefixed plexus.[53] Many cervical ribs will be incomplete but have a taut fibrous band, or "anlagen," connecting the bony tip to the first rib or deep fascia (see Figure 29.4, *B*). Such a fibrous band represents only one of many types or locations of fibrous bands that cause nerve compression in TOS patients.[99]

Roos[80,86] described nine different patterns of fibrous bands seen in clinical and cadaveric specimens, and Poitevin[71] reported three additional types of bands a decade later (Figure 29.7). The most frequently found bands were those seen to bowstring across the anterior concavity of the first rib, the "scalenus minimus" muscle band, and the fascial attachments between the anterior and middle scalene muscle groups, crossing the nerve roots of the brachial plexus in either an oblique or a perpendicular manner.

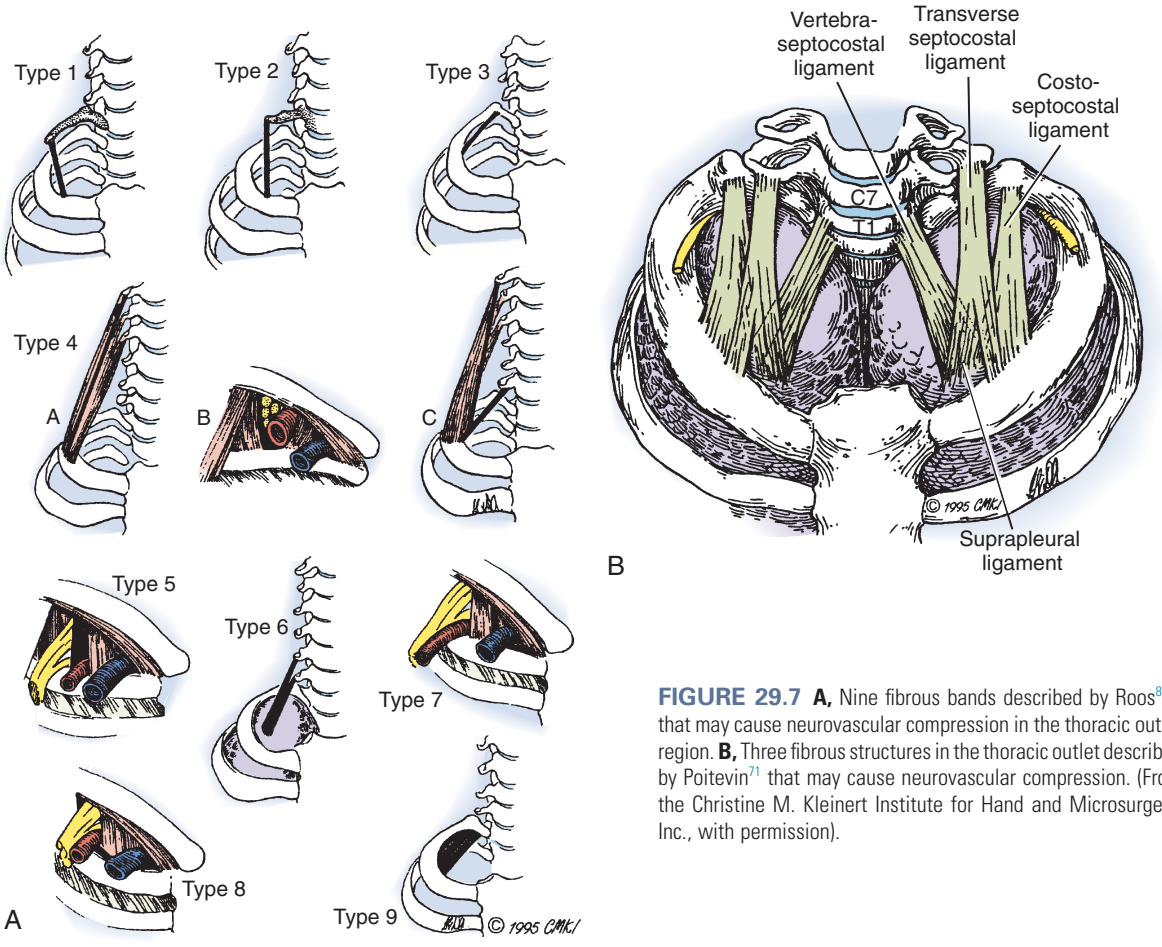

FIGURE 29.7 **A,** Nine fibrous bands described by Roos[80,85] that may cause neurovascular compression in the thoracic outlet region. **B,** Three fibrous structures in the thoracic outlet described by Poitevin[71] that may cause neurovascular compression. (From the Christine M. Kleinert Institute for Hand and Microsurgery, Inc., with permission).

Costoclavicular Triangle

The costoclavicular space is bounded anteriorly by the clavicle, subclavius muscle, and costocoracoid ligament; posteromedially by the first rib; and posterolaterally by the superior border of the scapula (see Figure 29.6). Physiologic narrowing of this space with limb movement is enhanced by the mobility of joints at both ends of the space's boundaries. A hypertrophied subclavius tendon insertion can apply compression specifically to the subclavian vein, as in Paget-Schroetter syndrome. Although there is little in the literature regarding the costocoracoid (or coracocostal) ligament, it can occasionally be much larger than the coracoacromial ligament and may firmly compress the plexus against the chest wall.

Subcoracoid or Pectoralis Minor Space

The subcoracoid space allows compression via three mechanisms. With arm abduction, the neurovascular bundle stretches around the coracoid, and external rotation of the scapula accentuates this pulley effect. Abduction also tenses the pectoralis minor tendon and, in some instances, the tendon and/or muscle belly may compress the plexus.

Histologic study of operative specimens from patients with TOS has demonstrated an increased amount of connective tissue in the scalene muscles, supporting theories of muscle imbalance or developmental abnormality that can lead to problems.[89] The influence of posture, repetitive strain, muscle imbalance, and eccentric muscle contraction have been extensively studied, and objective effects on muscle strength, endurance, and decreased sarcomere length have been documented.[23,25,88] It should be emphasized that the presence of these abnormalities must be correlated with an individual's growth and development, body habitus, and patterns of limb usage to identify the particular pathoanatomy.

CLINICAL FINDINGS

Because the vast majority of symptomatic patients are classified as having the electrically negative neurogenic type of TOS, the diagnosis is usually made by physical examination and provocative maneuvers. There is no substitute for experience in evaluating patients. Although clinical symptoms are highly variable, there are certain commonalities that warrant mention.

The most commonly reported complaints are chronic pain of insidious onset involving the shoulder girdle, neck, and upper back in association with paresthesias of the upper extremity. Paresthesias are present in up to 95% of patients with TOS and are the most common initial complaint.[106] Although it usually involves the medial arm, forearm, and ulnar two digits, paresthesias involving the median nerve distribution or the entire hand or arm are not uncommon. A patient may describe the pain as dull, nagging, or throbbing. Fatigue of the extremity when used in a provocative position is typical.

As in carpal tunnel syndrome, symptoms while driving and grooming are common. Women typically have difficulty doing their hair and frequently have to bend their heads down to limit arm deviation. Patients also complain of tenderness at the base of their necks. Nocturnal complaints are frequent but different from those associated with carpal tunnel syndrome. Some patients request narcotics, but they are rarely prescribed preoperatively. Tricyclic antidepressants, neurotropics, or benzodiazepines may help patients sleep. The clinician should exercise considerable caution when dispensing medications.

An association between distal nerve compression and TOS has been attributed to a form of double-crush syndrome.[45,49,56] Advocates of a double-crush theory have described carpal tunnel syndrome in 21 to 45% of patients with TOS; cubital tunnel syndrome in up to 10%; and, more rarely, radial tunnel syndrome, pronator syndrome, or cervical radiculopathy.[49,59] Critics believe that these "associations" are not actually separate areas of pathology but rather misdiagnoses.

Carroll and Hurst were the first to publish a large patient series with variable symptoms that they attributed to nerve compression at only one site.[10] Although in their study patients did have multiple areas of surgery, in-depth review of their symptoms revealed that relief was obtained by one procedure in each instance. These authors emphasized the difficulty of diagnosing carpal tunnel syndrome and differentiating it from TOS in patients with a primary complaint of shoulder pain. They also emphasized the importance of diagnosing and treating distal compression neuropathies in patients suspected of having TOS. These distal sites of compression are typically simpler and more economical to treat, with less risk to the patient.[51]

Others characterize TOS as a great mimicker and cite patients in whom the diagnosis of it is delayed because of multiple prior surgeries on distal nerves without relief.[72] In our practice, if we feel there is a diagnosis of TOS *and* a peripheral compression, and if the electrical studies are positive with very positive clinical findings for a distinct compression, and they respond appropriately to a discrete block, we will do a separate release of the involved nerve. Vague vascular complaints are very common in neurogenic TOS, including a sense of swelling and differential coolness of the hand, with or without discoloration. Complaints of migraine headaches are extremely common and, to a lesser extent, vertigo, memory loss, syncope, chest pain, eye irritation, and facial pain or numbness.[3,7,41,52,64,67]

Psychological issues can be secondary to chronic pain and the stress of being examined and treated by multiple practitioners, undergoing numerous tests without a definitive diagnosis, and unremitting symptoms.[32,47] Depression, anger, and frustration, especially when dealing with medical personnel, become more prevalent the longer the symptoms persist. For this reason, the concept of a multispecialty team approach, including psychological testing and therapy, may play an important role in dealing with such patients.

PHYSICAL EXAMINATION

Inspection and Palpation

A thorough physical examination with the patient in a gown and all concealing or constricting clothing, jewelry, and hair out of the way is essential. Because the history tends to be nonspecific and the clinical diagnosis in 97% of patients is made by physical examination alone, the initial patient evaluation must be comprehensive. A pain questionnaire may be helpful for both the patient and the clinician. Many unspoken issues can be gleaned from analysis of a patient's written responses on a pain questionnaire and an anatomic pain diagram (Figure 29.8).

The general appearance of the patient both standing and sitting should be noted, as follows:

- Does the patient slouch with the head in a forward position?
- Is the female patient particularly large breasted?
- Are there thick grooves in the shoulders from an "industrial-strength" brassiere?
- Is the neck held to one side?
- Is one shoulder drooping?
- Is there scapular asymmetry at rest or when moving the arms? If so, one must determine whether it is related to shoulder pathology or to muscle imbalance with or without neurologic deficit.

Important clues to muscle imbalance should be sought. The skin and contour of the anterior and posterior chest wall should be inspected.

Masses, fullness, and, in particular, tenderness in the supraclavicular and infraclavicular area, and venous engorgement or collaterals should be noted (see Figure 29.2). Most patients with TOS have moderate to significant tenderness in the anterior triangle and/or infraclavicular area as well. Dysesthesias and reproduction of radicular pain, when palpating these areas, is

Cervical Brachial Symptom Questionnaire ("CBSQ")

NAME _____ DATE _____

READ INSTRUCTIONS FIRST. This form is important for measuring the outcome of treatment.
Based on your experiences in the PAST WEEK, answer the following questions regarding how often symptoms would be likely to increase if you were to engage in certain activities.
Circle the number corresponding to how likely it would be for symptoms to increase during an activity so much that you would have to stop or modify the activity.
DO NOT LEAVE ANY BLANKS.
If a CONSTANT ongoing symptom would not be more noticeable during the activity, mark the answer "0."
If a symptom would increase during half of the instances of the activity, mark the answer "5."
Only mark "10" if your symptoms would increase during EVERY instance of the activity.

1. Pain going down the arm increases with neck movement, as in turning, flexing, or extending the neck.

0 1 2 3 4 5 6 7 8 9 10
It would NEVER happen this past week — This past week, it would happen ALWAYS

2. Pain in the arm or shoulder increases instantly with brief shoulder movement as in throwing something or in reaching behind the body.

0 1 2 3 4 5 6 7 8 9 10
It would NEVER happen this past week — This past week, it would happen ALWAYS

3. Hand or arm aches or fatigues with arm exercise, particularly with overhead or outstretched positioning.

0 1 2 3 4 5 6 7 8 9 10
It would NEVER happen this past week — This past week, it would happen ALWAYS

4. Hand or arm swells after arm exercise, including after any activities that require repetitive arm movements.

0 1 2 3 4 5 6 7 8 9 10
It would NEVER happen this past week — This past week, it would happen ALWAYS

5. Sensations of tingling or numbness in the hand or arm increase when reaching overhead or outwards. Examples include brushing hair or blow-drying hair, reaching for an overhead shelf, or working with arms overhead as in painting a ceiling or screwing in light bulbs.

0 1 2 3 4 5 6 7 8 9 10
It would NEVER happen this past week — This past week, it would happen ALWAYS

6. Sensations of tingling or numbness increase in hand or arm when awakening from sleep.

0 1 2 3 4 5 6 7 8 9 10
It would NEVER happen this past week — This past week, it would happen ALWAYS

FIGURE 29.8 Example of 3-page pain questionnaire. (From Jordan SE, Ahn SS, Gelabert HA: Differentiation of thoracic outlet syndrome from treatment-resistant cervical brachial pain syndromes: development and utilization of a questionnaire, clinical examination and ultrasound evaluation. *Pain Physician* 10:441–452, 2007. Official Journal of the American Society of Interventional Pain Physicians, Issue 3.)

Continued

7. Sensations of tingling or numbness increase in the hand or arm with repetitive finger movements as in writing, typing, sewing, playing musical instruments, or assembling objects.

0 1 2 3 4 5 6 7 8 9 10
It would NEVER happen this past week — This past week, it would happen ALWAYS

8. Sensations of tingling or numbness increase with prolonged or forceful grasping as in holding a steering wheel to drive, using tools, handling office instruments, or controlling industrial equipment.

0 1 2 3 4 5 6 7 8 9 10
It would NEVER happen this past week — This past week, it would happen ALWAYS

9. Sensations of tingling or numbness increase while bending the elbow or leaning on the elbow, for example, while holding a telephone receiver or leaning on a desk.

0 1 2 3 4 5 6 7 8 9 10
It would NEVER happen this past week — This past week, it would happen ALWAYS

10. Hand is clumsy or weak while trying to hold onto objects or while attempting to open jars, use keys to open a lock, pull zippers, or button clothing.

0 1 2 3 4 5 6 7 8 9 10
It would NEVER happen this past week — This past week, it would happen ALWAYS

11. Pain is caused by experiences that ordinarily are not painful. Examples include a light touch to the hand, arm, or neck, such as a light draft, the rub and tug of clothing, or the touch of something moderately hot or cold.

0 1 2 3 4 5 6 7 8 9 10
It would NEVER happen this past week — This past week, it would happen ALWAYS

12. Disabling pain that can last into the next day is caused by activities that ordinarily produce only mild discomfort. Examples include a light exercise session, a physical therapy treatment, or physical examination.

0 1 2 3 4 5 6 7 8 9 10
It would NEVER happen this past week — This past week, it would happen ALWAYS

13. Symptoms have occurred with the above activities in the past without recurrence in the past week.

Yes No (circle your answer) If the answer is "yes," please list by number and explain on back.

14. Hand becomes blue, red, swollen, sweaty, or hot. Yes No (circle answer) If "yes" explain on back.

FIGURE 29.8, cont'd

extremely important. The tone and bulk of the muscles of the neck, upper back, shoulder, arm, forearm, and hand need to be inspected by palpation and against resistance; two-point testing has not been particularly helpful. Provocative testing to assess distal sites of compression should be conducted before provocative testing for TOS; this is because once a provocative TOS test is conducted, a patient may complain of symptoms with just about every maneuver from that point forward during the examination. The examiner should start distally and work proximally, looking for carpal tunnel syndrome, tendinitis, cubital tunnel syndrome, rotator cuff problems, and cervical radiculopathy before testing for TOS.

Provocative Tests for Thoracic Outlet Syndrome

There are several standard provocative maneuvers for TOS. In general, the patient's symptoms must be reproduced or the radial pulse diminished or obliterated for a test to be considered positive. Older literature mentions the Adson, Wright, and Halstead tests, but they are frequently positive in the normal population and are neither sensitive nor specific enough, especially for neurogenic TOS. Anterior scalene bands that wrap around the subclavian artery are generally causative in this situation.

The Roos Test

This test is also called the 90-degree abduction external rotation test, the stick-up test, and the elevated arm stress test (EAST). The patient holds the arm(s) in the abducted, externally rotated position and pumps the hands open and closed quickly and repetitively for 3 minutes. A positive test requires reproduction of symptoms or rapid fatigue of the extremity (Figure 29.9). Patients with positional nerve compression can tolerate this

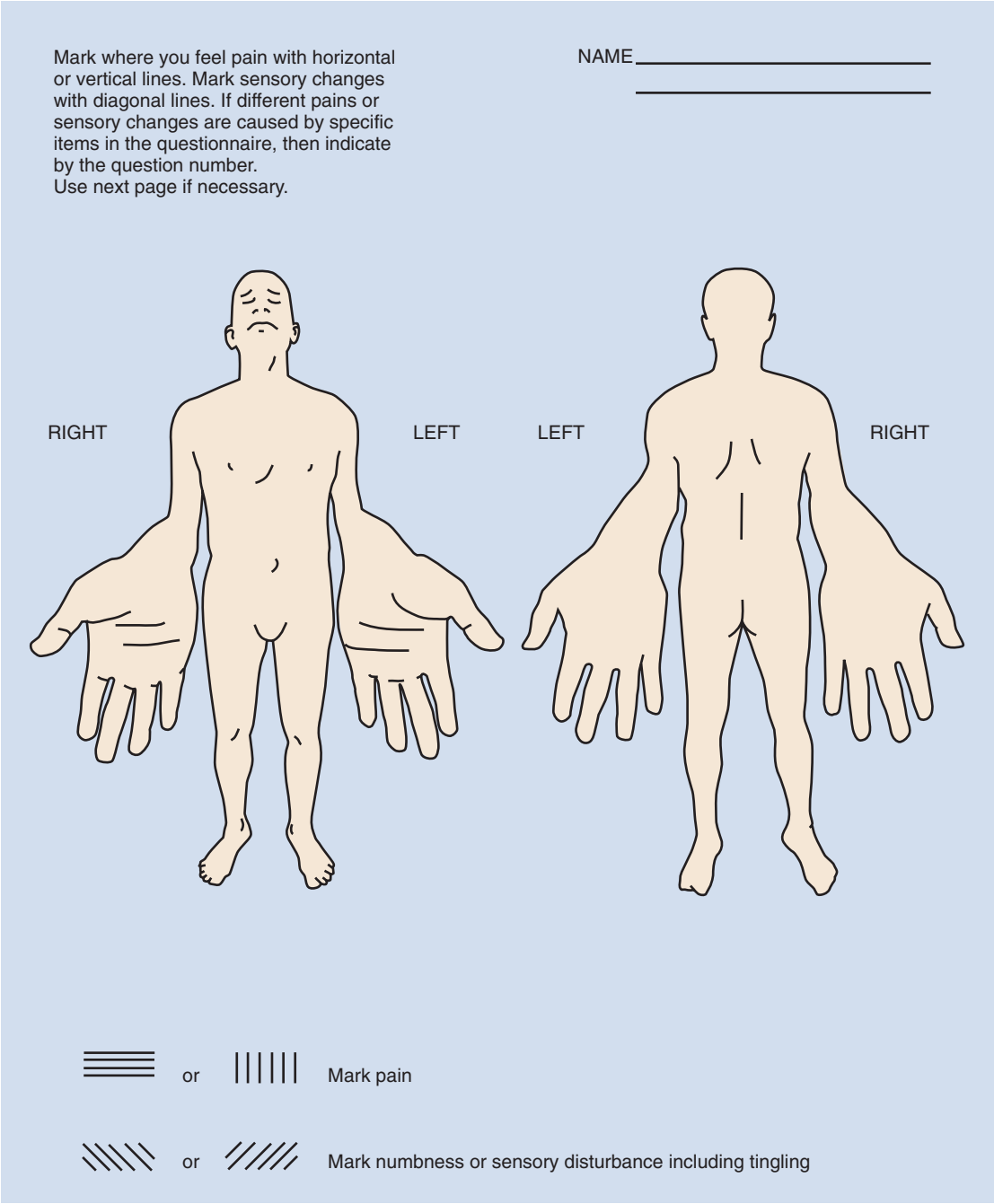

FIGURE 29.8, cont'd

position for 1 minute or less. This maneuver is thought by many to be the most sensitive and reproducible provocative maneuver for the patient with TOS.[81,84] The degree to which symptoms occur also indicates the severity of the compression, in a manner similar to Phalen's sign at the wrist. Changes in the radial pulse also should be noted at this time.

Upper-Limb Tension Test

In this test, the arms are elevated out to the sides with the elbows straight and the head facing forward. Next, with the arms still out, the wrists are dorsiflexed. Finally, the head is tilted away from the side being evaluated (Figure 29.10). In a patient with TOS, each subsequent maneuver elicits increasing discomfort and/or paresthesias as the tension on the plexus increases. This is Sanders' modification of the test described by Elvey.[90]

Scalene Injection

Although some physicians advocate diagnostic injection of the scalenes[89] with lidocaine during one of the initial encounters, this is perhaps best done under ultrasound guidance.[34,35] As an adjuvant to physical therapy, scalene injection with a long-acting anesthetic and corticosteroid has been advocated for the patient with palpable spasm of the scalenes. If the injection helps, it is highly diagnostic; if it makes no difference, it has not determined anything. If it helps, the injection may be worth repeating.



FIGURE 29.9 Demonstration of the Roos test with the patient making a tight fist and then relaxing repeatedly for 3 minutes. The arm should be elevated to the shoulder level and the elbow should be slightly more extended than in this photograph to eliminate conflicting ulnar nerve compression at the elbow.

DIAGNOSTIC STUDIES

Radiologic Evaluation

Radiographs of the cervical spine and/or chest should be part of the initial evaluation. This is especially true because many cervical ribs are missed on MRI. Other extremity films may be justified based on results of the physical examination. With neurogenic TOS, no computed tomography (CT) scans or invasive vascular studies are warranted. Noninvasive studies, while not necessarily warranted, may show mild compromise, but these changes are usually caused by soft tissue anomalies.

Vascular imaging is indicated only for those patients with physical evidence of acute vascular compromise. Otherwise, noninvasive testing using color duplex sonography and waveform analysis should be done initially. Color duplex sonography can visualize stenosis, thrombosis, or flow problems in the arterial and venous systems. It has been found to be 92% sensitive and 95% specific in the diagnosis of vascular compromise in patients with TOS.[46] Photoplethysmography (i.e., pulse volume recordings) can suggest arterial compression, which then can be followed by MR or CT angiography or arteriography, if the clinical situation warrants.[21]

Angiography remains the "gold standard" for evaluation of arterial TOS and provides the best visualization of arterial anatomy as well as the potential for therapeutic thrombolysis in the acute situation. Special attention should be given to evaluation of the bony structures in the thoracic outlet of any patient with suspected arterial compression because this is the most common cause of it, and any bone anomalies need to be surgically addressed. Conventional arteriography and venography (Figure 29.11) may demonstrate the presence of extrinsic compression. Unfortunately, they do not allow a clear depiction of the impinging anatomic structure and tend to be replaced by less invasive procedures (e.g., CT, MRI, sonography).

MRI of the brachial plexus has not been found to be beneficial in the routine evaluation of patients with neurogenic TOS. Multiple case reports describing MR techniques used to evaluate patients have been published during the past decade.[15,66] Improvements in software and magnet technology have improved the ability to identify pathoanatomy. Although the sensitivity of MRI is 79% in terms of detecting "distortions" of the brachial plexus from mass lesions (e.g., tumors, aneurysms), the false-positive rate is 10%, and the studies were not specific in terms of determining the cause or exact site of the distortion.[66]

MR angiography also has been described in isolated case reports[65] and may, at some point, replace standard angiography in the evaluation of patients with suspected arterial compression. Techniques have not been standardized, and availability is not widespread. MRI of the cervical spine and cervicothoracic junction has yielded diagnoses of syringomyelia and multiple sclerosis as well as cervical disk disease and should be considered when a positive Spurling test (see Chapter 28) or pain with neck motion is elicited, or if there are changes on the cervical radiographs.

Electrodiagnostic Evaluation

Although the typical patient with neurogenic TOS can have normal electrodiagnostic studies, these are still recommended as part of the initial workup and to rule out a distal nerve compression syndrome (e.g., carpal tunnel, cubital tunnel). Treatment of the distal compression may alleviate some of the complaints or at least make the remaining symptoms manageable by nonoperative means. Somatosensory-evoked potentials (SSEPs) have not been shown to be of value.[38,107]

A study by Passero and colleagues reported on positive electrodiagnostic studies in 30 patients with clinical symptoms of TOS and bony anomalies in the thoracic outlet.[68] They found that electromyographic (EMG) abnormalities were the first changes to be seen, followed by changes in F waves and, finally, SSEPs. Nerve conduction velocity changes were only seen belatedly in patients with long-standing anomalies and severe muscle atrophy. EMG evidence of chronic denervation of the intrinsic muscles of the hand was found in all patients with obvious neurologic findings.

Machanic and Sanders reported changes in the medial antebrachial cutaneous amplitude in a series of 41 patients with otherwise electrically negative neurogenic TOS.[48] From these studies, one may conclude that abnormalities in medial antebrachial cutaneous amplitude or distal sensory nerve action potential (SNAP) from the wrist to the digits in patients with lower trunk compression may be useful early findings in neurogenic TOS. EMG findings in the intrinsic muscles of the hand actually may be the earliest findings in TOS patients but are frequently dismissed by the neurologist.

TREATMENT

Nonoperative Treatment

There is universal agreement in the literature that nonoperative management is the first line of treatment for all patients with neurogenic TOS. Increased risk factors for failure of nonoperative treatment include obesity (based on BMI), poor cardiovascular condition, and failure to comply with a multimodality



FIGURE 29.10 Upper-limb tension test: **A-D,** The head is brought to the affected side. If there is significant pain with just the abduction or wrist extension, the author considers it highly positive. If the patient has pain with the wrist hyperextended and the head away, which is relieved by bringing the head to the affected side, this is also very positive.

treatment program that addresses poor posture and exacerbating activities, both at work and at home. Patients not compliant with conservative measures are not likely to comply with mandatory postop protocols either. These patients must commit themselves to significant lifestyle and workplace modifications to have any hope of a good outcome. Nutritional counseling, diet, and exercise programs must start simultaneously with treatment.

A conservative therapy program should consist of four stages. The first goal is to relieve pain and control progression of symptoms. Thus, stage I focuses on identification and treatment of myofascial trigger points, local areas of spasm, and tendinitis or bursitis. Moderate use of muscle relaxants, antidepressants, antiinflammatories, or sleeping aids may be necessary; however, the anticonvulsant gabapentin (Neurontin) or pregabalin (Lyrica) is the drug of choice. Most therapists advocate the use of moist heat or ice, transcutaneous electrical nerve stimulation, ultrasound, and other modalities at this stage; on the other hand, Novak argues that overuse of these modalities may encourage dependence on therapy.[61] Trigger-point injections and scalene muscle injections can be beneficial in the appropriate clinical setting.

Stage II is generally instituted concurrently and consists of using stretching, relaxation, breathing, and myofascial manipulation to restore normal mobility and a balanced posture to the cervical spine, shoulder girdle, and cervicothoracic region. Strengthening of the scalenes and deep tissue massage of the scalene area are to be avoided, as this will aggravate the condition. Cardiovascular conditioning and weight-loss programs should be instituted at this stage and are continued throughout the program. Pathologic postures, such as the head-forward position, lead to decreased overall flexibility of the cervicothoracic unit and compensatory cervical lordosis, thoracic flexion, internal shoulder rotation, and scapular abduction. Such postures are thought to lead to tightening of the anterior muscle groups and compensatory elongation of the posterior muscles. This pathologic muscle imbalance has been cited by MacKinnon, Novak, and others as being one of the key pathologic entities to identify and correct.[50,52,61–63,69] Attention to lumbar lordosis, leg-length discrepancy, and other dysfunctional postures is necessary.

Stage III consists of parascapular and core muscle strengthening (except for the scalenes), increasing endurance, and restoration of the patient to presymptomatic levels of function

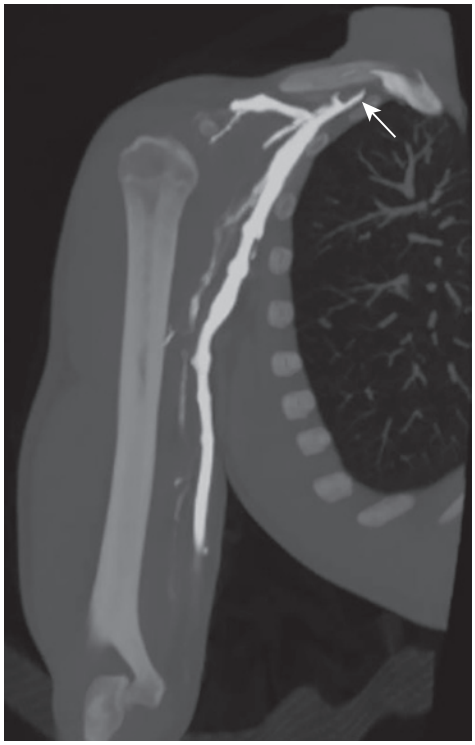

FIGURE 29.11 Venography of a patient with acute thrombosis of the subclavian and internal jugular (*arrow*).

CRITICAL POINTS *Initial Physical Examination, Diagnostic Evaluation, and Nonoperative Treatment*

Initial Physical Examination
- Initial comprehensive exam and patient history
- Patient must be undressed from the waist up so as to search for atrophy, swelling, venous engorgement, and scapular asymmetry

Sequence of Examination
- Observation
- Peripheral nerve examination
- Cervical spine evaluation
- TOS examination (the Roos, upper-limb tension test, anterior triangle tenderness, the Tinel, dysesthesias, infraclavicular tenderness)

Diagnostic Evaluation
- Radiographs of cervical spine or chest and other areas if indicated by history and physical exam
- Noninvasive vascular testing, if warranted
- Electrodiagnostic studies, including medial antebrachial cutaneous amplitude

Nonoperative Treatment
Neurogenic TOS
- Initiate four-stage physical therapy program, including postural and activity modification
- Nutritional counseling, as indicated

both at work and at home. The therapist must undertake this stage carefully because too vigorous an exercise or aerobic conditioning program can exacerbate symptoms.[102] It is important to establish realistic goals and understand that not all patients will be rendered pain-free.

If a patient graduates through the first three stages of treatment, stage IV consists of establishing a home program and returning the patient to the workplace. Analysis of the job site is frequently beneficial before return to work. Lifestyle changes and proper "work hygiene," consisting of taking breaks as necessary for stretching, breathing, and relaxation are important in the maintenance program. Necessary ingredients of the home exercise program include scalene stretching, cervical protraction and retraction, diaphragmatic exercises, pectoralis stretching, and shoulder circumduction exercises. The exercises should be done 10 times each, 3 times per day.[30,108] Some have advocated using custom-made scapular retraction harnesses, but these are rarely used.

The results of nonoperative treatment are variable and difficult to objectify, considering the lack of firm findings or diagnostic criteria. Reports of successful treatment range from 50 to 100%. Success is usually defined as avoidance of surgery, satisfactory pain relief, and return to work.

Operative Treatment

Operative treatment of TOS has evolved significantly during the past 70 years. Although Coote excised a cervical rib in 1860,[16] it was not until the next century that surgical management of TOS became accepted. In 1927, Adson and Coffey described their diagnostic maneuver for scalenus anticus syndrome and recommended anterior scalenotomy as a means of operative treatment.[2] In 1962, Clagett documented a high failure rate with scalenotomy alone and advocated first-rib resection via a posterior approach for patients with TOS.[14] The transaxillary approach to first-rib resection was introduced by Roos in 1966.[79]

During the 1980s, a combined transaxillary and supraclavicular approach was introduced as a means of resecting the first rib and releasing the scalenes.[73] Current approaches differ among surgeons and their subspecialties of surgery. The two most popular surgical approaches are the transaxillary and the supraclavicular. Atasoy recommends transaxillary resection of the first rib followed by transcervical anterior and middle scalenectomy.[4] Others use this technique for the "failed" or "recurrent" TOS patient. The isolated supraclavicular approach for anterior and middle scalenectomy without first-rib resection has been advocated as well.[12,77,93]

Although some surgeons prefer more limited procedures,[18] the most widely performed method for neurogenic TOS currently includes (1) excision or release of anomalous anatomy, (2) resection of the first rib if it is compressing the plexus or causing traction on the plexus, (3) excision of the anterior and middle scalene muscles, (4) neurolysis of the involved portions of the supraclavicular brachial plexus, and (5) possible release of the pectoralis minor tendon and or coracocostal ligament. Recently, Merele reported on a complete excision of the middle scalene and any compressive bands or ligaments alone, and does not resect the rib or anterior scalene (personal communication, Merele, M., Club Narakas, France, 2013).

Reported surgical results are similar as long as the first rib is removed, the scalenes are divided, and any anomalies are adequately decompressed. Some advocate the transaxillary

approach for safety because the brachial plexus and vessels do not need to be manipulated, although the intercostobrachial nerve is at risk. Others advocate the supraclavicular approach, even though the plexus and vessels have to be retracted, and injuries to the phrenic nerve have been reported. Which approach to use is largely a matter of surgeon preference.

For patients with vascular TOS and arterial compression, early or urgent decompression is favored, with removal of the responsible bony anomaly and arterial reconstruction as necessary. If no emboli or ulcerations in the vessel wall are present, simple arteriolysis may suffice. In patients with venous compression or Paget-Schroetter syndrome, early thrombolysis followed by first-rib resection is recommended; the procedures do not need to be done concomitantly. A workup for clotting disorders must be done. Once the area is decompressed, long-term anticoagulation is not thought to be necessary unless the patient has a thrombotic predisposition.

In neurogenic TOS, a patient who has failed to complete 3 months of physical therapy and other conservative measures and who has no evidence for a peripheral nerve compression is a candidate for surgery. Upper-extremity surgeons who surgically decompress the thoracic outlet may choose to collaborate with a vascular surgeon, depending on their experience and training. For neurogenic TOS, it is certainly reasonable for an upper-extremity surgeon who is knowledgeable in this area to proceed without a vascular surgeon depending on the requirements of the case.

❖ AUTHOR'S PREFERRED METHOD OF TREATMENT: Neurogenic Thoracic Outlet Syndrome

I obtain the informed consent for surgery from each patient. A thorough discussion of potential complications should include the major ones: death, major bleeding requiring vascular reconstruction, pneumothorax and placement of a chest tube, increased pain, plexus or peripheral nerve injury, phrenic nerve injury, stellate ganglion injury, and periincisional numbness. We draw the proposed incision points on the patient at the preoperative visit. The supraclavicular approach (Figure 29.12) is used for all neurogenic types and most vascular ones as well. Surgery is performed under loupe magnification with the patient in a barber-chair position. We have found that sandbags and turning or twisting the head increase tension in the plexus and therefore avoid them. Long-acting paralytic agents also should be avoided to allow for intraoperative nerve stimulation.

The incision used is slightly modified from that for doing an open reduction of the clavicle, located 1 to 2 cm above it. We curve it more posteriorly as we go laterally. It starts at the lateral border of the sternocleidomastoid muscle, and if the plexus can be palpated, we extend the incision slightly lateral (Figure 29.13). The greatest number of supraclavicular nerves are lateral, so staying as medial as possible can avoid some of them, although several must be sacrificed. The platysma and some of the sternocleidomastoid are divided and retracted with the skin flaps to maximize exposure. The external jugular vein should be retracted if possible, and the omohyoid should be divided (Figure 29.14). At this point the supraclavicular fat pad is mobilized from inferiorly and is retracted superiorly or laterally. Great care should be taken when elevating the fat pad to look for the suprascapular and long thoracic nerves and elevate the pad off and superior to it.

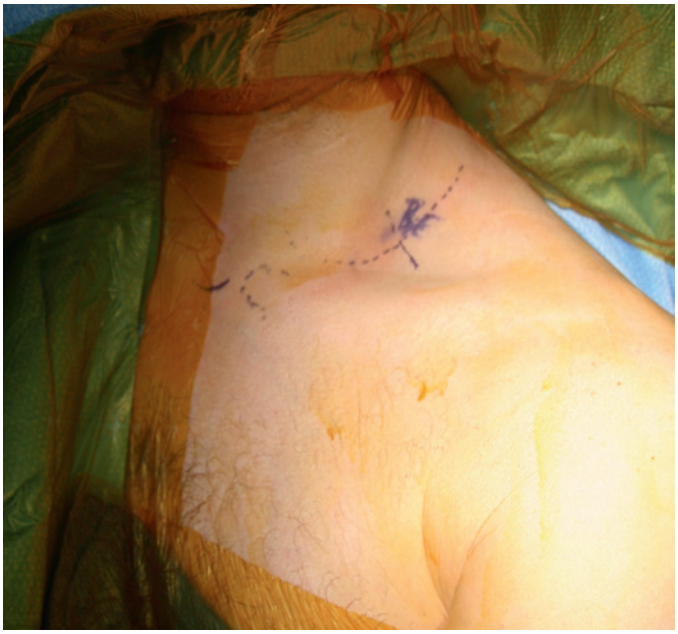

FIGURE 29.12 Preparation and draping should cross the midline; the sternal notch is the small solid medial mark. The incision (*dotted posterior line*) is centered on the plexus (*vertical solid line next to initials*); it curves more posterior than an incision for a clavicular repair.

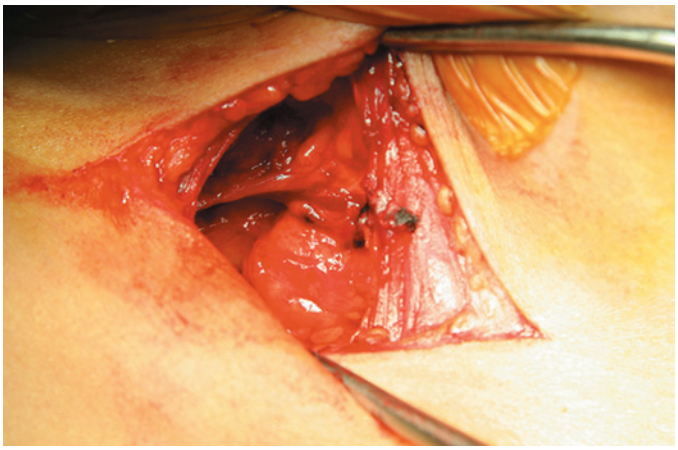

FIGURE 29.13 Any supraclavicular nerves have been divided along with the platysma and omohyoid muscles, exposing the anterior triangle fat overlying the plexus. The fat pad should be dissected bluntly and carefully because the suprascapular nerve may be encased within it.

With the plexus now visible, we expose and define the posterior border of the plexus consisting of the long thoracic and suprascapular nerves. The dorsal–scapular nerve or large cervical sensory nerves may appear here and should be looked for and avoided. A nerve stimulator can be helpful to define and positively identify the various nerves. The long thoracic nerve is mobilized proximally well into the middle scalene, and the branch coming from the middle trunk can be identified, decompressed, and preserved (Figure 29.15). The suprascapular nerve is now mobilized proximally and, if necessary, distally to the notch. Often branches of the deep transverse cervical artery or

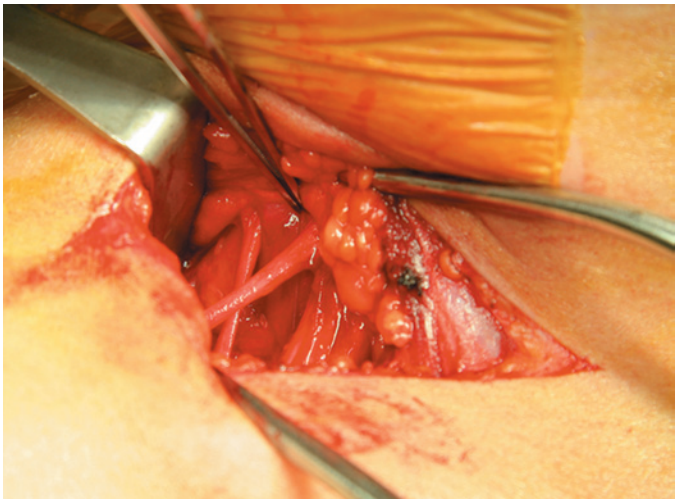

FIGURE 29.14 The posterior border of the plexus is defined here; note the long thoracic nerve exiting the middle scalene (forceps). Mobilize it proximally and distally to look for discrete compression in the scalene. In addition, look for a large contribution from C7. It is easy to mobilize the suprascapular nerve all the way to the scapular notch.

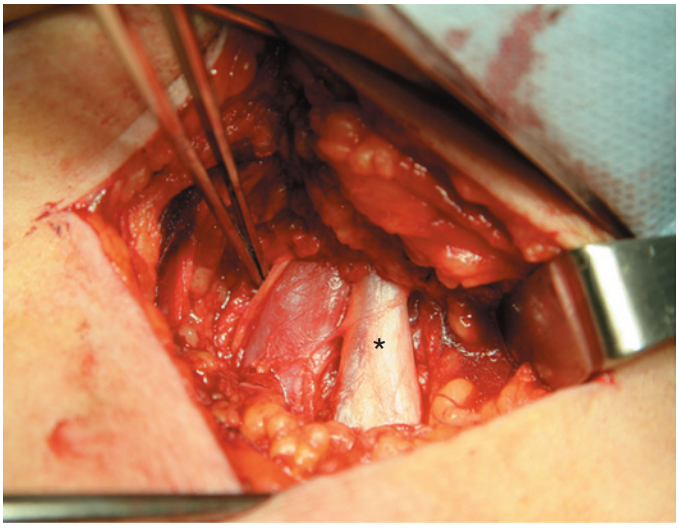

FIGURE 29.15 The anterior border is identified in this left-sided exposure. Note the phrenic nerve lying on the scalene (forceps), although it is rarely in this "classic" position. It should be looked for and carefully protected. Note that only the upper trunk is visible at this time (*asterisk*), but there is a space between the upper trunk and the scalene.

vein are entrapping the long thoracic nerve; these should be tied off with suture ligatures and divided. If vascular branches at the posterior border of the plexus are large, we divide them now, making mobilization of the subclavian artery easier. When the posterior border is defined, we move to the anterior aspect.

From the anterior aspect, we look for the phrenic nerve (Figure 29.15). It rarely lies on the scalene muscle as depicted in anatomy books. Frequently, it is very proximal on the scalene and has crossed medially well proximal to the rib. Sometimes it is very anterior and never touches the scalene, and sometimes it is actually lateral to the anterior scalene. If it is not easily found, the superficial surface of the anterior scalene is cleaned, and we find the medial border and elevate the internal jugular

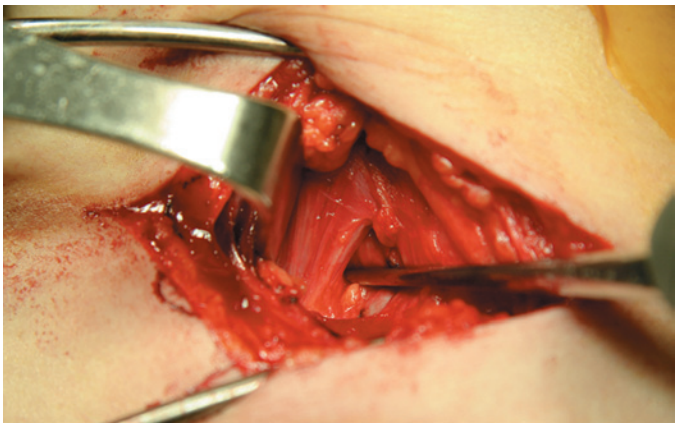

FIGURE 29.16 The space between the plexus and scalene is cleaned and opened. In a primary TOS there is always some fat and space between the artery, pleura, and scalene. Note the suction tip displacing the artery and going behind the scalene. It is not necessary to place anything here when dividing the scalene from the rib.

vein and other structures with a retractor and keep them anterior.

The subclavian artery is now identified and cleaned superficially for exposure, and the interval between the scalene and the artery is identified (Figure 29.16). This space is always present in patients who have not undergone previous surgery. Starting laterally and next to the artery, we divide the anterior scalene off the first rib. Usually, there is fat and space between the muscle and the pleura. The tendon at the rib insertion can be quite thick or very thin, and simply going slowly until the pleura is reached will avoid a pneumothorax. Once the anterior scalene is divided at the rib, it is excised as proximal as possible.

Again, care should be taken to avoid the phrenic nerve if it is coming across the muscle more proximally. Once the scalene has been excised, the subclavian artery is visible for a long way medially. Frequently, it has scalene bands around it either from the anterior scalene or from the middle scalene or scalene minimus. These bands are the cause of most of the vascular findings unless there is a definable skeletal abnormality. These bands and any tether should be excised.

Simple resection allows the artery to balloon up and have a better pulse (Figure 29.17) (see Video 29.1). If there was no deep transverse artery and vein on the posterior border, the subclavian artery should be mobile now and can be taken anterior and medial and away from the anterior border of the lower trunk. If the deep transverse vessels were there posteriorly, the artery is tightly tethered to the lower trunk and the deep vessels must be divided from the subclavian with ligatures (Figure 29.18). Once this is done the artery becomes mobile and can be taken away from the lower trunk. Orthopedists and hand surgeons breathe easier at this point.

Next, the first rib is cleaned of ligamentous structures and pleura. Frequently, a very thick pleural band is found coming from the posterior part of the rib or from a transverse process and discretely compresses the lower trunk; occasionally a neuroma can be seen or felt at this level (Figure 29.19). Now that the plexus is free and mobile anteriorly, the trunks can be mobilized easily and separated into upper, middle, and lower trunks. The middle scalene is incised from the first rib and the

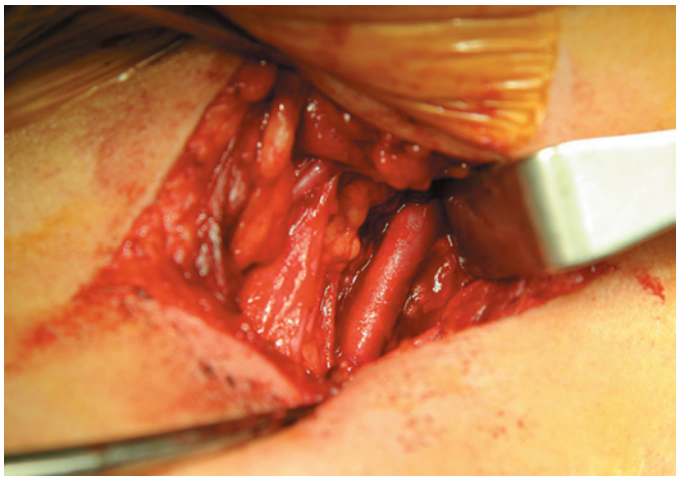

FIGURE 29.17 Once the anterior scalene has been completely excised, the subclavian artery is completely visible and can be cleaned of fibrous bands and scalene minimus that may wrap around it. If the subclavian artery is not mobile, the deep transverse cervical artery must be divided. (See also Video 29.1.)

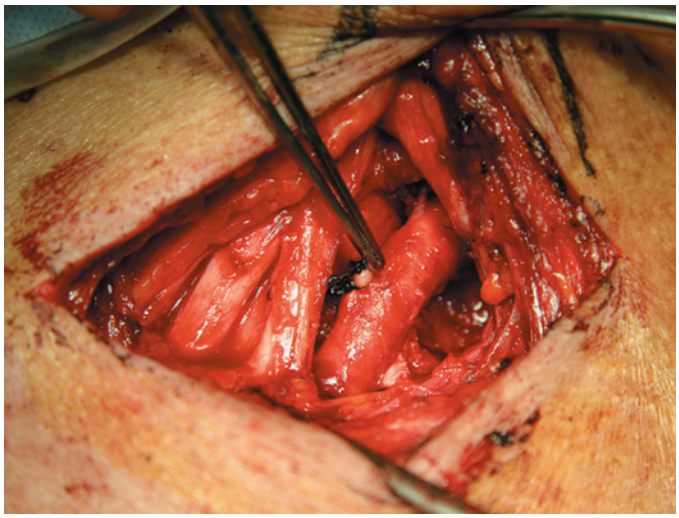

FIGURE 29.18 The deep transverse artery has been divided; if present, it lies between the middle and lower trunks and may be a source of lower trunk compression. Once it has been divided, access to the lower trunk and entire plexus is ensured.

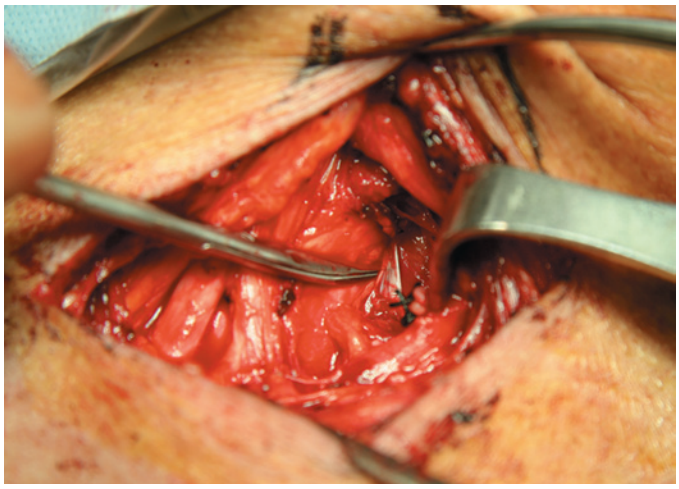

FIGURE 29.19 With the subclavian artery taken anterior and medially, the lower trunk behind the scissors is seen visibly compressed by a pleural band. Hourglass nerve constrictions and neuromas in continuity are frequently seen when these bands are excised.

vast majority or it resected, with care taken to avoid the long thoracic and dorsal–scapular nerves. The plexus is now completely free and mobile.

The C8 and T1 nerve roots are mobilized so that they are lying free across the top of the lung and rib. The arm is abducted and externally rotated now, and several items are evaluated with respect to the first rib. If the plexus is compressed between the clavicle and the first rib and if the lower trunk gets more tension with abduction and external rotation, or the C8—T1 roots are very short—the first rib is removed. Pressure is determined by placing a finger between the rib and clavicle, and if there is pressure on the finger with abduction and external rotation, the rib is removed.

Frequently, there is no pressure and the lower trunk actually has less tension with this position. If there are no further compressive elements or tension, the rib is left in place. Some surgeons routinely remove the first rib. Cervical ribs are easily and safely excised using this approach, and they are excised to the extent that all compressive elements are removed. It may be necessary to excise some of the transverse process of C7 as well, even in the absence of cervical ribs.

Should the surgeon elect to excise the rib, a microsaw is used and a cut made through the rib well anterior to the artery and medial to the posterior facet joint (Figure 29.20). The microsaw requires much less space than rib cutters, so the plexus is retracted much less. The intercalated piece is then gently dissected free and removed (Figure 29.21); this can be done without excessive traction on the plexus if the arm is supported during this portion of the process.

Now all compressive elements have been removed and the incision is closed after checking for air leaks (Figure 29.22). Positive pressure is maintained while the wound is filled with saline and any air bubbles are looked for. This step is repeated twice, and all fluid is carefully sucked out each time while the lung is expanded to lessen postoperative pain with respiration. The wound also is inspected for bleeding at this time.

Closure is done over a red rubber drain left in the lung's apex and another drain is placed subcutaneously. After closure, all air

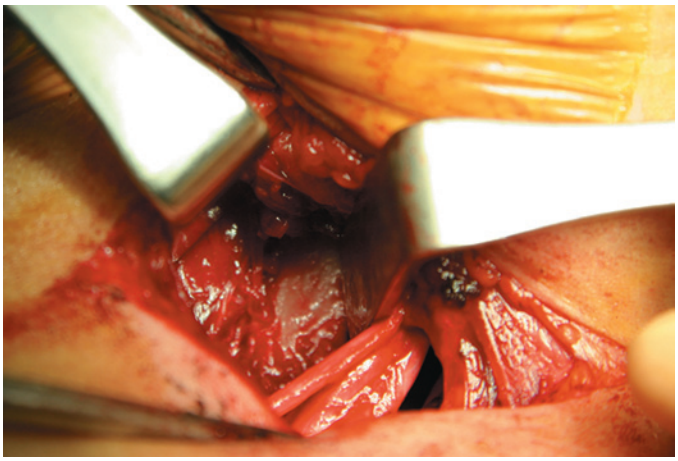

FIGURE 29.20 The pleura can now be taken off the rib, the plexus completely mobilized, and the rib excised. Note the posterior portion of the rib ready to be cut across. The plexus is easily retracted as the arm and shoulder are elevated, putting slack in the nerves. A small microoscillating saw requires much less space and retraction than a standard rib cutter.



FIGURE 29.21 Similarly, the plexus and artery are retracted away from the anterior portion of the rib; the rib is cut across here and then gently excised and removed. The majority of the rib can be easily excised in this manner. Note rib medial to the facet joint that should be removed if taking the rib.

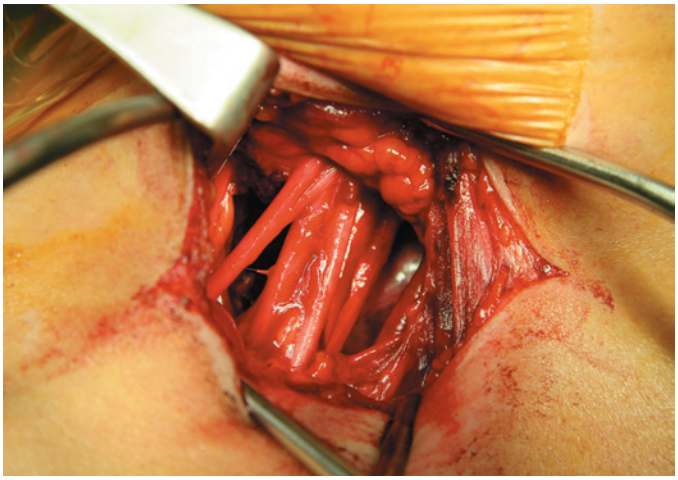

FIGURE 29.22 Note that the artery with the complete plexus is free and has nothing to further compress it. The lung is seen deep. The pleura is left open and closure done after checking for air leaks by maintaining positive pressure, covering the lung with saline, and looking for air bubbles.

is sucked out through the red drain, then it is removed. Patients who stay in the barber-chair position do not get air other than at the apex, and if there is no injury to the visceral pleura, simply removing the air this way has not presented any problems. During closure it is important to pull the fat pad back to the infraclavicular fat or fascia so that it covers the plexus. Skin closure method is the surgeon's choice.

The approach to use now routinely includes an infraclavicular incision, which is made in the skin lines medial to the coracoids; dissection is taken down to the coracoid in the interval between the deltoid and pectoralis major. The pectoralis minor tendon is identified and the plexus is examined deep into it. It is easy to sweep the area with a finger to check for any fibrous bands or constrictions. The arm is then abducted and externally rotated, and if the tendon compresses the plexus, it is incised from the medial border of the coracoid.

Next, look for any coracocostal ligaments, and if present, incise (Figure 29.23). The plexus is then mobilized off the chest

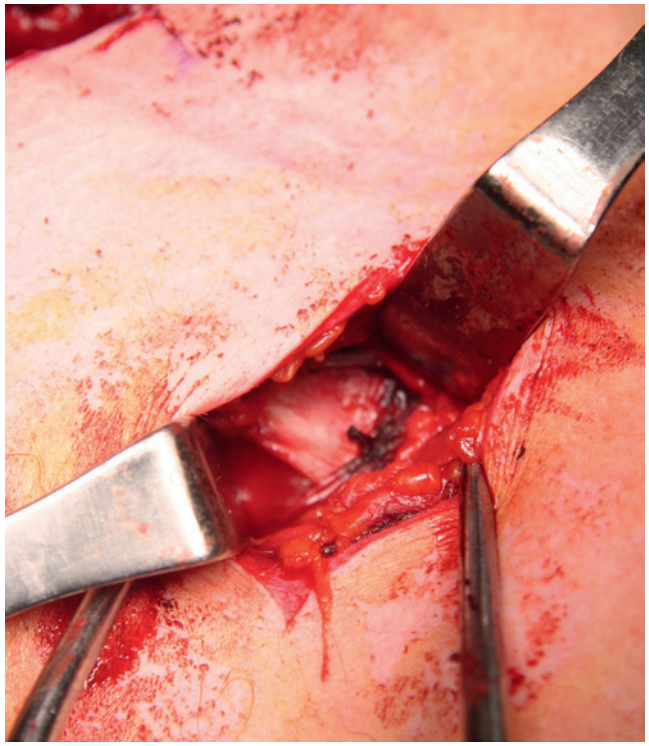

FIGURE 29.23 The infraclavicular incision on the medial border of the coracoid. Note the large coracocostal ligament arising from the medial border of the coracoid and inserting on the first or second rib and compressing the plexus underneath. It can be as large or larger than the CA ligament and should be divided.

wall. If no further entrapments are found, the wound is closed in a similar manner but without additional drains. Postoperatively, chest radiographs are taken in the recovery room. When awake, the patient is started on active abduction and external rotation. An arm sling is used for comfort only for a few days, then the patient begins physical therapy.

For the small percentage of patients with true vascular TOS, we also use a supraclavicular approach. Arterial reconstruction is done by a vascular surgeon, and neural decompression is done by an upper-extremity surgeon. Patients with venous problems undergo thrombolysis immediately, and several weeks later decompression is done by either team, depending on whether the remaining symptoms are neurogenic or vascular. An in-depth discussion of this is beyond the scope of this chapter.

Complications

Complications of nonoperative treatment are few and relatively minor, except in the rare case of a patient with electrically positive neurogenic or vascular TOS who refuses surgical intervention and experiences progression of the disease. Most patients report exacerbations of the symptoms if their physical therapy regimen emphasizes a vigorous strengthening program instead of stretching. There is also a risk of drug dependency, severe depression, or other psychiatric disorders if care is not taken to manage the patient's chronic pain and associated psychosocial issues. Certainly if emboli occur, significant peripheral problems may occur.

In contrast, complications of surgical treatment for TOS can be significant. Problems related to surgery were recognized as

early as the late 1800s, as recorded by Keen in his 1907 review of the subject.[36] It was not until a review by Dale in 1982 that some representation of the true incidence and extent of brachial plexus injuries was recognized.[17] His survey of the members of the International Cardiovascular Society revealed that 52% of the surgeons who responded had seen some sort of brachial plexus injury, and the numbers indicated that 273 injuries of varying degree had occurred. From this point forward it seems that clinicians began to take a more serious look at the signs for surgery and technique.

Although surgical treatment is deemed "successful" in approximately 80% of cases when careful patient selection is done, 20% of them end up with unsatisfactory outcomes.[101,105] Reported surgical complications include injuries to the subclavian artery or vein that have led to exsanguination and subsequent death, transection of phrenic or long thoracic nerves, and division of the medial cord or C8 nerve root.[37]

Additional surgical complications include hemothorax, pneumothorax, chylothorax, causalgia, and traction injuries to the plexus, including total paralysis and complete sensory loss.[29] Horner syndrome rarely occurs because of manipulation of the C8 and/or T1 nerve roots. Traction injuries are more common with the axillary approach. Although many brachial plexus injuries are transient, in unusual cases they require surgical treatment. Cutaneous nerve dysesthesias involving the intercostobrachial nerves, posterior cutaneous nerves, and supraclavicular nerves also have been known to occur almost universally. Although these dysesthesias generally resolve within 6 months, some may be present for a long time, and there will be an area of permanent numbness below the clavicle with the supraclavicular approach. It is extremely rare for these to be a significant problem because this approach is used for clavicular fractures with minimal reported difficulties.

Although the aforementioned complications account for some surgical failures, other patients have unsatisfactory outcomes with no surgical problems. Some believe that one of the largest reasons for "failed" TOS surgery is an incorrect diagnosis. A report by Kostic and Kulka analyzed reasons for failed surgery in 142 operations on 124 patients.[39] Missed diagnoses included glenohumeral or cervical arthritis and cervical disk herniation. Another patient had a Pancoast (i.e., pulmonary sulcus) tumor that was missed during the initial evaluation. For 13 patients, an additional operation was necessary because of inadequate or failed first-rib resection.

As experience with the surgical treatment of patients with TOS of all types increases, complications have decreased, and careful analysis of complications, failed surgery, and recurrent or persistent symptoms have been recognized and investigated. The majority of carefully selected patients with neurogenic TOS do well with surgical treatment.

Results

The results of operative and nonoperative treatment of TOS are difficult to objectively assess because there is no standardized means of patient diagnosis or assessment. Many patients in the electrically negative neurogenic TOS category have short-term symptoms precipitated by an isolated event, activity, or accident. These patients have symptoms that can be self-limited and improve with short courses of physical therapy, activity modification, and medication.

For patients with more persistent or severe symptoms, nonoperative treatment, such as the four-stage rehabilitation program advocated by Novak and colleagues, is recommended and successful, at least in the short term.[62] In one study, 44 patients with symptoms of TOS were followed for 12 months, and none was reported to be worse in terms of symptoms, lifestyle, or work activities. Of these patients, 4 of 44 were "not improved" and only 3 of 44 were "completely" improved. Most of them (i.e., 35 of 44) were either "partially" or "almost completely" better. Another report detailed 100% complete relief of symptoms in the short term with a multimodality therapy program.[97] The long-term outcome for these patients is not known and requires further study.

The literature that reviews surgical treatment is abundant and demonstrates a high degree of variability, with good to excellent results achieved in 24 to 100%.[8,28,31,44,57,64,89,92,112] This variability can be attributed to many factors, including the lack of objective outcome measures, diagnostic criteria, follow-up periods, and widely variable surgical techniques and training. Early results (at 3 months) show improvement, with a 90% or better success rate, and long-term results (>5 years) indicate an approximately 70% success rate (Figure 29.24).

A review by Sanders provides the most extensive summary of the literature to date.[89] This paper demonstrates that the combination of anterior and middle scalenectomies and first-rib resection yields the best results when compared with scalenotomy alone (99% vs. 57% satisfied). In Sanders' own series, in which subtotal scalenectomy alone was compared with first-rib resection and combined scalenectomy and rib resection, no difference between early and long-term results was noted.[87,89] Despite this, Sanders' current surgical technique includes a "complete" scalenectomy, and he believes that the combination of rib resection and scalenectomy yields "slightly" better results than either procedure alone.[54]

Patients with vascular or true neurogenic TOS are thought to have a better outcome with surgical treatment than those with the electrically negative type of TOS. However, in one of the few studies with disabilities of the arm, shoulder and hand (DASH) and the 12-Item Short Form Health Survey (SF-12) comparisons, Chang and colleagues reported that there was no difference in ability to return to work between the venous and neurogenic groups of patients.[11] The main variation was in the time required before returning to work. Interestingly, these authors' preoperative assessment identified low scores on the physical component scale, on par with patients with chronic congestive heart failure, and they did not return to normal baseline scores until 2 years postoperatively.[11] Similarly, there are supportive data to demonstrate that patients with work-related claims or litigation do worse than others, whether treated surgically or nonsurgically.[8,22,28,72,89] Sanders notes that patients with workers' compensation claims had 13 to 15% lower rates of success than all others.

Recurrent Symptoms After Surgical Treatment. Failure of surgical decompression of the thoracic outlet should be carefully scrutinized to determine whether there was a symptom-free interval. Failure to improve after adequate decompression or first-rib resection implies either incorrect diagnosis or other issues, including the potential for secondary gain. The rate of true recurrent symptoms is reported to be between 5% and 25%, and the symptoms tend to occur within 4 to 6 months

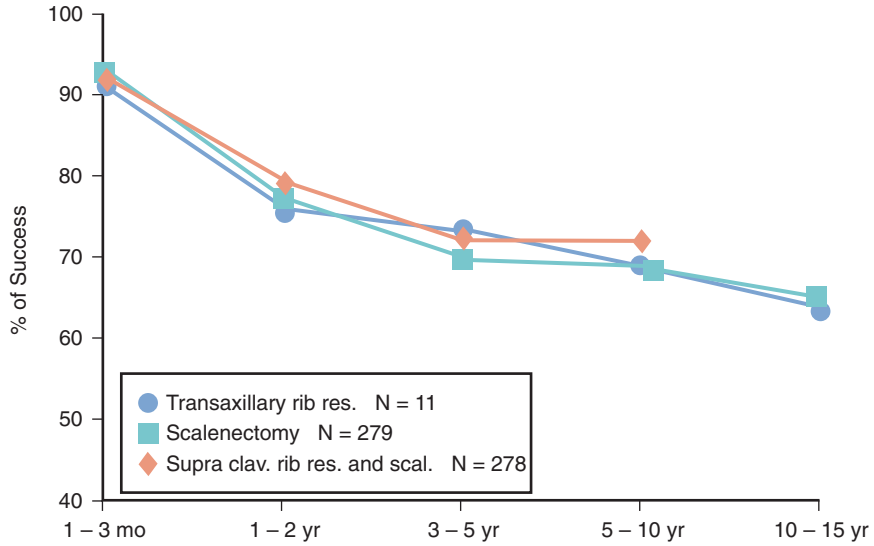

FIGURE 29.24 Results of three primary operations for thoracic outlet syndrome: transaxillary rib resection, scalenectomy, and supraclavicular rib resection and scalenectomy (supra clav. rib res. and scal.).

postoperatively.[4,5,55,57,58,70,89,92,94,98,104] Although patients undergoing anterior scalenotomy (now rarely performed) alone have a higher likelihood of recurrent symptoms, the recurrence rate for patients undergoing combined anterior and middle scalenectomies (14%) is similar to that of transaxillary first-rib resection alone (19%). Patients undergoing a combined first-rib resection and scalenotomy have the lowest recurrence rate (6%).[87,92]

In several reviews, the cause of recurrent symptoms was most frequently scar tissue around the brachial plexus or a retained or unstable segment of the first rib.[13,43,87,92,94] The supraclavicular approach seems to be the most popular one for revision surgery because it allows better access to the brachial plexus. It also allows access to supraclavicular fat, which can be used to wrap the plexus after neurolysis in an attempt to prevent recurrence of adhesions between the plexus and the scalenes.

The complication rate for secondary procedures is higher than that for primary procedures, with the incidence of pleural tears or pneumothorax as high as 62% in one series.[13] Results of reoperation for recurrent symptoms demonstrate early "improvement" or "success" in 74 to 90% of patients after surgery (3 months). Recurrence of symptoms and "surgical failure," however, occur in up to 59% of patients after 10 to 15 years. Surgical results correlate directly with the identification of residual anomalous anatomy, such as retained bone, periosteum, or an unstable residual rib, and are worse for patients in whom only scar tissue around the brachial plexus is found at the time of another operation.

Sympathectomy at the time of reoperation has been recommended to improve results but is not commonly performed.[81] Comparative analysis of reoperation techniques is impossible because of the small number of patients and the lack of a standardized objective means of preoperative or postoperative assessment.

CONCLUSION

Most upper-extremity surgeons perform few, if any, surgical procedures for TOS. A surgeon with a thorough understanding of and ability to recognize the problem can identify a large number of affected patients in a typical upper-extremity practice. Careful attention to details about the patient's history and physical examination is the key to diagnosis. The practitioner must recognize this and schedule appropriate time for the initial examination. Patients who demonstrate vascular or electrically positive neurogenic TOS should be considered early on for surgery or referred for operative consultation.

For those without obvious vascular compromise or electrical findings, conservative treatment can be successful in controlling symptoms in most patients, at least in the short term. Psychological assessment and support are essential on initial recognition of TOS, as are lifestyle and workplace modifications. Persistent symptoms warrant thorough radiographic evaluation, electrodiagnostic studies, and specialized diagnostic testing to identify bony or soft tissue anomalies and to rule out other treatable afflictions.

Selected patients who have failed to improve after several months of nonoperative treatment, and continue to have significant or progressive symptoms, may warrant surgical decompression.[60] Great care should be exercised in patient selection, especially in workers' compensation cases. A comprehensive approach that allows for complete plexus decompression, resection of anterior and middle scalene muscles, and first-rib resection should be used.

For patients who require operative treatment, careful consideration should be given to referral of them to a surgeon or surgical team that routinely performs TOS surgery. The treatment is best handled by a hand or upper-extremity surgeon who understands nerve compression because that is the underlying problem of TOS. There are several major centers in the United States that perform TOS surgery, and results of treatment of patients in them are predictably superior to the results of surgeons who perform <10 procedures a year. The ones who do perform operative treatment should have hands-on, individual training in the procedure to be used. They should be able to manage potential complications themselves or have a vascular or thoracic surgeon immediately available. Once learned, the procedure is not that difficult. If TOS is recognized early on

and treated properly, treatment results can be extremely satisfactory.

For Case Studies, Videos, and more, please visit ExpertConsult.com.

REFERENCES

1. Adams JT, DeWeese JA, Mahoney EB, et al: Intermittent subclavian vein obstruction without thrombosis. *Surgery* 63:147–165, 1968.
2. Adson AW, Coffey JR: Cervical rib: a method of anterior approach. *Ann Surg* 85:839–856, 1927.
3. Atasoy E: Thoracic outlet compression syndrome. *Orthop Clin North Am* 27:265–303, 1996.
4. Atasoy E: Combined surgical treatment of thoracic outlet syndrome: transaxillary first-rib resection and transcervical scalenectomy. *Hand Clin* 20:71–82, 2004.
5. Axelrod DA, Proctor MC, Geisser ME, et al: Outcomes after surgery for thoracic outlet syndrome. *J Vasc Surg* 33:1220–1225, 2001.
6. Bilbey JH, Muller NL, Connell DG, et al: Thoracic outlet syndrome: evaluation with CT. *Radiology* 171:381–384, 1989.
7. Bingham DH: Thoracic outlet syndrome: a misunderstood and potentially devastating problem. *Nebr Med J* 79:145–150, 1994.
8. Bredenburg C, Dardik H, Green RM, et al: Discussion of Green R, et al. Long-term follow-up after thoracic outlet decompression: an analysis of factors determining outcome. *J Vasc Surg* 14:745–746, 1991.
9. Bureau of Labor Statistics: *Annual survey of occupational injuries and illnesses (abstract),* Washington, DC, 1990, US Government Printing Office.
10. Carroll RE, Hurst LC: The relationship of thoracic outlet syndrome and carpal tunnel syndrome. *Clin Orthop* 164:149–153, 1982.
11. Chang DC, Rotellini-Coltvet MA, Mukherjee D, et al: Surgical intervention for thoracic outlet syndrome improves patient's quality of life. *J Vasc Surg* 49:630–635, 2009.
12. Cheng SWK, Reilly LM, Nelken NA, et al: Neurogenic thoracic outlet decompression: rationale for sparing the first rib. *Cardiovasc Surg* 3:617–623, 1995.
13. Cheng SWK, Stoney RJ: Supraclavicular reoperation for neurogenic thoracic outlet syndrome. *J Vasc Surg* 19:565–572, 1994.
14. Clagett OT: Presidential Address: Research and prosearch. *J Thorac Cardiovasc Surg* 44:153, 1962.
15. Collins JD, Disher AC, Miller TQ: The anatomy of the brachial plexus as displayed by magnetic resonance imaging: technique and application. *J Natl Med Assoc* 87:489–498, 1995.
16. Coote H: Pressure on the axillary vessels and nerve by an exostosis from cervical rib; interference with the circulation of the arm, removal of the rib and exostosis; recovery. *Med Times Gazette* 2:108, 1861.
17. Dale WA: Thoracic outlet compression syndrome. *Arch Surg* 117:1437–1445, 1982.
18. Dellon AL: The results of supraclavicular brachial plexus neurolysis (without first rib resection) in management of post-traumatic "thoracic outlet syndrome." *J Reconstr Microsurg* 9:11–17, 1993.
19. Dugas JR, Weiland AJ: Vascular pathology in the throwing athlete. *Hand Clin* 16:477–485, 2000.
20. Durham JR, McIntyre KE: Complications following surgical treatment of the thoracic outlet syndrome. In Bernared VM, Towne JB, editors: *Complications in vascular surgery,* Orlando, 1985, Grune & Stratton, pp 111–120.
21. Dymarkowski S, Bosmans H, Marchal G, et al: Three-dimensional MR angiography in the evaluation of thoracic outlet syndrome. *AJR Am J Roentgenol* 173:1005–1008, 1999.
22. Ellison DW, Wood VE: Trauma-related thoracic outlet syndrome. *J Hand Surg [Br]* 19:424–426, 1994.
23. Faulkner JA, Brooks SV, Opiteck JA: Injury to skeletal muscle fibers during contractions: conditions of occurrence and prevention. *Phys Ther* 73:911–921, 1993.
24. Fodor M, Fodor L, Cluce C: Anomalies of thoracic outlet in human fetuses: anatomical study. *Ann Vasc Surg* 25(7):961–968, 2011.
25. Friden J, Sjöstrom M, Ekblom B: Myofibrillar damage following intense eccentric exercise in man. *Int J Sports Med* 4:170–176, 1983.
26. Fujita K, Matsuda K, Sakai Y, et al: Late thoracic outlet syndrome secondary to malunion of the fractured clavicle: case report and review of the literature. *J Trauma* 50:332–335, 2001.
27. Gilliatt RW: Thoracic outlet syndrome. In Dyck PJ, Thomas PK, Lambert EH, et al, editors: *Peripheral neurology,* Philadelphia, 1984, WB Saunders, p 1409.
28. Green RM, McNamara J, Ouriel K: Long-term follow-up after thoracic outlet decompression: an analysis of factors determining outcome. *J Vasc Surg* 14:739–745, 1991.
29. Horowitz SH: Brachial plexus injuries with causalgia resulting from transaxillary rib resection. *Arch Surg* 120:1189–1191, 1985.
30. Howell J: Evaluation and management of thoracic outlet syndrome. In Donatelli R, editor: *Physical therapy of the shoulder,* New York, 1991, Churchill Livingstone.
31. Jamieson WG, Chinnick B: Thoracic outlet syndrome: fact or fancy? A review of 409 consecutive patients who underwent operation. *Can J Surg* 39:321–326, 1996.
32. Jamieson WG, Merskey H: The representation of the thoracic outlet syndrome as a problem in chronic pain and psychiatric management. *Pain* 22:195–200, 1985.
33. Johnson CR: Treatment of thoracic outlet syndrome by removal of first rib and related entrapments through posterolateral approach: a 22-year experience. *J Thorac Cardiovasc Surg* 68:536–545, 1977.
34. Jordan SE, Ahn SS, Gelabert HA: Differentiation of thoracic outlet syndrome from treatment-resistant cervical brachial pain syndromes: development and utilization of a questionnaire, clinical examination and ultrasound evaluation. *Pain Physician* 10:441–452, 2007.
35. Jordan SE, Ahn SS, Gelabert HA: Combining ultrasonography and electromyography for botulinum chemodenervation treatment of thoracic outlet syndrome: comparison with fluoroscopy and electromyography guidance. *Pain Physician* 10: 541–546, 2007.
36. Keen WW: The symptomatology, diagnosis and surgical treatment of cervical ribs. *Am J Med Sci* 133:173–218, 1907.
37. Kline DG, Hackett ER, Happel LH: Surgery for lesions of the brachial plexus. *Arch Neurol* 43:170–181, 1986.
38. Komanetsky RM, Novak CB, Mackinnon SE, et al: Somatosensory evoked potentials fail to diagnose thoracic outlet syndrome. *J Hand Surg [Am]* 21:662–666, 1996.
39. Kostic S, Kulka F: Reasons behind surgical failures in thoracic outlet syndrome. *Int Surg* 75:159–161, 1990.
40. Landry GJ, Moneta GL, Taylor LM, Jr, et al: Long term functional outcome of neurogenic thoracic outlet syndrome in conservatively and surgically treated patients. *J Vasc Surg* 33:292–297, 2001.
41. Leffert RD: Thoracic outlet syndromes. *Hand Clin* 8:285–297, 1992.
42. Lindgren K: Thoracic outlet syndrome with special reference to the first rib. *Ann Chir Gynaecol* 82:218–230, 1993.
43. Lindgren K, Leino E, Lepantalo M, et al: Recurrent thoracic outlet syndrome after first rib resection. *Arch Phys Med Rehabil* 72:208–210, 1991.
44. Lindgren K, Oksala I: Long-term outcome of surgery for thoracic outlet syndrome. *Am J Surg* 169:358–360, 1995.
45. Lishman WA, Russell WR: The brachial neuropathies. *Lancet* 2:941–946, 1961.
46. Longley DG, Yedlicka JW, Molina EJ, et al: Thoracic outlet syndrome: evaluation of the subclavian vessels by color duplex sonography. *AJR Am J Roentgenol* 158:623–630, 1992.
47. Luoma A, Nelems B: Thoracic outlet syndrome: thoracic surgery perspective. *Neurosurg Clin N Am* 2:187–226, 1991.
48. Machanic BI, Sanders RJ: Medial antebrachial cutaneous nerve measurements to diagnose neurogenic thoracic outlet syndrome. *Ann Vasc Surg* 22:248–254, 2008.
49. MacKinnon SE: Double and multiple "crush" syndromes—double and multiple entrapment neuropathies. *Hand Clin* 8:369–390, 1992.
50. MacKinnon SE, Novak CB: Evaluation of the patient with thoracic outlet syndrome. *Semin Thorac Cardiovasc Surg* 8:190–200, 1996.
51. MacKinnon SE, Novak CB: Thoracic outlet syndrome. *Curr Probl Surg* 39:1070–1145, 2002.
52. MacKinnon SE, Patterson GA, Novak CB: Thoracic outlet syndrome: a current overview. *Semin Thorac Cardiovasc Surg* 8:176–182, 1996.
53. Makhoul RG, Machleder HI: Discussion of Makhoul RG, Machleder HI: Developmental anomalies at the thoracic outlet: an analysis of 200 consecutive cases. *J Vasc Surg* 16:542–545, 1992.
54. Matsumura JS, Rilling WS, Pearce WH, et al: Helical computed tomography of the normal thoracic outlet. *J Vasc Surg* 26:776–783, 1997.
55. Maxwell-Armstrong CA, Noorpuri BS, Haque SA, et al: Long-term results of surgical decompression of thoracic outlet syndrome. *J R Coll Surg Edinb* 46:35–38, 2001.
56. McCarthy WJ, Yao JST, Schafer MF, et al: Upper extremity arterial injury in athletes. *J Vasc Surg* 9:297–327, 1989.
57. Mingoli A, Feldhaus RJ, Farina C, et al: Long-term outcome after transaxillary approach for thoracic outlet syndrome. *Surgery* 118:841–844, 1995.
58. Molina JE: Regarding "Long-term functional outcome of neurogenic thoracic outlet syndrome in surgically and conservatively treated patients." *J Vasc Surg* 34:760–761, 2001.
59. Narakas AO: The role of thoracic outlet syndrome in the double crush syndrome. *Ann Hand Surg* 9:329–340, 1990.
60. Nasim A, Sayers RD, Healey PA, et al: Surgical decompression of thoracic outlet syndrome: is it a worthwhile procedure? *J R Coll Surg Edinb* 42:299–323, 1997.
61. Novak CB: Conservative management of thoracic outlet syndrome. *Semin Thorac Cardiovasc Surg* 8:201–207, 1996.

CASE STUDY 29.1 Typical Adolescent With Delayed Diagnosis of TOS

K.C. was first seen when she was 8 and complaining of pain with popping in her right, dominant shoulder, especially after playing tennis. Her exam showed mild discomfort when her subscapularis and infraspinatus were tested. Her plain films and magnetic resonance imaging (MRI) at that time were normal. She was told to rest. Her shoulder settled down to some degree, but she presented a year later after experiencing a painful pop while roughhousing. At this time she had a +3 sulcus sign and a positive apprehension test but normal strength. She was felt to have a degree of multidirectional instability (MDI) and was started on physical therapy, which did not help much. She continued to have pain and only a few months later was noted to have increased only a +1 sulcus sign, increased translation in the automonous plane (AP), and had another MRI that was normal.

Subsequently, she improved to a small degree and 2 years later was seen again, this time with pain during volleyball and basketball games, having backed off tennis to a significant degree. She had excellent strength, normal motion, and only a trace sulcus sign and was felt to have scapular dyskinesis. K.C. was also having some arm and neck pain but cervical spine films were normal. She was started on home exercises and stretching and had some improvement and continued to play sports. Then while playing soccer, she was flipped over and landed on her head. She presented with neck pain that settled down in a few weeks with rest and returned to sports. However, a month later she began having neck, shoulder, and scapular pain; an MRI of her cervical spine was normal, so it was surmised that she was having myofascial pain. She continued to play tennis within the degree of discomfort that she could, did exercises intermittently, and continued to have shoulder and neck pain.

She then began to have periscapular pain without any new injury, continued shoulder pain and noted that her exercises actually aggravated the pain. She was diagnosed with scapular bursitis and started on exercises for that; had another MRI, which was normal; then began to have numbness with overhead activity (e.g., doing her hair). She also had significant numbness in her thumb with some pain. The mother noted that they had exhausted physical therapy and had even seen another orthopedist who had recommended a scope with capsular reconstruction.

When I saw the patient, she was complaining of pain in her right shoulder, to a lesser extent in her neck, and numbness and tingling down the arm into her fingers. She had to give up sports activities because they made her worse; exercises also had made her worse, as did doing her hair. She did not have any cold intolerance.

A physical exam showed mild scapular asymmetry at rest but no winging with motion, which was full. She had a markedly positive Roos score, a markedly positive upper-limb tension test, tenderness in her anterior triangle and infraclavicular as well. K.C.'s pulse weakened during the Roos test but did not go away. There was no atrophy around the shoulder or hand. She was shown how to do scalene stretching at home and started on Neurontin; these afforded her no improvement so she elected to have surgical intervention.

Surgery consisted of resection of anterior and middle scalene, complete neurolysis of the plexus to the neural foramen, excision of the coracocostal ligament, and examination of the infraclavicular plexus for possible pectoralis minor compression. She was found to have significant fibrosis of her posterior fat pad with scarring along both the suprascapular and long thoracic nerves. She also had a very thick pleura band compressing the lower trunk against the first rib, a coracocostal ligament pressing the plexus against the chest wall, but no impingement from the pectoralis minor.

The afternoon of surgery she was able to put her arm over her head easily without any numbness or tingling or change in pulse. At 7 months, she was playing tennis and other sports and only had minimal discomfort in her shoulder and occasional tightness in her chest. She really did not have any significant symptoms of shoulder instability. At 1 year K.C. had some headaches and neck pain that was felt not to be related to her TOS; her exam at that time showed a negative Roos test, negative upper-limb tension, no anterior triangle or infraclavicular tenderness, and excellent motion and strength of her shoulder and arm. She is now almost 3 years postop and has qualified for a tennis scholarship and is playing on a regular basis with only an occasional ache if she does other sports activities. She can do her hair and other overhead activities without any difficulty.

62. Novak CB, Collins ED, Mackinnon SE: Outcome following conservative treatment management of thoracic outlet syndrome. *J Hand Surg [Am]* 20:542–548, 1995.
63. Novak CB, Mackinnon SE, Patterson AG: Evaluation of patients with thoracic outlet syndrome. *J Hand Surg [Am]* 18:292–299, 1993.
64. Oates SD, Daley RA: Thoracic outlet syndrome. *Hand Clin* 12:705–718, 1996.
65. Ohkawa Y, Isoda H, Hasegawa S, et al: MR angiography of thoracic outlet syndrome. *J Comput Assist Tomogr* 16:475–477, 1992.
66. Panegyres PK, Moore N, Gibson R, et al: Thoracic outlet syndromes and magnetic resonance imaging. *Brain* 116:823–841, 1993.
67. Pang D, Wessel HB: Thoracic outlet syndrome. *Neurosurgery* 22:105–121, 1988.
68. Passero S, Paradiso C, Giannini F, et al: Diagnosis of thoracic outlet syndrome: relative value of electrophysiological studies. *Acta Neurol Scand* 90:179–185, 1994.
69. Peet RM, Henriksen JD, Anderson TP, et al: Thoracic outlet syndrome: evaluation of a therapeutic exercise program. *Proc Staff Meet Mayo Clin* 29:281–287, 1956.
70. Pietre R, Spiliopoulos A, Megevand R: Transthoracic approach in the thoracic outlet syndrome: an alternate operative route for removal of the first rib. *Surgery* 106:856–860, 1989.
71. Poitevin L: Proximal compression of the upper limb neurovascular bundle: an anatomic research study. *Hand Clin* 4:575, 1988.
72. Poole GV, Thomae KR: Thoracic outlet syndrome reconsidered. *Am Surg* 62:287–291, 1996.
73. Qvarfordt PG, Ehrenfeld WK, Stoney RJ: Supraclavicular radical scalenectomy and transaxillary first rib resection for the thoracic outlet syndrome. *Am J Surg* 148:111–116, 1984.
74. Ranney D: Thoracic outlet: an anatomical redefinition that makes sense. *Clin Anat* 9:50–52, 1996.
75. Redenbach DM, Nelems B: A comparative study of structures comprising the thoracic outlet in 250 human cadavers and 72 surgical cases of thoracic outlet syndrome. *Eur J Cardiothorac Surg* 13:353–360, 1998.
76. Reidler JS, Das DS, Schreiber JJ, et al: Thoracic outlet syndrome caused by synostosis of the first and second thoracic ribs: Two case reports and review of the literature. *J Hand Surg [Am]* 39(12):2444–2447, 2014.
77. Reilly LM, Stoney RJ: Supraclavicular approach for thoracic outlet decompression. *J Vasc Surg* 8:329–334, 1988.
78. Ribbe E, Norgren L, Hamrin A: Etiological factors in thoracic outlet syndrome. *Int Angiol* 3:113, 1984.
79. Roos DB: Transaxillary approach for the first rib resection to relieve thoracic outlet syndrome. *Ann Surg* 163:354, 1966.
80. Roos DB: Congenital anomalies associated with thoracic outlet syndrome: anatomy, symptoms, diagnosis and treatment. *Am J Surg* 132:771–778, 1976.
81. Roos DB: Sympathectomy for the upper extremities: anatomy, indications and techniques, new concepts in etiology, diagnosis and surgical treatment for thoracic outlet syndrome. In Greep DM, et al, editors: *Pain syndromes in the shoulder and arm: an integrated view*, The Hague, 1979, Martinus Nijhoff Publishers.
82. Roos DB: The place for scalenotomy and first rib resection in thoracic outlet syndrome. *Surgery* 92:1077–1085, 1982.
83. Roos DB: The thoracic outlet syndrome is underrated. *Arch Neurol* 47:327–330, 1990.
84. Roos DB: Thoracic outlet syndrome is underdiagnosed. *Muscle Nerve* 22:126–137, 1990.
85. Roos DB: Historical perspectives and anatomic considerations. *Semin Thorac Cardiovasc Surg* 8:183–189, 1996.
86. Roos DB, Owens JC: Thoracic outlet syndrome. *Arch Surg* 93:71–74, 1966.
87. Roos DB, Sanders R, Stoney RP: Discussion concerning Sanders RJ et al. Recurrent thoracic outlet syndrome. *J Vasc Surg* 12:398–400, 1990.
88. Sahrmann SA: *Diagnosis and treatment of movement impairment syndromes*, St. Louis, 2002, Mosby.
89. Sanders RJ: Results of the surgical treatment for thoracic outlet syndrome. *Semin Thorac Cardiovasc Surg* 8:221–228, 1996.
90. Sanders RJ, Hammond SL, Rao NM: Diagnosis of thoracic outlet syndrome. *J Vasc Surg* 46:601–604, 2007.
91. Sanders RJ, Haug CE: *Thoracic outlet syndrome: a common sequela of neck injuries*, Philadelphia, 1991, JB Lippincott.
92. Sanders RJ, Haug CE, Pearce WH: Recurrent thoracic outlet syndrome. *J Vasc Surg* 12:390–398, 1990.
93. Sanders RJ, Pearce WH: The treatment of thoracic outlet syndrome: a comparison of different operations. *J Vasc Surg* 10:626–634, 1989.
94. Sessions RT: Reoperation for thoracic outlet syndrome. *J Cardiovasc Surg* 30:434–444, 1909.
95. Smith T, Trojaborg W: Diagnosis of thoracic outlet syndrome: value of sensory and motor conduction studies and quantitative electromyography. *Arch Neurol* 44:1161–1163, 1987.
96. Sommerich CM, McGlathlin JD, Marras WS: Occupational risk factors associated with soft tissue disorders of the shoulder: a review of recent investigations in the literature. *Ergonomics* 36:697–717, 1993.
97. Thompson JF, Webster JHH: First rib resection for vascular complications of thoracic outlet syndrome. *Br J Surg* 77:555–557, 1990.
98. Thompson RW, Petrinec D, Toursakissian B: Surgical treatment of thoracic outlet compression syndromes: II. Supraclavicular exploration and vascular reconstruction. *Ann Vasc Surg* 11:442–451, 1997.
99. Troeng T: The anatomy of the thoracic outlet and the causes of thoracic outlet syndrome. *Vasa* 16:149–152, 1987.
100. Urschel HC, Jr: The transaxillary approach for treatment of thoracic outlet. *Semin Thorac Cardiovasc Surg* 8:214–220, 1996.
101. Urschel HC, Jr, Razzuk MA: The failed operation for thoracic outlet syndrome: the difficulty of diagnosis and management. *Ann Thorac Surg* 42:523–528, 1986.
102. Urschel HC, Jr, Razzuk MA: Improved management of the Paget-Schroetter syndrome secondary to thoracic outlet compression. *Ann Thorac Surg* 52:1217–1221, 1991.
103. Urschel HC, Jr, Razzuk MA: Upper plexus thoracic outlet syndrome: optimal therapy. *Ann Thorac Surg* 63:935–939, 1997.
104. Urschel HC, Jr, Razzuk MA: Neurovascular compression in the thoracic outlet: changing management over 50 years. *Ann Surg* 228:609–617, 1998.
105. Urschel HC, Jr, Razzuk MA, Albers JE, et al: Reoperation for recurrent thoracic outlet syndrome. *Ann Thorac Surg* 21:19–25, 1976.
106. Urschel HC, Jr, Razzuk MA, Hyland JW, et al: Thoracic outlet syndrome masquerading as coronary artery disease (pseudoangina). *Ann Thorac Surg* 16:239–248, 1973.
107. Veilleux M, Stevens JC, Campbell JK: Somatosensory evoked potentials: lack of value for diagnosis of thoracic outlet syndrome. *Muscle Nerve* 11:571–575, 1988.
108. Walsh MT: Therapist management of thoracic outlet syndrome. *J Hand Ther* 7:129–144, 1994.
109. Wehbe MA: Thoracic outlet syndrome. *Hand Clin* 20:1–130, 2004.
110. Wehbe MA, Leinberry CF: Current trends in treatment of thoracic outlet syndrome. *Hand Clin* 20:119–121, 2004.
111. Wilbourn AJ: Thoracic outlet syndrome. In Coutse D, editor: *Controversies in entrapment neuropathies*, Rochester, MN, 1984, American Association of Electromyography and Electrodiagnosis, p 28.
112. Wood VE, Ellison DW: Results of upper plexus thoracic outlet syndrome operation. *Ann Thorac Surg* 58:458–461, 1994.
113. Wood VE, Frykman GK: Winging of the scapular as a complication of first-rib resection: a report of 6 cases. *Clin Orthop* 149:160–163, 1980.

INDEX

Page numbers followed by "*f*" indicate figures, "*t*" indicate tables, "*b*" indicate boxes, and "*e*" indicate online content.

A
ABCDE acronym, for melanoma, 1977
ABCDEFG procedure (alphabet reconstruction), 1139
Abdominal wall flap, random, for burn deformities, 1944
Abduction, in restoration of thumb-index key pinch, in ulnar nerve palsy, 1058-1059
Abductor advancement, for radial collateral ligament injuries, 309
Abductor digiti minimi (ADM), 138
  transfer of
    in hypoplastic thumb reconstruction, 1292
    in median nerve palsy, 1032-1033, 1033*f*-1034*f*
Abductor pollicis longus (APL)
  imbrication of, for thumb-in-palm deformity, 1112
  transfer of, accessory slip of, 1058, 1058*f*
Abductorplasty, of flexor pollicis longus, for thumb-in-palm deformity, in spasticity, 1111-1112
Abscess
  antibiotic recommendations for, 21*t*
  nerve, in Hansen disease, 106, 109-110, 112-113, 113*f*-114*f*
  shooter's, 51-52
  subaponeurotic space, 37
    treatment for, 38
  subcutaneous space, 37
    treatment for, 38
  web space (collar-button), 37-38, 38*f*-39*f*
    case study, 38.*e*1*b*, 38.*e*1*f*
    treatment for, 38
      preferred method of, 39
Abuse, drug, infections caused by, 51-52
Acanthosis nigricans, 1959-1960
Acid burns, 1948-1949. *see also* Burns
Acid-fast stain, for infections, 65-66, 65*t*
Acquired immunodeficiency syndrome (AIDS), 119-121. *see also* Human immunodeficiency virus (HIV)
  bacillary angiomatosis in, 120-121, 120*f*
  cellular immune responses in, 119.*e*2
  classification and clinical diagnosis of, 119.*e*1-119.*e*2, 119.*e*1*t*
  clinical features of, 119.*e*2
  clinical manifestations of, 119-121
  etiology and epidemiology of, 119
Acquired immunodeficiency syndrome (AIDS) *(Continued)*
  herpes simplex virus in, 120
  indicator conditions, to hand surgery, 119.*e*1*t*
  Kaposi sarcoma in, 121
  treatment of, 121
Acral fibrokeratoma. *see* Digital fibrokeratoma
Acral lentiginous melanoma, 1978
Acral nevi, 1966
Acrosyndactyly, 1227, 1227*f*-1228*f*
  secondary to constriction ring syndrome, 1257
Actinic keratosis, 1972, 1972*f*
Actinobacillosis, 67-68
Actinomycetoma, 70-73
  clinical findings on, 71
  diagnosis of, 72
  etiology and epidemiology of, 70
  microbiology of, 70-71, 71*f*
  treatment of, 72-73
Actinomycosis, 68
Action potential, sensory nerve, in thoracic outlet syndrome, 968
Active stability, of proximal interphalangeal joint, 279
Activity modification, for epicondylitis, 865
Acupuncture, for complex regional pain syndrome, 1817
Acute compartment syndrome, 1763
  diagnosis of, 1765-1767
Acute injury
  in complex traumatic elbow dislocation
    clinical assessment of, 813-814
    imaging of, 814
    treatment of, 818-824
  in longitudinal forearm instability repair, 808
Acyclovir, for herpes simplex virus, 120
Adaptive misalignment, carpal, 463
Adaptive modalities, for complex regional pain syndrome, 1818
Adduction, of thumb, restoration of, 1056-1058
Adductor advancement, for radial collateral ligament injuries, 309
Adductor pollicis, transfer of, in median nerve palsy, 1041
Adenoid basal cell carcinoma, 1974
Adhesion formation, as complication of flexor tendon grafting, 224
Adipofascial flap, 1593
Adjuvant therapy, for heterotopic ossification, 857
Adrenergic compounds, for complex regional pain syndrome, 1813-1814, 1814*t*
Advancement flap(s), 1541-1542, 1547-1550, 1548*f*-1549*f*. *see also* Skin flap(s)
  palmar, for soft tissue defects of thumb, 1676-1677, 1677*b*
    with proximal releasing incision, 1677-1679, 1679*b*, 1679*f*
    without proximal releasing incision, 1677, 1678*f*
  V-Y, 1548-1550, 1549*f*-1551*f*
    in reconstruction of amputated fingertip
      Atasoy-Kleinert volar, 1712-1713, 1713*f*
      Kutler lateral, 1713-1714, 1714*f*
      volar advancement, 1714, 1715*f*
Aeromonas hydrophila, infection with, 1584
Aeromonas species, 48
Afterburn, 1927
Agee single-portal endoscopic technique, for carpal tunnel syndrome, 933-934
Algae infections, 116
Algorithm, management, for pain or paresthesia, 147*f*
Allen test
  for vascular disorders, 2036, 2037*f*
  for vascularity assessment, 1490
Allergic response, to regional anesthesia, 12-14
Allodynia, 1802
  definition of, 1799*t*
Allogeneic bone grafts, 1635-1636
Allograft(s). *see also* Autograft(s); Xenograft
  for mangling injuries, 1510
  of radial head, salvage using, 765
Al-Qattan's classification, of phalangeal neck fractures, 1431-1432, 1433*f*
Amelanotic melanoma, 1980
Amitriptyline, for complex regional pain syndrome, 1812*t*
Amlodipine, for complex regional pain syndrome, 1815*t*
Amniotic band syndrome, 1255-1258, 1256*f*-1257*f*, 1258*b*. *see also* Amniotic disruption sequence
Amniotic disruption sequence, 1255-1258, 1256*f*-1257*f*, 1258*b*

Amoxicillin, for anthrax, 69
Amphotericin B
for candidiasis, 85
for coccidioidomycosis, 85-86
for deep sporotrichosis, 88
for fungal infections, 79
spectrum of activity of, 79*t*
Amplitudes, in nerve conduction studies, 929
Amputation
below-elbow (transradial), 1737
digital tip, 1709-1717, 1709*f*, 1720*b*
case study of, 1737.*e*1*b*, 1737.*e*1*f*-1737.*e*3*f*
cross-finger pedicle flap for, 1714-1716, 1715*f*
with exposed bone, 1711-1717
free flaps in, 1717
island flaps in, 1717
preferred method of treatment for, 1717, 1722-1723
with skin or pulp loss only, 1709-1711
Smith and Albin thenar H-flap in, 1716, 1716*f*
thenar flap in, 1716
V-Y flap for
Atasoy-Kleinert volar, 1712-1713, 1713*f*
Kutler lateral, 1713-1714, 1714*f*
volar advancement, 1714, 1715*f*
of fingers. *see also* Ray amputation
toe transfer for. *see also* Toe transfer, in finger replacement
distal digit in, 1646-1647
multiple-digit in, 1648-1649
proximal, 1648, 1648*f*-1649*f*
digit in, 1647-1648
single digit in, 1646, 1647*f*
human bites and, 48-49
interscapulothoracic, 1756, 1757*f*
limb, major, 1753-1756
case study of, 1762.*e*1*b*, 1762.*e*1*f*-1762.*e*3*f*, 1762.*e*3*b*
indications for, 1753, 1754*f*
lumbrical-plus finger after, 1718
for macrodactyly, 1282
for mangling injuries, consideration of skeletal contribution in, 1492-1493
multiple-digit, 1735-1737, 1735*b*, 1736*f*, 1737*b*
neuromas after, 1522
pain management after, 1747-1749
of perionychium, 323-324, 324*f*-325*f*
postburn, 1942-1943
with preservation of basal joint
composite radial forearm flap for, 1697-1699, 1700*f*, 1699.*e*1*f*
osteoplastic reconstruction for, 1696-1697, 1697.*e*1*f*
Gillies "cocked-hat" flap in, 1696, 1697*f*
Amputation *(Continued)*
two-stage
stage 1, 1696-1697, 1698*f*
stage 2, 1697, 1697.*e*1*f*
pollicization for, index/long finger stump in, 1699-1703, 1702*f*-1704*f*, 1705*b*
principles of, 1708*b*
ray, 1719-1730, 1735*b*. *see also* Ray amputation
replantation after, 1478-1479. *see also* Replantation
through carpus, 1737
through distal interphalangeal joint, 1717-1719, 1718*f*
with disarticulation, 1717-1718
through phalanx
middle, 1718-1719, 1719*f*-1720*f*
proximal, 1719, 1721*f*-1722*f*
through proximal interphalangeal joint, 1719
of thumb
with destruction of basal joint, 1703-1704
with preservation of basal joint, 1696-1699
subtotal, 1688-1691
dorsal rotational flap, 1691-1694
regional and distant flaps, 1694-1696
Z-plasty procedures, four flap, 1690-1691, 1690*b*, 1691*f*-1692*f*
toe transfer for, 1646. *see also* Toe transfer, in thumb replacement
"Z"-plasty procedures, 1689-1691
simple, 1689, 1690*f*, 1689.*e*1*f*
transhumeral, 1754-1756
transradial, 1753-1754, 1754*f*
upper extremity, rehabilitation after, 1757-1758
wrist disarticulation, 1737-1738, 1739*f*
preferred method of treatment of, 1737-1738
Amputation stump, posttraumatic neuralgia in, 1010.*e*5
Amyloid, deposition of, tendinopathy in, 1906-1907, 1906*f*
Amyoplasia, 1365
Analgesia, definition of, 1799*t*
Anastomosis. *see also* Microvascular surgery
distal sleeve, for vascular disorders, 2051, 2051*f*
end-to-end, for vascular disease, 2051, 2051*f*
end-to-side, for vascular disease, 2051, 2051*f*
vascular, in toe transfer, 1668
Anatomy, Dupuytren surgery and, 138
Anconeus flap transolecranon approach, to distal humeral fractures, 714-715, 716*f*
Anemia, Fanconi, radial deficiency associated with, 1289, 1290*t*, 1329*t*
Anemones, venomous, 1791-1792
Anesthesia, 1-16
coronoid fracture-dislocation examination under, 819
in elbow arthroscopy, 886, 888*f*
for elbow contracture release, 849
general, 1
for humeral fracture fixation, 710-711
regional, 1-14, 14*b*
advantages of, 3
complications of
allergy as, 12-14
neurapraxia as, 12, 12*b*
incidence of, 12
management of, 12, 13*f*
sepsis as, 12-14
contraindications to
absolute, 1
relative, 1-2
disadvantages of, 3
drugs, commonly used, 4*t*
equipment for, 4
historical techniques of, 5-6
continuous peripheral nerve catheters, 5
minimum effective dose, 5-6
indications for, 2-3
microvascular surgery patients, 2
patients with rheumatoid arthritis, 3
pediatric patients, 2
pregnant patients, 2-3
intravenous, 10-11
for limiting use of, 3*b*
preferred method of, 11-12
specific blocks, 6-8, 6*f*
axillary, 8, 8*f*
infraclavicular, 7-8, 7*f*
interscalene, 6, 7*f*
supplementary, 8-11
at digit, 9-10, 10*f*-11*f*
at elbow, 8
at wrist, 8-9, 9*f*
supraclavicular, 6-7, 7*f*
toxicity of, 4*b*
ultrasound-guided, 5, 7*f*
regional, for complex regional pain syndrome, 1811
for stiff finger and hand, 340
Anesthetic procedure, for Dupuytren disease, 145
Anesthetic skin patch, for Hansen disease, 104
Aneurysmal bone cyst, 2024-2025, 2024*f*-2025*f*
Aneurysms, 2054, 2055*f*
Angiography. *see also* Arteriography
prior to free flap transfer, 1577
Angiomatosis, bacillary, AIDS and, 120-121

Angular osteotomies. *see also* Osteotomy
  for forearm fracture malunion, 801-803, 802*f*
Angulation
  after metacarpal fractures, dorsal, 246, 246*f*-247*f*
  after phalangeal fractures
    apex volar, 266, 266*f*
    lateral, 266-267, 266*f*
  after volar plate arthroplasty, 290
Animal(s), venomous, 1788-1795
  caterpillars, 1788, 1789*f*
  cnidarians, 1791-1792, 1792*f*
  fish, 1792-1795, 1793*f*-1794*f*
  sea urchins, 1792, 1792*f*
  snakes, 1789-1791, 1790*f*-1791*f*
  spiders, 1788-1789, 1789*f*
Animal bites, 46-48
  antibiotic recommendations for, 21*t*
Ankylosis, complete, of neuropathic joint, as contraindication to total elbow arthroplasty, 909
Anterior compartment portals, in elbow arthroscopy, 888-890
Anterior drawer test, in midcarpal instability, 460
Anterior (transolecranon) fracture-dislocation, of elbow, 784.*e*13*b*, 784.*e*13*f*-784.*e*14*f*
Anterior transposition, of ulnar nerve, 947
Anterolateral portals, in elbow arthroscopy, 889-890, 890*f*
  distal, 890
  proximal, 889
Anterolateral thigh flap, 1597, 1598*f*
  for burn deformity, 1945
  for mangling injuries, 1513-1515, 1516*f*
Anteromedial portals, in elbow arthroscopy, 888-889
  proximal, 888-889, 889*f*
Anthrax, 56-57, 57*f*, 68-69, 69*f*
  cutaneous, 68-69, 69*f*
    treatment of, 69
Antibiotics, for common infections, 21*t*
Anticoagulation therapy, regional anesthesia and, 2
Anticonvulsants, for complex regional pain syndrome, 1813, 1813*t*
Antidepressants, for complex regional pain syndrome, 1811-1812, 1812*t*
Antifungal agent, activity of, spectrum of, 79*t*
Antiinflammatory medications, for carpal tunnel syndrome, 932-933
Antimony, injection of, for leishmaniasis infection, 117
Antisepsis, for Dupuytren disease, 145
Antituberculous drugs, 100-103, 101*t*
Antivenin, snake, 1789
AO/ASIF classification
  of distal humerus fractures, 703
  of distal radial fracture, 524, 526*f*
Apert syndrome, 1210*f*
  classification of, 1228*t*
  in syndactyly, 1227-1232, 1229*f*
    planning of, groin flaps in, 1228-1230, 1230*f*
Apex volar angulation, as complication of phalangeal fractures, 266, 266*f*
Apical ectodermal ridge (AER)
  in embryogenesis, 1208
  removal of, 1209, 1210*f*-1211*f*
Aponeurosis, of finger, 338.*e*3, 338.*e*5*f*
Arcade of Fröhse, 950-951
Arcade of Struthers, 699, 941, 941*f*
Arcing, 1947
Arm
  compartments of
    release of, 1769, 1769*f*
  mangling injuries of, treatment of, 1515-1519, 1519*f*-1520*f*
  release of, 1770-1771
Arm flap, lateral. *see* Lateral arm flap
Arsenical keratosis, 1972
Artelon implant, for carpometacarpal joint osteoarthritis, 362
Arterial injury, contaminant, 1008
Arterial repairs, in replantation, 1482
Arterial trauma
  closed, 2042-2047, 2044*f*-2046*f*
    complications of, 2046-2047, 2047*f*-2048*f*
    preferred method of treatment of, 2046-2047, 2047*f*
  open, 2040-2042, 2040*f*
    complications of, 2042
    postoperative care after, 2042
    preferred method of treatment of, 2040-2042, 2041*f*-2042*f*
    vein grafting for, 2041, 2041*f*, 2042*b*, 2043*f*
Arterialized venous flaps, 1577
Arteriography, of recipient site, in vascular bone grafting, 1615
Arteriovenous malformations, high-flow, 2056, 2057*f*
Artery(ies). *see also named artery, e.g.*, Radial artery
  defects of, free flaps for, 1609
  preparation of, in toe transfer, 1666
Arthritis. *see also under specific joint*
  posttraumatic, 906, 907*f*
    of elbow, 827
    preoperative assessment of, 906
    preoperative planning of, 906
  psoriatic, 1834-1836
    digital deformity in, 1836, 1836*f*
    thumb deformity in, 1836
    wrist deformity in, 1836
  rheumatoid, 905-906, 906*f*, 1842-1857. *see also* Rheumatoid arthritis
    physical examination of, 905
    preoperative evaluation of, 905-906
    preoperative planning of, 905-906
Arthritis *(Continued)*
  scaphotrapeziotrapezoid, carpal misalignment secondary to, 464
  septic. *see* Septic arthritis
  tuberculous, 96-97, 97*f*
Arthritis mutilans
  arthrodesis for, 1899-1900
  of thumb, 1897
Arthrodesis, 1127
  for arthritis mutilans, 1899-1900
  of carpometacarpal joint, for CMC osteoarthritis
    expected outcomes on, 368
    operative techniques in, 364, 364*f*
    treatment for, 361
  of glenohumeral joint, 1090, 1090*f*
  intercarpal, for wrist arthritis, 690
  of interphalangeal joint, 1899
    distal, 346-349, 349*b*
      author's preferred method of treatment for, 347-349, 348*f*
      complications of, 349
      critical points in, 349*b*
      expected outcomes for, 349
      indications and contraindications of, 346-347
      postoperative management and expectations for, 349
      preoperative planning for, 347
      in rheumatoid arthritis, for swan neck deformity, 1880-1882, 1880*t*
        with screw, 1881, 1881*f*
      studies of, fixation and outcomes, 347*t*
      technique for, 347, 348*f*
    proximal, 349-352
      author's preferred method of treatment for, 350, 351*f*
      complications of, 352
      critical points in, 351*b*
      expected outcomes on, 352
      indications and contraindications for, 349
      postoperative management and expectations for, 350-352
      preoperative planning for, 349
      in rheumatoid arthritis, for swan neck deformity, 1887, 1887*f*
      technique for, 349-350, 350*f*
    of thumb, in ulnar nerve palsy, 1059
  lunotriquetral, 457*b*
  of metacarpophalangeal joint, 352-353, 352*b*
    in spasticity, for swan neck deformity, 1116, 1117*b*, 1117*f*
    for thumb deformities, 1899
    in ulnar nerve palsy, 1059
  midcarpal, 461, 462*f*
  scaphoid-capitate, 448
  scaphoid-lunate-capitate, 448
  scaphoid-trapezium-trapezoid, 447
  scapholunate, 447

Arthrodesis *(Continued)*
of shoulder
for brachial plexus injury, 1190-1192
preferred method of, 1192, 1194*b*, 1194*f*
vascularized allograft fibular construct for, 1622*f*
of thumb, in ulnar nerve palsy, 1059
of wrist, 373-417
after failed total wrist arthroplasty, 404, 404*f*-405*f*
for brachial plexus injury, 1202
capitolunate in, with scaphoid excision, 394-395, 395*f*
history of, 396
with intramedullary pins, critical points in, 404*b*
limited, history of, 377
lunotriquetral, 387-389
indications and contraindications in, 387-388
patients and, 389
pearls, 389, 389*f*
pitfalls of, 389
postoperative management for, 388
preferred method of, 388
osteoarthritis and, common radiographic pattern for, 376, 377*f*
partial fusions of, 377
preoperative assessment of, 374-377
physical examination of, 374
radiographic evaluation of, 374-377, 375*f*-376*f*
radiographic patterns of disease for, 376-377, 377*f*
radiolunate fusion in, 377-380
critical points in, 381*b*
indications for, 377, 379*f*
net analysis of literature in, 380
pitfalls of, 380
postoperative management for, 380
preferred method of, 378-380, 381*f*-382*f*
technique for, 377, 379*f*-380*f*
radioscapholunate in, 385-386
complications of, 375*f*, 386
critical points in, 388*b*
indications and contraindications in, 385, 385*f*
patients and, 386, 388*f*
postoperative care for, 386
preferred method of, 385-386, 386*f*-387*f*
rheumatoid arthritis and
choice of operation in, 1863
complications of, 1867
with metacarpophalangeal joint arthroplasty, 1867-1878
partial fusion in, 1864-1866, 1864*f*
radiographic patterns of, 376-377
tendon transfers in, 1853-1854

Arthrodesis *(Continued)*
scaphocapitate in, 380-385
athletic participation in, 384
contraindications in, 380
critical points in, 384*b*
fixation for, 383, 383*f*
indications for, 383
patients on, 384-385
postoperative expectations in, 384
postoperative management of, 384
preferred method of, 383-384, 383*f*
scapholunate in, 387
scaphotrapeziotrapezoidal fusion in, 389-390
contraindications in, 389
indications for, 389
patients and, 390-391, 392*f*
preferred method of, 390, 391*f*
surgical techniques for, 377-416
alternative techniques for, 390-391
fixation for, alternative methods of, 393-394
total, 395-401
closure in, 399, 401*f*
complications of, 400, 401*f*-402*f*
postoperative management of, 399
preferred method of, 396-399, 396*f*-400*f*
for scapholunate dissociation, 450
triquetrohamate fusion in, 389
Arthrography
of carpal instability, 432
of distal radioulnar joint, 486
of lunotriquetral dissociation, 454
Arthrogryposis, 1365-1390, 1366*f*-1367*f*
diagnostic imaging of, 1366
history of, 1365
patterns of hand deformities in, 1388*t*
pertinent anatomy in, 1367
physical examination for, 1365-1366, 1369*f*
preoperative evaluation of, 1365-1367
surgical procedures for, 1368-1390, 1371*f*
bipolar latissimus dorsi transfer in, 1376-1378, 1378*b*
camptodactyly release in, 1387-1390, 1389*b*
carpal wedge osteotomy, 1380-1382, 1382*b*
elbow extension contracture release in, 1372-1376
humeral external rotation osteotomy in, 1368-1372
radial osteotomy, with and without ulnar osteotomy in, 1378-1380, 1380*b*
thumb reorientation osteotomy and/or metacarpophalangeal chondrodesis, 1383-1387, 1386*b*
thumb contractures in, 1368*t*
treatment of, historical review of, 1370*t*
types of, 1368*t*

Arthrolysis, arthroscopic, for wrist arthritis, 691
Arthropathy, hemophilic, 909
preoperative considerations of, 909
Arthroplasty
of carpometacarpal thumb, for thumb CMC osteoarthritis
expected outcomes on, 368
treatment for, 361-362
distal resection, for scaphoid nonunion advanced collapse, 622-623
of elbow, total, 905-920, 919*b*
complications of, 914-915, 914*f*
contraindications to, 909
for fractures of distal humerus, 906-907, 908*f*
for hemophilic arthropathy, 909
historical review of, 909, 910*t*
mortality rates and, 918
paratricipital exposure for, 711.*e1b*, 711.*e1f*-711.*e2f*
postoperative management and expectations after, 913-918
for posttraumatic arthritis, 906, 907*f*
for primary osteoarthritis, 907-909
for rheumatoid arthritis, 905-906, 906*f*
total replacement in, for distal humeral fractures, 709-710, 710.*e1b*, 710.*e1f*
geriatric, 710.*e1b*, 710.*e1f*
hemihamate, for proximal interphalangeal joint fracture-dislocation, 294
case study on, 315.*e1b*, 315.*e1f*-315.*e2f*
hemiresection-interposition, for radioulnar joint arthritis, 503-504, 504*f*
of metacarpophalangeal joint, 358
of proximal interphalangeal joint, 353-358
complications of, 358, 358*f*
critical points in, 356*b*
expected outcomes on, 356-357
indications and contraindications for, 353
postoperative management and expectations for, 356-358
preferred method of, 354-356, 354*f*-356*f*
preoperative planning of, 353
technique for, 353-354, 354*f*
of radial head, 745
outcome of, 759-760
as preferred treatment, 752-754, 755*f*-756*f*, 756*b*
resection, for carpometacarpal joint osteoarthritis
expected outcomes on, 366-368, 367*t*
as operative technique, 363-364, 363*f*
as treatment, 361
surface replacement, 356-357

Arthroplasty *(Continued)*
for swan neck deformity, in rheumatoid arthritis, 1886-1890, 1886*f*-1887*f*
contraindication to, 1887, 1887*f*
indications for, 1887
outcomes of, 1889-1890, 1890*f*
rehabilitation after, 1889
surgical approaches to, 1887-1889, 1888*f*
of trapeziometacarpal joint, in rheumatoid arthritis, 1900-1901
ulnar head implant, 508-510
operative technique for, 509-510, 509*f*
outcomes of, 510, 510*f*
volar plate, for proximal interphalangeal joint fracture-dislocation, 284
complications of, 290
postoperative management of, 290
preferred method for, 288-290, 289*f*, 290*b*
of wrist, 373-417
total
critical points in, 415*b*
failed, after wrist arthrodesis, 404, 404*f*-405*f*
history of, 405-407
for scapholunate dissociation, 450
Arthroscopic fixation, fracture management by, 899-902
of capitellar fractures, 899, 900*f*
of coronoid fractures, 899-901, 901*f*
of radial head fractures, 902
Arthroscopic osteocapsular arthroplasty, 893
Arthroscopy
of carpal instability, 432
carpometacarpal, for thumb CMC osteoarthritis, 362, 364
of distal radioulnar joint, 487
distraction, for stiff elbow, 856
of elbow, 885-904
advanced procedures of, 903
anesthesia and positioning in, 886, 888*f*
pertinent anatomy and portals in, 886-891, 889*f*
complications of, 903
contracture release in, 849
contributions to, 892*t*
for epicondylitis, 868
historical review of, 891
instrumentation in, 891, 891*f*
for lateral epicondylitis, 897-899, 898*f*
pertinent anatomy in, 886-891, 889*f*
portals in, 886-891, 889*f*
preoperative evaluation in, 885-886
diagnostic imaging in, 886, 887*f*-888*f*
physical examination in, 885
types of operations in, 892-903
Arthroscopy *(Continued)*
for lunotriquetral dissociation, 454
for scapholunate dissociation, 449
of wrist, 653-696
anatomy in, 658-660, 658*f*-661*f*
for arthritis, 689-691
for carpal instability, 661-665
complications of, 694
DRUJ, 660-661
dry, 658
ganglionectomy and, 688-689
general setup for, 653, 654*f*
for interosseous ligament injuries, 661, 661*t*, 662*f*-663*f*
for Kienböck's disease, 691-692, 691*t*, 692*f*
portal placement in, 653-656, 653.*e*1*t*
1-2, 654
3-4, 653-654, 654*f*-656*f*, 653.*e*1*t*
4-5, 653-654, 653.*e*1*t*
6-R and 6-U, 654, 654*f*, 653.*e*1*t*
accessory thumb carpometacarpal, 657-658
distal radioulnar, 657-658, 653.*e*1*t*
midcarpal, 656-657, 653.*e*1*t*
radiocarpal, 653-656, 654*f*-656*f*
scaphotrapeziotrapezoidal, 657
trapeziometacarpal, 657, 658*f*
volar, 655-656, 653.*e*1*t*
small joint, 694.*e*1
for traumatic injuries, 677-687, 677*f*
Class IA, 677, 677*f*
Class IB, 678, 678*f*-679*f*
Class IC, 682-683, 683*f*-684*f*
Class ID, 683, 684*f*
without avulsion, 683-685, 685*f*-686*f*
Arthrosis, after ulnar fractures, 784
Articular bone loss, associated with humeral fractures, 726, 726.*e*1*b*, 726.*e*1*f*-726.*e*6*f*, 726.*e*4*b*
Articular fracture(s)
of distal humerus
classification of, 704-705, 704*f*-705*f*
multiplanar involvement of, 722
variant, 725
of distal radius, management of, 568-573
type III-compression fractures, 571-572
type II-shear fractures, 568-571, 569*f*, 568.*e*14*b*, 568.*e*14*f*-568.*e*19*f*, 568.*e*17*b*
type IV-radiocarpal fracture-dislocation, 572-573, 573*f*, 573.*e*1*f*-573.*e*3*f*, 573.*e*2*b*
type V-combined/complex injury, 573, 574*f*, 573.*e*4*b*, 573.*e*4*f*-573.*e*7*f*
elbow arthroscopy for, 899
of phalanges, 249-251
at base, 249-251, 251*f*-253*f*
in children, 1436-1437
Articular fracture(s) *(Continued)*
preferred method of treatment for, 1437
at condyle, 249, 250*f*-251*f*
at head, 249
in children, 1431
preferred method of treatment for, 1431, 1432*f*
preferred method of treatment of, 251-255, 254*f*-256*f*
at shaft, 251
of radial head, management of, 749, 750*f*-751*f*
Articular loss
complete, 726.*e*4*b*, 726.*e*4*f*-726.*e*6*f*
partial, 726.*e*1*b*, 726.*e*1*f*-726.*e*3*f*
Articular malunion
after metacarpal fractures, 247
after phalangeal fractures, 267
Articular osteotomies, for radial fracture, 580-581, 582*f*, 581.*e*1*b*, 581.*e*1*f*-581.*e*6*f*
Articular surface, of distal humerus, classification of, 703-705
ASMI technique, 837
Aspergillosis, 84-85
Aspirin
after congenital pseudoarthrosis of ulna surgery, 1357
after free flap transfer, 1582
after toe transfer, 1669
Atasoy-Kleinert volar V-Y flap, in reconstruction of amputated fingertip, 1712-1713, 1713*f*
Athletes, scaphoid fractures in, management of, 603
Atypical antidepressants, for complex regional pain syndrome, 1812*t*
Autograft(s). *see also* Allograft(s); Xenograft
for forearm fracture nonunion, 800
hemihamate, for proximal interphalangeal joint fracture-dislocation, 284
outcomes of, 293
postoperative protocol for, 293
preferred technique for, 291-293, 291*f*-294*f*, 293*b*
Autologous blood, injection of, for epicondylitis, 865
Autonomic nervous system, in complex regional pain syndrome
dysfunction of, 1802-1803
evaluation of, 1807
Avanta SR TMC prosthesis, 361-362
Avascular necrosis
after radial head fractures, 761, 761*f*
of capitate, 649
vascularized bone grafting for, 1613
Avulsion fracture(s)
of metacarpal bases, 244
of radius, 527

Avulsion injury(ies). *see also* Mangling injuries
of brachial plexus, free muscle transfer for, 1180-1184
complications of, 1184
donor muscle selection in, 1181-1182
operative technique of, 1181-1183, 1181*f*-1182*f*, 1184*b*
outcome of, 1184, 1184*f*
postoperative protocol for, 1183
subsequent surgery for, 1183-1184
of nail bed, 321, 321*f*
of triceps, 878-881, 879*f*, 881*b*
preferred method of treatment of, 880-881, 880*f*-881*f*
Axial fracture-dislocations, in complex carpal instability, 473-475, 474*f*-475*f*
Axial instability, after radial head fractures, 764-766, 765*f*-766*f*
Axial-pattern flap(s), 1539-1540, 1540*f*, 1574. *see also* Skin flap(s)
distant, 1564-1568
groin, 1564-1568, 1564*f*, 1566*f*-1567*f*, 1568*b*
for mangling injuries, 1511, 1511*f*
regional, 1552-1554
cutaneous, 1554
fasciocutaneous, 1555, 1555*f*. *see also* Fasciocutaneous flap(s)
fillet, 1552-1554, 1554*f*
latissimus dorsi, 1561-1562, 1562*f*, 1563*b*
musculocutaneous, 1561-1562
neurovascular island, 1552-1554, 1553*f*
radial artery forearm, 1555-1558, 1556*f*-1559*f*, 1559*b*
reversed posterior interosseous artery, 1558-1561, 1560*f*
ulnar artery forearm, 1558
transposition, 1543-1545
digital artery island, 1546-1547, 1548*f*
flag, 1545, 1545*f*
kite flap (first dorsal metacarpal artery flap), 1545-1546, 1546*f*
second dorsal metacarpal artery flap, 1546, 1547*f*
Axilla, contractures of, postburn, 1943-1944
Axillary block, 8, 8*f*
Axonal transport, 981
Axonotmesis, 1148, 1010.*e*1-1010.*e*2, 1010.*e*2*t*

B

Bacillary angiomatosis, AIDS and, 120-121, 120*f*
Bacillus anthracis, 56, 68-69. *see also* Anthrax
Bacteria
in Hansen disease, 103-104
in wound, determination of, 1530
Bacterial infections. *see also specific infection*
chronic, 67-77
actinobacillosis, 67-68
actinomycosis, 68
anthrax, 68-69, 69*f*
botryomycosis, 69-70
brucellosis, 70
eight-pack tissue culture for, 65*t*
etiology, diagnosis, and treatment of, 63*t*
mycetoma, 70-73, 71*f*, 72*b*
neutrophilic dermatoses, 75-77, 77*f*
pyoderma gangrenosum, 75-77, 76*f*
syphilis, 73-74, 73*f*
tularemia, 74
yaws, 74-75, 75*f*
of nails, 331, 331*f*
Ballistic injuries, associated with humeral fractures, 726
Ballottement test, 693
Barton fracture, 525*f*, 527. *see also* Radius, distal, fracture of
dorsal, management of, 568, 569*f*-570*f*
Basal cell carcinoma, 1973-1975, 1976*f*
classification of, 1974, 1974*t*, 1976*f*
of perionychium, 334
treatment of, 1974-1975, 1977*f*-1978*f*
Basal cell nevus syndrome. *see* Gorlin syndrome
Basal joint
of thumb
composite radial forearm flap for, 1697-1699, 1700*f*, 1701*b*, 1699.*e*1*f*
osteoplastic reconstruction for, 1696-1697, 1697.*e*1*f*
of thumb, amputation with preservation of, 1696-1699
pollicization for, index/long finger stump in, 1699-1703, 1702*f*-1704*f*, 1705*b*
Basilar styloid fracture, 559-561
Bayne classification, modified, of radial longitudinal deficiency, 1328, 1329*t*
BCC. *see* Basal cell carcinoma
Beals syndrome, arthrogryposis in, 1367*f* and camptodactyly, 1388
Bell classification, modified, of brachydactyly, 1239, 1241*t*
Below-elbow amputation, 1737. *see also* Amputation
Bending fractures, of radius, 527, 567-568, 568.*e*1*b*, 568.*e*1*f*-568.*e*13*f*, 568.*e*3*b*, 568.*e*7*b*, 568.*e*9*b*, 568.*e*11*b*
Benign juvenile melanoma, 1966
Bennett fracture, 272-273
operative management of, 274*b*
treatment of
complications of, 273
expected outcomes of, 273
preferred method of, 272, 272*f*-273*f*
Biceps
rupture of, 871-878, 878*b*
diagnosis of, 871-872, 872*f*
postoperative treatment protocol after, 877-878
treatment of, 872-873
for acute complete tears, 875-878
complications of, 874
expected outcomes of, 874
for partial tears, 874-875
pertinent anatomy of, 873-874, 873*f*-875*f*
preferred method of, 874-875
single-incision technique in, 875
two-incision repair of, 875-877, 876*f*-878*f*
transfer of, to triceps, in tetraplegic patient, 1127-1129, 1128*f*, 1129*b*
Bicolumnar fractures, of distal humerus, 702, 702*f*
in healthy bone, 721-724, 721*b*
Bier block, 10-11
Bilayer matrix wound dressing, 1711-1712, 1712*f*
Bilhaut-Cloquet procedure, for thumb duplication, 1307, 1307*f*, 1310-1313
Biobrane glove, for burns, 1932, 1932*f*
Biofeedback, for complex regional pain syndrome, 1817
Biologic severity, of Dupuytren disease, 132-133
Biology, Dupuytren surgery and, 138
Biomechanics
in humeral fracture fixation, 719-720
of injured hand, 1492-1495, 1493*f*
case study for, 1492.*e*1*b*, 1493.*e*2*f*, 1492.*e*1*f*, 1493.*e*1*f*, 1492.*e*2*f*, 1493.*e*1*b*
of radial head, 737-740, 739*f*-740*f*
of scaphoid fractures, 590-591
of shoulder, 1186
of thumb opposition, 1026
of wrist, 423-426, 423*f*, 425*f*-426*f*
Biopsy
in Hansen disease
nerve, 106, 108-109
skin, 108, 108*t*
for musculoskeletal tumors, 1990-1992
excisional, 1991-1992
incisional, 1991
needle, 1990-1991
open, 1991, 1991*f*, 1992*b*
of soft tissue sarcoma, 2015
Bioresorbable screw, for scaphoid fractures, 596
Bipolar latissimus dorsi transfer, for arthrogryposis, 1376-1378, 1378*b*
complications of, 1378
contraindications to, 1376
indications for, 1376
postoperative management and expectations after, 1378

Bipolar latissimus dorsi transfer, for arthrogryposis *(Continued)*
preferred method of, 1378
technique of, 1376-1378, 1377*f*
Bipolar transplantation
of latissimus dorsi muscle, 1198
of pectoralis major muscle, 1199-1201
Bisphosphonates, for complex regional pain syndrome, 1815, 1816*t*
Bites
animal, 46-48. *see also specific animal*
antibiotic recommendations for, 21*t*
human, 48-50, 49*f*-50*f*
Blastomycosis, 85
Bleeding, postoperative, after free flap transfer, 1582
Bleomycin, intralesional injection of, for warts, 122-123
Blisters, 1927
Blood, autologous, injection of, for epicondylitis, 865
Blood clotting, perioperative management of, 909
Blood supply
to hook of hamate, 632
of lunate, 638, 640*f*
to perionychium, 318, 319*f*
of radial head, 739
of scaphoid bone, 590, 590*f*
Blood vessels. *see also* Artery(ies)
repair of, in microvascular toe transfer, for hypoplastic digits, 1269
Blue nevus, 1966. *see also* Nevus (nevi)
Body-powered prostheses, 1740, 1740*f*-1741*f*, 1758, 1759*f*
Bone(s). *see also named bone, e.g.*, Humerus
defects of, free flaps for, 1609
exposed, fingertip amputation with, 1711-1717
growth stimulators of, 607
healthy, bicolumnar fractures in, 721-724, 721*b*
heterotopic, after radial head fractures, 764, 764*f*
preparation of, in toe transfer, 1644-1645, 1666
transverse removal of, in cleft hand, 1246
Bone cysts
aneurysmal, 2024-2025, 2024*f*-2025*f*
unicameral, 2024, 2024*f*
Bone graft(s)
for arthritis mutilans, 1900, 1900*f*
conventional, biology of, 1612
corticocancellous, in osteotomies, 577
for distal radius fractures, alternatives to, 546.*e6t*
iliac, 543-546
for Kienbock disease, 643
based on fourth and fifth extensor compartment arteries, 643-644, 643*f*-644*f*
Bone graft(s) *(Continued)*
based on second or third metacarpal, 644, 645*f*
technique for vascularized bundle implantation in, 644-646, 645*f*-646*f*
for mangling injuries, 1500, 1521, 1522*f*
for scaphoid nonunion
1,2 ICSRA in, 617-618, 617*f*-618*f*
Fernandez-Fisk wedge graft, 612-614, 613*f*
Green's modification of Russe technique in, 610-611, 610*f*
harvesting of, percutaneous, 615-616
hybrid Russe procedure in, 611-614, 611*f*-613*f*
Matti technique in, 610-611
Matti-Russe technique in, 610-611
nonvascularized, 610, 610*f*
outcomes of, 618
percutaneous, arthroscopic technique in, 615
postoperative care after, 616
radial, vascular anatomy of, 617
substitute, 615
vascularized, 616-617
from dorsal capsular pedicle, 619, 619.*e1b*, 619.*e1f*-619.*e3f*
from femoral condyle, 619, 620*f*
from iliac crest, 619
pedicled on volar carpal artery, 618-619, 619*f*
from thumb metacarpal, 619
vascularized, 1612-1642
advantages of, 1613
biologic failure of, 1613
biology of, 1612
for carpal defects, 1613-1614
complications of, 1615-1617
donor site in, 1614-1615
complications related to, 1628-1629
exposure and pedicle dissection, 1627
from femoral condyle, 1625-1627, 1626*f*
from fibula, 1613*f*, 1618*f*
following trauma, 1624
from humerus, 1634
from iliac crest, 1620-1621
indications for, 1613-1614
long bone reconstruction and, 1617-1624
manufactured, 1634-1635
medial femoral condyle corticoperiosteal flap harvest, 1627-1628
medial femoral condyle graft aftercare, 1628
medial femoral condyle osteochondral graft harvest, 1628
medial femoral condyle vascularized, 1628, 1628*f*
Bone graft(s) *(Continued)*
pedicle *versus* free flap, 1612
periosteal, 1624-1634
from pisiform, 1634
postoperative monitoring of, 1615
preoperative planning for, 1614-1615
recipient site in, 1614
results of, 1637-1639
from rib, 1634
from scapula, 1634
selection of, 1614-1615
Bone grafting, 792
for ulnar shaft fractures, 796
Bone loss
associated with humeral fractures, 726
segmental, vascularized bone grafting for, 1613
results of, 1621-1624
in thumb deformities, 1899, 1900*f*
Bone scan, 1615, 1615*f*
prior to free flap transfer, 1577
radioactive. *see* Scintigraphy
Bone tumors, 1987-2035
benign, 2020-2026
aneurysmal bone cyst as, 2024-2025, 2024*f*-2025*f*
chondromyxoid fibroma as, 2023
enchondroma as, 2020-2021, 2020*f*, 2021*b*
giant cell tumor as, 2025-2026, 2026*f*-2027*f*, 2027*b*
Maffucci syndrome as, 2021
multiple enchondromatosis as, 2021, 2022*f*
osteoblastoma as, 2023-2024
osteochondroma as, 2022
osteoid osteoma as, 2023, 2023*f*
periosteal chondroma as, 2021-2022, 2022*f*
unicameral bone cysts as, 2024, 2024*f*
malignant, 2026-2032
chondrosarcoma as, 2026-2027, 2028*f*
Ewing's sarcoma as, 2028-2031, 2030*f*
metastatic, 2031-2032, 2031*f*
osteogenic sarcoma as, 2027-2028, 2029*f*
Bone-ligament-bone grafts, scapholunate ligament replacement with, 442-443
Botryomycosis, 69-70
Botulinum toxin (Botox)
for lateral epicondylitis, 865
for shoulder weakness and deformity, in brachial plexus birth palsy, 1410
for spasticity, 1088
for vasospastic disorders, 2053
Boutonnière deformity, 169, 1931, 1940, 172.*e1b*, 172.*e1f*-172.*e2f*
acute, open, 170, 171*b*, 171*f*
preferred method of treatment of, 170-171

Boutonnière deformity *(Continued)*
chronic, closed, 171-172, 174*b*
Curtis staged reconstruction of, 172-174, 173*f*
surgical techniques to, 172-174
exercise program for, 170*f*
lateral band mobilization and relocation for, 172
pathomechanics of, 169*f*
in rheumatoid arthritis, of fingers, 1890-1894
stage I, 1891-1892
extensor tenotomy for, 1891-1892, 1891*f*
stage II, 1892-1893, 1892*f*
stage III, 1893-1894
joint fusion for, 1893-1894, 1893*f*
treatment options for, 1891*t*
tendon grafts for, 172
tenotomy for, 172
of thumb, 1894-1896, 1895*f*
operative treatment
indications for, 1894-1896, 1895*t*, 1896*f*
options of, 1895*t*
Bowen disease, 1972, 1973*f*
Bowing, traumatic, of forearm, 1460-1461, 1461*f*
operations for, 1464
Boxer's fracture, 233-236
closed reduction of, 233-234, 234*f*
open reduction of, 235
operative management of, 237*b*
preferred method of treatment of, 235-236, 235*f*-236*f*
Boyes' preoperative classification, in flexor tendon grafting, 202*t*
Boyes tendon transfer, for radial nerve palsy, 1070-1071, 1071*b*
postoperative management of, 1071
Brachial plexus, 6*f*
anatomy of, 1391, 1392*f*
surgical, 1146, 1147*f*
catheters, 3, 5
Brachial plexus block
axillary and, 8
interscalene and, 6
perivascular, in anticoagulation therapy, 2
supraclavicular and, 6-7
Brachial plexus injury, 1146-1207
after thoracic outlet syndrome surgery, 974-975
classification of, 1146-1148
electrodiagnostic evaluation of, 1153
gunshot causing, 1149
history of, 1150
imaging evaluation of, 1152-1153, 1152*f*
mechanisms of, 1148-1149
neuropathic pain management in, 1203
patterns of, 1149-1150
from penetrating trauma, 1149
Brachial plexus injury *(Continued)*
physical examination of, 1150-1152, 1151*f*-1152*f*
preoperative evaluation of, 1150-1153
pulmonary function tests in, 1153
surgery for
approaches to, 1155-1158, 1155*f*
infraclavicular exploration in, 1157-1158, 1157*f*
supraclavicular exploration in, 1156-1157, 1156*f*
choline acetyltransferase activity in, 1158-1159
considerations for, 1154-1158
contraindications to, 1153-1154
decisions and priorities of repair in, 1159-1160
elbow reconstruction in, 1192-1202
complications of, 1196
free muscle transfer in, 1202, 1202*f*, 1203*b*
latissimus dorsi transfer in, 1197-1198, 1199*f*, 1200*b*
outcomes of, 1196
pectoralis major muscle transfer in, 1198-1202, 1200*f*-1201*f*, 1201*b*
postoperative protocol for, 1196
preferred methods of, 1195-1202, 1195*f*, 1196*b*
triceps-to-biceps transfer in, 1196-1197, 1197*b*, 1197*f*
free muscle transfer in, 1178-1185
indications for, 1153
informed consent for, 1154
intraoperative assessment in, 1158-1159
nerve action potentials in, 1158, 1158*f*
nerve grafting in, 1160-1163, 1161*f*
nerve reimplantation in, 1185
nerve repair in, 1160
nerve transfer in, 1163-1177
neurolysis in, 1160
preparation and positioning for, 1154-1155
shoulder arthrodesis in, 1190-1192
preferred method of, 1192, 1194*b*, 1194*f*
shoulder reconstruction in, 1186
tendon transfer in, 1187
somatosensory and motor evoked potentials in, 1158
timing of, 1154
wrist arthrodesis in, 1202
traction causing, 1148-1149, 1148*f*
Brachial plexus palsy, pediatric, 1391-1424
diagnosis and differential diagnosis of, 1393
elbow in, 1417-1419, 1418*f*
forearm in, 1419, 1420*f*
hand in, 1419-1421
Brachial plexus palsy, pediatric *(Continued)*
natural history of, 1397
nerve surgery for, 1397-1407, 1401*b*
postoperative management for, 1407, 1408*t*
preferred treatment in, 1406-1407
results of, 1399
technique of, 1400-1404
nerve grafting in, 1397, 1398*f*, 1400-1404, 1401*f*-1404*f*
nerve transfers in, 1404-1406, 1405*f*-1407*f*
timing of, 1398
pertinent anatomy in, 1391-1392, 1392*f*
preoperative evaluation of, 1392-1396, 1393*f*, 1394*t*, 1396*b*
secondary musculoskeletal problems in, 1408-1417, 1409*f*
shoulder weakness and deformity in
historical review of, 1411-1412, 1412*b*
operations for, 1412-1416, 1413*f*-1416*f*
expected outcome of, 1417*b*
postoperative management of, 1416-1417
preferred treatment of, 1416, 1417*f*
preoperative evaluation of, 1409-1411, 1410*f*-1412*f*
wrist in, 1419-1421
Brachioradialis, transfer of
to extensor carpi radialis brevis, in cerebral palsy, 1101, 1101*f*
to extensor pollicis brevis, for thumb-in-palm deformity, 1110-1111, 1112*b*, 1112*f*
to flexor pollicis longus, in median nerve palsy, 1043, 1044*f*
in tetraplegic patient
to flexor pollicis longus, 1141
to flexor pollicis longus, in House's one-stage key pinch reconstruction, 1131, 1132*b*, 1134-1135
Brachioradialis muscle flap, for mangling injuries, 1515, 1519*f*
Brachioradialis-splitting approach, to radial tunnel syndrome, transmuscular, 951, 951*f*
Brachybasophalangy, 1238-1239
Brachydactyly, 1238-1243, 1244*b*
Bell classification of, modified, 1239, 1241*t*
clinical features of, 1241, 1242*f*
epidemiologic findings in, 1239
management of, 1241-1243, 1242*f*-1243*f*
pathologic findings in, 1239-1240, 1240*f*
preferred method of treatment for, 1243
syndromes associated with, 1240*t*

Brachymesophalangy, 1238-1239
Brachymetacarpia, 1238-1239, 1241-1242
Brachytelephalangy, 1238-1239
Brachytherapy, 2016
Brand tendon transfer, for radial nerve palsy, 1071, 1071*b*, 1071*f*
Braun prosthesis, 361-362
Bretylium, for complex regional pain syndrome, 1815*t*, 1816
Brown recluse spider venom, 1788
Brucellosis, 70
Brunelli flap, for soft tissue defects of thumb, 1681*f*
Brunelli ligament reconstruction technique, for scapholunate dissociation, 443, 444*b*, 444*f*-446*f*
Bryan-Morrey "triceps-sparing" approach, to distal humeral fractures, 713-714, 714*f*
Buck-Gramcko technique, for short metacarpal lengthening, 1242-1243, 1243*f*
Bundle sutures, completion of, 994*f*
Bunnell intrinsic tightness test, 339, 339*f*
Bunnell repair, of extensor tendon laceration, 158, 159*f*
Bunnell tendon-to-bone pull-out technique, modified, 206, 207*f*
Bunnell's opponensplasty, in median nerve palsy, 1030*f*, 1031
Bunnell's "tendon T" operation, in restoration of metacarpal arch, 1059
Buoy flap, in monitoring of bone grafts, 1615
Bupivacaine, characteristics of, 4*t*
Burns, 1926-1957, 1954*b*
  anatomy in, 1926
  chemical, 1948-1951
    agents and tissue damage by, 1952*t*
    management of, 1949-1951, 1950*f*-1951*f*
  classification of, 1928-1929, 1928*b*, 1929*f*
  complications of, 1935
    early hypergranulation as, 1935
    graft loss as, 1935
  deformities after, 1935-1944
    amputation, 1942-1943
    axillary contractures, 1943-1944, 1944*f*
    boutonnière, 1940
    claw, 1937-1938, 1939*f*
    contractures of the dorsum of the hand, 1940-1941, 1942*f*
    contractures of the thumb, 1938-1939, 1941*f*
    digital flexion contracture, 1939-1940
    elbow contractures, 1943, 1943*f*
    nail bed, 1937, 1939*f*
    prevention of, 1936
Burns *(Continued)*
    treatment of, 1936-1944, 1937*f*-1938*f*
    volume deficiencies and contour irregularities in, 1941-1942, 1942*f*
    web space syndactyly and interdigital contractures, 1938, 1940*f*
  depth of, determination of, 1929
  electrical, 1945-1948
    clinical manifestations of, 1946-1947, 1947*f*
    complications in, 1948
    epidemiologic findings in, 1945
    mechanism and classification of, 1946
    pathophysiologic conditions in, and properties of electricity, 1945-1946
    rehabilitation in, 1948
    treatment of, 1947-1948
      general management in, 1947
      surgical management in, 1947-1948, 1949*f*
  epidemiologic findings in, 1926
  frostbite, 1951-1953
    diagnosis of, 1952
    pathophysiologic findings in, 1952
    treatment of, 1952-1953, 1953*b*
  management of
    anterolateral thigh flaps in, 1945
    control of edema in, 1929
    débridement in, 1933
    escharotomy in, 1929-1930, 1930*f*
    excision and grafting in, 1932-1935, 1933*f*-1934*f*
    flap coverage in, 1934, 1935*f*
    forearm flaps in, 1945
    free serratus fascial flap in, 1945
    groin flap in, 1944
    initial evaluation in, 1927-1931
    lateral arm flap in, 1945
    local wound care in, 1931-1932, 1932*f*
    random abdominal wall flap in, 1944
    splinting in, 1930-1931, 1931*f*
    tensor fasciae latae flap in, 1944-1945
    treatment goals in, 1927, 1928*f*
  pathophysiology of, 1926-1927, 1927*f*
  reconstructive tools for, 1944-1945
  rehabilitation after, 1953-1954, 1953*f*-1954*f*
Bursa, radial and ulnar, infections of, 32-34
Bursitis, tuberculous, 96
Buruli ulcer, 92-93, 93*f*

C

Cadaver triangular ligament, 156*f*
Calcific tendinitis, 57-58, 1905-1906, 1906*f*
Calcinosis, 58*f*, 1840
Calcitonin, for complex regional pain syndrome, 1815, 1816*t*
Calcium channel blockers (CCBs)
  for complex regional pain syndrome, 1814, 1815*t*
  for vasospasm, 2044, 2053
Camitz opponensplasty, in median nerve palsy, 1033-1034, 1034*f*-1035*f*
Camptodactyly release, for arthrogryposis, 1387-1390, 1389*b*
  complications of, 1390
  contraindications to, 1388
  indications of, 1387-1388, 1388*f*-1389*f*, 1388*t*
  postoperative management and expectations after, 1390
  preferred method of, 1389
  technique of, 1388-1389
Cancellous trabeculae, 739
Candidiasis, 85
Capillaroscopy, nailfold, for vascular disorders, 2039
Capillary leak, 1927
Capillary refill, postoperative, in free flap transfer, 1582
Capitate, 660*f*
  avascular necrosis of, 649
  fracture of, 629-631, 629*b*
    in children, 1447, 1447*f*
    incidence of, 625*t*
    mechanism of injury in, 630, 630*f*
    radiographic features of, 630, 631*f*
    treatment of, 630-631, 632*f*
Capitate-lunate instability pattern (CLIP) wrists, 461
Capitate-lunate-hamate-triquetrum fusion, 391-393
  alternative methods of fixation for, 393-394
  contraindications for, 392
  critical points on, 395*b*
  indications for, 391-392, 392*f*
  postoperative management for, 393
  preferred method of, 392-393, 393*f*-394*f*
Capitellum, fracture of, 737, 738*f*. *see also* Humerus, distal, fractures of; Radius, head of, fracture of
  arthroscopic fixation of, 899, 900*f*
  classification of, 703, 703*f*-704*f*
  complex, 725-726, 725.*e*3*b*, 725.*e*3*f*-725.*e*4*f*
  simple, 725
  variant, 725
Capitolunate arthrodesis, with scaphoid excision, 394-395, 395*f*
Capreomycin, dosage of, 101*t*
Capsular contracture, of stiff joint, 339-340
Capsular shrinkage
  arthroscopic, technique for, 693
  for midcarpal instability, 460

Capsulectomy, of distal radioulnar joint contracture
dorsal, 510
outcomes of, 511
volar, 510-511
Capsulodesis
dorsal, in scapholunate dissociation, 442, 442*f*
palmar, of metacarpophalangeal joint, in ulnar nerve palsy, 1049-1050, 1049*f*, 1050*b*
Capsuloligamentous components, of radiocapitellar joint, 813
Capsulotomy
for metacarpophalangeal joint contractures, 341.*e*1
in secondary reconstruction after mangling injury, 1523-1524
Carbamazepine, for complex regional pain syndrome, 1813*t*
Carcinoma, 1959
Cardinal signs, in early diagnosis, for Hansen disease, 105-107
Carpal bone(s). *see also named bone, e.g.*, Scaphoid; Wrist
alignment of, measurement of, in wrist instability, 430, 430*f*-431*f*
distal row of
kinematics of, 423, 423*f*
ligaments of, 422-423
stabilization of, 425
fracture of, 588-652
in children, 1448*b*
incidence of, 625*t*
in mangling injuries, treatment of, 1500
other than scaphoid, 624-649
growth in, 1444
isolated, dislocation of, in complex carpal instability, 475-476, 475*f*
ossification centers of, 1444
proximal row of
kinematics of, 423
stabilization of, 425
stability of, soft tissue structures in, 1444-1445
Carpal collapse
lunotriquetral dissociation with, 451
chronic, treatment of, 456
lunotriquetral dissociation without
acute, treatment of, 455
chronic, treatment of, 455-456, 455*f*-456*f*
Carpal height ratio, measurement of, in wrist instability, 430, 431*f*
Carpal instability, 418, 433-463
analysis of, 433, 433*t*, 434*f*
chart of, 661*t*
chronicity of, 433
classification of, 434
complex, 465
axial fracture-dislocations in, 473-475, 474*f*-475*f*
Carpal instability *(Continued)*
isolated carpal bone dislocations in, 475-476, 475*f*
perilunate dislocations in
dorsal
greater-arc injuries and, 470
lesser-arc injuries and, 465-470, 465*f*-466*f*
treatment of, 465-470
palmar, 472, 474*f*
perilunate fracture-dislocations in, dorsal, 470-472
transscaphoid, 470-471
transscaphoid-transcapitate, 471-472, 472*f*
transtriquetrum, 472, 473*f*
treatment of, 472, 473*f*
radiocarpal dislocations in, 473
as contraindication for capsular release, 691
definition of, 433
diagnosis of, 428-432
arthrography in, 432
arthroscopy in, 432
cineradiography in, 432
clinical examination in, 428
computed tomography scans in, 430-431, 431*f*
magnetic resonance imaging in, 432
measurement of bone alignment in, 430, 430*f*-431*f*
radiological examination in, 428-430
additional views, 429-430, 429*f*
distraction views, 431
routine views, 428-429, 428*f*-429*f*
stress views, 431, 432*f*
ultrasonography in, 432
direction of, 433
dissociative, 434-457
lunotriquetral, 450-457
scapholunate, 434-450. *see also* Scapholunate dissociation
etiology of, 433
location of, 433
mechanics of, 661
nondissociative, 457-463, 458*f*
midcarpal, 459
radiocarpal, 458-459, 458*f*
severity of, 433
wrist arthroscopy for, 661-665
Carpal kinematics, 423-424, 423*f*, 425*f*
Carpal kinetics, 424-426
Carpal ligament(s)
injury to
distal radial fracture associated with, 575
pathomechanics of, 426-428, 427*f*
intrinsic, 421*f*-422*f*, 422-423
Carpal malalignment, defined, 529, 530*f*
Carpal misalignments, 463-464
adaptive, 463
secondary to deformity of distal radius, 463-464
Carpal misalignments *(Continued)*
secondary to deformity of lunate, 464
secondary to deformity of scaphoid, 464
secondary to STT arthritis, 464
Carpal stabilization
ligaments in, 425, 425*f*
muscles in, 425-426, 426*f*
Carpal tunnel, ganglion in, 2009
Carpal tunnel decompression, expected outcome after, 935
Carpal tunnel release, open, 934-935, 934*f*, 935*b*
Carpal tunnel syndrome, 930-935
anatomy of, 930-932, 930*f*-932*f*
management of
nonoperative, 932-933
surgical, revision of, preferred method of, 1822-1823, 1823*f*
provocative tests for, 926*t*
recurrent, 954-955
revision surgery for, 954-955
treatment of, operative, 933-935
Agee single-portal endoscopic technique in, 933-934
Chow two-portal endoscopic technique in, 933
postoperative care after, 935
preferred method of, 934-935, 934*f*, 935*b*
Carpal wedge osteotomy, for arthrogryposis, 1380-1382, 1382*b*
complications of, 1382
contraindications to, 1380-1381
indications for, 1380, 1381*f*
postoperative management and expectations after, 1382
preferred method of, 1382
preoperative planning in, 1381
technique of, 1381, 1382*f*
Carpectomy, proximal row
arthroscopic, 690
for scaphoid nonunion advanced collapse, 623
for scapholunate dissociation, 450
Carpometacarpal boss, 2007
clinical characteristics of, 2007, 2007*f*
complications in, 2007
operative technique for, 2007, 2007*f*-2008*f*
postoperative care for, 2007
Carpometacarpal (CMC) joint(s)
fusion of, in tetraplegic patient, House's one-stage key pinch reconstruction and, 1134, 1135*f*
injuries of, 175
of thumb, 312-315
dislocations of, 312-315
anatomy in, 312, 312*f*
historical review of, 312
postoperative management and expectations in, 314-315

Carpometacarpal (CMC) joint(s) *(Continued)*
preoperative evaluation of, 312-313, 313*f*
treatment of, 313-314
preferred method of, 313, 314*b*, 314*f*
osteoarthritis of, 359-369
anatomy and biomechanics of, 359-360, 360*f*
complications of, 368-369, 369*f*
critical points on, 366*b*
diagnostic imaging of, 359, 359*f*
epidemiologic findings on, 359
evaluation of, 359
expected outcomes on, 366-368, 367*t*
indications and contraindications for, 360-362
operative techniques on, 362-364
physical examination for, 359
postoperative management and expectations for, 366-369
preferred method of treatment for, 364-365, 365*f*-366*f*
treatment for, 360-364
nonoperative, 360-361
other procedures and devices for, 362
Carpometacarpal fracture-dislocations, 244-246
multiple, 245
preferred method of treatment of, 245-246, 245*f*-246*f*
of ring finger, 244
of small finger, 244-245
Carpus. *see also named bone, e.g.*, Scaphoid; Wrist
amputation through, 1737
indications for vascularized bone grafting in, 1624-1625
Cast(s). *see also* Immobilization
postoperative, in tetraplegic patient, 1138-1139
for proximal interphalangeal joint contractures, 340.*e*2
Cast index, 1449, 1453*f*
Casting, for distal radius fractures, 516.*e*1
Cat bites, infection from, 46-47
Catch-up clunk phenomenon, in midcarpal instability, 459
Caterpillars, venomous, 1788, 1789*f*
Catfish, marine and freshwater, venomous, 1792-1793, 1793*f*, 1793.*e*1*f*
Causalgia, 1797
nerve injury and, 1010.*e*3
CBSQ. *see* Cervical Brachial Symptom Questionnaire ("CBSQ")
CCH success, 133
CD4+ T-cell, in acquired immunodeficiency syndrome, 119.*e*1, 119.*e*1*t*
Cellulitis, 17
antibiotic recommendations for, 21*t*
Cement burns, treatment of, 1951
Central hand deficiencies. *see* Cleft hand
Central nervous system, in complex regional pain syndrome, ablative techniques and, 1817
Central slip, 338.*e*5
anatomic integrity of, 155-156, 157*f*
Central slip tenotomy, for swan neck deformity, 1115, 1116*b*, 1116*f*
Centralization
of extensor tendons, 413-414
in management of radial longitudinal deficiency, 1329-1331, 1332*f*
Cerclage wiring
for metacarpal shaft fractures, 239, 237.*e*1*t*
for proximal interphalangeal joint fracture-dislocation, 283-284, 284*f*
postoperative protocol for, 291
preferred method for, 291-293, 291*f*
Cerebral palsy, 1080
Cervical Brachial Symptom Questionnaire ("CBSQ"), 965*f*-967*f*
Cervical incision, transverse, in brachial plexus surgery, 1155-1156, 1155*f*
Cervical nerve(s)
brachial plexus formed from, 1146, 1391, 1392*f*. *see also* Brachial plexus *entries*
C5-C6 injury of, 1149
author's preferred treatment of, 1159
decisions and priorities of repair for, 1159
C5-C7 injury of, 1149
decisions and priorities of repair for, 1159
C5-T1 (pan-plexus) injury of, 1150
author's preferred treatment of, 1160
decisions and priorities of repair for, 1159-1160
C8-T1 injury of, 1149-1150
decisions and priorities of repair for, 1159
Cervical nerve root, impingement of, Spurling test for, 927
Cervical nerve transfer, C7, for brachial plexus injury, 1173-1176, 1175*f*-1176*f*
author's preferred technique for, 1176
complications of, 1176
outcomes of, 1176
postoperative care after, 1176
surgical anatomy in, 1175
Cervical plexus nerves, transfer of, for brachial plexus injury, 1177
Cervical ribs
anatomic variants of, 961*f*
in thoracic outlet syndrome, 963
Cervical spine
involvement of, in rheumatoid arthritis, 1833
in thoracic outlet syndrome, 960*f*
Chang Gung Memorial Hospital, toe transfers at, from 1985-2012, 1672*t*
Charcot-Marie-Tooth disease, 923
CHARGE syndrome, radial deficiency and, 1290*f*, 1290*t*
Chauffeur's fracture, 525*f*, 527
management of, 569-570, 570*f*-571*f*
Cheiralgia paresthetica, 947-948
Chemical burns, 1948-1951. *see also* Burns
agents and tissue damage by, 1952*t*
management of, 1949-1951, 1950*f*-1951*f*
Chemical sympathectomy, for complex regional pain syndrome, 1819-1820
Chemotherapy, extravasation, skin loss due to, 1570
Chevron-type slot graft, for short metacarpal lengthening, 1242-1243, 1242*f*
Children
brachial plexus palsy in, 1391-1424. *see also* Brachial plexus palsy, pediatric
flexor tendon reconstruction in, 223-224, 224*b*
indications of, 223
preferred technique of, 224
hand, wrist, and forearm fractures in, 1425-1475. *see also* Fracture(s), pediatric; Fracture(s), *under specific bone*
regional anesthesia in, 2
scaphoid fracture in, 607-608
trigger digits in, 1916
tuberculous osteomyelitis in, 98
Chloroprocaine, characteristics of, 4*t*
Choke vessels, 1540
Choline acetyltransferase activity, in brachial plexus surgery, 1158-1159
Chondral defects, wrist arthritis and, 689, 690*f*
Chondrodesis, for thumb-in-palm deformity, 1112
Chondrodysplasia
Grebe, 1214, 1215*f*
Hunter-Thompson, 1214
Chondroectodermal dysplasia, postaxial polydactyly in, 1232, 1233*f*
Chondroma, periosteal, 2021-2022, 2022*f*
Chondromyxoid fibroma, 2023
Chondrosarcoma, 2026-2027, 2028*f*
Chow two-portal endoscopic technique, for carpal tunnel syndrome, 933
Chromosome disorders, radial longitudinal deficiency associated with, 1329*t*
Chronic exertional compartment syndrome, 1767-1768
Chronic nerve compression, pathophysiology of, 921-924, 922*f*
Chronic regional pain syndrome, after distal radial fracture, 576

Cineradiography
of carpal instability, 432
of lunotriquetral dissociation, 454, 454*f*
of midcarpal instability, 460
Ciprofloxacin, for anthrax, 69
Circular plate fixation, for scaphotrapeziotrapezoid fusion, 390
Clasped thumb, 1324-1325, 1324*f*, 1325*b*
clinical features of, 1324
treatment of, 1324-1325, 1325*f*
Clavicle
bone loss or nonunion of, vascularized grafting for, 1636
as recipient site, in bone grafting, 1636
Claw-hand deformity
postburn, 1930, 1937-1938, 1939*f*
in ulnar nerve palsy, 1047-1056. *see also* Ulnar nerve palsy
postoperative management of, 1056
surgical correction for, 1048-1056
Burkhalter and strait in, 1054-1055
dynamic tendon transfers in, 1051-1056
extensor carpi radialis longus transfer in
dorsal route of, 1054, 1054*f*
flexor route of, 1055, 1055*f*
extensor indicis proprius and extensor digiti minimi transfers in, 1053-1054
flexor and extensor muscle transfer in, 1054-1056
flexor carpi radialis transfer in, 1055-1056
Fowler's wrist tenodesis in, 1051, 1051*f*
palmar capsulodesis of MP joint (Zancolli) in, 1049-1050, 1049*f*, 1050*b*
palmaris longus four-tail transfer in, 1056
Parkes static tenodesis in, 1050-1051, 1050*f*
Riordan static tenodesis in, 1050
static techniques in, 1048-1051
Stiles-Bunnell procedure in, modified, 1051, 1052*f*
superficialis transfer in, 1051-1053
modifications of, 1051-1053
results of, 1053
Clear cell sarcoma, 2020
Cleft, closure of, first web space release and, 1246-1251, 1246*f*, 1249*f*-1251*f*, 1254*f*
Cleft hand, 1244-1255, 1244*f*, 1255*b*
characteristics of, 1245, 1245*t*
classification of, 1245, 1245*t*
clinical features of, 1245
etiologic findings in, 1244, 1245*t*
surgical treatment for, 1245-1255
in absent thumb deformity, 1251, 1254*f*
Cleft hand *(Continued)*
in cleft deformity, 1246-1251
expected outcomes for, 1255
first web space release and cleft closure in, 1246-1251, 1246*f*, 1249*f*-1251*f*, 1254*f*
indications for surgery, 1245-1246
management of the feet, 1251-1255
Miura and Komada technique in, 1251, 1252*f*
Snow-Littler procedure in, 1248, 1248*f*
surgical management of the progressive deformity in, 1246, 1284*f*
syndactyly release in, 1245*f*, 1246
transverse bone removal in, 1246
in type IIB and III, 1251, 1254*f*
Ueba technique in, 1251, 1253*f*
Clenched fist injury, 48-49, 49*f*
Clinodactyly, 1270-1273, 1271*f*, 1273*b*
classification of, 1271*t*
epidemiologic findings in, 1270-1271, 1272*f*
expected outcomes, 1273
management of, 1272, 1273*f*-1274*f*
preferred technique of, 1272-1273
phalangeal anatomy in, 1271-1272
Clofazimine, for multibacillary Hansen disease, 109
Clonidine, for complex regional pain syndrome, 1814
Closed reduction
cast immobilization with
for lesser-arc injuries, 466-467, 467*f*
for perilunate fracture-dislocations, 470-471
with a cast or splint, of phalangeal shaft fractures, 256-257, 257*f*
of distal radial fracture, 530-531
technique for, 530-531, 531*f*-534*f*
of metacarpal neck fractures, 233-234, 234*f*
percutaneous pin fixation with
for lesser-arc injuries, 467-468, 467*f*
for perilunate fracture-dislocations, 471
percutaneous pinning and
of metacarpal shaft fractures, 237-238, 238*f*
of phalangeal shaft fractures, 257, 258*f*-259*f*
plaster immobilization and, of metacarpal shaft fractures, 237, 237*f*
Closed tendon sheath irrigation, for pyogenic flexor tenosynovitis, 30-31, 30*f*
Clostridial myonecrosis, 56
Cnidarians, venomous, 1791-1792, 1792*f*
Coccidioidomycosis, 85-86
Cold sensitivity, vasospasm and, 2052
Cold-stress testing, for vascular disorders, 2039
Collagenase clostridium histolyticum, enzymatic fasciotomy with, for Dupuytren disease, 140
Collar-button abscess, 37-38, 38*f*
case study, 37-38, 38.*e*1*b*, 38.*e*1*f*
treatment for, 38, 39*f*
preferred method of, 39
Collateral ligament(s). *see also* Radial collateral ligament; Ulnar collateral ligament
anatomy of, 338.*e*1, 338.*e*1*f*
injury to, grading of, 279
lateral (LCL), 830
anatomy of, 813, 832, 832*f*
diagnostic imaging of, 831, 831*f*
instability of
ligament reconstruction for
complications in, 835
contraindications to, 833
indications for, 832-833
outcomes in, 835
postoperative management and expectations of, 835
preoperative evaluation of, 830-831
technique in, 833-835, 834*f*
magnetic resonance image of, 831*f*
physical examination of, 830-831
ulnar, 832
medial (MCL), 830
anatomy of, 813, 836-837, 836*f*
anterior bundle of, 836, 839*f*
diagnostic imaging of, 835-836, 836*f*
instability of
ligament reconstruction for
complications in, 840
contraindications to, 837
indications for, 837
outcomes in, 840
postoperative management and expectations of, 839-840
preoperative evaluation of, 835-836
technique in, 837, 838*f*, 840*f*
magnetic resonance image of, 836*f*
physical examination of, 835
posterior bundle of, 836
transverse bundle of, 836
release of, in metacarpophalangeal joint contracture, 340
Colles' fracture, 524-527, 524*f*, 567
malunited, 579*f*
treatment of, 531*f*
Color, of flap, postoperative, 1582, 1582*f*
Column concept, of distal humeral fractures, 701-703
Columnar classification, of distal radial fracture, 524, 527*f*
"Come-along" flexion splint, for elbow contracture, 857, 858*f*

Comminuted fractures
of capitellum, 703, 704*f*
combined articular and supracondylar, 722, 722.*e1b*, 722.*e1f*-722.*e2f*
minimally, management of, 721-722, 721.*e1b*, 721.*e1f*-721.*e2f*
of radial head, management of, 749, 752*f*-753*f*, 755*f*
supracondylar involvement in, 722
Community-acquired infections (CA-MRSA), methicillin-resistant *S. aureus* (MRSA) and, 18
Compartment pressure, measurement of, 1767*t*
Compartment release, sixth, 511-512
Compartment syndrome, 1763-1772, 1772*b*
acute, 1763
diagnosis of, 1765-1768, 1765*f*, 1766*t*
etiologic findings and incidence of, 1764-1765, 1765*f*
events in recognition and understanding of, 1764*t*
exercise-induced, 1763
exertional, 1763
diagnosis of, 1767-1768
impending, 1763
injuries causing, 1766*b*
localized, 1767*f*
in mangling injuries, 1490
neonatal, 1763-1764, 1764*f*
pathophysiologic findings of, 1765, 1765*f*
pertinent anatomy of, 1768
postoperative, 1
snakebite-induced, preferred method of treatment of, 1791
treatment of, 1768-1772
outcomes and expectations after, 1771-1772
postoperative management and, 1771
preferred method of, 1769
types of, 1763-1764
Complete articular loss, 726.*e4b*, 726.*e4f*-726.*e6f*
Complex fracture, of distal radius, management of, 573, 574*f*, 573.*e4b*, 573.*e4f*-573.*e7f*
"Complex instability of the carpus" (CIC), 465
Complex lateral column fracture, 725.*e3b*, 725.*e3f*-725.*e4f*
Complex posterior olecranon fracture-dislocation, of elbow, 784.*e1b*, 784.*e2f*-784.*e3f*
Complex regional pain syndrome (CRPS), 1797-1827, 1829-1830
Budapest criteria in, 1797, 1799*b*, 1804*t*
clinical definitions of, 1797, 1798*f*, 1805*t*
demographics of, 1801-1802
diagnostic testing for, 1805-1807
Complex regional pain syndrome (CRPS) *(Continued)*
autonomic control in, 1807
endurance testing in, 1809-1810
magnetic resonance imaging in, 1805
pain threshold evaluation in, 1805
radiography in, 1805
scintigraphy in, 1806-1807, 1806*f*
sympathetic blockade in, 1808-1809
thermography in, 1809
historical review of, 1797-1798
mechanical nociceptive focus of, 1804-1805
neural dystrophic focus in, management of, 1820
neural injury of
diagnosis of, 1820-1821
preferred method of treatment of, 1821-1822
surgical management of, 1820-1821
painful median nerve and, management of patients with, 1822*b*
physical examination in, 1803-1804
physiology of, 1798-1801, 1800*f*
psychological factors and effects in, 1802
psychological problems mimicking, 1802
staging of, 1810
symptoms and signs of, 1802-1803, 1803*f*
synonyms for, 1798*b*
terms used in, 1799*t*
treatment of, 1810-1811
acupuncture in, 1817
adaptive modalities in, 1818
adrenergic compounds in, 1813-1814
amputation in, 1824
anticonvulsants in, 1813
antidepressants in, 1811-1812, 1812*t*
biofeedback in, 1817
bisphosphonates in, 1815
calcitonin in, 1815, 1816*t*
calcium channel blockers in, 1814, 1815*t*
chemical sympathectomy in, 1819-1820
CNS ablative techniques in, 1817
corticosteroids in, 1814-1815, 1815*t*
epidural agents in, 1816-1817
free radical scavengers in, 1816
hand therapy in, 1818
implantable devices in, 1817
ketamine in, 1815-1816
level of evidence for, 1817
membrane-stabilizing agents in, 1813
multidisciplinary approach to, 1811
multidisciplinary team approach to, 1818
neuromuscular blocking agents in, 1815
Complex regional pain syndrome (CRPS) *(Continued)*
parenteral medications in, 1815*t*, 1816
patient expectations in, 1818-1819
pharmacologic interventions, 1811
preferred method of, 1818
surgical outcomes and complications in, 1820
surgical sympathectomy in, 1820
types of, 1798*t*
Complex tissue loss, vascularized bone grafting for, 1613
Composite contracture, severe, treatment for, Dupuytren disease and, 143
Composite defects, free flaps for, 1609
Composite flaps, 1577. *see also* Free flap(s)
for mangling injuries, 1515-1519, 1520*f*
Composite rib-serratus anterior-latissimus dorsi osteomuscular flap, 1635*f*
Composite (tension band) wiring. *see also* Tension band wiring
for metacarpal shaft fractures, 239, 237.*e1t*
Compound muscle action potentials (CMAPs), 929
Compression fracture, of radius, 527
management of, 571-572
Compression neuropathy(ies), 921-958
evaluation of, 924-930, 925*f*-926*f*
cutaneous pressure thresholds in, 928
electrodiagnostic studies in, 928-930
electromyography in, 929
light moving touch in, 928
nerve conduction studies in, 929
provocation tests in, 924-927, 926*t*
sensory, 927-928
shoulder and scapular movement in, 927
two-point discrimination in, 928
vibration thresholds in, 928
in Hansen disease, 112, 112*f*
of median nerve, 930-938. *see also* Carpal tunnel syndrome
in elbow and forearm, 935-938, 936*f*, 939*b*
anatomy of, 936
operative technique of, 937-938
postoperative care after, 938
preferred method of, 937-938, 937*f*-938*f*
pathophysiology of, 921-924, 922*f*
double-crush mechanism in, 922-923
longitudinal nerve mobility in, 923
systemic conditions and personal factors in, 923
of radial nerve, 947-949. *see also* Interosseous nerve syndrome, posterior; Radial tunnel syndrome

Compression neuropathy(ies) *(Continued)*
proximal, 953
superficial, 947-949, 948*f*
surgery for previously failed procedures in, 953-956
of ulnar nerve, 938-947. *see also* Guyon canal compression
Compression plating, for radial shaft fractures, 791, 793-794, 795*f*
contouring of, 792
Computed tomographic (CT) myelography, of brachial plexus injury, 1152
Computed tomography (CT)
in brachial plexus birth palsy, 1395-1396, 1408, 1409*f*
of carpal instability, 430-431, 431*f*
of distal radial fracture, 522-523, 523*f*
of distal radioulnar joint, 486, 486*f*
of musculoskeletal tumors, 1990
prior to free flap transfer, 1577
in radioulnar synostosis, 803-804, 804*f*
of scaphoid fractures, 592
Computer adaptive test (CAT), 1395
Computer-aided design and computer-aided manufacture (CAD/CAM), 1761
Concertina deformity, 464
Conduction block, in responses to nerve injury, 983-984
prolonged, 1010.*e*1-1010.*e*2
Conduction studies, of compression neuropathies, 929
Conduit, synthetic, in neuroma, 1014-1019, 1015*b*
Condylar fractures, of phalanges, 249, 250*f*-251*f*
operative management of, 250*b*
Congenital absence, of digits, reconstructive, options for, 1650-1651, 1653*f*
Congenital pseudarthrosis, vascularized bone grafting for, 1624
Conjoined lateral band, 338.*e*3, 338.*e*5, 338.*e*5*f*
Connective tissue
diseases of, 1832-1903. *see also specific disease e.g.*, Rheumatoid arthritis
elements of, 981-982, 981*f*
features of, 982
Conservative wrist, in rheumatoid arthritis, 376, 378*f*
Constriction ring syndrome, 1255-1258, 1256*f*-1257*f*, 1258*b*. *see also* Amniotic disruption sequence
classification of, 1255, 1256*t*
clinical features of, 1255, 1257*f*
etiologic findings in, 1255
management of, 1255-1258
treatment of, 1256-1257
Contagious pustular dermatitis, 123-124, 124*f*
Continuous autonomic blockade, for complex regional pain syndrome, 1817, 1817*f*
Continuous passive motion (CPM), 853
device, for elbow contracture, 857-858
Contracture(s)
of axilla, postburn, 1943-1944, 1944*f*
congenital, 1365
digital flexion, postburn, 1939-1940
of distal radioulnar joint, 510-511
after radial fracture, 582-584
operative technique for, 510-511
outcomes of, 511
of dorsum of hand, postburn, 1940-1941, 1942*f*
Dupuytren. *see* Dupuytren contracture (DC)
of elbow. *see also* Elbow, stiff
in arthrogryposis, 1366
causes and prevention, 843-844, 844*f*
classification of, matching operative plan and, 848-849
duration of, 845
postburn, 1943, 1943*f*
release of
anesthesia for, 849
for arthrogryposis, 1372-1376, 1376*b*
complications of, 1376
contraindications for, 1373
indications for, 1372-1373, 1373*f*-1375*f*
postoperative management and expectations after, 1376
preferred method for, 1376
technique of, 1373-1376, 1375*f*
for fixed deformity, 1092-1093, 1092*b*, 1093*f*
indications for, 847
timing of, 845, 846*f*
extrinsic, assessment of, 339-340
of fingers, after separation of syndactyly, 1221, 1228-1230
first web space
postburn, 1938, 1940*f*
in scleroderma, 1841
flexion, after proximal interphalangeal joint arthroplasty, for fracture-dislocation, 290
intrinsic
after trauma, 343.*e*1-343.*e*2
with muscle fibrosis, 343.*e*2
assessment of, 339-340
of metacarpophalangeal joint
extension, release of, 340-341
late posttraumatic interosseous, 343.*e*1-343.*e*2, 343.*e*2*f*
nonoperative treatment of, 340.*e*1
operative treatment of, preferred method of, 1823-1824, 1824*f*
posttraumatic, 295-296, 296*b*, 296*f*
prevention and correction of, in tendon transfers, 1023
Contracture(s) *(Continued)*
of proximal interphalangeal joint
extension, release of, 341-343, 343*f*
flexion, release of, 341
expectations and outcomes in, 341.*e*2
preferred approach for, 341, 342*f*
late posttraumatic
interosseous, 343.*e*1-343.*e*2, 343.*e*2*f*
intrinsic, 343.*e*1
nonoperative treatment of, 340.*e*1-340.*e*2
release of, in secondary reconstruction, 1523-1524
of shoulder, in arthrogryposis, 1365
of thumb, postburn, 1938-1939, 1941*f*
Volkmann, 1772-1786, 1773*f*. *see also* Volkmann contracture
ischemic, 1764
Conventional graft, 1612
Cooper ligament, 836
Corals, venomous, 1791-1792, 1792*f*
Cord(s), of Dupuytren disease, 129-131
digital, 145
patterns of, 137-138, 137*f*
Cord traction, in procedure, for Dupuytren disease, 146-147
Core decompression, for Kienbock disease, 646
Core sutures, of zone 2 tendon lacerations, 188, 188*f*-189*f*
Coronal shift, 561-563
Coronoid fractures, arthroscopic fixation of, 899-901, 901*f*
Coronoid process
anatomy of, 770-771, 772*f*
fracture of
in complex traumatic elbow dislocation, 815, 816*f*
preferred technique of, 820-822, 821*b*, 822*f*
treatment of, in acute injury, 819-820
treatment of, 780
preferred method of, 782
Corset suture, 158-159
Cortical reorganization, 143
Corticoperiosteal flap, vascularized, in grafting from femur, 1625*f*
Corticosteroids
for complex regional pain syndrome, 1814-1815, 1815*t*
for epicondylitis, 865
for trigger finger, 1908
technique of injection of, 1909-1910, 1917
Cortisone, for complex regional pain syndrome, 1815*t*
Costoclavicular triangle, in thoracic outlet syndrome, 962*f*, 964
Cotton-Loder position, for distal radius fractures, 516.*e*1

Crepitus, in mangling injuries, 1490
CREST acronym, 1839
Cronin's technique, of digital separation, in syndactyly, 1220-1221, 1223*f*, 1225*f*
Cross-arm flap(s), for first web space coverage, 1695-1696, 1695*f*
Cross-finger flap(s), 1550-1552, 1551*f*. *see also* Skin flap(s)
  pedicle, in reconstruction of amputated fingertip, 1714-1716, 1715*f*
  reversed, 1552
  for soft tissue defects of thumb
    dual innervated, 1684, 1685*f*, 1684.*e2f*
    innervated, 1681-1684, 1681*b*
    radial-innervated, 1682-1684, 1683*f*, 1684*b*, 1684.*e1f*
  to thumb, 1680-1681, 1682*f*, 1681.*e1f*
CRPS. *see* Complex regional pain syndrome (CRPS)
Crush injury, 1763
Crush syndrome, 1763
Cryosurgery, 1960-1961, 1961*f*
  for aneurysmal bone cyst, 2025
Cryotherapy, for warts, 122
Cryptococcosis, 86
Crystalline tendinopathy, 1905-1907
  in amyloid deposition, 1906-1907, 1906*f*
  in calcific tendinitis, 1905-1906, 1906*f*
  in gout, 1905, 1905*f*
  in hydroxyapatite deposition, 1906
  in ochronosis, 1907
  in pseudogout, 1906
Cubital tunnel, anatomy of, 941-942, 941*f*
Cubital tunnel syndrome, 940-947
  clinical diagnosis of, 941
  nonoperative management of, 942, 942*f*
  operative treatment of, 942-947
    intramuscular transposition in, 945
    medial epicondylectomy in, 943-944, 943*f*-944*f*
    postoperative care after, 947
    preferred method of, 945-947, 946*f*
    in situ decompression in, 943
    subcutaneous anterior transposition in, 944, 944*f*-945*f*
    submuscular transposition in, 945, 945*f*
  provocative tests for, 926*t*
  recurrent, 955-956
    revision surgery for, 955-956
  surgery of, 948*b*
Culture, of infections, 65, 65*t*
Curettage, 1960, 1961*f*
Curtis staged reconstruction, for boutonnière deformity, 172-174, 173*f*, 174*b*
Curved longitudinal incision, for web space abscess, 38, 39*f*
Curvilinear incision
  for derotational osteotomy, 1415, 1415*f*
  in modified Henry approach, to radial tunnel syndrome, 952
Cutaneous flaps, 1575-1576, 1575*f*. *see also* Skin flap(s)
Cutaneous horns, 1970, 1971*f*
Cutaneous nerve(s)
  grafting of, in brachial plexus reconstruction, 1162
  lateral, grafting of, 997
  medial, grafting of, 997, 997*f*
Cutaneous nerve block, for skin grafting, in outpatient surgery, 1538
Cutaneous nerve dysesthesias, in thoracic outlet syndrome, 975
Cutaneous neuroma, after amputation, 1011*f*, 1010.*e5*
Cutaneous pressure thresholds, in compression neuropathies, 928
Cycloserine, dosage of, 101*t*
Cyst(s)
  bone of. *see* Bone cysts
  epidermal inclusion, 1966-1968, 1969*f*. *see also* Epidermal inclusion cysts
  ganglion, 1997-1998. *see also* Ganglion(s)
  mucous. *see* Mucous cyst
  nail, 328, 328*f*
  phaeomycotic, 84
Cystic basal cell carcinoma, 1974
Cysticercosis, 118

D

Dactylitis, tuberculous, in children, 98
DANE-TJ technique, 837
Dapsone
  for actinomycetoma, 72-73
  for Hansen disease, 103, 109
  for spider bites, 1789
Darrach procedure, 1838
  for radioulnar joint arthritis, 505-506, 506*f*
  for radioulnar joint disability, 582
Dart-thrower's motion, 424
DASH. *see* Disabilities of the Arm, Shoulder, and Hand (DASH)
de la Caffinière prosthesis, 361-362
de Quervain disease, 948, 1916-1919, 1917*f*, 1918*b*, 1919*f*
  treatment of, 1916-1919
    complications of, 1919
    nonoperative, 1916-1917
    preferred method of, 1918-1919
    surgical, 1917-1919
Débridement
  for AIDS, 119-120
  for aspergillosis, 84-85
  of burns, 1933
    electrical, 1948
  for cryptococcosis, 86
  for Hansen disease, 104
    in Lucio reaction, 112
  inadequate, free flap contraindicated in, 1574-1575
  of mangling injuries, 1496-1499, 1499*b*
Débridement *(Continued)*
    case study for, 1499.*e1b*, 1499.*e2f*-1499.*e3f*
    "second-look", 1524
  for mucormycosis, 87-88
  for mycobacterial infections, 91
  of necrotizing soft tissue infections, 55
  for nontuberculous mycobacteria, 103
  for osteoarthritis, 893-897, 896*b*
    indications and contraindications of, 893
    outcomes of, 896-897
    postoperative management of, 894-896
    preoperative planning of, 893
    technique of, 893-894, 895*f*-896*f*
  for osteomyelitis, 43, 46
  for sporotrichosis, 88
  of torn ligament edges, in scapholunate dissociation, 439-440
  for tuberculous arthritis, 96
  for tuberculous osteomyelitis, 100
  for warts, 122
  wound, for free flap transfer, 1578-1579, 1578*b*, 1579*f*
Decompression
  of radial nerve, 949, 949*f*
  in situ, for cubital tunnel syndrome, 943
Deep fibers, 134
Deep finger flexor tendons, in rheumatoid arthritis, rupture of, 1857
Deep head, of interosseous muscles, 338.*e3*, 338.*e5f*
Deep space infections, 34-40, 40*b*
  antibiotic recommendations for, 21*t*
  palmar, 34-36, 34*f*, 35*t*, 36*f*-37*f*
  subfascial, 36-40
Deep transverse intermetacarpal ligament (DTIL), 1723
Deformities, of the hand and fingers, 1217-1288
Dejerine-Klumpke palsy, 1149-1150
Delayed suture, of nerve injury, 994-996, 995*f*-996*f*
Delayed treatment
  clinical assessment of, 814
  imaging of, 814
Delayed union, secondary bone graft for, 1615-1616
Deltoid muscle, posterior, transfer of, to triceps, in tetraplegic patient, 1129, 1130*f*
Demineralized bone matrix (DBM) putty, for scaphoid nonunions, 670, 670*f*
Derby test, for lunotriquetral dissociation, 451
"Dermacarrier", 1534, 1534*f*
Dermadesis, for swan neck deformity, in rheumatoid arthritis, 1882
Dermal lesions, 1966-1968
Dermatitis, pustular, contagious, 123-124, 124*f*

Dermatofibroma, 1966, 1968*f*
Dermatofibrosarcoma protuberans, 1983, 1985*f*, 2018-2019, 2019*f*
Dermatomes, in skin grafting, 1532-1533
Dermatoses, neutrophilic, 75-77
  clinical findings on, 76-77
  diagnosis of, 77, 77*f*
  etiology and epidemiology of, 75-76
  treatment of, 77
Dermofasciectomy, for Dupuytren disease, 139*t*, 142-143, 143*f*
Derotational osteotomy. *see also* Osteotomy
  humeral, for shoulder weakness and deformity, in brachial plexus birth palsy, 1415, 1415*f*
  for proximal radioulnar synostosis, 1351-1352, 1352*f*-1353*f*
Desipramine, for complex regional pain syndrome, 1812*t*
Desmoplastic melanoma, 1980
Dexamethasone
  for de Quervain disease, 1917
  intravenous, for postoperative swelling, 857
Dextran
  after free flap transfer, 1582
  after toe transfer, 1669
Diabetic hand infections, 53-54
Diagnostic imaging, for musculoskeletal tumors, 1990
Diathesis factors, of Dupuytren disease, 132-133
Die-punch fracture, 524, 525*f*
Differential forearm lengthening, for hereditary multiple exostoses of forearm, 1360
Digit(s). *see also* Finger(s); Toe(s)
  absence of, treatment of, 1258
  dislocations and ligament injuries of, 278-317
  distraction of, in absent finger reconstruction, 1262
  Dupuytren disease in, 134-136, 135*f*
  function and mobility of, 338
  multiple amputated, replantation of, 1479
  reduction of, in management of macrodactyly, 1281-1282
  replantation of, 1477, 1484*b*
  separation and resurfacing of, in syndactyly, 1220-1221, 1223*f*-1226*f*
  spasticity in
    examination of, 1084-1085, 1085*f*
    flexor tendon tightness in, operative management of, 1102-1106, 1104*f*
    preferred method of, 1105-1106
  supernumerary, removal of, 1233-1234
  threatened at birth, treatment of, 1255-1256
  venous congestion of, 1482-1483
Digit Widget, for proximal interphalangeal joint contractures, 341, 342*f*
Digital artery, ligation of, in pollicization for thumb hypoplasia, 1295, 1297*f*
Digital artery island flap, 1546-1547, 1548*f*
Digital clawing, in tetraplegia, 1142-1143
  Lasso procedure for, 1142-1143
Digital cords, in planning, for Dupuytren disease, 145
Digital deformity
  in joints, 1840
  in psoriatic arthritis, 1836, 1836*f*
  in scleroderma, 1839-1840, 1839*f*
  in systemic lupus erythematosus, 1838
Digital extension, spasticity in
  operative management of, 1095-1102, 1097*f*, 1097*t*
  treatment of, preferred method of, 1101-1102, 1102*f*-1103*f*
Digital fibrokeratoma, 1966
Digital fibroma, of infancy, 2014, 2014*f*
Digital fibromatosis, infantile, 1968, 1970*f*
Digital flexion, contracture of, postburn, 1939-1940
Digital growth, limiting, in management of macrodactyly, 1278-1281
Digital keratoacanthoma, distal, 1971-1972
Digital nerve(s)
  identification and dissection of, in pollicization for thumb hypoplasia, 1295, 1296*f*
  relationship and distribution of, 10*f*
  repair of, 1481
    preferred method of treatment of, 1009
    results of, 1008-1009
      conduits and homografts for, 1009, 1009*t*
      recovery of sensation after, 1009*t*
  transfer of, in ulnar nerve palsy, 1061
Digital nerve block, 9-10
  subcutaneous, 11*f*
  transmetacarpal, 11*f*
  transthecal, 10*f*
  use of epinephrine in, 10
Digital vein, repair of, 1481
Digital-brachial index, for vascular disorders, 2039
Dimple, in planning, for Dupuytren disease, 145
Direct fovea (DF) portal, for arthroscopy of wrist, 657
Direct muscular neurotization, for nerve injury, 1001, 1001*f*
Direct suture, of nerve injury, 993-994, 994*f*-995*f*
Disabilities of the Arm, Shoulder, and Hand (DASH) score, 924, 975
Disarticulation
  elbow, 1754-1756
  of wrist, 1737-1738, 1753-1754, 1754*f*
Disarticulation *(Continued)*
  preferred method of treatment of, 1737-1738
Dislocation(s). *see also* Fracture-dislocation
  of carpal bones, isolated, in complex carpal instability, 475-476, 475*f*
  of carpometacarpal joint of thumb, 312-315
    anatomy in, 312, 312*f*
    historical review of, 312
    postoperative management and expectations for, 314-315
    preoperative evaluation of, 312-313, 313*f*
    treatment of, 313-314
      preferred method of, 313, 314*b*, 314*f*
  of distal interphalangeal joint, 296-297, 297*f*
  of elbow
    complex traumatic, 813-829. *see also* Elbow, dislocation of
    in radial head fracture, 815, 815*f*
    simple, 818-819
  of epiphysis, in children, 1429, 1430*f*
  infantile, 1413
  of lunate, pathomechanics of, 427-428
  of metacarpophalangeal joint
    anatomy in, 298, 298*f*
    complete (complex), 299
    complications of, 300
    dorsal, 298-300
    outcomes of, 300
    postoperative management of, 300
    preferred method of treatment for, 300, 300*b*
    preoperative evaluation of, 299, 299*f*
    radial collateral ligament rupture in, 300-301
    simple, 299
    surgical techniques for, 299-300
    of thumb, 310-311
      historical perspective on, 310-311
      postoperative management and expectations in, 311
      preoperative evaluation of, 311
      treatment of, 311
    volar, 300
  of proximal interphalangeal joint, 279-293
    acute dorsal, 279-280
    lateral, 280
    posttraumatic fibrosis and contracture in, 295-296
    volar, 280-281
      treatment of, 280-281
  of radial head, congenital, 1347-1349, 1347*t*, 1348*f*-1349*f*, 1350*b*
  in radial head fractures, 737
  of radioulnar joint, distal, 492
  of scaphoid, 475, 475*f*

Dislocation(s) *(Continued)*
of thumb interphalangeal joint, 296-297
of trapezium, 476
of trapezoid, 476
Displaced fracture(s)
with comminution and/or dislocation of elbow, 781
of radial head, 736
without comminution and proximal to midpoint of olecranon (type IIA), 781
Distal forearm injuries, 179, 179.*e*1*b*, 179.*e*1*f*
Distal interphalangeal (DIP) joint, 42-43, 42*f*
amputation of
with disarticulation, 1717-1718
to metacarpophalangeal joint, 1717-1719, 1718*f*
anatomy of, 338.*e*3, 338.*e*3*f*
arthrodesis of, 346-349
author's preferred method of treatment for, 347-349, 348*f*
complications of, 349
critical points in, 349*b*
expected outcomes for, 349
indications and contraindications of, 346-347
postoperative management and expectations after, 349
preoperative planning for, 347
in rheumatoid arthritis, for swan neck deformity, 1880-1882, 1880*t*
with screw, 1881, 1881*f*
studies of, fixation and outcomes, 347*t*
technique for, 347, 348*f*
dislocation of, 296-297, 297*f*
Elson test in, 156
ganglion of, 333, 333*f*-334*f*, 334*b*
Landsmeer's theory in, 157
stiffness of, after volar plate arthroplasty, 290
Distal intrinsic release, 343.*e*1, 343.*e*1*f*
Distal juncture technique, for tendon graft, 208, 209*f*
Distal oblique bundle (DOB), 482
Distal radioulnar joint (DRUJ)
arthroscopy of wrist, 660-661
reconstruction of, for rheumatoid arthritis, 1860-1863, 1861*f*-1862*f*
Distal radioulnar ligament reconstruction, 496-498, 497*f*
Distal segment, of nerve, 984-985, 985*f*
Distal sleeve anastomosis, for vascular disorders, 2051, 2051*f*
Distal tendon juncture, 206, 207*f*
Distal ulnar excision reconstruction, 1860-1863
Distal ulnar resection, 1862*b*
Distant flaps, 1540, 1563-1568
axial-pattern, 1564-1568
groin, 1564-1568, 1564*f*, 1566*f*-1567*f*, 1568*b*
random-pattern, 1563-1564
Distraction osteogenesis, metacarpal lengthening with, in brachydactyly, 1242-1243
Distraction plate fixation, of distal radial fracture, open reduction with, 557-559, 558*f*, 560*f*
Distraction-compression osteogenesis, treatment of nonunion of forearm bones using, 803
Docking technique, 837, 839
Dog bites, infection from, 46-47
Dome osteotomy, physiolysis and, for Madelung deformity, 1342-1344, 1342*f*-1343*f*
Donor muscle, selection of, for free transfers in brachial plexus injury, 1179, 1202
Donor nerve, in brachial plexus reconstruction, selection of, 1161-1162, 1202
Donor site(s)
for flaps, 1540-1541
for free flaps, 1576*t*
morbidity of, after congenital pseudoarthrosis of ulna surgery, 1357
for skin graft
care of, 1538
in managing injuries, 1511
split-thickness, 1531-1532, 1532*t*
for toe transfer
morbidity of, 1670
rehabilitation of, 1671
for vascularized bone grafts, 1614-1615
Donor tendon, 1036
Doppler flowmetry, laser, for vascular disorders, 2039
Dorsal angulation, as complication of metacarpal fractures, 246, 246*f*-247*f*
Dorsal capsule release, arthroscopic arthrolysis and, 691
Dorsal Dupuytren nodules (DDN), 129
signs of, 129-130, 131*f*
treatment of, 143
Dorsal hand skin, 1528, 1529*f*
Dorsal inlay graft, vascularized, placement of, 1632
Dorsal intercalated segment instability (DISI), 418-419
Dorsal interosseous muscle, 338.*e*3, 338.*e*5*f*. *see also* Interosseous muscle(s)
Dorsal paronychial tissue, assessment, of for digit perfusion, 1490, 1490*f*
Dorsal plate fixation, of distal radial fracture, open reduction with, 547-552, 548*f*
Dorsal radiocarpal ligament (DRCL), 421-422
repair of, 665*f*
tears of, 665
Dorsal radiotriquetral ligament, 421-422
Dorsal radius pedicle grafts, specific, 1630-1632
Dorsal retinacular ganglion, 2009, 2010*f*
Dorsal wrist injuries, 178-179
preferred method of treatment of, 179
Dorsum of the hand, contractures of, postburn, 1940-1941, 1942*f*
Double crush phenomenon, nerve injury and, 1-2
Double free muscle transfer, for brachial plexus injury, 1181-1183
Double-barrel flap, vascularized, in grafting from fibula, 1620
Double-crush mechanism, in compression neuropathies, 922-923
Doxepin, for complex regional pain syndrome, 1812*t*
Doxycycline
for actinomycetoma, 73
for anthrax, 69
for syphilis, 74
Drainage, of nerve abscess, 113
Dressing(s)
bilayer matrix wound, 1711-1712, 1712*f*
for burns, 1934
changes and healing by secondary intention, 1709-1711, 1710*f*
in free flap transfer, 1581-1582
postoperative, after syndactyly treatment, 1226-1227
semiocclusive, 1711
Unna boot, 1538
Drug(s). *see also* Multidrug therapy (MDT); *specific drug or drug therapy*
abuse of, infections caused by, 51-52
for complex regional pain syndrome, 1811
outcome of, 1819
parenteral, 1819
resistance to, in Hansen disease, 109
used in regional anesthesia, 4*t*
Drug-susceptibility tests, for infections, 66
"Drunken face" symptom, of snakebite, 1789
Dry arthroscopy
for arthroscopic arthrolysis, 691
for wrist, 658
Duchenne sign, 1046
Dull nail, 330
Duplication
of ring finger, 1234, 1235*f*. *see also* Polydactyly, central
of thumb, 1304-1315
Dupuytren contracture (DC), 128. *see also* Dupuytren disease (DD)
appearance of, 130
treatment of, historical points in, 138, 139*t*

Dupuytren disease (DD), 128-151
associated conditions with, 128-129
demographics, 128-129, 129*f*
diagnostic imaging of, 134
genetic biomarkers of, 129
heritability and, 128
historical review of, 138, 139*t*
pathology of, 136-138, 136*f*-137*f*
physical examination of, 129-131, 130*f*
preoperative evaluation of, 129-134
prevalence of, 129*f*
skin landmarks of, 132, 133*f*
staging in, 131-134
treatment of, recontracture and, 134*t*
types of operations for, 138-143, 139*t*, 148*b*
dermofasciectomy, 142-143, 143*f*
fasciectomy, 140-142
indications and options for, 140*t*
minimally invasive procedures of, 139-140
open surgical procedures and, 140-143, 141*t*
patient instructions in, 144-145
planning in, 145
postprocedure in, 148
procedures of, 145-148
regional fasciectomy, 141-142, 142*f*
segmental fasciectomy, 141-142
Dynadesis, for scapholunate dissociation, 443, 443*f*
Dynamic splints, for joint stiffness, 340.*e*1, 340.*e*1*f*
Dysesthesia(s)
cutaneous nerve, in thoracic outlet syndrome, 975
definition of, 1799*t*
Dysfunctional postures, in factitious disorders, 1828-1829, 1830*f*-1831*f*
Dysplastic nevus syndrome, 1966, 1967*f*
Dystrophic epidermolysis bullosa, syndactyly in, 1231-1232, 1232*f*

E

Early recontracture, of Dupuytren disease, 133-134, 134*t*
Eccrine poroma, 1964
Ecthyma contagiosum, 123-124, 124*f*
Edema
after posttraumatic interosseous contracture, 343.*e*1
control of, in burn management, 1929
"Eight-pack" tissue culture, 65, 65*t*
Elbow
anterior (transolecranon) fracture-dislocation of, 784.*e*13*b*, 784.*e*13*f*-784.*e*14*f*
arthritis of, posttraumatic, 827
arthroplasty of, total, 905-920. *see also* Arthroplasty, of elbow, total
arthroscopy of, 885-904
Elbow *(Continued)*
advanced procedures of, 903
anesthesia and positioning in, 886, 888*f*
complications of, 903
contributions to, 892*t*
for epicondylitis, 868
historical review of, 891
instrumentation in, 891, 891*f*
pertinent anatomy in, 886-891, 889*f*
portals in, 886-891, 889*f*
preoperative evaluation in, 885-886
diagnostic imaging in, 886, 887*f*-888*f*
physical examination in, 885
types of operations in, 892-903
in brachial plexus birth palsy, 1417-1419, 1418*f*
complex posterior olecranon fracture-dislocation of, 784.*e*1*b*, 784.*e*2*f*-784.*e*3*f*
contracture of. *see* Contracture(s), of elbow
disarticulation of, 1754-1756
dislocation of
complex traumatic, 813-829
classification of, 814-817
clinical assessment of, 813-814
complications of, 826-827
definition of, 813
expected outcomes after, 826
functional anatomy in, 813, 814*f*
historical review of, 817-818
imaging of, 814
olecranon fracture-dislocations in, 816-817, 816*f*
patterns of injury of, 814-817
posterolateral rotational injury in, 814-815
postoperative management after, 825-826
preoperative evaluation of, 813-814
in radial head fracture, 815, 815*f*
reconstruction for, 825, 825*f*
treatment options for, 818-825
in acute injuries, 818-824
in delayed treatment, 824-825, 826*b*
varus posteromedial rotational injury in, 817, 818*f*
posterior, with fracture of olecranon process, 784.*e*11*b*, 784.*e*11*f*-784.*e*12*f*
in radial head fractures, 737
simple, 818-819
displaced fractures with comminution and/or dislocation of, 781
epicondylitis of
lateral, 863-864. *see also* Epicondylitis, lateral
medial, 864-865. *see also* Epicondylitis, medial
Elbow *(Continued)*
extension of, in tetraplegic patient, tendon transfer for, 1127-1129
biceps to triceps, 1127-1129, 1128*f*, 1129*b*
posterior deltoid to triceps, 1129, 1130*f*
flexion of, reconstruction of, in brachial plexus injury, 1192-1202
complications of, 1196
free muscle transfer in, 1202, 1202*f*, 1203*b*
latissimus dorsi transfer in, 1197-1198, 1199*f*, 1200*b*
outcomes of, 1196
pectoralis major muscle transfer in, 1198-1202, 1200*f*-1201*f*, 1201*b*
postoperative protocol for, 1196
preferred methods of, 1195-1202, 1195*f*, 1196*b*
triceps-to-biceps transfer in, 1196-1197, 1197*b*, 1197*f*
golfer's, 864. *see also* Epicondylitis, medial
instability of
after release, 855-856, 856*f*
after ulnar fractures, 783, 783*f*
recurrent, after dislocation, 826
instability of, chronic, 830-842
lateral, 830-835
diagnostic imaging of, 831, 831*f*
ligament reconstruction for
complications in, 835
contraindications to, 833
indications for, 832-833
outcomes in, 835
postoperative management and expectations in, 835
preoperative evaluation of, 830-831
technique in, 833-835, 834*f*
pertinent anatomy in, 832, 832*f*
physical examination for, 830-831
medial, 835-840
diagnostic imaging of, 835-836, 836*f*
ligament reconstruction for
complications in, 840
contraindications to, 837
indications for, 837
outcomes in, 840
postoperative management and expectations of, 839-840
preoperative evaluation of, 835-836
technique in, 837, 838*f*, 840*f*
pertinent anatomy in, 836-837, 836*f*
physical examination for, 835
lateral ligamentous anatomy of, 739, 740*f*
mangling injuries of, treatment of, 1515-1519, 1519*f*-1520*f*

Elbow *(Continued)*
poor-quality soft tissues at, as contraindication to elbow arthroplasty, 909
presence of infection at, as contraindication to elbow arthroplasty, 909
spasticity in
examination of, 1084
operative management of, 1090-1093
treatment of, preferred method of, 1091*f*, 1092-1093
stability of, anatomy of, 772-773
stiff
after dislocation, 827
after humeral fracture fixation, management of, 731
arthroscopic release of, 902-903
causes and prevention of, 843-844, 844*f*
history of, 844-845
imaging of, 847-848
pain and, 845
patient history of, 844-845
postoperative management after, 857-858
posttraumatic, categories of, 844*t*
preoperative assessment of, 844-849, 844*t*
assessment of ulnohumeral joint surface after trauma, 847
duration of contracture and timing of release in, 845, 846*f*
examination of ulnar nerve in, 847
motion loss and effect on function in, 845-847
patient's age, 844-845
preoperative discussion prior, 848
treatment of, 843-862
arthroscopic release in, 849
complications of, 859-860
failure to achieve improved motion as, 860
heterotopic ossification as, 859
joint infection as, 859
nerve palsy as, 859
pin tract infections as, 859
recurrent stiffness as, 859
soft tissue deficiencies as, 859
wound necrosis as, 859, 860*f*
contracture release in, anesthesia for, 849, 853*b*
expectations and results of, 858-859
open release in, 849-853
lateral approach to, 852-853
medial "over-the-top" approach, 849, 852*b*
postoperative care, immediate, 853
special circumstances in, 853-856
Elbow *(Continued)*
distal humerus fracture after open reduction with internal fixation, 853-854
distal humerus fracture nonunion, 854
distraction arthroplasty, 856
excessive muscle tightness, 856
head trauma and brain injury, 854, 854*f*
supplementary blocks at, 8
tennis, 863-864. *see also* Epicondylitis, lateral
Elbow pads, for cubital tunnel syndrome, 942
Elderly, distal humeral fractures in, 707-710
open reduction and internal fixation of, 707-709, 709*t*
total elbow replacement for, 709-710, 709*t*, 710.*e*1*b*, 710.*e*1*f*
Electrical injuries, 1945-1948
clinical manifestations of, 1946-1947, 1947*f*
epidemiologic findings in, 1945
mechanism and classification of, 1946
pathophysiologic conditions in, and properties of electricity, 1945-1946
treatment of, 1947-1948
general management in, 1947
surgical management in, 1947-1948, 1949*f*
Electrical stimulation, for spasticity, 1088
Electrically negative neurogenic thoracic outlet syndrome, 960-961
Electrodesiccation, 1961
Electrodiagnostic studies, in compression neuropathies, 928-930
Electromyography (EMG)
in brachial plexus injury, 1153
in compression neuropathies, 929
in neurapraxia, 12
in pediatric brachial plexus palsy, 1396
Electroporation, 1946
Electrosurgery, 1961
for warts, 123
Electrothermal ligament shrinkage
in midcarpal instability, 460
in scapholunate dissociation, 439-440
of scapholunate interosseous ligament, 664, 664*f*
Elevated arm stress test, for thoracic outlet syndrome, 966-967
Ellipsoid universal I wrist design, 406
Elliptical excision, 1961, 1963*f*
Elliptical incision, in removal of supernumerary digits, 1233-1234, 1233*f*
Ellis-van Creveld syndrome, postaxial polydactyly in, 1232, 1233*f*
Elson test, 155-156, 157*f*
Embryogenesis
genes and molecular abnormalities in, 1212-1214
key milestones in, 1209*t*
of limbs, 1208-1215, 1210*f*
musculoskeletal system development in, 1211-1212, 1213*f*
signaling centers in, 1208
signaling pathways during, 1210*t*
systemic considerations, 1214-1215
Emergency treatment, of mangling injuries, 1495-1496, 1496*b*, 1497*f*, 1498*t*
Encapsulation, implant, after metacarpophalangeal joint arthroplasty, 1877-1878
Enchondroma, 2020-2021, 2020*f*, 2021*b*
Enchondromatosis, multiple, 2021, 2022*f*
Endoscopy, for carpal tunnel syndrome
Agee single-portal, 933-934
Chow two-portal, 933
End-to-end anastomosis, for vascular disease, 2051, 2051*f*
End-to-side anastomosis, for vascular disease, 2051, 2051*f*
End-to-side flexor digitorum profundus, tendon juncture of, 220
Endurance testing, in complex regional pain syndrome, 1809-1810
Entubulation, of nerve injury, 999-1000
Envenomation, animals associated with, 1788-1795
caterpillars, 1788, 1789*f*
cnidarians, 1791-1792, 1792*f*
fish, 1792-1795, 1793*f*-1794*f*
sea urchins, 1792, 1792*f*
snakes, 1789-1791, 1790*f*-1791*f*
spiders, 1788-1789, 1789*f*
Enzymatic fasciotomy, for Dupuytren disease, 139*t*
with collagenase clostridium histolyticum, 140
Epicondylectomy, medial, for cubital tunnel syndrome, 943-944, 943*f*-944*f*
Epicondylitis
lateral, 863-864, 871*b*
diagnosis of, 864
etiology, associations, and pathophysiology of, 863
history of, 863
presentation of, 863-864
recurrent, surgical treatment of, 866
surgical treatment of, 866
medial, 864-865, 871*b*
diagnosis of, 864-865
etiology and pathogenesis of, 864
presentation of, 864
surgical treatment of, 867
preferred method of, 868-870, 869*f*-870*f*
treatment of, 865-870
arthroscopic technique of, 868
expected outcomes of, 867

Epicondylitis *(Continued)*
nonoperative, 865-866
preferred method of, 867-868, 867*f*-869*f*
surgical, 866-867
Epidermal inclusion cysts, 1966-1968, 1969*f*, 2009-2010, 2011*f*
Epidermal lesions, 1962-1964
Epidural agents, for complex regional pain syndrome, 1816-1817
Epinephrine, in digital nerve block, 10
Epineural repair, of nerve injury, 994
Epiphyseal bracket resection, 1272, 1274*f*
Epiphyseal dislocation, in children, 1429, 1430*f*
Epiphyseal fracture
of distal phalanx, 248-249, 248*f*
of metacarpals, in children, 1437
preferred method of treatment for, 1437
Epiphyseal transfer, grafting for, 1624
Epiphysiodesis, for macrodactyly, 1278-1281, 1280*f*
Epitendinous suture, of zone 2 tendon lacerations, 188
Epithelioid sarcoma, 2017
Eponychial deformities, 329
Equipment, for regional anesthesia, 4
Erb-Duchenne palsy, 1149
Erb's palsy, 1393
Escharotomy, for burns, 1929-1930, 1930*f*
Essex-Lopresti injuries, 764-765
Essex-Lopresti prosthetic reconstruction, of radial head, 764-765, 765*f*-766*f*
Ethambutol
dosage of, 101*t*
for tuberculosis, 100-101
Ethionamide, dosage of, 101*t*
Etidocaine, characteristics of, 4*t*
Eumycetoma, 70-73
clinical findings on, 71
diagnosis of, 72
etiology and epidemiology of, 70
microbiology of, 70-71
treatment of, 73
Ewing's sarcoma, 2028-2031, 2030*f*
author's preferred method of treatment for, 2030-2031
Excision. *see* Surgical excision
Excisional biopsy
elliptical, 1961
for musculoskeletal tumors, 1991-1992
Exercise(s)
nerve gliding, for carpal tunnel syndrome, 933
"six-pack," for distal radial fractures, 531, 534*f*
Exercise-induced compartment syndrome, 1763
Exertional compartment syndrome, 1763
diagnosis of, 1767-1768
Exostoses
multiple, hereditary, of forearm and elbow, 1357-1362, 1358*f*-1361*f*, 1362*b*
subungual, 2022
Expendable donor, in tendon transfers, 1025
EXT genes, mutations of, 1357
Extension contracture. *see also* Contracture(s)
metacarpophalangeal joint, release of, 340-341
Extension splint, resting, for elbow contracture, 857
Extensor carpi radialis brevis
brachioradialis transfer to, 1101, 1101*f*, 1110-1111, 1112*b*, 1112*f*
extensor carpi ulnaris transfer to, 1099, 1099*b*, 1100*f*
flexor carpi ulnaris transfer to, 1097-1098, 1098*f*, 1099*b*
pronator teres transfer to, 1101, 1101*f*
transfer of
in restoration of thumb adduction, 1056-1057, 1057*f*, 1057*t*
in tetraplegic patient, to brachioradialis, 1131, 1131*f*, 1132*b*
Extensor carpi radialis intermedius, in wrist extension, 152
Extensor carpi radialis longus, transfer of
in median nerve palsy, 1035-1036
to index profundus, 1044, 1044*f*
operative technique for, 1863
to restore wrist balance, in rheumatoid arthritis, 1863
in tetraplegic patient, to flexor digitorum profundus, 1134
in ulnar nerve palsy
dorsal route of, 1054, 1054*f*
flexor route of, 1055, 1055*f*, 1060
Extensor carpi ulnaris, 152, 154*f*, 1863
lateral collateral ligament and, 832
stabilization of, 511-512, 512*f*
tendinitis of, 1921-1922, 1922*f*
surgical treatment, 1922, 1922*f*
tenodesis of, 1140
tenosynovitis and subluxation of, 511-512, 511*f*
operative technique for, 511-512, 512*f*
outcomes of, 512
transfer of
in median nerve palsy, 1034-1035
to restore wrist balance, in rheumatoid arthritis, 1863
wrist spasticity and, to extensor carpi radialis brevis, 1099, 1099*b*, 1100*f*
Extensor compartment artery
fifth, bone grafting using, 1630, 1630*f*
fourth, bone grafting using, 1629-1630
graft, 5 plus 4, 1632
Extensor compartment(s)
first, ganglion of, 2009, 2010*f*
fourth and fifth, stenosis of, 1921
Extensor digiti minimi (EDM), 152, 153*f*
transfer of
in median nerve palsy, 1036, 1036*f*
in ulnar nerve palsy
combined with extensor indicis proprius, 1053-1054
for little finger abduction, 1060, 1060*f*
for metacarpal arch restoration, 1059-1060
Extensor digitorum brevis manus muscle (EDBM), 152, 153*f*
Extensor digitorum communis (EDC), 153-154, 154*f*
in proximal phalanx, 154
spasticity and, flexor carpi ulnaris transfer to, 1099-1100, 1100*b*
tenodesis of, in tetraplegic patient, House two-stage reconstruction and, 1137, 1138*f*
Extensor indicis proprius (EIP), transfer of
to first dorsal interosseous, 1058-1059
in median nerve palsy, 1031-1032, 1032*f*
in restoration of thumb adduction, 1058
in ulnar nerve palsy, combined with extensor digiti minimi, 1053-1054
Extensor pollicis brevis, imbrication of, for thumb-in-palm deformity, 1112
Extensor pollicis longus
in cerebral palsy
rerouting of, for thumb-in-palm deformity, 1110, 1111*b*, 1111*f*
transfer of, for thumb-in-palm deformity, 1110
entrapment, 1921, 1921*f*
in rheumatoid arthritis, rupture of, treatment of, 1850-1851, 1850*f*
in tetraplegic patient
extensor digitorum communis transfer to, 1141
tenodesis of, House's one-stage reconstruction and, 1135, 1135*f*
transfer of, in median nerve palsy, 1037-1040, 1039*f*-1041*f*
alternative, 1040-1041
Extensor proprius tendons, for tendon graft, 206
Extensor retinaculum, pulley reconstruction using, 222
Extensor tendon(s). *see also specific tendon*
anatomy of, 152-157, 152.*e*1*b*
juncturae tendinum, 152-154, 153*f*
in muscles, 152
variations of, 153
at the wrist level, 152, 153*f*
centralization of, in total wrist replacement, 413-414, 414*f*

Extensor tendon(s) *(Continued)*
of finger, rupture of, 1852-1853, 1854*f*-1855*f*
diagnosis of, 1849-1850, 1849*f*
multiple-tendon, 1852
with metacarpophalangeal joint disease, 1854
reconstruction for, 1852-1857
options for reconstruction in, 1852-1857
in ring and small finger, 1852, 1853*f*
single-tendon, 1851-1852, 1852*f*
treatment of, 1850-1851, 1850*f*, 1851*t*
ganglions of, 2008, 2010*f*
injury to. *see* Extensor tendon injury
long toe, for tendon graft, 205-206
repair of, 1481
in rheumatoid arthritis, of metacarpophalangeal joint
centralization of, 1875-1876, 1875*f*
rupture of, 1850-1851
preferred method of treatment of, 1851
of wrist, tenosynovitis of, 1843-1845
preferred method of treatment of, 1843-1845, 1843*f*-1844*f*
wrist extensors, 1843-1845
complications, 1845
postoperative management, 1845, 1845*f*
Extensor tendon injury, 152-182
treatment of, 158-162, 162*b*
complications in, 161-162
outcomes in, 161, 161*t*
postoperative management in, 160-161, 161*t*
suture repair techniques in, 158-159
zone(s) of, 158, 158*f*
1, distal interphalangeal joint. *see also* Mallet finger injury; Mallet thumb injury
acute, 162-165, 166*b*, 162.*e*1*b*, 162.*e*1*f*
anatomy of, 162
classification of, 162, 163*t*
incidence of, 162
management of, 163
mechanism of, 162
preferred method of treatment of, 164-165, 165*f*
treatment for, 163-164, 164*f*
chronic, 165-166
treatment of, 166-169
postoperative management of, 160
techniques for, repair, 159
2, middle phalanx, 169
postoperative management of, 160
techniques for, repair, 159, 160*f*
3, proximal interphalangeal joint, 169*f*-170*f*, 169.*e*1*b*,
Extensor tendon injury *(Continued)*
169.*e*1*f*-169.*e*2*f*, 172.*e*1*b*, 172.*e*1*f*. *see also* Boutonnière deformity
closed, 171-172
open, 170, 171*f*
lacerations in, 171
postoperative management of, 160, 169-174
preferred method of treatment of, 170-171
techniques for, repair, 159, 160*f*
4, proximal phalanx, 174
postoperative management of, 160
preferred method of, repairs, 174
techniques for, repair, 159, 160*f*
5, carpometacarpal joint, 174-175
postoperative management of, 160
techniques for, repair, 159, 160*f*
6, metacarpal level, 175-177, 178*f*, 175.*e*1*b*, 175.*e*1*f*
chronic, 177
postoperative management of, 160
preferred method of treatment of, 177
techniques for, repair, 159
7, dorsal wrist, 178-179
injuries and rupture in, chronic, 179, 179*f*
postoperative management of, 160
preferred method of treatment of, 179
techniques for, repair, 159
8, distal forearm, 179, 179.*e*1*b*, 179.*e*1*f*
9, proximal forearm, 179-180
Extensor tendon-splitting approach, to radial head, 745-746, 748*f*
Extensors, repetitive contraction of, microtrauma due to, 863. *see also* Epicondylitis, lateral
External fixation
of distal radial fracture, 532-539, 538*f*
augmented, 535-539, 539*b*, 541*f*-542*f*, 535.*e*1*f*
hybrid, 539.*e*1*f*
technique for, 533-535, 539*f*-541*f*
for mangling injuries, 1500, 1502*f*-1503*f*
of metacarpal shaft fractures, 241, 237.*e*1*t*
of proximal and middle phalangeal fracture, 261
of radial shaft fractures, intramedullary rods and, 793, 793*f*-794*f*, 795*b*
External fixator, for segmental metacarpal loss, 244*f*
External fixator pin clusters, 539
Extraarticular intracapsular fractures, of humerus, 702-703, 702*f*. *see also* Humerus, distal
Extraarticular osteotomy. *see also* Osteotomy
for radial fracture, 577, 578*b*, 578*f*-579*f*
Extraoctave fracture, in children, 1435, 1436*f*
Extraosseous nutrient vessels, in bone grafting, 1629-1630
Extraplexal nerve transfers, for brachial plexus injury, 1177
Extrinsic extensors, anatomy of, 338.*e*4-338.*e*5, 338.*e*6*f*
Extrinsic flexor function, restoration of, 1778-1781, 1781*f*
Extrinsic ligaments, of wrist, 420-422, 421*f*

F

Factitious disorders, 1828-1831
differential diagnosis of, 1829-1830
management of, 1830
mistaken diagnoses of, 1829-1830
recognizable, 1828-1829
Fanconi anemia, radial deficiency associated with, 1289, 1290*t*
longitudinal, 1329*t*
Farm yard pox, 123-124, 124*f*
Fasciectomy, for Dupuytren disease, 140-142
comparison of, 141*t*
Fasciitis
necrotizing, 17, 54-55, 54*f*
animal bites and, 48
antibiotic recommendations for, 21*t*
case study, 55.*e*1*b*, 55.*e*1*f*
diabetic hand infections and, 54
fungal, 55, 55*f*
shooter's abscesses and, 51
nodular, 2014
Fasciocutaneous flap(s)
axial-pattern, regional, 1555, 1555*f*
free, 1575-1576. *see also* Free flap(s)
for mangling injuries, 1513, 1514*f*
Fasciotomy
for compartment syndrome, 1764
contraindications to, 1769
indications for, 1769
prophylactic, 1769
for Dupuytren disease, 139*t*, 140
Fat graft, physiolysis and, for Madelung deformity, 1339-1342, 1341*f*
Fat pad sign, in radial head fractures, 734-736, 735*f*
FCR sling suspensionplasty, 363
Feldon's two-pin modification, 1865-1866, 1866*f*
Felon, 25-28, 26*f*, 28*b*
clinical presentation and evaluation of, 25
pertinent anatomy in, 25-26
postoperative management of, 28
treatment for, 26-28
operative, 26, 27*f*, 27*t*
preferred methods of, 26-28
Felty syndrome, in rheumatoid arthritis, 1833

Femoral condyle
bone graft from, for scaphoid nonunion, 619, 620*f*
medial
grafts, 1625-1629
osteochondral graft harvest, 1628
vascularized bone graft from, 1625-1627, 1626*f*
Fernandez-Fisk wedge graft, for scaphoid nonunion, 612-614, 613*f*
FGFR2 gene, mutation of, 1227-1228
Fibrin clot glue, in suturing, 996
Fibroma
chondromyxoid, 2023
digital, of infancy, 2014, 2014*f*
juvenile aponeurotic, 2014
Fibromatosis
of palmar and digital fascia. *see* Dupuytren contracture
subcutaneous pseudosarcomatous, 2014
Fibrosarcoma, 2018
Fibrosis, posttraumatic, of proximal interphalangeal joint, 295-296, 296*b*, 296*f*
Fibrotic band, arthroscopic arthrolysis and, 691
Fibrous histiocytoma, malignant, 2019, 2019*f*
Fibula
anatomy of, 1617
grafting from
for congenital pseudoarthrosis of ulna, 1356
vascularized, 1617-1620, 1617*f*-1618*f*
complications of, 1620, 1620*f*
donor results, 1621, 1622*f*
double-barrel flap in, 1620
with muscle, 1620
osteocutaneous flap in, 1619
in upper extremity, 1622-1623, 1623*f*
with skin flap, 1619
Filarial infection, 117-118
Fillet flap, 1552-1554, 1554*f*. *see also* Skin flap(s)
Finger(s). *see also* Digit(s); Digital *entries*
absence of, 1255-1270, 1270*b*
in constriction ring syndrome, 1255-1258, 1257*f*, 1258*b*
microvascular toe transfer for, 1263-1270, 1265*f*-1268*f*
reconstruction for, 1261-1270
complications of, 1262
distraction of digits in, 1262
free phalangeal transfer in, 1260*f*, 1261-1262
preferred method of, 1262
hand preparation in, 1262, 1262*f*
harvesting of graft in, 1262, 1263*f*
placement of graft in, 1262, 1263*f*
surgical outcomes for, 1270
transposition of rays in, 1245*f*, 1263, 1264*f*
Finger(s) *(Continued)*
in symbrachydactyly, 1258-1260
transverse, acquired causes of, 1261-1270
amputation of. *see also* Ray amputation
multiple-digit, 1735-1737, 1735*b*, 1736*f*, 1737*b*
toe transfer for. *see also* Toe transfer, in finger replacement
distal digit in, 1646-1647
multiple digits in, 1648
proximal digit in, 1647-1648
single digit in, 1646, 1647*f*
aponeurosis of, 338.*e*3, 338.*e*5*f*
bones of. *see* Phalanx (phalanges)
deformities of, 1217-1288, 1879-1894
boutonnière. *see* Boutonnière deformity
claw-hand. *see* Claw-hand deformity
extension of, 154-155
biomechanics of, 158
extensors, 152
rupture of, 1851-1852
fifth, amputation of, preferred method of treatment of, 1732-1733, 1733*f*-1734*f*
flexor tendons of. *see also* Flexor tendon(s)
tenosynovitis of, 1848-1849
preferred method of treatment of, 1848-1849, 1848*f*
hypoplastic, microvascular toe transfer for, in finger absence, 1263-1270, 1265*f*-1268*f*
index
amputation of, 1721-1723, 1723*f*
preferred method of treatment of, 1722-1723, 1724*f*
independent extension of, 153
mangling injuries and, 1493
resection/transplantation of, in distraction procedures, stump of, pollicization of, 1699-1703, 1702*f*-1704*f*, 1705*b*
injury
dorsal, 1737.*e*1*f*
palmar, 1737.*e*1*f*
joints of. *see* Distal interphalangeal (DIP) joint; Interphalangeal (IP) joint; Metacarpophalangeal (MCP) joint(s); Proximal interphalangeal (PIP) joint
little, abduction of, correction of, 1060
long, amputation of, 1723, 1725*f*
without transposition, 1723-1726, 1725*f*-1726*f*
mangling injuries of, treatment of, 1512-1515, 1512*f*-1517*f*
reconstruction of, microvascular toe transfer in, 1263-1270
rheumatoid arthritis of. *see* Rheumatoid arthritis, of fingers
Finger(s) *(Continued)*
ring
amputation of
preferred method of treatment of, 1731-1732, 1732*f*
with transposition of fifth metacarpal, 1732-1733, 1733*f*-1734*f*
duplication of, 1214*f*
restoration of, 1060-1061
suture to middle finger, 1060-1061, 1061*f*
without transposition, 1730-1733
small, amputation of, 1734-1735
preferred method of treatment, 1734-1735, 1735*f*-1736*f*
stiff, 338-344. *see also* Stiffness, of finger and hand
thumb and, restoration of pinch between, in ulnar nerve palsy, index abduction techniques in, 1059
transposition of, long finger, amputation with, 1726-1730, 1728*f*
trigger, 1322, 1323*f*
Finger extension test, resisted, in scapholunate dissociation, 436
Finger flexion
free functional muscle transfer for, 1782*b*
reconstruction of, 1777
tendon transfer for, 1779*b*
Fingernail(s). *see* Nail(s)
Fingertip(s), amputation of, 1709
cross-finger pedicle flap for, 1714-1716, 1715*f*
free flaps in, 1717
island flaps in, 1717
with skin or pulp loss only, 1709-1711
Smith and Albin thenar H-flap in, 1716, 1716*f*
thenar flap in, 1716
V-Y flap(s) for
Atasoy-Kleinert volar, 1712-1713, 1713*f*
Kutler lateral, 1713-1714, 1714*f*
volar advancement, 1714, 1715*f*
Finkelstein sign, in radial nerve compression, 948
First metacarpal osteotomy, for carpometacarpal joint osteoarthritis
expected outcomes on, 366
as operative technique, 362, 362*f*
as treatment, 361
First-degree burns, 1928. *see also* Burns
Fish, venomous, 1792-1795, 1793*f*-1794*f*
Fisher classification, of scaphoid fractures, 593
Fish-mouth incision, for felon, 27*f*, 27*t*

Fixation. *see also* Kirschner pin/wire fixation; Pin fixation; Plate fixation; Screw fixation; Wire fixation
devices for, external, for proximal interphalangeal joint contractures, 341, 342*f*
of Galeazzi-type fracture-dislocations, 792-793, 792*f*
hinged, after elbow contracture release, 855, 855*f*
of humeral fractures
principles in, 717-726, 719*f*, 717.*e*1*b*, 717.*e*1*f*-717.*e*2*f*
sequence of, 724
posterior approach for radial shaft, 790-791, 790*f*-791*f*
of scaphoid fractures
arthroscopy-assisted, 603
mechanics of, 595-596
rigid, 596-597
techniques in, for proximal interphalangeal joint arthrodesis, 350
in toe transfer, 1666-1668
of ulnar fractures, early failure of, 782, 782*f*-783*f*
Fixed-angle implants, in osteotomies, 578
Flap(s)
advancement, 1541-1542, 1547-1550, 1548*f*-1549*f*
"V-Y", 1548-1550, 1549*f*-1551*f*
axial-pattern, 1539-1540, 1540*f*. *see also* Axial-pattern flap(s)
for burns, 1934, 1935*f*
chemotherapeutic extravasation skin loss and, 1570
diamond shaped, in cleft hand surgery, 1247-1248, 1247*f*
distant, 1540, 1563-1568. *see also* Distant flaps
failure in, 1570-1571
salvage of, 1571
fasciocutaneous, 1555, 1555*f*
free, 1575-1576
for mangling injuries, 1513, 1514*f*
free, 1540, 1554
local, 1540-1542. *see also* Local flaps
transposition, 1542. *see also* Transposition flaps
postoperative care for, 1570-1571
preferred method in, 1568-1570, 1568*t*
raising, 1541
random-pattern, 1539. *see also* Random-pattern flap(s)
regional, 1540, 1550-1558. *see also* Regional flap(s)
staging of, 1540
in syndactyly surgery, preferred method of, 1219*f*, 1224-1225, 1226*f*-1227*f*
types of, 1539-1541, 1539*t*
wound preparation for, 1540-1541
Flat (plane) warts, 121
Flatt's classification, of macrodactyly, 1275-1276, 1276*t*
Flexible-hinge silicone arthroplasty, 406
Flexion, of wrist, kinematics in, 423-424
Flexion contractures, after volar plate arthroplasty, 290
Flexion deformity
as complication, of flexor tendon grafting, 225
in proximal interphalangeal joint contractures, 340.*e*2
Flexion splint, "come-along", for elbow contracture, 857, 858*f*
Flexor carpi radialis
tendinitis of, 1922-1923
anatomy of, 1922-1923
treatment of, 1923
nonoperative, 1923
operative technique, 1923
transfer of
for radial nerve palsy, 1071, 1071*b*, 1071*f*
for ulnar nerve palsy, 1055-1056
Flexor carpi ulnaris, transfer of
for radial nerve palsy, 1067-1070, 1067*f*-1069*f*
postoperative management of, 1069
potential problems of, 1069-1070
in spasticity
to extensor carpi radialis brevis, 1097-1098, 1098*f*, 1099*b*
to extensor digitorum communis, 1099-1100, 1100*b*
Flexor digiti quinti, 338.*e*4
Flexor digiti quinti brevis, 338.*e*3
Flexor digitorum longus, for tendon graft, 206
Flexor digitorum profundus (FDP)
anatomy of, 185
avulsion of, 187-188, 187*f*
in rheumatoid arthritis, rupture of, 1856-1857
tendon juncture of, end-to-side, 220, 221*f*
in tetraplegic patient, side-to-side transfer of, 1141
Flexor digitorum superficialis (FDS)
anatomy of, 185, 185*f*
finger in, salvage procedure of, 226
postoperative care of, 226
technique in, 226, 226*f*
FPL reconstruction using, 216.*e*1*f*
insertion, replantation and, 1477, 1478*f*
opponensplasty of, in hypoplastic thumb reconstruction, 1292-1295, 1293*b*, 1293*f*-1295*f*
pulley reconstruction using, 222, 222*f*
in rheumatoid arthritis, rupture of, 1857
tenodesis of, 1737.*e*2*f*
for intrinsic muscle spasticity, 1114
transfer of, 219-220, 220*f*, 220.*e*1*f*
in restoration of thumb adduction, 1057-1058, 1057*f*
Flexor hallucis longus muscle (FHL), 1619
Flexor hinge splint, wrist-driven, 1130-1131, 1131*f*
Flexor origin slide, for Volkmann contracture
complications of, 1785, 1778.*e*1*f*
outcomes of, 1782, 1784*f*-1785*f*
Flexor pollicis brevis (FPB), transfer of, in median nerve palsy, 1041
Flexor pollicis longus (FPL)
anatomy of, 185
lacerations of, 190
loss of, function, 219
in rheumatoid arthritis, rupture of, treatment of, 1856, 1856*f*
in tetraplegic patient
brachioradialis transfer to, 1141
in House one-stage reconstruction, 1134-1135
pronator teres tendon transfer to, 1138
split transfer of, in House's one-stage reconstruction, 1135, 1136*b*, 1136*f*
in thumb-in-palm deformity, in cerebral palsy, abductorplasty for, 1111-1112
transfer of, in median nerve palsy, 1037, 1038*f*
alternative, 1037, 1038*f*-1039*f*
Flexor pronator slide, 1777-1778, 1778*f*, 1780*f*
for Volkmann contracture, 1779*b*
Flexor tendon(s)
anatomy of, 185-186, 185*f*-186*f*
blood supply to, 186, 186*f*
digital, in cerebral palsy, tightness of, 1084-1085, 1085*f*
operative management of, 1102-1106, 1104*f*
of elbow, for spasticity, lengthenings of, 1091-1092, 1091*f*, 1092*b*
fractional lengthening of, for spasticity, 1102-1103, 1104*b*, 1105*f*
ganglion of, volar retinacular, 2005, 2005*f*
grafting of
complications following, 224-226
adhesion formation as, 224
future concepts of, 225-226
infection as, 225
late flexion deformity as, 225
lumbrical-plus finger as, 225
mechanical failure of the implant as, 224
proximal interphalangeal joint as, hyperextension of, 225
pulley disruption as, 224
quadriga syndrome as, 224-225
rupture in, 224
synovitis as, 225, 225.*e*1*f*
extensor indicis proprius tendon harvest in, 206

Flexor tendon(s) *(Continued)*
flexor digitorum longus tendon harvest in, 206, 207*f*
long toe extensor tendon harvest in, 205-206, 206*f*
palmaris longus tendon harvest in, 204, 204*f*
plantaris tendon harvest in, 204-205, 205*f*
single-stage
flexor digitorum profundus and flexor digitorum superficialis tendons disrupted, 202-211, 203*f*, 207*b*
biology of, 203
Boyes' preoperative classification, 202*t*
distal juncture technique of, 209*f*-210*f*, 210
donor for, 203-206
incorporation of, 211
indications for, 202
initial exploration of, 202
placement of, 210
postoperative care of, 211
preferred technique of, 209-210
proximal juncture technique of, 210-211, 210*f*-211*f*
flexor digitorum profundus tendon disrupted, flexor digitorum superficialis tendon intact, 211-212, 212*b*, 214*b*
expectations of, 212
indications for, 211-212, 212*f*-213*f*
postoperative care of, 212
technique of, 212
two-stage, reconstruction, 212-217
alternative techniques in, 213-214, 215*f*
composite tissue transfer methods of, 214
indications for, 212-214
stage I in, 217*b*
postoperative care of, 216
preferred technique of, 214-216, 215*f*-216*f*
stage II in, 218*b*
postoperative care of, 217
technique of, 216-217, 216*f*-218*f*
tissue response to a silicone implant in, 213
issues, in procedure, for Dupuytren disease, 147
pulley system of, 186, 186*f*
repair of, 1481
rupture of
as complication of phalangeal fractures, 269
in rheumatoid arthritis
diagnosis of, 1850
treatment of, 1856-1857, 1856*f*

Flexor tendon(s) *(Continued)*
sheath, proximal portion of, 1723
tenodesis of, for swan neck deformity, in rheumatoid arthritis, 1882-1883, 1882*f*
tenosynovitis of, 1848-1849
antibiotic recommendations for, 21*t*
preferred method of treatment of, 1848-1849, 1848*f*
pyogenic, 28-32, 30*f*-31*f*, 32*b*
septic, 31.*e*1*b*, 31.*e*1*f*
of wrist, tenosynovitis of, preferred method of treatment of, 1848-1849, 1848*f*
"Z" -lengthening of, for spasticity, 1103-1104, 1104*b*
zones of, 185-186, 185*f*
Flexor tendon injury, 183-230
preoperative evaluation of, 183-185, 185*f*
reconstruction of, 199-226
in children, 223-224, 224*b*
indications of, 223
preferred technique of, 224
complications following, 224-226
adhesion formation as, 224
future concepts of, 225-226
infection as, 225
late flexion deformity as, 225
lumbrical-plus finger as, 225
mechanical failure of the implant as, 224
proximal interphalangeal joint as, hyperextension of, 225
pulley disruption as, 224
quadriga syndrome as, 224-225
rupture in, 224
synovitis as, 225, 225.*e*1*f*
grafting of, single-stage, 202-211
patient selection of, 199, 199*f*
pulley system in, 221-223
indications of, 221
postoperative care of, 223
preferred technique of, 222-223, 223*f*
using a flexor digitorum superficialis tendon, 222, 222*f*
using a free tendon graft, 221-222, 222*f*
using artificial materials, 222
using the extensor retinaculum, 222
using the volar plate, 222
secondary, in zones 3, 4, and 5, 219-221
expectations of, 221
indications of, 219
interposition graft of, 219-220, 219*f*
postoperative care of, 221
tenolysis, 199-202, 202*b*
adhesion formation of, agents that may limit, 200
expectations following, 201-202

Flexor tendon injury *(Continued)*
postoperative care following, 201
preferred technique of, 200-201, 201*f*
preoperative evaluation of, 199-200, 200*f*
of thumb, 217-219, 220*b*
indication of, 217-218
staged tendon, 219
technique of, 218-219
repair of
acute, 183-198
complications following, 198
contributions to, 184*t*
expected outcomes of, 195
general principles of, 199*b*
in partial tendon lacerations, 190
rehabilitation after, 195-198
surgical treatment of, 186-194
in tendon lacerations in zones 3, 4, and 5, 190
surgical techniques for, 194
in zone 1 tendon lacerations or avulsions, 187-188, 187*f*, 191*b*
postoperative rehabilitation of, 195-198, 196*f*-197*f*
tendon repair in, 191-194, 194*f*
tendon-to-bone repair, 190, 192*f*-193*f*
in zone 2 tendon lacerations, 188-190, 188*f*-189*f*, 195*b*
postoperative rehabilitation of, 195-198, 196*f*-197*f*
tendon repair in, 191-194, 193*f*-194*f*
Flexor-pronator muscle
origin, slide of, in cerebral palsy
at forearm, 1094-1095, 1094*f*
at wrist and digit, 1102
repair of, in medial "over-the-top" approach, to open release of elbow contracture, 852, 852*b*
Flow-through flap, 1577
Fluconazole
for candidiasis, 85
for coccidioidomycosis, 86
for cryptococcosis, 86
for deep sporotrichosis, 88
for eumycetoma, 73
for fungal infections, 79, 90
of nails, 330-331
for histoplasmosis, 86-87
for paronychia, 81
for protothecosis, 116
spectrum of activity of, 79*t*
for sporotrichosis, 83
Flucytosine
for cryptococcosis, 86
for fungal infections, 79-80
spectrum of activity of, 79*t*
Fluid therapy, after electrical injury, 1947
Fluoroscopy, reduction of screw malposition with, 605

Fluoxetine, for complex regional pain syndrome, 1813*t*
Fluvoxamine, for complex regional pain syndrome, 1813*t*
Foot deformity, in cleft hand, management of, 1251-1255
Forearm
  anomalies of, classification of ulnar deficiency based on, 1337*t*
  axis of rotation of, 786, 787*f*
  in brachial plexus birth palsy, 1419, 1420*f*
  compartments of, release of, 1769-1770, 1770*f*-1771*f*
  defects of, skin flaps for, 1568-1570, 1568*t*
  diaphyseal fractures of, in children, 1458-1471, 1471*b*
    epidemiology of, 1459-1460
    historical review of, 1462-1464
    pertinent anatomy in, 1461-1462
    postoperative expectations and management of, 1470-1471
    preoperative evaluation of, 1460-1461, 1461*f*-1463*f*
    types of operations in, 1464-1471
  disorders of, 786-812
  distal, musculoskeletal tumors of, excision of, 1996, 1996*f*-2000*f*
  fractures of, both bones, 797-798
    nonunion and malunion of, 799-803
    postoperative management and expectations after, 798
    posttraumatic radioulnar synostosis after, 803-804. *see also* Radioulnar synostosis
    preferred method of treatment of, 797-798, 798*f*
    preoperative evaluation of, 797
    removal of hardware from radius and ulna in, 798-799
  functional anatomy of, 786, 787*f*
  lengthening of, for ulnar deficiency, 1338, 1340*f*
  longitudinal axis instability of, 804-809
    complications of, 809
    interosseous ligament reconstruction in, 808-809
    one-bone forearm technique in, 808-809
    pertinent anatomy in, 806, 806*f*
    postoperative expectations after, 809
    preferred methods of, 808-809
    prevention of instability in, 806-807
    restoration of radius and ulna with radioulnar joint reduction in, 807
  malformations and deformities of, 1328-1364
    case study for, 1362.*e*1*b*, 1362.*e*1*f*-1362.*e*4*f*
  malunions of, 498-500, 499*f*
Forearm *(Continued)*
  mangling injuries of, treatment of, 1515, 1518*f*-1519*f*
  pronation of, in tetraplegic patient, 1129-1130, 1130*f*
    group 0, 1130-1131, 1131*f*
    group 1, 1131-1133, 1131*f*-1132*f*, 1132*b*, 1133*t*
    groups 2 and 3, 1133-1135, 1133*t*, 1135*f*-1136*f*, 1136*b*-1137*b*
    groups 4 and 5, 1135-1140, 1137*f*-1138*f*, 1139*b*, 1140*f*
    groups 6 and 7, 1140-1141
    group 8, 1141-1142, 1142*f*
    group 9, 1142, 1143*f*
  as recipient site, in bone grafting, 1636-1637
  spasticity in
    examination of, 1084
    operative management of, 1093-1095
    treatment of, preferred method of, 1095, 1096*f*
  Volkmann contracture of
    restoration of intrinsic function after, 1783
    Tsuge classification for, 1774*t*
Forearm compartment syndrome, nerve dysfunction associated with, 1783
Forearm flap(s)
  for burn deformities, 1945
  composite, for reconstruction of, amputated thumb, 1697-1699, 1700*f*, 1699.*e*1*f*
  for mangling injuries, 1513, 1514*f*-1515*f*
  radial, 1588-1591, 1589*f*, 1591*b*
    anatomy in, 1588-1589
    operative technique in, 1589-1591, 1590*f*, 1592*f*
Foreign bodies, infection and, 57-58
Foreign body lesions, 2010
Forequarter amputation, preferred method of treatment for, 1756, 1758*f*
Four-corner fusion, with scaphoid excision, 391
Fourth-degree burns, 1929
Fovea, ulnar, 479, 481*f*
Fovea sign, 489
Fowler's wrist tenodesis, in ulnar nerve palsy, 1051, 1051*f*
Fractional palmar intrinsic lengthening, for swan neck deformity, 1114-1115
Fractional tendon lengthening, for spasticity, 1102-1103, 1104*b*, 1105*f*
Fracture(s)
  after metacarpophalangeal joint arthroplasty, 1877
  of capitate, in children, 1447, 1447*f*
  of carpal bones, 588-652
    incidence of, 625*t*
    in mangling injuries, treatment of, 1500
    other than scaphoid, 624-649
Fracture(s) *(Continued)*
  of coronoid process. *see also* Coronoid process, fracture of
    in complex elbow dislocation, 815, 816*f*
    treatment of, 780
      preferred method of, 782
  of distal humerus, 906-907, 908*f*
    preoperative assessment of, 906-907
  of forearm. *see also* Forearm, fractures of
    both bones, 797-798
    diaphyseal, in children, 1458-1471, 1471*b*
  of hamate, 631-634, 633*b*
    body of, 634, 634*f*-635*f*
    in children, 1447-1448, 1448*f*
    hook of, 631-634, 632*f*
      blood supply to, 632
      clinical and radiographic presentation of, 631-632, 632*f*
      postoperative care for, 634
      treatment of, 632-634, 634*f*
    incidence of, 625*t*
  of humerus, distal, 697-733. *see also* Humerus, distal
  of lunate, 636-637, 637*b*
    incidence of, 625*t*
    in Kienbock disease, 639
    mechanism of injury in, 637-638, 638*f*
    radiographic presentation of, 637-638
    treatment of, 638, 639*f*
  of metacarpal bones, 231-248
  pediatric, 1425-1475
    epidemiology of, 1459-1460
    of forearm, diaphyseal, 1458-1471
      historical review of, 1462-1464
      pertinent anatomy in, 1461-1462
      postoperative expectations and management of, 1470-1471
      preoperative evaluation of, 1460-1461, 1461*f*-1463*f*
      types of operations in, 1464-1471
    of hand, 1425-1442
      epidemiology of, 1425-1426, 1426*f*
      historical review of, 1428, 1428*b*
      pertinent anatomy in, 1427-1428
      preoperative evaluation of, 1426-1427, 1427*f*
      types of operations for, 1428-1442
    of wrist, 1442-1457
      epidemiology of, 1442-1443
      pertinent anatomy in, 1444-1445
      preoperative evaluation of, 1443-1444
      types of operations for, 1445-1457
  to perionychium, 322-323, 322*f*-323*f*
  of phalanges, 248-270
  of pisiform, 634-636, 635*b*, 636*f*
    in children, 1448, 1449*f*
    incidence of, 625*t*
  of radius

Fracture(s) *(Continued)*
distal, 516-587. *see also* Radius, distal, fracture of
at head, 734-769. *see also* Radius, head of, fracture of
at shaft, 786-795. *see also* Radius, shaft of, fracture of
of scaphoid, 426, 588-624
biomechanics of, 590-591
cause of, 588
in children, 607-608
classification of, 592-593, 594*t*
clinical presentation of, 591
delayed presentation of waist fracture in, 603
diagnosis of, 591
distal radius and, fractures of, 603-604
examination of, 591-592
imaging of, 592, 593*f*
incidence of, 588, 589*f*, 625*t*
management of, 594-596
algorithm for, 594*t*
in athletes, 603
at distal pole, 594
incomplete, through waist, 594
mechanics of fracture fixation in, 595-596
at proximal pole, 595
at waist, 595
nonsurgical treatment for, cost of, 605-607
physical examination of, 591, 591*f*
rigid fixation for, 596-597
surgical treatment for, 597-603
arthroscopy-assisted percutaneous fixation in, 603
complications of, 605
cost of, 605-607
dorsal percutaneous Slade technique in, 598
fixation in, palmar percutaneous method of, 601-603, 602*f*
mini-open screw in, palmar approach to, 600-601, 600*f*
open reduction and internal fixation in, 597-598
palmar percutaneous method in, 600
pitfalls for, 601*b*, 601*f*-602*f*
postoperative care, 602-603
preferred, 597-598, 597*f*
waist fracture, displaced, 598-599, 599*f*
stability of, 527-530
stabilization of, 791
stress, after bone grafting, 1616-1617, 1616*f*
of thumb, 270-275
in children, 1439-1442
of trapezium, 626-629, 627*b*, 627*f*
imaging of, 628
incidence of, 625*t*
Fracture(s) *(Continued)*
mechanism of injury in, 626-628, 628*f*
treatment of, 628-629, 628*f*-629*f*
of trapezoid, 636, 636*b*
incidence of, 625*t*
of triquetrum, 427, 624-626, 625*b*
body, 625-626
in children, 1447, 1447*f*
clinical and radiographic features of, 626
dorsal cortical, 624-625, 626*f*
incidence of, 625*t*
patterns of, 624-626
treatment of, 626, 627*f*
volar avulsion, 626
of ulna
complete, surgical treatment of, 1464-1466, 1465*f*-1467*f*
preferred method of treatment of, 1466-1468
distal and midshaft, 795-797
proximal, 770-785
ulnar styloid, 493, 493*f*
Fracture-dislocation
axial, in complex carpal instability, 473-475, 474*f*-475*f*
of carpometacarpal, 244-246
multiple, 245
preferred method of treatment of, 245-246, 245*f*-246*f*
of ring finger, 244
of small finger, 244-245
Galeazzi, fixation of, 792-793, 792*f*
of olecranon process, 774-775, 774*f*-776*f*, 816-817, 816*f*
anterior (transolecranon), 774-775, 775*f*, 784.*e*13*b*, 784.*e*13*f*-784.*e*14*f*
complex posterior, 784.*e*1*b*, 784.*e*2*f*-784.*e*3*f*
posterior, 784.*e*4*b*, 784.*e*4*f*-784.*e*5*f*, 784.*e*6*b*, 784.*e*7*f*-784.*e*8*f*, 784.*e*15*b*, 784.*e*15*f*-784.*e*17*f*, 784.*e*25*b*, 784.*e*25*f*-784.*e*27*f*
posterior Monteggia lesion, 817, 817*f*
transolecranon, 816-817, 816*f*
treatment of, 780, 822-823, 823*f*
hinged external fixation in, 823-824, 824*b*, 824*f*
perilunate, 470-472
transscaphoid, 470-471
transscaphoid-transcapitate, 471-472, 472*f*
transtriquetrum, 472, 473*f*
treatment of, 472, 473*f*
of proximal interphalangeal joint, 281-282, 281*f*
chronic, 293-294
stable, 281-282
tenuously stable, 282
treatment of, 281*f*
preferred method of, 284-294, 284*f*
Fracture-dislocation *(Continued)*
unstable, 282, 282*f*
treatment of, 282-293
cerclage wiring in, 283-284, 284*f*
complications of, 290
dynamic skeletal traction in, 283
extension block pinning in, 283
extension block splinting in, 282-283
hemihamate autogenous grafting in, 284
open reduction with internal fixation in, 283
technique for, 291-293, 292*f*-294*f*, 293*b*
volar plate arthroplasty in, 284
volar, 280
radiocarpal, management of, 572-573, 573*f*, 573.*e*1*f*-573.*e*3*f*, 573.*e*2*b*
transscaphoid perilunate, 604-605, 606*f*-607*f*
unreduced, late treatment of, 472, 473*f*
Fragment-specific classification, of distal radial fracture, 524, 526*f*
Fragment-specific fixation, of distal radial fracture, open reduction with, 552-557, 555*f*-556*f*, 558*b*
Free flap(s), 1540, 1554, 1574-1611
classification of, 1575-1577
composite flaps, 1577
cutaneous flaps, 1575-1576, 1575*f*
muscle and musculocutaneous flaps, 1576
perforator flaps, 1576-1577
venous flaps, 1577
contraindications for, 1574-1575
donor sites for, 1576*t*
failing, saving of, 1583-1585, 1585*b*
leeches for, 1582*f*, 1583-1584
operating room exploration and, 1583-1584
thrombolytic agents and, 1584-1585
indications for, 1574
infection in, 1585
monitoring of, 1582-1583
bleeding in, 1582
capillary refill in, 1582
color, 1582, 1582*f*
other techniques in, 1583
operative technique for, 1578-1582
dressings in, 1581-1582
flap harvesting in, 1580-1581
flap insetting in, 1581, 1581*f*
pedicle dissection in, 1581
peduncle length and accessibility in, 1580
recipient vessels in, 1579-1580
skeletal stabilization in, 1579
skin pattern in, 1579, 1590*f*
tissue defect in, examination of, 1577
wound débridement in, 1578-1579, 1578*b*, 1579*f*
zone of injury, avoiding, 1580, 1600*f*

Free flap(s) *(Continued)*
patient care in, 1582
postoperative care for, 1582-1583
preoperative assessment in, 1577-1578, 1578*f*
angiography prior to, 1577
patient preparation in, operating room, 1578
in reconstruction of amputated fingertip, 1717
selection of, 1608-1609
for artery, defects of, 1609
for bone, defects of, 1609
for composite defects, 1609
for sensation, defects of, 1609
for soft tissue defects, 1608-1609
for tendon, defects of, 1609
specific, 1585-1609
anterolateral thigh, 1597, 1598*f*
groin, 1593-1597, 1595*f*-1596*f*
lateral arm, 1585-1588, 1586*f*-1587*f*, 1588*b*
latissimus dorsi, 1597-1602. *see also* Latissimus dorsi muscle flap
tailored, 1599*f*, 1602-1603
radial forearm, 1588-1591, 1589*f*, 1591*b*. *see also* Radial forearm flap
rectus abdominis, 1604
scapular, 1591-1593, 1593*b*. *see also* Scapular flap
sensory flaps, from first web space of foot, 1605-1608, 1606*f*, 1608*b*
serratus anterior, 1603, 1603*f*
temporoparietal fascial flap, 1604-1605, 1604*f*, 1605*b*
thoracodorsal artery perforator flap, 1602-1603
vascularized, in grafting from fibula, 1619
Free functional muscle transfer, for Volkmann contracture, outcomes of, 1782-1783
Free radical scavengers, for complex regional pain syndrome, 1816
Free serratus fascial flap, for burn deformities, 1945
Freeman-Sheldon syndrome, arthrogryposis in, 1366*f*
Freeze-thawed muscle graft (FTMG), 999
excision of neuroma by, repair and, 1014*b*, 1015*f*
Froment sign, 1046-1047
Frostbite injuries, 1951-1953
diagnosis of, 1952
pathophysiologic findings in, 1952
treatment of, 1952-1953, 1953*b*
Frykman classification, of distal radial fracture, 524.*e*1, 524.*e*1*f*
Full-thickness grafts, 1530-1531. *see also* Skin graft/grafting, full-thickness
Functioning free muscle transfer (FFMT)
for brachial plexus injury, 1152-1153
for Volkmann contracture, complications of, 1785-1786
Fungal infections
chronic, 77-90
classification of, 77-78
cutaneous, 80, 80*f*
deep, 84-89
diagnosis of, 63*t*, 78-79
eight-pack tissue culture for, 65*t*
epidemiology of, 77-78
etiology of, 63*t*, 77-78
newly emerging, 89-90
risk factors associated with, 78*t*
subcutaneous, 80-84
treatment of, 63*t*, 79-80, 79*t*
of nails, 330-331
Fungal necrotizing fasciitis, 55, 55*f*

G

Gabapentin, 969
for complex regional pain syndrome, 1813*t*
Gait analysis, before and after toe transfer, 1670
Galeazzi fracture
in children, 1470
fixation of, 792-793, 792*f*
Gamekeeper's thumb, 306-308, 1897
historical review of, 303
operative treatment of
indications for, 1897
options for, 1897*t*
postoperative management and expectations in, 308
preoperative evaluation of, 306-307
treatment of, preferred method for, 308, 308*b*
types of operations for, 307-308, 307*f*
Ganglion(s), 1997-2010
anatomy of, 1999
arthroscopic excision of, surgical technique for, 688-689, 688*f*-689*f*
in carpal tunnel, 2009
clinical characteristics of, 1997-1999, 1999*t*
of distal interphalangeal (DIP) joint, 333, 333*f*-334*f*, 334*b*
of dorsal wrist, 2001-2003
author's preferred method of treatment for, 2001-2003
clinical characteristics of, 2001, 2001*f*
complications in, 2003
operative technique for, 2001-2003, 2001*f*-2003*f*
postoperative care for, 2003
of extensor tendons, 2008, 2010*f*
of first extensor compartment (dorsal retinacular), 2009, 2010*f*
in Guyon canal/distal ulnar nerve, 2009
intraosseous, 2009, 2010*f*
of occult dorsal carpal, 2003-2004
Ganglion(s) *(Continued)*
pathogenesis of, 1999-2001
of proximal interphalangeal joint, 2007-2008, 2008*f*-2009*f*
treatment of
nonoperative, 2001
operative, 2001
of volar retinacular (flexor tendon sheath), 2005, 2005*f*
of volar wrist, 2004-2005
author's preferred method of treatment for, 2004-2005
clinical characteristics of, 2004, 2004*f*
complications in, 2005
operative technique in, 2004-2005, 2004*f*
postoperative care for, 2005
Ganglionectomy, arthroscopic, of wrist, 688-689
Ganglionic blockade, for complex regional pain syndrome, 1816
Gangrene
of digits and distal palm, 1762.*e*3*f*
gas, 54-56
antibiotic recommendations for, 21*t*
Gangrenosum, pyoderma, 75-77
clinical findings on, 76-77, 76*f*
diagnosis of, 77
etiology and epidemiology of, 75-76
treatment of, 77
Gantzer muscle, 935-936
Gap formation, of zone 2 tendon lacerations, 188-189, 189*f*
Gap index, 1449, 1453*f*
Garrod pads. *see* Dorsal Dupuytren nodules (DDN)
Gas gangrene, 54-56
antibiotic recommendations for, 21*t*
Gate theory, of pain, 1801
Gatifloxacin, dosage of, 101*t*
Geissler technique, for scaphoid fractures, 666-668, 666*f*-668*f*
Gelling, after elbow contracture release, 859
Gender, Dupuytren disease and, 129
General anesthesia, 1
Genetic biomarkers, of Dupuytren disease, 129
Geriatric total elbow arthroplasty, 710.*e*1*b*, 710.*e*1*f*
Germinal matrix, of nails, 318
Giant cell tumors
of bone, 2025-2026, 2026*f*-2027*f*, 2027*b*
of tendon sheath, 2012, 2012*b*
Giant hairy congenital nevi, 1966, 1967*f*
Gigantism anomaly, in macrodactyly, 1276*t*, 1277, 1280*f*
Gillies "cocked-hat" flap, for amputated thumb reconstruction, 1696, 1697*f*
"Gilula's lines", 428, 428*f*

Glenohumeral arthrodesis, in brachial plexus injury, 1192, 1194*b*, 1194*f*
Glenohumeral joint
  arthrodesis of, 1090, 1090*f*
  deformity of, in brachial plexus birth palsy, 1408-1409, 1409*f*
Glomus tumor(s), 2056, 2058*f*
  of perionychium, 334, 335*f*
Gnathostomiasis, 117
Gore-Tex glove, filled with silver sulfadiazine, for burns, 1931, 1932*f*
Gorlin syndrome, 1972-1973, 1974*f*
Gout, 57-58
  tendinopathy in, 1905, 1905*f*
  tophaceous, 58*f*
Gracilis muscle
  dissection of, 1783*f*
  harvest of, for free functioning muscle transfer, in brachial plexus injury, 1179-1180, 1180*f*
  transfer of, 1781
Gracilis muscle flap, for mangling injuries, 1515, 1518*f*
Graft(s)
  bone-ligament-bone, scapholunate ligament replacement with, 442-443
  chevron-type slot, for short metacarpal lengthening, 1242-1243, 1242*f*
  fat, for Madelung deformity, 1339-1342, 1341*f*
  for nail bed, harvest of, 322, 322*f*
  rupture of, as complication, of flexor tendon grafting, 224
  versus tendon transfers, 1065
  toe eponychial, 329
Grafting. *see* Skin graft/grafting
Granular cell tumors, 2013-2014, 2013*f*
Granuloma
  interdigital, 118
  pyogenic, 1970, 1971*f*
  of nails, 332, 332*f*
Grasp
  reconstruction of, free muscle transfer for, after brachial plexus avulsion, 1180-1184
    complications of, 1184
    donor muscle selection in, 1181-1182
    operative technique of, 1181-1183, 1181*f*-1182*f*, 1184*b*
    outcome of, 1184, 1184*f*
    postoperative protocol for, 1183
    prerequisites of, 1181
    subsequent surgery for, 1183-1184
  spasticity and, evaluation of, 1085
Grayson ligament, 134-136
Greater arc injuries, in dorsal perilunate fracture-dislocations, 470
Grebe chondrodysplasia, 1214, 1215*f*
  central polydactyly in, 1234, 1234*f*
Greenstick fractures, 1461, 1462*f*-1463*f*
  operations for, 1464
Groin flap(s), 1564-1568, 1564*f*, 1566*f*-1567*f*, 1568*b*
  for burn deformities, 1944
  in first web space reconstruction, 1228-1230, 1230*f*
  free, 1593-1597, 1595*f*-1596*f*
  for mangling injuries, 1512, 1512*f*-1513*f*
Guepar prosthesis, 361-362
Gunshot injury, to brachial plexus, 1149
Guyon canal
  anatomy of, 939, 939*f*
  ganglions of, 2009
Guyon canal compression, 938-940
  postoperative care in, 940
  preferred treatment of, 939-940, 940*b*
  provocative tests for, 926*t*
  recurrent, 956

H

Hahn-Steinthal fracture, of capitellum, 703, 703*f*
Hairy congenital nevi, giant, 1966, 1967*f*
Hamartomas, lipofibromatous, 2011-2012
Hamate, 660*f*
  fracture of, 631-634, 633*b*
    body of, 634, 634*f*-635*f*
    in children, 1447-1448, 1448*f*
    hook of, 631-634, 632*f*
      blood supply to, 632
      clinical and radiographic presentation of, 631-632, 632*f*
      postoperative care for, 634
      treatment of, 632-634, 634*f*
    incidence of, 625*t*
Hand
  amputee, rehabilitation process of, 1746-1747, 1747*b*
  in brachial plexus birth palsy, 1419-1421
  compartments of, release of, 1770
  defects of, skin flaps for, 1568-1570, 1568*t*
  fractures of, in children, 1425-1442
    epidemiology of, 1425-1426, 1426*f*
    historical review of, 1428, 1428*b*
    pertinent anatomy in, 1427-1428
    preoperative evaluation of, 1426-1427, 1427*f*
    types of operations for, 1428-1442
  mangling injuries of, treatment of, 1512-1515, 1512*f*-1517*f*
  osteoarthritic, treatment of, 345-372
  preparation of, for replantation, 1479
  prosthetics, 1738-1745
  as recipient site, in bone grafting, 1637
  stiffness of, 338-344. *see also* Stiffness, of finger and hand
    after bending fractures, 567-568
  Volkmann contracture of, 1783-1785
Hand preparation
  for free phalangeal transfer, in finger reconstruction, 1262, 1262*f*
  for microvascular toe transfer, of hypoplastic digits, 1267-1268
Hand therapy, for complex regional pain syndrome, 1818
Hand-foot-genital syndrome, 1213-1214
Hangnail, 331
Hansen disease (HD), 103-116
  classification of, 104-105
    lepra reaction in, 111*t*
  clinical, bacteriologic, histologic, and immunologic features of, 105*t*
  clinical pathology of, 104
  diagnosis of, 105-109, 115*b*
    cardinal signs in, 105-107, 106*f*-107*f*
    tests in, 107-109
  for ENL reaction, 110
  epidemiology of, 103
  etiology of, 103
  indications for steroids in, 116*b*
  for lepra reaction, 111*t*
  for Lucio reaction, 110-111
  multibacillary, 109
  nerve abscess in, 112-113, 113*f*-114*f*
  paucibacillary, 109
  treatment of, 109-116
    for compression neuropathy, 112, 112*f*
    for deformities, 114-115, 115*f*
    for nerve abscess, 112-113
    pain in, relief of, 109-113, 110*f*
    preservation of sensation, 113-114
    reactions, 111-112
    rehabilitation in, 115
    resource materials in, 115-116
    restoration of sensibility, 114
    for reversal reaction, 110
Hardware removal, from radius and ulna, after both-bone forearm fractures, 798-799
Harvest technique, in vascularized bone grafting, 1630-1631, 1631*f*
Healing, of scaphoid nonunion, prognosis for, 620-621
Healing time, for phalangeal fractures, 256
Hematoma
  after posttraumatic interosseous contracture, 343.*e*1
  management of, in resection arthroplasty, 363
  in skin grafting, 1537
  subungual, 318-319, 320*f*
Hemiarthroplasty, of wrist, 414-416
Hemiepiphyseal stapling, of distal radius, 1359-1360, 1360*f*
Hemihamate arthroplasty, for proximal interphalangeal joint fracture-dislocation, 294
  case study on, 315.*e*1*b*, 315.*e*1*f*-315.*e*2*f*

Hemihamate autogenous grafting, for proximal interphalangeal joint fracture-dislocation, 284
  outcomes of, 293
  postoperative protocol for, 293
  preferred technique for, 291-293, 291*f*-294*f*, 293*b*
Hemihypertrophic macrodactyly, 1282
Hemipulp flaps, transfer of, from toes to fingers, 1647
Hemiresection-interposition arthroplasty, for radioulnar joint arthritis, 503-504, 504*f*
Hemitrapeziectomy, arthroscopic, technique for, 693-694
Hemophilic arthropathy
  preoperative considerations of, 909
  total elbow arthroplasty for, 909
Henry approach, to radial tunnel syndrome, 951-952, 951*f*
  modified, 952
Heparin
  after free flap transfer, 1582
  for vasospastic disorders, 2054
Herbert classification, of scaphoid fractures, 593
Herbert screws
  for distal humeral fractures, 718
  for distal interphalangeal joint arthrodesis, in swan neck deformity, 1881*f*
Herbert-Whipple technique, for scaphoid fractures, 669-670, 669*f*-670*f*
Hereditary motor-sensory neuropathy, 923
Hereditary multiple exostoses, of forearm, 1357-1362
  pertinent anatomy in, 1359, 1359*f*
  preoperative evaluation for, 1357-1359, 1358*f*
  surgical treatment of, 1359-1361, 1360*f*-1361*f*
    contraindications to, 1359
    postoperative management and expectations after, 1361-1362
    preferred technique for, 1362, 1362*b*
Hereditary neuropathy with liability to pressure palsies (HNPP), 923
Heritability, of Dupuytren disease, 128
Herpes simplex virus (HSV) infection
  AIDS and, 120
  of fingers, 52-53, 52*f*
Herpetic whitlow, 52-53, 52*f*
Heterodigital flap reconstruction, for soft tissue defects of thumb, 1679-1681, 1680*f*
  cross-finger flap
    dual innervated, 1684, 1685*f*
    innervated, 1681-1684, 1681*b*
    radial-innervated, 1682-1684, 1683*f*, 1684*b*, 1684.*e*1*f*
    to thumb, 1680-1681, 1682*f*, 1681.*e*1*f*
  first dorsal metacarpal artery island flap, 1684-1686, 1686*f*
Heterodigital flap reconstruction, for soft tissue defects of thumb *(Continued)*
  neurovascular island pedicle flap, 1686-1687, 1688*f*, 1689*b*
Heterotopic bone, after radial head fractures, 764, 764*f*
Heterotopic ossification
  adjuvant therapy for, 857
  after biceps rupture surgery, 874
  after burns, 1943
  after elbow contracture release, 859
  after elbow dislocation, 826-827
  after humeral fractures, 730-731, 730*f*
  after radial head fractures, 764
  classification of, 803, 804*t*
  stiffness of, 784
High-flow arteriovenous malformations, 2056, 2057*f*
High-pressure injection injuries, 57
High-velocity injuries, of radius, 527
Hinged fixation, after elbow contracture release, 855, 855*f*
Hirudo medicinalis, 1584
Histiocytoma. *see also* Dermatofibroma
  malignant fibrous, 2019, 2019*f*
Histoplasmosis, 86-87
Hockey-stick incision, for felon, 27*f*, 27*t*
Holstein-Lewis spiral fracture, radial nerve palsy associated with, 1074
Holt-Oram syndrome, 1214
  radial deficiency associated with, 1289, 1290*t*
  longitudinal, 1329*t*
  in triphalangeal thumb, 1315, 1318*f*
Homografts, 1000
  for digital nerve repair, 1009
Horner's syndrome, 1149-1150, 1152*f*
  in brachial plexus birth palsy, 1393, 1406
Hospital for Sick Children Active Movement Scale (AMS), 1394, 1396*t*
Hotchkiss classification, of radial head fractures, 736, 736*t*
House's reconstruction, in tetraplegic patient
  one-stage key pinch, 1134-1135, 1137*b*
    brachioradialis to flexor pollicis longus transfer in, 1134-1135
    carpometacarpal fusion in, 1134, 1135*f*
    extensor pollicis longus tenodesis in, 1135, 1135*f*
    split flexor pollicis longus transfer in, 1135, 1136*b*, 1136*f*
  two-stage grasp, pinch, and release, 1137-1139, 1139*b*
    extensor phase in, 1137-1138
    flexor phase in, 1138, 1139*f*
HOX genes, 1213-1214
HOXD13 gene, mutation of, 1234
"H"-type injury, of distal humerus, 702, 702*f*, 718-719. *see also* Humerus, distal
Huber opponensplasty, in median nerve palsy, 1032-1033, 1033*f*-1034*f*
Human bites, 48-50, 49*f*-50*f*
  antibiotic recommendations for, 21*t*
  wounds, zone 5 injuries, of extensor tendon, 174-175
Human immunodeficiency virus (HIV), 119-121. *see also* Acquired immunodeficiency syndrome (AIDS)
  less common malignant tumors and, 1983, 1984*f*
Human papilloma virus (HPV), and verruca vulgaris, 1962
Humeral external rotation osteotomy, for arthrogryposis, 1368-1372, 1371*b*
  complications of, 1372
  contraindications to, 1368-1370, 1371*f*
  indications for, 1368
  preoperative planning for, 1370
  technique of, 1370, 1372*f*
Humeral graft, for lateral collateral ligament, 833
Humeral tunnel, for lateral collateral ligament, 833, 834*f*
Humerus
  distal
    anatomy of, 698-699, 699*f*-701*f*
    fractures of, 697-733, 906-907, 908*f*
      ballistic injuries associated with, 726
      bicolumnar, 702, 702*f*, 721-724, 721*b*
      bone loss associated with, 726
      classification of, 699-705
        AO/ASIF, 703
        articular fracture patterns in, 703-705, 704*f*-705*f*
        capitellum and, 703, 703*f*-704*f*
        column concept in, 701-703
        trochlear and, 703-704
      complications of, 728-731
        heterotopic ossification as, 730-731, 730*f*
        infection as, 729
        nonunion of distal humerus as, 728
        nonunion of olecranon osteotomy as, 728-729, 729*f*
        stiffness as, 730-731, 730*f*
        ulnar neuropathy as, 729-730
      considerations and potential pitfalls of, 720-721
      elbow stiffness after, 853-854
      expectations after, 727-728
      fixation principles in, 717-726, 719*f*
      historical review of, 705-707, 706*t*, 708*t*
      implant biomechanics in, 719-720
      operative management of, 707-731
        anconeus flap transolecranon approach to, 714-715, 716*f*

Humerus *(Continued)*
anesthesia in, 710-711
Bryan-Morrey "triceps-sparing" approach to, 713-714, 714*f*
in elderly, 707-710
exposures in, 711-717, 711*f*, 718*b*
lateral approach to, 715-717, 717*f*
olecranon osteotomy in, 711-712, 713*f*
open fractures and, 707
open reduction and internal fixation in, 707-709, 709*t*
paratricipital approach to, 711, 712*f*, 711.*e*1*b*, 711.*e*1*f*-711.*e*2*f*
patient position in, 710-711, 710*f*
in polytrauma patients, 707
preferred method of, 720
timing of, 707-711
total elbow replacement in, 709-710, 709*t*, 710.*e*1*b*, 710.*e*1*f*
triceps-reflecting anconeus pedicle approach to, 714, 715*f*
triceps-splitting approach to, 712-713, 713.*e*1*b*, 713.*e*1*f*-713.*e*4*f*
physical examination of, 697
postoperative care for, 726-727
preoperative assessment of, 906-907
preoperative evaluation of, 697-698
radiographic examination of, 697-698, 698*f*-699*f*
simple, 725
supracondylar, 721
transcondylar, 721
unicolumnar, 724-725, 725.*e*1*b*, 725.*e*1*f*-725.*e*2*f*
nonunion of, elbow contracture and, 854
external rotation osteotomy of, for arthrogryposis, 1368-1372, 1371*b*
fractures of, associated with radial nerve palsy, 1074-1076
early, 1074
if no return at longer waiting period, 1075, 1075*f*
nerve exploration in, at 6 to 8 weeks, 1074-1075, 1075*f*
preferred method of, 1075
as recipient site, in vascularized bone grafting, 1636
rotational osteotomy of, 1089, 1089*f*
for ulnar deficiency, 1335, 1338
"Humpback" deformity, scaphoid, 430-431, 464, 1445, 1446*f*
Hunter-Thompson chondrodysplasia, 1214
brachydactyly associated with, 1239-1240
Hutchinson's freckle. *see* Lentigo maligna
Hybrid prostheses, in prosthetics, 1759
Hybrid Russe procedure, in bone graft, for scaphoid nonunion, 611-614, 611*f*-613*f*
Hydrofluoric acid burns, treatment of, 1951, 1951*f*, 1952*t*
Hydrotherapy, for frostbite, 1953
Hydroxyapatite, deposition of, tendinopathy in, 1906
Hyperalgesia, 1802
definition of, 1799*t*
Hyperesthesia, definition of, 1799*t*
Hyperextension, of proximal interphalangeal joint, 294-295
Hypergranulation, early, after burns, 1935
Hyperkeratosis, 1959-1960
Hyperostotic macrodactyly, 1279*f*, 1282
Hyperpathia, 1802
definition of, 1799*t*
Hypodermic needle, 146
Hypoesthesia, definition of, 1799*t*
Hypoglossal nerve transfer, for brachial plexus injury, 1177
Hyponychial deformities, 329-330, 329*f*
Hypothenar hammer syndrome, 2042
Hypothenar muscles, 338.*e*4
Hypothenar space
infections of
characteristics of, 35*t*
treatment for, 36, 37*f*
pertinent anatomy in, 35

I

Iliac bone graft, for distal radial fracture fixation, harvesting of, 543-546
Iliac crest
bone graft from, for scaphoid nonunion, 619
flap, 1620-1621
vascularized grafting from
complications of, 1621
donor results in, 1621
in upper extremity, 1622-1623, 1623*f*
iLIMB digits, 1737.*e*3*f*
Imipramine, for complex regional pain syndrome, 1812*t*
Immobilization, closed reduction with
for lesser-arc injuries, 466-467, 467*f*
for perilunate fracture-dislocations, 470-471
Immune responses, cellular, in AIDS, 119.*e*2
Impaction, ulnar, 582
Impaired vascularity, vascularized bone grafts and, 1615
Impending compartment syndrome, 1763
Implant(s)
Artelon, 362
infections of, 50-51
mechanical failure of, as complication of flexor tendon grafting, 224
in metacarpophalangeal joint, arthroplasty, flexible, 1872-1875, 1872*f*-1875*f*
preferred method of treatment in, 910-913, 912*f*-913*f*
pyrocarbon
for metacarpophalangeal joint arthroplasty, 358
for proximal interphalangeal joint arthroplasty, 357
in radial head arthroplasty, 752-754, 755*f*-756*f*, 756*b*
for rigid fixation, of scaphoid fractures, 596
silastic
for metacarpophalangeal joint arthroplasty, 358
for proximal interphalangeal joint arthroplasty, 357
types of, 909-913, 911*f*
Improved prosthetic control, 1760-1761, 1760*f*
In situ bypass, for vascular disorders, 2049-2052
In situ decompression, for cubital tunnel syndrome, 943
Incision(s)
for complex traumatic elbow dislocation, 824-825
fasciectomy, for Dupuytren disease, 141-142, 142*f*
in operative procedure, to ulnar fractures, 776
in surgical approach
to toe transfer, 1665-1666
to trigger finger, 1910*f*-1911*f*
Incisional biopsy
elliptical, 1961
for musculoskeletal tumors, 1991
Inclination, 419
Inclusion cysts, epidermal, 2009-2010, 2011*f*
Index rotation flap, 1383
Infantile digital fibromatosis, 1968, 1970*f*
Infection(s)
acute, 17-61
anthrax, 56-57, 57*f*
of bite wounds
animal, 46-48
human, 48-50, 49*f*-50*f*
caused by parenteral drug abuse, 51-52
common, 20-22
antibiotic recommendations for, 21*t*
deep space, 34-40, 40*b*
collar-button abscess, 37-38, 38*f*-39*f*, 38.*e*1*b*, 38.*e*1*f*

Infection(s) *(Continued)*
palmar, 34-36, 34*f*, 35*t*, 36*f*-37*f*
subfascial, 36-40
felon, 26*f*-27*f*, 27*t*, 28*b*
flexor tenosynovitis
pyogenic, 28-32, 30*f*, 32*b*
septic, 31.*e*1*b*, 31.*e*1*f*
mallet deformity, 43
osteomyelitis, 43-46, 45*t*, 46*f*, 43.*e*1*b*, 43.*e*1*f*
Parona space, 33
paronychia
acute, 20-22, 20*f*, 22*b*, 22*f*
chronic, 23-25, 24*f*-25*f*, 25*b*
radial bursa, 32-33
in septic
arthritis, 40-41
boutonnière deformity, 43
ulnar bursa, 33
in wrist joint, 41-43, 42*f*, 44*f*
diabetic hand, 53-54
evaluation of, 18-19
general principles of, 17-19
in herpetic whitlow, 52-53, 52*f*
melanoma as, 58.*e*1*b*, 58.*e*1*f*
methicillin-resistant *Staphylococcus aureus*, 18, 18*f*
mimickers of, 57-58, 58*f*
necrotizing, 54*f*-56*f*, 55.*e*1*b*, 55.*e*1*f*
nosocomial, 18
prosthetic and implant, 50-51
in septic thrombophlebitis, 52
types of, 17
principles in, 19, 20*b*
of upper extremity, with HIV, 53
after elbow contracture release
joint, 859
pin tract, 859
after humeral fracture, 729
after metacarpophalangeal joint arthroplasty, 1878
after total elbow arthroplasty, 909, 916-918
after ulnar fractures, 782-783
chronic, 62-127
bacterial, 67-77
etiology, diagnosis, and treatment of, 63*t*
culturing of, 65, 65*t*
isolation in, 66
diagnosis of, 62-64, 63*t*
direct visualization of, by staining, 65-66
drug-susceptibility tests for, 66
evaluation of, 66-67
fungal, 77-90, 78*t*-79*t*
etiology, diagnosis, and treatment of, 63*t*
Hansen disease and, 103-116, 105*t*, 106*f*-107*f*, 110*f*, 111*t*, 112*f*-113*f*, 115*b*
Infection(s) *(Continued)*
laboratory techniques for, 64-67
microbial nucleotide sequences of, detection of, 66
mycobacterial, 90-103, 91*t*
etiology, diagnosis, and treatment of, 63*t*
occupational, 118
parasitic, 116-118
etiology, diagnosis, and treatment of, 63*t*
pathogenic-specific antigens and antibodies for, detection of, 66
prototheca, 116-118
etiology, diagnosis, and treatment of, 63*t*
protozoal, 116-118
etiology, diagnosis, and treatment of, 63*t*
scabies and, 118-119
specimen collection and handling of, guidelines for, 64-65, 65*t*
treatment of, 67, 67*t*
viral, 119-125
etiology, diagnosis, and treatment of, 63*t*
as complication
of flexor tendon grafting, 225
of phalangeal fractures, 269
effect of, on wound healing, 1530
of free flaps, 1585
of perionychium
acute, 330-331
chronic, 331-332, 332*f*
to regional anesthesia, 1
secondary, after burns, 1935, 1936*f*
vascularized bone grafting and, 1624
Infiltrative fasciitis, 2014
Informed consent, for brachial plexus surgery, 1154
Infraclavicular block, 7-8, 7*f*
Infraclavicular brachial plexus, 1146
injury to, 1150
decisions and priorities of repair for, 1160
surgical approach to, 1157-1158, 1157*f*
Infraclavicular nerve block, for contracture release, 849
Inspection, in thoracic outlet syndrome, 964-966, 965*f*-967*f*
Instability
after ulnar fractures, 783, 783*f*
posteromedial varus rotational, 784.*e*9*b*, 784.*e*9*f*-784.*e*10*f*
Intercarpal arthrodesis
limited, for midcarpal instability, 461, 462*f*
for wrist arthritis, 690
Intercarpal fusion, for scaphoid nonunion advanced collapse, 623-624
1,2 Intercompartmental supraretinacular artery
bone grafting using, 1629
for scaphoid nonunion, 1630-1632
inlay graft, vascularized bone graft, 1637
for scaphoid nonunion, 617-618, 617*f*-618*f*
2,3 Intercompartmental supraretinacular artery, bone grafting using, 1629
Intercostal nerve
surgical anatomy of, 1169, 1170*f*
transfer of
for brachial plexus injury, 1169-1172, 1170*f*
to musculocutaneous nerve, 1171, 1171*f*, 1172*b*
complications of, 1172
contraindications to, 1171-1172
outcomes of, 1172
postoperative care after, 1171
Interdigital commissure, release of, in syndactyly, 1219-1220, 1219*f*-1222*f*
Interdigital granuloma, 118
Interdigital pilonidal sinus, barber's, 118
Interfragmentary compression screws, for metacarpal shaft fractures, 240, 240*f*, 237.*e*1*t*
Interligamentous sulcus, 420
Intermediate column
single-fragment fractures of, 571-572, 572.*e*1*b*, 572.*e*1*f*-572.*e*2*f*, 572.*e*3*b*, 572.*e*4*f*-572.*e*6*f*
three- and four-part injuries to, 572
Intermediate fibers, 134
Internal fixation
of radial head fractures, "safe zone" for, 738-739, 739*f*
role of, in vascularized bone grafting, 1637
Internal splint, for radial nerve palsy, 1065
International Association for the Study of Pain (ISAP), 1797, 1799*b*
International classification of surgery, for tetraplegia, 1123*t*, 1133*t*
Interosseous ligament, reconstruction of, in longitudinal forearm instability repair, 808-809
Interosseous membrane (IOM), 482
reconstruction of central band of, 807-808, 807*f*-808*f*
Interosseous muscle(s)
anatomy of, 338.*e*3-338.*e*4, 338.*e*4*f*-338.*e*5*f*
contracture of, posttraumatic, 343.*e*1
dorsal, 1770, 1772*f*
slide of, for intrinsic muscle spasticity, 1113-1114
Interosseous nerve
anatomy of, 936
posterior, 886-887
palsy of, 1064, 1064*f*

Interosseous nerve syndrome
anterior, 937
posterior, 949-952
release of, 953*b*
Interosseous wiring, 259, 260*f*, 259.*e1t*
for metacarpal shaft fractures, 239, 237.*e1t*
Interphalangeal (IP) joint
distal. *see* Distal interphalangeal (DIP) joint
extensor lag, proximal, as complication of phalangeal fractures, 268-269
in mangling injuries, treatment of, 1493
proximal. *see* Proximal interphalangeal (PIP) joint
in rheumatoid arthritis, boutonnière deformity and, 1898
of thumb
arthrodesis of, in ulnar nerve palsy, 1059
dislocation of, 296-297
Interposition graft, for flexor tendon, 219-220, 219*f*
Interscalene block(s), 6, 7*f*
bilateral procedures and, 2
continuous peripheral nerve catheters and, 5
Interscalene triangle, in thoracic outlet syndrome, 963, 963*f*
Interscapulothoracic amputation, 1756, 1757*f*, 1762.*e2f*
Intersection syndrome, 1916, 1920-1921, 1920*f*
Intraarticular anesthetic joint injection, for Dupuytren disease, 148
Intraarticular fractures
of humerus, 701-702. *see also* Humerus, distal
in mangling injuries, treatment of, 1499
Intracarpal pronosupination, 424
Intramedullary fixation
for forearm diaphyseal fracture stabilization, in children, 1465, 1467*f*
of metacarpal shaft fractures, 239-240, 239*f*, 237.*e1t*
of proximal and middle phalangeal fracture, 259
Intramedullary implants, 559, 561*f*-562*f*, 559.*e1b*, 559.*e1f*-559.*e3f*
radial, for wrist fractures, 1465, 1467*f*
Intramedullary pins
fusion of, for patients with rheumatoid arthritis, 401-404, 402*f*-403*f*
wrist arthrodesis with, critical points in, 404*b*
Intramedullary rods
of distal and midshaft ulnar fractures, 796
of radial shaft fractures, 793, 793*f*-794*f*, 795*b*
Intramuscular transposition, of ulnar nerve, for cubital tunnel syndrome, 945
Intraosseous ganglion, 2009, 2010*f*
Intraplexal nerve transfers, for brachial plexus injury, 1176-1177
Intravenous regional block, 10-11
Intrinsic lateral band release, for intrinsic muscle spasticity, 1114, 1114*f*
Intrinsic ligaments, of wrist, 421*f*-422*f*, 422-423
Intrinsic muscle, spasticity in, 1085
release or slide of origin of, for thumb-in-palm deformity, 1108-1109, 1108*f*
swan neck deformity and, 1113-1117, 1113*f*
Intrinsic tendons, of metacarpophalangeal joint, in rheumatoid arthritis
crossed transfer of, 1869-1870
release of, 1869, 1869*f*
Intrinsic-minus deformities, 1117-1118
Ion channels, voltage-gated, 980-981
Irrigation, closed tendon sheath, for pyogenic flexor tenosynovitis, 30-31, 30*f*
Ischemia
etiology of, 2036-2038, 2037*f*-2038*f*
metabolic changes after, 1488
Island flap(s)
neurovascular, for soft tissue defects of thumb, 1684-1686, 1686*f*
pedicle, 1540
in reconstruction of amputated fingertip, 1717
Isolated displaced fractures, of radial head fractures, management of, 741-742, 742*f*
Isoniazid
dosage of, 101*t*
for tuberculosis, 100
cutaneous, 92
Itraconazole
for aspergillosis, 84-85
for blastomycosis, 85
for coccidioidomycosis, 86
for cryptococcosis, 86
for deep sporotrichosis, 88
for eumycetoma, 73
for fungal infections, 79, 90
cutaneous, 80
of nails, 330-331
for histoplasmosis, 86-87
for protothecosis, 116
spectrum of activity of, 79*t*
for sporotrichosis, 83, 83*b*

J

Jackson-Pratt drain, 947
Jahss maneuver, 1438
Jellyfish, venomous, 1792, 1792*f*
Jobe technique, modified, 837
Joint(s)
arthroplasty of, 1866-1867, 1867*f*
in mangling injuries
reconstruction of, 1499-1500, 1501*f*-1504*f*, 1502*b*
case study for, 1499.*e1b*, 1499.*e2f*-1499.*e3f*
salvage or fusion of, 1493-1494, 1494*f*
manipulation of, for swan neck deformity, in rheumatoid arthritis, 1879-1890, 1880*t*
measurements, of Dupuytren disease, 132, 132*f*
preoperative evaluation of, 1644-1645
Joint anesthetic injection, for Dupuytren disease, 148, 148*f*
Joint-leveling procedures, for Kienbock disease, 642
Joule's law, 1946
Junctional nevi, 1965-1966
Juncturae tendinum, 152-154
in extensor tendon, 1060
Juvenile aponeurotic fibroma, 2014

K

Kanamycin, dosage of, 101*t*
Kapandji technique, of double intrafocal, wire fixation, for distal radial fracture, 532, 537*f*
Kaposi sarcoma, AIDS and, 121
Keratoacanthoma, 1971, 1972*f*
Keratohyalin, 1958
Keratolytic therapy, for warts, 122
Keratosis
actinic, 1972, 1972*f*
arsenical, 1972
seborrheic, 1964, 1966*f*
Ketamine, for complex regional pain syndrome, 1815-1816
Ketoconazole
for blastomycosis, 85
for deep sporotrichosis, 88
for eumycetoma, 73
for fungal infections, 79
cutaneous, 80
for histoplasmosis, 86-87
for protothecosis, 116
spectrum of activity of, 79*t*
Keyser-Eaton marsupialization, of nail fold, 331-332
Kienbock disease, 639
clinical presentation of, 640
etiologic findings in, 639-648
imaging of, 641
radiographic presentation of, 640, 641*f*
staging of, 640-641, 641*t*
treatment of, 641-647
joint-leveling procedures in, 642
preferred method for, 647-648
of stage I, II or IIIA, with ulnar-negative variance, 641-646

Kienbock disease *(Continued)*
radial-shortening osteotomy in, 642-643, 642*f*
vascularized bone grafting in, 643
of stage I, II or IIIA with ulnar-positive or ulnar-neutral variance, 646
capitate shortening with capitate-hamate fusion in, 646
closing wedge radial osteotomy in, 646, 647*f*
core decompression in, 646
of stage IIIB, 646-647, 648*f*
of stage IV, 647
vascularized bone grafting for, 1624-1625, 1633*f*
lunate, 1638-1639
wrist arthroscopy for, 691-692, 691*t*, 692*f*
Kirner deformity, 1273-1275, 1274*f*, 1275*b*
anatomy in, 1274, 1275*f*
epidemiologic findings in, 1274, 1274*f*
management of, 1274-1275
preferred method of treatment of, 1275
Kirschner pin/wire fixation, 393, 394*f*
of distal humeral fractures, 717
of distal radial fracture, 531
in hemihamate reconstruction, 292-293, 294*f*
for lesser-arc injuries, 467
for metacarpal shaft fractures, 238-239, 238*f*, 237.*e*1*t*
for metacarpophalangeal joint contractures, 341.*e*1
for perilunate fracture-dislocations, 471
for pilon fracture, 283, 283*f*
in pollicization for thumb hypoplasia, 1298-1299, 1300*f*
in proximal interphalangeal joint arthrodesis, in swan neck deformity, 1881-1882
for rigid fixation, of scaphoid fractures, 596
in scapholunate dissociation, 439
sequence of, 724
for ulnar fractures, 777*f*, 778
in wrist arthroscopy, 663
"Kissing" lesions, 1968, 1970*f*
Kite flap, 1545-1546, 1546*f*
Klumpke palsy, 1149-1150
Knuckle pads. *see* Dorsal Dupuytren nodules (DDN)
Kocher approach, to radial head fractures, 745, 747*f*
Kocher-Lorenz fracture, of capitellum, 703, 703*f*
Kocher's lateral approach, to distal humeral fractures, 715, 717*f*
Koebner phenomenon, 374
Krackow stitch
in triceps avulsion repair, 880, 880*f*-881*f*
in two-incision biceps rupture repair, 876, 877*f*
Krackow-Thomas repair, of extensor tendon laceration, 158-159, 159*f*
Krukenberg procedure, for below-elbow transverse failure of formation, 1346
Kutler lateral V-Y flap, in reconstruction of amputated fingertip, 1713-1714, 1714*f*

L

Lacerations
of extensor tendon. *see also* Extensor tendon injury
zone 5 injuries, 174
zone 6 injuries, 177
stellate, of nail bed, 320, 320*f*
Lactation, de Quervain disease of, 1917
Lambda pattern fracture, of distal humerus, 702, 702*f*. *see also* Humerus, distal
Landsmeer ligament. *see* Oblique retinacular ligament (ORL)
Laser Doppler flowmetry, for vascular disorders, 2039
Laser(s), implanted, in monitoring of vascularized
bone grafts, 1615
Lasso procedure, of Zancolli
digital clawing treated with, 1142-1143, 1142*f*
in tetraplegia, 1125*f*, 1141
Late recontracture, of Dupuytren disease, 134, 134*t*
Latency, in nerve conduction studies, 929
Lateral angulation, as complication of phalangeal fractures, 266-267, 266*f*
Lateral approach, to open release, of elbow contracture, 852-853
postoperative care after, 853
Lateral arm flap
anatomy, 1585-1586
for burn deformities, 1945
free, 1585-1588, 1586*f*-1587*f*, 1588*b*
for mangling injuries, 1515, 1517*f*
operative technique in, 1585-1586
Lateral band, 338.*e*3, 338.*e*5*f*
mobilization of
and relocation of, for boutonnière deformity, 172
in swan neck deformity, 1884-1885, 1885*f*
Lateral band tenodesis, for proximal interphalangeal joint subluxation, 294-295
Lateral collateral ligament, repair of, in complex traumatic elbow dislocation, 819
Lateral column fracture, complex, 725.*e*3*b*, 725.*e*3*f*-725.*e*4*f*
Lateral epicondylitis, arthroscopy for, 897-899, 898*f*
Lateral positioning, in elbow arthroscopy, 886, 888*f*
Lateral projection, carpal injury and, 429
Lateral slips, 338.*e*5
Lateral tendon, 338.*e*3, 338.*e*5*f*
Latissimus dorsi muscle
anatomy of, 1599-1601
transfer of
for elbow reconstruction, in brachial plexus injury, 1197-1198, 1199*f*, 1200*b*
for shoulder reconstruction, in brachial plexus injury, 1188
Latissimus dorsi muscle flap, 1561-1562, 1562*f*, 1563*b*
free, 1597-1602, 1598*f*-1601*f*, 1602*b*
tailored, 1599*f*, 1602-1603
for mangling injuries, 1515, 1520*f*
operative technique, 1601-1602
"Law of diminishing returns," in metacarpophalangeal joint extension contracture, 340
Leather-Mills valvulotome, for vascular disorders, 2050, 2050*f*
Leeches
animal bite and, 48
for free flap failure, 1582*f*, 1583-1584
Leiomyosarcoma, 2020
Leishmaniasis infection, 116-117
Lentigo maligna, 1978, 1980*f*
Lentigo simplex, 1965
Lepra reaction, in Hansen disease, 110
classification of, 111*t*
treatment of, 111*t*
Lepromin skin test, for Hansen disease, 107-108
Leprosy. *see* Hansen disease (HD)
Leri-Weill dyschondrosteosis, 1213-1214, 1214*f*
Lesser-arc injuries, in dorsal perilunate dislocations, 465-470, 465*f*-466*f*
Levofloxacin, dosage of, 101*t*
Lichtman classification, of Kienbock disease, 641*t*
Lidocaine
in Bier block, 10-11
characteristics of, 4*t*
for complex regional pain syndrome, 1814*t*
Ligament(s)
definition of, 838
of elbow, 739, 740*f*
reconstruction, for carpometacarpal joint osteoarthritis
operative techniques, 362-363
treatment, 361
of scaphoid, 589-590, 589*f*
Ligamentoplasty, using tendon graft, in scapholunate dissociation, 443-446
Ligamentotaxis, 516.*e*1
Ligamentum subcruetum, 481, 481*f*
Light moving touch, in compression neuropathy evaluation, 928
Limb, threatened at birth, treatment of, 1255-1256

Limb amputation, major, 1753-1756
case study of, 1762.e1b, 1762.e1f-1762.e3f, 1762.e3b
indications for, 1753, 1754f
Limb bud, 1208, 1209f
formation of, 1212b
Limb development
anteroposterior, 1210-1211, 1212f, 1213t
dorsoventral, 1211
during embryogenesis, 1208
key milestones in, 1209t
proximodistal, 1209-1210, 1210f-1211f
spatial axes of, 1209-1211
Limb function, poor, free flap contraindicated in, 1575
Limited open reduction, of distal radial fractures, 536
Lipofibromatosis, macrodactyly associated with, 1276-1277
Lipofibromatous hamartomas, 2011-2012
Lipomas, 2011
Liposarcoma, 2017-2018, 2018f
Liquefaction necrosis, 1948-1949
Little finger
restoration of, 1060-1061
suture to middle finger, 1060-1061, 1061f
Littler flap. *see* Neurovascular island flap
LMB spring finger extension splint, 340.e1f
Local fasciectomy, for Dupuytren disease, 139t
Local flaps, 1540-1542
transposition flaps, 1542
axial-pattern, 1543-1545
flag, 1545, 1545f
random-pattern, 1542
rhomboid, 1543, 1544f
"Z"-plasty, 1542, 1542f, 1543b
four-flap, 1543, 1543f
Localized compartment syndrome, 1767f
Long bone reconstruction, vascularized bone grafting for, 1617-1624
Long toe extensor tendon, for tendon graft, 205-206
Loose body, arthroscopic removal of, 892-893
indications and contraindications of, 892
outcomes of, 893
postoperative management of, 893
preoperative planning of, 892
technique of, 892-893
Lucio reaction, in Hansen disease, 110-111, 111t
Luck classification, of staging, in Dupuytren disease, 131
Lumbrical canal, palmar space infection through, 36
Lumbrical muscles, anatomy of, 338.e4, 338.e6f
Lumbrical-plus finger deformity
after amputation, 1718
as complication of flexor tendon grafting, 225
Lunate, 660f
blood supply to, 638, 640f
bone grafting to, 1632
deformity of, carpal misalignment secondary to, 464
dislocation of, 427-428
fractures of, 636-637, 637b
incidence of, 625t
in Kienbock disease, 639
mechanism of injury in, 637-638, 638f
radiographic presentation of, 637-638
treatment of, 638, 639f
Lunate triquetrum arthrodesis, 457b
Lunate triquetrum dissociation, pathomechanics of, 427
Lunocapitate angle, measurement of, in wrist instability, 430
Lunocapitate dislocation, pathomechanics of, 427-428
Lunotriquetral arthrodesis, 387-389
author's preferred method of treatment for, 388
indications and contraindications for, 387-388
patients and, 389
pearls on, 389f
pitfalls of, 389
postoperative management for, 388
Lunotriquetral dissociation, 450-457
diagnosis of, 451-454
arthrography in, 454
arthroscopy in, 454
cineradiography in, 454
physical examination in, 451-452, 452f
radiographic examination in, 452-454, 452f-453f
pathomechanics of, 450-451, 451f
treatment of, 454-457, 455f-456f
preferred method of, 457
Lunotriquetral ligament, 422, 422f
interosseous, 660f
carpal instability and, 661
tears of, associated with distal radial fracture, 542
Lunotriquetral synchondrosis, 451-452
Lymphangiosarcoma, 1981-1983
Lymphangitis, nodular, differential diagnosis and treatment for, 83, 84t
Lymphatic basins, evaluation of, 1981, 1982f-1983f
Lymphatics, of nail bed, 318
Lymphedema, factitious, 1828, 1829f

M

Macrodactyly, 1275-1285, 1276f-1278f, 1285b
anatomy of, 1278
expected outcomes, 1285
Macrodactyly *(Continued)*
Flatt's classification of, 1275-1276, 1276t
gigantism anomaly in, 1276t, 1277, 1280f
hemihypertrophic, 1282
hyperostotic, 1279f, 1282
management of, 1278-1285, 1280t
amputation in, 1282
limiting digital growth in, 1278-1281
preferred method of, 1281f, 1282-1285, 1283f-1285f
reducing the digit in, 1281-1282
nerve territory-oriented, 1278
progressive, 1276-1277, 1284f
static, 1276-1277
Macules, pigmented, 1965
Madelung deformity, 1213-1214, 1214f, 1339-1345, 1344b, 1345f
bilateral, 1339, 1340f
preoperative evaluation for, 1339, 1340f-1341f
surgical treatment of, 1339-1344
expected outcomes from, 1345, 1345f
preferred technique for, 1344, 1344f
Maestro implant, 407, 407f
Maffucci syndrome, 2021
Magnetic resonance arthrography, for medial collateral ligament, 835-836
Magnetic resonance imaging (MRI)
of biceps rupture, 871-872, 872f
in brachial plexus birth palsy, 1395-1396, 1408, 1409f
of brachial plexus injury, 1152
of carpal instability, 432
in complex regional pain syndrome, 1805
of distal radioulnar joint, 486-487, 487f
of Kienbock disease, 641
for musculoskeletal tumors, 1990
prior to free flap transfer, 1577
of scaphoid fractures, 592
of triceps avulsions, 879, 879f
Malignant fibrous histiocytoma, 2019, 2019f
Malignant peripheral nerve sheath tumor, 2019
Malignant tumors, less common, 1981-1983
dermatofibrosarcoma protuberans as, 1983, 1985f
human immunodeficiency virus (HIV) and, 1983, 1984f
lymphangiosarcoma (Stewart-Treves syndrome) as, 1981-1983
Merkel cell (neuroendocrine) carcinoma as, 1981, 1984f
metastatic tumors as, 1983, 1985f
sweat gland tumors as, 1983
Mallet deformity, 43
Mallet finger injury
acute, 162-165, 166b, 162.e1b, 162.e1f
classification of, 162
incidence of, 162

Mallet finger injury *(Continued)*
mechanism of, 162
type I
management of, 163
nonoperative treatment of, 163
operative treatment of, 163
preferred method of treatment of, 164, 165*f*
type II
management of, 163
preferred method of treatment of, 164
type III
management of, 163
preferred method of treatment of, 164
type IV
complications of, 164
management of, 163-165
nonoperative treatment of, 163-164
operative treatment of, 164, 164*f*
preferred method of treatment of, 164-165
chronic, 165-166
Fowler tenotomy for, 166, 167*f*
preferred treatment of, 168-169
skin imbrication for, 166
spiral oblique retinacular ligament reconstruction for, 168, 168*f*
swan neck deformity associated with, treatment of, 166-169, 169*f*
classification of, 162, 163*t*
Mallet thumb injury, 169
Mallet's classification, of brachial plexus palsy, 1394, 1395*f*
Malone's "golden period", 1758
Malposition, of screws, fluoroscopy and surgical navigation to reduce, 605
Malrotation
after metacarpal fractures, 246-247, 247*f*
after phalangeal fractures, 266
Malunion
of distal radial fracture, 576-582, 578*b*, 579*f*-580*f*
of forearm fractures, 799-803
postoperative management and expectations after, 803
preferred method of treatment of, 800-801
preoperative evaluation of, 799-800, 799*f*-801*f*
rotational or angular osteotomies for, 801-803, 803*f*
of metacarpal fractures, 246-247
articular, 247
of phalangeal fractures, 266, 266.*e*1*b*
articular, 267
osteotomy for, 267*b*
of radial head fractures, 762-763, 762*f*
of radius and forearm, 498-500, 499*f*
Mangled upper extremity. *see* Mangling injuries
Mangling injuries, 1486-1527, 1487*f*
classification of, 1486-1487, 1487*b*
examination of, 1489-1492, 1490*f*-1492*f*
history of, 1489
initial evaluation of, 1489-1492
mechanisms and pathophysiology of, 1487-1489, 1488*f*
principles of, 1486, 1486*b*
treatment of
amputation/skeletal contribution in, 1492-1493
complications of, 1524
emergency, 1495-1496, 1496*b*, 1497*f*, 1498*t*
evolution in, 1495
expected outcomes in, 1524-1525
goals in, 1492-1495, 1493*f*
joints in, 1493-1494, 1494*f*
operative, 1496-1519
debridement/wound excision in, 1496-1499, 1499*b*
nerve repair/reconstruction in, 1508, 1508*b*
skeletal/joint reconstruction in, 1499-1500, 1501*f*-1504*f*
tendon repair/reconstruction in, 1500-1505, 1505*b*
vascular repair/reconstruction in, 1505-1508, 1506*f*-1507*f*, 1508*b*
postoperative management/rehabilitation after, 1519-1521, 1521*b*, 1521*f*
recommended approach to, 1495-1519
secondary procedures in, 1521-1524, 1522*f*-1523*f*, 1524*b*
soft tissue coverage in, 1508-1519, 1509*f*-1510*f*, 1521*b*
of elbow and arm, 1515-1519, 1519*f*-1520*f*
of fingers, hand, and wrist, 1512-1515, 1512*f*-1517*f*
of forearm, 1515, 1518*f*-1519*f*
nerves and, 1495
tendons in, 1494-1495
Maprotiline, for complex regional pain syndrome, 1812*t*
Marine organisms, animal bites and, 47-48
Marsupialization, surgical technique of, for chronic paronychia, 81.*e*1, 81.*e*1*f*
Martin-Gruber anastomosis, between median and ulnar nerves, 1046
Mason classification, of radial head fractures, 736, 736*f*
Matsen's technique, of compartment pressure measurement, 1765
Matti-Russe technique, in bone graft, for scaphoid nonunion, 610-611
Mayo classification, of olecranon fractures, 773-774
Mayo Clinic classification, of distal radial fracture, 524.*e*1, 524.*e*2*f*
Mayo Elbow Performance Score, 707-708
McCabe Cold Sensitivity Severity Scale, 1802
Mechanical failure, of total elbow arthroplasty, 915-916, 916*f*-918*f*
Mechanical passive device, 1737.*e*3*f*
Medial epicondyle, medial collateral ligament on, 839*f*
Medial femoral condyle bone flap, 1637, 1638*f*
Medial femoral condyle corticoperiosteal flap harvest, 1627-1628
Medial femoral condyle osteochondral flap, 1637-1638, 1639*f*
Medial femoral condyle osteochondral graft harvest, 1628
Medial femoral condyle vascularized bone graft harvest, 1628, 1628*f*
Medial "over-the-top" approach, to open release, of elbow contracture, 849-852, 850*f*-851*f*, 852*b*
capsular exposure in
anterior, 851-852
posterior, 850*f*-851*f*, 852
flexor-pronator muscle repair in, 852
patient position and preparation for, 850
postoperative care after, 853
skin incision for, 850-851
superficial exposure for, 850-851
ulnar nerve transposition in, 852
Medial tendon, 338.*e*3, 338.*e*5*f*
Median nerve(s)
anatomy of, variations of, in carpal tunnel syndrome, 930-932, 930*f*-932*f*
compression of. *see also* Carpal tunnel syndrome
in elbow and forearm, 935-938, 936*f*, 939*b*
anatomy of, 936
operative technique of, 937-938
postoperative care after, 938
preferred method of, 937-938, 937*f*-938*f*
injury to, distal radial fracture associated with, 575
repair of, 1008*b*
high, 1007*t*
primary *versus* delayed, 1008, 1008*t*
recovery after, 1005*t*
age and, 1007*t*
factors that affect, 1006-1008
results of, 1005-1008
grading of, 1006*t*
methods of, 1006*t*
in tidy wounds by level, 1007*t*
in war wounds by level, 1010.*e*2*t*
transfer of, to brachialis muscle, in musculocutaneous nerve transfer, for brachial plexus injury, 1167-1169, 1168*f*, 1169*b*

Median nerve block
at elbow, 8
at wrist, 9, 9*f*
Median nerve palsy, 1025-1045
high, 1042-1045
expectations and patient counseling in, 1045
management options in, 1045*b*
preferred method of treatment for, 1044-1045
tendon transfers in, 1026-1036
low, 1025-1042
expectations and patient counseling in, 1042
preferred method of treatment for, 1041-1042
tendon transfers for, 1026-1036
postoperative management of, 1041
for severe nerve deficits, 1036-1041, 1036*f*
thumb opposition in
biomechanics of, 1026
tendon transfers for, 1026-1036
ulnar nerve palsy combined with, 1062, 1063*t*
Medical Research Council grading, of muscle, 1394
in tetraplegia, 1122, 1123*t*
Medications, for rheumatoid arthritis, 905
Melanocytes, 1965-1966
Melanocytic nevus, 1965
Melanoma, 1977-1981, 1980*f*
acral lentiginous, 1978
amelanotic, 1980
benign juvenile, 1966
desmoplastic, 1980
local surgical excisional treatment for, 1980-1981
lymphatic basins in, evaluation of, 1981, 1982*f*-1983*f*
nodular, 1980, 1980*f*
of perionychium, 335, 335*f*
survival rates for, 336
prognosis and staging of, 1980, 1981*t*
subungual, 1978
superficial spreading, 1978, 1980*f*
Melanonychiae, 332-333
Melone classification, of distal radial fracture, 524.*e*1, 524.*e*2*f*
Melonychia, longitudinal, 1966, 1968*f*
Membrane-stabilizing agents, for complex regional pain syndrome, 1813
Meniscus homologue, 482, 482*f*
Mennen's technique, of EPL opponensplasty, 1040-1041
Mepivacaine, characteristics of, 4*t*
Merkel cell (neuroendocrine) carcinoma, 1981, 1984*f*
Meshed grafting, 1533-1534, 1533*f*
preparation of, 1534, 1534*f*
Metacarpal arch, transverse, restoration of, 1059-1060
Metacarpal artery flap
first dorsal, 1545-1546, 1546*f*
second dorsal, 1546, 1547*f*
Metacarpal artery flap, first dorsal, for soft tissue defects of thumb, 1684-1686, 1686*f*
Metacarpal bone(s)
extensor tendon injury over, 175-177, 175.*e*1*b*, 175.*e*1*f*
preferred method of treatment of, 177
of fingers, musculoskeletal tumors of, excision of, 1994-1996, 1995*f*
first, musculoskeletal tumors of, excision of, 1994, 1995*f*
fracture of, 231-248
at base, 244-246
avulsion fractures of, 244
in children, 1439
preferred method of treatment of, 245-246, 246*f*, 1439
in children, 1437-1439, 1439*b*
complications of, 246-248
dorsal angulation as, 246, 246*f*-247*f*
malrotation as, 246-247, 247*f*
malunion as, 246-247
articular, 247
nonunion, 247-248
osteomyelitis, 247
at head, 231-233, 232*f*
preferred method of treatment of, 233
types of, 232*b*
indications for fixation of, 232*b*
at neck, 233-236, 237*b*
in children, 1437-1438
closed reduction of, 233-234, 234*f*
open reduction of, 235
preferred method of treatment of, 235-236, 235*f*-236*f*, 1438
segmental metacarpal loss and, 243-244, 244*f*
preferred method of treatment of, 243-244
at shaft, 236-243
in children, 1438
closed reduction and percutaneous pinning in, 237-238, 238*f*
closed reduction and plaster immobilization of, 237, 237*f*
expected outcomes of, 243
open reduction for, 238-241
cerclage and interosseous wiring in, 239
composite (tension band) wiring in, 238*f*, 239
external fixation in, 241
fracture stabilization techniques in, 237.*e*1*t*
interfragmentary compression screws in, 240, 240*f*
Metacarpal bone(s) *(Continued)*
intramedullary fixation in, 239-240, 239*f*
Kirschner wires in, 238-239, 238*f*
plate fixation in, 240-241
preferred method of treatment of, 241-243, 242*f*, 1438-1439, 1439*f*
stabilization techniques in, 237.*e*1*t*
in mangling injuries, treatment of, 1500
second, vascularized bone graft from, 1634
short, in brachydactyly, lengthening of, 1242-1243, 1242*f*-1243*f*
Metacarpal hand, 1269
reconstruction of, 1649-1650, 1651*f*-1653*f*
type I, 1649, 1650*t*
type II, 1650*t*
Metacarpophalangeal (MCP) joint(s), 42, 1840-1841
anatomy of, 338.*e*1, 338.*e*1*f*
arthrodesis of, 352-353, 352*b*
in spasticity, for swan neck deformity, 1116, 1117*b*, 1117*f*
of thumb, in ulnar nerve palsy, 1059
arthroplasty of, 358, 1879*b*
contractures of
extension, release of, 340-341
late posttraumatic interosseous, 343.*e*1-343.*e*2, 343.*e*2*f*
nonoperative treatment of, 340.*e*1
deformity of, in scleroderma, 1839*f*
dislocations of
anatomy in, 298, 298*f*
complete (complex), 299
complications of, 300
dorsal, 298-300
outcomes of, 300
postoperative management of, 300
preferred method of treatment for, 300, 300*b*
preoperative evaluation of, 299, 299*f*
radial collateral ligament rupture in, 300-301
simple, 299
surgical techniques for, 299-300
volar, 300
extension of, 154-155
extensor tendon in, 155*f*
locked, 301
in mangling injuries, 1494
palmar capsulodesis of, in ulnar nerve palsy, 1049-1050, 1049*f*, 1050*b*
pertinent anatomy and biomechanics of, 346
rheumatoid arthritis of, 1867-1878
ligamentous reconstruction for, 1898-1901
synovectomy for with extensor mechanism reconstruction, 1898

Metacarpophalangeal (MCP) joint(s) *(Continued)*
stiffness of. *see also* Stiffness, of finger and hand
articular surface of, 338-339
examination of, 339
tendon rupture with, multiple tendons in, 1854
of thumb, 301-312
anatomy of, 301-302
dislocations of, 310-311
historical perspective on, 310-311
postoperative management and expectations in, 311
preoperative evaluation of, 311
treatment of, 311
radial collateral ligament injuries in, 308-310
Stener lesion in, 302-303, 303*f*
historical review of, 303
postoperative management and expectations in, 306
treatment of, 303, 304*f*-305*f*, 306*b*
ulnar collateral ligament injuries in
acute, 302-306
chronic, 306-308
volar instability of, chronic, 311-312
Metallic arthroplasty, of radial head, 764
Metaphyseal fracture, bicortical, of distal radius, in children, 1448-1453, 1450*f*-1452*f*, 1454*f*
preferred method of treatment for, 1453-1454
Metaphyseal posterior Monteggia fracture, 784.*e*23*b*, 784.*e*23*f*-784.*e*24*f*
Metaphysis, bending fractures of, 524-527
Metastases, of musculoskeletal tumors, 1989
Metastatic tumors, 1983, 1985*f*
of bone, 2031-2032, 2031*f*
Metatarsal artery, first dorsal
anatomy of, 1606, 1606*f*
in sensory flap from first web space of foot, 1606-1608, 1607*f*
Methicillin-resistant *Staphylococcus aureus* (MRSA), 18, 18*f*
antibiotic recommendations for, 21*t*
Methylprednisolone, for stiff finger, postoperative management of, 341
Mexiletine, for complex regional pain syndrome, 1814*t*
Michigan Hand Outcomes Questionnaire (MHQ), 924
Microbial nucleotide sequences, detection of, 66
Microvascular flow, regulation of, in complex regional pain syndrome, 1807-1808, 1807*f*-1810*f*
Microvascular surgery, regional anesthesia for, 2
Midanterolateral portal, in elbow arthroscopy, 889-890
Midcarpal fusion, scaphoidectomy and, 449-450
Midcarpal joint
instability of, nondissociative, 459
diagnosis of, 459-461
differential diagnosis of, 460-461
pathomechanics of, 459, 459*f*
physical examination in, 460
proximal row, volar, 459-461
radiographic examination in, 460
treatment of, 460-461, 461*f*-462*f*
preferred, 462-463
osseous anatomy of, 420
portals of
for arthroscopic arthrolysis, 691
for arthroscopy of wrist, 656-657, 653.*e*1*t*
Midcarpal ligaments, 422
Midpalmar space
infections of, 34*f*
characteristics of, 35*t*
clinical presentation and preoperative evaluation of, 34-35
treatment for, 36, 37*f*
preferred method of, 39
pertinent anatomy of, 35
Midposterolateral portal, in elbow arthroscopy, 890-891
Milker's interdigital granuloma, 118
Milker's nodule, 123-124, 124*f*
Miller criteria, for extensor tendon function, 161, 161*t*
Mirror hand(s), 1237-1238, 1237*f*, 1238*b*
classification of, 1212*f*, 1213*t*, 1238*t*
etiologic findings, 1237-1238
treatment of, 1238, 1238*f*-1239*f*
Mitsuda reaction, in Hansen disease, 107-108
Miura and Komada technique, in cleft hand surgery, 1251, 1252*f*
Moberg's techniques, in tetraplegia, of passive key pinch reconstruction, 1132, 1132*f*
Mohs micrographic surgery, 1962, 1965*f*
Moles, 1966
Monteggia fracture-dislocation, in children, 1468-1470, 1469*f*-1470*f*, 1469*t*
Monteggia fractures
classification of, 773, 773*f*
metaphyseal posterior, 784.*e*23*b*, 784.*e*23*f*-784.*e*24*f*
posterior (Bado type 2), 773, 773*f*
plate loosening after operative treatment of, 784.*e*28*b*, 784.*e*28*f*-784.*e*29*f*
ulnohumeral instability after, 784.*e*30*b*, 784.*e*30*f*
preoperative evaluation of, 770
treatment of, 780, 780*f*, 781*b*
plate fixation in, 778, 779*f*
Monteggia fractures *(Continued)*
type A posterior, 784.*e*1*b*, 784.*e*2*f*-784.*e*3*f*, 784.*e*15*b*, 784.*e*15*f*-784.*e*17*f*
Monteggia lesion, posterior, 817, 817*f*
classification of, 817
Moray eel, nonvenomous, injury caused by, 1795*f*
Morbidity, donor site, in toe transfer, 1670
Morpheaform (sclerosing) BCC, 1974
Motion
amplitude of, in tendon transfers, 1023-1025
improved, after elbow contracture release, 860
loss of
assessment of, in stiff elbow, 845-847
as complication of phalangeal fractures, 268
Motion protocol, after biceps rupture repair, 878
Motor conduction velocity, for cubital tunnel syndrome, 942
Motor evoked potentials (MEPs), in brachial plexus surgery, 1158
Motor rehabilitation, after toe transfer, 1670-1671
Motor-sensory neuropathy, hereditary, 923
Moxifloxacin, dosage of, 101*t*
Mucormycosis, 87-88, 89*b*
Mucous cyst, 2005-2006
clinical characteristics of, 2005-2006, 2005*f*
complications in, 2006
operative technique for, 2006, 2006*f*
preferred method of treatment for, 2006
Multidisciplinary approach, to complex regional pain syndrome, 1811
Multidisciplinary team approach, for complex regional pain syndrome, 1818
Multidrug therapy (MDT)
for Hansen disease, 109
for mycobacterial tenosynovitis, 95-96
for tuberculosis, 100-103, 101*t*
Multiple enchondromatosis, 2021, 2022*f*
Multiple joints, involvement in rheumatoid arthritis, 905
Multiple warts, 121
Muscle(s). *see also named muscle*
fibula with, in vascularized grafting, 1620
free transfer of
for brachial plexus injury, 1152-1153, 1178-1185
donor muscle selection in, 1179
grasp reconstruction with, 1180-1184
complications of, 1184
donor muscle selection in, 1181-1182

Muscle(s) *(Continued)*
operative technique of, 1181-1183, 1181*f*-1182*f*, 1184*b*
outcome of, 1184, 1184*f*
postoperative protocol for, 1183
prerequisites for, 1181
subsequent surgery for, 1183-1184
operative procedures for, 1179-1185, 1180*f*
for elbow flexion, in delayed cases, 1202, 1202*f*, 1203*b*
prerequisites for, 1178-1179
single-stage, for prehension, 1185, 1185*f*
work capacity of, 1023, 1024*t*
Muscle flaps. *see also specific muscle flap e.g.*, Latissimus dorsi muscle flap
free, 1576
Muscle grading system, Medical Research Council, in tetraplegia, 1122, 1123*t*
Muscle strengthening, for thoracic outlet syndrome, 969-970
Muscle tightness
excessive, elbow contracture with, 856
in spasticity, 1085
Muscle transfer, flexor and extensor, in ulnar nerve palsy, 1054-1056
Muscular neurotization, direct, for nerve injury, 1001, 1001*f*
Muscular release, in spasticity, evaluation of, 1085
Musculocutaneous flap(s), 1561-1562, 1576. *see also* Skin flap(s); *specific muscle flap*
free, 1576, 1597-1602. *see also* Free flap(s)
Musculocutaneous nerve transfer, for brachial plexus injury, 1165-1166, 1165*f*
intercostal nerve to, 1171, 1171*f*, 1172*b*
complications of, 1172
contraindications to, 1171-1172
outcomes of, 1172
postoperative care after, 1171
median nerve transfer to brachialis motor branch in, 1167-1169, 1168*f*, 1169*b*
operative procedure for, 1165
outcomes of, 1166
triceps transfer to axillary nerve in, 1172-1173, 1173*f*-1174*f*
outcomes of, 1174*b*, 1174*f*
ulnar nerve transfer to biceps in, 1166-1167, 1166*f*-1167*f*
outcomes of, 1167, 1167*f*
Musculocutaneous neurectomy, for spasticity, 1090-1091
Musculoskeletal tumors
benign, excision for, 1992
biopsy for, 1990-1992
excisional, 1991-1992
incisional, 1991
needle, 1990-1991
open, 1991, 1991*f*, 1992*b*
definitive treatment for, 1992-1996
diagnosis and management of, 1987-1988
evaluation protocol for, 1989-1992, 1989*f*
excision of, 1993-1996
from finger metacarpals, 1994-1996, 1995*f*
from first metacarpal, 1994, 1995*f*
from phalanx
distal, 1993, 1993*f*
middle, 1993-1994, 1993*f*-1994*f*
from wrist and distal forearm, 1996, 1996*f*-2000*f*
histologic grade and surgical staging of, 1988-1989, 1988*t*-1989*t*
laboratory studies for, 1990
location (site) of, 1989
malignant, excision for, 1992-1993
metastases of, 1989
Musculotendinous components, of radiocapitellar joint, 813
Mycetoma, 70-73
clinical findings on, 71
diagnosis of, 72, 72*b*
differential diagnosis of, 72
etiology and epidemiology of, 70
microbiology of, 70-71
staging of, 71-72, 71*f*
treatment of, 72-73
Mycobacterial infections, 90-103
antituberculous drugs for, multidrug therapy regimens and, 100-103, 101*t*
cutaneous tuberculosis and, 91-92
deep infections and, 93-100, 94*f*-95*f*
eight-pack tissue culture for, 65*t*
etiology, diagnosis, and treatment of, 63*t*
growth rates of, 91*t*
nontuberculous, 90-103
diagnosis and treatment of, 102*t*
subcutaneous tuberculosis and, 92-93, 93*f*
tuberculous, 90-103
Mycobacterial tenosynovitis, 93-96, 94*f*-95*f*
Mycobacterium avium, 91, 93
Mycobacterium haemophilum, 91
Mycobacterium leprae, 92, 103
Mycobacterium marinum, 93, 94*f*
Mycobacterium scrofulaceum, 93, 95*f*
Mycobacterium tuberculosis, 91-93
Mycobacterium ulcerans, 65, 92-93, 93*f*
Myelography
in brachial plexus birth palsy, 1395-1396
of brachial plexus injury, 1152, 1152*f*
Myoblastomas, granular cell, 2013-2014, 2013*f*
Myocutaneous flaps, 1576
Myoelectric devices, in prosthetics, 1759
Myoelectric hands, types of, 1742*f*
Myofascial manipulation, for thoracic outlet syndrome, 969
Myofibroblast, Dupuytren disease and, 131
extracellular matrix, cycle of, remodeling, 136*f*
gene expression of, 136
Myonecrosis, 56, 56*f*

N

Nager syndrome, radial longitudinal deficiency associated with, 1329*t*
Nail(s)
absence of, 326-328, 328*f*
anatomy of, 20-21
dull, 330
germinal matrix of, 318
hooking of, 329, 329*f*
infections of
bacterial, 331, 331*f*
fungal, 330-331
nonadherence of, 326, 327*f*
pincer, 330, 330*f*, 331*b*
split, 326, 326*f*-327*f*
Nail bed
acute injuries of, delayed treatment in, 324
amputation in, 323-324, 324*f*-325*f*
anatomy of, 319*f*
avulsion of, 321, 321*f*
cornified, 328, 328*f*
defect of, 321-322, 322*f*
graft for, harvest of, 322, 322*f*
postburn deformities of, 1937, 1939*f*
repair of, 319-321, 320*f*
scarring of, 325
stellate lacerations of, 320, 320*f*
Nail cysts, 328, 328*f*
Nail fold
infection of
acute, 20-22, 22*b*, 22*f*-23*f*
chronic, 23-25, 24*f*-25*f*, 25*b*
Keyser-Eaton marsupialization of, 331-332
paronychia and, 81
syphilis and, 73-74
treatment of, 81.*e*1
Nail graft, vascularized, in toe transfer flap design and elevation in, 1661-1663
flap designs and elevation, 1661-1663, 1663*f*
indications, 1661, 1662*f*
Nail horns, 1711
Nail ridges, 325-326
Nail spikes, 328, 328*f*
Necrosis
avascular
after radial head fractures, 761, 761*f*
of capitate, 649
vascularized bone grafting for, 1613

Necrosis *(Continued)*
wound, after elbow contracture release, 859, 860*f*
Necrotizing fasciitis, 17, 54-55, 54*f*
animal bites and, 48
antibiotic recommendations for, 21*t*
case study, 55.*e*1*b*, 55.*e*1*f*
diabetic hand infections and, 54
fungal, 55, 55*f*
shooter's abscesses and, 51
Needle biopsy, for musculoskeletal tumors, 1990-1991
Needle depth penetration, 146*f*
Needle fasciotomy, for Dupuytren disease, 139*t*
percutaneous, 140
Needle maneuvers, in procedure, for Dupuytren disease, 146, 146*f*
Needle problems, in procedure, for Dupuytren disease, 147
Needle size, in procedure, for Dupuytren disease, 146
Negative pressure wound therapy
for mangling injuries, 1509, 1510*f*
for skin grafting, 1536
Nerve(s)
anatomy of, 980, 980*f*
conduction studies of, in compression neuropathies, 929
exploration of, in radial nerve palsy with humeral fractures
at 6 to 8 weeks, 1074-1075, 1075*f*
early, 1074
if no return at longer waiting period, 1075, 1075*f*
preferred method of, 1075
gap of, 1007-1008
iatrogenic injuries to, operations for, 1013*t*
issues, in procedure, for Dupuytren disease, 147
longitudinal mobility of, in compression neuropathies, 923
into muscle
implantation of, 1018*f*
translocation of, 1017-1019
preparation of, in toe transfer, 1645, 1666
reconstruction of, in brachial plexus injury
primary, 1154, 1160-1177
secondary, 1154, 1186-1202
reimplantation of, 1185
repair of
in mangling injuries, 1508, 1508*b*
in microvascular toe transfer, for hypoplastic digits, 1269
in radial nerve palsy, 1065
in toe transfer, 1668
Nerve abscess, in Hansen disease, 112-113, 113*f*-114*f*
drainage technique for, 113
treatment of, 112-113
Nerve action potentials (NAPs), in brachial plexus surgery, 1158, 1158*f*
Nerve bed, preparation of, 993
Nerve biopsy, for Hansen disease, 108-109
fine-needle nerve aspiration technique and, 108-109
open, 109
Nerve block(s)
axillary, 8, 8*f*
for complex regional pain syndrome, continuous autonomic, 1817
infraclavicular, 7-8, 7*f*
interscalene, 6, 7*f*
supplementary, 8-11
at digit, 9-10, 10*f*-11*f*
at elbow, 8
at wrist, 8-9, 9*f*
supraclavicular, 6-7, 7*f*
Nerve compression
chronic, pathophysiology of, 921-924, 922*f*
electrodiagnostic studies and, 929-930
Nerve conduction studies, 12
in brachial plexus injury, 1153
Nerve conduction velocity (NCV), 1396
Nerve gliding exercises, for carpal tunnel syndrome, 933
Nerve graft/grafting, 996-999, 999*b*
in brachial plexus birth palsy, 1397, 1398*f*-1399*f*, 1400-1404, 1401*f*-1404*f*
in brachial plexus reconstruction, 1160-1163
allografts in, 1163
coaptation and, 1162-1163, 1162*f*
conduits in, 1163
conventional, 1161-1162, 1161*f*
donor nerve for, 1161-1162
indications for, 1160
operative procedure for, 1160-1161, 1161*f*
other options for, 1162
postoperative care for, 1177
choice of, 996-999, 997*f*-998*f*
for mangling injuries, 1522, 1523*f*
other methods of, 999-1000
postoperative care after, 999
suturing of, 998*f*
tendon transfer *versus*, nerve repair and, for radial nerve palsy, 1065
vascularized, 999
Nerve injury
after radial head fractures, 761
aggravating, 1-2
cause of, 1003
classification of, 982, 982*t*, 984*b*
clinical diagnosis of, 985-991, 986*f*, 990*b*
depth of, 986*t*
digital, repair of, 1008-1009, 1009*t*
preferred method of treatment of, 1009
electrodiagnosis of, 988-989, 988*t*
Nerve injury *(Continued)*
imaging of, 989, 990*f*
lesions in
continuity in, 989-990
distribution and diagnosis of, 1010.*e*1
level of the lesion in, 1002-1003
mangling
evaluation of, 1492
repair/reconstruction of, 1508*b*
restoration of sensation in, 1495
nature of, 1003
level and, 1007
neurologic examination of, 987-988
physical examination of, 986-988, 987*f*
repair of, 979-1022
alternative methods of, 999-1000
closure in, 996
delay in, 1003
effects of, 1005*t*
denervation and reinnervation of, electromyographic findings in, 989*t*
epineurial, 994
exposure in, 991
grafting in, 996-999, 997*f*-998*f*, 999*b*
indications for, 979-982, 980*f*
neurolysis in, 992-993
outcomes of, 1010.*e*2*t*
postoperative care after, 996
recovery after, 1001-1009
factors in prognosis of, 1002-1003, 1003*b*
measurement of, grading and, 1001-1003, 1002*t*
results of, 1003-1009, 1003*t*-1004*t*
grading, 1002*t*
rehabilitation after, 1009-1010, 1010*b*
resection of a damaged nerve of, 991-992
surgical interventions for
considerations before, 990-991
consultation and operative record in, 991
outcomes of, 1010.*e*3-1010.*e*5
techniques of, 991-1001
suturing in, methods of, 993-996
delayed, 994-996, 995*f*-996*f*
direct, 993-994, 994*f*
end-to-end, 993
fibrin clot glue in, 996
responses to, 982-985, 983*f*
conduction block in, 983-984
stretch injury as, 985
Wallerian degeneration in, 984-985
severity of, in war wounds, 1010.*e*1, 1010.*e*1*t*
Tinel sign in, 986, 987*b*
war wounds and, 1010.*e*1-1010.*e*5
Nerve palsy
after elbow contracture release, 859
peripheral, constriction ring associated with, treatment of, 1256

Nerve percussion test, 924
Nerve reconstruction, 1777, 1777*f*
in brachial plexus birth palsy, 1397-1398
Nerve status
postoperative, assessment of, 1
in rheumatoid arthritis, 905
Nerve surgery, for brachial plexus birth palsy, 1397-1407, 1401*b*
postoperative management for, 1407, 1408*t*
preferred treatment, 1406-1407
results of, 1399
technique of, 1400-1404
nerve grafting in, 1397, 1398*f*, 1400-1404, 1401*f*-1404*f*
nerve transfers in, 1404-1406, 1405*f*-1407*f*
timing of, 1398
Nerve territory-oriented macrodactyly, 1278
Nerve transfer, 1000-1001
in brachial plexus birth palsy, 1398, 1398*f*-1399*f*, 1404-1406, 1405*f*-1407*f*
for brachial plexus injury, 1163-1177
contralateral C7, 1173-1176, 1175*f*-1176*f*
author's preferred technique for, 1176
complications of, 1176
outcomes of, 1176
postoperative care after, 1176
surgical anatomy in, 1175
extraplexal, 1177
indications for, 1163
intercostal nerve in, 1169-1172, 1170*f*
intraplexal, 1176-1177
musculocutaneous nerve in, 1165-1166, 1165*f*
intercostal nerve to, 1171, 1171*f*, 1172*b*
complications of, 1172
contraindications to, 1171-1172
outcomes of, 1172
postoperative care after, 1171
median nerve transfer to brachialis motor branch in, 1167-1169, 1168*f*, 1169*b*
operative procedure for, 1165
outcomes of, 1166
triceps transfer to axillary nerve in, 1172-1173, 1173*f*-1174*f*
outcomes of, 1174*b*, 1174*f*
ulnar nerve transfer to biceps in, 1166-1167, 1166*f*-1167*f*
outcomes of, 1167, 1167*f*
postoperative care for, 1177
spinal accessory nerve in, 1163-1166, 1163*f*
Nerve transfer *(Continued)*
suprascapular nerve in, 1164-1165, 1164*f*
outcomes of, 1165, 1165*f*
in radial nerve palsy, 1075-1076
Neural dystrophic focus, in complex regional pain syndrome, management of, 1820
Neurapraxia, 12, 12*b*, 983-984, 1148
management of, 12, 13*f*
Neurectomy
musculocutaneous, for spasticity, 1090-1091
of ulnar motor, for intrinsic muscle spasticity, 1114, 1115*f*
Neurilemomas, 2012, 2013*f*
Neuritis
Parsonage-Turner, 936
silent, in Hansen disease, 114
Neurofibroma, 1968, 1969*f*
Neurofibromatosis, pseudoarthrosis and, 1354, 1355*f*
Neurofibrosarcoma, 2019
Neurologic deficit
deep flexor compartment with, 1776-1777
deep flexor compartment without, 1776
severe, 1777
superficial flexor compartment with, 1776-1777
Neurolysis
in brachial plexus birth palsy, 1397
for brachial plexus injury, 1160
Neuroma(s), 1746*f*, 1748-1749, 1749*f*, 1749*t*
after amputation, 1011*f*, 1522, 1010.*e*5
in complex regional pain syndrome, 1822
peripheral, 1010-1019
containment of, 1015, 1016*f*
excision of
repair and, 1014*b*, 1015*f*
transposition into muscle and, 1017*b*
managing, summary of, 1018*b*
pathophysiology of, 1011-1012
preferred method of treatment of, 1014
prevention of, 1012, 1012*f*
translocation of, 1015-1016, 1016*f*
transposition of
into bone, 1016
into conduit, 1017
into vein, 1016-1017
treatment of, 1012-1019
chemical methods for, 1013
operations for, 1013-1019, 1013*t*
Neuromuscular blocking agents, for complex regional pain syndrome, 1815
Neuropathic joint, complete ankylosis of, 909
Neuropathic pain, 1010.*e*2-1010.*e*3
definition of, 1797, 1799*t*
diagnosis of, 1011*b*
Neuropathy(ies)
compression. *see* Compression neuropathy(ies)
hereditary motor-sensory, 923
ulnar
after humeral fractures, 729-730
after ulnar fracture, 783-784
Neurosensory flap, transfer of, from first web space
flap design and elevation in, 1660-1661
indications for, 1658-1659, 1660*f*-1661*f*
Neurostenalgia, nerve injury and, 1010.*e*3-1010.*e*4
Neurotization, for brachial plexus injury, 1163
Neurotmesis, 1148
Neurovascular island flap, 1552-1554, 1553*f*
for soft tissue defects of thumb, 1686-1687, 1688*f*, 1689*b*
Neurovascular spiral bundle, of Dupuytren disease, 138
Neutropenia, 1833
Neutrophilic dermatoses, 75-77
clinical findings on, 76-77
diagnosis of, 77, 77*f*
etiology and epidemiology of, 75-76
treatment of, 77
Nevus (nevi)
acral, 1966
blue, 1966
giant hairy congenital, 1966, 1967*f*
junctional, 1965-1966
melanocytic, 1965
subungual, 332-333, 332*f*-333*f*
Nifedipine, for complex regional pain syndrome, 1815*t*
Night splinting
for arthrogryposis, 1380
for epicondylitis, 865
Night splints, for cubital tunnel syndrome, 942
90-degree abduction external rotation test, 966-967
Nociceptive focus, identification of, in complex regional pain syndrome, 1804-1805
Nociceptive pain, 1797
definition of, 1797, 1799*t*
Nodular fasciitis, 2014
Nodular lymphangitis, differential diagnosis and treatment for, 83, 84*t*
Nodular melanoma, 1980, 1980*f*
Nodular skin, diffuse, of Dupuytren disease, 130*f*
Nodules
Dorsal Dupuytren, 129
pathology of, 136
signs of, 129-130, 131*f*
treatment of, 143
rheumatoid, 1841-1842, 1841*f*

Nonadherence
hyponychial, 329-330
of nails, 326, 327*f*
Nonarticular bone loss, associated with humeral fractures, 726
Nonarticular fractures, of phalanges, 255-256
at neck, 255-256, 256*f*-257*f*
at shaft, 256
expected outcomes of, 264-265
preferred method of treatment of, 261
Nondisplaced fractures, of distal radius, treatment of, 567
Nonmetacarpal hand, multiple-digit amputation, 1648
Nonmicrosurgical coverage, of upper extremity, 1528-1573
flap coverage, local and regional, 1539-1571
skin grafting. *see* Skin graft/grafting
Nonoperative management, of radial head fractures, 741-742, 742*f*
outcome of, 756-758
Nonsteroidal antiinflammatory drugs (NSAIDs), infections and, 19
Nontuberculous mycobacterial infections, 90-103
diagnosis and treatment of, 101, 102*t*
special features of, 101-103
Nonunion
of distal humeral fracture, 728
associated with elbow contracture, 854
of distal radial fracture, 576
of forearm fractures, 799-803
postoperative management and expectations after, 803
preferred method of treatment of, 800-801
preoperative evaluation of, 799-800, 799*f*-801*f*
of metacarpal fractures, 247-248
of olecranon osteotomy, 728-729, 729*f*
of phalangeal fractures, 267-268, 268*f*-269*f*
of radial head fractures, 762
of scaphoid fractures, 588-624
biologic stimulation of, 607
bone graft for, nonvascularized, 610, 610*f*
in children, 1445, 1446*f*
case study for, 1445.*e*1*b*, 1445.*e*1*f*-1445.*e*3*f*
of distal pole, 622
dysvascular, 616-619, 616*f*
evaluation of, 608-609
activity level in, 609
age in, 609
amount of deformity and malalignment in, 608
arthritis in, presence and location of, 609
bone loss in, 608
Nonunion *(Continued)*
comorbidities in, 609
fracture site in, 608
length of time in, 609
pain or dysfunction in, 609
previous treatment in, 608
salvageability of fragment in, 609
vascularity of fragments in, 608
implications of, 590-591, 591*f*
management of, 608-624
preferred method for, 621
open dorsal technique for, 614-615
operative treatment for, 609-619, 609*t*
prognosis for healing in, 620-621
proximal pole, 614-616
treatment for, preferred, 621*t*
unsalvageable proximal pole, 621
vascularized bone grafting for, results of, 1637-1638
without arthritis, 609-611
without substantial bone loss, 609
of ulnar fractures, 783, 784*f*, 784.*e*31*b*, 784.*e*31*f*
No-reflow phenomenon, in mangling injuries, 1488
Nortriptyline, for complex regional pain syndrome, 1812*t*
Nosocomial infections, 18
Notta nodule, in trigger thumb, 1321, 1321*f*, 1915*f*
Nubbin, residual, after suture ligation of ulnar polydactyly, 1233, 1233*f*
Nucleic acid amplification, for infections, 66

O

Oblique fibers, 338.*e*3, 338.*e*5*f*
Oblique retinacular ligament (ORL), 156-157
Occupational infections, chronic, 118
Ochronosis, tendinopathy in, 1907
Ohm's law, 1946
Olecranon fractures, 773-774, 774*f*
posterior dislocation of elbow associated with, 784.*e*11*b*, 784.*e*11*f*-784.*e*12*f*
Olecranon osteotomy, for distal humeral fractures, 711-712, 713*f*, 724*b*
nonunion of, 728-729, 729*f*
technique of, 722-724
Olecranon process
anatomy of, 771-772
fracture-dislocations of, 774-775, 774*f*-776*f*, 816-817, 816*f*
anterior (transolecranon), 774-775, 775*f*
complex posterior, 784.*e*1*b*, 784.*e*2*f*-784.*e*3*f*
posterior, 784.*e*4*b*, 784.*e*4*f*-784.*e*5*f*, 784.*e*6*b*, 784.*e*7*f*-784.*e*8*f*, 784.*e*15*b*, 784.*e*15*f*-784.*e*17*f*, 784.*e*25*b*, 784.*e*25*f*-784.*e*27*f*
posterior Monteggia lesion, 817, 817*f*
Olecranon process *(Continued)*
transolecranon, 816-817, 816*f*
treatment of, 780, 822-823, 823*f*
hinged external fixation in, 823-824, 824*b*, 824*f*
posterior dislocation of elbow associated with, 784.*e*11*b*, 784.*e*11*f*-784.*e*12*f*
Olecranon (type IIA), displaced fractures without comminution and proximal to midpoint of, 781
Ollier disease, 2021, 2022*f*
One wound-one scar concept, of mangling injuries, 1486, 1487*f*
Open biopsy, for musculoskeletal tumors, 1991, 1991*f*, 1992*b*
Open carpal tunnel release, 934-935, 934*f*, 935*b*
Open fractures
in children, 1468
of distal radius, 573-575
Open reduction
of condylar fracture of proximal phalanx, 254*f*
of displaced bicondylar proximal phalangeal fracture, 256*f*
limited, of distal radial fractures, 536
of metacarpal neck fractures, 235
of metacarpal shaft fractures, 238-241, 237.*e*1*t*
with pin fixation, of proximal and middle phalangeal fracture, 258-259, 259.*e*1*t*
for proximal interphalangeal joint dislocation, 280
Open reduction and internal fixation (ORIF)
of coronoid fracture-dislocation, 819-820
of distal humeral fractures, in elderly, 707-709, 709*t*
of distal radial fracture, 547-559, 547*f*
distraction plating technique in, 557-559, 558*f*, 560*f*
dorsal plate approach to, 547-552, 548*f*
fragment-specific fixation in, 552-557, 558*b*
volar plate approach to, 548-552, 549*f*-553*f*, 554*b*
for forearm nonunion, 800-801
for lesser-arc injuries, 468-470, 468*f*, 469*b*, 470*f*
for perilunate fracture-dislocations, 471, 471*f*
of proximal and middle phalangeal fracture, 257, 259*f*-260*f*
for proximal interphalangeal joint fracture-dislocation, 283
outcomes of, 288
postoperative protocol for, 288
preferred method for, 287-288, 288*b*, 288*f*

Open reduction and internal fixation (ORIF) *(Continued)*
of radial head fractures, 743
outcome of, 758
as preferred treatment, 746-750, 750*f*-752*f*, 751*b*
of scaphoid fracture
dorsal approach/mini-open approach to, 597-598
palmar approach to, 599-600
for scapholunate dissociation, 440-442, 441*f*
triceps-splitting, 713.*e*1*b*, 713.*e*1*f*-713.*e*4*f*
Operating room
exploration of, free flap failure, 1583-1584
patient preparation in, preoperative, 1578
Opponens digiti quinti, 338.*e*4
Opponensplasty
for median nerve palsy
high, 1042-1045
brachioradialis-to-FPL transfer, 1043, 1044*f*
complications of, 1044
ECRL-to-index profundus, 1044, 1044*f*
expectations and patient counseling in, 1045
extrinsic transfers in, 1043
preferred method for, 1044-1045
restoration of opposition in, 1043
summary of, 1044-1045, 1045*t*
thumb opposition restoration in, 1043
timing and selection of, 1043
low
abductor digiti minimi (Huber), 1032-1033, 1033*f*-1034*f*
adductor pollicis and flexor pollicis brevis, 1041
Bunnell, 1030*f*, 1031
compromise, for severe nerve deficits, 1036-1041, 1036*f*
expectations in, 1042
extensor carpi radialis longus, 1035-1036
extensor carpi ulnaris, 1034-1035
extensor digiti minimi, 1036, 1036*f*
extensor indicis proprius, 1031-1032, 1032*f*
extensor pollicis longus, 1037-1040, 1039*f*-1041*f*
alternative, 1040-1041
flexor pollicis longus, 1037, 1038*f*
alternative, 1037, 1038*f*-1039*f*
history of, 1026
insertions in, 1027-1029, 1028*f*
management of, 1042*b*
palmaris longus (Camitz), 1033-1034, 1034*f*-1035*f*
Opponensplasty *(Continued)*
patient counseling in, 1026-1027, 1042
postoperative management of, 1041
preferred method of, 1041-1042
prevention and preoperative treatment of contractures prior to, 1027
principles of, 1027
pulley, 1030, 1030*f*
pulley design in, 1027
results of, 1027-1029, 1028*t*, 1029*f*
Royle-Thompson, 1030-1031
selection of motor for transfer in, 1027
standard, 1029-1034
superficialis, 1029-1031
management principles in, 1029*b*
outcomes of, 1042*t*
for tetraplegia, 1138, 1141
Opposition posts, in prostheses, 1740
Optimum timing, in Dupuytren surgery, 139
Oral medications, preferred method of treatment, 1819
Orf infection, human, 123-124, 124*f*
Osseous fibular flap, 1617-1619
Osseous fixation, anticipated, in replantation, 1478
Ossification, centers of, in carpal bones, 1444
Osteoarthritis
after radial head fractures, 763, 763*f*
debridement for, 893-897, 896*b*
indications and contraindications of, 893
outcomes of, 896-897
postoperative management of, 894-896
preoperative planning of, 893
technique of, 893-894, 895*f*-896*f*
of hand, 345
small joints of, 345-358
diagnostic imaging of, 346
historical review on, 346, 347*f*
pertinent anatomy and biomechanics of, 346
physical examination of, 345-346, 346*f*
preoperative evaluation of, 345-346
primary, 907-909
of thumb, 345
carpometacarpal joint of, 359-369
anatomy and biomechanics of, 359-360, 360*f*
complications of, 368-369, 369*f*
critical points on, 366*b*
diagnostic imaging of, 359, 359*f*
epidemiologic findings on, 359
evaluation of, 359
Osteoarthritis *(Continued)*
expected outcomes on, 366-368, 367*t*
indications and contraindications for, 360-362
operative techniques on, 362-364
physical examination for, 359
postoperative management and expectations on, 366-369
preferred method of treatment for, 364-365, 365*f*-366*f*
treatment for, 360-364
wrist arthrodesis and, radiographic patterns of, 376, 377*f*
Osteoblastoma, 2023-2024
Osteochondroma, 2022
of forearm, 1358-1359
location of, 1359, 1359*f*
removal of, 1359-1360
contraindications to, 1359
postoperative management and expectations after, 1361-1362
subungual, 2022
Osteocutaneous fibula, 1613*f*
Osteocutaneous flap, vascularized, in grafting from fibula, 1619
Osteogenesis, distraction, metacarpal lengthening with, in brachydactyly, 1242-1243
Osteogenic sarcoma, 2027-2028, 2029*f*
Osteoid osteoma, 2023, 2023*f*
Osteolysis, 1835-1836
Osteomyelitis, 43-46
classification of, 45*t*
clinical presentation and evaluation of, 45-46, 46*f*
coccidioidal, 85
as complication, of metacarpal fractures, 247
complications of, 46
cryptococcal, 86
fungal, 89
septic joint progression to, 43.*e*1*b*, 43.*e*1*f*
sporotrichal, 88
treatment for, 46
tuberculous, 97-100
in adult, 98-100, 99*f*
in children, 98, 98*f*
treatment of, 100
vascularized bone grafting for, 1613
Osteonecrosis, 639-649
of scaphoid, 1445
Osteoperiosteal sleeve, for split thumbs, 1307-1309, 1309*f*-1310*f*
Osteophyte, 333
Osteoplastic reconstruction, of amputated thumb, with preservation of basal joint, 1696-1697, 1697.*e*1*f*
Gillies "cocked-hat" flap in, 1696, 1697*f*
two-stage
stage 1, 1696-1697, 1698*f*
stage 2, 1697, 1697.*e*1*f*

Osteoplasty, of sigmoid notch and ulna, in chronic radioulnar joint instability, 498, 498*f*
Osteosynthesis, in microvascular toe transfer, for hypoplastic digits, 1269
Osteotomy, 1756
  for articular malunion, of phalangeal fractures, 267*b*
  closing wedge radial, for Kienbock disease, 646, 647*f*
  corrective, for clinodactyly, 1272
  derotational
    for brachial plexus birth palsy, 1415, 1415*f*
    for proximal radioulnar synostosis, 1351-1352, 1352*f*-1353*f*
  first metacarpal, for carpometacarpal joint osteoarthritis
    expected outcomes on, 366
    as operative technique, 362, 362*f*
    as treatment, 361
  multiple, using three-dimensional modeling, 1344
  olecranon, for distal humeral fractures, 711-712, 713*f*, 724*b*
    creation of, 722, 723*f*
    fixation of, 722-724
    nonunion after, 728-729, 729*f*
  for radial fracture
    articular, 580-581, 582*f*, 581.*e*1*b*, 581.*e*1*f*-581.*e*6*f*
    dorsal approach to, 577-578, 579*f*
    extraarticular, 577, 578*b*, 578*f*
    malunited Smith, 580, 580.*e*4*f*
    ulnar-shortening, 580
    volar approach to, 578-580, 581*f*, 580.*e*1*b*, 580.*e*1*f*-580.*e*2*f*
    Watson's trapezoidal, 580.*e*3, 580.*e*3*f*
  radial-shortening, for Kienbock disease, 642-643, 642*f*
  rotational
    for forearm fracture malunion, 801-803, 802*f*
    of humerus, for ulnar deficiency, 1335, 1338
  thumb reorientation. *see* Thumb reorientation osteotomy
  ulnar-shortening, 501-503, 502*f*, 1455
Outcome score, of Dupuytren disease, 133
Outerbridge-Kashiwagi procedure, 849, 894
Outpatient surgery, in skin grafting, 1538
Overlap syndrome, 1839
Oxacillin-resistant *Staphylococcus aureus* (ORSA), shooter's abscess and, 51

P

Padgett dermatome, 1532-1533, 1532*f*
Paget-Schroetter syndrome, 960, 960*f*
Pain
  acute *versus* chronic, 1801, 1801*f*
  assessment of, in stiff elbow, 845
Pain *(Continued)*
  in complex regional pain syndrome, 1799*t*
  definition of, 1799*t*
  mediators of, 1800-1801
  mediators/receptor control of, 1800-1801
  perception of, 1799
  physiology of, 1798-1801, 1800*f*
  relief of, for Hansen disease, 109-113, 110*f*
  sympathetic, definition of, 1799*t*
Pain management
  neuropathic, in brachial plexus injury, 1203
  postamputation, 1749*b*
Pain questionnaire, 925*f*-926*f*
Pain threshold, evaluation of, in complex regional pain syndrome, 1805
Palm, Dupuytren disease in, 134
Palmar advancement flap(s), for soft tissue defects of thumb, 1676-1677, 1677*b*
  with proximal releasing incision, 1677-1679, 1679*b*, 1679*f*
  without proximal releasing incision, 1677, 1678*f*
Palmar cutaneous nerve, anatomy of, 936
Palmar fascia, in Dupuytren disease. *see also* Dupuytren disease (DD)
  anatomy of, 134, 135*f*
Palmar hand skin, 1528, 1529*f*
Palmar nevi, 1966
Palmar radiocarpal ligaments, 420, 421*f*
Palmar radius pedicle grafts, 1632-1634
Palmar space infections
  characteristics of, 35*t*
  clinical presentation and preoperative evaluation of, 34-35
  pertinent anatomy in, 35
  treatment for, 35-36
Palmar ulnocarpal ligaments, 420-421, 421*f*
Palmar V sign, in scapholunate dissociation, 437
Palmaris longus
  absence of, 1070
  transfer of
    to first dorsal interosseous, 1059
    in median nerve palsy, 1033-1034, 1034*f*-1035*f*
Palmaris longus four-tail transfer, in ulnar nerve palsy, 1056
Palmaris longus tendon, for tendon grafts, 203-204
Palmer's classification, of triangular fibrocartilage complex lesions, 487*t*, 488*f*
  class 1A tear in, 489, 677*f*
  class 1B tear in, 489, 678, 678*f*-679*f*
  class 1C tear in, 489, 489*f*
  class 1D tear in, 489-490, 490*f*
Palpation, in thoracic outlet syndrome, 964-966, 965*f*-967*f*
Palsy
  brachial plexus, in children, 1391-1424
  cerebral, 1080. *see also* Cerebral palsy
  Dejerine-Klumpke, 1149-1150
  Erb-Duchenne, 1149, 1393
  median nerve, 1025-1045. *see also* Median nerve palsy
  peripheral nerve, constriction ring associated with, treatment of, 1256
  posterior interosseous nerve, 1064, 1064*f*
  radial nerve, 1064-1076. *see also* Radial nerve palsy
  ulnar nerve, 1045-1062. *see also* Ulnar nerve palsy
Paneva-Holevich reconstruction, FDS-FDP, 213-214, 215*f*
Pan-plexus (C5-T1) injury, 1150
  decisions and priorities of repair for, 1159-1160
Panton-Valentine leukocidin (PVL), methicillin-resistant *S. aureus* (MRSA) and, 18
Pantrapezial degenerative disease, as contraindication for thumb arthroscopy, 693
Paprika sign, 1578
Para-aminosalicylic acid, dosage of, 101*t*
Parasitic infections, chronic, 116-118
  etiology, diagnosis, and treatment of, 63*t*
  worm, 117-118
Paratricipital approach, to distal humeral fractures, 711, 712*f*, 711.*e*1*b*, 711.*e*1*f*-711.*e*2*f*
Paratricipital exposure, for total elbow arthroplasty, 711.*e*1*b*, 711.*e*1*f*-711.*e*2*f*
Parenteral medications, for complex regional pain syndrome, 1815*t*, 1816
  authors' preferred method of, 1819
Paresthesia
  definition of, 1799*t*
  with needle movement, for Dupuytren disease, 147-148, 147*f*
Parkes static tenodesis, in ulnar nerve palsy, 1050-1051, 1050*f*
Parona space infections, 32-34
  clinical presentation and preoperative evaluation of, 33
  pertinent anatomy in, 33
  postoperative management of, 34
  treatment of, 33-34
    open, 33-34
    preferred method of, 34
Paronychia
  acute, 20-22, 22*b*, 22*f*-23*f*
  antibiotic recommendations for, 21*t*
  chronic, 23-25, 24*f*-25*f*, 25*b*, 81, 81*f*, 81.*e*1*f*
Paronychial fold, formation of, in management of syndactyly, 1221-1222

Parosteal osteochondromatous proliferation, bizarre, 2022
Paroxetine, for complex regional pain syndrome, 1813*t*
Parsonage-Turner neuritis, 936
Partial articular loss, 726.*e*1*b*, 726.*e*1*f*-726.*e*3*f*
Partial hand silicone prosthesis, 1737.*e*3*f*
Partial wrist fusion, for arthritic wrist, 690
Passive key pinch reconstruction, in tetraplegia, 1131-1133, 1132*f*
Passive motion rehabilitation, postoperative, of zone 2 tendon lacerations, 189
Passive stability, of proximal interphalangeal joint, 279
Patient refusal, to regional anesthesia, 1
Patient surveillance, 1960
Patient-Specific Functional Scale (PSFS), 924
Peau d'orange skin, 54
Pectoral nerve transfer, for brachial plexus injury, 1176-1177
Pectoralis minor space, in thoracic outlet syndrome, 964
Pectoralis muscle, transfer of
  for elbow reconstruction, in brachial plexus injury, 1198-1202, 1200*f*-1201*f*, 1201*b*
  for shoulder reconstruction, in brachial plexus injury, 1188
Pediatric Outcomes Data Collection Instrument (PODCI), 1394-1395
Penetrating trauma, to brachial plexus, 1149
Penicillin, for actinomycosis, 68
Penicillin G, for syphilis, 74
Percutaneous needle fasciotomy (PNF), for Dupuytren disease, 140, 143-144
Percutaneous pin fixation, of distal radial fracture, 531-532, 535*f*-537*f*
Percutaneous trigger digit release, 1913-1914, 1913*b*-1914*b*, 1913*t*, 1914*f*
Perforator flaps, 1576-1577
Periarterial sympathectomy, of vasospastic disease, 2053*f*-2054*f*, 2054
Perilunate fracture-dislocations, 427
  dorsal, 470-472
    in complex carpal instability
      greater-arc injuries and, 470
      lesser-arc injuries and, 465-470, 465*f*-466*f*
    transscaphoid, 470-471
    transscaphoid-transcapitate, 471-472, 472*f*
    transtriquetrum, 472, 473*f*
    treatment of, 465-470, 472, 473*f*
      preferred method of, 470
  palmar, 472, 474*f*
  transscaphoid, arthroscopic treatment of, 604-605, 606*f*-607*f*
Perilunate instability
  acute, treatment of, 456
  chronic, treatment of, 456-457, 457*f*
Perionychium, 318-337. *see also* Nail bed
  anatomy of, 318, 319*f*
  complications to, postoperative, 325-330
    absence as, of nails, 326-328, 328*f*
    dull nail as, 330
    eponychial deformities as, 329
    hyponychial deformities as, 329-330, 329*f*
    nail ridges as, 325-326
    nail spikes, cysts, and cornified nail bed as, 328, 328*f*
    nonadherence as, 326, 327*f*
    split nail as, 326, 326*f*-327*f*
  infections of
    acute, 330-331
    chronic, 331-332, 332*f*
  postoperative management of, 324-325
  preoperative evaluation for, 318, 319*f*
  tumors of, 332-336
    benign, 332-334
    malignant, 334-336, 335*f*
  types of operation for, 318-324
    in amputation, 323-324, 324*f*-325*f*
    in avulsion, 321, 321*f*
    in delayed treatment of acute injuries, 324
    in fracture, 322-323, 322*f*-323*f*
    in nail bed defect, 321-322, 322*f*
    in nail bed graft, harvest of, 322, 322*f*
    in nail bed repair, 319-321, 320*f*
    in subungual hematoma, 318-319, 320*f*
Periosteal chondroma, 2021-2022, 2022*f*
Periosteal graft, vascularized, 1624-1634
Peripheral nerve implant, for complex regional pain syndrome, 1817
Peripheral neuroma, 1010-1019
Peripheral ulnar-sided tears
  knotless technique for, 680, 680*f*-683*f*
  Tuohy needle technique for, 678-679
Perivascular blocks, regional anesthesia and, 12
Phaeomycotic cysts, 84
Phalangeal line test, 1427, 1427*f*
Phalanx (phalanges)
  amputation through
    middle, 1718-1719, 1719*f*-1720*f*
    proximal, 1719, 1721*f*-1722*f*
  delta, 1271
  distal
    fracture of, 248-249, 322-323
      in children, 1428-1431, 1431*b*
      classification of, 248.*e*1*t*
      complications of, 249
      epiphyseal, 248-249, 248*f*
      preferred method of treatment for, 1429
      shaft, 248
        in children, 1428-1429
Phalanx (phalanges) *(Continued)*
    tuft, 248
      in children, 1428-1429
  musculoskeletal tumors of, excision of, 1993, 1993*f*
  fracture of, 248-270
    antibiotics in the management of, 270
    articular, 249-251
      at base, 249-251, 251*f*-253*f*
        in children, 1436-1437
        preferred method of treatment for, 1437
      at condyle, 249, 250*f*-251*f*
      at head, 249
        in children, 1431
        preferred method of treatment for, 1431, 1432*f*
      preferred method of treatment of, 251-255, 254*f*-256*f*
      at shaft, 251
    biomechanical testing in, 261.*e*1
    closed reduction and percutaneous pinning in, 257, 258*f*-259*f*
    closed reduction with a cast or splint in, 256-257, 257*f*
    complications of, 266-269
      apex volar angulation as, 266, 266*f*
      entrapment as, 269
      flexor tendon rupture as, 269
      infection as, 269
      lateral angulation as, 266-267, 266*f*
      loss of motion as, 268
      malrotation as, 266
      malunion as, 266, 266.*e*1*b*
        articular, 267
        osteotomy for, 267*b*
      nonunion as, 267-268, 268*f*-269*f*
      proximal interphalangeal joint extensor lag as, 268-269
      shortening as, 267
    displaced
      stable after closed reduction, 261
      unstable after closed reduction, 261-263
        spiral and oblique, 261-262
        transverse, 262-263, 263*f*-265*f*
      unstable and comminuted, 263-264
    external fixation in, 261
    healing time for, 256
    indications for fixation of, 232*b*
    infected, treatment of, 270
    intramedullary fixation in, 259
    at neck, in children, 1431-1434, 1433*f*
      preferred method of treatment for, 1434, 1435*f*
    nonarticular, 255-256
      at neck, 255-256, 256*f*-257*f*
      at shaft, 256
        expected outcomes of, 264-265
        preferred method of treatment of, 261

Phalanx (phalanges) *(Continued)*
nondisplaced and stable, 261
open reduction and internal fixation in, 257
open reduction with pin fixation in, 258-259, 260*f*
plate fixation in, 260-261
screw fixation in, 259-260
at shaft, in children, 1434-1435
preferred method of treatment for, 1435, 1436*f*
surgical approaches in, 257-258, 259*f*-260*f*
of thumb, 270
extraarticular thumb fractures, 270, 270*f*
free transfer of, in absent finger, 1261-1262, 1262*f*
complications of, 1262
in mangling injuries, treatment of, 1499
middle
anatomy of, 154, 156*f*
angulation of, after proximal interphalangeal joint arthroplasty, for fracture-dislocation, 290
fracture of, 249-265
in children, 1431-1437, 1437*b*
musculoskeletal tumors of, excision of, 1993-1994, 1993*f*-1994*f*
proximal
anatomy of, 154, 155*f*
fracture of, 249-265
at base, 265-266
in children, 1431-1437, 1437*b*
unicondylar, operative management of, 250*b*
injuries of, 174
preferred method of, repairs, 174
Phalen test, for nerve compression, 924-927
Phenol burns, treatment of, 1951, 1952*t*
Phenoxybenzamine, for complex regional pain syndrome, 1814, 1814*t*
Phentolamine, for complex regional pain syndrome, 1814
Phenytoin, for complex regional pain syndrome, 1813*t*
Phosphorus burns, white, treatment of, 1951, 1952*t*
Phrenic nerve transfer, for brachial plexus injury, 1177
Physical examination, in rheumatoid arthritis, 905
Physical therapy, after elbow contracture release, 857-858
Physiolysis, for Madelung deformity, 1339-1342
dome osteotomy and, 1342-1344, 1342*f*-1343*f*
fat grafting and, 1339-1342, 1341*f*
Physis(es)
arrest of, 1457
case study for, 1457.*e*1*b*, 1457.*e*1*f*-1457.*e*5*f*
surgical intervention for, 1455, 1457*f*
vascularized bone grafting for, 1613
fibula with, vascularized bone grafting for, 1619-1620
fracture of
in distal phalanges, of children, 1429, 1429*f*-1430*f*
preferred method of treatment for, 1430-1431
in distal radius, of children, 1454, 1455*b*
postoperative expectations and management of, 1455-1457
preferred method of treatment for, 1454-1455, 1456*f*-1460*f*
in middle and proximal phalanges, of children, 1435-1436, 1436*f*
preferred method of treatment for, 1436
Pigmented epidermal lesions, 1965-1966
Pigmented macules, 1965
Pigmented villonodular tenosynovitis, 2012, 2012*b*
Pilomatricoma, 1968, 1969*f*
Pilon fracture, of PIP joint, 282, 283*f*
Pin clusters, external fixator, 539
Pin fixation
of distal radial fracture, 531-532, 535*f*-537*f*
in metacarpophalangeal joint extension contracture, 340
Pin plate, in fragment-specific fixation, 554, 556*f*
Pincer nail, 330, 330*f*, 331*b*
Pinning, extension block, for proximal interphalangeal joint fracture-dislocation, 283
"Pins-and-plaster" technique, for distal radius fractures, 516.*e*1
Pisiform
anatomy of, 419
fracture of, 634-636, 635*b*, 636*f*
in children, 1448, 1449*f*
incidence of, 625*t*
"Pisiform boost splint," for volar instability of the proximal row, 460, 461*f*
Pivot shift test, 830
Plantaris tendon, for tendon grafts, 204-205
Plastic deformation, of forearm, 1460-1461, 1461*f*
operations for, 1464
Plate fixation
of both-bone forearm fractures, 798*b*
circular, for scaphotrapeziotrapezoid fusion, 390
of distal and midshaft ulnar fractures, 796
Plate fixation *(Continued)*
of humeral fractures, 717
of metacarpal shaft fractures, 240-241, 237.*e*1*t*
of Monteggia fractures, 778, 779*f*
of nonunion or malunion of radius or ulna, 803*b*
of proximal and middle phalangeal fracture, 260-261
for proximal interphalangeal joint arthrodesis, 350
of radial shaft, 795*b*
for scaphoid fractures, 597
of ulnar fractures, 778-779, 779*f*, 780*b*, 784.*e*22*b*, 784.*e*22*f*
for wrist arthrodesis, critical points in, 400*b*
Plating systems, locked, 796
Platysma motor branch transfer, for brachial plexus injury, 1177
Poikilothermia, 1766
Poland syndrome, syndactyly in, 1231, 1231*f*
Pollicization, 1295-1299, 1295.*e*1*b*, 1295.*e*1*f*-1295.*e*3*f*
complications of, 1303*t*
of index finger, and removal of hypoplastic triphalangeal thumb, 1320, 1320*f*
of index finger stump, 1699-1703, 1702*f*-1704*f*, 1705*b*
of long finger stump, 1699-1703, 1702*f*-1704*f*
pitfalls of, 1303*t*
procedure of, 1295-1299, 1295*b*, 1296*f*-1301*f*
results of, 1301-1303, 1302*f*
Polydactyly, 1232-1236
central, 1234-1236, 1237*b*
epidemiologic findings, 1234, 1234*f*-1235*f*
treatment of, 1235-1236, 1235*f*-1236*f*
ulnar, 1232-1234, 1232*f*-1233*f*, 1234*b*
classification and treatment of, 1233, 1233*f*
epidemiologic findings, 1232
surgical technique for, 1233-1234, 1233*f*
Polymethyl methacrylate beads, antibiotic-impregnated, 1500, 1504*f*
Polymorphonuclear neutrophils (PMNs), in mangling injuries, 1488, 1488*f*
Polytrauma, distal humeral fractures in, management of, 707
Porokeratosis, 1970, 1971*f*
Poroma, eccrine, 1964
Portal sequence, in procedure, for Dupuytren disease, 146
Portals, for arthroscopy of wrist, 653-656, 653.*e*1*t*
1-2, 654
3-4, 653-654, 654*f*-656*f*, 653.*e*1*t*
4-5, 653-654, 653.*e*1*t*

Portals, for arthroscopy of wrist *(Continued)*
6-R and 6-U, 654, 654*f*, 653.*e*1*t*
accessory thumb carpometacarpal, 657-658
distal radioulnar, 657-658, 653.*e*1*t*
midcarpal, 656-657, 653.*e*1*t*
radiocarpal, 653-656, 654*f*-656*f*
scaphotrapeziotrapezoidal, 657
trapeziometacarpal, 657, 658*f*
volar, 655-656, 653.*e*1*t*
Portuguese man o' war, venomous, 1792*f*
Position of function, 1930-1931
Position of safety, 1930-1931, 1931*f*
Positioning
for complex traumatic elbow dislocation, 824-825
in elbow arthroscopy, 886, 888*f*
Posterior central portal, in elbow arthroscopy, 890
Posterior compartment portals, in elbow arthroscopy, 890-891, 890*f*
Posterior dislocation, of elbow, associated with fracture of olecranon process, 784.*e*11*b*, 784.*e*11*f*-784.*e*12*f*
Posterior drawer test, in midcarpal instability, 461
Posterior interosseous artery flap, reversed, 1558-1561, 1560*f*
Posterior Monteggia fracture
metaphyseal, 784.*e*23*b*, 784.*e*23*f*-784.*e*24*f*
plate loosening after operative treatment of, 784.*e*28*b*, 784.*e*28*f*-784.*e*29*f*
type A, 784.*e*1*b*, 784.*e*2*f*-784.*e*3*f*
ulnohumeral instability after, 784.*e*30*b*, 784.*e*30*f*
Posterior Monteggia lesion, 817, 817*f*
Posterior olecranon fracture-dislocation, 784.*e*4*b*, 784.*e*4*f*-784.*e*5*f*, 784.*e*6*b*, 784.*e*7*f*-784.*e*8*f*, 784.*e*15*b*, 784.*e*15*f*-784.*e*17*f*
failed operative fixation of, 784.*e*25*b*, 784.*e*25*f*-784.*e*27*f*
Posteroanterior (palm down) projection, carpal injury and, 428, 428*f*-429*f*
Posterolateral compartment portals, in elbow arthroscopy, 891
Posterolateral portal, in elbow arthroscopy
distal, 891
proximal, 890
Posterolateral rotatory drawer test, 830
Posterolateral rotatory instability (PLRI), 830
Posteromedial varus rotational instability pattern, 784.*e*9*b*, 784.*e*9*f*-784.*e*10*f*
Postoperative swelling, intravenous dexamethasone for, 857
Posttraumatic arthritis
of elbow, 827
preoperative assessment of, 906
Posttraumatic arthritis *(Continued)*
preoperative planning for, 906
total elbow arthroplasty for, 906, 907*f*
Posttraumatic neuralgia, nerve injury and, 1010.*e*4-1010.*e*5
Postures
abnormal, 923-924, 923*f*
dysfunctional, 1828-1829, 1830*f*-1831*f*
Potassium iodide, for sporotrichosis, 83
Pox, farm yard, 123-124, 124*f*
Prazosin, for complex regional pain syndrome, 1814, 1814*t*
Prednisone
for chronic bacterial infections, 67
in Hansen disease
for lepra reaction, 111*t*
for Lucio reaction, 111-112
for pyoderma gangrenosum, 77
Pregabalin (Lyrica), 969
Pregnancy
de Quervain disease of, 1917
regional anesthesia for, 2-3
Prehension, free muscle transfer for, single-stage, 1185, 1185*f*
Preiser disease, 648-649
Pressure therapy, postburn, 1953, 1954*f*
Pressure thresholds, cutaneous, in compression neuropathies, 928
Prestyloid recess (PSR), 659*f*
Primary arterial coaptation, 1482
Procaine, characteristics of, 4*t*
Profundus tendon, superficialis transfer to, in spasticity, 1104-1105, 1106*f*, 1107*b*
Progressive macrodactyly, 1276-1277, 1284*f*
Progressive recontracture, of Dupuytren disease, 133-134, 134*t*
Pronator, insertion of, release of, 1095
Pronator syndrome, 936-937
Pronator teres
rerouting of, for spasticity, 1095, 1096*b*
transfer of, to extensor carpi radialis brevis, for spasticity, 1101, 1101*f*
Prone positioning, in elbow arthroscopy, 886
Proprioception, wrist, reeducation of, 439
Prosthesis
customized, for mangled hand, 1492, 1493*f*
hand, after amputation, 1738-1745, 1743*f*, 1743*t*-1744*t*, 1745*f*, 1746*b*
types of, 1740-1745, 1740*f*
infections of, 50-51
longevity of, in total elbow arthroplasty, 914
passive, 1758
Prosthetic control, improved, 1760-1761, 1760*f*
Prosthetic designs, 1758-1759, 1759*f*
improved, 1761
Prosthetic rehabilitation
current, 1756-1758
frontiers in, 1759-1761
Prosthetic replacement, of elbow, 905
Prothionamide, dosage of, 101*t*
Prototheca wickerhamii, 116
Protothecosis, 116
etiology, diagnosis, and treatment of, 63*t*
Protozoal infections, chronic, 116-118
etiology, diagnosis, and treatment of, 63*t*
Protriptyline, for complex regional pain syndrome, 1812*t*
Provocative tests
for compression neuropathies, 924-927, 926*t*
for thoracic outlet syndrome, 966-967
Proximal interphalangeal (PIP) joint, 42, 42*f*, 278-296, 1840
amputation through, 1719
anatomy of, 338.*e*1-338.*e*3, 338.*e*2*f*
pertinent, 278, 279*f*, 346
arthrodesis of, 349-352
complications of, 352
critical points in, 351*b*
expected outcomes on, 352
indications and contraindications for, 349
postoperative management and expectations on, 350-352
preferred method of treatment for, 350, 351*f*
preoperative planning for, 349
technique for, 349-350, 350*f*
arthroplasty of, 353-358
complications of, 358, 358*f*
critical points in, 356*b*
expected outcomes on, 356-357
indications and contraindications for, 353
postoperative management and expectations on, 356-358
preferred method of treatment for, 354-356, 354*f*-356*f*
preoperative planning of, 353
technique for, 353-354, 354*f*
arthroscopy of, 694.*e*1
biomechanics of, 346
central slip deficiency of, in tetraplegic patient, 1143
intrinsic tenodesis for, 1143, 1143*f*
central slip of, anatomic integrity of, 155
contractures of
extension, release of, 341-343, 343*f*
flexion, release of, 341
expectations and outcomes in, 341.*e*2
preferred approach for, 341, 342*f*
late posttraumatic
interosseous, 343.*e*1-343.*e*2, 343.*e*2*f*
intrinsic, 343.*e*1

Proximal interphalangeal (PIP) joint *(Continued)*
nonoperative treatment of, 340.*e*1-340.*e*2
treatment for, Dupuytren disease and
needling, 148, 148*f*
severe, 143, 144*f*
deformity, in systemic lupus erythematosus, 1838
dislocations of, 279-293
acute dorsal, 279-280
lateral, 280
posttraumatic fibrosis and contracture in, 295-296, 296*b*, 296*f*
volar, 280-281
treatment of, 280-281
Elson test in, 156
extensor mechanism in, 156*f*
fracture-dislocations of, 281-282, 281*f*
chronic, 293-294
stable, 281-282
tenuously stable, 282
treatment of, 281*f*
preferred method of, 284-294, 284*f*
unstable, 282, 282*f*
treatment of, 282-293
volar, 280
ganglion of, 2007-2008, 2008*f*-2009*f*
hyperextension of, as complication of flexor tendon grafting, 225
injury to, 169-174, 169.*e*1*b*, 169.*e*1*f*-169.*e*2*f*
clinical evaluation of, 279
open, 170
preferred method of treatment of, 170-171
preoperative evaluation of, 278-279
radiographic evaluation of, 278-279, 279*f*
in intrinsic muscle spasticity, 1114
little finger, of Dupuytren disease, 138
rheumatoid arthritis of, 1878-1879, 1879*f*
swan neck deformity in, 1879-1890, 1880*t*
type I, 1879-1883, 1881*f*
type III, 1883-1885
type IV, 1886-1890
synovectomy for, 1878-1879
stiffness of. *see also* Stiffness, of finger and hand
articular surface of, 338-339
examination of, 339
subluxations of, 294-295, 295*f*
Proximal row, wrist
dorsal instability of, 461-462
volar instability of, 459-461
Proximal tendon juncture, 208, 210*f*
Pseudoarthrosis, congenital, of ulna, 1354-1357, 1357*b*
Pseudogout, 57-58
tendinopathy in, 1906
Pseudosarcomatous fasciitis, 2014
Psoriatic arthritis, 1834-1836
digital deformity in, 1836, 1836*f*
thumb deformity in, 1836
wrist deformity in, 1836
Psychological impairment, in tetraplegia, 1126-1127
Psychological problems, mimicking complex regional pain syndrome, 1802
Pterygium, 329
Pulley system
design of, for opponensplasty, 1027
disruption of, as complication of flexor tendon grafting, 224
of flexor tendon, 186, 186*f*
reconstruction of, 221-223, 223*b*
indications of, 221
postoperative care of, 223
preferred technique of, 222-223, 223*f*
using a flexor digitorum superficialis tendon, 222, 222*f*
using a free tendon graft, 221-222, 222*f*
using artificial materials, 222
using the extensor retinaculum, 222
using the volar plate, 222
in toe preparation, 1666
Pull-out sutures, for tendon graft, 207-208, 208*f*-209*f*
Pulmonary function tests, in brachial plexus injury, 1153
Pulp flaps, transfer of, from toes to fingers, 1659-1660
Pulp loss, fingertip amputation with, 1709-1711
Pulsed electromagnetic field (PEMF) therapy, for scaphoid fractures, 607
Pulvertaft end-weave technique, modified, for tendon graft, 210-211, 210*f*
Punch biopsy, 1961, 1963*f*
Pustular dermatitis, contagious, 123-124, 124*f*
Putti sign, 1408
Pyarthrosis, antibiotic recommendations for, 21*t*
Pyoderma gangrenosum, 57-58, 75-77
clinical findings on, 76-77, 76*f*
diagnosis of, 77
etiology and epidemiology of, 75-76
treatment of, 77
Pyogenic flexor tenosynovitis, 28-32, 32*b*
clinical presentation and preoperative evaluation of, 28-29
pertinent anatomy in, 29
treatment for, 29-31
operative, 30-31, 30*f*
preferred methods of, 31, 31*f*
Pyogenic granuloma, 57-58, 58*f*, 1970, 1971*f*
of nails, 332, 332*f*
Pyrazinamide (PZA)
dosage of, 101*t*
for tuberculosis, 100
Pyridoxine, for tuberculosis, 100, 103
Pyrocarbon implant
for metacarpophalangeal joint arthroplasty, 358
for proximal interphalangeal joint arthroplasty, 357

Q

Quadriga syndrome, as complication of flexor tendon grafting, 224-225
Quantitative sudomotor axon reflex test (QSART), 1802-1803

R

Radial artery
anatomy of, 787, 1588-1589
in forearm flap, 1555-1558, 1556*f*-1559*f*, 1559*b*
puncture, 2036
Radial bow, assessment of, 787, 788*f*
Radial bursal infections, 32-34
clinical presentation and preoperative evaluation of, 33
pertinent anatomy in, 32-33
postoperative management of, 34
treatment for
open, 33-34
preferred method of, 34
Radial collateral ligament
anatomy of, 739, 740*f*
injury of, 308-310
anatomy in, 308-309
in metacarpophalangeal joint dislocation, 300-301
postoperative management and expectations in, 310
preoperative evaluation of, 309
treatment of, 309
preferred method of, 309-310, 310*b*, 310*f*
types of operations for, 309-310
Radial deficiency, syndromes associated with, 1289, 1290*t*
Radial forearm flap, 1588-1591, 1589*f*, 1591*b*
composite, for reconstruction of amputated thumb, 1697-1699, 1700*f*, 1701*b*, 1699.*e*1*f*
for mangling injuries, 1513, 1514*f*-1515*f*
operative technique for, 1589-1591, 1590*f*, 1592*f*
Radial head excision
in hereditary multiple exostoses of forearm, 1360
in proximal radioulnar synostosis, 1353

Radial longitudinal deficiency, 1328-1334, 1334*b*
  Bayne classification of, 1328, 1329*t*
  pertinent anatomy in, 1328
  preoperative evaluation of, 1328, 1330*f*
  surgical treatment of, 1329-1334, 1331*f*
    expected outcomes of, 1334, 1335*f*
    postoperative management and expectations after, 1334
    preferred method of, 1333-1334, 1334*f*
    preliminary soft tissue distraction in, 1329-1330, 1331*f*-1332*f*
    ulnar lengthening in, 1329, 1333, 1333*f*
  syndromes associated with, 1328, 1329*t*
Radial lunate ligament, 658-659, 658*f*
Radial midcarpal portal, 660*f*
Radial nerve
  anatomy of, 786-787, 788*f*, 950-951, 951*f*
  compression of, 947-949. *see also* Radial tunnel syndrome
    postoperative care of, 949
    proximal, 953
      operative technique of, 953
      postoperative care of, 953
    superficial, 947-949, 948*f*
  in cross-finger flap, for thumb reconstruction, 1682-1684, 1683*f*, 1684*b*, 1684.*e*1*f*
  excessive deviation of, after tendon transfer, 1069-1070
  innervation of, 1064*t*
  intermediate zone injuries of, repair of, outcomes of, 1004*t*
  repair of
    effects of delay in, 1005*t*
    recovery after, 1005*t*
    results of, 1003-1005
      grading of, 1003*t*
  restoration of, 1076
    outcome of, 1076
    technique of, 1076
  sensory branch of
    anatomy of, 948, 948*f*
    decompression of, 949, 949*f*
    release of, 950*b*
  superficial, in complex regional pain syndrome, surgical management of, 1821-1822, 1821*f*
Radial nerve block
  at elbow, 8
  at wrist, 9, 9*f*
Radial nerve palsy, 1064-1076, 1064*f*
  associated with fractures of humerus, 1074-1076
    early, 1074
    if no return at longer waiting period, 1075, 1075*f*
    nerve exploration in, at 6 to 8 weeks, 1074-1075, 1075*f*
    preferred method of treatment of, 1075
Radial nerve palsy *(Continued)*
  associated with Holstein-Lewis spiral fracture, 1074
  nerve transfer in, 1075-1076
  nonoperative treatment of, 1064-1065, 1065*f*
  operative treatment of, 1065-1074
    tendon transfers in, 1066-1074, 1067*t*, 1070*b*
      flexor carpi radialis, 1071, 1071*b*, 1071*f*
      flexor carpi ulnaris, 1067-1070, 1067*f*-1069*f*
        postoperative management of, 1069
        potential problems of, 1069-1070
      historical review of, 1066, 1066*f*, 1066*t*
      nerve repair and graft *versus*, 1065
      outcome of, 1072
      preferred method of, 1072-1074, 1073*f*-1074*f*
      superficialis in, 1070-1071, 1071*b*
        postoperative management of, 1071
      timing of, 1065-1066
  patient requirements for, 1064
  secondary, 1074
Radial osteotomy
  articular, 580-581, 582*f*, 581.*e*1*b*, 581.*e*1*f*-581.*e*6*f*
  closing wedge, for Kienbock disease, 646, 647*f*
  dorsal approach to, 577-578, 579*f*
  extraarticular, 577, 578*b*, 578*f*
  malunited Smith, 580, 580.*e*4*f*
  ulnar-shortening, 580
  volar approach to, 578-580, 581*f*, 580.*e*1*b*, 580.*e*1*f*-580.*e*2*f*
  Watson's trapezoidal, 580.*e*3, 580.*e*3*f*
  with and without ulnar osteotomy, 1378-1380, 1380*b*
    complications of, 1380
    contraindications to, 1379
    indications for, 1378-1379
    postoperative management and expectation after, 1379-1380
    preferred method of, 1379
    preoperative planning in, 1379
    technique of, 1379, 1380*f*
Radial styloidectomy
  for scaphoid nonunion advanced collapse, 622
  for scapholunate dissociation, 449
Radial translation, 561-563
Radial tunnel syndrome, 949-952
  nerve anatomy in, 950-951, 951*f*
  operative techniques for, 951-952
    anterior (modified Henry) approach to, 952
    posterior (Henry or Thompson) approach to, 951-952, 951*f*
Radial tunnel syndrome *(Continued)*
    postoperative care after, 952
    preferred method of, 952, 952*f*
    transmuscular brachioradialis-splitting approach to, 951, 951*f*
  release of, 953*b*
Radial-to-axillary transfer, 1404, 1407*f*
Radiocapitellar joint, 813
  capsuloligamentous components of, 813
  musculotendinous components of, 813
Radiocarpal joint
  fracture-dislocation of, management of, 572-573, 573*f*, 573.*e*1*f*-573.*e*3*f*, 573.*e*2*b*
  instability of, nondissociative, 458-459, 458*f*
  osseous anatomy of, 419-420
  rheumatoid arthritis of, 1858-1863
    reconstruction of, 1863-1866
      partial, 1864-1866, 1864*f*
    synovectomy for, 1858-1859, 1859*f*
Radiocarpal ligaments
  dorsal, 421-422
  palmar, 420, 421*f*
Radiography
  of capitate fracture, 630
  in complex regional pain syndrome, 1805
  of distal humeral fracture, 697-698, 698*f*-699*f*, 906-907
  of distal radial fracture, 520-523, 521*f*-523*f*, 520.*e*1*f*
  of distal radioulnar joint, 484-485, 485*f*
  for free flaps, 1577
  of Galeazzi-type fracture-dislocations, 792, 792*f*
  of hamate fracture, hook of, 631-632, 632*f*
  of Kienbock disease, 641, 641*f*
  of lunate fracture, 637-638
  of mangled extremity, 1490, 1491*f*
  plain, for musculoskeletal tumors, 1990
  of proximal interphalangeal joint injury, 278-279, 279*f*
  of radial head fractures, 734-736, 735*f*
  of radioulnar synostosis, 803-804, 804*f*
  of trapezium fracture, 628
  of triquetrum fracture, 626
Radiological examination
  of carpal injury, 428-430
    additional views, 429-430, 429*f*
    distraction views, 431
    routine views, 428-429, 428*f*-429*f*
    stress views, 431, 432*f*
  of lunotriquetral dissociation, 452-454, 452*f*-453*f*
  of midcarpal instability, 460
  of scapholunate dissociation, 436, 437*f*
Radiolunate angle, measurement of, in wrist instability, 430

Radiolunate fusion, 377-380
author's preferred method of treatment for, 378-380, 381*f*-382*f*
critical points in, 381*b*
indications for, 377, 379*f*
net analysis of literature in, 380
pitfalls of, 380
postoperative management for, 380
technique for, 377, 379*f*-380*f*
Radioscaphocapitate (RSC) ligament, 589-590, 589*f*
Radioscaphoid-lunate fusion, and distal scaphoidectomy, 448-449, 449*f*
Radioscapholunate fusion, 385-386
complications of, 375*f*, 386
critical points in, 388*b*
indications and contraindications in, 385, 385*f*
patients and, 386, 388*f*
postoperative care for, 386
preferred method of treatment for, 385-386, 386*f*-387*f*
Radioulnar inclination, kinematics in, 423*f*, 424
Radioulnar joint
distal, 479-515, 480*f*
anatomy of, 479-483, 480*f*-483*f*
arthritis of, 503-507
distal ulnar resection (Darrach procedure) for, 505-506, 506*f*
hemiresection-interposition arthroplasty for, 503-504, 504*f*
Sauvé-Kapandji procedure for, 504-505, 505*f*
stabilization of resected distal ulna in, 506-507, 507*f*
arthrography of, 486
arthroscopy of, 487
biomechanics of, 479-483
computed tomography of, 486, 486*f*
contracture of, 510-511
after radial fracture, 582-584
operative technique for, 510-511
extensor carpi ulnaris in, tenosynovitis and subluxation of, 511-512, 511*f*
operative technique for, 511-512, 512*f*
outcomes of, 512
failed ulnar resection in, 507-508, 507*f*
fracture of, injuries associated with
classification of, 527, 528*f*-529*f*
treatment of, 563, 564*f*-565*f*
instability of
acute, 491-493, 491*f*-492*f*
evaluation of, 492
simple dislocations in, 492
triangular fibrocartilage complex repair (class 1B injury) in, 492-493
ulnar styloid fractures in, 493, 493*f*
Radioulnar joint *(Continued)*
chronic, 494-498, 495*f*
author's preferred treatment for, 496-498, 497*f*
evaluation of, 494
osteoplasty of sigmoid notch and ulna in, 498, 498*f*
outcomes in, 498
treatment for, 494-498, 496*f*
magnetic resonance imaging of, 486-487, 487*f*
physical examination for, 483-484, 484*f*
radiography of, 484-485, 485*f*
radius and forearm malunions in, 498-500, 499*f*
residual disability of, procedures for, 581-582, 583*f*, 584*t*
scintigraphy of, 487
ulnar head implant arthroplasty in, 508-510
operative technique for, 509-510, 509*f*
outcomes of, 510, 510*f*
ulnar impaction syndrome in, 500-503, 500*f*
author's preferred treatment for, 502, 502*f*
evaluation of, 500-501
treatment of, 501-503
partial distal ulnar resection (wafer procedure), 497*f*, 501, 501*f*
ulnar-shortening osteotomy, diaphyseal and metaphyseal, 501-503
ultrasonography of, 485
portals of, for arthroscopy of wrist, 657-658, 653.*e*1*t*
rheumatoid arthritis of, 1858-1863
distal ulnar excision and reconstruction for, 1860-1863
complications of, 1862-1863
synovectomy for, 1858-1859, 1859*f*
Radioulnar ligaments
anatomy of, 481, 481*f*
distal, reconstruction of, 496-498, 497*f*
role of, 482
Radioulnar synostosis, 803-804, 803*f*-804*f*, 804*t*
postoperative management and expectations of, 804
posttraumatic, 1457
preferred method of, 804, 805*f*
proximal, 1349-1354, 1354*b*
classification of, 1351*t*
pertinent anatomy in, 1350
preoperative evaluation of, 1349-1350, 1350*f*-1351*f*
surgical treatment of, 1351-1353
derotation osteotomy in, 1351-1352, 1352*f*-1353*f*
expected outcomes in, 1354
Radioulnar synostosis *(Continued)*
postoperative management and expectations after, 1354
preferred method of, 1353
radial head excision in, 1353
resection in, 1351
Radius
congenital pseudoarthrosis of, 1354-1357, 1357*b*
deformity of, carpal misalignment secondary to, 463-464
distal
anatomy of, 516-520, 518*f*-519*f*
fracture of, 516-587, 671-672
articular, management of, 568-573
bending, 527, 567-568, 568.*e*1*b*, 568.*e*1*f*-568.*e*13*f*, 568.*e*3*b*, 568.*e*7*b*, 568.*e*9*b*, 568.*e*11*b*
carpal ligament injuries associated with, 575
in children, 1448-1455, 1458*b*
preferred method of treatment for, 1448
classifications of, 523-527
AO, 524, 526*f*
associated radioulnar joint injuries in, 527, 528*f*-529*f*
columnar, 524, 527*f*
Fernandez, 524-527, 528*f*-529*f*
fragment-specific, 524, 526*f*
Frykman, 524.*e*1, 524.*e*1*f*
Mayo Clinic, 524.*e*1, 524.*e*2*f*
Melone, 524.*e*1, 524.*e*2*f*
stability in, 527-530
complications of, 575-584
chronic regional pain syndrome as, 576
malunion as, 576-582, 578*b*, 579*f*-580*f*
nonunion as, 576
radioulnar joint contracture as, 582-584
tendon rupture as, 576
eponyms for, 527
evaluation of, 516-523
pertinent anatomy in, 516-520, 518*f*-520*f*
radiographic pathoanatomy in, 520-523, 521*f*-523*f*, 520.*e*1*f*
injuries associated with, 573-575
median nerve injury associated with, 575
metaphyseal, bicortical, in children, 1448-1453, 1450*f*-1452*f*, 1454*f*
preferred method of treatment for, 1453-1454
nondisplaced, treatment of, 567
open, 573-575
operative technique for, 672-676, 672*f*-676*f*
physeal, in children, 1454, 1455*b*

Radius *(Continued)*
postoperative expectations and management of, 1455-1457
preferred method of treatment for, 1454-1455, 1456*f*-1460*f*
radioulnar joint injury associated with, treatment of, 563, 564*f*-565*f*
recognition of patterns in, 523-530, 524*f*-525*f*
scaphoid fracture associated with, 603-604
treatment of, 530-564
arthroscopic reduction and percutaneous fixation in, 541-546, 543*f*
augmented, 535-539, 539*b*, 541*f*-542*f*, 535.*e*1*f*
bone graft substitutes in, 543, 544*t*, 543.*e*1*f*-543.*e*5*f*, 543.*e*2*b*
case-based approach to, 566-567
closed reduction in, 530-531, 531*f*-534*f*
concomitant soft tissue injuries and, 542
in elderly, 566
evidence-based decision making in, 564-573, 565*t*
external fixation in, 532-539, 538*f*
iliac bone graft harvest in, 543-546
open reduction and internal fixation in, 547-559, 547*f*-550*f*
outcomes and expectations in, 575
percutaneous pin fixation in, 531-532, 535*f*-537*f*
rationale for, 516, 517*t*
technique for, 533-535, 539*f*-541*f*
ulnar column instability in, 559-564
preferred method of treatment of, 563-564
malunion of, 498-500, 499*f*
fracture of
in children
complete, surgical treatment of, 1464-1466, 1465*f*-1467*f*
preferred method of treatment for, 1466-1468
single-bone, 1464-1466
in mangling injuries, treatment of, 1500
grafts of, vascular anatomy of, 617
head of
anatomy of, 737-740, 739*f*-740*f*, 772
biomechanics of, 737-740, 739*f*-740*f*
Radius *(Continued)*
congenital dislocation of, 1347-1349, 1348*f*, 1350*b*
preoperative evaluation of, 1347-1348, 1348*f*
surgical treatment of, 1348-1349
expected outcomes for, 1349
preferred method of, 1349
resection in, 1348, 1349*f*
versus traumatic dislocation, 1347*t*
fracture of, 734-769
arthroscopic fixation of, 902
classification of, 736, 736*t*
clinical assessment of, 734, 735*f*
complication of, 761-766
avascular necrosis as, 761, 761*f*
axial instability as, 764-766, 765*f*-766*f*
heterotopic bone as, 764, 764*f*
malunion as, 762-763, 762*f*
nerve injury as, 761
nonunion as, 762
osteoarthritis as, 763, 763*f*
stiffness as, 764, 764*f*
valgus instability as, 764
displaced, 736
elbow dislocation with, complex traumatic, 815, 815*f*
nonoperative management of, 819
operative treatment of, 819, 820*f*
treatment of, 819
evaluation of, 734-740
historical review of, 740-741
imaging of, 734-736, 735*f*-736*f*
injuries associated with, 736-737, 737*f*-738*f*
internal fixation in, "safe zone" for, 738-739, 739*f*
postoperative management and expectations of, 756-766
protocol in, 760-761, 760*f*
treatment of, 780
arthroplasty of, 745, 752-754, 755*f*-756*f*, 756*b*, 759-760
closure in, 756, 757*f*
delayed excision in, 743-744, 744*f*, 759
excision of, 744-745, 750-752, 753*f*, 754*b*
fragment excision in, 743, 746, 748*b*, 749*f*, 758-759
initial, 741, 742*f*
nonoperative, 741-742, 742*f*, 756-758
open reduction with internal fixation in, 743, 746-750, 750*f*-752*f*, 751*b*, 758
operative, 743-756
options in, 741-756, 742*f*
preferred method of, 745-756
primary resection of, 759
Radius *(Continued)*
surgical approach to, 745-746, 746*f*-748*f*
removal of hardware from, after both-bone forearm fractures, 798-799
restoration of length of, with radioulnar joint reduction, for longitudinal forearm instability, 807
shaft of
fracture of, 786-795
bone grafting of, 792
complications in, 795
evaluation of, 786
Galeazzi, fixation of, 792-793, 792*f*
intramedullary rods and external fixation for, 793, 793*f*-794*f*, 795*b*
pertinent anatomy in, 786-787, 788*f*
postoperative management and expectations in, 794-795
preferred method of treatment of, 793-794, 795*f*
preoperative considerations for, 786
stabilization of, 791-792
surgical approaches to, 789-795
anterior, 789-790, 789*f*-790*f*
posterior, 790-791, 790*f*-791*f*
nonunion and malunion of, 799-803
styloid, fracture of, shear, 569-570, 570*f*-571*f*
Radius pedicle grafts, 1629-1634
dorsal, 1629-1632
Random-pattern flap(s), 1539
distant, 1563-1564
for mangling injuries, 1511, 1511*f*
regional, 1550-1552
cross-finger, 1550-1552, 1551*f*
reversed, 1552
division of, 1552
transposition, 1542
Ray(s), transposition of, in absent finger reconstruction, 1245*f*, 1263-1270
Ray amputation, 1719-1730, 1735*b*
of index finger, 1721-1723, 1723*f*
mangling injuries and, 1493
preferred method of treatment of, 1722-1723, 1724*f*
of long finger, 1723, 1725*f*
preferred method of treatment of, 1728-1730, 1729*f*-1731*f*
with transposition, 1726-1730, 1728*f*
preferred method of treatment, 1728-1730, 1729*f*-1731*f*
without transposition, 1730-1733
preferred method of treatment, 1725-1726, 1727*f*-1728*f*
of ring finger, 1730-1733
preferred method of treatment of, 1731-1733, 1732*f*, 1734*f*

Ray amputation *(Continued)*
with transposition of fifth metacarpal, 1732-1733, 1733*f*-1734*f*
without transposition, 1730-1733
of small finger, 1734-1735
Raynaud disease, 2052
Recipient site(s), 1540-1541
for toe transfer, preparation of, 1665-1666
for vascularized bone graft, 1614
Reconstructive wrist, in rheumatoid arthritis, 376, 378*f*
Recontracture, of Dupuytren disease, 133-134, 134*t*
Rectus abdominis muscle flap, 1604
Recurrence assessment, of Dupuytren disease, 133-134, 134*t*
Redisplacement, after volar plate arthroplasty, 290
Reduction and fixation, arthroscopic, for distal radial fracture, 541-546, 543*f*
Reduction-association of the scapholunate (RASL) procedure, for scapholunate dissociation, 446-447, 446*f*
Reflex sympathetic dystrophy, 1012
Regional anesthesia, 1-14
Regional fasciectomy, for Dupuytren disease, 141-142, 142*f*
Regional flap(s), 1540, 1550-1558
axial-pattern, 1552-1554
cutaneous, 1554
fasciocutaneous, 1555, 1555*f*
fillet, 1552-1554, 1554*f*
latissimus dorsi, 1561-1562, 1562*f*, 1563*b*
musculocutaneous, 1561-1562
neurovascular island, 1552-1554, 1553*f*
radial artery forearm, 1555-1558, 1556*f*-1559*f*, 1559*b*
reversed posterior interosseous artery, 1558-1561, 1560*f*
ulnar artery forearm, 1558
random-pattern, 1550-1552
cross-finger, 1550-1552, 1551*f*
reversed, 1552
division of, 1552
for thumb reconstruction, with questionable remaining length, 1694-1696
Rehabilitation
after burns, 1953-1954, 1953*f*-1954*f*
electrical, 1948
after mangling injuries, 1519-1521, 1521*b*, 1521*f*
after metacarpophalangeal joint arthroplasty, 1876-1877, 1876*f*-1877*f*
complications of, 1877-1878
after proximal interphalangeal joint arthroplasty, for swan neck deformity, in rheumatoid arthritis, 1889
after toe transfer
donor site, 1671
motor, 1670-1671
sensory, 1671
for Hansen disease, 115
postoperative, in tetraplegic patient, 1138-1140
Re-Motion implant, 406, 407*f*
surgical technique for, 410-413, 411*f*-414*f*
Reperfusion, 1482
Replantation, 1476-1485
contraindications for, 1476-1477
of digit, 1477, 1484*b*
expected outcomes for, 1483
future directions for, 1483-1484
general considerations in, 1476-1478
emergency management in, 1476
epidemiology in, 1476
patient selection in, 1476-1478
indication for, 1477*f*
intraoperative technique for, 1478-1482
amputated part, preparation of, 1478-1479, 1479*f*
arterial repairs, 1482
digital nerve repairs, 1481
digital vein repairs, 1481
extensor tendon repairs, 1481
flexor tendon repairs, 1481
osseous fixation in, 1481
preparation of the hand, 1479, 1479*f*
reperfusion in, 1482
replantation, 1479-1481
skin closure in, 1482
locating distal veins for, 1481*b*
major, 1480-1481, 1480*f*, 1484*b*
postoperative protocol for, 1482-1483
preparing for, technical considerations in, 1478
Resection
primary, of radial head, outcome of, 759
of pseudoarthrosis of ulna, 1356
of radial head, for congenital dislocation, 1348, 1349*f*
of radial head, outcome of, 759
of synostosis, radioulnar, 1351
Resection arthroplasty, for carpometacarpal joint osteoarthritis
expected outcomes on, 366-368, 367*t*
as operative technique, 363-364, 363*f*
as treatment, 361
Reserpine, for complex regional pain syndrome, 1815*t*
Resisted finger extension test, in scapholunate dissociation, 436
Resisted isometric elbow flexion, 740
Resource materials, for Hansen disease, 115-116
Resting extension splint, for elbow contracture, 857
Restorative wrist, in rheumatoid arthritis, 376, 378*f*
Reticular ligament, reconstruction of, for swan neck deformity, in rheumatoid arthritis, 1883
Retinacular ligament, oblique, 156-157
spiral, reconstruction, technique of, 168, 168*f*
Retroclavicular brachial plexus, 1146
injury to, 1150
Revascularization, of mangled extremity, 1505, 1506*f*-1507*f*
Reversal reaction (leprae type 1), in Hansen disease, 110, 111*t*
Reversed cross-finger flap, 1552
Reversed dart-thrower's motion, 424
Rhabdomyosarcoma, 2020
Rheumatoid arthritis, 1842-1857
arthrodesis, of wrist, complications of, 1867
crossed intrinsic transfer for, 1869-1870
extensor tendon relocation for, 1870, 1870*f*
of fingers, 1876-1877
boutonnière deformity in, 1890-1894
stage I, 1891-1892
extensor tenotomy for, 1891-1892, 1891*f*
stage II, 1892-1893, 1892*f*
treatment options for, 1891*t*
hand deformities, 1835*f*
intrinsic release for, 1869, 1869*f*
medical considerations of, 1833
of metacarpophalangeal joints, 1867-1878
arthroplasty for, 1870-1878
contraindications to, 1871-1872, 1871*f*
extensor tendon centralization in, 1875-1876, 1875*f*
flexible implant, 1872-1875, 1872*f*-1875*f*
indications for, 1871, 1871*f*
options in, 1872
outcome of, 1878
rehabilitation after, 1876-1877, 1876*f*-1877*f*
technical points in, 1876
etiology of, 1867
surgical treatment of
contraindications to, 1868
indications for, 1868, 1868*f*
nodulosis in, 1841-1842
patients with, intramedullary pin fusion for, 401-404, 402*f*-403*f*
physical examination of, 905
preoperative evaluation of, 905-906
preoperative planning of, 905-906
of proximal interphalangeal joint, swan neck deformity in, 1879-1890, 1880*t*

Rheumatoid arthritis *(Continued)*
type I, 1879-1883, 1881*f*
type III, 1883-1885
type IV, 1886-1890
arthroplasty for, 1890*b*
contraindications to, 1887, 1887*f*
indications for, 1887
joint fusion for, 1886
outcome of, 1889-1890, 1890*f*
rehabilitation after, 1889
surgical approaches to, 1887-1889, 1888*f*-1889*f*
regional anesthesia for, 3
soft tissue procedures for, 1880*t*
surgery for
considerations in, 1832-1833
staging hand, 1833-1834, 1834*t*, 1835*f*
swan neck deformity in, 1879-1890, 1880*t*
type I, 1879-1883, 1881*f*, 1899*f*
dermadesis, 1882
distal joint fusion for, 1882
flexor tendon tenodesis, 1882-1883, 1882*f*
retinacular ligament reconstruction for, 1883
with screw, 1881
type II, 1883
intrinsic release for, 1883
type III, 1883-1885
joint manipulation for, 1883
lateral band mobilization for, 1884-1885, 1885*f*
skin release, 1883-1884, 1884*f*
type IV, 1886-1890
synovectomy for, 897, 1868, 1878-1879
with soft tissue reconstruction, 1868
postoperative management of, 1870
techniques of, 1868-1870
tendon rupture in, 1849-1851
extensor
diagnosis of, 1849-1850
with metacarpophalangeal joint disease, 1854
multiple-tendon, 1852
treatment of, 1850-1851, 1850*f*
flexor
diagnosis of, 1850
treatment of, 1856-1857, 1856*f*
options for reconstruction in, 1852-1857
in ring and small finger, 1852, 1853*f*
single-tendon, 1851, 1852*f*
tenosynovitis in, 1842-1849, 1842*f*
anatomy of, 1842-1843
associated with proximal interphalangeal joint stiffness, 1885-1886
preferred method of treatment of, 1843-1845, 1843*f*-1844*f*
Rheumatoid arthritis *(Continued)*
in wrist extensors, 1843-1845
complications, 1845
postoperative management, 1845, 1845*f*
in wrist flexors, 1853-1854
preferred method of treatment of, 1845-1848, 1846*b*, 1846*f*-1847*f*
total elbow arthroplasty for, 905-906, 906*f*
variants of, 1834-1841
of wrist, 1857-1867
arthrodesis of
choice of operation for, 1863
complications of, 1867
with metacarpophalangeal joint arthroplasty, 1867-1878
partial fusion in, 1864-1866, 1864*f*
radiographic patterns of, 376-377
tendon transfers in, 1853-1854
natural history of, 1857-1858, 1858*f*
treatment of, 1858-1863
Rhomboid flap, 1543, 1544*f*
Ribs
cervical
anatomic variants of, 961*f*
in thoracic outlet syndrome, 963
osteochondral autograft reconstruction, of proximal pole, in scaphoid nonunion, 621
vascularized bone graft from, 1634
Rifampin
for cutaneous tuberculosis, 92
dosage of, 101*t*
for multibacillary Hansen disease, 109
for paucibacillary Hansen disease, 109
Riordan static tenodesis, in ulnar nerve palsy, 1050
Rolando fractures, of thumb, 273-275, 274*f*-275*f*
preferred method of treatment of, 274-275
Roos classification, of thoracic outlet syndrome, 961
Roos test, for thoracic outlet syndrome, 966-967, 968*f*
Ropivacaine, characteristics of, 4*t*
ROR2 gene, mutation of, 1239-1240
Rose thorn disease, 82-83, 82*f*-83*f*, 83*b*, 84*t*. *see also* Sporotrichosis
Rotary instability, of scaphoid, 418
Rotational flap(s), 1541-1542
dorsal, for thumb reconstruction, with questionable remaining length, 1691-1694
phalangization of, 1691-1694, 1693*f*-1694*f*, 1694.*e*1*f*
Rotational injury
posterolateral
in elbow instability, 740
posterolateral, in elbow dislocation, 814-815
Rotational injury *(Continued)*
varus posteromedial, in elbow dislocation, 817, 818*f*
Rotational instability pattern, posteromedial varus, 784.*e*9*b*, 784.*e*9*f*-784.*e*10*f*
Rotational osteotomy. *see also* Osteotomy
for forearm fracture malunion, 801-803, 802*f*
of humerus, 1089, 1089*f*
for ulnar deficiency, 1335, 1338
Rothmund-Thomson syndrome, radial longitudinal deficiency associated with, 1329*t*
Royle-Thompson opponensplasty, in median nerve palsy, 1030-1031
Russe classification, of scaphoid fractures, 593
Russe technique, Green's modification of, in bone graft, for scaphoid nonunion, 610-611, 610*f*

S

Sad, hostile, anxious, frustrating, and tenacious (SHAFT) syndrome, 1802
Sagittal band(s), 153
of extrinsic extensors, 338.*e*4
injury, anatomy of, 177*f*
lacerations in, 174
reconstruction of, methods of, 178*f*
rupture, closed, 175, 176*f*
preferred method of treatment of, 175
splint, 177*f*
Salter-Harris fracture
classification of, 1427, 1427*f*
type I, 1429
type II, 1428, 1440-1441
type III, 1428, 1430*f*
of thumb, 1439
type IV, 1428
type V, 1428
Salvage, using allografts, of radial head, 765
Salvage technique/procedures
for free flap failure, 1583-1585, 1585*b*
leeches in, 1582*f*, 1583-1584
operating room exploration and, 1583-1584
thrombolytic agents and, 1584-1585
one-bone forearm technique, for longitudinal forearm instability, 808
for scaphoid nonunion advanced collapse, 622-624
Salvage wrist, in rheumatoid arthritis, 377, 378*f*
Sarcoid, tenosynovitis in, 1907
Sarcoma(s), 1959
Ewing's, 2028-2031, 2030*f*
osteogenic, 2027-2028, 2029*f*
soft tissue, 2015-2020, 2017*b*
biopsy of, 2015
clear cell sarcoma as, 2020

Sarcoma(s) *(Continued)*
clinical picture of, 2015, 2016*f*
dermatofibrosarcoma protuberans as, 2018-2019, 2019*f*
epithelioid, 2017
fibrosarcoma as, 2018
leiomyosarcoma as, 2020
liposarcoma as, 2017-2018, 2018*f*
malignant fibrous histiocytoma as, 2019, 2019*f*
malignant peripheral nerve sheath tumor as, 2019
operative treatment for, 2015-2017
rhabdomyosarcoma as, 2020
staging of, 2015
synovial, 2017
Sauvé-Kapandji procedure
arthrodesis, for radioulnar joint disability, 582, 583*f*
for hereditary multiple exostoses, 1362
for radioulnar joint arthritis, 504-505, 505*f*
for radioulnar joint disability, in rheumatoid arthritis, 1860
Scabies, chronic, 118-119
Scalene injection, diagnostic, for thoracic outlet syndrome, 967
Scaphocapitate arthrodesis, 380-385
athletic participation in, 384
author's preferred method of treatment for, 383-384, 383*f*
contraindications in, 380
critical points in, 384*b*
fixation for, 383, 383*f*
indications for, 383
patients on, 384-385
postoperative expectations in, 384
postoperative management of, 384
Scaphocapitate ligament, 589-590, 589*f*
Scaphocapitate syndrome, 471
Scaphoid
anatomy of
bony and ligamentous, 588-590, 589*f*
vascular, 590, 590*f*
complex injuries of, 603-605
deformity of, carpal misalignment secondary to, 464
dislocation of, 475, 475*f*
distal, resection of, 622-623
excision of
with capitolunate arthrodesis, 394-395, 395*f*
and four-corner fusion, 391-393
author's preferred method of treatment for, 392-393, 393*f*-394*f*
critical points in, 395*b*
fracture of, 426, 588-624
biomechanics of, 590-591
cause of, 588
in children, 607-608, 1442, 1443*f*, 1445, 1445*f*-1446*f*
Scaphoid *(Continued)*
preferred method of treatment for, 1446-1447
classification of, 592-593, 594*t*
clinical presentation of, 591
delayed presentation of waist fracture in, 603
diagnosis of, 591
distal radius and, fractures of, 603-604
examination of, 591-592
imaging of, 592, 593*f*
incidence of, 588, 589*f*, 625*t*
management of, 594-596, 666
algorithm for, 594*t*
in athletes, 603
at distal pole, 594
Geissler technique in, 666-668, 666*f*-668*f*
Herbert-Whipple technique in, 669-670, 669*f*-670*f*
incomplete, through waist, 594
mechanics of fracture fixation in, 595-596
at proximal pole, 595
Slade technique in, 668-669, 668*f*
at waist, 595
nonsurgical treatment for, cost of, 605-607
physical examination of, 591, 591*f*
rigid fixation for, 596-597
surgical treatment for, 597-603
arthroscopy-assisted percutaneous fixation in, 603
complications of, 605
cost of, 605-607
dorsal percutaneous Slade technique in, 598
fixation in, palmar percutaneous method of, 601-603, 602*f*
mini-open screw in, palmar approach to, 600-601, 600*f*
open reduction and internal fixation in, 597-598
palmar percutaneous method in, 600
pitfalls for, 601*b*, 601*f*-602*f*
postoperative care, 602-603
preferred, 597-598, 597*f*
waist fracture, displaced, 598-599, 599*f*
vascularized bone grafting for, 1624
nonunion of, results of, 1637-1638
malunion of, treatment of, 621-622
nonunion of, 588-624
arthroscopic reduction of, 670
biologic stimulation of, 607
bone graft for, nonvascularized, 610, 610*f*
classifications of, 670*t*
of distal pole, 622
dysvascular, 616-619, 616*f*
evaluation of, 608-609
Scaphoid *(Continued)*
activity level in, 609
age in, 609
amount of deformity and malalignment in, 608
arthritis in, presence and location of, 609
bone loss in, 608
comorbidities in, 609
fracture site in, 608
length of time in, 609
pain or dysfunction in, 609
previous treatment in, 608
salvageability of fragment in, 609
vascularity of fragments in, 608
implications of, 590-591, 591*f*
management of, 608-624
preferred method for, 621
open dorsal technique for, 614-615
operative treatment for, 609-619, 609*t*
prognosis for healing in, 620-621
proximal pole, 614-616
treatment for, preferred, 621*t*
unsalvageable proximal pole, 621
without arthritis, 609-611
without substantial bone loss, 609
osteitis of, 648
preparation, for bone grafting, 1631
projection, carpal injury and, 429
Scaphoid nonunion advanced collapse (SNAC), 435, 591
salvage procedures for, 622-624
Scaphoid ring sign, in scapholunate dissociation, 436, 437*f*
Scaphoid shift test, in scapholunate dissociation, 436, 436*f*
Scaphoid-capitate arthrodesis, in scapholunate dissociation, 448
Scaphoidectomy
midcarpal fusion and, 449-450
radioscaphoid-lunate fusion and, 448-449, 449*f*
Scaphoid-lunate-capitate arthrodesis, in scapholunate dissociation, 448
Scaphoid-trapezium-trapezoid arthrodesis, in scapholunate dissociation, 447
Scapholunate advanced collapse (SLAC) wrist, 435
arthroscopy for, 665
Scapholunate angle
increased, in scapholunate dissociation, 436-437, 437*f*
measurement of, in wrist instability, 430
Scapholunate arthrodesis, 387, 447
Scapholunate ballottement test, 436-437
Scapholunate dissociation, 434-450
diagnosis of, 435-436
ballottement test in, 436-437
physical examination in, 435-436
radiological examination in, 436, 437*f*

Scapholunate dissociation *(Continued)*
resisted finger extension test in, 436
scaphoid shift test in, 436
pathomechanics of, 426, 434-435, 435*f*
treatment of, 437-447, 438*b*
preferred method of, 449*f*, 450
Scapholunate interosseous ligament, 658-659, 659*f*
carpal instability and, 661
grade I injury to, 662*f*
grade II injury to, 662*f*
grade III injury to, 662*f*
grade IV injury to, 663*f*
Scapholunate joint
increased space in, 436, 437*f*
Kirschner wire fixation of, 439
reduction-association of, 446-447, 446*f*
Scapholunate ligament, 422, 422*f*
injury to
stage I: partial, treatment in, 438-447, 438*t*
stage II: complete, repairable, treatment in, 438*t*, 440, 440*f*-441*f*
stage III: complete, nonrepairable, normally aligned scaphoid, treatment in, 438*t*, 441-442, 442*f*
stage IV: complete, nonrepairable, reducible flexion deformity of scaphoid, treatment in, 438*t*, 443, 444*f*-445*f*
stage V: reducible carpal collapse, plus instability of radiolunate joint and normal joint cartilage, treatment in, 438*t*, 447, 447*f*-448*f*
stage VI: irreducible carpal collapse, with normal joint cartilage, treatment in, 438*t*, 447
stage VII: with irreducible malalignment and cartilage degeneration, treatment in, 438*t*, 449
interosseous, 589-590, 589*f*
tears of, associated with distal radial fracture, 542
Scapholunate-intercarpal-carpal (SLIC) screw, 663, 663*f*
Scapholunotriquetral tenodesis, 445*f*
Scaphotrapeziotrapezoid arthritis, carpal misalignment secondary to, 464
Scaphotrapeziotrapezoidal fusion, 389-390
alternative techniques for, 390-391
author's preferred method of treatment for, 390, 391*f*
contraindications for, 389
indications for, 389
patients on, 390-391, 392*f*
Scaphotrapeziotrapezoidal joint
portal of, for arthroscopy of wrist, 657
resection arthroplasty of, 693-694
Scaphotrapezoid portal, for arthroscopy of wrist, 657
Scapula
evaluation of, in compression neuropathies, 927
vascularized bone graft from, 1634
Scapular flap, 1554
free, 1591-1593, 1593*b*
anatomy in, 1591, 1593*f*
for mangling injuries, 1515, 1518*f*
operative technique for, 1591-1593, 1594*f*
Scarring
after skin grafting, control of, 1538
of eponychium, 329
of nail bed, 325
postburn, 1953
Schwannomas, 2012, 2013*f*
malignant, 2019
Scintigraphy
in complex regional pain syndrome, 1806-1807, 1806*f*
of distal radioulnar joint, 487
in Kienbock disease, 640
for musculoskeletal tumors, 1990
Sclerodactyly, 1839
Scleroderma, 1839-1840
authors' method of, 1840
calcinosis, 1839
digital deformity in, 1839-1840, 1839*f*
first web contracture in, 1841
proximal interphalangeal joint deformity in, 1838
vascular insufficiency and, 1841
Scratch collapse test, for nerve compression, 927
Screw(s)
bioresorbable, for scaphoid fractures, 596
malposition of, fluoroscopy and surgical navigation to reduce, 605
Screw fixation
in capitate-lunate-hamate-triquetrum fusion, 393-394
of distal humeral fractures, 719
of proximal and middle phalangeal fracture, 259-260
of radial shaft fractures, 793-794, 795*f*
of scaphoid fractures, 596-597, 596*f*
guidewire placement in, 600
length of screw in, 600-601
in scaphotrapeziotrapezoid fusion, 390
sequence of, 724
of ulnar fractures, 778-779, 779*f*, 780*b*
Sea urchins, venomous, 1792, 1792*f*
Seborrheic keratosis, 1964, 1966*f*
Second-degree burns
deep partial-thickness, 1928, 1929*f*
superficial partial-thickness, 1928, 1929*f*
Secretan disorder, 177
Segmental fasciectomy, for Dupuytren disease, 141
Segmental metacarpal loss, 243-244, 244*f*
Selective serotonin reuptake inhibitors, for complex regional pain syndrome, 1812, 1813*t*
Self-report questionnaires, 924
Semipronated (oblique) projection, carpal injury and, 429
Semmes-Weinstein monofilaments, 928
Senile lentigo. *see* Solar lentigo
Sensation
defects in, free flaps for, 1609
preservation of, in Hansen disease, 113-114
Sensibility, restoration of
in Hansen disease, 114
in ulnar nerve palsy, 1061
Sensory evaluation, in compression neuropathies, 927-928
Sensory flaps, from first web of foot, 1605-1608, 1606*f*, 1608*b*
Sensory nerve action potential (SNAP), 929
in thoracic outlet syndrome, 968
Sensory rehabilitation, after toe transfer, 1671
Sentinel lesion, of neonatal compartment syndrome, 1763-1764
Sepsis, regional anesthesia and, 12-14
Septic arthritis, 40-41
clinical presentation and patient evaluation of, 40-41
postoperative management of, 43
treatment for, 41
Septic boutonnière deformity, 43
Septic flexor tenosynovitis, 31.*e*1*b*, 31.*e*1*f*
Septic tenosynovitis, 1907
Septic thrombophlebitis, 52
Serial casting, for proximal interphalangeal joint contractures, 340.*e*2
Serial static splints, for joint stiffness, 340.*e*1, 340.*e*1*f*
Serratus anterior free muscle flap, 1603, 1603*f*
Sertraline, for complex regional pain syndrome, 1813*t*
Seymour fractures, in children, 1429, 1429*f*
Shaft fractures
of metacarpal, 236-243
closed reduction and percutaneous pinning in, 237-238, 238*f*
closed reduction and plaster immobilization of, 237, 237*f*
expected outcomes of, 243
open reduction for, 238-241
cerclage and interosseous wiring in, 239
composite (tension band) wiring in, 238*f*, 239
external fixation in, 241
fracture stabilization techniques in, 237.*e*1*t*

Shaft fractures *(Continued)*
interfragmentary compression screws in, 240, 240*f*
intramedullary fixation in, 239-240, 239*f*
Kirschner wires in, 238-239, 238*f*
plate fixation in, 240-241
preferred method of treatment of, 241-243, 242*f*
of phalanx
distal, 248
nonarticular, 256
expected outcomes of, 264-265
preferred method of treatment of, 261
of thumb, 271-272, 271*f*
SHAFT (sad, hostile, anxious, frustrating, and tenacious) syndrome, 1802
Shave biopsy, 1961, 1962*f*
Shear test, for lunotriquetral dissociation, 451, 452*f*
Shearer's disease, 118
Shearing fracture
of capitellum, 703, 703*f*, 737, 738*f*
of radius, 527
dorsal, isolated, 568, 569*f*-570*f*
management of, 568-573, 569*f*, 568.*e*14*b*, 568.*e*14*f*-568.*e*19*f*, 568.*e*17*b*
Shooter's abscess, 51-52
Shortening, as complication of phalangeal fractures, 267
Shoulder
anatomy of, 1186
arthrodesis of, for brachial plexus injury, 1190-1192
preferred method of, 1192, 1194*b*, 1194*f*
biomechanics of, 1186
contractures of, in arthrogryposis, 1365
examination of, in compression neuropathies, 927
free muscle transfers in, 1178-1179
as recipient site, in vascularized bone grafting, 1636
reconstruction of, in brachial plexus injury, 1186
tendon transfer in, 1187
preferred procedure for, 1189-1190, 1193*f*
spasticity in
examination of, 1084, 1084*f*
operative management of, 1088-1090
treatment of, preferred method of, 1090
stiffness of, after bending fractures, 567-568
weakness and deformity in, in brachial plexus birth palsy, 1408
historical review of, 1411-1412, 1412*b*
Shoulder *(Continued)*
operations for, 1412-1416, 1413*f*-1416*f*
expected outcome of, 1417*b*
postoperative management of, 1416-1417
preferred treatment of, 1416, 1417*f*
preoperative evaluation of, 1409-1411, 1410*f*-1412*f*
Shoulder internal rotation deformity, soft tissue release of, 1088-1089
contraindications to, 1088-1089
indications for, 1088
preoperative planning for, 1089
technique for, 1089
SHOX gene, mutation of, 1339
Shriners Burn Institute, 1529
Shunts, in major replantation, 1480-1481, 1480*f*
Sigmoid notch, 479, 480*f*, 516, 522*f*
osteoplasty of, and ulna, in chronic radioulnar joint instability, 498, 498*f*
Silastic implant
for metacarpophalangeal joint arthroplasty, 358
for proximal interphalangeal joint arthroplasty, 357
Sildenafil, for Raynaud disease, 2053
Silent neuritis, in Hansen disease, 114
"Silhouette" capsulotomy, 584
Silicone sheeting
for burns, 1954
for skin grafting, postoperative care of, 1538
Silver sulfadiazine, glove filled with, for burns, 1931, 1932*f*
Single-column fractures, 701, 701*f*
Single-stage flexor tendon grafting
flexor digitorum profundus and flexor digitorum superficialis tendons disrupted, 202-211, 203*f*, 207*b*
biology of, 203
Boyes' preoperative classification, 202*t*
distal juncture technique of, 209*f*-210*f*, 210
donor for, 203-206
incorporation of, 211
indications for, 202
initial exploration of, 202
placement of, 210
postoperative care of, 211
preferred technique of, 209-210
proximal juncture technique of, 210-211, 210*f*-211*f*
flexor digitorum profundus tendon disrupted, flexor digitorum superficialis tendon intact, 211-212, 212*b*, 214*b*
expectations of, 212
indications for, 211-212, 212*f*-213*f*
postoperative care of, 212
Single-tendon transfer, for radial nerve palsy, 1071-1072
"Six-pack" exercises, for distal radial fractures, 531, 534*f*
Sixth dorsal compartment release, 511-512
Skeletal system, in mangling injuries
evaluation of, 1490
reconstruction of, 1499-1500, 1501*f*-1504*f*, 1502*b*
Skier's thumb, 302-306
Skin, 1528
anthrax in, 68-69, 69*f*
treatment of, 69
chronic paronychia in, 81
treatment of, 81.*e*1, 81.*e*1*f*
closure of
in replantation, 1482
in toe transfer, 1668
on contractures, 340.*e*2
dorsal hand, 1528, 1529*f*
fungal infections of, 80
grafts. *see* Skin graft/grafting
histologic finding of, 1528, 1529*f*
injury of, response to, 1529, 1529*f*
mycetoma in, 71
treatment of, 73
palmar hand, 1528, 1529*f*
pattern of, in free flap transfer, 1579, 1590*f*
preparation of, in toe transfer, 1645
sporotrichosis in, 82, 83*f*
tuberculosis infection of, 91-92
tularemia in, 74
yaws in, 74-75
Skin biopsy, for Hansen disease, 108, 108*t*
Skin flap(s). *see also* Flap(s)
fibula with, 1619
free. *see* Free flap(s)
for paronychial fold formation, in syndactyly, 1221-1222
Skin graft/grafting, 1528-1538
for burns, 1932-1935, 1933*f*-1934*f*
composite, 1709
for digital resurfacing, in syndactyly, 1221, 1225*f*-1226*f*
donor sites for
care of, 1538
in mangling injuries, 1511
filling the defect with, 1536-1537, 1536*f*-1537*f*
full-thickness, 1534-1535, 1535*b*, 1535*f*
choice of graft for, 1535-1536, 1536*f*
technique of obtaining, 1534-1535
general considerations in, 1528-1531
loss of, after burns, 1935
for mangling injuries
donor sites of, 1511
postoperative management of, 1519-1521
type of, 1510
negative pressure wound therapy in, 1536

Skin graft/grafting *(Continued)*
in outpatient surgery, 1538
postoperative care for, 1537-1538
primary closure
in reconstruction of amputated fingertip, 1711
semiocclusive dressings, 1711
skin substitutes for, 1531
skin thickness in, 1531
guidelines for, 1532*t*
split-thickness, 1531-1534, 1533*b*
choice of donor sites for, 1531-1532, 1532*t*
dermatomes for, 1532-1533
Padgett, 1532-1533, 1532*f*
Zimmer air, 1533
harvesting, 1532
meshed. *see* Meshed grafting
split-thickness, in reconstruction of amputated fingertip, 1711
substitution by, 1528-1529
temporary storage of, 1528-1538
timing of, 1530
types of, 1530
Skin lesions, for Hansen disease, 107, 107*f*
Skin loss, fingertip amputation with, 1709-1711
Skin necrosis, after phalangeal transfer, for digital augmentation, 1262
Skin patch, anesthetic, for Hansen disease, 106
Skin protuberances, in constriction ring syndrome, 1257, 1257*f*
Skin release, for swan neck deformity, in rheumatoid arthritis, 1883-1884, 1884*f*
Skin repair, in microvascular toe transfer, 1269
Skin test, lepromin, for Hansen disease, 107-108
Skin tumors, of hand and upper extremity, 1958-1986
anatomy and clinical examination of, 1958-1960, 1959*f*
basal cell carcinoma and, 1973-1975, 1976*f*
classification of, 1974, 1974*t*, 1976*f*
treatment of, 1974-1975, 1977*f*-1978*f*
dermal lesions in, 1966-1968
diagnostic procedures and nonsurgical treatment for, 1960-1961, 1960*f*-1963*f*
epidermal lesions in, 1962-1964
pigmented, 1965-1966
seborrheic keratosis as, 1964, 1966*f*
sweat glands and, 1964
warts as, 1962-1964
malignant, less common, 1981-1983
dermatofibrosarcoma protuberans as, 1983, 1985*f*
human immunodeficiency virus (HIV) and, 1983, 1984*f*
Skin tumors, of hand and upper extremity *(Continued)*
lymphangiosarcoma (Stewart-Treves syndrome) as, 1981-1983
Merkel cell (neuroendocrine) carcinoma as, 1981, 1984*f*
metastatic tumors as, 1983, 1985*f*
sweat gland tumors as, 1983
melanoma, 1977-1981, 1980*f*
local surgical excisional treatment for, 1980-1981
lymphatic basins in, evaluation of, 1981, 1982*f*-1983*f*
prognosis and staging of, 1980, 1981*t*
nonhemangiomatous vascular lesions in, 1968-1970
premalignant, indeterminate behavior lesions and, 1970-1972
actinic keratosis as, 1972, 1972*f*
arsenical keratosis as, 1972
Bowen disease as, 1972, 1973*f*
cutaneous horns as, 1970, 1971*f*
distal digital keratoacanthoma as, 1971-1972
keratoacanthoma as, 1971, 1972*f*
porokeratosis as, 1970, 1971*f*
squamous cell carcinoma, 1975-1977, 1979*f*-1980*f*
surgical lesion excision for, 1962, 1964*f*-1965*f*
syndromal conditions in, 1972-1973
Gorlin syndrome in, 1972-1973, 1974*f*
xeroderma pigmentosum in, 1973, 1975*f*
Skipping lesions, 1946
Slade technique
percutaneous, dorsal, for scaphoid fracture, 598
for scaphoid fractures, 668-669, 668*f*
Slaughterman's interdigital granuloma, 118
Slit-skin smears, for Hansen disease, 108, 108*t*
Slow intermittent passive positioning device, for elbow contracture, 857-858
Smaller-gauge needles, 146
Smith and Albin thenar H-flap, in reconstruction of amputated fingertip, 1716, 1716*f*
Smith fractures, 524-527, 525*f*
malunited, 580, 580.*e*4*f*
Snakes, venomous, 1789-1791, 1790*f*-1791*f*
preferred method of treatment of, 1791
Snow-Littler procedure, in cleft hand surgery, 1248, 1248*f*
"Snuffbox tenderness", 591
Sockets system, 1759
Soft tissue
contractures, 340.*e*2
at elbow, poor-quality, as contraindication to elbow arthroplasty, 909
Soft tissue coverage
in mangling injuries, 1495, 1521*b*
technique of, 1508-1519, 1509*f*-1517*f*
poor, acceptable length and, thumb reconstruction for, 1676, 1676*f*
Soft tissue defects
examination of, prior to free flap transfer, 1577
free flap selection influenced by, 1608-1609
of thumb
heterodigital flaps in, 1679-1681, 1680*f*
palmar advancement flaps in, 1676-1677, 1677*b*
reconstruction of, 1687-1688
Soft tissue deficiencies, after elbow contracture release, 859
Soft tissue distraction, preliminary, in management of radial longitudinal deficiency, 1329-1330, 1331*f*-1332*f*
Soft tissue envelope, in posttraumatic arthritis, 906
Soft tissue flaps, for split thumbs, types III and IV, 1307-1309, 1308*f*
Soft tissue infections, necrotizing, 54-56, 54*f*-55*f*
Soft tissue reconstruction
of midcarpal ligaments, 460-461, 461*f*
of scapholunate ligament, 442
synovectomy with, in rheumatoid arthritis, of metacarpophalangeal joint, 1868
postoperative management after, 1870
Soft tissue release
and balancing, in management of radial longitudinal deficiency, 1331-1333, 1333*f*
of shoulder internal rotation deformity, 1088-1089
contraindications to, 1088-1089
indications for, 1088
preoperative planning for, 1089
technique for, 1089
Soft tissue tumors, 1987-2035
benign, 1997-2014
fibromatoses as, 2014
foreign body lesions as, 2010
ganglions and mucous cysts, 1997-2010, 1999*t*. *see also* Cyst(s); Ganglion(s)
giant cell tumors as, of tendon sheath, 2012, 2012*b*
granular cell tumors as, 2013-2014, 2013*f*
lipofibromatous hamartomas as, 2011-2012

Soft tissue tumors *(Continued)*
lipomas as, 2011
neurofibromas as, 2012
schwannomas (neurilemomas) as, 2012, 2013*f*
malignant, 2015-2020
soft tissue sarcomas as, 2015-2020, 2017*b*
SoftHand prosthetic component (SoftHand Pro), 1740-1741
Solar lentigo, 1965
Solid (nodular) BCC, 1974
Somatosensory evoked potentials (SSEPs)
in brachial plexus surgery, 1158
in thoracic outlet syndrome, 968
Sonography, for musculoskeletal tumors, 1990
Spacer wires, for segmental metacarpal loss, 244*f*
Spastic thumb adductor, insertion of, release of, 1109-1110, 1109*f*, 1110*b*
Spastic thumb intrinsic muscles, release or slide of origin of, 1108-1109, 1108*f*
Spasticity, 1080-1121
botulinum toxin for, 1088
diagnostic testing of, 1085-1086
dynamic electromyography of, 1086, 1087*f*
evaluation of, 1081-1082
imaging of, 1085
of intrinsic muscle, 1085
release or slide of, for thumb-in-palm deformity, 1108-1109, 1108*f*
operative management of, 1088-1118
elbow in, 1090-1093
preferred method of, 1091*f*, 1092-1093
types of, 1090
forearm in, 1093-1095
preferred method of, 1095, 1096*f*
intrinsic muscle spasticity and digital swan neck deformity in, 1113-1117, 1113*f*
preferred method of, 1116-1117
shoulder in, 1088-1090
preferred method of, 1090
types of, 1088
thumb-in-palm deformity in, 1106-1113, 1107*t*
preferred method of, 1112-1113
wrist and digital extension in, 1095-1102, 1097*f*, 1097*t*
preferred method of, 1101-1102, 1102*f*-1103*f*
wrist and digital flexor tightness in, 1102-1106, 1104*f*
preferred method of, 1105-1106
outcome studies of, 1118
physical examination of, 1082-1085, 1082*f*, 1083*t*
in tetraplegia, 1126-1127
Spasticity *(Continued)*
therapy for, 1086-1088, 1088*f*
treatment considerations of, 1081-1086, 1081*f*
Specimen, collection and handling, guidelines for, 64-65, 65*t*
Spiders, venomous, 1788-1789, 1789*f*
Spinal accessory nerve transfer
for brachial plexus injury, 1163-1166, 1163*f*, 1164*b*
to suprascapular, 1404, 1405*f*
Spinal cord stimulation implant, for complex regional pain syndrome, 1817
Spine, cervical, in thoracic outlet syndrome, 960*f*
Spiral bundle, of Dupuytren disease, 145
neurovascular, 138
Spitz nevus. *see* Benign juvenile melanoma
Splenomegaly, 1833
Splint/splinting
for burns, 1930-1931, 1931*f*, 1953, 1953*f*-1954*f*
in camptodactyly release, 1388
for clasped thumb, 1325
dynamic, for joint stiffness, 340.*e*1, 340.*e*1*f*
extension block, for proximal interphalangeal joint fracture-dislocation, 282-283
flexor hinge, wrist-driven, 1130-1131, 1131*f*
for Kirner deformity, 1274-1275
night
for arthrogryposis, 1380
for cubital tunnel syndrome, 942
for epicondylitis, 865
for trigger thumb, 1321
"playing," for ulnar collateral ligament injury, 303
postoperative, for mangling injuries, 1519, 1521*f*
for radial nerve palsy, 1065, 1065*f*
internal, 1065
static
after elbow contracture release, 857
for joint stiffness, 340.*e*1, 340.*e*1*f*
progressive, for joint stiffness, 340.*e*1, 340.*e*1*f*
serial, for joint stiffness, 340.*e*1, 340.*e*1*f*
sugar tong, for distal radial fracture, 531, 532*f*
in thumb reorientation osteotomy, 1383
for trigger finger, 1910
wrist, for carpal tunnel syndrome, 932
Split flexor pollicis longus (FPL) tenodesis, 1059
Split nail, 326, 326*f*-327*f*
Split thumb, 1305
Split-hand/split-foot (SHSF) syndrome, 1244
Split-thickness grafts, 1528-1530. *see also* Skin graft/grafting, split-thickness
Sporotrichosis, 82-83, 83*b*
clinical findings on, 82, 82*f*
deep (extracutaneous), 88
diagnosis of, 82-83, 83*f*, 84*t*
etiology and epidemiology of, 82
treatment of, 83
Spurling test, for cervical nerve root impingement, 927
Spurt test, 1482
Squamous cell carcinoma, 1975-1977, 1979*f*-1980*f*
of perionychium, 334-335, 335*f*
SSEPs. *see* Somatosensory evoked potentials (SSEPs)
"S"-shaped incision, in transmuscular brachioradialis-splitting approach, for radial tunnel syndrome, 951, 951*f*
Stable fractures (type II), nondisplaced, preferred method of, 781
Staphylococcal scalded skin syndrome, 17
Staphylococcus aureus, 17, 1834-1835
methicillin-resistant, 18, 18*f*
Staple fixation
in capitate-lunate-hamate-triquetrum fusion, 393, 394*f*
for scaphoid fractures, 596
in scaphotrapeziotrapezoid fusion, 390
Stapling, hemiepiphyseal, of distal radius, 1359-1360, 1360*f*
Static macrodactyly, 1276-1277
Static splints
for elbow contracture, 857
for joint stiffness, 340.*e*1, 340.*e*1*f*
Static techniques, in ulnar nerve palsy, 1048-1051
Steindler flexorplasty, 1418, 1418*f*
Steindler procedure, modified, for elbow reconstruction, in brachial plexus injury, 1195-1196, 1195*f*, 1196*b*
Stener lesion, 302-303, 303*f*
historical review of, 303
postoperative management and expectations in, 306
treatment of, 303, 304*f*-305*f*, 306*b*
Stewart-Treves syndrome, 1981-1983
Stick-up test, 966-967
Stiffness
after bending fractures, minimization of, 567-568
after humeral fracture, 730-731, 730*f*
after radial head fractures, 764, 764*f*
after ulnar fracture, 784
of finger and hand, 338-344
case study on, 343.*e*3*b*, 343.*e*3*f*-343.*e*7*f*
pathophysiologic findings in, 338, 339*f*
treatment of, 338-343

Stiffness *(Continued)*
evaluation and planning of, 338-340
nonoperative intervention for, 340
operative intervention for, 340-343
recurrent, after elbow contracture release, 859
of thumb, after pollicization, 1303
Stiles-Bunnell procedure, in ulnar nerve palsy, modified, 1051, 1052*f*
Stiletto flap, 1383
Stingrays, venomous, 1793
Straight line of pull, in tendon transfers, 1025
Streptobacillus moniliformis, 47
Streptokinase, for free flap failure, 1585
Streptomycin
for actinomycetoma, 70-73
dosage of, 101*t*
for tuberculosis, 92-93, 100, 101*t*
Stress fractures, after bone grafting, 1616-1617, 1616*f*
Stretch injury, in responses to nerve injury, 985
Styloid
radial, shear fractures of, 569-570, 570*f*-571*f*
of ulna, fracture of, 493, 493*f*
Styloidectomy, radial
for scaphoid nonunion advanced collapse, 622
for scapholunate dissociation, 449
Subaponeurotic space abscess, 37
treatment of, 38-39
Subclavian artery, in thoracic outlet syndrome, 972
Subcoracoid space, in thoracic outlet syndrome, 964
Subcutaneous anterior transposition, of ulnar nerve, for cubital tunnel syndrome, 944, 944*f*-945*f*
Subcutaneous digital nerve block, 9-10, 11*f*
Subcutaneous flap, 1593
Subcutaneous fungal infections, 80-84
classification of, 80-81
paronychia and, chronic, 81, 81*f*, 81.*e*1, 81.*e*1*f*
phaeomycotic cysts and, 84
sporotrichosis and, 82-83, 82*f*-83*f*, 83*b*, 84*t*
Subcutaneous nodules, 1836
Subcutaneous pseudosarcomatous fibromatosis, 2014
Subcutaneous space abscess, 37
treatment of, 38-39
Subfascial space infections, deep, 36-40, 38*f*
clinical presentation and evaluation of, 37-38
pertinent anatomy in, 38
Subfascial space infections, deep *(Continued)*
postoperative management of, 39-40
treatment for, 38-39
preferred method of, 39
Subluxating nerve, 885
Subluxation
of extensor carpi ulnaris, 511-512, 511*f*
of metacarpophalangeal joint, simple, 299
of proximal interphalangeal joint, 294-295, 295*f*
of scaphoid, 435
Submuscular transposition, of ulnar nerve, for cubital tunnel syndrome, 945, 945*f*
Subungual hematoma, 318-319, 320*f*
Subungual melanoma, 1978
Subungual nevi, 332-333, 332*f*-333*f*
Subungual osteochondroma, 2022
Suction drainage, closed, after open release of elbow contracture, 853
Sudeck atrophy, classic, 1805
Sudomotor activity, assessment of, in complex regional pain syndrome, 1808
Sugar tong splint, for distal radial fracture, 531, 532*f*
Superficial basal cell carcinoma, 1974
Superficial displacement, of Dupuytren disease, 138
Superficial fibers, 134
Superficial finger flexor tendons, in rheumatoid arthritis, rupture of, 1857
Superficial head, of interosseous muscles, 338.*e*3, 338.*e*5*f*
Superficial intradermal anesthetic injection, 145
Superficial palmar fascia, anatomy of, in Dupuytren disease (DD), 134
Superficial radial nerve, grafting of, 997
Superficial spreading melanoma, 1978, 1980*f*
Superficialis
harvest of, 1029-1030
opponensplasties, in median nerve palsy, 1029-1031
transfer of
to profundus tendon, in cerebral palsy, 1104-1105, 1106*f*, 1107*b*
in radial nerve palsy, 1070-1071, 1071*b*
postoperative management of, 1071
in ulnar nerve palsy, 1051-1053
modifications of, 1051-1053
results of, 1053
Supine position, in elbow arthroscopy, 886
Supraclavicular brachial plexus, 1146
surgical approach to, 1156-1157, 1156*f*
Supraclavicular nerve block, 6-7
bilateral procedures and, 2
ultrasound-guided, 7*f*
Supracondylar fractures, of distal humerus. *see also* Humerus, distal
management of, 721
Suprascapular nerve transfer, for brachial plexus injury, 1164-1165, 1164*b*, 1164*f*
outcomes of, 1165, 1165*f*
Sural nerve, grafting of, 997, 997*f*
in brachial plexus reconstruction, 1161-1162, 1161*f*
Surface replacement arthroplasty, 356-357
Surgical excision
for burns, 1932-1935, 1933*f*
lesion, 1962, 1964*f*-1965*f*
primary wide, for musculoskeletal tumors, 1992
of radial head, 744-745
delayed, 743-744, 744*f*
outcome of, 759
as preferred treatment, 750-752, 753*f*, 754*b*
of radial head fragments, 743
outcome of, 758-759
as preferred treatment, 746, 748*b*, 749*f*
of ulnar anlage, in management of ulnar deficiency, 1336-1338, 1339*f*
of warts, 123
Suspension system, 1759
Suture
in biceps rupture repair, 877, 878*f*
for extensor tendon laceration repair, 158-159
in triceps avulsion repair, 880, 880*f*-881*f*
Swan neck deformity, 294
classification of, 1880*t*
intrinsic muscle spasticity and, 1113-1117, 1113*f*
treatment of, preferred method of, 1116-1117
in rheumatoid arthritis, of fingers, 1879-1890, 1880*t*
type I, 1879-1883, 1881*f*, 1899*f*
type II, 1883
type III, 1883-1885
type IV, 1886-1890
of thumb, 1896-1897, 1896*f*
operative treatment
indications for, 1896-1897, 1896*t*, 1897*f*
options for, 1896*t*
treatment of, 295*f*
options for, 1880*t*
Sweat gland tumors, 1983
Symbrachydactyly, 1231, 1258-1260, 1261*b*
classification of, 1258-1259, 1258*t*
clinical features of, 1258-1259

Symbrachydactyly *(Continued)*
management of, 1260
in monodactylic type, 1260
in oligodactylic type, 1260
in peromelic type, 1260, 1261*f*
in short finger types, 1260
types of, 1258, 1258*f*
anatomy in, 1259-1260, 1259*f*
Sympathectomy
for complex regional pain syndrome
chemical, 1819-1820
surgical, 1820
summary of role of, 1820
Sympathetic blockade, in complex regional pain syndrome, 1808-1809
Sympathetic nervous system, in complex regional pain syndrome, function of, 1803
Syndactyly, 1217-1227, 1232*b*
in acrosyndactyly, 1227, 1227*f*-1228*f*
in Apert syndrome, 1227-1232, 1228*t*, 1229*f*
classification of, 1217
cleft hand and, 1244, 1245*f*
release of, 1246-1251, 1249*f*-1251*f*
complete, 1217, 1218*f*
complex, 1217, 1218*f*-1219*f*
in dystrophic epidermolysis bullosa, 1231-1232, 1232*f*
epidemiologic findings of, 1217, 1218*f*
expected outcomes for, 1232
incomplete, 1217
management considerations for, 1217-1227, 1218*f*
commissure reconstruction in, 1219-1220, 1219*f*-1220*f*
complications of, 1223
outcome of, 1222-1223
paronychial fold formation in, 1221-1222
preferred method of, 1219*f*, 1223*f*, 1224-1227, 1226*f*-1227*f*
separation and resurfacing of digits in, 1220-1221, 1223*f*-1225*f*
pathologic findings in, 1217
in Poland syndrome, 1231, 1231*f*
preoperative evaluation of, 1217
simple, 1217, 1218*f*
special cases of, 1227-1232
surgery for, 1218
timing of, 1219, 1219*f*
in symbrachydactyly, 1231
web space, postburn, 1938, 1940*f*
Synergism, in tendon transfers, 1025
Synostosis
radioulnar, 803-804, 803*f*-804*f*, 804*t*. *see also* Radioulnar synostosis
tibiofibular, 1356, 1356*f*
Synovectomy
in mycobacterial tenosynovitis, 95
of proximal interphalangeal joint, 1878-1879
for rheumatoid arthritis, 897
Synovectomy *(Continued)*
of metacarpophalangeal joints and, 1868
soft tissue reconstruction
postoperative management after, 1870
techniques of, 1868-1870
of thumb, with reconstruction of extensor mechanism, 1898
of wrist, 1859
for wrist arthritis, arthroscopic, 689-690
Synovial sarcoma, 2017
Synovitis, as complication of flexor tendon grafting, 225, 225.*e1f*
Synpolydactyly, 1213-1214, 1213*f*-1214*f*, 1218, 1234, 1235*f*
treatment of, 1235-1236
Syphilis, 73-74, 73*f*
Systemic lupus erythematosus, 1837-1839, 1837*f*
authors' preferred method of treatment for, 1838
digital deformity in, 1838
proximal interphalangeal joint deformity in, 1838
thumb deformity in, 1838-1839
wrist deformity in, 1837-1838
Systemic sclerosis, 1839

T
"T" fractures, 699, 702, 702*f*. *see also* Humerus, distal
Taenia solium, 118
Tapeworm infection, 118
Targeted-muscle reinnervation (TMR), 1760
Teardrop angle, in distal radial fracture, 520, 521*f*
Telangiectasias, 1968-1970
Temporomandibular joint, involvement of, in rheumatoid arthritis, 1833
Temporoparietal fascial flap, 1604-1605, 1604*f*, 1605*b*
Ten test, of A-beta fibers, 928
Tendinitis
calcific, 1905-1906, 1906*f*
extensor carpi ulnaris, 1921-1922, 1922*f*
flexor carpi radialis, 1922-1923
treatment, 1923
nonoperative, 1923
operative technique, 1923
Tendinopathy, 1904-1925
case study of, 1922.*e1b*, 1922.*e1f*-1922.*e2f*, 1922.*e3f*, 511.*e1f*, 511.*e2f*, 511.*e3f*-511.*e4f*, 1922.*e4f*, 511.*e1b*
crystalline, 1905-1907
in amyloid deposition, 1906-1907, 1906*f*
in calcific tendinitis, 1905-1906, 1906*f*
in gout, 1905, 1905*f*
in hydroxyapatite deposition, 1906
Tendinopathy *(Continued)*
in ochronosis, 1907
in pseudogout, 1906
elbow, 863-884
Tendon(s). *see also named tendon, e.g.*, Flexor pollicis longus (FPL)
adherence, of stiff joint, 339-340
anatomy of, 1842-1843
defects of, free flaps for, 1609
in mangling injuries, 1494-1495
examination of, 1490-1492, 1492*f*
repair/reconstruction of, 1500-1505, 1505*b*
preparation of, in toe transfer, 1645
repair of
in microvascular toe transfer, for hypoplastic digits, 1269
in toe transfer, 1667-1668
rupture of, 863-884
in rheumatoid arthritis, 1849-1851
extensor
diagnosis of, 1849-1850, 1849*f*
with metacarpophalangeal joint disease, 1854
multiple-tendon, 1852
reconstruction for, 1852-1857, 1853*f*
single-tendon, 1851, 1852*f*
treatment of, 1850-1851, 1850*f*
flexor
diagnosis of, 1850
treatment of, 1856-1857
options for reconstruction in, 1852-1857
in ring and small finger, 1852, 1853*f*
Tendon entrapment, 1907-1908
causative factors of, 1907-1908
of fingers and thumb, 1908
histologic findings in, 1907
at wrist, 1920-1923
Tendon graft
for boutonnière deformity, 172, 172*f*
for chronic lateral instability, 833-835
for chronic medial instability, 838
Tendon juncture
distal, 206, 207*f*
proximal, 208, 210*f*
Tendon sheath
anatomy of, 1842-1843
giant cell tumors of, 2012, 2012*b*
Tendon transfer, 1025*b*
combination of EIP and EDC, for pinch, 1058
early, for nerve injuries, 1061
for median nerve palsy, 1025-1045. *see also* Opponensplasty, for median nerve palsy
high, 1042-1045
expectations and patient counseling in, 1045
preferred method for, 1044-1045
summary of, 1044-1045, 1045*t*

Tendon transfer *(Continued)*
low, 1025-1042
expectations and patient counseling in, 1042
postoperative management of, 1041
preferred method of, 1041-1042
for severe nerve deficits, 1036-1041, 1036*f*
in patient with fused wrist, 1853-1854
principles of, 1023-1025, 1186-1190
for radian nerve palsy, 1066-1074, 1067*t*, 1070*b*
flexor carpi radialis in, 1071, 1071*b*, 1071*f*
flexor carpi ulnaris in, 1067-1070, 1067*f*-1069*f*
postoperative management of, 1069
potential problems of, 1069-1070
historical review of, 1066, 1066*f*, 1066*t*
versus nerve grafting, 1065
outcome of, 1072
preferred method of, 1072-1074, 1073*f*-1074*f*
superficialis in, 1070-1071, 1071*b*
postoperative management of, 1071
timing of, 1065-1066
for rheumatoid arthritis, of wrist, 1863
for scapholunate dissociation, 443, 443*f*
for shoulder reconstruction, in brachial plexus injury, 1187
preferred procedure for, 1189-1190, 1193*f*
single, 1025
in tetraplegic patient, 1127
elbow extension, 1127-1129
biceps to triceps, 1127-1129, 1128*f*, 1129*b*
technique, 1140, 1140*f*
in ulnar nerve palsy, dynamic, 1051-1056
for Volkmann contracture, complications of, 1785
Tendon "Z" -lengthening, for spasticity, 1103-1104, 1104*b*
Tendon-to-bone repair
preferred technique of, 190, 192*f*-193*f*
of zone 1 tendon lacerations or avulsions, 187
Tendovaginitis, stenosing, 1907
Tennis elbow, 897
Tenodesis, 1127
flexor, for swan neck deformity, in rheumatoid arthritis, 1882-1883, 1882*f*
flexor digitorum superficialis, for intrinsic muscle spasticity, 1114
lateral band, for proximal interphalangeal joint subluxation, 294-295
Tenodesis *(Continued)*
spiral, in scapholunate dissociation, 447-450, 447*f*-448*f*
in tetraplegic patient
extensor carpi ulnaris, 1140
House's one-stage reconstruction and, 1135, 1135*f*
intrinsic, House two-stage reconstruction and, 1137-1138, 1138*f*
PIP central slip deficiency treated with, 1143, 1143*f*
Zancolli's staged reconstruction for, 1134
three-ligament, in scapholunate dissociation, 443, 444*b*, 444*f*-445*f*
in ulnar nerve palsy
Fowler's wrist, 1051, 1051*f*
Parkes, 1050-1051, 1050*f*
Riordan, 1050
Tenodesis effect, 1426-1427, 1427*f*
Tenolysis
extensor, 340
reconstruction of, in flexor tendon injury, 199-202, 202*b*
adhesion formation of, agents that may limit, 200
expectations following, 201-202
postoperative care following, 201
preferred technique of, 200-201, 201*f*
preoperative evaluation of, 199-200, 200*f*
in secondary reconstruction after mangling injury, 1523-1524
Tenosynovectomy
digital, 1848-1849, 1848*f*
dorsal, 1843-1845, 1843*f*-1844*f*
flexor, 1845-1848, 1846*b*, 1846*f*-1847*f*
volar, 1847*b*
Tenosynovitis
candidiasis and, 85
chronic, 101, 1907
coccidioidal, 85
cryptococcal, 86
defined, 1904
of extensor carpi ulnaris, 511-512, 511*f*
in Hansen disease, 109-110, 110*f*
histoplasmosis and, 86
mycobacterial, 93-96, 94*f*-95*f*
in mycobacterial infections, 90-91
pigmented villonodular, 2012, 2012*b*
proliferative, 1904-1919
in rheumatoid arthritis, 1842-1849, 1842*f*, 1904
anatomy in, 1842-1843
associated with proximal interphalangeal joint stiffness, 1885-1886
in digital flexors, 1848-1849
preferred method of treatment of, 1848-1849, 1848*f*
preferred method of treatment, 1843-1845, 1843*f*-1844*f*
Tenosynovitis *(Continued)*
in wrist extensors, 1843-1845
complications, 1845
postoperative management, 1845, 1845*f*
in wrist flexors, 1845-1848
preferred method of treatment of, 1845-1848, 1846*b*, 1846*f*-1847*f*
in sarcoidosis, 1907
septic, 1907
sporotrichosis and, 88
types of, 66
Tenotomy
for boutonnière deformity, in rheumatoid arthritis, 1891*f*
central slip, for swan neck deformity, 1115, 1116*b*, 1116*f*
tendon, terminal, for boutonnière deformity, 172-174
Tension band wiring, for ulnar fractures, 777, 778*b*, 784.*e*18*b*, 784.*e*18*f*-784.*e*21*f*
Tensor fasciae latae flap, for burn deformities, 1944-1945
Terazosin, for complex regional pain syndrome, 1814, 1814*t*
Terbinafine, for fungal infections of nails, 330-331
Terminal tendon, of interosseous muscles, 338.*e*3, 338.*e*5*f*
"Terry Thomas sign", 436
Tetanus prophylaxis, 19
current guidelines for, 1496, 1498*t*
Tetracaine, characteristics of, 4*t*
Tetracyclic antidepressants, for complex regional pain syndrome, 1811, 1812*t*
Tetraplegia, 1122-1145, 1144.*e*1*b*
diagnostic imaging for, 1124
forearm pronation in, 1129-1130, 1130*f*
group 0, 1130-1131, 1131*f*
group 1, 1131-1133, 1131*f*-1132*f*, 1132*b*, 1133*t*
group 2 and 3, 1133-1135, 1133*t*, 1135*f*-1136*f*, 1136*b*-1137*b*
group 4 and 5, 1135-1140, 1137*f*-1138*f*, 1139*b*, 1140*f*
group 6 and 7, 1140-1141
group 8, 1141-1142, 1142*f*
group 9, 1142, 1143*f*
future areas of research in, 1143-1144
historical review of, 1125, 1126*t*
indications and contraindications to, 1126-1127, 1127*b*
intrinsic reconstruction in, 1142-1143
outcomes of, 1144
pathogenesis of, 1122, 1123*t*
pertinent anatomy in, 1124-1125, 1125*f*
physical examination of, 1123-1124, 1124*f*
preoperative evaluation of, 1122-1124, 1123*t*-1124*t*

Tetraplegia *(Continued)*
psychological impairment in, 1126-1127
spasticity in, 1126-1127
surgery for
digital clawing in, 1142-1143
elbow extension tendon transfer in, 1127-1129
biceps to triceps, 1127-1129, 1128*f*, 1129*b*
international classification for, 1123*t*, 1133*t*
types of operations for, 1127
Thenar crease approach, 35-36, 36*f*
Thenar flap(s), in reconstruction of amputated fingertip, 1716
Smith and Albin, 1716, 1716*f*
Thenar muscle, absence of, in thumb hypoplasia, 1292
Thenar space
infections of, 34*f*
characteristics of, 35*t*
treatment for, 35, 36*f*
preferred method of, 39
pertinent anatomy in, 35
Thermography, in complex regional pain syndrome, 1809
Thigh
anterolateral, free flap from, 1513-1515, 1516*f*, 1597, 1598*f*
anterolateral, free flap from, for burn deformities, 1945
Third-degree burns, 1928-1929, 1929*f*
Thomine coefficient, 133
Thompson APL sling, 363*f*
Thompson approach, to radial tunnel syndrome, 951-952, 951*f*
Thoracic intercostal nerves, transfer of, for brachial plexus birth palsy, 1405-1406
Thoracic outlet, anatomy of, 962, 962*f*
Thoracic outlet syndrome, 959-978
arterial, 959-960, 960*f*
case study in, 977.*e*1*b*
classification of, 959-961
Roos, 961
Wilbourn, 959
clinical findings in, 964
diagnostic studies of, 968, 970*b*
electrodiagnostic evaluation of, 968
epidemiology of, 962, 962*f*
history of, 959
neurogenic, 960
electrically negative, 960-961
true, 960, 961*f*
physical examination of, 964-967, 970*b*
inspection and palpation, 964-966, 965*f*-967*f*
provocative tests for, 966-967
radiologic evaluation of, 968, 970*f*
recurrent, after surgical treatment, 975-976
treatment of, 968-976
Thoracic outlet syndrome *(Continued)*
complications of, 974-975
nonoperative, 968-970, 970*b*
operative, 970-971
recurrent symptoms after, 975-976
preferred method of, 971-976, 971*f*-974*f*
results of, 975-976, 976*f*
venous, 960, 960*f*
Thoracodorsal artery perforator flap, 1602-1603
Thoracodorsal nerve transfer, for brachial plexus injury, 1177
Thoracoepigastric flap, for soft tissue defects of thumb, 1680*f*
Thoracoscopic sympathectomy, for vasospastic disease, 2053
Thrombocytopenia-absent radius (TAR) syndrome, radial deficiency associated with, 1289, 1290*t*
longitudinal, 1329*t*
Thrombolytic agents, for free flaps failing, saving of, 1584-1585
Thrombosis
after toe transfer, 1669
in ulnar artery, 2042, 2045*f*, 2053
venous, 2054-2055
Through-and-through incision, for felon, 27*f*, 27*t*
Thumb
absent, 1255-1270
in cleft hand, management of, 1251, 1254*f*
with acceptable length and poor soft tissue coverage, 1676-1677, 1676*f*, 1677*b*
heterodigital flap in, 1679-1681, 1680*f*
dual innervated, 1684, 1685*f*
first dorsal metacarpal artery, 1684-1686, 1686*f*
innervated, 1681-1684, 1681*b*
radial-innervated, 1682-1684, 1683*f*, 1684*b*, 1684.*e*1*f*
with proximal releasing incision, 1677-1679, 1679*b*, 1679*f*
without proximal releasing incision, 1677, 1678*f*
adduction of, restoration of, 1056-1058
after total amputation with preservation of basal joint, pollicization for, injured digit in, 1699-1703
arthritis mutilans of, 1897
arthrodesis for, 1899-1900
arthrodesis of, in ulnar nerve palsy, 1059
basal joint of
amputation with preservation of, 1696-1699
composite radial forearm flap for, 1697-1699, 1700*f*, 1701*b*, 1699.*e*1*f*
Thumb *(Continued)*
osteoplastic reconstruction for, 1696-1697, 1697.*e*1*f*
pollicization for, index/long finger stump in, 1699-1703, 1702*f*-1704*f*, 1705*b*
carpometacarpal joint of, 312-315
clasped, 1324-1325
contractures of, postburn, 1938-1939, 1941*f*
deformity of, 1289-1292, 1894-1901
pathophysiology of, 1894, 1894*t*
preferred method of treatment of, 1839
psoriatic arthritis in, 1836
secondary to joint destruction, 1897-1901
in systemic lupus erythematosus, 1838-1839
type I, 1894-1896, 1895*f*
type II, 1896
type III, 1896-1897
type IV, 1897
type V, 1897
duplication of, 1304-1315, 1315*b*
classification of, 1304, 1304*t*
clinical features of, 1304-1305, 1306*f*
complications of, 1313-1315
epidemiologic findings in, 1304
general considerations in, 1304-1305
treatment of, 1305-1315
outcomes of, 1310-1313, 1316*f*
in type I or II split thumb, 1305-1307, 1306*f*-1307*f*
in type III or IV split thumbs, 1307-1310, 1308*f*-1313*f*
in type V or VI split thumbs, 1310
in type VII split thumb, 1310, 1313*f*-1316*f*
and first web, classification of ulnar deficiency based on, 1338*t*
flexion, reconstruction of, 1779*b*
flexor tendon reconstruction of, 217-219, 220*b*
free tendon graft in, 218-219
technique in, 218-219
indication of, 217-218
staged tendon reconstruction in, 219
floating, 1291, 1291*f*
fractures of, 270-275
articular, avulsions of, 271
in children, 1439-1442
diaphyseal, in children, 1440
at metacarpal base, 272-273
in children, 1440-1441, 1441*f*
preferred method of treatment for, 1441-1442, 1442*f*
complications of, 273
expected outcomes of, 273
operative management of, 274*b*
preferred method of treatment of, 272, 272*f*-273*f*
at metacarpal head, 271

Thumb *(Continued)*
phalangeal, 270
in children, 1439
preferred method of treatment for, 1439-1440, 1440*f*
extraarticular, 270, 270*f*
Rolando, 273-275, 274*f*-275*f*
preferred method of treatment of, 274-275
at shaft, 271-272, 271*f*
function of, reconstruction of, 1777
heterodigital flap in, neurovascular island flap, 1686-1687, 1688*f*, 1689*b*
hypoplasia of, 1289-1303, 1290*f*, 1304*b*
classification of, 1290-1292, 1290*t*
diagnosis of, 1289
treatment for, 1292-1303
complications of, 1303, 1303*t*, 1304*f*-1305*f*
results of, 1301-1303, 1302*f*
type I, 1290
type II, 1290, 1291*f*, 1290.*e*1*b*, 1290.*e*1*f*-1290.*e*3*f*
type III, 1290, 1291*f*
type IV, 1291, 1291*f*
type V, 1291
interphalangeal joints of, 296-297
mangling injuries of, treatment of, 1493
opposition of
absence of, 1320
biomechanics of, 1026
deficit and deformity in, 1026
in median nerve palsy, tendon transfers for, 1026-1036. *see also* Opponensplasty, for median nerve palsy
history of, 1026
opponensplasty insertions in, 1027-1029, 1028*f*
patient counseling in, 1026-1027
prevention and preoperative treatment of contractures prior to, 1027
principles of, 1027
pulley design in, 1027
results of, 1027-1029, 1028*t*, 1029*f*
selection of motor for transfer in, 1027
osteoarthritic, treatment of, 345-372
with questionable remaining length, 1688-1691
regional and distant flaps for, 1694-1696
"Z"-plasty procedures, 1689-1691
four-flap, 1690-1691, 1690*b*, 1691*f*-1692*f*
simple, 1689, 1690*f*, 1689.*e*1*f*
reconstruction of, 1292-1295, 1293*b*, 1674-1707
after partial or complete traumatic loss, 1675-1704
Thumb *(Continued)*
after total amputation with destruction of basal joint, 1703-1704
after total amputation with preservation of basal joint, 1696-1699
composite radial forearm flap for, 1697-1699, 1700*f*, 1701*b*, 1699.*e*1*f*
case study of, 1705.*e*1*b*-1705.*e*4*b*, 1705.*e*1*f*-1705.*e*4*f*
general considerations in, 1675
historical review of, 1674-1675
microvascular toe transfer in, 1263-1270, 1266*f*
osteoplastic, 1696-1697, 1697.*e*1*f*
postburn, 1942-1943
of soft tissue defects of, 1687-1688
techniques for, 1898-1901
replantation of, 1477*f*, 1481
skier's, 302-306
split, 1305
in tetraplegic patient, control options for, 1141
trigger, 1320-1322
triphalangeal, 1315-1320
Thumb carpometacarpal arthroscopy, 692-694
Thumb metacarpophalangeal joint epiphyseal arthrodesis, for thumb-in-palm deformity, 1112
Thumb reorientation osteotomy, and/or metacarpophalangeal chondrodesis, 1383-1387, 1386*b*
complications of, 1387
contraindications to, 1383
indications for, 1383, 1383*f*
postoperative management and expectations after, 1386-1387
preferred method of, 1385-1386
preoperative planning for, 1383
technique of, 1383-1385, 1384*f*-1387*f*
Thumb-index key pinch, in ulnar nerve palsy, restoration of, 1056-1060
index abduction techniques in, 1058-1059
joint arthrodesis in, 1059
thumb adduction procedures in, 1056-1058
Thumb-index web space, narrowing of, treatment of, 1292, 1293*f*
Thumb-in-palm deformity
classification of, 1107*t*
spasticity in
examination of, 1085, 1086*f*
operative management of, 1106-1113, 1107*t*
preferred method of, 1112-1113
Tibial bone graft, harvesting technique for, 546, 546.*e*1*b*, 546.*e*2*f*-546.*e*5*f*, 546.*e*6*t*
Tibiofibular synostosis, 1356, 1356*f*
Tightrope device, 693.*e*1
Tinel sign, 924
in brachial plexus injury, 1152
in cubital tunnel syndrome, 940-941
in nerve injury, 986, 987*b*
Tissue culture, eight-pack, 65*t*
Tissue damage, chemical agents causing, 1952*t*
Tissue decompression techniques, for electrical injuries, 1947-1948
Tissue defect, examination of, prior to free flap transfer, 1577
Tissue devascularization, in mangling injuries, 1487-1488
Tissue equilibrium, in tendon transfers, 1023
Tissue loss, complex, vascularized bone grafting for, 1613, 1613*f*
Tissue plasminogen activator (t-PA), for free flap failure, 1585
Tissue resistance, in electrical injuries, 1946
Titanium grommets, implant protection with, 1878
Tocainide, for complex regional pain syndrome, 1813, 1814*t*
Toe(s)
dissection of, anatomy in, 1651-1654, 1654*f*
extensor tendon harvest, technique of, 205-206, 206*f*
great, transfer of, in thumb replacement
indications for, 1654, 1655*f*
preferred method of treatment of, 1654-1656
second
toe transfer of, in finger replacement
flap design and elevation, 1656, 1657*f*
indications of, 1656, 1657*f*-1658*f*
preferred method of treatment of, 1663
transfer of, with third toe in adjacent finger replacement, 1663, 1664*f*
third, toe transfer of, in finger replacement, 1663, 1664*f*
second, harvesting of, in microvascular toe transfer for hypoplastic digits, 1268-1269, 1268*f*
Toe transfer, 1643
bone and joint preparation for, 1666
at Chang Gung Memorial Hospital, from 1985-2012, 1672*t*
complications of, 1669
donor site morbidity in, 1670
in finger replacement
after distal digit amputation, 1646-1647
after multiple-digit amputation, 1648

Toe transfer *(Continued)*
after proximal digit amputation, 1647-1648
after single-digit amputation, 1646, 1647*f*
anatomy in, 1651-1654, 1654*f*
combined second and third toes in, 1663-1665, 1664*f*
preferred method of treatment, 1664-1665
combined third and fourth toes in, 1665
combined triple-toe, 1665
first web neurosensory flap, 1660-1661
pulp and hemipulp flaps in, 1647
second toe in, 1656-1657, 1657*f*-1658*f*
flap elevation and design in, 1656, 1657*f*
indications for, 1656, 1657*f*-1658*f*
preferred method of treatment of, 1656-1657
third toe in, 1663, 1664*f*
vascularized nail graft in, 1661-1663, 1662*f*
wraparound flap in, 1657-1658, 1659*f*
flap design of, 1658
indications of, 1657-1658
gait analysis before and after, 1670
general considerations in, 1643-1645
initial care in, 1644-1645
microvascular, for hypoplastic digits, 1265*f*
choice of technique for, 1263-1264
contraindications for, 1266-1267
of great toe, 1269
in hand with no digits, 1266, 1266*f*-1267*f*
indications for, 1264-1265, 1265*f*
presurgical assessment in, 1267
reconstruction of fingers and, 1265-1266, 1266*f*
reconstruction of thumb and, 1265
surgical technique of, 1267-1270
hand preparation in, 1267-1268
nerve repairs, 1269
osteosynthesis in, 1269
postoperative care, 1269
results of, 1269-1270, 1270*f*
retrieving of second toe in, 1268-1269, 1268*f*
secondary surgery, 1270
skin repair in, 1269
tendon repairs in, 1269
vessel repairs in, 1269
nerve preparation for, 1666
outcome of, 1671
postoperative management after, 1668-1669
preoperative evaluation in, 1644-1645, 1644*f*
Toe transfer *(Continued)*
primary *versus* secondary, 1645, 1646*f*
reconstructive options in, 1646-1654
finger amputation and
distal, 1646-1647
multiple, 1648
proximal, 1647-1648
single, 1646, 1647*f*
rehabilitation after, 1670-1671
thumb amputation and, 1646
toe dissection, 1651-1654, 1654*f*
secondary procedures in, 1669-1670
skeletal fixation in, 1666-1667, 1667*f*-1668*f*
surgical techniques of, 1654-1668
combined second and third toes transplantation, 1664*f*
preferred method of treatment, 1664-1665
combined third and fourth toes transplantation, 1663-1665
combined triple-toe transplantation, 1665
first web neurosensory flap in, 1660-1661
great toe transplantation in, total or trimmed, 1654-1656
recipient site preparation, 1665-1666, 1666*f*
second toe transplantation in, partial or total, 1656-1657
second toe wrap around flap in, 1658
tendon and pulley preparation, 1666
third toe transplantation in, 1663, 1663*f*-1664*f*
tendon repair in, 1667-1668
in thumb replacement
great toe in
indications for, 1654, 1655*f*
preferred method of treatment of, 1654-1656
postburn, 1943
skin incisions for, 1665-1666
wraparound flap in, 1657-1658, 1659*f*
flap design in, 1658
indications for, 1657-1658
toe fixation in, 1666-1668
venous preparation for, 1666
Tophi, gouty, 57-58, 58*f*
Topical medications, 1960, 1960*f*
Toronto Test Score, 1394, 1396*t*
Torus fracture, in children, 1448
recommended treatment of, 1448, 1450*f*
Total elbow arthroplasty (TEA), 905-920, 919*b*
complications of, 914-915, 914*f*
contraindications to, 909
for fractures of distal humerus, 906-907, 908*f*
geriatric, 710.*e*1*b*, 710.*e*1*f*
for hemophilic arthropathy, 909
Total elbow arthroplasty (TEA) *(Continued)*
historical review of, 909, 910*t*
mortality rates and, 918
paratricipital exposure for, 711.*e*1*b*, 711.*e*1*f*-711.*e*2*f*
postoperative management and expectations after, 913-918
of posttraumatic arthritis, 906, 907*f*
for primary osteoarthritis, 907-909
for rheumatoid arthritis, 905-906, 906*f*
Total wrist arthrodesis, 395-401
author's preferred method of treatment for, 396-399, 396*f*-400*f*
closure in, 399, 401*f*
complications of, 400, 401*f*-402*f*
postoperative management of, 399
Total wrist replacement, 404-414, 406*f*
centralization of extensor tendons in, 413-414, 414*f*
patients on, 414
preoperative evaluation for, 407
Toxicity
prevention of, 4*b*
systemic, prevention of, 4*b*
Traction, dynamic skeletal, for proximal interphalangeal joint fracture-dislocation, 283
outcomes of, 287
postoperative protocol for, 286-287
preferred method for, 285-287, 285*f*-287*f*, 286*b*
Traction injury, to brachial plexus, 1148-1149, 1148*f*
Transcondylar fractures, of distal humerus. *see also* Humerus, distal
management of, 721
Transfixation pins, for segmental metacarpal loss, 244*f*
Transhumeral amputation, 1755-1756, 1756*f*
with elbow disarticulation, 1754-1756, 1759*f*
Transmetacarpal digital nerve block, 9, 11*f*
Transmuscular brachioradialis-splitting approach, to radial tunnel syndrome, 951, 951*f*
Transolecranon (anterior) fracture-dislocation, of elbow, 784.*e*13*b*, 784.*e*13*f*-784.*e*14*f*
Transolecranon fracture-dislocations, 816-817, 816*f*
Transplantation, toe-to-hand, 1643-1673. *see also* Toe transfer
Transposition flaps, 1542
axial-pattern, 1543-1545
flag, 1545, 1545*f*
random-pattern, 1542
rhomboid, 1543, 1544*f*
"Z"-plasty, 1542, 1542*f*, 1543*b*
four-flap, 1543, 1543*f*

Transradial amputation, 1737, 1754, 1755*f*
  with wrist disarticulation, 1753-1754, 1754*f*
Transscaphoid perilunate fracture-dislocations, 470-471
  arthroscopy for, 670-671, 671*f*-672*f*
Transscaphoid-transcapitate-perilunate fracture-dislocations, 471-472, 472*f*
Transthecal digital nerve block, 9, 10*f*
Transtriquetrum-perilunate fracture-dislocations, 472, 473*f*
Transverse deficiency, 1345-1346, 1346*b*
  evaluation of, 1345-1346, 1346*f*
  pertinent anatomy in, 1346
  surgical treatment of, 1346
    expected outcomes for, 1346
    preferred technique for, 1346, 1347*f*
Transverse fibers, of interosseous muscles, 338.*e*3, 338.*e*5*f*
Transverse intercarpal ligaments, 422
Transverse retinacular ligament, 338.*e*5
Trapeziometacarpal joint
  degenerative disease of, arthroscopy for, 693
  portals of, for arthroscopy of wrist, 657, 658*f*
Trapezium
  dislocation of, 476
  fractures of, 626-629, 627*b*, 627*f*
    imaging of, 628
    incidence of, 625*t*
    mechanism of injury in, 626-628, 628*f*
    treatment of, 628-629, 628*f*-629*f*
Trapezius tendon, transfer of, for shoulder reconstruction, in brachial plexus injury
  contralateral lower, 1189, 1191*f*-1192*f*
  lower, 1188-1189, 1189*f*-1191*f*
  upper, 1187-1188
Trapezoid
  dislocation of, 476
  fractures of, 636, 636*b*
    incidence of, 625*t*
Trapezoidal osteotomy, Watson's, for radial fracture, 580.*e*3, 580.*e*3*f*
Trauma
  associated with distal radial fracture, 573
  in elbow instability, 830
  elbow stiffness caused by, 902-903
Traumatic brain injury, 1080-1081
Traumatic left midcarpal amputation, 1738*f*
Traumatic loss of digits in pediatric hand, 1650-1651
Trazodone, for complex regional pain syndrome, 1812*t*
Triad repair, terrible, 822*b*
Triangular fibrocartilage complex (TFCC), 480-481, 1444-1445
  injuries to
    class IA, 677*f*
    class IB, 678, 678*f*-679*f*
    class II, 687-688
Triangular fibrocartilage complex (TFCC) *(Continued)*
    radial-sided, knotless repair of, 685, 686*f*-687*f*
    treatment of, 676-677
  lesions in, 487-491
    author's preferred method of treatment for, 490-491, 490*f*
    outcomes in, 491
    Palmer's classification of, 487*t*, 488*f*
      class 1A tear in, 489
      class 1B tear in, 489
      class 1C tear in, 489, 489*f*
      class 1D tear in, 489-490, 490*f*
  neurovascular supply to, 483, 483*f*
  repair of (class 1B injury), 492-493
Triangular ligament, 156*f*, 338.*e*5
  function of, 154
Triceps
  advancement and excision of, in ulnar fracture management, 777, 777*b*
  avulsions and rupture of, 878-881, 879*f*, 881*b*
    preferred method of treatment of, 880-881, 880*f*-881*f*
  partial tears of, 880
  in tetraplegic patient, biceps transfer to, 1127-1129, 1128*f*, 1129*b*
  transfer of
    to axillary nerve, in musculocutaneous nerve transfer, for brachial plexus injury, 1172-1173, 1173*f*-1174*f*
      outcomes of, 1174*b*, 1174*f*
    to biceps, for elbow reconstruction, in brachial plexus injury, 1196-1197, 1197*b*, 1197*f*
Triceps-reflecting anconeus pedicle (TRAP) approach, to distal humeral fractures, 714, 715*f*
Triceps-splitting approach, to distal humeral fracture, 712-713, 713.*e*1*b*, 713.*e*1*f*-713.*e*4*f*
Triceps-splitting open reduction and internal fixation, 713.*e*1*b*, 713.*e*1*f*-713.*e*4*f*
Trigger digits, 1908-1915
  in childhood, 1916
  classification of, 1908
  demographics of, 1908
  outcomes of steroid injection for, 1909*t*
  pathologic findings of, 1908
Trigger finger, 1322, 1323*f*, 1908
  classification of, 1908
  demographics of, 1908
  splinting in, 1910
  surgical treatment of, 1910-1914, 1911*f*
  treatment of, 1909-1914
    complications, 1914-1915
    preferred method of, 1914
    surgical, 1917-1919, 1918*f*
      open trigger digit release in, 1912-1913, 1912*f*
Trigger finger *(Continued)*
      percutaneous trigger digit release in, 1913-1914, 1913*b*-1914*b*, 1913*t*, 1914*f*
      skin incisions, 1911-1912, 1911*f*-1912*f*
      topographic anatomy, 1911-1912, 1911*f*-1912*f*
    technique of injection of, 1917, 1917*f*
Trigger thumb, 1320-1322, 1322*b*
  congenital, 1915-1916
    treatment, 1915-1916
      surgical technique, 1915-1916
  incidence and etiologic findings of, 1320-1321, 1321*f*
  treatment of, 1321-1322
    natural history in, 1321
    nonoperative, 1321
    surgical, 1321-1322, 1322*f*
Trimethoprim-sulfamethoxazole
  for actinomycetoma, 72-73
  for tuberculosis arthritis, 97
Triphalangeal thumb, 1315-1320, 1317*f*-1319*f*, 1320*b*
  management of, 1318-1319
  treatment of, 1319-1320
    absence of thumb opposition in, 1320
    concomitant anomalies, 1320
    extra interphalangeal joint in, 1319-1320
    length and angulation in, 1319
    thumb/index finger web space, 1320, 1320*f*
Triquetral-hamate portal, for arthroscopy of wrist, 657
Triquetrocapitate ligaments, 423
Triquetrohamate fusion, 389
Triquetrohamate ligaments, 423
Triquetrum, 660*f*
  fracture of, 427, 624-626, 625*b*
    body, 625-626
    in children, 1447, 1447*f*
    clinical and radiographic features of, 626
    dorsal cortical, 624-625, 626*f*
    incidence of, 625*t*
    patterns of, 624-626
    treatment of, 626, 627*f*
    volar avulsion, 626
Triquetrum-ulnar lunate ligaments, plication of, 665
Triscaphe arthrodesis, 389. *see also* Scaphotrapeziotrapezoidal fusion
Trochlear fractures. *see also* Humerus, distal
  classification of, 703-704
Trochlear notch, ulnar, anatomy of, 770, 772*f*
Tsuge classification, of Volkmann contracture, 1774, 1774*t*
Tsuge tendon transfer, for radial nerve palsy, 1071, 1071*b*, 1071*f*

Tsuge's procedure, for macrodactyly, 1278-1281, 1280*f*, 1282*f*
Tubed pedicle flap, 1540
Tuberculosis
  cutaneous, 91-92
  multidrug therapy for, 100-103, 101*t*
  subcutaneous, 92-93
Tuberculous arthritis, 96-97, 97*f*
Tuberculous bursitis, 96
Tuberculous osteomyelitis, 97-100, 98*f*-99*f*
Tubiana staging, in Dupuytren disease, 131-132
Tuft fracture
  of distal phalanx, 248
  of phalanx, distal, 1428-1429
Tumors
  bone, 1987-2035
  classification and staging of, 1988-1989
  excision, defects caused by, vascularized bone grafting for, 1623-1624, 1623*f*
  malignant, less common, 1981-1983. *see also* Malignant tumors, less common
  musculoskeletal. *see* Musculoskeletal tumors
  of perionychium, 332-336
    benign, 332-334
    malignant, 334-336, 335*f*
  skin, of hand and upper extremity, 1958-1986. *see also* Skin tumors, of hand and upper extremity
  soft tissue, 1987-2035. *see also* Soft tissue tumors
Tuohy needle technique, for peripheral ulnar-sided tears, 678-679
Turnbuckle splint, for elbow contracture, 857, 858*f*
Two-point discrimination, in compression neuropathies, 928
Two-stage flexor tendon reconstruction, 212-217
  alternative techniques in, 213-214, 215*f*
  composite tissue transfer methods of, 214
  indications for, 212-214
  stage I in, 217*b*
    postoperative care of, 216
    preferred technique of, 214-216, 215*f*-216*f*
  stage II in, 218*b*
    postoperative care of, 217
    technique of, 216-217, 216*f*-218*f*
  tissue response to a silicone implant in, 213

U

Ueba technique, in cleft hand surgery, 1251, 1253*f*
Ulceration, 1840
  factitious, 1828, 1829*f*
Ulna
  congenital pseudoarthrosis of, 1354-1357, 1357*b*
    preoperative evaluation of, 1354, 1354*f*-1355*f*
    surgical treatment of, 1354-1357, 1355*f*-1356*f*
      postoperative management and expectations after, 1357
  coronoid process of, anatomy of, 770-771, 772*f*
  deviation deformity of, in brachial plexus birth palsy, 1420
  distal
    dome (pole) of, 479
    excision of, with radioulnar joint reconstruction, in rheumatoid arthritis, 1860-1863
      complications of, 1862-1863
    fracture of, distal radial fracture with, 1455
    resection of, 505-506, 506*f*
      failed, 507-508, 507*f*
      partial, 497*f*, 501, 501*f*
      stabilization of, 506-507, 507*f*
  distal and midshaft, fractures of, 795-797
    complications in, 797
    direct ulnar fixation of, 796
    intramedullary rods for, 796
    pertinent anatomy in, 795-796, 796*f*
    plate fixation of, 796, 797*b*
    postoperative management and expectations after, 797
    preferred method of treatment of, 796-797
    preoperative evaluation for, 795
    preoperative planning for, 796
  fractures of
    in children
      complete, surgical treatment of, 1464-1466, 1465*f*-1467*f*
        preferred method of treatment for, 1466-1468
      single bone, 1464-1466
    in mangling injuries, treatment of, 1500
  lengthening of, in management of radial longitudinal deficiency, 1329, 1333, 1333*f*
  osteoplasty of, and sigmoid notch, in chronic radioulnar joint instability, 498, 498*f*
  proximal
    anatomy of, 770-773
    fractures of, 770-785
      classification of, 773-775
      complications of, 782-784
        arthrosis as, 784
        early failure of fixation as, 782, 782*f*-783*f*
        infection as, 782-783
        instability as, 783, 783*f*
Ulna *(Continued)*
        nonunion as, 783, 784*f*, 784.*e*31*b*, 784.*e*31*f*
        stiffness of heterotopic ossification as, 784
        ulnar neuropathy as, 783-784
      expected outcome of, 782
      historical review of, 775-776
      operative procedure of, 776-782
        excision and triceps advancement in, 777, 777*b*
        Kirschner wire technique in, 777*f*, 778
        plate and screw fixation in, 778-779, 779*f*, 780*b*, 784.*e*22*b*, 784.*e*22*f*
        preferred method of, 781-782
        screw technique in, 778
        skin incision in, 776
        tension band wiring in, 777, 778*b*, 784.*e*18*b*, 784.*e*18*f*-784.*e*21*f*
      patterns of, 773-775
      postoperative management and expectations of, 782
      postoperative protocol of, 782
      preoperative evaluation of, 770, 771*f*
  removal of hardware from, after both-bone forearm fractures, 798-799
  restoration of length of, with radioulnar joint reduction, for longitudinal forearm instability, 807
  shaft, nonunion and malunion of, 799-803
  styloid of, fractures of, 493, 493*f*
  trochlear notch of, 770-773, 772*f*
Ulnar anlage, excision of, in management of ulnar deficiency, 1336-1338, 1339*f*
Ulnar artery, 2044*f*
  bypass of, 2046-2047, 2047*f*, 2054
    complications of, 2046-2047, 2047*f*-2048*f*
  in forearm flap, 1558
  occlusion and aneurysm formation in, 2044*f*
  thrombosis in, 2042, 2045*f*, 2053
Ulnar bursal infections, 32-34
  clinical presentation and preoperative evaluation of, 33
  pertinent anatomy in, 33
  postoperative management of, 34
  treatment for
    open, 33-34
    preferred method of, 34
Ulnar collateral ligament
  anatomy of, 739, 740*f*
  injury to, in metacarpophalangeal joint of thumb
    acute, 302-306
    chronic, 306-308

Ulnar collateral ligament *(Continued)*
historical review of, 303
open repair technique for, 304-306, 304*f*-305*f*
postoperative management and expectations in, 306
preoperative evaluation of, 302
Stener lesion in, 302-303
treatment of, 303
preferred, 304*f*-305*f*, 306*b*
types of operations for, 304-306
insufficiency of, thumb hypoplasia, treatment of, 1292, 1292*f*
lateral, 832
Ulnar column, instability of, in distal radial fracture, 559-564
preferred method of treatment for, 563-564
Ulnar deficiency, 1334-1339, 1339*b*
classifications of, 1338*t*
pertinent anatomy in, 1335, 1337*t*-1338*t*
preoperative evaluation, 1334-1335, 1336*f*
surgical treatment of, 1335-1339, 1337*f*-1338*f*
excision of ulnar anlage in, 1336-1338, 1339*f*
expected outcomes of, 1339
preferred method of, 1338-1339
rotational osteotomy of humerus in, 1335, 1338
untreated, 1335, 1337*f*
Ulnar detethering, for hereditary multiple exostoses of forearm, 1360-1361
Ulnar deviation, recurrent, after metacarpophalangeal joint arthroplasty, 1877
Ulnar distraction lengthening, for hereditary multiple exostoses of forearm, 1360, 1361*f*
Ulnar fragment, volar, surgical approach to, 555-557, 557*f*
Ulnar head implant arthroplasty, distal, 508-510
operative technique for, 509-510, 509*f*
outcomes of, 510, 510*f*
Ulnar impaction syndrome, 500-503, 500*f*, 582
author's preferred treatment for, 502, 502*f*
evaluation of, 500-501
treatment of, 501-503
partial distal ulnar resection (wafer procedure), 497*f*, 501, 501*f*
ulnar-shortening osteotomy, diaphyseal and metaphyseal, 501-503
Ulnar lunate ligament, 659*f*
Ulnar motor neurectomy, for intrinsic muscle spasticity, 1114, 1115*f*
Ulnar nerve, 1005-1008
after humeral fractures, 729
compression of, 938-947. *see also* Guyon canal compression
distal, ganglions of, 2009
examination of, in stiff elbow, 847
repair of, 1008*b*
distal transfers to, 1008
high, 1007*t*
primary *versus* delayed, 1008, 1008*t*
recovery after, 1005*t*
age and, 1007*t*
factors that affect, 1006-1008
results of, 1005-1008
grading of, 1006*t*
methods of, 1006*t*
methods of, 1006*t*
in tidy wounds by level, 1007*t*
in war wounds, by level, 1010.*e*2*t*
surgical anatomy of, 1166
transfer of, to biceps, in musculocutaneous nerve transfer, for brachial plexus injury, 1166-1167, 1166*f*-1167*f*
outcomes of, 1167, 1167*f*
transposition of, 885
intramuscular, 945
in medial "over-the-top" approach to open release of elbow contracture, 852, 852*b*
subcutaneous anterior, 944, 944*f*-945*f*
submuscular, 945, 945*f*
Ulnar nerve block
at elbow, 8
at wrist, 9, 9*f*
Ulnar nerve palsy, 1045-1062
anomalous innervation patterns in, 1046
claw hand in, 1047-1056. *see also* Claw-hand deformity, in ulnar nerve palsy
clinical signs of, 1046-1047
high, 1060-1062
isolated, preferred method of treatment of, 1061-1062
low, 1047
median nerve palsy combined with, 1062, 1063*t*
pattern of paralysis in, 1046
restoration of function in, 1047
surgical correction for
assessment of outcome in, 1047-1048, 1047*t*, 1048*f*
Bunnell's "tendon T" operation in, 1059
index abduction techniques in, 1058-1059
little finger abduction correction in, 1060
metacarpal arch restoration in, 1059-1060
restoration of sensibility in, 1061
Ulnar nerve palsy *(Continued)*
thumb adduction procedures in, 1056-1058
thumb joint arthrodesis in, 1059
wasted intermetacarpal spaces and, 1061
thumb-index key pinch in, restoration of, 1056-1060
index abduction techniques in, 1058-1059
joint arthrodesis in, 1059
thumb adduction procedures in, 1056-1058
Ulnar neuropathy
after humeral fractures, 729-730
after ulnar fracture, 783-784
Ulnar osteotomy, radial osteotomy with and without, 1378-1380
complications of, 1380
contraindications to, 1379
indications for, 1378-1379
postoperative management and expectation after, 1379-1380
preferred method of, 1379
preoperative planning in, 1379
technique of, 1379, 1380*f*
Ulnar polydactyly, 1232-1234, 1234*b*
classification and treatment of, 1233, 1233*f*
epidemiologic findings, 1232
surgical technique for, 1233-1234, 1233*f*
Ulnar portal, distal, in elbow arthroscopy, 891
Ulnar styloid fixation, 559-561
Ulnar translocation, in radiocarpal instability, 458-459, 458*f*
Ulnar translocation ratio, measurement of, in wrist instability, 430, 431*f*
Ulnar variance, 480
measurement of, in wrist instability, 430
method of perpendiculars for, 485, 485*f*
negative, in stages I, II or IIIA Kienbock disease, 641-646
positive or neutral, in stages I, II or IIIA Kienbock disease, 646
Ulnar-humeral joint, functional anatomy of, 813, 814*f*
Ulnar-shortening osteotomy
for class 1B tear, 490-491, 490*f*
for ulnar impaction syndrome, 501-503, 502*f*
Ulnocapitate ligament, 420-421, 481-482
Ulnocarpal ligaments, 481-482
palmar, 420-421, 421*f*
Ulnocarpal stress testing, 484, 484*f*
Ulnohumeral instability, after posterior Monteggia fracture, 784.*e*30*b*, 784.*e*30*f*
Ulnohumeral joint, surface of, assessment of, in stiff elbow, 847
Ulnotriquetral (UT) ligament, 659*f*
Ultrasonic probes, in monitoring of vascularized bone grafts, 1615

Ultrasonography
axillary block and, 8
for brachial plexus birth palsy, 1411, 1411*f*
of carpal instability, 432
of distal radioulnar joint, 485
infraclavicular nerve block and, 7*f*
regional anesthesia and, 5
supraclavicular nerve block and, 6-7, 7*f*
Undisplaced fractures, of radial head fractures, management of, 741-742, 742*f*
Unicameral bone cysts, 2024, 2024*f*
Unicolumnar fractures, of distal humerus. *see also* Humerus, distal
management of, 724-725, 725.*e*1*b*, 725.*e*1*f*-725.*e*2*f*
Unicolumnar injury, 725.*e*1*b*, 725.*e*1*f*-725.*e*2*f*
Unilateral longitudinal incision, for felon, 27*f*, 27*t*
Universal II implant, 406
surgical technique for, 407-410, 408*f*-411*f*
Unna boot dressing, 1538
Unstable fractures, external fixation for, 535
Upper extremity
amputation, rehabilitation after, 1757-1758
bone defects of, vascularized bone grafting for, 1614
compartments of, 1768*t*, 1771.*e*1*b*
embryology of, 1208-1216, 1209*t*
fibular and iliac crest grafts in, 1622-1623, 1623*f*
loss of, 1756-1757
mangling injuries to, 1486-1527, 1487*f*
nonmicrosurgical coverage of, 1528-1573
Upper limb tension test, for thoracic outlet syndrome, 967, 969*f*
Urokinase, for free flap failure, 1585

V

VACTERL syndrome, radial deficiency associated with, 1289, 1290*t*, 1329*t*
Vacuum-assisted wound closure (VAC), 51
Valacyclovir, for herpes simplex virus, 120
Valgus instability, after radial head fractures, 764
Valgus stress test, 743-744, 744*f*
Valproic acid, for complex regional pain syndrome, 1813*t*
Varus posteromedial rotational injury, in elbow dislocation, 817, 818*f*
Varus rotational instability pattern, posteromedial, 784.*e*9*b*, 784.*e*9*f*-784.*e*10*f*
Varus stress test, 743-744, 744*f*
Vascular anastomoses, in toe transfer, 1668
Vascular lesions, nonhemangiomatous, 1968-1970
Vascular pedicle, 1574
Vascular system
anatomy of, 2036, 2037*f*
disorders of, 2036-2059
arterial
closed, 2042-2047, 2044*f*-2046*f*
complications of, 2046-2047, 2047*f*-2048*f*
preferred method of treatment of, 2046-2047, 2047*f*
open, 2040-2042, 2040*f*
complications of, 2042
postoperative care after, 2042
preferred method of treatment of, 2040-2042, 2041*f*-2042*f*
vein grafting of, 2041, 2041*f*, 2042*b*, 2043*f*
evaluation of, 2038-2039, 2039*f*, 2040*b*
management of, 2040-2056
distal sleeve anastomosis of, 2051, 2051*f*
end-to-end anastomosis of, 2051, 2051*f*
preoperative evaluation in, 2048-2049, 2049*f*
in situ bypass of, 2049-2052, 2050*f*
complications of, 2051-2052, 2052*f*
insufficiency of, in scleroderma, 1840
malformations of, 2055-2056
in mangling injury, repair/reconstruction of, 1505-1508, 1506*f*-1507*f*, 1508*b*
case study of, 1505.*e*1*b*, 1505.*e*1*f*-1505.*e*3*f*
Vascular territory, 1539
Vascularity, of wound, 1530
Vascularized bone grafts. *see* Bone graft(s)
Vascularized composite tissue allotransplantation, 1483-1484
Vascularized medial femoral trochlea osteocartilaginous flap reconstruction, in scaphoid nonunion, 619, 619.*e*4*b*, 619.*e*4*f*-619.*e*5*f*
Vascularized nail graft, in toe transfer flap design and elevation in, 1661-1663, 1662*f*
flap designs and elevation in, 1661-1663, 1663*f*
indications for, 1661, 1662*f*
Vascularized nerve graft, 999
Vasospasm, after toe transfer, 1669
Vasospastic disorders, management of, 2052-2054
nonsurgical, 2053
operative, 2053-2054, 2053*f*-2054*f*
postoperative, anticoagulation and, 2054
Vectors, infections and, 46-58
Vein grafting
for ischemia, 2037-2038
for open arterial trauma, 2041, 2041*f*, 2042*b*, 2043*f*
postoperative care after, 2042
reversed, for aneurysm, 2054, 2055*f*
Vein(s)
dissection of, 1479, 1479*f*
distal, location of, for replantation, 1481*b*
preparation of, in toe transfer, 1666
Venograph, in thoracic outlet syndrome, 968, 970*f*
Venomous injuries
of hand, 1794*b*
management of, 1788-1796, 1795*b*
case study of, 1793.*e*1*b*, 1793.*e*1*f*
Venous flaps, free, 1577
Venous malformations, 2055-2056, 2056*f*
Venous thrombosis, 1482, 2054-2055
Verruca plana, 1962
Verruca vulgaris, 121, 1962. *see also* Warts
of perionychium, 333
Vesicles, anthrax, 68-69, 69*f*
Vessels
preparation of, in toe transfer, 1645
resection of, 1478-1479, 1479*f*
Vibration thresholds, in compression neuropathies, 928
Vibrio infections, 48
Vibrometers, fixed-frequency and variable-frequency, 928
Vickers ligament, in Madelung deformity, 1339
release of, 1339, 1340*f*
Villonodular tenosynovitis, pigmented, 2012, 2012*b*
Viral infections, chronic, 119-125
acquired immunodeficiency syndrome (AIDS) and, 119-121, 119.*e*1*t*
etiology, diagnosis, and treatment of, 63*t*
human orf and, 123-124, 124*f*
Milker's nodule and, 124-125
warts and, 121-123, 122*f*
Viral warts. *see* Verruca vulgaris
Vitamin C, for complex regional pain syndrome, 1811, 1816*t*
Volar advancement V-Y flap, in reconstruction of amputated fingertip, 1714, 1715*f*
Volar approach
for thenar space, 35-36, 36*f*
transverse, 39, 39*f*
zigzag, 38-39, 39*f*
Volar capsulectomy, arthroscopic arthrolysis and, 691
Volar incision, for felon, 27*f*, 27*t*
Volar instability, of thumb metacarpophalangeal joint, chronic, 311-312
Volar intercalated segment instability (VISI), 418-419

Volar interossei, 338.e3-338.e4
Volar ligament reconstruction, of thumb carpometacarpal joint, technique of, 313-314, 314f
Volar plate
  of metacarpophalangeal (MP) joint, 338.e1, 338.e2f
  of proximal interphalangeal joint, 338.e2f, 340.e1, 338.e1-338.e3
  pulley reconstruction using, 222
Volar plate arthroplasty, for proximal interphalangeal joint fracture-dislocation, 284
  complications of, 290
  postoperative management of, 290
  preferred method for, 288-290, 289f, 290b
Volar plate fixation, of distal radial fracture, open reduction with, 548-552, 549f-553f, 554b
Volar portals, for arthroscopy of wrist, 655-656, 653.e1t
Volar proximal interphalangeal dislocations, 280-281
  treatment of, 280-281
    closed, 280-281
    open reduction in, 281
    outcomes of, 281
    preferred method of, 280-281
Volar radial (VR) portal, for arthroscopy of wrist, 655-656
Volar release, 1770
Volar retinacular (flexor tendon sheath) ganglion, 2005, 2005f
Volar skin, 1528
Volar surgical approach, for contractures, 341.e1, 341.e1f
Volar ulna (VU) portal, for arthroscopy of wrist, 656
Volar wrist ganglions, arthroscopic excision of, surgical technique for, 688-689, 689f
Volar wrist synovectomy, for rheumatoid arthritis, 1847b, 1859
Volkmann contracture, 1772-1786, 1773f
  classification of, 1773-1774, 1774f-1775f
  complications of, 1785-1786
  flexor pronator slide for, 1779b
  of hand, 1783-1785
  ischemic, 1764
    surgical options for management of, 1776t
  late management of, 1785b
  moderate, 1778.e1b, 1778.e1f
  neonatal, 1763-1764, 1764f
  operative treatment of
    bone procedures in, 1775-1776
    soft tissue procedures in, 1776
  outcomes of, 1781-1783
  preferred methods of treatment, 1776-1781
Volkmann contracture *(Continued)*
  severe, 1782.e1b
  treatment of, 1774-1786
    operative, 1775-1776
Volkmann test, for digital flexor tendon, 1084-1085, 1085f
Voltage-gated ion channels, 980-981
von Recklinghausen disease, 2012
"V-Y" advancement flap, 1548-1550, 1549f-1551f

W
Wafer procedure, for ulnar impaction syndrome, 497f, 501, 501f
Wafer resection, of ulnar head, arthroscopic, 687-688, 687f
Waist fracture, in scaphoid, delayed presentation of, 603
Wallerian degeneration, in responses to nerve injury, 984-985, 984f
War Nerve Injuries Clinic (WNIC), 1010.e1
Wartenberg syndrome, 948
Warts, 121-123, 1962-1964
  classification of, 121
  common verrucated, 121
  diagnosis, 121
  flat (plane), 121
  multiple, 121
  treatment of, 121-123, 122f
  viral, of perionychium, 333
Wasted intermetacarpal spaces, 1061
Watershed, 1540
Watson's trapezoidal osteotomy, for radial fracture, 580.e3, 580.e3f
Web creep, after separation of syndactyly, 1223, 1226f
Web space
  abscess of, 37-38, 38f
    treatment for, 38, 39f
      preferred method of, 39
  Dupuytren disease in, 134
  first
    contracture of
      postburn, 1938, 1940f
      in scleroderma, 1841
    cross-arm flap coverage of, 1695-1696, 1695f
    of foot
      neurosensory flap, from indication, 1658-1661
      sensory flaps from, 1605-1608, 1606f, 1608b
    scarring of, after pollicization, 1303
  normal, 1217
  pertinent anatomy in, 38
  in syndactyly, 1217, 1218f
  thumb/index
    classification of ulnar deficiency based on, 1338t
    narrowing of, 1292, 1293f
  in triphalangeal thumb, 1320, 1320f
Weck-Goulian knife set, 1532, 1532f
Wedge graft, for scaphoid nonunion, 612-614
  anterior, technique of, 614, 614f
  arguments against, 614
  Fernandez-Fisk, 612-614, 613f
Wedge osteotomy
  for clinodactyly, 1272, 1273f
  for Kirner deformity, 1274-1275, 1275f
  for Madelung deformity
    dorsal closing, of distal radius and ulnar shortening, 1344
    radial opening, 1344
  for malunited radial fracture, 577
Wedge resection arthrodesis, of wrist, in cerebral palsy, 1102
Weilby sling, 363, 363f
Weinstein Enhanced Sensory Test, 928
Weiss-Hastings classification, of unicondylar fractures, 250f
White phosphorus burns, treatment of, 1951, 1952t
Whitlow, herpetic, 52-53, 52f
Wire fixation, double intrafocal, of distal radial fracture, 532, 537f
Worm (nematode) infection, parasitic, 117-118
Wound(s)
  bacterial content determination of, 1530
  gunshot, to brachial plexus, 1149
  human bite, zone 5 injuries, of extensor tendon, 174-175
  in mangling injuries, excision of, 1496-1499, 1499b
    case study for, 1499.e1b, 1499.e2f-1499.e3f
  preparation of, for flap transfer, 1540-1541
  tissue defects of
    examination of, prior to free flap transfer, 1577
    free flap selection influenced by, 1608-1609
  vascularity of, 1530
Wound care, local, for burns, 1931-1932, 1932f
Wound closure, negative pressure therapy for, in mangling injuries, 1509, 1510f
Wound healing
  infection on, effect of, 1530
  moist, for burns, 1931
Wound necrosis, after elbow contracture release, 859, 860f
W-plasty, in constriction ring surgery, 1256-1257
Wraparound flap procedure, in toe transfer, for finger/thumb replacement, 1658
Wrist, 418-478
  amputation through
    with disarticulation, 1737-1738, 1739f, 1753-1754, 1754f

Wrist *(Continued)*
preferred method of treatment of, 1737-1738
anatomy of, 419-423, 419*t*
ligamentous, 420-423, 421*f*
osseous, 419-420, 420*f*
arthrodesis of, 373-417. *see also* Arthrodesis, of wrist
combined, 1866-1867, 1867*f*
operative technique for, 1865, 1865*f*
partial, 1864-1865
arthroplasty of, 373-417. *see also* Arthroplasty, of wrist
arthroscopy of. *see* Arthroscopy, of wrist
biomechanics of, 423-426, 423*f*, 425*f*-426*f*
in brachial plexus birth palsy, 1419-1421
deformity of, 1328-1364
in psoriatic arthritis, 1836
in systemic lupus erythematosus, 1837-1838
dislocation of, 465-476
definition of, 465
disorders of, 426-476
diagnosis of, 428-432
pathomechanics of, 426-428
flexion-extension of, kinematics in, 423-424
fracture of, in children, 1442-1457
epidemiology of, 1442-1443, 1443*f*
pertinent anatomy in, 1444-1445
preoperative evaluation of, 1443-1444, 1444*f*
types of operations for, 1445-1457
ganglions of
dorsal, 2001-2003
author's preferred method of treatment for, 2001-2003
clinical characteristics of, 2001, 2001*f*
complications in, 2003
operative technique for, 2001-2003, 2001*f*-2003*f*
postoperative care for, 2003
volar, 2004-2005
author's preferred method of treatment for, 2004-2005
clinical characteristics of, 2004, 2004*f*
complications in, 2005
Wrist *(Continued)*
operative technique in, 2004-2005, 2004*f*
postoperative care for, 2005
hemiarthroplasty of, 414-416
mangling injuries of, treatment of, 1512-1515, 1512*f*-1517*f*
musculoskeletal tumors of, excision of, 1996, 1996*f*-2000*f*
physical examination of, 374
proprioception reeducation of, 439
radioulnar inclination of, kinematics in, 423*f*, 424
range of motion of, 373-374
as recipient site, in vascularized bone grafting, 1637
reconstruction of, with scapholunate/scaphoid nonunion advanced collapse, 391-393
alternative methods of fixation for, 393-394
author's preferred method of treatment for, 392-393, 393*f*-394*f*
contraindications for, 392
critical points on, 395*b*
indications for, 391-392, 392*f*
patients on, 394
postoperative management for, 393
spasticity in
examination of, 1084-1085, 1085*f*
extension of, operative management of, 1095-1102, 1097*f*, 1097*t*
preferred method of, 1101-1102, 1102*f*-1103*f*
flexor tendon tightness in, operative management of, 1102-1106, 1104*f*
preferred method of, 1105-1106
stability, definition of, 433
stabilization of, 425, 425*f*-426*f*
supplementary blocks at, 8-9, 9*f*
tendon entrapment, 1920-1923
total replacement of, 404-414, 406*f*
centralization of extensor tendons in, 413-414, 414*f*
patients on, 414
preoperative evaluation for, 407
Wrist joint, infections of, 41-43
postoperative management of, 43, 44*f*
Wrist splinting, for carpal tunnel syndrome, 932

X
Xenograft. *see also* Allograft(s); Autograft(s)
for mangling injuries, 1510
Xeroderma pigmentosum, 1973, 1975*f*

Y
"Y" fractures, of distal humerus, 699, 702, 702*f*. *see also* Humerus, distal

Z
Zancolli's procedure
Lasso-type, 1142
digital clawing treated with, 1142-1143, 1142*f*
in tetraplegia, 1125*f*, 1141
in ulnar nerve palsy, 1049-1050, 1049*f*, 1050*b*
Zancolli's staged reconstruction, in tetraplegia, 1134
Zigzag incision
in brachial plexus surgery, 1155-1156, 1155*f*
in phalangeal transfer, 1262, 1263*f*
Zimmer air dermatome, 1533
Zone of injury
in extensor tendon, 158, 158*f*
in mangled extremity, 1488-1489
Zone of polarizing activity (ZPA)
in embryogenesis, 1208
in mirror hand, 1237
Z-plasty(ies), 1542, 1542*f*, 1543*b*. *see also* Flap(s)
in constriction ring surgery, 1256-1257
double-opposing, for commissure reconstruction, in syndactyly, 1219-1220, 1220*f*
four-flap, 1543, 1543*f*
for commissure reconstruction, in syndactyly, 1220, 1221*f*
for thumb reconstruction, with questionable remaining length, 1690-1691, 1690*b*, 1691*f*-1692*f*
for thumb-index web space, 1320
for web narrowing, in thumb hypoplasia, 1292, 1293*f*
for thumb reconstruction, 1898
with questionable remaining length, 1689-1691
four-flap, 1690-1691, 1690*b*, 1691*f*-1692*f*
simple, 1689, 1690*f*, 1689.*e*1*f*

This page intentionally left blank

CLINICAL KEY™

Smarter search. Faster answers.



Smarter, Faster Search for Better Patient Care

Unlike a conventional search engine, ClinicalKey is specifically designed to serve doctors by providing three core components:

1 Comprehensive Content

The most current, evidence-based answers available for every medical and surgical specialty.

2 Trusted Answers

Content supplied by Elsevier, the world's leading provider of health and science information.

3 Unrivaled Speed to Answer

Faster, more relevant clinical answers, so you can spend less time searching and more time caring for patients.

Start searching with ClinicalKey today!

Visit ***ClinicalKey.com*** for more information and subscription options.

ELSEVIER

Wolfe • Hotchkiss • Pederson • Kozin • Cohen

Green's Operative Hand Surgery

Seventh Edition


HAND


WRIST

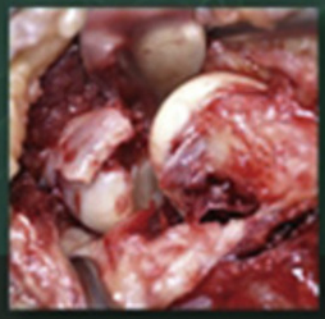
ELBOW


PEDIATRICS

ELSEVIER

GREEN'S

OPERATIVE HAND SURGERY

This page intentionally left blank

GREEN'S

OPERATIVE HAND SURGERY

Seventh Edition

Editor in Chief

Scott W. Wolfe, MD
Professor of Orthopaedic Surgery
Weill Medical College of Cornell University;
Emeritus Chief, Hand and Upper Extremity Surgery
Attending Orthopaedic Surgeon
Hospital for Special Surgery
New York, New York

Editors

Robert N. Hotchkiss, MD
Associate Professor of Clinical Orthopaedic Surgery
Weill Medical College of Cornell University;
Associate Attending Orthopaedic Surgeon
Director of Clinical Research
Hospital for Special Surgery
New York, New York

William C. Pederson, MD, FACS
Adjunct Professor of Surgery
The University of Texas Health Science Center;
Fellowship Director
The Hand Center of San Antonio
San Antonio, Texas

Scott H. Kozin, MD
Professor
Department of Orthopaedic Surgery
Temple University School of Medicine;
Chief of Staff
Shriners Hospitals for Children
Philadelphia, Pennsylvania

Mark S. Cohen, MD
Professor
Director, Orthopaedic Education
Director, Hand and Elbow Section
Department of Orthopaedic Surgery
Rush University Medical Center
Chicago, Illinois

ELSEVIER

ELSEVIER

1600 John F. Kennedy Blvd.
Ste 1800
Philadelphia, PA 19103-2899

GREEN'S OPERATIVE HAND SURGERY, SEVENTH EDITION ISBN: 978-1-4557-7427-2

Copyright © 2017 by Elsevier, Inc. All rights reserved.
All contributors retain copyright to the original photographs and video.

No part of this publication may be reproduced or transmitted in any form or by any means, electronic or mechanical, including photocopying, recording, or any information storage and retrieval system, without permission in writing from the publisher. Details on how to seek permission, further information about the Publisher's permissions policies and our arrangements with organizations such as the Copyright Clearance Center and the Copyright Licensing Agency, can be found at our website: www.elsevier.com/permissions.

This book and the individual contributions contained in it are protected under copyright by the Publisher (other than as may be noted herein).

Notices

Knowledge and best practice in this field are constantly changing. As new research and experience broaden our understanding, changes in research methods, professional practices, or medical treatment may become necessary.

Practitioners and researchers must always rely on their own experience and knowledge in evaluating and using any information, methods, compounds, or experiments described herein. In using such information or methods they should be mindful of their own safety and the safety of others, including parties for whom they have a professional responsibility.

With respect to any drug or pharmaceutical products identified, readers are advised to check the most current information provided (i) on procedures featured or (ii) by the manufacturer of each product to be administered, to verify the recommended dose or formula, the method and duration of administration, and contraindications. It is the responsibility of practitioners, relying on their own experience and knowledge of their patients, to make diagnoses, to determine dosages and the best treatment for each individual patient, and to take all appropriate safety precautions.

To the fullest extent of the law, neither the Publisher nor the authors, contributors, or editors, assume any liability for any injury and/or damage to persons or property as a matter of products liability, negligence or otherwise, or from any use or operation of any methods, products, instructions, or ideas contained in the material herein.

Previous years copyrighted: 2011, 2005, 1999, 1993, 1988, 1982

Library of Congress Cataloging-in-Publication Data

Names: Wolfe, Scott W., editor. | Hotchkiss, Robert N., editor. | Pederson, William C., editor. | Kozin, Scott H., editor. | Cohen, Mark S., 1960- , editor.
Title: Green's operative hand surgery / [edited by] Scott W. Wolfe, Robert N. Hotchkiss, William C. Pederson, Scott H. Kozin, Mark S. Cohen.
Other titles: Operative hand surgery
Description: Seventh edition. | Philadelphia, PA : Elsevier, [2017] | Includes bibliographical references and index.
Identifiers: LCCN 2015049498 | ISBN 9781455774272 (hardcover : alk. paper)
Subjects: | MESH: Hand—surgery
Classification: LCC RD559 | NLM WE 830 | DDC 617.5/75059—dc23
LC record available at http://lccn.loc.gov/2015049498

Executive Content Strategist: Dolores Meloni
Content Strategist: Maureen Iannuzzi
Publishing Services Manager: Catherine Jackson
Project Manager: Kate Mannix
Design Direction: Margaret Reid

Printed in China

Last digit is the print number: 9 8 7 6 5 4 3 2 1

Working together to grow libraries in developing countries
www.elsevier.com • www.bookaid.org

CONTRIBUTORS

Brian D. Adams, MD
Professor of Orthopedic Surgery
Baylor College of Medicine
Baylor-St. Luke's Medical Center
Houston, Texas

Julie E. Adams, MD
Associate Professor of Orthopaedic Surgery
Department of Orthopaedic Surgery
Mayo Clinic Health System
Austin, Minnesota

Nidal F. AlDeek, MD, MSc
Department of Plastic and Reconstructive Surgery
Chang Gung Memorial Hospital
Taipei, Taiwan

Edward A. Athanasian, MD
Clinical Professor of Orthopedic Surgery
Weill Cornell Medical College;
Chief, Hand Surgery
Hospital for Special Surgery;
Division of Orthopedics
Department of Surgery
Memorial Sloan Kettering Cancer Center
New York, New York

George S. Athwal, MD, FRCSC
Associate Professor and Consultant
HULC, St. Joseph's Health Care
University of Western Ontario
London, Ontario, Canada

Kodi Azari, MD, FACS
Professor
Orthopaedic Surgery and Plastic Surgery
David Geffen School of Medicine at UCLA
Los Angeles, California

Donald S. Bae, MD
Associate Professor of Orthopaedic Surgery
Department of Orthopaedic Surgery
Harvard Medical School;
Attending Surgeon
Department of Orthopaedic Surgery
Boston Children's Hospital
Boston, Massachusetts

Mark E. Baratz, MD
Vice Chairman
Department of Orthopaedic Surgery
Allegheny General Hospital
Pittsburgh, Pennsylvania

David P. Barei, MD, FRCSC
Professor
Department of Orthopaedic and Sports Medicine
University of Washington;
Director
Orthopedic Trauma Fellowship
Harborview Medical Center
Seattle, Washington

Andrea S. Bauer, MD
Pediatric Hand Surgeon
Department of Orthopaedic Surgery
Shriners Hospital for Children Northern California;
Assistant Clinical Professor
Department of Orthopaedic Surgery
UC Davis School of Medicine
Sacramento, California

Rolfe Birch, MChir, FRCS
Professor
Neurological Orthopaedic Surgery
University College
London, Great Britain

Allen T. Bishop, MD
Professor
Department of Orthopedic Surgery
Mayo Clinic College of Medicine;
Consultant
Division of Hand Surgery
Department of Orthopedic Surgery
Mayo Clinic
Rochester, Minnesota

Paul S. Cederna, MD
Robert O'Neal Collegiate Professor of Plastic Surgery
Section Head, Plastic Surgery
Professor, Department of Biomedical Engineering
University of Michigan School of Medicine
Ann Arbor, Michigan

Neal C. Chen, MD
The Philadelphia and South Jersey Hand Centers, P.C.;
Assistant Professor
Orthopaedic Surgery
Thomas Jefferson University Hospital,
Philadelphia, Pennsylvania

Mark S. Cohen, MD
Professor
Director, Orthopaedic Education
Director, Hand and Elbow Section
Department of Orthopaedic Surgery
Rush University Medical Center
Chicago, Illinois

Roger Cornwall, MD
Associate Professor of Orthopaedic Surgery and Developmental Biology
Clinical Director of Pediatric Orthopaedics
Cincinnati Children's Hospital Medical Center
Cincinnati, Ohio

Timothy R.C. Davis, FRCS, ChM, BSc, MB
Honorary Professor
Nottingham University;
Hand Surgeon
Nottingham University Hospitals
Nottingham, United Kingdom

Charles S. Day, MD, MBA
Associate Professor of Orthopaedic Surgery
Director, Orthopaedic Curriculum
Harvard Medical School;
Orthopaedic Hand and Upper Extremity Surgery
Beth Israel Deaconess Medical Center
Boston, Massachusetts

Rafael J. Diaz-Garcia, MD
Attending Surgeon
Department of Surgery
Division of Plastic Surgery
Allegheny Health Network;
Clinical Assistant Professor
Department of Plastic Surgery
University of Pittsburgh School of Medicine
Pittsburgh, Pennsylvania

George S.M. Dyer, MD
Orthopaedic Hand Surgeon
Department of Orthopaedic Surgery
Brigham and Women's Hospital
Boston, Massachusetts

Charles Eaton, MD
Executive Director
Dupuytren Foundation
Palm Springs, Florida

Bassem T. Elhassen, MD
Assistant Professor of Orthopaedic Surgery
Department of Orthopaedics
Mayo Clinic
Rochester, Minnesota

Paul Feldon, MD
Chief, Hand Surgery Service
Newton Wellesley Hospital
Newton, Massachusetts;
Clinical Associate Professor of Orthopaedic Surgery
Tufts University School of Medicine
Boston, Massachusetts

Jeffrey B. Friedrich, MD, FACS
Associate Professor of Surgery and Orthopaedics
Department of Surgery
University of Washington
Seattle, Washington

Marc Garcia-Elias, MD, PhD
Consultant Hand Surgeon
Hand and Upper Extremity Surgery
Institut-Kaplan
Barcelona, Spain

William B. Geissler, MD
Professor and Chief, Alan E. Freeland Chair of Hand Surgery
Division of Hand and Upper Extremity Surgery
University of Mississippi Health Care
Jackson, Mississippi

Günter Germann, MD, PhD
Professor of Plastic and Hand Surgery
ETHIANUM Heidelberg Clinic for Plastic, Reconstructive, and Aesthetic Surgery, Preventative Medicine
The University of Heidelberg
Heidelberg, Germany

Vidal Haddad, Jr., MD, MSc, PhD
Associate Professor
Department of Dermatology
Botucatu Medical School
São Paulo State University
Botucatu, São Paulo, Brazil

Douglas P. Hanel, MD
Professor
Department of Orthopaedic and Sports Medicine
Director of Orthopaedic Education
University of Washington
Seattle, Washington

Hill Hastings, MD
Past Clinical Professor, Orthopedic Surgery
Indiana University
Telluride, Colorado

James P. Higgins, MD
Chief of Hand Surgery
The Curtis National Hand Center
MedStar Union Memorial Hospital
Baltimore, Maryland

Robert N. Hotchkiss, MD
Associate Professor of Clinical Orthopaedic Surgery
Weill Medical College of Cornell University;
Associate Attending Orthopaedic Surgeon
Director of Clinical Research
Hospital for Special Surgery
New York, New York

Manuel Hrabowski, MD
ETHIANUM Heidelberg Clinic for Plastic, Reconstructive, and Aesthetic Surgery, Preventative Medicine
Heidelberg, Germany

Michelle A. James, MD
Professor of Clinical Orthopaedic Surgery
Chief, Pediatric Orthopaedic Service
UC Davis School of Medicine;
Chief, Orthopaedic Surgery
Shriners Hospital for Children of Northern California
Sacramento, California

Neil F. Jones, MD
Chief of Hand Surgery
University of California Irvine Medical Center;
Professor of Orthopaedic Surgery and Professor of Plastic and Reconstructive Surgery
University of California Irvine School of Medicine
Orange, California;
Attending Hand Surgeon
Shriners Hospital
Los Angeles, California

Jesse B. Jupiter, MD
Hansjörg Wyss Professor of Orthopaedic Surgery
Harvard Medical School;
Hand and Upper Extremity Division
Massachusetts General Hospital
Boston, Massachusetts

Sanjeev Kakar, MD, MRCS
Associate Professor
Department of Orthopaedic Surgery
Mayo Clinic
Rochester, Minnesota

Morton L. Kasdan, MD
Clinical Professor of Plastic Surgery
University of Louisville
Louisville, Kentucky

Simon P. Kay, BA, BM BCh, FRCS (Plas), FRCSE (Hon)
Consultant Plastic Surgeon
Department of Plastic Surgery
Leeds Teaching Hospitals NHS Trust;
Professor of Hand Surgery
University of Leeds
Leeds, Great Britain

Graham J.W. King
Director, Roth McFarlane Hand and Upper Limb Centre
Chief of Surgery
St. Joseph's Health Centre;
Professor of Orthopaedic Surgery and Biomedical Engineering
Western University
London, Ontario, Canada

L. Andrew Koman, MD
Professor and Chair
Department of Orthopaedic Surgery
Wake Forest School of Medicine
Winston-Salem, North Carolina

Scott H. Kozin, MD
Clinical Professor
Department of Orthopaedic Surgery
Temple University School of Medicine;
Chief of Staff
Shriners Hospital for Children
Philadelphia, Pennsylvania

Steve K. Lee, MD
Associate Professor of Orthopaedic Surgery
Weill Cornell Medical College;
Associate Attending Orthopaedic Surgeon
Orthopaedic Surgery
Hospital for Special Surgery
New York, New York

Fraser J. Leversedge, MD
Associate Professor and Vice-Chair
Director, Hand, Upper Extremity, and Microvascular Surgery Fellowship
Department of Orthopaedic Surgery
Duke University
Durham, North Carolina

Nina Lightdale-Miric, MD
Assistant Clinical Professor of Orthopaedic Surgery
Keck School of Medicine
University of Southern California;
Director, Hand and Upper Extremity Surgery
Children's Hospital Los Angeles
Los Angeles, California

Graham D. Lister, MD
Former Professor and Chief
Division of Plastic Surgery
University of Utah School of Medicine
Salt Lake City, Utah

Alberto L. Lluch, MD, PhD
Consultant Hand Surgeon
Hand and Upper Extremity Surgery
Institut-Kaplan
Barcelona, Spain

Dean S. Louis, MD
Professor of Surgery
University of Michigan
Ann Arbor, Michigan

Susan E. Mackinnon, MD, FRCSC
Schoenberg Professor and Chief
Division of Plastic and Reconstructive Surgery
Washington University School of Medicine
St. Louis, Missouri

David B. McCombe, MBBS, MD, FRACS
Senior Lecturer
Department of Surgery
St. Vincent's Hospital
University of Melbourne
Melbourne, Victoria, Australia

Greg Merrell, MD
Indiana Hand to Shoulder Center
Indianapolis, Indiana

Richard Meyer, MD
Associate Professor
Department of Surgery
University of Alabama
Birmingham, Alabama

Lewis H. Millender, MD[†]
Clinical Professor of Orthopaedic Surgery
Tufts University School of Medicine
Boston, Massachusetts

Peter M. Murray, MD
Professor and Chairman
Department of Orthopaedic Surgery
Consultant
Department of Orthopaedic Surgery and Neurosurgery
Mayo Clinic;
Staff Physician
Department of Orthopaedic Surgery
Nemours Children's Clinic
Jacksonville, Florida

Edward A. Nalebuff, MD
Emeritus Surgeon
New England Baptist Hospital;
Emeritus Professor of Orthopaedic Surgery
Tufts University School of Medicine
Boston, Massachusetts

David T. Netscher, MD
Clinical Professor of Plastic Surgery and Orthopedic Surgery
Baylor College of Medicine
Houston, Texas;
Adjunct Professor of Clinical Surgery
Weill Medical College;
Adjunct Professor of Clinical Surgery
Cornell University
New York, New York

Christine B. Novak, PT, PhD
Associate Professor
Division of Plastic and Reconstructive Surgery
University of Toronto;
Scientist and Research Associate
University Health Network
Toronto, Ontario, Canada

Mukund R. Patel, MD, FACS
Chief of Hand Surgery
Associate Clinical Professor, Orthopedic Surgery
New York University Medical Center;
Attending Hand Surgeon
Hospital for Joint Diseases;
Chief of Hand Surgery
Department of Orthopedics
Richmond University Medical Center
New York, New York

William C. Pederson, MD, FACS
Adjunct Professor of Surgery
The University of Texas Health Science Center;
Fellowship Director
The Hand Center of San Antonio
San Antonio, Texas

Tom Quick, MB, MA(Hons)Cantab, FRCS(Tr & Orth)
Consultant Surgeon
Peripheral Nerve Injury Unit
Royal National Orthopaedic Hospital
Middlesex, United Kingdom;
Honorary Consultant
Defence Medical Rehabilitation Centre
Headley Court
Surrey, United Kingdom;
Honorary Consultant Surgeon
Great Ormond Street Hospital for Sick Children;
Honorary Senior Lecturer
Institute of Orthopaedics and Musculoskeletal Science
University College Hospital
London, United Kingdom

David Ring, MD, PhD
Professor of Orthopaedic Surgery
Harvard Medical School;
Chief of Hand Surgery
Massachusetts General Hospital
Boston, Massachusetts

Marco Rizzo, MD
Professor
Department of Orthopedic Surgery
Chair, Division of Hand Surgery
Mayo Clinic
Rochester, Minnesota

Trajano Sardenberg, MD, PhD
Professor of Orthopaedic, Traumatology, and Hand Surgery
Department of Surgery and Orthopaedics
Botucatu Medical School
São Paulo State University
Botucatu, São Paulo, Brazil

John Gray Seiler III, MD
Clinical Professor of Orthopaedic Surgery
Emory University
Georgia Hand, Shoulder, & Elbow Surgery
Atlanta, Georgia

Frances Sharpe
Assistant Clinical Professor of Orthopedics
University of Southern California, Keck School of Medicine;
Orthopedics and Hand Surgery
Southern California Permanente Medical Group
Fontana, California

[†]Deceased.

Alexander Y. Shin, MD
Professor & Consultant
Orthopedic Surgery
Mayo Clinic
Rochester, Minnesota

Beth Paterson Smith, PhD
Professor
Department of Orthopaedic Surgery
Wake Forest School of Medicine
Winston-Salem, North Carolina

Thomas L. Smith, PhD
Professor
Department of Orthopaedic Surgery
Wake Forest School of Medicine
Winston-Salem, North Carolina

Nicole Z. Sommer, MD, FACS
Associate Professor
Department of Plastic Surgery
Southern Illinois School of Medicine
Springfield, Illinois

Robert J. Spinner, MD
Chair, Department of Neurologic Surgery
Burton M. Onofrio Professor of Neurosurgery
Professor of Orthopedics and Anatomy
Mayo Clinic
Rochester, Minnesota

Scott P. Steinmann, MD
Professor of Orthopaedic Surgery
Department of Orthopaedic Surgery
Mayo Clinic
Rochester, Minnesota

Milan V. Stevanovic, MD
Director of the Joseph H. Boyes Hand Fellowship Program
Professor of Orthopedics and Surgery
Department of Orthopedics
University of Southern California Keck School of Medicine
Los Angeles, California

Robert J. Strauch, MD
Professor of Orthopaedic Surgery
Columbia University Medical Center
New York, New York

Andrew L. Terrono, MD
Chief, Hand Surgery Service
New England Baptist Hospital;
Clinical Professor of Orthopaedic Surgery
Tufts University School of Medicine
Boston, Massachusetts

Ann E. Van Heest, MD
Professor and Vice Chair of Education
Department of Orthopedic Surgery
University of Minnesota
Minneapolis, Minnesota

Nicholas B. Vedder, MD
Professor & Chief of Plastic Surgery
Department of Surgery
University of Washington
Seattle, Washington

Peter M. Waters, MD
John E. Hall Professor of Orthopaedic Surgery
Harvard Medical School;
Orthopedic Surgeon in Chief
Children's Hospital
Boston, Massachusetts

Fu-Chan Wei, MD
Department of Plastic and Reconstructive Surgery
Chang Gung Memorial Hospital
Taipei, Taiwan

Scott W. Wolfe, MD
Professor of Orthopaedic Surgery
Weill Medical College of Cornell University;
Emeritus Chief, Hand and Upper Extremity Surgery
Attending Orthopaedic Surgeon
Hospital for Special Surgery
New York, New York

Elaine Yang, MD
Clinical Instructor
Department of Anesthesiology
Weill Cornell Medical College;
Assistant Attending
Department of Anesthesiology and Critical Care Medicine
Hospital for Special Surgery
New York, New York

Dan A. Zlotolow, MD
Associate Professor of Orthopaedics
Temple University School of Medicine;
Attending Physician
Shriners Hospital for Children
Philadelphia, Pennsylvania

FOREWORD FOR THE SEVENTH EDITION

Who would have thought when the first edition of *Operative Hand Surgery* was published in 1982 that nearly three and a half decades later we would be publishing the seventh edition and the book would be sold in more than 50 countries? The success of this book has been due to three main factors: (1) Careful selection of experienced authors with recognized expertise who are willing to invest the huge time and energy commitment that it takes to write an outstanding chapter (and people who are willing to make that commitment are becoming increasingly difficult to recruit); (2) meticulous dissection and critique of each chapter by the editors, another job that requires a mammoth expenditure of hours; and (3) the worldwide explosion of interest in hand surgery and the blossoming of national hand societies throughout the world (56 at last count). In 1982, we were fortunate to be at the right place at the right time.

A huge debt of gratitude is due to the contributors of the seventh edition, who made the decision to write a chapter, which demanded that they forego more pleasurable or financially productive pursuits. I am especially grateful to Scott Wolfe, who picked up the mantle of editor-in-chief and has devoted the time and effort necessary to oversee and direct the last two editions. He has more than justified the confidence we had in choosing him for this job over many other equally qualified hand surgeons. To my good friends and former practice partners, Bob Hotchkiss and Chris Pederson, I cannot thank you enough for what you have done to stick with this book through several editions. Over many years, we have laughed, we have cried, and we have anguished together over the peaks and valleys of bringing to life this large body of work. And to the new editors, Scott Kozin and Mark Cohen, I extend my appreciation for their commitment to this demanding process. Your only reward will be knowing that someone, somewhere will benefit from your efforts.

One other person deserves credit that is long overdue. Lewis Reines was president of the American division of Churchill Livingstone in the late 1970s, and *Operative Hand Surgery* was his idea. I had wanted to do a small book on some topic in hand surgery, but Lew said, "No, do the big book." This text would never have come into being without his foresight, encouragement, and expert guidance during those early years.

David P. Green, MD
San Antonio, TX
September 2016

PREFACE

"See one, do one, teach one" was the mantra of our past generation of surgical mentors. This rubric was emblematic of a surgical apprenticeship style of learning that had been effective for centuries. But implicit in this approach is a trial and error mentality that may only have worked in a day of lower expectations and a more narrow understanding of disease. The last half century has witnessed an explosion of technological advancements, increased scientific knowledge base, and surgical complexity, coupled with parallel changes in health care financing, regulation, and work hour restrictions that challenge our ability to teach effectively.

The average adult learner requires not one, but *seven* exposures to learn a new concept, and retention becomes even more difficult if the learning occurs over a short, intense study period. Similarly, psychological theory holds that it may take as many as 10,000 repetitions to master a technique or a skill. How then can a medical student, or even an accomplished surgeon, master a surgical reconstruction of a disorder that he or she may only see twice in a career? Benjamin Franklin quipped, "Experience keeps a dear school, but fools will learn in no other." Experience alone is not a panacea, however, as one can practice and engrain incorrect techniques. Experience should be accompanied by feedback and reinforcement, such that when skill acquisition is accompanied by reading, learning, and coaching, repetition will lead to mastery.

Enter *Green's Operative Hand Surgery*, a concept that was introduced 35 years and six editions ago, and one that has remained the backbone of hand surgical learning since. David Green invited recognized masters of specific hand surgical techniques to pool their talents to create an enduring resource of expert techniques, a synthesis of current publications and novel research, and the hugely successful guide to success: the *Author's Preferred Technique.* In this book, you can immerse yourself in concise tutorials of what works and what doesn't, learn the evidence and the anecdotes that contribute to success, and enlist the surgical mentoring of nearly a hundred recognized experts in hand surgery. The electronic version of *Green's Operative Hand Surgery,* available at ExpertConsult.com, does not simply duplicate the written content but expands on it, with volumes of illustrative cases, an expert classroom of 60 video techniques, classic chapters from archived editions, and regular online updates of emerging techniques that promise to change the landscape of tomorrow's hand surgery. Through the intensely dedicated work of its five editors, *Green's* can sharpen the skills of hand surgeons worldwide and excite present and future students of hand surgery. Welcome to *Green's Operative Hand Surgery*, seventh edition.

Scott W. Wolfe, MD

ACKNOWLEDGMENTS

Publishing a multimedia reference of this magnitude requires an enormous team effort and unanimity of purpose. I'd first like to thank Dave Green for his confidence in entrusting his brainchild with me and for giving me the amazing opportunity to expand our hand educational borders across the globe. On behalf of our readership, a huge shout-out to our expert authors for their countless hours away from family and work, their exquisite attention to the details and principles of *Operative Hand Surgery*, and their dedication to education. Many of our authors wrote their chapters single-handedly, which, in the spirit of the inaugural edition of *Green's*, gives our readers firsthand exposure to their thoughts, tips, and techniques. What may be less apparent is the luster given to each chapter by our incredible editorial team, whose proficiency and dedication make *Green's* the foundational resource of hand surgery. I am indebted to my trusted colleagues Bob Hotchkiss and Chris Pederson, who have devoted their expertise in microsurgery and elbow reconstruction for more than twenty years and five editions to hone these gems to perfection. We are incredibly fortunate to have attracted Scott Kozin, a thought leader in pediatrics and congenital hand, to complete a comprehensive revision of our pediatric section in the sixth edition. With the seventh edition, I'm delighted to welcome longtime friend and colleague Mark Cohen, also a prolific writer and exemplary educator, as our newest associate editor. Special thanks as well to Jonathan Isaacs and David Dennison, whose innovative ideas and commitment will make the electronic version of *Green's Operative Hand Surgery* a true living, interactive, and fully accessible bridge between the print editions.

I'd particularly like to thank the outstanding staff of Elsevier for assuring the highest quality print and online publications. From its inception six years ago, the content strategy team of Don Scholz, Helene Caprari, and Dolores Meloni have sculpted the first fully integrated print and online edition to ensure that *Green's* is available where you are. I'm indebted to my go-to person and content strategist Maureen Iannuzzi, who choreographed the entire production from its start to its launch, gently coaxing, convincing, and cajoling our writers and editors across the finish line. Special thanks to our illustrator, Wendy Beth Jackelow, for bringing these pages to life with abundant new color drawings, and to our project manager, Kate Mannix, for transforming our concepts and documents into the published multimedia finale.

Most importantly, I want to thank my family: my incredible children, William, Elizabeth, and Christian, for giving me free passes for too many weekends holed up in the office; and most of all, my wife Missy: my best friend, historian, and trusted advisor, whose sacrifice, patience, and wisdom inspired me to complete this work.

Scott W. Wolfe, MD

This page intentionally left blank

CONTENTS

VOLUME 1

PART I Basic Principles

1 **Anesthesia,** 1
Elaine Yang

PART II Hand

2 **Acute Infections of the Hand,** 17
Milan V. Stevanovic and Frances Sharpe
3 **Chronic Infections,** 62
Mukund R. Patel
4 **Dupuytren Disease,** 128
Charles Eaton
5 **Extensor Tendon Injury,** 152
Robert J. Strauch
6 **Flexor Tendon Injury,** 183
John Gray Seiler III
7 **Fractures of the Metacarpals and Phalanges,** 231
Charles S. Day
8 **Dislocations and Ligament Injuries of the Digits,** 278
Greg Merrell and Hill Hastings
9 **Perionychium,** 318
Nicole Z. Sommer
10 **Treatment of the Stiff Finger and Hand,** 338
Robert N. Hotchkiss
11 **Treatment of the Osteoarthritic Hand and Thumb,** 345
Peter M. Murray

PART III Wrist

12 **Wrist Arthrodesis and Arthroplasty,** 373
Marco Rizzo
13 **Wrist Instabilities, Misalignments, and Dislocations,** 418
Marc Garcia-Elias and Alberto L. Lluch
14 **Distal Radioulnar Joint,** 479
Brian D. Adams and Fraser J. Leversedge
15 **Distal Radius Fractures,** 516
Scott W. Wolfe
16 **Fractures of the Carpal Bones,** 588
Steve K. Lee
17 **Wrist Arthroscopy,** 653
William B. Geissler

PART IV Elbow and Forearm

18 **Fractures of the Distal Humerus,** 697
David P. Barei and Douglas P. Hanel
19 **Fractures of the Radial Head,** 734
Graham J.W. King
20 **Fractures of the Proximal Ulna,** 770
George S.M. Dyer and David Ring
21 **Disorders of the Forearm Axis,** 786
Mark E. Baratz
22 **Complex Traumatic Elbow Dislocation,** 813
George S.M. Dyer and Jesse B. Jupiter
23 **Chronic Elbow Instability: Ligament Reconstruction,** 830
Mark S. Cohen
24 **Treatment of the Stiff Elbow,** 843
Robert N. Hotchkiss
25 **Elbow Tendinopathies and Tendon Ruptures,** 863
Julie E. Adams and Scott P. Steinmann
26 **Elbow Arthroscopy,** 885
George S. Athwal
27 **Total Elbow Arthroplasty,** 905
Mark S. Cohen and Neal C. Chen

PART V Nerves

28 **Compression Neuropathies,** 921
Susan E. Mackinnon and Christine B. Novak
29 **Thoracic Outlet Compression Syndrome,** 959
Richard Meyer

VOLUME 2

30 **Nerve Injury and Repair,** 979
Rolfe Birch and Tom Quick
31 **Principles of Tendon Transfers of Median, Radial, and Ulnar Nerves,** 1023
Timothy R.C. Davis
32 **Spasticity: Cerebral Palsy and Traumatic Brain Injury,** 1080
Scott H. Kozin and Nina Lightdale-Miric
33 **Tetraplegia,** 1122
Ann E. Van Heest
34 **Traumatic Brachial Plexus Injury,** 1146
Robert J. Spinner, Alexander Y. Shin, Bassem T. Elhassan, and Allen T. Bishop

PART VI Pediatric Hand

35 **Embryology of the Upper Extremity,** 1208
Scott H. Kozin
36 **Deformities of the Hand and Fingers,** 1217
Simon P. Kay, David B. McCombe, and Scott H. Kozin
37 **Deformities of the Thumb,** 1289
Scott H. Kozin
38 **Malformations and Deformities of the Wrist and Forearm,** 1328
Michelle A. James and Andrea S. Bauer

39 **Arthrogryposis,** 1365
Dan A. Zlotolow
40 **Pediatric Brachial Plexus Palsy,** 1391
Roger Cornwall and Peter M. Waters
41 **Hand, Wrist, and Forearm Fractures in Children,** 1425
Donald S. Bae

PART VII Bone and Soft Tissue Reconstruction

42 **Replantation,** 1476
James P. Higgins
43 **Mangled Upper Extremity,** 1486
Jeffrey B. Friedrich and Nicholas B. Vedder
44 **Nonmicrosurgical Coverage of the Upper Extremity,** 1528
William C. Pederson
45 **Free Flaps to the Hand and Upper Extremity,** 1574
Neil F. Jones and Graham D. Lister
46 **Vascularized Bone Grafting,** 1612
Allen T. Bishop and Alexander Y. Shin
47 **Toe-to-Hand Transplantation,** 1643
Fu-Chan Wei and Nidal F. AlDeek
48 **Thumb Reconstruction,** 1674
Kodi Azari

PART VIII Other Disorders of the Upper Extremity

49 **Digital Amputations,** 1708
Sanjeev Kakar
50 **Major Limb Amputations and Prosthetics,** 1753
Rafael J. Diaz-Garcia and Paul S. Cederna
51 **Compartment Syndrome and Volkmann Ischemic Contracture,** 1763
Milan V. Stevanovic and Frances Sharpe
52 **Management of Venomous Injuries,** 1788
Vidal Haddad, Jr., and Trajano Sardenberg
53 **A Practical Guide for Complex Regional Pain Syndrome in the Acute Stage and Late Stage,** 1797
L. Andrew Koman, Beth Paterson Smith, and Thomas L. Smith
54 **Factitious Disorders,** 1828
Dean S. Louis and Morton L. Kasdan
55 **Rheumatoid Arthritis and Other Connective Tissue Diseases,** 1832
Paul Feldon, Andrew L. Terrono, Edward A. Nalebuff, and Lewis H. Millender
56 **Tendinopathy,** 1904
Scott W. Wolfe
57 **Burned Hand,** 1926
Günter Germann and Manuel Hrabowski
58 **Skin Tumors of the Hand and Upper Extremity,** 1958
David T. Netscher
59 **Bone and Soft Tissue Tumors,** 1987
Edward A. Athanasian
60 **Vascular Disorders of the Hand,** 2036
William C. Pederson

Classic Chapters*

Classic: General Principles
Classic: Radial Nerve
Classic: Stiff Joints
Classic: Principles of Microvascular Surgery
William C. Pederson

Index, I1

*Available on ExpertConsult.com

VIDEO CONTENTS

PART II: Hand

Chapter 4 Dupuytren Disease

4.1 Collagenase injection for Dupuytren contracture—Larry Hurst

Chapter 5 Extensor Tendon Injury

5.1 Subluxation of extensor carpi ulnaris—Robert J. Strauch

Chapter 6 Flexor Tendon Injury

6.1 Flexor tendon repair—Scott W. Wolfe

6.2 Paneva-Holevich technique for chronic tendon laceration—John S. Taras and Robert A. Kaufman

Chapter 11 Treatment of the Osteoarthritic Hand and Thumb

11.1 Volar approach for proximal interphalangeal joint implant arthroplasty—Peter C. Amadio

11.2 Physical examination for osteoarthritis of the thumb—Peter M. McMurray

PART III: Wrist

Chapter 12 Wrist Arthrodesis and Arthroplasty

12.1 Re-motion total wrist arthroplasty—Marco Rizzo

12.2 Radiolunate arthrodesis with ligament-sparing approach—Marco Rizzo

Chapter 13 Wrist Instabilities, Misalignments, and Dislocations

13.1 Dorsal view of a dissected cadaveric wrist set in a jig that allows isometric loading of different tendons—Marc Garcia-Elias and Alberto Lluch

13.2 Dynamic 3D computed tomography (also known as 4D computed tomography) of a patient with a scapholunate dissociation while performing dart thrower's exercises—Marc Garcia-Elias and Alberto Lluch

13.3 Clinical example of a catch-up clunk phenomenon in a patient with carpal instability nondissociative-volar intercalated segmental instability—Marc Garcia-Elias and Alberto Lluch

13.4 Volar approach of a perilunate dislocation—Marc Garcia-Elias and Alberto Lluch

Chapter 14 Distal Radioulnar Joint

14.1 Dynamic ultrasound for tendinopathy—Scott W. Wolfe

Chapter 15 Distal Radius Fractures

15.1 Insertion of a novel intramedullary device for locked fixation of articular fractures—Scott W. Wolfe

Chapter 16 Fractures of the Carpal Bones

16.1 Arthroscopic fixation scaphoid of nonunion—William Geissler and Joseph F. Slade

Chapter 17 Wrist Arthroscopy

17.1 Diagnostic arthroscopy—Scott W. Wolfe

PART IV: Elbow and Forearm

Chapter 19 Fractures of the Radial Head

19.1 Open reduction and internal fixation of the radial head—Graham J.W. King

19.2 Radial head replacement—Wright Medical Technology

Chapter 25 Elbow Tendinopathies and Tendon Ruptures

25.1 Endobutton single-incision repair of the distal biceps tendon—Julie A. Adams and Scott P. Steinmann

PART V: Nerves

Chapter 28 Compression Neuropathies

28.1 Carpal tunnel release—standard—Susan E. Mackinnon, Christine B. Novak, and Andrew Yee

28.2 Carpal tunnel release–extended—Susan E. Mackinnon, Christine B. Novak, and Andrew Yee

28.3 Median nerve forearm decompression–standard—Susan E. Mackinnon, Christine B. Novak, and Andrew Yee

28.4 Median nerve release in the forearm—Susan E. Mackinnon, Christine B. Novak, and Andrew Yee

28.5 Guyon canal and carpal tunnel release–standard—Susan E. Mackinnon, Christine B. Novak, and Andrew Yee

28.6 Submuscular ulnar nerve transposition–standard—Susan E. Mackinnon, Christine B. Novak, and Andrew Yee

28.7 Transmuscular ulnar nerve transposition—Susan E. Mackinnon, Christine B. Novak, and Andrew Yee

28.8 Posterior interosseous nerve release—Susan E. Mackinnon, Christine B. Novak, and Andrew Yee

28.9 Revision carpal tunnel release—Susan E. Mackinnon, Christine B. Novak, and Andrew Yee

28.10 Revision carpal tunnel release, part I—Susan E. Mackinnon, Christine B. Novak, and Andrew Yee

Chapter 29 Thoracic Outlet Compression Syndrome

29.1 Resection with improved pulse—Scott W. Wolfe

Chapter 32 Spasticity: Cerebral Palsy and Traumatic Brain Injury

32.1 Athetoid cerebral palsy—Scott H. Kozin

32.2 Upper extremity examination of hemiplegia—Scott H. Kozin

Chapter 33 Tetraplegia

33.1 Brachioradialis to flexor pollicis longus and extensor carpi radialis longus to flexor digitorum brevis transfers—Scott H. Kozin

33.2 Biceps to triceps transfer—Scott H. Kozin

33.3 Patient outcome video after biceps to triceps, brachioradialis to flexor pollicis longus, and extensor carpi radialis longus to flexor digitorum brevis transfers—Scott H. Kozin

33.4 Additional patient outcome video after biceps to triceps, brachioradialis to flexor pollicis longus, and extensor carpi radialis longus to flexor digitorum brevis transfers—Scott H. Kozin
33.5 Patient outcome video after biceps to triceps, brachioradialis to flexor pollicis longus, and extensor carpi radialis longus to flexor digitorum brevis transfers—Scott H. Kozin
33.6 Additional patient outcome video after biceps to triceps, brachioradialis to flexor pollicis longus, and extensor carpi radialis longus to flexor digitorum brevis transfers—Scott H. Kozin

PART VI: Pediatric Hand

Chapter 36 Deformities of the Hand and Fingers
36.1 Cleft hand—Scott H. Kozin
36.2 Symbrachydactyly—Scott H. Kozin

Chapter 37 Deformities of the Thumb
37.1 Opposition transfer and ulnar collateral ligament reconstruction for type II thumb hypoplasia—Scott H. Kozin and Dan A. Zlotolow
37.2 Thumb reconstruction follow-up 1—Scott H. Kozin
37.3 Thumb reconstruction follow-up 2—Scott H. Kozin
37.4 Pollicization type IIIB thumb hypoplasia with vascularized adipose flap—Dan A. Zlotolow and Scott H. Kozin
37.5 Testimonial: Tucker's story—Scott H. Kozin

Chapter 39 Arthrogryposis
39.1 Stiletto flap metacarpophalangeal joint chondrodesis for the clasped thumb—Scott H. Kozin and Dan A. Zlotolow

Chapter 40 Pediatric Brachial Plexus Palsy
40.1 Brachial plexus examination of the infant—Scott H. Kozin
40.2 Ulnar-to-musculocutaneous nerve transfer (Oberlin transfer)—Scott H. Kozin
40.3 Open joint reduction and latissimus dorsi/teres major tendon transfer—Scott H. Kozin

Chapter 41 Hand, Wrist, and Forearm Fractures in Children
41.1 Closed reduction and percutaneous fixation of a unicondylar fracture—Scott H. Kozin
41.2 Open reduction and screw fixation of scaphoid fracture with distal radial bone graft and superficial volar branch of the radial artery vascular pedicle transfer—Dan A. Zlotolow
41.3 Closed reduction and percutaneous pinning of a distal radius fracture—Scott H. Kozin

PART VIII: Other Disorders of the Upper Extremity

Chapter 49 Digital Amputations
49.1 Flexor digitorum superficialis tenodesis for proximal phalangeal amputation—Sanjeev Kakar

Chapter 51 Compartment Syndrome and Volkmann Ischemic Contracture
51.1 Surgical technique of upper extremity fasciotomy, cadaver demonstration—Milan V. Stevanovic and Frances Sharpe
51.2 Ten-year follow-up on flexor origin slide for "moderate"-type Volkmann contracture—Milan V. Stevanovic and Frances Sharpe
51.3 Eighteen-month follow-up on functional free muscle transfer for finger flexion for "severe"-type Volkmann contracture—Milan V. Stevanovic and Frances Sharpe

Chapter 55 Rheumatoid Arthritis and Other Connective Tissue Diseases
55.1 Metacarpophalangeal arthroplasty in rheumatoid arthritis—Andrew L. Terrono

Chapter 56 Tendinopathy
56.1 Percutaneous trigger finger release—Mukund R. Patel
56.2 Dynamic ultrasound—Scott W. Wolfe

Nerve Injury and Repair

Rolfe Birch and Tom Quick

Although the decision to operate on a nerve is usually straightforward, as in the case of an open wound or when the injury is associated with unstable orthopedic trauma or vascular or tendon injury, it is not always as easy. The primary reasons to operate include (1) to confirm or establish a diagnosis, (2) to restore continuity to a severed or ruptured nerve, and (3) to relieve a nerve of an agent that is compressing, distorting, or occupying it.

INDICATIONS

Indications for operating on a nerve after an injury include the following:

- Complete paralysis after a wound to a major nerve
- Complete paralysis affecting a nerve after surgery or an injection near it
- Complete paralysis after a closed injury, especially a high-energy one with severe damage to soft tissues and the skeleton
- Complete paralysis after a closed-traction injury of the brachial plexus
- A nerve lesion associated with an arterial injury
- A nerve lesion associated with a fracture or dislocation requiring urgent open reduction and internal fixation
- Deterioration of a nerve injury while under observation
- Failure to progress toward recovery in the expected time after a closed injury
- Failure to recover from a conduction block (CB) within 6 weeks of injury
- Persistent pain
- Treatment of a painful neuroma

The aim of the operation is to preserve or restore function. This is achieved by preserving or restoring innervation of the skin, muscle, soft tissues, skeleton, and other target organs.

When a nerve is severed, repair offers the only chance of meeting this goal. The repair may be done by suture or by graft. If the proximal stump is irreparably damaged or if there is no continuity between the proximal stump and the spinal cord, transfer of other nerves to the distal stump may be possible. If the distal stump is irreparably damaged, direct implantation of nerves into the muscle (i.e., muscular neurotization) may be possible. When a neurologic injury is, by whatever means, irreparable, palliation may be achieved by musculotendinous transfer or another reconstruction method.

The sooner the distal segment is reconnected to the proximal segment, thus to the cell body, the better the result. In the extreme case of replantation after traumatic amputation, O'Brien showed that primary suture of nerves gave the only hope of recovery.[141] The prognosis for recovery is governed by two factors that outweigh all others: (1) the violence of the injury and (2) the interval between injury and repair. George Bonney introduced a policy of urgent repair of both nerves and arteries at St. Mary's Hospital in London in the early 1960s. Improved results after urgent repair have been reported for the median and ulnar nerves,[20,105,123] the radial nerve,[165] and the musculocutaneous nerve.[146]

Kato and colleagues showed that recovery of function and relief of pain were decisively better with immediate repair of a closed-traction lesion of the brachial plexus.[89] The spinal accessory nerve seems to be an exception to the rule that fast repair improves outcome. Impressive recovery of function along with relief of pain has been seen in cases in which repair of that nerve was delayed for many months (Figure 30.1).[32] Urgent repair of nerves damaged by penetrating missile wounds is recommended by Oullette.[147] This policy is followed by our military colleagues working in the Selly Oak Hospital in Birmingham, United Kingdom. Decisive evidence for early repair is provided by Glasby and coworkers, who demonstrated that regeneration was impaired by delay and that it was further impaired by associated long-bone fracture, arterial injury, hematoma, or fibrosis.[58,61,62]

The amount of experience, special equipment, surgical skill, and a first-rate support staff are all necessary for beneficial results. Uncomplicated open wounds and nerves can be left for 24 h to receive attention from an experienced surgeon. When a nerve injury is associated with damage to a major blood vessel with an impending threat of peripheral ischemia or with increasing pressure within a fascial compartment, delay is not acceptable.[96] Such an injury is an emergency, as it is with cases of open fracture or fracture–dislocation.

The following are reasons to not proceed with repair of a transected nerve:

- The general condition of the patient. After having saved a life or limb by means of successful arterial repair, the patient, the anesthetist, and the surgeon may well have had enough.
- The attributes and skills of the operating team and the availability of specialized equipment.
- Uncertainty about the viability or state of the nerve trunks. This is particularly valid when the nerve has been torn by a saw or a bullet.
- The risk for local or systemic sepsis. If the local soft tissue damage and contamination from an open fracture or high-velocity gunshot wound are severe, it is better to wait until the soft tissue bed stabilizes before proceeding with nerve repair.



FIGURE 30.1 A 16-year-old-girl experienced severe pain and scapular dysfunction after iatrogenic injury of the spinal accessory nerve. Four years later the nerve was repaired. Pain disappeared on the day after the operation. Function is illustrated 9 months after nerve repair.

- When the condition of the nerve is such that function will more surely and more rapidly be restored by musculotendinous transfer.

ANATOMY

The nervous system is a mechanism that alerts the organism to changes within its internal structures or its external environment and enables reaction to these changes. The peripheral nervous system connects the central nervous system (CNS) to the periphery. It includes the cranial nerves, the spinal nerves with their roots and rami, the peripheral nerves, and the peripheral components of the autonomic nervous system. Peripheral nerves contain motor fibers to the endplates of skeletal muscles; sensory fibers from organs with endings in skin, muscle, tendon, and joint; and autonomic fibers to blood vessels, sweat glands, and hair follicle musculature. The concentration of functional capacity is unmatched by any other system. Severance of a 7-mm-diameter median nerve in an adult effectively devastates the function of the hand and forearm.

The essential component of the system is the cell body with its dendrites and elongated axons. The *axon* is a column of neuronal cytoplasm (*axoplasm*) enclosed by a cell membrane (*axolemma*). Thomas and associates described the axoplasm as a "fluid cytosol in which are suspended formed elements."[181] The cytoskeleton contains microtubules, neurofilaments, and a matrix; it provides the apparatus for axoplasmic transport.

The nerve fiber is defined as the axon and its enveloping Schwann cell sheath, which are contained within a basal lamina or basement membrane (Figure 30.2). Nerve fibers are either

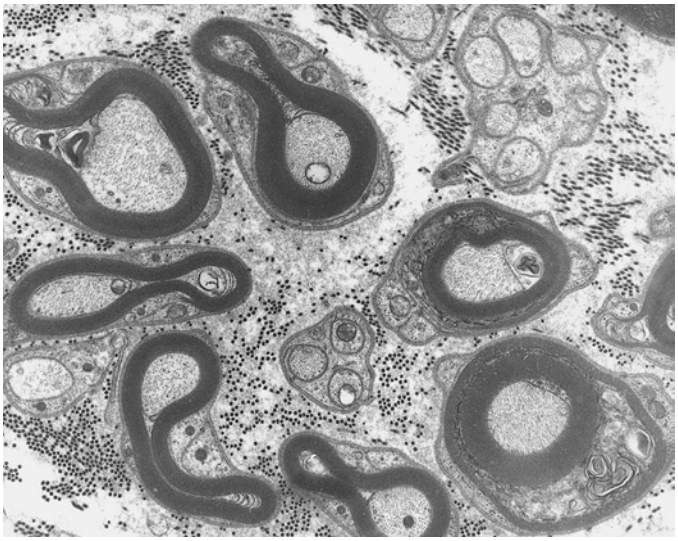

FIGURE 30.2 Proximal stump of the fifth cervical nerve 24 h after traction rupture. Nonmyelinated fibers are enveloped in clusters by Schwann cell cytoplasm; large myelinated fibers are present (original magnification ×19,500).

myelinated or nonmyelinated. Larger axons are wrapped along their length by a continuous series of Schwann cells and a myelin sheath, which is laid down in spiral layers by the surface of the cell. Smaller, nonmyelinated fibers are contained in bundles by similar columns of Schwann cells. The nodes of Ranvier represent the points of contiguity of adjacent Schwann cells.

The caliber of nonmyelinated axons varies from 0.4 to 1.25 μm. The smallest and slowest conducting nonmyelinated nerve fibers are approximately 1 μm in diameter and subserve autonomic activity, thermal sense, and delayed pain sensibility. Myelinated nerve fibers range from 2 to 22 μm in diameter and are classified according to their caliber, speed of conduction, and function. The largest and fastest conducting elements are somatic afferent and efferent myelinated fibers that are approximately 20 μm in diameter. An outstanding review of this field is provided by Lawson.[104]

The specialized property of nerve fibers is their ability to propagate action potentials. In nonmyelinated nerve fibers, a wave of depolarization spreads continuously along the axon and is attenuated by the large capacitance of the axolemma such that the velocity of conduction is restricted to about 1 m/s. In myelinated nerve fibers, myelin restricts electrical activity to the nodes of Ranvier so that the impulse has to travel in leaps from one node to the next by saltatory conduction. The speed of conduction is actually much greater. Demyelination leads to a decrease in conduction velocity and, if severe, to a complete conduction block.

Voltage-Gated Ion Channels

Exchange of ions across the axon's membrane occurs through voltage-gated ion channels. In nonmyelinated nerve fibers these channels are distributed along the length of the axon membranes. In myelinated nerve fibers they are concentrated at the node of Ranvier. Voltage-gated potassium channels are densely concentrated at the paranode, under the cover of myelin lamellae. These channels act to stabilize membrane potential and

inhibit conduction. Voltage-gated sodium channels are exposed at the node and permit the influx of sodium ions, which lowers the potential difference across the membrane and thus facilitates conduction. A number of ion channels have been described, and some sodium channels are specific to nociceptor fibers. Changes in the density and expression of such ion channels may underlie some of the phenomena of pain occurring after injury to nerves. This is a field of fundamental importance, and significant new work is appearing all the time. The matter has been extensively reviewed by Chiu.[38]

Axonal Transport

The axon functions to transport materials to and from the cell body. Two forms of transport are recognized: fast and slow.[28] Slow transport is centrifugal and is associated with the transport of cytoskeletal elements, including membrane proteins, secretory proteins, and peptides. Rates of transport are 1 to 4 mm/day, about the same as the rate of peripheral regeneration after axonotomy. The centripetal or retrograde fast component acquires elements from the terminal by endocytosis, such as nerve growth factor (NGF) and other neurotrophins, and conveys them to the cell body within multifascicular bodies. Rates of fast transport are 200 to 400 mm/day. Axonal transport is oxygen dependent, and it is sensitive to temperature. Interference with the process leads to marked slowing or cessation of conduction and, when prolonged, to degeneration of nerve cells.

The Schwann cells, skin, and other target organs are rich sources of NGF and other neurotrophins that are essential for development, maturation, and maintenance of cell bodies. Deprivation of this supply by transection of a peripheral nerve can lead to central cell death. This is most apparent when the injury is violent and close to the neural axis and even more so in the immature CNS. This matter has been reviewed in detail by Windebank and McDonald.[196]

Connective Tissue Elements

Nerve fibers are embedded in the endoneurium, which contains longitudinally orientated cells, abundant collagen fibrils, and blood vessels. Nerve fibers are aggregated into fascicles by the *perineurium*, a connective tissue layer composed of flattened cell processes alternating with layers of collagen; it is a diffusion barrier. The perineurium is a strong membrane with high resistance to compression from without, distention from within, and longitudinal traction.[109]

The epineurium is the most abundant of all the connective tissue elements of a nerve trunk and occupies between 60 and 85% of its cross-sectional area.[174] It is more loosely applied than the perineurium and contains numerous longitudinally orientated blood vessels. The epineurium is condensed at its surface as a glistening, translucent membrane, and in an uninjured nerve, individual fascicles can be seen within the perineurium surrounded by an opaque pearly white membrane. Jabaley describes the epineurium as internal and external.[85] Epineurium ensheathes the entire nerve and lies between the fascicles, where it blends with the perineurium and aggregates a number of these fascicles into discrete bundles. Jabaley cautions: "In both dissection and suturing the principal reason for avoiding perineurial injury is to avoid injury to the internal milieu, the conducting portion of the nerve."

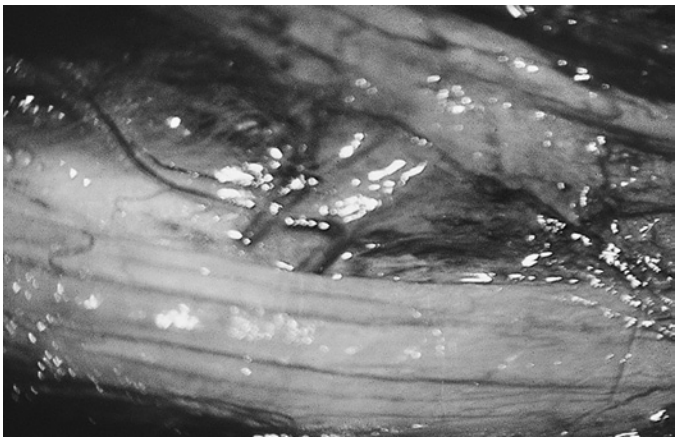

FIGURE 30.3 Blood supply of the ulnar nerve seen at surgery. The nerve lies in a foamy, glistening adventitia containing longitudinal vessels running in the external epineurium. Deeper vessels run in the epineurium between individual fascicles (original magnification ×40).

There is one further connective tissue structure that is of great clinical significance, the adventitial "paraneurium" or "mesoneurium." This loose areolar tissue permits the nerve to glide; at intervals, vascular pedicles pass through this layer to the nerve trunk. Lundborg described a rich blood supply, the *intrinsic* epineurial, perineurial, and endoneurial plexus and the *extrinsic* regional vessels that course through the mesoneurium (Figure 30.3).[110] These two systems form "separate but extensively interconnected microvascular systems." Some of these extrinsic pedicles are so well formed (e.g., those arising from the superior ulnar collateral vessels) that they provide the basis for free vascularized nerve grafts.

A number of nerves are more richly supplied than others. At the knee, the tibial nerve has a far richer blood supply than the common peroneal nerve.[86] This fact may explain the notoriously poor outlook for the peroneal nerve when it is ruptured at the knee. The radial nerve in the axilla and upper part of the arm is supplied by branches from the adjacent profunda arteries.[165] After high transection of the nerve and the adjacent artery, the distal segment of it becomes relatively ischemic; this may explain the rather poor results seen after repair of such high lesions. It must be noted that the blood supply to the roots of the spinal nerves within the spinal canal is far less robust.[121]

It is the mesoneurium that permits normal nerve gliding. Wilgis and Murphy found that the brachial plexus has an excursion of at least 15 mm in relation to the position of the arm and that the median and ulnar nerves at the elbow move through an average distance of 7.3 and 9.8 mm with full motion.[194] The greatest excursion of peripheral nerves occurs at the wrist, proximal to the carpal tunnel; here, the median and ulnar nerves have 15.5 and 14.8 mm of longitudinal gliding, respectively. Injury or surgical intervention that compromises gliding of the nerve impairs function. Tethering of a nerve also may cause severe neuropathic pain. Wilgis commented on the effects of injury on gliding: "In other words, the length of the nerve substance has been shortened because of the injury. Because of this overall shortening, excursion cannot take place."[193]

The importance of retaining or restoring gliding of peripheral nerves and preventing their tethering or entrapment

cannot be overemphasized. The connective tissue of a nerve trunk consists of a collection of sliding interphase zones that permit considerable excursion of the epineurium within the adventitial mesoneurium and of the individual bundles within the deep layer of the epineurium. Among the most important of Millesi and associates' many contributions is their recognition of the importance of this function.[127] They argue for preservation of the "gliding apparatus" in a paper that should be widely read.

Functional Segregation

Sunderland described the arrangement of fascicles and of bundles of fascicles along the course of nerve trunks and showed branching, fusion, and changes in number. These findings have been interpreted as casting doubt on the possibility of achieving accurate coaptation of the ends of divided nerves.[174] In fact, Sunderland demonstrated a degree of topographic segregation of nerve fibers according to function over considerable lengths of the trunks. Microneurographic studies have confirmed these findings.[158]

The distribution of nerve fibers within bundles in nerves of the brachial plexus has been analyzed extensively.[25,133,166] The segregation of nerve fibers is established more proximally, such that the suprascapular nerve can be traced to an anterior bundle within C5 at the level of the anterior tubercle. One bundle that controls the radial extensors of the wrist can be consistently displayed by stimulation within the posterior division of the upper trunk when exploration is performed within 36 to 48 hours after transection. It is this segregation that permits procedures such as transfer of one fascicle of the ulnar nerve destined for the flexor muscles of the forearm to reinnervate the motor nerve of the biceps.

Features of Connective Tissue

The list that follows contains the features of connective tissue:

- The endoneurium provides connective tissue support for nerve fibers. The resistance of the nerve trunk to stretching injury is granted by the undulating course of nerve fibers within the fascicles. As Tupper states, "individual fascicles are identified by the spiral bands of Fontana located in the perineurium. If longitudinal tension is applied to the perineurium, these bands disappear, indicating that they are tension wrinkles, probably affording some protection from stretch deformation."[187,188] Resistance to stretch is further provided by the connective tissue sheaths, most especially the perineurium.
- The perineurium is responsible for maintaining the physiologic milieu of the conducting elements. It is a strong diffusion barrier. Breaching the perineurium interferes with conduction and provokes demyelination of the underlying nerve fibers. Section of the perineurium leads to "pouting out" of the endoneurium and nerve fibers.
- The epineurium contains many blood vessels and protects the nerve against compression. It occupies between 60 and 85% of the nerve's cross-sectional area, and it is most abundant at points where the nerve traverses joints. It is the connective tissue sheath of particular surgical interest.
- The adventitial mesoneurium conveys extrinsic segmental blood vessels to the nerve trunks. It enables gliding of the nerve.

RESPONSES TO INJURY

Focal injury to a nerve causes one of two lesions to the axons within (Table 30.1). In the conduction block the axon remains anatomically intact but conduction of action potentials is blocked at the level of the lesion. The distal axon remains alive and conduction in this distal segment persists. Recovery will be complete if the cause is removed (i.e., nondegenerative lesion). If the axon is transected, the distal segment loses conduction and the process of Wallerian degeneration ensues.[191] There are two types of this degenerative lesion.

If the basal lamina remains intact, the proximal axon can regenerate into the distal Schwann cell tube in an orderly manner if the cause of the lesion has been removed. If the basal lamina has been interrupted, spontaneous regeneration is imperfect, disorderly, and may not occur at all. Seddon[160] recognized the fundamental distinction between CB and the degenerative lesion in the terms *neurapraxia* for CB, *axonotmesis* for the degenerative lesion with an intact basal lamina, and *neurotmesis* where the nerve had been completely severed. This classification was drawn from a study of 650 nerve lesions during war. The injury was in continuity in 537 of these among which only 117 "pure" lesions could be identified. Only one-third of the lesions fell unequivocally into the neurotmesis category—that is, the whole nerve had been divided.

Many serious injuries leave the nerve trunk in anatomical continuity such as the traction lesions of the cords stretched over the dislocated head of humerus, or the sciatic trunk in posterior dislocation of the femoral head. This problem is encountered in many lesions caused by penetrating projectiles. Some of the nerve fibers remain intact but others sustain CB. The remaining nerve fibers undergo Wallerian degeneration; in some there is spontaneous recovery, (i.e., axonotmesis) while others never recover (i.e., neurotmesis). There is selective vulnerability among various types of nerve fibers.

In ischemic injuries the larger myelinated fibers (Mnf) lose conduction across the lesion earlier than the smaller Mnf and the nonmyelinated fibers (nMnf). This selective vulnerability of different populations of nerve fibers that exist is perceived during the classic experiment of applying a cuff inflated to

TABLE 30.1 Classification of Focal Mechanical Nerve Injury

I. Focal conduction block	A. Transient	1. Ischemic 2. Other
	B. More persistent	1. Demyelinating 2. Axonal constriction
II. Axonal degeneration	A. With preservation of the basal laminal sheaths of nerve fibers	
	B. With partial section of the nerve	
	C. With complete transection of the nerve	

Source: Modified from Thomas PK, Holdorff B: Neuropathy due to physical agents. In Dyck PJ, Thomas PK, Griffin JW, et al, editors: *Peripheral neuropathy*, ed 3, Philadelphia, 1993, WB Saunders.[182]

suprasystolic pressure around the arm. Large Mnf are affected first; nMnf and autonomic fibers escape. The observer experiences a loss of superficial sensibility, then a graduated loss of muscle power. The first pain response is lost soon after superficial sensibility fails; the delayed pain response is still detectable after 40 min of ischemia. Pilo- and vasomotor functions are scarcely affected. All modalities recover within a few minutes of the cuff's release. The unpleasant quality of the residual delayed pain sensation and the burst of painful "pins and needles" after release of the cuff gives an insight into the feelings of patients affected by dysesthesia.

It is very difficult for the clinician to quantify these component lesions, and the best one can do is to estimate the predominant lesion for the whole nerve. Sunderland[173] introduced a rather more elaborate system of classifying injury. Five degrees of severity were named ranging from a simple CB to loss of continuity. Some clinicians find this classification from a pioneer in the field to be of more practical use to them than Seddon's system.[160] We, on the contrary, have tended toward further simplification of "degenerative" and "nondegenerative" (i.e., conduction block) and believe that the first question to be asked by the clinician is: Is this lesion degenerative or nondegenerative?

It is always important to remember that the continuing action of the agent responsible for the initial injury causes deepening (i.e., worsening) of the lesion to the axons and the nerve fibers, from CB through degenerative lesion (i.e., axonotmesis) and finally to a nonrecoverable degenerative lesion (i.e., neurotmesis) (Figure 30.4). Loss of conduction is the hallmark of critical ischemia.

Conduction Block (Also Called Neurapraxia)

There are a number of causes of CB. The distinction between them is somewhat artificial as ischemic anoxia is a common factor to all. Compression of a nerve sufficient to cause mechanical deformation of the myelin sheath also must interfere with its circulation. There are some well-defined patterns as described in the following subsections.

Transient Ischemic Conduction Block

There is an anoxic block of axoplasmic transport and an ion channel function. This is seen during surgery for the exposure of limb nerves with an inflated tourniquet. Stimulation of the nerve evokes a brisk muscular response by transmission through the neuromuscular junction, which diminishes before disappearing after about 30 minutes. Conduction within the nerve itself can be detected for about another 30 minutes. On the other hand, direct stimulation of the muscle provokes a twitch that can be elicited for nearly 2 h. The loss of the direct response to muscle stimulation signals impending muscle death.

Persistent Anoxic Conduction Block

This is caused by the slowly progressing ischemia of expanding hematoma or by bleeding into compartments. It is common in nerves strangled by scars. The nerve defect progresses over a period of weeks or months. Relief of pain and recovery of function is often dramatic after adequate decompression and, if need be, resurfacing with healthy skin. The importance of ischemic anoxia in these lesions is shown by this speed of improvement.

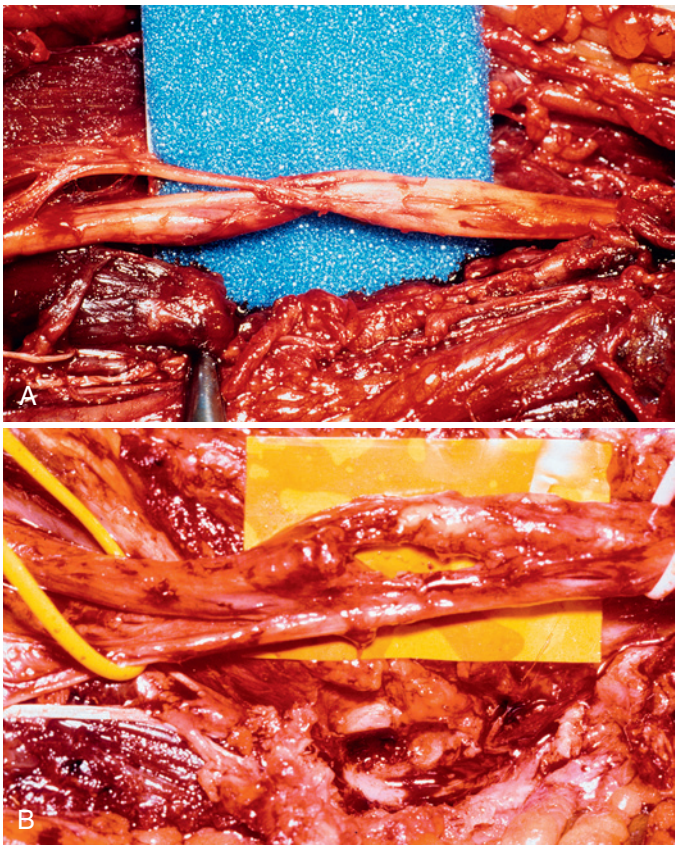

FIGURE 30.4 A nerve lesion gets deeper due to persistence of compressive agent. **A,** Complete recovery of conduction block ensued, followed extrication of this median nerve from a supracondylar fracture 3 days after a 9-year-old girl's injury. **B,** Absence of recovery after release of this median nerve from a supracondylar fracture 8 weeks after a 13-year-old girl's injury.

Persistent Conduction Block in Focal Myelin Deformation and Demyelination

Severe prolonged compression causes myelin deformation that is squeezed proximally and distally at the margins of compression. There is compaction of the axoplasm within the zone of compression, extrusion of the cytoskeleton at the margins, and distortion of the adjacent nodes of Ranvier.[56] A not uncommon presentation is the "Saturday night palsy" of the radial nerve distal to triceps, often caused by substance-induced deep sleep, resulting in sustained pressure on the affected arm. Neurophysiological investigations generally show normal conduction and a normal return to a full pattern of motor units of ordinary appearance within 2 to 3 months. This type of lesion is one of pure conduction block.

Persisting Conduction Block in Projectile Injuries

Mechanical deformation plays a part in these lesions, but the mechanisms are not clear. One pattern caused by momentary displacement of the nerve was described by Mitchell et al[128]:

> *This condition of local shock is curious. A man is shot in the thigh, the ball passes near the sciatic nerve and instantly the whole limb is paralyzed; within a few minutes or at the close of a day or a week the volitional control in part returns, but finally he may be left with some single group of muscles permanently paralyzed.*

The characteristic features of this type of CB include:

- Paralysis exceeds loss of sensation
- Nerves responsible for proprioception are more profoundly affected than those conveying light touch sensation
- Vaso- and sudomotor function is minimally affected

Another type of persisting CB has been recognized in recent conflicts.[18] The patient is exposed, at close range, to the shock wave of an explosion without any wound or fracture, or there are signs of significant injury to the soft tissues at the level of the nerve lesion. In such cases the smallest fibers are the most profoundly affected and may not recover. In 45 cases of CB caused by penetrating objects that exhibited the classic pattern, the mean time to recovery was 3.8 months (0.6-6). In the 71 cases caused by an explosion it was 47 months (2.5-10.2). This lesion is especially important when the tibial nerve is involved in a severe injury to the lower limb at a time when an urgent choice must be made between salvage and amputation. Loss of plantar sensation has been used as an indicator toward amputation in such cases. However, recovery of plantar sensation was good, or at least useful, in 42 of 47 severely injured lower limbs. There was complete loss of plantar sensation when these patients were assessed in the field hospital. Plantar sensory loss in and of itself is *not* a sound signal for amputation after missile or blast injuries.

CRITICAL POINTS *Classification*

- The most useful clinical classification of nerve lesions distinguishes CB (neurapraxia) from degeneration (axonotmesis and neurotmesis). In the former, the axon is intact; in the latter, the axon is divided and the Wallerian degeneration process ensues.
- A diagnosis of CB should not be made if (1) the nerve palsy is complete, (2) there is vasomotor and sudomotor paralysis in the territory of the nerve, and (3) a Tinel sign is noted at the level of the lesion.
- Conduction block is unlikely if (1) there is neuropathic pain and (2) there is a wound over the path of the nerve.
- A strong Tinel sign at the level of the lesion indicates that axons are ruptured.

Wallerian Degeneration

Wallerian degeneration affects the nerve distal and proximal to the point of axonal interruption, and it extends to affect the cell body. It can be seen as a process by which the environment of a normal nerve, so inimical to regeneration, is transformed into one that is actively receptive to regenerating axons, at least for a limited period (Figure 30.5). This comforting thought must be set against the reality of clinical practice: Wallerian degeneration cannot occur in an ischemic limb, for it is energy-dependent. The nerve simply dies.

The harmful consequences of Wallerian degeneration are certainly much less severe in cases (i.e., axonotmesis) where the basal lamina remains intact. This is especially so on the cell body of the neuron because the regenerating axon is able to reestablish contact with the distal Schwann cells rapidly, restoring the flow of neurotrophins from these and from the target tissues. The extent of central cell death is much less.

The changes are briefly summarized in the following subsections.



FIGURE 30.5 Wallerian degeneration: The appearance of the distal stump of the ulnar nerve 3 weeks after transection shows axonal disintegration (original magnification ×3400).

The Distal Segment

This list describes the outcomes of the distal segment of the nerve:

- Conduction is lost. Landau[99] found that the interval between injury and the last observation of the neuromuscular response ranged from 66 to 121 h. Our own observations of motor conductivity after preganglionic injury to the brachial plexus suggests that the motor response ceases about 3 days after injury. In one case stimulation of the avulsed ventral roots of the spinal nerves evoked a motor response 132 h after injury. Such persisting conduction in the distal segment of a nerve during the first 2 days excludes a second, more distal lesion, or ischemia of the distal segment.
- There is an enormous increase in the number of Schwann cells, both fibroblasts and macrophages. The macrophages are responsible for clearing the debris of axoplasm and myelin. The Schwann cells change their phenotype and downregulate expression of genes important for the maintenance of myelin, nodes, and paranodes. The fibroblasts deposit endoneurial collagen—a process that is apparent in clinical specimens by 3 weeks.
- There are substantial changes in the expressions of neurotrophins, such as the brain derived neurotrophic factor (BDNF) and neurotrophins 3 and 4, in muscle and in the distal nerve. These reach a peak at 7 days after injury.[144]

As time passes, more and more collagen is deposited and the number of Schwann cells decreases, and these change their phenotype to one less receptive to regenerating axons. These changes occur at varying intervals according to the nature of

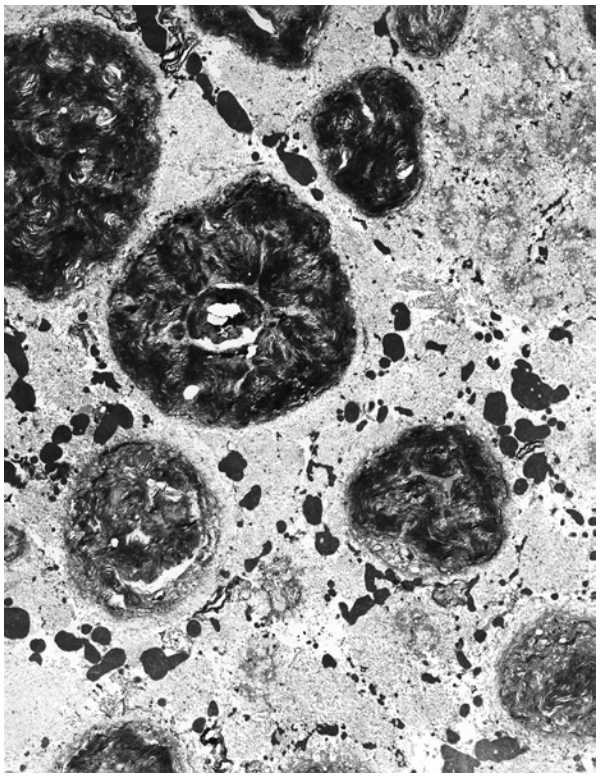

FIGURE 30.6 Example of a biopsy taken 8-mm proximal to the stump of a ruptured median nerve 3 months following injury. The associated rupture of the axillary artery was not repaired. Widespread fibrosis, disintegration of axons, persistent myelin fragments that were not cleared by macrophages, and very scanty evidence of cellular and regenerative activity (original electron microscopy ×4880).

the injury. Ischemia hinders, indeed it may prevent, the completion of Wallerian degeneration and concomitant regeneration (Figure 30.6). The evidence from the cellular and molecular responses suggests that the peak of "receptivity" to regenerating axons in the distal segment lies between 1 and 3 weeks after injury.

The Proximal Segment and the Cell Body

This list describes the events that occur in the proximal segment and the cell body of the nerve:[74]

- The caliber of the proximal axons diminishes proximally—that is, amplitude and velocity of conduction falls.
- There are rapid changes in the expression of ion channels in the cell bodies in the dorsal root ganglion (DRG) within minutes of injury. After preganglionic injury there are extensive changes in the expression of genes regulating neuronal activity in those neurons.
- Chromatolysis can occur in the cell body after axonopathy, which may proceed to dissolution of the cell body. Cell loss is more severe in more proximal axonotomy and it is more severe in the neonate than in the adult.
- The death of motor neurons in the anterior horn is particularly severe after avulsion of the ventral root. It is curious that cutting or rupture of the central processes of cell bodies in the DRG does not produce such clear-cut changes.
- Dyck et al[52] studied the spinal cords of two patients who had previously undergone amputation of a limb. There was extensive loss of cells in the anterior horn of the relevant segments, and they stated that "loss of target tissue by axonotomy leads to atrophy and then loss of motor neurons."
- Suzuki et al[175] examined the cervical cord, the roots, and the ganglia of a patient who died 38 years after amputation of the upper limb. There was neuronal loss in the anterior horn and the DRG and diminution of the larger Mnf in the ventral and dorsal roots.
- Carlstedt[34] estimated that about one-half of all motor neurons have disappeared by 2 weeks after avulsion of the ventral root and urges swift action to restore contact between the cell body and the periphery, with its supply of neurotrophins.

Stretch Injury

Peripheral nerves outside the spinal canal have considerable tensile strength, but function is damaged by elongation of 12% or greater. Lundborg and Rydevik showed that venous flow is blocked when a nerve is stretched by 8% of its resting length and that stretching by 16% produces ischemia.[114] In the early stages of stretching of a nerve, elongation is enabled by stretching of the epineurium and straightening of the irregular course of the fibers within the fascicles.

Haftek observed: "Before rupture of the epineurium the damage to the nerve fibers is either neurapraxia or axonotmesis, because the endoneurial sheath and Schwann fibers remain intact."[72] With continued traction, the caliber of the fibers is diminished, the endoneurial space narrows, and myelin is disrupted. Finally, rupture occurs when all elements, including the epineurium, are torn. Clinicians engaged in the correction of long-standing deformity of a limb or seeking to lengthen such limbs must bear the preceding facts in mind. The authors have seen some very serious injuries to nerves and to arteries that complicate such operations.

CLINICAL DIAGNOSIS

Examination of a patient who has just been injured is not easy. The clinician's task is made more difficult if the patient has a head injury or is under the influence of drugs or alcohol. The history of the accident is extremely important, and evidence provided by witnesses, or by paramedical emergency staff, is invaluable. When a nerve has stopped working and there is a wound over the course of it, the diagnosis is nerve transection until substantiated to be otherwise. The extent of the lesion is shown by weakness or paralysis of muscle and by the extent of loss of cutaneous sensation. There are pitfalls: (1) considerable variation in the cutaneous innervation of the skin of the hand by the median and ulnar nerves and (2) considerable compensatory activity of uninvolved muscles such that trick movements may mislead the examiner.

Inman et al showed, as long ago as 1944, that the supraspinatus is the abductor of the shoulder[84]; however, many texts continue to repeat the erroneous notion that the deltoid is responsible for shoulder abduction. Many patients can elevate the arm fully even though the deltoid muscle is paralyzed. This persisting error explains many cases of undue delay before the diagnosis of circumflex palsy is made, and it also explains the reason why so many cases of rupture of the rotator cuff are erroneously diagnosed as examples of injury to the circumflex nerve (Figure 30.7). The authors have seen instances in which



FIGURE 30.7 Full abduction following complete rupture of the axillary nerve. Typically, elevation is maintained if the suprascapular nerve and the rotator cuff are intact. Note complete insensate patch over deltoid (*hatched marking*).

TABLE 30.2 Depth of Nerve Injury

	Conduction Block	Axonotmesis or Neurotmesis
Typical etiology	Compression Low-energy transfer of long bone fracture	Open injuries High-energy fractures and dislocations
Loss of sensory modalities	Some preserved, usually pinprick (sharp/dull)	All modalities absent
Muscle power	Paralysis sometimes patchy and incomplete	Complete paralysis
Sympathetic function	Usually preserved	Sympathetic paralysis (injured part is warm and dry)
Tinel's sign	Absent	Present

elbow flexion via the brachioradialis (BR) muscle has led to delay in diagnosis of transection of the musculocutaneous nerve. Sympathetic paralysis, however, is a sure sign of interruption of axons (Table 30.2). The skin in the territory of the affected nerve becomes red and dry. Severe pain indicates continuing damage, hardly consistent with the diagnosis of a nondegenerative CB.

Analysis of the force expended on the limb is particularly important in the diagnosis of nerve injury resulting from closed fractures or fracture–dislocations. The extent of the force exerted on the nerve trunk can be estimated by the velocity at impact or the height of the fall. Local bruising at the tip of the shoulder or linear abrasions in the neck indicate that there has been violent separation of the forequarter from the neck. Linear bruising of the skin is indicative of rupture of axial structures. Radiographs are useful in showing the extent of displacement of bone fragments and imperfect reduction, or a block to reduction implies interposition of soft tissues. Regarding nerves injured in the arm or the elbow, Seddon thought that recovery could be anticipated if two conditions were met: (1) reasonable apposition of the bony fragments and (2) "complete certainty that there is no threat of ischemia of the forearm muscles."[162]

Physical Examination of Nerve Injury

Tinel Sign

The Tinel sign is one of the most valuable indicators in medicine. Properly elicited and interpreted, it permits the clinician to understand the level and the severity of a nerve lesion and, in later examinations, to show whether regeneration is occurring. The authors have found that it is detectable on the day of injury. The sign is of supreme importance in the urgent analysis of a closed-traction lesion of the brachial plexus. If percussion in the posterior triangle of the neck evokes strong, indeed painful, sensory symptoms as far as the elbow, rupture of C5 is likely. If percussion radiates to the radial aspect of the forearm and to the thumb, rupture of C6 should be expected. If the sign extends to the back of the hand, a similar injury to C7 is predicted.

The validity of a Tinel's sign was analyzed in 300 consecutive cases of closed-traction supraclavicular lesions that subsequently underwent surgery. The prediction, made on the basis of the presence or absence of the Tinel sign, was confirmed for C6 and for C7 in more than 90% of cases and for C5 in about 85%.

Determination of this important clinical feature is simple enough. The examiner taps lightly along the course of the affected nerve in a distal-to-proximal direction. When the finger percusses over the zone of regenerating fibers, the patient will state that there is a sensation of pins and needles, which may be quite painful, in the cutaneous distribution of the nerve. The clinical significance of the Tinel sign can be summarized as follows:

- A strongly positive Tinel sign over a lesion soon after injury indicates rupture of the axons. This sign has been found regularly on the day of injury, most especially with closed-traction rupture.
- Regeneration of axons, either spontaneous or after repair of the nerve, can be confirmed when the centrifugally moving Tinel sign is persistently stronger than that at the suture line.
- After a repair that is going to fail, the Tinel sign at the suture line remains stronger than that at the growing point.
- Failure of distal progression of the Tinel sign in a closed lesion indicates rupture or another lesion impeding regeneration.
- The Tinel sign advances more swiftly in cases of axonotmesis (i.e., ~2 mm/day) than it does after nerve repair. It also is faster in the proximal segment of the limb than in the distal. In the axilla, rates of progress of 3 mm/day are not unusual.

Injury

The single most important determinant of outcome is the violence of the injury to the nerve and the limb, and the extent of

CRITICAL POINT *The Tinel Sign*

- The Tinel sign should be reserved for traumatic neuropathy and is indicative of a degenerative lesion, not a conduction block.
- Tinel himself made a clear distinction between the preceding and the sensitivity of the nerve trunk in cases of "neuralgia."[184]

destruction of nerve tissue is a reflection of this. For the past 30 years nerve injuries have been classified into three groups:

1. *Tidy wound:* Caused by knife, glass, or the surgeon's scalpel. Damage is confined to the wound. Primary repair of all divided structures is desirable.
2. *Untidy wound:* Commonly caused by open fractures or by penetrating projectile injury. There is extensive tissue damage with a high risk for sepsis. Arterial injury is common. A contaminated wound from a close-range shotgun injury is one example in which urgent repair cannot be entertained. There is a risk for sepsis from dead or devitalized tissue or from unrecognized small fragments of foreign material; the extent of intraneural longitudinal damage cannot easily be ascertained in a freshly exposed wound. Sepsis greatly compounds the problem by causing even more longitudinal destruction within the nerve. The International Red Cross Wound Classification system set forth by Coupland[42] will be of particular interest to those treating penetrating injuries.
3. *Closed-traction injury:* Such injuries are very destructive of nerves and axial vessels.[170] There is wide retraction of ruptured nerves and vessels, together with considerable longitudinal damage within the ruptured trunk. The outcome after nerve repair for this type of injury, when complicated by an arterial lesion, is the worst of all the groups (Figure 30.8).

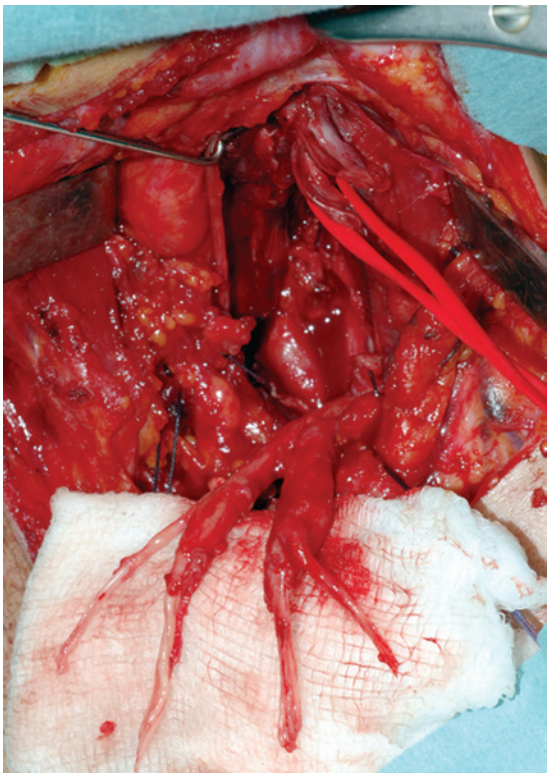

FIGURE 30.8 Closed traction lesion of the brachial plexus exposed 4 days after injury. The patient came off his motorcycle at 40 mph and his shoulder struck a tree. The red sling surrounds the stump of C6, the stump of C5 lies above it, and the stump of C7 lies deep to it. The phrenic nerve is retracted above, and the subclavian artery is seen at the base of the wound.

Neurologic Examination

Examination should allow the clinician to extend the knowledge imparted by the history to permit making an accurate diagnosis. All findings should be recorded in such a manner that the record will be intelligible later, not only to the examiner but also to others. Unfortunately, the signs of acute nerve injury have to be sought at a time when the patient may be least able to cooperate; that is, soon after being wounded when there is likely to be distress and the patient's general condition may be affected by loss of blood and/or other injuries.

Frequently, examination has to be done in the often unfavorable surroundings of an emergency department. The patient may be a distressed child, an older juvenile, an adolescent, or an adult; the last three groups may be affected by alcohol or drugs or by both. These are not conditions for a quiet and comprehensive "neurologic examination," yet this is the time when nerve injury must at least be recognized if the best results are to be obtained from treatment. At all times the examiner should bear in mind that if there is a wound over the line of a main nerve and if there is any suggestion of loss of sensibility or impairment of motor function in the distribution of that nerve, it must be regarded as having been cut until and unless it is determined to be otherwise.

Some of the most serious mistakes in the diagnosis and treatment of patients with injured nerves are made because the examiner fails to accurately assess the depth of the injury; that is, to distinguish between degenerative and nondegenerative injury and to estimate the extent of each type of nerve lesion. Some atavistic urge seems to cause clinicians to play down the severity of a nerve injury. Perhaps beneath this urge is a feeling that if a serious injury has taken place, much difficult, and possibly unrewarding, work is going to be required. The tendency is, of course, particularly marked in cases of closed injury and of injury during surgery. Too often the mantra "neurapraxia" is pronounced; too often the soothing words "just some bruising of the nerve" are uttered.

The early signs of nerve injury are alteration or loss of sensibility, weakness or paralysis of muscles, vasomotor and sudomotor paralysis in the distribution of the affected nerve or nerves, and abnormal sensitivity over the nerve at the point of injury. One almost infallible sign is always present during the first 48 h after deep injury to a nerve with a cutaneous sensory component; because of the involvement of small as well as large fibers, the skin in the area of the affected nerve is warm and dry.

Peripheral ischemia is usually signaled by pain, but in cases where the vascular injury is associated with fracture, the significance of that pain may not be recognized. Ischemia affects the large fibers of a peripheral nerve first; discriminative sensibility and vibration sense are the first to be affected.[115] It is not easy to test these subtle signs when ischemia is developing in a multitrauma state with a major vascular injury, but if action is not taken until after superficial sensibility is lost, it will be too late.

As much as possible, responsiveness to a light touch, a pinprick, and vibration and position sense should be tested, and the area of skin affected should be recorded. The time it takes

to respond to a pinprick, if possible, should be noted. Anhidrosis is easily observable; vasomotor paralysis is shown by warming of the skin and, in the fingertips, by capillary pulsation as well as by changing color. It is helpful for the clinician to assess, as accurately as possible, the innervation of all muscles distal to the site on the day of injury and at subsequent examinations.

A table of manual muscle strength in the patient's record is useful in monitoring progression or absence of nerve recovery. The authors use the grading system of the Medical Research Council (MRC) to chart recovery of denervated muscle after injury or repair. In addition, a camera is a valuable aid to recording details in an emergency setting. Most patients are able to describe, with accuracy, the boundary between skin with normal sensation and that with diminished or abnormal sensation and also the boundary between abnormal and complete loss of sensation. Patients should be asked to mark these areas with a colored skin pencil for anesthetized skin and then with a red marker for skin with abnormal sensation, then the limb is photographed. The photograph is kept with the patient's files. These areas of loss or impairment of sensation can be recorded on standard charts of the hand, the upper limb, and the lower limb, and this, too, provides a useful permanent record.

Electrodiagnosis

According to Smith, "[n]erve conduction studies and electromyography should be considered as an extension of the clinical examination of nerve, muscle, and the neuromuscular junction."[168] The study of nerve conduction advises the clinician about the health of axons; about their myelination; and when applied to the proximal stump of a nerve, whether there is continuity between the exposed nerve and the spinal cord. Conduction across the nerve lesion indicates that at least some of the axons are intact.

After transection of a nerve, axons become unexcitable and neuromuscular transmission fails. Direct stimulation of the nerve distal to the level of the lesion elicits no response. However, some conduction is maintained for several days after nerve transection before Wallerian degeneration is complete.

Fibrillation potentials are one of the earliest electromyographic signs of muscle denervation, but their onset depends on the distance between the site of the nerve lesion and the muscle. There may be an interval of 10 to 14 days before fibrillations are seen. Reappearance of voluntary motor unit potential activity indicates that reinnervation is taking place, and electromyographic evidence of it usually precedes clinical evidence of recovery. The finding of a few motor units showing reinnervation, even at an early stage after injury, does not, however, imply that full recovery of a nerve will take place.

Electrodiagnostic evaluation needs to be done and interpreted by an expert and further considered by an informed surgeon. The findings of these investigations must be interpreted with great care during the first 10 to 14 days after transection of a nerve. In an analysis of incomplete lesions of large nerve trunks (e.g., those seen in the sciatic nerve after hip arthroplasty), the clinician may be lulled into a false sense of security by electrodiagnostic evidence of an incomplete lesion. Such evidence should not be taken to imply that full recovery can be anticipated. Unless the nerve has been wholly transected, it is likely that there will be mixed elements of neurotmesis, axonotmesis, and prolonged CB.

The subject is comprehensively reviewed by Smith,[168] from whose work Tables 30.3 and 30.4 are taken. This study correlates electrodiagnostic findings with Seddon's classification of nerve injury. As Smith says, however:

> *The distinction between neurapraxia and axonal degeneration of partial or complete degree is difficult in the acute stages of nerve injury, prior to evidence of denervation in the form of fibrillation potentials on electromyography. Therefore, electrodiagnostic tests cannot reliably differentiate a neurapraxic lesion from one with Wallerian degeneration in the first few days after nerve injury.*

Dellon emphasized that such studies are not a substitute for obtaining a careful history and physical examination, that normal values do not necessarily indicate absence of neurologic abnormality, and that abnormal electrodiagnostic findings do not mean that the patient requires operative treatment![45]

It is within the operating theater that electrodiagnostic effort is of particular value.[94] Bonney and Gilliatt demonstrated persisting conduction in sensory fibers when the DRG has become separated from the dorsal horn of the spinal cord with traction

TABLE 30.3 Electrodiagnostic Features of Nerve Injury

Type of Nerve Injury	SAP	CMAP	Conduction Velocity	EMG
Conduction block (neurapraxia)	Reduced amplitude proximal to the block. Normal amplitude distal to the block.		Usually preserved	No or sparse fibrillations Characteristic IP of normal MUPs firing Rapid rates with reduced IP
Axonotmesis	↑	↓	Normal/reduced to a degree dependent on the severity of axonal degeneration and the fiber type involved	Fibrillations Reduced IP, ↓firing rate of MUPs Evidence of reinnervation dependent on age of lesion
Neurotmesis	A	A	Unmeasurable	Profuse fibrillations No voluntary MUPs

A, Absent; *CMAP,* compound muscle action potential; *MUP,* motor unit potential; *IP,* interference pattern; *SAP,* sensory action potential; ↓, decreased; ↑, increased.

Source: From Smith SJM. Electrodiagnosis. In Birch R, Bonney G, Wynn Parry CB, editors: *Surgical disorders of the peripheral nerves*, London, 1998, Churchill Livingstone.

TABLE 30.4 Electromyographic Findings in Denervation and Reintervation

Denervation	Spontaneous activity (i.e., fibrillations, positive sharp waves in acute denervation; fasciculations and complex repetitive discharges in chronic denervation)
Reinnervation	
• Early	Normal motor units with increased duration because of late potentials (i.e., satellite fibers incorporated via collateral sprouting)
• Ongoing	Moderate-amplitude polyphasic motor units of long duration, unstable firing because of variable conduction along unmyelinated sprouts, and low safety margin of neuromuscular transmission
• Late	Large-amplitude polyphasic motor units with stable transmission

Source: From Smith SJM. Electrodiagnosis. In Birch R, Bonney G, Wynn Parry CB, editors: *Surgical disorders of the peripheral nerves*, London, 1998, Churchill Livingstone.

injuries of the brachial plexus.[26] This principle was extended to intraoperative investigation. Landi and associates recorded cortical evoked potentials from nerve stumps stimulated at surgery with scalp electrodes.[100]

Operative neurophysiologic studies have been performed in more than 5000 operations on adults and children since 1977. Application of the technique to diagnosis of birth lesions of the brachial plexus has been described.[11,22] For simple stimulation and observation of motor responses, only the simplest unipolar or bipolar stimulator is necessary. For stimulation and recording from muscle and nerve and for recording conduction across a lesion, a more elaborate apparatus is required. We formerly used Medelec MS91 (Viasys Health Care, Madison, WI), which features a bipolar stimulator with platinum electrodes, but now uses the Medelec/TEAC Synergy (Peachtree City, GA) monitoring system; its electrodes are available from Ambu (Ballerup, Denmark).

In recording of somatosensory-evoked potentials (SSEPs), the reference electrode is placed on the forehead at the hairline, the ground electrode at the temple, and the recording electrode on the skin surface overlying the second or third intervertebral space. A sterile handheld bipolar stimulator is used to stimulate the nerve directly. Before preparing the limb, the stimulator is used to record signals from the median and ulnar nerves. The uninjured side acts as a control. The median and ulnar nerves are stimulated at the wrist on the injured side and the signals recorded. SSEPs are recorded at a stimulus rate of 3 to 5 pulses/s, a duration of 2.0 ms, and an intensity of 150 to 300 V, with signals averaged from between 50 and 200 sweeps. The stimulus rate for the handheld bipolar stimulator is 3 to 5 pulses/s at an intensity of 3 to 15 V.

For measuring conduction across a lesion, sterile handheld bipolar stimulators are placed on either side of it, and the ground electrode is placed in a convenient adjacent area. The skin is first prepared with abrasive paste and alcohol wipes to lower resistance, and the aim for reference and recording electrode impedance is balanced and should be below 2.0 kΩ. Once the surface electrodes are positioned, they should be secured with tape.

The quality of the traces may be adversely affected by a number of factors: ambient noise interference from electrical equipment in the theater, mobile phones, and deep fibrosis of the nerve; an operating site that is either too wet or too dry also can cause interference with intraoperative recordings. SSEPs are relatively unaffected by anesthetics, but prolonged use of muscle relaxants must be avoided because they prevent observation of muscle activity.

Kline and Hudson have related their extensive experience in the use of electrodiagnostic techniques for the analysis of injured peripheral nerves.[91,92] Compound nerve action potentials are used to measure regeneration into the distal nerve by stimulating and recording across the site of a lesion. The outcome of the investigation, as it relates to clinical outcome, was described for nearly 1000 nerves with serious lesions in continuity in both the upper and lower limbs. Four hundred thirty-eight nerves showed a recordable nerve action potential traversing the lesion. Neurolysis was performed, and of these nerves, 404 (92%) improved to at least a useful functional result. In another 428 nerves no nerve action potential could be recorded and repair was performed. Of these, 240 (56%) eventually regained useful function. Other important data were collected on nerves for which partial repair was done, with preservation of individual bundles that had recordable nerve action potentials.

Imaging

High-resolution ultrasonography (i.e., 17 MHz) has great potential in the early detection of ruptures or other serious injuries to nerves (Figure 30.9, *A, B*). It has been shown to be reliable in identifying the nerve, confirming the level of injury, and demonstrating continuity or interruption of fascicles.[185] The authors have found that interpretation of ultrasound findings is much more difficult in cases evaluated late, where there is abundant fibrosis around the nerves.

Lesions in Continuity

Whether to leave a lesion in continuity alone or whether to resect and bridge the gap is a most difficult decision, made more so when there is clinical evidence of some recovery. The decision is easier when a number of intact fascicles can be seen traversing the lesion. The consistency and the diameter of the neuroma are helpful. The firmer and the larger, indeed the more florid the neuroma, the less likely recovery will be good.

The most informative method is to stimulate above the lesion and to record from the nerve or from individual fascicles below it; a response with good amplitude may well indicate a good prognosis. A response in individual fascicles may allow separation of an intact part of a nerve from the damaged portion.

It is important to remember the potential limitations of intraoperative studies of nerve conduction. Detection of conduction across a lesion does not guarantee good recovery of function. We were always able to record conduction across the neuroma of the ruptured upper trunk in birth lesions of the brachial plexus.[11] It is usual to find that there is some conduction across lesions of the sciatic nerve inflicted during arthroplasty of the hip; however, it has been found that this does not guarantee adequate recovery or reduction of pain. On several occasions, a lesion of the spinal accessory nerve has been left

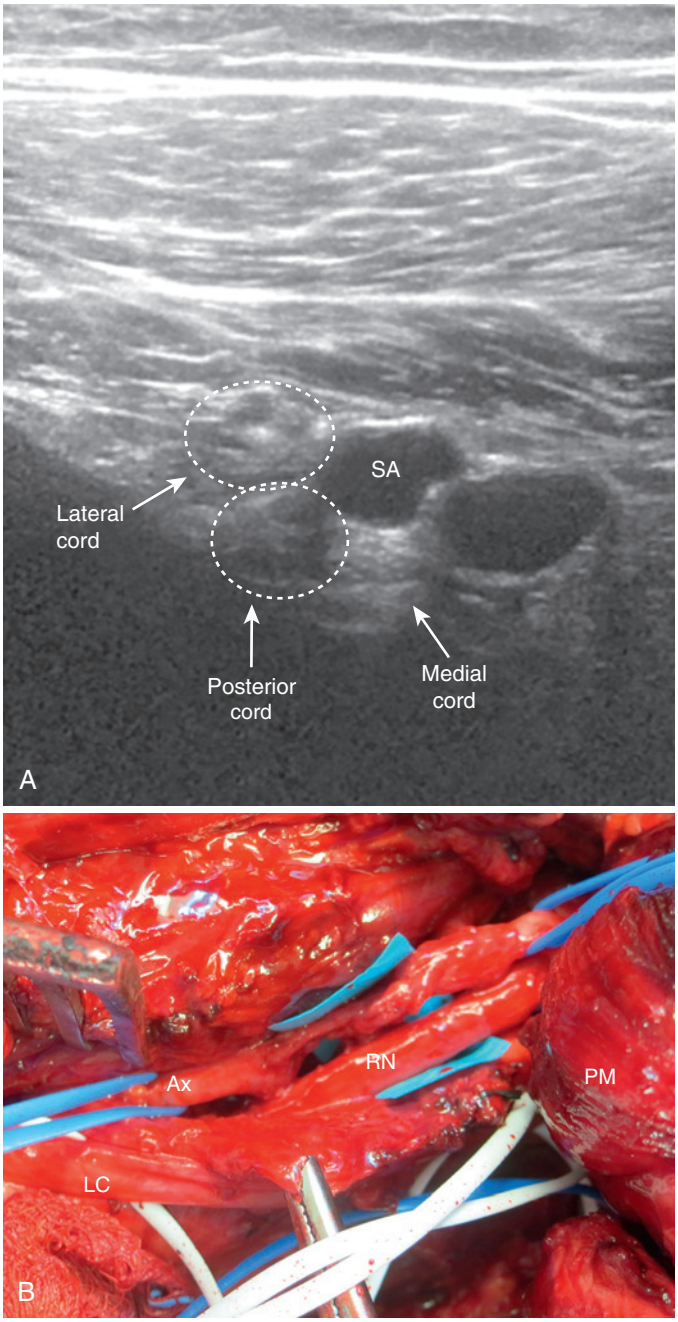

FIGURE 30.9 High-resolution ultrasound and clinical correlation of infraclavicular closed brachial plexus traction injury of axillary and musculocutaneous nerves. **A,** Ultrasound axial image at 17 MHz demonstrates severe thickening and loss of fascicular architecture in posterior and lateral cords, with preservation of normal appearance in the medial cord. **B,** Operative exposure (proximal right) demonstrating retraction of scar encasement (Kocher clamp) around radial (RN) and axillary (Ax) nerve divisions of posterior cord and scarred but conducting lateral cord after neurolysis. Ax nerve recovered following nerve transfer from pectoralis major branches, and musculocutaneous nerve recovered spontaneously. *LC,* Lateral cord; *PM,* pectoralis minor, retracted; *SA,* subclavian artery. (**A,** © Ogonna Nwawka, MD, Hospital for Special Surgery, New York; **B,** © Scott W. Wolfe, MD.)

alone because conduction through it was demonstrable. This was a mistake and it proved necessary to return to the area, resect the lesion, and graft it.

The integrity of the perineurium is a valuable guide to the surgeon. The presence of intact bundles (fascicles) crossing the lesion is, for us at any rate, a strong deterrent to resectioning. No one should forget the lesson of case 3 in the series of Birch and St. Clair Strange.[21] There, exploration plus decompression of the sciatic nerve in the notch 3 years after the injury was rapidly followed by relief of pain and recovery from a paralysis affecting the common peroneal component. The lesion was, of course, a CB prolonged by external causes.

Montgomery and coauthors reported a similarly gratifying outcome after neurolysis of the sciatic nerve in a patient who had endured severe pain for a number of years.[130] The lesion was predominantly a conduction block, prolonged and maintained by fibrosis tethering of the nerve after total hip arthroplasty.

Even more remarkable is the case described by Camp and associates.[33] The patient had been suffering intractable and increasing pain for 18 years. Pain was eliminated by neurolysis of the ulnar nerve, which had become adherent to the pulsatile vein graft used to repair the brachial artery. That lesion was a CB prolonged by external causes; the pain was neurostenalgia.

CRITICAL POINTS *Neurophysiologic Diagnosis*

- Neurophysiologic investigations distinguish between a CB and degenerative lesions.
- Neurophysiologic investigations cannot distinguish between a favorable degenerative lesion (axonotmesis) and an unfavorable degenerative lesion (neurotmesis). This distinction can be made only by the passage of time or by exposure of the nerve.
- A steadily advancing Tinel sign indicates axonotmesis.

Considerations Before Surgical Intervention

Taking all of the preceding in account, the following should be considered before performing surgery:

- Lifesaving or limb-saving measures come first. The surgeon has a duty to assess a patient's ability to undergo a prolonged intervention.
- For cases reviewed late, indolent wounds and infections must be cleared. The texture of the skin may require massage and oiling.
- Nonunion of a long bone can be dealt with at the same time as a nerve repair. A torn rotator cuff is repaired either at the same time as the circumflex nerve or after it is repaired.
- Deep scars from a penetrating projectile injury, or from burns, present a most hostile bed for nerve grafts. These areas will need replacement with healthy full-thickness skin flaps, pedicled or free, before nerve repair.
- The timing for treatment of a severe fixed deformity from uncorrected paralysis or ischemic fibrosis should be adapted to the individual patient's needs. Serial plaster of Paris splinting is particularly useful in overcoming fixed flexion deformity of the wrist, the proximal interphalangeal (PIP) joints, and the elbow.[82] Immobilization of the part is necessary after elongation of tendons, or after muscle slide or capsulotomy, and in such cases the authors prefer to repair the nerve at the same time.
- Is it worthwhile? Are other, simpler measures available? Birch et al[8] note that:

By the time the changes of degeneration are present the patient is a better candidate for the examination halls than

for restorative treatment. The object of the clinician must be to make the diagnosis before the signs of peripheral degeneration have appeared: that is, before the best time for intervention has passed.

- Paralysis caused by neglected high radial, high ulnar, or common peroneal nerve lesions may be treated by the appropriate musculotendinous transfer.
- Static or dynamic splinting is helpful to patients by diminishing their disability; by giving an indication of what is expected to be achieved; and, of course, by ensuring that these modalities are ready for a course of postoperative treatment.
- Patients appreciate a comprehensible statement of what has happened, what can be done, and when it can be completed. It is helpful for them to know for how long they must plan to be away from work, doing curtailed daily activities, and driving.
- A quarter of all of the authors' patients have suffered iatrogenic nerve injuries. In our opinion, it is the clinician responsible for treating an iatrogenic situation who should take charge, give clear advice, set out a clear-cut plan of action, and avoid a partisan approach. Advise patients that appropriate records of operative findings will be released promptly to their legal advisors and that clinicians do not prepare medicolegal reports.

CONSULTATION AND OPERATIVE RECORD

It is appropriate to attempt to establish a diagnosis and set out a plan of action at the first consultation with the patient. This information is sent, in a letter of opinion, to the referring consultant and the family practitioner; the letter sets out a time course that indicates how long the patient must wait to return to normal daily activities. Copies of *all* correspondence should go to the family practitioner, who is the "conductor of the orchestra." Many patients are already working with a physiotherapist or occupational therapist, and letters are sent to them at the patient's address. This is particularly useful when treating children. Communication with other colleagues is essential, and it is the basis of adequate continuing care for patients who come from far away. Any necessary dynamic or static splints are made at that first consultation.

The operative record should be carefully maintained with the following and supplemented with a diagram and photographs.

1. *Preoperative evaluation:* Information about limb dominance, the nature of the patient's work, the cause and date of the injury, associated injuries, summary of preoperative neurologic deficits, and relevant information from ancillary investigations. The characteristics, distribution, and severity of the pain and the strength and distribution of the Tinel sign are recorded.
2. *Findings:* Information about electrodiagnostic studies, as well as a description of the lesions.
3. *Repair:* The state of the stumps after resection and the gap after resection must always be included.
4. *Records:* Findings from electrodiagnostic studies and material taken for histologic examination or for research purposes.
5. *Postoperative care:* Particularly important is setting out the timing for removal of sutures, the use duration and changing of splinting, the timing and method of working with physiotherapists or occupational therapists, and the treatment of neuropathic pain, together with an indication of possible later reconstructive operations.
6. *Comment:* Summing up of the lesion, of actions taken, of indications for expected outcome, and of later work necessary. The record should be factual and avoid criticism of other colleagues. The facts can speak for themselves.

OPERATIVE TECHNIQUES

Nerve Resection and Neurolysis

Exposure

The surgical exposure must be adequate to secure proximal control of damaged blood vessels; the nerve trunks; and, if need be, the underlying skeleton. A number of excellent monographs and texts are available that discuss exposure of the peripheral nerves, and the one by Kline et al is particularly impressive.[95] One exposure that has been found extremely useful is that developed by Fiolle and Delmas[55] because it is the method of choice for exposure of the neurovascular axis from the second part of the subclavian artery to the terminal part of the axillary artery.

Full display of the supraclavicular, retroclavicular, and infraclavicular plexus, the second part of the subclavian to the terminal axillary artery, and the axillary and subclavian veins deep in the clavicle is achieved. It is most valuable for new cases of laceration or rupture of the great vessels deep in or below the clavicle, and in later cases of false aneurysm or for repair of the nerves after primary vascular repair (see Figure 30.8). It is the exposure of choice for closed-traction lesions and infraclavicular rupture of both vessels and nerves.[14] (For a more detailed discussion of the exposure and techniques for brachial plexus surgery, see Chapter 34.)

Surgeons can and should do more to prevent postoperative pain. The authors infiltrate the line of the incision with local anesthetic (i.e., 0.25% levobupivacaine) and epinephrine 1:200,000 before cutting the skin. The maximum dose is 2 mg/kg of body weight. When amputating the lower limb, a circumferential block of the midthigh's skin is combined with the sciatic nerve block maintained through an epidural catheter, with its tip adjacent to the nerve, before proceeding to amputation. The infusion is maintained for 48 h after the operation. Other nerves are infiltrated with local anesthetic before cutting them. Nerves providing cutaneous sensation require attention during exposure—patients do not take kindly to unexpected nerve lesions!

"Short incisions are long on difficulty" (Scott Wolfe, personal communication 2008). Incisions need to be adequate and, whenever possible, extensile. There is no place for short incisions. Exposure of the nerve trunk and vessels is more easily done in unscarred tissue planes, proximal and distal to the site of the lesions, which are displayed by dissection from above and below.

Resection of a Damaged Nerve

The extent of resection of a damaged stump is easy enough in a tidy wound from a knife or from glass. Resection is minimal

(i.e., 1 mm or less). In an acute closed-traction rupture, remarkably little resection is needed, just what is sufficient to display an orderly and recognizable architecture of bundles. When the procedure is performed within 72 h of injury, stimulation of distal stumps can provide information about the level where the nerve is still physiologically active. In the proximal stump it may be possible to demonstrate the point along the nerve where conduction is preserved. For an acute closed-traction rupture, the following is suggested: nerves are resected back until discrete pouting bundles become evident. The authors have found that the amount of nerve resected should be no more than 1 cm from either end.

Diagnosis is usually easier the earlier the exploration is done. Not only is the field free of scar tissue, but also the axons of the distal stump continue to conduct so that the bundles with predominant motor function can be identified. With early surgery it is possible to match the fascicular arrangements of the stumps; as time goes by, such matching becomes increasingly more difficult. With delay there is progressive intraneural scarring.

Technical Aspects. General anesthesia is usually necessary because of the duration of the operation, particularly if a nerve graft is to be harvested from another limb. Muscle relaxants should be avoided to permit nerve stimulation and recording. Whenever possible, display of the limbs' nerves is more easily done in a bloodless field. One must remember the effect of tourniquet ischemia on conduction, which has an onset in about 15 minutes and results in a temporary complete CB within 30 minutes.

These operations are time-consuming, often unpredictably so, and it is especially important to protect pressure points at the knee, elbow, and elsewhere. Operations on nerves of the neck carry the risk of an air embolism.

Apparatus and Instruments. The apparatus and instruments should be carefully maintained and include the following:

- Simple stimulators are used when no more than a straightforward motor response is sought.
- A more elaborate apparatus is required for stimulation and recording from both nerve and muscle (see earlier).
- For magnification, use loupes and an operating microscope such as OPMI 6SD FC and OPMI 6 (Carl Zeiss, Oberkochen). The stand is the universal S3B (Carl Zeiss, Oberkochen).
- In addition to a fine soft tissue set, special requirements include instruments for internal fixation of bone and a fine vascular instrument.
- DeBakey scissors and forceps are useful for handling nerves.
- A range of sutures is used; 6-0 and 7-0 nylon on an 8-mm vascular needle is useful for epineurial suturing. Finer sutures of 8-0, 9-0, and 10-0 should be used for perineurial suturing, for nerve transfer, and in grafting.
- Appropriate needle holders, fine forceps, and scissors for working under a microscope should be available.
- Fine skin hooks, plastic slings, light clips, and malleable retractors are necessary.
- Fibrin clot glue[201] was regularly used at the Royal National Orthopaedic Hospital and St. Mary's Hospital until the early 1980s. The raw material then became unavailable and a commercial product was reintroduced. Most surgeons now use Tisseel (Baxter Health Care Ltd., Thetford, Norfolk, UK). The aprotinin solution must be diluted (1:4) with sterile water; otherwise, there is a risk of inducing fibrosis. The undiluted preparation is reserved for hemostasis. The tip of the needle attached to the prepared syringe should be directed away from the junction between the grafts and stump or the level of nerve repair, or displacement may occur at the line of repair. Steady gentle pressure needs to be exerted so that a film of the fluid bathes the repair and thus seals it. Fibrin clot glue acts as an envelope around the nerve but offers no resistance to tension.
- Careful closure of the tissue layers over the nerve repair is important for enhancing the security of the repair, and careful and appropriately maintained splinting of the limb is as essential as after conventional suturing methods. Narakas provided a particularly good review; he thought that his results were improved by 15%.[135]
- All tissues must be treated gently. Healing of the wound without infection and recovery of the nerve lesion depend on tissue viability. Avoidance of infection by careful handling of the tissues and accurate hemostasis is more important than antibiotics.
- The operating field should be maintained as free of blood as possible but kept moist by regular saline irrigation.
- Nerves need to be handled with extreme care. They should be retracted with very fine skin hooks in the epineurium or with plastic slings. They should not be mobilized over such a length that the blood supply is impaired.
- Use a tourniquet as little as possible. Klenerman's manual is an important contribution.[91] The attractive idea of releasing a tourniquet for a while before reinflating it has been subjected to criticism by Concannon and colleagues.[41]
- Bipolar diathermy is essential.

Neurolysis

There has been confusion about the meaning of the term *neurolysis*, most especially in the distinction between "external" and "internal" neurolysis.[57] External neurolysis involves freeing the nerve from a constricting or a distorting agent; in this procedure the epineurium is not breached. Decompression of the median nerve at the wrist and decompression of the lower trunk of the brachial plexus in neurogenic thoracic outlet syndrome (TOS) are examples of external neurolysis. Extrication of a nerve trunk from within a fracture or a joint, and liberation by dissection of a nerve from a bed of scar tissue, are other examples. External neurolysis is certainly valuable when it is used to free a nerve from an external distorting or compressing agent as long as that agent is not likely to recur. Removal of a nerve from a bed of scar tissue will succeed only if the nerve can be replaced in a bed free of scar tissue. Even then there is bound to be some recurrence of scar tissue.

Internal (i.e., *interfascicular*) neurolysis involves the exposure of fascicles by epineurotomy with partial removal of the epineurium and separation of individual fascicles, if necessary, by removal of interfascicular scar tissue. The procedure entails division and removal of the interfascicular epineurium. There are few indications for internal neurolysis:

- Separation of intact fascicles from damaged ones in nerves that have suffered partial transection (neuroma in continuity)
- For the purpose of transfer, separation of an individual fascicle from a nerve

- Separation of intact fascicles during removal of a benign but infiltrative tumor
- During the preparation of a stump for the reception of nerve grafts in delayed repair

Methods of Suturing

Much has been written about the relative advantages of perineurial (i.e., *fascicular*) and epineurial sutures. Spinner offers an excellent review in which he states that the "fascicular" suture is useful in distal median and ulnar repairs, he emphasizes that the most important cause of failure of a suture is "inadequate resection of injured nerve back to healthy tissue."[169] The authors continue to use a fascicular suture for primary repair of clean transections of most trunk nerves and expect to use a group fascicular suture in cases of delayed treatment. Repair of the epineurium is important because it adds strength to the repair; seals the nerve trunk off from adjacent tissue; and restores, as much as possible, a gliding plane between the nerve trunks and adjacent tissue.

The techniques for nerve suturing have been written about a lot. It is preferable for operating surgeons to use their own judgment about what is appropriate, while always bearing in mind the primary aim of repair, which is to coapt as accurately as possible, healthy nerve without undue interference of the perineurium or blood supply and without undue tension (see later).

Protection of the repair by carefully regulated flexion of adjacent joints is essential. Surgeons should use the technique with which they are most confident and that is the most appropriate. In nerve repair in general, it is difficult to say that there is a "right" or a "wrong" way of doing things. However, as Brushart says in commenting on the timing of repair: "In peripheral nerve surgery, the first repair must be the best repair possible."[31]

Preparation of the Nerve Bed. Preparation of the bed for nerve repair is of utmost importance. The repaired nerve must not be left to lie against a naked tendon; the synovium must be drawn together. Similarly, lacerated muscle belly is a very unfavorable bed for a nerve repair, and rotation of either adjacent synovium or undamaged fat should be done.

Direct Suture or Graft? End-to-end suture is preferable as long as the gap after resection is small, little mobilization of the nerve is needed to close the gap, and the repaired nerve lies without tension and without excessive flexion of the adjacent joints. Clark and colleagues demonstrated very clearly the detrimental effects of tension on a nerve repair.[39]

The authors do not think that end-to-end suturing of the nerves of the brachial plexus above the clavicle or of the accessory nerve is ever practicable and always prefer to use interposed grafts even if they are short. The nerves cannot be effectively mobilized, and it is difficult to protect the repair by splinting or with an orthosis.

Elastic recoil of nerve stumps occurs once the trunk has been severed, and it is much easier to overcome this recoil without undue tension on the nerve when the operation is performed within days of the injury. The longer surgery is delayed, the more likely it is that grafting will be required because the stumps become embedded in scar tissue, resulting in an increase in interneural scarring.

Direct observation indicates that anterior transposition of nerves, such as the ulnar or the radial, gains, at most, 3 cm. Experience shows that it is necessary to use grafts for all delayed repairs of the median nerve in the forearm and for all repairs in which 1 cm of the nerve has been lost.

One simple test about the advisability of direct suturing of a nerve trunk at the wrist or in the forearm involves passing an epineurial suture of 7-0 nylon with the wrist flexed to no more than 30 degrees. If this suture draws the stumps together without tearing the epineurium and without causing blanching of the epineurial vessels, suturing is a reasonable solution. Failing that, grafting is necessary.

The authors have found grafting necessary in all cases of closed-traction rupture of the supraclavicular brachial plexus, in virtually all cases of compound nerve injury caused by fracture, and in a great majority of nerves transected in "untidy" wounds. Colleagues and we have used grafts in about 80% of cases, a figure that seems rather high; however, it may reflect the pattern of nerve injury cases referred to this unit.

Palliative Musculotendinous Transfer or Distal Nerve Transfer? The rapid onset of paralytic deformity that soon becomes fixed is a real problem in high lesions of the ulnar nerve, and it is even worse in combined high lesions of the median and ulnar nerves. Paradoxically, the problem is intensified if regeneration into the flexor muscles of the forearm is robust. The problem is even more serious in the lower limb when there is imbalance in recovery between the tibial and common peroneal nerves. If recovery of the small muscles of the hand can be anticipated by virtue of a steadily progressing Tinel sign and, at the right time, by electromyographic proof of distal reinnervation, then carefully made orthoses may serve to maintain joint mobility for the 6 or 9 months it takes before small muscle recovery is enough to rebalance the joints.

If this recovery cannot be anticipated, then the question of distal nerve transfer comes to the fore. There can be no doubt that a well-performed muscle transfer leads to a well-balanced hand. However, potential motors may be unavailable because of the extent of the nerve injury, or the extensor muscles of the forearm have been damaged. Furthermore, muscle transfers do nothing for sensation. The important possibilities of distal nerve transfer in the upper limb are reviewed by Lee and Wolfe[106] (see also Isaacs, Moore: Distal nerve transfers).

Direct Suture. Use the terms *primary suture* when the operation is performed within 5 days of injury and *delayed primary suture* when up to 3 weeks has passed. Some resection, of a millimeter or so, of the nerve stump is always necessary after a few days, even in cases of clean sectioning with a knife or razor. A *secondary suture* is used for repairs performed 3 weeks or longer after injury, and it involves resection of neuroma proximally and glioma distally.

The median and ulnar nerves commonly are sectioned at the wrist in "tidy wounds"—the ideal case for primary suturing—as follows:

1. The limb is prepared with an aqueous antimicrobial solution. Iodine- and alcohol-based preparations are to be avoided.
2. A tourniquet cuff is placed about the arm but is not inflated until the limb has been prepared and exposure can be started. The cuff remains inflated for exposure and identification of all divided structures ideally, as well as for repair of the flexor tendons, their synovium, and the radial and ulnar artery, but it is best to always release the tourniquet at 1 h. In all

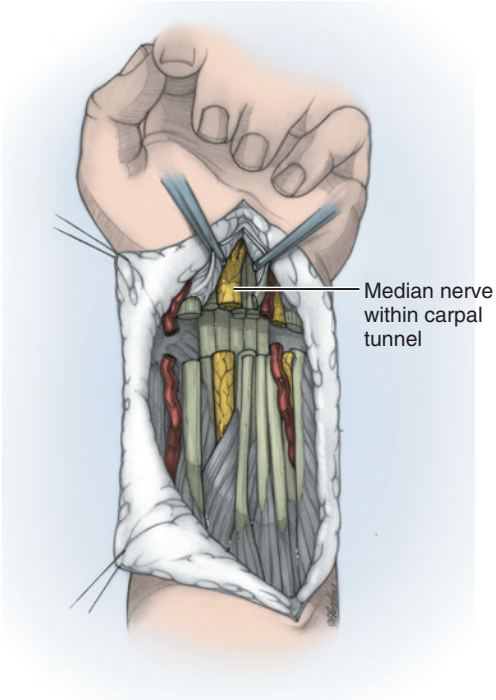

FIGURE 30.10 Identification is not always easy; for example, the authors have seen the median nerve sutured to the tendon. Note the extension of the incision so that normal tissues are exposed to enable accurate definition of what is and what is not damaged. (© Elizabeth Martin.)

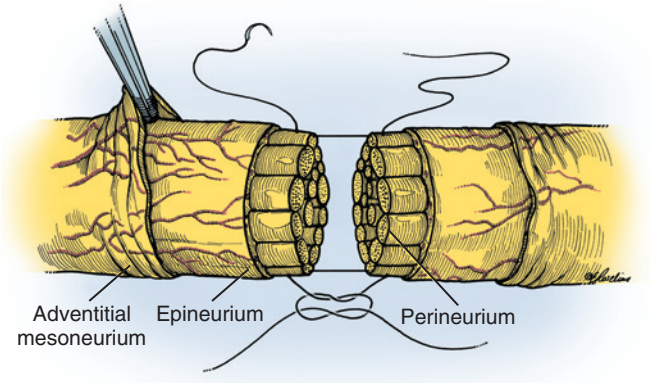

FIGURE 30.11 Note the retraction of the flimsy and loose adventitia to expose the true epineurium and fine sutures passing through the condensed internal epineurium and perineurium of selected bundles. (© Elizabeth Martin.)

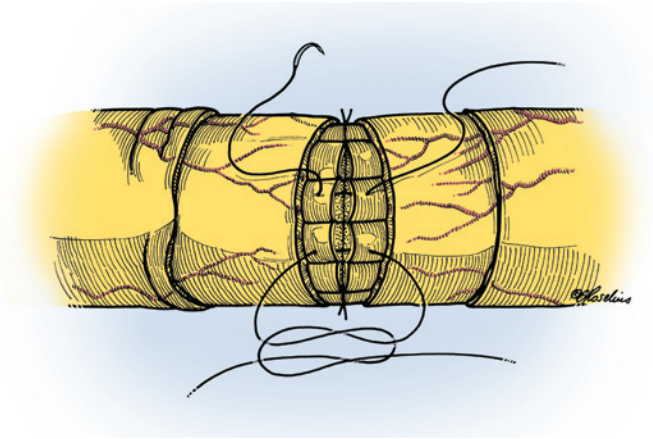

FIGURE 30.12 Completion of the bundle sutures. (© Elizabeth Martin.)

operations the tourniquet is released before nerve repair or grafting. Repair of the nerve trunks is done last after repair of other tissues.

3. Bleeding from epineurial vessels along the surface of the median nerve, or even within its substance, can be troublesome, and if this fails to respond to gentle pressure, careful use of a bipolar diathermy set at low amplitude is necessary.
4. The incision is extended so that all divided structures can be displayed. In a deep wound with damage to the arteries of the wrist, the authors open the carpal tunnel to help identify injured structures and to diminish the risk of later compression of the median nerve within the tunnel (Figure 30.10).
5. The tendons are repaired with a core and epitendinous suture. Repair of the synovium around each tendon is, it is believed, an essential step to diminish adhesions between the tendon and the nerve repair. The nerve must be allowed to glide between the synovial layers. Arteries are repaired with interrupted 8-0 nylon sutures.
6. The adventitial mesoneurial tissue is pushed back from each stump to expose the true epineurium (Figure 30.11). Matching of the nerve stumps is aided by the varying size of the fascicles and by the orientation of epineurial blood vessels. A sketch of each nerve face helps to orient and plan suture placement.
7. Matched bundles, identified by their size and by their position in the nerve, are drawn together with perineurial 10-0 nylon sutures (Figure 30.12). For the median nerve, between 6 and 8 key bundles should be sutured in this manner to coapt the nerve faces as accurately as possible. The repair is then completed by passing 9-0 nylon sutures through the perineurium and epineurium (Figure 30.13). The nerve can be rotated on a saline-soaked dental swab, first from one side and then from the other so that the whole circumference of the nerve is accessible.

With this method between 18 and 25 sutures are necessary to repair the adult median nerve at the wrist.

Epineurial Repair. The bundles are oriented as much as possible, and the epineurium is united with 2 lateral 8-0 nylon sutures, the ends of which are left long. Repair of the anterior face is completed with 3 or 4 more 7-0 nylon sutures. The nerve is then rotated by manipulation of the lateral sutures so that the posterior epineurium can be united. It is in a fresh wound that the disadvantages of epineurial repair are best. The bundles may twist around within the epineurium.

Delayed Suture. It is preferable to raise a flap rather than to reopen the old scar (Figure 30.14). There will be considerable thickening of the external epineurium and the perifascicular epineurium. This layer is now robust enough to take a suture. The mobility of the bundles of fascicles within the epineurium is very much reduced.

The nerve may have formed two bulbs, separated by a gap (i.e., a neuroma proximally and a glioma distally), or a neuroma "in continuity" (Figure 30.15). Use the following procedure:

1. The first stage of the operation requires resection of the terminal bulbs until a recognizable pattern of healthy pouting

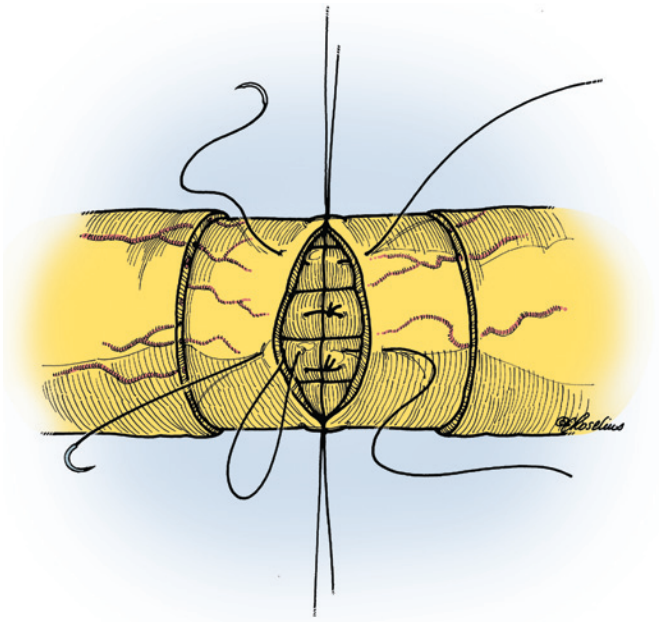

FIGURE 30.13 Finally, suturing of the epineurium proper ensures a strong repair. (© Elizabeth Martin.)

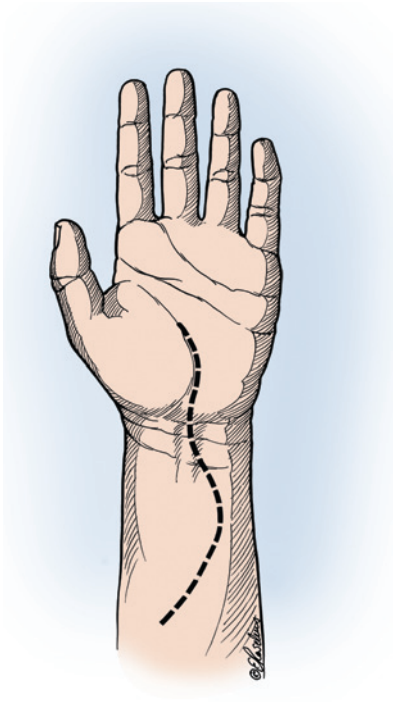

FIGURE 30.14 A transverse scar at the crease overlies the divided median nerve. The incision was placed to allow elevation of a flap over the nerve. (© Elizabeth Martin.)

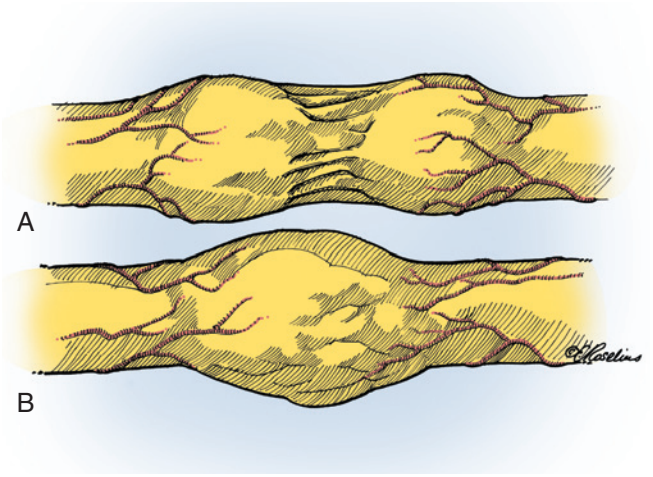

FIGURE 30.15 The nerve lesion may appear as double bulbs: neuroma proximally and glioma distally (**A**), or as a neuroma "in continuity" (**B**). (© Elizabeth Martin.)

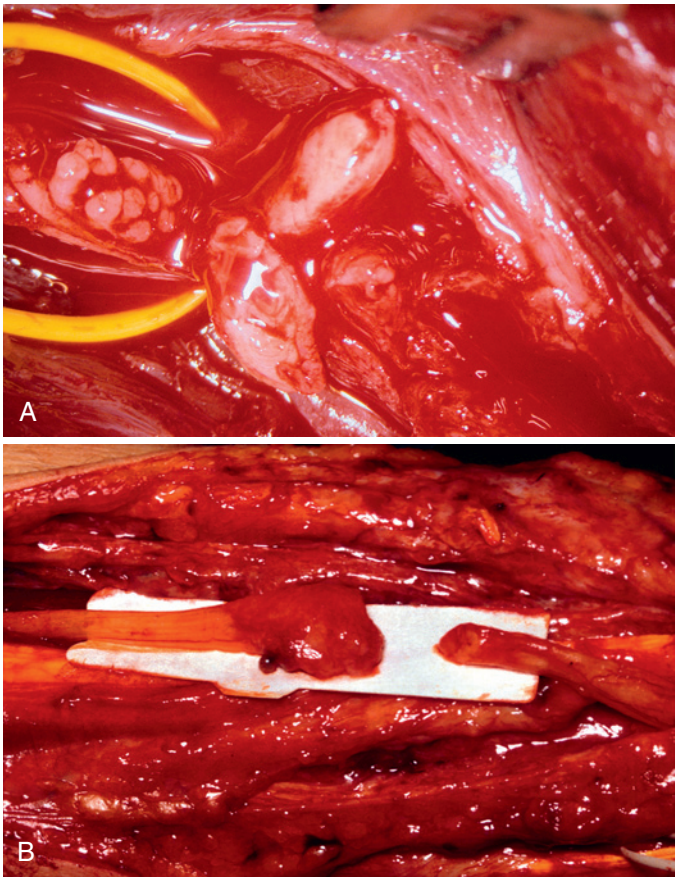

FIGURE 30.16 Preparation of nerve stumps 3 months after rupture of the radial nerve. **A,** The rupture is displayed here. **B,** Resection was done until clearly the separate pouting bundles were evident.

fascicles is reached Figure 30.16, *A, B*) The temptation to resect as little as possible (i.e., to minimize the gap between the prepared nerve faces) must be resisted.

2. Palpation of the nerve stump is very helpful in distinguishing the fibrous, or firm scarred segment, from the softer, more pliable and less fibrosed part. It is preferable to use a fresh scalpel blade and section at 2- to 3-mm intervals until a soft nerve face with recognizable bundle architecture is reached.
3. A trial of drawing the two stumps together with 6-0 or 7-0 nylon is done with the elbow extended and the wrist in neutral.
4. Once the nerve faces have been prepared, a sketch of the surfaces is useful as a memory aid.

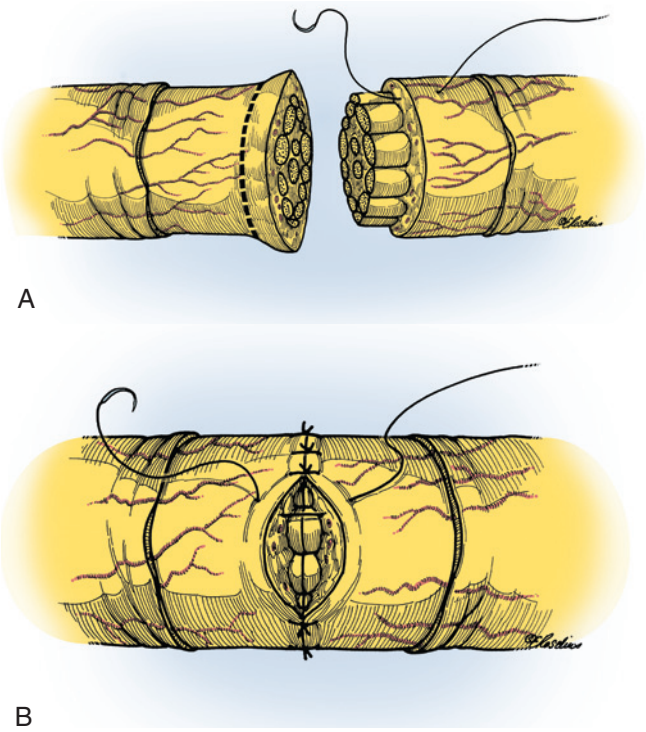

FIGURE 30.17 **A,** Scar tissue was resected back to healthy pouting bundles, and the proximal stump on the left awaits one final cut, marked by the interrupted lines. Placement of the epineurial suture is indicated on the right in the distal stump. **B,** Completion of epineurial suturing of the nerve. (© Elizabeth Martin.)

5. Adventitia and external epineurium should be trimmed away.
6. Ideal placement of the suture is through the internal epineurium around individual fascicles or bundles of fascicles. Sutures of 8-0 nylon should be used (Figure 30.17, *A, B*).

The authors think that the technical aspects of delayed or secondary suturing are somewhat easier than those for primary suturing.

Use of Fibrin Clot Glue in Suturing. The technique of suturing can be modified when using fibrin clot glue and less sutures are used. The most important are those that draw together, as accurately as possible, the larger bundles, with the topographic orientation being secured as best as one can. Some 6 or 8 of the larger bundles can be drawn together in this manner, and another 6 or so of the epineurial sutures are then used to complete the repair. Fibrin clot glue is then applied while avoiding injection of the fluid into the suture line. The authors prefer to use this glue if available rather than an abundance of sutures.

Closure and Postoperative Care

A patient and careful assistant is invaluable at this stage to perform the following; to see an elegant repair torn apart by careless handling of the limb is, to say at the least, disheartening:

1. Local anesthetic (0.5% levobupivacaine) instilled around the proximal, median, and ulnar stumps will greatly ease postoperative pain. It is a good idea to use antibiotics for prolonged operations or when arterial repair has been done; give a bolus 750 mg dose of cefuroxime. The skin is sutured then with interrupted stitches.
2. The elbow, wrist, and joints of the hand now must be restricted so that the flexor tendon and the nerve repairs are protected. Extremes of joint positioning should be avoided.
3. The splint used should hold the elbow at 90 degrees of flexion, the wrist at between 30 and 40 degrees of flexion, the metacarpophalangeal (MP) joints at about 70 degrees of flexion, and the PIP joints at no more than 30 degrees of flexion. The dorsal splint extends to the tips of the fingers and the palmar splint to the PIP joints only.
4. Splints should be bandaged so that there is restriction but not rigid immobilization. Gentle, active flexion of the fingers and the thumb is encouraged from the outset. The arm is supported in a sling, but gentle, active lateral rotation and elevation of the shoulder to 90 degrees needs to be encouraged from the first postoperative day.
5. At 3 weeks the splints and sutures are removed.
6. The next splint does not restrict the elbow. The wrist is splinted to prevent extension beyond 20 degrees. The dorsal hood, which again extends to the tips of the fingers, limits the MP joints to 30 degrees of flexion and the PIP joints to 30 degrees. Increasingly, vigorous active flexion of the fingers and thumb is now permitted, and gentle, active flexion at the wrist is also encouraged within the confines of the splint, bandaged as it is to the forearm and hand.
7. With direct suturing of nerves in the elbow region, a hinged splint is applied at 3 weeks after surgery. This permits active flexion but blocks extension. The range of permitted movement is increased at weekly intervals by adjusting the hinge.
8. By 6 weeks the splints are discarded, and vigorous, active flexion against resistance is introduced. Now, gentle passive stretching exercise can be begun for the fingers and the thumb.
9. Some protection must be given to the suture line of the nerve for a minimum of 6 weeks, and the key to this is to modify the range of excursion of the wrist joint. It is also important, however, to encourage gentle, early active movements within the confines of the splint and bandages to diminish the risk of the nerve becoming rigidly embedded within scar tissue.

Nerve Grafting

Choice of Graft

Wherever possible, cutaneous nerves from the damaged limb are used for grafting. The authors prefer the medial cutaneous nerve of the forearm if available. The superficial radial nerve and the lateral cutaneous nerve of the forearm provide potentially valuable innervation to the skin of the hand, and neither should be used unless the parent nerve is irretrievably damaged. The ipsilateral sural nerve should never be used for repair of a low lesion of the tibial nerve because this adds to denervation of the heel's skin. These patients are better off losing one of the forearm's medial cutaneous nerves.

No graft should be elevated until the injured nerves have been exposed, the extent of the lesion defined, and the gap between the prepared nerve faces measured. This is a good time for the surgeon to pause for a few minutes of reflection so that the repair can be properly planned. This is particularly important when repairs of several main nerves are necessary. In such cases it is best to prepare a map of the proximal and distal faces, outline the pattern of bundles in each stump, and record the length of the gap. Then, a calculation of the number of grafts

required is made for each nerve, as well as their disposition and length. We always cut grafts to about 15% more than the measured gap.

The *medial cutaneous nerve* requires longitudinal exposure and is best identified lying adjacent to the axillary vein within the brachial sheath. The nerve is picked up with a light nerve hook and traced proximally into the axilla while avoiding damage to adjacent nerves. In the middle part of the arm the medial cutaneous nerve divides into an anterior and a posterior branch. It perforates the deep fascia shortly after this division. Both of the divisions are used and traced down to the level of the elbow (Figure 30.18), where about 25 cm of nerve can be obtained. Do not confuse the medial cutaneous nerve with the ulnar nerve; stimulate it if in doubt.

For grafting with the *sural nerve*, the patient is placed prone for repair of the sciatic nerve or its divisions. Otherwise, he or she is placed supine and the limb is held up by the heel by a sturdy assistant or the knee is flexed to about 70 degrees with the foot held on the operating table. The nerve is approached through a posterior midline longitudinal incision that preserves the short saphenous veins; it is best identified above the lateral malleolus, then trace it proximally. It lies lateral to the short saphenous vein until the nerve perforates the deep fascia of the leg, generally at the junction of the upper two-thirds and the lower one-third of the limb.

Gentle traction on the nerve here with a phrenic hook will identify the branches of it, which can be cut cleanly with fine vascular scissors. It can now be identified where it arises from the tibial nerve in the popliteal fossa, and gentle traction here will confirm whether there is a communicating branch coming down from the common peroneal nerve (Figure 30.19). It is possible to deliver the nerve into the popliteal fossa, which has the advantage of stripping it of much of its adventitia. Avoid traction on the tibial or common peroneal nerves. Respect the short saphenous vein; it may be needed later.

The *superficial radial nerve* is used only when there is an irreparable lesion of the main nerve or of C5 and C6. It is delivered through separate incisions—first at the wrist by identifying the trunk where it emerges from between the BR and extensor carpi radialis longus (ECRL) by following the branches down, and dividing them at equivalent levels. The radial trunk is displayed between the BR and brachialis. The superficial radial nerve component is identified by light traction on it, which enables its delivery into the elbow wound—a maneuver that has the advantage of stripping it of much of its adventitia. At this point 25 to 30 cm of nerve is available. Do not confuse it with the posterior interosseous nerve! Use gentle traction.

The *lateral cutaneous nerve* of the forearm is used when the musculocutaneous nerve is irreparably damaged, when repair of that nerve is confined to restoration of elbow flexion, or when a short length of graft is needed for an adjacent major nerve. The nerve passes just lateral to the biceps tendon, and it can be displayed in the plane between the biceps and brachialis in the lower part of the arm. About 15 cm of useful nerve can be retrieved.

The trunk to be grafted is prepared. It is extremely important that the bed into which the grafts must lie be as healthy as possible. Unscarred synovium or fat is best—"raw" muscle is not a good bed; use of bone or a metal implant is hopeless.

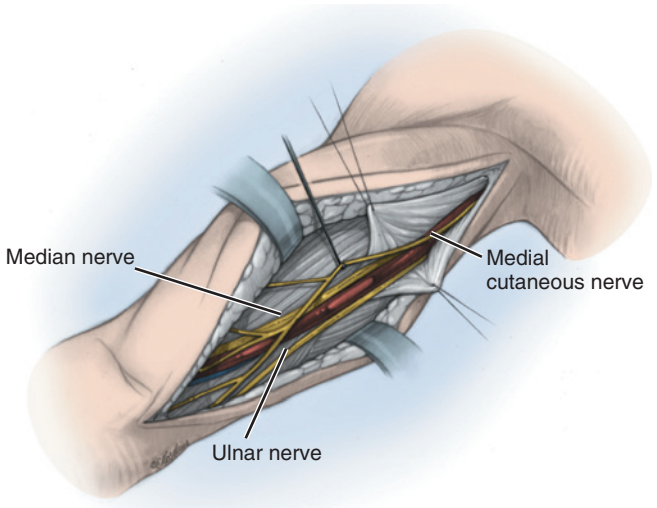

FIGURE 30.18 The medial cutaneous nerve of the forearm has a close relationship to the axillary and brachial veins. It must not be confused with the ulnar nerve! (© Elizabeth Martin.)

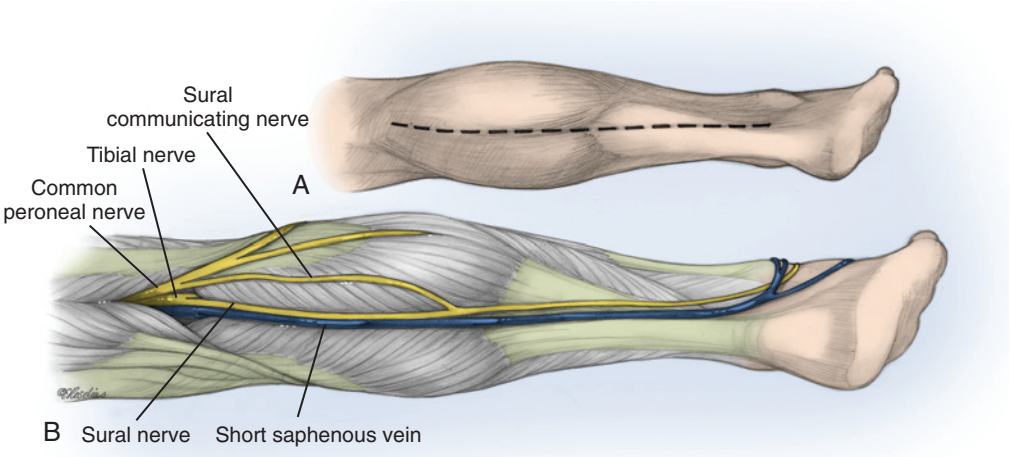

FIGURE 30.19 Course of the sural nerve. It is easier to identify this nerve in the distal part of the wound just lateral to the Achilles tendon. The communicating branch arising from the common peroneal nerve is quite variable but usually is present. (© Elizabeth Martin.)

The gap between the nerve faces is measured with the elbow extended and the wrist in neutral. The length of the graft must exceed this by at least 15% because of the inevitable shrinking of the prepared graft as a result of elastic recoil. At all times the graft is handled with care and kept in a blood-stained swab or one soaked with lactated Ringer solution. Adventitia is cleared by gentle dissection with a fresh scalpel or microscissors; nerves exposed for grafting must be handled as carefully as any other nerve.

The grafts are placed to permit as accurate a topographic matching as possible. The greater the defect in the nerve trunk, the more difficult such matching will be. One of the advantages of primary grafting in an acute injury is that nerve stimulation enables some understanding of the orientation of bundles distally by observing muscular response.

The grafts are cut into lengths with either a fresh scalpel blade or a pair of vascular scissors. So that the fascicles protrude, 2 to 3 mm must be scrupulously cleared of adventitia and superficial epineurium at the end of the graft, which is sewn into place. Because the individual strands of graft are likely to be about the same size as an individual fascicle or a bundle of fascicles, the suture joins the epineurium of the graft to the perineurium of the bundle (Figure 30.20). Two lateral sutures of 9-0 nylon are used for each graft.

When a large number of grafts need to be done, it is possible to use 2 or 3 grafts as a foundation for the others. As much as possible of each graft is led from a fascicle to a matching fascicle in the other stump. It is very important, once the repair has been completed at both ends, to inspect the grafts and the suture lines to make certain that one or the other junction lines has not been disturbed. Fibrin clot glue, if available, is a great help in nerve grafting. Far fewer sutures are needed, and much time is saved (Figure 30.21).

Further security for the grafts can be provided by using tiny pieces of absorbable sponge to act as a buttress while the grafts are being placed and sutured. In many situations of repair of deep-seated nerves at the elbow or in the proximal part of the forearm, careful apposition of the overlying muscle planes enfolds the grafts and undoubtedly enhances the security of the arrangement; however, at the same time it tends to congregate them into one mass.

Millesi begins his dissection of the fascicle roots in healthy nerve above and below the lesion and makes the section at the

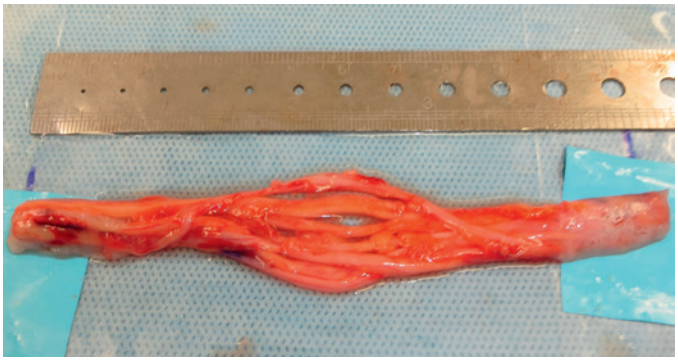

FIGURE 30.21 Preparation of 12-cm cable graft using 7 segments of sural nerve, reversed in polarity and bundled together at each end with fibrin glue. Central portions are left free to allow revascularization. Fibrin glue simplifies graft neurrorhaphy and minimizes the need for sutures. (© Scott W. Wolfe, M.D.)

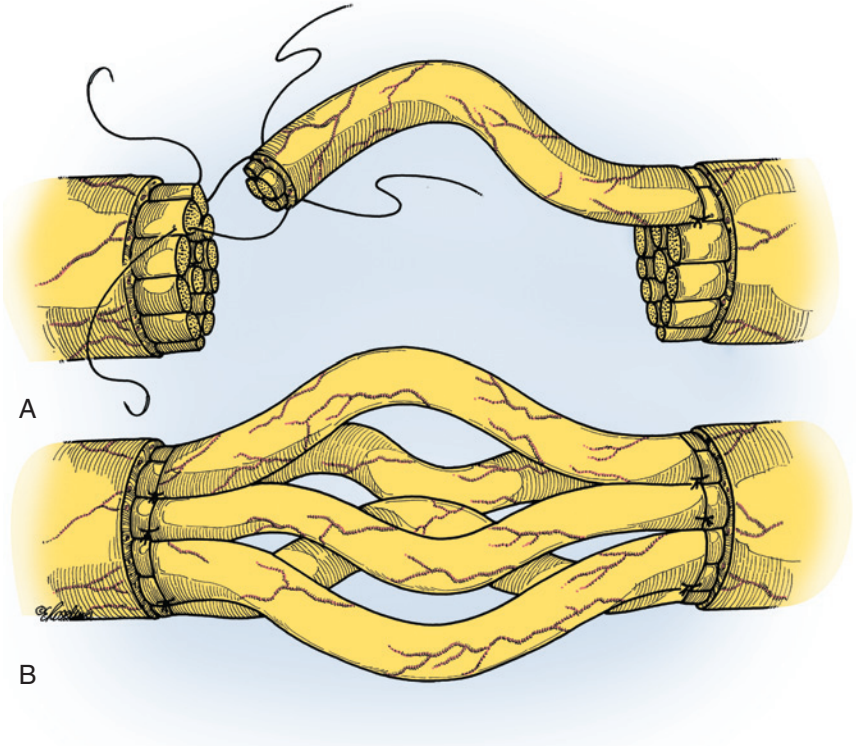

FIGURE 30.20 **A, B,** Shown here is suturing of grafts. Note that they really lie quite loosely. A suture is passed through the epineurium of the graft and through the perineurium and condensed internal epineurium around the individual bundles of the nerve trunk itself. (© Elizabeth Martin.)

point at which each group loses its healthy appearance.[126] In the distal stump, the fascicle groups are traced back from the point of identification of their destination to a level just distal to the lesion. The fascicular patterns of the distal and proximal stumps are matched, and individual grafts are used to unite the fascicular groups. Millesi resects fascicular groups at different levels and then uses very fine sutures through interfascicular epineurium or perineurium for coaptation, which results in grafts interdigitating with the fascicles of the stump.

CRITICAL POINTS *Nerve Grafting*

- Prepare the whole limb for access to grafts.
- Use the tourniquet for as short a time as possible.
- Exposures must be adequate.
- It should be possible to repair the radial and ulnar arteries and the flexor tendons with the tourniquet in place.
- Gliding planes *must* be restored; the synovium should be repaired around the tendons and between them and the nerve.
- Nerve repair should always be done after release of the tourniquet.
- Direct suturing is difficult in the arm and probably impossible above the collar bone or when more than roughly 1 cm of the nerve trunk has been lost. The situation for the great nerves in the lower limb is different because of the paucity of available graft.
- One can never have too much graft. Allow for retraction of the repaired nerves and of the graft itself.
- The graft should be cut in the wound, with 15 to 20% excess, after laying the whole graft loosely in place.
- Prolonged and careful protection of nerve repair is important; about 6 weeks is needed for the upper limb and as long as 12 weeks for the lower limb.
- The clinician must be constantly aware of the risk for fixed deformity, lack of use atrophy, and neuropathic pain.
- Ultimately, the best rehabilitation is return to normal life and activities.

Postoperative Care

One of the main principles of grafting is that tension on the nerve repair be avoided, and for this reason splinting need not be as prolonged as it is after suture of the nerve. For grafting of the median and the ulnar nerves at the wrist, the forearm and hand should be splinted as for primary suturing for the first 3 weeks. At that time, the fingers and thumb can be set free and a simple "doorstop" plaster of Paris splint, which blocks extension of the wrist beyond 30 degrees but permits full flexion, is applied. The extension block splint is discarded at 6 weeks from the day of surgery.

Other Methods of Grafting and Alternative Methods of Repair

For many years surgeons have endeavored to improve the results of grafting or even to replace nerves with alternative materials. Some methods, grounded in considerable experimental work, have yielded careful clinical studies.

Vascularized Nerve Graft

Survival of a graft depends on its revascularization. Seddon concluded from his work and that of his colleagues during the 1940s and 1950s that "there is a critical diameter for survival of a graft taken from [a] normal nerve: the radial nerve falls within the limit, the common peroneal nerve [is] beyond it."[163] Pedicle grafting was introduced to enhance the viability of larger nerve trunks such as the ulnar.[171] This led to the development by Jamieson and Bonney in the 1970s of the free vascularized ulnar nerve graft perfused by the ulnar artery and vena comitantes or by the ulnar collateral vessels.[17]

The authors and colleagues used this graft for 68 cases of traction injury to the supraclavicular brachial plexus when avulsions of the eighth cervical and the first thoracic nerve precluded recovery of the ulnar nerve.[7] We aimed to restore useful function within the hand by reinnervation of the median nerve. Potentially useful hand function was regained in just 3 cases: 2 young adults operated on within 4 days of injury and 1 child who was 3 years old and operated on at 8 weeks after injury. Only rarely was our aim achieved.

The evidence accumulated is not decisively in favor of vascularized nerve grafts, although there may be indications when the gap is long and the bed is severely scarred. We were not able to demonstrate an overwhelming improvement in results with vascularized ulnar nerve grafts when compared with traditional cutaneous nerve grafts.

Freeze-Thawed Muscle Graft

The freeze-thawed muscle graft (FTMG) introduced by Glasby and colleagues in 1997 is a method that has been used extensively in laboratory and clinical studies.[61] Hall showed that axonal regrowth through short acellular muscle grafts requires a sustained supply of Schwann cells, perineurial cells, and fibroblasts.[73] Thomas and colleagues defined a particular role for FTMGs in the repair of damaged cutaneous nerves for treatment of the painful states arising from such damage.[180] Although an adequate supply of nerve is available for grafting in such cases, it seems perverse to inflict a lesion on a cutaneous nerve of a patient suffering from the results of damage to another nerve.

A paper of importance by Pereira and colleagues who treated the leprotic hand and foot by replacing the damaged segment of the median or tibial nerve with FTMGs.[150] Most patients recovered protective sensation, and their ulcers healed; doubtless, a number of amputations were prevented. One intriguing finding was improvement in the condition of the skin in one-third of the contralateral feet.

Entubulation

There was considerable interest in the use of synthetic tubes or vein grafts for the repair of nerves during World War I, and the relative failure of these methods probably brought about a degree of prejudice against the use of nerve grafting. In 1997, Lundborg and associates presented significant work in a prospective randomized trial in which silicone entubulation was compared with suturing of the median and ulnar nerves of 18 patients.[112] Seven nerves were sutured; in 11 others, the nerve stumps were placed within a silicone tube. Each stump was sutured within the tube with one fine suture so that a gap of 3 to 4 mm was left. A precise assessment of outcome was conducted; however, no significant difference between the two groups could be detected.

Hall reviewed the requirements and defects of conduits made from collagen, various polysaccharides, and synthetic polymers and urged that future work be directed toward manipulation of the growth cone, for this determines the path

of a growing axon, and also toward the neglected field of encouraging Schwann cell outgrowth from nerve stumps.[75,76] It seems that the upper limit of a defect repairable by these methods is 3 cm. De Ruiter et al[47] found scant evidence of the superiority of empty, hollow biodegradable nerve tubes over conventional repairs and advised careful evaluation of their use with large mixed or motor nerves to avoid unnecessary failures and disenchantment.

Homografts

A new product, Avance® nerve graft (Axogen Inc., Alachua, FL), has been developed. An acellular, hypoimmunogenic human nerve scaffold is prepared by washing, denaturing, and irradiation. Satisfactory results have been reported for human digital nerve repairs.[178] The success of hand transplantation is one dramatic example of a homograft. Ninlovic et al emphasized that survival of the transplanted hand alone is not a justification for this serious intervention[137]; an operational hand must be restored. They achieved precisely that with 3 bilateral and 1 unilateral hand transplants. The course of treatment is exceptionally arduous and prolonged for the patient and the treating team. The patient must be robust in spirit, the technique meticulous, and rehabilitation must be started early and be intense. Glaus et al discuss the obstacles to regeneration in the transplanted hand.[63] Immunosuppression cannot be safely withdrawn until the regenerated host axons have been enveloped in and myelinated by host Schwann cells that have migrated into the graft.

Our experience with FTMG, conduits, and homografts in the treatment of painful neuroma is described later in this chapter.

Nerve Transfer

The idea of transferring an uninjured nerve to the distal stump of an injured nerve is not new. Narakas described early work and pointed out that the principles for many operations now performed were recognized decades ago.[134] Addas and Midha provided a valuable review of this field[1]; they said:

> *[N]erve transfers tend to take the surgeon away from exploring the injury site, the brachial plexus, which carries the potential for surgeons to not even offer an anatomic nerve reconstruction, even in situations when these are perfectly appropriate.… With the increasing use of transfers, newly trained peripheral nerve surgeons are less likely to have exposure to the brachial plexus and they will be increasingly unfamiliar with the detailed anatomy and intraoperative electrophysiology assessment of the lesion.*

These are important warnings; the authors offer two more.

The first is that no nerve of vital function should be used for the sake of a nonvital function. A birth lesion of the phrenic nerve is a life-threatening complication. The senior author inadvertently damaged the phrenic nerve of 2 infants during the course of repair of a birth lesion of the brachial plexus. Both infants required prolonged treatment in a neonatal intensive care unit (NICU), and one required plication of the paralyzed hemidiaphragm. Our unit has seen a number of adults with severe injuries to the brachial plexus who experienced significant ventilatory impairment because of the associated lesion of the phrenic nerve.

The second reservation relates to the central purpose of nerve transfer. Reinnervation of muscle, to be successful, must involve reinnervation of the deep afferent pathway from the muscle spindles and the Golgi tendon organs. This fact may account for the disappointing results after transfer of the hypoglossal nerve because the afferent pathway from the tongue passes through the lingual nerve. Blaauw and colleagues condemned this transfer because of the resulting high morbidity and disturbance of speech.[23] We have seen one adult patient after transfer of both hypoglossal nerves who suffered a very serious disturbance in speech and swallowing for as long as 6 months after surgery.

Hara, Nagano, and their colleagues refined intercostal nerve transfer for the treatment of avulsion injuries of the brachial plexus and achieved very good results. In addition, the team in Osaka has gone on to reveal important evidence about the adaptation of the central nervous system.[88,117,132] This work has been extended in important contributions from Malessy and colleagues.[116] Carlstedt recommends nerve transfer "in cases where intraspinal repair of a lumbosacral plexus lesion is impossible; [for example], when there is no proximal, ventral root stump to use for reconstruction."[35]

One example is described in an important paper from Lang, Borges, and Carlstedt.[101] The patient, a 5-year-old girl, had bilateral, asymmetric injuries of the lumbosacral plexus. Paralysis of the abductors of the hip on one side was treated by placing a graft between the superior gluteal nerve and two bundles within the femoral nerve. Paralysis of the extensor muscles of the knee on the other side was treated by transfer of intercostal nerves 10 and 11 to the femoral nerve. The child was able to walk independently 18 months later.

We have performed more than 1500 nerve transfers since 1986. Nearly all of them were in patients with severe injuries to the brachial plexus. Some are particularly reliable and important. Of particular significance is reinnervation of the paralyzed serratus anterior by transfer of the deep division of the intercostal nerve of T3 and T4 to the nerve of the serratus anterior. This operation has been successful in about 90% of cases; by stabilizing the winging scapula, reinnervation of shoulder abduction or external rotation, or both, is potentiated.

Oberlin and colleagues' operation has been successful in our hands in more than 70% of cases.[140] The spinal accessory nerve is a very powerful motor when transferred without an interposed graft to the suprascapular nerve. Functional elevation and lateral rotation at the shoulder were achieved in more than 70% of 250 patients when the lesion was confined to the fifth and sixth cervical spinal nerves. Power is enhanced by reinnervation of the circumflex nerve during the same operation.[107] Transfer of the accessory nerve to the nerve to the biceps is a reliable operation, although an interposed nerve graft is necessary. Our experience with intercostal transfer does not match that of our Japanese friends and colleagues. Functional flexion at the elbow was regained in just less than 40% of 300 patients, but some of them experienced a welcome improvement in pain.

Success has followed in a smaller number of operations in which the intercostal nerves were transferred to other nerves (e.g., the thoracodorsal, the medial pectoral, the circumflex), to the medial head of the triceps, and to the extensor carpi radialis brevis (ECRB). It has been found that nerve transfer is useful

in reinnervating the ventral root of avulsed spinal nerves for injuries to the brachial plexus. More than 120 nerves have been repaired by transferring the ventral root to the spinal accessory nerve to the stump of an adjacent spinal nerve that has been ruptured, or to a bundle within an intact adjacent spinal nerve. At least one function was restored in more than 70% of the repairs.

Gu and coworkers have used the contralateral seventh cervical nerve to reinnervate the limb after complete avulsion of the brachial plexus.[70] Some of Professor Gu's work on patients in Shanghai was reviewed, and the result for one of them was impressive. We use contralateral transfer in patients with a complete bilateral lesion of the brachial plexus where one limb is particularly compromised by arterial and musculoskeletal injury. In one such case the two ruptured spinal nerves in the worst limb were transferred to the contralateral limb. A limited conventional transfer (i.e., accessory nerve to the biceps nerve and intercostal nerve to the median nerve) was used in the limb with a rupture of the axillary artery. Nerve transfer should never be seen as a substitute for exploration of the lesion and repair of a rupture whenever that is possible. We consider these complementary techniques.

Direct Muscular Neurotization

This is useful for lesions of the axillary or musculocutaneous nerves in which the nerve has been avulsed directly from the muscle, or if the distal stump of the nerve is wrecked.[29] The proximal stump is prepared in the usual way and two lengths of graft, usually from the medial cutaneous nerve of the forearm, are united to the proximal stump and then implanted into the muscle through short incisions in its epimysium. About 10 portals of entry are fashioned to implant the terminal branches of the graft. These may be sutured or secured with fibrin clot glue (Figure 30.22).[51]

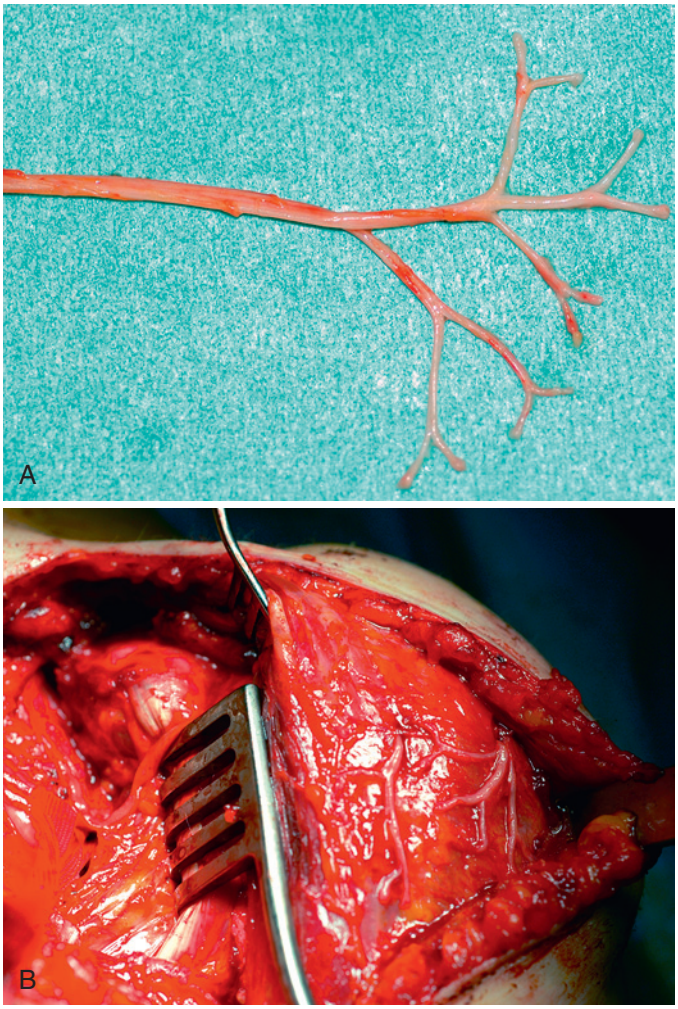

FIGURE 30.22 Muscular neurotization: **A,** The nerve graft is prepared. **B,** It is passed from the proximal stump of the axillary nerve and implanted into muscle.

RECOVERY AFTER REPAIR

The quality of recovery after repair depends chiefly on the number of axons reaching their correct targets and on the later development and myelination of these axons. Some factors that influence this regeneration process include the following:

- Delay between injury and repair
- Quality of the apposed nerve ends
- Quality and accuracy of fascicular matching
- Degree of damage to the nerve ends during the repair operation
- Length of gap after resection of the damaged nerve stumps
- Number of channels provided by the interposed graft for regenerating columns
- Extent of fibroblastic infiltration of the stumps and interposed graft
- Rate of regeneration

With regard to the speed of axonal regeneration, it is variable and estimated to be about 1 mm/day, which corresponds to the rate of slow transport of neurofilament protein. That rate is substantially faster in children, and it is almost certainly faster after primary than after secondary repair. Lundborg suggested that regeneration occurs more rapidly proximally than distally.[111] It has been suggested that the rate is 2 mm/day after suturing clean wounds of the nerves in the infraclavicular fossa and in the proximal part of the lower limb. Such wounds are closer to the nerve cell than are the more distal injuries.

Measurement of Recovery and Grading of Outcomes

It is a fairly straightforward matter to measure recovery in proximal functions at the thoracoscapular and shoulder joints and in nerves with no cutaneous distribution. It is much more difficult in the main mixed nerves of the upper and lower limbs. The problem was addressed by Highet who proposed a system for recording motor and sensory function. He was lost at sea when his ship was torpedoed, and the project was completed by Seddon and other members of the Nerve Injury Committee of the MRC. The modified system was used in the 5 special hospitals designated for the treatment of war nerve injuries and was used in the outcome studies set out in the MRC Special Report of 1954[161] (Table 30.5).

Sensory analysis included measurement of two-point discrimination and assessment of object and texture recognition. The Highet/Seddon method of recording sensibility (see Table 30.5) offers a reasonable method for recording and measuring progress. As is the case with all such schemes, it has obvious

TABLE 30.5 The Medical Research Council (Highet/Seddon, 1954) System

Motor Recovery	
M0	No contraction
M1	Return of perceptible contraction in the proximal muscles
M2	Return of perceptible contraction in both the proximal and distal muscles
M3	Return of perceptible contraction in both the proximal and distal muscles to such a degree that all *important* muscles are sufficiently powerful to act against resistance
M4	Return of function as in stage M3 with the addition that all *synergic* and independent movements are possible
M5	Complete recovery
Sensory Recovery	
S0	Absence of sensibility in the autonomous area
S1	Recovery of deep cutaneous pain sensibility within the autonomous area of the nerve
S2	Return of some degree of cutaneous pain and tactile sensibility within the autonomous area
S3	Return of some degree of superficial cutaneous pain and tactile sensibility within the autonomous area with disappearance of any previous overreaction
$S3^+$	Return of sensibility as in stage S3 with the addition that there is some recovery of 2-point discrimination within the autonomous area
S4	Complete recovery

Source: From Birch R, Bonney G, Wynn Parry CB. Results. In *Surgical disorders of the peripheral nerves*, London, 1998, Churchill Livingstone.

TABLE 30.6 Grading of Results

	Grade
Motor Recovery	
M4 or better	Good
M3	Fair
M2	Poor
M1 and 0	Bad
Sensory Recovery	
S4 (normal) or $S3^+$	Good
S3	Fair
S2	Poor
S1 and 0	Bad

Note: The Peripheral Nerve Injury Unit of the Royal National Orthopaedic Hospital groups "poor" and "bad" together. Rarely is the grade "excellent" used for results when function is almost indistinguishable from normal.
Source: From Birch R, Bonney G, Wynn Parry CB. Results. In *Surgical disorders of the peripheral nerves*, London, 1998, Churchill Livingstone.

disadvantages; however, no comprehensive method has been devised yet that does not have the disadvantage of overwhelming complexity.

Much can be learned from inspection of the skin of the hand. Recovery of the sympathetic vasomotor and sudomotor fibers is apparent from the texture and color of palmar skin and by lightly drawing the examining fingers across injured and uninjured hands. Some patients are able to give an estimate of the difference in the quality of sensation in simple percentage terms; 10% as good, or 50% as good, on the normal side. Along these lines, the simple "ten test" has been validated to be reliable and rapid for evaluating sensation following nerve injury and repair, wherein the injured part is graded by the patient on a Likert scale of 1 to 10 as a percentage of their normal part.[172]

Grading of Outcomes

Grading of outcomes is used to describe the results of nerve repair. However, it is believed that "outcome" should reflect the final state of the patient: his or her ability to work, function in daily life, and be independent. We prefer to use "result" to describe what happens to the whole nerve, using the Highet/Seddon systems (see Table 30.5). These are supplemented by measures of localization and object recognition in the hand and by an estimation of sympathetic vaso- and sudomotor recovery. Persisting pain, allodynia, or cold sensitivity downgrades the result irrespective of motor or sensory recovery.

Persisting spontaneous pain after a well-executed repair of a main nerve is unusual and is an indicator for reexploration in the early months. "Overreaction" is common as recovery progresses, especially for the median, ulnar, and tibial nerves. If there is evidence of robust continuing regeneration, spontaneous improvement can be anticipated. Cold sensitivity is a serious problem because it may prevent the return to work of patients who must use their unprotected hands in cold conditions. Persisting pain and cold sensitivity push the results of palmar digital nerve repairs into the poor category as a painless numb finger has become a painful numb finger. The whole nerve is graded as good, fair, poor, or bad (Table 30.6). Occasionally, the grade "excellent" is permitted. Grading is modified according to the level of lesion in the long nerves, the extent of deformity, or trophic change that influences the final outcome.

Factors in Prognosis. The MRC Special Report defined a number of factors that determine outcome after repair of nerves.[161] Five of these are particularly important: age, level of the lesion, nature of the nerve injury, delay from injury to repair, and cause of the injury.

Age. A properly performed urgent repair of the median[81] and ulnar[24] nerves at the wrist will be followed by function indistinguishable from normal in infants or young children,[10] a result scarcely seen in adults. However, children are not at all immune to the deleterious effect of delay or to depression of regeneration after violent proximal injuries. Furthermore, the risk for progressive deformity in the growing limb from uncorrected muscular imbalance can be extremely high.

Level of the Lesion. The effect of the level of the injury is most evident in longer nerves such as the radial, median, and ulnar. A properly executed urgent repair of the ulnar nerve at the wrist usually results in useful function in the small muscles of the hand, but this is the exception, even with excellent primary suturing of tidy wounds of the ulnar nerve in the axilla. Repair of the posterior interosseous nerve is generally successful in restoring extension of the fingers and thumb, but this is unusual after repair of the radial nerve proximal to the spiral

groove. However, urgent repair of stab wounds or even of closed-traction ruptures of C5, C6, and C7, or the upper and middle trunks, often achieves results as good as or even better than those seen after repair of combined injuries to the terminal nerve branches of the plexus in more distal lesions. We have found that combining grafting of ruptures of C5 and C6 with transfer of the accessory to the suprascapular nerve often is followed by very impressive recovery of function at the shoulder.[4]

Nature of the Nerve Injury. There is no such thing as a pure motor or pure sensory peripheral nerve. The palmar digital cutaneous nerves contain within them many postganglionic sympathetic efferent fibers. Nerves that have no cutaneous innervation (e.g., the spinal accessory or the suprascapular) contain within them large numbers of afferent fibers. In the spinal accessory nerve these fibers are nociceptors. In the suprascapular nerve there are afferent fibers from muscle spindles and from joint structures. However, it is the case that nerves innervating one or two muscles (i.e., the accessory nerve to the serratus anterior, musculocutaneous) fare better than those with extensive territories of cutaneous and muscle innervation (e.g., median, radial, and ulnar). The unfavorable reputation of the superficial radial and the medial cutaneous nerves of the forearm is well deserved. Accidental damage to these nerves, especially in their terminal parts, regularly produces severe neuropathic pain.

Delay From Injury to Repair. The evidence of the harmfulness of delay is overwhelming. The long and wearisome debate about the timing of nerve repair should be relegated to the dustbin of history. The passage of every week sees progressive atrophy of target tissues distally and progressive deterioration of the capacity within the CNS for regeneration. Local changes include retraction of the divided nerve stumps from elastic recoil and increasing fibrosis within these stumps such that the gap between the healthy nerve ends increases.

It is in repairs of the supraclavicular brachial plexus that the effect of delay on regeneration through grafts of ruptured spinal nerves is most evident. In one series of 228 patients surgically treated between 2000 and 2004, we found that 52.5% of the grafts performed within 7 days of injury were successful (52 patients)—that is, at least one function was restored. The overall success rate for all grafts was 33.5%.[9]

The few cases of return of useful hand function followed urgent grafts of ruptured spinal nerves.[48] These findings tend to support the concept of urgent restoration of contact between the proximal axon and its cell body and the distal Schwann cell columns. Nerve transfer, for such lesions, is based on motor neuron pools that have not been damaged, and delay, of up to several months, is less harmful than it is for grafts.

Cause of the Injury. There are two aspects to this factor. First, one must consider the extent of damage to the nerve and loss of neural substance. The length of the defect between nerve stumps is a material factor in outcome after repair. The outlook for a nerve repaired after the extensive destruction of a close-range blast or deep burn is far worse than after severance by knife. The second thing to consider is the extent of injury to the tissues of the limb as a whole. Neglected peripheral ischemia is the most serious. It is almost inconceivable that a complacent attitude is still taken, from time to time, for the treatment of a pulseless upper or lower limb.

CRITICAL POINTS *Prognosis*

- The single most important factor in the prognosis after injury to a nerve is the violence of that injury and the extent of the damage to the limb as a whole.
- Associated arterial injury is particularly significant.
- The chief factor related to prognosis within the control of the clinician is delay between injury and repair.

Results

This section describes treatment results for the radial, median, ulnar, and digital nerves. Because injuries to the median and ulnar nerves are primarily acute and distal with short reinnervation distances, an "excellent" category is included for nearly normal function and sensation.

Radial Nerve

The radial nerve, the largest of the terminal branches of the brachial plexus, is probably the most commonly injured of the key nerves in the upper limb. For many patients, radial palsy is more disabling than median or ulnar lesions. The first 8 to 10 cm of the nerve are supplied by intraneural vessels because there is no accompanying nutrient artery, so transection at its origin may render this proximal segment relatively ischemic. Bleeding from the profunda vessels may compress the injured nerve in the spiral groove.

The nerve lies closest to bone where it pierces the lateral intermuscular septum and passes through a short tunnel bounded by bone and fascia. This is a tethering point and is a common level of rupture or entrapment. Of the main peripheral nerves, the radial nerve is the most favorable for return of function spontaneously or after repair. The cutaneous component is relatively small, while the entry to the motor branches is more proximal than it is in the median or ulnar nerves. This view is tempered by two factors: the level and the cause of lesion. Our system for grading recovery is set out in Table 30.7.

TABLE 30.7 Grading of Results in Lesions of the Radial Nerve

	For High Lesions Above Nerves to Triceps	For Intermediate Lesions Between Medial Head of Triceps and Brachioradialis	For Low Lesions Below the Posterior Interosseous Nerve
Good	Elbow extension ≥ MRC grade 4 Wrist extension ≥ MRC grade 3	Wrist extension ≥ MRC grade 4 Finger and thumb extension ≥ MRC grade 3	Full independent extension of the digits ≥ MRC grade 4
Fair	Elbow extension ≥ MRC grade 3 Wrist extension ≥ MRC grade 2	Wrist extension ≥ MRC grade 3 Finger and thumb extension ≥ MRC grade 2	Extension of digits ≥ MRC grade 3
Poor	Less than above	Less than above	Less than above

The *high-level lesion* is demarcated by paralysis of triceps. The segment of the nerve at risk is short and lesions often extend into the distal part of the posterior cord. In our series the most common cause was closed traction from violent shoulder hyperextension/abduction, which was associated with rupture of the axillo-brachial artery (30%), a skeletal injury (70%), and in most cases with rupture or stretch lesions of adjacent nerves. Wounds from a projectile are frequent, and the destruction of soft tissues adds to treatment problems. Simple wounds from a knife, glass, or scalpel are uncommon. Elbow extension is important, more so than elbow flexion, for many patients; its recovery is the first object of treatment of high-level radial nerve lesions. Treatment is especially difficult when the nerve has been avulsed from muscle.

The experiences of the Louisiana State University Health Sciences Center (LSUHC) with high (axilla) stretch lesions is encouraging.[90] Neurolysis of the 29 nerves with translesional continuous noninvasive arterial pressure (CNAP) led to recovery to a mean of 4.1 using the LSUHC scale—that is, the mean recovery in the 32 grafts was 2.7, indicating that most patients regained at least elbow extension against gravity or better. Pan et al explored 39 high-level lesions.[148] There were 29 graft repairs and 10 neurolyses. Recovery was deemed good when muscles reached MRC grade 3 (against gravity) or better. The outcomes for all 39 lesions was: extension at elbow 95%, extension at wrist 79%, and extension of digits 31% (Table 30.8).

War wounds and civilian gunshot wounds in the axillary region are notorious for the high incidence of arterial injury and fracture. Roganovic and Petkovic considered that only 4 of the 10 high-level repairs were useful; however, closer examination of their results suggests that elbow extension against gravity was regained by 8 patients.[154]

The intermediate segment is the most commonly injured portion of the nerve. It extends from beyond the triceps branches to the posterior interosseous nerve, although the lateral head may be involved in lesions within the spiral groove. Some surgeons subdivide this segment into the spiral groove and the lateral arm components. Fractures of the humerus are the most common cause of nerve injuries in civilian practice. Regrettably, more and more lesions are inflicted during surgical treatment of these fractures. In war injuries, the fracture is but one component of a complex wound.

Radial palsy in closed civilian fractures of the humerus occurs in about 8% of cases.[154] Recovery of the nerve may be anticipated in most cases if closed reduction secures coaptation of the bone fragments without a gap. Of course, there must be no hint of ischemia of the forearm's muscles. If surgical treatment is elected, it is wise to expose the affected nerve. The surgeon must assume that the nerve has been cut if a complete lesion occurs during treatment of that fracture unless the nerve was seen to be intact along the length of the wound before closing the skin. Radial palsy that complicates an open fracture requires exposure of the nerve during debridement of the wound.

Spontaneous Recovery. Favorable signs are often detectable at 6 to 8 weeks after injury. In a prospective study Bowden and Scholl found, in axonotmesis, that the mean delay before activity returned in the appropriate muscle was 64 days.[27] In our

TABLE 30.8 Outcomes of Intermediate Zone Injuries of the Radial Nerve

Series	No. of Repairs	Suture Repairs/Grafts	Wrist Extension MRC 3+ or Better	Digital Extension MRC 3 or Better	Independent Extension and Abduction of the Thumb
Zachary (1954)[202] War injuries[a]	114	114/0	90%	61%	31%
Seddon (1975)[162] Civilian	63	63/0	75%	55%	
Kim et al. (2001)[90] Civilian, includes high lesions	81	34/47	84%	66.7%	
Roganovic (2005)[153] War injuries[b]	107	56/75	88.8%	66.7%	
Pan et al. (2010)[148] Civilian, includes high lesions[c]	98	22/76	93.9%	85.7%	52%
PNI Series 1—1975-1994[g] Civilian and war wounds, includes high lesions[d]	242	73/169	58%	29.7%	
PNI Series 2 (2000-2007)[165] Civilian, includes high lesions[e]	72	0/72	83.3%	64%	

Notes:

[a]Patients lost to follow-up (42%) was twice as high as that for other nerves. It is likely that many of those dropping out chose tendon transfer. Zachary's series excludes the most severe injuries that could not be sutured.

[b]The number of grafts versus sutures is provided for the whole series and is not specified for intermediate repairs.

[c]Results for *all* lesions are presented whether they were repaired or not. Strength of MRC grade 3 or better was deemed good.

[d]Series 1. Includes 52 cases of proximal injuries. Results for these, mainly closed-traction injuries, and also other patients with rupture of axillary or brachial arteries, were generally poor.[19]

[e]Series 2. Includes proximal injuries. There were no "tidy" wounds in this group, which was restricted to open untidy or closed-traction lesions.

experience (PNI, Series 2),[8] the interval before recovery was detected in the first distal muscle in 52 cases that had no operation was: 15 (28%) within 35 days, 17 (32.6%) between 36 and 70 days, and 20 (38.5%) between 71 and 105 days. Some of the patients were referred after an interval of 2 or 3 months. They showed clear signs of recovery that would have been detectable some weeks before they presented for treatment. A progressing Tinel sign was followed by spontaneous recovery in 103 of the series 2 cases, including 41 in which a static sign was converted into a progressive one by neurolysis. There were 5 misleading signs of improvement. The extensor muscles of the forearm had been damaged by ischemia or direct injury in 3. In 2 more, the nerve was explored because the anticipated muscle recovery had not occurred; part of the nerve was caught in the fracture.

Duration of Follow-Up. There is scant difference in the outcome at 3 and 5 years in Zachary's series,[202] but there was a striking difference between years 2 and 3; 17.9% were graded good (M4) at 2 years and 42.5% at 3 years. This probably accounts for the inferior levels of recovery recorded by Woodhall and Beebe who analyzed outcomes at 2 years.[197]

Delay. Although some researchers have recorded a detectable falling off of recovery where delay exceeded 6 months, the authors have found that prognosis is affected by much shorter delays. In peripheral nerve injury (PNI) Series 1,[19] 49% of the 77 nerves repaired within 14 days attained a good result; only 28% of the 169 late repairs reached this grade; the mean delay in these was 190 days (i.e., 15-440). Comparison of Series 1 and 2 outcomes[8] for the open chaotic wounds and closed-traction ruptures is illuminating, as shown in Table 30.9. The two cohorts are comparable by severity of injury and by technique of repair because all were graft repairs. The obvious difference is the interval between injury and repair.

The Nerve Defect. With direct sutures, recovery was worse when gaps exceeded 5 cm. In graft repairs, defects in excess of 8 cm were associated with inferior results. However, in common with other studies, we have seen good outcomes using grafts of up to 15 cm in length.

The *distal segment* includes the posterior interosseous and superficial radial nerves—one of the best and one of the worst of peripheral nerve injuries. Repair of the PNI is usually rewarding; the outcome was good in 16 of 18 in Shergill and associates' series.[165] Similarly, encouraging outcomes have been reported by others.[131,148,154,165] Good results cannot be expected when target muscles have been destroyed by ischemia or a missile (see Table 30.8); surgical exploration is more difficult when the lesion is distal to the supinator because of the leash of fine branches. The serious problem of the divided superficial radial nerve is considered in the Painful Neuroma section of this chapter.

Conclusions. This section has described treatment results for the radial nerve; consider the following:

- The outcome after repair of the radial nerve is generally better than that for the median and ulnar nerves. The superficial radial nerve is a significant exception.
- Every reasonable effort should be made to regain extension of the elbow and wrist by nerve repair or transfer.
- Operating on a closed fracture converts it into an open one no matter how small the incision. If surgical treatment of a closed fracture with radial palsy is undertaken, the nerve should be exposed.
- A radial palsy that complicates surgical intervention in the arm means that the nerve has been cut unless and until proven otherwise.
- Radial palsy is crippling. Well-made orthoses help. The surgeon must be alert to the risk of fixed deformity.
- Early forearm tendon transfers are indicated when prognosis is poor (e.g., high traction injury, long defect, late presentation).

Median and Ulnar Nerves

The median nerve is the foundation of hand function. Delicate, intricate, and precise work is enabled by the dense innervation of the palmar skin and by a complex deep afferent pathway. The sympathetic nerves contribute to the strength and durability of the skin. While the somatic motor component is important, outcome measures emphasize sensory recovery. Muscle function is the main contribution from the ulnar nerve and grading systems reflect this. The sensory component is vital; an insensate little finger is a hazard, especially so when it lies in abduction. Useful and predictable muscle and nerve transfers are available to replace motor function. There are none that effectively restore sensation with the rare exception of infants with particularly severe birth lesions of the brachial plexus. The length of follow-up is important. Gaul noted that the intrinsic muscles could continue to improve for 5 years or more,[59] while Nicholson and Seddon recorded S3 or better sensory function in median nerves improving from 38% at 3 years to 65% at 5 years.[136]

It seems that the ulnar nerve fares worse than the median and radial nerves except after primary repairs in the distal forearm and wrist. Murovic analyzed outcomes in 1837 lesions of the three nerves at all levels treated at the LSUHC between 1967 and 1997.[131] The proportion of repairs of complete lesions (i.e., proximal to anterior and posterior interosseous nerves) reaching grade 3 or better, using the LSUHC scale, is shown in Table 30.10.

Although the Highet/Seddon systems and the MRC muscle scale are important, their defects are especially evident in the

TABLE 30.9 Effects of Delay in Radial Nerve Repairs: Untidy Wounds and Traction Ruptures

PNI Series 1: mean delay, 190 days[8]	114 grafts	32 good (28.1%)	30 fair (26.4%)	52 poor (45.6%)
PNI Series 2: mean delay, 58 days[165]	72 grafts	36 good (50%)	22 fair (30.6%)	14 poor (19.6%)

TABLE 30.10 Recovery After Repair of Radial, Median, and Ulnar Nerves

	Radial	Median	Ulnar
Number of repairs	74	88	85
Number reaching grade 3 or more (%)	61 (82.4%)	69 (78%)	58 (68.2%)

Source: From Murovic JA. Upper-extremity peripheral nerve injuries (2009).[131]

assessment of hand function, as they apportion no contribution of pain or allodynia to outcome. Rosén and Lundborg introduced an evaluation system that consists of three domains: sensory, motor, and pain or discomfort.[155,156] A mean score is allocated to each domain and their sum provides a total score for the whole nerve. We go further, bearing in mind that pain or cold sensitivity that is severe enough to prevent normal use of the hand or to prevent return to work must downgrade the result regardless of motor and sensory recovery. Our systems are described in Tables 30.11 and 30.12.

Factors That Affect Recovery

Age. Age plays a fundamental role in outcomes of median and ulnar nerve injury.[81] In a review by McEwan, including 141 lesions of median and ulnar nerves at all levels, there were 62 primary and 32 secondary suture repairs.[120] Recovery in children, in age group of up to 14 years, was compared with what was seen in patients who were 15 or older. Motor recovery was good in 39 of 47 (83%) of the children's repairs; it was good in 15 of 37 (40.5%) in older patients. Sensory recovery was good in 48 of 50 (96%) children's nerves; this level was reached in only 33 of 43 (76.7%) of the older patients. Seddon compared recovery with age for 584 repairs of median and ulnar nerves at all levels (Table 30.13).[164] The connection between age and recovery holds true for digital nerves as well.

In a recent review, Chemnitz et al reported 55 low median and ulnar nerve repairs in 45 patients at a median follow-up of 31 years.[37] Sensory recovery was significantly better in patients under the age of 11. Motor recovery was close to normal in both groups, and cold sensitivity was not a problem in either.

The generally held view that recovery after nerve repair is better in children than it is in adults requires some discussion. The following are factors that work against a successful outcome in repair of children's nerves:

- There are profound biologic differences between immature and mature peripheral nervous systems. The developing CNS is more vulnerable to injury than that of adults. This is, of course, particularly important in the study of obstetric brachial plexus palsy. Myelination is not complete in the neonate, and conduction velocity at term is about half that found in normal adults. Motor conduction velocity reaches adult levels at about 3 years of age; sensory conduction velocity perhaps a little earlier.
- Dissociation of the insensate hand from function is a remarkably constant finding in young children. If a child cannot feel a body part, that part is ignored; it may even be mutilated.

TABLE 30.11 Grading of Results in Median and Ulnar Nerves Repaired in the Infraclavicular Region, the Axilla, and the Arm (High-Level Lesions)

Median	
Good	Long flexor muscles MRC 4 or better Localization to digit, without hypersensitivity Return of sweating
Fair	Long flexor muscles MRC 3 or 3+ Protective sensation. Moderate or no hypersensitivity Sweating diminished or absent
Poor	Long flexor muscles MRC 2 or less Protective sensation but severe hypersensitivity *or* no sensation
Ulnar	
Good	FCU and FDP little and ring MRC 4 or better Intrinsic muscles MRC 2 or better Localization to little and ring fingers; no hypersensitivity Return of sweating
Fair	FCU and FDP little and ring fingers MRC 3 or 3+ No intrinsic muscle function Protective sensation little and ring fingers No, or moderate hypersensitivity Little or no sweating
Poor	FCU and FDP little and ring fingers MRC 2 No intrinsic muscle function Protective sensation with severe hypersensitivity *or* no sensation No sweating

TABLE 30.12 Methods of Grading Results of Median and Ulnar Nerves Injured Below the Elbow (Low-Level Lesions)

Grade	Motor	Sensory	Highet/Seddon Equivalent
Excellent	Power MRC 5 No wasting or deformity No trophic changes	Function indistinguishable from normal hand Good stereognosis, no hypersensitivity 2PD[a] equivalent to uninjured digits	Good M5, S4
Good	Power MRC 4 to 5 Abolition of paralytic deformity Minimal pulp wasting	Accurate speedy localization Can recognize texture or objects Minor cold sensitivity and hypersensitivity 2PD < 8 mm at tips of fingers	Good M5, S3+
Fair	MRC 3 or more Some sweating Pulp wasted	Accurate localization to digit No stereognosis 2PD > 8 mm Significant cold sensitivity and hypersensitivity	Fair M3, S3
Poor	MRC 3 or less No sweating Trophic changes	No sensation or severe cold sensitivity and hypersensitivity	Bad M0, 1, S0, S1, or S2

[a]2PD = 2-point discrimination

The slow course to recovery after repair of a severe lesion of the young child's brachial plexus is, perhaps, a reflection of the importance of maturation of the afferent pathways.[25] There is often a profound lag between electromyographic evidence of reinnervation and functional use of the affected muscles in birth lesions of the brachial plexus.[3]

- Denervation of the limb in a growing child causes disturbance in growth. In the lower limb this may cause severe deterioration of function.
- The muscular imbalance consequent to neurologic injury in a growing child may provoke severe and progressive deformity. A striking example of this in the upper limb is the medial rotation contracture at the shoulder that complicates obstetric brachial plexus palsy. The effect on the stance of the foot after an irreparable tibial or common peroneal lesion is severe, and that deformity superimposed on a limb and foot that is shortened after injury to the lumbosacral plexus, or the divisions of the sciatic nerve, is crippling.

There is, however, much clinical evidence showing that children's recovery of sensibility is very much better than it is in adults and that sensibility is rarely attended by neuropathic pain. Primary repair for children should be performed whenever possible.

Level and Nature of Injury. It is difficult to separate the effects of these two factors. The tidy wound is more frequent in the low lesions while the devastating traction rupture, so often associated with tearing of the axillary or subclavian artery, is largely confined to high injuries. Ischemia and projectiles destroy the forearm flexor muscles, complicating assessment of the outcome of nerve repair for these injuries. Table 30.14 outlines results of high-level repairs drawn from several of the larger series. The isolated effect of level in clean wounds is further illustrated in Table 30.15. Generally, motor recovery of the ulnar hand muscles is poor.

Nerve Gap. The critical gap, beyond which recovery is detectably impaired, is surprisingly low. The literature is at times conflicting and is likely confounded by age, wound severity, and complexity of injury; however, there is a general consensus that increased gap or graft length degrades outcomes when all other factors are equal. Sakellarides, reporting on 172 upper-limb nerve lesions, found good recovery in 76% of suture repairs with gaps of 2.5 cm or less but in only 23% of those with gaps of 3 cm or more.[157]

Today, most surgeons would use grafts for gaps of 3 cm or more. Secer et al noted a direct relationship between graft length and good results in ulnar nerve repairs: 3 cm or less, 47.1%; 3.1 to 5 cm, 17.5%; 5.1 to 7 cm, 10.9%.[159] There were no good results when grafts exceeded 7.1 cm. Roganovic et al

TABLE 30.13 Recovery and Age: Median and Ulnar Nerves (Seddon[118])

Age in Years	Number of Nerves Graded Good	Percentage
0-10	35	71
11-15	47	57.6
16-20	106	33
21-60	231	24.7

TABLE 30.15 Recovery of Median and Ulnar Nerves in Tidy Wounds by Level

	MEDIAN		ULNAR	
PNI Series[8]	Number of Repairs/Good	%	Number of Repairs/Good	%
High, 1975-2000 Adults and children	22/8	36.4	15/5	33.3
Low, 1979-1986 Age 15-55 Forearm and wrist	55/33	60	52/29	54.7

TABLE 30.14 High Repairs of Median and Ulnar Nerves

	MEDIAN		ULNAR	
Series	No. Repairs and Type	Grades (%)	No. Repairs and Type	Grades (%)
Zachary (1954)[202] War wounds[a]	($n = 94$) All suture repairs	Good—25.6 Fair—62.7	($n = 101$) All suture repairs	Good—5 Fair—22.8
Seddon (1975)[164] Civilian[b]	($n = 45$) All suture repairs	Good—35.5 Fair—5.1	($n = 85$) All suture repairs	Good—20 Fair—60
LSUHC (2008) (Spinner in Kim) Civilian[c]	($n = 60$) Suture and graft repairs ($n = 29$) Neurolysis	3 or better—78.3 3 or better—93.1	($n = 32$) Suture and graft repairs ($n = 25$) Neurolyses	3 or better—65.6 3 or better—88
Secer et al. (2007)[159] War wounds[d]			($n = 166$) Suture and graft repairs	M3—44 S3—43.7
PNI (2011)[9] Civilian[e]	($n = 117$) Suture and graft repairs	Good—14.5 Fair—41	($n = 99$) Suture and graft repairs	Good—10 Fair—47.5

[a]Grading by Highet/Seddon scale.
[b]Grading by Highet/Seddon scale; children included.
[c]Grading by LSUHC system; many patients reached higher grades especially after neurolysis.
[d]Grading by Highet/Seddon scale; results include some repairs of partial lesions and some neurolyses.
[e]Includes children; see Birch R. The closed supraclavicular lesion (2011).[9]

estimated that the critical gap between good and poor results of war injuries was around 5 cm in both median and ulnar nerves.[152,153] We are not sure what to make of this. Grafting has transformed nerve repair, at least when the gap is such that direct suture would be futile or impossible. Our experience of satisfactory results from grafts of 10 cm or even more is matched by reports from many other studies.

Concomitant Arterial Injury. Leclerq et al[105] reported on a series of ulnar nerve forearm and wrist lacerations treated by primary direct suture[52] or graft.[33] This important paper established that repair of the ulnar artery for 45 of their patients enhanced nerve regeneration. The outcomes for the suture repairs were artery intact or patent after repair: M3 (81.5%), S3 (74%). For those in which the artery was ligated or subsequently thrombosed: M3 (53%), S3 (53.8%). The difference was more striking in the grafts, demonstrating M3/S3 recovery in 73% of the artery patent group versus 22% in the others. Cold sensitivity was less in hands with a patent artery.

Merle et al[123] reported the Nancy experience with 150 median and ulnar repairs for 131 patients and identified a similar relationship of inferior nerve outcomes among those with failed arterial repairs. We think that regular repair of the ulnar artery is one of the most significant advances in the treatment of nerve lacerations over the past 40 years.

Primary Versus Delayed Repair. Table 30.16 displays the results of primary, delayed, and graft repair of 106 median and ulnar nerves in tidy wounds at the wrist and forearm, and it clearly demonstrates the superiority of primary repair. There is little controversy that undue delay degrades the results of nerve repair in otherwise clean lacerations. However, primary repair alone is not an assurance of good outcomes, as was observed in more than half of the delayed repairs in this series.

The causes of failure were multiple, including suture of nerves to tendons, the use of circumferential entubulating materials, and the use of coarse or braided sutures. Three additional factors contributed to the failure of otherwise technically satisfactory repairs: dense adhesions between nerves and tendons, compression of the median nerve within the carpal tunnel, and failure to repair the ulnar artery. Primary repair of a nerve and its associated structures is a very demanding task, and close attention to every step of the procedure is required. Similar conclusions were made by Mohseni et al who used equivalent surgical techniques and methods of assessment for 105 repairs.[129]

Distal Transfers to the Ulnar Nerve. Distal transfer of the terminal anterior interosseous nerve to the motor branch of the ulnar nerve can be used in select high-level ulnar nerve repairs. Battiston and Lanzetta used a double distal nerve transfer; the anterior interosseous nerve (AIN) before its entry into the pronator quadratus was passed to the motor component of the ulnar nerve and the palmar cutaneous (PCN) branch of the median was crossed to the sensory component.[6] Sensory recovery was $S3^+$ or S4 for all 7 patients. In 6 of the 7, muscle recovery abolished paralytic deformity. The strength of pinch and grip nearly doubled in this cohort. Novak and Mackinnon reported on 8 patients treated with AIN motor transfer alone, allowing spontaneous recovery of sensation through the repaired ulnar nerve.[138] Recovery in the muscles was very good; lateral pinch grip strength rose from 2.2 to 13.8 lb and power grip from 8.8 to 61.2 lb.

There are conditions attached to this elegant and successful transfer, however. The prognosis for the ulnar nerve must be known, and the procedure should be done almost exclusively on high disruptions of the ulnar nerve. The median nerve must be normal or near normal. The target tissues need to be healthy; it is futile to use this method after a blast injury to the hand. Finally, there is the disproportion in the numbers of motor–nerve fibers in the AIN (~1000) versus >4000 in the motor division of the ulnar. However, axons are lost in all repairs or grafts, whatever the technique, and there is always collateral sprouting of motor axons. We are certain that this method would have been very helpful to some patients with high-level injuries.

TABLE 30.16 1977-1985 Results of 106 Tidy Wound Repairs in 95 Adult Patients

(Youngest = 15 years)

Grade	Nerve	Primary Repair of 48 Nerves	Delayed Repair of 25 Nerves	Graft of 35 Nerves
Excellent—8 nerves	Median	3	0	0
	Ulnar	5	0	0
Good—49 nerves	Median	16	5	4
	Ulnar	15	2	7
Fair—3-9 nerves	Median	7	8	8
	Ulnar	2	5	9
Poor—10 nerves	Median	0	2	2
	Ulnar	0	3	5

CRITICAL POINTS *Repair of Radial, Median, and Ulnar Nerves in the Arm*

- Primary suture repairs are technically demanding.
- Arteries and gliding planes must be repaired.
- Decompression of the carpal tunnel is advisable for deep wounds in the forearm and after arterial repair.
- Transposition of the ulnar nerve at the elbow provides between 2 and 3 cm of additional length.
- In secondary repairs, expect the unexpected; be ready to graft.
- Plan the incision to provide good skin coverage over the repair site.
- Preparation of the bed is extremely important for secondary repairs.
- Early controlled movements of the digits within the confines of a splint are encouraged.

Digital Nerve Repair

Digital nerve injuries are often low energy, penetrating, and isolated; however, if they are part of a complex hand injury, measurement of outcome is made difficult. Goldie et al studied 30 digital nerve repairs in 27 patients including 7 digital artery repairs.[65] In comparison with the other hand, 37% of the patients regained normal 2-point discrimination but only 27% graded their outcome as excellent, and 40% reported persistent hypersensitivity. Brushart reviewed 9 reports totaling 207 digital nerves and reported 40% S4 (52% $S3^+$and 8% S3 or less) in 22 suture repairs and 40% S4 (40% $S3^+$ and 20% S3 or less) in

127 grafts of less than 15 mm.[30] The graft results worsened to 20% S4 (50% S3+ and 30% S3 or less) in grafts of more than 15 mm.

The common finding running throughout the literature on digital nerve injuries is that younger patients do better than adults (Table 30.17), and short defects do better than long. Neither of these factors is under the surgeon's control. Onne showed 100% S4 recovery in patients under 14 and only a 43% S3+ recovery in those over 14.[145]A digital nerve laceration in a tidy wound, first and foremost, should be repaired as soon as possible. Primary suture repair is possible in the majority of cases encountered.

Conduits and Homografts for Digital Nerve Repair. A systematic review by Paprottka et al identified 72 separate studies showing the results of 2997 nerve repairs, including 1383 end-to-end repairs, 31 end-to-side repairs, 384 nerve grafts, 115 artificial conduits, 102 vein reconstructions, and 56 muscle vein reconstructions.[149] No one method held an advantage over another. Rinker and Liau performed a prospective study and randomized any case with a digital nerve gap of more than 4 mm to either a polyglycolic acid conduit tube or an autogenous vein graft.[151] They enrolled 42 patients (36 conduit vs. 32 vein) with 76 nerve repairs, then compared the results of assessment of static and moving 2-point discrimination of 68 of the repairs at 6 and 12 months. The treated nerve deficits were on average 10 mm long (range 4-25 mm). These authors found equivalent results from the two groups. Table 30.18 presents a compilation of the results of multiple techniques for bridging a digital nerve gap.

TABLE 30.17 Recovery of Sensation After Repair of 129 Digital Nerves

	NUMBER OF NERVES (%)	
	Adults	Children (14 Years or Less)
Good	43 (42.2%)	25 (92.6%)
Fair	35 (34.3%)	2 (7.4%)
Poor	24 (23.5%)	0
Total	**102**	**27**

❖ AUTHORS' PREFERRED METHOD OF TREATMENT: Digital Nerve Repair

Damaged tissue must be resected; a small graft will perform better than a repaired nerve with damaged ends, or a nerve sutured under tension. For a single nerve with a gap of under 2 cm, we use a conduit. For those gaps of 2 cm or more (or for multiple nerve deficits) we use an autograft. We consider the PIN at the wrist as a good donor, generally, with a good size match and useful length. The authors have seen one case of a PIN neuroma from graft harvest, which appeared to be tethered to the fourth compartment extensor tendons and painfully restricted wrist and finger movement. We also utilize the medial cutaneous nerve of the arm for graft reconstruction. We encourage early movement at 3 weeks with a dorsal blocking cast to facilitate gliding within the range possible without tension.

REHABILITATION

Rehabilitation is the staged withdrawal of support while patients reintegrate themselves into normal daily life. Repair of the nerve is but the first step in patients' rehabilitation. The prognosis is now clear, the time to recovery is prolonged, and the implications for employment can be severe. Cold sensitivity is the reason that many skilled workers in trades, such as butchery, fishery, or outdoor engineering, are unable to return to work. Surgeons must involve themselves in the process of reintegration of patients and act to support and encourage and to intervene if the occasion arises. They are in a good position to advise occupational health physicians and others and, from time to time, to act as an advocate for the patient in difficult and depressing dealings with the employer, agents of the government, or legal professionals.

The aims of rehabilitation are as follows:

- Objective assessment of disability and accurate measurement of outcome

TABLE 30.18 Outcomes From Differing Methods of Bridging a Digital Nerve Gap

Series	No. of Repairs	% S3+ or Greater	Mean Reconstructive Gap (Range, mm)
Laveaux et al (2010)[103] Autograft nerve	15	81[a]	Less than 30
Tang et al (1993)[177] Vein	18	61	20 (5-58)
Lohmeyer et al (2009)[108] Conduit	15	75	12.5 (10.8-18.2)
Meek et al (2013)[122] Conduit	235	75	Uncertain
Taras et al (2011)[179] Conduit	22	59	12 (5-15)
Rinker and Liau (2011)[151] Conduit	41	See paper—only average 2PD quoted	9 (4.5-13.7)
Taras et al (2013)[178] Homograft nerve	18	39	11 (5-30)

- Reduction of the degree of disability by physical and other therapies
- Return of patients to their original work, to modified work, or to other suitable work
- Restoration of patients' ability to live in their own home, to enjoy recreation and social activities, and to be independently mobile

The approach is, of course, multidisciplinary, and the field has been reviewed in a number of studies.[16,199] Specific treatment may be indicated for the following:

1. *Fixed deformity, weakness, loss of endurance, loss of balance, and a lack of confidence:* Planned and graduated physiotherapy, combined with serial splinting, is useful here, but it must be structured with well-defined goals; a system of short, sharp bursts of treatment with clearly defined objectives is preferable. It does a patient no good at all to be preoccupied with dilatory attendance at hospital outpatient departments for months or years.
2. *Neuropathic pain, as opposed to the pain of regeneration, and cold sensitivity:* This is a rare complication after properly conducted repair. It must be treated vigorously by physical measures, including massage, transcutaneous electrical nerve stimulation (TENS), percussion, and active mobilization and use of the limb. A carefully supervised regimen of drugs, including opiates and psychotropic and membrane-stabilizing agents, may be necessary. Omer[143] wrote:

   There are only two principles in the treatment of established pain syndrome involving the upper extremity: to relieve the subjective pain experience and to institute active function of the involved extremity.… The best functional activity occurs when the patient returns to daily work. Patients who continue functional activities will ultimately "cure" themselves.

3. *Functional training and functional splinting:* Restoration of function for return to unsupported daily life and to work can be helped by occupational therapy and by functional splinting. In a fully equipped rehabilitation unit, appropriate facilities are available for stimulation and replication of actions used in the patient's work and daily life. The simplest splints can greatly aid a patient with partial paralysis and improve the hand's function.
4. *Return to work:* Professional occupational counselors are available to advise on the possibilities for return to work, and a liaison between them and the surgeon can be very helpful to the patient. In 1969, Brewerton introduced the concept of a hospital employment advisor at the Royal National Orthopaedic Hospital; that person was available to help patients who were likely to experience problems returning to work. The patient was seen while in the hospital. Problems can be discussed and, in favorable cases, difficulties can be resolved before discharge. The advisor, with the patient's agreement, can make contact with the employer and discuss return-to-work prospects.
5. *Assessment, Retraining, and Mobility:* When a disability is so severe (i.e., permanent) that it prevents patient's return to the former position, the question of retraining may be raised. The advisor can arrange for such patients to be seen at one of numerous employment assessment centers, which may lead to specialized training courses. The employment advisor and the occupational therapist can help in the matters of transportation and mobility. For example, patients with serious disabilities of one upper limb were able to handle a car with an automatic transmission, adjustments for the steering wheel, and a hand brake.

The principles of rehabilitation were established by Robert Jones in the United Kingdom during the First World War. That work was further developed in military rehabilitation hospitals during the Second World War. Important contributions came from units set up to deal with casualties from industries such as mining, ship building, and the merchant marines. Many important lessons from this work are at risk of being neglected by too many clinicians in civilian practice. The work now being done at the Joint Services Medical Rehabilitation Centre at Headley Court (Surrey) is scarcely matched in most hospitals. It is the duty of the operating surgeon to take an active role throughout the rehabilitation process.

Recovery of sensibility in adults depends on reestablishing the central analysis of input of new patterns, and much can be done to aid recovery by reeducation of that central perception. Wynn Parry and Salter recorded our early experiences, which, at that time, was largely based on residential retraining.[200] Dellon argued persuasively that such retraining is an essential part of rehabilitation after nerve suture.[44] Imai and associates measured the improvement in hand function after sensory reeducation and showed a substantial improvement in the ability of the patient to recognize small objects and considerable improvement in the recognition of moving 2-point discrimination.[83] Training should be started as soon as the patient can recognize stimuli at the fingertips, and it aims to improve function by improving the qualities of localization and recognition. An hour's transcutaneous stimulation before the start of a session may ease hypersensitivity or even allodynia.

Lundborg and colleagues provided an excellent review of central plasticity in relation to hand surgery and described the functional reorganization of the somatosensory cortex.[113] The impressive work with sense substitution by this group shows how "sleeping sensibility" can be awakened and some stereognosis regained. The quality of reinnervation is not necessarily related to function. For the purpose of research, both academic tests of sensory restoration and tests of function need to be used.

CRITICAL POINTS *Rehabilitation*

- Rehabilitation is the staged withdrawal of support.
- The process must be supervised by a clinician from start to finish.
- Further surgery, such as palliative musculotendinous transfers, should be seen as an integral part of the of rehabilitation process.

For the current experience of treating war wounds, please see ExpertConsult.com.

THE PERIPHERAL NEUROMA

Unlike successful peripheral nerve repair, a neuroma is the inevitable, unavoidable, and biologic response of the proximal

WAR WOUNDS—CURRENT EXPERIENCE

The War Nerve Injuries Clinic (WNIC) was established in 2004 by this chapter's senior author within the National Defence Medical Rehabilitation Centre at Headley Court (Epsom, Surrey). This ensured that almost all casualties with significant nerve injuries were seen in an acute rehabilitation setting after the completion of the early stages of reconstructive surgery at the base hospital—Queen Elizabeth Hospital, Birmingham. Most nerve repairs were carried out there at about 3 weeks from injury. Some suture repairs were performed in a field hospital at Camp Bastion in Afghanistan. Information about 651 nerve injuries (NI) in 250 patients was collected. Cases of transient conduction block (CB) where recovery was complete by 3-4 weeks were excluded.

The purposes of the WNIC included:

- Definition of accurate diagnosis and prognosis. This was the single most important step for many patients.
- Establishment of a diagnosis and cause of persisting or delayed onset neuropathic pain.
- Improve prognosis by nonsurgical methods, reduce joint contractures, and improve the texture and hypersensitivity of skin and scar.
- Undertake surgical procedures to relieve pain and improve the prognosis of nerves, some already repaired, whenever recovery was not progressing. Persisting neuropathic pain was a major indication in 104 (41.6%) of the 250 patients.

In a separate group of patients—those requiring revision of amputation stumps—persisting pain was an important indication in 47 patients (78 stumps). The outcome of these is considered separately from patients with nerve injury.

Severity of Injury

Although mortality among battle casualties has been reduced, the *morbidity* caused by injuries to the limbs and their peripheral nerves is profound. The severity of the injuries associated with nerve injury in this series is probably unparalleled. About 60% of the nerve injuries were caused by explosions, the remainder by fragments or gunshots. The injuries were massive energy transfers in 48%. The new injury severity score was higher, at 18.35, in survivors with nerve injury than it was in all surviving casualties (11.74).[19] Limb amputation occurred in 81 (32.4%) of the patients with nerve injury. There were 12 double and 4 triple amputations. Associated injuries in the same limb included fractures in 149 patients (59.6%) and arterial injury in 110 (44%). Soft tissue damage and its consequences was measured at the first presentation (eTable 30.1). Around 70% of patients sustained 2 or more nerve injuries.

The first operation is critical to the success of all subsequent reconstructive interventions. Rarely is postischemic fibrosis encountered, a tribute to the quality of treatment in field hospitals. An account of the principles underpinning the first surgical intervention can be found online at ExpertConsult.com. The essential elements of modern battlefield orthopedic surgery include:

- Interventions are time-limited and restricted to the identification and correction of life- and limb-threatening injuries.
- Early and vigorous resuscitation with blood products.
- Control and repair of major vessels with extensive decompression of muscle compartments.
- Vigorous pain control using high doses of opiates and continuous peripheral nerve blockade (CPNB).
- Prompt transfer to home nation's base hospital for definitive reconstruction.

eTABLE 30.1 Soft Tissue Injury[a]

Grade	Muscle Loss	Joint Contracture	Skin Loss
Moderate	ROM > 50% Strength 3-4	Loss of ROM 25-50%	Tethering to bone and muscle Loss of passive ROM in adjacent joints 25-50%
Severe	ROM < 50% Strength 0-2[b]	Loss of ROM > 50%	Tethering to bone or muscle Loss of passive ROM at adjacent joints > 50%
No. of patients and %	91 (36.4)	101 (40.4)	128 (51.2)

[a]Measured at first attendance before completion of active treatment.
[b]Strength is graded on the MRC muscle scale.
ROM, Range of movement.

Distribution and Diagnosis of Lesion

Of all nerve injuries, 56% were in the upper limb and 44% in the lower. The most commonly injured nerves were tibial, ulnar, common peroneal, median, and radial.[18,19] The sciatic trunk was studied by its two constituent main nerves. There were 32 cases of lumbosacral plexus injury—14 involved the brachial plexus. Our initial diagnosis for the predominant lesion of the whole nerve was a CB in 241 nerves (37%), axonotmesis in 259 nerves (39.8%), and neurotmesis in 151 nerves (23.2%). There were three causes of failure to match prediction of recovery:

1. The proportion of nerve fibers with unfavorable lesions (neurotmesis) was underestimated.
2. The extent of damage to the target tissues, particularly in the leg and foot.
3. The most common cause was the continuing action of a noxious agent that impeded, or even reversed, recovery.

Many of these lesions exemplify the slowly evolving anoxic prolonged CB of ischemia caused by constriction. Worsening pain or the onset of new pain accompanied by gradual loss of function were the hallmarks.

Prolonged Conduction Block

The characteristics of a prolonged CB caused by missile versus blast have been outlined previously. At final review, patient recovery was graded good in 94%, fair in 2.7%, and poor in 3.3%.

Axonotmesis

eTable 30.2 shows that this lesion was diagnosed by demonstrating continuity at the first operation, a progressing Tinel sign,

and sequential muscle recovery at intervals consistent with axonal regeneration. A secondary operation was performed on 32 patients (41 nerves) because of pain and failure to progress. Nerves were found to be constricted by ectopic bone, deep fibrosis, or fibrosis deep to split skin grafts. Of these 24 wounds required resurfacing with fasciocutaneous flaps. The outcome before and after second operations is also shown in the table. Pain relief was usual. This sometimes unmasked recovery that had been suppressed; in other patients spontaneous recovery resumed.

Repairs

The outcomes of 23 suture repairs and 103 grafts are summarized in eTable 30.3. The decision to reexplore the suture repairs was straightforward—on the basis of a static Tinel sign and/or pain. Three repairs were successfully revised. External neurolysis, supplemented by continuous PNB relieved pain in 5 patients who went on to regain at least useful function. The main indication for the reexploration of 19 grafts was pain. Eight grafts of median and tibial nerves were revised in the hope of recovering useful sensation—4 were successful. The chief reason for the high failure rate of the grafts was the condition of the bed and of the overlying skin. The fibrosis deep to split skin grafts often formed a vice around the nerves. Roganovic and Secer published their results from high, intermediate, and low repairs of the median and ulnar nerves from projectile, gunshot, and shrapnel injuries (eTable 30.4).[152,153,159]

Neuropathic Pain

In spite of the early and vigorous approach to pain control (outlined on ExpertConsult.com), we soon found that the analysis and treatment of neuropathic pain was a dominant component of the work of WNIC. It developed during the course of treatment and recovery in nearly all of the 104 patients (41.6%) who came for further surgical intervention. They had not responded to adequate trials of physical methods, drugs, and nerve blocks. The decision to reexplore was usually made in joint consultation with Lt. Col. D. Aldington, Director of the Pain Service at Headley Court, where many of the preoperative regional or plexus blocks were carried out; this contributed to diagnoses and to the reduction of diffuse pain and allodynia provoked by central sensitization.

Pathophysiological Basis of Neuropathic Pain

The events triggered by a nerve wound sweep centripetally from the site of injury through the proximal axon, the dorsal root ganglion to the dorsal horn and higher centers. At times, the symptoms and signs evoked by these changes appear so bizarre that they lead to suspicion that the patient is not of sound mind—a conclusion that is almost always wrong.

The changes were summarized by Wall and Gutnick[189,190]:

> *With a latency of milliseconds combinations of afferent signals and of descending controls operate a rapid and powerful gate control. With a latency of minutes, impulses in C-fibers change the excitability of peripheral endings and of spinal cord circuits. With a latency of days, chemical transport in C-fibers from areas of damage further modifies cord connectivity with a disappearance of inhibition and an expansion of receptive fields. With a latency of weeks and months, anatomical degeneration produces secondary changes in deafferented cells with atrophy, sprouting, and abnormal firing patterns.*

eTABLE 30.2 Axonotmesis—Effects of Revision Surgical Procedures

Grade	Before Second Operation No. of Nerves and %	After Second Operation No. of Nerves and %
Good	129 (50)	141 (54.4)
Fair	66 (25.5)	81 (31.3)
Poor	64 (24.5)	37 (14.3)

eTABLE 30.4 Median and Ulnar Nerve Repairs of War Wounds by Level

Delay in Excess of 3 Months Was Often Inevitable

Level	No. of Repairs	MOTOR: No. and %, M3 or Better	SENSORY: No. and %, S3 or Better
Median – Roganovic (2005)[153]			
High	20	4 (20%)	2 (10%)
Intermediate	55	15 (27.3%)	25 (45.5%)
Low	16	14 (87.5%)	11 (68.8%)
Ulnar – Roganovic (2004)[152]			
High	19	2 (22.2%)	1 (11.1%)
Intermediate	65	22 (33.8%)	38 (58.5%)
Low	44	37 (84%)	34 (77.3%)
Ulnar – Secer et al. (2007)[159]			
High	166	73 (44%)	72 (43.3%)
Intermediate	87	31 (35.6%)	55 (63.2%)
Low	154	127 (82.5%)	137 (89%)

eTABLE 30.3 Outcomes of the 126 Nerve Repairs

	BEFORE SECOND OPERATION			AFTER SECOND OPERATION		
	Good	Fair	Poor	Good	Fair	Poor
Suture repairs	9	7	7	15	8	0
Grafts	11	39	53	19	43	41
Total (%)	**20 (15.9)**	**46 (36.5)**	**60 (47.6)**	**34 (27)**	**51 (40.5)**	**41 (32.5)**

The consequences of these changes and their effects, as experienced by the patient, are outlined next:

- There is spontaneous firing in the cutaneous nociceptor and other afferent neurons. These are perceived as spontaneous painful sensory symptoms (i.e., dysesthesiae) such as constant burning, constant pins and needles, or paroxysmal shooting pains.[134,135]
- There is spontaneous firing of the neurons of the deep afferent pathway that causes the deep, poorly localized pain so characteristic after transection of the spinal accessory or long thoracic nerves.
- There is a lowering of the threshold to stimulus of nociceptor and other afferent neurons that contributes to hypersensitivity of the skin and sensitivity of the nerve to percussion.[139]
- There is axons and cell bodies sensitization in the dorsal root ganglion, and central sensitization within the dorsal horn. The response in the dorsal horn is amplified by loss of inhibition from peripheral afferents and central descending pathways, so receptive fields rapidly expand. This leads to the expression of pain beyond the distribution of the injured nerve and is heightened by new synapses within the cord such as the sprouting from low threshold and Aβ afferents terminating in laminae III and IV into lamina II to synapse with the high-threshold, smaller, nociceptor neurons.[140–142] This central sensitization leads to the spread of spontaneous and evoked pain beyond the territory of the injured nerve.
- The phenotype of the mechanoreceptors changes because of the altered expression of receptors and voltage-gated ion channels. This is the basis of allodynia, where normally innocuous stimuli begin to evoke pain.
- Afferent and efferent fibers in the sympathetic system, which are conveyed with the nerve trunks, are involved in the injury, affected by it, and may to some extent provoke or maintain symptoms and signs arising from abnormalities at the level of the lesion or more centrally. As Schott[143] observed, the diffuse and extensive central terminations of the visceral afferent fibers[146] and the potential for interaction with other systems, particularly at the spinal level, could account for autonomic and motor phenomena including tremor, dystonia, and more complex movement disorders. The convergence of visceral and somatic afferents into lamina V of the dorsal horn[147] underlies a very serious example of central sensitization, where bladder and bowel activity makes the pain of high sciatic or lumbosacral plexus lesions worse.

It is important to remember that the changes induced in neurons in the CNS by a peripheral lesion may be reversed by correction of that lesion.

Cellular and Molecular Events

Immunohistochemical studies have been done of tissues excised during operation for spontaneous pain, allodynia, and the hypersensitivity of skin and scar. The general pattern is one of Wallerian degeneration associated with abnormal regeneration of axons expressing nociceptive receptors (eFigure 30.1). The new axons grow into the epidermis and proliferate around blood vessels. There is a relative increase in nerve growth factor (NGF), which is essential for the survival and maturation of smaller sensory and nociceptive neurons, that sensitizes the relatively reduced number of new axons. The increased expression of the heat (and capsaicin) receptor TRPV1 may contribute to heat allodynia; the increased expression of the cool (and menthol) receptor TRPV8 similarly may move toward cool allodynia. These findings confirm and extend earlier civilian work.

Oaklander et al showed that complex regional pain syndrome (CRPS) type 1 is specifically associated with focal distal nerve injury and degeneration of small diameter axons. Skin biopsies from a patient with CRPS type 1 revealed a 29% reduction in the density of nerve terminals in skin affected by mechanical allodynia and heat pain.[139] Albrecht et al examined tissues from limbs amputated from two patients with CRPS and concluded that myriad clinical symptoms had detectable neuropathological correlates.[2] Nearly all components of cutaneous innervation demonstrated abnormalities.

Willner and Low set out some excellent guiding principles governing the treatment of neuropathic pain,[195] as follows:

1. Removal of the cause
2. Promotion of healing or regeneration
3. Correction of the microenvironment of the nerve
4. Restoration of afferent pathways
5. Reduction of sympathetic hyperactivity
6. Modulation of central inhibitory pathways
7. Alteration of pain thresholds by modification of emotional or behavioral components of pain interpretation

Neuropathic pain following a focal injury of a nerve will require surgery to correct the first 5, and nonoperative and pharmacologic measures for the last three.

Outcomes of Surgical Intervention

The characteristics of the three main syndromes—causalgia, neurostenalgia, and posttraumatic neuralgia—of neuropathic pain are described by Birch.[8] A good outcome meant the staged withdrawal of opiates and other drugs, return to the full program of rehabilitation or retraining, or to duty or work. A fair outcome enabled the patient to have a good night's sleep and to participate in rehabilitation and normal activities of daily living while continuing with appropriate medication. A poor result meant no measurable change.

Causalgia

Spontaneous resolution is a well-known feature of this terrible pain. It occurred in 13 patients who gave a clear history of onset within 48 h of injury and subsequent resolution by about 2 weeks (5.2%). Three patients required surgical intervention for delayed onset causalgia. The nerves involved were the lower trunk of the brachial plexus, the medial cord, and the median nerve in the axilla. In two cases there had been "blow out" of arterial repair because of secondary, fungal infection. In the third, infective nonunion of the clavicle led to fierce compression of the lower trunk. Correction of the cause, adequate neurolysis, and continuous peripheral nerve block (CPNB) maintained for at least three days relieved pain. Final recovery of nerve function was good in all three cases.

Neurostenalgia—58 Patients

There were three groups, as follows.

1. An intact or recovering nerve became constricted or irritated by a bone fragment, ectopic bone, retained suture, or other foreign material. Pain was relieved by adequate decompression for 11 of 13 patients and improved for 1 more. Nerve

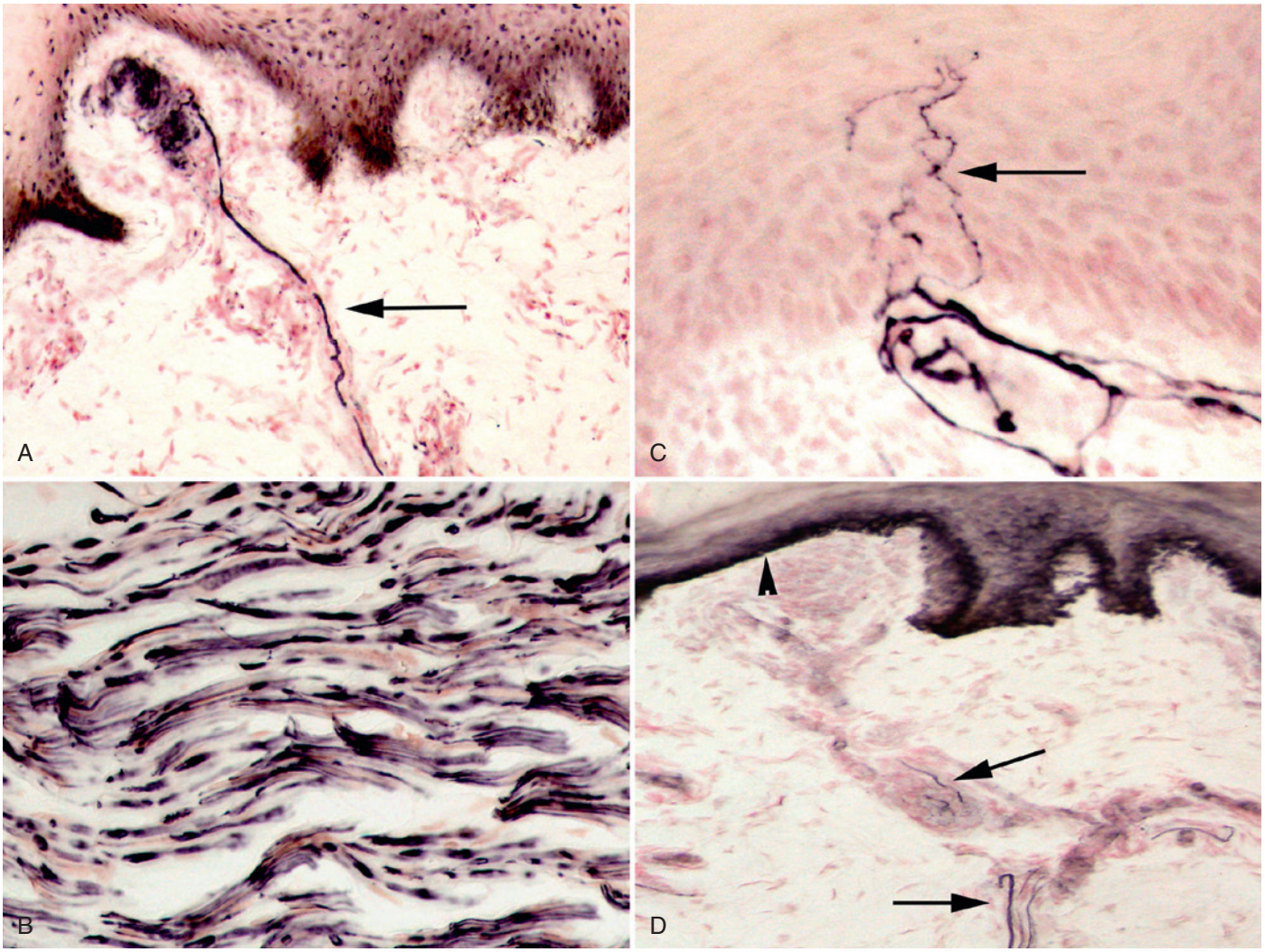

eFIGURE 30.1 Skin biopsy immunohistochemistry from a lower limb amputated for chronic allodynia. **A,** Subepithelial TRPM8 (cool and menthol receptor) fibers *(arrows),* ×40 magnification. **B,** PGP9.5 (structural marker) staining of injured nerve showing ovoid structures typical of Wallerian degeneration. **C,** Increased infraepithelial *(arrow)* and subepithelial TRPV1 (heat and capsaicin receptor) fibers ×40 magnification. **D,** Basal keratinocytes *(arrowhead)* and subepithelial NGF immunoreactive fibers *(arrows)* ×40 magnification. (Courtesy of Professor Praveen Anand.)

recovery was determined by the extent of intraneural disruption and the duration of action of the causal agent.

2. An intact or recovering nerve became compressed or tethered by a deep scar, sometimes related to a vascular repair or previous deep sepsis. Pain was relieved or improved for 6 patients. Its persistence in 1 was one factor in the patient electing below-knee amputation.
3. An intact, recovering, or repaired nerve became constricted by fibrosis deep to a split skin graft (SSG). Neurolysis, excision of scar, and overlying SSG with resurfacing by fasciocutaneous flaps was performed in 38 patients. Pain was relieved in 34 and improved in 2 more. Obliteration of the epineurial vessels was a common finding at exposure, and it was usual to see refilling of the vessels with a "blushing" of the compressed segment after decompression. Most patients reported improvement in the first 24 to 48 h after operation. Of all the patients, 51 reported significant relief of pain, 3 some improvement, and 4 no improvement. None of the patients thought that their situation had been made worse.

Posttraumatic Neuralgia—42 Patients

The following three patterns were identified:

1. Posttraumatic neuralgia (PTN) following injury to a cutaneous nerve. Multiple and often incomplete injuries to cutaneous nerves were common with blast wounds. Persisting PTN from lesions of the cutaneous branches of the common peroneal and tibial nerves was one factor leading to delayed amputation of 9 lower limbs after blast injuries. Nine patients had surgical treatment for cutaneous neuromas by resection of the neuroma or resection and implantation into muscles; of those 4 reported some improvement.
2. PTN and a painful scar. This was a very difficult problem in limbs with potential for good recovery but where cutaneous branches of the underlying main nerves terminated in scar or became tethered to SSG. Pain was improved for 3 patients by excision of the scar and resurfacing with a fasciocutaneous flap.
3. PTN from transection of a main nerve or after failure of repair. The poor state of the tissues surrounding the nerve

was the main cause. Scarring deep to SSG was important to 11 patients in this group. Treatment involved revision of scar, revision of arterial repair where necessary, repair or revision repair of the nerve, and provision of healthy skin cover. Pain was relieved in 9 patients. Pain was a main reason for revising 8 grafts, which improved 5 of them.

In all, pain was relieved or reduced in 29 of the 42 patients with PTN.

PTN in Amputation Stump

Amputation in the field hospital is done to save lives; this is not the place for elaborate reconstruction. Revision surgery to achieve a sound stable stump is inevitable. However, pain relating to the neuroma was a major factor in proceeding to revision surgery in 47 patients (78 stumps). The neuroma had become tethered in unhealthy tissue or distorted by bone fragments and heterotopic ossification. The important distinction between pain arising peripherally from that caused by central sensitization was made by:

- Worsening of sensory disturbance and pain by physical stimulation or prosthesis
- Presence of an intensely painful Tinel sign
- Abolition of pain by local anesthetic block of the proximal segment of the nerve
- Dystonia and other movement disorders
- Convergence of visceral and somatic afferent pathways after lumbosacral or high sciatic lesions

Revision operations involved excision of scar, bone spikes, ectopic bone, and thorough nerve decompression. Then, the nerves were cut cleanly so that the refashioned nerve lay deep to the deep fascia, preferably deep to muscle. Skin cover was provided by reorientation of existing flaps and, in 19 patients, by fasciocutaneous flaps. Pain was improved in 43 patients who were able to use their prostheses freely; it was unchanged in 4.

Central stimulation of the spinal cord or deep brain has been used in 8 patients with intractable PTN. Central stimulation may be anticipated when there is intractable neuralgia in a damaged limb, unrelieved by amputation, or when it is feared that amputation will make the situation worse.

Some General Lessons

The modern understanding of nerve lesions, Wallerian degeneration, regeneration, and the factors governing those processes comes from the principles and techniques of nerve surgery gained in war experiences. Some lessons of general interest can be drawn from recent involvement, none of them is new! The tasks of any nerve injury clinic, particularly one that receives patients with severe or multiple injuries, are as follows:

- Establish an accurate diagnosis, plan, and prognosis. The Nerve Injury Clinic is a pain clinic. It must diagnose the cause of persisting neuropathic pain and then institute a rational plan of treatment. Ideally, a physician with particular experience with medication and regional blockade will be a member of the team; close cooperation with such a physician is next best.
- Subspecialization risks fragmentation. A patient is not helped by traveling back and forth, seeing different doctors in various clinics, sometimes receiving conflicting advice. There should be one physician in overall charge who acts as the conductor of the orchestra.
- Nerve repair and, in particular, grafts must be deferred until there is healthy skin cover.
- Revision of stumps for which amputation was done as an emergency should be planned.
- Causalgia and neurostenalgia respond well to correction of the cause.

The treatment of posttraumatic neuralgia, particularly that arising from cutaneous nerves, was the most difficult and unsatisfactory among the three main syndromes.

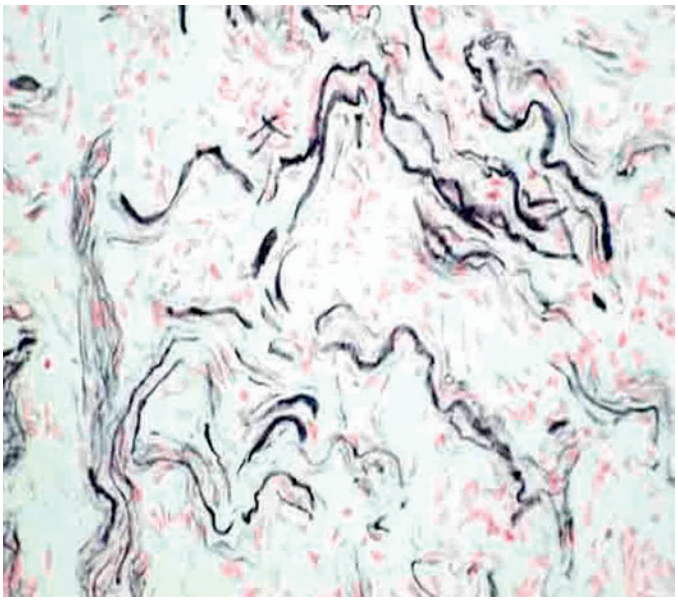

FIGURE 30.23 Image of a painful cutaneous neuroma. The organization of the nerve fibers, which are immunoreactive for nerve growth factor, is chaotic (original magnification ×40).

stump after it has been divided in situations in which regenerating axons are impeded from reentering the distal stump. The swelling of the terminal bulb of the proximal stump that ensues contains Schwann cells; fibroblasts; blood vessels; and, above all, numerous regenerating axons that are partially myelinated or not at all myelinated. The normal organization into bundles is replaced by chaos (Figure 30.23).

Severe and persisting pain arising from a neuroma is unusual; most clean transections of major nerves do not provoke severe neuropathic pain. Two processes provoke severe pain in relation to neuromas. The first is persistent mechanical or chemical irritation of the axons within the neuroma. The second is the development of spontaneous and disturbing sensory symptoms caused by persistent stimulation of the axons within the neuroma and accompanied by the development of spontaneous activity of neurons within the DRG, within the dorsal horn of the spinal cord, and even at more proximal levels within the CNS. Severe pain from neuromas is more likely after partial injuries to nerve trunks, and it is a particularly serious problem after injuries to the terminal branches of nerves of cutaneous sensation, including the medial cutaneous nerve of the forearm, the superficial radial nerve, the sural nerve, and the long saphenous nerve. It is a remarkable and unexplained fact that clean removal of these nerve trunks for the purpose of repairing a major nerve is very rarely attended by severe pain, whereas significant pain is really quite common after accidental damage to the terminal branches of these same cutaneous nerves.

In complete or terminal neuromas, the nerve trunk has been divided. The term *partial neuroma* or *neuroma in continuity* is applied to nerves in which some bundles are intact, and it is in these nerves that the possibility of resecting the damaged portion and repairing it seems logical. Neuromas in amputation stumps present a particular problem because there is no possibility of reconnecting the divided nerves with the peripheral stumps.

CRITICAL POINTS *Diagnosis of Neuropathic Pain*

- Distinguish between spontaneous symptoms, painful or otherwise, and evoked pain such as allodynia.
- Note any extension of pain beyond the proper area of the nerve.
- Close analysis of the patient's description combined with physical examination enables the clinician to recognize distinct patterns or syndromes of neuropathic pain.

Pathophysiology

Terms that are commonly used include the following:

- *Paresthesia*, or a spontaneous abnormal sensation
- *Dysesthesia*, or an unpleasant spontaneous normal sensation
- *Hyperesthesia*, or increased sensitivity to a stimulus that would not normally be painful
- *Hyperalgesia*, or an increased response to a stimulus that is normally painful
- *Allodynia*, or perception of a nonpainful stimulus as painful
- *Hyperpathia*, or a state of exaggerated and very painful response to stimulation

Pain from a neuroma is one subtype of neuropathic pain caused by a lesion of the nervous system, usually the peripheral nerves.

For more information, see the Neuropathic Pain section on ExpertConsult.com.

Some neuropathic pain states are exceptionally severe, and they are characterized by persistence, intractability, disproportion between the extent of the lesion and the severity of the pain, and the fact that the pain is no longer necessary for survival of the organism. Neuropathic pain usually is associated with sensory or motor disturbance and quite often with sympathetic dysfunction. The sensory symptoms described by patients are sometimes so clear that diagnosis of the cause and some understanding of the subsequent pattern of physiologic events are possible from the person's history alone. (For a detailed discussion of the diagnosis and treatment of neuropathic pain and complex regional pain syndrome [CRPS], see Chapter 53.)

The spontaneous symptoms of neuropathic pain indicate that there is spontaneous firing of nerve fibers within the neuroma itself or within the neurons of the DRG, the dorsal horn of the spinal cord, or higher, or within both the neuroma and neurons. Michaelis and coworkers provided one explanation for the spontaneous deep-seated pain that is often so severe.[124] Nerves to the rat gastrocnemius were sectioned, which induced bursting—spontaneous discharges from neurons of the DRG. The conduction velocity, ranging from 5 to 30 m/sec, indicated activity in the axotomized myelinated afferents from the muscle. These authors commented that "these findings provide evidence that after peripheral nerve injury, both axotomised as well as intact afferent neurones from skeletal muscles … generate ongoing activity within the DRG." The situation is analogous to bursting or electrical pain seen after avulsion injuries of the brachial plexus—such pain can be terrible. Here, of course, the spontaneous activity occurs inside the neurons situated within the dorsal horn of the spinal cord.

Mechanical allodynia can be very severe in patients with painful neuromas, and one possible mechanism for this was described by Woolf and coworkers; they described the highly

ordered segregation of primary afferents in the dorsal horn of the spinal cord of rats.[198] Low-threshold mechanoreceptors terminate in laminae 3 and 4, whereas high-threshold nociceptors terminate in laminae 1 and 2 and in 5. After ligation of the sural nerve, low-threshold Aβ afferents were shown to sprout into laminae 2. Woolf et al commented that "if the low-threshold mechanoreceptive afferent terminals that sprout into lamina 2 establish functional contacts with cells that normally would have a monosynaptic nociceptor input, this could lead to inappropriate responses to innocuous peripheral stimulae."

At the same time, there is often continuing provocation of nociceptor fibers by the persisting action of the noxious agent and by the effects of local inflammatory agents that sensitize axotomized nerve fibers, as shown by Wall and Gutnick in studies of fundamental importance.[189,190] This reminds one of the account of the first Lord Nelson, who suffered constant "stump" pain after the amputation of his right upper limb through the arm. Years afterward, the pain was suddenly relieved when the ligature around the median nerve came loose and was discharged through the wound. Perhaps the best explanation for the immediate onset of disproportionate neuropathic pain comes from Lawson, who related that inflammatory mediators can reduce the activation threshold of voltage-gated sodium channels expressed in the small- and medium-sized DRG neurons, most of which are nociceptors, within minutes or hours.[104]

Clinicians have learned to be wary of systems of classification that seek to provide a unitary hypothesis for various neuropathic pain states. The term *reflex sympathetic dystrophy* was only slightly less unsatisfactory than "sympathetically maintained pain" and "sympathetically independent pain." Events may show that classification into CRPS types 1 and 2 may suffer the same fate. CRPS type 1 assumes no injury to a peripheral nerve, but this was discounted by Oaklander and colleagues, who demonstrated extensive axonopathy in demyelination in cases thus labeled.[139] These findings have been confirmed by other investigators. CRPS type 2 is extremely unsatisfactory, for it is so far-reaching as to be meaningless. The authors have seen far too many patients who were labeled with these "diagnoses" and subjected to months or years of useless or even harmful treatment with drugs and various forms of nerve blocks.

Pain states caused by iatrogenic injuries to cutaneous nerves often prove resistant to all forms of treatment. Piling of treatment onto treatment in pain clinics usually makes patients worse. The cause is both central and peripheral. Centrally, there is alteration of the mechanisms of analysis and modification of impulses. Peripherally, there is alteration of incoming impulses because of loss of the normal pattern of cutaneous innervation. Axonal sprouting from adjacent cutaneous nerves may cause further confusion of the pattern of innervation.

An excellent review from Gold outlines some of these mechanisms.[64] The model studied was ligation of spinal nerves in mammals. Gold summarized the evidence that allodynia, hyperalgesia, and spontaneous pain occur because of changes in the primary afferent neurons in the DRG. The allodynia and hyperalgesia arise from uninjured afferent fibers; the constant spontaneous pain arises from injured afferents. Repair seems to be particularly appropriate when pain spreads beyond the territory of the nerve, with allodynia and even hyperpathia in adjacent skin. Here, the only possible way to rectify the situation is to restore volleys of afferent impulses from reinnervated skin and thus hope to reverse the changes in the dorsal horn.

Prevention

Treatment of a painful neuroma is deeply unsatisfactory. The number of operative techniques described is so large that it is clear that not one is wholly reliable. Prevention is best. A painful neuroma is a rare occurrence after well-executed suturing of a transected nerve, particularly when attention has been paid to restoring the gliding plane for the nerve and repairing the damaged adjacent tissue. Tupper and Booth found that a well-sealed epineurial repair of a severed nerve rarely resulted in a painful neuroma,[188] and Herndon and Hess[80] believed:

> *When operating on or near nerves, prevention of injury in neuroma formation should be foremost in the surgeons' mind … great care [should be] taken when working around nerves to prevent the iatrogenic injury during exploration. This is especially true for such operative procedures as ganglion excision at the wrist or release of the first dorsal compartment in de Quervain's tenosynovitis.*

This advice should be remembered by all clinicians during operations and applied during surgery on the elbow, the knee, the ankle, and the foot (Figure 30.24).

Treatment

A painful neuroma may not be the sole explanation for a patient's loss of function and, in itself, is not an indication for surgery. As Dobyns advised, the clinician should take time to establish the diagnosis and elicit important background information about the cause of the injury, as well as contributing factors, including possible litigation and compensation.[49]

Occupational therapists can be asked to see these patients and provide a measure of the functional disturbance. Advice can be given about how to maintain the body part taking the

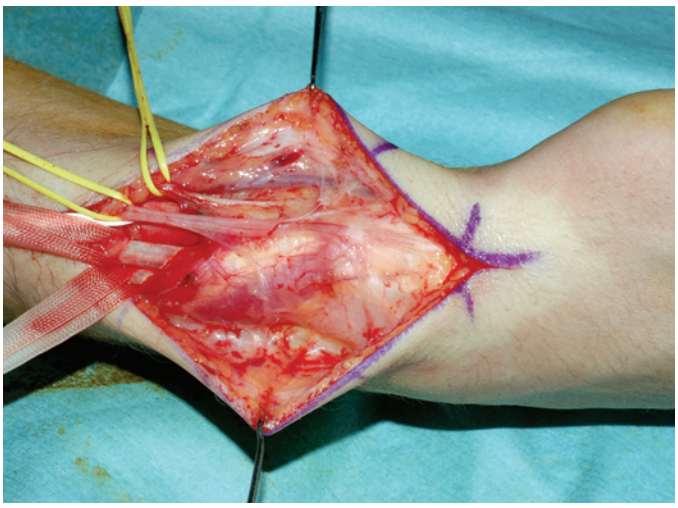

FIGURE 30.24 The wrist is a dangerous area. The lateral cutaneous nerve to the forearm (*above*) and the superficial radial nerve (*below*) lie in close relationship to the tendons on the radial side, which is illustrated here during the course of tendon transfer. The *white sling* marks the tendon of the brachioradialis; the two tapes mark the tendons of the extensor carpi radialis longus and extensor carpi radialis brevis.

TABLE 30.19 1975-2000 Operations for Painful Neuromas of Cutaneous (Sensory) Nerves

Nerve	No.	Neurolysis	Repair	Resection With or Without Translocation
Upper Limb				
Supraclavicular nerve and cervical plexus	16	4	7	5
Medial cutaneous nerve of the forearm	49	12	16	21
Medial cutaneous nerve of the arm—internal brachial	3	2	1	
Superficial radial nerve	136	18	82	36
Lateral cutaneous nerve of the forearm	6	2	2	2
Palmar digital nerve	185	20	128	37
Palmar median nerve	12	2	10	
Dorsal cutaneous ulnar nerve	13	5	5	3
Total	**420**	**61**	**244**	**115**
Lower Limb				
Lateral cutaneous nerve of the thigh	11	5	2	4
Sural nerve	35	8	13	14
Saphenous nerve (including the infrapatellar branches)	31	11	10	10
Plantar cutaneous nerve	26	4	17	5
Terminal branches of the common peroneal nerve	24	4	10	10
Total	**127**	**32**	**52**	**43**

activities of daily function into account. Simple padded finger stalls—used to cover one or more fingers in situations where a full glove is unnecessary—can ease the situation of a hypersensitive or tender digit. Custom-made padded straps can protect a neuroma of the superficial radial nerve or palm, or cutaneous or median nerve, from mechanical irritation.

A trial use of TENS will do no harm. It has been found to be useful only occasionally; in fact quite a number of symptoms of painful neuromas are exacerbated by the TENS technique. Such nonoperative practices (e.g., taping, percussion, massage, or ultrasound) do no harm and may help patients "take charge" of their problems. Wynn Parry described extensive experience in the treatment of painful neuromas using a vigorous program of desensitization and functional retraining, supplemented by blocking of the affected nerve with local anesthetic or guanethidine—a sympatholytic drug.[199]

Chemical Methods

A number of sclerosing agents have been used in an attempt to suppress axonal regeneration. Smith and Gomez injected triamcinolone with local anesthetic directly into the neuroma and surrounding tissues.[167] The treatments were successful in half the patients after a single injection and in 80% after multiple injections. Thirty-four neuromas in 22 patients were treated. The technique was less successful when used for deeper neuromas in the palm and wrist; it seemed to be most effective for digital neuromas. The authors have no personal experience with this technique; some patients referred after trying it found the method too painful to continue.

Operations

General Principles. Tables 30.19 and 30.20 present the number of operations performed for injuries to nerves of cutaneous sensibility. Over half were for nerves damaged in the course of surgery or other interventions. The consequences of iatrogenic damage to tiny cutaneous nerves can be particularly severe. In most cases the nerves were cut, although sometimes they were ligated and then cut. These patients experienced spontaneous or induced pain, hyperesthesia and hyperalgesia, and even allodynia and hyperpathia. One patient was seen who eventually underwent amputation of an upper limb for persistent pain after damage to the superficial radial nerve at the wrist. In that particular case, refusal of the defendant (i.e., clinician) to agree to a reasonable early settlement was a significant factor in prolonging and magnifying the patient's complaints.

TABLE 30.20 Operations for Iatrogenic Injuries to Nerves of Cutaneous Sensibility

Nerve	No. of Nerves
Neck and Upper Limb	
Supraclavicular nerve and cervical plexus	11
Medial cutaneous nerve of the forearm	15
Superficial radial nerve	92
Palmar, including the palmar cutaneous branch of the median nerve	42
Dorsal branch of the ulnar nerve	11
Total	**171**
Lower Limb	
Lateral cutaneous nerve of the thigh	8
Saphenous nerve, including the infrapatellar branch	21
Sural nerve	24
Plantar nerve	21
Terminal branches of the common peroneal nerve	16
Total	**90**

A partial neuroma is a common and difficult problem. Usually, neurolysis with a 24- to 48-h infusion of local anesthetic is

advisable, during which time the patient is encouraged to move the body part with the aim of restoring nerve gliding. This can be very effective for nerves tethered by a focus of scar. If the procedure fails, consideration is given to resection and repair or repair and translocation. Gould described a very logical and systematic algorithmic approach that includes nonoperative methods.[68] The nerve is blocked with local anesthetic, followed by a course of antiinflammatory and membrane-stabilizing agents combined with desensitization and other therapy techniques. If this fails, surgery in which neurolysis is combined with wrapping of the nerve by a vein or a vascularized fascia is performed. Gould evaluated implanted nerve stimulators in a helpful way.[67] Excision of the nerve is reserved for those with recalcitrant nerve pain.

❖ AUTHORS' PREFERRED METHOD OF TREATMENT

The primary aim of surgery is to reconnect, whenever possible, the central and distal stumps of the damaged nerve so that regenerating axons can propagate to their proper targets. Surgical repair offers the chance for restoration of the normal afferent volleys of impulses and thus restores the ordinary inhibitory effects of these impulses on central neurons. If reconnection is impossible, the damaged proximal stump must be moved to a less unreceptive and a less exposed place. Translocation of the proximal stump into other tissues, such as muscle, may permit a new connection between regenerating axons and the host tissue.

The principles of surgery on nerves were described earlier in this chapter. These steps apply in the exposure and treatment of a neuroma. A tourniquet is useful. Particular care is needed in exposing the damaged nerve, and it is better to reveal that trunk proximally, in healthy tissue, and then work distally to the site of the lesion. The nerve must be handled with exacting care and traction avoided. Specific attention must be paid to the nerve bed, and wherever possible the quality of that bed should be improved by excision of any scar so that the repaired nerve can lie on healthy tissue, preferably synovium or fat. If the bed is unsuitable or the distal stump is beyond salvage, the affected nerve should be ligated with a suture and the neuroma excised; the nerve is then transposed completely proximal to the zone of injury and buried deep within a muscle belly.

It has been our practice, for a number of years, to infiltrate the line of the incision with local anesthetic before cutting the skin. This is extended in the treatment of a painful neuroma by leaving an indwelling catheter adjacent to the proximal stump, thereby permitting infusion of local anesthetic for a minimum of 24 h after surgery. We use an epidural catheter that is taped securely to the skin. Local anesthetic (0.25% levobupivacaine) is administered by bolus injections at 4-h intervals or by continuous infusion. It is essential that the injured limb be used from the outset, and postoperative splinting must do no more than protect the repaired or transferred nerve. The patient should be encouraged to move the fingers, to massage them, and to use them during the very early postoperative phase.

Operations for Terminal Neuroma. The many techniques described for dealing with neuromas can be broken down into four groups: (1) secondary repair or grafting, (2) resection of the neuroma, (3) containment of the neuroma, and (4) translocation of the neuroma.

Repair of the Nerve. The ideal method of treatment is the one that restores a normal input of nonpainful impulses. The principle of restoring continuity to a nerve, if the proximal and distal stumps are available, is recommended by many authors and we agree. Repair permits orderly regeneration of axons and contains them in a nonhostile environment thus ensuring the lack of a symptomatic neuroma. Furthermore, this process is capable of reversing many of the changes that occur along the peripheral nerve and in the CNS.

Guse and Moran reviewed 66 patients at an average of 240 months after their operations.[71] Of those, 11 were treated by transposition into muscle or bone, 17 by simple excision, and 28 by repair. Failure was defined as continuing severe pain; the requirement for a further operation; and a disabilities of the shoulder, arm, and hand (DASH) score greater than one standard deviation beyond the patient population mean. The failures were: 5 of 11 (45%) of the transpositions, 10 of 17 (59%) of the excisions, and 5 of 28 (18%) of the repairs. For the painful radial neuroma in the forearm, universal agreement on nerve repair was lacking. Kim et al found that resection of the proximal segment is preferable to repair; 16 of 19 patients so treated experienced significant pain relief.[90]

In some cases repair is not possible, the most obvious ones being amputation or an atrophied distal stump. There is, too, the problem of injuring another nerve when the gap between healthy surfaces demands a graft. An FTMG is considered to be a significant advance. Thomas et al[180] described results in 50 cases. Most of the patients had been through prolonged courses of nonoperative treatment, and some had had prior surgical treatment. Results were better in the upper than in the lower limb where 73% (11 of 15) of cases showed improvement or elimination of pain symptoms (for 4 of these some sensation was restored) in comparison to only 28% (2 of 7) of cases in the lower limb where pain was reduced. Failure was frequent when the gap was longer than 4 cm. This is the preferred technique for the upper limb where the defect is, at the most, 4 cm.

CRITICAL POINTS *Excision of Neuroma and Repair by FTMG*

- After preparation of the nerve a nearby muscle is exposed. Palmaris longus and flexor carpi radialis are suitable in the upper limb.
- A block of muscle is cut parallel to the fibers that must be at least 2½ times the length of the nerve defect.
- The muscle is wrapped in aluminum foil and placed in liquid nitrogen until effervescence ceases (~45 s). The package is then placed in sterile saline at room temperature for at least 3 min to encourage further cellular lysis through osmosis.
- The graft always contracts to about half of its fresh length. Fragmentation is a problem in grafts >3 cm in length.
- The graft is now cut to size using vascular scissors, allowing about 20% excess in length and diameter. It is sutured to the proximal and distal nerve stumps. Fibrin clot glue is used to seal the suture lines.
- The repair is immobilized the same as for a graft (Figure 30.25).

Repair by Synthetic Conduit. Should the gap between proximal and distal nerve stumps be too large for an FTMG, we find it difficult to argue that sacrificing one sensory function is justified to restore another. Dividing another sensory nerve (with

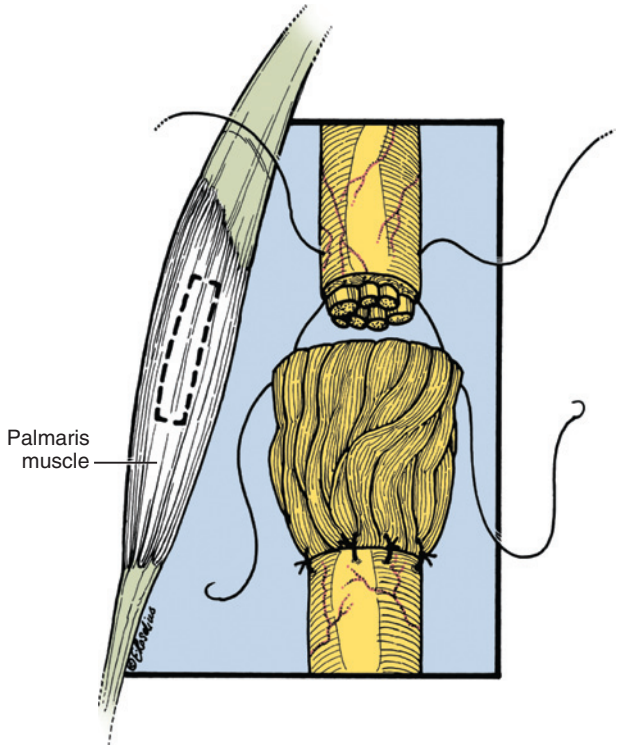

FIGURE 30.25 Freeze-thawed muscle graft: The neuroma has been resected so that healthy, pouting faces are displayed. A block of muscle has been taken from the palmaris longus, and surgeons aim for a length of muscle at least 2× as long as the defect in the nerve to allow for shrinkage. After freezing and thawing, the block of muscle tissue is lightly sutured between the nerve faces. The diameter of the muscle block is greater than that of the recipient nerve. As always, tension must be avoided. (© Elizabeth Martin.)

CRITICAL POINTS *Neuroma Excision and Conduit-Assisted Repair*

- The neuroma is identified and freed from scar.
- Resection of the two ends is made back to healthy, pouting fascicles. The maximum length of the conduit is 30 mm and the gap should be several millimeters less.
- The conduit is prepared for application by immersion in body temperature Ringer's lactate until soft and pliable. The prepared ends of the divided nerve are brought into a conduit with a slightly larger diameter and held with two opposing sutures of 9-0 or 10-0 nylon through the epineurium and the collagen conduit.
- The repair is protected the same as for a graft.

Resection of the Neuroma

There are strict indications for using this procedure:

- Persistent pain and dysesthesia
- No hope of reuniting the damaged nerve
- Palpable tender neuroma in the line of the damaged nerve
- Presence or possibility of irritation of the neuroma by adherence to moving muscle or tendon
- No suggestion of symptom magnification by the patient
- No previous excision of neuroma

the chance, however small, of creating another neuroma) to attempt to recreate the function of another seems to be inviting worsening of the problem. This is particularly true if there has been central sensitization into other cutaneous territories.

It is our standard practice, whenever possible, to use a conduit to restore continuity across a symptomatic neuroma. Thomsen et al showed success with this approach, gaining a 100% rate of removal of pain, a 50% rate of good or excellent recovery of sensory function, and a 60% rate of the cohort with no cold intolerance.[183] In our series of 40 such repairs, 77% (31 of 40) of cases have been successful in removing the painful symptoms of a neuroma, while nearly half had return of useful sensory function at 2 years. When taken alone, the 18 upper-limb cases had a success rate of 89% (16 of 18) in removing neuroma pain. In cases where the conduit repair failed to relieve pain, symptoms were improved by secondary surgery—relocating the neuroma to muscle—for 6 of 9 patients. In restoring continuity across the neuroma there is still the fall-back option of revision surgery to cut the nerve and translocate the neuroma.

It is best to excise the neuroma with the terminal 10 cm of the proximal nerve so that the distal end of the proximal stump lies in more or less unscarred tissue and, if possible, in unscarred muscle. A new neuroma is, of course, bound to develop; one can only hope that it will not grow at such a site or to such a size that it causes trouble.

Containment of the neuroma. A number of methods have been described to contain the fascicles within the nerve trunk and thus reduce cellular and axonal proliferation.[176] Kline and Hudson suggested sealing the ends of the fascicles with bipolar diathermy.[93] Herndon reviewed methods of ligature and epineurial closure.[78,80] Tupper and Booth described resection of fascicles within a sleeve of epineurium that is ligated.[188] Forty-five neuromas in 28 patients were treated in this manner, and there was considerable improvement in symptoms in 81% of them. Tupper and Booth thought that this method was better than simple neurectomy, but they stated that the number of cases was too small for the results to be considered conclusive.

Epineurial sleeve. With the use of the microscope, the nerve is transected proximal to the neuroma. The epineurium is then carefully peeled back over the nerve trunk. Each fascicle is identified and individually sectioned 1 cm proximally. The empty epineurial tube is then double-ligated with 6-0 nylon. The nerve end is subsequently placed in adjacent healthy tissue (Figure 30.26).

Martini and Fromm also created an epineurial sleeve and then sealed it with Histoacryl® glue (butyl-2-cynoacrylate).[118] They compared this method with others, including simple nerve ligation and epineurial ligation and found that the smallest number of painful neuromas formed in subjects in whom the glue was used.

Translocation of the nerve

Without excision of the neuroma. This method was introduced by Herndon and colleagues, who recommended it when the distal portion of the severed nerve was absent or irreparable so that repair could not be performed.[79] Every effort is made to keep the neuroma intact with its mature encapsulating scar while transposing it en bloc to another area free of scar and not subjecting it to repeated trauma.

The neuroma with its fibrous capsule is carefully isolated. A proximal area that is free of scar and away from local trauma is selected, preferably deep to a muscle, in a web space, or between the shafts of adjacent metacarpals. A dorsal site is preferable to a palmar location, which might lead to pressure on the

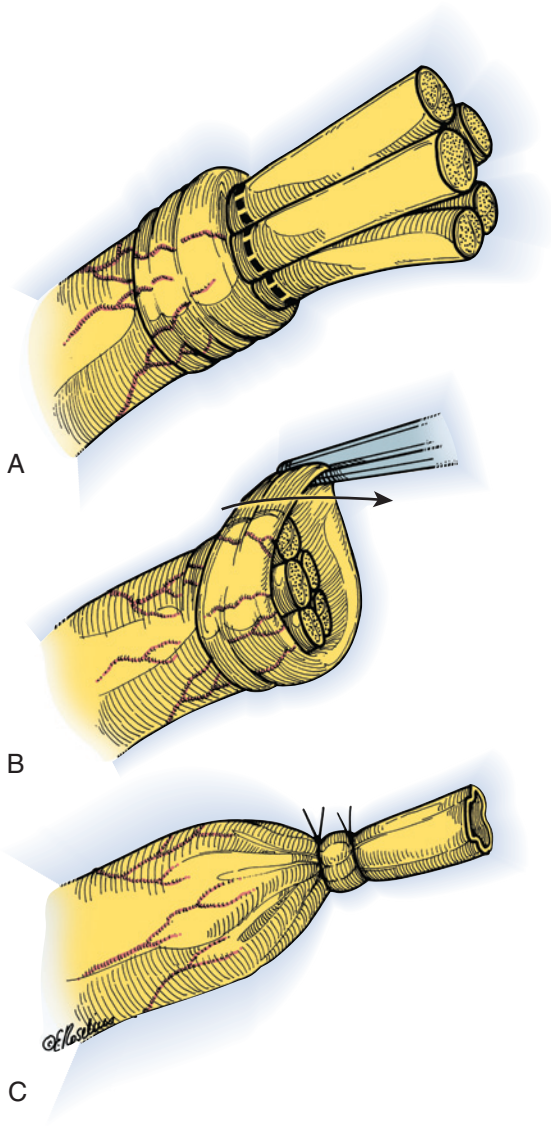

FIGURE 30.26 The neuroma has been excised (**A**) after the epineurium was pushed back. It is then drawn over the freshly cut bundles (**B**), and then the epineurial sleeve is ligated (**C**). (© Elizabeth Martin.)

neuroma with manual activity such as the gripping of tools (Figure 30.27).

The neuroma with its nerve is then carefully dissected proximally until the neuroma bulb can be transferred to its new location without tension on the nerve. A fine absorbable suture is then placed through the capsule (not the neuroma) and tied. Another knot is tied 3 to 4 mm away from the neuroma. The free ends of the suture are then channeled subcutaneously and passed through the skin proximal to the location selected for the neuroma. This suture is drawn through the skin and tied while maintaining a 3- to 4-mm separation between the dermis and the neuroma. The nerve trunk is carefully examined to make certain that no tension or twisting exists along its path. A similar technique is used when the neuroma is buried in muscles. For neuromas in the finger stumps, it is preferred to transfer the nerve end into the web space; for neuromas in the palm, the nerve ends are transferred to the dorsum of the hand between the metacarpals.

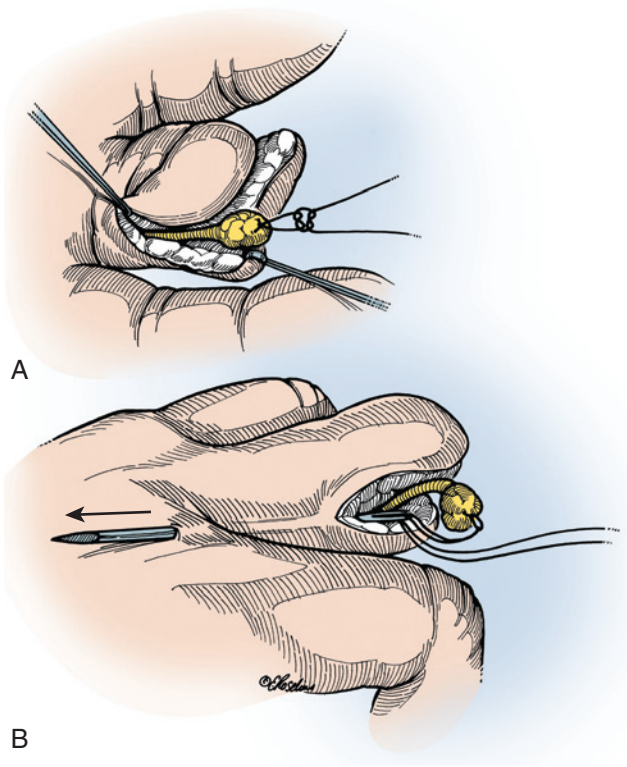

FIGURE 30.27 Translocation of a neuroma: With this technique the neuroma is not excised; it is mobilized with the nerve (**A**) and then drawn backward into proximal healthy and unscarred tissue (**B**). The nerve must lie loosely and tension must be avoided. (© Elizabeth Martin.)

The authors have not used this method but can see that it is logical in cases in which pain from the neuroma is obviously related to compression or to mechanical stimulation. The technique avoids the risk of igniting further neurophysiologic changes by inflicting another lesion on the damaged peripheral nerve. Success is less likely when there is spontaneous pain in the skin beyond the proper territory of the damaged nerve.

Transposition into bone. The nerve end may be implanted within the medullary canal of bone. A high rate of success was achieved by Mass and colleagues[119] and by Goldstein and Sturim.[66] This operation aims to contain the nerve stump within a compartment, thus restricting the size of the neuroma and also protecting it from direct trauma. These authors emphasized some important technical details:

- There should be adequate mobilization of the nerve.
- There should be an absence of tension on the transferred nerve.
- The nerve should not be angulated where it enters bone.

It is unwise to implant the nerve just distal to a joint that will inevitably subject it to traction. Hazari and Elliot have considerable experience with this method in the treatment of digital neuromas.[77] Their current practice is to relocate nerves into metacarpals except in cases of very distal injury because this reduces the risk of traction on the transferred nerve.

Transposition into vein. Balcin et al found that transposition of the proximal nerve into a vein led to neuromas that appeared more orderly and less florid.[5] The method was more reliable than transposition into muscle in distal lower-limb neuromas. The technique secludes the nerve from surrounding

tissues, and it is possible that the vascular endothelium is less receptive to regenerating axons than skin or subcutaneous tissue. The nerve is inserted in a retrograde direction so that the valves do not block the nerve's stump and potentially provoke a disorganized neuroma.

Koch followed 25 patients for an average of 43.6 (19-64) months.[97] There were 17 upper-limb neuromas and 8 in the lower limb. Pain was diminished in 23 of 25 patients. Our own experience with this technique in 26 cases of lower-limb neuroma is encouraging, with all patients experiencing decline or relief of their pain. One patient, with a saphenous symptomatic neuroma, came for another operation because we had failed to detect smaller branches close to the distal end had also become neuromatous.

Transposition into a conduit. Painful neuromas in the foot and ankle, especially the calcaneal nerve, are disabling and very difficult to treat. In an impressive recent study, Gould et al used collagen type 1 conduits to encase the nerve stump and lead them way from pressure and entrapment areas.[69] This usually involved placing the conduit from the plantar area toward the dorsum. These authors underscored the importance of ensuring that the tube not be so loose that the nerve escapes nor so tight that a neuroma develops at the point of entry. Fifty patients (69 nerves) were treated, including many with aggravated pain after excision of a so-called Morton's neuroma; there were 4 calcaneal neuromas. The average follow-up was 36 months (6-55). Pain was eliminated in 24 patients (48%) and considerably reduced in 13 (26%). Of the patients with calcaneal neuromas, 3 of 4 were relieved of their pain. Pain got worse in 3 cases; 2 saw a decline by sympathetic block and the third by dorsal column stimulation.

Silicone tubes. Dahlin and Lundborg reviewed the use of tubes for peripheral nerve repair.[43] They also related their preliminary experience in using silicone tubes for the treatment of painful neuromas. The concept was based on observations from experimental morphologic studies. These authors indicated that when a proximal nerve end was introduced into a silicone tube or a mesothelial tube that exceeded a critical length, and lacked a distal nerve segment, no or limited axonal regeneration occurred inside the tube. The proximal nerve end extended only a few millimeters into the tube and formed a cone-shaped structure without forming a true neuroma.

This nerve structure does not show the typical neurophysiologic characteristics, such as spontaneous activity, of a painful neuroma. The axons growing into such tubes remain quiet. A number of painful neuromas have been treated with the preceding method, with the silicone tubes being at least 20 mm in length. Dahlin and Lundborg related that most of their patients reported improvement or, in some cases, substantial relief from neuroma pain.[43]

We have no experience with these techniques; our aim is to restore neuronal continuity if possible but if not prefer to locate the encapsulated neuroma or the cut nerve end into muscle. We do not see the advantage to introducing foreign material to contain the neuroma when there are endogenous tissue options—muscle primarily, but vein if this is not possible.[97]

Translocation of nerve into muscle. Promising work comes from Dellon and Mackinnon, who found that relocating the superficial radial nerve into the undersurface of the BR was an effective way of treating neuromas.[46] Evans and Dellon successfully treated 13 end-neuromas of the palmar cutaneous branch of the median nerve by translocation into the pronator quadratus.[54] Patients required immobilization of the wrist for several weeks and some for several months. In most patients spontaneous pain disappeared, pressure pain was abolished, and the end result was great improvement. Atherton and colleagues suggested that the success of this method rests on moving the nerve from NGF-rich areas (i.e., the skin and subcutaneous areas) to NGF-poor areas (i.e., bone and muscle).[4]

Elliot and Sierakowski reported on the outcome of relocation of 158 symptomatic neuromas of the wrist and hand that were implanted into hand intrinsic muscles, brachioradialis, or pronator quadratus.[53] They stated that 90% of patients reported improved symptoms. Interestingly, 14 of 158 (9%) of patients continued to have symptoms at the original site after relocation (10 were classified as severe). This illustrates the challenging nature of diagnosis as to which nerves are contributing to the symptoms and also the limited options for treatment available in such cases.

We translocate the injured nerve stump into muscle for cases in which repair is not possible, when there is no distal stump, or when the site of repair would be so close to the skin that mechanical sensitivity would persist. The method has been used in more than 30 cases of terminal neuromas of the superficial radial and the palmar cutaneous nerve of the median nerve, the infrapatellar branch of the saphenous nerve, and branches of the sural nerve and the superficial division of the common peroneal nerve close to the ankle. No patient has been made worse; most experienced useful improvement.

CRITICAL POINTS *Neuroma Excision and Transposition into Muscle*

- A conscious choice is made that restoring continuity across the nerve lesion is not practical.
- The neuroma is exposed, and the parent trunk is gently mobilized at least 10 cm proximally, avoiding traction.
- The neuroma is sectioned so that a healthy face with pouting bundles is seen.
- The nerve is neurolyzed proximally so as to free a significant length of it (~4 cm).
- The free length of nerve is used to identify the point on a local muscle where the distal end can be buried without tension.
- The epimysium is incised.
- The nerve trunk is then drawn into a tunnel within the muscle, using a length of silicone as a sling around the nerve and pulling it through the muscle and depositing the nerve deep in the muscle.
- The muscle is ranged by putting the adjacent joint through a full range of movement to ensure that there is no tension on the translocated nerve.
- No sutures are placed in the nerve; it is stabilized by closing the epimysial incision with fine absorbable sutures and also bathing the entry point in fibrin clot glue (Figure 30.28).
- We place an (epidural type) anesthetic infusion catheter to lie tension-free adjacent to the nerve as it enters the muscle. Through this we infuse a steady flow of levobupivacaine 0.25% at a rate of 2 to 5 mL/h for 24 h postoperatively. The catheter exits the skin through a more proximal puncture wound and is very gently withdrawn after this period.
- If required, the adjacent joint is positioned in 20 degrees of flexion with a plaster splint for 10 days. Early movement of other proximal and distal joints is encouraged.

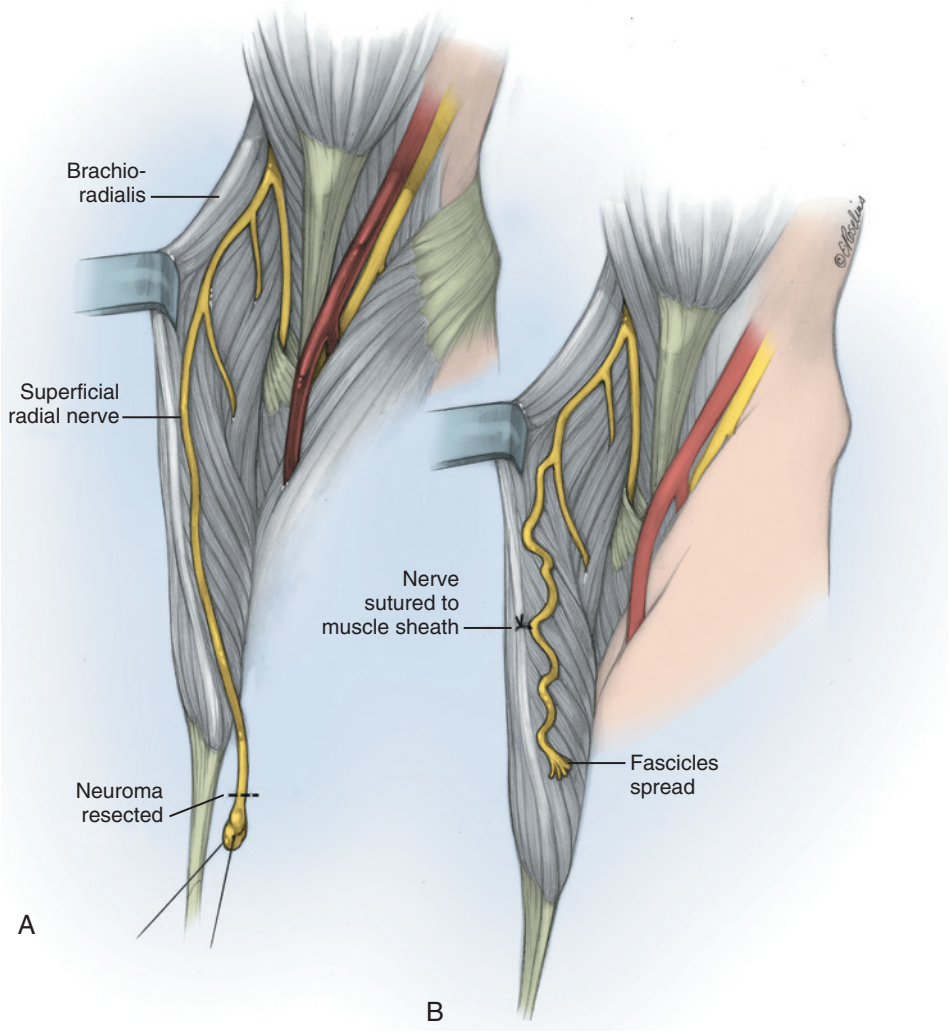

FIGURE 30.28 Implantation of a nerve into muscle: **A,** In this case, the superficial radial nerve is exposed and mobilized. **B,** The neuroma is resected and the individual fascicles are gently eased apart. The nerve is implanted within the brachioradialis muscle in a tunnel and very lightly sutured to the muscle sheath, avoiding any tension. The nerve must lie very loosely when using this technique. (© Elizabeth Martin.)

Most patients show improvement with this procedure, but it is reserved for cases in which the problem is largely one of mechanical irritation of a nerve. When spontaneous symptoms indicate firing of central neurons, and when there is hyperalgesia of the skin within the area supplied by adjacent nerves of cutaneous sensation, the outlook is more uncertain. For these cases a good practice is to begin a course of agents (e.g., gabapentin) that stabilize the nerve membrane; this is continued for at least 3 months after the operation is performed.

Langley and Anderson suggested that a state of inhibition of regeneration was induced in their proposal to suture one nerve trunk to another in amputation stumps.[102] Kon and Bloem applied this to the palmar digital nerves by suturing one to another or, when the injury was unilateral, by suturing the dorsal to the palmar branches.[98] The principle of the preceding operations is to sequester regenerating axons within the epineurial sheath. The authors' limited experience with this technique has not been successful, so it is not recommended.

CRITICAL POINTS *Summary of Neuroma Management*

- Avoidance is best. Far too many painful neuromas are caused by surgeons. Respect the nerves of cutaneous sensation.
- Swift action is important.
- The nerve should be repaired if at all possible.
- Translocation is the next best method.
- Infusion of local anesthetic is an integral part of any operation on a painful neuroma.
- The operation must be seen as an integral part of rehabilitation.
- Work with a colleague who is particularly interested in neuropathic pain. This should be seen as a collaborative venture.
- Clinicians should not transfer patients to pain clinics without making every reasonable effort to establish a diagnosis.

For Case Studies, Videos, and more, please visit ExpertConsult.com.

REFERENCES

1. Addas BM, Midha R: Nerve transfers for severe nerve injury. *Neurosurg Clin N Am* 20:27–38, 2009.
2. Albrecht PJ, Hines S, Eisenberg E, et al: Pathologic alterations of cutaneous innervation and vasculature in affected limbs from patients with complex regional pain syndrome. *Pain* 120(3):244–266, 2006.
3. Anand P, Birch R: Restoration of sensory function and lack of long-term chronic pain syndromes after brachial plexus injury in human neonates. *Brain* 125:113–122, 2002.
4. Atherton DD, Taherzadeh O, Facer P, et al: The potential role of nerve growth factor (NGF) in painful neuromas and the mechanism of pain relief by their relocation to muscle. *J Hand Surg [Br]* 31:652–656, 2006.
5. Balcin H, Erba P, Wettstein R, et al: A comparative study of two methods of surgical treatment for painful neuroma. *J Bone Joint Surg Br* 91(6):803–808, 2009.
6. Battiston B, Lanzetta M: Reconstruction of high ulnar nerve lesions by distal double median to ulnar nerve transfer. *J Hand Surg Am* 24(6):1185–1191, 1999.
7. Birch R: Brachial plexus injury: the London experience with supraclavicular tract lesions. *Neurosurg Clin N Am* 20:15–23, 2009.
8. Birch R: Compound nerve injury. In *Surgical disorders of the peripheral nerves*, London, 2010, Springer, pp 303–373.
9. Birch R: The closed supraclavicular lesion. In *Surgical disorders of the peripheral nerves*, London, 2011, Springer, pp 375–427.
10. Birch R, Achan P: Peripheral nerve repairs and their results in children. *Hand Clin* 16:579–597, 2000.
11. Birch R, Ahad N, Kono H, et al: Repair of obstetric brachial plexus palsy. Results in 100 children. *J Bone Joint Surg Br* 87:1089–1095, 2005.
12. Birch R: Reactions to injury. In *Surgical disorders of the peripheral nerves*, ed 2, London, 2011, Springer, pp 77–114.
13. Birch R: The closed supraclavicular lesion. In *Surgical disorders of the peripheral nerves*, ed 2, London, 2011, Springer, pp 375–428.
14. Deleted in review.
15. Birch R: Regeneration and recovery. In *Surgical disorders of the peripheral nerves*, London, 2011, Springer, pp 115–144.
16. Birch R: Rehabilitation. In *Surgical disorders of the peripheral nerves*, ed 2, London, 2011, Springer, pp 607–630.
17. Birch R, Dunkerton M, Bonney G, et al: Experience with the free vascularised ulnar nerve graft in repair of supraclavicular lesion of the brachial plexus. *Clin Orthop Relat Res* 237:96–104, 1988.
18. Birch R, Misra P, Stewart MPM, et al: Nerve injuries sustained during warfare: part I—Epidemiology. *J Bone Joint Surg Br* 94(4):523–528, 2012.
19. Birch R, Misra P, Stewart MPM, et al: Nerve injuries sustained during warfare: part II—outcomes. *J Bone Joint Surg Br* 94(4):529–535, 2012.
20. Birch R, Raji ARM: Repair of median and ulnar nerves. *J Bone Joint Surg Br* 73:154–157, 1991.
21. Birch R, St Clair Strange FG: A new type of peripheral nerve lesion. *J Bone Joint Surg Br* 72:312–313, 1990.
22. Bisinella G, Birch R, Smith SJM: Neurophysiological predictions of outcome in obstetric lesions of the brachial plexus. *J Hand Surg [Br]* 28:148–152, 2003.
23. Blaauw G, Sauter Y, Lacroix C, et al: Hypoglossal nerve transfer in obstetrical brachial plexus palsy. *J Plast Reconstr Surg* 59:474–478, 2006.
24. Bolitho DG, Boustred M, Hudson DA, et al: Primary epineurial repair of the ulnar nerve in children. *J Hand Surg [Am]* 24:16–20, 1999.
25. Bonnel F, Canovas F: Anatomy of the brachial plexus of the new born and the adult. Macroscopic and histologic structures. In Alnot J-Y, Narakas A, editors: *Traumatic brachial plexus injuries*, Paris, 1996, Expansion Scientifique Française, pp 3–13.
26. Bonney G, Gilliatt RW: Sensory nerve conduction after traction lesion of the brachial plexus. *Proc R Coll Med* 51:365–367, 1958.
27. Bowden RE, Scholl DA: Rates of regeneration. *Spec Rep Ser Med Res Counc (G B)* 282:16–24, 1954.
28. Brimijoin S: 2005 Axonal transport: properties, mechanisms and role in nerve disease. In Dyck PJ, Thomas PK, editors: *Peripheral neuropathy*, ed 4, Philadelphia, 2005, WB Saunders, pp 387–409.
29. Brunelli G, Monini L: Direct muscular neurotisation. Proceedings of the Second Congress of the International Federation of Societies for Surgery of the Hand. *J Hand Surg [Am]* 10:993–994, 1985.
30. Brushart TM: Nerve repair and grafting: degenerative changes in muscle. In Green DP, Hotchkiss RN, Pederson WC, editors: *Green's operative hand surgery*, ed 4, New York, 1999, Churchill Livingstone, pp 1384–1385.
31. Brushart TM: Primary versus secondary repair. In Green DP, Hotchkiss RN, Pederson WC, editors: *Green's operative hand surgery*, ed 4, New York, 1999, Churchill Livingstone, pp 1386–1387.
32. Camp SJ, Birch R: Injuries to the spinal accessory nerve: a lesson to surgeons. *J Bone Joint Surg Br* 93(1):62–67, 2011.
33. Camp SJ, Milano R, Sinisi M: Intractable neurostenalgia of the ulnar nerve abolished by neurolysis 18 years after injury. *J Hand Surg Eur Vol* 33:45–46, 2008.
34. Carlstedt T: *Central nerve plexus injury*, London, 2007, Imperial College Press.
35. Carlstedt T: Outcome of nerve transfer. In *Central nerve plexus injury*, London, 2007, Imperial College Press, pp 70–72.
36. Deleted in review.
37. Chemnitz A, Bjorkman A, Dahlin LB, et al: Functional outcome thirty years after median and ulnar nerve repair in childhood and adolescence. *J Bone Joint Surg Am* 95(4):329–337, 2013.
38. Chiu SY: Channel function in mammalian axons and support cells. In Dyck PJ, Thomas PK, editors: *Peripheral neuropathy*, ed 4, Philadelphia, 2005, WB Saunders, pp 95–112.
39. Clark WL, Trumble TE, Swiontowski MF, et al: Nerve tension and blood flow in a model of immediate and delayed repairs. *J Hand Surg [Am]* 17:677–687, 1992.
40. Deleted in review.
41. Concannon MJ, Kester CG, Welsh CF, et al: Patterns of free radical production after tourniquet ischaemia: implications for the hand surgeon. *Plast Reconstr Surg* 89:846–857, 1992.
42. Coupland RM: *War wounds of limbs*, Oxford, 1993, Butterworth Heinemann.
43. Dahlin LB, Lundborg G: Use of tubes in peripheral nerve repair. *Neurosurg Clin N Am* 12:341–352, 2001.
44. Dellon AL: Results of nerve repair in the hand. In Dellon AL, editor: *Evaluation of sensibility and re-education of sensation in the hand*, Baltimore, 1981, Williams & Wilkins, pp 193–202.
45. Dellon AL: Pitfalls in interpretation of electrophysiological testing. In Gelberman RH, editor: *Operative nerve repair and reconstruction* (vol 1), Philadelphia, 1991, JB Lippincott, pp 185–196.
46. Dellon AL, Mackinnon SE: Treatment of the painful neuroma by neuroma resection and muscle implantation. *Plast Reconstr Surg* 77:427–438, 1986.
47. De Ruiter GCW, Spinner RJ, Yaszemski MJ, et al: Nerve tubes for peripheral nerve repair. *Neurosurg Clin N Am* 20:91–106, 2009.
48. Dickson JK, Biant LC: A good outcome following complete injury of the brachial plexus: long-term analysis of the management of two patients. *J Bone Joint Surg Br* 92(4):540–544, 2010.
49. Dobyns JH: Pain dysfunction syndrome. In Gelberman RH, editor: *Operative nerve repair and reconstruction*, Philadelphia, 1991, JB Lippincott, pp 1489–1495.
50. Duteille F, Petry D, Poure L, et al: A comparative clinical and electromyographic study of the median and the ulnar nerves injuries at the wrist in children and adults. *J Hand Surg [Br]* 26:58–60, 2001.
51. Dy CJ, Kitay A, Garg R, et al: Neurotization to innervate the deltoid and biceps: 3 Cases. *J Hand Surg [Am]* 38(2):237–240, 2013.
52. Dyck PJ, Nukada H, Lais CA, et al: Permanent axotomy: a model of chronic neuronal degeneration produced by axonal atrophy, myelin remodelling and regeneration. In Dyck PJ, Thomas PK, Lambert EH, et al, editors: *Peripheral neuropathy*, Philadelphia, 1984, WB Saunders, pp 660–690.
53. Elliot D, Sierakowski A: The surgical management of painful nerves of the upper limb: a unit perspective. *J Hand Surg Eur Vol* 36(9):760–770, 2011.
54. Evans GRD, Dellon AL: Implantation of the palmar cutaneous branch of the median nerve into the pronator quadratus for treatment of painful neuroma. *J Hand Surg [Am]* 19:203–206, 1994.
55. Fiolle J, Delmas J: *The surgical exposure of the deep-seated blood vessels*, Cumston DG (ed and trans), London, 1921, W Heinemann, pp 61–67.
56. Fowler TJ, Danta G, Gilliatt RW: Recovery of nerve conduction after a pneumatic tourniquet: observations on the hind-limb of the baboon. *J Neurol Neurosurg Psychiatry* 35(5):638–647, 1972.
57. Frykman GK, Adams J, Bowen WW: Neurolysis. *Orthop Clin North Am* 12:325–342, 1981.
58. Fullerton AC, Glasby MA, Lawson GM: Immediate and delayed nerve repair using freeze-thawed muscle autografts in complex nerve injuries. Associated long bone fracture. *J Hand Surg [Br]* 23:360–364, 1998.
59. Gaul JS, Jr: Intrinsic motor recovery—A long-term study of ulnar nerve repair. *J Hand Surg [Am]* 7(5):502–508, 1982.
60. Deleted in review.
61. Glasby MA, Fullerton AC, Lawson GM: Immediate and delayed nerve repair using freeze-thawed muscle autografts in complex nerve injuries. Cavitation, fibrosis and haematoma. *J Hand Surg [Br]* 22:479–485, 1997.
62. Glasby MA, Fullerton AC, Lawson GM: Immediate and delayed nerve repair using freeze-thawed muscle autografts in complex nerve injuries. Associated arterial injury. *J Hand Surg [Br]* 23:354–359, 1998.
63. Glaus SW, Johnson PJ, Mackinnon SE: Clinical strategies to enhance nerve regeneration in composite tissue allotransplantation. *Hand Clin* 27(4):495–509, 2011.
64. Gold MS: Spinal nerve ligation: what to blame for the pain and why: topical review. *Pain* 84:117–120, 2000.
65. Goldie BS, Coates CJ, Birch R: The long term result of digital nerve repair in no-man's land. *J Hand Surg [Br]* 17(1):75–77, 1992.

66. Goldstein SA: Sturim HS. Intraosseous nerve transposition for treatment of painful neuromas. *J Hand Surg [Am]* 10:270–274, 1985.
67. Gould JS: Digital nerves. In Gelberman RH, editor: *Operative nerve repair and reconstruction*, Philadelphia, 1991, JB Lippincott, pp 453–460.
68. Gould JS: Treatment of the painful injured nerve in continuity. In Gelberman RH, editor: *Operative nerve repair and reconstruction*, Philadelphia, 1991, JB Lippincott, pp 1541–1550.
69. Gould JS, Naranje SM, McGwin G, et al: Use of collagen conduits in management of painful neuromas of the foot and ankle. *Foot Ankle Int* 34(7):932–940, 2013.
70. Gu YD, Zhang GM, Chen DS, et al: Seventh cervical nerve root transfer from the contralateral healthy side for treatment of brachial plexus root avulsion. *J Hand Surg [Br]* 17:518–521, 1992.
71. Guse DM, Moran SL: Outcomes of the surgical treatment of peripheral neuromas of the hand and forearm: a 25-year comparative outcome study. *Ann Plast Surg* 71(6):654–658, 2013.
72. Haftek J: Stretch injury of peripheral nerve. *J Bone Joint Surg Br* 52:354–365, 1970.
73. Hall S: Axonal regeneration through acellular muscle grafts. *J Anat* 190:57–71, 1997.
74. Hall S: Nerve repair: a neurobiologist's view. *J Hand Surg [Br]* 26:129–136, 2001.
75. Hall S: The response to injury in the peripheral nervous system. *J Bone Joint Surg Br* 87:1309–1319, 2005.
76. Hall SM: Biomaterials for the repair of peripheral nerves. In di Silvio L, editor: *Cellular response to biomaterials*, Cambridge, 2009, Woodhead, pp 252–290.
77. Hazari A, Elliot D: Treatment of end-neuromas, neuromas-in-continuity and scarred nerves of the digits by proximal relocation. *J Hand Surg [Br]* 29:338–350, 2004.
78. Herndon JH: Neuromas. In Green DP, Hotchkiss RN, Pederson WC, editors: *Green's operative hand surgery*, ed 4, New York, 1999, Churchill Livingstone, pp 1469–1480.
79. Herndon JH, Eaton RG, Littler JW: Management of painful neuromas in the hand. *J Bone Joint Surg Am* 58:369–373, 1976.
80. Herndon JH, Hess AV: Neuromas. In Gelberman RH, editor: *Operative nerve repair and reconstruction*, Philadelphia, 1991, JB Lippincott, pp 1525–1540.
81. Hudson DA, Bolitho DG, Hodgett K: Primary epineurial repair of the median nerve in children. *J Hand Surg [Br]* 22:54–56, 1998.
82. Hunter E, Laverty J, Pollock R, et al: Nonoperative treatment of fixed flexion deformity of the proximal interphalangeal joint. *J Hand Surg [Br]* 24:281–283, 1999.
83. Imai H, Tajima T, Natsumi Y: Successful re-education of functional sensibility after median nerve repair at the wrist. *J Hand Surg [Am]* 16:60–66, 1991.
84. Inman VT, Saunders JB, Abbott LC: Observation on the function of the shoulder joint. *J Bone Joint Surg* 26:1–31, 1944.
85. Jabaley ME: Internal topography of peripheral nerves as related to repair. In Gelberman RH, editor: *Operative nerve repair and reconstruction*, Philadelphia, 1991, JB Lippincott, pp 231–240.
86. Kadiyala RK, Ramirez A, Taylor AE, et al: The blood supply of the common peroneal nerve in the popliteal fossa. *J Bone Joint Surg Br* 87:337–342, 2005.
87. Deleted in review.
88. Kanamura A, Suzuki S, Sibuya M, et al: Sensory reinnervation of muscle receptor in human. *Neuroscience* 161:27–29, 1993.
89. Kato N, Htut M, Taggart M, et al: The effects of operative delay on the relief of neuropathic pain after injury to the brachial plexus. *J Bone Joint Surg Br* 88:756–759, 2006.
90. Kim DH, Kam AC, Chandika P, et al: Surgical management and outcome in patients with radial nerve lesions. *J Neurosurg* 95(4):573–583, 2001.
91. Klenerman L: *The tourniquet manual—Principles and practice*, London, 2003, Springer-Verlag.
92. Kline DG, Hudson AR: Grading results. In *Nerve injuries*, Philadelphia, 1995, WB Saunders, pp 87–99.
93. Kline DG, Hudson AR: Nerve action potential recordings. In *Nerve injuries*, Philadelphia, 1995, WB Saunders, pp 101–116.
94. Kline DG, Hudson AR: Operative care and techniques. In *Nerve injuries*, Philadelphia, 1995, WB Saunders, pp 118–145.
95. Kline DG, Hudson AR, Kim DH: *Atlas of peripheral nerve surgery*, Philadelphia, 2001, WB Saunders.
96. Klink BK, Kleinart JM: Upper extremity vascular injuries. In Gupta A, Kay SPJ, Sceker LR, editors: *The growing hand*, St. Louis, 2000, CV Mosby, pp 659–664.
97. Koch H: Painful neuroma—mid-term results of resection and nerve stump transposition into veins. *Eur Surg* 43(6):378–381, 2011.
98. Kon M, Bloem JJ: The treatment of amputation neuromas in fingers with a centrocentral nerve union. *Ann Plast Surg* 18:506–508, 1987.
99. Landau WM: The duration of neuromuscular function after nerve section in man. *J Neurosurg* 1953.
100. Landi A, Copeland SA, Wynn Parry CB, et al: The role of somatosensory evoked potentials and nerve conduction studies in the surgical management of brachial plexus injuries. *J Bone Joint Surg Br* 62:492–496, 1980.
101. Lang EM, Borges J, Carlstedt T: Surgical treatment of lumbosacral plexus injuries. *J Neurosurg Spine* 1:64–71, 2004.
102. Langley JN, Anderson HK: The union of different kinds of nerve fibers. *J Physiol* 31:365–391, 1904.
103. Laveaux C, Pauchot J, Obert L, et al: Retrospective monocentric comparative evaluation by sifting of vein grafts versus nerve grafts in palmar digital nerves defects. Report of 32 cases. *Ann Chir Plast Esthet* 55(1):19–34, 2010.
104. Lawson SN: The peripheral sensory nervous system: dorsal root ganglion neurones. In Dyck PJ, Thomas PK, editors: *Peripheral neuropathy*, ed 4, Philadelphia, 2005, WB Saunders, pp 163–202.
105. Leclercq DC, Carlier AJ, Khuc T, et al: Improvement in the results in sixty-four ulnar nerve sections associated with arterial repair. *J Hand Surg [Am]* 10:997–999, 1985.
106. Lee SK, Wolfe SW: Nerve transfers for the upper extremity: new horizons in nerve reconstruction. *J Am Acad Orthop Surg* 20(8):506–517, 2012.
107. Leechavengvongs S, Witoonchart K, Uerpairojkit C, et al: Nerve transfer to deltoid muscle using the nerve to the long head of the triceps, part II: a report of 7 cases. *J Hand Surg [Am]* 28:633–638, 2003.
108. Lohmeyer JA, Siemers F, Machens HG, et al: The clinical use of artificial nerve conduits for digital nerve repair: a prospective cohort study and literature review. *J Reconstr Microsurg* 25(1):55–61, 2009.
109. Lundborg G: The nerve trunk. In *Nerve injury and repair*, London, 1988, Churchill Livingstone, pp 32–63.
110. Lundborg G: Vascular systems. In *Nerve injury and repair*, London, 1988, Churchill Livingstone, pp 42–46.
111. Lundborg G: Nerve regeneration. In *Nerve injury and repair*, London, 1988, Churchill Livingstone, pp 149–195.
112. Lundborg G, Rosen B, Dahlin L, et al: Tubular versus conventional repair of median and ulnar nerves in the human forearm: early results from a prospective, randomised clinical study. *J Hand Surg [Am]* 22:99–106, 1997.
113. Lundborg G, Rosen B, Lindberg S: Hearing as a substitution for sensation: a new principle for artificial sensibility. *J Hand Surg [Am]* 24:219–224, 1999.
114. Lundborg G, Rydevik B: Effects of stretching the tibial nerve of the rabbit: preliminary study of the intraneural circulation of the barrier function of the perineurium. *J Bone Joint Surg Br* 55:390–401, 1973.
115. Mackinnon SE, Dellon AL: Ischaemia of nerve: loss of vibration sensibility. In *Surgery of the peripheral nerve*, New York, 1988, Thieme Medical, p 57.
116. Malessy MJS, Bakker D, Dekker AJ, et al: Functional magnetic resonance imaging and control over the biceps muscle after intercostal-musculocutaneous nerve transfer. *J Neurosurg* 98:261–268, 2003.
117. Mano Y, Nakamuro T, Tamara R, et al: Central motor re-organisation after anastomosis of the musculocutaneous and intercostal nerves following clinical root avulsion. *Ann Neurol* 38:15–20, 1995.
118. Martini A, Fromm B: A new operation for the prevention and treatment of amputation neuromas. *J Bone Joint Surg Br* 71:379–383, 1989.
119. Mass DP, Ciano MC, Tortosa R, et al: Treatment of painful hand neuromas by their transfer into bone. *Plast Reconstr Surg* 74:182–185, 1984.
120. McEwan LE: Median and ulnar nerve injuries. *Austral NZ J Surg* 32(2):89–104, 1962.
121. McManis PG, Low PA, Lagerlund TD: Nerve blood flow and microenvironment. In Dyck PJ, Thomas PK, editors: *Peripheral neuropathy*, ed 4, Philadelphia, 2005, WB Saunders, p 671.
122. Meek MF, Coert JH: Recovery of two-point discrimination function after digital nerve repair in the hand using resorbable FDA- and CE-approved nerve conduits. *J Plast Reconstr Aesthet Surg* 66(10):1307–1315, 2013.
123. Merle M, Amend P, Cour C, et al: Microsurgical repair of peripheral nerve lesions: a study of 150 injuries of the median and ulnar nerves. *Peripheral Nerve Repair Regen* 2:17–26, 1986.
124. Michaelis M, Lui XG, Janig W: Axotomised and intact muscle afferents but no skin afferents develop ongoing discharges of dorsal root ganglion origin after peripheral nerve lesion. *J Neurosci* 20:2742–2748, 2000.
125. Deleted in review.
126. Millesi H: Interfascicular nerve grafting. *Orthop Clin North Am* 12:287–301, 1981.
127. Millesi H, Zoch G, Rath T: The gliding apparatus of peripheral nerve: its clinical significance. *Ann Chir Main Memb Super* 9:87–97, 1990.
128. Mitchell SW, Morehouse GR, Keen WW: *Gunshot wounds and other injuries of nerves*, Philadelphia, 1864.
129. Mohseni M-A, Pour JS, Pour JG: Primary and delayed repair and nerve grafting for treatment of cut median and ulnar nerves. *Pak J Biol Sci* 13(6):287–292, 2010.
130. Montgomery AS, Birch R, Malone A: Sciatic neurostenalgia: caused by total hip arthroplasty, cured by later neurolysis. *J Bone Joint Surg Br* 87:410–411, 2005.
131. Murovic JA: Upper-extremity peripheral nerve injuries: a Louisiana State University Health Sciences Center literature review with comparison of the operative outcomes of 1837 LSUMC median, radial, and ulnar nerve lesions. *Neurosurgery* 65(4 Suppl):A11–A17, 2009.

132. Nagano A, Tsuyama N, Ochiai N, et al: Direct nerve crossing with the intercostal nerve to treat avulsion injuries of the brachial plexus. *J Hand Surg [Am]* 14:980–985, 1989.
133. Narakas AO: Surgical treatment of traction injuries of the brachial plexus. *Clin Orthop Relat Res* 133:71–90, 1978.
134. Narakas AO: Thoughts on neurotisation of nerve transfers in irreparable nerve lesions. In Tertzis JK, editor: *Microreconstruction of nerve injuries*, Philadelphia, 1987, WB Saunders, pp 447–454.
135. Narakas AO: The use of fibrin clot glue in repair of peripheral nerves. *Orthop Clin North Am* 19:187–199, 1988.
136. Nicholson OR, Seddon HJ: Nerve repair in civil practice; results of treatment of median and ulnar nerve lesions. *Br Med J* 2(5053):1065–1071, 1957.
137. Ninkovic M, Weissenbacher A, Gabl M, et al: Functional outcome after hand and forearm transplantation: what can be achieved? *Hand Clin* 27(4):455–465, 2011.
138. Novak CB, Mackinnon SE: Distal anterior interosseous nerve transfer to the deep motor branch of the ulnar nerve for reconstruction of high ulnar nerve injuries. *J Reconstr Microsurg* 18(6):459–464, 2002.
139. Oaklander AL, Rismiller JG, Gelman LB, et al: Evidence of focal small-fibre axonal degeneration in complex regional pain syndrome-1 (reflex sympathetic dystrophy). *Pain* 120:235–243, 2006.
140. Oberlin C, Beal D, Bhatia A, et al: The ulnar nerve. In Alnot J-Y, Narakas A, editors: *Traumatic brachial plexus injuries*, Paris, 1996, Expansion Scientifique Française, pp 46–49.
141. O'Brien B: Microsurgery in the treatment of injuries. In McKibbin B, editor: *Recent advances in orthopaedics*, Edinburgh, 1975, Churchill Livingstone, pp 235–279.
142. Omer GE: Injuries to nerves of the upper extremity. *J Bone Joint Surg Am* 56:1615–1624, 1974.
143. Omer GE: The management of pain. In Lamb DW, editor: *The paralysed hand*, Edinburgh, 1987, Churchill Livingstone, pp 216–231.
144. Omura T, Sano M, Omura K, et al: Different expressions of BDNF, NT3, and NT4 in muscle and nerve after various types of peripheral nerve injuries. *J Peripher Nerv Syst* 10(3):293–300, 2005.
145. Onne L: Recovery of sensibility and sudomotor activity in the hand after nerve suture. *Acta Chir Scand Suppl* Suppl 300:1–69, 1962.
146. Osborne AWH, Birch R, Munshi P, et al: The musculocutaneous nerve: results of 85 repairs. *J Bone Joint Surg Br* 82:1140–1142, 2000.
147. Oullette EA: Gunshot wounds. In Gupta A, Kay SPJ, Scheker LR, editors: *The growing hand*, St. Louis, 2000, CV Mosby, pp 717–724.
148. Pan C-H, Chuang DC-C, Rodríguez-Lorenzo A: Outcomes of nerve reconstruction for radial nerve injuries based on the level of injury in 244 operative cases. *J Hand Surg Eur Vol* 35(5):385–391, 2010.
149. Paprottka FJ, Wolf P, Harder Y, et al: Sensory recovery outcome after digital nerve repair in relation to different reconstructive techniques: meta-analysis and systematic review. *Plast Surg Int* 4:1–17, 2013.
150. Pereira JH, Palande DD, Narayanakumar TS, et al: Nerve repair by denatured muscle autografts promotes sustained sensory recovery in leprosy. *J Bone Joint Surg Br* 90:220–224, 2008.
151. Rinker B, Liau JY: A prospective randomized study comparing woven polyglycolic acid and autogenous vein conduits for reconstruction of digital nerve gaps. *J Hand Surg [Am]* 36(5):775–781, 2011.
152. Roganovic Z: Missile-caused ulnar nerve injuries: outcomes of 128 repairs. *Neurosurgery* 55(5):1120–1129, 2004.
153. Roganovic Z: Missile-caused median nerve injuries: results of 81 repairs. *Surg Neurol* 63(5):410–418, discussion 418–19, 2005.
154. Roganovic Z, Petkovic S: Missile severances of the radial nerve. Results of 131 repairs. *Acta Neurochir (Wien)* 146(11):1185–1192, 2004.
155. Rosén B, Lundborg G: A model instrument for the documentation of outcome after nerve repair. *J Hand Surg [Am]* 25:535–543, 2000.
156. Rosén B, Lundborg G: A new model instrument for outcome after nerve repair. *Hand Clin* 19(3):463–470, 2003.
157. Sakellarides H: A follow-up study of 172 peripheral nerve injuries in the upper extremity in civilians. *J Bone Joint Surg Am* 44-A:140–148, 1962.
158. Schady W, Ochoa JL, Torebjork HE, et al: Peripheral projections of fascicles in the human median nerve. *Brain* 106:745–760, 1983.
159. Secer HI, Daneyemez M, Gonul E, et al: Surgical repair of ulnar nerve lesions caused by gunshot and shrapnel: results in 407 lesions. *J Neurosurg* 107(4):776–783, 2007.
160. Seddon HJ: Three types of nerve injury. *Brain* 66:237–288, 1943.
161. Seddon HJ, editor: *Peripheral nerve injuries*, Medical Research Council Special Report, Series No. 282, London, 1954, Her Majesty's Stationery Office.
162. Seddon HJ: Common causes of nerve injury. In *Surgical disorders of peripheral nerves*, ed 2, Edinburgh, 1975, Churchill Livingstone, pp 67–88.
163. Seddon HJ: Nerve grafting and kindred procedures. In *Surgical disorders of peripheral nerves*, ed 2, Edinburgh, 1975, Churchill Livingstone, pp 287–302.
164. Seddon HJ: Results of repair of the nerves. In *Surgical disorders of peripheral nerves*, ed 2, Edinburgh, 1975, Churchill Livingstone, pp 303–314.
165. Shergill G, Birch R, Bonney G, et al: The radial and posterior interosseous nerves: results of 260 repairs. *J Bone Joint Surg Br* 83:646–649, 2001.
166. Slingluff CL, Terzis JK, Edgerton MT: The quantitative microanatomy of the brachial plexus. In Terzis JK, editor: *Microreconstruction of nerve injuries*, Philadelphia, 1987, WB Saunders, pp 285–324.
167. Smith JR, Gomez NH: Local injection therapy of neuromata of the hand with triamcinolone acetonide: a preliminary study of twenty-two cases. *J Bone Joint Surg Am* 52:71–83, 1970.
168. Smith SJM: Electrodiagnosis. In Birch R, Bonney G, Wynn Parry CB, editors: *Surgical disorders of the peripheral nerves*, London, 1998, Churchill Livingstone, pp 467–490.
169. Spinner RJ: Operative care and technique. In Kim DH, Midha R, Murovic JA, et al, editors: *Kline and Hudson's nerve injuries*, ed 2, Philadelphia, 2008, WB Saunders, pp 87–106.
170. Stenning M, Drew S, Birch R: Low-energy arterial injury at the shoulder with progressive or delayed nerve palsy. *J Bone Joint Surg Br* 87:1102–1106, 2005.
171. Strange FG: An operation for pedicle nerve grafting. *Br J Surg* 34:423–425, 1947.
172. Strauch B, Lang A, Ferder M, et al: The ten test. *Plast Reconstr Surg* 99(4):1074–1078, 1997.
173. Sunderland S: A classification of peripheral nerve injuries producing loss of function. *Brain* 74:491–516, 1961.
174. Sunderland S: Peripheral nerve trunks. In *Nerve and nerve injuries*, ed 2, Edinburgh, 1978, Churchill Livingstone, pp 31–60.
175. Suzuki H, Oyanagi K, Takahashi H, et al: A quantitative pathological investigation of the cervical cord, roots and ganglia after long-term amputation of the unilateral upper arm. *Acta Neuropathol* 85(6):666–673, 1993.
176. Swanson AB, Boeve NR, Lumsden RM: The prevention and treatment of amputation neuromata by silicone capping. *J Hand Surg [Am]* 2:70–78, 1977.
177. Tang JB, Gu YQ, Song YS: Repair of digital nerve defect with autogenous vein graft during flexor tendon surgery in zone 2. *J Hand Surg [Br]* 18(4):449–453, 1993.
178. Taras JS, Amin N, Patel N, et al: Allograft reconstruction for digital nerve loss. *J Hand Surg Am* 38(10):1965–1971, 2013.
179. Taras JS, Jacoby SM, Lincoski CJ: Reconstruction of digital nerves with collagen conduits. *J Hand Surg [Am]* 36(9):1441–1446, 2011.
180. Thomas M, Stirratt A, Birch R, et al: Freeze-thawed muscle grafting for painful cutaneous neuromas. *J Bone Joint Surg Br* 76:474–476, 1994.
181. Thomas PK, Berthold CH, Ochoa J: Microscopic anatomy of the peripheral nervous system. In Dyck PJ, Thomas PK, Griffin JW, et al, editors: *Peripheral neuropathy*, ed 3, Philadelphia, 1993, WB Saunders, pp 28–92.
182. Thomas PK, Holdorff B: Neuropathy due to physical agents. In Dyck PJ, Thomas PK, Griffin JW, et al, editors: *Peripheral neuropathy*, ed 3, Philadelphia, 1993, WB Saunders, pp 990–1014.
183. Thomsen L, Bellemere P, Loubersac T, et al: Treatment by collagen conduit of painful post-traumatic neuromas of the sensitive digital nerve: a retrospective study of 10 cases. *Chir Main* 29(4):255–262, 2010.
184. Tinel J: *Nerve wounds*, London, Baillière Tindall & Cox, Authorized translation. Rothwell F, revised and edited by Joll CA, 1917.
185. Toros T, Karabay N, Ozaksar K, et al: Evaluation of peripheral nerves of the upper limb with ultrasonography: a comparison of ultrasonographic examination and the intra-operative findings. *J Bone Joint Surg Br* 91-B(6):762–765, 2009.
186. Tsao BE, Wilbourn AJ: The medial brachial fascial compartment syndrome following axillary arteriography. *Neurology* 61:1037–1041, 2003.
187. Tupper JW: Fascicular repair. In Gelberman RH, editor: *Operative nerve repair and reconstruction*, Philadelphia, 1991, JB Lippincott, pp 295–304.
188. Tupper JW, Booth DM: Treatment of painful neuromas of sensory nerves in the hand: a comparison of traditional and newer methods. *J Hand Surg [Am]* 1:144–151, 1976.
189. Wall PD, Gutnick M: Ongoing activity in peripheral nerves: the physiology and pharmacology of impulses arising from a neuroma. *Exp Neurol* 43:580–593, 1974.
190. Wall PD, Gutnick M: The properties of afferent nerve impulses originating from a neuroma. *Nature* 248:740–742, 1974.
191. Waller A: Experiments on the section of the glossopharyngeal and hypoglossal nerves of the frog, and observations of the alterations produced thereby in the structure of their primitive fibres. *Philos Trans R Soc Lond* 140:423–429, 1850.
192. Deleted in review.
193. Wilgis EFS: Longitudinal excursion of nerves: nerve repair and grafting. In Green DP, editor: *Operative hand surgery*, ed 2, New York, 1988, Churchill Livingstone, pp 1377–1378.
194. Wilgis EFS, Murphy R: The significance of longitudinal excursion in peripheral nerves. *Hand Clin* 2:761–766, 1987.
195. Willner C, Low PA: Pharmacologic approaches to neuropathic pain. In Dyck PJ, Thomas PK, Griffin JW, et al, editors: *Peripheral neuropathy*, ed 3, Philadelphia, 1993, Saunders, pp 1709–1720.

196. Windebank AJ, McDonald ES: Neurotrophic factors in the peripheral nervous system. In Dyck PJ, Thomas PK, editors: *Peripheral neuropathy*, ed 4, Philadelphia, 2005, WB Saunders, pp 377–386.
197. Woodhall B, Beebe GW, editors: *Peripheral nerve regeneration*, Washington, DC, 1956, VA Medical Monograph, U.S. Government Printing Office.
198. Woolf CJ, Shortland P, Coggleshall RE: Peripheral nerve injury triggers central sprouting of myelinated afferents. *Nature* 355:75–78, 1992.
199. Wynn Parry CB: *Rehabilitation of the hand*, ed 4, London, 1981, Butterworths.
200. Wynn Parry CB, Salter RM: Sensory re-education after median nerve lesions. *J Hand Surg [Br]* 8:250–257, 1976.
201. Young JZ, Medawar PB: Fibrin suture of peripheral nerves. *Lancet* 2:126–128, 1940.
202. Zachary RB: Results of nerve suture. In Seddon HJ, editor: *Peripheral nerve injuries*, MRC Special Report, Series No. 282, London, 1954, Her Majesty's Stationery Office, p 354.

Principles of Tendon Transfers of Median, Radial, and Ulnar Nerves

Timothy R. C. Davis

Acknowledgment: This chapter is based on the chapters in previous editions of Green's Operative Hand Surgery, *which were written by George Anderson, William Burkhalter, David Green, John Ingari, and George Omer, as well as Nicholas Barton, who was my coauthor for the fourth edition. My tendon transfer experience cannot match that of any of these previous authors, and I must confess that my thoughts and views on tendon transfer surgery have been molded by reading the previous editions' chapters, as well as by revisiting all the research articles they wrote and cited. The previous authors of these chapters have therefore been my teachers and mentors and I am indebted to their labors.*

PRINCIPLES

Damage to one of the three main nerves of the hand causes loss of function due to paralysis of muscles and loss of sensation. Tendon transfers can be used to re-create the functions of some of the paralyzed muscles but cannot restore normal strength and coordination. Loss of function due to loss of sensation cannot be restored by tendon transfers but is often well accommodated by the eyes. This accommodation is lost when the eyes cannot see the hand such as in darkness or when the hand is in a pocket or bag searching for an object. The loss of sensation after radial nerve injury is minimal and does not involve critical areas of the hand, whereas the loss of motor function is major and significantly impacts function. Thus, tendon transfers to restore radial nerve motor function have the potential to greatly improve hand function and the patient's well-being and ability to pursue a "normal" life. In contrast, the loss of sensation after a median nerve injury involves the most critical areas of the hand and, absent sensation or dysesthesia, will reduce the potential benefit of tendon transfers to restore lost motor function.

The principles of tendon transfer surgery[13] are frequently reiterated but often forgotten. They were established by surgeons such as Mayer[114] and Bunnell[42] and must be adhered to regardless of whether the transfers are to restore medial, radial, or ulnar nerve motor function.

Prevention and Correction of Contracture

Maximum passive motion of all joints must be present before a tendon transfer can be performed. This is because no tendon transfer can move a stiff joint, and it is impossible for a joint to have a greater range of active motion postoperatively than its preoperative range of passive movement. Soft tissue and joint contractures are easier to prevent than to correct, so it is imperative that all of them are kept supple after any nerve injury, particularly those with associated soft tissue injuries.

Tissue Equilibrium

The timing of tendon transfers is controversial, but all authors agree that no transfer should be done until the local tissues are in optimal condition. Steindler's expression, "tissue equilibrium," implies that soft tissue induration has resolved, the wounds have matured, the joints are supple, and the scars are as soft as they are likely to become. Performing tendon transfers, or any elective operation, before tissue equilibrium has been reached is to invite disaster. If scar tissue remains after maximum recovery has been achieved, then the surgeon must consider providing new skin coverage with flaps before transfer. Alternatively, she or he must use transfers that avoid the scarred areas. Tendon transfers work best when passed between the subcutaneous fat and deep fascial layer and are unlikely to work at all in a scar pathway. Brand[27] emphasized the concept of gentle tunneling using a blunt-tipped instrument and probing natural tissue planes to find the path of least resistance. When performing tendon transfers, the surgeon should minimize the likelihood of new scar formation, and skin incisions should be planned so that tendon junctures do not lie directly underneath them.[135]

Adequate Strength

The muscle chosen as the donor for transfer must be sufficiently strong to perform its new function in its altered position. The relative strengths (and excursions) of the donor muscle, as well as the muscles whose function they will replace, should be as well matched as possible (Table 31.1). The work capacity of a muscle is related to its volume.[32]

Transfer of a muscle to replace the function of another inevitably weakens it, typically by one grade on the rather imprecise Medical Research Council (MRC) grading system.[135,142] Thus, muscles that have been previously denervated, but have regained function, should only be used if they have regained near-normal strength.

Amplitude of Motion

The surgeon must have an appreciation of the amplitude of tendon excursion for each muscle. This is proportional to the length of its individual muscle fibers (see Table 31.1).[27,200] Lieber

TABLE 31.1 Resting Muscle-Fiber Lengths and Tension Fractions of Muscles With Functions Commonly Restored With Tendon Transfers and Potential Transfer Motors

	Resting Muscle-Fiber Length (cm)	Tension Fraction (%)
Radial Nerve Palsy		
Brachioradialis	16.1 (10.9-21.3)	2.4
Extensor carpi radialis brevis*	6.1	4.2
Extensor carpi radialis longus	9.3	3.5
Extensor carpi ulnaris	4.5	4.5
Extensor digitorum communis*	5.5-6.0	0.9-1.7
Extensor indicis proprius	5.5	1.0
Extensor digiti minimi	5.9	1.0
Extensor pollicis longus*	5.7	1.3
Extensor pollicis brevis	4.3	0.8
Abductor pollicis longus	4.6	3.1
Median		
Intrinsic (Paralyzed in Low and High Palsy)		
Abductor pollicis brevis*	3.7	1.1
Flexor pollicis brevis*	3.6	1.3
Opponens pollicis*	2.4	1.9
Extrinsic (paralyzed in high palsy)		
Pronator teres	5.1	5.5
Palmaris longus	5.0	1.2
Flexor carpi radialis*	5.2	4.1
Flexor pollicis longus*	5.9	2.7
Flexor digitorum profundus, index*	6.6	2.7
Flexor digitorum profundus, middle*	6.6	3.4
Flexor digitorum superficialis, middle	7.0	3.4
Flexor digitorum superficialis, ring	7.3	3.0
Ulnar		
Intrinsic (Paralyzed in Low and High Palsy)		
Adductor pollicis brevis*	3.6	3.0
First dorsal interosseous*	2.5	3.2
Second and fourth dorsal interossei (combined)*	1.5	6.2
First and third palmar interossei (combined)*	1.6	3.5
Abductor digiti minimi*	4.0	1.4
Ring and little finger lumbricals (combined)	5.5	0.2
Extrinsic (Paralyzed in High Palsy)		
Flexor carpi ulnaris	4.2	6.7
Flexor digitorum profundus (ring)	6.8	3.0
Flexor digitorum profundus (little)	6.2	2.8

*Muscles with functions that are commonly restored with tendon transfers.
From Brand PW, et al: Relative tension and potential excursion of muscles in the forearm and hand. *J Hand Surg* 6:209–219, 1981.

and colleagues have assessed muscle characteristics with intraoperative laser diffraction; however, this technique is not widely used and is complex.[100,101] Boyes[22] suggested the use of the following values for practical purposes.

Wrist flexors and extensors have excursion amplitudes of approximately 33 mm, whereas the finger extensors and extensor pollicis longus (EPL) have 50 mm and the finger flexors have 70 mm excursions, respectively. Thus, a wrist flexor cannot be expected to restore the full range of active motion provided by a finger extensor, the function of which it is replacing. However, the range of active finger motion provided by a wrist flexor can be augmented through the tenodesis effect of active flexion and extension of the wrist; that is, wrist extension reduces tension in a flexor carpi radialis (FCR) to extensor digitorum communis (EDC) transfer and allows finger flexors to produce greater finger flexion. In contrast, wrist flexion increases tension in this transfer and allows it to produce increased "active" finger extension. This tenodesis effect explains the adage that the wrist should never, if at all possible, be fused in a person requiring tendon transfers. Excursion amplitude can

also be increased by extensive dissection of the muscle from its surrounding fascial attachments. This is particularly true of the brachioradialis (BR).

Straight Line of Pull

The transfer must run in a straight line from its own origin to the insertion of the tendon it is to drive. If a tendon transfer does not run in a straight line, increased force needs to be expended to overcome friction with the surrounding soft tissues and the transfer will try to migrate so that it does run in a straight line. Sometimes this is not possible—for example, in an extensor indicis proprius (EIP) or flexor digitorum superficialis (FDS) opponensplasty—and the transfer must then pass around a robust pulley that cannot migrate over time (i.e., the ulna in an EIP opponensplasty) because this would result in loss of or restricted function. The transfer must run in a straight line from its origin to the pulley, and from the pulley to the insertion of the tendon it is to drive; in addition, the angular change in direction of the transfer at the pulley should be as small as possible to minimize friction and adhesion formation.

One Tendon–One Function

A single transferred tendon cannot be expected to perform two dissimilar active actions. If a transfer has two insertions that perform dissimilar active functions, it will act predominantly on the tighter insertion.[171] However, one transfer can be attached to multiple tendons that all have similar functions. Thus, the FCR can be attached to the EDC tendons of all four fingers (and, if necessary, the EPL) to actively extend them simultaneously, but not individually. Also the extensor carpi radialis longus (ECRL) tendon can be attached to a lateral band of the extensor apparatus of each finger to restore intrinsic function in all four fingers. A tendon transfer can also restore one active function and provide an additional and different passive function. For example, an opponensplasty can be attached to the insertion of abductor pollicis brevis (APB) and also the extensor mechanism of the thumb: (1) the initial attachment is to restore active opposition, and (2) the second is to passively restrict flexion of the thumb interphalangeal (IP) joint which is sometimes a problem in combined median and ulnar nerve palsies.

Synergism

Synergy of activity of the donor and "recipient" muscles and/or tendons is generally considered advantageous, and synergistic transfers should be selected if at all possible. However, Omer[136] and Brand[29] both believe that any transfer can be reeducated to fulfill its new function, especially in children, provided the restored function is of benefit to the patient.

Wrist extension usually occurs with finger flexion, and both sets of muscles are activated concurrently by the brain when gripping. On this premise, it is argued that patients find it easiest to train a wrist flexor to restore finger extension. A possible exception to this rule is the use of the superficialis (sublimis) tendons, which have more independent cortical control than other muscles in the hand.

Expendable Donor

Transfer of a musculotendinous unit must not result in unacceptable loss of function. Thus, there should always be at least one other musculotendinous unit providing the same function as the one being transferred so that the original function of the transfer is not completely lost. One should not transfer both the ECRL and extensor carpi radialis brevis (ECRB) to restore new functions because active wrist extension would be lost. The same is true for FCR and flexor carpi ulnaris (FCU).

An additional well-known guideline is suggested—that is, the paralyzed "recipient" muscle/tendon, with a function that is to be replaced by a transfer, should not be divided to allow the transfer to be attached end-to-end unless there is no prospect of spontaneous recovery of the muscle. If there is any prospect of recovery, then an end-to-side attachment is preferred.

CRITICAL POINTS *Tendon Transfer*

- An elective tendon transfer should never be performed in the presence of unhealed wounds.
- Optimal passive joint motion must be restored before tendon transfer.
- The transfer must not pass through areas of scar tissue or under skin grafts, and surgical incisions should not be placed directly over the transfer.
- Whenever possible, cutaneous sensibility should be restored before tendon transfer.
- The normal function of the transferred muscle must be expendable.
- The transferred muscle must be under voluntary control and must have an independent action.
- Transferred muscle must have sufficient amplitude and power to perform its new function; thus, reinnervated muscles should be used only if fully recovered.
- If the transfer cannot perform its new function with a straight line of pull from its origin to its insertion, it should pass through no more than one pulley. Acute angulation of the transfer at the pulley should be avoided.
- Synergism between the muscle's original and new actions facilitates rehabilitation.

MEDIAN NERVE PALSY

The aim of reconstructive surgery in median nerve palsy is to restore lost motor function, in particular, thumb opposition, flexor pollicis longus (FPL), and index finger profundus function. Attempts to restore sensibility in the hand, specifically to the thumb tip, with neurovascular island skin flaps generally have been abandoned,[39] but sensory nerve transfer is possible.[15,144] The benefits of reconstructive surgery are, to a large extent, determined by the quality of hand sensation,[29] contralateral hand function, and the patient's motivation[136] and ability to adapt to any sensory loss.

Median nerve injuries are classified as "high" or "low" depending on whether the lesion is proximal or distal to the origin of the anterior interosseous nerve in the proximal forearm. In low injuries, the thenar intrinsic muscles innervated by the median nerve, usually the APB, opponens pollicis, and superficial head of the flexor pollicis brevis (FPB), are paralyzed. In high injuries, the pronator teres, the FCR, all the finger superficiales, the index and middle finger profundi, the FPL, and the pronator quadratus muscles are also paralyzed.

Low Median Nerve Palsy

Polio was the predominant cause of thenar muscle intrinsic paralysis in the first half of the 20th century. Because this disease

causes a pure motor deficit, it provides an ideal indication for opponensplasty. The two world wars also produced a large number of median nerve injuries that were frequently complex and occurred in conjunction with other nerve and severe soft tissue injuries. The present indications for restoration of thumb opposition include compressive and traumatic disruptions of the median nerve; leprosy; neurologic diseases (e.g., Charcot-Marie-Tooth disease), spinal muscular atrophy, and syringomyelia; and congenital absence of the thenar muscles.

Biomechanics of Thumb Opposition

Thumb opposition is a complex movement requiring trapeziometacarpal joint abduction, flexion, and pronation. Retroposition, the opposite movement, is a combination of trapeziometacarpal joint adduction, extension, and supination. Axial thumb rotation, usually 90 degrees of pronation and 60 degrees of supination, occurs on the spheroid area of the saddle-shaped trapezial articular surface. Pronation is probably an obligatory passive movement that occurs during circumduction toward the palm as a result of the force-couple produced by thumb intrinsic muscle contraction and passive tension within the dorsal trapeziometacarpal ligament. Retroposition probably also occurs passively during thumb extension as a result of the force-couple produced by contraction of the EPL, and the extensor pollicis brevis (EPB), and the abductor pollicis longus (APL) muscles and passive tension within the radiopalmar (anterior oblique) ligament. Although the force-couples may be the prime mechanism of axial rotation, other mechanisms must exist inasmuch as thumb pronation is preserved after trapeziectomy.

The prime muscle of thumb opposition is the APB, although both the opponens pollicis and FPB also produce some opposition. The adductor pollicis (AP) and the two extrinsic thumb extensors cause thumb retroposition, whereas the FPL can act either as a muscle of opposition or retroposition, depending on the position of the thumb.

The classic description of thumb intrinsic muscle innervation is that the APB, the opponens pollicis, and the FPB are supplied by the motor branch of the median nerve whereas the adductor pollicis is supplied by the deep branch of the ulnar nerve. However, there is considerable diversity in the pattern of innervation, and clinical studies suggest that all the thenar muscles are innervated, in part at least, by either the ulnar (2%) or the median (2%) nerve in a few instances. Furthermore, the FPB remains functional in 73% of complete median and 58% of complete ulnar nerve injuries, thus demonstrating that this muscle frequently has a dual median and ulnar innervation.[165] Anatomic dissection suggests that the median nerve supplies the APB, the opponens pollicis, and the superficial head of the FPB in 63%, but only the APB and the opponens pollicis in 30% of hands.[134]

Zancolli and Cozzi believe that the superficial head of the FPB has dual median and ulnar innervation in 30% of hands, whereas its deep head has dual innervation in 79% of cases and is exclusively supplied by the ulnar nerve in 19% of them.[206] They also believe that the oblique head of the adductor pollicis has dual ulnar and median innervation in 35% of cases, whereas its transverse head is practically always (96%) innervated by the ulnar nerve. Although some of these findings are contradictory, the variability of thenar muscle innervation explains why thumb abduction and opposition are frequently retained after complete median nerve injuries.[20,105]

The Deficit and the Deformity

Thumb abduction and opposition are frequently retained after isolated median nerve injury as a result of preserved ulnar nerve function. Jensen[84] believed that opponensplasty was required in only 14% of median nerve injuries, and it is my experience that reasonable opposition is commonly retained in complete median nerve transections. Furthermore, I find that satisfactory thumb opposition is usually retained in severe carpal tunnel syndrome, even in the presence of significant thenar wasting. Of the patients of Foucher and colleagues with severe carpal tunnel syndrome, 7% had absent or inadequate thumb opposition.[65] All the thenar intrinsic muscles were paralyzed after combined median and ulnar nerve injuries; in this situation, thumb opposition was absent and the patient was only able to flex the thumb across the palm by using the FPL. In combined ulnar and high median nerve injuries, resting thumb posture tends to be extended and supinated by the unopposed extrinsic extensor muscles.

Tendon Transfers to Restore Thumb Opposition

History. Steindler is credited with performing the first opponensplasty in 1917. He attached a radial slip of the FPL tendon onto the dorsum at the base of the thumb's proximal phalanx.[184] Shortly afterward, Cook used the extensor digiti minimi (EDM) for an opponensplasty[190] and Ney attached either the palmaris longus (PL) or FCR to the EPB tendon, which was rerouted through the carpal tunnel.[126] Huber[80] in 1921 and Nicolaysen[127] in 1922 described ADM opponensplasty.

Bunnell[42] in 1924 and Camitz[48] in 1929 both reported that the PL tendon could be satisfactorily elongated with a strip of palmar aponeurosis so that it could be used in an opponensplasty without the need for a tendon graft. To maximize thumb opposition, Bunnell recommended passing the transferred tendon through a pulley on the ulnar border of the wrist so that it ran subcutaneously across the palm to its thumb insertion.[42,43] Thompson[192] used the ulnar border of the palmar aponeurosis as a pulley for Royle's superficialis transfer.[166] A limitation of both the palmaris and superficialis transfers is that they are useful only for low median nerve palsies. Aguirre and Caplan, in 1956, first described extensor indicis proprius opponensplasty, which can be used for both high and low median nerve palsies and does not require manufacture of a pulley or a tendon graft.[3]

Patient Counseling. Although the indication for an opponensplasty is loss of opposition, the need for surgery is loss of function due to loss of opposition. If loss of opposition is unilateral, especially if it affects the nondominant hand, then the consequent loss of function may be minimal and insufficient to warrant surgery. Additionally, if there is also loss of or absent sensation in the median nerve territory, this may reduce any potential benefit of an opponensplasty because the loss of function is primarily due to the loss of sensation. Careful patient counseling about the possible functional benefit, the rehabilitation process, and the likely outcome of surgery (this may be somewhat less than the published success rates for restoration of opposition movement) is mandatory. The surgeon must have a clear picture of the functional disability and be confident that

this is due to the loss of opposition and not to other factors (e.g., sensory impairment or joint stiffness).

General Principles of Tendon Transfer With Reference to Opponensplasty

Prevention and Preoperative Treatment of Contractures. With median nerve palsy and complete intrinsic paralysis, the thumb may adopt a supinated and adducted position, and a first web space contracture can develop. This is readily prevented by passive thumb abduction and opposition exercises, supplemented by abduction splints as needed. Temporary internal splintage of the thumb metacarpal in abduction with a Kirschner wire may be indicated when there is an associated acute severe thenar or first web space soft tissue injury and thus a high risk of first web space contracture.

Established soft tissue contractures must be corrected either before or during opponensplasty because no opponensplasty has sufficient strength to improve a preoperative passive loss of opposition. Failure to detect and correct contractures preoperatively is a common cause of failure.[37] First web space contractures are generally due to contractures of the skin and deep fascia on its extensor surface[29] and usually can be readily detected. However, contracture of the dorsal capsule of the trapeziometacarpal joint, which restricts opposition but permits abduction, is detected only by careful clinical examination.[115] If supervised physiotherapy and splintage[54] fail to correct a contracture, surgical release is indicated.

In the absence of any injury to the thenar muscles or the base of the thumb, first web contractures usually can be released satisfactorily through a dorsal web space incision. The fascia over the adductor pollicis and the first dorsal interosseous muscles is released and the dorsal web space skin widened with a skin graft or flap.[29,124] Isolated capsular contractures of the trapeziometacarpal joint should be released through a small incision over the base of this joint.[115] In severe contractures, both rotational osteotomy at the base of the thumb metacarpal[166] and trapeziectomy[70] have been recommended. An osteotomy modifies rather than improves the range of thumb movement. For a more comprehensive discussion of thumb web contractures, see Chapter 48.

Selection of Motor for Transfer. The normal function of the muscle selected for opponensplasty must be expendable, and it should have strength and potential for excursion similar to that of the APB and opponens pollicis muscles, the functions of which it is to replace. The ideal opponensplasty motor should have a tension fraction similar to that of the combined APB and opponens pollicis tension (1.1 + 1.9 = 3.0) and a muscle-fiber length that is at least as long as that of the APB (see Table 31.1). The greater the potential for excursion of the transfer, the greater the margin of error when setting the transfer's tension.

It is also advantageous to select a motor with a tendon that is long enough to reach the thumb metacarpophalangeal (MP) joint, thus avoiding the need for a tendon graft. This makes the operation less complicated and reduces the likelihood of troublesome adhesions. Finally, rehabilitation is simpler if the selected motor acts synergistically with the APB.

Pulley Design. Because true thumb opposition is restored best by transfers that run subcutaneously across the palm, parallel to the APB muscle, all extrinsic opponensplasties should pass around a stout fixed pulley in the region of the pisiform on the ulnar border of the wrist.[43] It is important that a pulley is strong and generates minimal soft tissue resistance. Opponens transfers from the forearm extensor compartment generally use the distal ulna as the pulley, and most of these transfers are simply passed through a wide subcutaneous tunnel on the ulnar border of the distal forearm. Alternatively, some extensor muscle opponensplasties pass through and use a window in the interosseous membrane as the pulley, in which case it is important to make a very large window.

The Camitz procedure does not classically employ a pulley and thus is less effective in providing true opposition. If a forearm flexor compartment muscle is used for opponensplasty, a pulley has to be manufactured on the ulnar border of the wrist. Numerous designs have been described, and these are discussed later in the chapter in the Superficialis Transfers section.

Opponensplasty Insertions. Many insertions have been described (Figure 31.1), including one discussed by Curtis,[54] and these can be broadly divided into single- and dual-insertion techniques. Dual insertion aims to allow the tendon transfer to perform two functions, usually active opposition and either passive stabilization of the MP joint or restriction of IP joint flexion, both of which are beneficial in combined median and ulnar nerve palsies. Bunnell[43] recommended and others used a drill hole in the dorsoulnar aspect at the base of the thumb proximal phalanx as their opponensplasty insertion point to produce thumb pronation as well as abduction. However, pronation occurs passively when the thumb is abducted and flexed,[206] and biomechanical studies suggest that attaching the opponensplasty to the APB insertion on the radial aspect of the thumb MP joint produces at least as good an opposition as the Bunnell and other commonly used insertions.[53,97,163] Thus, the APB insertion is now widely used in isolated median nerve palsies.

Dual insertions into the APB insertion and either the dorsal MP joint capsule or the thumb extensor expansion[9,45,84,160] are probably unnecessary in isolated median nerve palsy, although they may be useful in a completely intrinsic-minus thumb.[52] Use of the EPB tendon and its insertion is reserved for complex cases when the extensor carpi ulnaris (ECU) is selected as the opponensplasty motor.[149]

Results. The majority of papers on opponensplasty report a high percentage of excellent and good results and attribute most failures to persistent contractures or technical problems. There is no universally accepted method of classifying the results of opponensplasty, but recent papers are probably more stringent than earlier articles in their assessment of outcomes. Unfortunately, it is impossible to compare the results and complication rates of different opponensplasties because of multiple variables, including: (1) the underlying disease process (e.g., polio, leprosy, nerve injury), (2) the neurologic deficit (e.g., low median, high median, or combined median and ulnar), (3) the sensory defect, and (4) the potential for spontaneous recovery. For example, if transfers are performed early when there is still potential for recovery, restoration of excellent opposition may be incorrectly attributed to the opponensplasty instead of nerve regeneration. Sixty-six percent of the patients who regain or never lose good opposition after median nerve repair[43] and loss of thenar muscle function, 66% frequently recover after carpal tunnel release.[68,129]

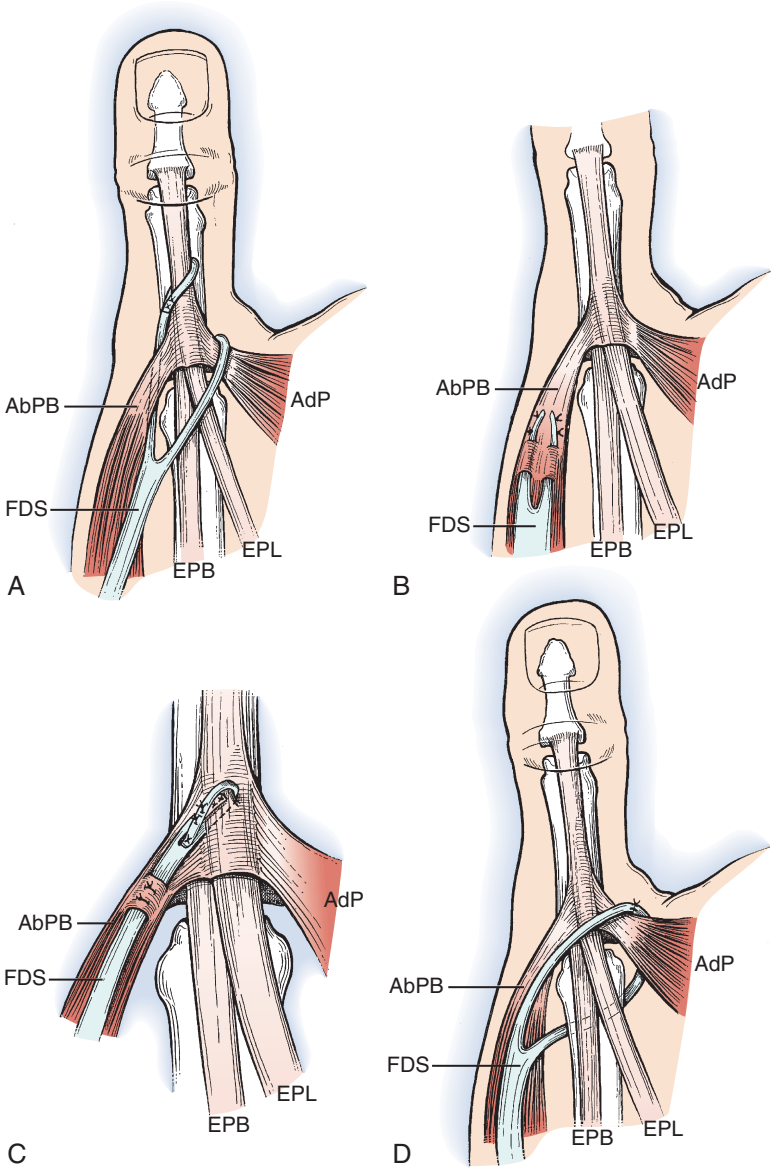

FIGURE 31.1 A-D, Techniques of distal attachment as described by Brand, Littler, Riordan, and Royle-Thompson. *AbPB*, Abductor pollicis brevis; *AdP*, Adductor pollicis brevis; *EPB*, extensor pollicis brevis; *EPL*, extensor pollicis longus; *FDS*, flexor digitorum superficialis.

Many papers classify an excellent result as one in which physically powerful opposition with full mobility is restored. A fair result is one with either full but weak opposition or limited but strong opposition.[83] Sundararaj and Mani graded their results in leprosy according to the range of opposition and the position of the thumb IP joint[187] (Table 31.2). In contrast, Foucher and colleagues objectively measured active thumb abduction, opposition, and rotation occurring on movement of the thumb from full active retroposition to opposition.[65]

Nevertheless, the surgeon's objective and the patient's subjective assessments of outcome are not always in agreement. Although a patient may demonstrate good muscle opposition to the surgeon in the clinic and be believable when saying that the opponensplasty is of functional benefit, the person may not use the newly restored opposition in everyday life. This is especially the case with combined median and ulnar nerve palsies, where the patient frequently finds it easier and faster to

TABLE 31.2 Two Methods of Assessment of Opponensplasty Surgery

Sundararaj and Mani,[187] 1984		Jacobs and Thompson,[83] 1960*
Excellent	Opposition to ring or little fingertip with IP joint extended	75% of function of opposite thumb when normal *or*
Good	Opposition to index or middle fingertip with IP joint extended	<20 degrees of difference between the planes of the opposed thumbnail and the palm with good power
Fair	Thumb IP joint flexes during opposition	Full, though weak, opposition or Restricted, but strong, opposition *or*
Poor	No opposition restored	No opposition restored

*Jacobs and Thompson did not subdivide excellent and good results.

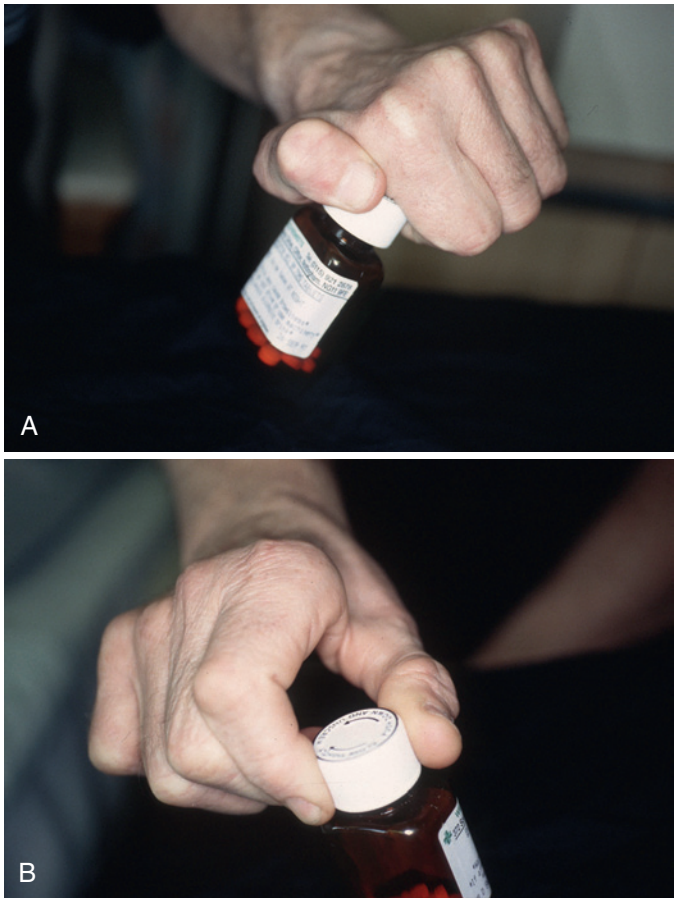

FIGURE 31.2 A patient with bilateral T1 neuropathy due to neurological disease. **A,** Left hand before extensor indicis proprius (EIP) opponensplasty demonstrating lateral "squeeze" between the retroposed thumb and the side of the index finger. The patient can only pick up objects from a table top with forearm fully pronated. **B,** Right hand after EIP opponensplasty showing that thumb-to-index pulp pinch is now possible. This allows the patient to pick up objects from flat surfaces without full forearm pronation and allows person to better see what is being done.

hold objects between the sides of the thumb and hand (lateral pinch) by using the EPL to adduct and supinate the thumb (Figure 31.2).[29]

Four Standard Opponensplasties. There are four widely used, reliable opponensplasties, at least one of which will be appropriate for the vast majority of clinical situations:

1. Flexor digitorum superficialis (FDS) opponensplasty
   a. Royle-Thompson technique
   b. Bunnell technique
2. EIP opponensplasty
3. Huber transfer (ADM)
4. Camitz procedure (PL)

Superficialis Opponensplasties. There is no universally accepted "best technique" of superficialis transfer, and a wide variety of different harvest techniques, pulley constructions, and transfer insertions are used, as described in the following subsections. The ring finger superficialis is widely used as the opponensplasty motor. However, because this may weaken power grip, some surgeons prefer to use the middle finger superficialis if it is available. Potential transfer insertions have been discussed earlier in this chapter.

Superficialis tendon harvest. Royle[166] and Thompson[192] both divided the ring finger superficialis tendon at its insertion onto the middle phalanx through a transverse insertion within the basal finger crease. However, it has subsequently been recognized that several superficialis harvest techniques, including division at its insertion, can cause donor digit proximal interphalangeal (PIP) joint flexion contractures or, especially in the supple Asian hand, swan-neck and other deformities.

CRITICAL POINTS *Management Principles in Opponensplasty*

- Surgery is needed when loss of opposition causes a meaningful functional deficit for the patient.
- The surgeon should adhere to all general principles of tendon transfer.
- Established soft tissue contractures must be corrected before or during opponensplasty; careful preoperative evaluation is essential.
- The ideal opponensplasty motor should have a tension fraction of around 3.0 and a muscle-fiber length at least as long as the APB.
- An appropriate pulley should be chosen to ensure a line of pull that replicates the APB.
- Tendon grafts should be avoided.
- Rehabilitation is simpler if the selected motor acts synergistically with the APB.
- Whenever possible, a single insertion of the transferred tendon is preferable.

North and Littler[130] suggested that division of the superficialis tendon at its insertion destroys the vincula and disrupts the blood supply to the profundus tendon; furthermore, surgical trauma may create scar tissue within the flexor sheath and PIP joint capsule, thus causing adhesions and/or contracture. They recommended division of the superficialis tendon proximal to its bifurcation through a window between the A1 and A2 pulleys with the finger fully flexed. This avoids injury to the flexor sheath at the level of the PIP joint and leaves behind a 3-cm length of superficialis tendon that glides freely within the flexor sheath. With this technique, 8 of 16 patients experienced no problems in the donor digit and the remainder only lost an average of 8 degrees extension of the PIP joint. None experienced any major disability or deformity. Other surgeons have recommended that the distal tags of the donor superficialis tendon be left long and sutured across the palmar plate to reinforce it and prevent hyperextension.[84]

In a study series of 116 superficialis opponensplasties for leprosy,[10] the ring finger superficialis tendon was harvested through either a midlateral approach or a Bruner incision on the flexor surface of the finger. Extension lag at the distal interphalangeal (DIP) joint and fixed-flexion deformities at the PIP joint occurred in 44% and 8% of cases, respectively, when the lateral approach was used but in only 8% and 0% of cases, respectively, when the Bruner incision was used. These authors believed that the high complication rates associated with the lateral approach were due to scar tissue and adhesion formation around the lateral bands of the extensor hood, which are retracted during this exposure. However, in another series of 100 leprosy patients with ulnar, median, or combined nerve palsies, no correlation was found between harvest technique and donor digit morbidity and deformity.[34]

Swan-neck deformities and DIP joint extension lags occurred in 15% and 29% of the donor fingers, respectively. The DIP joint extension lags were usually less than 20 degrees, unless associated with a swan-neck deformity, in which case they could be as much as 80 degrees. In addition, 26% of the cases in this study developed a fixed-flexion deformity of the PIP joint (50–70 degrees), and PIP joint flexion was reduced in 16%. These authors concluded that postoperative deformity in superficialis donor digits is multifactorial and depends on the preoperative condition of the PIP joint, the method of superficialis harvest, the surgeon's skill, the postoperative rehabilitation regime, the expertise of the therapist, and the patient's motivation.

Many surgeons believe that division of the superficialis tendon at its insertion increases the risk of swan-neck deformity. Furthermore, this technique usually requires an additional palmar incision to split the distal superficialis tendon and free it from the profundus tendon. Because sufficient superficialis tendon length for opponensplasty is provided by harvesting the superficialis tendon through an incision in the distal aspect of the palm,[130] there seems little point in risking a more distal division.

The pulley. Passing the superficialis tendon around the FCU tendon in the distal forearm was a popular and simple pulley design,[20,103,111] but this technique has fallen out of favor because the pulley is not fixed and migrates proximally. Thus, the transfer gradually adopts an increasingly longitudinal line of action and becomes less efficient with time (Figure 31.3).

Bunnell described several pulley designs for use with superficialis and other forearm flexor opponensplasties.[43] These included looping a free tendon graft around the FCU tendon and using a strip of the flexor carpi ulnaris tendon based on its attachment to the pisiform. Although the use of a distally based strip of FCU as a pulley was popular, its raw surface may encourage adhesion formation, and radial migration of this pulley has been observed over a period of years. To prevent this migration, the distally based slip of FCU tendon can be attached to the ECU tendon.[168] The angle between the distal edge of the flexor retinaculum and the ulnar border of the palmar aponeurosis is used effectively as a pulley in the Thompson-Royle transfer,[83,192] and good opposition is also restored when a window in the flexor retinaculum is used as the pulley.[18,117,179] Guyon's canal can also be used as a pulley,[26,146] and although radial migration may occur, this does not necessarily reduce the effectiveness of the opponensplasty.[10]

Biomechanical studies, including those done by Cooney et al[53] and Lee et al,[97] have shown that the function of an opponensplasty can be modified to an individual patient's requirements by altering the position of the pulley. Use of the FCU tendon or an FCU loop maximizes palmar abduction whereas use of a Guyon's canal, or the angle created by the distal edge of the flexor retinaculum and the ulnar border of the palmar aponeurosis, produces the closest approximation of the thumb tip to the little finger.[97] In addition, placing the pulley so that the transfer's line of action passes toward the pisiform produces maximal thumb abduction and opposition but only a small amount of flexion at the thumb MP joint, whereas placing it so that the transfer's line of pull passes distal to the pisiform produces more thumb MP joint flexion and less abduction.[53] Thus, a distally placed pulley may benefit patients with combined ulnar and median nerve palsies and paralyzed FPB muscles.

Surgical techniques

Royle-Thompson opponensplasty. With this technique, a 3-cm longitudinal incision is made at the base of the palm on the radial border of the hypothenar eminence.[166,192] The ulnar border of the palmar aponeurosis is exposed and retracted radially, and the ring finger superficialis tendon is identified as it emerges from the carpal tunnel proximal to the superficial palmar arch. This tendon is then divided distally through a transverse incision at the base of the digit and delivered into the

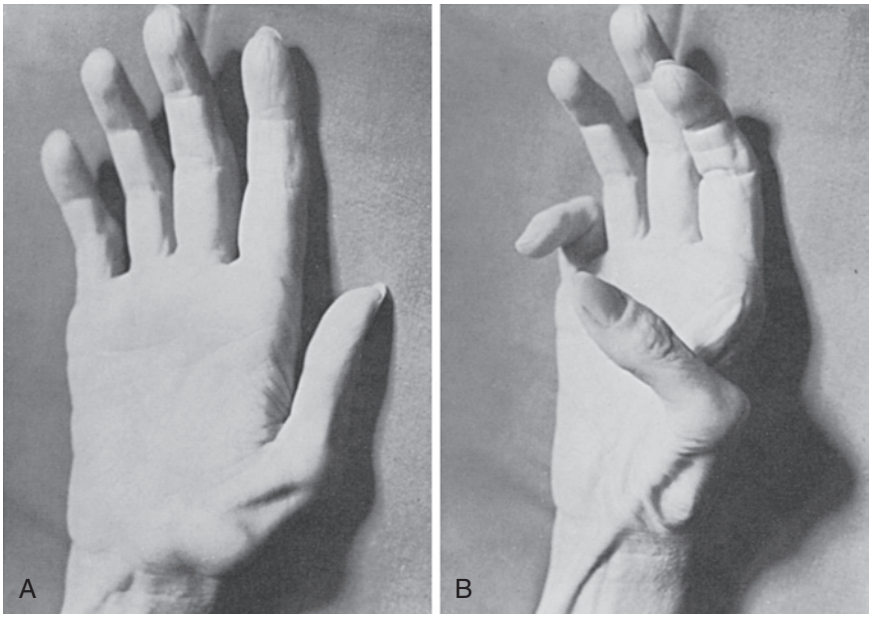

FIGURE 31.3 **A, B,** A poor Bunnell superficialis (flexor digitorum superficialis) transfer. There was no fixed pulley at the pisiform. The transfer has migrated and is now acting more as a flexor of the metacarpophalangeal joint than as a real abductor/opposer. Satisfactory opposition needs a fixed pulley near the pisiform.

palmar wound so that it passes ulnar to the palmar aponeurosis. A third incision is made over the dorsum of the thumb MP joint, and a wide subcutaneous tunnel is created between this and the palmar incision. The superficialis tendon is passed through this tunnel, with the angle created by the distal edge of the flexor retinaculum and the ulnar border of the palmar aponeurosis acting as the pulley. The transfer is then attached to the thumb by one of the many insertion techniques. Although Thompson originally used a dual insertion that stabilized the thumb MP joint, he subsequently used the APB insertion.[83]

The tourniquet is released and hemostasis is obtained before the incisions in the palm and at the base of the ring finger are closed. The superficialis transfer attachment to the thumb is then sutured while the thumb is held in full opposition. Because the ring finger superficialis tendon has a significant potential for excursion and crosses the wrist joint, adjusting the tension is not as critical as with other transfers, and there is a considerable margin for error. However, the transfer's tension should be adjusted so that it is tight when the thumb is fully opposed and the wrist is in neutral. Postoperatively, Thompson held the thumb in opposition for 4 to 6 weeks with spiral adhesive strapping that allowed some active thumb movement; in addition, Rath advocated early mobilization of this transfer.[154] However, most surgeons immobilize the thumb in full opposition with a cast for several weeks.

Results. Some surgeons believe that this opponensplasty does not produce as wide a thumb abduction as some other transfers because it runs along the path of the superficial head of the FPB and not that of the APB muscle. However, the results were excellent or good in 8 of Thompson's 10 original opponensplasties,[192] and a subsequent report described excellent or good results in 78% of 94 opponensplasties.[83]

Bunnell's opponensplasty. Bunnell's precept for restoration of full thumb opposition was that the transfer should run in line with the fibers of the APB to an insertion on the dorsoulnar aspect of the thumb proximal phalanx. Because his transfer passes distal to the axis of rotation of the MP joint, it also flexes that joint.

Technique. The ring finger superficialis tendon is divided at the base of this digit by using one of the previously described techniques. An incision is then made over the ulnar neurovascular bundle, just proximal to the wrist crease, and the ring finger superficialis tendon is identified. The distal portion of the FCU tendon is then exposed and cut halfway across, 4 cm proximal to its insertion on the pisiform. The tendon is then split into two equal halves up to its pisiform insertion, thus creating a distally based strip of tendon tissue. The free end of this tendon slip is sutured back onto its base at the pisiform to create a fixed pulley through which the superficialis tendon can pass easily. Care should be taken to not make this loop too tight. An incision is then made on the dorsum of the thumb, and a wide subcutaneous tunnel is created across the palm between the two incisions. A hole large enough to accommodate the superficialis tendon is then drilled from the dorsoulnar cortex to the radial cortex of the base of the proximal phalanx. The ring finger superficialis is delivered into the wrist incision and passed through the pulley and then along the subcutaneous tunnel into the dorsal thumb incision.

Next, the tourniquet is released, hemostasis is achieved, and the skin incisions at the base of the ring finger and at the wrist are closed. The superficialis tendon is then passed superficial to the EPL tendon across the dorsum of the thumb MP joint. It is then passed through the drilled hole in the base of the proximal phalanx in a dorsoulnar-to-radiopalmar direction. Once the tendon has been passed through the drill hole, the transfer's tension is set so that the thumb lies in full opposition with the wrist in neutral. The transfer is then sutured back onto itself or to the radial border periosteum. Alternatively, it can be held with a pull-out suture tied over a dental roll or attached to the proximal phalanx with suture anchors.

Results. Jensen used the Bunnell opponensplasty and reported good opposition in 22 of his 27 superficialis transfers.[84]

EIP Opponensplasty. The EIP opponensplasty (Figure 31.4) was favored by Burkhalter, who wrote earlier editions of this chapter, and is popular in high median nerve palsy and other instances when the ring and middle finger FDS tendons are unavailable. It has become increasingly preferable to the superficialis transfer in low median nerve palsies because it does not weaken grip and causes little, if any, functional disability.[45]

Technique. A short incision is made over the index finger MP joint, and the EIP tendon is divided immediately proximal to the extensor hood. Some surgeons recommend that a contiguous slip of the extensor hood be harvested with the tendon to lengthen the transfer.[45] However, this is unnecessary, and if the extensor hood is not properly repaired, its radial and ulnar halves may subluxate palmarly and cause an extensor lag.[41] A long incision is then made on the dorsoulnar aspect of the distal forearm, the extensor indicis tendon is delivered into this wound, and its muscle is freed of soft tissue attachments in the distal third of the forearm. It is important to retrieve the tendon proximal to the extensor retinaculum for adequate tendon length and line of pull. Sometimes this is only possible after soft tissue connections between the extensor indicis and index communis tendons have been divided through a small incision on the back of the hand.

Next, small incisions are made in the pisiform area and on the dorsoradial aspect of the thumb MP. A wide subcutaneous tunnel is then developed from the extensor surface of the forearm to the thumb incision, passing around the ulnar border of the wrist and across the palm. The extensor indicis tendon is passed through this tunnel while making certain that the tendon goes superficial to the FCU tendon; inadvertently passing it beneath the FCU tendon may later result in compression of the ulnar nerve. The tourniquet is then released and hemostasis obtained before the wrist and index finger incisions are closed. The distal attachment of this transfer depends on the clinical setting. In isolated median nerve palsies, it is simply attached to the APB tendon with the wrist in 30 degrees of flexion and the thumb in maximum opposition.

In combined median and ulnar nerve palsies with an intrinsic-minus thumb, the transfer is attached in sequence to the APB tendon, the MP joint capsule, and the EPL tendon over the proximal phalanx, as described by Riordan.[160] The transferred tendon can reach this new origin if the thumb is fully opposed and the wrist is flexed. This attachment restricts IP joint flexion and thus allows the FPL to flex the MP joint more effectively and substitute for the paralyzed FPB.[45] Postoperatively, the hand is immobilized with the wrist in flexion and the thumb in full opposition for 3 to 4 weeks.

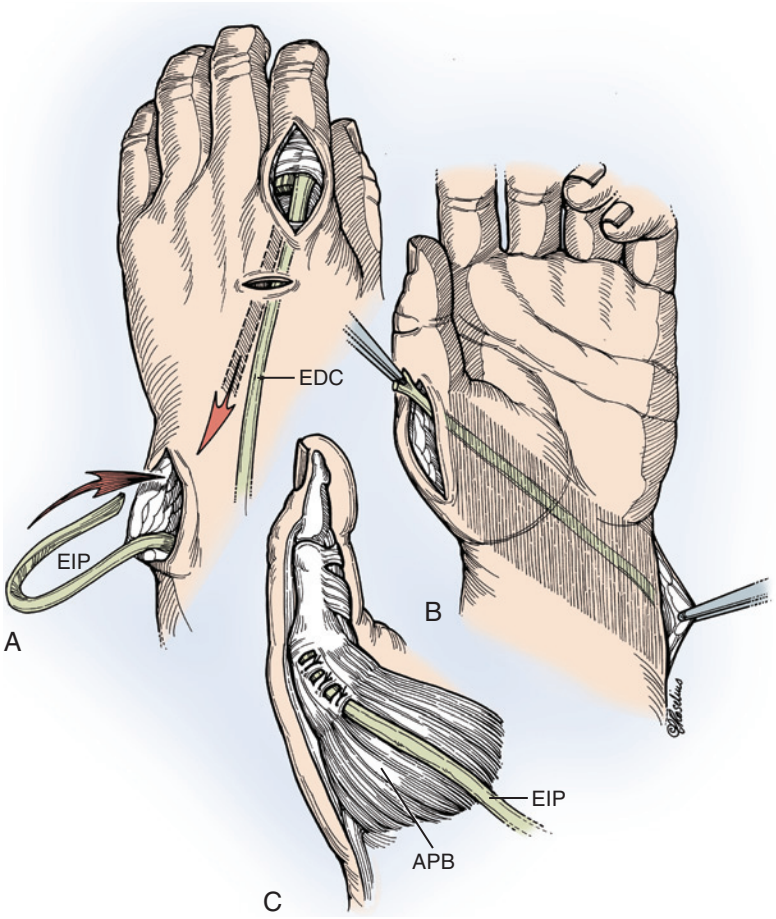

FIGURE 31.4 Extensor indicis proprius (EIP) transfer. **A,** The tendon is divided and delivered into a large dorsoulnar wrist incision; this may require an additional incision on the dorsum of the hand immediately distal to the extensor retinaculum, where the EIP and index extensor digitorum communis (EDC) tendons can be attached to each other. **B,** The muscle belly of the EIP is mobilized and placed on the ulnar aspect of the wrist and its tendon is passed through a subcutaneous tunnel around the wrist to an incision over the thumb metacarpophalangeal joint. **C,** The transfer is then sutured to the abductor pollicis brevis (APB) tendon.

Results. Burkhalter and colleagues reported the results of extensor indicis opponensplasty in 65 trauma cases, which included 32 combined ulnar and median nerve, 13 high median nerve, and 2 brachial plexus injuries.[45] Of the patients, 86% achieved excellent results, with powerful opposition to within 20 degrees of the plane of the palm of the hand. Perceived additional benefits of this transfer included ease of surgery (performed satisfactorily by residents) and rehabilitation (its excursion is naturally augmented by a wrist tenodesis effect). A disadvantage is that extensor indicis muscle-fiber length is shorter than that of the APB and the ring finger superficialis, so thumb extension may be restricted.

Anderson and associates used this transfer in 12 high and 28 low median nerve palsies caused by leprosy, trauma, and other conditions.[9] In contrast to Burkhalter's description, they attached the transfer to the thumb with the wrist in neutral and the thumb fully abducted and extended. Excellent or good results were seen in 88% of the cases monitored for more than a year. These workers subsequently compared these results with those achieved by superficialis transfer and concluded that the EIP transfer should only be used in supple hands.[10]

ADM (Huber) Opponensplasty. The ADM opponensplasty (Figure 31.5), described independently by Huber[80,81] and Nicolaysen,[127,128] was popularized by Littler and Cooley[104] who considered the ADM a close substitute for the APB. This transfer also improves the hand's appearance by increasing the bulk of the thenar eminence.

Technique. A midlateral incision is made on the ulnar border of the little finger proximal phalanx and extended proximally and radially to the distal palmar crease. It then runs along the radial border of the hypothenar eminence and curves ulnarly as it crosses the distal wrist crease. The two ADM insertions (i.e., base of the proximal phalanx and extensor apparatus) are divided, and this muscle is then freed of soft tissue attachments by retrograde dissection toward its pisiform origin. When mobilizing the proximal portion of the ADM, great care must be taken to not damage its thin neurovascular pedicle, which is on its dorsoradial aspect.

Alternatively, this pedicle can be identified by exposing the ulnar nerve and artery proximally at the wrist and tracing them distally. Once the neurovascular bundle has been isolated, the transfer's length is increased by elevating the abductor origin from the pisiform while carefully retaining an attachment on the FCU tendon by dissecting a tendinous slip proximally. The transfer's only remaining soft tissue attachments are then its neurovascular pedicle and the FCU tendon. Next, a dorsoradial

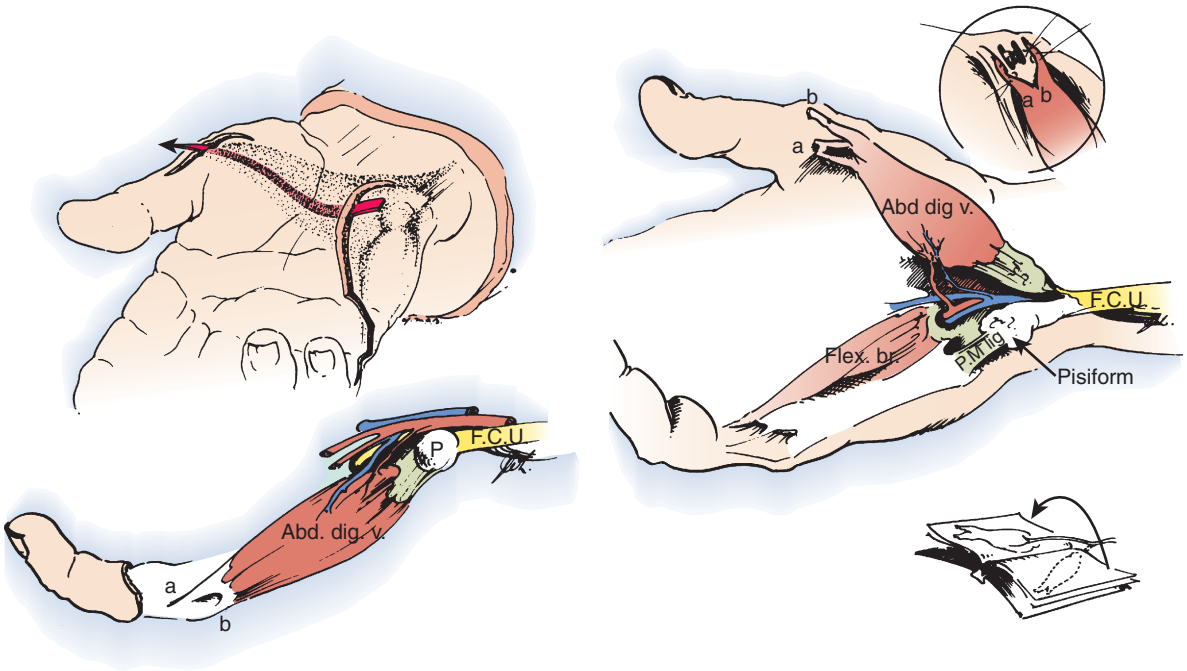

FIGURE 31.5 Huber abductor digiti minimi (ADM) opponensplasty. Two incisions are required to expose and transfer the ADM (*Abd. dig. v.*). The neurovascular structures enter the muscle proximally on its deep and radial aspect. The muscle is freed from the other hypothenar muscles, and its origin on the pisiform (P) is elevated while preserving a tendinous attachment to the tendon of the flexor carpi ulnaris (F.C.U.). The ADM is then rotated 180 degrees on its long axis and passed subcutaneously to the area of the thumb MP joint. The distal attachment is to the APB muscle. *Flex. br.*, flexor digiti minimi brevis; *P.M. lig.*, pisometacarpal ligament. (From Littler JW, Cooley SGE: Opposition of the thumb and its restoration by abductor digiti quinti transfer. *J Bone Joint Surg Am* 45:1389–1484, 1963, with permission.)

incision is made over the thumb MP joint and a wide subcutaneous tunnel is created between this incision and the area immediately proximal to the pisiform; this is easier if a third skin incision is made in the thenar crease at the base of the thenar eminence (not shown in Figure 31.5).

The ADM muscle is then turned through 180 degrees on its long axis to reduce the tension on its neurovascular bundle (as if turning the page of a book), passed through the subcutaneous tunnel, and attached to the APB insertion. Because the ADM muscle has only sufficient length to just reach the APB insertion, it is invariably attached under adequate tension. Postoperatively, the thumb is immobilized in a cast in full opposition for 4 weeks. The position of the wrist is not critical inasmuch as the transfer does not cross this joint.

Results. Littler and Cooley performed four Huber transfers, one of which failed and became fibrotic, probably as a result of vascular insufficiency.[104] They considered this transfer difficult and recommended that it be performed only when simpler opponensplasties are contraindicated. Furthermore, primate studies have highlighted this transfer's precarious blood supply, which is significantly reduced by dividing its pisiform insertion.[59] In light of these concerns, many surgeons[95] retain the pisiform origin and lengthen the transfer with a short tendon graft when necessary.

Others, in complete contrast, have completely released the origin of ADM and left it to reattach itself by scar tissue formation.[49] Wissinger and Singsen preserved the pisiform origin in 15 Huber transfers and reported one failure as a result of transfer fibrosis.[201] Twelve of their cases achieved excellent results with no donor site morbidity (Figure 31.6). Many surgeons use the Huber transfer as the opponensplasty of choice in pediatric patients with congenital thenar muscle deficiencies (see Chapter 37).

Palmaris Longus Opponensplasty (Camitz). The Camitz PL opponensplasty (Figure 31.7) is a simple transfer that is usually performed for loss of abduction and opposition occurring as a complication of severe carpal tunnel syndrome.[48] The procedure, which can be performed under regional anesthesia at the same time as carpal tunnel release, restores palmar abduction rather than opposition. Even though thumb opposition and abduction may recover after carpal tunnel release,[68] this will probably take many months; thus, it is reasonable to perform a Camitz procedure at the same time as carpal tunnel release for patients with severe thenar wasting and functional disability.[105] This transfer is not recommended for traumatic median nerve injuries because the PL, which lies directly over the median nerve, and the overlying skin are usually also scarred and damaged. However, its use has been utilized in this situation in young children.[12]

Technique. Preoperatively, the presence of the PL tendon is confirmed by opposing the thumb to the little finger with the wrist flexed. A longitudinal skin incision starting 2 cm proximal to the distal wrist crease and running to the proximal palmar crease is made in line with the ring finger. Care needs to be taken to identify and avoid injury to the palmar cutaneous branch of the median nerve, which lies just radial to the PL tendon. The palmaris longus tendon is freed up in the forearm and into the palm, where a 1-cm-wide strip of palmar aponeurosis is

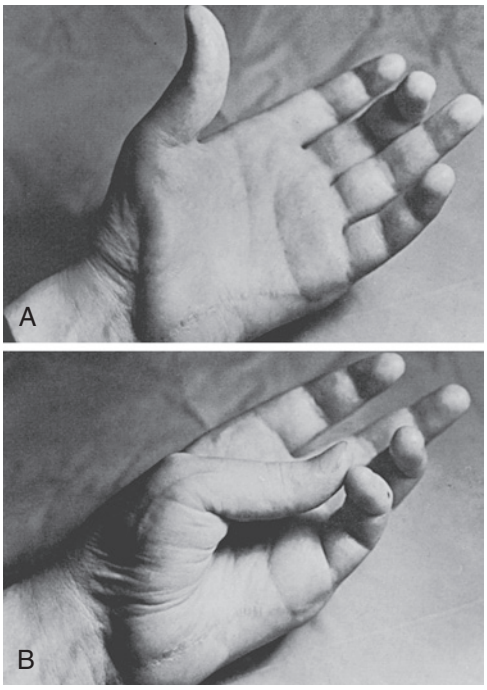

FIGURE 31.6 **A, B,** Huber abductor digiti minimi opponensplasty after satisfactory function has been restored, at least partly because the direction of pull is really from the pisiform.

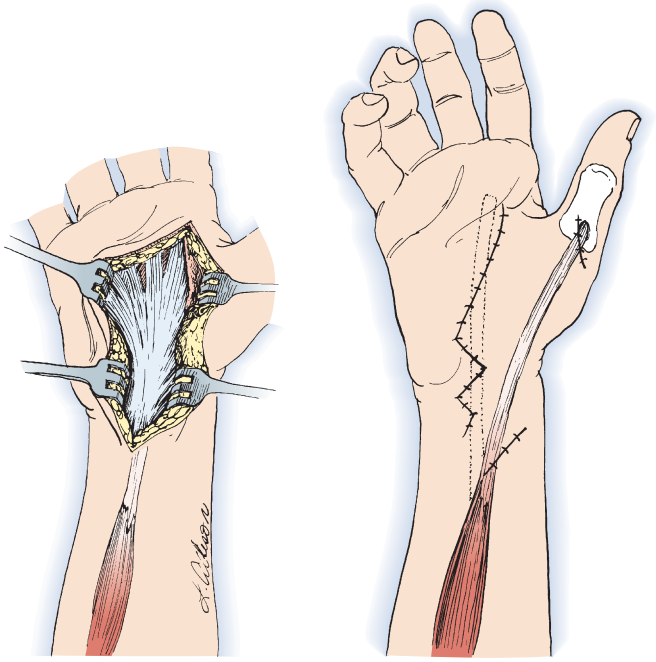

FIGURE 31.7 Camitz transfer. The palmaris longus is elongated with a strip of palmar aponeurosis and attached to the abductor pollicis brevis insertion.

dissected out in continuity with the tendon. The carpal tunnel is decompressed, and a second incision is made over the dorsoradial aspect of the thumb MP joint. A wide subcutaneous tunnel is then developed between this joint and the distal forearm incision, through which the PL tendon and its aponeurotic extension are passed.

The palmar skin incision is then closed and the tendon transfer is usually attached to the APB insertion, with or without another attachment to the dorsal MP joint capsule, to increase opposition.[35,105,191] Foucher and coworkers favor attachment to either the EPB tendon or the dorsal capsule of the MP joint in an effort to restore opposition as well as abduction.[65] Whichever distal attachment is used, it is sutured with the thumb in full opposition, the MP joint extended, and the wrist in neutral. The thumb incision is then closed, and a light cast, holding the wrist in neutral and the thumb opposed, is worn for 4 weeks. A night splint is then worn for another week.

Results. In a series of 73 Camitz procedures performed for severe carpal tunnel syndrome by Foucher and coworkers, 50% of the patients regained good opposition within 1 year and 91% regained good thumb abduction and satisfactory opposition by 16 to 102 months.[65] Attaching the PL tendon to the dorsal capsule of the MP joint or the EPB tendon restricted MP joint movement slightly (15–25 degrees) in 20% of the patients in this series. Braun[35] successfully used the Camitz procedure to reestablish thumb abduction in 28 cases, whereas Terrono and colleagues[191] improved thumb function in 27 of 29 cases and believed that formal physiotherapy was unnecessary (Figure 31.8).

What we call the Camitz transfer was actually first described by Bunnell,[42] who also suggested passing the PL tendon through a pulley close to the pisiform to create a more oblique line of pull and restore opposition. Passage of the transfer through a window in the flexor retinaculum has also been suggested.[106] If the superficial head of the FPB muscle is innervated by the ulnar nerve, this may provide pronation and thus allow use of a standard Camitz procedure to restore good opposition.

Other Opponensplasties. Other opponensplasties include the ECU, ECRL, and EDM opponensplasties.

ECU Opponensplasty. The ECU opponensplasty described by Phalen and Miller[149] allows the ECU to be used as an opponensplasty, without the need for a free tendon graft, by incorporating the EPB tendon and its insertion.[91,126]

Technique. A short incision is made on the dorsoradial border of the distal forearm, and the EPB tendon is divided at its musculotendinous junction, just proximal to the first extensor compartment. An incision is then made on the extensor surface of the thumb MP joint, and the EPB tendon is delivered into this wound while preserving its insertion on the proximal phalanx. Next, an "L"-shaped incision is made on the ulnar border of the wrist, its short arm passing transversely along the flexor wrist crease toward the PL insertion. A wide subcutaneous tunnel running from the thumb MP joint to the pisiform area is then created across the palm. The EPB tendon is passed proximally through this tunnel, and the ECU tendon is then divided close to its insertion on the base of the fifth metacarpal.

When harvesting the ECU, care should be taken to identify and preserve the dorsal-ulnar sensory nerve. This tendon is withdrawn back under the extensor retinaculum and freed of soft tissue attachments throughout the distal third of the forearm. It is then passed around the ulnar border of the distal forearm and sutured to the EPB tendon while the thumb is opposed to the base of the middle finger with its MP and IP joints extended. Postoperatively, the thumb is immobilized in opposition with the wrist in neutral for 3 to 4 weeks.

Results. Wood and Adams performed this procedure on 12 patients' complex cases with few available motors, and in 4



FIGURE 31.8 A patient presented with long-standing carpal tunnel syndrome and thenar muscle atrophy with loss of abduction and opposition. A Camitz transfer was performed at the same time as a carpal tunnel release, and excellent thumb abduction was restored. Thumb pronation was provided by the weak flexor pollicis brevis.

instances they observed radial deviation wrist deformities that caused severe grip weakness.[202] This may have occurred as a result of FCU paresis or paralysis, but an anomalous ECRL insertion onto the radial rather than the dorsal border of the index metacarpal was also implicated. In two patients the radial deviation deformity was corrected by transferring the ECRL tendon to the distal ECU stump.

There are three other problems with this transfer. First, the EPB tendon is sometimes nonexistent. Second, an MP joint flexion deformity may occur if the EPB tendon is dissected out from the extensor hood right up to its insertion; in contrast, if it is not dissected out sufficiently distally, it can cause MP joint hyperextension. Third, a tendinous slip sometimes connects the EPB and EPL tendons; if this is present, it must be divided because the transfer may otherwise cause unwanted extension of the IP joint.

ECRL Opponensplasty. The tendon of the ECRL muscle can be lengthened with a standard tendon graft.[76] Alternatively, the ECRL (or ECRB) tendon may be detached distally at its insertion onto the index metacarpal, brought out into a wound in the dorsal forearm, and carefully split in half longitudinally, such that one strip remains attached to the muscle and the other half is free. The free strip of tendon is then sutured to the distal end of attached strip to lengthen the tendon. Next, the transfer is passed through a wide subcutaneous tunnel around the ulna, just proximal to the pisiform, and inserted into the APB attachment and EPL.[11] Alternatively, Kaplan and coworkers elongated the ECRL tendon with the EPL tendon for four patients with isolated median or combined median and ulnar nerve injuries.[90]

Technique. A skin incision is made over the dorsum of the distal radius, and the EPL tendon is divided at its musculotendinous junction. The ECRL tendon is then divided close to its insertion and freed of soft tissue attachments in the distal forearm. Next, the EPL tendon is delivered into a second incision on the extensor surface of the thumb MP joint and a third skin incision is made on the border of the wrist at the level of the ulnar styloid process. Wide subcutaneous tunnels are then



FIGURE 31.9 EDM transfer for opposition of the thumb. Note the position at the time of surgery **(A)** and postoperative active abduction and rotation of the thumb **(B, C),** even with an immobile wrist.

created across the palm and around the ulnar border of the wrist/distal forearm. The EPL tendon is passed through the palmar tunnel to the wrist's ulnar border, where it is sutured to the ECRL tendon with the wrist flexed and the thumb abducted and opposed. Postoperatively, the hand is immobilized with the wrist flexed and the thumb opposed in a below-elbow cast for 3 weeks.

Results. In Kaplan and coworkers' small series, all thumbs regained abduction and opposition and thumb IP joint flexion and extension were preserved.[90] Henderson also used the ECRL in five patients, all of whom regained satisfactory opposition.[76] Baek and colleagues who prefer this transfer to the use of the EIP, which they consider allows only weak opposition, achieved excellent results in 10 of 11 cases.[11]

EDM Opponensplasty. The EDM can be used for an opponensplasty, particularly when the EIP is not available, usually because it has been used or will be used for another transfer.[170] It is important for the surgeon to have an alternate transfer in mind, in the event that the EDM is determined to be insufficient or absent.

Technique. An incision is made over the little finger MP joint and the EDM tendons (i.e., usually two tendons) are identified on the ulnar side of the little finger's common extensor tendon. These tendons and, in continuity with them distally, a central slip of the extensor hood are freed distally and withdrawn proximally into a large incision on the dorsoulnar aspect of the distal forearm. The tendons are then freed of soft tissue attachments in the distal third of the forearm, and the little finger extensor hood is carefully repaired with interrupted, nonabsorbable sutures. The transfer is then passed outside of the extensor retinaculum, around the ulnar border of the wrist, and subcutaneously across the palm by using the technique described for EIP transfer. In the original description of this transfer, it was attached to the APB, the extensor expansion, and the EPL tendon over the base of the proximal phalanx. Postoperatively, the thumb is immobilized in opposition with the wrist in neutral for 3 weeks.

Results. Schneider reported good opposition in 8 of 10 cases, most of which were combined median and ulnar nerve injuries[170] (Figure 31.9). The donor tendon is not long enough on its own, so a portion of the extensor hood must be taken to ensure adequate length. Despite careful repair of the hood, this author encountered extension lag of the little finger after the transfer.

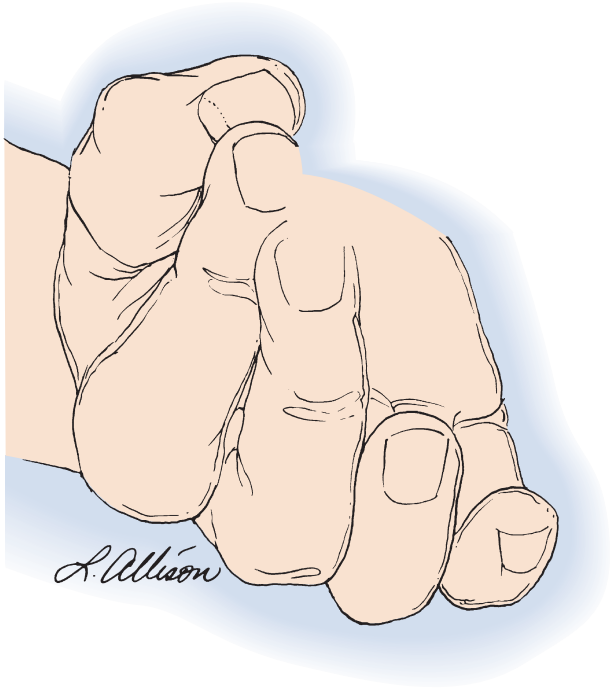

FIGURE 31.10 With hyperflexion of the interphalangeal joint, a moment for supination of the thumb occurs if the index finger contacts the thumb with power. Brand calls this the crank-handle effect.

Tendon Transfers ("Compromise Opponensplasty") for Severe Nerve Deficits

In a complete or nearly complete intrinsic-minus thumb, such as occurs in combined median and ulnar nerve palsies, the FPL and EPL muscles both adduct and supinate the thumb. Furthermore, the combined overactivity of these two extrinsic muscles causes the IP joint to hyperflex and the MP joint to extend. The hyperflexed IP joint prevents the thumb pulp from meeting the index finger properly in either pulp or key pinch, and the fingers tend to strike the nail or the dorsum of the thumb, which is disabling and causes thumb supination (Figure 31.10). However, a patient usually can hold objects between the adjacent sides of

the thumb and hand (lateral squeeze) and often prefers this "pinch" to that provided by an opponensplasty that the patient therefore does not use (see Figure 31.2).[29] It is thus an attractive concept, which stems from the days of poliomyelitis, to use one of these extrinsic thumb muscles for an opponensplasty.

In progressive severe paralysis, a combination of two tendon transfers—one to provide opposition and the other to restore FPB function—is a luxury and the hand may not have sufficient function to benefit from true opposition.[119] In such instances, restoration of short flexor action alone often provides adequate thumb function. This can be produced by a single-tendon transfer and thumb joint fusion or, less commonly, IP joint tenodesis.[111]

FPL Opponensplasty. An FPL transfer only provides limited pronation and is used for patients with severe hand paralysis for whom pinch of the thumb pulp to the sides of the index or long fingers is more important than pinch to the pulp. The desired end result is a single-axis thumb that can clear the fingers and oppose the fingertips and their sides with considerable power.

Technique. The distal attachment of the FPL is exposed and divided through a zigzag incision on the flexor surface of the IP joint. A "Y" incision is then made over the dorsum of that joint, and the EPL tendon is divided at its insertion to expose the IP joint that is fused in extension. The FPL tendon is delivered into an incision on the radiopalmar aspect of the wrist. Sometimes this is possible only after adhesions between the tendon and the radial palmar bursa have been divided through a further incision at the level of the A1 pulley. The FPL is then passed around a pulley on the ulnar border of the hand; any of the superficialis transfer pulleys described earlier in this chapter can be used.

If the Thompson pulley is chosen, a palmar incision is made in line with the ulnar border of the ring finger. Next, the FPL tendon is passed through the carpal tunnel, between the superficialis and profundus flexor tendons, and is delivered into the palmar incision. An incision is then made over the dorsoradial aspect of the thumb MP joint, and the FPL tendon is passed through a wide subcutaneous tunnel into this incision. After the tourniquet has been released and hemostasis obtained, all incisions, except the last one, are closed.

The FPL tendon is usually attached to the superficial head of the FPB rather than the APB. This allows the transfer to stabilize the MP joint in slight flexion as well as abduct and, to a lesser extent, pronate the thumb. Furthermore, if the APB is used as the insertion, thumb opposition and flexion will be much weaker. Because the FPL muscle has a large potential excursion, setting the tension in this transfer is relatively easy and the thumb should rest in almost full opposition at the end of the procedure.

The hand is immobilized postoperatively with the wrist in 40 degrees of flexion and the thumb in full opposition for 3 weeks. Rehabilitation is then begun by using active wrist extension to bring the thumb into opposition. This is followed by exercises to increase the strength of the transfer.

Results. Burkhalter believed that this transfer had distinct advantages for the completely intrinsic-minus thumb, in which case short flexor action is more important than opposition. He found that EPL overactivity tended to disappear, and his patients quickly realized that they had a functional short flexor muscle and no longer needed to use the EPL as a secondary thumb adductor (Figure 31.11). After this transfer, the patient uses the EPL to move the thumb away from the fingers and the FPL opponensplasty for prehension activity.

Alternative FPL Opponensplasties. Makin transferred the FPL "in continuity," without dividing the tendon or its insertion, by passing it through an oblique osteotomy in the proximal phalanx so that it spirals around the proximal phalanx and the MP joint[108] (Figure 31.12). Oberlin and Alnot used a similar technique in 11 intrinsic-minus thumbs and reported very good results in 8 of the 9 cases reviewed.[133] Rather than passing the FPL tendon through an osteotomy, they passed it through either the IP or the MP joint, which was then fused. They stressed that the transfer must pass over the extensor surface of the MP joint and not over the dorsum of the proximal phalanx, which can cause a flexion deformity of the MP joint (Figure 31.13). These authors recommended this transfer for completely intrinsic-minus thumbs in high nerve injuries but favored EIP opponensplasty and MP joint arthrodesis if there were no fixed deformity of the IP joint.

EPL Opponensplasty. In some cases of peripheral nerve disease or spastic paralysis, when the only functioning thumb extrinsic or intrinsic motors are the EPL, EPB, and APL, an IP joint flexion contracture may occur even though the FPL is weak or totally paralyzed. This is due to a tenodesis effect of the FPL, which occurs as the functioning thumb muscles extend and supinate the trapeziometacarpal and MP joints. In this situation, the extension and supination deformity at the base of the thumb may be corrected by an intermetacarpal bone block (i.e., static correction) or an EPL opponensplasty (Figure 31.14) if this muscle is under voluntary control. If a spastic EPL is transferred, the thumb will lie in front of (and get in the way of) the fingers because the APL on its own is not sufficiently strong to hold the thumb out of the palm.

Technique. An incision is made on the extensor surface of the proximal phalanx and MP joint of the thumb. The EPL tendon, with a contiguous central portion of the extensor expansion, is then freed from its insertion on the distal phalanx while preserving the lateral portions of the extensor hood over the proximal phalanx and the MP joint. This tendon is then withdrawn into an incision on the extensor surface of the wrist and distal forearm, and a further incision is made near the pisiform. The EPL tendon is passed through a wide subcutaneous tunnel that runs around the ulnar border of the wrist and across the palm to the initial thumb incision. Next, the thumb MP joint is fused in almost full extension and some pronation (Figures 31.15 and 31.16).

The transferred EPL tendon is then looped around the lateral portions of the extensor hood at the level of the MP joint and sutured back onto itself. The two lateral portions of the extensor hood over the proximal phalanx are sutured together, thereby restoring continuity of the EPL and preserving extension of the IP joint. The IP joint is then held in extension with Kirschner wires, and the hand is immobilized with the thumb in full opposition and the wrist in 40 degrees of flexion. It is most important for the fixation of the MP arthrodesis to be secure so that this transfer can be mobilized actively within 4 weeks, while the arthrodesis is not yet solid. At that stage the patient should be taught to differentiate between EPL and APL function. It is also important after completion of the transfer that it is possible for the fingers to clear the thumb with the wrist in

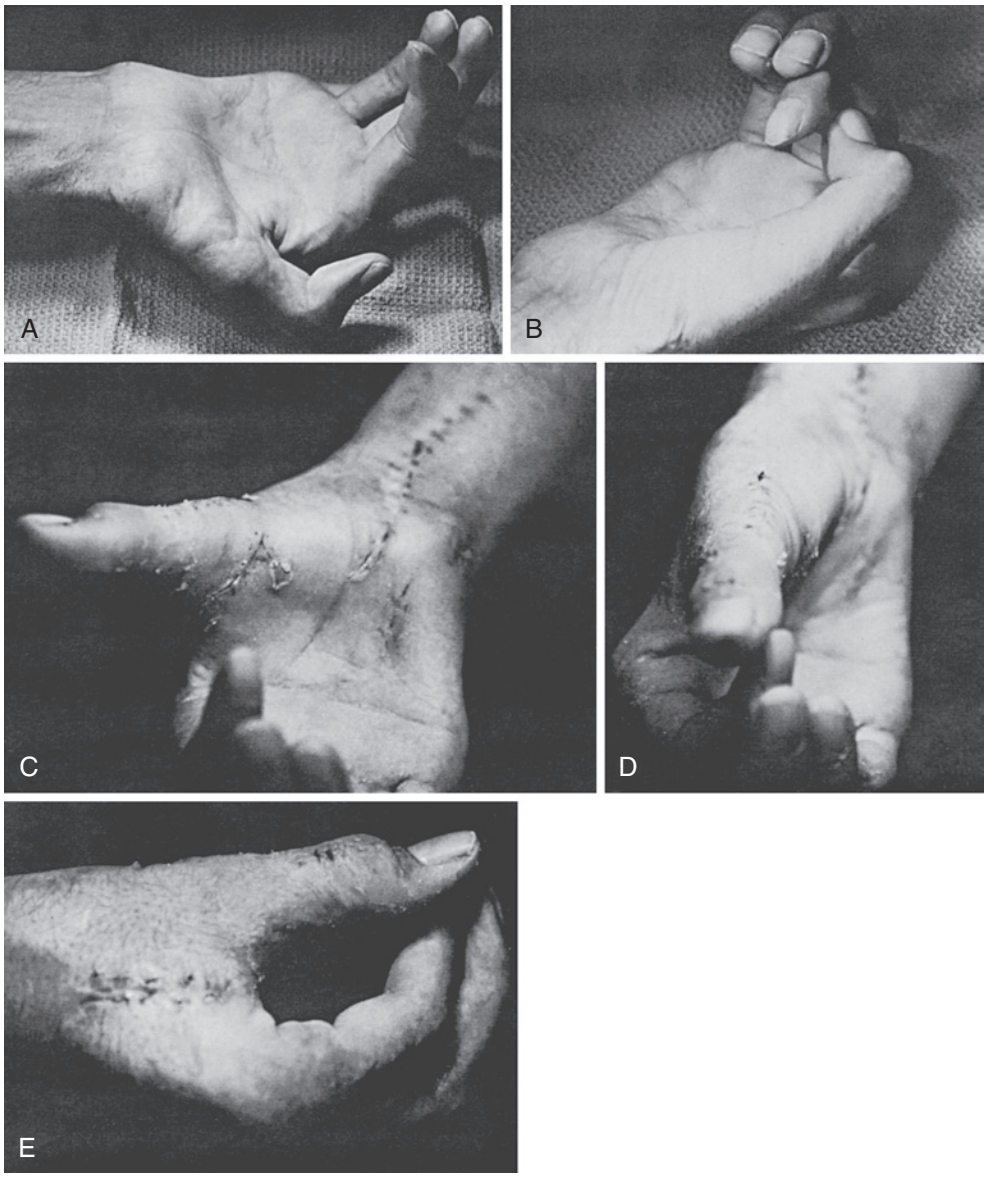

FIGURE 31.11 Flexor pollicis longus (FPL) opponensplasty. **A, B,** A 25-year-old man presented with a brachial plexus injury and the equivalent of an intrinsic-minus thumb. The thumb extrinsic muscles were causing metacarpophalangeal joint extension and interphalangeal (IP) joint hyperflexion. An FPL opponensplasty and thumb IP arthrodesis restored short thumb flexor and extensor pollicis longus (EPL) function. **C**-**E,** Improved thumb function was apparent as soon as the cast was removed. The EPL now functions not as an adductor but as an extensor, and the FPL now functions as a short flexor replacement. The pulley for the transfer was at the pisiform, and its distal attachment was the abductor pollicis brevis tendon.

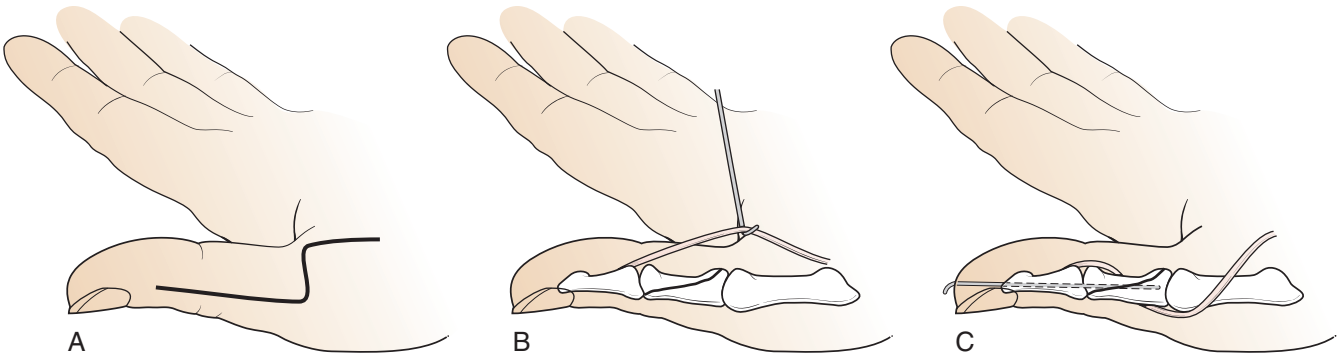

FIGURE 31.12 Makin's flexor pollicis longus (FPL) opponensplasty. **A,** A bayonet incision is made on the radial aspect of the thumb. The radial neurovascular bundle is protected and the proximal phalanx is exposed by subperiosteal dissection around its circumference. The flexor sheath is released throughout its length to allow retraction of the FPL tendon. **B,** An oblique osteotomy is made in the proximal phalanx and the FPL tendon is passed through this so that distally it passes around the ulnar border of this bone. It then runs over the extensor surface of the metacarpophalangeal joint before passing radially over the neck of the metacarpal. **C,** The osteotomy is then stabilized with a longitudinal Kirschner wire until union. (Redrawn from Makin M: Translocation of the flexor pollicis longus tendon to restore opposition. *J Bone Joint Surg Br* 49B:458–461, 1967, with permission.)

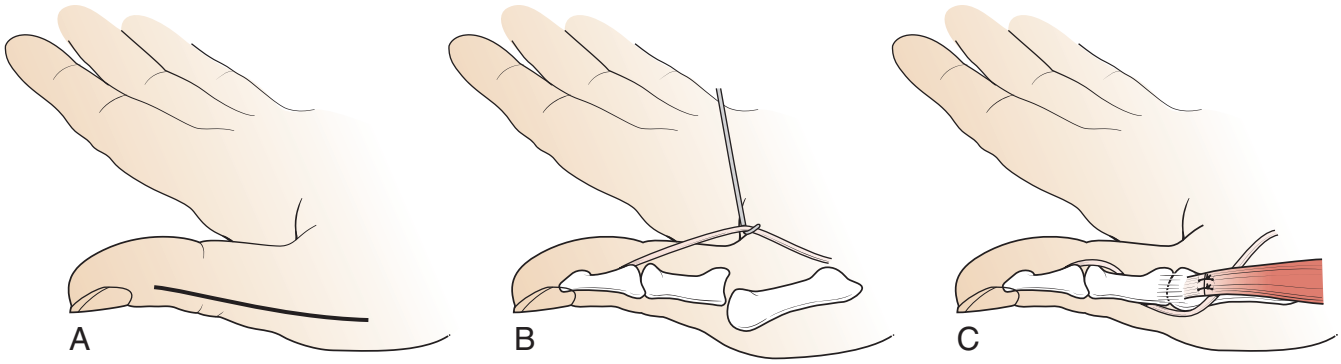

FIGURE 31.13 Oberlin's flexor pollicis longus (FPL) opponensplasty. **A,** A longitudinal incision is made on the radial aspect of the thumb. The radial neurovascular bundle is protected and the flexor sheath is released throughout its length to allow retraction of the FPL tendon. **B,** The soft tissue attachments to the proximal phalanx are released circumferentially from its neck distally to the metacarpophalangeal (MP) joint; then the joint capsule is completely divided and the FPL tendon is passed through it so that distally it passes around the ulnar border of the shaft of the proximal phalanx. It then runs over the extensor surface of the MP joint before passing radially over the neck of the metacarpal. **C,** The MP joint is then fused and stabilized until union. The position of the FPL can be fixed on the radial aspect of the neck of the metacarpal by dividing the insertion of abductor pollicis brevis, placing FPL under the tendon and then repairing the insertion. This transfer can be performed through the interphalangeal joint rather than the MP joint, in which case it is the former that is fused; great care must be taken to ensure that the transfer passes over the back of the MP joint. If it passes over the back of the proximal phalanx, it may flex the MP joint.

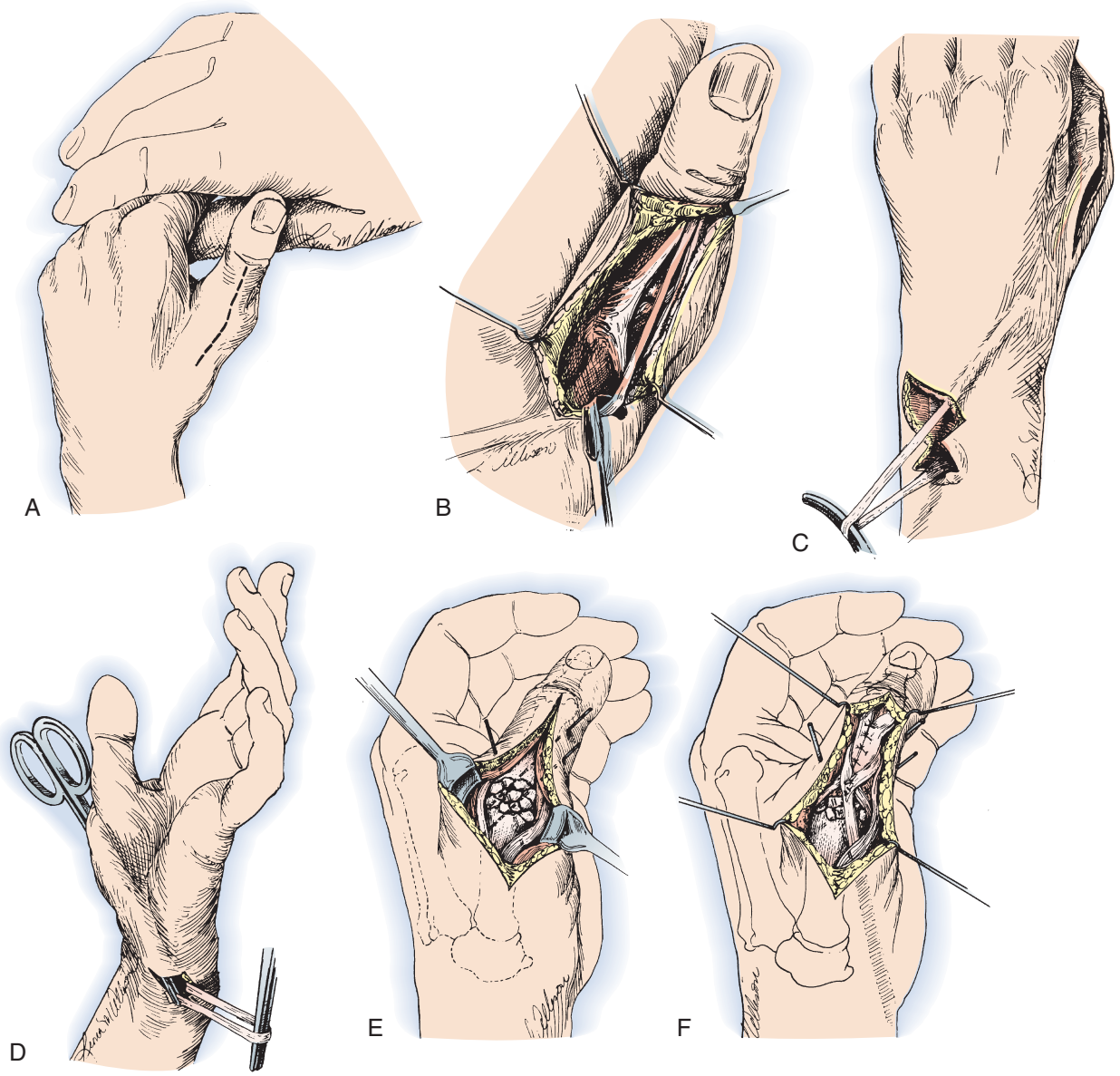

FIGURE 31.14 Extensor pollicis brevis (EPL) opponensplasty. **A, B,** The middle portion of the EPL tendon is exposed over the proximal phalanx and removed in continuity with the main EPL tendon proximal to the metacarpophalangeal (MP) joint. **C-E,** The transfer is then passed around the ulnar border of the wrist, and the thumb MP joint is fused. **F,** The two lateral portions of the EPL tendon over the proximal phalanx are sutured together, and the transfer is sutured around them. The interphalangeal joint is temporarily pinned in extension to protect the transfer while it heals. (From Riley WB, Mann RJ. Burkhalter WE: Extensor pollicis longus opponensplasty. *J Hand Surg* 5:217–220, 1980, with permission.)

neutral because, after this transfer, only the EPB and APL extend the thumb.

Results. Riley and colleagues[157] used this transfer in 11 patients with progressive neurologic disease (e.g., syringomyelia and Charcot-Marie-Tooth) or traumatic high median or combined median and ulnar nerve intrinsic paralyses. They reported satisfactory results in view of the severity of the original motor deficit and found that the APL and EPB muscles were always able to extend the thumb sufficiently to clear the palm and not impede finger flexion (Figure 31.17). However, all the patients had a diminished range of retroposition.

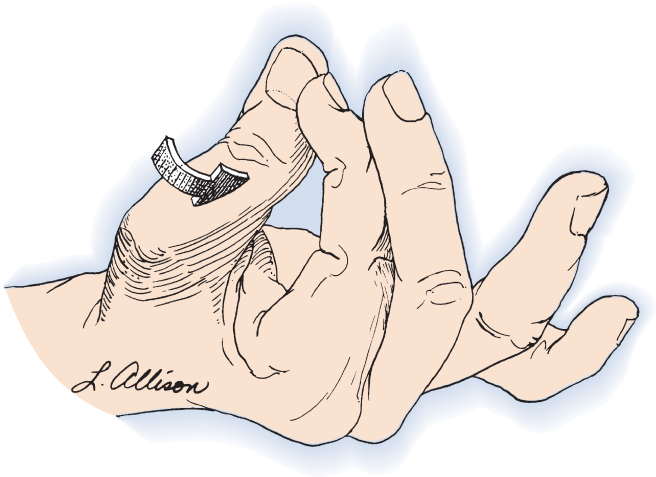

FIGURE 31.15 If the thumb metacarpophalangeal joint is fused in flexion, the index finger exerts a powerful supinatory effect on it during pinch. The moment arm is the entire length of the distal and proximal phalanges of the thumb. This is the same crank-handle effect as shown in Figure 31.10, but with an even longer moment arm.

Alternative EPL Opponensplasties. Moutet and associates[123] and Mennen[116] have used EPL opponensplasties more routinely, both for isolated and combined median nerve injuries. However, instead of transferring the EPL tendon around the ulnar border of the wrist, they both passed it through a window in the interosseous membrane. Moutet and associates then passed it around either the FCR (isolated median nerve injury) or FCU (combined median and ulnar nerve injury) tendon, and both sutured the transfer back onto the divided distal end of the EPL. Neither fused the MP joint.

Mennen's Technique of EPL Opponensplasty. The EPL tendon is exposed through an incision on the extensor surface of the MP joint and divided 1 cm proximal to this joint.[116] This tendon is then delivered into a second incision on the extensor surface of the forearm. The tendon and its muscle are freed of soft tissue attachments throughout the distal half of the forearm. An incision is made on the flexor surface of the forearm 3 cm proximal to the wrist crease and just radial to the ulnar artery. The interosseous membrane is then exposed between the ulnar neurovascular bundle and the finger flexor tendons, and a window is made that is large enough to easily accommodate the distal portion of the EPL muscle.

A subcutaneous tunnel is then created between the incisions on the anterior of the forearm and back of the thumb, and the EPL tendon is passed through the interosseous membrane and subcutaneously along the thenar eminence to the extensor surface of the thumb MP joint. Here it is passed under the EPB tendon and reattached to its own distal stump with a 1-cm overlap. The thumb is immobilized in a short-arm thumb spica

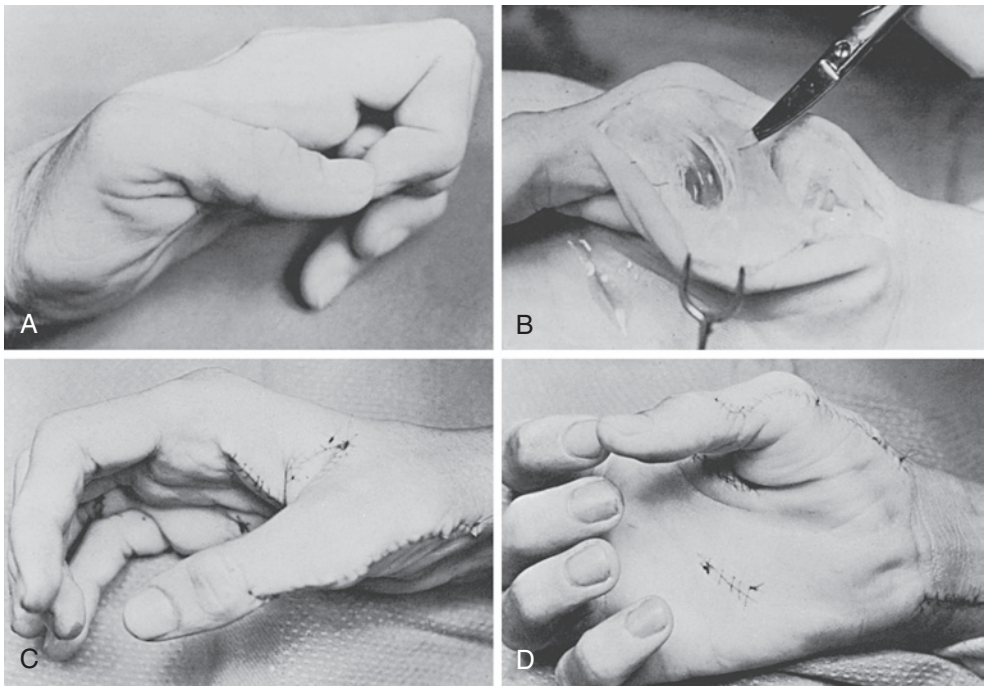

FIGURE 31.16 **A, B,** A completely intrinsic-minus thumb in which only a single motor was used to reconstruct function. In spite of adequate release **(C),** this patient needs either a metacarpophalangeal (MP) joint arthrodesis in full extension or a second transfer to restore short flexor–adductor function. As the patient attempts to pinch the thumb and the index finger together **(D),** thumb MP joint flexion produces a tremendous crank-handle action.

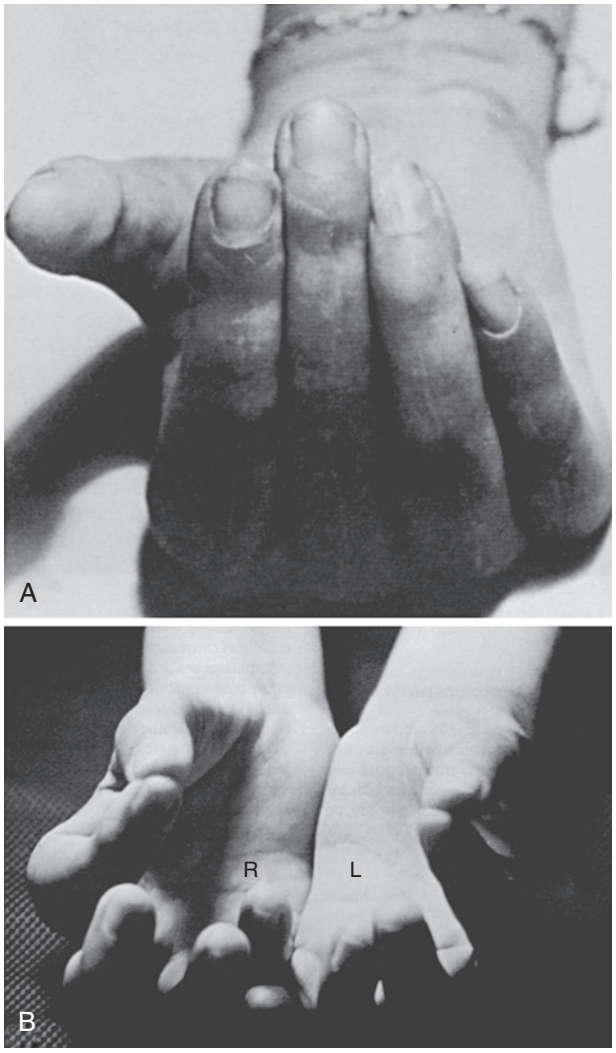

FIGURE 31.17 This patient with Charcot-Marie-Tooth disease has undergone arthrodesis of the thumb metacarpophalangeal (MP) joint as well as an extensor pollicis longus opponensplasty. **A,** The abductor pollicis longus can move the thumb clear of the fingers so that it does not interfere with power grip. **B,** In addition, notice that the MP joint of the left thumb has been arthrodesed in hyperpronation, whereas on the right it has been fused in an almost neutral position. The crank-handle effect is much less obvious in the left thumb, which suggests that fusion of the MP joint in hyperpronation, as well as full extension, is preferable for patients with combined median and ulnar nerve palsy.

cast for 4 weeks, and a dynamic opposition splint is then used for another 4 weeks.

Results. By using this technique, Mennen regained normal opposition between the thumb and little finger pulp in 26 of 35 cases and also found that normal power of extension of the thumb's IP joint was retained. In the series by Moutet and associates, 14 of 16 patients recovered functional opposition[123] and the results remained satisfactory 13 years later.[69]

Adductor Pollicis and FPB Opponensplasties. De Vecchi[58] transferred the adductor pollicis to the insertion of the superficial head of the FPB. This transfer requires an extensive palmar incision that extends from the adductor insertion across the palm toward the middle finger metacarpal and then proximally toward the base of the thumb. The carpal tunnel is opened, and the median nerve and its branches are protected. The adductor tendon is then divided at its insertion and freed from the FPB. It is passed superficial to the index finger flexor tendons, the index/middle common digital neurovascular bundle, and the FPL tendon and attached to the superficial head of the FPB. This transfer restores FPB function and provides some thumb pronation but does not produce true opposition.

Orticochea transferred the ulnar-innervated deep head of the FPB around the extensor surface of the thumb and attached it to the aponeurosis of the adductor tendon.[143]

Postoperative Management of Opponensplasty. The thumb is usually immobilized in opposition for 3 weeks after opponensplasty. However, early controlled mobilization is possible with a robust attachment of the transfer to the APB insertion and MP capsule.[154] The wrist should also be immobilized if the tendon transfer crosses the flexor surface of this joint. Transfers of muscles with relatively short excursions (e.g., the EIP) should be relaxed by immobilizing the wrist in 30 degrees of flexion and the thumb in full opposition. However, after transfer of muscles with larger excursions (e.g., the superficialis) the wrist can be immobilized in neutral with the thumb in full opposition. If the transfer is attached to either the extensor mechanism or the APB insertion, the IP joint of the thumb probably should also be immobilized in full extension.

Some find it useful to maintain thumb opposition postoperatively by using cyanoacrylate glue to stick the skin of the thumb tip to the little finger at the end of the operation, before the transfer's tension is set. With desquamation, the thumb is spontaneously released from the little finger after 2 to 3 weeks. After 3 weeks, all splintage usually can be discarded and most patients quickly regain thumb control. The emphasis should be on early restoration of wrist movement, which will alternately relax and tighten the opponensplasty.

Under certain conditions, such as high combined median and ulnar nerve palsies and diseases (e.g., Charcot-Marie-Tooth disease and leprosy), the thumb extensors are strong and unbalanced and the sensory loss is profound; in these conditions the patient may stretch the transfer if the thumb is mobilized after 3 weeks. In addition, it is advisable to protect the opponensplasty for 3 months with splints that prevent full adduction, supination, and extension of the thumb.

❖ AUTHOR'S PREFERRED METHOD OF TREATMENT: Low Median Nerve Palsy

My enthusiasm for reconstructive surgery in median nerve palsy is tempered by the belief that sensation is the prime determinant of hand function in this situation. I thus believe that isolated injuries to the motor branch of the median nerve and focal pure motor deficits caused by nonprogressive or slowly progressive neurologic disease are the best indications for opponensplasty. The more severe the sensory deficit, the less likely the patient is to benefit from reconstructive surgery.

Therefore, I believe that opponensplasty is rarely indicated for combined complete median and ulnar nerve injuries in adults because permanent sensory deficit is often severe even after careful nerve repair. In my practice, few patients require or request an opponensplasty after isolated traumatic division of the median nerve; in fact many never lose opposition, presumably because of anomalous thenar muscle innervation.

In combined nerve deficits it is imperative that both the patient and the surgeon consider whether the loss of opposition, taken in isolation from the rest of the neurologic deficit,

is causing sufficient disability to justify further surgery and rehabilitation. This is especially the case in times of job insecurity and financial uncertainty, when time away from work may result in job loss. Many of my patients, especially those with unilateral loss of opposition, adapt well and minimize their disability so that an opponensplasty is not indicated.

My favored transfers are the Camitz procedure and the EIP transfer. I used to favor the Royle-Thompson superficialis transfer but was converted to the EIP transfer by the papers of Burkhalter, who wrote previous editions of this chapter, and discussions with Nicholas Barton, coauthor for the fourth edition of this chapter. I use the Camitz procedure for patients with loss of opposition secondary to carpal tunnel syndrome and perform this transfer at the same time as carpal tunnel release, even though I believe that thenar muscle function will recover in a considerable number of cases. I do this because the procedure has low morbidity and complication rates and requires little rehabilitation. Also the recovery of thenar muscle function is unpredictable and may not occur for over a year.

The Camitz procedure does require general or regional anesthesia, whereas most of my carpal tunnel releases are done under local infiltration anesthesia. Restoration of thumb abduction in these patients may produce immediate improvement in hand function if median nerve sensation has not been completely lost and there is a reasonable prospect for sensory regeneration.

In other instances, I now favor the EIP transfer, which rarely causes any donor site morbidity, provided that the index finger extensor hood is not damaged. Furthermore, this transfer uses a natural pulley (i.e., ulnar border of the wrist) that is resilient and cannot migrate. In isolated median nerve transfers, this transfer is inserted into the APB tendon. I have not experienced significant loss of thumb extension after this transfer and have found rehabilitation and reeducation straightforward.

With more complex upper limb paralyses, it is important to assess the disability carefully, ascertain which musculotendinous units are available for transfer, and consider the probable effects of loss of the transfer's normal function before making any decision.

Expectations and Patient Counseling for Low Median Nerve Palsy

What I tell the patient about the expected outcome depends on (1) whether the underlying neurologic pathology is progressive (progressive neurologic disease) or static (nerve injury after regeneration period); (2) the functional disability attributable to the isolated loss of opposition; and (3) the functional disability attributable to other problems in the hand, such as sensory loss, and loss of other motor functions. This author would advise a motivated patient with an otherwise normal hand (e.g., isolated injury to the motor branch of the median nerve) that restoration of opposition with either an EIP, FDS, or ADM transfer should restore useful opposition and improve hand function considerably in 7 or 8 of every 10 cases. I tell patients with loss of opposition due to severe carpal tunnel syndrome that they will regain thumb abduction in a similar number of instances but that the functional benefit of this depends to a great extent on the recovery of lost sensation in the thumb and index and middle fingers after the carpal tunnel release.

TABLE 31.3 Outcomes of Opponensplasty

Procedure	"Satisfactory" Outcomes*
Superficialis transfers	
Royle-Thompson technique (Jacobs and Thompson[83])	78%
Bunnell (Jensen[84])	81%
Extensor indicis proprius transfer	
Trauma (Burkhalter et al.[45])	88%
Leprosy (Anderson et al.[9])	88%
Abductor digiti minimi Wissinger and Singsen[201]	80%
Palmaris longus Foucher et al.[65]; Terrono et al.[191]	91-93%

*See Table 31.2 and the Results heading under General Principles of Tendon Transfer With Reference to Opponensplasty for discussion of assessment of outcome.
Please note that various studies use different insertions and different criteria for assessing outcomes.

For more complex cases, such as loss of opposition after combined median and ulnar nerve injuries, I tell patients that opposition can be restored in 7 or 8 of every 10 cases; however, I stress that their loss of opposition is (usually) only causing a small amount of their total hand disability and that they may not gain any significant functional benefit from a successful opponensplasty. In my opinion, before recommending surgery, there has to be convincing evidence that the loss of opposition, rather than loss of sensation or other motor deficits, is causing loss of function.

When dealing with progressive neurologic disease, it is vital to have the opinion of the treating neurologist regarding the likely course and speed of progression of the condition and to be aware of whether the deficit is and/or will be purely motor or combined sensory and motor. I then carefully discuss the likely short- and long-term benefits of an opponensplasty with the patient so that he or she can make an informed decision on its probable impact on hand function (Table 31.3).

CRITICAL POINTS *Management of Low Median Nerve Palsy*

- The more severe the sensory deficit, the less likely the patient is to benefit from reconstructive surgery.
- Expected patient outcomes depend on the underlying neurologic pathology (i.e., progressive or static), the functional disability attributed to the isolated loss of opposition, and the functional disability attributable to other problems in the hand (e.g., sensory loss, other motor functions).

High Median Nerve Palsy

In high median nerve paralysis, all the flexor compartment forearm muscles, apart from the ulnar-innervated FCU and the profundi to the little and ring fingers, are paralyzed. However, the working part of the profundus muscle often provides a full, although weak, range of middle finger flexion.

The primary aim of tendon transfers in high median nerve palsy is to restore flexion of the index finger and thumb, as well as opposition. Only the brachioradialis, ECRL, and ECU are available and suitable for transfer to the extrinsic flexors, and

the ECU has concerns as noted earlier. Thus, the brachioradialis is generally used to restore FPL function and, when needed, the ECRL to restore index finger profundus function. As these muscles have less potential excursion than the index profundus and FPL (see Table 31.1), satisfactory results can be obtained only if the patient can amplify the transfer's excursion by actively flexing and extending the wrist; full finger and thumb flexion and extension are then achieved by the tenodesis effect of extending and flexing the wrist, respectively. In most cases, however, adequate index flexion can be attained using side-to-side transfer to the functioning profundus tendons, obviating the need for ECRL transfer. If there is any hope of subsequent motor recovery, these transfers should be performed in an end-to-side fashion.

Timing and Selection of Extrinsic and Intrinsic Transfers

The selection and timing of tendon transfers for both intrinsic and extrinsic paralysis in high median nerve lesions depend on the prognosis for the median nerve injury, as well as the surgeon's assessment and the patient's perception of the functional disability.

In patients with median nerve palsy, the sensory loss is probably the most important single disability and, if permanent, dramatically reduces the functional benefit of tendon transfers, particularly for restoration of opposition. Although some surgeons believe that severe sensory loss, which is likely to be permanent in an adult, is a strong contraindication to tendon transfers, others argue that eyesight can provide sensory input and some hand function remains. Therefore, they believe that a mobile, opposable thumb is probably more useful than one that cannot reach the remaining areas of the hand with normal sensation.[46]

The functional deficit associated with a high median lesion is so profound that some surgeons advocate early end-to-side tendon transfers for selected patients to restore either opposition alone or opposition and extrinsic muscle function.[46] These early transfers maintain motor function during nerve regeneration and act as an internal splint, thereby preventing contractures and eliminating the need for cumbersome external splints that may severely limit patients' ability to use the hand. If patients ultimately regain some function in the muscles involved, the transfers act in synergy and provide additional power, whereas if no recovery occurs, the transfers act as a permanent substitute.

Extrinsic Transfers

Good extrinsic muscle function is usually restored after repair of a high median nerve laceration, in which case transfers to restore flexion of the thumb and index finger are not required. However, these should be considered if there is no evidence of extrinsic muscle recovery several months after a nerve repair. For practical purposes, extrinsic tendon transfers are indicated only when a high median nerve injury is not repaired or is grafted. If one decides not to perform early extrinsic tendon transfers, it is essential that mobility of the thumb and index finger are maintained until recovery occurs.

Restoration of Thumb Opposition

As previously mentioned, many patients retain thumb opposition after median nerve injury and do not require an opposition transfer. Burkhalter, who had a wealth of expertise[102] and wrote this chapter for previous editions, believed that those who lost opposition should undergo an opposition transfer soon after neurorrhaphy or grafting and before sensory recovery. His rationale was that the likelihood of recovery of thumb intrinsic muscle function after high median nerve injury is low.

Another reason to pursue early opponensplasty is to allow the patient to pick up objects with the forearm in any position of rotation. Patients who have lost thumb opposition and abduction use the APL and the extrinsic extensor muscles to position their thumb when picking up an article from a table. Although the thumb–index web is open, the thumb is supinated and extended because all the muscles are supinators. With the thumb in this position, the patient can pick up objects from a flat surface only by fully pronating the hand, either by pronating the forearm or internally rotating the shoulder (see Figure 31.2). Thus, the patient cannot see the palm of the hand and cannot use sight as a substitute for the median nerve sensory loss, which renders motor function of little use to the person. If a patient is able to use a paralyzed hand to pick up articles and transfer objects from hand to hand in a position other than full pronation, the FPB is probably still functioning and an opponensplasty is not needed.

Restoration of Opposition in High Median Nerve Palsy

In high median nerve palsy, the EPL, EIP, and EDM are most readily available for opposition transfer. They position the thumb well, do not create significant donor morbidity, and do not require lengthening with a tendon graft. Although strong opposition can be restored with the FCU, which may be elongated with a paralyzed superficialis tendon,[72,82] this is not advised because it eliminates the only functioning wrist flexor. Moreover, strong thumb opposition is not required as long as there are functioning intrinsic muscles capable of acting as a short flexor or short flexor substitute.

Brachioradialis-to-FPL Transfer

To achieve 30-mm excursion, the brachioradialis muscle must be freed of all soft tissue and fascial attachments throughout the distal two-thirds of the forearm. This involves dissection well proximal to the musculotendinous junction because the peripheral fibers of this muscle are inserted onto the deep fascia of the forearm.[29] The transfer's tension is set so that all three thumb joints can be fully passively extended when the wrist is flexed 30 degrees; again, and for the same reason mentioned for the ECRL-to-index profundus transfer, excessive tension must be avoided. Because the brachioradialis originates above it, the elbow is placed in approximately 45 degrees of flexion during tensioning. Although this degree of tension does not allow full IP joint flexion, it stabilizes it, improves thumb strength, and prevents a disabling flexion contracture from developing (Figure 31.18). Most precision pinch activities are performed with the thumb IP joint fully extended.

Because the prime function of the brachioradialis is elbow flexion, its usefulness as a transfer depends on elbow position. When the elbow is extended, reasonably powerful thumb flexion is usually provided, but thumb flexion is much weaker when the elbow is flexed. For this reason Brand and others have considered fixing the brachioradialis origin distal to the elbow[29,137]; however, this practice is not widely performed.

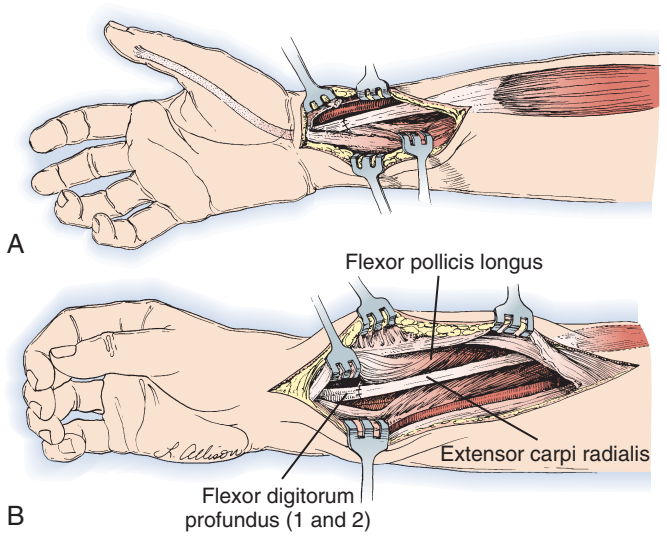

FIGURE 31.18 Extrinsic reconstruction using brachioradialis-to-flexor pollicis longus **(A)** and extensor carpi radialis longus-to-index and long finger profundi **(B)** transfers. The transfers shown here are end-to-end but should be done in an end-to-side fashion if there is to be any chance of recovery.

ECRL-to-Index Profundus Transfer

An ECRL-to-index profundus transfer (Figure 31.19) is performed only in patients who need additional strength on the radial side of the hand and are unlikely to obtain significant reinnervation after nerve repair. Usually, index finger range of flexion, but not strength, is restored by side-to-side suturing of the index and the conjoint middle, ring, and little fingers' profundus tendons in the distal forearm. If an ECRL transfer is indicated, its tension is adjusted so that the finger is virtually fully extended when the wrist is flexed 30 degrees and is fully flexed when the wrist is extended 30 to 45 degrees. If this transfer is placed in excessive tension, flexion contractures can result and cause considerable disability.

Complications

Swan-neck deformities can develop in patients with hyperextensible PIP joints after high median paralysis due to unopposed intrinsic action on the PIP joint with paralysis of the FDS. The deformity develops gradually as the PIP palmar plates stretch and may cause disability with locking of these joints in extension.

High Median Nerve Palsy Summary

In a high median nerve injury, the surgeon should consider performing an opposition transfer if forearm pronation is used as a substitute motion. If the nerve has been repaired, extrinsic transfers are seldom required because satisfactory extrinsic muscle function is usually regained. If the patient needs a nerve graft, especially if this is done late or under unfavorable conditions (e.g., a long graft or a poor bed), useful extrinsic functional recovery is unlikely and one should consider performing early extrinsic end-to-side transfers and/or a side-to-side transfer of the index and conjoint profundus tendons. All these intrinsic and extrinsic transfers can be performed at the same time.

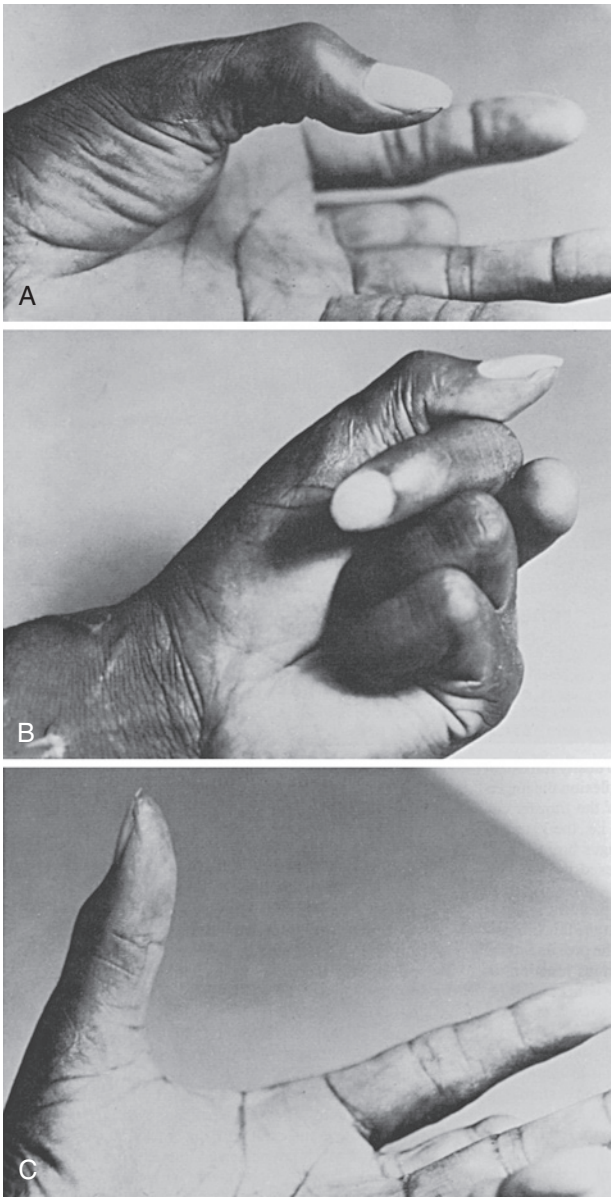

FIGURE 31.19 High median nerve palsy treated with brachioradialis-to-flexor pollicis longus (FPL) and extensor carpi radialis longus-to-index finger profundus tendon transfers. **A, B,** There is good FPL power but a limited range of active interphalangeal joint flexion when the wrist is held still. **C,** Note the absence of either thumb or index finger flexion contractures.

❖ AUTHOR'S PREFERRED METHOD OF TREATMENT: High Median Nerve Palsy

Again, my enthusiasm for reconstructive surgery is tempered by the belief that sensation is the prime determinant of hand function and because I believe that sensory recovery after a high median nerve repair in adults is always poor and is even worse if a nerve graft is required. Furthermore, I believe that nerve repair hardly ever restores lost opposition, although useful reinnervation of the forearm flexor muscles undoubtedly occurs. For these reasons, I do not favor early extrinsic tendon transfers and only restore opposition if, after maximal recovery has occurred, both the patient and the surgeon believe that this will

improve hand function. Most patients will adapt and increasingly use their normal arm (even if this is the nondominant arm) for precision function; I thus rarely attempt to restore opposition when there is a combined median sensory and motor deficit. If an opposition transfer is indicated, I favor EIP transfer.

I use the brachioradialis transfer for restoration of thumb flexion, especially for conditions in which there is relative sensory sparing, and use an end-to-side attachment unless there is no prospect of later reinnervation. I do not believe that an ECRL transfer to restore index finger flexion is needed often and prefer to join the index and the common (i.e., middle, ring, and little) profundi tendons in a side-to-side fashion. Although this does not restore power to the index finger, I believe that the condition of the hand is usually too poor to benefit from an ECRL transfer, especially if there is a marked sensory deficit.

CRITICAL POINTS *Management Options in High Median Nerve Palsy*

- Because worthwhile sensory recovery is so unlikely in these cases for adults, opponensplasty is typically not beneficial.
- The goal of any repair is to create the best possible "helper" hand; precision function must be assumed by the other hand.

Expectations and Patient Counseling for High Median Nerve Palsy

It is imperative to stress to adult patients with high median nerve damage that they have suffered a severe injury and will never regain normal hand sensation, strength, or function. They should be aware that the aim of all surgery is to create the best possible "helper" hand, although this will always have rudimentary function when compared with their normal contralateral one. The author thus does not enthusiastically recommend opponensplasty in the presence of severe sensory loss in the median nerve distribution because most patients will use their other hand for fine-pinching tasks, even after a "successful" opponensplasty. In contrast, I do recommend tendon transfers for persistent loss of the thumb and finger extrinsic flexor function. However, it is important to stress that restored thumb and finger flexion will be weak, although with sensory input provided by the eyes, it should allow rudimentary use of the hand to hold and steady light objects.

High Median Nerve Palsy Summary

Tendon transfers (Table 31.4) can restore selected motor functions as a result of high and low median nerve palsy, but their ability to improve function is restricted by the severity of any associated sensory loss. Numerous opposition transfers have been described, and almost every possible motor has been used. Many pulleys are available, and there are numerous methods of distal attachment. The main reasons for failure of opposition transfers are persistent thumb contractures (recognized or unrecognized) and selection of a less than adequate motor. Early opposition transfer has been recommended for patients who use forearm pronation as a substitute for the paralyzed APB. Extrinsic tendon transfers for high median nerve palsy are usually required only when the injury is bridged with a nerve graft or left untreated.

ULNAR NERVE PALSY

Ulnar nerve injuries also are classified as "high" or "low." Low injuries occur distal to the origins of the motor branches to the FCU and ring and little finger flexor digitorum profundus (FDP) muscles. Strength of the extrinsic hand muscles is unaffected but sensation is lost on the ulnar border of the hand and in the ring and little fingers, and the ulnar innervated intrinsic muscles are paralyzed. This results in weakness of thumb pinch,

TABLE 31.4 Summary of Possible Opponensplasties

Motor	Pulley	Reference
Ring finger superficialis	Angle between flexor retinaculum and palmar aponeurosis	Jacobs and Thompson[83]; Thompson[192]
	FCU tendon	Beasley[13]; Littler[102]
	FCU loop	Bunnell[43]; Jensen[84]
	FCU/ECU sling	Sakellaides[168]
	Flexor retinaculum window	Bohr[18]; Michelinakis and Vourexakis[117]; Snow and Fink[179]
	Guyon's canal	Anderson et al[10]; Brand[26]; Palande[146]
EIP	Ulnar border of wrist/forearm	Aguirre and Caplan[3]; Anderson et al[9]; Anderson et al[10]; Burkhalter et al[45]
ADM	None	Huber[80]; Littler and Cooley[104]; Nicolaysen[127]; Wissinger and Singsen[201]
PL	None	Braun[35]; Camitz[48]; Foucher et al[65]; Littler and Li[105]; Terrono et al[191]
	Window in flexor retinaculum	MacDougal[106]
	Near pisiform	Bunnell[42]
ECU	Ulnar border of wrist/forearm	Kessler[90]; Ney[126]; Phalen and Miller[149]; Wood and Adams[202]
ECRL	Ulnar border of wrist/forearm	Baek et al[11]; Henderson[76]; Kaplan et al[89]
EDM	Ulnar border of wrist/forearm	Schneider[170]
EPL	Ulnar border of wrist/forearm	Riley et al[157]
	Intraosseous membrane	Gerard et al[69]; Mennen[116]; Moutet et al[123]
FPL	Thumb proximal phalanx/MP joint	Makin[108]; Oberlin and Alnot[133]

claw deformity, loss of the fingers' normal pattern of flexion, and significant loss of hand dexterity and strength. High injuries occur above the origin of the motor branches to the FCU and ring and little finger FDP muscles. In this situation, loss of active ring and little DIP joint and wrist flexion compound these findings; although paradoxically, the claw deformity tends to be less severe.

The ulnar nerve usually innervates the hypothenar muscles (i.e., ADM, flexor digiti minimi, and opponens digiti minimi), all the interossei muscles of the fingers, the lumbricals for the ring and little fingers, and the adductor pollicis muscle. In addition, the FPB muscle frequently (79%) has a dual median and ulnar innervation.

Ulnar nerve palsy is common with leprosy in areas where this disease is endemic, but in most parts of the world it commonly occurs after a traumatic injury to the nerve or by severe compression of it in the cubital tunnel (see Chapter 3). Less frequently the ulnar nerve may be compressed in Guyon's canal at the wrist, which may result in loss of intrinsic muscle function without loss of sensation. Injury to the medial cord of the brachial plexus, compression of T1 nerve root, and neurological diseases such as syringomyelia, hereditary motor and sensory neuropathy (HMSN—Charcot-Marie-Tooth disease), poliomyelitis, and motor neuron disease may mimic ulnar nerve palsy.

Patterns of Paralysis

The motor branch of the ulnar nerve can be lacerated in the hand's palm after it has given off its branches to the hypothenar muscles, and this results in paralysis of the adductor pollicis muscle and the interossei for the index, middle, and ring fingers while the hypothenar muscles retain normal function and sensation in the ring and little fingers is preserved. The motor branch of the ulnar nerve can also be damaged or compressed in the distal portion of Guyon's canal such that ring- and little-finger sensation is normal but there is a loss of function in all the ulnar innervated intrinsic muscles, including those of the hypothenar eminence.

Ulnar nerve injury or compression in the proximal portion of Guyon's canal causes loss of sensation on the palmar aspects of the hypothenar eminence and ring and little fingers as well as loss of function in all of the ulnar-innervated intrinsic muscles. However, sensation is preserved on the dorsoulnar aspect of the hand as this is provided by the dorsal branch of the ulnar nerve that arises in the distal forearm and perforates the deep fascia 6 to 8 cm proximal to the wrist. Only ulnar nerve injuries in or above the cubital tunnel cause loss of function in the FCU and the ring and little finger FDP muscles. The characteristic deformity of ulnar nerve palsy is clawing of the ulnar two digits because their lumbrical and interosseous muscles are innervated by the ulnar nerve, whereas the lumbricals of the index and middle fingers are supplied by the median nerve and continue to function. A low ulnar nerve palsy demonstrates more severe clawing of the ring and small digits than a high palsy because of unopposed IP flexion of the FDP.

Anomalous Innervation Patterns

Anomalous innervation of the muscles of the hand and wrist is not uncommon and may cause errors in diagnosis and management. Innervation of the four FDP muscles may vary from all ulnar to all median, or each can have a dual innervation. The ring finger lumbrical has dual innervation in 50% of upper extremities,[89] and in such a hand a complete ulnar nerve palsy only results in clawing of the little finger. The first dorsal interosseous is innervated completely or partially by the median nerve in 10% of hands and by the radial nerve in 1% of hands.[89] The dorsoulnar border of the hand can be supplied by the superficial branch of the radial nerve, and this may lead to confusion concerning the level of an ulnar nerve lesion.

The Martin-Gruber—1763 and 1870, respectively—anastomosis is a motor–nerve interconnection between the median (or anterior interosseous) and ulnar nerves in the proximal forearm that is found in 17% of people.[99,112,198] It has four variations: 60% are type I with motor branches from the median nerve traveling with the ulnar nerve to innervate some "median" intrinsic muscles; 35% are type II, with motor branches from the median nerve innervating some "ulnar" intrinsic muscles (most commonly the first dorsal interosseous); 3% are type III, with motor fibers from the ulnar nerve traveling with the median nerve and innervating some "median" intrinsic muscles; and 1% are type IV, with motor fibers from the ulnar nerve traveling with the median nerve to innervate some "ulnar" intrinsic muscles.[99]

The 1897 Riche-Cannieu anomalous connection occurs between the motor branches of the ulnar and median nerves in the hand. Its presence can result in median nerve innervation of all of the lumbricals, such that finger clawing does not occur after a complete ulnar nerve injury. It may also explain the continued function of the median nerve–innervated thenar muscles after a complete division of the median nerve.[51]

Clinical Signs of Ulnar Nerve Palsy

There are many clinical signs and specific tests for loss of ulnar nerve motor function. Clawing, with hyperextension at MP joint and flexion at IP joints, is the characteristic resting posture of the ring and little fingers (Duchenne sign). The Bouvier maneuver is used to test the integrity of the central slip and the lateral bands of the extensor expansion. Hyperextension of the clawed finger MP joints is blocked and they are held in slight flexion. Attempted extension of the fingers will then result in full active extension of the PIP and DIP joints if the normal anatomy of the extensor expansion is preserved.

A sensitive way of detecting mild, as well as severe, loss of ulnar nerve function is to place the hand flat on a tabletop with the fingers abducted. The patient is then asked to abduct the middle finger from side to side (Pitres-Testut sign); not only can the strength of radial and ulnar abduction be assessed (tests second and third dorsal interosseous muscle strength) but also, if the patient is asked to move the middle finger from side to side as fast as possible, the coordination and ease of this maneuver can be compared with the normal hand to reveal subtle losses of motor function. Another sign of loss of ulnar nerve function is the inability to cross the middle finger dorsally over the index finger, or the index over the middle finger (a test of the first palmar interosseous and second dorsal interosseous muscles).

The Froment sign, marked thumb IP joint flexion when pinching sheets of paper between the thumb and index finger, indicates paralysis of the AD and first dorsal interosseous muscles with replacement of their pinch function by FPL. The Wartenberg sign is the inability to adduct the extended little

finger to touch the extended ring finger. This is due to the EDM abducting the little finger (despite paralysis of the hypothenar muscles), unopposed by the third palmar interosseous, which is also paralyzed.

Restoration of Function in Ulnar Nerve Palsy

The main aims of reconstructive surgery in "low" ulnar nerve palsy are to improve thumb pinch, correct finger clawing, and restore the normal pattern of finger flexion. "High" ulnar nerve surgery also can be performed to restore ring and little finger distal IP joint flexion. Attempts to restore sensibility to the ring and little fingers are possible,[144] but not normally performed and the loss of sensation in ulnar nerve palsy is not as devastating as in median nerve palsy. Surgical procedures also have been devised to restore the concavity of the transverse metacarpal arch and correct little-finger abduction deformity; however, the former type of procedure is rarely performed now.

The Ulnar Claw Hand and Its Management

Low Ulnar Nerve Palsy

Clawing of the fingers in ulnar nerve palsy is due to the combined paralysis of the interosseous muscles of all the fingers and the lumbricals of the ring and little fingers. These intrinsic muscles flex the MP and extend the PIP and DIP joints of the fingers; loss of their resting tone results in the "intrinsic minus" posture of hyperextension at the MP joints and flexion at the IP joints. Clawing due to isolated ulnar nerve disease is most marked in the ring and little fingers whose interossei and lumbricals are all paralyzed; it occurs, however, in all four fingers in 63% of cases as a result of Hansen disease, even though the index and middle finger lumbricals are innervated by the median nerve.[171] Clawing is more apparent during use of the hand than when it is at rest. Marked clawing of the fingers occurs most commonly in those with mobile, lax finger joints and is less common in those with stiffer fingers (e.g., Caucasian manual laborers).

In addition to the static-claw deformity, loss of intrinsic muscle function can affect the normal dynamics of finger movement. In a normal hand the MP joints flex before the IP joints when gripping an object, such that the object is drawn into the palm of the hand. In ulnar paralysis, however, the distal interphalangeal joints flex first, followed by the PIP joints and then the MP joints, such that the object is not guided into the palm, but instead is pushed out of the palm by the fingertips.

When assessing an ulnar claw hand, it is important to ascertain whether all the finger joints have a full range of active and passive movement and whether correction of the hyperextension at the metacarpophalangeal joints results in full extension of the IP joints (the Bouvier maneuver). If this is the case, then operations that address the MP joint hyperextension (i.e., capsulodesis or tenodesis of the MP joint or Zancolli-type tendon transfers) should completely correct the deformity. If the PIP joints remain flexed when the MP joint hyperextension is corrected, but can be passively fully extended, then a static procedure will not correct IP joint flexion; thus, a tendon transfer is needed in order to provide a flexion force at the MP joints and an extension force at the PIP joints. However, with claw hands that have been present for a long time, the dorsal transverse retinacular fibers of the extensor mechanism, which normally prevent palmar migration of the lateral bands, may stretch; this allows the lateral bands to migrate palmar to the axis of rotation of the PIP joint and become flexors, rather than extensors, of these joints.

A secondary hyperextension deformity of the DIP joint may then occur, as with a Boutonnière deformity. In this situation the lateral bands need to be reconstructed such that they pass dorsal to the axis of rotation of the proximal interphalangeal joint. Failure to do this before performing a tendon transfer into the lateral bands will exacerbate rather than improve the deformity. If there are fixed-flexion deformities of the IP joints, then these need to be corrected before surgery.

Outcome of Surgery Assessments

Assessment of the outcome of procedures for ulnar nerve palsy should be done at no less than 6 months follow-up.[141] Even then the comparison of the reported outcomes of various procedures to correct clawing of the fingers is difficult due to the heterogenicity of patient profiles in studies. Factors include the etiology of the ulnar nerve palsy (i.e., static or progressive), the level of the lesion (i.e., high or low), the presence of an isolated ulnar or combined median and ulnar nerve palsy, the presence or absence of joint contractures, and differences in patients' overall joint mobility.

Careful review of the operative techniques used by various authors demonstrates that few surgeons use exactly the same surgical techniques and rehabilitation programs (e.g., one, two, or four tendons may be used for the FDS transfer, with the number varying from patient to patient in some studies). Finally, the movement and function being restored are complex, and different authors have used a variety of techniques for assessing the outcomes of their procedures. To my knowledge only one study has assessed the outcomes of these operations with a validated hand function assessment (e.g., Jebsen functional examination or the Purdue pegboard[75]), and none has used an outcome questionnaire such as the DASH (Table 31.5).

Brand classified the outcomes as "excellent," "good," "fair," and "poor" by assessing pictures of a patient trying to adopt six

TABLE 31.5 Outcomes of Ulnar Claw-Hand Correction Surgery

	"Satisfactory" Outcomes*
Zancolli capsulodesis	
Trauma (Brown,[40] Leddy et al[96])	47% or 93%
Superficialis transfer	
Leprosy (Brandsma and Ottenhoff-De Jonge[34])	56%
Trauma (Hastings and McCollam[75])	83%
ECRB/ECRL transfer—extensor route	
Leprosy (Brand[24])	71%
Trauma (Burkhalter and Strait[47])	94%
ECRB/ECRL transfer—extensor route	
Leprosy (Palande[147])	90%

*See Section Outcomes of Surgery Assessment in this chapter for discussion of assessment of outcome.
Please note that various studies use different criteria for assessing outcome, and insertions of transfers vary between studies.

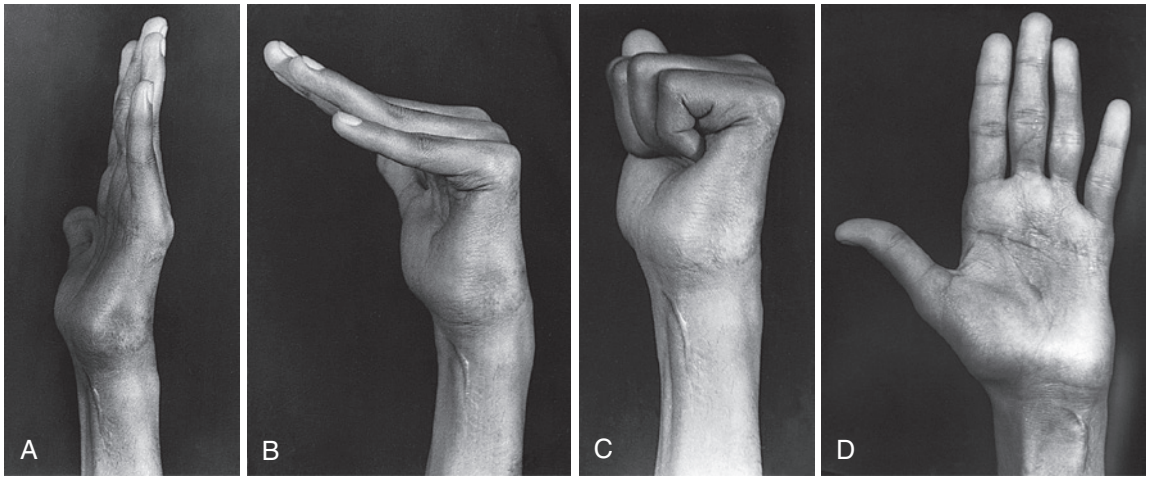

FIGURE 31.20 Proximal ulnar palsy due to Hansen disease. **A-D,** Correction of the claw deformity with ability to fully extend and flex the fingers and attain the lumbrical position (5-year follow-up).

standard postures with the wrist fixed in neutral; this was performed to ensure that the transfer was active and not simply acting as a tenodesis.[24]

1. Ability to extend fully and freely all the fingers' joints with no extension lag or fixed-flexion deformity and no hyperextension at the PIP joints or flexion at the distal interphalangeal joints (the latter two would indicate intrinsic transfer overactivity) (Figure 31.20, *A*).
2. Ability to flex the finger MP joints without flexion at the IP joints (adopt the "lumbrical plus" position) (Figure 31.20, *B*).
3. Ability to flex the IP joints without flexing the MP joints (adopt the hook position).
4. Ability to flex the fingers fully and make a tight fist (Figure 31.20, *C*).
5. Ability to open the hand without abduction of the fingers or hyperextension of the MP joints (Figure 31.20, *D*).
6. Restoration of separate lumbrical movement of each finger, such that each can flex at the MP joint without flexing the IP joints while the other fingers remain straight. (This is possible because the transfer normally provides a balancing tone between the long flexor and extensor finger muscles that move the finger.)

Burkhalter and Strait[47] assessed improvement in grip strength, correction of claw deformity, and improvement in the pattern of flexion, while Palande assessed the appearance of the hand with the fingers actively extended by measuring the resting angles of the metacarpophalangeal and proximal interphalangeal joints.[147] Malaviya[109] determined outcome by assessing the "working space" of the fingers, and Özkan et al[145] used a combination of grip strength and parts of Brand's assessment; while Hastings and McCollam measured range of motion and grip strength and performed hand function tests.[75]

Most of these assessments are based on strength, movement, and posture rather than restoration of function; nowadays, none would be considered satisfactory. However, they were adequate for the time, and those devised by Brand[24] and Burkhalter[47] where probably "ahead of their time."

In summary it is difficult to compare the outcomes of various procedures and it should be recognized that some are better suited than others to the individual circumstances of particular patients, such that there is no "universal" best technique for correction of the finger-claw deformity.[171] Even if a variety of techniques are compared in the same study using the same outcome technique, heterogenicity in the conditions of the affected arms make critical comparison of the techniques difficult or impossible.[145]

Surgical Techniques for Correction of the Ulnar Claw Hand

Many techniques have been described to correct clawing of the fingers, and these can be divided into static and dynamic procedures that are discussed in the following subsections.

Static Techniques. These prevent hyperextension of the finger MP joints by either shortening their palmar capsules or creating "checkrein" ligaments/tenodeses. Although bone blocks to prevent MP joint hyperextension,[118] proximal flexor sheath release to cause bowstringing of the extrinsic finger flexors,[44] and excision of an ellipse of skin and fascia from the palm of the hand to shorten the length of the palm (i.e., fasciodermadesis) have been described, these procedures are rarely used currently.

To reiterate, static procedures will only correct clawing of the fingers satisfactorily if passive flexion of their MP joints results in extension of their PIP joints (the Bouvier maneuver). If there are extension lags of the PIP joints in this position, then the use of a static procedure is contraindicated; if there are significant fixed-flexion deformities of the IP joints, then these need to be corrected with therapy, splinting, or surgical release before transfer. Static procedures avoid the need for tendon transfers, thus sparing potential motor tendons for other transfers. However, they do not restore the normal pattern of flexion of the fingers because IP flexion will continue to occur prior to MP flexion. In addition, there is the apprehension that they will stretch out over time, leading to recurrence of the deformity. This author's sense is that attenuation is less likely to occur with tenodeses using tendon grafts rather than palmar capsular reefing. Most experienced surgeons would favor a dynamic tendon transfer to a static procedure if a motor is available and there are no other contraindications.

Palmar Capsulodesis of the MP Joint (Zancolli). Zancolli described using longitudinal incisions over the A1 pulley of each affected finger; however, a transverse incision in the distal palmar crease improves exposure when two or more fingers require treatment.[204] The A1 pulley of each finger is completely divided, as for a trigger finger release, and the flexor tendons are retracted to one side to expose the palmar plate of the MP joint. Two parallel longitudinal incisions are made in the palmar plate and its insertion onto the metacarpal neck is released, thus creating a capsular flap with its base attached to the base of the proximal phalanx. The MP joint is hyperextended to improve the exposure and a small transverse bone tunnel is created in the metacarpal neck with a fine awl or Kirschner wire.

The metacarpal neck is roughened with a curette or bur to create a bleeding bed for adherence of the capsular imbrication. Zancolli then passed a monofilament wire through the tunnel and the flap of the palmar plate, with sufficient tension, to maintain the MP joint in 20 degrees of flexion; then he firmly twisted the ends of the wire and cut them to lie flat on the metacarpal. However, a small bone anchor with an attached 3-0 vicryl suture is also ideal for attaching the capsular flaps onto metacarpal necks.

The capsuloplasties are performed sequentially from the index to the little MP joint. Postoperatively the hand is splinted using a palmar plaster slab with the wrist in neutral, the MP joints in 20 degrees of flexion, and the IP joints free. Immobilization is maintained for 5 weeks and the hand is then mobilized.

Omer modified Zancolli's technique by cutting away a triangular portion of the deep transverse metacarpal ligament (DTML) on each side of the palmar plate flap[139] (Figure 31.21), which is probably unnecessary. He also recommended excision of a 1.5-cm-wide ellipse of palmar skin to prevent stretching of the volar plate[40] and immobilizing the hand with the MP joints flexed for 6 weeks.[96]

Results. Brown reported the outcome of this procedure in 44 cases, most of which occurred during the Vietnam conflict.[40] All had at least 15 degrees of hyperextension of the MP joints and 15 degree extension losses at the PIP joints; those with irreparable nerve injuries underwent early surgery as soon as other wounds permitted. He modified Zancolli's technique by advancing the capsular flap further, such that it created 60 degrees of fixed-flexion deformity at the MP joint, and sutured it to the periosteum of the metacarpal and dorsal wall of the flexor sheath; this most likely was not as robust an attachment as that used by Zancolli.

Most hands underwent ring and little finger capsulodeses, and all were followed up for 12 to 32 months. Five patients required early revision surgery for recurrence of clawing and in another 18 cases the claw deformity gradually recurred, reaching the original preoperative severity in 9 cases. However, no progression of the recurrent claw deformity was seen after 12 months. Ten hands were left with fixed-flexion deformities of more than 30 degrees of the MP joints and 9 hands developed fixed-flexion deformities of the PIP joints as a result of adhesions between the flexor tendons and the capsulodesis; these required treatment with a tenolysis. Overall Brown felt the surgeries had improved function and achieved their aim in 21 of the 44 hands. He considered that some of the complications he encountered probably were attributable to associated tendon injuries in severe forearm wounds.

In contrast, Leddy et al performed the procedure on 56 fingers of 24 hands using Zancolli's transosseous wiring technique to secure the capsular flap to the metacarpal.[96] They attached the capsulodesis to hold the MP in as little flexion as possible; sufficient to just produce full extension of the PIP joint, the amount being determined preoperatively. They also released the proximal 2 to 3 cm of the finger flexor sheath to the middle third of the proximal phalanx to allow the flexor tendons to bowstring over the MP joints and reported

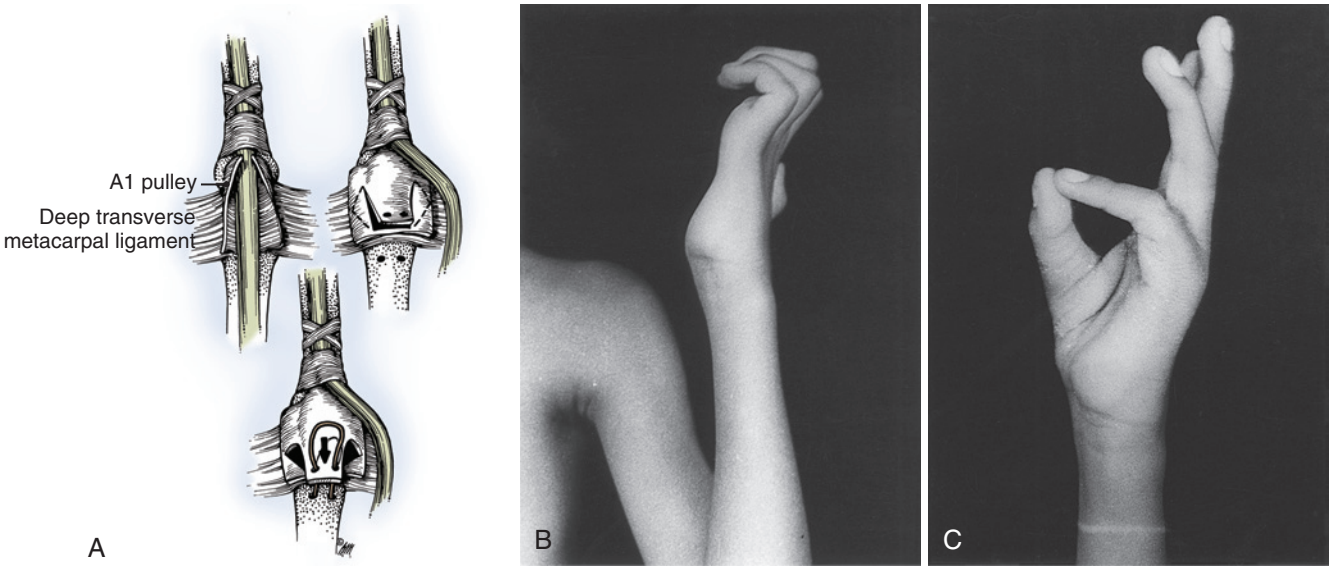

FIGURE 31.21 **A,** Omer's modification of Zancolli's capsulodesis of the metacarpophalangeal joint in static correction of claw-finger deformity.[204] Omer advised excision of triangular segments of the deep transverse metacarpal ligament on either side to allow the flap of volar plate to be proximally advanced in a straight line. The palmar plate is anchored into the metacarpal neck. **B,** Claw hand due to residual poliomyelitis in a 14-year-old with hypermobile joints and decreased strength of the extrinsic flexors and extensors. **C,** Palmar capsulodesis with good correction of claw-hand deformity at 3-year follow-up.

correction of clawing in 53 of the 56 fingers, with no recurrence of clawing after 3 months.

There is thus controversy regarding the outcome of this procedure that is most commonly used now to address idiopathic mobile camptodactyly of the little finger. However, a troublesome flexion contracture of the MP joint can result if the palmar plate is advanced too far proximally on the metacarpal, or if the pulley release is continued beyond the A1 pulley; recurrence of clawing can occur even if the capsular flap is firmly anchored to the metacarpal. Anderson considered that this and other static procedures were not ideal for those engaged in heavy manual labor at factories, farms, or fields.[8]

CRITICAL POINTS *Modified MP Joint Volar Capsulodesis*

Pearls
- Ensure there is no lag or contracture at the PIP joint.
- Reasonably strong long flexor and extensor extrinsic muscles.

Technical Points
- Release only the A1 pulley.
- Make two parallel incisions on the palmar plate and capsule 6 to 8 mm apart.
- Raise a distally based flap of palmar plate and capsule.
- Create a transverse bone tunnel or insert a bone anchor in the neck of the metacarpal.
- Advance the palmar plate/capsular flap sufficiently to flex the MP joint 10 to 15 degrees.
- Anchor the flap through the bone tunnel or bone anchor with a nonabsorbable suture.
- Immobilize with the MP joints in 40 to 45 degrees of flexion.
- Allow movement of IP joints from postoperative days 1 to 2.
- Remove cast after 4 weeks.
- Provide a knuckle bender splint for a minimum of 6 weeks thereafter.

Pitfall
- Ensure that the thick portion of the palmar plate/capsule combination is anchored to the neck of the metacarpal.

Late Postoperative Precaution
- Avoid passive stretching of the MP joint.

Riordan Static Tenodesis. With the Riordan technique, the extensor carpi radialis longus and extensor carpi ulnaris tendons are split longitudinally into two equal halves throughout their lengths.[159,162] One half of each is divided transversely at the musculotendinous junction in the forearm, leaving the other half intact to continue to actively extend the wrist. The divided halves of each tendon are turned distally, leaving their insertions on the bases of the index and little finger metacarpals undisturbed, and each is divided in half longitudinally to produce a total of four slips.

The radial lateral band of the extensor apparatus is exposed through an incision on the side of the proximal phalanx of each finger and a tendon slip is passed through the interosseous space and lumbrical canal (i.e., palmar to the deep transverse metacarpal ligament) to emerge in the finger incision where it is sutured to the radial lateral band. The tenodesis is sutured with the wrist in 30 degrees of extension, the MP joints in 80 degrees of flexion, and the IP joints extended; the hand is immobilized in this position for 3 weeks. The hand is then mobilized with the wrist splinted in extension for a further 2 weeks. The ECU can be used in isolation if only the ring and little fingers are involved.

Riordan recommended placing the transfer in too much tension, rather than too little, because he considered that excessive tension can be corrected by passive stretching if necessary. He reserved this procedure for cases in which a suitable motor was not available for a dynamic transfer.

Parkes Static Tenodesis. Two free tendon grafts (usually palmaris longus and a plantaris tendon) are needed if all four fingers require correction and each is divided into two strips. The radial side of the extensor expansion of each finger is exposed through a midlateral incision that curves slightly dorsally at the level of the PIP joint. Parkes advised scarifying the superficial surfaces of the extensor expansion at the proposed site of graft attachment.[148] A palmar incision is made in the shape of a "7" with its transverse limb located at the distal palmar crease, and the palmar aponeurosis is reflected with the skin to expose the lumbrical muscles (Figure 31.22, *A*). The lumbrical sheath of each finger is opened and a strip of tendon graft is passed down each into the finger incisions.

The grafts are sutured to the radial lateral band of each finger with nonabsorbable sutures and the incisions are closed. Next, the proximal part of the palmar incision is retracted to expose the flexor retinaculum, and the proximal end of each strip of graft is passed through its distal portion. The grafts are pulled tight and then sutured onto the retinaculum with the IP joints in full extension and the MP joints in gently increasing degrees of flexion (index: 30 degrees; little: 45 degrees). Hemostasis is achieved, the palmar incision is closed, and the hand is immobilized in the "intrinsic-plus" position for 3 weeks.

Omer modified Parkes' procedure to obtain equal tension in adjacent pairs of fingers and to minimize the length of tendon

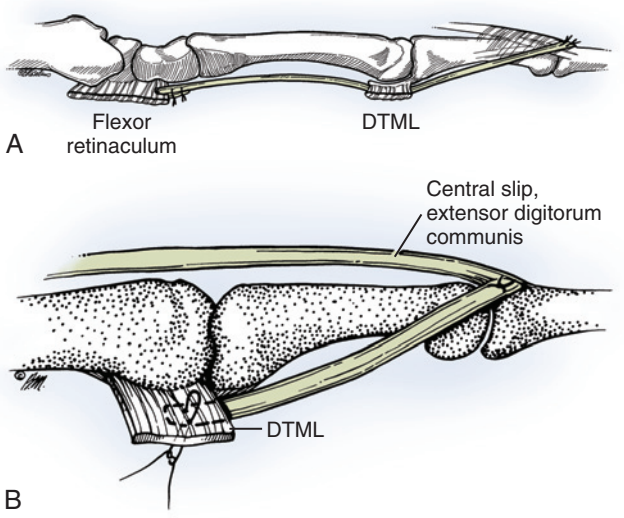

FIGURE 31.22 **A,** A Parkes static tenodesis connecting the flexor retinaculum (FR) to the radial side of the extensor apparatus over the proximal interphalangeal joint. The tendon graft passes palmar-to-volar to the deep transverse metacarpal ligament (DTML). **B,** Omer's modification with the free graft connecting the central slip of the extensor apparatus and the DTML.

graft.[139] In this modification, the tendon graft is first attached to the ulnar lateral band of the ring finger and then passed around the deep transverse metacarpal ligament and sutured to the radial lateral band of the little finger (Figure 31.22, *B*). A similar tenodesis is done with the index and long fingers. This technique has worked satisfactorily in my hand surgeries, at least in the short term.

Fowler's Wrist Tenodesis Technique. The Fowler procedure uses active wrist motion to tension static tendon grafts.[159] Free tendon grafts are sutured to the extensor retinaculum of the wrist and passed through the intermetacarpal spaces into the palm, through the lumbrical canals (i.e., palmar to the deep transverse metacarpal ligament); then they are sutured onto the lateral bands of the extensor expansions of the four fingers (Figure 31.23). The grafts are tensioned with the wrist in 30 degrees of extension, the MP joints in 80 degrees of flexion, and the IP joints in full extension.

Disadvantages. Theoretically this wrist-powered tenodesis is effective only when the patient flexes the wrist to tighten the graft and produce active MP flexion with IP joint extension. However, Riordan deemed that it was effectively a tenodesis with little if any gliding of the grafts with wrist motion.[159]

Dynamic Tendon Transfers. Many transfers have been described to correct finger clawing, and they use a variety of muscles as motors, both wrist and finger flexors and extensors, and a number of various insertions. Table 31.1 shows the resting muscle lengths and tension fractions of these muscles, as well as those of the interossei and lumbricals with functions that they will in part replace. Whichever muscle is selected as the motor for transfer, it must pass palmar to the axis of rotation of the finger MP joints to achieve flexion; this is accomplished by passing the transfer palmar to the transverse metacarpal ligament. All tendon transfers for correction of clawing cross the wrist joint, and their action can be amplified by the tenodesis effect of wrist motion. Wrist flexion will tighten transfers that cross the dorsal surface of this joint and wrist extension will tighten those that run palmar to it.

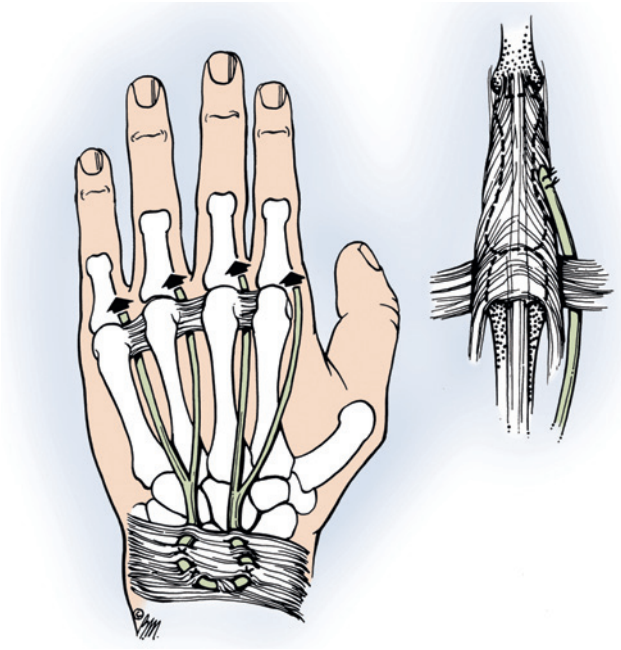

FIGURE 31.23 Fowler's dynamic tenodesis to control claw-finger deformity. The free tendon graft is attached to the central part of the extensor retinaculum, and strips are passed through the intermetacarpal spaces and lumbrical canal to insert into the lateral bands of the extensor expansions of the fingers.

Insertions for Dynamic Transfers. Several possible insertions are available, and the choice will fine-tune the function of the transfer. Insertion of the transfer to the proximal phalanx or onto the A1 pulley of the flexor sheath will provide pure flexion of the MP joints, whereas suture to the radial lateral bands of the middle, ring, and little fingers and radial or ulnar lateral band of the index finger[171] will produce flexion (and some abduction) as well as extension of the IP joints. Suture of the transfer to the A2a or entire A2 pulley will produce a greater moment arm and thus stronger flexion of the MP joints.

Finally, suturing onto the insertions of the dorsal interosseous muscles at the bases of the proximal phalanges will provide MP flexion and abduction. However, as highlighted by Anderson, this insertion has a much smaller flexor moment at the MP joint than either a lateral band or A1 pulley insertion.[8] It thus provides weaker MP flexion than the other insertions and is only useful in mobile claw deformities in supple hands that do not require a great MP flexion force to correct. In such hands, it probably has a lower risk of producing "overcorrection" (intrinsic-plus) deformities than other insertions.

Superficialis Tendon Transfer Techniques and Modifications. Stiles and Forrester-Brown are credited with the first description of a dynamic tendon transfer to correct finger clawing and transferred one slip of each superficialis tendon into the corresponding extensor digitorum tendon over the proximal phalanx.[185] Bunnell modified their transfer by rerouting both slips of all the superficialis tendons through the lumbrical canals and anchoring them to both the radial and ulnar lateral bands of the extensor mechanism[44] (i.e., Stiles-Bunnell procedure). Bunnell's aim was to correct the claw deformity and also restore MP abduction and adduction, but the Stiles-Bunnell operation was beset with problems resulting from its complexity, adhesion formation, and the conversion of the prime flexors of the PIP joints (FDS) into powerful extensors of the joints. It often resulted in the development of overcorrection and intrinsic-plus deformities in the fingers after 1 or 2 years.[25]

Modified Stiles-Bunnell procedure. Littler modified the Stiles-Bunnell procedure by only using one (usually the middle finger) superficialis tendon, and this has become the standard technique for correction of finger clawing.[103] The FDS of the middle finger is detached and retrieved into a palmar incision and split lengthwise into four equal slips. One slip is passed through the lumbrical canal of each finger, palmar to the deep transverse metacarpal ligament, and is sutured onto the radial lateral band of the extensor apparatus (Figure 31.24, *A*). Each slip is sutured with the wrist in 30 degrees of palmar flexion, the MP joints in 80 to 90 degrees of flexion, and the IP joints in full extension (Figure 31.25). The use of the ring, but not the middle, finger superficialis tendon for this procedure is contraindicated in high ulnar nerve palsy or when the profundus of the ring finger is weak.

Modifications of the superficialis transfer. Littler's transfer, the modified Stiles-Bunnell procedure, has itself been modified by many surgeons to subtly alter its function and reduce the risk of potential complications.[103] The modifications are primarily related to its insertion.

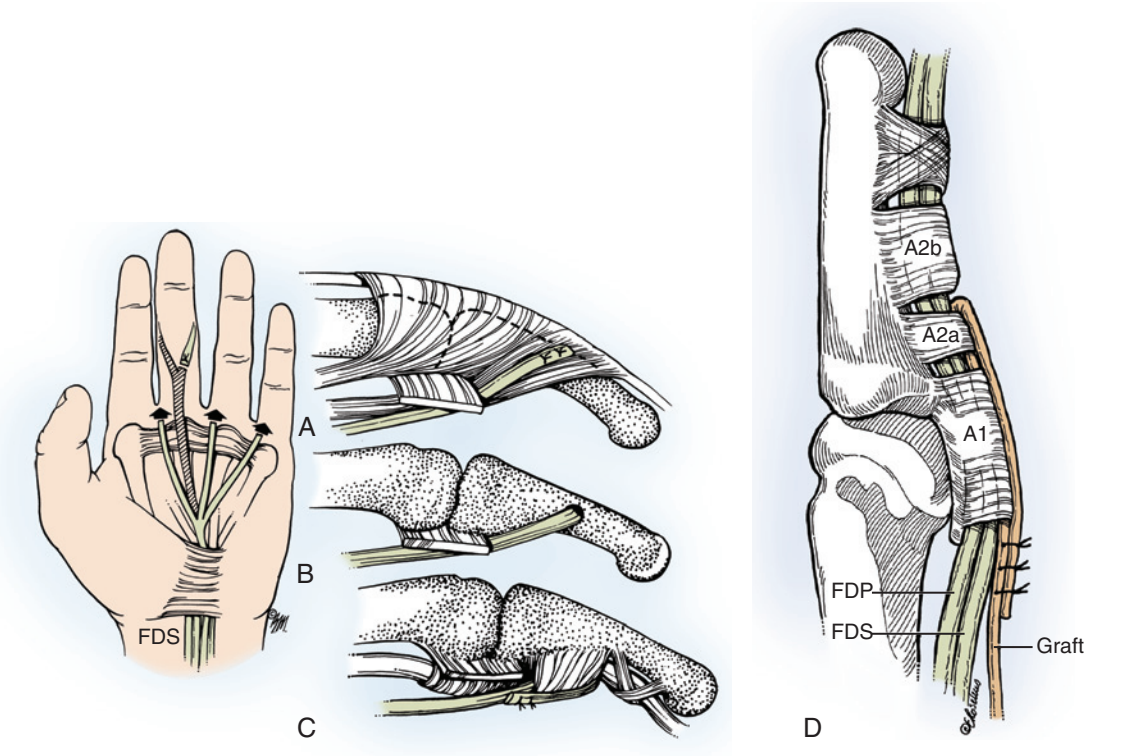

FIGURE 31.24 Transfer of flexor digitorum superficialis (FDS) to correct claw deformity. Half of its distal tendon is tenodesed across the proximal interphalangeal joint to prevent hyperextension. The FDS is split into four tails that pass palmar to the deep transverse metacarpal ligament and are inserted onto either **(A)** the lateral band of the extensor apparatus, **(B)** the proximal phalanx, or **(C)** the A1 or A2 pulley—A2 pulley attachment shown. **D,** Extended "lasso" insertion using the A1 and A2a pulleys. A slip of the flexor superficialis tendon is passed under these pulleys, folded back over them, and sutured onto itself. Zancolli only lassoed the A1 pulley. *FDP,* Flexor digitorum profundus.

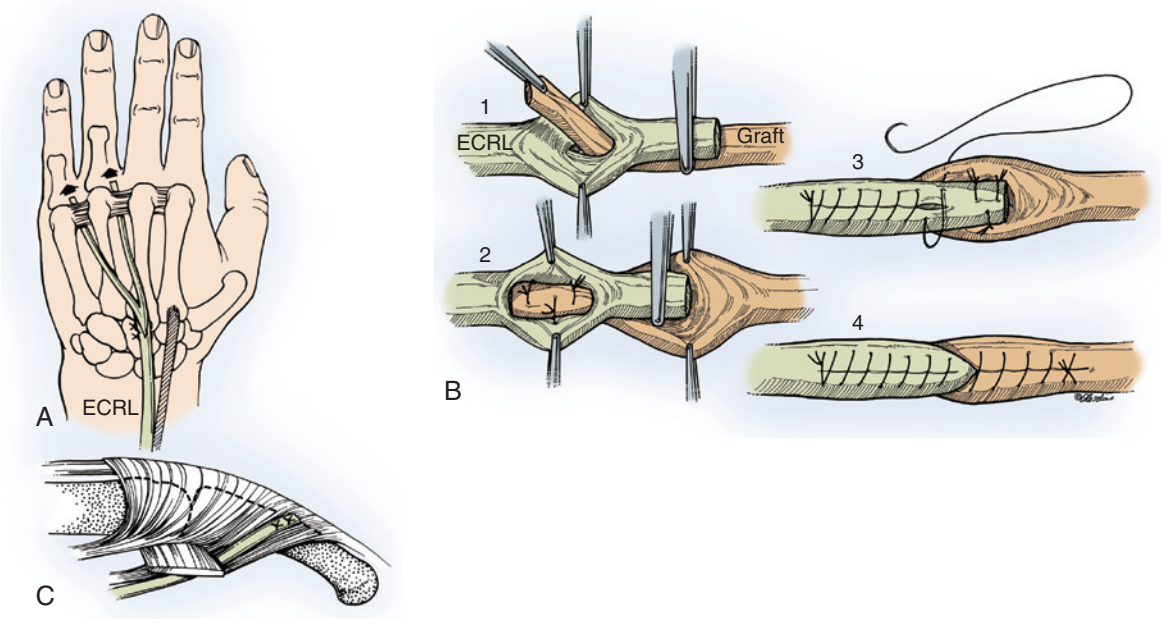

FIGURE 31.25 **A,** Dorsal route transfer of the extensor carpi radialis longus (ECRL) that is lengthened with a free graft. **B,** The wrap-around technique for anastomosis of the ECRL and free graft. The slips are passed through the intermetacarpal spaces and passed palmar to the deep transverse metacarpal ligament and through the lumbrical canals. **C,** The slips are inserted into the radial lateral bands of the extensor expansions of the three ulnar fingers and either the radial or ulnar lateral band of the index finger.

Burkhalter[46,47] inserted the superficialis slips onto the proximal phalanx in patients with traumatic ulnar nerve palsy so as to avoid the risk of PIP joint hyperextension that can occur when the transfer is attached to the lateral band of the extensor apparatus (see Figure 31.24, *B*). For the same reason, Riordan[158] recommended attachment of the tendon slips to the A1 pulley if the PIP joints are lax and hyperextend (see Figure 31.24, *C*).

Zancolli usually looped the tendon slips beneath the entire A1 pulleys (i.e., lasso technique).[205] He used a single transverse skin incision at the level of the distal palmar crease for all the digits to ensure adequate exposure. However, he sometimes preferred to use the first and second dorsal interosseous tendons, rather than the A1 pulleys, as the insertions for superficialis tendon slips for the index and middle fingers, intending to restore finger abduction as well as proximal phalangeal flexion.[205] Palande extended this principle to correct intrinsic-minus hands associated with reversal of the transverse metacarpal arch.[147]

Omer preferred the A2 pulley instead of the A1 pulley (see Figure 31.24, *C*) as the insertion site to increase the force of MP flexion.[139] He tensioned the transfers with the forearm supinated and the wrist flat on the table with MP joints in 45 degrees of flexion. He intentionally placed the transfer for the little finger under greater tension than the ring finger because failure of claw deformity correction is more common in that digit.

Anderson[8] as well as Oberlin[132] performed "extended pulley insertions," looping a slip of the superficialis tendon around both the A1 and the proximal portion of the A2 (A2a) pulleys (see Figure 31.24, *D*) in each finger. Anderson[8] thinks this is a compromise that provides better mechanical advantage for flexion of the MP joint than an A1 pulley insertion, but it avoids excessively powerful MP flexion that can occur when the whole length of the A2 pulley is used.

Shah modified the superficialis transfer and only addressed clawing of the ring and little fingers.[174] In each of these digits he exposed the A1 pulley, opened the flexor sheath distal to this, and divided the superficialis tendon as far distally as possible. He then pulled the cut end of the tendon out of the window in the flexor sheath, pulled it down over the outer surface of the intact A1 pulley, and sutured it onto itself with the finger MP joint flexed to 90 degrees. He performed the surgery under local anesthetic and reported good results in 12 of 15 cases due to leprosy. Hastings and McCollam performed the same procedure, though not under local anesthetic, whenever the claw correction surgery was restricted to the ring and/or little finger and the little finger had an adequate FDS.[75]

Results. Superficialis transfers do not increase grip strength[75] and risk donor-site morbidity, such as the development of swan-neck and other deformities, as described earlier.[34]

Brandsma and Ottenhoff-De Jonge reported full correction of clawing in 16 and improved clawing in 43 of 76 hands with leprosy that underwent either middle or ring finger FDS transfer to the affected fingers.[34] They used an insertion into either a lateral band or the A1 pulley. Hastings and McCollam assessed three-year outcomes of FDS transfers using Zancolli's lasso insertion onto the A1 pulley in 23 digits of 12 hands, predominantly involving the ring and little fingers.[75] These procedures were performed for traumatic ulnar nerve injuries with no evidence of functional intrinsic recovery, and, whenever possible, utilized the FDS tendon of an involved finger as the donor for that digit. Thus, in most hands both the ring FDS tendon was lassoed around the ring finger A1 pulley and the little FDS tendon was lassoed around the little finger A1 pulley.

Correction of the claw deformity was achieved in 19 of the 23 fingers, with 2 of the failures due to preoperative fixed-flexion contractures of the proximal interphalangeal joints. Although grip strength was not improved and functional disability persisted, most patients felt that the procedure had subjectively improved their dexterity. Four fingers developed minor swan-neck deformities, and these authors recommend the procedure for supple, ligamentously lax individuals who do not require increased power.

Anderson inserted the four slips of the middle finger FDS into the A1 and A2a pulleys of each finger in 20 hands affected with Hansen disease, all of which had undergone hand therapy preoperatively to address joint contractures. He obtained excellent and good claw corrections in most of the fingers with an average postoperative MP joint flexion contracture of 10 degrees.[8] He considered that, due to strong flexion moment, the procedure may not be ideally suited for patients with hypermobile joints. Oberlin[132] also utilized the A1 and A2a pulley as his insertion and, like Hastings and McCollam, used one FDS for each finger. He achieved satisfactory results in a group of 19 patients with Hansen disease who had no access to therapy, such that many underwent surgery with uncorrected fixed PIP joint contractures. Overcorrection (i.e., swan-neck deformity) was noted in two hyperlax fingers.

Extensor Indicis Proprius and Extensor Digiti Minimi Transfers. Fowler's technique uses small longitudinal or curved incisions made on the dorsal aspects of the index and little MP joints, and the extensor indicis proprius and extensor digiti minimi tendons are exposed and sectioned.[159] A dorsal transverse incision is then made just distal to the wrist, and the two tendons are retrieved into this and each is split lengthwise into two sections. The four slips are passed through the interosseous spaces, palmar to the deep transverse metacarpal ligament, and inserted onto the radial aspect of the extensor apparatus of each finger.

This procedure may produce excessive tension in the extensor apparatus and lead to intrinsic-plus deformities. It may also cause reversal of the normal metacarpal arch and, occasionally, extensor weakness in the little finger. Riordan, who found the transfer technically difficult to do, wondered whether it acted primarily as a tenodesis[159]; and he felt that the length of the transfer was insufficient such that it had to be inserted in excessive tension that could result in an intrinsic-plus deformity.[158] He therefore modified Fowler's technique by splitting the EIP into two slips and passing these through the third and fourth interosseous spaces, palmar to the transverse metacarpal ligament, before inserting them onto the radial lateral bands of the ring and little fingers. The transfer of the relatively long EIP tendon to the relatively short ring and little fingers allowed it to be sutured in the correct tension. If there was a combined median and ulnar nerve palsy, Riordan harvested a tendon graft (i.e., palmaris longus), split it longitudinally in two, and passed the slips through the first and second interosseous spaces to insertions on the radial lateral bands of the index and middle fingers. He then sutured the proximal end of the graft to the EIP, which replaced the intrinsic function in all four fingers.

Anderson[8] addresses the problem of insufficient length of the EIP and EDM transfers by harvesting 1-cm-long strips of the extensor hood apparatus in continuity with their tendons rather than dividing the tendons at the MP joint level.[41] Careful closure of the extensor hood is critical to prevent postoperative extensor tendon subluxation.

Transfers Using Wrist Flexor and Extensor Muscles. Brachioradialis and wrist extensor and flexor muscles have been used as motors for transfers to correct clawing. Such transfers, by increasing the force of MP flexion with a motor that does not usually contribute to finger flexion, theoretically should also improve hand strength. All these transfers require lengthening with free grafts to provide sufficient length to reach the insertion site, unless it is possible to split the transfer's motor tendon and use half of it as the graft.[110]

Dorsal route transfer of ECRB/ECRL. This transfer was described by Brand.[24] The extensor carpi radialis longus or brevis tendon is exposed at the distal end of the radius through a short transverse incision and withdrawn into a second transverse incision 8 cm proximally in the distal forearm (see Figure 31.25). The plantaris (or the palmaris longus if stout) tendon is harvested and attached to the distal end of the motor's tendon. Brand advised a "wraparound" technique of anastomosis, which resulted in its surface being covered with epitenon with no cut end of either the graft or the extensor tendon exposed, in order to reduce adhesion formation (see Figure 31.25, *B*). The plantaris tendon is split into four tails and, using tendon-passing forceps, these are passed into the original incision over the distal radius.

Dorsoradial incisions are made at the base of middle, ring, and little fingers, and the radial lateral band of each and the ulnar lateral band of the index finger are identified. Tendon tunneling forceps are passed from the finger incisions, through the lumbrical canals (palmar to the deep transverse metacarpal ligaments), and intermetacarpal spaces to emerge in the wrist wound. The tendon grafts for each of the fingers are passed and stitched in equal tension, suturing the index finger first, then the little, and finally the middle and ring fingers (Figure 31.26). The tension is set so that the transfers are completely relaxed with the wrist in 45 degrees of extension, the MP joints flexed to 70 degrees, and the IP joints extended. This position is maintained for 3 weeks in a light plaster cast.

Brand stressed that it was important not to allow the fingers to rest in the claw position during reeducation and rehabilitation, and he splinted each finger in extension. This encourages free MP joint movement with resisted active extension of the wrist.

Results. Brand assessed the outcome of the ECRB procedure in 246 hands affected by leprosy, of which 183 had a combined high ulnar and low medium nerve paralysis.[24] At an average follow-up of 2 years he observed excellent or good results in 71% of cases. He found reeducation following this transfer difficult, although he judged that it worked better than the Littler (modified Stiles-Bunnell) transfer. He was also concerned that (1) wrist extension slackened the graft, such that the patient had to learn to avoid wrist extension while activating the ECRB transfer; and (2) adhesions would form where the tendon grafts (extending the transfer) passed through the intermetacarpal spaces. For these reason Brand devised a flexor route transfer for ECRL. Riordan also had trouble retraining patients because the wrist extensor normally relaxes when the fingers are extended, but he still considered that this transfer produced good results.[162]

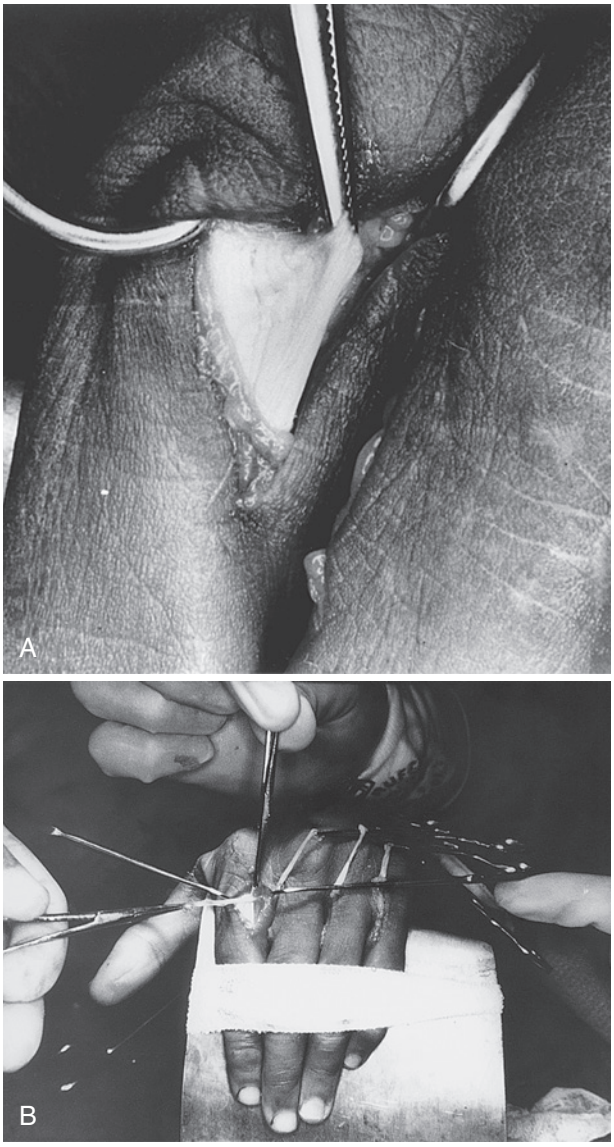

FIGURE 31.26 Lateral band insertion technique. **A,** Exposure of the lateral band of the extensor apparatus. A fine hemostat holds the edge of the lateral band to exert proximal traction and remove the slack from within the apparatus. **B,** The hand and wrist are positioned while the assistant gently holds the lateral bands. The tension on the tendon slips is adjusted before they are sutured to the ulnar lateral band of the index finger and sequentially to the radial lateral bands of the little, ring, and middle fingers.

Burkhalter and Strait. These authors modified the Brand extensor route ECRL transfer by passing it to only the ring and little fingers and inserting the tendon slips into the bases of their proximal phalanges[47] (see Figure 31.24, *B*). This was because of concern that insertion into the lateral bands might cause hyperextension of the IP joints. The ECRL is lengthened with a split-tendon graft and passed through the third and fourth intermetacarpal spaces, ensuring that (1) the anastomosis between the ECRL and the graft is situated well proximal to the intermetacarpal spaces; and (2) sufficient intermetacarpal fascia is removed to minimize the risk of troublesome adhesions. At

the finger, each tendon slip is passed through a transverse drill hole in the proximal phalanx and held with a pull-out suture technique.

Postoperative immobilization is continued for 4 weeks, with the wrist maintained in 45 degrees of extension with the MP joints in 60 degrees of flexion. Postoperative reeducation is done by contracting the ECRL to obtain finger flexion. IP joint extension is not dynamically augmented by this transfer but is improved through the tenodesis effect of MP flexion. The authors reported successful outcomes in 51 of 54 complex posttraumatic cases, in terms of increased grip strength, correction of claw deformity, and improvement in the pattern of flexion.[47] Flexor digitorum superficialis, the ECRB, or the brachioradialis can also serve as the motor for this procedure.

Flexor route transfer of ECRL (Brand method modified by Omer). Brand later recommended passage of the ECRL transfer (with attached graft) through the carpal tunnel rather than the intermetacarpal spaces[24] and biomechanical studies suggest this transfer route is more mechanically efficient.[98] The ECRL tendon is preferred over the ECRB, which is the most important wrist extensor. A transverse incision is made over the index metacarpal base and the insertion of the ECRL is divided (Figure 31.27, *A*). A second transverse incision is made on the dorsoradial aspect of the forearm 8 to 10 cm proximal to the radial styloid, and the ECRL is retrieved into this. The ECRL tendon is then passed deep to the brachioradialis into an incision on the palmar aspect of the forearm 6 to 8 cm proximal to the wrist joint.

The ECRL tendon is lengthened with a plantaris or PL tendon graft, taking care to ensure that the anastomosis is covered with a layer of epitenon (i.e., wraparound technique[24]) and lies proximal to, and will never enter, the carpal tunnel. The tendon graft is split into four tails. An incision is made in the midpalmar region, along the thenar crease, and the palmar fascia is separated to expose the superficial palmar arch. A long tendon retriever is introduced into the palmar wound and passed dorsal to the superficial palmar arch and through the carpal tunnel into the incision on the palmar aspect of the forearm. The four tails of the tendon graft are passed into the palmar wound (see Figure 31.27, *B*), then incisions are made on the dorsoradial aspects of the bases of the middle, ring, and little fingers.

Each tail of the tendon graft is individually passed with tendon retrieving forceps from the palm, through the lumbrical canal, and into the dorsoradial finger wounds. The wounds on the wrist, forearm, and palm are closed before tensioning the graft. With the wrist in 45 degrees of flexion, the MP joints in 70 degrees of flexion, and the IP joints straight, the graft slips are sutured to the lateral bands of the extensor expansions (i.e., radial lateral band for the middle, ring, and little fingers and ulnar lateral band for the index finger), taking care that the four fingers are set in the same tension (see Figure 31.26). The tourniquet is released and hemostasis is secured before skin closure. The hand is placed in a well-padded plaster cast with the wrist in neutral position, the MP joints in 80 degrees of flexion, and the IP joints straight.

Results. Brand did not report his results for this transfer, but found reeducation/rehabilitation easier than after the dorsal ECRB transfer, probably because the transfer tightens with wrist extension (passes palmar to the wrist joint).[24] He noted that the transfer sometimes restricted wrist extension and accepted the theoretical danger of injuring/compressing the median nerve in the carpal tunnel. Malaviya[109] observed loss of median nerve function in 1 of his 12 ECRL transfers through the carpal tunnel, but others have found that median nerve dysfunction is not increased by passing transfers through the carpal tunnel.[33] Malaviya also observed that the ECRL tendon, if bulky, can be split longitudinally into two halves; one can be freed at the musculocutaneous junction and used instead of palmaris longus or plantaris as a tendon graft to lengthen the transfer.

Palande evaluated the outcome of Brand's flexor route transfer in 32 hands affected by leprosy at a follow-up of 2 years using his method for assessing outcome.[147] Overall, approximately 90% of hands achieved fair-to-good results in terms of appearance, ability to attain the intrinsic-plus position, and extent of finger flexion, although only 28% achieved satisfactory restoration of the transverse metacarpal arch. Even though 18% of the 128 fingers developed hyperextension deformities (mobile) of their proximal interphalangeal joints, the procedure and its rehabilitation increased grip strength by 25%.

Disadvantages. The need for a free tendon or fascia lata[147] graft to lengthen the wrist extensor motor unit can result in adhesions, and multiple steps of the procedure require increased operative time.

Flexor carpi radialis transfer. Riordan[158,162] devised the FCR transfer for use in patients with longstanding claw hands who habitually flexed the wrist to attempt to extend their clawed fingers (tenodesis maneuver). The intention was to simultaneously correct swan-neck and wrist flexion deformities.

The flexor carpi radialis tendon is divided at the wrist and elongated with a brachioradialis, plantaris, or palmaris longus tendon graft that is split into four longitudinal strips. These are passed subcutaneously around the radial metaphysis to the extensor side of the forearm, then through the intermetacarpal spaces and lumbrical canals to their attachments on the radial lateral bands of the involved fingers.

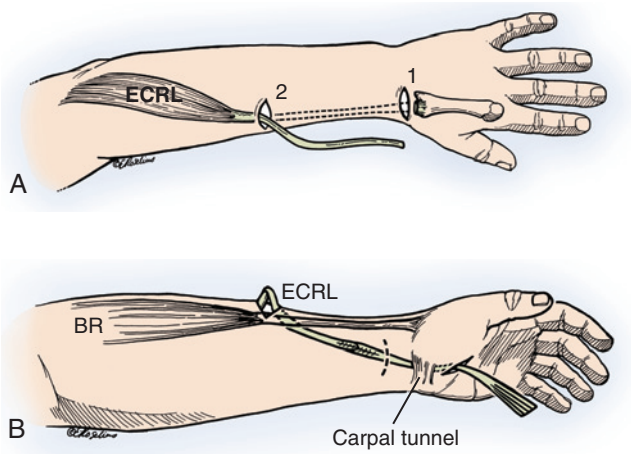

FIGURE 31.27 Transfer of extensor carpi radialis longus (ECRL) tendon for claw-hand correction. **A,** ECRL is sectioned at its insertion to the base of the index metacarpal (1) and withdrawn into a second incision (2) in the forearm. **B,** A tendon passer is passed from a midpalmar incision through the carpal tunnel under the brachioradialis (BR) and into the forearm incision to retrieve the lengthened ECRL tendon. Finger incisions are then made to attach the transfer to the lateral bands of the fingers.

Disadvantage. This operation removes the only wrist flexor in a high ulnar palsy, so in this situation may be contraindicated.

Palmaris longus four-tail transfer. The palmaris longus is used as the motor, is divided at its insertion into the palmar fascia, and is withdrawn proximally into the forearm.[66] It is lengthened with a tendon graft and tunneled subcutaneously (palmar to the transverse palmar ligament) into a midpalmar incision. The rest of the procedure is as described for the Brand's ECRL flexor route transfer, but some prefer to insert the transfer into the interosseous tendons[147] rather than the lateral bands of the extensor expansion. Although a relatively weak donor, this procedure is useful for younger patients with supple hands who have a well-developed, strong palmaris longus. Taylor et al found no difference in the outcome of this transfer and an ECRL transfer routed through the carpal tunnel (both inserted into the lateral bands).[189] They advocate its use in all patients with a well-developed palmaris longus tendon and a hypermobile or mobile hand on the basis that there was likely to be less donor morbidity. Grip strength was not assessed in this study but manual labor workers reported satisfactory outcomes.

Postoperative Management of Tendon Transfers for Claw Finger Correction

It is standard to immobilize the hand after transfer for 3 to 4 weeks with the wrist close to neutral, the MP joints fully flexed, and the IP joints extended (i.e., intrinsic-plus position). Therapy designed to incorporate the transfer into hand function is then commenced, avoiding heavy gripping and lifting for 12 weeks. However, Rath[155] mobilized his four-tailed FDS to A1 pulley transfers on postoperative day 2 and reported more rapid rehabilitation. He used Pulvertaft weaves to strengthen the Zancolli loop insertions of the tendon slips on the A1 pulleys and observed no cases of transfer dehiscence.

Restoration of Thumb–Index Key Pinch and Tip Pinch

Thumb adduction force in a normal hand is primarily provided by adductor pollicis, with the first dorsal interosseous acting as a force-couple to prevent distraction and dorsal subluxation of the trapeziometacarpal (TM) joint.[29] However, contraction of the radial head of the first dorsal interosseous can contribute significantly to the force of thumb adduction when the index finger is stabilized.[178] Loss of adductor pollicis, FPB, and first dorsal interosseous muscle function results in weakness of TM joint adduction and thumb MP flexion, such that the thumb has weak key and tip pinch. Biomechanical studies suggest that a 75 to 80% loss of power pinch occurs in patients with ulnar nerve palsy,[71] and this is explained by the combined tension capability of the adductor pollicis and FPB of 4.3%, which is nearly double that of the FPL (2.7%), as well as their large moment at the TM joint.[29]

In ulnar nerve palsy the EPL and the FPL muscles are the only remaining adductors of the thumb,[178] and both only provide weak adduction. Their actions in the absence of the ulnar intrinsic muscles contribute to collapse of the thumb into a "Z"-deformity if the joints are hypermobile, characterized by hyperextension of the MP and flexion of the IP joint. Thumb pinch can only occur with flexion of the IP joint (i.e., Froment's sign), such that the ability to roll small objects between the thumb and index finger tips is diminished.

The aims of reconstructive surgery to the thumb in ulnar nerve palsy are restoration of strong adduction of the first metacarpal, active flexion of the hyperextended MP joint, and active extension of the hyperflexed IP joint in order to regain power and precision function. Although the thumb is of prime importance for pinch, the index finger MP joint needs to be stabilized so that this finger does not drift ulnarward away from the thumb.

Dynamic Procedures to Restore Thumb Adduction

ECRB as Motor (Smith). A dorsal transverse wrist incision is made and the ECRB is divided at its insertion on the middle finger metacarpal base.[178] The proximal end of this tendon is retrieved into a second transverse incision just proximal to the extensor retinaculum. A third transverse incision is made between the dorsal aspects of the index and middle finger metacarpals, over the proximal end of the second intermetacarpal space, and the dorsal interosseous fascia is incised and a small window is created in the intermetacarpal space by excising some of the paralyzed interosseous muscles. A longitudinal incision is then made on the ulnar side of the MP joint of the thumb and a curved hemostat is tunneled from this incision, deep (dorsal) to the transverse head of adductor pollicis, through the window in the index/middle interosseous space and into the dorsal hand wound.

A tendon graft, usually palmaris longus, is passed through this tunnel to the thumb and is sutured to the tendon of the adductor pollicis. The proximal end of the tendon graft is then passed subcutaneously into the most proximal–distal forearm incision where it is sutured to the ECRB tendon. The tension is set such that the thumb lies just palmar to the index finger when the wrist is in neutral. With the wrist extended, the thumb should then fall into abduction, while with the wrist in flexion the thumb should lie firmly against the palm. Postoperatively the hand is immobilized with the thumb in a neutral position and the wrist in 40 degrees of extension. After 3 weeks the plaster cast is exchanged for a protective splint and the patient is encouraged to perform active range-of-motion exercises.

Omer[136] thought that ECRB was the best transfer for restoration of adduction of the thumb but favored passing the transfer through the middle/ring rather than the index/middle intermetacarpal space, then superficial to the transverse head of adductor pollicis and dorsal to the flexor tendons. Insertion of the transfer onto the strong fascia over the abductor tubercle of the thumb (Figure 31.28) may improve pronation for pinch.[61] Brachioradialis, ECU,[23] and ECRL[180] can be used as motors instead of ECRB, with an identical operative technique.

Results. Smith performed this operation in 15 patients with paralysis or loss of the adductor muscle. In 8 he simultaneously performed a tendon transfer to the first dorsal interosseous tendon, using extensor indicis proprius (ESP) in 4 cases and an accessory slip of the APB in the other 4. He reported one episode of synovitis at the index/middle interspace, but 14 of his 15 patients reported significant improvement. Overall thumb pinch strength was doubled by the procedure, rising from 25% preoperatively to 50% postoperatively of the strength of the contralateral thumb (Table 31.6).

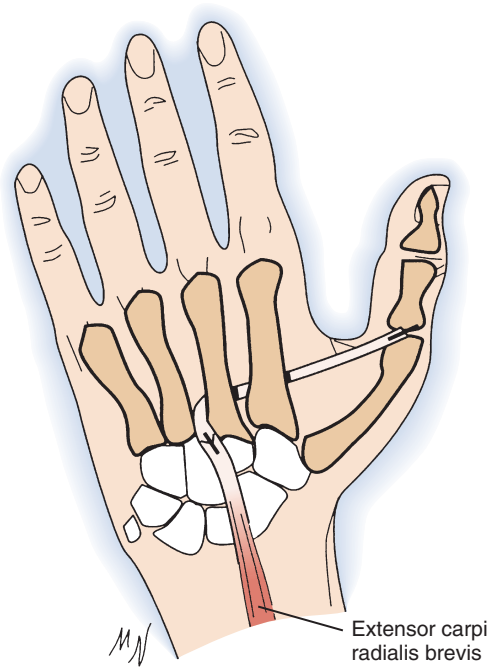

FIGURE 31.28 Transfer of the extensor carpi radialis brevis extended with a free tendon graft. This is passed through the interspace between the middle and ring metacarpals and across the palm (i.e., palmar to the adductor pollicis muscle and dorsal to the finger flexor tendons and neurovascular structures) to insert into the adductor tendon or the fascia over the abductor tubercle of the thumb metacarpal.

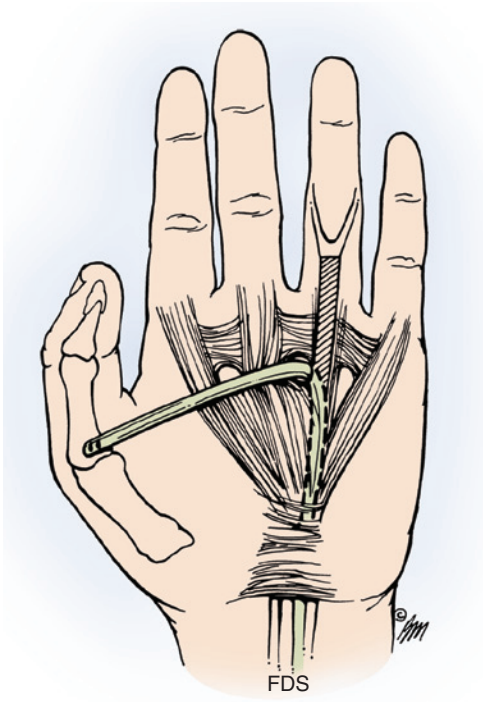

FIGURE 31.29 Transfer of the flexor digitorum superficialis (FDS) to restore thumb adduction. The natural window in the palmar fascia overlying the neck of the middle finger metacarpal is used as a pulley and the transfer is attached to the abductor tubercle of the thumb. This transfer will add power to key pinch but will weaken power grip.

TABLE 31.6 Outcomes of Surgery to Improve Thumb Pinch Strength

	Pinch Strength Achieved*
ECRB as Motor	
Trauma (Smith[178])	50% of contralateral thumb
Trauma (Solonen and Bakalin[180])	40% of normal
Trauma (Fisher[63])	73% of contralateral thumb

*Additional tendon transfers to improve index finger abduction sometimes are performed.

Solonen and Bakalin performed transfers to restore thumb pinch strength in 34 patients with ulnar nerve palsies.[180] They performed combined transfers using a variety of motors, predominantly ECRL, ECRB, or the ring finger FDS for the thumb adductor transfer and FDS, PL, EIP, or ECRB/L as a motor for the index finger abductor. The transfer for thumb adduction, if an extensor, was routed as described by Smith[178] (see previously) but attached to the adductor tendon. The transfer for index finger abduction used the extensor tendons of the thumb as a pulley in order to improve its moment arm and then ran palmar to the axis of the MP joint and inserted into the tendon of the first dorsal interosseous. Postoperatively the wrist, thumb, and index finger were immobilized for 4 weeks.

At a follow-up period of between 4 months and 8 years the authors reported that thumb key and pinch strength were restored to a mean of 40% of normal and that this improved patients' ability to perform activities of daily living. Limited thumb opposition and palmar and radial abduction, as well as restricted active extension of the thumb carpometacarpal (CMC), MP, and IP joints, were sometimes observed but patients did not complain about this; thus, it was felt that the restored pinch strength outweighed the losses of movement attributable to tendon transfers. Morbidity due to the harvest of the donor muscles for the transfer also was noted, including restricted active extension of the wrist (e.g., ECRB and ECRL) and limited extension of the fingers if FDS tendons were utilized.

Fisher used the ECRL tendon as a motor to reconstitute thumb adduction, lengthening this with the palmaris longus or a long toe extensor.[63] As described by Smith, they attached the tendon graft to the tendon of adductor pollicis, but they passed it through the middle/ring rather than the index/middle intermetacarpal space. Index finger abduction was augmented with one of the slips of the APL tendon.[125] Although the results of only 9 of 27 patients could be assessed, all in retrospect felt the transfer had been of benefit. Six adductor pollicis and six dorsal interosseous transfers were physically powerful and produced good function. Thumb opposition and abduction was not significantly restricted and key pinch strength was doubled in the 3 cases in which it had been recorded preoperatively. Overall, a thumb key pinch strength that was 73% of the contralateral thumb was achieved.

FDS as Motor (Edgerton and Brand). The ring finger FDS is released in the finger and withdrawn into a palmar incision, as described by Edgerton and Brand.[61] It is then passed around a natural pulley, either a natural window in the palmar fascia overlying the neck of the middle finger metacarpal (Figure 31.29) or the free distal edge of the vertical septa running from

the palmar fascia onto the middle finger metacarpal. The use of a pulley prevents the otherwise inevitable gradual migration of the transfer radialward that will render the procedure ineffective. The transfer then runs across the palm parallel to the transverse head of adductor pollicis to the thumb. It runs superficially to the palmar fascia if the former pulley is used and deep to it, the neurovascular bundles, and the finger flexor tendons if the latter is used. If there is an isolated ulnar nerve palsy, the tendon is inserted onto the adductor tubercle, whereas if there is a combined ulnar and median nerve palsy, it is inserted into the radial expansion of the extensor apparatus of the thumb to provide additional pronation.

Brown also used this transfer and advised use of the free distal edge of the vertical septa running from the palmar fascia onto the middle finger metacarpal for the pulley so that the transfer could be passed deep to the palmar fascia, finger flexor tendons, and neurovascular bundles.[38] He found that transfers running superficial to the palmar fascia caused "bowstringing" of the palmar skin and discomfort when large objects were held.

Goldner divided the middle finger FDS and brought it into an incision at the ulnar side of the pronator quadratus muscle in the distal forearm.[71] He then passed the transfer through the interosseous membrane to the dorsum of the hand, around the ECU, which acted as a pulley, and under the finger extensor tendons to the thumb. One slip of the FDS was sutured to the ulnar aspect of the proximal phalanx and the other to the adductor tendon insertion.

Extensor Indicis as a Motor (Brown). A longitudinal incision is made over the neck and MP joint of the index finger and the EIP is detached from the extensor hood over the midportion of the proximal phalanx, as descried by Brown.[38] The incision is retracted ulnarly to expose the middle/ring intermetacarpal space and a curved hemostat is used to pass the transfer through this space into a small incision, made onto the tip of the hemostat, in the palm at about the level of the proximal palmar crease. The transfer is then passed along the transverse muscle belly of the adductor pollicis, deep to the finger flexor tendons and neurovascular bundles, and is sutured to this muscle's insertion. Proper tension is achieved by suturing the transfer in moderate tension with the wrist in neutral and the thumb and index metacarpals parallel to each other. Brand considered the EDC (index) too weak to provide adequate thumb adduction strength.[29]

Combination of EIP and EDC (Little) Tendon Transfers for Pinch

The aim of this transfer is to improve both thumb adduction and abduction of the index finger to strengthen pinch, according to Robinson et al.[164] The ulnar slip of the EDC (Little) is detached at the MP level of the little finger and retracted to the level of the wrist, just distal to the extensor retinaculum. It is the passed superficially across the dorsum of the hand to the adductor tubercle of the thumb. The EIP is divided at the dorsal hood of the MP joint and passed around the thumb extensor tendons, looped around the first dorsal interosseous, and attached to the radial aspect of the base of the index proximal phalanx, thus making the EIP an abductor of the index finger. In a small series study of 6 patients, pinch improved to 30 to 50% of normal and index abduction to 30 to 50% of normal after 48 months.[164]

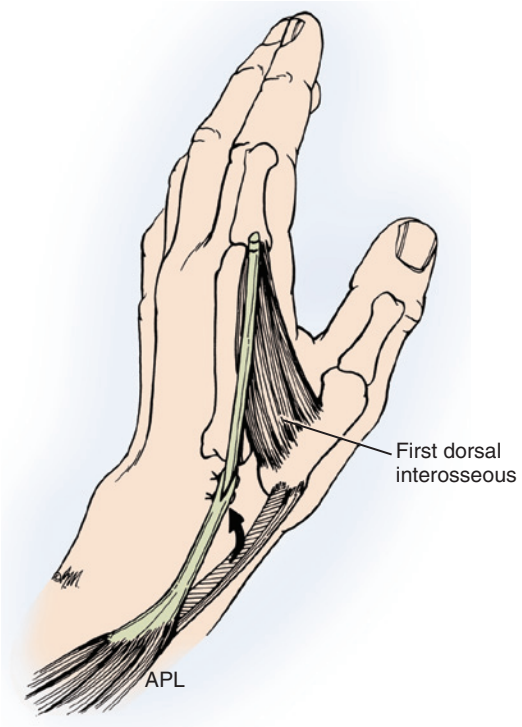

FIGURE 31.30 Tendon transfer to improve index finger abduction. An accessory slip of the abductor pollicis longus (APL) is harvested and lengthened with a free tendon graft that is inserted into the tendon insertion of the first dorsal interosseous.

Index Abduction Techniques

Accessory Slip of APL Transfer. Neviaser et al[125] described this technique as an alternative to the use of an EIP transfer, which they and others felt was unsatisfactory. The APL is exposed distal to the first dorsal compartment and one of its slips, which inserts onto and extends the thumb metacarpal base, is identified and preserved (Figure 31.30). Another accessory slip is detached and a subcutaneous tunnel is created from the radial styloid to an incision on the radial side of the proximal phalanx of the index finger. A palmaris longus or plantaris-free graft is attached to the insertion of the first dorsal interosseous, passed through the subcutaneous tunnel, and interwoven into the abductor pollicis slip with the index finger and wrist in neutral position. Although this transfer does not appreciably increase the force of tip pinch, it is thought to provide the index finger with better stability and versatility than simply bracing it against the other fingers.[178]

EIP Transfer to First Dorsal Interosseous. The EIP tendon is extended with a thin strip of the extensor hood of the index finger, divided, and withdrawn into a short transverse incision at the wrist. It is then passed under the index finger EDC and around the radial border of the index metacarpal and inserted into the first dorsal interosseous tendon, palmar to the axis of motion of the MP joint. The index finger extensor hood must be carefully repaired[41] and transfer must be sutured under considerable tension.[38] Modifications of this transfer include improving its force vector by rerouting it to pass around the extensor tendons at the wrist[180] or splitting it into two slips and inserting one slip into the first dorsal interosseous and the other into the adductor pollicis.

Disadvantages. Neviaser et al[125] and others considered this transfer unsatisfactory and inadequate, perhaps because of its short moment arm and narrow angle of approach. Smith noted that some patients developed radial-deviation of the index finger MP joint after this procedure.[178]

Palmaris Longus to the First Dorsal Interosseous. The palmaris longus muscle–tendon unit is lengthened, as for the Camitz procedure, with a strip of palmar fascia and is tunneled subcutaneously across the dorsum of the base of the thumb and along the radial side of the index finger metacarpal where it runs alongside first dorsal interosseous muscle.[77] It is inserted into the tendon of the first dorsal interosseous muscle. The wrist is immobilized for 3 weeks in 10 degrees of extension with the MP joint of the index finger in 30 degrees of flexion and 20 degrees of abduction.

Other Techniques for Restoring Index Finger Abduction. Bruner transferred the EPB to the tendon of the first dorsal interosseous, but this is probably too weak for effective function. DeAbreu transferred two muscles, which were also probably too weak, to restore pinch: the EPB tendon to the tendinous insertion of the first dorsal interosseous and the EIP tendon to the insertion of the adductor pollicis muscle.[57] Graham and Riordan transferred the ring finger FDS to the first dorsal interosseous to produce strong abduction of the index finger.[74] The technique is contraindicated in high ulnar nerve palsy secondary to FDP weakness.

Arthrodesis of Thumb MP and IP Joints to Restore Pinch

In an intrinsic-minus thumb the loss of adductor pollicis and FPB function results in the extension or hyperextension of the MP joint and flexion of the IP joint during pinch (ie, Froment's sign) because the extrinsic thumb muscles cannot control these two joints independently. Fixed deformities of the MP (hyperextension) and IP (flexion) joints can develop but, even if none is present, the position of the thumb results in a poor pinch function. Pinch function and strength can be improved by fusion of either the thumb MP or IP joint because the FPL and EPL will then have better control of movement at the remaining joint.

Brown demonstrated this by observing that splinting of an ulnar-palsied thumb IP joint increases pinch strength by 1 to 2 kg.[38] It is important to realize that a fixed deformity of the remaining joint is a contraindication for arthrodesis of the other. Most surgeons with extensive experience in treating ulnar nerve palsy prefer to use tendon transfers to restore adductor pollicis function and thus improve thumb pinch.

Arthrodesis of the MP Joint. This procedure often preferred to IP joint fusion because the retained IP joint motion better preserves the ability to roll small objects between the thumb and fingers during pinch. Anderson considers that MP arthrodesis is indicated when there is a severe MP hyperextension contracture or marked hyperextension of this joint during key pinch with pain and instability.[8] It is also indicated when MP hyperextension develops after a tendon transfer to restore thumb adduction.[136] The MP joint should be fused in no more than 15 degrees of flexion; otherwise, a "crank handle" action may occur during pinch, resulting in external rotation of the thumb so that only end-to-side pinch, and not tip-to-tip pinch, is possible with the index finger.[27] Brand placed the MP joint in 15 degrees of flexion, 5 degrees of abduction, and 15 degrees of pronation. Any of a number of techniques can be used to fuse the MP joint; these are described in Chapter 7.

Arthrodesis of the IP Joint. Tubiana preferred IP joint arthrodesis to fusion of the MP joint[195]; however, Brown observed that, although thumb pinch strength improved, thumb dexterity was sometimes lost, so he reserved this procedure for patients with IP joint instability.[38] The loss of dexterity was probably the result of the loss of IP joint motion, preventing the patient from effectively rolling small objects between his or her thumb and index finger pulp. The IP joint is usually fused in 20 to 30 degrees of flexion but the ideal position for fusion varies from patient to patient; usually, it can be determined by observing the position of the contralateral thumb during pinch.[38] There are a large quantity of techniques for IP joint fusion; some of them are described in Chapter 8.

Split FPL Tenodesis. This is an alternative to IP fusion and was devised to stabilize the thumb IP joint in tetraplegia.[121] The FPL is exposed at the level of the proximal phalanx through a palmar longitudinal incision and the radial half of this tendon is divided at its insertion on the distal phalanx and split away from the intact ulnar half to the level of the base of the proximal phalanx. The EPL is exposed through a dorsal–longitudinal incision over the proximal phalanx and the radial slip of the FPL is passed subcutaneously around the radial border of this bone and is sutured to the EPL close to its insertion. Thus, the FPL provides balanced flexion and extension forces to the IP joint that is thus stabilized and cannot hyperflex.

Restoration of the Transverse Metacarpal Arch

The intrinsic muscles, through a combination of adduction, abduction, and flexion at the MP joints, produce digital rotation. This rotation occurs during precision grip, tool handling, and cupping of the hand to hold water or grasp large objects. In ulnar nerve palsy, the ability of the hand to make a cup or contour itself around an object is lost, such that simple acts (e.g., opening the lid of a jar or turning a valve) become clumsy. Several tendon transfers, which partially restore the normal curve of the transverse metacarpal arch, have been described.

Bunnell's "Tendon T" Operation. An FDS is detached from a finger, retrieved proximally in the palm, and attached to the middle of a free tendon graft that is passed dorsal to the flexor tendons, as described for Bunnell's operation.[23] One end of the tendon graft is inserted into the radial aspect of the base of the thumb's proximal phalanx and the other is inserted into the ulnar aspect of the neck of the little finger metacarpal to form a "T." Contraction of the superficialis produces adduction and flexion of the thumb and the little finger, so the T is converted into a Y with restoration of the metacarpal arch. Brown considered this transfer inadequate in both strength and excursion for restoration of thumb pinch.[38] Littler modified the procedure by detaching and splitting an FDS tendon and inserting one slip into the adductor tubercle of the thumb and the other into the ulnar aspect of the base of the proximal phalanx of the little finger, thereby avoiding the need for a free tendon graft.[103]

EDM Transfer (Ranney). The extensor digiti minimi is divided in a step-cut manner at its normal insertion, and the remaining strip is sutured to the EDC of the little finger—that is, the Ranney transfer.[152] The EDM tendon is withdrawn into a dorsal incision in the forearm and is tunneled into the flexor compartment of it between the APL and the FCR. The EDM tendon is

then passed subcutaneously to the neck of the fifth metacarpal where it is attached. Omer reported that a similar effect can be produced by looping the FDS of the little finger around the deep transverse metacarpal ligament (DTML) of the fourth intermetacarpal space.[139]

Palande's Modification of Brand's Flexor Route Transfer of ECRL. Brand's flexor ECRL transfer for the correction of finger clawing is modified by creating 5, instead of 4, tails to the tendon/fascia lata graft, as modified by Palande.[147] Instead of attaching the tails to the lateral bands of the fingers, a transverse incision is made in the distal palmar crease to expose the hypothenar, interosseous, and lumbrical muscles. The thick fascia overlying the interossei tendons in each of the three interdigital spaces is excised and a nylon suture is passed around each pair (one palmar, one dorsal) of interossei tendons that are tied together. The five slips of the tendon graft are tunneled dorsally, the lateral four along the lumbricals and the medial one in a similar plane. With the wrist in neutral, the MP joints in 55 degrees of flexion, the IP joints extended, and the little finger CMC joint flexed, the medial tail is sutured to the hypothenar muscle–tendon junction. After that, the middle three are looped around and sutured to each of the tied pairs of interossei tendons and the lateral tail is sutured to the first dorsal interosseous muscle/tendon.

Palande found that this procedure produced equivalent results to the original Brand procedure for the correction of finger clawing and had a reduced rate of hyperextension deformity at the PIP joints.[147] In addition, it produced good restoration of the transverse metacarpal arch in 15 of 16 hands affected by leprosy and increased grip strength from an average of 12 to 15 kg.

Correction of Little Finger Abduction Deformity

The EDM, as well as the ADM, can abduct the little finger through its indirect insertion into the abductor tubercle on the proximal phalanx. The third palmar interosseous counters this effect in normal hands but, along with ADM, is paralyzed in ulnar nerve palsy, leaving the EDM unopposed (i.e., Wartenberg's sign).

Split EDM Transfer. The ulnar half of the EDM tendon is detached from the extensor hood of the little finger at the MP joint and retrieved through an incision just distal to the extensor retinaculum. A palmar incision that extends obliquely from the distal–palmar crease to the proximal–digital crease is made to expose the deep transverse metacarpal ligament and the flexor sheath of the little finger (Figure 31.31). The EDM tendon is passed through the fourth intermetacarpal space into the palm. If the little finger is not in a claw position, the tendon slip is sutured onto the insertion of its MP radial collateral ligament on the proximal phalanx. If the little finger is clawed as well as abducted, the tendon slip is inserted onto a radially based flap of the flexor tendon sheath just distal to the A1 pulley. For tensioning, the wrist is held in neutral and the MP joint is in 20 degrees of flexion. The ring and little finger MP joints are splinted in flexion for 4 weeks with the wrist extended, but the IP joints are left free, and motion is encouraged to prevent adhesion formation around the flexor tendons.

Junctura Tendinum and Medial EDC Slip of Ring Finger Transfer (Voche and Merle). A proximally based 3- to 4-cm strip of tendon is created from the central third of the ring finger extensor tendon just proximal to the MP joint using the Voche and Merle procedure.[199] The ulnar and radial portions of the ring finger extensor tendon are then sutured together and the central tendon strip is passed palmar to the deep transverse metacarpal ligament and sutured either to the insertion of the radial collateral ligament of the MP joint on the proximal phalanx of the little finger or to the radial aspect of the extensor hood of this digit. It is imperative that the tendon slip has sufficient length because a short slip will invariably loosen the extensor mechanism of the ring finger. The transfer is tensioned such that the little finger is not abducted when the fingers are extended and it has 20 degrees less flexion than the ring finger when the finger MP joints are flexed. The hand is immobilized in a splint that holds the wrist in extension and the ring and little fingers' MP joints flexed with their IP joints extended.

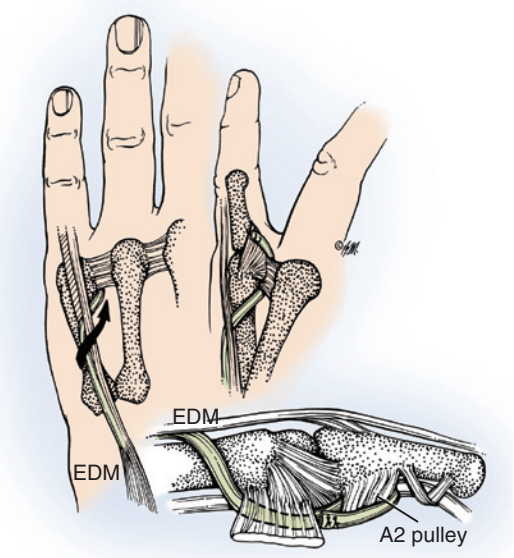

FIGURE 31.31 Transfer of the ulnar half of the extensor digiti minimi (EDM) to correct persistent abduction of the little finger. The ulnar half of the tendon is passed deep into the deep transverse metacarpal ligament and sutured to the phalangeal attachment of the radial collateral ligament of the metacarpophalangeal joint of the little finger. If the little finger is clawed as well as abducted, it is inserted onto the A1 or A2 pulley of the flexor sheath.

High Ulnar Nerve Palsy

Restoration of Ring and Little Finger Flexion and Strength

In a high ulnar nerve palsy the FDP muscles for the ring and little fingers are paralyzed so that they have no active flexion at their DIP joints and rely on FDS function, which may be rudimentary or absent in the little finger, for MP and PIP flexion.

Little and Ring Finger FDP Suture to the Middle Finger FDP. The profundus tendons of the ring and little fingers can be sutured to the profundus tendon of the middle finger in the forearm, leaving the index profundus free for individual function (Figure 31.32). This will not increase overall grip strength of the hand, and an alternative option is tenodeses of the ring and little finger DIP joints using their paralyzed FDP tendons. Transfer of the FCR to the FCU can also be performed to restore strong flexion and ulnar deviation of the wrist.

Brand did not consider that loss of the FCU or the ring and little fingers' FDP caused a significant functional problem and advised against tendon transfers to restore these functions.[26] He

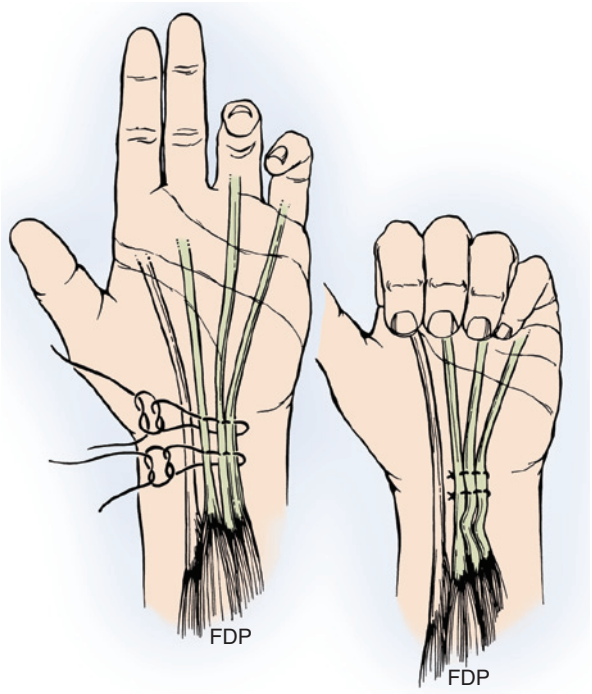

FIGURE 31.32 Tenodesis of the paralyzed ulnar-innervated profundus tendons of the ring and little fingers to the median-innervated flexor digitorum profundus (FDP) of the middle finger to restore active distal interphalangeal joint flexion of the ring and little fingers. This will not increase power for gross grip. Two or three transverse sutures are required.

usually treated isolated high ulnar nerve lesions in the same manner as low lesions, with the exception that an FDS tendon must *never* be harvested for use in tendon transfer from a finger with weak or absent profundus function.

Anderson,[8] who has vast experience with the management of leprosy, deems it unwise to correct intrinsic muscle paralysis before restoration of adequate extrinsic flexion power; this is because the patient will find it difficult to close the hand fully and will continue to have a weak grip despite claw correction. He recommends a side-to-side suture of the middle FDP to the ring and little FDP in the distal forearm, but warns the patient that this operation probably will exaggerate the claw deformity. The hand is immobilized for 3 weeks, after which muscle strengthening exercises are performed for 4 weeks. Care should be taken to prevent IP joint contractures before performing transfers for claw deformity.

Restoration of Sensibility

Loss of sensibility on the ulnar border of the hand and loss of proprioception in the little finger can produce significant functional limitations. For patients with Hansen disease, successful medical treatment does not restore sensation and insensate digits continue to be a problem for the rest of their lives. Repeated ulceration at the tips of the digits can lead to absorption and shortening despite the success of tendon transfers to correct the claw deformity.

Digital Nerve Transfer. Stocks et al transferred the functioning median-supplied ulnar digital nerve of the middle finger to the nonfunctioning ulnar digital nerve of the little finger and reported that 85% of their 13 patients regained sensibility levels of S3+ or S4.[186] Others (e.g., Ozkan et al[144]) also have observed success with this technique that may be beneficial to patients who present late after ulnar nerve injuries and those with trophic changes; however, clinically evident tissue loss precludes attempts at reinnervation.

Anderson transferred a neurovascular cutaneous island flap from the ulnar side of the pulp of the middle finger to the pulp of the little finger in patients with chronic ulnar nerve injury due to trauma or burns.[8]

Wasted Intermetacarpal Spaces

Severe intermetacarpal atrophy can be quite disfiguring and may represent a barrier to social reintegration with Hansen disease. Dermal grafts can mask interosseous wasting and are most successfully performed between the thumb and index metacarpals.[85] The patient must be informed that this "cosmetic" procedure is not always successful in the long term because the transplanted tissue may become atrophic and resorb with time.

Early Tendon Transfers (Internal Splints) for Nerve Injuries

Burkhalter introduced the concept of early tendon transfers after nerve repair to prevent the development of deformities and contractures, improve coordination of residual muscle–tendon units, and stimulate sensory reeducation during nerve recovery.[46] The transfers function as internal splints for the paralyzed muscles and, in the event of a failure of useful nerve regeneration, provide a permanent solution.

❖ AUTHOR'S PREFERRED METHOD OF TREATMENT: Isolated Ulnar Nerve Palsy, Including Patient Counseling

The hand is a most complex structure, with 38 muscles working in a coordinated fashion to control its motion.[135] Transfer of two or three tendons cannot be expected to restore the fine function of the many intrinsic muscles whose function is lost with a complete ulnar nerve lesion. It thus must be stressed to the patient that the aim of surgery for ulnar nerve palsy is to improve rather than restore normal function. Restoration of function by tendon transfer, tenodesis, joint capsule reefing, or joint fusion must produce a benefit that outweighs (1) the permanent loss of any donor muscle's function or loss of joint mobility, (2) the inconvenience of the temporary loss of hand function due to the surgery and postoperative rehabilitation with splintage, and (3) the risk of complications and failure.

The loss of sensation is not as devastating in ulnar nerve palsy as in median nerve palsy, and the loss of motor function in a low lesion primarily involves fine dexterity and grip strength. However, much function is retained and this led one of my late senior orthopedic colleagues to comment: "the ulnar nerve is a luxury to the manual worker." Although I would not endorse this sweeping statement, it contains some truth with regard to my practice in the United Kingdom where injury at the wrist is the most common cause of ulnar nerve palsy.

This type of injury often occurs in men with thickset hands and MP joints that do not naturally hyperextend, such that an unsightly claw deformity does not develop. Such patients often adapt to the loss of ulnar nerve function and the consequent grip and pinch weakness, altered rhythm of finger flexion, and loss of dexterity by favoring their other hand for tasks they have difficulty performing with the injured one. Many decline

reconstructive surgery when the option is discussed openly and honestly and it is stressed that its aim is to improve specific functions, rather than restore normal function, and that surgery and postoperative management will necessitate considerable time off work. This is because some are afraid of losing their employment if they take a prolonged absence from work and many, while awaiting ulnar nerve recovery after primary repair of the nerve injury, realize that they are capable, with adaption, of their normal activities and work even if there is little or no recovery of nerve function. With other patients, discussion of their objective for having surgery reveals that improved hand strength is the primary aim.

It is my belief, perhaps wrongly, that none of the tendon transfers used to restore finger intrinsic muscle function and correct finger clawing provides significant improvements in hand grip strength. I wonder whether some of the strength improvement reported after such surgery might be a result of intensive rehabilitation effort after the surgery rather than the surgery itself. Therefore, I do not encourage surgery to restore finger intrinsic function as a means to improve grip strength. I also feel that transfers or fusions to improve thumb strength are unlikely to restore more than 50% of normal thumb strength and am thus cautious when discussing these procedures.

It must be stressed that my views are based on my clinical practice, and that the patients I see probably have completely different requirements and aims to those with Hansen disease who may have supple hands with PIP joints that naturally hyperextend. In such patients severe claw deformities frequently occur, and this may not only cause significant loss of function but also carry a social stigma. For some patients the hand disability may be both of a physical and a mental nature as observed by Brand who stressed the importance of the surgeon looking and examining patients' hands with respect in order to build a bond of trust between the surgeon and the patient.[31]

Although restoration of function is my main objective for surgery for finger clawing, I suspect that for many patients the aesthetic appearance is often of great concern and that this is sometimes concealed from me. Aesthetic improvement may be an acceptable indication for surgery for patients with severe claw deformity who are conscious of its appearance, provided they are fully aware of the risk of failure and complications and have the necessary commitment to the surgery and its rehabilitation process.

For correction of clawing and improvement in the pattern of movement of the fingers, I favor, when available, using the ring finger FDS as the motor and split its tendon into two slips that are attached around the A1 pulleys of the ring and little fingers. Rightly or wrongly I only perform transfers to the fingers that are clawed at rest, thus do not usually address the index and middle fingers. I find this the most straightforward transfer for correction of clawing and improving the dynamics of finger motion, but I have encountered some troublesome deformities in the donor ring finger. Hyperextension deformity is probably rarer in stiffer Caucasian hands than supple Asian hands, and I harvest the FDS through a Bruner incision at the level of the PIP joint, which may reduce the risk of donor complications.

I have found that insertion onto the lateral bands is more complex and with patients I have treated that the PIP joints almost invariably extend fully when MP joint hyperextension is blocked such that use of this insertion is rarely indicated. For further detail on the specific indications and surgical technical points regarding the subtle differences between available transfers and tendon insertions, I refer the reader to the excellent works of Brand, Burkhalter, Omer, and others that are included in the reference list for this chapter.

For the thumb I think that many patients do not need an adductor-plasty because they are not disabled by reduced pinch strength that is still adequate for their everyday activities.[178] If, however, a modest increase in thumb pinch strength is the aim of surgery, I would utilize the ECRB transfer, as modified by Omer,[136] and stress to the patient that this probably will only restore approximately 50% of normal thumb strength. In other cases I favor fusion of the MP joint to fusion of the IP joint to allow pinch between the thumb pulp and the fingers; however, this is only offered if the "tip" thumb pinch is causing functional disability. I believe that fusion of the IP joint reduces the patient's ability to roll objects between his or her thumb and fingers much more than fusion of the MP joint. I have not used the split FPL tenodesis in this situation, but Scott Wolfe, the editor of this section of this book, finds that its use in combination with an ECRB adductor-plasty provides strong lateral pinch and a much more functional hand for patients with C8/T1 brachial plexus injuries.

I do not perform tendon transfers to restore the concave transverse metacarpal arch nor do my patients find small finger abduction sufficiently disabling to require tendon transfer.

Before embarking on surgery for ulnar, as well as median, nerve palsy, I firmly believe that the potential benefits and drawbacks of the proposed surgery should be honestly discussed with the patient, who should be given time to reflect and recognize that surgery cannot restore normality. Both the surgeon and the patient must clearly understand the functional aims of the patient, and the surgeon should perform the simplest procedure possible to fulfill these aims. Many doyens of tendon transfer surgery have stressed the need for simple surgery,[135] and I firmly believe that the less complicated the surgery, the simpler the subsequent rehabilitation and the greater the chance of a satisfied patient. Complexity invites failure.[141]

COMBINED MEDIAN AND ULNAR NERVE PALSIES

Combined "low" injuries to the median and ulnar nerves are severe injuries that result in total loss of sensation to the palmar surface of the hand and complete loss of intrinsic muscle function; there is no chance of preservation of any intrinsic function through anomalous nerve interconnections (e.g., the Martin-Gruber anastomosis). The situation is even worse in combined "high" injuries because of the additional loss of all extrinsic wrist, thumb, and finger flexor function. In addition, such injuries, if due to trauma, are frequently accompanied by severe associated soft tissue, bony, vascular, and skin coverage issues or infection, which further complicates management and requires an individualized approach. The management of these combined palsies is complex. Omer, in an earlier edition of this book, described possible procedures to improve hand function in these cases[138]; they are summarized in Tables 31.7 and 31.8.

TABLE 31.7 Combined Low (Distal) Median and Ulnar Palsy

Needed Function	Preferred Transfer	Alternative Transfer
Thumb adduction—key pinch	ECRB with free tendon graft between third and fourth metacarpals to abductor tubercle of thumb (APB tendon)	FDS (long) to abductor tubercle of the thumb with palmar fascia and flexor tendons as pulleys
Thumb abduction—opposition	EIP around pisiform pulley through thenar muscle tunnel to APB tendon insertion and EPL tendon	PL to APB tendon insertion *or* FDS (ring) to APB tendon
Thumb–index tip pinch	APL slip with free tendon graft to first dorsal interosseous tendon and arthrodesis of thumb MP joint	EPB or PL to first dorsal interosseous tendon (if thumb MP joint has been arthrodesed)
Metacarpal (palmar) transverse arch and adduction for little finger	EDM tendon split and ulnar half-passed palmar to deep transverse metacarpal ligament to radial collateral ligament of MP joint of little finger or A2 pulley of flexor sheath	FDS (little) to deep transverse metacarpal ligament between fourth and fifth metacarpal *or* FDS (long or ring) combined as single transfer for thumb adduction and metacarpal arch
Power flexion for proximal phalanges and integration of MP and IP motion (clawed fingers)	ECRL or BR to all 4 fingers using four-tailed free tendon graft and flexor sheath insertion (A2 pulley) or lateral bands of dorsal apparatus	FCR (if wrist flexion contracture) with four-tailed free tendon graft to either flexor sheath (A2 pulley) or dorsal apparatus
Radial and ulnar palmar sensibility	Superficial radial nerve translocation or cutaneous neurovascular island	Cross-finger index-to-thumb fillet flap (superficial radial nerve)

APB, Abductor pollicis brevis; *APL*, abductor pollicis longus; *BR*, brachioradialis; *ECRB*, extensor carpi radialis brevis; *ECRL*, extensor carpi radialis longus; *EDM*, extensor digiti minimi; *EIP*, extensor indicis proprius; *EPB*, extensor pollicis brevis; *EPL*, extensor pollicis longus; *FCR*, flexor carpi radialis; *FDS*, flexor digitorum superficialis; *IP*, interphalangeal; *MP*, metacarpophalangeal; *PL*, palmaris longus.

TABLE 31.8 Combined High (Distal) Median and Ulnar Palsy

Needed Function	Preferred Transfer	Alternative Transfer
Thumb adduction—key pinch (AP)	ECRB with free tendon graft between third and fourth metacarpals to abductor tubercle of thumb	BR or EIP with free tendon graft between third and fourth metacarpals to abductor tubercle of thumb (APB tendon)
Thumb flexion (IP joint)	BR to FPL in forearm	Tenodesis of FPL distal to MP joint of thumb
Thumb abduction—opposition (APB)	EIP around pisiform pulley to insertion of APB *plus* EPL tendons	EPL or ECU with graft around pisiform pulley to APB tendon (thumb MP joint is fused and no active motion at IP joint)
Thumb–index (or long) pinch (tip pinch)	Arthrodesis of thumb MP joint *and* APL slip with free tendon graft to first dorsal interosseous tendon	EPB or PL to dorsal interosseous tendon *and* fusion of thumb MP joint
Finger flexion (FDP)	ECRL to all 4 tendons of FDP with possible tenodesis of distal IP of ulnar 3 fingers	Biceps brachii extended with FCR tendon to tendons of FDP
Clawed fingers—power for flexion of proximal phalanx *and* integration of MP and IP motion	Tenodesis of all 4 digits with free tendon graft from dorsal-carpal ligament volar to deep transverse metacarpal ligament to lateral bands of extensor apparatus or from deep transverse metacarpal ligament to extensor apparatus	Capsulodesis of MP volar capsule *or* Arthrodesis of PIP joints *or* Arthrodesis of MP joints
Metacarpal (palmar) arch and adduction for little finger	EDM to deep transverse metacarpal ligament 2 (EDC of little finger must be active)	EDM to radial lateral bands (extensor hood) of ring and little fingers (Fowler-Bunnell)
Wrist flexion		ECU to insertion of FCU
Radial and ulnar volar sensibility	Superficial radial-innervated index fillet flap to palm *or* First dorsal-metacarpal artery neurovascular island	Superficial radial nerve translocation *or* Free vascularized nerve graft

APB, Abductor pollicis brevis; *APL*, abductor pollicis longus; *BR*, brachioradialis; *ECRB*, extensor carpi radialis brevis; *ECRL*, extensor carpi radialis longus; *ECU*, extensor carpi ulnaris; *EDC*, extensor digitorum communis; *EDM*, extensor digiti minimi; *EIP*, extensor indicis proprius; *EPB*, extensor pollicis brevis; *EPL*, extensor pollicis longus; *FCR*, flexor carpi radialis; *FCU*, flexor carpi ulnaris; *FDP*, flexor digitorum profundus; *FPL*, flexor pollicis longus; *IP*, interphalangeal; *MP*, metacarpophalangeal; *PIP*, proximal interphalangeal; *PL*, palmaris longus.

RADIAL NERVE PALSY

Loss of radial nerve function in the hand creates a significant disability. This is predominantly a result of loss of active wrist extension and the consequent awkward flexed position of the wrist that does not allow a powerful grip.[94] The loss of finger and thumb extension also causes difficulty with grasping objects, and restricts interosseous muscle function with a loss of active finger abduction. Tendon transfers to restore function in radial nerve palsy are the best and the most predictable in the upper extremity; however, as pointed out by Riordan[161]: "There is very little hope that errors in technique can be overcome by local adaptation. The success or failure of an operation depends on the technical competence of the operator and his painstaking after-care." Riordan also noted that "there is usually only one chance to obtain good restoration of function in such a paralyzed hand."[162]

Most injuries of the radial nerve occur distal to the branches to the triceps in the upper arm, and loss of triceps function in higher radial nerve palsies is usually compensated for by gravity passively extending the elbow unless the arm is held above shoulder height. For this reason, transfers to restore triceps function are not included in this chapter.

Brachial neuritis can cause an isolated palsy of the posterior interosseous branch of the radial nerve. With this condition, wrist extension, including the inevitable associated radial deviation (Figure 31.33), is retained as the radial nerve innervates the ECRL before it divides into its two terminal branches: the posterior interosseous (motor) and superficial (sensory) branches. Additionally, the ECRB receives its innervation in most limbs (58%) from the superficial radial nerve rather than from the posterior interosseous nerve.[182]

ANATOMY

The posterior interosseous nerve splays out into multiple thin branches as it emerges from the supinator about 8 cm distal to the elbow joint. Spinner has likened this to the cauda equina, and repair of the individual branches is difficult.[182] Difficulty in repairing untidy injuries at this level often has an important influence on the timing of tendon transfers. Abrams and associates produced the best reference on the innervation order and location of motor branches of the radial nerve[1] (Table 31.9). Although they found the order of innervation variable, knowledge of the general patterns and variations is important for the surgeon for following recovery after radial nerve injuries.



FIGURE 31.33 A patient with posterior interosseous nerve palsy. The extensor carpi radialis longus is intact but the extensor carpi radialis brevis and extensor carpi ulnaris are paralyzed, resulting in radial deviation of the wrist in extension.

A surgeon who plans to perform transfers for radial nerve palsy must have a comprehensive three-dimensional understanding of the anatomy of the flexor and extensor muscles of the forearm. This is a complex area of anatomy that is difficult to master, so continual review is mandatory.

Requirements for a Patient With Radial Nerve Palsy

A patient with an irreparable radial nerve palsy needs to be provided with (1) wrist extension, (2) finger (MP joint) extension, and (3) a combination of thumb extension and abduction. The motors available for transfer for a patient with isolated radial nerve palsy include all the extrinsic muscles innervated by the median and ulnar nerves. This multitude of available motors provides the surgeon with an almost limitless number of possible combinations for transfers. However, one or two combinations of transfers are used by the majority of surgeons in most instances. Unless a patient has a painful neuroma, the sensory part of the radial nerve usually can be ignored because loss of sensibility in its territory (a variably sized area of skin on the hand's radial side of the dorsum) does not cause disability.

Nonoperative Treatment

The most important aspects of nonoperative management of a patient with radial nerve palsy are maintenance of full passive range of motion in all joints of the wrist and hand and prevention of contractures, including contracture of the thumb–index web. For most patients, the constant supervision of a therapist is not required, but the patient must be taught very soon after the original nerve injury how to perform an appropriate exercise program to keep the joints supple. It is the patient's responsibility to do the exercises, and the role of the therapist at this point is to teach the patient and to monitor progress to ensure that the exercise program is performed correctly.

Many types of splints have been described for patients with radial nerve palsy. Most incorporate some type of dynamic outriggers to extend the fingers and thumb with elastic traction while allowing full active flexion. These can make dressing awkward and require careful selection of clothing. In my opinion few, if any, patients need or want such elaborate

TABLE 31.9 Innervation Order of Muscles: Radial Nerve

BR	EDM
ECRL	APL
Supinator*	EPL
ECRB	EPB
EDC	EIP
ECU	

*The supinator is included for completeness, but cannot be tested clinically.

APL, Adductor pollicis longus; *BR,* brachioradialis; *ECRB,* extensor carpi radialis brevis; *ECRL,* extensor carpi radialis longus; *ECU,* extensor carpi ulnaris; *EDC,* extensor digitorum communis; *EDM,* extensor digiti minimi; *EIP,* extensor indicis proprius; *EPB,* extensor pollicis brevis; *EPL,* extensor pollici longus.

splinting that can interfere with, rather than improve, function. Patients' individual needs should dictate the type of splint and most find an "off-the-shelf" inconspicuous $10 cock-up wrist splint, which stabilizes the wrist, restores adequate and, often remarkably good, function without interfering with clothing. Such a splint often substantially increases grip strength.[46]

A person who does data entry and wishes to continue working might be able to do so with the dynamic finger and thumb extension splint (Figure 31.34), whereas an insurance salesperson who is more concerned about appearance would probably be content with a small, inconspicuous volar cock-up wrist splint. If a wrist splint is worn only during the day, then Brand recommends that a splint, which holds the wrist and fingers in extension, be worn at night; otherwise, the disturbed balance of the wrist can result in loss of fiber length of the flexor muscles, making it more difficult to achieve normal balance after the final nerve recovery or operation.[30]

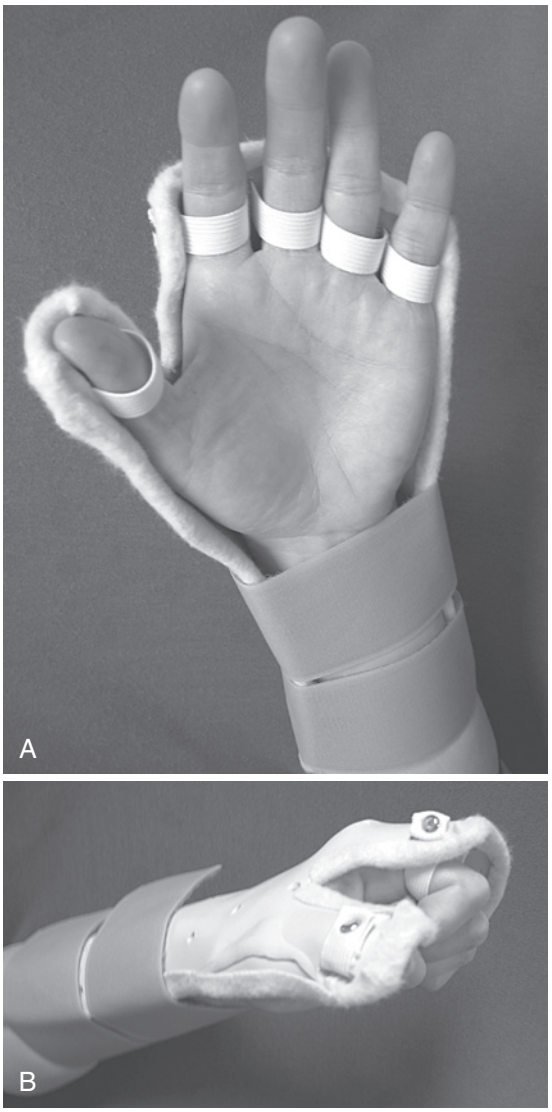

FIGURE 31.34 Many types of splints have been designed for patients with radial nerve palsy, and many provide dynamic finger extension. **A,** With one of the less cumbersome designs, passive metacarpophalangeal extension is provided by simple elastic webbing beneath the proximal phalanges. **B,** Active flexion of proximal interphalangeal joints is not impeded.

Early Transfers (Internal Splint)

Burkhalter believed that the greatest functional loss after radial nerve injury is weakness of power grip as a result of loss of wrist extension. Consequently, he has been a strong advocate of early palliative tendon (PT)-to-ECRB transfer.[46] This eliminates the need for an external splint and significantly improves power grip and hand function. He suggested that the transfer be done at the same time as radial nerve repair or as soon as possible thereafter. The tendon juncture is done end-to-side so that the ECRB remains in continuity and can function in its own right as a wrist extensor should successful reinnervation occur. This author has no experience with "early" transfer and would be cautious of its use; that is, except in cases in which there is little or no hope of useful recovery of radial nerve function, "tissue equilibrium" in the operative field, and patient enthusiasm for the procedure. It may have more value in practices that encounter a different spectrum of radial nerve palsies.

Operative Treatment

Nerve Repair and Graft Versus Tendon Transfers

The first decision to make for a patient who has an established radial nerve palsy is whether to attempt belated repair of the nerve or to restore lost function with tendon transfers. The time since injury is a critical factor, but late repair of the radial nerve can produce reasonably good results at least in part because the nerve is almost entirely motor and the paralyzed muscles are often reasonably close to the site of injury. However, if the prognosis for recovery of function after nerve repair is poor, it would seem prudent to proceed directly to tendon transfers and avoid subjecting the patient to an additional 4 to 6 months of waiting for function to return before resorting to tendon transfers.

When attempting late repair, the surgeon must be prepared to do nerve grafts if the gap is too great to overcome by direct epineurial repair without tension. Several authors have shown reasonable results with belated grafting of the radial nerve. Samardzic and colleagues[169] grafted gaps of 2 to 10 cm, but Kallio and coworkers[88] concluded that results were better if the grafts were <5 cm.

Timing of Tendon Transfers

Brown advised early transfers to restore wrist, finger, and thumb extension when there was a poor prognosis for the radial nerve injury and its repair.[39] He advised ignoring the nerve and proceeding directly to the tendon transfers if there was a nerve defect of more than 4 cm, a large wound or extensive scarring, or skin loss over the nerve. However, if a good repair of the nerve is achieved, most would wait several months (at least 5 or 6 after injury in the middle third of the upper arm) to allow nerve regeneration to occur. They would only proceed to tendon transfers if it was clear that inadequate muscle reinnervation had occurred by both clinical and electrodiagnostic criteria.

Bevin suggested a policy of never repairing the radial nerve and proceeding directly to tendon transfers.[16] This reduced the period of disability after injury to 8 weeks (7.5 months after nerve repair); however, most would agree that the results of radial nerve repair are sufficiently good to warrant routine repair in most cases, especially for younger patients.

There does not seem to be any time limit as to how long a delay can be tolerated before transfers are done after nerve

injury. Brodman reported successful transfers 24 years after radial nerve injury, despite what he described as "gelatinous degeneration" (i.e., translucent appearance) of the paralyzed tendons at the time of operation.[36]

Historical Review

World War I and World War II enabled a few individuals to accumulate a lifetime of experience in a very short period,[172] and most of the articles that established the fundamentals of transfers for radial nerve palsy were published in the immediate postwar years.

Jones is credited with being the major innovator of radial nerve transfers, and the "classic" Jones transfer[86] has been quoted and misquoted many times, partly because he described at least two slightly different combinations of transfers (Table 31.10). Although Jones transfers became popular, the only part of them that has been universally accepted is the use of the PT to provide active wrist extension. A few authors have favored wrist arthrodesis, but most believe that it is important to maintain wrist motion. The only current controversy regarding the pronator transfer centers on the optimal insertion of the PT.

Major disagreement arises concerning the optimal method of restoring finger extension and thumb extension and abduction. Jones used both the FCU and FCR, and in 1922 Starr was the first to transfer the PL and the FCR, leaving the FCU intact.[183] Zachary convincingly illustrated the benefit of leaving one wrist flexor intact.[203] In 1996, Gaur and Swarup used the FCR and the FCU, but reaffirmed the principle that improved functional results were achieved if the FCU was spared to maintain flexion and ulnar deviation of the wrist.[67] Scuderi refined the PL to rerouted EPL transfer, emphasizing the important principle that function is better when the transfer is done into only one tendon.[172] The results of these and other studies gradually evolved into what has been referred to by some as the "standard" set of tendon transfers for radial nerve palsy:

- PT to ECRB
- FCU to EDC—index finger (II), small finger (V)
- PL to rerouted EPL

In France, a slightly modified version of this set (i.e., FCU to EDC and EPL; PL to EPB and APL) is known as the Merle d'Aubigné procedure.[93]

There is still disagreement on the best combination of transfers. In 1960, Boyes[21] advocated using the Starr FCR transfer instead of the FCU to restore finger extension.[50] His reasoning was that the FCU is a more important wrist flexor than the FCR because the normal axis of wrist motion is from dorsal-radial to volar-ulnar. Support for this concept was provided by Brand's biomechanical and clinical studies that led him to believe that the FCU should not be used as a tendon transfer for two reasons: (1) the FCU is too strong and its excursion is too short for transfer to the finger extensors, and (2) its function as the prime ulnar stabilizer of the wrist is too important to sacrifice.[27] Despite these theoretical concerns, studies have shown no functional loss of power grip with the FCU set.[60,153]

Another reason for not using the FCU (or, for that matter, the FCR) set of transfers is that it cannot provide simultaneous wrist and finger extension. Because the amplitude of the wrist flexors is only ~33 mm and the amplitude of the finger extensors is 50 mm; full active extension of the fingers with an FCU or FCR transfer can be achieved only by simultaneous flexion of the wrist, relying on the tenodesis effect of the transfer (Figure 31.35). Boyes therefore suggested that the superficialis (sublimis) tendons, with their greater excursion (70 mm), would be better motors for finger extensors and devised a combination of transfers that also provided more independent control of the thumb and index finger:

- PT to ECRL and ECRB
- FCR to EPB and APL
- FDS long finger (III) to EDC (via interosseous membrane)
- FDS ring finger (IV) to EPL and EIP (via interosseous membrane)

Tendon Transfers

Three sets of transfers are currently favored for radial nerve palsy (Table 31.11). All use the PT to restore wrist extension. There has been much discussion as to which transfers provide the best finger and thumb extension, but despite potential theoretical benefits and drawbacks for each of the three common transfers (FCR-to-PL, FCU-to-PL, FDS III + IV), all can produce very similar outcomes.[122]

TABLE 31.10 Jones Transfers

1916[86]
PT-to-ECRL and ECRB
FCU-to-EDC III–V
FCR-to-EIP, EDC II, and EPL
1921[87]
PT-to-ECRL and ECRB
FCU-to-EDC III–V
FCR-to-EIP, EDC II, EPL, EPB, and APL

APL, Adductor pollicis longus; *ECRB*, extensor carpi radialis brevis; *ECRL*, extensor carpi radialis longus; *EDC*, extensor digitorum communis; *EIP*, extensor indicis proprius; *EPB*, extensor pollicis brevis; *EPL*, extensor pollici longus; *FCR*, flexor carpi radialis; *FCU*, flexor carpi ulnaris; *PT*, palliative tendon.

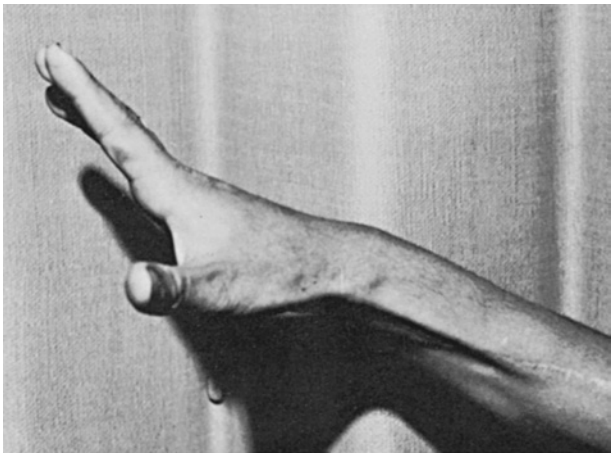

FIGURE 31.35 A wrist flexor transferred to the finger extensors does not have sufficient amplitude of excursion to extend wrist and fingers simultaneously. After flexor carpi ulnaris-to-extensor digitorum communis transfer, this patient uses the tenodesis effect created by active flexion of the wrist to enhance the effective excursion of the tendon and achieve excellent active extension of the fingers.

TABLE 31.11 Best Combination of Tendon Transfers for Radial Nerve Palsy

FCR Transfer (Starr,[183] Tsuge and Adachi[194])
PT-to-ECRB
FCR-to-EDC
PL to rerouted EPL
Superficialis Transfer (Boyes[21]; Chuinard et al[50])
PT-to-ECRL and ECRB
FDS III to EDC
FDS IV to EIP and EPL
FCR-to-APL and EPB
FCU Transfer
PT-to-ECRB
FCU-to-EDC
PL to reroute EPL

APL, Adductor pollicis longus; *ECRB,* extensor carpi radialis brevis; *ECRL,* extensor carpi radialis longus; *EDC,* extensor digitorum communis; *EIP,* extensor indicis proprius; *EPB,* extensor pollicis brevis; *EPL,* extensor pollici longus; *FCR,* flexor carpi radialis; *FCU,* flexor carpi ulnaris; *FDS,* flexor digitorum superficialis; *PL,* palmaris longus; *PT,* palliative tendon

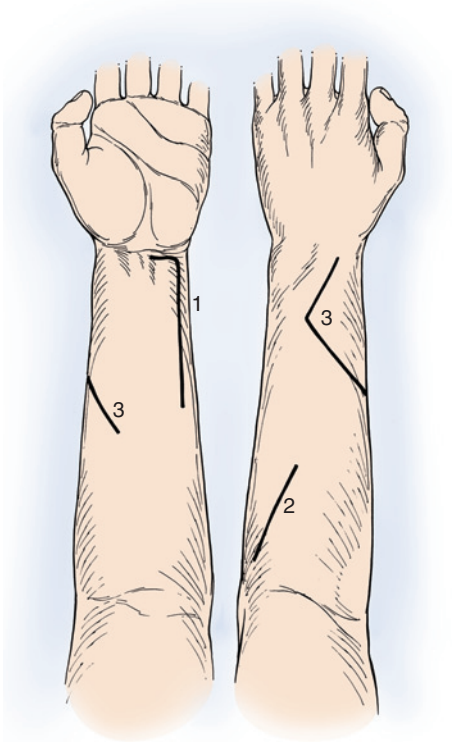

FIGURE 31.36 Incisions used in a flexor carpi ulnaris combination of transfers (see text). (Copyright © Elizabeth Martin.)



FIGURE 31.37 This instrument designed by Carroll facilitates division of extensive fascial attachments of the muscle belly of the flexor carpi ulnaris.

For a patient with posterior interosseous nerve palsy, the PT transfer is unnecessary to restore wrist extension. In addition, an isolated posterior interosseous nerve palsy provides perhaps the most compelling indication for the FCR transfer; static radial deviation postural deformity may occur when the only remaining ulnar deviator is transferred.

Flexor Carpi Ulnaris Transfer. The first incision in FCU transfer (Figure 31.36) is directed longitudinally over the FCU in the distal half of the forearm. Its distal end is "J"-shaped, with the transverse extension being long enough to reach the PL tendon. The FCU tendon is transected just proximal to the pisiform and freed up as far proximally as the incision allows. Separation of this muscle from its particularly dense fascial attachments is facilitated by a special tendon stripper designed by Carroll (Figure 31.37). If this stripper is not available, the dissection of the FCU can be done under direct vision by extending the first incision more proximally. The muscle belly of the FCU is very long, extending usually to within a few centimeters of the insertion of the tendon on the pisiform. Many facilitate the transfer of this tendon by excising the muscle belly from the distal half of the tendon, which also makes the muscle less prominent as it passes around the ulnar border of the forearm.

The second incision begins 4 cm below the medial epicondyle and angles across the dorsum of the proximal forearm, aimed directly toward Lister's tubercle. The deep fascia overlying the FCU muscle belly is excised, and the remaining fascial attachments to the muscle are incised. It is imperative that the FCU be completely freed up so that its entire muscle belly and tendon can be transferred into the proximal wound to redirect the muscle. The limiting factor in the dissection is the innervation of the FCU, which enters the muscle in its proximal 4 cm, so the dissection must not extend this far proximally.

The third incision begins on the palmar-radial aspect of the mid-forearm, passes dorsally around the radial border of the forearm in the region of the insertion of the PT, and then angles back radially on the back on the dorsum of the distal forearm toward Lister's tubercle. The tendon of the PT is identified in the palmar aspect of the wound and followed to its insertion on the radius. It is vital that the PT tendon be elongated by freeing up its insertion with an attached long strip of periosteum. This ensures that it has sufficient length to create a strong tendon juncture (Figure 31.38). Tubiana and colleagues emphasized that the PT muscle–tendon unit must be freed up proximally to divide adhesions to improve subsequent excursion.[196] The PT muscle and tendon are passed subcutaneously around the radial border of the forearm, superficial to the BR and ECRL, to be inserted into the ECRB just distal to its musculotendinous junction.

A tendon passer or large Kelly clamp is passed from the dorsal wound (third incision) subcutaneously around the ulnar border of the forearm, and the tendon of the FCU is pulled into the dorsal wound (Figure 31.39). At this point the FCU muscle belly is further trimmed if there is still excessive muscle overlying the ulnar border of the forearm. It is imperative that the FCU's line of pull be as straight as possible from the medial epicondyle to the EDC tendon just proximal to the dorsal retinaculum. If the previous dissection has not freed up all the

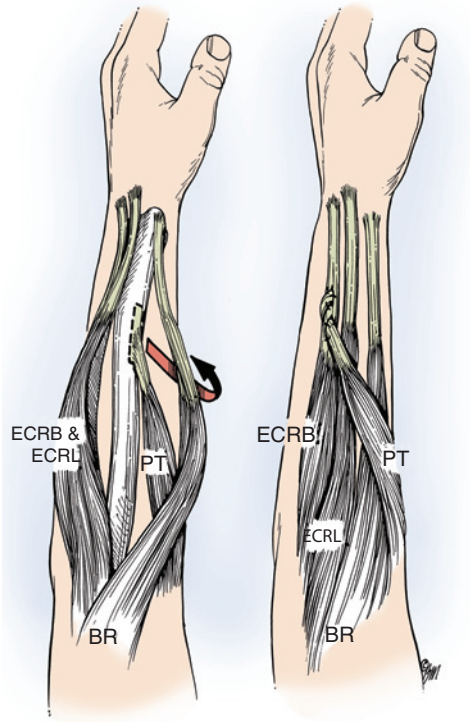

FIGURE 31.38 Palliative tendon (PT)-to-extensor carpi radialis brevis (ECRB) transfer. It is vital to take a strip of periosteum in continuity with PT insertion to ensure adequate length for transfer. *BR,* Brachioradialis; *ECRL,* extensor carpi radialis longus. (Copyright © Elizabeth Martin.)

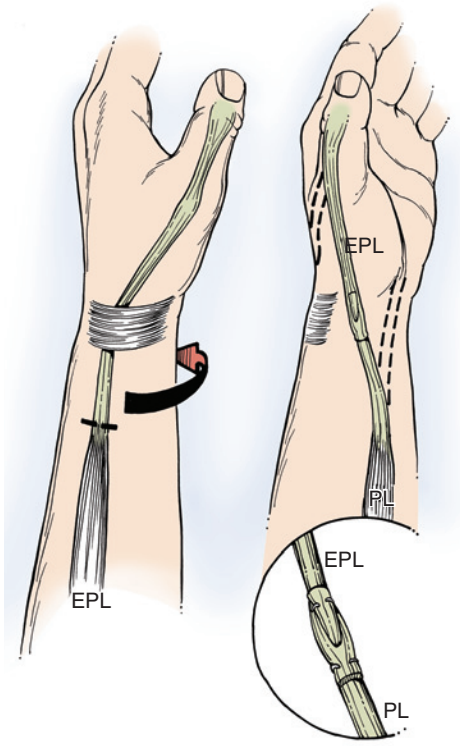

FIGURE 31.40 Palmaris longus (PL) to rerouted extensor pollicis longus (EPL) transfer. By rerouting EPL out of dorsal retinaculum, the transfer creates a combination of abduction and extension force on the thumb. (Copyright © Elizabeth Martin.)

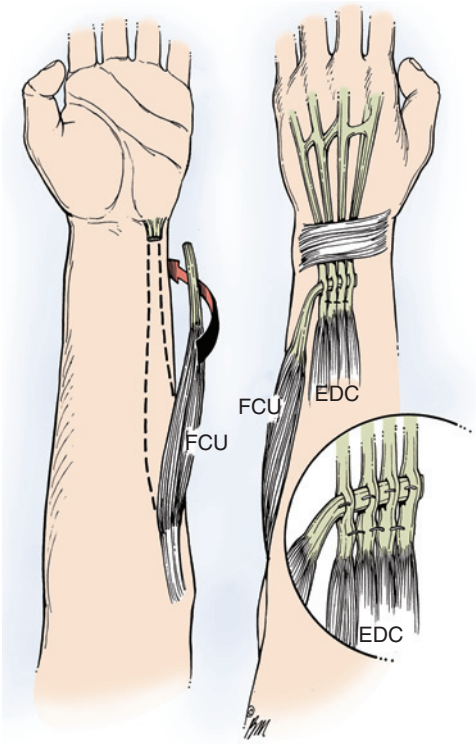

FIGURE 31.39 Flexor carpi ulnaris (FCU)-to-extensor digitorum communis (EDC) transfer. FCU must be freed up extensively to create a direct line of pull from its origin to the new insertion into EDC tendons just proximal to dorsal retinaculum. End-to-side juncture is shown here. Moberg and Nachemson[120] suggested that 4 to 5 cm of paralyzed EDC tendons be resected proximal to the juncture. This allows an end-to-end suture and a more direct line of pull. (Copyright © Elizabeth Martin.)

fascial attachments of the FCU, it is impossible to achieve this important direct pull.

The EPL muscle is identified in the dorsal wound; it is divided at its musculotendinous junction, removed from Lister's canal, and passed across the anatomic snuffbox toward the palmar aspect of the wrist (Figure 31.40). The PL tendon is transected at the wrist, and the muscle–tendon unit is freed up proximally until a straight line of pull between the PL and the rerouted EPL tendon is achieved. The PL tendon is delivered into the dorsal wound in the region of the snuffbox.

A variation in technique recommended by Moberg and Nachemson is to open the dorsal retinaculum "to prevent ischemic necrosis of the tendons secondary to postoperative edema."[120] This author is unaware of this being a common problem, but their modification does provide a straighter line of pull.

At this point, I release the tourniquet, establish hemostasis, and close the first and second incisions. Setting the proper tension in the transfers is a tricky task, but is crucial to the outcome of the operation. It is difficult to describe precisely how to adjust tension in tendon transfers, and a certain amount of experience is essential to be able to "feel" the proper tension. Generally, one should err on the side of suturing extensor tendon transfers too tight rather than too loose because the extensors tend to stretch over time.

The tendons must be tight enough to provide full extension of the wrist, fingers, and thumb, yet not so tight as to limit flexion of the digits. Green sutured the PT to ECRB (*not* including the ECRL) just distal to the musculotendinous junction. The long tongue of periosteum at the end of the PT tendon is

woven through the tendon of the ECRB as a Pulvertaft weave and secured with multiple 3-0 or 4-0 nonabsorbable sutures. Even if a tongue of periosteum has been harvested with the PT insertion, this does not always provide a secure tendon juncture, in which case it can be reinforced with a short strip of free tendon graft taken from the ECRL. I believe the periosteal strip aids weaving of PT into ECRB but has insufficient strength for the pull of the transfer, such that it is imperative that tendon (not just periosteum) be woven into the tendon. If this cannot be achieved then I believe a graft is mandatory. The transfer is sutured with the PT in maximum tension and the wrist in at least 45 degrees of extension.

The FCU transfer is then sutured. Omer weaved the FCU tendon end-to-side through the EDC tendons at a 45-degree angle just proximal to the dorsal retinaculum (Figure 31.39).[140] Moberg and Nachemson[120] suggested that better results can be achieved if 4 to 5 cm of inactivated EDC muscle tendon is resected just proximal to the intended site of suture, allowing an end–end juncture and a more direct line of pull.[62] Most authors do not include the EDM in the transfer for fear of creating excessive tension in the small finger.

Green determined whether to include it by pulling on the EDC tendons (proximal to the intended site of juncture) with an Allis clamp. If the small finger extended adequately, the EDM was not included, but if there was an extensor lag in the small finger (signifying an inadequate slip of EDC to the small finger), the EDM was included. It is important to suture the FCU tendon into each EDC slip separately and to adjust the tension in the EDC tendons individually so that all four MP joints extend synchronously and evenly. Green secured the junctures with the wrist and MP joints in neutral (0 degrees) and the FCU under maximum tension. An assistant to help hold the tension while the tendons are sutured is vital.

Retraction on the distal end of the third incision allows completion of the third and final juncture (PL to rerouted EPL) in the region of the anatomic snuffbox superficial to the dorsal retinaculum. The tendons should run in line with the first metacarpal (Figure 31.41), and the juncture is made with the wrist in neutral, the thumb extended, and maximum tension on EPL and PL tendons.

The tension must be tested by passively moving the wrist to show the synergistic action of the new transfer. With the wrist in extension, it should be possible to easily flex the fingers completely into the palm, and with the wrist in flexion, the MP joints should pull into full extension but not hyperextend. The third incision is closed while an assistant stabilizes the position of the wrist and hand to protect the transfers. Closing of all three wounds with subcuticular sutures avoids unattractive crosshatches in the scars.



FIGURE 31.41 Photo of the palmaris longus to rerouted extensor pollicis longus transfer. The line of pull is essentially in line with the thumb's metacarpal.

Postoperative Management. In the operating room, a long arm splint is applied that immobilizes the forearm in 15 to 30 degrees of pronation, the wrist in approximately 45 degrees of extension, the MP joints in slight (10–15 degrees) flexion, and the thumb in maximum extension and abduction. The PIP joints of the fingers are left free. Because limited elbow motion does not cause undue tension on the suture lines, a single sugar tong splint is a satisfactory alternative to a long arm splint. The splint and sutures are removed at 10 to 14 days, and a further long arm cast is applied in the same position as noted previously. The cast is removed 4 weeks postoperatively and a short arm splint is applied to hold the wrist, fingers, and thumb in extension. This should be worn for 2 weeks, though is removed intermittently for exercise.

A planned exercise program, begun at week 4, under the guidance of an experienced hand therapist, is very beneficial. A well-motivated patient should have good control of function by 3 months, although many patients need 6 months to reach maximum recovery.

Potential Problems

Excessive radial deviation after FCU harvest. Removing the FCU (an important wrist flexor and the only remaining ulnar deviator) from the wrist may contribute to radial deviation of the hand. This condition is likely to be aggravated further if the PT is inserted into the ECRL, which is a strong radial deviator. Even if the transfer is into the more centrally located ECRB, there may be some radial deviation due to the insertion of this tendon or intercommunication between it and the ECRL.[5] Radial deviation is particularly severe in patients with posterior interosseous nerve palsy who have a normally functioning, strong ECRL; removal of the FCU of these patients can seriously aggravate the radial deviation problem. Several solutions to the problem have been suggested.

Avoidance. Green considered significant preoperative radial deviation or a patient with posterior interosseous nerve palsy to be a contraindication to FCU transfer.

Alter the insertion. If the FCU transfer must be used, it is possible to reduce the tendency to radial deviation by altering the insertions of the radial wrist extensors at the time of PT transfer. Such surgery increases the complexity of the procedure, increases the number of tendon junctures, and carries the risk of increased morbidity and failure, especially when performed only occasionally. The "simplest" way to do this is to resect the distal 2 to 3 cm of the ECRL tendon and suture the tendon more proximally into the adjacent ECRB, eliminating any possibility of pull through the ECRL insertion.

A more radical approach is to transfer the distal end of the ECRB into the tendon of the ECU or to cut the ECU at its musculotendinous junction, transpose the proximal end across the forearm, and include it in the PT-to-ECRB transfer.[167] Brand did not favor this approach because the ECU has a very small moment for extension, and such an altered insertion would limit the total extension moment of the PT.[28] He preferred to

CRITICAL POINTS *Tendon Transfers*

PT to ECRB

- Take a strip of periosteum from the radius in continuity with the PT insertion to lengthen the transfer.
- Free up the muscle proximally to gain maximum excursion.
- Pass the tendon around the radial border of the forearm superficial to the BR and ECRL.
- Suture only into the ECRB—do not include the ECRL—just distal to the musculotendinous junction.
- Tension:
  - Wrist in 45 degrees of extension
  - PT under maximum tension
  - If necessary, reinforce juncture with a strip of free tendon graft

FCU to EDC

- Do not use FCU for tendon transfer in posterior interosseous nerve palsy.
- The FCU must be freed up extensively, requiring a long incision.
- Generously excise muscle from the distal half of the tendon to reduce bulk.
- Free up the muscle sufficiently to allow it to be redirected obliquely across the forearm.
- Protect the muscle's innervation in the proximal muscle belly.
- Create a straight line of pull from the medial epicondyle to the EDC.
- Tendon juncture: weave the FCU through the EDC tendons at a 45-degree angle well proximal to the dorsal retinaculum.
- Include the EDM only if there is a lag in extension of the small finger.
- Tension:
  - Wrist in neutral (0 degrees)
  - MP joints in neutral (0 degrees)
  - FCU under maximum tension

PL to Rerouted EPL

- Transect the EPL at its musculotendinous junction.
- The EPL tendon is rerouted to pass along the radial border of the thumb metacarpal.
- The tendon juncture of PL to EPL is in the snuffbox superficial to the dorsal retinaculum in line with the thumb metacarpal.
- Tension:
  - Wrist in neutral (0 degrees)
  - Maximum tension on distal stump of EPL
  - PL under maximum tension

attach the PT to the ECRL and ECRB together proximally and then detach the insertion of ECRL and reinsert it into the base of the fourth metacarpal. Tubiana and colleagues also preferred to centralize the insertion of the ECRL.[196] In addition to the different moment arms of ECRL and ECRB for wrist extension and radial deviation, they were also concerned about adhesions between the two tendons. They sutured the PT to the ECRB only, but also rerouted the insertion of the ECRL. The ECRL tendon is divided at its insertion into the base of the second metacarpal, freed up proximally to its musculotendinous junction, rerouted beneath the dorsal retinaculum in the fourth (EDC) compartment, and fixed to the base of the third and fourth metacarpals with sutures and staples.

Absence of the palmaris longus. In this situation, several authors have suggested including the EPL into the FCU-to-EDC transfer, although this approach significantly limits thumb abduction. Bevin suggested including all of the thumb extrinsics (i.e., EPL, EPB, and APL) in the FCU-to-EDC transfer that seriously violates the "one tendon–one function" principle.[16] However, patients with a similar transfer retained some independent thumb and finger function, such that they could actively flex their finger MP joints while holding the thumb in extension and radial abduction.[4] This apparent example of independent dual actions of a transfer may be due to greater tension in the contracting FDP and finger intrinsic muscles than in the relaxed FPL tendon altering the line of pull of the transfer.

Milford advocated the use of the BR, which is possible only in posterior interosseous nerve palsy.[61] If the BR is used, its muscle belly must be extensively freed up to augment its excursion. Beasley commented that the BR is difficult to reeducate during the rehabilitation program.[14] Tsuge and Adachi substituted the FDS III or IV for an absent PL.[194]

Superficialis Transfer (Boyes). A long incision is made on the palmar-radial aspect of the mid-forearm, and the tendons of the PT, ECRL, and ECRB are exposed using the procedure described by Boyes.[21,50] The pronator teres is harvested and transferred to the ECRB as just discussed. The superficialis (sublimis) tendons of the long and ring fingers are exposed through a transverse incision in the distal palm or through separate transverse incisions at the base of each finger. The tendons are divided proximal to the chiasma, freed up, and delivered into the forearm wound. Just proximal to the pronator quadratus, two 1 cm × 2 cm windows are created in the interosseous membrane, one on each side of the anterior interosseous artery. Care should be taken to protect the anterior and posterior interosseous vessels.

Numerous authors, including Adams et al and Beasley,[2,14] recommend that the muscle bellies of the transferred muscles be passed through the interosseous space to minimize adhesions; this may necessitate larger openings in the interosseous membrane. Others prefer to route the superficialis tendons around the radial and ulnar borders of the forearm in an effort to avoid tendon adherence, although ulnar nerve compression can occur when the FDS is transferred ulnarly.[193] Passing the transfer deep into the ulnar bundle and immediately superficial to the periosteum of the ulna avoids this complication.

A J-shaped incision is made on the dorsum of the distal forearm: The transverse limb runs from the radial styloid to the ulnar styloid, and the longitudinal limb extends proximally along the ulna. The FDS III is routed between the FDP and FPL, and the FDS IV is routed to the ulnar side of the profundus muscle mass and both are then passed through the openings in the interosseous membrane into the dorsum of the forearm. Care must be taken to avoid a band of fascia on the superficialis muscle belly and kinking of the median nerve. The FDS III is interwoven into the tendons of the EIP and EPL, and the FDS IV is interwoven into the EDC. The EDM is not included, and the recipient tendons are not divided proximal to the tendon juncture. The suture lines are placed proximal to the dorsal retinaculum, which should be excised over the proximal parts of the third and fourth compartments if there is danger of impingement by the tendon junctures.

The tension is set with an assistant clenching the patient's fingers and thumb into a fist and bringing the wrist into 20 degrees of extension. This position is maintained until all the transferred tendons are attached to their new insertions under "considerable tension."[156]

Finally, the FCR tendon is exposed through a transverse incision at the base of the thumb then divided and freed up sufficiently to allow it pass in a straight line to APL where it is woven into, and sutured to, the multiple slips of this tendon. The original description of Boyes included insertion into the EPB, but this contravenes the "one tendon–one function" rule.

It is important to deflate the tourniquet before wound closure because of possible damage to the interosseous vessels and potential serious bleeding.[142]

CRITICAL POINTS *FDS to EDC and EPL*

- Divide the FDS tendons into III and IV in the distal palm proximal to the chiasma.
- To minimize adhesions in passing through the interosseous membrane, excise a large opening in the interosseous membrane and pass the muscle bellies through.
- Tension:
  - Wrist in 20 degrees of extension
  - Fingers and thumb held in a fist by an assistant
  - FDS under maximum tension

Postoperative Management. Postoperative splints are applied and worn for 4 weeks, at which time the sutures are removed and a splint is worn day and night, except during exercise periods, for a further 2 weeks. All external support is discontinued at 6 weeks postoperatively. The exercise program should emphasize specific control of the superficialis muscles to try to take advantage of the greater excursion of these tendons. It should not use the tenodesis techniques that are useful after synergistic (i.e., FCU and FCR) transfers.

Flexor Carpi Radialis Transfer (Brand, Tsuge). A straight longitudinal incision is made in the distal half of the palmar-radial aspect of the forearm between the FCR and PL. The PT-to-ECRB transfer, when required, is performed as for the other transfers. Both tendons are identified, transected near their insertions, and freed up to the middle of the forearm to allow redirection to their new insertions. A second longitudinal incision is made on the dorsum, extending from just distal to the dorsal retinaculum to the mid-forearm.

The FCR is passed around the radial border of the forearm through a subcutaneous tunnel, which is created with a blunt-nosed instrument that probes natural tissue planes to find the path of least resistance.[27] The juncture between the FCR and EDC can be made by leaving the EDC in continuity (as for FCU shown earlier in Figure 31.39), but Brand recommended division of the EDC tendons to allow an end-to-end juncture (Figure 31.42). Brand suggested burying each cut tendon end to avoid multiple exposed raw tendon ends.[28] The finger extensor tendons all are tested for extension of the MP joint, and "four good tendons are chosen."[28] These are divided at their musculotendinous junctions; withdrawn distally, superficial to the intact dorsal retinaculum; and redirected to a point over the distal radius, where they can meet the FCR tendon in a straight line.

A preliminary suture between the EDC tendons before sectioning, inserted with the four tendons lying along the line of pull of the transfer, is helpful to maintain equal tension within them and thus ensure that all the fingers extend in unison.

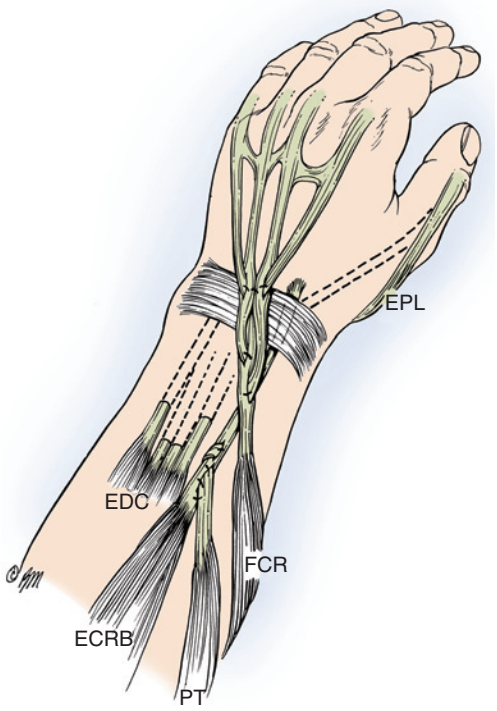

FIGURE 31.42 Flexor carpi radialis (FCR)-to-extensor digitorum communis (EDC) transfer. Brand[28] suggested that EDC tendons be transected and transposed superficial to dorsal retinaculum to create a straight-line, end-to-end juncture with the FCR. *ECRB,* Extensor carpi radialis brevis; *EPL,* extensor pollicis longus; *PT,* palliative tendon. (Adapted from Brand PW: Tendon transfers in the forearm. In Flynn JE, editor: *Hand surgery*, ed 2, Baltimore, 1975, Williams & Wilkins, pp 189–200, with permission. Redrawn by Elizabeth Martin.)

Brand left the two best tendons long to join the FCR, suturing the other two to their neighbors more distally. The two slips of the EDC are then passed into slits in the FCR and their ends are buried in a further slit (see Figure 31.42). The tension is again checked before suture of the juncture and cutting and burying the two EDC tendon stumps. This author recommends suturing the tendons with the wrist and MP joints in neutral and the FCR tendon under maximum tension. Tsuge and Adachi modified the FCR transfer by passing it through the interosseous membrane to obtain a straighter line of pull.[194] The PL to rerouted EPL transfer is performed as described earlier. If the PL is absent, the EPL is joined with the FCR-to-EDC transfer.[28]

CRITICAL POINTS *FCR-to-EDC Transfer*

- Divide the FCR near its insertion and pass it subcutaneously around the radial border of forearm.
- Divide the EDC tendons just proximal to the retinaculum, and reposition the stumps superficial to the retinaculum.
- Tension:
  - Wrist in neutral (0 degrees)
  - MP joints in neutral (0 degrees)
  - FCR under maximum tension

Single-Tendon Transfer. Gousheh and Aratesh described an isolated transfer of the FCU for radial nerve palsy to the EDC, EIP, and EPL, without an additional PL-to-ECRB transfer as a

simple alternative to multiple tendon transfers in 108 patients with radial nerve palsy.[73] The authors cited the simplicity of the procedure, reduced operating time, and quite adequate hand function despite incomplete restoration of wrist extension.

Outcome of Radial Transfers. A retrospective assessment of 22 isolated radial nerve transfers at a mean follow-up of 6.3 years demonstrated that the majority of patients were capable of working, though 6 of 7 were unable to resume their previous intense manual employment.[177] Weakness of power grip and wrist strength were noted, but it was felt that 21 of the 22 had achieved improved function. Altintas et al assessed 77 patients 60 months after transfers using the FCR muscle to restore finger extension in 19 cases and the FCU muscle in 56 cases[6]; 73% of contralateral side wrist extension and 32% of contralateral digital extension were regained. Power grip was reduced to 49% and pinch grip was reduced to 28%. The mean DASH score was 15 ± 9, indicating good function, and 89% of patients remained employed.

Moussavi et al compared the use of FCR, FCU, or FDS III + IV for restoration of finger extension in 41 Iranian patients with isolated radial nerve palsies.[122] They found no difference in the outcomes of these three procedures, except that all three of patients who were able to extend their fingers and wrist at the same time had undergone FDS transfers. They reported mean DASH scores of 30 to 38 for the three treatment groups and that 30 of their 41 patients were able to return to work without difficulty.

Dabas et al assessed the objective outcomes of 10 patients who underwent an early transfer of pronator teres to ECRB as treatment of a high radial nerve palsy.[55] At 6-month follow-up there were median increases of 48% in power grip, 162% in tip pinch, 90% in key pinch, and 98% in palmar pinch from the preoperative values; however, decreased palmar flexion was seen in four patients. There was one unsatisfactory result. The authors advised early tendon transfer to quickly improve hand function and avoid the need for splintage while awaiting reinnervation of wrist extensors.

❖ AUTHOR'S PREFERRED METHOD OF TREATMENT

I very much recommend tendon transfers for patients with no prospect of recovery of radial nerve function because I believe this surgery markedly improves hand function in most instances, predominantly by restoring strong active wrist extension. I explain the need for 6-week splintage of the arm but advise that hand function is very much improved in most cases within 12 weeks of surgery. I also advise tendon transfers for patients with posterior interosseous nerve palsies with no prospect of recovery, provided they feel the loss of function due to loss of thumb and finger extension warrants surgery; a 6-week period of splintage of the forearm, wrist, and hand; and a 12-week recovery period. In my experience most, but not all, decide on surgery, although the elderly with a posterior interosseous palsy due to a deep giant lipoma frequently decline.

My favored transfers for restoration of function in radial palsy are PT-to-ECRB, FCR-to-EDC, and PL-to-EPL. I use FCR-to-EDC and PL-to-EPL for posterior interosseous nerve palsies. For both I use a single longitudinal incision on the radial border of the forearm (Figure 31.43). This allows exposure of both the flexor and extensor compartments of the forearm, harvest of the three donors, and creation of all three junctures. I believe the PT-to-ECRB transfer is the most critical because restoration of wrist extension alone dramatically improves hand function. Some of my patients with longstanding posterior interosseous nerve palsies, who all have retained wrist extension, do not consider the loss of finger and thumb extension a sufficient problem to justify the risks and inconvenience of tendon transfer surgery to restore these functions.

In contrast, my experience is that all patients with a radial nerve palsy wish to undergo transfers in the hope (and expectation) of improved hand function. I almost always create an end-to-side PT–ECRB juncture, in case of a late recovery of radial nerve function, and agree with Green that there is often "not quite enough" PT tendon to weave into the ECRB, even if the tendon is elongated with periosteum (which I always do). I thus also have no hesitation about reinforcing this juncture with a tendon graft (i.e., a thin strip of ECRL) which is weaved into the PT and ECRB tendons on either side of the juncture.

I used to find setting the correct tension in all four EDC tendons difficult, but now use a technique that overcomes this problem. I pass a sling around the tendons but not the EIP or EDM. My assistant then pulls powerfully on the sling to draw the distal portions of the four tendons directly into the line of the planned FCR–EDC transfer. This should fully extend all four finger MP joints. My assistant then holds this position while I pass a sturdy vicryl tie around all four EDC tendons, just distal to the sling, and tie it as tightly as possible; this entraps the four tendons and prevents further relative movement of one against the other. I then use a robust vicryl suture to firmly tie the four EDC tendons together, distal to the "cerclage tie." Having done this I perform an end-to-side transfer and weave the FCR into the EDC mass with the fingers extended and the wrist in 30 degrees extension.

Alternatively, after insertion of the vicryl sutures to join the EDC tendons, one can divide them just distal to the circlage tie and then create an end-to-end juncture. I realize that this technique may appear unsophisticated, but it works in my hands, possibly because this transfer to restore finger extension is predominantly driven by the tenodesis effect of the wrist, such that soft tissue adhesions proximal to the wrist do not impede its function.

PL is harvested through the same incision and the EPL is readily mobilized and released from the third extensor compartment. I join the two, end-to-side, with a Pulvertaft weave, although others prefer an end-to-end juncture created by simply spiraling these two thin tendons around each other and then suturing them together with three or four "in-and-out" sutures. I use a direct line of pull with no pulley. I have contemplated using the ulna as a pulley to pass the PL subcutaneously around the forearm's ulnar border to re-create the normal line of pull of the EPL. This can be done through the single radial border incision described earlier.

If there is no prospect of recovery of radial nerve function, the EPB and APL tendons can be divided and removed from the first extensor compartment then used as a pulley for this transfer. The proximally divided EPL is passed through it and then joined to the PL. Absence of PL is frustrating, so I either incorporate EPL into the FCR–EDC juncture or do not reconstruct EPL function because many patients manage satisfactorily with only passive extension of the thumb. My policy may be borne out of ignorance, but I wonder if transfer of the ring

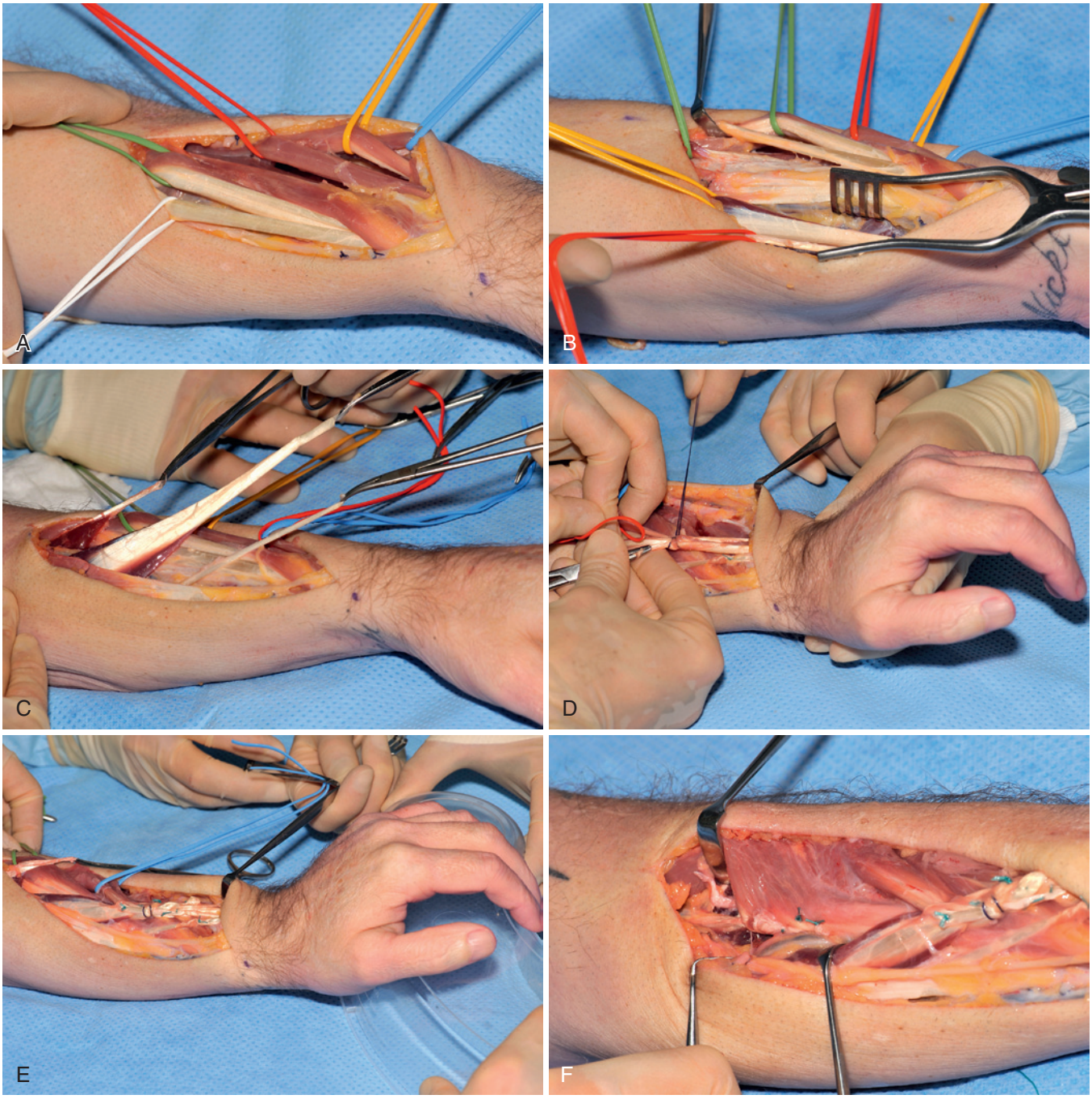

FIGURE 31.43 This author's preferred approach and technique of tendon transfer for radial nerve palsy. **A,** The procedure is performed through a single longitudinal incision on the radial aspect of the forearm. The recipient tendons—extensor carpi radialis brevis (ECRB; green sling), extensor pollicis longus (EPL; red sling), extensor digitorum communis (EDC; yellow sling), and extensor digitorum minimi (EDM; blue sling)—are identified on the extensor compartment of the forearm; the extensor carpi radialis longus is within the white sling. Distally muscle is trimmed away to expose the EPL, EDC, and EDM tendons on all aspects at the level of the proposed junctures. This facilitates sturdy tendon-to-tendon junctures. **B,** The donor tendons—palmaris longus (PL; green sling), flexor carpi radialis (FCR; yellow sling), and PL (red sling)—are identified on the flexor compartment of the forearm. **C,** The donor tendons are divided as far distally as possible (PL and FCR at the wrist). The palliative tendon (PT) has a long insertion that runs obliquely around the radius and gradually thins and "mutates" from tough tendon proximally to thin and weak periosteum distally. I scrape this off the radius with a scalpel blade until "normal" periosteum is reached distally. The three donor muscles are then mobilized proximally to allow redirection and a straight line of pull from the medial epicondyle to the recipient tendon. **D,** After an end-to-side, PL-to-extensor pollicis longus juncture has been completed (Pulvertaft weave with 2-0 vicryl), the EDC and EDM tendons are gathered together and pulled tight in the line of pull of the transferred FCR so that all the finger metacarpophalangeal joints are extended. A strong 0-vicryl tie is then passed around them and tied firmly, fixing the tendons together at the correct lengths. **E,** The EDC and EDM tendons are then sutured together with further 2-0 vicryl sutures to create "one extensor" tendon, and the FCR is joined end-to-side with a Pulvertaft weave. **F,** PT is joined to ECRB, again end-to-side using a Pulvertaft weave with 2-0 vicryl.

Continued

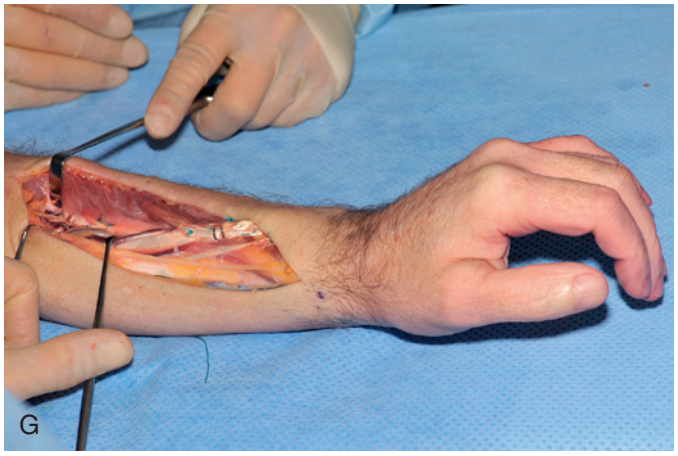

FIGURE 31.43, cont'd G, The transfers are complete. Note the resting position of the wrist, thumb, and fingers. Also note all the transfers pass deep into the brachioradialis tendon and radial nerve (both seen just above the flexor surface of the skin incision in all figures). I intentionally apply too much tension because my transfers always end up looser than anticipated. In addition, the procedure is much easier if plentiful assistants' hands are available.

finger FDS tendon to EPL produces an overall gain in function to the patient.

I have very little experience with use of the FCU–EDC transfer, which in my view has no obvious benefit, practical or theoretical, over the FCR–EDC transfer. I also have only rarely used the Boyes FDS–EDC/EPL transfers. Even though aware of its theoretical benefits (i.e., may allow combined active wrist and finger extension), most patients are satisfied with the outcome of FCR–EDC transfers. I wonder whether, though unproven, FDS harvest may reduce hand strength and dexterity, and whether this would outweigh any benefit from improved finger extension.

Radial Nerve Palsy Associated With Fractures of the Humerus

The most common radial nerve palsy encountered by most hand surgeons occurs after fracture of the shaft of the humerus. About 12% of these fractures are complicated by radial nerve injury,[176] and there is at least one published article supporting virtually any plan of management, but common sense must prevail and patient preference be considered.

There are basically three ways in which radial nerve palsy seen with a humeral shaft fracture can be managed, as described in the following subsections.

Early Exploration of the Nerve

Historically, some authors have advocated that all radial nerve injuries associated with humeral shaft fractures should be treated with early exploration. The perceived benefits are listed next:

1. Assessment of the nerve (intact, contused, entrapped in the fracture site, impaled on a fragment, or lacerated) with early treatment, when necessary, and provision of a prognosis and likely requirement of tendon transfers.
2. Stabilization of the fracture by internal fixation may protect the radial nerve from further damage.
3. Early operation is technically easier and safer.

The main issue with this strategy is whether early exploration will identify a significant number of patients with a "surgically correctable" lesion of the radial nerve.

When considering the reported rates of radial nerve damage, one must reflect on the source of the clinical material. Studies that have advocated early exploration often have based their conclusions on a series of patients treated in referral centers where the percentage of complicated problems and failures from other treatment facilities is unusually high. Conversely, studies from major trauma centers, where a consecutive series of patients with humeral shaft fractures complicated by radial nerve palsy are studied, find that most regain radial nerve function and agree that nonoperative management is the treatment of choice.[17,19,150,175]

Foster and coworkers found nerve laceration or entrapment in 9 of 14 open humeral shaft fractures they treated operatively.[64] However, Kettelkamp and Alexander found *no* surgically correctable lesions in any of the 16 radial nerves they explored.[92] In addition, Sonneveld and colleagues explored 14 cases and found only one "injured" (i.e., contused and not divided) nerve,[181] and Dabezies and coworkers encountered only one lacerated nerve in 15 patients.[56] No nerves were entrapped, and all intact nerves recovered.

The proximal spike of the Holstein-Lewis spiral fracture of the distal humerus may injure the radial nerve as it occurs within the area where the nerve is closely apposed to the bone and tethered by the lateral intermuscular septum.[78] Holstein and Lewis advised early operative intervention for patients with this fracture and an accompanying radial nerve palsy[78]; however, others have reported that early operative treatment is unnecessary, including Szalay and Rockwood.[188] They studied 15 patients with this combination of injuries and all 11 who were treated without exploration attained complete nerve recovery. The nerve was found to be in continuity in the 4 patients in whom exploration was carried out, and all regained normal radial nerve function.[188]

It used to be believed that a secondary radial nerve palsy (not present initially and present after fracture reduction) was an absolute indication for immediate nerve exploration. However, there is convincing evidence today that secondary radial nerve paralysis can be treated nonoperatively with a good expectation for full recovery in most cases.[19,175]

Nerve Exploration for Failure to Improve Spontaneously

Exploration of the radial nerve at 6 to 8 weeks after onset, if there is no evidence of recovery, had been advocated in the past, but Mast et al reported that less than half of the nerves that recovered spontaneously did so in less than 12 weeks.[113] Amillo and associates recommended surgical exploration at 3 months if there was no clinical or electrophysiologic signs of nerve recovery.[7] However, it is well documented that the initial signs of motor recovery may not appear until 4 or 5 months after a radial nerve palsy associated with a fractured humerus.

The work of Seddon regarding nerve regeneration after axonotmesis suggests nerve-fiber regeneration occurs at the rate of approximately 1 mm/day following a latent period of 30 days.[173] On this basis the maximum length of time that may be required for the first signs of motor recovery to occur can be estimated by measuring the distance on the radiograph from the fracture site to the point of innervation of the BR muscle,

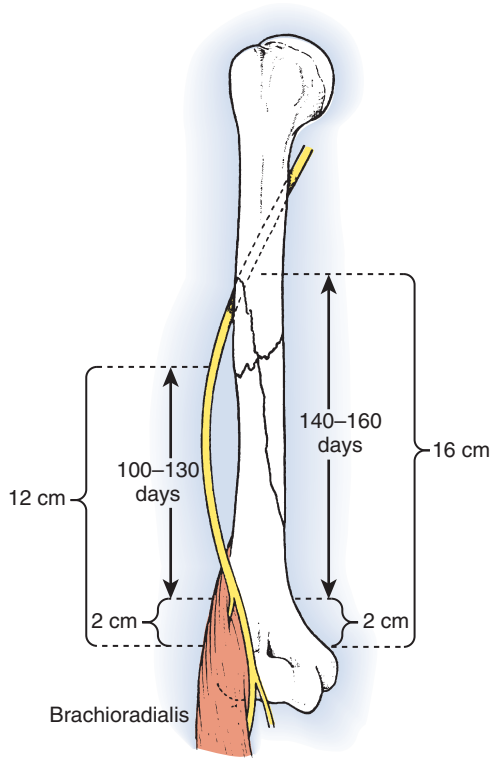

FIGURE 31.44 Calculation of time that must elapse before signs of recovery can be expected after fractures of the shaft of the humerus that cause axonotmesis of the radial nerve. The information on the left is for a transverse fracture, and the information on the right is for an oblique fracture. (From Seddon H: *Surgical disorders of the peripheral nerves*, ed 2, Edinburgh, 1975, Churchill Livingstone, with permission.)

which is approximately 2 cm above the lateral epicondyle. In most midshaft humerus fractures, this distance is 90 to 120 mm (Figure 31.44), indicating regeneration times of between 17 and 21 weeks.

Evidence of reinnervation on electromyography may precede the clinical appearance of motor function by approximately 4 weeks.[151] Therefore, if the decision is to treat the fracture nonoperatively, it is logical to wait 4 to 5 months before proceeding with exploration if there is no return of nerve function. The major advantages of this plan of management are: (1) unnecessary operative intervention is avoided in most patients, (2) most of these patients achieve full recovery of the radial nerve without surgical treatment, and (3) the humerus fracture usually heals.

A question that must be raised is whether the delay in nerve repair for the very few patients in whom neurorrhaphy becomes necessary is excessive and reduces the chance for good functional recovery. Historically, delays of 12 months or longer were not considered likely to jeopardize functional motor return after nerve repair, but this view has been challenged recently.

In the past most humeral shaft fractures were treated nonoperatively, but operative fixation is preferred now for a significant number of these injuries. It the surgeon feels that the fracture characteristics make operative fixation preferable, then the nonfunctioning radial nerve should be explored at the same time. In addition, there is currently the dilemma on how to manage a radial nerve palsy, which develops after operative fixation of a shaft's fracture of the humerus, using an operative field that puts the radial nerve at risk of damage from a retractor, scalpel blade, power drill, tap, or plate. The decision here will depend on many factors, including (1) the expertise of the surgeon who performed the fracture fixation, (2) the operation notes, (3) recollections (if any) of the condition of the radial nerve at the end of the surgery, (4) whether the radial nerve was seen during the procedure, and (5) patient preference for expectant treatment or reoperation.

A recent systematic review reported the overall prevalence of radial nerve palsy as a complication of fractures of the shaft of the humerus to be 12%.[176] Of the patients initially treated, 88% of 581, of which 149 underwent an exploration at least 8 weeks after injury, recovered. Of those treated with early exploration, 85% recovered. The time until onset of recovery ranged from 2 to 28 weeks (mean recovery time = 7 weeks), and the recovery rates were similar for primary and secondary (i.e., after reduction of fracture) palsies.

Overall, 397 radial nerves were explored at some time after fracture. The nerve was intact or contused in 46%, trapped within the fracture in 13%, and divided in 23%. It is obvious that the rate of nerve division does not represent the overall division rate because many of the injuries had been treated expectantly initially, and those explored later represented the subset in which the radial nerve had not recovered. Those who recovered spontaneously with expectant treatment are excluded and by definition had an intact nerve.

❖ AUTHOR'S PREFERRED METHOD OF TREATMENT

My policy is to advise expectant treatment to most patients with radial nerve palsy associated with humeral shaft fractures that have been managed nonoperatively. I only consider exploration of the nerve after a realistic waiting period, estimated on the basis of Seddon's work (see Figure 31.44). If, however, the fracture requires plate fixation, the radial nerve should be identified and examined during the procedure. My biggest dilemma is the patient who presents with a radial nerve palsy after plate fixation of the humerus. In this scenario I review the operation notes to see whether the radial nerve was identified and protected throughout the procedure and also discuss the procedure with the surgeon who fixed the fracture.

This helps a surgeon estimate the likelihood of the nerve being intact and capable of spontaneous recovery with axonotmesis, or divided/crushed (by a plate) with no prospect of recovery. I then discuss the options of immediate reexploration, or expectant treatment for at least 12 weeks, with the patient and together we devise an agreed-on treatment plan that suits the patient's circumstances and psyche and reflects his or her preferences.

I agree with David Green that it is illogical to explore the radial nerve at 6 to 12 weeks. If the decision has been made to await spontaneous recovery of function, then sufficient time must be allowed and <12 weeks is insufficient.

Nerve Transfer as an Alternative to Tendon Transfer

Direct transfer of functioning, intact nerves to denervated muscles (neurotization) is used to restore function in patients with brachial plexus palsy when no other option is available. The same concept has been reported in a few cases to restore wrist, finger, and thumb extension in radial nerve palsy[107]; forearm pronation after median nerve palsy[79]; and finger intrinsic

muscle function after high ulnar nerve palsy.[131] The technique is based on one of the principles of tendon transfer: that the loss of the normal function of the muscle(s) used for harvest of the donor nerve(s) is not critical, and that its loss can be accommodated by other functioning musculotendinous units. Neurotization is not an option if: (1) the paralyzed musculotendinous unit with a function that is to be restored was damaged in the injury that caused the nerve palsy; (2) the musculotendinous unit is tethered by scar tissue; and (3) a prolonged time interval between nerve injury and neurotization has resulted in the inability of the recipient muscle to function after reinnervation.[197] The potential benefits of neurotization over tendon transfers are that it avoids the needs for prolonged splintage to protect transfers or multiple skin scars to fashion the musculotendinous transfers. However, the recovery of function is protracted in comparison to tendon transfer.

Restoration of Radial Nerve Function

Restoration of function is achieved by exposing: (1) the median nerve and its branches for FDS and FCR/PL; (2) the radial nerve and its branch to the ECRB and; (3) the posterior interosseous nerve. The FDS branch is neurotized to the nerve to ECRB, and the FCR/PL branch to the posterior interosseous nerve.[107]

Technique. Through a single volar-radial incision in the proximal forearm, the radial nerve, the posterior interosseous nerve, and the median nerve are exposed. The "donor" median nerve branches to the FDS, FCR, and PL visually and is confirmed with a nerve stimulator. The "recipient" radial nerve branch to the ECRB, and the posterior interosseous nerve, are also identified. The donor nerves are transected as distally as possible and the recipient nerves are transected as close to their muscle insertions as feasible, while allowing tension-free coaptation.

Outcome. Restoration of virtual full extension of the wrist and fingers with grade 4 power was reported in a single case, with the first evidence of reinnervation occurring at 6 months.[107] Restoration of median nerve extrinsic muscle function can be achieved by neurotization of: (1) the branches of the radial nerve to ECRB to the branch of the median nerve to pronator teres, and (2) the branch of the radial nerve to supinator to the anterior interosseous nerve. Reinnervation of PT commenced after 4 months and FPL and index FDP at 8 months. After 18 months, grade 4 strength was achieved.[79]

REFERENCES

1. Abrams RA, Ziets RJ, Lieber RL, et al: Anatomy of the radial nerve motor branches in the forearm. *J Hand Surg [Am]* 22:232–237, 1997.
2. Adams J, Wood VE: Tendon transfers for irreparable nerve damage in the hand. *Orthop Clin North Am* 12:403–432, 1981.
3. Aguirre SC, Caplan S: Sobre secuelas de lesion alta e irreparable de nervios mediano y cubital, y su tratamiento. *La Prensa Medica Argentina* 43:2341–2346, 1956.
4. Al-Qattan MM: Tendon transfer for radial nerve palsy: a single tendon to restore finger extension as well as thumb extension/radial abduction. *J Hand Surg Eur Vol* 37:855–862, 2012.
5. Albright JA, Linburg RM: Common variations of the radial writs extensors. *J Hand Surg [Am]* 3:134–138, 1978.
6. Altintas AA, et al: Long-term results and the disabilities of the arm, shoulder, and hand score analysis after modified Brooks and D'Aubigne tendon transfer for radial nerve palsy. *J Hand Surg [Am]* 34:474–478, 2009.
7. Amillo S, Barrios RH, Martinez-Peric R, et al: Surgical treatment of the radial nerve lesions associated with fractures of the humerus. *J Orthop Trauma* 7:211–215, 1993.
8. Anderson GA: Ulnar nerve palsy. In Green D, et al, editors: *Green's operative hand surgery*, 2005, Elsevier, pp 1161–1196.
9. Anderson GA, Lee V, Sundararaj GD: Extensor indicis proprius opponensplasty. *J Hand Surg [Br]* 16B:334–338, 1991.
10. Anderson GA, Lee V, Sundararaj GD: Opponensplasty by extensor indicis and flexor digitorum superficialis tendon transfer. *J Hand Surg [Br]* 17B:611–614, 1992.
11. Baek GH, Jung JM, Yoo WJ, et al: Transfer of extensor carpi radialis longus or brevis for opponensplasty. *J Hand Surg [Br]* 24:50–53, 1999.
12. Baluch N, Borschel GH: Use of adjunctive palmaris longus abductorplasty (Camitz) tendon transfer in pediatric median nerve injury. *J Plast Reconstr Aesthet Surg* 66:726–728, 2013.
13. Beasley RW: Principles of tendon transfer. *Orthop Clin North Am* 1:433–438, 1970.
14. Beasley RW: Tendon transfers for radial nerve palsy. *Orthop Clin North Am* 1:439–445, 1970.
15. Bertelli JA, Ghizoni MF: Very distal sensory nerve transfers in high median nerve lesions. *J Hand Surg [Am]* 36:387–393, 2011.
16. Bevin AG: Early tendon transfer for radial nerve transection. *Hand* 8:134–136, 1976.
17. Bleeker WA, Nijsten MW, ten Duis HJ: Treatment of humeral shaft fractures related to associated injuries. A retrospective study of 237 patients. *Acta Orthop Scand* 62:148–153, 1991.
18. Bohr HH: Tendon transposition in paralysis of the opposition of the thumb. *Acta Chir Scand* 105:45–54, 1953.
19. Bostman O, et al: Radial palsy in shaft fracture of the humerus. *Acta Orthop Scand* 57:316–319, 1986.
20. Boswick JA, Stromberg WB: Isolated injury to the median nerve above the elbow. *J Bone Joint Surg Am* 49A:653–658, 1967.
21. Boyes J: Tendon transfers for radial palsy. *Bull Hosp Jt Dis* 21:97–105, 1960.
22. Boyes JH: Selection of a donor muscle for tendon transfer. *Bull Hosp Jt Dis* 23:1–4, 1962.
23. Boyes JH: *Bunnell's surgery of the hand*, Philadelpia and Montreal, 1964, J.B. Lippincott.
24. Brand P: Tendon grafting: Illustrated by a new operation for intrinsic paralysis of the fingers. *J Bone Joint Surg Br* 43:444–453, 1961.
25. Brand PW: Paralytic claw hand; with special reference to paralysis in leprosy and treatment by the sublimis transfer of Stiles and Bunnell. *J Bone Joint Surg Br* 40-B:618–632, 1958.
26. Brand PW: Tendon transfers for median and ulnar nerve paralysis. *Orthop Clin North Am* 1:447–454, 1970.
27. Brand PW: Biomechanics of tendon transfer. *Orthop Clin North Am* 5:205–230, 1974.
28. Brand PW: Tendon transfers in the forearm. In JE F, editor: *Hand surgery*, Baltimore, 1975, Williams & Wilkins, pp 189–200.
29. Brand PW: *Clinical mechanics of the hand*, St Louis, 1985, CV Mosby.
30. Brand PW: Biomechanics of tendon transfers. *Hand Clin* 4:137–154, 1988.
31. Brand PW: The pursuit of happiness. *J Hand Surg* 17A:593–597, 1992.
32. Brand PW, Beach RB, Thompson DE: Relative tension and potential excursion of muscles in the forearm and hand. *J Hand Surg* 6:209–219, 1981.
33. Brandsma JW, Brand PW: Median nerve function after tendon transfer for ulnar paralysis. *J Hand Surg [Br]* 10:30–32, 1985.
34. Brandsma JW, Ottenhoff-De Jonge MW: Flexor digitorum superficialis tendon transfer for intrinsic replacement. Long-term results and the effect on donor fingers. *J Hand Surg [Br]* 17B:625–628, 1992.
35. Braun RM: Palmaris longus tendon transfer for augmentation of the thenar musculature in low median palsy. *J Hand Surg* 3:488–491, 1978.
36. Brodman H: Tendon transfer for old radial nerve paralysis. *Arch Surg* 76:24–27, 1958.
37. Brown P: Adduction-flexion contracture of the thumb. Correction with dorsal rotation flap and release of the contracture. *Clin Orthop Relat Res* 88:161, 1972.
38. Brown P: Reconstruction for pinch in ulnar intrinsic palsy. *Orthop Clin North Am* 5:323–342, 1974.
39. Brown PW: The time factor in surgery of the upper-extremity peripheral nerve injury. *Clin Orthop Related Res* 68:14–21, 1970.
40. Brown PW: Zancolli capsulorrhaphy for ulnar claw hand. Appraisal of forty-four cases. *J Bone Joint Surg Am* 52:868–877, 1970.
41. Browne EZ, Teague MA, Snyder CC: Prevention of extensor lag after indicis proprius tendon transfer. *J Hand Surg* 4:168–172, 1979.
42. Bunnell S: Reconstructive surgery of the hand. *Surg, Gynecol Obst* 34:259–274, 1924.
43. Bunnell S: Opposition of the thumb. *J Bone Joint Surg Am* 20:269–284, 1938.
44. Bunnell S: Surgery of the intrinsic muscles of the hand other than those producing opposition of the thumb. *J Bone Joint Surg Am* 24:1–3, 1942.
45. Burkhalter W, Christensen RC, Brown P: Extensor indicis proprius opponensplasty. *J Bone Joint Surg Am* 55A:725–732, 1973.
46. Burkhalter WE: Early tendon transfer in upper extremity peripheral nerve injury. *Clini Orthop Related Res* 104:68–79, 1974.

47. Burkhalter WE, Strait JL: Metacarpophalangeal flexor replacement for intrinsic-muscle paralysis. *J Bone Joint Surg Am* 55:1667–1676, 1973.
48. Camitz H: Uber die behandlung der oppositionslahmung. *Acta Orthop Scand* 65:77–81, 1929.
49. Cawrse NH, Sammut D: A modification in technique of abductor digiti minimi (Huber) opponensplasty. *J Hand Surg [Br]* 28:233–237, 2003.
50. Chuinard RG, Boyes JH, Stark HH, et al: Tendon transfers for radial nerve palsy: use of superficialis tendons for digital extension. *J Hand Surg [Am]* 3:560–570, 1978.
51. Clifton E: Unusual innervation of the intrinsic muscles of the hand by median and ulnar nerve. *Surg* 23:12–31, 1948.
52. Cooney WP: Tendon transfer for median nerve palsy. *Hand Clin* 4:155–165, 1988.
53. Cooney WP, Linscheid RL, An KN: Opposition of the thumb: an anatomic and biomechanical study of tendon transfers. *J Hand Surg [Am]* 9A:777–786, 1984.
54. Curtis RM: Opposition of the thumb. *Orthop Clin North Am* 5:305–321, 1974.
55. Dabas V, Suri T, Surapuraju PK, et al: Functional restoration after early tendon transfer in high radial nerve paralysis. *J Hand Surg Eur Vol* 36:135–140, 2011.
56. Dabezies EJ, Banta CJ, 2nd, Murphy CP, et al: Plate fixation of the humeral shaft for acute fractures, with and without radial nerve injuries. *J Orthop Trauma* 6:10–13, 1992.
57. De Abreu LB: Early restoration of pinch grip after ulnar nerve repair and tendon transfer. *J Hand Surg [Br]* 14:309–314, 1989.
58. DeVeechi J: Opposicion del pulgar fisiopatoliga una nerva operaction transplante del abuctor. *Bol Soc Cir Uruguay* 32:423, 1961.
59. Dunlap J, Manske PR, McCarthy JA: Perfusion of the abductor digiti quinti after transfer on a neurovascular pedicle. *J Hand Surg [Am]* 14A:992–995, 1989.
60. Dunnet WJ, Housden PL, Birch R: Flexor to extensor tendon transfers in the hand. *J Hand Surg [Br]* 20:26–28, 1995.
61. Edgerton MT, Brand PW: Restoration of abduction and adduction to the unstable thumb in median and ulnar paralysis. *Plast Reconstr Surg* 36:150–164, 1965.
62. Entin MA: Restoration of function of paralyzed hand. *Surg Clin North Am* 44:1049–1059, 1964.
63. Fischer T, Nagy L, Buechler U: Restoration of pinch grip in ulnar nerve paralysis: extensor carpi radialis longus to adductor pollicis and abductor pollicis longus to first dorsal interosseus tendon transfers. *J Hand Surg [Br]* 28B:28–32, 2003.
64. Foster RJ, Swiontkowski MF, Bach AW, et al: Radial nerve palsy caused by open humeral shaft fractures. *J Hand Surg [Am]* 18:121–124, 1993.
65. Foucher G, Malizos C, Sammut D, et al: Primary palmaris longus transfer as an opponensplasty in carpal tunnel release. A series of 73 cases. *J Hand Surg [Br]* 16B:56–60, 1991.
66. Fritschi EP: Nerve involvement in leprosy; the examination of the hand; the restoration of finger function. In Fritschi EP, editor: *Reconstructive surgery in leprosy*, Bristol, 1971, John Wright & Sons, pp 11–65.
67. Gaur SC, Swarup A: Radial nerve palsy caused by injections. *J Hand Surg [Br]* 21:338–340, 1996.
68. Gelberman RH, et al: Results of treatment of severe carpal-tunnel syndrome without internal neurolysis of the median nerve. *J Bone Joint Surg Am* 69A:896–903, 1987.
69. Gerard P, Picard F, Moutet F, et al: Reanimation de l'opposition par le long extenseur du pouce. A propos de huit cas revus a 11 ans. *Annales de Chirurgie de la Main et du Membre Superieur* 13:328–333, 1994.
70. Goldner J, Clippinger F: Excision of the greater multangular bone as an adjunct to mobilization of the thumb. *J Bone Joint Surg Am* 41A:627–639, 1959.
71. Goldner JL: Tendon transfers for irreparable peripheral nerve injuries of the upper extremity. *Orthop Clin North Am* 5:343–375, 1974.
72. Goldner JL, Irwin CE: An analysis of paralytic thumb deformities. *J Bone Joint Surg Am* 32A:627–639, 1950.
73. Gousheh J, Arasteh E: Transfer of a single flexor carpi ulnaris tendon for treatment of radial nerve palsy. *J Hand Surg [Br]* 31:542–546, 2006.
74. Graham WC, Riordan D: Sublimis transplant to restore abduction of index finger. *Plast Reconstr Surg Transp Bull* 2:459–462, 1947.
75. Hastings H, 2nd, McCollam SM: Flexor digitorum superficialis lasso tendon transfer in isolated ulnar nerve palsy: a functional evaluation. *J Hand Surg [Am]* 19: 275–280, 1994.
76. Henderson ED: Transfer of wrist extensors and brachioradialis to restore opposition of the thumb. *J Bone Joint Surg Am* 44A:513–522, 1962.
77. Hirayama T, Atsuta Y, Takemitsu Y: Palmaris longus transfer for replacement of the first dorsal interosseous. *J Hand Surg [Br]* 11:84–86, 1986.
78. Holstein A, Lewis GM: Fractures of the humerus with radial-nerve paralysis. *J Bone Joint Surg Am* 45:1382–1388, 1963.
79. Hsiao EC, Fox IK, Tung TH, et al: Motor nerve transfers to restore extrinsic median nerve function: case report. *Hand (NY)* 4:92–97, 2009.
80. Huber E: Hilfsoperation bei median Uhlahmung. *Dtsch Arch Klin Med* 136:271–275, 1921.
81. Huber E: Relief operation in the case of paralysis of the median nerve. *J Hand Surg [Br]* 29B:35–37, 2004.
82. Irwin CE: Transplants to the thumb to restore function of opposition: end results. *South Med J* 35:257–262, 1942.
83. Jacobs B, Thompson TC: Opposition of the thumb and its restoration. *J Bone Joint Surg Am* 42A:1015–1026, 1960.
84. Jensen EG: Restoration of opposition of the thumb. *Hand* 10:161–167, 1978.
85. Johnson HA: Dermis graft for post-leprosy muscular wasting in the hand. *Plast Reconstr Surg Transplant Bull* 27:624–626, 1961.
86. Jones R: Ii. On suture of nerves, and alternative methods of treatment by transplantation of tendon. *Br Med J* 1:641–643, 1916.
87. Jones R: Tendon transplantation in cases of musculospiral injuries not amenable to suture. *Am J Surg* 35:333–335, 1921.
88. Kallio PK, Vastamaki M, Solonen KA: The results of secondary microsurgical repair of radial nerve in 33 patients. *J Hand Surg [Br]* 18:320–322, 1993.
89. Kaplan E, Spinner M: Normal and anomalous innervation patterns in the upper extremity. In Omer G, Spinner M, editors: *Management of peripheral nerve problems*, Philadelphia, 1980, Saunders, pp 75–99.
90. Kaplan I, Dinner M, Chait L: Use of extensor pollicis longus tendon as a distal extension for an opposition transfer. *Plas Reconstr Surg* 57:186–190, 1976.
91. Kessler I: Transfer of extensor carpi ulnaris to tendon of extensor pollicis brevis for opponensplasty. *J Bone Joint Surg Am* 51A:1303–1308, 1969.
92. Kettelkamp DB, Alexander H: Clinical review of radial nerve injury. *J Trauma* 7:424–432, 1967.
93. Kruft S, von Heimburg D, Reill P: Treatment of irreversible lesion of the radial nerve by tendon transfer: indication and long-term results of the Merle d'Aubigné procedure. *Plast Reconstr Surg* 100:610–616, discussion 617–618, 1997.
94. Labosky DA, Waggy CA: Apparent weakness of median and ulnar motors in radial nerve palsy. *J Hand Surg [Am]* 11:528–533, 1986.
95. Latimer J, Shah M, Kay S: Abductor digiti minimi transfer for the restoration of opposition in children. *J Hand Surg [Br]* 19B:653–658, 1994.
96. Leddy JP, Stark HH, Ashworth CR, et al: Capsulodesis and pulley advancement for the correction of claw-finger deformity. *J Bone Joint Surg Am* 54:1465–1471, 1972.
97. Lee DH, Oakes JE, Ferlic RJ: Tendon transfers for thumb opposition: a biomechanical study of pulley location and two insertion sites. *J Hand Surg [Am]* 28:1002–1008, 2003.
98. Lee DH, Rodriguez JA, Jr: Tendon transfers for restoring hand intrinsic muscle function: a biomechanical study. *J Hand Surg [Am]* 24:609–613, 1999.
99. Leibovic SJ, Hastings H, 2nd: Martin-Gruber revisited. *J Hand Surg [Am]* 17:47–53, 1992.
100. Lieber RL, Jacobson MD, Fazeli BM, et al: Architecture of selected muscles of the arm and forearm: anatomy and implications for tendon transfer. *J Hand Surg [Am]* 17:787–798, 1992.
101. Lieber RL, Ponten E, Burkholder TJ, et al: Sarcomere length changes after flexor carpi ulnaris to extensor digitorum communis tendon transfer. *J Hand Surg [Am]* 21:612–618, 1996.
102. Linscheid RL, William E: Burkhalter. *J Hand Surg [Am]* 17A:969–970, 1992.
103. Littler JW: Tendon transfers and arthrodeses in combined median and ulnar nerve paralysis. *J Bone Joint Surg Am* 31A:225–234, 1949.
104. Littler JW, Cooley SGE: Opposition of the thumb and its restoration by abductor digiti quinti transfer. *J Bone Joint Surg Am* 45A:1389–1484, 1963.
105. Littler JW, Li CS: Primary restoration of thumb opposition with median nerve decompression. *Plast Reconstr Surg* 39:74–75, 1967.
106. MacDougal BA: Palmaris longus opponensplasty. *Plast Reconstr Surg* 96:982–984, 1995.
107. Mackinnon SE, Roque B, Tung TH: Median to radial nerve transfer for treatment of radial nerve palsy. Case report. *J Neurosurg* 107:666–671, 2007.
108. Makin M: Translocation of the flexor pollicis longus tendon to restore opposition. *J Bone Joint Surg Br* 49B:458–461, 1967.
109. Malaviya GN: Comparative evaluation of effectiveness of different motor muscles in modified lasso procedure for correction of finger clawing. *J Hand Surg [Br]* 28:597–601, 2003.
110. Malaviya GN: Radial half of extensor carpi radialis longus tendon as graft to elongate muscle tendon unit for correction of finger clawing. *Plast Reconstr Surg* 111:1914–1917, 2003.
111. Mangus DJ: Flexor pollicis longus tendon transfer for restoration of thumb opposition. *Plast Reconstr Surg* 52:155–159, 1973.
112. Mannerfelt L: Studies on the hand in ulnar nerve paralysis. A clinical-experimental investigation in normal and anomalous innervation. *Acta Orthop Scand Suppl* 87:1, 1966.
113. Mast JW, Spiegel PG, Harvey JP, Jr, et al: Fractures of the humeral shaft: a retrospective study of 240 adult fractures. *Clin Orthop Relat Res* 254–262, 1975.
114. Mayer L: The physiological method of tendon transplantation. *Surg Gynecol Obstet* 22:182–197, 1916.
115. Mayer L: Operative reconstruction of the paralysed upper extremity. *J Bone Joint Surg* 21:377–383, 1939.

116. Mennen U: Extensor pollicis longus opposition transfer. *J Hand Surg [Am]* 17A: 809–811, 1992.
117. Michelinakis E, Vourexakis H: Tendon transfer for intrinsic-muscle paralysis of the thumb in Charcot-Marie Tooth neuropathy. *Hand* 13:276–278, 1981.
118. Mikhail IK: Bone block operation for clawhand. *Surg Gynecol Obstet* 118:1077–1079, 1964.
119. Moberg E: *The upper limb in tetraplaegia: a new approach to surgical rehabilitation,* Stuttgart, 1978, Georg Thieme Verlag.
120. Moberg E, Nachemson A: Tendon transfers for defective long extensors of the wrist and fingers. *Acta Chir Scand* 133:31–34, 1967.
121. Mohammed KD, Rothwell AG, Sinclair SW, et al: Upper-limb surgery for tetraplegia. *J Bone Joint Surg Br* 74:873–879, 1992.
122. Moussavi AA, Saied A, Karbalaeikhani A: Outcome of tendon transfer for radial nerve paralysis: Comparison of three methods. *Indian J Orthop* 45:558–562, 2011.
123. Moutet F, Frere G, Massart P: Reanimation of thumb opposition by the extensor pollicis longus. Report of sixteen cases. *Annales de Chirurgie de la Main* 5:36–41, 1986.
124. Mutz SB: Thumb web contracture. *Hand* 4:236–246, 1972.
125. Neviaser RJ, Wilson JN, Gardner MM: Abductor pollicis longus transfer for replacement of first dorsal interosseous. *J Hand Surg [Am]* 5:53–57, 1980.
126. Ney KW: A tendon transplant for intrinsic hand muscle paralysis. *Surg Gynecol Obstet* 33:342–348, 1921.
127. Nicolaysen J: Transplantation des m abductor dig V. Die Fenlander Oppositions Fehigkeit des Daumens. *Dtsch Z Chir* 168:133, 1922.
128. Nicolaysen J: Transplantation of the M. abductor dig. V. where there is no ability to oppose the thumb. *J Hand Surg [Br]* 29B:38–39, 2004.
129. Nolan WB, III, Alkaitis D, Glickel SZ, et al: Results of treatment of severe carpal tunnel syndrome. *J Hand Surg [Am]* 17A:1020–1023, 1992.
130. North ER, Littler JW: Transferring the flexor superficialis tendon: Technical considerations in the prevention of proximal interphalangeal joint disability. *J Hand Surg* 5:498–501, 1980.
131. Novak CB, Mackinnon SE: Distal anterior interosseous nerve transfer to the deep motor branch of the ulnar nerve for reconstruction of high ulnar nerve injuries. *J Reconstr Microsurg* 18:459–464, 2002.
132. Oberlin C: Zancolli's "lasso" operation in intrinsic palsy of leprous origin. A study of twenty-six cases. *Ann Chir Main* 4:22–30, 1985.
133. Oberlin C, Alnot JY: Opponensplasty through translocation of the flexor pollicis longus. Technique and indications. *Annales de Chirurgie de la Main* 7:25–31, 1988.
134. Olave E, Prates JC, Del Sol M, et al: Distribution patterns of the muscular branch of the median nerve in the thenar region. *J Anat* 186:441–446, 1995.
135. Omer GE: The technique and timing of tendon transfers. *Orthop Clin North Am* 5:243–252, 1974.
136. Omer GE: Reconstruction of a balanced thumb through tendon transfers. *Clin Orthop Related Res* 195:104–116, 1985.
137. Omer GE: Tendon transfers for combined traumatic nerve palsies of the forearm and hand. *J Hand Surg [Br]* 17B:603–610, 1992.
138. Omer GE: Combined nerve palsies. In Green D, Hotchkiss R, Pederson W, editors: *Green's operative hand surgery*, New York, 1999, Churchill Livingstone, pp 1542–1555.
139. Omer GE: Ulnar nerve palsy. In Green D, Hotchkiss R, Pederson W, editors: *Green's operative hand surgery*, New York, 1999, Churchill Livingstone, pp 1526–1541.
140. Omer GE, Jr: Evaluation and reconstruction of the forearm and hand after acute traumatic peripheral nerve injuries. *J Bone Joint Surg Am* 50:1454–1478, 1968.
141. Omer GE, Jr: Tendon transfers in combined nerve lesions. *Orthop Clin North Am* 5:377–387, 1974.
142. Omer GE, Jr: Reconstructive procedures for extremities with peripheral nerve defects. *Clin Orthop Relat Res* 80–91, 1982.
143. Orticochea M: Use of the deep bundle of the flexor pollicis brevis to restore opposition in the thumb. *Plast Reconstr Surg* 47:220–224, 1971.
144. Ozkan T, Ozer K, Gulgonen A: Restoration of sensibility in irreparable ulnar and median nerve lesions with use of sensory nerve transfer: long-term follow-up of 20 cases. *J Hand Surg [Am]* 26:44–51, 2001.
145. Ozkan T, Ozer K, Gulgonen A: Three tendon transfer methods in reconstruction of ulnar nerve palsy. *J Hand Surg [Am]* 28:35–43, 2003.
146. Palande DD: Opponensplasty in intrinsic-muscle paralysis of the thumb in leprosy. *J Bone Joint Surg Am* 57A:489–493, 1975.
147. Palande DD: Correction of intrinsic-minus hands associated with reversal of the transverse metacarpal arch. *J Bone Joint Surg Am* 65:514–521, 1983.
148. Parkes A: Paralytic claw fingers—a graft tenodesis operation. *Hand* 5:192–199, 1973.
149. Phalen GS, Miller RC: The transfer of wrist extensor muscles to restore or reinforce flexion power of the fingers and opposition of the thumb. *J Bone Joint Surg* 29:993–997, 1947.
150. Pollock FH, Drake D, Bovill EG, et al: Treatment of radial neuropathy associated with fractures of the humerus. *J Bone Joint Surg Am* 63:239–243, 1981.
151. Postacchini F, Morace GB: Fractures of the humerus associated with paralysis of the radial nerve. *Ital J Orthop Traumatol* 14:455–464, 1988.
152. Ranney DA: Reconstruction of the transverse metacarpal arch in ulnar palsy by transfer of the extensor digiti minimi. *Plast Reconstr Surg* 52:406–412, 1973.
153. Raskin KB, Wilgis EF: Flexor carpi ulnaris transfer for radial nerve palsy: functional testing of long-term results. *J Hand Surg [Am]* 20:737–742, 1995.
154. Rath S: Immediate active mobilization versus immobilization for opposition tendon transfer in the hand. *J Hand Surg [Am]* 31:754–759, 2006.
155. Rath S: Immediate postoperative active mobilization versus immobilization following tendon transfer for claw deformity correction in the hand. *J Hand Surg [Am]* 33:232–240, 2008.
156. Reid RL: Radial nerve palsy. *Hand Clin* 4:179–185, 1988.
157. Riley WB, Mann RJ, Burkhalter WE: Extensor pollicis longus opponensplasty. *J Hand Surg* 5:217–220, 1980.
158. Riordan D: Tendon transfers for median, ulnar or radial palsy. *Hand* 1:42–46, 1969.
159. Riordan DC: Tendon transplantations in median-nerve and ulnar-nerve paralysis. *J Bone Joint Surg Am* 35A:312–320, 1953.
160. Riordan DC: Tendon transfers for nerve paralysis of the hand and wrist. *Curr Pract Orthop Surg* 2:17–40, 1964.
161. Riordan DC: Radial nerve paralysis. *Orthop Clin North Am* 5:283–287, 1974.
162. Riordan DC: Tendon transfers in hand surgery. *J Hand Surg [Am]* 8:748–753, 1983.
163. Roach SS, Short WH, Werner FW, et al: Biomechanical evaluation of thumb opposition transfer insertion sites. *J Hand Surg [Am]* 26:354–361, 2001.
164. Robinson D, Aghasi MK, Halperin N: Restoration of pinch in ulnar nerve palsy by transfer of split extensor digiti minimi and extensor indicis. *J Hand Surg [Br]* 17:622–624, 1992.
165. Rowntree T: Anomalous innervation of the hand muscles. *J Bone Joint Surg Br* 31B:505–510, 1949.
166. Royle ND: An operation for paralysis of the thumb intrinsic muscles of the thumb. *JAMA* 111:612–613, 1938.
167. Said GZ: A modified tendon transference for radial nerve paralysis. *J Bone Joint Surg Br* 56:320–322, 1974.
168. Sakellarides HT: Modified pulley for opponens tendon transfer. *J Bone Joint Surg Am* 52A:178–179, 1970.
169. Samardzic M, Grujicic D, Milinkovic ZB: Radial nerve lesions associated with fractures of the humeral shaft. *Injury* 21:220–222, 1990.
170. Schneider LH: Opponensplasty using extensor digiti minimi. *J Bone Joint Surg Am* 51A:1297–1301, 1969.
171. Schwarz RJ, Brandsma JW, Giurintano DJ: A review of the biomechanics of intrinsic replacement in ulnar palsy. *J Hand Surg Eur Vol* 35:94–102, 2010.
172. Scuderi C: Tendon transplants for irreparable radial nerve paralysis. *Surg Gynecol Obstet* 88:643–651, 1949.
173. Seddon HJ: Nerve lesions complicating certain closed bone injuries. *J Am Med Assoc* 135:691–694, 1947.
174. Shah A: Correction of ulnar claw hand by a loop of flexor digitorum superficialis motor for lumbrical replacement. *J Hand Surg [Br]* 9:131–133, 1984.
175. Shah JJ, Bhatti NA: Radial nerve paralysis associated with fractures of the humerus. A review of 62 cases. *Clin Orthop Relat Res* 171–176, 1983.
176. Shao YC, Harwood P, Grotz MR, et al: Radial nerve palsy associated with fractures of the shaft of the humerus: a systematic review. *J Bone Joint Surg Br* 87:1647–1652, 2005.
177. Skoll PJ, Hudson DA, de Jager W, et al: Long-term results of tendon transfers for radial nerve palsy in patients with limited rehabilitation. *Ann Plast Surg* 45:122–126, 2000.
178. Smith RJ: Extensor carpi radialis brevis tendon transfer for thumb adduction—a study of power pinch. *J Hand Surg [Am]* 8:4–15, 1983.
179. Snow JW, Fink GH: Use of a transverse carpal ligament window for the pulley in tendon transfers for median nerve palsy. *Plast Reconstr Surg* 48:238–240, 1971.
180. Solonen KA, Bakalim GE: Restoration of pinch grip in traumatic ulnar palsy. *Hand* 8:39–44, 1976.
181. Sonneveld GJ, Patka P, van Mourik JC, et al: Treatment of fractures of the shaft of the humerus accompanied by paralysis of the radial nerve. *Injury* 18:404–406, 1987.
182. Spinner M: The radial nerve. In *Injuries to the major branches of peripheral nerves of the forearm*, Philadelphia, 1972, WB Saunders, pp 28–65.
183. Starr C: Army experiences with tendon transference. *J Bone Joint Surg Am* 4:3–21, 1922.
184. Steindler A: Flexor plasty of the thumb in thenar palsy. *Surg Gynecol Obstet* 50:1005–1007, 1930.
185. Stiles H, Forrester-Brown M: *Treatment of injuries of peripheral spinal nerves*, London, 1922, Frowde & Hodder & Stoughton.
186. Stocks GW, Cobb T, Lewis RC, Jr: Transfer of sensibility in the hand: a new method to restore sensibility in ulnar nerve palsy with use of microsurgical digital nerve translocation. *J Hand Surg [Am]* 16:219–226, 1991.
187. Sundararaj GD, Mani K: Surgical reconstruction of the hand with triple nerve palsy. *J Bone Joint Surg Br* 66B:260–264, 1984.

188. Szalay E, Rockwood CA: The Holstein-Lewis fracture revisited. *Orthop Trans* 7:516, 1983.
189. Taylor NL, Raj AD, Dick HM, et al: The correction of ulnar claw fingers: a follow-up study comparing the extensor-to-flexor with the palmaris longus 4-tailed tendon transfer in patients with leprosy. *J Hand Surg [Am]* 29:595–604, 2004.
190. Taylor RT: Reconstruction of the hand. *Surg Gynecol Obstet* 32:237–248, 1921.
191. Terrono AL, Rose JH, Mulroy J, et al: Camitz palmaris longus abductorplasty for severe thenar atrophy secondary to carpal tunnel syndrome. *J Hand Surg [Am]* 18A:204–206, 1993.
192. Thompson TC: A modified operation for opponens paralysis. *J Bone Joint Surg* 26:632–640, 1942.
193. Tomaino MM, Wasko MC: Ulnar nerve compression following flexor digitorum superficialis tendon transfers around the ulnar border of the forearm to restore digital extension: case report. *J Hand Surg [Am]* 23:296–299, 1998.
194. Tsuge K, Adachi N: Tendon transfer for extensor palsy of forearm. *Hiroshima J Med Sci* 18:219–232, 1969.
195. Tubiana R: Palliative treatment of paralytic deformities of the thumb. *Orthop Clin North Am* 4:1141–1160, 1973.
196. Tubiana R, Miller HWt, Reed S: Restoration of wrist extension after paralysis. *Hand Clin* 5:53–67, 1989.
197. Tung TH, Mackinnon SE: Nerve transfers: indications, techniques, and outcomes. *J Hand Surg [Am]* 35:332–341, 2010.
198. Deleted in review.
199. Voche P, Merle M: Wartenberg's sign. A new method of surgical correction. *J Hand Surg [Br]* 20:49–52, 1995.
200. Wehbe MA, Hunter JM: Flexor tendon gliding in the hand. Part I. In vivo excursions. *J Hand Surg [Am]* 10:570–574, 1985.
201. Wissinger HA, Singsen EG: Abductor digiti quinti opponensplasty. *J Bone Joint Surg Am* 59A:895–898, 1977.
202. Wood VE, Adams J: Complications of opponensplasty with transfer of extensor carpi ulnaris to extensor pollicis brevis. *J Hand Surg [Am]* 9A:699–704, 1984.
203. Zachary RB: Tendon transplantation for radial paralysis. *Br J Surg* 34:358–364, 1946.
204. Zancolli EA: Claw-hand caused by paralysis of the intrinsic muscles: a simple surgical procedure for its correction. *J Bone Joint Surg Am* 39-A:1076–1080, 1957.
205. Zancolli EA: *Structural and dynamic bases of hand surgery*, ed 2, Philadelphia, 1979, Lippincott.
206. Zancolli EA, Cozzi EP: *Atlas of surgical anatomy of the hand*, New York, 1992, Churchill Livingstone.

32

Spasticity
Cerebral Palsy and Traumatic Brain Injury

Scott H. Kozin and Nina Lightdale-Miric

Acknowledgment: The authors wish to acknowledge and thank Dr. Michele Gerwin Carlson. Her efforts in the previous edition of this text provided the foundation for this chapter.

These videos may be found at *ExpertConsult.com:*

32.1 Athetoid cerebral palsy *(Courtesy Shriners Hospital for Children, Philadelphia.)*

32.2 Upper extremity examination of hemiplegia *(Courtesy Shriners Hospital for Children, Philadelphia.)*

Cerebral palsy and traumatic brain injury are upper motor neuron central nervous system diseases that result in decreased function, muscle imbalances, and deformity of the upper limb. Cerebral palsy, the most common childhood motor disability, results from brain injury occurring in a fetus or infant in the perinatal period (in utero, during birth, or in infancy) or in a premature infant in whom the brain is still developing. Traumatic brain injury is secondary to intracranial masses, sequelae following surgery to treat brain lesions, infection, vascular insult, or head trauma.

CEREBRAL PALSY

The incidence of cerebral palsy is approximately 2 to 4 per 1000 live births. The condition is considerably more prevalent in premature infants with a very low birth weight (<3.3 pounds). The development of neonatal intensive care, and the resulting increased rates of survival of these infants, may have led to a rise in incidence of cerebral palsy.[174] Typically thought of as an anoxic brain injury during birth, perinatal asphyxia describes a small percentage of cases. Neonatal encephalopathy, exposure to teratogens, genetic abnormalities, brain malformations, multiple births, intracranial hemorrhage, prematurity, metabolic diseases (jaundice and kernicterus), and infection have been identified as more common etiologic factors leading to the brain injury.

The classification of cerebral palsy is based on the location of the injury in the brain, number of involved extremities, level of spasticity, presence of associated movement disorders, and level of functional use. Some texts distinguish between congenital and acquired cerebral palsy based on age of onset. Spasticity, or hypertonicity, results from dysregulated reflex-arc messaging from the upper motor neurons of the medullary pyramid to the motor end plates of the limb musculature. The increased tone may be phasic or continuous and eventually results in myostatic contractures. Concomitant extrapyramidal involvement causing additional movement disorders such as dystonia, athetosis, ataxia, and flaccidity may also be present. Spastic involvement of one muscle is often coupled with flaccid involvement of its antagonist. Variable tone and muscle imbalance across limb segments result in abnormal upper limb position and function. Sensation and reflex feedback pathways are also invariably disrupted.

Cerebral palsy is considered an irreversible and nonprogressive brain injury. However, progressive muscular fibrosis, joint contracture, limb length differences, osteopenia, and atrophy occur over time. Spastic deformities in the upper extremity most often result in shoulder internal rotation, elbow flexion, forearm pronation, wrist flexion, finger flexion, intrinsic spasticity, and thumb-in-palm deformity. The age of the child at the time of the brain injury, as well as the extent and location of the cerebral involvement, is predictive of motor, sensory, and seizure involvement, as well as the child's ultimate intelligence, coordination, and prognosis.[82,180]

TRAUMATIC BRAIN INJURY

Traumatic brain injury is a leading cause of disability and death in the United States.[12,55,69,87,91] An estimated 1.5 million Americans sustain a traumatic brain injury annually, and about 50,000 of these people die.[3,110] Brain tumors and vascular malformations, sequelae from the surgical removal of such tumors or malformations, and infection are less common causes of traumatic brain injury. Approximately one third of traumatic brain injury survivors still require assistance with activities of daily living 1 year following injury. Most traumatic brain injuries occur in individuals who are younger (<45 years old), and those who survive have a normal life span.[55] The enormous lifetime costs of traumatic brain injury were estimated to be $56 billion in the United States in 1995.[3,110]

In traumatic accidents, falls, and abuse cases, the Glasgow Outcome Scale is frequently used to predict the outcome after brain injury.[95] Patients with lower scores have a substantially higher incidence of severe sequelae. Age and duration of coma are also important determinants of neurologic outcome after brain injury, regardless of its severity.[172] Brainstem involvement, as indicated by the presence of decerebrate or decorticate posturing, has a poor prognosis. Heterotopic ossification can be a complication of traumatic brain injury.[47]

When neurologic recovery has been optimized, the brain-injured patient often has residual limb deformities, including spasticity, movement disorders, contracture, and muscle imbalance similar but not equivalent to cerebral palsy. Surgical procedures for limb deformity and dysfunction can be performed after the patient plateaus in therapy-assisted recovery. Surgery can rebalance the remaining abnormal muscle forces, correct the residual deformities, and prevent joint contractures.[142]

TREATMENT CONSIDERATIONS

Treatment of the upper limb in children and adults with cerebral palsy and traumatic brain injury includes surgical procedures and pharmacologic and other nonsurgical therapeutic modalities. A multidisciplinary team is necessary to manage all elements of their care. Cooperative efforts of a caregiver team and the cumulative treatment of surgeons, neurologists, and therapists result in the best outcomes. All treatment options share the goals of increasing functional use, including communication and independence with daily living, decreasing pain, managing spasticity, and prevention and correction of deformity, as well as improving hygiene or self-confidence with limb repositioning. Importantly, patients with dystonia, athetosis, poor voluntary control, and limited sensory function may be made worse by surgical intervention. However, the focus of this chapter is surgical decision making and surgical technique.

Goldner and colleagues estimated that less than 20% of children with cerebral palsy and less than 30% of children with traumatic brain injury are potential candidates for surgical procedures of the upper extremity.[57,98] Surgery of the upper extremity in cerebral palsy is reparative and often palliative but not curative.[33,126] Historically, only 50% of operations of the upper extremity are performed to achieve functional improvement. Treatment aimed at improving function of the upper extremity cannot restore normal limb function. Appearance concerns and hygiene are other major factors that influence treatment.[27,28,113]

Surgery should address the entire extremity when formulating a plan. When possible, elbow, wrist, and finger flexion deformities should be corrected at the same setting (Figure 32.1). This may lead to a lengthy surgery, and the surgical team should prepare for and discuss the order of each individual component in order to maximize the limited tourniquet time and minimize the anesthesia time. Correction of the elbow deformity without correction of the wrist deformity or correction of the wrist deformity without correction of the finger deformity can decrease overall function and have distressing outcomes. Studies have shown improved use of the arm in functional activities and better incorporation into daily life after well-timed and well-planned upper extremity surgery has been performed.[20,188] A detailed evaluation combined with appropriate patient selection and careful decision making will reliably provide positive treatment outcomes.[101,201]

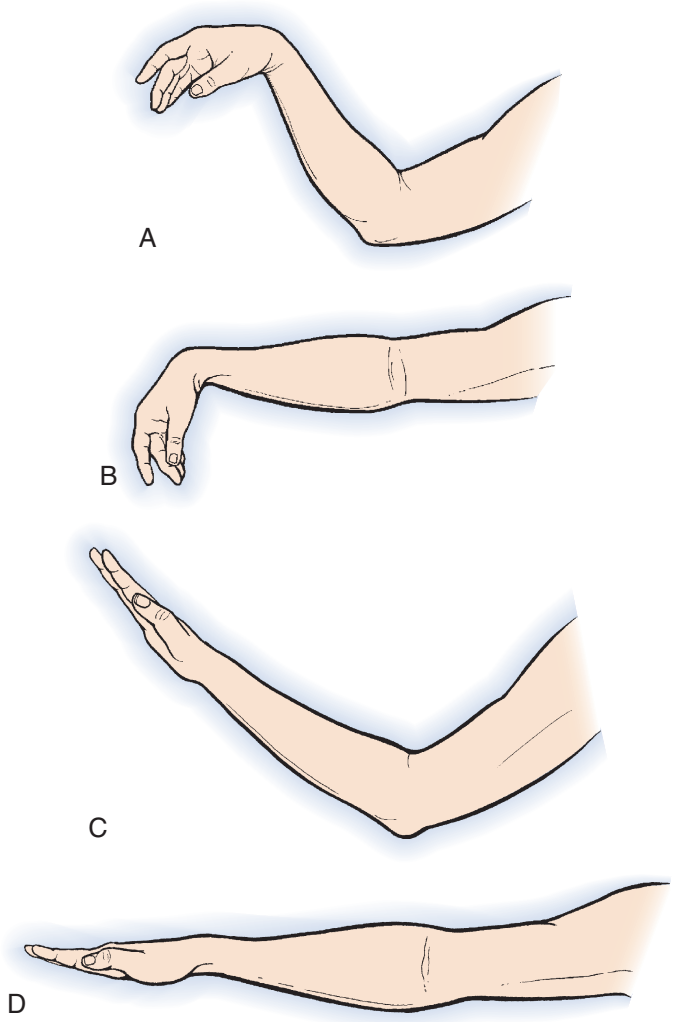

FIGURE 32.1 Concurrent correction of elbow and wrist flexion deformities is important to improve limb function. **A,** Wrist and elbow flexion deformity. **B,** Correction of the elbow alone leaves the wrist flexed. **C,** Correction of the wrist alone does not improve the patient's ability to position the hand in space. **D,** Correction of the wrist and elbow places the hand in a neutral position with maximal reach.

Evaluation

A careful and thorough examination of each patient is mandatory. The evaluation should include the patient's underlying disease, developmental stage, intellectual aptitude, motor function, and sensibility. The patient's ability to access therapy and support resources is equally important. An inventory of the patient's provider team is required (e.g., parents, caregiver, pediatrician, neurologist, occupational therapist, physical therapist, social worker). Surgical results will not be optimized unless the patient is able to obtain therapy, maintain hygiene, and obtain accommodations at home and in school. In addition, an essential component of the evaluation is to exclude other treatable diagnoses for cerebral dysfunction and to determine if the disorder is progressive. Multiple visits and examinations are required to accurately appreciate the extent of a movement disorder and to fully determine all the prognostic factors.

Evaluation of a patient with spasticity must include an accurate assessment and a documented list of treatment expectations. Asking the patient and/or caregiver what they expect to achieve is mandatory to avoid unrealistic hopes. The Canadian Occupational Performance Measure (COPM)[111] and Goal Attainment Scaling[13] are unlike other standardized patient-reported outcome instruments due to the individualized approach used to establish goals. The COPM capitalizes on a semistructured interview that reflects the usual interaction

between an occupational therapist, who approaches practice from a client-centered framework, and his or her client. Through this interview, parents and children identify performance activities that are perceived as important by the parent, child, and/or society; performance is rated on a scale between 0 (cannot do) and 10 (can do very well), and the activities are used to establish goals for treatment. Scores between baseline and reassessment are calculated to evaluate outcomes of treatment. Although individuals may differ in their ideas of what constitutes successful outcomes, research suggests that a change of two or more points reflects meaningful change.

It is important to identify patients who have little voluntary control, marked dystonia, or limited sensibility because these individuals will obtain limited functional benefit from surgical intervention. A simple interview of the patient (and the parent or caregivers) can elicit the activities that the patient can and cannot perform with the spastic extremity, but other procedures are also valuable in individualizing treatment, such as prognostic testing, including functional scores, video analysis, electromyography, and imaging studies.[202] Carlson and associates found that reviewing the videotape compared to the office visit examination will change the operative plan in 75% of patients.[22]

Evaluation is particularly challenging in nonverbal patients, families with language barriers, and young patients. In cerebral palsy, upper limb dysfunction is usually noted by 1 year of age, as the infant fails to obtain normal developmental milestones, such as crawling, pulling to stand, passing objects from hand to hand, or a developing oppositional pinch.[45] Infants may develop a more primitive key pinch (thumb to side of index finger) versus oppositional pinch.[46] Maintenance of primitive reflexes also reflects a central nervous system disease process.

Physical Examination

Physical examination of the spastic upper extremity is challenging and requires experience, a relaxed clinical atmosphere, multiple office visits, and a team approach. Recognition of contraindications to surgery and predictors of poor outcome via the physical examination directs treatment decision making. Despite their best intentions, patients often have difficulty cooperating during the examination. Asking patients to perform activities with both extremities can ensure that they comprehend instructions, even if they can only perform the task with one. Each extremity should be evaluated separately and any mirror movements noted. Although spastic deformities in the upper extremity most often result in shoulder internal rotation, elbow flexion, forearm pronation, wrist flexion, finger flexion, intrinsic spasticity, and thumb-in-palm deformity (Figure 32.2), many variations exist.

The examination must accomplish several tasks that serve as clinical guidelines. The surgeon's examination begins with casual conversation, such as asking the patient his or her age and assessing caregivers. The resting position of the limbs should be noted. Ask the patient and/or caregivers exactly why they are seeing a surgeon and identify treatment goals. If age and intelligence are appropriate, ask the child to perform active movements such as hands over the head, hands from knee to mouth, elbow flexion and extension, supination and pronation, open and closing of the hands, and clapping. Passive range of

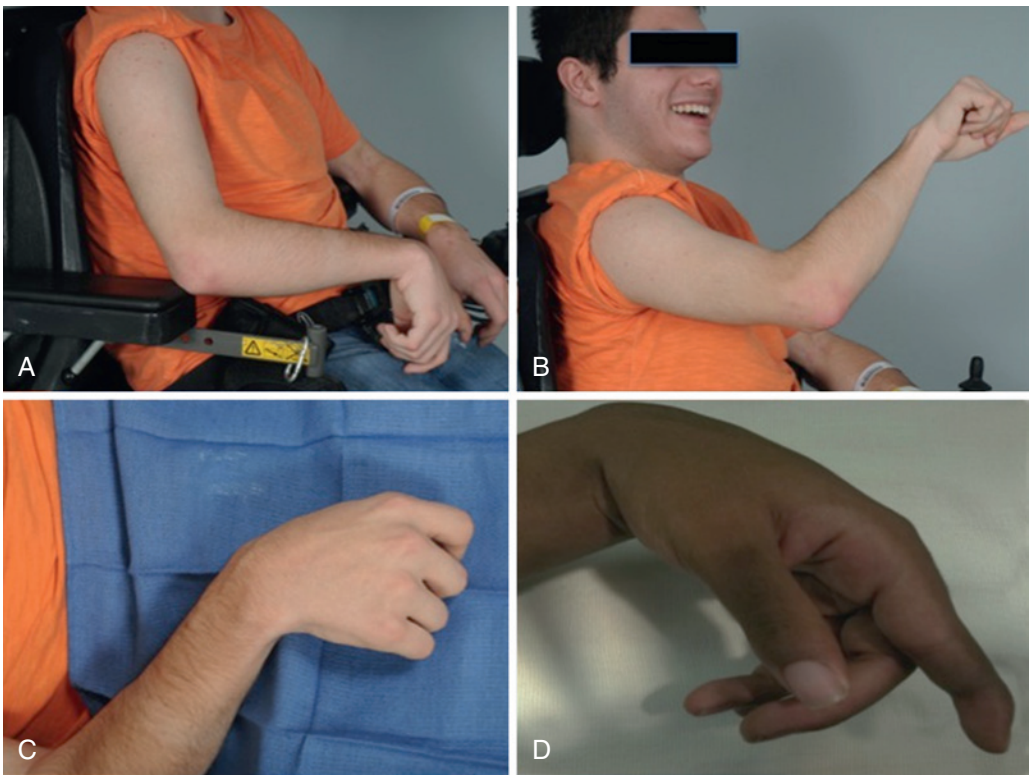

FIGURE 32.2 Spastic posturing in the upper extremity. **A** and **B,** Shoulder internal rotation, elbow flexion, forearm pronation, and thumb in palm and fist with active wrist extension. **C** and **D,** Wrist flexion and ulnar deviation with finger swan neck deformities. (Courtesy of Shriners Hospital, Philadelphia, and Children's Hospital, Los Angeles.)

motion of all joints is then measured. The muscle strength of all involved and the potential donor muscles for transfer are measured. Hyperreflexia and clonus are noted. Patterned hand function, as well as muscle spasticity and contracture, are identified. Spasticity must be distinguished from muscle and/or joint contracture.[155,211] When relaxed, patients with muscle spasticity demonstrate full passive range of motion of an affected joint, whereas in those with muscle or joint contracture the passive movement remains limited. Muscle contracture and joint contracture often coexist in older or skeletally mature patients; joint contracture is less common in younger children. Muscle spasticity can be overcome by applying gentle sustained resistance to the spastic force. Several grading systems for spasticity exist, such as the Modified Tardieu Scale[181] and Modified Ashworth Scale[10] (Table 32.1). Inspection for potential hygiene problems should include the axilla, antecubital fossa, volar wrist flexion crease, palm, and interdigital spaces.

Spasticity is classically classified by the number of limbs involved: monoplegia (one extremity), hemiplegia (one arm, one leg), diplegia (two legs), triplegia (two legs, one arm), and quadriplegia (all four extremities). Motor function is also classified as spastic, flaccid, and athetoid[211] (Video 32.1). Many patients have a combination of movement patterns. Spastic involvement of a muscle is often coupled with flaccid involvement of its antagonist, potentiating the deformity from imbalance. The surgeon should observe the patient for underlying movement disorders, especially dystonia. *Dystonia* is defined as "involuntary sustained or intermittent muscle contractions causing twisting and repetitive movements, abnormal postures or both."[158] Hypotonic, hypertonic, hyperkinetic, and mixed tone movement disorders should also be noted and are known to correlate with poorer surgical outcomes.

In addition to motor assessment, intellectual capacity and sensory function also correlate with severity and surgical outcomes in children with cerebral palsy and traumatic brain injury. In the cooperative child, stereognosis is easily tested with two or three simple objects such as a coin, poker chip, paperclip, or key in each hand.[96] The hand position and function may alter one's ability to perform sensory testing.[11,25,192,210] The child's intellectual or cognitive impairments are harder to assess in an office visit; asking the child to follow voluntary commands or perform tasks such as placing the hand to the mouth and noting the child's school level or integration into a normal or specialized classroom are ways of establishing a baseline.

A standardized task performance evaluation can assist in quantifying the severity of impairment and in identifying patterns of hand function. The House Classification and the Manual Ability Classification System describe how children with cerebral palsy use their hands to handle objects in daily activities and reflect the child's typical performance[66] (Tables 32.2 and 32.3). Videotaping or functionally evaluating the patient performing routine activities or using scored functional tests (e.g., Jebsen-Taylor hand function test, box and blocks test, pegboard test) may be helpful, although the child may perform well for the surgeon but use different functions at home or when unobserved. Other validated evaluation tools, including the Modified (Modified) Ashworth Scale, Modified Tardieu Scale, Melbourne Assessment of Unilateral Upper Limb

TABLE 32.1 Modified Tardieu Scale and Modified Modified Ashworth Scale

Grade	Modified Tardieu Scale	Modified Modified Ashworth Scale
0	No resistance to passive ROM	No increase in muscle tone with passive ROM
1	Slight resistance with no clear catch	Slight increase in tone; catch and release or minimal resistance with ROM
2	Clear catch at precise angle, halting passive ROM, followed by release	Marked increase in muscle tone, catch in middle range, and resistance through remainder of ROM, still easily moved
3	Fatigable clonus (<10 seconds with resistance) occurring at precise angle	Considerable increase in muscle tone, passive movement is difficult
4	Infatiguable clonus (>10 seconds)	Rigid in flexion or extension

ROM, Range of motion.

TABLE 32.2 Manual Ability Classification System (MACS) of Hand Function

Level	Description
I	Handles objects easily and successfully
II	Handles most objects but with somewhat reduced quality and/or speed of achievement
III	Handles objects with difficulty; needs help to prepare and/or modify activities
IV	Handles a limited selection of easily managed objects in adapted situations
V	Does not handle objects and has severely limited ability to perform even simple actions

TABLE 32.3 House Classification of Hand Function

Score	Designation	Activity Level
0	Does not use	Does not use
1	Poor passive assist	Uses as stabilizing weight only
2	Fair passive assist	Can hold onto object placed in hand
3	Good passive assist	Can hold object and stabilize for use by other hand
4	Poor active assist	Can actively grasp object and hold it weakly
5	Fair active assist	Can actively grasp object and stabilize it well
6	Good active assist	Can actively grasp object, stabilize it well, and manipulate it against other hand
7	Spontaneous use, partial	Can perform bimanual activities easily; occasionally uses hand spontaneously
8	Spontaneous use, complete	Uses hand completely independently, without reference to other hand

Function, Quality of Upper Extremity Skills Test, Shriners Hospital Upper Extremity Evaluation, and Assisting Hand Assessment, can grade upper extremity disability and guide treatment.[10,38,68,88,104,144,198] Many other instruments have been designed to quantify parent and child self-assessment of upper extremity function in children with cerebral palsy.[14] The correlation of three-dimensional motion analysis is still being studied as a prognostic and classification tool.

Physical Examination Key Points and Clinical Guidelines

Shoulder. The most common position of rest of the shoulder in a patient with spasticity is internal rotation. Internal rotation and adduction posturing of the shoulder is caused mainly by spasticity and/or contracture of the subscapularis and pectoralis major muscles. The latissimus dorsi and teres major muscles can also contribute. Over time, glenohumeral dysplasia, capsular contracture, and thickening of the surrounding fascia add to the deformity. Less frequently, a severe external rotation and abduction posture of the shoulder occurs secondary to spasticity or contracture of the rotator cuff muscles (Figure 32.3). The physician must determine whether the limitations in shoulder motion interfere with the patient's ability to position the hand in space for function.

Elbow. The physician may observe dynamic elbow position when the patient is walking, running, and performing activities with the contralateral extremity.[147] The predominant elbow spastic deformity is flexion. The initial cause is related to spasticity or contracture of any or all of the elbow flexors (biceps, brachialis, brachioradialis). Long-standing deformities can also result in soft tissue and joint contractures. The severity of the flexion deformity is variable. Some patients have only dynamic posturing (involuntary flexion with walking or effort) or a smidge of elbow contracture. Other patients have severe hyperflexion with antecubital skin breakdown and intertriginous infections.

Traditionally, an elbow flexion contracture was considered mostly an aesthetic or hygienic problem[77]; however, even mild dynamic posturing or contracture can be problematic for the patient and family. Appearance is an important factor, especially for hemiplegic patients, and correction is commonly requested. In contrast, a substantial flexion deformity interferes with activities of daily living and leads to skin breakdown in the antecubital fossa. Lessening a severe contracture can allow a patient to use the forearms to assist in wheelchair transfers, touch a picture board or use technology to communicate, reach the tray top of a wheelchair, or touch a wider sphere of objects in his or her environment (increase in workable reach space). In less severe flexion deformities, release of the contracture can allow for the use of crutches or walkers, facilitate two-handed manipulation of objects away from the body, and increase independence with activities of daily living.



FIGURE 32.3 External rotation and abduction posturing of the shoulder is rare and significantly limits function. (Copyright © Michelle Gerwin Carlson.)

Forearm. Pronation positioning of the forearm is mainly caused by spasticity of the pronator teres. The position is initially passively correctable; however, a fixed deformity occurs over time secondary to contracture of the interosseous membrane or disruption of the radioulnar joint(s). Pronation deformity may interfere with bimanual use of the extremity in two-handed manipulation of objects (e.g., carrying a tray). With a pronation contracture, the palms cannot face each other and the manipulation of small objects between the hands is also difficult. With severe spasticity, patients are forced to assume a reverse grasp posture, using the ulnar aspect of the hand to grasp objects, because they are unable to present the radial aspect of the hand.[119] Internal rotation contracture of the shoulder exacerbates the pronation deformity as the shoulder is unable to compensate. Rarely, radial head dislocation (in 2% of patients)[1] or distal radioulnar joint dislocation may occur and further limit the passive range of motion of the forearm.

Palpate the pronator teres during passive supination of the forearm to identify spasticity. Evaluate active supination, pronation, and the position of the forearm at rest. Examine the distal and proximal radioulnar joint for dislocation, subluxation, or instability. Palpate for the radial head in supination and pronation and determine radial head alignment. During task performance, determine if forearm rotation is adequate for workspace, midline, and overall task performance.

Wrist and Digits. The wrist often assumes a flexed posture. There are several potential causes, including weak wrist extensors, tight or spastic wrist flexors, and volar wrist capsular contracture. The flexed attitude of the wrist causes several functional problems. Wrist flexion weakens grip secondary to the decreased mechanical advantage of the digital flexors and shift of the length-tension curve. Severe contractures can lead to hygiene issues.

Observation of wrist position during hand use is critical to assess object acquisition and release. The physician can also determine patterns of usage and assess spastic muscles. For example, if the wrist deviates in an ulnar direction with flexion, spasticity of the flexor carpi ulnaris (FCU) is likely. Circumduction during attempted wrist extension implies that the patient is using the extensor carpi ulnaris (ECU) to augment wrist extension. Passive wrist motion should be measured and recorded. Incomplete passive extension implies contracture of the wrist flexors or even the radiocarpal joint. The muscles about the wrist should be palpated during active movement. An assessment of spastic muscles and/or those muscles firing excessively should be determined. For example, firing of the FCU or the flexor carpi radialis (FCR) during digital opening implies spasticity or an exaggerated response to facilitate digital opening.

The Volkmann angle is commonly used to assess digital flexor tendon tightness as it might be used in a patient with

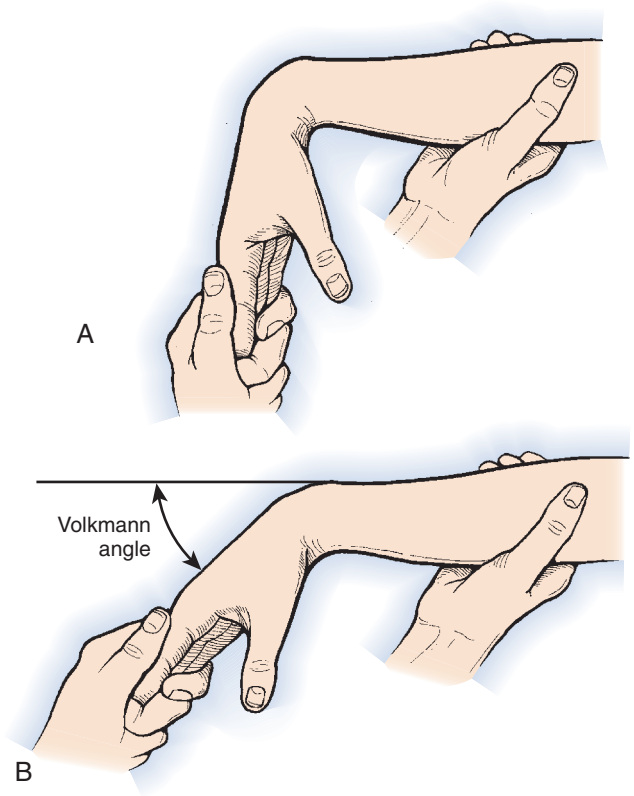

FIGURE 32.4 Volkmann test for digital flexor tendon tightness. **A,** The digits are held extended with the wrist flexed. **B,** The wrist is extended with the digits extended. With no flexor tendon tightness, full extension of the wrist should be possible. Wrist extension to less than neutral (Volkmann angle) indicates the need for surgical intervention.

compartment syndrome (Figure 32.4). The angle is measured with the wrist flexed and the digits held completely extended; the wrist is passively brought into maximal extension.[175] In the absence of flexor tendon tightness, composite full wrist extension and finger extension can be achieved. With digital flexor contracture, the wrist cannot be extended to neutral without flexion of the digits. Subsequently, one can assess whether the flexor digitorum superficialis (FDS) or flexor digitorum profundus (FDP) is spastic by holding the wrist in extension while passively extending the digits. When passive proximal interphalangeal (PIP) joint extension is limited, FDS spasticity should be suspected (FDP spasticity may also be present). If the PIP joints have full passive extension but the distal interphalangeal (DIP) joints remain flexed, FDP spasticity should be suspected.

Evaluate a patient's grasp and release ability with the wrist flexed and extended (Video 32.2). Poor grasp is often secondary to weak or absent wrist extension, because a flexed wrist slackens the digital flexor muscles and minimizes the potential for force production. Inability to extend the wrist may be caused by weak or absent wrist extensors or by spastic wrist flexors. The strength of grasp can be improved with a tendon transfer to increase wrist extensor power. Poor release is the result of weak or absent digital extensors. Patients with impaired release are unable to actively extend the digits or are only able to extend the digits when the wrist is flexed. When the wrist is passively held in extension, active digital extension is impossible. An isolated transfer to improve wrist extension in this case is contraindicated as the patient will be unable to extend the digits for object acquisition. The physician could consider a series of tendon transfers to augment wrist and digital extension.

Intrinsic muscle tightness leads to a resting position of metacarpophalangeal (MP) joint flexion and interphalangeal (IP) joint extension. When a patient with intrinsic tightness attempts digital extension, the MP joints periodically flex. If a patient is a candidate for digital flexor tendon lengthening, the intrinsic muscles must be carefully examined. If the intrinsics are spastic, release of the digital flexors without release of the intrinsics will result in a hand with flexed MP joints and extended PIP joints. Intrinsic tightness is best evaluated by the Bunnell test, which is performed by passive flexion of the PIP joints while the MP joints are held sequentially in full extension and in flexion. When fixed intrinsic tightness is present, passive motion of the PIP joint is greater with the MP joints flexed than when extended. This test should be performed in wrist flexion because if the digital flexors are tight, they can overpower the intrinsic muscles. If swan neck deformities of the PIP joints are present, they should be evaluated for cause and flexibility. Extrinsic extensor tendon over pull or intrinsic muscle spasticity can yield swan neck deformities. Local anesthetic block of the ulnar nerve at the wrist can be an effective way to demonstrate (both to the surgeon and the patient) the effect of intrinsic muscle release. Ulnar nerve block can also help differentiate intrinsic spasticity from fixed intrinsic or PIP contractures.

Thumb. The thumb-in-palm deformity is a challenging problem to rectify. Correction of the thumb-in-palm deformity is a careful balancing act among multiple muscles, tendons, and joints. Correction of the thumb-in-palm deformity is often performed concurrently with tendon transfer surgery to augment wrist extension. Hence, testing of the thumb-in-palm deformity should be done in wrist flexion and extension. Thumb extension occurs in a radial direction in the plane of the hand, and thumb abduction occurs in the plane perpendicular to the palmar surface (Figure 32.5). The adequacy of the first web space should be assessed with measurements of the passive and active web space angle. The muscles about the thumb should be assessed for spasticity or contracture, including the adductor pollicis brevis (APB), flexor pollicis brevis (FPB), first dorsal interosseous, flexor pollicis longus (FPL), abductor pollicis longus (APL), extensor pollicis brevis (EPB), and extensor pollicis longus (EPL). In addition, the thumb should be evaluated for hyperextension at the MP joint and volar plate laxity.

Diagnostic Testing

Imaging

There is a limited role for imaging in the treatment of patients with cerebral palsy or traumatic brain injury. Documenting joint subluxation or frank dislocation, especially of the radial head and distal ulna, may explain bony blocks to joint motion. Degenerative changes, fracture, infection, avascular necrosis, or concurrent congenital musculoskeletal disease may also be identified on imaging. Functional brain magnetic resonance imaging has been studied as an accurate predictor of upper extremity function in upper motor neuron disease and a useful outcomes measurement tool to document cortical reorganization after treatment.[74a,83]



FIGURE 32.5 **A** and **B,** Dynamic thumb-in-palm deformities flexion into the palm with digit extension and interfere with grasp and prevent the manipulation of large objects. **C** and **D,** Severe thumb contracture with fixed joint degenerative changes and skin and soft tissue contracture. (**A,** Copyright Michelle Gerwin Carlson. **C** and **D,** Reproduced with permission of Children's Orthopaedic Center, Los Angeles.)

Electromyography

Dynamic electromyography can be helpful in identifying spastic and flaccid muscles and determining phasic activity. Electromyography has been advocated in the decision-making process for surgery,[77,92,130,157,195] although some believe that the information gained is no more valuable than that obtained from serial physical examinations.[114a] Dynamic electromyography often requires a combination of surface electrodes and fine-wire examination of the deeper muscles of the elbow, forearm, and hand. Volitional activity as well as patterned activity should be evaluated to identify muscles that are firing normally in phase versus those that are firing out of phase, firing continuously, or not firing at all (Figure 32.6).

In the elbow, the biceps, brachialis, and brachioradialis can be evaluated by electromyography for spasticity and possible surgical release. Similarly, the adductor pollicis muscle can be assessed to determine its role in thumb-in-palm deformity. Weak or absent wrist extension to produce grasp or digital extension to yield release can be accessed via electromyographic response of the wrist extensors or digital flexor muscles, respectively. Dynamic electromyography can help identify inappropriate muscle firing, as well as those muscles that would be best for transfer. Out-of-phase or continuous firing of the FCU and digital flexors is frequently seen; this characteristic makes them poor donors for transfer. Activity of the digital and radial wrist extensors is often absent on electromyographic studies. The ECU findings are more variable.

Muscles firing during digital release are good candidates for transfers to improve digital extension, and those firing in grasp are good choices for wrist extension transfers.[77,195] The FCU, FCR, brachioradialis, pronator teres, ECU, and extensor carpi radialis longus (ECRL) can all be studied to determine which muscles are active in grasp and which muscles are active in release.[77,78] Continuous activity in a muscle is a relative, although not absolute, contraindication for transfer, because some data suggest that phasic activity can develop after transfer.[132,157]

Specially trained personnel are required to perform dynamic electromyographic tests, and many laboratories do not have this technical support. In addition, in the lower extremity, electromyography has been shown to alter performance due to discomfort.[4a] The overall applicability of upper extremity dynamic electromyography remains questionable.

NONOPERATIVE MANAGEMENT

Therapy

The role of nonoperative management in the treatment of cerebral palsy and traumatic brain injury cannot be overemphasized. The therapists play a critical role in the treatment paradigm and in the education of the patient and caregiver. Therapeutic intervention includes passive range-of-motion movements, splint fabrication, and implementation of adaptive strategies and devices. Passive range-of-motion movements and splinting are instituted to maintain supple joint structures and prevent fixed contractures. The therapist must be skilled in splint fabrication because the limbs are prone to skin breakdown secondary to spasticity and altered sensibility. In fact, severe spasticity is a contraindication to splint fabrication because "rebound" spasticity (Figure 32.7) can lead to skin breakdown.

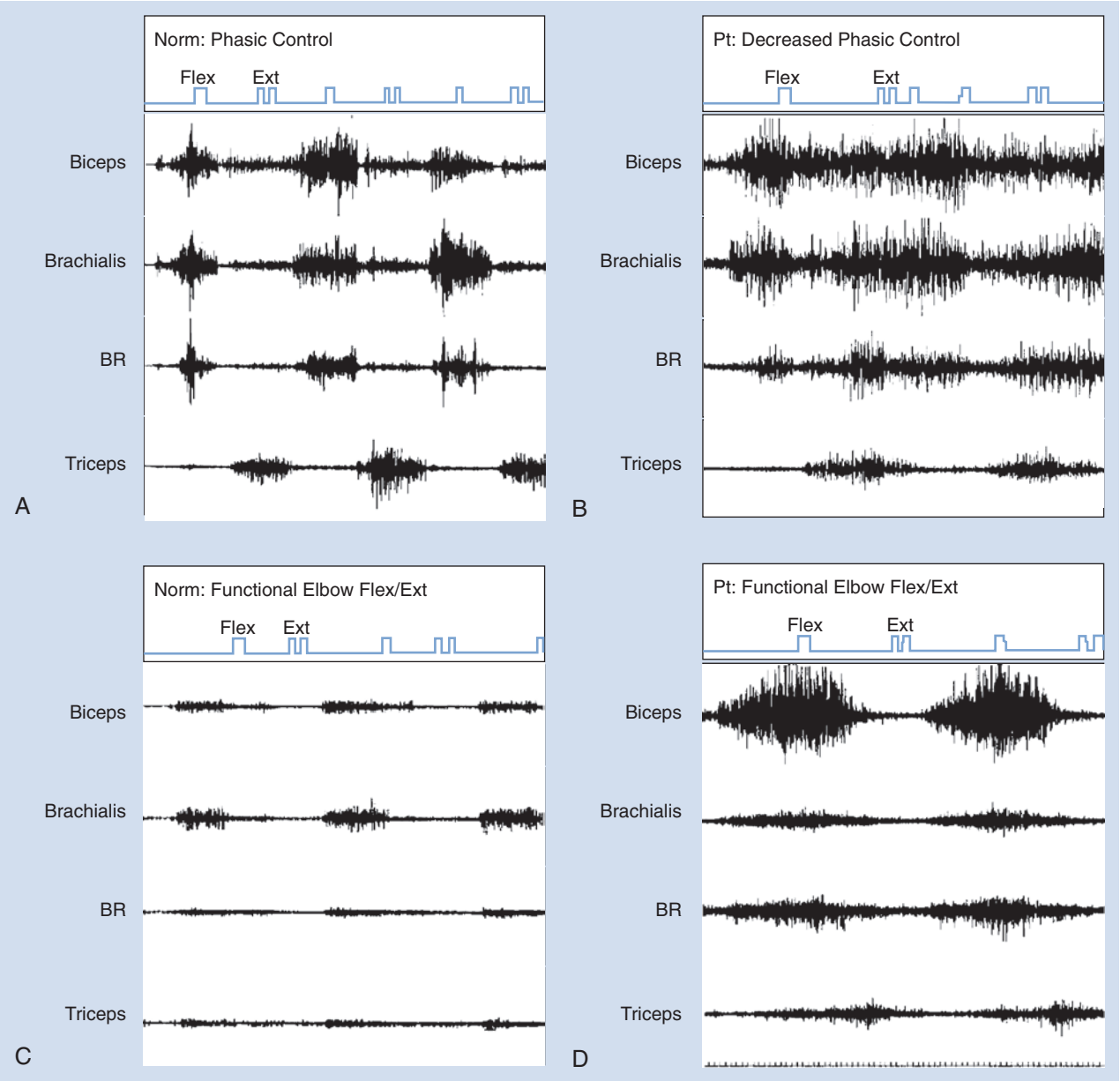

FIGURE 32.6 Dynamic electromyograms of the elbow. **A,** Normal phasic control in maximal contraction. Note the alternation in firing between flexion and extension. **B,** In this patient there is loss of phasic control, and the elbow flexors fire in flexion and extension. **C,** Normal functional use. A patient is asked to lift a light object, and the amount of contraction decreases from maximal effort (compare with **A**). **D,** In this patient there is loss of functional grading, because even when the patient lifts a light object, there is almost maximal contraction. *BR,* Brachioradialis; *Flex,* flexion; *Ext,* extension.

The therapist has a critical role in eliciting active movement and encouraging usage of the spastic limb. Incorporation of the spastic limb into daily activity is a challenging problem, especially in hemiplegia. Hemiplegic patients can perform tasks more easily, faster, and with more spontaneity with the uninvolved limb. The spastic hand is often dubbed the "helper hand." Nonetheless, active usage promotes activity within the sensorimotor cortex homunculus dedicated to the hand and is necessary to maintain these pathways. In the pediatric population, therapists will use play as a means of promoting limb usage. Grasping and manipulation of objects of different sizes and shapes are used to promote different prehension patterns. Constraint-induced movement therapy forces the use of the affected side by restraining the unaffected side. The constraint can be holding the uninvolved limb and allowing prehension only with the affected side.[36,112,139] The constraint also can be more restricting, such as splinting or casting of the unaffected side. Electrical stimulation of weak or neglected muscles combined with therapy may also provide additional benefits.[26,75,159,160,207,208]

The therapist also plays a role as an educator with respect to diagnosis and treatment and comprehension of the child's future level of independence, intellectual ability, and other abilities. In cerebral palsy, the parents are often overwhelmed and are searching for answers. A skilled therapist can answer most of the questions and defer to the physician with queries regarding surgical management. The parents do need to mourn the "loss of the perfect child," and grieving is a necessity. Some



FIGURE 32.7 Splinting of the severely flexed wrist is difficult. Volar splinting of the wrist stimulates the palm, increasing the pathologic flexion response, which tends to make the patient "flex out" of the splint. Dorsal splinting is mechanically ineffective. (Copyright Michelle Gerwin Carlson.)

parents are unable to cope with the added burden and should be referred to a psychiatrist, psychologist, or other mental health provider. In traumatic brain injury, the psychological burden can be overwhelming for both the patient and the caregiver; psychotherapy can be beneficial in handling the added stress.

The therapist also plays a critical role following surgery. Therapy protocols are established for tendon lengthenings, muscle releases, and tendon transfers. These involve three stages: immobilization, mobilization, and incorporation. A skilled therapist will maximize the outcome.

Medical Management

Medical management may include injectables, orals, or implantable intrathecal devices. Muscle relaxants such as benzodiazapenes and baclofen, as well as antiseizure medications, have a clear role in management of limb function and position but are rarely managed by the surgeon.[131]

Botulinum Toxin

Botulinum toxin (Botox®) is a useful adjunctive treatment for spasticity. Botulinum toxin type A blocks the release of acetylcholine at the presynaptic neuromuscular junction, which temporarily weakens the injected muscle.[8,48,99,100,103] When used in the appropriate dosage and carefully injected, botulinum toxin has a high safety profile. A maximum total dose of 10 U/kg is given. The use of botulinum toxin for spasticity is off-label and should be discussed with the patient and caregiver beforehand.

The indications for botulinum toxin injection are variable depending upon the patient and reasoning.[50,51,53] Botulinum toxin can be injected to temporarily decrease spasticity and allow more intense therapy to resolve any tightness. For example, children with cerebral palsy can have some increased spasticity and tightness during periods of rapid growth. Botulinum toxin injection can lessen the tightness and resolve any impending contracture. Botulinum toxin can also be used to assess and forecast the effect of lengthening a muscle-tendon unit. This assessment may prevent surgery that would not be beneficial and/or would result in diminished function.[35]

❖ Authors' Preferred Technique for Botulinum Toxin Injection

Botulinum toxin injection is performed in the clinic or the operating room, depending on the age of the patient and muscle(s) to be injected. Older patients and superficial muscles can be injected after the application of topical lidocaine cream or use of a ShotBlocker (Bionix Development Corporation, Toledo, OH). Younger patients and deeper muscles may require sedation or anesthesia. Deeper muscles can require electrical stimulation or ultrasound to verify appropriate needle placement. Botulinum toxin is prepared by diluting it with preservative-free saline. An insulated needle connected to an electrical stimulation unit or under direct ultrasound observation is inserted into the target muscle. Placement within the correct muscle is verified by stimulation prior to injection.

The protocol following injection varies with the indication. For patients with increasing tightness, a cast is applied for 3 week to maximize the stretch. For patients who require functional assessment, no daytime immobilization is required.

OPERATIVE MANAGEMENT

Shoulder

Types of Operative Procedures

A spastic shoulder that does not respond to therapy and botulinum toxin is typically treated by lengthening or release of the tight muscles.[109] Tendon transfers about the shoulder for cerebral palsy or traumatic brain injury have not been effective. In severe cases, humeral osteotomy can reposition the limb in space.[165] In athetoid patients, recurrent dislocation of the glenohumeral joint should be treated with glenohumeral arthrodesis.[79]

An inventory of the patient's spastic muscles will direct surgical management. Typically, the subscapularis and pectoralis major muscles are the major culprits and must be lengthened to lessen the internal rotation and adduction contracture. Less commonly, the latissimus dorsi and teres major muscles are released at the same time. External rotation spasticity can also be relieved by release of the supraspinatus, infraspinatus, and teres minor. Patients with severe external rotation spasticity are unable to maneuver through a doorway. Internal rotational humeral osteotomies may be required to improve wheelchair positioning.

Soft Tissue Release of Shoulder Internal Rotation Deformity

Indications. Mild axillary hygiene access or dynamic shoulder contracture can usually be treated with stretching. Failed nonoperative treatment and recurrent axillary hygiene issues or inability of a patient to position a functional hand in space are indications for surgery.

Contraindications. Release of the internal rotators should not be performed in patients with subluxation or dislocation of the shoulder, because this may exacerbate the instability.[98] These patients are better candidates for shoulder fusion. A relative contraindication to soft tissue surgery is weak external shoulder rotators. Contracture will recur soon after surgery if range of

motion is not maintained by therapy and strengthening of opposing muscles.

Preoperative Planning. Careful clinical examination of the muscles while the patient is awake is necessary to determine whether the shoulder muscle involvement is dynamic or passive. Once the patient is asleep, passive contractures can be detected. Preoperative imaging should be considered if glenohumeral subluxation, dislocation, or degenerative disease is suspected.

Technique. An axillary or deltopectoral incision is made in the anterior aspect of the shoulder. The tendon of the pectoralis major is identified along the posterior surface of the muscle. Fractional lengthening is performed by cutting the tendon at its musculotendinous junction. The deltopectoral interval is further divided to expose the underlying subscapularis. The subscapularis tendon insertion is identified as it inserts on the lesser tuberosity and is divided or "Z"-lengthened. A "Z"-lengthening is preferred primarily because it preserves some function of the tendon, prevents excessive external rotation posture, and helps prevent anterior dislocation of the shoulder. Subscapularis lengthening can also be accomplished using muscle slide through a longitudinal incision along the lateral border of the scapula. The subscapularis is elevated in an extraperiosteal plane from the anterior surface of the scapula beginning inferiorly and progressing superiorly.[18] The shoulder joint does not need to be opened unless one is performing a glenohumeral fusion. An external rotation abduction splint or shoulder spica cast is worn for 4 to 6 weeks, followed by range-of-motion exercises.

Rotation Osteotomy of the Humerus

Indications. An extremely contracted shoulder may not be amenable to soft tissue release. Humeral osteotomy can reposition the limb in space and enhance function. Humeral osteotomy will not address axillary hygiene issues.

Contraindications. Poor hand function is a relative contraindication to humeral osteotomy. However, concomitant surgery to improve hand function can be performed at the same setting.

Preoperative Planning. The amount of external rotation to improve function needs to be determined prior to surgery. A skilled therapist is invaluable to ensure the correct amount of rotation necessary. The right amount of rotation will enhance external rotation activities and preserve internal rotation and midline functions.

Technique. A medial, lateral, or deltopectoral approach can be used. We prefer the medial approach for numerous reasons. First, the approach is straightforward and goes between the median and ulnar nerves.[2,108] Second, the configuration of the medial humerus is suitable for plate and screw fixation. Third, the arm rests directly on the arm table after osteotomy, which facilitates fixation. Last, the medial incision heals nicely and is well concealed.

No tourniquet is used. The planned incision is infiltrated with bupivacaine and epinephrine prior to prepping and draping. A medial incision is made overlying the intermuscular septum and midshaft of the humerus. The superficial nerves are protected. The intermuscular septum is identified and excised. The ulnar nerve is retracted in a posterior direction while the median nerve and brachial artery are retracted in an anterior direction. The diaphysis of the humerus is exposed.

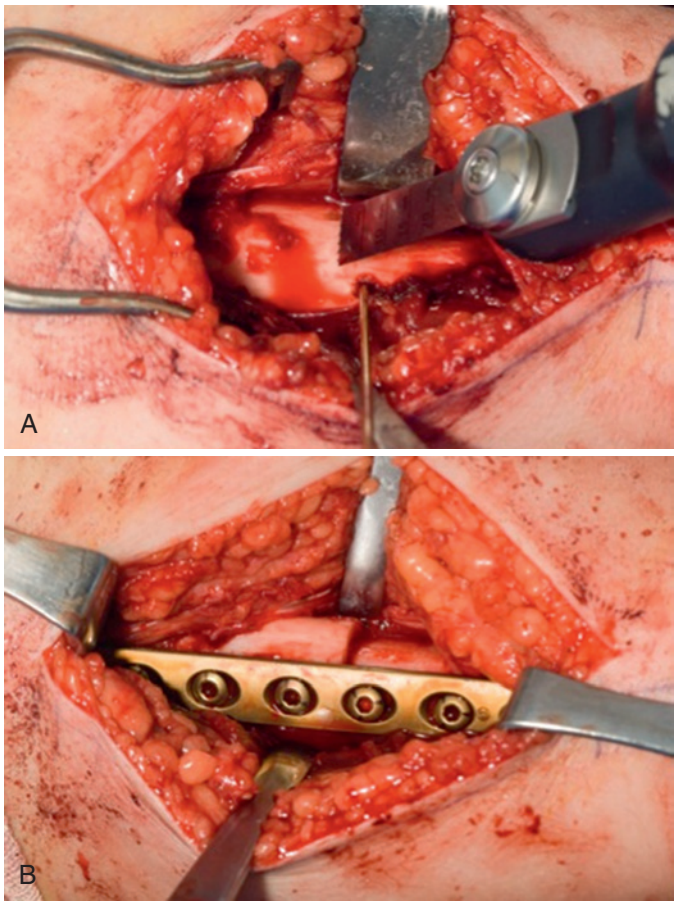

FIGURE 32.8 **A,** A Kirschner wire is drilled in an oblique angle to simulate the amount of correction, and a fine bladed saw is used for osteotomy. **B,** The humerus is externally rotated, the osteotomy is reduced, and the plate and screws are applied. (Courtesy of Shriners Hospital for Children, Philadelphia.)

A 6- to 8-hole plate is chosen for fixation. The size depends on the girth of the humerus; usually, 3.5 mm is sufficient in an adolescent or adult. The plate is placed over the humerus and the proximal 3-4 bicortical screws are placed through the plate and humerus. The periosteum is not incised along the entire humerus but only over the osteotomy site (Figure 32.8, *A*). Prior to performing the osteotomy, a Kirschner wire is placed in the distal fragment to mark the amount of desired correction. The wire is placed in line with a hole in the plate. The plate is removed and the humeral osteotomy performed using an oscillating saw; during the procedure, irrigation is necessary to minimize thermal necrosis. Following completion of the osteotomy, the humerus is rotated so that the screw holes and Kirschner wire are aligned. The wire is passing through a hole in the plate. By means of the predrilled screw holes, the plate is affixed to the proximal fragment. The osteotomy is reduced and the distal fragment is secured with screws using standard compression techniques (see Figure 32.8, *B*).

Following surgery, a large bulky dressing is applied from the hand to the axilla. No splint is used; however, a sling must be worn to prevent stress across the osteotomy site. The dressings are removed and a humeral brace is fabricated 3 weeks after surgery. The brace is worn for about 1 month until radiographic and clinical union is evident.

Glenohumeral Joint Arthrodesis

Indications. Instability or painful glenohumeral joint subluxation is the main indication for arthrodesis.

Contraindications. Absent scapular control is a contraindication for shoulder fusion. The patient must have ample parascapular muscles to control the fused glenohumeral joint.

Preoperative Planning. The goal is to determine the optimal position for fusion. The standard position is 30 degrees of abduction, 30 degrees of internal rotation, and 30 degrees of forward flexion (Figure 32.9, *A*). The position may vary, however, in the impaired patient, depending on the patient's function and overall needs.

Technique. Numerous operative techniques have been described to achieve union.[148] An extended deltopectoral approach provides wide exposure to the glenohumeral joint. The articular cartilage is removed from the humeral head and glenoid. Exposed cancellous bone is mandatory for union. Rigid internal fixation is preferred, using dual plate fixation (see Figure 32.9, *B*). One plate is placed across the scapular spine and onto the lateral humerus. A second plate is secured across the acromion and onto the humerus. Additional fixation can be obtained with large cancellous screws from the lateral humerus into the glenoid. Bone graft may be added to further promote healing. Postoperative immobilization varies from an abduction pillow to a shoulder spica cast, depending on the quality of the bone and rigidity of the fixation.



FIGURE 32.9 **A,** Glenohumeral arthrodesis using dual-plate fixation. **B,** Shoulder is positioned in 30 degrees of abduction, 30 degrees of internal rotation, and 30 degrees of forward flexion to allow hand-to-mouth activity. (Courtesy of Shriners Hospital for Children, Philadelphia.)

❖ Authors' Preferred Method of Treatment

Nonoperative management is the mainstay of treatment for shoulder spasticity. Spasticity and/or contractures that do not respond to stretching and botulinum toxin can be treated with surgery. An inventory of the potential spastic muscles is delineated by repeated physical examinations.

Moderate spasticity and contracture are treated by lengthening of the spastic and tight muscles. Lengthening of the subscapularis and pectoralis major is preferred to prevent overcorrection. Pectoralis major lengthening is performed by fractional lengthening of the muscle-tendon junction. Subscapularis lengthening is accomplished via "Z"-lengthening using a deltopectoral approach or muscle slide through a longitudinal incision along the lateral border of the scapula. The subscapularis is elevated in an extraperiosteal plane from the anterior surface of the scapula beginning inferiorly and progressing superiorly.[18]

If the latissimus dorsi and teres major muscles are spastic offenders, their tendons are released from the insertion on the humerus.

Severe contracture and limb malposition are treated by humeral osteotomy, with the caveat that axillary hygiene will not be altered. Glenohumeral joint arthrodesis is reserved for instability or painful glenohumeral joint subluxation.

Elbow

Types of Operative Procedures

Spastic dynamic elbow flexion contractures can be surgically addressed by denervation, lengthening, or myotomy of the muscles crossing the anterior aspect of the elbow. Muscle contracture release options include either individual lengthening or release of the biceps, brachialis, and/or brachioradialis. In addition, the flexor-pronator mass may be a contributor to the elbow flexion contracture. A concomitant flexor-pronator slide may be necessary.

Fixed, long-standing contractures result in additional skin, soft tissue, and joint factors. Release requires more extensive surgery, including skin "Z"-plasty and possible capsular release; the rate-limiting factor is often the stretch of neurovascular structures. Therefore, we try to avoid capsular procedures but favor serial casting following surgical lengthening and/or release of the skin, fascia, and muscles to make additional gains in elbow extension.

Musculocutaneous Neurectomy

Indications. Musculocutaneous neurectomy is rarely performed. Neurectomy is reportedly effective for spastic deformity of less than 30 degrees.[79,114,143,164] Neurectomy denervates the biceps and brachialis and results in active elbow flexion through the remaining brachioradialis. Full passive range of motion of the joint is necessary because this procedure does not correct contractures about the joint.

Contraindications. Musculocutaneous neurectomy is an "all-or-none" treatment, and no fine-tuning of tension in the muscles or separate biceps or brachialis release is possible. This

may explain its decline in usage. It is contraindicated in patients with functional elbows that bring the hand into positions necessary for activities of daily living. Neurectomy addresses only muscular spasticity and is contraindicated when fixed contracture exists. Additionally, musculocutaneous neurectomy results in a sensory deficit in the lateral arm in the distribution of the lateral antebrachial cutaneous nerve. Neurectomy of only the motor branches preserves this sensibility.

Preoperative Planning. Preoperative lidocaine or bupivacaine block of the musculocutaneous nerve along the proximal medial aspect of the biceps is often performed prior to formal neurectomy. The temporary paralysis assists in differentiating the contribution of abnormal muscle tone from fixed contracture and helps predict the results following neurectomy. The block also identifies the amount of elbow flexion possible through the brachioradialis muscle. A preoperative dynamic electromyogram (surface or fine wire) may also be helpful in determining patterns of spasticity.[92]

Technique. The musculocutaneous nerve is exposed through an axillary or medial arm incision. The musculocutaneous nerve is identified emanating from the lateral cord of the brachial plexus. Stimulation yields elbow flexion and confirms identification. A 1-cm segment of musculocutaneous nerve can be removed; however, isolation and resection of the motor braches are preferred. No postoperative immobilization is necessary.[114,167]

Elbow Flexor Lengthenings for Dynamic Spasticity

Indications. Lengthening or release of the biceps, brachialis, and brachioradialis is a direct approach to spastic flexion contracture of the elbow.[6,24,42,58,98,116,117,125,165] The procedure can increase elbow active extension by about 40 degrees, with minimal loss of flexion arc or functional flexion power.[126]

Contraindications. Contraindications to isolated lengthenings include skin, capsular, and joint contractures. Patients must have strong active elbow flexion preoperatively, or lengthening of the flexors may weaken the elbow and negate hand-to-mouth activities.

Preoperative Planning. Serial clinical examinations are necessary to properly identify the muscles that require lengthening. Results of previous treatments, including passive stretch therapy, splinting/casting, and botulism toxin injections, are useful in predicting the outcome and guiding surgical planning. Dynamic electromyography may again be helpful to distinguish the contributions of individual muscles to the deformity.[92]

Technique. The patient is placed supine on the operating room table. The entire extremity is prepped and draped. A sterile circular tourniquet is applied (HemaClear, OHK Medical Devices, Grandville, MI) that exsanguinates during application. For purely dynamic spasticity, a transverse incision across the antecubital fossa is made. Antecubital veins are mobilized or ligated. The lateral antebrachial cutaneous nerve, emerging from the interval between the biceps and brachialis lateral to the biceps tendon, is identified and retracted laterally. The lacertus fibrosus is identified and the median nerve and brachial artery are appreciated deep to the lacertus fibrosus. The radial nerve is isolated between the brachioradialis and brachialis muscles.

The brachioradialis is usually treated by myotomy. The muscle is isolated from the extensor carpi radialis brevis (ECRB) and the radial nerve. The muscle is cut using electrocautery for complete release. Deep to the biceps tendon, the brachialis muscle-tendon junction is identified. A fractional lengthening is performed by cutting the tendon, leaving the muscle alone (Figure 32.10). The biceps may or may not be lengthened

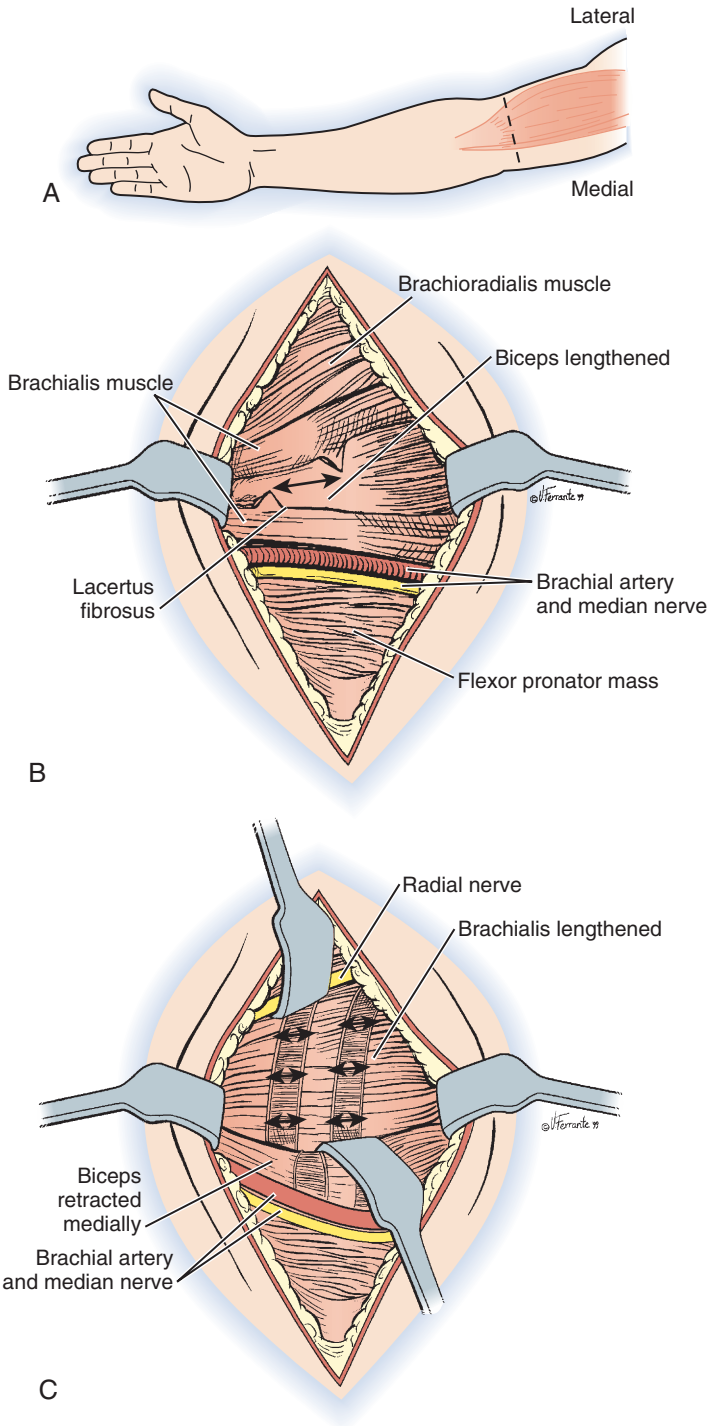

FIGURE 32.10 Fractional lengthening of the elbow flexors. **A,** Through a transverse incision in the antecubital fossa, the lacertus fibrosus is transected, and the neurovascular bundle and lateral antebrachial cutaneous nerves are identified and protected. **B,** "Z"-lengthening of the biceps tendon with medial and lateral tenotomies. **C,** Fractional lengthening of the brachialis through the musculotendinous junction and subperiosteal release of the proximal brachioradialis from the distal humerus through the same incision. After spreading of the tenotomies, the overlapping region of the biceps tendon is secured with three sutures.

depending upon the preoperative examination for spasticity and its contribution to forearm supination. The decision is not always straightforward. If the biceps is lengthened, a fractional lengthening is performed at the muscle-tendon junction.

The wound is closed with absorbable suture. A long-arm cast is applied with the elbow in full extension. The cast is worn for 3 weeks, followed by range of motion and splint fabrication.

Elbow Contracture Release for Fixed Deformity

Indications. Fixed elbow contractures require a more extensive release. In general, functional upper extremities with an elbow flexion contracture of more than 40 degrees should be addressed. In the nonfunctional upper extremity, a flexion contracture that results in difficulties in dressing or recurrent intertriginous infections should be treated. Release of a severe elbow flexion contracture often results in a satisfying improvement in function and hygiene. A 45-degree improvement in the flexion contracture of the extremity is usually obtained. Many patients are able to accomplish tasks that were difficult before surgery. In a wheelchair-bound patient, flexion deformities of more than 100 degrees make assistance during transfers difficult and manipulation of objects or technologic devices on a tabletop impossible. Elbow release improves the ability to work at a tabletop and assist in transfers. Ambulatory patients can expect an improvement in use of the arm in two-handed activities and in the workable reach space of the extremity.

Contraindications. Patients with weak elbow flexion may have a functional loss of elbow flexion after full elbow release. The risks of loss of elbow flexion must be weighed against the benefits of improved position and hygiene of the extremity. Therapy, splinting, serial casting, and stretching should be maximized prior to surgical intervention.

Technique. The patient is placed supine on the operating room table. The entire extremity is prepped and draped. A sterile circular tourniquet is applied (HemaClear, OHK Medical Devices, Grandville, MI) that exsanguinates during application. For a fixed contracture, an "S"-shaped or "Z"-plasty incision is made centered over the antecubital fossa (Figure 32.11). Antecubital veins are mobilized or ligated. The lateral antebrachial cutaneous nerve, emerging from the interval between the biceps and brachialis lateral to the biceps tendon, is identified and retracted laterally. The lacertus fibrosus is identified and incised from the biceps tendon. The median nerve and brachial artery are visualized. The radial nerve is isolated between the brachioradialis and brachialis muscles.

The brachioradialis is treated by myotomy. The muscle is isolated from the ECRB and the radial nerve. The muscle is cut using electrocautery for complete release. The biceps tendon is traced from its muscular origin to the radial tuberosity. The tendon is lengthened by "Z"-plasty along its entire length. Deep to the biceps tendon, the brachialis muscle-tendon junction is identified. A fractional lengthening is performed by cutting the tendon, leaving the muscle alone. The amount of extension gained is assessed. Any additional tight fascia is released. The neurovascular bundle is often the rate-limiting factor. Therefore, additional capsular release would not achieve considerable gains in extension. Additional gains in elbow position can be made by serial casting following surgery.

The biceps tendon lengthening is repaired with a tendon weave or end-to-end repair using a nonabsorbable suture. The wound is closed with absorbable suture. A long-arm cast is applied with the elbow in full extension. The cast is worn for 4 weeks, followed by range-of-motion movements and splint fabrication.[93,94]

❖ Authors' Preferred Method of Treatment

Treatment decisions are based on repeated examinations and frank conversations with the patient and family. Nonoperative measures should be exhausted prior to surgery. Dynamic elbow spasticity that is not responsive to therapy can be treated by surgery via a transverse incision across the antecubital fossa, as described above (see Figure 32.10). This procedure is often performed during concomitant procedures to address the wrist, fingers, and/or thumb. Fixed contractures are less responsive to therapy. Contractures that interfere with care or function require surgery. The details of a more extensive procedure are detailed above. An "S"-shaped or "Z"-plasty incision is necessary to allow ample skin for closure. The neurovascular

CRITICAL POINTS *Elbow Muscle Release and Lengthening for Dynamic Spasticity or Fixed Flexion Contracture*

Indications
- Dynamic elbow spasticity that has not been responsive to therapy
- Fixed flexion contracture greater than 40 degrees that interferes with function or hygiene

Preoperative Evaluation
- Individualize patient goals.
- Perform repeated clinical examinations.
- Maximize nonoperative modalities and consider botulinum toxin to predict surgical outcomes.
- Dynamic electromyography may be helpful in identifying spastic muscles.

Pearls
- Apply a sterile circular tourniquet (HemaClear, OHK Medical Devices, Grandville, MI) that exsanguinates during application and allows complete access to the elbow.
- Always identify and protect the neurovascular structures early in the procedure because they may be displaced by the spastic muscles and/or contracture.

Technical Points
- Make a transverse antecubital incision for dynamic spasticity and an "S"-shaped or "Z"-plasty incision for a fixed deformity.
- Identify the lateral antebrachial cutaneous nerve.
- Mild biceps lengthening via fractional technique; more extensive lengthening requires "Z"-lengthening.
- Mobilize the neurovascular bundle from the anterior surface of the brachialis prior to brachialis fractional lengthening.
- Identify the radial nerve in the interval between the brachialis and brachioradialis.

Pitfalls
- Failure to identify the neurovascular structures can lead to iatrogenic injury.
- Inadequate hemostasis can lead to postoperative hematoma.
- Careless skin handling can lead to wound dehiscence.

Postoperative Care
- Cast application is preferred to allow for wound and tendon healing.
- Begin active and passive range-of-motion exercises following cast removal.

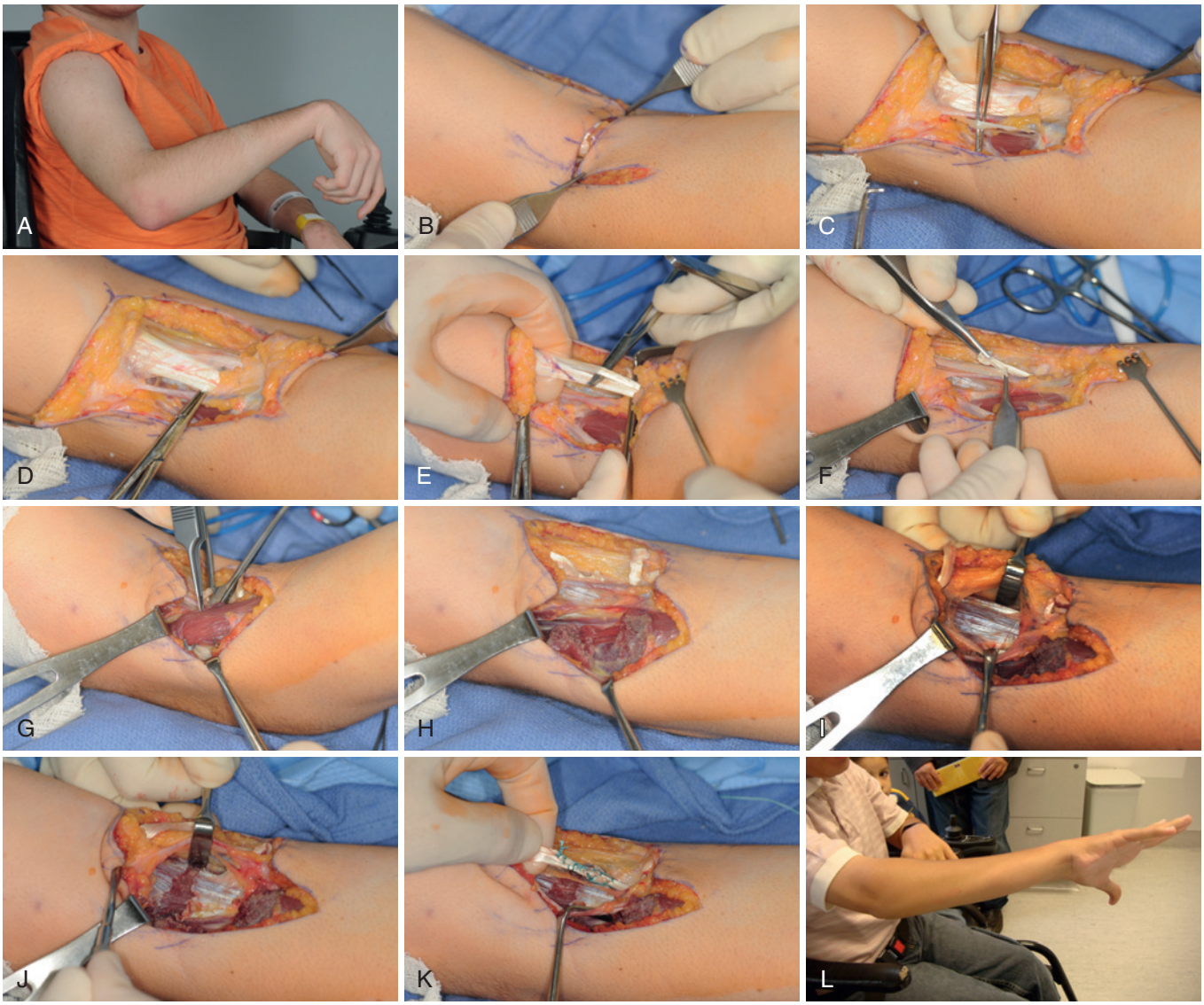

FIGURE 32.11 Elbow static contracture release. **A,** Preoperatively, the patient has a severe static flexion contracture of his elbow; passive extension is lacking at more than 90 degrees even with the patient asleep. **B,** "Z"-plasty incision in the antecubital fossa. **C,** The lateral antebrachial cutaneous nerve is protected. **D,** The lacertus fibrosus is transected. **E** and **F,** The biceps tendon is "Z"-lengthened. **G** and **H,** Myotomy and subperiosteal dissection origin of the brachioradialis. Note that the radial nerve branches to the brachioradialis are preserved. **I,** The brachialis tendon is visualized deep to the biceps, and the neurovascular bundle is retracted medially. **J,** Fractional lengthening and myotomy of the brachialis. **K,** After complete release of the anterior capsule, the "Z"-lengthened biceps tendon is repaired with ethibond suture. **L,** Postoperative elbow extension. (Courtesy of Shriners Hospital for Children, Philadelphia.)

structures must be identified and protected. Postoperative serial casting may be used to further improve elbow extension. Biceps lengthening may result in a "Popeye" deformity contour of the anterior arm.

Forearm

The forearm is the "forgotten joint" with regard to movement and balance in a child with spasticity. The forearm is articulated at its proximal and distal ends (proximal and distal radioulnar joints). The movement is balanced by two muscles that supinate (biceps and supinator) and two muscles that pronate (pronator teres and pronator quadratus).

Types of Operative Procedures

The spastic forearm is classically positioned in hyperpronation. Several operative procedures have been described to decrease the spastic pronation force on the forearm. Brachialis and brachioradialis transfers have also been described.[134,135] Release of the pronator teres can be performed at its origin by a flexor-pronator muscle slide or at its insertion by a pronator teres tenotomy or rerouting. Studies have reported that pronator rerouting results in an increase in active supination of between 46 and 78 degrees,[17,73,118] compared with 54 degrees for pronator tenotomy.[173] However, in these reports the arc of motion was unchanged after pronator rerouting. This suggests that pronator teres rerouting may only reposition the forearm versus function as an active supinator. This finding has changed our approach to the spastic forearm, and we less commonly perform pronator teres rerouting. The pronator quadratus should not be released during pronator teres release, because this may result in loss of pronation, which is critical for "tabletop" and many technology-based activities of daily living and communication.[153]

A forearm positioned in pronation for a prolonged period will become contracted in this position, with structural changes to the proximal and distal radioulnar joints. Tendon transfers are contraindicated with a fixed contracture or radial head dislocation.[140] Options include interosseous membrane release combined with tendon transfer, osteotomy of the radius and/or ulna, or the one-bone forearm procedure.[49,106]

The surgeon must consider the entire operative plan for the extremity because other operative procedures to improve wrist extension can also improve supination. In the laboratory, FCU to ECRB transfer achieved 84 degrees of supination, brachioradialis rerouting achieved 33 degrees of supination, and pronator rerouting was unable to achieve supination past neutral.[30] However, these numbers may be different in vivo and may depend on the amount of pronation spasticity and phasic activity of transferred muscles. For example, FCU to ECRB transfer for wrist extension clinically increased supination by an average of 22 degrees.[9,193]

Flexor-Pronator Origin Muscle Slide

Indication. The flexor-pronator origin muscle slide was initially designed to release the ischemic muscles after established forearm compartment syndrome.[44,86,136,182,204] The procedure releases the pronator teres as well as the wrist and digital flexors. In addition to releasing the pronation contracture of the forearm, the flexor-pronator mass that originates from the medial epicondyle can contribute to elbow flexion contracture. The procedure can be extended in a proximal direction to release other contractures about the elbow as well.

Contraindication. The flexor-pronator muscle slide is an "all-or-none," technically demanding procedure requiring surgical experience. The procedure can cause excessive weakness of the finger flexors and overcorrection of pronation deformity.[44]

Technique. The patient is placed supine on the operating room table. The entire extremity is prepped and draped. A sterile circular tourniquet is applied (HemaClear, OHK Medical Devices, Grandville, MI) that exsanguinates during application. A long incision is made along the medial corridor from above the elbow to the ulnar styloid. The skin is incised, and hemostasis is obtained with electrocautery. Loupe magnification is used throughout the procedure.

The ulnar nerve is identified and traced through the cubital tunnel. Proximal dissection is performed so that any investing fascia around the ulnar nerve and the arcade of Struthers is released. The nerve is released to the point where it can be transposed in an anterior direction (Figure 32.12).

The flexor-pronator mass is incised directly off the ulna down to the medial collateral ligament. The collateral ligament is carefully preserved. The muscle is sequentially released from the ulna all the way to the wrist.

Subsequently, the release continues in an ulnar to radial direction. The release courses superficial to the brachialis muscle, where the median nerve and brachial artery are identified. The bifurcation into the radial and ulnar arteries is protected.

Directly on the interosseous membrane, the anterior interosseous nerve and artery are protected. Dissection proceeds superficial to the nerve and artery until the radius is

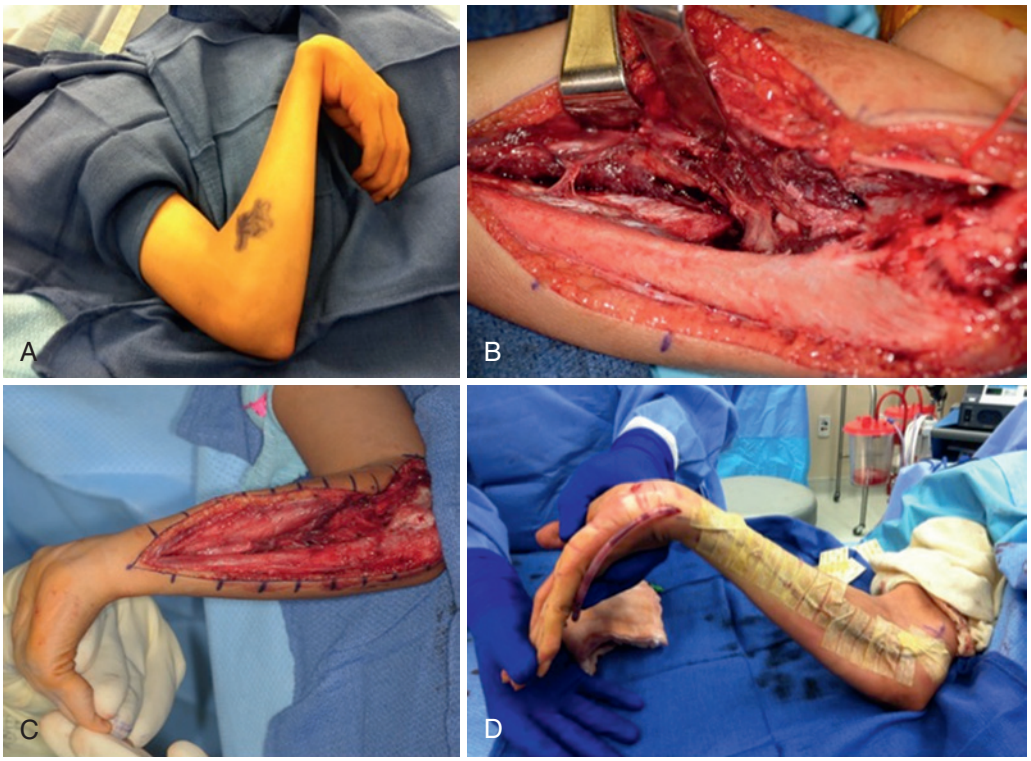

FIGURE 32.12 Flexor origin slide. **A,** Severe wrist and finger flexion deformity. **B,** Ulnar border incision with transposition of the ulnar nerve and dissection of all pronator and flexor forearm and finger muscle origins from the periosteum and interosseous ligament. **C,** Full extrinsic wrist and finger extension can be achieved; intrinsics may be released separately. **D,** Closure over a drain and casting in full finger and wrist extension. (Reproduced with permission of Children's Orthopaedic Center, Los Angeles, and Shriners Hospital for Children, Philadelphia.)

encountered. Any taut muscle that originates from the radius (FDS, FPL) is released from its proximal origin.

The release is continued until the wrist and fingers can be extended completely. Closure is straightforward, leaving the ulnar nerve in an anterior position. We often place a deep drain beneath the flexor-pronator mass. A long-arm cast is applied with the wrist and digits in extension. The forearm is positioned in midsupination.

The arm is immobilized in a cast for 4 weeks with the elbow extended to 45 degrees, the forearm supinated, and the wrist and digits in extension. A removable splint is continued for 4 additional weeks, allowing removal for range-of-motion movements and therapy. After 2 months, splinting is converted for night use; it is discontinued 1 month later unless there is a tendency for recurrence of the deformity.

Release of Pronator Insertion

Indication. Pronator insertion release alleviates the deforming force of the pronator teres muscle.[58,72,73,173] Release alone is indicated in patients who have excessive pronation but no voluntary control of pronation. In patients who do not have active supination, a tendon transfer may be necessary to augment supination even after release of the pronator.

Contraindication. Isolated pronator release in patients who lack active supination will not improve the deformity. Fixed deformity requires additional interosseous membrane release, osteotomy of the radius and/or ulna, or a one-bone forearm procedure.

Technique. Topographically, the pronator teres insertion is just proximal to the radial sensory nerve as it exits from beneath the brachioradialis muscle.[106] A straight or curvilinear radial boarder incision allows direct access to the pronator insertion. Small branches of the lateral antebrachial cutaneous nerve are identified and protected. The radial sensory nerve is isolated between the brachioradialis and the ECRL. Proximal to the radial sensory nerve, the brachioradialis is elevated to expose the underlying radius. The tendon of the pronator is isolated inserting into the radius. A tenotomy of the entire tendon is performed under direct visualization.

After release, primary closure and an above-the-elbow cast or sugar tong splint is placed to keep the forearm in supination for 4 to 6 weeks. A removable supination splint is worn for an additional 4 weeks, with place-and-hold active and passive supination and active pronation exercises as part of the protocol.

Pronator Teres Rerouting

Indication. Rerouting of the pronator converts this muscle to a supinator.[17,41,73,118,153,173] Clinical results demonstrate a 50% increase in supination and correction of the reverse grasp position. It is indicated in patients who have active control of the pronator and lack active supination. The tendon can be released and rerouted through the interosseous space; alternatively, the pronator can be "Z"-lengthened and the distal portion brought around the radius and through the interosseous membrane from dorsal to volar, where it is woven into the proximal tendon.[72]

Contraindication. Pronator teres rerouting should be used sparingly in patients without active pronation control as the transfer will act only as a tether.

Technique. The patient is placed supine on the operating room table. The entire extremity is prepped and draped. A sterile circular tourniquet is applied (HemaClear, OHK Medical Devices, Grandville, MI) that exsanguinates during application. A longitudinal incision is made over the radial aspect of the forearm. The superficial branches of the lateral antebrachial cutaneous nerves are mobilized. The radial sensory nerve is identified emanating from the brachioradialis muscle-tendon. The nerve is traced in a proximal direction and the brachioradialis muscle is elevated. Just proximal to this point, the pronator teres tendinous attachment to the radius is identified.

The pronator muscle is released and dissected in a proximal direction to facilitate rerouting. A spacious window is made in the interosseous membrane to accommodate the transfer. The pronator teres tendon is lengthened in a "Z" fashion.[5] The distal part of the tendon is rerouted from dorsal to volar through the window in the interosseous membrane. The distal part is sutured back to the proximal part under slight tension. Alternatively, the pronator teres tendon is detached and transferred through the interosseous membrane and around the radius and reattached to its former insertion site with transosseous sutures or suture anchors with the forearm in supination.

❖ Authors' Preferred Method of Treatment

Mild pronation contracture of the forearm is treated by release or rerouting of the pronator teres insertion (Figure 32.13). In patients with active supination, we prefer a pronator tenotomy. If the patient has active pronation but no active supination, rerouting of the pronator is performed. In patients who have a pronation contracture combined with wrist and finger flexion deformity, a flexor-pronator muscle slide is preferred. In patients with a moderate to severe pronation deformity, an osteotomy of the radius and/or ulna or a one-bone forearm procedure is preferred.

Wrist and Digital Extension

Types of Operations

Balance of the wrist and digits is important to improve hand function in children with spasticity.[37,190] Decision making to match the best procedure with an individualized patient predominantly relies on the degree of wrist and finger joint contractures as well as tone and muscle spasticity of the wrist and digital flexors. If assessment is difficult, median and/or ulnar nerve blocks can temporarily eliminate the flexor spasticity and allow a better evaluation.[119] Ulnar deviation of the wrist may compound a flexion deformity and may be caused by a spastic or contracted FCU and/or ECU. The muscle causing the deformity can be cut, lengthened, or used as a transfer to augment its antagonist.

An integral part of the examination is the evaluation of digital function during wrist motion (Figure 32.14). If the patient cannot actively extend the wrist to neutral, the wrist should be held in neutral by the examiner while the patient attempts active digital extension. Grasp and release must be evaluated to ensure that improvements in wrist extension will not decrease digital extension and affect object acquisition (see Video 32.2). Similarly, the patient may rely on ulnar deviation of the wrist to increase thumb abduction for acquiring objects for pinch. If wrist ulnar deviation is lessened, a concurrent procedure to augment thumb abduction may be necessary.

A patient who would benefit from greater wrist extension may be helped by several available operative

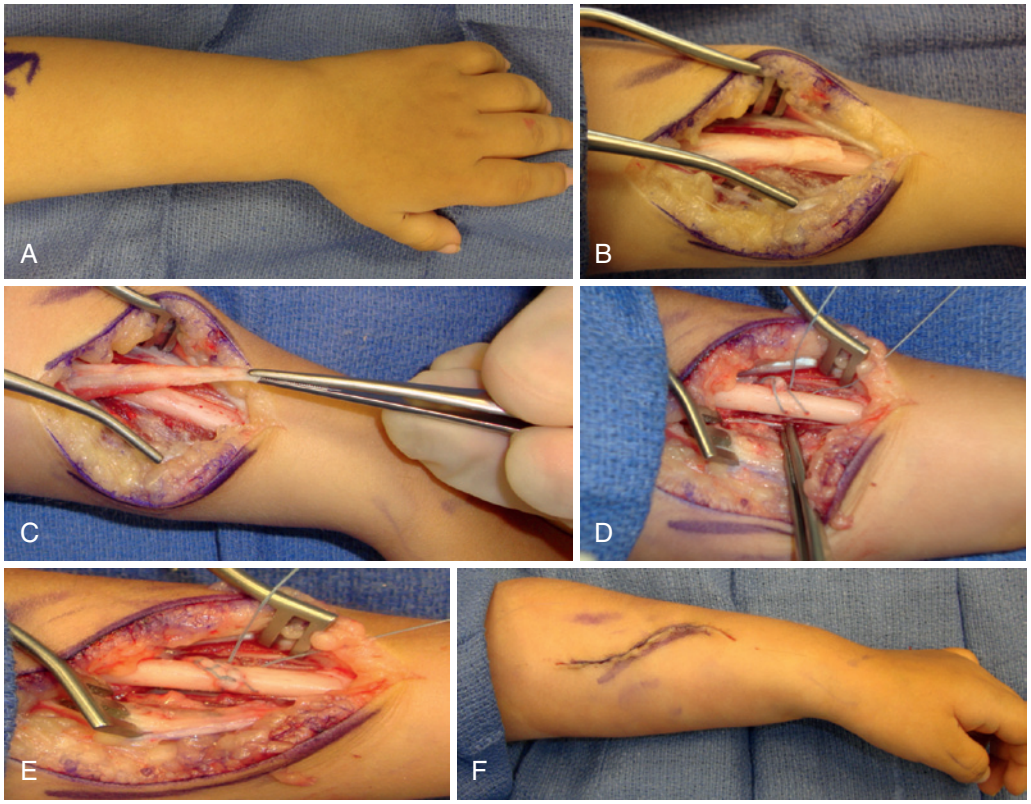

FIGURE 32.13 Pronator rerouting. Through a longitudinal incision in the middle aspect of the forearm **(A)**, the pronator is taken down from its insertion on the radius and routed through the interosseous septum (from volar to dorsal) **(B** and **C)** and reattached to a drill hole in the dorsal radial radius **(D** and **E)**. **F,** Closed incision with passively improved supination. (Reproduced with permission of Children's Orthopaedic Center, Los Angeles.)

CRITICAL POINTS *Pronator Teres Tenotomy or Rerouting*

Indications
- Pronator tenotomy: active supination short of neutral
- Pronator rerouting: weak to no active supination with volitional pronator teres

Contraindications
- No active pronation control
- Fixed deformity

Preoperative Evaluation
- Test for active supination and pronation.

Pearl
- Identify the pronator teres insertion just proximal to the radial sensory nerve as it exits from beneath the brachioradialis muscle.

Technical Points
- Make a longitudinal incision on the radial aspect of the midforearm.
- Protect the medial antebrachial cutaneous nerve.
- Identify the superficial radial nerve.
- Develop the interval between the brachioradialis and the wrist extensors.
- For pronator release, simply divide the tendon completely.
- For pronator rerouting, elevate the insertion of the pronator with a periosteal sleeve.
  - Expose the radius at the level of the insertion.
  - Incise the interosseous membrane at this level over a 2-cm distance.
  - Pass the pronator from volar to dorsal through the interosseous membrane with a right-angled clamp.
  - Suture the pronator to a drill hole in the radial aspect of the radius or use suture anchors in the radius.

Pitfall
- Pronator release or rerouting will not be efficacious in patients with substantial contracture of the forearm. Additional interosseous membrane release, osteotomy of the radius and/or ulna, or a one-bone forearm procedure is necessary.

Postoperative Care
- Use a sugar tong splint or long-arm cast for 1 month with the wrist and forearm in neutral position or midsupination.
- Remove immobilization at 1 month and fabricate a splint that positions the forearm in neutral position or midsupination.
- During the second month, the splint is removed only for therapy.
- Discontinue the splint at 2 months after surgery.



FIGURE 32.14 A patient with good active digital extension but absent wrist extension. (Copyright Michelle Gerwin Carlson.)

techniques that would accomplish this and improve function. Potential donors include the ECU,[54,98,116,119,151] FCU,[28,54,58,63,70-72,78,81,116,156,157,179,183,186,203,205] pronator teres,[32,54,137] and brachioradialis.[124,137] Donor tendons are usually transferred to the ECRB due to its central location on the third metacarpal. When transferring the FCU, an alternative route through the interosseous membrane has been described to decrease the ulnar-deviating force on the wrist,[137] but this also decreases the supination effect of the transfer.[194] The choice of donor is based on a careful physical examination and surgical experience.

In patients with severe fixed wrist capsular contractures, a proximal row carpectomy may be an adjunct to allow extension of the wrist to neutral before tendon transfers can be performed.[133,186] However, this combination is uncommonly performed because proximal row carpectomy yields a small gain in passive wrist extension. Wrist arthrodesis can be used to improve hygiene or function, however[4,67,74,146]; fusion may downgrade function due to loss of the tenodesis effect on the digital tendons.[156] In a child, an epiphyseal arthrodesis or chondrodesis (wrist fusion that preserves the physeal plate) can be performed to allow continued growth if the patient has adequate ossification of the epiphysis and carpal bones. However, fusion is difficult to achieve secondary to the abundant pediatric cartilage.[58]

Weak digital extension is less common than weak wrist extension and is associated with more severe disability.[119] Transfer of the FCU to the extensor digitorum communis (EDC)[58,64,98,116,123] has been recommended to improve digital extension while also improving wrist extension. Tendon transfers always perform best when "asked" to perform a single task, and the surgeon must be careful about "asking" too much from an already compromised muscle-tendon unit. Tendon transfers for digital extension are useful in patients who are unable to actively extend their fingers when the wrist is in extension. Zancolli and Zancolli defined three types of finger extension deformities and suggested a treatment algorithm[212] (Table 32.4). Patients with poor wrist and digital extension may benefit from a combination of tendon transfers, such as FCU to EDC and either ECU or pronator teres to ECRB.

Results of wrist extension transfers have demonstrated improved function in approximately 80% of patients.[9,71,78] FCU to ECRB transfer has shown good results, with an average

TABLE 32.4 Finger Extension Deformities and Their Treatment

Type	Deformity	Treatment
I	Active digital extension possible with wrist extended less than 20 degrees from neutral	No treatment or minimal fractional lengthening of digital and/or wrist flexors
II	Active digital extension possible with wrist flexed more than 20 degrees from neutral	Fractional lengthening of digital flexors in addition to augmentation of wrist extension and/or flexor carpi ulnaris tenotomy
III	No active digital extension	Augmentation of digital extension with flexor carpi ulnaris transfer to extensor digitorum communis

Zancolli EA, Zancolli ER, Jr: Surgical management of the hemiplegic spastic hand in cerebral palsy. *Surg Clin North Am* 61:395–406, 1981.

improvement in resting wrist posture from 41 degrees of flexion to 11 degrees and an improvement in the arc of motion, with increased wrist extension and a compensatory loss of flexion. The total range of motion is unchanged after this procedure, although wrist extension has been shown to improve by 35 to 45 degrees.[9,149,183,186,203] The greatest improvement in function of the hand is seen in patients without flexion contractures who use a wrist flexion to augment digital opening when attempting digital extension.[71] Children with dystonia, neglect, poor stereognosis, and little voluntary limb control will demonstrate inferior outcomes after all wrist extension tendon transfers.[205]

Flexor Carpi Ulnaris to Extensor Carpi Radialis Brevis Transfer (Green's Transfer)

Indication. FCU to ECRB transfer is indicated in patients who have a dynamic wrist flexion deformity, flexible wrist joint, intact although possibly weak finger extensors, and absent or weak wrist extension.[107]

Contraindication. A nonfunctioning FCR is a relative contraindication because the result will be loss of active wrist flexion and a wrist extension deformity. Preoperative FCU evaluation by electromyography can be helpful because children with dystonia and irregular phasic contractions will have unreliable results.[189] If the finger extensors are absent, the FCU may be more appropriately transferred to the EDC. If the wrist joint is inflexible and the digital flexors are tight, additional concurrent procedures need to be performed to provide reliable outcomes after FCU to ECRB transfer.[138]

Technique. The FCU can be harvested through multiple small incisions or a single long ulnar border incision (Figure 32.15). If smaller transverse or longitudinal incisions are used, the first incision is made over the FCU insertion on the pisiform at the wrist flexion crease. Tension on the tendon allows the proximal aspect of the tendon to be palpated. The more proximal incisions are made at proximal palpable points on the tendon in the forearm. Transverse incisions are more aesthetic, but care must be taken to protect the ulnar neurovascular bundle during harvest. In addition, the large muscular and sheath attachments of the FCU along the ulna may make passing the tendon beneath the skin difficult. Following FCU identification within each transverse incision, the FCU is transected at its insertion on the

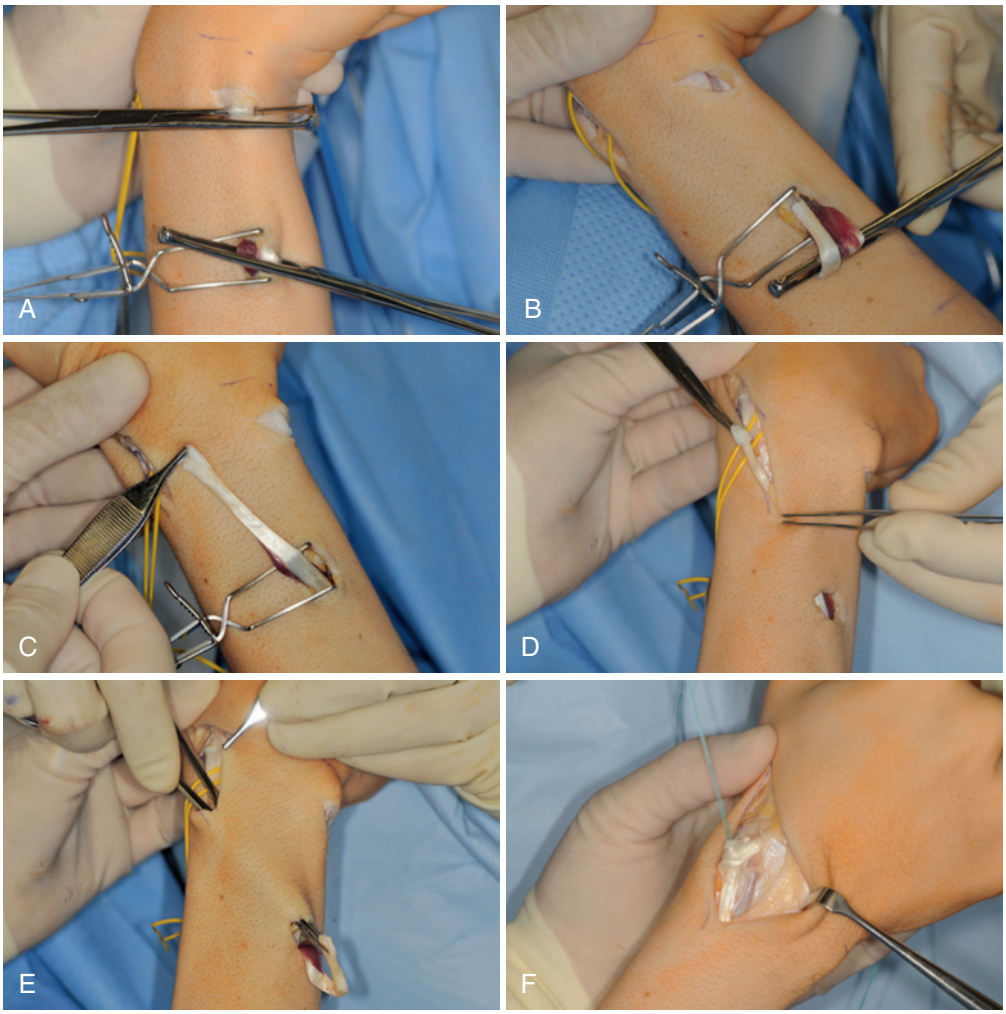

FIGURE 32.15 Flexor carpi ulnaris to extensor carpi radialis brevis transfer. **A** and **B,** The flexor carpi ulnaris tendon is harvested through two volar incisions, one distal at the pisiform and the other over the midforearm. The flexor carpi ulnaris can be harvested using a tendon stripper inserted distally. **C,** The tendon is wrapped over the forearm to mark the site of attachment to the extensor carpi radialis brevis tendon. **D** and **E,** An incision can then be made at this spot and the tendon tunneled subcutaneously. **F,** The length gained from the subcutaneous tunnel allows easy weaving in a Pulvertaft fashion. (Courtesy of Shriners Hospital, Philadelphia.)

pisiform and progressively mobilized through the proximal incisions. The transverse incisions are recommended for surgeons who have considerable experience. Alternately, the incisions can be made longitudinally. To ensure adequate length and estimate insertion location, the tendon is passed around the ulnar aspect of the forearm, over the skin, to the point where it intersects with the ECRB. The goal is to insert the tendon at the wrist rather than within the forearm. This maneuver also ensures ample tendon to allow a Pulvertaft weave. A transverse or longitudinal incision is made over the ECRB at the intended weave site. A subcutaneous tunnel is created from the dorsal incision to the volar ulnar wound. The tunnel should be deep to the subcutaneous tissue and sensory nerves but superficial to all tendons. Care should be taken to ensure that this tunnel is as direct as possible. Any fibrous septa between the FCU and ECU are opened widely to prevent kinking of the muscle as it passes along the ulnar border.

The FCU is passed through this tunnel toward the ECRB insertion. A Pulvertaft weave is performed between the two tendons, with each weave secured with nonabsorbable sutures. The weave should be done with maximal tension on the tendon ends while the wrist is held in neutral to slight extension. Usually, only one or two weaves can be performed. Following the initial weave, tension should be assessed by allowing the wrist to sit in its resting position. Neutral to slight extension is preferred; too loose or too tight is bad.[183] Care should be taken to ensure that the weave does not encroach on the intersection with the EPL or the extensor retinaculum. If this does occur, the EPL can be transposed and/or a portion of the retinaculum divided.

The wrist is immobilized in 30 degrees of extension for 3 to 4 weeks. A splint is worn for 4 to 6 weeks and removed for hygiene, activities, and range-of-motion exercises. Standard tendon transfer training is performed by a hand therapist. Electrical stimulation and biofeedback training can be helpful in patients having difficulty firing the transfer. Nighttime splinting is continued for an additional 3 to 4 weeks and then discontinued.

CRITICAL POINTS *Flexor Carpi Ulnaris to Extensor Carpi Radialis Brevis Transfer*

Indications
- Inability to actively extend the wrist to neutral with a functioning FCU and FCR
- Adequate finger extension with the wrist positioned in extension

Contraindications
- No active control of the FCR
- Dystonia

Pearl
- After tendon transfer, the wrist should passively rest in neutral to slight extension.

Pitfalls
- If weak digital extension is not addressed concurrently, wrist extensor transfer will worsen digital extension and object acquisition.
- Overtightening of the transfer will result in a fixed wrist extension posture and impair digital extension.

Technical Points
- Begin to harvest the FCU at the pisiform because length is always an issue.
- Mobilize the FCU muscle-tendon up to the midforearm.
- Drape the FCU over the skin from the volar wound to the dorsal forearm to assess the location of the tendon weave.
- Create a Pulvertaft weave of the FCU into the ECRB with maximal tension on the tendon and the wrist in neutral to slight extension.

Postoperative Care
- The wrist is splinted in 30 degrees of extension.
- One month after surgery, fabricate a removable wrist extension splint and begin therapy.

Extensor Carpi Ulnaris to Extensor Carpi Radialis Brevis Transfer

Indications. This transfer has become our preferred technique in patients who require augmentation of wrist extension. The ECU is poorly positioned to extend the wrist, however; transfer to the ECRB upgrades this function.

Contraindication. This procedure is contraindicated in patients without any active wrist extension or with existing resting radial deviation of the wrist.

Technique. The technique involves a series of transverse incisions. The first incision is over the ulnar head to isolate the ECU by incising the sixth compartment. The second incision is 6 cm proximal, and the ECU muscle-tendon junction is isolated. The ECU tendon is transected distally at its insertion at the base of the small metacarpal by rolling the tendon with an Allis tissue forceps (Jarit, Elmsford, NY) to deliver the distal tendon into the wound. The ECU is pulled into the proximal transverse incision. The tendon is passed over the skin to the point where it intersects with the ECRB. The goal is to insert the tendon distal to the retinaculum. A transverse incision is made over the ECRB at the intended weave site. A subcutaneous tunnel is created to pass the tendon. The ECU is woven through the ECRB and tension is set to maintain the wrist in slight extension. Following the weave, tension should be assessed by allowing the wrist to sit in its resting position. Neutral to slight extension is the goal. The coaptation is reinforced by an additional weave or side-to-side sutures (Figure 32.16).

This transfer is routinely performed in conjunction with fractional lengthening of the FCU. Immobilization and rehabilitation protocols are similar to those described for the FCU to ECRB transfer.

CRITICAL POINTS *Extensor Carpi Ulnaris to Extensor Carpi Radialis Brevis Transfer*

Indications
- Weak extension of the wrist, especially with ulnar deviation during attempted wrist extension
- Weak extension of the wrist, with the FCU used as a donor for EDC transfer

Pearls
- Routinely lengthen any spastic FCU.
- After transfer, the wrist should passively rest in neutral position or slight extension.

Pitfalls
- If weak digital extension is not addressed concurrently, wrist extensor transfer will hamper digital extension and object acquisition.
- Overtightening of the transfer will impair digital extension.

Technical Points
- Transverse incisions are preferred.
- Transect the ECU as distally as possible.
- Perform a Pulvertaft weave of the ECU into the ECRB with the wrist in neutral position to slight extension.

Postoperative Care
- The wrist is splinted in 30 degrees of extension.
- One month after surgery, fabricate a removable wrist extension splint and begin therapy.

Flexor Carpi Ulnaris to Extensor Digitorum Communis Transfer

Indication. The FCU to EDC transfer is indicated in patients with weak or absent active digital extension.

Contraindication. This transfer is contraindicated in patients with good digital extension and weak wrist extension. The FCR must be volitional. A constantly spastic FCR muscle is a poor donor.

Technique. The FCU is harvested as previously described. The point of attachment to the EDC is identified, with the FCU tendon draped across the skin. A transverse or longitudinal incision is made over the EDC, and the tendons to the index through little fingers are identified. A subcutaneous tunnel is created between the dorsal and ulnar incisions, and the FCU is passed through this tunnel and out the dorsal wound over the EDC. Tension is applied to the EDC tendons to position the MP joints in full extension with the wrist in neutral. The four EDC tendons are sutured together to allow a normal cascade to the fingers before transfer. The FCU is passed through the intact EDC tendons in an ulnar to radial direction, beginning at the small finger EDC tendon and progressing to the index finger

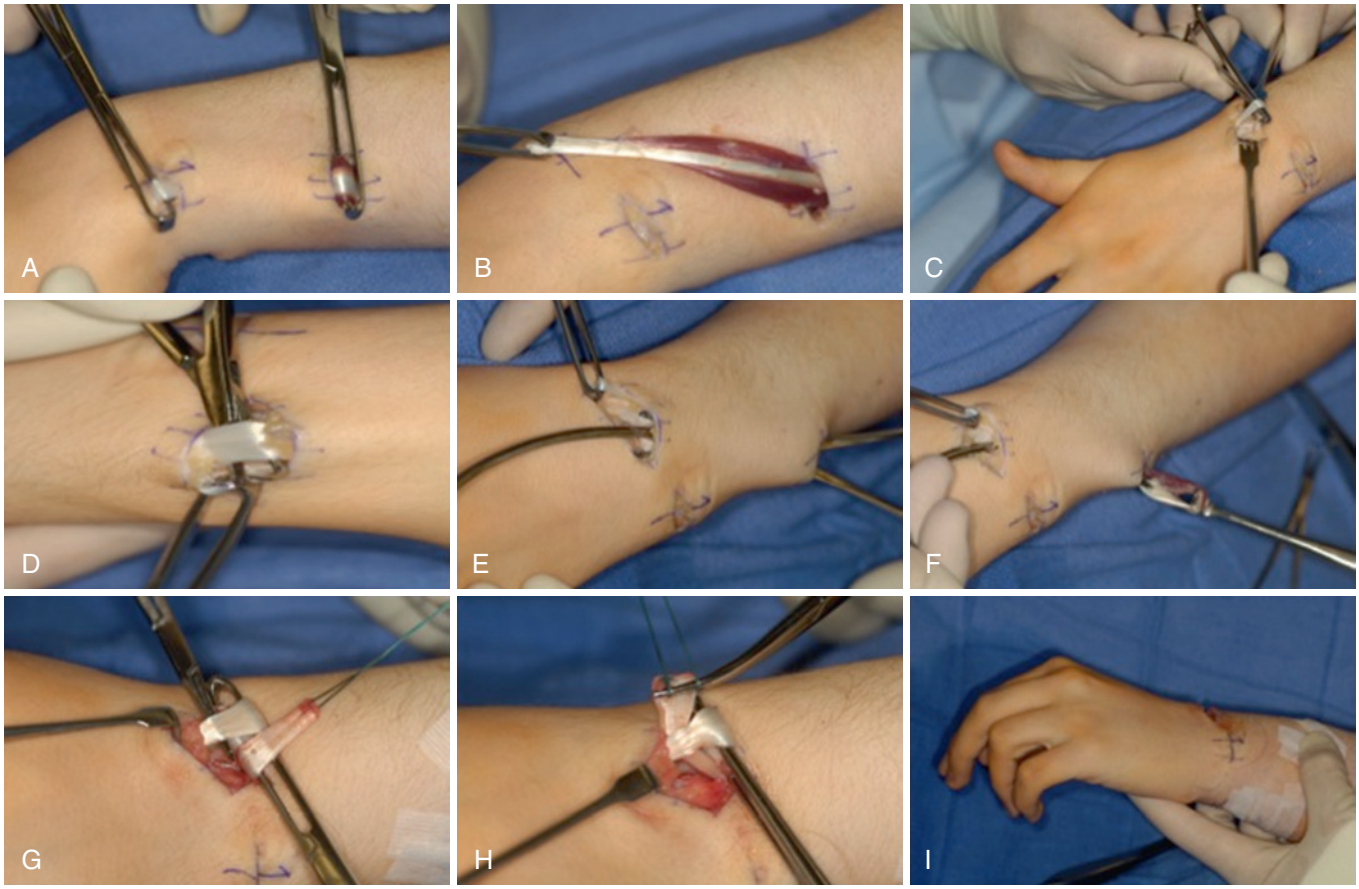

FIGURE 32.16 Extensor carpi ulnaris to extensor carpi radialis brevis transfer. **A,** The extensor carpi ulnaris tendon is harvested through two dorsal incisions, one distal at the carpal insertion and the other over the midforearm. **B,** The tendon is wrapped over the forearm to mark the site of attachment to the extensor carpi radialis brevis tendon. **C,** The incision can then be made at this spot, and the extensor pollicis longus is transposed from the third to the first compartment. **D,** The extensor carpi radialis brevis is identified, and the tendon is tunneled subcutaneously **(E** and **F)**. A Pulvertaft weave **(G** and **H)** is made to complete the transfer and stabilize the wrist **(I)** in a neutral position. (Courtesy of Shriners Hospital for Children, Philadelphia.)

tendon. This is done proximal to the retinaculum, with the retinaculum left in place to prevent bowstringing. Each weave is sewn into place with nonabsorbable sutures. The FCU is passed back in a radial to ulnar direction through the EDC tendons and sutured in place. If length permits, it may be passed a third time.

The extremity is immobilized for 4 weeks in a splint with the wrist in 30 degrees of extension and the digits fully extended. A removable forearm-based splint is fabricated, maintaining digital extension for another 4 weeks; it is removed for therapy and range-of-motion exercises. Night splinting is continued as necessary to avoid recurrence of the deformity.

CRITICAL POINTS *Flexor Carpi Ulnaris to Extensor Digitorum Communis Transfer*

Indications
- Weak or absent active digital extension, with full passive digital extension
- Functioning FCU and FCR

Pearl
- If digital flexors are tight, test for active digital extension with the wrist in flexion.

Pitfall
- The FCR must be strong, or a wrist extension deformity may result.

Technical Points
- Harvest the FCU tendon as for the FCU to ECRB transfer.
- Identify the location of transfer, as in the FCU to ECRB protocol.
- Make a transverse incision in the dorsal forearm over the EDC junction.
- Identify the EDC tendons to the index, long, ring, and little fingers, and suture them together distally, creating a normal cascade, while applying tension proximally.
- Make a subcutaneous tunnel from the volar wound to the dorsal wound and pass the FCU tendon.
- Weave the transected FCU into the intact EDC with the wrist in neutral and maximal tension on the EDC.

Postoperative Care
- Apply a dressing with a forearm-based digital extension splint for 4 weeks.
- Fabricate a removable splint for 4 weeks and begin range-of-motion exercises.
- Discontinue splinting at 8 weeks after surgery.

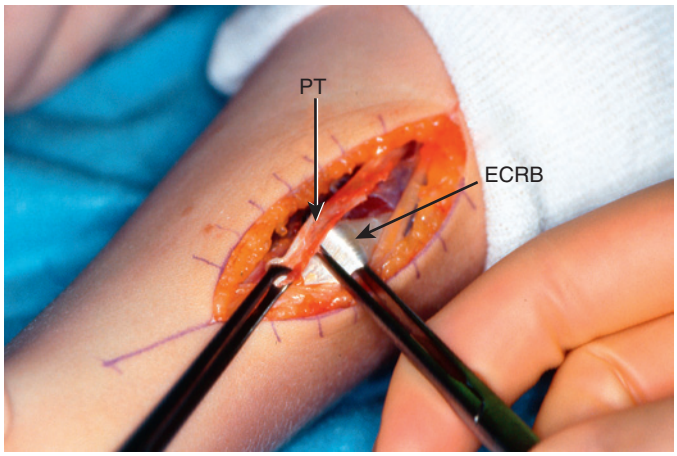

FIGURE 32.17 The pronator teres (PT) tendon is harvested with a strip of periosteum and transferred to the extensor carpi radialis brevis (ECRB) tendon. (Courtesy of Shriners Hospital for Children, Philadelphia.)

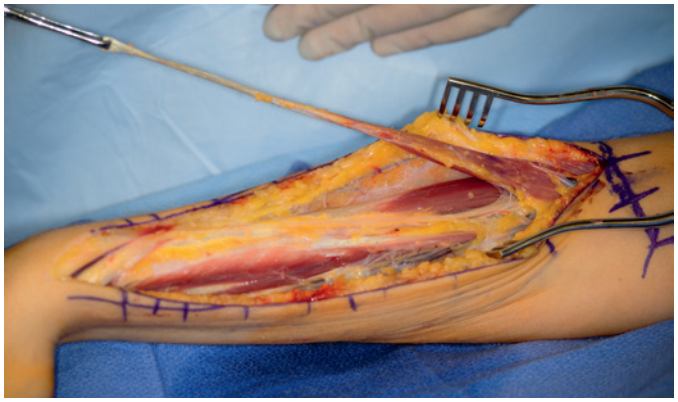

FIGURE 32.18 Brachioradialis tendon is released and mobilized into the proximal third of the forearm to maximize available excursion. (Courtesy of Shriners Hospital for Children, Philadelphia.)

Pronator Teres to Extensor Carpi Radialis Brevis Transfer

Indication. This procedure is an option in patients without a functioning FCR, in whom harvest of the FCU is contraindicated. Fractional lengthening of a spastic FCU should be done in conjunction with pronator transfer. The pronator teres is a viable candidate for augmentation of wrist extension when the FCU or ECU is unavailable.

Contraindications. This procedure limits the arc of motion of the wrist as a result of the short excursion of the pronator and is relatively contraindicated in patients with pronator spasticity. Patients who are dependent on wrist flexion for digital extension may have increased difficulty opening the hand.

Technique. A longitudinal incision is made over the insertion of the pronator in the radial midforearm. The subcutaneous tissue is dissected, and the medial antebrachial cutaneous and superficial radial nerves are identified and protected. The interval between the brachioradialis and the wrist extensors is developed, and the insertion of the pronator is identified. The pronator teres is elevated from the radius with an extended periosteal sleeve (Figure 32.17). A Pulvertaft weave can be performed between the pronator teres and intact ECRB. Tension is set so that there is maximal tension on each tendon, and the wrist is in a neutral position to slight extension. The resting posture of the wrist should also be neutral position to slight extension.

Immobilization is as described for the FCU to ECRB transfer.

Brachioradialis to Extensor Carpi Radialis Brevis Transfer

Indication. The brachioradialis can be effective for transfer when other motor muscles are unavailable. The muscle originates above the elbow; firing requires concomitant active elbow extension to prevent unwanted elbow flexion. The muscle must be dissected into the proximal forearm to increase its excursion.[105a]

Technique. The brachioradialis is approached through a long longitudinal radial incision (Figure 32.18). The brachioradialis insertion on the distal radius is identified and transected while the radial artery and nerve are protected. The brachioradialis is mobilized proximally and freed from the ECRL and FCR. The tendon is placed adjacent to the ECRB. The brachioradialis is woven into the ECRB with the goal of establishing slight wrist extension with the elbow extended.

The arm is immobilized in a long-arm cast for 4 weeks. We prefer to have the elbow in flexion to lessen tension during the healing process. A short-arm removable splint is worn for another 4 weeks while range-of-motion exercises and therapy are initiated. Night splinting is continued as indicated.

❖ Authors' Preferred Method of Treatment

In the functional hand, the decision to perform a transfer to the wrist or digital extensors is based on the physical examination (see Video 32.2). First, testing of active digital extension is performed with the wrist held in a neutral position (Figure 32.19). If full active extension is possible, no transfer is necessary for the digital extensors. If full active digital extension is not possible but the digits can be extended passively, a transfer to motor the digital extensors is considered. We prefer an FCU to EDC transfer for this deformity. A transfer to the wrist extensors in this situation without addressing the fingers would worsen hand function because the patient would be unable to open the fingers and acquire objects.

If passive extension of the digits is limited when the wrist is held in full extension, a fractional lengthening of the digital flexors is necessary. Active digital extension is tested with the wrist flexed. Good digital extension indicates that a transfer will probably not be necessary after release of the tight digital flexors. Limited active digital extension with the wrist flexed, however, indicates that a transfer will be necessary to augment extension in addition to lengthening of the digital flexors. Usually, the FCU to EDC transfer is a good option.

After testing digital extension, wrist extension should be tested. It is helpful to think of wrist flexion deformities as being in three groups: functional, dynamic, and static. Patients with functional deformities of the wrist may have good active range of motion, but when they are performing activities, the wrist drops into flexion. Treatment involves fractional lengthening of the spastic flexors (usually, the FCU). No transfer for wrist extension is needed.

Dynamic deformities of the wrist, by definition, have no static contracture component. Patients may or may not have some limited active extension but cannot extend the wrist to

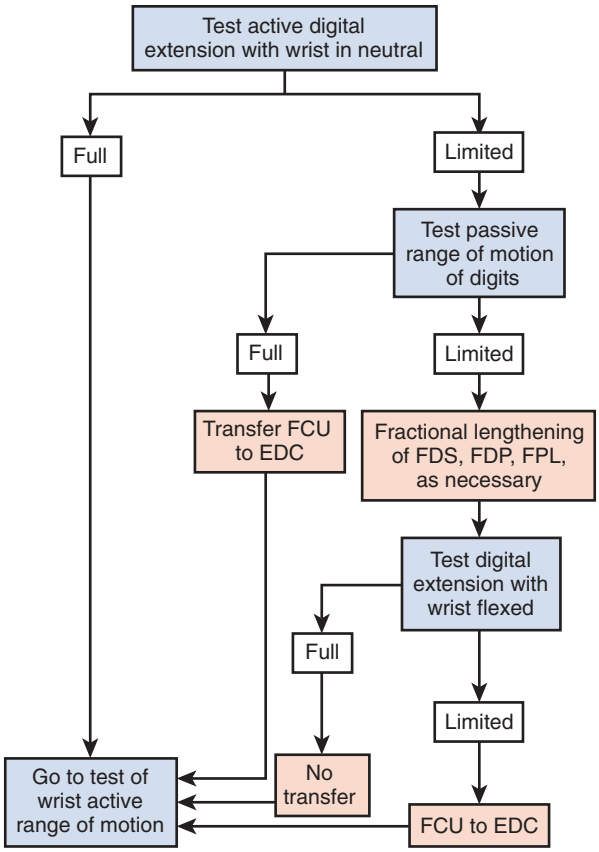

FIGURE 32.19 Algorithm for evaluation of digital extension. *EDC*, Extensor digitorum communis; *FCU*, flexor carpi ulnaris; *FDP*, flexor digitorum profundus; *FDS*, flexor digitorum superficialis; *FPL*, flexor pollicis longus.

neutral. Passive extension of the wrist and digits should be evaluated. If there is full passive extension of the wrist and digits, a transfer to augment wrist extension is indicated. We prefer an FCU to ECRB or ECU to ECRB transfer depending on the clinical examination findings and the amount of wrist extension force necessary. The FCU will provide more force but carries the risk of too much wrist extension. In contrast, the ECU has less force but has the risk of suboptimal wrist extension.

Fixed or static wrist flexion contractures usually occur in older children or adults. A contracture that interferes with function may warrant treatment. Rarely, a tendon transfer is possible; a decision about this can be made at the time of surgery. After release or lengthening of the wrist flexors, the passive extension of the wrist is assessed. If passive extension to neutral is possible, an FCU to ECRB transfer may be performed. In a wrist with no active flexion or extension prior to surgery, wrist arthrodesis is preferred following tenotomy of the FCR, FCU, and palmaris longus (Figure 32.20). The position of wrist fusion must be carefully designed to correlate with digit tenodesis.[67] A flat or neutral plate is most commonly used because digital extension is weak. Substantial weakness of digital extension requires fusion in some flexion to augment digital opening.

Wrist and Digital Flexor Tendon Tightness

Condition

Wrist and digital flexor tightness should be addressed concurrently with wrist and digit extension weakness to provide reliable outcomes. Wrist flexion deformity is caused primarily by spasticity or contracture of the FCU tendon, with lesser contributions from the FCR and the palmaris longus. Digital flexor tightness can also contribute to the wrist flexion deformity and is measured by the Volkmann angle (see Figure 32.4). In extreme digital flexor tendon tightness, no extension of the wrist is possible when the digits are held extended. Active or passive extension of the wrist to less than neutral identifies flexor tendon tightness that needs to be addressed surgically (Figure 32.21).

Types of Operative Procedures

There are several procedures for lengthening the flexor tendons, including the flexor-pronator slide,[85,136,186,204] fractional lengthening procedure,[54,63,116,122,123,186] "Z"-lengthening procedure,[63] and superficialis to profundus transfer.[16] Less commonly, bony shortening (proximal row carpectomy)[133,162,186] or wedge resection arthrodesis is done.[119] Wrist flexor tendons may be lengthened by fractional lengthening or "Z"-lengthening. If both the FCR and FCU are involved, at least one should be kept in continuity to enable active wrist flexion, although it may be lengthened.

All digital flexor tendon lengthenings temporarily if not permanently weaken the power of the muscle, but this is compensated for by an increase in grip strength secondary to improved extension of the wrist. Weakening of the flexors is minimized by fractional lengthening and is most pronounced with superficialis to profundus transfer. Superficialis to profundus transfer is used primarily when hygiene is the main goal because limited digital flexion and grasp are expected.[16] The effect of "Z"-plasty lengthening falls between these two lengthening techniques.

Bony procedures are reserved for skeletally mature patients. Maintenance of wrist mobility and tendon transfers are desirable when possible.

Flexor-Pronator Muscle Slide

Indications. A flexor origin slide is indicated when substantial function of the digits is not expected and the forearm is contracted into pronation. In addition, selective lengthening of the digital and wrist flexors is not possible.

Technique. See the description earlier in the section on the forearm.

Fractional Tendon Lengthening

Indications. Fractional flexor tendon lengthening is indicated in the functional hand when the digits cannot be fully straightened with the wrist held passively at neutral but they can be fully straightened when the wrist is flexed. Fractional flexor tendon lengthening is the optimal way to lengthen the flexor tendons, with the least risk of excessive lengthening of the tendons and a weakened grip.

Contraindication. If the digits cannot be fully extended with the wrist flexed, fractional tendon lengthening is not likely to produce enough length. "Z"-lengthening or superficialis to profundus transfer should be considered in these cases.

Technique. The musculotendinous junctions of the digital flexor tendons can be palpated on the midaspect of the volar forearm. Exposure is gained through a 4-cm longitudinal incision centered over the musculotendinous junction. Enough of the musculotendinous junction must be exposed to allow two



FIGURE 32.20 Wrist arthrodesis. Indications for skeletally mature static contracture **(A** to **C)** may require additional volar tenotomy of the flexor carpi radialis, flexor carpi ulnaris, and palmaris longus. **D** to **H,** Dorsal incision with transposition of the extensor pollicis longus and elevation of the fourth and second compartments**;** proximal row carpectomy, and removal of cartilage from surfaces; plate fixation of the wrist in neutral under compression. (Courtesy of Shriners Hospital for Children, Philadelphia.)

tenotomies in this region. Two oblique tenotomies are made at least 1 cm apart in the musculotendinous junction of each tendon to be lengthened (Figure 32.22). The distal tenotomy should be at least 2 cm proximal to the distal aspect of the musculotendinous junction. The muscular portion of the musculotendinous junction must be kept intact. The wrist is held in neutral, and gentle passive extension of the digits just short of the desired length is performed. The digits should not be fully extended. Overcorrection of the digits during surgery will result in excessive weakening of the flexor tendons and possible swan neck deformities of the fingers.

The arm is immobilized in a plaster splint with the wrist in neutral for 4 weeks. Unrestricted finger motion is allowed immediately postoperatively, and the patient is instructed on the use of digital extension exercises to actively adjust the fractional lengthening. The plaster splint is removed at 4 weeks, and a removable wrist splint is applied to allow wrist range of motion and therapy. At 8 weeks, splinting is discontinued unless recurrence of the deformity requires night splinting. Postoperatively, if the patient has difficulty actively extending the digits, a volar digital stretching splint may be added.

Tendon "Z"-Lengthening

Indication. "Z"-lengthening produces a greater amount of tendon lengthening than fractional lengthening. Z"-lengthening is frequently used to lengthen the FPL tendon when it cannot be fully extended even with the wrist fully flexed. In this situation, it is unlikely that fractional lengthening will be sufficient. For the FPL, the amount of lengthening performed should be 0.5 mm for every degree of desired correction (e.g., 2.5 cm for a 50-degree contracture).[60] However, the formula is based on clinical experience without scientific evidence.

Contraindication. "Z"-lengthening is not used for individualized digital flexors when the procedure is deemed inadequate to provide sufficient length. A flexor origin slide or superficialis to profundus transfer is effective and unlikely to cause uneven lengthening.

Technique. A longitudinal incision is made in the volar forearm over the tendon to be lengthened. As much of the tendon as possible is exposed. A longitudinal split is made in the tendon in a proximal to distal fashion, extended as long as possible. The effective lengthening of the tendon will be twice the length of this longitudinal split minus the length needed for

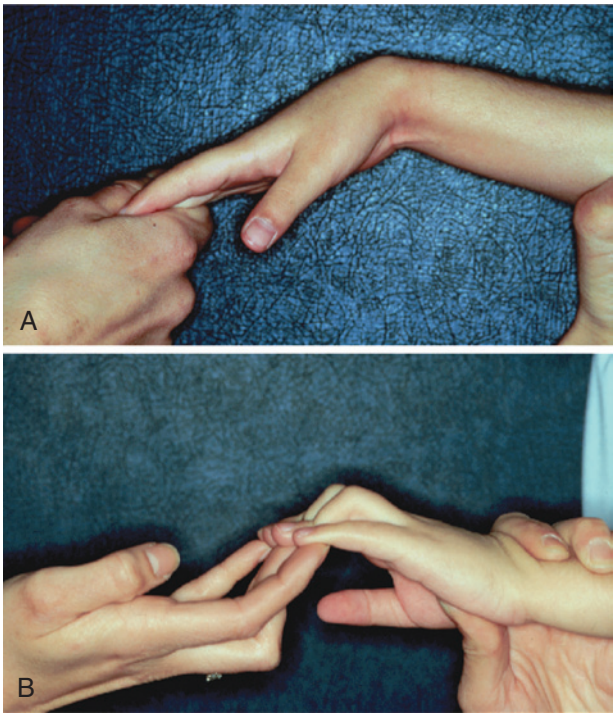

FIGURE 32.21 Flexor tendon tightness. **A**, Tight digital flexors allow wrist extension to only minus 45 degrees with the digits held extended. **B**, With the wrist held extended, the digits cannot be passively fully extended. (**A** and **B**, Copyright Michelle Gerwin Carlson.)

CRITICAL POINTS *Fractional Tendon Lengthening*

Indication
- For patients unable to fully passively extend their fingers with the wrist in neutral

Pearl
- If the surgeon cannot fully passively extend the patient's fingers with the wrists flexed, fractional lengthening will not produce adequate tendon lengthening.

Pitfall
- Resist the temptation to fully passively extend the digits intraoperatively because this may lead to overlengthening that will impair grasp.

Technical Points
- Make a 4-cm longitudinal incision centered over the musculotendinous junction of the digital flexors in the forearm.
- Perform two oblique tenotomies in the musculotendinous junction of each tendon spaced 1 cm apart.
- Perform tenotomies at least 2 cm proximal to the most distal aspect of the musculotendinous junction.

Postoperative Care
- Immobilize the wrist in neutral position for 4 weeks with the digits not included.
- Immediately begin digital active and passive range-of-motion exercises.
- If the patient has difficulty extending the digits, add a volar digital extension splint.

the repair. The hemitendon is divided radially at one end and ulnarly at the other to complete the transection of the tendon. The ends are woven with a Pulvertaft or side-to-side technique at the desired tension. For the wrist flexors, the tension should be set with the wrist in a neutral position. For the thumb, the tension should be set with the wrist at neutral and the thumb MP and IP joints in slight flexion. With extension of the wrist, the thumb should cross the index finger. With flexion of the wrist, the thumb should be able to be fully extended out of the palm.

After wrist flexor tendon lengthening, the wrist is immobilized in slight flexion for 4 weeks. For the FPL, the wrist is immobilized in slight flexion and the thumb in neutral for 4 weeks. After 4 weeks, a removable splint is applied, and therapy and range-of-motion exercises are begun. Splinting is discontinued at 8 weeks.

CRITICAL POINTS *Tendon "Z"-Lengthening*

Indications
- Tight wrist flexors or for FPL tendon lengthening
- Produces more tendon lengthening than fractional lengthening

Pearls
- Always make the arms of the "Z" as long as possible.
- Effective lengthening is two times the length of the split minus the length of the repair.

Pitfall
- If the arms of the "Z" are too short, sufficient lengthening of the tendon will not occur.

Technical Points
- Make a longitudinal split in the tendon.
- Divide the hemitendon slip on opposite sides of the tendon proximally and distally.
- Overlap the proximal and distal ends of the tendon in a side-to-side fashion with the desired tension, and use horizontal mattress sutures or a running suture.

Postoperative Care
- Immobilize the wrist and thumb (for FPL lengthening) in neutral position for 4 weeks.
- Begin active and passive range-of-motion exercises at 4 weeks.
- Wear a removable splint for 4 weeks.

Superficialis to Profundus Tendon Transfer

Indication. The superficialis to profundus transfer is indicated when substantial contracture of the digital flexors is present and the fingers cannot be passively extended even with the wrist fully flexed. If the FPL is contracted, it is usually treated with "Z"-lengthening as described above.[15]

Contraindication. This procedure should be used with extreme caution in patients with functional use of the hand because it results in substantial weakening of grip.

Technique. Through a longitudinal incision in the distal forearm, the superficialis and profundus tendons are identified. With the fingers in a normal cascade, the profundus tendons are sutured together distally and the superficialis tendons are

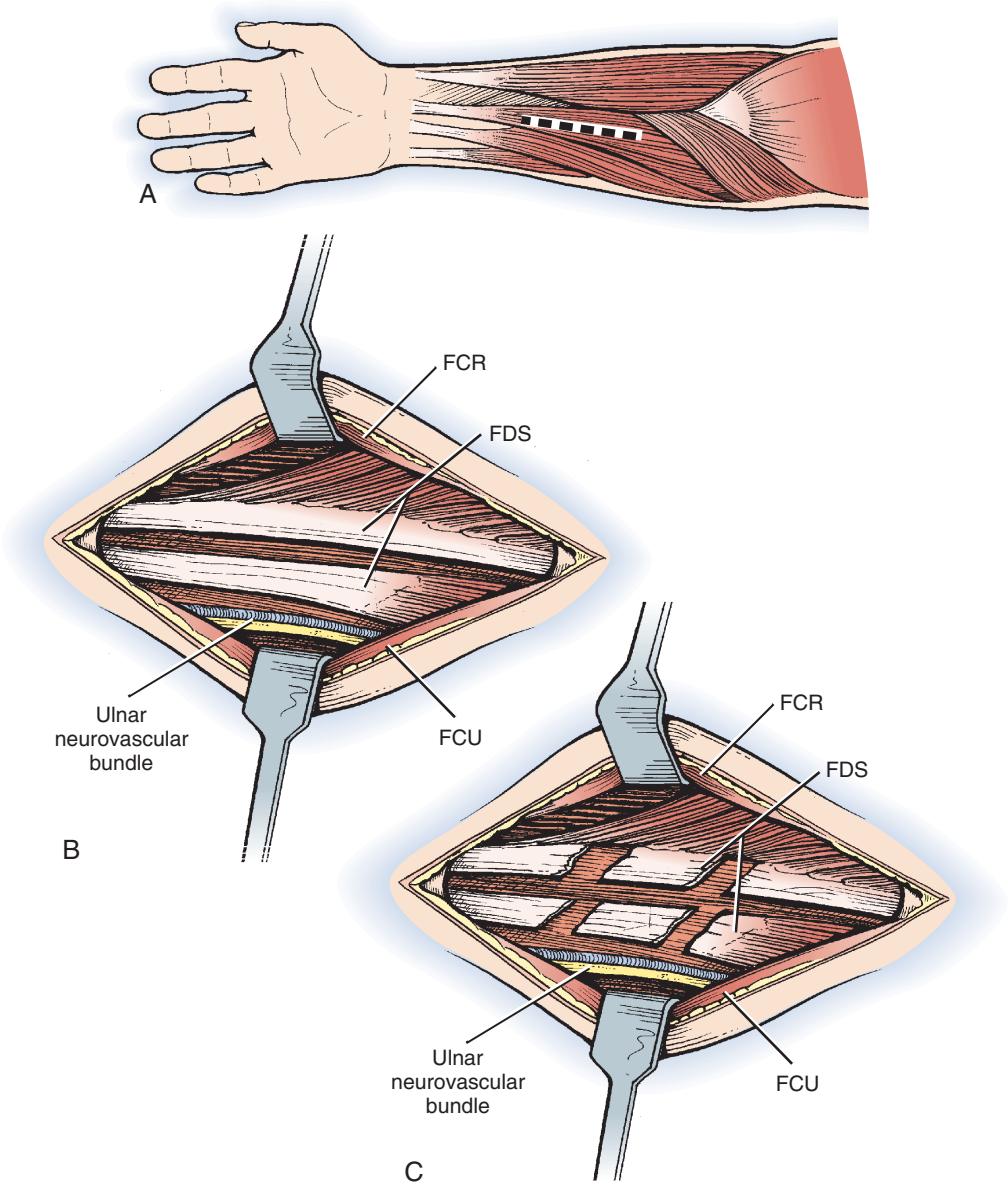

FIGURE 32.22 Fractional lengthening of the digital flexors. **A,** The incision is planned over the musculotendinous junction of the digital flexors. **B,** The ulnar neurovascular bundle and flexor carpi radialis (FCR) are retracted, and the superficial flexors (flexor digitorum superficialis [FDS]) are exposed. **C,** Two oblique incisions are made in the tendinous portion of each musculotendinous junction (see text for precise locations). The bridging muscle fibers are preserved. The flexor digitorum superficialis can then be retracted, and the flexor digitorum profundus is addressed in a similar fashion. *FCU,* Flexor carpi ulnaris.

sutured together proximally before transection. The superficialis tendons are transected distally, and the profundus tendons are transected proximally. Tension during repair is set with the wrist at neutral and the digits flexed 45 degrees at the MP and PIP joints (alternatively, the wrist is flexed 20 degrees and the MP and PIP joints are flexed 20 degrees). With the wrist extended 45 degrees, the digits should touch the palm; with wrist flexion, the digits should be able to be fully extended. The repair is performed in a side-to-side fashion (Figure 32.23).

The arm is immobilized for 4 weeks with the wrist in neutral, the MP joints flexed 90 degrees, and the PIP joints in extension. A removable splint is then used for 4 weeks, and range-of-motion exercises and therapy are begun. At 8 weeks, splinting is discontinued.

❖ Authors' Preferred Method of Treatment

If the wrist cannot be extended at all from the fully flexed position, "Z"-lengthening of the wrist flexor tendons (FCR, FCU) is usually necessary. If partial extension is possible, fractional lengthening is usually sufficient.

If the fingers can be fully passively extended with the wrist flexed, we perform fractional lengthening to allow extension of the digits with the wrist extended. Fractional lengthening has the added benefit of permitting minute adjustments in tension and allowing the patient to increase the lengthening with active digital extension in the immediate postoperative period. If the digits cannot be fully extended with the wrist flexed, "Z"-lengthening or superficialis to profundus transfer is necessary.

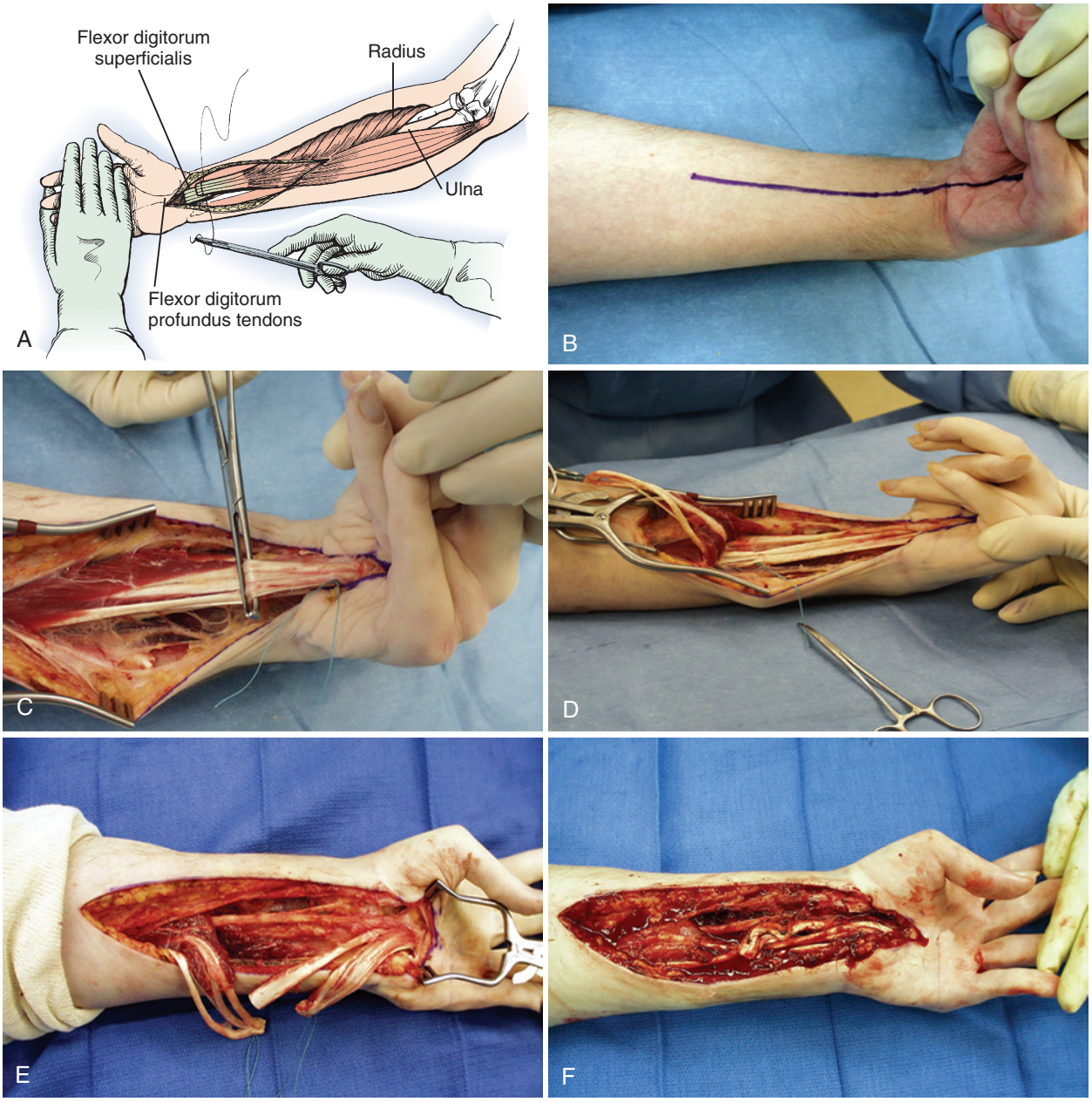

FIGURE 32.23 **A,** Superficialis to profundus tendon transfer. The four superficialis tendons are sutured together distally and transected for transfer. The profundus tendons are sutured together proximally and cut. The fingers are extended, and the distal ends of the superficialis tendons are sutured en masse to the proximal end of the profundus tendons. **B** to **F,** Intraoperative photographs of a superficialis to profundus tendon transfer. (**A,** From Keenan MA, Kozin SH, Berlet AC: *Manual of orthopaedic surgery for spasticity,* New York, Raven Press, 1993.)

"Z"-lengthening of the digital flexors is tedious, because nine "Z"-lengthenings are usually required (four FDS, four FDP, one FPL). We prefer superficialis to profundus transfer with "Z"-lengthening of the FPL. In a nonfunctional hand with tight wrist and digital flexors, carpal wedge resection and wrist arthrodesis provide a stable platform, improve position/hygiene, and effectively lengthen the finger flexors (see Figure 32.20).

Thumb-in-Palm Deformity

Condition

Flexion of the thumb into the palm of the hand is one of the greatest obstacles to good hand function in patients with spasticity. The cause of thumb-in-palm deformity is multifactorial and often difficult to decipher. When evaluating a child with this deformity, four key elements must be considered: (1) spastic flexors and adductors, (2) flaccid extensors and abductors, (3) hypermobile MP joint, and (4) web space skin contracture. The spastic thumb flexors and adductors are the FPL, adductor pollicis, first dorsal interosseous, and FPB. Spasticity of these muscles can be identified by examining the extremity during use and by passively abducting the thumb while palpating the tendons. During use, the thumb metacarpal assumes an adducted position when the adductor and first dorsal interosseous are spastic. Similarly, the spastic FPB flexes the MP joint. FPL spasticity is examined with the wrist held in both flexion

CRITICAL POINTS *Superficialis to Profundus Transfer*

Indications
- Substantial contracture of the digital flexors
- No ability to passively extend the fingers even with the wrist flexed
- Difficulties with hygiene

Pearls
- In patients with comorbidities, this procedure can be done under regional anesthesia.
- If the FPL is contracted, it will require "Z"-lengthening.

Pitfall
- Overlengthening of the transfer will weaken the digits and can result in a hyperextension deformity of the fingers.

Technical Points
- Make a longitudinal incision over the volar forearm centered over the musculotendinous junction.
- Transect the superficialis tendons distally and the profundus tendons proximally.
- Suture the tendons individually if there is function of the digits, and suture them together if there is little function.
- If tendons are to be sutured as a group, suture the profundus tendons together distally and the superficialis tendons proximally before transection to maintain the normal cascade.
- Tension the repair with the wrist in neutral position and the digits flexed 45 degrees at the MP and PIP joints.
- With wrist extension, the fingers should touch the palm, and with wrist flexion, full extension of the fingers should be possible.
- Repair the tendon ends in a side-to-side fashion.

Postoperative Care
- Immobilize the wrist in neutral with the MP joints flexed 90 degrees and the PIP joints in extension for 4 weeks.
- Use a removable splint for 4 weeks and begin active and passive range-of-motion exercises.

and extension, to demonstrate flexion of the thumb MP and IP joints. If the thumb IP joint is fixed in full flexion when the wrist is positioned at neutral and the thumb metacarpal is gently abducted, the FPL needs to be lengthened.[84]

Extensor and abductor functions of the thumb are performed by the EPB, EPL, and APL. Function of each of these muscles should be tested with the wrist flexed and extended. Often the EPL functions well, and when the patient reaches for an object, the IP joint extends, despite the flexion and adduction of the thumb metacarpal.[115]

MP joint hypermobility is a concern when considering tendon transfers to augment abduction and extension. If the MP joint can be passively extended beyond neutral, these transfers may produce undesirable hyperextension of the MP joint instead of abduction and extension of the thumb ray. In addition, any release of the adductor pollicis lessens MP joint flexion. Last, a soft tissue contracture of the skin of the web space can exacerbate the deformity.

Several classification systems of thumb-in-palm deformity have been developed.[84,120,151] (House and colleagues[84] and Sakellarides and coworkers[151] both described four-part classifications (Tables 32.5 and 32.6).

Types of Operative Procedures

Operative procedures are directed at each of the four elements of the deformity: (1) release of the spastic intrinsic and extrinsic flexor and adductor muscles, (2) augmentation of the weak extensor and abductor muscles, (3) stabilization of the thumb MP joint, and (4) release of the skin web space contracture.[21]

Spasticity of the thumb intrinsics is present in almost all thumb-in-palm deformities. Attention should be directed to the adductor pollicis, FPB, and first dorsal interosseous muscles. If flexion of the thumb MP joint is not a noteworthy component of the deformity, the FPB is probably not involved. Release of the adductor can be performed at its origin or insertion.[56,65,80,84,86,90,98,116,121,137,151,163,177,185,191,212] Hoffer and colleagues[80] recommended that if selective control of the adductor can be demonstrated by dynamic electromyography, release of its origin to preserve function should be performed. If there is no

TABLE 32.5 House Classification of Thumb-in-Palm Deformity

Type	Description	Involved Elements
1	Simple metacarpal adduction contracture	Spastic adductor and first dorsal interosseous
2	Metacarpal adduction contracture with MP flexion deformity	Spastic adductor, first dorsal interosseous, flexor pollicis brevis
3	Metacarpal adduction contracture with MP hyperextension and instability	Spastic adductor, first dorsal interosseous, extensor pollicis brevis
4	Metacarpal adduction contracture, MP and interphalangeal deformities	Spastic adductor, first dorsal interosseous, flexor pollicis longus

MP, Metacarpophalangeal.
House JH, Gwathmey FW, Fidler MO: A dynamic approach to the thumb-in-palm deformity in cerebral palsy: evaluation and results in fifty-six patients. *J Bone Joint Surg Am* 63:216–225, 1981.

TABLE 32.6 Sakellarides Classification of Thumb-in-Palm Deformity

Type	Elements	Treatment
1	Weak extensor pollicis longus	Transfer of palmaris or flexor carpi radialis to extensor pollicis longus
2	Spastic or contracted thumb intrinsics	Release of thenar muscles, first dorsal interosseous, contracted thumb release, web space release as needed
3	Weak abductor pollicis longus	Rerouting of abductor pollicis longus around flexor carpi radialis
4	Spastic or contracted flexor pollicis longus	"Z"-lengthening of flexor pollicis longus

Sakellarides HT, Mital MA, Matza RA, Dimakopoulos P: Classification and surgical treatment of the thumb-in-palm deformity in cerebral palsy and spastic paralysis. *J Hand Surg [Am]* 20:428–431, 1995.

voluntary control of the adductor, release of the muscle from its insertion should be performed. The spastic FPL should be lengthened.[157]

Augmentation of thumb extension and abduction with a variety of tendon transfers has been described, including the brachioradialis,[56,124,149,163] palmaris longus,[56,84] FCR and FCU,[56,65,84,86,90,157,163,177] ECRL and ECRB,[121,163] and FDS.[27,54,56,63,137,157] Results of brachioradialis to APL transfer have not demonstrated significant improvement in active abduction,[163] but transfer to the EPB may be more successful.

Other procedures to improve extension include rerouting of the EPL and FPL abductorplasty.[19,39,56,119,145,151,157,167,169,185,191] Imbrication of the APL and EPB has also been described and is effective when EPL function is weak.[54,62,121,129,179]

Augmentation of thumb extension and abduction causes undesirable MP joint hyperextension and is less effective for thumb ray abduction if the MP joint can hyperextend passively more than 20 degrees. Arthrodesis or chondrodesis of the MP joint prevents hyperextension,[54,58,84,86,105,156,178,179] and the resulting limitation of flexion is an advantage in the correction of thumb-in-palm deformity. MP joint capsulodesis has been described but is less reliable.[29,52,161,167] Metacarpal bone block with fusion of the thumb carpometacarpal (CMC) joint has been described,[27,56,141,156,171] but it is seldom performed because it markedly decreases pinch and makes it difficult for the hand to get into smaller openings such as shirtsleeves.

Finally, in hands with no functional motors available for transfer to abduct the thumb, transfer of the abductor end to side to the FCR tendon can provide a passive tenodesis.[84] However, this tenodesis may attenuate over time. Soft tissue contracture of the skin of the first web space should be addressed in these patients.[19,39,54,84,86,137,185,191]

Release or Slide of the Origin of Spastic Thumb Intrinsic Muscles

Indication. Release of the origin of the thumb intrinsic muscles is indicated when there is selective control of the muscles but they are contributing to the deformity.

Contraindication. If there is no selective control of the adductor pollicis, release of the muscle from its origin is less likely to be effective, and release of its insertion should be performed.

Technique. Under tourniquet control, a curved incision is made along the thenar crease extending from the wrist to the base of the index finger (Figure 32.24).[119,120] The thenar muscles (abductor pollicis, opponens pollicis, and FPB) are sharply elevated from their origins on the transverse carpal ligament. The thumb is progressively abducted to maintain tension on the thenar muscles as they slide in a distal direction. The recurrent motor branch of the median nerve must be identified and protected. Once the superficial thenar muscles have been released, attention is directed to the deeper adductor muscle.

The adductor pollicis is exposed in the interval between the common digital nerve of the index and long fingers and the flexor tendons of the long finger. The origin of the muscle from the third metacarpal is dissected free in a distal to proximal direction. The deep palmar arch and motor branch of the ulnar nerve are identified between the oblique and transverse heads of the adductor and protected. Complete detachment of the muscle origin from the metacarpal is necessary. The proximal extent of the deep exposure is limited by the deep vascular arch.

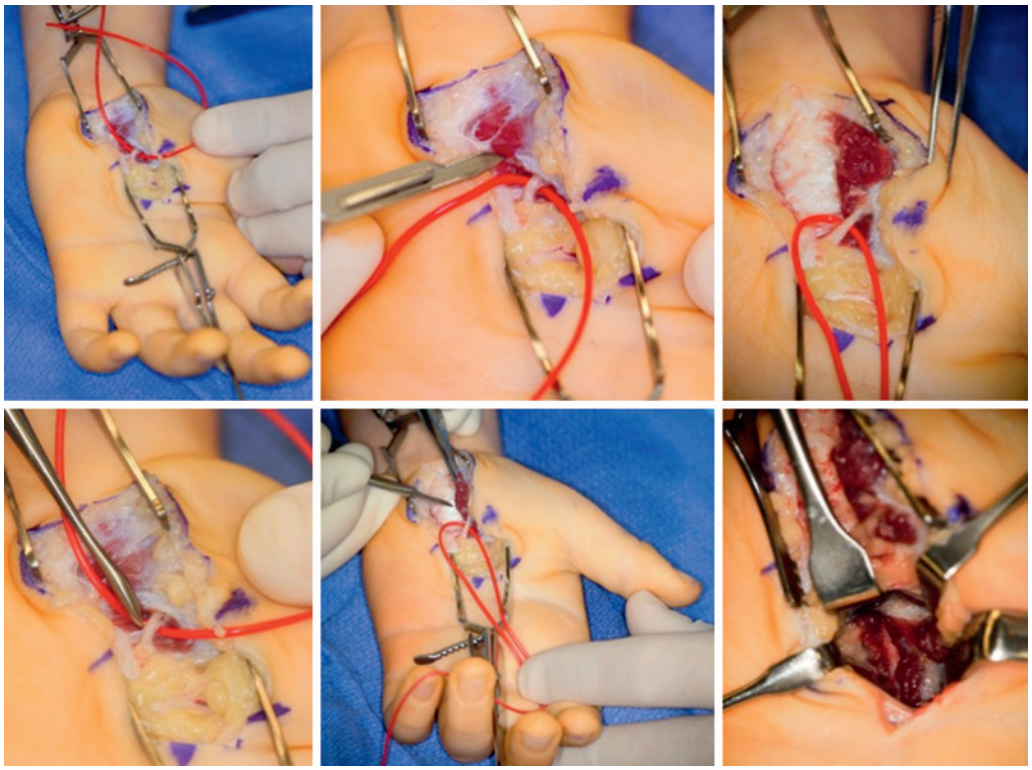

FIGURE 32.24 Nine-year-old with spastic thumb-in-palm deformity treated with slide of the origin of the thumb. (Courtesy of Shriners Hospital for Children, Philadelphia.)



FIGURE 32.25 Correction of thumb-in-palm deformity. **A,** Thumb-in-palm prevents this patient from grasping a bottle. **B,** Double-opposing "Z"-plasty for release of the adductor pollicis and the first dorsal interosseous. **C,** The adductor is visualized volarly, and the first dorsal interosseous dorsally. **D,** Release of the tendinous portion of the adductor with the muscular attachment left intact. **E,** Complete release of the adductor and first dorsal interosseous muscles. **F,** Postoperative appearance of the hand. **G,** The patient is now able to grip a bottle. (**A** to **G,** Copyright Michelle Gerwin Carlson.)

The FPB can be identified in the proximal part of the incision and detached from the transverse carpal ligament if an MP flexion deformity is present. The origin of the first dorsal interosseous can be released through this incision or through a separate longitudinal incision over the dorsal aspect of the thumb metacarpal. The muscle's origin is dissected off the metacarpal, with care taken to protect the princeps pollicis vessels at the base of the metacarpal.

The thumb and wrist are immobilized for 4 weeks in neutral position with the thumb abducted and the MP joint in neutral. A removable thumb spica splint is worn for 4 more weeks while therapy and range-of-motion exercises are begun. Splinting is discontinued at 8 weeks, unless a tendency for recurrence of the deformity requires night splinting.

Release of the Insertion of the Spastic Thumb Adductor

Indications. If there is no voluntary control of the adductor pollicis, tenotomy at its insertion is effective. If selective control of the muscles is present, release of the myotendinous junction (fractional lengthening) or muscle slide can be performed, leaving muscle fibers in continuity.

Technique. The adductor pollicis and first dorsal interosseous are approached through a double opposing "Z"-plasty of the thumb web space (Figure 32.25). The oblique and transverse heads of the adductor tendon are identified and detached from the metacarpal and sesamoid or fractionally lengthened. To fractionally lengthen the adductor, an oblique incision of the tendon is made near the myotendinous junction, and the thumb is gently abducted to allow sliding of the muscle fibers. The first dorsal interosseous origin from the first metacarpal can be visualized in the depths of the wound dorsal to the adductor and can be dissected off the metacarpal. The princeps pollicis artery must be protected. If the MP joint is unstable, a capsulodesis or arthrodesis can be performed through this incision. Arthrodesis is preferred over capsulodesis. For a capsulodesis, the capsule is incised just proximal to the ulnar sesamoid and pulled in a proximal direction. Two nonabsorbable sutures are placed between the sesamoid and the periosteum of the metacarpal with the MP joint in slight flexion. Immobilization can be augmented by Kirschner wire fixation. A 0.045-inch Kirschner wire can stabilize the CMC joint in maximal extension and abduction. Another 0.045-inch Kirschner wire can stabilize the MP joint in 10 degrees of flexion.

The wrist is immobilized for 4 weeks in neutral position with the thumb abducted. At 4 weeks the Kirschner wires are removed, and a removable thumb spica splint is worn for another 4 weeks while therapy and range-of-motion exercises are begun. Splinting is discontinued at 8 weeks, unless a

CRITICAL POINTS *Release of the Insertion of Spastic Thumb Intrinsic Muscles*

Indication
- For adduction deformity of the thumb without voluntary control of the adductor. If selective control of the adductor muscle is present, fractional lengthening or muscle slide is preferred.

Preoperative Evaluation
- The thumb should be examined in wrist flexion and extension to note the contribution of FPL spasticity.
- The dimension of the thumb web spaces should be assessed with active motion and passive stretch to differentiate spasticity from contracture.
- Patients should be evaluated during functional activities because thumb adduction spasticity may be exacerbated with use.

Pearls
- If spasticity of the FPL is shown by flexion of the IP joint when the wrist is held in neutral, the tendon must be lengthened.
- Fractional lengthening of the FPL is sufficient if the IP joint is not tight when the wrist is positioned in flexion.
- If the FPL is tight in wrist flexion, a "Z"-lengthening of the tendon is necessary.

Pitfall
- Be prepared to augment thumb abduction-extension if this movement is weak.

Technical Points
- Make a double opposing "Z"-plasty of the first web space.
- Detach the adductor tendon from the metacarpal and sesamoid.
- Elevate the origin of the first dorsal interosseous muscle from the thumb metacarpal.
- Protect the princeps pollicis artery.
- If necessary, perform MP joint capsulodesis by advancing the volar capsule, producing 10 degrees of flexion of the MP joint.
- MP arthrodesis is more reliable than capsulodesis.
- Fix the CMC joint in maximal extension with a 0.045-inch Kirschner wire.
- Stabilize the MP joint in 10 degrees of flexion if a capsulodesis has been performed.

Postoperative Care
- Apply a short-arm thumb spica splint for 4 weeks.
- Remove pins at 4 weeks and begin active and passive range-of-motion exercises.
- Use a fabricated thumb spica splint for 4 more weeks.
- Discontinue splinting at 8 weeks.

tendency for recurrence of the deformity requires additional night splinting.

Extensor Pollicis Longus Transfer

Indication. This procedure is indicated in patients who have a functioning EPL and thumb metacarpal adduction posture. The normal EPL has an adductor moment, and rerouting redirects this vector onto extension. EPL transfer is performed in conjunction with release or slide of the thumb intrinsic muscles. More commonly, EPL rerouting rather than transfer is performed. Rerouting avoids cutting the tendon (see the following).

Contraindication. Absence of a functioning EPL is a contraindication.

Technique. The EPL is exposed through a longitudinal incision radial to the Lister tubercle, just proximal to the extensor retinaculum.[19,115,167,185,191] A second incision is made over the dorsal aspect of the MP joint to expose the EPL and extensor aponeurosis. The EPL is transected at this level with a strip of extensor aponeurosis that is 10 by 4 mm, which has been dissected out from the proximal phalanx in its midportion. A running 4-0 monofilament suture is used to close the defect in the extensor aponeurosis. The tendon is withdrawn through the proximal wrist incision. A hemostat or small tendon passer is passed from the thumb incision, through the first dorsal compartment, and out the dorsal wrist incision. The instrument grasps the EPL and pulls the tendon out of the first dorsal compartment and out of the thumb wound. The EPL is passed through the MP joint capsule and sutured into place. If the MP joint passively hyperextends, the repair should be done into the proximal metacarpal to decrease its hyperextension effect. The repair should be done with enough tension to hold the thumb metacarpal in extension.

The hand is placed in a short-arm thumb spica cast for 1 month with the wrist in 30 degrees of extension. The thumb metacarpal is positioned in maximal extension and abduction and the MP joint in slight flexion. A removable splint is applied for an additional 4 weeks, and range-of-motion exercises and therapy are begun. The splint is discontinued at 2 months, and night splinting is instituted only if there is a tendency for recurrence of the deformity.

Extensor Pollicis Longus Rerouting

Indication. EPL rerouting is indicated in patients lacking thumb abduction and extension with active EPL function.[19,191] This procedure should be performed concurrently with a release or slide of the insertion of the thumb intrinsic muscles. The procedure is simpler than EPL transfer and favored by most surgeons.

Contraindication. Absence of active EPL function is a contraindication to this procedure.

Technique. Through a transverse or longitudinal incision at the Lister tubercle, the retinaculum over the third dorsal compartment is incised (Figure 32.26). The EPL is removed from its compartment and allowed to migrate in a radial direction by releasing any subcutaneous septa. A radially based piece of retinaculum or a proximally based slip of APL is harvested. The retinaculum or slip of abductor is looped about the EPL and sewn to the most volar aspect of the retinaculum or the volar radial periosteum.

Patients are placed in a short-arm thumb spica splint for 4 weeks. The Kirschner wires are removed, and a removable splint is fabricated. Hand therapy is recommended. After 4 weeks, the splint is removed and activities of daily living are encouraged.

Brachioradialis to Extensor Pollicis Brevis Transfer

Indication. Brachioradialis to EPB transfer is indicated in patients who lack thumb extension and abduction and have poor EPL function.

Contraindication. This procedure is contraindicated in patients who lack voluntary control of the brachioradialis with elbow flexion.

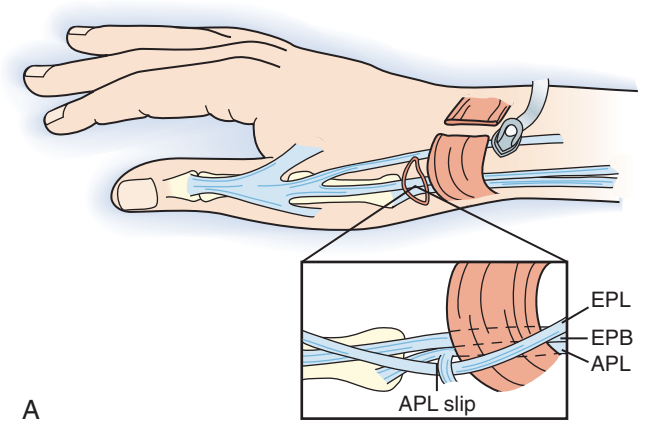

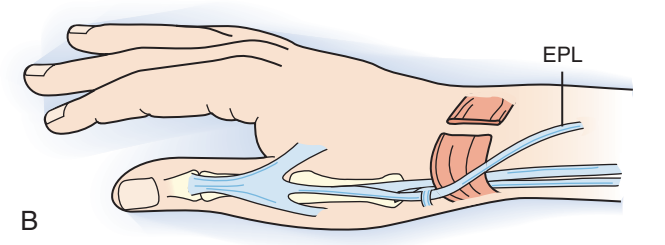

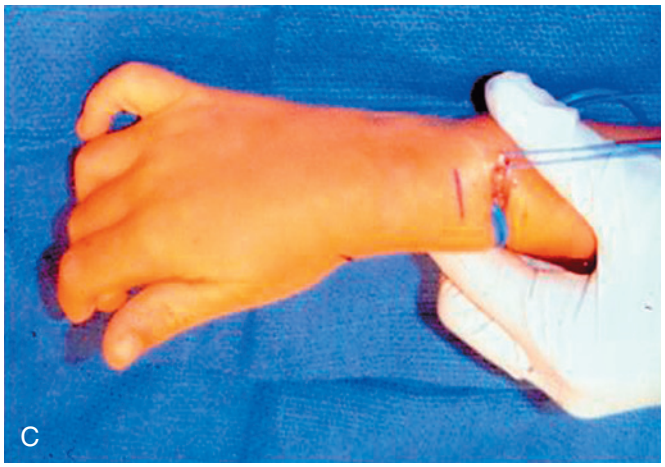

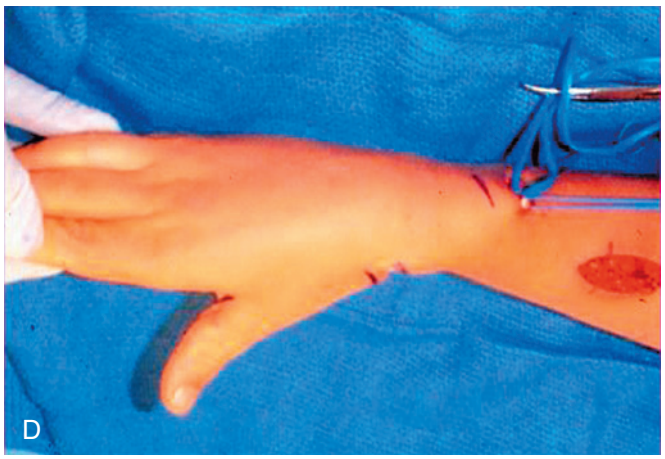

FIGURE 32.26 Extensor pollicis longus (EPL) rerouting. **A,** After release of the extensor pollicis longus from the third dorsal compartment, the extensor pollicis longus is identified through a radial incision distal to the styloid. A proximally based slip of abductor pollicis longus (APL) is harvested and sutured to the radial periosteum, creating a radial pulley for the extensor pollicis longus. **B,** After rerouting, the extensor pollicis longus has an abduction-extension line of pull. **C,** Intraoperative photograph demonstrating the pull of the untreated extensor pollicis longus, causing adduction of the thumb ray and interphalangeal extension. **D,** After rerouting of the extensor pollicis longus, its pull causes thumb abduction. *EPB*, Extensor pollicis brevis. (**C** and **D,** Copyright Michelle Gerwin Carlson.)

CRITICAL POINTS *Extensor Pollicis Longus Rerouting*

Indications
- Poor thumb abduction-extension
- Release or slide of the thumb intrinsic muscles at the same time

Preoperative Evaluation
- Patients must have good active EPL function with the wrist held in neutral position.

Pearl
- Mobilize the EPL in a radial direction as much as possible.

Technical Points
- Make an incision at the Lister tubercle.
- Open the retinaculum of the third dorsal compartment.
- Translocate the EPL tendon in a radial direction.
- Use the extensor retinaculum or a proximally based slip of APL to construct a pulley.
- Wrap the extensor retinaculum or the slip of APL around the EPL and suture it to the volar periosteum of the radius or the volar first dorsal compartment.

Postoperative Care
- Manage as for thumb intrinsic release.
- Encourage thumb usage early; concerns about tendon healing are less important than concerns about EPL redirection.

Technique. The brachioradialis is approached through a long longitudinal radial incision. The brachioradialis insertion on the distal radius is identified and transected while the radial artery and nerve are protected. The brachioradialis is mobilized proximally and freed from the ECRL and FCR into the proximal forearm (Figure 32.27).

The first dorsal compartment is opened, and the EPB is confirmed via traction. The APL has no effect on the MP joint, whereas the EPB tendon extends the MP joint. The EPB is transected as proximally as possible at the musculotendinous junction and woven into the brachioradialis tendon. During the weave, maximal tension is placed on the two tendon ends with the wrist in neutral and the elbow flexed.

The postoperative regimen is the same as for EPL transfer, with occasional reeducation necessary to reinforce thumb extension with elbow flexion against resistance.

Flexor Pollicis Longus Abductorplasty

Indication. This procedure is indicated for patients with a supple thumb metacarpal adduction contracture when the FPL is spastic and needs to be released or when the EPL is not functioning and cannot be used for transfer.

Contraindications. It is contraindicated in patients who already have a weak pinch. FPL abductorplasty is also contraindicated in patients who have an MP fusion, because IP fusion or tenodesis is required after this procedure.

Technique. The FPL tendon is identified through a radial midlateral incision from the middle of the distal phalanx to the neck of the thumb metacarpal. The FPL is transected midway over the proximal phalanx. The distal stump can be used as a tenodesis of the IP joint or a formal arthrodesis can be

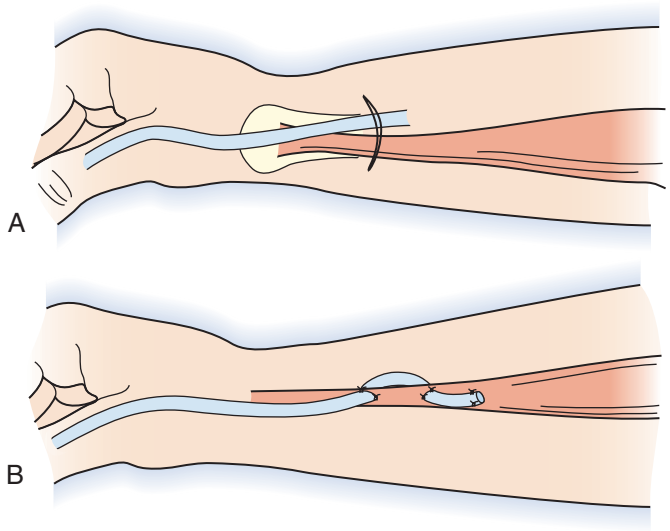

FIGURE 32.27 Brachioradialis to extensor pollicis brevis (EPB) transfer. **A** and **B,** Through a transverse incision, the brachioradialis is harvested distally and the EPB proximally. The EPB is woven into the brachioradialis; alternatively, a surgeon's knot can be placed between the two tendons.

CRITICAL POINTS *Brachioradialis to Extensor Pollicis Brevis Transfer*

Indication
- Patients lacking thumb abduction and extension with poor EPL function

Preoperative Evaluation
- Patients should have voluntary control of the brachioradialis with elbow flexion.

Pearl
- The EPB tendon is identified as the most ulnar tendon in the first dorsal compartment.

Pitfall
- This transfer must be tight; if it is too loose, adequate thumb abduction will not be accomplished.

Technical Points
- Release the brachioradialis at its insertion into the radius and mobilize it into the proximal forearm.
- Transect the EPB tendon as proximally as possible at the musculotendinous junction.
- Weave the EPB into the brachioradialis with maximal tension on the two tendons with the wrist in neutral.

Postoperative Care
- Manage as described for EPL transfer.
- Reeducation is occasionally necessary to reinforce thumb extension with elbow flexion against resistance.

performed. A second longitudinal incision is made over the volar wrist radial to the tendon of the FCR and proximal to the wrist flexion crease. The FPL is identified deep in this wound and withdrawn. A subcutaneous tunnel is created from the proximal wound to the distal wound through which the FPL is passed. The FPL is sutured to the MP joint capsule as described for EPL redirection.

The arm is immobilized in a short-arm thumb spica cast for 4 weeks with the wrist in 30 degrees of flexion and the thumb metacarpal fully extended and abducted. A removable splint is worn for an additional 4 weeks while range-of-motion exercises and therapy are started. After 8 weeks, night splinting is used as needed if there is a tendency for recurrence of the deformity.

Imbrication of the Abductor Pollicis Longus and Extensor Pollicis Brevis Tendons

Indication. Imbrication of the APL and EPB tendons can augment thumb abduction and extension in patients with weak EPL function who are not candidates for EPL rerouting. This procedure is truly relegated to the status of a second-tier procedure.

Technique. A skin incision is made over the first dorsal compartment, and the retinaculum is incised along its dorsal aspect. The tendons of the APL and EPB are plicated with a hemostat and sewn together with a nonabsorbable suture.

Alternatively, the tendons can be plicated distally, through a small incision at the APL's insertion on the metacarpal base, thus avoiding release of the first dorsal retinacular pulley and the attendant loss of abduction moment. The tendons can also be joined proximally in the forearm if another procedure necessitates a proximal forearm incision.

The wrist is immobilized for 4 weeks in 30 degrees of extension with the thumb metacarpal in full abduction and extension. A removable splint is used for 4 weeks to allow for therapy and range-of-motion exercises. Splinting is discontinued at 8 weeks, and night splinting is used only for recurrence of the deformity.

Thumb Metacarpophalangeal Joint Epiphyseal Arthrodesis (Chondrodesis)

Indication. MP joint epiphyseal arthrodesis is indicated for a hyperextensible MP joint in a growing child, when tendon transfers to augment extension or abduction are planned.

Contraindication. Arthrodesis is contraindicated when an IP arthrodesis is contemplated.

Technique. The MP joint is approached through a dorsal incision.[65,191] The interval between the EPL and EPB is split, and subperiosteal dissection of the articular surface of the proximal phalanx and metacarpal head is performed. Care should be taken not to extend the resection of the joint surface too distal on the proximal phalanx to protect the physes. The articular surface is removed with a knife to expose the ossification center of the proximal phalanx; the subchondral bone of the metacarpal can be removed with an oscillating saw. The osteotomies are performed to position the joint in neutral. The MP joint is fixed with one or two Kirschner wires.

Immobilization of the wrist and MP joint is accomplished with a thumb spica cast until bony union is observed at 4 to 6 weeks.

❖ Authors' Preferred Method of Treatment

The spastic thumb-in-palm deformity remains one of the most difficult and frustrating problems to treat. We find that the best approach is to identify and address the four key elements: spastic or contracted flexors and adductors, weak or absent extensors and abductors, MP hypermobility, and skin web space contracture. The spastic muscles are lengthened or released. The



FIGURE 32.28 **A,** Multiple swan neck deformities of the fingers after traumatic brain injury. **B,** Note that combined flexion is not lost. **C,** Multiple boutonnière deformities.

weak extensors are augmented by rerouting or tendon transfer. MP hypermobility is stabilized by chondrodesis or arthrodesis. Any web space contracture is released and the skin is reoriented by "Z"-plasty.

Despite attention to detail, some recurrence is frequent and frustrating. Problematic recurrence requires reassessment of the persistent deforming forces and repeat surgery. In some cases, fusion of the MP and CMC joints is necessary to position the thumb as a stable post for prehension.

Intrinsic Muscle Spasticity and Digital Swan Neck Deformity

Condition

Intrinsic spasticity in the hand causes flexion at the MP joints and extension at the PIP joints. Over time, swan neck deformities of the digits result, although overpull of the digital extensors to augment lack of wrist extension contributes to this deformity.[168,175,187] Swan neck deformity is rarely a functional problem unless the PIP joints lock into hyperextension secondary to the dorsally dislocated lateral bands. The patient will complain of difficulty initiating flexion (Figure 32.28). More commonly, the deformity is an appearance concern. The functional and aesthetic benefit of correcting PIP hyperextension can be demonstrated to the patient preoperatively with the use of figure-of-eight extension block splints. Figure-of-eight splints may be the sole method of treatment.

Similarly, the MP flexion component causes difficulty only if severe, because it is usually overpowered by the EDC. However, the MP flexion deformity may become more pronounced after correction of a wrist flexion deformity because of the effective weakening of the EDC tendons. Lengthening procedures for the digital flexors may also unmask intrinsic spasticity, especially in patients with traumatic brain injury (Figure 32.29).

Types of Operative Procedures

Intrinsic spasticity can be treated by three methods: intrinsic muscle origin slide, ulnar motor neurectomy, and fractional lengthening of the intrinsics.[123,168] Intrinsic muscle lengthening or origin slide corrects the spasticity of the muscle, decreases the contracture, and retains some function. Ulnar motor neurectomy eliminates the spasticity of the intrinsics[164] at the expense of all intrinsic function. Neurectomy does not reduce any component of myostatic contracture. The effectiveness of an ulnar motor neurectomy can be assessed with an ulnar nerve block at the wrist.



FIGURE 32.29 This patient has had release of the long flexors, but the intrinsic muscles were not addressed. The severe metacarpophalangeal flexion and proximal interphalangeal extension of the fingers significantly limit function, and he still has an interdigital hygiene problem. (Copyright Michelle Gerwin Carlson.)

PIP hyperextension can also be corrected with lateral band translocation, superficialis tenodesis or central slip tenotomy.[18a,23,40,187] The superficialis tendon can be repaired either to bone[150,175] or to the fibroosseous pulley.[119,187]

Interosseous Muscle Slide

Indication. This procedure should be performed when MP flexion is inhibiting hand function or causing interdigital hygiene problems. Some intrinsic function is retained, and the contracture across the MP joint is decreased.

Contraindication. This procedure should not be performed to improve appearance alone.

Technique. A transverse incision is made on the dorsum of the hand at the midmetacarpal level, or two longitudinal incisions are made in the interspaces between the index and long fingers and ring and little fingers. The interosseous muscles are identified with retraction of the extensor tendons. Subperiosteal

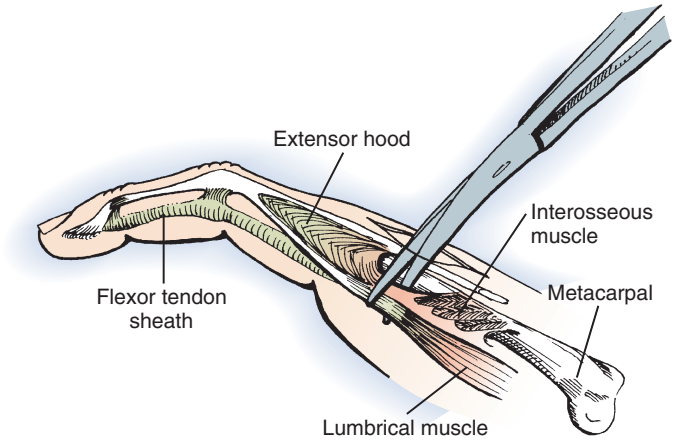

FIGURE 32.30 Isolation and release of the intrinsic interosseous and lumbrical muscles. (From Keenan MA, Kozin SH, Berlet AC: *Manual of orthopaedic surgery for spasticity*, New York, 1993, Raven Press.)



FIGURE 32.31 Photographs of intrinsic-plus **(A)** and intrinsic-minus **(B)** deformities.

dissection is performed to release both the dorsal and the volar interosseous muscles. The MP joints are brought into full passive extension with the PIP joints flexed. If MP joint extension is still tight, a Kirschner wire can be used to hold the MP joints extended for 4 weeks.

The MP joints are immobilized in full extension for 4 weeks. A removable splint is then applied for 4 weeks, and therapy and range-of-motion exercises are begun. Splinting is discontinued at 8 weeks, and night splinting is instituted only if there is a tendency for recurrence of the deformity.

Intrinsic Lateral Band Release

In a hand that has intrinsic muscle contractures and for which a dynamic electromyogram shows no volitional activity, lateral band releases are performed (Figure 32.30). A midline longitudinal incision is made over the dorsum of the MP joint and proximal phalanx of each finger. Dissection is carried out on both the ulnar and radial sides of the extensor mechanism. The palmar edge of the lateral bands is identified. The lateral band and oblique fibers of the extensor hood are transected on each side. Care is taken to preserve the transverse fibers of the sagittal extensor hood.

Recurrent intrinsic-plus deformities are common (Figure 32.31, *A*). This is thought to be secondary to residual attachment of the interosseous muscles to the base of the proximal phalanges. To prevent recurrent deformities, the surgeon should consider concomitant neurectomy of the motor branch of the ulnar nerve in the Guyon canal.

Ulnar Motor Neurectomy

Indication. Ulnar motor neurectomy is a straightforward approach to decrease intrinsic muscle spasticity, but it results in complete loss of intrinsic function. It should be used when good digital function is not anticipated and hygiene is the primary goal. A primary indication is improvement in hand function after ulnar nerve block.

Contraindication. This is contraindicated when good digital function is expected. It may result in a clawhand deformity.

Technique. A 3- to 4-cm incision is made over the ulnar nerve and artery in the Guyon canal (Figure 32.32). The ulnar neurovascular bundle is identified proximally and traced distally after releasing the volar carpal ligament. The ulnar nerve divides into a superficial sensory branch and a deep motor branch within the Guyon canal. The deep motor branch is isolated as it courses around the hook of the hamate, and a section of the motor branch is excised. A nerve stimulator can be used to confirm the identity of the motor branch before transection. No postoperative immobilization is necessary.

Flexor Digitorum Superficialis Tenodesis of the Proximal Interphalangeal Joint

Indication. This procedure is indicated for PIP hyperextension that is hindering active flexion of the digit.

Contraindication. This procedure is contraindicated if the FDP in the involved finger is nonfunctional.

Technique. A midaxial or Bruner incision can be performed. The radial slip of the FDS tendon is identified. The radial slip of the FDS tendon is identified beneath the A1 pulley and transected proximally. The radial slip is secured to the middle to distal third of the proximal phalanx using a transosseous or suture anchor technique. The PIP joint is stabilized to produce a 20-degree flexion contracture The PIP joint is held in this position with a Kirschner wire.

The Kirschner wire is removed at 2 to 3 weeks, and range-of-motion movement is begun with active and passive flexion and an extension block splint that limits extension to 20 degrees. Full range of motion is allowed after 8 weeks.

Fractional Palmar Intrinsic Lengthening

Indication. This procedure is indicated for mild intrinsic spasticity. The digits are best examined with the wrist flexed, because digital flexor tightness can mask intrinsic spasticity. This procedure seems simple but is relatively difficult to perform.

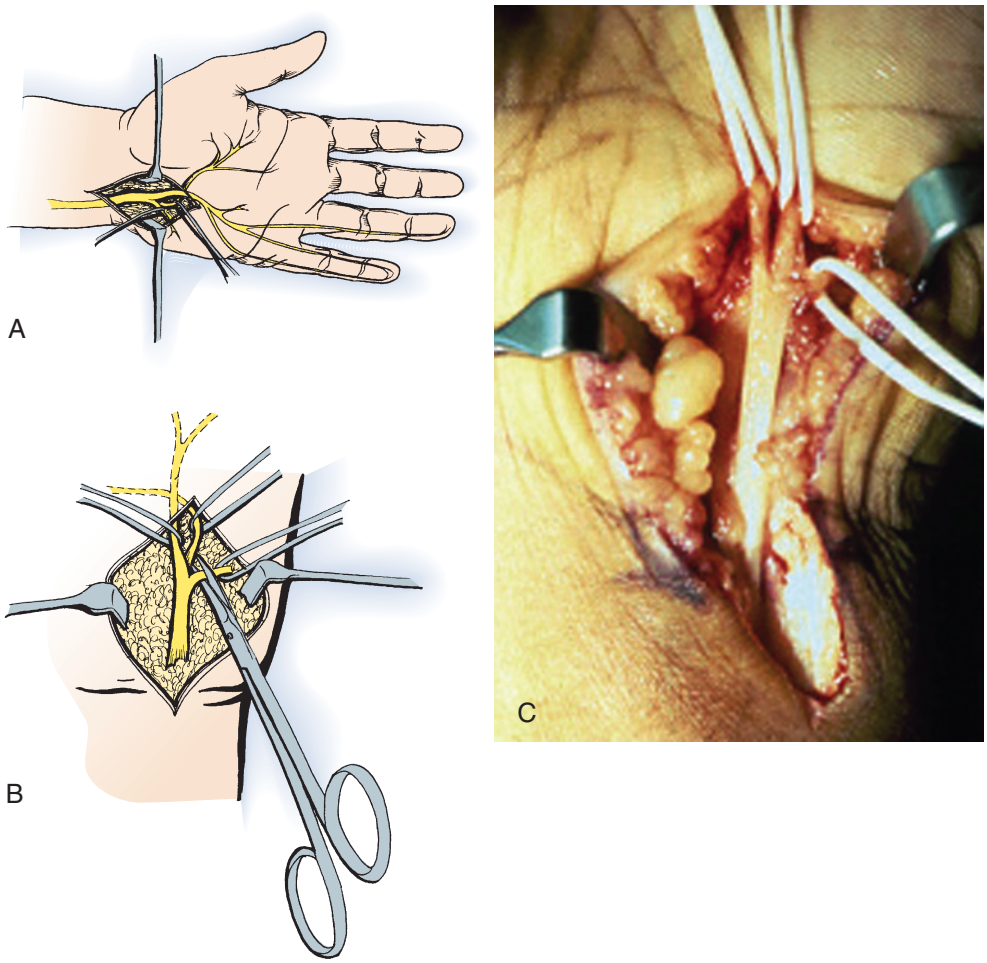

FIGURE 32.32 **A** to **C,** Isolation of the motor branches of the ulnar nerve distal to the Guyon canal. (From Keenan MA, Kozin SH, Berlet AC: *Manual of orthopaedic surgery for spasticity,* New York, 1993, Raven Press.)

Contraindication. This procedure is contraindicated in patients with long flexor weakness. They may be relying on their intrinsic muscles for MP function and functional use of their fingers.

Technique. A transverse incision is made at the level of the distal palmar crease of the hand. It should extend from radial to ulnar, that is, from the index flexors to the little finger flexors. The interosseous spaces between the flexors and metacarpals are developed, and care is taken to protect the neurovascular bundles. The volar interosseous muscles are identified and fractionally lengthened (cutting the tendinous portion of the musculotendinous junction). The deep fascia is divided, and the dorsal interosseous muscles can be similarly lengthened.

No postoperative immobilization is necessary, and early range-of-motion movement is encouraged.

Central Slip Tenotomy

For swan neck deformity of the PIP joints, central slip tenotomy can be an effective treatment.[18a,23] Patients must have active digital flexion when the digits are held passively in the corrected position or recurrence of the deformity is inevitable because the lateral bands remain dorsal. PIP tenodesis is effective to treat the deformity, but it is difficult to set the appropriate tension, and the procedure does not rectify the underlying problem.

Indication. This procedure is indicated in patients with active swan neck deformity of the PIP joints greater than 20 degrees.

Contraindication. Patients who cannot actively flex their PIP joints when the digit is held in the corrected position are likely to have a recurrence of the deformity. In patients who use their EDC to obtain wrist extension, tendon transfer for wrist extension is the solution.

Technique. A transverse incision is made dorsally, approximately 1 cm proximal to the PIP joint, and the extensor mechanism is identified (Figure 32.33). A forceps is used to grasp the center of the tendon, and gentle traction facilitates identification of the separation between the central slip and the lateral bands. The central slip is transected transversely, and the lateral bands are left intact. As the central slip is transected, the demarcation between it and the lateral bands becomes more apparent. The skin is closed with absorbable sutures, and the PIP joint is fixed with a Kirschner wire in slight flexion.

The digits are splinted for 4 weeks, at which point the splint and Kirschner wires are removed. Molded oval figure-of-eight splints are applied to the PIP joints, and active flexion is begun. Active extension should be limited to minus 10 degrees by the figure-of-eight splint. At 8 weeks postoperatively, the splints are discarded and full range of motion is allowed. Patients are informed that they can expect correction of the deformity to within 10 degrees of neutral.

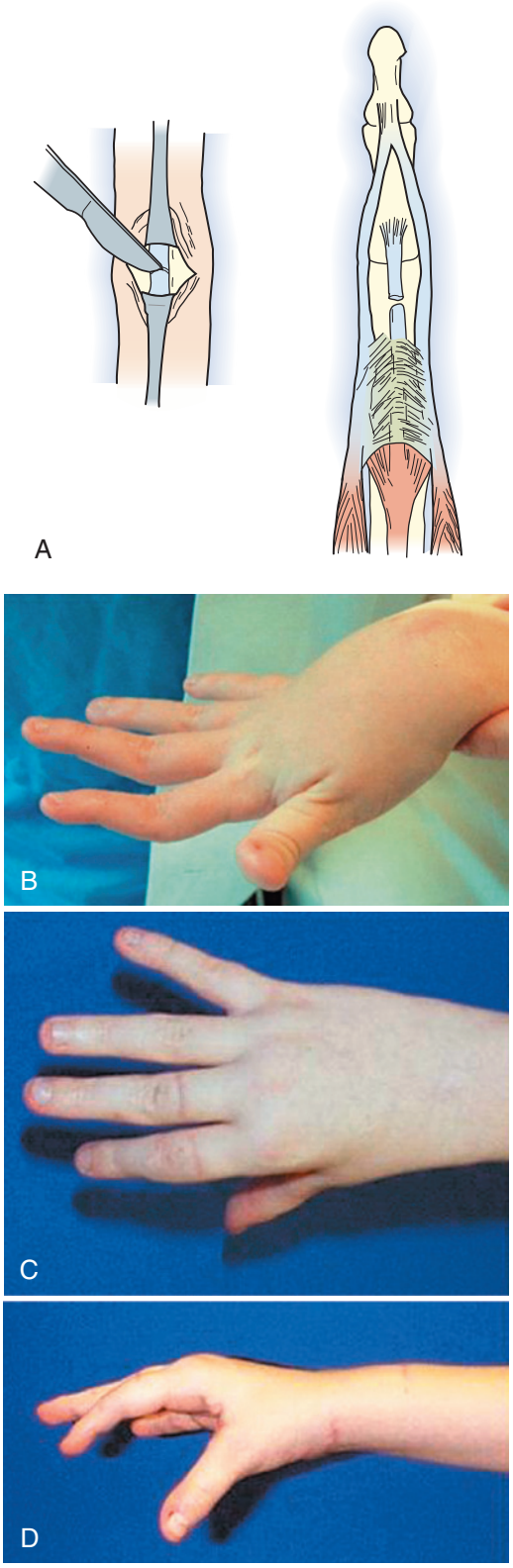

FIGURE 32.33 Central slip tenotomy for swan neck deformity. **A,** A transverse incision is made just proximal to the proximal interphalangeal joint, and a tenotomy of the central slip is performed, leaving the lateral bands intact. **B,** Preoperative swan neck deformity. **C,** The healed incision is visible proximal to the proximal interphalangeal joint. **D,** Postoperative correction of the swan neck deformity. (**B** to **D,** Copyright Michelle Gerwin Carlson.)

CRITICAL POINTS *Central Slip Tenotomy*

Indication
- Patients with active swan neck deformity greater than 20 degrees

Preoperative Evaluation
- Check for active digital flexion when the PIP is held in neutral position.

Pearl
- Grasping the extensor mechanism and lifting with a forceps can facilitate identification of the demarcation between the central slip and the lateral bands.

Technical Points
- Transect the central slip, leaving the lateral bands intact.
- Transfix the PIP joint in slight flexion with a Kirschner wire.

Pitfall
- Be sure to transect the entire central slip but not the lateral bands.

Postoperative Care
- Splint the digit for 4 weeks.
- Remove the pin at 4 weeks and apply an oval figure-of-eight splint.
- The splint should limit extension to –10 degrees.
- At 8 weeks, allow full range of motion and discontinue splinting.

Metacarpophalangeal Joint Arthrodesis

Indication. Patients with marked MP flexion deformity and fixed contracture that does not improve with ulnar nerve block.

Contraindication. Patients must have functioning long digital flexors or MP fusion will eliminate any functional flexion of the digit.

Technique. A longitudinal incision is made over each MP joint to be fused. The extensor hood is incised and the capsule is incised longitudinally. The collateral ligaments are released from the metacarpal head, and the articular surface of the metacarpal head and base of the proximal phalanx are removed with an oscillating saw. The metacarpal osteotomy should be performed to create a cascade of flexion through the arthrodesis from 20 degrees for the index finger to 40 degrees for the little finger. Care must be taken not to produce a radial or ulnar angular deformity through the fusion site. A 2.0-mm plate is contoured and used to fix the metacarpal to the proximal phalanx with two or three screws proximally and distally. Alternatively, a headless compression screw can be used, avoiding the plate and screw construct (Figure 32.34). The capsule is closed and the extensor hood is repaired with interrupted nonabsorbable suture.

The hand is immobilized for 4 weeks in a forearm-based extension splint with the wrist in neutral and the digits extended. Subsequently, a fabricated palm-based splint across the MP joints with the PIP joints free is worn until union is demonstrated on radiographs. We inform the patients to expect improved use of the hand because of the ability to place objects in the palm with the MP joints extended. As long as patients have digital flexion, the improved position of the MP joints outweighs the loss of MP motion.

❖ Authors' Preferred Method of Treatment

We treat mild intrinsic spasticity with fractional lengthening of the intrinsics with good results and little loss of function. We



FIGURE 32.34 Anteroposterior and lateral x-rays following metacarpophalangeal arthrodesis and internal fixation with headless screws. (Courtesy of Shriners Hospital for Children, Philadelphia.)

CRITICAL POINTS *Metacarpophalangeal Joint Arthrodesis*

Indication
- Patients with MP flexion deformity not improved by ulnar nerve block

Preoperative Evaluation
- Ulnar nerve block identifies flexible deformities.
- Function of the long digital flexors should be assessed.

Pearl
- If there is considerable spasticity of the flexors or extensors, intraoperative botulinum toxin may lessen postoperative spasticity and ease the postoperative course.

Technical Points
- Make a longitudinal incision over each MP joint.
- Incise the extensor hood.
- Incise the capsule longitudinally, and release the collateral ligaments.
- Remove the articular surface of the metacarpal and phalanx with an oscillating saw.
- Produce a cascade of flexion of 20 degrees in the index finger to 40 degrees in the little finger.
- Fix MP fusion with a 2-mm plate or headless compression screw.
- Close the capsule and extensor hood.

Pitfall
- Arthrodesis in too much MP flexion, especially of the fifth finger, will make it difficult to acquire objects.

Postoperative Care
- Apply a forearm-based splint for 4 weeks.
- Use a fabricated palm-based splint across the MP joints with the PIP joints free until union is demonstrated.

often perform this procedure along with lengthening of the long flexors. Swan neck deformities of the digits without intrinsic spasticity (from overpull of the digital extensors) and with adequate active wrist extension are treated with central slip tenotomies at the PIP joints. Severe MP flexion deformity from intrinsic spasticity is very difficult to correct. Ulnar motor block identifies the amount of correction possible with ulnar motor neurectomy. We prefer neurectomy to interosseous muscle slide in patients with poor hand function. Ulnar block often incompletely corrects the deformity because of fixed capsular contractures of the MP joints. In these patients, MP arthrodesis may be necessary to improve the position of the fingers; its use retains some hand function at the IP joints. Additionally, shortening can be accomplished through the arthrodesis, helping to lengthen the tight extrinsic flexors. Prior to any intrinsic release or ulnar neurectomy, it is imperative to determine that the intrinsic muscles are not contributing to function; otherwise, hand function will be adversely affected.

Intrinsic-Minus Deformities

A less common deformity pattern is the intrinsic-minus hand. In these patients, the intrinsic muscles have normal or weakened tone but there is spasticity of the extrinsic finger flexors. There may be increased tone in the extrinsic extensors as well. This pattern results in a clawhand posture, with hyperextension of the MP joints and flexion of the PIP and DIP joints (see Figure 32.31, *B*). Ulnar nerve compression or disease must be considered in the differential diagnosis. Resultant hyperextension contracture of the MP joint capsule is common and may require surgical release. Following release, excessive tension on the dorsal skin should be avoided to prevent subsequent wound breakdown and skin necrosis. The MP joints are pinned in the

reduced position for 4 weeks. Treatment of an MP hyperextension deformity may also require lengthening of the extrinsic digital flexors or superficialis to profundus transfers, as described earlier. A volar plate capsulodesis may also be necessary to maintain MP flexion for function and appearance.

On occasion, hyperextension deformities of the MP joints are not correctable with soft tissue releases. This can usually be determined preoperatively by placing the wrist in maximum extension and assessing MP flexion. If this position does not alter the tension across the hyperextended MP joints, soft tissue release alone is unlikely to correct the deformity. In these cases, a closing wedge flexion osteotomy of the distal metacarpal corrects the deformity and lessens the chance of compromising the viability of dorsal skin over the MP joint. The osteotomy is fixed with a small dorsal plate or wires.

OUTCOME STUDIES

Accurate quantitative and qualitative assessment of outcomes after treatment of spasticity of the upper extremity involves diagnostic tests, standardized observation, performance measures, and patient-reported outcome instruments. These tools are used for spasticity diagnostics, classification of severity, identification of treatment goals, longitudinal monitoring, design of treatment decision-making algorithms, and evaluating and comparing outcomes. Few studies of spasticity have been rigorous enough to be level 1 evidence in this field.[197,211] A rare multicenter prospective study recently compared therapy alone, botulinum toxin, and surgery in children with hemiplegia. The surgical group had a more significant improvement in the upper limb.[188] Computerized adaptive testing is an emerging measurement technology that provides a scale for future research and clinical studies.[130a]

The current treatment of the spastic limb is both challenging and rewarding. The surgeon and patient can find the outcome gratifying but also sometimes frustrating.[138] Improving limb posture, position, and gross motor function is possible in limbs with controlled spasticity and some volitional control.[89] Improving movements such as elbow flexion/extension, forearm supination/pronation, wrist flexion/extension, and gross grasp/release is a realistic goal. In contrast, it is not possible to enhance limb function in the face of uncontrollable spasticity (e.g., athetosis) or lack of volitional activity.

Restoring fine motor function and dexterity is a far-reaching goal. The surgeon's ability to restore the fine balance between coordinated intrinsic and extrinsic hand action is hampered by the disconnect between afferent and efferent signals. The restoration of these coordinated tasks has frustrated surgeons for decades and will continue to exasperate surgeons in the future until the root cause problem can be solved.

For Case Studies, Videos, and more, please visit ExpertConsult.com.

REFERENCES

1. Abu-Sneineh AK, Gabos PG, Miller F: Radial head dislocation in children with cerebral palsy. *J Pediatr Orthop* 23(2):155–158, 2003.
2. Abzug JM, Chafetz RS, Gaughan JP, et al: Shoulder function after medial approach and derotational humeral osteotomy in patients with brachial plexus birth palsy. *J Pediatr Orthop* 30:469–474, 2010.
3. Adekoya N, et al: Surveillance for traumatic brain injury deaths—United States, 1989-1998. *MMWR Surveill Summ* 51:1–14, 2002.
4. Alexander RD, Davids JR, Peace LC, et al: Wrist arthrodesis in children with cerebral palsy. *J Pediatr Orthop* 20:490–495, 2000.

4a. American Association of Electrodiagnostic Medicine/American Academy of Physical Medicine and Rehabilitation: Technology review: dynamic electromyography in gait and motion analysis. *Muscle Nerve* 22(Suppl 8):S233–S238, 1999.

5. Amrani A, Dendane MA, Alami ZF: Pronator teres transfer to correct pronation deformity of the forearm after an obstetrical brachial plexus injury. *J Bone Joint Surg Br* 91:616–618, 2009.
6. Anakwenze OA, Namdari S, Hsu JE, et al: Myotendinous lengthening of the elbow flexor muscles to improve active motion in patients with elbow spasticity following brain injury. *J Shoulder Elbow Surg* 22(3):318–322, 2013.
7. Deleted in review.
8. Autti-Ramo I, Larsen A, Peltonen J, et al: Botulinum toxin injection as an adjunct when planning hand surgery in children with spastic hemiplegia. *Neuropediatrics* 31:4–8, 2000.
9. Beach WR, Strecker WB, Coe J, et al: Use of the Green transfer in treatment of patients with spastic cerebral palsy: 17-year experience. *J Pediatr Orthop* 11:731–736, 1991.
10. Bohannon RW, Smith MB: Interrater reliability of a modified Ashworth scale of muscle spasticity. *Phys Ther* 67:206–207, 1987.
11. Bolanos AA, Bleck EE, Firestone P, et al: Comparison of stereognosis and two-point discrimination testing of the hands of children with cerebral palsy. *Dev Med Child Neurol* 31:371–376, 1989.
12. Botte MJ, Keenan MA: Brain injury and stroke. In Gelberman RH, editor: *Operative nerve repair and reconstruction*, Philadelphia, 1991, JB Lippincott, pp 1413–1451.
13. Bovend'Eerdt TJ, Dawnes H, Johansen-Berg H, et al: Evaluation of a modified Jebsen Test of Hand Function and the University of Maryland Arm Questionnaire for Stroke. *Clin Rehabil* 18(2):194–202, 2004.
14. Boyce WF, Gowland C, Rosenbaum PL, et al: The gross motor performance measure: Validity and responsiveness of a measure of quality of movement. *Phys Ther* 75:603–613, 1995.
15. Braun RM, Vise GT: Sublimis to profundus tendon transfers in the hemiplegic upper extremity. *J Bone Joint Surg Am* 55:873, 1973.
16. Braun RM, Vise GT, Roper B: Preliminary experience with superficialis to profundus tendon transfer in the hemiplegic upper extremity. *J Bone Joint Surg Am* 56:466–472, 1974.
17. Bunata RE: Pronator teres rerouting in children with cerebral palsy. *J Hand Surg [Am]* 31(3):474–482, 2006.
18. Carlioz H, Brahimi L: Place of internal disinsertion of the subscapularis muscle in the treatment of obstetric paralysis of the upper limb in children. *Ann Chir Infant* 12:159–167, 1971.

18a. Carlson EJ, Carlson MG: Treatment of swan neck deformity in cerebral palsy. *J Hand Surg [Am]* 39(4):768–772, 2014.

19. Carlson MG: The treatment of thumb in palm deformity in cerebral palsy. *Atlas Hand Surg* 7:119, 2002.
20. Carlson MG, Athwal GS, Bueno RA: Treatment of the wrist and hand in cerebral palsy. *J Hand Surg [Am]* 31:483–490, 2006.
21. Carlson MG, Brooks C: Tendon transfers for thumb-in-palm deformity. *Atlas Hand Clin* 7:119–131, 2000.
22. Carlson MG, Brooks C: The effect of altered hand position and motor skills on stereognosis. *J Hand Surg [Am]* 34(5):896–899, 2009.
23. Carlson MG, Gallagher K, Spiritos M: Easy surgical treatment of dynamic digital swan neck deformity in cerebral palsy. *J Hand Surg [Am]* 32:1418–1422, 2007.
24. Carlson MG, Hearns KA, Inkellis E, et al: Early results of surgical intervention for elbow deformity in cerebral palsy based on degree of contracture. *J Hand Surg [Am]* 37(8):1665–1671, 2012.
25. Carlson MG, Spincola LJ, Lewin J, et al: Impact of video review on surgical procedure determination for patients with cerebral palsy. *J Hand Surg [Am]* 34(7): 1225–1231, 2009.
26. Carmick J: Clinical use of neuromuscular electrical stimulation for children with cerebral palsy: II. Upper extremity. *Phys Ther* 73:514–527, 1993.
27. Carroll RE: The treatment of cerebral palsy in the upper extremity. *Bull N Y Orthop Hosp* 3:3–9, 1958.
28. Carroll RE, Craig FS: The surgical treatment of cerebral palsy: I. The upper extremity. *Surg Clin North Am* 30:385–396, 1951.
29. Chait LA, Kaplan I, Stewart-Lord B, et al: Early surgical correction in the cerebral palsied hand. *J Hand Surg [Am]* 5:122–126, 1980.
30. Cheema TA, Firoozbakhsh K, DeCarvalho AF, et al: Biomechanic comparison of 3 tendon transfers for supination of the forearm. *J Hand Surg [Am]* 31:1640–1644, 2006.
31. Deleted in review.

32. Colton CL, Ransford AO, Lloyd-Roberts GC: Transposition of the tendon of the pronator teres in cerebral palsy. *J Bone Joint Surg Br* 58:220–223, 1976.
33. Cooper W: Surgery of upper extremity in spastic paralysis. *Q Rev Pediatr* 7:139–144, 1952.
34. Deleted in review.
35. Corry IS, Cosgrove AP, Walsh EG, et al: Botulinum toxin A in the hemiplegic upper limb: a double blind trial. *Dev Med Child Neurol* 39:185–193, 1997.
36. Crocker MD, Mackay-Lyons M, McDonell E: Forced use of the upper extremity in cerebral palsy: a single-case design. *Am J Occup Ther* 51:824–833, 1997.
37. Dahlin LB, Komoto-TuFvesson Y, Salgeback S: Surgery of the spastic hand in cerebral palsy: improvement in stereognosis and hand function after surgery. *J Hand Surg [Br]* 23:335–339, 1998.
38. Davids JR, Peace LC, Wagner LV, et al: Validation of the Shriners Hospital for Children upper extremity evaluation. *J Bone Joint Surg Am* 88:326–333, 2006.
39. Davids JR, Sabesan VJ, Ortmann F, et al: Surgical management of thumb deformity in children with hemiplegic-type cerebral palsy. *J Pediatr Orthop* 29(5):504–510, 2009.
40. de Bruin M, van Vliet DC, Smeulders MJ, et al: Long-term results of lateral band translocation for the correction of swan neck deformity in cerebral palsy. *J Pediatr Orthop* 30(1):67–70, 2010.
41. de Roode CP, James MA, Van Heest AE: Tendon transfers and releases for the forearm, wrist, and hand in spastic hemiplegic cerebral palsy. *Tech Hand Up Extrem Surg* 14(2):129–134, 2010.
42. Dy C, Pean C, Hearns K, et al: Long-term results following surgical treatment of elbow deformity in patients with cerebral palsy. *J Hand Surg [Am]* 38(12):2432–2436, 2013.
43. Deleted in review.
44. El-Said NS: Selective release of flexor origin with transfer of flexor carpi ulnaris in cerebral palsy. *J Bone Joint Surg Br* 83:259–262, 2001.
45. Erhardt RP: Sequential levels of prehension development. *Am J Occup Ther* 28(10):592–596, 1974.
46. Erhardt RP: Sequential levels in the visual-motor development of a child with cerebral palsy. *Am J Occup Ther* 41(1):43–49, 1987.
47. Evans CD: Assessment of disability after head injury. *Rheumatol Rehabil* 15:168–169, 1976.
48. Ezaki M, Malungpaishrope K, Harrison RJ, et al: On a botulinum toxin A injection as an adjunct in the treatment of posterior shoulder subluxation in neonatal brachial plexus palsy. *J Bone Joint Surg Am* 92:2171–2177, 2010.
49. Ezaki M, Oishi SN: Technique of forearm osteotomy for pediatric problems. *J Hand Surg [Am]* 37(11):2400–2403, 2012.
50. Fehlings D, Novak I, Berweck S, et al: Botulinum toxin assessment, intervention and follow-up for paediatric upper limb hypertonicity: international consensus statement. *Eur J Neurol* 17(Suppl 2):38–56, 2010.
51. Fehlings D, Rang M, Glazier J, et al: An evaluation of botulin-A toxin injections to improve upper extremity function in children with hemiplegic cerebral palsy. *J Pediatr* 137:331–337, 2000.
52. Filler BC, Stark HH, Boyes JH: Capsulodesis of the metacarpophalangeal joint of the thumb in children with cerebral palsy. *J Bone Joint Surg Am* 58:667–670, 1976.
53. Friedman A, Diamond M, Johnston MV, et al: Effects of botulinum toxin A on upper limb spasticity in children with cerebral palsy. *Am J Phys Med Rehabil* 79:53–59, quiz 75–78, 2000.
54. Gelberman RH: Cerebral palsy. In Gelberman RH, editor: *Operative nerve repair and reconstruction*, Philadelphia, 1991, JB Lippincott, pp 1455–1475.
55. Gennarelli TA: Mechanisms of brain injury. *J Emerg Med* 11(Suppl 1):5–11, 1993.
56. Gob A: The treatment of spastic thumbs in palm deformity. *Reconstr Surg Traumatol* 13:51–57, 1972.
57. Goldner JL: Reconstructive surgery of the hand in cerebral palsy and spastic paralysis resulting from injury to the spinal cord. *J Bone Joint Surg Am* 37:1141–1154, 1955.
58. Goldner JL: Upper extremity reconstructive surgery in cerebral palsy or similar conditions. *Instr Course Lect* 18:169–177, 1961.
59. Deleted in review.
60. Goldner JL: Upper extremity surgical procedures for patients with cerebral palsy. *Instr Course Lect* 28:37–66, 1979.
61. Deleted in review.
62. Goldner JL: Surgical reconstruction of the upper extremity in cerebral palsy. *Instr Course Lect* 36:207–235, 1987.
63. Goldner JL: Surgical reconstruction of the upper extremity in cerebral palsy. *Hand Clin* 4:223–265, 1988.
64. Goldner JL, Ferlic DC: Sensory status of the hand as related to reconstructive surgery of the upper extremity in cerebral palsy. *Clin Orthop Relat Res* 46:87–92, 1966.
65. Goldner JL, Koman LA, Gelberman RH, et al: Arthrodesis of the metacarpophalangeal joint of the thumb in children and adults: adjunctive treatment of thumb-in-palm deformity in cerebral palsy. *Clin Orthop Relat Res* 253:75–89, 1990.
66. Gong HS, Chung CY, Park MS, et al: Functional outcomes after upper extremity surgery for cerebral palsy: comparison of high and low manual ability classification system levels. *J Hand Surg [Am]* 35(2):277–283, 2010.
67. Gong HS, Kang JY, Lee JO, et al: Wrist arthrodesis with volar plate fixation in cerebral palsy. *Tech Hand Up Extrem Surg* 14(2):69–72, 2010.
68. Gordon AM, Duf SV: Fingertip forces during object manipulation in children with hemiplegic cerebral palsy. I: Anticipatory scaling. *Dev Med Child Neurol* 41:166–175, 1999.
69. Gormley ME, Jr: Management of spasticity in children. Part 2: oral medications and intrathecal baclofen. *J Head Trauma Rehabil* 14:207–209, 1999.
70. Green WT: Tendon transplantation of the flexor carpi ulnaris for pronation-flexion deformity of the wrist. *Surg Gynecol Obstet* 75:337–342, 1942.
71. Green WT, Banks HH: Flexor carpi ulnaris transplant and its use in cerebral palsy. *J Bone Joint Surg Am* 44:1343–1352, 1962.
72. Gschwind C, Tonkin M: Surgery for cerebral palsy: Part I. Classification and operative procedures for pronation deformity. *J Hand Surg [Br]* 17:391–395, 1992.
73. Gschwind CR: Surgical management of forearm pronation. *Hand Clin* 19(4):649–655, 2003.
74. Hargreaves DG, Warwick DJ, Tonkin MA: Changes in hand function following wrist arthrodesis in cerebral palsy. *J Hand Surg [Br]* 25:193–194, 2000.

74a. Himmelmann K, Uvebrant P: Function and neuroimaging in cerebral palsy: a population-based study. *Dev Med Child Neurol* 53(6):516–521, 2011.

75. Hines AE, Crago PE, Billian C: Functional electrical stimulation for the reduction of spasticity in the hemiplegic hand. *Biomed Sci Instrum* 29:259–266, 1993.
76. Hoffer MM: Cerebral palsy. In Green DP, editor: *Operative hand surgery*, ed 3, New York, 1993, Churchill Livingstone, pp 215–223.
77. Hoffer MM: The use of pathokinesiology laboratory to select muscles for tendon transfers in the cerebral palsy hand. *Clin Orthop Relat Res* 288:135–138, 1993.
78. Hoffer MM, Lehman M, Mitani M: Long-term follow-up on tendon transfers to the extensors of the wrist and fingers in patients with cerebral palsy. *J Hand Surg [Am]* 11:836–840, 1986.
79. Hoffer MM, Lehman M, Mitani M: Surgical indications in children with cerebral palsy. *Hand Clin* 5:69–74, 1989.
80. Hoffer MM, Perry J, Garcia M, et al: Adduction contracture of the thumb in cerebral palsy: a preoperative electromyographic study. *J Bone Joint Surg Am* 65:755–759, 1983.
81. Hoffer MM, Perry J, Melkonian GJ: Dynamic electromyography and decision-making for surgery in the upper extremity of patients with cerebral palsy. *J Hand Surg [Am]* 4:424–431, 1979.
82. Holmström L, Vollmer B, Tedroff K, et al: Hand function in relation to brain lesions and corticomotor-projection pattern in children with unilateral cerebral palsy. *Dev Med Child Neurol* 52(2):145–152, 2010.
83. Horridge KA, Johnston J, Phatak V, et al: Magentic resonance imaging of the brain in children and young people with cerebral palsy: who reports matters? *Dev Med Child Neurol* 53(4):375–377, 2011.
84. House JH, Gwathmey FW, Fidler MO: A dynamic approach to the thumb-in-palm deformity in cerebral palsy: evaluation and results in fifty-six patients. *J Bone Joint Surg Am* 63:216–225, 1981.
85. Inglis AE, Cooper W: Release of the flexor-pronator origin for flexion deformities of the hand and wrist in spastic paralysis: a study of 18 cases. *J Bone Joint Surg Am* 48:847–857, 1966.
86. Inglis AE, Cooper W, Bruton W: Surgical correction of thumb deformities in spastic paralysis. *J Bone Joint Surg Am* 52:253–268, 1970.
87. Jennett B: Prediction of outcome and complications after head injury. *Ned Tijdschr Geneeskd* 118:895, 1974.
88. Johnson LM, Randall MJ, Reddihough DS, et al: Development of a clinical assessment of quality of movement for unilateral upper-limb function. *Dev Med Child Neurol* 36:965–973, 1994.
89. Johnstone BR, Richardson PW, Coombs CJ, et al: Functional and cosmetic outcome of surgery for cerebral palsy in the upper limb. *Hand Clin* 19(4):679–686, 2003.
90. Keats S: Surgical treatment of the hand in cerebral palsy: correction of thumb-in-palm and other deformities: report of nineteen cases. *J Bone Joint Surg Am* 47:274–284, 1965.
91. Keenan MA: The orthopaedic management of spasticity. *J Head Trauma Rehabil* 2:62–71, 1987.
92. Keenan MAE, Haider TT, Stone LR: Dynamic electromyography to assess elbow spasticity. *J Hand Surg [Am]* 15:607–614, 1990.
93. Keenan MAE, Kozin SH, Berlet AC: Contracture releases in the non-functional arm. In Keenan MAE, Kozin SH, Berlet AC, editors: *Manual of orthopaedic surgery for spasticity*, New York, 1993, Raven Press.
94. Keenan MAE, Kozin SH, Berlet AC: Surgical procedures to improve upper extremity function. In Keenan MAE, Kozin SH, Berlet AC, editors: *Manual of orthopaedic surgery for spasticity*, New York, 1993, Raven Press.

95. King JT, Jr, Carlier PM, Marion DW: Early Glasgow Outcome Scale scores predict long term functional outcome in patients with severe traumatic brain injury. *J Neurotrauma* 22(9):947–954, 2005.
96. Kinnucan E, Van Heest A, Tomhave W: Correlation of motor function and stereognosis impairment in upper limb cerebral palsy. *J Hand Surg [Am]* 35(8):1317–1322, 2010.
97. Deleted in review.
98. Koman LA, Gelberman RH, Toby EB, et al: Cerebral palsy: management of the upper extremity. *Clin Orthop Relat Res* 253:62–74, 1990.
99. Koman LA, Mooney JF, III, Smith B, et al: Management of cerebral palsy with botulinum A toxin: preliminary investigation. *J Pediatr Orthop* 13:489–495, 1993.
100. Koman LA, Paterson Smith B, Balkrishnan R: Spasticity associated with cerebral palsy in children: guidelines for the use of botulinum A toxin. *Paediatr Drugs* 5:11–23, 2003.
101. Koman LA, Sarlikiotis T, Smith BP: Surgery of the upper extremity in cerebral palsy. *Orthop Clin North Am* 41(4):519–529, 2010.
102. Deleted in review.
103. Koman LA, Smith BP, Williams R, et al: Upper extremity spasticity in children with cerebral palsy: a randomized, double- blind, placebo-controlled study of the short-term outcomes of treatment with botulinum A toxin. *J Hand Surg [Am]* 38:435–446, 2013.
104. Koman LA, Williams RM, Evans PJ, et al: Quantification of upper extremity function and range of motion in children with cerebral palsy. *Dev Med Child Neurol* 50:910–917, 2008.
105. Kowalski MF, Manske PR: Arthrodesis of digital joints in children. *J Hand Surg [Am]* 13:874–879, 1988.
105a. Kozin SH, Bednar M: In vivo determination of available brachioradialis excursion during tetraplegia reconstruction. *J Hand Surg [Am]* 26(3):510–514, 2001.
106. Kozin SH, Hines B: Anatomical approach to the pronator teres. *Tech Hand Up Extrem Surg* 6:152–154, 2002.
107. Kreulen M, Smeulders MJ: Assessment of flexor carpi ulnaris function for tendon transfer surgery. *J Biomech* 41(10):2130–2135, 2008.
108. Lancaster G, Kozin SH, Porter S: The medial approach to the humerus. *Tech Hand Up Extrem Surg* 4:201–206, 2000.
109. Landi A, Cavazza S, Caserta G, et al: The upper limb in cerebral palsy: surgical management of shoulder and elbow deformities. *Hand Clin* 19:631–648, vii, 2003.
110. Langlois JA, et al: Traumatic brain injury-related hospital discharges: results from a 14-state surveillance system, 1997. *MMWR Surveill Summ* 52:1–20, 2003.
111. Law M, Baptiste S, McColl M, et al: The Canadian occupational performance measure: an outcome measure for occupational therapy. *Can J Occup Ther* 57(2):82–87, 1990.
112. Law M, Cadman D, Rosenbaum P, et al: Neurodevelopmental therapy and upper-extremity inhibitive casting for children with cerebral palsy. *Dev Med Child Neurol* 33:378–387, 1991.
113. Lomita C, Ezaki M, Oishi S: Upper extremity surgery in children with cerebral palsy. *J Am Acad Orthop Surg* 18(3):160–168, 2010.
114. Maarrawi J, Mertens P, Luaute J, et al: Long-term functional results of selective peripheral neurotomy for the treatment of spastic upper limb: prospective study in 31 patients. *J Neurosurg* 104(2):215–225, 2006.
114a. Malfait N, Sanger TD: Does dystonia always include co-contraction? A study of unconstrained reaching in children with primary and secondary dystonia. *Exp Brain Res* 176(2):206–216, 2007.
115. Manske PR: Redirection of extensor pollicis longus in the treatment of spastic thumb-in-palm deformity. *J Hand Surg [Am]* 10:553–560, 1985.
116. Manske PR: Cerebral palsy of the upper extremity. *Hand Clin* 6:697–709, 1990.
117. Manske PR, Langewisch KR, Strecker WB, et al: Anterior elbow release of spastic elbow flexion deformity in children with cerebral palsy. *J Pediatr Orthop* 21:772–777, 2001.
118. Manske PR, Strecker WB: Pronator teres rerouting for spastic rotational forearm deformities in cerebral palsy. *Surg Rounds Orthop* 1:39–44, 1987.
119. Manske PR, Strecker WB: Cerebral palsy, brain injury, stroke: spastic disorders of the upper extremity. In Peimer CA, editor: *Surgery of the hand and upper extremity*, vol 2, New York, 1996, McGraw-Hill, pp 1517–1538.
120. Matev I: Surgical treatment of spastic "thumb-in-palm" deformity. *J Bone Joint Surg Br* 45:703–708, 1963.
121. Matev IB: Surgical treatment of flexion-adduction contracture of the thumb in cerebral palsy. *Acta Orthop Scand* 41:439–445, 1970.
122. Matsuo T, Lai T, Tayama N: Combined flexor and extensor release for activation of voluntary movement of the fingers in patients with cerebral palsy. *Clin Orthop Relat Res* 250:185–193, 1990.
123. Matsuo T, Matsuo A, Hajime T, et al: Release of flexors and intrinsic muscles for finger spasticity in cerebral palsy. *Clin Orthop Relat Res* 384:162–168, 2001.
124. McCue FC, Honner R, Chapman WC: Transfer of the brachioradialis for hands deformed by cerebral palsy. *J Bone Joint Surg Am* 52:1171–1180, 1970.
125. Mital MA: Lengthening of the elbow flexors in cerebral palsy. *J Bone Joint Surg Am* 61:515–522, 1979.
126. Mital MA, Sakellarides HT: Surgery of the upper extremity in the retarded individual with spastic cerebral palsy. *Orthop Clin North Am* 12:127–141, 1981.
127. Deleted in review.
128. Deleted in review.
129. Mortens J: Surgery of the hand in cerebral palsy. *Acta Orthop Scand* 36:441–452, 1965.
130. Mowery CA, Gelberman RH, Rhoades CE: Upper extremity tendon transfers in cerebral palsy: electromyographic and functional analysis. *J Pediatr Orthop* 5:69–72, 1985.
130a. Mulcahey MJ, Merenda L, Tian F, et al: Computer adaptive test approach to the assessment of children and youth with brachial plexus birth palsy. *Am J Occup Ther* 67(5):524–533, 2013.
131. Nogen AG: Medical treatment for spasticity in children with cerebral palsy. *Childs Brain* 2:304–308, 1976.
132. Nylander G, Carlstrom C, Adolfsson L: 4.5-Year follow up after surgical correction of upper extremity deformities in spastic cerebral palsy. *J Hand Surg [Br]* 24:719–723, 1999.
133. Omer GE, Capen DA: Proximal row carpectomy with muscle transfers for spastic paralysis. *J Hand Surg [Am]* 1:197–204, 1976.
134. Ozkan T, Bicer A, Aydin HU, et al: Brachialis muscle transfer to the forearm for the treatment of deformities in spastic cerebral palsy. *J Hand Surg Eur Vol* 38(1):14–21, 2013.
135. Ozkan T, Tuncer S, Aydin A, et al: Brachioradialis re-routing for the restoration of active supination and correction of forearm pronation deformity in cerebral palsy. *J Hand Surg [Br]* 29:265–270, 2004.
136. Page CM: An operation for the relief of flexion contracture in the forearm. *J Bone Joint Surg Am* 5:233–234, 1923.
137. Parry RG: Surgical correction of the spastic hand. *Surg Clin North Am* 56:673–684, 1976.
138. Patterson JM, Wang AA, Hutchinson DT: Late deformities following the transfer of the flexor carpi ulnaris to the extensor carpi radialis brevis in children with cerebral palsy. *J Hand Surg [Am]* 35(11):1774–1778, 2010.
139. Pierce SR, Daly K, Gallagher KG, et al: Constraint-induced therapy for a child with hemiplegic cerebral palsy: a case report. *Arch Phys Med Rehabil* 83:1462–1463, 2002.
140. Pletcher DFJ, Hoffer MM, Koffman DM: Non-traumatic dislocation of the radial head in cerebral palsy. *J Bone Joint Surg Am* 58:104–105, 1976.
141. Pollock GA: Surgical treatment of cerebral palsy. *J Bone Joint Surg Br* 44:68–81, 1962.
142. Pontén E, Ekholm CL, Eliasson AC: Bimanuality is improved by hand surgery in children with brain lesions: preliminary results in 18 children. *J Pediatr Orthop B* 20(6):359–365, 2011.
143. Purohit AK, Raju BS, Kumar KS, et al: Selective musculocutaneous fasciculotomy for spastic elbow in cerebral palsy: a preliminary study. *Acta Neurochir (Wien)* 145:473–478, 1998.
144. Randall M, Carlin JB, Chondros P, et al: Reliability of the Melbourne Assessment of Unilateral Upper Limb Function. *Dev Med Child Neurol* 43:761–767, 2001.
145. Rayan GM, Saccone PG: Treatment of spastic thumb-in-palm deformity: a modified extensor pollicis longus tendon rerouting. *J Hand Surg [Am]* 21:835–839, 1996.
146. Rayan GM, Young BT: Arthrodesis of spastic wrist. *J Hand Surg [Am]* 24:944–952, 1999.
147. Riad J, Coleman S, Miller F: Arm posturing during walking in children with spastic hemiplegic cerebral palsy. *J Pediatr Orthop* 27(2):137–141, 2007.
148. Richards RR, Sherman RMP, Hudson AR, et al: Shoulder arthrodesis using a pelvic reconstruction plate: a report of 11 cases. *J Bone Joint Surg Am* 70:416–421, 1988.
149. Roth JH, O'Grady SE, Richards RS, et al: Functional outcome of upper limb tendon transfers performed in children with spastic hemiplegia. *J Hand Surg [Br]* 18:299–303, 1993.
150. Saintyves G, Genet F, Allieu Y, et al: Surgical management of spasticity of the intrinsic muscles of the long fingers in adults after cerebral palsy, 68 operated hands. *Chir Main* 30(1):46–51, 2011.
151. Sakellarides HT, Kirvin FM: Management of the unbalanced wrist in cerebral palsy by tendon transfer. *Ann Plast Surg* 35:90–94, 1995.
152. Deleted in review.
153. Sakellarides HT, Mital MA, Lenzi WD: Treatment of pronator contractures of the forearm in cerebral palsy by changing the insertion of the pronator radii teres. *J Bone Joint Surg Am* 63:645–652, 1981.
154. Sakellarides HT, Mital MA, Matza RA, et al: Classification and surgical treatment of the thumb-in-palm deformity in cerebral palsy and spastic paralysis. *J Hand Surg [Am]* 20:428–431, 1995.
155. Samilson RL: Principles of assessment of the upper limb in cerebral palsy. *Clin Orthop Relat Res* 47:105–115, 1966.
156. Samilson RL, Green WL: Long-term results of upper limb surgery in cerebral palsy. *Reconstr Surg Traumatol* 13:43–50, 1972.

157. Samilson RL, Morris JM: Surgical improvement of the cerebral-palsied upper limb: electromyographic studies and results of 128 operations. *J Bone Joint Surg Am* 46:1203–1216, 1964.
158. Sanger TD, Delgado MR, Gaebler-Spira D, et al: Task Force on Childhood Motor Disorders. Classification and definition of disorders causing hypertonia in childhood. *Pediatrics* 111(1):e89–e97, 2003.
159. Scheker LR, Chesher SP, Ramirez S: Neuromuscular electrical stimulation and dynamic bracing as a treatment for upper-extremity spasticity in children with cerebral palsy. *J Hand Surg [Br]* 24:226–232, 1999.
160. Scheker LR, Ozer K: Electrical stimulation in the management of spastic deformity. *Hand Clin* 19:601–606, 2003.
161. Schuurman AH, Bos KE: Treatment of volar instability of the metacarpophalangeal joint of the thumb by volar capsulodesis. *J Hand Surg [Br]* 18:346–349, 1993.
162. Sherk HH: Treatment of severe rigid contractures of cerebral palsied upper limbs. *Clin Orthop Relat Res* 125:151–155, 1977.
163. Silver CM, Simon SD, Litchman HM, et al: Surgical correction of spastic thumb-in-palm deformity. *Dev Med Child Neurol* 18:632–639, 1976.
164. Sindou MP, Simon F, Mertens P, et al: Selective peripheral neurotomy (SPN) for spasticity in childhood. *Childs Nerv Syst* 23(9):957–970, 2007.
165. Skoff H, Woodbury DF: Management of the upper extremity in cerebral palsy. *J Bone Joint Surg Am* 67:500–503, 1985.
166. Deleted in review.
167. Smeulders M, Coester A, Kreulen M: Surgical treatment for the thumb-in-palm deformity in patients with cerebral palsy. *Cochrane Database Syst Rev* (4): CD004093, 2005.
168. Smith RJ: Intrinsic muscles of the fingers: function, dysfunction and surgical reconstruction. *Instr Course Lect* 24:200–220, 1975.
169. Smith RJ: Flexor pollicis longus abductorplasty for spastic thumb-in-palm deformity. *J Hand Surg [Am]* 7:327–334, 1982.
170. Deleted in review.
171. Stelling FH, Meyer LC: Cerebral palsy; the upper extremity. *Clin Orthop Relat Res* 14:70–79, 1959.
172. Strauss DJ, Shavelle RM, Anderson TW: Long-term survival of children and adolescents after traumatic brain injury. *Arch Phys Med Rehabil* 79:1095–1100, 1998.
173. Strecker WB, Emanuel JP, Dailey L, et al: Comparison of pronator tenotomy and pronator rerouting in children with spastic cerebral palsy. *J Hand Surg [Am]* 13:540–543, 1988.
174. Surveillance of Cerebral Palsy in Europe (SCPE): Prevalence and characteristics of children with cerebral palsy in Europe. *Dev Med Child Neurol* 44(9):633–640, 2002.
175. Swanson AB: Surgery of the hand in cerebral palsy and the swan-neck deformity. *J Bone Joint Surg Am* 42:951–964, 1960.
176. Deleted in review.
177. Swanson AB: Surgery of the hand in cerebral palsy and muscle origin release procedures. *Surg Clin North Am* 48:1129–1138, 1968.
178. Swanson AB: Surgery of the hand in cerebral palsy. In Flynn JE, editor: *Hand surgery*, Baltimore, 1982, Williams & Wilkins, pp 476–488.
179. Szabo RM, Gelberman RH: Operative treatment of cerebral palsy. *Hand Clin* 1:525–543, 1985.
180. Tachdjian MO, Minear WL: Sensory disturbances in the hands of children with cerebral palsy. *J Bone Joint Surg Am* 40:85–90, 1958.
181. Tardieu G, Shentoub S, Delarue R: A la Recherche d'une technique de mesure de la spasticite. *Neurologique* 91:143–144, 1954.
182. Thevenin-Lemoine C, Denormandie P, Schnitzler A, et al: Flexor origin slide for contracture of spastic finger flexor muscles: a retrospective study. *J Bone Joint Surg Am* 95(5):446–453, 2013.
183. Thometz JG, Tachdjian M: Long-term follow-up of the flexor carpi ulnaris transfer in spastic hemiplegic children. *J Pediatr Orthop* 8:407–412, 1988.
184. Deleted in review.
185. Tonkin M, Freitas A, Koman A, et al: The surgical management of thumb deformity in cerebral palsy. *J Hand Surg Eur Vol.* 33(1):77–80, 2008.
186. Tonkin M, Gschwind C: Surgery for cerebral palsy: II. Flexion deformity of the wrist and fingers. *J Hand Surg [Br]* 17:396–400, 1992.
187. Tonkin MA, Hughes J, Smith KL: Lateral band translocation for swan-neck deformity. *J Hand Surg [Am]* 17(2):260–267, 1992.
188. Van Heest A, Bagley A, Molitor F, et al: Tendon transfer surgery in upper-extremity cerebral palsy is more effective than botulinum toxin injections or regular, ongoing therapy. *J Bone Joint Surg Am* 97(7):529–536, 2015.
189. Van Heest A, Stout J, Wervey R: Garcia Follow-up motion laboratory analysis for patients with spastic hemiplegia due to cerebral palsy: analysis of the flexor carpi ulnaris firing pattern before and after tendon transfer surgery. *J Hand Surg [Am]* 35(2):284–290, 2010.
190. Van Heest AE: Surgical management of the wrist and finger deformity. *Hand Clin* 19:657–665, 2003.
191. Van Heest AE: Surgical technique for thumb-in-palm deformity in cerebral palsy. *J Hand Surg [Am]* 36(9):1526–1531, 2011.
192. Van Heest AE, House J, Putnam M: Sensibility deficiencies in the hands of children with spastic hemiplegia. *J Hand Surg [Am]* 18:278–281, 1993.
193. Van Heest AE, House JH, Cariello C: Upper extremity surgical treatment of cerebral palsy. *J Hand Surg [Am]* 24:323–330, 1999.
194. Van Heest AE, Murthy NS, Sathy MR, et al: The supination effect of tendon transfer of the flexor carpi ulnaris to the extensor carpi radialis brevis or longus: a cadaveric study. *J Hand Surg [Am]* 24(5):1091–1096, 1999.
195. Van Heest AE, Ramachandran V, Stout J, et al: Quantitative and qualitative functional evaluation of upper extremity tendon transfers in spastic hemiplegia caused by cerebral palsy. *J Pediatr Orthop* 28(6):679–683, 2008.
196. Deleted in review.
197. van Munster JC, Maathuis KG, Haga N, et al: Does surgical management of the hand in children with spastic unilateral cerebral palsy affect functional outcome? *Dev Med Child Neurol* 49(5):385–389, 2007.
198. Wagner LV, Davids JR: Assessment tools and classification systems used for the upper extremity in children with cerebral palsy. *Clin Orthop Relat Res* 470(5):1257–1271, 2012.
199. Deleted in review.
200. Deleted in review.
201. Waters PM, Van Heest AE: Spastic hemiplegia of the upper extremity in children. *Hand Clin* 14:119–134, 1998.
202. Waters PM, Zurakowski D, Patterson P, et al: Interobserver and intraobserver reliability of therapist-assisted videotaped evaluations of upper-limb hemiplegia. *J Hand Surg [Am]* 29(2):328–334, 2004.
203. Wenner SM, Johnson KA: Transfer of the flexor carpi ulnaris to the radial wrist extensors in cerebral palsy. *J Hand Surg [Am]* 13:231–233, 1988.
204. White WF: Flexor muscle slide in the spastic hand: the Max Page operation. *J Bone Joint Surg Br* 54:453–459, 1972.
205. Wolf TM, Clinkscales CM, Hamlin C: Flexor carpi ulnaris tendon transfers in cerebral palsy. *J Hand Surg [Br]* 23:340–343, 1998.
206. Deleted in review.
207. Wright PA, Granat MH: Improvement in hand function and wrist range of motion following electrical stimulation of wrist extensor muscles in an adult with cerebral palsy. *Clin Rehabil* 14:244–246, 2000.
208. Wright PA, Granat MH: Therapeutic effects of functional electrical stimulation of the upper limb of eight children with cerebral palsy. *Dev Med Child Neurol* 42:724–727, 2000.
209. Deleted in review.
210. Yekutiel M, Jariwala M, Stretch P: Sensory deficit in the hands of children with cerebral palsy: a new look at assessment and prevalence. *Dev Med Child Neurol* 36:619–624, 1994.
211. Zancolli EA, Goldner JL, Swanson AB: Surgery of the spastic hand in cerebral palsy: report of the Committee on Spastic Hand Evaluation. *J Hand Surg [Am]* 8:766–772, 1983.
212. Zancolli EA, Zancolli ER, Jr: Surgical management of the hemiplegic spastic hand in cerebral palsy. *Surg Clin North Am* 61:395–406, 1981.

33

Tetraplegia

Ann E. Van Heest

These videos may be found at *ExpertConsult.com*:

33.1 Brachioradialis to flexor pollicis longus and extensor carpi radialis longus to flexor digitorum brevis transfers. *(Courtesy Dr. Scott Kozin, Shriners Hospital for Children, Philadelphia.)*

33.2 Biceps to triceps transfer. *(Courtesy Dr. Scott Kozin, Shriner's Hospital for Children, Philadelphia)*

33.3 Patient outcome video after biceps to triceps, brachioradialis to flexor pollicis longus, and extensor carpi radialis longus to flexor digitorum brevis transfers. *(Courtesy Dr. Scott Kozin, Shriners Hospital for Children, Philadelphia.)*

33.4 Additional patient outcome video after biceps to triceps, brachioradialis to flexor pollicis longus, and extensor carpi radialis longus to flexor digitorum brevis transfers. *(Courtesy Dr. Scott Kozin, Shriners Hospital for Children, Philadelphia.)*

33.5 Patient outcome video after biceps to triceps, brachioradialis to flexor pollicis longus, and extensor carpi radialis longus to flexor digitorum brevis transfers. *(Courtesy Dr. Scott Kozin, Shriners Hospital for Children, Philadelphia.)*

33.6 Additional patient outcome video after biceps to triceps, brachioradialis to flexor pollicis longus, and extensor carpi radialis longus to flexor digitorum brevis transfers. *(Courtesy Dr. Scott Kozin, Shriners Hospital for Children, Philadelphia.)*

The annual incidence of spinal cord injury is approximately 12,000 new cases each year in the United States. The patient's age at the time of injury has increased over time; since 2010, the average age at injury has been 28.7 years. Demographics of spinal cord injury patients since 2010 show that 80% of injuries occur in males and 20% in females; 52% in single persons and 48% in married persons; and 67% in Caucasians, 24% in African-Americans, 8% in Hispanics, and 2% in Asian-Americans. The most common causes of spinal cord injury since 2010 have been motor vehicle accidents (37%), falls (29%), violence (14%), and sports trauma (9%). Since 2010, the most frequent neurologic categories of spinal cord injury, at the time of discharge, have been incomplete tetraplegia (41%), incomplete paraplegia (19%), complete paraplegia (18%), and complete tetraplegia (12%). *Tetraplegia* refers to a spinal cord injury sustained to one of the eight cervical segments of the spinal cord, whereas *paraplegia* refers to spinal cord injury in the thoracic, lumbar, or sacral segment of the spinal cord. This chapter will deal with patients sustaining tetraplegic spinal cord injuries that leave a neurologic deficit in hand function.[74]

GENERAL CONSIDERATIONS IN TETRAPLEGIA

Pathogenesis

The cervical spinal cord contains eight cervical segments encased in the seven cervical vertebrae. The bone and ligamentous structure of the cervical spine allows a wide range of motion, thus exposing the cervical spinal cord to increased risk of injury. Injury occurs most commonly through a flexion deformity with bone or disk compression of the cord after fracture or dislocation or through traction on the cord with translation due to spine instability.[39] Over days and weeks, acute hemorrhage and edema subside, followed by local reparation and finally scar formation. The area of injured spinal cord can vary in width and length and is termed the *injured metamere.* Nerve function above the injured metamere is normal; nerve function within the injured metamere is absent; nerve function below the injured metamere may be stimulated if the lower motor neuron unit is unharmed.[16]

The muscles that are innervated above the level of injury have normal strength. The muscles that are innervated below the level of injury may be flaccid or have some elements of spasticity. The strength of muscles at the level of injury may improve over time, most commonly within a year of injury. Ditunno and colleagues[24] and Waters and associates[89] reported upper limb strength recovery rates using manual muscle testing and the British Medical Research Council grading system (Table 33.1).[17] One third of muscles classified as grade 0 at 1 month after injury improved to grade 3 at 4 to 6 months after injury; improvement was documented in some cases up to 24 months after injury. All upper limb muscles with an initial strength of grade 1 improved to at least grade 3 by 1 year after injury, with the exception of the triceps. If a muscle's strength was grade 2 or better at 1 month after injury, the median time for full recovery was 6 months.

Preoperative Evaluation

The reconstructive surgeon is less concerned with the specific level of cervical injury than with the remaining strength of each muscle in the upper limb. Classically, tetraplegic patients have been classified by the injured cervical spine segment of C1-C7. Formerly, it was assumed that the level of paralysis and sensory loss coincided with the bony injury, producing a precise transverse spinal cord lesion. Careful examination of tetraplegic patients has shown that there is frequently little relationship between the level of the skeletal lesion and the spinal cord lesion; lesions may be asymmetric, and there may be unusual patterns of spared sensory or motor function. A classification

for spinal cord injury commonly used by surgeons other than hand surgeons is the American Spinal Injury Association (ASIA) classification.[64] This classification is based on intact muscle groups.

The classification used in this chapter was developed by an international group of hand surgeons in 1978 in Edinburgh[62,63] and modified in 1984 at Giens, France. The International Classification for Surgery of the Hand in Tetraplegia (ICS) grades the level of the spinal cord injury based on the number of muscles with grade 4 strength below the elbow and includes ICS levels 0 to 9 (Table 33.2). The ICS level characterizes the most common patterns of presentation, based on the number of functional muscles below the elbow. A muscle is defined as functional if it demonstrates grade 4 or better strength by manual muscle testing.

Another aspect of patient evaluation includes assessment of the general suitability for surgery. An assessment based on age, occupation, interests, level of education, learning capacity, economic support, family and agency support, personality type, and understanding of what can and cannot be expected from surgical treatment needs to be explored with the patient and the spinal cord injury management team.

Physical Examination

After a thorough history of the injury and associated medical conditions is obtained, a physical examination is performed, including sensory and motor testing to establish the patient's group (ICS level 0 to 9). Manual muscle testing (see Table 33.1) is performed on all muscle groups in the upper extremity. The surgeon can make a working list of which tendons are available for transfer (those having grade 4 strength or higher) and which muscles are paralyzed (those having grade 1 strength or lower). Once the muscles with grade 4 strength have been identified, the patient is assigned a group number (see Table 33.2). For example, a patient with grade 4 strength of the brachioradialis (BR), both radial wrist extensors, the pronator teres (PT), and the flexor carpi radialis (FCR) would be classified as a group 5 patient. One of the difficulties in physical examination is distinguishing between group 2 and group 3 injuries. In group 2 patients, only the extensor carpi radialis longus (ECRL) has

TABLE 33.1 Muscle Grading System of the British Medical Research Council

Grade	Description
0	No contraction
1	Flicker or trace of contraction
2	Active movement with gravity eliminated
3	Active movement against gravity
4	Active movement against gravity and resistance
5	Normal power

Reproduced from *Aids to the examination of the peripheral nervous system*, London, Her Majesty's Stationery Office, 1976. With kind permission from the UK Medical Research Council.

TABLE 33.2 International Classification for Surgery of the Hand in Tetraplegia*

Sensibility†	Motor Group‡	Characteristics	Function
O or Cu	0	No muscle below elbow suitable for transfer	
O or Cu	1	BR	Flexion and supination of the elbow
O or Cu	2	ECRL	Extension of the wrist
O or Cu	3§	ECRB	Extension of the wrist
O or Cu	4	PT	Pronation of the wrist
O or Cu	5	FCR	Flexion of the wrist
O or Cu	6	Finger extensors	Extrinsic extension of the fingers
O or Cu	7	Thumb extensor	Extrinsic extension of the thumb
O or Cu	8	Partial digital flexors	Extrinsic flexion of the fingers
O or Cu	9	Lacks only intrinsics	Extrinsic flexion of the fingers
O or Cu	X	Exceptions	

*Developed at the First International Conference on Surgical Rehabilitation in the Upper Limb in Tetraplegia, Edinburgh, Scotland, 1978, and modified at the Second International Conference, Giens, France, 1984. This classification does not include the shoulder; it is a guide to the forearm and hand only. Determination of patient suitability for posterior deltoid to triceps transfer or biceps to triceps transfer is considered separately.

†Afferent input, both ocular (O) and cutaneous (Cu), is recorded using the method described by Moberg. When vision is the only afferent available, the designation is "O." Assuming there is 10-mm two-point discrimination or less in the thumb and index finger, the correct classification is "Cu," indicating that the patient has adequate cutaneous sensibility. If two-point discrimination is more than 10 mm (i.e., inadequate cutaneous sensibility), the correct designation is "O." The sensibility designation precedes the motor group (e.g., O2).

‡Motor grouping assumes that all listed muscles are Medical Research Council grade 4 or better, and a new muscle is added for each group; for example, a group 3 patient's BR, ECRL, and ECRB are rated at least grade 4.

§Caution: To determine the strength of the ECRB, see text.

BR, Brachioradialis; *ECRL,* extensor carpi radialis longus; *ECRB,* extensor carpi radialis brevis; *FCR,* flexor carpi radialis.

From Moberg EA, McDowell CL, House JH: Third international conference on surgical rehabilitation of the upper limb in tetraplegia (quadriplegia), *J Hand Surg [Am]* 14:1064–1066, 1989; McDowell CL, Moberg EA, House JH: The second international conference on surgical rehabilitation of the upper limb in tetraplegia (quadriplegia), *J Hand Surg [Am]* 11:604–608, 1986.



FIGURE 33.1 To determine whether a patient is in group 2 or group 3, the physician can palpate the extensor carpi radialis brevis (ECRB), a long flat muscle, and the extensor carpi radialis longus (ECRL), a more bulbous muscle. In thinner individuals, both muscles can be palpated as muscle strength is tested (Bean sign). If the Bean sign is present, indicating that both the ECRL and ECRB are firing, and the patient has wrist extension strength of grade 4 or 5, the patient is in group 3, and the muscle belly of the ECRL can be palpated.

TABLE 33.3 Preoperative Workup for the Assessment of Muscle Strength Testing

Function Needed by the Patient	Muscles to Be Tested and Graded
Elbow flexion	Biceps, brachialis
Elbow extension	Triceps
Wrist extension	ECRL, ECRB, ECU
Wrist flexion	FCR, FCU
Finger extension	EDC, EIP, extensor digiti quinti
Finger flexion	FDP, FDS
Thumb extension/abduction	EPL, EPB, APL
Thumb flexion/opposition	FPL, APB, opponens, flexor pollicis brevis
Intrinsics	Adductor pollicis, interossei, lumbricals

APB, abductor pollicis brevis; *APL,* abductor pollicis longus; *ECRL,* extensor carpi radialis longus; *ECRB,* extensor carpi radialis brevis; *ECU,* extensor carpi ulnaris; *EDC,* extensor digitorum communis; *EIP,* extensor indicis proprius; *EPB,* extensor pollicis brevis; *EPL,* extensor pollicis longus; *FCR,* flexor carpi radialis; *FCU,* flexor carpi ulnaris; *FDP,* flexor digitorum profundus; *FDS,* flexor digitorum superficialis; *FPL,* flexor pollicis longus.

strength of grade 4 or higher, and physical examination reveals significant radial deviation of the wrist with resisted wrist extension. In group 3 patients, both the ECRL and the extensor carpi radialis brevis (ECRB) have strength of grade 4 or higher. In a group 3 patient, the wrist extends with less radial deviation and often grade 1 to 3 strength is present in the PT, the next most caudal muscle. In thinner patients, the ECRL, a flat muscle, and the ECRB, a more bulbous muscle, can be palpated while muscle strength is being tested (Figure 33.1).

In addition to manual muscle testing, the surgeon must also examine the passive range of motion to evaluate joint and muscle contractures and the resting posture of the hand. The examiner can induce a tenodesis effect by passively flexing the wrist while observing passive myostatic tensioning of the digital extensors; the reverse effect of passive digital grasp can be induced with passive wrist extension. The hand must have passive mobility or tenodesis ability to achieve what the patient needs; for example, if the thumb rests in a fully supinated position and lacks any tenodesis for thumb flexion or opposition, tendon transfers will be ineffective without skeletal stabilization (carpometacarpal [CMC] fusion) in a key pinch position.

The next step is to determine the patient's needs, as shown in Table 33.3, and match the needs with the muscles available for transfer. For example, in a group 4 patient, the BR is available because the patient has the biceps and brachialis for elbow flexion (and, therefore, no function will be lost with the transfer); the ECRL is available because the patient has the ECRB for wrist extension. The PT can also be used for transfer, but this could result in diminished pronator power and loss of strength for manual wheelchair function. To complete the assessment, the muscles available for transfer (BR, ECRL) are matched with the needed functions (thumb extension and abduction, finger extension, thumb flexion and opposition, finger flexion, intrinsics) using principles of tendon transfer surgery (see Chapter 31), combined with other surgical options such as arthrodesis and tenodesis. In a group 4 patient, strength of grasp and pinch is deemed most important; thus the BR and ECRL are selected for finger and thumb flexion. The BR will be transferred to the flexor pollicis longus (FPL) because it has (and needs) less excursion, and the ECRL will be transferred to the flexor digitorum profundus (FDP) tendons, which need greater excursion. Surgical adjuncts will be used to pre-position the thumb in key pinch with a CMC fusion and to provide thumb and finger extension through an extensor pollicis longus (EPL) and extensor digitorum communis (EDC) tenodesis. If necessary, intrinsic reconstruction can be added during a second staged surgery if joint imbalance manifests. By evaluating what the patient has, what the patient needs, and what is available, the surgeon can determine the optimal combination of transfers and adjunctive procedures to restore function.

Diagnostic Imaging

At the time of the acute spinal cord injury, advanced diagnostic imaging is performed to determine the extent of spinal cord and skeletal injury and to assess the patient for spinal column stabilization procedures. Most patients with spinal cord injury have a rehabilitation team responsible for their care during the acute injury phase and subsequent rehabilitation. As noted in the pathogenesis section above, neurologic recovery after spinal cord injury does not fully stabilize until 12 months after the injury. Most hand surgeons become involved in the rehabilitation process for hand reconstruction 1 year after the spinal cord injury has occurred; at this stage, no further diagnostic imaging is routinely indicated.

PERTINENT ANATOMY

Injuries of the spinal cord produce a different nerve deficit than do central nervous system deficits, brachial plexus injuries, or isolated peripheral nerve injuries. The pattern seen with a spinal cord injury is based on segmental innervation; this concept means that the anterior horn cells in the spinal cord are arranged in a pattern from cephalad to caudad. Motor nuclei form longitudinal columns crossing several segmental levels, innervating the peripheral musculature in a predictable manner.

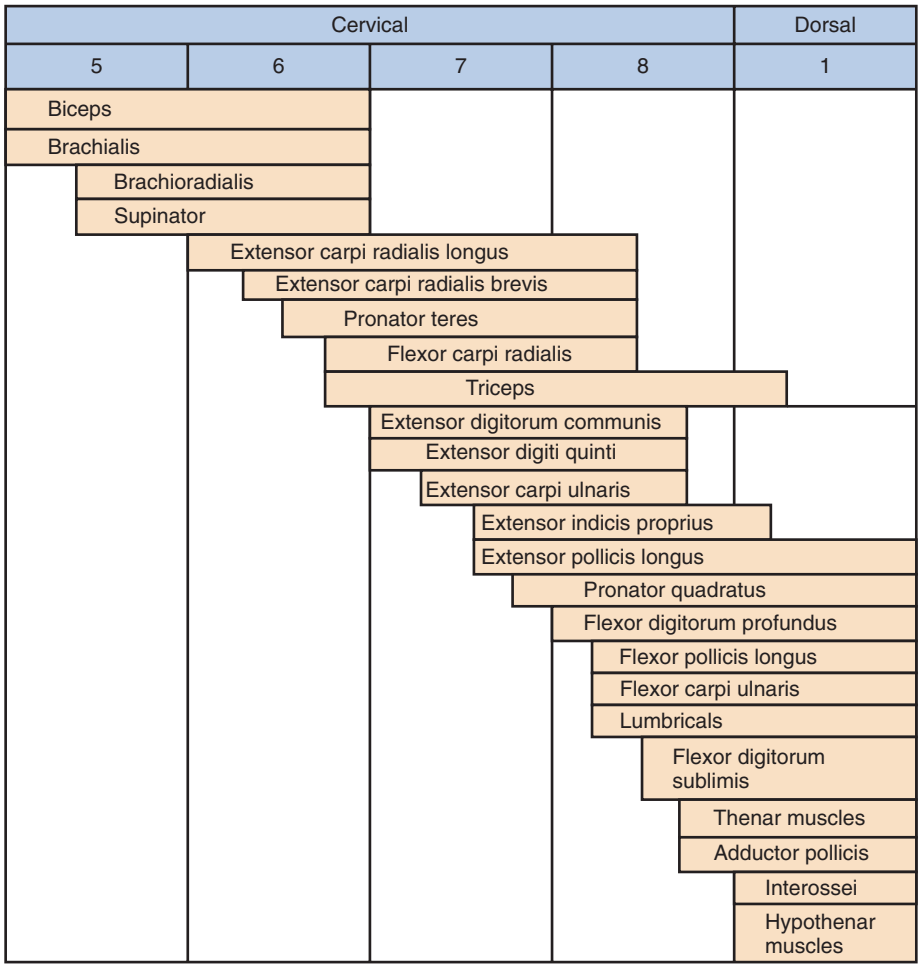

FIGURE 33.2 Segmental innervation of muscles of the elbow, forearm, and hand. Although not shown in this figure, the deltoid and biceps are both innervated from the C5-C6 level. Both the deltoid and the biceps receive their innervation from a higher level on the cervical cord than the triceps. (See Zancolli EA: *Structural and dynamic bases of hand surgery*, ed 2, Philadelphia, 1979, JB Lippincott.)

Figure 33.2 shows the segmental anatomy, based on Zancolli's clinical experience with tetraplegic patients.[96] When a spinal cord injury occurs, the motor nuclei cephalad to the injury will be functional; the motor nuclei at or caudad to the level of the injury will be nonfunctional.

Historical Review

Before the 1960s, the poor prognosis and low survival rate of patients with spinal cord injury precluded the need for upper extremity reconstruction. As the prognosis and medical care of patients with spinal cord injury improved, so did the surgical advancements in tendon transfer surgery. As shown in Table 33.4, advancements in tendon transfer surgery that were initiated by Bunnell were applied to tetraplegic patients by Moberg, Lamb, Zancolli, and Freehafer. Patients and physicians are now enthusiastic about the potential benefits of a well-designed and well-executed surgical plan for upper limb reconstruction in those with tetraplegia.

In addition to hand surgery reconstruction, significant research on and clinical treatment with a neuroprosthesis was performed from the 1980s to the 2000s. The use of electrical current for muscle stimulation in patients with spinal cord injury led Keith and associates at Case Western University to develop a fully implantable functional neuromuscular stimulation neuroprosthetic system.[47,49,75] This technology takes advantage of paralyzed muscles that are no longer under cortical control (due to spinal cord injury) but have intact spinal reflex arcs. The anterior horn cell of the motor units for eligible muscles must be uninjured to preserve the spinal reflex arc; the muscles are generally located below the level of the direct spinal cord injury. These muscles can be stimulated to contract with relatively weak electrical currents. Muscle signals, nerve signals, or volitional movements (above the level of spinal cord injury), typically from the contralateral shoulder or neck, are used to control the device.

The neuroprosthesis is indicated for tetraplegic patients for whom standard surgical procedures or orthotic devices cannot provide useful improved function or who have exhausted these options.[46] Most commonly, the neuroprosthesis is implanted in patients in groups 0, 1, 2, and 3. More than 250 adults and children have received the neuroprosthesis system worldwide.[7,12,18,20-22,41,71,73,76,83] As of 2008, the company that manufactured the device discontinued its production; second-generation 12-channel devices with telemetry and myoelectric control are available under research protocols and have shown promise in achieving independent two-handed use.[48]

TABLE 33.4 Historical Review of Surgical Reconstruction in the Tetraplegic Patient

Author	Publication and Year	Importance
Bunnell	*Surgery of the Hand*, 2nd ed, 1948	C6-C7 treated with tendon transfer/tenodesis
Nickel, Perry, Garrett	*J Bone Joint Surg Am* 45:933–952, 1963	Development of useful function in severely paralyzed hand
Wilson	*J Bone Joint Surg Am* 38:1019–1024, 1956	Provision of automatic grasp by flexor tenodesis
Street and Stambaugh	*Clin Orthop Relat Res* 13:155–163, 1959	Finger flexor tenodesis
Lipscomb, Elkins, Henderson	*J Bone Joint Surg Am* 40:1071–1080, 1958	Two-stage surgical grasp and release for C6-C7 fracture-dislocation patients
Freehafer and Mast	*J Bone Joint Surg Am* 49:648–652, 1967	First description of brachioradialis to wrist extension in "high" cervical injuries
Zancolli	*Structural and Dynamic Bases of Hand Surgery*, 1968	Comprehensive review of anatomic bases of tendon transfers and operative options, including two-stage reconstruction for grasp-pinch and release
Lamb and Landry	*Hand* 3:31–37, 1971	Flexor phase surgical technique and results; principles of tendon transfer and results
Lamb and Chan	*J Bone Joint Surg Am* 65:291–298, 1983	Surgical reconstruction of upper limb in traumatic tetraplegia
Lamb	*J Hand Surg [Br]* 14:143–144, 1989	Upper limb surgery in tetraplegia
Zancolli	*Clin Orthop Relat Res* 112:101–113, 1975	Surgery with strong wrist extension preserved (97 cases), treated with two-stage reconstructions
Moberg	*J Bone Joint Surg Am* 57:196–206, 1975	Posterior deltoid to triceps transfer and single-stage pinch tenodesis
Moberg	*The Upper Limb in Tetraplegia: A New Approach to Surgical Rehabilitation*, 1978	Classification based on sensibility and available grade 4 muscles; importance of key pinch position
[First] International Conference on Surgical Rehabilitation in the Upper Limb in Tetraplegia (Edinburgh, Scotland, 1978)	Reported in *J Hand Surg [Am]* 4:387–390, 1979	First international classification for surgery of the hand based on sensibility, motors available below elbow, and hand function
Peckham, Marsolais, Mortimer	*J Hand Surg [Am]* 5:462–469, 1980	First description of use of functional electrical stimulation for restoration of key pinch
Hentz, Brown, Keoshian	*J Hand Surg [Am]* 8:119–131, 1983	Functional assessment of upper limb after reconstructive surgery
Second International Conference (Giens, France, 1984)	Reported in *J Hand Surg* 11:604–608, 1986	Classification modified; still in use (see Table 33.2)
Allieu, Benichou, Teissier	*Chirurgie* 112:736–742, 1986	Report of 52 reconstructions with 28 posterior deltoid to triceps transfers complicated by stretching in 7 cases
Waters, Moore, Graboff, Paris	*J Hand Surg [Am]*, 10:385–391, 1985; *J Hand Surg*, 1987	Key pinch using BR to FPL and elbow extension transfers to increase pinch strength
House and Shannon	*J Hand Surg [Am]* 10:22–29, 1985	Opposition transfers vs. fusion for thumb control
House, Comadoll, Dahl	*J Hand Surg [Am]* 17:530–538, 1992	One-stage key pinch with thumb CMC fusion
McCarthy, House, Van Heest	*J Hand Surg [Am]* 22:596–604, 1997	Intrinsic reconstructions

BR, Brachioradialis; *CMC,* carpometacarpal; *FPL,* flexor pollicis longus.

Indications and Contraindications for Operative Intervention

The goal of tetraplegic hand reconstructive surgery is to increase the patient's independence; thus, the indication for operative treatment is functional impairment that can be improved through surgical reconstruction. Candidates for surgery include patients whose injury occurred at least 12 months ago, who have a stable upper extremity motor examination, and whose functional impairments can be improved by hand reconstruction. Ideally, the patient is free from contractures, pain, and spasticity; has the ability to comply with the postoperative rehabilitation regimen; has appropriate postoperative support services available; and is highly motivated to improve hand function. It is also critical that the patient be medically stable, including bowel and bladder function, blood pressure control, and no urinary tract infection or decubitus ulcers.

Two factors have had a uniformly adverse effect on the results of surgical treatment: spasticity and psychological problems. Spasticity that cannot be controlled by the patient is a strong contraindication to surgery. Freehafer and colleagues[29] and Moberg[66] stated that some spasticity might be helpful, but judging the degree of spasticity that is compatible with good results is very difficult; in fact, Moberg noted such an error in his poor results group. Psychological impairment, unrealistic expectations, insufficient motivation to complete the operative and postoperative protocols, and inadequate social support mechanisms should be assessed before surgery. Patients who want to have reconstructive surgery and are strongly motivated to improve their functional status are more likely to obtain a better outcome. The surgeon and patient must be able to communicate effectively and share *realistic* expectations of the benefits of surgery. Allowing a prospective patient to visit a

postoperative patient with a similar condition is particularly useful.

CRITICAL POINTS *Indications and Contraindications for Operative Intervention*

Indications

- Cervical spine injury with upper limb partial paralysis
- Stabilized motor recovery (12 months since injury)
- Functional deficits that can be improved with surgery
- Medically stable (blood pressure, bowel and bladder function)
- Infection free (decubitus ulcers, bladder)
- Full passive range of motion
- Realistic goals with good motivation and desire
- Personal and social stability to carry out rehabilitation and staged procedures (if necessary)

Contraindications

- Spasticity
- Contractures
- Chronic pain problems
- Psychological instability

TYPES OF OPERATIONS FOR TETRAPLEGIA

Three types of surgical procedures are most commonly performed: tendon transfer, tenodesis, and arthrodesis.

Tendon Transfer

Provided that the patient has adequate voluntary muscle control and strength of potential donor muscles, tendon transfers are preferred over tenodesis or arthrodesis because these restore active control and strength. However, the primary problem after spinal cord injury is a paucity of adequate donor muscles available for transfer. It is critical to ensure that sacrifice of a potential donor muscle for transfer will not create another functional deficit. The available muscles are prioritized first for wrist extension, then for pinch, then for grasp, and finally for release functions. Tendon transfer principles, including donor availability, donor strength, amplitude of excursion, passive mobility of recipient joints, and condition of the soft tissue bed, must be followed (see Chapter 31). When transfer options are exhausted, remaining hand functions are achieved through tenodesis and/or arthrodesis.

Tenodesis

Tenodesis is defined as the movement of one joint produced by the motion of an adjacent (usually proximal) joint. For instance, with active or passive extension of the wrist, the fingers and thumb spontaneously flex; with wrist flexion, the fingers and thumb extend. Although the finger and thumb muscles are paralyzed, there is sufficient remaining myostatic tension to induce reciprocal action of the digital flexor and extensor tendons that cross the wrist joint. Spinal cord injury patients learn to use the tenodesis effect naturally and commonly have functional but very weak pinch or grasp owing to the tenodesis effect alone. The tenodesis effect can be enhanced surgically without the need to transfer an active muscle. Passive tenodesis procedures anchor the paralyzed tendon proximal to the wrist joint to decrease effective tendon excursion and thus increase digital movement with active wrist movement. Common tenodesis techniques include those for finger flexion and extension, as well as for thumb flexion, extension, and abduction. Tenodesis can also be used to improve function of the intrinsic muscles of the fingers and thumb.

Arthrodesis

Arthrodesis is useful in the thumb to make this multiarticular joint more stable and easier to control. Combinations of tendon transfers and tenodesis procedures can be used at the CMC, metacarpophalangeal (MP), and interphalangeal (IP) joints to provide effective positioning and control of the thumb to produce pinch function. Particularly in the index finger, proximal interphalangeal (PIP) joint fusions can be used to stabilize a digit to provide a post for pinch. The wrist is never fused because the tenodesis effect would be lost. Surgical techniques for arthrodesis are no different in the paralytic hand; when possible, rigid fixation should be chosen to allow some weight bearing and early mobilization for tendon transfer rehabilitation.

Surgical reconstruction is based on the patient's International Classification group (see Table 33.2). Elbow procedures are presented first, followed by procedures used for grasp, pinch, and release.

ELBOW EXTENSION TENDON TRANSFER

For patients lacking active elbow extension, two options exist for reconstruction: deltoid to triceps transfer and biceps to triceps transfer.[87] Active elbow extension assists the patient in reaching objects above the shoulder level, improves driving ability, aids in wheelchair propulsion, permits pressure relief, and facilitates independent transfer.[6,25,81,84] Additionally, active elbow extension provides an antagonist to elbow flexion, which facilitates improved function through tenodesis after hand reconstructions that use the BR as a tendon transfer.[13] Pinch strength has been shown by Brys and Waters[13] to improve from 0.15 to 3.9 pounds in wrist extension in patients after elbow extension tendon transfers that improve elbow extension strength.

The biceps and the deltoid are innervated from the spinal cord at a higher level than the triceps. The posterior deltoid to triceps transfer has been used extensively over the past 30 years, but more recently, the medially routed biceps to triceps transfer has been used more frequently.

Biceps to Triceps Tendon Transfer

The biceps to triceps tendon transfer is my preferred method for establishing elbow extension (Figure 33.3). The biceps is used as the donor muscle. To ensure that function will not be lost with transfer of the tendon, the strength of the brachialis as an elbow flexor and of the supinator as a forearm supinator must be verified before transfer. Manual muscle testing is performed, testing elbow flexion, attempting to isolate the brachialis by supinating the forearm, and allowing relaxation of the biceps. This can be verified by palpating the groove between the more tubular biceps anteriorly and the flatter brachialis posteriorly to differentially test strength. In reviewing the segmental innervations of the upper limb from the spinal cord (see Figure

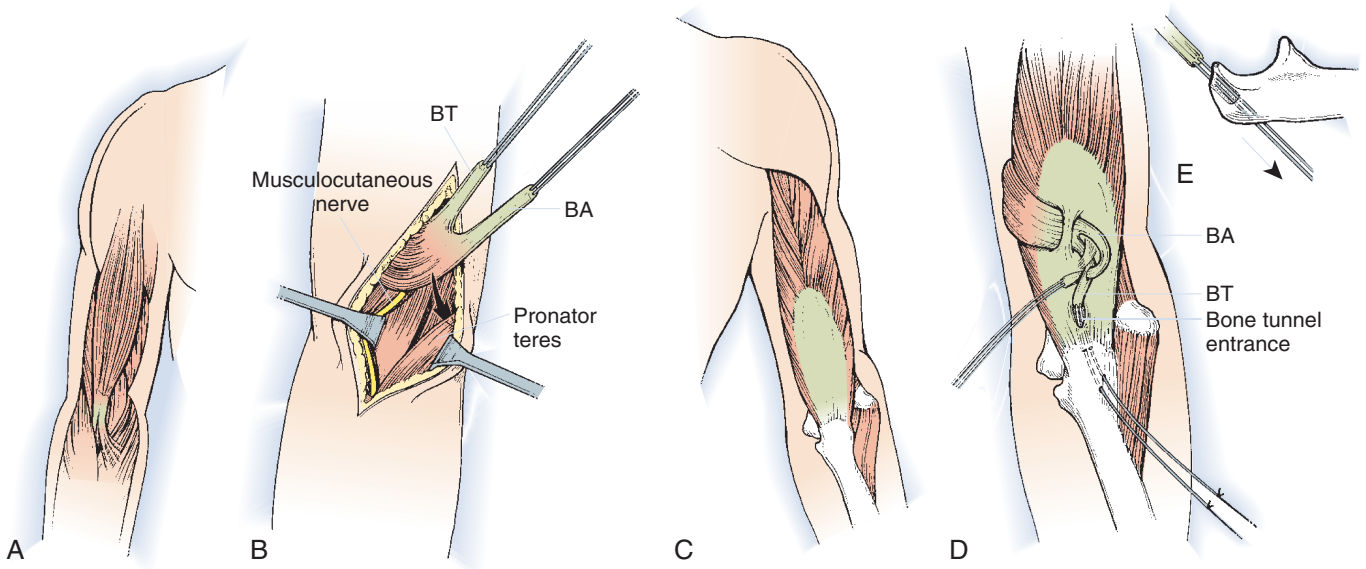

FIGURE 33.3 Biceps to triceps transfer. **A** and **B**, The biceps tendon (BT) and bicipital aponeurosis (BA; lacertus fibrosus) are released, and the muscle belly is mobilized proximally through an anterior incision. **C** and **D,** The biceps is rerouted medially around the arm in the subcutaneous plane and inserted by braiding the tendon "tails" into the triceps tendon. **E**, Direct insertion of the biceps tendon into a bone tunnel in the olecranon, with heavy sutures tied over bone. This provides strong fixation, permitting relatively early mobilization.

33.2), note that the biceps, brachialis, and supinator are all innervated at about the same level (C5-C6). If the patient has strong wrist extension, the spinal cord lesion should be below C6, sparing the biceps, brachialis, supinator, and wrist extensors, but above the innervation of the paralyzed triceps. Such findings on clinical examination verify that transfer of the biceps will not lead to a functional loss. Electromyography is generally not necessary as part of the routine evaluation.

The biceps to triceps tendon transfer can be performed using a medial[52,80] or a lateral[26,34,69] routing technique. The lateral technique was first described by Friedenberg[34] in 1954 and later reported by Zancolli.[95,97] No loss of active elbow flexion was noted, although flexor strength was diminished by 24%. In 1988 Ejeskar[26] reported his results using the lateral routing technique in five patients, including the first complication of radial nerve palsy. Because the radial nerve is the only functioning peripheral nerve in these patients, such a complication is devastating and has subsequently been noted by others using the lateral routing technique. Thus, medial routing is strongly preferred.

The procedure is performed with the patient supine, a roll under the operative shoulder blade, and the limb draped free with a sterile tourniquet high on the arm. The incision extends from the midhumerus on the medial side, transversely across the antecubital crease, and courses distally, centered over the biceps insertion on the radial tuberosity.[52] The lateral antebrachial cutaneous nerve is identified and protected as the biceps tendon is dissected free from its medial and lateral fascial attachments and sharply dissected off its insertion on the bicipital tuberosity. The lacertus fibrosus is freed from the forearm fascia during the dissection and is preserved as a second tail of the biceps tendon for subsequent weaving. The muscle is raised proximally, with care taken to preserve the musculocutaneous nerve running on the surface of the brachialis muscle.

A second (posterior) incision is made over the distal one third of the triceps tendon, passing lateral to the olecranon to avoid subsequent olecranon pressure ulceration and allowing an adequate skin bridge with the medial incision. A subcutaneous tunnel is made medially from the anterior wound to the posterior wound, creating a line of pull that is straight and free for medial rerouting of the biceps. The medial intermuscular septum may need to be partially resected, and care is taken to protect the neighboring ulnar nerve. The biceps tendon is passed from the anterior wound into the posterior wound, superficial to the ulnar nerve. A bone tunnel is created in the tip of the olecranon with a drill bit of 4 to 8 mm to receive the terminal end of the biceps tendon. The biceps length usually allows two or three weaves through the triceps tendon before it is inserted into the olecranon drill hole. A No. 5 nonabsorbable grasping suture is placed into the end of the biceps tendon and passed through the bone tunnel using Keith needles, tying the grasping suture over bone.

The transfer is tensioned to allow 60 to 90 degrees of passive elbow flexion. The lacertus fibrosus is interwoven through the biceps to triceps weaves to further secure the tendon weave. Postoperatively, the elbow is placed in about 30 degrees of flexion in a long-arm cast for 4 weeks. A flexion block splint (hinged elbow orthosis) is then used full time, and 15 degrees of flexion is added each week until full flexion and adequate arm control are achieved. Strengthening exercises are then added.

The strength of the biceps to triceps transfer continues to improve for at least a year, resulting in substantial improvements in performing activities of daily living. Published series have reported functional improvements for overhead, reaching, and driving activities.[26,51,52,96,97] No clinical loss of active flexion has been reported, although flexor strength was diminished by 24% in one series.[97] Mulcahey and coworkers[72] published a randomized prospective comparison of posterior deltoid to biceps transfer versus biceps to triceps with medial routing transfer. These authors reported that at 2 years, seven of eight

arms treated with biceps to triceps transfer had antigravity use of the arm, whereas only one of eight arms treated with posterior deltoid to triceps transfer had antigravity use of the arm.

CRITICAL POINTS *Biceps to Triceps Tendon Transfer*

Indications
- Availability of biceps as donor (adequate brachialis and supinator strength)
- Full passive range of motion or an elbow flexion contracture of less than 30 degrees
- Absent triceps function

Preoperative Evaluation
- Verify brachialis and supinator strength.
- Obtain elbow passive range of motion (splint if necessary).

Pearl
- Medial routing avoids the possible complication of radial nerve palsy.

Technical Points
- Anterior and posterior incisions are used, with an adequate skin bridge.
- Mobilize the biceps tendon, with the lacertus fibrosus included.
- Use No. 5 Ethibond grasping suture in the biceps tendon.
- Ensure a straight line of pull around the *medial* distal one third of the humerus.
- Perform two to three weaves of biceps tendon into triceps tendon.
- Insert the terminal end of the biceps tendon into the bone tunnel at the tip of the olecranon.

Pitfall
- A posterior incision over the olecranon is a potential pressure sore area.

Postoperative Care
- Long-arm cast in 30 degrees of flexion for 4 weeks
- Full-time flexion block splint, increasing 15 degrees per week until full range of motion is achieved
- Strengthening begins at 8 weeks, starting with a powder board to eliminate gravity.

Posterior Deltoid to Triceps Tendon Transfer

The posterior deltoid to triceps transfer uses the posterior third and the posterior half of the middle third of the deltoid muscle as a donor to provide active elbow extension (Figure 33.4). An interposition tendon graft is used, and the triceps tendon serves as the insertion. The posterior deltoid is tested before surgery by supporting the limb in 90 degrees of shoulder abduction and palpating the muscle for bulk and selective control while testing the strength of shoulder extension. Scapular stabilization and control are also necessary to maximize the effectiveness of the transfer.

The procedure is performed with the patient in a lateral decubitus position with the shoulder forequarter draped free. An incision is made from the tip of the posterior corner of the acromion distally to the deltoid tubercle insertion. Dissection is along the posterior border of the deltoid, leading into its insertion onto the deltoid tubercle. The axillary nerve courses about 5 cm distal to the acromion on the deep surface of the deltoid and must be protected as the posterior half of the middle deltoid is dissected with the posterior deltoid and freed from its insertion. A separate incision is made over the distal one third of the humerus to expose the triceps tendon. A subcutaneous tunnel is made, connecting the two incisions for placement of an interposition graft.

Several alternatives exist for the interposition graft. Moberg[66] originally used toe extensors from the second, third, and fourth toes to allow at least three weaves at each attachment site. Alternative graft materials have included fascia lata,[37] tibialis anterior,[53,58] and extensor carpi ulnaris (ECU).[54] Alternatively, Castro-Sierra and Lopez-Pita[15] used the central one third of the triceps. In this method, a 1-cm strip from the central one third of the triceps is harvested from its insertion in a retrograde manner (proximally based), mobilizing it sufficiently to graft back to the distal end of the posterior deltoid. Reflecting the central third of the triceps with a bone block and internally fixing this to a bone block from the deltoid insertion has also been described.[65]

After the interpositional graft has been placed, the transfer is sewn into place and tensioned with the shoulder in 30 to 40 degrees of abduction and no forward flexion, so that the elbow can flex to 60 degrees with moderate tension. Most commonly, a well-padded long-arm cylinder cast is applied to hold the elbow in about 10 degrees of flexion. The wrist can be left free. Forward flexion and shoulder adduction are avoided during the 6 weeks of cast immobilization. Gentle active exercises are performed to slowly gain elbow flexion for the next 3 months with a rate of 5 to 10 degrees of increased flexion per week.

Posterior deltoid to triceps transfers are compromised by the prolonged shoulder and elbow immobilization required postoperatively, as well as tendon graft elongation over time.[23,68,77,78] Elongation of the tendon graft leads to decreased strength over time. Friden and colleagues[30] used intraoperative metal markers at the ends of the tendon grafts and measured an average of 2.3 cm of elongation after 2 years. They changed their postoperative regimen to include longer elbow extension immobilization, and increased shoulder abduction. Follow-up of five patients using this regimen using the same markers averaged 0.8 cm.

PROCEDURES FOR PRODUCING FOREARM PRONATION

Pronation is important to patients who have only active wrist extension (groups 2 and 3). These patients use the automatic or tenodesis effect for grasp, but if the hand cannot be pronated, gravity cannot be used to provide a tenodesis effect for digital extension and release. Those patients using a tenodesis brace need pronation for the same reason.

Zancolli produced pronation by converting the biceps into a forearm pronator. He rerouted the tendon around the radius, converting the biceps from a supinator to a pronator.[94]

Biceps Rerouting Procedure

The biceps is rerouted from a supinator moment arm wrapping counterclockwise around the proximal radius, to a pronator moment arm wrapping clockwise around the proximal radius (Figure 33.5). This procedure can be done in isolation or in combination with one of the hand reconstructive procedures listed below. Indications for surgery are passive mobility of the forearm into pronation, without active pronation, as well as a

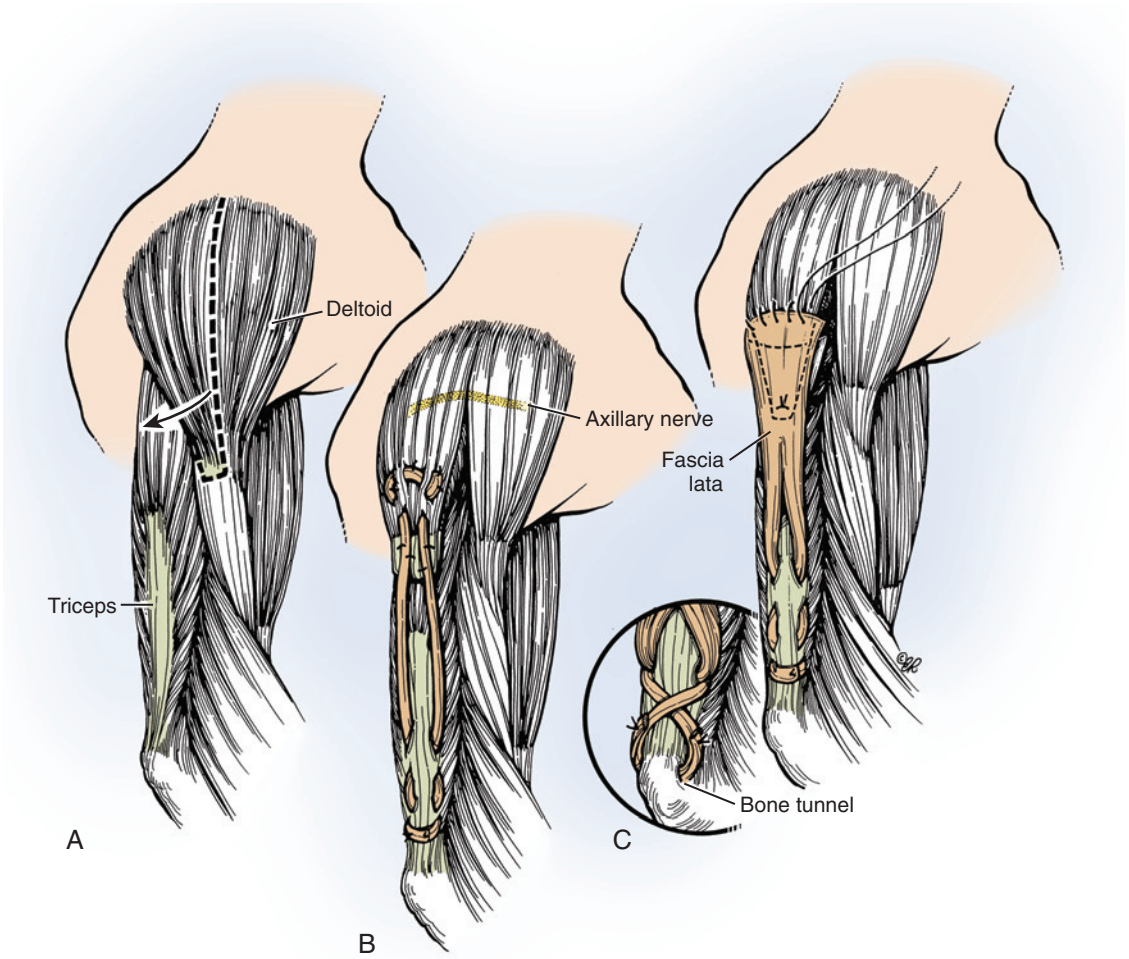

FIGURE 33.4 Deltoid to triceps transfer. **A,** The posterior border of the muscle belly is isolated, preserving as much of the tendinous insertion as possible. **B,** Tendon grafts are laced into the distal end of the deltoid muscle belly and triceps aponeurosis. **C,** Fascia lata is used rather than tendon grafts. Direct insertion into the olecranon through a bone tunnel can be performed with either type of graft. (Copyright © Elizabeth Martin. See also Moberg EA: Surgical treatment for absent single-hand grip and elbow extension in quadriplegia. *J Bone Joint Surg Am* 57:196–206, 1975.)

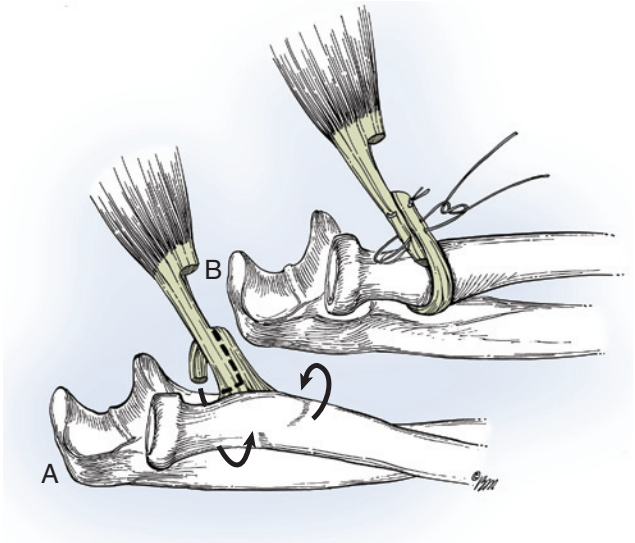

FIGURE 33.5 Zancolli's method for rerouting the insertion of the biceps tendon to provide pronation of the forearm. Half the tendon is passed behind the neck of the radius **(A)** and then sutured into the remaining biceps tendon **(B)**. (Copyright Elizabeth Martin. See also Zancolli EA: *Structural and dynamic bases of hand surgery*, ed 2, Philadelphia, 1979, JB Lippincott.)

biceps tendon of grade 5 strength that is a deforming force as a supinator leading to dysfunctional supination posturing. The biceps needs to be available for transfer, but not for transfer to the triceps to provide elbow extension strength.

A curvilinear incision is made from the proximal ulna, across the elbow crease, to past the radial neck on the radial side of the forearm. Dissection exposing the biceps from its musculotendinous junction to its insertion on the radial tuberosity is performed with coagulation or protection of the multiple venous structures. The biceps tendon is split longitudinally over a segment of 8 to 10 cm, and both ends are tagged. The forearm is placed in full supination, and the distal end of the biceps tendon is passed around the radial side of the radial neck using a long, curved, right-angle clamp, passing the tendon directly next to the bone. The proximal end of the Pulvertaft tendon is woven back into the distal end with two to three Pulvertaft weaves and secured using nonabsorbable 0-0 suture.

OPERATIONS FOR GROUP 0 PATIENTS

By definition, patients in this group have no muscle groups below the elbow with grade 4 strength to provide restoration of

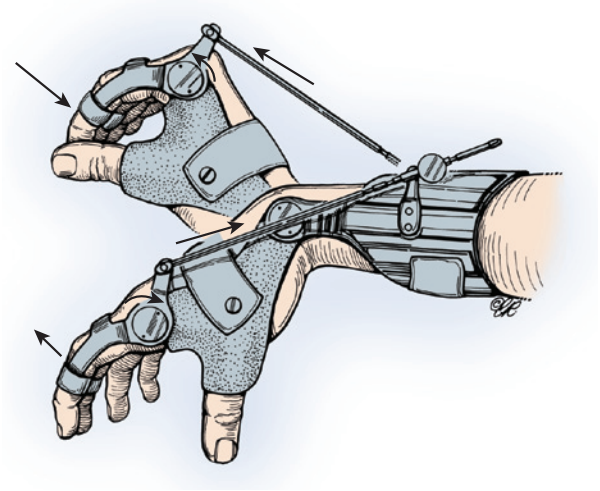

FIGURE 33.6 The wrist-driven flexor hinge splint uses the principle of synergistic action. As the wrist is extended, the fingers are flexed to bring them into contact with the thumb, which is fixed. As the wrist is flexed, the fingers are extended. (Courtesy of T. Engen, MD. Copyright Elizabeth Martin.)

pinch function. Elbow extension transfers should be performed as described earlier. Some group 0 patients may have both a weak BR and a weak ECRL. Assessing the strength of the BR muscle is difficult and requires an experienced examiner. It is best performed by having the patient flex the elbow against resistance while the examiner evaluates BR muscle tension by palpitating and trying to deflect the muscle belly. Transfer of the BR to the radial wrist extensors may provide sufficient strength to extend the wrist against resistance; this tendon transfer technique is described later for group 1 patients. Because the muscle's strength is no better than grade 3, the patient needs good elbow extension to serve as an antagonist to the BR transfer to enhance wrist extension function. If sufficient wrist extensor strength is obtained, a wrist-driven hinged tenodesis splint can be used (Figure 33.6), or a passive pinch tenodesis reconstruction can be considered.

OPERATIONS FOR GROUP 1 PATIENTS

In group 1 patients the BR has grade 4 or greater strength, and all other muscle groups below the elbow have less than grade 4 strength. Because elbow flexion is provided by the biceps and brachialis (innervated above the level of the BR), the BR is available for tendon transfer to provide wrist extension, which is the most necessary basic function. Lateral key pinch can be provided by tenodesis using a wrist-driven tenodesis splint (see Figure 33.6) or by surgical reconstruction. If a tenodesis splint is not used, two procedures are necessary for group 1 patients, and both can be done simultaneously: BR to ECRB transfer for active wrist extension, and passive key pinch reconstruction.

Brachioradialis to Extensor Carpi Radialis Brevis Tendon Transfer

Freehafer and Mast[28,29] describe a "utilitarian" incision on the radial side of the forearm near the junction of the proximal and middle thirds; its length is variable, depending on the exposure needed. The BR is on the radial aspect of the forearm, the ECRL is dorsal and parallel to it, and the ECRB is on the ulnar side of the ECRL. The tendons are exposed by opening their sheaths.

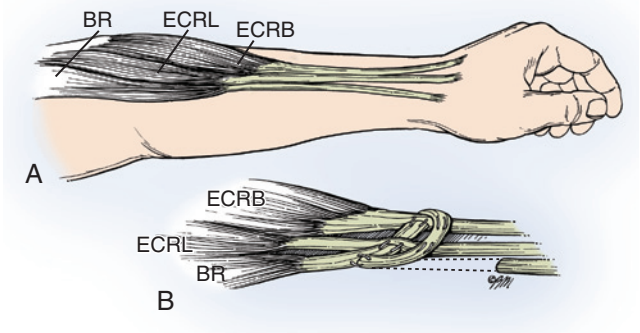

FIGURE 33.7 Brachioradialis (BR) transfer to extensor carpi radialis longus (ECRL) and extensor carpi radialis brevis (ECRB). An important technical detail is that the BR muscle belly must be mobilized completely to the elbow, taking care to protect its nerve supply from the radial nerve. I prefer to weave the BR three times into the wrist extensor (ECRB). Usually the ECRL is not included in the juncture (see text).

The BR tendon is dissected off its insertion and mobilized toward the elbow sufficiently to increase its excursion to 3 cm or more.[50] Special care is required to protect the superficial radial nerve, which courses beneath the BR muscle and becomes superficial between the BR and ECRL tendons (Figure 33.7). The BR tendon is passed through into the ECRB tendon, and secured with two to three Pulvertaft weaves. The BR tendon is usually woven through and sutured only to the ECRB tendon so as not to induce a radial deviation posture of the wrist, which would occur with transfer to the ECRL tendon. The tension should be set with the elbow at 45 degrees of flexion, with tension sufficient to hold the wrist in neutral. With the elbow flexed, the wrist should passively flex, and with the elbow extended, the transfer should tighten. Postoperatively, a long-arm cast is applied in the operating room to hold the elbow in 90 degrees of flexion and the wrist in 45 degrees of extension. The cast is removed at 4 weeks, and active range of motion is started; a removable splint is used for an additional 4 weeks to support the wrist when the patient is not exercising. Strengthening and functional use are then advanced, with night splinting only if necessary. Transfer of the BR to a weak or nonfunctioning radial wrist extensor should provide adequate strength for the use of a hinged tenodesis splint or surgical reconstruction of a passive pinch function.

Passive Key Pinch Reconstruction

To say that reconstruction of the paralyzed thumb for pinch function is a difficult proposition is an understatement at best. In activities of daily living, lateral key pinch is most useful. Although pulp-to-pulp pinch was described by Bunnell[14] in 1944 and referred to by Curtis[19] as an "opponodesis," this procedure has largely been abandoned because opposition pinch is beyond the scope of restoration in high-level injuries.[3,90] Skeletal control of three segmental joints (CMC, MP, and IP) must be combined with tenodesis vectors that appropriately position the thumb for effective pinch and release.

Because no additional muscles are available in this group (after BR to ECRB transfer), tenodesis of the FPL is used to produce a weak pinch, motored by active wrist extension (from the BR to ECRB transfer). Tenodesis of the EPL is used for release of pinch, activated through passive wrist flexion. Alternatives to passive key pinch tenodesis reconstruction include a

CRITICAL POINTS *Brachioradialis to Extensor Carpi Radialis Brevis Tendon Transfer*

Indications
- Group 1 patients with at least grade 4 BR strength and less than grade 4 strength of wrist extension
- Group 0 patients with grade 3 BR strength and less than grade 4 strength wrist extension

Preoperative Evaluation
- Strength testing (br, ecrl, ecrb)
- general indications and contraindications (spasticity, contractures, chronic pain, psychological or medical instability)

Pearl
- Full mobilization of the BR is needed to achieve excursion of 3 cm or more.

Technical Points
- A "utilitarian" radial-side incision extends proximally to fully mobilize the BR from its fascial attachments.
- Perform BR to ECRB tendon transfer with two to three tendon weaves sewn in place.
- Adjust tension so that with 45 degrees of elbow flexion, the wrist rests at neutral. With elbow extension, the wrist extends; with elbow flexion, the wrist flexes (not too tight and not too loose).

Pitfalls
- Inadequate BR excursion
- Inadequate tendon weaves
- Protect superficial branch of radial nerve

Postoperative Care
- From 0 to 4 weeks: long-arm cast
- From 4 to 8 weeks: active range of motion with protective wrist cock-up splint
- After 8 weeks: strengthening and functional use; optional night splint

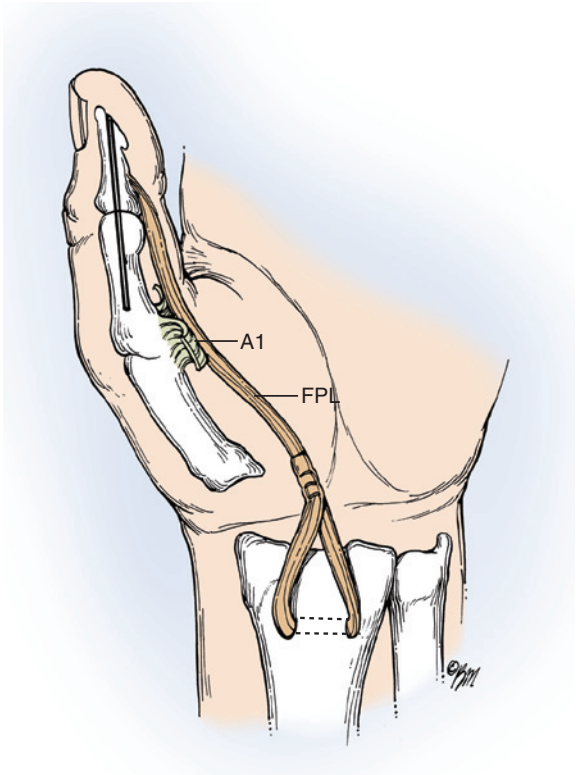

FIGURE 33.8 The classic Moberg passive key pinch reconstruction includes flexor pollicis longus (FPL) tenodesis to the radius at the proximal edge of the pronator quadratus and Kirschner wire fixation of the interphalangeal (IP) joint to prevent premature flexion (Froment sign). Additional optional steps include A1 pulley release to increase FPL torque at the metacarpophalangeal (MP) joint and fixation of the extensor pollicis brevis to the dorsal first metacarpal to avoid MP hyperflexion. This classic combination is seldom used because it has undergone many modifications, as described in the text. (Copyright Elizabeth Martin.)

tenodesis splint (see Figure 33.6) or functional electrical stimulation (see later).

As described by Bunnell[14] and popularized by Moberg,[66] the following combination has been recommended for passive key pinch reconstruction:

- FPL tenodesis to the radius at the proximal edge of the pronator quadratus
- Kirschner wire fixation of the IP joint to prevent premature and excessive flexion (Froment sign)

Additional optional steps include:

- A1 pulley release to increase FPL flexion axis at the MP joint
- Tenodesis of the extensor pollicis brevis (EPB) to the dorsal first metacarpal to avoid MP hyperflexion

This combination is classically referred to as the Moberg tenodesis pinch reconstruction (Figure 33.8).

Moberg's procedure has been modified to change the technique of FPL tenodesis so that it is divided high in the forearm, delivered into a volar wound over the MP joint through the flexor sheath proximal to the A1 pulley, and rerouted across the palm, deep to the flexor tendons and neurovascular bundles. The FPL tendon is passed proximally via the Guyon canal and is anchored onto the volar aspect of the radius. This change in pull provides a greater adduction moment arm, in addition to flexion. This modification, termed the Brand-Moberg tenodesis, was reviewed by Hentz and associates[38,39] and found to provide less pinch power than the original Moberg tenodesis.

Alternative techniques for the FPL tenodesis include fixation of the FPL tendon around the distal ulna as a "winch procedure," as described by Brummer.[11] Forearm supination helps activate the tenodesis as it "winds up" the ulna, which pulls the thumb into lateral pinch. This is generally not acceptable, because most functional activities are not carried out with simultaneous supination, wrist extension, and thumb pinch; however, for very high level involvement, the tenodesis strength of wrist extension is augmented by the strength of forearm supination.

Moberg stressed the importance of key pinch and described techniques for creating it,[66,68] and Hentz[39] modified Moberg's original tenodesis as follows:

- Stabilization of the thumb IP joint by pin fixation, fusion, or split FPL transfer (see the section on intrinsic reconstruction)
- FPL tenodesis to the distal radius to obtain the correct tension for lateral pinch
- Stabilization of the MP joint: if more than 45 degrees of flexion is present, use EPB and EPL tenodesis to the dorsal first metacarpal with a bone anchor suture; if more than 10 degrees of passive hyperextension is present, use a volar capsulodesis or an MP arthrodesis

Results of this procedure are superior for groups 2 and 3; group 1 patients fare less well because fewer muscles are available. Ejeskar and Dahllof[27] reported a typical series with an average final pinch strength of 0.7 kg. However, pinch *power* may be less important than thumb positioning.

❖ AUTHOR'S PREFERRED METHOD OF TREATMENT

Because of the common supination posturing of the thumb after a modified Moberg-type reconstruction, I prefer to add a CMC arthrodesis as described by House and colleagues[38] to better control thumb position in the active one-stage key pinch reconstruction (Table 33.5). For group 1 patients, the Hentz modification of the Moberg procedure, as described earlier, remains the procedure of choice.

TABLE 33.5 Surgical Guidelines Based on International Classification Group

ICS Group*	Author's Preferred Method of Treatment
1	BR to ECRB FPL tenodesis *Option:* split FPL tenodesis
2	BR to FPL CMC fusion EPL tenodesis *Option:* split FPL tenodesis
3	BR to FPL CMC fusion EPL tenodesis *Option:* split FPL tenodesis
4 and 5	House two-stage procedure: Extensor phase EDC tenodesis (*option:* BR to EDC) EPL tenodesis *Options:* CMC fusion, intrinsic tenodesis Flexor phase ECRL to FDP BR to FPL (*option:* PT to FPL) *Options:* adduction-opponensplasty (BR or PT with FDS graft), split FPL tenodesis, lasso procedure
6	ECRL to FDP BR to FPL (*option:* PT to FPL) EPL tenodesis (*option:* EPL to EDC) *Options:* CMC fusion or adduction-opponensplasty (BR or PT with FDS free graft), split FPL tenodesis, lasso procedure (BR or PT to FDS)
7	ECRL to FDP BR to FPL (*option:* PT to FPL) *Options:* CMC fusion or adduction-opponensplasty (BR or PT with FDS free graft), split FPL tenodesis, lasso procedure (BR or PT to FDS)
8	FDP side to side BR to FPL *Options:* opponensplasty (BR or PT with FDS graft), split FPL tenodesis, lasso procedure (BR or PT to FDS)

BR, Brachioradialis; *CMC,* carpometacarpal; *ECRB,* extensor carpi radialis brevis; *ECRL,* extensor carpi radialis longus; *EDC,* extensor digitorum communis; *EPL,* extensor pollicis longus; *FDP,* flexor digitorum profundus; *FDS,* flexor digitorum superficialis; *FPL,* flexor pollicis longus; *PT,* pronator teres.
*See Table 33.2.

OPERATIONS FOR PATIENTS IN GROUPS 2 AND 3

By definition, patients in groups 2 and 3 have a functional BR and wrist extension strength. It is difficult to determine the differential strength of the ECRL (group 2) and ECRB (group 3). If the patient has grade 4 or greater strength of the ECRL and grade 0 strength of the ECRB, the wrist will posture in radial deviation; however, such a large difference between ECRL and ECRB strength is uncommon. More commonly, both the ECRL and ECRB show active function, making it difficult to clearly differentiate group 2 (grade 4 or greater ECRL) from group 3 (grade 4 or greater ECRL and ECRB). If the ECRB has less than grade 4 strength and the ECRL is transferred, the result is devastating, with functional loss of wrist extension.

Methods have been described to test ECRL versus ECRB strength. Mohammed and coworkers[70] described the Bean sign: a groove between the ECRL and ECRB if both are firing at grade 4 or greater strength. Moberg[67] stated that the only way to measure differential ECRB and ECRL strength is with surgical exploration: With the use of local anesthesia, a needle is passed through the ECRB tendon and hooked up to a 5-kg weight. If the ECRB can lift at least 5 kg, the ECRL can be used without risk of loss of wrist extension function. Allieu[2] stated that if PT function is present, the two radial wrist extensor strengths can be assumed to be intact. Hentz and LeClerq[39] stated that in 25 years they had only one patient who was treated as a group 3 patient with transfer of the ECRL but was actually group 2, with resultant loss of wrist extension function. They recommended transfer of the ECRL only if the ECRB has grade 5 (not grade 4) strength. Most surgeons recommend using the ECRL for transfer and leaving the ECRB in place, because its insertion is central and the ECU is paralyzed.[38,60,96]

Review of the literature shows a variety of options for groups 2 and 3 patients. The BR is always available for transfer and has been used in a variety of ways. Street and Stambaugh[86] recognized the value of side pinch or "key grip" in 1959 and, in an attempt to increase the strength of pinch, transferred the BR to the FPL. Moberg[66] reported four patients with BR to FPL transfer and found the FPL tenodesis to be stronger than the transfer. In most cases, House and coworkers[37,42] transferred the BR to the FPL for a one-stage active key pinch reconstruction, and House's group and Zancolli[94] preferred to fuse the thumb CMC joint in 30 degrees of abduction to improve positioning.

Moberg used the BR to improve the release phase of the grasp-release sequence. He placed traction on the EPL, EPB, and abductor pollicis longus (APL) tendons at surgery to determine which gave the best abduction and then transferred the BR to that tendon. He did this operation as a second-stage procedure, following construction of a simple key grip (lateral pinch). He reported that the additional abduction was not as useful for the patient as he had anticipated.[66]

For group 3 patients, Zancolli[96] recommended a two-stage reconstruction. The first stage consists of (1) extensor tenodesis of the thumb and fingers, (2) intrinsic tenodesis using the "lasso" procedure to reduce clawing, and (3) thumb IP joint fusion. The second stage includes (1) ECRL to FDP tendon

transfer, (2) BR to FPL tendon transfer, (3) a volar thumb MP capsulodesis if the thumb MP joint is hyperextended, and (4) a volar tenodesis of the EPB tendon if the thumb is in excessive extension.

Zancolli's Staged Reconstruction for Group 3 Patients

Stage 1: Extensor Tenodesis

An 8- to 10-cm longitudinal incision is made on the radial side of the forearm to expose the dorsum of the radius proximal to the extensor retinaculum. A window large enough to accept the distal stumps of the common extensor tendons (which have been divided just distal to the musculotendinous junction) is made on the dorsum of the radius. Suturing the distal stumps together before severing the tendons preserves tendon balance. Stout nonabsorbable or wire sutures are passed through the tendon ends and brought through two drill holes made proximal to the window. Tension on the sutures draws the tendon stumps snugly into the bone window, and the sutures are tied to each other. The tension is set so that the finger MP joints are extended to 0 degrees with the wrist in slight palmar flexion. Next, a strip of the APL tendon is freed through the original radial longitudinal incision and is kept small enough to pass it proximally through the tunnel of the EPL, around the Lister tubercle, and into the window on the dorsum of the radius, where it and the tendon of the EPL are sutured to the bone with wire. This tenodesis produces thumb extension. Arthrodesis of the thumb IP joint is done in slight flexion to prevent hyperflexion of the joint and to facilitate side pinch. Additionally, a lasso is performed, as described later in the intrinsic rebalancing section.

Stage 2: Extensor Carpi Radialis Longus to Flexor Digitorum Profundus Transfer

When scar resolution is complete and the tenodesis is functional, the second-stage operation is done. The same radial lateral incision used in stage 1 is reopened to expose the ECRL and FDP tendons at their musculotendinous junction in the wrist crease. The ECRL is detached as distal as possible, delivered proximal to the retinaculum, and dissected proximally to improve its excursion and create a straight line of pull for its new insertion. The ECRL tendon is passed into the volar forearm, woven through each of the profundus tendons in an end-to-side fashion, and sutured with care to produce balance among all the fingers. Three Pulvertaft weaves are desired, and 2-0 nonabsorbable suture is used. Preliminary tension on the fingers should be observed during passive wrist flexion and extension with the elbow in varying degrees of flexion. Final tension should be set so that the fingers and thumb come together in a lateral pinch with the wrist in approximately 20 degrees of dorsiflexion and the elbow at 90 degrees. The tension is set loosely enough to allow easy release of the fingers during passive wrist flexion and so that the digital tips touch the palm with the wrist in full passive extension.

Next, the BR is detached from its insertion (leaving a short stump) and dissected well proximally so that maximal excursion can be obtained. The BR is sutured to the FPL with tension set to achieve lateral pinch with the wrist in approximately 20 degrees of extension and the elbow at 90 degrees (the same as in the ECRL transfer). If the thumb MP joint is hyperextended, a volar capsulodesis is recommended. The flexor tendon sheath is exposed through a transverse incision just proximal to the thumb MP joint flexion crease. The sheath is opened, and the FPL is retracted away from the volar plate. Care should be taken to protect the digital nerves. A longitudinal incision is made in the volar plate to expose and roughen the surface of the neck of the metacarpal. Two holes are drilled in the bone to receive a nonabsorbable suture. Alternatively, mini-suture anchors can be used. The volar plate is pulled proximally and sutured against the bone. Tension is set with the MP joint in 10 degrees of flexion.

Zancolli also constructs a volar tenodesis of the EPB tendon if the thumb is in excessive extension and lateral pinch is impaired. Through the radial incision, the EPB tendon is divided as far proximally as possible. The tendon is passed through the FCR tunnel and sutured into the short distal stump of the BR, which was left in place when it was divided for transfer previously. Tension is set to hold the thumb in complete abduction with the wrist in moderate extension.

❖ AUTHOR'S PREFERRED METHOD OF TREATMENT

To avoid the loss of wrist extensor strength, my preference is to treat patients in groups 2 and 3 identically—not transferring either the ECRL or the ECRB. For groups 2 and 3 patients, I prefer House's one-stage active key pinch reconstruction[37] consisting of CMC fusion, BR to FPL tendon transfer, EPL tenodesis, split FPL transfer for stabilization of the thumb IP joint, and, if the index finger does not flex sufficiently to be a post for key pinch, a lasso procedure (see Table 33.5). Because most patients in groups 2 and 3 have adequate natural tenodesis and balance of the paralyzed fingers, reconstructive efforts are focused on the thumb.

House's One-Stage Key Pinch Reconstruction for Patients in Groups 2 and 3[42,43]

Carpometacarpal Fusion

A 3- to 4-cm incision is made, centered over the CMC joint in the interval between the APL and abductor pollicis brevis (APB). After exposure of the joint, a Kirschner wire is placed from the thumb metacarpal to the index metacarpal to preposition the thumb in the desired key pinch position: about 20 degrees of extension, 30 to 40 degrees of palmar abduction, and 10 degrees of pronation. The pulp of the thumb should be able to pinch against the radial side of the index finger at the PIP level. A thin slice of articular cartilage is resected from the base of the thumb metacarpal and the distal trapezium, using a small oscillating saw and taking care to minimize bone stock loss. The Kirschner wire is withdrawn from the index metacarpal, the joint surfaces are firmly opposed, and the Kirschner wire is advanced back into the index metacarpal, securing the thumb position before final internal fixation. After appropriate positioning adjustments are made, final fixation is secured with a mini–fragment blade plate (Figure 33.9).

Brachioradialis to Flexor Pollicis Longus Tendon Transfer

The BR tendon is exposed through the same radial-side utilitarian incision. The tendon is divided at its insertion and freed from its investing fascia to the proximal third of the forearm, taking care to protect the superficial radial nerve lying directly



FIGURE 33.9 Miniblade plate carpometacarpal (CMC) fusion. CMC fusion is best achieved using stable internal fixation; this allows mobilization of the hand when the tendon transfers are ready for active motion at 4 weeks after surgery.

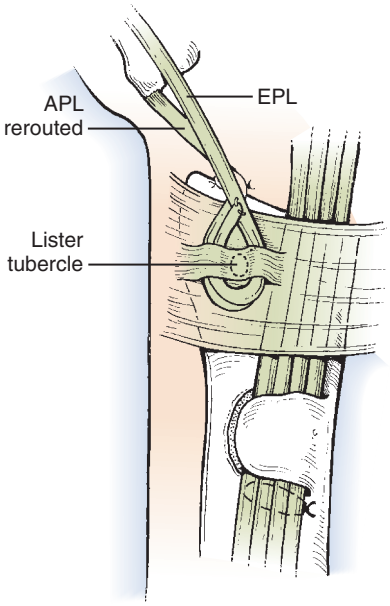

FIGURE 33.10 Extensor pollicis longus (EPL) tenodesis is woven through the extensor retinaculum, around the Lister tubercle, and back onto itself. This loop can be augmented by a bone anchor suture at the Lister tubercle if necessary. *APL,* Abductor pollicis longus.

underneath. This extensive mobilization of the BR is required to produce at least 3 cm of excursion. Through the radial incision, the FCR, flexor digitorum superficialis (FDS) tendons, and median nerve are gently retracted ulnarly to expose the FPL tendon. The BR is transferred under (dorsal to) the radial artery and woven into the FPL tendon with two to three Pulvertaft weaves and secured using 2-0 braided nonabsorbable suture, beginning the first weave at the musculotendinous junction. Tension is adjusted so that when the elbow is in about 45 degrees of flexion and the wrist is in neutral, the thumb is in neutral. With 20 degrees of wrist extension, the thumb should come into a key pinch position.

Extensor Pollicis Longus Tenodesis

Through the same incision, the proximal portion of the EPL tendon is exposed after identifying and protecting the superficial radial nerve. The tendon is divided at the level of the musculotendinous junction. The EPL is left in the third dorsal compartment, and the proximal portion of the tendon is woven through the extensor retinaculum just radial to the Lister tubercle and woven back into itself distal to the retinaculum. This creates an EPL loop around the Lister tubercle (Figure 33.10); fixation can be augmented with a bone anchor into the Lister tubercle if necessary. The APL tendon can undergo tenodesis with the EPL if greater thumb abduction, in addition to extension, is desired.

Split Flexor Pollicis Longus Transfer

The split FPL transfer is used to correct hyperflexion of the thumb IP joint due to intrinsic loss (Froment sign), which can prevent proper placement of the pulp onto the index finger for key pinch. In this procedure, half the FPL tendon is rerouted to the terminal extensor tendon to balance the IP joint.

In Sinclair's method of split FPL distal tenodesis (Figure 33.11),[70] the FPL is split through a longitudinal volar incision over the proximal phalanx. The radial half is detached and transferred subcutaneously to the dorsum, where it is sutured to the EPL, thus equalizing the pull on the volar and dorsal sides of the IP joint. I prefer a zigzag palmar incision to provide access for splitting the FPL from the divided A1 pulley to its terminal insertion on the distal phalanx. The oblique pulley is left intact. The radial half of the FPL is mobilized proximal to the oblique pulley and rerouted around the radial border to a longitudinal dorsal incision. The radial half of the FPL is woven into the EPL. The tendon is usually set so that the IP joint rests in about 30 degrees of flexion and contacts the side of the index finger in an appropriate key pinch position. The IP joint may be pinned for 4 weeks in slight flexion.

If the index finger does not flex into a key pinch position as part of the hand's natural tenodesis, index finger MP joint flexion can be enhanced through use of a lasso tenodesis (described later).

OPERATIONS FOR PATIENTS IN GROUPS 4 AND 5

By definition, patients in these groups have BR and wrist extension (ECRL and ECRB), grade 4 or greater strength in the PT (group 4) and FCR (group 5), and less than grade 4 strength in all other muscle groups below the elbow.

In patients in group 4, the PT should be considered for transfer; however, because the PT provides strong action for manual wheelchair propulsion, its use should be avoided if this is important to the patient. Zancolli[96] transferred the PT to the FCR to further enhance the strength of the wrist-activated

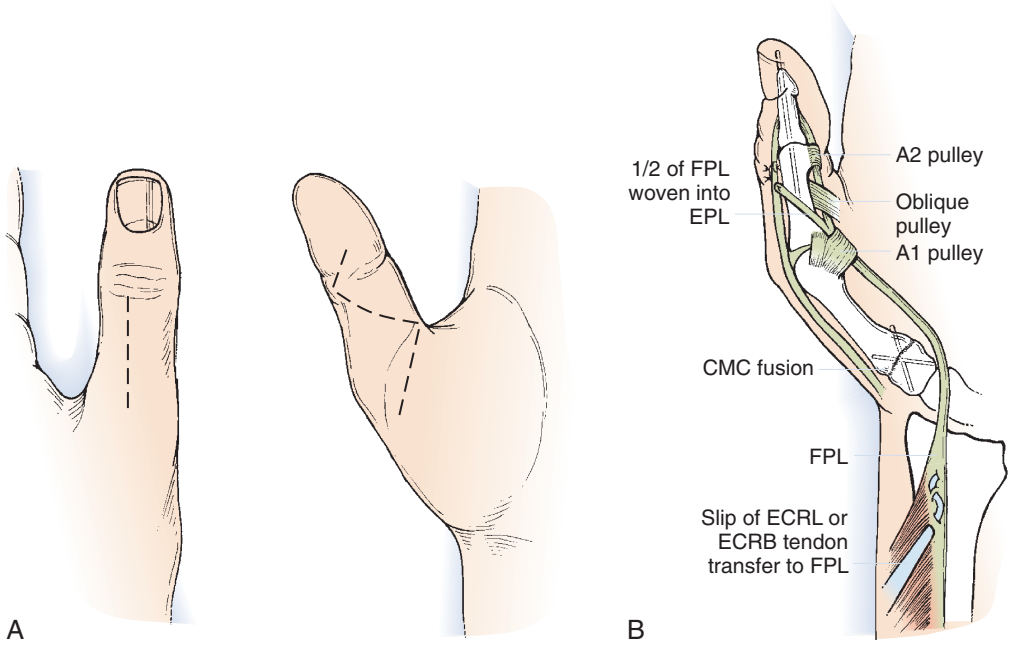

FIGURE 33.11 Split flexor pollicis longus (FPL) distal tenodesis. **A,** Dorsal and palmar incisions. **B,** Transfer of the radial half of the FPL to the extensor pollicis longus (EPL) improves thumb intrinsic balance by stabilizing the metacarpophalangeal and interphalangeal joints, providing more effective lateral pinch. *CMC,* Carpometacarpal; *ECRB,* extensor carpi radialis brevis; *ECRL,* extensor carpi radialis longus. (See Mohammed KD, Rothwell AG, Sinclair SW, et al: Upper limb surgery for tetraplegia. *J Bone Joint Surg Br* 74:873–879, 1992.)

CRITICAL POINTS *Split Flexor Pollicis Longus Tendon Transfer*

Indication
- All patients undergoing transfer to the FPL tendon with IP joint flexion greater than 60 degrees or the Froment sign, which precludes effective key pinch positioning of the thumb pulp onto the side of the index finger

Preoperative Evaluation
- Joint stability assessment of thumb CMC, MP, and IP range of motion
- Intraoperative assessment of the effect of FPL pull on the thumb pulp in "hitting" the side of index finger as the FPL is tensioned

Pearl
- Many patients benefit from this procedure as a part of an overall reconstruction.

Technical Points
- Tension can be set to allow some IP joint flexion with FPL activation, but as the dorsal tenodesis of the split FPL into the EPL tightens, no further flexion will occur.
- The tendon weave can occur over the dorsal proximal phalanx as needed.

Pitfall
- Incorrect tension of the FPL tendon weave

Postoperative Care
- From 0 to 4 weeks: cast or Kirschner wire–cast immobilization of the thumb IP joint
- From 4 to 8 weeks: thumb spica splint
- After 8 weeks: strengthening and active functional use with nighttime bracing if needed

tenodesis of digital extension. House and Walsh[40] described transferring the PT to the FPL as part of a two-stage reconstruction; House[40] does not believe that transferring the PT produces a significant loss of pronation.

The wrist flexion strength of patients in group 5 improves antagonist power for the wrist extension–driven tenodesis function of the fingers. Lipscomb and colleagues[60] in 1958 and Lamb and Landry[55] in 1971 reported transfer of the FCR in group 5 patients, but House[41] prefers to leave the FCR in place to preserve maximal wrist control.

In groups 4 and 5, the BR, ECRL, and PT muscles are available for transfer. The ECRB and the FCR are generally preserved to retain good wrist control. Because there are more muscles available in patients in groups 4 and 5, the surgeon most commonly chooses a two-stage reconstruction of grasp (flexor phase) and release (extensor phase), using the method described by either House or Zancolli. At the first stage (extensor phase), the thumb is positioned and tenodesis of the extensor tendons is performed. At the second stage (flexor phase), the thumb and finger flexor tendons are activated for grasp and the finger intrinsics are activated for balance. Other options include a simple lateral pinch reconstruction or a single-stage reconstruction that prioritizes grasp.[45]

❖ AUTHOR'S PREFERRED METHOD OF TREATMENT

I prefer the House two-stage reconstruction using a thumb CMC arthrodesis to stabilize the thumb in an optimal position (see Table 33.5). However, when bilateral reconstruction is performed, one thumb is arthrodesed and the second thumb undergoes adduction-opponensplasty transfer to maximize mobility (Figure 33.12).[39,44] One of the available motors (usually

CRITICAL POINTS *House's One-Stage Key Pinch Procedure*

Indications
- Group 1 patients using FPL for passive tenodesis
- Groups 2 and 3 patients with greater than grade 4 wrist extensor strength using BR to FPL for active pinch

Preoperative Evaluation
- Verify BR and wrist extensor strength
- Evaluate thumb position and index finger position in their "natural tenodesis" pattern to verify that this combination of FPL tenodesis, EPL tenodesis, and CMC fusion will obtain the desired thumb position.

Pearl
- The thumb is tensioned so that it "hits" the lateral aspect of the PIP joint of the index finger with 20 degrees of wrist extension and opens with wrist flexion, providing adequate clearance for release.

Technical Points
- CMC fusion: Stable minifragment fixation after parallel CMC joint surfaces are prepared, positioning the thumb in 40 degrees of abduction, 25 degrees of extension, and 10 degrees of pronation, so the thumb "hits" the lateral aspect of the PIP joint of the index finger.
- EPL tenodesis: Tenodesis of the EPL is performed around the Lister tubercle and woven through the extensor retinaculum and back through itself, tightly enough to allow full thumb opening with passive wrist flexion and full passive thumb flexion with passive wrist extension.
- BR to FPL transfer (groups 2 and 3): full mobilization of the BR tendon and Pulvertaft weave to the FPL
- Split FPL transfer for IP stabilization
- If the fingers do not pull into enough flexion to allow a stable base for key pinch reconstruction, a lasso procedure may be necessary (see later).

Pitfall
- Check thumb position based on both elbow flexion-extension and wrist flexion-extension, because the BR crosses both joints. Tension is adjusted so that when the elbow is in about 45 degrees of flexion and the wrist is in neutral, the thumb is in neutral. With 20 degrees of wrist extension, the thumb should come into a key pinch position. With 20 degrees of wrist flexion, tenodesis should cause the thumb to be positioned in extension.

Postoperative Care
- From 0 to 4 weeks: short-arm thumb spica cast in neutral to protect from active flexion-extension of the thumb
- From 4 to 8 weeks: active range of motion with protective forearm-based thumb splint
- After 8 weeks: strengthening and functional use with night splint if necessary

the BR) is lengthened with a tendon graft (taken from the paralyzed FDS)[9,38] to motor the opponensplasty.

House's Two-Stage Grasp, Pinch, and Release Procedure

Stage 1: Extensor Phase

A CMC fusion is performed using the previously described technique, and an EPL tenodesis is performed using House's technique (see earlier). House prefers a different EDC technique than that described by Zancolli.[45]

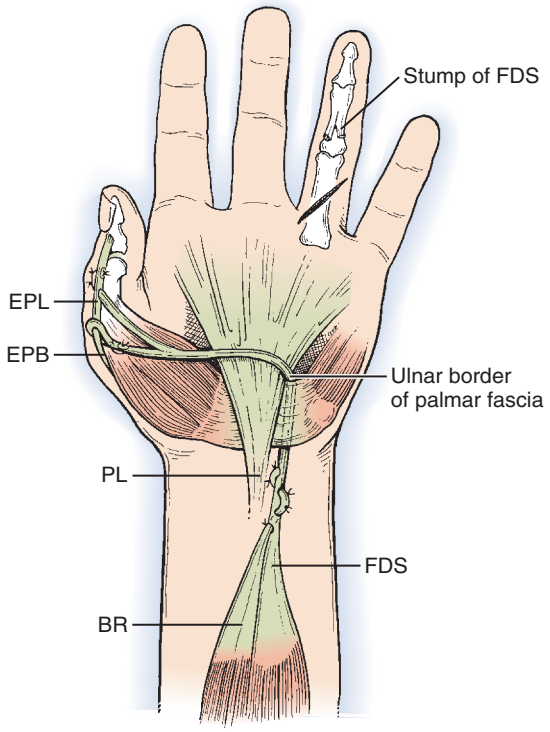

FIGURE 33.12 Adduction-opponensplasty. A motor is transferred to the paralyzed flexor superficialis as an "in situ tendon graft." It is rerouted around a palmar fascial "pulley" to a dual insertion that controls thumb rotation and stabilizes the metacarpophalangeal and interphalangeal joints, for more effective lateral pinch. The brachioradialis (BR) is usually used as the motor in group 5, and the flexor carpi ulnaris is used in group 7 or 8. *FDS,* Flexor digitorum superficialis; *EPB,* extensor pollicis brevis; *EPL,* extensor pollicis longus; *PL,* palmaris longus. (See House JH, Shannon MA: Restoration of strong grasp and lateral pinch in tetraplegia: a comparison of two methods of thumb control in each patient. *J Hand Surg [Am]* 10:22–29, 1985.)

Extensor Digitorum Communis Tenodesis. Finger extension is produced by tenodesis of the common extensors to the distal radius (Figure 33.13). The antebrachial fascia is opened from the proximal edge of the extensor retinaculum to the musculotendinous junction of the extensor digitorum tendons through the radial incision. Retracting the extensor indicis proprius (EIP) and the common extensors ulnarward exposes the floor of the fourth dorsal compartment. A 2- by 2-cm flap of periosteum of the distal radius is elevated on the metaphysis of the radius, leaving it attached on its ulnar side. A 2-cm bone window is created. Next, the common extensor tendons are sutured together with the fingers in balance using 2-0 nonabsorbable suture, transected proximal to the suture, and inserted into the bone window. The periosteal flap is sewn over the extensor tendons using a 2-0 braided, nonabsorbable suture. The tension is adjusted so that when the wrist is passively flexed to 30 degrees, the MP joints extend to 0 degrees; full finger passive flexion is possible with full wrist extension.

Intrinsic Tenodesis. Intrinsic tenodesis can also be performed in this stage to correct inadequate digital PIP extension. A free tendon graft is routed through the lumbrical canals, volar to the deep transverse metacarpal ligament and around the second metacarpal (as shown in Figure 33.13, *A*), and braided and sutured into the lateral bands and central slips of adjacent fingers. The same technique is used for the ring and little fingers

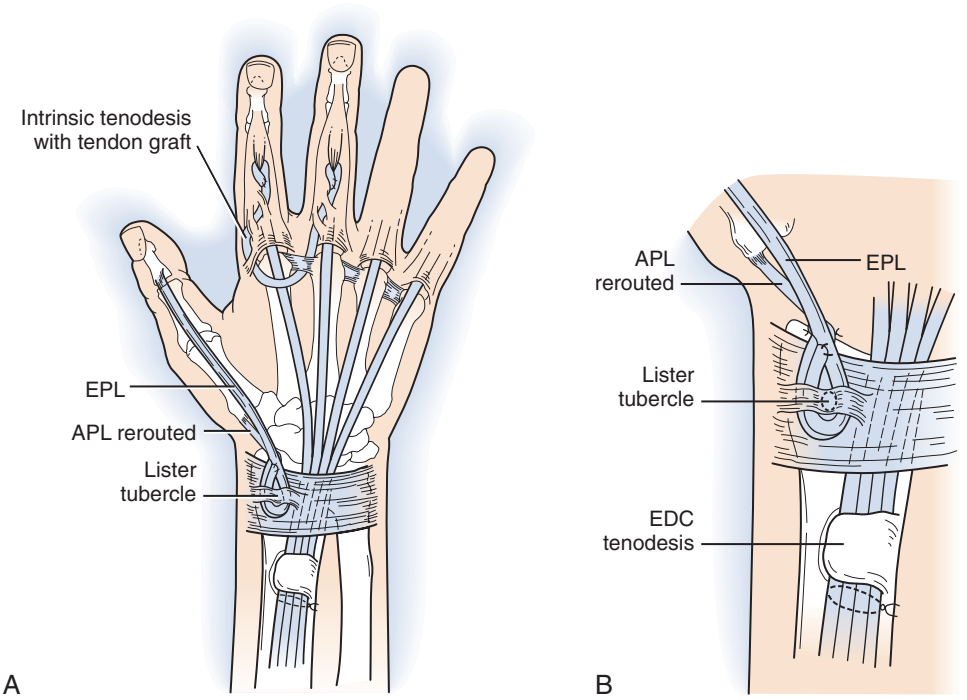

FIGURE 33.13 Stage 1 (extensor phase) of House's two-stage reconstruction for patients in group 5. **A,** Intrinsic tenodesis may be performed for inadequate interphalangeal extension. A free tendon graft is routed through the lumbrical canals, volar to the deep transverse metacarpal ligament and around the second metacarpal, and braided and sutured into the lateral bands and central slips of adjacent digits. The same technique can be used for the ring and little fingers (around the fourth metacarpal). **B,** Tenodesis of the extensor digitorum communis (EDC) is accomplished by fixation of the tendons into a "horseshoe window" in the distal radius with a heavy suture that also balances the relative tension of all four fingers. The extensor pollicis longus (EPL) and abductor pollicis longus (APL) (rerouted through the third dorsal compartment) are usually passed around the Lister tubercle and braided together to provide balanced thumb abduction and extension and sutured in a loop around the extensor retinaculum. (Copyright Elizabeth Martin. See also House JH, Shannon MA: Restoration of strong grasp and lateral pinch in tetraplegia: a comparison of two methods of thumb control in each patient. *J Hand Surg [Am]* 10:22–29, 1985.)

(around the fourth metacarpal) when IP joint extension is inadequate in those digits.[39]

Postoperative Casting and Rehabilitation. The patient is placed in a short-arm cast for 4 weeks of immobilization, with the fingers included in a position of MP extension and the PIP joints in full extension (if intrinsic reconstruction was performed concurrently). A thumb spica component is used to hold the CMC in the fused position. After 4 weeks, the same position is held with a volar forearm-based resting splint. Active range of motion with light activities of daily living is initiated. After 8 weeks the splint is worn only at night, and strengthening exercises are added. The second stage is usually planned 3 months after the extensor phase surgery.

Stage 2: Flexor Phase

The ECRL is transferred to the FDP tendons, using the technique described earlier. If the BR was not used in the extensor phase, it is transferred to the FPL. If the BR was used, the pronator is transferred to the FPL for pinch (Figure 33.14). Although several options exist, my preference is CMC fusion, EDC tenodesis, and EPL tenodesis (extensor phase), followed by ECRL to FDP and BR to FPL transfers (flexor phase). With bilateral procedures, I perform a BR adduction-opponensplasty instead of a CMC arthrodesis (in the flexor phase) and transfer the pronator to the FPL for pinch. Alternatively, the BR can be transferred to the EDC and EPL instead of tenodesis in the extensor phase, followed by ECRL to FDP and PT to FPL transfers (flexor phase). I find the extensor tenodesis more reliable than the BR transfer for digital extension in groups 4 and 5.

Pronator Teres to Flexor Pollicis Longus Tendon Transfer. The PT is harvested from its radial insertion through the radial incision. The tendon length can be augmented by elevating the attached radial periosteum distally for 4 to 5 cm. The muscle should be lifted and dissected proximally to increase its excursion, and the tendon-periosteal extension is transferred to the FPL. Tension should be set so that the thumb comes into contact with the lateral side of the index finger when the wrist is passively extended to 20 degrees.

Opponensplasty. The adduction-opponensplasty is produced by transferring a motor to the paralyzed flexor superficialis as an "in situ tendon graft." It is rerouted around a palmar fascial "pulley" to a dual insertion that controls thumb rotation and stabilizes the MP and IP joints for more effective lateral pinch. The BR is usually used as the motor in group 5 (see Figure 33.12). As described later for groups 7 and 8, the flexor carpi ulnaris (FCU) can be used as the motor.[39]

Postoperative Casting and Rehabilitation

The patient is placed in a long-arm dorsal extension block cast with the fingers included for 4 weeks of immobilization; MP extension is blocked at 30 degrees, PIP joints are blocked at 30 degrees of extension, and thumb extension is blocked at the MP

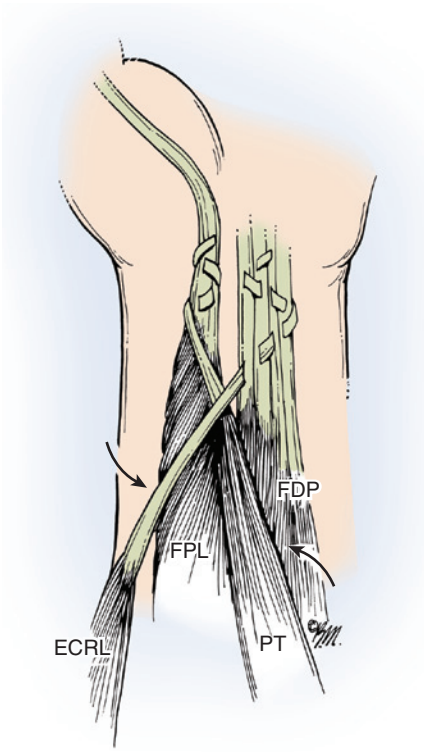

FIGURE 33.14 Stage 2 (flexor phase) of House's reconstruction includes both extensor carpi radialis longus (ECRL) to flexor digitorum profundus (FDP) tendon transfer and pronator teres (PT) to flexor pollicis longus (FPL) tendon transfer. Another option would be ECRL to FDP and brachioradialis to FPL tendon transfers. (Copyright Elizabeth Martin. See also House JH, Shannon MA: Restoration of strong grasp and lateral pinch in tetraplegia: a comparison of two methods of thumb control in each patient. *J Hand Surg [Am]* 10:22–29, 1985.)

and IP joints. After 4 weeks the same position is held with a dorsal forearm-based resting splint. Active range of motion with light activities of daily living is initiated. After 4 additional weeks the splint is worn only at night, and strengthening exercises are added.

Alternative Techniques for Patients in Groups 4 and 5

Alternative techniques for reconstruction of groups 4 and 5 have recently been described by Friden and colleagues.[33] They have used a single-stage grip, pinch, and release advanced balanced combined digital extensor flexor grip (ABCDEFG) procedure, or "alphabet reconstruction." They also describe using this technique for group 3 patients with verified grade 5 strength of both the ECRL and ECRB. If used for higher-level patients (those in group 5 or above), not all seven elements of the reconstruction would be necessary.

ABCDEFG Procedure (Alphabet Reconstruction)

This procedure has seven components, all of which may be used for each patient or some of which can be chosen based on the specific passive mobility or tenodesis pattern.[33] The seven elements of the reconstruction include:

1. BR to FPL tendon transfer to provide pinch
2. ECRL to FDP tendon transfer to provide grasp
3. EPL tenodesis for passive thumb extension
4. ECU tenodesis to provide balanced wrist extension (without excessive radial deviation)
5. Split FPL transfer to prevent the Froment sign
6. Thumb CMC fusion to pre-position the thumb in key pinch position
7. Intrinsic tenodesis to provide passive PIP extension

The technique for each of the elements of this procedure is described in this chapter, except for the ECU tenodesis, which is not described as part of other reconstructive plans.

CRITICAL POINTS *House's Two-Stage Grasp, Pinch, and Release Procedure*

Indications
- Group 4 patients with BR, ECRL, ECRB, and PT strength grade 4 or 5 or greater
- Group 5 patients with BR, ECRL, ECRB, PT, and FCR strength grade 4 or 5 or greater

Preoperative Evaluation
- Verify muscle strength testing.
- General indications and contraindications (spasticity, contracture, chronic pain, psychological or medical instability)

Pearl
- Use of at least three tendon weaves increases strength at the tendon weave junctions.

Technical Points

Extensor Phase
- CMC fusion for stable thumb, positioning the thumb in 40 degrees of abduction, 25 degrees of extension, and 10 degrees of pronation, so that the thumb "hits" the lateral aspect of the PIP joint of the index finger
- EDC and EPL tenodesis for passive finger and thumb extension
- Option: BR to EDC and EPL tendon transfers for active finger and thumb extension

Flexor Phase
- ECRL to FDP tendon transfer for active finger flexion
- BR to FPL tendon transfer for active thumb pinch
- Option: PT to FPL tendon transfer for active thumb pinch (if BR was used in extensor phase)
- Option: thumb adduction-opponensplasty using BR and FDS tendon graft, performed in bilateral reconstructions instead of CMC fusion on one side

Pitfall
- Inappropriate tension: not too tight and not too loose

Postoperative Care
- From 0 to 4 weeks
- Extensor phase: short-arm thumb spica cast with thumb IP extension and finger MP extension
- Flexor phase: long-arm cast with dorsal extension block with the fingers and thumb included, with MP extension blocked at 30 degrees, PIP extension blocked at 30 degrees, and thumb extension blocked at the MP and IP joints
- From 4 to 8 weeks: active range of motion with protective forearm-based thumb splint
- After 8 weeks: strengthening and functional use with night splint if necessary

Extensor Carpi Ulnaris Tenodesis

As part of the tetraplegic hand reconstruction, excessive radial deviation can be corrected by the ECU tenodesis procedure.[79] A curved incision is made at the wrist over the sixth compartment. The extensor retinaculum is opened over the ECU tendon, which is elevated with a tendon hook. The tendon is shortened approximately 2 cm by folding the tendon and securing it with two size 2-0 double mattress nonabsorbable sutures, and then sutured onto the joint capsule of the ulnar head with two 4-0 absorbable sutures. Passive position of the wrist decreases radial deviation but maintains flexion and extension.

Reinholdt and associates[79] present 18 patients treated with a tetraplegia hand reconstruction that included ECU tenodesis and compared this with a historical control group of 33 patients treated without ECU tenodesis. The ECU tenodesis group had less radial deviation deformity and had 6.1 kg of grip strength compared with 2.1 kg of grip strength in the control group. No differences in pinch strength were noted.

Other differences between the alphabet reconstruction and the techniques described in this chapter are the intraoperative tendon transfer technique and the postoperative rehabilitation.

Tendon Transfer Technique

In this tendon transfer technique,[10,32] the BR to FPL tendon transfer and the ECRL to FDP tendon transfer are sewn with a side-to-side tendon to tendon attachment that allows more aggressive and active postoperative rehabilitation. A 5-cm overlap between the tendon donor and tendon recipient is made. A single slit is made in the recipient tendon and the donor tendon is passed through and overlapped for a 5-cm segment. Running 3-0 nonabsorbable sutures are placed along both sides of the overlapping tendons as shown in Figure 33.15. One double-loop suture secures each free end of each tendon using 3-0 nonabsorbable suture.

Postoperative Rehabilitation. Active range of motion begins on the first postoperative day and is allowed in a protective manner for the first 4 weeks following operation. During this time, full flexion of the digits is not allowed (at least 2 cm of the fingertip to palm distance is required to protect the intrinsic tenodesis). Resting splints are used for protection, maintaining the wrist in neutral position and the MP joints in 60 degrees of flexion. A protective splint for the CMC and IP joints of the thumb is also used. Between 4 and 8 weeks following the operation, the patient continues to wear the protective splints, but the patient removes them for functional activity training. All restrictions and splints are removed by 12 weeks after surgery.

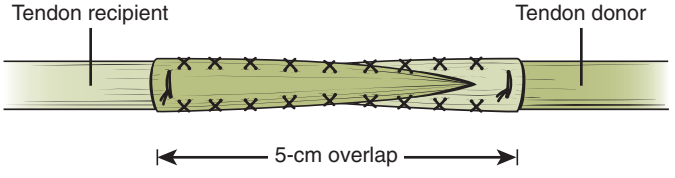

FIGURE 33.15 Side-to-side weave consists of the donor tendon inserting through one incision in the recipient tendon with cross-stitch running 3-0 nonabsorbable sutures back and forth down both sides and one double-loop 3-0 nonabsorbable suture at each tendon free end.

Reinholdt and colleagues[33] reported on 14 patients with 16 hands treated with the alphabet reconstruction and rehabilitation, and compared this group with a historical control group of 15 patients with 18 hands treated with two-stage reconstruction. All patients were in ICS group 4. In the alphabet group, grip strength was 6.5 kg, compared with 1.6 kg in the control group. Pinch strength was similar in the two groups. The opening of the first web space was 5.5 cm in the alphabet group, compared with 3 cm in the control group. Complications included one tenolysis, one ruptured intrinsic tenodesis that required another repair, and one subsequent tendon transfer for digital opening. Four patients could not make a full fist with a 1- to 2-cm gap between fingertip and distal palmar crease.

OPERATIONS FOR PATIENTS IN GROUPS 6 AND 7

Patients in group 6 have at least grade 4 strength of the group 5 muscles (BR, ECRL, ECRB, PT, FCR) as well as the EDC. Patients in group 7 have at least grade 4 strength of the EPL in addition to the functioning muscles of group 6. In these two groups a separate extensor phase is not required, and reconstruction involves a flexor phase consisting of an ECRL to FDP transfer and a BR to FPL transfer. An intrinsic reconstruction is added as needed.

Because these patients have active unopposed digital extension, they often present with a characteristic "flat hand" appearance.[39] Their digital function is not significantly greater than that of patients in groups 4 and 5, because they lack active grasp and release. Of note, patients with this lower level of spinal cord injury also have stronger shoulder and elbow control, so their ability to position the hand in space is usually excellent. These patients benefit greatly from grasp and pinch reconstructive surgery. Results after surgery in groups 6 and 7 patients are much better than in those with higher-level injuries; their improved shoulder control and normal extensor function give them more precise control.

For group 6 patients, the finger extensors are strong but EPL function is either absent or too weak to extend the thumb adequately. The EPL can undergo tenodesis or transfer into the digital extensors to improve thumb extension. This can be done in conjunction with the flexor transfers or staged, based on the surgeon's preference.

For group 7 patients, both finger and thumb extensors are strong, so the flexor phase alone is performed. Thumb control can be achieved through either CMC fusion or opponensplasty, depending on the thumb's stability and position as well as the patient's preference. Many patients prefer opponensplasty for one thumb and fusion for the other.[37] Intrinsic reconstruction can also be done to augment digital grasp in patients with severe clawing.

❖ AUTHOR'S PREFERRED METHOD OF TREATMENT

The ECRL is transferred to the FDP for active finger flexion as described earlier, and the BR or PT is transferred to the FPL for active pinch. My preference is to transfer the BR to the FPL for active pinch, preserving the PT for wheelchair propulsion (see Table 33.5). In addition, the following thumb control and intrinsic reconstructions can be added.

Extensor Pollicis Longus to Extensor Digitorum Communis Transfer (Group 6 Patients)

A half-thickness slip of the EPL tendon is braided through the index EDC. This transfer is performed such that the length-tension relationship of the EPL is unchanged, ensuring that relative tension will be maintained between the EDC and EPL tendons. The tendons are firmly sutured together with three or four horizontal mattress sutures of 2-0 nonabsorbable, braided polyester. If the common extensor tendon to the index finger is small, additional common extensor tendons can be included to produce a strong union.

Thumb Control Options

Examination for joint instability is essential. The CMC joint can be fused to provide key pinch positioning, as described earlier. If the MP is hyperextensile, it can be stabilized by advancing the volar plate proximally and anchoring it to the metacarpal neck with sutures or a suture anchor. Zancolli[96] has also described a volar capsulodesis technique employing sesamoid fusion. The radial or ulnar sesamoids are lifted in continuity with the attached volar plate, decorticated, and fixed with sutures or Kirschner wires to a denuded area on the volar metacarpal neck.

A hyperflexed IP joint can be stabilized using the split FPL technique described earlier (see Figure 33.11). Additional power and positioning control can be provided by performing an opponensplasty using the BR or PT as a motor, as described earlier. My preference is to perform a CMC fusion on one side and an opponensplasty on the other side to provide different types of thumb functions for the patient.[37]

Intrinsic Reconstruction: The Lasso Procedure

These patients have excellent selective digital control because their digital extensors are intact, but they may benefit from an active lasso procedure to compensate for the loss of intrinsic function. Palsy of the intrinsics in patients with functioning extrinsic extensors and flexors leads to digital "roll-up," which makes effective grasp difficult. Digital roll-up occurs when the distal interphalangeal (DIP) joint flexes before the PIP, and the MP joint fails to flex. Such hand positioning makes it difficult to grasp large objects.

The Zancolli lasso procedure helps initiate MP flexion as the first stage of digital grasp, followed by PIP and finally DIP flexion, to enable grasping of large or cylindrical objects. Because the FDS is nonfunctional, transfer of the BR or PT to the FDS provides a motor to power the lasso procedure.

Postoperative Casting and Rehabilitation

The patient is placed in a long-arm dorsal extension block cast with the fingers included for 4 weeks of immobilization; MP extension is blocked at 30 degrees, the PIP joints are blocked at 30 degrees of extension, and thumb extension is blocked at the MP and IP joints. If an extensor tenodesis is included, the PIP joints are held in full extension. After 4 weeks the same position is held with a dorsal forearm-based resting splint, with removal of the splint three to five times a day for initiation of active range of motion and light activities of daily living. After 8 weeks the splint is worn only at night, and strengthening exercises are added.

OPERATIONS FOR GROUP 8 PATIENTS

Group 8 patients have grade 4 strength of all the group 7 muscles (BR, ECRL, ECRB, PT, FCR, EDC, EPL) as well as an intact FCU and partial finger flexion (FDP). Usually, the long flexors to the ulnar digits (ring and small fingers) are stronger than those to the thumb, index, and long fingers. Patients in group 8 also lack intrinsic function.

Flexion of the index and long fingers can be strengthened by suturing the FDP of all four digits to one another in the distal forearm. To augment thumb IP flexion, the BR can be transferred to the FPL. Finally, intrinsic balance must be assessed and addressed surgically.

❖ AUTHOR'S PREFERRED METHOD OF TREATMENT

My preferred technique is Zancolli's two-stage reconstruction.

Stage 1: Extrinsic Transfers

Flexor Digitorum Profundus Side-to-Side Transfer. The four profundus tendons are exposed through a longitudinal approach along the FCU tendon. The ulnar neurovascular bundle is retracted to the ulnar side, and the profundus tendons are easily exposed by gentle radial retraction of the median nerve and FDS tendons. A site in the distal forearm is selected for side-to-side suture of the four profundus tendons. The peritenon is scraped away from the tendons for a distance of 3 cm, and the tendons are sutured together with horizontal mattress sutures using 2-0 nonabsorbable suture. Half the FDP of the index finger is woven transversely across the other FDP tendons to ensure proper relative tension among the four tendons.[40] The fingers should be evenly balanced during the connection.

Brachioradialis to Flexor Pollicis Longus Transfer. As described earlier, the BR is transferred directly to the FPL and connected by braiding the tendon of the BR into the tendon of the FPL with the wrist in neutral and the thumb just touching the side of the index finger, with mild tension on the BR.

Stage 2: Intrinsic Reconstruction

Opponensplasty. The opponens transfer can be motored by the FCU, and the palmaris longus (PL) can be used as a free tendon graft (if the PL is not present, a toe extensor or the plantaris tendon can be used) to extend the tendon of the FCU to its insertion into the ulnar side of the base of the proximal phalanx of the thumb. The FCU is exposed through an "L"-shaped incision over its insertion, with the transverse arm of the "L" in the wrist crease. The FCU tendon is split in half for a distance of 3 to 4 cm proximal to its insertion, and half the tendon is divided, leaving the hemitendon segment attached distally on the pisiform. The cut end of this segment is sutured to itself at the insertion to create a loop. The other half is detached from the pisiform and attached to the proximal end of the free tendon graft using a braiding technique. A subcutaneous tunnel is created from the loop to the MP joint of the thumb. The tendon graft is passed through the loop at the pisiform and through the subcutaneous tunnel and attached to the tendon of the APB at the base of the proximal phalanx. Tension is adjusted so that with the wrist in neutral, the thumb pulp just touches the radial side of the index finger. With wrist extension, the thumb is positioned in wide abduction.

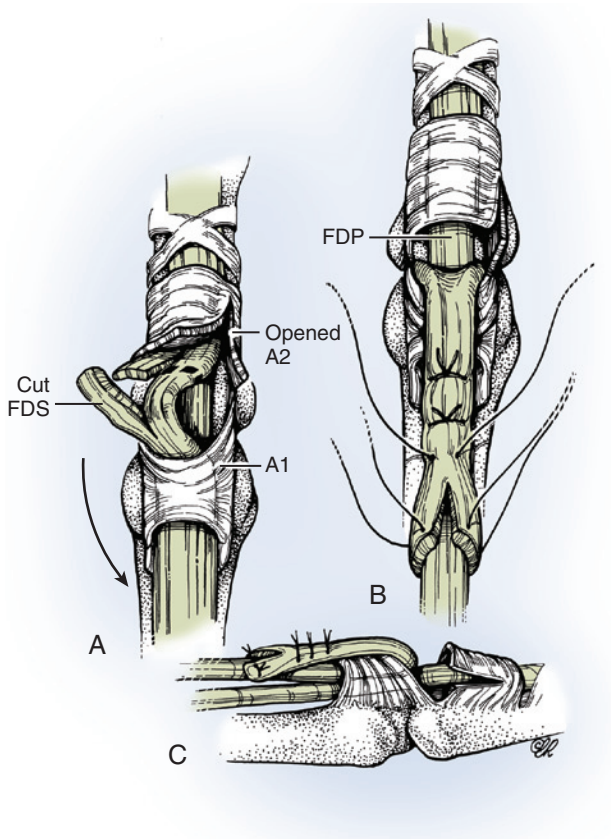

FIGURE 33.16 **A** to **C,** Zancolli's lasso operation is an intrinsic balancing operation that can be used to improve metacarpophalangeal joint flexion and lessen interphalangeal joint flexion deformities with early digital "roll-up." *FDP,* Flexor digitorum profundus; *FDS,* flexor digitorum superficialis. (Copyright Elizabeth Martin. See also Zancolli EA: *Structural and dynamic bases of hand surgery*, ed 2, Philadelphia, 1979, JB Lippincott.)

Intrinsic Tenodesis. Intrinsic balance in the hand can be improved by preventing MP hyperextension (clawing) with a lasso procedure, or by improving PIP flexion posturing with an intrinsic tenodesis procedure. The intrinsic tenodesis uses a free tendon graft (as described below) to improve PIP extension, which enhances digital opening. Use of intrinsic tenodesis as part of the reconstruction has been shown to improve grip strength.[61]

Zancolli's Lasso Procedure. Because the FDS lacks grade 4 strength, Zancolli[96] recommended transfer of the ECRL to the FDS to produce active control of the lasso intrinsic reconstruction. After the lasso procedure has been completed (Figure 33.16), tension on the ECRL transfer is set so that with the wrist in neutral, the MP joints of the fingers are at 0 degrees. With the wrist in extension, the MP joints should be flexed 30 to 40 degrees.

OPERATIONS FOR GROUP 9 PATIENTS

Patients in group 9 have functioning FDS muscles, as well as all the other extrinsic finger and thumb flexors and extensors, but they do not have intrinsic muscle innervation. This is the least common group of patients with tetraplegia,[39] and, in many ways, they can be treated much like patients with combined low median and ulnar peripheral nerve palsy. These patients benefit most from opponensplasty and intrinsic reconstructions, tailored to the intrinsic imbalance present. The Zancolli lasso operation is generally more effective because the superficialis muscles are under voluntary control in group 9 patients.

INTRINSIC RECONSTRUCTION

Intrinsic reconstruction procedures are adjuncts to extrinsic tendon reconstructions and thus refine and improve their results. Intrinsic reconstructive procedures are tendon transfers or tenodesis procedures that improve intrinsic balance in the fingers or thumb, or both. Extrinsic reconstructive procedures done in conjunction with intrinsic reconstructions result in greater final grip strength than those done without intrinsic reconstructions.[2] Intrinsic reconstruction can be done at the same time as the extrinsic reconstruction or as a separate staged procedure, and it must be tailored to the particular intrinsic imbalance present. In patients with little digital imbalance, intrinsic reconstruction is not necessary.

Patient evaluation includes an assessment of digital balance. Evaluation of passive motion of the joints is necessary, as is assessment of dynamic deformity and position of the fingers with wrist tenodesis. At the MP joint, lack of intrinsics leads to MP hyperextension deformity (clawing). At the PIP joint, spasticity of the FDS muscles or central slip deficits (stretched or incompetent) can lead to PIP joint flexion deformities and early digital "roll-up" during grasp. The Zancolli lasso procedure helps initiate MP flexion as the first stage of digital flexion, followed sequentially by PIP and DIP flexion, making the patient's grasp of large cylindrical objects more natural and effective.

❖ AUTHOR'S PREFERRED METHOD OF TREATMENT

The most common intrinsic imbalances and their recommended treatments include the following:

- Hyperflexion of the thumb IP joint (Froment sign): treated with split FPL transfer
- Clawing of the digits with MP hyperextension of the fingers and PIP flexion with early digital "roll-up": treated with Zancolli passive or active lasso procedure
- PIP flexion deformity due to central slip deficiency: treated with intrinsic tenodesis

Digital Clawing

The goal of the lasso procedure is to prevent MP joint hyperextension or clawing of the fingers during finger extension.[61] The lasso procedure uses the FDS to flex the MP joints. For patients with a PIP flexion deformity associated with FDS spasticity, the lasso procedure has the added benefit of removing the FDS as a spastic deforming force at the PIP joint and transferring it to a more useful position as an MP flexor. The lasso procedure is recommended during the flexor phase for patients in groups 3 to 8 with excessive clawing deformity of their digits. It can be performed with a paralyzed FDS tendon as a passive tenodesis when appropriate motors are not available, or it can be augmented with a tendon transfer to create an active transfer.

Lasso Procedure. A single transverse incision, or separate Bruner incisions, is made across the MP flexion creases; the A1 and A2 pulleys are exposed, protecting the neurovascular bundles. The proximal and distal limits of the A1 pulley are

identified at the base of each digit. Tension is applied to each A1 pulley using forceps to be certain that a transfer around the A1 pulley will pull the MP joint into flexion; if it does not, the proximal portion of the A2 pulley should be included in the transfer attachment. Once the surgeon is sure that MP flexion will occur, the sheath is opened transversely at that point. Both slips of the FDS are divided distal to the A2 pulley, near the middle phalanx insertion, leaving a small tail to prevent recurvatum. The FDS tendon is delivered into the palmar wound through the transverse opening in the pulley sheath, looped back over the transverse pulley, and sutured with an interweave technique into the FDS tendon itself using 4-0 nonabsorbable suture (see Figure 33.16). After the first suture is inserted, appropriate tension is confirmed by observing MP joint motion in response to passive tenodesis wrist motion. With the wrist extended, the MP joints should flex in a uniform cascade. As the wrist is passively flexed, all MP joints should extend fully but not hyperextend. The same procedure is repeated in each finger. If the FDS to the small finger is vestigial, the ring finger FDS can be split into two tails and delivered to both the ring and small fingers.

The patient is placed in a short-arm dorsal extension block cast with the fingers included for 4 weeks of immobilization; the wrist is slightly flexed, the MP joints are blocked at 30 degrees of flexion, and the PIP joints are free. After 4 weeks the same position is held with a dorsal forearm-based resting splint. Active range of motion with light activities of daily living is initiated. After 4 weeks, the splint is worn only at night, and strengthening exercises are added.

Proximal Interphalangeal Central Slip Deficiency

In patients with significant PIP joint flexion deformities due to central slip deficiency, an intrinsic tenodesis with a free tendon graft can be included in the extensor phase to increase the effect of intrinsic balancing.[61] A free tendon graft is passed volar to the axis of rotation of the MP joint (using the intermetacarpal ligaments as the proximal anchor) and dorsal to the axis of rotation of the PIP joint; it is then inserted into the central slip of the extensor tendon. Thus, extension of the MP joint by the extrinsic muscles provides PIP joint extension through a tenodesis effect.

Intrinsic Tenodesis. Any fixed PIP contractures should be released in a staged procedure to ensure full PIP mobility before considering intrinsic tenodesis. The intrinsic tenodesis is performed in the extensor phase of reconstruction after tenodesis of the extrinsic finger extensors (Figure 33.17). The EIP, extensor digiti minimi, PL, or toe extensor tendons can be harvested for use as a free tendon graft. For grafting the index and long fingers, a curvilinear incision is made over the dorsal radial aspect of the index metacarpal neck. The extensor mechanism is exposed over the index metacarpal. The EIP tendon graft is divided just proximal to the sagittal band and retrieved through a counterincision proximal to the retinaculum. A curvilinear incision is made from the radial midlateral line over the proximal phalanx, continuing dorsally over the PIP joint. Subcutaneous dissection is performed to follow the lateral band from the lumbrical canal to the central slip. A tendon passer is gently passed in retrograde fashion from the midlateral incision through the lumbrical canal (*palmar* to the intermetacarpal ligament) and out of the index metacarpal incision. The tendon graft is threaded through this path, palmar to the intermetacarpal ligament. A similar incision is made on the midlateral aspect of the proximal phalanx of the long finger, and the tendon passer is similarly passed through the lumbrical canal, palmar to the intermetacarpal ligament and ulnar to the index metacarpal neck. The proximal end of the tendon graft is passed dorsal to the index extensor tendon over the index metacarpal neck and retrieved with the tendon passer. The free graft is woven and sewn to the index finger central slip using 4-0 absorbable suture; it is then tensioned by suturing to the middle finger central slip so that the PIP joints are in nearly full extension when the MP joints are in full extension. When the wrist is in extension and the MP joints are in flexion, passive flexion of the PIP joints should be possible without undue tension. The same procedure can be performed for the ring and small digits by harvesting the extensor digiti minimi tendon and using it as a free graft.[40]

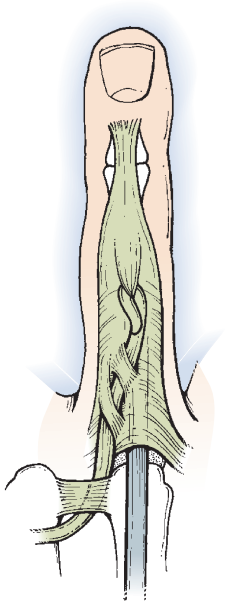

FIGURE 33.17 Intrinsic tenodesis technique. Close-up view illustrates weaving of the free graft from under the deep transverse metacarpal ligament, in line with the lateral band, and into the central slip. This simulates intrinsic function with the graft volar to the axis of the MP joint for MP flexion and dorsal to the axis of the PIP joint for PIP extension (see also Figure 33.13, *A*).

The patient is placed in a short-arm cast with the fingers included for 4 weeks of immobilization; the MP joints are held at 30 degrees of flexion, and the PIP joints are held at full extension. After 4 weeks the same position is held with a volar forearm-based resting splint. Active range of motion with light activities of daily living is initiated. After 4 additional weeks the splint is worn only at night, and strengthening exercises are added.

FURTHER AREAS OF RESEARCH

The ultimate goal of spinal cord injury research would be repair of the spinal cord and return of neurologic function. Although this goal has not been achieved, other work has been done to try to improve the return of neurologic function. Another area of research has been the use of nerve transfers in tetraplegia. In

reports of transfer to the axillar nerve branches to the triceps, and supinator motor branches to the posterior interosseous nerve, the outcomes have not been beneficial enough to warrant routine use. Risk of loss of existing nerve function must be weighed in these experimental procedures.[4,5,31,60]

OUTCOMES

Measurement of outcomes in surgery for tetraplegia has traditionally focused on range of motion, pinch, and grip strength. The World Health Organization has provided a framework for evaluating the consequences of disease through the *International Classification of Functioning, Disability, and Health*.[92] This framework has been evaluated for patients with spinal cord injury.[82] The classification measures not only impairment but also activity limitation and restrictions. Impairment is measured by objective physician-determined parameters such as range of motion and grip pinch strength. Quality of life is further assessed by outcome questionnaires such as the Quadriplegia Index of Function[35] and the Tetraplegia Hand Activity Questionnaire.[56] This broader view of outcome assessment incorporates not only traditional measurements of physical impairment but also quality-of-life issues.

CONCLUSION

Hand and upper extremity reconstruction is only one facet of the medical care and support services necessary for rehabilitation after spinal cord injury. The most useful evaluation of the tetraplegic patient involves the creation of a working list of what the patient *has* (grade 4 strength or higher) and what the patient *needs* (grade 1 strength or lower). The surgeon must determine which muscles are available for transfer and which muscles best match the patient's needs. The success of tendon transfer depends on a working understanding of the principles of work capacity, amplitude, and direction of pull. Reconstruction combines tendon transfers with appropriate combinations of arthrodesis and tenodesis. Assessment of outcomes for tetraplegic upper extremity reconstruction continues to improve and allows the comparison of interventions.[1,8,36,37,57,70,85,88,91]

For Case Studies, Videos, and more, please visit ExpertConsult.com.

REFERENCES

1. Ainsley J, Voorhees C: Reconstructive hand surgery for quadriplegic persons. *Am J Occup Ther* 39:715–721, 1985.
2. Allieu Y: *Rehabilitation chirurgicale de membre superieur du tetraplegique*, Cahiers, SOFCOT, 1988.
3. Allieu Y, Coulet B, Chammas M: Functional surgery of the upper limb in high level tetraplegia. *Tech Hand Up Extrem Surg* 4:50–68, 2000.
4. Bertelli JA, Ghizoni MF: Single stage surgery combing nerve and tendon transfers for bilateral upper limb reconstruction in tetraplegic patient: case report. *J Hand Surg [Am]* 38:1366–1369, 2013.
5. Bertelli JA, Ghizoni MF, Tacca CP: Transfer of the teres minor motor branch for triceps reinnervation in tetraplegia. *J Neurosurg* 114(5):1457–1460, 2011.
6. Betz RR: Upper extremity management. In Betz RR, Mulcahey MJ, editors: *The child with a spinal cord injury: symposium: Phoenix, Arizona, December 8–11, 1994*, Rosemont, IL, 1996, American Academy of Orthopaedic Surgeons, pp 373–458.
7. Biering-Sorensen F, Gregersen H: [Improved function of the hand in persons with tetraplegia using electric stimulation via implanted electrodes]. *Ugeskr Laeger* 162:2195–2198, 2000.
8. Bottero L, Houssin B: [Isokinetic dynamometric evaluation of rehabilitation results of elbow extension in tetraplegic patients]. *Ann Chir Plast Esthet* 45:419–424, 2000.
9. Brand PW: *Clinical mechanics of the hand*, St Louis, 1985, CV Mosby.
10. Brown SH, Hentzen ER, Kwan A, et al: Mechanical strength of the side to side versus Pulvertaft weave tendon repair. *J Hand Surg [Am]* 35(4):540–545, 2010.
11. Brummer H: The winch operation: the Second International Conference on Surgical Rehabilitation in Tetraplegia, Giens, France. *J Hand Surg [Am]* 9:608–611, 1984.
12. Bryden AM, Memberg WD: Electronically stimulated elbow extension in persons with C5/C6 tetraplegia: a functional and physiological evaluation. *Arch Phys Med Rehabil* 81:80–88, 2000.
13. Brys D, Waters RL: Effect of triceps function on the brachioradialis transfer in quadriplegia. *J Hand Surg [Am]* 12:237–239, 1987.
14. Bunnell S: *Surgery of the hand*, Philadelphia, 1944, JB Lippincott.
15. Castro-Sierra A, Lopez-Pita A: A new surgical technique to correct triceps paralysis. *Hand* 15:42–46, 1983.
16. Coulet B, Allieu Y, Chammas M: Injured metamere and functional surgery of the tetraplegic upper limb. *Hand Clin* 18:399–412, 2002.
17. Council of Medical Research: *Aids to the investigation of peripheral nerve injuries*, 2nd rev ed, London, 1943, His Majesty's Stationery Office.
18. Crago PE, Memberg WD: An elbow extension neuroprosthesis for individuals with tetraplegia. *IEEE Trans Neural Syst Rehabil Eng* 6:1–6, 1998.
19. Curtis RM: Tendon transfers in the patient with spinal cord injury. *Orthop Clin North Am* 5:415–423, 1974.
20. Davis SE, Mulcahey MJ: Outcomes of upper-extremity tendon transfers and functional electrical stimulation in an adolescent with C5 tetraplegia. *Am J Occup Ther* 51:307–312, 1997.
21. Davis SE, Mulcahey MJ: Self-reported use of an implanted FES hand system by adolescents with tetraplegia. *J Spinal Cord Med* 21:220–226, 1998.
22. Davis SE, Mulcahey MJ: Outcome of functional electrical stimulation in the rehabilitation of a child with C5 tetraplegia. *J Spinal Cord Med* 22:107–113, 1999.
23. DeBeneditti M: Restoration of elbow extension power in the tetraplegic patient using the Moberg technique. *J Hand Surg [Am]* 4:86–89, 1979.
24. Ditunno JEJ, Stover S, Freed M: Motor recovery of the upper extremities in the traumatic quadriplegia: a multicenter study. *Arch Phys Med Rehabil* 73:431–436, 1992.
25. Dunkerley AL, Ashburn A, Stack EL: Deltoid triceps transfer and functional independence of people with tetraplegia. *Spinal Cord* 38:435–441, 2000.
26. Ejeskar A: Upper limb surgical rehabilitation in high level tetraplegia. *Hand Clin* 4:585–599, 1988.
27. Ejeskar A, Dahllof A: Results of reconstructive surgery in the upper limb of tetraplegic patients. *Paraplegia* 26:204–208, 1988.
28. Freehafer AA, Mast WA: Transfer of brachioradialis to improve wrist extension in high spinal-cord injury. *J Bone Joint Surg Am* 49:648–652, 1967.
29. Freehafer AA, Vonhaam E, Allen V: Tendon transfer to improve grasp after injuries of the cervical spinal cord. *J Bone Joint Surg Am* 56:951–959, 1974.
30. Friden J, Ejeskar A, Dahlgren A: Protection of the deltoid to triceps tendon transfer repair. *J Hand Surg [Am]* 25:144–149, 2000.
31. Fridén J, Gohritz A: Brachialis-to-extensor carpi radialis longus selective nerve transfer to restore wrist extension in tetraplegia: case report. *J Hand Surg [Am]* 37(8):1606–1608, 2012.
32. Friden J, Reinholdt C: Current concepts in reconstruction of hand function in tetraplegia. *Scand J Surg* 97(4):341–346, 2008.
33. Friden J, Reinholdt C, Turcsanyii I, et al: A single-stage operation for reconstruction of hand flexion, extension, and intrinsic function in tetraplegia: the alphabet procedure. *Tech Hand Up Extrem Surg* 15(4):230–235, 2011.
34. Friedenberg ZB: Transposition of the biceps brachii for triceps weakness. *J Bone Joint Surg Am* 36:656–658, 1954.
35. Gresham G, Labi M, Dittmar R, et al: The Quadriplegia Index of Function (QIF): sensitivity and reliability demonstrated in a study of thirty quadriplegic patients. *Paraplegia* 24:38–44, 1986.
36. Harvey L, Crosbie J: Effects of elbow flexion contractures on the ability of people with C5 and C6 tetraplegia to lift. *Physiother Res Int* 6:76–82, 2001.
37. Hentz VR, Brown M, Keoshian LA: Upper limb reconstruction in quadriplegia: functional assessment and proposed treatment modifications. *J Hand Surg [Am]* 8:119–131, 1983.
38. Hentz VR, House JH, McDowell CL: Rehabilitation and surgical reconstruction of the upper limb in tetraplegia: an update. *J Hand Surg [Am]* 17:964–967, 1992.
39. Hentz VR, LeClercq C: *Surgical rehabilitation of the upper limb in tetraplegia*, London, 2002, WB Saunders.
40. House JH: *Personal communication*. 2003.
41. House JH: *Personal communication*. 2009.
42. House JH, Comadoll J, Dahl AL: One stage key pinch and release with thumb carpal-metacarpal fusion in tetraplegia. *J Hand Surg [Am]* 17:530–538, 1992.

CASE STUDY 33.1 Upper Extremity Reconstruction in Persons With Tetraplegia

Kara C was a 15-year-old girl who was injured in August of 2000 as a result of diving into a 3-foot-deep pool. She was treated with a halo brace for 13 weeks and had inpatient acute rehabilitation for 5 months. In September of 2001, Kara C was admitted to the Shriners Hospital for evaluation:

- American Spine Injury Association C5-C6
- On bladder and bowel program
- Mobility by means of a power wheelchair
- Bilateral FDS spasticity

Right	Muscle	Left
5/5	Biceps and brachialis	4/5
5/5	Brachioradialis	5/5
0/5	Triceps	0/5
5/5	Supinator	5/5
1/5	Pronator	2/5
1/5	FCR	2+/5
0/5	FCU	0/5
0/5	Palmaris	0/5
4/5	ECRL	5/5
4/5	ECRB	5/5
0/5	ECU	0/5
0/5	FDP	0/5
0/5	FDS	0/5
0/5	EDC	1/5

ICSHT Classification:

- Right 3
- Left 3

Treatment, May 16, 2002, Left:

- Split FPL transfer
- BR to FPL transfer
- ECRL to FDP transfer (Video 33.1)
- Biceps to triceps (Video 33.2)
- FDS fractional lengthening

Treatment, May 22, 2003, Right:

- Split FPL transfer
- BR to FPL transfer
- Biceps to triceps
- FDS lengthening of index through small fingers

Outcome:

Oucome after treatment is shown in Videos 33.3 and 33.4.

Videos 33.5 and 33.6 show Kara C's outcome after several years.

Scott H. Kozin

43. House JH, Gwathmey F, Lundsgaard DK: Restoration of strong grasp and lateral pinch in tetraplegia due to cervical spinal cord injury. *J Hand Surg [Am]* 10:22–29, 1976.
44. House JH, Shannon MA: Restoration of strong grasp and lateral pinch in tetraplegia: a comparison of two methods of thumb control in each patient. *J Hand Surg [Am]* 10:22–29, 1985.
45. House JH, Walsh T: Two stage reconstruction of the tetraplegic hand. In Strickland JW, editor: *Master techniques in orthopaedic surgery: the hand*, Philadelphia, 1998, Lippincott Raven, pp 229–266.
46. Keith MW: Neuroprostheses for the upper extremity. *Microsurgery* 21:256–263, 2001.
47. Keith MW, Peckham HP: Functional neuromuscular stimulation neuroprostheses for the tetraplegic hand. *Clin Orthop Relat Res* 233:25–33, 1988.
48. Kilgore KL, Hoyen HA, Bryden AM, et al: An implanted upper-extremity neuroprosthesis using myoelectric control. *J Hand Surg [Am]* 33:539–550, 2008.
49. Kilgore KL, Peckham HP: Synthesis of hand grasp using functional neuromuscular stimulation. *IEEE Trans Neural Syst Rehabil Eng* 36:761–770, 1989.
50. Kozin SH, Bednar M: In vivo determination of available brachioradialis excursion during tetraplegia reconstruction. *J Hand Surg [Am]* 26:510–514, 2001.
51. Kozin SH, Schloth C: Bilateral biceps-to-triceps transfer to salvage failed bilateral deltoid-to-triceps transfer: a case report. *J Hand Surg [Am]* 27:666–669, 2002.
52. Kuz JE, Van Heest AE, House JH: Biceps-to-triceps transfer in tetraplegic patients: report of the medial routing technique and follow-up of three cases. *J Hand Surg [Am]* 24:161–172, 1999.
53. Lacey SH, Wilber RG, Peckham PH: The posterior deltoid to triceps transfer: a clinical and biomechanical assessment. *J Hand Surg [Am]* 11:542–547, 1986.
54. Lamb DW, Chan KM: Surgical reconstruction of the upper limb in traumatic tetraplegia: a review of 41 patients. *J Bone Joint Surg Am* 65:291–298, 1983.
55. Lamb DW, Landry R: The hand in quadriplegia. *Hand* 3:31–37, 1971.
56. Land N, Odding E, Duivenvoorden H, et al: Tetraplegia Hand Activity Questionnaire (THAQ): the development, assessment of arm-hand function-related activities in tetraplegic patients with a spinal cord injury. *Spinal Cord* 42:294–301, 2004.
57. Landi A, Mulcahey MJ, Caserta G, et al: Tetraplegia: update on assessment. *Hand Clin* 18:377–389, 2002.
58. LeClercq C, McDowell CL: Fourth international conference on surgical rehabilitation of the upper limb in tetraplegia. *Ann Chir Main Memb Super* 10:258–260, 1991.
59. Deleted in review.
60. Mackinnon SE, Yee A, Ray WZ: Nerve transfers for the restoration of hand function after spinal cord injury. *J Neurosurg* 117(1):176–185, 2012.
61. McCarthy CK, House JH, Van Heest A: Intrinsic balancing in reconstruction of the tetraplegic hand. *J Hand Surg [Am]* 22:596–604, 1997.
62. McDowell CL, Moberg EA, House JH: The second international conference on surgical rehabilitation of the upper limb in tetraplegia (quadriplegia). *J Hand Surg [Am]* 11:604–608, 1986.
63. McDowell CL, Moberg EA, Smith AG: International conference on surgical rehabilitation of the upper limb in tetraplegia. *J Hand Surg [Am]* 4:387–390, 1979.
64. Medical Research Council: *Aids to the investigation of peripheral nerve injuries*, rev ed 2, London, 1976, His Majesty's Stationery Office.
65. Mennen U, Boonzaier AC: An improved technique of posterior deltoid to triceps transfer in tetraplegia. *J Hand Surg [Br]* 16:197–201, 1991.
66. Moberg EA: Surgical treatment for absent single-hand grip and elbow extension in quadriplegia. *J Bone Joint Surg Am* 57:196–206, 1975.
67. Moberg EA: Upper limb surgical rehabilitation in tetraplegia. In Evarts CM, editor: *Surgery of the musculoskeletal system* (vol 1). New York, 1990, Churchill Livingstone, pp 915–941.
68. Moberg EA, Lamb DW: Surgical rehabilitation of the upper limb in tetraplegia. *Hand* 12:209–213, 1980.
69. Moberg EA, McDowell CL, House JH: Third international conference on surgical rehabilitation of the upper limb in tetraplegia (quadriplegia). *J Hand Surg [Am]* 14:1064–1066, 1989.
70. Mohammed KD, Rothwell AG, Sinclair SW, et al: Upper limb surgery for tetraplegia. *J Bone Joint Surg Br* 74:873–879, 1992.
71. Mulcahey MJ, Betz RR: Implanted functional electrical stimulation hand system in adolescents with spinal injuries: an evaluation. *Arch Phys Med Rehabil* 78:597–607, 1997.
72. Mulcahey MJ, Lutz C, Kozin SH, et al: Prospective evaluation of biceps to triceps and deltoid to triceps for elbow extension in tetraplegia. *J Hand Surg [Am]* 28(6): 964–971, 2003.
73. Mulcahey MJ, Smith BT: Functional neuromuscular stimulation: outcomes in young people with tetraplegia. *J Am Paraplegia Soc* 17:20–35, 1994.
74. National Spinal Cord Injury Statistical Center: Spinal cord injury facts and figures at a glance. *J Spinal Cord Med* 36(5):568–569, 2013.
75. Peckham HP, Keith MW: Restoration of functional control by electrical stimulation in the upper extremity of the quadriplegic patient. *J Bone Joint Surg Am* 70:144–148, 1988.
76. Peckham HP, Marsolais EB, Mortimer JT: Restoration of key grip and release in the C6 tetraplegic patient through functional electrical stimulation. *J Hand Surg [Am]* 5:462–469, 1980.
77. Rabischong E, Benoit P, Benichou M: Length-tension relationship of the posterior deltoid to triceps transfer in C6 tetraplegic patients. *Paraplegia* 31:33–39, 1993.
78. Raczka R, Braun R, Waters RL: Posterior deltoid-to-triceps transfer in quadriplegia. *Clin Orthop Relat Res* 187:163–167, 1984.
79. Reinholdt C, Friden J: Rebalancing the tetraplegic wrist using extensor carpi ulnaris tenodesis. *J Hand Surg Eur Vol* 38(1):22–28, 2012.
80. Revol M, Briand E, Servant JM: Biceps-to-triceps transfer in tetraplegia: the medial route. *J Hand Surg [Br]* 24:235–237, 1999.
81. Richards RR: *Soft tissue reconstruction in the upper extremity*, New York, 1995, Churchill Livingstone.
82. Sinnott K, Dunn J, Rothwell A: Use of the ICF conceptual framework to interpret hand function outcomes following tendon transfer surgery for tetraplegia. *Spinal Cord* 42:396–400, 2004.
83. Smith BT, Mulcahey MJ: Quantitative comparison of grasp and release abilities with and without functional neuromuscular stimulation in adolescents with tetraplegia. *Paraplegia* 34:16–23, 1996.
84. Smith RJ: *Tendon transfers of the hand and forearm*, Boston, 1987, Little Brown.
85. Sollerman C, Ejeskar A: Sollerman hand function test: a standardized method and its use in tetraplegic patients. *Scand J Plast Reconstr Surg Hand Surg* 29:167–176, 1995.
86. Street DM, Stambaugh HD: Finger flexor tenodesis. *Clin Orthop Relat Res* 13:155–163, 1959.
87. Van Heest A: Elbow extension tendon transfer. *Atlas Hand Clin* 7:97–108, 2002.
88. Vanden Berghe A, Van Laere M: Reconstruction of the upper extremity in tetraplegia: functional assessment, surgical procedures and rehabilitation. *Paraplegia* 29:103–112, 1991.
89. Waters RL, Adkins R, Yakura J: Motor and sensory recovery following complete tetraplegia. *Arch Phys Med Rehabil* 74:242–247, 1993.
90. Weiss AA, Kozin SH: Tendon transfers for lateral pinch. *Atlas Hand Clin* 7:67–77, 2002.
91. Wijman CA, Stroh KC: Functional evaluation of quadriplegic patients using a hand neuroprosthesis. *Arch Phys Med Rehabil* 71:1053–1057, 1990.
92. World Health Organization: *International classification of functioning, disability, and health*, Geneva, 2002, WHO.
93. Deleted in review.
94. Zancolli EA: Surgery for the quadriplegic hand with active strong wrist extension preserved: a study of 97 cases. *Clin Orthop Relat Res* 112:101–113, 1975.
95. Zancolli EA: Functional restoration of the upper limbs in traumatic quadriplegia. In Zancolli EA, editor: *Structural and dynamic bases of hand surgery*, ed 2, Philadelphia, 1979, JB Lippincott, pp 229–262.
96. Zancolli EA: *Structural and dynamic bases of hand surgery*, ed 2, Philadelphia, 1979, JB Lippincott.
97. Zancolli EA: Tetraplegia. In McFarlane RM, editor: *Unsatisfactory results in hand surgery: the hand and upper limb*, New York, 1987, Churchill Livingstone, pp 274–280.

34

Traumatic Brachial Plexus Injury

Robert J. Spinner, Alexander Y. Shin, Bassem T. Elhassan, and Allen T. Bishop

Acknowledgments: The authors wish to acknowledge the contributions of Professors Rod Hentz and Kazuteru Doi, who wrote an earlier rendition of this chapter on brachial plexus injury in adults, and those of Marie-Noëlle Hébert-Blouin, who assisted with the previous chapter.

In the early 19th century, well before microsurgical equipment and techniques were developed, surgeons published encouraging results of brachial plexus reconstruction.[107] Subsequently, others reported poor results and high complication rates.[25] Little else was published on reconstruction of the brachial plexus until the 1970s and 1980s, when surgeons began to apply the fascicular nerve grafting techniques described by Millesi to birth and traumatic injuries of the brachial plexus. These pioneers established indications and techniques for plexus reconstruction and reported better recovery in operated patients than in those observed without surgical reconstruction.*

In the late 1980s and early 1990s, advances occurred in diagnostic and surgical techniques. New surgical procedures and experimental nonoperative treatments were introduced. In the late 1990s, very aggressive reconstructions using extraplexal sources for reinnervation of vascularized muscle transfers were reported. In the past 10 years, the role of nerve transfers has expanded. The introduction of novel distal nerve transfers has changed the way in which brachial plexus surgery is being performed. Although full recovery of function after brachial plexus reconstruction still remains unachievable, the exciting developments of the past several years have considerably improved surgical outcomes, and future directions for research are promising.

SURGICAL ANATOMY

The brachial plexus is formed from five cervical nerves, typically C5, C6, C7, C8, and T1 (Figure 34.1), and is generally divided into five anatomic sections, nerves, trunks, divisions, cords, and terminal branches. The spinal nerves are formed by coalescence of the ventral and dorsal nerve rootlets as they pass through the spinal foramen (Figure 34.2). The dorsal root ganglion holds the cell bodies of the sensory nerves and lies within the confines of the spinal canal and foramen. Each spinal nerve sends a small dorsal ramus to the paraspinal musculature. The remaining large ventral rami of the lower four cervical (C5-C8) and T1 spinal nerves emerge from the foramina as the first section of the brachial plexus.

The C5 and C6 and the C8 and T1 nerves merge and form the upper and lower trunks, respectively. C7 continues distally as the middle trunk, with no clear demarcation point for this change in nomenclature. The point of convergence of the C5 and C6 nerves, known as the Erb point, marks the spot at which the suprascapular nerve emerges. Nerves and trunks are located above the clavicle and collectively form the *supraclavicular plexus*. Each trunk then divides beneath (dorsal to) the clavicle into anterior and posterior divisions (the *retroclavicular plexus*). The posterior divisions from all trunks merge to become the posterior cord, and the anterior divisions of the upper and middle trunks merge to form the lateral cord. The anterior division from the lower trunk continues distal to the clavicle as the medial cord. The lateral cord splits into two terminal branches, the musculocutaneous nerve and the lateral cord contribution to the median nerve. The posterior cord forms the axillary nerve and the radial nerve, and the medial cord gives off the medial cord contribution to the median nerve, as well as the ulnar nerve. The cords and terminal branches arising from them collectively make up the *infraclavicular plexus*.

Additional branches of clinical importance at the proximal nerve level include a C5 contribution to the phrenic nerve, the dorsal scapular nerve (C5), and formation of the long thoracic nerve from C5, C6, and C7. The only trunk branches are the suprascapular nerve and the nerve to the subclavius muscle, both from the upper trunk. There are no muscular branches from the retroclavicular plexus. The lateral pectoral nerve arises at the division level in the retroclavicular plexus. Infraclavicularly, the posterior cord gives off the lateral pectoral nerve. The posterior cord gives off branches (proximal to distal) that include the upper subscapular nerve, the thoracodorsal nerve, and the lower subscapular nerve. The medial cord gives off the medial pectoral nerve, the medial antebrachial cutaneous nerve, and the medial brachial cutaneous nerve.

CLASSIFICATION OF NERVE INJURIES

Nerve injuries are generally classified according to the Seddon[178] and Sunderland[196] classifications. Both classifications overlap; Seddon classified nerve injuries into three different categories: neurapraxia, axonotmesis, and neurotmesis; Sunderland expanded Seddon's axonotmetic category, for a total of five degrees of nerve injury: first-degree (neurapraxia), second- to fourth-degree (axonotmesis), and fifth-degree (neurotmesis) injuries. Basic knowledge of the different degrees of nerve injury is necessary to understand the need for observation in some patients and for surgical intervention in others.

*See references 4, 32, 83, 98, 140, 141, 157, 158, 179, and 204.

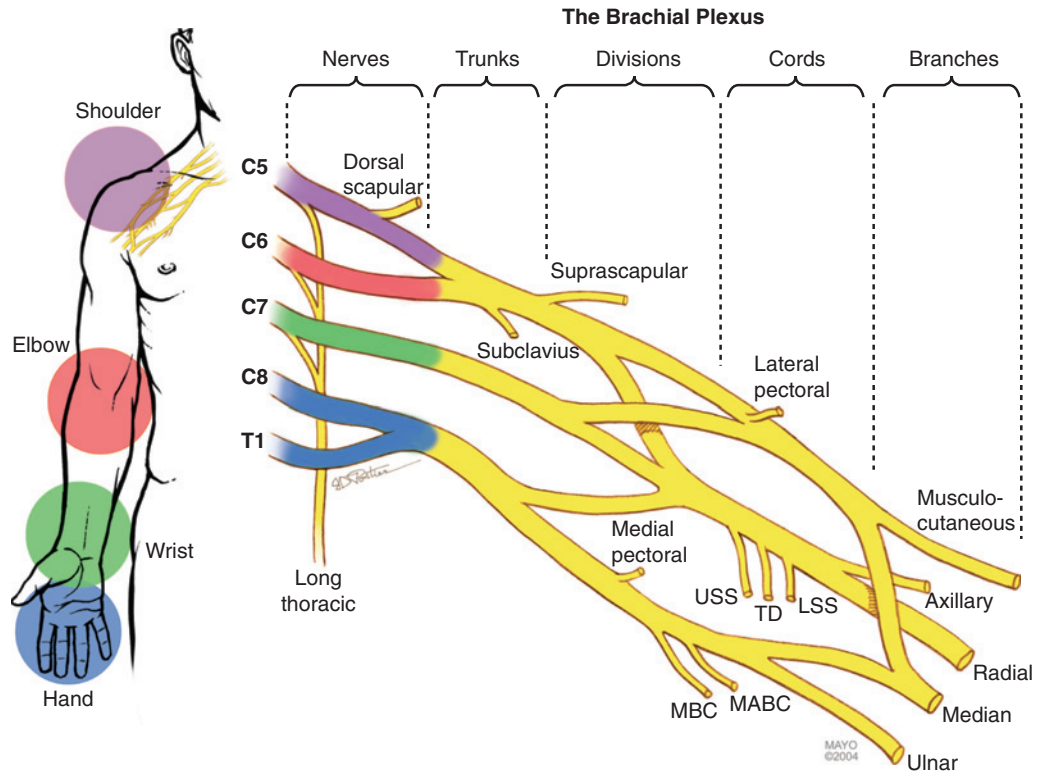

FIGURE 34.1 Anatomy of the brachial plexus. Localization of brachial plexus lesions is dependent on detailed understanding of brachial plexus anatomy. This illustration is reviewed with patients at the time of their initial evaluation. *LSS*, Lower subscapular nerve; *MABC*, medial antebrachial cutaneous nerve; *MBC*, medial brachial cutaneous nerve; *TD*, thoracodorsal nerve; *USS*, upper subscapular nerve. (By permission of Mayo Foundation for Medical Education and Research. All rights reserved.)

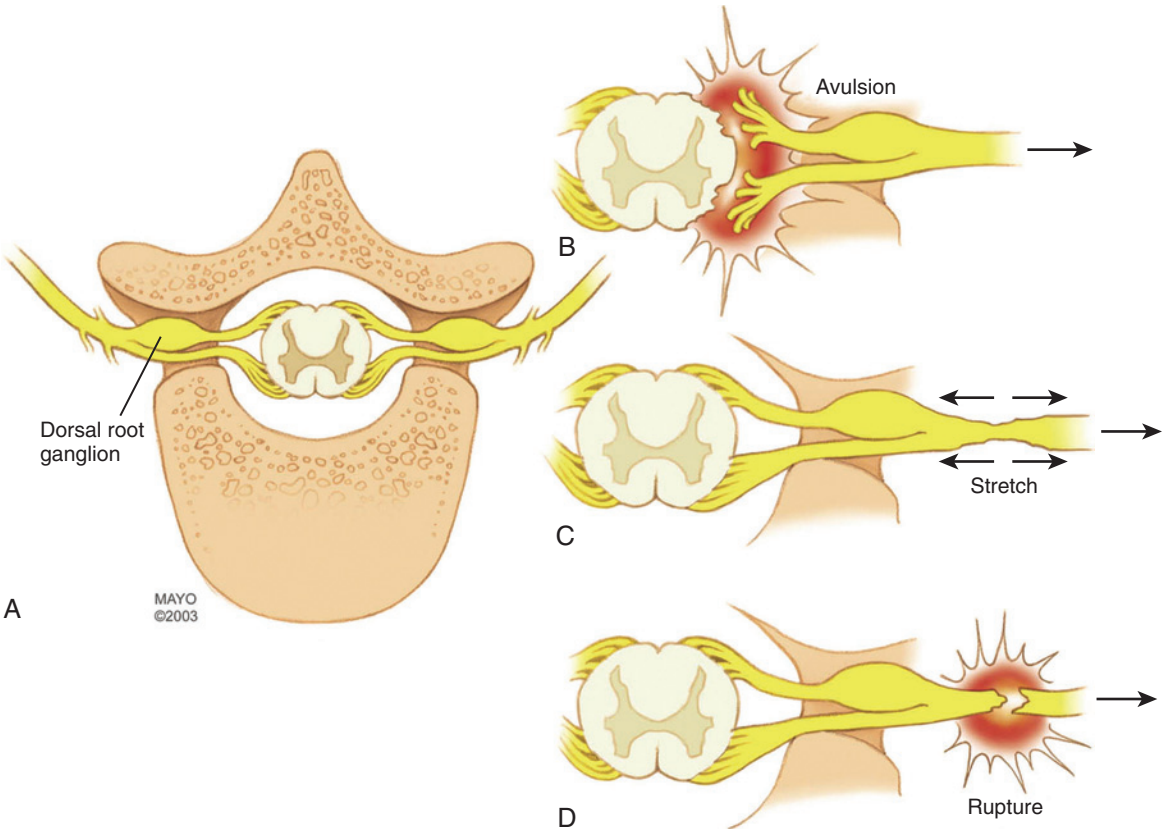

FIGURE 34.2 **A** to **D,** Traction injury to the brachial plexus may cause nerve injuries of varying severity in the same patient. Such injuries include avulsion (preganglionic injury) of nerve roots from the spinal cord (for practical purposes, cannot be repaired), stretch (postganglionic injury) of different magnitudes (sometimes spontaneous recovery possible), and extraforaminal rupture of the nerve or trunk (can be repaired with surgery). (By permission of Mayo Foundation for Medical Education and Research. All rights reserved.)

In neurapraxia (first-degree injury), there is a focal conduction block at the site of injury. Wallerian degeneration does not occur, and as the conduction block resolves, neurologic function returns. These injuries do not require surgical intervention, and recovery occurs within hours to weeks. In axonotmesis (second- to fourth-degree injury), the axons are disrupted and wallerian degeneration occurs distal to the injury. However, the nerve remains in gross continuity. Stretch injury is the most common mechanism. Depending on the severity of the injury, regeneration may occur (at a rate of 1 mm/day or 1 inch/month) or not. To better describe axonotmetic lesions, Sunderland further classified them into second-degree injury (axon disrupted, but intact endoneurium, perineurium, and epineurium), third-degree injury (axon and endoneurium disrupted, but intact perineurium and epineurium), and fourth-degree injury (axon, endoneurium, and perineurium disrupted, but intact epineurium). In second-degree injury, regeneration and neurologic recovery are expected but will require several months or even years. In very proximal injuries with distal targets (such as the proximal ulnar nerve or lower trunk lesions), muscle atrophy or motor end-plate degeneration may occur before regeneration is completed and prevent functional recovery. In third- and fourth-degree injury, regeneration may occur to a variable degree or may not occur at all, and these lesions may require surgical intervention. Finally, in neurotmesis (fifth-degree injury), the nerve is completely disrupted and there is no continuity. These lesions cannot spontaneously recover and surgical intervention is necessary. In brachial plexus injuries, neurotmetic lesions include postganglionic ruptures and preganglionic avulsions.

MECHANISMS OF TRAUMATIC BRACHIAL PLEXUS INJURY

Traction Injury

Most traumatic injuries of the brachial plexus are due to traction or stretch injury.[50,108] These brachial plexus injuries are caused by varying amounts of energy imparted to the plexus that may result in different injuries ranging from mild stretch to rupture or avulsion (see Figure 34.2).[117] Low-energy traction trauma, not severe enough to cause rupture or avulsion, typically causes injuries with a potential for spontaneous regeneration, such as neurapraxia (Sunderland type I) or lower degrees of axonotmesis (Sunderland types II and III). Experimental evidence also suggests that low-energy injuries may interfere with brachial plexus microcirculation and cause ischemic injury.[109] High-energy injuries are associated with more significant damage to the plexus that may include rupture of plexal elements (Sunderland type V) or avulsion of nerve roots from the spinal cord. When a combination of incomplete rupture and avulsions occurs, some spontaneous recovery may take place, but early microneurosurgical reconstruction generally improves the functional outcome. If the shoulder-neck angle is forcibly widened by downward traction on the arm, damage is imparted first to the upper nerves (C5 and C6)/upper trunk and/or C7/middle trunk (Figure 34.3); if the scapulohumeral angle is forcibly widened, damage is imparted first to the lower nerves (C8 and T1) and the lower trunk. If the impact is extreme, all levels can sustain damage.[50] Anatomic studies have determined that the supporting tissue anchoring the upper nerves (C5 and C6)

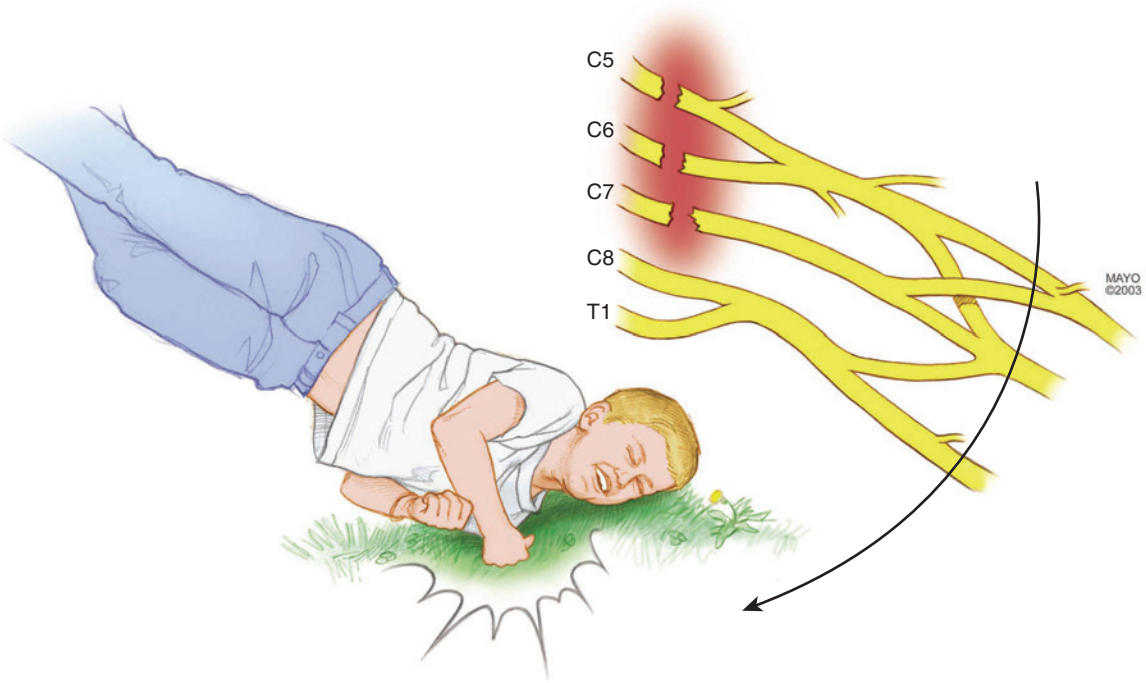

FIGURE 34.3 Patterns of injury can often be predicted. Upper brachial plexus injuries occur when the shoulder is forced downward and the head is forced to the opposite side. (By permission of Mayo Foundation for Medical Education and Research. All rights reserved.)

to the vertebral foramina is significantly stronger than the supporting tissue of the lower nerves (C8 and T1). This anatomic arrangement predicts that the more caudal structures of the brachial plexus (i.e., the C8-T1 nerves) are more likely to be avulsed from the spinal cord,[98] whereas the more cranial structures of the brachial plexus are more likely to stretch or rupture after exiting the neural foramina (i.e., the C5-C6 nerves). In approximately two thirds of traction injuries involving the brachial plexus, the injury is located in the supraclavicular region; in the other third, the injury is retroclavicular or infraclavicular and involves the divisions, cords, or terminal nerves.[108] In some patients, a double-level (supraclavicular and infraclavicular) injury can occur and should be considered. The principal factors determining the extent of injury are the energy imparted by the blow and, to a lesser degree, the direction and the relationship of the arm to the neck during the injury.

An individual patient may have different degrees of injury at different nerve levels; for example, the C8 and T1 roots may be avulsed, the C7 nerve or middle trunk may be ruptured (Sunderland type V), and the upper trunk may remain intact but with varying degrees of internal damage (Sunderland types I to IV). Within an individual brachial plexus element, individual axons and fascicles may also suffer various degree of injury. This variability in the degree of injury affecting each plexal element explains why spontaneous recovery may occur in some plexal elements but not in others. Extensive longitudinal injury is also common and at times results in injury to the retroclavicular and infraclavicular plexus (divisions and cords or terminal branches, respectively), as well as the roots, nerves, and trunks cephalad to the clavicle.

The same high-energy traction injury that damages the brachial plexus may also cause other injuries. Approximately 75% of traumatic brachial plexus injuries are associated with head injury, thoracic trauma, and fractures or dislocations (or both) of the cervical spine or ipsilateral upper extremity; 20% of patients have associated vascular trauma.[207] These associated injuries, such as fractures, dislocations, and vascular injuries (from either an associated hematoma, pseudoaneurysm, or arteriovenous fistula), can further damage the brachial plexus.

Gunshot Injury

Most commonly, the plexal elements are in continuity following a gunshot injury, but in a small proportion of patients, some elements may be transected. The injury will depend on the caliber, velocity, and angle of incidence of the missile. Low-velocity missiles usually damage nerve elements by direct impact; high-velocity missiles can injure nerves by direct impact (which transects the nerves) or, more commonly, by shock wave and cavitation effects (which contuse or stretch the nerves).[108] Because the injury is often in continuity, some patients will have spontaneous recovery. Others do not recover, however, and will require surgical exploration; high-velocity injuries are more likely to cause extensive damage and to fail to recover spontaneously. Gunshot wounds may cause associated vascular injuries that may require emergency or delayed repair; the latter may occur over time as a result of the formation of a pseudoaneurysm, which can compress the plexus, produce progressive loss of function, and require an intervention on the vessel(s) or nerves, or both.

Penetrating Trauma

The brachial plexus is occasionally injured by sharp (caused by knives or glass) or blunt (caused by fan and motor blades, chainsaws, or animal bites) penetrating trauma.[108] Iatrogenic injuries have also been reported from various surgical procedures. As expected, most patients have brachial plexus elements in discontinuity (i.e., transected); however, despite the mechanism of injury, some patients have a lesion with a degree of continuity. Because of the high suspicion of transection of one or more nerves, these patients require nerve exploration. A third of these patients require vascular surgery, which is often performed concomitantly.[108] In these patients, as in patients with gunshot wounds or traction injuries, an associated hematoma, pseudoaneurysm, or arteriovenous fistula may compress the plexus and require intervention because of progressive neurologic deterioration.

COMMON PATTERNS OF BRACHIAL PLEXUS INJURY

In brachial plexus injuries, any combination of stretch, rupture, and avulsion can occur. However, certain patterns are more frequent, such as supraclavicular injuries (upper brachial plexus, including the nerves and trunks, often described by the pattern of root involvement; i.e., C5-C6, C5-C7, C8-T1, or pan-plexus), retroclavicular injuries (divisions), and infraclavicular injuries (cords and terminal branches).

C5-C6 Injury

Approximately 15% of patients[108] have injury to the C5 and C6 nerves or to the junction where they form the upper trunk (Erb point). These patients have deficits in shoulder stability, abduction, and external and internal rotation (supraspinatus and infraspinatus, deltoid, subscapularis), as well as in elbow flexion (biceps, brachialis, and brachioradialis) and forearm supination (biceps, supinator). Sensory deficit will be present in the C5 and C6 distributions. Elbow extension is normal, as is wrist and hand function. This pattern of injury is commonly referred to eponymously as Erb or Erb-Duchenne palsy in recognition of the early work of Wilhelm Heinrich Erb and Guillaume Duchenne on peripheral nerve injury.

C5-C7 Injury

In approximately 20% to 35% of patients,[108] weakness of muscles innervated by C5 and C6, as described earlier, will be accompanied by a partial or complete C7 or middle trunk injury. In these patients, there will be variable weakness of the elbow, wrist, and sometimes finger extensors. The C7 contribution to wrist and finger extension and even to the flexor digitorum profundus muscles varies between patients and leads to different degrees of weakness. Sensory disturbances in the proximal part of the arm, as well in the thumb and index and middle fingers, may be present. This at times is referred to as an Erb-plus pattern.

C8-T1 Injury

Approximately 10% of patients[108] (even less in our experience) have supraclavicular lesions isolated to the C8 and T1 nerves. These patients will have weakness of the hand intrinsics, as well

as variable weakness of the hand extrinsics and finger extensors, depending on the C7 contribution to these territories. Sensory loss in the ulnar digits, medial aspect of the forearm, and distal part of the arm may be present. Involvement of the lower roots can result in Horner syndrome, which is noted on examination by meiosis (constricted pupil), ptosis of the upper eyelid, anhidrosis, and enophthalmos (see the section Physical Examination). This rare pattern of injury is often referred to as Klumpke or Dejerine-Klumpke palsy.

Pan-Plexus (C5-T1) Injury

Traumatic injury to the entire brachial plexus (C5-T1) occurs in 50% to 75% of patients with supraclavicular brachial plexus injuries.[108] These patients most commonly have a completely flail arm and insensate hand. Occasionally, certain elements may be partially injured. Even with complete pan-plexus injuries, postganglionic injury (particularly of C5) is often present, with preganglionic lesions affecting other nerves.

Infraclavicular and Terminal Branch Injury

Retroclavicular or infraclavicular brachial plexus injuries may involve injuries at the division or cord level. Clavicular fracture is often present in these cases. A few patterns are more commonly seen, including injuries to the posterior cord (radial and axillary nerve distributions), as well as isolated axillary or suprascapular nerve injuries.

PREOPERATIVE EVALUATION

A comprehensive preoperative evaluation that includes a detailed history, physical examination, imaging, and electrodiagnostic evaluation is essential to determine the location and severity of the brachial plexus injury and appropriate management. The goal is first to determine whether there is potential for spontaneous and functionally significant recovery, which warrants further observation. If no recovery is seen within the first 2 to 3 months, surgery is indicated. In cases in which surgery is indicated, determining whether the injury is preganglionic or postganglionic will also help in planning the surgical approach and possible reconstructive options. In preganglionic injuries, the nerve root is nonfunctional (avulsed from the spinal cord) and, for practical purposes, cannot be repaired or grafted. The presence of a preganglionic injury at one or more levels indicates a more severe injury with a lower probability of spontaneous recovery; thus, earlier surgical intervention may be warranted. No single finding or evaluation can tell the surgeon whether the injured plexus requires a surgical intervention. All the information must be analyzed and each patient requires an individualized approach.

Patients at our institution are evaluated in a multidisciplinary clinic, first by a neurologist and then by a team of surgeons skilled in primary and secondary reconstruction. A physiatrist and physical/occupational therapist are also involved in the care of each patient. They teach and emphasize the importance and timing of passive and active range-of-motion exercises before and after any operation. Decisions regarding management are discussed and planned collectively. We believe that this type of team approach best addresses the short- and long-term needs of these patients with complex injuries.

History

A good history of the injury mechanism is helpful in determining its severity. High-energy traction injuries, such as motor vehicle or motorcycle injuries, will probably be more severe, with less potential for spontaneous recovery, than low-energy traction injuries, such as falls. Still, some falls, especially those associated with musculoskeletal injuries, may result in severe nerve lesions that do not recover spontaneously. Nerve deficits from lacerations, either sharp or blunt, will not recover spontaneously (except in the rare case in which the nerve elements were not transected) and should be explored acutely or subacutely (see the section on Timing of Surgery). On the contrary, the majority of gunshot wounds associated with brachial plexus injury should be observed because most lesions are in continuity and have the potential for spontaneous recovery.

When a patient with brachial plexus injury is evaluated acutely in the emergency room; the airway, breathing, and circulation should be evaluated and stabilized; and the standard trauma evaluation guidelines should be followed. If the patient sustained high-energy trauma, a thorough search for associated life- and limb-threatening injuries should be conducted. In patients with head or spinal cord injuries,[88] brachial plexus injury is often underdiagnosed; the opposite may also occur if the surgeon focuses on the upper extremity and fails to diagnose an associated head or incomplete spinal cord injury. Every patient should therefore be asked about loss of consciousness and paresthesias or weakness affecting the other extremities.

The presence of associated injuries (especially vascular injury, ipsilateral upper extremity musculoskeletal injury, scapulothoracic dissociation, rib fractures, pneumothorax and hemothorax, lung contusion, spine fracture and spinal cord injury, and traumatic brain injury) should be considered and documented. Associated injuries may indicate a more severe injury with less potential for spontaneous recovery and may influence the available reconstructive options. Severe pain in an anesthetic extremity may be due to deafferentation, as seen in patients with root avulsion injuries. When evaluated weeks to months after the injury, the patient should be questioned about any improvement in function or pain since the injury.

Physical Examination

The examination of patients with brachial plexus injury must be carried out in a standardized and detailed manner. The objective is to establish the location of the nerve injury (preganglionic [i.e., root] or postganglionic [i.e., nerve, trunk, division, cord, or branches]) and the severity of the lesion (i.e., partial or complete for each element of the brachial plexus) (see Figures 34.1 and 34.2). Careful systematic motor and sensory examination of the entire limb should be performed and recorded (Figure 34.4). Serial examinations over the first few months after injury may help determine the presence or absence of ongoing nerve regeneration and the prognosis for functional recovery.

The motor and sensory innervation of the upper extremity is well known and assists the surgeon in predicting the location of nerve lesions. Terminal branches can be assessed by examination of the fingers and wrist (median, ulnar, and radial nerves), elbow (musculocutaneous and high radial nerves), and shoulder (suprascapular or axillary nerves). Involvement of the

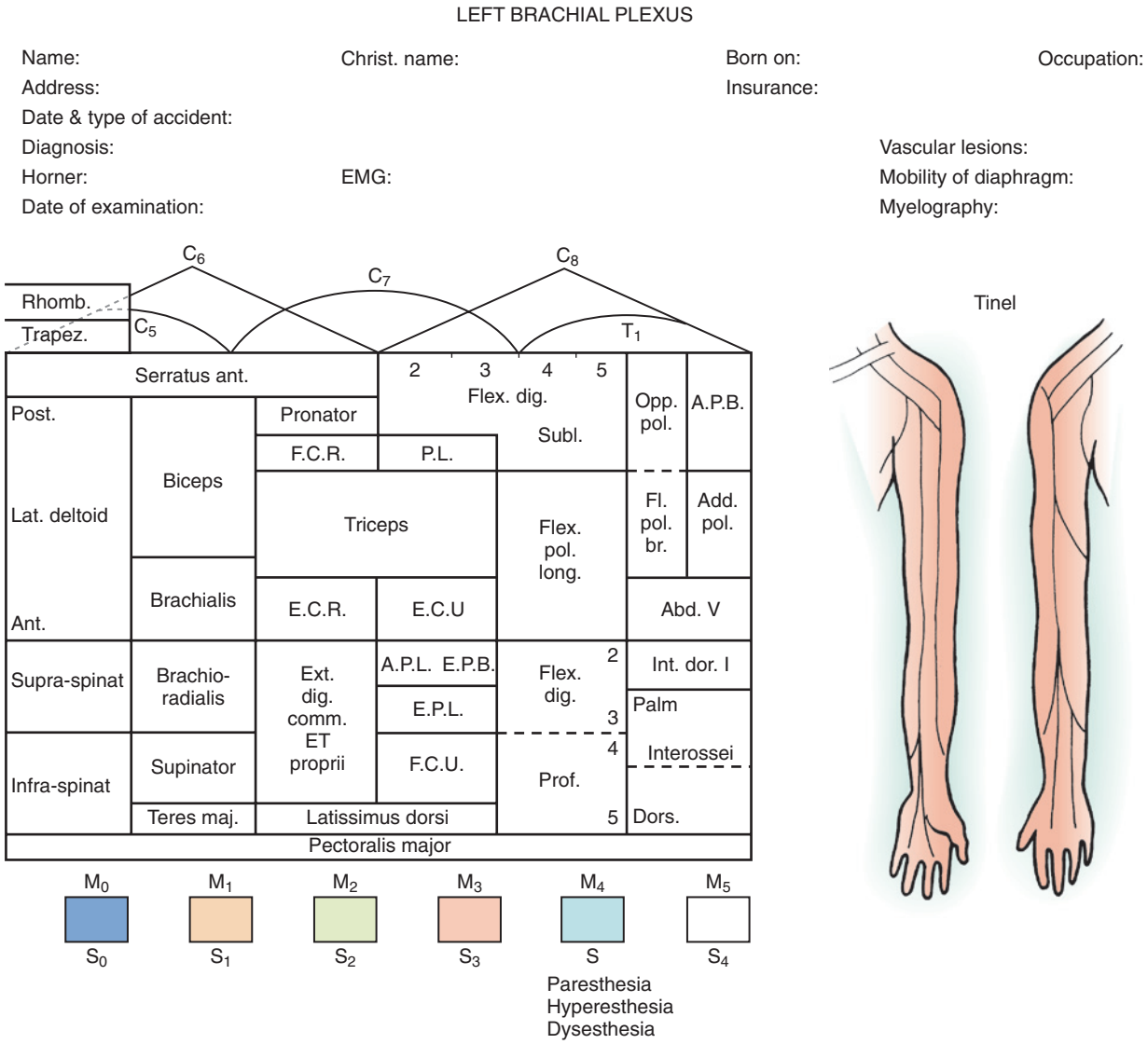

FIGURE 34.4 Motor and sensory findings must be accurately documented preoperatively and postoperatively. Most brachial plexus surgeons use some variation of this format introduced by Merle d'Aubigne to record the data.

latissimus dorsi (thoracodorsal nerve), sternal head of the pectoralis major (medial pectoral nerve), and clavicular head of the pectoralis major (lateral pectoral nerve) implies a lesion at least at the posterior, medial, and lateral cord levels, respectively. Involvement of the suprascapular nerve (supraspinatus and infraspinatus for shoulder abduction and external rotation, respectively) indicates a lesion at this terminal branch or at the upper trunk level. Finally, loss of function of the rhomboid (dorsal scapular nerve derived from C5) and serratus anterior (long thoracic nerve from C5 to C7) is an important indicator of a proximal lesion or preganglionic injury.

There is some variability in plexus anatomy and root contribution to individual muscle innervation. For example, a prefixed plexus receives significant innervation from the C4 nerve and a postfixed plexus receives innervation from the T2 nerve; these variations are reported commonly by anatomists.[134] The dorsal scapular nerve may on occasion receive innervation from the C4 nerve root, such that rhomboid activity may be identified by electrical studies in the presence of a C5 avulsion injury. Unusual motor and sensory impairment that is not distributed in the proper territory of the cervical and peripheral nerves may indicate incomplete nerve injury and some recovery.

Certain findings on physical examination suggest preganglionic injury of the brachial plexus; if present, these findings imply a lower probability of spontaneous recovery and a higher probability of finding an avulsed root at exploration. As stated earlier, injury to the rhomboid and serratus anterior indicates a proximal nerve injury and suggests a preganglionic injury of the upper neural elements, whereas the presence of Horner syndrome (Figure 34.5) on the affected side strongly correlates with avulsion of the lower elements (i.e., the C8 or T1 roots, or both).[98] Because the T1 sympathetic ganglion is close to the T1 root, an avulsion injury may interrupt sympathetic outflow and be manifested as Horner syndrome. Absence of a Tinel sign or of tenderness to percussion in the neck also suggests a preganglionic injury. Finally, muscular atrophy of the paraspinal muscles, which is associated with root avulsion, may be associated with shifting of the head away from the injured side.

Physical examination findings suggesting a postganglionic or more distal injury include the presence of tenderness to percussion in the supraclavicular or infraclavicular region, absence of sweating in the distribution of the injured nerve (sympathetic interruption), and minimal preservation of movement (partial injury). An advancing Tinel sign is suggestive of a recovering lesion.

The examination should also include testing of the distal spinal accessory nerve (cranial nerve XI), which supplies the trapezius muscle. It is frequently used for reconstruction options as a nerve transfer but can occasionally be injured concomitantly at the time of traumatic brachial plexus injury. In all patients, stability and active and passive range of motion of the joints should be assessed preoperatively. To rule out a concomitant spinal cord injury, a lower extremity neurologic examination (that includes reflexes) should be performed. The vascular system of the affected upper extremity should be assessed by palpation or Doppler examination of distal vascular flow, as well as for thrills or bruits in the infraclavicular and supraclavicular fossae.

Imaging Evaluation

Radiographs of the cervical spine, chest, shoulder girdle, and humerus should be obtained in patients with high-energy traumatic brachial plexus palsy to rule out associated upper limb fractures and dislocations. Chest radiographs should include anteroposterior inspiration and expiration views and should be examined for the presence of rib fractures and for activity of the diaphragm. A paralyzed (i.e., elevated) diaphragm indicates a proximal (probably preganglionic) brachial plexus injury because it is supplied by the phrenic nerve, which originates from the proximal C3-C5 nerves. The presence of cervical transverse process fractures is also associated with brachial plexus avulsion injuries. First or second rib fractures are associated with brachial plexus injuries. Rib fractures may be important if the intercostal nerves are to be considered for nerve transfers (≈10% of the intercostal nerves will be damaged by rib fractures in our experience).



FIGURE 34.5 The presence of Horner syndrome (i.e., ptosis, miosis, anhidrosis, and enophthalmos caused by paralysis of the sympathetic nerves), as seen in the left eye, is associated with avulsion of the C8 and T1 nerve roots. (By permission of Mayo Foundation for Medical Education and Research. All rights reserved.)

Myelography[152] and computed tomographic (CT) myelography,[150,202] although invasive, have been considered the most reliable methods for detecting root avulsions (Figure 34.6). Myelographic findings have been classified by Nagano and colleagues' modified scheme[152] into six categories, from normal roots, to ventral or dorsal root avulsions (or both), to the presence of traumatic pseudomeningoceles. Myelography or CT myelography is typically performed at least 3 to 4 weeks after the injury; such a delay will allow a potential blood clot in the area of the root avulsion to dissolve and the pseudomeningocele to form and be visualized on imaging.

More recently, magnetic resonance imaging (MRI) has been used increasingly[41,155] to evaluate patients with traumatic brachial plexus injury; in some centers it has supplanted CT myelography. MRI can reveal traumatic pseudomeningoceles, large neuromas, rootlet abnormalities, associated inflammation and edema, and mass lesions. Newer techniques have improved the detection of nerve root avulsions by MRI.[7,65]

Finally, the vasculature to the injured upper extremity should be assessed, especially when a functioning free muscle transfer (FFMT) is being considered. In the authors' experience, a normal peripheral pulse on examination does not preclude a vascular injury affecting the major vessels. We generally evaluate the vasculature with magnetic resonance angiography; special attention is given to our preferred source of arterial

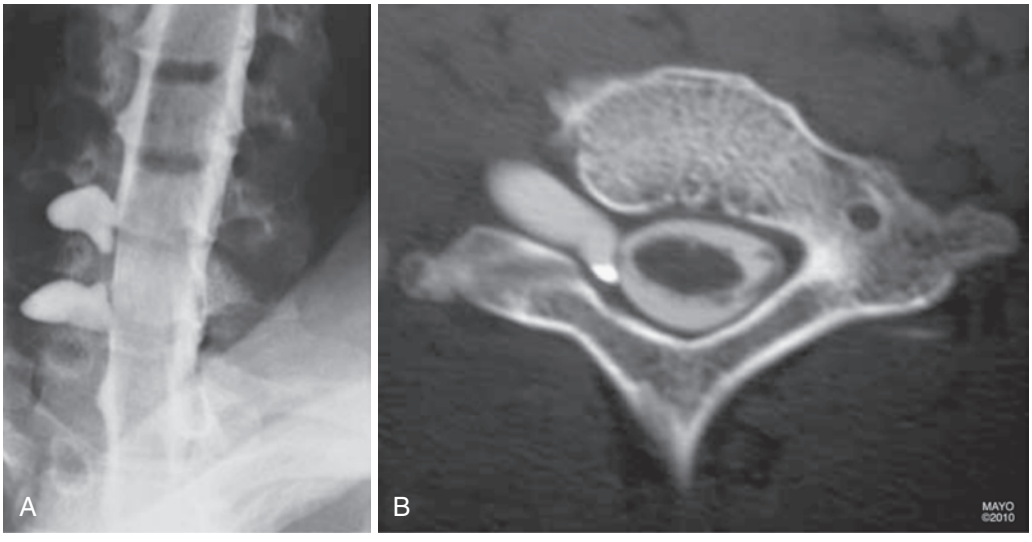

FIGURE 34.6 Myelography shows two right-sided cervical pseudomeningoceles **(A)**, one of which is seen on the axial computed tomographic myelogram **(B)**. The left side is normal. (By permission of Mayo Foundation for Medical Education and Research. All rights reserved.)

supply for FFMT, the thoracoacromial trunk. Other adequate options to formally evaluate the vasculature include CT angiography and conventional angiography.

Pulmonary Function Tests

Patients with a history of chest wall trauma (e.g., rib fractures, pneumothorax, hemothorax) and those found to have phrenic nerve dysfunction should have pulmonary function tests performed to better characterize their pulmonary function. These evaluations, with assessment by a pulmonologist if necessary, will help determine whether the patient will tolerate intercostal nerve transfers. Unless the preoperative pulmonary function test results are very low (i.e., <40% of expected, but no definitive criteria exist), a patient can generally tolerate up to four or five intercostal nerve transfers even if concomitant phrenic nerve dysfunction is present.

Electrodiagnostic Evaluation

Electrodiagnostic studies are an integral component of the evaluation of traumatic brachial plexus injury. These studies can confirm the diagnosis, localize and characterize (i.e., partial vs. complete) the nerve lesion, and assess for subclinical evidence of recovery. A baseline examination should be done 3 to 4 weeks after the traumatic injury, when wallerian degeneration has occurred, to ensure that the electrodiagnostic study reflects the degree of nerve injury. Serial electrodiagnostic studies complement the physical examination when assessing for recovery and reinnervation. The electrodiagnostic evaluation should include electromyography (EMG) and nerve conduction studies (NCSs). EMG evaluates and records the electrical activity of muscles both at rest and with activity. Changes reflective of a denervation injury include the presence of fibrillation potentials at rest and absent (complete injury) or reduced (partial injury) motor unit potentials with voluntary effort. Over time, nascent motor unit potentials (low in amplitude, polyphasic in configuration, and of variable duration) may appear and suggest reinnervation. Several muscles, difficult to test clinically, can be evaluated by EMG to help localize the lesion. For example, the rhomboids, serratus anterior, and cervical paraspinal muscles, if affected and abnormal on EMG, may suggest a very proximal or preganglionic injury. The trapezius muscle should be evaluated, especially if the spinal accessory nerve is being considered as a potential donor for nerve transfer. NCSs, especially sensory nerve action potentials (SNAPs), are also helpful to evaluate the level of the nerve injury. With preganglionic injuries, the dorsal root ganglion, where the sensory neuron cell body is located, is intact. The distal axons do not undergo wallerian degeneration, because they remain connected to the cell body; thus, the SNAP is preserved. However, the patient is insensate because the sensory neurons are not connected to the central nervous system (i.e., spinal cord and brain). The finding of intact SNAPs in the presence of dermatomal anesthesia is pathognomonic of a root avulsion injury. In postganglionic injuries, the sensory axons will degenerate and the SNAP will be lost. On occasion, a segmental or longitudinal injury will cause both preganglionic and postganglionic lesions, and the SNAP will be absent in the presence of a root avulsion injury. On the contrary, motor conduction will be absent with both preganglionic and postganglionic injuries because the motor axons will have undergone wallerian degeneration (i.e., because their cell body is located in the anterior horn of the spinal cord).

Whenever possible, a follow-up electrodiagnostic study is performed 6 to 12 weeks after the initial study to assess for recovery. Although an advancing Tinel sign and the presence of nascent units are encouraging findings, they need to be taken into consideration along with improvement in clinical function; these findings do not necessarily eliminate the need for surgery.

INDICATIONS FOR SURGERY

Multiple studies on the exploration and reconstruction of brachial plexus traction injuries suggest the value of surgical intervention in many of these patients. Surgery is indicated in patients with no hope for spontaneous recovery or for further recovery. This principle applies to patients with traumatic brachial plexus injuries from any mechanism. All patients with laceration injuries in proximity to the brachial plexus should undergo exploration because in the vast majority of these injuries (sharp or blunt), there is no possibility of spontaneous improvement and surgery is clearly indicated. In patients with gunshot injuries, an initial potential for spontaneous recovery exists because the nerves are usually in continuity. The same applies to patients with traction injuries. However, after a period of observation (see Timing of Surgery), surgery is indicated if there is no clinical or electrophysiologic evidence of recovery. Signs of electrophysiologic recovery that do not translate to clinical recovery within a short period of observation should not be viewed as meaningful recovery, and such patients should be considered for a surgical intervention. If it were possible to clearly identify patients with complete nerve root avulsion or nerve rupture, a surgical intervention could be performed without the observation period because these injuries cannot recover spontaneously. However, at present, no definitive study or sign is sufficiently reliable; the decision should be made after analyzing the different evaluations (history, physical examination, imaging studies, electrodiagnostic studies) in the context of time.

CONTRAINDICATIONS TO SURGERY

Absolute contraindications to surgery for the reconstruction of brachial plexus injury are few. Stiffness and contractures, age, medical comorbidity, associated traumatic brain injury, and associated spinal cord injury should be considered in the decision process and may need to be addressed, but they are not generally contraindications. The main contraindication is unrealistic goals or unwillingness of the patient to undergo the procedure. Before a decision to operate is reached, it is therefore crucial to inform the patient about the possible surgical options, risk-benefit ratio, postoperative rehabilitation program, success rate, long recovery time, and possibility of additional surgery. This discussion should be individualized to each patient according to that patient's specific injury, needs and expectations, and goals and priorities (set by the treating team and patient). Surgery is also not usually indicated for patients with spontaneous ongoing recovery in all involved elements because outcomes will generally be better without surgery in such patients. We believe that the rare patient with a C8-T1 lesion has a relative contraindication to primary nerve repair or grafting because

of the limited ability for successful regeneration to reach the hand. Forearm nerve transfers or secondary reconstruction with tendon transfer may yield more predictable results. Finally, if more than a year has passed since the injury, primary plexus reconstruction is generally contraindicated, except perhaps in a young patient. In select cases, distal nerve transfers may be considered up to 18 months after the injury.

TIMING OF SURGERY

Timing of brachial plexus reconstructive surgery is based on three principles: (1) Better functional outcomes occur in patients with spontaneous recovery who do not require a surgical intervention; (2) surgical intervention is indicated for patients with no hope for spontaneous recovery or for further recovery; and (3) most series demonstrate that the surgical outcome is inversely proportional to the time interval from injury to surgery (i.e., outcomes are better if surgery is performed earlier). Based on these principles, primary nerve reconstruction may ideally be initiated immediately (within days) after injury or in a delayed fashion (within months). Timing of secondary reconstructive procedures is discussed separately.

Primary (Nerve) Reconstruction

Immediate Surgery

In patients with plexus deficits and a sharp open injury, immediate exploration plus repair is indicated. Immediate surgery allows direct repair of the lacerated elements. In patients with blunt laceration injury to the plexus, surgical intervention is also clearly necessary, but the timing of the surgery is controversial and less definite. A subacute (within 3 to 4 weeks) surgical intervention may be preferable; time will allow better definition of the zone of nerve injury. Occasionally, a reconstructive brachial plexus surgeon gets the opportunity to assess the degree of damage to the plexus at the time of injury when emergency vascular reconstruction of an injured subclavian or axillary artery is performed by the vascular surgeons. This may occur with sharp or blunt laceration injuries and with traction injuries. The supraclavicular and infraclavicular regions may be explored, the damage to the plexus mapped, and the plexus reconstruction planned. If the nerves are sharply divided, they can be repaired immediately; if they are bluntly transected or ruptured, they may be tagged with radiopaque vascular clips (to allow identification) and loosely coapted to prevent retraction. The injury can then be reexplored 3 to 4 weeks later to allow the zone of damage to be better demarcated. If the nerves are avulsed, reconstruction can be performed immediately or at a second setting, depending on the situation and condition of the patient; finally, if the nerves are stretched but in continuity, a period of observation will be necessary.[140,156]

Delayed Surgery

Surgery is delayed in patients who have a potential for spontaneous recovery or for injuries that require time to become better defined. In patients with closed traction injuries or gunshot injuries (because most are in continuity), surgery is performed after a period of observation if there is no evidence of spontaneous clinical or electrophysiologic recovery. Even though outcomes are better if surgery is performed earlier, a balance must be reached such that patients demonstrating early spontaneous recovery (i.e., who will probably fare well) do not undergo surgery. The timing of surgery needs to be individualized based on multiple factors, including the mechanism of injury, findings on physical examination and imaging, and the surgeon's preference. Patients with a low probability of spontaneous recovery may undergo surgery earlier, and patients with a high probability of spontaneous recovery may be observed longer. However, there are no universal guidelines and different opinions exist in the literature. Our preference is to explore and perform primary nerve reconstruction early in patients in whom there is a high suspicion of root avulsion based on the history/mechanism, physical examination, electrophysiologic studies, or imaging studies. At our institution we are not performing surgery extremely early, as is advocated by some.[23] We operate on patients with pan-plexal lesions 2 to 3 months after injury if they have no evidence of recovery but have imaging evidence of avulsions. In patients without this high suspicion of root avulsion and no adequate signs of recovery, we perform exploration 3 to 6 months after the injury. We may wait longer (5 to 6 months) for patients with a higher chance of spontaneous recovery, such as those with incomplete brachial plexus palsy or complete brachial plexus palsy without evidence of root avulsion. An early intervention may not allow sufficient time for spontaneous recovery; however, we believe that routine use of intraoperative monitoring (such as nerve action potentials [NAPs]) will help determine whether there is early subclinical evidence of recovery at the time of exploration. We seldom wait for more than 6 months because long delays diminish the outcomes of the reconstructive procedure.

Secondary Reconstruction

For adult patients initially seen late (i.e., >12 months after the injury), primary nerve reconstructive procedures are associated with significantly poorer results. In select cases, distal nerve transfers can still be considered even later (i.e., <18 months). However, secondary reconstructive procedures, such as tendon transfer, FFMT (gracilis muscle), and bony or soft tissue procedures, may be indicated and can be done at any time.

OPERATIVE CONSIDERATIONS

Informed Consent

The possible surgical options, risk-benefit ratio, postoperative rehabilitation program, expected outcome with or without surgery, and long reinnervation period should be discussed in detail with the patient and his or her family. The patient should have realistic expectations and a clear understanding of the goals and priorities of the planned surgery. The surgical approach should be individualized according to the patient's comfort level (acceptable risks and set of goals).

Preparation and Positioning

The surgical procedure, in particular its indeterminate duration and the need to perform intraoperative stimulation and recordings, should be discussed with the anesthesiologist. Long-acting paralytic agents, muscle relaxants, and agents depressing cortical responses should be avoided. Adequate vascular access should be obtained and an indwelling urinary catheter should be inserted. After induction of anesthesia and intubation, the

patient is positioned in the supine position. The head is turned to the contralateral side, the upper part of the body is elevated, and a small pillow is placed beneath the ipsilateral scapula to bring the shoulder forward. Proper padding and positioning to protect bony prominences are necessary because brachial plexus reconstructive procedures are lengthy. Surgical preparation and draping should include the ipsilateral neck, mandible, hemithorax, axilla, entire upper extremity, and both lower extremities (for possible nerve grafts). Some surgeons use tourniquets placed on the upper part of the thighs that can be inflated just before sural nerve graft harvesting. The arm is prepared and draped freely; this will permit the response to nerve stimulation to be observed and appropriate changes in arm positioning to be made during the procedure if needed. Tight circumferential elastic drapes are avoided on the extremities because of the long duration of surgery and possible swelling. If planning is being done to use the contralateral C7 nerve for transfer, the contralateral neck and hemithorax should be included in the surgical field. The surgeon should be prepared to expose both the supraclavicular and infraclavicular portions of the brachial plexus, harvest nerve grafts (sural nerve, superficial radial nerve, or vascularized ulnar nerve), or perform nerve transfers if required.

Electrodes required for intraoperative electrophysiologic monitoring (such as motor evoked potentials [MEPs] and somatosensory evoked potentials [SSEPs]) are placed. A bipolar microcoagulator, nerve stimulator, magnifying loupes, and operative microscope should be available for the surgical procedure.

Surgical Approaches to the Brachial Plexus

The elements of the brachial plexus are exposed through a supraclavicular approach (i.e., nerves, trunks, suprascapular nerve) or an infraclavicular approach (i.e., cords, terminal branches). Depending on the pattern of injury, a combined approach may be necessary. The divisions, which are retroclavicular, can be accessed through one or both approaches. With introduction of the newer nerve transfers, some surgeons do not routinely explore the brachial plexus in all patients, even if a proximal nerve would be available for grafting, believing that nerve transfers provide a more reliable option. We recommend routinely exploring the proximal brachial plexus, except in specific patients who are initially seen late and have a more reliable, distal nerve transfer option. When a pan-plexus injury is present, less than 20% of patients are reported to have avulsions of all five roots of the plexus[98]; we therefore believe that exploration is warranted because a proximal nerve can often be found for grafting.

The variability in surgical approaches to the brachial plexus is mainly in the incisions used to expose the supraclavicular or infraclavicular brachial plexus and in the reconstructive approach used. Traditionally, a zigzag skin incision (Figure 34.7) was used: the supraclavicular incision begins at the angle of the jaw and follows the posterior border of the sternocleidomastoid to the midclavicular area; the infraclavicular incision begins at the clavicular insertion of the sternocleidomastoid (connecting with the supraclavicular incision), courses laterally toward the coracoid process, and extends laterally to the deltopectoral groove and into the arm. These incisions are connected to achieve a wide exposure. However, connecting these incisions increases the risk for scar hypertrophy, and some surgeons prefer to use separate transverse skin incisions. An alternative is to expose the supraclavicular plexus with a transverse incision, parallel to the clavicle, and the infraclavicular plexus with an incision over the deltopectoral groove. These two incisions can be connected if required. Some surgeons use a transverse cervical skin incision between the posterior tubercle of the C5 transverse process and the anterior tubercle of the C6 transverse process to expose the C5 and C6 nerves and an incision that runs transversely over the clavicle to expose the C7, C8, and T1 nerves. Our preference, for exposure of the supraclavicular plexus, is to use a single transverse 5- to 6-cm cervical incision, off midline, parallel to and approximately two to three fingerbreadths above the clavicle (Figure 34.8). With this approach

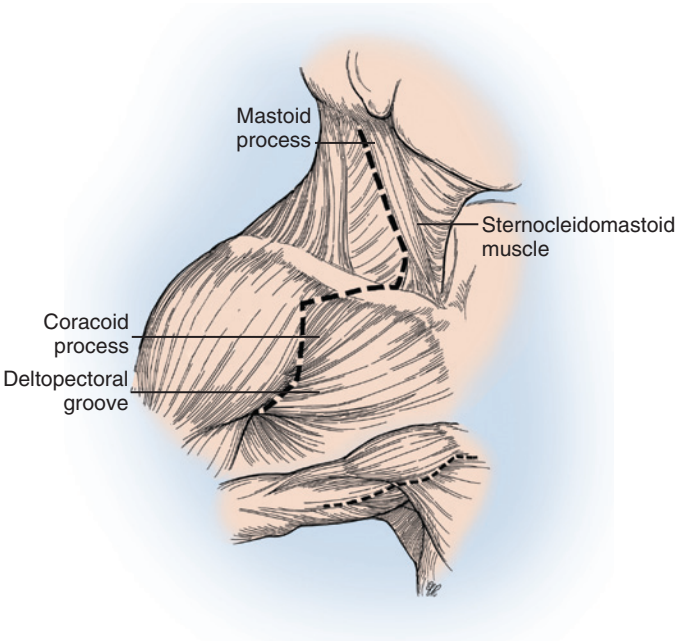

FIGURE 34.7 Classic zigzag skin incision used for exploration of the brachial plexus from the vertebral foramen to the terminal branch level in patients with traumatic brachial plexus injuries. The distal limb of the incision can be extended into the arm as needed. (Copyright © Elizabeth Martin.)



FIGURE 34.8 Our preferred skin incisions for surgical exploration of the brachial plexus. A transverse neck incision allows exposure of the supraclavicular brachial plexus and spinal accessory nerve. A deltopectoral skin incision allows exposure of the infraclavicular portion of the brachial plexus. (By permission of Mayo Foundation for Medical Education and Research. All rights reserved.)

we can expose the C5 through T1 nerves. We expose the infraclavicular plexus with a second incision overlying the deltopectoral interval. The skin incision may be infiltrated with a vasopressor agent to decrease bleeding.

Supraclavicular Exploration

After the skin incision, the platysma is incised and the cutaneous branches of the cervical plexus are identified and protected. Skin flaps that include the platysma are carefully raised both superiorly and inferiorly. We generally do not encounter the spinal accessory nerve in the proximal portion of this exposure where it exits beneath the sternocleidomastoid muscle; however, we can easily identify it more distally near the medial border of the trapezius muscle if necessary (see the section on Nerve Transfer). The external jugular vein on the surface of the sternocleidomastoid muscle is dissected and retracted. Dissection proceeds along the posterolateral margin of the sternocleidomastoid muscle, which is retracted medially. The superficial layer of the deep cervical fascia and cervical fat pad are opened and retracted. The dissection is extended to the superior border of the clavicle. The omohyoid muscle and transverse cervical vessels are identified, divided, and retracted medially and laterally. The first brachial plexus element to be visualized is usually the upper trunk. Medially, the phrenic nerve is found on the anterior surface of the anterior scalene muscle (Figures 34.9 and 34.10). Contraction of the diaphragm after electrical nerve stimulation can confirm identification of this nerve except in patients with phrenic nerve dysfunction (e.g., very proximal or preganglionic C5 nerve injury). The phrenic nerve should be mobilized with care. The anterior scalene muscle can then be resected safely to expose the proximal cervical nerves. When traced proximally, the C5 phrenic contribution will be visualized, thereby confirming identification of the C5 nerve. Careful dissection medial to the phrenic nerve may be necessary in patients with proximal C5 injury; iatrogenic injury to vital neck structures should be avoided. The upper trunk is exposed proximally and its C5 and C6 nerve origin identified. The C5 nerve is usually smaller, superior, lateral, and more vertical than the C6 nerve. The upper trunk is dissected distally to its anterior and posterior divisions, as well as to the origin of the suprascapular nerve. The C7 nerve and middle trunk can be isolated between the anterior and middle scalene muscles, more medial, posterior, and horizontal than the C6 nerve. Even more inferior and posterior are the C8 and T1 nerves (forming the lower trunk), which are closely associated with the subclavian artery. Mobilization of the clavicle may help improve exposure. Osteotomy of the clavicle in our experience is only seldom performed in treating posttraumatic brachial plexopathies. The clavicular head of the sternocleidomastoid muscle may also be detached from the clavicle to improve exposure. In most cases, however, the C8 and T1 nerves are not specifically exposed, because their repair is rarely, if ever, indicated in our opinion, given the poor outcome after reconstruction of these lower nerve injuries in adults.

If the upper roots are avulsed, the rootlets and swollen dorsal root ganglia may be found twisted and lying either behind the clavicle or slightly above it in the region of the C8 nerve. If the upper plexus nerves or the upper trunk or middle trunk (or both) is ruptured, the distal ends typically lie behind the

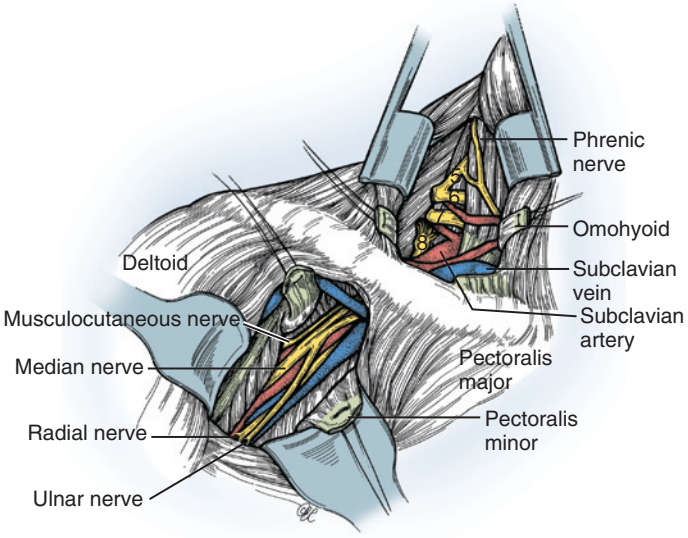

FIGURE 34.9 Key anatomic landmarks include the omohyoid muscle and the pectoralis minor muscle. The supraclavicular portion of the brachial plexus lies deep to the omohyoid and the infraclavicular portion lies deep to the pectoralis minor. These muscles are divided between ligatures for later approximation. With dissection of the deltopectoral groove, the lateral cord is the most superficial structure. In this example, the upper trunk and the C7 nerve are ruptured and the C8 nerve is avulsed (note the rootlets attached to the swollen dorsal root ganglion). (Copyright © Elizabeth Martin.)

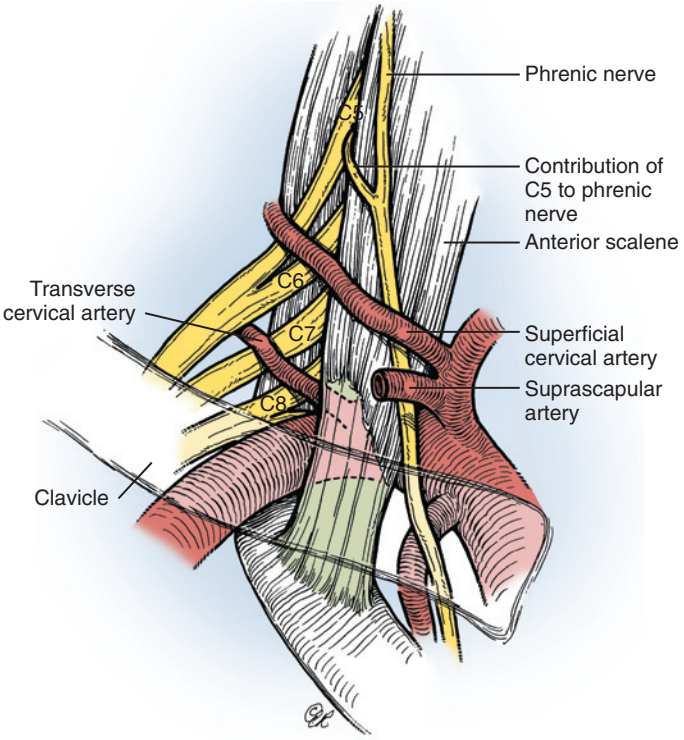

FIGURE 34.10 Exposure of the supraclavicular brachial plexus. Additional landmarks helpful in identifying the various nerves include the phrenic nerve contribution from the C5 nerve and the transverse cervical (scapular) artery, which frequently crosses over the C7 nerve. The C8 nerve is located just above and posterior to the subclavian artery, whereas the T1 nerve is almost directly posterior to the artery. Division and resection of a portion of the anterior scalene muscle are necessary to obtain proximal exposure of the spinal nerves. (Copyright © Elizabeth Martin.)

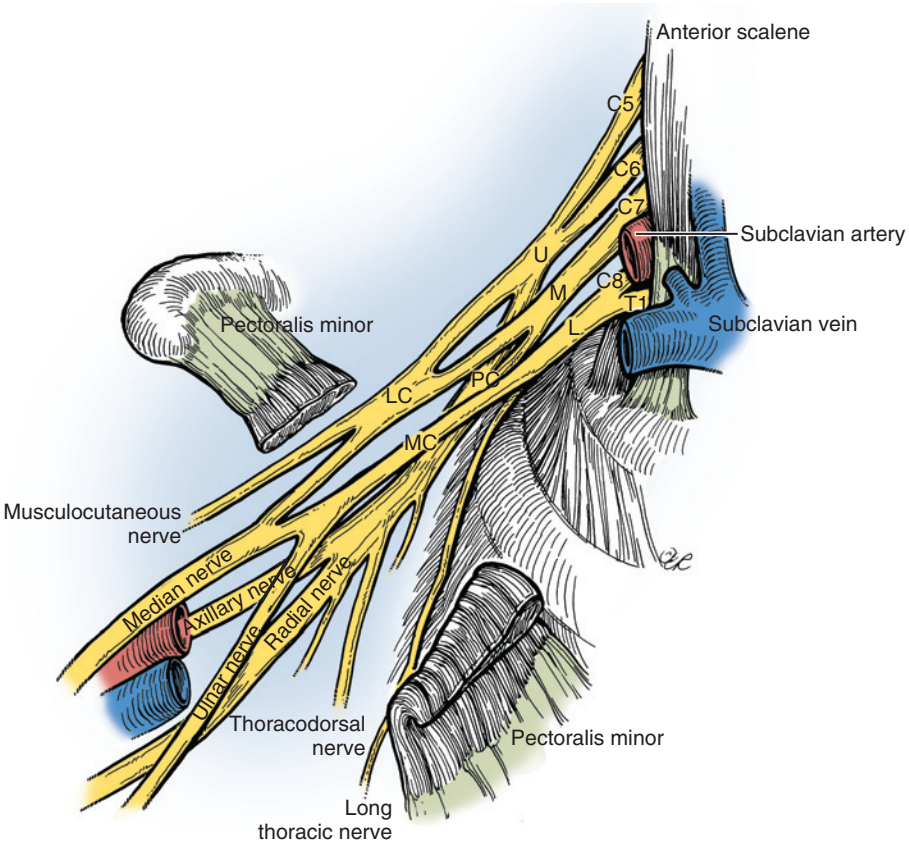

FIGURE 34.11 Exposure of the infraclavicular brachial plexus is often done in conjunction with exploration of the supraclavicular brachial plexus. *L*, Lower trunk; *LC*, lateral cord; *M*, middle trunk; *MC*, medial cord; *PC*, posterior cord; *U*, upper trunk. (Copyright © Elizabeth Martin.)

clavicle. The avulsed (often) or ruptured (infrequently) C8 and T1 structures are usually found much closer to their respective foramina than is the case with C5 or C6.

Infraclavicular Exploration

When indicated, the infraclavicular approach to the brachial plexus will expose the cords and branches (Figure 34.11). After the skin incision, the deltopectoral interval is developed to expose the cephalic vein, which is preserved and retracted laterally. The pectoralis major may be taken down from its humeral insertion and retracted as needed for exposure. A portion of its tendon is left on the humerus for reattachment, and the tendinous footprint is tagged with sutures for ease of closure. The infraclavicular plexus is explored by detaching the tendinous origin of the pectoralis minor from the coracoid process and tagging and retracting it. The clavipectoral fascia, which envelops the pectoralis minor, is incised to expose the lateral cord, which is superficial and lateral to the axillary artery. The thoracoacromial artery and its accompanying veins are identified and tagged if an FFMT or vascularized nerve graft is planned. The posterior cord is slightly lateral and deep to the artery, and the medial cord is medial and deep to the axillary artery. Care should be taken to preserve the medial and lateral pectoral nerves arising at this level. Electric stimulation can be helpful for identifying these nerves, which often consist of multiple branches. The lateral cord is identified by following the median nerve from distal to proximal. At this point the musculocutaneous nerve can be seen branching laterally and piercing the coracobrachialis muscle. The median nerve can also be followed proximally to identify the medial cord, which is then followed distally to the ulnar, medial brachial cutaneous, and medial antebrachial cutaneous nerves. Medial and deep to the axillary artery and vein and coursing laterally is the radial nerve. It is followed proximally to the posterior cord; the axillary nerve can be seen branching from the posterior cord. Once the supraclavicular and infraclavicular brachial plexuses are exposed, the retroclavicular area can be addressed. A tunnel is made under the clavicle from the neck to the deltopectoral area with a gloved finger. The most lateral part of the clavicular attachment of the pectoralis major muscle is detached; the subclavius muscle is divided. Crossing vessels, including the suprascapular vessels, should be ligated. By elevating the clavicle with a retractor or heavy tape, the divisions of the brachial plexus are exposed. If and when clavicular osteotomy is needed, predrilling of the screws for plate fixation should be done before the clavicle is divided. Patients with a history of clavicular fracture require special attention; in these cases, blunt dissection underneath the clavicle can be difficult. The risk for major vascular and pleural damage must be considered, especially if the lower brachial plexus elements are exposed medially.

If extensive scarring is present, especially fibrosis related to previous vascular injury or reconstruction, identification of major neurovascular structures in "normal" tissue planes is the rule before proceeding toward the zone of pathology. Release of

the insertion of the pectoralis major and in some cases the conjoined tendon may improve the exposure and facilitate safe dissection. Use of a Doppler device allows mapping of an arterial bypass graft.

INTRAOPERATIVE CONCERNS

Intraoperative Assessment

Direct inspection or palpation (or both) of the brachial plexus in our experience has not proved to be a reliable means of predicting preganglionic versus postganglionic injury or of assessing (postganglionic) neuromas-in-continuity. For example, in some cases of preganglionic injury, there is little scarring of the brachial plexus, which might suggest a minor injury but in fact reflects a more proximal injury (i.e., at the root–spinal cord interface). In other cases, a large neuroma-in-continuity may be recovering but may not have yet reached the distal musculature.

For these reasons, intraoperative electrodiagnostic assessment can be performed; we recommend and routinely use it. Surgical strategies are tailored to the intraoperative findings. Our intraoperative assessment includes the use of SSEPs, MEPs, and NAPs. Spinal evoked potentials[151] can replace SSEPs. Biochemical evaluation by determining choline acetyltransferase (ChAT) activity[77,214] is also used by some groups. If a nerve root or trunk is divided surgically in preparation for nerve grafting, frozen-section histologic analysis of the transected portion can be performed quickly for assessment of relative fascicular preservation and intraneural scarring.[129,211]

Somatosensory and Motor Evoked Potentials

SSEPs and MEPs help determine whether the spinal nerves are in continuity with the spinal cord; they evaluate the integrity of the intraforaminal and intraspinal sensory and motor pathways. SSEPs are based on the principle that it is possible to record very low amplitude potentials on the scalp (over the parietal cortex) after stimulating a contralateral peripheral nerve in the upper or lower limb. MEPs are motor compound action potentials recorded from surgically exposed spinal nerves after central stimulation. Both SSEPs and MEPs have been used to identify root avulsion during brachial plexus surgery.[195,205]

For SSEPs and MEPs, an electrode (which can act either as a stimulator or as a recorder) is placed on the available proximal cervical nerves and stimulations are performed. We rely partly on this examination to confirm the integrity of a proximal nerve that is being considered for grafting.

An important limitation is the fact that the sensory (posterior) roots and motor (anterior) roots may be differentially injured. When an SSEP is present, it does not signify that the motor roots are intact, and vice versa. Another limitation is that SSEPs are easily affected by the depth of anesthesia and technical difficulties; simultaneous recording of SSEPs after peripheral nerve stimulation in the unaffected upper limb is therefore recommended. MEP recording and interpretation are also sometimes challenging and require a team experienced with the technique.

Nerve Action Potentials

NAPs evaluate the presence of functioning axons, both sensory and motor, over a segment of nerve. Although they can be used to assess preganglionic injury, we routinely use SSEPs and MEPs instead for this purpose. We do use NAPs to assess all postganglionic neuromas-in-continuity. Stimulating and recording electrodes are placed directly on the nerve, proximal and distal to a neuroma-in-continuity (Figure 34.12). At least 4 cm of separation is required to record reliable NAPs. If a good NAP is present across a neuroma-in-continuity, the likelihood of significant functional recovery over time is high and the lesion should undergo neurolysis but not resection. We do not routinely use compound muscle action potential recordings in assessing incomplete lesions. Based on a large basic science and clinical experience, Kline and colleagues have shown that when no NAP is obtained across a neuroma-in-continuity, this lesion has minimal potential for spontaneous recovery and should be resected and grafted.[110,111,167]

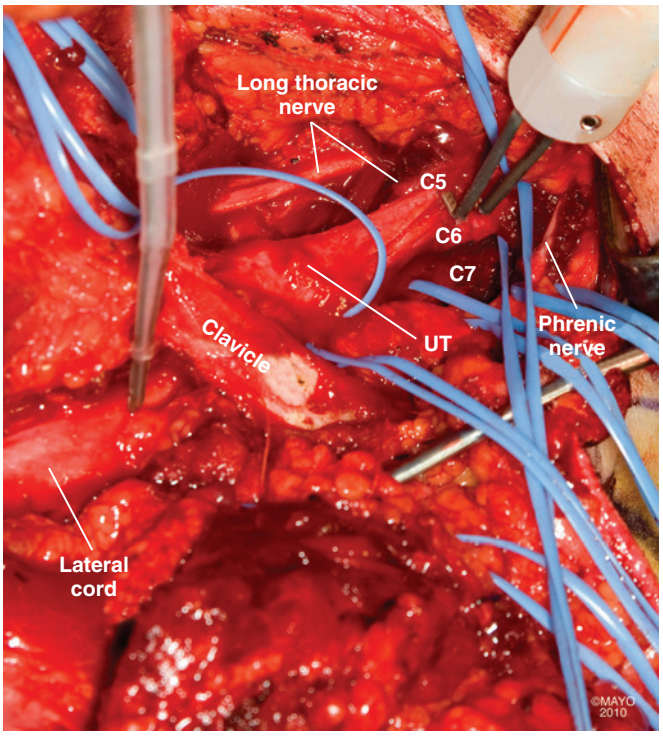

FIGURE 34.12 Intraoperative nerve action potentials are being performed across an upper trunk (UT) neuroma-in-continuity. Stimulation of C6 and recording from the lateral cord are shown. (By permission of Mayo Foundation for Medical Education and Research. All rights reserved.)

While performing intraoperative electrodiagnostic testing, we also observe the effects of direct nerve stimulation on muscle contraction. The phrenic or other functioning proximal nerves can serve as a normal positive control.

Choline Acetyltransferase Activity

ChAT activity has been used clinically to differentiate between motor and sensory fascicles intraoperatively during nerve grafting procedures[77,214] and also to determine the availability of the proximal nerve stump as a donor motor nerve during brachial plexus surgery. ChAT is an enzyme of acetylcholine synthesized in the nerve cell body and transported by axonal flow to the nerve terminals. Its activity is higher in motor fascicles than in sensory fascicles, and this differential expression can be used to identify motor fascicles of good quality (ChAT activity

> 2000 cpm[95,96]). Recent investigations have demonstrated that ChAT may not be as reliable as previously reported.[208] This fact, in addition to the prolonged time of testing, makes the use of this test difficult in the clinical situation.

Intraoperative Decisions and Priorities of Repair

Primary brachial plexus nerve reconstruction is based on functional priorities, depends on intraoperative assessment of the nerve damage and available motor axon donors, and is individualized intraoperatively. When only some elements of the brachial plexus are injured or the nerve gaps are short, we prefer to reestablish continuity to all injured parts by using every available donor nerve. When all brachial plexus elements are injured or the nerve gaps are long, this approach becomes impossible; autologous donor nerve tissue is not available to restore continuity to all parts of the brachial plexus, and priorities for reconstruction should be set. The priorities for reconstruction are based on three factors: (1) the functional significance, (2) the likelihood of regaining function after nerve reconstruction (proximal muscles are reinnervated more successfully than distal muscles), and (3) the degree of difficulty in restoring function by secondary reconstructive surgery.

C5-C6 Injury

For a patient with an injury limited to the upper plexus nerves (C5 and C6), the priorities are regaining elbow flexion and shoulder stability, abduction, and external rotation. Elbow flexion is generally achieved by reinnervation of the biceps and brachialis muscles (via the anterior division of the upper trunk, the musculocutaneous nerve proper, or the motor branches to the biceps and brachialis). Shoulder stability, abduction, and external rotation are usually obtained with reinnervation of the deltoid (via the posterior division of the upper trunk, the axillary nerve proper, or the anterior division of the axillary nerve) and supraspinatus and infraspinatus muscles (via the suprascapular nerve).

❖ AUTHORS' PREFERRED TREATMENT OF C5-C6 INJURY

In the majority of patients with C5-C6 loss of function, we explore the brachial plexus and perform intraoperative recordings. In a patient with a nonrecovering postganglionic injury (i.e., a postganglionic neuroma-in-continuity with a negative NAP or a postganglionic nerve rupture), we typically reinnervate the shoulder by using interpositional grafts between the C5 nerve stump and the posterior division of the upper trunk and suprascapular nerve. Another option that we may use for shoulder reinnervation is an interpositional graft between the C5 nerve stump and the posterior division of the upper trunk combined with transfer of the spinal accessory nerve to the suprascapular nerve. In patients in whom a functional C5 nerve stump is not identified or in those explored late (>6 to 9 months after injury), we perform double-nerve transfers (to axillary and suprascapular nerves) for shoulder reinnervation. Our preferred technique includes a spinal accessory nerve transfer to the suprascapular nerve and a triceps motor branch transfer to the anterior motor branch of the axillary nerve. Consistent with recent literature authored by others,[22,80,183] for elbow reinnervation, we typically perform fascicular nerve transfer(s) preferentially over C6 nerve grafting. Our preferred combination is transfer of an ulnar nerve fascicle to the biceps motor branch, sometimes combined with a second nerve transfer of a median nerve fascicle to the brachialis motor branch. Recent reports have demonstrated that the addition of the second transfer has not statistically improved outcomes.[35,135]

C5-C7 Injury

Patients with C5-C7 injuries have deficits in shoulder motion and elbow flexion (as do patients with C5-C6 injury), as well as variable deficits in elbow extension (triceps) and wrist extension. The priorities for primary nerve reconstruction are similar to those in patients with C5-C6 injury: regaining elbow flexion and shoulder stability, abduction, and external rotation. In addition, if elbow extension (uncommon) or wrist extension is severely affected, these problems should be addressed. The approach for nerve reconstruction differs because of the variable degree of weakness and the available donor motor axons. Generally, a combination of nerve grafts (if proximal nerves are available) and nerve transfers (spinal accessory, intercostals, pectoralis, thoracodorsal, ulnar and median nerve fascicles) is performed.

C8-T1 Injury

Patients with this pattern of injury have weakness in the extrinsic and intrinsic muscles of the hand and more variable wrist weakness. The indications, timing, and approach to reconstruction are controversial. As stated previously, nerve grafting is not appropriate for these rare injuries, because of the long reinnervation distances. Some surgeons are performing distal nerve transfers in patients with C8-T1 lesions when seen early.[21,30,31,92,164] Because patient numbers are small, the results of such procedures have yet to be firmly determined. One can certainly perform early or delayed tendon transfers for an isolated C8-T1 injury.[19] An individualized approach is required, with careful assessment of the strength of potential available donors. Reconstruction of thumb flexion, finger flexion, opposition, and intrinsic-minus claw deformity, as well as finger and thumb extension, will be necessary. If C7 is also affected and tendon transfer options are limited, the use of FFMT may also be appropriate.

Pan-Plexal Injury

In patients with complete pan-plexal injuries, our priorities of repair, in order of importance, include the following:

1. Elbow flexion by reinnervation of the biceps/brachialis muscle
2. Shoulder stabilization, abduction, and external rotation by reinnervation of the suprascapular and axillary nerves
3. Hand sensation by reinnervation of the lateral cord (C6-C7 distribution)
4. Wrist and finger flexion. (When hand reconstruction is performed, the triceps muscle should also be considered for reinnervation because it is a useful antagonist of elbow flexion; as such, it potentiates the strength of an FFMT that crosses the elbow joint.)
5. Wrist and finger extension
6. Intrinsic hand muscle function

In patients with complete root avulsions of the brachial plexus, no functioning nerves are available proximally to restore function to the extremity. In these situations, there are no

local musculotendinous transfers available for restoration of extremity function. Intact extraplexal nerves (spinal accessory, intercostal, C3 and C4 roots) can be transferred and coapted to the distal peripheral nerve of the brachial plexus as a method for reinnervation of critical sensory or motor nerves.

❖ AUTHORS' PREFERRED TREATMENT OF PAN-PLEXUS INJURY

Conventional goals in patients with pan-plexus injury include a stable shoulder and elbow flexion with or without some hand sensation. Advances in microsurgical techniques, as well as novel application of FFMTs in the acute setting (<6 months after injury), have enabled us to achieve rudimentary prehension in select patients. In all patients, we explore the supraclavicular brachial plexus in the hope of finding some viable and usable nerves from the proximal stumps; even in cases with evidence of multiple avulsions based on preoperative testing, exploration may occasionally reveal a viable nerve stump. In our experience, only rarely do we find more than one proximal nerve stump that can be used for nerve grafting in severe brachial plexus injuries. If available, we use this stump to reinnervate shoulder targets (axillary and suprascapular nerves). Our highest priority for nerve reconstruction in patients with complete injury is elbow flexion. For this reason, we have chosen to doubly reinnervate elbow flexion when possible, often using intercostal nerve transfers to the biceps motor branch in addition to a gracilis FFMT neurotized by the intercostals as well. Shoulder abduction, stability, and especially external rotation are provided either by using spinal accessory nerve transfer to the suprascapular nerve (when no available nerves are present) or by leaving the spinal accessory nerve intact and performing a delayed lower trapezius tendon transfer for external rotation. Other options remain for later shoulder reconstruction if these measures prove unsuccessful. When additional nerve resources are available (i.e., more than one viable nerve), we will also target the serratus anterior or pectoralis major.

If hand reinnervation is attempted, a single-stage gracilis FFMT is used for both elbow flexion and finger flexion. The shoulder is stabilized with nerve grafts to either the suprascapular nerve or axillary nerve, or both, from an available cervical nerve stump or with a planned secondary trapezius tendon transfer. The spinal accessory nerve is transferred to a triceps branch with an intervening nerve graft for reinnervation of elbow extension. Sensation in the median nerve distribution of the hand is provided by the transfer of sensory branches of the intercostal nerves to the lateral cord contribution of the median nerve. Secondary surgeries to provide stability to the hand and assist in rudimentary grasp are performed between 4 and 6 months after the index brachial plexus reconstruction. These secondary surgeries include both selected fusions and soft tissue balancing. The fusions include wrist arthrodesis, thumb carpometacarpal arthrodesis (to place the thumb in palmar abduction and pronation), and thumb interphalangeal joint arthrodesis. The soft tissue balancing is primarily achieved with passive flexor digitorum superficialis lasso procedures to create a metacarpophalangeal joint contracture for prevention of a claw deformity. Other options for hand reanimation have also been proposed, including a two-stage FFMT[64] and contralateral C7 (entire or half [hemi]) transfer to the median nerve,[186] as well as extended phrenic nerve transfers to the median nerve.[213]

Infraclavicular and Terminal Branch Injuries

Variable findings are due to different injury patterns in isolation or combination. Intraoperative NAP recordings are used in each case, and nerve grafting is commonly performed when NAPs are absent, when the zone of injury is relatively short, and provided good proximal and distal nerve architecture is maintained. Concomitant or staged tendon transfers may be considered for denervated muscles with long reinnervation distances. Nerve transfers, if available donors exist, may be preferable in patients initially seen 6 to 12 months after injury. For example, in cases of posterior cord injury, we would typically excise the neuroma and perform nerve grafting to the axillary nerve and to triceps nerve branches, and standard tendon transfers would be used for wrist, finger, and thumb extension.

PRIMARY NERVE RECONSTRUCTION

Neurolysis

The indication for neurolysis after traumatic brachial plexus injury is the intraoperative finding of a postganglionic neuroma-in-continuity and a positive (present) NAP. In most of these cases, the integrity of the proximal nerves is confirmed with intraoperative SSEPs and MEPs; however, in patients with a clearly isolated infraclavicular injury, testing of evoked potentials may not be necessary.

Microsurgical neurolysis consists of liberating the nerve from adhesions to neighboring tissue at the epineurial level (external neurolysis). Occasionally, internal neurolysis is indicated and performed under the microscope. This consists of longitudinal incisions made in the fibrotic layers of the epineurium and the epifascicular epineurium; all fascicles are completely separated to remove the surrounding scar tissue.

Direct Nerve Repair

Direct nerve repair is preferable to nerve grafts if it can be performed without excessive tension. However, neurorrhaphy is rarely possible after traumatic brachial plexus injury, except in cases of sharp transection that are explored early. Mobilization of the nerve stumps may make direct repair possible in some situations. In rare cases, direct repair of individual nerves or nerve branches with focal neuromas that are resected may be possible, provided that the nerve ends can be mobilized sufficiently.

Nerve Grafting

Indications

Nerve grafting is indicated in patients with postganglionic nerve ruptures or with postganglionic neuromas that do not conduct a NAP. In these cases, the nerve is in continuity with the spinal cord and has maintained viable motor axons that can be grafted to specific targets. When nerve transfer options exist, some surgeons prefer them to nerve grafting. Our preference, unless the surgery is performed late, the muscle targets are very distal, or the graft length is long (>10 cm), is to use nerve grafting when proximal nerves are available and in good condition.

Operative Procedure

Nerve grafting consists of the coaptation of interpositional grafts (e.g., cable grafts of the sural or other cutaneous nerves)

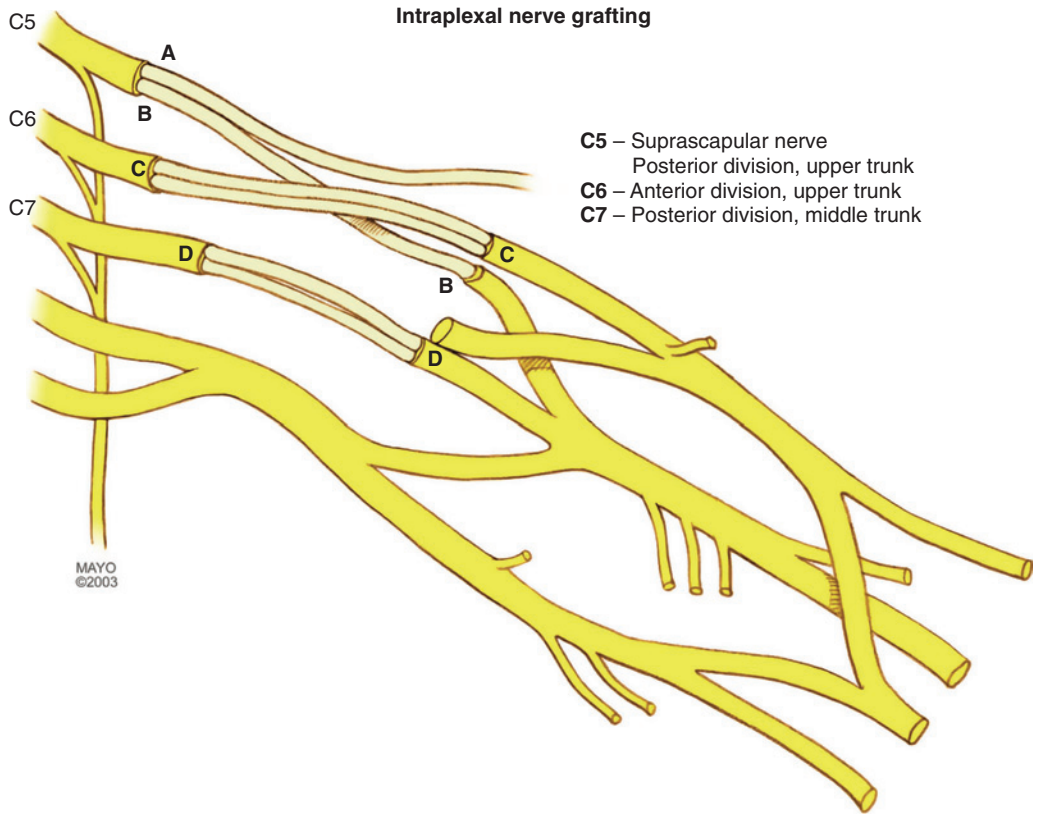

FIGURE 34.13 Anatomic reconstruction of the brachial plexus is done whenever possible with intraplexal nerve grafts: C5 to shoulder targets, C6 to elbow flexors, and C7 to extensor muscles. *A,* Suprascapular nerve; *B,* posterior division, upper trunk; *C,* anterior division, upper trunk; *D,* posterior division, middle trunk. (By permission of Mayo Foundation for Medical Education and Research. All rights reserved.)

between the desired nerve stumps. Generally, the C5 nerve is used to target shoulder stability, abduction, and external rotation (suprascapular nerve, axillary nerve, or posterior division of the upper trunk), the C6 nerve to target elbow flexion (anterior division of the upper trunk or musculocutaneous nerve), and the C7 nerve to target elbow extension (posterior division of the middle trunk or radial nerve) (Figure 34.13).

Conventional Nerve Grafting With the Sural Nerve

The most commonly used donor nerve for brachial plexus injury is the sural nerve, a purely sensory nerve that innervates a small area on the dorsolateral region of the foot (Figure 34.14). If harvested from the popliteal fossa to the lateral aspect of the ankle, up to 35 to 40 cm of donor nerve can be obtained from each leg. The sural nerve can be harvested in the supine position by placing a pad beneath the donor-side buttock to internally rotate the leg because this nerve is located posteriorly in the calf. The sural nerve can be dissected and mobilized with the leg in extension or with the knee flexed. Alternatively, an assistant can hold the leg elevated during harvest. The use of a tourniquet at the upper thigh level is optional; however, if used, surgeons must make certain that the limb tourniquets are deflated and disconnected or removed after harvesting the nerve grafts. Different techniques can be used, including multiple transverse or vertical incisions, a single incision along the course of the nerve (which is our preference), and even the use of an endoscope. The nerve is first identified between the lateral malleolus and Achilles tendon in the subcutaneous tissues

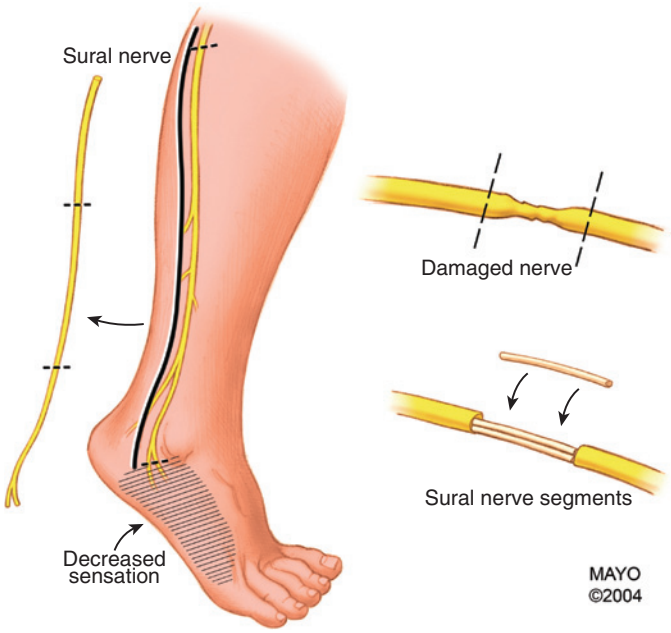

FIGURE 34.14 The sural nerve is a commonly used donor for interpositional nerve grafting of postganglionic lesions. This illustration is reviewed with patients to discuss the incision, technique, and morbidity (expected sensory loss and potential for neuropathic pain in the dorsolateral aspect of the foot). (By permission of Mayo Foundation for Medical Education and Research. All rights reserved.)

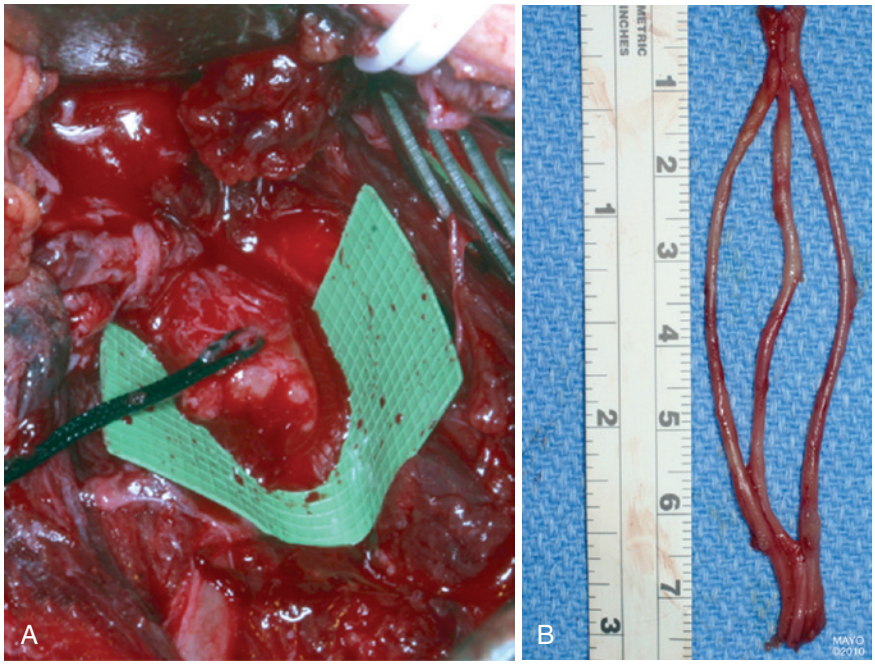

FIGURE 34.15 **A,** A ruptured C5 nerve is being used as the donor axonal source. **B,** Three sural grafts have been prepared in a cable to reconstruct shoulder targets. (By permission of Mayo Foundation for Medical Education and Research. All rights reserved.)

adjacent to the lesser saphenous vein. Gentle traction is applied, and the remaining portion is harvested up to the popliteal fossa; dissection of the nerve graft should be as atraumatic as possible. The nerve is transected as far distally and proximally as possible. The skin wound is closed in layers, and the legs are wrapped in elastic bandages.

Other Nerve Graft Options

If needed, other cutaneous nerves may be used as interpositional grafts, including the superficial radial, medial brachial or antebrachial cutaneous, lateral antebrachial cutaneous, and dorsal ulnar cutaneous nerves. For long defects or when a large-diameter graft is required, some recommend vascularized nerve grafts (pedicled or free). The most common vascularized nerve graft is the ulnar nerve (when it is nonfunctional), as described later with contralateral C7 transfer, but the radial nerve (if nonfunctional) and even the sural nerve[63] may also be used as vascularized nerve grafts.[24]

Coaptation

Coaptations should be performed without tension, and the grafts should ideally fill the cross-sectional area of the stumps. Usually, two or three segments of graft are cut and used to fill the area (Figure 34.15). When possible, different fascicular patterns are matched individually to lead the regenerating axons to the proper motor fascicles of the distal nerve. An understanding of the anatomic topography of the nerves at different levels can be helpful to align fascicles. Several 8-0 to 10-0 nylon epineurial sutures are commonly placed between each nerve graft and the proximal and distal nerves under microscope or loupe magnification. Tissue adhesive can be used to approximate multiple strands of nerve graft and simplify the coaptation with proximal and distal nerves (Figure 34.16). We generally

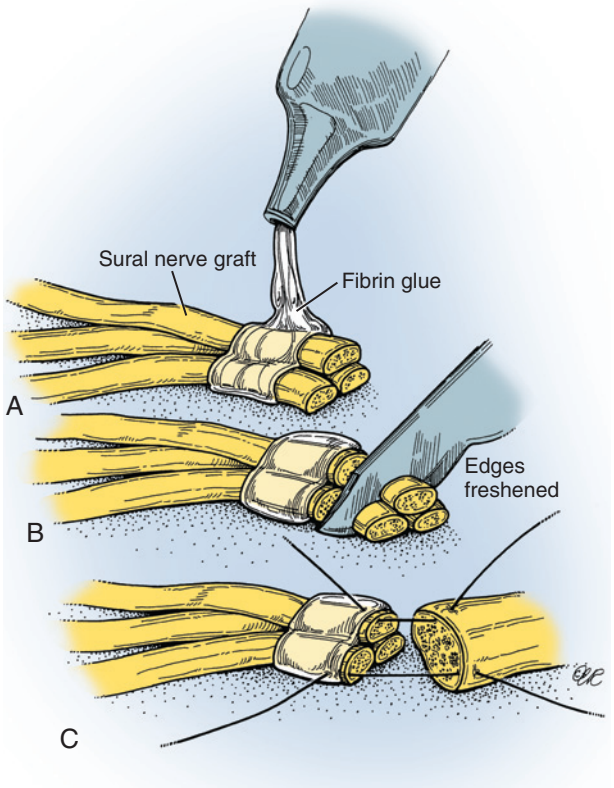

FIGURE 34.16 Nerve repair with tissue adhesive. The graft strands are first glued together **(A),** the graft ends are freshened with a sharp blade **(B)** and then coapted with conventional epineurial sutures **(C).** (Copyright © Elizabeth Martin.)

reinforce the nerve coaptation sites with the use of a bivalved nerve conduit and tissue adhesive.

Nerve Conduits

Nerve conduits are increasingly being used in nerve surgery for small-caliber (more commonly sensory) nerves, for short nerve gaps, or as an adjunct to nerve repair or transfer; however, in proximal brachial plexus injuries, this technique is not recommended at this time as a substitute for nerve grafts.

Processed Nerve Allografts

The use of nerve allografts that have been decellularized by a variety of methods has gained popularity in short-gap digital sensory nerve defect reconstruction as well as larger mixed nerve defect reconstruction. Use of these allografts in proximal brachial plexus reconstruction or for long nerve or motor graft reconstruction is not recommended at this time unless nerve autograft is unavailable.[86]

Nerve Transfer

The terms *nerve transfer*, *neurotization*, and *nerve crossing* have been used interchangeably in the literature[138] and describe the transfer of a normal or nearly normal fascicle or nerve branch to an important sensory or motor nerve that has sustained irreparable proximal damage. The term *nerve transfer* is used most frequently in the current literature; *nerve transfer* and *neurotization* will be used in this text without distinction. It should be noted that *muscular neurotization* is different in that the term describes direct implantation of nerve ends into a denervated muscle for reinnervation.

The indications for nerve transfer are irreparable preganglionic injury, selected postganglionic injury, and reinnervation of FFMTs. Important attributes of nerve transfers are as follows: They are closer to the end organ (which means that there is increased likelihood of more rapid recovery or more reliable recovery, or both). There is delivery of a large number of "pure" axons. Repair takes place outside the injured and scarred zone. Nerve grafting, with its two repair sites, is avoided. Rehabilitation is more easily accomplished, especially with synergistic transfers.

Common intraplexal and extraplexal nerve transfers are described in the following sections.

Spinal Accessory Nerve Transfer

SURGICAL ANATOMY

The spinal accessory nerve (cranial nerve XI) innervates the sternocleidomastoid and trapezius muscles. It originates in the posterior cranial fossa from spinal and cranial nerve roots, passes through the jugular foramen, and divides into an internal branch (containing fibers originating from the "cranial part"), which joins the vagus (X) nerve, and an external branch (consisting of fibers from the "spinal part"), which innervates the sternocleidomastoid and trapezius muscles. After supplying the sternocleidomastoid muscle, the nerve descends obliquely in the posterior triangle of the neck between the superficial and deep layers of the deep cervical fascia (Figure 34.17). In this area the nerve is embedded in loose connective tissue and is in contact with the cervical lymph node chain. This is the most common location for iatrogenic injuries to the spinal accessory nerve during lymph node biopsies. The spinal accessory nerve provides two or three branches to the upper part of the trapezius muscle before passing under its anterior edge. Intramuscularly, the nerve follows an oblique caudal course toward the middle and lower parts of the trapezius and gives off branches to the muscle throughout its course. There is great variability in connections between the spinal accessory nerve and the roots of the cervical plexus.[54]

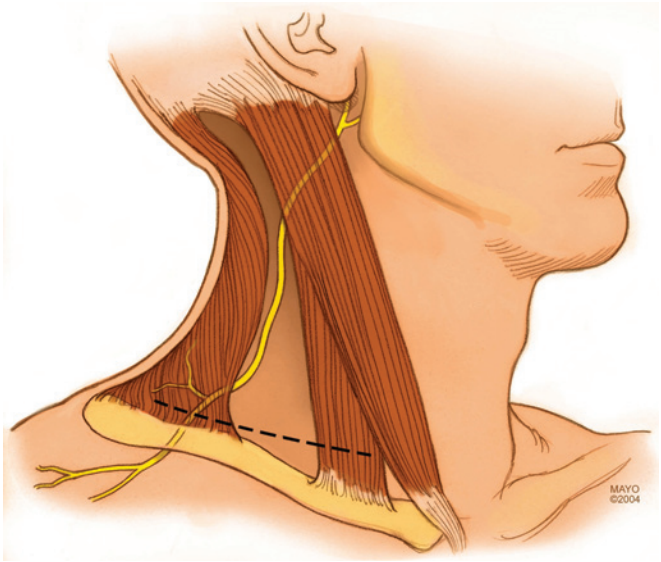

FIGURE 34.17 The course of the spinal accessory nerve. The nerve can readily be identified in the lateral portion of a supraclavicular incision on the anterior surface of the trapezius muscle several centimeters above the clavicle. (By permission of Mayo Foundation for Medical Education and Research. All rights reserved.)

Spinal Accessory Nerve Dissection. As with exploration of the supraclavicular plexus, turning the neck to the contralateral side and elevating the shoulder and neck off the surgical table facilitate access to the spinal accessory nerve. Muscle relaxation is avoided to allow the use of electrical stimulation to confirm identification of the spinal accessory nerve.

The spinal accessory nerve is usually taken from the posterior border of the sternocleidomastoid muscle and traced as far as possible along the undersurface of the trapezius to its decussation, where it is transected. The nerve can be transferred to the supraclavicular area for neurotization.[185] Although this is the most popular approach to the spinal accessory nerve, there are some disadvantages. First, it creates a large longitudinal scar on the neck. Second, this extensive approach can inadvertently denervate proximal branches to the upper part of the trapezius, which should be preserved.

Our preferred technique uses the lateral portion of the transverse supraclavicular cervical incision described above; this approach makes a less conspicuous scar over the clavicle. The spinal accessory nerve can be identified several centimeters above the clavicle on the anterior surface of the trapezius. This nerve should not be confused with more superficial cervical plexus elements that may run in similar directions. These branches from the cervical plexus can be distinguished from the spinal accessory nerve by their size, which is comparatively small, and by the response of the nerves to electrical stimulation. The spinal accessory nerve should produce vigorous contraction of the trapezius.

The spinal accessory nerve should be dissected as far distally as possible. A proximal branch to the upper portion of the trapezius should be preserved. The nerve can then be divided and transferred. Some authors transect the spinal accessory nerve more proximally, just distal to the sternocleidomastoid muscle; we do not recommend this approach, because an intervening nerve graft will be required to reach the distal target, which may reduce the success of the procedure.

Contraindications. Patients with spinal accessory nerve dysfunction preoperatively are not candidates for this procedure. Because trapezius function is difficult to assess on physical examination in patients with paralyzed shoulder muscles, preoperative EMG can help identify an abnormality. Intraoperative stimulation is the definitive assessment of spinal accessory nerve function.

Complications. There are generally no serious complications from this procedure as long as the proximal branch of the spinal accessory nerve to the upper fibers of the trapezius muscle is preserved. If the proximal branch to the trapezius is injured, shoulder depression and dysfunction may occur.

Transfer to the Suprascapular Nerve. The suprascapular nerve, which innervates the supraspinatus and infraspinatus muscles, originates from the upper trunk 2 to 3 cm above the clavicle. In some patients, its origin can be higher, whereas in those with ruptures or avulsion injuries of the upper trunk, the nerve can retract to the retroclavicular or infraclavicular area. The suprascapular nerve courses laterally and posteriorly, deep to the omohyoid muscle, and enters the supraspinatus fossa through the suprascapular notch, deep to the superior transverse scapular ligament. The nerve then traverses the supraspinatus fossa deep to the supraspinatus muscle and winds around the lateral border of the spine of the scapula (the spinoglenoid notch) to enter the infraspinatus fossa. Its course renders it particularly vulnerable to traction lesions at the suprascapular notch, at the spinoglenoid notch, and within the supraspinatus and infraspinatus fossae. The suprascapular nerve is dissected bluntly with finger dissection to the suprascapular notch to confirm its integrity. This is done even when the location of a lesion proximal to the upper trunk is obvious to ensure that a secondary (distal) lesion is not present. To perform the nerve transfer, the suprascapular nerve is transected at its origin from the upper trunk (Figure 34.18). If there is no scarring, it may be possible to dissect it further proximally and separate it from the upper trunk to increase the available length. The suprascapular nerve is coapted to the spinal accessory nerve without an intervening nerve graft.

Others have proposed a posterior approach when the spinal accessory nerve is used to reinnervate the suprascapular nerve, particularly when a segmental injury to the suprascapular nerve at the suprascapular notch is suspected.[12,52,93] The advantage of this approach is a more distal repair to a healthy portion of the suprascapular nerve. The disadvantage is perhaps a reduced number of myelinated axons in the more distal terminal spinal accessory nerve and the need for prone or lateral decubitus positioning to enable a posterior approach to the scapula. Both the spinal accessory and the suprascapular nerves can be exposed via a transverse incision at the superior border of the scapula. The suprascapular nerve is located midway between the superior angle of the scapula medially and the acromion laterally. After identifying the nerve at the suprascapular notch, the superior transverse ligament is divided, and the nerve is dissected as far proximally as possible. The spinal accessory nerve is located at a point 40% of the distance between the dorsal midline (spinous processes) and the acromion. It can be identified deep to the trapezius muscle, which is separated parallel to the course of its fibers. The spinal accessory nerve is divided as far distally as possible to achieve a coaptation without tension.

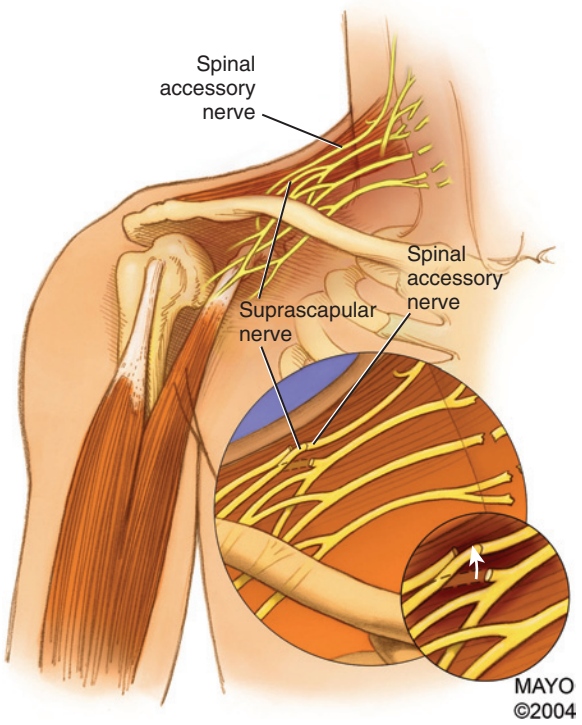

FIGURE 34.18 Transfer of the spinal accessory nerve to the suprascapular nerve. (By permission of Mayo Foundation for Medical Education and Research. All rights reserved.)

CRITICAL POINTS *Transfer of the Spinal Accessory Nerve to the Suprascapular Nerve*

Indications
- Most commonly used for C5-C6, C5-C7, and complete plexus injuries
- Ideal for injuries that have occurred less than 6 to 9 months previously

Pearls
- Spare the most proximal branch of the spinal accessory nerve.
- Sufficient distal dissection will permit direct transfer of the spinal accessory nerve to the suprascapular nerve without an intervening nerve graft.

Technical Points
- Use a transverse skin incision over the distal clavicle.
- Transfer only the middle and distal branches of the spinal accessory nerve.

Pitfall
- Outcomes are less favorable in patients with C5-C7 or complete injuries.

Postoperative Care
- Shoulder immobilization is maintained for 3 weeks.
- EMG-documented reinnervation begins by 6 months postoperatively.

Expected Outcomes. The expected outcome of transfer of the spinal accessory nerve to the suprascapular nerve for restoration of shoulder abduction is influenced by multiple factors, including the type of injury (C5-C6 vs. pan-plexus injury)[20,199] and the number of transfers performed (concomitant axillary reinnervation or not).[34] The range of outcomes reported in the literature is wide. A metaanalysis of the world literature reported that 92% of patients recovered some antigravity shoulder abduction with nerve transfer to the suprascapular nerve.[139] Multiple other groups[20,34,46,128,206] have reported a range of results, with mean degrees of abduction of between 45 and 122 degrees. Patients with an isolated C5-C6 palsy seem to have better outcomes than patients with a C5-C7 palsy, who seem to have better outcomes than those with a complete brachial plexus injury.[20,206] The function of the serratus anterior muscle may play a role in these outcomes. Patients with partial innervation of the serratus anterior (from an intact C7 nerve) may achieve significantly better range of shoulder abduction and flexion because of better scapular stability. The variability in results may also be due to the difficulty and complexity of assessing the outcome of shoulder motion (either by range of motion or muscle grading). The outcome of transferring the spinal accessory nerve to the suprascapular nerve for restoration of external rotation is less frequently reported, but it varies from 0 to 118 degrees of external rotation,[20,206] depending on the injury pattern and the studies (Figure 34.19).

Transfer to the Musculocutaneous Nerve. Transfer of the spinal accessory nerve to the musculocutaneous nerve is occasionally used to restore elbow flexion[185] (Figure 34.20). However, we more frequently choose to transfer ulnar nerve fascicles (in C5-C6 injuries) or intercostal nerves (in pan-plexus injuries) to the motor branch of the biceps. Use of the spinal accessory nerve requires an interposition nerve graft, which may degrade results.[139]

Operative Procedure. The musculocutaneous nerve may be exposed through an extended deltopectoral or a proximal arm skin incision. The musculocutaneous nerve originates from the lateral cord of the brachial plexus just distal to the coracoid process. After it pierces the coracobrachialis muscle, the nerve runs on the deep surface of the biceps. The musculocutaneous nerve then gives rise to the motor branch or branches to the biceps, which enter the muscle approximately 12 cm distal to the acromion. Two types of distribution of motor branches to the two heads of the biceps are found: a common trunk (pattern 1), which will divide into two branches (to the short and long heads of the biceps), and two separate nerve branches (pattern 2), the branch to the short head generally originating more proximally on the musculocutaneous nerve. Intercommunicating nerve fibers can be found between the motor branches. After traveling a distance within the short and long heads of the biceps (median distance of 1 and 2 cm, respectively, in pattern 1 or 3 cm for each branch in pattern 2), the main branches divide into terminal branches distributed throughout the muscle bellies. The musculocutaneous nerve then gives rise to the motor branch or branches of the brachialis muscle (≈17 cm distal to the acromion) and continues as the lateral antebrachial cutaneous nerve. Once the musculocutaneous nerve and its branches are identified and dissected, the nerve is cut just after it branches to the coracobrachialis muscle. A sural nerve graft (typically 9 to 10 cm long) is used to connect the spinal accessory nerve to the musculocutaneous nerve. The nerve graft is usually placed beneath the clavicle, coapted first to the spinal accessory nerve and then to the musculocutaneous nerve. The neurotization is performed with 9-0 or 10-0 nylon without tension under magnification with the operating microscope.



FIGURE 34.19 This patient with a C5-C7 lesion regained excellent external rotation after transfer of a spinal accessory nerve to the suprascapular nerve. Note the supraclavicular transverse incision. (By permission of Mayo Foundation for Medical Education and Research. All rights reserved.)

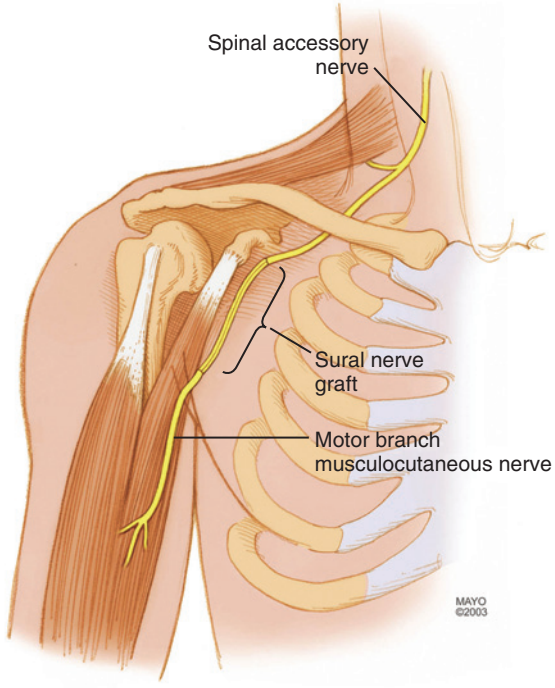

FIGURE 34.20 The spinal accessory nerve can be used to neurotize the musculocutaneous nerve (as shown) or the biceps and brachialis branches with an interpositional graft. (By permission of Mayo Foundation for Medical Education and Research. All rights reserved.)

Expected Outcomes. A metaanalysis of the outcome of transfer of the spinal accessory nerve to the musculocutaneous nerve for restoration of elbow flexion showed that 77% of patients achieved biceps strength of M3 and 29% achieved strength of M4.[139] The results of spinal accessory nerve transfer (with an interpositional graft) versus intercostal nerve transfer (without an interpositional graft) for restoration of M3-strength elbow flexion were comparable (77% vs. 72%), but significantly lower for restoration of M4-strength elbow flexion (29% vs. 41%; $P < .001$).[139]

Ulnar Nerve Fascicular Transfer to the Biceps Motor Branch

In patients with preserved C8-T1 function, transfer of a functioning ulnar nerve motor fascicle for reinnervation of the biceps muscle has gained popularity because of its technical ease and reliability.[161] This technique has largely replaced the use of intercostal nerve transfers for reinnervation of elbow flexion in cases of C5-C6 palsy. It is often done in patients with C5-C6 injury in conjunction with other nerve transfers, such as transfer of the spinal accessory nerve to the suprascapular nerve and the triceps motor branch to the axillary nerve for reconstruction of shoulder function. Some authors have recommended not performing this technique in patients with C5-C7 injury (because the ulnar nerve is formed by C7-T1) because there may be insufficient motor fibers to reinnervate the biceps and maintain strength in the ulnar-innervated muscles. However, we and others have used it in patients with C5-C7 injury and have achieved satisfactory recovery without any sequelae of ulnar nerve weakness.

SURGICAL ANATOMY

The larger of the two terminal branches of the medial cord of the brachial plexus continues as the ulnar nerve, whereas the smaller terminal branch is the medial cord contribution to the median nerve. In the axilla and upper part of the arm, the ulnar nerve runs inferior and medial to the axillary artery. It passes anterior to the triceps muscle and enters the ulnar groove between the medial epicondyle of the humerus and the olecranon. In the upper half of the arm, the ulnar nerve has rich interfascicular connections and 6 to 10 fascicles, each of which contains both motor and sensory nerve fibers. According to Sunderland's intraneural topography,[196] the posteromedial fascicles contain the motor fibers to the forearm muscles and the anterolateral fascicles tend to contain the motor fibers to the intrinsic muscles of the hand.

Dissection and Transfer. Both the musculocutaneous and ulnar nerves are exposed through a longitudinal medial skin incision in the proximal upper part of the arm. The musculocutaneous nerve and its three branches (motor branch to the biceps, motor branch to the brachialis, and lateral antebrachial cutaneous nerve) are identified. After the type of motor branch to the biceps (common or separated branches pattern) is confirmed, the branch is divided sufficiently proximal to be long enough to reach the ulnar nerve (Figures 34.21 and 34.22). The

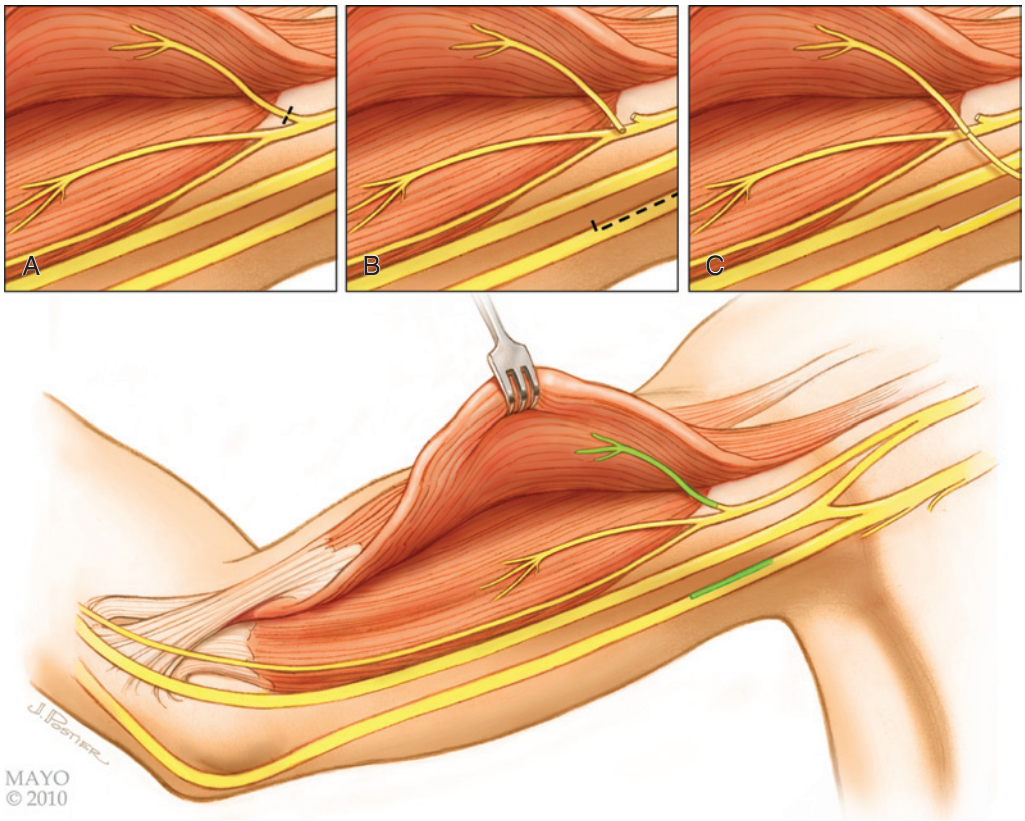

FIGURE 34.21 Ulnar fascicular transfer to the biceps motor branch (Oberlin method). **A,** The biceps motor branch is identified and carefully dissected from the musculocutaneous nerve. **B,** The ulnar nerve undergoes internal neurolysis, and a nerve stimulator is used to choose an appropriately sized fascicle for stimulation of wrist flexion without stimulation of intrinsic hand function. **C,** The ulnar nerve fascicle is divided and transferred under an operative microscope to the biceps motor branch. (By permission of Mayo Foundation for Medical Education and Research. All rights reserved.)

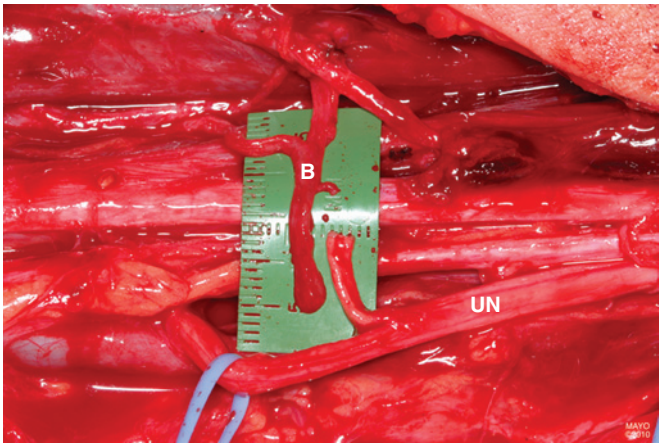

FIGURE 34.22 Operative example of the Oberlin transfer before neurorrhaphy. *B,* Biceps motor common branch; *UN,* ulnar nerve. (By permission of Mayo Foundation for Medical Education and Research. All rights reserved.)

ulnar nerve is identified and intraepineurial dissection is performed under loupe or microscope magnification. The ulnar fascicles are tested with a nerve stimulator, and the fascicles that innervate the flexor carpi ulnaris muscle, generally located posteromedially, are identified. Others that do not use nerve stimulation have not reported complications[115]; the ulnar nerve fascicles at this level are mixed and redundant, and all fascicles contain a mix of motor and sensory nerve fibers. Depending on the size of the motor branch to the biceps, one or two fascicles are selected. These chosen fascicles are transected under magnification and with enough length to approximate to the biceps motor branch without tension. They are coapted to the motor branch with 9-0 or 10-0 nylon epineural suture and reinforced with fibrin glue.

Contraindications. Patients with ulnar nerve distribution weakness and sensory deficit preoperatively are not candidates for this technique.

Complications. Some patients will experience transient numbness in the ulnar nerve distribution postoperatively. These sensory changes will improve over a period of days to months and are rarely permanent. Occasionally, patients will have transient muscle weakness of the ulnar-innervated hand intrinsic muscles. Few permanent deficits have been reported. Most patients gain powerful grip and pinch strength during the postoperative rehabilitation program; it may be better than their preoperative strength. Whether this is due to progressive muscle strengthening exercises or a tincture of time in a patient who is spontaneously recovering is unknown.

Expected Outcomes. Most authors emphasize the quick reinnervation of the biceps muscle after this procedure as an important advantage. Many patients have good recovery of biceps contraction beginning several months after the procedure. More than 90% of patients achieved biceps strength of British Medical Research Council (BMRC) grade 3 or 4 (Figure 34.23)[115]; outcomes are better in patients with C5-C6 patterns of injury than in those with C5-C7 injury.[162]

Median Nerve Fascicular Transfer to the Brachialis Motor Branch

Recently, double-nerve transfer to restore elbow flexion has been described.[125,127] This procedure combines reinnervation of the biceps muscle as described earlier with reinnervation of the brachialis muscle, a second powerful elbow flexor (Figure 34.24). Double neurotization has improved outcomes in some series.[125,127] In patients with C5-C7 injury patterns, single-nerve transfer of a median nerve fascicle may be selected over an ulnar nerve fascicle depending on the distribution of the hand and forearm weakness. As is the case with the ulnar nerve fascicular transfer, some authors have recommended not performing this technique in patients with C5-C7 injury. However, we and others have used it in patients with C5-C7 injury and achieved satisfactory recovery without adverse sequelae. The question of whether a single-nerve transfer versus a double-nerve transfer for elbow flexion is necessary has been the subject of recent publications. Our group compared the torque strength of a single-fascicle versus a double-fascicle nerve transfer to the biceps and brachialis motor branches, respectively.[35] Overall, single-nerve transfers did not outperform double-nerve transfers and the two types of transfers had similar torque strength. In a prospective comparative study, elbow flexion strength did not differ between groups treated with a single-fascicle or double-fascicle transfer.[135] For this reason, the surgeon needs to carefully decide if the second fascicle transfer from the median nerve to the brachialis is necessary in their patients.



FIGURE 34.23 Excellent recovery of biceps bulk and strength after an ulnar nerve fascicular transfer. (By permission of Mayo Foundation for Medical Education and Research. All rights reserved.)

Dissection and Transfer. The same medial arm exposure described for the ulnar nerve fascicular transfer is used to expose the median nerve and the brachialis motor branch. As described previously, the musculocutaneous nerve is identified in the proximal part of the arm. The biceps motor branch is seen, and several centimeters more distally, the brachialis motor branch is identified along with the lateral antebrachial cutaneous nerve. Identification of the brachialis motor branch can be confirmed by seeing it enter the muscle. It is distinguished from

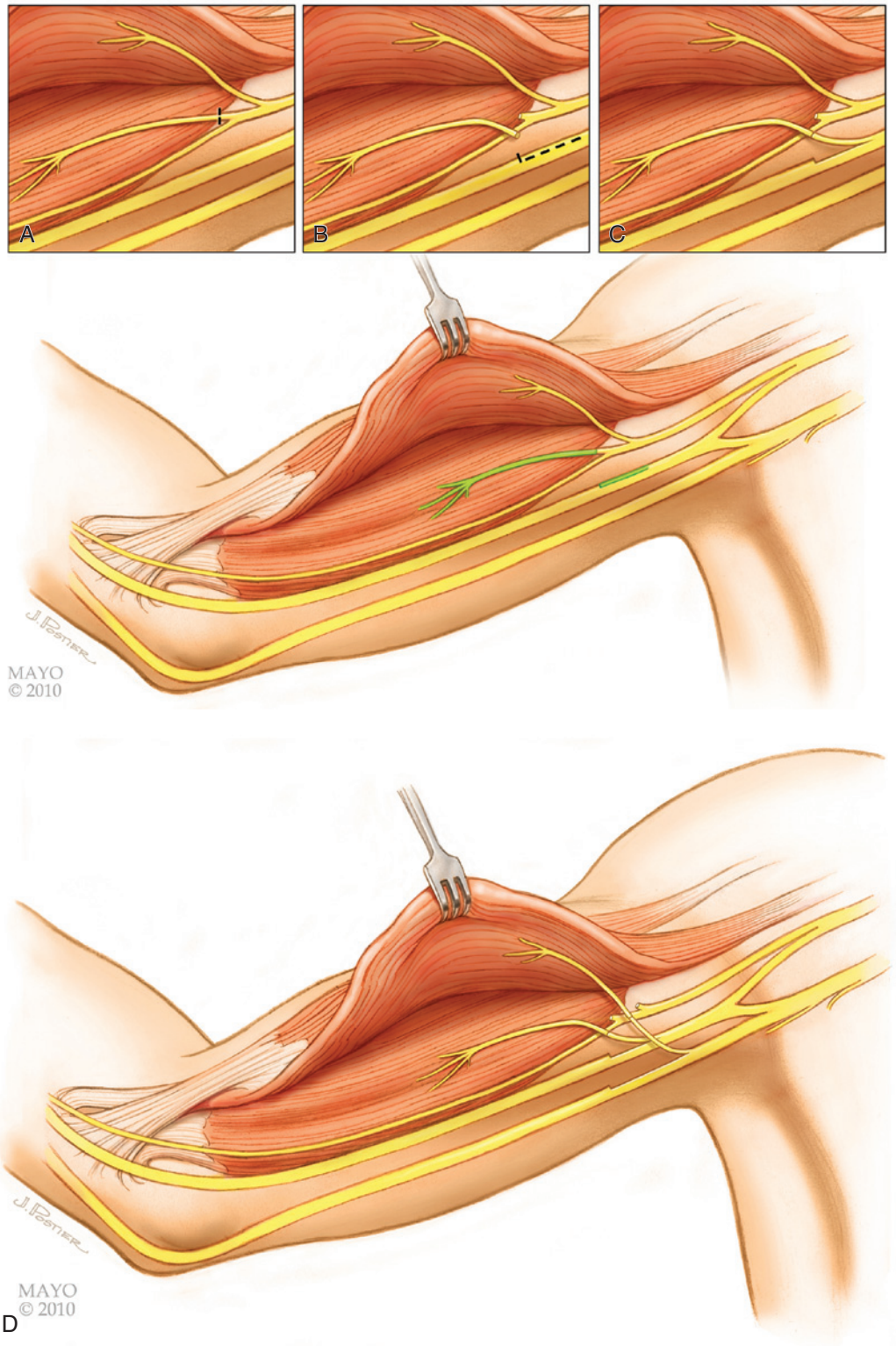

FIGURE 34.24 Median fascicular transfer to the brachialis motor branch. **A,** The brachialis motor branch is identified and carefully dissected from the musculocutaneous nerve. **B,** The median nerve is identified and undergoes internal neurolysis. A nerve stimulator is used to identify an appropriately sized fascicle that stimulates the wrist flexors. **C,** The median nerve fascicle is then transferred to the brachialis motor branch under the operative microscope. **D,** This technique is often done in conjunction with ulnar nerve fascicular transfer to the biceps branch. (By permission of Mayo Foundation for Medical Education and Research. All rights reserved.)

the lateral antebrachial cutaneous nerve, which is larger and runs more superficially; gentle traction on the lateral antebrachial cutaneous nerve will tent the skin in the proximal part of the forearm. The brachialis branch can be dissected proximally up to the common stem, where the biceps branch originates. The median nerve is identified near the brachial artery and vein; it is the largest of the nerves at this level. The nerve is dissected intraepineurially under magnification, and several fascicles are isolated. We prefer to map the nerve with a portable stimulator to identify a fascicle producing wrist flexion (via the flexor carpi radialis). Other groups have used fascicles innervating the flexor digitorum superficialis. The chosen fascicle is dissected over a segment long enough that when it is divided distally, it can be transferred and reach the brachialis motor branch. The nerves are coapted with epineurial 9-0 or 10-0 nylon suture without tension and reinforced with fibrin glue.

Contraindications. Patients with weakness in the median nerve distribution preoperatively are not candidates for this technique.

Complications. As for ulnar nerve fascicular transfers, some patients will experience transient numbness in the median nerve distribution postoperatively that will improve over a period of days to months and is rarely permanent. Occasionally, patients will have transient muscle weakness of the intrinsic hand muscles innervated by the median nerve. Few permanent deficits have been reported.

CRITICAL POINTS *Ulnar and/or Median Nerve Fascicular Transfer*

Indications
- Most commonly used for reconstruction of elbow flexion in patients with C5-C6 injury
- Used occasionally for patients with C5-C7 injury and preserved median and ulnar nerve function
- Ideally done less than 6 to 9 months after injury

Pearls
- Technical ease of the surgery
- Reliable, earlier recovery
- Limited skin incision and less invasive surgery
- Possibly a viable salvage surgery for patients initially seen 9 to 15 months after injury

Technical Points
- Division and transfer to a motor branch of the biceps brachii muscle or brachialis muscle, or both
- Meticulous intraneural dissection of the ulnar and median nerves
- Selection of the fascicles for transfer with the aid of a portable stimulator

Pitfall
- Improper selection of fascicles, leading to transient or permanent ulnar or median nerve deficit

Postoperative Care
- A shoulder immobilizer is maintained for 3 weeks.
- Reinnervation begins 3 to 6 months after surgery.

Intercostal Nerve Transfer

Intercostal nerves have been widely used over several decades for reinnervation of the musculocutaneous nerve,[47,114,142,154] and their application has been extended to reinnervation of the triceps, deltoid, and serratus anterior muscles; an FFMT; and for hand sensation. Historically, transfer to more distal motor targets has been attempted, but the long-term outcomes of these transfers were unreliable and too frequently they were functionless. Currently, intercostal to musculocutaneous nerve transfers are most frequently performed for reconstruction of elbow flexion in patients with pan-plexus injuries, and less commonly for patients with upper brachial plexus injury (C5-C6 or C5-C7). They are likewise used for innervation of the triceps and median sensory reinnervation in the second stage of a double FFMT for prehensile reconstruction (discussed later).

Patients who are being considered for this procedure should be selected with caution if they have a history of rib fracture, thoracotomy, or chest tube placement because there is an incidence of an unusable corresponding intercostal nerve. Although it is possible to use both the sensory and motor components of each intercostal nerve to provide sensory and motor reinnervation,[47,102] motor reinnervation alone is usually the goal of this procedure. In our experience, the third to sixth intercostal nerves have the most length for reaching the musculocutaneous nerve. By extending the dissection anteriorly to the costochondral junction, sufficient intercostal nerve length is gained, which permits direct coaptation to the target motor branch and thus eliminates the need for interpositional nerve grafts. There are anthropomorphic differences between races, and it has been the experience of some authors that direct transfer may be more difficult in caucasian individuals. The second or seventh intercostal nerve can also be used as needed, but adequate length and good positioning for transfer are less reliable for the musculocutaneous nerve. The second intercostal is readily transferred to the long thoracic nerve in patients with C5-C7 injuries and a denervated serratus. Finally, transfer of the first intercostal nerve to the suprascapular nerve was suggested in an anatomic study and case report.[71]

SURGICAL ANATOMY

Intercostal nerves run within the intercostal space along the pleural side of the internal intercostal muscles (Figure 34.25). Posteriorly, these nerves pass between the two layers of intercostal muscles that insert on the posterior thirds of the ribs. Just posterior to the axilla, they enter deep to the intercostal muscles and run anteriorly between the transverse thoracic muscles and the endothoracic aponeurosis. The lateral cutaneous branch pierces the intercostal muscle toward the skin and divides into a dorsal and a ventral branch. The anterior cutaneous branch pierces the pectoralis major close to the sternum and ramifies into the skin.

Intercostal Nerve Dissection. The third to sixth intercostal nerves are explored through an inframammary incision extending from the midaxillary line to the costochondral junction (Figure 34.26). This incision typically connects with the proximal arm incision used for exposure of the musculocutaneous nerve. Other groups are using different incisions, such as a vertical one in the anterior axillary line or a shorter transverse one on the chest, with tunneling of the intercostal nerves; we have found that with the classic inframammary incision we can achieve dissection of multiple intercostal nerves of adequate length. The subcutaneous tissue and underlying pectoralis major and minor muscles are elevated from their distal

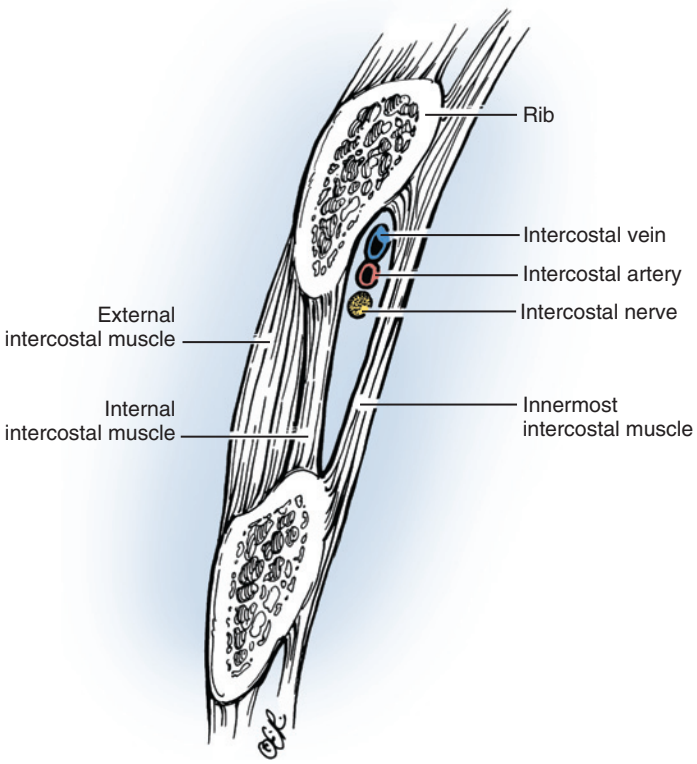

FIGURE 34.25 Anatomy of the intercostal nerve. (Copyright © Elizabeth Martin.)

insertions so that the muscles themselves are not injured. In the axillary region, the intercostobrachial nerve, a large branch of the second intercostal nerve, is identified and protected. Care should be taken to not injure this nerve, because it may be used as a donor nerve for sensory restoration of the hand. The anterior surfaces of the selected ribs, as well as their intercostal musculature, are exposed. When the serratus anterior muscle is functional, it should be preserved with its nerve supply; the long thoracic nerve is found on the chest wall coursing down posterior to the midaxillary line along with the thoracodorsal vessels. The anterior surface of each rib is incised and the periosteum is circumferentially elevated while great care is taken not to injure the underlying pleura. We prefer to mobilize the rib with a periosteal elevator, place an umbilical tape around it, and with the help of an assistant elevating the rib, identify and dissect the intercostal nerve. We do not perform osteotomy of the rib or partial rib resection as is occasionally done by others. The intercostal nerve is identified by carefully incising the periosteal sleeve of the rib in the midclavicular line. This incision is performed at the caudal border of the rib where the motor intercostal nerve is located. The motor intercostal nerve can also be identified by tracing the lateral sensory branch proximally, if it was previously identified, or by finding the flash of bleeding from the intercostal artery and vein, which are in close proximity to the nerve. Electrical stimulation can be used to confirm the motor branch. When identified, the nerve is

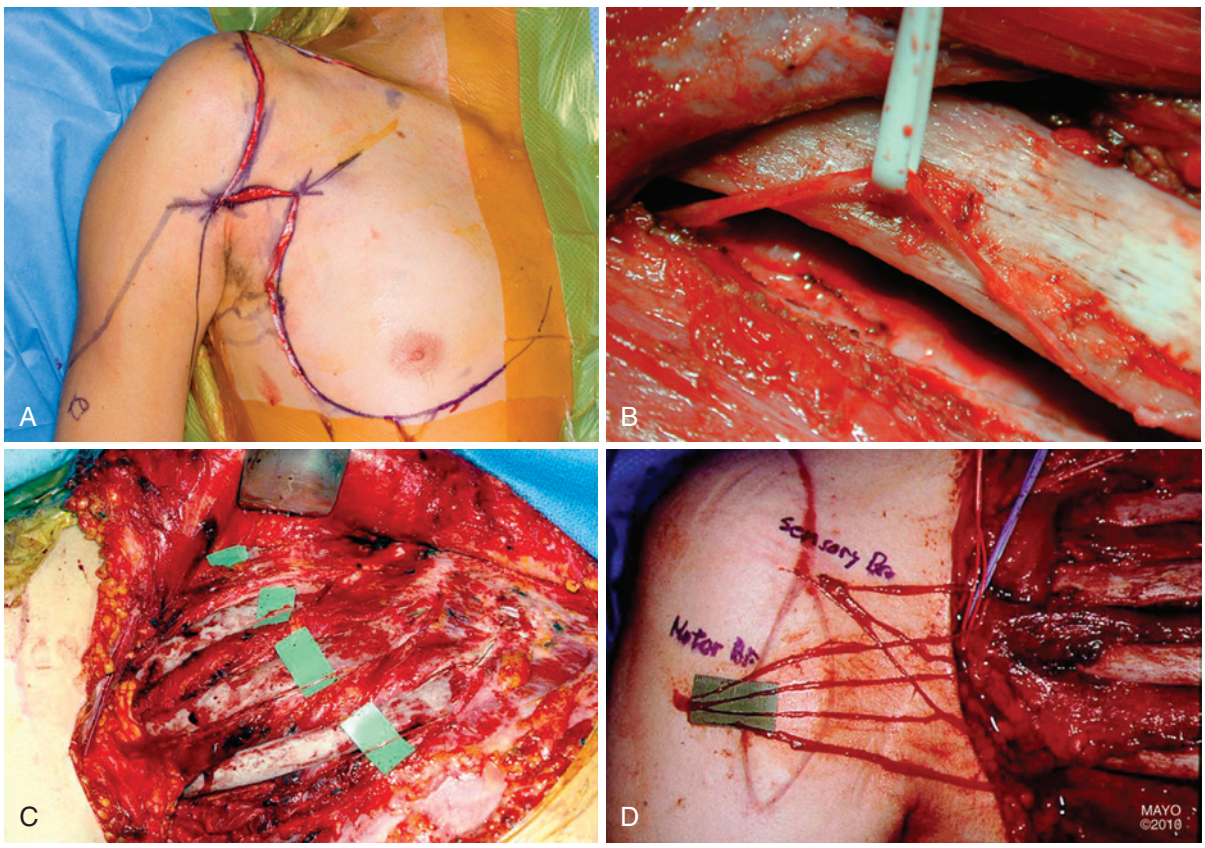

FIGURE 34.26 Intercostal nerve harvesting. **A,** Inframammary incision. **B,** Close-up of intercostal nerve exposure. **C,** Full-field view after harvesting several intercostal nerves from the costochondral junction to the mid-axillary line. **D,** Sensory and motor intercostal nerves destined for targeted sensory and motor nerve transfer, respectively. (By permission of Mayo Foundation for Medical Education and Research. All rights reserved.)

mobilized in a vessel loop and dissected. The motor branch is traced anteriorly toward the costochondral junction by gentle spreading of the intercostal muscles to gain the required length to reach the target nerves. The nerve is dissected to the midaxillary or posterior axillary line posteriorly. The lateral cutaneous sensory branch of the nerve (larger than the motor nerve) is found at a point between the anterior and midaxillary lines; it may be separated from the motor component as far posteriorly as necessary. Care is taken to open the rib periosteum posteriorly and inferiorly so that it will not compress the nerve once it is reflected for transfer. The technique is repeated for harvesting the other intercostal nerves required for reconstruction. After appropriate dissection, each intercostal nerve is transected distally and passed through the serratus anterior muscle into the axillary region. Pleural tear and air leak should be noted and treated either by pleural repair, tight skin closure, or placement of a chest tube, depending on the extent of the tear or leak.

Transfer to the Musculocutaneous Nerve. When intercostal nerves are used for restoration of elbow flexion, three or four intercostal nerves are generally coapted to the musculocutaneous nerve; an alternative is to transfer two to three intercostal nerves directly to the biceps motor branch (Figure 34.27). To accomplish the nerve transfer, dissection of the musculocutaneous nerve is performed as described in a previous section. Special care is taken when dissecting the motor branch to the biceps, occasionally with the brachialis motor branch, proximally toward its branching from the lateral cord to separate the motor (biceps and brachialis motor branch) and sensory (lateral antebrachial cutaneous nerve) portions of the musculocutaneous nerve as far proximally as possible. This technique will maximize the number of motor fibers and minimize the number of sensory fibers that will be targeted by the transfer. Moreover, it will provide a biceps (with or without the brachialis) motor branch with enough length to reach the transferred intercostal nerves without any tension and without the use of intervening nerve grafts. This retrograde dissection of the musculocutaneous nerve should be done carefully, and one should err on cutting on the lateral antebrachial cutaneous portion of the musculocutaneous nerve so that the biceps motor branch portion of the nerve is not injured or thinned. If the length of the biceps motor branch is insufficient for direct transfer, we prefer to perform the intercostal nerve transfer into the musculocutaneous nerve itself. We always try to perform a direct intercostal nerve transfer (i.e., without the use of interpositional grafts) because of the improved outcomes with this technique, even if this translates into the use of an intercostal nerve that has been transected distally. Others, knowing that the intercostal nerves have more motor axons in their proximal parts, prefer to use the more proximal portion of the intercostal nerves (e.g., just distal to the lateral sensory branches). Transferring intercostal nerves requires balancing use of the proximal intercostal nerve (more motor axons) and performing direct transfers without the use of intervening nerve grafts (better outcomes). The nerve repair is done with the arm abducted and externally rotated to ensure that these motions will not lead to undue tension on the coaptation site.

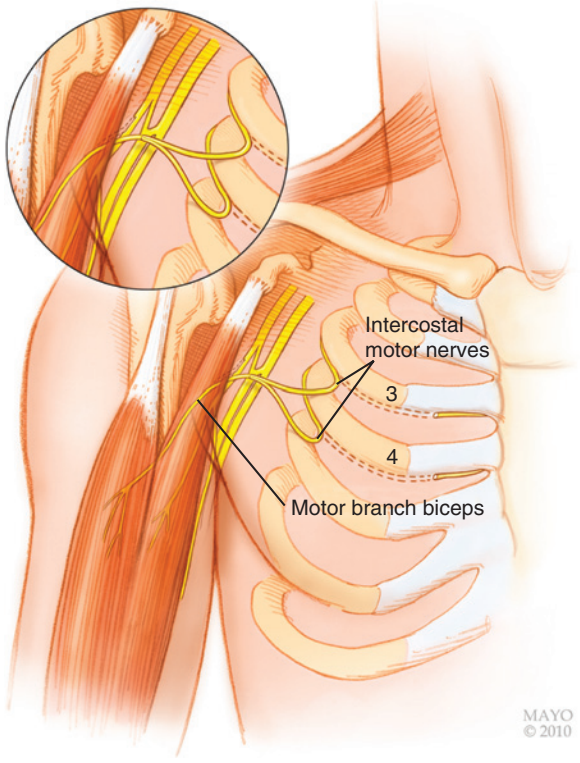

FIGURE 34.27 Intercostal neurotization (T3-T4) of the biceps branch of the musculocutaneous nerve. (By permission of Mayo Foundation for Medical Education and Research. All rights reserved.)

Postoperative Care Specific to Intercostal Nerve to Musculocutaneous Nerve Transfer. An early sign of reinnervation is the presence of chest pain when the biceps is pinched (positive squeeze test); this sign may be apparent 4 to 5 months postoperatively. Proximal biceps contraction without elbow joint movement, especially during deep inspiration, is usually recognized by 6 to 8 months postoperatively. With further reinnervation, distal biceps contraction without elbow joint movement is seen and a Tinel sign may appear in the distal part of the arm, lateral to the biceps tendon. Percussion of this area causes tingling in the chest; it develops around 12 months postoperatively. Elbow flexion against gravity generally appears 12 to 18 months after surgery, and voluntary flexion against resistance is recovered gradually.[47]

A relationship between elbow movement and respiration is observed for 4 to 8 months after motor recovery, and volitional small action potentials synchronized with respiratory movement are noted. After 12 months, patients learn to flex the joint voluntarily without relating it to their respiratory rhythm. Twenty-four months after surgery, the respiratory rhythm will still affect the interval of spiked discharges on EMG, but after 32 months, biceps activity is completely distinct from the respiratory cycle. Involuntary muscle contractions continue to occur when the patient coughs or sneezes.[154] Some authors recommend aerobic conditioning programs with deep inspiration exercises (treadmill, stationary bike, abdominal "crunches") to expedite recovery in the postoperative period, although no definitive studies are available.

Contraindications. Patients with a history of chest trauma, rib fractures, or phrenic nerve dysfunction can still be candidates for intercostal nerve transfer. However, both the surgeon and the patient should be aware that rib fractures are associated with

CRITICAL POINTS *Intercostal Nerve Transfer to the Musculocutaneous Nerve*

Indications
- Most commonly performed in patients with complete brachial plexus injuries; also C5-C6, C5-C7
- Ideally done less than 6 to 9 months after injury

Pearls
- This procedure is reliable in achieving elbow flexion in the hands of an experienced surgeon.
- Distal dissection of the intercostal nerve to the costochondral junction and proximal dissection of the biceps motor branch will allow direct nerve transfer without an intervening nerve graft.

Technical Points
- Expose the third to sixth intercostal nerves through an inframammary incision.
- Each intercostal nerve dissection and transfer is done without osteotomy of the ribs.
- Proximal dissection of the motor nerve to the biceps (to separate it from the musculocutaneous nerve) is performed.
- Direct neurorrhaphy of the intercostal nerves without tension provides a better outcome.
- The repair is done with the arm maximally externally rotated and abducted 90 degrees.

Pitfalls
- Pleural tear
- Technically demanding
- Separation of the nerve repair when neurorrhaphy is performed under tension

Postoperative Care
- Shoulder immobilization is maintained for 3 weeks.
- Gradual increases in shoulder range of motion are made to avoid tension on the repairs.
- Reinnervation starts approximately 6 to 9 months postoperatively.

a 10% chance of the associated intercostal nerve not being functional. Moreover, preoperative pulmonary function tests may be useful to assess respiratory reserve, especially in patients with concomitant phrenic nerve dysfunction; very rarely do low pulmonary function test results prevent use of the intercostals.

Complications. Intercostal nerve harvesting can generally be performed safely. Pleural effusion and acute respiratory distress syndrome are rare. Pulmonary function normalizes by 3 months.[42] Lack of tension at the coaptation site and proper positioning of the shoulder are imperative to prevent rupture of the nerve repair and subsequent failure of the transfer.

Expected Outcomes. Intercostal to musculocutaneous nerve transfers without interposition grafts for restoration of elbow flexion achieve strength of at least M3 in 72% of patients. If interpositional nerve grafts are used, only 47% of patients will achieve strength of M3 or better. A metaanalysis did not show significant differences in outcome with the transfer of two or three to four intercostal nerves without an intervening graft, but the analysis lacked sufficient power.[139] The time interval between the trauma and the reconstructive surgery and the age of the patient may influence the outcome.[47,154]

Transfer of the Triceps Motor Branch to the Axillary Nerve

This nerve transfer has been widely accepted (Figures 34.28 and 34.29) and used for patients with strong triceps function (usually isolated C5-C6 injuries) in an effort to provide dual muscular reinnervation for the shoulder.

Dissection and Transfer. A longitudinal incision is made on the posterior aspect of the arm from the acromion to the midarm region. The deltoid is retracted superiorly. The axillary nerve is identified in the quadrilateral space. It is useful to identify and trace the axillary sensory branch back toward the quadrilateral space to help identify the main nerve. The anterior division of the axillary nerve is selectively targeted. It is dissected toward the quadrilateral space and transected as far proximally as possible. Depending on the size match, the axillary nerve proper is occasionally reinnervated by one or more triceps motor branches; more commonly, we perform reinnervation of only the anterior division of the axillary nerve. A theoretical rationale for targeting the entire nerve is to simultaneously reinnervate the teres minor muscle, which may improve strength of external rotation.[18]

Next, the interval between the long and lateral heads of the triceps is deepened to expose the radial nerve and its branches to the three heads of the triceps. We typically select the triceps long head motor branch, as originally described by Leechavengvongs and colleagues,[116] and confirm its identity and functionality with stimulation. The chosen triceps motor branch is mobilized proximally and distally, including all subbranches to the muscle. One should determine how long the triceps branch needs to be to reach the anterior division of the axillary nerve before distal transection of this branch. If needed, release of the teres major fascia is performed to increase proximal mobilization of the motor branch. Direct repair can then be accomplished without tension. Some have recommended the use of different triceps branches; there is no agreement on the importance of each triceps head, and triceps weakness is rare regardless of the branch used, provided that the triceps muscle was of normal strength preoperatively.

Contraindications. Patients with triceps weakness preoperatively (BMRC grade < 4) are not candidates for this technique. Differential EMG studies of all three heads can be helpful for decision making, particularly in patients with a partial C7 injury.

Complications. Immediately postoperatively, patients may have some transient triceps weakness. This weakness typically seems to be related more to lack of effort, pain, or fear than to a new neurologic deficit. We have not observed new triceps weakness on physical examination at the first postoperative visit.

Expected Outcomes. Deltoid contraction is often noticeable by 6 months (Figure 34.30). Leechavengvongs and coauthors reported a 124-degree arc of motion in patients with concomitant transfer of the spinal accessory nerve to the suprascapular nerve.[116] The operative results in patients with C5 and C6 avulsions were better than those in patients with C5, C6, and C7 avulsions. The outcome of our isolated axillary nerve injuries treated with this transfer resulted in a BMRC grade that averaged 3.5 ± 1.1. Deltoid muscle strength correlated with the age of the patient, delay from injury to surgery, and body mass index of the patient. In the multiple linear regression model, the delay from injury to surgery, age of the patient, and body

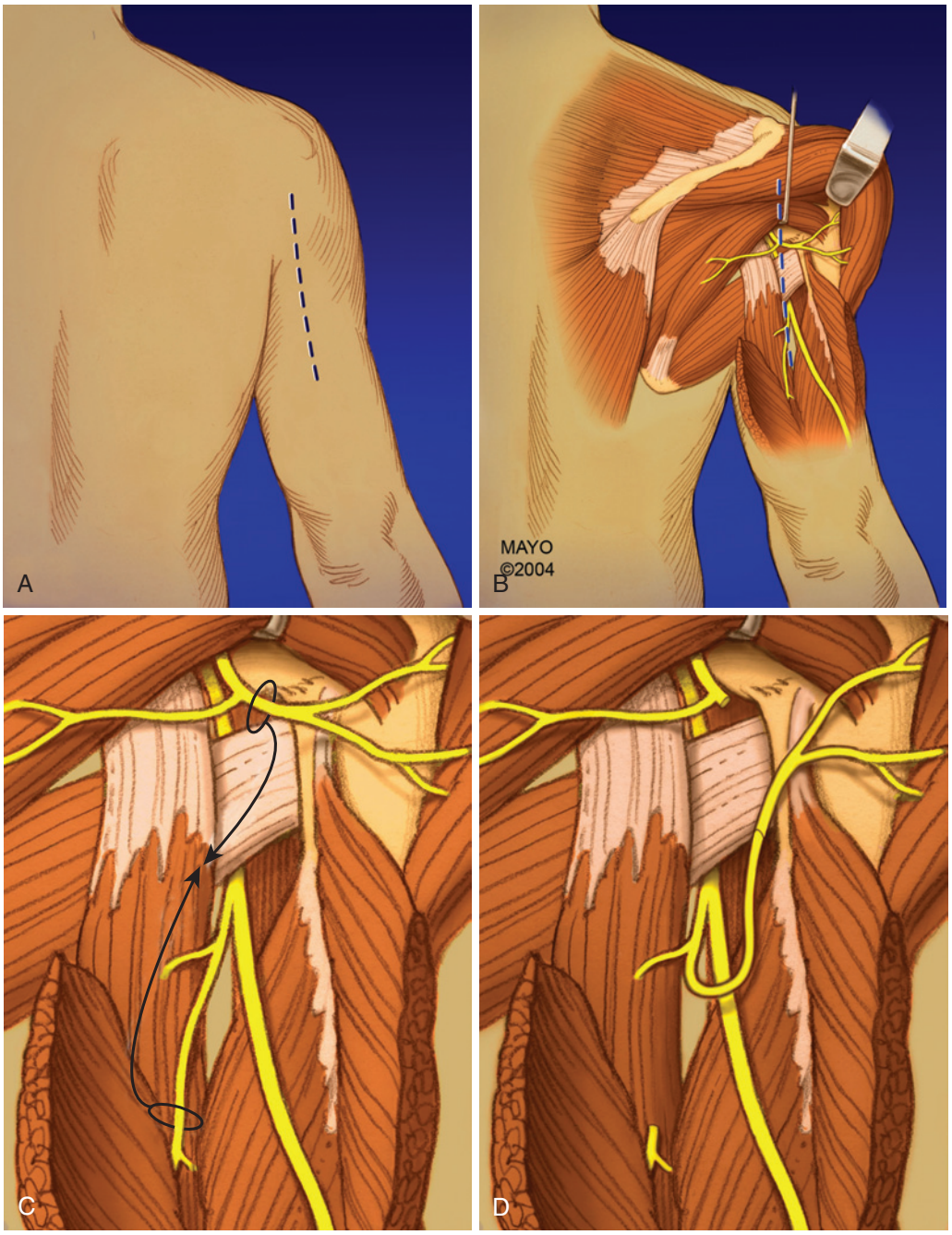

FIGURE 34.28 Transfer of the right triceps branch to the axillary nerve (Leechavengvongs procedure). **A,** Skin incision. **B,** Identification of the axillary nerve in the quadrilateral space and the radial nerve and triceps branches in the triangular interval. **C,** The long head triceps motor branch is selected and transferred to the anterior division of the axillary nerve. **D,** Direct nerve repair without tension. (By permission of Mayo Foundation for Medical Education and Research. All rights reserved.)

mass index of the patient were the important factors, in that order, that affected the outcome of this procedure.[120]

Contralateral C7 Nerve Transfer

Contralateral C7 nerve transfer remains a controversial option with three potential issues: (1) whether it can be done safely, (2) whether it works well enough to justify the risk, and (3) whether independent function can be relearned in adults. Some surgeons have difficulty accepting that this normal nerve can generally be transected and transferred without any neurologic sequelae. Based on a large clinical experience in Asia over a period of several decades, the safety and efficacy of this procedure have become accepted by many. It has been used as a donor nerve for shoulder, elbow, and hand targets (Figure 34.31) and in some cases as a donor for an FFMT with variable reported outcomes. The ability of adult patients to learn independent function is also unknown. When transfer of the contralateral C7 nerve is being considered, the risks associated with the procedure must be carefully weighed against its potential benefit.

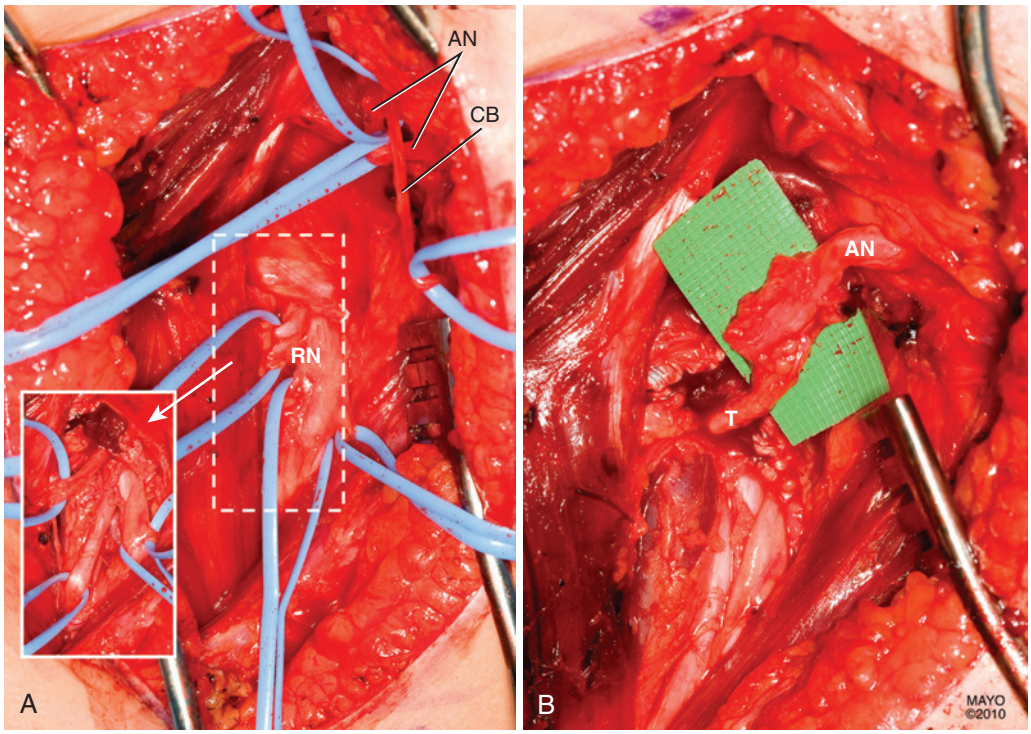

FIGURE 34.29 Transfer of the right triceps branch to the axillary nerve (Leechavengvongs procedure). **A,** The axillary nerve (AN), radial nerve (RN), and triceps branches have been identified (*inset*). Note the cutaneous branch (CB) of the axillary nerve. **B,** The long head triceps motor branch (T) has been transected distally and is about to be coapted to the anterior division of the axillary nerve (AN). (By permission of Mayo Foundation for Medical Education and Research. All rights reserved.)

CRITICAL POINTS *Transfer of the Triceps Motor Branch to the Axillary Nerve*

Indications
- Most commonly for patients with C5-C6 injuries
- Patients with a C5-C7 pattern if triceps strength is good
- Ideally done for injuries incurred less than 6 to 9 months earlier

Pearls
- Avoid the temptation of selecting too small a triceps nerve branch (inadequate size match).
- The sensory cutaneous branch of the axillary nerve can be followed to help identify the axillary nerve.
- Sufficient mobilization allows direct coaptation of the triceps branch and anterior division of the axillary nerve without a nerve graft.

Technical Points
- Use a posterior arm skin incision below the deltoid to the midarm region.
- Transfer a large enough triceps motor branch (one or two) to achieve an adequate size match.
- Perform direct (without graft) coaptation to the anterior division of the axillary nerve.

Pitfall
- Less favorable outcomes in patients with C5-C8 injury or triceps weakness of less than BMRC grade 4 preoperatively

Postoperative Care
- Shoulder immobilization is maintained for 3 weeks.
- EMG-documented reinnervation occurs by 6 months postoperatively.



FIGURE 34.30 This 12-year-old boy underwent a right triceps motor branch transfer for an isolated axillary nerve lesion after initially being seen 12 months earlier. At 10 months postoperatively he had already demonstrated good bulk in the deltoid and a full arc of abduction. Note the healed incision. (By permission of Mayo Foundation for Medical Education and Research. All rights reserved.)

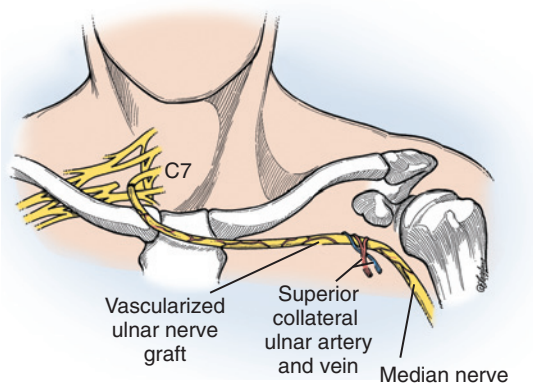

FIGURE 34.31 Contralateral C7 nerve transfer to the median nerve using a vascular pedicled graft of the ulnar nerve based on the superior collateral ulnar artery and vein. (Copyright © Elizabeth Martin.)

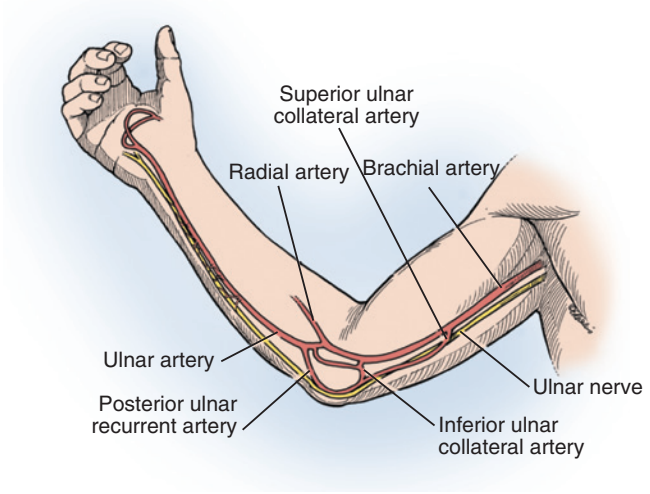

FIGURE 34.32 Vascular anatomy of the ulnar nerve. (Copyright © Elizabeth Martin.)

SURGICAL ANATOMY

Although anatomic variability exists, the supraclavicular plexus usually receives contributions from five spinal nerves: C5, C6, C7, C8, and T1. It is important to realize that each spinal nerve generally sends axons to more than one major nerve and, in turn, each major nerve contains axons from more than one spinal nerve. Accordingly, muscles in the upper limb are often innervated by multiple nerves. Although the C7 spinal nerve contributes to the posterior cord as well as to the median, musculocutaneous, and even ulnar nerves, C7-innervated muscles are cross-innervated by other spinal nerves, primarily C6 and C8. Because isolated C7 division does not result in significant loss of any individual muscle function, both the ipsilateral and contralateral C7 nerve roots are a potential transferable source of axons.[90] The posterior portion of C7 contains more motor fibers than the anterior portion does. Both the entire nerve and half of the C7 nerve (the latter procedure done to minimize risk) have been harvested with similar, albeit transient, deficits.

Contralateral C7 Nerve Dissection and Transfer. When contralateral C7 nerve transfer is planned, the contralateral neck and shoulder should be prepared and draped. The contralateral "normal" plexus is exposed as described earlier. Many groups routinely expose all five nerves of the brachial plexus to determine its anatomic configuration and the contribution of each spinal nerve. The contralateral C7 nerve is identified. It may be divided into two portions at the level of the middle trunk or dissected distally to its anterior and posterior divisions. The motor function produced by the nerve is evaluated with a nerve stimulator. If the entire contralateral C7 nerve is being used as a transfer, elbow and wrist extension with C7 nerve stimulation is evaluated before its division. Recognizing the potential devastating effects of permanent weakness in the one remaining normal upper limb, we believe that if stimulation of C7 produces any contraction of hand muscles, its use is contraindicated. The nerve is transected distally at the level of the middle trunk or at the anterior and posterior divisions. When half of the contralateral C7 is transferred, the half producing maximal pectoralis major contraction is selected and transected distally. A subcutaneous tunnel is prepared in the upper chest region that leads to the skin incision in the ipsilateral brachial plexus. A prespinal[210] or intraspinal (from a separate posterior exposure) route can shorten the distance for subsequent regeneration in comparison with the subcutaneous route.

If the contralateral C7 nerve is used to neurotize the median nerve in a patient with a pan-plexus injury, the ipsilateral ulnar nerve can be used as pedicled graft based on the superior ulnar collateral (SUC) vessels to eliminate the need for vascular anastomosis (Figure 34.32). The SUC artery arises from the medial surface of the brachial artery at the midhumeral level, 14 to 22 cm proximal to the medial epicondyle of the humerus. It pierces the medial intermuscular septum, courses distally posterior to it, and joins the ulnar nerve on its posterior surface. The artery accompanies the ulnar nerve for 4 to 15 cm and gives rise to an average of three arteriae nervorum, which pass directly into the nerve. The SUC artery descends between the medial epicondyle and the olecranon. It ends deep to the flexor carpi ulnaris muscle by anastomosing with the posterior ulnar recurrent artery and the inferior ulnar collateral artery. Venae comitantes accompany the SUC artery and terminate in the venae comitantes of the brachial artery.

If the ulnar nerve is to be used as a pedicled vascularized nerve graft, its distal end is cut at the wrist and mobilized in its full length to the level of the SUC by dividing the dorsal cutaneous branch as well as the motor branches to the extrinsic finger and wrist flexors (Figure 34.33). The distal stump is passed under the skin of the upper part of the chest to the exposed contralateral (entire or hemi) C7 nerve. Bleeding should be seen from the end of the vascularized nerve. The C7 nerve is matched and coapted to the distal end of the ulnar nerve. The proximal end of the ulnar nerve is divided proximal to the SUC at a level that allows direct connection to the target nerve, such as the median nerve in the proximal part of the arm. When a vascularized ulnar nerve is not used in cases of C5 to C8 root avulsion or in cases of distal ulnar nerve injury, a vascularized superficial radial nerve or sural nerve graft can be used. For shoulder targets, some groups have recommended using the ulnar nerve as a free vascularized nerve graft. In this case, the proximal end of the ulnar nerve is connected to the contralateral C7 nerve first, and the SUC artery and vein are anastomosed to locally available vessels such as the ipsilateral thoracodorsal trunk or

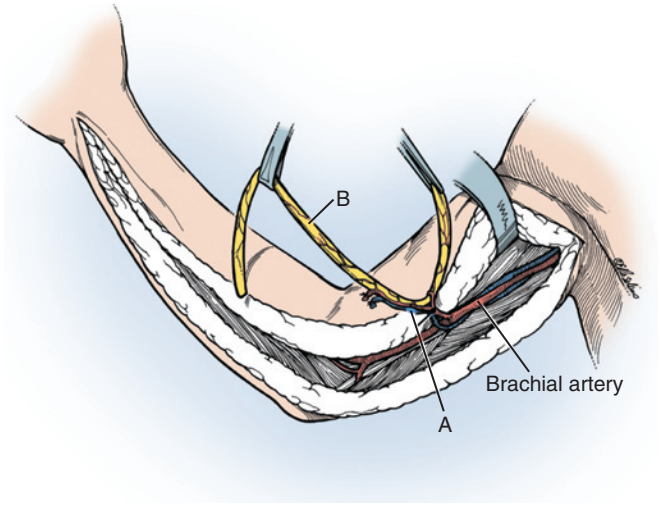

FIGURE 34.33 A vascularized ulnar nerve graft with a pedicle containing the superior ulnar collateral artery and vein. *A* points to the segmental vascular pedicle, and *B* points to the longitudinal vascularity. (Copyright © Elizabeth Martin.)

the contralateral transverse cervical artery and vein. The distal end of the ulnar nerve is passed into the subcutaneous tunnel in the upper chest region and connected to the target nerve in the supraclavicular or infraclavicular region, such as the suprascapular nerve or the posterior cord. Other groups have used two conventional sural nerve grafts to connect the hemicontralateral C7 nerve to the shoulder targets.

Postoperative Care Specific to Contralateral C7 Nerve Transfer. For the first 3 weeks postoperatively, the ipsilateral upper limb is immobilized. Over time, regeneration into the repaired nerve can be traced by an advancing Tinel sign. Because of the long distance to target muscles, reinnervation may take several years. After reinnervation, reeducation of the targeted muscle or muscles with EMG biofeedback techniques is started. Usually, muscles reinnervated by the contralateral C7 nerve can be activated by adducting, internally rotating, and extending the contralateral shoulder and by extending the contralateral elbow. A rehabilitation protocol for muscle strengthening is then initiated so that patients can try to learn to activate the muscle without assistance of the contralateral limb.

Complications. Immediately after surgery, temporary motor deficits can occur in shoulder extension and adduction, elbow extension, forearm pronation, wrist extension, and hand movement. Latissimus dorsi weakness can often be detected. Full functional recovery is usually documented within 6 months, and no long-term functional deficits have been reported in the literature.[90,186] Sensory abnormalities in the C7 distribution are expected in all patients undergoing contralateral C7 transfer[123,197] and may resolve after a few months or persist.

When an anatomic variation is present, such as a prefixed plexus with a significant C4 contribution or a postfixed plexus with a substantial T2 contribution (and a diminished C5 component), considerable deficits can occur after C7 transfer. Millesi suggested that preliminary ligation of the C7 nerve with subsequent patient evaluation, before division (at a subsequent stage), prevents this complication.[140] Others recommend exploration of all five nerves and examination for the existence of a prefixed or postfixed plexus by identification of normal anatomic relationships and intraoperative use of electrical nerve stimulation.

The other potential complication is the development of severe neuropathic pain from division of the contralateral, normal C7 nerve. This problem has been particularly noted by surgeons in Europe and appears to be much less common in Asian patients.

If contralateral C7 nerve transfer is being considered, informed consent should be obtained; the complications and expected benefits of this procedure should be exhaustively discussed with the patient and family before a decision is made. Despite reports of minimal complications in the literature, the possibility of complications in the contralateral donor arm exists. Contralateral C7 transfer should not be undertaken without a thorough understanding of the potential risks and complications associated with this procedure.

Expected Outcomes. Despite many authors recommending contralateral C7 nerve transfer to the median nerve, our outcomes have been disappointing, and patients achieve only minimal recovery of forearm motor strength, far from functional recovery.[90,186] Other authors have recommended using the contralateral C7 to neurotize the suprascapular nerve or posterior cord or musculocutaneous nerve because of a better functional outcome.

❖ AUTHORS' PREFERRED TECHNIQUE

Because of other options for achieving hand prehension and our poor results with this technique, we have abandoned the use of hemicontralateral C7 transfer, which was performed in more than 50 adults at our institution.[174] We still occasionally perform a contralateral C7 nerve transfer in children with pan-plexal injuries acquired at birth or caused by trauma.

Other Nerve Transfers

Other intraplexal and extraplexal sources of nerve transfer have been introduced or are being investigated in an attempt to expand the available donors for primary nerve reconstruction in patients with brachial plexus injury. These transfers are less commonly used than the ones described earlier and will be discussed only briefly. In patients with partial brachial plexus injuries, intraplexal sources include the ipsilateral C7, medial pectoral, and thoracodorsal nerves; in patients with pan-plexus injuries, extraplexal sources include the phrenic, hypoglossal, platysma motor branch, and cervical plexus nerves, which are also available in patients with partial injuries. The use of a more "aggressive" approach to nerve transfer allows the reconstruction of additional targets, the reconstruction of more distal targets, and the possibility of improving outcomes. However, these transfers are still controversial because of different opinions on their risk-benefit ratio and functional outcome.

Intraplexal Nerve Transfers

Ipsilateral C7 Nerve Transfer. In patients with C5-C6 brachial plexus injury, transfer of a portion (anterior division) or the whole ipsilateral C7 nerve has been suggested and used by some groups.[89] Use of the ipsilateral C7 nerve is an extension of the contralateral C7 transfer as described previously.

Medial Pectoral Nerve Transfer. Transferring the medial pectoral nerve to reinnervate brachial plexus elements is not a novel technique but remains controversial. Several authors have advocated use of the medial pectoral nerve for upper-pattern

avulsion injuries to reinnervate the musculocutaneous or axillary nerve, or an isolated long thoracic nerve, with good success. Other authors do not recommend its use and instead prefer to use available alternative nerve transfers and to preserve the innervation of the pectoralis muscles for shoulder adduction. Because there are typically several large branches of the medial pectoral nerve, it is possible to use one branch while maintaining innervation of the pectoralis sternal head. The muscle is synergistic to shoulder abduction, and transfers to the axillary nerve have been reported with success.

Thoracodorsal Nerve Transfer. The thoracodorsal nerve, which innervates the latissimus dorsi, has been proposed and used by some as a donor nerve for transfer. It originates from the posterior cord and receives nerve fibers from the seventh, eighth, and sometimes sixth cervical nerves. It has been used to neurotize the long thoracic nerve,[206] as well as the musculocutaneous and axillary nerves.[173] The better functional outcomes obtained after nerve reconstruction in patients with preserved serratus anterior function suggest that reinnervation of the serratus anterior may be beneficial. Generally, sufficient length can be obtained (8 to 19 cm) for tension-free direct coaptation with all target nerves.

Extraplexal Nerve Transfers

Phrenic Nerve Transfer. The phrenic nerve, located directly within the surgical field of the supraclavicular plexus, is an attractive source for nerve transfer. Because of its C3 and C4 contributions, it is often functional even in cases of complete brachial plexus avulsion. The phrenic nerve has been used to neurotize the suprascapular, musculocutaneous, and axillary nerves; excellent results have been achieved by several Asian and European groups.[91,126,198] The techniques used include (1) supraclavicular harvesting with direct coaptation (e.g., suprascapular nerve neurotization), (2) supraclavicular harvesting with the use of intervening nerve grafts (e.g., musculocutaneous or axillary nerve neurotization), and (3) harvesting via a video-assisted thoracic surgery approach[212] in which a longer phrenic nerve is obtained, one that can be directly transferred to the musculocutaneous nerve without an intervening nerve graft or extended with an interpositional graft to the median nerve.[213]

Despite good results obtained by certain groups,[91,126,198] many surgeons have been reluctant to sacrifice the phrenic nerve because of the potential consequences of hemidiaphragm paralysis. The literature reports a 10% initial decrease in vital capacity and pulmonary function test results with few subjective symptoms, which return to baseline within 6 to 24 months. Long-term data are only beginning to emerge. Most studies have included young, thin, Asian patients, and extrapolation of the pulmonary risks to older, heavier patients, for example, is difficult. Our group has used the phrenic nerve as a transfer in 10 patients but stopped after the occurrence of serious but transient postoperative respiratory difficulties in one patient and lack of normalization of pulmonary function test values after 2 years in several others.

Hypoglossal Nerve Transfer. The hypoglossal nerve, commonly used to neurotize the facial nerve, has been suggested as a possible donor nerve for neurotization of brachial plexus elements. Both hemihypoglossal transfers and complete hypoglossal nerve transfers (with the use of an intervening nerve graft) have been attempted in small series with disappointing results.[78,130] A few patients (complete hypoglossal nerve transfer) had morbidity related to the donor site, but despite tongue movement–related EMG activity in target muscles, only a few patients with a complete hypoglossal transfer achieved muscle strength of grade 3 or better. Regardless of the degree of reinnervation, no patient regained voluntary control of the reinnervated muscle. A single patient who underwent hemihypoglossal transfer to the musculocutaneous nerve has been reported to have independent BMRC grade 4 elbow flexion at long-term (8 years) follow-up.[17] Because of the largely poor results reported in the literature, hypoglossal nerve transfer is typically not an option for reconstruction of brachial plexus injuries.

Platysma Motor Branch Transfer. A recent anatomic study and case report proposed the platysma motor branch (from the facial nerve) as a nerve donor.[17] In this single case, the motor branch of the platysma was used to neurotize the pectoralis major muscle with an intervening nerve graft. There was no deficit noted in platysma (lip depressor) function, probably because of supplementary innervation from the cervical plexus, and the patient regained shoulder adduction strength of M4. Further studies are needed, but use of the platysma motor branch seems promising because it is an expendable nerve, it can be sectioned without deficit, and relearning of motor control can be achieved.

Transfer of Cervical Plexus Nerves. Cervical plexus anterior nerves have been proposed for neurotization of elements of the brachial plexus.[32] However, many surgeons consider the cervical plexus nerves to be predominantly sensory nerves and therefore not useful for motor neurotization.

Postoperative Care for Nerve Grafts and Nerve Transfers

In the immediate postoperative period after nerve repairs, our preference is to maintain the limb in a shoulder immobilizer for 3 weeks to allow strengthening of the nerve repair. However, others do not immobilize the limb. In all patients, physiotherapy is restarted after this period (3 weeks), with attention initially directed toward maintaining passive movement of all joints in the affected upper extremity. Follow-up is performed at regular intervals for a minimum of 2 to 3 years (preferably 5 years). When early clinical or electrophysiologic signs of motor reinnervation appear, active muscle exercises are started. Physiotherapy focused on reeducation and strengthening, including biofeedback, is very important. With therapy, patients can improve their control of the reinnervated muscles, and in those with antagonistic cocontractions, it can decrease the problem.

Timing of reinnervation of the target muscles depends on the length from the nerve donor source and the muscle end plates. Visible and palpable muscle contractions are not seen for an additional 2 months, and the strength of the muscle gradually increases afterward.

In patients with traumatic brachial plexus injury, long-term follow-up is necessary regardless of whether primary nerve surgery has been performed. Over time, patients can be evaluated for secondary reconstructive options once reinnervation has plateaued. Frequently, function can be further improved or refined with a range of surgical interventions, from minor to complex. The possible options are discussed in the later section on Secondary Reconstruction.

FUNCTIONING FREE MUSCLE TRANSFER

An FFMT is the microvascular transfer of a muscle, as well as its nerve, for the purpose of restoring limb function. Use of an FFMT for brachial plexus reconstruction was first reported by Ikuta and colleagues, who used it to restore elbow flexion in a child seen in delayed fashion.[103] Subsequently, FFMT has become an attractive option for many brachial plexus injuries, certainly in late presentations with absent function due to delay in referral or failed prior nerve surgery. Another valuable role has been to restore grasp in acute cases with avulsion of four or more nerve roots.[1,14,64,68,181] The use of a long muscle with a proximally located neurovascular pedicle, such as the gracilis, makes such reconstructions possible. A viable gracilis transfer, when fixed to the clavicle proximally and tunneled to the forearm, can animate the wrist or hand. Because the motor point of the muscle is located at the shoulder, a nerve transfer to this area will reinnervate the muscle within 6 months or less. Because of the long distances, conventional or vascularized nerve grafts for reinnervation of the forearm and hand musculature have been demonstrated to be ineffective.

In this section, use of FFMT for reconstruction after acute brachial plexus injuries (primary reconstruction, primarily for grasp) is discussed. Its use in chronic situations, primarily for elbow flexion, is provided as part of secondary reconstruction options later in this chapter. The basic science, anatomy, and principles of free muscle transfer are briefly included but are described in detail in articles by Manktelow and by Doi and colleagues.[60,132,133] We refer the reader to these detailed articles for this important theoretical information.

Prerequisites for Functioning Free Muscle Transfer

Shoulder and Elbow

Free muscle transfers performed in the first 3 to 6 months after brachial plexus injury are indicated primarily to restore prehension. Independent hand function requires fingers to independently close for grasp and open for release, with independent thumb positioning for key, precision, and chuck pinch. The complex coordinated activity of the many wrist, thumb, and finger extrinsic and intrinsic muscles required for this activity cannot generally be restored in adult patients with a global or complete plexus injury. The goal of achieving even simple composite grasp by nerve grafting or transfer has proven unreliable. Free microsurgical transfer of one or more expendable autogenous lower extremity muscles eliminates the problem of any preexisting period of muscle denervation. Proper selection of a transferred muscle, having both sufficient length and a proximal motor point, results in both a shortened reinnervation time and ability to move the wrist and/or finger motors. Motor control is generally provided by an extraplexal nerve transfer, because most acute cases for which FFMT is a consideration will have four or five nerve root avulsions.

Shoulder stability, as well as simultaneous reconstruction of elbow flexion and antagonist elbow extension function, is essential when restoring hand and wrist function with an FFMT.[60] The concept of "one muscle, one function," important in planning tendon transfers, also applies to free muscle transfer. A gracilis muscle fixed to the clavicle and acromion and used to provide finger flexion must first cross the glenohumeral, elbow, and wrist joints. If not addressed by other means, FFMT contraction will first act to reduce shoulder subluxation resulting from paralysis of the rotator cuff and deltoid, diminishing the muscle's potential excursion and force available for distal joints. Restoration of shoulder stability, whether by nerve graft, tendon transfers, or arthrodesis of the glenohumeral articulation, is imperative.

At the elbow, the need to provide an active stabilizing antagonist muscle is even more important. The same gracilis muscle crossing anterior to the axis of rotation will use most of its available force and excursion elbow flexion moment *unless* triceps (extensor) function is provided. The wrist must also be positioned by arthrodesis or a separate free muscle transfer if useful finger flexion is to be achieved. These concepts have been clearly detailed by Doi and coworkers.[64,66,68]

Other important prerequisites for FFMT include adequate skin coverage, a stable and well-vascularized bed for tendon gliding, an available motor nerve, vasculature permitting successful microvascular anastomoses, and supple finger joints. Patients must be willing and able to undergo a complex and lengthy microsurgical procedure and comply with a supervised postoperative rehabilitation protocol that minimizes problems associated with scar formation and strengthens and reeducates the neurotized muscle flap for the needed function. Preoperative planning must assess these requirements and should include vascular imaging (arteriogram, CT or MRI angiogram) and assessment of skin and tissue quality, as well as passive joint range of motion (shoulder, elbow, wrist, and hand). There must be an expendable motor nerve in the vicinity of the muscle neurovascular pedicle. In most brachial plexus injury cases, this will mean an extraplexal source, most commonly cranial nerve XI (spinal accessory nerve) or two to three intercostal motor nerves. Other nerves may be used as available, including regenerated contralateral C7 nerve transfer or elements of the brachial plexus in partial injuries.[184] Function of the spinal accessory nerve is assessed by strength testing of the trapezius and by EMG. Intercostal motor function is generally not practically measured preoperatively. We have found intercostal nerve injury to be relatively infrequent even in the presence of rib fracture.[113] Availability of adequate numbers of extraplexal nerve donors cannot be absolutely assured preoperatively, however. Intraoperative assessment by nerve stimulation may require a change in surgical plans and goals.

Vascular injuries are common in adult brachial plexus injury, occurring in 10% or more of patients.[194] The incidence is higher when the first rib is fractured. Avulsion of the subclavian or axillary vessels is generally considered a contraindication for free muscle transfer because patency of the thoracoacromial or thoracodorsal vessels is usually needed for FFMT to be successful. At times, collateral flow may permit filling of these vessels. If imaging of the subclavian and axillary branches shows that their blood flow is sufficient, even when a more proximal arterial occlusion is present, FFMT may be successful and provide appropriate function.[97]

Some patients with avulsion injury develop a stiff and edematous intrinsic-minus posture with a flattened palm and fixed finger metacarpophalangeal joint extension. Success in these situations will require restoration of supple joints or later positioning of metacarpophalangeal joints in a flexed posture by tenodesis, capsulodesis, or arthrodesis. In addition, total active motion of fingers can be improved by stabilizing the

wrist with an arthrodesis. This has been found to be useful in the double free muscle procedure described in the following,[2] as well as in single free muscle transfers for finger and thumb grasp/pinch.

Selection of a Donor Muscle

When planning free muscle transfer, a suitable potential donor muscle must have a vascular pedicle permitting transfer, sufficient length and excursion for its new role, and adequate force, and must also be expendable. The latissimus dorsi, gracilis, adductor longus, and rectus femoris muscles have all been used as donor muscles for FFMT and meet the general criteria just listed.[3] When reconstruction is planned for elbow flexion alone, another option is to reinnervate the ipsilateral latissimus dorsi and transfer it as a functioning pedicled flap. This is ideally performed within 6 to 9 months after injury. In addition, it is used occasionally as a free functioning transfer from the contralateral side. The rectus femoris muscle is also a powerful muscle and can be used to restore elbow flexion. Transient reduction in knee extension strength occurs after its harvest, so some physiotherapy is required. It provides a good fit for strength but not excursion when compared with the biceps.

The gracilis is the most frequently used free functioning muscle. It is a strap muscle rather than a pennate muscle, with excellent fiber length, but it has considerably less cross-sectional area than the biceps that it is intended to replace. Thus, data suggest that it is poorly matched for strength but well matched for needed excursion. Experience has demonstrated that both the gracilis and the latissimus can provide useful function.[60] The gracilis generates sufficient force to flex the elbow against gravity in most cases, however, and has other desirable qualities. Most importantly, the proximal position of its neurovascular pedicle permits rapid reinnervation from either the spinal accessory or intercostal motor nerves, whereas its length and shape facilitate its passage into the forearm to animate the wrist and hand. Sananpanich, Tu, and Pookhang and colleagues have described the use of a combined gracilis/adductor longus transfer, using a common vascular pedicle and two independent obturator nerve branches to permit a one-stage double-muscle transfer useful for combined finger flexion and wrist extension, for example.[175] The same flap has been used by others to provide shoulder abduction and elbow flexion.[200,201]

Operative Procedures

Gracilis Harvest

The gracilis is a superficial muscle that lies on the medial aspect of the thigh. A branch of the obturator nerve enters the muscle obliquely just cephalad to the major vascular pedicle, at a point 6 to 12 cm from its origin. The dominant arterial supply is provided by a branch from the profunda femoris artery 8 to 12 cm from the muscular origin and is approximately 4 to 6 cm long. The vascular pedicle is dissected between the adductor magnus (posteriorly) and adductor longus (anteriorly).

Harvest of the gracilis[84] for FFMT starts with identification of the distal tendon at the tibial insertion (Figure 34.34). A longitudinal incision is made over the pes anserinus, and the sartorius fascia is elevated. The pes anserinus is identified. The superior tendon is that of the gracilis muscle, whereas the inferior tendon is that of the semitendinosus muscle. The gracilis tendon is isolated; its distal attachment is maintained. A distal medial thigh incision is made to identify the myotendinous junction of the gracilis. All attachments to the gracilis tendon are freed at this level. By distal and outward retraction, the muscle is placed on tension and can easily be palpated; the outline of the underlying muscle is drawn on the skin along its length.

The gracilis is routinely transferred with a proximal skin paddle for postoperative flap monitoring.[133] A handheld Doppler device is used to identify myocutaneous perforators in the proximal third of the muscle flap. An elliptical incision is designed to incorporate these perforators in the skin paddle. The anterior incision is made, and dissection is directed toward the adductor longus muscle. The fascia over the adductor longus muscle is incised and mobilized with the skin paddle to preserve any septocutaneous perforators. The adductor longus thus exposed is retracted gently anteriorly to expose the interval between the adductor longus and adductor magnus. The gracilis covers this interval superficially. Its major vascular pedicle can be visualized traversing this interval perpendicularly, entering the gracilis together with its obturator motor nerve. The motor branch from the superficial division of the obturator nerve follows an oblique course toward the gracilis, lying in the same adductor interval cephalad to the vessels and oriented approximately 45 degrees to them. It is identified with a nerve stimulator at this point and mobilized toward the obturator foramen. Additional motor and cutaneous branches encountered may be preserved by blunt proximal mobilization from the nerve, providing a longer gracilis motor nerve stump, often 10 cm or more in length. It is important to maximize the nerve length if a nerve graft is to be avoided. This is particularly true when the spinal accessory nerve is used and the gracilis motor nerve must be passed into the supraclavicular fossa.

The major vascular pedicle is adherent to the adductor longus due to multiple vascular perforators to this muscle. These must be identified and ligated, thus progressively mobilizing the arteriovenous pedicle from medial toward its profunda femoris artery and vein origin. Dissection can be continued to the profunda vessels to obtain the maximal pedicle length. The posterior incision of the skin paddle is made, and dissection is directed posteriorly to the fascia covering the adductor magnus muscle. The adductor magnus fascia is incised and mobilized to form a fascial sling together with the adductor longus fascia that envelops the gracilis muscle and helps to ensure skin paddle viability.

Before harvest and division of the muscle's proximal and distal attachments, resting tension can be marked with sutures placed at 5-cm intervals to facilitate appropriate tensioning of the muscle. The distal tendon is divided, passed into the proximal thigh wound, and pulled through. The secondary pedicle is identified and ligated at this time. The fascial sling around the gracilis is preserved by complete release of the fascia from the adductor magnus and adductor longus muscles. The distal tendon is temporarily replaced in its native bed, and the proximal tendon is released from the pubic ramus. The vascular pedicle is not divided until the recipient site is fully prepared, preferably by a second surgical team. This includes dissection of the recipient vessels, donor nerves, as well as fixation in the proximal clavicle and acromion. A subcutaneous tunnel or pocket is prepared in the arm and the distal tendon of insertion exposed, depending upon the purpose of the procedure. Only

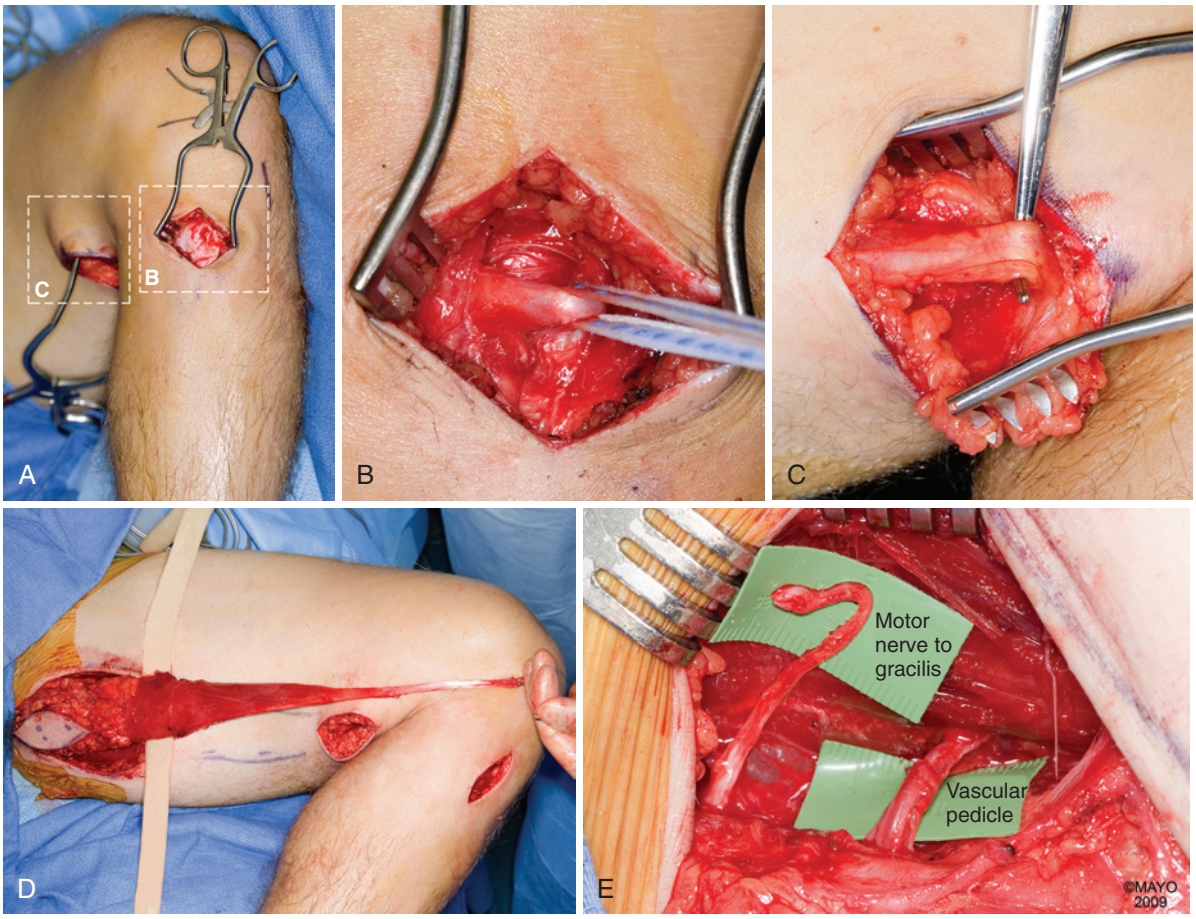

FIGURE 34.34 Gracilis harvest for free functioning muscle transfer. **A,** Harvest begins with distal exposure of the gracilis tendon via a longitudinal incision made over the pes anserinus. After the gracilis tendon is identified, a distal medial thigh incision is made to identify the gracilis myotendinous junction. The *dashed boxes* are insets that are further clarified in **B** and **C. B,** The gracilis tendon (*in umbilical tape*) is identified underneath the sartorius fascia; the cephalad tendon is the gracilis, whereas the caudad one is the semitendinosus. **C,** The gracilis myotendinous junction is identified in the distal medial thigh incision. All attachments between the myotendinous junction and the distal insertion are then released. **D,** The proximal gracilis muscle is dissected while maintaining a fascial sling around it to preserve the septocutaneous perforators. A skin paddle with myocutaneous perforators is taken with the muscle to act as a monitoring flap. **E,** The vascular pedicle and motor nerve are identified in the interval between the adductor longus and gracilis muscles. The motor branch to the gracilis is dissected as far proximally as possible. The vascular pedicle is dissected laterally to the profunda femoris vessels, which requires identification and ligation of the vascular perforators to the adductor longus muscle. (By permission of Mayo Foundation for Medical Education and Research. All rights reserved.)

then is the vascular pedicle ligated proximally and divided. Any remaining soft tissue attachments are released, and the muscle is transferred to the arm.

Once transferred, the proximal tendon is expeditiously secured to the acromion and clavicle. We use suture anchors preplaced in the lateral aspect of the clavicle and acromion to quickly attach the gracilis. The muscle is placed in a premade subcutaneous tunnel and provisionally secured to adjacent tissue in its final position, but without distal tenorrhaphy and adjustment of final tension until the vascular connections and nerve transfer are completed. The vascular anastomoses are typically performed to a branch of the thoracoacromial artery end-to-end and the cephalic vein end-to-end. Perfusion is reestablished with less than 1 hour of ischemia time. Meticulous neurorrhaphy to two to three intercostal motor nerves or to the spinal accessory nerve is performed with epineural sutures and fibrin glue as close to the muscle as possible to minimize reinnervation time. When intercostal neurorrhaphy is performed, the shoulder is abducted 90 degrees and maximally externally rotated to minimize the effect of later shoulder motion on nerve tension.

Appropriate muscle tension is important for a good result and can most easily be achieved by restoration of the original muscle resting length via superficial sutures placed at measured intervals along the length of the muscle before dissection as originally described by Manktelow and colleagues.[131,133] Observation of an appropriate tenodesis effect of the transfer is another indication of appropriate resting muscle length.

Free Muscle Transfer for Reconstruction of Grasp After Complete Avulsion of the Brachial Plexus

Rationale. One of the major advances in brachial plexus surgery has been the application of FFMT in the acute setting. As described by Doi and associates, the goal is to obtain voluntary elbow flexion and extension, hand sensation, and grasp and release function in patients with avulsion of four or five nerve

roots.[62,64,68] After complete brachial plexus avulsion, several surgical approaches have been developed to restore prehension.[58,59,141,144] The goal of obtaining grasp in these adult patients has been elusive, the most promising other method being transfer of the contralateral C7 nerve with a bridging vascularized ulnar nerve graft.

A potential method to obtain hand function is the restoration of active wrist extension, with a later Moberg key pinch procedure (thumb interphalangeal joint arthrodesis and flexor pollicis longus tenodesis, resulting in a tenodesis-powered prehensile pinch powered by wrist extension). Unlike the patients with spinal cord injury for whom the key grip procedure was designed, a patient with a brachial plexus injury maintains both a normal contralateral upper limb and normal lower extremity function. Further, most activities of daily living can be accomplished with one hand. Patients with complete brachial plexus palsy need restoration of a few important bimanual activities, such as lifting with a bimanual hook grasp or holding a bottle while opening its cap rather than key pinch.[67,68] A powerful grip independent of the contralateral limb and the independent use of both hands are desirable in brachial plexus injury. Active rather than passive (tenodesis) finger flexion is imperative for a powerful grip.

Release of grasp is another useful function in prehension. Release reconstructed by secondary tenodesis of the finger extensor tendons, as in a Moberg-type reconstruction, will need gravity-aided wrist flexion[143-145,215] and can be achieved only with the elbow flexed. This synergistic action cannot be accomplished when the elbow is extended. To achieve voluntary finger extension independent of elbow position, a second free muscle transfer is required. The complexity of this undertaking for the patient, the surgeons, and the therapist, as well as the need for all aspects of the procedure to function properly, makes this procedure among the most challenging and, when successful, most rewarding of the reconstructive options for a patient with a complete avulsive injury.

Prerequisites for Grasp Surgery. Stability of the shoulder and elbow joints is necessary for proper transmission of the power of the transferred muscle to achieve effective hand function. Double free muscle transfer acts to supplement shoulder stabilization but may not be adequate. Shoulder stabilization can be achieved by scapulohumeral arthrodesis when shoulder instability persists after double FFMT, but also by a variety of existing and newly described tendon transfer options.[73] Restoration of both extension and flexion of the elbow is extremely important for optimal use of the hand in day-to-day activities. Although elbow flexion is readily accomplished with nerve or tendon transfer, triceps reanimation has proven difficult.[141] The use of a functioning muscle crossing the elbow to reconstruct finger flexion or extension cannot function without some means of reconstructing elbow extension.[69] A patient may, for example, demonstrate powerful wrist extension or finger flexion when asked, but only when using the opposite hand to stabilize and prevent involuntary elbow flexion. Bimanual use does not occur unless elbow extension is restored. Available intercostal nerves are used to neurotize the triceps brachii muscle for elbow extension. This enables the patient to stabilize the elbow independently, without need of the contralateral hand, and use the powerful finger flexion afforded by the muscle transfer effectively.

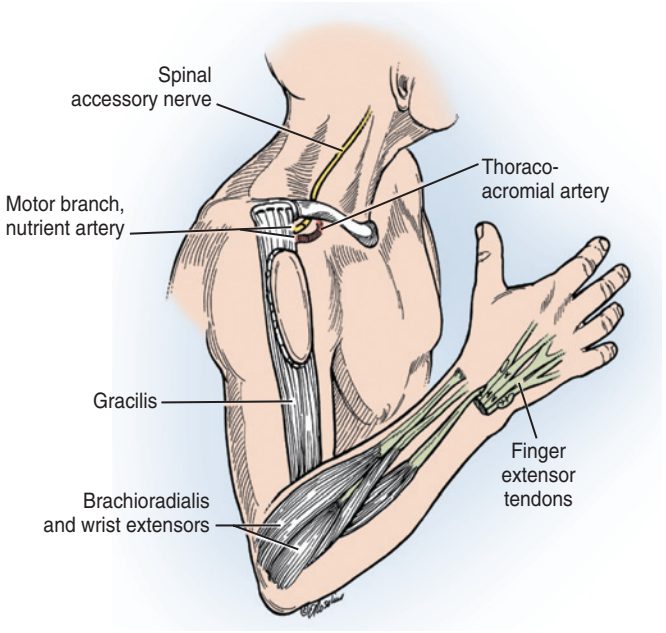

FIGURE 34.35 The first-stage operative procedure for reconstruction of prehension after complete brachial plexus avulsion is a free muscle transfer to restore elbow flexion and finger extension simultaneously. The gracilis is transferred and innervated by the spinal accessory nerve. (Copyright © Elizabeth Martin.)

Operative Technique

Double Free Muscle Transfer. Our modified double free gracilis muscle transfer technique consists of five reconstructive steps performed in two operative procedures. During the first operation, the steps are (1) exploration of the brachial plexus and reconstruction of the proximal ruptured motor nerves, if possible; and (2) transplantation of the contralateral gracilis, neurotized by the spinal accessory nerve, for elbow flexion and finger or wrist extension (Figure 34.35). In the second operation, three remaining steps are performed: (3) a second free functioning gracilis transfer, neurotized by the fifth and sixth intercostal nerves, for finger flexion (Figure 34.36); (4) use of the third and fourth intercostal nerves to neurotize the motor branch of the triceps brachii muscle for elbow extension (Figures 34.37 and 34.38); and (5) coaptation of the intercostal sensory rami to the medial cord of the brachial plexus to restore sensibility of the hand (see Figure 34.38). In addition, a sixth set of procedures for secondary reconstruction are often required, including tendon transfers for glenohumeral stabilization and abduction/external rotation, as well as arthrodesis of the thumb carpometacarpal and/or interphalangeal joints and the wrist joint. Tenolysis of one or both of the transferred muscles may also be necessary.

Timing of the various reconstructive procedures is important and guided by several criteria. Steps 1 and 2 are performed at the first stage of the operation, and steps 3 to 5 are performed at the second stage, usually 2 or 3 months after the first operation. The secondary reconstruction is done approximately 1.5 years after the first stage of the operation, depending on the extent of recovery.

Brachial plexus exploration is described in detail earlier. In the first stage, simultaneous elbow flexion and finger extension are reconstructed with an FFMT by using the spinal accessory

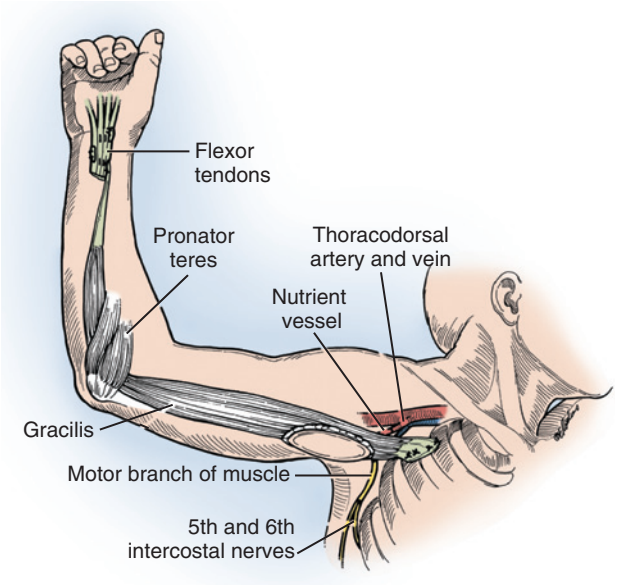

FIGURE 34.36 The second-stage procedure for reconstruction of prehension after complete brachial plexus avulsion is a free muscle transfer to restore finger flexion. The gracilis is transferred and is innervated by the fifth and sixth intercostal (T5 and T6) nerves. (Copyright © Elizabeth Martin.)

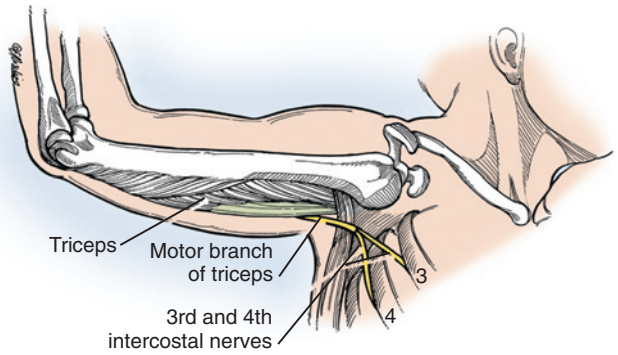

FIGURE 34.37 Intercostal (T3 and T4) nerve transfer to the motor branch of the triceps brachii is also performed in the second-stage procedure for reconstruction of prehension after complete brachial plexus avulsion. The goal of this neurotization is to stabilize the elbow against the antagonist flexors. (Copyright © Elizabeth Martin.)

as the motor nerve. We have preferentially connected the muscle for wrist extension rather than the extensor digitorum, as described by Doi, for three reasons: (1) The free muscle at times is not able to extend the wrist as well as the fingers, thereby resulting in wrist drop and poor hand function; (2) the development of independent wrist extension augments grasp strength by the tenodesis effect; and (3) the release function of fingers is still possible with passive wrist flexion. The donor gracilis muscle from the contralateral thigh is selected because the orientation and location of its neurovascular bundle match the site of the donor vessels. The length of the gracilis muscle should be sufficient to span the distance between the acromion and midforearm without tension. This is verified by measuring the length of the gracilis muscle from its pubic origin to its tibial insertion. The donor muscle is harvested from its proximal origin to the distal attachment.

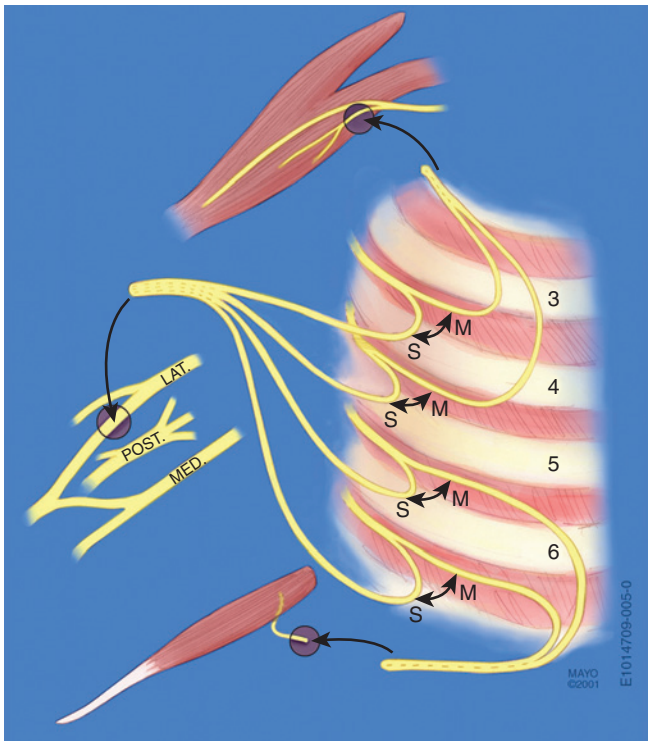

FIGURE 34.38 Composite summarizing our modification of the second stage of Doi's procedure for prehension. A second free muscle transfer and nerve transfers for elbow extension and sensory restoration are performed simultaneously. *LAT.*, Lateral cord; *M*, motor; *MED.*, medial cord; *POST.*, posterior cord; *S*, sensory. (By permission of Mayo Foundation for Medical Education and Research. All rights reserved.)

Correct muscle tension is critical for good postoperative function. Before detaching the muscle, the resting length of the muscle is reproduced and silk sutures can be placed on the surface of the muscle at 5-cm intervals, as described by Manktelow and colleagues.[132,133]

The distal portion of the spinal accessory nerve is dissected, divided, and transferred. The motor nerve of the transferred muscle is passed behind the clavicle and coapted to the distal branch of the spinal accessory nerve in the supraclavicular area. The nutrient vessels of the free gracilis muscle are anastomosed to the thoracoacromial artery and vein or to the cephalic vein. The transferred muscle is placed superficially over the anterior part of the deltoid and is attached to the acromion with nonabsorbable sutures or a soft tissue anchoring system. A simple and straight route for the free muscle is created from its new origin to its final insertion to maximize the force of contraction. It is placed on the anterolateral aspect of the arm and dorsal surface of the forearm. To prevent bowstringing, the free muscle is passed deep to the brachioradialis and radial wrist extensor muscles just distal to the elbow.

This position of the muscle is optimal for elbow flexion and finger extension; however, grip strength may weaken when the elbow is flexed. Correct muscle tension is reproduced in the upper limb before final suturing of the muscle to the finger or wrist extensors. The original muscle length is restored by stretching the muscle until the distance between the markers is once again 5 cm. Tension is adjusted with the shoulder in 60 degrees of abduction and 15 degrees of anterior flexion, the

elbow in 150 degrees of flexion, the wrist in neutral, and the fingers in full extension. After adjusting the tension, the position of coaptation is marked over the tendon of the extensor digitorum and the donor muscle tendon. The elbow is flexed to 90 degrees, and with the wrist in neutral and the fingers fully flexed, the tenorrhaphies between the donor muscle tendon and extensor digitorum tendon are completed at the previously marked sites. The appropriateness of tension in the transfer is evaluated by using the tenodesis principle.

Reconstruction of finger flexion is done by using a second free muscle transfer. It is performed 2 to 3 months after the first operation, once improvement is noted in postoperative contracture of the elbow and finger joints. The third to sixth intercostal nerves are dissected as far as the midclavicular line and transferred to the axillary region. The fifth and sixth intercostal nerves are used as the donor motor nerve for the second gracilis muscle transplant. The gracilis is harvested from the ipsilateral thigh after ensuring that it will reach the midforearm from the second rib. The proximal end is sutured to the second and third ribs. To activate finger flexion, it is placed on the medial aspect of the upper part of the arm and forearm so that it does not act as a secondary elbow flexor.

The distal gracilis tendon is passed deep to the flexor pronator origin, just distal to the elbow, to lie adjacent to the flexor digitorum profundus muscles and tendons. The flexor digitorum profunda tendons are first interconnected to provide a cascade of increasing flexion from the index finger to the small finger, and they are then joined with the gracilis tendon with a Pulvertaft weave; an additional flexor carpi radialis tendon graft is often required to prolong the gracilis. Muscle tension is determined with the principles described earlier. When the tension is adjusted, the shoulder, elbow, and wrist are in the same position as described earlier. The fingers are kept in full flexion. The nutrient vessels of the gracilis are anastomosed to the thoracodorsal artery and vein. The fifth and sixth intercostal nerves are transferred directly without tension and without an intervening nerve graft to the motor nerve of the second muscle transplant. The third and fourth intercostal nerves are similarly transferred to the motor branch of the triceps brachii muscle to activate the elbow extensors.

To restore hand sensibility, the sensory rami of the intercostal nerves are sutured to the medial cord contribution to the median or ulnar nerve or to the lateral cord contribution to the median nerve of the brachial plexus at the second operation. The sensory-dominant fascicles of the medial cord can be easily distinguished from the motor-dominant fascicles by measuring SNAPs, if available. Sensory nerve fibers do not undergo wallerian degeneration, because most dorsal ganglion cells survive after preganglionic injury to the nerve roots.

Postoperative Protocol. Postoperative monitoring of the muscle is important, because prompt detection of vascular impairment may allow salvage of the gracilis flap. A variety of methods are in clinical use, including implantable Doppler systems, duplex sonography, near infrared spectroscopy laser Doppler flowmetry, and, recently, assessment of muscle contractility.[57] We have generally relied upon skin perfusion for monitoring, together with Doppler examination of the cutaneous perforators. Aftercare is critical for outcomes. Conventionally, the elbow is immobilized for 6 weeks in a position of 100 degrees of elbow flexion and neutral supination of the forearm in a shoulder immobilizer. After this period, passive range of motion is begun, avoiding shoulder abduction greater than 60 degrees if intercostal nerves have been transferred. Once reinnervation has begun, active range-of-motion exercises (with gravity eliminated and aided by electromyographic biofeedback) are begun. Maximum recovery requires 18 to 24 months.

Recently, this conventional postoperative regimen has been compared with an early passive mobilization protocol that began immediate elbow and digit passive mobilization.[61] Doi uses compression of the tendinous portion of the transferred gracilis at the elbow to move the fingers beginning 1 week after surgery, with the elbow in extension to apply tension to the transferred muscle. Early motion has prevented the need for tenolysis in the early motion group, as compared with a 26% incidence of tenolysis with conventional methods.

Low-intensity electrical stimulation of the paralyzed target muscles (the two transferred gracilis muscles, the triceps brachii, and the supraspinatus and infraspinatus if the suprascapular nerve has been repaired) can be started during the third postoperative week and may be continued until EMG-confirmed reinnervation is noted in the muscles. An early motion protocol as described by Doi may provide superior results rather than 6 weeks of elbow and finger immobilization.

After EMG documentation of reinnervation of the transferred muscle (usually 3 to 8 months postoperatively), EMG biofeedback techniques are started to train the transferred muscles to move the elbow and fingers. Muscular reeducation is indicated when patients display minimal active contraction of an identified muscle or muscle group. The initial goal of reeducation is for patients to reactivate voluntary control of the muscle. As the muscle strengthens, active motion begins, first with gravity eliminated and lastly against gravity. Rehabilitation should continue for at least 2 years after surgery so that use of the reconstructed hand for daily activities can be mastered.

Subsequent Surgery. Following recovery of extrinsic finger flexion, paralysis of intrinsic muscles innervated by the median and ulnar nerves will result in a worsening claw deformity and impaired pattern of grasp and pinch. Absence of lumbrical function causes the reanimated flexor digitorum profundus tendons to initiate flexion at the interphalangeal joints, preventing an efficient wrapping of the hand around the desired object. This results in a resting claw finger stance that may in time become a fixed deformity with metacarpophalangeal joint hyperextension and proximal interphalangeal joint flexion. Postoperative physiotherapy, including a lumbrical bar or hand-based anticlaw splint, may be helpful, as well as one of the variety of anticlaw passive tenodesis procedures described in the literature. In addition, the thumb is unable to pinch effectively due to unopposed thumb interphalangeal flexion and lack of active motors to position the metacarpophalangeal and carpometacarpal joints. There is a need to "simplify" the multiple joint chain of the thumb, most frequently by arthrodesis of the carpometacarpal or interphalangeal joints, or both.[85] Most patients will also benefit from a wrist arthrodesis to enhance the effect of an FFMT for finger function. Claw deformity can be improved by a passive Zancolli lasso or other static anticlawing procedures (see Chapters 31 and 33 for details of these procedures).

Basic sensory functions such as protective sensation and position sense should be restored when motor function is being

reconstructed in a severely paralyzed limb. Supraclavicular (cervical plexus) or intercostal nerve transfers provide limited sensibility of the hand after double FFMT.

CRITICAL POINTS *Double Free Muscle Transfer for Reconstruction of Prehensile Function*

Indications
- Total paralysis of the brachial plexus
- Acute cases less than 6 months after injury
- No injury to the subclavian artery, spinal accessory nerve, and intercostal nerves
- Age younger than 40 years

Preoperative Evaluation
- Normal function of the trapezius muscle
- Supple joints

Pearls
- The basic function of the upper extremity, prehension, can be restored by this procedure.

Technical Points
- Dissection of the donor nerve and recipient vessels: obtaining maximum length of intercostal motor nerves
- Harvest of the donor muscle
- Suture of the proximal attachment of the muscle
- Suture of the motor nerve of the muscle: for intercostal nerves, with the shoulder abducted 90 degrees and maximally externally rotated
- Vascular anastomosis of the nutrient vessels of the muscle
- Suture of the distal tendon of the muscle to the target muscle in proper tension
- Performance of the procedures accompanying nerve transfer for shoulder reconstruction in the first stage and performance of nerve transfers for elbow extension and sensory reconstruction in the second stage

Pitfall
- Proximal joint stability is imperative to achieve useful recovery.

Postoperative Care
- The shoulder is immobilized in 30 degrees of abduction and flexion and 60 degrees of internal rotation with the elbow in 100 degrees of flexion, the wrist in neutral position, and the fingers in forced flexion or extension, depending on the reconstruction; the reconstruction is protected by a shoulder immobilizer for 3 weeks. Thereafter, shoulder abduction is restricted to 60 degrees to prevent inadvertent tension on the intercostal nerve transfer.
- EMG-documented reinnervation begins 3 to 8 months postoperatively.

Complications. Vascular compromise after FFMT is fortunately infrequent, and reinnervation of the muscle is generally successful. Adhesions of the transferred muscle to the surrounding tissue are a problem that may be minimized by an early range-of-motion protocol. The most important factor affecting the outcome for grasp is the extent of recovery of the triceps, as previously explained. If reinnervation of the triceps brachii fails, secondary reconstruction, such as reinnervated infraspinatus or deltoid transfer to the triceps brachii, is recommended to restore elbow stability.

If the glenohumeral joint remains unstable even after recovery of these muscles, glenohumeral tendon transfers or arthrodesis should be performed. Care must be taken to prevent fractures of the proximal humerus after arthrodesis. After recovery of active finger motion, arthrodesis of the thumb carpometacarpal joint and/or interphalangeal joint may be helpful. In addition, tenodesis flexion of the metacarpophalangeal and interphalangeal joints of the thumb and proximal and distal interphalangeal joints of the fingers may augment stable pinch function. A passive Zancolli lasso procedure may be used to minimize the expected claw deformity manifesting as flexor digitorum profundus function improves.

Expected Outcome. Thirty of 36 patients undergoing reconstruction by the double free muscle procedure and monitored for more than 24 months after the second free muscle transfer (mean follow-up, 40 months) were assessed for the long-term outcome of prehension, including motion and stability of the shoulder and elbow (Figure 34.39), voluntary and independent motion of the fingers, sensibility, and performance of activities of daily living.[64,66] The functional outcome of prehension according to the authors' classification was excellent in 6 patients (which implies restoration of more than 90 degrees of elbow flexion, dynamic stability of the elbow while moving the fingers, and more than 60 degrees of total active motion of the fingers), good in 11 patients (same as excellent, except for total active motion of 30 to 60 degrees), fair in 3 patients (total active motion of less than 30 degrees), and poor in 10 patients. Satisfactory results (excellent and good) were achieved in 17 of 30 patients (57%).

Half the patients recovered sensibility of the palm and adequate positional sense. However, protective sensation in the ulnar side of the hand and fingers was not recovered in half of the patients. Minor injury and burns can easily occur in these parts of the hand.



FIGURE 34.39 Good elbow flexion was achieved in this patient who underwent a two-stage double free functioning muscle transfer for elbow flexion and grasp. (By permission of Mayo Foundation for Medical Education and Research. All rights reserved.)

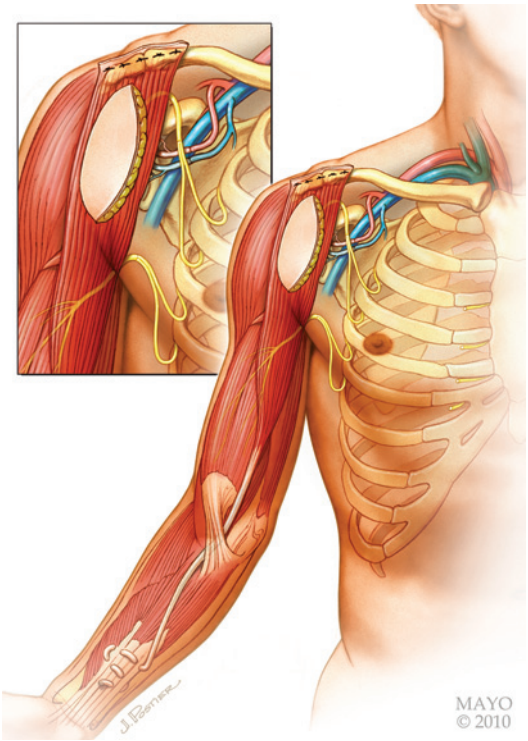

FIGURE 34.40 In our one-stage free functioning muscle transfer for prehension, motor intercostals are transferred to the biceps and free functioning muscle. (By permission of Mayo Foundation for Medical Education and Research. All rights reserved.)

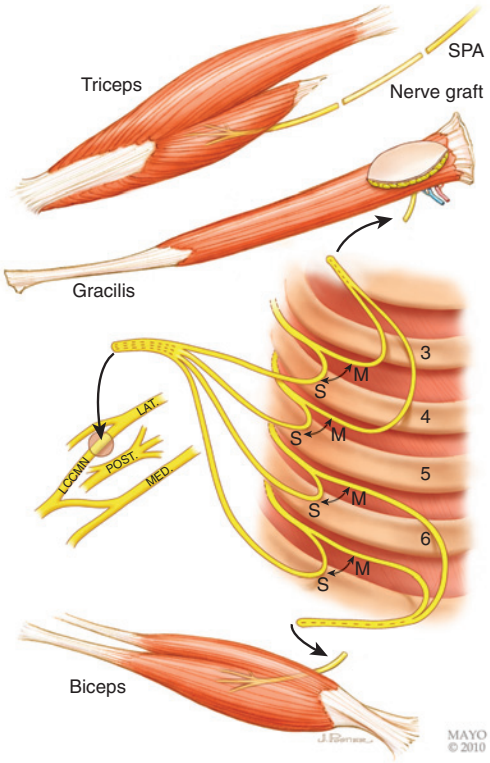

FIGURE 34.41 Composite highlighting our current one-stage procedure to achieve prehension. The spinal accessory nerve is used to reinnervate the triceps. Motor intercostals are transferred to the native biceps and to a free functioning muscle transfer for combined elbow and finger flexion. Sensory intercostals are transferred to the lateral cord contribution of the median nerve. *LAT.*, Lateral cord; *LCCMN*, lateral cord contribution to the median nerve; *M*, motor; *MED.*, medial cord; *POST.*, posterior cord; *S*, sensory; *SPA*, spinal accessory nerve. (By permission of Mayo Foundation for Medical Education and Research. All rights reserved.)

Single-Stage Functioning Free Muscle Transfer for Prehension

Despite reported success with double FFMT for prehension, it remains a daunting undertaking for both the surgeon and patient. Two to three major surgeries followed by significant dedicated rehabilitation may be both financially and emotionally difficult for patients. It has been our current practice to use a single FFMT in one operation that can provide elbow flexion and extension, grasp, and sensation. Only finger extension is not reconstructed. The indications for this method are the same as for a double free muscle transfer: avulsion of four or five nerve roots. It is important that surgery be performed no later than 6 to 8 months following injury so that critical triceps function can be restored.

A supraclavicular exploration is performed, and if a viable proximal stump is available (i.e., postganglionic injury), sural nerve grafts are used to target the suprascapular and axillary nerves. Two intercostal motor nerves (T5 and T6) are transferred to the biceps motor branch of the musculocutaneous nerve, and another pair (T3 and T4) to a free functioning gracilis. The gracilis is attached to the acromion and distal clavicle, and the distal tendon is woven into the flexor digitorum profundus and flexor pollicis longus to produce finger flexion and thumb pinch (Figures 34.40 and 34.41). An antecubital pulley must be used to avoid bowstringing. The intact lacertus fibrosus, reinforced if needed by weaving the flexor carpi ulnaris across the antecubital fossa to the lateral epicondyle and back, is generally used for this purpose. To balance the elbow flexion motion, the spinal accessory nerve is transferred to the triceps branches of the radial nerve with an interpositional nerve graft (often the superficial radial nerve). A secondary wrist and thumb carpometacarpal and interphalangeal joint arthrodesis is performed when motor function returns, usually accompanied by a passive Zancolli lasso procedure to prevent an intrinsic-minus claw deformity.

The outcomes of the single-stage FFMT for hand and elbow function have been encouraging. Although the results of the double-stage FFMT described by Doi and associates[64] are anecdotally better than those of the single-stage FFMT, the rudimentary grasp has been beneficial for our patients. The fiscal and psychological burden of undergoing two extensive surgical procedures within 6 weeks has been challenging in our patient population. A single-stage major surgery with secondary minor surgeries (for wrist fusion and thumb interphalangeal and carpometacarpal fusions) has been better accepted by our patients. We have been using the procedure for approximately 7 years and are in the process of analyzing our results.

Nerve Reimplantation

Experimental studies of the implantation of avulsed ventral roots into the spinal cord in rats, cats, and then primates over a period of several decades suggested that spinal motor neuron axons may regenerate.[36] These studies led to small clinical trials.[37] This procedure, pioneered by Carlstedt and colleagues, remains controversial and is still under investigation.

SECONDARY RECONSTRUCTION

Shoulder Reconstruction in Adult Patients With Brachial Plexus Injury

Persistent shoulder instability and lack of mobility are common and debilitating problems in adult patients with brachial plexus injury. The lack of shoulder mobility significantly hinders use of the upper extremity even if the elbow, wrist, and fingers are functioning normally. Recovery of deltoid and rotator cuff function is often incomplete, regardless of whether brachial plexus reconstruction has been performed; such incomplete recovery results in poor abduction and limited or no external rotation.[20,206] Traditionally, recovery of active elbow flexion and reduction of shoulder subluxation, which lead to improvement in glenohumeral stability and pain, are interpreted as clinical successes. However, with the limited or absent shoulder external rotation, most of these patients maintain an internal rotation position of the shoulder, and this in turns results in a "hand-on-belly position." In these instances, patients cannot position the hand in front of the body in the coronal plane, thereby resulting in significant limitation of the functional use of the limb.

Options for improving shoulder function and stability include fusion and tendon transfers. Shoulder fusion is a reliable procedure for stabilizing the glenohumeral joint; however, it is irreversible and relies entirely on scapulothoracic motion for shoulder motion. The procedure is consequently contraindicated in patients with limited scapulothoracic motion or paralysis of the periscapular muscles.[51,160] Saha[172] and Goldner[87] both recommended tendon transfer for a paralytic shoulder and used shoulder fusion only as a last resort. We agree with these authors, and it is our preference to attempt shoulder reconstruction with either nerve transfers or tendon transfers and leave shoulder fusion as a salvage procedure when no other options exist.

Because of the complexity of shoulder joint motion, it is important to have a basic understanding of the biomechanics of the shoulder before attempting shoulder reconstruction with tendon transfers. In this section, the basic biomechanics of the shoulder and the anatomy and function of the muscles around the shoulder will be reviewed. Both classic and novel tendon transfers for paralytic shoulder reconstruction will be discussed.

BASIC BIOMECHANICS AND RELEVANT ANATOMY OF THE SHOULDER

Fourteen muscles work around three joints (glenohumeral, acromioclavicular, and sternoclavicular joints) and one scapulothoracic articulation to create three-dimensional shoulder motion. Eight muscles specifically move the glenohumeral joint, including the latissimus dorsi, pectoralis major, deltoid, supraspinatus, infraspinatus, subscapularis, teres minor, and teres major. The first two muscles originate from the chest wall, spine, and clavicle, and the latter six originate on the scapula and insert on the humerus. Additionally, six muscles support the scapula on the chest wall and include the serratus anterior, trapezius, rhomboid minor, rhomboid major, levator scapulae, and pectoralis minor. These muscles originate from the chest wall and spine and insert onto the scapula.

Goldner divided the muscles around the shoulder into four functional groups: group 1, *the prime movers*, includes the clavicular head of the pectoralis major and deltoid; group 2, *the stabilizers*, includes the subscapularis, supraspinatus, and infraspinatus; group 3, *the depressors*, includes the teres major, biceps, latissimus dorsi, pectoralis major, and triceps; and group 4, *the accessory stabilizers of the scapula*, includes the trapezius, serratus anterior, pectoralis minor, levator scapulae, and rhomboids.[85] The concepts described by Saha and Goldner imply that smooth and normal shoulder function requires stable and normal scapulothoracic motion in addition to a normal deltoid and rotator cuff.[75]

The muscle's ability to contract and move an articulation is related to its tendon excursion. It has been shown that the excursion of the rotator cuff muscles is considerably less than that of the deltoid muscle with simple scapular plane abduction, thus implying that the rotator cuff muscles are the primary stabilizers of the glenohumeral joint during shoulder motion.[99] The stabilizing effect of the rotator cuff muscles (via a force couple created by the subscapularis anteriorly and the infraspinatus posteriorly) resists a relative upward shearing moment at the glenohumeral joint created by the contracting deltoid muscle during early abduction. To illustrate this concept, it should be understood that effective function of the deltoid (prime mover of the shoulder) is significantly compromised if the stabilizing function of the rotator cuff is lost or deficient.

Among the four rotator cuff muscles, the subscapularis and infraspinatus are the most important ones in stabilizing and contributing to the overall abduction moment arm to the shoulder. It has been estimated that the functional contribution of the supraspinatus to the overall abduction moment arm is only 14%; the subscapularis, 52%; and the infraspinatus and teres minor combined, 32%.[15,106] Similarly, the subscapularis provides 42% of the internal rotation moment, and the infraspinatus and teres minor combined provide 45% of the external rotation moment.[106] The importance of the infraspinatus in abduction and external rotation has been demonstrated by Gerber and coworkers, who showed that a nerve block to paralyze the infraspinatus led to loss of only approximately 45% of abduction strength and 70% of external rotation strength of the shoulder independent of the abduction angle.[82]

The accessory stabilizers of the scapula are an important group of muscles that stabilize and mobilize the scapula on the chest wall and are essential to complement shoulder motion in abduction and flexion.[87] The serratus anterior muscle is an important complement to deltoid function.[53] Better shoulder functional outcomes have been reported in patients with brachial plexus injury who had partial or full recovery or preservation of the serratus anterior than in those without serratus function.[206] Therefore, when tendon transfers about the shoulder are planned, the first priority is given to reconstruction of the prime movers and stabilizers, followed by the scapular stabilizers/movers. In most adult brachial plexus cases, reconstruction of active scapular stabilization by tendon transfer is rarely possible because of the scarcity of available adequately functioning muscles.

Principles of Tendon Transfer

There are well-known important principles that should be followed to improve the chance for successful tendon transfer, and

they are discussed in Chapter 31.[28] Understanding the relative tension and potential excursion of the shoulder muscles is essential for preoperative planning.[99] All parameters should be taken into consideration, although a perfect match of donor-to-recipient tendon tension, excursion, and vector is not possible.

Tendon Transfer for Reconstruction of Shoulder Function

It has classically been taught that reconstruction of shoulder flexion-abduction is the primary priority in reconstruction of a paralytic shoulder. However, in discussing priorities of reconstruction with our patients, we have found that the majority of patients complain most about the lack of external rotation, even more so than the lack of forward flexion or abduction. External rotation of the shoulder is a critically important function in daily activities and is performed by the infraspinatus and teres minor muscles. External rotation allows the humerus to be rotated away from the body so that when elbow flexion occurs, the hand and forearm can clear the abdomen or chest wall. An inability to externally rotate the shoulder to clear the abdomen or place the hand in front of the body can be frustrating, especially when elbow flexion is good or close to normal.

One of the most important factors in determining outcome after shoulder reconstruction in patients with brachial plexus injury is the level and degree of brachial plexus injury. In previous reports on shoulder reconstruction by tendon transfer after brachial plexus injury, detailed evaluation of the available muscles around the shoulder and the feasibility of transfer of these muscles to restore the biomechanics of the shoulder are not adequately addressed. For example, shoulder instability is expected after brachial plexus injury because of paralysis of the rotator cuff muscles (dynamic stabilizers of the shoulder). The techniques described to stabilize the shoulder address the sequelae rather than the biomechanical cause of the instability, and subsequently, glenohumeral fusion for shoulder subluxation has been described to solve this problem.

Prerequisites necessary for tendon transfer about the shoulder include a shoulder that has an adequate soft tissue envelope and is passively mobile. Pain and limb edema must be controlled before surgery. Finally, a cooperative patient who understands the objectives of the surgery and participates in the arduous rehabilitation process is necessary for success.[119] Other relevant questions related to the tendon transfer procedure that should be addressed before surgery include the following:

1. Restoration of which function or functions will yield the greatest functional result?
2. What muscles are available?
3. Are the available muscles expendable, and do they have sufficient strength (M4 or greater), adequate excursion, and a proper vector to permit function?

Decisions are based on a large number of anatomic, biomechanical, and clinical outcome studies. In the adult shoulder there is little information to guide the surgeon. Relatively few functional muscles are available, and their expendability is unclear. Accurate isolation and determination of strength are difficult because of the complex forces about the shoulder girdle. In plexus injuries, the trapezius, levator scapulae, and rhomboids have been reported to be preserved or recovered in 96% of patients.[159] The trapezius innervation is extraplexal, and the dorsal scapular nerve supplying the rhomboids and levator scapulae receives contributions from more proximal cervical nerves.[159] Additional muscle groups may be available in patients with incomplete plexus palsy as well, which greatly expands the opportunity for reconstruction. Finally, division of multipennate muscles into their functional subcomponents, as described by Herzberg and colleagues,[99] can provide additional tendon transfer options.

Upper Trapezius Transfer

Historically, the trapezius is the most common tendon transfer performed for adult patients with brachial plexus injury, including those who undergo spinal accessory nerve transfer as part of their brachial plexus reconstruction.* In most of these patients, the upper part of the trapezius is preserved and hypertrophies over time, thereby gaining sufficient strength for transfer.[53] Trapezius transfer was described by Hoffa in 1891, followed by Lewis in 1910 and Lange in 1911. Tendon prolongation with fascia lata led to poor results attributed to stretching and scarring.[171] Bateman reported transfer of the muscle along with its acromial insertion into the proximal end of the humerus in 1955,[16] later modified by Saha,[172] whose name is now associated with the operation.[171] However, Saha originally defined three basic shoulder functions that need to be reconstructed with available nonparalyzed local muscles. He rarely recommended this transfer in isolation, and he was an advocate of multiple tendon transfers in an attempt to restore normal shoulder function. However, it should be mentioned that most of his patients were younger and had shoulder weakness or paralysis as a result of poliomyelitis rather than traumatic brachial plexus injury. There is a significant difference in the pattern of weakness and muscles available for transfer between these two groups of paralytic conditions. The transfers that were performed for polio were selected on the basis of the type of paralysis and residual power of the available local muscles.[177] Most commonly, it was recommended that transfer of the upper trapezius be used to restore function of the deltoid and clavicular head of the pectoralis major, which Saha called the "prime movers." He transferred the levator scapulae or sternocleidomastoid muscle to replace the supraspinatus, which he described as a vertical "steerer." The anterior horizontal steerer (subscapularis) can be substituted for by the pectoralis minor, the upper two slips of the serratus anterior, or a residual part of the pectoralis major. The posterior horizontal steerers (infraspinatus, teres minor) can be replaced by a part of the latissimus dorsi or teres major.

Despite Saha's recommendation for multiple tendon transfers to restore shoulder function in the paralytic polio shoulder, most of what has been published in the literature as the Saha procedure refers to the single, upper trapezius tendon transfer. Kotwal and coauthors reported an average of 60% of good results with upper trapezius transfer using the Saha technique.[112] Nineteen percent of their patients had a poor outcome, with persistent subluxation of the glenohumeral joint. Aziz and associates reported a reduction in shoulder joint subluxation after upper trapezius transfer in all their patients, with an average of 40 degrees of abduction and flexion gained.[11] Karev reported on a single case of severe atrophy of the deltoid, supraspinatus,

*See references 11, 16, 105, 112, 148, and 170 to 172.

and infraspinatus with an intact subscapularis after excision of a neurilemmoma of the brachial plexus.[105] The patient underwent upper trapezius transfer 6 months after his original surgery and had almost full return of shoulder function. In this single case, it is likely that the remarkable gains were the result of spontaneous improvement of the native deltoid and rotator cuff. Monreal and colleagues reported a reduction in glenohumeral subluxation and an average gain of 40 degrees of abduction and flexion after upper trapezius transfer in 10 patients with brachial plexus injury.[149]

Ruhmann and coworkers repeatedly published the outcome of upper trapezius transfer in adult patients with brachial plexus injury.[170,171] Originally, the Saha technique was used, although in more recent publications the method has been modified.[170,171] In Saha's technique, the trapezius is detached from the spine of the scapula and transferred with the acromion to the proximal humerus just distal to the greater tuberosity. Fixation is provided by two 6.5-mm cancellous screws with the shoulder positioned in 80 to 90 degrees of abduction. In the modified technique, the partially detached deltoid is sutured in a medial direction on top of the trapezius muscle. This technique may transmit additional power by contraction of any remaining deltoid fibers. The authors demonstrated increased function in all patients and decreased multidirectional instability in 95% of patients. The mean increase in abduction and flexion was around 30 degrees.[171] The best results were achieved in patients with a functioning biceps, coracobrachialis, triceps, or pectoralis major muscle, or any combination of these muscles. The improved outcome in this group of patients is most likely related to the additional number of functioning muscles, as well as the less severely injured patient cohort. In these patients the average abduction was 42 degrees and the average flexion was 56 degrees. By contrast, those with a completely flail shoulder (presumably complete brachial plexus injuries) gained just 28 degrees of abduction and 19 degrees of flexion. None of these studies addressed the lack of shoulder external rotation and focused solely on shoulder stability and shoulder abduction-flexion.

Latissimus Dorsi Transfer

Latissimus dorsi tendon transfer, with or without teres major transfer, is commonly used in patients with residual brachial plexus birth palsy to restore abduction and external rotation.[119] This transfer has not been used traditionally in adult patients. Most pediatric plexus injuries involve C5 and C6; in such injuries, some latissimus function is preserved. In addition, partial recovery of deltoid and subscapularis function is usually present and is critical for transfer of the latissimus dorsi to be effective. Accordingly, some authors consider paralysis of the deltoid and subscapularis muscles to be contraindications to transfer of the latissimus dorsi.[81] In patients without deltoid and subscapularis function, latissimus transfer to the greater tuberosity may magnify the inferior subluxation and adduction-extension of the shoulder. When latissimus dorsi transfer is performed to reconstruct irreparable rotator cuff tears in the presence of a normal subscapularis and deltoid, however, it functions appropriately as a humeral head depressor and external rotator.

An alternative use of the latissimus dorsi muscle is as a bipolar transfer in which the muscle is rotated about its vascular pedicle to improve its position and vector.[55,79,104] For example, reconstruction of anterior deltoid function requires release of the latissimus origin and insertion, rotation of the muscle 180 degrees, passage through the deltopectoral interval, and attachment to the acromion and humerus. Itoh and coauthors reported good results in 10 patients.[104] All of them had a good shoulder contour, six had active flexion of more than 90 degrees, and all but one had M4 power. De Smet[55] and Ferrier and associates[79] used the same technique with similarly good results. It should be emphasized that most of these patients had isolated paralysis of the deltoid and a partially innervated or completely normal rotator cuff.

Pectoralis Muscle Transfer. Hou and Tai reported on seven patients who underwent transfer of the upper portion of the pectoralis either alone (four patients) or combined with upper trapezius transfer (three patients) for deltoid paralysis.[100] They defined the functional anatomy of the pectoralis major muscle as having three parts: clavicular (originating from the clavicle), sternocostal (originating from the first to sixth sternocostal regions), and abdominal (originating from the junction of the lower sternocostal and rectus abdominis fascia). These muscular parts converge laterally and insert along the lateral lip of the bicipital groove. The tendinous portions of the clavicular and upper sternocostal heads make up the anterior tendon. These portions of the muscle are supplied by the thoracoacromial artery and innervated by the lateral pectoral nerve, whereas the lower or abdominal head is supplied by either the thoracoacromial artery or the internal thoracic branch of the axillary artery and innervated by the medial pectoral nerve. During transfer of the pectoralis major muscle, the upper portions (clavicular and upper sternocostal parts) are harvested on their pedicle, and the muscle is then turned over 180 degrees with the deep surface being superficial. The muscular portion is attached to the lateral aspect of the clavicle and the acromion, whereas the tendinous portion is anchored to the deltoid tuberosity of the humerus. In isolation, this technique restored an average of 40 degrees of abduction. When an upper trapezius transfer was added, however, the average abduction improved to 70 to 90 degrees with forward flexion of 60 to 150 degrees. Lin and coauthors reported similarly good results in patients with brachial plexus injury.[121] Shoulder mobility and stability were improved in all their patients. Functioning and preservation of the pectoral nerves are prerequisites in considering and undertaking this transfer.

Lower Trapezius Transfer

Our original description of lower trapezius transfer to restore shoulder external rotation was in a patient who sustained a brachial plexus injury that resulted in complete paralysis of the deltoid, infraspinatus, and teres minor.[74] The trapezius was prolonged by insertion of an Achilles tendon allograft at the infraspinatus tendon footprint. The patient gained 70 degrees of external rotation and was very satisfied with the outcome of surgery. The authors subsequently reported the outcome of lower trapezius transfer isolated or combined with multiple tendon transfer in 52 patients with brachial plexus injury.[73] All patients had a stable shoulder at the latest follow-up, with significant improvement of shoulder external rotation but only marginal improvements of shoulder abduction and flexion.

If a single tendon transfer is planned to restore external rotation, our original technique involves using an incision placed medial to the scapula, through which the lower trapezius is

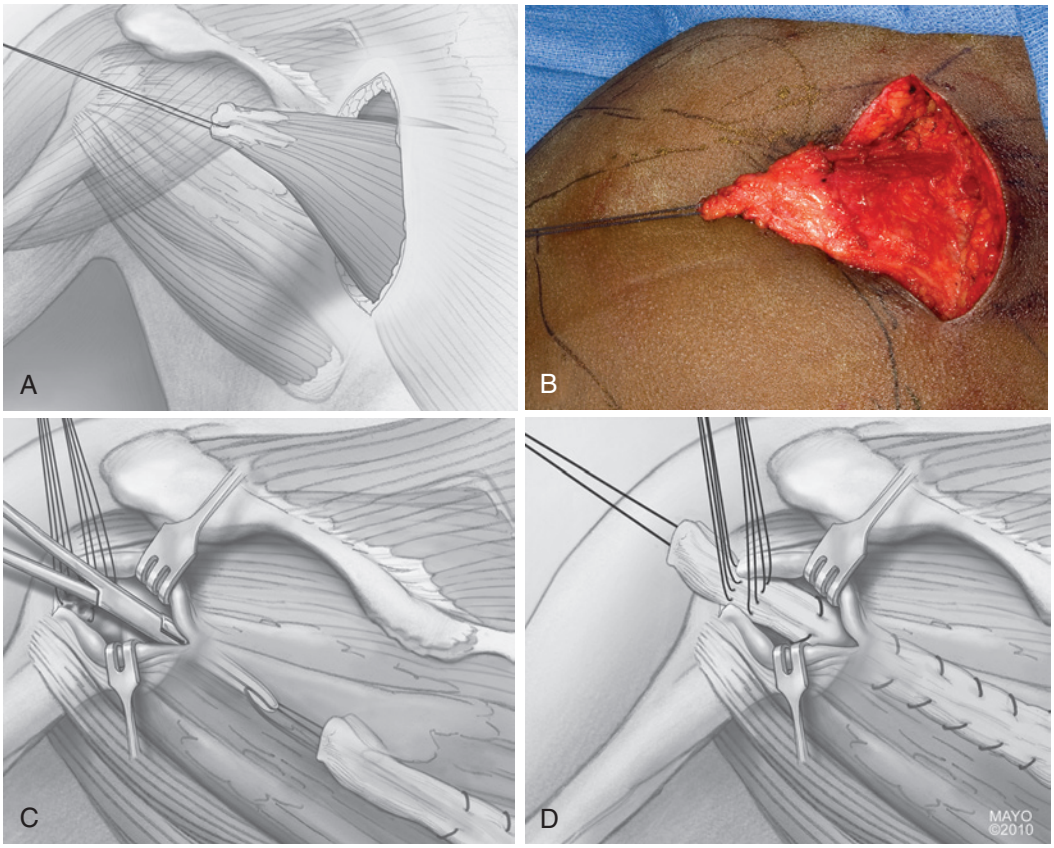

FIGURE 34.42 **A,** Lower trapezius tendon transfer starts with an incision medial to the scapula to harvest the lower portion of the trapezius. **B,** Intraoperative photograph demonstrating the lower trapezius tendon harvested through this approach. **C,** After an Achilles allograft is used to prolong the trapezius tendon, it is passed beneath the deltoid and infraspinatus to get to the level of the infraspinatus insertions. **D,** The Achilles tendon allograft is appropriately tensioned and secured to the infraspinatus footprint. (By permission of Mayo Foundation for Medical Education and Research. All rights reserved.)

harvested (Figure 34.42, *A* and *B*). The muscle is lengthened (with an Achilles or posterior tibialis tendon allograft or a hamstring autograft), passed underneath the deltoid and infraspinatus, and anchored to the infraspinatus insertion site (see Figure 34.42, *C* and *D*). However, after the original 52 patients on whom we reported, we performed more than 50 additional tendon transfers using the lower trapezius for shoulder external rotation, as an isolated transfer or combined with other tendon transfers; in the latter cases, the trapezius was transferred directly to the infraspinatus. Because almost all patients with brachial plexus injury have an intact infraspinatus tendon insertion, we were able to obtain on average 5 to 7 cm in length of the infraspinatus tendon with additional dissection (Figure 34.43); this allowed direct transfer of the lower trapezius tendon to the infraspinatus tendon without the need for tendon allograft augmentation (Figures 34.44, *A* to *C*).

Contralateral Lower Trapezius Origin Transfer

In the absence of available muscles in the ipsilateral side of the injury to transfer to the infraspinatus to restore shoulder external rotation, contralateral trapezius transfer is a unique and, possibly, the only option available to achieve this purpose.

We have demonstrated in a prior cadaveric and human volunteer study that the contralateral lower trapezius, when prolonged with lumbosacral fascia, is feasible for transfer to the affected infraspinatus to restore shoulder external rotation.[76] The contralateral lower trapezius muscle origin is detached from the thoracic spine and transferred to the denervated infraspinatus tendon (Figure 34.45, *A* to *C*). We have performed this transfer in 12 patients, with a very rewarding outcome of restoring shoulder external rotation (Figure 34.46, *A* and *B*).

Recently, Satbhai and colleagues demonstrated encouraging results in three patients who underwent contralateral trapezius transfer to restore shoulder external rotation after they regained elbow flexion from free muscle transfer.[176] The patients experienced an average improvement of more than 95 degrees of external rotation arc and an average improvement in Disabilities of the Arm, Shoulder, and Hand (DASH) scores of 14 points. No patients experienced any donor site deficits in range of motion.

❖ AUTHORS' PREFERRED PROCEDURE

Consideration of shoulder reconstruction should take place when the initial decision is being made on how to reconstruct the upper extremity. It is our routine practice to include a discussion of shoulder reconstructive options, as well as priorities of treatment, with each patient. Even after reinnervation and recovery from nerve grafting or transfers, secondary surgery may be needed to improve the stability and function of the shoulder.

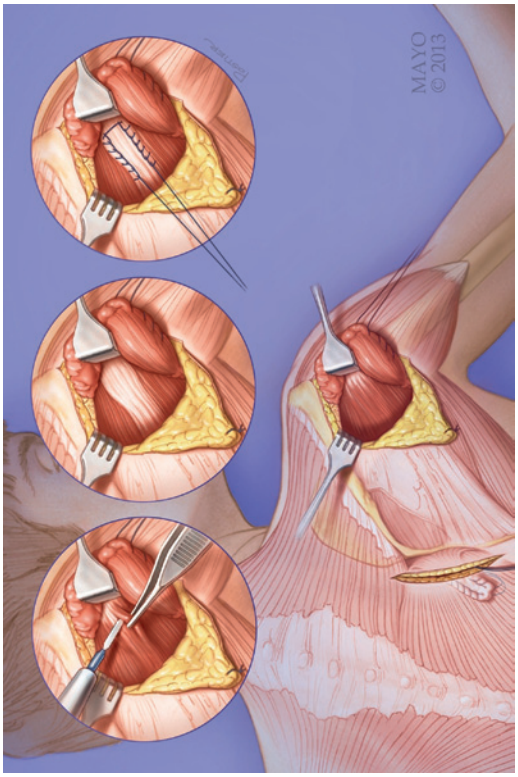

FIGURE 34.43 Exposure of the infraspinatus with dissection and exposure of the tendinous portion of the infraspinatus tendon by teasing the muscle fibers off the tendon. (By permission of Mayo Foundation for Medical Education and Research. All rights reserved.)

It has been our preference to restore both the rotator cuff force couple (subscapularis and infraspinatus) and deltoid function. To have effective shoulder abduction by the deltoid muscle, both the subscapularis and infraspinatus need to be functioning appropriately because they are more important contributors to abduction than the supraspinatus and provide additional rotational control. In complete brachial plexus injuries, the trapezius and levator scapulae are usually functioning, and the serratus anterior may be available, depending on the type of injury. We have observed that the three parts of the trapezius (upper, middle, and lower) are activated independently, so they could potentially be used independently as separate transfers. For this reason the upper and middle trapezius can be used for transfer to stabilize and possibly improve shoulder abduction (Figure 34.47, *A* and *B*). Additionally, the levator scapulae (reported by Narakas[159]) can be used, and finally, depending on the type of injury, the upper serratus anterior muscle (reported by Saha[172]) may also be available. Our current reconstruction options for a completely paralytic shoulder include transfer of the upper serratus or pectoralis minor (if functioning) to the subscapularis insertion for internal rotation, the levator scapulae to the supraspinatus for abduction, the lower trapezius to the infraspinatus for external rotation, and the upper and middle trapezius to the deltoid for abduction. If the latissimus is functioning with enough strength, it is also added as a bipolar transfer for shoulder contouring and to improve shoulder flexion. These potential transfers are our preferred method, but their combined use has not been substantiated yet in the literature. Thirty-nine out of the 52 patients on whom we previously reported underwent multiple tendon transfers, and though almost all of them had significant improvement of shoulder external rotation, the improvement in shoulder flexion and abduction was not statistically significant.

We did modify our original technique of upper/middle trapezius transfer; in this modification, we no longer perform acromial osteotomy as part of the transfer because we believe this decreases the lever arm of the transferred trapezius. We have been transferring the upper and middle trapezius prolonged with Achilles tendon allograft on top of the acromion and inserting the transfer on the proximal humerus at the site of the deltoid insertion (Figure 34.48, *A* and *B*). We have observed better improvement in shoulder abduction with this technique.

When options are more limited, we prefer to reconstruct external rotation alone because we believe that the ability to position the hand anterior to the coronal plane restores greater overall function than does abduction alone. For this reason, in patients who have no muscles available for transfer on the side of injury, contralateral lower trapezius origin transfer is performed to the infraspinatus tendon to restore shoulder external rotation.

Shoulder Arthrodesis

Shoulder arthrodesis is a well-established operative procedure that involves fusion of the humeral head to the glenoid. Indications include total paralysis after brachial plexus injuries and upper-type paralysis.[13,146,169,209] We prefer procedures other than shoulder arthrodesis because the decreased arc of shoulder motion after arthrodesis limits use of the reconstructed hand after prehensile reconstruction. In contrast, other brachial plexus centers routinely perform arthrodesis of the glenohumeral joints to use the available nerve sources for elbow flexion-extension and prehension.

Patients have reported difficulty with turning during sleep, and fracture of the humerus is not a rare complication of shoulder arthrodesis. Contraindications to shoulder arthrodesis include extensive paralysis of the trapezius and shoulder stabilizers (levator scapulae, serratus anterior, or rhomboid muscles); if these scapular stabilizing muscles are paralyzed, scapulothoracic subluxation or pain will result. Richards and coworkers[165,166] reported that if these muscles are nonfunctional, the extremity will be severely impaired despite successful glenohumeral fusion.[5] In these cases, scapulothoracic fusion will be required to alleviate pain. Providing stability of the glenohumeral joint by fusion can be helpful if the patient is to be able to move the elbow and fingers, even if glenohumeral arthrodesis results in some instability of the scapulothoracic joint.

The shoulder is a difficult joint to fuse because the humerus has a long lever arm, the area of contact at the glenohumeral joint is small, and additionally paralyzed muscles cannot contribute as a compressive force to aid in union. The optimum position for arthrodesis of the shoulder is debatable. Patients with total paralysis of the brachial plexus and normal function of the trapezius and serratus anterior muscles should undergo arthrodesis in 30 to 40 degrees of abduction and flexion and 30 degrees of internal rotation. In contrast, in total paralysis of the brachial plexus with absence of serratus anterior or trapezius

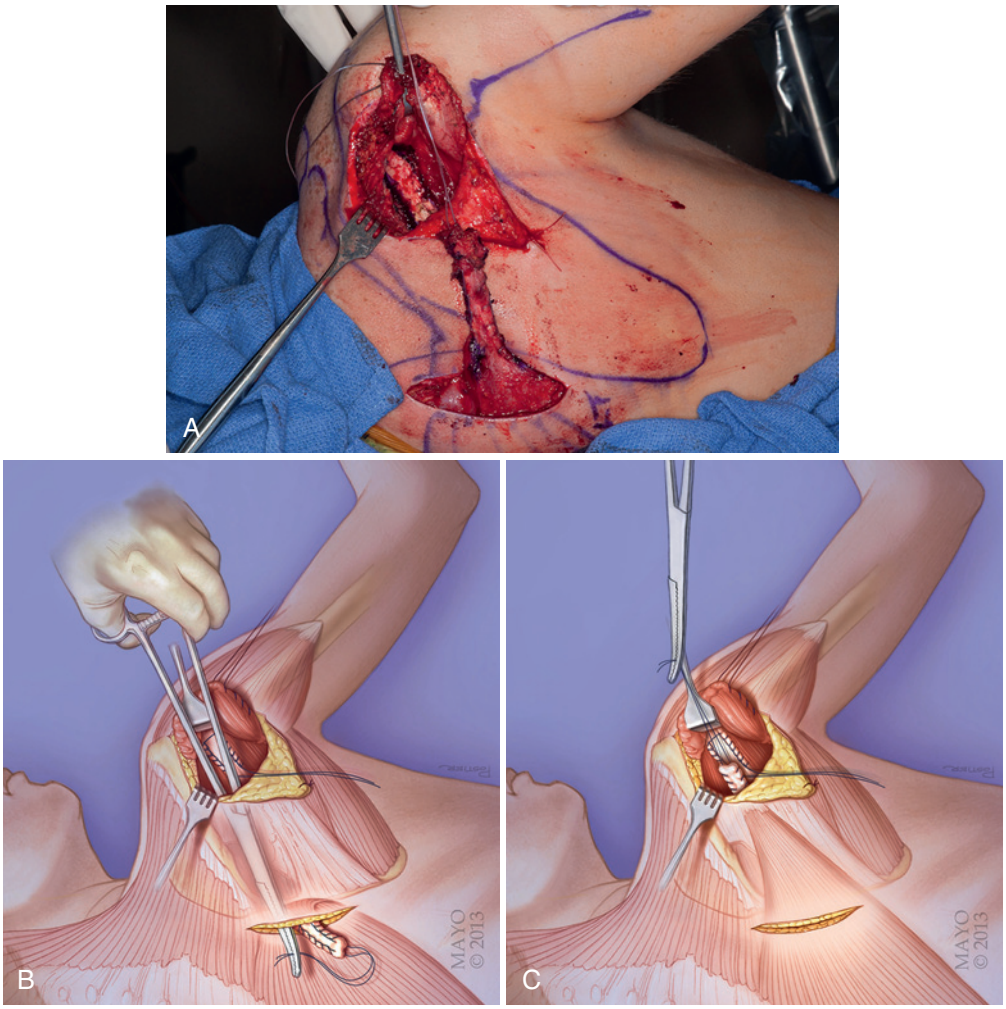

FIGURE 34.44 **A,** Intraoperative picture showing the lower trapezius muscle and tendon harvested and retrieved through a medial incision, and the infraspinatus tendon dissected and exposed and tacked with a nonabsorbable suture through the lateral incision. **B** and **C,** After creating a large tunnel, the lower trapezius could be retrieved from the medial incision to the lateral incision, and direct repair of the tendinous portions of the lower trapezius and infraspinatus is possible while the shoulder is placed in maximal external rotation. (By permission of Mayo Foundation for Medical Education and Research. All rights reserved.)

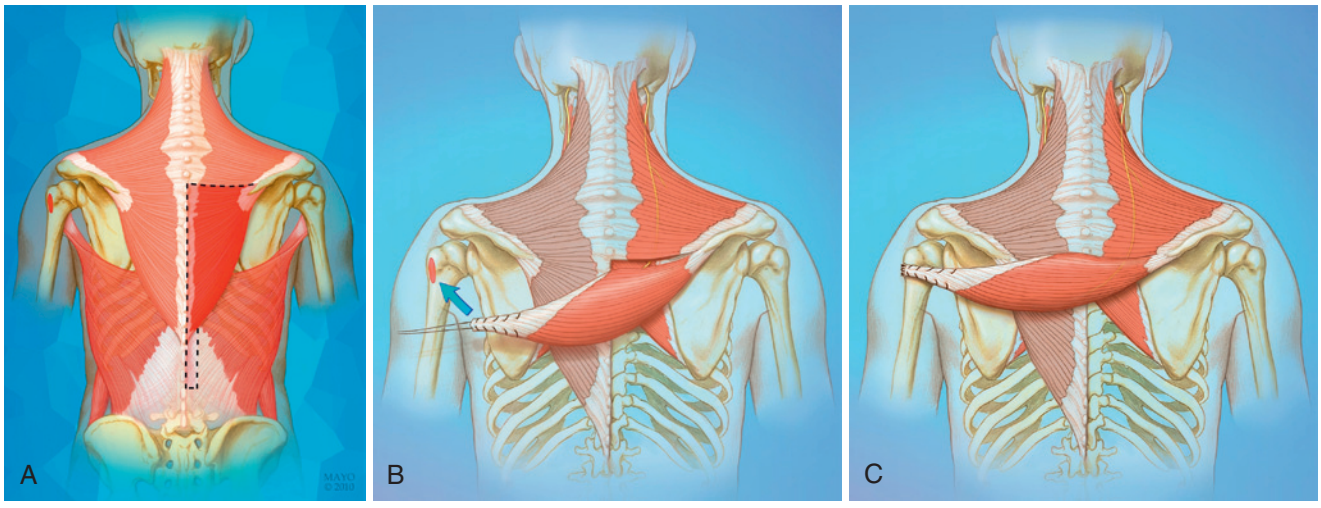

FIGURE 34.45 **A,** Drawing showing the marking of the lower trapezius muscle prolonged with a strip of lumbosacral fascia. **B** and **C,** Transfer of the contralateral lower trapezius origin prolonged with lumbosacral fascia to the ipsilateral infraspinatus insertion. (By permission of Mayo Foundation for Medical Education and Research. All rights reserved.)

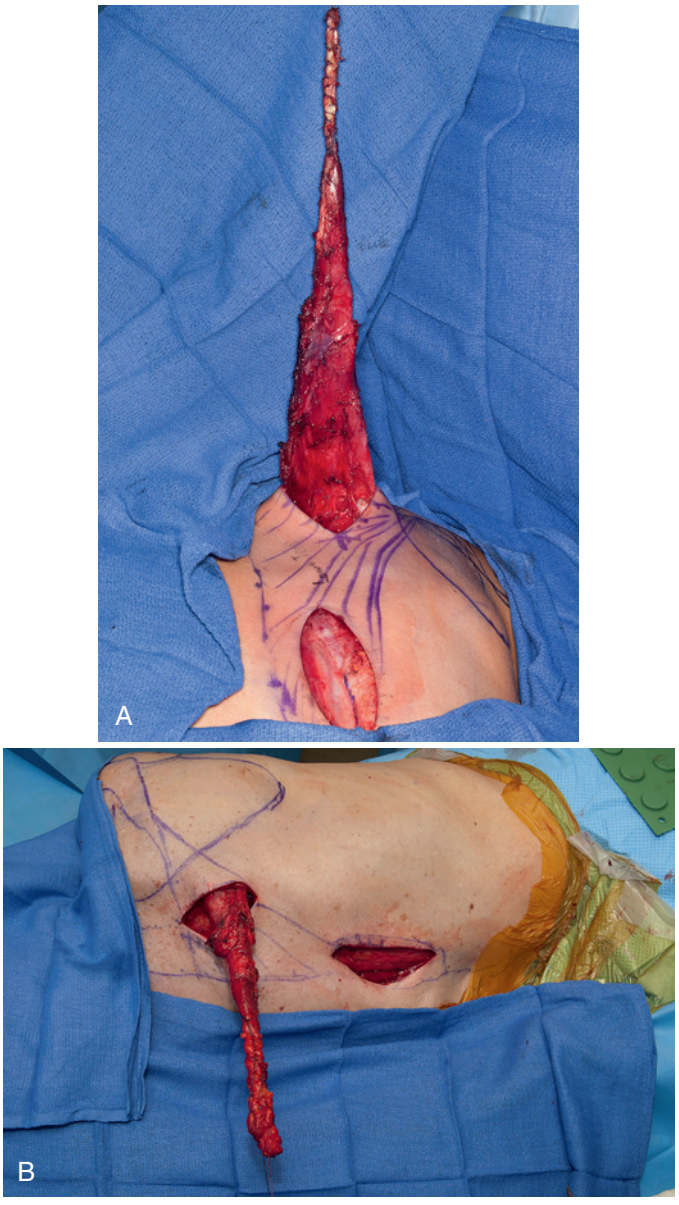

FIGURE 34.46 **A,** Intraoperative picture showing harvesting of the lower trapezius origin prolonged with lumbosacral fascia though two separate incisions and retrieving the muscle through the proximal (superior) incision. **B,** Intraoperative picture showing the ease of transferring the contralateral trapezius origin to the ipsilateral shoulder. (By permission of Mayo Foundation for Medical Education and Research. All rights reserved.)

function, shoulder arthrodesis should be avoided and possibly performed only when inferior shoulder subluxation is associated with extensive symptoms. In this situation, the position of arthrodesis should be 20 degrees of abduction, 10 degrees of flexion, and 30 degrees of internal rotation.

Many operative techniques for shoulder arthrodesis have been described.[43,56,153] Rigid internal fixation with a long 4.5-mm reconstruction plate and compression screws across the glenohumeral joint has been reported with good results. However, it carries the risk of increased devascularization and occasional problems from prominent screws and loosening of the hardware in osteoporotic bone. External fixation has its own complications, including neurovascular injury, pin tract infection, pin loosening, and fractures through pin sites, but it is particularly useful for infected joints.

❖ AUTHORS' PREFERRED METHOD: Glenohumeral Arthrodesis

We prefer to use long cancellous screws and a reconstruction plate for transarticular fixation of both the glenohumeral and acromiohumeral joints, supplementing the fixation with autogenous bone graft. The operation is performed in the beach-chair position. Through a posterior incision that follows the spine of the scapula and extends down the lateral humeral head and shaft, the posterior half of the deltoid is detached from the scapular spine and acromion and retracted distally. All soft tissue under the acromion is removed, and the rotator cuff muscles are also detached from the greater and lesser tuberosities to expose the joint capsule, glenohumeral joint, and acromiohumeral joint. Articular cartilage from each joint is removed to facilitate contact of the subchondral bone of the humeral head and glenoid cavity. Bone graft from the iliac crest is then inserted into the subacromial space. The glenohumeral and acromiohumeral joints are transfixed with long cannulated screws of 7.3 mm in diameter in the position of 30 degrees of abduction-flexion and internal rotation. Because most patients with brachial plexus injury have osteopenic bones, adequate compression of the acromion on the superior surface of the humerus is important. This allows additional contact surface, which may maximize the fusion rate. A 4.5-mm pelvic reconstruction plate is contoured to the scapular spine and humerus and secured in place, which adds substantially to the stiffness of the fusion construct. Cancellous bone chips are used to pack the vacant space of both joints (Figure 34.49).

Postoperative Protocol. A splint is used to immobilize the glenohumeral joint until radiographic union, which may take up to 4 months. Movement of the elbow and distal joints is encouraged. Gentle passive and active range of motion of the scapulothoracic joint is initiated, and radiographs are taken monthly until bone union occurs.

Expected Outcome. The purpose of shoulder arthrodesis after brachial plexus injuries is to stabilize the glenohumeral joint and permit the patient to move the upper part of the arm through the scapulothoracic joint with the use of innervated scapular muscles. The postoperative range of shoulder movement depends on the residual strength of the periscapular muscles, such as the trapezius, levator scapulae, serratus anterior, latissimus dorsi, and rhomboid muscles.

Previous reports have shown a satisfactory outcome of range of scapulothoracic motion, with an average of 60 degrees of abduction and flexion,[48,51,166,168] because most of the patients had normal function of the serratus anterior muscle. In a recent study by Atlan and associates of 54 patients who underwent shoulder fusion for a paralytic shoulder in the setting of brachial plexus injury, the authors reported improved abduction of at least 45 degrees in 65% of patients and improved active shoulder rotation of at least 45 degrees in 65% of patients.[9] They recommended the use of abundant subacromial bone graft to decrease the risk of pseudarthrosis.

Late Reconstruction of Elbow Function

Paralysis of elbow flexion resulting from brachial plexus injury should be addressed when feasible by nerve repair, graft, or

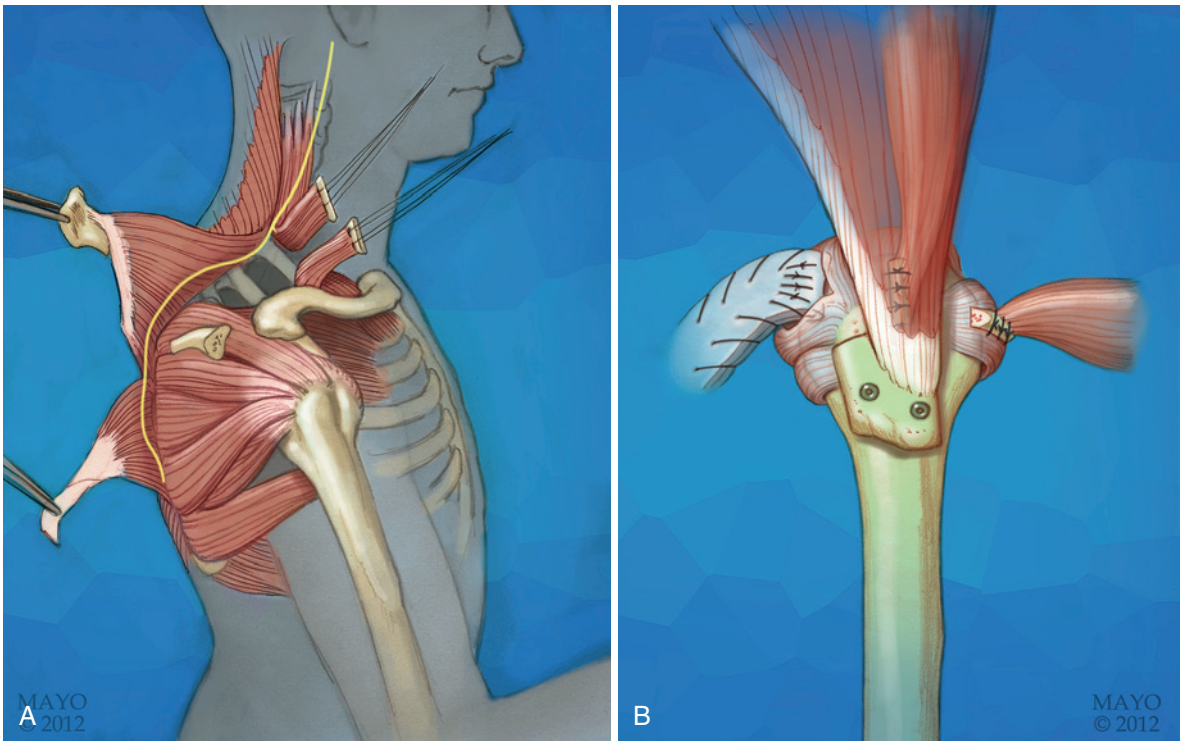

FIGURE 34.47 **A,** Drawing of multiple tendon harvest seen from the shoulder perspective before the transfer. Notice that the upper/middle trapezius is harvested with its bony insertion on the acromion to be used for the transfer. **B,** Multiple tendon transfer to the shoulder with the acromial attachment of the upper/middle trapezius internally fixed to the proximal humerus. (By permission of Mayo Foundation for Medical Education and Research. All rights reserved.)

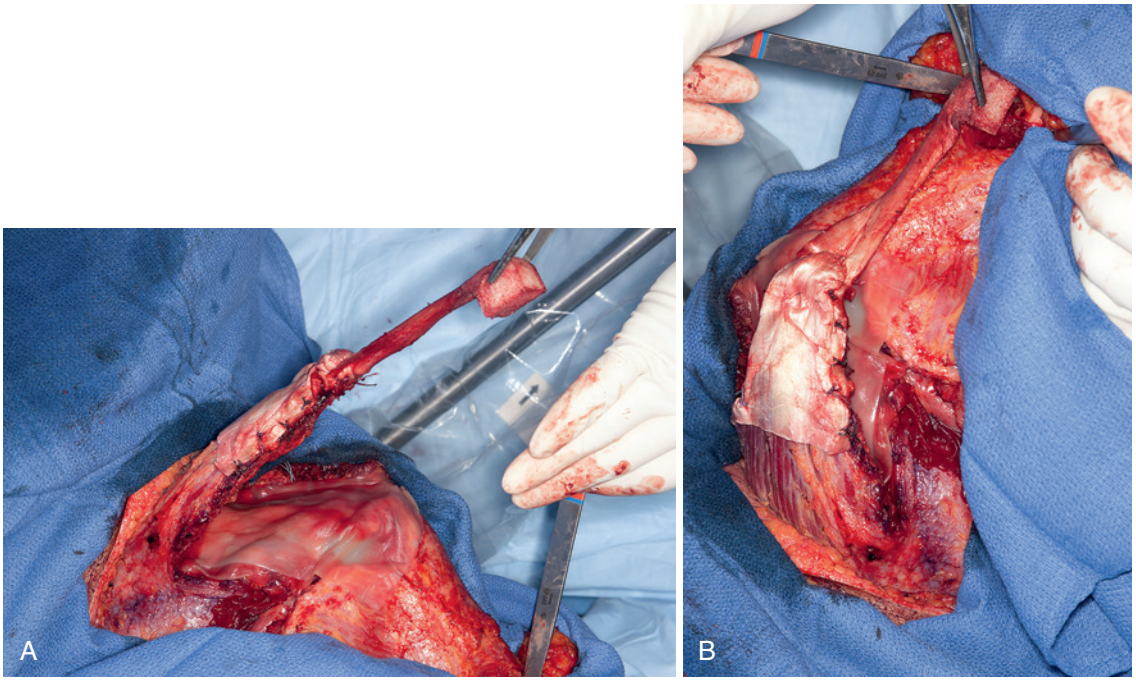

FIGURE 34.48 **A** and **B,** Modification of the upper/middle trapezius transfer by detaching the muscle, prolonging it with Achilles tendon allograft with its bony insertion, and attaching the bony insertion of the tendon to the level of the deltoid insertion. TenoGlide (Integra Life Sciences, Plainsboro, NJ) is placed on the acromion to decrease the risk of adhesion between the transferred trapezius and the row bone exposed on top of the acromion. (By permission of Mayo Foundation for Medical Education and Research. All rights reserved.)

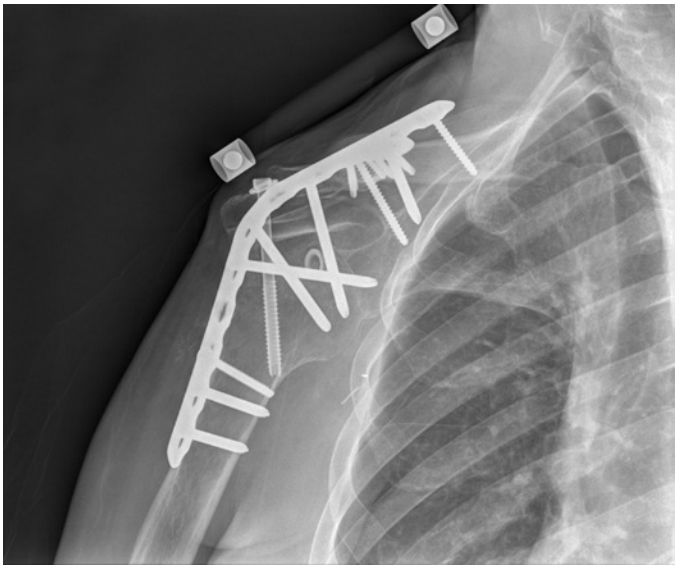

FIGURE 34.49 Healed shoulder fusion in patient with brachial plexus injury and normal periscapular muscle function. (By permission of Mayo Foundation for Medical Education and Research. All rights reserved.)

CRITICAL POINTS *Glenohumeral Arthrodesis*

Indications
- Failed or neglected cases with glenohumeral instability or arthritis
- Total or upper-type paralysis with or without paralysis of the serratus anterior
- Normally functioning trapezius

Preoperative Evaluation
- Good strength of the trapezius and rhomboid
- No contracture of the scapulothoracic joint

Pearls
- Provides stability to the shoulder
- Improvement in range of shoulder motion, depending on the strength of the scapulothoracic muscles

Technical Points
- Posterior saber-cut skin incision
- Removal of all soft tissues, including the rotator cuff in the subacromial joint
- Removal of cartilage of the subacromial and glenohumeral joints
- Iliac bone graft between the acromion and humeral head
- Transarticular fixation of the subacromial and glenohumeral joints with large cannulated screws of 7.3 mm in diameter in the position of 30 degrees of abduction-flexion and internal rotation of the shoulder
- Bone chips in vacant areas around the joints

Pitfalls
- Postoperative fracture of the humerus
- Risk of nonunion
- Impairment of turning during sleep

Postoperative Care
- Splint or shoulder immobilizer for 3 months
- Gentle range-of-motion exercises of the scapulothoracic joint
- Radiographs monthly until healing

transfer in the first 6 to 9 months after injury. Thereafter, nerve reconstruction becomes increasingly less reliable and generally fails when delayed 12 or more months because of irreversible ultrastructural changes in muscle. In some cases, even early intervention may be impossible because of extensive damage to the anterior compartment of the arm, including muscle scarring or loss of or injury to the motor nerve at its motor innervation point. In these cases other options are needed to restore elbow flexion. Such options broadly include tendon transfers and FFMT. Examples of tendon transfer include proximal advancement of the flexor-pronator origin (Steindler's flexorplasty)[189-191] and transfer of the pectoralis major,* pectoralis minor,[188] sternocleidomastoid,[33,117] triceps,[39] and latissimus dorsi muscles.[101,147,216] Microsurgical transplantation of autogenous muscle (FFMT) to replace the function of the damaged anterior arm compartment will also be discussed.

Tendon transfer can generally be used only with incomplete brachial plexus injury because most transfers other than the sternocleidomastoid are innervated by brachial plexus nerves. The final outcome is influenced by a number of factors, including the cross-sectional area, fiber length, and vector of the transferred muscle, as well as fascial connections, the number of joints crossed, and the function of antagonist muscles. In brachial plexus injury, it is common to encounter donor muscles that have partial denervation resulting from the original plexus injury. The adequacy of such a muscle is not necessarily easy to predict preoperatively, although a BMRC grade of 4 (submaximal muscle strength against resistance) is generally regarded as the minimum required. Preoperative evaluation of muscle power can be difficult, however, as when more than one muscle contributes to a given motion (e.g., latissimus dorsi for shoulder adduction) or the muscle has dual innervation (pectoralis major). Unfortunately, BMRC grading is notoriously imprecise in assessing the ability of a muscle to do work, especially following its transfer to a new location.

The alternative of FFMT is appealing, although technically more challenging and requiring a lengthy recovery time. Prerequisites include an adequate and stable soft tissue bed; blood vessels in good condition for microsurgical anastomoses; and an available expendable donor muscle with a favorable vascular supply, a single motor nerve, and strength and excursion comparable to one or more elbow flexors. Additionally, motor nerves must be available for transfer to the motor nerve of the transplanted muscle. In brachial plexus cases, the original nerve pathways are injured, most commonly at the C5-C6 nerve or upper trunk level. Because rapid reinnervation of the muscle is required to prevent muscle atrophy and loss of motor end plates, nerve transfers from previously uninjured nerves are preferred. Two or more intercostal motor nerves, the spinal accessory nerve, or the fascicles of the ulnar nerve[94] that innervate the flexor carpi ulnaris are the most common choices. Alternatively, free muscle transfer may be delayed until motor nerve reinnervation from a proximal repair or transfer has occurred.

When selecting the best procedure for a given patient from the available choices, one must consider multiple factors, including the specifics of the nerve injury; elapsed time from

*See references 8, 29, 40, 49, 101, 149, and 216.

injury; status of the soft tissue envelope, blood vessels, and muscle; expertise of the surgical team; and desires and expectations of the patient. A careful history, physical examination, and evaluation by electrophysiologic testing and appropriate imaging studies are required. Patient education and informed participation in the decision making are imperative.

❖ AUTHORS' PREFERRED METHODS

Modified Steindler Procedure. Arthur Steindler described a method to restore flexor function to the elbow in a classic 1918 article.[118,189,192] The flexor-pronator muscles arising from the medial epicondyle are transposed to a more proximal and anterior position on the humerus to increase their moment arm for elbow flexion. As with all potential candidates for tendon transfer, preoperative evaluation of the strength of the donor muscles is critical to the success of the muscle transfer. After transfer, these muscles (the pronator teres, flexor carpi radialis, palmaris longus, flexor carpi ulnaris, and flexor digitorum superficialis) continue to provide their original function in addition to elbow flexion; consequently, they must have normal or nearly normal power (BMRC grades 4 to 5). Results are generally better in patients who require only augmentation of weak elbow flexion or who can flex the elbow before surgery and achieve wrist flexion and forearm pronation with gravity eliminated (the Steindler effect). In the absence of a demonstrable Steindler effect, the postoperative result is likely to be less optimal. Unlike isolated C5-C6 injury, patients with C5-C7 palsy may have wrist and finger extensor weakness in addition to absent elbow flexion. In these patients concomitant wrist arthrodesis should be considered.[148] We prefer the modified technique described by Mayer and Green.[137]

Operative Procedure. The midpoint of the incision lies just posterior to the medial epicondyle of the humerus. It is directed proximally and anteriorly for 8 to 10 cm over the distal upper part of the arm and distally over the anterior aspect of the forearm for 8 to 10 cm along the course of the pronator teres muscle (Figure 34.50, *A*). The resulting anterior skin flap is retracted gently anteriorly and laterally, and the posterior margin is undermined to identify the ulnar nerve at the medial epicondyle. The articular branch is sacrificed, but the branches to the flexor carpi ulnaris are preserved and protected while the nerve is mobilized for 5 cm distal to the elbow. The median nerve is similarly identified deep to the proximal border of the pronator teres. Its muscular branches to the pronator originate 2.5 to 5 cm proximal to the elbow on its medial side and must be preserved. The common flexor pronator origin is next detached, along with a 1.5-cm fragment of medial epicondylar bone with an osteotome (see Figure 34.50, *B*), while protecting the median and ulnar nerves and their muscular branches. The anterior bundle of the medial collateral ligament must be preserved at the distal, deep aspect of the epicondyle. Once the epicondylar osteotomy is complete, mobilization of the muscle from the ulna continues until the bone fragment and muscle origin can be advanced to a point 5 to 8 cm proximal to the original position with the elbow acutely flexed to 130 degrees.

In the original Steindler technique, the tendon of origin was attached to the medial intermuscular septum and fascia. Mayer subsequently transferred the entire medial epicondyle and moved the attachment point to the anterior aspect of the humerus. This modification is preferred because (1) the attachment to bone is stronger than to fascia and (2) the more anterior position reduces the pronating tendency of the original transfer. Elbow flexion accompanied by marked pronation of the forearm compromises hand function.

In this technique it is helpful to predrill (and tap) the medial epicondyle before detachment. The median nerve and brachial artery are mobilized and retracted medially. The brachialis is split longitudinally to expose the humerus. It is prepared with

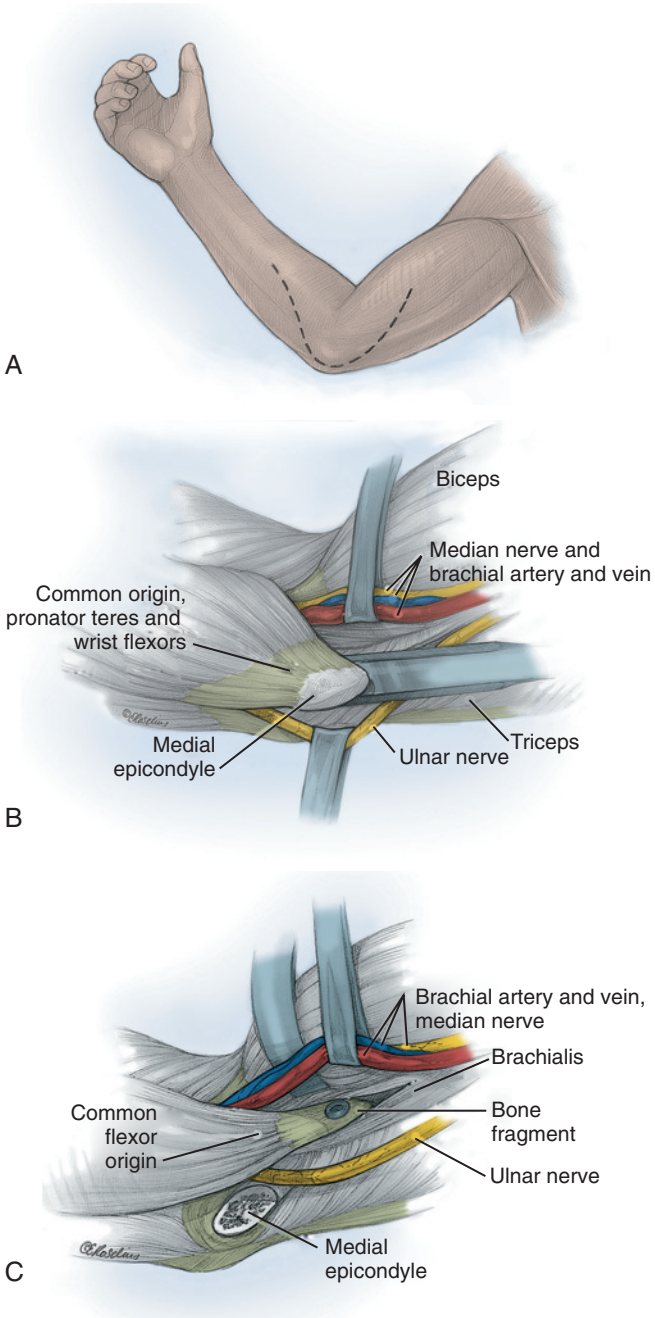

FIGURE 34.50 Authors' preferred Steindler procedure for reconstruction of elbow flexion. **A,** Skin incision. **B,** The common origin of the pronator and wrist flexor muscles is dissected and detached, along with a fragment of bone from the medial epicondyle with an osteotome while care is taken not to injure the ulnar and median nerves and brachial vessels. **C,** The bone fragment with the common origin of the pronator and wrist flexor muscles is fixed to the anterior surface of the humerus with a screw and suture anchors. (Copyright © Elizabeth Martin.)

a bur or osteotome, followed by fixation of the medial epicondyle and flexor-pronator group with a 3.5-mm screw to the anterior aspect of the humerus. We augment the screw fixation with two additional suture anchors inserted into the humerus around the drill hole. The anchor sutures are tied to the flexor pronator origin with the elbow flexed 130 degrees and the forearm supinated (see Figure 34.50, *C*). The proximal portion of the wound is closed and the dressing is applied.

Postoperative Protocol. The elbow is maintained in 100 degrees of flexion until union of the medial epicondyle fragment, generally by 6 to 8 weeks. Passive flexion of the elbow, wrist, and fingers commences just after the operation. Active flexion of the wrist and fingers with the elbow in full flexion is started in the third week. Extension of the elbow, wrist, and fingers is allowed from the seventh week after surgery. Postoperative rehabilitation and muscle reeducation take several months, with the goal of full active elbow flexion and a 30-degree elbow extension lag. The flexion contracture results in an increased mechanical advantage for initiation of flexion. The strength of the transferred muscles, the duration of immobilization, and the strength of the opposing triceps muscle all affect the outcome.[124]

Complications. The main complications of the Steindler transfer are pronation and flexion contractures. Pronation contractures are related to (1) preoperative absence of active supination and (2) an increased mechanical advantage of the pronator teres as a result of its proximal shift. Inserting the transfer more anteriorly and laterally on the humerus diminishes this tendency, but if no active supination is present, pronation deformity may remain a problem. The incidence in the literature varies from 28% to 50%.[38,72,122] A flexion contracture in excess of 30 degrees is uncommon and is usually treated by more intensive therapy, including passive range-of-motion exercises, stretching, and splinting.

Dutton and Dawson reported transient ulnar nerve paresthesias in two patients.[72] Lindholm and Einola reported two patients with postoperative ulnar nerve paresthesias, one of whom was still having symptoms at follow-up.[122]

Expected Outcomes. Published results of the Steindler flexorplasty reflect a high degree of success in achieving a functional range of elbow flexion against gravity, particularly when performed for poliomyelitis. Steindler achieved 79.5% good results (flexion against gravity of not less than 90 degrees) in 39 cases.[192] Using strict criteria for success, Mayer and Green recorded 11 excellent, 5 good, 4 fair, and 2 poor results in 22 flexorplasties.[137] Lindholm and Einola found that 50 of their 61 patients achieved a range of flexion of at least 90 degrees.[122] Eleven were able to lift a weight heavier than 1 kg at right angles. Dutton and Dawson noted that 20 patients had excellent or good function of the transferred muscles.[72] Eighteen could lift at least 1 to 2 kg through an arc of full elbow motion.

Monreal reported the results of 12 Steindler procedures performed in patients with incomplete C5-C7 brachial plexus palsy who had recovered elbow flexion of M2 or less.[148] Eleven patients were found to have good or very good outcomes based on the criteria established by Alnot and Abols,[6] and one patient had insufficient active flexion of the elbow. All underwent simultaneous wrist fusion. These results emphasize the role of late reconstruction by tendon transfer, when spontaneous recovery or nerve surgery results in insufficient strength. It should be noted that the strength of elbow flexion after a Steindler flexorplasty is limited.

CRITICAL POINTS *Flexor-Pronator Muscle Transfer (Steindler Procedure)*

Indications
- Inadequate active elbow flexion in upper (C5-C6 or C5-C7) brachial plexus palsy
- Elapsed time from injury of more than 6 to 9 months
- Normal or nearly normal power of the forearm flexor-pronator muscles
- Good shoulder control

Preoperative Evaluation
- Good strength of the forearm flexor-pronator muscles
- Positive Steindler effect

Pearls
- Use an anterior humeral fixation point and secure bony fixation.

Technical Points
- Longitudinal curved skin incision from the distal third of the upper part of the arm to the proximal third of the forearm
- Protection and mobilization of the ulnar nerve
- Identification of the median nerve, brachial artery, and veins
- Osteotomy of the medial epicondyle of the humerus, including the forearm flexor and pronator muscle origin, with predrilling of the medial epicondyle
- Longitudinal split of the brachialis muscle
- Subperiosteal dissection and shaving of the anterior cortex of the humerus
- Holes drilled in the humerus to accept the screws
- Fixation of the medial epicondyle with the forearm muscles to the humerus with a compression screw

Pitfall
- Pronation or flexion contracture of the elbow

Postoperative Care
- Immobilization of the elbow in 100 degrees of flexion for 6 weeks
- Passive flexion of the elbow, wrist, and fingers immediately after surgery
- Active flexion of the wrist and fingers 3 weeks postoperatively
- Active and passive extension of the elbow, wrist, and digits 7 weeks postoperatively

Triceps-to-Biceps Transfer. Use of the triceps muscle to replace the biceps is a technically straightforward method that produces reliable elbow flexion in patients with upper (C5-C6 or C5-C7) plexus palsy. It is considered undesirable by some because of the functional loss of active elbow extension that must necessarily result. It prevents overhead use of the arm should shoulder function recover, will adversely affect the ability to transfer from bed to wheelchair, and will prevent the use of a cane or crutch in others. There are instances, however, when its use is reasonable. In patients with poor elbow flexion and prominent cocontraction of a weak biceps and strong triceps, transfer of the triceps immediately solves both issues. The simplicity of the procedure and the relatively rapid postoperative recovery from it make it more desirable for many patients when other options are more complex.

Operative Procedure. The patient is positioned in a semisitting position with the extremity draped free. The incision

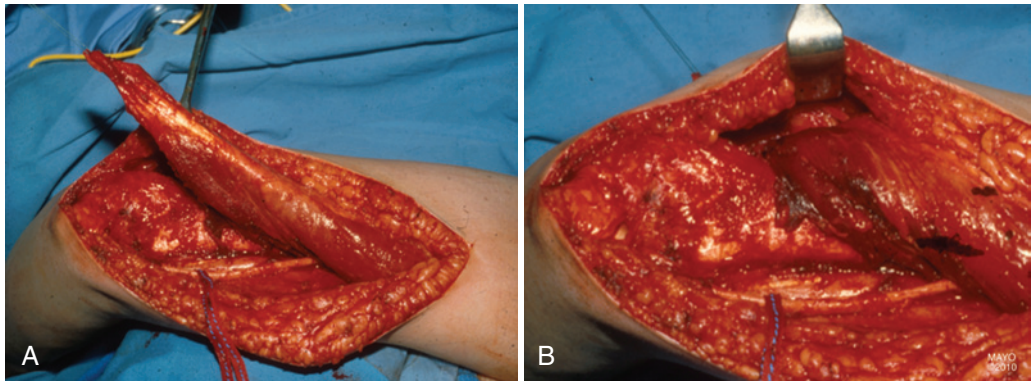

FIGURE 34.51 Triceps to biceps transfer. **A,** The triceps has been mobilized and the ulnar nerve protected. **B,** The triceps has been transferred to the biceps tendon via a lateral route after identifying and protecting the radial nerve. (By permission of Mayo Foundation for Medical Education and Research. All rights reserved.)

begins proximally in the posterior midline of the humerus and extends laterally and distally to the olecranon and along the subcutaneous border of the ulna for 5 cm (Figure 34.51). The ulnar nerve is exposed and protected medially and the triceps tendon is released, along with a tail of periosteum from the ulna. The medial head is mobilized while protecting the radial nerve in the spiral groove proximally. The medial and lateral edges of the tendon are brought together and tubed. The biceps tendon is exposed through a separate antecubital incision and the triceps tendon passed to it laterally through a subcutaneous tunnel. The distal end of the triceps tendon has a large nonabsorbable suture placed as a grasping suture with two long tails (Krackow-type suture). The radial insertion of the biceps tendon is identified and a bur hole is used to create a unicortical hole of 7 to 8 mm. Drill holes are placed through the opposite cortex with a 1-cm cortical bone bridge and the sutures are passed through the unicortical side through the drill holes and tied with the elbow in 90 degrees of flexion. Alternatively, a suture button technique can be employed or a Pulvertaft weave to the biceps tendon with nonabsorbable suture can be performed. If the triceps tendon is passed through a bone tunnel and secured to bone, the triceps and biceps tendon should be sewn together with large nonabsorbable, interrupted figure-of-eight sutures.

Postoperative Protocol. The elbow is maintained at 90 degrees with the forearm supinated for 6 weeks, followed by active exercises.

Complications. Complications are infrequent, with none reported in recent literature.

Expected Outcomes. Most authors report elbow flexion of between 116 and 125 degrees.[27,39] Little formal physiotherapy is required. An elbow flexion contracture will result but is generally less than 25 degrees. A contracture greater than 30 degrees can be treated by static or dynamic splinting and intensive physiotherapy.

Latissimus Dorsi Transfer. The latissimus dorsi is innervated by the thoracodorsal nerve (C6-C8) and may therefore be partially denervated in brachial plexus injuries requiring reconstruction of elbow flexion (C5-C6 pattern). Thus, assessment of latissimus strength is of critical importance. Because the latissimus dorsi generally works in concert with other shoulder internal rotators, such assessment can be difficult. The most accurate assessment is obtained by positioning the patient's arm over the buttocks, elbow extended, while grasping the patient's wrist with one hand. The patient is asked to maintain this position while the examiner pulls the arm laterally and anteriorly. It is helpful to use the other hand to palpate the strength of the contraction by grasping the latissimus at the posterior wall of the axilla. The fully contracting muscle must be able to strongly resist the examiner. Comparison with the opposite side is helpful.

Operative Procedure. Latissimus dorsi transfer has been described in two variations: moving the origin alone (unipolar) or moving both the origin and insertion (bipolar). Bipolar transplantation is preferable for several reasons. The mechanical efficiency of the transplant is increased by the more anterior placement of the origin onto the coracoid process, the proper length is easier to determine when the distal insertion is completed first, and there is less chance of the neurovascular pedicle kinking.

CRITICAL POINTS *Triceps-to-Biceps Transfer*

Indications
- C5-C6 or C5-C7 palsy

Preoperative Evaluation
- Grade 4 to 5 triceps
- Triceps/biceps cocontraction

Pearls
- Reliable method with rapid recovery

Technical Points
- Medial head mobilized, tubed, and passed from the lateral aspect to the antecubital fossa

Pitfalls
- Loss of active elbow extension will occur.

Postoperative Care
- Immobilization at 90 degrees is maintained for 6 weeks.

Bipolar transplantation. The operation is performed in four steps[216]:

1. Division of the origin and insertion of the latissimus dorsi muscle while preserving its neurovascular pedicle
2. Exposure of both ends of the biceps muscle through separate incisions
3. Transposition of the latissimus dorsi muscle beneath a cutaneous bridge in the axilla to the anterior aspect of the humerus; if necessary, resection of the biceps muscle to provide sufficient room for the latissimus dorsi
4. Fixation of the latissimus muscle to the coracoid process and biceps tendon

The technique described is the preferred approach used by Dr. Milan Stevanovic.[193] The patient is positioned in the lateral decubitus position, and the upper extremity is draped free. A longitudinal incision is made parallel to the lateral border of the latissimus dorsi muscle and extends from the posterior border of the axilla to the iliac crest, with incorporation of a skin paddle beginning 6 to 8 cm distal to the axillary fold. It should be 4 to 6 cm in width, with a length equal to that of the biceps muscle belly, elliptical in shape, and centered over the middle of the muscle. Dissection of the muscle is begun along its distal lateral border and proceeds medially and proximally. Initial dissection elevates the posterior and anterior skin flaps from the underlying fascia and muscle. With the muscle thus exposed, the arm is positioned in 180 degrees of abduction and forward flexion. The resting muscle length is marked with sutures at 5-cm intervals to facilitate later tensioning. Deep dissection proceeds from distal to proximal, with division of the origin and inclusion of the overlying fascial tissue. The dissection proceeds by mobilizing the vertebral border and separating the muscle at the inferior angle of the scapula from the deeper-lying rhomboid medially and the teres major and minor laterally. The thoracodorsal neurovascular pedicle is visualized on the deep muscle surface by developing the plane over the anterior border of the muscle. The lumbar fascial and posterior pelvic origins of the muscle are divided and the muscle is lifted off the chest wall with its attached neurovascular pedicle. The pedicle must be sufficiently mobilized to avoid kinking, which requires ligation of its serratus anterior branch and multiple (four to six) more proximal perforating branches. All fascia surrounding the pedicle must be completely released to maximize muscle mobility and minimize the potential for kinking of the pedicle. The tendon of insertion is sectioned at the humerus, and two Krackow 2-0 nonabsorbable sutures are placed.

A transverse incision 3 to 5 cm long is made at the coracoid, and an additional longitudinal incision is made along the more distal biceps muscle to the level of the antecubital fossa to completely expose the muscle belly and distal tendon. Four mattress sutures are placed in the biceps tendon, medial and lateral at the musculotendinous junction and medial and lateral more distally at the tendinous portion of the biceps, in preparation for securing the latissimus dorsi to the distal biceps tendon (Figure 34.52).

A subcutaneous pocket is created in the axilla to accommodate the latissimus by elevating the medial flap of the deltopectoral incision in a plane superficial to the axillary fascia, wide enough to admit four fingers. The muscle is tubularized by bringing the vertebral border to the lateral border and is secured with fascial sutures placed every 2 to 3 cm. The humeral insertion is moved proximally and anteriorly to the coracoid by blunt dissection below the tendon of the pectoralis major to create a tunnel for its passage.[187] Fixation is performed after the muscle is anchored distally.

The origin of the latissimus dorsi is passed under the axillary skin bridge into the deltopectoral incision while protecting its neurovascular pedicle from kinking or tension. The muscle is now stretched to restore the previously marked resting length. The elbow should be fully extended. Proximally, the tubularized latissimus should lay superficial to the biceps muscle. Distally, at the musculotendinous junction and biceps tendon, the latissimus dorsi is wrapped 360 degrees around the tendon and secured with the previously placed sutures. The proximal tendon is anchored to the coracoid process or the acromion with suture anchors and adjusted to maintain the elbow in approximately 100 degrees of flexion with full supination. Before skin closure, the pedicle should be checked both with a Doppler device and by direct visualization of the pedicle and skin. Any dark blood in the vein would indicate stretching or compression of the pedicle and requires inspection and correction. Two deep drains are placed and kept at the donor site until output is less than 5 mL in 24 hours to prevent seroma formation.

Postoperative Protocol. The arm is kept immobilized in a sling with an abduction pillow for 8 to 9 weeks. At 4 weeks we have the patient start isometric contraction of the transferred muscle while at 90 degrees. After 9 weeks, we have the patient begin working on slowly regaining extension at a rate of 10 to 20 degrees per week. Reeducation of the transferred latissimus dorsi muscle is accomplished initially by simultaneous shoulder extension and elbow flexion. Eventually, the patient will be able to flex the elbow in any shoulder position. Biofeedback by means of EMG is useful during postoperative reeducation of the transferred muscle. Later, exercise against resistance will produce powerful flexion of the elbow.

Complications. Weakness of elbow flexion may occur if the latissimus was partially denervated by the original plexus injury or if tensioning of the transfer was inadequate. Revision of the transfer tension may be performed at a later date.

Expected Outcomes. The outcomes reported are all from small patient series or case reports.[10,26,101] Zancolli and Mitre reported on eight patients who underwent bipolar transplantation of the latissimus dorsi.[216] The total arc of active flexion ranged from 105 to 140 degrees, and flexion strength varied from 0.7 to 5 kg. Flexion contractures of 10 degrees and 15 degrees occurred in two, and active supination of 20 to 50 degrees was achieved in six. Moneim and Omer achieved satisfactory flexion (100 degrees or more) in three of five patients.[147] The other two initially had paralysis of the latissimus dorsi and achieved only 65 to 70 degrees of flexion. Preoperative EMG evaluation of the muscle and the presence of normal (grade 5) strength were recommended. Botte and Wood noted satisfactory function in four of five patients treated by unipolar or bipolar latissimus dorsi transfer; flexion averaged 87 degrees (range, 35 to 130 degrees).[27]

Pectoralis Major Muscle Transfer. Both unipolar transfer and bipolar transfer of the pectoralis major have been reported. Our preference is the use of bipolar transfer without a fascial graft.[33,180]

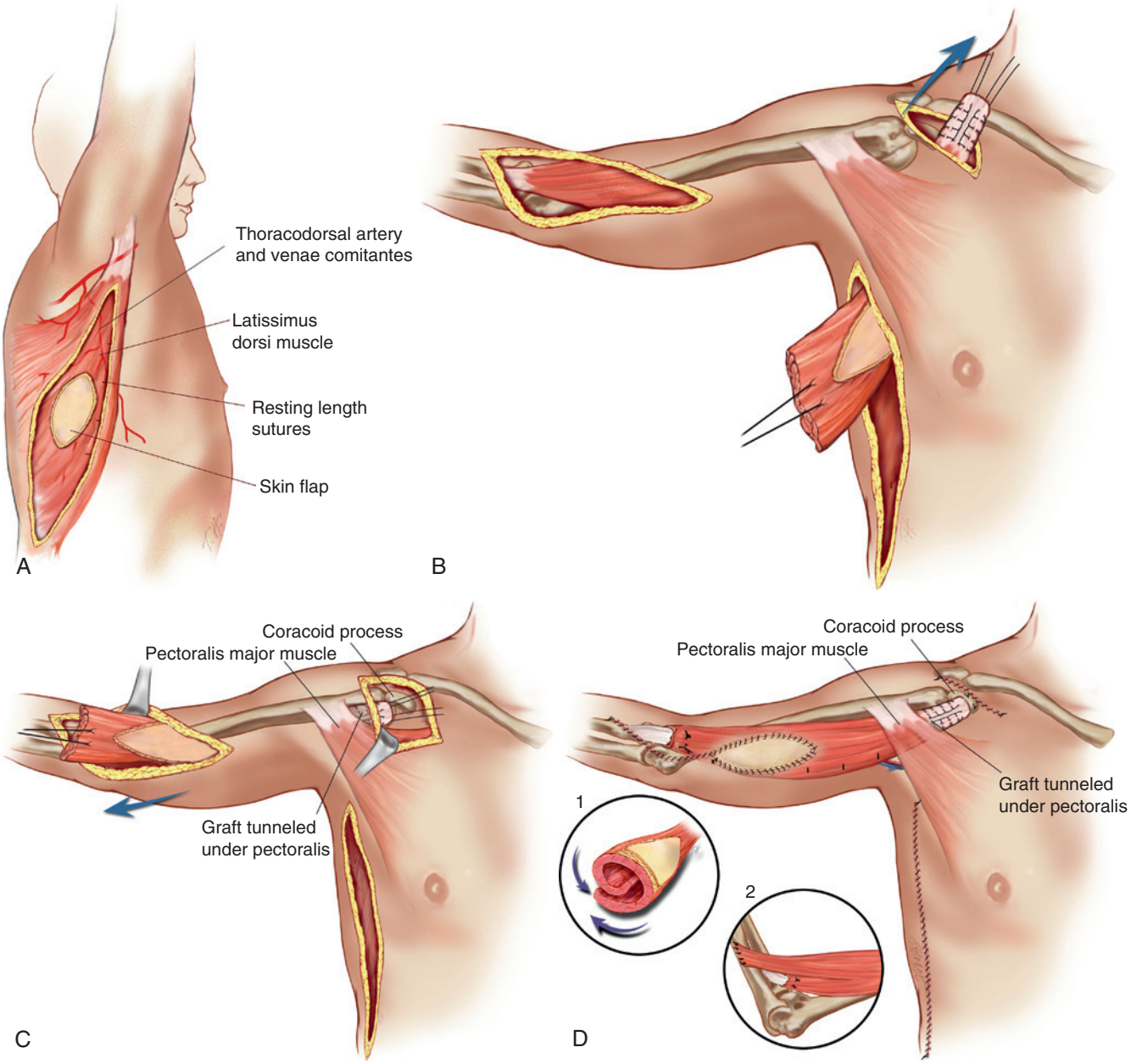

FIGURE 34.52 Pedicled bipolar latissimus transfer for elbow flexion. **A,** The latissimus is outlined, and an anteriorly based skin paddle is designed on the muscle. The flap is based on the thoracodorsal artery and vein and is innervated by the thoracodorsal nerve. With the arm abducted fully, sutures are placed in the muscle every 10 cm to assist in determining the resting length of the muscle. **B,** The latissimus is mobilized, the proximal origin is detached from the humerus, and the distal insertion is dissected free. Krackow-type sutures are placed in the proximal tendon. **C,** A tunnel is created under the pectoralis muscle large enough to pass the latissimus muscle. When passing the muscle, care must be taken not to twist or kink the vascular pedicle. The proximal latissimus tendon is sewn to the coracoid with heavy nonabsorbable sutures, and a tunnel (or open incision) is created on the anterior arm to the level of the biceps tendon attachment. **D,** The distal latissimus muscle is tubularized (1) and sewn into the biceps tendon and/or ulna (2). It is tensioned by using the previously placed sutures described in **A**. The skin paddle is used to assist in skin closure and as a monitor for the viability of the latissimus. (With permission of Milan Stevanovic.)

Operative Procedure. Prerequisites for this technique are that the sternocostal portion of the pectoralis major muscle be of normal strength and the elbow have full passive range of motion.[187]

Complete bipolar transplantation of the pectoralis major. The bipolar transfer was described by Carroll and Kleinman (Figures 34.53 and 34.54).[40] The patient is placed in the supine position with a flat bolster under the blade of the scapula and the upper extremity draped free. A long, curvilinear incision is made along the anterior thorax from the seventh sternocostal joint proximally to two fingerbreadths inferior to the clavicle. The incision continues laterally to the coracoid process and then distally along the anteromedial aspect of the arm to the level of the axilla. Alternatively, an inframammary incision may be used and extended proximally in the anterior axillary line. The muscle is exposed subcutaneously by elevating a large flap

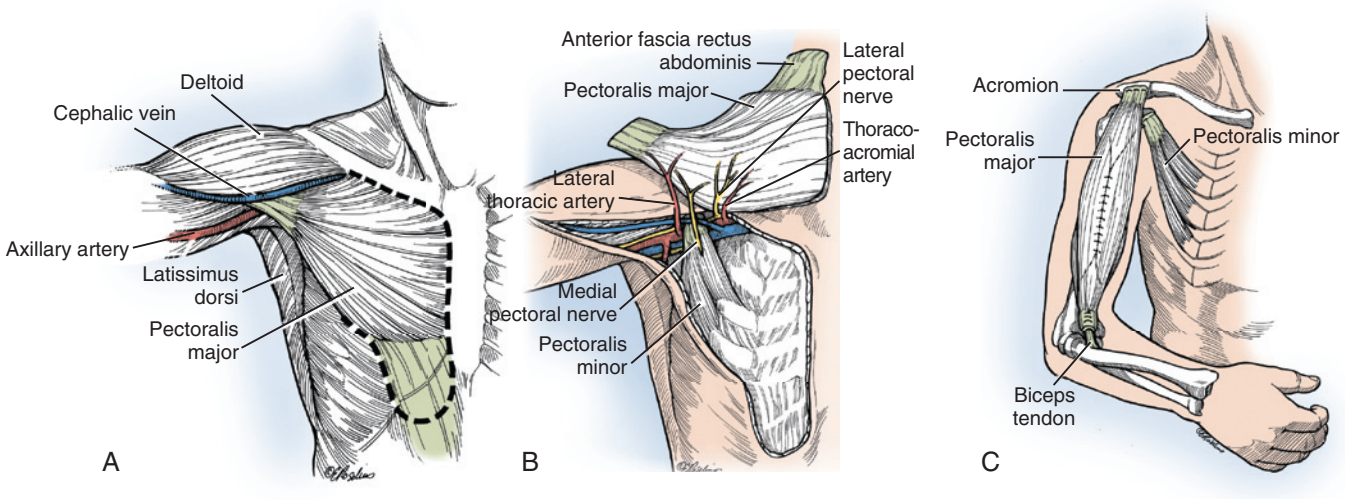

FIGURE 34.53 Authors' preferred method of transfer of the pectoralis major for elbow flexion. **A,** The entire mass of the pectoralis major muscle is detached from the clavicle, sternum, and ribs while taking a portion of the anterior rectus fascia. Note the *dashed line* indicating the border of the transplant. **B,** The pectoralis major muscle with the anterior fascia of the rectus is elevated based on branches of the thoracoacromial artery and veins and innervated by the medial and lateral pectoral nerves. **C,** The humeral attachment of the pectoralis major muscle is sutured to the acromion, and the origin of the pectoralis major along with the anterior rectus fascia is sutured to the biceps tendon. (Copyright © Elizabeth Martin.)

CRITICAL POINTS *Latissimus Dorsi Transfer for Elbow Flexion*

Indications
- Insufficient elbow flexion more than 6 to 9 months after Erb (C5-C6) paralysis
- Chronic, isolated paralysis of the musculocutaneous nerve
- Adequate latissimus dorsi strength

Preoperative Evaluation
- Assess the strength of the latissimus dorsi muscle.

Pearls
- During dissection, inclusion of superficial fascia with muscle facilitates fixation of the muscle origin. Ligation of multiple thoracodorsal perforators improves its mobility and helps prevent kinking.
- Appropriate tensioning and careful postoperative care optimize results.
- Reliable recovery and satisfactory power of elbow flexion are achieved when latissimus function is nearly normal.
- Flexion contractures of the elbow are unusual.

Technical Points
- Bipolar transfer is preferred.
- Use the lateral decubitus position with the extremity draped free.
- Harvest the entire latissimus dorsi from the fascial origin of the ilium to the humeral insertion through a longitudinal incision along the anterior muscle border.
- Dissect and protect the thoracodorsal neurovascular pedicle.
- Transfer the muscle subcutaneously beneath the axilla to the upper part of the arm through a deltopectoral incision.
- Pass the muscle beneath a subcutaneous skin bridge to the elbow. Suture the fascial origin of the muscle to the biceps tendon.
- Tension is adjusted by suturing the humeral attachment of the muscle to the coracoid process in 100 degrees of elbow flexion.
- Close the skin.

Pitfalls
- It is difficult to estimate the strength of the latissimus dorsi muscle.
- Distal repair and tensioning can be difficult.

Postoperative Care
- Immobilize the elbow in 100 degrees of flexion and the shoulder in 30 degrees of flexion and abduction with a shoulder pillow type of splint for 4 weeks, followed by a sling and gradual stretching/strengthening for an additional 4 to 5 weeks.

of skin and breast with either approach. Once the acromion and the entire pectoralis major muscle are exposed, a second curvilinear incision is made over the antecubital fossa with its transverse limb across the fossa and the longitudinal limb extending medially and distally for 6 cm. The entire pectoralis major muscle is detached from its origin along the medial half of the clavicle and its sternocostal border. A 12- by 6-cm strip of anterior rectus abdominis fascia is included and used to create a distal tendon of insertion. Care must be taken during dissection to avoid injury to both the lateral and medial pectoral neurovascular bundles, which are easily damaged.[187] The lateral pectoral nerve lies close to the costal margin of the muscle proximally and the deltopectoral groove laterally and passes in proximity to the thoracoacromial trunk. The medial pectoral nerve lies deep to the pectoralis minor muscle; it supplies small but powerful muscular branches that penetrate the pectoralis minor to reach the pectoralis major.

The entire muscle mass is carefully rotated 90 degrees on its two neurovascular pedicles. Distally, the rectus fascia with adjacent muscle is rolled into a tube and secured and reinforced with nonabsorbable suture. The muscular origin and attached rectus sheath are directed through the subcutaneous tunnel to the incision in the antecubital fossa. With the elbow flexed 135 degrees, the fascial tube is secured to the biceps tendon with

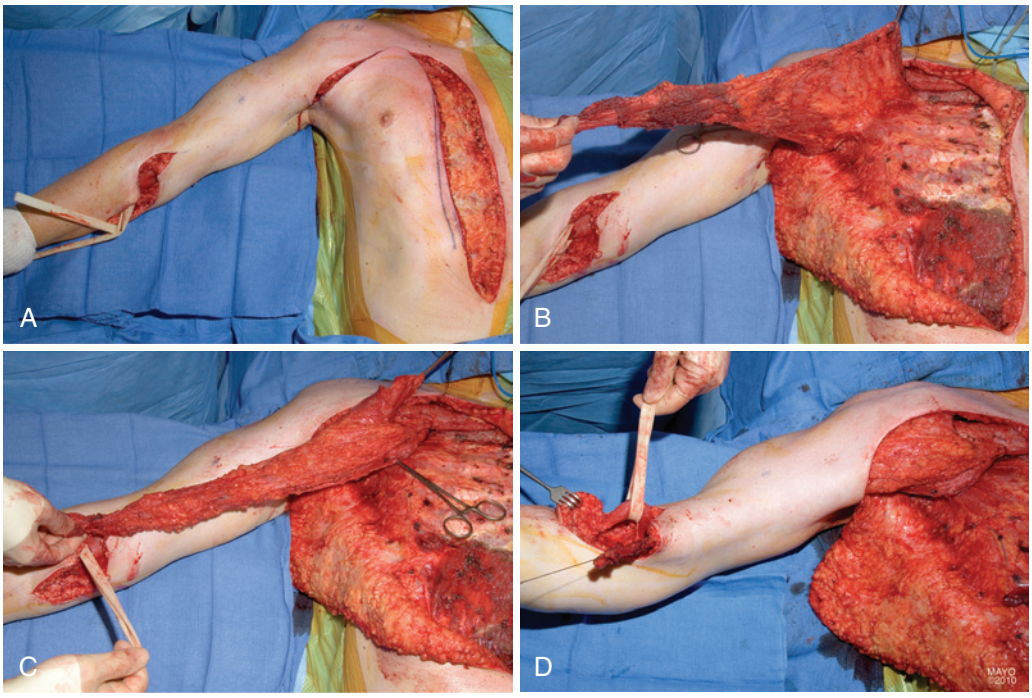

FIGURE 34.54 Transfer of the pectoralis major for elbow flexion. **A,** Skin incisions include an extensive incision that starts in the axilla, curves across the chest, and heads caudad to the level of the ipsilateral rectus abdominis. A second incision is made to expose the antecubital fossa and the biceps tendon. **B,** The two heads of the pectoralis major are carefully dissected while preserving the neurovascular bundles. Additionally, a long fascial strip from the rectus is taken to extend the transfer (held in the fingers of the surgeon's hand). **C,** The anterior rectus sheath is being entubulated before being sutured to the biceps tendon. The proximal humeral attachment is secured to the clavicle. **D,** A tunnel is created and the muscle is passed between the two incisions. The pectoralis major is then sutured distally to the biceps tendon. (By permission of Mayo Foundation for Medical Education and Research. All rights reserved.)

CRITICAL POINTS *Pectoralis Major Muscle Transfer for Elbow Flexion*

Indications
- Neglected cases or residual C5-C6 or musculocutaneous paralysis or paresis

Preoperative Evaluation
- Manual muscle testing of both the sternocostal head (innervated by the medial pectoral) and clavicular head (innervated by the lateral pectoral) of the pectoralis major

Pearls
- Inclusion of anterior rectus fascia simplifies connection to the biceps tendon of insertion.
- Results are dependent on normal function of the medial pectoral nerve.

Technical Points
- Supine position
- Curved longitudinal skin incision from the anterior aspect of the chest to the axilla and upper part of the arm
- Elevation of the entire clavicular, sternal, and costal origin with the anterior rectus sheath
- Protection of the medial and lateral pectoral nerves during mobilization
- Bipolar transfer of the origin to the elbow and the insertion to the acromion
- Suturing of the humeral attachment to the acromion under tension

Pitfalls
- Weak tension when suturing the muscle
- Relative cosmetic contraindication in women

Postoperative Care
- Immobilization of the elbow in 100 degrees of flexion and the shoulder in 60 degrees of flexion and abduction with a pillow for 4 weeks, followed by a sling and gradual extension for 4 to 5 weeks

nonabsorbable sutures. The tendon of insertion is directed proximally and anchored securely to the anterior acromion with nonabsorbable sutures through drill holes.

Postoperative Protocol. Postoperative immobilization and rehabilitation after pectoralis major muscle transfer are the same as for latissimus dorsi transfer.

Expected Outcomes. Botte and Wood reported satisfactory results in all five patients who underwent bipolar pectoralis major transfer but cautioned against using it in women because of the cosmetic disfigurement.[27] Matory and associates transferred the lower sternocostal segment of the pectoralis major in seven patients and achieved a functional range of elbow flexion (mean, 98 degrees) in all.[136] Loss of extension was just 15 to 25 degrees, and sustained flexion strength averaged 8 lb. Tsai and others performed a modified bipolar transplantation of the pectoralis major (with the lateral half of the clavicular origin

left intact), supplemented with a unipolar transfer of the pectoralis minor, in four patients.[203] Three of the four achieved excellent results (full extension with at least 60 degrees of flexion), and the other patient required a secondary Steindler flexorplasty.

Complications. Doyle and associates reported on two patients in whom transient nerve palsy developed after pectoralis major transfer, one median and one radial nerve palsy.[70] Both problems resolved completely after several weeks. Simultaneous contraction of the triceps, when the elbow is flexed, by the transposed pectoralis major has been reported.[180] All three patients had brachial plexus injuries and initially had paralysis of the triceps and elbow flexors. Axonal confusion after regeneration seems to be the probable explanation, but the complication cannot be predicted.

Free Muscle Transfer for Elbow Flexion in Delayed Cases

Indications. In the complete or upper type of brachial plexus injury, FFMT is indicated to restore elbow flexion when no local muscles of adequate strength are available for tendon transfer or when nerve transfer to the elbow flexors is inadvisable because of chronicity or muscle damage. The operation is technically more difficult in very young, small children and less successful in older individuals. Satisfactory results are not usually obtained in patients older than 65 years because of poor reinnervation of the transferred muscle. Other problems such as elbow joint damage, capsular contractures, vascular injury, poor soft tissues or skin coverage, and systemic injury or illness may limit the indications for this procedure, as well.

Vascular injuries to the subclavian artery, in particular to the thoracoacromial trunk, are a relative contraindication. Dissection through dense scar tissue in proximity to a subclavian artery injury or arterial reconstruction is technically challenging. If attempted at all, surgical confirmation of adequate vessels to permit microvascular anastomoses to the free functioning muscle is required before muscle harvest, and a vascular surgery team should be available in the operating theater if needed. If adequate arterial and venous sources cannot be identified, the muscle transfer should be aborted.

Donor Nerve Selection. Selection of the donor nerve depends on the availability of functioning nerves after the brachial plexus injury and any subsequent attempt at reconstruction. For late reconstruction of elbow flexion, the spinal accessory nerve is our donor motor nerve of choice (Figure 34.55). Proximal intercostal motor nerves (third to sixth ribs) are also commonly used because their position relative to the axilla permits direct transfer with sufficient length. We have found the results of these sources to be equivalent in ultimate strength and time to reinnervation of the muscle.[14] When these proximal intercostal nerves have already been used, more inferior intercostal nerves can be harvested. In C5-C6 or C5-C7 paralysis, the ulnar nerve offers an excellent option as a donor motor nerve for innervated muscle transfer.[94] In rare instances, other options may be considered, such as the use of a regenerated local nerve or contralateral C7 transfer.

Donor Muscle Selection. When selecting a functioning free muscle, one must consider its vascular and nerve innervation, cross-sectional area (a measure of ability to do work), and fiber length and excursion (to determine adequate excursion), all in comparison with the biceps brachii parameters.[60] The muscle must also be expendable, with minimal donor site morbidity. It

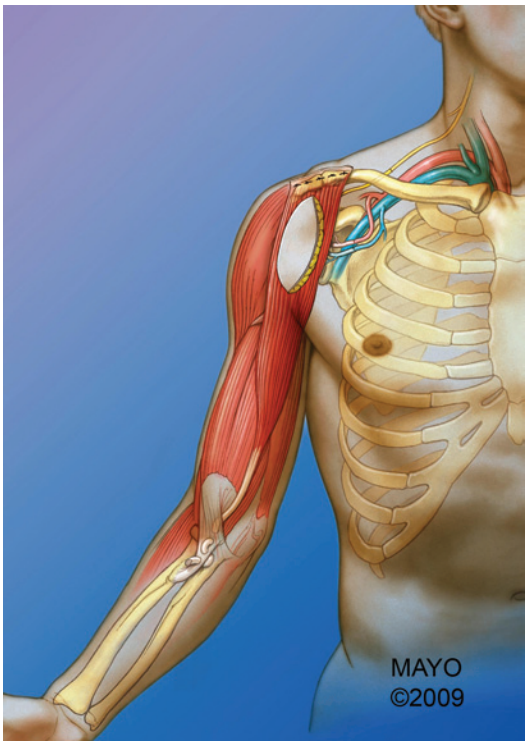

FIGURE 34.55 Free functioning muscle transfer for elbow flexion in a patient who was initially seen late after injury. In this illustration the spinal accessory nerve is transferred to the gracilis motor branch. Alternatively, intercostal nerves can be used, depending on the availability of nerve sources. The thoracoacromial vessels are used for the vascular repairs. (By permission of Mayo Foundation for Medical Education and Research. All rights reserved.)

can be expected to function best when used for a single purpose, but it may be used to both flex the elbow and extend the wrist, for example. A variety of muscles have been used as FFMTs, but the gracilis is certainly the most commonly used. The rectus femoris and latissimus dorsi are occasionally selected.

Operative Procedure. The technique is previously discussed in this chapter.

Expected Outcomes. More than 90% of patients who have undergone FFMT for elbow flexion have recovered more than 90 degrees of elbow flexion after transfer of the spinal accessory nerve or intercostal nerves.[45,64] Patients older than 40 years did not consistently recover comparable degrees of elbow flexion despite successful reinnervation to the transferred muscle. The final quantitative assessment of muscle strength showed 10% to 20% of the mean values of normal elbow flexion more than 2 years after surgery.

Wrist Arthrodesis. Nerve reconstruction for brachial plexus injury seldom restores function of the extrinsic wrist and finger motors. Recovery of grasp, whether spontaneous or the result of FFMT, may also be impaired by wrist extensor paralysis. When tendon transfer is not possible because of the lack of available motors (generally the case in adult traumatic plexus injury), the wrist may be supported with splintage. Long-term use of splints is often poorly tolerated and may result in skin breakdown over insensate skin. A wrist arthrodesis in these instances can be of benefit (see Chapter 12).

CRITICAL POINTS ***Free Muscle Transfer for Elbow Flexion***

Indications
- Delayed treatment (>6 to 9 months after injury)
- Failed cases after nerve grafting or nerve transfer
- Patients younger than 40 years

Preoperative Evaluation
- Available donor nerves and recipient vessels for vascular anastomosis
- Available expendable donor muscle
- Stable or reconstructible shoulder joint
- Supple elbow, adequate soft tissue envelope

Pearls
- Ischemic time should be kept to less than 60 minutes.
- Two teams (one for harvest and one for preparation of the recipient site) optimize surgical time.

Technical Points
- Minimization of ischemic time by ligating the muscle vascular pedicle only when the recipient site is fully prepared and the microscope is positioned for repair
- Proximal muscle fixation to the clavicle followed immediately by end-to-end or end-to-side microvascular anastomoses to the recipient artery and vein
- Direct transfer of the donor nerve to the FFMT motor nerve without an intervening graft
- Suture of the distal attachment of the muscle in its correct tension

Pitfalls
- Prolonged ischemia time
- Suture of tendons with incorrect tension

Postoperative Care
- Immobilization of the shoulder and elbow for 6 weeks. External rotation of the shoulder should be neutral with the elbow flexed 90 degrees.

NEUROPATHIC PAIN MANAGEMENT

Last, but not least, is the management of neuropathic pain in patients with traumatic brachial plexus injuries. Despite interventions to improve or restore function in the affected upper extremity, neuropathic pain may remain an important problem; the quality of life of patients with chronic neuropathic pain is significantly reduced. In patients with traumatic brachial plexus injury, the development of severe intractable neuropathic pain is highly variable. For example, intractable pain is very rarely reported to develop in Asian patients, whereas severe neuropathic pain develops in many American and European patients. Pain will develop in up to 80% of patients with a traumatic brachial plexus injury and will persist in 20%.[217] The pathogenesis of the pain is not well understood but may include postganglionic neuromas in some patients and central mechanisms of deafferentation pain attributed to segmental hyperactivity in the dorsal horn cells in patients with avulsion injuries.

Effective management of neuropathic pain in these patients requires (1) early recognition and treatment, (2) a multidisciplinary team, and (3) identification and targeting of physiologic as well as social and psychological factors. Nonsurgical options include psychosocial interventions (such as counseling, relaxation therapy, biofeedback, and support groups), rehabilitation (such as physical therapy and desensitization), and pharmacotherapy (combination of antidepressants, anticonvulsants, and analgesics). If the pain remains intractable over time despite aggressive nonsurgical management, surgical options should be considered. In some patients with postganglionic injury, neurolysis, neuroma resection, or nerve grafting of affected neural elements (or any combination of these therapies) may afford some relief of pain. Patients with root avulsions and chronic neuropathic pain may be candidates for radiofrequency destruction of the dorsal root entry zone (DREZ lesioning) of affected levels. With careful patient selection and adequate technique, the success rate can be as high as 66% to 90% at 4-year follow-up,[163,182] but it tends to decrease to 50% with longer follow-up.[44] Finally, central nervous system neuromodulation therapies such as spinal cord, motor cortex, or deep brain stimulation are increasingly being used by some groups to treat refractory neuropathic pain and can be considered.

REFERENCES

1. Adams JE, Kircher MF, Spinner RJ, et al: Complications and outcomes of functional free gracilis transfer in brachial plexus palsy. *Acta Orthop Belg* 75:8–13, 2009.
2. Addosooki A, Doi K, Hattori Y, et al: Role of wrist arthrodesis in patients receiving double-free muscle transfers for reconstruction following complete brachial plexus paralysis. *J Hand Surg [Am]* 37:277–281, 2012.
3. Akasaka Y, Hara T, Takahashi M: Free muscle transplantation combined with intercostal nerve crossing for reconstruction of elbow flexion and wrist extension in brachial plexus injuries. *Microsurgery* 12:346–361, 1991.
4. Allieu Y: Exploration and direct treatment of neural lesions in traumatic paralysis caused by stretching of the brachial plexus in the adult. *Rev Chir Orthop Reparatrice Appar Mot* 63:107–122, 1977.
5. Alnot JY: Traumatic brachial plexus lesions in the adult: indications and results. *Hand Clin* 11:623–631, 1995.
6. Alnot JY, Abols Y: Reanimation de la flexion du coude par transfers tendineux dans les paralysies traumatiques du plexus brachial de l'adulte: apropos de 44 blesses. *Rev Chir Orthop Reparatrice Appar Mot* 70:313–323, 1984.
7. Amrami KK, Port JD: Imaging the brachial plexus. *Hand Clin* 21:25–37, 2005.
8. Atkins RM, Bell MJ, Sharrard WJ: Pectoralis major transfer for paralysis of elbow flexion in children. *J Bone Joint Surg Br* 67:640–644, 1985.
9. Atlan F, Durand S, Fox M, et al: Functional outcome of glenohumeral fusion in brachial plexus palsy: a report of 54 cases. *J Hand Surg [Am]* 37(4):683–688, 2012.
10. Axer A, Segal D, Elkon A: Partial transposition of the latissimus dorsi. A new operative technique to restore elbow and finger flexion. *J Bone Joint Surg Am* 55:1259–1264, 1973.
11. Aziz W, Singer RM, Wolff TW: Transfer of the trapezius for flail shoulder after brachial plexus injury. *J Bone Joint Surg Br* 72:701–704, 1990.
12. Bahm J, Noaman H, Becker M: The dorsal approach to the suprascapular nerve in neuromuscular reanimation for obstetric brachial plexus lesions. *Plast Reconstr Surg* 115:240–244, 2005.
13. Barr JS, Freiberg JA, Colonna PC, et al: A survey of end results on stabilisation of the paralytic shoulder. *J Bone Joint Surg Br* 24:699–707, 1942.
14. Barrie KA, Steinmann SP, Shin AY, et al: Gracilis free muscle transfer for restoration of function after complete brachial plexus avulsion. *Neurosurg Focus* 16(5):E8, 2004.
15. Bassett RW, Browne AO, Money BF: Glenohumeral muscle force and moment mechanics in a position of shoulder instability. *J Biomech* 23:403–412, 1990.
16. Bateman JE: *The shoulder and environs*, St. Louis, 1955, Mosby.
17. Bertelli JA: Platysma motor branch transfer in brachial plexus repair: report of the first case. *J Brachial Plex Peripher Nerve Inj* 2:12, 2007.
18. Bertelli JA, Ghizoni MF: Reconstruction of C5 and C6 brachial plexus avulsion injury by multiple nerve transfers: spinal accessory to suprascapular, ulnar fascicles to biceps branch, and triceps long or lateral head branch to axillary nerve. *J Hand Surg [Am]* 29(1):131–139, 2004.
19. Bertelli JA, Ghizoni MF: Brachialis muscle transfer to reconstruct finger flexion or wrist extension in brachial plexus palsy. *J Hand Surg [Am]* 31:190–196, 2006.
20. Bertelli JA, Ghizoni MF: Transfer of the accessory nerve to the suprascapular nerve in brachial plexus reconstruction. *J Hand Surg [Am]* 32:989–998, 2007.

21. Bertelli JA, Ghizoni MF: Transfer of supinator motor branches to the posterior interosseous nerve in C7-T1 brachial plexus palsy. *J Neurosurg* 113(1):129–132, 2010.
22. Bhandari PS, Deb P: Management of isolated musculocutaneous injury: comparing double fascicular nerve transfer with conventional nerve grafting. *J Hand Surg [Am]* 40(10):2003–2006, 2015.
23. Birch R: Brachial plexus injury: the London experience with supraclavicular traction lesions. *Neurosurg Clin North Am* 20:15–23, 2009.
24. Birch R, Dunkerton M, Bonney G, et al: Experience with the free vascularized ulnar nerve graft in repair of supraclavicular lesions of the brachial plexus. *Clin Orthop Relat Res* (237):96–104, 1988.
25. Boome RS, Kaye IC: Obstetric traction injuries of the brachial plexus: natural history, indications for surgical repair, and results. *J Bone Joint Surg Br* 70:57l–576, 1988.
26. Bostwick J, Nahai F, Wallace JG, et al: Sixty latissimus dorsi flaps. *Plast Reconstr Surg* 63:31–41, 1979.
27. Botte MJ, Wood MB: Flexorplasty of the elbow. *Clin Orthop Relat Res* 245:110–116, 1989.
28. Brand PW, Beach RB, Thompson DE: Relative tension and potential excursion of muscles in the forearm and hand. *J Hand Surg [Am]* 6:209–219, 1981.
29. Brooks DM, Seddon HJ: Pectoral transplantation for paralysis of the flexors of the elbow: a new technique. *J Bone Joint Surg Br* 41:36–43, 1959.
30. Brown JM, Mackinnon SE: Nerve transfers in the forearm and hand. *Hand Clin* 24:319–340, 2008.
31. Brown JM, Shah MN, Mackinnon SE: Distal nerve transfers: a biology-based rationale. *Neurosurg Focus* 26(2):E12, 2009.
32. Brunelli G: Neurotization of avulsed roots of the brachial plexus by means of anterior nerves of the cervical plexus. *Int J Microsurg* 55:529–531, 1980.
33. Bunnell S: Restoring flexion to the paralytic elbow. *J Bone Joint Surg Am* 33:566–567, 1951.
34. Cardenas-Mejia A, O'Boyle CP, Chen TK, et al: Evaluation of single-, double-, and triple-nerve transfers for shoulder abduction in 90 patients with supraclavicular brachial plexus injury. *Plast Reconstr Surg* 122:1470–1478, 2008.
35. Carlsen BT, Kircher MF, Spinner RJ, et al: Comparison of single vs. double nerve transfers for elbow flexion after brachial plexus injury. *Plast Reconstr Surg* 127:269–276, 2011.
36. Carlstedt T: Functional recovery after ventral root avulsion and implantation in the spinal cord. *Clin Neurol Neurosurg* 95(Suppl):109–111, 1993.
37. Carlstedt T, Anand P, Hallin R, et al: Spinal nerve root repair and reimplantation of avulsed ventral roots into the spinal cord after brachial plexus injury. *J Neurosurg* 93:237–247, 2000.
38. Carroll RE, Gartland JJ: Flexorplasty of the elbow. *J Bone Joint Surg Am* 35:706–710, 1953.
39. Carroll RE, Hill NA: Triceps transfer to restore elbow flexion: a study of 15 patients with paralytic lesions and arthrogryposis. *J Bone Joint Surg Am* 52:239–244, 1970.
40. Carroll RE, Kleinman WB: Pectoralis major transplantation to restore elbow flexion to the paralytic limb. *J Hand Surg [Am]* 4:501–507, 1979.
41. Carvalho GA, Nikkah G, Matthies C, et al: Diagnosis of root avulsions in traumatic brachial plexus injuries: value of computerized tomography myelography and magnetic resonance imaging. *J Neurosurg* 86:69–76, 1997.
42. Chalidapong P, Sananpanich K, Kraisarin J, et al: Pulmonary and biceps function after intercostal and phrenic nerve transfer for brachial plexus injuries. *J Hand Surg [Br]* 29:8–11, 2004.
43. Charnley J, Houston JK: Compression arthrodesis of the shoulder. *J Bone Joint Surg Br* 46:614–620, 1964.
44. Chen HJ, Tu YK: Long term follow-up results of dorsal root entry zone lesions for intractable pain after brachial plexus avulsion injuries. *Acta Neurochir Suppl* 99:73–75, 2006.
45. Chuang DC, Epstein MD, Yeh MC, et al: Functional restoration of elbow flexion in brachial plexus injuries: results in 167 patients (excluding obstetric brachial plexus injury). *J Hand Surg [Am]* 18:285–291, 1993.
46. Chuang DC, Lee GW, Hashem F, et al: Restoration of shoulder abduction by nerve transfer in avulsed brachial plexus injury: evaluation of 99 patients with various nerve transfers. *Plast Reconstr Surg* 96:122–128, 1995.
47. Chuang DC, Yeh MC, Wei FC: Intercostal nerve transfer of the musculocutaneous nerve in avulsed brachial plexus injuries: evaluation of 66 patients. *J Hand Surg [Am]* 17:822–888, 1992.
48. Clare DJ, Wirth MA, Groh GI, et al: Current concept review. Shoulder arthrodesis. *J Bone Joint Surg Am* 83:593–600, 2001.
49. Clark JMP: Reconstruction of biceps brachii by pectoral muscle transplantation. *Br J Surg* 34:180–181, 1946.
50. Coene LN: Mechanisms of brachial plexus lesions. *Clin Neurol Neurosurg* 95(Suppl):S24–S29, 1993.
51. Cofield RH, Briggs BL: Glenohumeral arthrodesis: operative and long-term functional results. *J Bone Joint Surg Am* 61:668–677, 1979.
52. Colbert SH, Mackinnon S: Posterior approach for double nerve transfer for restoration of shoulder function in upper brachial plexus palsy. *Hand* 1:71–77, 2006.
53. Comtet JJ, Herzberg G, Naasan IA: Biomechanical basis of transfers for shoulder paralysis. *Hand Clin* 5(1):1–14, 1989.
54. Dailiana ZH, Mehdian H, Gilbert A: Surgical anatomy of spinal accessory nerve: is trapezius functional deficit inevitable after division of the nerve? *J Hand Surg [Br]* 26:137–141, 2001.
55. De Smet L: The latissimus dorsi flap for reconstruction of a paralysed deltoid. *Acta Chir Belg* 104:328–329, 2004.
56. De Velasco Polo G, Cardoso Monterrubio A: Arthrodesis of the shoulder. *Clin Orthop Relat Res* 90:178–182, 1973.
57. Dodakundi C, Doi K, Hattori Y, et al: Postoperative monitoring in free muscle transfers for reconstruction in brachial plexus injuries. *Tech Hand Up Extrem Surg* 16:48–51, 2012.
58. Doi K: Obstetric and traumatic pediatric palsy. In Peimer CA, editor: *Surgery of the hand and upper extremity*, New York, 1996, McGraw-Hill, pp 1443–1463.
59. Doi K: New reconstructive procedure for brachial plexus injury. *Clin Plast Surg* 24:75–85, 1997.
60. Doi K, Hattori Y, Tan SH, et al: Basic science behind functioning free muscle transplantation. *Clin Plast Surg* 29:483–495, 2002.
61. Doi K, Hattori Y, Yamazaki H, et al: Importance of early passive mobilization following double free gracilis muscle transfer. *Plast Reconstr Surg* 121:2037–2045, 2008.
62. Doi K, Kuwata N, Muramatsu K, et al: Double muscle transfer for upper extremity reconstruction following complete avulsion of the brachial plexus. *Hand Clin* 15:757–767, 1999.
63. Doi K, Kuwata N, Sakai K, et al: A reliable technique of free vascularized sural nerve grafting and preliminary results of clinical applications. *J Hand Surg [Am]* 12:677–684, 1987.
64. Doi K, Muramatsu K, Hattori Y, et al: Restoration of prehension with the double free muscle technique following complete avulsion of the brachial plexus: indications and long-term results. *J Bone Joint Surg Am* 82:652–666, 2000.
65. Doi K, Otsuka K, Okamoto Y, et al: Cervical nerve root avulsion in brachial plexus injuries: magnetic resonance imaging classification and comparison with myelography and computerized tomography myelography. *J Neurosurg* 96:277–284, 2002.
66. Doi K, Sakai K, Fuchigami Y, et al: Reconstruction of irreparable brachial plexus injuries with reinnervated free-muscle transfer. *J Neurosurg* 85:174–177, 1996.
67. Doi K, Sakai K, Kuwata N, et al: Reconstruction of finger and elbow function after avulsion of the brachial plexus. *J Hand Surg [Am]* 16:796–803, 1991.
68. Doi K, Sakai K, Kuwata N, et al: Double free-muscle transfer to restore prehension after complete avulsion of brachial plexus. *J Hand Surg [Am]* 20:408–414, 1995.
69. Doi K, Shigetomi M, Kaneko K, et al: Significance of elbow extension in reconstruction of prehension with reinnervated free muscle transfer following complete brachial plexus avulsion. *Plast Reconstr Surg* 100:364–372, 1997.
70. Doyle JR, James PM, Larson LJ, et al: Restoration of elbow flexion in arthrogryposis multiplex congenita. *J Hand Surg [Am]* 5:149–152, 1980.
71. Durand S, Oberlin C, Fox M, et al: Transfer of the first intercostal nerve to supra- and infraspinatus muscles: an anatomical study and report of the first case. *J Hand Surg Eur Vol* 34:196–200, 2009.
72. Dutton RO, Dawson EG: Elbow flexorplasty: an analysis of long-term results. *J Bone Joint Surg Am* 63:1064–1069, 1981.
73. Elhassan B, Bishop AT, Hartzler RU, et al: Tendon transfer options about the shoulder in patients with brachial plexus injury. *J Bone Joint Surg Am* 94:1391–1398, 2012.
74. Elhassan B, Bishop A, Shin A: Trapezius transfer to restore external rotation in a patient with a brachial plexus injury. A case report. *J Bone Joint Surg Am* 91:939–944, 2009.
75. Elhassan B, Endres NK, Higgins LD, et al: Massive irreparable tendon tears of the rotator cuff: salvage options. *Instr Course Lect* 57:153–166, 2008.
76. Elhassan BT, Wagner ER, Bishop AT: Feasibility of contralateral trapezius transfer to restore shoulder external rotation: part I. *J Shoulder Elbow Surg* 21:1363–1369, 2012.
77. Engel J, Ganel A, Melamed R, et al: Choline acetyltransferase for differentiation between human motor and sensory fibers. *Ann Plast Surg* 4:376–380, 1980.
78. Ferraresi S, Garozzo D, Ravenni R, et al: Hemihypoglossal nerve transfer in brachial plexus repair: technique and results. *Neurosurgery* 50:332–335, 2002.
79. Ferrier J, Owens T, Singer D: Functional reconstruction of the shoulder with latissimus dorsi pedicle flap and a hemiarthroplasty: a case report. *J Hand Surg [Am]* 20:284–287, 1995.
80. Garg R, Merrell GA, Hillstrom HJ, et al: Comparison of nerve transfers and nerve grafting for traumatic upper plexus palsy: a systemic review and analysis. *J Bone Joint Surg Am* 93:819–829, 2011.
81. Gerber C: Latissimus dorsi transfer for the treatment of irreparable tears of the rotator cuff. *Clin Orthop Relat Res* 275:152–160, 1992.

82. Gerber C, Blumenthal S, Curt A, et al: Effect of selective experimental suprascapular nerve block on abduction and external rotation strength of the shoulder. *J Shoulder Elbow Surg* 16:815–820, 2007.
83. Gilbert A, Tassin IL: Surgical repair of the brachial plexus in obstetrical paralysis. *Chirurgie* 110:70–75, 1984.
84. Giuffre JL, Bishop AT, Shin AY: Harvest of an entire gracilis muscle and tendon for use in functional muscle transfer: a novel technique. *J Reconstr Microsurg* 28:349–358, 2012.
85. Giuffre JL, Bishop AT, Spinner RJ, et al: Wrist, first carpometacarpal joint, and thumb interphalangeal joint arthrodesis in patients with brachial plexus injuries. *J Hand Surg [Am]* 37:2557–2563.e2551, 2012.
86. Giusti G, Willes WF, Kremer T, et al: Return of motor function after segmental nerve loss in a rat model: comparison of autogenous nerve graft, collagen conduit, and processed allograft (AxoGen). *J Bone Joint Surg Am* 94:410–417, 2012.
87. Goldner JL: Strengthening of the partially paralyzed shoulder girdle by multiple muscle-tendon transfers. *Hand Clin* 4:232–236, 1988.
88. Grundy DJ, Silver JR: Combined brachial plexus and spinal cord trauma. *Injury* 15:57–61, 1983.
89. Gu YD, Cai PQ, Xu F, et al: Clinical application of ipsilateral C7 nerve root transfer for treatment of C5 and C6 avulsion of brachial plexus. *Microsurgery* 23:105–108, 2003.
90. Gu YD, Chen DS, Zhang GM, et al: Long-term functional results of contralateral C7 transfer. *J Reconstr Microsurg* 14:57–59, 1998.
91. Gu YD, Ma MK: Use of the phrenic nerve for brachial plexus reconstruction. *Clin Orthop Relat Res* 323:119–121, 1996.
92. Gu YD, Wang H, Zhang L, et al: Transfer of brachialis branch of musculocutaneous nerve for finger flexion: anatomic study and case report. *Microsurgery* 24:358–362, 2004.
93. Guan SB, Hou CL, Chen DS, et al: Restoration of shoulder abduction by transfer of the spinal accessory nerve to suprascapular nerve through a dorsal approach: a clinical study. *Chin Med J* 119:707–712, 2006.
94. Hattori Y, Doi K, Baliarsing AS: A part of the ulnar nerve as an alternative donor nerve for functioning free muscle transfer: a case report. *J Hand Surg [Am]* 27:150–153, 2002.
95. Hattori Y, Doi K, Kaneko K, et al: Intraoperative measurement of choline acetyltransferase activity to evaluate the functional status of donor nerve during reinnervated free muscle transfer: a preliminary report. *J Hand Surg [Am]* 23: 1034–1037, 1998.
96. Hattori Y, Doi K, Ohi R, et al: Clinical application of intraoperative measurement of choline acetyltransferase activity during functioning free muscle transfer. *J Hand Surg [Am]* 26:645–648, 2001.
97. Hattori Y, Doi K, Sakamoto S, et al: Complete avulsion of brachial plexus with associated vascular trauma: feasibility of reconstruction using the double free muscle technique. *Plast Reconstr Surg* 132:1504–1512, 2013.
98. Hentz VR, Narakas AD: The results of microneurosurgical reconstruction in complete brachial plexus palsy: assessing outcome and predicting results. *Orthop Clin North Am* 19:107–114, 1988.
99. Herzberg G, Urien JP, Dimnet J: Potential excursion and relative tension of muscles in the shoulder girdle: relevance of tendon transfers. *J Shoulder Elbow Surg* 8:430–437, 1999.
100. Hou CL, Tai YH: Transfer of the upper pectoralis major flap for functional reconstruction of the deltoid muscle. *Chin Med J* 104:753–757, 1991.
101. Hovnanian AP: Latissimus dorsi transplantation for loss of flexion or extension at the elbow; a preliminary report on technic. *Ann Surg* 143:493–499, 1956.
102. Ihara K, Doi K, Sakai K, et al: Restoration of sensibility in the hand following complete brachial plexus injuries. *J Hand Surg [Am]* 21:381–385, 1996.
103. Ikuta Y, Yoshioka K, Tsuge K: Free muscle graft as applied to brachial plexus injury—case report and experimental study. *Ann Acad Med Singapore* 8:454–458, 1979.
104. Itoh Y, Sasaki T, Ishiguro T, et al: Transfer of latissimus dorsi to replace a paralyzed anterior deltoid. *J Bone Joint Surg Br* 69:647–651, 1987.
105. Karev A: Trapezius transfer for paralysis of the deltoid. *J Hand Surg [Br]* 11:81–83, 1986.
106. Keating IF, Waterworth P, Shaw-Dunn J: The relative strength of the rotator cuff muscles. *J Bone Joint Surg Br* 75:137–141, 1993.
107. Kennedy R: Suture of the brachial plexus in birth paralysis of the upper extremity. *BMJ* 1:298–301, 1903.
108. Kim DH, Murovic JA, Tiel RL, et al: Mechanisms of injury in operative brachial plexus lesions. *Neurosurg Focus* 16(5):E2, 2004.
109. Kitamura T, Takagi K, Yamaga M, et al: Brachial plexus stretching injuries: microcirculation of the brachial plexus. *J Shoulder Elbow Surg* 4:118–123, 1995.
110. Kline DG, Happel LT: Penfield Lecture. A quarter century's experience with intraoperative nerve action potential recording. *Can J Neurol Sci* 20:3–10, 1993.
111. Kline DG, Hudson AR: *Nerve injuries. operative results for major nerve injuries, entrapments and tumors*, Philadelphia, 1995, WB Saunders.
112. Kotwal PP, Mittal R, Malhotra R: Trapezius transfer for deltoid paralysis. *J Bone Joint Surg Br* 80:114–116, 1998.
113. Kovachevich R, Kircher MF, Wood CM, et al: Complications of intercostal nerve transfer for brachial plexus reconstruction. *J Hand Surg [Am]* 35:1995–2000, 2010.
114. Krakauer JD, Wood MB: Intercostal nerve transfer for brachial plexopathy. *J Hand Surg [Am]* 19:829–835, 1994.
115. Leechavengvongs S, Witoonchart K, Uerpairojkit C, et al: Nerve transfer to biceps muscle using a part of the ulnar nerve in brachial plexus injury (upper arm type): a report of 32 cases. *J Hand Surg [Am]* 23:711–716, 1998.
116. Leechavengvongs S, Witoonchart K, Uerpairojkit C, et al: Nerve transfer to deltoid muscle using the nerve to the long head of the triceps, part II: a report of 7 cases. *J Hand Surg [Am]* 28:633–638, 2003.
117. Leffert RD: *Brachial plexus injuries*, New York, 1985, Churchill Livingstone.
118. Leffert RD: Brachial plexus. In Green D, Hotchkiss RN, Pederson WC, editors: *Green's operative hand surgery*, ed 4, New York, 1993, Churchill Livingstone.
119. Leffert RD, Pess GM: Tendon transfers for brachial plexus injury. *Hand Clin* 4:273–288, 1988.
120. Lee JY, Kircher MF, Spinner RJ, et al: Factors affecting outcome of triceps motor branch transfer for isolated axillary nerve injury. *J Hand Surg [Am]* 37:2350–2356, 2012.
121. Lin H, Hou C, Xu Z: Transfer of the superior portion of the pectoralis major flap for restoration of shoulder abduction. *J Reconstr Microsurg* 25:255–260, 2009.
122. Lindholm TS, Einola S: Flexorplasty of paralytic elbows: analysis of late functional results. *Acta Orthop Scand* 44:1–11, 1973.
123. Liu J, Pho RW, Kour AZ, et al: Neurologic deficit and recovery in the donor limb following cross-C7 transfer in brachial-plexus injury. *J Reconstr Microsurg* 13:237–242, 1997.
124. Liu TK, Yang RS, Sun JS: Long-term results of the Steindler flexorplasty. *Clin Orthop Relat Res* 296:104–108, 1993.
125. Liverneaux PA, Diaz LC, Beaulieu JY, et al: Preliminary results of double nerve transfer to restore elbow flexion in upper type brachial plexus palsies. *Plast Reconstr Surg* 117:915–919, 2006.
126. Luedemann W, Hamm M, Blomer U, et al: Brachial plexus neurotization with donor phrenic nerves and its effect on pulmonary function. *J Neurosurg* 96:523–526, 2002.
127. Mackinnon SE, Novak CB, Myckatyn TM, et al: Results of reinnervation of the biceps and brachialis muscles with a double fascicular transfer for elbow flexion. *J Hand Surg [Am]* 30:978–985, 2005.
128. Malessy MJ, de Ruiter GC, de Boer KS, et al: Evaluation of suprascapular nerve neurotization after nerve graft or transfer in the treatment of brachial plexus traction lesions. *J Neurosurg* 101:377–389, 2004.
129. Malessy MJ, van Duinen SG, Feirabend HK, et al: Correlation between histopathological findings in C-5 and C-6 nerve stumps and motor recovery following nerve grafting for repair of brachial plexus injury. *J Neurosurg* 91(4):636–644, 1999.
130. Malessy MJA, Hoffman CFE, Thomeer RTWM: Initial report on the limited value of hypoglossal nerve transfer to treat brachial plexus avulsions. *J Neurosurg* 91:601–604, 1999.
131. Manktelow RT: Functioning microsurgical muscle transfer. *Hand Clin* 4:289–296, 1988.
132. Manktelow RT, McKee NH: Free muscle transplantation to provide active finger flexion. *J Hand Surg [Am]* 3:416–426, 1978.
133. Manktelow RT, Zuker RM, McKee NH: Functioning free muscle transplantation. *J Hand Surg [Am]* 9:32–39, 1984.
134. Mansat M: Surgical topographic anatomy of the brachial plexus. *Rev Chir Orthop Reparatrice Appar Mot* 63:20–26, 1977.
135. Martins RS, Siqueira MG, Heise CO, et al: A prospective study comparing single and double fascicular transfer to restore elbow flexion after brachial plexus injury. *Neurosurgery* 72:709–714, discussion 714–715; quiz 715, 2013.
136. Matory WE, Morgan WJ, Breen T: Technical considerations in pectoralis major transfer for treatment of the paralytic elbow. *J Hand Surg [Am]* 16:12–18, 1991.
137. Mayer L, Green W: Experiences with Steindler flexorplasty of the elbow. *J Bone Joint Surg Am* 36:775–789, 1954.
138. Meals RA, Nelissen RG: The origin and meaning of "neurotization." *J Hand Surg [Am]* 20(1):144–146, 1995.
139. Merrell GA, Barrie KA, Katz DL, et al: Results of nerve transfer techniques for restoration of shoulder and elbow function in the context of a meta-analysis of the English literature. *J Hand Surg [Am]* 26:303–314, 2001.
140. Millesi H: Surgical management of brachial plexus injuries. *J Hand Surg [Am]* 2:367–378, 1977.
141. Millesi M: Brachial plexus injuries: management and results. In Terzis JK, editor: *Microreconstruction of nerve injuries*, Philadelphia, 1987, WB Saunders, pp 347–360.
142. Minami M, Ishii S: Satisfactory elbow flexion in complete (preganglionic) brachial plexus injuries: produced by suture of third and fourth intercostal nerves to musculocutaneous nerve. *J Hand Surg [Am]* 12:1114–1118, 1987.

143. Moberg E: Surgical treatment for absent single-hand grip and elbow extension in quadriplegia: principles and preliminary experience. *J Bone Joint Surg Am* 57: 196–206, 1975.
144. Moberg E: Reconstruction hand surgery in tetraplegia: stroke and cerebral palsy: some basic concepts in physiology and neurology. *J Hand Surg [Am]* 1:29–34, 1976.
145. Moberg E: *The upper limb in tetraplegia: a new approach to surgical rehabilitation*, Stuttgart, Germany, 1978, Thieme.
146. Mohammed NS: A simple method of shoulder arthrodesis. *J Bone Joint Surg Br* 80:620–623, 1998.
147. Moneim MS, Omer GE: Latissimus dorsi muscle transfer for restoration of elbow flexion after brachial plexus disruption. *J Hand Surg [Am]* 11:135–139, 1986.
148. Monreal R: Steindler flexorplasty to restore elbow flexion in C5-C6-C7 brachial plexus palsy type. *J Brachial Plex Peripher Nerve Inj* 2:15, 2007.
149. Monreal R, Paredes L, Diaz H, et al: Trapezius transfer to treat flail shoulder after brachial plexus palsy. *J Brachial Plex Peripher Nerve Inj* 2:2, 2007.
150. Morris RF, Hasso AN, Thompson JR, et al: Traumatic dural tears: CT diagnosis using metrizamide. *Radiology* 152:444–446, 1984.
151. Murase T, Kawai H, Masatomi T, et al: Evoked spinal potential for diagnosis during brachial plexus surgery. *J Bone Joint Surg Br* 75:775–781, 1993.
152. Nagano A, Ochiai N, Sugioka H, et al: Usefulness of myelography in brachial plexus injuries. *J Hand Surg [Br]* 14:59–64, 1989.
153. Nagano A, Okinaga S, Ochiai N, et al: Shoulder arthrodesis by external fixation. *Clin Orthop Relat Res* 247:97–100, 1989.
154. Nagano A, Tsuyama N, Ochiai N, et al: Direct nerve crossing with the intercostals nerve to treat avulsion injuries of the brachial plexus. *J Hand Surg [Am]* 14:980–985, 1989.
155. Nakamura T, Yabe Y, Hirouchi Y, et al: Magnetic resonance myelography in brachial plexus injury. *J Bone Joint Surg Br* 79:764–769, 1997.
156. Narakas A: Lesions in stretching the brachial plexus: various possibilities and lesional associations. *Rev Chir Orthop Reparatrice Appar Mot* 63:44–54, 1977.
157. Narakas A: Indications and results of direct surgical treatment in lesions caused by stretching of the brachial plexus: I. Indications for direct surgical treatment. *Rev Chir Orthop Reparatrice Appar Mot* 63:88–106, 1977.
158. Narakas AO: Brachial plexus surgery. *Orthop Clin North Am* 12:303–323, 1981.
159. Narakas AO: Muscle transposition in the shoulder and upper arm for sequelae of brachial plexus palsy. *Clin Neurol Neurosurg* 95(Suppl):S89–S91, 1993.
160. Neer CS, Hawkins RJ: A functional analysis of shoulder fusions. *J Bone Joint Surg Br* 59:508–510, 1977.
161. Oberlin C, Beal D, Leechavengvongs S, et al: Nerve transfer to biceps muscle using a part of ulnar nerve for C5-C6 avulsion of the brachial plexus: anatomical study and report of four cases. *J Hand Surg [Am]* 19:232–237, 1994.
162. Oberlin C, Bhatia A: Biceps neurotization using the ulnar nerve. In Alnot JY, Narakas A, editors: *Traumatic brachial plexus injuries*, Paris, 1996, Expansion Scientifique Française, pp 196–198.
163. Raslan AM, McCartney S, Burchiel KJ: Management of chronic severe pain: spinal neuromodulatory and neuroablative approaches. *Acta Neurochir Suppl* 97:33–41, 2007.
164. Ray WZ, Yarbrough CK, Yee A, et al: Clinical outcomes following brachialis to anterior interosseous nerve transfers. *J Neurosurg* 117:604–609, 2012.
165. Richards RR, Sherman RMP, Hudson AR, et al: Shoulder arthrodesis using a pelvic-reconstruction plate. A report of eleven cases. *J Bone Joint Surg Am* 70:416–421, 1988.
166. Richards RR, Waddell JP, Hudson AR, et al: Shoulder arthrodesis for the treatment of brachial plexus palsy. *Clin Orthop Relat Res* 198:25–28, 1985.
167. Robert EG, Happel LT, Kline DG: Intraoperative nerve action potential recordings: technical considerations, problems, and pitfalls. *Neurosurgery* 65:97–104, 2009.
168. Rouholamin E, Wootton R, Jamieson AM: Arthrodesis of the shoulder following brachial plexus injury. *Injury* 22:271–274, 1991.
169. Rowe CR: Arthrodesis of the shoulder used in treating painful conditions. *Clin Orthop Relat Res* 173:92–96, 1983.
170. Ruhmann O, Schmolke S, Bohnsack M, et al: Reconstructive operations for the upper limb after brachial plexus palsy. *Am J Orthop* 33:351–362, 2004.
171. Ruhmann O, Schmolke S, Bohnsack M, et al: Trapezius transfer in brachial plexus palsy. Correlation of the outcome with muscle power and operative technique. *J Bone Joint Surg Br* 87:184–190, 2005.
172. Saha AK: Surgery of the paralyzed and flail shoulder. *Acta Orthop Scand Suppl* 97:5–90, 1967.
173. Samardzic MM, Grujicic DM, Rasulic LG, et al: The use of thoracodorsal nerve transfer in restoration of irreparable C5 and C6 spinal nerve lesions. *Br J Plast Surg* 58:541–546, 2005.
174. Sammer DM, Kircher MF, Bishop AT, et al: Hemi-contralateral C7 transfer in traumatic brachial plexus injuries: outcomes and complications. *J Bone Joint Surg Am* 94:131–137, 2012.
175. Sananpanich K, Tu YK, Pookhang S, et al: Anatomic variance in common vascular pedicle of the gracilis and adductor longus muscles: feasibility of double functioning free muscle transplantation with single pedicle anastomosis. *J Reconstr Microsurg* 24:231–238, 2008.
176. Satbhai NG, Doi K, Hattori Y, et al: Contralateral lower trapezius transfer for restoration of shoulder external rotation in traumatic brachial plexus palsy: a preliminary report and literature review. *J Hand Surg Eur Vol* 39(8):861–867, 2014.
177. Schottstaedt ER, Larsen LJ, Bost FC: Complete muscle transposition. *J Bone Joint Surg Am* 37:897–919, 1955.
178. Seddon H: *Surgical disorders of the peripheral nerves*, ed 2, New York, 1975, Churchill Livingstone.
179. Sedel L: The results of surgical repair of brachial plexus injuries. *J Bone Joint Surg Br* 64:54–66, 1982.
180. Segal A, Seddon HJ, Brooks DM: Treatment of paralysis of the flexors of the elbow. *J Bone Joint Surg Br* 41:44–50, 1959.
181. Shin AY, Spinner RJ, Steinmann SP, et al: Adult traumatic brachial plexus injuries. *J Am Acad Orthop Surg* 13:382–396, 2005.
182. Sindou MP, Blondet E, Emery E, et al: Microsurgical lesioning in the dorsal root entry zone for pain due to brachial plexus avulsion: a prospective series of 55 patients. *J Neurosurg* 102:1018–1028, 2005.
183. Socolovsky M, Martins RS, DiMasi G, et al: Upper brachial plexus injuries: grafts vs ulnar fascicle transfer to restore biceps muscle function. *Neurosurgery* 71 (2 Suppl Operative):ONS 227–ONS 232, 2012.
184. Soldado F, Bertelli J: Free gracilis transfer reinnervated by the nerve to the supinator for the reconstruction of finger and thumb extension in longstanding C7-T1 brachial plexus root avulsion. *J Hand Surg [Am]* 38:941–946, 2013.
185. Songcharoen P, Mahisavariya B, Chotigavanich C: Spinal accessory neurotization for restoration of elbow flexion in avulsion injuries of the brachial plexus. *J Hand Surg [Am]* 21:387–390, 1996.
186. Songcharoen P, Wongtakul S, Mahaisavariya B, et al: Hemi-contralateral C7 transfer to median nerve in the treatment of root avulsion brachial plexus injury. *J Hand Surg [Am]* 26:1058–1064, 2001.
187. Soucacos PN, Vekris MD, Zoubos AB, et al: Secondary reanimation procedures in late obstetrical brachial plexus palsy patients. *Microsurgery* 26(4):343–351, 2006.
188. Spira E: Replacement of biceps brachii by pectoralis minor transplant: report of a case. *J Bone Joint Surg Br* 39:126–127, 1957.
189. Steindler A: A muscle plasty for the relief of flail elbow in infantile paralysis. *Interstate Med J* 25:235–241, 1918.
190. Steindler A: Orthopaedic reconstruction work on hand and forearm. *N Y Med J* 108:1117–1119, 1918.
191. Steindler A: Tendon transplantation in the upper extremity. *Am J Surg* 44:260–271, 1939.
192. Steindler A: Muscle and tendon transplantation at the elbow. *AAOS Instr Course Lect Reconstr Surg* 2:276–282, 1944.
193. Stevanovic M, Sharpe F, Itamura JM: Treatment of soft tissue problems about the elbow. *Clin Orthop Relat Res* 370:127–137, 2000.
194. Sturm JT, Perry JF, Jr: Brachial plexus injuries from blunt trauma—a harbinger of vascular and thoracic injury. *Ann Emerg Med* 16:404–406, 1987.
195. Sugioka H, Tsuyama N, Hara T, et al: Investigation of brachial plexus injuries by intraoperative cortical somatosensory evoked potentials. *Arch Orthop Trauma Surg* 99:143–151, 1982.
196. Sunderland S: *Nerves and nerve injuries*, ed 2, New York, 1978, Churchill Livingstone.
197. Sungpet A, Suphachatwong C, Kawinwonggowit V: Sensory abnormalities after the seventh cervical nerve root transfer. *Microsurgery* 19:287–288, 1999.
198. Sungpet A, Suphachatwong C, Kawinwonggowit V: Restoration of shoulder abduction in brachial plexus injury with phrenic nerve transfer. *Aust N Z J Surg* 70:783–785, 2000.
199. Suzuki K, Doi K, Hattori Y, et al: Long-term results of spinal accessory nerve transfer to the suprascapular nerve in upper-type paralysis of brachial plexus injury. *J Reconstr Microsurg* 23:295–299, 2007.
200. Terzis JK, Kostopoulos VK: Free muscle transfer in posttraumatic plexopathies: part III. The hand. *Plast Reconstr Surg* 124:1225–1236, 2009.
201. Terzis JK, Kostopoulos VK: Free muscle transfer in posttraumatic plexopathies: part 1: the shoulder. *Ann Plast Surg* 65:312–317, 2010.
202. Trojaborg W: Clinical, electrophysiological, and myelographic studies of 9 patients with cervical spinal root avulsions: discrepancies between EMG and x-ray findings. *Muscle Nerve* 17:913–922, 1994.
203. Tsai T, Kalisman M, Burns J, et al: Restoration of elbow flexion by pectoralis major and pectoralis minor transfer. *J Hand Surg [Am]* 8:186–190, 1983.
204. Tsuyama N, Hara T: Intercostal nerve transfer in the treatment of brachial plexus injury of the root avulsion type. *Excerpta Med* 291:351–353, 1972.
205. Turkof E, Millesi H, Turkof R, et al: Intraoperative electroneurodiagnostics (transcranial electrical motor evoked potentials) to evaluate the functional status of anterior spinal roots and spinal nerves during brachial plexus surgery. *Plast Reconstr Surg* 99:1632–1641, 1997.

206. Uerpairojkit C, Leechavengvongs S, Witoonchart K, et al: Nerve transfer to serratus anterior muscle using the thoracodorsal nerve for winged scapula in C5 and C6 brachial plexus root avulsions. *J Hand Surg [Am]* 34:74–78, 2009.
207. van der Werken C, de Vries LS: Brachial plexus injury in multitraumatized patients. *Clin Neurol Neurosurg* 95(Suppl):30–32, 1993.
208. Vathana T, Nijhuis TH, Friedrich PF, et al: An experimental study to determine and correlate choline acetyltransferase assay with functional muscle testing after nerve injury. *J Neurosurg* 120:1125–1130, 2014.
209. Vastamaki M: Shoulder arthrodesis for paralysis and arthrosis. *Acta Orthop Scand* 58:549–553, 1987.
210. Wang SF, Li PC, Xue YH, et al: Contralateral C7 nerve transfer with direct coaptation to restore lower trunk function after traumatic brachial plexus avulsion. *J Bone Joint Surg Am* 95:821–827, 2013.
211. Wolfe SW, Johnsen PH, Lee SK, et al: Long-nerve grafts and nerve transfers demonstrate comparable outcomes for axillary nerve injuries. *J Hand Surg [Am]* 39(7):1351–1357, 2014.
212. Xu WD, Gu YD, Xu JG, et al: Full-length phrenic nerve transfer by means of video-assisted thoracic surgery in treating brachial plexus avulsion injury. *Plast Reconstr Surg* 110:104–111, 2003.
213. Xu WD, Lu JZ, Qiu YQ, et al: Hand prehension recovery after brachial plexus avulsion injury by performing a full-length phrenic nerve transfer via endoscopic thoracic surgery. *J Neurosurg* 108:1215–1219, 2008.
214. Yajima H, Kawanishi K, Ohgushi H, et al: Experimental study on choline acetyltransferase activity for brachial plexus injury. *Microsurgery* 16:679–683, 1995.
215. Zancolli EA: Surgery for the quadriplegic hand with active strong wrist extension preserved: a study of 97 cases. *Clin Orthop Relat Res* 112:101–113, 1975.
216. Zancolli EA, Mitre H: Latissimus dorsi transfer to restore elbow flexion. An appraisal of eight cases. *J Bone Joint Surg Am* 55:1265–1275, 1973.
217. Zorub DS, Nashold BSJ, Cook WA: Injury of the brachial plexus: a review with implications on the therapy of intractable pain. *Surg Neurol* 2:347–353, 1974.

35

Embryology of the Upper Extremity

Scott H. Kozin

Congenital anomalies affect 1 to 3% of newborns, and approximately 10% of these children have upper extremity abnormalities.[16,42] The incidence of congenital anomalies has not changed appreciably over the last decade. Congenital limb anomalies are second only to congenital heart disease in the incidence of birth malformations.[6] Most anomalies occur spontaneously or are inherited.[57] Few malformations are attributed to teratogens.[21,41,56] Limb anomalies can be produced in animal models; this has increased our knowledge of and insight into limb development.[34]

Recent advancements in understanding limb anomalies are directly related to our increased understanding of embryogenesis. Knowledge of hominoid limb development has been greatly expanded by the experimental embryologists. Animal models with limb patterning similar to that of humans have been used to dissect and manipulate crucial signaling centers that affect limb development and orientation.[48,49,55] Research on gene misexpression and loss of function has enhanced our understanding of limb formation.[6,48] There is intense work focusing on genotype-phenotype correlations that may have substantial clinical implications. The hand surgeon is uniquely positioned between clinical care and genetic research. He or she must possess a basic comprehension of embryogenesis and limb formation to comprehend congenital limb anomalies and to communicate relevant knowledge to the family of an affected child. Parents may initially bear a tremendous amount of guilt, and the role of disseminating information is the responsibility of the physician caring for the family.

EMBRYOGENESIS

Limb development begins during embryogenesis with events that affect the position and orientation of each limb and the number of limbs that appear (Table 35.1).[39] The limb bud is first visualized at 26 days after fertilization when the embryo is about 4 mm in length (crown-rump length), or about the size of a piece of rice.[62,66] The bud rapidly develops through 47 days of life until the embryo is close to 20 mm in length, or the size of a lima bean. Fifty-two to 53 days after gestation, the embryo is 22 to 24 mm long and the fingers are entirely separate.[30] Eight weeks after fertilization, embryogenesis is complete and all limb structures are present.[6,49,55] At this point, the joints form as condensation of the chondrogen creates dense plates between future bones.[11] Joint cavitation further forms the articulation, although proper joint development requires motion for modeling of the ultimate joint surface. Most upper extremity congenital anomalies occur during this 4- to 8-week period of rapid and fragile limb development. After 8 weeks' gestation, the fetal period commences, with differentiation, maturation, and enlargement of existing structures.

The limb bud represents an outgrowth of the mesoderm into the overlying ectoderm. Two sources of cells migrate from their origins into the limb bud.[6,11] The cells from the lateral plate mesoderm become bone, cartilage, and tendon. The cells from the somatic mesoderm form the muscular, nervous, and vascular elements of the limb bud (Figure 35.1).

In order to comprehend limb development and to explain it to families, the physician must appreciate the signaling centers that control the three spatial axes of limb development: proximodistal, anteroposterior, and dorsoventral.[11] Each of these limb growth axes contains a signaling center (i.e., a group of cells) that is responsible for establishing the corresponding axes; they are the apical ectodermal ridge (AER), the zone of polarizing activity (ZPA), and the Wingless type (Wnt) signaling centers (Table 35.2).[6,49,55] A coordinated effort between the AER, ZPA, and Wnt pathways is necessary for proper limb patterning and axes development.[11,22,36] The three signaling centers are interdependent, so that the loss of one signal results in compromise of the entire system.[44] There is considerable cross talk between these signaling pathways during limb development.

Programmed cell death plays an important part in limb development. Programmed cell death is an active process that is genetically controlled to eliminate unwanted cells during embryogenesis.[10] Apoptotic cells undergo a degeneration process with DNA fragmentation and are eventually engulfed by phagocytic cells. Genetic control of cell death is necessary during limb bud formation. For example, the digits initially develop as webbed fingers. Extraneous tissue between fingers must undergo apoptosis and interdigital necrosis for finger separation. Failure of interdigital apoptosis results in syndactyly.[65] Interestingly, bone morphogenetic proteins (BMPs), widely recognized for their role in chondrogenesis and osteogenesis, trigger apoptotic pathways of the interdigital mesenchyme to produce separated fingers.[10] BMP antagonist can

TABLE 35.1 Key Milestones in the Development of the Human Upper Limb*

Week	Day	Upper Limb	Lower Limb
4	24	Swelling appears in region of upper limb bud	
	28	Scattered blood vessels	Appearance of lower limb bud
5	32	Upper limb AER	
		Early marginal vessel	
		Early brachial plexus development	
	33	Hand plate appears	Lower limb AER
		Humeral mesenchymal condensations	
6	37	Humeral chondrification	Lumbosacral plexus
		Radial and ulnar mesenchymal condensations	
		Brachial plexus with radial, median, and ulnar nerves to the elbow	
		Early muscle masses	
	41	Finger rays (webbed)	Mesenchymal condensations of femur, tibia, fibula, and tarsus
		Radial, ulnar, and metacarpal chondrification	
7	44	Interdigital apoptosis	Chondrification of femur, tibia, and fibula
		Scapular and humeral head chondrification	
		Chondrification of carpals and proximal phalanges	
		Trapezius innervated (accessory nerve)	
		Major muscles distinguishable	
	48	Chondrification of middle phalanges	
		Shoulder and elbow interzones (joint cavity formation)	
8	51	Chondrification of distal phalanges	
	52	Ossification of humerus	
		Ossification of radius	
		All muscles distinguishable	
		Wrist and carpal interzones	
	54	Ulnar ossification	Ossification of femur and tibia
	57	Scapular ossification	Ossification of fibula
		Intramembranous ossification of distal tip of distal phalanges	Chondrification of tarsus and digits

*Selected milestones for the lower limb are provided for comparison.
Adapted from O'Rahilly R, Gardner E: The timing and sequence of events in the development of the limbs in the human embryo. *Anat Embryol (Berl)* 148:1, 1975.
AER, Apical ectodermal ridge.

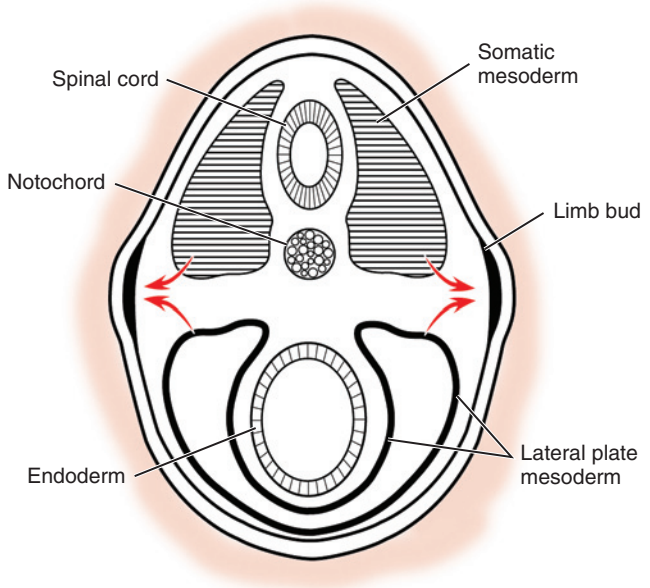

FIGURE 35.1 Axial view of an embryo. The lateral plate mesoderm forms the bone, cartilage, and tendon, and the somatic mesoderm forms the muscle, nerve, and vascular elements of the limb. (Adapted from Riddle RD, Tabin C: How limbs develop. *Sci Am* 280:74–79, 1999.)

block BMP signaling and prevent apoptosis and interdigital necrosis. For example, bats have web limbs, and BMP is blocked during their limb embryogenesis.[40] Similarly, altered signaling of fibroblast growth factors, such as occurs in Apert syndrome, can negate BMP-mediated apoptosis, resulting in syndactyly (Figure 35.2).

Spatial Axes of Limb Development and Their Signaling Centers

Proximodistal Limb Development

The limb develops in a proximal to distal direction, with the shoulder forming before the elbow and the elbow before the wrist. This progression is controlled by the AER, a thickened layer of ectoderm that condenses over the limb bud.[11] This signaling center guides the underlying mesoderm to differentiate into appropriate structures.[6,49] Removal of the AER results in limb truncation, and ectopic implantation of the AER causes additional limbs to form (Figures 35.3 and 35.4).[11,49,61,66] The secreted proteins within the AER that yield this effect are fibroblast growth factors.[28,37] In fact, removal of the AER can be overcome by application of fibroblast growth factors (Figure 35.5). Mice deficient in various fibroblast growth factors have complete transverse limb defects.[15,38,54]

When explaining this to a parent, we can say that we know the AER was not physically removed. However, we do have evidence to suggest that bleeding or ischemia within the AER resulted in its failure to work properly.[17]

Transverse deficiencies are usually sporadic without any underlying reason. Concern for teratogen exposure is raised when multiple limbs are involved, suggesting a widespread insult to all developing limb buds. Transverse differences are not inheritable, and future children are unlikely to be affected.

Anteroposterior Limb Development

The limb also develops in an anteroposterior (i.e., radioulnar or preaxial-postaxial) direction. The ZPA resides within the posterior margin of the limb bud and functions as a signaling center for anterior to posterior limb development.[6,48] This signaling pathway polarizes the limb into a radial margin and an ulnar border.[60] The signaling molecule within this pathway is the sonic hedgehog compound.[48] Transplantation of the ZPA or sonic hedgehog protein causes mirror duplication of the ulnar

TABLE 35.2 Signaling Pathways During Embryogenesis

Signaling Center	Responsible Substance	Action	Anomaly
Apical ectodermal ridge	Fibroblast growth factors	Proximal to distal limb development, interdigital necrosis	Transverse deficiency
Zone of polarizing activity	Sonic hedgehog protein	Radioulnar limb formation	Mirror hand
Wnt pathway	Transcription factor, Lmx-1	Ventral and dorsal limb axis	Nail patella syndrome, abnormal nail and pulp arrangement

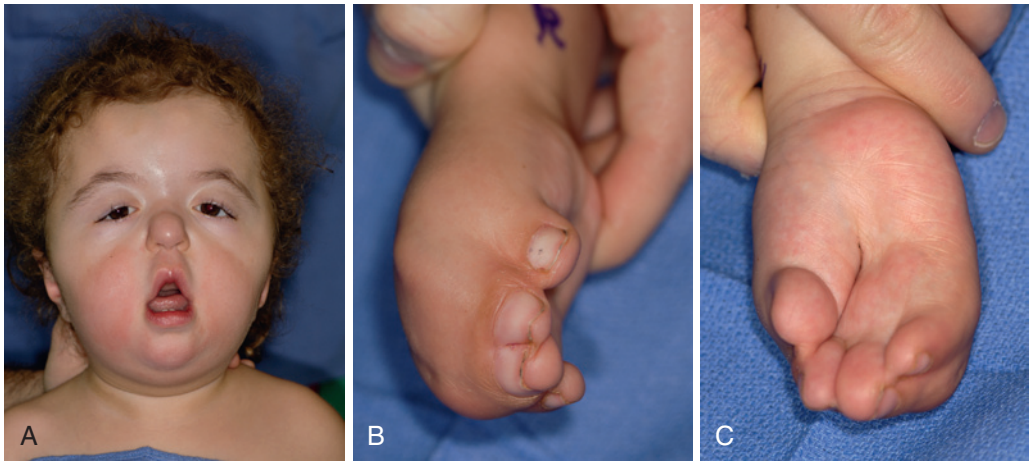

FIGURE 35.2 Two-year-old with Apert syndrome. **A,** Typical facies. **B,** Dorsal view of right hand with severe syndactyly, including web between thumb and index finger. **C,** Palmar view of right hand with deep crevasses. (Courtesy of Shriners Hospital for Children, Philadelphia.)

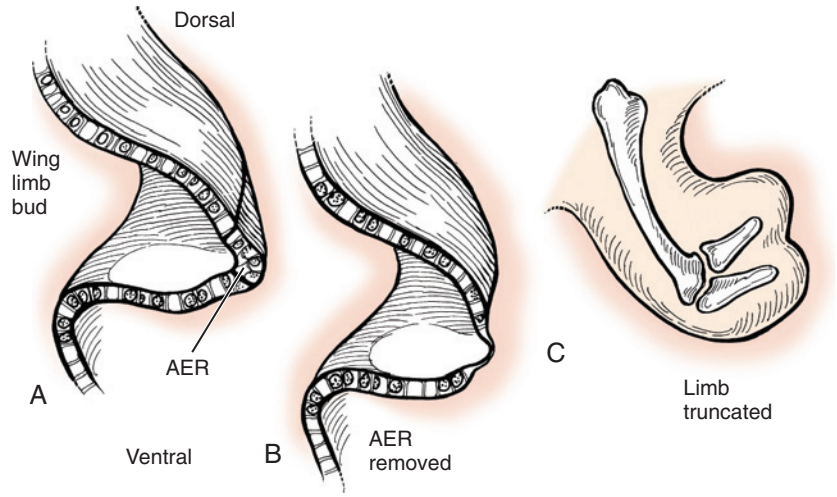

FIGURE 35.3 Removal of the apical ectodermal ridge (AER) from the developing limb bud results in limb truncation. (Adapted from Riddle RD, Tabin C: How limbs develop. *Sci Am* 280:74–79, 1999.)

aspect of the limb (Figure 35.6).[11] The extent of duplication is dose dependent, and greater transference results in more replication (Figure 35.7).[59] This explains the variable numbers of fingers and different phenotypes of mirror hands (Table 35.3).[3] Mutant mice that express sonic hedgehog protein in the anterior limb bud are polydactylous, with duplication of their ulnar digits.[29] Triphalangeal thumbs arise secondary to point mutations resulting in ectopic sonic hedgehog compound at the anterior margin of the limb bud.[23]

Sonic hedgehog compound is also expressed in a gradient fashion, and the duration of exposure of a digit to it determines the identity of the digit. The anterior digits (index and long fingers) are exposed for the shortest time, and the small digit is exposed for the longest time.[27,52]



FIGURE 35.4 Short below-the-elbow transverse deficiency with residual nubbins attributed to loss of apical ectodermal ridge function. (Courtesy of Shriners Hospital for Children, Philadelphia.)

Dorsoventral Limb Development

Dorsoventral limb development, or the process of differentiation between the dorsum of the finger with a fingernail and the volar surface abundant with pulp tissue, is not as well understood.[11] The Wnt signaling pathway resides in the dorsal ectoderm and controls this spatial development. The pathway produces a transcription factor, Lmx-1, which induces the mesoderm to adopt dorsal characteristics.[47] In the ventral ectoderm, the Wnt pathway is blocked by a product of the gene Engrailed-1 (En-1). Mice lacking the Wnt pathway have ventralization of the dorsal surface (i.e., biventral limbs with palmar pads on both sides of the foot).[20,43] In contrast, mice lacking Engrailed-1 develop dorsalization of the volar surface (i.e., bidorsal limbs).[25]

Differences affecting this pathway are relatively rare. Loss of Lmx-1 is associated with nail patella syndrome.[14] Occasionally, children will present with anomalies that have an extraneous nail or abnormal pulp development. These abnormalities are related to the Wnt signaling pathway and occur sporadically without any definable cause.[2]

Musculoskeletal System Development

The muscular blastema and the chondrogenic blastema form the muscles and bones, respectively.[4] The chondrogenic blastema is located in the central portions, where the oxygen tension is relatively low. The muscular blastema resides in the periphery, where the oxygen tension is higher. The muscles form sequentially from proximal to distal, separating from the muscular blastema. The chondrogenic blastema also forms from proximal to distal, with the cartilage undergoing ossification to form bones.

The joints form in interzones between the ends of two blastemas. A joint capsule surrounds the interzone, and the intervening blastemas undergo cavitation within the center of the interzone to produce a joint space. Joint fluid is produced within this space and cartilage caps the two ends of the bones. Failure of this process results in synostosis across the intended joint, such as a proximal radioulnar joint or an ulnohumeral

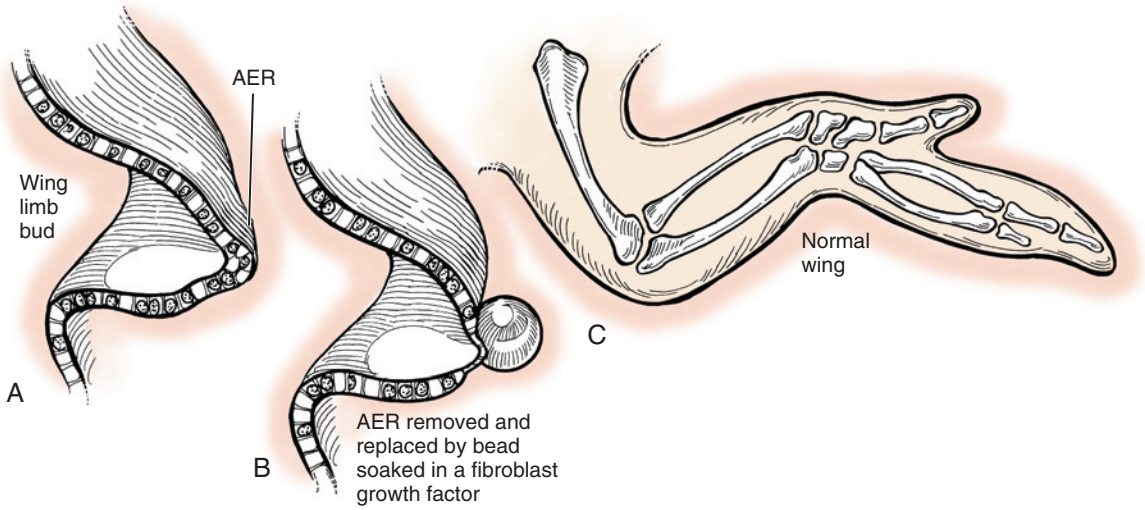

FIGURE 35.5 Removal of the apical ectodermal ridge (AER) and replacement with fibroblast growth factors can result in normal limb formation. (Adapted from Riddle RD, Tabin C: How limbs develop. *Sci Am* 280:74–79, 1999.)

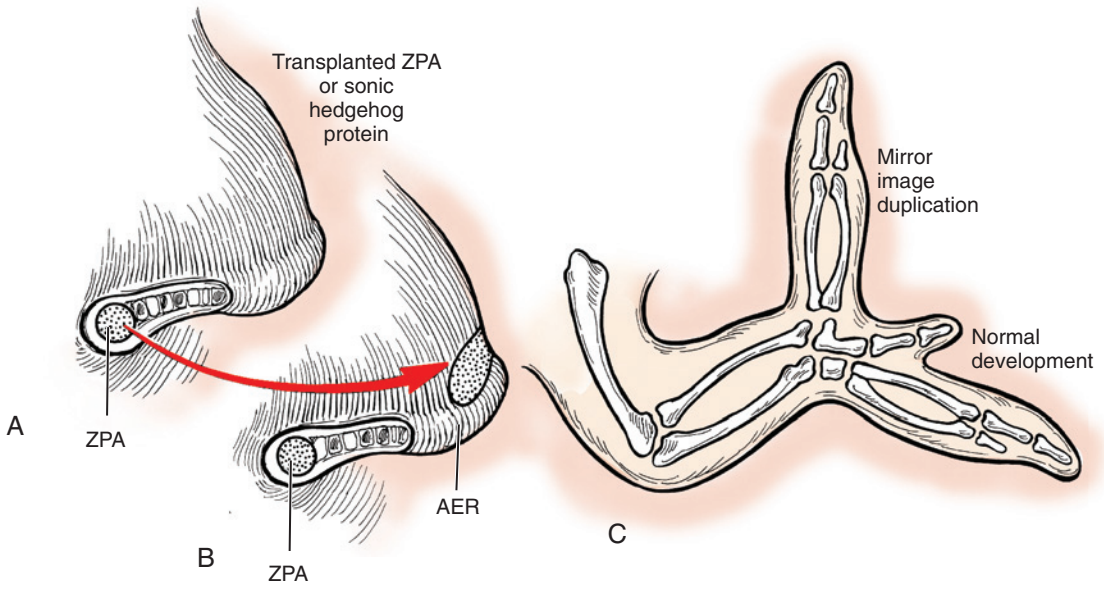

FIGURE 35.6 Transplantation of the zone of polarizing activity (ZPA) or sonic hedgehog protein causes mirror image duplication of the ulnar aspect of the limb. *AER,* Apical ectodermal ridge. (Adapted from Riddle RD, Tabin C: How limbs develop. *Sci Am* 280:74–79, 1999.)



FIGURE 35.7 Mirror hand with seven fingers explained by transplantation of the zone of polarizing activity or sonic hedgehog protein. (Courtesy of Shriners Hospital for Children, Philadelphia.)

joint (Figure 35.8). Motion is necessary to form a mobile functioning joint. In the absence of movement, such as arthrogryposis, the joint space is infiltrated by fibrous tissue, yielding an immobile joint (Figure 35.9).

Genes and Molecular Abnormalities

The spatial axis of limb development is only one aspect of limb formation. Mutations encoding signaling proteins, receptor molecules, and transcription factors can alter the normal limb arrangement and yield anomalies. The number of congenital anomalies seen by the practicing hand surgeon identifiable at the molecular level increases each year. Despite the accelerated pace of discovery, only a small number of limb anomalies have been mapped to specific chromosomal segments and are less defined at the molecular level.[6] Many of these differences, however, are genetically linked with variable patterns of inheritance. Accurate diagnosis is mandatory, and referral for genetic consultation warranted. Parents need appropriate counseling regarding the different expressions and phenotypes across the spectrum of a particular mutation. A continuing misconception is that an affected parent with a mild phenotype feels that his or her anomaly (heart and/or hand) is "not so bad and, therefore, my children will be fine like me." Based on this misperception, he or she proceeds with pregnancy, naïve to the concept of variable expression and inconsistent phenotypes. Subsequently, the affected child may be considerably more affected and the parents are not prepared to handle such

CRITICAL POINTS *Limb Bud Formation*

- Limb bud formation commences approximately 4 weeks after gestation begins and is complete by 8 weeks. The majority of limb anomalies occur within this time of rapid and fragile limb development.

Signaling Centers

- Three signaling centers control the spatial axes of limb development. The apical ectodermal ridge (AER) governs proximodistal limb formation, the zone of polarizing activity (ZPA) manages anteroposterior (i.e., radioulnar) limb formation, and the Wingless type (Wnt) signaling center directs dorsoventral limb formation.

Molecular Abnormalities

- The HOX and T-box genes encode transcription factors crucial for limb formation. Mutations within the HOX gene locus have been identified as the causes of synpolydactyly, hand-foot-genital syndrome, and Madelung deformity associated with Leri-Weill dyschondrosteosis. T-box gene abnormalities have been linked to Holt-Oram syndrome and ulnar-mammary syndrome.
- Cartilage-derived morphogenetic protein appears paramount to digital length; deficiencies have been associated with various forms of brachydactyly, such as Grebe and Hunter-Thompson chondrodysplasias.



FIGURE 35.8 Radiographs of bilateral proximal radioulnar joint synostosis secondary to failure of interzone necrosis. (Courtesy of Shriners Hospital for Children, Philadelphia.)



FIGURE 35.9 In children with arthrogryposis, lack of intrauterine motion results in stiff extremities that typically posture with the shoulders adducted and internally rotated, elbows extended, wrists flexed and ulnarly deviated, and thumb in the palm with stiff digits. (Courtesy of Shriners Hospital for Children, Philadelphia.)

TABLE 35.3 Classification of Mirror Hands

Type	Name	Clinical Features
1	Ulnar dimelia	Multiple fingers with two ulnas Type A: Each ulna well formed Type B: Preaxial ulna hypoplastic
2	Intermediate form	Multiple fingers with two ulnas and one radius
3	Intermediate form	Multiple fingers with one ulna and one radius Type A: Radius well formed Type B: Hypoplastic radius
4	Syndromic form	Bilateral, mirror feet and nasal defects characteristic Type A: Laurin-Sandrow syndrome: two ulnas Type B: Martin syndrome: one ulna and one radius
5	Multiple hand	Complete duplication of the hand, including the thumb; forearm normal

Adapted from Al-Quattan MM, Al-Thunayan M, Decordier M, et al: Classification of the mirror hand: multiple hand spectrum. *J Hand Surg [Br]* 23:534–536, 1998.



FIGURE 35.10 Two-year-old female with familial synpolydactyly of the long and ring fingers. (Courtesy of Shriners Hospital for Children, Philadelphia.)

involvement. Appropriate counseling prior to pregnancy can alleviate this misconception and educate the parents as to the facts surrounding inheritance rates and possible clinical findings.

The HOX and T-box genes encode transcription factors crucial for limb formation and exhibit some control over upper limb formation.[6,19,32,35,50,63] Abnormalities in HOX and T-box gene production alter limb constitution. The extent of malformation is related to the number and extent of gene irregularities.[6,13] HOX genes are important for the patterning of many tissues in the developing embryo. Mutations within the HOX gene locus have been identified as the cause of several types of human differences. Synpolydactyly and hand-foot-genital syndrome have been related to mutations within the HOX genes (Figures 35.10 and 35.11).[18,31,33,64] Madelung deformity associated with Leri-Weill dyschondrosteosis has also been connected



FIGURE 35.11 X-ray reveals concealed ring finger duplication with angular deformities. (Courtesy of Shriners Hospital for Children, Philadelphia.)

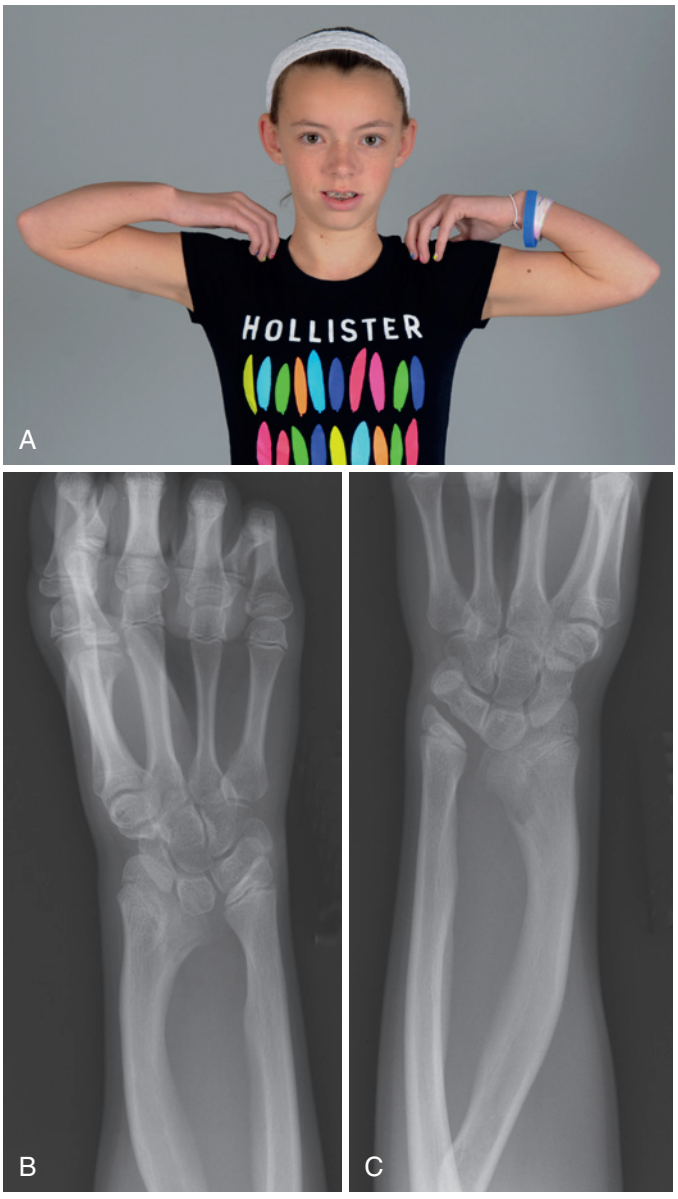

FIGURE 35.12 Twelve-year-old with short stature, bilateral shortened forearms, and Leri-Weill dyschondrosteosis. **A,** Clinical appearance of bilateral Madelung deformity. **B,** Left wrist radiograph with classic findings associated with Madelung deformity. **C,** Right wrist x-ray with similar findings. (Courtesy of Shriners Hospital for Children, Philadelphia.)

to HOX gene defects (Figure 35.12).[51] These three entities are autosomal dominant conditions, although Leri-Weill dyschondrosteosis affects females more severely. This information is critical to relay to affected families and justifies genetic counseling.

The T-box genes are a highly conserved family of transcription factors that govern both limb and organ system development.[1,9] Altered expression of T-box products can affect the anteroposterior (i.e., radioulnar) development of the limb. The combination of a cardiac defect and radial deficiency (e.g., Holt-Oram syndrome) has been specifically linked to the production of transcription factor Tbx5.[7,8,24] Holt-Oram syndrome is an autosomal dominant trait with variable phenotypes, and affected families would benefit from genetic counseling. T-box gene mutations have also been linked to limb anomalies associated with a variety of systemic syndromes, including ulnar-mammary syndrome (Tbx3 mutation), which is associated with postaxial limb anomalies.[5,6,46]

The family of BMPs are expressed in the developing limb.[11] Cartilage-derived morphogenetic protein appears paramount to digital length during embryogenesis. Deficiencies in a cartilage-derived morphogenetic protein are associated with various forms of brachydactyly. Grebe and Hunter-Thompson chondrodysplasias are associated with severe brachydactyly and have been directly related to a cartilage-derived morphogenetic protein deficiency (Figure 35.13).[45,58]

Systemic Considerations

During the period of embryogenesis, other organ systems are also developing and maturing. Errors affecting limb formation can also disturb formation of these systems. Certain upper limb anomalies are associated with concomitant systemic disorders (e.g., radial deficiency).[12,26] Other limb anomalies occur in isolation or are combined with other musculoskeletal problems (e.g., ulnar deficiency).[53] Some limb anomalies, such as central deficiency, can be associated with a systemic condition (EEC syndrome: triad of ectrodactyly, ectodermal dysplasia, and facial clefting) or can be linked to other musculoskeletal anomalies, such as lower limb hemimelia. Identifying anomalies that occur in isolation and anomalies associated with systemic ailments is mandatory. Many of the systemic illnesses are more important than the limb anomaly and require accurate evaluation to prevent life-threatening consequences.

The basic molecular events of hand formation are being discovered at a rapid rate. The complex interaction between signaling centers, genes, and molecular events complicates direct linkage between an abnormality and a particular limb



FIGURE 35.13 Hands of a child with Grebe chondrodysplasia and severe brachydactyly associated with a cartilage-derived morphogenetic protein deficiency. (Courtesy of Shriners Hospital for Children, Philadelphia.)

difference. In addition, variable amounts of gene and molecular damage result in innumerable different phenotypes. Application of this basic science knowledge to the clinical setting is a necessary linkage. The National Institutes of Health website provides a mechanism for keeping abreast of current knowledge. Links to the Online Mendelian Inheritance in Man database offer valuable information regarding genes and disease. This information is readily available, frequently updated, and invaluable when evaluating children with congenital deficiencies.

REFERENCES

1. Agulnik SI, Papaioannou VE, Silver LM: Cloning, mapping, and expression analysis of TBX15, a new member of the T-box gene family. *Genomics* 51:68, 1998.
2. Al-Qattan MM: Classification of dorsal and ventral dimelia in humans. *J Hand Surg Eur Vol* 38:928, 2013.
3. Al-Qattan MM, Al-Thunayan M, De Cordier M, et al: Classification of the mirror hand-multiple hand spectrum. *J Hand Surg [Br]* 23:534, 1998.
4. Al-Qattan MM, Yang Y, Kozin SH: Embryology of the upper limb. *J Hand Surg [Am]* 34:1340, 2009.
5. Bamshad M, Root S, Cary JC: Clinical analysis of a large kindred with the Pallister ulnar-mammary syndrome. *Am J Med Genet* 65:325, 1996.
6. Bamshad M, Watkins WS, Dixon ME, et al: Reconstructing the history of human limb development: lessons from birth defects. *Pediatr Res* 45:291, 1999.
7. Basson CT, Bachinsky DR, Lin RC, et al: Mutations in human TBX5 cause limb and cardiac malformation in Holt-Oram syndrome. *Nat Genet* 15:30, 1997.
8. Basson CT, Crowley GS, Solomon SD, et al: The clinical and genetic spectrum of the Holt-Oram syndrome (heart-hand syndrome). *N Engl J Med* 330:885, 1996.
9. Chapman DL, Garvey N, Hancock S, et al: Expression of the T-box family genes, Tbx1-Tbx5, during early mouse development. *Dev Dyn* 206:379, 1996.
10. Chen Y, Zhao X: Shaping limbs by apoptosis. *J Exp Zool* 282:691, 1998.
11. Daluiski A, Yi SE, Lyons KM: The molecular control of upper extremity development: implications for congenital hand anomalies. *J Hand Surg [Am]* 26:8, 2001.
12. Damore E, Kozin SH, Thoder JJ, et al: The recurrence of deformity after surgical centralization for radial clubhand. *J Hand Surg [Am]* 25:745, 2000.
13. Davis AP, Witte DP, Hsieh-Li HM, et al: Absence of radius and ulna in mice lacking hoxa-11 and hoxd-11. *Nature* 375:791, 1995.
14. Dreyer SD, Zhou G, Baldini A, et al: Mutations in LMX1B cause abnormal skeletal patterning and renal dysplasia in nail patella syndrome. *Nat Genet* 19:47, 1998.
15. Fallon JF, Lopez A, Ros MA, et al: FGF-2: apical ectodermal ridge growth signal for chick limb development. *Science* 264:104, 1994.
16. Flatt A: *The care of congenital hand anomalies*, St. Louis, 1994, Quality Medical Publishing.
17. Gonzalez CH, Marques-Dias MJ, Kim CA, et al: Congenital abnormalities in Brazilian children associated with misoprostol misuse in first trimester of pregnancy. *Lancet* 351:1624, 1998.
18. Goodman FR, Bacchelli C, Brady AF, et al: Novel HOXA13 mutations and the phenotypic spectrum of hand-foot-genital syndrome. *Am J Hum Genet* 67:197, 2000.
19. Innis JW, Mortlock DP: Limb development: molecular dysmorphology is at hand! *Clin Genet* 53:337, 1998.
20. Johnson RL, Tabin C: Molecular models for vertebrate limb development. *Cell* 90:979, 1997.
21. Kato H, Ogino T, Minami A, et al: Experimental study of radial ray deficiency. *J Hand Surg [Br]* 15:470, 1990.
22. Laufer F, Nelson CE, Johnson RL, et al: Sonic hedgehog and Fgf-4 act through a signaling cascade and feedback loop to integrate growth and patterning of the developing limb bud. *Cell* 79:993, 1994.
23. Lettice LA, Hill AE, Devenney PS, et al: Point mutations in a distant sonic hedgehog cis-regulator generate a variable regulatory output responsible for preaxial polydactyly. *Hum Mol Genet* 17:978, 2008.
24. Li Q, Newbury-Ecob RA, Terrett JA, et al: Holt-Oram syndrome is caused by mutations in TBX5, a member of the Brachyury (T) gene family. *Nat Genet* 15:21, 1997.
25. Loomis CA, Harris E, Michaud J, et al: The mouse Engrailed-1 gene and ventral limb patterning. *Nature* 382:360, 1996.
26. Lourie GM, Lins RE: Radial longitudinal deficiency. A review and update. *Hand Clin* 14:85, 1998.
27. Malik S: Polydactyly: phenotypes, genetics and classification. *Clin Genet* 85:203, 2014.
28. Mariani FV, Ahn CP, Martin GR: Genetic evidence that FGFs have an instructive role in limb proximal-distal patterning. *Nature* 453:401, 2008.
29. Masayu H, Sagai T, Wakana S, et al: A duplicated zone of polarizing activity in polydactylous mouse mutants. *Genes Dev* 9:1645, 1995.
30. Moore KL: *The developing human: clinically oriented embryology*, Philadelphia, 1988, W.B. Saunders.
31. Mortlock DP, Innis JW: Mutation of Hoxa13 in hand-foot-genital syndrome. *Nat Genet* 15:179, 1997.
32. Mortlock DP, Post LC, Innis JW: The molecular basis of hypodactyly (Hd): a deletion in Hoxa13 leads to arrest of digital arch formation. *Nat Genet* 13:284, 1996.
33. Muragaki Y, Mundlos S, Upton J, et al: Altered growth and branching patterns in synpolydactyly caused by mutations in HOXD13. *Science* 272:548, 1996.
34. Naruse T, Takahara M, Takagi M, et al: Early morphological changes leading to central polydactyly, syndactyly, and central deficiencies: an experimental study in rats. *J Hand Surg [Am]* 32:1413, 2007.
35. Nelson CE, Morgan BA, Burke AC, et al: Analysis of Hox gene expression in the chick limb bud. *Development* 122:1449, 1996.
36. Niswander L, Jeffrey S, Martin GR, et al: A positive feedback loop coordinates growth and patterning in the vertebrate limb. *Nature* 371:609, 1994.
37. Niswander L, Martin GR: FGF-4 expression during gastrulation, myogenesis, limb and tooth development in the mouse. *Development* 114:755, 1992.
38. Niswander L, Tickle C, Vogel A, et al: FGF-4 replaces the apical ectodermal ridge and directs outgrowth and patterning of the limb. *Cell* 75:579, 1993.
39. O'Rahilly R, Gardner E: The timing and sequence of events in the development of the limbs in the human embryo. *Anat Embryol (Berl)* 148:1, 1975.
40. Oberg KC, Feenstra JM, Manske PR, et al: Developmental biology and classification of congenital anomalies of the hand and upper extremity. *J Hand Surg [Am]* 35:2077, 2010.
41. Ogino T, Kato H: Clinical and experimental studies on ulnar ray deficiency. *Handchir Mikrochir Plast Chir* 20:330, 1988.
42. Parker SE, Mai CT, Canfield MA, et al: Updated National Birth Prevalence estimates for selected birth defects in the United States, 2004-2006. *Birth Defects Res A Clin Mol Teratol* 88:1008, 2010.
43. Parr BA, McMahon AP: Dorsalizing signal Wnt-7a required for normal polarity of D-V and A-P axes of mouse limb. *Nature* 374:350, 1995.
44. Pearse RV, Tabin CJ: The molecular ZPA. *J Exp Zool* 282:677, 1998.
45. Polinkovsky A, Robin NH, Thomas JT, et al: Mutations in CDMP1 cause autosomal dominant brachydactyly type C. *Nat Genet* 17:18, 1997.
46. Ramirez RN, Kozin SH: Ulnar mammary syndrome. *J Hand Surg [Am]* 39:803, 2014.
47. Riddle RD, Ensini M, Nelson C, et al: Induction of the LIM homeobox gene Lmx1 by WNT7a establishes dorsoventral pattern in the vertebrate limb. *Cell* 83:631, 1995.
48. Riddle RD, Johnson RL, Laufer E, et al: Sonic hedgehog mediates the polarizing activity of the ZPA. *Cell* 75:1401, 1993.
49. Riddle RD, Tabin C: How limbs develop. *Sci Am* 280:74, 1999.
50. Rodriguez-Esteban C, Tsukui T, Yonei S, et al: The T-box genes Tbx4 and Tbx5 regulate limb outgrowth and identity. *Nature* 398:814, 1999.
51. Ross JL, Scott C, Jr, Marttila P, et al: Phenotypes associated with SHOX deficiency. *J Clin Endocrinol Metab* 86:5674, 2001.
52. Scherz PJ, McGlinn E, Nissim S, et al: Extended exposure to Sonic hedgehog is required for patterning the posterior digits of the vertebrate limb. *Dev Biol* 308:343, 2007.

53. Schmidt CC, Neufeld SK: Ulnar ray deficiency. *Hand Clin* 14:65, 1998.
54. Sekine K, Ohuchi H, Fujiwara M, et al: FgF10 is essential for limb and lung formation. *Nat Genet* 21:138, 1999.
55. Shubin N, Tabin C, Carroll S: Fossils, genes and the evolution of animal limbs. *Nature* 388:639, 1997.
56. Taussig HB: A study of the German outbreak of phocomelia. The thalidomide syndrome. *JAMA* 180:1106, 1962.
57. Temtamy SA, McKusick VA: The genetics of hand malformations. *Birth Defects Orig Artic Ser* 14:1, 1978.
58. Thomas JT, Kilpatrick MW, Lin K, et al: Disruption of human limb morphogenesis by a dominant negative mutation in CDMP1. *Nat Genet* 17:58, 1997.
59. Tickle C: The number of polarizing region cells required to specify additional digits in the developing chick wing. *Nature* 289:295, 1981.
60. Tickle C: Genetics and limb development. *Dev Genet* 19:1, 1996.
61. Tickle C: The contribution of chicken embryology to the understanding of vertebrate limb development. *Mech Dev* 121:1019, 2004.
62. Uthoff HK: *The embryology of the human locomotor system*, Berlin, 1990, Springer-Verlag.
63. Wolfman NM, Hattersley G, Cox K, et al: Ectopic induction of tendon and ligament in rats by growth and differentiation factors 5, 6, and 7, members of the TGF-gene family. *J Clin Invest* 100:321, 1997.
64. Zakany J, Duboule D: Synpolydactyly in mice with a targeted deficiency in the HoxD complex. *Nature* 384:69, 1996.
65. Zakeri Z, Quaglino D, Ahuja HS: Apoptotic cell death in the mouse limb and its suppression in the hammertoe mutant. *Dev Biol* 165:294, 1994.
66. Zaleske DJ: Development of the upper limb. *Hand Clin* 1:383, 1985.

Deformities of the Hand and Fingers

Simon P. Kay, David B. McCombe, and Scott H. Kozin

These videos may be found at *ExpertConsult.com:*

36.1 Cleft hand

36.2 Symbrachydactyly. (Courtesy Shriner's Hospital for Children, Philadelphia.)

SYNDACTYLY

Syndactyly describes a variable fusion of the soft tissue or skeletal elements or both of adjacent digits, and it occurs when the normal processes of digital separation and web space formation fail to some degree. During normal development, the digits form as condensations of mesoderm within the terminal paddle of the embryonic upper limb. Spaces form between the fingers in a distal to proximal direction to the level of the normal web space by a process of regulated apoptosis.[140] This process is dependent on the apical ectodermal ridge and the molecular signaling of several cytokines, including bone morphogenetic proteins, transforming growth factor-β, fibroblast growth factors, and retinoic acid.[51,52,75,107,115] The normal web space slopes 45 degrees in a dorsal to palmar direction from the metacarpal heads to the midproximal phalanx (Figure 36.1). The second and fourth webs are wider than the third web, allowing greater abduction of the index and small fingers. The first web space is a broader diamond-shaped expanse of skin composed of the glabrous skin of the palm and thinner mobile skin dorsally.

General Considerations

Epidemiologic Findings

Isolated syndactyly is a common congenital anomaly of the hand, with an incidence of approximately 1 in 2000. It occurs bilaterally in 50% of cases. Between 10 and 40% of cases demonstrate a positive family history that is inherited as an autosomal dominant trait. Variable expressivity and incomplete penetrance account for the male predominance (2:1) and the variable phenotype that is often seen within a family pedigree. Syndactyly is also seen with other deformities, such as polydactyly, clinodactyly, brachydactyly, symphalangism, and synostosis, as part of a broader anomaly of a child's hand, either as a sporadic occurrence or as part of a syndromic association. In isolated syndactyly, the long finger/ring finger web space is most commonly affected (57%), followed by the ring finger/small finger web space (27%). Thumb/index finger and index finger/long finger web syndactylies are the least common. In syndromic cases, the thumb/index finger and index finger/long finger web spaces are relatively more frequently affected.

Pathologic Findings and Classification

The conjoined digits may show abnormalities of the nails, the digital neurovascular bundles, the skeleton, and the tendon systems. The skin envelope of the fused digits is inadequate to resurface the circumference of each independent digit. The abnormal underlying fascia has a continuous thickened, lateral digital sheet that spans the length of the syndactyly across the potential interdigital web space. Syndactyly is described as *complete* if the web space extends to include the fingertip and *incomplete* when the web space occurs anywhere between the normal commissure and the fingertips. *Simple syndactyly* has only skin or soft tissue connections (Figure 36.2). The joints are usually normal, and the flexor tendon and extensor tendon mechanisms are usually independent. The digital neurovascular anatomy is usually normal, although the bifurcation of the common digital structures may be distal to the level of a normal web. *Complex syndactyly* is marked by skeletal anomalies. The most common form of complex syndactyly is a side-to-side fusion at the distal phalangeal tuft level (Figure 36.3). This distal synostosis is usually reflected in a synonychia with loss of the paronychial fold and flattening of the nail matrix across the bony mass. *Complex complicated syndactylies* are those with accessory phalanges or digits interposed within the abnormal web space. The incidence of tendon and neurovascular abnormalities increases with the complexity of the syndactyly.

Preoperative Evaluation

When evaluating a patient with syndactyly, the important features to consider are which web space(s) is involved, the extent of the syndactyly, the involvement of the nail, and the presence of other anomalies. Lack of differential motion between the digits may indicate bony fusion or an extra digit, or both, concealed within the conjoined digits. Examination should include the entire upper limb, the contralateral hand, the chest wall, and the feet. Radiographs may reveal skeletal fusion, a concealed extra digit (synpolydactyly), or other bony or articular deformities. Further imaging with ultrasound or magnetic resonance imaging can be useful in determining the flexor tendon and vascular anatomy in complex cases.

Management Considerations

Syndactyly can have cosmetic, functional, or developmental impacts on the growing child. The appearance of the hand is

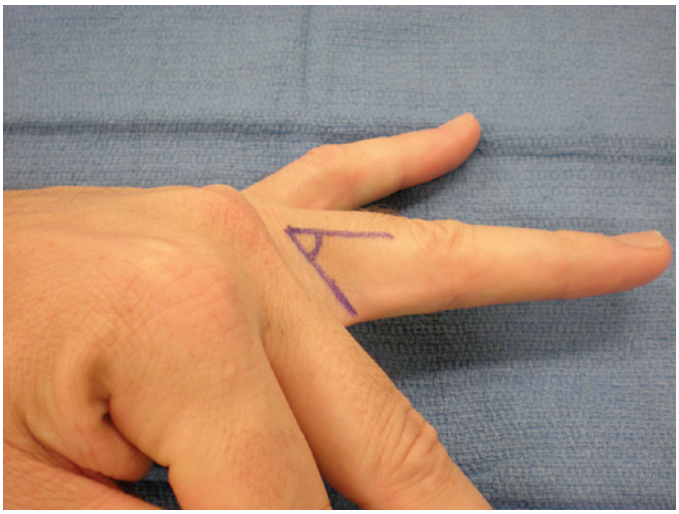

FIGURE 36.1 The normal web of skin slopes 45 degrees in a dorsal to palmar direction from the metacarpal heads to the level of the midproximal phalanx.

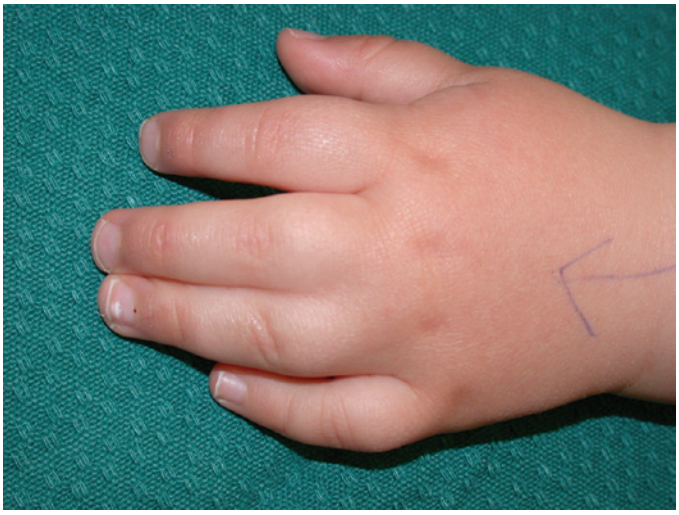

FIGURE 36.2 Simple and complete syndactyly between the third and fourth rays.

altered, more so with complete complicated forms of syndactyly. Syndactyly of the first web space hampers grasp and the development of pinch. Syndactyly of the second, third, and fourth web spaces inhibits independent digital motion, particularly abduction, and therefore reduces the span of the hand. Syndactyly between digits of unequal length causes tethering of the longer digit, which deviates toward the shorter digits and may also cause a flexion contracture at the proximal interphalangeal joint (PIP) that progresses with growth (Figures 36.4 and 36.5).

Surgery is indicated for most cases, but contraindications include mild incomplete syndactyly without functional impairment, medical conditions that preclude surgery, or complex syndactylies that risk further functional impairment with attempted separation. On occasion, there are insufficient components in the fused mass to produce independent, stable, and mobile digits (Figures 36.6 and 36.7). This situation typically arises in central brachysyndactyly or synpolydactyly, and separation risks reducing function.



FIGURE 36.3 Radiograph of complex syndactyly with distal skeletal fusion.



FIGURE 36.4 Fifty-year-old man who never underwent treatment for his bilateral syndactyly. Differential growth has deviated the longer digits.



FIGURE 36.5 Dorsal view of a right hand with angular deformities of the ring and small fingers.



FIGURE 36.6 Clinical picture of complex syndactyly with a conjoined digit. (Courtesy of Shriners Hospital for Children, Philadelphia.)



FIGURE 36.7 X-ray of complex syndactyly with fusion of adjacent phalanges that prohibits separation. (Courtesy of Shriners Hospital for Children, Philadelphia.)

Several important surgical principles apply to the correction of syndactyly, including the timing of the procedure or procedures, staging the releases of multiple web space syndactylies, creation of a commissure, techniques of separation and resurfacing of the digits, and postoperative dressing and aftercare.

Timing of Surgery

Syndactyly release has been performed in the neonatal period[89] or during infancy, or it has been delayed until childhood. Long-term reviews by Flatt[63] and Ger[71] have shown better outcomes with release after 18 months, although early surgery may be dictated by progressive skeletal deviation or deformity.[97] The goal is to complete all the releases by school age. Syndactyly involving multiple web spaces requires staging of the release procedures because only one side of an affected digit should be released at a time to avoid vascular compromise of the skin flaps or digits. Syndactyly of all web spaces is usually treated in two stages. The first procedure separates the thumb/index finger and long finger/ring finger web spaces. Three months later, a second procedure separates the index finger/long finger and ring finger/small finger web spaces. In addition, the first procedure can be combined with isolated release of the fingertips and distal phalangeal fusions of all the digits to reduce the tethering effect between surgical procedures.



FIGURE 36.8 A proximally based rectangular flap from the dorsum of the syndactyly is the most frequently used method to reconstruct the commissure. (Courtesy of Shriners Hospital for Children, Philadelphia.)

Commissure Reconstruction

A basic tenet of syndactyly release is reconstruction of the interdigital commissure with a local skin flap. The most frequently used methods incorporate a proximally based rectangular flap raised from the dorsum of the syndactyly (Figure 36.8).[18] Several modifications have been proposed, including a trapezoid-shaped dorsal flap or a dorsal flap supplemented with lateral wings used to resurface the digits adjacent to the commissure.[55,69,122,150] Alternative choices for commissure skin are available. Skin from the dorsum of the hand raised as an island flap can be advanced in a "V-Y" fashion into the web space.[40,147,161] The palmar surface of the syndactyly alone or in combination with the dorsal surfaces of the syndactyly can be introduced into the web space as opposing triangular flaps. Where the syndactyly is incomplete and restricted to the proximal digit, the web may be repositioned by deepening or lengthening the

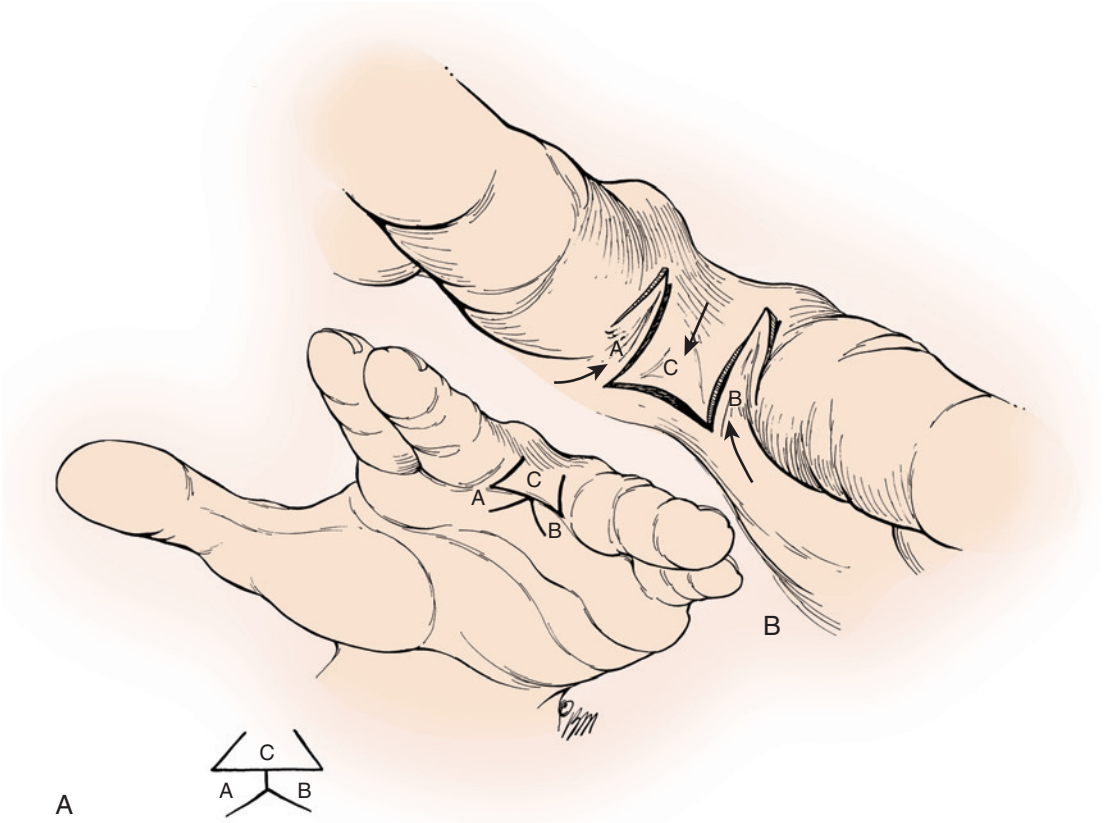

FIGURE 36.9 The double-opposing "Z"-plasty or butterfly flap is occasionally useful for mild degrees of web deepening. **A,** The palmar "V" of this flap may be given a stem to convert it to a "Y." **B,** The classic double-opposing "Z"-plasty and the flap transfers after mobilization. (Copyright © Elizabeth Martin.)

existing web alone by a simple "Z"-plasty, a four-flap "Z"-plasty, or a double-opposing "Z"-plasty (butterfly flap) (Figure 36.9). Other methods in this situation include combinations of local flaps, such as the three-flap web-plasty or an "X-M"-plasty.[53] Incomplete syndactyly can be deceptive, as there often appears to be an abundance of local skin available. However, following commissure reconstruction and transposition of the local flaps, a skin defect is common in the proximal digital surface, with excess skin located distally. Brennan has described a technique to address this situation by raising the distal skin as island flaps that are advanced in a proximal direction and combined with triangular flaps for commissure reconstruction.[29]

Syndactyly of the first web space presents a special problem and varies in extent. First web syndactyly is more common in syndromic disorders such as Apert syndrome and is often associated with a thumb deformity. It hampers hand function more severely than does syndactyly of the other web spaces. Mild to moderate first web space syndactyly can be treated with a local flap, such as a four-flap "Z"-plasty (Figure 36.10). Other options include a transposition flap from the index finger, a combination of transposition flaps from the radial and ulnar borders of the index and thumb, respectively, or a "V-to-Y" advancement of the central web.[42]

Severe syndactyly with marked thumb/index web narrowing may require more skin than is available in local flaps. In this situation, skin may be imported from the dorsum of the hand after tissue expansion[41] or as a rotation advancement flap (Figure 36.11).[40] Pedicled flaps such as the radial forearm[77] or free flaps from distant sites such as the groin can also be used.[84] Despite the complexity, free flaps import skin of excellent quality to the hand in cases of severe skin deficiency associated with syndromic syndactyly.

Separation and Resurfacing of the Digits

Release of syndactyly requires careful planning to optimize use of the available skin and to allow surgical exposure for separation of digits and structures. Incision design must be placed such that inevitable scar contraction will avoid joint or web space contracture. Numerous patterns of skin incisions have evolved, including laterally based triangular and rectangular flaps. Cronin's technique of a combination of palmar and dorsal triangular flaps with matched zigzag incisions on both surfaces of the conjoined digits remains the basis of most techniques (Figure 36.12).[44] Modifications of this pattern have been proposed to redistribute the available skin in an unequal manner to avoid skin grafting on both sides of the commissure (Figure 36.13). Syndactyly release has also been performed with straight-line midlateral incisions closed with skin grafts, which are splinted to prevent contracture and subsequently serially excised to leave an acceptable midlateral scar,[142] or with direct closure after defatting of the skin flaps.[145] This is a departure from the traditional technique but may be of benefit when grafts and scars are at risk of pigmentation and hypertrophy. Another alternative approach is the "open finger" technique of Sommerlad, where the residual skin defects resulting from separation of the digits are left open to heal by secondary intention.[154]

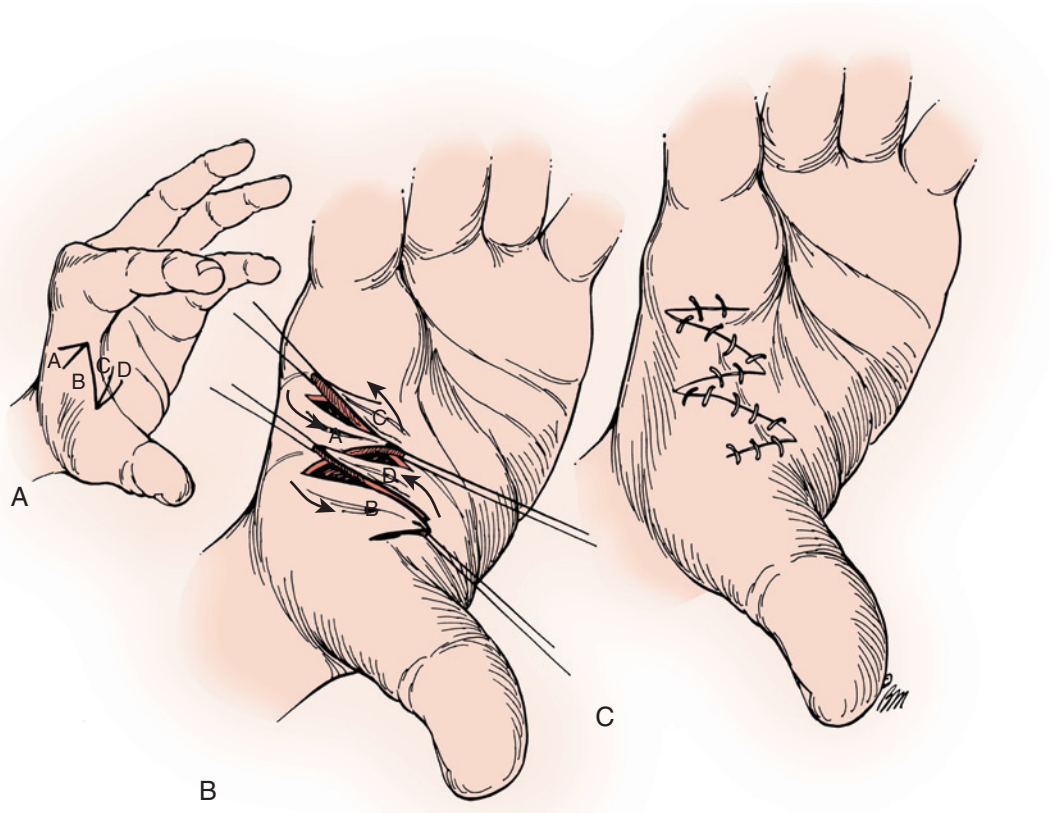

FIGURE 36.10 The standard four-flap "Z"-plasty often used for deepening broader webs such as the thumb web. **A,** The incisions are outlined. **B,** The flaps have been mobilized and crossed. **C,** Closure. (Copyright © Elizabeth Martin.)

However, most surgeons fear the secondary cicatrix formation with scar contracture and hypertrophic scarring and so are reluctant to endorse this method.

Separation of the digits requires division or excision of fascial interconnections between the digits, with care taken to identify and preserve the individual neurovascular bundles and the venous plexus on the dorsum of the digits and of the commissure flap (Figures 36.14 and 36.15). Bifurcation of the common digital nerve and artery may be distal to the planned position of the web space. In this situation, the digital artery can be ligated provided the other side of the digit is unoperated or the contralateral digital artery is known to be intact. Otherwise the web release is limited to the level of the arterial bifurcation or the artery is extended with a vein graft (very rarely necessary). When multiple digits are released, each digit must have at least one digital artery remaining; hence, the importance of precise operative records in such cases. Distal bifurcation of the digital nerve is managed by interfascicular dissection and proximal separation.

Resurfacing the digits is achieved with the palmar and dorsal flaps raised from the conjoined digits supplemented with skin grafts. Full-thickness skin grafts are preferred over split-thickness skin grafts to lessen secondary graft contracture. Skin grafts are usually obtained from the inguinal donor site.[99] Alternative donor sites include the antecubital fossa, the hypothenar border of the hand (Figure 36.16), the forearm/wrist (Figures 36.17 and 36.18), and the skin of an accessory digit. The foreskin has been used,[124] although it tends to take poorly and develop pigmentation. The authors favor the medial upper arm, believing skin from this area is less likely to manifest unpredicted hair growth at maturity and is less likely to develop pigmentation than the inguinal grafts. Regardless of the chosen donor site, a careful explanation and consent are mandatory because the scar may hypertrophy.

Resurfacing the digits without skin graft has been performed to improve overall skin match and to avoid the risk of contracture associated with graft loss.[74] This technique may require some reduction of digital diameter by excising the subcutaneous fat of the digit while preserving the dorsal venous system. Extensive defatting, however, carries the risk of vascular or nerve injury and may lead to a thin finger after the involution of the fat of infancy. Another option to avoid skin grafting is to import skin from the dorsum of the hand and/or adjacent digits (Figure 36.19). The authors favor a dorsal flap from each adjacent finger as part of a trilobed commissural flap. In theory, more skin can be generated with tissue expanders, although this technique has limited success in syndactyly.[9] Tissue expansion has also been achieved with transverse soft tissue stretching through the use of a distraction frame. Neither of these techniques has been widely adopted.

Paronychial Fold Formation

Release of a complete syndactyly, particularly when associated with distal phalangeal fusion, requires the formation of a paronychial fold. The distal phalangeal tufts may be covered using the technique described by Buck-Gramcko. Laterally based long narrow triangular flaps are raised from the hyponychium of the conjoined digital mass and folded around to form the lateral

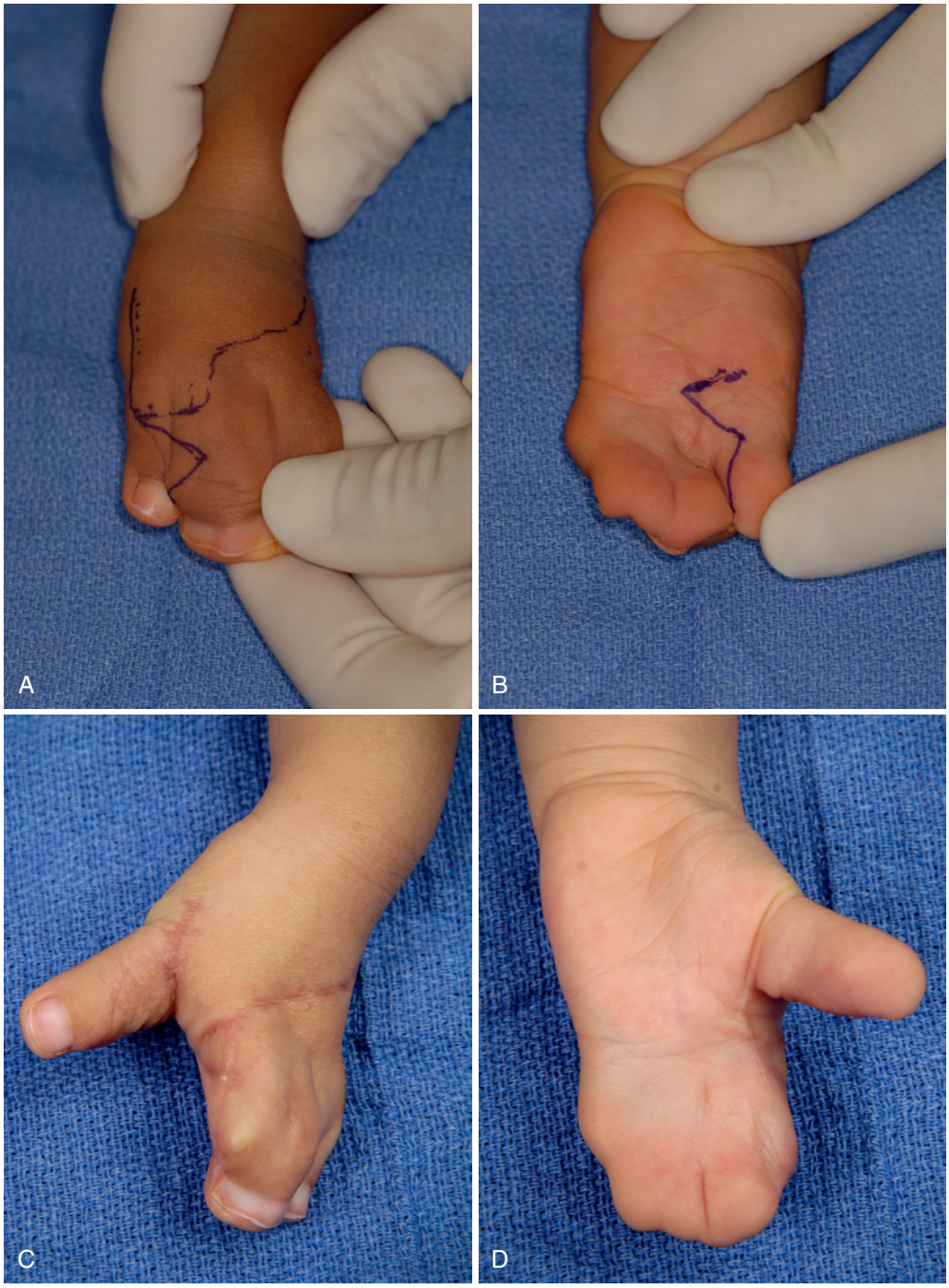

FIGURE 36.11 Three-year-old with severe syndactyly and marked thumb/index finger web narrowing. **A,** First web space reconstruction using dorsal flap. **B,** Palmar view with intended level of commissure. **C,** Postoperative appearance of thumb/index finger web space. **D,** Palmar view with thumb out of the palm. (Courtesy of Shriners Hospital for Children, Philadelphia.)

nail fold (Figure 36.20). Alternatively, the defect may be resurfaced with a skin flap from the conjoined pulp for one of the nail folds and a subcutaneous fat flap from the conjoined pulp covered with a graft for the other nail fold. Distant skin flaps including a thenar flap have been used,[88] but this technique requires delayed division and a second surgical procedure and in all but the youngest child, risks a PIP joint contracture. A composite graft of skin and subcutaneous fat harvested from the toe can also be used to reconstruct the fingertip.[153]

Outcome

The complexity and technical demands of syndactyly release are often underestimated. What appears to be simple surgery requires careful three-dimensional planning, careful technique, and meticulous wound closure. The procedure is often time consuming and demands patience. An acceptable outcome with independent digits that are freely mobile is usually achieved with simple syndactyly separation. In contrast, the outcome after complex syndactyly separation is often limited

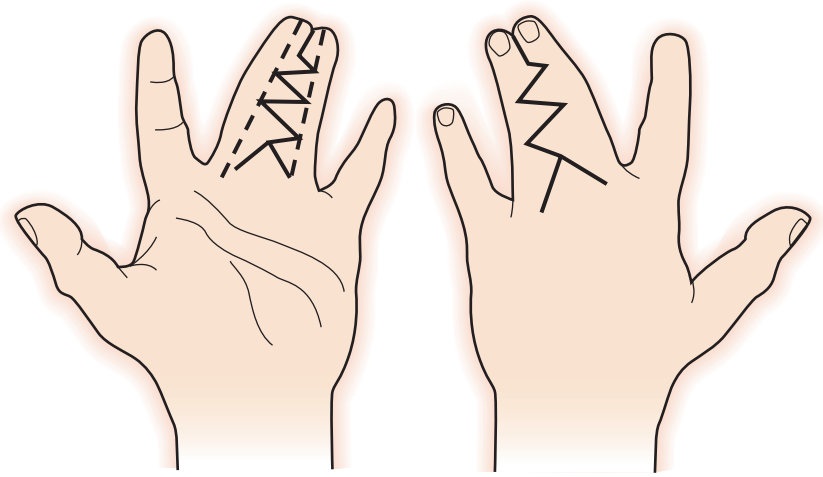

FIGURE 36.12 Cronin technique of a combination of palmar and dorsal triangular flaps with matched zigzag incisions on both surfaces of the conjoined digits. (From Cronin TD: Syndactylism: results of zig-zag incision to prevent postoperative contracture. *Plast Reconstr Surg* 18:460–468, 1956.)

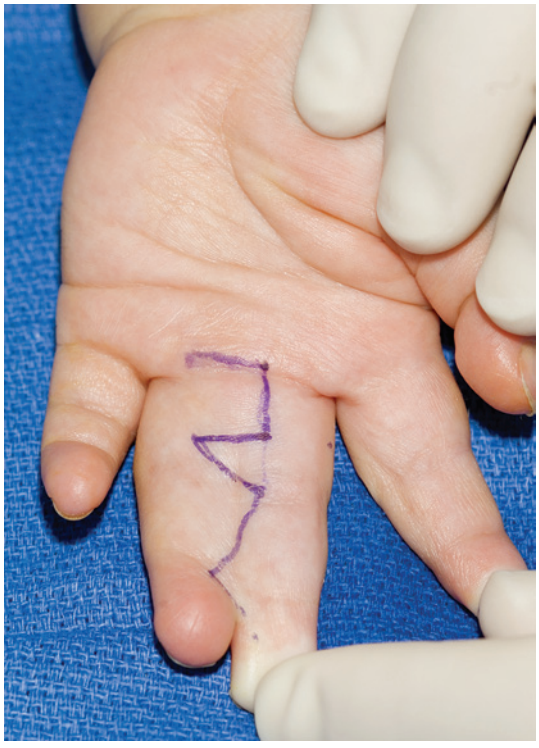

FIGURE 36.13 Modifications consisting of a palmar rectangular flap to resurface the proximal area of a digit adjacent to the commissure so that skin grafting on both sides of the commissure can be avoided. (Courtesy of Shriners Hospital for Children, Philadelphia.)

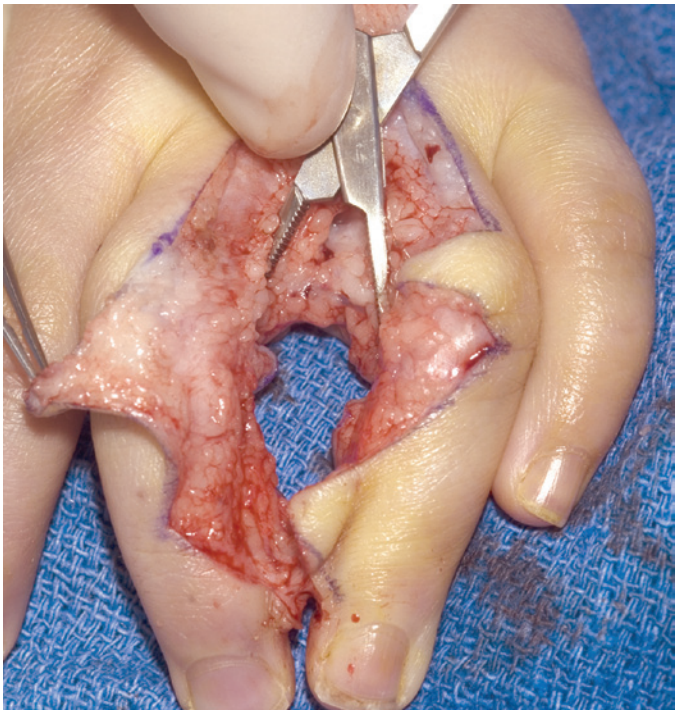

FIGURE 36.14 Lateral spreading of the digits places the intervening tissue under tension and facilitates digital separation. (Courtesy of Shriners Hospital for Children, Philadelphia.)

by associated anomalies and severe skin shortage, which result in increased scarring and diminished mobility.[73]

Complications

Early complications include vascular compromise, infection, wound dehiscence, and graft loss. Tension-free wound closure is mandatory to prevent dehiscence and may require judicious defatting or skin grafts or both. Over time, the commissure may be drawn in a distal direction (web creep) by scar contraction (Figure 36.21). Poor flap design with placement of longitudinal scars at the base of the finger can precipitate web creep.[11] Web creep is also associated with areas of skin graft loss that heal by secondary intention, the use of split-thickness grafts, or the dehiscence of the commissure flap. Joint contractures are a result of contracture of scars on the palmar surface of the interphalangeal (IP) joint. This complication may require scar revision with further skin grafting or, where there is adequate skin, a "Z"-plasty to reorient and lengthen the scar. In the fingertip, inadequate soft tissue bulk and scarring can produce a beaked nail deformity or an inadequate paronychial fold.[34] Lastly, joint instability may occur after separation of complex syndactyly owing to insufficient collateral ligaments.

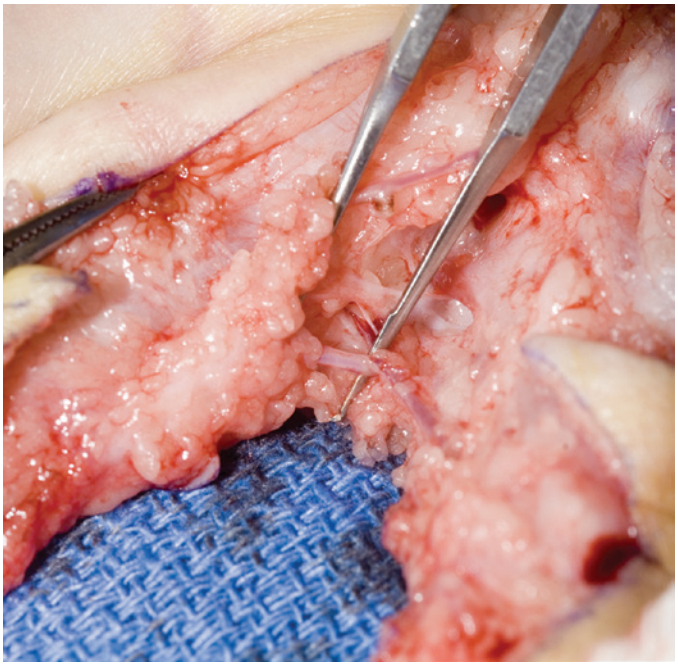

FIGURE 36.15 The bifurcation between the common and proper neurovascular structures requires identification. (Courtesy of Shriners Hospital for Children, Philadelphia.)

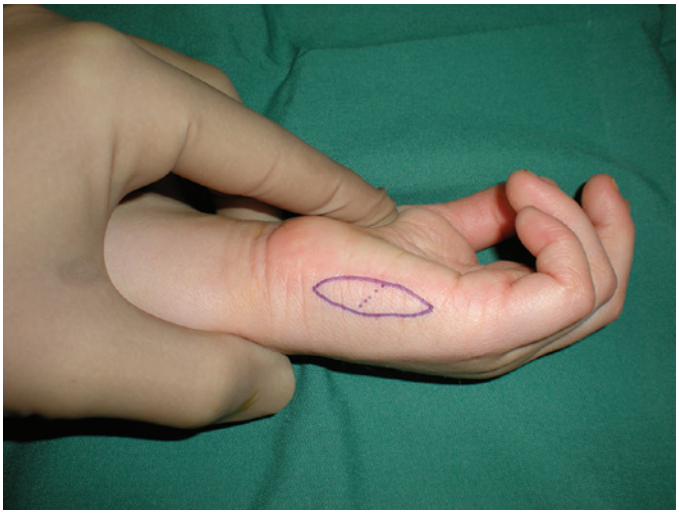

FIGURE 36.16 Full-thickness skin graft harvested from the hypothenar border of the hand for incomplete syndactyly.

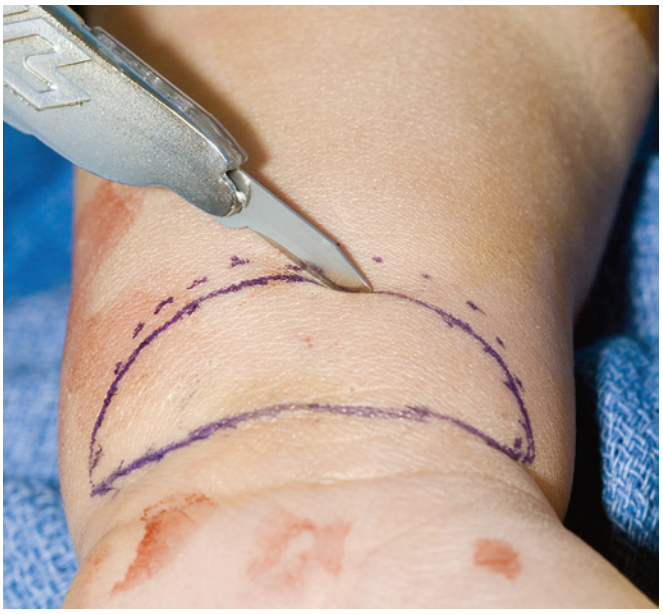

FIGURE 36.17 Smaller amounts of graft can be taken from the distal wrist crease in an elliptical fashion. (Courtesy of Shriners Hospital for Children, Philadelphia.)



FIGURE 36.18 Primary closure of the distal wrist crease harvest site. (Courtesy of Shriners Hospital for Children, Philadelphia.)

❖ AUTHORS' PREFERRED METHOD OF TREATMENT

In simple syndactyly, the preferred technique depends on the specifics of the deformity. Where the syndactyly is incomplete or loose and resurfacing without skin graft is feasible, that is our preferred method. Because incisions differ between techniques, the decision of whether a graft will be needed must be made prior to surgery.

Release of syndactyly is performed with the patient under general anesthesia using a tourniquet and loupe magnification.

If release will involve skin grafts, an hourglass-shaped dorsal flap is preferred for commissure reconstruction (see Figure 36.8). The flap begins at the level of the metacarpal heads and extends for two thirds of the length of the proximal phalanx. On the palmar surface of the dorsal commissure flap, a rectangular flap is fashioned to resurface the proximal area of a digit adjacent to the commissure (see Figure 36.13). The proximal transverse incision represents the palmar level of commissure reconstruction, and the distal transverse edge equals the length of the dorsal commissure flap. Subsequently, interdigitating zigzag dorsal and palmar flaps are constructed distal to the dorsal commissure and palmar rectangular flap. The dorsal zigzag incision begins at one distal corner of the commissure flap, whereas the palmar incision starts at the opposite corner of the rectangular flap (see Figures 36.8 and 36.13). The dorsal incision extends to the midline of the PIP joint of the adjacent finger and back across to the midline of the distal interphalangeal (DIP) joint. At this level, the incision



FIGURE 36.19 Fifteen-month-old with isolated left long finger/ring finger syndactyly and substantial coronal skin. **A,** Dorsal view. **B,** Palmar view. **C,** Triangular lateral extension (seagull flap) can allow direct closure over the dorsum of the finger and spare the amount of tissue required in the transverse direction. **D,** Volar incision. **E,** Identification of neurovascular bifurcation. **F,** Commissure flap inset and lateral wings closed. **G,** Volar view following complete closure without skin graft. **H,** Dorsal view of the same completed procedure. (Courtesy of Shriners Hospital for Children, Philadelphia.)

extends distally between the tips of the interconnected digits. The palmar flaps are based opposite the dorsal flaps (mirror images) with the base centered over the opposite PIP and DIP joints to allow for interdigitation. It can be helpful to mark the level of the peak of each flap with encircling ink-stained suture material to facilitate accurate apposition of the peak on one digit with the trough of the opposite digit. This orientation minimizes the tendency for formation of a flexion scar contracture and maximizes coverage potential. The palmar rectangular flap (opposite the dorsal commissure flap) and zigzag construction is often biased to cover one digit entirely, leaving residual bare areas on the adjacent digit that requires skin grafting. This has an advantage in requiring fewer grafts and a shorter operative time.

The flaps are elevated by sharp dissection with hemostasis using bipolar electrocautery. Dorsal flaps are elevated first, preserving the paratenon surrounding the extensor tendon. Next, the palmar flaps are raised and the underlying neurovascular bundles identified distally. The digits are separated from distal to proximal while protecting the neurovascular bundles. Manual spreading of the digits places the intervening tissue under tension, which facilitates digital separation (see Figure 36.14). The sturdy transverse fascial bands are incised to allow for sufficient proximal placement of the commissure. The bifurcation between the common and proper neurovascular structures is identified during proximal dissection (see Figure 36.15). A distal split of the digital nerves is easily separated by microdissection. The surgical options when the arterial bifurcation is



FIGURE 36.20 Laterally based triangular flaps from the hyponychium of the conjoined digital mass are folded around to form the lateral nail fold. (Courtesy of Shriners Hospital for Children, Philadelphia.)

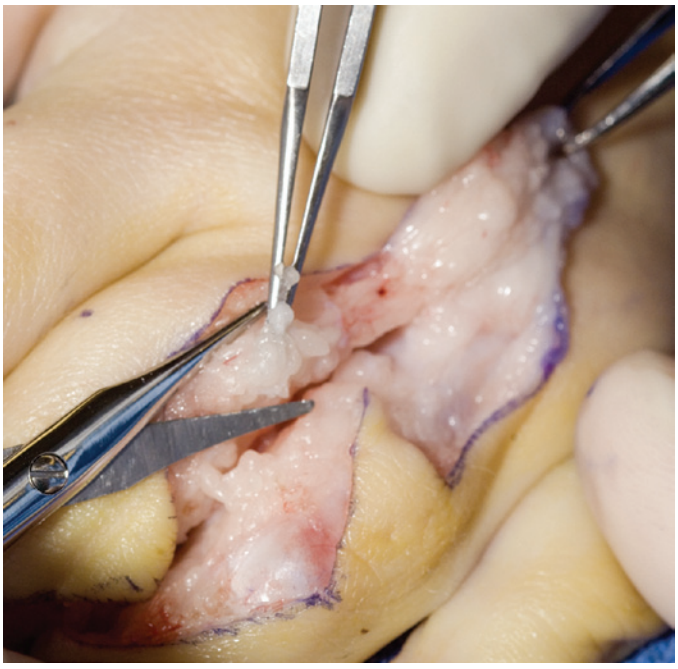

FIGURE 36.22 The adjacent sides of the separated digits are defatted before insetting the flaps. (Courtesy of Shriners Hospital for Children, Philadelphia.)



FIGURE 36.21 Web creep and angulatory deformity after separation of syndactyly. (Courtesy of Shriners Hospital for Children, Philadelphia.)

distal to the desired web position are described in the text above. Ligation of a proper digital artery for an acceptable commissure placement is usually required. Selection of the proper digital artery to ligate depends on the status of the proper digital artery on the adjacent sides of the digits being separated. If both digits have intact proper digital arteries on both sides, the smaller artery is usually ligated. However, if one of the digits still requires additional surgery (e.g., staged syndactyly release), then ligation of the larger artery may be considered. If the status of the opposite digital artery is unclear, microvascular clamps are applied to the digital arteries and the tourniquet is deflated to ensure adequate perfusion of each digit.

Before insetting of the flaps, the adjacent sides of the separated digits are defatted (Figure 36.22). Defatting decreases the tension across the flaps and improves the overall appearance of the separated digits. Abnormal or contracted fascial structures may be encountered and are also released or excised at the time of this defatting. The commissure flap is sutured first to assess placement and configuration of the web space. Subsequently, the interdigitating flaps are approximated, avoiding excessive tension. An absorbable 5-0 or 6-0 suture is used for closure, and sutures are placed very close to the skin edges to avoid cross-hatched scarring. The remaining skin defects are covered with full-thickness skin graft (Figures 36.23 and 36.24).

In select cases, an experienced surgeon may decide that skin grafts may be avoided with a trilobed dorsal flap for construction of the commissure. This design requires the harvesting of skin from the dorsum of the adjacent digits, and so, in return for a potentially more pliable web and no pigmented skin grafts, a less discrete dorsal scar is formed.

Proper postoperative dressings are an essential part of the operation. The dressings must apply gentle compression across the skin graft sites and protect the separated digits. Nonadherent dressings and moist cotton are placed into the web spaces and reinforced with large amounts of soft gauze. In young children, the compressive hand dressing is reinforced by above-the-elbow plaster or a soft cast (Scotchcast, 3M, St. Paul, MN) to prevent inadvertent removal. The elbow is positioned in at least 90 degrees of flexion to minimize the chances of the cast sliding off the arm. The dressings are removed 3 weeks after surgery, and then gentle washing and wound care are needed. The wounds are protected until they are dry and healed. Normal hand use is allowed after the dressing has been removed.



FIGURE 36.23 Dorsal appearance after flap closure and full-thickness skin grafting. (Courtesy of Shriners Hospital for Children, Philadelphia.)



FIGURE 36.24 Volar appearance after flap closure and full-thickness skin grafting. (Courtesy of Shriners Hospital for Children, Philadelphia.)

Physiotherapy is usually not required. Once healing has taken place, an elasticized compression glove may be fitted and worn for up to 3 months for scar management. Scar massage, silicone gel sheets, or elastomere products can be used to treat areas of hypertrophic scarring.



FIGURE 36.25 Acrosyndactyly in amniotic disruption sequence with a sinus tract or cleft from the dorsal to the palmar surface of the conjoined digits.

SPECIAL CASES OF SYNDACTYLY

Acrosyndactyly

Acrosyndactyly is a syndactyly with a fenestration between the digits proximal to the distal fusion and is characteristic of constriction ring syndrome (amniotic disruption sequence) (Figure 36.25). It is bilateral in 50% of cases and is associated with absent digits in 50% of patients. The syndactyly can vary from a simple syndactyly to a complex anomaly with distal fusion of multiple digits producing a jumble of fingertips. The sinus is variable in size (from the size of a pin tract to a broad passage) and is usually distal to the normal commissure level (Figure 36.26). The digits distal to the constriction ring may be edematous, atrophic, or skeletally disrupted.

Management is dependent on the severity of the distal deformity and the position and size of the sinus. Mild deformities with well-preserved distal digits can be released with the standard techniques as described previously. The sinus may be incorporated during resurfacing of the digits or excised. For more complex deformities, staged release of the fingertips followed by delayed commissure reconstruction is recommended. Staging allows unimpeded growth of the digits. In severe deformities, amputation of disorganized or atrophic fingertips may be preferred because the potential for reuniting them with the parent digit is limited. In addition to the syndactyly release, associated constriction rings can be managed by excision and "V-Y" plasty.

Apert Syndrome

Apert syndrome describes the combination of bicoronal craniosynostosis and midfacial hypoplasia with severe complex syndactyly of the hands and feet.[60] It is due to a mutation of the fibroblast growth factor receptor type 2 gene (FGFR2), which

TABLE 36.1 Classification of Apert Hand Deformities

Type	First Web	Central Mass	Fourth Web
Type I Obstetrician hand or spade hand	Incomplete simple syndactyly	Digital mass flat in palmar plane. Good metacarpophalangeal joints with variable degree of symphalangism at interphalangeal joints	Incomplete simple syndactyly
Type II Mitten hand or spoon hand	Complete simple syndactyly	Digital mass forms palmar concavity with splaying of metacarpals proximally and tight fusion of fingertips distally with synonychia of central digital mass	Complete simple syndactyly
Type III Hoof hand or rosebud hand	Complete complex syndactyly	Thumb incorporated into mass, which is tightly cupped; synonychia of all digits apart from the small finger; skeletal abnormalities of index ray; Complicated by paronychial infections and maceration of palmar skin	Simple syndactyly, usually with metacarpal synostosis of fourth and fifth metacarpals

Blauth W, Schneider-Sickert F: Symbrachydactylies. In Blauth W, Schneider-Sickert F, editors: *Congenital deformities of the hand*, Berlin, 1981, Springer-Verlag, pp 249–271; Upton J: Apert syndrome: classification and pathologic anatomy of limb anomalies. *Clin Plast Surg* 18:321–355, 1991.



FIGURE 36.26 Severe banding resulting in a conglomeration of digits with a vessel loop through a small sinus. (Courtesy of Shriners Hospital for Children, Philadelphia.)

is located on chromosome 10q.[184] Several other acrocephalosyndactyly syndromes have been identified; however, the hand deformities are typically less complex than those of Apert syndrome. In addition to the characteristic hand deformity, upper limb manifestations include abnormalities of the shoulder and elbow. The development of the glenohumeral joint is asymmetric, with relative overgrowth of the greater tuberosity and a hypoplastic glenoid fossa. Shoulder movements become more restricted with growth. Elbow anomalies most commonly involve the radiocapitellar articulation.[7,119,128]

The hand deformities in Apert syndrome include complex syndactyly of the index, long, and ring fingers and a simple syndactyly between the ring and small fingers. Varying degrees of first web space syndactyly prevent useful prehension, which is exacerbated by radial clinodactyly of the thumb (Figure 36.27). The fingers are short, and IP joints are stiff in the central rays. In the most severe cases, the distal phalanges of all of the fingers are fused to each other and growth of the fingers results in a rosebud or bunched appearance with a deep hollow in the palm caused by the tethering distally.[171] Frequently, nail fold infections result from overlapping and ingrowth of the tightly adjacent nail plates. A capitohamate coalition and synostosis between the ring and small metacarpals is frequent (Figure 36.28). This finding is clinically important because it prevents opposition of the fifth digit toward an already restricted thumb. There is an inverse relationship between the severity of the hand and craniofacial deformities. The hand deformity has been classified according to the involvement of the first web space and conformation of the central mass (Table 36.1).

The management of hand anomalies in patients with Apert syndrome must be performed in concert with the management of the craniofacial and other associated anomalies. In practice, this is complex surgery requiring careful coordination between hand surgeons and the craniofacial service. The goal of surgery is to complete separation of the digits and correct the thumb deformity before 2 years of age to allow for growth and the development of function. Surgery to mobilize the small finger by release of the ring and small metacarpals' synostosis may be beneficial because it allows cupping of the palm and some function between the often better articulated fifth finger and the thumb. Surgery is rarely performed about the shoulder and elbow.

Separation of the digits requires careful planning. Reconstruction of an adequate first web space is the first priority. Sequential single-stage release of the skin and fascia, intrinsic muscle lengthening, and capsulotomy of the carpometacarpal (CMC) joint allow the thumb ray to be positioned in 45 degrees of abduction (Figure 36.29). Minor first web space narrowing can be addressed with local flaps such as a four-flap "Z"-plasty. Considerable narrowing with deficient skin requires a dorsal advancement rotation flap[61] or preliminary tissue expansion on the dorsum of the hand.[41] We prefer to use a transposition flap from the radial border of the index finger for incomplete thumb/index finger syndactyly. The index finger flap can

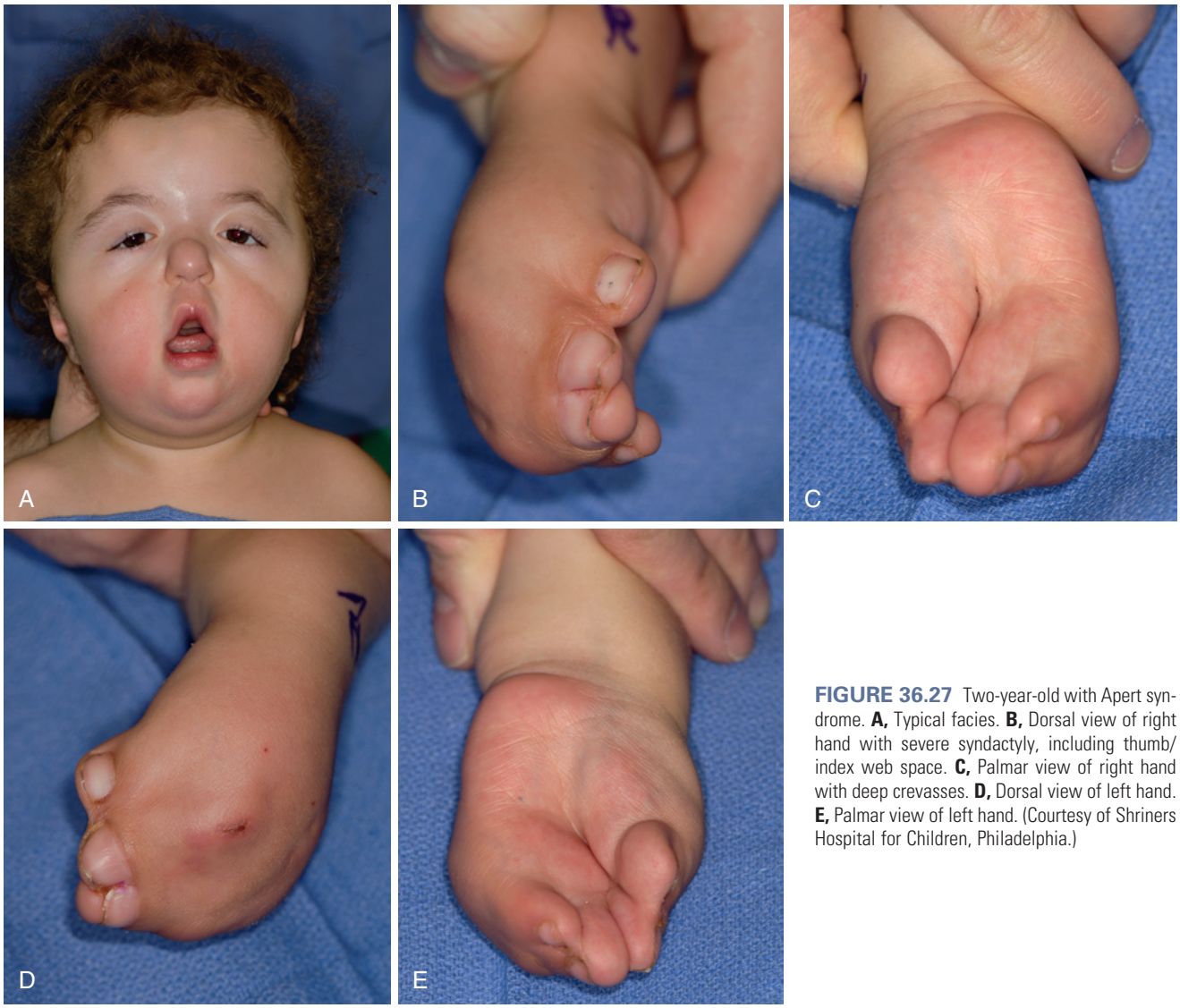

FIGURE 36.27 Two-year-old with Apert syndrome. **A,** Typical facies. **B,** Dorsal view of right hand with severe syndactyly, including thumb/index web space. **C,** Palmar view of right hand with deep crevasses. **D,** Dorsal view of left hand. **E,** Palmar view of left hand. (Courtesy of Shriners Hospital for Children, Philadelphia.)

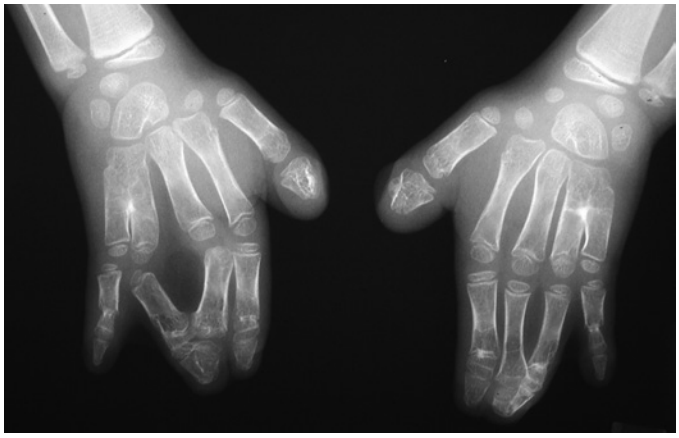

FIGURE 36.28 Bilateral hand x-rays of a child with Apert syndrome. Note the coronal complex syndactyly of the distal ends of the central digits, capitohamate coalitions, and synostosis between the ring and small finger metacarpals. (Courtesy of Shriners Hospital for Children, Philadelphia.)

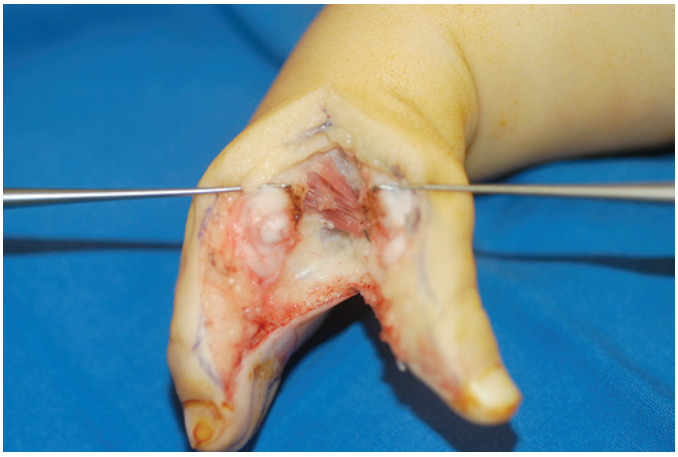

FIGURE 36.29 Release of the first web space with sequential release of the skin and fascia, intrinsic muscle lengthening, and capsulotomy of the carpometacarpal joint to position the thumb in abduction.



FIGURE 36.30 A free groin flap for severe contracture of the first web space.



FIGURE 36.31 Restoration of substantial soft tissue within the first web space after a free groin flap.

lengthen the first web space and be positioned into the thenar crease to correct any associated flexion-adduction contracture. For severe contracture of the first web space, Buck-Gramcko has described successful release with a large dorsal rotation flap,[32] but our preference is to import new skin to the very deficient hand integument. A free groin is used (Figure 36.30), and this allows the import of large areas of pliable skin while minimizing the donor defect. The groin donor has the potential disadvantage of future pigmentation and hair growth, but the vessels lie within the territory of the flap and appose themselves to the recipient vessels accurately. Substantial tissue is placed within the first web space (Figures 36.31 and 36.32). Contrary to prevalent belief, the vessels within the first web space and the flap are adequate for microvascular anastomosis. However, this is daunting microsurgery, requiring highly specialized anesthesia, and should only be contemplated in units with the resources and experience to perform this surgery. The least disfiguring alternative is probably the dorsal rotation advancement flap; we eschew the pedicled forearm flaps because of the scarring that results and the division of a major axial vessel.



FIGURE 36.32 Another view of restoration of substantial soft tissue within the first web space after a free groin flap.

The thumb clinodactyly must be corrected with an osteotomy of the phalanx. An opening wedge osteotomy and a bone graft are preferred to lengthen the shortened thumb. This is best done at the same stage, so that the fixation of the thumb web space release is combined with fixation of the bone graft. The bone graft can be taken from the division of the synostosis between the fourth and fifth metacarpals. Usually, there is a resultant skin shortage on the radial aspect of the thumb that can be addressed with "Z"-plasty.

Release of the finger syndactylies is usually staged,[173] though release of the syndactyly in a single stage has been reported.[80] Anomalies of the neurovascular bundles are common. The surgical plan is influenced by the extent of the first web space reconstruction and the status of the index finger. A severely deformed index finger may be sacrificed if it is unlikely to yield a stable finger of adequate length, though our preference is to preserve all digits. More information about the skeletal abnormality can be assessed with three-dimensional computed tomography, which may be combined with the craniofacial imaging.[82]

When the thumb is released, the opportunity may be taken in the tightly bunched or rosebud hand to release the distal osseous unions via a simple linear incision and to line the raw lateral surfaces with skin grafts, thereby converting the tight bunched hand into the flat "spade" of the type I deformity.[171] This simple maneuver prevents growth distortion, buys time to allow other surgeries, and also serves to prevent the recurrent nail infections that can dominate the early months of hand care in these children. Subsequent releases of the multiple syndactylies are staged to avoid surgery to both sides of the digit at the same sitting.

In this way, we have staged the release of the severely deformed hand by releasing the distal osseous fusion and dividing the common nail plate through dorsal incisions between the distal digits. This converts the complex syndactyly to a simple syndactyly and releases the digits from the osseous tether. The interdigital defects are resurfaced with full-thickness grafts to allow some differential motion between the digits. The grafts generate enough pulp skin to provide adequate pulp and

paronychial flaps for the release of the fingers at a later stage. The digits in the Apert hand are stiff in extension, and therefore the release of the proximal part of the syndactyly can be achieved with a straight-line incision, as there is not the same risk of IP joint contracture with longitudinal scars in these digits. The defects are resurfaced with full-thickness grafts, which may need to be harvested as a lower abdominal ellipse rather than from the groin because of the extensive area of graft required. Emphasis does need to be given to the commissure reconstruction to allow freedom of independent metacarpophalangeal joint movement. A dorsal commissure flap is usually used.

Surgery to free the small finger may be required if the finger is functional. Release of the synostosis between the ring and small metacarpals should include fascia or fat interposition to prevent recurrence. Upton's experience suggests that this procedure is best delayed until 5 years of age to decrease the incidence of recurrence, although we like to use the bone resected as a graft for the thumb clinodactyly. Therefore, we accept the risk of recurrence requiring an additional release. The position of the fifth ray may be improved by release of the CMC joint to allow flexion of the metacarpal.

Symbrachydactyly

Symbrachydactyly is from the Greek for "short webbed digits." Symbrachydactyly occurs sporadically but may be a feature of Poland syndrome. The anomaly is almost always unilateral, and the severity varies from almost complete absence of digits to relatively well-formed short fingers. When the digits are well formed, the syndactyly component requires intervention. The technique may be modified to include division of the transverse metacarpal ligament to increase the mobility and apparent length of the fingers, though the commissure should not be placed in such a proximal position between the metacarpal heads that there is a risk of producing a narrowed, "V"-shaped web space.

Poland Syndrome

Poland syndrome has been attributed to disruption of the blood flow in the subclavian artery in the embryo (hence, it is also called subclavian artery disruption sequence); a spectrum of hypoplastic anomalies in the upper limb is produced. The syndrome consists of absence of a shoulder girdle muscle and abnormalities in the hand, which may be very minor. In fact, there is no correlation between the severity of each component of the deficiencies. Commonly seen conditions are aplasia of the sternocostal head of the pectoralis major (although the clavicular head may also be absent); brachydactyly affecting the index, long, and ring fingers; hypoplasia of the hand; and syndactyly of the digits. The chest wall anomalies may be extensive and include hypoplasia of the breast, aplasia of the pectoralis minor and latissimus dorsi, and skeletal thoracic wall anomalies (Figure 36.33). The hand deformity is variable, but the central digits are most commonly affected and are generally shortened secondary to an undersized middle phalanx. The syndactyly is usually simple and either complete or incomplete. Surgical separation follows the timing and technique described previously. In our service we like to set up a treatment schedule extending from infancy to sexual maturity that combines the management of the thoracic deformity (usually, by ipsilateral muscle transfer) with staged reconstruction of the female breast.



FIGURE 36.33 Poland syndrome with considerable breast underdevelopment and an absent nipple. (Courtesy of Shriners Hospital for Children, Philadelphia.)

The hand surgery should be integrated into this treatment schedule.

Dystrophic Epidermolysis Bullosa

Syndactyly in dystrophic epidermolysis bullosa is not truly a congenital anomaly but rather a consequence of the scarring from this blistering condition of the squamous epithelial surfaces. Epidermolysis bullosa encompasses a rare heterogeneous group of congenital blistering conditions.[143] The skin structure is disrupted by a loss of the normal adhesion between the various lamina of the skin. The variants are classified according to the level and cause of blistering. Epidermolysis bullosa simplex variants blister at the basal keratinocyte level, junctional epidermolysis bullosa blisters within the lamina lucida of the basement membrane, and dystrophic epidermolysis bullosa blisters because of abnormal anchoring collagen VII fibrils within the papillary dermis. Dystrophic epidermolysis bullosa is associated with repeated dermal injury. The inevitable scarring produces syndactyly and contracture in the hands. Autosomal dominant and recessive forms of dystrophic epidermolysis bullosa have been recognized, with the recessive form being the most severe. Typically, the hand deformity progresses toward flexion contractures of the digits that become cocooned into a common mass (Figure 36.34). The thumb can be included within the cocoon. The hand problem, however, is only part of a complex condition that requires a multidisciplinary approach to management. These patients should be managed in specialized multidisciplinary centers with experts in treating the skin, gastrointestinal, ocular, oral, oncologic, psychological, and



FIGURE 36.34 The hand deformity in dystrophic epidermolysis bullosa with flexion contractures of the digits, which have become cocooned into a common mass.

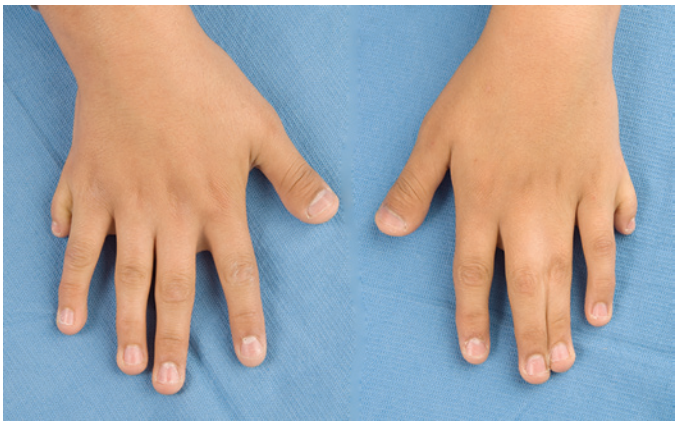

FIGURE 36.35 Twelve-year-old with bilateral postaxial polydactyly. The left hand also has long finger/ring finger syndactyly. (Courtesy of Shriners Hospital for Children, Philadelphia.)

anesthetic aspects of the disease. The hand surgery is based around release and resurfacing of the syndactyly and contractures. Radical release, particularly of the first web space, is recommended to maintain some hand function.[162] The syndactyly (also named pseudosyndactyly) in this condition is usually caused by adhesion between digits and can be achieved with blunt dissection after removal of the encasing membrane of scar. The dermal scarring generally produces flexion contractures of the digits or first web contractures. We believe that the maintenance of the first web space is the key to useful hand function in these children. For this reason, we consider free tissue transfer from an unscarred flexion area of the body (such as the groin) to be desirable where other considerations permit. Local flaps are usually impossible because of the extensive scarring and cocooning in these highly abnormal hands. The skin deficits can be allowed to heal by secondary intention or by using the skin of the cocoon, skin flaps from filleted fingers, or grafts. Split-thickness skin grafts are preferred, although we have successfully used free groin flaps to resurface the vital first web space. Despite initially satisfactory results, recurrence is common, with reoperation rates of over 50%.[162]

Expected Outcomes

The expected outcome of syndactyly release in children with simple syndactyly is a natural-appearing web commissure with pliable skin, unrestricted function, and no distal creep of the web with time; however, it may be complicated by contracture or hypertrophy of the scars associated with surgery and lead to distal creep of the web position. This may require further surgery to reposition the web. The outcomes in complex or complicated cases depend on the extent of the osseous syndactyly and associated anomalies, which often lead to stiffness or deformity of the digit or digits.

CRITICAL POINTS *Syndactyly*

- Syndactyly may involve only the soft tissue (simple) or include bony connections (complex).
- Atypical forms of syndactyly are labeled *complicated* and involve either convoluted soft tissue abnormalities or a hodgepodge of abnormal bones. Many atypical configurations occur in conjunction with a variety of syndromes.
- Mild incomplete syndactyly that does not interfere with function does not require treatment. In contrast, simple syndactyly of any considerable degree warrants surgical reconstruction of the web space for improved function and appearance.
- Border digits (thumb/index finger and ring/small finger web spaces) have marked differences in their respective lengths and should be separated within the first few months of life. This prevents tethering of the longer digit, which results in a flexion contracture and rotational deformity.
- Syndactyly that combines digits of relatively equal length (e.g., long/ring finger web space) negates the development of deformity. Separation may be delayed until the child is older and the hand larger to facilitate surgical reconstruction.
- Surgical reconstruction should only include one side of an affected digit at a time to avoid vascular compromise of the skin flaps or digit, or both.
- Surgical reconstruction of the commissure must be free of skin graft. Creation of a flap to recreate the commissure avoids interdigital contracture.
- Complex syndactyly is more challenging to treat, especially as the degree of bony union increases.

POLYDACTYLY

Ulnar Polydactyly

Epidemiologic Findings

Polydactyly can occur on the preaxial (radial) and postaxial (ulnar) sides of the limb. Postaxial polydactyly is frequently inherited via an autosomal dominant pattern but has a variable penetrance pattern. Postaxial polydactyly is more common in Africans and African-Americans. The polydactyly can be bilateral (Figure 36.35). Preaxial polydactyly is more frequent in Caucasians. The prevalence of postaxial polydactyly in African-Americans is estimated to be 1 in 143 live births. In comparison, the prevalence of postaxial polydactyly in Caucasians is estimated to be 1 in 1339 live births.[177] Postaxial polydactyly in a Caucasian individual is sometimes indicative of an underlying syndrome (e.g., chondroectodermal dysplasia or Ellis–van Creveld syndrome) (Figure 36.36).



FIGURE 36.36 Postaxial polydactyly in chondroectodermal dysplasia or Ellis–van Creveld syndrome. The dorsal view demonstrates the characteristic nail dysplasia. (Courtesy of Shriners Hospital for Children, Philadelphia.)



FIGURE 36.37 One-year-old with bilateral postaxial polydactyly. A ligature clip has been placed at the base for amputation. (Courtesy of Shriners Hospital for Children, Philadelphia.)

Classification and Treatment

The supranumerary digit is either well developed (type A) or rudimentary and pedunculated (type B). A small nubbin or scrawny postaxial element (type B) can be removed by ligating the base in the nursery or using local anesthesia with epinephrine and electrocautery in the office (Figure 36.37). Suture or vessel clips can be applied to the base of the digit. The digit will turn gangrenous and fall from the hand. A residual bump or nubbin is the most common complication (Figure 36.38), though other complications have been reported.[81,129]



FIGURE 36.38 Residual nubbin after suture ligation of postaxial polydactyly. (Courtesy of Shriners Hospital for Children, Philadelphia.)

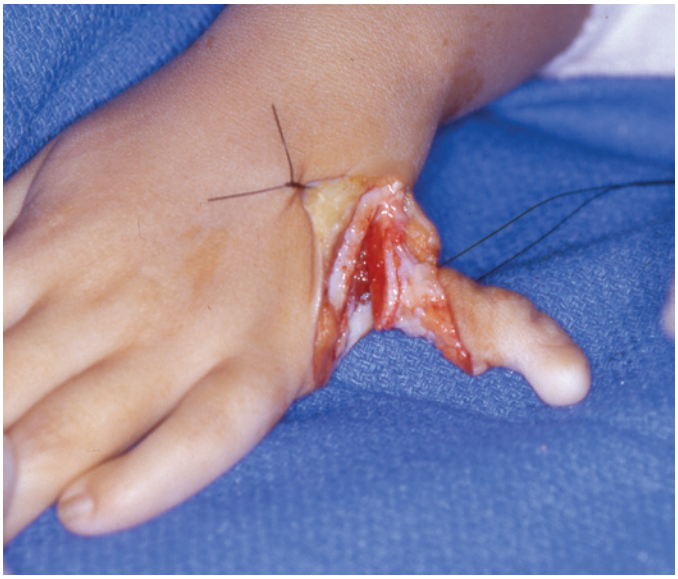

FIGURE 36.39 Elliptical incision around a postaxial digit extended in a proximal direction to allow adequate exposure and removal of the extra digit. (Courtesy of Shriners Hospital for Children, Philadelphia.)

A well-developed or nearly normal digit (type A) requires operative ablation. The extra digit is removed, and any important functional parts (e.g., ulnar collateral ligament and abductor digiti quinti) are transferred to the adjacent finger.

Surgical Technique

An elliptical incision around the digit is outlined (Figure 36.39). The incision is extended in a proximal direction to allow adequate exposure. Anomalous tendons are removed with the extra digit. The digital nerves are incised and the digital arteries coagulated. If the ablated digit contains the abductor digiti quinti, the muscle and tendon to the adjacent digit are transferred to

restore digital abduction. The skin is closed with absorbable suture and the limb immobilized in a long-arm cast for 3 weeks to protect any ligament and/or muscle-tendon transfer.

CRITICAL POINTS *Postaxial Polydactyly*

- Postaxial polydactyly is frequently inherited in an autosomal dominant pattern but has a variable penetrance pattern. Postaxial polydactyly is more common in African-Americans and preaxial polydactyly is more frequent in white individuals.
- A small nubbin or rudimentary postaxial element can be removed safely by tying the base in the nursery or using local anesthesia and electrocautery in the office.
- Well-developed postaxial polydactyly requires operative ablation with transfer of any important parts (e.g., ulnar collateral ligament and abductor digiti quinti) to the adjacent finger.

Central Polydactyly

Epidemiologic Findings

Central polydactyly is an extra digit within the hand as opposed to along its borders. Central polydactyly is uncommon in comparison with border polydactyly. The ring digit is the most common duplication, followed by the long finger and finally the index digit. Central polydactyly occurs in isolation or as part of a syndrome, such as Grebe chondrodysplasia (Figure 36.40). The central polydactyly may be hidden within a concomitant syndactyly (i.e., synpolydactyly) (Figures 36.41 and 36.42). Identification of synpolydactyly requires careful examination supplemented by radiographic verification (Figure 36.43). Central polydactyly (ring finger duplication) combined with syndactyly has a familial inheritance pattern and has been linked to a gene mutation (HOXD13 gene) on chromosome 2.[126]



FIGURE 36.40 Fourteen-year-old female with Grebe chondrodysplasia and severe brachydactyly associated with a cartilage-derived morphogenetic protein deficiency. **A,** Right hand. **B,** Left hand. **C,** Right foot. **D,** Left foot. (Courtesy of Shriners Hospital for Children, Philadelphia.)



FIGURE 36.41 Dorsal view of a 2-year-old girl with familial synpolydactyly. (Courtesy of Shriners Hospital for Children, Philadelphia.)



FIGURE 36.43 X-ray revealing a concealed ring finger duplication with angular deformities. (Courtesy of Shriners Hospital for Children, Philadelphia.)



FIGURE 36.42 Palmar view of synpolydactyly with a wide base about the proximal phalanges. (Courtesy of Shriners Hospital for Children, Philadelphia.)



FIGURE 36.44 One-year-old with central polydactyly consisting of five fingers with full motion and function. (Courtesy of Shriners Hospital for Children, Philadelphia.)

Treatment

Treatment depends on the status and extent of the extra digit and the presence or absence of concurrent anomalies, such as syndactyly. A central polydactyly that has a fully formed digit and normal function does not require removal to restore the normal complement of digits (Figure 36.44). An isolated central polydactyly with limited motion is treated by resection of the ray. The span of the hand is maintained by transposition of the adjacent digits or intermetacarpal ligament reconstruction (or both). Synpolydactyly is treated by separation of the syndactyly and reduction of the concealed polydactyly. Surgery is

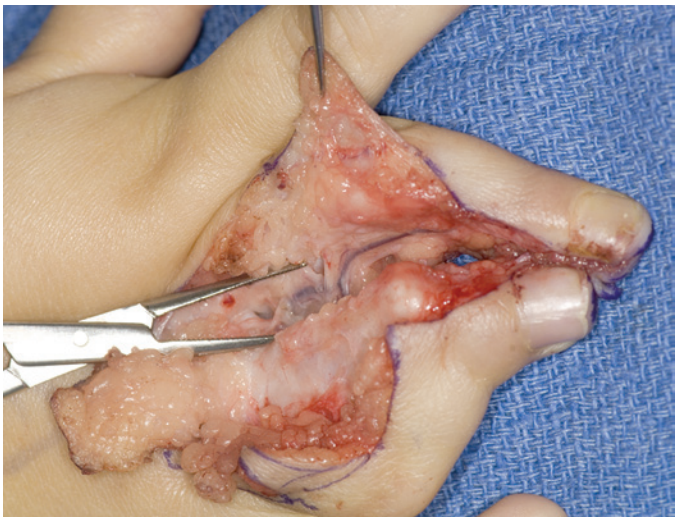

FIGURE 36.45 Child depicted in Figure 36.1 treated with a wide dorsal exposure to isolate the underlying bony elements and neurovascular structures. (Courtesy of Shriners Hospital for Children, Philadelphia.)



FIGURE 36.46 Abnormal bony elements are treated by a combination of resection and osteotomy to improve alignment. (Courtesy of Shriners Hospital for Children, Philadelphia.)



FIGURE 36.47 Postoperative results with improved alignment and structure. (Courtesy of Shriners Hospital for Children, Philadelphia.)



FIGURE 36.48 Partial index finger polydactyly with concomitant thumb duplication. (Courtesy of Shriners Hospital for Children, Philadelphia.)

quite difficult and is unlikely to restore normal motion and alignment. Complete removal of the redundant bones is difficult to accomplish without jeopardizing joint structure or digital circulation. Wide surgical exposure is necessary. Flaps are designed for extensive exposure of the underlying bony elements and isolation of the neurovascular structures (Figure 36.45). Creativity and intraoperative flexibility may be required to restore the best functioning digit with components from each part (Figure 36.46). A combination of resection and osteotomy is often necessary to obtain the best digit possible (Figure 36.47). The result is often incomplete resection of the surplus bones, which enhances appearance but does not improve motion. Partial central polydactyly is treated with principles similar to those used for reconstruction of the duplicated thumb (Figure 36.48). Multiple surgeries may be required for central polydactyly, and the outcome may still be disappointing. Similar to complex syndactyly, duplicated digits with complicated connections may be better left untreated rather than separated into individual digits with limited motion and instability.

MIRROR HAND

Mirror hand is a rare congenital anomaly characterized by symmetric duplication of the limb in the midline. Typically, there is a central digit with three digits on each side that represent the middle, ring, and small digits in mirrored symmetry (Figure 36.49).[15] Despite the seven digits, the thumb is absent. Within the forearm, there are two ulnas but no radius is present. The ulnas support duplicated ulnar carpal elements (Figure 36.50); hence the term *ulnar dimelia*. The preaxial ulna is often short, and the hand is positioned in radial deviation. The soft tissue anatomy is bizarre and complicated. Unpredictable anatomic variations are commonplace. Varying degrees of the deformity complicate the classification and treatment strategies.

The theory that mirror hand is part of a spectrum that culminates in the exceedingly rare anomaly of multiple hands has been presented (Table 36.2).[4]

CRITICAL POINTS *Central Polydactyly*

- Central polydactyly is uncommon in comparison with border polydactyly.
- Central polydactyly may be hidden within a concomitant syndactyly (i.e., synpolydactyly).
- Synpolydactyly is difficult to treat. Separation of the syndactyly and reduction of the concealed polydactyly often result in incomplete resection of the extra bones without an increase in motion.
- Central synpolydactyly with complicated connections may better be left untreated than separated into individual digits with limited motion and instability.

Etiologic Findings

The etiologic findings have been attributed to replication of the signaling center that controls radioulnar development. The zone of polarizing activity (ZPA) within the posterior margin of the limb bud polarizes the limb into a radioulnar axis and governs preaxial-postaxial limb development.[45] Transplantation of the ZPA or its signaling molecule, sonic hedgehog protein, causes mirror duplication of the ulnar aspect of the limb (see Embryology section).

Examination of the mirror hand begins with an inventory of the number and function of the digits. The amount of wrist,

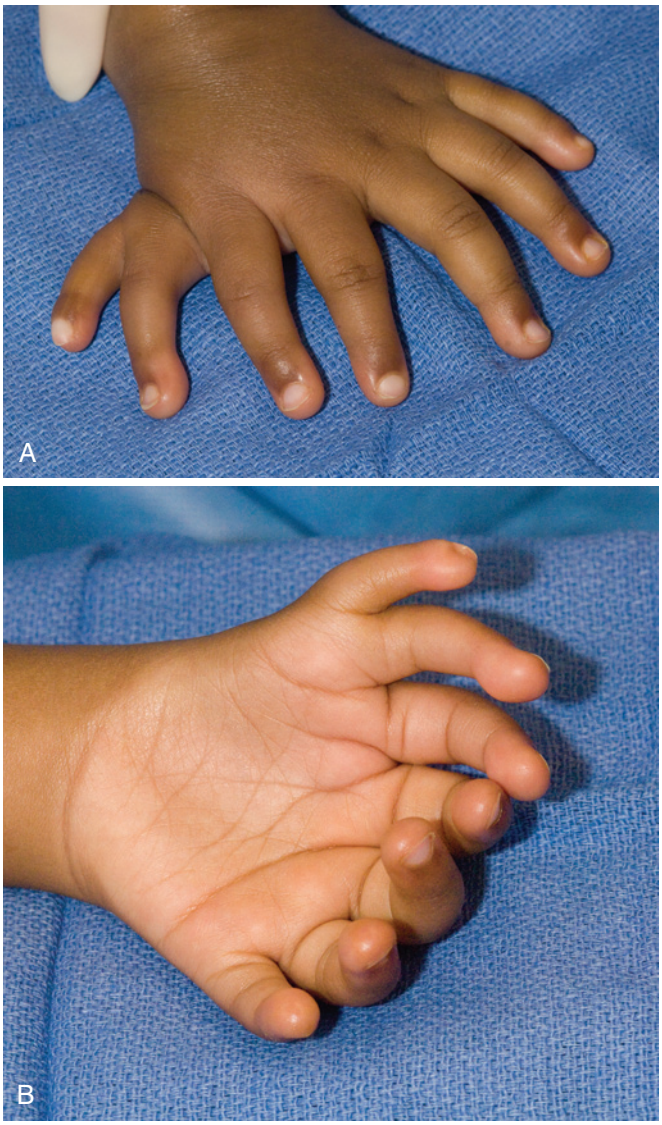

FIGURE 36.49 **A** and **B,** One-year-old girl with a left mirror hand and seven digits. (Courtesy of Shriners Hospital for Children, Philadelphia.)

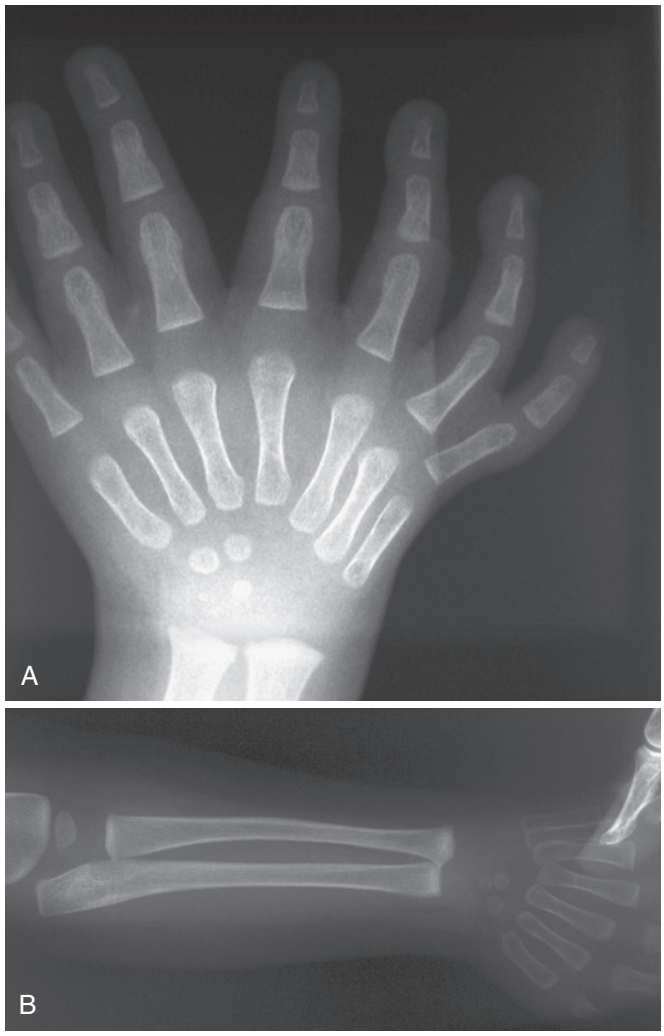

FIGURE 36.50 Two-year-old girl with a left mirror hand. **A,** Hand x-ray showing seven rays and early ossification of the ulnar carpus. **B,** Forearm x-ray showing two ulnas and no true radius. (Courtesy of Shriners Hospital for Children, Philadelphia.)

forearm, and elbow motion is recorded. Limited wrist extension is common secondary to concomitant deficiency of the wrist extensor tendons. There is limited forearm and elbow motion because the presence of two ulnas prevents normal movement. The amount of elbow flexion present is variable and is related to the degree of abnormal elbow anatomy.

TABLE 36.2 Classification of Mirror Hands

Type	Name	Clinical Features
1	Ulnar dimelia	Multiple fingers with two ulnas Type A: Each ulna well formed Type B: Preaxial ulna hypoplastic
2	Intermediate form	Multiple fingers with two ulnas and one radius
3	Intermediate form	Multiple fingers with one ulna and one radius Type A: Radius well formed Type B: Hypoplastic radius
4	Syndromic form	Bilateral, mirror feet and nasal defects characteristic Type A: Sandrow syndrome: two ulnas Type B: Martin syndrome: one ulna and one radius
5	Multiple hand	Complete duplication of the hand, including the thumb; forearm normal

Adapted from Al-Quattan MM, Al-Thunayan M, Decordier M, et al: Classification of the mirror hand–multiple hand spectrum. *J Hand Surg [Br]* 4:534–536, 1998.

Treatment

Treatment is designed to reduce the number of digits to four and reconstruct a thumb from the deleted digits. Selective ablation of the supernumerary digits and thumb reconstruction are the mainstays of surgery. The procedure must reconstruct the first web space and augment the motor function of the preserved thumb via tendon transfer (Figure 36.51). The principles of pollicization and the use of "spare parts" guide construction of the thumb (Figure 36.52).[6,16] We select the most mobile radial digit for pollicization and remove the stiffer radial digits (Figure 36.53). The skin forming the ablated digits is used to augment the first web space (Figure 36.54).

CRITICAL POINTS *Mirror Hand*

- Mirror hand is rare and characterized by symmetric duplication of the limb in the midline. Typically, there is a central digit with three digits on each side and absence of the thumb.
- The forearm often has two ulnas but no radius is present.
- The etiologic findings have been attributed to transplantation or replication of the ZPA from the posterior margin of the limb bud into the anterior region.
- Treatment consists of reduction of the number of digits to four and reconstruction of a thumb from the deleted digits.

BRACHYDACTYLY

The term *brachydactyly* describes a short finger in which the elements of the digital skeleton are present but one or more are

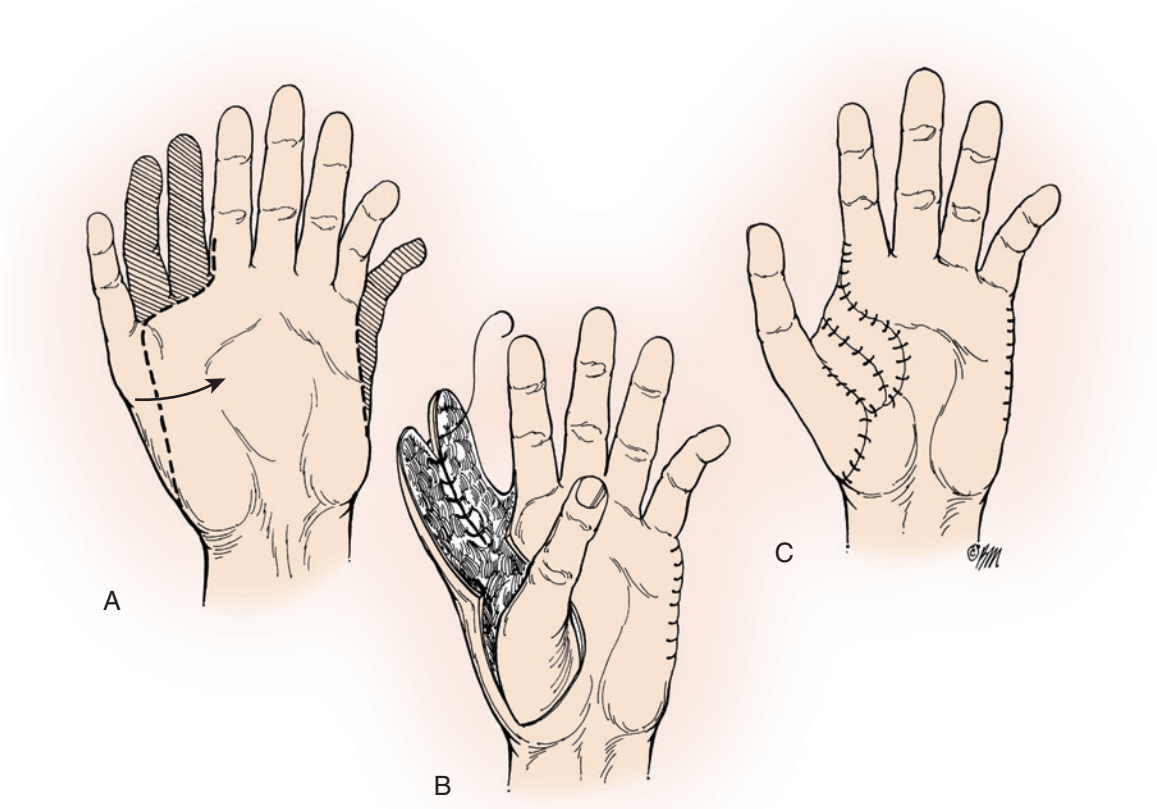

FIGURE 36.51 A to **C,** When eight digits are present, the most preaxial digit may be retained and undergo pollicization, whereas the second and third digits are filleted to surface the first web space. Amputation of the most postaxial digit improves the cascade alignment of the four residual fingers.



FIGURE 36.52 Child depicted in Figure 36.51 treated by ablation of the most radial two digits at the time of pollicization. (Courtesy of Shriners Hospital for Children, Philadelphia.)

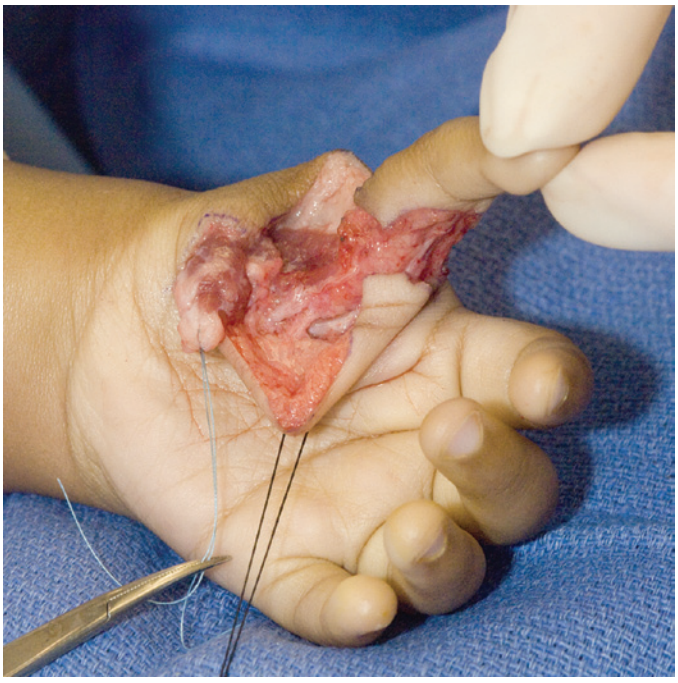

FIGURE 36.53 The most mobile radial digit undergoes pollicization. (Courtesy of Shriners Hospital for Children, Philadelphia.)



FIGURE 36.54 Final appearance after ablation and pollicization. (Courtesy of Shriners Hospital for Children, Philadelphia.)

reduced in size. The description can be extended by specification of the bone involved. *Brachytelephalangy, brachymesophalangy*, and *brachybasophalangy* refer to short distal, middle, and proximal phalanges, respectively. *Brachymetacarpia* refers to shortening of the metacarpal. These specific terms are rarely used anymore, because *brachydactyly* has become the preferred term. Brachydactyly may occur in isolation, as part of a complex hand anomaly, as a constituent of a generalized syndrome, or as a consequence of trauma (Table 36.3). The functional and aesthetic aspects of brachydactyly can range from minimal to considerable, depending on the degree of shortening and the status of the remaining digits. The diagnostic aspects and genetic implications are pertinent to the patient and family.

Epidemiologic Findings

Brachydactyly, as a feature of congenital hand anomalies, is quite common. Anomalies in which brachydactyly is the dominant feature are rare and are typically inherited anomalies with an autosomal dominant pattern of inheritance. These have been classified by Bell into brachydactyly types A to E based on phenotypes expressed within pedigrees. Following the initial description in 1951, the classification has been modified by numerous authors, with additions of variants and subclassifications (Table 36.4).[19] Brachydactyly may also occur as a sporadic anomaly or may be part of a systemic syndrome that does not conform to the classification (Figure 36.55). For example, short metacarpals are seen with pseudohypoparathyroidism or pseudopseudohypoparathyroidism. Lastly, noncongenital brachydactyly can occur after growth plate injury from trauma, infection, or frostbite.

Pathologic Findings

Recent research has identified candidate genes for some forms of brachydactyly through pedigree analysis and DNA examination. Various mutations have been identified that affect digital length. Brachydactyly E[158] has been linked to a Glypican 1 gene mutation on Ch2q; brachydactyly B[144] has been associated with mutations of *ROR2*, a tyrosine kinase receptor gene at Ch9q22; brachydactyly A1[68] has been related to nucleotide mutations

TABLE 36.3 Syndromes Associated With Brachydactyly (Kellam Classification)

Generalized brachydactyly	Achondroplasia Hypochondroplasia Diastrophic dwarfism Mucopolysaccharidosis Multiple epiphyseal dysplasia Spondyloepiphyseal dysplasia Metaphyseal dysostosis Peripheral dysostosis Dyschondrosteosis Hereditary multiple exostosis Ollier disease Weill-Marchesani syndrome Ellis–van Creveld syndrome Orofaciodigital syndrome
Underdevelopment of distal phalanges	Pycnodysostosis Cleidocranial dysostosis Fanconi anemia Progeria Larsen syndrome Keutel syndrome Pudiger syndrome Coffin-Siris syndrome
A3 brachydactyly (short middle phalanx of little finger)	Down syndrome Poly X syndrome Russell-Silver syndrome Coffin-Siris syndrome Orofaciodigital syndrome (types I and II) Otopalatodigital syndrome Thrombocytopenia–absent radius syndrome Noonan syndrome
D brachydactyly (stub thumb brachydactyly)	Tabatznik syndrome Rubinstein-Taybi syndrome Robinow syndrome
Brachydactyly with metacarpal shortening	Turner syndrome Albright hereditary osteodystrophy Pseudohypoparathyroidism Pseudopseudohypoparathyroidism
Brachydactyly with short first metacarpal	Holt-Oram syndrome Fanconi anemia Progressive myositis ossificans Otopalatodigital syndrome Diastrophic dwarfism
Brachydactyly with polydactyly	Ellis–van Creveld syndrome Orofaciodigital syndrome
Brachydactyly with syndactyly	Cornelia de Lange syndrome Apert syndrome
Brachydactyly with cone-shaped epiphyses	Trichorhinophalangeal syndrome Langer-Giedion syndrome Acrodysostosis
Miscellaneous	Du Pan syndrome Hand-foot-uterus syndrome

From Kelikian H: *Congenital deformities of the hand and forearm*, Philadelphia, 1974, WB Saunders and Kellam DA: Familial and hereditary anomalies producing brachydactylia of hands: Roentgen manifestations. *J Am Osteopath Assoc* 70(1):78–100, 1970.

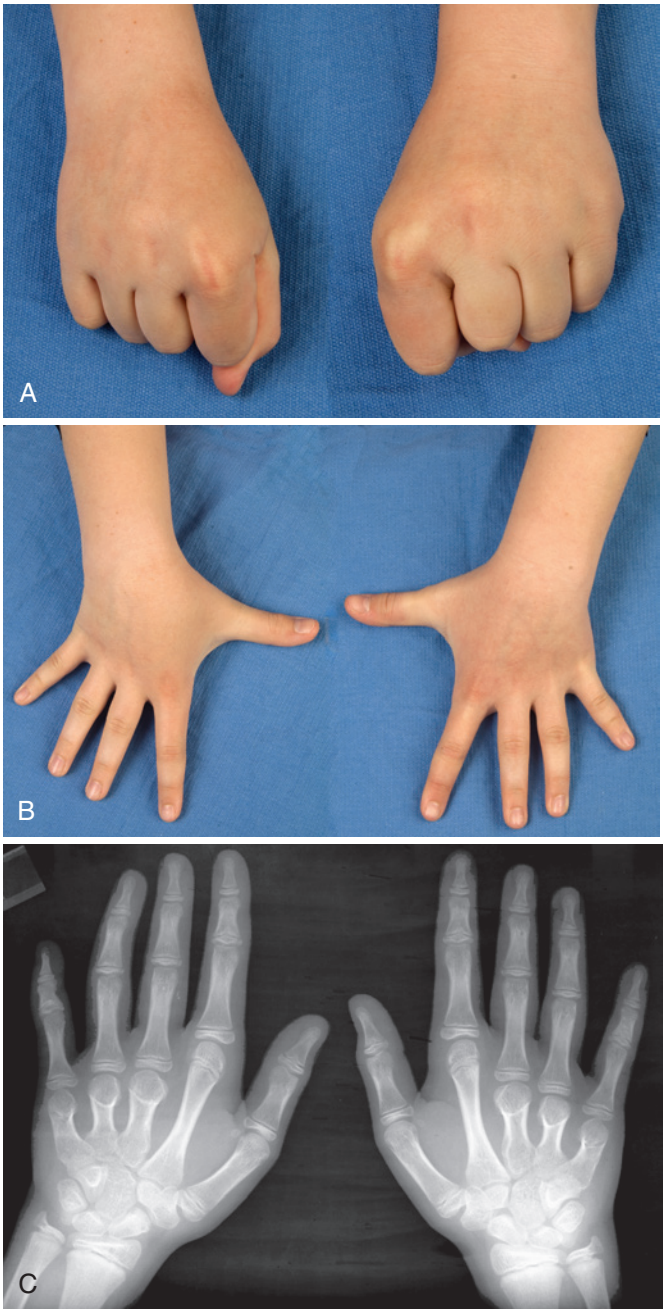

FIGURE 36.55 Ten-year-old with isolated bilateral short long, ring, and small finger metacarpals. **A,** Loss of knuckle contour on fist formation. **B,** Shortened long, ring, and small fingers apparent on hand opening. **C,** X-rays with shortened long, ring, and small finger metacarpals. (Courtesy of Shriners Hospital for Children, Philadelphia.)

within the Indian hedgehog gene; and brachydactyly C[59] has been associated with mutations in the gene for growth differentiation factor-5. Deficiencies in a cartilage-derived morphogenetic protein have also been associated with various forms of brachydactyly. The Grebe and Hunter-Thompson chondrodysplasias are associated with severe brachydactyly and have been directly related to a cartilage-derived morphogenetic protein deficiency (see Figure 36.40).[10] These mutations account for some forms of brachydactyly; however, a variety of additional genetic mutations have yet to be determined to explain the numerous phenotypes.

TABLE 36.4 Modified Bell Classification of Brachydactyly

Type A	A1: Farabee brachydactyly	Principal feature: Short middle phalanges (sometimes fused to distal phalanges). Associated feature: short proximal phalanges of thumbs and great toes.
	A2: Mohr-Wriedt brachydactyly[114]	Principal feature: Short delta phalanx deformity of middle phalanges, index fingers, and second toes.
	A3: Bauer brachydactyly–clinodactyly (brachymesophalangy V)	Principal feature: Short rhomboid or delta middle phalanx of the small finger.
	A4: Temtamy brachydactyly[160]	Principal feature: Short middle phalanges of index and small fingers. Associated features: Ring finger middle phalanx short, middle phalanges of toes short, and talipes calcaneovalgus.
	A5: Bass brachydactyly[17]	Principal feature: Absent middle phalanges, hypoplastic nails in fingers and toes. Associated feature: Hypoplastic distal phalanges.
Type B	Mackinder brachydactyly	Principal feature: Hypoplastic distal phalanges with absent nails. Associated features: Thumbs and great toes may be normal or duplication of distal phalanges may occur; symphalangism. Syndactyly.
Type C	Drinkwater brachydactyly[49]	Principal feature: Short middle phalanx of index and middle fingers. Short delta middle phalanx of small finger. Hyperphalangism of index and middle fingers, with ulnar deviation of these digits. Associated features: Short metacarpals. Symphalangism.
Type D	Breitenbecker brachydactyly (stub thumb)	Principal feature: Short distal phalanx of thumb.
Type E	Bell brachydactyly (brachymetacarpia/ brachymetatarsia)[19]	Principal feature: Short metacarpals and metatarsals with phalanges of normal length. Associated features: Short stature.
	Subclassified by Hertzog	Joint laxity.
	Type E1	Short fourth metacarpals and metatarsals.
	Type E2	Variable combinations of short metacarpals and phalanges.
	Type E3	Variable combinations of short metacarpals and normal phalanges.
Other types	Pitt-Williams brachydactyly[130]	Short distal phalanges of ulnar digits, short metacarpals, and normal stature.
	Sugarman brachydactyly[156]	Short proximal phalanges with symphalangism.
	Smorgasbord brachydactyly	Combination of types A2 and D brachydactyly.

From McKusick V: *Mendelian Inheritance in Man: a catalogue of human genes and genetic disorders*, Baltimore, 1994, Johns Hopkins University Press.

Clinical Features

The severity of the digital shortening is variable. Mild shortening may be apparent only because the normal cascade of the digits is disrupted. The most commonly affected phalanx is the middle phalanx, which is the last component of the digital skeleton to ossify. The small finger and the index finger are the most commonly affected digits. Associated anomalies, such as syndactyly, clinodactyly, and/or symphalangism, also exist and often create a greater functional problem than the brachydactyly (Figure 36.56). Careful examination of the remainder of the upper limb, the pectoral girdle, the contralateral upper limb, and the lower limbs is a requisite. Additional limb or chest wall involvement may lead to a diagnosis of a specific form of brachydactyly or a more inclusive anomaly, such as Poland syndrome. Examination of parents and siblings may reveal further evidence of an inherited anomaly, although the phenotype may not be uniform throughout the affected family members because of variable expression. Traumatic brachydactyly is usually identified via a history of injury and subsequent radiographs that reveal physeal arrest.

Management

The management of brachydactyly depends on the degree of shortening, associated anomalies, and status of the remaining digits. In a complex anomaly, brachydactyly may be a relatively minor component compared with the syndactyly, clinodactyly, or symphalangism (or any combination of these abnormalities). As an isolated deformity, the indications for intervention are aesthetic and functional. The appearance of the hand is most affected when there is disruption of the normal hand cascade, particularly the central digits. A short central metacarpal head may be palpable in the palm and interfere with power grip.

Isolated shortening of one metacarpal (brachymetacarpia) is a common finding and commonly affects the ring finger metacarpal in girls. Enthusiasm for surgery on the part of the parents, patient, or surgeon must be tempered by potential problems of lengthening, including joint stiffness, contracture, and loss of hand function. Lengthening of the shortened digital skeleton requires subperiosteal osteotomy of the shortened element, distraction to the desired length, and either bone grafting or



FIGURE 36.56 X-ray of brachydactyly (shortened middle phalanges) combined with clinodactyly and variably shaped phalanges.

fixation until the intercalated subperiosteal defect has ossified (callatosis) or waiting for the bone of the lengthened skeleton to regenerate. The technique varies with regard to the approach, configuration of the osteotomy, and method of bone lengthening (i.e., immediate lengthening versus gradual distraction osteogenesis).

The majority of lengthening techniques have used a dorsal approach to the phalanx or metacarpal. Saito and colleagues[139] described a palmar approach for lengthening short central metacarpals to avoid the dorsal scar, although care is required to preserve the deep branch of the ulnar nerve. Most authors achieve lengthening using a simple transverse osteotomy and a distraction frame for lengthening. Single-stage lengthening has been performed using a variety of bony cuts to achieve stability, including a step-cut osteotomy, chevron osteotomy (Figure 36.57), or dowel-shaped osteotomy. Immediate lengthening of the metacarpal may require soft tissue release, reconstruction of the transverse metacarpal ligaments, and/or advancement of the origins of the interosseous muscles (Figure 36.58). Intercalary bone graft is not usually required in young children but may be required in teenagers, and the callatosis is stabilized with the distraction frame until the skeleton is consolidated. The alternative approach is distraction osteogenesis with osteotomy and gradual lengthening using a distraction frame.[127] Alignment is best maintained with two fixation pins on each side of the osteotomy to prevent palmar or dorsal angulation. Dhalla and colleagues[47] described a technique suited to small bones

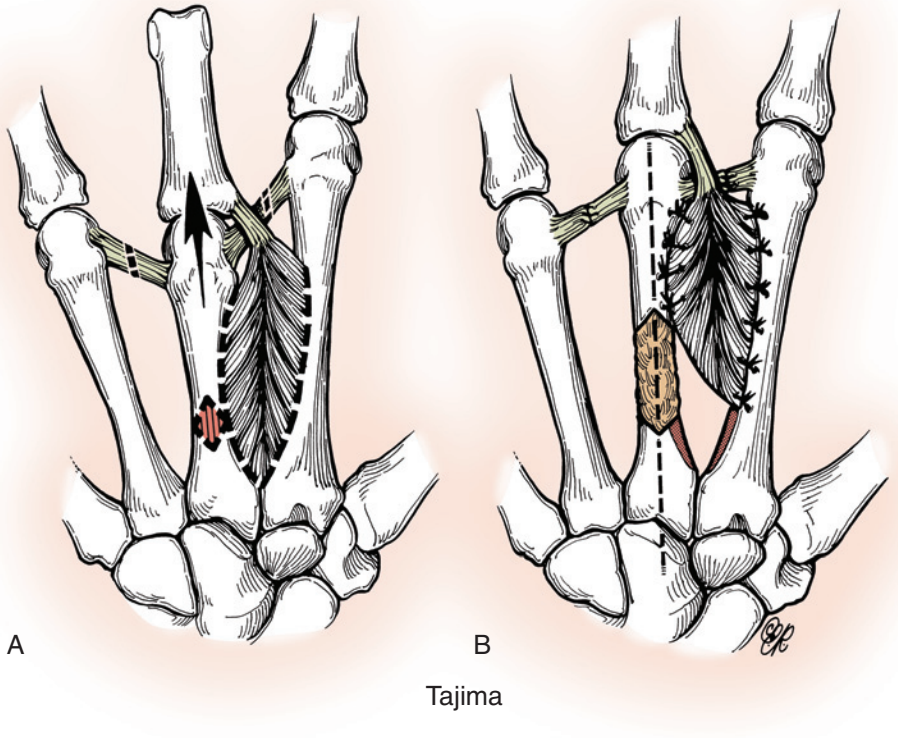

FIGURE 36.57 **A** and **B,** Chevron-type slot graft used to lengthen the metacarpal, as described by Tajima. (Copyright © Elizabeth Martin.)

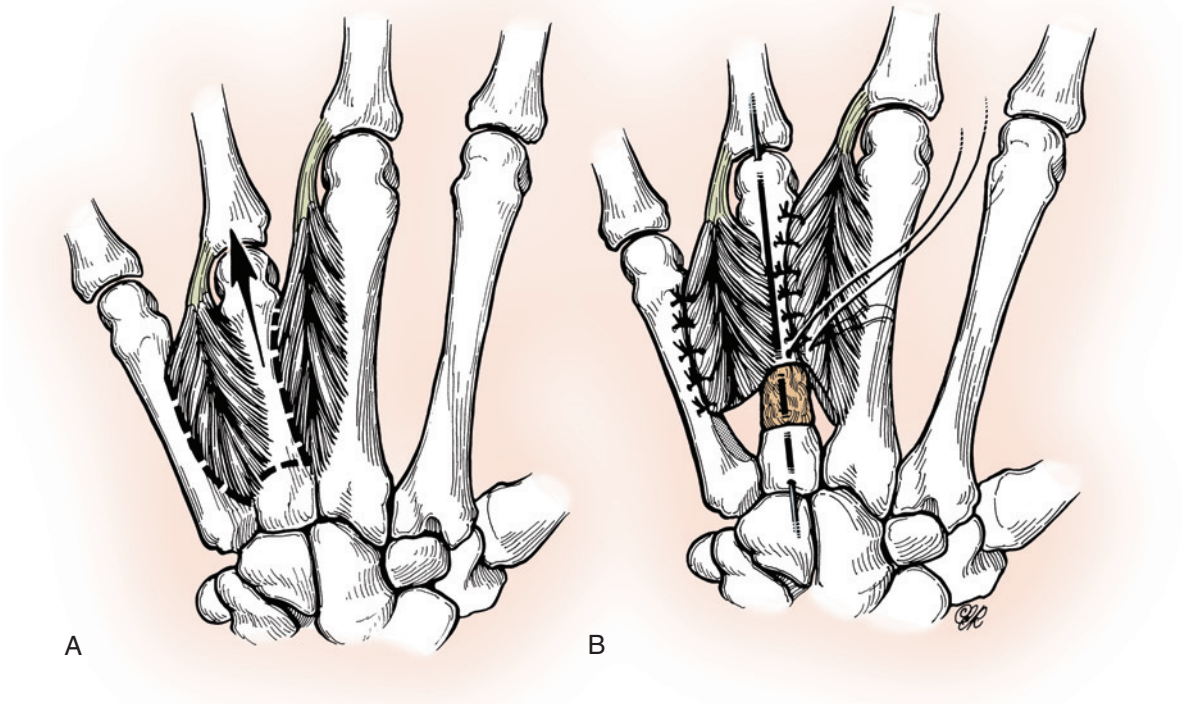

FIGURE 36.58 **A** and **B,** Buck-Gramcko technique for lengthening a short metacarpal. (Copyright © Elizabeth Martin.)

using only one pin on each side of the osteotomy, supplemented with an intramedullary Kirschner wire to maintain alignment. Advantages of distraction callatosis are concomitant soft tissue lengthening, limiting contracture and stiffness, and the formation of regenerate bone that can negate the need for bone graft. Published results of distraction lengthening for congenital short digits and metacarpals are positive, with mean gains in length of up to 15 mm without the need for bone grafting.[8,47,92] Distraction osteogenesis, however, is time consuming and requires cooperation of the patient and parents. The external fixation frame is often in place for more than 4 months to achieve consolidation of the skeleton. Pin loosening and pin site infections can complicate the process, and skeletal lengthening may exceed the soft tissue envelope capacity, producing tender bony prominence of the fingertip.

❖ AUTHORS' PREFERRED METHOD OF TREATMENT

The authors' treatment preference for brachydactyly secondary to short phalanges is to avoid surgery. Hand function is often normal in patients with brachydactyly, and lengthening is complex; it often produces a stiff or contracted digit, and the aesthetic result may be disappointing. Distraction lengthening of the phalanges has been used in selected cases of shortening combined with an associated deformity, such as angulation. Immediate lengthening combined with angulatory correction is the preferred approach for brachydactyly combined with angulation. An opening wedge osteotomy and insertion of a trapezoidal bone graft restore alignment and achieve length in a single setting. A closing wedge osteotomy should be avoided in a short digit. On occasion, a single flail shortened hypoplastic digit within an otherwise normal or nearly normal hand is treated by ray amputation.

For brachydactyly secondary to a short metacarpal, lengthening is often recommended to restore the hand contour, particularly if a central metacarpal is involved, as is often the case. The authors' preference is distraction lengthening using a uniaxial distractor. The first stage requires application of the external fixator and osteotomy. Two open or percutaneous pins are placed into the metacarpal on each side of the planned osteotomy site. A dorsal approach is used with the aid of an image intensifier to ensure accurate placement. A distraction frame is applied across the metacarpal. The metacarpal is exposed at the site of osteotomy with retraction of the extensor tendon(s) and cutaneous nerves. A longitudinal incision is made in the periosteum, and subperiosteal dissection is performed to expose the osteotomy site while preserving a sleeve of periosteum. A transverse osteotomy is performed using an osteotome or fine-bladed saw, and the wound is closed. Distraction of the osteotomy site is begun between 4 and 7 days after surgery at a rate of 0.25 to 0.5 mm twice a day. Distraction continues until the desired length is achieved. The frame is not removed until consolidation of the metacarpal (i.e., three cortices visualized on the anteroposterior and lateral films) is apparent radiographically. In some cases, secondary bone grafting may be required. Throughout the period of distraction and consolidation, the patient requires close supervision by the surgeon and hand therapist to ensure that digital range of motion is maintained. Regular radiographs are required to assess the progress of the distraction and identify potential complications of pin displacement and/or failure of the apparatus.

CRITICAL POINTS *Brachydactyly*

- Brachydactyly refers to shortening of the digit or ray within the hand. It can occur sporadically or as part of a syndrome, including a number of inherited anomalies with specific patterns of skeletal anomaly.
- The functional and aesthetic impact of brachydactyly varies according to the extent of shortening, the number of digits involved, and whether associated anomalies such as syndactyly, clinodactyly, or symphalangism are present as well.
- The most commonly affected bone is the middle phalanx, which is the last component of the digital skeleton to ossify.
- Short bones may be lengthened either by bone grafting or by distraction osteogenesis. This may be of specific functional benefit for restoration of pinch function or, in the case of brachymetacarpia, for restoration of the normal cascade of the hand.
- The potential complications of lengthening in a congenitally shortened skeleton relate to the associated soft tissues. Joint contracture or stiffness can develop in the lengthened digit and, in some cases, in adjacent normal digits. Enthusiasm for lengthening, particularly of the markedly shortened digit, must be tempered by this consideration.

CENTRAL HAND DEFICIENCIES

Central deficiency of the hand or cleft hand has been considered a longitudinal deficiency affecting the central digits, and in the past it was grouped with radial and ulnar longitudinal deficiencies, though its position in the classification of congenital hand anomalies is controversial. The hallmark of central longitudinal deficiency is a "V"-shaped cleft in the center of the hand, which may or may not be associated with the absence of one or more digits. Historically, central deficiency was subdivided into typical and atypical types (Figure 36.60), although the latter has long been recognized as symbrachydactyly,[103] which is considered a transverse rather than a longitudinal deficiency. Maisel[102a] proposed that the clinical spectrum of central deficiencies was a progression from a central soft tissue defect to complete absence of all digits. Digital suppression progresses in a radial direction so that in the monodactylous form, the most ulnar finger is preserved (Figure 36.59). This observation is not based on embryogenesis but does represent the clinical findings. Reviews of the clinical findings[113,126,168] in combination with animal models have led to the proposal that because cleft hand is commonly found in association with syndactyly, both simple and osseous, and central polydactyly (Figure 36.61), the disorder is related to a failure of induction of the central digital rays rather than a suppression. A modified International Federation of Societies for Surgery of the Hand (IFSSH) classification has been proposed to include a "failure of finger ray induction group" that includes typical cleft hand, central polydactyly, and (bony) syndactyly.[46]



FIGURE 36.59 Bilateral central deficiency with considerable suppression of the central rays. (Courtesy of Shriners Hospital for Children, Philadelphia.)

Etiologic Findings

The cause of the cleft hand anomaly has been deduced from animal models, particularly the *dactylaplasia* mouse, which expresses a cleft phenotype in its heterozygote form. In this model, the central segment of the apical ectodermal ridge degenerates, leaving the radial and ulnar segments intact. Ogino and colleagues[120,126] have produced rats with cleft hand/foot deformity and central polydactyly and/or osseous syndactyly with teratogen exposure. Fetal studies in this model have identified a combined ectodermal and mesodermal injury in the developing limb bud with disruption of normal signaling. It is proposed that this disruption leads to failure of normal digital ray induction.

A cleft hand is commonly inherited as an autosomal dominant trait and is associated with a number of syndromes (Table 36.5). The most common syndromes are split-hand/split-foot (SHSF) and EEC syndrome (ectrodactyly, ectodermal dysplasia, and cleft lip/palate).[35,76,85,131] SHSF is usually inherited as an autosomal dominant pattern with variable penetrance. Five gene mutation loci have been identified to date and the phenotype can vary substantially between and within individuals, though some characteristics such as preaxial involvement appear to relate to specific mutations.[57] The variable expressivity and reduced penetrance cause difficulty in predicting future phenotypes in an affected family.



FIGURE 36.60 X-ray of a 3-year-old with cleft hand. Anteroposterior view shows a proximal phalanx within the cleft oriented in a transverse direction. (Courtesy of Shriners Hospital for Children, Philadelphia.)



FIGURE 36.61 **A** to **C,** Syndactyly between the thumb and index finger as part of a true cleft hand. This was separated at the same time as transposition of the index ray and closure of the cleft.

TABLE 36.5 Conditions in Which a Cleft Limb May Be a Feature

	Condition*
EEC syndrome	(129900)
Cornelia de Lange syndrome	(122430)
Acrorenal syndrome	(102520)
Focal dermal hypoplasia	(305600)
Ectrodactyly and cleft palate syndrome	(129830)
Ectrodactyly and mandibulofacial dysostosis	(183700)
Ectrodactyly and macular dystrophy	(185800)

*Online Mendelian Inheritance in Man database number.
EEC, Ectrodactyly–ectodermal dysplasia–clefting.
From www.omim.org

TABLE 36.6 Characteristics of Cleft Hand

Typical Cleft Hand	Atypical Cleft Hand (Symbrachydactyly)
Autosomal dominant	Sporadic
Limbs are involved	No limbs are involved (no feet)
"V"-shaped cleft	"U"-shaped cleft
Finger nubbins are not present	Finger nubbins may be present
Syndactyly (especially of first web)	

TABLE 36.7 Classification of Central Deficiency

Type	Description	Characteristics
I	Normal web	Thumb web space is not narrowed
IIA	Mildly narrowed web	Thumb web space is mildly narrowed
IIB	Severely narrowed web	Thumb web space is severely narrowed
III	Syndactylized web	Thumb and index rays are syndactylized; web space is obliterated
IV	Merged web	Index ray is suppressed; thumb web space is merged with the cleft
V	Absent web	Thumb elements are suppressed; ulnar rays remain; thumb web space no longer present

Clinical Features

The condition may be unilateral or bilateral and may or may not involve the feet. The extent of cleft hand varies from generation to generation, and the characteristics are described in Table 36.6. The manifestations of cleft hand may vary from only a very minor cutaneous cleft without absence of the finger to a severe form in which only the little finger remains. Syndactyly between the digits bordering the cleft is common: the first web space is often narrowed. Duplications can also occur adjacent to the cleft. Within the cleft, metacarpals may or may not be present, and transverse tubular bones may be present and may further widen the cleft as they grow. Phalangeal anomalies often coexist, including longitudinally bracketed epiphyses or double phalanges. The metacarpal anomalies are variable, including absence within the cleft, bifid metacarpals supporting one finger, and duplication. The anomaly is often bilateral, and in the SHSF phenotype it is associated with comparable defects in the feet. Although proximal enabling structures such as muscle-tendon units and nerves are frequently absent, some structures are present to variable degrees.

Classification

Many classifications exist[13,23,31,46,62,141,176]: in our experience, the most useful is that of Manske and Halikis, which concentrates on the status of the first web space (Table 36.7).[104] This classification acknowledges that more extensive clefts merge with the first web space and produce a wide and competent web. More extensive cleft formation, however, can involve the thumb, which is hypoplastic or even absent.

Surgical Treatment

Indications for Surgery

Flatt memorably described the cleft hand as a "functional triumph, but a social disaster" because many cleft hands, although stigmatizing the child, function well.[63] A family with one or more generations of cleft hands may avoid surgery for their children because they perceive function as excellent and aesthetic improvement as marginal. Such opinions require sensitive handling when outlining the indications for surgery and the surgical plan. Surgery should improve both appearance and function but should never downgrade either. Many authors have attested to the psychological consequences of cleft hand, and the moving account of Walker in Flatt's text[63] highlights the psychosocial complexities faced by families with this condition. It is surely axiomatic that no physician should add to the misery

of these patients and their families by the outdated practice of using animalistic comparators such as *lobster claw* or *pincer*.

Several broad indications for surgery are recognized: (1) progressive deformity (caused by deforming syndactyly or transverse bones); (2) deficient first web space; (3) deformity of the cleft; (4) the absent thumb; or (5) the feet. The deformity comes as a shock in a family previously unaffected, and it may be inappropriate and unnecessary to propose early surgery to parents still adjusting to these unexpected circumstances.[27,93] Most parents, however, will accept surgery to prevent worsening of the deformity. Indications for early surgery include the separation of syndactyly between digits of unequal length (especially the thumb and index finger) and the removal of transverse bones that result in widening of the cleft during growth and progressive deformity. Most of the other surgical procedures are less urgent and may be reserved until the child is between 1 and 2 years of age.

Surgical Management of the Progressive Deformity

Removal of Transverse Bones. Removal of transverse bones from within the cleft can prevent progression of deformity and serve as a prerequisite for closure of the cleft. The transverse bone may originate and insert from either the metacarpal or proximal phalanx.[3] The bone may join the metacarpophalangeal (MCP) joints, and removal requires preservation or reconstruction of the collateral ligaments about the joint or joints. Articular surface sculpting of the remaining joint may be required.

Syndactyly Release. Syndactyly may affect the border rays of the hand. Early release is indicated to prevent progressive deviation of the longer ray (see Figure 36.61). Release of the syndactyly is performed according to the principles detailed above, with specific attention paid to the digital artery anatomy, which may be abnormal, particularly for digits adjacent to the cleft where the common digital artery is likely to be deficient.

Surgical Management of the Cleft Deformity

Release of the First Web Space and Closure of the Cleft. The classification proposed by Manske and Halikis[104] has focused attention on the importance of the first web space morphologic condition in dictating surgical treatment of the cleft hand (Figure 36.62). In type IIA cases, the first web space is mildly narrowed and a cleft is present between the index finger and the

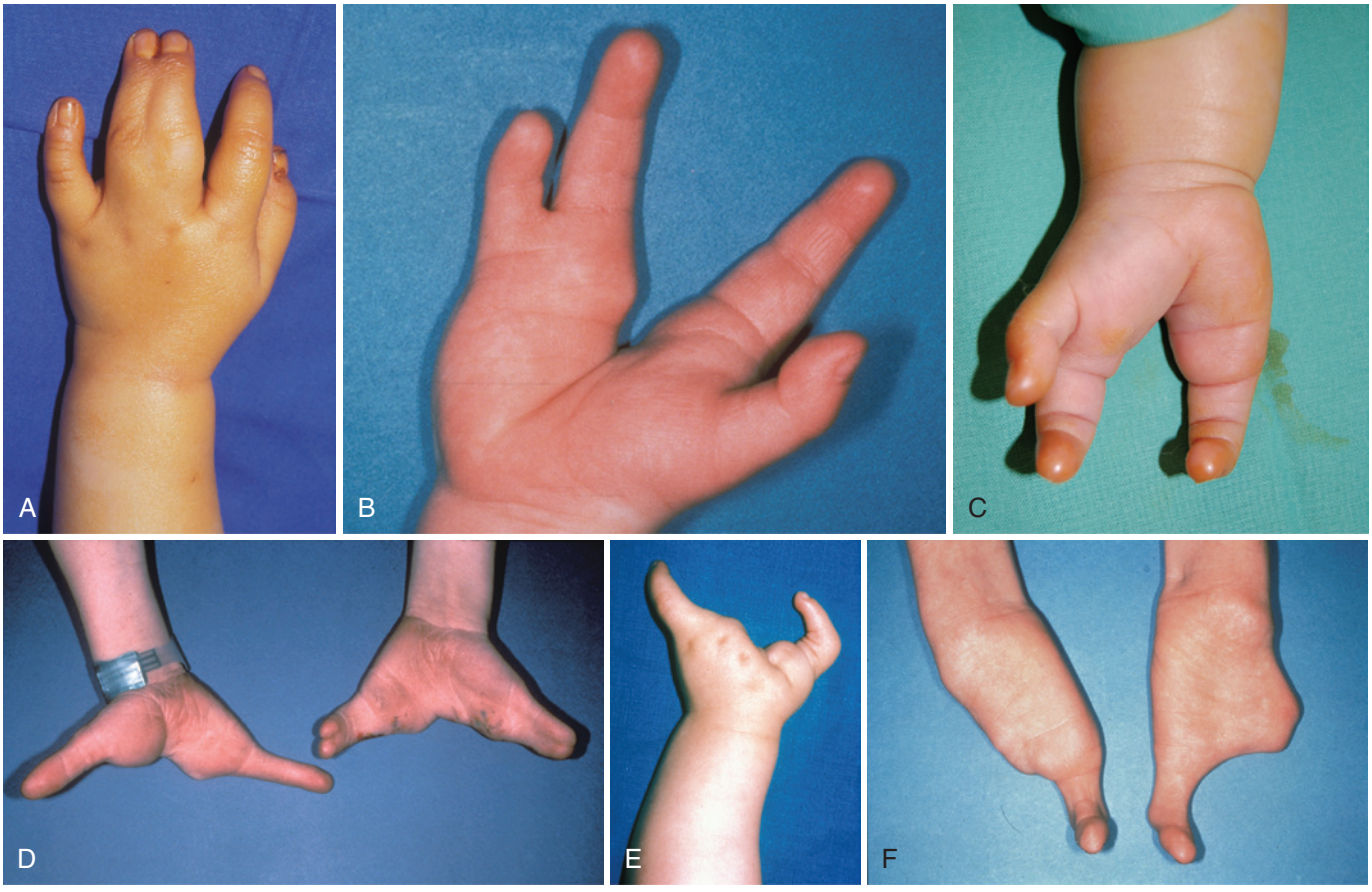

FIGURE 36.62 **A** to **F,** These images illustrate the Manske and Halikis classification and also some aspects of the teratologic sequence in cleft hand. **A,** Type I hand with a normal web space between the thumb and index finger. A very minor cleft is present between the second and third rays and syndactyly between the third and fourth rays. **B,** Type IIa hand in which the thumb web space is mildly narrowed. Note the suppression of the central ray with a deep cleft and minor syndactyly between the ring finger and little finger. **C,** Type IIb cleft hand with a severely narrowed first web space and deletion of the third and fourth rays. **D,** Type III cleft hand (untreated) on the right side and type IV cleft hand on the left. On the right side the thumb and index fingers have untreated syndactyly that completely obliterates the first web space. The central ray is absent, and the fourth and fifth rays are also syndactylized. **E,** Type IV cleft hand with a merged web space. The two border rays are present, but the index ray and other central rays are suppressed, and the first web space merges with the cleft. **F,** Bilateral type V cleft hands. The thumb web space and the thumb are absent, and only the ulnar digit remains.

ring finger, with complete absence of the central ray. Concomitant syndactyly of the ulnar digits is often present. In type IIB hands, the first web space is more severely constricted and the cleft element more variable. Type III cleft hands have a complete syndactyly between the thumb and index finger. Type IV cleft hands possess a thumb web space that is merged with the cleft. Type V cleft hands have suppression of the thumb elements without a thumb web space.

Release of a slightly narrow first web space may require simple skin release from volar to dorsal across the narrowed first web space. Release of complete first web space syndactyly may require formal separation, with release of the thick fascia or muscles within the abnormal web space. In these cases, it will also be necessary to import new skin into the web space. In cases of index finger/thumb syndactyly, the thumb may be rotated into the plane of the other digits and a metacarpal rotation osteotomy may be required to realign the thumb. Such an osteotomy is not simply a matter of transverse division of the tubular bone and rotation with fixation: unless longitudinal soft tissue structures, including tendons, intrinsic muscles, and the periosteum, are freed and given new vectors of force, the digit will progressively derotate, returning to the original form. Frequently, a short disc of bone must be removed during rotation osteotomy to avoid imparting undue torsion on the tissues as rotation occurs.

The cleft incision is designed to re-create the commissure after the cleft is narrowed. For this purpose, a small commissural flap is prepared on one border of the cleft and a recipient defect planned on the other border of the cleft (Figure 36.63). Closure of the cleft can free skin to be used for resurfacing of the widened first web space. Snow and Littler described an elegant but complex technique[152] that has been elaborated on by Flatt (Figure 36.64 and Video 36.1). The cleft skin is raised as a palmar-based flap and designed to transpose into the first web space (Figure 36.65). The position and dimensions of the first web space will change after translocation of the index ray. The viability of this palmar flap depends on preservation of the intrinsic blood supply, and dissection must maintain the

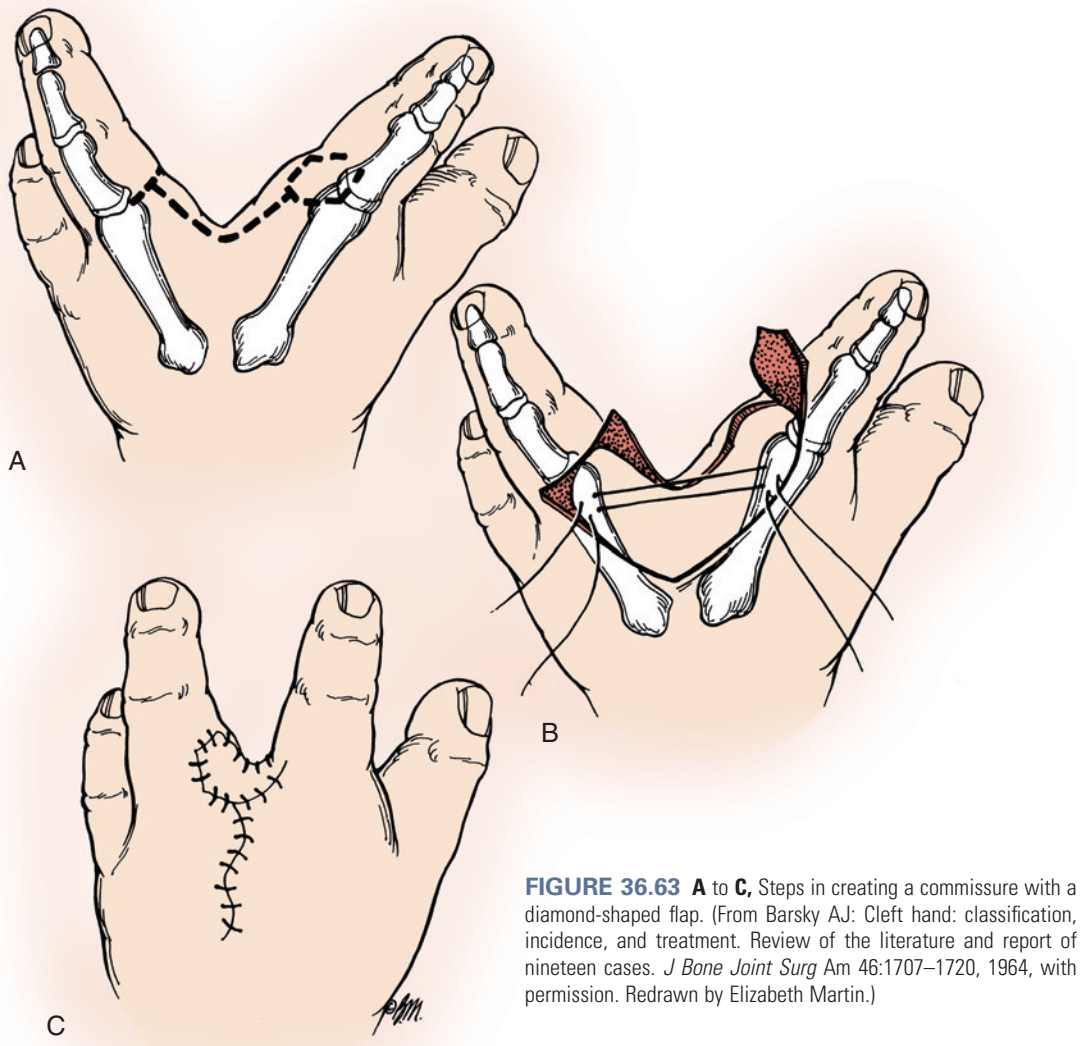

FIGURE 36.63 **A** to **C,** Steps in creating a commissure with a diamond-shaped flap. (From Barsky AJ: Cleft hand: classification, incidence, and treatment. Review of the literature and report of nineteen cases. *J Bone Joint Surg* Am 46:1707–1720, 1964, with permission. Redrawn by Elizabeth Martin.)

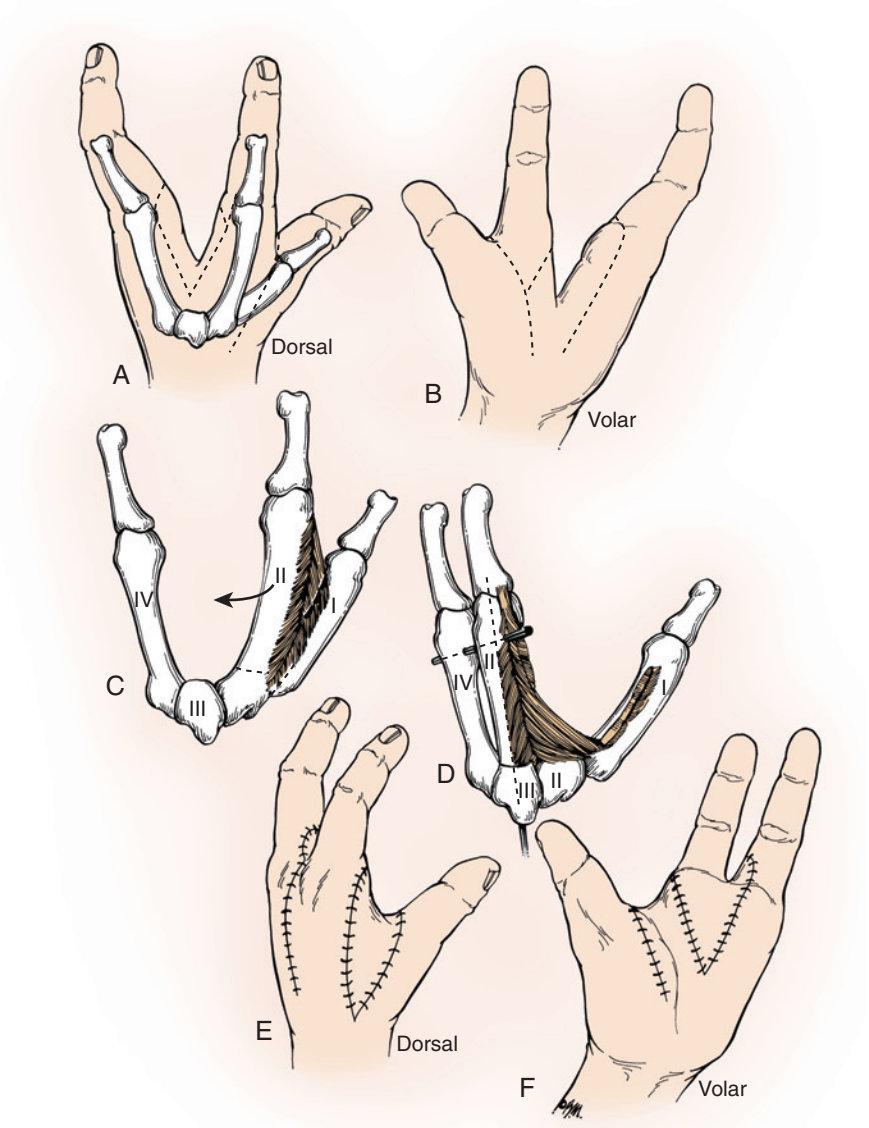

FIGURE 36.64 **A** to **F,** The Snow-Littler procedure. The cleft is raised as a palmar-based flap, with a small radial flap preserved for recreation of the commissure. The first web space is released, which may require division of the first dorsal interosseous origin and surrounding fascia. The second metacarpal is transposed and fixed to the remnant of the base of the third metacarpal if present. Fixation is achieved with axial and transverse wires, and careful attention must be given to correction of rotation at this point. The palmar flap is transferred, and the new commissure between the second and fourth rays is re-created.

subdermal plexus. If possible, a digital artery should be included with the flap to transform its blood supply from random to axial.

Relocation of the index finger to the base of the third metacarpal widens the first web space and decreases the amount of flap transposition. The index finger must be carefully positioned to prevent malrotation and scissoring during finger flexion. The osteosynthesis at the base of the metacarpal is usually performed with a Kirschner wire or interosseous sutures (or both), although miniplate fixation is now preferred by the authors. In those cases without a base of the third metacarpal to receive the index transposition, the cleft may be closed by wedge excision of the index metacarpal or within the carpus to widen the thumb-index web and realign the fingers.

Foucher and coauthors[66] reported a series where carpal osteotomies were used to relocate the ulnar digits centrally to close deep and wide clefts. Reconstruction of the intermetacarpal ligament should be used to reinforce the cleft closure and to prevent splaying of the digits, as in the technique of Saito and colleagues or Ogino, which uses the A1 pulleys from the digits (Figure 36.66) unfolded toward each other and overlapped. The final stage in cleft closure is creation of a commissure across the cleft. The commissure flap previously outlined is raised and inset (see Figure 36.64).[13] The Snow-Littler procedure is far from a simple procedure: the planning and execution can be difficult, and the transposed flap may not inset into the correct position. Supplementary skin grafts may be necessary. In addition, the flap may undergo partial necrosis because its length substantially exceeds its breadth. Rider and coworkers[135] have reported a low rate of flap necrosis, but a third of patients required revision, and supplementary skin grafting was required in tight first web spaces.



FIGURE 36.65 Sixteen-month-old child with bilateral cleft hand. **A,** Left hand, dorsal view. **B,** Left hand, palmar view. **C,** Narrow thumb/index finger web space. **D,** Intended cleft closure. **E,** Dorsal skin design. **F,** Volar skin design. **G,** Flap elevation from dorsal to palmar with preservation of an axial artery to the flap. **H,** Continued dissection along the palmar aspect of the hand. **I,** Protection of the adjacent neurovascular bundles. **J,** Incision for widening of thumb/index finger web space. **K,** Protection of princeps pollicis artery and division of intervening muscle. **L,** Volar view following adequate release of the thumb/index finger web space.

Continued



FIGURE 36.65, cont'd **M,** Closing wedge osteotomy at the base of the index finger to close the cleft and align the finger. **N,** Improved alignment of index finger and cleft closure following osteotomy. **O,** Kirschner wire fixation of osteotomy. **P,** Barsky flap elevated from long finger for commissure reconstruction. **Q,** Cleft skin rotated into widened thumb/index finger web space. **R,** Dorsal closure. **S,** Palmar closure. **T,** Incorporation of hand into activities of daily living, such as grasping a large object. (Courtesy of Shriners Hospital for Children, Philadelphia.)

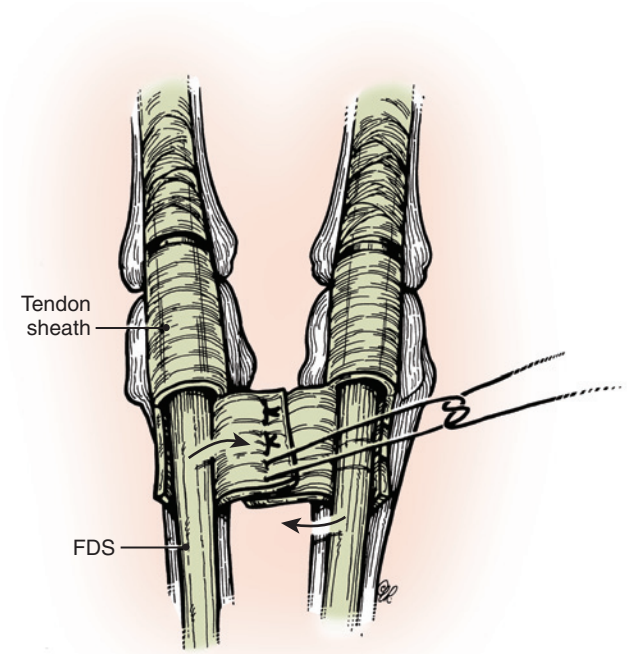

FIGURE 36.66 The deep transverse metacarpal ligament is reconstructed by using the flexor sheaths (part of the A1 or A2 pulleys) of the index and ring fingers. *FDS,* Flexor digitorum superficialis.

Miura and Komada[110] and more recently Upton[172] have described techniques that allow the transposition of the index finger into the central position and redrape the palmar and dorsal skin as separate flaps to create the first web (Figure 36.67). The cleft is incised from side to side across its leading edge. The index finger is raised on its neurovascular bundles and transposed by osteosynthesis with the third metacarpal or by angulation osteotomy.

Ueba[170] also describes a less complicated procedure using transverse flaps from either border of the cleft and transposition of the index digit (Figure 36.68). The flaps from either side of the cleft are used to resurface the palm, the dorsal aspect of the metacarpal head of the transposed digit, and the ulnar part of the first web space. Ueba also used slips of tendon material to connect the common extensor tendons of the digits bordering the cleft to prevent digital separation during extension. This technique allows a simpler approach to cleft closure but has the aesthetic disadvantage of transferring palmar skin to dorsal and dorsal skin to palmar.

In reality, the surgeon versed in congenital hand surgery will treat type IIB and type III cleft hands on an individual basis, borrowing elements of the above technique(s). In cases in which there is a small digital remnant within the cleft, the use of a bilobed flap technique may also transport a large amount of pliable, vascularized skin into the first web space (Figure 36.69). Rarely, when a tight or narrow first web space is associated with a small, narrow, or shallow cleft, a distant flap to import skin may be needed. Again, this will follow standard plastic surgical techniques and attempts to codify treatment break down in these unique circumstances.

An acceptable outcome is ensured by adherence to the principles of adequate first web release, resurfacing of the first web with enough vascularized pliable tissue, transposition of the most radial finger, re-creation of an intermetacarpal ligament, and recreation of a commissure about the cleft.

In the type IV cleft hands, the first web space is merged with the cleft and function does not require creation of a first web space. Surgical effort is usually directed toward mobility and/or position of the thumb or ulnar digit to promote pinch and grasp.

In type V cleft hands, there is no cleft or web space and the thumb is very deficient. Surgery for this group is considered in the next section.

Surgical Management of the Absent Thumb Deformity

Creation of a radial digit is the priority in the management of the type V cleft hand. In some cleft hands, a digit or digits may be positioned on the radial side of the hand albeit in the plane of the ulnar digit. Separation and rotation of this radial ray may re-create a functional and useful hand but require distant flap cover for the first web space. Options include free or pedicled flaps from the forearm and groin.

An absent radial ray can only be replaced by free toe transfer. In contrast to microsurgical toe transfer in children for other indications, transfer for cleft hand is fraught with problems.[95,96,175] Not only is the hand anatomy highly abnormal, with suppression of many of the proximal longitudinal structures that might be expected to drive a transferred toe, but the feet themselves are often abnormal. In the bifid foot with a tibial and fibular ray, it is the fibular ray that bears weight, and the angulated and abnormal tibial ray may be harvested, and is often ablated to enable shoe fitting. Experience with such free toe transfers is limited. A child who underwent transfer of the tibial rays of the foot to the hands is shown in Figure 36.70. A number of interesting clinical and anatomic findings were found. First, flexor and extensor tendons were connected around the distal part of the limb and had adequate excursion after division. Second, vessels and cutaneous nerves were readily found on exploration aided by 10-mHz Doppler examination (angiography was not performed in either the foot or hand). Last, useful function was achieved despite limited power and range of motion. Prehension provided useful holding and manipulative abilities otherwise unachievable in a hand with a single inflexible digit.

Surgical Management of the Feet

The foot deformity in cleft hand often parallels the hand deformity.[1,146,185] The hand surgeon may or may not also be involved in the feet, but his or her opinion will often be sought at the time of consultation. Blauth and Borisch[22a] have classified the foot deformities that occur with cleft formation into six types. Types I and II have only minor abnormalities without absence of metatarsals, whereas the metatarsals are progressively absent in the remaining types. Type VI is the monodactylous cleft foot in which the fibula ray is always the last remaining ray.

The status of the great toe ray or tibial ray presents a challenge in surgical decision making in the foot. It is fairly common to see patients with great toe polydactyly and deviation in whom the decision about preservation and correction of the tibial ray is required. In our experience, the fibular ray is always the more important and the tibial ray may be present but may not participate in weight bearing. In those rare cases in which a microsurgical transfer is considered from the feet, it is likely



FIGURE 36.67 Two-year-old with cleft hand. **A,** Dorsal view. **B,** Palmar view. **C,** Upton skin design with Barsky flap for commissure reconstruction. Transverse incision of the cleft, allowing for ulnar translocation of the radial border ray. **D,** Palmar incision drawn. **E,** Neurovascular isolation and release of the first dorsal interosseous from the thumb. **F,** Closure following index metacarpal osteotomy to align the digits. **G,** Dorsal view with Kirschner wire fixation. **H,** Grasp between thumb and index. (Courtesy of Shriners Hospital for Children, Philadelphia.)

that the feet will also be severely afflicted, with perhaps only two rays remaining. In these cases, reluctance to sacrifice the tibial ray is understandable. Nonetheless, this ray can be transferred, although waiting until the child is of an age to undergo gait analysis is wise.

Rarely is surgery indicated for cleft foot. When it is, it is usually because of difficulty in fitting footwear because of either duplication or deviation of the border digits. This may be corrected either by osteotomy or excision of trapezoidal phalanges. Occasionally, as in the hand, resection of a transverse bone may be necessary. The common experience is that despite a quite bizarre appearance in the feet, function is remarkably good and gait is rarely considerably impaired.

In summary, surgical treatment for children with central deficiency is challenging but can provide good functional and aesthetic results. In more severe forms, ingenuity of the surgeon is required. In these cases, the surgeon must discuss with parents how experience over generations shows that despite the adverse appearance, children will adapt and learn to use their hands in a way that might have been considered impossible when they were born. Surgery should improve appearance and function, or both, but should never downgrade either. Surgical correction should be planned according to a schedule that recognizes the urgency of some aspects of treatment and the discretionary nature of others. The overriding determinant of hand function is the first web space, and this structure is the basis of the most

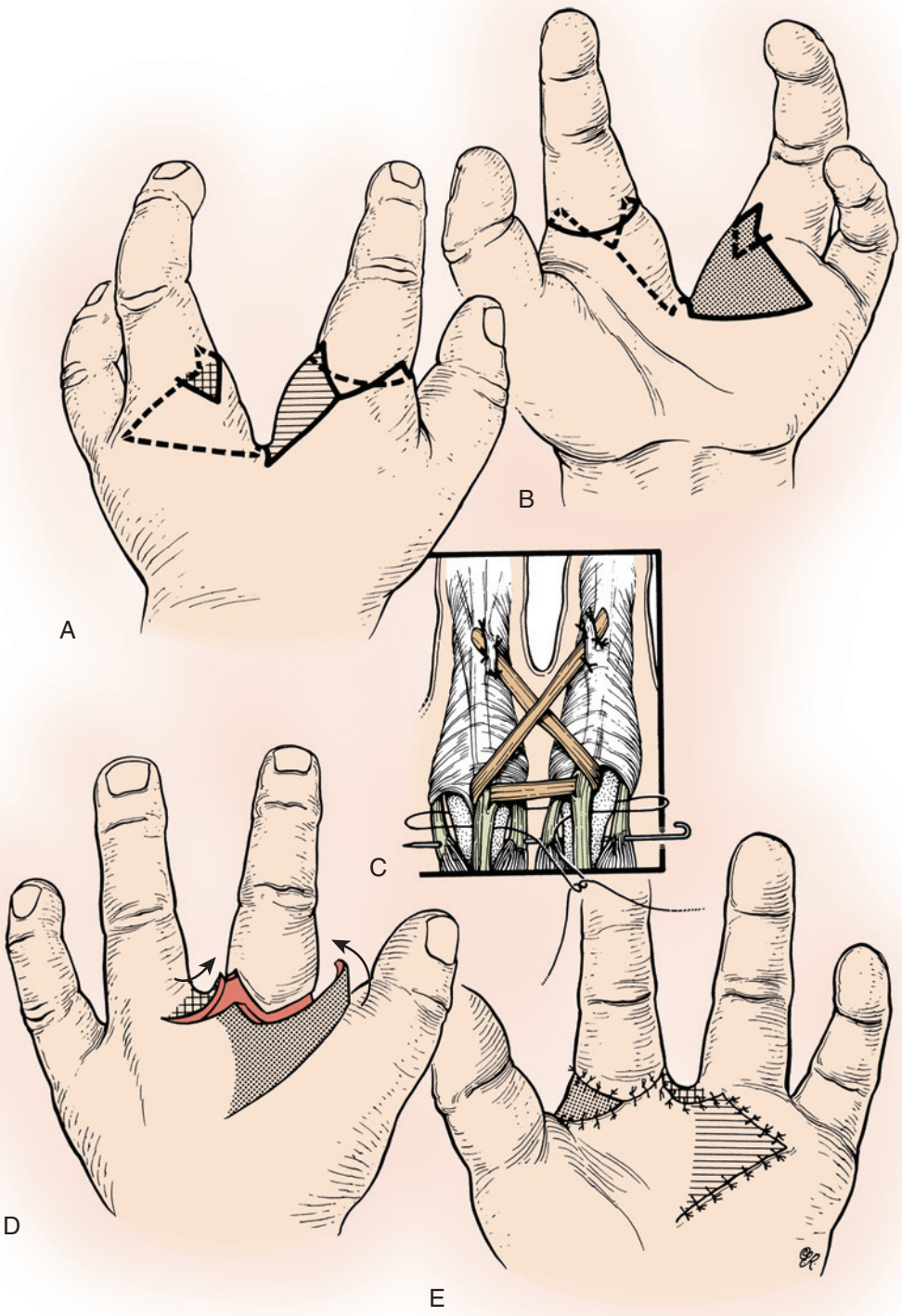

FIGURE 36.68 **A** to **E,** Ueba technique for treatment of a typical cleft hand with one ray suppressed. Ueba used a tendon graft between the extensor tendons of the border digits **(C)**, but this is not an essential component of the procedure, and the Ogino method of creation of a transverse palmar ligament is used (see Figure 36.66). The disadvantage of this technique lies in the transfer of palmar skin dorsally or radially in the cleft, and vice versa. (Copyright © Elizabeth Martin.)



FIGURE 36.69 Clinical photograph **(A)** and radiograph **(B)** of a type IIB cleft hand with a digital remnant in the central cleft and a narrowed first web space. **C,** A bilobed flap has been designed on the dorsum of the hand. The flap from the index finger will resurface the first web space and in turn be replaced by a flap from the dorsum of the digital remnant to be excised. The flap is not transposed; rather, the index ray is translocated ulnarward. **D,** A palmar view noting the incision for release of the first web space, *cross-hatching* of the area of skin to be excised, and the small radially based flap of Barsky for recreation of a commissure. **E,** The digital remnant and contents of the cleft have been excised, and the small flaps from the A2 pulleys on either border of the cleft are being sutured together according to the technique of Ogino to recreate a metacarpal ligament. **F,** The cleft has been closed, the remnant excised, and the flaps transposed to resurface both the first web space and the donor defect from the dorsum of the index finger. **G,** Palmar view.

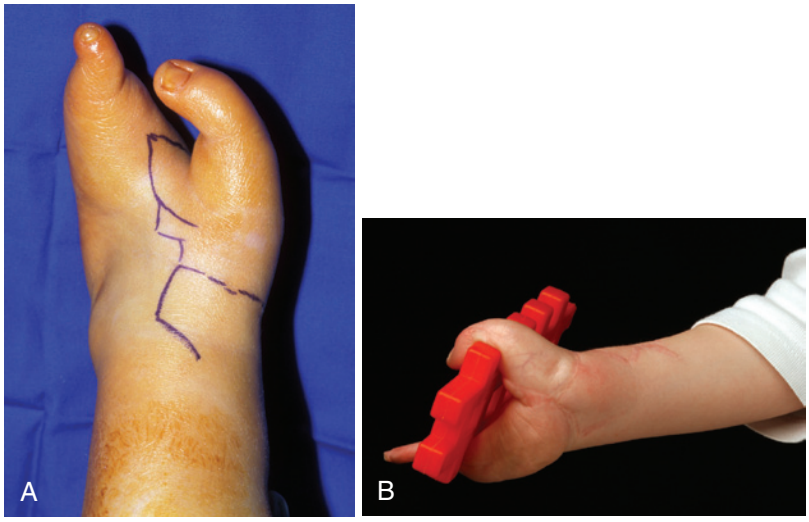

FIGURE 36.70 **A,** Foot of a child with a monodactylous cleft hand and a stiff single digit. Only the fibular toe is used for walking, and the tibial toe hinders footwear. **B,** Free toe transfer resulted in a two-digit hand with some prehension and function.

useful classification. Microvascular transfers from the foot can be useful in highly selected cases. If amputation in the foot is being contemplated, use of the part in the hand should be considered.

CRITICAL POINTS *Central Hand Deficiencies*

- True cleft hand is distinct from atypical cleft hand, which is recognized as part of the teratologic sequence of symbrachydactyly.
- Cleft hand is commonly inherited as an autosomal dominant trait and is associated with SHSF and EEC syndrome (ectrodactyly, ectodermal dysplasia, and cleft lip/palate).
- Surgery is considered for a variety of indications, including progressive widening of the cleft secondary to transverse lying bones, a narrowed first web space, and the widened cleft.
- Indications for early surgery are separation of syndactyly between digits of unequal length, especially the thumb and index finger, and removal of the transverse bones that result in progressive widening of the cleft.
- In cases of thumb/index finger syndactyly, the first web space requires reconstruction. The technique depends on the severity of the syndactyly. Complete syndactyly can be released and the cleft closed in a single setting. The skin from the cleft is rotated into the first web space to create supple tissue.

Expected Outcomes

The expected outcome from surgery will vary, as expected, according to the degree of deformity. For children with a preserved thumb, good function can usually be achieved by repositioning of the digital rays and reconstruction of a first web space. Children without a thumb present a substantial challenge for thumb reconstruction in a hand with abnormal proximal anatomy.

ABSENCE OF FINGERS OR THUMB

When considering absence of digits, the absence may be in either a transverse or longitudinal direction. In a transverse deficiency, the digit(s) is absent but the proximal supporting structures required to support digital function are present albeit to a variable extent. Examples of transverse absence include ring constriction syndrome, symbrachydactyly, and idiopathic transverse absence. In longitudinal deficiency, the supporting structures are severely deficient or absent. Examples are thumb absence in radial deficiency, absence of ulnar digits in ulnar dysplasia, and central absences in central deficiency or true cleft hand.

Reconstruction of transverse absence may be achievable by replacing the absent distal part (e.g., by microvascular toe transfer), which is then enabled by the proximal neurovascular and musculotendinous structures. Reconstruction of longitudinal absence requires replacement of the absent part and most of the enabling proximal structures, as in pollicization of the index finger for thumb absence.

Constriction Ring Syndrome (Amniotic Disruption Sequence or Amniotic Band Syndrome)

Amniotic disruption sequence is characterized by partial or complete circumferential constrictions around limbs, digits, or other body parts.[78] Consequences include acrosyndactyly of digits, terminal absence or amputation, and localized swelling with digital edema distal to constrictions (Figure 36.71).

Etiologic Findings

Streeter, in 1930, and others have proposed that this syndrome was caused by vascular disruption in the embryo. Others believe that it is due to amniotic disruption with release of amniotic bands that encircle and strangulate limbs or parts of limbs in utero. It is also postulated that the limb may become entrapped within the ruptures of the amniotic wall.[165] The most prevalent theory is amniotic disruption with release of amniotic bands, based on the appearance of the circumferential constrictions strangling the digit or other body parts and also upon the recovery of amputated digits from within the womb.

Clinical Features

The constrictions may be completely or incompletely circumferential and may occur anywhere on the body but are most commonly seen on the limbs. A consequence of these constrictions may be amputation or near amputation with distal edema. In severe cases, the limb viability is threatened. The constriction may also produce fusion of the digits to adjacent or nonadjacent digits, producing either a complicated syndactyly (see Figure 36.71, *C*) and/or acrosyndactyly with a distal fusion of the digits and a proximal sinus between them. From the hand surgeon's perspective, the most important thing about the transverse absence in amniotic disruption sequence is that the proximal structures of the hand are almost normal (Figure 36.72). Amputations or absences may occur at any level of the limb and have even been described in the head and neck. Lesser constrictions may be responsible for some rare cases of facial clefting. The digital stumps may exhibit tapering skeletal elements with tight skin cover. Where the distal limb is present, the skin distal to the constriction ring may be hard and swollen with an uncompressible edema. Nerve palsies have been associated with constriction ring sequelae and are present from birth (Figure 36.73).[169] The authors have found that these palsies, if explored surgically, are associated with absence of the nerve distally, further confusing the ideas on pathogenesis. Heterotopic reimplantation of amputated digits rarely occurs and is managed individually.[163]

Classification

Constriction syndromes are classified as a whole entity and subclassified according to limb manifestations (Table 36.8). These classifications are not useful for directing treatment but may assist in collaborative research.

Management

Treatment of the Digit or Limb Threatened at Birth. The condition is increasingly diagnosed in utero,[12] and the hand surgeon may be called upon to offer a clinical opinion to the parents. It is wise to confine this opinion to generalities prior to term. On rare occasions, a proximal ring may cause overt distal ischemia. Surgical release of the constriction may be appropriate. Survival of the limb is often questionable, and amputation is usually required. In utero release of lower limb constriction rings has been performed successfully with preservation of the limb[136] and is worth considering in proximal severe constrictions identified on antenatal ultrasound. However, the risks to the mother



FIGURE 36.71 Manifestations of the amniotic disruption sequence. **A,** Typical ring constrictions of digits. **B,** Pallor of the finger distal to the ring constriction in a neonate. **C,** Acrosyndactyly with the digits fused at their distal parts and proximal cutaneous clefts. **D,** Amputation secondary to constriction rings.

TABLE 36.8 Classification of Constriction Rings

Type	Description
1	Simple constriction rings
2	Rings accompanied by distal deformity, with or without lymphedema
3	Rings accompanied by distal fusion: acrosyndactyly
(a) Type I	Tips are joined
(b) Type II	Tips are joined: webs too distal
(c) Type III	Tips are joined: no web. Complex syndactyly with proximal sinus
4	Amputation

Adapted from Patterson T: Congenital ring-constrictions. *Br J Plast Surg* 14:1–31, 1961.

and child must be considered. Currently, fetoscopic band release is limited to progressive edema and loss of circulation that most likely will result in loss of the limb. The place for fetoscopic surgery is still emerging,[87] and the physician must tell the family that the risk of spontaneous abortion is 6% to 10% following global fetoscopic procedures.

Treatment of Nerve Palsies. A peripheral nerve palsy may occur underlying a constriction ring. The value of electrodiagnostic evaluation is questionable.[182] Successful outcomes following decompression of the nerve compression have been described, although the authors and others have seen cases with limited nerve continuity and no improvement after surgery.[48,169]

Treatment of the Constriction Ring. Treatment is aimed at both functional and aesthetic improvement. The mainstays are excision of the ring and subcutaneous tissue combined with "Z"-plasty or "W"-plasty. This technique elongates and reorients the scar to allow relaxation and concealing of the constriction. Mutaf and Sunay[119a] have recently reported on a rectangular flap



FIGURE 36.72 Normal structures are present proximal to the constriction ring. The intrinsic muscles, flexor tendons, and neurovascular structures are identifiable.

technique that focuses on correction of the contour with interposing dermofat flaps raised from the cleft, without lengthening the skin scar. The importance of correcting the contracture within the subcutaneous layer has been emphasized by Upton. Previously, circumferential surgery was not recommended at a single setting; however, complete circumferential excision may be performed safely.[79] An exception to circumferential surgery is two rings that are closely adjacent. In this case, it is prudent to release the rings one at a time.

Treatment of Acrosyndactyly. Acrosyndactyly secondary to amniotic disruption sequence is separated according to the principles of syndactyly reconstruction (see Syndactyly). Separation requires attention to the commissure, resurfacing of the digital surfaces, and attention to the nail and pulp. The sinus is usually too distal to incorporate into the commissural skin flaps and so it is often excised and the skin yielded used as a full-thickness graft. Additional attention may be directed toward release of concomitant constriction rings. The timing of separation is important because connected but nonadjacent digits are often of unequal length, which creates angulatory deformities during growth. Release of the distal connection is often enough to resolve this tethering effect, and definitive separation and commissure reconstruction may be deferred until the child is older.

Treatment of Skin Protuberances. Skin protuberances are often present in amniotic disruption sequence. These lumps are present on the dorsum of the fingers and appear firm and edematous. These protuberances may be treated via numerous techniques. "Z"-plasty is often unsatisfactory, and excision is preferred with resurfacing using full-thickness skin grafts (Figure 36.74).

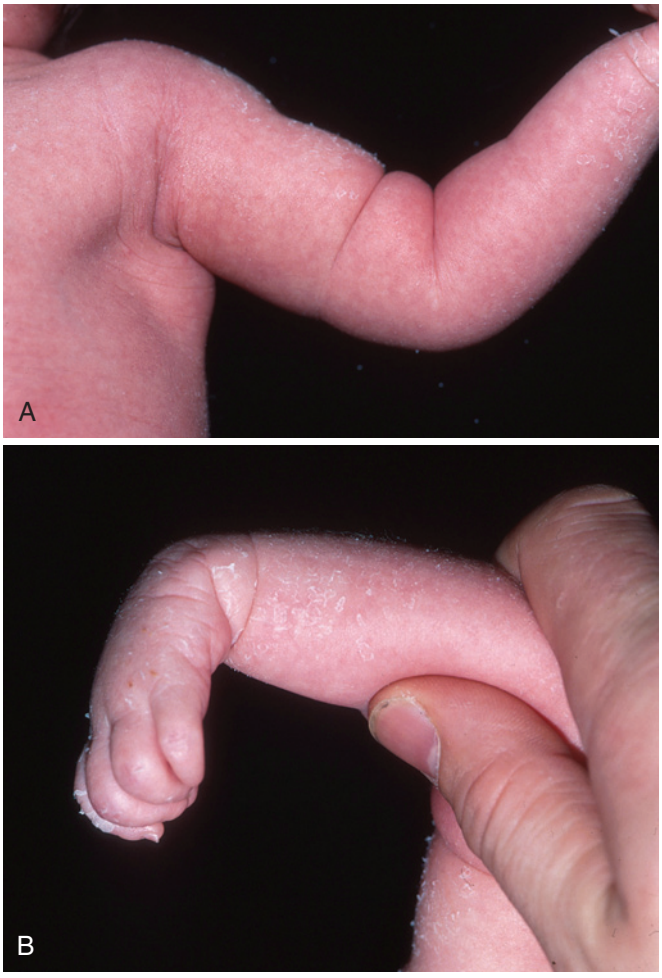

FIGURE 36.73 **A,** A constriction ring around the arm in a newborn child. **B,** Associated radial nerve palsy.



FIGURE 36.74 Dorsal skin lumps are common and can be treated by excision and skin grafting.

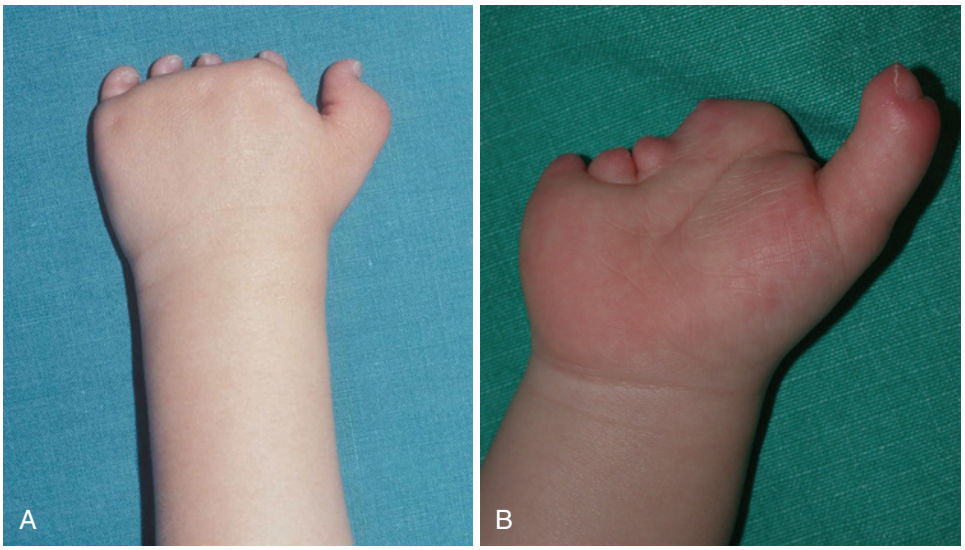

FIGURE 36.75 Types of symbrachydactyly. **A,** Symbrachydactyly with a reasonable thumb but absent fingers represented by nubbins with nail remnants. **B,** Complete absence of the fingers that becomes more pronounced toward the ulnar side of the hand.

Treatment of Digital Absence. Digital absence is common in ring constriction syndrome. The number of absent digits is variable. The digits appear similar to a transverse absence. The proximal enabling structures are present and may be used to control and drive a transferred digit. The means of reconstructing profound absence of digits is addressed later.

CRITICAL POINTS *Amniotic Disruption Sequence (Amniotic Band Syndrome or Constriction Ring Syndrome)*

- Amniotic disruption sequence is characterized by partial or complete circumferential constrictions around limbs or digits.
- The consequences of amniotic disruption sequence include syndactyly of digits, terminal absence, and digital edema distal to the constrictions. Occasionally, a peripheral nerve injury may occur secondary to a constriction.
- Mild constriction rings are treated by excision and lude syndac.
- Release of syndactyly follows the standard techniques of digital separation and resurfacing. Early release of the distal connection, however, with delayed formal separation and reconstruction of the commissure may be considered to relieve the tethering effect between digits of unequal length.

Symbrachydactyly

Symbrachydactyly is a term (fused short fingers) used to describe a spectrum of deformity ranging from digital hypoplasia to aplasia or deficiency of the hand or forearm. The condition has been difficult to place within the IFSSH classification[157] because the anomaly displays features of undergrowth, failure of differentiation, and failure of formation.[38,112] Symbrachydactyly shares features with transverse absence and may represent the end stage of this spectrum.[91,186] Blauth and Gekeler[24] originally classified symbrachydactyly into four types in a progressive spectrum of deficient digits: short finger type, cleft hand type, monodactylous type, and peromelic type. The most severe types, monodactylic and peromelic, are characterized by transverse absence of digits and the presence of rudimentary distal nubbins or stumps, which may include remnants of nail plate, bone, or cartilage (Figure 36.75). An alternative classification has been proposed and focuses on the number of phalanges missing (Table 36.9). This scheme also identifies a teratologic sequence passing from the presence of five digits to complete midforearm amputation.

TABLE 36.9 Classification of Symbrachydactyly

Type	Description
1. Triphalangia type	A hand with no missing bone; all four fingers should have three phalanges, even though some phalanges (often the middle phalanges) are short
2. Diphalangia type	A hand in which one phalanx (usually the middle one) is missing in one or more digits
3. Monophalangia type	A hand that has a finger or fingers with only one phalanx
4. Aphalangia type	A hand in which all three phalanges are missing in a digit or digits
5. Ametacarpia type	A hand with absence of a metacarpal bone as well as three phalanges in a digit or digits
6. Acarpia type	A hand that has absence of all the digits and partial or complete absence of the carpal bones
7. Forearm amputation type	An arm with absence of the distal portion of the forearm; usually, there are rudimentary digits on the stump

Adapted from Yamauchi Y, Tanabu S: Symbrachydactyly. In Buck-Gramcko D, editor: *Congenital malformations of the hand and forearm*, London, 1998, Churchill Livingstone, pp 149–157.

Clinical Features

Symbrachydactyly occurs sporadically. There appears to be a spectrum of deficiency, beginning with short middle phalanges, extending to absence of the central rays, and culminating in

absence of the entire hand. The defect is believed to be mesodermal, which explains the remaining distal finger ectodermal structures (pulp, nail fold, and nail). This results in the characteristic "nubbins" or "buds" that represent vestiges of digits and are the hallmark of symbrachydactyly (see Figure 36.75).[112]

Symbrachydactyly may occur with Poland syndrome, with unilateral hand hypoplasia associated with absence of some shoulder girdle muscles. The sternal head of the pectoralis major muscle is most commonly absent, although considerable chest wall deformity may also be present. The correlation between these conditions and other syndromes with similar findings is unknown. Previously, there existed some confusion between oligodactyly (i.e., few finger form of symbrachydactyly) and cleft hand.[13,111] The central deficiencies form of symbrachydactyly was previously called atypical cleft hand; however, the deformity is now known to be transverse rather than longitudinal, with the implications for reconstruction as discussed below.

ANATOMY

Each form of symbrachydactyly occupies a place on the continuum from the normal hand through the various degrees of deficiency to complete absence of the hand. The severity of deficiency correlates with the degree of aberrant anatomy (see Table 36.9). As stated previously, the presence of proximal enabling structures offers hope for reconstruction of functioning digits (Figure 36.76).

In all degrees of symbrachydactyly, the central rays are the most abnormal. In the mild forms (types 1, 2 and 3), the skeletal elements are the most affected. The middle phalanges are reduced in size and may be absent. Because mild symbrachydactyly rarely requires surgical exploration, little is known about the aberrant soft tissue anatomy apart from the incomplete simple syndactyly that is apparent on clinical examination.

In more severe symbrachydactyly (type 4), the central rays virtually disappear and are replaced by finger nubbins with aponeurotic attachments to extrinsic tendons around the end of the hypoplastic metacarpals. The nubbins may contain small remnants of phalanges that articulate with the metacarpal. These nubbins have vestigial connections via the palmar aponeurotic and retinacular system to the extrinsic tendons. This connection is apparent by the ability of the nubbins to pucker into the palm during hand use. In the absence of phalangeal remnants, the metacarpals are usually small and may only be present at their bases. The fifth finger is least affected; however, it typically lacks a middle phalanx. It usually has a competent MCP joint and a variably stable distal joint, which is commonly radially deviated. This angulation is partly the result of the oblique pull by the extensor tendon, which bridges the "U"-shaped cleft. The thumb is also variable in form. The first web space may be narrowed, and the thumb may lack full circumduction at the basal joint. The extrinsic flexor tendons often share a muscle belly and may be coalesced into a single tendon mass within the carpal canal. Lumbrical muscles are usually absent even when digits are present, and interosseous intrinsics are absent or highly abnormal. The extensor tendons along the dorsum of the hand appear quite normal and often have independent extensor indicis proprius or extensor digiti quinti tendons.

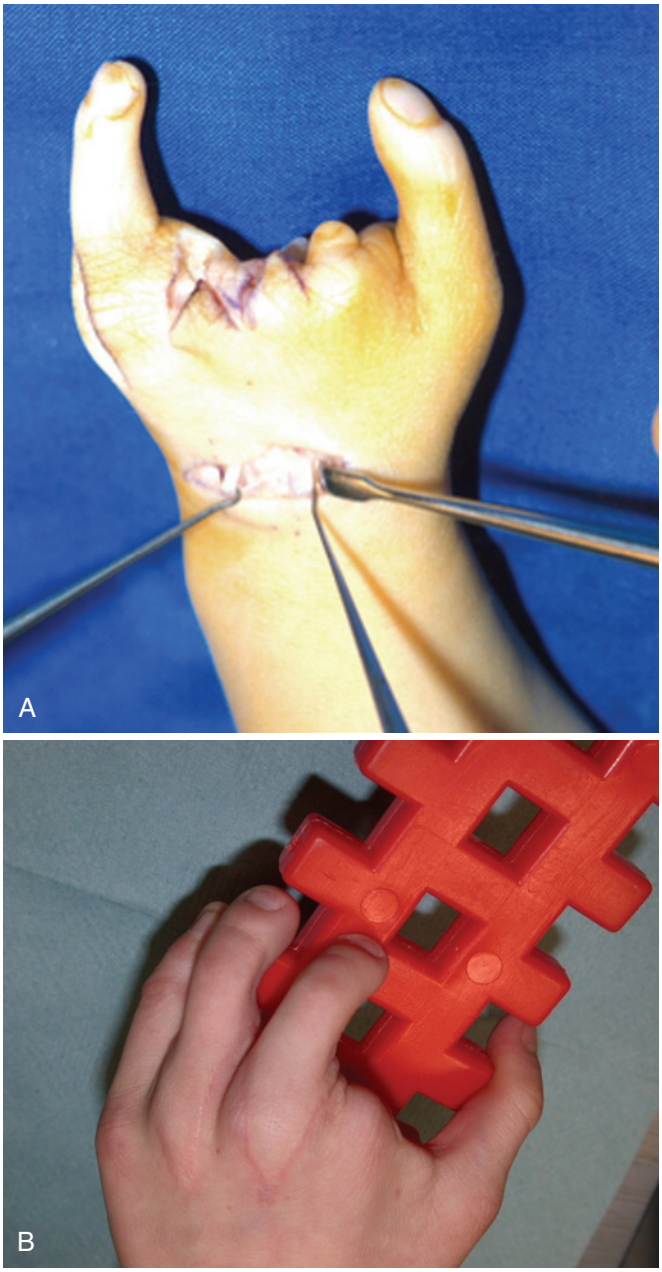

FIGURE 36.76 A, Oligodactylic form of symbrachydactyly. Exploration revealed the presence of extensor and flexor tendons and nerves providing adequate components to allow reconstruction with double second toe transfer. **B,** Good prehensile function achieved with free toe transfers contributing to stability and strength of pinch.

In the advanced monodactylic or single-digit form of symbrachydactyly (type 5), the anatomy is widely abnormal. Surgical attempts at reconstruction have provided considerable information about the aberrant anatomy. The thumb may or may not have a proximal phalanx. The extrinsic tendons end in a conjoined fashion at the level of the metacarpal end. The aberrant rays may lack even vestigial metacarpals, and the fifth ray is usually represented by a short metacarpal. Flexor tendons are conjoined and end at the tips of the skeletal rays. The flexor tendons attach to the extensors and to the aponeurotic system, which yields a variable amount of movement of the finger

nubbins. The extensor tendons are disordered and may be conjoined, although the extensor indicis proprius or extensor digiti quinti are often still distinct. The wrist extensors appear normal. The excursion of the extensor tendons is variable. In general, a wrist and nubbins that are active and mobile correlate with tendons that have some useful excursion. The tendons may be conjoined, and Vilkki[175] has recommended exploration into the forearm to divide the donor tendon from any common muscle belly to prevent a quadriga effect.

In the more severe degrees of symbrachydactyly (types 6 and 7), there are no useful intrinsic muscles to the fingers. Nerve abnormalities are common. In our experience gained from exploration of over 300 cases, the radial nerve is almost always present, regardless of the severity. In contrast, the median and ulnar nerves are small and may be absent. The presence of a thumb or fifth finger implies the presence of the corresponding median or ulnar nerve. Rarely, complete absence of all major nerves in the hand may be found. The peromelic form of symbrachydactyly (type 6) has severe skeletal absence. There may or may not be a carpal row and particular attention should be paid to the status of the thumb ray CMC joint (see the following). The wrist motors may be present. The flexor or extensor tendons of the fingers may be vestigial but have minimal excursion.



FIGURE 36.77 Severe symbrachydactyly that is a candidate for free phalangeal transfer. The thumb has a metacarpal, and tethering of skin to the underlying tendons indicates the presence of active motors.

Management

Treatment of Short Finger Types (Types 1, 2, and 3). This group of symbrachydactyly has short fingers with small or absent middle phalanges. It may be associated with syndactyly, especially of the fifth finger. This fifth finger often deviates in a radial direction. Function is usually excellent (Video 36.2). Release of the incomplete syndactyly of the webs may produce an apparent lengthening of the digits and improved span of the hand. Where the skeletal elements of the digits are hypoplastic and the soft tissues and skin of the digits are relatively preserved, the digit can be stabilized and augmented with a free phalangeal bone graft, although expectations for useful growth in such grafts should be muted, as we indicate in the following.

Treatment of the Oligodactylic (Few Fingers) Type (Type 4). This type of symbrachydactyly is characterized by some degree of absence of the central three rays (Figure 36.77). The nubbins that represent the central digits usually have no considerable function, and the nail remnants can cause local irritation and infection due to the paronychial deformity. Nail remnants and/or nubbins can be removed by simple excision. Prehension can usually be achieved with a pincer grasp between the thumb and fifth finger. Depending on the stability and orientation of these digits, the capacity for prehension can be improved with osteotomy of the metacarpals. The potential for tendon transfers to augment the power of pinch is limited because of the paucity of adequate long tendons in the limb. The first web can be narrow, and the span of grasp can be improved by soft tissue release and lengthening of web with local flaps.

The addition of digits to the deficient central hand with vascularized toe transfers is possible in these hands because skeletal remnants and extrinsic tendons are present in most. The rationale for digital construction is to improve the power of pinch with a greater opposable pulp area to improve pinch. The carrying function of the hand can also be improved. Although the transferred digits retain the appearance of the toe, they are less discordant than may be expected and the appearance of the oligodactylic hand is improved. There is controversy as to whether this surgery is justified in children who are likely to adapt well and develop reasonable prehensile function with the thumb and ulnar elements present; our experience justifies free toe transfer, however. If a fifth ray and thumb are already present, these digits will be used in preference for fine manipulations, but the addition of two central rays by transfer of second toes from each foot offers further options for large or heavy object grasp, with subsequent benefits in function and patient-reported benefits in the appearance and completeness of the hand.

Treatment of Monodactylic (Single-Finger) Type (Type 5). The hand with this type of symbrachydactyly lacks all fingers and has only a thumb, which is of varying size and quality. A markedly deficient thumb may be present with a very short metacarpal and underdeveloped basal articulation. The digits are represented by metacarpal bases and finger nubbins with nail remnants. These nubbins have vestigial connections via the palmar aponeurotic and retinacular system to the extrinsic tendons. This connection is apparent by the ability of the nubbins to pucker into the palm during hand use. The wrist is usually sufficient for function. Free toe transfer is a surgical option to improve function.

Treatment of Peromelic (Short-Limb) Types (Types 6 and 7). The hand with this type of symbrachydactyly has only nubbins with nail remnants. There is a transverse absence at or about the metacarpal row, although more proximal absences may be seen. Finger nubbins may even be noted on a midforearm stump. Reconstruction of prehensile function is difficult because there are limited proximal structures. Vilkki has used a free vascularized toe transfer to the radial side of the distal forearm to achieve lateral pinch, although this should be performed either distal to the radial epiphysis or after growth has ceased[175]; otherwise, the toe will be left behind in the midforearm as the radius grows in length (Figure 36.78).



FIGURE 36.78 Failure to place the vascularized toe transfer distal to the radial epiphysis will result in a toe that will be left behind in the midforearm as the radius grows in length. (Courtesy of Shriners Hospital for Children, Philadelphia.)

CRITICAL POINTS *Symbrachydactyly*

- Symbrachydactyly is a spectrum of deficiencies that begins with short middle phalanges, extends to absence of the central rays, and culminates in absence of the entire hand.
- Treatment of symbrachydactyly is variable and depends on the degree of digital suppression. Mild forms with a competent thumb and digit or digits require no treatment. Severe forms with an absent thumb or absent fingers may benefit from extraperiosteal phalanx transfer or microsurgical toe-to-hand transfer.

Acquired Transverse Absence of Fingers in Children

Acquired cases of transverse absence are also seen in childhood. Traumatic amputation is prevalent in countries that use child labor in the manufacturing industry. These injuries may be bilateral and pose extraordinary challenges in reconstruction.[178] Other traumatic causes include burns, electrocution, thrombosis, and embolism. Lastly, infection may lead to gangrene of the extremities, primarily from meningococcal septicemia.

Construction or Reconstruction of Fingers

There are three main ways to augment the existing digit or ray in a child. The digit may be lengthened by a bone graft (most commonly, a free phalangeal transfer from the foot) or by distraction, or may have composite parts of another digit transferred to it (on-top plasty). Where the digits are absent, the digit(s) can be constructed by free vascularized toe transfer.

Free Phalangeal Transfer. In the adult, many surgeons have found that the placement of bone grafts on the terminal part of the skeleton of a digit results in early and complete resorption of that graft. Resorption, however, is not invariably the case in the child. There are many descriptions of enduring transfers of whole or partial phalanges from within either the hand or foot. Some authors have reported poor results in terms of growth using this technique,[178] whereas others have reported growth and improved function.[33,72,164] Radocha and colleagues[132] have defined three important conditions for success in these transfers if growth is to be observed: (1) transfer must be done before the age of 15 months; (2) periosteum must be included in the transfer; and (3) collateral ligaments and tendon insertions must be repaired.

The authors agree that the earlier the transfer is completed, the better the chance of any subsequent growth. The inclusion of periosteum allows more rapid revascularization of the free transfer, probably through inosculation, which may help to conserve the bone. The role of load across the physis is uncertain, but Radocha and colleagues[132] found unequivocal evidence that attachment of ligaments and tendons to the transferred bone was important. The best growth results in our children have been seen in those cases in which the phalanx was affixed to the proximal skeleton using chondrodesis, presumably increasing the amount of force transduced across the growth plate. Using the phalanx as a hemiarthroplasty at the MP level, however, has produced mobile and stable digits. For stability, there must be some long remnants of the flexor and extensor tendons at the level of the nubbin and the phalanx must be secured by direct soft tissue repair. Once consolidated, the phalanges have been shown to be robust enough to tolerate distraction lengthening.[121]

The phalanges should not be harvested from the second toes unless microvascular toe transfer has been excluded as an option. Free phalangeal transfers are not a simple reconstructive option. While a successful transfer may grow and add function, this result is not inevitable, because wound complications and skin necrosis can result from oversizing the graft and, in the longer term, the surviving phalanx can be unstable and prone to angular deformity. In addition, the donor site in the foot can be troublesome and a source of morbidity unless properly managed. Overall, the results of free phalangeal transfers appear inconsistent, and ample discussion with the familiy is necessary prior to surgery. For the most part, our practice prefers whole vascularized toe transfer compared with free phalangeal transfer because of the greater growth, mobility, and stability. The ideal recipient for free phalangeal transfer is a patient with a digital ray with a small remnant of proximal phalanx with tendon attachments and a suitable skin envelope. Free phalangeal transfer is especially useful in the thumb in cases of monodactylic symbrachydactyly (see Figure 36.77). In these cases, the fingers can be constructed from two toe transfers (see later), and the free phalangeal transfer augments the length of an otherwise competent thumb.

The requisite in the hand is a mobile, flexible adequate skin envelope, which is common in transverse absence or symbrachydactyly. The transfers should be planned in patients who can expect to have some functional improvement and are not indicated in patients who will have no increase in prehensile function. The absence of extrinsic tendon function is a relative contraindication. The parents must be aware of the potential aesthetic side effects for the foot, which are more important in patients undergoing concomitant microvascular toe transfer. Finally, the procedure is relatively contraindicated in the older child; we do not offer this treatment in children older than 15 months of age.

The donor site in the foot is a serious limitation of this technique. Methods for dealing with this have included suturing together the extensor and flexor tendons in the gap left by the phalanx, but our experience has been that the options to prevent

a short floppy toe(s) are limited. In an attempt to minimize the donor deficit, we have inserted a cylindrical apophyseal bone graft from the iliac crest, which has improved the appearance at the foot donor site.

❖ AUTHORS' PREFERRED METHOD OF TREATMENT FOR FREE PHALANGEAL TRANSFER

Preparation of the hand. Under tourniquet, the empty skin nubbins may be approached either by dorsal or volar longitudinal incision. The skin may be closed using a "Z"-plasty when additional length is required. The nubbin is opened, and some fat is removed to accommodate the toe phalanx. Gentle traction on the nubbin with a skin hook reveals the extent of the cavity created for the transfer. The metacarpal head is evaluated and usually has a thin layer of articular cartilage overlying the epiphyses of the metacarpal. The metacarpal head is capped with a coalescence of the flexor and extensor tendons (Figure 36.79). The authors' preference is to incise this in a cruciate manner and to raise the dorsal and volar capsule with the extensor and flexor tendons. The radial and ulnar parts of the capsule are preserved as collateral ligaments. Each of these elements will subsequently be repaired to the phalangeal transfer.

In children with a remnant of proximal phalanx, the procedure is simpler, because the tendons do not require exploration. The end of the residual phalanx is prepared for chondrodesis with the free toe phalanx.

Harvesting the graft. The toe phalanx is approached through a zigzag incision on the dorsum of the toe. The harvested phalanx is usually the proximal phalanx of the third or fourth toe. The second toe may be preferred in cases in which microsurgical toe transfer is not being considered. After the dorsal exposure, the extensor apparatus is split in the midline of the digit and the toe phalanx dissected from its surrounding attachments, leaving the periosteum intact. The fibrous flexor sheath is divided laterally on the volar surface, taking care not to injure the flexor tendon. The distal capsular attachments are incised adjacent to the phalanx. The phalanx is harvested with the volar plate and capsular attachments (Figure 36.80). Frequently, a small cap of the distal portion of the proximal phalanx is retained within the toe.

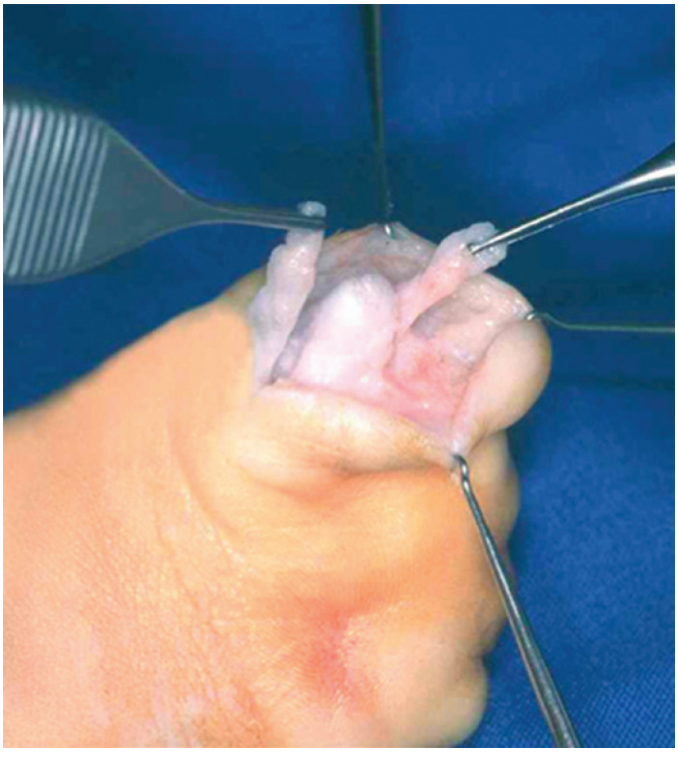

FIGURE 36.79 The flexor and extensor tendons are identified and separated over the metacarpal head.

The donor defect may be closed in a variety of ways. Some have advocated simple longitudinal Kirschner wire fixation, whereas others have recommended suturing the flexor and extensor tendons together to serve as a spacer.[33] We prefer harvesting a cylindrical graft from the iliac crest that is capped with apophyseal cartilage (see Figure 36.80). The graft is placed into the toe with the apophyseal cartilage directed proximally. The tubular cancellous bone abuts the small fragment of distal toe phalanx that was retained within the foot. The graft and toe construct are fixed with a longitudinal Kirschner wire. The extensor tendons and skin are repaired. This pin is removed 4 to 6 weeks later.[26]

Placement of the graft. The graft is transferred to the hand. The volar capsular attachments and flexor tendon within the hand are sutured to the volar plate on the free phalangeal graft. The graft is transfixed with a longitudinal Kirschner wire passed from proximal to distal and exiting through the apex of the skin envelope (Figure 36.81). This wire is withdrawn, the phalangeal graft aligned with the metacarpal head, and the wire advanced to fix the graft in place. The wire should be placed with as little trauma and heat dissipation as possible to avoid physeal plate injury. The collateral ligaments are repaired to the lateral margins of the capsule at the metacarpal head. The dorsal capsule and extensor tendon are repaired to the dorsal capsule of the free phalangeal graft. The skin is closed either with a "Z"-plasty or directly with absorbable sutures, and the hand is immobilized in an above-elbow cast. The Kirschner wires in the foot and the hand are removed 4 to 6 weeks after surgery. The parents may move the phalanx gently.

Complications. Complications include skin necrosis and absent growth of the transferred phalanx. Skin necrosis occurs when the transferred phalanx is too large for the skin envelope. Absent growth is more likely in the older child, when the tendons or ligaments are not repaired or when the periosteum is not included in the transfer. Scarring may occur in the foot, especially when a longitudinal incision is used. Contraction may result in dorsal displacement of the toes that may become unstable.[70] In addition, the donor defect may be worse in cases in which the extensor and flexor tendons have been sutured together as a "spacer." This technique may lead to unstable toes that angulate and override adjacent digits.

Distraction of Digits. Osteotomy of one of the skeletal elements of the short ray and distraction using an external fixator can lengthen the digit.[105] The procedure can only be used where the phalanx or metacarpal is long enough to accommodate a distraction frame. The bone generated in the distraction gap may be adequate for stability or augmented prior to removal of the frame with bone graft. A limited gain in length can be achieved, which may improve prehension, particularly in the thumb that is too short to reach the ulnar digit(s). The procedure is time consuming and requires a cooperative family and patient.



FIGURE 36.80 **A,** The bone graft, including the apophysis, is harvested from the iliac crest with a tubular osteotome. **B,** The proximal phalanx has been harvested from the third toe (with the second toe preserved for possible future microvascular transfer). The tubular bone graft to replace the phalanx has been fixed with a longitudinal wire.



FIGURE 36.81 Toe proximal phalanx in place with Kirschner wire fixation and extensor tendon attachment.

Transposition of Rays. This technique involves transposition of rays to allow prehension. In certain hands, the thumb lacks enough excursion to reach the fingers. Transposition of a finger or fingers into a more radial position can allow pinch or grasp. Transposition may be combined with microvascular toe transfer to enhance hand function (Figure 36.82).

Microvascular Toe Transfer for Hypoplastic Digits. Single-stage microvascular toe-to-hand transfer is not a new concept. The technique has primarily been used for posttraumatic conditions in adults. Before the 1990s, relatively few reports dealt with children. Lister reviewed 12 toe transfers for congenital deficiency of the thumb and reported good return of sensibility but poor return of IP motion.[100] Kay and colleagues extended the indications to include reconstruction of the congenital hand with an absent thumb or finger.[95]

Choice of Technique. For adults, many variations of toe transfers have been developed, including the wraparound free flap,[117] the twisted toe transfer,[65] the double-toe transfer,[95,125] the great toe transfer,[125] and the trimmed toe transfer.[181] The donor defect must be minimized, especially in children. For this reason, we are reluctant to transfer anything other than the second toe. This limits the reconstruction to two digits, although fortunately the commonest indication in children is symbrachydactyly, which is invariably unilateral. In traumatic cases with bilateral injuries, the decisions about sacrifice of more toes for hand function are correspondingly far more difficult. These

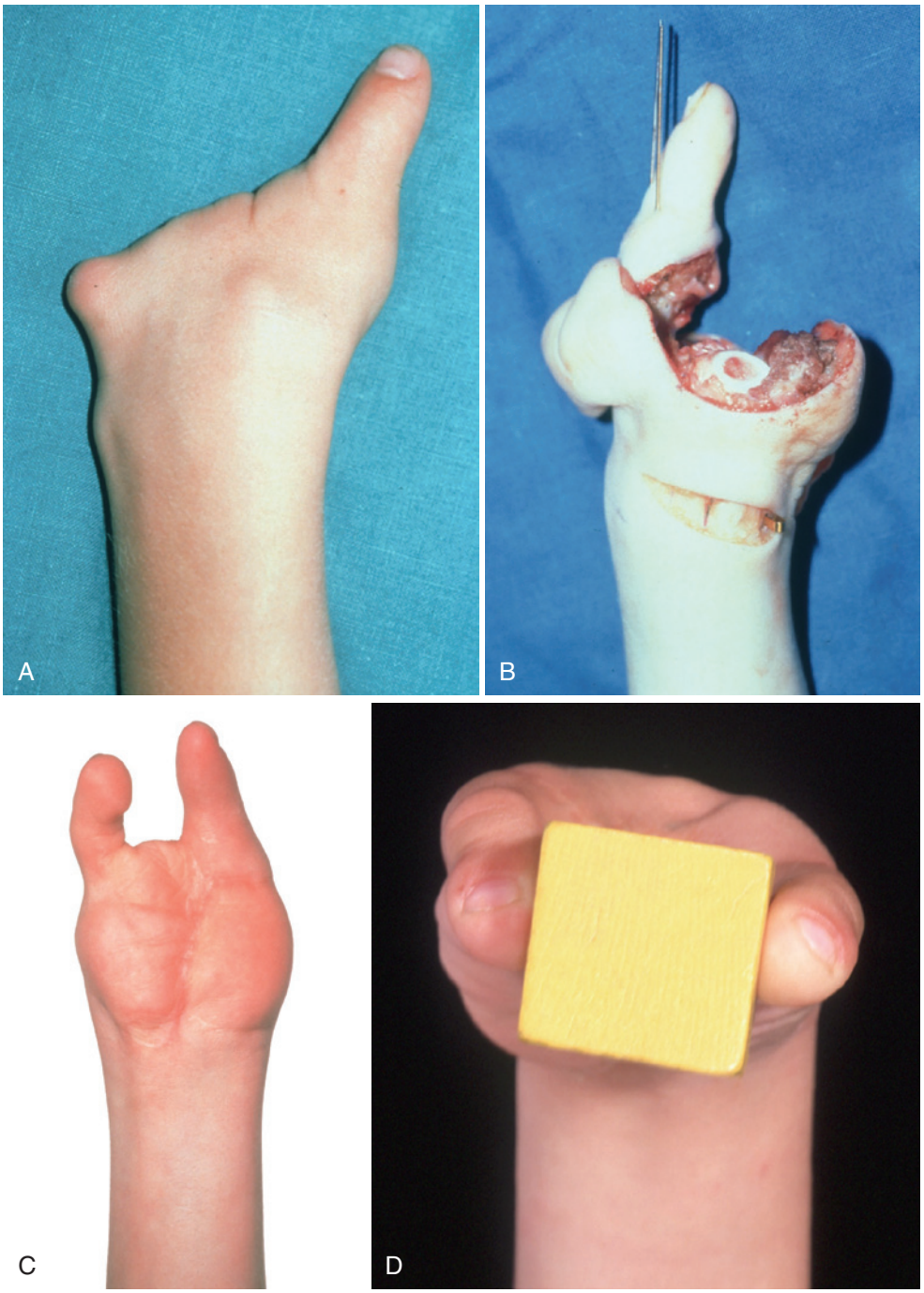

FIGURE 36.82 **A,** The left hand of a child with congenital digital absence. Although a thumb ray is present, there is no active or passive movement at any level in that ray, including the basal joint. The hand has no prehensile function. **B,** Rather than creating a mobile ulnar ray against a static radial ray, it was decided to transfer the existing "thumb" to the ulnar border of the digit as a microvascular pedicle transfer. A single second toe transfer to the radial ray was undertaken at the same procedure to create a thumb. **C,** Postoperative result with the static ulnar ray and the thumb present on the radial ray. **D,** Strong small-object pinch and grasp resulted from this combination of transfers.

second toes can be transferred in separate operations or in the same operation (synchronous bilateral second toe transfer). In very select cases, when either single or bilateral second toe transfer is not appropriate or possible, transfer of the great toe may be considered with caution. The aesthetic defect is greater and there may be functional consequences. Rarely, a wrap-around free flap or partial toe transfer may be used, but only in the older child because growth is not a property of such transfers.

Indications. The indications for digital reconstruction include transverse deficiencies in the thumb and/or fingers (Figure 36.83). Longitudinal deficiency has been a contraindication because of the deficient proximal structures, such as tendons and nerves. Transfer of an adjacent digit usually

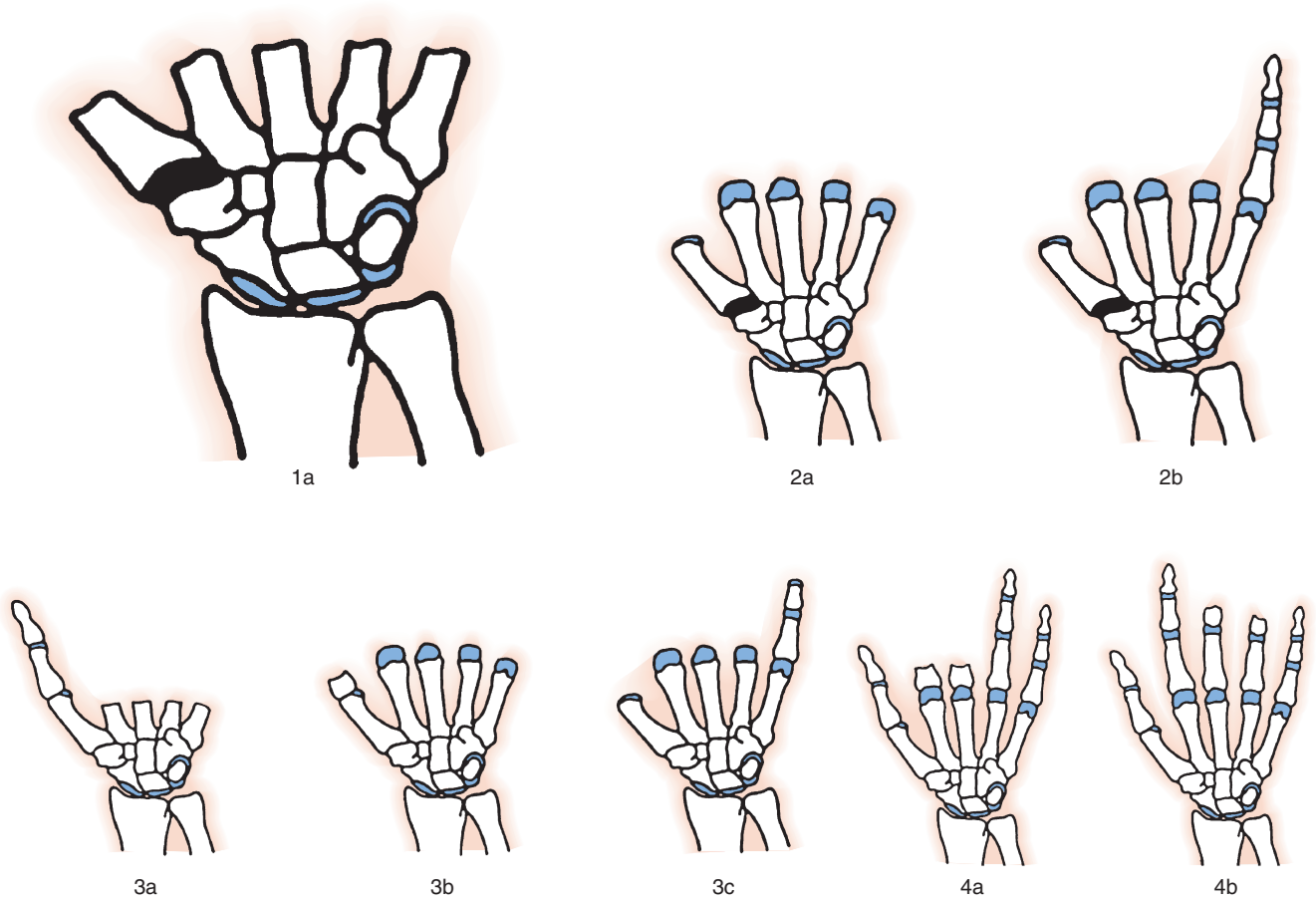

FIGURE 36.83 A simple grouping of common types of congenital transverse deficiencies in the hand based on the authors' experience of the reconstructive options available and the probable functional outcome. Group 1a: The absence is at a proximal level through the base of the metacarpal or at the carpometacarpal level. There is no circumduction in the thumb ray, and here bilateral second toe transfers will allow pincer grip between the toe pulps. It is likely that a choice will have to be made between small- or large-object grasp because the range of motion in the reconstructed toes is unlikely to allow both. Group 2a: The absences are at the distal level of the metacarpals, and the basal joint of the thumb is competent. Reconstruction at this level with one toe on the first ray and one toe on the fourth ray will allow good small- and large-object grasp with competent pulp-to-pulp pinch by virtue of the basal motion in the thumb. Group 2b: Distal metacarpal loss with a poorly competent basal joint but the presence of a relatively normal fifth ray. The mobility present in all the joints of the fifth ray, including the basal joint, means that any reconstruction on the thumb ray will probably allow both small- and large-object grasp. Single toe transfer to the thumb ray is therefore indicated, and the optional transfer of a further toe to the ring finger ray is unlikely to result in great improvement. One further option in this situation is microvascular pollicization of the fifth ray and a double toe transfer to the hand on the third and fourth rays. This has the advantage of producing a fuller hand but retaining and restoring mobility in the first ray. Group 3a: Proximal metacarpal level in the hand with a competent and strong first ray. Here, bilateral second toe transfer on the fourth and fifth rays will produce a strong and competent hand even if relatively little motion is restored in the transferred digits. Group 3b: Distal metacarpal absence with the presence of a metacarpophalangeal joint in the thumb. If the patient is seen early in life, free phalangeal transfer in the thumb will convert the patient's hand to essentially a group 3a hand and allow bilateral second toe reconstruction in the hand rays. Group 3c: This common type has a competent fifth finger but requires one toe to reconstruct a competent thumb, and a further toe may then be used on the ring ray to add power and volume to the hand. Groups 4a and 4b: This type of transverse absence is most commonly seen in ring constriction syndrome where function of the hand is already excellent. Little or no functional improvement will result from microsurgical toe transfers, but there are potentially considerable cosmetic benefits from creating a fuller hand. Although function in the hand itself is already good, good function in the reconstructed digits can be expected as a result of the relatively normal structures present proximally in the hand.

reconstructs longitudinal deficiency. In the monodactylous cleft hand, however, we have found tendons and nerves that are available for transfer. This demonstrates the blurring of the clear-cut distinction between categories of digital absence.

Reconstruction of the Thumb. Traumatic or congenital transverse thumb deficiency is the ideal indication for microsurgical toe transfer. The most important determinant of useful outcome is the presence of a stable and mobile CMC joint.[95,96] The recipient structures vary according to the cause of the absence. The proximal structures are virtually normal in ring constriction syndrome. Useful recipient structures are also found in symbrachydactyly or transverse arrest and are more likely to be present when there is a considerable metacarpal remnant. The lack of IP joint motion after transfer reflects the limited amplitude of the extrinsic tendons.[54,101]

Reconstruction of the Fingers. Reconstruction of the fingers is not as common as reconstruction of the thumb. Reconstruction may be indicated after trauma or congenital absence when there is a reasonable thumb present. In such cases, bilateral second toe transfer creates a competent three-digit hand with

powerful pinch and grasp. The presence of existing MCP joints enhances surgical outcome. However, absent MCP joints may still allow satisfactory function. A patient with symbrachydactyly with a thumb and a small finger that is short, deviated, and unstable may be a candidate for bilateral second toe transfer to create a more complete hand. Such cases occupy the borderline between the functional and aesthetic indications for toe transfer. In the absence of proximal phalangeal remnants, we have usually preferred to chondrodese the base of the toe proximal phalanx to the head of the finger metacarpal, accepting less movement in return for more stability. Some surgeons transfer the metatarsophalangeal joint from the foot,[175] but this joint can be laterally unstable and is bulky. In addition, the metatarsophalangeal joint is capable of hyperextension, which is detrimental to prehension.

The Hand With No Digits. Transverse arrest or severe symbrachydactyly without digits requires reconstruction of the thumb and fingers to create any prehensile function. These cases are challenging, and the outcome depends on the level of absence and the competence of the basal joint of the thumb. A substantial thumb metacarpal remnant may be enhanced by bony augmentation. Even a free phalangeal transfer may be attempted to create an articulated thumb, although this should be approached with caution. Successful transfer may change the reconstruction from a hand that requires thumb and finger reconstruction to one that requires only finger restoration.

If thumb augmentation is unlikely to produce a competent digit, the surgeon may consider one transfer to the thumb and one to the finger rays (Figure 36.84). Poor or absent basal joint function requires placement of the digits facing each other. The majority of the movement will originate from the IP joints of the thumb and finger. Postoperative motion is often poor and limits the functional benefits of such transfer. If surgery is selected, a decision must be made to position the transfers to touch in maximum flexion or to place them more widely apart. The former allows small object grasp, whereas the latter allows larger object acquisition. In our experience, small object grasp is preferred to allow the child to hold fine objects such as paper, buttons, and shoelaces.

In the presence of a reasonable basal joint, a second toe is placed on the thumb and another placed on the third or fourth ray. The transfer may create a composite joint, using one articular surface from the toe and one from the finger. The preferred approach, however, is to perform a chondrodesis or arthrodesis between the base of the proximal phalanx in the toe and the shaft of the metacarpal in the thumb and finger. This technique has the additional benefit of stability and precise orientation of the digit, although in the presence of a basal joint allowing circumduction, the alignment of the toe is less critical and eventual function much greater.

Finally, a decision is required regarding the length of the digit to be created. The initial temptation is to create long digits; however, long digits may look bizarre in a two-digit hand (Figure 36.85). This altered appearance may be disturbing for the child compared with shorter digits that allow the hand to appear more compact and natural. The physis of the transferred digit is retained for growth, which may require some resection of the thumb metacarpal to coordinate the length of the thumb and finger.

Contraindications. Contraindications to toe transfer in children are diminishing over time. There are few contraindications from an anatomic viewpoint. Absence of recipient nerves is a contraindication to surgery. We warn parents that when no recipient nerve is found, surgery will be aborted. This is a rare occurrence; even though the median nerve is commonly absent, there is usually an ulnar nerve and dorsal cutaneous nerves, including substantial radial sensory nerves. An exception to this generalization is found when the digital metacarpal remnants



FIGURE 36.84 **A,** Two simultaneous second toe transfers for symbrachydactyly with absent digits at the metacarpal level. There was a competent thumb basal joint. **B,** Useful large-object grasp with considerable power. **C,** Small-object pinch as a result of limited circumduction at the thumb basal joint.

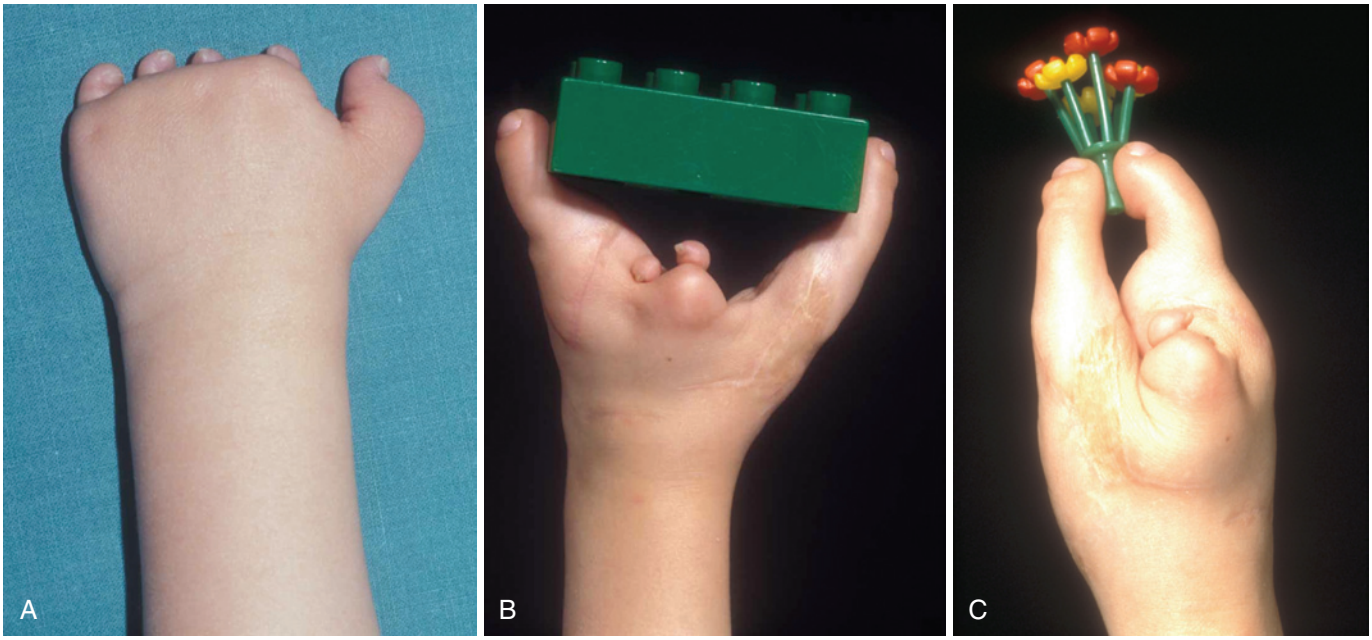

FIGURE 36.85 **A,** Transverse arrest in the hand of a 2-year-old girl. The thumb is absent from the midmetacarpal level distally and is represented by a skin envelope devoid of skeleton. **B,** This child underwent bilateral second toe transfer with one toe to the first and one toe to the fourth ray. An alternative might have been free phalangeal bone graft to the thumb and a double toe transfer to the hand. In this case, the digits have a long, narrow look that gives the hand the appearance of clefting. However, large-object grasp is successfully created. The child refused removal of the skin nubbins within the cleft. **C,** The same hand exhibits good small-object grasp by virtue of the mobility of the basal joint. The length of the digits contributes to their range and power, but they have the disadvantage of poor appearance.

get progressively shorter passing from radial to ulnar: in such situations, we have found the absence of both the median and ulnar nerves to be increasingly frequent. The absence of adequate donor tendons is also a contraindication.

As discussed above, in the transverse absence group, motors are usually present, although the tendons may be conjoined with limited excursion. But, limited IP excursion of a transferred toe may still provide power and an adequate functional result depending on the type of grasp being sought with the surgery. An extremely proximal level of transverse absence (e.g., the distal carpal row or radiocarpal level) will produce a disappointing result, and prosthetic alternatives should be considered. Absence or deformity of the toes precludes surgery.

The most considerable contraindications are the psychosocial considerations within the family and competence within the surgical unit. Careful assessment of and counseling for the family and child are essential to ensure an adequate understanding of the aims and consequences of surgery, to accept the donor defect, and to manage the consequences of either a successful or an unsuccessful procedure.[20,28,94]

The age of the child is a relative contraindication. Absolute rules about indications and contraindications in respect to age of the child do not exist. We have found no benefit in performing the procedure before 1 year of age, and an analysis of long-term outcomes suggests some disadvantages in terms of ultimate range of motion. There are benefits in completing the surgery before school age, and this reconstruction is rarely accomplished in a single stage. After the age of 6 years, the child becomes involved in the choice of surgery, and this may pose additional problems because the child has enough autonomy to refuse surgery but not enough competence to make reasonable decisions based on future function.

Presurgical Assessment. Angiography is not required unless there is unusual concern about the proximal vasculature. In over 300 transfers for congenital defects in children, we have never failed to find suitable recipient vessels on exploration. In cases of loss secondary to meningococcal septicemia, we have performed angiography only to find normal large vessels reflecting the microvascular nature of this condition. Preoperative assessment by a child's anesthesiologist is required, because the procedure is lengthy and the child must be healthy. Ideally, the same surgeon and anesthetist should collaborate on all cases to maximize the team's experience.

Surgical Technique. The authors prefer to have a single surgical team, believing that any perceived benefit in time saved with two surgical teams is dissipated in divided responsibility, potential confusion, and the lack of space around the operative site in small children. We can perform a bilateral synchronous double-toe transfer in 5 to 8 hours with a single surgical team. Tourniquet times on the feet are less than an hour. Tourniquet times on the hand reach 2 hours as the four anastomoses are completed.

Hand preparation. The hand is explored under tourniquet control. The dorsal exposure is via a transverse incision at the wrist crease. This incision avoids unsightly, often parallel, longitudinal or zigzag incisions on the dorsum of the hand. The extensor tendons, veins, and dorsal branches of the radial or ulnar nerve are identified and marked. Proximal excursion of the extensor tendons is confirmed via traction. The tendon with the greatest excursion is chosen as the donor tendon. When more than one tendon is required, either the extensor indicis proprius or extensor digiti quinti is used in an attempt to achieve some independent function. The venous anastomosis is planned on the dorsum of the hand, and the arterial

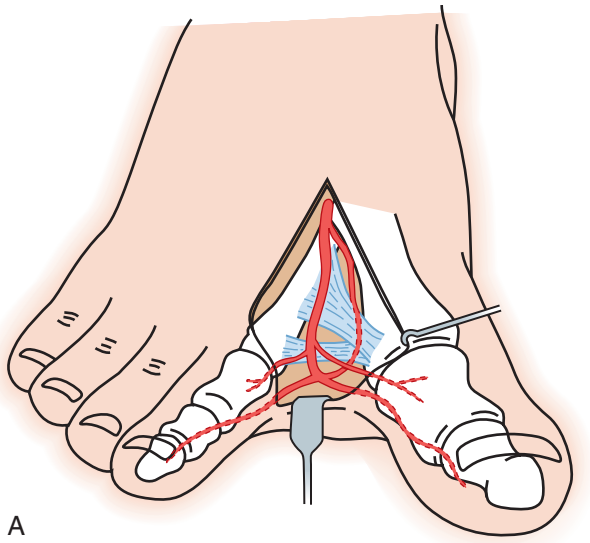

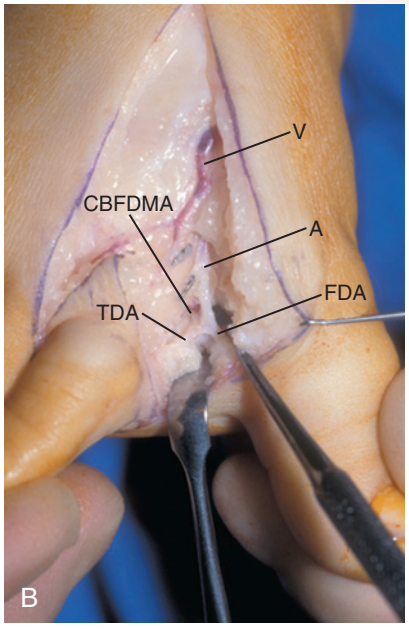

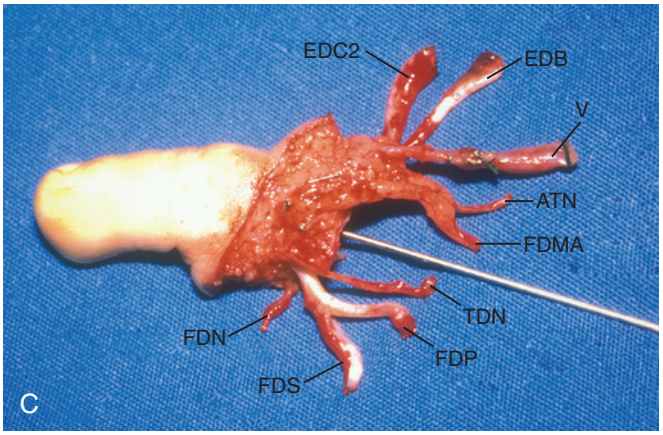

FIGURE 36.86 **A,** The first web space is approached in a distal to proximal direction. The fibular vessel of the great toe is most easily identified and traced proximally to the communication with the first dorsal metatarsal artery, the first plantar metatarsal artery, and the tibial vessel to the second toe. The exact architecture of the junction between these vessels is variable, but all these named vessels are usually present, although either the plantar or the dorsal may be predominant. The dorsal branches to the toes arise from the dorsal metatarsal artery as shown. **B,** The vessels of the first web space. The fibula digital artery (FDA) of the great toe is seen clearly and, when traced proximally, leads to the junction between the first dorsal metatarsal artery (A) and the communicating branch for the first dorsal metatarsal artery to the plantar artery arterial system (CBFDMA). At or about the same level, the tibial digital artery (TDA) of the second toe arises. The dorsal vein (V) and the fibular dorsal artery (FDA) are also clearly seen. **C,** The second toe has been harvested and a Kirschner wire introduced through the base of the proximal phalanx in preparation for osteosynthesis. The individually identified structures are noted: the extensor digitorum communis (EDC2) tendon; the extensor digitorum brevis (EDB) tendon; the dorsal vein (V), a tributary of the long saphenous vein; the dorsal digital nerve, a branch of the anterior tibial nerve (ATN); the first dorsal metatarsal artery (FDMA); the tibial digital nerve (TDN); the flexor digitorum profundus (FDP) tendon; the flexor digitorum superficialis (FDS) tendon; and the fibula digital nerve (FDN).

anastomosis is planned for the palmar surface or in the anatomic snuffbox.

The skin incisions for the recipient site are planned to result in a transverse scar on the palmar surface and a "V"-shaped scar on the dorsum. This shape allows insetting of a tongue of dorsal foot skin. The level of bony union is identified and marked. The proximal palmar exposure is accomplished via a zigzag incision. The median and/or ulnar nerves are identified at the level of the carpal canal along with the flexor tendons. The ulnar artery, the superficial palmar arch, and the radial artery within the anatomic snuffbox are examined and identified for later use.

Retrieving the second toe (points relative to children). The skin pattern on the toe is designed with reference to the defect in the hand, usually incorporating a "V"-shaped flap of dorsal skin. The harvest begins under tourniquet control using the entire skin incision, including a dorsal linear incision running between the first and second metatarsals. A single dorsal vein is isolated. In the child, the major veins lie in a distinctly deeper layer of subcutaneous fat than the smaller superficial veins. We have developed a method for defining the vascular anatomy of the toe in a retrograde distal-to-proximal manner.[94,95,179] An assistant separates the first and second toes, and the fibular digital artery of the great toe is identified (Figure 36.86). The artery is traced to its common origin with the second toe vessel. From this bifurcation, both the plantar and dorsal metatarsal arteries may be traced in a proximal direction. This technique facilitates early selection of the artery for anastomosis. In two thirds of cases, there is a sizeable first dorsal metatarsal artery for anastomosis and the plantar artery and vessel to the great toe can be divided. The proximal dissection of the dorsal artery is then straightforward. In one third of cases, the plantar artery must be used for anastomosis and the dissection is more difficult, but in these young, flexible patients, it is considerably easier than in the corresponding situation in the adult. Plantar dissection is facilitated by use of a spreader retractor to widely

and forcefully separate the first and second metatarsals. The deep peroneal branch of the anterior tibial nerve is harvested and usually lies closely applied to the vein and first dorsal metatarsal artery. Both of the plantar digital nerves of the second toe are dissected in a proximal direction and separated from the adjacent component of the common digital nerve.

The flexor tendons are exposed at the proximal edge of the flexor sheath just proximal to the metatarsophalangeal joint. The tendons are retracted distally with the ankle flexed, allowing division deep within the sole of the foot. The bone transection is performed through the metatarsophalangeal joint. Other authors have preferred to incorporate the metatarsophalangeal joint as a mobile joint (but this has disadvantages as well as benefits; see previously). The tourniquet is deflated, perfusion of the toe is confirmed, and hemostasis is achieved. The vascular pedicle is divided just before transfer to the hand.

Osteosynthesis. After the toe is separated from the foot, the bone is prepared on the back table. When the osteosynthesis is planned at the base of the phalanx, the epiphyseal cartilage is progressively shaved away until the pink blush of subchondral bone is encountered. In some cases, a composite joint can be formed between the articular surface of the base of the proximal phalanx of the toe and the articular surface of the metacarpal. Longitudinal Kirschner wires are preferred. The wires cause little damage to the growing epiphyses, are quick to apply, and are adequate to achieve union in these young hands. Crossed Kirschner wires interfere with the adjacent toes, risk damage to the digital vessels, and do not allow correction of rotation after preliminary placement. Interosseous wire and plates are not used because of the proximal growing epiphyses.

Tendon repairs. The toe is brought to the hand, and after osteosynthesis the extensor tendons are repaired. The tendons are passed deep to dorsal skin and fat and are repaired by weave at the wrist level. Two extensor tendon repairs are preferred. After extensor tendon repair, any extensor tendon that passes to an absent ray is divided to prevent a tethering or quadriga effect because the proximal extensor muscles may share a common belly.

Selection of the flexor tendon is more difficult. In symbrachydactyly or transverse absence, inadequate excursion is common. Unless individual flexor digitorum profundus and flexor digitorum superficialis tendons are present in the hand, only the toe flexor digitorum profundus is repaired. An overlapping repair or a weave is performed. The toe flexor digitorum superficialis tendon is cut short and, again, any tendon anlage passing to an absent ray is divided to prevent the quadriga effect from the conjoined proximal muscle mass.

Nerve repairs. Repair as many nerves as possible using the microscope. The nerve repair should be as proximal as possible to ensure good recipient nerve quality in the hand.

Vessel repairs. A single artery and a single vein are repaired. Other authors have recommended repair of more vessels; this confers neither a theoretical nor a practical advantage in our opinion, however, as the failure rate is exceedingly low. Vein grafts are not needed. A warm pack is applied to the limb and the tourniquet is deflated. The transferred digit is observed for 10 or 15 minutes to ensure vascular patency.

Skin repair. The skin is loosely closed with absorbable sutures at wide intervals to allow blood to ooze from the wounds. No attempt is made to close the wound completely and so tension is avoided. Most children will require scar revision surgery, so the use of split-skin grafts is encouraged rather than tight closure. The exception to this tenet is the dorsum of the hand. Considerable swelling may create shear forces on the vein as it passes beneath the distal edge of the dorsal palmar skin and, therefore, skin closure should be complete. The hand is gently wrapped without compression and a plaster slab applied with the elbow at 90 degrees.

Postoperative care. The child is admitted to the critical care unit in a temperature-controlled room for 24 hours after surgery. Core and peripheral temperature, pulse, central venous pressure, and urine output are all monitored. The child is kept relatively sedated and has indwelling regional local anesthetic infusions. The child is discharged to go home 3 to 5 days after surgery. Dressings are changed 6 weeks after surgery, usually under general anesthesia. The Kirschner wires are removed and the digits gently manipulated. A thermoplastic splint is fabricated for nighttime use and during challenging physical activity. Parents are instructed in passive and active motion and to protect the insensate digit from harm, especially self-inflicted harm. The parents are warned that during reinnervation, the child will experience uncomfortable dysesthesias that are normal and transient.

Additional indications and technical alternatives. Another indication for microvascular toe transfer is traumatic loss of digits. Toe transfers have been reported in children for the reconstruction of traumatic defects, including the metacarpal hand. In some cases, these defects are bilateral, and the use of a single toe from each foot will not produce adequate reconstruction of function. The use of transfers from the great toe (wraparound flap or trimmed toe transfer) and the use of monobloc transfer of the second and third toes have been necessary in some of these cases.[102,180]

Transfers from the great toe. Transfers from the great toe are favored in adults for certain aspects of hand reconstruction.[39,98,106,116,181,187] In the congenital hand, great toe transfer is seldom indicated because reconstruction can usually be accomplished using the second toe. In some traumatic defects, however, great toe transfer may be necessary. Considerable aesthetic morbidity results from harvesting the whole great toe. Parents are reluctant to allow such harvest. The wraparound free flap from the great toe contains no epiphysis and is usually unsuitable in the growing child. The wraparound free flap may be used in the older child or in distal digital injuries with soft tissue avulsion.

The metacarpal hand. Loss of most or all of the digits may be a result of trauma. The metacarpals may be spared, and the thumb may or may not escape injury. Adequate function can be expected when the thumb has been amputated distal to the middle of the proximal phalanx and if a portion of the proximal phalanges of the fingers is present. Any more proximal loss usually results in poor function. Such hands are best reconstructed using some form of free toe transfer.[180]

Results. The results of toe transfer in children have been reported.[90,95,100,134] In general, the procedure has been demonstrated to be reliable, with a low microvascular failure rate and with good sensory recovery and functional improvement noted. Growth continued in the transferred toes in the reported series.

The senior author initially reported on 66 toe transfers in 40 children. All but 3 children achieved motion in their transferred



FIGURE 36.87 Results after double synchronous second toe transfer in a child with transverse absence of all fingers but a competent thumb. There was recovery of good sensibility and some prehension.

toes. The mean total range of active motion was 60 degrees and was independent of the number of tendons repaired. The passive range was always greater than the active range. Grasp function was useful and satisfactory for both small and large objects in the majority of cases (Figure 36.87). Sensibility recovery showed two-point discriminations of between 4 and 5 mm. Currently, over 300 transfers have been performed with the loss of a single partial toe transfer. The thumb ray was the most common recipient, and the fourth ray was the second most common beneficiary.

Additional attention has focused on the psychological aspects of surgery. The vast majority of parents (84%) and children (88%) thought the hand was improved after surgery. Only one adult and one child thought the hand looked worse. Scarring was not a dominant complaint of the parents and was virtually ignored by the children. Most parents (80%) believe the hand was incorporated into function most of the time. No adverse effect of toe transfer from the psychosocial viewpoint was found. These results are supported by Richardson and coworkers in their review.[133] The reconstructive surgery appears to have a positive response on the child and family.

Secondary surgery. Microsurgery rarely offers a one-stage reconstruction, and secondary procedures are usually necessary. The need for adjustment of the skin, bone, and tendon transfers is common. Procedures include pulp plasty, scar revision, excision of skin graft, and tenolysis. Opposition transfers and rotation osteotomies may also be needed. Secondary surgery is usually deferred for at least 18 months to allow scar maturation, joint motion, and the incorporation of the transfer into use.

CRITICAL POINTS *Absence of Fingers*

- Digital absence or hypoplasia is due to either longitudinal or transverse absence or hypoplasia. This is an important distinction because of the probable nonexistence, in longitudinal absence, versus the probable presence, in transverse absence, of the supporting neurovascular and motor structures for digital function.
- Transverse digital absence may be a consequence of constriction ring syndrome or be due to the hypoplasia associated with the symbrachydactyly spectrum.
- Symbrachydactyly is a spectrum of deficiency, beginning with short middle phalanges that can extend to absence of the central rays and culminating in absence of the entire hand.
- Treatment of symbrachydactyly depends on the degree of digital suppression. Mild forms with a competent thumb and digit or digits require no treatment. Severe forms with an absent thumb or absent fingers may benefit from extraperiosteal phalanx transfer or microsurgical toe-to-hand transfer.

Expected Outcomes

The outcomes of digital reconstruction depend on the surgery and the extent of hypoplasia in the hand. Augmentation of existing digits with free phalangeal grafts may improve pinch and grasp, but growth is limited and the stability of the graft is variable. The addition of digits to the hand by vascularized toe transfer may add or assist in the development of pinch and grasp in an otherwise limited hand. In general, these procedures should not be undertaken unless the surgery is expected to add at least one new prehension pattern. In rare cases, appearance may be a relative indication, and a satisfactory outcome then depends on the child's and peers' perception.

CLINODACTYLY

Clinodactyly is angulation of the digit in the radioulnar plane distal to the MCP joint (Figure 36.88). Minor angulation, particularly of the small finger, is common to the point of normalcy. It is noteworthy that clinodactyly has been defined as angulation of more than 10 degrees. The anomaly arises because the shape of one (or more) of the phalanges is either triangular or trapezoidal and the alignment of the associated IP joint is deviated away from perpendicular to the normal longitudinal axis of the finger. The abnormal shape develops as a result of asymmetric longitudinal growth.

Epidemiologic Findings

The true incidence of clinodactyly is difficult to ascertain, with figures ranging from 1% to 19.5%. Clinodactyly presents most commonly as an isolated radial inclination of the small finger, owing to the middle phalanx adopting a triangular or trapezoidal shape. This form of clinodactyly is inherited as an autosomal dominant trait and is often bilateral. Expression of the trait is variable, with males more likely to express the phenotype. Clinodactyly is also seen as part of many syndromes and complex hand anomalies.

Severe clinodactyly may present in the neonate or infant, although most cases present later as the angulation becomes more obvious with growth. The reason for presentation is usually appearance, because compensatory abduction of the

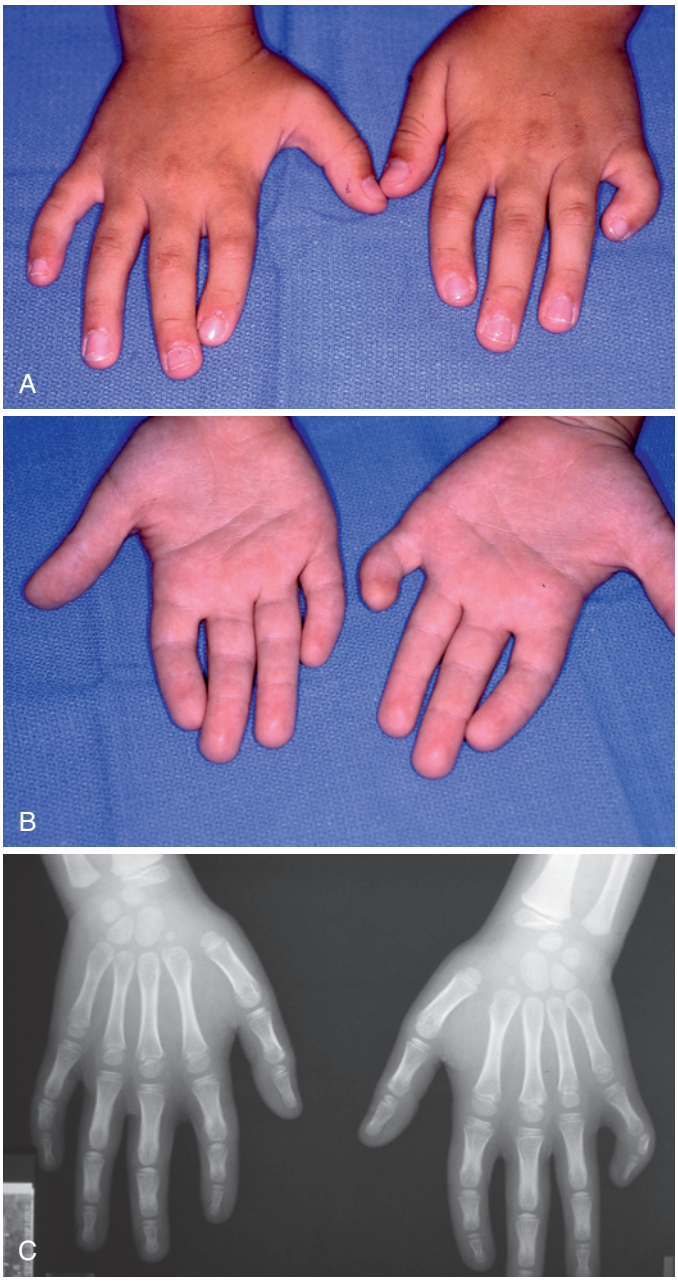

FIGURE 36.88 Five-year-old with bilateral small finger camptodactyly, left more severe than right. **A,** Dorsal view. **B,** Palmar view. **C,** Anteroposterior radiograph. (Courtesy of Shriners Hospital for Children, Philadelphia.)

small finger will prevent substantial interference with flexion. Thumb or central digit clinodactyly may cause functional impairment secondary to altered flexion of the fingers or limit pinch.

The radiographic appearance varies with the age of the patient and degree of bony involvement. In the skeletally mature patient, a triangular or trapezoidal bone will be apparent (see Figure 36.88). In the skeletally immature patient, the secondary center of ossification may be malformed, traverse around the base of the phalanx, and travel along the shortened side of the bone (Figure 36.89). The most severe form of longitudinal epiphyseal bracket forms a "C" shape as the bracket that unites the proximal and distal growth centers. Clinodactyly can be

TABLE 36.10 Classification of Clinodactyly Deformity

Type of Deformity	Area of Deformity	Angulation of Deformity	Associated Deformity
Simple	Middle phalanx	Less than 45 degrees	
Simple complicated	Middle phalanx	More than 45 degrees	
Complex	Bone and soft tissue	Less than 45 degrees	Syndactyly
Complex complicated	Bone and soft tissue	More than 45 degrees	Polydactyly or macrodactyly

Cooney WP: Camptodacytyly and clinodactyly. In Carter P, editor: *Reconstruction of the child's hand*, Philadelphia, 1991, Lea & Feibiger.

classified according to cause or pathologic condition; the most useful classification is that proposed by Cooney (Table 36.10).[43]

ANATOMY

The longitudinal growth of tubular bones such as the phalanges is generated at the epiphyseal growth plate, with axial alignment maintained by factors intrinsic and extrinsic to the growth plate. An abnormal growth plate secondary to a congenital anomaly or postnatal insult will produce progressive deformation with growth. The growth plate anomaly associated with clinodactyly is the "C"-shaped physeal plate extending along one side of the bone, forming a bracket that restricts longitudinal growth on one side of the bone. The pathologic finding was described initially by Jones in his description of triangular or "delta" phalanges in severe clinodactyly. The pathologic condition has been described as a longitudinal epiphyseal bracket, and a spectrum of severity and a classification system have been described. When complete ossification of the bracket occurs early, no longitudinal growth is possible and a short triangular bone, the *delta phalanx*, is produced. If the bracket is incomplete or is cartilaginous, some longitudinal growth occurs and the phalanx is trapezoidal. The epiphyseal bracket affects the middle phalanx most commonly, because this is the last bone to ossify in the digital skeleton. The epiphyseal bracket may also occur in the proximal phalanx or within the extra phalanx in hyperphalangism. More complex variants of the anomaly exist, with the *dual* or *kissing delta phalanx* occurring in specific syndromic anomalies such as *Rubinstein-Taybi syndrome* and *Cenani-Lenz syndactyly*.[56] Acquired causes of clinodactyly include trauma to the growth plate from injury or frostbite or inflammatory arthritis with asymmetric physeal closure. Bone tumors can also produce a secondary angular deformity, though this is usually related to asymmetric deformity of the joint surface produced by expansion of juxtaarticular tumors rather than tethering of the growth plate.

Although the skeletal anomaly generates the angulation of the finger, the underlying soft tissues are affected. Severe angulation leads to soft tissue shortening on the concave side of the digit and possible displacement of the extensor mechanism. This soft tissue deformation requires consideration during surgical correction.

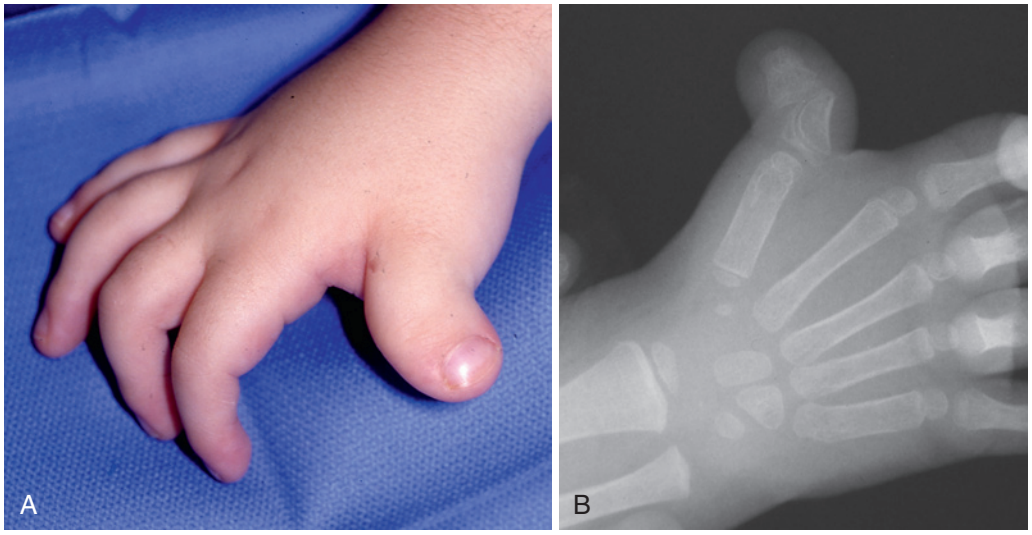

FIGURE 36.89 Three-year-old with Rubinstein-Taybi syndrome. **A,** Thumb clinodactyly. **B,** Anteroposterior x-ray with longitudinal epiphyseal bracket. (Courtesy of Shriners Hospital for Children, Philadelphia.)

Management

The majority of patients with isolated clinodactyly of the small finger present with an aesthetic rather than a functional problem. Surgery should be avoided in these cases, because any improvement in appearance occurs at the risk of scarring and stiffness. Surgical correction is indicated for severe clinodactyly with shortening and angulation, particularly where the radial digits or thumb are involved and angular deformity interferes with pinch.

Splinting for clinodactyly is fruitless. Correction of the skeletal anomaly requires either an osteotomy to realign the digit or resection of the longitudinal epiphyseal bracket to release the longitudinal growth potential of the shortened side of the digit. Realignment of the axis of the digit with an osteotomy may be achieved with a closing wedge or opening wedge, or a combined procedure, the reverse wedge osteotomy. The closing wedge osteotomy (Figure 36.90) is attractive because of its relative simplicity and reliability; however, in the shortened digit a further loss of length may be unacceptable. An increase or maintenance of length is possible with either an opening wedge or a reverse wedge osteotomy. Bone graft is required for an opening wedge osteotomy; this presents its own difficulties in the small child, in whom donor sites are restricted. The reverse wedge osteotomy is technically challenging in the small bones of the child's hand and requires access to both sides of the digit.

Corrective osteotomy is indicated in moderate deviation that interferes with function. If possible, correction is best deferred until skeletal maturity to allow ample time for bone growth. In the skeletally immature patient, osteotomy is technically challenging, with risks of incomplete or excess correction or physeal injury with the additional consequences. In severe clinodactyly or thumb clinodactyly, earlier surgery may be required. Corrective osteotomy tries to achieve a single-stage correction. The soft tissue deficit on the concave side may be addressed with a "Z"-plasty.[151] In severe angulations, "Z"-plasty may be inadequate and a rotational flap or step advancement flap described by Evans and James[58] may be required. For the severe types, realignment of the extensor mechanism may also be necessary to maintain balance of the corrected digit. Clinodactyly in the triphalangeal thumb or hyperphalangism of the fingers may be addressed by excision of the extra malformed phalanx. Ligament reconstruction or arthrodesis of the adjacent joints is obligatory to restore stability.

An alternative to corrective osteotomy is epiphyseal bracket resection and fat grafting (Figure 36.91).[174] This procedure is based on the premise that resection of the bracket will allow the normal portion of the epiphyseal growth plate to generate "catch-up" longitudinal growth on the shortened side and produce angulatory correction over 1 to 2 years. The procedure is performed through a midlateral incision on the short side of the phalanx. The cartilaginous or bony bracket is resected until metaphyseal bone is exposed from dorsal to volar and the growth plate is defined. The defect created is filled with fat, harvested from the forearm, to fill the dead space and prevent fusion across the growth plate. The procedure is limited to patients with open growth plates and is best performed early, although Vickers has performed the procedure with good results on children with only 1 to 2 years of growth remaining.[174] In a review of this procedure,[36] a group of 23 children with 35 operated fingers obtained a mean correction of 11 degrees after a mean follow-up period of 3.2 years. Further analysis revealed that better results were obtained with surgery before the age of 6 years. In addition, fingers with angulation of more than 40 degrees had a greater degree of improvement (20 degrees) compared with those with less than 40 degrees of preoperative angulation (7.5 degrees). Bracket resection does not preclude the use of corrective osteotomy for residual angulation and requires minimal splinting or postoperative immobilization.

❖ AUTHORS' PREFERRED METHOD OF TREATMENT

The preferred approach for mild to moderate clinodactyly is to avoid surgery. Surgery is especially rejected in the common mild deformity of the small finger. When the angulation is considerable and the phalanx is a delta phalanx, early epiphyseal bracket resection and fat grafting may be performed. When the patient presents with substantial angulation and is skeletally mature,

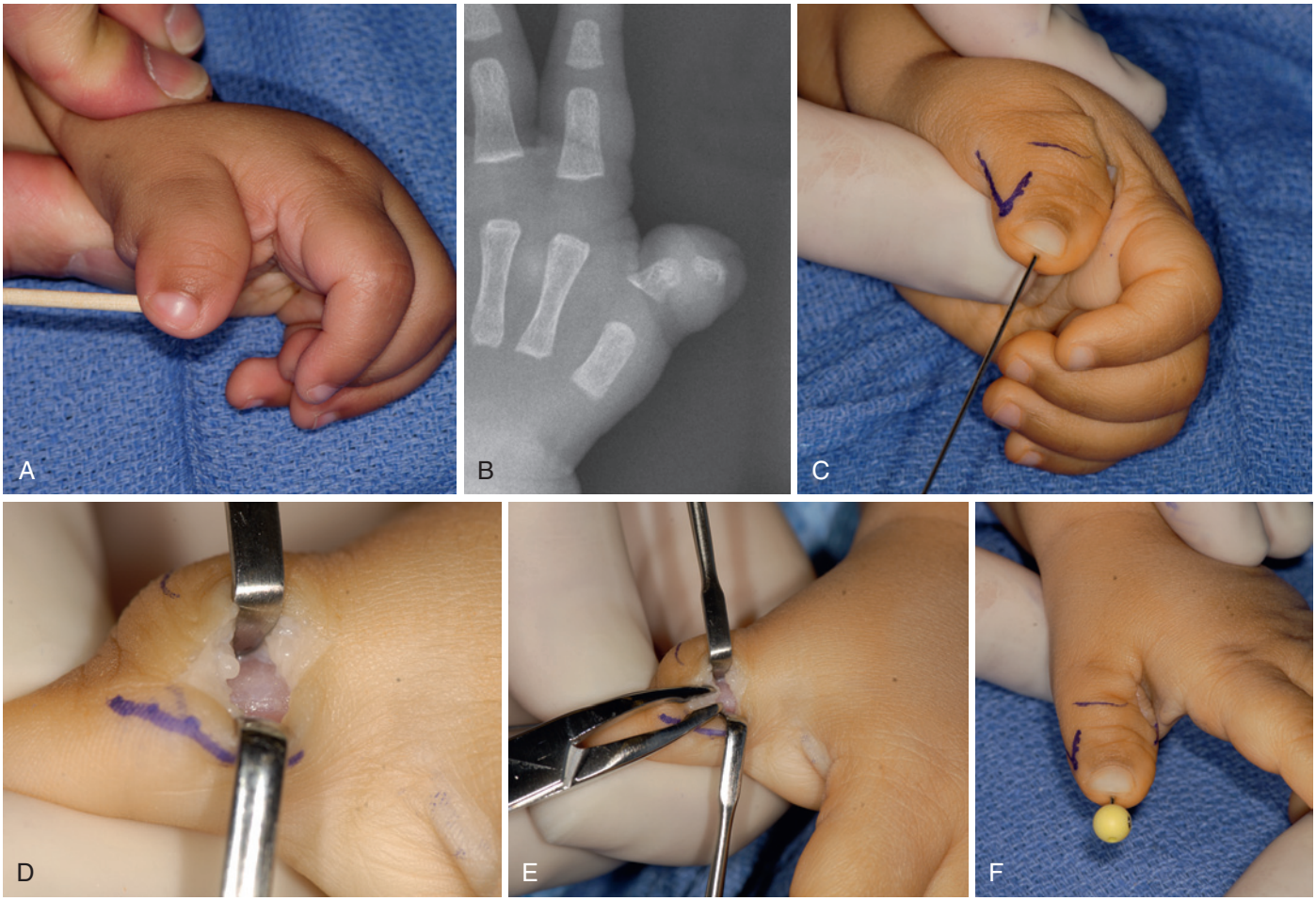

FIGURE 36.90 One-year-old with thumb clinodactyly attributed to abnormal configuration of proximal phalanx. **A,** Preoperative appearance. **B,** Anteroposterior radiograph. **C,** Kirschner wire drilled from tip of thumb into proximal phalanx. **D,** Midlateral approach to the phalanx with elevation of the extensor and flexor tendons. **E,** Rongeur to remove a bony wedge. **F,** Thumb manipulated to crack the remaining concave cortex and longitudinal Kirschner wire is advanced across the osteotomy site. (Courtesy of Shriners Hospital for Children, Philadelphia.)

the decision is based on the configuration of the phalanx. The trapezoidal phalanx tolerates the shortening of a closing wedge osteotomy, whereas a triangular bone will benefit from an opening wedge osteotomy. After corrective osteotomy, fixation is achieved with an axial Kirschner wire. The associated soft tissue deficit with severe clinodactyly can be addressed with the bipedicle step advancement flap described by Evans and James.[58] A reverse wedge osteotomy is technically demanding in small triangular phalanges, and a simple osteotomy is preferred with the addition of bone graft. In patients with thumb clinodactyly, a primary corrective osteotomy is performed to produce a well-aligned thumb column rather than rely on gradual correction with growth after bracket resection.

Expected Outcomes

The expected outcome of surgery in the case of osteotomy is correction of the deformity; however, this may be complicated by stiffness of the digit as a result of scarring and adhesions, so one must balance the extent of the deformity against this risk before deciding on surgery. The outcomes of epiphysiolysis vary according to the extent of growth potential remaining in the digit at the time of surgery.

CRITICAL POINTS *Clinodactyly*

- Clinodactyly is angulation of the digit in the radioulnar plane distal to the MCP joint.
- Minor angulation, particularly of the small finger, is common to the point of normalcy. The cause is usually an abnormal trapezoidal shape of the middle phalanx that leads to radial deviation of the distal IP joint.
- Greater angulation may be secondary to a "longitudinal diaphyseal bracket" or a "longitudinal epiphyseal bracket" along the middle phalanx.
- Mild to moderate clinodactyly requires no treatment.
- Substantial clinodactyly requires realignment of the digit via a closing wedge, an opening wedge, or a reverse wedge osteotomy. The soft tissue deficit on the concave side must also be addressed.

KIRNER DEFORMITY

Kirner deformity is characterized by progressive palmar-radial curvature of the distal phalanx of the digit, usually affecting the small finger. The deviation occurs in two planes, a different situation than the deviation in a single radioulnar plane that occurs in clinodactyly.

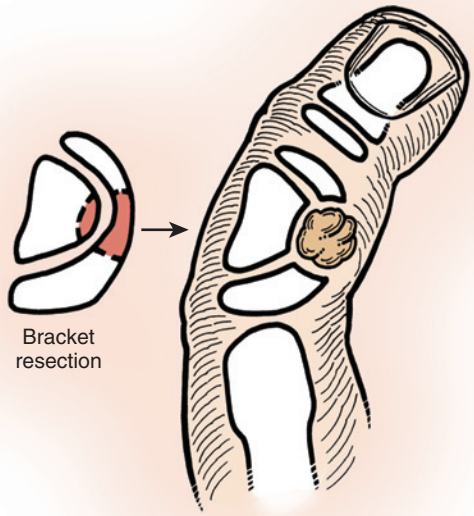

FIGURE 36.91 Bracket resection option for the treatment of clinodactyly caused by a delta phalanx. (Adapted from Upton J: Congenital anomalies of the hand and forearm. In McCarthy JG [editor-in-chief], May JW, Littler JW [volume editors]: *Plastic surgery*, vol 8, the hand, part 2, Philadelphia, 1990, WB Saunders, pp 337–340, with permission. Redrawn by Elizabeth Martin.)



FIGURE 36.92 Clinical appearance of Kirner deformity of the right small finger.

Epidemiologic Findings

The incidence ranges from 0.15% to 0.25% of the population, and females are affected twice as frequently as males. The deformity may be inherited as an autosomal dominant trait with incomplete penetrance. The homozygous state is responsible for expression of the deformity in multiple digits and both hands. The deformity occurs sporadically in at least half of the cases. A distinction between the familial and sporadic cases is the age of onset, and this forms the basis of a classification proposed by Song.[155] Early-onset or congenital Kirner deformity is present at birth and associated with a family history. The deformity does not progress with growth. Late-onset Kirner deformity develops in late childhood or adolescence and is sporadic in incidence. Initially, swelling along the dorsum of the distal phalange(s) of the small fingers develops in one or both hands. There may be some discomfort associated with this stage, but usually the swelling is painless. The deformity ensues with the development of the palmar-radial curvature of the distal fingertip (Figure 36.92), which is marked by the clubbed or beaked appearance of the fingernail. Once established, the deformity is stable. Joint motion at the distal IP joint is preserved.

Kirner deformity has been seen in cases of Cornelia de Lange syndrome, Silver syndrome,[148] Turner syndrome, and Down syndrome. The differential diagnosis in the unilateral deformity is a delayed presentation of distal phalangeal trauma, particularly a physeal fracture with palmar angulation or burn or frostbite injury to the physis. A thorough history together with the physical and x-ray findings usually enables a confident diagnosis.

ANATOMY

Kirner deformity has been attributed to an abnormality of the physis of the distal phalanx. The subsequent distal deformity develops secondary to either asymmetric physeal growth or traction across the damaged physis from the flexor tendon. An alternative and attractive theory suggests that an abnormally distal insertion point of the flexor digitorum profundus tendon leads to excessive traction on the developing skeleton[21,50] or a normal flexor tendon acting on an abnormal osteopenic distal phalanx. A vascular cause for the deformity has also been postulated.

Kirner deformity is characterized by distortion and widening of the physeal plate along with curvature of the diaphysis of the distal phalanx (Figure 36.93). Radiographs show an abnormality of the epiphysis with the palmar lip of the epiphysis relatively lengthened and the metaphyseal margin of the physis sclerotic and ragged. Physeal plate closure is delayed and begins in the dorsal half of the physis. The histologic condition of the phalanx at this stage demonstrates lysis at the junction of the metaphysis and physis. Later, the diaphyseal curvature is well established, and in the mature form of the deformity, the physis has completely fused and normal bone density is restored throughout the deformed phalanx.

Management

Kirner deformity has little effect on function. Musicians and keyboard operators may identify specific problems related to small finger position. The indication for surgery is primarily restoration of the finger appearance. The patient must be counseled carefully about the potential risks of surgery and expected results.

Splinting the small finger into extension has been reported as effective in relieving discomfort in the early swelling stage of the deformity, although no benefit in prevention or correction of deformity was obtained. Other investigators have reported prolonged serial splinting useful in correcting the deformity if

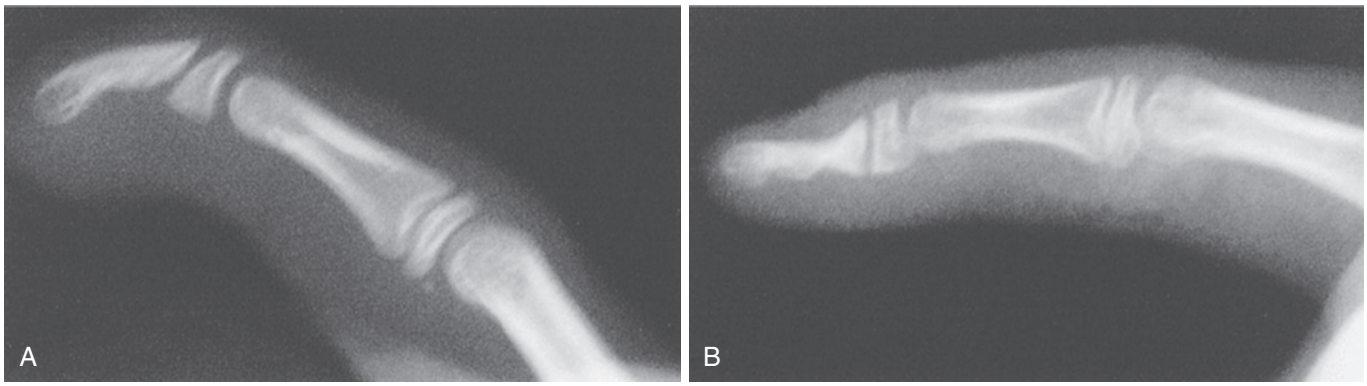

FIGURE 36.93 Preoperative **(A)** and postoperative **(B)** radiographs of Kirner deformity treated with an osteotomy.

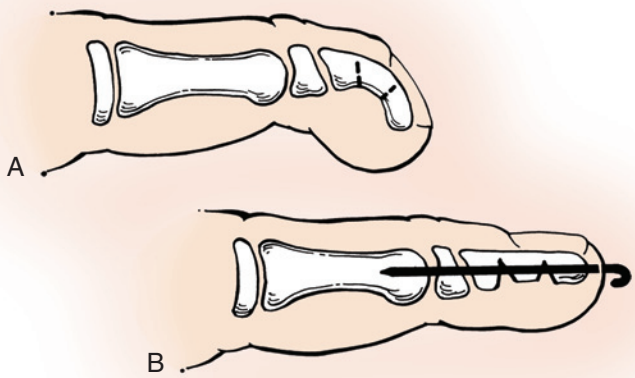

FIGURE 36.94 **A** and **B,** Multiple opening wedge volar osteotomies are used to straighten the distal phalanx over a Kirschner wire. (Adapted from Carstam N, Eiken O: Kirner's deformity of the little finger. *J Bone Joint Surg Am* 52:1663–1665, 1970, with permission. Redrawn by Elizabeth Martin.)

it has been applied in the early stages and before completion of growth. Benatar has reported the correction of the deformity by early release of the abnormal component of the long flexor tendon insertion.[21] If the epiphysis remains open, another option is to perform a dorsal hemiepiphysiodesis or resect a dorsal wedge including the dorsal growth plate to prevent progression of the deformity. For the mature deformity, corrective osteotomies have been used to improve the alignment of the phalanx and corresponding nail growth (Figure 36.94). The deformity has been addressed with a dorsal closing wedge osteotomy or, alternatively, two or three opening wedge osteotomies of the volar cortex to unfold the phalanx. The technique of distraction lengthening has also been used to correct the deformity.[118]

❖ AUTHORS' PREFERRED METHOD OF TREATMENT

Splinting can be attempted in the early stages of the deformity, although it needs to be rigorously monitored to be effective in preventing or correcting the deformity. Although there may be a role for early surgery as recommended by Benatar,[21] we do not routinely divide the distal part of the flexor tendon insertion to limit the deforming force on the developing bone. Usually, corrective surgery is deferred until the patient is able to participate in the decision-making process, because surgery is primarily performed for appearance rather than function. The authors' preference is to use volar osteotomies to correct the phalangeal curvature. The nail plate is removed and a radial dorsolateral incision preserving the paronychial fold is used to expose the distal phalanx. The osteotomies are planned distal to the flexor tendon insertion. Two or three are used, depending on the size of the phalanx. The volar periosteum is incised, and the dorsal periosteum is preserved so it can act as a hinge for the correction and prevent injury to the overlying nail matrix. The osteotomies are performed with a sharp osteotome. The curvature of the phalanx is corrected, and fixation is accomplished with an axial Kirschner wire. The Kirschner wire is left in place until the osteotomies have healed. The digit is protected with a splint during the healing process.

CRITICAL POINTS *Kirner Deformity*

- Kirner deformity is characterized by progressive palmar-radial curvature of the distal phalanx of the small finger.
- The precise cause is unknown.
- Radiographs reveal distortion and widening of the physeal plate along with curvature of the diaphysis of the distal phalanx.
- Kirner deformity develops in late childhood or adolescence, with initial swelling along the dorsum of the distal phalanx. Subsequently, a palmar-radial curvature of the distal fingertip develops over time.
- Kirner deformity has little functional effect, and the indications for surgery are limited.

MACRODACTYLY

Macrodactyly is a descriptive term used for a disproportionately large digit noted at birth or that develops within the first years of life. Both the soft tissue and skeletal elements are diffusely enlarged in the affected digit(s). Several alternative terms have been used, including *megalodactyly*, *gigantism*, *macrodystrophia lipomatosa*, and *macrodactylia fibrolipomatosis*. *Macrodactyly* is the widely recognized term that is preferred.

Macrodactyly is uncommon. In Flatt's series of upper extremity anomalies, the incidence of macrodactyly was 0.9%.[64]

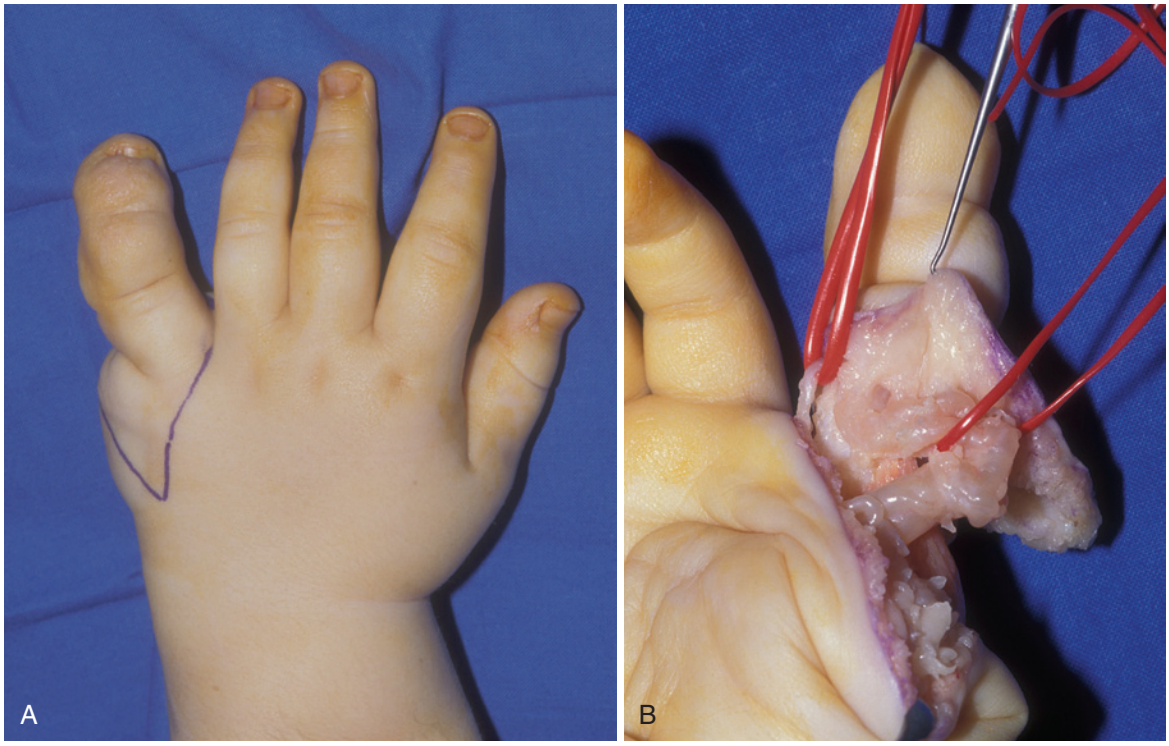

FIGURE 36.95 **A** and **B,** Macrodactyly of the fifth finger associated with lipofibromatous change in the ulnar digital nerve along with a normal radial digital nerve.

Most cases appear sporadically without evidence of inheritance. The most common form of macrodactyly is as an isolated anomaly associated with lipofibromatosis of the proximal nerve (Figure 36.95). Macrodactyly may also be part of a more diffuse hypertrophy or a component of a broader syndrome such as neurofibromatosis. Digital overgrowth can also occur secondary to a specific lesion within the digit, such as a tumor (soft tissue or bone), vascular malformation, or lymphedema. These cases are not considered true macrodactyly, because the overgrowth is secondary to the specific lesion.

Flatt's classification of macrodactyly centers on the pathologic basis of the deformity (Table 36.11). The original classification has been supplemented by the addition of the type IV group.

Macrodactyly associated with lipofibromatosis is often noted at birth or develops within the first 3 years of life. The growth of the enlarged digit may be disproportionate *(progressive macrodactyly)*, or the digits may maintain a consistent proportion to the remainder of the hand (*static macrodactyly*). A recent report noted the development of the progressive growth pattern in two children initially diagnosed with the static form of macrodactyly after a debulking procedure. The anomaly is usually unilateral and may affect more than one digit. Enlargement of multiple digits is two to three times more common than enlargement of a single digit. The index finger is the most frequently affected digit, particularly in combination with the thumb or long finger. Affected radial digits usually deviate in a radial direction. In contrast, affected ulnar digits deviate in an ulnar direction. Where two digits are involved, the deviation is usually divergent (Figure 36.96). Enlarged thumbs are typically

TABLE 36.11 Classification of Macrodactyly

Type	Description
Type I: Gigantism and lipofibromatosis	Macrodactyly associated with enlarged nerves infiltrated with fat within the digit and extending proximally through carpal tunnel; most common form of macrodactyly deformity
Type II: Gigantism and neurofibromatosis	Macrodactyly usually occurs in conjunction with plexiform form of neurofibromatosis and is often bilateral; may be osteochondral masses associated with the enlarged skeleton
Type III: Gigantism and digital hyperostosis (see Figure 36.99)	Hyperostotic form of macrodactyly with osteochondral periarticular masses developing in infancy; no significant nerve enlargement; very rare and not hereditary; the digits are nodular and stiff, and there may be other skeletal anomalies
Type IV: Gigantism and hemihypertrophy	Rare anomaly without known inheritance pattern or etiologic pattern; macrodactyly part of hemihypertrophy; all digits involved, but less severe than type I or II; deformity marked by intrinsic muscle hypertrophy or abnormal intrinsic anatomy; deformities present with flexion contracture, ulnar deviation, and an adducted thumb deformity

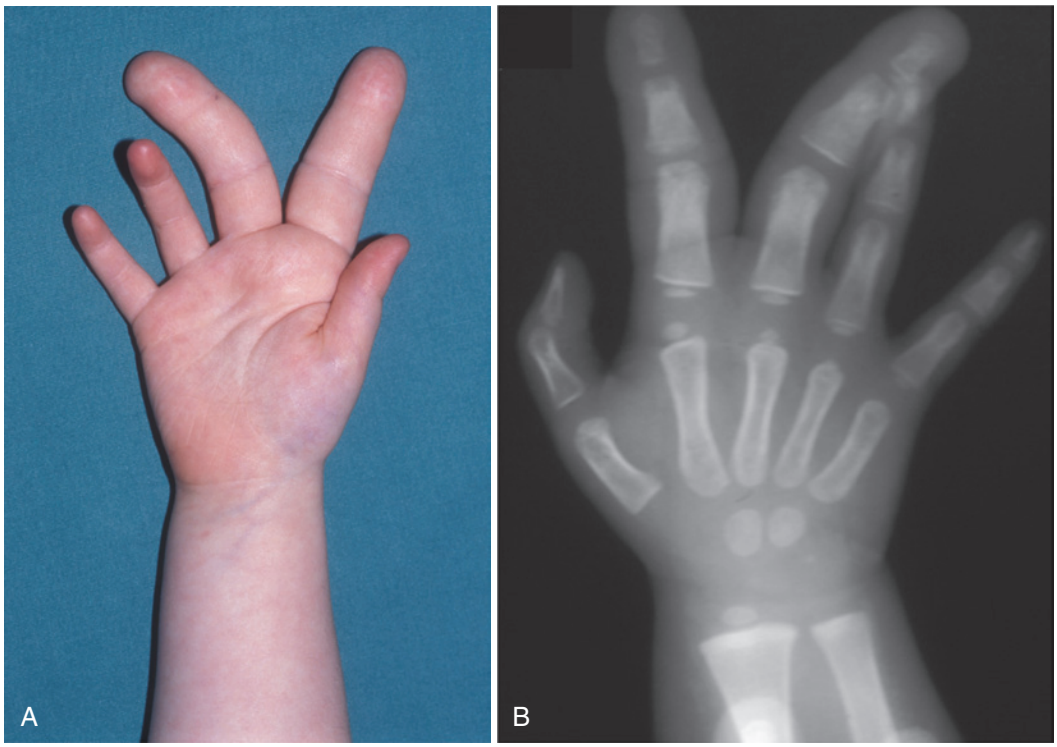

FIGURE 36.96 **A** and **B,** Macrodactyly of two adjacent fingers. The fingers usually deviate away from each other.

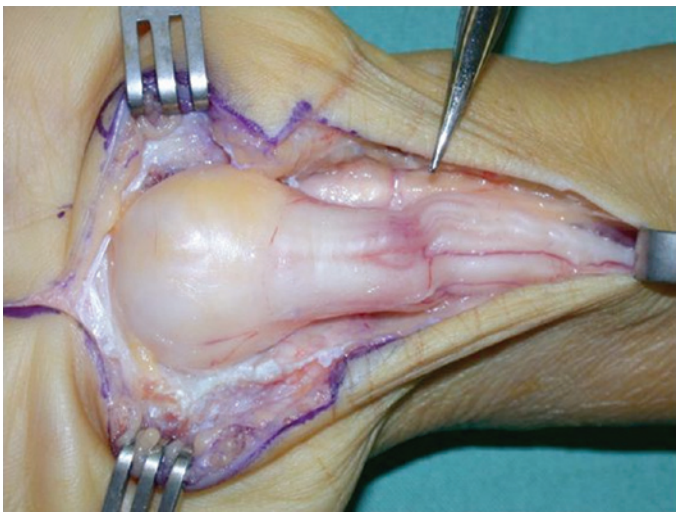

FIGURE 36.97 Median nerve involvement in a patient with macrodactyly of the thumb. This resulted in carpal tunnel syndrome, which required decompression.

abducted and extended. Osseous growth and deviation continues until physeal closure: however, soft tissue enlargement may continue into adulthood. The enlarged digits stiffen during growth, which further limits function.

Radiographs reveal an enlarged skeleton with advanced bone age compared with the normal digits (see Figure 36.96). The phalanges may be trapezoidal with deviation of the digit. Osteoarthritic changes may be noted early with osteophyte development. If angiography is performed, one of the digital arteries is often enlarged. Apart from the obvious digital deformity, soft tissue swelling in the palm may be present associated with fatty infiltration of either the median or ulnar nerves (Figure 36.97). This may be severe enough to result in a compression neuropathy. The thickening of the flexor sheath may produce triggering if digital range of motion is preserved. Syndactyly is seen in 10% of cases (Figure 36.98).

Macrodactyly associated with neurofibromatosis is diagnosed by the characteristic cutaneous stigmata (pigmented skin lesion, café-au-lait spots, multiple neurofibromas, pedunculated skin tumors, and ocular lesions) of type I neurofibromatosis.

Hyperostotic macrodactyly is rare and can be distinguished on clinical examination by nodular enlargement of the digit and profound loss of motion secondary to periarticular osteochondral mass formation (Figure 36.99). Although unusual, concurrent peripheral nerve lipofibromatosis has been reported with hyperostotic macrodactyly. The radiographic appearance of the periarticular osteochondral masses confirms the diagnosis.

Macrodactyly may also be part of a broader gigantism anomaly affecting the entire limb or body part in addition to the enlarged digit. The gigantism may be *segmental gigantism*, affecting only a part of one limb; *hemihypertrophy*, affecting one side of the body (associated with neurofibromatosis or Klippel-Trénaunay syndrome); or *crossed gigantism*, affecting regions on both sides of the body (Figure 36.100). Sometimes the hemihypertrophy can be subtle, but if a patient has macrodactyly of all digits, the remainder of the limb should carefully be examined for enlargement.

Other syndromes that feature digital enlargement include Ollier disease (multiple enchondromas), Maffucci syndrome (multiple hemangiomas and enchondromas), Klippel-Trénaunay-Weber syndrome (cutaneous hemangioma, atypical varicose veins, and hemihypertrophy), and Proteus syndrome[183] (hamartomatous dysplasia with features of macrodactyly, pigmented nevi, and subcutaneous hamartomas). Proteus syndrome is



FIGURE 36.98 **A** and **B,** Macrodactyly with associated syndactyly. This combination occurs in about 10% of patients.

extremely variable with regard to phenotype and associated anomalies.

ANATOMY

The cause of true macrodactyly is unknown. Potential mechanisms have been postulated, including an abnormal nerve supply leading to unimpeded growth, an increase in blood supply, and/or an abnormal humoral mechanism stimulating growth. The most convincing theory is based on the association between peripheral nerve pathologic findings and macrodactyly, because the most common type of macrodactyly is associated with fatty infiltration and enlargement of the nerve associated with the digit (see Figure 36.95). This lipofibromatosis of the nerve has been alternatively reported as a fibrolipoma,[30,138] lipofibroma, or hamartoma.[5,123] Although it is commonly associated with macrodactyly, lipofibromatosis of the nerve can occur in isolation.[149] The macroscopic findings are an increased amount of subcutaneous fat, an enlarged tortuous digital nerve(s), and skeletal overgrowth in all dimensions. Most macrodactyly occurs in a single digit or in a region innervated by a single nerve. Where a common digital nerve is affected, the digits it supplies diverge, leading to speculation that the overgrowth is greater in the territory supplied by that nerve and hence the divergence, and also to speculation that the affected nerve itself causes the overgrowth. This speculation is not confirmed. The term *nerve territory–oriented macrodactyly* describes this relationship.

Typically, the palmar aspect of the finger is more affected than the dorsal aspect, and the distal finger is more enlarged than the proximal finger. The tendons have a normal appearance, although the flexor tendon sheath may be thickened. Histologic findings of the digital tissues show thickening of the skin with decreased sweat gland density, abundant subcutaneous fat with increased fibrous stroma, fatty infiltration of the digital nerves with endoneural and perineural fibrosis, and enlarged digital arteries. The bony structure shows wide medullary canals, irregular trabeculae, and thickening of the periosteum. Macrodactyly associated with neurofibromatosis is similar, although the plexiform nerve has an increased fibrovascular stroma and nodular appearance rather than fibrolipomatosis changes.

Exostoses and other skeletal deformities may be noted in the enlarged digit. Hyperostotic macrodactyly is marked by periarticular exophytic osteocartilaginous masses (see Figure 36.99) and is typically not associated with enlargement of the associated peripheral nerve.

Management

Macrodactyly is a disfiguring anomaly. Patients usually present in childhood, although they may present later with a compression neuropathy secondary to pathologic enlargement of affected nerve(s). Children with macrodactyly are often subject to teasing and have social difficulties. As a consequence, the hand is often concealed and ignored. Indications for surgery include functional and aesthetic improvements. The enlarged digit(s) often obstructs grasp and pinch.

Macrodactyly is extremely difficult to treat. The progressive and diffuse nature prevents complete correction to normal. The expectations of the parents and sometimes the child must be carefully managed prior to surgery. In particular, the inability to establish a normal digit and the probable need for multiple stages of surgery should be established. Available surgical options can be divided into procedures that limit ongoing growth, that reduce the size of the digit, or that correct deviation, or amputation (Table 36.12). The procedures may be combined at the same time or staged according to the patient's needs. In addition, carpal tunnel or Guyon canal decompression may be needed in cases with concurrent compressive neuropathy (see Figure 36.97).

Limiting Digital Growth

Proposed methods to limit growth include ligation of the digital arteries, compression bandaging, stripping the digital nerves, or resection of the digital nerve.[86] The most reliable method,

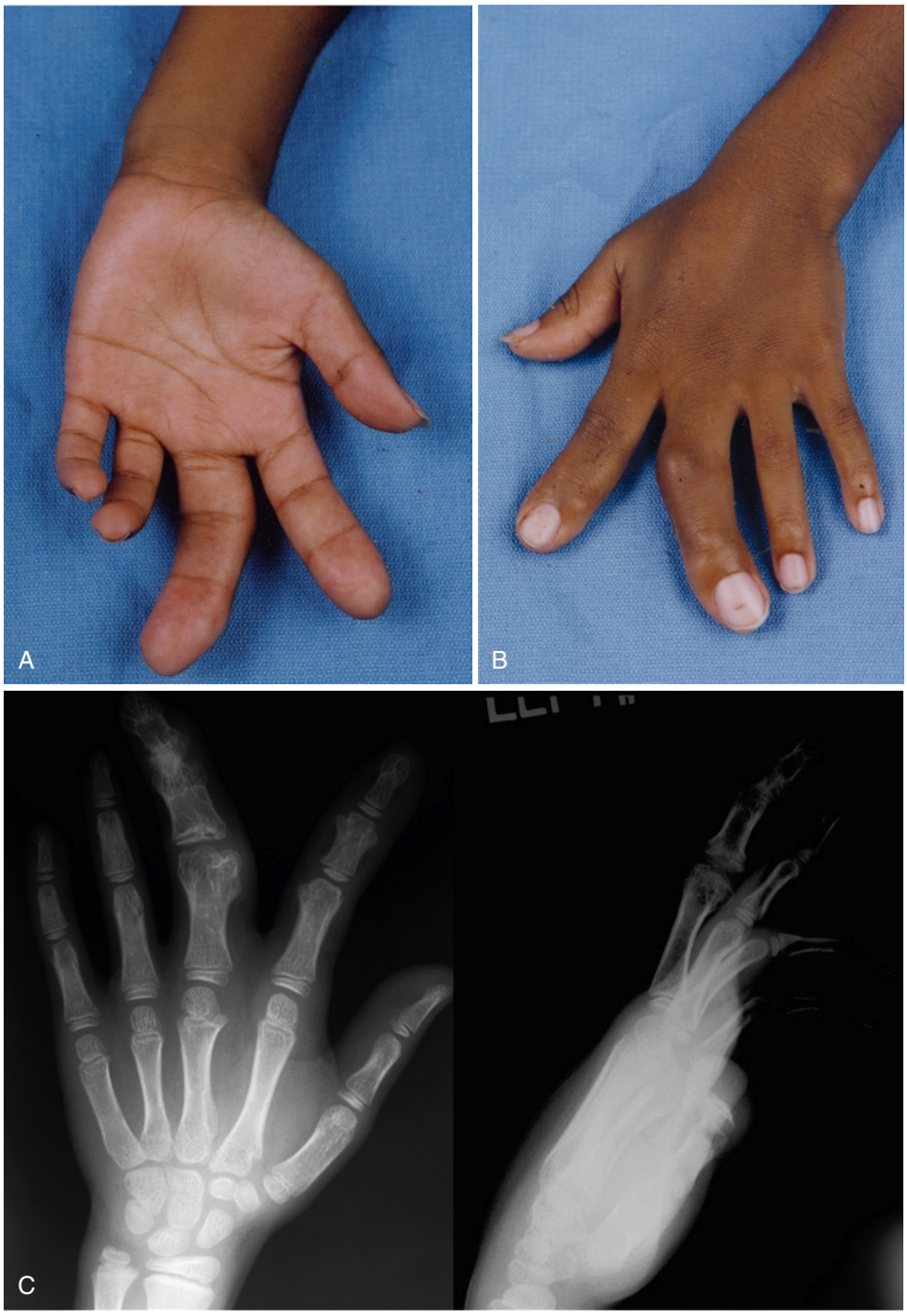

FIGURE 36.99 Hyperostotic macrodactyly. **A,** Palmar view of the hand of a 6-year-old boy with macrodactyly of the left index and middle fingers. **B,** Dorsal view. **C,** Radiographs showing periarticular exophytic osteocartilaginous masses. (Courtesy of Shriners Hospital for Children, Philadelphia.)

however, is epiphysiodesis.[86] This may be accomplished by various methods, including burring or drilling, resection of the epiphyseal plate, or physeal stapling in larger bones. Epiphysiodesis is performed when the digit reaches the length of the corresponding digit in the parent of the same gender as the child. Digital deviation can be corrected simultaneously by a closing wedge resection of the physis (Figure 36.101). Progressive deviation can also be managed by hemiepiphysiodesis on the convex side of the digit, although not as reliably as corrective osteotomy. Percutaneous Kirschner wires are often required to stabilize the phalanx after physeal resection, particularly if combined with a wedge osteotomy. Complications of physeal arrest include joint stiffness, excessive bone formation at the site of the physis, or secondary angulation after incomplete physeal destruction. Physeal arrest does not reduce soft tissue growth or the transverse (appositional) growth of the skeleton. Nerve



FIGURE 36.100 Nine-year-old with neurofibromatosis and enlarged left arm and hand. (Courtesy of Shriners Hospital for Children, Philadelphia.)

TABLE 36.12 Treatment of Macrodactyly

Goal of Treatment	Procedure		
Limiting growth	Digital nerve stripping Epiphysiodesis		
Digit reduction	Soft tissue Skeletal	Debulking Terminalization Reposition nail unit on shortened skeleton Resection of distal portion of nail and pulp	Palmar pedicle (Barsky procedure)[14,63] Dorsal pedicle (Tsuge procedure)[166] Nail island flap[137] Tsuge[167] Hoshi[83] Fujita[67] Bertelli[22]
Correction of deviation	Closing wedge osteotomy (combined with epiphysiodesis as required)		
Correction of thumb macrodactyly	Metacarpophalangeal arthrodesis Millesi procedure[109]		
Amputation	Ray amputation (with transposition of digit for central ray amputation)		

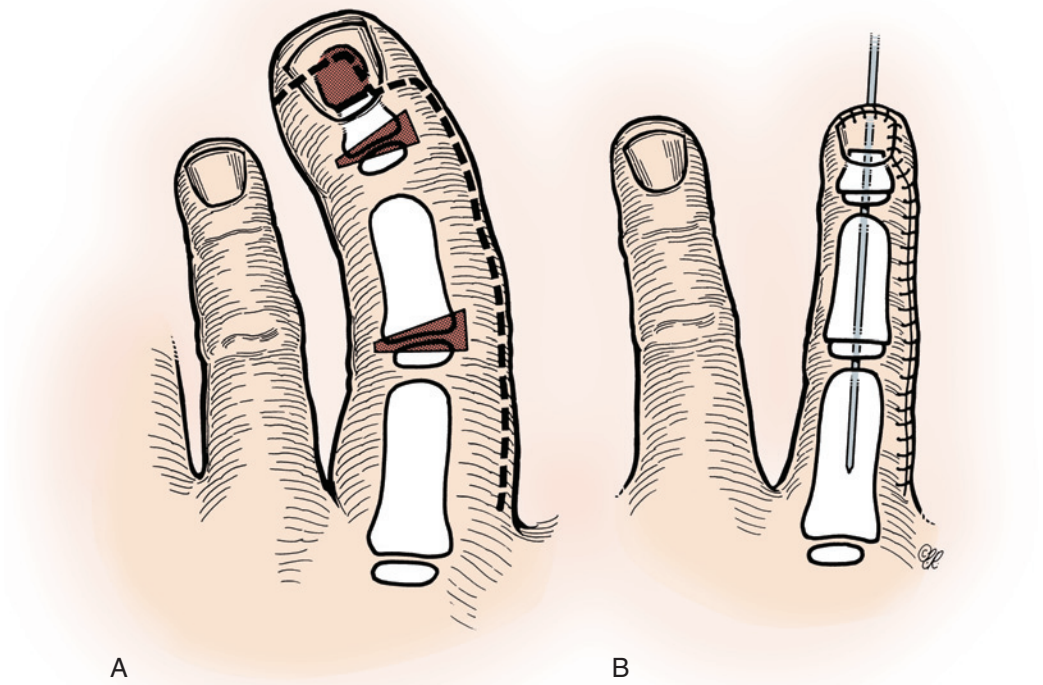

FIGURE 36.101 **A** and **B,** Excision of the epiphyseal plate and partial removal of the bone by osteotomy can stop growth and correct angulation all in one maneuver, as suggested by Tsuge. (Copyright © Elizabeth Martin.)

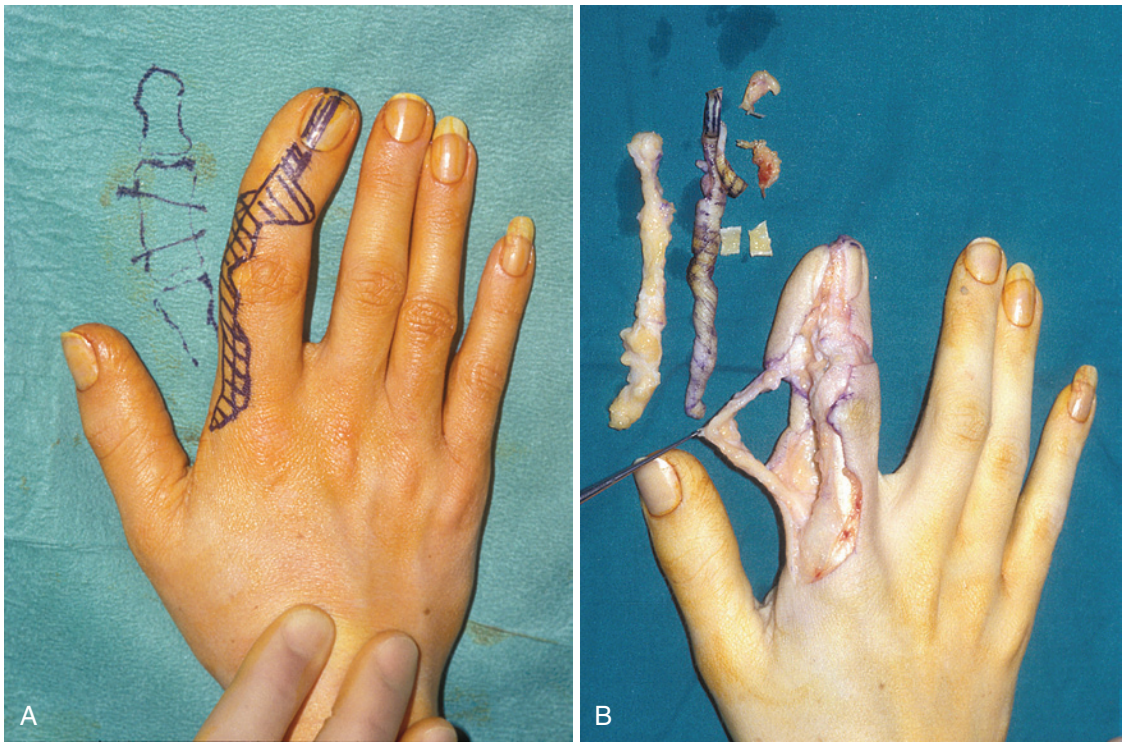

FIGURE 36.102 **A** and **B,** Reduction of the index finger by using a combination of angulation osteotomy, resection of skin and fat, debulking of the enlarged digital nerve, and narrowing of the nail bed.

resection and repair or grafting is rarely recommended, given the risk of adding the insult of a permanent sensory deficit to the already stiff and deformed digit.

Reducing the Digit

Debulking the soft tissues reduces the size of the enlarged digit (Figure 36.102). Usually, one side of the digit is debulked at a time. The digit is approached through a midlateral incision. Skin flaps are elevated to the volar and dorsal midline, and the neurovascular bundle is dissected from the subcutaneous fat. The fat is resected, and the excess skin is excised. Care must be taken to maintain viability of the undermined skin flaps. An alternative approach is to address the palmar aspect of the finger via a Bruner incision.

Skeletal reduction can be achieved by either narrowing or shortening. Narrowing the skeleton can be achieved by burring the sides of the phalanges or performing a longitudinal ostectomy. This ostectomy is limited by the attachment of the flexor sheath and has been complicated by hematoma and/or joint stiffness. Skeletal shortening can be achieved by several techniques. A deviated digit can be shortened and realigned via corrective ostectomy. A trapezoid rather than a wedge resection has been recommended to increase shortening. Excision of the middle phalanx has also been reported,[159] with a stable joint created between the distal and proximal phalanges. The amount of resection, however, is limited by the telescoping of the excessive soft tissue. The simplest procedure is "terminalization" of the enlarged digit, although the loss of the nail may only exacerbate the appearance of deformity.

Several techniques attempt to preserve the nail and shorten the digit. The Barsky procedure involves shortening the digit by filleting the distal phalanx, excising the skin over the dorsum of the middle phalanx, and placing the nail on the end of the middle phalanx.[14] Flatt modified this technique by preserving the distal part of the distal phalanx and fusing this to a shortened middle phalanx to reduce the skeleton.[64] Considerable bony shortening (>3 cm) may require concomitant flexor digitorum profundus shortening. The excess palmar skin produced by the shortening can be excised at a second stage. The use of a palmar pedicle maintains a reliable blood supply and good sensation in the distal finger. In contrast, the Tsuge procedure preserves the nail on a dorsal skin pedicle, including the dorsal cortex of the distal phalanx[166] (Figure 36.103). The digit is shortened, with excision of the pulp and the palmar part of the distal phalanx. The nail is fitted into a recess on the dorsum of the middle phalanx. A fold of skin is produced on the dorsum of the digit, which can be revised with a second procedure.[167] The dorsal pedicle, however, has proven to be unreliable in the fingers but has been used in the toes with success. The Rosenberg technique[137] transposed the nail farther by raising the nail unit as an island flap on the digital neurovascular pedicle. After excision of the distal phalanx and pulp, the nail unit was repositioned on the dorsum of the middle phalanx.

An alternative to transposing the nail unit onto a shortened skeleton is to reduce the nail and shorten the digit further with segmental ostectomies along the length of the digit. Tsuge narrowed the width of the nail and distal phalanx by ostectomies and shortened the digit by excision of the MCP joint. Hoshi and associates combined soft tissue debulking and skeletal shortening with excision of the tip of the distal phalanx and nail, proximal shortening with DIP arthrodesis, and debulking via the convex side of the deviated digit.[83] Using a similar

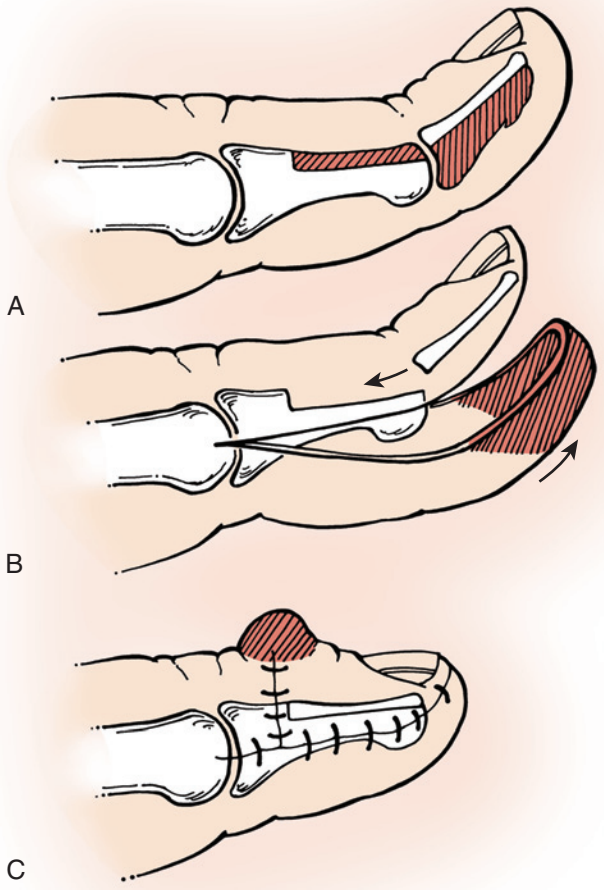

FIGURE 36.103 Tsuge method for reducing the length of a macrodactylous finger. **A,** The incision is midlateral to the end of the finger. The volar part of the distal phalanx and the dorsal part of the middle phalanx are removed. **B,** Excess volar skin and soft tissues are removed from the end of the finger. **C,** The dorsal part of the distal phalanx and nail are recessed to fit the middle phalanx. The remaining excess dorsal soft tissue can be removed later. (Copyright © Elizabeth Martin.)

technique, Akinci reported good results in a series of older children and adults who had undergone combined skeletal and soft tissue debulking based on the concave neurovascular bundle.[2] Fujita and colleagues raised a palmar flap, including the radial neurovascular bundle along the length of the digit, which left the ulnar neurovascular bundle, skeleton, and flexor tendon on the dorsal flap.[67] The ulnar one third and distal end of the palmar flap and the radial one third and tip of the distal phalanx and nail were excised to match each other. The thumb can be addressed using similar techniques. Debulking is similar, and shortening can be performed via MCP arthrodesis. Millesi devised a more complicated pattern of reduction osteotomies that preserves joint motion. The nail width and length are reduced, but the central nail is excised. This technique often results in ridging of the nail.[108]

The number and variety of techniques described are testament to the difficulty in achieving a result acceptable to the surgeon and patient, and hence there is motivation for further refinement of the operations for this condition.

Amputation

The ultimate reduction procedure is amputation. This procedure is an option for macrodactyly isolated to a single digit or showing progressive uncontrollable growth (Figure 36.104). Amputation of the thumb should be avoided unless the overgrowth is so great as to preclude any function. Ray amputation of a border digit and transmetacarpal amputation of a central digit and adjacent digit transposition are the procedures of choice.

In cases where amputation is considered early, it can be possible to sometimes offer digit substitution with transfer from the foot; if the native MCP joints are competent, this is very effective. Alternatively, an adjacent digit can be moved into the thumb position by pollicization (Figure 36.105).

Hyperostotic Macrodactyly

Loss of motion can be addressed with ostectomy of the osteochondral masses, which may include part of the volar plate. Recurrence is the rule, and arthrodesis is often required after the digit attains adult length. Implant arthroplasty of the MCP joints has been used in very select cases.

Hemihypertrophic Macrodactyly

In hemihypertrophic macrodactyly, contracture of the digit(s) is common, which further impairs motion. Contracture release, debulking of the hypertrophic intrinsic musculature, and soft tissue rebalancing has been performed in a limited number of cases. Skeletal correction may also be required.

❖ AUTHORS' PREFERRED METHOD OF TREATMENT

Macrodactyly is a devastating anomaly for the child and represents a social stigma, focus of anxiety for parents, and a technical challenge for the surgeon. Multiple procedures are required, and the end result may be unsatisfactory. In contrast, the authors believe that ray amputation is a worthwhile procedure and should be considered early, before the patient invests in multiple procedures to salvage a deformed digit with limited function. Most parents with young children find this a difficult decision and prefer digit-preserving surgery. Experienced surgeons, however, will take the time and convey the trials and tribulations with reduction surgery. The cost to the family and child of multiple operations during childhood must be weighed and the ultimate outcome of a stiff, scarred, and still enlarged digit discussed. There is no doubt that the challenge of macrodactyly reduction can appeal to enthusiastic and skillful surgeons, but this enthusiasm must be tempered with realism.

The surgical plan is based on digital involvement, size of the digit(s), estimated adult length, degree of motion, and overall alignment. For digital conservation in young children, improving the appearance before school age is indicated. Debulking of subcutaneous fat with isolation of the neurovascular bundle is performed via a midlateral approach (see Figure 36.102). One side of the digit is debulked at a time, with a 3-month interlude between operations. This debulking can be combined with corrective osteotomy for deviated digits.

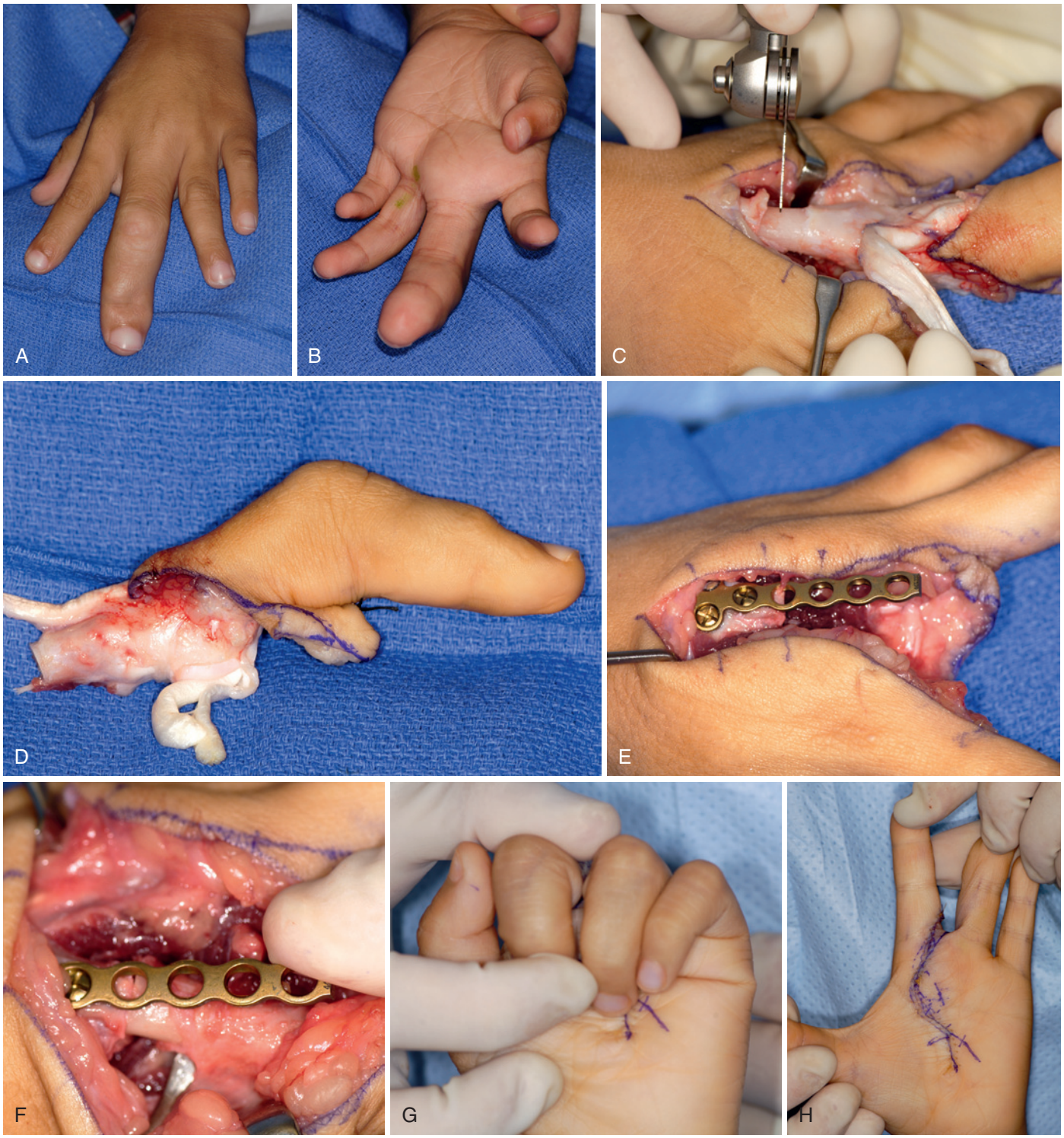

FIGURE 36.104 Four-year-old boy with isolated left long finger macrodactyly treated with early ray resection and index finger transposition. **A,** Preoperative dorsal view. **B,** Preoperative palmar view. **C,** Long finger metacarpal osteotomy. **D,** Specimen removed. **E,** Plate and screw fixation at the long finger metacarpal base in preparation of index finger transposition. **F,** Index finger transposed to long metacarpal. **G,** Tenodesis and digital alignment checked. **H,** Volar closure.

Continued

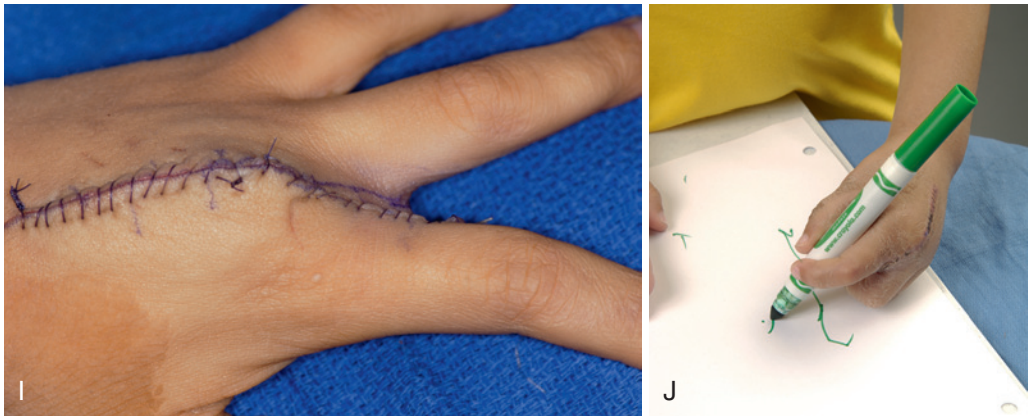

FIGURE 36.104, cont'd **I,** Dorsal closure. **J,** Incorporation of hand into daily activity. (Courtesy of Shriners Hospital for Children, Philadelphia).



FIGURE 36.105 Three-year-old girl with progressive macrodactyly of the left thumb and index digits. **A,** Clinical appearance. **B,** Volar skin design **C,** Dorsal skin design. **D,** Enlarged median nerve and superficial arch isolated. **E,** Digital nerves supplying the long finger are separated from median nerve hamartoma. **F,** Amputation of thumb and index finger with preservation of the index metacarpal. **G,** Long finger metacarpal is removed. **H,** The long finger is inset into the base of the index metacarpal with careful positioning. **I,** Final position after the skin is inset. (Courtesy of Shriners Hospital for Children, Philadelphia.)



FIGURE 36.106 **A** and **B,** Unsightly macrodactylous digits that have gradually lost motion and stiffened over time as a consequence of surgical reduction and progression of the deformity.

When the digit has reached adult length, longitudinal growth can be terminated with epiphysiodesis of all the phalanges. A midlateral approach is performed with physeal plate ablation using a blade, curet, cautery, or drill. Fluoroscopy guidance is helpful. The physeal plate resection can be configured as a closing wedge osteotomy to correct alignment of the digit (see Figure 36.101). The skeleton is stabilized with Kirschner wires at each level. The soft tissues can be debulked at this procedure.

If a digit exceeds adult length, a shortening procedure is recommended. The procedure used depends on the location and extent of excess. Minimal shortening can be accomplished by reduction of the distal fingertip pulp and nail using the method of Hoshi.[83] Excessive length requires distal phalanx excision and repositioning of the nail to the dorsum via a nail island flap. For the thumb, MCP joint resection and arthrodesis are preferred. These techniques address digital length and alignment, but excessive soft tissue and nail contribute to persistent disfigurement. This deformity can be addressed with debulking, nail bed excision, and longitudinal removal of bone. The procedures are difficult and limited by the finger's vascularity, joint stability, and flexor tendon integrity. Recurrence is common, and functional deterioration with continued growth is prevalent (Figure 36.106). At this point, patients often consider amputation, because removal of the digit may actually improve hand function.

Expected Outcomes

Outcomes in macrodactyly are very dependent on the condition of the hand initially, but no procedure results in a normal appearance, and final function depends on the extent of resection and the stiffness of the reduced digits.

CRITICAL POINTS *Macrodactyly*

- The most common form of macrodactyly is an isolated anomaly associated with lipofibromatosis of the proximal nerve.
- The cause is unknown.
- Most cases of macrodactyly occur in a single digit or in a region innervated by a single nerve (also known as *nerve territory–oriented macrodactyly*).
- Macrodactyly is often noted at birth or develops within the first 3 years of life. Growth of the enlarged digit may be disproportionate (*progressive macrodactyly*), or the digits may maintain a consistent proportion to the remainder of the hand (*static macrodactyly*).
- Macrodactyly is extremely difficult to treat. Its progressive and diffuse nature prevents complete correction to normalcy. Despite multiple surgeries to remove the extraneous tissues, the end result may be unsatisfactory.
- Ray amputation for progressive macrodactyly should be considered early before the patient invests in multiple procedures to salvage a deformed digit with limited function.

For Case Studies, Videos, and more, please visit ExpertConsult.com.

REFERENCES

1. Abraham E, et al: Congenital cleft-foot deformity treatment. *J Pediatr Orthop* 19:404–410, 1999.
2. Akinci M, Ay S, Ercetin O: Surgical treatment of macrodactyly in older children and adults. *J Hand Surg [Am]* 29:1010–1019, 2004.
3. Aleem AW, et al: The transverse bone in cleft hand: a case cohort analysis of outcome after surgical reconstruction. *J Hand Surg [Am]* 39(2):226–236, 2014.
4. Al-Qattan MM, et al: Classification of the mirror hand-multiple hand spectrum. *J Hand Surg [Br]* 23(4):534–536, 1998.

5. Al-Qattan MM: Lipofibromatous hamartoma of the median nerve and its associated conditions. *J Hand Surg [Br]* 26(4):368–372, 2001.
6. Al-Qattan MM, et al: Thumb reconstruction without formal pollicization in mirror hand deformity: a series of four cases. *J Hand Surg Eur Vol* 38(9):940–947, 2013.
7. Anderson PJ, et al: The elbow in syndromic craniosynostosis. *J Craniofac Surg* 9(3):201–206, 1998.
8. Arslan H: Metacarpal lengthening by distraction osteogenesis in childhood brachydactyly. *Acta Orthop Belg* 67(3):242–247, 2001.
9. Ashmead D, Smith P: Tissue expansion for Apert's syndactyly. *J Hand Surg Eur Vol* 20:327–330, 1995.
10. Bamshad M, Root S, Carey JC: Clinical analysis of a large kindred with the Pallister ulnar-mammary syndrome. *Am J Med Genet* 65(4):325–331, 1996.
11. Barabas AG, Pickford MA: Results of syndactyly release using a modification of the Flatt technique. *J Hand Surg Eur Vol* 39:984–988, 2014.
12. Barros M, et al: Revisiting amniotic band sequence: a wide spectrum of manifestations. *Fetal Diagn Ther* 35(1):51–56, 2014.
13. Barsky A: Cleft hand: Classification, incidence and treatment. Review of the literature and report of nineteen cases. *J Bone Joint Surg Am* 46:1707–1720, 1964.
14. Barsky AJ: Macrodactyly. *J Bone Joint Surg Am* 49(7):1255–1266, 1967.
15. Barton NJ, Buck-Gramcko D, Evans DM: Soft-tissue anatomy of mirror hand. *J Hand Surg [Br]* 11(3):307–319, 1986.
16. Barton NJ, et al: Mirror hand treated by true pollicization. *J Hand Surg [Br]* 11(3):320–336, 1986.
17. Bass HN: Familial absence of middle phalanges with nail dysplasia: a new syndrome. *Pediatrics* 42(2):318–323, 1968.
18. Bauer T, Tondra J, Trusler H: Technical modification in repair of syndactylism. *Plast Reconstr Surg* 17:385–391, 1956.
19. Bell J: On brachydactyly and symphalangism. In Penrose L, editor: *The treasury of human inheritance*, London, 1951, Cambridge University Press, pp 1–31.
20. Bellew M, Kay S: Psychological aspects of toe to hand transfer in children: Comparison of views of children and their parents. *J Hand Surg [Br]* 24:712–718, 1999.
21. Benatar N: Kirner's deformity treated by distal detachment of the flexor digitorum profundus tendon. *Handchir Mikrochir Plast Chir* 36:166–169, 2004.
22. Bertelli JA, Pigozzi L, Pereima M: Hemidigital resection with collateral ligament transplantation in the treatment of macrodactyly: A case report. *J Hand Surg [Am]* 26(4):623–627, 2001.

22a. Blauth W, Borisch NC: Cleft feet. Proposals for a new classification based on roentgenographic morphology. *Clin Orthop Relat Res* 258:41–48, 1990.

23. Blauth W, Falliner A: [Morphology and classification of cleft hands]. *Handchir Mikrochir Plast Chir* 18(3):161–195, 1986.
24. Blauth W, Gekeler J: Morphology and classification of symbrachydactylia. *Handchirurgie* 4:123–128, 1971.
25. Deleted in review.
26. Bourke G, Kay SP: Free phalangeal transfer: donor-site outcome. *Br J Plast Surg* 55(4):307–311, 2002.
27. Bradbury ET, Hewison J: Early parental adjustment to visible congenital disfigurement. *Child Care Health Dev* 20(4):251–266, 1994.
28. Bradbury ET, et al: Decision-making by parents and children in paediatric hand surgery. *Br J Plast Surg* 47(5):324–330, 1994.
29. Brennan MD, Fogarty BJ: Island flap reconstruction of the web space in congenital incomplete syndactyly. *J Hand Surg Eur Vol* 29:377–380, 2004.
30. Brodwater BK, et al: Macrodystrophia lipomatosa with associated fibrolipomatous hamartoma of the median nerve. *Pediatr Surg Int* 16(3):216–218, 2000.
31. Buck-Gramcko D: Cleft hands: classification and treatment. *Hand Clin* 1(3):467–473, 1985.
32. Buck-Gramcko D: Congenital malformations: Syndactyly and related deformities. In Nigst H, et al, editors: *Hand surgery*, New York, 1988, Thieme Medical Publishers, p 12.
33. Buck-Gramcko D, Pereira JA: Proximal toe phalanx transplantation for bony stabilization and lengthening of partially aplastic digits. *Ann Chir Main Memb Super* 9(2):107–118, 1990.
34. Bulic K: Long-term aesthetic outcome of fingertip reconstruction in complete syndactyly release. *J Hand Surg Eur Vol* 38(3):281–287, 2013.
35. Bystrom EB, Sanger RG, Stewart R: The syndrome of ectrodactyly, ectodermal dysplasia, and clefting (EEC). *J Oral Surg* 33(3):192–198, 1975.
36. Caouette-Laberge L, et al: Physiolysis for correction of clinodactyly in children. *J Hand Surg [Am]* 27(4):659–665, 2002.
37. Deleted in review.
38. Cheng JC, Chow SK, Leung PC: Classification of 578 cases of congenital upper limb anomalies with the IFSSH system—a 10 years' experience. *J Hand Surg [Am]* 12:1055–1060, 1987.
39. Cobbett JR: Free digital transfer. Report of a case of transfer of a great toe to replace an amputated thumb. *J Bone Joint Surg Br* 51(4):677–679, 1969.
40. Colville J: Syndactyly correction. *Br J Plast Surg* 42(1):12–16, 1989.
41. Coombs CJ, Mutimer KL: Tissue expansion for the treatment of complete syndactyly of the first web. *J Hand Surg [Am]* 19(6):968–972, 1994.
42. Coombs CJ, Thomas DJ: The Manta Ray flap: a technique for first web space release. *Tech Hand Up Extrem Surg* 14(1):41–45, 2010.
43. Cooney WP: Camptodacytyly and clinodactyly. In Carter P, editor: *Reconstruction of the child's hand*, Philadelphia, 1991, Lea & Feibiger.
44. Cronin T: Syndactylism: Results of zig-zag incision to prevent postoperative contracture. *Plast Reconstr Surg* 18:460–468, 1956.
45. Daluiski A, Yi SE, Lyons KM: The molecular control of upper extremity development: Implications for congenital hand anomalies. *J Hand Surg [Am]* 26(1):8–22, 2001.
46. De Smet L: Classification for congenital anomalies of the hand: the IFSSH classification and the JSSH modification. *Genet Couns* 13(3):331–338, 2002.
47. Dhalla R, Strecker W, Manske PR: A comparison of two techniques for digital distraction lengthening in skeletally immature patients. *J Hand Surg [Am]* 26(4): 603–610, 2001.
48. Di Meo L, Mercer DH: Single-stage correction of constriction ring syndrome. *Ann Plast Surg* 19(5):469–474, 1987.
49. Drinkwater H: Hereditary abnormal segmentation of the index and middle fingers. *J Anal Psychol* 50:177, 1916.
50. Dubrana F, et al: Kirner's deformity. 4 case reports and review of the literature. *Ann Chir Main Memb Super* 14(1):33–37, 1995.
51. Dunker N, Schmitt K, Krieglstein K: TGF-beta is required for programmed cell death in interdigital webs of the developing mouse limb. *Mech Dev* 113(2):111–120, 2002.
52. Dupe V, et al: Essential roles of retinoic acid signaling in interdigital apoptosis and control of BMP-7 expression in mouse autopods. *Dev Biol* 208(1):30–43, 1999.
53. Eaton CJ: Three-flap web-plasty. *J Hand Surg [Am]* 17(3):583–585, 1992.
54. Eaton CJ, Lister GD: Toe transfer for congenital hand defects. *Microsurgery* 12(3):186–195, 1991.
55. Ekerot L: Syndactyly correction without skin-grafting. *J Hand Surg [Br]* 21(3):330–337, 1996.
56. Elliott AM, et al: The duplicated longitudinal epiphysis or "kissing delta phalanx": evolution and variation in three different disorders. *Skeletal Radiol* 33:345–351, 2004.
57. Elliott MA, et al: Discrepancies in upper and lower limb patterning in split hand foot malformation. *Clin Genet* 68:408–423, 2005.
58. Evans DM, James NK: A bipedicled neurovascular step-advancement flap for soft tissue lengthening in clinodactyly. *Br J Plast Surg* 45(5):380–384, 1992.
59. Everman DB, et al: The mutational spectrum of brachydactyly type C. *Am J Med Genet* 112(3):291–296, 2002.
60. Fearon JA, Podner C: Apert syndrome: evaluation of a treatment algorithm. *Plast Reconstr Surg* 131(1):132–142, 2013.
61. Fereshetian S, Upton J: The anatomy and management of the thumb in Apert syndrome. *Clin Plast Surg* 18(2):365–380, 1991.
62. Flatt A: A test of a classification of congenital anomalies of the upper extremity. *Surg Clin North Am* 50:509–516, 1970.
63. Flatt A: *The care of congenital hand anomalies*, St Louis, 1977, CV Mosby.
64. Flatt A: *The care of congenital hand anomalies*, St Louis, 1994, Quality Medical Publishing, pp 296–306.
65. Foucher G, et al: Microsurgical free partial toe transfer in hand reconstruction: a report of 12 cases. *Plast Reconstr Surg* 65(5):616–627, 1980.
66. Foucher G, et al: Radial shift of the ulnar fingers: A new technique for special cases of longitudinal central deficiency. *J Hand Surg Eur Vol* 156–161, 2006 31.
67. Fujita S, Kodama K, Watanabe H: Treatment of macrodactyly. *Keiseigeka* 26:420–428, 1983.
68. Gao B, et al: Mutations in IHH, encoding Indian hedgehog, cause brachydactyly type A-1. *Nat Genet* 28(4):386–388, 2001.
69. Gao W, et al: Dorsal pentagonal local flap: a new technique of web reconstruction for syndactyly without skin graft. *Aesthetic Plast Surg* 35(4):530–537, 2011.
70. Garagnani L, et al: Long-term donor site morbidity after free nonvascularized toe phalangeal transfer. *J Hand Surg [Am]* 37(4):764–774, 2012.
71. Ger E: Syndactyly. In Buck-Gramcko D, editor: *Congenital malformations of the hand and forearm*, London, 1998, Churchill Livingstone, pp 131–140.
72. Gohla T, Metz C, Lanz U: Non-vascularized free toe phalanx transplantation in the treatment of symbrachydactyly and constriction ring syndrome. *J Hand Surg Eur Vol* 30B:446–451, 2005.
73. Goldfarb CA, Steffen JA, Stutz CM: Complex syndactyly: aesthetic and objective outcomes. *J Hand Surg [Am]* 37(10):2068–2073, 2012.
74. Greuse M, Coessens BC: Congenital syndactyly: defatting facilitates closure without skin graft. *J Hand Surg [Am]* 26(4):589–594, 2001.
75. Guha U, et al: In vivo evidence that BMP signaling is necessary for apoptosis in the mouse limb. *Dev Biol* 249(1):108–120, 2002.
76. Gul D, Oktenli C: Evidence for autosomal recessive inheritance of split hand/split foot malformation: a report of nine cases. *Clin Dysmorphol* 11(3):183–186, 2002.
77. Gulgonen A, Gudemez E: Reconstruction of the first web space in symbrachydactyly using the reverse radial forearm flap. *J Hand Surg [Am]* 32:162–167, 2007.

78. Guzman-Huerta ME, et al: Amniotic band sequence: prenatal diagnosis, phenotype descriptions, and a proposal of a new classification based on morphologic findings. *Rev Invest Clin* 65(4):300–306, 2013.
79. Habenicht R, et al: Ten-year experience with one-step correction of constriction rings by complete circular resection and linear circumferential skin closure. *J Plast Reconstr Aesthet Surg* 66(8):1117–1122, 2013.
80. Harvey I, et al: The Apert hand—angiographic planning of a single-stage, 5-digit release for all classes of deformity. *J Hand Surg [Am]* 37(1):152–158, 2012.
81. Heras L, Barco J, Cohen A: Unusual complication of ligation of rudimentary ulnar digit. *J Hand Surg [Br]* 24(6):750–751, 1999.
82. Holten IW, et al: Imaging of the Apert syndrome hand using three-dimensional CT and MRI. *Plast Reconstr Surg* 99(6):1675–1680, 1997.
83. Hoshi E, Tajima T, Watanabe Y: Results of our treatment for macrodactyly. *Seikeigeka* 24:1183–1185, 1973.
84. Hough M, Fenn C, Kay SP: The use of free groin flaps in children. *Plast Reconstr Surg* 113(4):1161–1166, 2004.
85. Ianakiev P, et al: Split-hand/split-foot malformation is caused by mutations in the p63 gene on 3q27. *Am J Hum Genet* 67(1):59–66, 2000.
86. Ishida O, Ikuta Y: Long-term results of surgical treatment for macrodactyly of the hand. *Plast Reconstr Surg* 102(5):1586–1590, 1998.
87. Javadian P, et al: Perinatal outcome after fetoscopic release of amniotic bands: a single-center experience and review of the literature. *Ultrasound Obstet Gynecol* 42(4):449–455, 2013.
88. Johansson SH: [Nail fold formation using a thenar flap in complete syndactylia]. *Handchir Mikrochir Plast Chir* 14(4):199–203, 1982.
89. Jones N, Upton J: Early release of syndactyly within six weeks of birth. *Orthop Trans* 17:360–361, 1992.
90. Jones NF, Hansen SL, Bates SJ: Toe-to-hand transfers for congenital anomalies of the hand. *Hand Clin* 23:127–136, 2007.
91. Kallemeier PM, et al: An assessment of the relationship between congenital transverse deficiency of the forearm and symbrachydactyly. *J Hand Surg [Am]* 32:1408–1412, 2007.
92. Kato H, et al: Callotasis lengthening in patients with brachymetacarpia. *J Pediatr Orthop* 22(4):497–500, 2002.
93. Kay S: Talking with parents and children. In Gupta A, Kay S, Scheker L, editors: *The growing hand*, London, 2000, Mosby.
94. Kay S, Coady M: The role of microsurgery and free tissue transfer in the reconstruction of the paediatric upper extremity. *Ann Acad Med Singapore* 24(4 Suppl): 113–123, 1995.
95. Kay SP, Wiberg M: Toe to hand transfer in children. Part 1: technical aspects. *J Hand Surg [Br]* 21(6):723–734, 1996.
96. Kay SP, et al: Toe to hand transfer in children. Part 2: functional and psychological aspects. *J Hand Surg [Br]* 21(6):735–745, 1996.
97. Keret D, Ger E: Evaluation of a uniform operative technique to treat syndactyly. *J Hand Surg [Am]* 12(5 Pt 1):727–729, 1987.
98. Koshima I, et al: Sixty cases of partial or total toe transfer for repair of finger losses. *Plast Reconstr Surg* 92:1331–1338, 1993.
99. Kozin S: Syndactyly. *J Am Soc Surg Hand* 1:1–13, 2001.
100. Lister G: Microsurgical transfer of the second toe for congenital deficiency of the thumb. *Plast Reconstr Surg* 82(4):658–665, 1988.
101. Lister G: *The hand. Diagnosis and indications*, 3rd ed, New York, 1993, Churchill Livingstone.
102. Lutz B, Wei F: Basic principles on toe-to-hand transplantation. *Chang Gung Med J* 25:568–576, 2002.
102a. Maisels DO: Lobster-claw deformities of the hands and feet. *Br J Plast Surg* 23:269–282, 1970.
103. Manske PR: Symbrachydactyly instead of atypical cleft hand. *Plast Reconstr Surg* 91(1):196, 1993.
104. Manske PR, Halikis MN: Surgical classification of central deficiency according to the thumb web. *J Hand Surg [Am]* 20(4):687–697, 1995.
105. Matsuno T, et al: Bone lengthening for congenital differences of the hands and digits in children. *J Hand Surg [Am]* 29:712–719, 2004.
106. May JW, Jr, Bartlett SP: Great toe-to-hand free tissue transfer for thumb reconstruction. *Hand Clin* 1(2):271–284, 1985.
107. Merino R, et al: The BMP antagonist Gremlin regulates outgrowth, chondrogenesis and programmed cell death in the developing limb. *Development* 126(23): 5515–5522, 1999.
108. Millesi H: Correction of macrodactyly in adults by means of multiple osteotomy. *Zentralbl Chir* 91(40):1472–1475, 1966.
109. Millesi H: Macrodactyly: A case study. In Littler J, Carmer L, Smith J, editors: *Symposium of reconstructive hand surgery*, St Louis, 1974, CV Mosby, p 173.
110. Miura T, Komada T: Simple method for reconstruction of the cleft hand with an adducted thumb. *Plast Reconstr Surg* 64(1):65–67, 1979.
111. Miura T, Suzuki M: Clinical differences between typical and atypical cleft hand. *J Hand Surg [Br]* 9(3):311–315, 1984.
112. Miura T, Nakamura R, Horii E: The position of symbrachydactyly in the classification of congenital hand anomalies. *J Hand Surg [Br]* 19(3):350–354, 1994.
113. Miura T, et al: Cleft hand, syndactyly and hypoplastic thumb. *J Hand Surg [Br]* 17(3):365–370, 1992.
114. Mohr O, Wriedt C: A new type of hereditary brachyphalangy in man. *Washington Carnegie Inst* 295:5–64, 1919.
115. Montero J, et al: Role of FGFs in the control of programmed cell death during limb development. *Development* 128(11):2075–2084, 2001.
116. Morrison WA: Microvascular nail transfer. *Hand Clin* 6(1):69–76, discussion 77, 1990.
117. Morrison WA, O'Brien B, MacLeod AM: Thumb reconstruction with a free neurovascular wrap-around flap from the big toe. *J Hand Surg [Am]* 5:575–583, 1980.
118. Moser N, Rosslein R: [A new method for treating the Kirner deformity with the SM-Fix phalangeal distractor]. *Handchir Mikrochir Plast Chir* 28(1):34–38, 1996.
119. Murnaghan LM, et al: A clinicoradiologic study of the shoulder in Apert syndrome. *J Pediatr Orthop* 27(7):838–843, 2007.
119a. Mutaf M, Sunay M: A new technique for correction of congenital constriction rings. *Ann Plast Surg* 57(6):646–652, 2006.
120. Naruse I, Kameyama Y: Prevention of polydactyly manifestation in Polydactyly Nagoya (Pdn) mice by administration of cytosine arabinoside during pregnancy. *Teratology* 34(3):283–289, 1986.
121. Netscher D, Richards WT: Rational treatment for multiple digit congenital absence. Case report of nonvascularized toe phalangeal transfers and distraction lengthening for symbrachydactyly. *Ann Plast Surg* 56:211–215, 2006.
122. Niranjan N, De Carpentier J: A new technique for the division of syndactyly. *Eur J Plast Surg* 13:101–104, 1990.
123. Nogueira A, et al: Hyperostotic macrodactyly and lipofibromatous hamartoma of the median nerve associated with carpal tunnel syndrome. *Chir Main* 18(4):261–271, 1999.
124. Oates SD, Gosain AK: Syndactyly repair performed simultaneously with circumcision: use of foreskin as a skin-graft donor site. *J Pediatr Surg* 32(10):1482–1484, 1997.
125. O'Brien BM, et al: Microvascular great toe transfer for congenital absence of the thumb. *Hand* 10(2):113–124, 1978.
126. Ogino T: Teratogenic relationship between polydactyly, syndactyly and cleft hand. *J Hand Surg [Br]* 15(2):201–209, 1990.
127. Ogino T, Kato H, Ishii S: Digital lengthening in congenital hand deformities. *J Hand Surg [Br]* 19(1):120–129, 1994.
128. Panthaki ZJ, Armstrong MB: Hand abnormalities associated with craniofacial syndromes. *J Craniofac Surg* 14(5):709–712, 2003.
129. Patillo D, Rayan GM: Complications of suture ligation ablation for ulnar polydactyly: a report of two cases. *Hand (N Y)* 6(1):102–105, 2011.
130. Pitt P, Williams I: A new brachydactyly syndrome with similarities to Julia Bell types B and E. *J Med Genet* 22(3):202–204, 1985.
131. Qumsiyeh MB: EEC syndrome (ectrodactyly, ectodermal dysplasia and cleft lip/palate) is on 7p11.2-q21.3. *Clin Genet* 42(2):101, 1992.
132. Radocha RF, Netscher D, Kleinert HE: Toe phalangeal grafts in congenital hand anomalies. *J Hand Surg [Am]* 18(5):833–841, 1993.
133. Richardson EF, Wey PD, Hoffman LA: Surgical management of syndactyly in a dog. *J Am Vet Med Assoc* 205(8):1149–1151, 1994.
134. Richardson PWF, Johnstone BR, Coombs CJ: Toe-to-hand transfer in symbrachydactyly. *Hand Surg* 9:11–18, 2004.
135. Rider MA, et al: An experience of the Snow-Littler procedure. *J Hand Surg [Br]* 25(4):376–381, 2000.
136. Ronderos-Dumit D, et al: Endoscopic release of limb constriction rings in utero. *Fetal Diagn Ther* 21(3):255–258, 2006.
137. Rosenberg L, Yanai A, Mahler D: A nail Island flap for treatment of macrodactyly. *Hand* 15(2):167–172, 1983.
138. Ruppert V, et al: [Fibrolipomatous hamartoma of the nerve—a rare etiology of macrodactyly. A case report]. *Handchir Mikrochir Plast Chir* 31(1):53–56, 1999.
139. Saito H, et al: One-stage elongation of the third or fourth brachymetacarpia through the palmar approach. *J Hand Surg [Am]* 26(3):518–524, 2001.
140. Salas-Vidal E, Valencia C, Covarrubias L: Differential tissue growth and patterns of cell death in mouse limb autopod morphogenesis. *Dev Dyn* 220(4):295–306, 2001.
141. Sandzen SC, Jr: Classification and functional management of congenital central defect of the hand. *Hand Clin* 1(3):483–498, 1985.
142. Sawabe K, Suzuki Y, Suzuki S: Temporal skin grafts following straight incision for syndactyly correction. *Ann Plast Surg* 55:139–142, 2005.
143. Sawamura D, Nakano H, Matsuzaki Y: Overview of epidermolysis bullosa. *J Dermatol* 37(3):214–219, 2010.
144. Schwabe GC, et al: Distinct mutations in the receptor tyrosine kinase gene ROR2 cause brachydactyly type B. *Am J Hum Genet* 67(4):822–831, 2000.
145. Sharma RK, et al: End-of-skin grafts in syndactyly release: description of a new flap for web space resurfacing and primary closure of finger defects. *Hand (N Y)* 4(1):29–34, 2009.

146. Sharma S, Chhetri A, Singh A: Congenital cleft foot and hand. *Indian Pediatr* 36(9):935–938, 1999.
147. Sherif MM: V-Y dorsal metacarpal flap: a new technique for the correction of syndactyly without skin graft. *Plast Reconstr Surg* 101(7):1861–1866, 1998.
148. Silver H: Asymmetry, short staure, and variations in sexual development. *Am J Dis Child* 107:495–515, 1964.
149. Silverman TA, Enzinger FM: Fibrolipomatous hamartoma of nerve. A clinicopathologic analysis of 26 cases. *Am J Surg Pathol* 9(1):7–14, 1985.
150. Smith P, Harrison S: The "seagull" flap for syndactyly. *Br J Plast Surg* 35:390–393, 1982.
151. Smith RJ: Osteotomy for "delta-phalanx" deformity. *Clin Orthop Relat Res* 123:91–94, 1977.
152. Snow JW, Littler LJ: Surgical treatment of cleft hand. In *Transactions of the fourth international congress of plastic surgery (Rome)*, Amsterdam, 1967, Excerpta Medica, pp 888–893.
153. Sommerkamp TG, et al: The pulp plasty: a composite graft for complete syndactyly fingertip separations. *J Hand Surg [Am]* 17(1):15–20, 1992.
154. Sommerlad BC: The open finger technique for release of syndactyly. *J Hand Surg [Br]* 26(5):499–500, 2001.
155. Song W, Koh K: Kirner's deformity: progressiveness and classification. *Surg Radiol Anat* 27:459–462, 2005.
156. Sugarman GI, Hager D, Kulik WJ: A new syndrome of brachydactyly of the hands and feet with duplication of the first toes. *Birth Defects Orig Artic Ser* 10(5):1–8, 1974.
157. Swanson AB, Swanson GD, Tada K: A classification for congenital limb malformations. *J Hand Surg [Am]* 8(5 Pt 2):693–702, 1983.
158. Syrrou M, et al: Glypican 1 gene: good candidate for brachydactyly type E. *Am J Med Genet* 108(4):310–314, 2002.
159. Tan O, et al: Middle phalangectomy: A functional and aesthetic cure for macrodactyly. *Scand J Plast Reconstr Surg Hand Surg* 40:362–365, 2006.
160. Temtamy S, McKusick V: The genetics of hand malformations. In Bergsma D, editor: *Birth defects: original article series*, New York, 1978, Alan R Liss, pp 187–299.
161. Teoh LC, Lee JYL: Dorsal pentagonal island flap: A technique of web reconstruction for syndactyly that facilitates direct closure. *Hand Surg* 9:245–252, 2004.
162. Terrill PJ, et al: The surgical management of dystrophic epidermolysis bullosa (excluding the hand). *Br J Plast Surg* 45(6):426–434, 1992.
163. Tiwari VK, Sarabahi S, Mulla Rani UK: Heterotopic implantation of amputated digits following constriction ring syndrome: a case series. *J Plast Reconstr Aesthet Surg* 66(12):1815–1817, 2013.
164. Tonkin MA, Deva AK, Filan SL: Long term follow-up of composite non-vascularized toe phalanx transfers for aphalangia. *J Hand Surg Eur Vol* 30:452–458, 2005.
165. Torpin R, Faulkner A: Intrauterine amputation with the missing membrane found in the fetal membranes. *JAMA* 198:185–187, 1966.
166. Tsuge K: Treatment of macrodactyly. *Plast Reconstr Surg* 39(6):590–599, 1967.
167. Tsuge K: Treatment of macrodactyly. *J Hand Surg [Am]* 10(6 Pt 2):968–969, 1985.
168. Tsuge K, Watari S: Surgical treatment of cleft hand and its associated deformities. *Bull Hosp Jt Dis Orthop Inst* 44(2):532–541, 1984.
169. Uchida Y, Sugioka Y: Peripheral nerve palsy associated with congenital constriction band syndrome. *J Hand Surg [Br]* 16(1):109–112, 1991.
170. Ueba Y: Plastic surgery for the cleft hand. *J Hand Surg [Am]* 6(6):557–560, 1981.
171. Upton J: Apert syndrome: classification and pathologic anatomy of limb anomalies. *Clin Plast Surg* 18:321–355, 1991.
172. Upton J: Simplicity and treatment of the typical cleft hand. *Handchir Mikrochir Plast Chir* 36:152–160, 2004.
173. Van Heest AE, House JH, Reckling WC: Two-stage reconstruction of apert acrosyndactyly. *J Hand Surg [Am]* 22(2):315–322, 1997.
174. Vickers D: Clinodactyly of the little finger: a simple operative technique for reversal of the growth abnormality. *J Hand Surg [Br]* 12(3):335–342, 1987.
175. Vilkki SK: Advances in microsurgical reconstruction of the congenitally adactylous hand. *Clin Orthop Relat Res* 314:45–58, 1995.
176. Watari S, Tsuge K: A classification of cleft hands, based on clinical findings: theory of developmental mechanism. *Plast Reconstr Surg* 64(3):381–389, 1979.
177. Watson BT, Hennrikus WL: Postaxial type-B polydactyly. Prevalence and treatment. *J Bone Joint Surg Am* 79(1):65–68, 1997.
178. Wei FC: Toe transfer in children: The traumatic defect. In Gupta A, Scheker L, Kay S, editors: *The growing hand*, London, 1998, Mosby–Year Book.
179. Wei FC, Silverman RT, Hsu WM: Retrograde dissection of the vascular pedicle in toe harvest. *Plast Reconstr Surg* 96(5):1211–1214, 1995.
180. Wei FC, et al: Metacarpal hand: classification and guidelines for microsurgical reconstruction with toe transfers. *Plast Reconstr Surg* 99(1):122–128, 1997.
181. Wei FC, et al: Reconstruction of the thumb with a trimmed-toe transfer technique. *Plast Reconstr Surg* 82(3):506–515, 1988.
182. Weinzweig N: Constriction band-induced vascular compromise of the foot: classification and management of the "intermediate" stage of constriction-ring syndrome. *Plast Reconstr Surg* 96(4):972–977, 1995.
183. Wiedemann H-R, et al: The proteus syndrome: Partial gigantism of the hand and/or feet, nevi, hemihypertrophy, subcutaneous tumours, macrocephaly or other skull anomalies and possible accelerated growth and visceral affections. *Eur J Pediatr* 140:5–12, 1983.
184. Wilkie A, Slaney S, Oldridge M: Apert syndrome results from localized mutations of FGFR2 and is allelic with Crouzon syndrome. *Nature Genet* 9:165–171, 1995.
185. Wood V, Peppers T, Shook J: Cleft-foot closure: A simplified technique and review of the literature. *J Pediatr Orthop* 17:501–504, 1997.
186. Yamauchi Y: Symbrachydactyly. In Buck-Gramcko D, editor: *Congenital malformations of the hand and forearm*, London, 1998, Churchill-Livingstone, pp 149–157.
187. Yoshimura M: Toe-to-hand transfer. *Plast Reconstr Surg* 66(1):74–84, 1980.

Deformities of the Thumb

Scott H. Kozin

Acknowledgment: The author would like to acknowledge Brian W. O'Doherty, Coordinator of Visual Media Services. His photographic excellence was necessary for completion of this manuscript.

These videos may be found at *ExpertConsult.com:*

37.1 Opposition transfer and ulnar collateral ligament reconstruction for type II thumb hypoplasia
37.2 Thumb reconstruction follow-up 1
37.3 Thumb reconstruction follow-up 2
37.4 Pollicization type IIIB thumb hypoplasia with vascularized adipose flap
37.5 Testimonial: Tucker's story

THUMB HYPOPLASIA

Thumb hypoplasia is considered part of radial deficiency even with normal forearm architecture. Hence, associated anomalies need to be considered during the initial evaluation. The workup must include entities such as VACTERL association, thrombocytopenia–absent radius syndrome, Holt-Oram syndrome, CHARGE (*c*oloboma of the eye, *h*eart defects, *a*tresia of the choanae, *r*etardation of growth and/or development, *g*enital and/or urinary abnormalities, and *e*ar abnormalities and deafness) syndrome, and Fanconi anemia (Table 37.1 and Figure 37.1). An evaluation of all possibly affected organ systems can be life-saving. The workup should include renal ultrasound, echocardiography, spine radiographs, a complete blood count, and a chromosomal challenge test.[76]

Failure to ascertain the diagnosis of an associated syndrome will have lifelong ramifications for the child, family, and physician. This consequence is particularly evident in children with Fanconi anemia that can be diagnosed early with a chromosomal challenge test before the onset of bone marrow failure. Timely diagnosis allows for years of searching for an appropriate bone marrow match that may prevent the child from dying from aplastic anemia. Patients with thumb hypoplasia and other physical findings, specifically café-au-lait spots and short stature, have an increased risk of having Fanconi anemia.[91] Innovative techniques, such as preimplantation genetic determination, allow the parents to have another child with matching blood characteristics and without Fanconi anemia. At birth, the cord blood can be harvested and used as donor blood for the affected Fanconi anemia child. Numerous hand surgeons and pediatricians fail to consider the diagnosis of Fanconi anemia in children with thumb hypoplasia, leaving the child and the family to suffer the consequences of a painful terminal illness that could otherwise have been treated.

General Considerations in Thumb Hypoplasia

Diagnosis

The diagnosis of thumb hypoplasia is dependent on the degree of deficiency and the presence or absence of any associated anomalies. The combination of thumb hypoplasia and profound radial deficiency is typically diagnosed shortly after birth because the infant's forearm is foreshortened and the hand deviated in a radial direction. Substantial thumb hypoplasia is also recognized early in infancy because there is marked asymmetry between the thumbs. In contrast, mild thumb hypoplasia may go unidentified for years, and the patient may not present to the physician until adolescence. This late presentation is often perplexing to the patient and disconcerting to the parents. The parents cannot understand how they failed to recognize the child's hypoplasia before adolescence. They often relate the thumb hypoplasia to some form of recent trauma and question the diagnosis. Our explanation is quite simple: "As one gets older, the activities of daily of life become more complicated, and therefore subtle differences are not recognizable until the child is older." For example, buttoning, keyboarding, and tying shoes are tasks performed as the child becomes older and are not completed during infancy and early childhood. This explanation removes any feeling of fault and allows the family to focus on the treatment to correct the problem.

The diagnosis is based on the physical examination findings and corresponding x-rays. The length, girth, motion, and stability are important parts of the examination. If there is unilateral involvement, the length and girth are usually compared with the thumb on the contralateral side. A thumb of normal length reaches the point just proximal to the proximal interphalangeal (PIP) joint of the adjacent index finger. On x-ray, a normal thumb is approximately 70% as long as the proximal phalanx of the adjacent index finger. The thumb girth and nail width are approximately 133% and 105%, respectively, of the index finger girth and nail width.[30] The overall thumb motion is assessed along with specific movement at the carpometacarpal (CMC), metacarpophalangeal (MCP), and interphalangeal (IP) joints. Similarly, the stability of each of these joints is assessed by clinical examination and stress testing. Instability of the MCP and/or CMC joints is commonly associated with thumb hypoplasia and directly influences the surgical treatment algorithm. An account of present and absent intrinsic and extrinsic muscles is necessary in order to formulate a surgical plan.

TABLE 37.1 Syndromes or Associations With Radial Deficiency

Syndrome or Association	Characteristics
Holt-Oram syndrome	Heart defects, most commonly cardiac septal defects
Thrombocytopenia–absent radius syndrome	Thrombocytopenia present at birth (may require transfusions) but improves over time
VACTERL association	Vertebral abnormalities, anal atresia, cardiac abnormalities, tracheoesophageal fistula, esophageal atresia, renal defects, radial dysplasia, lower limb abnormalities
Fanconi anemia	Aplastic anemia not present at birth; develops at about 6 years of age
CHARGE syndrome	Coloboma of the eye, heart defects, atresia of the nasal choanae, retardation of growth and/or development, genital and/or urinary abnormalities, and ear abnormalities and deafness



FIGURE 37.1 Three year-old child with coloboma of the eyes associated with CHARGE (*c*oloboma of the eye, *h*eart defects, *a*tresia of the choanae, *r*etardation of growth and/or development, *g*enital and/or urinary abnormalities, and *e*ar abnormalities and deafness) syndrome. (Courtesy of Shriners Hospital for Children, Philadelphia.)

Classification

The Blauth classification of thumb hypoplasia truly guides management (Table 37.2).[39,76] Type I hypoplasia is minor generalized hypoplasia usually affecting the thenar muscles. As stated beforehand, this slight degree of hypoplasia may present later in life as hand function becomes more intricate and demanding. Type I thumb hypoplasia may or may not warrant treatment, depending on the functional impact. If the lack of opposition is causing functional difficulties, a tendon transfer is recommended.

Type II hypoplasia has distinct findings that guide treatment (Figure 37.2 and Case Study 37.1). There is absence of the thenar muscles innervated by the recurrent branch of the median nerve (the abductor pollicis brevis, opponens pollicis, and superficial head of the flexor pollicis brevis) (see Figure 37.2, *A*). The deep head of the flexor pollicis brevis, innervated by the ulnar nerve, is usually present, and it provides MCP joint flexion. The MCP is usually unstable, with laxity or incompetency of the ulnar collateral ligament (UCL) (see Figure 37.2, *B*). The MCP joint can also be globally unstable, with incompetency of both the ulnar and radial collateral ligaments. The thumb/index finger or first web space is narrowed and the intervening skin is taut (see Figure 37.2, *C*). The web space can appear to be less narrow because the unstable MCP joint drifts into valgus, masking the narrow web space.

TABLE 37.2 Thumb Deficiency Classification and Treatment Paradigm

Type	Findings	Treatment
I	Minor generalized hypoplasia	No treatment
II	Absence of intrinsic thenar muscles First web space narrowing Ulnar collateral ligament (UCL) insufficiency	Opponensplasty First-web release UCL reconstruction
III	Similar findings as type II plus: Extrinsic muscle and tendon abnormalities Skeletal deficiency A: Stable carpometacarpal joint B: Unstable carpometacarpal joint	A: Reconstruction B: Pollicization
IV	Pouce flottant, or floating thumb	Pollicization
V	Absence	Pollicization

Type III hypoplasia has the same characteristics as type II hypoplasia with the addition of extrinsic muscle and tendon deficiencies. Absence or hypoplasia of the extrinsic extensors (extensor pollicis longus and extensor pollicis brevis) or flexors (flexor pollicis longus) requires an observant examination of the active movement at the MCP and IP joints. Type III hypoplasia is subdivided into types IIIA and IIIB, which is a crucial differentiation in the treatment paradigm. A type IIIA thumb has a stable CMC joint that is worthy of reconstruction and can provide a worthwhile prehensile thumb. A type IIIB thumb has an unstable CMC joint that requires ablation and pollicization. The unstable CMC joint precludes successful reconstruction because the surgery cannot overcome the basal joint instability. A simple explanation to parents is that this effort would be similar to "trying to build a house without a stable foundation." Multiple valiant surgical attempts to reconstruct the CMC joint have yielded inferior results (outcome and function) compared with a successful index finger pollicization.[40,42]

Differentiating between a type IIIA (stable) and a type IIIB (unstable) thumb can be difficult in some cases, but it is fundamental to formulation of a treatment plan. The first metacarpal base and the trapezium do not ossify until about 6 years of age. Therefore, plain radiographs are often unreliable for evaluation of the CMC joint architecture. In a grossly hypoplastic CMC joint, the metacarpal base tapers to a point and the proximal metacarpal is absent (Figure 37.3). However, this plain x-ray finding is not present in milder type III hypoplasia. Advanced imaging studies, such as ultrasound or magnetic resonance imaging (MRI), can be helpful to visualize and evaluate the integrity of the cartilaginous metacarpal base and the trapezium.[76] Repeat examinations, however, may be equally as reliable to detect a thumb unworthy of reconstruction. A child with an unstable CMC joint usually completely ignores the thumb and uses the index finger and long finger for scissor pinch. In addition, the index finger pronates and the long

CASE STUDY 37.1

Andres was a 9-year-old with type II thumb hypoplasia (eFigure 37.1). Thumb reconstruction was planned, using the present CMC and thumb of adequate girth.

The surgical technique is displayed in eFigure 37.2 and Video 37.1. The long-term outcome is shown in eFigure 37.3 and Videos 37.2 and 37.3.

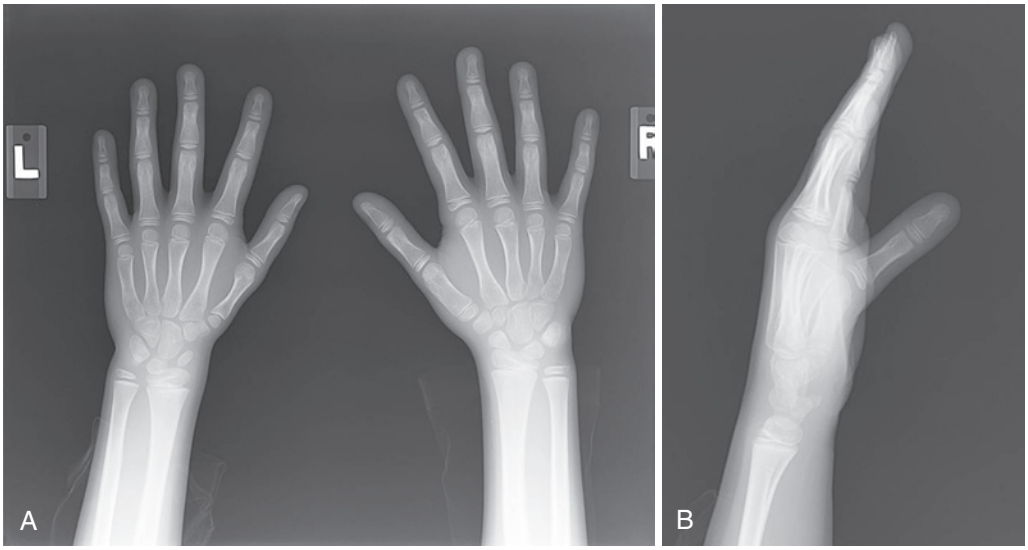

eFIGURE 37.1 **A** and **B,** Type II thumb hypoplasia. (Courtesy of Shriners Hospital for Children, Philadelphia.)

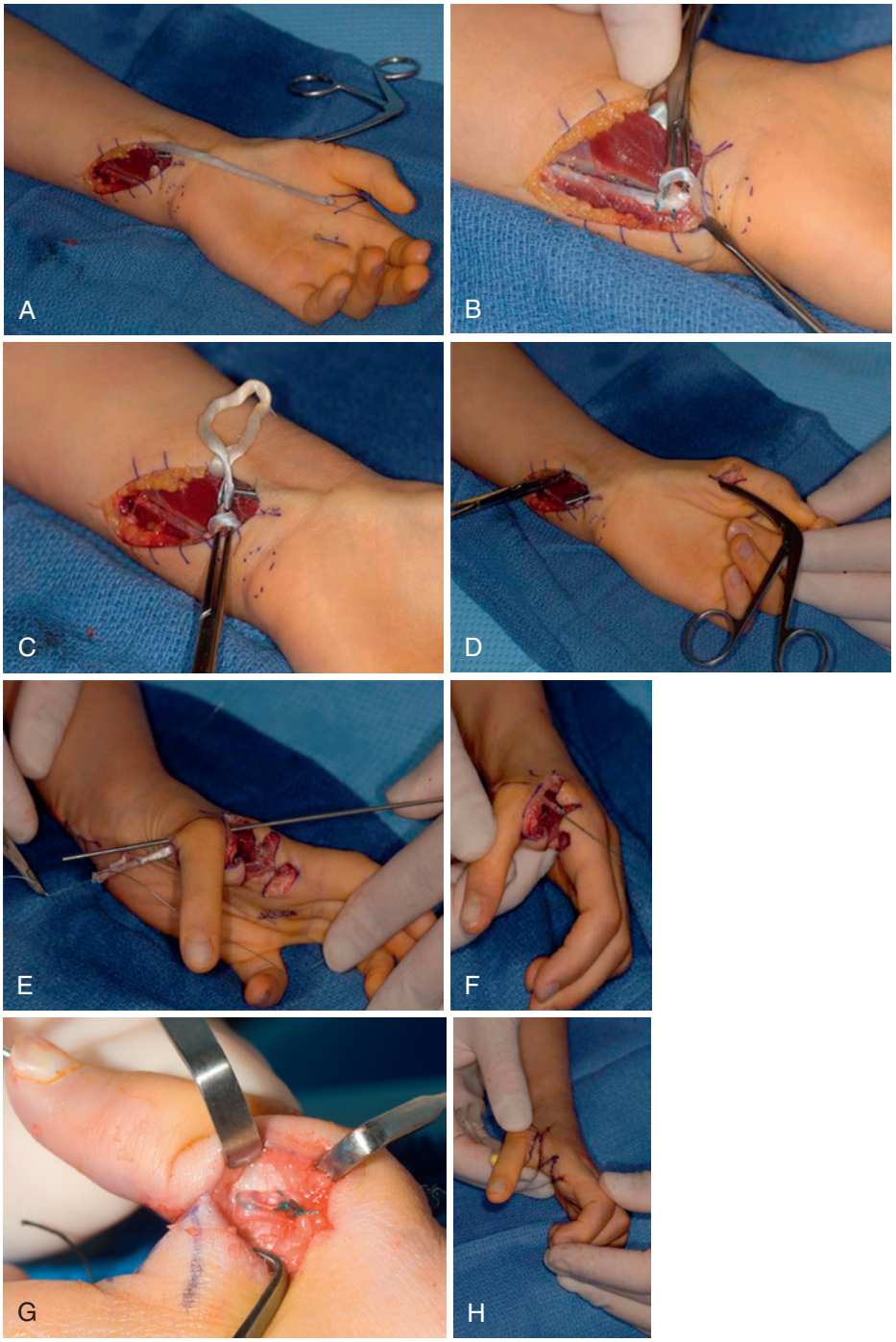

eFIGURE 37.2 Surgical technique. **A,** Flexor digitorum superficialis (FDS) harvest. **B,** Flexor carpi ulnaris pulley. **C,** FDS through pulley. **D,** FDS through subcutaneous tunnel. **E,** FDS through metacarpal head. **F,** FDS along ulnar metacarpophalangeal joint. **G,** Ulnar collateral ligament reconstruction. **H,** Pinning and four-flap "Z"-plasty closure. (Courtesy of Shriners Hospital for Children, Philadelphia.)

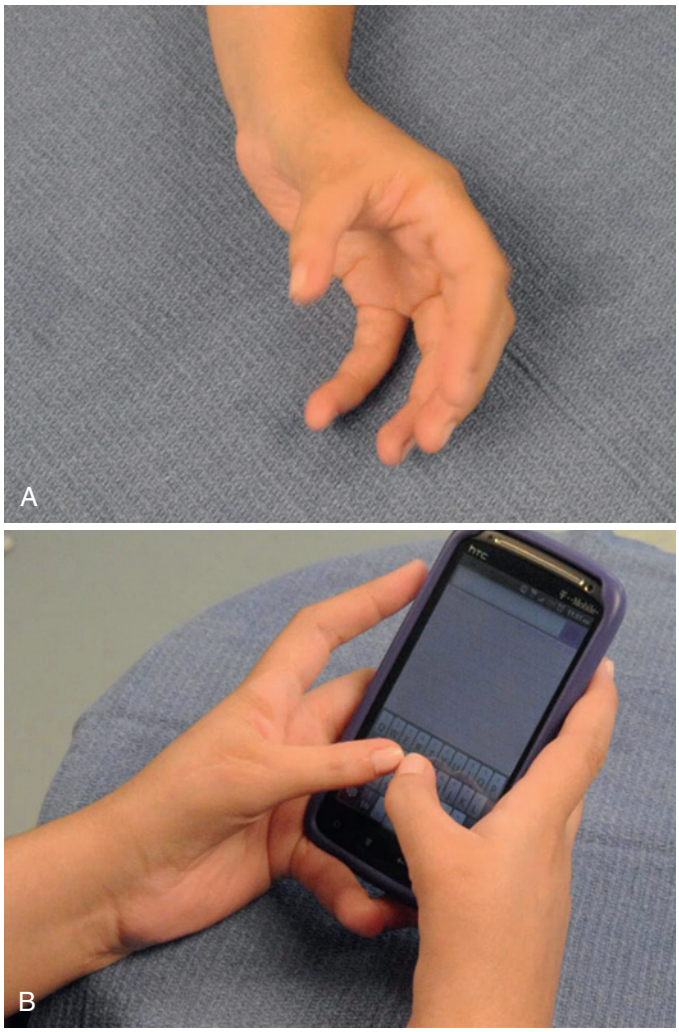

eFIGURE 37.3 **A** and **B,** Long-term outcome. (Courtesy of Shriners Hospital for Children, Philadelphia,)

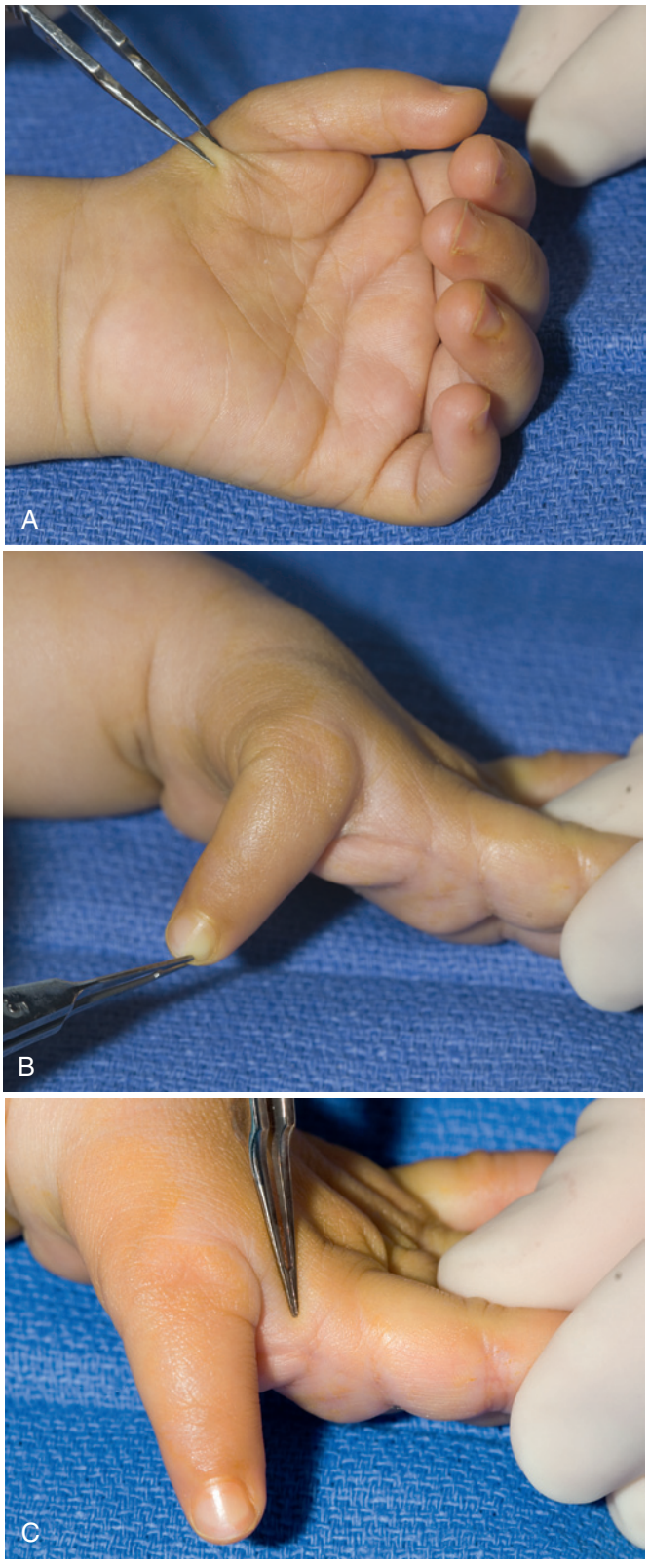

FIGURE 37.2 Two-year-old with type II left thumb deficiency. **A,** Absent thenar muscles. **B,** Ulnar collateral ligament insufficiency. **C,** Narrow thumb/index finger web space. (Courtesy of Shriners Hospital for Children, Philadelphia.)



FIGURE 37.3 Radiograph of a 2-year-old revealing a thumb metacarpal that tapers to a point, indicative of an unstable carpometacarpal joint. (Courtesy of Shriners Hospital for Children, Philadelphia.)



FIGURE 37.4 One year-old with severe type IV thumb hypoplasia (pouce flottant or floating thumb). (Courtesy of Shriners Hospital for Children, Philadelphia.)

finger/index finger web space widens. In these circumstances, thumb reconstruction is contraindicated and index pollicization is preferred.

Type IV hypoplasia represents a profound deficiency known as a *pouce flottant*, or *floating thumb* (Figure 37.4). The thumb remnant is attached to the hand solely by a narrow bridge of skin containing a single neurovascular element. The thumb is floppy and is entirely ignored.

Type V hypoplasia is complete absence of the thumb. On occasion, there will be a small skin nubbin present.

Thumb hypoplasia can also be found in children with ulnar deficiency (Figure 37.5). The treatment for thumb hypoplasia

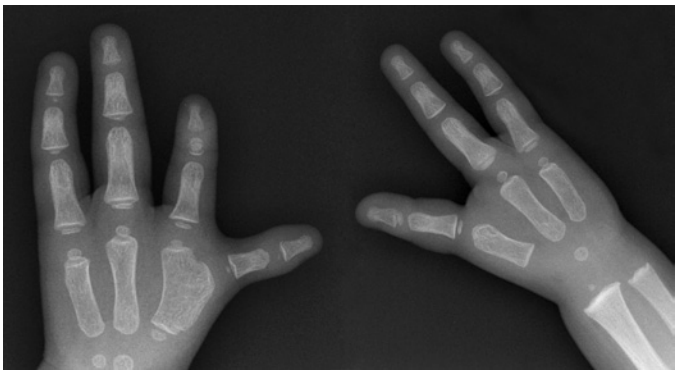

FIGURE 37.5 Radiograph of 4-year-old with bilateral ulnar deficiency and marked left thumb hypoplasia. (Courtesy of Shriners Hospital for Children, Philadelphia.)

in ulnar deficiency and radial deficiency is the same. Pollicization is indicated for marked thumb hypoplasia. The surgical technique for pollicization is similar, with minor modifications, such as skin design.

The standard indications for pollicization can be expanded to include a thumb smaller than a small finger.[40] This decision to ablate the thumb and pollicize the index finger requires a prolonged conversation with the parents about the rationale for this recommendation. Parents generally come to understand that "function trumps form" and that thumb ablation and index finger pollicization will result in a thumb that is more functional than the small, scrawny thumb that may be formed by reconstruction.[22] When in doubt, parents are given a list of other parents who have made a similar difficult decision regarding thumb ablation. This parent-to-parent communication is invaluable.

Treatment for Thumb Hypoplasia

An experienced hand therapist is invaluable in the evaluation of the child with a hypoplastic thumb. Although there is little need for nonoperative management, the hand therapist's input is essential and can provide support for the family and facilitate the decision-making process. Following surgery, the therapist becomes a primary care provider who directly affects the success of the procedure.

The classification schema guides treatment. Type I hypoplasia usually does not warrant surgical intervention, because the functional impairment is negligible. Type II or IIIA hypoplasia diminishes function and often requires surgery to provide stability, improve motion, and enhance function. Type IV or V hypoplasia requires index finger pollicization if the index finger is "suitable" for becoming a thumb. A stiff index finger will be a stiff thumb and may not enhance hand function. Therefore, determining the risk/benefit ratio of pollicization requires ample thought and consideration. The operation should follow the Peter Carter 2-4 rule: For some children, surgery can indeed be done "to" them, but it may not necessarily be "for" them. We have slightly modified the 2-4 rule to state that the operation should be done "to" the patient and "for" the patient.

Thumb Reconstruction

Thumb reconstruction for type II and IIA hypoplasia requires addressing all the deficient elements. The narrowed thumb/index finger web space, MCP instability, and thenar muscle absence all require treatment. Thumb/index finger web space narrowing is treated with skin rearrangement and soft tissue release. A four-flap "Z"-plasty lengthens the tight skin and provides a rounded contour to the web space. The theoretical increase in length is 150%.[9] The deeper soft tissue release includes the investing fascia around the adductor pollicis. The princeps pollicis artery and its branches must be identified and protected before division of the fascia. An extremely tight web space may also require partial release of the adductor muscle and/or first dorsal interosseous muscle to obtain adequate breadth.

MCP instability necessitates stabilization. Unidirectional instability with an incompetent UCL is the most common finding. Ligament reconstruction can be performed with local tissue or preferably the residual length of donor tendon from the opposition transfer. Bidirectional or global instability is more challenging to manage. Reconstruction of both the radial and ulnar collateral ligaments with a tendon graft is an option. MCP joint chondrodesis is preferred, however, to achieve firm stability and provide a stable platform for the opposition transfer to function. The details of MCP joint chondrodesis are discussed in Chapter 39. UCL insufficiency can be secondary to an anomalous connection between the flexor pollicis longus and extensor pollicis longus muscles (i.e., *pollex abductus*).[19,48,83] The pollex abductus attenuates the UCL over time and prevents active thumb IP joint motion. The key to determining its presence is the physical examination prior to surgery. During attempted thumb IP flexion, the MCP joint deviates into valgus rather than bending the IP joint. Surgery must release the pollex abductus when UCL reconstruction is performed.

Thenar absence requires a tendon transfer to provide thumb opposition. There are a variety of donor muscle-tendon units to choose from, including the flexor digitorum superficialis (FDS) (long or ring finger), abductor digiti minimi, extensor carpi ulnaris, and extensor indicis proprius.[69] Each donor muscle-tendon unit has its advocates and its advantages and disadvantages. The long or ring finger FDS is preferred because of its length, power, expendability, and synergism and the technical ease with which it can be used. If the FDS is unavailable, the other donor options are considered.

Flexor Digitorum Superficialis Opponensplasty With Ulnar Collateral Ligament Reconstruction. The patient is placed supine on the operating room table (Box 37.1 and see Videos 37.2 and 37.3). The procedure is usually performed under general anesthesia. A single dose of intravenous preoperative antibiotics is administered. The limb is prepped and draped in sterile fashion. Chlorhexidine gluconate and alcohol prep (ChloraPrep, CareFusion, Leawood, KS) is preferred and may be more effective than Betadine prep in eliminating bacteria.[71] In addition, when chlorhexidine is used, iodine, which can migrate beneath the tourniquet and cause burns, need not be used.

The limb is exsanguinated and the tourniquet is inflated. The incisions are carefully drawn (Figure 37.6). The narrowed thumb/index finger web space is widened via a four-flap "Z"-plasty. Each limb of the "Z"-plasty should be equal in length. The radial limb can be extended in a proximal direction to expose the UCL and the MCP joint. The ring finger FDS tendon is isolated at the base of the finger and in the distal forearm. A short oblique incision is made at the base of the ring finger, and



FIGURE 37.6 Four-flap "Z"-plasty to widen the narrowed thumb/index finger web space. (Courtesy of Shriners Hospital for Children, Philadelphia.)

BOX 37.1 Surgical Steps in Thumb Reconstruction

Limb is exsanguinated and the tourniquet is inflated
Four-flap "Z"-plasty of thumb/index finger web space with release of tight fascia
Ring finger FDS tendon is isolated at base of finger and in distal forearm
Thoracodorsal neurovascular pedicle is isolated
Ring finger FDS tendon pulled through carpal tunnel and into forearm
Radial one half of the distal 2 to 3 cm of FCU tendon made into a loop for the FDS tendon
Ring finger FDS tendon passed through the FCU loop
Skin incision along the radial side of thumb MCP joint
Subcutaneous tunnel is made between the radial side of thumb and the volar forearm FCU loop
FDS tendon is passed under the skin to the radial side of the thumb
Metacarpal head is isolated and a 0.045-inch Kirschner wire drilled across the metacarpal head parallel to the joint surface
Hole is enlarged with a drill bit to allow passage of the FDS tendon
MCP joint is reduced and stabilized with a longitudinal 0.045-inch Kirschner wire drilled antegrade from the tip of the thumb across the MCP joint
FDS tendon is passed through the drill hole to ulnar side of thumb for ligament reconstruction
FDS tendon is sutured to the surrounding bone and periosteum along the radial side of the thumb while setting the appropriate tension in the tendon transfer
FDS tendon is directed to the base of the proximal phalanx and sutured directly into the bone to reconstruct the UCL
Skin is closed with absorbable suture and the limb is immobilized in a long-arm thumb spica cast for 3 weeks

FCU, Flexor carpi ulnaris; *FDS*, flexor digitorum superficialis; *MCP*, metacarpophalangeal; *UCL*, ulnar collateral ligament.

a zigzag or oblique incision is made along the volar ulnar forearm. The flexor carpi ulnaris (FCU) tendon is also isolated. An additional skin incision is made along the radial side of thumb MCP joint to expose the ultimate site for FDS tendon attachment. The FDS tendon is identified at the base of the ring finger and separated from the flexor digitorum profundus (FDP) tendon. The FDS tendon is also isolated in the forearm (Figure 37.7). The FDS tendon is tagged with a suture and cut at the base of the ring finger while the underlying FDP tendon is guarded. An Allis tissue forceps (Jarit, Hawthorne, NY) is placed around the ring finger FDS tendon in the forearm and used to roll the tendon through the carpal tunnel (Figure 37.8). If the FDS tendon fails to roll into the forearm, it must be retrieved into the hand using tag suture. An assessment for FDP and FDS attachments and/or entrapment within the Camper chiasm is performed.



FIGURE 37.7 Ring finger flexor digitorum superficialis tendon is identified at the base of the finger and within the forearm. (Courtesy of Shriners Hospital for Children, Philadelphia.)

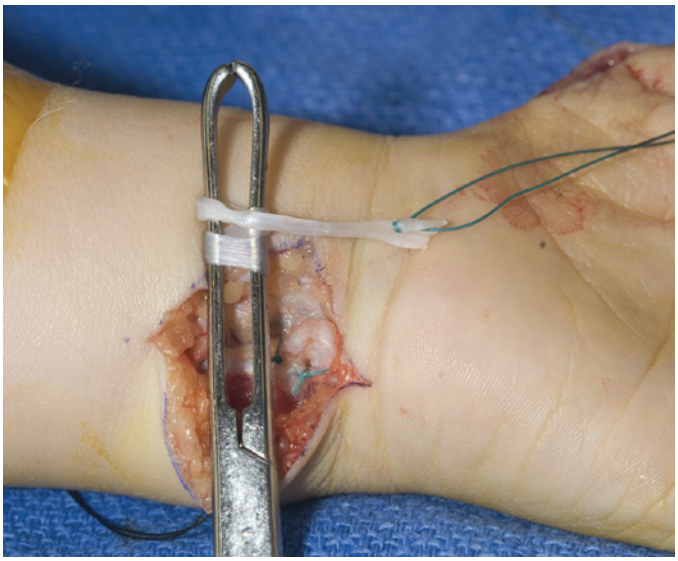

FIGURE 37.8 Ring finger flexor digitorum superficialis tendon rolled into volar forearm incision. (Courtesy of Shriners Hospital for Children, Philadelphia.)

An FCU tendon loop is constructed as a pulley for the FDS tendon. The distal 2 to 3 cm of FCU tendon is isolated. The radial half of the FCU tendon is harvested, preserving its distal attachment into the pisiform (Figure 37.9). The radial half of the tendon is passed through the retained FCU at the pisiform and sutured to form a loop. The ring finger FDS tendon is

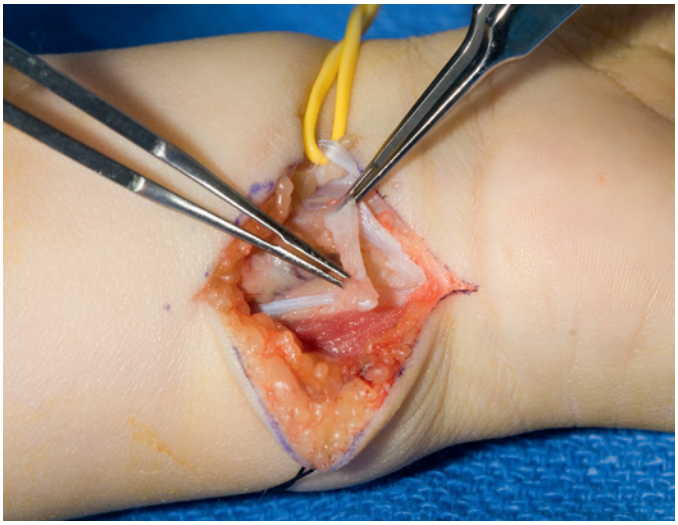

FIGURE 37.9 One half of the distal 2 to 3 cm of the flexor carpi ulnaris tendon is used to construct a pulley for the flexor digitorum superficialis tendon. (Courtesy of Shriners Hospital for Children, Philadelphia.)

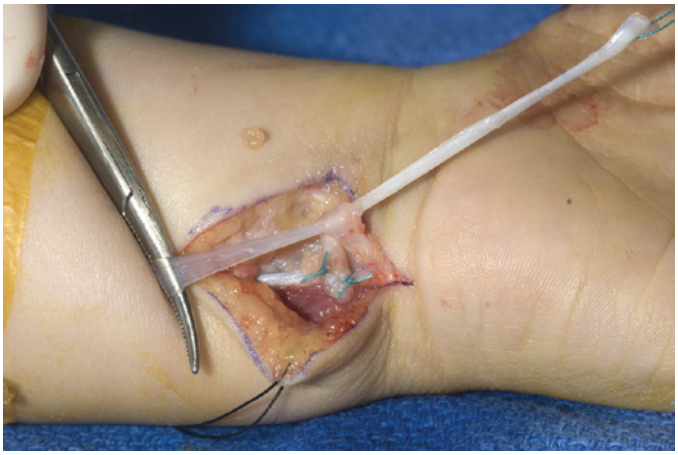

FIGURE 37.10 Ring finger flexor digitorum superficialis tendon is passed through the flexor carpi ulnaris loop. (Courtesy of Shriners Hospital for Children, Philadelphia.)

passed through the FCU loop prior to transfer across the palm (Figure 37.10).

A subcutaneous tunnel is made between the radial side of thumb and the volar forearm incision for channeling the ring finger FDS tendon. The FDS tendon is passed under the skin to the radial side of the thumb (Figure 37.11). The metacarpal head is isolated and a 0.045-inch Kirschner wire drilled across the metacarpal head parallel to the joint surface (Figure 37.12). Minifluoroscopy ensures appropriate Kirschner wire positioning. The hole is enlarged with a drill bit to allow passage of the FDS tendon. The MCP joint is reduced and stabilized with a longitudinal 0.045-inch Kirschner wire drilled antegrade from the tip of the thumb across the MCP joint. The wire is cut short and a Jurgan pin ball (Jurgan Development and Manufacturing, Madison, WI) applied. The FDS tendon is passed through the drill hole to the ulnar side of the thumb for ligament reconstruction (Figure 37.13). If the diameter of the tendon is too large, one slip of the FDS can be removed.



FIGURE 37.11 The flexor digitorum superficialis tendon is passed through the subcutaneous tunnel to the radial side of the thumb. (Courtesy of Shriners Hospital for Children, Philadelphia.)



FIGURE 37.12 Kirschner wire is drilled across the metacarpal head parallel to the joint surface. (Courtesy of Shriners Hospital for Children, Philadelphia.)

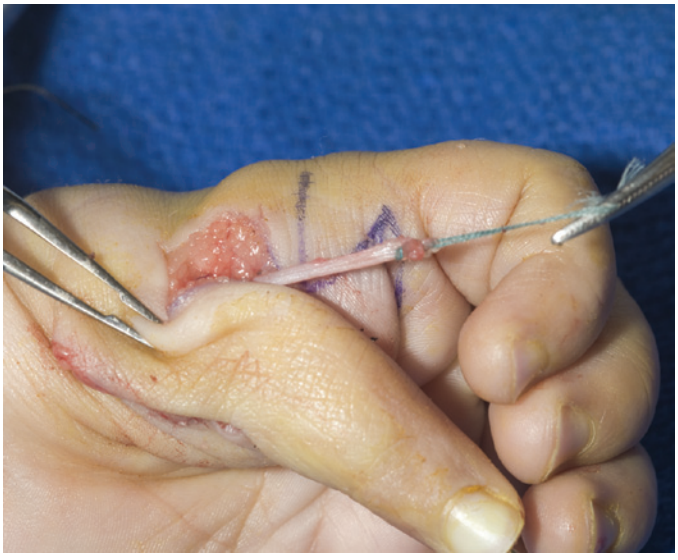

FIGURE 37.13 Flexor digitorum superficialis tendon is passed through the metacarpal head to the ulnar side of thumb. (Courtesy of Shriners Hospital for Children, Philadelphia.)



FIGURE 37.14 Flexor digitorum superficialis tendon is used to reconstruct the ulnar collateral ligament. Note longitudinal Kirschner wire exiting tip of the thumb. (Courtesy of Shriners Hospital for Children, Philadelphia.)

At this point, the wrist is placed into slight extension and the FDS tendon tensioned until the thumb is positioned in opposition. Tenodesis is used to assess tension, and after correct tension is achieved, the FDS tendon is sutured to the surrounding bone and periosteum along the radial side of the thumb. This maneuver sets the tension in the opposition tendon transfer. Typically, the tendon can be seen tenting the skin when the wrist is placed into extension. The remaining FDS tendon that had been passed through the metacarpal head is used to reconstruct the UCL. The FDS tendon is directed to the base of the proximal phalanx and sutured directly into the bone. Usually, the FDS tendon is long enough that it can be passed back onto itself to complete a double-stranded repair (Figure 37.14).

The skin is closed with absorbable suture and the limb is immobilized in a long-arm thumb spica cast for 3 weeks. The Kirschner wire is removed and a short-arm thumb spica splint is fabricated. Active motion and therapy are initiated. Protective splinting of the thumb is continued until 3 months after surgery.

Pollicization

Pollicization is indicated for types IIIB, IV, or V hypoplasia. The technique is similar for each type, with subtle variations depending upon whether a hypoplastic thumb is present or absent. In type IIIB hypoplasia, vascularized fat from the ablated thumb can be used to augment the first web space or thenar eminence.[76,84] In type IV or V hypoplasia, this option is unavailable.

Pollicization Procedure. The current technique of pollicization represents a consolidation of contributions from surgeons over the past 100 years (Box 37.2, Case Study 37.2, and see Video 37.4).[40,49] Following general anesthesia, the child is placed in the supine position. Preoperative antibiotics are routinely administered. The extremity is prepped and draped in sterile fashion. A sterile pediatric tourniquet (Delfi Medical Innovations, Vancouver, Canada) is placed on the upper arm. Exsanguination should be gentle so that some filling of the digital vessels can be maintained in order to facilitate visualization.

BOX 37.2 Surgical Steps in Pollicization

Limb is gently exsanguinated and the tourniquet is inflated
- Skin incision proposed by Ezaki and Carter
- Palmar skin is incised and the radial neurovascular bundle is isolated
- Dissection proceeds in an ulnar direction to identify the common digital vessels to the index finger/long finger web space
- Proper digital nerves to the ulnar side of the index finger and the radial side of the long finger are isolated
- Proper digital artery to the long finger is ligated with a ligature clip
- First annular pulley of the index finger is incised
- Divide intermetacarpal ligament between index finger and long finger
- Dorsal skin incision is sharply elevated with preservation of dorsal veins
- The first dorsal and palmar interossei muscles are released with a portion of the hood
- Metacarpal index finger is shortened by a saw cut at the metaphyseal flare and a knife cut through the physis leading to an epiphysiodesis
- Index metacarpophalangeal joint is fixed into hyperextension using nonabsorbable suture material passed through the epiphysis and dorsal capsule
- Kirschner wire drilled antegrade through the metacarpal epiphysis, into the proximal phalanx, and out the proximal interphalangeal joint
- Kirschner wire used as a joystick to align the index metacarpal into 45 degrees of abduction and 100 to 120 degrees of pronation
- Kirschner wire is drilled retrograde across the metacarpal base into the carpus
- Transfer the first dorsal interosseous to the radial lateral band and the first palmar interosseous to the ulnar lateral band about the PIP joint
- Skin is closed with absorbable suture with resection of any redundant skin and Kirschner wire is cut short

The skin incision must allow index finger transposition and reconstruction of an abundant thumb/index finger web space. The skin incision proposed by Marybeth Ezaki and Peter Carter is used because it allows more glabrous skin to be placed along the palmar aspect of the index finger (Figure 37.15).[39] The palmar skin is incised first, and the radial neurovascular bundle is isolated, although the artery can be extremely small. In children with type IIIB or IV hypoplasia, the single vessel to the hypoplastic thumb can be traced to the radial neurovascular bundle of the index finger to ease identification (Figure 37.16). The dissection next proceeds in an ulnar direction to identify the common digital vessels to the index finger/long finger web space (Figure 37.17). The proper digital nerves to the ulnar side of the index finger and the radial side of the long finger are isolated. Proximal nerve microdissection is required to further separate the proper digital nerves prior to pollicization. On occasion, as the dissection of the digital nerve proceeds in a proximal direction, one will encounter a neural loop that encircles the artery. This loop must be addressed to prevent constriction of the artery during index finger transposition. The loop can be widened to avoid arterial compression or the smaller of the two nooses can be cut. The proper digital artery to the long finger is ligated with a ligature clip (Figure 37.18). This allows tension-free index finger pollicization vascularized by the radial digital artery and the common digital artery to the index finger/long finger web space. The ligature clip acts as a visual reminder of the location of the proper digital artery.

The first annular pulley of the index finger is incised to prevent buckling of the flexor tendons after index finger

CASE STUDY 37.2 Pollicization

Emma is a 4-year-old with ulnar deficiency and marked left thumb hypoplasia (eFigure 37.4). Treatment included bone and joint reorganization and muscle reorganization:

Bone and joint reorganization:

- DIP joint → IP joint
- PIP joint → MCP joint
- MCP joint → CMC joint
- Metacarpal → Trapezium

Muscle reorganization:

- First PI → adductor pollicis
- First DI → abductor pollicis brevis
- Extensor indicis proprius → extensor pollicis longus
- Extensor digitorum communis → abductor pollicis longus

The surgical procedure is demonstrated in Video 37.4 and eFigure 37.5.

The challenging rehabilitation required communication and experience (eFigure 37.6), but a successful outcome was achieved (eFigure 37.7 and Video 37.5).

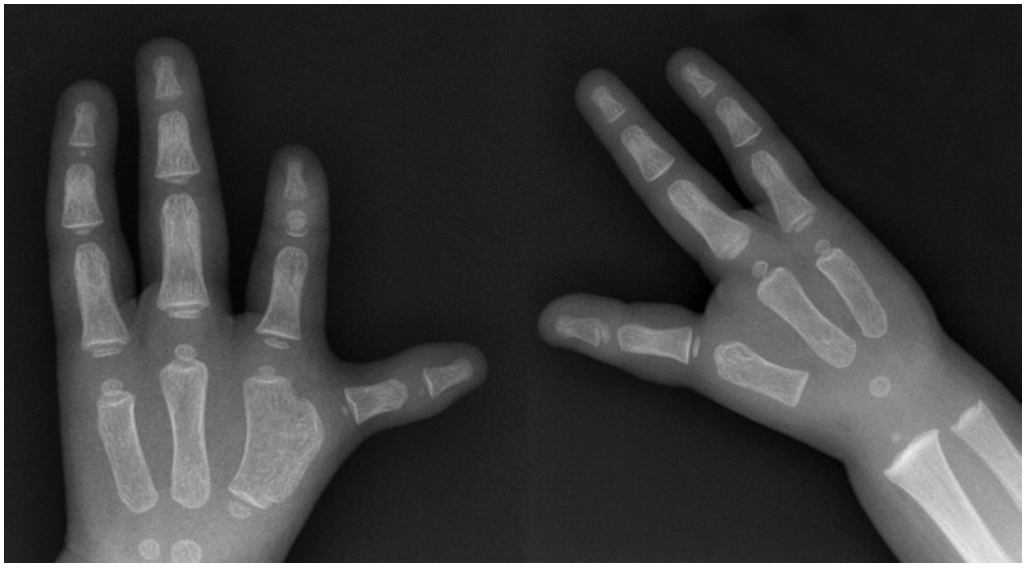

eFIGURE 37.4 Left thumb hypoplasia. (Courtesy of Shriners Hospital for Children, Philadelphia.)

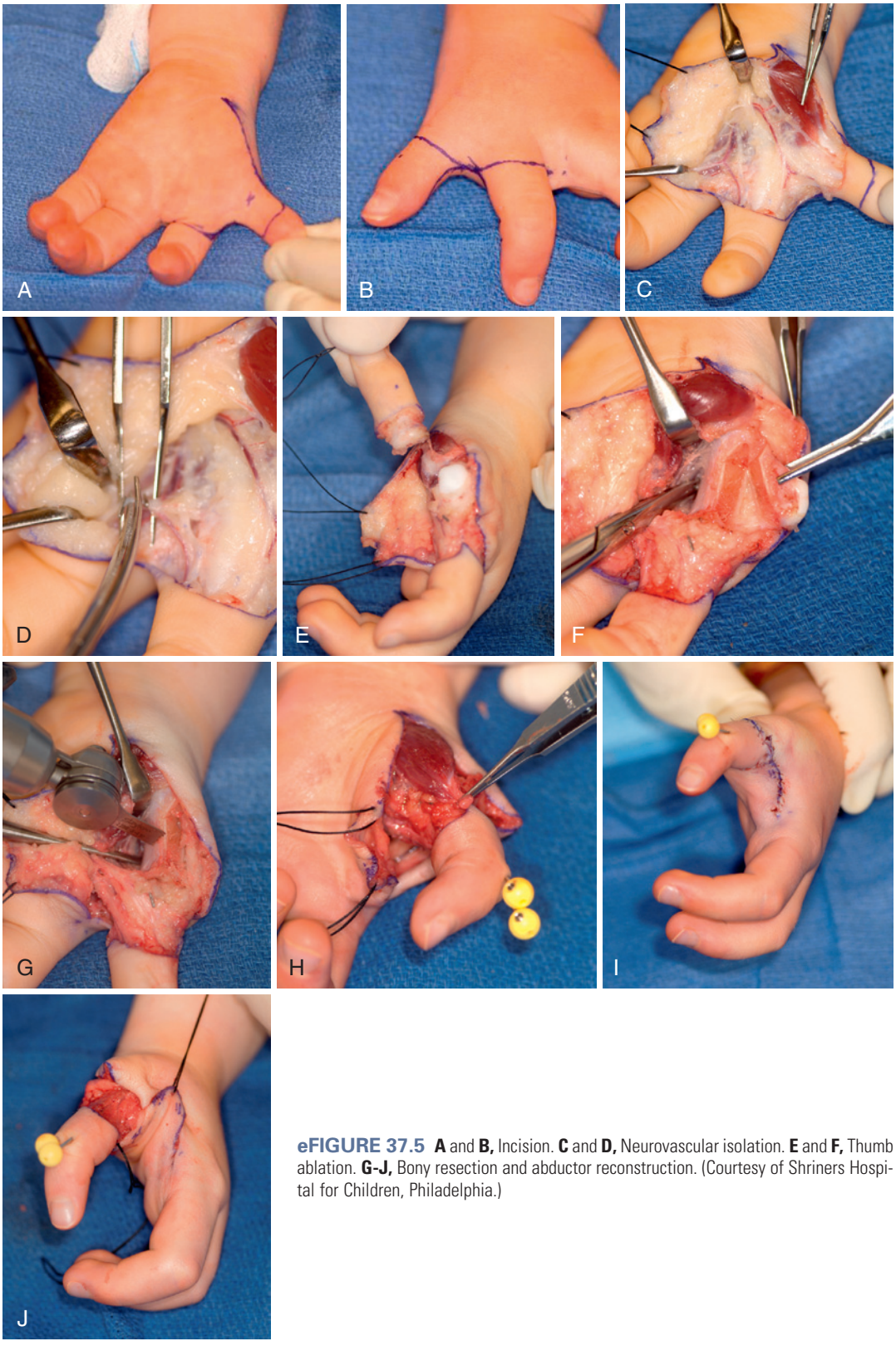

eFIGURE 37.5 **A** and **B,** Incision. **C** and **D,** Neurovascular isolation. **E** and **F,** Thumb ablation. **G-J,** Bony resection and abductor reconstruction. (Courtesy of Shriners Hospital for Children, Philadelphia.)



eFIGURE 37.6 Rehabilitation. (Courtesy of Shriners Hospital for Children, Philadelphia.)



eFIGURE 37.7 **A** through **D,** Outcome. (Courtesy of Shriners Hospital for Children, Philadelphia.)

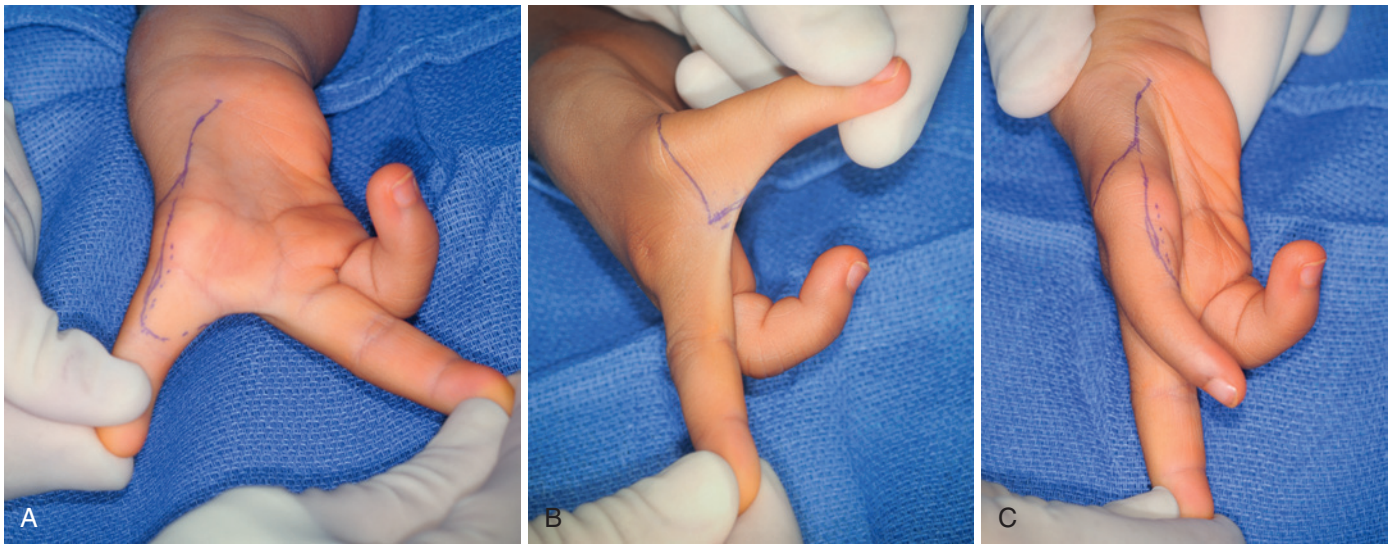

FIGURE 37.15 Four-year-old with absent thumb and ulnar deficiency. **A,** Volar skin incision that allows more glabrous skin to be placed along the palmar aspect of the index finger. **B,** Dorsal incision design. **C,** Radial incision for access to the thumb metacarpal base. (Courtesy of Shriners Hospital for Children, Philadelphia.)



FIGURE 37.16 In this child with type IIIB thumb hypoplasia, the single vessel to the hypoplastic thumb was traced to the radial neurovascular bundle of the index finger to ease identification. (Courtesy of Shriners Hospital for Children, Philadelphia.)

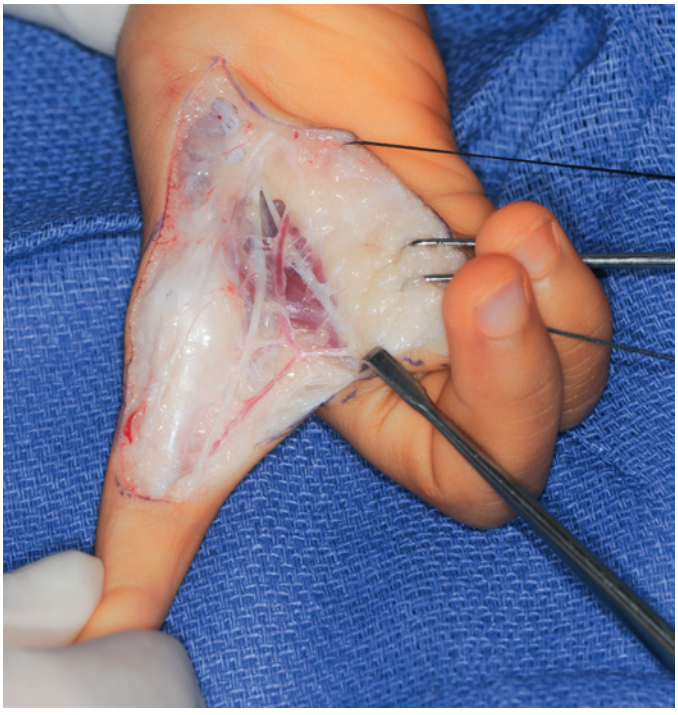

FIGURE 37.17 Ulnar dissection to identify the common digital vessels to the index finger/long finger web space. (Courtesy of Shriners Hospital for Children, Philadelphia.)

shortening (Figure 37.19). The intermetacarpal ligament is also divided (Figure 37.20). The dorsal skin incision is sharply elevated with preservation of as many dorsal veins as possible. The extensor or flexor tendons are not shortened, because these musculotendinous structures adapt over time.

The first dorsal and palmar interosseous muscles are dissected to their attachments into the extensor hood (Figures 37.21 and 37.22). The interosseous muscles and tendons are released with a portion of the hood in expectation of transfer. The tendons must be carefully dissected from the MCP joint collateral ligaments to avoid entering the joint. The neurovascular bundles must also be shielded during elevation of the interossei. Prior to cutting the metacarpal, the eventual insertion sites for the tendon transfers are identified and tagged within the extensor mechanism over the PIP joint. This facilitates later transfer of the first dorsal and first palmar tendons into the radial and ulnar lateral bands, respectively.

The index finger must be shortened. The distal cut is made directly through the physis using a knife (Figure 37.23). This

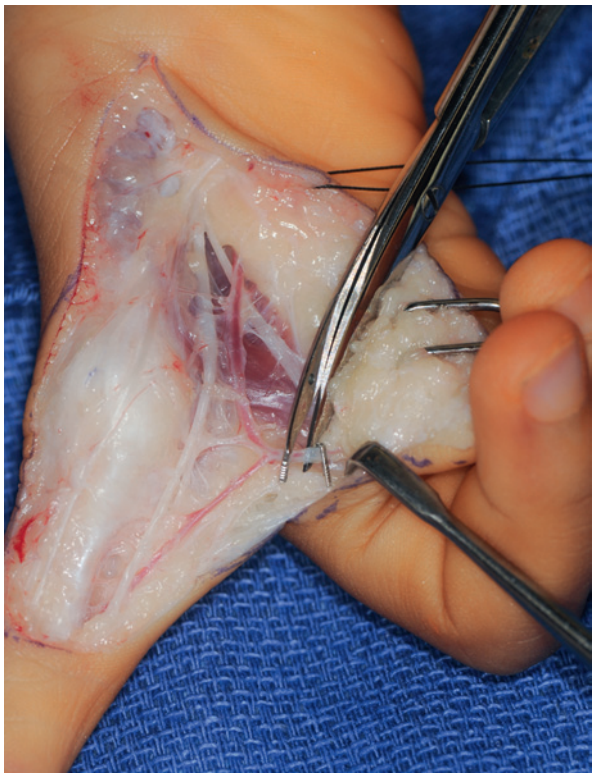

FIGURE 37.18 Ligation of the proper digital artery to the long finger with ligature clips. (Courtesy of Shriners Hospital for Children, Philadelphia.)

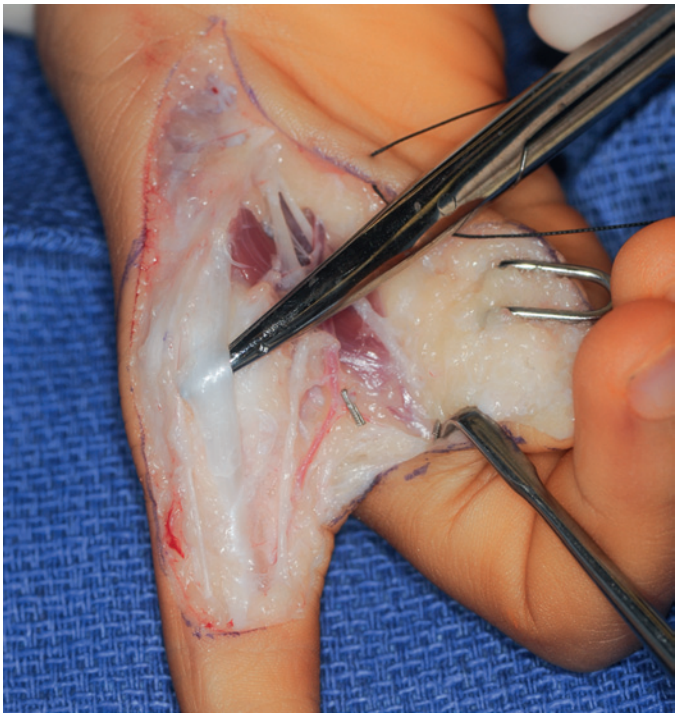

FIGURE 37.19 Incision of the first annular pulley to prevent buckling of the flexor tendons after index finger shortening. (Courtesy of Shriners Hospital for Children, Philadelphia.)

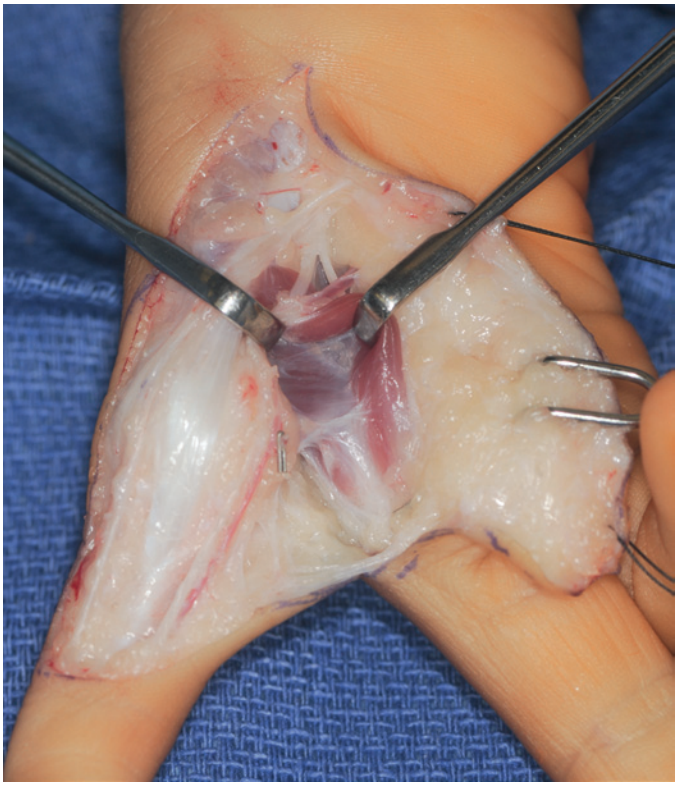

FIGURE 37.20 The intermetacarpal ligament is also divided. (Courtesy of Shriners Hospital for Children, Philadelphia.)



FIGURE 37.21 Dissection of the first palmar interosseous muscle with a portion of the extensor hood. (Courtesy of Shriners Hospital for Children, Philadelphia.)



FIGURE 37.22 Dissection of the first dorsal interosseous muscle. (Courtesy of Shriners Hospital for Children, Philadelphia.)

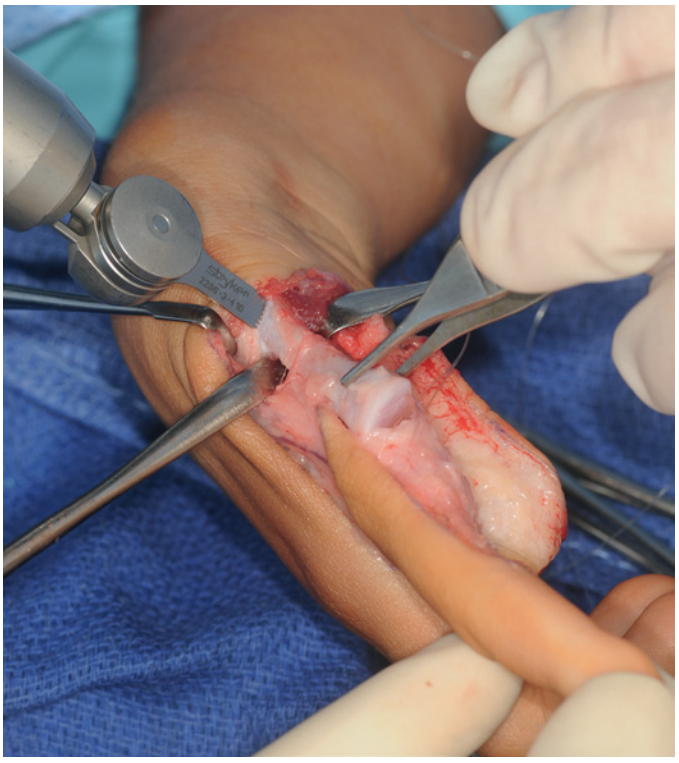

FIGURE 37.24 Fine-bladed saw is used to cut the metacarpal base through the metaphyseal flare in the plane of the intended thumb. (Courtesy of Shriners Hospital for Children, Philadelphia.)

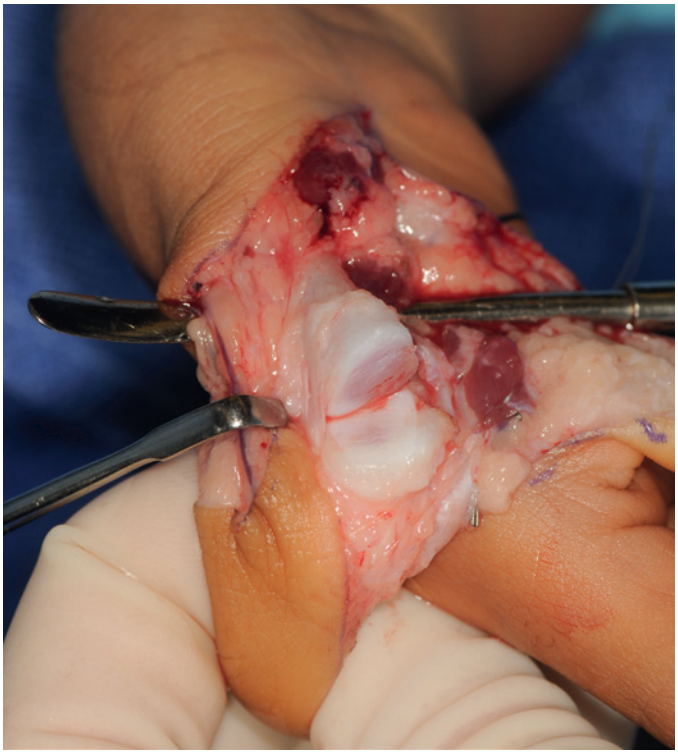

FIGURE 37.23 Distal metacarpal cut directly through the physis. (Courtesy of Shriners Hospital for Children, Philadelphia.)

physeal cut leads to growth plate ablation (epiphysiodesis) to prevent unwanted growth of the index metacarpal. A fine-bladed saw is used to cut the metacarpal base through the metaphyseal flare in the plane of the intended thumb (Figure 37.24). The index metacarpal bone is removed from its base to the epiphysis (Figure 37.25). A rongeur is used to widen the base by opening or pedaling the surrounding cortex to promote healing (Figure 37.26).

The normal index MCP joint hyperextends and the normal thumb CMC joint does not hyperextend. To correct this discrepancy, the index MCP joint is fixed into hyperextension, placing the remaining metacarpal head into flexion (Figure 37.27). This is achieved by suturing the MCP joint into hyperextension using a suture material passed through the epiphysis and dorsal capsule. Subsequently, a Kirschner wire is placed through the metacarpal epiphysis or the base of the proximal phalanx (Figure 37.28). The Kirschner wire is drilled through the proximal phalanx and out the PIP joint (Figure 37.29). This Kirschner wire is used as a joystick to facilitate index finger positioning (Figure 37.30). Interosseous sutures are rarely used to augment fixation. The index finger metacarpal epiphysis is aligned anterior to its metaphyseal base with meticulous positioning into 45 degrees of abduction and 100 to 120 degrees of pronation (Figure 37.31). Once the position is deemed satisfactory, the Kirschner wire is drilled retrograde across the metacarpal base into the carpus. The Kirschner wire is cut short and a Jurgan pin ball is applied. Further stability is achieved via tendon transfer of the first dorsal interosseous to the radial lateral band and the first palmar interosseous to the ulnar lateral band about the PIP joint (Figure 37.32). The skin is judiciously

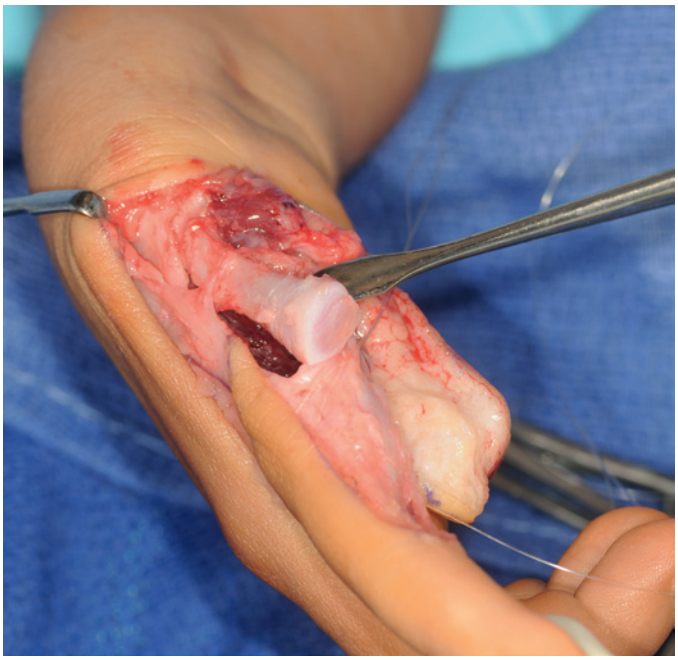

FIGURE 37.25 The index metacarpal bone is removed from its base to the epiphysis. (Courtesy of Shriners Hospital for Children, Philadelphia.)

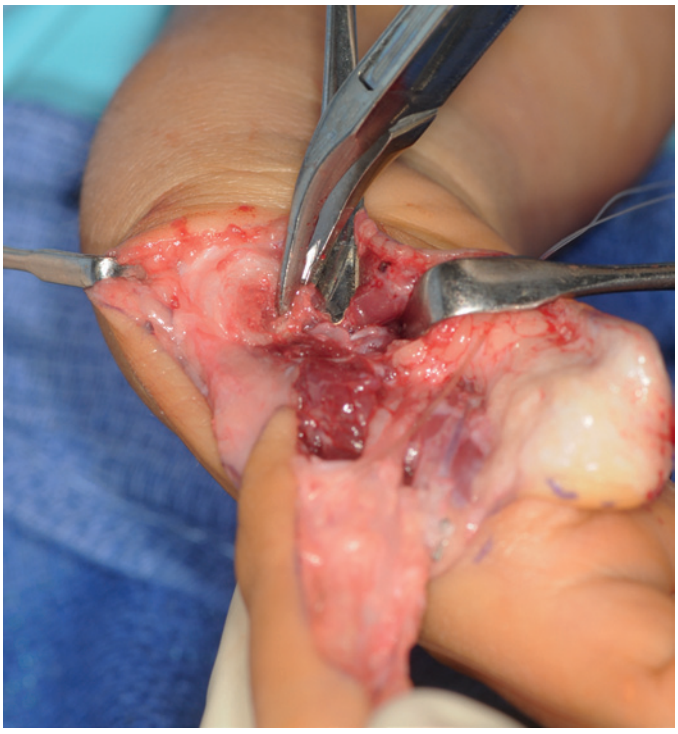

FIGURE 37.26 Rongeur to widen the base by pedaling the surrounding cortex. (Courtesy of Shriners Hospital for Children, Philadelphia.)

inset with absorbable suture. Any redundant skin is excised (Figure 37.33). Whenever possible, the first web space suture line is advanced dorsally to minimize any suture line within the commissure (Figure 37.34). The tourniquet is deflated and the "thumb" observed for 5 minutes. The arterial circulation typically returns rapidly, although vasospasm can result. Time,



FIGURE 37.27 The index metacarpophalangeal joint is fixed into hyperextension, placing the remaining metacarpal head into flexion. (Courtesy of Shriners Hospital for Children, Philadelphia.)

warm soaks, and patience routinely lead to resolution. Persistent lack of blood inflow requires exploration for arterial spasm that can resolve with lidocaine, arterial kinking, or iatrogenic injury. Venous congestion is a more common problem that requires reapplication of a looser dressing and/or release of any taut sutures.

Once adequate arterial ingress and venous egress has been established, the postoperative dressings are applied. Adequate fluffy dressings are necessary to equalize the anterior-posterior and medial-lateral dimensions of the hand. This allows uniform compression without constriction. A long-arm soft cast (Scotchcast Soft Cast Casting Tape, 3M, St. Paul, MN) is applied with the elbow flexed to more than 100 degrees and a substantial supracondylar mold to decrease the chance of unintended removal. This fiberglass casting tape can be unwrapped in the clinic, avoiding the frightening cast saw. The child is admitted overnight with the arm elevated to promote venous drainage. The thumb can be covered the next day if vascularity has been maintained throughout.

The Kirschner wire is removed 4 weeks after surgery and a short-arm thumb spica splint is fabricated. Occupational therapy is started with an emphasis on thumb usage. The initial goal is large object acquisition followed by acquisition of smaller objects and eventually fine pinch. Standard wound care is also performed consisting of scar massage and softening techniques. Active motion and therapy are initiated. Protective splinting of the thumb is continued until 3 months after surgery.

Outcome

Thumb Reconstruction. The results for thumb reconstruction for type II or IIIA hypoplasia are difficult to decipher because

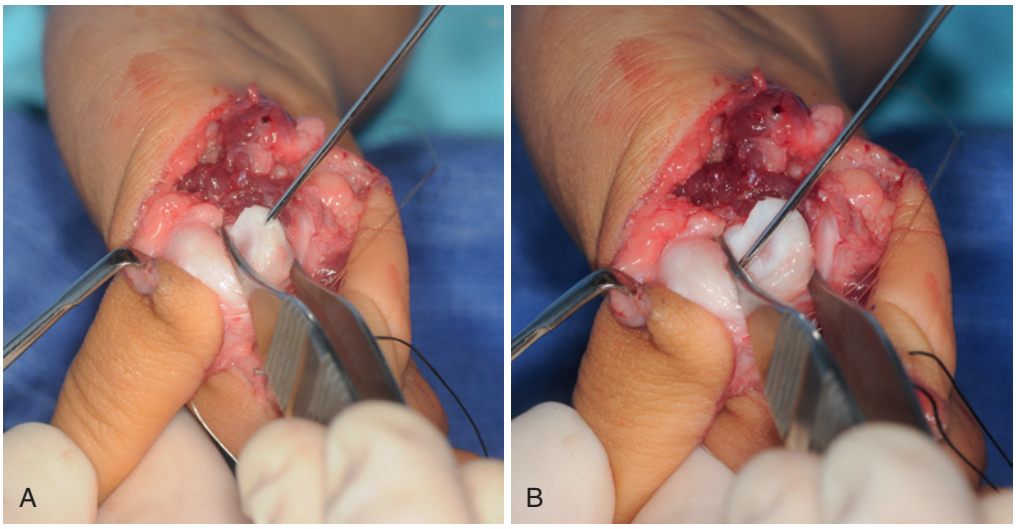

FIGURE 37.28 Antegrade Kirschner wire placement. **A,** Through the metacarpal epiphysis. **B,** Through the base of the proximal phalanx. (Courtesy of Shriners Hospital for Children, Philadelphia.)

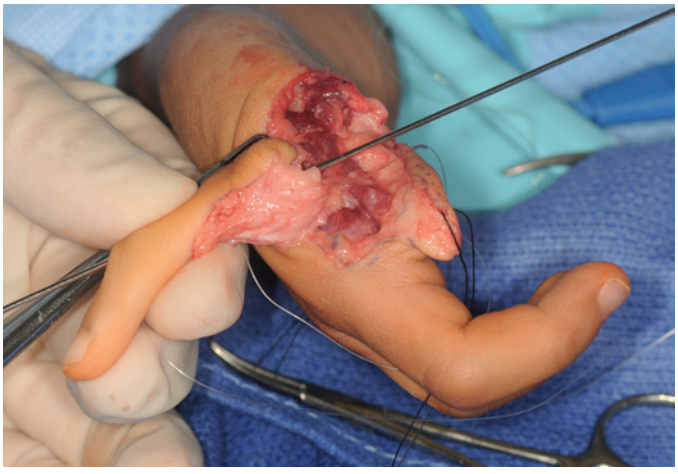

FIGURE 37.29 Kirschner wire drilled through the proximal phalanx and out the proximal interphalangeal joint. (Courtesy of Shriners Hospital for Children, Philadelphia.)



FIGURE 37.30 Kirschner wire used as a joystick to position the index finger. (Courtesy of Shriners Hospital for Children, Philadelphia.)



FIGURE 37.31 Once the index finger has been positioned in adequate abduction and pronation, the Kirschner wire is drilled retrograde across the metacarpal base into the carpus. (Courtesy of Shriners Hospital for Children, Philadelphia.)

comparison among studies is confounded by the heterogeneity of the patient populations, severity of the hypoplasia, and reconstructive techniques used. If the surgical plan for reconstruction has addressed each deficient component of the thumb, the function following reconstruction is usually good compared with the function present before surgery, regardless of the outcome measure employed (Figure 37.35).[41] Some degree of MCP joint stiffness is inevitable after ligament reconstruction, however; this stiffness has little impact on functional outcome as long as the IP and CMC joints are supple.

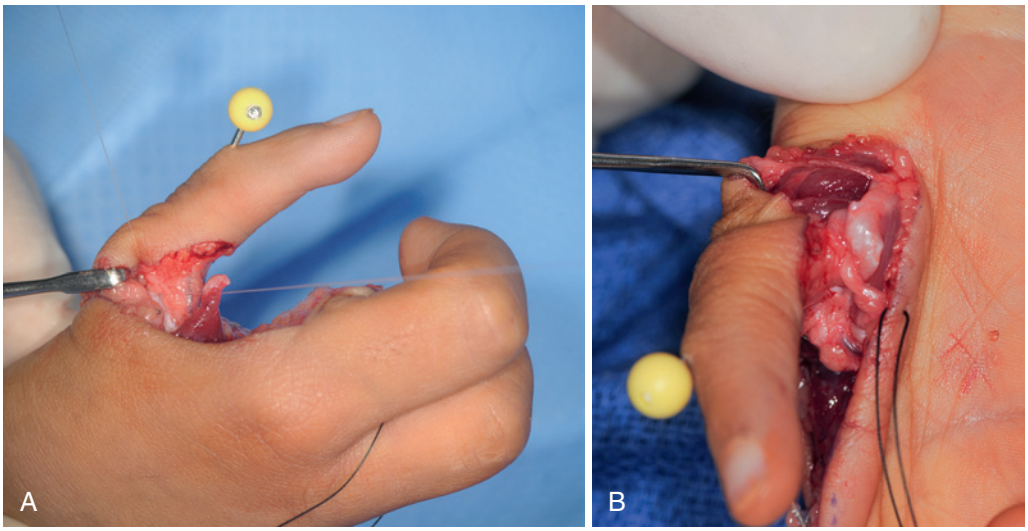

FIGURE 37.32 Tendon transfer to restore intrinsic function to the thumb. **A,** First palmar interosseous to the ulnar lateral band about the proximal interphalageal joint. **B,** First dorsal interosseous to the radial lateral band. (Courtesy of Shriners Hospital for Children, Philadelphia.)



FIGURE 37.33 The skin is inset and any redundant skin is excised. (Courtesy of Shriners Hospital for Children, Philadelphia.)



FIGURE 37.34 The skin is carefully inset to maximize the first web space and optimize the appearance. (Courtesy of Shriners Hospital for Children, Philadelphia.)

The results of tendon transfers, bone lengthening, and joint stabilizations for higher-grade hypoplastic thumbs are poor compared with the results of pollicization.[2] Children who require a five-digit hand for cultural reasons may gain some benefit from these procedures as long as the family has realistic expectations.

Pollicization. The results after pollicization depend mainly on the preoperative status of the index finger and surrounding musculature. Index finger pollicization provides better functional and aesthetic results in isolated thumb hypoplasia than it does in patients with an associated hypoplastic or absent radius. A mobile index finger moved to the thumb provides stability for grasp and agility for fine pinch (Figure 37.36).[42] Parents are extremely grateful and amazed at the results, often providing moving testimonials (see Video 37.5). In contrast, a stiff index finger in the thumb position provides a stable thumb

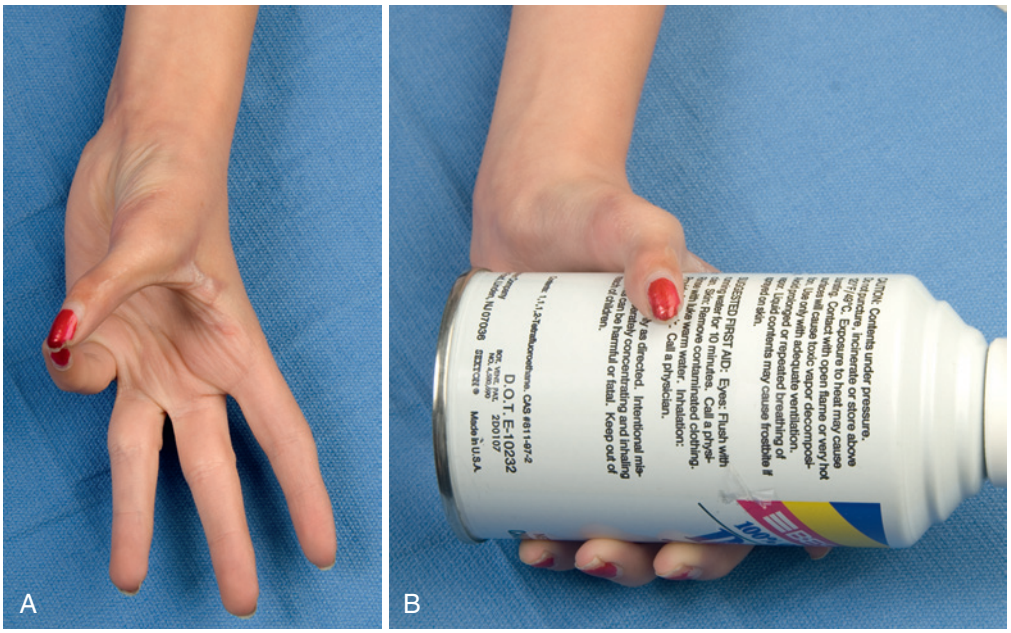

FIGURE 37.35 Ten-year-old child following left flexor digitorum superficialis tendon opposition transfer. **A,** Excellent opposition to the small finger. **B,** Improved ability to acquire large objects. (Courtesy of Shriners Hospital for Children, Philadelphia.)

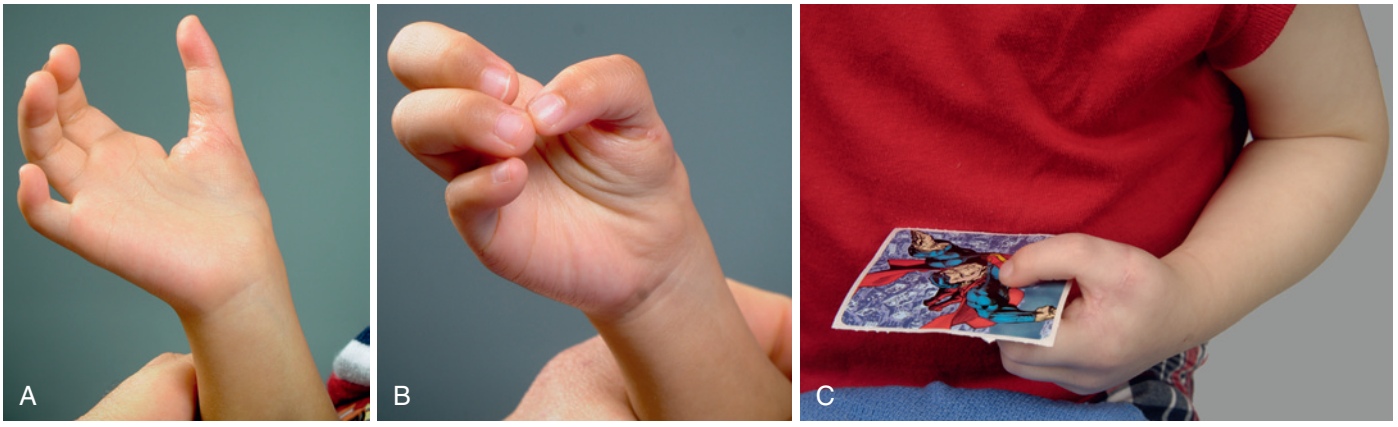

FIGURE 37.36 Three-year-old following index finger pollicization. **A,** Overall appearance. **B,** Movement pattern. **C,** Pinching a sticker. (Courtesy of Shriners Hospital for Children, Philadelphia.)

post for gross grasp but is unlikely to participate in fine pinch. Scissoring of adjacent digits is usually preferred for fine pinch in these cases. A pollicization that is stiff, weak, poorly positioned, and/or unstable will be bypassed in favor of the scissor pinch between adjacent long and ring fingers.

A recent study correlated the primary caretaker's subjective impressions of outcome to objective measures and found that children who had difficulty peeling a sticker from its backing tended to scissor pinch between the long and ring fingers and ignored the thumb for small object manipulation. In these children, the new thumb IP and MCP motion was poor.[98]

Children with a preoperative ulnar-sided grasp pattern secondary to perfect ulnar digit(s) finger mobility and stiff radial digits (often seen in patients with radial longitudinal deficiencies) will maintain their ulnar-sided grasp after pollicization and ignore the new thumb. Patients with mirror hands or five-fingered hands tend to have suboptimal results as well, although the reasons are unclear. One reason may be that the pollicized digit in these patients is more akin to a long finger than an index finger and may therefore lack the same independence of function or cortical representation.

The results of pollicization continue into adulthood, with long-term studies showing sustained functional use of the thumb.[10] In the majority of cases where the child used the index finger as a thumb prior to surgery, pollicization results in good to near-normal hand function in the long term. With no associated conditions that could lessen the outcome, the child can expect about one third of the strength of an unaffected thumb. Large object manipulation is typically better than small object manipulation, but overall, approximately 95% of patients integrate the thumb into daily tasks.[39] The objective and aesthetic outcomes following pollicization have been compared with those of normal thumbs.[29] Generally, the thumb created by pollicization was slightly longer than normal and

smaller in girth. The most frequently cited negative perceptions of the thumb were decreased girth, excessive length, and angulation.

Timing of the surgery has not been demonstrated to affect functional outcomes, although most clinicians feel that operations done in younger patients better take advantage of cortical plasticity. Others have argued that social factors should be the impetus for surgery because the index finger already has cortical representation as a thumb and timing is less important. Pollicization simply makes the index finger appear and work more like a true thumb.[39]

Cortical plasticity and motor relearning are hypothesized to play a critical role in functional development following pollicization. There is a large region of the sensorimotor cortex homunculus dedicated to the hand, and much of it is devoted to the thumb. Researchers are deciphering and understanding the changes in the sensorimotor cortex following injury, repair, and reconstruction.[3] Techniques include transcranial magnetic stimulation, electroencephalography, magnetoencephalography, functional MRI, structural MRI, and positron emission tomography.[23,26,28] Human cortical plasticity is a complex process that involves the unveiling of formerly quiescent connections and sprouting of active afferents from nearby cortical and/or subcortical regions.

Following hand transplantation, the original sensorimotor cortex map for hand activation is reestablished.[50] The transplantation reverses the sensorimotor cortex loss that followed the hand amputation. Similarly, successful toe transfer to the hand produces temporal activation within the sensorimotor cortex consistent with cortical plasticity.[50] Functional MRI has confirmed that when a patient learns to use the toe transfer there is an enlargement in the motor cortical representation. Practice amplifies the changes within the sensorimotor cortex. As the new motor skill is mastered, there is an ensuing decrease in the amount of cortical representation.[3,50] The precise effects of pollicization have yet to be studied, however; similar sensorimotor cortex changes are likely. Undoubtedly, essential alterations must occur in the sensorimotor cortex as the index finger becomes a thumb.

Another factor to consider when deciding on the timing of surgery is the size of the hand. Although the precise best age at which to perform surgery is unknown, the advantages of early surgery are lessened by the anatomic size of the neurovascular and musculocutaneous structures. Pollicization at about 1 to 2 years of age allows some hand growth and still takes advantage of infant and toddler brain plasticity. Late presentation is not a contraindication for pollicization, however; the adolescent likely has less brain plasticity and is often astounded about the change in his or her hand. Preoperative discussion and review of pictures is mandatory to lessen the astonishment following the initial dressing removal.

Complications

Pollicization is a complex procedure with a host of big and small complications. Acute complications are related to vascular compromise. Arterial insufficiency results in failure of the thumb to "pink up" despite time, patience, and warm soaks. Immediate exploration is necessary for arterial kinking or injury. The principal problem needs to be rectified to preserve the arterial inflow into the thumb. The second vascular problem involves venous egress as the thumb turns blue. Rectification requires a series of steps, including loosening of the dressings or release of taut sutures. Subsequently, strict elevation is necessary to promote venous drainage. Loss of the index finger due to vascular compromise after pollicization is rare, with an estimated incidence of 0.2% when a skilled surgeon has performed the operation.[40]

Long-term complications are related to scarring, stiffness, bony problems, and limited motion (Table 37.3). First web space scarring and cicatrix require therapeutic modalities, such as silicone elastomer and massage. Dense recalcitrant scarring requires additional surgery to resurface the web space. Stiffness may be inherent in the index finger prior to pollicization and may not be amenable to treatment. Iatrogenic stiffness related to the surgery requires therapy to mobilize the thumb. Persistent stiffness may have a surgical solution, such as tendinous adhesions. Careful examination is necessary to determine the underlying cause. Bony problems can be related to joint instability, poor thumb positioning, or excessive thumb length. CMC joint instability is uncommon even with a fibrous union. Symptomatic instability, however, warrants revision surgery. A thumb positioned in excessive supination or pronation requires osteotomy and repositioning (Figure 37.37). A long thumb attributed to ongoing growth at the metacarpal physis requires epiphysiodesis and possible metacarpal shortening (Figure 37.38). Limited active motion in the presence of satisfactory passive motion is amenable to tendon transfer, such as an opposition transfer.

TABLE 37.3 Pollicization Pitfalls and Complications

Complication	Causes	Management
First web space contracture	Insufficient web space reconstruction, loss of skin flap, scar formation	Therapeutic modalities Revision web space deepening via "Z"-plasty or dorsal rotational flap
Stiffness	May be attributed to preoperative condition of index finger or secondary to scarring related to surgery	Therapy; inherent stiffness not correctable; surgical adhesions can be treated by tenolysis
Excessive length	Failure to ablate index metacarpal growth plate	Epiphysiodesis and/or ostectomy of metacarpal
Malrotation	Technical error (underrotation or overrotation) or loss of fixation during postoperative care	Rotational osteotomy
Lack of opposition	Primary deficiency in intrinsic muscles or inability to reconstruct interossei	Opposition tendon transfer



FIGURE 37.37 Overrotation of the index finger can result in a thumb that is poorly aligned for pinch. (Courtesy of Shriners Hospital for Children, Philadelphia.)

CRITICAL POINTS *Thumb Hypoplasia*

- Thumb hypoplasia occurs in varying grades and is part of radial deficiency. Therefore, appropriate workup for associated anomalies is necessary.
- The underdeveloped thumb has been classified into five types that guide treatment. The presence or absence of a stable CMC joint is the pivotal factor of retention and reconstruction versus ablation and pollicization.
- Pollicization is the procedure of choice for types IIIB, IV, and V hypoplasias. Attempts at microsurgical joint transfer to restore the CMC joint in types IIIB and IV hypoplasias have been reported; however, the results appear mediocre compared with those of index finger pollicization.
- Pollicization requires a carefully designed skin incision and meticulous surgical technique following the steps outlined in the text. The neurovascular anatomy must be dissected with ligation of the radial digital artery to the thumb. The index finger metacarpal is removed from the physis to its base. The thumb is carefully positioned and the intrinsic muscles (abductor pollicis brevis and adductor pollicis) are reconstructed with the first dorsal interosseous and first palmar interosseous, respectively.
- Results after pollicization are related to numerous factors, including the status of the index digit, the surgical technique, and the ability to restore intrinsic muscle function. Early good results in childhood persist into adulthood.

THUMB DUPLICATION

General Considerations in Thumb Duplication

Epidemiologic Findings

Polydactyly can occur on the preaxial (radial) and postaxial (ulnar) sides of the limb. Preaxial polydactyly is more common in Caucasians, and postaxial polydactyly is more frequent in African-Americans.[18,90] Preaxial polydactyly is also documented in high proportions in Native Americans and many Asian populations.[32,45] Even though preaxial thumb duplication demonstrates a racial predilection toward Caucasian children, most cases are unilateral, sporadic, and without systemic problems.[18]

TABLE 37.4 Classification of Duplicated Thumbs

Type	Duplicated Elements
I	Bifid distal phalanx
II	Duplicated distal phalanx
III	Bifid proximal phalanx
IV	Duplicated proximal phalanx*
V	Bifid metacarpal phalanx
VI	Duplicated metacarpal phalanx
VII	Triphalangeal component

*Most common type.
Adapted from Wassel HD: The results of surgery for polydactyly of the thumb: a review, *Clin Orthop Relat Res* 125:175–193, 1969.

Classification

Thumb duplication has been classified in various ways based on the degree of skeletal replication (Table 37.4).[88] In the Wassel classification, the extent of duplication is defined and indexed according to whether the components are attached proximally (bifid) or completely separated (duplicated). The most common type is duplicated proximal and distal phalanges that share a common articulation with a bifid metacarpal head (≈50% of cases).[1,18,88] Various adaptations and modifications have been added to this scheme, but the basic premise remains unchanged.[35,67,95] There are some types of thumb duplications that defy classification.

Clinical Features

The diagnosis of thumb duplication is usually straightforward, especially in type IV duplication (Figure 37.39, *A* and *B*). A subtle type I or II duplication, however, may not be readily apparent on physical examination and is only diagnosed by widening of the nail plate (Figure 37.40). The parents are questioned regarding family members with extra digits, as a positive family history may be present. X-rays are routinely obtained and assist in defining the extent of duplication. However, surgical exploration may reveal a cartilaginous connection that is not visualized by x-ray. This operative finding reclassifies a type II thumb to a type I and a type IV thumb to a type III. The surgeon needs to be aware of this possible surgical finding, which may alter the operative plan.

The initial examination includes observation of thumb usage, palpation of the bony elements, and assessment of joint stability. Passive motion, varus/valgus stress testing of the joints, palpation of tendons (especially flexor tendons), and observation of the skin crease may be helpful. Little or absent passive motion at the bifurcation site of the minor thumb (most radial one) suggests an odd-numbered Wassel type I, III, or V. One of the duplicated elements is usually dominant and preferred for prehension. Serial examinations can be performed because the need for treatment is not urgent. Surgery is usually performed

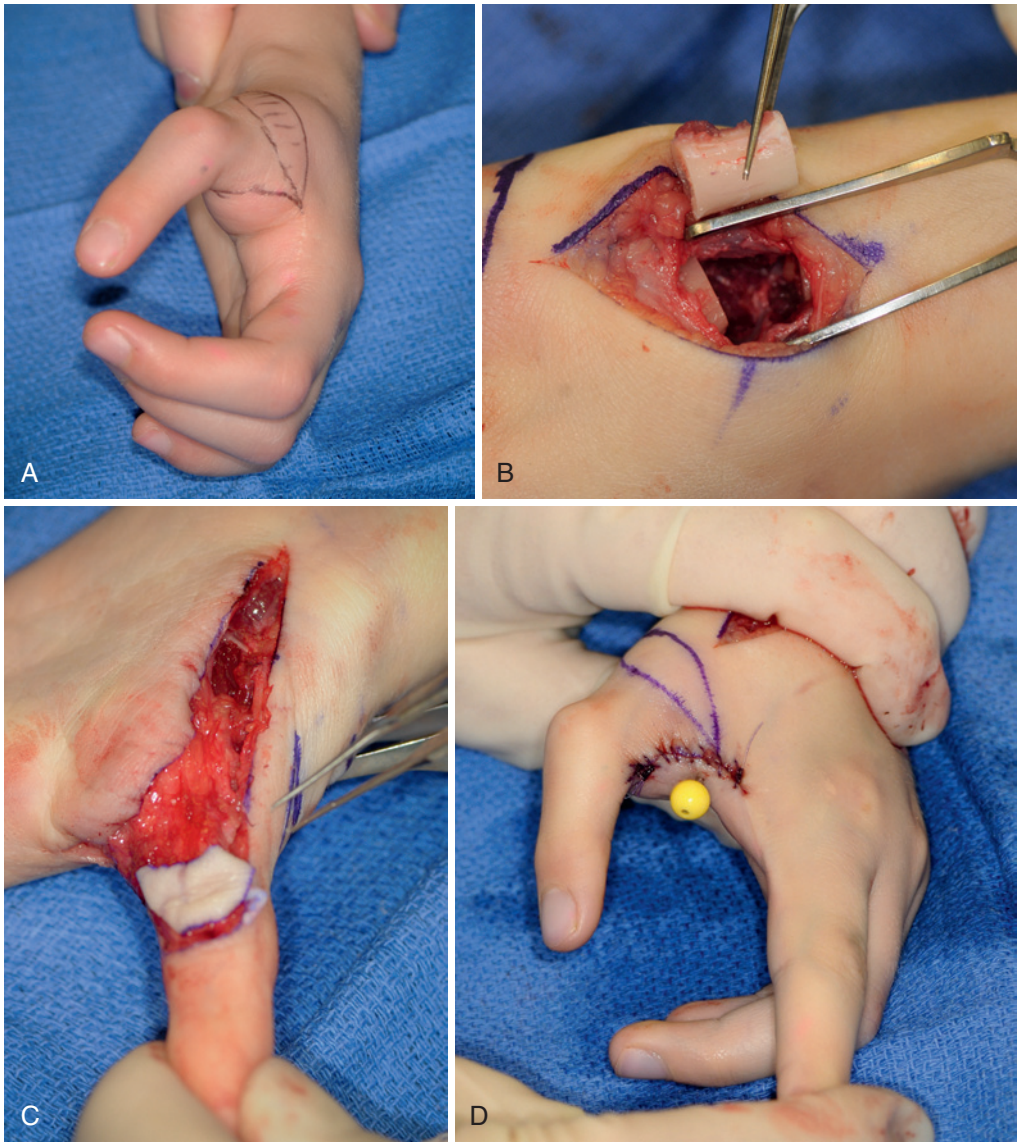

FIGURE 37.38 Six-year-old with a long thumb attributed to ongoing growth at the metacarpal physis. **A,** Clinical appearance of elongated thumb. **B,** Bony resection and epiphysiodesis. **C,** Skin reduction. **D,** Final appearance. (Courtesy of Shriners Hospital for Children, Philadelphia.)

at about 1 year of age, prior to the development of thumb/index finger pinch.

Several investigators have noted that the thumb is not truly duplicated.[18,20,46] Neither component is as robust as a normal thumb. Each thumb is thinner than normal and has diminished mobility. The term *split thumb* seems more appropriate.[18,20] This terminology also makes parents aware that the reconstructed thumb may be smaller in girth after surgery. However, the length of the reconstructed thumb will be similar to that of the other side. The split parts may share bony elements, tendons, ligaments, joints, neurovascular structures, and nails. The surgical goal is to create the best thumb possible using portions of each component to construct a properly aligned and functional thumb, so-called spare parts surgery.[14,18] The ideal reconstruction aligns the thumb along a longitudinal axis, stabilizes the joints, balances the motor functions, provides an adequate nail plate without deformity, and restores sufficient thumb size.[14,18,46,54,64] Reconstruction or preservation of the collateral ligaments is critical for duplications that arise from the joint surface (Wassel II, IV, and VI).

Treatment of Thumb Duplication

Type I or II Split Thumbs

Treatment of type I or II split thumbs depends on the extent and size of each duplicated part. A subtle type I or II duplication that has a common nail and is well aligned does not require treatment (see Figure 37.40). Asymmetric type I or II duplication with distinct components is treated by ablation of the smaller thumb, with transfer of the collateral ligament and centralization of the extensor tendon (Figure 37.41). The skin incision is designed to ensure adequate soft tissue coverage of the retained component. Inadequate soft tissue along the side of the retained thumb (e.g., pulp tissue) can be supplanted with a flap from the deleted component. This will augment the girth and width of the retained thumb and make it comparable to that of the uninvolved side. Proximal exposure is obtained by a zigzag

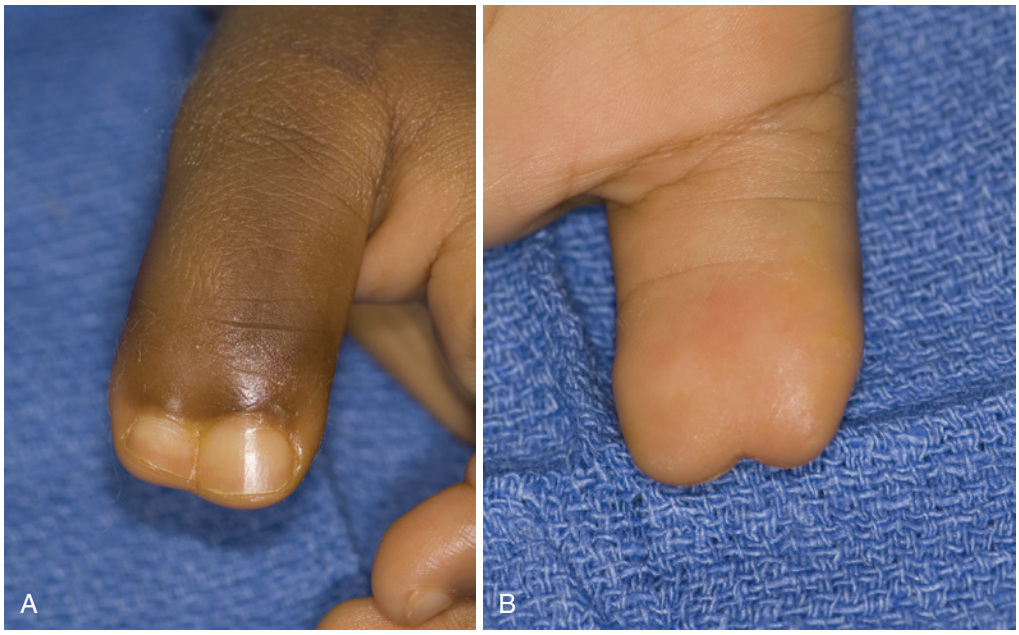

FIGURE 37.39 **A** and **B,** One-year-old with a duplicated left thumb (type IV duplication). (Courtesy of Shriners Hospital for Children, Philadelphia.)

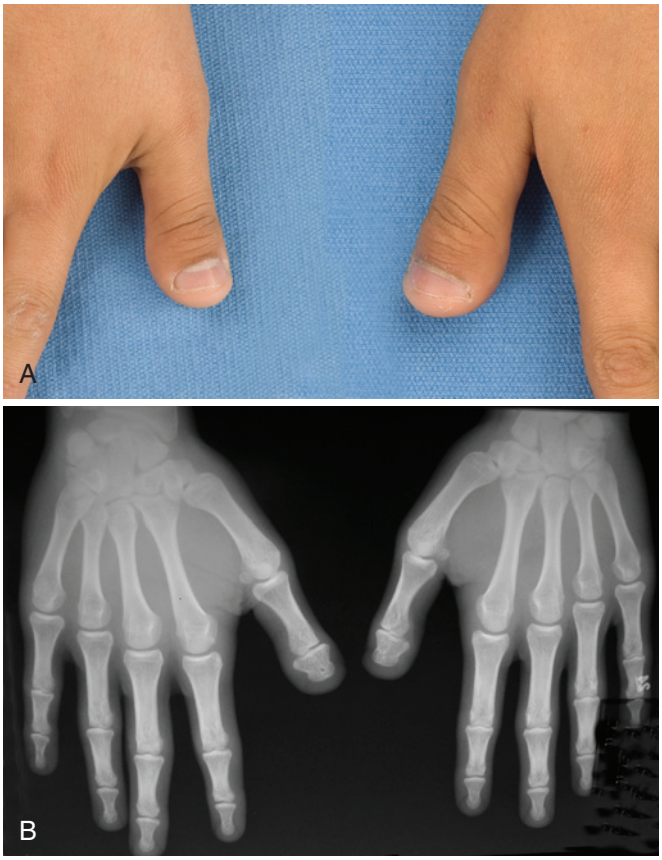

FIGURE 37.40 **A** and **B,** Clinical picture and x-rays of bilateral subtle type I duplication with widened nail plate. (Courtesy of Shriners Hospital for Children, Philadelphia.)



FIGURE 37.41 Asymmetric type II duplication with dominant radial component. (Courtesy of Shriners Hospital for Children, Philadelphia.)

approach. The extensor tendon to the lesser component is removed with the digit. The remaining tendon is centralized along the retained component. The tendon can be detached and reattached in the midline, or the eccentric portion can be folded over to the midline.[14,18] The flexor tendon(s) are treated in a similar fashion; however, exposure of the retained flexor system is more limited. The collateral ligament from the deleted component is elevated with an osteoperiosteal sleeve and attached via periosteal suture to the reconstructed thumb (Figure 37.42).[51] The IP joint is inspected any for articular anomalies, such as a separate facet for the deleted component. This facet is removed with an osteotome, rongeur, or bone-biter to narrow the articular surface and properly align the joint with the retained component. The neurovascular bundles are preserved to ensure circulation and sensation to the thumb. Additional extraarticular malalignment may require corrective osteotomy

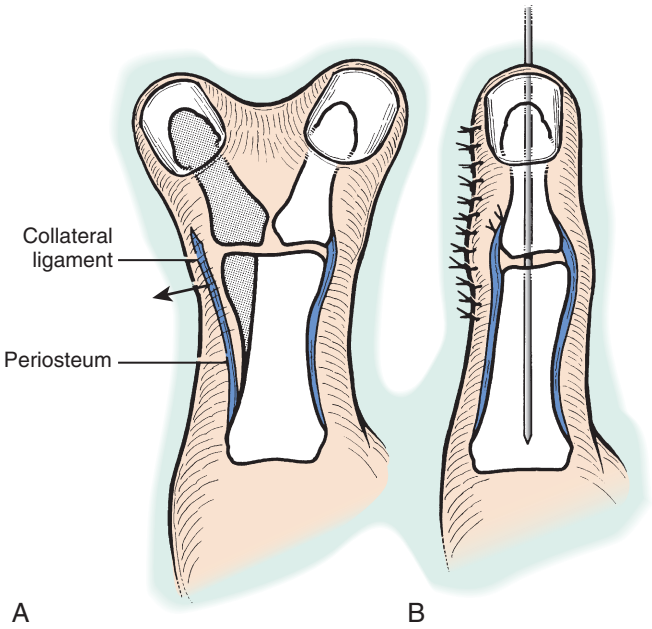

FIGURE 37.42 **A** and **B,** Angular deformity of the residual digit may be corrected by shifting the digit on a smooth common articular surface and creating a snug collateral ligament repair.

to ensure longitudinal alignment of the thumb (see Wassel VII case for details). This realignment is done using a closing wedge osteotomy with a scalpel blade or bone cutter to align the IP joint perpendicular to the thumb axis. A percutaneous Kirschner wire is placed antegrade from the thumb tip across the IP joint. If an osteotomy is performed, this wire also crosses the osteotomy site. The incision is closed with absorbable sutures, and a long-arm thumb spica cast is applied. The cast and Kirschner wire are removed 4 to 5 weeks after surgery. A short-arm thumb spica splint is fabricated; it is removed for therapy and gentle activities. The splint is discontinued 8 to 12 weeks after surgery, depending on the specific procedure performed and aggressiveness of the child.

Symmetric thumb duplication is difficult to treat. Wedge resection of the central portions of the bone and nail from each component and approximation of the retained borders can be performed (Bilhaut-Cloquet procedure) (Figure 37.43). The epiphyses are usually not included in the wedge for fear of growth plate injury. The retained bone is coapted and secured with suture or transverse Kirschner wire fixation. This operation is difficult, and subsequent nail deformity and IP joint stiffness are common problems.[17,82] Baek and colleagues[4] have utilized a modified Bilhaut-Cloquet technique for Wassel type II and III thumbs, for bifid thumbs are symmetric and the nail size is less than two thirds of the contralateral thumb. This technique is extraarticular and preserves a single physis while combining the nail and underlying bone into a single structure (Figure 37.44). In a type III thumb, the distal components are combined in a similar fashion with removal of the redundant proximal phalanx.

Type III or IV Split Thumbs

Type III or IV duplication is treated with selection of a dominant thumb and ablation of the lesser counterpart (Figure 37.45). This decision is not always straightforward and requires careful examination. If the components are equal, the ulnar thumb is preserved to retain the UCL for pinch. The soft tissue(s) from the ablated thumb are used to augment the retained thumb. The skin incision is designed to ensure adequate soft tissue coverage of the retained component. Inadequate soft tissue along the side of the retained thumb (e.g., pulp tissue) and eponychial fold can be addressed with a flap from the deleted component (Figure 37.46, *A* and *B*). This will augment the girth and width of the retained thumb and make it comparable to that of the uninvolved side (Figure 37.47).

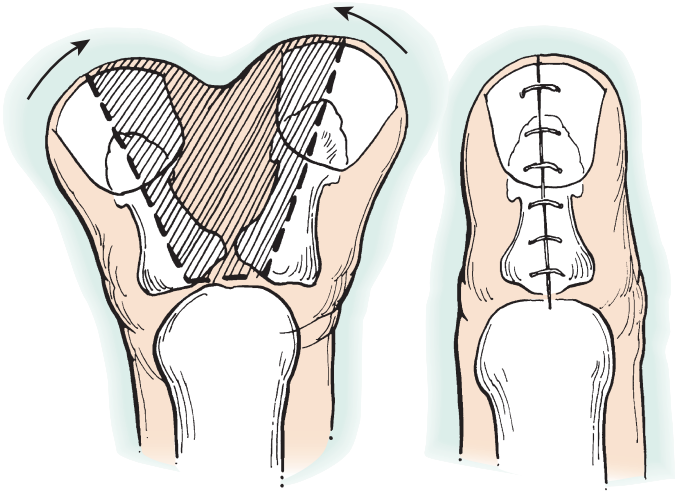

FIGURE 37.43 The classic Bilhaut-Cloquet procedure, in which the lateral portions of two distal phalanges are joined in the midline after excision of the excess central soft and osseous tissues.

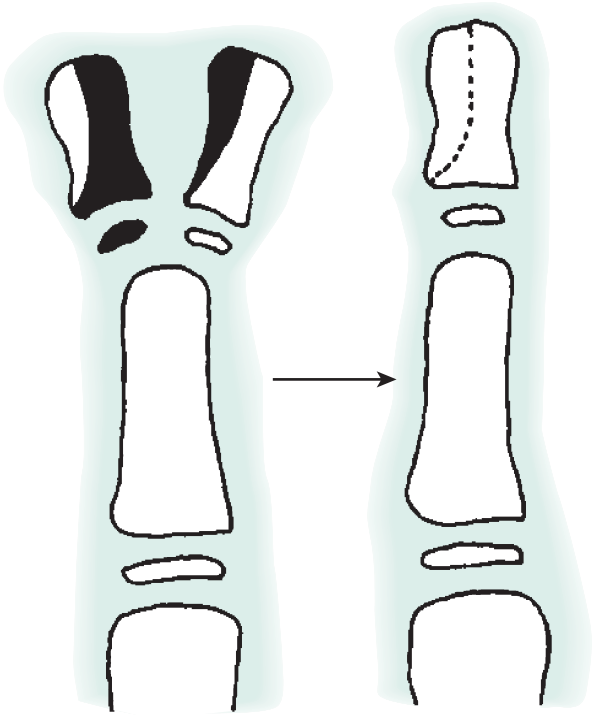

FIGURE 37.44 Drawing of modified Bilhaut-Cloquet procedure applied to a Wassel type II duplication.



FIGURE 37.45 Radiograph of 1-year-old with Wassel type IV duplication. (Courtesy of Shriners Hospital for Children, Philadelphia.)



FIGURE 37.47 A soft tissue flap from the deleted component is preserved to augment the retained thumb. (Courtesy of Shriners Hospital for Children, Philadelphia.)



FIGURE 37.46 **A** and **B,** Dorsal and volar skin incision for Wassel type IV reconstruction. (Courtesy of Shriners Hospital for Children, Philadelphia.)



FIGURE 37.48 An osteoperiosteal sleeve is raised from the deleted thumb with the collateral ligament and eventually transferred to the reconstructed thumb. (Courtesy of Shriners Hospital for Children, Philadelphia.)



FIGURE 37.49 Removal of the radial thumb after complete dissection. (Courtesy of Shriners Hospital for Children, Philadelphia.)

Proximal exposure is obtained by a zigzag approach. The collateral ligament is retained with an osteoperiosteal sleeve from the deleted thumb and transferred to the preserved thumb (Figure 37.48).[18,51] After separation from the ulnar or dominant thumb, the radial or lesser thumb is removed (Figure 37.49). In a type IV thumb, the joint surface of the metacarpal is routinely inspected for a separate facet that articulates with the deleted component. Removal of this facet with preservation of the collateral ligament via a proximal osteoperiosteal sleeve is necessary (Figure 37.50). This articular modification correctly aligns the thumb and prevents progressive angulatory deformity. Additional extraarticular malalignment may require corrective osteotomy to ensure longitudinal alignment of the thumb. This realignment can been done using a closing wedge osteotomy to align the joint surfaces in a parallel manner. Tendon realignment is also necessary to centralize the tendons along the retained thumb. Any thenar intrinsic muscles that are attached to the deleted thumb are transferred to the retained thumb. Typically, the abductor pollicis brevis inserts into the radial thumb and must be detached with an osteoperiosteal sleeve along with the radial collateral ligament (Figure 37.51). This composite is reattached to the retained ulnar thumb via periosteal suture to restore joint stability and abductor function (Figure 37.52, *A* and *B*).

In some type IV thumbs, the nail fold does not require reconstruction (Figure 37.53). However, the exact same steps are required during thumb reconstruction. Adhering to the surgical principles will result in a well-aligned thumb.

In a type III thumb, the entire physis and collateral ligament maybe preserved to maintain motion, prevent any chances of MCP joint instability, and avoid damage to the physis (Figure 37.54, *A* and *B*). The osteotomy is designed to preserve the entire proximal phalanx base, and an osteoperiosteal sleeve is not raised (Figures 37.55 and 37.56).



FIGURE 37.50 Removal of the radial facet with scalpel from the metacarpal head. (Courtesy of Shriners Hospital for Children, Philadelphia.)

In cases of ligament reconstruction, the percutaneous Kirschner wire may be placed antegrade from the thumb tip or obliquely across the MCP joint to maintain alignment during the healing process. The incision is closed with absorbable sutures and a long-arm thumb spica cast applied. The cast and

Kirschner wire are removed 4 to 5 weeks after surgery. A short-arm thumb spica splint is fabricated, which is removed for therapy and gentle activities. The splint is discontinued 8 to 12 weeks after surgery.

Type V or VI Split Thumbs

Treatment of type V or VI duplication uses similar principles, with the added complexity of additional intrinsic reconstruction. In addition, the thumb/index finger web space may be narrowed. A concomitant "Z"-plasty or dorsal advancement transposition flap may be required.

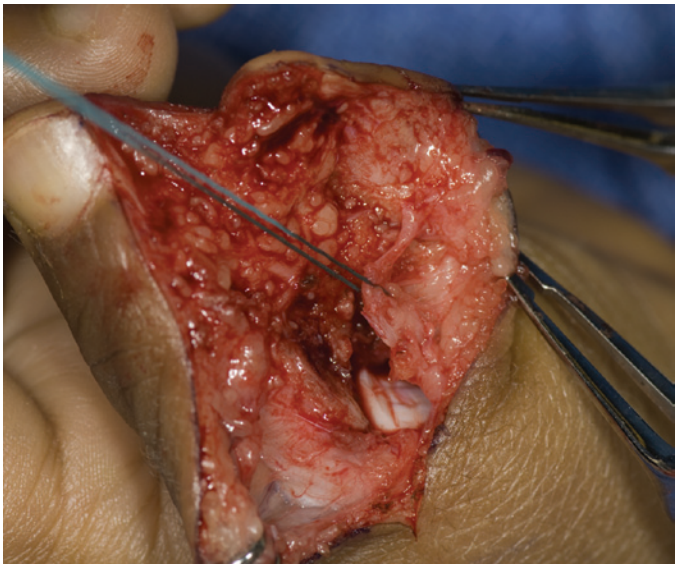

FIGURE 37.51 Osteoperiosteal sleeve radial collateral ligament and abductor pollicis brevis for reconstruction of thumb. (Courtesy of Shriners Hospital for Children, Philadelphia.)

Type VII Split Thumb

A type VII triphalangeal thumb utilizes the principles outlined above for reconstruction (Figure 37.57, *A* and *B*). The x-rays require scrutiny for surgical planning (Figure 37.58). The lesser thumb is excised using an osteoperiosteal sleeve for ligament reconstruction (Figures 37.59 and 37.60). Any persistent bony malalignment requires osteotomy (Figure 37.61). The tendons must be centralized over the reconstructed thumb (Figure 37.62). The skin is closed with absorbable suture (Figure 37.63). The Kirschner wire is removed 1 month after surgery (Figure 37.64). If the retained component is triphalangeal, the extra joint is an added problem. A joint reduction procedure with chondrodesis across the joint with the least motion will reduce the number of joints. This procedure can be done at the time of thumb reconstruction or as a second-stage procedure.

In some cases, the preferred elements for reconstruction come from both thumbs and truly represent "spare parts surgery." An on-top-plasty utilizes the better distal aspect of the deleted thumb and the superior proximal aspect of the retained thumb (Figure 37.65, *A* and *B*). The neurovascular bundles must be carefully dissected and mobilized to allow transposition. Proper rotation and Kirschner wire fixation are critical (Figure 37.66).

Outcomes

The results vary with the degree and complexity of the thumb duplication. Satisfactory results are readily obtainable in type I, II, and IV duplications.[24,43] Less satisfactory results are prevalent in types III, V, and VI and in triphalangeal thumbs.[35,68] The acceptable girth of the reconstructed thumb is unclear, although estimations range from 25% to 33% less than the normal thumb depending on the reconstruction technique.[14,78,82]

The Bilhaut-Cloquet procedure is difficult to perform and its outcome poorly documented.[14,24,35,54,82] Subsequent nail



FIGURE 37.52 **A** and **B,** Following closure, dorsal and volar views of reconstructed type IV thumb. (Courtesy of Shriners Hospital for Children, Philadelphia,)

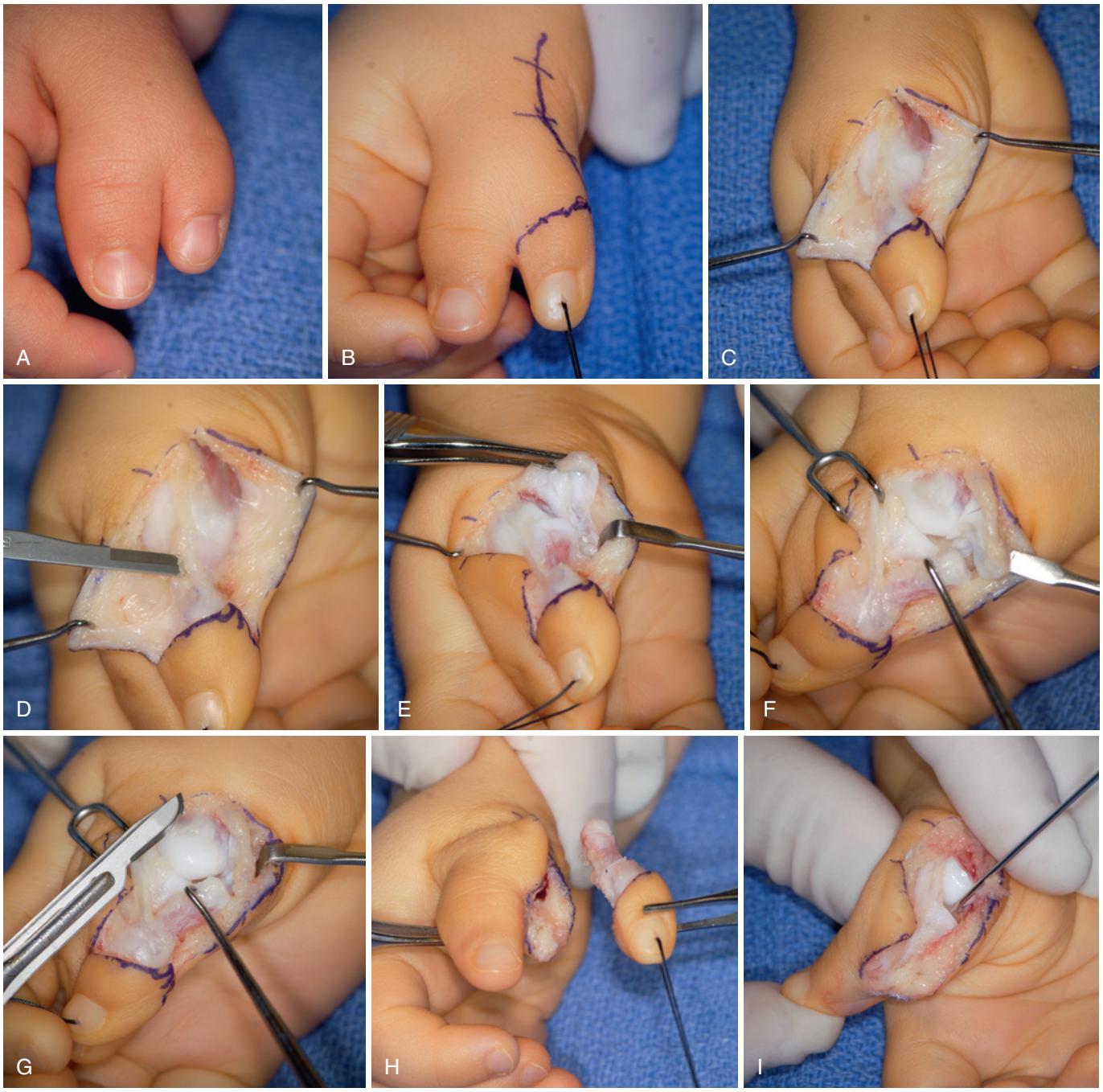

FIGURE 37.53 One-year-old with Wassel type IV duplication. **A,** Clinical appearance with ulnar component dominant. **B,** Skin design. **C,** Skin flaps elevated. **D,** Osteoperiosteal sleeve sharply elevated. **E,** Proximal elevation of osteoperiosteal sleeve from metacarpal. **F,** Joint inspection. **G,** Removal of metacarpal head facet articulating with radial component. **H,** Radial component discarded. **I,** Antegrade Kirschner wire placement.

Continued

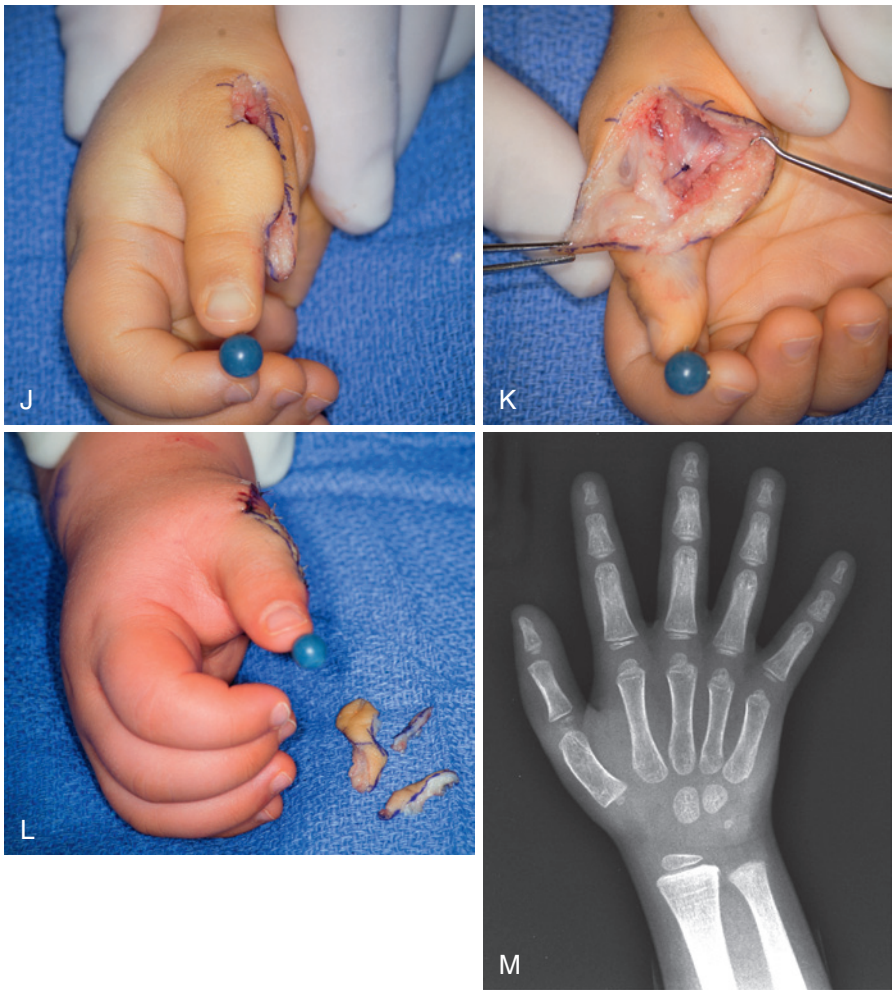

FIGURE 37.53, cont'd **J,** Joint reduction and Kirschner wire fixation. **K,** Osteoperiosteal sleeve attached to ulnar component. **L,** Skin closure. **M,** Radiograph 1 year after surgery. (Courtesy of Shriners Hospital for Children, Philadelphia.)

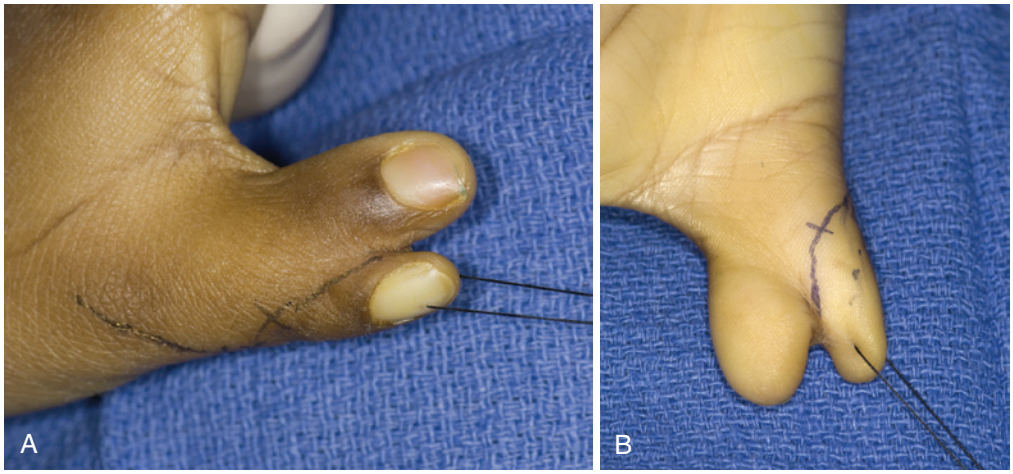

FIGURE 37.54 **A** and **B,** One-year-old with a duplicated left thumb (type III duplication) and 90 degrees of metacarpophalangeal joint motion. (Courtesy of Shriners Hospital for Children, Philadelphia.)

deformity and IP joint stiffness are common (Figure 37.67).[24,31] Most authors have either abandoned this procedure or reserve its use for symmetric distal type I or II duplication.[18,35,78,79,82] However, Baek and colleagues[4] have reported promising results using an extraarticular technique in a small cohort of children. Nail deformity was avoided and IP motion was maintained.

Complications

The reconstructed thumb is frequently smaller than the normal thumb unless adequate pulp tissue can be transferred form the deleted component. In addition, angulation, joint instability, limited motion, and scar contracture are common problems.[35,68] Reoperation rates of between 20% and 25% have been reported.[58,60] More complicated thumb duplications create more postoperative problems. Any offset in bone axis, persistent joint instability, or tendon malalignment will lead to problems. Joint instability and/or imbalanced tendon action will cause thumb deviation and a "Z"-deformity over time. The approach to the malaligned thumb is to consider the potential underlying cause(s).[58,60] Treatment requires restoration of parallel joint surfaces, restitution of joint stability, and realignment of tendon(s).

Poor motion and persistent instability are even more difficult to treat. Joint contracture often results after articular modification followed by subsequent scarring and arthrofibrosis.



FIGURE 37.55 Radiograph of type III duplication with planned osteotomy to preserve base and collateral ligament. (Courtesy of Shriners Hospital for Children, Philadelphia.)



FIGURE 37.56 Removal of radial component and preservation of bony base. (Courtesy of Shriners Hospital for Children, Philadelphia.)

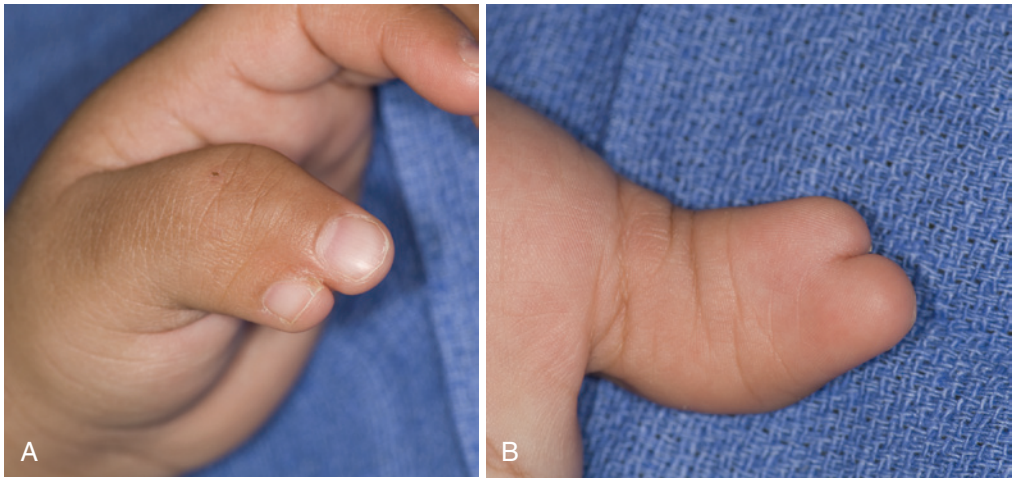

FIGURE 37.57 **A** and **B,** One-year-old with a duplicated left thumb (type VII duplication) and dominant ulnar thumb. (Courtesy of Shriners Hospital for Children, Philadelphia.)



FIGURE 37.58 Radiograph revealing triphalangeal ulnar component (type VII duplication) and trapezoid-shaped proximal phalanx. (Courtesy of Shriners Hospital for Children, Philadelphia.)

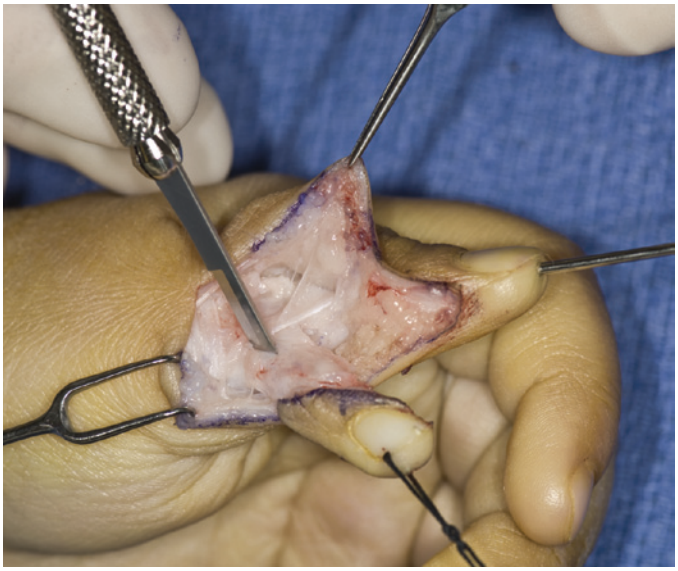

FIGURE 37.59 Radial thumb excised with osteoperiosteal sleeve to preserve collateral ligament. (Courtesy of Shriners Hospital for Children, Philadelphia.)

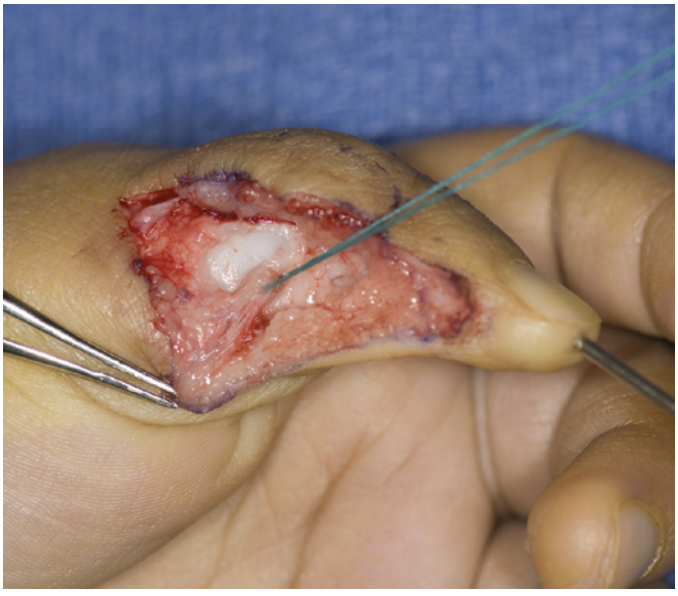

FIGURE 37.60 Retrograde Kirschner wire placed to maintain metacarpophalangeal joint alignment and osteoperiosteal sleeve (*green suture*) repaired to proximal phalanx. (Courtesy of Shriners Hospital for Children, Philadelphia.)



FIGURE 37.61 Persistent angulation required phalangeal osteotomy for alignment. (Courtesy of Shriners Hospital for Children, Philadelphia.)



FIGURE 37.62 Extensor mechanism centralized over reconstructed thumb. (Courtesy of Shriners Hospital for Children, Philadelphia.)



FIGURE 37.63 Final appearance after thumb reconstruction. (Courtesy of Shriners Hospital for Children, Philadelphia.)

Few treatment options are available to restore motion. The thumb with preservation of passive motion without active motion, however, may benefit from tenolysis. Persistent instability combined with limited motion requires ligament reconstruction or arthrodesis. In general, arthrodesis or chondrodesis is preferred to reliably restore stability and alignment.

Enlargement about the MCP joint is also a later problem after surgery (Figure 37.68). This protuberance is usually secondary to inadequate removal of an intraarticular facet in a type IV duplication (Figure 37.69). Arthrotomy and removal of the extra facet will rectify this problem (Figure 37.70). The collateral ligament must be preserved and reattached (Figure 37.71).



FIGURE 37.64 Radiograph after pin removal demonstrates good alignment and healed phalangeal osteotomy. (Courtesy of Shriners Hospital for Children, Philadelphia.)

CRITICAL POINTS *Thumb Duplication*

- A supranumerary thumb is not a true duplication, because neither component is as robust as a normal thumb. The term *split thumb* is more appropriate.
- Thumb duplication has been classified in various ways based on the degree of skeletal replication. The most common type involves duplicated proximal and distal phalanges that share a common articulation with a bifid metacarpal head (≈50% of cases).
- The ideal reconstruction aligns the thumb along a longitudinal axis, stabilizes the joints, balances the motor functions, provides adequate nail plate without deformity, and restores sufficient thumb size. This often requires using portions of each component, so-called spare parts surgery.
- Surgery requires careful planning and meticulous technique to address the nail, skin coverage, joint congruity, and tendon alignment.
- Any residual offset in bone axis, persistent joint instability, or tendon malalignment will lead to thumb deviation and a "Z"-deformity over time.

TRIPHALANGEAL THUMB

Triphalangeal thumb can occur as an isolated anomaly, can be associated with a systemic abnormality (e.g., Holt-Oram syndrome or FA), or can be concurrent with thumb duplication (Wassel type VII) (Figure 37.72).[18,21] Triphalangeal thumb can also occur with other congenital differences, such as polysyndactyly, thumb hypoplasia, or central deficiency (Figure 37.73).[16,87]

Triphalangeal thumbs can be divided into two distinct forms. The first type has an extra phalanx of variable size within a

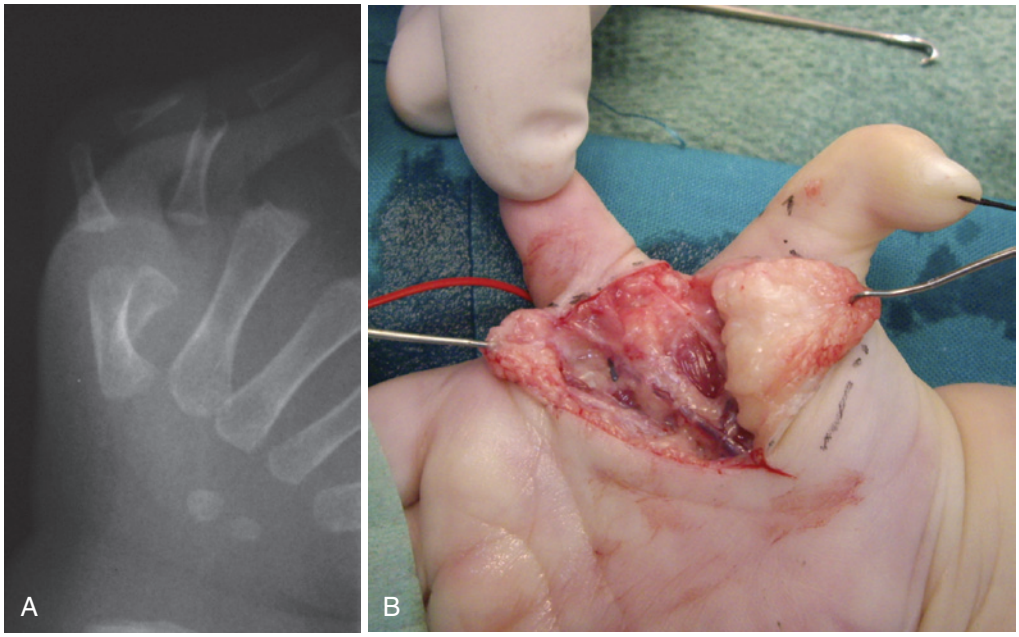

FIGURE 37.65 Two-year-old with complex duplicated thumb. Ulnar thumb has better distal components but no metacarpal base. Radial thumb has better base but no distal motion. **A,** Radiograph. **B,** Operative exposure for on-top-plasty with isolation of neurovascular bundles to ulnar thumb. (Courtesy of Francisco Soldado, MD.)



FIGURE 37.66 Kirschner wire fixation after on-top-plasty. (Courtesy of Francisco Soldado, MD.)



FIGURE 37.67 Eight-year-old following Bilhaut-Cloquet procedure with nail deformity and interphalangeal joint stiffness. (Courtesy of Shriners Hospital for Children, Philadelphia.)



FIGURE 37.68 Four-year-old following reconstruction of Wassel IV duplication with prominent metacarpophalangeal joint. (Courtesy of Shriners Hospital for Children, Philadelphia.)



FIGURE 37.69 Radiograph shows enlarged metacarpal head with persistent radial facet that articulated with excised thumb. (Courtesy of Shriners Hospital for Children, Philadelphia.)



FIGURE 37.70 Arthrotomy and removal of extra facet using osteotome. (Courtesy of Shriners Hospital for Children, Philadelphia.)



FIGURE 37.71 Final appearance after intraarticular ostectomy. (Courtesy of Shriners Hospital for Children, Philadelphia.)



FIGURE 37.72 Thirty-year-old female with Holt-Oram syndrome and bilateral triphalangeal thumbs. (Courtesy of Shriners Hospital for Children, Philadelphia.)



FIGURE 37.73 One-year-old child of mother depicted in Figure 37.72. Child has hypoplastic triphalangeal thumbs and Holt-Oram syndrome. (Courtesy of Shriners Hospital for Children, Philadelphia.)



FIGURE 37.74 Mother and son (see Figure 37.75) with bilateral triphalangeal thumbs of similar appearance. **A,** The mother has slightly longer thumbs with moderate angulation. **B,** Radiographs reveal a trapezoid middle phalanx.

relatively normal appearing thumb (Figures 37.74 and 37.75). The extra phalanx may be triangular, trapezoidal, or rectangular in shape.[56,94] The second variety has a fully developed phalanx that lies in the plane of the fingers. This form is considered a five-fingered hand and probably represents an absent thumb with index polydactyly (Figure 37.76).[73] As with most divisions, there are triphalangeal thumbs that appear to be a pedigree of the two types with characteristics of each form. In addition, the type of triphalangeal thumb can vary across generations.

Both forms of triphalangeal thumbs are inherited as an autosomal dominant trait with variable expressivity and high penetrance.[13,33,56,94] Parents need appropriate genetic counseling regarding the different expressions and phenotypes across the spectrum of a particular mutation. Triphalangeal thumb can also be sporadic in occurrence.

Management Considerations

The management of the triphalangeal thumb can be divided into individual components.[66] The definitive treatment depends on the type of triphalangeal thumb and the presence or absence of any concomitant anomalies, such as thumb duplication. There are multiple elements of the triphalangeal thumb that may require management, including the length and angulation of the digit, the extra IP joint, the status of the thumb/index finger web space, and the presence or absence of thumb opposition.

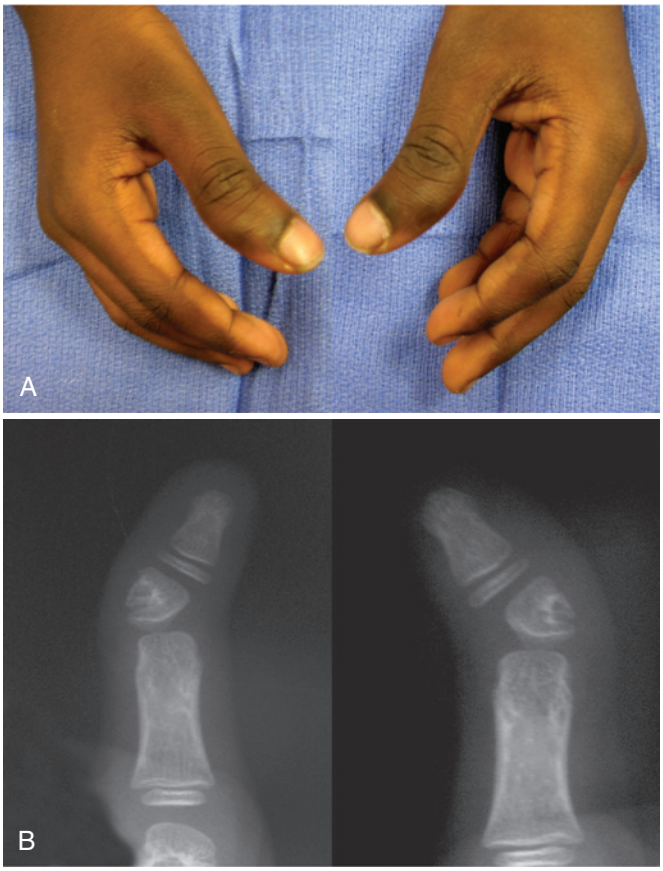

FIGURE 37.75 Child has similar appearance and angulation. **A,** Slightly longer thumbs with apex ulnar angulation. **B,** Radiographs show a more triangular middle phalanx.



FIGURE 37.76 A fully developed phalanx that lies in the plane of the finger is considered a five-fingered hand. (Courtesy of Shriners Hospital for Children, Philadelphia.)

The timing of treatment also depends on any concomitant anomalies. The goal is to reconstruct a thumb with adequate function prior to the development of oppositional pinch, which occurs between 12 and 18 months of age. The treatment of minor length discrepancy or angulation can be delayed until later in life. The proposed plan should be completed prior to school age.

Treatment of Triphalangeal Thumb

Length and Angulation

The extra phalanx has a variable shape and natural history. The length and shape of the extra phalanx will determine the length and alignment. The growth rate of the extra phalanx is variable. Initial treatment consists of observation to assess growth potential. Surveillance also allows an assessment of motion at each IP joint, which is an important factor during reconstruction. The extra bone may ultimately be rudimentary, demonstrate little growth, and require no treatment. In contrast, continual or asymmetric growth will lead to excessive length or progressive angulation, respectively. The angulation is usually in an apex ulnar direction.

A small, wedge-shaped middle phalanx that causes progressive deviation requires excision with ligament reconstruction.[34,66] Surgery is best performed at about 1 year of age. A dorsal approach is preferred, with a longitudinal incision through the extensor mechanism. The extra phalanx is isolated and its size delineated. Osteoperiosteal sleeves are elevated from each side that includes the collateral ligaments. The extra phalanx is removed and the collaterals reattached. The distal and proximal phalanges are coapted and secured with a longitudinal Kirschner wire. This wire skewers the phalanges and provides immobilization until ligamentous healing occurs. The incision is closed with absorbable sutures and a long-arm thumb spica cast applied. The cast and Kirschner wire are removed 6 weeks after surgery. A short-arm thumb spica splint is fabricated, which is removed for therapy and gentle activities. The splint is discontinued 6 weeks after surgery. Lateral pinch should be minimized for the first 3 months to prevent radial deviation at the IP joint. This benign-appearing operation can result in multiple problems, including instability, joint stiffness, and insufficient motion.[34] In fact, I try to avoid simple excision and prefer leaving a small middle phalanx that has negligible effect on thumb function alone. If the phalanx affects alignment and function, a joint reduction procedure is performed as outlined below.

Extra Interphalangeal Joint

The extra IP joint has a variable amount of motion. The extra joint is of little consequence with regard to function. A large, wedge-shaped extra phalanx can produce excessive length with or without deviation. Excision of the phalanx should not be performed, because subsequent instability is common. Fusion of the abnormal phalanx with the distal or proximal phalanx combined with bone shortening removes the extra joint, realigns the thumb, and provides the correct length. The joint with the greatest motion is preserved and the joint with the least movement fused.

A dorsal approach is preferred with a longitudinal incision through the extensor mechanism. The extra phalanx and adjacent joints are isolated. An arthrotomy is performed at the joint with the least motion and is avoided at the joint with maximum motion. The bone is resected from both sides of the joint to shorten and realign the thumb. Asymmetric bony resection corrects any angulatory deformity. The bones are coapted after bony resection. A Kirschner wire is passed retrograde from the tip of the thumb across the osteotomy site for internal fixation. The extensor tendon is approximated and the skin is closed with

absorbable sutures. A long-arm thumb spica cast is applied. The cast and Kirschner wire are removed 5 weeks after surgery. A short-arm thumb spica splint is fabricated; it is removed for therapy and gentle activities.

Thumb/Index Finger Web Space

A narrow web space hampers thumb function. Mild thumb/index finger syndactyly can be managed by web deepening. A four-flap "Z"-plasty deepens the web and provides a more rounded contour than a two-flap configuration.[36,96] Moderate involvement requires a local dorsal rotation advancement flap for adequate deepening. The web space treatment strategy is similar to that for the narrow thumb/index finger web space for thumb hypoplasia.

A five-fingered hand has no web space. Pollicization provides an opposable digit and a thumb/index finger web space.[7,36] The technique is the same as that for an absent or grade V hypoplastic thumb. A two-stage technique to create an opposable digit has also been described.[15] The first stage involves joint reduction, and the second stage combines rotational osteotomy with opposition transfer. A hypoplastic triphalangeal thumb requires removal, and the index finger undergoes pollicization (Figure 37.77).

Absence of Thumb Opposition

The five-fingered hand is often hampered by the lack of an opposable digit. Lack of opposition prohibits thumb function. Tendon transfer to restore opposition is required, using either the FDS or abductor digiti minimi as a donor (see section on thumb hypoplasia). If the thumb/index finger web space is narrow, concomitant web space widening is required. Joint reduction can be performed at the time of tendon transfer or as a secondary procedure.

Concomitant Anomalies

A triphalangeal thumb combined with thumb duplication is treated according to the principles of thumb reconstruction for duplication.[95] Usually, the dominant component is preserved and the nondominant part deleted with use of any important elements (e.g., collateral ligaments). If the triphalangeal component is preserved, treatment of the extra phalanx is based on the above guidelines. The treatment of the triphalangeal portion of the anomaly can be performed at the same time as duplication reconstruction or delayed until later.

A triphalangeal thumb shared with a central deficiency is treated by combining the principles of cleft and triphalangeal thumb reconstruction. The degree of cleft formation and the status of the thumb/index finger web space are critical components. A complete thumb/index finger web syndactyly warrants early thumb separation. The skin from the cleft can be transposed into the thumb/index finger commissure to resurface this web space (Snow-Littler flap).[38,75]



FIGURE 37.77 Index finger pollicization and removal of hypoplastic triphalangeal thumb. (Courtesy of Shriners Hospital for Children, Philadelphia.)

CRITICAL POINTS *Triphalangeal Thumb*

- Triphalangeal thumbs can be divided into two distinct forms. The first type has an extra phalanx of variable size within a relatively normal-appearing thumb. The second variety has a fully developed phalanx that lies in the plane of the fingers; the hand is considered a five-fingered hand.
- The inheritance pattern is usually an autosomal dominant trait with variable expressivity and high penetrance. Genetic consultation is warranted.
- The extra phalanx in a triphalangeal thumb may be triangular, trapezoidal, or rectangular in shape. The growth rate of the extra phalanx is variable, and initial treatment consists of observation to assess growth potential.
- A large, wedge-shaped extra phalanx requires fusion of the abnormal phalanx with an adjacent phalanx combined with bone removal. The joint with the greatest motion is preserved and the joint with the least movement fused.
- A five-fingered hand is treated with pollicization of the nonopposable radial digit.

TRIGGER THUMB

General Considerations in Trigger Thumb

Incidence and Etiologic Findings

Trigger thumb is about ten times more common than trigger finger.[8,63] The exact incidence has become more clearly defined. Ger and colleagues[25] initially reported an incidence of 1 patient per 2000 live births, based on a small sample size. Recently, Kikuchi and Ogino[37] performed neonatal medical checks and subsequent follow-up. They noted an incidence of trigger thumb at 1 year of age of 3.3 cases per 1000 live births. Bilateral involvement is present in approximately 25 to 30% of children.[8,70]

The term *congenital* is probably a misnomer because widespread evaluations of newborns have failed to discover a trigger thumb.[70,74] Slakey and Hennrikus[74] screened 4719 newborn infants for the presence of a trigger thumb and noted no cases of triggering, locking, nodule formation, or fixed flexion contracture. Moon[62] examined 7700 neonates within the first few days of life, and Kikuchi and Ogino[37] examined 1116 babies within 14 days after birth and noted no trigger thumbs. These results suggest that trigger thumb most likely is not present at birth but rather develops with postnatal growth. Furthermore, the term *trigger* is inaccurate because the vast majority of children presents with a fixed flexion deformity of the thumb IP joint (Figure 37.78). A confounding diagnostic factor is the fact that infants posture with their thumb in flexion, which may delay detection.[74]



FIGURE 37.78 Trigger thumb with fixed flexion deformity of the interphalangeal joint. (Courtesy of Shriners Hospital for Children, Philadelphia.)



FIGURE 37.79 Notta nodule is palpated just proximal to the A1 pulley. (Courtesy of Shriners Hospital for Children, Philadelphia.)

Sugimoto[77] has classified trigger thumb into four stages:

Stage I (tumor type): There is a Notta nodule, but no snapping is observed during IP flexion and extension.

Stage II (active triggering): Triggering is observed when the IP joint is actively extended.

Stage III (passive triggering): The IP joint cannot be extended actively, and triggering is observed when the IP joint is extended passively.

Stage IV (rigid type): The IP joint cannot be passively extended (i.e., a fixed flexion deformity exists).

The exact etiologic findings have become better defined with ultrasound studies.[85] Ultrasound imaging of all pediatric trigger thumbs demonstrated normal echotexture of the flexor pollicis longus without evidence of inflammation or trauma. Triggering occurred when the cross-sectional area of the flexor pollicis longus exceeded the cross-sectional area at the A1 pulley (i.e., size mismatch). Triggering resolved when this size disparity was eliminated. Palpation of the nodular thickening of the flexor tendon, or Notta nodule, is readily apparent just proximal to the A1 pulley (Figure 37.79). This nodule is present in all stages and is the sine qua non of a trigger thumb.[70] Passive manipulation into extension may produce a noticeable click or pop in stages III and IV. No further diagnostic testing is necessary, as the history and physical examination are pathognomonic for trigger thumb.

Treatment

The natural history, rate of spontaneous resolution, effectiveness of splint therapy, and timing of surgery remain controversial.

Natural History

The reported spontaneous recovery rate is highly variable. Dinham and Meggitt[12] reported that approximately 30% of trigger thumbs diagnosed prior to 1 year of age resolved, and about 10% diagnosed at between 6 months and 1 year of age resolved spontaneously. Higher rates of resolution have been reported from Japan with longer follow-up periods. Michifuri and associates[57] reported a spontaneous resolution rate of slightly greater than one half of trigger thumbs during a follow-up period of 5.2 years. Sugimoto[77] also found that during an observation period of between 7 months and 12 years, spontaneous resolution occurred in over one third of patients. Baek and colleagues[5] prospectively followed 71 thumbs in 53 children. No treatment such as passive stretching or splinting was rendered. Forty-five thumbs (63%) resolved spontaneously. The median time from the initial visit to resolution was 48 months. These results suggest that trigger thumbs in children retain the potential to spontaneously resolve if followed for a prolonged period.

Nonoperative Treatment

Watanabe and coworkers[89] reported their results following nonoperative treatment consisting of only passive flexion and extension of the affected thumb performed by the mother. Fifty-six thumbs out of 58 demonstrated improvement, especially those that were flexible (stage I). The role of splinting is controversial because the reported success rate varies greatly.[65,74] Success has been reported in 24 out of 33 digits (73%) with nighttime splinting for an average of 10 months' duration.[65] Nemoto and colleagues[65] described a series of 40 trigger digits that were treated by the application of a thumb splint keeping the IP joint in hyperextension during naptime and at night. Twenty-nine thumbs recovered completely, and only three patients required operative treatment. Lee and associates[44] compared the results of splint therapy and observation in a group of 62 reducible trigger thumbs in 50 children. Splinting resulted in complete or partial resolution in 22 of 31 thumbs (71%), whereas observation alone resulted in complete or partial resolution in 7 of 31 thumbs (23%).

Surgical Treatment

The precise timing of surgery is dependent on multiple factors, including the age of the child, degree of deformity, patience of the family, and surgeon preference. We know that a delay in surgery up to 3 years of age is not detrimental with regard to contracture or motion.[74] Therefore, some period of observation seems reasonable, especially in children less than 1 year of age. Children with painful triggering and a rigid deformity (stage IV) older than 1 year of age should undergo surgery. Children older than 1 year with earlier stages of active triggering (stage II) or

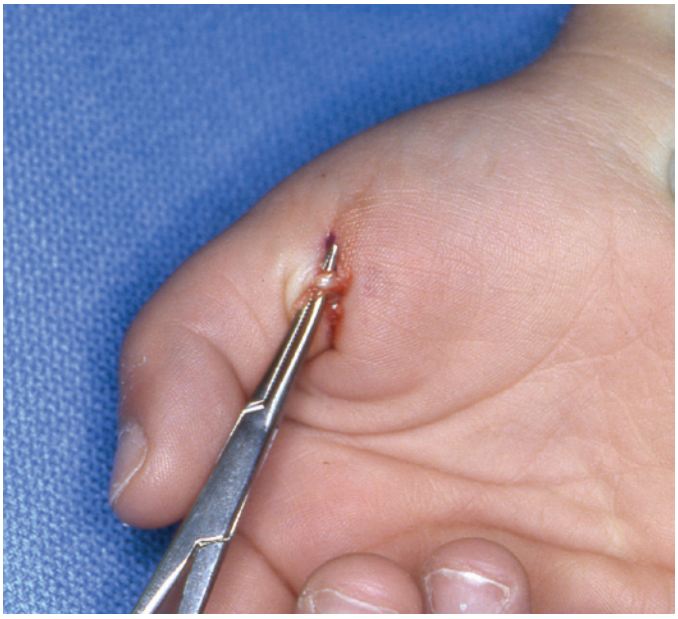

FIGURE 37.80 Radial digital nerve is identified and protected before pulley release. (Courtesy of Shriners Hospital for Children, Philadelphia.)

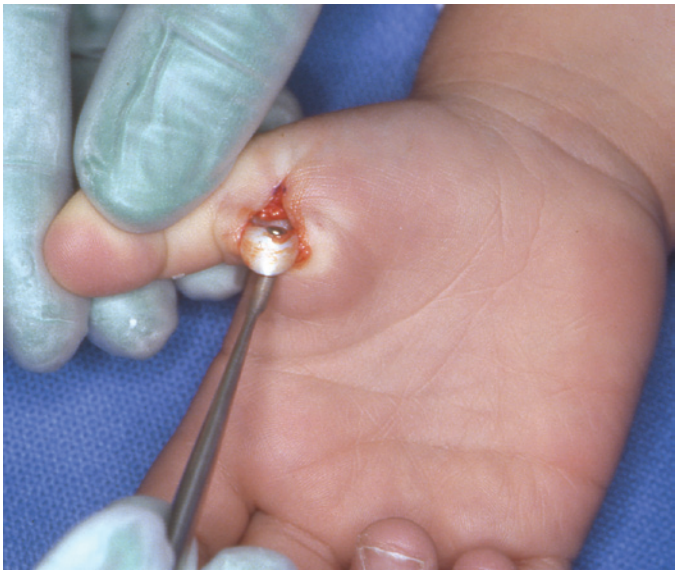

FIGURE 37.81 The flexor pollicis longus is isolated after release of the first annular pulley. (Courtesy of Shriners Hospital for Children, Philadelphia.)

passive triggering (stage III) can continue with nonoperative measures or proceed with surgery. The ultimate choice rests on the surgeon and family; an explanation of the risks and benefits is needed. At our institution, we still recommend surgery for most children older than 1 year of age with persistent triggering.

Surgical Technique. Surgery is performed under general anesthesia, tourniquet control, and loupe magnification. Make a transverse incision over the first annular pulley. Incise only the skin. Spread in a longitudinal fashion through the subcutaneous tissue. Identify and protect the radial digital nerve (Figure 37.80). Isolate the first annular pulley. Release the pulley to expose the flexor pollicis longus (Figure 37.81). Do not address the nodular thickening of the flexor pollicis longus. Inspect the proximal and distal sides to ensure that no further tendon contraction occurs with full flexion and extension of the thumb. Irrigate and close with absorbable suture. Place the child in a forearm-based thumb spica soft cast (Scotchcast Soft Cast Casting Tape, 3M, St. Paul, MN) or just a soft dressing with the IP joint extended. Deflate the tourniquet and awaken the child. Remove the dressings 1 week later and allow the child to return to normal function. Therapy is usually not necessary.

Percutaneous release has been suggested and performed for trigger thumbs in children.[86] However, the same risk of radial digital nerve injury is present in children that is present in adults. In addition, this technique does not negate the use of anesthesia. Currently, I do not offer this technique as a surgical option.

Outcome

Trigger thumb release is uniformly successful, and recurrences are rare.[8,12,63,74] The literature reports that the short-term and long-term results of surgical treatment of pediatric trigger thumb have been excellent.[52,53] Complications are uncommon and are related to surgical technique. Persistent triggering is usually secondary to inadequate release of the flexor tendon sheath. Other complications include wound issues, scarring, tendon bowstringing after release of the oblique pulley, and numbness secondary to digital nerve injury.

Trigger Fingers

Trigger fingers in children are uncommon and less straightforward.[8] In children, trigger fingers are different from trigger thumbs, and the role of nonoperative treatment is even less clear.[8,65,81] In addition, simple release of the first annular pulley may not resolve the triggering. An abnormal relationship between the FDP and FDS tendons, proximal decussation of the superficialis tendon, nodular formation within the flexor tendons, and tightness of the second and/or third annular pulleys have all been implicated as potential reasons. The surgeon must be prepared to perform a more diligent search for alternative causes when release of the first annular pulley does not resolve the triggering. Routine release of the A3 pulley and resection of a slip of the FDS are performed to resolve triggering[8,72] (Figure 37.82). The surgeon should also remember that multiple digit involvement can be associated with inflammatory arthritis, juvenile diabetes, and mucopolysaccharide disorders.

CRITICAL POINTS *Trigger Thumb*

- Trigger thumbs are not "congenital" but rather acquired problems related to a discrepancy between a tight flexor tendon sheath and an enlarged flexor pollicis longus.
- The classic finding is a fixed flexion contracture of the IP joint and a palpable nodule over the flexor pollicis longus tendon.
- Observation and/or splinting can be attempted, especially in children less than 1 year of age; the success rate is variable.
- Surgery involves release of the A1 pulley; the radial digital nerve must be protected.
- Trigger fingers in children are uncommon and less straightforward.
- Trigger finger surgery involves release of the first annular pulley that usually does not resolve the triggering release of the A3 pulley. FDS is usually required.
- Multiple trigger fingers can be associated with inflammatory arthritis, juvenile diabetes, and mucopolysaccharide disorders.

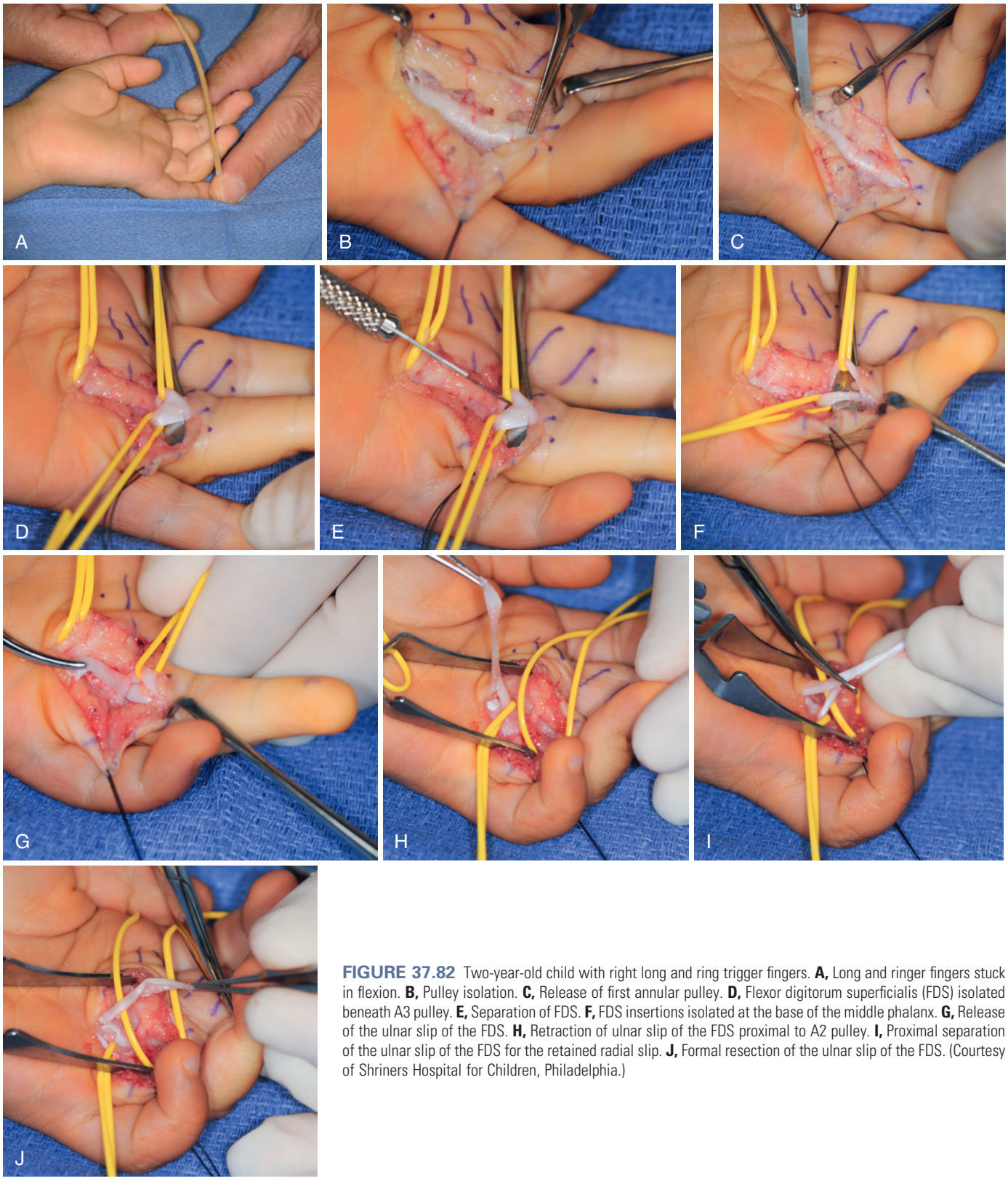

FIGURE 37.82 Two-year-old child with right long and ring trigger fingers. **A,** Long and ringer fingers stuck in flexion. **B,** Pulley isolation. **C,** Release of first annular pulley. **D,** Flexor digitorum superficialis (FDS) isolated beneath A3 pulley. **E,** Separation of FDS. **F,** FDS insertions isolated at the base of the middle phalanx. **G,** Release of the ulnar slip of the FDS. **H,** Retraction of ulnar slip of the FDS proximal to A2 pulley. **I,** Proximal separation of the ulnar slip of the FDS for the retained radial slip. **J,** Formal resection of the ulnar slip of the FDS. (Courtesy of Shriners Hospital for Children, Philadelphia.)

CLASPED THUMB

Congenital clasped thumb refers to a spectrum of thumb anomalies. The range of anomalies commences with mild deficiencies of the thumb extensor mechanism and progresses to severe abnormalities of the thenar muscles, web space, and soft tissues. The initial classifications attempted to subdivide the disorders into individual types and remain inclusive.[80,92] This scheme has not been useful in the clinical setting. A more practical approach has been proposed by McCarroll[55] and expanded by Mih.[59] A type I clasped thumb is usually supple, and the extensor mechanism is either absent or hypoplastic (Figure 37.83). A type II clasped thumb is complex with additional finding(s) of joint contracture, collateral ligament abnormality, first web space contracture, and thenar muscle abnormality (Figure 37.84). A type III clasped thumb is associated with arthrogryposis or its associated syndromes, such as MASA (mental retardation, aphasia, shuffling gait, and adducted thumbs) (Figure 37.85). In this case, the extensor mechanism may have minimal or no abnormality.

This section will discuss the treatment of the relatively mild type I and II clasped thumbs. The more severe type III form is discussed under the congenital contracture section and arthrogryposis.

Clinical Features

The diagnosis of clasped thumb is often delayed because an infant frequently holds the thumb within the palm for the first 3 to 4 months. At presentation, the thumb rests in flexion with an extension lag. Most commonly, the extension lag is present only at the MCP joint, which implies hypoplasia of the extensor pollicis brevis muscle tendon unit.[6,93] Additional extensor pollicis longus and/or abductor pollicis longus anomalies have also been reported (see Figure 37.84).[59,97] Diagnosis of these deficiencies is based on thumb and joint position. Simultaneous extension lag at the IP joint indicates a concomitant deficiency of the extensor pollicis longus. Concurrent metacarpal adduction implies insufficiency of the abductor pollicis longus.

Treatment of Clasped Thumb

Initial treatment of the type I clasped thumb is splinting of the affected joint(s) in extension. The goal is to prevent additional attenuation of the hypoplastic extensor mechanism and to allow hypertrophy over time. Full-time splinting for 2 to 6 months has been shown to be effective. Miura[61] reported on 96 hands in 66 patients that underwent splint application. Good results were obtained in 70% of children that were splinted within 12 months of birth. In contrast, splinting was effective in only 21% of children more than 1 year after birth and none older than 2 years of age. Lin and colleagues[47] reported on 11 infants (17 thumbs) with congenital clasped thumb treated with splinting. The functional results were excellent in 15 and good in 2 patients.

Surgery is warranted for children who have failed splinting or present after 2 years of age. The degree of impairment, however, must be considered during formulation of a treatment



FIGURE 37.83 A type I clasped thumb with absence of the extensor pollicis brevis. (Courtesy of Shriners Hospital for Children, Philadelphia.)

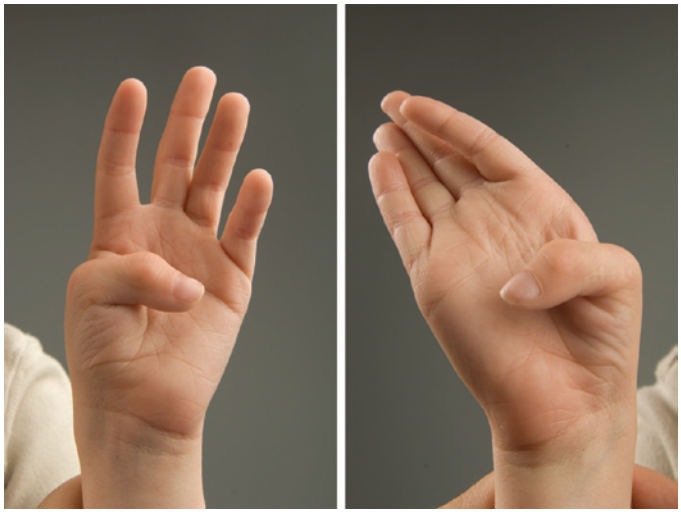

FIGURE 37.84 One-year-old child with more severe clasped thumbs and deficiencies of extensor pollicis longus and brevis. (Courtesy of Shriners Hospital for Children, Philadelphia.)



FIGURE 37.85 A type III clasped thumb in a child with arthrogryposis. (Courtesy of Shriners Hospital for Children, Philadelphia.)



FIGURE 37.86 Adolescent with bilateral untreated clasped thumbs and minimal functional impairment. (Courtesy of Shriners Hospital for Children, Philadelphia.)

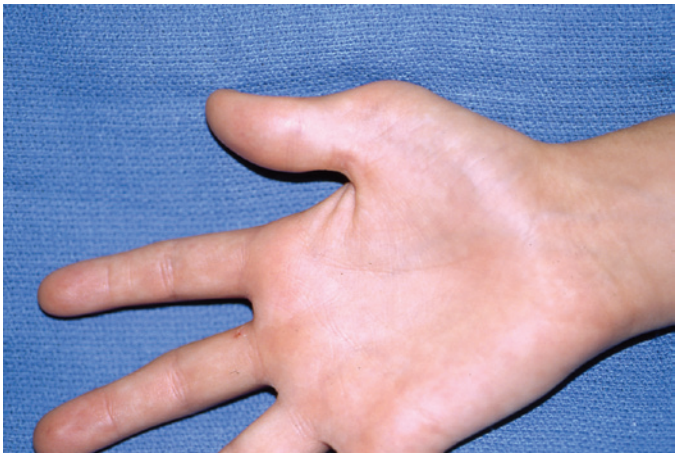

FIGURE 37.87 Clasped thumb with metacarpophalangeal joint flexion contracture. (Courtesy of Shriners Hospital for Children, Philadelphia.)

plan. Mild MCP joint extension lag does not hinder hand function and does not always require treatment (Figure 37.86). Frequently, adolescents are seen with a mild clasped thumb that has never been treated and report no problems.

Considerable lack of thumb extension that interferes with grasp warrants treatment. Any associated thumb MCP joint or thumb/index finger web space contracture requires treatment (Figure 37.87). Initially, serial casting or splinting may be tried to stretch the taut skin and correct the contracture. Residual contracture correction must be incorporated into the surgical plan. In a type I clasped thumb, skin and subcutaneous tissue release is usually enough to correct the contracture. Thumb/index finger space deficiency is treated with standard techniques of four-flap "Z"-plasty or dorsal rotation advancement flap (see section on hypoplastic thumb). Palmar skin deficiency requires a rotational flap into the palmar aspect of the thumb MCP joint. A modified dorsal rotation advancement flap, which broadens the apex and increases its length, has been described.[27] This flap design places the suture line far beyond the web, which may lessen web space contracture.

A second incision is performed over the dorsum of the thumb metacarpal and proximal phalanx. The extensor apparatus is explored. The extensor pollicis brevis tendon is usually present but is small and attenuated. A tendon transfer is performed to augment thumb extensor function. The donor tendons depend upon availability and expendability. The extensor indicis proprius tendon is the first choice, but it may or may not be present.[59,93] Absence of the extensor indicis proprius requires selection of an alternative donor tendon. Options are the FDS or abductor digiti minimi muscle.[11,59] The tendon transfer is secured into the attenuated tendon and/or the base of the proximal phalanx. The limb is placed in a long-arm thumb spica cast with the MCP joint in extension for 4 weeks. The cast is removed and a short-arm thumb spica splint fabricated. Gradual active flexion of the thumb is encouraged. The splint is worn only at night beginning at 6 weeks and is discontinued at 12 weeks following surgery.

CRITICAL POINTS *Clasped Thumb*

- Congenital clasped thumb refers to a spectrum of extensor mechanism deficiencies that range from mild to severe.
- A mild clasped thumb is usually supple and possesses an extensor lag at the MCP joint indicative of a deficiency of the extensor pollicis brevis.
- Initial treatment is splinting is objectively effective in children younger than 1 year of age.
- Surgery is indicated for children who have failed splinting or who present at an older age and have a functional impairment.
- Surgical goals are to correct any soft tissue contracture that has developed over time and to augment extensor function via tendon transfer.

For Case Studies, Videos, and more, please visit ExpertConsult.com.

REFERENCES

1. Al Qattan MM: The distribution of the types of thumb polydactyly in a Middle Eastern population: a study of 228 hands. *J Hand Surg Eur Vol* 35:182, 2010.
2. Aliu O, Netscher DT, Staines KG, et al: A 5-year interval evaluation of function after pollicization for congenital thumb aplasia using multiple outcome measures. *Plast Reconstr Surg* 122:198–205, 2008.
3. Anastakis DJ, Malessy MJA, Chen R, et al: Cortical plasticity following nerve transfer in the upper extremity. *Hand Clin* 24:25–444, 2008.
4. Baek GH, Goug HS, Chung MS, et al: Modified Bilhaut-Cloquet procedure for Wassel type II and III polydactyly of the thumb. *J Bone Joint Surg Am* 89:534–541, 2007.
5. Baek GH, Kim JH, Chung MS, et al: The natural history of pediatric trigger thumb. *J Bone Joint Surg Am* 90:980, 2008.
6. Broadbent TR, Woolf RM: Flexion-adduction deformity of the thumb-congenital clasped thumb. *Plast Reconstr Surg* 34:612–616, 1964.
7. Buck-Gramcko D: Pollicization of the index finger. Method and results in aplasia and hypoplasia of the thumb. *J Bone Joint Surg Am* 53:1971, 1605-1617.
8. Cardon LJ, Ezaki M, Carter PR: Trigger finger in children. *J Hand Surg [Am]* 24:1156, 1999.
9. Chao JD, Huang JM, Wiedrich T: Local hand flaps. *J Hand Surg [Am]* 1:25–44, 2001.
10. Clark DI, Chell J, Davis TR: Pollicisation of the index finger. A 27-year follow-up study. *J Bone Joint Surg Br* 80:631–635, 1998.
11. Crawford HH, Horton CE, Adamson JE: Congenital aplasia or hypoplasia of the thumb and finger extensor tendons. *J Bone Joint Surg Am* 49:82–91, 1966.
12. Dinham JM, Meggitt BF: Trigger thumbs in children. A review of the natural history and indications for treatment in 105 patients. *J Bone Joint Surg Br* 56:153, 1974.
13. Dobbs MB, Dietz FR, Gurnett CA, et al: Localization of dominantly inherited isolated triphalangeal thumb to chromosomal region 7q36. *J Orthop Res* 18:340–344, 2000.

14. Dobyns JH, Lipscomb PR, Cooney WP: Management of thumb duplication. *Clin Orthop Relat Res* 195:26–44, 1985.
15. El-Karef E: The non-opposable triphalangeal thumb: a new technique of management. *J Hand Surg [Br]* 29:544–551, 2004.
16. Elliott AM, Reed MH, Evans JA: Triphalangeal thumb in association with split hand/foot: a phenotypic marker for SHFM3? *Birth Defects Res A Clin Mol Teratol* 79:58–61, 2007.
17. Evans D: Polydactyly of the thumb. *J Hand Surg [Br]* 18:3–4, 1993.
18. Ezaki M: Radial polydactyly. *Hand Clin* 6:577–588, 1990.
19. Fitch RD, Urbaniak JR, Ruderman RJ: Conjoined flexor and extensor pollicis longus tendons in the hypoplastic thumb. *J Hand Surg [Am]* 9:417–419, 1984.
20. Flatt A: *The care of congenital hand anomalies*, St. Louis, 1994, Quality Medical Publishing.
21. Flatt AE: Extra thumbs. In *The care of congenital hand anomalies*, St. Louis, 1994, Quality Medical Publishing, pp 120–145.
22. Foucher G, Medina J, Navarro R: Microsurgical reconstruction of the hypoplastic thumb, type IIIB. *J Reconstr Microsurg* 17:9–15, 2001.
23. Friston KJ, Frith CD, Liddle PF, et al: Comparing functional (PET) images: the assessment of significant change. *J Cereb Blood Flow Metab* 11:690–699, 1991.
24. Ganley TJ, Lubahn JD: Radial polydactyly: an outcome study. *Ann Plast Surg* 35:86–89, 1995.
25. Ger E, Kupcha P, Ger D: The management of trigger thumb in children. *J Hand Surg [Am]* 16:944, 1991.
26. Gevins A, Leong H, Smith ME, et al: Mapping cognitive brain function with modern high-resolution electroencephalography regional modulation of high resolution evoked potentials during verbal and non-verbal matching tasks. *Trends Neurosci* 18:429–436, 1995.
27. Ghani HA: Modified dorsal rotation advancement flap for release of the thumb web space. *J Hand Surg [Br]* 31:226–229, 2006.
28. Giraux P, Sirigu A, Schneider F, et al: Cortical reorganization in motor cortex after graft of both hands. *Nat Neurosci* 4:691–692, 2001.
29. Goldfarb CA, Deardorff V, Chia B, et al: Objective features and aesthetic outcome of pollicized digits compared with normal thumbs. *J Hand Surg [Am]* 32:1031–1036, 2007.
30. Goldfarb CA, Gee AO, Heinze LK, et al: Normative values for thumb length, girth, and width in the pediatric population. *J Hand Surg [Am]* 30:1004–1008, 2005.
31. Goldfarb CA, Patterson JM, Maender A, et al: Thumb size and appearance following reconstruction of radial polydactyly. *J Hand Surg [Am]* 33:1348, 2008.
32. Graham TJ, Ress AM: Finger polydactyly. *Hand Clin* 14:49–64, 1998.
33. Gurnett CA, Bowcock AM, Dietz FR, et al: Two novel point mutations in the long-range SHH enhancer in three families with triphalangeal thumb and preaxial polydactyly. *Am J Med Genet A* 143:27–32, 2007.
34. Horii E, Nakamura R, Makino H: Triphalangeal thumb without associated abnormalities: clinical characteristics and surgical outcomes. *Plast Reconstr Surg* 108:902–907, 2001.
35. Horii E, Nakamura R, Sakuma M, et al: Duplicated thumb bifurcation at the metacarpophalangeal joint level: factors affecting surgical outcome. *J Hand Surg [Am]* 22:671–679, 1997.
36. Hovius SE, Zuidam JM, de Wit T: Treatment of the triphalangeal thumb. *Tech Hand Up Extrem Surg* 8:247–256, 2004.
37. Kikuchi N, Ogino T: Incidence and development of trigger thumb in children. *J Hand Surg [Am]* 31:541, 2006.
38. Kozin SH: Syndactyly. *J Am Soc Surg Hand* 1:1–13, 2001.
39. Kozin SH: Deformities of the thumb. In Wolfe SW, Hotchkiss RN, Pederson WC, et al, editors: *Green's operative hand surgery*, ed 6, Philadelphia, 2010, Elsevier Churchill Livingstone.
40. Kozin SH: Pollicization: the concept, technical details, and outcome. *Clin Orthop Surg* 4:18–35, 2012.
41. Kozin SH, Ezaki M: Flexor digitorum superficialis opponensplasty with ulnar collateral ligament reconstruction for thumb deficiency. *Tech Hand Up Extrem Surg* 14(1):46–50, 2010.
42. Kozin SH, Weiss AA, Webber JB, et al: Functional results after index finger pollicization for congenital aplasia or hypoplasia of the thumb. *J Hand Surg [Am]* 17:880–884, 1992.
43. Larsen M, Nicolai JP: Long-term follow-up of surgical treatment for thumb duplication. *J Hand Surg [Br]* 30:276–281, 2005.
44. Lee Z-L, Chang C-H, Yang W-Y, et al: Extension split for trigger thumb in children. *J Pediatr Orthop* 26:785, 2006.
45. Leung PC, Chan KM, Cheng JC: Congenital anomalies of the upper limb among the Chinese population in Hong Kong. *J Hand Surg [Am]* 7:563–565, 1982.
46. Light TR: Treatment of preaxial polydactyly. *Hand Clin* 8:161–175, 1992.
47. Lin SC, Huang TH, Hsu HY, et al: A simple splinting method for correction of supple congenital clasped thumbs in infants. *J Hand Surg [Br]* 24:612–614, 1999.
48. Lister G: Pollex abductus in hypoplasia and duplication of the thumb. *J Hand Surg [Am]* 16:626–633, 1991.
49. Littler JW: On making a thumb: one hundred years of surgical effort. *J Hand Surg [Am]* 1:35–51, 1976.
50. Manduch M, Bezuhly M, Anastakis DJ, et al: Serial fMRI assessment of the primary motor cortex following thumb reconstruction. *Neurology* 59(8):1278–1281, 2002.
51. Manske PR: Treatment of duplicated thumb using a ligamentous/periosteal flap. *J Hand Surg [Am]* 14:728–733, 1989.
52. Marek DJ, Fitoussi F, Bohn DC, et al: Surgical release of the pediatric trigger thumb. *J Hand Surg [Am]* 36:647, 2011.
53. McAdams TR, Moneim MS, Omer GE, Jr: Long-term follow-up of surgical release of the A(1) pulley in childhood trigger thumb. *J Pediatr Orthop* 22:41, 2002.
54. McCarroll HR, Jr: Congenital anomalies: a 25-year overview. *J Hand Surg [Am]* 25:1007–1037, 2000.
55. McCarroll HRJ: Congenital flexion deformities of the thumb. *Hand Clin* 1:567–575, 1985.
56. Merolli A, Tranquilli Leali P, Cataldi L: Autosomal dominant transmission of bilateral "opposable" triphalangeal thumb. *Chir Organi Mov* 84:381–386, 1999.
57. Michifuri Y, Murakami T, Kumagai S, et al: Natural history of the trigger fingers in children. *Seikei Geka* 29:1978, 1648.
58. Mih AD: Complications of duplicate thumb reconstruction. *Hand Clin* 14:143–149, 1998.
59. Mih AD: Congenital clasped thumb. *Hand Clin* 14:77–84, 1998.
60. Miura T: An appropriate treatment for postoperative Z-formed deformity of the duplicated thumb. *J Hand Surg [Am]* 2:380–386, 1977.
61. Miura T: Flexion deformities of the thumb. In Buck-Gramcko D, editor: *Congenital malformations of the hand and forearm*, London, 1998, Churchill Livingstone, pp 425–429.
62. Moon WN: Trigger digits in children. *J Hand Surg [Br]* 26:11, 2001.
63. Mulpruek P, Prichasuk S, Orapin S: Trigger finger in children. *J Pediatr Orthop* 18:239, 1998.
64. Naasan A, Page RE: Duplication of the thumb. *J Hand Surg [Br]* 19:355–360, 1994.
65. Nemoto K, Nemoto T, Terada N, et al: Splint therapy for trigger thumb and finger in children. *J Hand Surg [Br]* 21:416, 1996.
66. Ogino T, Ishii S, Kato H: Opposable triphalangeal thumb: clinical features and results of treatment. *J Hand Surg [Am]* 19:39–47, 1994.
67. Ogino T, Ishii S, Minami M: Radially deviated type of thumb polydactyly. *J Hand Surg [Br]* 13:315–319, 1988.
68. Ogino T, Ishii S, Takahata S, et al: Long-term results of surgical treatment of thumb polydactyly. *J Hand Surg [Am]* 21:478–486, 1996.
69. Ratner JA, Peljovich A, Kozin SH: Update on tendon transfers for peripheral nerve injuries. *J Hand Surg [Am]* 35:1371–1381, 2010.
70. Rodgers WB, Waters PM: Incidence of trigger digits in newborns. *J Hand Surg [Am]* 19:364, 1994.
71. Saltzman MD, Nuber GW, Gryzlo SM, et al: Efficacy of surgical preparation solutions in shoulder surgery. *J Bone Joint Surg Am* 91:1949–1953, 2009.
72. Shah AS, Bae DS: Management of pediatric trigger thumb and trigger finger. *J Am Acad Orthop Surg* 20:206, 2012.
73. Shiono H, Ogino T: Triphalangeal thumb and dermatoglyphics. *J Hand Surg [Br]* 9:151–152, 1984.
74. Slakey JB, Hennrikus WL: Acquired thumb flexion contracture in children: congenital trigger thumb. *J Bone Joint Surg Br* 78:481, 1996.
75. Snow J, Littler J: Surgical treatment of cleft hand. In *Transactions of the Society of Plastic and Reconstructive Surgery: 4th Congress in Rome*, Amsterdam, 1967, Excerpta Medica Foundation, pp 888–893.
76. Soldado F, Zlotolow DA, Kozin SH: Thumb hypoplasia. *J Hand Surg [Am]* 38:1435–1444, 2013.
77. Sugimoto Y: Treatment of trigger digit in children. *Seikei Geka* 34:1047, 1991.
78. Tada K, Kurisaki E, Yonenobu K, et al: Central polydactyly—a review of 12 cases and their surgical treatment. *J Hand Surg [Am]* 7:460–465, 1982.
79. Tonkin MA, Bulstrode NW: The Bilhaut Cloquet procedure for Wassel types III, IV and VII thumb duplication. *J Hand Surg Eur Vol* 32:684, 2007.
80. Tsuyuguchi Y, Masada K, Kawabata H, et al: Congenital clasped thumb: a review of forty-three cases. *J Hand Surg [Am]* 10:613–618, 1985.
81. Tsuyuguchi Y, Tada K, Kawaii H: Splint therapy for trigger finger in children. *Arch Phys Med Rehabil* 64:75, 1983.
82. Tuch BA, Lipp EB, Larsen IJ, et al: A review of supernumerary thumb and its surgical management. *Clin Orthop Relat Res* 125:159–167, 1977.
83. Tupper JW: Pollex abductus due to congenital malposition of the flexor pollicis longus. *J Bone Joint Surg Am* 51:1285–1296, 1969.
84. Upton J, Sharma S, Taghinia AH: Vascularized adipofascial island flap for thenar augmentation in pollicization. *Plast Reconstr Surg* 122:1089–1094, 2008.
85. Verma M, Craig CL, DiPietro MA, et al: Serial ultrasound evaluation of pediatric trigger thumb. *J Pediatr Orthop* 33:309, 2013.
86. Wang H-C, Lin G-T: Retrospective study of open versus percutaneous surgery for trigger thumb in children. *Plast Reconstr Surg* 115:2005, 1963.

87. Wang ZQ, Tian SH, Shi YZ, et al: A single C to T transition in intron 5 of LMBR1 gene is associated with triphalangeal thumb-polysyndactyly syndrome in a Chinese family. *Biochem Biophys Res Commun* 355:312–317, 2007.
88. Wassel HD: The results of surgery for polydactyly of the thumb. *Clin Orthop Relat Res* 64:175–193, 1969.
89. Watanabe H, Hamada Y, Toshima T, et al: Conservative treatment for trigger thumb in children. *Arch Orthop Trauma Surg* 121:388, 2001.
90. Watson BT, Hennrikus WL: Postaxial type-B polydactyly. Prevalence and treatment. *J Bone Joint Surg Am* 79:65–68, 1997.
91. Webb ML, Rosen H, Taghinia A, et al: Incidence of Fanconi anemia in children with congenital thumb anomalies referred for diepoxybutane testing. *J Hand Surg [Am]* 36:1052–1057, 2011.
92. Weckesser EC, Reed JR, Heipel KG: Congenital clasped thumb (congenital flexion-adduction deformity of the thumb). A syndrome, not a specific entity. *J Bone Joint Surg Am* 50:1417–1428, 1968.
93. White JW, Jensen WE: The infant's persistent thumb-clutched hand. *J Bone Joint Surg Am* 24:680–688, 1952.
94. Wood VE: Treatment of the triphalangeal thumb. *Clin Orthop Relat Res* 120:188–200, 1976.
95. Wood VE: Polydactyly and the triphalangeal thumb. *J Hand Surg [Am]* 3:436–444, 1978.
96. Woolf RM, Broadbent TR: The four-flap Z-plasty. *Plast Reconstr Surg* 49:48–51, 1972.
97. Zadek I: Congenital absence of the extensor pollicis longus of both thumbs. Operation and cure. *J Bone Joint Surg Am* 16:432–434, 1934.
98. Zlotolow DA, Tosti R, Ashworth S, et al: Developing a Pollicization Outcomes Measure. *J Hand Surg [Am]* 39:1784–1791, 2014.

38

Malformations and Deformities of the Wrist and Forearm

Michelle A. James and Andrea S. Bauer

Acknowledgments: The authors would like to acknowledge Mike Bednar, MD, who authored the previous edition of this chapter. We would also like to acknowledge Scott Oishi, MD, Brian O'Doherty, MD, and Scott Kozin, MD, for providing additional text, radiographs, and photos that have enhanced our chapter.

RADIAL LONGITUDINAL DEFICIENCY (CASE STUDY 38.1)

Preoperative Evaluation

Radial longitudinal deficiency (RLD) is a spectrum of malformations affecting the structures of the radial side of the forearm (radius, radial carpus, and thumb), including hypoplasia of the bones and joints, muscles and tendons, ligaments, nerves, and blood vessels.[57] In the Oberg, Manske, Tonkin classification of congenital hand differences, RLD is categorized as a malformation of the radial-ulnar axis.[87] RLD is an uncommon condition, although it is the most common type of congenital longitudinal deficiency. A population-based study in Finland found RLD in nearly 1:5000 live births.[66]

Children with RLD should undergo thorough and serial examinations of both upper extremities. RLD is frequently bilateral and asymmetric, and manifestations may be subtle. Because the radius and many organ systems develop at the same time, a systemic workup is required. RLD is commonly associated with several congenital syndromes, such that only a third of patients with RLD present with an isolated upper extremity malformation (Table 38.1).[44] Therefore, a complete physical examination must be performed and consultation with a clinical geneticist is recommended. In addition, radiographic and serologic tests mentioned in the following are required.

Although children with bilateral and severe RLD have functional impairment as a result of thumb dysfunction, wrist instability, and short upper extremities, there is no difference in long-term activity and participation levels between those with mild versus severe RLD.[51] For some children with RLD, independent performance of activities of daily living, such as fastening buttons and zippers or accomplishing personal hygiene, may be difficult, prompting consideration for surgery.

Radiographs tend show the degree of involvement of the radius, thumb, and carpus dependent upon the degree of ossification and/or previous surgical intervention. Classification of the RLD is by radiographic studies.[55] Spine x-rays, renal ultrasound, and echocardiography are required to assess for associated anomalies.[44]

Persons with RLD have a high incidence of medical and musculoskeletal anomalies which escalate with increasing severity of the deficiency.[44] In addition to genetic counseling, testing for Fanconi anemia is recommended.[123] We recommend a chromosomal breakage test for all children with deficiencies of the thumb and radial border of the forearm. Additional findings, such as abnormal skin pigmentation (*café au lait spots*), kidney abnormalities, growth retardation, and microcephaly, add to the suspicion of Fanconi anemia. Failure to ascertain the diagnosis of Fanconi anemia will have lifelong ramifications for the child, family, and physician. Fanconi anemia can be diagnosed before the onset of bone marrow failure. Timely diagnosis allows for years of preparation to search for an appropriate bone marrow match that may prevent the child from dying from aplastic anemia. Innovative techniques, such as preimplantation genetic determination, allow the parents to have another child with matching blood characteristics and without Fanconi anemia. At birth, the cord blood can be harvested and used as a donor for the affected Fanconi anemia child. Numerous hand surgeons and pediatricians fail to consider the diagnosis of Fanconi anemia in children with RLD, leaving the child and the family to suffer the consequences of a painful terminal illness that could otherwise have been treated.

RLD is associated with other upper extremity anomalies, including humeral hypoplasia, proximal radioulnar synostosis, congenital radial head dislocation, and finger stiffness. Less common associations include metacarpal synostoses and syndactyly.[56] Infrequent findings are contralateral radial polydactyly[102] and phocomelia.[42]

PERTINENT ANATOMY

Bayne and Klug classified RLD into four types based on the radiographic severity of the radial deficiency (Table 38.2).[10] James and associates modified this classification to include patients with deficiency of the thumb or carpus in the presence of a radius of normal length (Figure 38.1).[57] This classification is used in combination with the modified Blauth scheme for classifying thumb hypoplasia.[55]

Types of Operations

Indications for treatment vary with the severity of the deformity and the age of the patient. Children with type 0 or 1 or mild type 2 radial deficiencies may require only stretching and splinting. When considerable radial deviation is present, tendon transfers and soft tissue releases may be indicated.[83] Severe type 2 radial deficiency is difficult to treat. Lengthening of the radius may be possible,[75] or centralization of the carpus on the end of the ulna may be performed to achieve stability and improve the likelihood that the child will be able to use a reconstructed thumb. A recent large study found that patients with RLD who underwent centralization showed improvements in both subjective measurements (such as appearance) and objective measurements (such as alignment, grip strength, and finger and wrist range of motion) compared with patients who did not undergo surgery.[67]

We have previously recommended bony centralization, including (if necessary) carpal resection and ulnar epiphyseal shaving, to correct the wrist instability and radial deviation in types 3 and 4 RLD. Although bony centralization is still performed by some surgeons, others prefer not to resect the carpus or shave the distal ulna because of the high rate of recurrent deformity and complications such as wrist stiffness and forearm growth impairment that may be caused by iatrogenic damage to the ulnar physis.

The best results of centralization are obtained when aberrant radial wrist extensors can be transferred to help maintain the new position and the centralization is done before 1 year of age (as long as general anesthesia is not precluded by other manifestations of the child's syndrome such as cardiac problems or thrombocytopenia). Before centralization, serial casting or application of a distraction device, or both, facilitates stretching of the taut radial soft tissue structures, thereby diminishing the soft tissue tension and the likelihood that bony resection will be required during centralization.[43,117] Preliminary external distraction is most helpful for older children with untreated type 3 or 4 radial deficiency. A bilobed skin flap or dorsal rotation flap may help redistribute excess tissue from the ulnar to the radial side of the wrist.[32,120]

With unilateral type 3 or 4 involvement, the affected forearm is usually only half as long as the unaffected forearm. This deficit in length has been surgically addressed by ulnar lengthening via distraction osteogenesis.[93] Lengthening can be performed in older children after centralization. However, lengthening procedures may affect the future growth of the ulna, such that repeated lengthenings will be required to maintain the relative gain in length.[137]

Vilkki described the combination of soft tissue distraction and microvascular epiphyseal transfer for the treatment of type 4 radial deficiency (Figure 38.2).[125] Historically, attempts to treat radial deficiency by surgical transfer of nonvascularized growing bone were unsuccessful because the graft failed to grow. Although Vilkki's early results are promising, the technique is technically demanding and the outcome at skeletal maturity is not yet known.

Preliminary Soft Tissue Distraction

Unilateral and circumferential fixators have been used successfully to distract the radial soft tissues before centralization (Figure 38.3).[43,117] The fixator is applied across the wrist via an open technique for pin placement to protect the anomalous

TABLE 38.1 Syndromes Associated With Radial Deficiency

Syndrome	Other Anomalies	Inheritance
VACTERL	Spinal, renal, gastrointestinal, cardiac	Sporadic
Holt-Oram	Cardiac (septal defects); other upper extremity malformations	Autosomal dominant
TAR	Thrombocytopenia, anemia; radius absent but thumb present	Autosomal recessive
Fanconi anemia	Pancytopenia	Autosomal recessive
Chromosome aberrations (trisomies 13 and 18)	Multiple	Sporadic
Nager, Rothmund-Thomson, IVIC	Craniofacial	Varies with the syndrome

IVIC, Instituto Venzolano de Investigaciones Cientificas; *TAR*, thrombocytopenia–absent radius; *VACTERL*, vertebral, anal, cardiac, tracheoesophageal, renal/radial, limb.

TABLE 38.2 Modified Bayne Classification of Radial Longitudinal Deficiency

Type	Thumb	Carpus	Distal Radius	Proximal Radius
N	Hypoplastic or absent	Normal	Normal	Normal
0	Hypoplastic or absent	Absence, hypoplasia, or coalition	Normal	Normal, radioulnar synostosis, or congenital dislocation of the radial head
1	Hypoplastic or absent	Absence, hypoplasia, or coalition	>2 mm shorter than the ulna	Normal, radioulnar synostosis, or congenital dislocation of the radial head
2	Hypoplastic or absent	Absence, hypoplasia, or coalition	Hypoplasia	Hypoplasia
3	Hypoplastic or absent	Absence, hypoplasia, or coalition	Physis absent	Variable hypoplasia
4	Hypoplastic or absent	Absence, hypoplasia, or coalition	Absent	Absent

Modified from Bayne LG, Klug MS: Long-term review of the surgical treatment of radial deficiencies. *J Hand Surg [Am]* 12:169–179, 1987; and James MA, McCarroll HR, Jr, Manske PR: The spectrum of radial longitudinal deficiency: a modified classification. *J Hand Surg [Am]* 24:1145–1155, 1999.



FIGURE 38.1 Types of radial deficiency. **A,** Type N. **B,** Type 0 (absent scaphoid). **C,** Type 1. **D,** Type 2. **E,** Type 3. **F,** Type 4 (after centralization).

anatomy and gradually distracted until the wrist can be centralized without residual radial deviation after the external fixator is loosened or removed (Figure 38.4).

Centralization

Although the wrist and forearm are profoundly abnormal in a radially deficient limb, the anomalies are predictable. All the radial forearm structures are deficient to varying degrees. The radial wrist extensors and extrinsic thumb motors are usually absent or aberrant. The radial nerve is generally absent below the elbow. The median nerve is always present and is frequently the most prominent structure on the radial side of the wrist. The radial artery is usually absent.[120] Occasionally, a child with RLD has an elbow extension contracture. In this case, centralization is contraindicated, as wrist radial deviation is needed for the child's hand to reach the face.

The incision begins at the level of the distal end of the ulna just radial to the midline, extends toward the ulna in a transverse direction, and then forms an ellipse to excise excess skin and subcutaneous tissue, or alternately, excess tissue is rotated from the ulnar to the radial side.[120] The dorsal ulnar sensory nerve is preserved, and the extensor retinaculum is exposed. The extensor carpi ulnaris is isolated as it inserts into the base of the fifth metacarpal. The extensor retinaculum is raised as a radially based flap and the finger extensor tendons are retracted radially. The radial wrist extensors are generally absent or adherent to the dorsal capsule and devoid of proximal musculature; their remnants are isolated and elevated with a piece of dorsal capsule.

The wrist capsule is incised in a transverse direction over the ulnocarpal joint to expose the distal end of the ulna (Figure 38.5). The carpal bones are often palmar and radial to

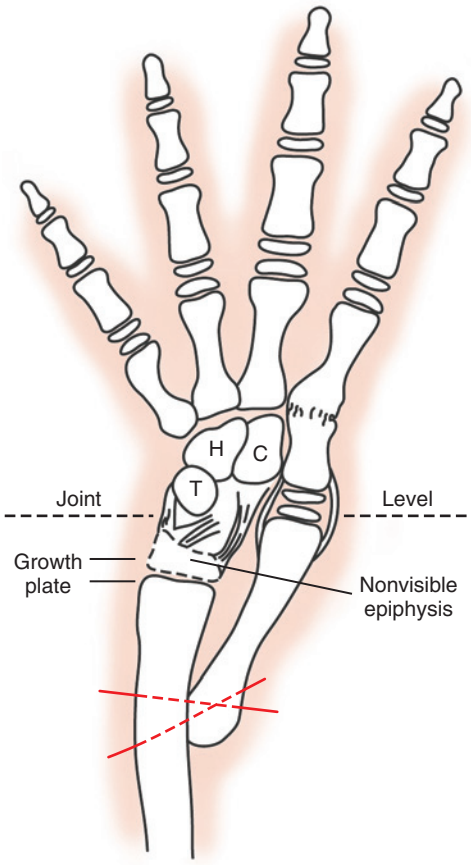

FIGURE 38.2 Diagram of free toe transfer to support the radial side of the wrist. The proximal phalanx of the toe is fused to the base of the second metacarpal, and the proximal metatarsal is affixed to the side of the distal ulna. *C*, Capitate; *H*, hamate; *T*, triquetrum.

the distal ulna. The ulna is freed from its soft tissue attachments distal to the physis, and the carpal bones are detached from the palmar capsule. The carpus is then reduced onto the distal ulna. If reduction cannot be achieved, the radial structures are examined for any persistent taut tissue. In severe cases without preliminary distraction, adequate reduction cannot be achieved and alternative measures are necessary. Surgical options include carpectomy or limited shaving of the distal ulnar epiphysis while avoiding injury to the growth plate or the application of an external fixator, postoperative distraction, and delayed formal centralization.

The reduction is maintained by placing a Kirschner wire through the carpus and third metacarpal into the ulnar shaft. If the ulnar angulation is greater than 30 degrees, a closing wedge osteotomy is performed at the apex of the deformity and secured with the same Kirschner wire. In severe deformity, separate Kirschner wires are often necessary. The wrist capsule is imbricated, and, if present, the radial wrist extensors are transferred into the extensor carpi ulnaris tendon. The extensor carpi ulnaris is tightened by detaching and advancing the tendon or imbrication to increase soft tissue tension on the ulnar side. The retinacular flap is passed underneath the finger extensors to reinforce the wrist capsule. Excess skin and subcutaneous tissue are excised, and the wound is closed with absorbable suture. A long-arm bulky compressive dressing is applied and covered with a long-arm fiberglass splint or cast.

Soft Tissue Release and Balancing

If the carpus cannot be passively reduced onto the end of the ulna, a soft tissue release and balancing procedure is performed instead of a formal centralization (Figure 38.6). The major difference between these two operations is that carpectomy and

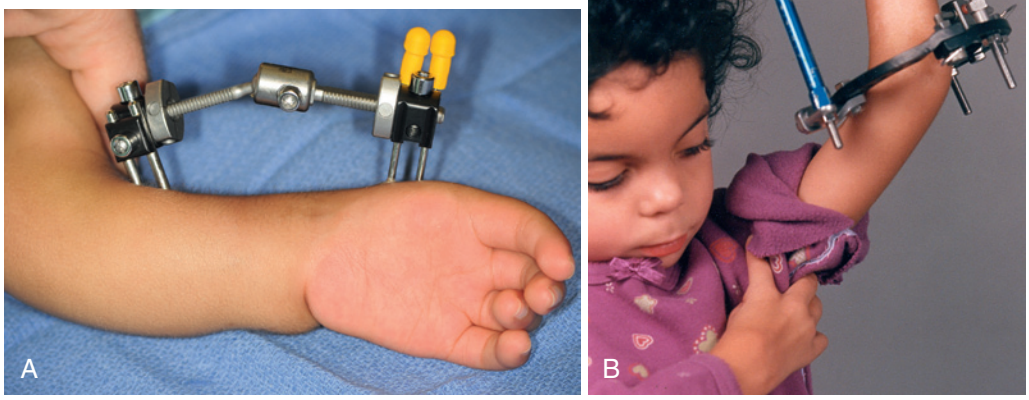

FIGURE 38.3 Radial deficiency with rigid deformity is often treated with preliminary soft tissue distraction, **A,** Uniplanar device along the radial side of the forearm. **B,** Multiplanar device for additional control of hand and forearm. (Courtesy of Shriners Hospital for Children, Philadelphia.)

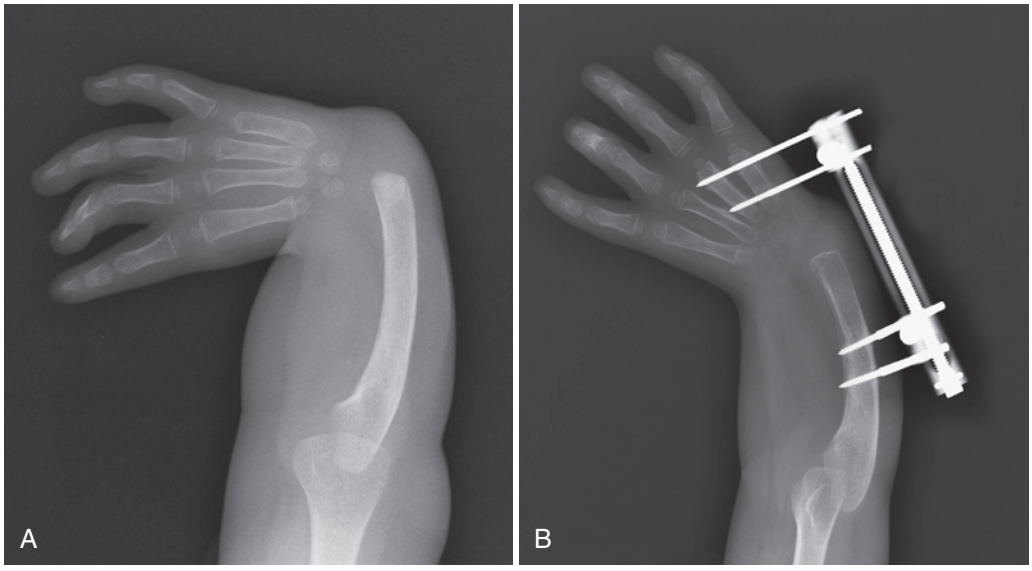

FIGURE 38.4 Three-year-old with bilateral radial deficiency. **A,** Preoperative x-ray of right forearm and hand. **B,** X-ray after distraction to lengthen soft tissues and ease centralization. (Courtesy of Shriners Hospital for Children, Philadelphia.)

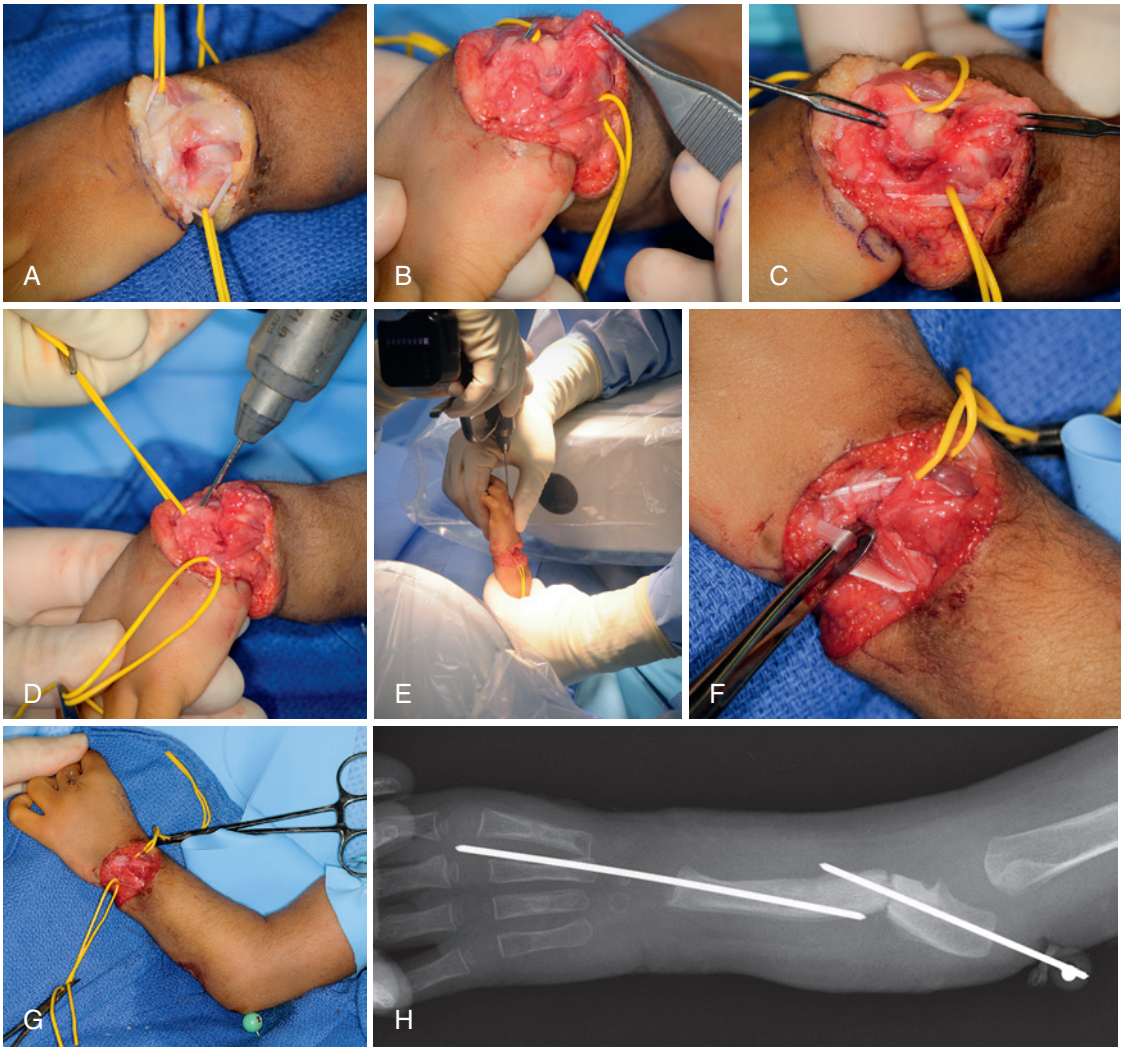

FIGURE 38.5 A 1½-year-old male with isolated left type 4 radial deficiency and absent thumb treated with preliminary distraction and centralization. **A,** Following fixator removal, an elliptical dermodesis incision is made and the underlying tendons are identified. **B,** Ulnocarpal capsulotomy. **C,** Ulnar head isolated. **D,** Antegrade 0.62-inch Kirschner wire. **E,** Kirschner wire passed retrograde across ulnocarpal joint. **F,** Extensor carpi ulnaris imbrication. **G,** Concomitant ulnar osteotomy and overall alignment. **H,** Postoperative x-ray with Kirschner wires across ulnocarpal joint and ulnar osteotomy.



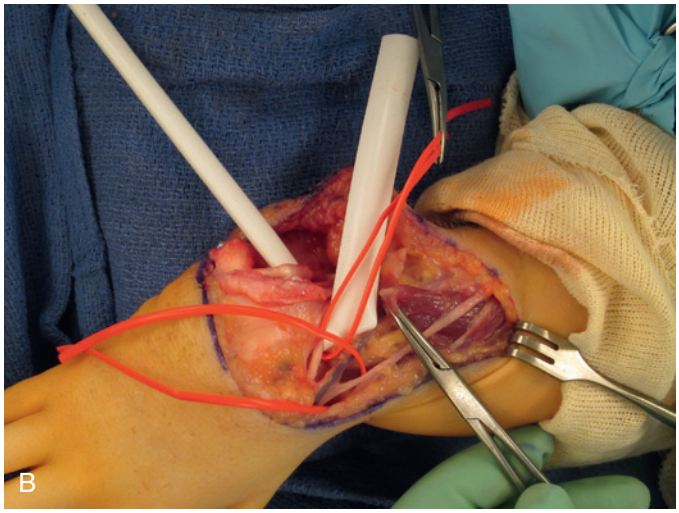



FIGURE 38.6 **A,** Severe radial deviation in a patient with type 4 radius deficiency. **B,** Abnormal extensor musculature is identified and released. **C,** Skin is closed using a dorsal rotational flap. A small pin is used to hold the soft tissue in position, although no bony work has been done. Note modest improvement in radial deviation.



FIGURE 38.7 Bilateral uniplanar lengthening after successful centralization. (Courtesy of Shriners Hospital for Children, Philadelphia.)

shaving of the distal ulnar epiphysis are not performed, and the hand and carpus are either not pinned or are pinned in the best position possible, accepting some translocation or dislocation.

Ulnar Lengthening

This procedure is rarely indicated. When it is performed, the principles of distraction lengthening are followed (Figure 38.7).[93] A uniplane or multiplane fixator is used, depending on any concomitant angular bony correction needed. For application of a circumferential frame, two half-pins and one transfixion wire are used proximal to the osteotomy. One half-pin and two transfixion wires (one in the ulna and one in the metacarpals) are placed distal to the osteotomy. For a uniplane fixator, two pins each are placed proximal and distal to the osteotomy. We prefer a uniplane fixator with a hinge at the midpoint, to allow correction of the radial bow at the time of fixator application. Any residual radial deviation is corrected at the time of fixator application or during the distraction. Acute bony correction can be achieved with a closing wedge osteotomy followed by distraction osteogenesis. Distraction is initiated approximately 1 week after application of the fixator and is continued at 1 mm/day divided into two to three increments. Radiographic progress of bone regeneration is monitored weekly. The rate of lengthening is slowed if regeneration is lagging. The child and family are taught lengthening techniques and exercises to maintain elbow and digit motion. The ulna can usually be lengthened by 30% to 50%. The fixator is maintained during consolidation of the bony regenerate, which generally takes twice as long as the lengthening phase. The fixator is not removed until a total of three cortices are visualized on the anteroposterior and lateral x-rays. Occasionally, supplemental bone grafting is necessary to augment union.

❖ AUTHORS' PREFERRED METHOD OF TREATMENT

Range-of-motion exercises for soft tissue stretching are started shortly after birth. The parents are instructed in stretching exercises, to be performed with each diaper change. Once the child's arm is large enough for splinting, generally around 3 months of age, a custom-fabricated long-arm Orthoplast splint (North Coast Medical, Gilroy, CA) is made for nighttime use in addition to the daytime stretches (Figure 38.8). The parents are



FIGURE 38.8 An example of a custom thermoplastic splint for nighttime stretching.

instructed to continue stretching the wrist several times each day for at least the child's first year. In certain children, neither pollicization nor centralization is indicated. These children typically have a mobile and dexterous small finger along with a stiff index finger. Pinch and grasp are accomplished using the ulnar side of the hand (ulnar grasp pattern) and straightening the wrist would eliminate the ulnar digits from approaching objects. This shift in position may be detrimental to the child's overall function and independence.

If the child is a candidate for centralization and is able to safely undergo general anesthesia around age 1 year, surgical correction is planned. If the wrist can be passively reduced preoperatively, formal centralization is performed. If not, preliminary distraction is performed followed by centralization. If incompletely correctable at the time of surgery, soft tissue release and balancing may be warranted. Prolonged pin fixation followed by long-term splinting is necessary to minimize recurrence. Ulnar lengthening is reserved for mature older children or teenagers. Lengthening requires realistic expectations and emotional stamina on the part of the patient and family. Preoperative counseling and psychological assessment are helpful. The support of a limb-lengthening team, including a nurse, social worker, and occupational therapist, is also essential.

Expected Outcomes

Long-term follow-up studies of bony centralization report problems with recurrence and stiffness (Figure 38.9).[27] The wrists tend to be either flexible and deviated or stiff and straight. Centralization has been shown to improve the appearance of the extremity but has not been proved to routinely enhance function. Some experienced pediatric hand surgeons have abandoned formal centralization in favor of soft tissue reconstruction, such as a bilobed skin flap combined with musculotendinous releases and tendon transfers (Figure 38.10).[126a,127]

Postoperative Management and Expectations

After soft tissue balancing, the extremity is placed in a cast for at least 8 weeks. Subsequently, a long-arm splint, custom-fabricated to maintain the wrist position, is worn full time for 3 to 6 months and then at night until skeletal maturity is reached.

Complications of ulnar lengthening are common, especially pin tract infections, which usually resolve with local care and antibiotics. Finger stiffness may occur during the lengthening process and is treated by slowing the distraction rate and therapy. A second procedure to place bone graft at the osteotomy site is occasionally necessary to achieve union.

CRITICAL POINTS *Treatment of the Wrist in Radial Longitudinal Deficiency*

- The basic goals of treatment are to (1) correct the radial deviation of the wrist, (2) balance the wrist on the forearm, (3) maintain wrist and finger motion, (4) promote growth of the forearm, (5) reconstruct the thumb deficiency, and (6) improve the function of the extremity.
- Passive stretching and splinting of the taut radial structures are initiated during infancy.
- Centralization and/or soft tissue release combined with tendon transfer is indicated in children with radial wrist deviation and insufficient support of the carpus.
- Thumb hypoplasia is addressed at a second stage after wrist centralization.
- The incision for centralization is planned to allow excision of excess tissue.
- The extensor carpi ulnaris is tightened and the extensor retinaculum is preserved.
- After releasing the taut structures, the carpus is pinned to the end of the distal ulna, avoiding removal of the carpal bones or shaving of the ulnar epiphysis.
- If the surgeon elects to remove carpal bones or shave the ulnar epiphysis, great care should be taken to not damage the ulnar physis.
- Despite numerous technical modifications to preserve alignment, some recurrence of the radial deficiency is universal. Currently, long-term maintenance of the carpus on the end of the ulna without sacrificing wrist mobility or stunting forearm growth remains a daunting task.

ULNAR DEFICIENCY

Preoperative Evaluation

Ulnar deficiency occurs approximately once in 25,000 live births and is 4 to 10 times less common than radial deficiency.[66] Ulnar deficiency occurs sporadically and is not associated with systemic conditions as occurs in children with radial deficiency. It is, however, associated with other musculoskeletal abnormalities that warrant careful physical examination supplemented by radiographs.

Unilateral ulnar deficiency is more common than bilateral deficiency.[116] Children with ulnar deficiency have hypoplasia of the entire upper extremity. The elbow is malformed or fused (i.e., radiohumeral synostosis) in the majority of cases (Figure 38.11).[116] The ulna may be partially or completely absent, and a cartilaginous ulnar "anlage" may be present.[80] The hand and carpus are always affected; occasionally, isolated hand involvement is seen.[49] About 90% of hands are missing digits, 30% have syndactyly, and 70% have thumb abnormalities (Figure 38.12).[22,116]

The other musculoskeletal anomalies that may accompany ulnar deficiency include proximal femoral focal deficiency, fibular deficiency, phocomelia, and congenital scoliosis.[116]

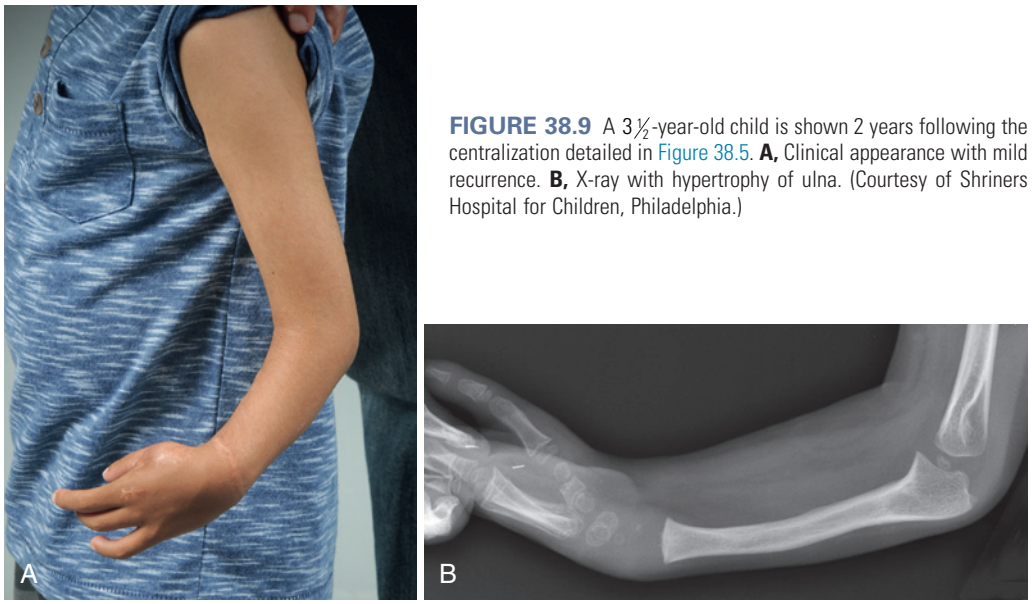

FIGURE 38.9 A 3½-year-old child is shown 2 years following the centralization detailed in Figure 38.5. **A,** Clinical appearance with mild recurrence. **B,** X-ray with hypertrophy of ulna. (Courtesy of Shriners Hospital for Children, Philadelphia.)

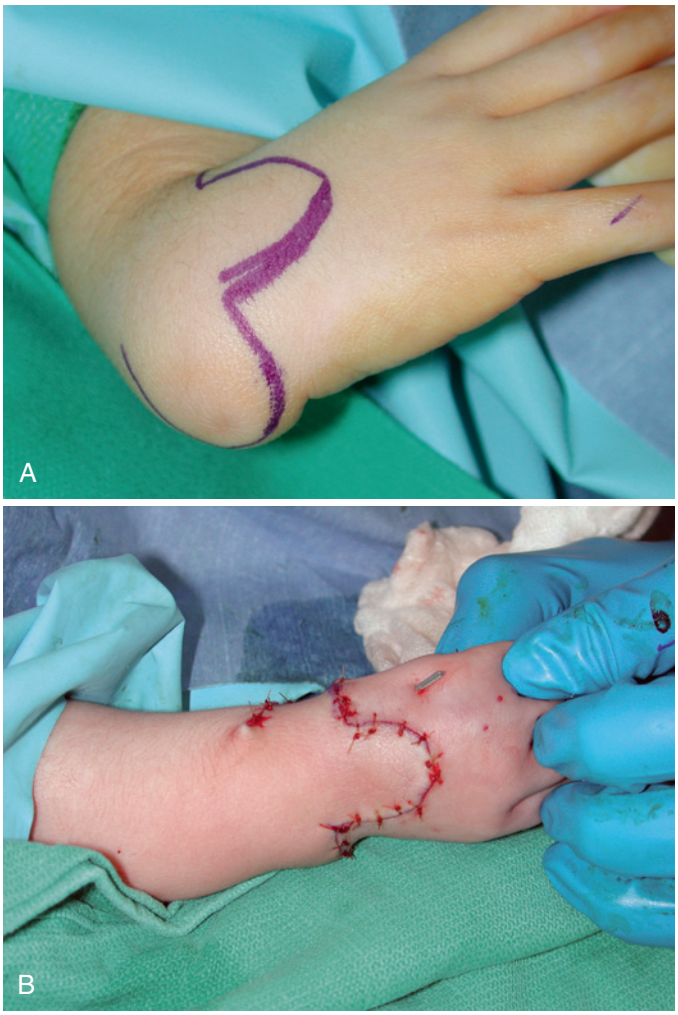

FIGURE 38.10 **A,** Bilobed rotational skin flap. **B,** Flap inset after musculotendinous releases and tendon transfers. (Courtesy of Marybeth Ezaki, MD.)

Radiographs should be taken of both upper extremities, both lower extremities, and the spine. Ulnar deficiency is rarely associated with anomalies of other organ systems.

PERTINENT ANATOMY

Most classification systems are based on elbow and forearm anomalies (Table 38.3).[80,116] To supplement these systems, Cole and Manske described a classification system based on thumb and first web anomalies (Table 38.4),[22] and Havenhill and colleagues included ulnar hand and carpal deficiencies without forearm or elbow involvement.[49]

Types of Operations

Surgical indications for many of the hand anomalies associated with ulnar deficiency are well established. Hand function is improved by release of the syndactyly and reconstruction of the thumb and first web deficiencies. Procedures that may be indicated include deepening of the first web space, opponensplasty, rotational osteotomy of the thumb metacarpal, and pollicization.[22]

With marked internal rotation of the limb combined with radiohumeral synostosis, the hand rests on the buttock or flank, and children may be unable to reach their mouth or place their hand on top of their head. Over time, children may compensate for this position and obtain adequate function (Figure 38.13). In recalcitrant cases, external rotation osteotomy of the humerus improves the position of the hand and the overall function of the limb.[80] Forearm rotational osteotomy is rarely necessary, even though the forearm is usually supinated. Rarely, the internal rotation deformity may recur with growth, necessitating a repeat external rotation osteotomy at skeletal maturity.

The indications for surgical treatment of ulnar deviation of the wrist and instability of the forearm are less certain. Several authors have reported that ulnar deviation at the wrist is due to tethering by the ulnar anlage, a fibrocartilaginous structure

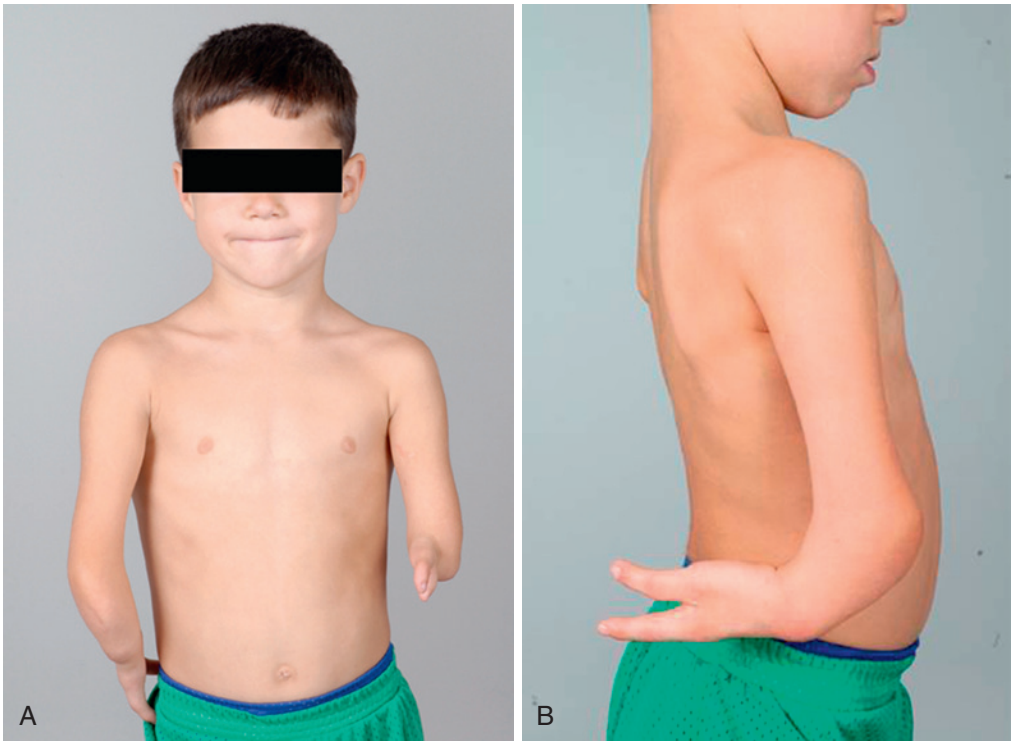

FIGURE 38.11 Four-year-old with bilateral ulnar deficiency. **A,** Frontal view showing asymmetric differences. **B,** Right hand in the classic "hand on flank" position. (Courtesy of Shriners Hospital for Children, Philadelphia.)

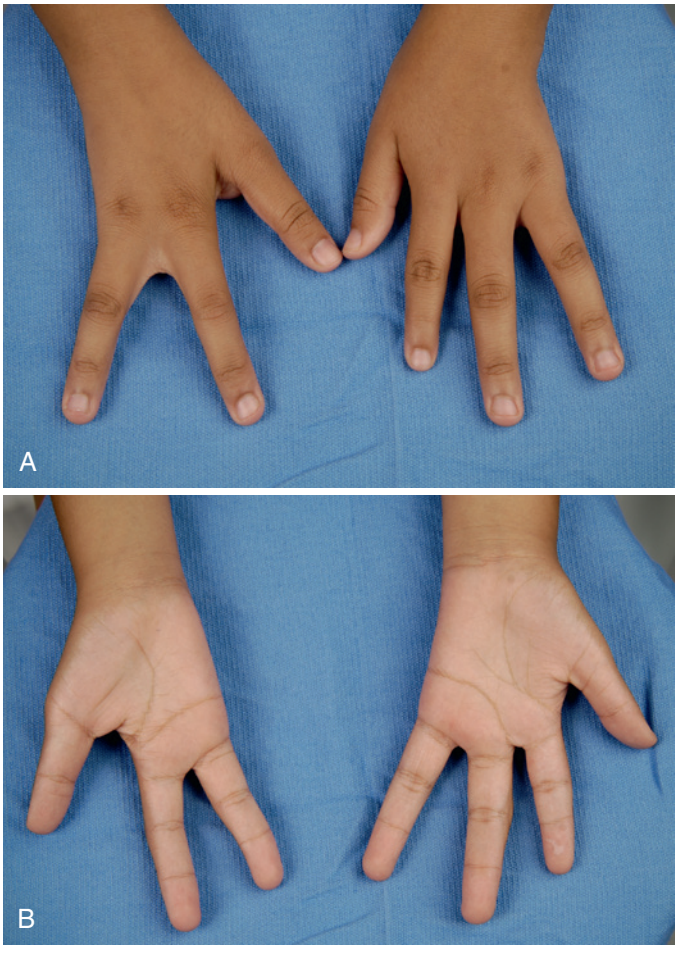

FIGURE 38.12 Nine-year-old with ulnar deficiency isolated to her hands. **A,** Dorsal view with three digits on the right hand and four digits on the left hand. **B,** Palmar view. (Courtesy of Shriners Hospital for Children, Philadelphia.)

occasionally found in the forearm of children with ulnar deficiency (Figure 38.14), hypothesizing that the ulnar anlage fails to grow with the radius and causes increasing ulnar deviation. Proponents of this theory have advocated early excision of the ulnar anlage to prevent progressive deformity.[16] Others, however, have shown that increasing ulnar deviation is uncommon, and therefore resection of the anlage should be reserved for documented progression.[80] The indications for surgical treatment of the forearm are even less defined. Some authors advocate surgical construction of a one-bone forearm to enhance forearm stability[108]; however, complete loss of forearm rotation may be detrimental to function.[16] The surgeon must remember that despite substantial differences, these children are adaptive and ingenious, especially with parental support and therapy guidance.

Thumb Reconstruction (Deepening of the First Web, Opponensplasty, Pollicization)

See Chapter 48.

Release of Syndactyly

See Chapter 36.

Excision of the Ulnar Anlage

The ulnar remnant is approached via a longitudinal incision along the ulnar border of the forearm (Figure 38.15). The ulnar extrinsic flexor muscles are often absent. The anlage will be adjacent to the ulnar neurovascular bundle, which must be protected as the anlage is dissected off its carpal attachment. The entire anlage need not be removed; removal of the distal third is adequate to release the tether. The subcutaneous tissue and skin are closed with absorbable suture and a long-arm cast is applied. The wrist is positioned as close to neutral as possible.

TABLE 38.3 Classifications of Ulnar Deficiency Based on Elbow and Forearm Anomalies

Characteristics	Kummel (1895)	Ogden et al (1976)	Riordan (1986)	Bayne (Dobyns 1993)	Swanson et al (1984)	Miller et al (1986)
Elbow						
Normal/near-normal humeroradial joint	I					
Humeroradial synostosis	II		III	IV	III	D
Radial head dislocation	III					A, B*
Ulnar Length						
Normal-length ulna						
Ulnar hypoplasia		I		I	I	
Partial ulnar aplasia		II	II	II		
Complete ulnar aplasia		III	I	III	II	
Other Upper Extremity Characteristics						
Congenital wrist amputation					IV	
Internal rotation deformity below the shoulder						C†

*B, radial head dislocation with complete absence of the ulna and cubital webbing.
†Humeroradial synostosis with variable absence of the ulna and associated internal rotation deformity.
Modified from Cole RJ, Manske PR: Classification of ulnar deficiency according to the thumb and first web. *J Hand Surg [Am]* 22:479–488, 1997.

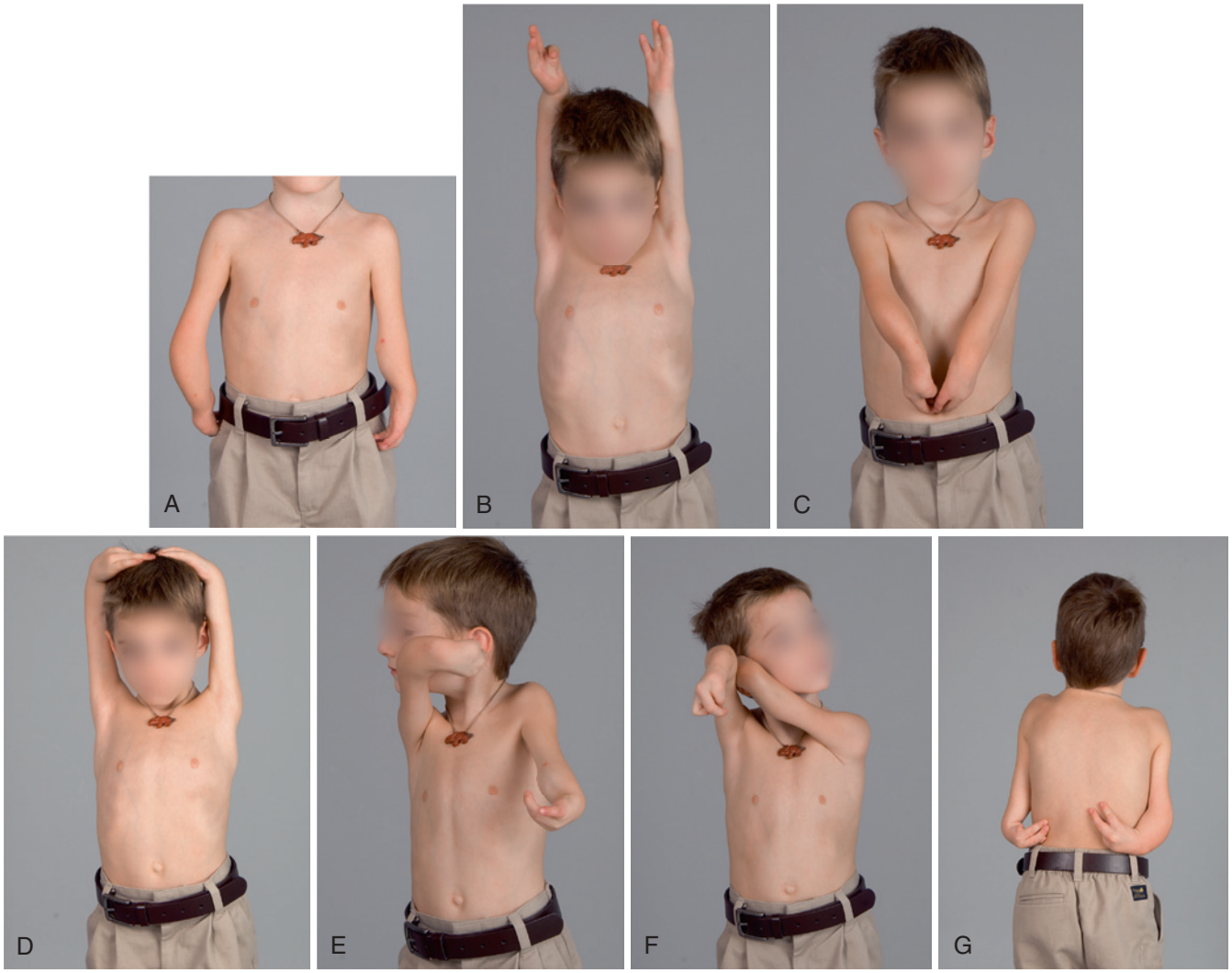

FIGURE 38.13 Six-year-old with untreated bilateral ulnar deficiency. **A,** Resting posture with the left hand facing backward. **B,** Overhead reach. **C,** Midline activity. **D,** Touching the top of the head for washing hair. **E,** Touching the left ear with the right hand. **F,** Touching the left ear with the right hand by using the left arm as an assist. **G,** Reaching back with both hands. (Courtesy of Shriners Hospital for Children, Philadelphia.)

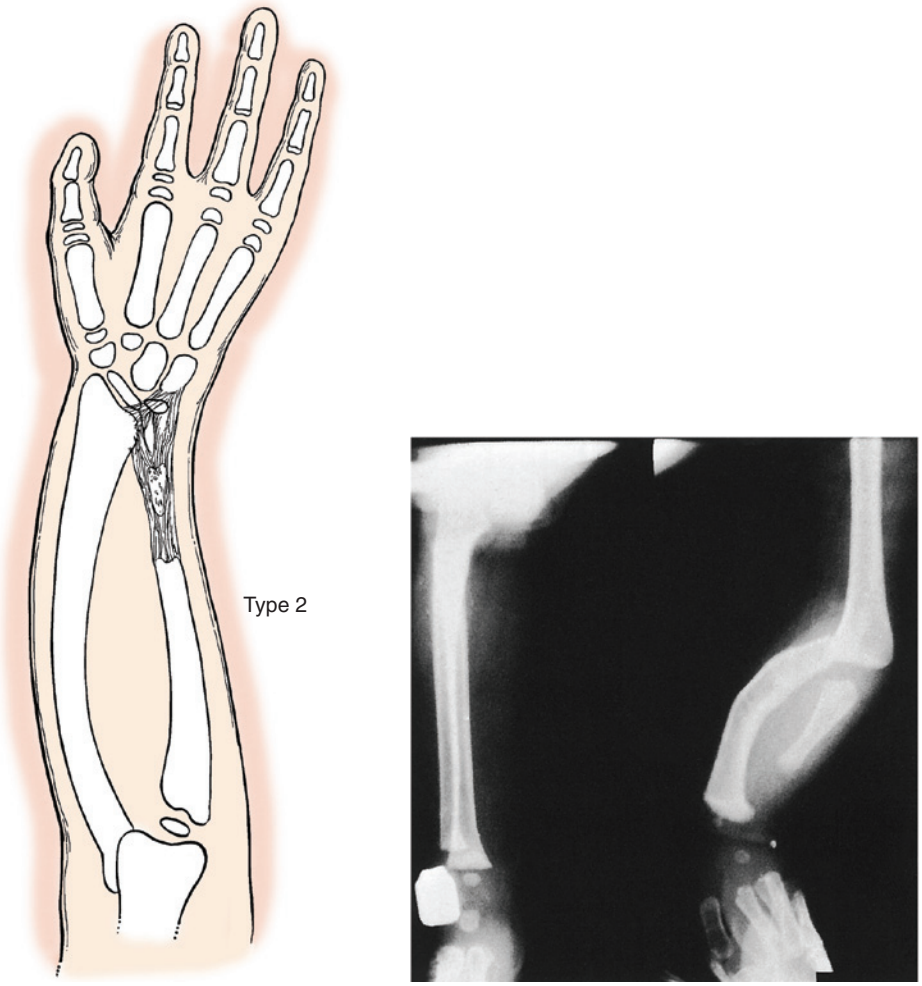

FIGURE 38.14 An ulnar anlage acts as a tethering force on the distal radius and wrist.

TABLE 38.4 Classification of Ulnar Deficiency According to Thumb and First Web Anomalies

Type	Characteristics
A	Normal first web space and thumb
B	Mild first web and thumb deficiency
C	Moderate to severe first web and thumb deficiency; possible loss of opposition; malrotation of the thumb into the plane of the fingers; thumb/index finger syndactyly; absent extrinsic tendon function
D	Absent thumb

Modified from Cole RJ, Manske PR: Classification of ulnar deficiency according to the thumb and first web. *J Hand Surg [Am]* 22:479–488, 1997.

Casting is maintained for 6 weeks and followed by a short-arm splint that is worn at night until skeletal maturity.

Rotational Osteotomy of the Humerus

The distal end of the humerus is approached via a lateral incision.[80] Careful dissection is performed through the subcutaneous tissue, with care taken to visualize the radial nerve, which may be anomalous. The alignment of the humerus is marked by electrocautery or by inserting parallel Kirschner wires above and below the planned osteotomy site. A transverse osteotomy is performed, and the distal fragment is rotated until the hand can be placed in front of the trunk. Tight soft tissues may require bone shortening to prevent a traction injury to the neurovascular structures. The osteotomy is fixed with crossed Kirschner wires or a small plate. The subcutaneous tissue and skin are closed with absorbable suture. A well-fitted long-arm cast is applied and attached to the body with a Velpeau-type dressing.

Forearm Lengthening

This operation is rarely indicated (Figure 38.16).

Creation of a One-Bone Forearm

This operation is rarely indicated.

❖ AUTHORS' PREFERRED METHOD OF TREATMENT

Excision of the ulnar anlage is reserved for children with progressive ulnar deviation of the wrist. The anlage may be resected at the same time as hand reconstruction, usually at around 1 year of age. Humeral rotational osteotomy is reserved for children who are impaired by inability to reach their hand to the

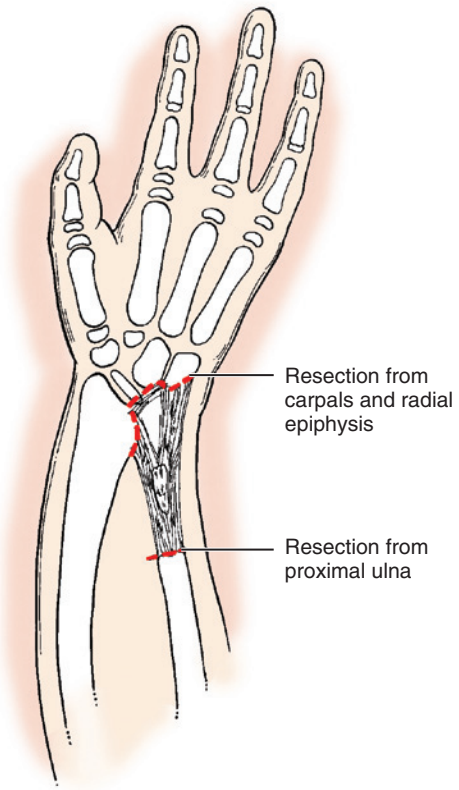

FIGURE 38.15 Excision of the ulnar anlage. This may prevent further ulnar deviation of the hand.

midline or to their face and head. Surgery is performed after children are old enough to evaluate their ability to perform activities of daily living. This age allows additional determination of the optimal limb position for function.

CRITICAL POINTS *Ulnar Deficiency*

- Ulnar deficiencies are associated with other musculoskeletal abnormalities that warrant careful physical examination supplemented by radiographs (e.g., congenital scoliosis).
- The forearm is difficult to manage and treatment should be individualized. Treatment is dependent on forearm stability, available elbow motion, and function. Surgery to restore motion for synostosis across the elbow or forearm (or both) is unsuccessful.
- Ulnar deficiencies may be accompanied by thumb anomalies ranging from a narrow web space to an absent thumb, which are a major predictor of function. The thumb deficiency limits prehensile activity and is treated by principles similar to those for isolated thumb hypoplasia.

Expected Outcomes

Children with unilateral ulnar deficiency generally function well, but those with radiohumeral synostosis, absent or stiff fingers, or bilateral deficiencies are more impaired.

MADELUNG DEFORMITY

Preoperative Evaluation

Madelung deformity consists of excessive radial and palmar angulation of the distal radius caused by a growth disturbance of the palmar and ulnar portion of the distal radial physis, although it may involve the entire radius.[138] The exact cause of this growth disturbance is still unknown. It may be due to a bony lesion in the ulnar portion of the distal radial physis and/or an abnormal palmar ligament tethering the lunate to the radius proximal to the physis (Vickers ligament) (Figure 38.17).[124] Madelung deformity is usually bilateral, and the deformity typically becomes clinically apparent in early adolescence. The underlying cause of this deformity is often Leri-Weill dyschondrosteosis, a genetic condition with a dominant inheritance pattern and 50% penetrance[79] that is due to a mutation in a short-stature homeobox-containing (*SHOX*) gene.[36] Repetitive loading of the wrist in a growing child may also cause partial physeal arrest. The resultant appearance is similar to Madelung deformity.[30]

The distal ulna of the affected wrist is dorsally prominent, and the distal radius appears to have a dorsal concavity in the lateral view (Figure 38.18). Ulnar deviation and extension may be decreased. The forearm is shorter than normal. Despite the clinical appearance, there is minimal functional impairment. In advanced cases, however, pain may limit function. Standard measurements have been established to characterize the severity of the deformity.[76]

Types of Operations

No treatment is necessary for painless deformities. However, physiolysis combined with release of the abnormal ligament should be considered for asymptomatic, skeletally immature patients. The most common motivation for surgery is appearance. Many patients dislike the distal forearm concavity and dorsal prominence of the distal ulna and request surgical correction.

A recalcitrant, painful deformity is an obvious indication for treatment. Physiolysis combined with release of the Vickers ligament[124] may reduce the pain and gradually improve the deformity during growth. However, most patients do not complain of pain until adolescence, when there is insufficient growth remaining for physiolysis to correct the deformity. In these instances, physiolysis and ligament resection may be combined with ulnar epiphyseodesis and/or a dome osteotomy of the radius.[48] In a skeletally mature patient with wrist pain, there are multiple options for correction of the deformity and relief of pain, including (1) ligament resection and dome osteotomy,[48] (2) radial closing wedge osteotomy and ulnar shortening,[95] (3) radial opening wedge osteotomy,[29] (4) radial osteotomy and distal ulnar resection,[95,128] and (5) radial osteotomy and the Sauvé-Kapandji procedure.[106]

For complex deformities in skeletally mature patients, three-dimensional modeling may be helpful to plan correction using multiple osteotomies. This technique is still in its early stages of development, but it seems to allow more precise correction than standard osteotomy techniques. To date, there is only one case report in the literature of using three-dimensional computer simulated bone modeling in Madelung deformity.[53]

Physiolysis

The radius is approached through a longitudinal palmar incision (Figure 38.19).[124] Exposure proceeds ulnar to the palmaris longus and flexor carpi radialis tendons to protect the radial artery and median nerve. The distal edge of the pronator

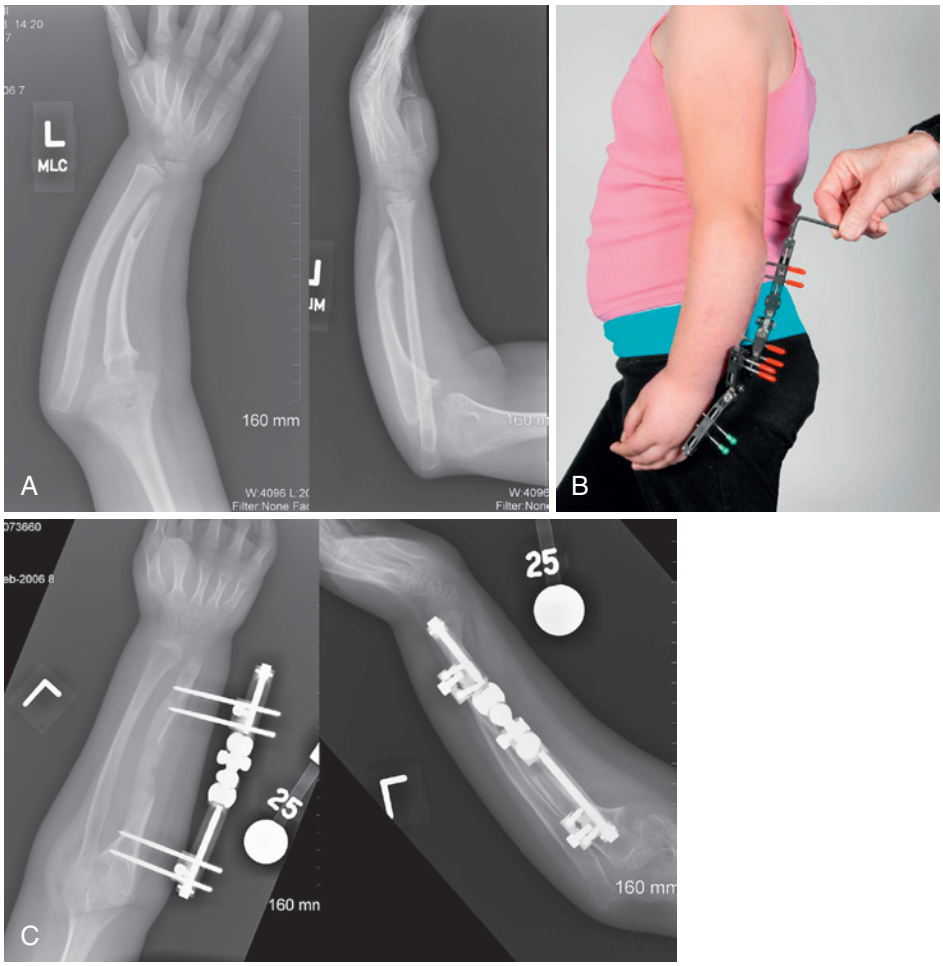

FIGURE 38.16 Ulnar lengthening for ulnar deficiency. **A,** Preoperative radiographs demonstrating significant dislocation of the radial head. **B,** Uniplanar external fixator in place. **C,** Postoperative radiographs demonstrating bone regeneration through the osteotomy site, with improved position of the radial head. Complete reduction of the radial head was not attempted given the long-standing nature of the deformity.

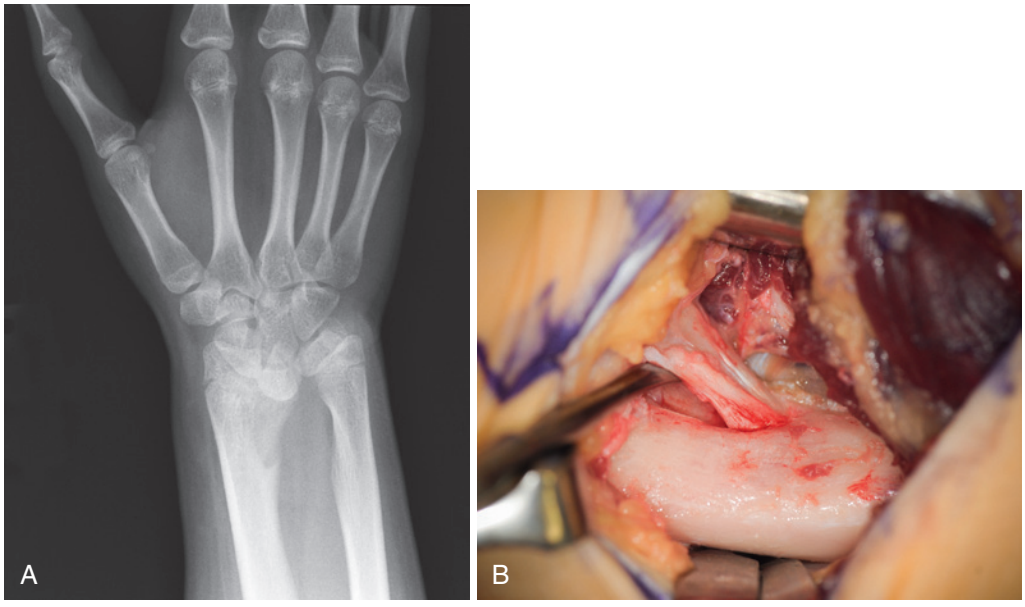

FIGURE 38.17 Seventeen-year-old female with Madelung deformity and prominent ulna. **A,** X-ray with increased radial inclination and ulnar-positive variance. Note radiolucency in the metaphysis of the radius consistent with the presence of a Vicker ligament. **B,** Operative findings with a markedly thickened Vicker ligament. (Courtesy of Shriners Hospital for Children, Philadelphia.)

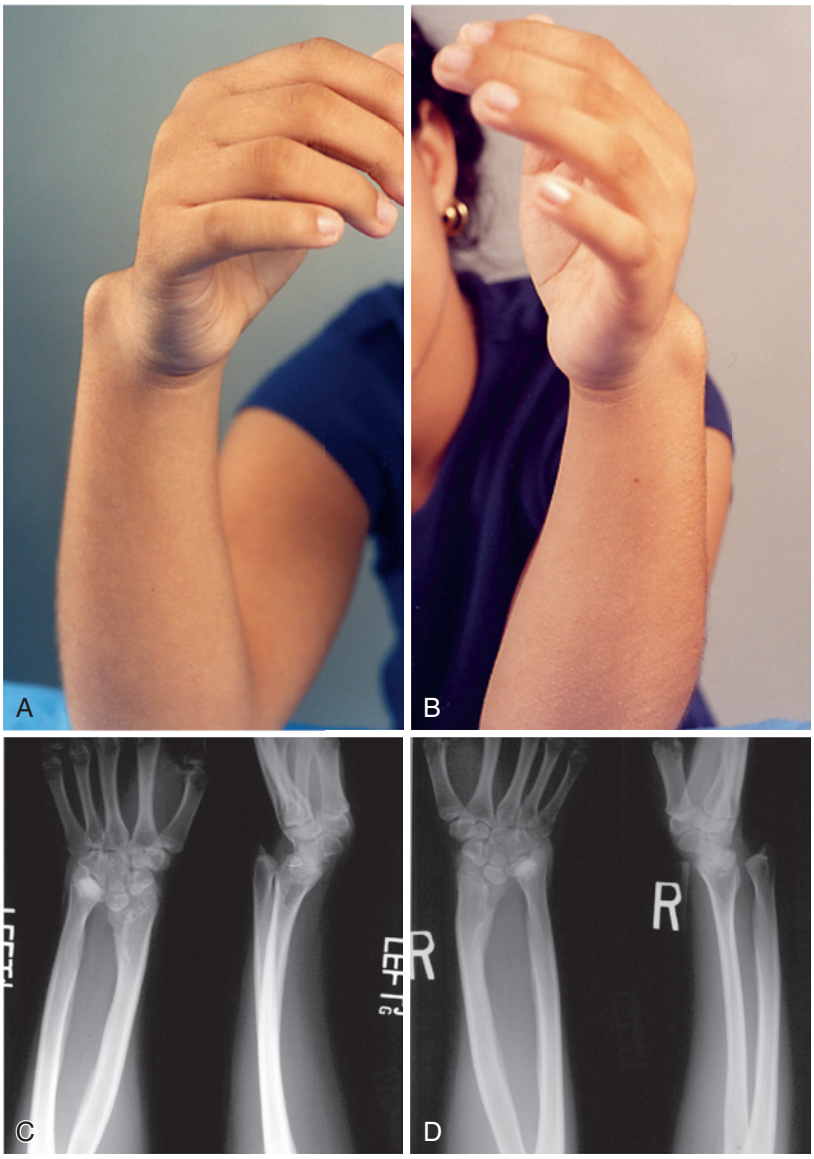

FIGURE 38.18 Bilateral Madelung deformity in a 14-year-old. **A,** Right wrist with the hand palmar and pronated with respect to the long axis of the forearm. The distal ulna appears prominent dorsally. **B,** Left wrist with similar clinical features. **C,** Anteroposterior and lateral x-rays of the left wrist and forearm showing increased radial inclination and the ulna positioned dorsal relative to the distal radius. **D,** Right wrist x-rays with similar radiographic findings. (Courtesy of Shriners Hospital for Children, Philadelphia.)

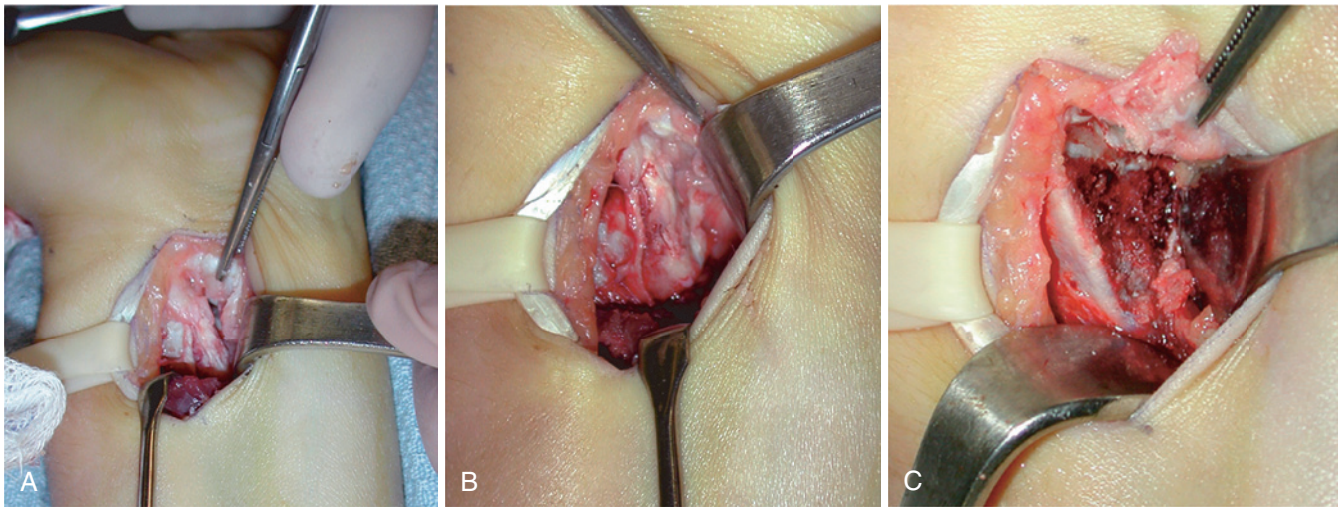

FIGURE 38.19 Early Madelung deformity treated by physiolysis and fat grafting. **A,** Palmar approach. **B,** Vickers ligament identified (*in forceps*). **C,** Ligament released. (Courtesy of Shriners Hospital for Children, Philadelphia.)

quadratus muscle is located. A flap of distal radial periosteum that includes the Vickers ligament is raised in a proximal to distal direction. The flap is elevated until the physis is identified, which appears narrow and wavy. The lunate is carefully protected. Any tethering fibrous tissue and bone about the physis are removed. A fat graft may be inserted into any physeal defect to inhibit bone formation. The fat graft is held in place by the surrounding soft tissue. The skin is closed with running absorbable suture, and the forearm is immobilized in a bulky compressive dressing with a removable wrist splint. A similar procedure can be done dorsally for reverse Madelung deformity.

Physiolysis and Dome Osteotomy

A longitudinal palmar incision is made starting just proximal to the wrist crease along the flexor carpi radialis tendon (Figure 38.20).[48] The radial artery is protected, and the pronator quadratus is incised near its radial border while leaving a cuff of tissue for later repair. Ulnar reflection of the pronator quadratus reveals the Vickers ligament, which is released from the radial metaphysis and reflected distally. The metaphysis of the distal radius is exposed. A biplanar dome osteotomy is performed with curved osteotomes or a curved oscillating saw. The dome osteotomy can be convex like a smile or concave like a frown depending upon surgeon preference. The distal radius fragment is manipulated from an anterior ulnar position to a dorsal ulnar position. The dome shape of the osteotomy makes this complex three-dimensional deformity easier to correct than with a simple wedge osteotomy. A Steinmann pin may be used as a joystick to position the distal fragment. The distal fragment is pinned to the proximal fragment after coverage of the lunate has been achieved. Definitive fixation can be accomplished by

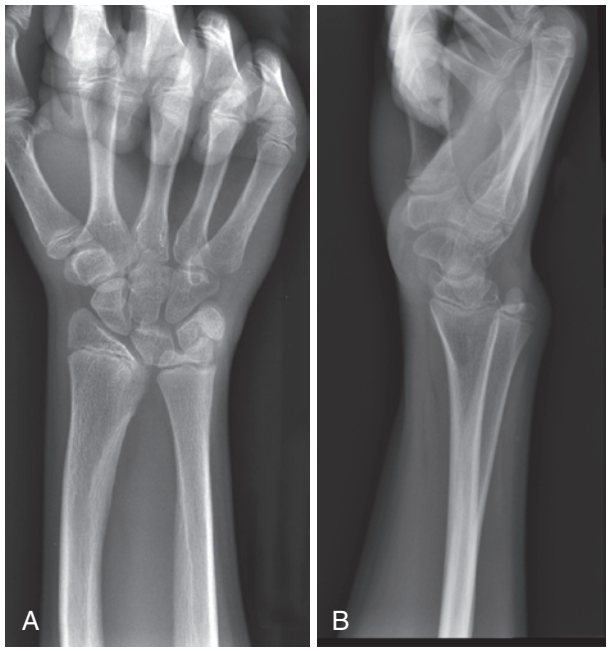

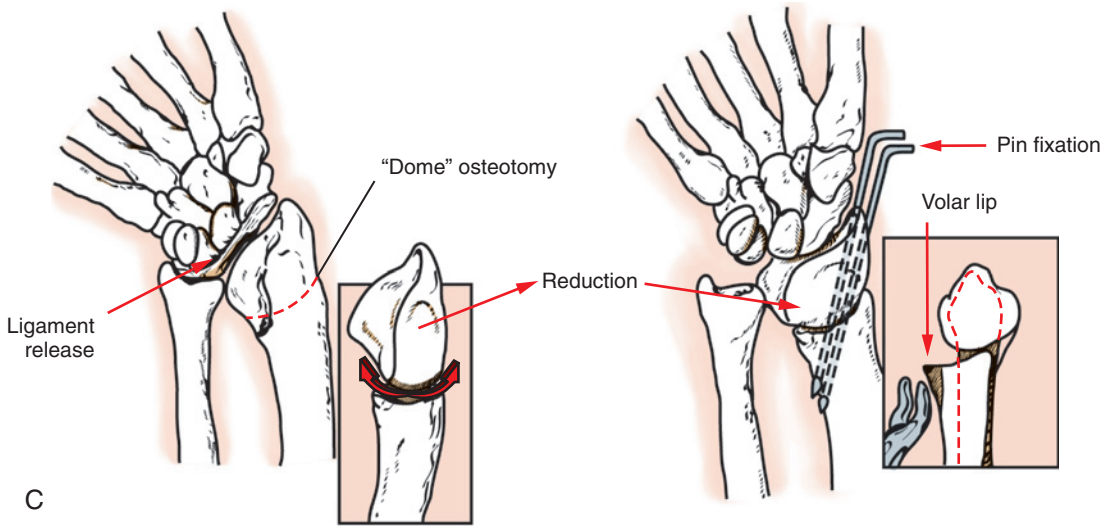

FIGURE 38.20 Eleven-year-old with Madelung deformity. **A,** Anteroposterior x-ray. **B,** Lateral x-ray. **C,** Technique of ligament release and dome osteotomy.

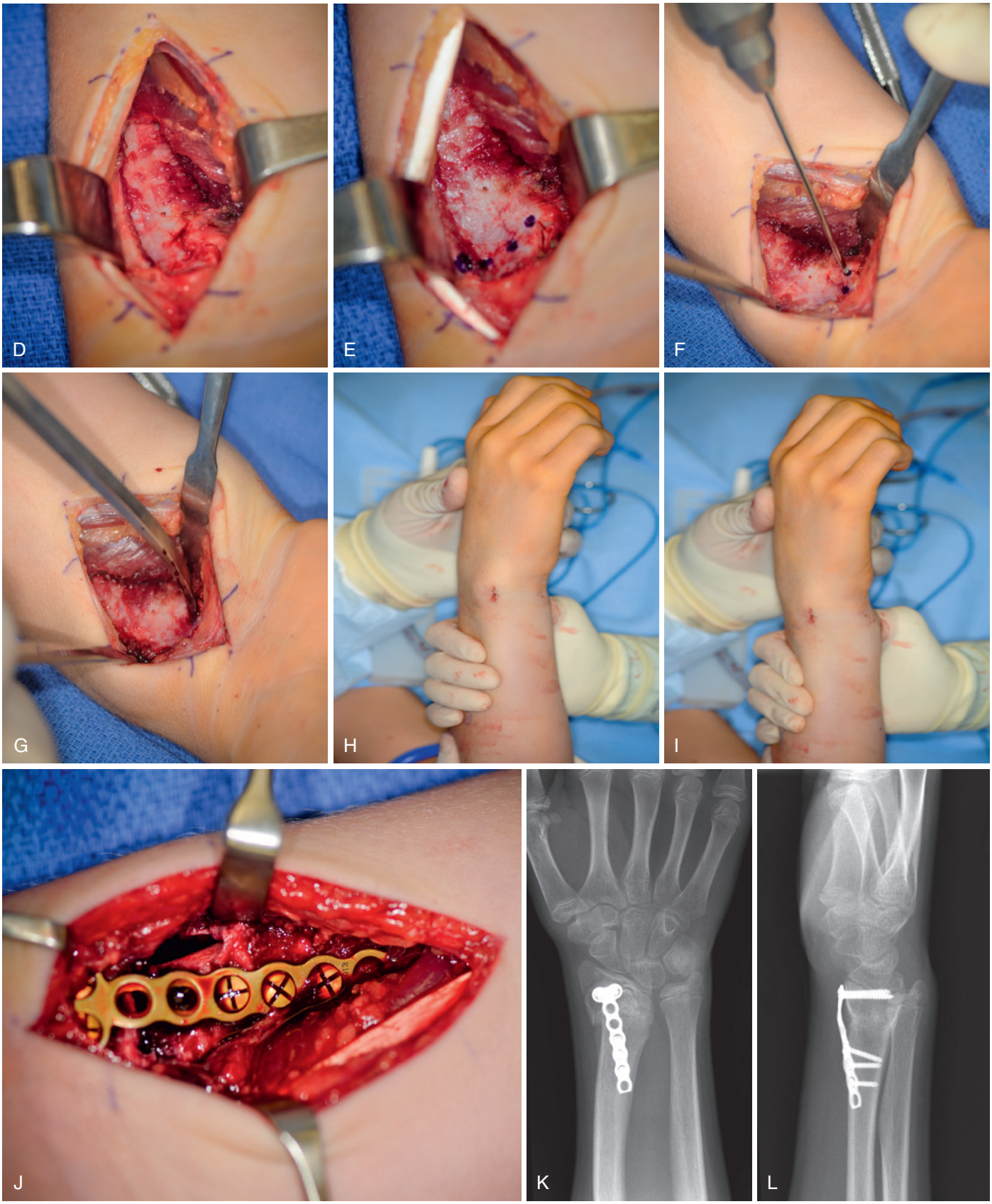

FIGURE 38.20, cont'd **D,** Exposure of volar radius. **E,** Dome configuration. **F,** Kirschner wire perforation. **G,** Osteotome. **H,** Before correction. **I,** After correction. **J,** Plate and screw fixation. **K,** Postoperative anteroposterior x-ray with improved coronal alignment. **L,** Postoperative lateral x-ray with improved sagittal alignment. (Courtesy of Shriners Hospital for Children, Philadelphia.)

two parallel pins inserted from the radial styloid across the osteotomy site or a plate and screw construct contoured across the osteotomy. The palmar step-off of the proximal fragment is removed with a rongeur; the dorsal step-off will remodel after the osteotomy heals. If possible, the pronator is repaired. The subcutaneous tissue and skin are closed with absorbable suture. A long-arm splint or cast is applied. The pins are removed after 6 weeks, and the osteotomy is protected for an additional 4 to 6 weeks with a removable splint.

Dorsal Closing Wedge Osteotomy of the Distal Radius and Ulnar Shortening

The size and shape of the radial wedge osteotomy are planned according to the preoperative radiographs and amount of deformity.[95] The goal is to restore palmar and radial tilt. The osteotomy is performed at the point of maximum angulation through either a dorsal or volar approach. Plate fixation is preferred. The ulna is shortened with standard techniques. The goal is to obtain a neutral or slight ulnar-minus variance. Dynamic compression plate fixation is preferred.

Multiple Osteotomies Using Three-Dimensional Modeling

Three-dimensional imaging of the deformity is most easily achieved via computed tomography (CT) scanning with three-dimensional reconstruction. Because bilateral involvement is typical of the Madelung deformity, the use of the contralateral wrist as a model for comparison can be difficult. If the contralateral wrist is asymptomatic and not severely affected, it can be used as the comparison model. Other options for comparison models include generic bone models and those of prior patients. Using the appropriate computer software, the three-dimensional models of the affected bone are superimposed onto the goal model and osteotomies planned. From these data, physical bone models are fabricated using three-dimensional printing techniques, along with customized guides to assist with plate and screw placement and the pre-planned osteotomy sites.

Radial Opening Wedge Osteotomy

See the work of de Paula and colleagues.[29]

Distal Radial Osteotomy and Distal Ulnar Resection

See earlier for distal radial osteotomy, and see Watson and associates for details of distal ulnar resection.[128]

Distal Radial Osteotomy and the Sauvé-Kapandji Procedure

See earlier for distal radial osteotomy and Shroven and colleagues for details of the Sauvé-Kapandji procedure.[106]

❖ AUTHORS' PREFERRED TECHNIQUE

Physiolysis alone may provide satisfactory correction in a young patient with early Madelung deformity (Figure 38.21). However, when initially seen, most patients have considerable deformity and limited growth potential. Physiolysis combined with dome osteotomy is the most common procedure for mild to moderate deformity without distal radioulnar joint (DRUJ) degeneration. This can be done prior to skeletal maturity using smooth pins for fixation. Osteotomy of the radius in conjunction with some form of ulnar resection is warranted in older patients with DRUJ arthritis.

CRITICAL POINTS *Madelung Deformity*

- Madelung deformity is characterized by radial and palmar angulation of the distal radius caused by a growth disturbance in the palmar and ulnar portion of the distal radial physis (Figure 38.22).
- The growth disturbance may be due to a combination of a bony lesion in the ulnar portion of the distal radial physis and an abnormal palmar ligament tethering the lunate to the radius proximal to the physis (Vickers ligament).
- No treatment is necessary for a painless deformity. However, asymptomatic skeletally immature patients with progressive deformity should be considered for physiolysis and release of the abnormal ligament.
- Most patients are first seen in adolescence with limited growth potential and considerable deformity. In these cases, physiolysis and ligament resection are combined with osteotomy to realign the radius.

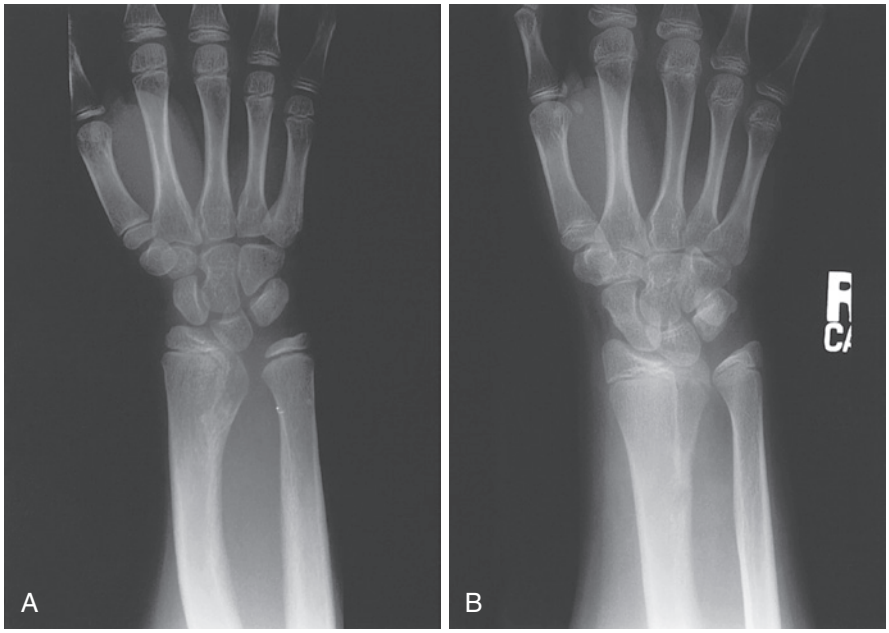

FIGURE 38.21 **A,** Preoperative radiograph showing Madelung deformity of the right wrist of a skeletally immature girl. **B,** Postoperative film of the same wrist 28 months after physiolysis. Longitudinal growth has been restored, and there has been no increase in deformity.

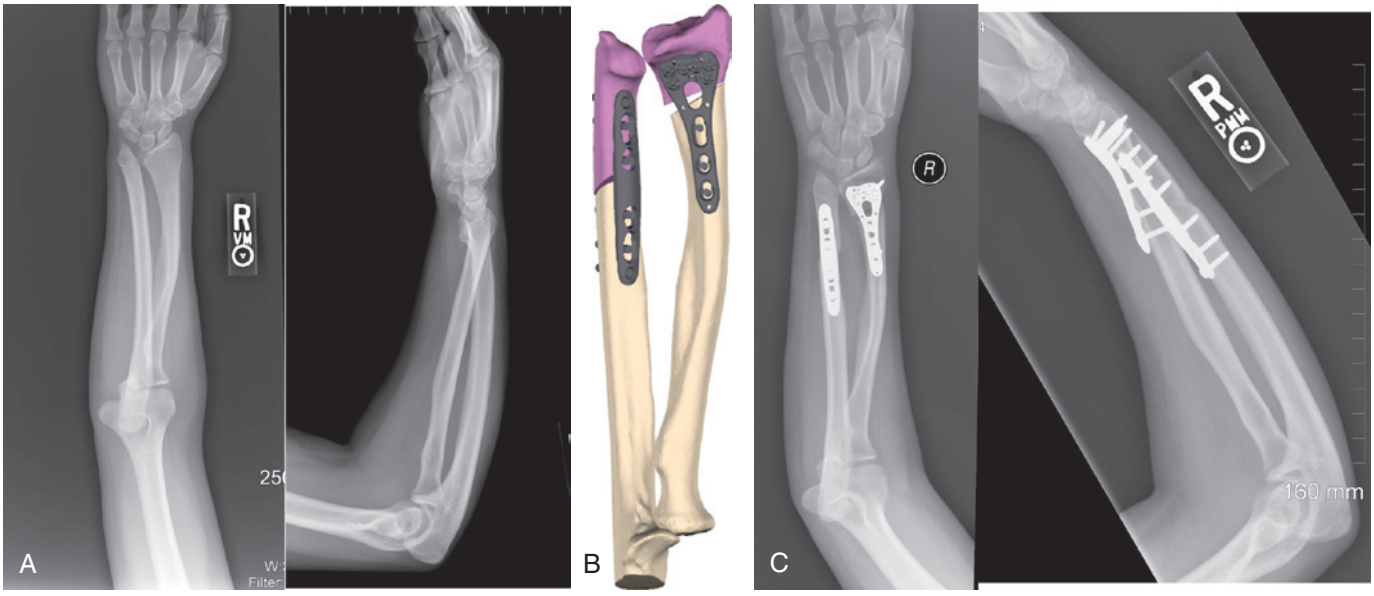

FIGURE 38.22 **A,** Preoperative radiograph showing severe Madelung deformity of the right wrist of a skeletally mature girl. **B,** Preoperative computer model demonstrating planned correction of the radius and ulna. **C,** Postoperative radiographs. (Courtesy of Shriners Hospital for Children, Northern California.)

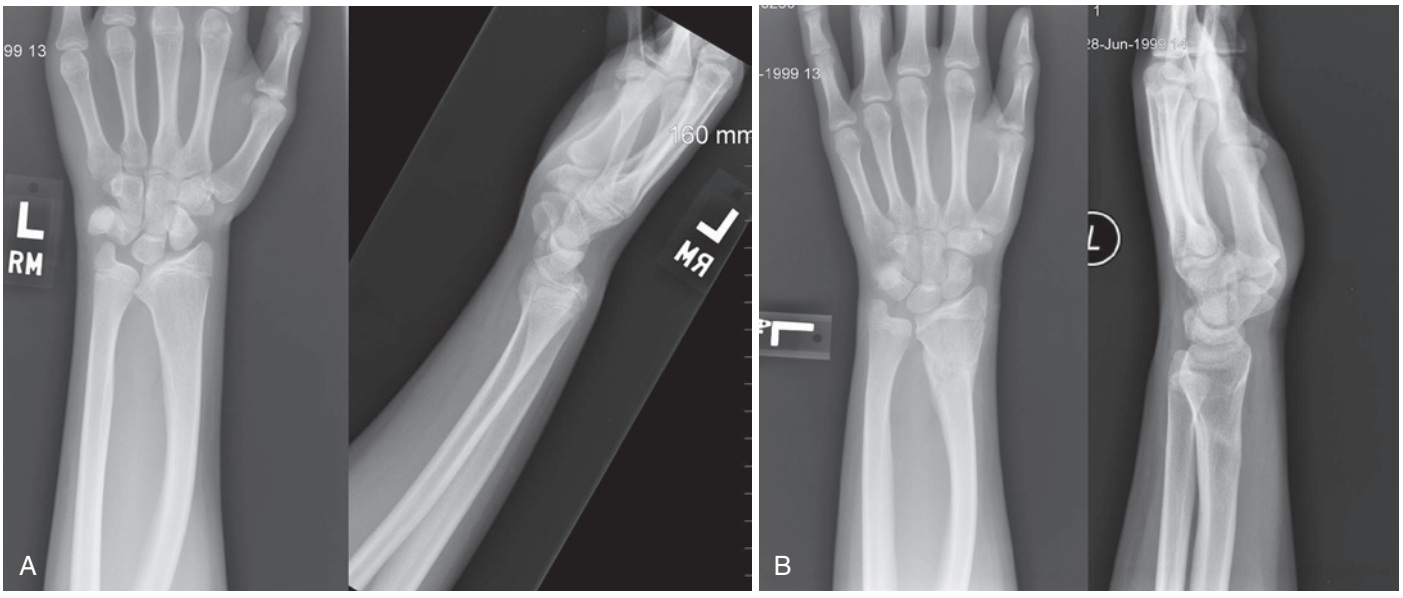

FIGURE 38.23 **A,** Preoperative Madelung's deformity. **B,** Postoperative correction with a dome osteotomy through the distal radial metaphysis. (Courtesy of Shriners Hospital for Children, Northern California.)

Expected Outcomes

Physiolysis alone is unlikely to yield satisfactory correction except in young patients with mild deformity. In most cases, dorsal wrist pain is relieved by distal radial osteotomy and DRUJ pain by ulnar shortening, with several reports of good long-term results.[95] Both dome osteotomy and closing wedge radial osteotomy improve appearance by reducing the dorsal concavity associated with Madelung deformity (Figure 38.23). Ulnar shortening reduces the dorsal distal ulnar prominence. Three-dimensional modeling can be used to create a patient-specific plan of multiple osteotomies for precise correction of this complex deformity.

TRANSVERSE DEFICIENCY

Evaluation

Transverse deficiency, often inaccurately termed *congenital amputation*, occurs when the upper limb fails to form below a certain level. The most common level of failure of formation is at the proximal part of the forearm or below the elbow (Figure 38.24), followed by transcarpal, distal forearm, and through-humerus (above-elbow) failure. This condition is almost always unilateral.[134] In the previous edition of this chapter, this condition was referred to as "transverse failure of formation." It is now more commonly referred to as transverse deficiency and



FIGURE 38.24 A child with a right short, below-elbow transverse deficiency. (Courtesy of Shriners Hospital for Children, Northern California.)

categorized as a failure of axis formation or differentiation of the entire upper limb.[87]

Transverse deficiency is sporadic. The most prevalent theory of causation is vascular compromise of the developing limb bud or apical ectodermal ridge (see Chapter 35).[50] Risk factors include maternal use of misoprostol (Cytotec), alcohol, tobacco, or cocaine, as well as low maternal intake of riboflavin.[25,35,40,71,100] but for most cases the cause is unknown.

PERTINENT ANATOMY

The diagnosis is readily apparent, although there is variability in the length of the residual limb. The most common transverse deficiency is at the level of the proximal forearm. The elbow generally has full flexion and extension. Forearm rotation is frequently restricted by proximal radioulnar abnormalities. Finger nubbins are usually present at the distal end of the limb, which may be evidence of an intrauterine attempt at limb regeneration.[41] Elbow and forearm radiographs should be obtained.

Types of Operations

Some parents want their infant's nubbins removed, but older children with nubbins rarely request this procedure. Children with nubbins use them for sensory feedback and manipulation of small, light objects. Some surgeons remove these nubbins routinely, arguing that the resulting stump is more aesthetically pleasing and easier psychologically for the family, but this is not our current practice. We believe removal of finger nubbins from the distal end of the amputation stump is not indicated unless they frequently become infected or the small nails become problematic.

There have been isolated reports of forearm lengthening for transverse below-elbow deficiency.[2] However, this procedure has a high complication rate and has not been proven to help with function.

The Krukenberg procedure may be indicated in rare instances. The radius and ulna are separated and the muscles reattached such that the radius pinches against the ulna. This procedure is traditionally reserved for blind bilateral distal forearm amputees because it provides unilateral prehension with sensory feedback. However, it may occasionally be indicated for a sighted child with below-elbow deficiency and a long forearm.[64,68] To date there are few published data regarding functional improvements after this procedure, and the appearance of the Krukenberg forearm is strikingly abnormal.

Great improvements have been made in hand transplantation, such that more than 70 hand transplants have been performed for adults with upper extremity amputations due to trauma.[85] Parents of children with congenital limb deficiency may ask about this procedure. At this time, hand transplantation is contraindicated for children with transverse deficiency. They are unlikely to have formed muscles to move a transplanted hand, and the risks of prolonged immunosuppressive medications outweigh the potential benefits, as their level of functioning is extremely high.

❖ AUTHORS' PREFERRED TECHNIQUE

The greatest challenge in the treatment of children with transverse deficiency is helping parents adjust their often unrealistically high expectations of prosthetic technology. Good communication is important and should focus on numerous areas, including the remarkable abilities of the child with or without the prosthesis (Figure 38.25), the opportunity to try different prostheses as the child grows, and the need for improved prosthetic technology. Surgery is rarely required.

CRITICAL POINTS *Transverse Deficiency*

- Congenital transverse deficiency is classified according to the last remaining bone segment. A short below-elbow type of failure of formation is the most common transverse deficiency of the upper extremity.
- The residual limb is usually well cushioned, with rudimentary nubbins or dimpling often found on the end.
- These anomalies are generally unilateral, sporadic, and rarely associated with other anomalies.
- Prostheses have not been found to improve performance of everyday activities.
- Surgery is not usually indicated.

Expected Outcomes

Cognition and developmental milestones are generally normal, except that a child with a very short arm may not crawl. Children with unilateral below-elbow transverse deficiencies have few if any functional deficits. Prostheses do not improve performance of everyday activities[54] and are frequently abandoned.[28] Specialized prostheses may assist in the performance of higher-level activities, such as mountain bike riding or playing a violin.



FIGURE 38.25 Eight-year-old competitive swimmer with right below-elbow transverse deficiency. **A,** Clinical picture. **B,** Swimming prosthesis to facilitate competition. (Courtesy of Shriners Hospital for Children, Philadelphia).

CONGENITAL DISLOCATION OF THE RADIAL HEAD

Preoperative Evaluation

Congenital dislocation of the radial head (CDRH) is the most common congenital anomaly of the elbow and is usually bilateral.[97] CDRH may be sporadic or familial, but its cause is unknown. The radial head may be dislocated in an anterior, posterior, or lateral direction. Almquist and coworkers reported that 47% of dislocations are anterior, 43% are posterior, and 10% are lateral.[4] About 60% of congenital radial head dislocations are accompanied by other upper extremity congenital anomalies, whereas the remaining 40% are isolated findings.[81] CDRH is associated with congenital radioulnar synostosis[81] and numerous syndromes, including Klinefelter, Cornelia de Lange, Ehlers-Danlos, and nail-patella syndromes.

A delay in medical evaluation is common with CDRH. The lack of forearm rotation is unrecognized until the complexities of daily activities amplify the problem, such as catching a ball or eating soup. CDRH is often recognized after a perceived elbow injury and may be erroneously attributed to that injury. When unilateral, CDRH may be difficult to distinguish from chronic traumatic dislocation (Table 38.5).[65] The initial complaint usually involves prominence and restricted elbow and forearm motion. Elbow "popping" or pain with activity is uncommon before adolescence. Magnetic resonance imaging (MRI) can be helpful in distinguishing CDRH from a traumatic dislocation. In CDRH, the radial head generally remains intracapsular, whereas in a traumatic radial head dislocation, the radial head usually tears through the elbow joint capsule. Additionally, the shapes of the cartilaginous radial head and capitellum can be assessed using MRI. In CDRH, the radial head is generally convex instead of concave, and the capitellum is hypoplastic and ovoid instead of round.

TABLE 38.5 Congenital Versus Traumatic Radial Head Dislocation

Feature	Congenital	Traumatic
Trauma	Sometimes	Always
Radial head	Dome shaped, no central concavity (anterior dislocation) Elongated and narrow (posterior dislocation)	Normal shape with a concavity
Bilateral	Common	Rare
Other anomalies	Common	Rare
Ulna	Shortened; possible palmar bow (anterior dislocation) or dorsal bow (posterior dislocation)	Normal
Capitellum	Hypoplastic or absent	Normal

Data from Mardam-Bey T, Ger E: Congenital radial head dislocation. *J Hand Surg [Am]* 4:316–320, 1979; and Kelly DW: Congenital dislocation of the radial head: spectrum and natural history. *J Pediatr Orthop* 1:295–298, 1981.

An anteriorly dislocated radial head is palpable just distal to the cubital fossa, whereas a posteriorly dislocated radial head is palpable and visible lateral to the capitellum. Posterior CDRH usually impedes terminal extension (≤30 degrees), and anterior CDRH may limit full flexion (Figure 38.26). Diminished forearm rotation in both pronation and supination is common. Slight limitation of wrist motion may be present.



FIGURE 38.26 Seven-year-old with bilateral posterolateral radial head dislocation. **A,** Clinical picture. **B,** Prominent radial head. **C,** Lack of full elbow extension and restricted forearm supination. (Courtesy of Shriners Hospital for Children, Philadelphia.)

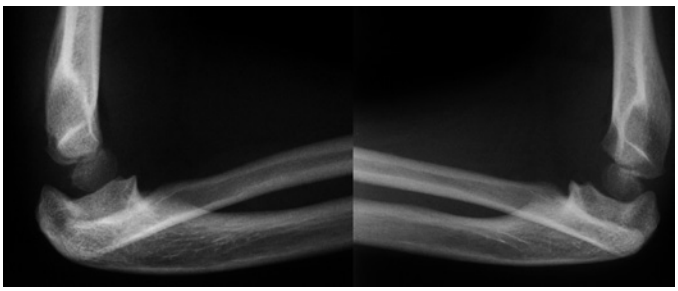

FIGURE 38.27 Lateral x-rays of a 7-year-old confirming bilateral posterolateral radial head dislocation. (Courtesy of Shriners Hospital for Children, Philadelphia.)

The limitation of elbow and forearm motion rarely causes considerable functional impairment. Certain activities that require the extremes of motion may be limited, such as accepting change and performing push-ups. In older children, erosions may develop between the radial head and capitellum and cause pain and additional loss of motion.

The diagnosis is generally confirmed by radiography (Figure 38.27). A line drawn through the longitudinal axis of the radial shaft does not bisect the capitellum. The radial head is dome shaped. The ulna bows, depending on the direction of the radial head dislocation. With anterior dislocations, the ulna bows into extension, whereas posterior dislocations cause a bow into flexion. Similar bowing, however, also occurs with unreduced Monteggia fracture-dislocations. Additional radiographic findings include dysplasia of the capitellum and ulnar-positive variance of the wrist.

Types of Operations

Surgical intervention is seldom necessary in childhood. Most children are asymptomatic and have minimal functional limitations.[31] Open reduction of a congenitally dislocated radial head with reconstruction of the annular ligament has not been consistently successful[4,81,104] and is not recommended at this time.

Radial Head Resection

In adolescence or adulthood, a dislocated radial head may become painful because of degenerative changes at the point of contact between the radial head and the distal humerus. This is the best indication for resection of the radial head, although appearance and limited forearm rotation are relative indications. In a small series with an average 10-year follow-up after surgery, Bengard and colleagues demonstrated that 25% of patients who underwent radial head excision for CDRH developed wrist pain requiring additional surgery.[11] For this reason, we recommend that radial head excision be reserved for patients with significant elbow pain, and that the operation be delayed until skeletal maturity whenever possible.

Excision of the radial head in posterior CDRH is performed using an approach through the interval between the extensor carpi ulnaris and the anconeus (Kocher approach) or directly over the prominent radial head (Figure 38.28). The capsule is incised with the forearm in maximum pronation. The capsular incision is not extended distal to the radial neck to avoid injuring the posterior interosseous nerve. Reverse retractors are placed around the radial neck. The radial head is excised with a saw perpendicular to the radial neck (Figures 38.29 and 38.30). The elbow is moved through a full range of motion to make sure that the proximal radius does not contact the distal humerus. Additional impingement requires further resection. The capsule is closed with nonabsorbable suture (Figure 38.31). The subcutaneous tissue and skin are closed, and the arm is placed in a long-arm splint with the elbow at 90 degrees and the forearm in neutral rotation for 7 to 10 days.



FIGURE 38.28 Lateral incision just anterior to the lateral epicondyle and extending in a distal direction over the radial head. A Freer elevator indicates the Kocher interval between the extensor carpi ulnaris and the anconeus. (Courtesy of Shriners Hospital for Children, Philadelphia.)

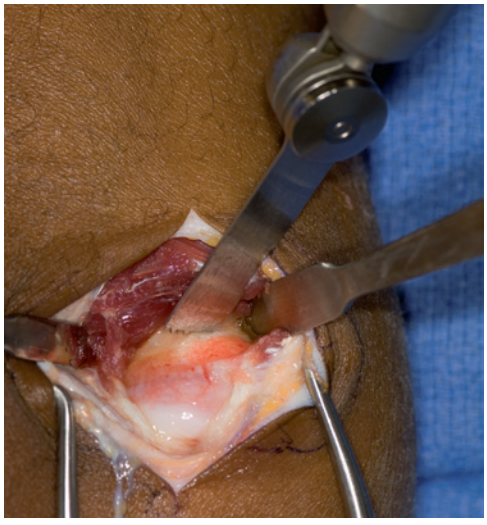

FIGURE 38.29 A longitudinal arthrotomy is performed to expose the radial head and neck. The radial head is excised with a saw perpendicular to the radial neck. (Courtesy of Shriners Hospital for Children, Philadelphia.)

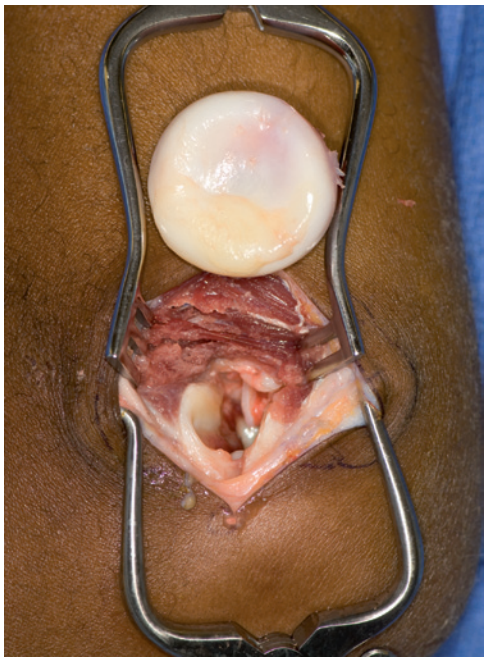

FIGURE 38.30 Radial head removed after osteotomy of the radial neck. (Courtesy of Shriners Hospital for Children, Philadelphia.)

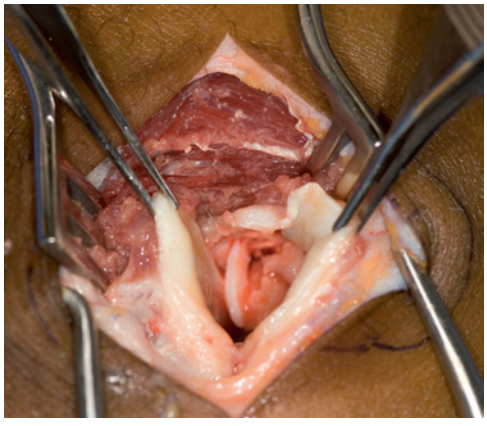

FIGURE 38.31 The capsule is carefully closed with nonabsorbable suture. (Courtesy of Shriners Hospital for Children, Philadelphia.)

❖ AUTHORS' PREFERRED METHOD OF TREATMENT

Because young children with CDRH are relatively asymptomatic, most cases are managed by observation. Open reduction with soft tissue reconstruction of the annular ligament to maintain the reduction is unreliable, frequently complicated by recurrent radial head dislocation and elbow stiffness. Although the newer literature on combining radial head reduction with corrective ulnar osteotomy, as done for chronic Monteggia fracture-dislocations, is intriguing, this procedure has yet to be proved effective for CDRH. The most unpredictable variable is the shape of the radial head. Even though MRI and arthrography may help assess head shape, it is difficult to maintain a reduction when the radial head is ovoid. In adolescents, pain and further restriction of motion may occur because of degenerative changes between the radial head and the distal humerus. Radial head excision reliably relieves pain, improves the appearance, and may increase the range of motion, although it may be complicated by wrist pain caused by incompetence of the interosseous membrane.

Expected Outcomes

Radial head excision for the treatment of CDRH reliably results in decreased elbow pain and improved rotation.[15] Complications include regrowth of the proximal radius, postoperative radioulnar synostosis, and cubitus valgus deformity.[15,62] Other potential complications include injury to the posterior interosseous nerve, proximal migration of the radius (Essex-Lopresti lesion), and wrist pain.[4,11,15]

PROXIMAL RADIOULNAR SYNOSTOSIS

Preoperative Evaluation

Congenital proximal radioulnar synostosis (PRUS) is an uncommon anomaly caused by failure of prenatal separation of

CRITICAL POINTS *Congenital Dislocation of the Radial Head*

- Dislocation of the radial head is usually bilateral. The radial head most commonly dislocates in an anterior or posterior direction. Lateral dislocation is less common.
- A delay in initial medical evaluation is frequent because the lack of forearm rotation is unrecognized until the complexities of daily activities amplify it, such as catching a ball or eating soup.
- The diagnosis is generally confirmed by radiography as the radial head fails to align with the capitellum. Other radiographic abnormalities include an ovoid shape of the radial head and hypoplasia of the capitellum.
- Surgery is seldom necessary in childhood. The limitation of elbow and forearm motion rarely causes considerable functional impairment.
- Open reduction of the radial head with reconstruction of the annular ligament has not been consistently successful. Ulnar distraction osteotomy may improve the odds of maintaining the reduction.
- In adolescence or adulthood, a dislocated radial head may become painful because of degenerative changes between the radial head and the distal humerus. Excision of the radial head reliably relieves pain and improves the appearance and may increase the range of motion, although it may cause wrist pain.

the radius and ulna, which normally occurs late in the first trimester.[103] PRUS is part of a spectrum of anomalies ranging from radial head abnormalities to complete synostosis and culminating in absence of the radial head.[103] PRUS may be sporadic or inherited as an autosomal dominant trait.[98] It is associated with other conditions in up to a third of affected children,[112] including thumb hypoplasia, carpal coalition, symphalangism, and clubfoot. Associated syndromes include Apert syndrome, arthrogryposis, fetal alcohol syndrome, and Klinefelter syndrome.[113]

Children with PRUS are usually seen initially between 2 and 6 years of age with painless absence of forearm rotation, the forearm fixed in pronation or supination (usually pronation), and a slight elbow flexion contracture (Figure 38.32).[112] Typically, a parent or teacher notices that the child has difficulty positioning the hand to catch a ball, drink from a cup, or accept small objects in an open palm or has trouble performing midline activities requiring the use of both hands (Figure 38.33). The delay in diagnosis is attributed to lack of requirement for forearm rotation in infants and the use of compensatory shoulder and wrist motion.[46,88] Forearm rotation must be assessed at the radial styloid and ulnar head to avoid measuring rotation through the radiocarpal, intercarpal, or carpometacarpal joints (Figure 38.34). Bilateral involvement is seen in approximately 60% of children, and the forearm is fixed in more than 60 degrees of pronation in approximately 40% of patients.[88,112] Children with bilateral involvement and forearms fixed in marked pronation have more functional limitations. In addition, PRUS is more often diagnosed during infancy in children whose arms are fixed in severe pronation and supination (Figure 38.35).

PRUS has been classified by Cleary and Omer into four types (Table 38.6). In children with PRUS and anterior dislocation of the radial head (type 4), an acute elbow flexion contracture may develop after either forced hyperflexion of the elbow or a prolonged period of flexion of the elbow,[73] possibly associated with an abnormal annular ligament–like structure.

PERTINENT ANATOMY

PRUS is initially cartilaginous and eventually ossifies, at which point it becomes visible on radiographs. The radial head may be dislocated. The synostosis is nearly always proximal, and the length of the synostosis varies.[103,112]

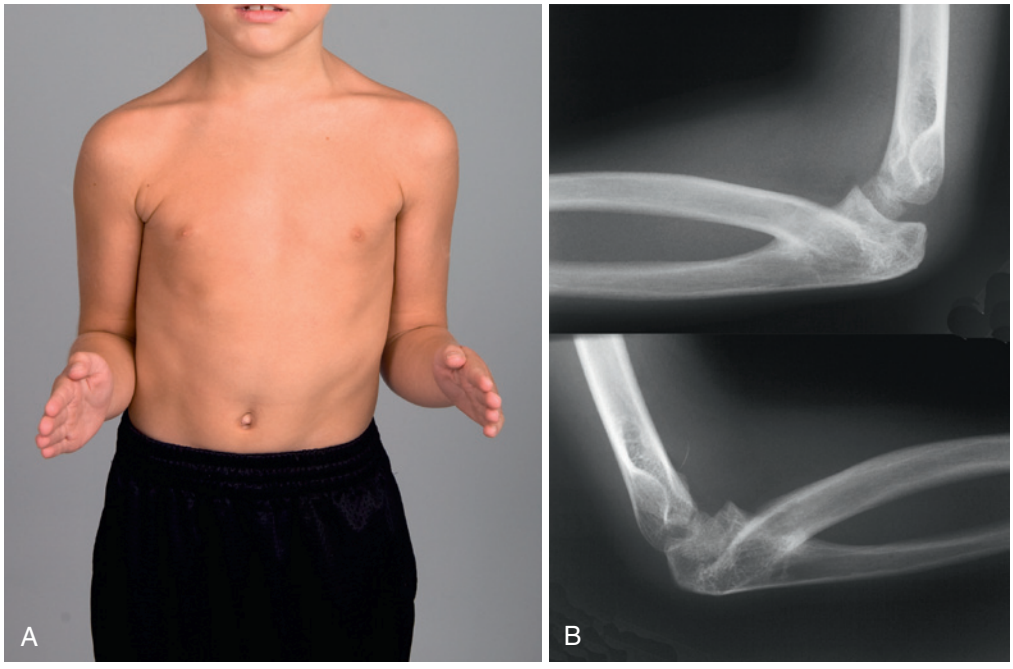

FIGURE 38.32 Seven-year-old with bilateral proximal radioulnar joint synostosis. **A,** Right forearm fused in neutral and left forearm fixed in slight pronation. **B,** X-rays confirming bilateral proximal radioulnar joint synostosis. (Courtesy of Shriners Hospital for Children, Philadelphia.)

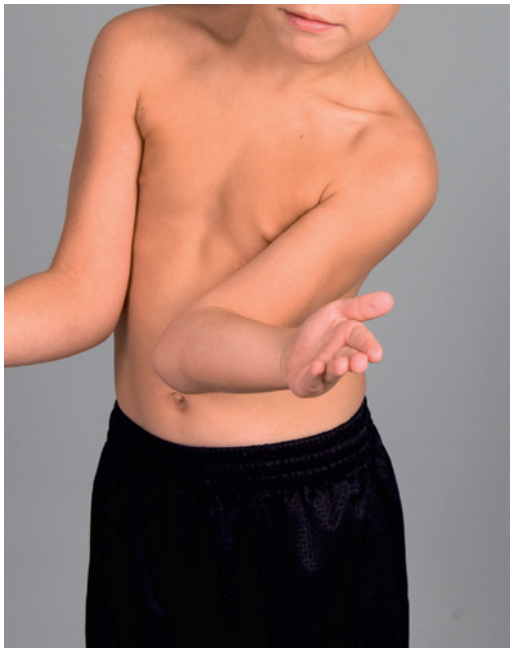

FIGURE 38.33 Shoulder adduction compensates for deficient supination during activities such as catching a ball. (Courtesy of Shriners Hospital for Children, Philadelphia.)



FIGURE 38.34 Forearm motion must be assessed at the distal radioulnar joint to avoid false interpretation of forearm movement. (Courtesy of Shriners Hospital for Children, Philadelphia.)

Types of Operations

Resection of Synostosis

Surgery to restore forearm rotation by resection of the synostosis has uniformly been unsuccessful.[82] A review of the literature showed that resection of the synostosis and mobilization of the forearm failed in 22 of 23 forearms.[60] Interposition of a free vascularized fascial flap between the separated forearm bones may prevent recurrence of the synostosis,[59,60,61] but the amount of forearm rotation gained is small.



FIGURE 38.35 One-year-old with left proximal radioulnar joint synostosis and extreme pronation that prohibits bringing the left hand to the mouth. (Courtesy of Shriners Hospital for Children, Philadelphia.)

TABLE 38.6 Classification of Proximal Radioulnar Synostoses

Type	Radiographic Findings
1	Synostosis does not involve bone; radial head reduced
2	Visible osseous synostosis; radial head reduced
3	Visible osseous synostosis; radial head hypoplastic and posteriorly dislocated
4	Short osseous synostosis; radial head anteriorly dislocated and mushroom shaped

Derotation Osteotomy

Fixed extreme pronation (>60 degrees) that interferes with function is an indication for derotation osteotomy[84,112]; unilateral PRUS does not usually cause sufficient functional impairment to warrant surgical repositioning. The timing of surgery is controversial. Recommendations vary from before school age to waiting for the child to choose an intended occupation.[112] The child's preoperative rotational position should be carefully measured and recorded. The optimal rotational position of the forearm is also controversial because the best position varies with the task. Preoperative evaluation by an occupational therapist can help determine the individual child's functional deficits and optimal forearm position. Recommendations for surgical treatment of lateral synostosis have been to place the dominant forearm in 10 to 20 degrees of pronation and the nondominant forearm in neutral rotation; with the increasing use of technology requiring bilateral forearm pronation, many surgeons will now place both forearms in slight pronation, however. For unilateral PRUS, the forearm is generally placed in 0 to 15 degrees of pronation.[112] A study of the optimal rotational position for a one-bone forearm indicated that 30 degrees of pronation provides the best function for writing and working with small objects with the dominant arm.[20] In cultures where supination

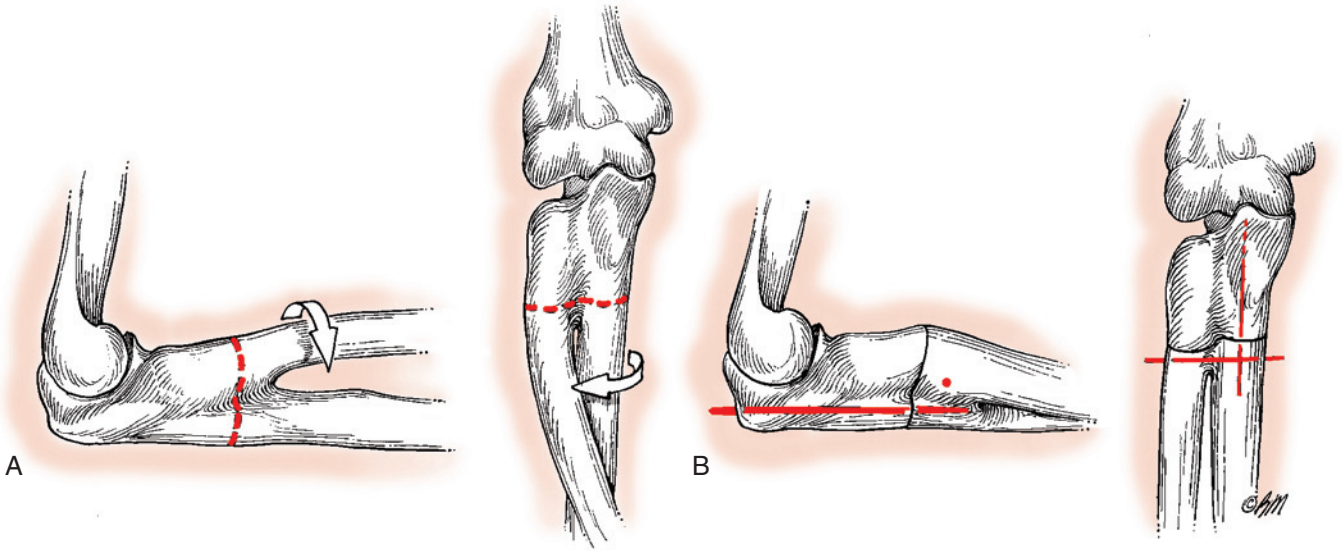

FIGURE 38.36 Rotational osteotomy for PRUS as described by Green and Mital. **A,** The desired position of rotation is attained by osteotomy through the synostosis mass. **B,** The new position is maintained by one longitudinal Kirschner wire and one transverse Kirschner wire that is incorporated into a cast. (Green WT, Mital MA: Congenital radioulnar synostosis: surgical treatment. *J Bone Joint Surg Am* 61:738–743, 1979.) (Copyright Elizabeth Martin.)

is more important for eating and hygiene, positioning the forearm in slight supination may be preferred.[111]

Derotation osteotomy is performed either through the fusion mass or through the proximal ulna and distal radius, and small Steinmann pins or a plate with screws is used for fixation (Figure 38.36).[46,82,88,112] Additional options include gradual correction with the Ilizarov method for severe deformity, two-stage osteoclasis without internal fixation, and osteotomy with bone morselization and cast immobilization.[13,34,70,84] If the desired amount of derotation is less than 30 degrees, an osteotomy at the distal radius alone may suffice.

A dorsal longitudinal incision is made along the subcutaneous border of the ulna at the level of the synostosis (Figure 38.37). The fusion mass is identified between the extensor and flexor carpi ulnaris muscles. Subperiosteal dissection is performed around the synostosis. A smooth Steinmann pin is placed from a percutaneous position through the olecranon apophysis into the intramedullary canal of the ulna under fluoroscopic guidance (Figure 38.38). The pin is positioned just proximal to the planned osteotomy site. A longitudinal mark is made across the osteotomy site to determine rotation. The osteotomy is performed with an oscillating saw through the fusion mass and distal to the coronoid process (Figure 38.39). The forearm is then rotated to the desired position. The osteotomy is transfixed with the longitudinal pin and an additional oblique pin (Figure 38.40). After closing the wound, the arm is placed in a splint or long-arm cast with the elbow flexed to 90 degrees. X-rays are taken to confirm fixation (Figure 38.41). The patient is admitted to the hospital overnight for strict elevation and neurovascular monitoring to check for compartment syndrome. The cast and pins are removed after bony union.

A substantial change in forearm rotation may result in traction injury to the posterior interosseous nerve or compartment syndrome. Methods to diminish neurovascular problems have been proposed, including resection of 5 mm of bone from the osteotomy site and prophylactic forearm fasciotomy.[18,88] Gradual sequential correction of severe forearm malposition with a two-stage osteoclasis technique[70,112] may also reduce this risk. One advantage of the procedure described above is that the oblique pin can be removed at bedside and the position of forearm rotation adjusted to diminish nerve traction; the morselization procedure also allows the position to be adjusted without reoperation if urgently indicated postoperatively.

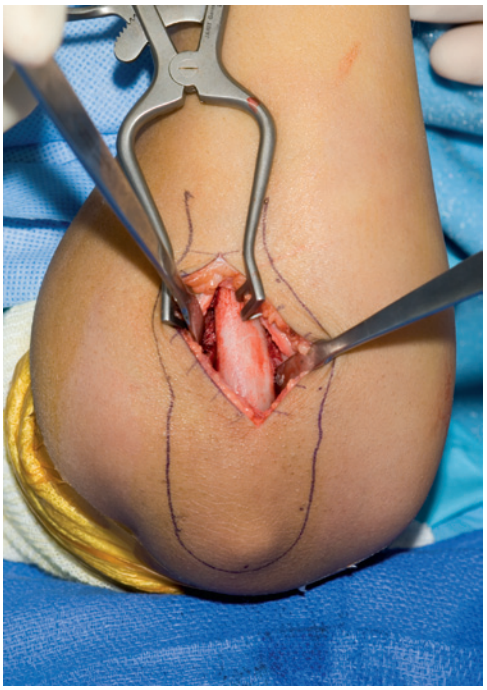

FIGURE 38.37 Exposure of the synostosis along the subcutaneous border of the ulna between the extensor carpi ulnaris and the flexor carpi ulnaris. (Courtesy of Shriners Hospital for Children, Philadelphia.)

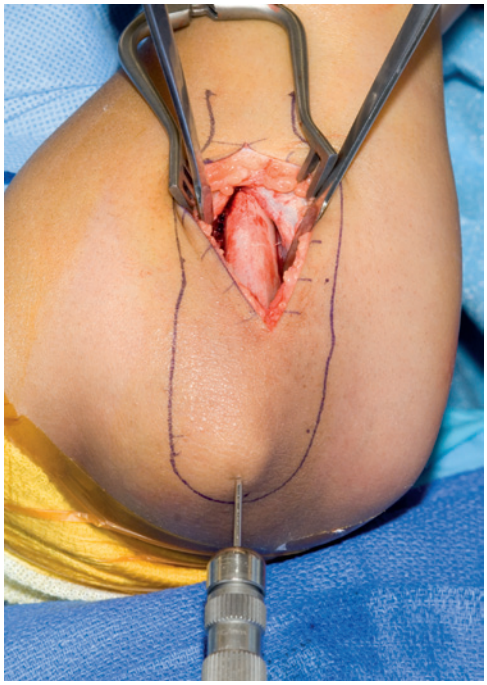

FIGURE 38.38 Steinmann pin inserted through the olecranon apophysis into the intramedullary canal of the ulna. (Courtesy of Shriners Hospital for Children, Philadelphia.)

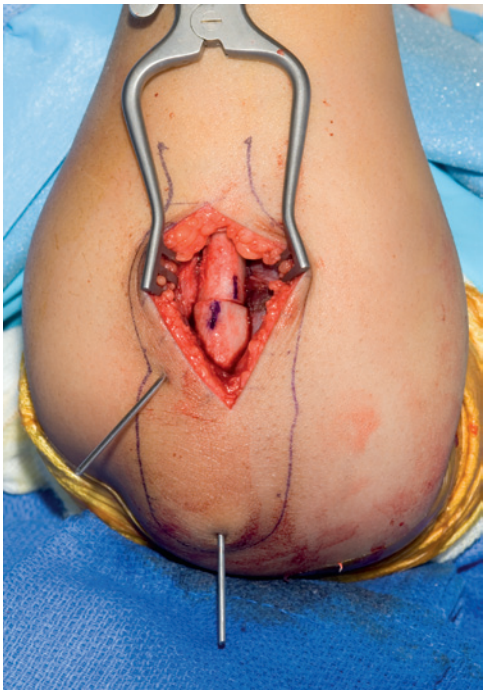

FIGURE 38.40 The forearm is rotated and the longitudinal wire is advanced across the osteotomy site. An additional percutaneous oblique Kirschner wire is placed across the osteotomy for rotational control. (Courtesy of Shriners Hospital for Children, Philadelphia.)

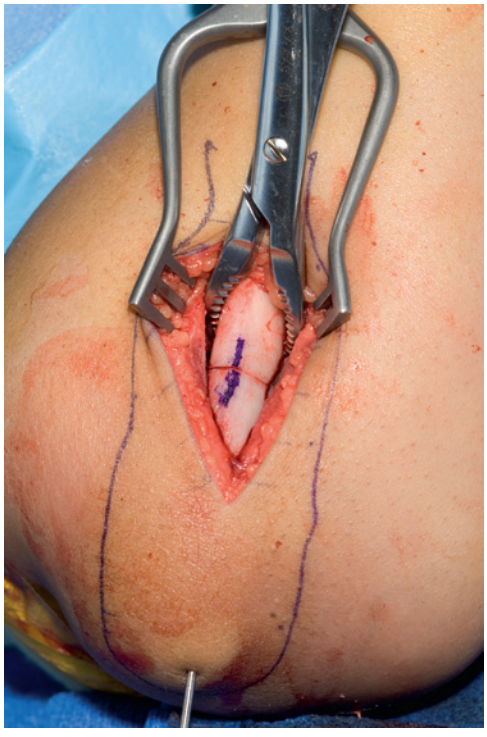

FIGURE 38.39 Transverse osteotomy through the fusion mass. (Courtesy of Shriners Hospital for Children, Philadelphia.)

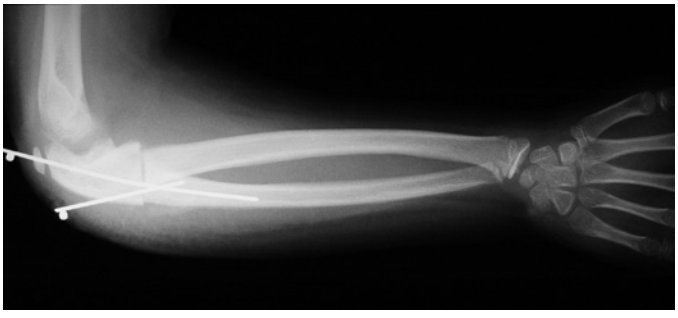

FIGURE 38.41 X-ray after rotational osteotomy confirms good fixation. (Courtesy of Shriners Hospital for Children, Philadelphia.)

Radial Head Excision

For the patient with an anteriorly dislocated radial head (Cleary and Omer type 4) who develops an acute elbow flexion contracture, radial head excision may reduce pain and restore motion.[121]

❖ AUTHORS' PREFERRED METHOD OF TREATMENT

Surgery should be considered when the forearm is fixed in more than 60 degrees of pronation. Derotational osteotomy is the preferred method of treating this condition. Before deciding to pursue surgical correction, preoperative evaluation by a pediatric occupational therapist can help determine the individual child's functional deficits and optimal forearm position. Many children can compensate for lost forearm rotation by increased rotation through the radiocarpal and intercarpal joints, so accurate evaluation of forearm versus hand position in supination and pronation is important. The patient and parents need to realize that derotational osteotomy will only change the position of the synostosis, not increase forearm motion; this can be a difficult concept to explain to laypeople. The technique of derotational osteotomy is described earlier.

Postoperative Management and Expectations

Complication rates are high in reported series.[46,112] Wrist and elbow pain has been reported in adolescents after surgical treatment, but there are few reports with long-term follow-up.[63] The most serious complications are vascular compromise and compartment syndrome, which occur more frequently with changes of more than 85 degrees in rotational position. Immediate intervention is required to reduce the correction and release the forearm fascia.[103] In Simmons and colleagues' series of 22 patients, 4 required an emergency second operation to remanipulate the osteotomy because of poor vascularity of the forearm.[112] Green and Mital reported one patient with a Volkmann contracture postoperatively.[46] If excessive correction is needed, a two-stage operation or an ulnar-shortening osteotomy is safer. Other complications include posterior interosseous nerve palsy (as a result of either intraoperative damage or traction from rotational change), loss of correction, and nonunion.[70,84,103] Ogino and Hikino reported two radial nerve palsies occurring in 13 operations, with recovery at 4 and 8 weeks postoperatively.[88] Simmons and associates reported one posterior interosseous nerve palsy that recovered at 6 weeks and three patients who lost correction of 60, 50, and 20 degrees.[112] Green and Mital reported two patients who required repeat osteotomy.[46]

CRITICAL POINTS *Proximal Radioulnar Synostosis*

- In PRUS, forearm rotation is absent and the forearm is usually fixed in pronation.
- Children are generally first seen between 2 and 6 years of age with painless absence of forearm rotation and a slight elbow flexion contracture. The delay in diagnosis is attributed to lack of requirement for forearm rotation in infants and the use of compensatory shoulder and wrist motion.
- PRUS is usually visualized on radiographs, although the connection is initially cartilaginous and ossifies over time. The length of the synostosis varies, and a concomitant radial head dislocation may be present.
- Extreme pronation or supination that interferes with function is an indication for surgery. A forearm fixed in more than 60 degrees of pronation generally warrants correction.
- Surgery to restore forearm rotation has uniformly been unsuccessful.
- Corrective osteotomy, either through the fusion mass or in the distal radius and proximal ulna, is the preferred surgical treatment to better position the forearm. Complications are common after corrective osteotomy and include compartment syndrome, vascular compromise, radial nerve palsy, and loss of correction.

Expected Outcomes

Rotational osteotomy for PRUS is a reliable procedure for realigning the forearm.[88,112] Most children and parents note improvement in hand positioning for activities of daily living and midline activities. Rotational malalignment does not recur.[18]

CONGENITAL PSEUDARTHROSIS OF THE ULNA OR RADIUS

Preoperative Evaluation

Congenital pseudarthrosis of the ulna occurs when a segment of the ulna, usually in the distal or middle third, is replaced by fibrous tissue (Figure 38.42). This condition is rare and generally associated with neurofibromatosis. Seventy percent of persons with ulnar pseudarthrosis have neurofibromatosis.[23] Familial pseudarthrosis associated with neurofibromatosis has been reported but is unusual.[23]



FIGURE 38.42 Radiographs demonstrating congenital pseudarthrosis of the ulna. Note the large radiolucent defect, very little callus formation, and tapered bone ends. Radial head is dislocated.

Neurofibromatosis is an autosomal dominant trait with variable penetrance and a high rate of spontaneous mutation that occurs in approximately 1 in 3000 live births and is the most common single-gene disorder.[126] Congenital pseudarthrosis, most commonly in the tibia, develops in 5% to 10% of people with neurofibromatosis,[24,126] but its cause is unknown. In the majority of cases, the pseudarthrosis contains fibrous tissue and not a neurofibroma. Pseudarthrosis may occasionally involve both the radius and ulna or the radius alone (Figure 38.43).[96,107]

Congenital pseudarthrosis of the ulna causes a progressive forearm deformity, diminished rotation, instability, and weakness, and it may be painful. The forearm is short, and the radius bears the entire load of the forearm, which leads to radial bowing and eventually to radial head dislocation. The pseudarthrosis is diagnosed on radiographs, which also reveal the extent of radial bowing and position of the radial head (see Figure 38.42).

Types of Operations

The goals of surgical treatment are to achieve bony union, stabilize the adjacent distal radioulnar and ulnocarpal joints, and allow continued skeletal growth.[8] Similar to tibial pseudarthrosis, attempts to achieve union with nonvascularized bone

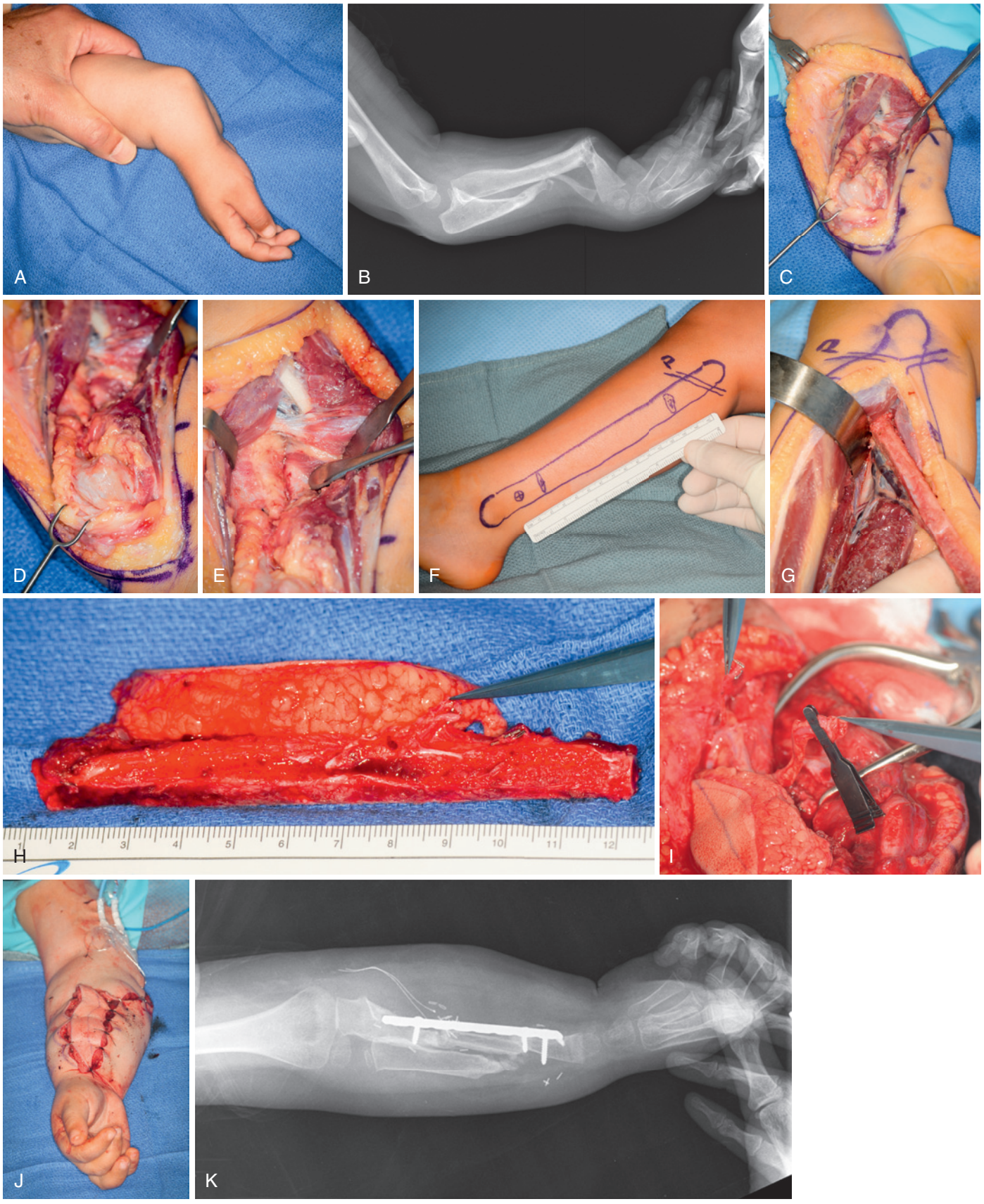

FIGURE 38.43 Four-year-old child with history of neurofibromatosis. He had fallen 1 year earlier and is presenting with persistent pain and deformity. **A,** Clinical picture of right forearm. **B,** X-ray with pseudarthrosis of the radius and ulna. **C,** Volar forearm exposure for free fibula from proximal ulna to distal radius. **D,** Distal radius exposure. **E,** Proximal ulna exposure. **F,** Free fibula preparation. **G,** Peroneal artery and venae comitantes. **H,** Free fibula with skin paddle. **I,** Radial artery for inflow. **J,** Loose closure and skin paddle. **K,** X-ray 3 months after surgery with early consolidation. (Courtesy of Shriners Hospital for Children, Philadelphia.)

grafting and immobilization usually fail.[89] Historically, creation of a one-bone forearm was the only option available to restore forearm stability.[92,126] Although external distraction techniques combined with compression across the pseudarthrosis may achieve short-term union in individuals with tibial pseudarthrosis,[91] in the forearm, differential lengthening of the paired bones results in loss of forearm rotation.

Resection of the pseudarthrosis and transfer of a free vascularized fibular graft to the defect reliably results in union. Preliminary distraction histogenesis may be necessary to achieve adequate soft tissue length. Fibular transfers maintain length and may preserve some forearm rotation.[3,74,96,107,130,135] A one-bone forearm may be necessary to restore forearm stability, especially when the pseudarthrosis affects both the radius and ulna (see Figure 38.43). Although follow-up of a large number of patients to skeletal maturity is pending, this technique is promising. In our series of five patients treated with this method, union occurred at an average of 10 months postoperatively, although one patient with a very distal pseudarthrosis of the ulna did require repeat surgery to achieve union.[9]

The donor fibula is contralateral to the pseudarthrosis to facilitate intraoperative positioning. Radiographs of both forearms and the donor leg are obtained. Preoperative arteriograms of the donor and recipient sites are not essential, but a preoperative Allen test is necessary to plan end-to-end versus end-to-side anastomosis of the ulnar artery to vascularize the fibular graft. The amount of fibular graft needed after resection of the pseudarthrosis is estimated. A minimum of the middle third of the fibula must be harvested to protect the nutrient artery. At least the middle half of the fibula can be harvested without knee or ankle instability. Some reports indicate that the distal 6 to 8 cm of fibula should be preserved to maintain ankle stability,[7,119,129] although other biomechanical studies indicate that only the distal 10% of the fibula is necessary to preserve ankle stability.[90] We prefer to perform a concomitant distal tibiofibular synostosis (Langenskiöld procedure) in children up to skeletal maturity to decrease the risk of valgus deformity at the ankle.

Two surgical teams are used to decrease operative time. The patient is placed in a floppy lateral decubitus position with the affected arm positioned along an arm board. The pseudarthrosis is exposed along the forearm, and the exposed neurovascular structures are isolated (see Figure 38.43, *C* to *E*). The entire pseudarthrosis is resected back to healthy bone at each end. The size of the defect determines the length of fibula resected.

Simultaneously, the fibula is harvested (see Figure 38.43, *F* to *H*). A longitudinal incision is made along the subcutaneous border of the fibula. The peroneal and soleus muscles are separated, and the fibular periosteum is left intact. The anterior tibial and peroneal vessels are isolated. Selection of the distal level for osteotomy is based on the amount of fibula required and the necessity to preserve ankle stability. After distal osteotomy, careful retraction of the fibula exposes the interosseous membrane, which is divided in its distal half. The proximal peroneal vessels and nerve are isolated. The proximal osteotomy is performed while protecting the neurovascular structures. At this point, the fibular segment can be externally rotated and the remaining interosseous membrane divided with preservation of the peroneal vessels adjacent to the middle third of the fibula.

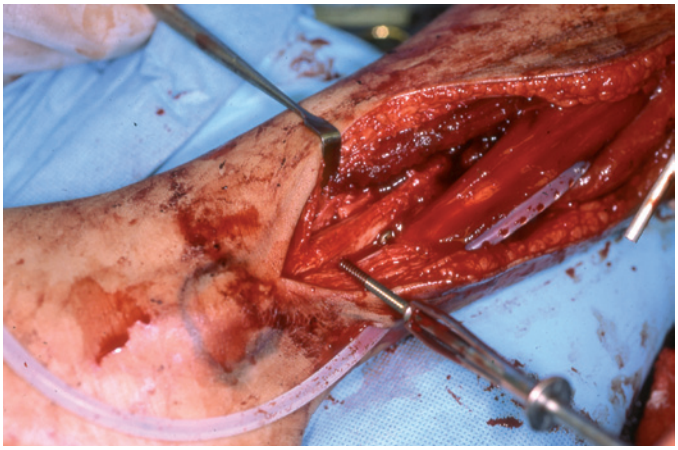

FIGURE 38.44 Distal tibiofibular synostosis performed to maintain ankle stability. (Courtesy of Shriners Hospital for Children, Philadelphia.)

The peroneal vessels are ligated at the level of the distal osteotomy. The tourniquet is deflated to ensure perfusion to the fibular segment. After the forearm is prepared, the peroneal artery and vein or veins are ligated proximally. The graft is passed to the arm and contoured to fit the deficit. Distal tibiofibular synostosis is performed to maintain ankle stability (Figure 38.44). Bone graft trimmed from the fibula or graft harvested from the iliac crest may be placed between the tibia and fibula. One or two syndesmosis screws are used for internal fixation. Care is taken to avoid placing screws through the distal tibial or fibular physis.

Internal fixation is used to secure the graft in place before vascular anastomosis. Both the recipient and donor bone are osteotomized in a step-cut or transverse fashion. The proximal osteotomy is always fixed with plate and screws. Frequently, the segment of distal metaphyseal bone that remains after resection of the pseudarthrosis is very short, thereby precluding plate fixation. Interfragmentary screw, Kirschner wire, or tension band fixation may be used to secure the graft distally. An end-to-end or end-to-side arterial anastomosis is performed between the peroneal and ulnar arteries. The peroneal veins are often larger than the venae comitantes and require anastomosis with subcutaneous veins about the forearm. Supplemental cancellous bone graft from the ends of the donor fibula or from the iliac crest can be placed at each end of the fibular graft to enhance union. The wound is closed with interrupted subcutaneous sutures and running absorbable skin sutures. A drain is placed if necessary. Long-arm and long-leg casts are applied.

In skeletally immature patients, Bae and associates proposed transferring the proximal fibular epiphysis with the vascularized fibular graft to allow subsequent skeletal growth.[8] Their series consisted of two children 3 and 5 years old in whom preoperative radiographs demonstrated atrophy, narrowing, and sclerosis of the entire distal ulna with obliteration of the intramedullary space and a paucity of callus formation. In these cases, the entire distal ulna was removed. To harvest the proximal fibular epiphysis, the proximal tibiofibular joint is opened and the lateral collateral ligament, biceps femoris, and peroneal muscle attachments are released. The peroneal nerve is isolated and protected. The graft is taken with both the peroneal and anterior tibial vascular pedicles to perfuse both the proximal

epiphysis and fibular diaphysis. This mandates vein graft reconstruction of the anterior tibial artery for two-vessel flow and adequate vascularity of the lower extremity. The triangular fibrocartilage and DRUJ capsules are repaired to the proximal fibular epiphysis. Follow-up of 33 months in one patient and 80 months in the other was reported to show skeletal growth matching radial growth. However, a recent report of two cases of epiphyseal transfer demonstrated premature physeal closure in both patients.[136]

❖ AUTHORS' PREFERRED METHOD OF TREATMENT

Débridement of the pseudarthrosis and placement of a vascularized fibular graft successfully restore ulnar length and stability in most cases. The authors recommend performing this operation in younger children, before the radial head dislocates. Surgical tibiofibular synostosis is especially important in younger children to prevent progressive ankle valgus deformity.

Postoperative Management and Expectations

The patency of the anastomosis may be monitored at the surgeon's discretion; monitoring options include harvesting of the fibula with a skin paddle or implantable flow monitors. Postoperatively, the patient is kept warm, calm (with sedation if necessary), and at bed rest for 72 hours. One baby aspirin (81 mg) per day is administered for 7 to 14 days. Caffeine and cigarette smoke are avoided.

Weight bearing on the affected leg is not allowed for 6 weeks. Radiographs of both extremities are obtained with casts off at 6 weeks. Casting is then continued until radiographic union is apparent at each site. The decision between long-arm and short-arm casting is made based on the age of the child, the location of the pseudarthrosis, and the strength of the internal fixation.

A vascularized fibular graft achieves a higher rate of union than any other operative treatment of ulnar pseudarthrosis other than the one-bone forearm.[130] Unlike creation of a one-bone forearm, vascularized fibular grafting preserves motion. This operation is best performed early to reduce the chance of progressive forearm deformity.[130]

Suzuki and coauthors reported three patients with 5- to 8-year follow-up after vascularized fibular grafting for ulnar pseudarthrosis.[115] Anterior bowing of the ulna and anterior dislocation of the radial head developed in two, and the other had considerable shortening of the ulna at the wrist. The authors noted that although free vascularized fibular grafting is the treatment of choice for congenital ulnar pseudarthrosis, patients must be monitored radiographically during growth. No published studies have reported follow-up to skeletal maturity.

Donor site morbidity is a frequent occurrence. Progressive ankle valgus deformity may develop in skeletally immature patients after fibular resection.[38,90] This can be prevented or at least minimized by preserving adequate distal fibular length,[90] inserting a distal tibiofibular syndesmosis screw, creating a synostosis between the distal tibia and fibula (Langenskiöld procedure), or any combination of these measures.[38,90] Distal tibiofibular synostosis is the preferred method of stabilization of the fibula to prevent ankle valgus deformity. Other donor site problems include objective motor weakness, pain, and sensory abnormalities.[69,119]

CRITICAL POINTS *Pseudarthrosis of the Ulna or Radius*

- Congenital pseudarthrosis of the ulna occurs when a portion (usually the distal or middle third) has been replaced by fibrous tissue.
- Congenital pseudarthrosis is rare and is usually associated with neurofibromatosis, although the cause is unknown and the pseudarthrosis does not generally contain a neurofibroma.
- Pseudarthrosis causes forearm deformity, instability, and weakness.
- The goal of surgical treatment is to achieve bony union, restore forearm integrity, stabilize the adjacent distal radioulnar and ulnocarpal joints, and allow continued skeletal growth.
- Resection of the pseudarthrosis combined with transfer of a free vascularized fibular graft to the defect is the preferred technique; complications include anterior ulnar bowing with anterior dislocation of the radial head, instability of the DRUJ, and valgus instability of the ankle.

ELBOW AND FOREARM DEFORMITY CAUSED BY MULTIPLE HEREDITARY EXOSTOSES

Preoperative Evaluation

Multiple hereditary exostoses (MHE) is a disorder of enchondral bone growth, inherited in an autosomal dominant pattern with high penetrance[105] and variable expressivity. Cartilaginous exostoses, also called osteochondromas, grow from the physes of long bones and from the pelvis, ribs, scapula, and vertebrae.[5] Many different names have been used to describe MHE, including multiple cartilaginous exostoses, diaphyseal aclasis, dyschondroplasia, hereditary deforming chondrodysplasia, and osteochondromatosis.[132] MHE is frequently confused with multiple enchondromatosis (Ollier disease), an entirely different condition. Multiple exostoses can also occur in other conditions, such as metachondromatosis and Langer-Giedion syndrome.[77] The prevalence of MHE is approximately 1 in 50,000.[105] MHE has an equal prevalence in both sexes, although males tend to have more severe involvement (Figure 38.45).[77] The most common sites of involvement are the knee, humerus, hip, scapula, ribs, distal radius and ulna, ankle, elbow, hands, feet, and pelvis.[109,122] Approximately half of all patients with MHE have forearm involvement.[14,19,31,32,58,105,131,132]

Genetic studies of families with this condition have mapped the chromosomal abnormality to at least three different genes.[17,77,78] The genes are termed *EXT* genes and are located on different chromosomes.[39,47] Because the *EXT* genes are tumor suppressor genes,[27,94,122,133] MHE has been classified as a familial neoplastic syndrome.[94]

A clinical "bump search" on all long bones is indicated if MHE is suspected but the diagnosis has yet to be established. Shoulder, elbow, forearm, wrist, and digit range of motion should be measured. Serial measurements of forearm rotation are used to document progressive forearm deformity, and the length of the ulna can be measured clinically to derive the proportional ulnar length. Clement and Porter demonstrated that a shorter proportional ulnar length (the length of the ulna described as a percentage of the patient's height) is a risk factor for eventual radial head dislocation.[21] They described a cut-off of proportional ulnar length of 13% or less in males and 12% or less in females as the point at which forearm

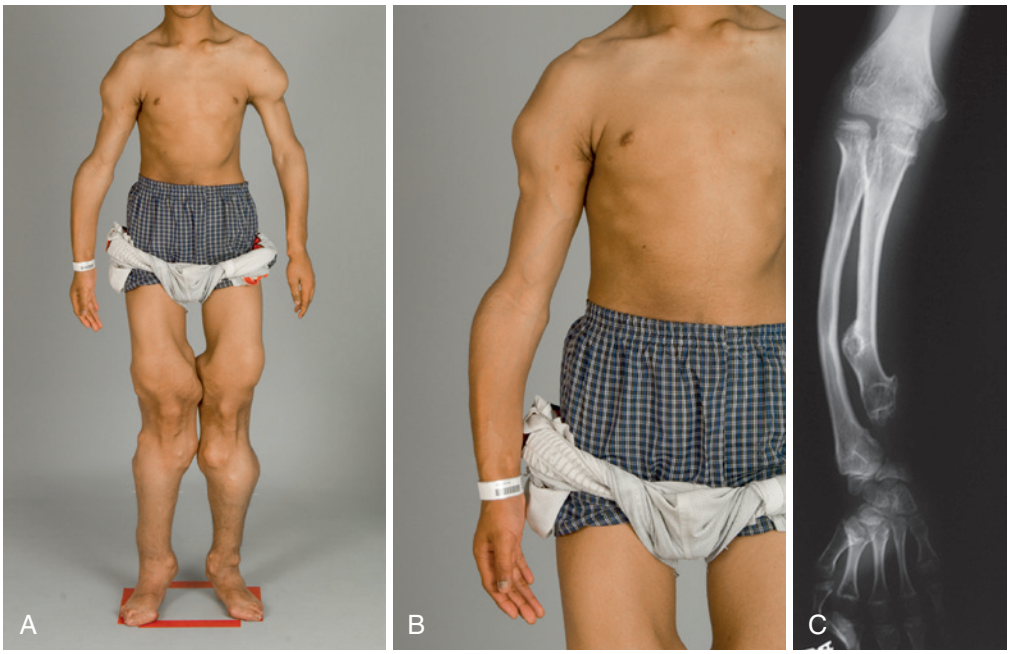

FIGURE 38.45 Sixteen-year-old boy with severe multiple hereditary exostoses. **A,** The upper and lower extremities are severely involved. **B,** Bowing of the right forearm. **C,** An x-ray shows ulnar shortening and radial bowing. The radiocapitellar joint is located. (Courtesy of Shriners Hospital for Children, Philadelphia.)

range of motion is likely to be below 100 degrees of rotation and thus limit activities of daily living. Radiographs should be obtained for any part of the extremity in which osteochondromas are suspected or that has a decreased range of motion. A thorough neurologic examination, including gait and reflexes, should be performed for all patients with MHE because intraspinal osteochondromas can lead to myelopathy.[6,99] Any neurologic abnormalities should prompt further workup. Occult intraspinal exostoses (without any neurologic symptoms) have been reported, in some instances leading to paralysis after minor trauma. In our practice, all patients with MHE undergo a screening spine MRI once they are able to do so without sedation, generally around the age of 5 or 6 years.

Most exostoses are asymptomatic and do not require removal. Exostoses removed before skeletal maturity may recur. However, exostoses may cause local discomfort, nerve or tendon impingement, decreased range of motion, and longitudinal and angulatory growth abnormalities.[17] Growth abnormalities may also occur in MHE in the absence of radiologically visible exostoses.[12] Several reports of adults with untreated forearm deformities secondary to MHE indicate that they maintain function and are comfortable with their appearance.[5,86,114] These reports question the role of aggressive surgical treatment to maintain or improve function. In evaluating the forearms of untreated adults with MHE, Noonan and colleagues demonstrated decreases in strength, motion, and function relative to controls; 77% were free of pain, only 13% thought that they were limited in performance of their jobs, and just 4% had evidence of osteoarthritis.[86] There were no radiographic measures that were associated with a poor outcome.

The exostosis may appear sessile (broad based) or pedunculated. More severe angular deformities appear to be associated with a predominance of sessile lesions.[17] Exostoses possess a cartilage cap and are larger than their radiographic appearance. MRI is not routinely performed but will reveal the size of the cartilaginous cap. It is the imaging technique of choice to evaluate for suspected malignant transformation.

Certain factors associated with exostosis about the forearm make the loss of forearm rotation over time more likely. On physical examination, reduced proportional ulna length is associated with radial head dislocation and diminished forearm rotation.[21] Radiographically, forearms with isolated osteochondromas of the distal ulna are more likely to develop radial head dislocation.[45] It is unknown if early ulnar lengthening has a long-term effect on forearm rotation.

Osteochondromas may cause local pain, visible deformity, and growth disturbance. Malignant transformation is uncommon. Local pain, caused by impingement of the osteochondroma on surrounding tissue, is a frequent indication for removal of the exostosis, which effectively relieves the pain. If forearm rotation is blocked by an exostosis, removal will often improve motion.

Forearm osteochondromas frequently cause a discrepancy in length of the radius and ulna.[109] The forearm deformities caused by growth arrest secondary to MHE are complex. Even when osteochondromas of the distal ulna are not visible on radiography, distal ulnar growth arrest is common; the ulnar physis appears to be especially susceptible to growth impairment, possibly because of its relatively small cross-sectional area. The resultant deformity is a length discrepancy between the two forearm bones. The radius becomes longer than the ulna and accepts the entire forearm load, which results in radial bowing, radial tilting, and dislocation of the radial head.[132] The increased radial inclination and lack of ulnar support position the wrist in ulnar deviation and cause the carpus to "slip" toward the

ulna.[14,21,109] The length discrepancy causes diminished forearm rotation.

Early removal of osteochondroma to retard or prevent progressive growth disturbances is controversial.[37,72] Hemiepiphyseal stapling of the radial side of the distal radius retards radial growth and allows correction of the radial articular angle and ulnar length discrepancy with growth.[132] Stapling may be performed in conjunction with ulnar lengthening in a skeletally immature child.[37] Ulnar lengthening may be performed in a single stage or by gradual distraction osteogenesis. Differential lengthening combined with angular correction can be used to reduce the radial head[52] because restoration of normal forearm anatomy may result in spontaneous reduction of the radial head. In patients with an isolated distal ulnar lesion, freeing the soft tissue tether between the ulna and ulnar-sided carpus and distal radius may prevent dislocation of the radial head. The dislocated radial head may become painful in adolescence; resection relieves the pain and removes the associated prominence.[5,72] Radial head resection may be indicated for pain, but it is delayed until skeletal maturity because removal of the radial head in a growing child may cause cubitus valgus or proximal radial overgrowth. Creation of a one-bone forearm may be used to salvage a severely disorganized forearm.[101]

In adults, an indication for excision of MHE is suspected malignant transformation. Symptoms and signs of malignant transformation include local pain and growth of an osteochondroma after skeletal maturity. Radiographic changes include internal lytic areas, erosion or destruction of the adjacent bone, and the presence of a soft tissue mass containing irregular calcifications.[122] Malignant transformation, however, is quite rare in the upper extremity.[118]

Contraindications to removal of osteochondromas are relative. Simple procedures, such as removal of symptomatic osteochondromas and dislocated radial heads, may improve the appearance and relieve pain with a low complication rate. Complicated procedures, such as forearm lengthening, are more likely to be associated with complications, but it is theoretically possible that ulnar lengthening may prevent radial head dislocation and loss of forearm rotation in selected patients.[1,21,45]

Careful preoperative neurologic and range-of-motion examinations and up-to-date radiographs are required before surgery. The patient, parents, and surgeon should agree on exactly which osteochondromas will be removed because there are often several present.

PERTINENT ANATOMY

Masada and associates developed a classification scheme for forearm deformities based on location of the osteochondromas.[58,72] This scheme is based on the location of the main forearm osteochondroma, the resultant deformity, and concomitant clinical problems. Type 1 is the most common form. The main osteochondroma is located in the distal ulna, which causes a short ulna and bowed radius (see Figure 38.45, *C*). The radial head remains located within the radiocapitellar joint. In type 2, the main osteochondroma is located in the distal ulna, which causes a short ulna, bowed radius, and dislocated radial head (Figure 38.46). Type 2 is subdivided into type 2a, with an osteochondroma on the proximal radial metaphysis, and type 2b, with no proximal radial osteochondroma. In type 3, the main osteochondroma is located in the distal radial metaphysis and the radius is relatively short.

Types of Operations

Removal of Osteochondroma

The osteochondroma is approached through a longitudinal incision centered over the tumor. The most readily available

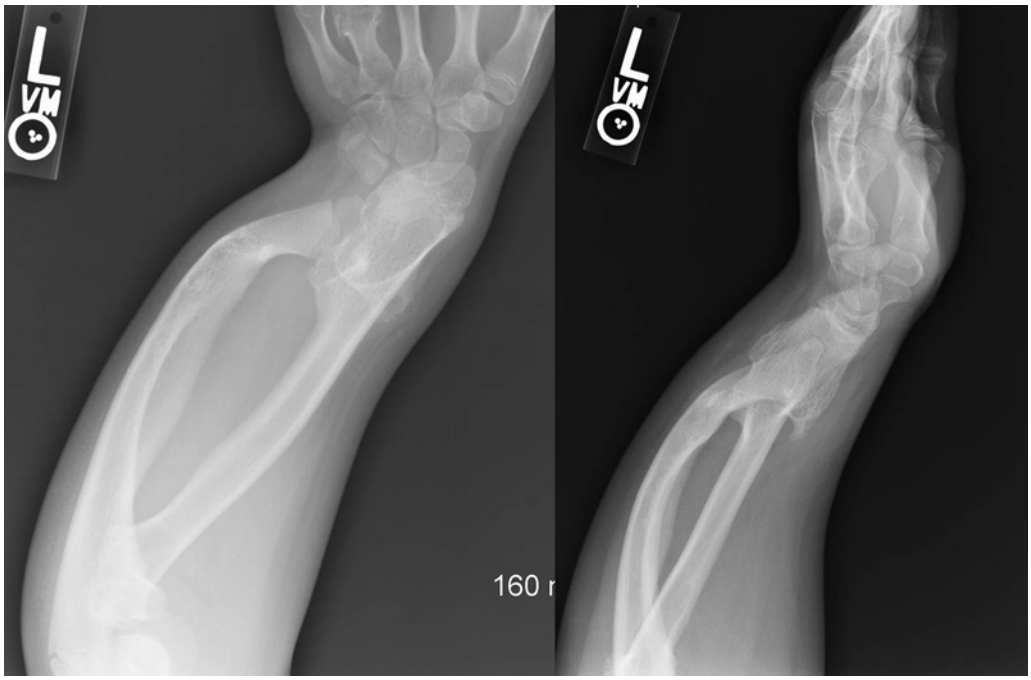

FIGURE 38.46 Radiographs of hereditary multiple exostoses of the right forearm. (Courtesy of Shriners Hospital for Children, Northern California.)

anatomic interval is used for the approach. Usually, the osteochondroma splits the surrounding structures and the approach is straightforward. Nerves or vessels (or both) may be wrapped around the pedicle of the tumor or flattened over its surface. These neurovascular structures are retracted, and the entire tumor, including the periosteum, is removed until a smooth bony contour remains. It is common for osteochondromas to be present on both the distal radius and ulna, such that both volar and dorsal approaches to the forearm may be required to fully remove the symptomatic tumors. In this case, prophylactic fasciotomy is recommended, and patients are admitted overnight to closely monitor their swelling.

Distal Radial Hemiepiphyseal Stapling

The radial aspect of the distal radial physis is approached through a transverse incision while taking care to avoid injuring the dorsal radial sensory nerve (Figure 38.47). Under radiographic guidance, three extraperiosteal staples are placed across the distal radial physis. Staples are placed on either side of the first dorsal compartment; usually there is room for 2 staples dorsal to the compartment, and one staple palmar to the compartment.[62a]

Radial Head Excision (Posterolateral Dislocation)

See the section on resection of the radial head under "Congenital Dislocation of the Radial Head." A substantial portion of the proximal radius may be dislocated in patients with MHE. In these cases, the posterior interosseous nerve should be visualized and protected to avoid injury.

Ulnar Distraction Lengthening

The ulna can be lengthened to maintain the relationship between the ulna and radius (Figure 38.48). Lengthening can also maintain radial head alignment and/or promote radial head reduction. Pins for a hinged uniplanar external fixation device are applied to the ulna, two pins proximal and two pins distal to the planned osteotomy site. The pins are placed perpendicular to the bone at each location, so that when the fixator is placed, the hinge can be straightened to eliminate any bowing of the ulna. Alternatively, an acute angular correction can be performed, followed by delayed distraction osteogenesis. Threaded bicortical pins are used. Once the pins are in place, the site of ulnar osteotomy is isolated. The periosteum is incised carefully. Retractors are used to protect the soft tissues, and a transverse osteotomy is made using an oscillating saw. The external fixator is applied. While the wound is still open, the device is used to lengthen and then recompress through the osteotomy site to ensure that there is no hindrance to lengthening. The osteotomy site is closed, including the periosteum. Patients return to the clinic in 5 to 7 days to start lengthening. Lengthening usually proceeds at 1 mm per day; patients return to the clinic weekly during the lengthening phase. Lengthening is slowed or stopped temporarily if there are any concerns about inadequate bone formation, excessive digital stiffness, or neurovascular problems. If the bone regenerates rapidly, lengthening can be temporarily sped up to 1.5 or 2 mm per day. Once the lengthening phase has been completed, the fixator remains in place until bone regeneration is complete, generally twice the time of the lengthening phase.

Differential Forearm Lengthening

This complex operation is uncommon and is beyond the scope of this text. See Dahl's detailed description of planning osteotomies, designing fixation, ulnar lengthening and angular correction, and radial head reduction.[26]

Ulnar Detethering

At times significant deformity can be present as a result of an ulnar tether, which is most often the sequela of premature ulnar

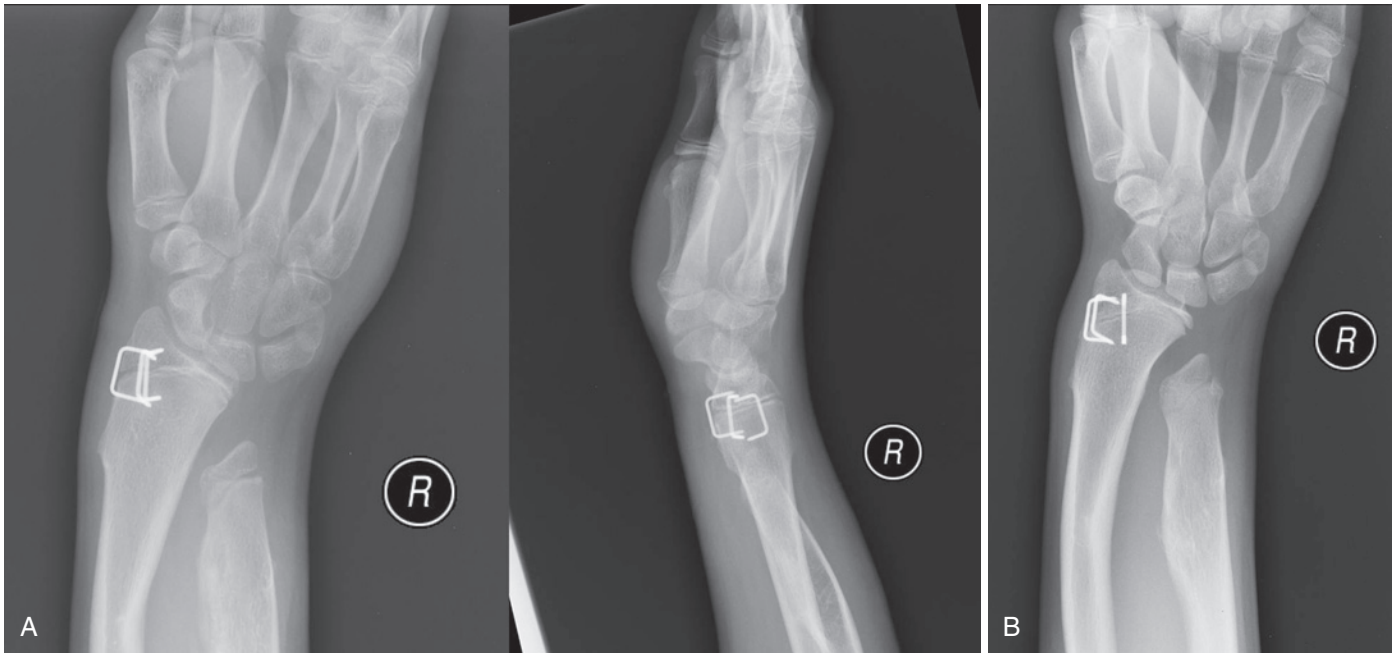

FIGURE 38.47 Distal radius hemiepiphyseal stapling. **A,** Anteroposterior and lateral radiographs after distal radius hemiepiphyseal stapling. **B,** Follow-up radiograph with correction of radial tilt.

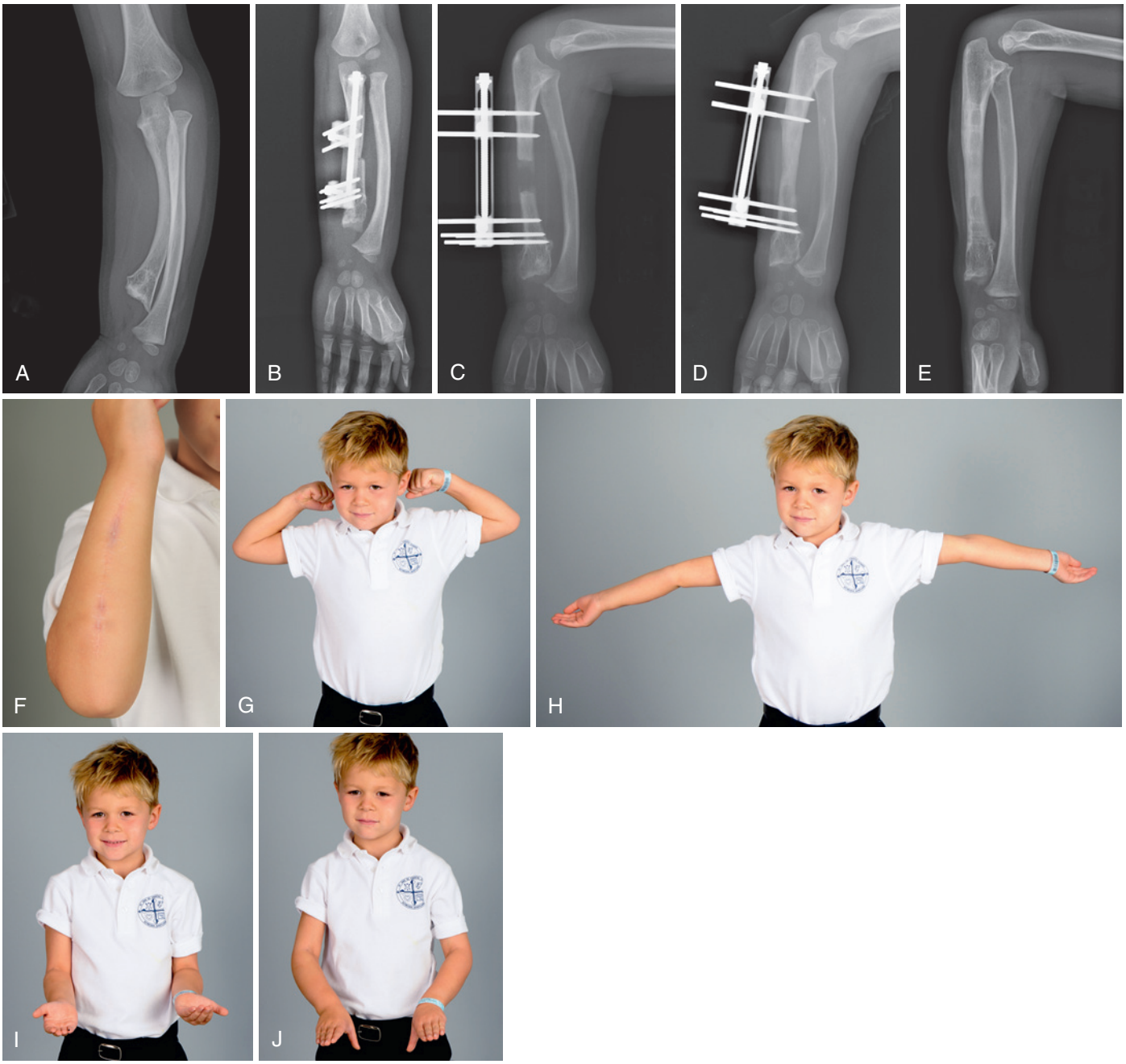

FIGURE 38.48 Four-year-old boy with isolated exostosis of the right distal ulna. **A,** Preoperative x-ray with shortened ulna and radial head subluxation. **B,** Acute angular correction and application of uniplanar external fixator. **C,** Distraction osteogenesis. **D,** Consolidation phase. **E,** X-ray following fixator removal with reduced radial head. **F,** Well-healed incision. **G,** Elbow flexion. **H,** Elbow extension. **I,** Forearm supination. **J,** Forearm pronation. (Courtesy of Shriners Hospital for Children, Philadelphia.)

physeal closure. To release this tether an incision is made over the area of the distal ulna, with release being accomplished by transecting the ulna through the epiphyseal or styloid area with the triangular fibrocartilage complex attached to the distal fragment. The extensor carpi ulnaris subsheath is also released because this can be an additional deforming force. At this point a corrective radial osteotomy can be performed, depending on the deformity present and/or growth potential remaining in the radius.

Postoperative Management and Expectations

For removal of distal forearm osteochondromas and distal radial hemiepiphyseal stapling, use of a soft dressing and wrist splint for 2 to 3 weeks is adequate immobilization. Radiographs of the distal radius should be obtained twice a year after hemiepiphyseal stapling, and the staples should be removed when the desired amount of radial tilt (usually 20 degrees) is attained.

Osteochondromas tend to grow until skeletal maturity. Recurrence is uncommon when resection is performed near

skeletal maturity. Hemiepiphyseal stapling can restore radial tilt when performed on patients with enough remaining growth. Radial head resection reliably relieves pain in persons with radial head dislocation. Differential forearm lengthening may improve the appearance and prevent radial head dislocation, but there is little evidence that function is improved.

Akita and coworkers reported the long-term results of surgery for forearm deformities in this condition.[1] Thirty-one forearms in 23 patients were monitored for an average of 13 years after surgery. The mean age at the time of surgery was 11 years. The most beneficial procedure was excision of the osteochondroma, which significantly improved forearm pronation and appearance. Corrective osteotomy and lengthening of the ulna were not found to be beneficial. Ulnar lengthening was the only surgery associated with complications, including nonunion, fracture of callus at the site of lengthening, and temporary radial nerve palsy. Although the radiographic parameters of ulnar variance, radial articular angle, and carpal slip were initially improved by the surgery, at final follow-up the deformities had progressed. In two patients with radial head dislocation before skeletal maturity, the radial head was reduced with corrective osteotomy of the radius, ulnar lengthening, and reconstruction of the annular ligament. At last follow-up, both had degenerative changes at the elbow and restricted forearm pronation. Two other patients with dislocation of the radial head at skeletal maturity were treated by radial head resection. Both had relief of pain and improvement in motion at follow-up. These authors concluded that forearm deformities are unrelated to function, and they no longer recommend corrective procedures for prevention of functional impairment.

Shin and colleagues reported outcomes after excision of the osteochondroma, ulnar lengthening, and the Sauvé-Kapandji procedure.[110] Although excision improved the range of motion of the forearm, the Sauvé-Kapandji procedure was shown to improve wrist stability, movement of the forearm, and radiographic appearance. The authors hypothesized that resection of the ulna reduces the tethering effect that the distal ulna has on the radial physis.

❖ AUTHORS' PREFERRED TECHNIQUE

Hemiepiphyseal stapling, resection of the osteochondroma, and removal of the radial head are simple operations with good results. Forearm rotation should be measured twice a year in children with MHE and forearm involvement. Progressive loss of forearm rotation is considered an indication for removal of osteochondromas. Freeing the tether between the radius and ulna, either by soft tissue release of the distal ulna, by ulnar osteotomy and lengthening, or with the Sauvé-Kapandji procedure, may prevent dislocation of the radial head when there is a solitary distal ulnar osteochondroma and progressive bowing of the radius. Early detection of radial head subluxation can be remedied with correction of the ulna via distraction osteogenesis. All children with MHE should be screened for intraspinal osteochondromas with a thorough neurologic examination; it is our preference to also obtain a screening MRI of the spine once the child is old enough to tolerate an MRI without sedation.

CRITICAL POINTS *Hereditary Multiple Exostoses*

- MHE is inherited in an autosomal dominant pattern with high penetrance. Cartilaginous exostoses (osteochondromas) grow from the physes of long bones and from the pelvis, ribs, scapula, and vertebrae.
- Most exostoses are asymptomatic and do not require removal. Early removal of osteochondromas with corrective osteotomies to retard or prevent progressive growth disturbances is controversial.
- Large exostoses may cause local pain from irritation of surrounding tissues. Simple removal is recommended. The risk of recurrence after removal is higher in younger children.
- Forearm deformities are common in MHE and are based on the location of the osteochondromas, although the forearm deformities are complex and not well understood.
- Hemiepiphyseal stapling of the radial side of the distal radius retards radial growth and allows correction of the radial articular angle and ulnar length discrepancy with growth.
- Ulnar lengthening may be performed in a single stage or by using gradual distraction osteogenesis. Differential lengthening combined with angular correction can be used to reduce the radial head.
- Malignant transformation is uncommon.

For Case Studies, Videos, and more, please visit ExpertConsult.com.

REFERENCES

1. Akita S, Yonenobu K, Murase T, et al: Long-term results of surgery for forearm deformities in patients with multiple cartilaginous exostoses. *J Bone Joint Surg Am* 89:1993–1999, 2007.
2. Alekberov C, Karatosun V, Baran O, et al: Lengthening of congenital below-elbow amputation stumps by the Ilizarov technique. *J Bone Joint Surg Br* 82:239–241, 2000.
3. Allieu Y, Reckendorf GMZ, Chammas M, et al: Congenital pseudarthrosis of both forearm bones: long-term results of two cases managed by free vascularized fibular graft. *J Hand Surg [Am]* 24:604–608, 1999.
4. Almquist EE, Gorden LH, Blue AL: Congenital dislocation of the head of the radius. *J Bone Joint Surg Am* 51:1118–1127, 1969.
5. Arms DM, Strecker WB, Manske PR, et al: Management of forearm deformity in multiple hereditary osteochondromatosis. *J Pediatr Orthop* 17:450–454, 1997.
6. Ashraf A, Larson AN, Ferski G, et al: Spinal stenosis frequent in children with multiple hereditary exostoses. *J Child Orthop* 7(3):183–194, 2013.
7. Babhulkar SS, Pande KC, Babhulkar S: Ankle instability after fibular resection. *J Bone Joint Surg Br* 77:258–261, 1995.
8. Bae DS, Waters PM, Sampson CE: Use of free vascularized fibular graft for congenital ulnar pseudarthrosis: surgical decision making in the growing child. *J Pediatr Orthop* 25:755–762, 2005.
9. Bauer AS, Singh AK, Amanatullah D, et al: Free vascularized fibular transfer with Langenskiöld procedure for the treatment of congenital pseudarthrosis of the forearm. *Tech Hand Up Extrem Surg* 17(3):144–150, 2013.
10. Bayne LG, Klug MS: Long-term review of the surgical treatment of radial deficiencies. *J Hand Surg [Am]* 12:169–179, 1987.
11. Bengard MJ, Calfee RP, Steffen JA, et al: Intermediate-term to long-term outcome of surgically and nonsurgically treated congenital, isolated radial head dislocation. *J Hand Surg [Am]* 37(12):2495–2501, 2012.
12. Bock GW, Reed MH: Forearm deformities in multiple cartilaginous exostoses. *Skeletal Radiol* 20:483–486, 1991.
13. Bolano LE: Congenital proximal radioulnar synostosis: treatment with the Ilizarov method. *J Hand Surg [Am]* 19:977–978, 1994.
14. Burgess RC, Cates H: Deformities of the forearm in patients who have multiple cartilaginous exostosis. *J Bone Joint Surg Am* 75:13–18, 1993.
15. Campbell CC, Waters PM, Emans JB: Excision of the radial head for congenital dislocation. *J Bone Joint Surg Am* 74:726–733, 1992.
16. Carroll RE, Bowers WH: Congenital deficiency of the ulna. *J Hand Surg [Am]* 2:169–174, 1977.
17. Carroll KL, Yandow SM, Ward K, et al: Clinical correlation to genetic variations of hereditary multiple exostosis. *J Pediatr Orthop* 19:785–791, 1999.

CASE STUDY 38.1

A boy with left type 4 radial deficiency was initially seen at 2 months of age. Stretching and splinting were instituted when he was 1½ years old (eFigure 38.1, *A* and *B*), and radiographs were taken at that time (eFigure 38.2). Treatment began with preliminary distraction (eFigure 38.3, *A* and *B*). Next, centralization was performed (eFigure 38.4, *A* to *J*). The final result is shown in eFigure 38.5, *A* and *B*. Pollicization was then performed (eFigure 38.6). The 2-year outcome is shown in eFigure 38.7.

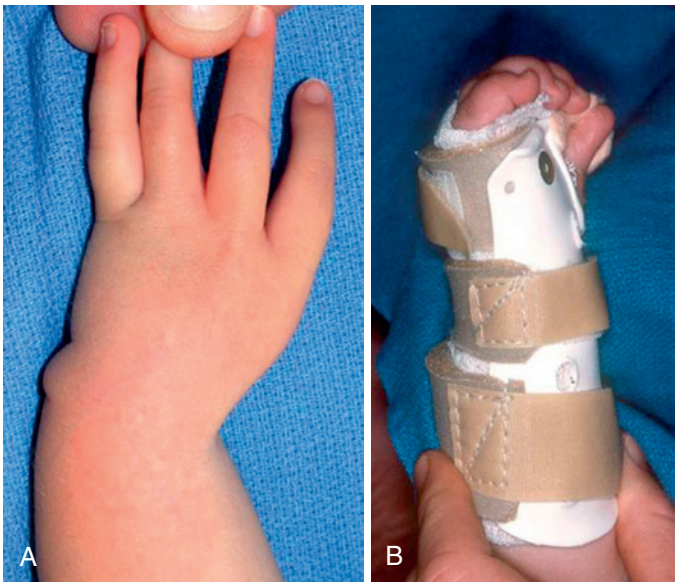

eFIGURE 38.1



eFIGURE 38.2

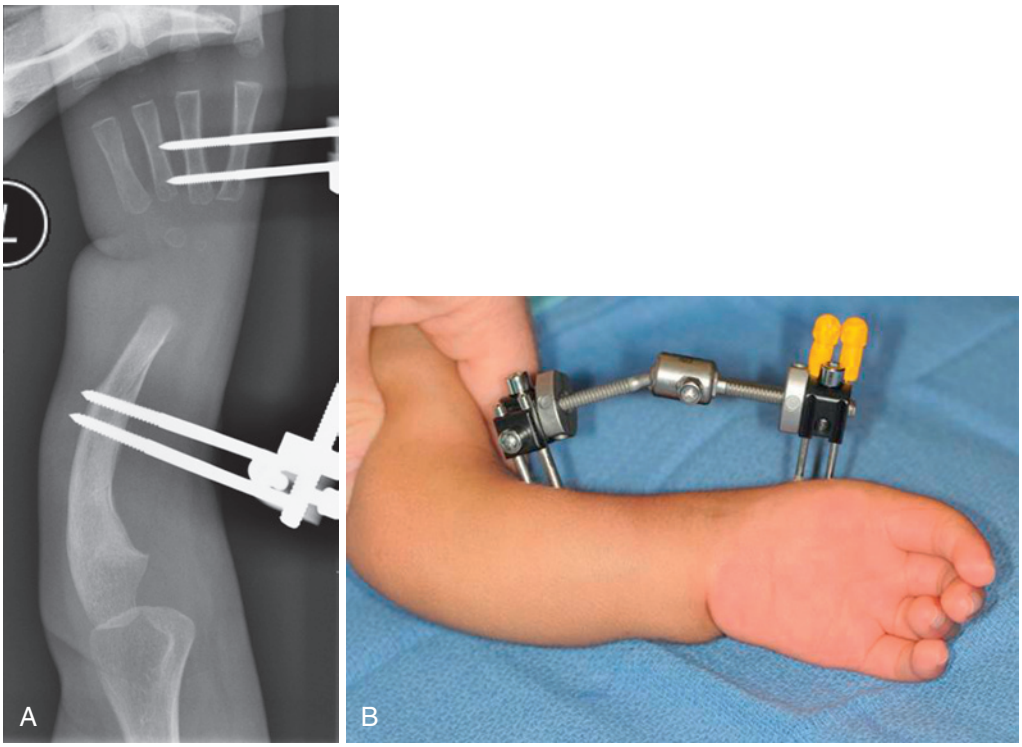

eFIGURE 38.3

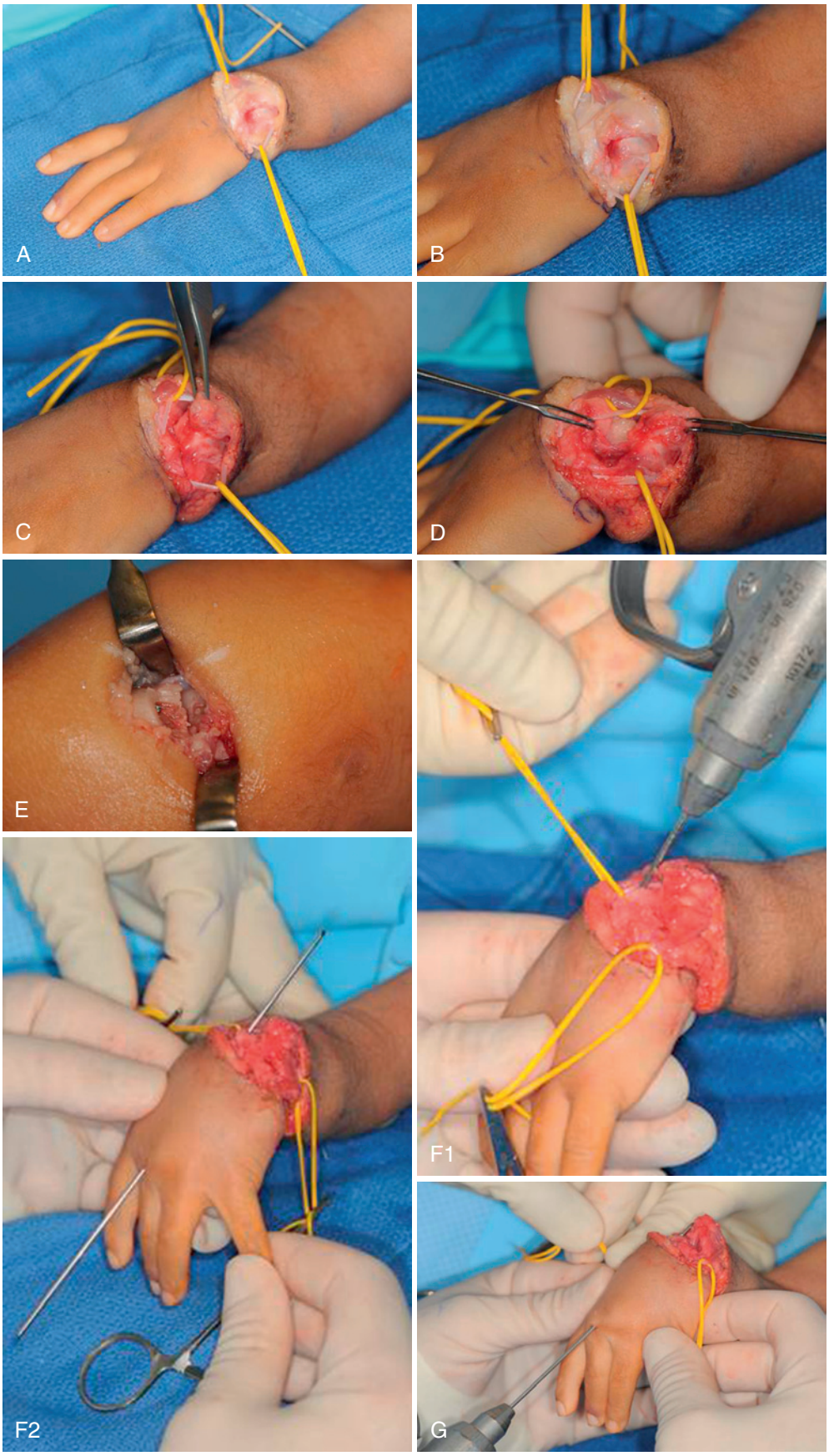

eFIGURE 38.4 **A,** Elliptical dermodesis incision. **B,** Isolate tendons. **C,** Open capsule. **D,** Identify ulnar head. **E,** Perform ulnar osteotomy. **F,** Antegrade 0.62-inch wire. **G,** Kirschner wire joystick.

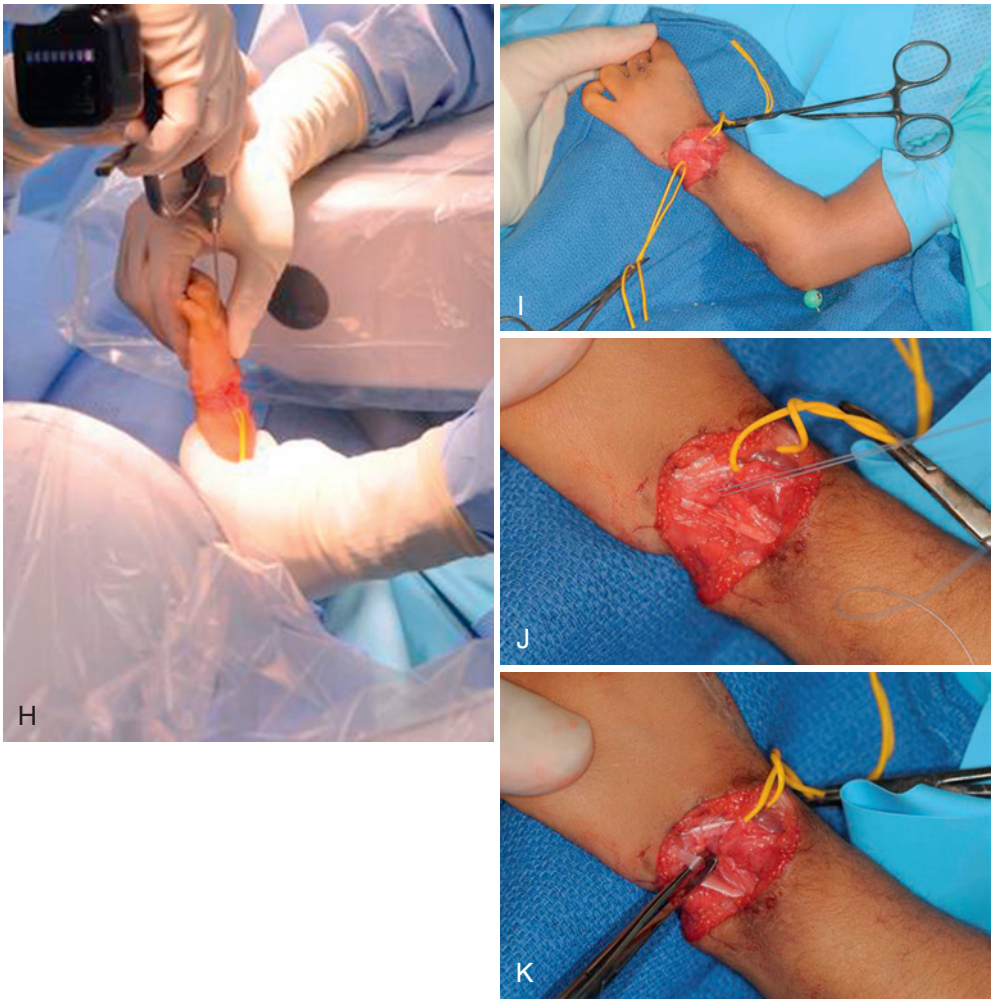

eFIGURE 38.4, cont'd **H,** Retrograde Kirschner wire. **I,** Pinning carpus and ulnar osteotomy. **J,** Capsular repair, centralize tendons. **K,** Extensor carpi ulnaris imbrication.

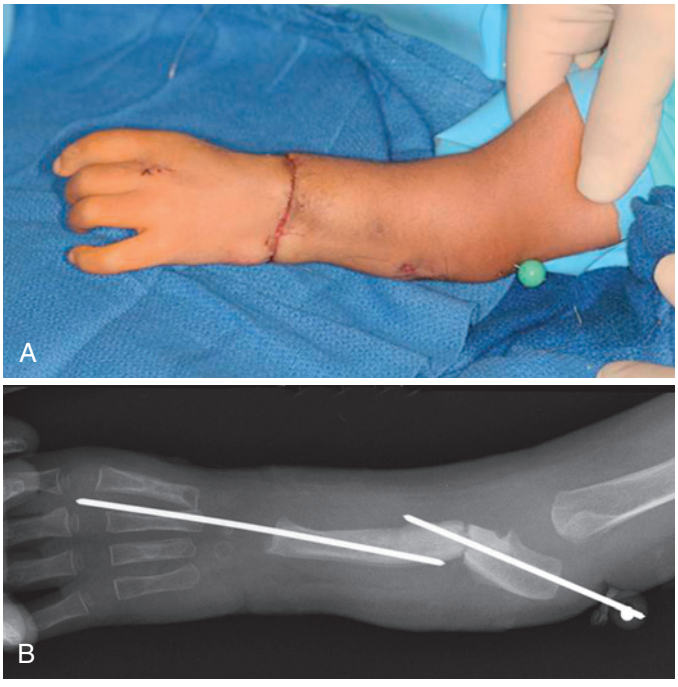

eFIGURE 38.5



eFIGURE 38.6



eFIGURE 38.7

18. Castello JR, Garro L, Campo M: Congenital radioulnar synostosis. Surgical correction by derotational osteotomy. *Ann Chir Main* 15:11–17, 1996.
19. Cates HE, Burgess RC: Incidence of brachydactyly and hand exostosis in hereditary multiple exostosis. *J Hand Surg [Am]* 16:127–132, 1991.
20. Chan PS, Blazer PE, Bozentka DJ, et al: Optimal position for the one-bone forearm. *J Hand Surg [Br]* 24:724–726, 1999.
21. Clement ND, Porter DE: Forearm deformity in patients with hereditary multiple exostoses: factors associated with range of motion and radial head dislocation. *J Bone Joint Surg Am* 4;95(17):1586–1592, 2013.
22. Cole RJ, Manske PR: Classification of ulnar deficiency according to the thumb and first web. *J Hand Surg [Am]* 22:479–488, 1997.
23. Craigen MA, Clarke NM: Familial congenital pseudarthrosis of the ulna. *J Hand Surg [Br]* 20:331–332, 1995.
24. Crawford AH, Schorry EK: Neurofibromatosis in children: the role of the orthopaedist. *J Am Acad Orthop Surg* 7:217–230, 1999.
25. Czeizel AE, Kodaj I, Lenz W: Smoking during pregnancy and congenital limb deficiency. *BMJ* 308:1473–1476, 1994.
26. Dahl MT: The gradual correction of forearm deformities in multiple hereditary exostoses. *Hand Clin* 9:707–718, 1993.
27. Damore E, Kozin SH, Thoder JJ, et al: The recurrence of deformity after surgical centralization for radial clubhand. *J Hand Surg [Am]* 25:745–751, 2000.
28. Davids JR, Wagner LV, Meyer LC, et al: Prosthetic management of children with unilateral congenital below-elbow deficiency. *J Bone Joint Surg Am* 88:1294–1300, 2006.
29. de Paula EJ, Cho AB, Junior RM, et al: Madelung's deformity: treatment with radial osteotomy and insertion of a trapezoidal wedge. *J Hand Surg [Am]* 31:1206–1213, 2006.
30. De Smet L, Claessens A, Fabry G: Gymnast wrist. *Acta Orthop Belg* 59:377–380, 1993.
31. Echtler B, Burckhardt A: Isolated congenital dislocation of the radial head. Good function in 4 untreated patients after 14-45 years. *Acta Orthop Scand* 68:598–600, 1997.
32. Evans DM, Gateley DR, Lewis JS: The use of a bilobed flap in the correction of radial club hand. *J Hand Surg [Br]* 20:333–337, 1995.
33. Deleted in review.
34. Ezaki M, Oishi SN: Technique of forearm osteotomy for pediatric problems. *J Hand Surg [Am]* 37(11):2400–2403, 2012.
35. Fantel AG, Barber CV, Mackler B: Ischemia/reperfusion: a new hypothesis for the developmental toxicity of cocaine. *Teratology* 46:285–292, 1992.
36. Flanagan SF, Munns CF, Hayes M, et al: Prevalence of mutations in the short stature homeobox containing gene (shox) in Madelung deformity of childhood. *J Med Genet* 39:758–763, 2002.
37. Fogel GR, McElfresh EC, Peterson HA, et al: Management of deformities of the forearm in multiple hereditary osteochondromas. *J Bone Joint Surg Am* 66:670–680, 1984.
38. Fragniere B, Wicart P, Mascard E, et al: Prevention of ankle valgus after vascularized fibular grafts in children. *Clin Orthop Relat Res* 408:245–251, 2003.
39. Francannet C, Cohen-Tanugi A, Le Merrer M, et al: Genotype-phenotype correlation in hereditary multiple exostoses. *J Med Genet* 38:430–434, 2001.
40. Froster UG, Baird PA: Congenital defects of the limbs and alcohol exposure in pregnancy: data from a population based study. *Am J Med Genet* 44:782–785, 1992.
41. Gardiner DM, Holmes LB: Hypothesis: terminal transverse limb defects with "nubbins" represent a regenerative process during limb development in human fetuses. *Birth Defects Res A Clin Mol Teratol* 94(3):129–133, 2012.
42. Goldfarb CA, Manske PR, Busa R, et al: Upper-extremity phocomelia reexamined: a longitudinal dysplasia. *J Bone Joint Surg Am* 87:2639–2648, 2005.
43. Goldfarb CA, Murtha YM, Gordon JE, et al: Soft-tissue distraction with a ring external fixator before centralization for radial longitudinal deficiency. *J Hand Surg [Am]* 31:952–959, 2006.
44. Goldfarb CA, Wall L, Manske PR: Radial longitudinal deficiency: the incidence of associated medical and musculoskeletal conditions. *J Hand Surg [Am]* 31:1176–1182, 2006.
45. Gottschalk HP, Kanauchi Y, Bednar MS, et al: Effect of osteochondroma location on forearm deformity in patients with multiple hereditary osteochondromatosis. *J Hand Surg [Am]* 37(11):2286–2293, 2012.
46. Green WT, Mital MA: Congenital radioulnar synostosis: surgical treatment. *J Bone Joint Surg Am* 61:738–743, 1979.
47. Hall CR, Cole WG, Haynes R, et al: Reevaluation of a genetic model for the development of exostosis in hereditary multiple exostosis. *Am J Med Genet* 112: 1–5, 2002.
48. Harley BJ, Brown C, Cummings K, et al: Volar ligament release and distal radius dome osteotomy for correction of Madelung's deformity. *J Hand Surg [Am]* 31: 1499–1506, 2006.
49. Havenhill TG, Manske PR, Patel A, et al: Type 0 ulnar longitudinal deficiency. *J Hand Surg [Am]* 30:1288–1293, 2005.
50. Holmes LB: Teratogen-induced limb defects. *Am J Med Genet* 112:297–303, 2002.
51. Holtslag I, Wijk IV, Hartog H, et al: Long-term functional outcome of patients with longitudinal radial deficiency: cross-sectional evaluation of function, activity, and participation. *Disabil Rehabil* 35(16):1401–1407, 2013.
52. Horii E, Nakamura R, Nakao E, et al: Distraction lengthening of the forearm for congenital and developmental problems. *J Hand Surg [Br]* 25:15–21, 2000.
53. Imai Y, Miyake J, Okada K, et al: Cylindrical corrective osteotomy for Madelung deformity using a computer simulation: case report. *J Hand Surg [Am]* 38:1925–1932, 2013.
54. James MA, Bagley AM, Brasington K, et al: Impact of prostheses on function and quality of life for children with unilateral congenital below-the-elbow deficiency. *J Bone Joint Surg Am* 88:2356–2365, 2006.
55. James MA, Green HD, McCarroll HR, Jr, et al: The association of radial deficiency with thumb hypoplasia. *J Bone Joint Surg Am* 86:2196–2205, 2004.
56. James MA, McCarroll HR, Jr, Manske PR: Characteristics of patients with hypoplastic thumbs. *J Hand Surg [Am]* 21:104–113, 1996.
57. James MA, McCarroll HR, Jr, Manske PR: The spectrum of radial longitudinal deficiency: a modified classification. *J Hand Surg [Am]* 24:1145–1155, 1999.
58. Jiya TU, Pruijs JE, van der Eijken JW: Surgical treatment of wrist deformity in hereditary multiple exostosis. *Acta Orthop Belg* 63:256–261, 1997.
59. Jones NF, Esmail A, Shin EK: Treatment of radioulnar synostosis by radical excision and interposition of a radial forearm adipofascial flap. *J Hand Surg [Am]* 29:1143–1147, 2004.
60. Kanaya F, Ibaraki K: Mobilization of a congenital proximal radioulnar synostosis with use of a free vascularized fascio-fat graft. *J Bone Joint Surg Am* 80:1186–1192, 1998.
61. Kawaguchi S, Kitamura M, Usui M: Proximal radioulnar synostosis treated with a free vascularised fascio-fat graft: report of two cases. *Hand Surg* 5:161–164, 2000.
62. Kelly DW: Congenital dislocation of the radial head: spectrum and natural history. *J Pediatr Orthop* 1:295–298, 1981.

62a. Kelly JP, James MA: Radiographic outcomes of hemiepiphyseal stapling for distal radius deformity due to multiple hereditary exostoses. *J Ped Ortho* 2015, in press.

63. Khalil I, Vizkelety T: Osteotomy of the synostosis mass for the treatment of congenital radio-ulnar synostosis. *Arch Orthop Trauma Surg* 113:20–22, 1993.
64. Kleeman LT, Shafritz AB: The Krukenberg procedure. *J Hand Surg [Am]* 38(1):173–175, 2013.
65. Kosay C, Akcali O, Manisali M, et al: Congenital anterior dislocation of the radial head: a case with radiographic findings identical to traumatic dislocation. *Eur J Radiol* 43:57–60, 2002.
66. Koskimies E, Lindfors N, Gissler M, et al: Congenital upper limb deficiencies and associated malformations in Finland: a population-based study. *J Hand Surg [Am]* 36(6):1058–1065, 2011.
67. Kotwal PP, Varshney MK, Soral A: Comparison of surgical treatment and nonoperative management for radial longitudinal deficiency. *J Hand Surg Eur Vol* 37(2):161–169, 2012.
68. Lawrence JF, Au K, Watts H: Letter regarding "The Krukenberg procedure." *J Hand Surg [Am]* 38(4):822, 2013.
69. Lee EH, Goh JC, Helm R, et al: Donor site morbidity following resection of the fibula. *J Bone Joint Surg Br* 72:129–131, 1990.
70. Lin HH, Strecker WB, Manske PR, et al: A surgical technique of radioulnar osteoclasis to correct severe forearm rotation deformities. *J Pediatr Orthop* 15:53–58, 1995.
71. Los FJ, Brandenburg H, Niermeijer MF: Vascular disruptive syndromes after exposure to misoprostol or chorionic villus sampling. *Lancet* 353:843–844, 1999.
72. Masada K, Tsuyuguchi Y, Kawai H, et al: Operations for forearm deformity caused by multiple osteochondromas. *J Bone Joint Surg Br* 71:24–29, 1989.
73. Masuko T, Kato H, Minami A, et al: Surgical treatment of acute elbow flexion contracture in patients with congenital proximal radioulnar synostosis. A report of two cases. *J Bone Joint Surg Am* 86:1528–1533, 2004.
74. Mathoulin C, Gilbert A, Azze RG: Congenital pseudarthrosis of the forearm: treatment of six cases with vascularized fibular graft and a review of the literature. *Microsurgery* 14:252–259, 1993.
75. Matsuno T, Ishida O, Sunagawa T, et al: Radius lengthening for the treatment of Bayne and Klug type II and type III radial longitudinal deficiency. *J Hand Surg [Am]* 31:822–829, 2006.
76. McCarroll HR, Jr, James MA, Newmeyer WL, 3rd, et al: Madelung's deformity: quantitative assessment of x-ray deformity. *J Hand Surg [Am]* 30:1211–1220, 2005.
77. McKusick VA: Exostoses, multiple, type I; EXT1. MIM number: 133700, 2003.
78. McKusick VA: Exostoses, multiple, type II; EXT2. MIM number: 133701, 2003.
79. McKusick VA: Leri-Weill dyschondrosteosis; LWD. MIM number: 127300, 2003.
80. Miller JK, Wenner SM, Kruger LM: Ulnar deficiency. *J Hand Surg [Am]* 11:822–829, 1986.

81. Miura T: Congenital dislocation of the radial head. *J Hand Surg [Br]* 15:477–481, 1990.
82. Miura T, Nakamura R, Suzuki M, et al: Congenital radio-ulnar synostosis. *J Hand Surg [Br]* 9:153–155, 1984.
83. Mo JH, Manske PR: Surgical treatment of type 0 radial longitudinal deficiency. *J Hand Surg [Am]* 29:1002–1009, 2004.
84. Murase T, Tada K, Yoshida T, et al: Derotational osteotomy at the shafts of the radius and ulna for congenital radioulnar synostosis. *J Hand Surg [Am]* 28:133–137, 2003.
85. Murphy BD, Zuker RM, Borschel GH: Vascularized composite allotransplantation: an update on medical and surgical progress and remaining challenges. *J Plast Reconstr Aesthet Surg* 66(11):1449–1455, 2013.
86. Noonan K, Levenda A, Snead J, et al: Evaluation of the forearm in untreated adult subjects with multiple hereditary osteochondromatosis. *J Bone Joint Surg Am* 84:397–403, 2002.
87. Oberg KC, Feenstra JM, Manske PR, et al: Developmental biology and classification of congenital anomalies of the hand and upper extremity. *J Hand Surg [Am]* 35:2066–2076, 2010.
88. Ogino T, Hikino K: Congenital radio-ulnar synostosis: compensatory rotation around the wrist and rotation osteotomy. *J Hand Surg [Br]* 12:173–178, 1987.
89. Ostrowski DM, Eilert RE, Waldstein G: Congenital pseudarthrosis of the ulna: a report of two cases and a review of the literature. *J Pediatr Orthop* 5:463–467, 1985.
90. Pacelli LL, Gillard J, McLoughlin SW, et al: A biomechanical analysis of donor-site ankle instability following free fibular graft harvest. *J Bone Joint Surg Am* 85:597–603, 2003.
91. Paley D, Catagni M, Argnani F, et al: Treatment of congenital pseudoarthrosis of the tibia using the Ilizarov technique. *Clin Orthop Relat Res* 280:81–93, 1992.
92. Peterson CA, Maki S, Wood MB: Clinical results of the one-bone forearm. *J Hand Surg [Am]* 20:609–618, 1995.
93. Peterson BM, McCarroll HR, Jr, James MA: Distraction lengthening of the ulna in children with radial longitudinal deficiency. *J Hand Surg [Am]* 32:1402–1407, 2007.
94. Porter DE, Simpson AH: The neoplastic pathogenesis of solitary and multiple osteochondromas. *J Pathol* 188:119–125, 1999.
95. Potenza V, Farsetti P, Caterini R, et al: Isolated Madelung's deformity: long-term follow-up study of five patients treated surgically. *J Pediatr Orthop B* 16:331–335, 2007.
96. Ramelli GP, Slongo T, Tschappeler H, et al: Congenital pseudarthrosis of the ulna and radius in two cases of neurofibromatosis type 1. *Pediatr Surg Int* 17:239–241, 2001.
97. Reichenbach H, Hormann D, Theile H: Hereditary congenital posterior dislocation of radial heads. *Am J Med Genet* 55:101–104, 1995.
98. Rizzo R, Pavone V, Corsello G, et al: Autosomal dominant and sporadic radio-ulnar synostosis. *Am J Med Genet* 68:127–134, 1997.
99. Roach JW, Klatt JW, Faulkner ND: Involvement of the spine in patients with multiple hereditary exostoses. *J Bone Joint Surg Am* 91(8):2009, 1942-1948.
100. Robitaille J, Carmichael SL, Shaw GM, et al: National Birth Defects Prevention Study: Maternal nutrient intake and risks for transverse and longitudinal limb deficiencies: data from the National Birth Defects Prevention Study, 1997-2003. *Birth Defects Res A Clin Mol Teratol* 85(9):773–779, 2009.
101. Rodgers WB, Hall JE: One-bone forearm as a salvage procedure for recalcitrant forearm deformity in hereditary multiple exostoses. *J Pediatr Orthop* 13:587–591, 1993.
102. Rotman MB, Manske PR: Radial clubhand and contralateral duplicated thumb. *J Hand Surg [Am]* 19:361–363, 1994.
103. Sachar K, Akelman E, Ehrlich MG: Radioulnar synostosis. *Hand Clin* 10:399–404, 1994.
104. Sachar K, Mih AD: Congenital radial head dislocations. *Hand Clin* 14:39–47, 1998.
105. Schmale GA, Conrad EU, 3rd, Raskind WH: The natural history of hereditary multiple exostoses. *J Bone Joint Surg Am* 76:986–992, 1994.
106. Schroven I, De Smet L, Zachee B, et al: Radial osteotomy and Sauve-Kapandji procedure for deformities of the distal radius. *Acta Orthop Belg* 61:1–5, 1995.
107. Sellers DS, Sowa DT, Moore JR, et al: Congenital pseudarthrosis of the forearm. *J Hand Surg [Am]* 13:89–93, 1988.
108. Sénès FM, Catena N: Correction of forearm deformities in congenital ulnar club hand: one-bone forearm. *J Hand Surg [Am]* 37(1):159–164, 2012.
109. Shapiro F, Simon S, Glimcher MJ: Hereditary multiple exostoses. Anthropometric, roentgenographic, and clinical aspects. *J Bone Joint Surg Am* 61:815–824, 1979.
110. Shin EK, Jones NF, Lawrence JF: Treatment of multiple hereditary osteochondromas of the forearm in children: a study of surgical procedures. *J Bone Joint Surg Br* 88:255–260, 2006.
111. Shingade VU, Shingade RV, Ughade SN: Results of single-staged rotational osteotomy in a child with congenital proximal radioulnar synostosis: subjective and objective evaluation. *J Pediatr Orthop* 34(1):63–69, 2014.
112. Simmons BP, Southmayd WW, Riseborough EJ: Congenital radioulnar synostosis. *J Hand Surg [Am]* 8:829–838, 1983.
113. Spiegel PG, Pekman WM, Rich BH, et al: The orthopedic aspects of the fetal alcohol syndrome. *Clin Orthop Relat Res* 139:58–63, 1979.
114. Stanton RP, Hansen MO: Function of the upper extremities in hereditary multiple exostoses. *J Bone Joint Surg Am* 78:568–573, 1996.
115. Suzuki O, Ishida O, Sunagawa T, et al: Congenital pseudoarthrosis of the ulna treated with a free vascularized fibular graft. *Plast Reconstr Surg* 115:1379–1384, 2005.
116. Swanson AB, Tada K, Yonenobu K: Ulnar ray deficiency: its various manifestations. *J Hand Surg [Am]* 9:658–664, 1984.
117. Taghinia AH, Al-Sheikh AA, Upton J: Preoperative soft-tissue distraction for radial longitudinal deficiency: an analysis of indications and outcomes. *Plast Reconstr Surg* 120:1305–1312, discussion 1313–1314, 2007.
118. Taniguchi K: A practical classification system for multiple cartilaginous exostosis in children. *J Pediatr Orthop* 15:585–591, 1995.
119. Vail TP, Urbaniak JR: Donor-site morbidity with use of vascularized autogenous fibular grafts. *J Bone Joint Surg Am* 78:204–211, 1996.
120. VanHeest A, Grierson Y: Dorsal rotation flap for centralization in radial longitudinal deficiency. *J Hand Surg [Am]* 32:871–875, 2007.
121. VanHeest AE, Lin TE, Bohn D: Treatment of blocked elbow flexion in congenital radioulnar synostosis with radial head excision: a case series. *J Pediatr Orthop* 33(5):540–543, 2013.
122. Vanhoenacker FM, Van Hul W, Wuyts W, et al: Hereditary multiple exostoses: from genetics to clinical syndrome and complications. *Eur J Radiol* 40:208–217, 2001.
123. Verlinsky Y, Rechitsky S, Schoolcraft W, et al: Preimplantation diagnosis for Fanconi anemia combined with HLA matching. *JAMA* 285:3130–3133, 2001.
124. Vickers D, Nielsen G: Madelung deformity: surgical prophylaxis (physiolysis) during the late growth period by resection of the dyschondrosteosis lesion. *J Hand Surg [Br]* 17:401–407, 1992.
125. Vilkki SK: Distraction and microvascular epiphysis transfer for radial club hand. *J Hand Surg [Br]* 23:445–452, 1998.
126. Vitale MG, Guha A, Skaggs DL: Orthopaedic manifestations of neurofibromatosis in children: an update. *Clin Orthop Relat Res* 401:107–118, 2002.
126a. Vuillermin C, Wall L, Mills J, et al: Soft tissue release and bilobed flap for severe radial longitudinal deficiency. *J Hand Surg* 40(5):894–899, 2015.
127. Wall LB, Ezaki M, Oishi S: Management of congenital radial longitudinal deficiency: controversies and current concepts. *Plast Reconstr Surg* 132(1):122–128, 2013.
128. Watson HK, Pitts EC, Herber S: Madelung's deformity. A surgical technique. *J Hand Surg [Br]* 18:601–605, 1993.
129. Weiland AJ, Moore JR, Daniel RK: Vascularized bone autografts. Experience with 41 cases. *Clin Orthop Relat Res* 174:87–95, 1983.
130. Witoonchart K, Uerpairojkit C, Leechavengvongs S, et al: Congenital pseudarthrosis of the forearm treated by free vascularized fibular graft: a report of three cases and a review of the literature. *J Hand Surg [Am]* 24:1045–1055, 1999.
131. Wood VE, Molitor C, Mudge MK: Hand involvement in multiple hereditary exostosis. *Hand Clin* 6:685–692, 1990.
132. Wood VE, Sauser D, Mudge D: The treatment of hereditary multiple exostosis of the upper extremity. *J Hand Surg [Am]* 10:505–513, 1985.
133. Wuyts W, Van Hul W: Molecular basis of multiple exostoses: mutations in the ext1 and ext2 genes. *Hum Mutat* 15:220–227, 2000.
134. Wynne-Davies R, Lamb DW: Congenital upper limb anomalies: an etiologic grouping of clinical, genetic, and epidemiologic data from 387 patients with "absence" defects, constriction bands, polydactylies, and syndactylies. *J Hand Surg [Am]* 10:958–964, 1985.
135. Yajima H, Tamai S, Ono H, et al: Vascularized bone grafts to the upper extremities. *Plast Reconstr Surg* 101:727–737, 1998.
136. Yang YF, Zhang GM, Huo ZQ, et al: Reconstruction of the distal ulnar epiphysis with vascularized proximal fibula including epiphysis in children after osteochondroma resection: report of two cases. *Plast Reconstr Surg* 132(5):784e–789e, 2013.
137. Yoshida K, Kawabata H, Wada M: Growth of the ulna after repeated bone lengthening in radial longitudinal deficiency. *J Pediatr Orthop* 31(6):674–678, 2011.
138. Zebala LP, Manske PR, Goldfarb CA: Madelung's deformity: a spectrum of presentation. *J Hand Surg [Am]* 32:1393–1401, 2007.

Arthrogryposis

Dan A. Zlotolow

These videos may be found at *ExpertConsult.com*:

39.1 Stiletto flap metacarpophalangeal joint chondrodesis for the clasped thumb

Any child with congenital joint contractures in two or more limbs can be classified as having *arthrogryposis multiplex congenita (AMC)*; the term does not specify any certain cause for the contractures. Arthrogryposis can result from environmental or genetic causes but is most often idiopathic. *Amyoplasia* is an idiopathic disorder with a wide range of levels of severity and anatomic involvement (Figure 39.1). *Distal arthrogryposes (DAs)* are genetic disorders with 11 discrete patterns, each with variable penetrance (Figures 39.2 to 39.4, Table 39.1).[3,15] The most common DAs are types 1, 2A, and 2B (DA1, DA2A, and DA2B). Arthrogryposis can also result from myriad disorders that compromise the central or peripheral nervous system or the musculature; currently, over 300 types have been identified.[9]

Although the cause of amyoplasia is unknown, the clinical findings result from a localized or generalized neuromuscular system underdevelopment. Muscles are either absent or hypoplastic, often replaced by fibrofatty tissue. Tendons and overlying fascia are often preserved even when no muscle is present, leading to tethering at the joints. It is not clear whether the primary insult is at the central nervous system (motor cortex), the peripheral nervous system (anterior horn cells), or the target organ (muscles), or a combination of the three, because aplasia or hypoplasia of any of these systems alone in utero would result in concomitant loss of the other systems. Maternal bicornuate uterus and oligohydramnios have been historically thought to increase the risk of amyoplasia,[20] yet recent studies have not found such a link.[9,13]

Children with amyoplasia have a characteristic appearance with high cheeks and button noses and "stork bite" hemangiomas over the occiput and the bridge of the nose.[14] Interestingly, there are a few identical twins in our practice with indistinguishable facial features, yet only one displays clinical signs and symptoms of amyoplasia. The hemangiomas are usually flat and small (Figure 39.5) but can be protuberant and even extend through the skull into the cranium. Even though the lesions are benign and most resolve or diminish over time, raised lesions should be imaged to evaluate for intracranial extension. Despite or perhaps as a result of diminution of the motor cortex, children tend to have average to above average intelligence.

PREOPERATIVE EVALUATION

History

Most children with arthrogryposis have no other medical conditions. Some, however, may have respiratory and gastrointestinal system involvement. A small percentage of children will have bowel atresia, abdominal wall defects, or gastroschisis. Approximately the same number will require mechanical ventilation at birth; they can typically be weaned to a tracheostomy and supplemental oxygen by their second or third year. Terminal limb deficits are more common in amyoplasia patients than in the general population. The family history is usually positive in DA and in other inheritable neuromuscular conditions, but it is otherwise negative. Quite a few children are adopted because their biologic parent is unable or unwilling to care for them, and the family history is therefore unavailable. The history should gauge the depth and resilience of the family support structure and the resources available.

Physical Examination

Building trust is critical to coaxing a meaningful examination from any child but doubly so for children with arthrogryposis, most of whom have already been traumatized by extensive medical interventions before ever seeing the upper extremity specialist. Begin with a global assessment of the child's cognitive, social, and physical abilities. Some children are quite affected, requiring feeding tubes and mechanical ventilation. A thorough intake worksheet can help to obtain a more complete picture of the child's needs (Figure 39.6). All of the joints of the upper limb should be examined for both active and passive motion. Watching the child play with a variety of differently shaped and sized toys is an effective way of judging the child's function. If possible, observe how the child eats finger foods or drinks from a bottle. There is no substitute for spending a few minutes playing with the child to gain a good understanding of who the child is as a person and what the child requires as a patient.

A more methodical examination of the upper limbs, when possible and age appropriate, proceeds from the shoulder to the fingertips. For the child who is unable or unwilling to respond to commands, having the child reach for toys and stickers followed by object manipulation may be the only way to examine the child. Assess every joint bilaterally in both active and passive motion as well as in the resting position. Internal rotation and adduction contractures of the shoulder are common; children with more than 90 degrees of active abduction and active external rotation past neutral rarely require any intervention about the shoulder.

Elbow flexion and/or extension contractures are also common and often suggest that there are underlying elbow flexors and extensors. The triceps is most often preserved and the elbow flexors are deficient, resulting in the more common elbow extension contractures. Occasionally, the triceps is weak or absent, causing an elbow flexion contracture. Finding the axis of rotation of the elbow in a child with less than 30 degrees of passive elbow flexion can be extremely difficult. Although historically the forearm has been thought to be in pronation in the majority of these children, most often the forearm is in neutral to slight pronation. The illusion of a pronation contracture is created by the internal rotation contracture of the shoulder combined with an extended elbow.



FIGURE 39.1 A child with amyoplasia demonstrating characteristic shoulders internally rotated with the elbows in extension and the wrists in flexion.

In patients with DA, the wrist is often in extension. Patients with amyoplasia typically have fixed wrist flexion contractures (see Figure 39.1). In the absence of active wrist extensors, some children will use the viable extensor digitorum communis (EDC) tendons to extend the wrist. This results in active extension to just shy of neutral but with concomitant metacarpophalangeal (MP) joints.

Hand function is highly variable, with intrinsic thumb flexion usually preserved even in the absence of other digital motion. There are several different patterns of hand deformities, some more commonly seen in specific AMC subtypes (Table 39.2).

Children with arthrogryposis often have lower limb involvement as well. A thorough examination of the lower limbs should be carried out by a pediatric orthopedic surgeon familiar with this disorder. The state of current and potential future ambulatory status is critical to the overall treatment strategy.

Children with arthrogryposis will typically visit the operating room several times for spine, upper extremity, and/or lower extremity correction before the age at which they become good candidates for muscle/tendon transfers (usually 6 years old or older). If the child is undergoing any procedures requiring sedation, an examination under anesthesia can be performed at the same time to determine the true extent of contractures. Percutaneous needle stimulation of individual muscles can be used to determine the suitability of the pectoralis major, latissimus dorsi, and gracilis for muscle transfer.

Diagnostic Imaging

Routine radiographs are unnecessary for patients with arthrogryposis. Some experts advocate lateral finger radiographs to evaluate phalangeal condyle hypoplasia in cases of camptodactyly. Neither computed tomography nor magnetic resonance imaging is necessary for the diagnosis or treatment of AMC. Electrodiagnostic studies are rarely necessary other than in evaluating specific neurogenic contracture syndromes. Muscle biopsy rarely yields useful information unless a specific, unusual diagnosis is being pursued.

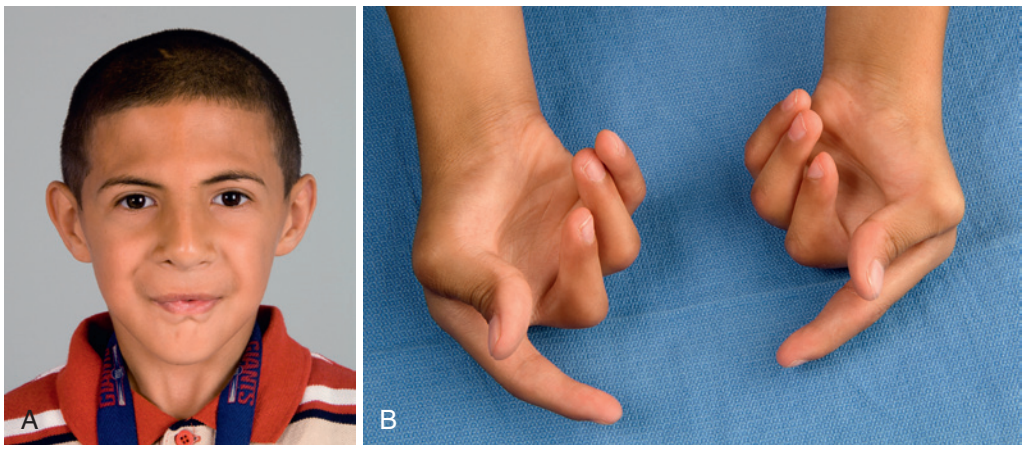

FIGURE 39.2 Distal arthrogryposis type 2A (Freeman-Sheldon syndrome) with whistling face, camptodactyly, and clasped thumb. **A,** Facial feature with whistling face. **B,** Hands with camptodactyly and clasped thumbs. (Courtesy of Shriners Hospital for Children, Philadelphia.)

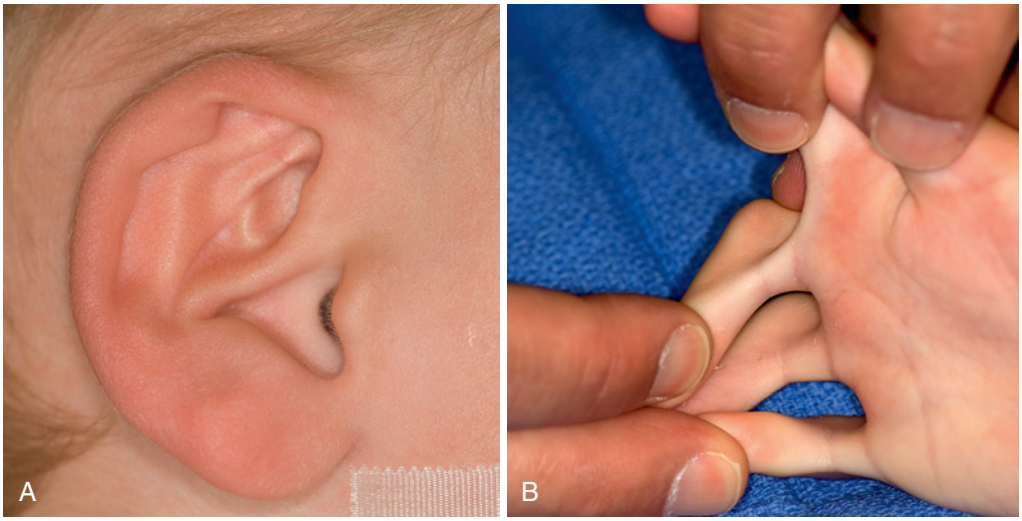

FIGURE 39.3 Distal arthrogryposis type 9A (Beals syndrome). **A,** Characteristic crumpled appearance of the upper helix of the external ear. **B,** Contractural arachnodactyly and proximal interphalangeal joint contractures. (Courtesy of Shriners Hospital for Children, Philadelphia.)

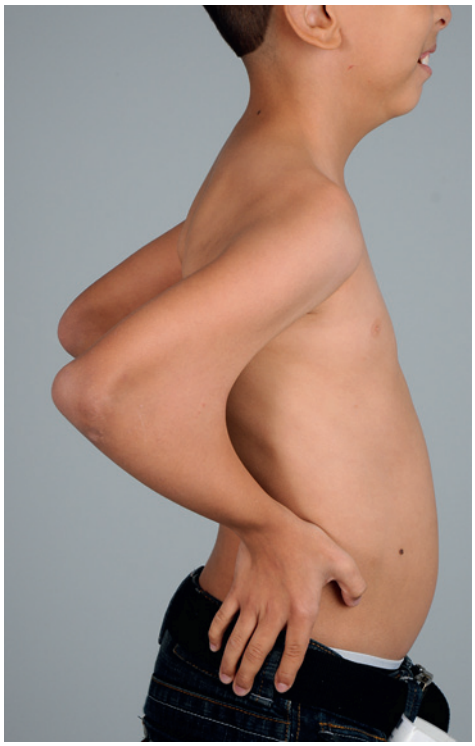

FIGURE 39.4 Distal arthrogryposis type 8A (Escobar syndrome) with multiple pterygia. (Courtesy of Shriners Hospital for Children, Philadelphia.)



FIGURE 39.5 A child with amyoplasia demonstrating the characteristic facies with a hemangioma over the nasal bridge. (Courtesy of Shriners Hospital for Children, Philadelphia.)

PERTINENT ANATOMY

Arthrogryposis affects the entire musculoskeletal system. Children with arthrogryposis have absent or hypotrophic muscles but may retain the associated tendons and overlying fascia. As the child grows, these noncontractile tissues can tether the joints, which may lead to joint contractures. Because the bones do not have the normal load of muscle activity or weight bearing, they may be severely osteopenic. Cortices in these children tend to be quite thick, but the bones are of small diameter and the medullary canal is nearly absent. The motor and mixed nerves are also small in caliber compared with those in other children of the same size. With thin bones and a hypoplastic musculature, the subcutaneous fat encompasses a larger than expected percentage of the bulk of the arms.

Historical Review

A historical review of milestones in the treatment of AMC is shown in Table 39.3.

TABLE 39.1 Distal Arthrogryposis Types

Distal Arthrogryposis Types	Other Name(s)	Label	Characteristic Findings
Distal arthrogryposis type 1	Common or typical	DA1	Camptodactyly, clasped thumb, clubfoot
Distal arthrogryposis type 2A	Freeman-Sheldon syndrome	DA2A	Whistling face, camptodactyly, clasped thumb, clubfoot, scoliosis
Distal arthrogryposis type 2B	Sheldon-Hall syndrome	DA2B	Prominent nasolabial folds, down-slanting palpebral fissures, small mouth, camptodactyly, clasped thumb, clubfoot
Distal arthrogryposis type 3	Gordon syndrome	DA3	Short stature, cleft palate
Distal arthrogryposis type 4	Scoliosis	DA4	Scoliosis, camptodactyly
Distal arthrogryposis type 5	Ophthalmoplegia, ptosis	DA5	Ptosis, strabismus, restrictive lung disease
Distal arthrogryposis type 6	Sensorineural hearing loss	DA6	Hearing loss, camptodactyly
Distal arthrogryposis type 7	Trismus-pseudocamptodactyly	DA7	Trismus, pseudocamptodactyly, short stature
Distal arthrogryposis type 8	Autosomal dominant multiple pterygium syndrome, Escobar syndrome	DA8	Multiple pterygia, camptodactyly, scoliosis, ptosis, down-slanting palpebral fissures
Distal arthrogryposis type 9	Beals syndrome (congenital contractural arachnodactyly)	DA9	Camptodactyly, arachnodactyly, kinked upper earlobe, tall stature
Distal arthrogryposis type 10	Congenital plantar contractures	DA10	Plantar contractures

Adapted from Bamshad M, Van Heest AE, Pleasure D: Arthrogryposis: a review and update. *J Bone Joint Surg Am* 91(Suppl 4):40–46, 2009.

TABLE 39.2 Classification of Thumb Contractures in Children With Arthrogryposis*

	JOINT POSITION	
Classification	CMC	MCP
Type 1	Extended	Flexed
Type 2	Flexed	Extended
Type 3	Flexed	Flexed

*Subtype A is passively correctable, and subtype B is not correctable.
CMC, Carpometacarpal; *MCP*, metacarpophalangeal.

SURGICAL PROCEDURES

The goal of any treatment plan for a child with arthrogryposis is to maximize functional independence for that child. For the lower extremities, the goals are ambulation and sitting. Traditionally, ambulation has trumped all other treatment goals. In many centers, the lack of expertise and familiarity with upper limb surgery relegates upper limb function to an afterthought. This dismissal is a disservice to these children and to the adults who care for them. Basic upper limb function is just as important to the well-being of these children as ambulation. For the upper extremity, the primary goals are to have "one hand to eat and one to wipe." They can be the same hand. The rate-limiting step in optimizing the child's independence is always finger and thumb motion. Independent self-feeding requires at least some hand function. The child must be able to acquire the food, grip it firmly enough to bring it to the mouth, and release it. Beyond that, the wrist and the elbow combined must have enough extension to reach the plate or the table and sufficient flexion to allow the hand to reach the mouth. Forearm and shoulder rotation need to allow the hand to face the plate and then the mouth. In very impaired children, independent feeding may be an unrealistic goal. A skilled therapist and the use of adaptive equipment may achieve some independence (Figure 39.7).

Perineal care can be performed through the legs or around the back. Both require sufficient hand function to hold toilet paper firmly. Children who wipe their buttocks through the legs require wrist flexion, elbow extension, and shoulder internal rotation. Children who wipe their buttocks around the back require forearm supination, elbow extension, and shoulder extension.

The next priorities on the functional ladder are bathing and dressing, followed by food preparation, driving, and other activities of daily living. Recreational activities and sports participation may be achievable in mildly affected children.

Humeral External Rotation Osteotomy

Indications

Children with arthrogryposis typically present with internal rotation and adduction contractures. Elbow extension contractures can create the appearance of a pronation contracture, but most often the posture results from internal rotation at the shoulder with the forearm most often in neutral. The deltoid, rotator cuff, pectoralis, latissimus dorsi, and periscapular muscles may be weak or absent. Although rarely responsive to passive stretching, a course of therapy is recommended. Capsular releases have not been effective. Internal rotation contractures are best treated with a humeral external rotation osteotomy. The medial approach requires visualization and retraction of the median and ulnar nerves but is more cosmetic and provides a better bony surface for plate application than the deltopectoral approach.[18] For the child with a severe elbow extension contracture, distinguishing between an internal rotation contracture at the elbow and a pronation contracture at the forearm can be difficult. For these children, we will perform an elbow release first, followed by a humeral rotational osteotomy if needed. We rarely perform bilateral procedures in these children because the margin of error is so small for losing midline function.

Contraindications

Relative contraindications include (1) insufficient internal rotation for perineal care, (2) older age with established crossover

Upper Extremity Arthrogryposis Assessment

Chief Complaint	_____
History of Present Illness	
Age _____mo/yr	Hand dominance R/L/Amb/unknown Male/Female
Gestational complications	oligohydramnios/bicornuate uterus/multiples(twin, triplet, quad)/other _____
Delivery	breech/vertex/shoulder/C-section/other _____
Diagnosis on prenatal US	No/Yes (_____wks)
Family history	None/Distal Arthrogryposis (type _____)/club feet/camptodactyly/other _____
	Other family members affected are mother/father/brother(s) age _____/sister(s) age _____/other _____
Respiratory Status	never supported/required intubation from _____ to _____/required tracheotomy from _____ to _____
Contractures at birth	
Shoulder	mobile/adduction contracture/internal rotation contracture/other _____
Elbow	mobile/flexion contracture/extension contracture
Forearm	mobile/supination/pronation contracture
Wrist	mobile/flexion contracture/extension contracture
Thumb	mobile/thumb-in-palm fixed/thumb-in-palm correctable
Fingers	mobile/flexion contracture/extension contracture
Functional Assessment	
Feeding (R/L/Amb)	unable/finger foods/regular utensils/modified utensils/feet/other _____
Perineal Care (R/L/Amb)	unable/through the legs/around the back/assistive devices only
Writing (R/L/Amb)	easy/difficult/with modified pen/with assistive devices _____
Ambulation	unable/single arm crutch (R/L)/bilateral crutches/AFO/AKFO/HKFO/other _____
Splints	
Elbow	extension/flexion night/day/full-time
Wrist	extension/flexion night/day/full-time
Hand	extension/flexion night/day/full-time
PMHx	_____
PSHx	_____
Meds	_____
Allergies	_____
SocHx	_____
ROS	cardiac -/+_____ pulmonary -/+_____
Other	

Examination				
General	well appearing/agitated/cooperative/uncooperative		stork bite (yes/no)	
Ambulation	normal/stiff legged/with single arm crutch (R/L)/with bilateral crutches/with AFO/with AKFO/scoots only/other_____			
Primary prehension, right	elbow/forearm/wrist/hand/passive fingers/active grasp/active pinch			
Primary prehension, left	elbow/forearm/wrist/hand/passive fingers/active grasp/active pinch			
Right side				
Shoulder	abduction active _____/passive _____		external rotation active _____/passive _____	
Elbow	flexion active _____/passive _____		extension active _____/passive _____	Pterigium yes/no
Forearm	supination active _____/passive _____		pronation active _____/passive _____	
Wrist	flexion active _____/passive _____		extension active _____/passive _____	
Thumb	CMC flexion active _____/passive _____		CMC extension active _____/passive _____	
	MP flexion active _____/passive _____		MP extension active _____/passive _____	
Fingers	MP flexion active _____/passive _____		MP extension active _____/passive _____	
	PIP flexion active _____/passive _____		PIP extension active _____/passive _____	
Camptodactyly	index_____	long_____	ring _____	small _____
Core muscle strength	pectoralis ____/5	latissimus ____/5		
Sensation	intact U M R/diminished to light touch U M R			
Skin	intact/scar(s) over shoulder/elbow/forearm/wrist/hand/thumb/fingers			
Vascularity	cap refill brisk/delayed			
Left side				
Shoulder	abduction active _____/passive _____		external rotation active _____/passive_____	
Elbow	flexion active _____/passive _____		extension active _____/passive _____	Pterigium yes/no
Forearm	supination active _____/passive _____		pronation active _____/passive _____	
Wrist	flexion active _____/passive _____		extension active _____/passive _____	
Thumb	CMC flexion active _____/passive _____		CMC extension active _____/passive _____	
	MP flexion active _____/passive _____		MP extension active _____/passive _____	
Fingers	MP flexion active _____/passive _____		MP extension active _____/passive _____	
	PIP flexion active _____/passive _____		PIP extension active _____/passive _____	
Camptodactyly	index_____	long_____	ring_____	small_____
Core muscle strength	pectoralis ____/5	latissimus ____/5		
Sensation	intact U M R/diminished to light touch U M R			
Skin	intact/scar(s) over shoulder/elbow/forearm/wrist/hand/thumb/fingers			
Vascularity	cap refill brisk/delayed			

FIGURE 39.6 An intake worksheet can be very helpful to get a thorough assessment of the child.

TABLE 39.3 Historical Review of Milestones in the Treatment of Arthrogryposis

Date	Article	Comments
1841	Otto AW: Monstrum humanum extremitatibus incurvatus: monstrorum sexcentrorum descriptio anatomica in Vratislaviae Museum [English translation], *Clin Orthop Relat Res* 194:44-53, 1985	"A human monster with inwardly curved extremities"
1897	Schanz A: Ein Fall von multiplen kongenitalen Kontracturen, *Z Orthop Chir* 5:9-15, 1897	"Multiple congenital contractures"
1905	Rosencranz E: Ueber kongenitale Kontracturen der oberen Extremitaten, *Z Orthop Chir* 14:52, 1905	"Arthrogryposis"
1923	Stern WG: Athrogryposis multiplex congenita, *JAMA* 81:1507, 1923	"Arthrogryposis multiplex congenita"
1925	Lewin P: Arthrogryposis multiplex congenita, *J Bone Joint Surg Am* 7:630-636, 1925	"Attempts to produce movable joints are not highly successful"
1952	Hillman JW, Johnson JTH: Arthrogryposis multiplex congenita in twins, *J Bone Joint Surg Am* 34:211-214, 1952	Reported two cases of monozygotic twins where only one of the twins was affected; concluded that the cause was not genetic
1958	Meade NG, Lithgow WC, Sweeney HJ: Arthrogryposis multiplex congenita, *J Bone Joint Surg Am* 40:1285-1309, 1958	Refuted preexisting idea that children with arthrogryposis were of below-normal intelligence; in their series of 40 patients, 29 had upper extremity involvement
1970	Carroll RE, Hill NA: A study of fifteen patients with paralytic lesions and arthrogryposis, *J Bone Joint Surg Am* 52(2):239-244, 1970	Unpredictable results with triceps to biceps transfers in eight patients with arthrogryposis
1973	Williams PF: The elbow in arthrogryposis, *J Bone Joint Surg Br* 55(4):834-840, 1973	Achieved an average of 65 degrees of elbow motion in four patients after tricepsplasty (posterior elbow release)
1984	Yonenobu K, Tada K, Swanson AB: Arthrogryposis of the hand, *J Pediatr Orthop* 4:599-603, 1984	Showed improvement in posture and function with soft tissue and bony procedures to correct thumb-in-palm deformities and finger contractures/ulnar drift
1985	Bennett JB, Hansen PE, Granberry WM, Cain TE: Surgical management of arthrogryposis in the upper extremity, *J Pediatr Orthop* 5:281-286, 1985	Created surgical treatment algorithm for the upper extremity that serves as the basis for current treatment paradigm
1985	Palmer PM, MacEwen GD, Bowen JR, Mathews PA: Passive motion therapy for infants with arthrogryposis, *Clin Orthop Relat Res* 194:54-59, 1985	Early passive stretching and serial splinting improved motion and function

grasp (Figure 39.8), and (3) absence of pectoralis function. Children who lack pectoralis function but retain triceps function will use an obligatory crossover grasp pattern that requires internal rotation.

Preoperative Planning

Plates and screws of the appropriate size are required and are often a size smaller than what would be expected for a humerus of an unaffected child of the same age.

Technique

Place the patient supine on a standard operating room table with a hand table. Regional anesthesia may be used to control postoperative pain along with general anesthesia. If a tourniquet is used, the Hemaclear tourniquet (Hemaclear, OHK Medical Devices, Grandville, MI) allows sufficient proximal exposure. If a tourniquet is not used, inject bupivacaine with epinephrine subcutaneously along the length of the intended incision. Prepare and drape the arm to the axilla.

Incise the skin and raise full-thickness subcutaneous flaps while preserving the medial brachial and antebrachial cutaneous nerves, as well as the basilic vein. Incise the fascia between the median and ulnar nerves along the intermuscular septum. Regular palpation is required to feel the humerus because muscle planes may not be clearly delineated. Using a periosteal elevator, expose the humerus extraperiosteally to a length sufficient to place a plate. Plates of 2.4 mm to 3.5 mm are used for this operation and should be appropriate for the size of the bone. Gently precontour the plate so as to provide compression on the far side of the bone.

Apply the plate provisionally to the proximal osteotomy fragment as far anterior as the soft tissues will allow. Remove the plate. Split the periosteum longitudinally and apply Hohmann retractors to protect the surrounding neurovascular structures. Perform a transverse osteotomy using a reciprocating saw while preserving the periosteal sleeve. Reapply the plate to the proximal fragment. Place a fracture reduction clamp around the distal fragment and the plate. Externally rotate the arm to the desired position of between neutral and 15 degrees of internal rotation. Provisionally clamp the distal humeral fragment to the plate and reassess the rotation of the arm. Sufficient internal rotation should be preserved to allow for midline function, such as perineal care. Fix the plate to the distal fragment with a single screw and reassess one more time (Figure 39.9, *A*). If the position of the arm is optimized, confirm the screw lengths and plate position using fluoroscopy (see Figure 39.9, *B*).

Close the subcutaneous layer and the skin in standard fashion. Place the elbow in 90 degrees of flexion and apply a sterile dressing followed by a long-arm splint with a side bar to prevent elbow extension. If the fixation was felt to be tenuous or the child is very active, a triangular wedge can be used to place the arm in a "gunslinger position" (Figure 39.10).



FIGURE 39.7 Adaptive equipment to facilitate feeding. **A,** Spoon in mouth for scooping food. **B,** Spoon placed in adaptive holder. **C,** Food placed in mouth. (Courtesy of Shriners Hospital for Children, Philadelphia.)

❖ AUTHOR'S PREFERRED METHOD OF TREATMENT

Alternative approaches to a humeral osteotomy include the posterior and anterolateral approaches. The advantages of the medial approach are primarily cosmetic, because the majority of children keep the shoulders adducted and conceal the scar. We are currently evaluating concomitant elbow release and humeral rotational osteotomy, but early results are not promising. For the time being, it is better to perform the elbow release at a separate time.



FIGURE 39.8 Children without elbow flexion or who have inadequate shoulder external rotation will use a crossover grasp pattern. (Courtesy of Shriners Hospital for Children, Philadelphia.)

CRITICAL POINTS *Humeral External Rotation Osteotomy*

- Make sure that the patient has internal rotation to spare before considering an external rotation osteotomy.
- Make sure that the internal rotation/pronation posture is truly coming from the shoulder and not from the forearm.
- If there is less than 30 degrees of elbow flexion, consider an elbow release prior to humeral osteotomy.
- For the medial approach, identify and gently retract the ulnar and median nerves.
- Apply the plate proximally first to simplify the procedure before making the osteotomy.
- Protect the radial nerve with Hohmann retractors deep to the periosteum while making the osteotomy.
- Gently precontour the plate to provide far-side compression.
- Test the amount of rotation several times before final fixation to ensure an optimal position.
- Use a gunslinger brace if the child is prone to falling or if the fixation is suboptimal.
- Use a fracture brace after 4 weeks if the osteotomy has not healed.
- Beware of long-term periimplant fractures.

Postoperative Management and Expectations

Expected Outcomes. Union is typically achieved between 4 and 6 weeks, although occasionally it may take up to 10 weeks. Remove the splint 4 weeks after surgery and outfit the child with a fracture orthosis (Figure 39.11) if union has not been achieved. Begin a passive range-of-motion protocol while maintaining the orthosis at all other times until union. Patients can expect improvements in hand-to-mouth and hand-to-neck activities

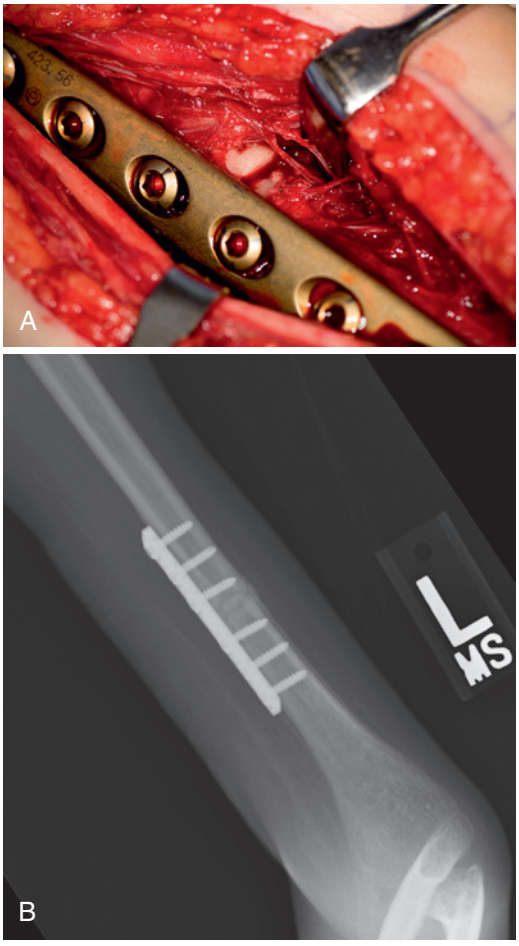

FIGURE 39.9 **A,** Intraoperative photograph and **B,** anteroposterior radiograph of a humeral rotational osteotomy performed via a medial approach. Note the relatively small caliber of the humerus compared with the length of the arm, as is commonly seen in children with amyoplasia.



FIGURE 39.10 A triangular wedge can be made out of rolls of cast padding to maintain the arm in a gunslinger position. (Adapted from Zlotolow DA, Thompson SJ: *Handbook of splinting and casting,* Philadelphia, 2011, Elsevier.)



FIGURE 39.11 A fracture orthosis can be used to protect the osteotomy site until union is achieved. (Courtesy of Shriners Hospital for Children, Philadelphia.)

if there is adequate elbow and shoulder motion. Bimanual tasks are also more easily performed because the hands should face each other after the osteotomy. Bilateral osteotomies may be required, but staging them is preferred.

Complications. Overrotation or underrotation is the most common complication. Typically, younger children will correct for overrotation but will not correct for underrotation. Older children, particularly those with minimal shoulder rotation, have a lesser margin for error. Neurapraxia of any of the major nerves can also occur, but more considerable nerve injuries are rare. If nerve function has not recovered after 2 to 3 months, electrodiagnostic studies are warranted. Infections and nonunions are rare, but delayed unions do occur, especially if there is a gap at the osteotomy site or if the periosteum was stripped. Fractures at the ends of the plate are an ongoing concern.

Elbow Extension Contracture Release

Indications

Most children with arthrogryposis lack adequate elbow flexion to oppose the working triceps, leading to extension contractures. Some children have active elbow flexion but no extension, leading to flexion contractures; pterygium is common in this group. Other children have only a jog of passive motion at the elbow. If the child cannot flex the elbow more than 30 degrees, the true axis of rotation of the elbow joint can be difficult to determine. Caretakers and health care professionals are discouraged from performing passive range of motion of these elbows because inadvertent collateral ligament damage or physeal injuries can result.

Impressive gains in elbow range of motion can be made in some children who can flex the elbow beyond 30 degrees. Progressive static splinting, as can be accomplished with an



FIGURE 39.12 An hourglass splint **(A)** can be used to help gain more elbow flexion both before and after surgery provided the patient has at least 60 degrees of flexion to begin with. Alternatives include an anteroposterior splint **(B)** or an adjustable static progressive splint **(C)**.

hourglass splint (Figure 39.12), will augment and preserve the gains made with therapy. Passive hand-to-mouth motion can allow the child to perform feeding and grooming tasks by pushing the arm against the knee or other arm, a desk, or a table, or by abducting the shoulder and allowing gravity to flex the elbow (Figure 39.13).

Indications for surgical release include less than 30 degrees of elbow flexion by 12 to 18 months of age and failure to achieve sufficient elbow flexion for self-feeding at any age.

Elbow flexion contractures are even more difficult to treat. The paradigm is the same initially, with passive range-of-motion exercises and splinting. Most children with elbow flexion contractures lack triceps function and some also lack active flexion. A pterygium across the antecubital fossa commonly accompanies elbow flexion contractures (Figure 39.14) and is a harbinger of a more recalcitrant problem. There is as yet no reliable surgical or nonsurgical technique to resolve these contractures.

Contraindications

Relative contraindications include (1) having a contralateral side elbow flexion contracture that prohibits perineal care and (2) a requirement of triceps function for ambulation.

Preoperative Planning

No specialized equipment is required.

Technique

Place the patient supine on a standard operating room table without a hand table. Prepare and drape the arm to the axilla. If a tourniquet is being used, a Hemaclear tourniquet (Hemaclear, OHK Medical Devices, Grandville, MI) allows sufficient proximal exposure. If a tourniquet is not being used, inject bupivacaine with epinephrine subcutaneously the length of the intended incision.

Define the anatomic landmarks of the elbow, beginning with the olecranon, by following the subcutaneous border of the ulna in a proximal direction. Confirm the position of the olecranon by identifying the medial and lateral epicondyles. If there is any doubt, fluoroscopic images are obtained.

The incision should run the entire length of the triceps tendon, at least midway up the brachium, curving ulnar to the olecranon. Raise full-thickness subcutaneous flaps both medially and laterally just past the level of the epicondyles. The ulnar nerve is identified just proximal to the cubital tunnel beneath a thick fasciotendinous band of the triceps that inserts onto the medial epicondyle and the ulnar side of the olecranon.



FIGURE 39.13 Children can use passive flexion of the elbow to feed themselves by pushing the forearm against the knee **(A)**, a table **(B)**, or the other arm **(C)** or by abducting the shoulder and allowing gravity to flex the elbow **(D)**.

Transpose the ulnar nerve anteriorly into a subcutaneous pocket, and suture the subcutaneous fat to the anterior aspect of the medial epicondyle to close the pocket (Figure 39.15, *A*). Make sure that the medial antebrachial cutaneous nerve and its branches are not sutured in the fat. After transposition, confirm that the ulnar nerve is not kinked or compressed anywhere along its new course.

Make a full-length triceps tendon incision in a distally based "V"-shape (see Figure 39.15, *B*), leaving enough tendon on the muscle to later perform a "V-to-Y" repair. Elevate the "V"-tendon flap off of the muscle using bipolar electrocautery up to the olecranon. Release any remaining triceps attachments to the medial and lateral epicondyles. Release the fat pad and the posterior capsule, keeping them in continuity with the proximal triceps muscle and tendon. Release the capsule along the medial and lateral gutters as distally as possible without destabilizing the medial and lateral ligaments (see Figure 39.15, *C*). Continue incremental releases until the elbow can flex past 90 degrees. The maximum flexion is usually 120 degrees. Forcing the elbow into flexion to gain additional motion not afforded by the release will lead to a transphyseal fracture of the distal humerus. If there is nothing left to release posteriorly or medially and laterally along the elbow but elbow flexion is still inadequate to reach the mouth, consider an anterior closing wedge humeral osteotomy just proximal to the olecranon fossa during this operation or at a later date, particularly if an external rotation osteotomy is required.

To optimize triceps excursion, elevate the medial head of the triceps off of the posterior humerus extraperiosteally to the level of the spiral groove (see Figure 39.15, *D*). Identify the radial nerve by following the lower lateral brachial cutaneous nerve to the spiral groove because the brachioradialis and brachialis are often absent and the nerve is usually hidden by fat in the lateral elbow and can be difficult to find.[28]

Repair the triceps in a "V-to-Y" procedure with the arm in maximal flexion using a braided nonabsorbable suture (see



FIGURE 39.14 Children with elbow flexion contractures often have a pterygium over the antecubital fossa.

Figure 39.15, *E*). If the length of the "V" is insufficient to allow for a primary repair, autograft or allograft may be used to bridge the gap. A properly planned triceps tendon flap and medial head elevation avoid this problem.

Reevaluate the ulnar nerve, and close the skin in layers. If there is a lot of tension on the wound, elbow extension can help as the wound is being closed. Apply a sterile dressing with the elbow in maximal flexion followed by a long-arm splint. If the soft tissue envelope is too edematous to allow for positioning of the elbow in maximal elbow flexion, flex the arm to the degree the soft tissues will tolerate and immobilize it in that position.

Remove the splint 2 weeks after surgery and outfit the arm with an hourglass splint (see Figure 39.15, *F*). Begin a passive range-of-motion protocol while maintaining the hourglass splint at all other times for 6 weeks. If soft tissue edema prevented splinting of the elbow past 90 degrees of flexion at the time of surgery, change the splint with the patient sedated 1 week after surgery to recover the missing flexion. Continue range-of-motion exercises through the fourth postoperative

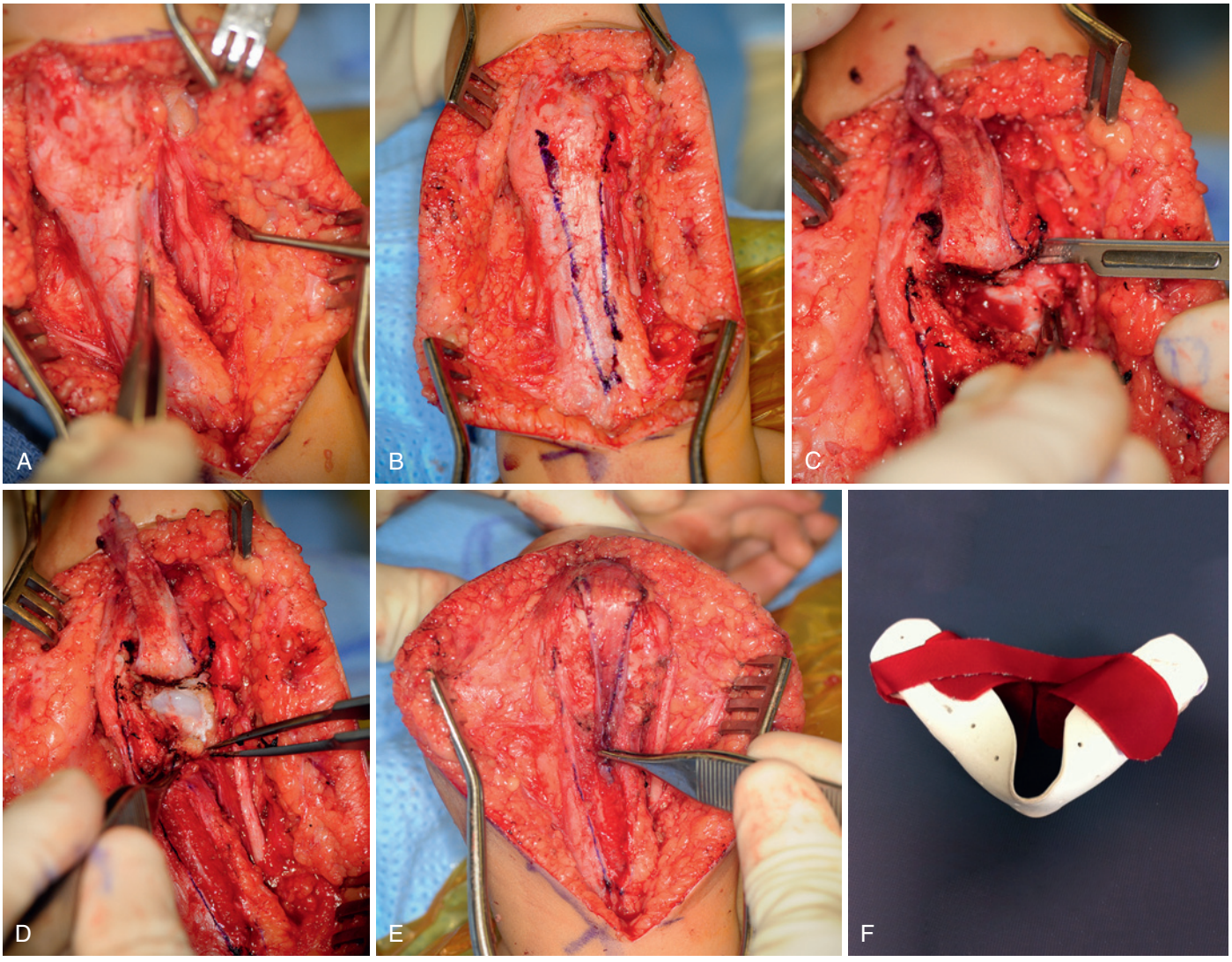

FIGURE 39.15 Releasing an elbow extension contracture requires transposition of the ulnar nerve **(A)**, creation of a "V"-shaped distally based triceps tendon flap **(B)**, release of the posterior capsule **(C)**, elevation of the medial head of the triceps **(D)**, and repair of the triceps in a "V-to-Y" fashion **(E)**. Postoperative splinting includes an hourglass splint **(F)**.

month while weaning the patient from the hourglass splint, so that it is used at night and during naps only. Alternate an elbow extension splint with the hourglass splint if elbow extension is difficult to recover.

❖ AUTHOR'S PREFERRED METHOD OF TREATMENT

There are multiple ways to lengthen the triceps and release the capsule. Some surgeons prefer a "W"-type triceps tendon flap, and this has worked as well for their patients as the "V-to-Y" flap. I prefer the "Y" flap procedure because it is simpler to perform and requires fewer suture lines. The key is to make the flaps the length of the triceps tendon to allow adequate overlap once the elbow is flexed. If the ends do not meet, a turndown flap or allograft/autograft is required.

To augment excursion of the triceps muscle itself rather than simply elongate the tendon, I also perform a slide of the medial head of the triceps to the level of the spiral groove. The muscle origin is released from the humerus above the periosteum with a bipolar cautery or blunt dissection. This usually allows the medial head to reach the olecranon and enhances the tendon repair.

CRITICAL POINTS *Elbow Extension Contracture Release*

- Transpose the ulnar nerve first to minimize the risk to the nerve.
- Make a long "V" incision in the triceps tendon, leaving just enough of a tendinous cuff intact on the proximal side to allow for tendon repair.
- Beware of false planes when releasing the capsule from the medial and lateral gutters; the physeal cartilage can look like capsule.
- Release the posterior capsule over the medial and lateral epicondyles.
- Maintain the collateral ligaments.
- Try for 120 degrees of flexion but settle for 90 degrees rather than jeopardizing the integrity of the collateral ligaments.
- Avoid forceful passive elbow flexion because it may cause physeal separation.
- Release the medial head of the triceps off of its origin to allow it to slide in a distal direction.
- Repair the triceps with the elbow in maximal flexion.
- Begin passive range of motion after 2 weeks.
- Use both an elbow flexion splint and an elbow extension splint as needed until the patient's range of motion stabilizes in the desired arc.

Postoperative Management and Expectations

Expected Outcomes. The results of triceps lengthening, posterior capsular release, and ulnar nerve transposition have been promising.[24] Terminal extension loss and triceps weakness are possible, but most children achieve sufficient passive flexion to feed themselves. The results are most predictable in children under the age of 3 years, but releases in older children are still possible with variable outcomes.[29] Active elbow flexion has been seen in some children after a release without tendon or muscle transfer, but this is rare and should not be expected.

Because of the potential loss of elbow extension after a release, bilateral releases are discouraged. Begin with the arm most likely to have an adequate hand for feeding (i.e., the dominant hand). Do not release the nondominant side until the child demonstrates at least the potential to carry out perineal care with the arm that has already undergone a release. Remember the doctrine "one hand to wipe and one hand to eat," but it can be the same hand.

Complications. Complications such as ulnar and/or radial nerve injury are rare, but triceps insufficiency and elbow stiffness do occur.

Bipolar Latissimus Dorsi Transfer

Indications

Active elbow flexion is rarely achievable in children with arthrogryposis. On occasion, an elbow release alone will allow a previously restrained biceps or brachialis to flex the elbow. The "new" active flexor function is typically a grade 1 or a weak grade 2, and rarely provides enough active flexion to truly enhance function. In a child with passive motion who would benefit from active elbow flexion, there are several options for achieving active flexion. Transfer of the entire triceps to the biceps has proven to be a poor option, with many children developing elbow flexion contractures.[26]

Transferring only the long head of the triceps may avoid the flexion contracture that results from transferring the entire triceps. However, proponents of this technique have yet to demonstrate a substantial improvement in function from this transfer.[11a] More experience with this transfer is needed before it can be recommended for widespread use.

Other options for restoring active elbow flexion are a Steindler flexorplasty,[12] a unipolar or bipolar pectoralis major transfer,[6,7] a bipolar latissimus dorsi transfer,[27] and a free muscle transfer.[16] When present, the latissimus dorsi is the best choice for restoring active elbow flexion. The pectoralis major transfer has also been described; there is a possibility for functional loss and cosmetic disfigurement, however.[6,19] Transfer of only the sternocostal portion of the pectoralis major may be a better option from the standpoint of appearance, but it may not be of sufficient strength.

Contraindications

Poor triceps function is a contraindication to any transfer for active elbow flexion. Patients who have had a previous triceps lengthening typically have compromised triceps strength and are usually not candidates for active elbow flexion transfers. If the latissimus is difficult to palpate, it is probably not suitable for transfer. Poor passive elbow flexion of less than 90 degrees is another contraindication.

Preoperative Planning

No specialized equipment is necessary.

Technique

After inducing general anesthesia, place the patient on a bean bag in a lateral decubitus position (Figure 39.16). Pad all bony prominences and place an axillary roll. Drape out from the midline on the back to the nipple line on the front and from the base of the neck to the iliac crest. The peroneal nerve should be protected from compression at the level of the fibular head.

Make an incision in line with the lateral border of the muscle, from the posterior axillary fold to about the midpoint of the posterior iliac crest. We tend not to use a skin paddle to augment the skin. Children with arthrogryposis generally have a small latissimus dorsi and abundant skin and subcutaneous fat in the



FIGURE 39.16 Eight-year-old boy with arthrogryposis and no active elbow flexion. **A,** Good passive elbow flexion. **B,** Harvest of the bipolar latissimus dorsi muscle on a thoracodorsal neurovascular pedicle. **C,** Latissimus dorsi muscle transferred from the back to the anterior of the arm. **D,** Latissimus dorsi attached to the biceps to complete the flexorplasty. Acceptable elbow flexion for hand-to-mouth activity after latissimus flexorplasty. (**A** to **D,** Courtesy of Shriners Hospital for Children, Philadelphia.)

arm. If a skin paddle is used, it should be small enough to allow primary closure of the harvest site.

Dissect down to the level of the latissimus dorsi fascia. Release the muscle from its attachments, maintaining meticulous hemostasis (see Figure 39.16, *B*). Identify the thoracodorsal artery, vein, and nerve as they emerge deep to the latissimus and trace them back to the axillary artery and the brachial plexus. Ligate the vascular branches to the serratus to gain maximal length on the pedicle. Identify and preserve the long thoracic nerve to the serratus running near the vascular branches. More proximally, the circumflex scapular artery and veins may need to be ligated to increase the length to the pedicle.

Once the pedicle is isolated, separate the latissimus from the teres major and expose the insertion. If the teres major and latissimus share a conjoined insertional tendon, divide the latissimus tendon as close to the humerus as possible while maintaining the teres insertion to bone. The axillary nerve and posterior circumflex humeral vessels are deep to the latissimus and teres major near their insertions onto the humerus. Place a Penrose drain around the latissimus insertion and provisionally close the donor incision with a few staples or towel clamps to prevent desiccation of the wound.

Open the deltopectoral interval down to the coracoid with an incision large enough to pass the latissimus. Expose the coracoid and place two transosseous sutures into the coracoid for later tendon fixation using braided, nonabsorbable sutures in older children or polydioxanone monofilament suture in skeletally immature children. Make an "S"-shaped incision at

the antecubital fossa and dissect down to the biceps tendon. If the child has no active pronation, consider transferring the latissimus to the brachialis or directly into the ulna instead. Surprisingly, most children will have a biceps tendon that flexes the elbow when pulled in a proximal direction even though there is often no muscle present. Create a generous subcutaneous tunnel from the distal to the proximal arm incision and pass a Penrose drain to mark the tunnel.

Create a subcutaneous tunnel from the deltopectoral interval to the proximal arm incision. Mark the path of the tunnel with a Penrose drain. Detach the latissimus insertion off of the bone with a periosteal cuff, taking care not to injure the adjacent posterior circumflex humeral vessels. Before passing the muscle, reevaluate the length and freedom of the pedicle one final time. Pass the latissimus into the proximal arm wound. It is safer to pass the origin side first because the origin is further from the pedicle than the insertion and is therefore less likely to put tension on the pedicle.

Check the tension on the pedicle continuously as the muscle is transferred (see Figure 39.12, *C*). Provisionally place the insertion over the coracoid and recheck the tension on the pedicle. The muscle should be vascularized and the pedicle should be loose without having been rotated. If the muscle is questionable or the pedicle is tight, return the latissimus to the harvest wound and revisit the pedicle to achieve more length. There may be a tethering vessel or a traversing band of axillary fascia limiting pedicle excursion. The tunnel position may need to be revised to shorten the distance the pedicle must travel.

Affix the insertion of the latissimus to the coracoid using the previously passed sutures. Pass the origin of the latissimus into the distal wound through the subcutaneous tunnel. The length should be more than adequate to reach the biceps tendon or the proximal ulna if necessary. Remove any excess muscle and tubularize the latissimus and suture the end to the biceps tendon or directly to the ulna just distal to the coronoid. The tension should be set so that the elbow is difficult to extend past 30 degrees of flexion.

Recheck the pedicle and reevaluate the condition of the muscle. If a skin paddle is being used, it can evaluate the vascularity of the flap. Alternatively, a Cook-Swartz Doppler flow monitor system (Cook Medical, Bloomington, IN) can be assembled. However, if the pedicle is loose and the muscle is well perfused, there is little need for postoperative monitoring of muscle viability.

Close the wounds in standard fashion with one or two large drains in the back, maintaining the elbow in flexion during the closure. Apply a sterile dressing and splint the arm with a sling in 90 degrees of flexion.

After 4 to 6 weeks, remove the splint and outfit the patient with a hinged elbow brace. The brace should be used at all times except for bathing. It is initially locked to prevent extension past 90 degrees but allow full flexion. Each week, the extension is advanced by 15 degrees as long as active flexion is maintained. By around 3 months after surgery, full extension should be achieved and the brace can be removed. Begin strengthening exercises once motion is restored.

❖ AUTHOR'S PREFERRED METHOD OF TREATMENT

Most parents understandably wish for their child to achieve active elbow flexion. Unfortunately, this is not possible for the majority of patients. Partial triceps transfers and pectoralis transfers have their proponents, but the results are unpredictable. As long as the latissimus dorsi is in good condition, the bipolar latissimus muscle transfer is a fairly reliable technique for achieving active elbow flexion. Another viable option is a free gracilis with a spinal accessory nerve transfer. A gait study may be required to make sure that the gracilis harvest will not interfere with ambulation. Lidocaine injection of the gracilis prior to gait analysis can help in simulating ambulation following harvest.

CRITICAL POINTS *Bipolar Latissimus Dorsi Transfer*

- Identify the neurovascular pedicle working medial to lateral on the undersurface of the latissimus dorsi.
- Ligate the vessels to the serratus and isolate the pedicle to the latissimus all the way to the brachial plexus and the axillary artery.
- Expose the entire latissimus dorsi before releasing it from the origin.
- Maintain the humeral insertion to protect the neurovascular pedicle from traction during the anterior exposure.
- Transfer the muscle origin first through the deltopectoral interval.
- Sew the insertion to the coracoid in a position that minimizes pedicle tension.
- Attach the origin to the biceps or the ulna depending on the status of active pronation.
- Tension the elbow so that at rest the arm sits in at least 30 degrees of flexion.
- Apply a long-arm splint or cast for 4 to 6 weeks, followed by a graduated extension protocol.

Postoperative Management and Expectations

Expected Outcomes. Strong antigravity elbow flexion is rarely achieved. The best that parents can typically expect is grade 3 to 5 with antigravity flexion within the passive range (see Figure 39-16, *E*). Outcomes depend almost entirely on the quality of the latissimus muscle.

Complications. Loss of the latissimus is possible but rare as long as meticulous care is taken both to harvest the pedicle and limit tension on the pedicle. The posterior wound is prone to seroma formation, and this can be mitigated with the use of postoperative drains.

Radial Osteotomy With and Without Ulnar Osteotomy

Indications

Contrary to what has been described, it is unusual to see a pronation contracture in a child with arthrogryposis. Rather, most children have internal rotation contractures at the shoulder, creating the illusion of pronation at the forearm. The forearm is most often in neutral. However, because each child is unique, the rotation of the shoulder and the rotation of the forearm should be assessed independently. Forearm osteotomies have been mistakenly performed on children to correct shoulder rotation and humeral osteotomies to correct forearm malrotation. The risk of misdiagnosis is greatest when the elbow is contracted in full extension. Prior to humeral or forearm osteotomies in these children, we typically perform an elbow release that allows a better position to evaluate shoulder and

forearm rotation. If the malrotation is at the forearm, a separate surgical procedure is performed to correct the pronation at a later date.

Children with limited elbow flexion and forearm pronation struggle with self-feeding. This difficulty is worsened by ulnar deviation at the wrist. However, pronation can be an asset to a child who goes through the legs for perineal care. Supination straps and passive range-of-motion exercises are first-line treatments to improve supination. If these fail, surgical correction can be achieved by a radial osteotomy, ulnar and radial osteotomies, or a one-bone forearm. Rarely, if the child has an active biceps, biceps rerouting can be considered. A therapist who is familiar with the child can be very helpful in determining the best resting position for the forearm.

A radial osteotomy is usually sufficient for rotational correction below 45 degrees. Beyond that, an ulnar osteotomy can be added for corrections up to 90 degrees. Alternatively, a one-bone forearm is more predictable and easier to accomplish.

Alterations in forearm position can influence the elbow via retensioning the biceps tendon. Repositioning the forearm also reorients the wrist position. Pronation allows gravity-assisted wrist flexion, and supination augments gravity-assisted wrist extension.

Contraindications

A child who requires pronation for perineal care should not undergo a neutralization osteotomy of the forearm.

Preoperative Planning

Any standard hand plating system can be used for osteotomy fixation, with compression plates usually in the range of 2 to 2.4 mm. Minifluoroscopy is also recommended.

Technique

Place the patient supine on a standard operating room table without a hand table. Regional anesthesia may be used to control postoperative pain along with general anesthesia. Confirm that the patient is truly in pronation. If the shoulder is internally rotated on examination, consider a humeral osteotomy first and then reassess the forearm position.

The arm is prepared and draped to the axilla. Exsanguinate the limb and apply a tourniquet on the upper arm. Incise the skin along the flexor carpi radialis (FCR) tendon just proximal to the wrist crease. Raise full-thickness subcutaneous flaps medially and laterally. Beware of the palmar cutaneous branch of the median nerve. Mobilize the tendon and incise the floor of the FCR sheath. Elevate the flexor pollicis longus (FPL) and the proximal portion of the pronator quadratus to expose the distal radial diaphysis. Apply a contoured six-hole compression plate of appropriate size to the volar distal aspect of the radius with the distal three holes. Make sure that the plate is proximal to the volar metaphyseal flare to avoid physeal injury. Remove the plate.

Split the periosteum longitudinally and place Hohmann retractors deep to the periosteum. Cut the bone and reapply the plate to the distal fragment. Clamp the proximal fragment to the plate and reassess the rotation of the forearm. If there is some active wrist extension or the wrist is contracted in extension, supinate the radius to between neutral and 30 degrees of pronation. If the wrist has no active extension, place the forearm in neutral. Keep in mind the optimal forearm position for either wiping or eating, or if possible both. If the child has insufficient shoulder rotation, elbow movement, and wrist motion to achieve both tasks, then determine which function is best left to the contralateral hand, and optimize the opposite function for the surgical arm. This determination is done prior to surgical intervention. Fix the plate to the proximal fragment and reassess rotation a final time.

If the radial osteotomy was insufficient to provide the desired amount of rotational correction, add a proximal ulnar osteotomy or convert to a one-bone forearm. For the ulnar osteotomy, incise the subcutaneous border of the ulna distal to the level of the coronoid. Insert the proximal three screws of a six-hole plate. Remove the plate.

Split the periosteum longitudinally and place Hohmann retractors deep to the periosteum, keeping the periosteum in continuity. Cut the bone and reapply the plate to the proximal fragment. Rotate the ulna and clamp the distal fragment to the plate. Fix the plate to the distal fragment and reassess one more time. If the position of the arm is optimized, confirm screw lengths and plate position using fluoroscopy.

For a one-bone forearm, extend the FCR approach across the forearm to the ulna with an "S"-shaped incision. Dissect a path along the interosseous membrane for the radius to be reduced to the ulna. Make a transverse ulnar osteotomy 1 cm proximal to the radial osteotomy (Figure 39.17). The staggered osteotomies create bony overlap to encourage union. Reapply the plate to the distal fragment of the radius. Clamp the proximal fragment of the ulna to the plate and assess the rotation of the forearm. Fix the plate to the ulna and reassess one more time. If the position of the arm is optimized, confirm screw lengths and plate position using fluoroscopy.

Close the subcutaneous layer and the skin. Apply a sterile dressing with the elbow in flexion and the forearm in the desired position. Apply a sugar-tong splint or a long-arm cast to prevent forearm rotation.

Remove the splint 2 weeks after surgery and convert to a long-arm cast until union. Then begin a range-of-motion protocol while maintaining a Munster splint at all other times for an additional 6 weeks. Continue range-of-motion exercises through the third postoperative month while weaning the patient to wearing the splint at night and during naps only.

❖ AUTHOR'S PREFERRED METHOD OF TREATMENT

A one-bone forearm is the most predictable operation for correcting forearm rotational deformities. Union in children is rapid and robust, and there is no risk of loss of correction over time. If a small amount of pronation is required and the child has an active supinator and a working biceps, biceps rerouting can be an effective technique and maintains motion. If a small amount of supination is required, a radial osteotomy can also be effective but may lose correction over time if there is no active supination.

Postoperative Management and Expectations

Expected Outcomes. Correction of a pronation deformity can be a life-changing event if it allows the child to self-feed for the first time. If it takes away or prohibits the acquisition of independence in the bathroom, loss of forearm pronation can have lifelong consequences.

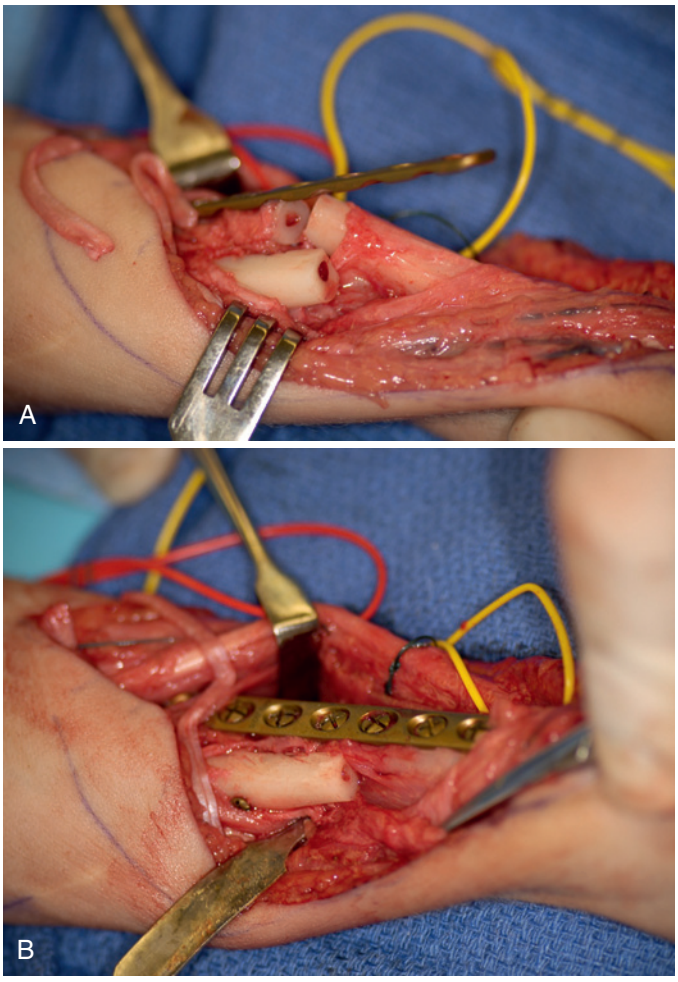

FIGURE 39.17 Creation of a one-bone forearm requires osteotomies of the radius and ulna. The ulnar osteotomy is made 1 cm proximal to the radial osteotomy **(A)** to allow for overlap of the cut bone ends once the distal radial fragment is fixed to the proximal ulnar fragment **(B)**.

CRITICAL POINTS *Radial Osteotomy With and Without Ulnar Osteotomy*

- Make sure that the deformity truly is in the forearm and not the shoulder before correcting forearm rotation.
- Confirm that self-feeding and perineal care will still be possible after the change in forearm position.
- Osteotomize just the radius for corrections of less than 45 degrees.
- For larger corrections, either create a one-bone forearm or perform dual radial and ulnar osteotomies.

Complications. Nonunion is rare, but malunions can occur from inadequate positioning in the operating room. Intraoperative reduction is confirmed by a careful intraoperative examination prior to definitive fixation. Malrotations of a few degrees are common, but more clinically important malrotations are rare.

Carpal Wedge Osteotomy

Indications

The carpal wedge osteotomy is a common upper limb procedure for children with arthrogryposis. However, the indications are few and the contraindications are many. More than for any other joint in the upper limb, decisions about altering a child's wrist position require a thorough assessment of the child's overall functional goals and limitations. In addition, the active and passive motions about the shoulder, elbow, forearm, and hand are critical components in the decision-making process.

The wrist position of children with arthrogryposis varies from child to child, with some children having one wrist in flexion and one in extension. Most patients with DA tend to have wrist extension contractures, whereas patients with amyoplasia have flexion contractures. Extension contractures at the wrist are well tolerated if the following criteria are met: (1) finger extension is sufficient to acquire and release objects, (2) forearm supination and elbow flexion are sufficient to get food to the mouth, and (3) forearm supination, shoulder extension, and elbow extension are sufficient to be able to wipe the perineum from behind. In some children, wrist flexion contractures can enhance function if the above noted criteria are not met.

Initial treatment consists of passive motion and night splinting. Unless splinting enhances function, splinting is avoided during the day to allow the child to play and to promote cortical/muscular development. Because surgical interventions in the wrist and hand have not been demonstrated to have better outcomes at a younger age, surgery can be delayed until the child's functional needs and capabilities are better defined.[11,25] Wait until the child fails to progress with therapy alone and perhaps even after the child is potty trained to determine the wrist flexion requirements. Because wrist flexion is so critical to being able to perform perineal care from the front, it is important for the child to be able to wipe from around the back before considering any procedure that limits wrist flexion.

Serial casting has not been shown to make a difference in the long term.[22] Extensor carpi ulnaris (ECU) to extensor carpi radialis brevis (ECRB) tendon transfers after serial casting may delay recurrence, but we have had minimal success with this strategy. The ECU muscle is often affected, particularly if the EDC is nonfunctional.

If the child has good finger extension, has sufficient pronation and elbow flexion to reach the mouth without the need of wrist flexion, and can perform perineal care around the back, the most reliable procedure to provide wrist extension is a carpal wedge osteotomy with ECU to ECRB transfer.[25] The best candidates have a reciprocal deformity of wrist flexion and MP extension (Figure 39.18). In cases where one hand is to be used for wiping and the other for eating, the eating hand can be considered for a carpal wedge osteotomy as long as finger extension, forearm pronation, and elbow flexion are adequate. The maximal amount of wrist extension that is desired is limited by the ability of the EDC to extend the fingers. Wrist extension past 30 degrees is unnecessary even if there is good finger extension beyond that amount of wrist extension.

Contraindications

Contraindications to correcting a child's wrist flexion contracture include (1) poor finger extension in maximal preoperative wrist extension, (2) obligatory wrist flexion for hand-to-mouth movement, (3) obligatory wrist flexion for perineal care, and (4) use of the back of the wrist for scooting along the



FIGURE 39.18 Children with limited wrist extension will use the extensor digitorum communis to extend the wrist, leading to a zigzag deformity of wrist flexion, metacarpophalangeal extension, and interphalangeal flexion. These patients are excellent candidates for a carpal wedge excision and tendon transfer for wrist extension.

ground for ambulation or for balance and support during standing or sitting. Most parents want their child to have their wrists in extension in the hopes of normalizing their appearance. However, the loss of the ability to ambulate, engage in perineal care, and self-feed is too high a price for aesthetic improvement.

Preoperative Planning

Large Kirschner wires and Steinmann pins should be available for fixation. A mini C-arm should be available.

Technique

Place the patient supine on a standard operating room table with a hand table. Regional anesthesia may be used to control postoperative pain along with general anesthesia. Apply a tourniquet to the upper arm.

Prepare and drape the arm to the tourniquet. Incise the skin either longitudinally or transversely across the dorsal wrist (Figure 39.19, *A*). The dorsal sensory branches from the radial and ulnar nerves are protected. Identify the ECU in its compartment and follow it out to its insertion at the base of the fifth metacarpal. Release the overlying sixth extensor compartment (see Figure 39.19, *B*). Make a separate incision just distal to the midforearm over the ECU muscle, approximately at the level of the ECU musculotendinous junction. Identify the ECU muscle and tendon. If there is no ECU muscle or the excursion is very limited, look for alternate tendons to transfer. Release the ECU from its insertion. Retrieve the tendon into the proximal wound and release the soft tissue adhesions from the forearm fascia to the ECU that may limit muscle excursion. Park the muscle in the proximal wound to keep it hydrated.

Mobilize the extensor pollicis longus (EPL) and elevate the second and fourth extensor compartments and their contents off of the wrist capsule and carpal bones. Divide the midcarpal joint capsule longitudinally and extend the incision along the capitate proximally and distally, staying out of the radiocarpal joint. Place a Hohmann retractor deep to the capsule on the medial and lateral carpal borders. In a child with minimal carpal ossification, use a knife to incise a dorsal and radially based carpal wedge. For older children, use a reciprocating saw. The cut should correct both wrist ulnar deviation and flexion (see Figure 39.19, *C*).

If there is any tension while placing the wrist in extension, make a longitudinal incision centered over the tight volar structures. Palpate the flexor compartment to identify tight structures, which usually includes the flexor carpi ulnaris. Lengthen the wrist flexors if there is muscle present, or resect the tendon and fascia of the wrist flexor if muscle is absent. If the ECU is inadequate, consider transferring one of the wrist flexors if present.

Once extension can more easily be achieved, augment fixation with Kirschner wires by inserting the wires through the osteotomy in an antegrade direction until they exit the distal hand (see Figure 39.19, *D*). Place transosseous sutures before closing the wedge (see Figure 39.19, *E*). Close the wedge and drive the Kirschner wires retrograde across the osteotomy. Crossing the radiocarpal joint with the Kirschner wires may be helpful to maintain the desired wrist posture but is usually not required. Tie the transosseous sutures if used (see Figure 39.19, *F*). Close the capsule.

Identify the ECRB tendon and open the second extensor compartment. Confirm that the tendon glides across the wrist and tenolyse the ECRB if there is no excursion. If there is no excursion even after tenolysis, cut the tendon proximally to be able to reroute it more effectively. Create a subcutaneous tunnel from the distal to the proximal wound and pass the ECU to the distal wound. Transfer the ECU to the ECRB using a modified Pulvertaft technique to minimize bulk (see Figure 39.19, *G*).[5] Bowstringing is not a concern, because the extension posture is only 30 degrees.

Close the wounds and apply a sterile dressing. Deflate the tourniquet and hold pressure for several minutes. Apply a short-arm splint or cast in maximal wrist extension.

If using a splint, convert to a cast after 2 weeks. Remove the cast and the pins 4 to 6 weeks after surgery, depending on the age of the child and the expected time to union. Children younger than 4 years of age typically heal in 4 weeks, whereas those older than 8 years require 6 weeks. If the carpal bones have not yet ossified, radiographs are not helpful in determining union of the chondrodesis.

Once the cast is removed, outfit the patient with an Orthoplast splint to be worn at all times except for bathing and therapy 3 to 5 times a day. Therapy consists of active and passive wrist extension and active wrist flexion. Passive wrist flexion is avoided. Digital motion should be encouraged. Two to 3 months after surgery, transition to just night-time splint use for another 3 to 4 months. Weight bearing is allowed at 3 months after surgery.

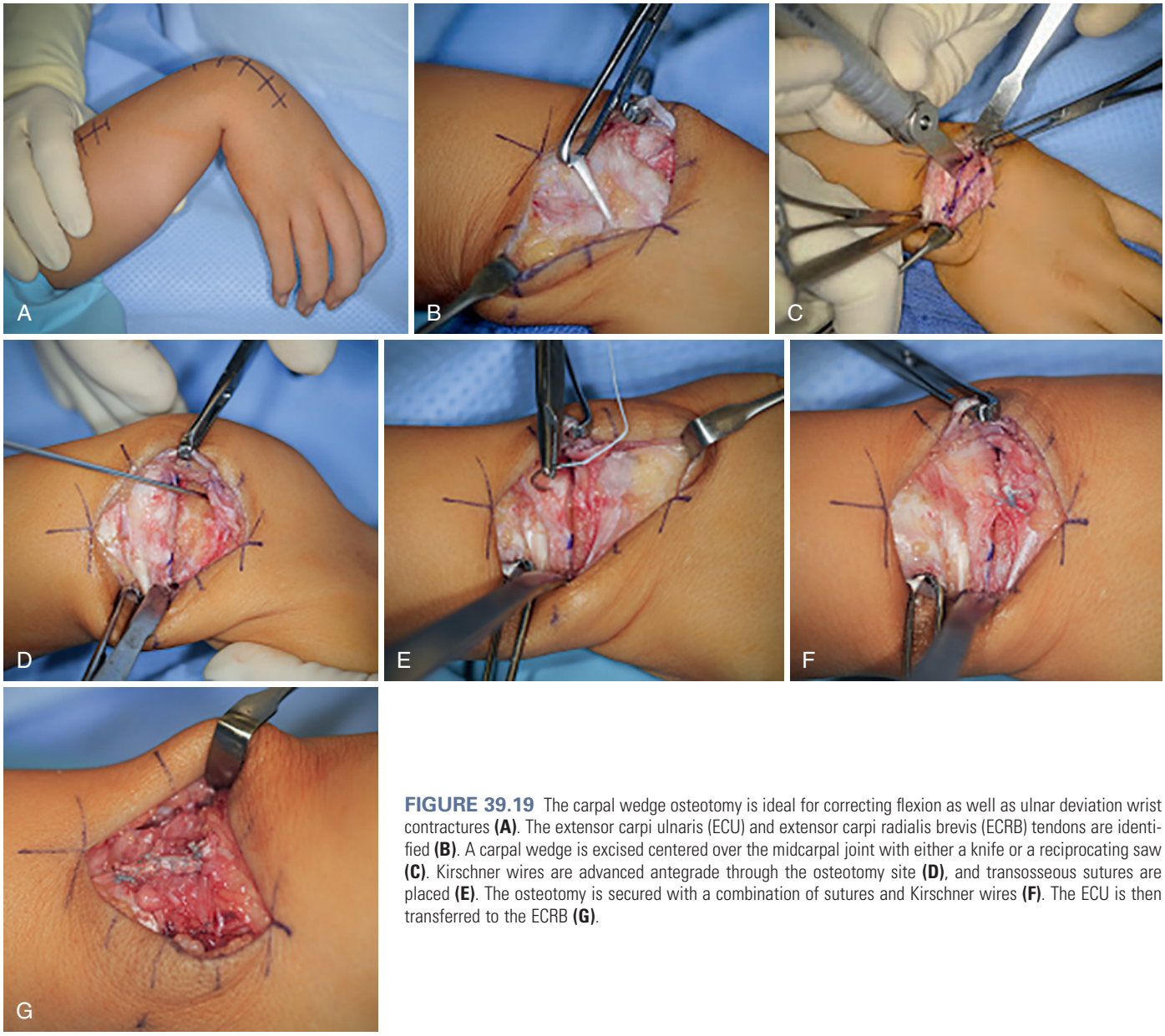

FIGURE 39.19 The carpal wedge osteotomy is ideal for correcting flexion as well as ulnar deviation wrist contractures **(A)**. The extensor carpi ulnaris (ECU) and extensor carpi radialis brevis (ECRB) tendons are identified **(B)**. A carpal wedge is excised centered over the midcarpal joint with either a knife or a reciprocating saw **(C)**. Kirschner wires are advanced antegrade through the osteotomy site **(D)**, and transosseous sutures are placed **(E)**. The osteotomy is secured with a combination of sutures and Kirschner wires **(F)**. The ECU is then transferred to the ECRB **(G)**.

❖ AUTHOR'S PREFERRED METHOD OF TREATMENT

When indicated, the carpal wedge osteotomy and tendon transfer is the most predictable option for improving wrist extension. Radiocarpal fusions in this age group are notoriously difficult to achieve, and when they succeed they limit motion.

Postoperative Management and Expectations

Expected Outcomes. The wrist position is reliably improved so that there is more extension even if there is no active wrist extension transfer. However, the correction is underwhelming and can deteriorate over time if there is no active wrist extension.

Complications. Nonunions are rare, but undercorrections are common. Loss of finger extension and increased finger stiffness can also occur.

CRITICAL POINTS *Carpal Wedge Osteotomy*

- Confirm that there are no contraindications to extending the child's wrist.
- Release any volar structures that are tethering the joint into flexion.
- Design a biplanar osteotomy to correct both ulnar deviation and flexion.
- Use pins and transosseous sutures for improved fixation.
- Transfer the ECU or any other available expendable tendon to provide active wrist extension.
- Use a modified Pulvertaft technique with a single Pulvertaft pass to minimize tendon bulk.
- Continue night splinting for several months after the osteotomy has healed.

Thumb Reorientation Osteotomy and/or Metacarpophalangeal Chondrodesis

Indications

The classic clasped thumb in arthrogryposis consists of extension at the first carpometacarpal (CMC) joint and flexion at the MP joint. This is more commonly seen in distal arthrogryposis, however, as the CMC joint generally follows the position of the wrist. Children with wrist flexion contractures, as are more commonly seen with amyoplasia, typically have CMC joint flexion contractures with the MP joint in extension. The MP joint can either be passively correctable or fixed in flexion. Interphalangeal joint motion is typically limited but most often positioned in extension. A flexion posture at all three joints is less common (see Table 39.2).

In the postnatal period, initiate treatment in passive range of motion until the child is old enough to be fitted with a splint. We prefer nighttime splints, but daytime splints can be used in severe cases or if they enhance function. Splints should expand the first web space, correct the thumb posture, and provide simultaneous correction of wrist and finger contractures. Tremendous gains can be made with passive motion and splinting in infants, and the parents should be encouraged to be active participants in their child's care. Gains can be seen up to approximately 5 years of age, but most children plateau after their second birthday.

A thumb-to-palm pinch may be desirable for function if other pinch patterns are not possible even with surgical reorientation of the thumb. Surgical options should seek to place the thumb in a position where it can best provide pinch and/or grasp, regardless of appearance. The surgical algorithm (Figure 39.20) depends on the posture of the CMC and MP joints, as well as on the passive motion of the joints. In general, fixed contractures require a fusion whereas passively correctable contractures can be treated with a tendon transfer. The preferred donor for tendon transfers to augment thumb extension is the extensor indicis proprius, but alternate donors such as the palmaris longus, flexor digitorum superficialis (FDS), and brachioradialis can be used. If the CMC joint is in extension and the MP joint has a flexion contracture that is not correctable, MP chondrodesis is the best option.

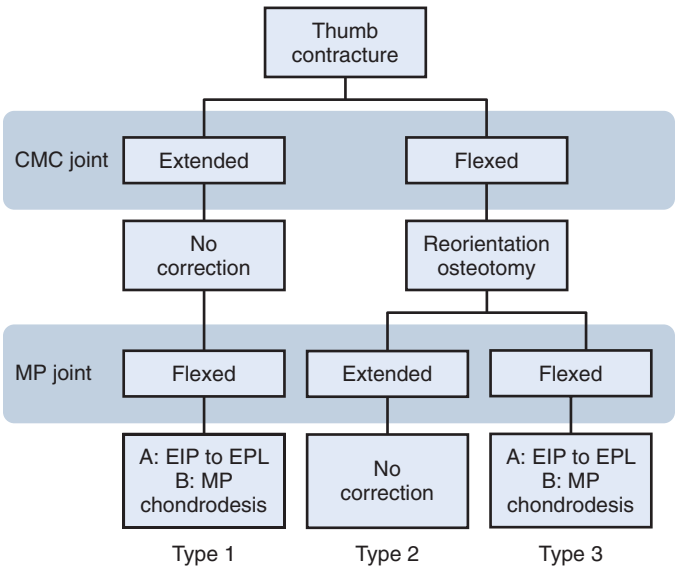

FIGURE 39.20 Surgical algorithm for thumb contractures in children with arthrogryposis. Subtype A is passively correctable, and subtype B is not correctable.

The more common thumb posture for children with amyoplasia is flexion at the CMC joint and extension at the MP joint. The thumb may oppose to one or several of the fingers, or typically only to the palm. Palm pinch is the only option if the fingers are stiff and fixed in extension. Some children have neither finger nor thumb active motion, and do not use their hands at all other than to push objects around. Patients with no digital motion usually lack any active motion in the upper extremity. If FPL function is preserved despite no other function, yet the thumb orientation prevents a useful prehension, the patient is a good candidate for a thumb reorientation osteotomy.[30] The goal of the osteotomy is to place the thumb into a position where it can best take advantage of the child's existing finger and thumb motion to provide pinch and/or grasp. The reorientation osteotomy typically results in a "sock puppet" type of position for the thumb, but other positions may be optimal depending on the child's needs and abilities.

Both type 1 and type 2 thumbs benefit from a first web space contracture release at the same time as a chondrodesis or reorientation osteotomy. Options for expanding the first web space include the four-flap Z-plasty, the Abdel Ghani dorsal rotation advancement flap,[1] and the index rotation (stiletto) flap.[8] For mild web space contractures with a passive extension at the MP joint, a four-flap Z-plasty will suffice (Figure 39.21, *A*). More severe web space contractures with no or minimal MP joint flexion contractures require the Abdel Ghani flap (see Figure 39.21, *B*). For patients with both fixed MP flexion and first web space contractures, the stiletto flap remains the best option (see Figure 39.21, *C*). When necessary, the stiletto flap can be extended into an Abdel Ghani type of flap to expand a very tight first web space (see Figure 39.21, *D*). Often, the first dorsal interosseous and adductor pollicis muscles are either tight or have been replaced with fibrous tissue and must be either lengthened or divided.

Contraindications

Contraindications include a fixed extension contracture at the CMC joint that would preclude opposition after the MP chondrodesis. Children with stiff fingers that would not reach the thumb even after reorientation or MP fusion are not candidates for thumb surgery.

Preoperative Planning

Kirschner wires and a reciprocating saw are required to perform both the reorientation osteotomy and the MP chondrodesis.

Technique

Place the patient supine on a standard operating room table with an arm table. Apply a tourniquet to the upper arm. Prepare and drape the arm to the tourniquet. Begin with a stiletto flap if appropriate (see Figure 39.21, *C*; Video 39.1). Mark the radial apex of the index finger's proximal interphalangeal (PIP) joint crease with a dot, and the entire thumb MP joint flexion crease with a line. Connect the dot to the most ulnar aspect of the line, and draw a divergent line from the dot to the dorsal aspect of

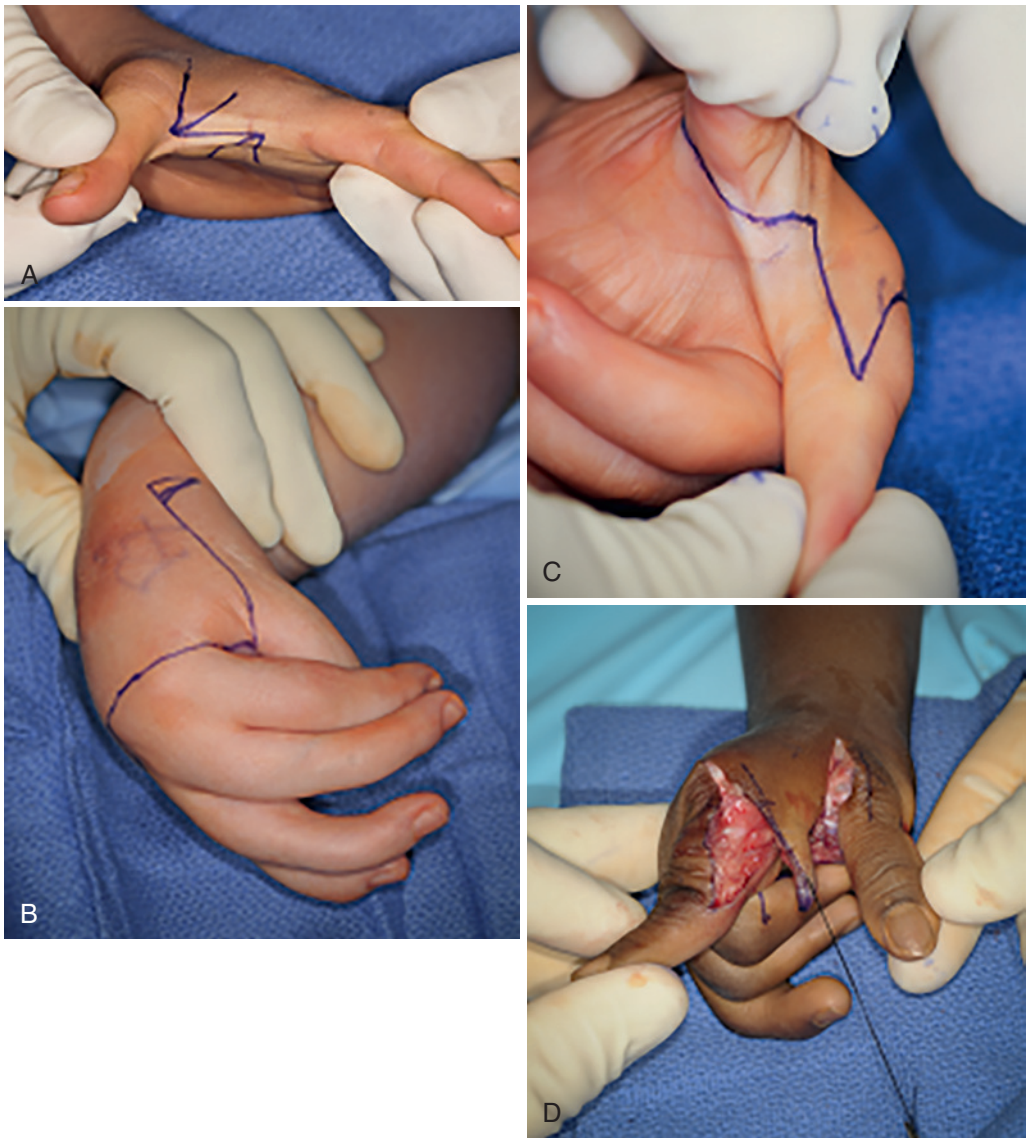

FIGURE 39.21 Multiple flap options exist for widening the first web space. The four-flap Z-plasty is reliable for mild contractures **(A)**. More severe contractures may benefit from a dorsal advancement flap **(B)**. If the thumb is clasped and the first web space is contracted, the index rotation (stiletto) flap is an excellent option **(C)**. If the web space is still tight after a stiletto flap, the flap can be extended into a dorsal advancement flap **(D)**.

the index MP joint. All limbs should be of equivalent lengths. It helps to imagine that the stiletto flap is merely a modified Z-plasty. Curving the more dorsal line provides a better contour for the web space along the thumb (Figure 39.22, *A*). Pinch the "V"-shaped flap together to confirm that there will be sufficient skin remaining on the index finger to close the donor site at the end.

Exsanguinate the arm and inflate the tourniquet. Incise the skin, keeping the stiletto flap in full thickness down to the fascial level. Preserve the dorsal sensory branch of the radial digital nerve to the index finger as it crosses deep to the flap. Identify and protect the princeps pollicis artery and its branches deep to the subcutaneous fat. Incise across the thumb MP joint crease, taking care not to injure the neurovascular bundles to the thumb (see Figure 39.22, *B*). Do not extend the MP joint while cutting across the MP flexion crease, because this places tension across the neurovascular bundles.

Release the fascia overlying the first dorsal interosseous and adductor pollicis muscles in the first web space (see Figure 39.22, *C*). If there is no muscle present, cut the vestigial tendons.

Make a separate longitudinal incision at the base of the thumb metacarpal between the extensor pollicis brevis (EPB) and EPL tendons. Split the periosteum longitudinally between the two tendons and retract the periosteum with two Hohmann retractors. The periosteum near the physis is adherent and should not be violated. Using a reciprocating saw, make an incomplete transverse osteotomy just distal to the physis. Referencing the thumbnail, make a second cut to create a dorsal closing wedge at the desired angle (Figure 39.23, *A*). Complete both cuts.

Pass two 0.035-inch or 0.045-inch Kirschner wires antegrade through the osteotomy site and down the thumb, keeping the wires as far from each other as possible at the osteotomy site to



FIGURE 39.22 The index rotation flap is the workhorse flap for the thumb in arthrogryposis. The limbs of the flap should be of equal length, with at most a 3:1 length-to-width ratio **(A)**. The metacarpophalangeal flexion crease is incised to create the space to inset the flap **(B)**. Divide the fascia over the first dorsal interosseous and adductor pollicis to allow expansion of the web space **(C)**.

maximize rotational control (see Figure 39.23, *B*). Leave the wires proud at the osteotomy site and use them to engage the canal of the metacarpal base. Reduce the osteotomy by extending, abducting, and pronating the thumb. Advance the Kirschner wires back across the osteotomy site. Make sure that the thumb is now in the optimal position to oppose to the fingers, typically in a "sock puppet" position (see Figure 39.23, *C*).

Alternatively, if the CMC joint is in extension and the MP joint is fixed in flexion, perform an MP chondrodesis instead of a reorientation osteotomy (Figure 39.24, *A*). Make an incision over the thumb MP joint between the EPB and EPL tendons. Split the capsule longitudinally between the tendons and cut the collateral ligaments (see Figure 39.24, *B*). Make a transverse cut just proximal to the articular surface of the metacarpal head (see Figure 39.24, *C*). Using a knife and a rongeur, resect the articular surface of the proximal phalanx to the level of the epiphyseal ossific nucleus but no further (see Figure 39.24, *D*). If the epiphysis has not begun to ossify, as is commonly the case in children under 3 years of age, resect only a minimal amount of articular surface so as not to damage the physis at the base of the proximal phalanx (see Figure 39.24, *E*). Provisionally reduce the chondrodesis to make sure that the thumb MP joint can be extended without undue tension on the volar neurovascular structures. Excessive tension can result in vasospasm or even intimal vessel injury that may lead to thumb ischemia or even necrosis. If there is tension, resect more of the metacarpal.

Once the chondrodesis reduces, pass one 0.045-inch Kirschner wire antegrade through the proximal phalanx and down the thumb, leaving the pin proud proximally. Reduce the chondrodesis and advance the Kirschner wire back across the joint. Make sure that the thumb is now in the optimal position to oppose to the fingers (see Figure 39.24, *F*) and adjust the fixation of the metacarpal osteotomy accordingly. Repair the extensor hood and joint capsule with slow absorbing suture. If the FPL is very tight, consider making a separate incision in the volar forearm and fractionally lengthening the FPL.

Wire placement can be confirmed either clinically or with the use of fluoroscopy. It is unnecessary to bury the pins. Rotate the stiletto flap into the thumb MP crease and close the wounds with absorbable suture. Apply a sterile dressing and deflate the tourniquet while holding pressure over the wound. Apply a short-arm thumb spica cast or splint.

Remove the cast 4 to 6 weeks after surgery, depending on the age of the child. Confirm union at the osteotomy site by x-ray and clinical examination (lack of tenderness) before removing the wires. Following pin removal, an Orthoplast thumb spica splint should be worn full time for a month except when bathing or doing range-of-motion exercises. Subsequently, transition to wearing the splint only at night for 2 months.

❖ AUTHOR'S PREFERRED METHOD OF TREATMENT

For children with fixed thumb-in-palm deformities who can flex their fingers over the thumb, the standard operation is the thumb MP chondrodesis with first web space expansion. The functional and aesthetic gains are typically dramatic, and most patients will ask for the same operation on the contralateral side once they realize the results.

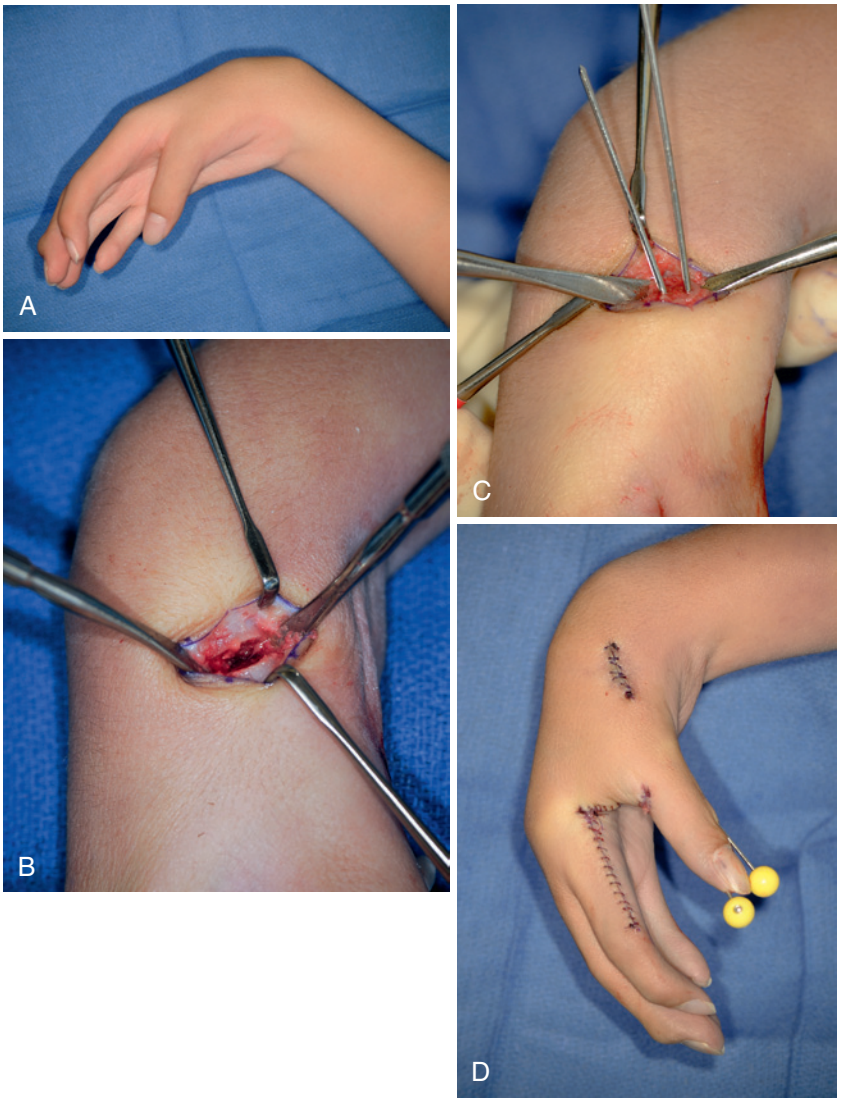

FIGURE 39.23 If the thumb and fingers are mobile but are not in a position to oppose to each other **(A)**, a thumb reorientation osteotomy can be considered. A skin flap, usually a stiletto, is used to open the first web space. The base of the metacarpal is osteotomized distal to the physis to place the carpometacarpal joint into an extension posture **(B)**. Two Kirschner wires are driven antegrade through the osteotomy site **(C)**. The thumb position is optimized into pronation, extension, and abduction and the osteotomy is secured with the two Kirschner wires. Closure of the skin flap completes the procedure **(D)**.

For children whose fingers do not reach the thumb and a thumb that does not reach the palm, pinch is not possible without reorientation of the thumb. The fingers must actively flex sufficiently to reach the thumb in its planned position in order to achieve postoperative pinch.

The stiletto flap is the workhorse flap for the thumb in arthrogryposis, allowing both expansion of the first web and resurfacing of the volar MP joint. It is rare in these children to require only first web space expansion, so a four-flap Z-plasty or an Abdel Ghani flap is less often used.

Postoperative Management and Expectations

Expected Outcomes. In the right patient, a thumb extension chondrodesis and first web space widening can increase function by improving pinch and grasp and can also dramatically improve the appearance of the hand. The thumb reorientation osteotomy in an older child can be similarly gratifying for the same reasons. However, children who undergo reorientation

CRITICAL POINTS *Thumb Reorientation Osteotomy and/or Metacarpophalangeal Chondrodesis*

- Ensure there is adequate finger flexion to merit a thumb reorientation or chondrodesis.
- Thumb reorientation osteotomy is used to correct CMC flexion.
- Thumb MP chondrodesis is used to correct MP flexion.
- MP chondrodesis alone will not address a CMC flexion contracture. A combination of MP chondrodesis and reorientation osteotomy may be required.
- Prior to surgery, assess the need for skin augmentation at the MP flexion crease and the first web space to choose the most appropriate skin flap.
- Release or lengthen the first dorsal interosseous and the adductor to allow expansion of the first web space and rotation of the first metacarpal.
- Make sure that the volar neurovascular bundles are not under tension after performing a chondrodesis.
- Lengthen the FPL if the interphalangeal joint remains tight after chondrodesis or reorientation.

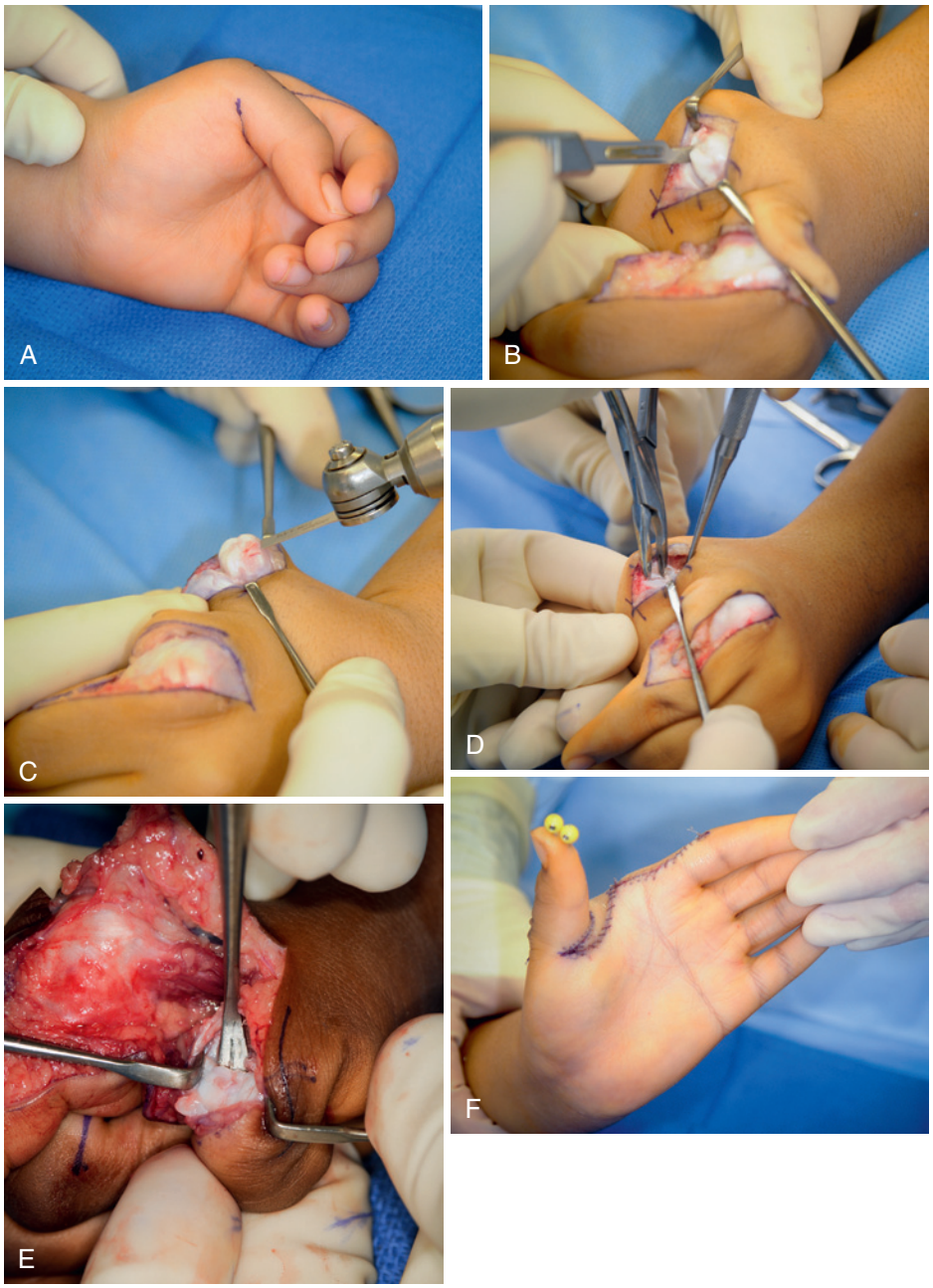

FIGURE 39.24 For type 1B thumbs, a metacarpophalangeal (MCP) chondrodesis and stiletto flap is a reliable option **(A)**. After elevating the stiletto flap, a separate incision is made over the thumb MCP joint. The joint is exposed between the extensor pollicis longus and extensor pollicis brevis tendons, and the collateral ligaments are divided **(B)**. The head of the metacarpal is removed with a reciprocating saw **(C)** followed by resection of the articular surface of the proximal phalanx **(D)**. In children older than 3 years of age, the ossific nucleus signals that the physis is near **(E)**. Fixation of the chondrodesis and closure of the skin flap dramatically improve the appearance of the hand **(F)**.

osteotomies typically have no hand function prior to surgery, and the functional gains are modest. Also, young children (<7 years) will often remodel their reorientation osteotomy over time and lose their correction.

Complications. Nonunion is rare in these cases. Malunions are possible and are usually the result of malrotation of the thumb. Nerve injury and vascular injury are rare. However, neurovascular injury can result in loss of the thumb. Great care should be taken not only to preserve the neurovascular structures during the dissection but to avoid excessive tension during joint reduction. If there is tension, resect more metacarpal prior to fixation.

Camptodactyly Release

Indications

Almost all children with upper extremity arthrogryposis have some degree of contracture of the fingers (Table 39.4). The fingers are typically rigid at the interphalangeal joints and fixed in extension. MC motion (at least, passive movement) is often preserved. Some children have reciprocal deformities with the wrist in flexion and the fingers in extension at the MP joints. Children with amyoplasia with no muscle function in the hands often present with symphalangism[2] fixed in extension (Figure 39.25). Rigid fingers function only to point or push objects

around a surface. There is currently no successful treatment for mobilizing stiff digits other than the occasional osteotomy to change the resting posture of the digits.

Camptodactyly is more common in DAs and can be a defining characteristic of specific syndromes such as *Beals syndrome* (contractural arachnodactyly). Camptodactyly can interfere with capturing objects in the hand, with some children developing a compensatory pinch-and-grasp pattern against the dorsum of the contracted fingers (Figure 39.26, *A*).

In the postnatal period, initiate treatment with passive range of motion until the child is old enough to be fitted with a splint. We prefer nighttime splints, but daytime splints can be used in severe cases or if they improve function. Splints should provide correction of wrist and finger contractures as well as simultaneous expansion of the first web space and improvement of the thumb posture. Gains can be made with passive motion and splinting, and parents should be encouraged to be active participants in their child's care.[4] Gains can typically be seen up to about 5 years of age, but most children plateau after their second birthday.

Radiographs are not useful for camptodactyly in young children. In older children, the condyles at the PIP joint will often appear hypotrophic (see Figure 39.26, *B*). Children with passively correctable camptodactyly are more likely to have well-formed condyles than children with fixed flexion contractures. In general, the more severe the condylar hypoplasia, the less correctable the deformity.

Many surgical schemes have been devised to correct camptodactyly.[10,17,23] Almost all surgical algorithms include a volar Z-plasty to release the tight pterygium at the PIP joint (see Figure 39.26, *C*). In addition to contributing to the contracture, the pterygium can make it difficult for the child to hold objects in the hand. Occasionally, the skin overlying the PIP joint is so tight that a full-thickness skin graft is needed to provide resurfacing instead of a Z-plasty.

The FDS is almost always tight and can be divided at the PIP joint (see Figure 39.26, *D*). If the camptodactyly is passively correctable and there is good FDS excursion, the FDS can be transferred to the lateral band to augment the extensor mechanism. However, FDS transfer may enhance digital extension at the expense of digital flexion (grasp). Another option is to use the FDS to enhance wrist extension, but this can only be done if there is sufficient finger extension to allow object acquisition and release with the wrist in neutral.

TABLE 39.4 Patterns of Hand Deformities in Arthrogryposis

Phenotype	Anatomic Findings	Typical Type of AMC
Clasped thumb	Contracted flexor pollicis longus and/or thenars, adductor, first dorsal interosseous, weak or absent extensors	All
Stiff straight thumb	Absence of thumb flexors and extensors	Amyoplasia
Windblown fingers	Ulnar deviation at metacarpophalangeal joints	Distal arthrogryposes
Claw fingers	Preserved extrinsic finger extensors, weak or absent intrinsics, weak wrist extensors	Amyoplasia
Camptodactyly	Contracted flexor digitorum superficialis, weak or absent extensor mechanism	All
Stiff straight fingers	Absence of finger flexors and extensors	Amyoplasia

AMC, Arthrogryposis multiplex congenita.



FIGURE 39.25 The typical position of the hand in a child with amyoplasia who has no hand function. The fingers are stiff and in nearly full extension. The thumb is a type 2B.

Contraindications

There are no practical contraindications to a volar Z-plasty. A relative contraindication for FDS tenotomy is lack of the flexor digitorum profundus (FDP) and intrinsic function.

Preoperative Planning

No special equipment is required.

Technique

Place the patient supine on the operating room table with an arm table. Apply a tourniquet to the upper arm. Begin with an examination under anesthesia. If the PIP joint itself is contracted, consider adding a joint release if the neurovascular structures allow. Determine if the FDS is tight by comparing the joint contracture in wrist flexion and extension. Lastly, look for any extensor mechanism tenodesis.

Prepare and drape the arm to the tourniquet. Inflate the tourniquet. Make a Z-plasty incision beginning along the ridge of maximal skin tension crossing the PIP flexion crease. Extend the incision in a "Z" shape to the apices of the PIP flexion creases at 60-degree angles. The "Z" should have equal length segments. Adjustments can be made to accommodate for more oblique lines of tension or for a more distal or proximal pterygium.

Identify the neurovascular bundles and retract them gently out of the way. Occasionally, the bundles may contribute to the contracture. Do not attempt to gain further passive extension

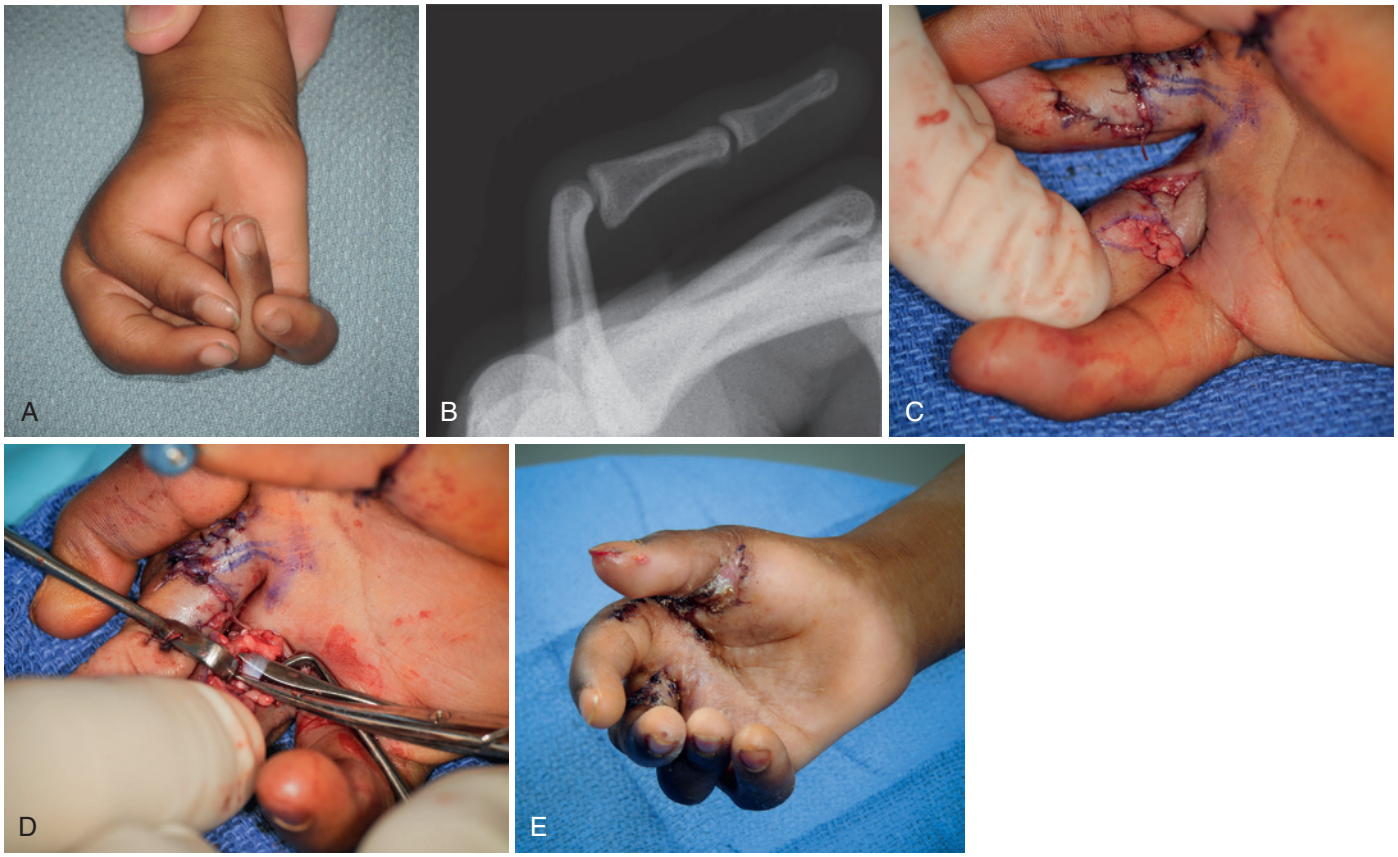

FIGURE 39.26 Camptodactyly can interfere with function, as seen in this child who was unable to place objects in his hand. His thumb opposed to the dorsum of his ring finger **(A)**. Radiographs typically demonstrate hypotrophic condyles at the proximal interphalangeal joint **(B)**. A thumb metacarpophalangeal chondrodesis and stiletto flap as well as camptodactyly releases of the long and ring fingers were performed. The Z-plasties were made along the lines of maximal tension **(C)**, and the flexor digitorum superficialis was released **(D)**. Clinical appearance at follow-up was improved **(E).**

than is allowed by the bundles. If the bundles can accommodate further PIP joint extension, test for FDS tightness by extending the wrist. If the child has a functioning FDP and a tight FDS, consider an FDS tenotomy just proximal to the fourth annular pulley.

In high-functioning patients with good FDS excursion and without an intrinsic PIP joint contracture, consider transferring the FDS to augment intrinsic function. Both a Zancolli lasso and a formal intrinsic-plasty have been described.[10,17,23]

After FDS release, any remaining contracture is likely from the joint itself. Depending on the tension of the neurovascular bundles, consider dividing the checkrein ligaments and the attachment of the accessory collateral ligament to the volar plate. Gently manipulate the joint to avoid a physeal fracture at the base of the middle phalanx. Application of a Kirschner wire is optional to hold the joint in maximal extension.

Close the wound with absorbable sutures and apply a sterile dressing. Deflate the tourniquet and check the finger for adequate perfusion. The arteries may be in spasm, and capillary refill may be delayed at first. If the fingers remain ischemic after 5 minutes, consider step-wise warming of the room, removing the dressings, blocking the sympathetic nerves with a lidocaine injection, and removing the pin (if used), in that order. Venous outflow is rarely an issue. Once perfusion is confirmed, apply a long-arm or short-arm cast or splint to maintain the fingers in extension.

Remove the splint or cast after 2 to 3 weeks, and remove the pin if used. Use an Orthoplast splint full time except during motion exercises and bathing for a further 6 weeks, followed by nighttime splinting until the contractures are stable.

❖ AUTHOR'S PREFERRED METHOD OF TREATMENT

Despite a few reports of good results with camptodactyly release overall, we have not had great success with anything other than releasing the pterygium and cutting the FDS. We have therefore decided that a Z-plasty is the standard treatment for camptodactyly, and we add an FDS tenotomy routinely if the FDP is functional and the FDS is tight.

If the child has the rare combination of inadequate active wrist extension, passive wrist extension past neutral, good finger extension, and camptodactlyly, the FDS can be transferred through the interosseous membrane to the ECRB tendon.

CRITICAL POINTS *Camptodactyly Release*

- Make the longitudinal portion of the Z-plasty along the crest of the pterygium in the line of maximal tension.
- Extend the digit only as much as the neurovascular bundles will allow.
- Tenotomize the FDS if the FDS is contributing to the contracture and the FDP is functional.
- Release the volar plate checkrein ligaments if the joint itself is tight.
- Pin the joint in maximal extension for 2 to 3 weeks following joint release.

Postoperative Management and Expectations

Expected Outcomes. The results of camptodactyly release are unpredictable, despite some favorable results in the literature.[10,17,23] It is rare that a patient will be worse off, unless one is attempting extensor mechanism augmentation. It is common, however, for the family to be underwhelmed by the degree of correction and to notice loss of correction over time.

Complications. Stiffness is the most common complication after any camptodactyly release. Digital nerve injury and vascular injury are possible and are most often traction injuries caused by straightening a bent finger.

SUMMARY

Arthrogryposis remains a challenging disease for the patient, the parents, and the treating practitioner. Fortunately, the initial joint contractures tend to improve over time with stretching and splinting. Each child follows his or her own path, however, with some returning to full function and other less fortunate children never developing any muscle tone. The type of arthrogryposis often suggests the nature and severity of the child's contractures, but each child is affected in a unique way and adapts to the limitations in a unique way. When a child is unable to adapt, guidance from an experienced therapist and communication with other children with arthrogryposis can help. The arthrogryposis community has accumulated many tricks to optimize function, with assistive devices and novel methods for achieving routine activities of daily living. The role of upper extremity treatment is to enhance the abilities of these children without compromising existing function. There is little margin for error in these children, and parents should be aware that any surgical intervention may risk compromising existing function. Surgery should be pursued only if the potential benefits in function outweigh the potential losses. Operating on one arm at a time provides a mechanism for the surgeon, patient, and family to judiciously assess the outcome.

Although the options are often limited and the results of surgery are not always predictable, helping these children transition from dependence to independence is tremendously rewarding. Sterling Bunnell's famous words, "to someone who has nothing, a little is a lot,"[21] particularly apply to these children.

For Case Studies, Videos, and more, please visit ExpertConsult.com.

REFERENCES

1. Abdel Ghani H: Modified dorsal rotation advancement flap for release of the thumb web space. *J Hand Surg [Br]* 31(2):226–229, 2006.
2. Baek GH, Lee HJ: Classification and surgical treatment of symphalangism in interphalangeal joints of the hand. *Clin Orthop Surg* 4(1):58–65, 2012.
3. Bamshad M, Jorde LB, Carey JC: A revised and extended classification of the distal arthrogryposes. *Am J Med Genet* 65(4):277–281, 1996.
4. Benson LS, Waters PM, Kamil NI, et al: Camptodactyly: classification and results of nonoperative treatment. *J Pediatr Orthop* 14(6):814–819, 1994.
5. Brown SHM, Hentzen ER, Kwan A, et al: Mechanical strength of the side-to-side versus Pulvertaft weave tendon repair. *J Hand Surg [Am]* 35(4):540–545, 2010.
6. Carroll RE, Kleinman WB: Pectoralis major transplantation to restore elbow flexion to the paralytic limb. *J Hand Surg [Am]* 4(6):501–507, 1979.
7. Clark J: Reconstruction of the biceps brachii by pectoralis muscle transplantation. *Br J Surg* 34:180–181, 1946.
8. Ezaki MB, Oishi SN: Index rotation flap for palmar thumb release in arthrogryposis. *Tech Hand Up Extrem Surg* 14(1):38–40, 2010.
9. Fahy MJ, Hall JG: A retrospective study of pregnancy complications among 828 cases of arthrogryposis. *Genet Couns* 1:3–11, 1990.
10. Foucher G, Loréa P, Khouri RK, et al: Camptodactyly as a spectrum of congenital deficiencies: a treatment algorithm based on clinical examination. *Plast Reconstr Surg* 117(6):1897–1905, 2006.
11. Foy CA, Mills J, Wheeler L, et al: Long-term outcome following carpal wedge osteotomy in the arthrogrypotic patient. *J Bone Joint Surg Am* 95(20):e150, 2013.

11a. Gogola GR, Ezaki M, Oishi SN, et al: Long head of the triceps muscle transfer for active elbow flexion in arthrogryposis. *Tech Hand Up Extrem Surg* 14:121–124, 2010.

12. Goldfarb CA, Burke MS, Strecker WB, et al: The Steindler flexorplasty for the arthrogrypotic elbow. *J Hand Surg [Am]* 29:462–469, 2004.
13. Hall JG: Uterine structural anomalies and arthrogryposis: death of an urban legend. *Am J Med Genet Part A* 161:82–88, 2013.
14. Hall JG, Reed SD, Driscoll EP, et al: Amyoplasia: a common, sporadic condition with congenital contractures. *Am J Med Genet* 15(4):571–590, 1983.
15. Hall JG, Reed SD, Greene G: The distal arthrogryposes: delineation of new entities: review and nosologic discussion. *Am J Med Genet* 11:185–239, 1982.
16. Kay S, Pinder R, Wiper J, et al: Microvascular free functioning gracilis transfer with nerve transfer to establish elbow flexion. *J Plast Reconstr Aesthet Surg* 63(7):1142–1149, 2010.
17. Koman LA, Toby EB, Poehling GG: Congenital flexion deformities of the proximal interphalangeal joint in children: a subgroup of camptodactyly. *J Hand Surg [Am]* 15(4):582–586, 1990.
18. Kozin SH: Medial approach for humeral rotational osteotomy in children with residual brachial plexus birth palsy. *Oper Tech Orthop* 17:88–93, 2007.
19. Lahoti O, Bell MJ: Transfer of pectoralis major in arthrogryposis to restore elbow flexion: deteriorating results in the long term. *J Bone Joint Surg Br* 87(6):858–860, 2005.
20. Miller ME, Dunn PM, Smith DW: Uterine malformation and fetal deformation. *J Pediatr* 94:387–390, 1979.
21. Shin AY: 2004-2005 Sterling Bunnell Travelling Fellow report. *J Hand Surg [Am]* 31(7):1226–1237, 2006.
22. Smith DW, Drennan JC: Arthrogryposis wrist deformities: results of infantile serial casting. *J Pediatr Orthop* 22(1):44–47, 2001.
23. Smith PJ, Grobbelaar AO: Camptodactyly: a unifying theory and approach to surgical treatment. *J Hand Surg [Am]* 23(1):14–19, 1998.
24. Van Heest A, James MA, Lewica A, et al: Posterior elbow capsulotomy with triceps lengthening for treatment of elbow extension contracture in children with arthrogryposis. *J Bone Joint Surg Am* 90:1517–1523, 2008.
25. Van Heest AE, Rodriguez R: Dorsal carpal wedge osteotomy in the arthrogrypotic wrist. *J Hand Surg [Am]* 38(2):265–270, 2013.
26. Van Heest A, Waters PM, Simmons BP: Surgical treatment of arthrogryposis of the elbow. *J Hand Surg [Am]* 23:1063–1070, 1998.
27. Zancolli E, Mitre H: Latissimus dorsi transfer to restore elbow flexion. *J Bone Joint Surg Am* 55:1265–1275, 1973.
28. Zlotolow DA, Catalano LW, Barron OA, et al: Surgical exposures of the humerus. *J Am Acad Orthop Surg* 14(13):754–765, 2006.
29. Zlotolow DA, Kozin SH: Posterior elbow release and humeral osteotomy for patients with arthrogryposis. *J Hand Surg [Am]* 37(5):1078–1082, 2012.
30. Zlotolow DA, Tiedeken NC: Reorientation osteotomy for the atypical clasp thumb in children with arthrogryposis. *Tech Hand Up Extrem Surg* 18(4):165–169, 2014.

Pediatric Brachial Plexus Palsy

Roger Cornwall and Peter M. Waters

Acknowledgments: The author wishes to recognize the work of previous authors, Drs. Robert Leffert, Vincent R. Hentz, and Michelle James, for their contributions to Green's Operative Hand Surgery *and this chapter. The outstanding assistance of Emily Reiff and Emily Eismann was instrumental to complete it.*

These videos may be found at *ExpertConsult.com:*

Video 40.1 Brachial plexus examination of the infant. *(Courtesy Shriners Hospitals for Children, Philadelphia.)*

Video 40.2 Ulnar-to-musculocutaneous nerve transfer (Oberlin transfer). *(Courtesy Shriners Hospitals for Children, Philadelphia.)*

Video 40.3 Open joint reduction and latissimus dorsi/teres major tendon transfer. *(Courtesy Shriners Hospitals for Children, Philadelphia.)*

This chapter discusses the diagnosis, treatment, and long-term expected outcomes of infants and children with neonatal brachial plexus palsies. Because the type and severity of neural injuries are variable, treatment and outcome are not uniform for all infants. In those children with mild neurapraxic lesions, spontaneous recovery is to be expected over the first several months of life, with complete recovery evident by age one.[60,63,179] In contrast, children with severe avulsion injuries experience a lifetime of disability despite extensive therapy and surgical management.[179]Although there have been many advances since Duchenne's (1872)[47] and Erb's (1874)[50] classic descriptions of infantile paralysis, many difficult challenges still remain. For instance, the treatment of severe injuries involving the entire brachial plexus with a combination of nerve ruptures and nerve avulsions remain insurmountable. Microsurgical reconstruction of the plexus in the first 3 to 9 months of life can improve the natural history. However, inability to directly repair avulsions of nerve roots from the spinal cord and the resulting relative paucity of donor nerves for reconstruction results in persistent and permanent impairment.[3,27,84,87,98,99,159]

Fortunately, the incidence of these multilevel avulsion and/or rupture injuries is relatively low (between 8% and 25%) for all brachial plexus birth palsies.[63,156,179] In addition, secondary musculoskeletal deformities are common in children with incomplete recovery in the first 1 to 3 years of life. Although nonoperative and operative intervention, such as contracture releases, tendon transfers, and osteotomies, may improve function, none can normalize limb function. The goal of this chapter is to explain the nature of the neurologic injury and its effect on the developing child. This knowledge will guide decision making regarding the initial neurological injury and its secondary musculoskeletal manifestations. Issues and controversies with incomplete evidence for decision making will also be addressed.

PERTINENT ANATOMY

Essential to any discussion of the natural history and treatment of a brachial plexus lesion is a thorough understanding of the anatomy. Therefore, a brief review of the pertinent anatomy is described (Figure 40.1).

The brachial plexus most commonly receives contributions contiguously from the fifth cervical (C5) through the first thoracic (T1) ventral spinal nerve roots. Prefixed cords (22%) receive an additional contribution from the C4 nerve root, whereas the much less common postfixed cords (1%) receive a contribution from T2.[9] The C5-6 nerve roots join to form the upper trunk, the C7 nerve root continues as the middle trunk, and the C8-T1 nerve roots combine to form the lower trunk. Each trunk bifurcates into anterior and posterior divisions. The posterior divisions of all three trunks make up the posterior cord. The anterior divisions of the upper and middle trunks form the lateral cord. Finally, the anterior division of the lower trunk forms the medial cord.

The major nerves of the upper extremity are terminal branches from the cords, with the ulnar nerve arising from the medial cord, the radial and axillary nerves from the posterior cord, the musculocutaneous nerve from the lateral cord, and the median nerve from branches of the medial and lateral cords. The other nerves to the upper extremity arise sequentially throughout the brachial plexus as illustrated in Figure 40.1. Of note, the dorsal scapular nerve arises from the C5 nerve root along with a branch to the phrenic nerve, the suprascapular nerve arises from the upper trunk, and the long thoracic nerve arises from the C5-7 nerve roots. In addition, the lateral pectoral nerve originates from the lateral cord and the medial pectoral from the medial cord. Finally, the thoracodorsal nerve and the upper and lower subscapularis nerves arise from the posterior cord. The proximal-to-distal orientation of the brachial plexus is nerve roots, trunks, divisions, cords, and terminal branches. The divisions are located behind the clavicle. Every muscle in the upper limb is innervated by the brachial plexus.

Surgical exploration and reconstruction of the brachial plexus require a thorough understanding of its three-dimensional anatomy. As noted, the brachial plexus extends proximally from the C5 to the T1 ventral nerve roots of the spinal cord and distally to the terminal branches in the upper brachium. In the neck, it is located between the anterior and middle scalene muscles. The plexus extends beneath the clavicle, superficial to the first rib, as it passes into the axilla. The plexus is divided into supraclavicular and infraclavicular portions. The brachial plexus is joined by the major blood vessels of the arm beneath the clavicle. As the plexus courses medial to the coracoid, the nerves are surrounded by the axillary artery.

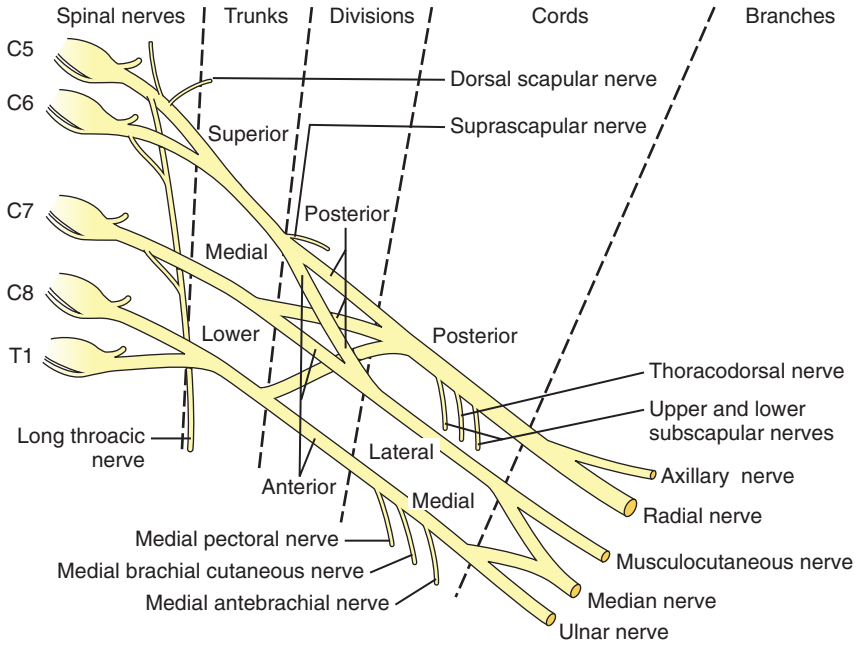

FIGURE 40.1 Normal anatomy of the brachial plexus.

The relationship of the cords to the artery gives them their appropriate medial, lateral, and posterior designations. Complete exposure of the brachial plexus often requires retraction or osteotomy of the clavicle, release of the muscular insertions to the coracoid, and release of the clavicular origin of the pectoralis major muscle.

PREOPERATIVE EVALUATION

Brachial plexus birth palsy has an incidence of 0.38 to 1.56 per 1000 live births.[55] The difference in incidence may depend on the type of obstetric care and the average birth weight of infants in different geographic regions.[87,149] Perinatal risk factors for brachial plexus palsy include large size for gestational age (macrosomia),[23,109,162] maternal diabetes, multiparous pregnancies, previous deliveries resulting in brachial plexus birth palsy,[8,159] prolonged labor, breech delivery,[57,159] shoulder dystocia,[77] and assisted (vacuum or forceps) and difficult deliveries.[77,164]

Maternal body mass index is on the rise in the United States and other well-developed countries of the world, and this is leading to increasing fetal size and a rising incidence of gestational diabetes. Both are risk factors for brachial plexus birth palsy.[112,188] Unfortunately, shoulder dystocia is often an unanticipated and unpredictable obstetric emergency.[58] Fetal distress may contribute to muscle hypotonia and provide less protection of the plexus from stretch or compression injury during delivery.[164]

Mechanically, shoulder dystocia[12,22,117,163] in vertex deliveries and difficult arm or head extraction in breech deliveries increase the risk for nerve injury.[57,159] The increased incidence of delivery by cesarean section may in part be due to an attempt to avoid dystocia and brachial plexus injuries. However, cesarean section does not guarantee prevention of a brachial plexus birth injury, although it decreases the incidence 100-fold.[11] Further complicating the etiology are reports citing evidence of intrauterine onset of paralysis.[80,134] Thus, prevention of the injury remains elusive, underscoring the importance of optimal treatment of the sequelae.

Most commonly, a brachial plexus birth palsy involves the upper trunk (C5-6 or Erb's palsy), potentially in combination with injury to C7 (extended Erb's palsy); less often, the entire plexus (C5-T1 or global palsy) is injured. Injuries are described classically as neurapraxia (Sunderland type I), axonotmesis (Sunderland types II to IV), neurotmesis (Sunderland type V), or avulsion (Figure 40.2). Mechanically, lesions have been described as stretch (Sunderland type I), varying degrees of rupture (Sunderland types II to V), and avulsion. Upper trunk extraforaminal ruptures are more common with vertex delivery and shoulder dystocia. The right upper limb is involved more often because of the more frequent left occiput anterior vertex presentation, which places the right shoulder behind the symphysis pubis. C5-6 root avulsions are particularly frequent with breech presentation and can at times be bilateral.[6,60,110] When the entire plexus is involved, a combination of stretch, rupture, and avulsion injuries can occur in various portions of the plexus.

A mechanical cause of infantile paralysis is the predominant theory on the etiology of brachial plexus birth palsy. The theory is based on extensive work that began with original descriptions of brachial plexopathy during delivery by Smellie[160] and Duchenne[47] and anatomic studies by Metaizeau.[113] However, there are rare reports of possible congenital causes of a birth palsy such as hypoplastic plexus.[61,134] In addition, it has been postulated that there may be abnormal in utero forces (maternal propulsive forces) acting on the posterior shoulder region and the plexus as the fetus passes over the sacral promontory before obstetric delivery. The pushing forces of uterine contractions in a dystocia situation have been studied to determine their contribution to neonatal nerve injury in these deliveries.[130]

Increased in utero pressure and subsequent traction across the plexus have been proposed as a possible root cause. In addition, the presence of an anomalous uterus, such as a bicornuate

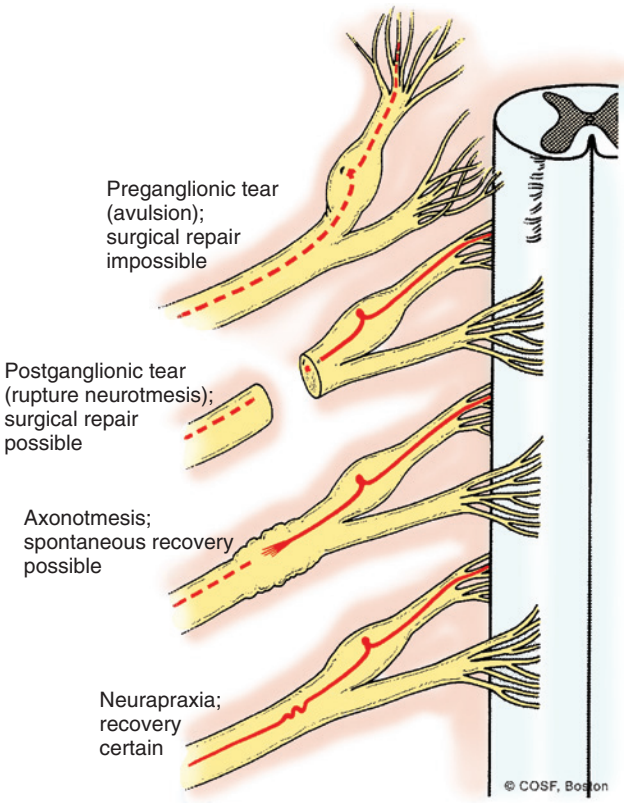

FIGURE 40.2 A severe traction injury to the brachial plexus may cause nerve injuries of varying severity in the same plexus. Such injuries include avulsion of the nerve root from the spinal cord (cannot be repaired), extraforaminal rupture of the root or trunk (can be surgically repaired), intraneural rupture of fascicles (some spontaneous recovery possible), and neurapraxia (recovery certain).



FIGURE 40.3 A 4-month-old child with left global brachial birth palsy and Horner syndrome. (Courtesy of Shriners Hospitals for Children, Philadelphia.)

or fibroid one, may decrease the space available for the infant and lead to compression across the brachial plexus.[81] These alternative causes have become contentious issues in a litigious society because the presence of a brachial plexus birth palsy may result in a malpractice suit against everyone participating in the birth of that infant, including the obstetrician, midwife, labor nurse, hospital, and others.[79,130]

The diagnosis of a brachial plexus birth palsy is predominantly by physical examination. The differential diagnosis includes pseudoparalysis as a result of fracture or, less commonly, infection; injury to the central nervous system or cervical spinal cord; neuromuscular disorders; and congenital anomalies of the upper limb that result in limited motion and strength. Because fracture of the clavicle can occur concomitantly with a birth palsy, radiographs are clinically indicated. A humeral shaft fracture can mimic a brachial plexopathy, although the two injuries do not tend to coexist in the same limb. Instead, a severely displaced humeral shaft fracture results in an isolated radial nerve palsy.

Generally, the diagnosis of a brachial plexus palsy is readily apparent. The spectrum of clinical findings is dependent on the extent of nerve injury and the timing of examination. The presence of Horner syndrome (i.e., ptosis, myosis, enophthalmos, anhidrosis) is worrisome for an avulsion injury in the lower roots and a poor prognosis (Figure 40.3). The recovery after birth is often dynamic with changing physical findings over the first few weeks and months of life. Patience is required to perform a reliable examination of an infant (Video 40.1). Observation of spontaneous movement, testing of neonatal reflexes, and stimulation of motor activity are necessary for an accurate examination. The most important aspect of the examination is to determine the prognosis for recovery.[98,179] Therefore, serial examinations on a 1- to 3-month basis during infancy are critical for prediction of outcome and determination of indications for surgical intervention.[46]

Narakas and Slooff attempted to clinically categorize the continuum of brachial plexus palsy into four groups.[124,125,159] The mildest clinical group (I) is represented by the classic upper trunk C5-6 (Erb's) palsy,[50] with initial absence of shoulder abduction and external rotation, elbow flexion, and forearm supination. Wrist and digital flexion and extension are intact. Successful spontaneous recovery is believed to occur in as many as 90% of infants in this group.[159] Group II represents an extended upper trunk lesion and includes additional involvement of C7, with the absence of wrist and digital extension added to the limitations noted for group I. These infants have the classic "waiter's tip" posture of their hand and wrist. The prognosis is worse with C5-7 involvement. Group III consists of a flail extremity but without a Horner syndrome. The most severe involvement (group IV) is manifested as a flail extremity with a Horner syndrome. These infants may have an associated phrenic nerve palsy with an elevated hemidiaphragm.[10] This is best assessed via dynamic study such as a chest fluoroscopy or ultrasound during breathing. These infants have limited chance of meaningful spontaneous recovery.

For prognostic reasons, it is important to determine whether the level of injury is preganglionic or postganglionic (see Figure 40.2). Because of the proximity of the ganglion to the spinal cord and the fact that the motor cell body is in the spinal cord,

TABLE 40.1 Indicators of Avulsion Injuries and Poor Prognosis for Recovery

Finding	Implication
Paraspinal muscle injury	Dorsal rami injury
Rhomboid injury	Dorsal scapular nerve (C5)
Scapular winging	Long thoracic (C5, C7, C8) injury
Horner syndrome	Cervicothoracic sympathetic injury
Hemidiaphragm paralysis	Phrenic nerve injury
Pseudomeningocele	Dura and arachnoid avulsion injury

preganglionic lesions are avulsions from the cord that will not spontaneously recover. By assessing the function of several nerves that arise close to the midline and the ganglion, one can frequently determine the level of the lesion by physical examination (Table 40.1). Specifically, the presence of Horner syndrome (sympathetic chain), an elevated hemidiaphragm (phrenic nerve), and a winged scapula (long thoracic nerve) and the absence of rhomboid (dorsal scapular nerve), all raise concern about a preganglionic lesion.

Preganglionic lesions can be reconstructed only by nerve transfers,[123] most commonly with the thoracic intercostal nerves,[85,105,122] a branch of the spinal accessory nerve,[83] or partial peripheral nerve transfers. Postganglionic ruptures have reconstructible proximal and distal nerves beyond the zone of injury. Thus, a postganglionic injury is a complex peripheral nerve lesion that can be reconstructed with intercalary nerve grafts. Peripheral nerve transfers can also be used to reconstruct these injuries. However, functional spontaneous recovery is also possible in postganglionic injuries, likely due to partial ruptures and redundant innervation pathways present at birth.[177] Narakas group I and those in Narakas II with complete biceps recovery by 4 months have a high likelihood of full function. Infants in groups III and IV are unlikely to achieve full function without surgical intervention.[158]

The majority of neonatal brachial plexus injuries involve the upper trunk.[62] The classic Erb palsy involves C5-6 (46%). The next most common injury (an extended upper trunk lesion or extended Erb's palsy) involves C5-7 (29%); with these injuries, the pattern is most frequently postganglionic. When the lower plexus is involved, preganglionic avulsions of C8-T1 are most common. The exception to this situation is an upper trunk lesion seen with a breech delivery. These nerve injuries tend to be preganglionic C5-6 avulsions from the spinal cord.[57]

Most authors use the timing of specific motor function recovery and the absence of recovery as an indication for surgical intervention.[62,99] Wyeth and Sharpe in 1917 advised surgical intervention if no recovery was seen by 3 months of life.[190] Gilbert and Tassin concurred with the 3-month time interval and used recovery of antigravity biceps function as the key indicator of spontaneous recovery of the brachial plexus.[60] Waters similarly found biceps recovery to be statistically reliable.[179] Laurent and colleagues advised monitoring biceps, triceps, and deltoid function.[98]

Clarke and associates described the timing of return of elbow flexion and elbow, wrist, finger, and thumb extension as discriminators of outcome and used a combined threshold score of motor recovery of these muscles as an indication for nerve surgery.[36,116] Ultimately, Clarke advised that recovery at 9 months be assessed with a "cookie test" (i.e., inability to bring a cookie to the mouth with the arm at the side) to predict outcome and determine the need for microsurgical intervention in difficult cases.

Grading recovery of specific muscles in an infant is difficult. Many centers use the Medical Research Council (MRC) muscle grading system to define results. The schema classifies muscle strength as 0 (no contraction), 1 (trace contraction), 2 (active motion with gravity eliminated), 3 (active motion against gravity), 4 (active motion against gravity and resistance), and 5 (normal power). However, this system requires volitional contraction, which is not feasible in an infant and difficult in a young child. Understanding this, Gilbert and Tassin modified the MRC grading system to a four-grade one of 0 (no contracture), 1 (contracture without movement), 2 (movement with gravity eliminated), and 3 (complete movement against the corresponding weight of the extremity).[106] The modified Mallet classification (Figure 40.4) provides a more global motor function of the upper trunk as opposed to isolated muscle testing.[1]

A sixth category of "internal rotation" has been added to better balance the Mallet classification with regard to external and internal rotation. This global abduction system assesses external rotation of hand-to-mouth, hand-to-neck, hand-to-spine, and hand-to-belly activities on a scale of 1 to 5. A score of 1 is no function, 5 is normal function, and grades 2 to 4 denote progressive improved strength, as shown in Figure 40.4. The majority of late 20th century papers on infantile brachial plexus have used these classification schemes to determine the results of spontaneous recovery and surgical intervention.

More recently, Clarke and coworkers advocated use of the Hospital for Sick Children Active Movement Scale (AMS) (Table 40.2), a grading system that divides muscle strength into movement with gravity eliminated (grades 0-4) and movement against gravity (grades 5-7).[37] This system requires that full active motion with gravity eliminated occur (grade 4) before scoring antigravity muscle strength (5-7). Thus, the presence of contractures that limit joint passive range of motion can limit the progression from grade 4 to grade 5 despite the muscle strength being adequate to move the limb against gravity. The Toronto Test Score[115] is a similar grading of specific muscle functions at the elbow, wrist, and hand, is used only in infancy to predict the need for surgical nerve reconstruction, and is not designed to track progressive recovery over time (Table 40.3). Thus, no scoring system is without limitations.

The Mallet,[107] Toronto Test Score,[11] and AMS are statistically reliable in terms of interobserver and intraobserver analyses.[16,40] As might be expected, intraobserver reliability is better than interobserver, and less complicated systems (Mallet) have higher reliability than more complicated schemes (AMS). The Pediatric Outcomes Data Collection Instrument (PODCI), which assesses parent and patient-reported function, has also been shown to be a reliable tool for measuring baseline function in children with chronic brachial plexus injuries against normative per age data, as well as for assessing postoperative changes in these children.[16,78] However, parent reports of their child's function can be confounded by litigation against the delivery team,[48] as this injury carries with it a strong emotional component that affects perceptions of function.[48] This

Modified Mallet classification (grade I = no function, Grade V = normal function)						
		Grade I	Grade II	Grade III	Grade IV	Grade V
Global abduction	Not testable	No function	 <30°	 30° to 90°	 >90°	Normal
Global external rotation	Not testable	No function	 <0°	 0° to 20°	 >20°	Normal
Hand to neck	Not testable	No function	 Not possible	 Difficult	 Easy	Normal
Hand on spine	Not testable	No function	 Not possible	 S1	 T12	Normal
Hand to mouth	Not testable	No function	 Marked trumpet sign	 Partial trumpet sign	 <40° of abduction	Normal
Internal rotation	Not testable	No function	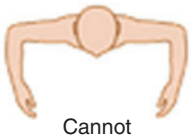 Cannot touch	 Can touch with wrist flexion	 Palm on belly, no wrist flexion	

FIGURE 40.4 Mallet modified classification system for grading shoulder function in a child. (From Mallet J: [Paralysie obstetricale du plexus brachial: traitement des sequelle: primaute du traitement de l'epaule: method d'expression des resultants.] *Rev Chir Orthop Reparatrice Appar Mot* 1972;58(Suppl 1):166–8.)

information is critical for comparing results and for assessing multicenter studies of therapeutic interventions for brachial plexus birth palsy.

Recently, the recognition that objective measurements and legacy measures may not correlate with enhanced function has resulted in a paradigm shift in outcome assessments. The initiative toward patient- or caregiver-reported outcomes has resulted in the development of reliable subjective measures. For children with brachial plexus palsy, Shriners Hospitals for Children has invested millions of dollars into patient-reported outcomes using the computer adaptive test (CAT) approach.[120,121] This methodology has been shown to correlate with legacy measures, discriminate among brachial plexus impairment levels, possess minimal floor and ceiling effects, and be less burdensome compared to previous measurement systems.

Invasive radiographic studies, such as myelography, combined myelography and computed tomography (CT), and magnetic resonance imaging (MRI),[2,45,66,116,169,184,186,192] have been used in an attempt to distinguish between preganglionic avulsion injuries and postganglionic extraforaminal ruptures.[178] Kawai compared all three techniques with operative findings in infants.[86] Myelography had an 84% true-positive rate with 4% false-positive and 12% false-negative rates. The addition of CT to myelography increased the true-positive rate to 94%. The presence of small diverticula was only 60% accurate in diagnosing an avulsion; however, the presence of large diverticula or

TABLE 40.2 Hospital for Sick Children Active Movement Scale Using AMS Measurements

Gravity Eliminated	Score
No contraction	0
Contraction, no motion	1
<50% motion	2
>50% motion	3
Full motion	4
Against Gravity	
<50% motion	5
>50% motion	6
Full motion	7
Shoulder abduction	2
Shoulder adduction	7
Shoulder flexion	2
Shoulder external rotation	0
Shoulder internal rotation	7
Elbow flexion	0
Elbow extension	7
Forearm supination	0
Forearm pronation	7
Wrist flexion	7
Wrist extension	2
Finger flexion	7
Finger extension	7
Thumb flexion	7
Thumb extension	7
Total	97

Adapted from Clarke HM, Curtis CG: An approach to obstetrical brachial plexus injuries. *Hand Clin* 11:563–580, 1995.

TABLE 40.3 Toronto Score

	Grade	Weight
No joint movement	0	0.0
Flicker	0	0.3
<50% ROM	1–	0.6
=50% ROM	1	1.0
>50% ROM	1+	1.3
Good but not full	2–	1.6
Full ROM	2	2.0
Elbow flexion (0-2)		
Elbow extension (0-2)		
Wrist extension (0-2)		
Finger extension (0-2)		
Thumb extension (0-2)		
Total	7	**6.8**

frank meningoceles was universally diagnostic. MRI had a true-positive rate similar to that of CT myelography but also allowed extraforaminal assessment of the plexus.[107] MRI allows evaluation for possible double-crush injuries. High spin echo MRI,[56] MR myelography, and MR neurography improve the resolution of MR analysis.[174] MRI has the potential advantage of sedation only inasmuch as myelography requires general anesthesia for an infant.[68] These radiographic studies may improve the quality of preoperative planning, but the final decision regarding the presence or absence of an avulsion injury is determined at the time of surgery.

Electrodiagnostic studies with electromyography (EMG) and nerve conduction velocity (NCV) have also been used in an attempt to improve diagnostic accuracy of the severity of the nerve injury.[132] The presence of normal sensory nerve conduction in the absence of motor nerve conduction is diagnostic of root avulsion. Absence of reinnervation at 3 months is suggestive of an avulsion. The H-reflex has been shown to help prognosticate outcome.[82] Unfortunately, the presence of motor activity in a muscle has not been accurate in predicting an acceptable level of clinical motor recovery in that muscle. With EMG, the presence of partial reinnervation can confuse the clinical picture.[8,22,166]

Studies have shown that nearly normal findings on EMG can be seen in infants with a severe lesion or even root avulsion.[42,105,159,174] Frequently, there are substantial discrepancies between preoperative electrodiagnostic testing (EMG and nerve conduction), intraoperative somatosensory evoked potential testing, and surgical findings. A potential source of this discrepancy is the plasticity of the infantile nervous system.[25] For example, Slooff documented innervation of the deltoid and biceps from C7 in the presence of avulsions of C5 and C6.[159] At this stage, it is clear that neurophysiologic studies may underestimate the severity of injuries and provide a false optimism regarding recovery.[38,172,173] It has been estimated that 20 to 25% of infants with a brachial plexus birth palsy will require microsurgical intervention and that the clinical information is the decisive factor in determining indications for surgery.[32] At present, most centers and brachial plexus microsurgeons ultimately rely on the physical examination findings over time to assess recovery and decide on surgical intervention.

CRITICAL POINTS

- The most common brachial plexus birth palsy involves the upper trunk (C5-6) and is also known as Erb's palsy.
- The second most common pattern involves C5-7 and is known as extended Erb's palsy.
- Involvement of the entire plexus (C5-T1) is called global or total brachial plexus palsy. This is the least common pattern.
- Erb's palsy has the best prognosis for spontaneous recovery. In contrast, global palsy has the worst prognosis for spontaneous resolution.
- Despite difficulty in assessing muscle strength in infants, serial physical examinations remain the best method for predicting prognosis for recovery.
- Current electrodiagnostic studies have been unreliable in predicting recovery.

NATURAL HISTORY

The natural history of neonatal brachial plexus palsy was initially thought to be uniformly favorable; however, recent studies portend a more guarded prognosis. Assessing history is complicated by the lack of true natural history studies. In a systematic review of 76 studies discussing the natural history of BPBP,[142] no paper met all four established criteria for an unbiased study, and only two studies met even two criteria; in these papers, residual neurological deficits existed in 20 to 30% of children. Subsequently, the rate of permanent neurological deficit has been found to be as high as 40%.[54] A true natural history likely may never be elucidated as doing so would require withholding treatment that has become recognized as beneficial for optimal outcomes. Despite limitations in natural history studies, there is sufficient evidence to draw certain conclusions, as follows.

- The majority of brachial birth palsies are transient. Infants who recover partial antigravity upper trunk muscle strength during the first 2 months usually have a full and complete recovery over the first 1 to 2 years of life.
- Infants who do not recover antigravity biceps strength by 5 to 6 months of life should undergo microsurgical reconstruction because successful surgery would result in a better outcome than the natural history alone.
- Infants with partial recovery of C5-7 antigravity strength during months 3 to 6 of life will have permanent, progressive limitations in motion and strength, as well as risk for the development of joint contractures in the affected limb.
- Infants with global injuries and avulsion injuries of the lower trunk with have the worse prognosis and most limitations with lifelong dysfunction in the arm and hand.

The major clinical dilemma resulting from the uncertainty regarding spontaneous neurologic recovery is to determine whether infants without antigravity return of C5-7 function at 3, 4, 5, or 6 months of age warrant surgical exploration and nerve reconstruction. These infants have varying degrees of rupture (Sunderland types II to IV), and their ultimate neuromuscular recovery without intervention or with just tendon transfers has still not been compared with their recovery after microsurgery plus tendon transfers. Ideally, this question would be addressed in a prospective randomized clinical trial with sufficient enrollment[26]; however, such a study has been difficult to perform due to varying clinical practices and beliefs among surgeons at different centers.

Parents, primary care physicians, and therapists are under substantial emotional pressure to do what they believe is best for the affected infant.[153] Unfortunately, despite strong opinions and at times solicitous pressure from specific medical centers, data are still insufficient to definitively answer the question.[19] Comparative analysis has shown that elbow flexion alone is an insufficient criterion to warrant nonoperative care and that useful motor function has been observed in patients without elbow flexion at 3 months of age.[53,161]

Disagreement among surgeons is common regarding surgical indications.[23] This lack of clarity creates large regional variations in care and makes decision making difficult for parents. Accessing information from support groups and the Internet is common. This input affects parents' decision making regarding care of their child.[111,153] The quality of that information, however, can be variable. The long-term outcome with regard to function, activities of daily living, pain, career choice, and personal life is limited. The minimal data collected by support groups infer ongoing difficulties in performing activities of daily living.[13] Pain, as evidenced by self-mutilating behavior, is rare in infants, occurring about 3 to 4% of the time.[108] Chronic pain in adulthood is thought to be uncommon but the true incidence has yet to be documented.

NERVE SURGERY

The role, timing, and technique for nerve reconstruction are controversial issues.[141] The original surgical interventions on the brachial plexus at the turn of the 20th century consisted of resection of the neuroma and direct repair. Kennedy[87a] initially described three cases in 1903 with subsequent reports by Wyeth and Sharpe[184] in 1917 and Taylor[166a] in 1920. In a report on 1100 infants with brachial plexopathy in 1925, Sever was uncertain of the benefit of surgical intervention.[153] By the 1930s, brachial plexus nerve surgery had fallen out of favor. The advent of microsurgical techniques and extensive work in the 1970s and 1980s by Narakas,[123,124] Millesi,[116a-c] and Gilbert[59-61] in Europe, Kawabata[83-85] and others in Asia, and Boome and Kaye in South Africa[27] led to the resurgence in brachial plexus microsurgical reconstruction. At this time, medical centers throughout the world have plastic surgery, neurosurgery, and orthopedic surgery subspecialty brachial plexus centers actively performing brachial plexus nerve reconstruction.

The spectrum of nerve surgery includes neurolysis, neuroma resection and nerve grafting, and nerve transfers. Direct repair is rarely performed because of the extensive nature of the lesion and inability to achieve a tension-free nerve repair without grafting. Although neurolysis has been performed extensively,[98,156] most centers have abandoned its independent use.[3] Clearly, there is no role for neurolysis in the presence of an avulsion injury. Neurolysis has been shown to have results no different from the natural history following total plexopathy, and the evidence is similar (although less conclusive) for injuries involving upper trunk rupture.

Gilbert and Whitaker strongly believe there is no role for neurolysis alone.[61] Laurent and colleagues advocated its use in conjunction with intraoperative electrodiagnostic studies. A neuroma-in-continuity was maintained if greater than 50% of a muscle action potential was found after neurolysis. Otherwise, the neuroma was resected and grafted. However, recovery of muscle strength following nerve grafting was greater than with neurolysis despite the fact that the preoperative status of the neurolysis patients was better compared to those patients who underwent nerve grafting.[98]

Capek and associates described better long-term results after resection and grafting of both conducting and nonconducting neuromas than with neurolysis despite initial worsening of the situation with resection and grafting.[30] Superiority of nerve grafting over neurolysis has also been shown by others.[102] The topic of neurolysis has been recently revisited,[14] although without clear evidence that neurolysis alone affects the natural history as many children would have improved spontaneously without surgery. Based on the present information, neurolysis alone is viewed as having little therapeutic benefit.

The standard nerve reconstruction strategy is resection of the neuroma and sural nerve grafting with extraforaminal

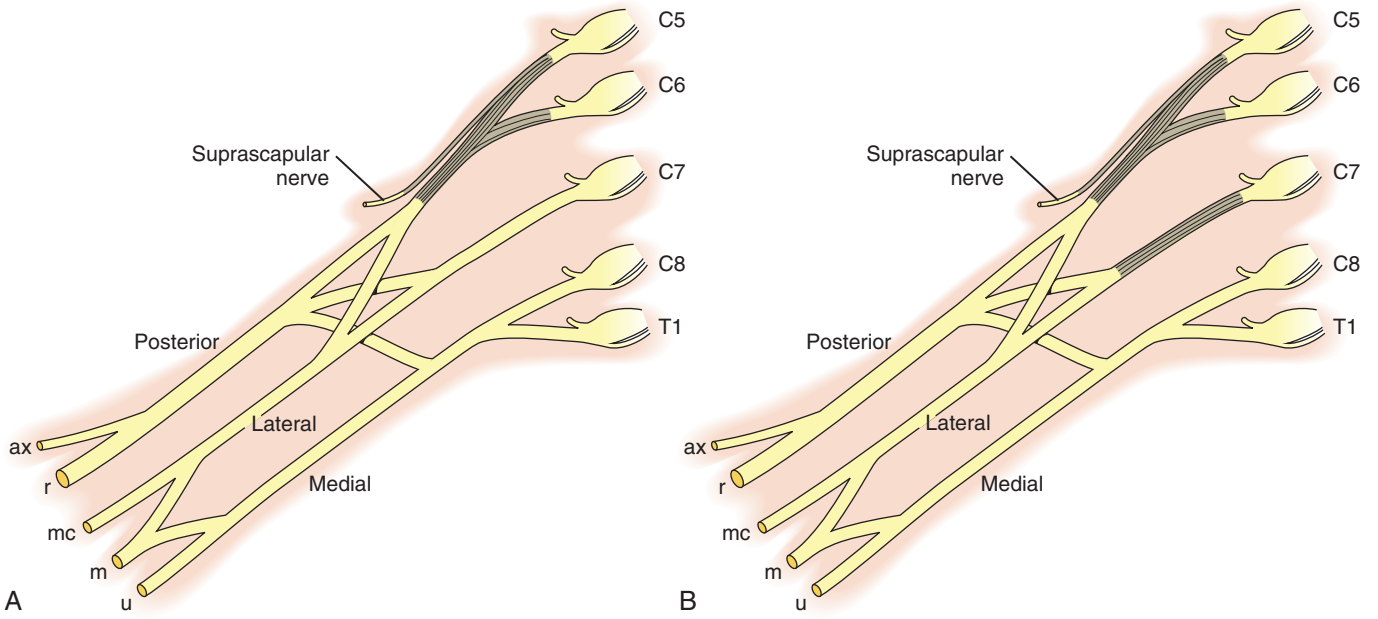

FIGURE 40.5 **A, B,** Nerve grafting strategies for upper trunk rupture. *ax*, Axillary; *m*, median; *mc*, musculocutaneous; *r*, radial; *u*, ulnar.

ruptures.[32] In an upper trunk (C5-6) rupture with an extraforaminal neuroma-in-continuity, resection of the neuroma and sural nerve grafting are performed from the C5 and C6 roots to the most proximal healthy nerve tissue of (1) the upper trunk anterior division, lateral cord, or musculocutaneous nerve; (2) the suprascapular nerve; or (3) the upper trunk posterior division, posterior cord, or axillary or radial nerves (Figure 40.5, *A*). If C7 is involved, additional grafting is necessary from C7 to the posterior cord (Figure 40.5, *B*). Nerve transfers are becoming more popular[4,25,129] for reconstruction of C5-6 and C5-7 injuries, with transfer of (1) the intercostals or partial ulnar nerve to the biceps motor branch, (2) a branch of the spinal accessory nerve to the suprascapular nerve, and (3) the radial nerve long head of the triceps motor branch to the axillary motor branch. Results of nerve transfers for upper plexus lesions appear to be equivalent to nerve grafting at the shoulder and elbow.[97,103]

In the case of ruptures and avulsions, nerve transfers in conjunction with nerve grafting are performed by using the thoracic intercostals (T2-4) (Figure 40.6) or a branch of the spinal accessory nerve (cranial nerve XI) after it innervates the trapezius (Figure 40.7). The spinal accessory can be harvested from an anterior or posterior approach (Figure 40.8). With total plexus avulsions, nerve transfers are the only reconstructive option and may include the intercostals, spinal accessory, contralateral C7, and even the hypoglossal nerve. Carlstedt and coworkers have done experimental and limited clinical work on direct reimplantation or grafting into the spinal cord,[31] but at present, the suboptimal results and the risk of causing cervical instability as a result of the laminotomy or injury to the nerves to uninvolved limbs does not warrant its use.

Gilbert and Whitaker as well as Slooff advocated that priority be given to microsurgical reconstruction of the hand in infants with extensive avulsions and limited nerve options.[61,159] Unlike adults, infants with brachial plexopathy have the potential to regain hand function after nerve grafting or nerve transfers, due to the shorter distance from the injury to the target muscles in the infant's upper limb. In each microsurgical case, the plan must be individualized depending on the time from injury, extent of the palsy, and available reconstructive options.

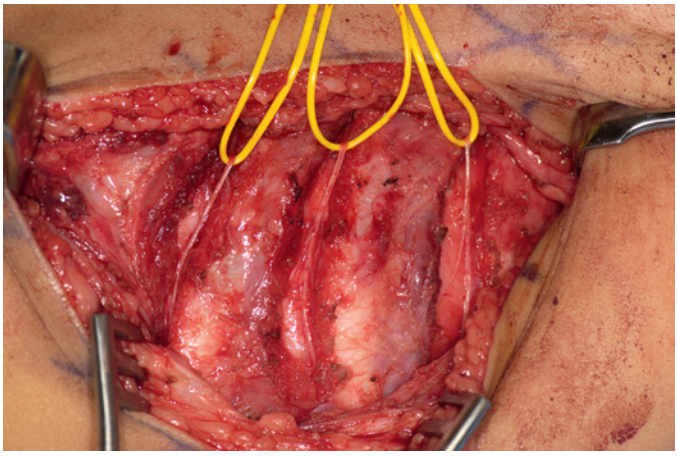

FIGURE 40.6 Nine-month-old with harvest of three intercostal nerves prior to transfer. (Courtesy of Shriners Hospitals for Children, Philadelphia.)

Although there is ongoing debate about the timing of microsurgical intervention, the most common criterion is the absence of return of biceps muscle function associated with (1) total plexopathy and Horner syndrome at 2 to 3 months or (2) an upper trunk lesion at 5 to 6 months. Reconstruction is performed between 3 and 9 months of age at various centers. The degree of muscle recovery is open to debate and interobserver error makes comparative analysis difficult. Gilbert and others advocated for microsurgery when recovery of antigravity biceps function is not seen by 3 months of life.[27,34,123] The reasons for early intervention include less risk for irreversible loss of motor endplates because of prolonged denervation and better parental acceptance of surgical intervention if performed while the limb is still flail or has minimal motion.

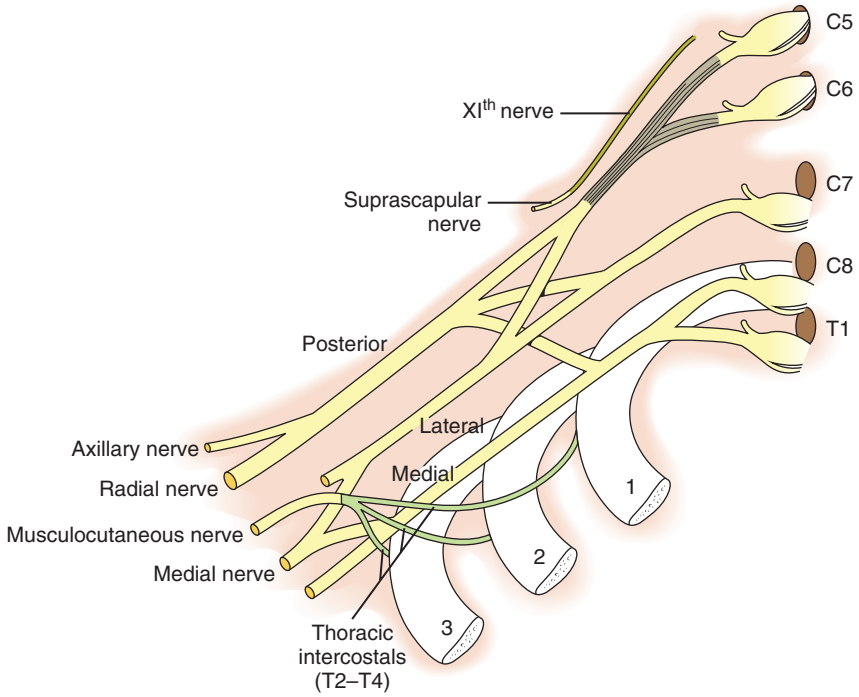

FIGURE 40.7 Nerve grafting strategies for nerve transfers and grafts.

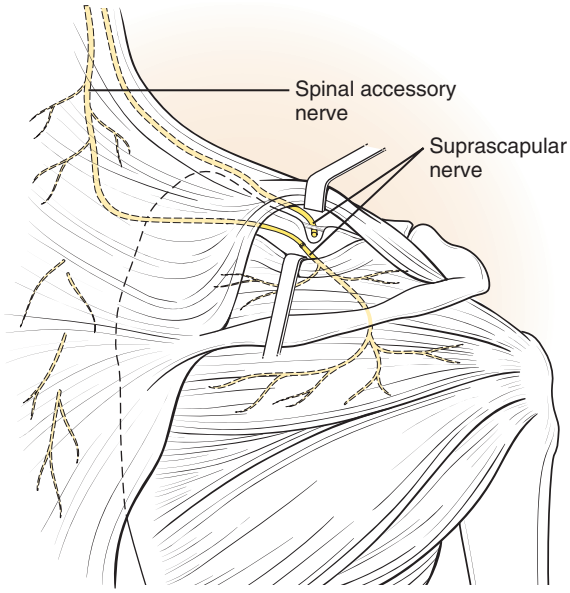

FIGURE 40.8 Schematic representation of a distal spinal accessory nerve transfer to the suprascapular nerve using the posterior approach. The proximal fibers innervating the superior and middle aspect of the trapezius muscle have been preserved, thus preventing a drooped shoulder.

Prospective studies by Al-Qattan[3] and Waters,[180] however, have indicated that recovery of antigravity biceps function by 4 and 5 months of age, respectively, results in outcomes that are equivalent to those of microsurgery, especially when combined with secondary tendon transfers to improve shoulder motion. Similarly, others have demonstrated functional results equivalent to nerve grafting in 12 to 55% of children treated conservatively despite lacking biceps function at 3 months old.[53,161] Finally, Clarke advocated microsurgery as late as 9 months for infants who fail the "cookie test" and thus have less than grade 6 biceps strength on the AMS. Microsurgical reconstruction at that relatively late time was overwhelmingly positive. Therefore, either the motor endplates of infants may be more resilient to irreversible demise than those of adults, or incomplete denervation of the affected muscles due to redundant innervation preserves motor endplate integrity.

Ultimately, the best time for microsurgical intervention in children with extraforaminal nerve rupture is still unknown. Comparative analysis indicates that biceps function alone is an insufficient criterion for operative management as some patients without biceps function by 3 months old recover useful limb function without microsurgery.[53,115,161] There is little consensus regarding the timing and type of procedures performed. Economic analysis indicates that microsurgical intervention at 3 months for nerve rupture is unlikely to be successful enough to produce cost savings for the payor.[28] Most centers and surgeons recommend that nerve surgery be indicated at 3 months for total plexus lesions and rarely indicated for an isolated rupture of the upper plexus.[35]

The problem with reviewing the results of microsurgery is that few patients (1) have long-term follow-up or (2) undergo microsurgery alone. Gilbert and Tassin's original study[60] compared microsurgery with spontaneous recovery. For C5-6 lesions, 100% recovered grade III shoulder motion spontaneously. In the nerve surgery cohort, 37% regained grade III and 63% obtained grade IV. With C5-7 lesions, 30% recovered grade II and 70% grade III with observation. With nerve surgery, 35% were grade II, 42% were grade III, and 22% were grade IV. Later, Gilbert and Whitaker[61] reported 81% shoulder function following C5-6 reconstruction in children with Mallet scores of III, IV, or V for abduction and 64% shoulder function in children who underwent total plexus reconstruction with Mallet scores of grade III or IV at greater than 2-year follow-up.[62]

When combined with secondary shoulder reconstruction, at 5 years these results increased to 70% shoulder function following C5-6 reconstruction with Mallet abduction class IV or V. Similarly, with total plexopathy reconstructions in which the hand was prioritized, at 2-year follow-up there were only 25% with grade III or IV shoulder function; 70% with grade III, IV, or V elbow function; and 35% with grade III or IV hand function using Gilbert's classification scheme. With the addition of secondary shoulder and hand procedures, this increased to 77% in the shoulder and 75% in the hand at 6-year follow-up. Gilbert maintains that nerve surgery not only improves function over natural history in selected patients but also increases the possibility for secondary tendon transfers. Long-term data from Sweden indicate that microsurgical patients still have deficiencies that may require assistance in activities of daily living.[89] The more severe the original injury, the more likely there will be permanent deficiencies.

These results should be compared to the natural history data available. Smith and coauthors published a study of 170 patients to assess the natural history of brachial plexopathy with regard to timing of biceps recovery.[161] Twenty-eight patients with absent biceps at 3 months of age were followed long term. Biceps contractions were observed in 20 patients (71%) by 6 months of age. Ultimately, 27 out of 28 had at least antigravity biceps muscle function. Patients who regained biceps between 3 and 6 months had better Mallet scores than patients who achieved biceps muscle function after 6 months of age. Twelve (55%) of the 22 patients who did not have brachial plexus surgery had class IV shoulder function. The authors concluded that the long-term function was favorable for the majority of C5-6 infants without nerve surgery.

Zancolli and Zancolli[194] found that 82% of affected infants monitored from birth had recovery of biceps function and that recovery in 75% began between months 4 and 5. Waters[179] addressed the same issue and found that of the 49 infants with no biceps recovery at 3 months, 42 recovered biceps function by 6 months. By assessing function at 2 years of age, infants with recovery of biceps function between 3 and 6 months had a progressive decrease in Mallet grades for abduction, external rotation, hand-to-mouth, and hand-to-neck activities stratified by month of biceps recovery.[179] In infants with biceps recovery between 3 and 6 months of age, recovery of function by Mallet grade was as follows: global abduction II (3%), III (52%), and IV (45%); global external rotation II (54%), III (31%), and IV (15%); hand-to-neck II (39%), III (33%), and IV (28%); and hand-to-mouth II (33%), III (24%), and IV (43%). These results are similar to Gilbert's published microsurgical results.

In addition, in both natural history and nerve surgery patients, secondary shoulder transfer and osteotomies improve function. For patients with recovery of biceps function between 3 and 6 months of life and later shoulder reconstruction, there will be an expected improvement to an average grade IV for all Mallet movements that involve external rotation and abduction. However, in both natural history and nerve surgery patients with incomplete recovery, there may be some deterioration in function with time.[132,165] A driving question is how different are patients who undergo nerve surgery at 3 months from those who recover biceps function between 3 and 6 months and undergo secondary reconstruction? This answer is critical to resolve the question as to whether unnecessary surgery is being performed or whether some centers are failing to perform nerve surgery at a young age. This controversy is presently unresolved because of lack of comparable data.[28,53,161]

The increasing use of nerve transfers further complicates the indications for nerve grafting. Nerve transfers utilize direct neurorrhaphy at a site closer to the target muscle. The more distal location of the neurorrhaphy allows a shorter regeneration time, faster recovery, and a longer window of time to await spontaneous recovery before fearing irreversible motor endplate demise. Therefore, surgeons may prolong the decision to intervene when viable nerve transfer options are available. Ladak et al reported results of 10 patients treated with three nerve transfers (i.e., spinal accessory to suprascapular, radial to axillary, and ulnar or median fascicle to musculocutaneous) at 10 to 18 months of age.[96] Recovery of function progressed between 6 and 24 months postoperatively, with ultimate function equivalent to published results of nerve grafting despite being performed at a later age.

Tse[168] demonstrated equivalent restoration of shoulder external rotation between patients treated with nerve grafting from C5 to the suprascapular nerve and those treated with a spinal accessory nerve to suprascapular nerve transfer; note that the latter patients had more severe brachial plexus injuries overall. Similar encouraging results of spinal accessory-to-suprascapular nerve transfer have been found by others, even in patients treated as late at 30 months of age.[150] Elbow flexion can also be restored by nerve transfer in properly selected patients. Little and colleagues, in a multicenter study, outlined the expected results and indications for ulnar and/or median fascicle transfer to restore elbow flexion and supination in neonatal brachial plexus palsies.[101] Elbow flexion could be reliably restored in children as old as 18 months of age, with supination recovery more dependent on age and with better supination following double-fascicle transfer (median and ulnar to both biceps and brachialis) over single-fascicle transfer to the biceps alone.

Ultimately, the decision between nerve grafting and nerve transfers should be individualized for each patient. Clearly, C5-6 avulsion injuries that cannot be treated with grafting are ideal candidates for nerve transfers. Similarly, dissociative recovery can occur, where only some of the muscles innervated by the upper trunk have recovered sufficient function, and the surgeon's goal is to restore innervation of the remaining paralyzed muscles without resecting the upper trunk and losing function of the muscles that have already recovered. In such cases, a la carte nerve transfers can be targeted to specific distal motor nerves. Nonetheless, precise indicators for nerve transfers remain unclear at the present time.

Surgical Technique: Nerve Grafting

The extent of surgical exposure depends on the level and severity of the injury. All microsurgical procedures in infants are performed under general anesthesia without the use of neuromuscular blocking agents. Both lower extremities are prepared for sural nerve graft harvest in cases of global palsies, although one sural nerve is generally sufficient for grafting isolated C5-6 injuries, so the other leg may be left undraped for venous access. Alternatives to nerve autograft, such as allograft and nerve conduits, have not yet been proven safe or effective in pediatric

CRITICAL POINTS

- The major determination for surgical intervention is the lack of recovery based on repeated physical examination.
- The role, timing, and technique of nerve surgery remain controversial issues.
- The spectrum of nerve surgery includes neurolysis, neuroma resection and nerve grafting, and nerve transfers. Direct repair is unlikely because of the etiology and extent of the lesion.
- Neurolysis has a limited role in brachial plexus birth palsy as long-term studies have not supported its efficacy.
- Neuroma resection with sural nerve grafting is the standard microsurgical care for extraforaminal ruptures, although nerve transfers have an evolving role. A combination of nerve grafting and nerve transfers is performed on infants with severe global lesions.

Expected Outcome With Nerve Surgery

- The outcome after microsurgery is difficult to decipher. Few studies have long-term follow-up or include patients who have undergone only microsurgery.
- Studies infer that successful nerve surgery performed between 5 and 8 months of age will have a better outcome compared to the natural history.
- Multicenter studies are necessary to truly elucidate the natural history and what will be the results of microsurgery.
- In contrast to adults, nerve grafting to the lower trunk can achieve hand function and should be a priority for children.

brachial plexus surgery. The shoulder girdle, chest, and neck are prepared for exposure of the brachial plexus and all possible planned nerve grafting and nerve transfer procedures (i.e., intercostals, spinal accessory, partial ulnar nerve, contralateral plexus).

The infant is placed supine, head tilted to the unaffected side, in a slight reverse Trendelenburg position to improve venous outflow from the head. For upper trunk ruptures, exposure can be performed through a transverse incision in the supraclavicular region. Dissection is carried out through the platysma and supraclavicular fascia to the plexus. The omohyoid muscle can be transected or retracted inferiorly. At times, the transverse cervical artery is transected (Figure 40.9). The phrenic nerve is identified, usually in a scarred position on the anterior scalene muscle or the anterior surface of the upper trunk neuroma (Figure 40.10), following the phrenic leads to the C5 root (Figure 40.11). The C5, C6, and C7 roots are sequentially exposed between the anterior and middle scalene muscles and labeled with Silastic loops. A decision is made regarding the integrity of each nerve root.

Electrophysiologic studies, inspection of the transected nerve under the microscope, and rapid histologic staining may all be factors in decision making. Generally, the upper roots are intact at the level of the foramina, and there is an

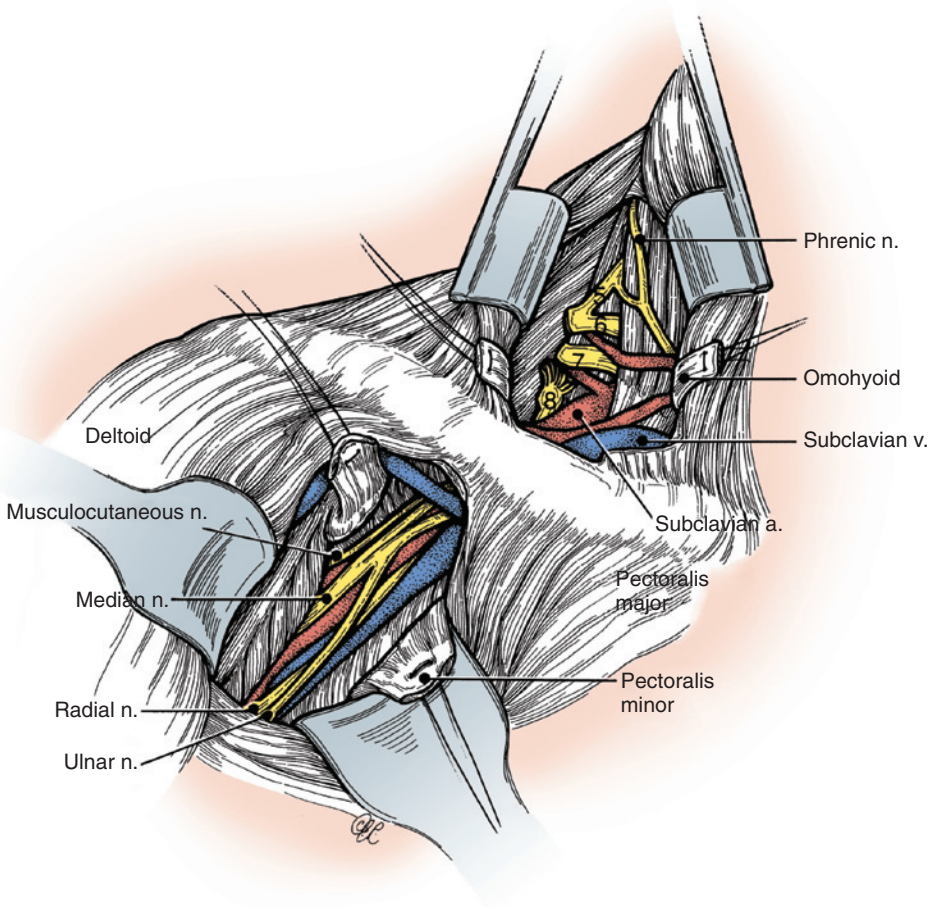

FIGURE 40.9 Key anatomic landmarks include the omohyoid muscle and the pectoralis minor muscle, which are divided between ligatures for later reapproximation. The C8 root is located just above and posterior to the subclavian artery, whereas the T1 root is almost directly posterior to the artery. With dissection of the deltopectoral groove, the lateral cord is the most superficial structure. In this example, the superior trunk and the C7 root are ruptured and the C8 root is avulsed (note the rootlets attached to the swollen dorsal root ganglion). (Copyright © Elizabeth Martin.)

extraforaminal neuroma at the junction where the C5 and C6 roots form the upper trunk (Erb's point). Distal dissection beneath the clavicle leads to identification of the divisions, cords, and major nerves. The axillary artery should also be identified and protected. In infants, the clavicle can often be left intact and mobilized with a Penrose drain or retractor for adequate exposure. If necessary, the clavicle can be transected obliquely and repaired with a suture through drill holes along with periosteal repair at the end of the operation.

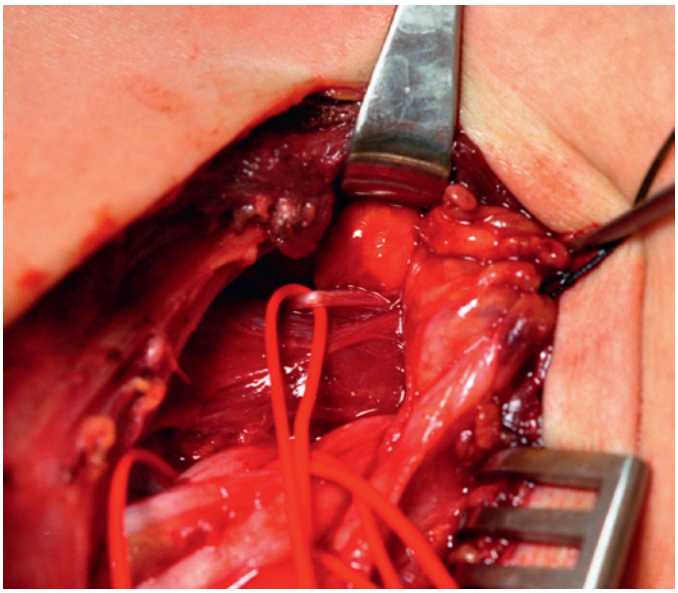

FIGURE 40.10 Phrenic nerve is isolated and protected. The nerve runs along anterior aspect of the anterior scalene. Patient is supine and head is to the right. (Courtesy of Shriners Hospitals for Children, Philadelphia.)

Sequentially the major nerves are identified. The suprascapular nerve is exposed and labeled with a Silastic loop, usually as it exits the upper trunk neuroma and passes posterior toward the suprascapular notch. The musculocutaneous nerve is identified, labeled, and exposed from distal to proximal for the lateral cord to the anterior division of the upper trunk until the neuroma is encountered. Similarly, the radial and axillary nerves are exposed and dissected to the posterior cord and posterior divisions of the upper, middle, and lower trunks. The posterior division of the lower trunk is generally intact, but the posterior division of the upper trunk and at times the middle trunk are usually encased in the neuroma. Intraoperative evoked potentials and nerve conduction are performed to determine the integrity of the nerve roots proximally and the peripheral nerves distally.

Some centers still advocate neurolysis if at least 50% of a normal action potential is generated across the neuroma by electrical stimulation.[99] However, Gilbert, Meyer, Laurent, Clarke, and their colleagues have all reported suboptimal results with neurolysis.[36,61,99,114] Therefore, transection of the fibrous neuroma proximally and distally and reconstruction of the defect with sural nerve grafts in an end-to-end fashion is frequently performed (Figure 40.12). The graft can be secured to the proximal and distal nerve ends using epineural sutures, fibrin glue, or both. The use of fibrin glue alone can dramatically decrease operative time and has become standard practice for many authors. Fibrin glue is particularly useful for the proximal neurorrhaphy given the difficulty of suturing within or adjacent to the neural foramen. With either neurorrhaphy

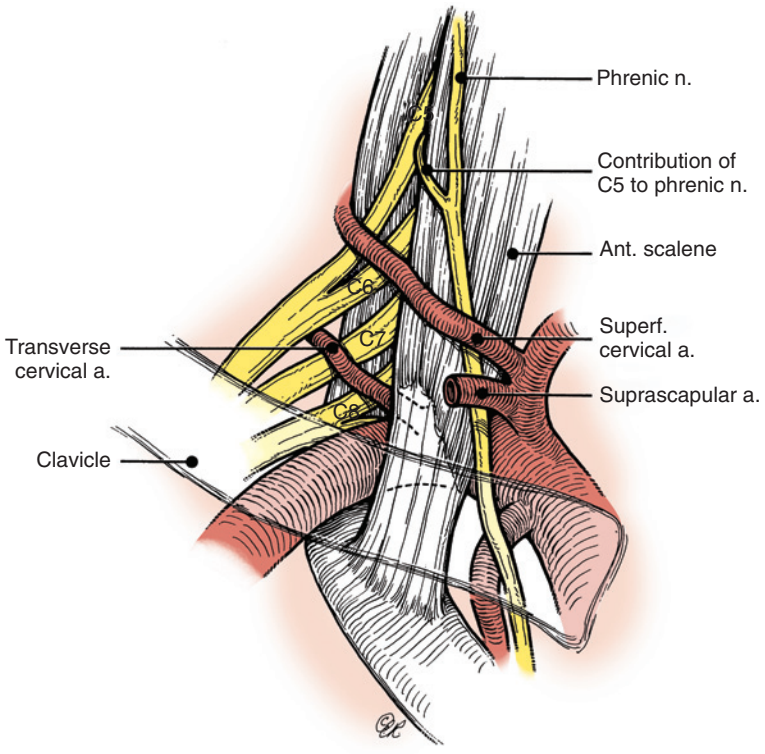

FIGURE 40.11 Additional landmarks helpful in identifying the various roots include the phrenic nerve contributions from the C5 root and the transverse cervical (scapular) artery, which frequently crosses over the C7 root. (Copyright © Elizabeth Martin.)

technique, however, it is important to cut the graft cables sufficiently long to avoid tension on the neurorrhaphy.

When avulsions are encountered, especially in the lower roots, more extensive exposure is necessary. This may include modifying the skin incision to a "Z" or using a second infraclavicular transverse incision to expose the infraclavicular area. Each nerve root is assessed closely to determine the viability of the root, which can be difficult because of partial avulsions. Electrophysiologic studies and histologic staining can augment direct microscopic observation. The C5 and C6 roots are usually intact with an extraforaminal rupture. The exception is an upper trunk lesion resulting from a breech delivery, in which case C5 and C6 are often avulsed. With severe lesions, C8 and T1 are usually avulsed and C7 is variable in integrity. Each case presents a unique intraoperative decision-making challenge. However, there are principles and general case scenarios with avulsions that can lead to the most optimal results.

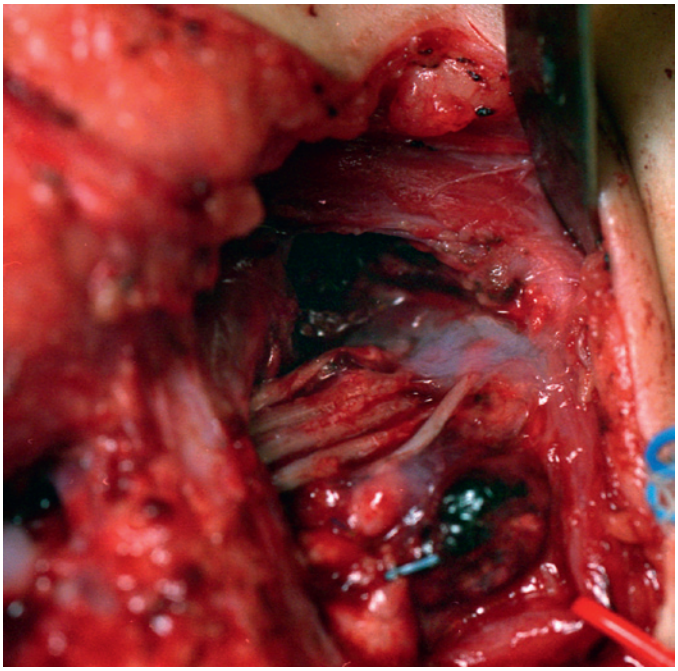

FIGURE 40.12 Six-month-old child with left brachial birth palsy. Supraclavicular exposure revealed ruptures at C5 and C6. Sural nerve grafts to upper trunk anterior division, upper trunk posterior division, and suprascapular nerve secured with fibrin glue. Child is supine and head is to the right. (Courtesy of Shriners Hospitals for Children, Philadelphia.)

- The C5, C6, and C7 nerve roots have extraforaminal ruptures, and C8 and T1 are avulsed. With three nerve roots available for grafting, it is possible to reconstruct the entire injured plexus. In this situation, the C5 and C6 nerve roots are transected to viable nerve and coapted by sural nerve grafting to the most viable proximal aspects of the suprascapular nerve and the medial, lateral, and posterior cords (see Figures 40.5, *B*, and 40.12).
- The C5 and C6 nerve roots have extraforaminal ruptures and C7, C8, and T1 have avulsions (Figure 40.13, *A*). This scenario means there is less viable proximal nerve. The hand receives priority with grafting from C5 or C6 to the medial (ulnar and median nerves) and lateral cords (musculocutaneous and median nerves) (Figure 40.13, *B*). Suprascapular nerve reconstruction is achieved either by nerve grafting or more commonly by transfer of the spinal accessory nerve. Reconstruction of the posterior cord may need to be abandoned or performed by transferring intercostal nerves to the musculocutaneous nerve and nerve grafting to the posterior cord.
- C5 is the only viable nerve root. This is the most difficult situation and requires prioritizing an anatomic site. In infants, it is advised that the hand be given priority with grafts from C5. A combination of spinal accessory and intercostal nerve transfers to the suprascapular, musculocutaneous, and median nerves along with C5 grafts to the lower

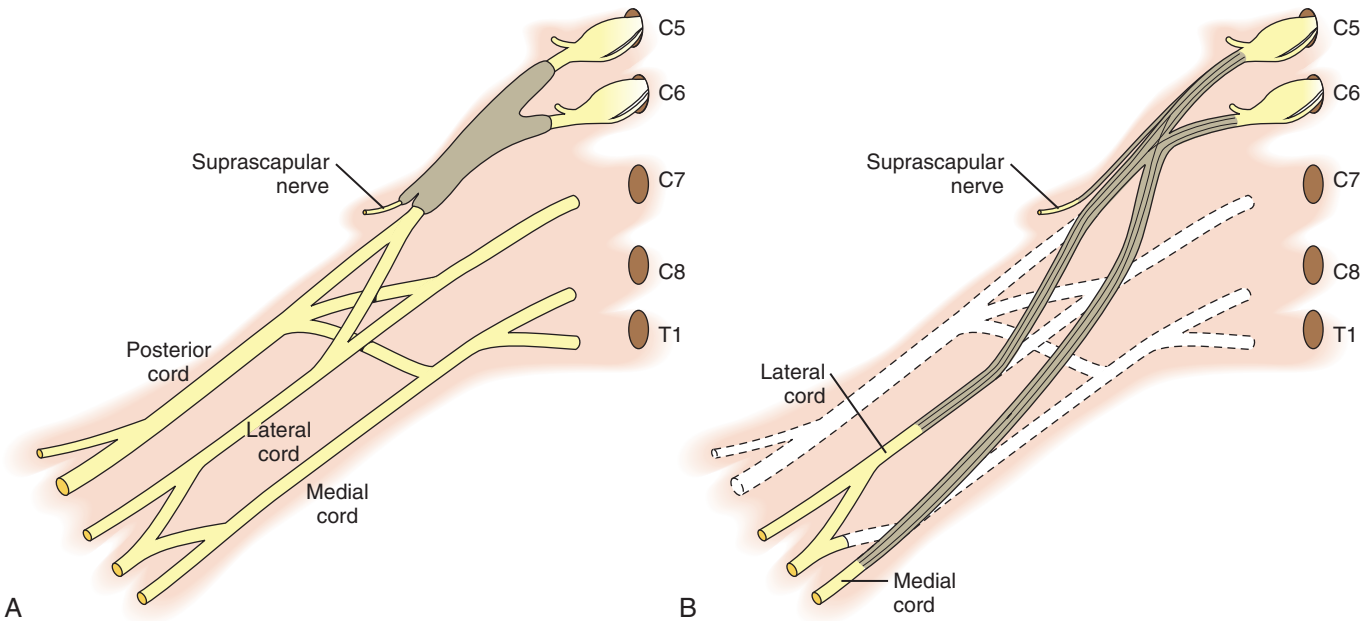

FIGURE 40.13 **A, B,** Combination grafting for a C5-7 rupture and C8-T1 avulsion.

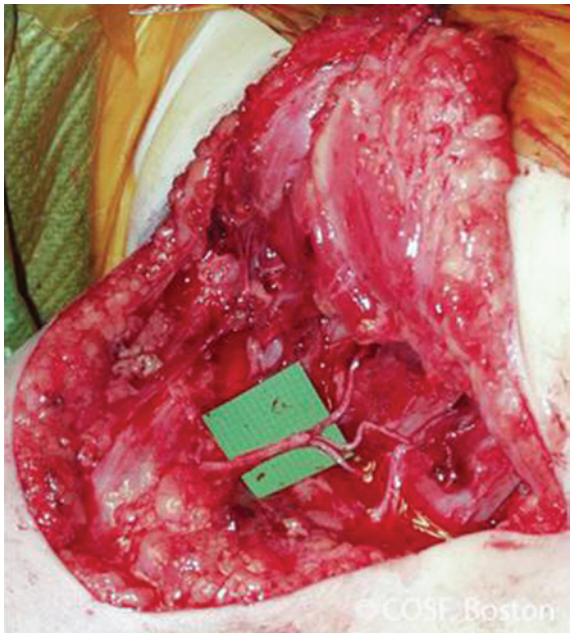

FIGURE 40.14 T2, T3, and T4 nerve transfers to the musculocutaneous motor branch for biceps reconstruction.

trunk is performed (Figure 40.14). The lower plexus is mobilized as much as possible to limit the length of the nerve grafts. Use of the contralateral C7 nerve may be necessary to maximally reconstruct the plexus, but published results are variable.[24] Reports of contralateral C7 transfer with short or no grafts through a retropharyngeal approach may prove promising in such cases,[191] although few centers are currently performing this technique.

Surgical Technique: Nerve Transfers

Nerve transfers can be performed as part of the reconstruction of an explored brachial plexus as described earlier or can be performed without formal exploration of the brachial plexus. The advantages of nerve transfers include a shorter axonal regeneration distance, no need for nerve grafts, and an operative field distant from the zone of injury and therefore no scarring. The techniques have been adequately described for transfers of the (1) spinal accessory to suprascapular nerve, (2) radial triceps branch to axillary nerve, and (3) median and/or ulnar fascicle to the musculocutaneous branches to the biceps and/or brachialis.

The spinal accessory to suprascapular nerve transfer can be performed through an anterior supraclavicular approach, although a posterior approach affords a more distal neurorrhaphy and the opportunity to free the suprascapular nerve from the suprascapular notch (see Figure 40.8).[24] The radial-to-axillary transfer is performed through an incision in the posterior arm, and the elbow flexion transfers are performed through a medial brachial approach. Therefore, performance of these three nerve transfers simultaneously requires exposure of the posterior shoulder and posterior and medial brachium. Such exposures can be accomplished with the patient in the lateral decubitus position. The dependent axilla is sufficiently protected with a lateral chest wall pad, and all bony prominences are well padded, paying careful attention to the lower extremities. The entire affected arm, chest wall, and scapular region is draped. Muscle relaxant is avoided to allow nerve stimulation.

For the spinal accessory to suprascapular nerve transfer, a transverse incision is made immediately superior to the spine of the scapula (Figure 40.15). The upper trapezius is elevated from the spine of the scapula and reflected superiorly to identify the supraspinatus muscle. The supraspinatus muscle is retracted inferiorly to expose the superior margin of the scapular body. The suprascapular notch is identified and its ligament is sectioned to expose the suprascapular nerve. The spinal accessory nerve is then identified on the anterior surface of the trapezius that is just medial to the scapular spine. The nerve is traced as distally as possible and then cut and rerouted superiorly and laterally, preserving as many proximal muscular branches as possible until it reaches the suprascapular nerve without tension. The suprascapular nerve is cut proximal to the notch and coapted to the spinal accessory nerve.

The radial-to-axillary transfer is performed through a transaxillary or posterior longitudinal midline incision in the arm, beginning at the inferior margin of the posterior deltoid and extending in a distal direction (Figure 40.16). The deltoid is retracted superiorly to identify the axillary nerve exiting the quadrangular space. The cutaneous branch of the axillary nerve is separated from the branches to the deltoid and teres minor muscles because transfer of the donor nerve into the cutaneous portion would dilute the axons available to the targeted muscles. The interval between the long and lateral heads of the triceps is then identified, and dissection is carried down to the teres major tendon.

The radial nerve is identified as it becomes posteriorly visible distal to the inferior margin of the teres major tendon. Branches to the long, medial, and lateral heads of the triceps are identified, and a suitable donor branch of sufficient caliber and function (determined by stimulation of the nerve branches producing strong contraction of the relevant portion of the triceps) is selected. The donor nerve is dissected into the triceps muscle belly and transected distally to produce enough length for coaptation to the axillary nerve. The triceps branch is then coapted to the deltoid branch of the axillary nerve after transecting the axillary nerve within the quadrangular space.

Transfer of ulnar and/or median nerve fascicles to the elbow flexors is accomplished through a longitudinal incision in the midbrachium (see Figure 40.16) (Video 40.2). The ulnar nerve is identified posterior to the intramuscular septum. The musculocutaneous nerve is usually identified by anterior retraction of the atrophic biceps muscle belly. The branch of the musculocutaneous nerve innervating the biceps is typically just deep the vascular pedicle to the muscle and runs more obliquely. The branch to the brachialis is located more distally. Donor fascicles from the ulnar and/or median nerves are selected through an epineurotomy and stimulation of individual fascicles to identify fascicles predominantly innervating the wrist flexors.

Because of the redundancy and interconnection of fascicles at this proximal level, no one fascicle will be strictly devoted to wrist flexion. Most fascicles produce some degree of finger flexion when stimulated, but a fascicle is chosen that does not innervate the intrinsic muscles of the hand. This redundancy avoids functional deficits in the median and ulnar nerves after these transfers. Once an appropriate fascicle is identified, it is dissected distal from the surrounding fascicles for 1 to 2 cm and

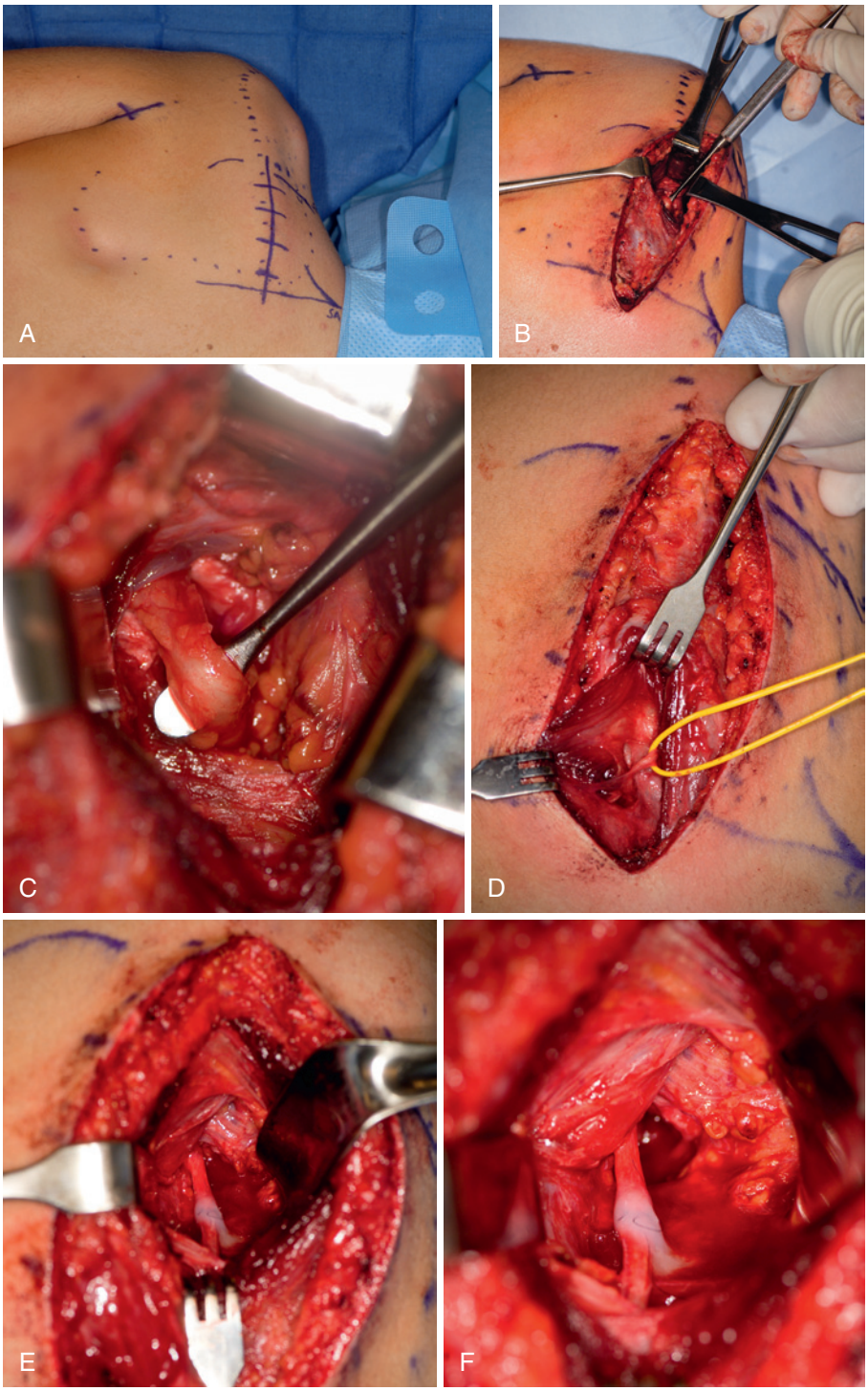

FIGURE 40.15 Technique of spinal accessory to suprascapular nerve transfer. **A,** Patient in lateral decubitus position and anatomic landmarks palpated. **B,** Suprascapular nerve isolated distal to suprascapular notch. **C,** Suprascapular notch release and close-up view of suprascapular nerve. **D,** Spinal accessory nerve identified deep to trapezius muscle. **E,** Spinal accessory to suprascapular nerve transfer. **F,** Nerve coaptation with suture and glue. (Courtesy of Shriners Hospitals for Children, Philadelphia.)

transected. The surgeon should cut the recipient musculocutaneous branch first and approximate it to the donor nerve before transecting the donor fascicle to ensure adequate length for coaptation. The donor and recipient nerves can then be coapted without tension.

Transfer of thoracic intercostal nerves (usually T2-4) are used when there are limited donor options and for more severe injuries (see Figure 40.6). A transverse chest wall or extended axillary incision can be used. The transverse chest incision is performed inferior to the nipple. The sensory branch of each intercostal nerve is isolated. Careful dissection under each rib is performed to isolate the segmental motor branch without injury to the adjacent blood vessels or underlying pleura. The rib is elevated with a double skin hook retractor. The motor branch

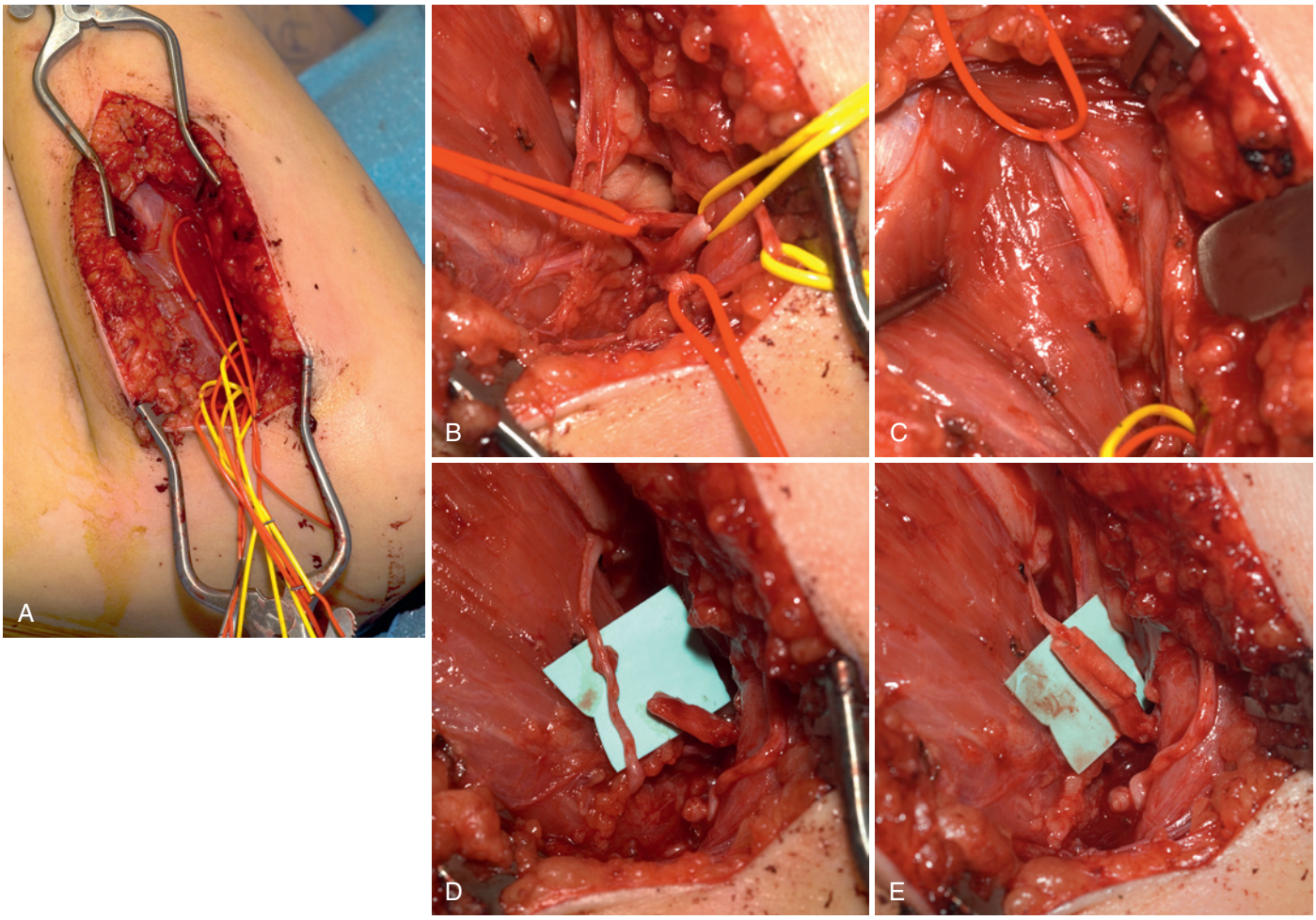

FIGURE 40.16 Technique of radial-to-axillary nerve transfer. **A,** Posterior exposure of left arm in a child with avulsions of C5 and C6. **B,** Isolation of axillary nerve and its branches as it exits the quadrangular space. **C,** Isolation of the specific nerve branches to the lateral, long, and medial heads of the triceps. The nerve branch to the medial head is usually selected as the donor nerve. **D,** The nerve branch to the medial head is cut sharply and reflected toward the axillary nerve, which has been cut proximal to the teres minor branch. **E,** The nerve ends are coapted using 9-0 nylon suture and fibrin glue. In this case, a nerve tube was placed around the repair site for augmentation. (Courtesy of Shriners Hospitals for Children, Philadelphia.)

of each intercostal is followed distal toward the anterior chest until it trifurcates. The motor branch is also dissected to the posterior axial fold to maximize length. Each intercostal nerve is cut, and all three motor branches are combined into one direct transfer, usually to the motor branch of the biceps. Direct transfer has better outcomes than use of an intercalary graft.

❖ AUTHORS' PREFERRED TREATMENT: Nerve Surgery

There is limited information available for the clinician to make decisions regarding the timing of microsurgical intervention and the outcome when comparing those patients with and without surgery, especially with the addition of secondary tendon transfers. Within these limitations, we treat the infants in the following ways:

- Observation of all infants with brachial plexus birth palsy who demonstrate antigravity biceps muscle recovery in the first 3 months of life is necessary. Physical therapy is performed until complete recovery to maintain a full range of motion of all joints of the upper limb, especially shoulder abduction and external rotation.
- If there is Horner syndrome and failure of recovery of some antigravity biceps strength by 3 months, microsurgery is performed at that time. Nerve grafts are performed if there are any intact nerve roots. Nerve transfers are uniformly necessary because of the limited viable nerve roots and inflow axons. Transfer of a branch of the spinal accessory nerve, thoracic intercostal nerves, or anterior fascicles of the ulnar nerve (see Figures 40.14 through 40.17) is performed as appropriate; this requires an intact C8-T1 root. The hand/wrist, elbow, and shoulder are prioritized in that order.
- If there is progressive recovery of wrist and finger extension without Horner syndrome, we wait until 5 to 6 months to determine whether some antigravity biceps strength will return. If there is still no adequate return of function, surgery is performed at that time. Neuroma resection and nerve grafts or nerve transfers are performed based on the intraoperative findings.
- All nonoperative patients are observed closely for the first 9 months to be certain that their recovery is progressive. In the

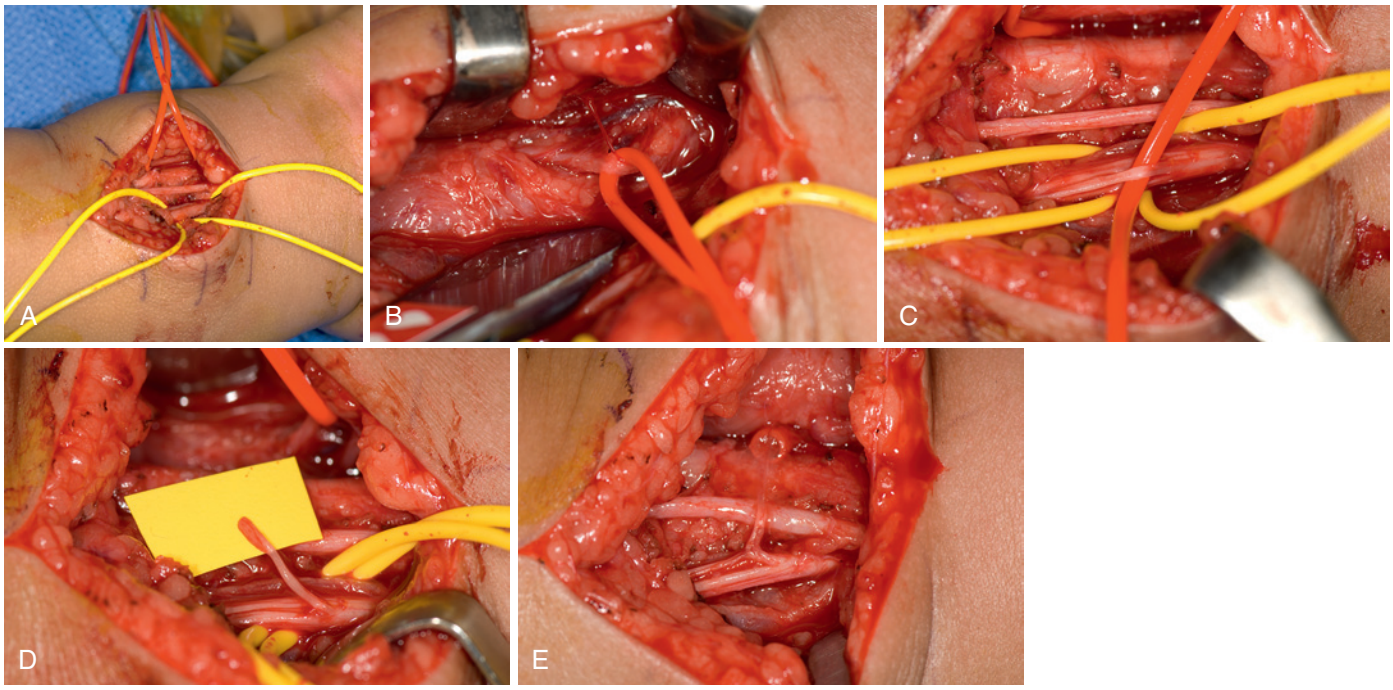

FIGURE 40.17 Technique of radial-to-axillary nerve transfer. **A,** Child's right arm with medial incision. Red vessel loop is around biceps motor branch from musculocutaneous nerve, yellow vessel loop is around ulnar nerve. **B,** Motor branch from musculocutaneous nerve to biceps muscle. **C,** A longitudinal epineurotomy along the ulnar nerve to identify the individual group fascicles and to isolate an expendable motor component. Adjacent parallel nerve is medial antebrachial cutaneous. **D,** Group fascicle of ulnar nerve to extrinsic muscles is divided and transferred toward the biceps motor branch. **E,** The group fascicle of the ulnar nerve is coapted to the biceps motor branch using 9-0 nylon suture and fibrin glue. In this case, a nerve tube was placed around the repair site for augmentation. (Courtesy of Shriners Hospitals for Children, Philadelphia.)

rare instances of failure of biceps recovery to progress to sufficient antigravity strength by month 9 (i.e., a positive "cookie test"), nerve surgery is performed, usually a nerve transfer to restore biceps function.

Postoperative Management: Nerve Surgery

Postoperative immobilization is achieved with a well-padded stockinette, sling, and swathe that bind the arm to the side. If there is any concern that neck motion will cause undue tension on the neural repairs, the neck is included in the immobilization. Lower extremity bandages for the sural nerve graft donor sites are removed 2 weeks postoperatively. Arm immobilization is discontinued at 4 weeks. Shoulder and arm range of motion is reinitiated to prevent the development of contractures. On occasion, a botulinum toxin (Botox®) injection in the internal rotators can be used at the time of nerve surgery to facilitate stretching postoperatively. In these cases, the child is placed in a shoulder spica cast with the shoulder in external rotation. The parents and therapists are informed that improved function will not occur for 6 to 18 months. However, failure to observe progressive recovery of the biceps by 6 to 9 months is concerning. Reexploration and additional microsurgery (i.e., nerve transfers) may be indicated for failure of biceps recovery by 9 to 12 months postoperatively.

Complications secondary to infection, bleeding, chylothorax, or a worsening neural condition are rare. At times, a phrenic nerve palsy can result in an elevated hemidiaphragm with exploration of the upper trunk, as the phrenic nerve is often involved in the scarring of the neuroma. The clinical scenario is not true respiratory depression or desaturation; rather, the child will have difficulty with feeding or recurrent respiratory infections. A phrenic nerve palsy is usually the result of traction on the nerve and resolves with time. A feeding specialist consultation may be necessary until recovery. If the diaphragmatic paralysis persists and affects respiratory function, a late diaphragmatic plication may be necessary. Nonunion of a clavicular osteotomy leads to chronic pain and decreased function. Treatment requires internal fixation and possibly bone grafting.[90]

The major complication of microsurgery is failure to achieve the desired outcome. If there is no recovery at 6 to 12 months postoperatively, observation will not improve function.[154] Either reexploration and further nerve reconstruction, or secondary regional tendon or free muscle transfers,[45,175] are warranted to improve outcome. Prior to surgery, it is imperative for parents to understand that perfect range of motion, strength, posture, and function are not achievable with nerve surgery.[90] However, functional improvement compared to the natural history is possible. Recovery of hand function is variable, depending on the original injury and microsurgical reconstruction. The mean Raimondi score was 4.57 for C5-6, 4.26 for C5-7, and 2.16 for total plexus patients (Table 40.4).[37] Avulsion injuries correlated with poor hand recovery. In addition, even with a positive outcome of hand function and strength, the majority of these patients require secondary tendon transfers to further improve usage.

TABLE 40.4 Raimondi Grading System for Hand Function*

Raimondi Grading System for Hand Function	Hand Grade
Complete paralysis or slight finger flexion or no use; useless thumb with no pinch; no or some sensation	0
Limited active flexion of fingers; no extension of wrist or fingers; possible lateral pinch of thumb; supinated forearm	I
Active extension of wrist gives passive flexion of fingers (by tenodesis); passive lateral pinch of thumb; pronated forearm	II
Complete active flexion of wrist and fingers; mobile thumb with partial abduction and opposition; some intrinsic balance; no active supination; good sensation; good possibilities for secondary surgery	III
Complete active flexion of wrist and fingers; active wrist extension; weak or absent finger extension; good thumb opposition with active intrinsics; partial active pronation and supination	IV
Grade IV plus active finger extension and near complete pronation and supination	V

*The grading system incorporates movement and sensation. Grades III, IV, and V are considered "good outcomes" after surgical intervention.

SECONDARY MUSCULOSKELETAL PROBLEMS

Neurologic injury during the neonatal period disturbs normal postnatal growth and development of the musculoskeletal system. Unless the nerve injury recovers within the first few weeks of life, such disturbances cause permanent and progressive secondary musculoskeletal problems. The two main manifestations of such disturbed development include joint contractures and bony deformity. The contractures substantially impair function and quality of life[17,18,78] and are the most common reason for surgery following a birth palsy. Contracture development is especially troublesome at the shoulder, where residual paralysis of muscles innervated by the upper trunk leads to restriction of passive glenohumeral motion and resulting glenohumeral dysplasia. The most conspicuous restriction of passive glenohumeral motion is the internal rotation contracture, which has been recognized and treated for more than a century.[52] One theory for the development of the shoulder internal rotation contracture is muscle imbalance between functioning internal rotators and paralyzed external rotators, leading to static internal rotation joint posturing and ultimate joint contracture.[135,180,184]

However, more recent investigations suggest that denervated rather than functioning muscles are responsible for contracture development. MRI studies have demonstrated the degree of the internal rotation contracture correlates with atrophy of the subscapularis, an internal rotator.[76,145] Furthermore, simple muscle imbalance cannot explain paradoxical contractures, where the joint becomes tight in the direction of the paralyzed muscles. The most notably paradoxical contracture is the elbow flexion contracture one that occurs in the setting of initial elbow flexor paralysis.[21,70,144] In fact, the elbow flexion contracture has been shown to correlate on MRI only with atrophy of the brachialis.[143] At the shoulder, one such paradoxical contracture is glenohumeral abduction that occurs following paralysis of the shoulder abductors.[48a,64,186] Because patients with this contracture cannot fully adduct the glenohumeral joint, adducting the arm to the side requires rotation of the scapula on the chest wall.[182] The resulting superior protrusion of the superior-medial angle of the scapula has been termed the Putti sign, after its initial description in 1932.[146] This abduction contracture exists in the setting of abductor muscle atrophy,[48a] again consistent with tightness of denervated muscle being responsible for the contracture. Furthermore, physical assessment[150a] and motion analysis[151] studies have demonstrated external rotation contractures as well as a greater than normal contribution of scapulothoracic motion to global shoulder motion, suggesting a functional ankylosis of the glenohumeral joint in all directions, consistent with contractures of all the denervated rotator cuff muscles.

Uncertainty regarding the precise etiology of glenohumeral contracture and dysplasia has led to attempts to investigate the pathophysiology in animal models of neonatal brachial plexus injury. Upper trunk neurotomy in rats and mice leads to glenohumeral dysplasia that closely resembles that in humans,[88,100,101] and the use of animal models for studying the effects of neonatal denervation on musculoskeletal growth and development has been established by several authors.[88,100,101,128] Using one such model, impaired growth of neonatally denervated muscle has been found to contribute to contracture pathogenesis.[126,128,187] Without normal neonatal innervation, muscles fail to grow sufficiently to keep up with skeletal growth, leading to relative muscle shortening and loss of passive joint range of motion. Early reinnervation prevents this impaired muscle growth and contractures but delayed reinnervation does not, suggesting a critical window of postnatal muscle development in which innervation is required for muscle growth. These findings have recently been replicated in similar animal models in different laboratories.[38a,107a]

Furthermore, impaired growth of denervated muscles can account for both the restriction of passive motion at the shoulder and elbow, as well as the axial plane deformity of glenohumeral dysplasia. Computer modeling of the human glenohumeral joint[32a,39] has demonstrated that the growth impairment identified in animal models is sufficient to both restrict the passive range of motion and increase the contact pressure on the posterior glenoid, consistent with glenoid retroversion and posterior glenohumeral subluxation. This effect may be exacerbated by muscle activity imbalance, whereby the shoulder is positioned in internal rotation by the functioning pectoralis major muscle and other internal rotators, worsening the eccentric posterior load on the glenoid. The interplay between denervation, muscle atrophy, and musculoskeletal growth is complex, and we are far from understanding the biological mechanisms of contracture development. Nonetheless, the shoulder contracture is more complex than a unidirectional internal rotation contracture, and the pathogenesis is more complex than a simple lack of mechanical stretch of the muscles or joint capsule. It is likely that a combination of contractures from impaired muscle growth and forces from muscle imbalance contribute to the pathoanatomy of glenohumeral dysplasia, as supported by a recent computational model.[39]

Glenohumeral deformity following a birth palsy was described in the early 20th century,[52,152] but more recent studies have defined risk factors and progressive deformities in more

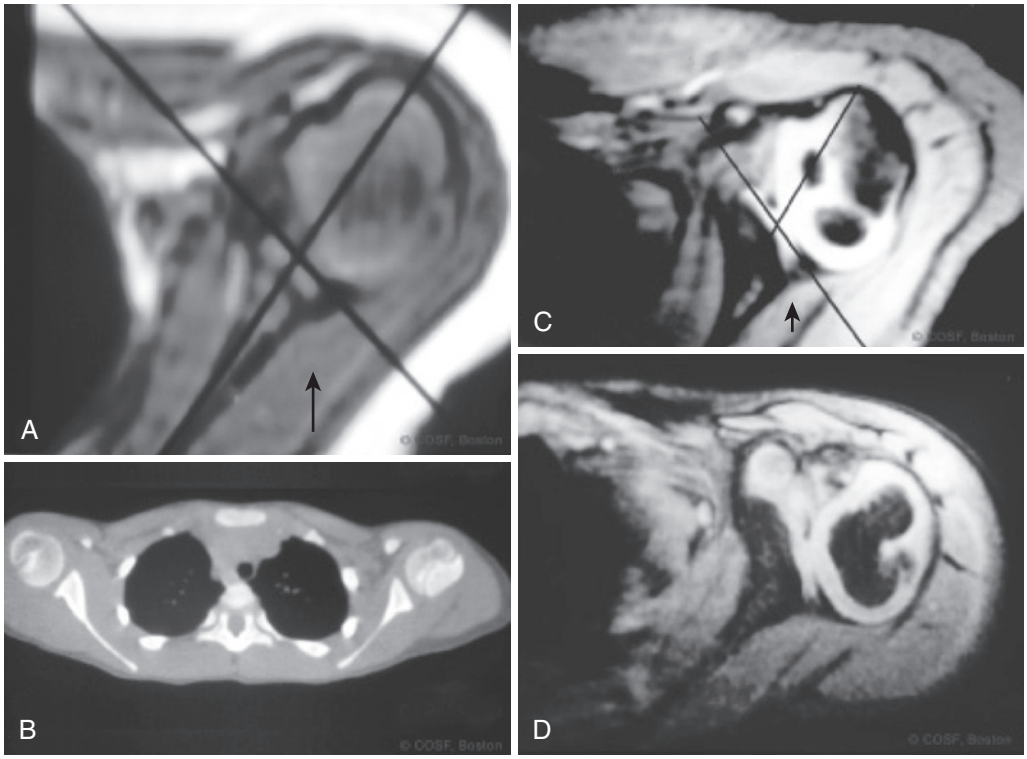

FIGURE 40.18 Radiographic types as determined with use of computed tomography (CT) or magnetic resonance imaging (MRI). **A,** MRI of a type I (normal) glenohumeral joint (<5-degree difference in glenoid version in comparison to that on the normal, contralateral side). The *bisecting line* extending from the spine of the scapula through the humeral head is outlined. The angle in the posterior medial quadrant is indicated by the *arrow*. Ninety degrees is subtracted from this measurement to determine glenoid version. **B,** CT scan of a glenohumeral joint with a type II deformity of the left shoulder. The deformity is minimal (>5-degree difference in glenoid version in comparison to that on the normal, contralateral side and no evidence of posterior subluxation of the humeral head). **C,** MRI of a glenohumeral joint with a type II deformity. There is moderate deformity of the glenoid with posterior subluxation of the humeral head (<35% of the head is anterior to the scapular line). The *scapular line* and the *tangential line* indicating the anterior and posterior cartilaginous margins of the glenoid are shown. The angle in the posterior medial quadrant is indicated by the *arrow*. **D,** MRI of a glenohumeral joint with a type IV deformity. There is progressive deformity (a false glenoid) and subluxation. (From Waters PM, Smith GR, Jaramillo D: Glenohumeral deformity secondary to brachial plexus birth palsy. *J Bone Joint Surg Am* 80:668–677, 1998.)

detail using arthrography,[138,189] CT, and MRI (Figure 40.18).[184,186] The glenohumeral deformity is progressive with age and appears very early in infancy as evidenced by ultrasound, MRI,[93] and clinical data.[73,136,180,194] Adapting Severin's classification of hip dysplasia, Waters and colleagues described various grades of deformity (Figure 40.5).[186] The deformity evolves sequentially by grade from normal (I) to increased glenoid retroversion (II), posterior glenohumeral subluxation with posterior glenoid dysplasia (III), development of a false glenoid (IV), to flattening of the humeral head and glenoid (V). In addition, on occasion a true infantile glenohumeral deformity (VI) occurs. Pearl and colleagues' arthrographic classification is similar.[138] The deformity is progressive without treatment.[186]

The infantile treatment options of physical therapy, splinting, Botox injections, and surgical interventions are all designed to reverse this process. Early intervention is advocated because this dysplasia occurs much sooner than previously thought, with nearly 10% of infants progressing to glenohumeral dislocation in the first year, even as early as 3 months.[41,119] Thus, there can be a subluxated or dislocated shoulder that needs to be addressed with "secondary" procedures even before the child is old enough to determine whether "primary" nerve surgery is necessary. Recognition of the early development of glenohumeral dysplasia is critical in the management of the shoulder following a birth palsy because early treatment of the glenohumeral joint deformity can reverse the process and preserve shoulder alignment.

Several studies have demonstrated remodeling of the glenohumeral dysplasia following release of the internal rotation contracture with or without muscle transfers to augment external rotation strength.[49,94,137,183] Even humeral head deformity has been shown to remodel following restoration of appropriate glenohumeral alignment.[147] However, it is still unknown beyond what age remodeling is no longer possible, or the severity of glenohumeral deformity that can be remodeled. Nonetheless, the possibility of restoring normal skeletal structure with early intervention underscores the importance of timely detection and management of glenohumeral dysplasia.

Preoperative Evaluation: Shoulder

Recovery of active muscle strength in infants is graded by the MRC system, the Mallet classification, AMS scores, or any combination of these systems. Assessing infants for shoulder function involves observation of spontaneous activity, neonatal reflex activity (i.e., Moro, asymmetric tonic neck, symmetric tonic neck), and stimulated activity with and without the assistance of gravity. Passive glenohumeral motion is assessed with stabilization of the scapula (Figure 40.19). Internal and external



FIGURE 40.19 Firm stabilization of the scapulothoracic joint to determine amount of glenohumeral joint external rotation. One hand is used to stabilize the scapular body and the other external hand rotates the shoulder. (Courtesy of Shriners Hospitals for Children, Philadelphia.)



FIGURE 40.20 External rotation 90 degrees of abduction while stabilizing the scapula against the thorax. (Courtesy of Shriners Hospitals for Children, Philadelphia).

rotation is performed both in adduction and in 90 degrees of abduction while stabilizing the scapula against the thorax (Figure 40.20). The degree of scapular winging posteriorly with internal rotation, superiorly with full adduction (Putti sign), and into the axilla with full abduction and forward flexion is assessed. It is important to palpate for posterior glenohumeral joint dislocation in the posterior soft spot because it is critical to not miss infantile dislocation. Dynamic instability is assessed by palpation posteriorly while measuring passive and active range of motion, especially with adduction and internal rotation. Tightness of the subscapularis is evaluated by measuring passive external rotation in adduction, again with scapular stabilization. Pectoralis major, latissimus dorsi, and teres major tightness is assessed by palpation with the shoulder abducted and externally rotated.

Infantile treatment of the shoulder focuses on maintaining full passive range of motion. Previous clinical recommendations for nerve protection by immobilization to prevent recurrent stretching during the first 4 to 6 weeks of life are no longer



FIGURE 40.21 Clinical photograph of a child with limited right shoulder external rotation and abduction. (Courtesy of Shriners Hospitals for Children, Philadelphia).

followed. Early motion is important to prevent contracture. Initially, a gentle home program is begun, followed by a formal physical therapy program with home supervision of infants who do not recover rapidly in the first month of life. Children with clavicle fractures are immobilized only until early healing, usually at 10 to 14 days old. Full passive glenohumeral range with scapular stabilization is the goal. Abduction and external rotation splints have been used in some centers to improve or maintain range of motion.

Compliance can be variable and Zancolli and Zancolli have expressed concern about the risk for injury to the physis and developing joint.[194] Botox injections have been used to decrease the force of contracting muscles. It has also been shown to allow closed reduction of dislocated shoulders in infancy, in some cases obviating the need for surgical reduction.[51] After Botox, a variety of modalities have been recommended including splints, spica casts, electrical stimulation, and intensified therapy. However, Botox injection does not address the underlying neuromuscular pathophysiology, and its effects on function may be short-lived unless the underlying muscle denervation is addressed.[15] Nonetheless, it is clear that the failure to maintain full passive range of motion of the joint leads to the development of glenohumeral deformity.[93,186,194]

If the child fails to recover external rotation strength, there are considerable functional consequences. External rotation of the shoulder in abduction is necessary to achieve above-horizontal shoulder activity (i.e., reaching the hand to the occiput or forehead) (Figure 40.21). Scapulothoracic winging can compensate for limited glenohumeral motion in all planes except external rotation. In this circumstance, the scapula abuts the posterior portion of the thorax. This leads to marked

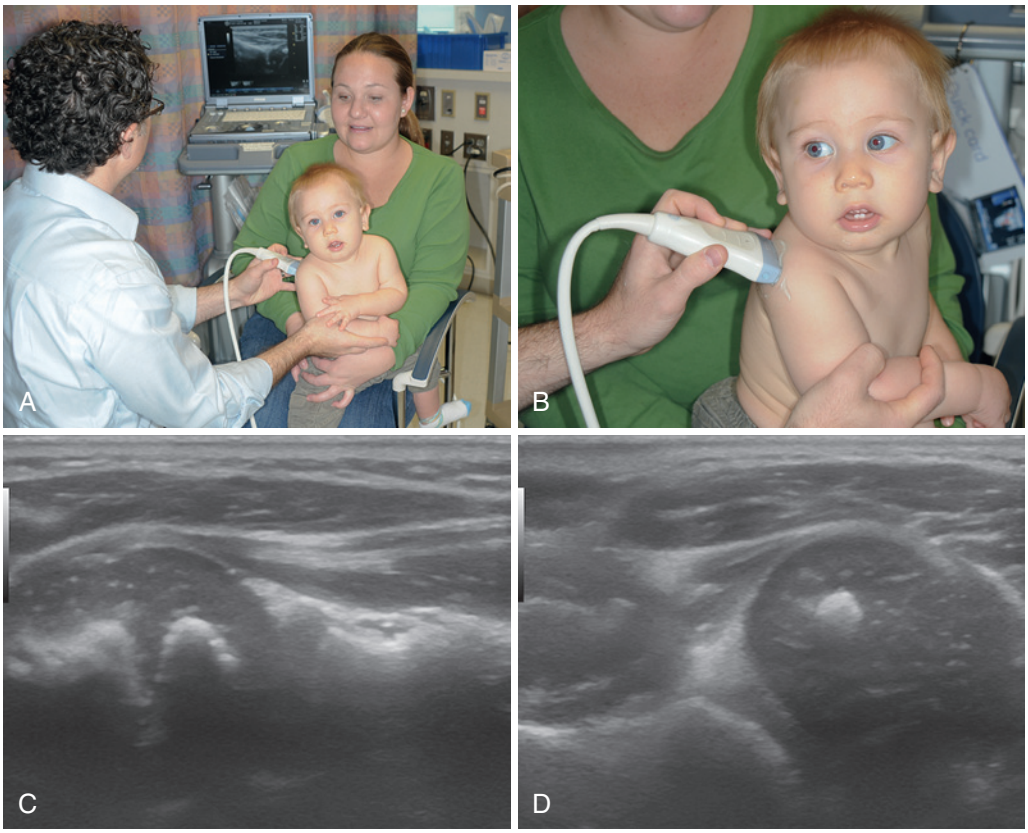

FIGURE 40.22 The posterior portal is the most useful in infants with brachial plexus birth palsy. **A,** Child seated on mom's lap and ultrasound positioned on posterior aspect of shoulder. **B,** Ultrasound probe placed along scapular spine and shoulder rotated into external and internal rotation for dynamic imaging. **C,** Normal shoulder with the hypoechoic cartilage surrounding the ossification centers that is located within anterior to the axis of the posterior scapular margin within the glenoid. **D,** Dysplastic shoulder with humeral head far posterior to the scapular margin. (Courtesy of Shriners Hospitals for Children, Philadelphia.)

limitation of function because of an inability to appropriately place the hand in space for many activities. More important, ligamentously lax children can compensate better by sliding the scapula across the thorax, which accounts for some of the differences in function in children with similar neurologic injuries and glenohumeral joint deformity. In addition, weakness about the shoulder limits hand use away from the body. These children have difficulty placing and maintaining the hand at a desired location in space.

Ultrasound can be used in infancy to evaluate the glenohumeral joint and proximal part of the humerus. Rare proximal humeral physeal fractures and glenohumeral joint dislocations can be detected by ultrasound. Similar to the hip, the joint can be assessed for congruency and dynamic stability by ultrasound (Figure 40.22).[119,144,186] Such a study can be done without sedation. Plain radiographs are not helpful to assess the glenohumeral joint during infancy because the secondary centers of ossification are absent until 6 months of age. Arthrograms provide a clearer picture of the joint and bone development than do radiographs in infants and children.[136]

An arthrographic classification of the glenohumeral joint deformity can be used.[92] However, most institutions use an MRI to assess the cartilaginous surfaces of the glenohumeral joint in young children.[20,138,139,186] In infants and young children, MRIs require sedation. The glenohumeral deformity progresses from posterior glenoid deformity (II), to humeral head subluxation and further glenoid dysplasia (III), to the development of a false glenoid (IV), and finally to flattening of both the glenoid and humeral head (V) (see Figure 40.18).

The degree of joint deformity can guide the surgeon in selection of the appropriate procedure. It is clear that with minimal joint deformity (grades I and II), releases or lengthening of contracted muscles and tendon transfers for improved external rotation and abduction have a favorable clinical outcome.[32] With more severe deformity of the joint (grade V and advanced grade IV), humeral derotational osteotomy improves function considerably but does little to correct joint deformity.[91,184] Arthroscopic releases (Figure 40.23) and joint reduction and open reduction (Figure 40.24; Video 40.3) of the glenohumeral joint in young children have both led to glenoid remodeling in patients with grades II, III, and IV deformity.[137,139,182] In selected cases with severe glenoid deformity, glenoid osteotomy can correct the retroversion by way of a posterior opening wedge osteotomy, although its place in the treatment armamentarium for glenohumeral dysplasia remains unclear.[44]

Historical Review: Shoulder

In 1888, Stimson[164a] described a posterior dislocation of the shoulder in a child with a brachial plexus birth palsy. Later, Whitman[189a] (1905) distinguished between a congenital dislocation and an acquired dislocation associated with a brachial plexopathy. Fairbanks (1913) performed operative reduction of a dislocation by anterior capsulotomy and subscapularis release.[52] L'Episcopo[52a] described the results of tendon

rebalancing procedures about the shoulder for obstetric paralysis in the 1930s, initially with the teres major alone and subsequently with the teres major and the latissimus dorsi muscles. Wickstrom[189b] defined a high incidence of permanent deficits about the shoulder with joint deformity.

Roper and later Hoffer, Wickenden, and Roper[75] described transferring the latissimus dorsi and teres major into the greater tuberosity region to improve not only external rotation but also abduction. Many authors since then have reported favorable results with tendon transfers about the shoulder in patients with residual brachial plexus birth palsies.[32,72,93,132,138,185,186] There is evidence that these transfers improve not only range of motion in abduction and external rotation but also outcome function as measured by aggregate Mallet and Pediatrics Outcomes Data Collection Instrument (PODCI)[16,43] scores.

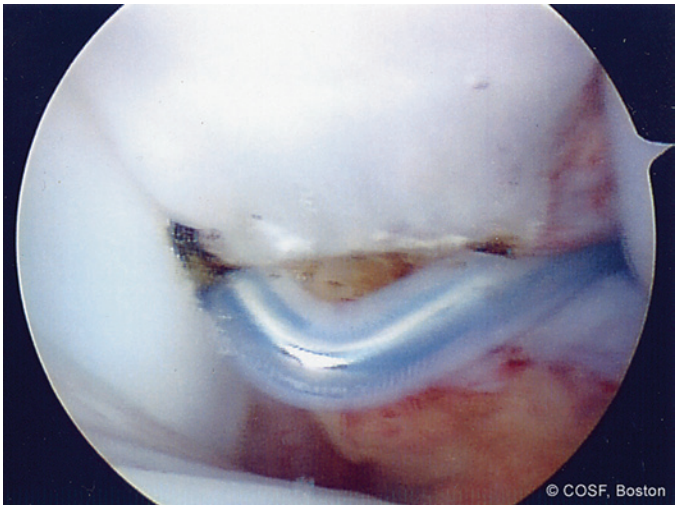

FIGURE 40.23 Arthroscopic release of a thickened anterior capsule and partial subscapularis release for treating an internal rotation and adduction contracture in a 14-month-old child.

CRITICAL POINTS

- Secondary musculoskeletal deformities are common in children with residual brachial plexus birth palsy.
- Impaired muscle growth from neonatal denervation leads to contractures, which together with muscle functional imbalance at the shoulder, lead to glenohumeral dysplasia.
- Glenohumeral dysplasia begins in infancy and progressively gets worse.
- Maintenance of passive motion through nonsurgical and surgical means can prevent contractures and dysplasia.
- Restoration of muscle functional imbalance can lead to remodeling of glenohumeral dysplasia.
- Imaging studies to evaluate the glenohumeral joint include ultrasounds and cartilage-sensitive MRIs.

Operations: Shoulder

Indications for surgical intervention about the shoulder include (1) infantile dislocation, (2) persistent internal rotation–adduction contracture despite extensive nonoperative management, (3) limitation of abduction and external rotation with plateauing of neural recovery, and (4) progressive glenohumeral

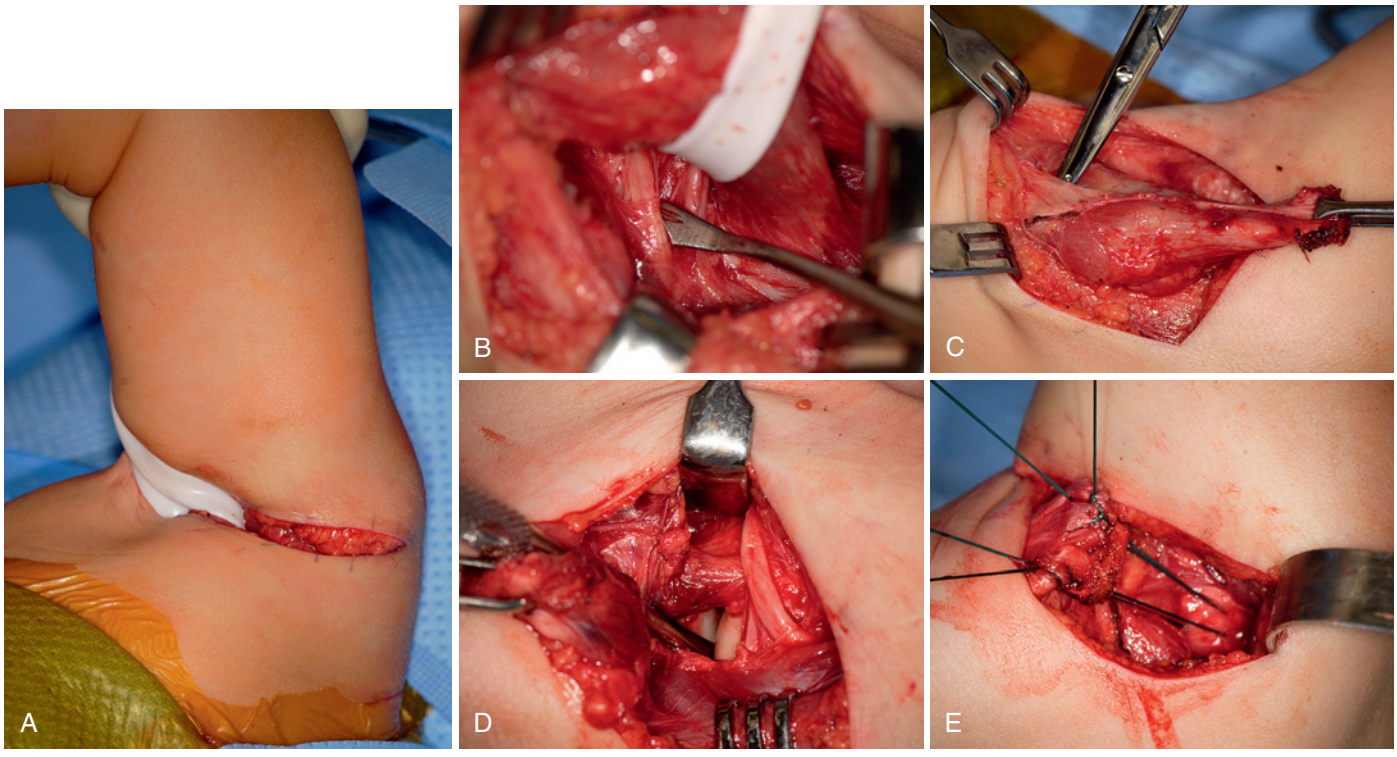

FIGURE 40.24 Technique for open joint reduction and tendon transfer. **A,** Axillary incision with penrose around latissimus dorsi and teres major. **B,** Identification of axillary nerve deep to latissimus dorsi and teres major. **C,** Mobilization of musculotendinous latissimus dorsi and teres major. **D,** Open joint reduction with protection of axillary nerve. **E,** Transfers of latissimus dorsi and teres major tendons using transosseous sutures. (Courtesy of Shriners Hospitals for Children, Philadelphia.)

deformity. The age at intervention depends on the problem and its severity.

Infantile dislocation is treated as early as it is recognized before the glenoid deficiency becomes unreconstructable. Ideally, this is within the first 3 to 12 months of life. Surgery can be performed arthroscopically or by open reduction. Arthroscopic reduction is performed in the lateral decubitus position. At this point, there is no infantile arm holder for distraction of the joint. A surgical assistant is required for distraction and appropriate positioning of the arm for arthroscopic examination and surgical release. Standard portals are used.

A hooked bipolar cautery or up-biting arthroscopic cutter is used for anterior-inferior release of the capsule and glenohumeral ligaments (see Figure 40.23). Partial release of the subscapularis tendon is preferred to complete release because of the risk for loss of internal rotation power and development of an external rotation contracture.[94,139,171] Often, release of the intraarticular portion of the subscapularis alone yields sufficient release to improve passive external rotation without capsular release. If a capsular release is performed, however, the axillary nerve needs to be protected. Rotation can be achieved, usually in the range of 30 to 70 degrees, with the arm adducted. Reduction is palpable following release with a clunk as the humerus is externally rotated. Reduction can be confirmed with intraoperative ultrasonography.

Open reduction can be performed with a transaxillary incision (see Figure 40.24; Video 40.3). Partial musculotendinous lengthening of the subscapularis and pectoralis major muscles is often required. Similar to arthroscopic reductions, in some cases joint reduction can be achieved by partial release of the subscapularis alone. If stable joint reduction and sufficient passive external rotation correction cannot be performed, then an open reduction is also performed. Partial anterior release of the thickened capsule and middle and inferior glenohumeral ligaments enables reduction of the humeral head.

Similar to arthroscopic reduction, overlengthening of the subscapularis must be avoided because it will lead to an external rotation contracture and loss of midline function. In some situations, there is a marked contracture of the deltoid and other shoulder girdle musculature, consistent with the shortening of neonatally denervated muscles, that may require similar lengthening to achieve reduction. A posterior capsulorrhaphy can be performed if necessary for joint stabilization after reduction. Overtightening of the joint capsule, however, needs to be avoided because it will limit postoperative glenohumeral motion; surgeons rarely tighten the posterior capsule.

For children younger than 12 to 24 months, it is unclear whether simultaneous transfer of the latissimus dorsi and teres major tendons to the greater tuberosity of the humerus should be performed because there is still the possibility of external rotation recovery with time. A transfer will provide immediate posterior joint support and prevent redislocation. In addition, staging tendon transfers after joint reduction can make the subsequent transfer more difficult. Postoperative immobilization in the reduced position is achieved with a shoulder spica splint or cast for 4 to 6 weeks.

In children with a progressive internal rotation–adduction contracture, the risk for progressive glenohumeral deformity increases. If therapy fails to maintain a nearly full passive arc of glenohumeral motion, intervention is recommended before marked deformity develops. Imaging of the shoulder by ultrasound or MRI is helpful in timing and planning appropriate interventions. Choices for correcting a progressive contracture include (1) Botox injections in the subscapularis pectoralis major and latissimus dorsi/teres major complex, followed by immobilization and subsequent therapy; (2) isolated subscapularis slide; (3) arthroscopic or open releases alone with or without concomitant tendon transfers.

Comparative data are unavailable to guide optimum treatment selection. Gilbert, Brockman, and Carlioz advised subscapularis lengthening for infants who fail to regain passive external rotation by 6 to 12 months of life despite extensive physical therapy.[59] The subscapularis can be lengthened by anterior "Z"-lengthening of the tendon, musculotendinous lengthening with a posterior axillary incision, or elevation of the subscapularis off the anterior portion of the scapula as a muscle slide. All techniques improve passive external rotation. Complications are rare, and improved shoulder motion and function are expected.[95,126,137,182]

As mentioned previously, arthroscopic or open release of the joint can be used to correct the contracture. Arthroscopic release alone in children younger than 3 or in combination with tendon transfers in older children are similar to open reduction alone or with tendon transfers; both lead to improved function, motion, and glenoid remodeling.[136-138] Overlengthening will result in an external rotation contracture and loss of internal rotation power (Figure 40.25). This limits important activities of daily living such as zippering and buttoning in the midline.

Children who fail to attain active abduction and external rotation are candidates for tendon transfers. Most commonly, this involves transfer of the latissimus dorsi and teres major to the insertion of the rotator cuff on the greater tuberosity



FIGURE 40.25 Overlengthening of the external rotators can result in loss of internal rotation. (Courtesy of Shriners Hospitals for Children, Philadelphia.)

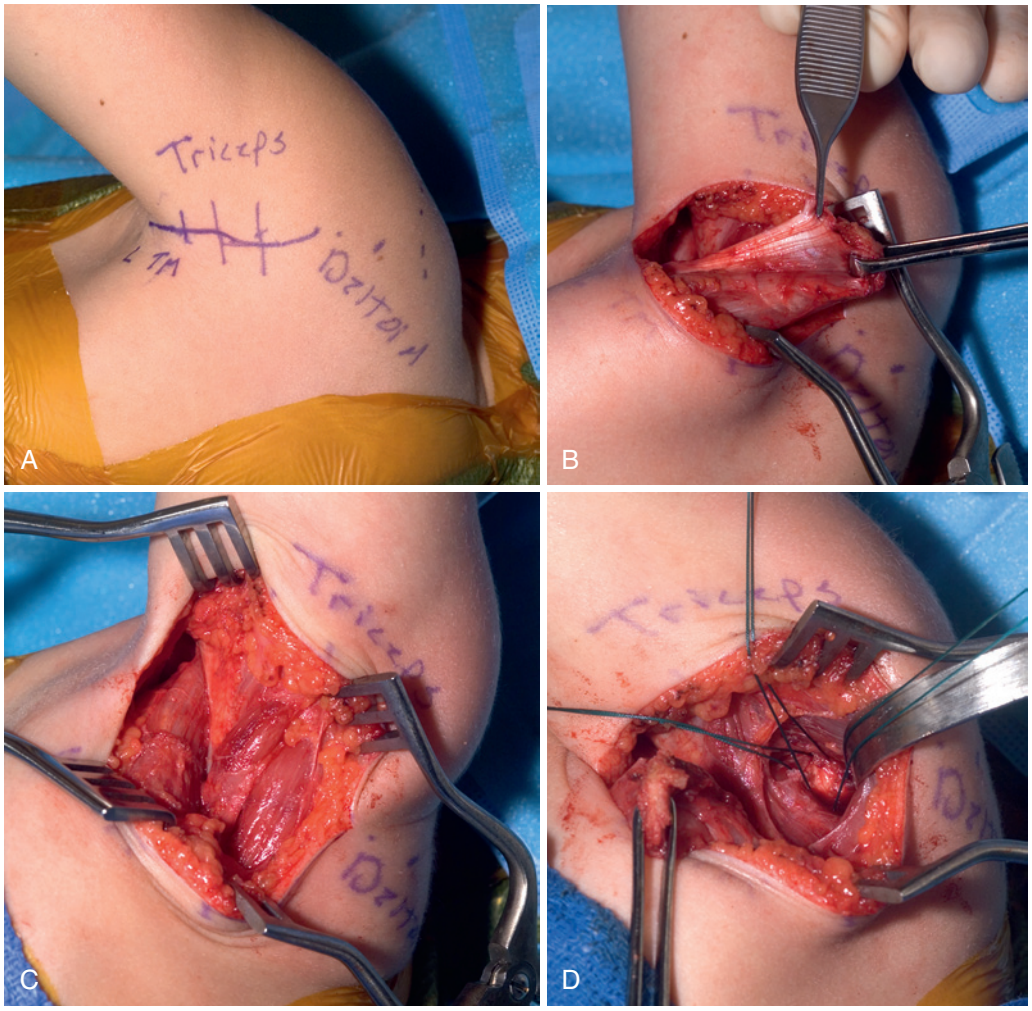

FIGURE 40.26 Technique for transfer of the latissimus dorsi and teres major to the insertion of the rotator cuff on the greater tuberosity. **A,** Posterior axillary incision from the tendon of the latissimus dorsi muscle to the posterior acromion. **B,** Latissimus dorsi and teres major tendons are traced to their humeral insertion and released with a strip of periosteum. **C,** The interval between the posterior deltoid and triceps is isolated. **D,** Sutures are placed into the interval between the infraspinatous and supraspinatous insertions. (Courtesy of Shriners Hospitals for Children, Philadelphia.)

(Figure 40.26). For children with an associated internal rotation contracture, joint release and reduction may be indicated as described in the preceding. Examination of passive range of motion in the operating room will complete the diagnosis regarding contractures of the pectoralis major, subscapularis, triceps, teres major, latissimus dorsi, and coracoid musculature. Surgery is performed in the lateral decubitus position. If the pectoralis major is contracted with external rotation of 90 degrees of abduction, a small 2- to 3-cm anterior axillary incision is used to perform musculotendinous lengthening.

Through the same incision, the origin of the coracobrachialis, short head of the biceps, and pectoralis minor can undergo musculotendinous lengthening while protecting the musculocutaneous nerve if there is a mild elbow flexion contracture. A second, small posterior axillary incision is made from the edge of the latissimus dorsi anteriorly to the inferior edge of the deltoid posterosuperiorly. In obese children or those requiring joint reduction, these two incisions can be joined to improve exposure (see Figure 40.24). The conjoint insertion of the latissimus dorsi and teres major often is isolated and released from the humerus. These muscles can be confused with the more posterior long head of the triceps. The muscles are mobilized for maximum excursion while identifying and protecting the neurovascular pedicle.

The interval between the triceps and deltoid is exposed. There are often crossing fascial connections between the triceps, latissimus, and axillary skin that need to be released to improve excursion and line of pull. The greater tuberosity and infraspinatus and supraspinatus tendons are identified. The axillary nerve and circumflex vessels are also identified and protected. The subacromial space is decompressed by removing any bursae. The glenoid and posterior humeral head should be easily palpable. If the joint is unstable or subluxed, joint reduction is performed with appropriate anterior–inferior capsular releases and muscle lengthenings. This usually involves lengthening of subscapularis as previously described; however, at times this also includes triceps musculotendinous lengthening when there is a tight scapulohumeral angle on the table. Finally, the latissimus dorsi and teres major tendons are inserted into the greater tuberosity at the supraspinatus–infraspinatus point.

Periosteal, tendinous, or transosseous sutures are appropriate for the young. Osseous suture anchors are rarely necessary in older children or adolescents. When placing bone anchors, however, care must be taken to avoid injury to the proximal humerus physis. The choice of tendon transfer insertion site depends on the desired function to be achieved by it. Superior insertion into the greater tuberosity restores abduction and external rotation in abduction, but does little to improve external rotation in adduction. Conversely, insertion of the transferred tendons inferior to the physis will improve external rotation more in adduction but less in abduction; this will not improve active abduction as the tendons pass inferior to the axis of shoulder abduction–adduction. Always check the passive range of motion before closure including testing for a Putti sign. Postoperative immobilization in appropriate mild abduction (30-40 degrees) and external rotation (>40 degrees) is maintained for 4 to 6 weeks.

If the glenohumeral joint is markedly deformed, a derotational humeral osteotomy is indicated for patients with functional limitations of abduction and external rotation. However, humeral head flattening alone does not preclude successful improvement in function from tendon transfers, since release of the contracture restores articulation between the glenoid and the still-rounded posterior portion of the humeral head. In cases with more severe deformity, a humeral osteotomy can reliably improve active abduction and external rotation motion and function as shown by aggregate Mallet and PODCI scores.[16,170,182] Under anesthesia, a final assessment of passive range of motion of the joint is performed. Frequently, these children have limited glenohumeral motion because of their deformity. It is critical that one understands the range of motion available because this will ultimately determine the degree of correction of humeral external rotation. A minimum of 90 degrees, and ideally greater than 120 degrees of passive motion, is required for successful reorientation of the humerus.

The goal is to have the hand reach the mouth, forehead, and occiput without losing the ability to reach the genitalia, abdomen, chest, or contralateral hand. Surgery is performed with the patient in a limited beach-chair position. The entire shoulder girdle region, including the scapula, is left exposed during preparation and draping. The proximal end of the humerus is exposed in an extended deltopectoral or medial arm incision. A curvilinear deltopectoral incision that takes into account the expected external rotation of the skin with correction will lessen the risk for unsightly hypertrophied scars (Figure 40.27). Subperiosteal exposure of the humerus is performed. If a deltopectoral approach is used, the osteotomy is performed just proximal to the deltoid insertion. If a medial approach is used, the osteotomy is performed distal to the deltoid insertion.

In the distal osteotomy site, the ulnar and radial nerves need to be protected. In the proximal osteotomy, the radial nerve needs to be protected. Securing the proximal screws of the plate before the osteotomy controls the humerus and facilitates correction. The proximal and distal aspects of the humerus are marked for the desired rotational correction, usually 40 to 90 degrees. It is important to protect the radial nerve during the osteotomy because it lies posterior to the humerus at this level. With derotation, the plate is temporarily fixed to be certain that the hand can reach the mouth, occiput, chest, abdomen, and genitalia. Definitive internal fixation is then performed (Figure 40.28). Postoperative immobilization depends on the age of the child and the strength of the internal fixation. Improvement in shoulder motion (average improvement of 64 degrees in external rotation) and function (improvement in average aggregate



FIGURE 40.27 Incision for osteotomy of the humerus to prevent scar hypertrophy.



FIGURE 40.28 Postoperative radiograph of proximal humeral transverse osteotomy with internal fixation.

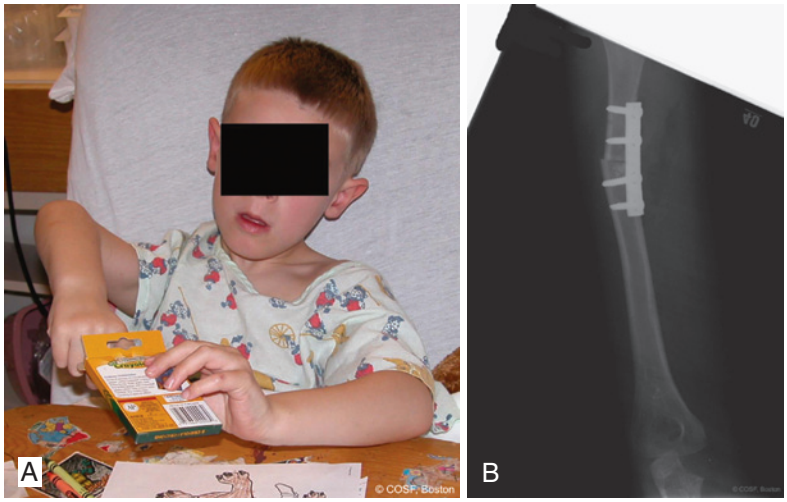

FIGURE 40.29 **A,** Clinical photograph of a patient with an abduction and internal rotation contracture. **B,** Radiograph of the osteotomy designed to increase external rotation and to decrease abduction.

Mallet score from 13 to 18 out of 25) is to be expected.[5,182] A combination of varus and external rotation osteotomy[182] can improve associated severe abduction contractures both functionally and cosmetically (Figure 40.29).

❖ AUTHORS' PREFERRED TREATMENT

Infants with brachial plexus birth palsy are followed closely for subluxation/dislocation or contractures about the shoulder joint. Clinical signs of dislocation (i.e., rapid loss of passive external rotation, apparently shortened humeral segment, asymmetric axillary skin folds, posteriorly palpable humeral head) warrant an ultrasound. If the glenohumeral joint is reduced but subluxatable, physical therapy is continued with renewed efforts to improve passive external rotation in both adduction and abduction. If the joint is subluxated/dislocated but reducible, consideration is given to a Botox injection and shoulder spica casting in external rotation to maintain a reduced position. Subsequently, therapy is restarted while awaiting further external rotator reinnervation. If the joint is dislocated and irreducible in external rotation, an MRI is performed to establish a baseline evaluation of the glenohumeral deformity. The joint is surgically reduced using techniques described previously. If surgical release is required for reduction of an infantile dislocation, we have found tendon transfers are usually necessary to prevent redislocation.

Even in the absence of an infantile subluxation or dislocation, an internal rotation and adduction contracture about the shoulder is common in infants and children with a residual brachial plexus birth palsy. Ideally, physical therapy for passive range of motion with scapular stabilization is begun in the first few weeks of life in an attempt to prevent contractures and joint deformity. If a contracture develops in the first 1 to 2 years that does not resolve within 3 months of supervised therapy, MRI is performed to assess the glenohumeral joint. If the joint is reduced, more intense therapy with or without Botox, splinting, and/or casting is continued. At times, an isolated scapularis lengthening or partial release is performed to allow functional external rotation.[59]

Unfortunately, joint deformity often occurs early in life. For children with mild deformity (type II), release of joint contracture and tendon (i.e., latissimus dorsi and teres major) transfers are performed. If the joint deformity is more severe (type III or IV), formal joint reduction is performed in conjunction with tendon transfers. A variety of techniques have been shown to be equally capable of improving function and allowing remodeling of the glenohumeral dysplasia, provided they restore passive range of motion, realign the humeral head with the center of the glenoid, and rebalance muscle forces acting across the glenohumeral joint. The glenoid will remodel most of the time but the limits and quality of glenoid remodeling over time in all scenarios is still unknown. If the joint deformity is too severe at any age (advanced type IV, type V), a humeral external rotation osteotomy is preferred.[5,181,182]

This procedure is done when it is determined that the joint is not reconstructible or the child is too old to remodel (Figure 40.30). This is common in adolescent patients with an internal rotation contracture, limited external rotation, and advanced deformity. The author has performed a posterior, opening wedge glenoid osteotomy with bone graft to provide posterior bony stabilization in children with reconstructible type IV deformities. However, the indication for and outcome from this procedure are still under investigation.

Postoperative Management

Infants and young children who have undergone open reduction or tendon transfers (or both) are immobilized in a shoulder spica cast or brace for 4 to 6 weeks. Generally, the position of immobilization is in mild abduction and external rotation with a scapular mold to maintain correction of contractures, to preserve joint reduction, and to protect the soft tissue repairs. Active and passive motion is initiated after immobilization. Improved active motion of forward flexion, abduction (improvement of >60 degrees), and external rotation (improvement of >45 degrees) is expected after tendon transfers. Global improved function is also expected as shown by aggregate Mallet scores, with average preoperative scores of 13, improving

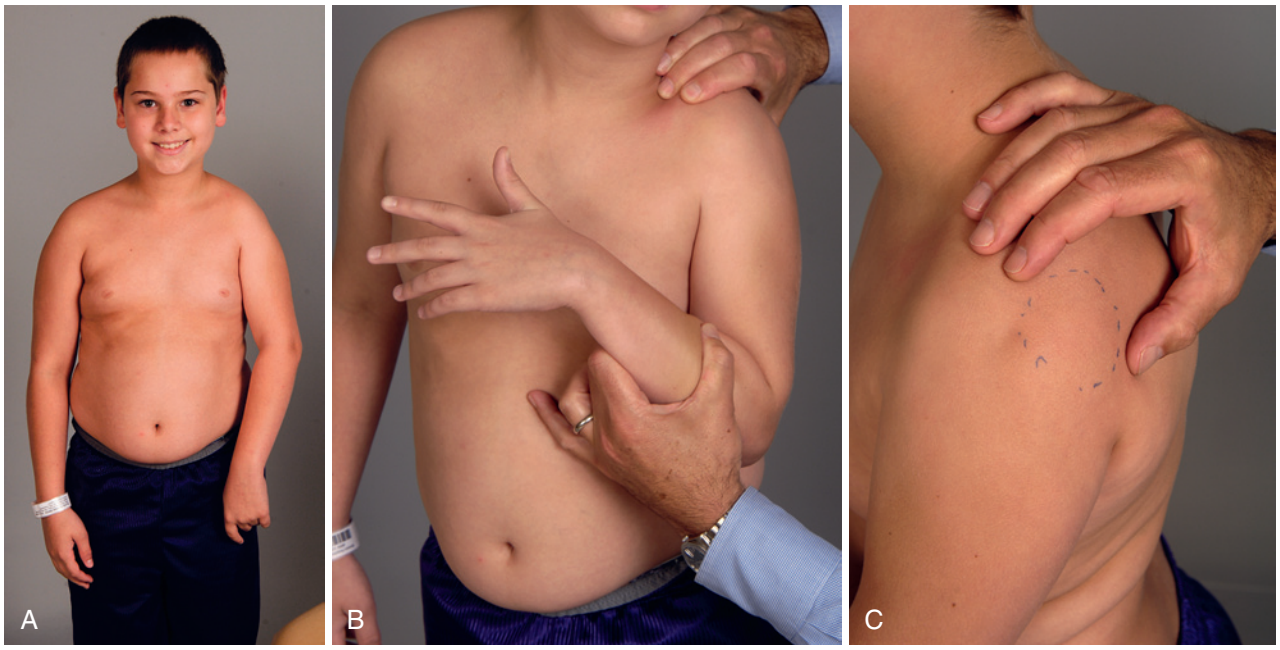

FIGURE 40.30 Nine-year-old with left residual BPP and frank shoulder subluxation prior to humeral osteotomy. **A,** Apparent shortening of the humeral segment. **B,** Lack of passive external rotation. **C,** Palpable fullness of the shoulder posterior to the glenoid. (Courtesy of Shriners Hospitals for Children, Philadelphia.)

to 18 out of 25 postoperatively.[180] In addition, improved hand use occurs because it can be better positioned in space.

Humeral osteotomies, with rigid internal fixation, are typically performed in children old enough to be immobilized with a sling and swathe for 4 weeks. Rehabilitation is initiated once bony healing has occurred. Outcomes with osteotomy are similar to those with tendon transfers. Equivalent increased function is expected, despite no net increase in overall range of motion.[180]

Complications are rare following these operations. Even in situations of marked weakness of the affected arm, the latissimus dorsi and teres major muscles provide a positive outcome after transfer, potentially by way of passive tenodesis.[180] The status of the glenohumeral joint determines the selection of specific surgical intervention. If the joint remains deformed, there may be continued restriction of motion after tendon transfer. Motion is the most limited in external rotation and adduction after transfer in the presence of joint deformity. Although there is increased scapulothoracic motion, it cannot compensate for all the limitations of glenohumeral motion. A secondary, humeral osteotomy with varus and external rotation may be necessary to remedy the marked trumpet posture and inability to externally rotate the arm from an adducted position. This situation could be viewed as failure to select the appropriate surgical technique.

Loss of internal rotation power and an external rotation contracture can occur with excessive soft tissue release or overcorrection with an osteotomy. If physical therapy fails to resolve the situation, an internal rotation osteotomy may be required to rebalance shoulder function. If an internal rotation osteotomy is to be performed, a segment of the humeral shaft may need to be removed to prevent tension on the radial nerve that gets pulled taut as the humeral shaft is internally rotated. Persistent joint deformity may occur. The risk for long-term pain and disability from a deformed joint is unknown, although the incidence appears to be much less compared to a dysplastic hip.

There may be some loss of function with time and growth in children after extraarticular tendon transfers. Long-term loss of active external rotation and recurrence of adduction–internal rotation contractures have been described.[91,132] The progressive loss of function reported in early studies may be due to underappreciation of the importance of glenohumeral alignment, or because of the persistent neuromuscular abnormalities affecting the growth of the muscles about the glenohumeral joint. Further investigation is required to design optimal interventions to restore and preserve muscle growth and development throughout skeletal growth.

EXPECTED OUTCOME

- Early diagnosis of glenohumeral joint deformity offers the possibility of arthroscopic or open reduction. Reduction is associated with glenohumeral joint remodeling over time.
- Tendon transfers about the shoulder improve overall range of motion, especially abduction and external rotation. However, tendon transfers alone do not result in joint remodeling.
- Derotational humeral osteotomy is indicated for older children with limited external rotation. Published results after osteotomy are positive.

ELBOW

Early in infancy, the major issue is failure of return of biceps function for elbow flexion. As mentioned in the preceding sections, this is one of the major indicators for nerve surgery intervention in the first 3 to 9 months of life. Fortunately, in the long term it is uncommon to have persistent lack of antigravity elbow flexion. Sometimes the perceived failure of elbow flexion

function results from aberrant reinnervation of the elbow flexors producing flexor–extensor cocontraction. This problem can be ameliorated by Botox injection into the triceps to temporarily prevent triceps recruitment. The child is then able to learn how to functionally recruit the innervation pathways to the elbow flexors, improving elbow flexion function well beyond the efficacy of the Botox injection.[69,148]

True failure to recover antigravity biceps strength is a disappointing end result to both natural history observation and nerve reconstruction. As described previously, however, elbow flexion can be improved with later nerve transfer, provided appropriate donor nerves are available. Other options available for failure of biceps recovery include regional tendon transfers and vascularized muscle transfers. Regional tendon transfers include the pectoralis major, latissimus dorsi, triceps, or forearm flexor–pronator muscle origin (Steindler flexorplasty). The donor muscles must be nearly normal in strength for successful transfer, and the loss of donor function cannot lead to worsening impairment. All three muscle groups have been used successfully. The latissimus dorsi and pectoralis major muscles need to be mobilized on their neurovascular pedicles without undue tension (Figure 40.31). Both are aligned from the proximal coracoid or acromion to the distal native biceps tendon, radial tuberosity, or coronoid.

In performing a Steindler flexorplasty, the medial epicondyle and origin of the forearm flexor–pronator mass is detached and secured to the central aspect of the distal humerus with a compression screw and washer. The ulnar nerve needs to be decompressed and protected. Doi has popularized the use of free gracilis vascularized muscle transfers.[45] For elbow flexion the gracilis is similarly secured proximally at the coracoid or acromion and distally at the native biceps tendon, radial tuberosity, or coronoid for elbow flexion alone; or it is extended down to the wrist or finger extensors for combined function. Nerve connection is via the intercostals, spinal accessory, or contralateral C7.[67,175] Results have been described as encouraging, with improved function and active motion (average of 125 degrees).

The development of an elbow flexion contracture is common in children with residual plexopathy affecting 62 to 89% of children following unresolved birth palsy.[21,193] These elbow contractures range from mild (10-30 degrees)[21, 167] to moderate (30-60 degrees) to severe (60-90 degrees),[7,71,176] limiting the functional range of elbow motion[118] and exacerbating the aesthetic deformity of an already short, malpositioned upper extremity.[7] The severity of elbow flexion contracture does not differ between upper and global plexus injuries, and in most cases the elbow flexor strength is less than elbow extensor strength; therefore it is unlikely that the contracture is caused by elbow flexors overpowering a weak triceps.[21,70,143,144,155]

Many authors have proposed numerous conflicting theories for etiology of the elbow flexion contracture, although recent work with an animal model demonstrates the contracture to occur from impaired growth of the denervated elbow flexor muscles.[126,128,187] Initial treatment of the elbow flexion contracture is physical therapy with stretching of the biceps, brachialis, and anterior elbow capsule. Nighttime splinting, including dynamic devices, may be helpful, although there is limited information to determine its cost effectiveness. Fortunately, most of these contractures are mild and less than 30 degrees; this mild degree of contracture does not limit activities of daily living. More substantial contractures (>60 degrees) may need to be addressed surgically.

Recommendations for surgical treatment vary widely, with proponents of no treatment,[74] serial casting,[71] surgical release,[65,193] external fixator distraction,[176] flexor-to-extensor muscle transfers,[33] and humeral osteotomy.[7] Anterior lengthening of the biceps and brachialis has a short-term positive benefit in our hands. However, postoperative rehabilitation is extensive, and with the persistence of impaired muscle growth, recurrence is high. Thus, the preference is perform surgery later in

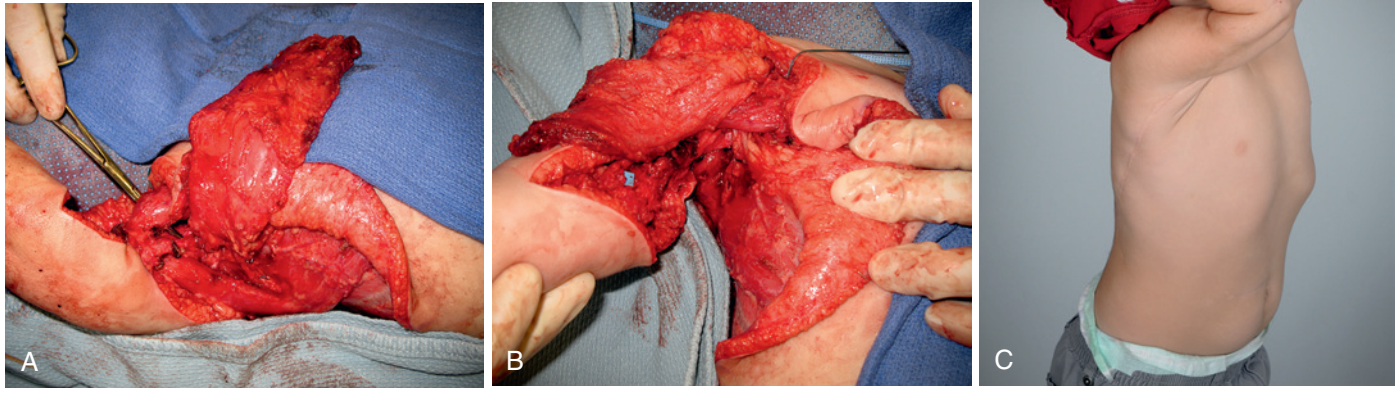

FIGURE 40.31 An 18-month-old with infraclavicular brachial plexus injury, absent elbow flexion, and insufficient soft tissue along the anterior arm. **A,** Latissimus dorsi muscle harvested on the thoracodorsal neurovascular pedicle prior to transfer beneath the pectoralis major muscle. **B,** Latissimus dorsi muscle passed under pectoralis major and into arm for restoration of elbow flexion. **C,** Postoperative right elbow flexion against gravity with well-healed posterior axillary incision. (Courtesy of Shriners Hospitals for Children, Philadelphia.)

adolescence to decrease the possibility of recurrence. Once again, methods to restore muscle growth must be elucidated to prevent the occurrence and progression of this contracture.

FOREARM

Limitation of active and passive forearm rotation occurs commonly in children with incomplete recovery. Limitation of active pronation, and supination, correlates with worsening Mallet scores and Narakas group IV patients.[157] Loss of active pronation was more common than loss of supination in one study series.[157] When combined with an internal rotation contracture and external rotation weakness of the shoulder, the rotational deficiency becomes more obvious. Early in life these children have posture in pronation, and they raise their hands toward their mouths with marked abduction, internal rotation, and a neutral or pronated forearm (trumpet sign). Correction of the shoulder problem will improve forearm posturing because shoulder adduction, shoulder external rotation, and forearm supination are complementary motions. In the absence of full biceps strength, however, there will often be some unresolved supination weakness. Therapy, splints, and electrical stimulation often resolve this problem. Surgery is rarely indicated for the supination loss alone because the degree of functional limitation is minimal.

Conversely, children with global brachial plexus palsies posture into elbow flexion and forearm supination, often with a marked contracture of both joints. There may be active wrist extension and potentially some limited finger flexion. The wrist is frequently contracted into extension because of the lack of antigravity flexor strength. These children use only their forearm for an assistive function such as lifting. They avoid active use of their hand, often far beyond what one would expect.[194] Frequently, they are bothered by their unsightly posture. Surgery is indicated to improve elbow extension, forearm pronation, and hand function. Factors that determine the type of operation include (1) triceps function, (2) passive range of pronation, (3) status of the proximal radioulnar joint, (4) wrist extension strength, and (5) available donor muscles.

The elbow flexion contracture is addressed with a brachialis musculotendinous lengthening procedure, biceps musculotendinous or "Z"-lengthening, and sometimes with anterior elbow capsular release. The lack of active pronation is most often addressed by rerouting the biceps tendon, as long as passive pronation is maintained. The biceps tendon is rerouted around the radial neck while protecting the posterior interosseous nerve so that the line of pull of the biceps provides forearm pronation. It is repaired in a "Z"-lengthened position to improve passive extension of the elbow. The brachioradialis can similarly be rerouted by passage of its tendon around the radius.[131] Fixed supination contracture can be addressed by interosseous membrane release, forearm osteotomy or osteotomies, or radioulnar fusion. Zancolli and Zancolli advocate an interosseous membrane release.[194]

Gilbert et al perform a radial osteotomy distally along with biceps rerouting.[62] With severe contractures, osteotomy of both the radius and ulna may be necessary and is usually performed at the metaphyseal–diaphyseal junction proximally in the ulna and distally in the radius with internal fixation (Figure 40.32). Forearm pronation osteotomy can be performed even in the setting of radial head dislocation at the elbow, much like a humeral osteotomy can improve arm position despite a dislocated glenohumeral joint. However, in the presence of distal radioulnar joint dislocation, creation of a single-bone forearm is the best solution. The forearm is positioned in neutral-to-mild pronation (20 degrees) in all these procedures to avoid overcorrection.

Antigravity wrist extension strength must be present for the hand to function in a pronated position, although the strength of this function can be difficult to assess when the forearm is constantly in the supinated position. Therefore, if weakness in wrist extension is seen once the forearm is pronated, a tendon transfer (i.e., flexor carpi ulnaris to extensor carpi radialis brevis) can be performed as long as active flexor carpi ulnaris function is seen preoperatively. Following correction of the supination deformity, patients are often pleased with the function and the aesthetic result because of more natural posturing of the arm and hand in social settings. Nonetheless, as with other contractures, fixed ones tend to get worse with time, thus recurrence can occur following osteotomy in early childhood.

WRIST AND HAND

Fortunately, the majority of children with a brachial plexus birth palsy have an upper trunk lesion with near-normal wrist and hand function. C7 functional recovery may be incomplete with some limitation of wrist and finger extension, but frequently there is sufficient compensatory function by redundant innervation or tenodesis to avoid surgery. With considerable finger extension weakness, a tendon transfer, usually the flexor carpi ulnaris to the digital extensors, is performed to improve extension.

There are individuals who have permanent, devastating limitations in their affected hand. The dilemma is that there are few options for improving hand function in these children later in life. Therefore, strategies during primary nerve surgery should aim to innervate the lower trunk. A retrospective review of 25 patients who underwent primary brachial plexus exploration and nerve grafting/transfers highlights this point.[104] Patients operated before 1995 had no attempt to reconstruct the lower trunk and had good hand function according to the Raimondi scale in only 3 of 8 patients. In patients operated on after 1995, priority was placed on reconstruction of the lower trunk, and results tended to improve with good to very good function in 8 of 14 patients.

In a similar study, useful hand function (grade 3 or higher on the Raimondi scale) was restored in 9 of 13 patients in whom the lower trunk was reconstructed but only 1 of 3 in whom the lower trunk was not reconstructed.[140] Thus, prioritizing the hand in nerve surgery with more severe brachial plexus birth palsies is necessary, as there are limited donor muscles for active transfer; generally, the muscles available are weak. Wrist stabilization may be necessary for functional transfers to work. This can be achieved by wrist (1) capsulodesis, (2) fusion of the radial epiphysis to the carpus in a skeletally immature patient, or (3) arthrodesis in a skeletally mature person. The results of these procedures show improvement, although rarely to the level of an independently functioning hand. Double free gracilis muscle transfers for prehension with complete avulsion of the

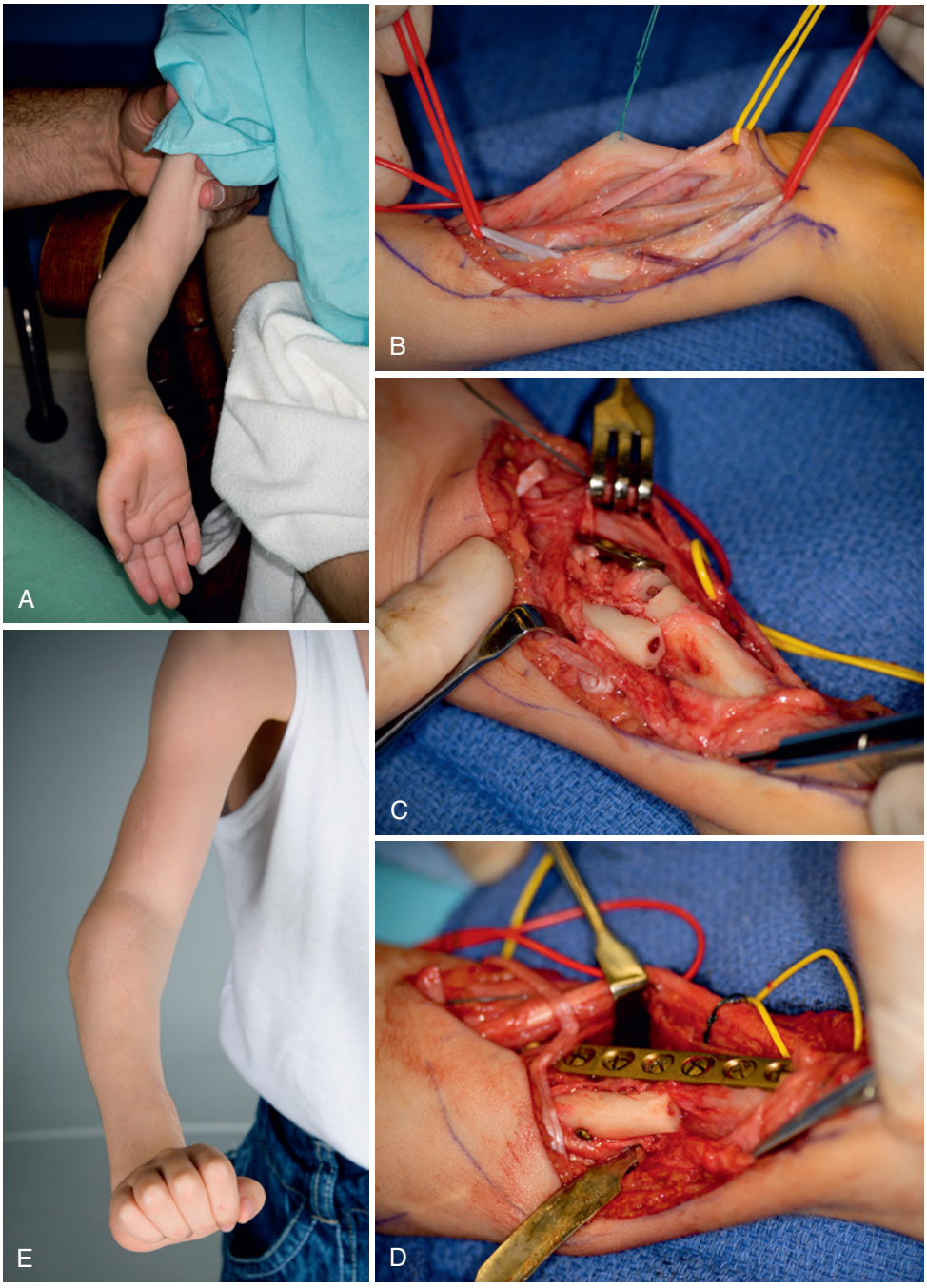

FIGURE 40.32 Eight-year-old male with residual right global brachial plexus birth palsy and fixed forearm supination deformity. **A,** Clinical deformity. **B,** Curvilinear incision and identification of the entire contents of the volar forearm. **C,** The radius is cut distal to the ulna and manually mobilized toward the proximal ulna. **D,** The forearm is rotated into the desired position and the ulna secured to the distal radius using dynamic compression. **E,** Final position of right forearm after osteotomy site. (Courtesy of Shriners Hospitals for Children, Philadelphia.)

brachial plexus have been performed with positive results even in the very young.[67]

Ulnar deviation deformity of the wrist is common in children with incomplete recovery of hand and wrist function. The deforming force is an unbalanced extensor carpi ulnaris or flexor carpi ulnaris (or both). Transfer of the deforming force to a more central location, usually to the extensor carpi radialis brevis, is recommended. This is usually performed at the same time as elbow and/or forearm procedures. There is often improvement in both function and appearance; however, the improvement is unlikely to achieve the desired independence and hand function.

Sensation is critical for function in the hand although it is difficult to assess in young children. A recent study tested hand sensation by Semmes-Weinstein monofilaments in 95 children over 6 years of age with brachial plexus birth palsies.[133] Impaired sensation was detected in 7 of 64 C5-6 patients, in 5 of 19 C5-7 patients, and in 4 of 12 C5-T1 patients. These findings

are consistent with another series of 105 patients in whom sensation correlated with number of nerve roots involved, with normal sensation in only 69% of C5-6 patients.[90] Even more difficult to assess is afferent innervation of the muscles, which allows joint proprioception. Elbow joint position sense has recently been found to be impaired following a brachial plexus birth palsy,[29] although the impact of this finding on hand and upper limb function remains to be determined.

For Case Studies, Videos, and more, please visit ExpertConsult.com.

REFERENCES

1. Abzug JM, Chafetz RS, Gaughan JP, et al: Shoulder function after medial approach and derotational humeral osteotomy in patients with brachial plexus birth palsy. *J Pediatr Orthop* 30:469–474, 2010.
2. Ahern V, Soo YS, Langlands AD: MRI scanning in brachial plexus neuropathy. *Australas Radiol* 35:379–381, 1991.
3. Al-Qattan MM: The outcome of Erb's palsy when the decision to operate is made at 4 months of age. *Plast Reconstr Surg* 106:1461–1465, 2000.
4. Al-Qattan MM: Oberlin's ulnar nerve transfer to the biceps nerve in Erb's birth palsy. *Plast Reconstr Surg* 109:405–407, 2002.
5. Al-Qattan MM: Rotation osteotomy of the humerus for Erb's palsy in children with humeral head deformity. *J Hand Surg [Am]* 27:479–483, 2002.
6. Al-Qattan MM: Obstetric brachial plexus palsy associated with breech delivery. *Ann Plast Surg* 51:257–264, discussion 265, 2003.
7. Al-Qattan MM: Total obstetric brachial plexus palsy in children with internal rotation contracture of the shoulder, flexion contracture of the elbow, and poor hand function. *Ann Plast Surg* 65:38–42, 2010.
8. Al-Qattan MM, Al-Kharfy TM: Obstetric brachial plexus injury in subsequent deliveries. *Ann Plast Surg* 37:545–548, 1996.
9. Al-Qattan MM, Clarke HM, Curtis CG: Klumpke's birth palsy. Does it really exist? *J Hand Surg [Br]* 20:19–23, 1995.
10. Al-Qattan MM, Clarke HM, Curtis CG: The prognostic value of concurrent Horner's syndrome in total obstetric brachial plexus injury. *J Hand Surg [Br]* 25:166–167, 2000.
11. Alexander JM, Leveno KJ, Hauth J, et al: Fetal injury associated with cesarean delivery. *Obstet Gynecol* 108:885–890, 2006.
12. Allen R, Sorab J, Gonik B: Risk factors for shoulder dystocia: an engineering study of clinician-applied forces. *Obstet Gynecol* 77:352–355, 1991.
13. Anand P, Birch R: Restoration of sensory function and lack of long-term chronic pain syndromes after brachial plexus injury in human neonates. *Brain* 125:113–122, 2002.
14. Andrisevic E, Taniguchi M, Partington MD, et al: Neurolysis alone as the treatment for neuroma-in-continuity with more than 50% conduction in infants with upper trunk brachial plexus birth palsy. *J Neurosurg Pediatr* 13:229–237, 2014.
15. Arad E, Stephens D, Curtis CG, et al: Botulinum toxin for the treatment of motor imbalance in obstetrical brachial plexus palsy. *Plast Reconstr Surg* 131:1307–1315, 2013.
16. Bae DS, Waters PM, Zurakowski D: Reliability of three classification systems measuring active motion in brachial plexus birth palsy. *J Bone Joint Surg Am* 85-A:1733–1738, 2003.
17. Bae DS, Waters PM, Zurakowski D: Correlation of pediatric outcomes data collection instrument with measures of active movement in children with brachial plexus birth palsy. *J Pediatr Orthop* 28:584–592, 2008.
18. Bae DS, Zurakowski D, Avallone N, et al: Sports participation in selected children with brachial plexus birth palsy. *J Pediatr Orthop* 29:496–503, 2009.
19. Bager B: Perinatally acquired brachial plexus palsy—a persisting challenge. *Acta Paediatr* 86:1214–1219, 1997.
20. Bahm J, Wein B, Alhares G, et al: Assessment and treatment of glenohumeral joint deformities in children suffering from upper obstetric brachial plexus palsy. *J Pediatr Orthop B* 16:243–251, 2007.
21. Ballinger SG, Hoffer MM: Elbow flexion contracture in Erb's palsy. *J Child Neurol* 9:209–210, 1994.
22. Baskett TF, Allen AC: Perinatal implications of shoulder dystocia. *Obstet Gynecol* 86:14–17, 1995.
23. Belzberg AJ, Dorsi MJ, Storm PB, et al: Surgical repair of brachial plexus injury: a multinational survey of experienced peripheral nerve surgeons. *J Neurosurg* 101:365–376, 2004.
24. Bhandari PS, Deb P: Dorsal approach in transfer of the distal spinal accessory nerve into the suprascapular nerve: histomorphometric analysis and clinical results in 14 cases of upper brachial plexus injuries. *J Hand Surg [Am]* 36:1182–1190, 2011.
25. Blaauw G, Slooff AC: Transfer of pectoral nerves to the musculocutaneous nerve in obstetric upper brachial plexus palsy. *Neurosurgery* 53:338–341, discussion 341–342, 2003.
26. Bodensteiner JB, Rich KM, Landau WM: Early infantile surgery for birth-related brachial plexus injuries: justification requires a prospective controlled study. *J Child Neurol* 9:109–110, 1994.
27. Boome RS, Kaye JC: Obstetric traction injuries of the brachial plexus. Natural history, indications for surgical repair and results. *J Bone Joint Surg Br* 70:571–576, 1988.
28. Brauer CA, Waters PM: An economic analysis of the timing of microsurgical reconstruction in brachial plexus birth palsy. *J Bone Joint Surg Am* 89:970–978, 2007.
29. Brown SH, Noble BC, Yang LJ, et al: Deficits in elbow position sense in neonatal brachial plexus palsy. *Pediatr Neurol* 49:324–328, 2013.
30. Capek L, Clarke HM, Curtis CG: Neuroma-in-continuity resection: early outcome in obstetrical brachial plexus palsy. *Plast Reconstr Surg* 102:1555–1562, discussion 1563–1564, 1998.
31. Carlstedt T, Anand P, Hallin R, et al: Spinal nerve root repair and reimplantation of avulsed ventral roots into the spinal cord after brachial plexus injury. *J Neurosurg* 93:237–247, 2000.
32. Chen L, Gu YD, Hu SN: Applying transfer of trapezius and/or latissimus dorsi with teres major for reconstruction of abduction and external rotation of the shoulder in obstetrical brachial plexus palsy. *J Reconstr Microsurg* 18:275–280, 2002.

32a. Cheng W, et al: Contributions of muscle imbalance and impaired growth to postural and osseous shoulder deformity following brachial plexus birth palsy: a computational simulation analysis. *J Hand Surg [Am]* 40(6):1170–1176, 2015.

33. Chuang DC, Hattori Y, Ma H, et al: The reconstructive strategy for improving elbow function in late obstetric brachial plexus palsy. *Plast Reconstr Surg* 109:116–126, discussion 127–129, 2002.
34. Chuang DC, Ma HS, Wei FC: A new strategy of muscle transposition for treatment of shoulder deformity caused by obstetric brachial plexus palsy. *Plast Reconstr Surg* 101:686–694, 1998.
35. Chuang DC, Mardini S, Ma HS: Surgical strategy for infant obstetrical brachial plexus palsy: experiences at Chang Gung Memorial Hospital. *Plast Reconstr Surg* 116:132–142, discussion 143–144, 2005.
36. Clarke HM, Al-Qattan MM, Curtis CG, et al: Obstetrical brachial plexus palsy: results following neurolysis of conducting neuromas-in-continuity. *Plast Reconstr Surg* 97:974–982, discussion 983–984, 1996.
37. Clarke HM, Curtis CG: An approach to obstetrical brachial plexus injuries. *Hand Clin* 11(4):563–581, 1995.
38. Colon AJ, Vredeveld JW, Blaauw G, et al: Extensive somatosensory innervation in infants with obstetric brachial palsy. *Clin Anat* 16:25–29, 2003.

38a. Crouch DL, et al: Biomechanical basis of shoulder osseous deformity and contracture in a rat model of brachial plexus birth palsy. *J Bone Joint Surg Am* 97(15):1264–1271, 2015.

39. Crouch DL, Plate JF, Li Z, et al: Computational sensitivity analysis to identify muscles that can mechanically contribute to shoulder deformity following brachial plexus birth palsy. *J Hand Surg [Am]* 39:303–311, 2014.
40. Curtis C, Stephens D, Clarke HM, et al: The active movement scale: an evaluative tool for infants with obstetrical brachial plexus palsy. *J Hand Surg [Am]* 27:470–478, 2002.
41. Dahlin LB, Erichs K, Andersson C, et al: Incidence of early posterior shoulder dislocation in brachial plexus birth palsy. *J Brachial Plex Peripher Nerve Inj* 2:24, 2007.
42. De Grandis D, Fiaschi A, Michieli G, et al: Anomalous reinnervation as a sequel to obstetric brachial plexus palsy. *J Neurol Sci* 43:127–132, 1979.
43. Dedini RD, Bagley AM, Molitor F, et al: Comparison of pediatric outcomes data collection instrument scores and range of motion before and after shoulder tendon transfers for children with brachial plexus birth palsy. *J Pediatr Orthop* 28:259–264, 2008.
44. Dodwell E, O'Callaghan J, Anthony A, et al: Combined glenoid anteversion osteotomy and tendon transfers for brachial plexus birth palsy: early outcomes. *J Bone Joint Surg Am* 94:2145–2152, 2012.
45. Doi K, Otsuka K, Okamoto Y, et al: Cervical nerve root avulsion in brachial plexus injuries: magnetic resonance imaging classification and comparison with myelography and computerized tomography myelography. *J Neurosurg* 96:277–284, 2002.
46. Donnelly V, Foran A, Murphy J, et al: Neonatal brachial plexus palsy: an unpredictable injury. *Am J Obstet Gynecol* 187:1209–1212, 2002.
47. Duchenne G: *De l'electrisation localisee et de son application a la pathologie et a la therapeutique*, Paris, 1872, Balliere.
48. Eismann EA, Bauer A, Kozin SH, et al: The relationship between medical malpractice litigation and parent reports of patient function following neonatal brachial plexus palsy. *J Bone Joint Surg Am* in press, 2014.

48a. Eismann EA, et al: Glenohumeral abduction contracture in children with unresolved neonatal brachial plexus palsy. *J Bone Joint Surg Am* 97(2):112–118, 2015.
49. El-Gammal TA, Saleh WR, El-Sayed A, et al: Tendon transfer around the shoulder in obstetric brachial plexus paralysis: clinical and computed tomographic study. *J Pediatr Orthop* 26:641–646, 2006.
50. Erb W: [Ueber eine eigenthumliche localisation von lahmungen in plexus brachialis.] *Verh Dtsch Natur Med* 2:1874.
51. Ezaki M, Malungpaishrope K, Harrison RJ, et al: Onabotulinum toxin A injection as an adjunct in the treatment of posterior shoulder subluxation in neonatal brachial plexus palsy. *J Bone Joint Surg Am* 92:2171–2177, 2010.
52. Fairbanks H: Birth palsy: subluxation of the shoulder-joint in infants and young children. *Lancet* 1:1217–1223, 1913.
52a. Fairbank HA: A lecture on birth palsy. Subluxation of the shoulder joint in infants and young children. *Lancet* 1:1217–1223, 1913.
53. Fisher DM, Borschel GH, Curtis CG, et al: Evaluation of elbow flexion as a predictor of outcome in obstetrical brachial plexus palsy. *Plast Reconstr Surg* 120:1585–1590, 2007.
54. Foad SL, Mehlman CT, Foad MB, et al: Prognosis following neonatal brachial plexus palsy: an evidence-based review. *J Child Orthop* 2009.
55. Foad SL, Mehlman CT, Ying J: The epidemiology of neonatal brachial plexus palsy in the United States. *J Bone Joint Surg Am* 90:1258–1264, 2008.
56. Francel PC, Koby M, Park TS, et al: Fast spin-echo magnetic resonance imaging for radiological assessment of neonatal brachial plexus injury. *J Neurosurg* 83:461–466, 1995.
57. Geutjens G, Gilbert A, Helsen K: Obstetric brachial plexus palsy associated with breech delivery. A different pattern of injury. *J Bone Joint Surg Br* 78:303–306, 1996.
58. Gherman RB, Chauhan S, Ouzounian JG, et al: Shoulder dystocia: the unpreventable obstetric emergency with empiric management guidelines. *Am J Obstet Gynecol* 195:657–672, 2006.
59. Gilbert A, Brockman R, Carlioz H: Surgical treatment of brachial plexus birth palsy. *Clin Orthop Relat Res* 39–47, 1991.
60. Gilbert A, Tassin JL: [Surgical repair of the brachial plexus in obstetric paralysis.] *Chirurgie* 110:70–75, 1984.
61. Gilbert A, Whitaker I: Obstetrical brachial plexus lesions. *J Hand Surg [Br]* 16:489–491, 1991.
62. Gilbert AH, Hentz VR, Tassin JL: Brachial plexus reconstruction in obstetrical palsy: operative indications and postoperative results. In Urbaniak J, editor: *Microsurgery for major limb reconstruction*, St. Louis, 1987, CV Mosby.
63. Greenwald AG, Schute PC, Shiveley JL: Brachial plexus birth palsy: a 10-year report on the incidence and prognosis. *J Pediatr Orthop* 4:689–692, 1984.
64. Gu YD, Chen L, Shen LY: Classification of impairment of shoulder abduction in obstetric brachial plexus palsy and its clinical significance. *J Hand Surg [Br]* 25:46–48, 2000.
65. Haerle M, Gilbert A: Management of complete obstetric brachial plexus lesions. *J Pediatr Orthop* 24:194–200, 2004.
66. Hashimoto T, Mitomo M, Hirabuki N, et al: Nerve root avulsion of birth palsy: comparison of myelography with CT myelography and somatosensory evoked potential. *Radiology* 178:841–845, 1991.
67. Hattori Y, Doi K, Ikeda K, et al: Restoration of prehension using double free muscle technique after complete avulsion of brachial plexus in children: a report of three cases. *J Hand Surg [Am]* 30:812–819, 2005.
68. Hazama A, Kinouchi K, Kitamura S, et al: Brachial plexus birth injuries: anaesthesia for surgical nerve reconstruction and preoperative myelography and computed tomographic myelography. *Paediatr Anaesth* 9:403–407, 1999.
69. Heise CO, Goncalves LR, Barbosa ER, et al: Botulinum toxin for treatment of cocontractions related to obstetrical brachial plexopathy. *Arq Neuropsiquiatr* 63:588–591, 2005.
70. Herring JA: Disorders of the upper extremity: Traumatic disorders: neonatal brachial plexus palsy. In Herring JA, editor: *Tachdjian's pediatric orthopaedics*, Philadelphia, 2002, WB Saunders.
71. Ho ES, Roy T, Stephens D, et al: Serial casting and splinting of elbow contractures in children with obstetric brachial plexus palsy. *J Hand Surg [Am]* 35:84–91, 2010.
72. Hoeksma AF, Ter Steeg AM, Dijkstra P, et al: Shoulder contracture and osseous deformity in obstetrical brachial plexus injuries. *J Bone Joint Surg Am* 85-A:316–322, 2003.
73. Hoeksma AF, Wolf H, Oei SL: Obstetrical brachial plexus injuries: incidence, natural course and shoulder contracture. *Clin Rehabil* 14:523–526, 2000.
74. Hoffer MM, Phipps GJ: Surgery about the elbow for brachial palsy. *J Pediatr Orthop* 20:781–785, 2000.
75. Hoffer MM, Wickenden R, Roper B: Brachial plexus birth palsies. Results of tendon transfers to the rotator cuff. *J Bone Joint Surg Am* 60(5):691–695, 1978.
76. Hogendoorn S, van Overvest KL, Watt I, et al: Structural changes in muscle and glenohumeral joint deformity in neonatal brachial plexus palsy. *J Bone Joint Surg Am* 92:935–942, 2010.
77. Hudic I, Fatusic Z, Sinanovic O, et al: Etiological risk factors for brachial plexus palsy. *J Matern Fetal Neonatal Med* 19:655–661, 2006.
78. Huffman GR, Bagley AM, James MA, et al: Assessment of children with brachial plexus birth palsy using the Pediatric Outcomes Data Collection Instrument. *J Pediatr Orthop* 25:400–404, 2005.
79. Jakobovits A: Medico-legal aspects of brachial plexus injury: the obstetrician's point of view. *Med Law* 15:175–182, 1996.
80. Jennett RJ, Tarby TJ: Disuse osteoporosis as evidence of brachial plexus palsy due to intrauterine fetal maladaptation. *Am J Obstet Gynecol* 185:236–237, 2001.
81. Jennett RJ, Tarby TJ, Kreinick CJ: Brachial plexus palsy: an old problem revisited. *Am J Obstet Gynecol* 166:1673–1676, discussion 1676–1677, 1992.
82. Kao JT, Sharma SC, Curtis CG, et al: The role of the brachioradialis H reflex in the management and prognosis of obstetrical brachial plexus palsy. *Handchir Mikrochir Plast Chir* 35:106–111, 2003.
83. Kawabata H, Kawai H, Masatomi T, et al: Accessory nerve neurotization in infants with brachial plexus birth palsy. *Microsurgery* 15:768–772, 1994.
84. Kawabata H, Masada K, Tsuyuguchi Y, et al: Early microsurgical reconstruction in birth palsy. *Clin Orthop Relat Res* 215:233–242, 1987.
85. Kawabata H, Shibata T, Matsui Y, et al: Use of intercostal nerves for neurotization of the musculocutaneous nerve in infants with birth-related brachial plexus palsy. *J Neurosurg* 94:386–391, 2001.
86. Kawai H, Tsuyuguchi Y, Masada K: Identification of the lesion in brachial plexus injuries with root avulsion: a comprehensive assessment by means of preoperative findings, myelography, surgical exploration, and intraoperative diagnosis. *Br J Plast Surg* 51:43–50, 1989.
87. Kay SP: Obstetrical brachial palsy. *Br J Plast Surg* 51:43–50, 1998.
87a. Kennedy R: Suture of the brachial plexus in birth paralysis of the upper extremity. *BMJ* 1:298–310, 1903.
88. Kim HM, Galatz LM, Das R, et al: Musculoskeletal deformities secondary to neurotomy of the superior trunk of the brachial plexus in neonatal mice. *J Orthop Res* 28:1391–1398, 2010.
89. Kirjavainen M, Remes V, Peltonen J, et al: Long-term results of surgery for brachial plexus birth palsy. *J Bone Joint Surg Am* 89:18–26, 2007.
90. Kirjavainen M, Remes V, Peltonen J, et al: The function of the hand after operations for obstetric injuries to the brachial plexus. *J Bone Joint Surg Br* 90:349–355, 2008.
91. Kirkos JM, Kyrkos MJ, Kapetanos GA, et al: Brachial plexus palsy secondary to birth injuries. *J Bone Joint Surg Br* 87:231–235, 2005.
92. Kon DS, Darakjian AB, Pearl ML, et al: Glenohumeral deformity in children with internal rotation contractures secondary to brachial plexus birth palsy: intraoperative arthrographic classification. *Radiology* 231:791–795, 2004.
93. Kozin SH: Correlation between external rotation of the glenohumeral joint and deformity after brachial plexus birth palsy. *J Pediatr Orthop* 24:189–193, 2004.
94. Kozin SH, Boardman MJ, Chafetz RS, et al: Arthroscopic treatment of internal rotation contracture and glenohumeral dysplasia in children with brachial plexus birth palsy. *J Shoulder Elbow Surg* 19:102–110, 2010.
95. Kozin SH, Chafetz RS, Barus D, et al: Magnetic resonance imaging and clinical findings before and after tendon transfers about the shoulder in children with residual brachial plexus birth palsy. *J Shoulder Elbow Surg* 15:554–561, 2006.
96. Ladak A, Morhart M, O'Grady K, et al: Distal nerve transfers are effective in treating patients with upper trunk obstetrical brachial plexus injuries: an early experience. *Plast Reconstr Surg* 132:985e–992e, 2013.
97. Ladak A, Spinner RJ: Double fascicular nerve transfer for elbow flexion: is 2 better than 1? *Neurosurgery* 72:1055–1056, 2013.
98. Laurent JP, Lee R, Shenaq S, et al: Neurosurgical correction of upper brachial plexus birth injuries. *J Neurosurg* 79:197–203, 1993.
99. Laurent JP, Lee RT: Birth-related upper brachial plexus injuries in infants: operative and nonoperative approaches. *J Child Neurol* 9:111–117, discussion 118, 1994.
100. Li Z, Barnwell J, Tan J, et al: Microcomputed tomography characterization of shoulder osseous deformity after brachial plexus birth palsy: a rat model study. *J Bone Joint Surg Am* 92:2583–2588, 2010.
101. Li Z, Ma J, Apel P, et al: Brachial plexus birth palsy-associated shoulder deformity: a rat model study. *J Hand Surg [Am]* 33:308–312, 2008.
102. Lin JC, Schwentker-Colizza A, Curtis CG, et al: Final results of grafting versus neurolysis in obstetrical brachial plexus palsy. *Plast Reconstr Surg* 123:939–948, 2009.
103. Little KJ, Zlotolow DA, Soldado F, et al: Early functional recovery of elbow flexion and supination following median and/or ulnar nerve fascicle transfer in upper neonatal brachial plexus palsy. *J Bone Joint Surg Am* 96:215–221, 2014.
104. Maillet M, Romana C: Complete obstetric brachial plexus palsy: surgical improvement to recover a functional hand. *J Child Orthop* 3:101–108, 2009.
105. Malessy MJ, Thomeer RT: Evaluation of intercostal to musculocutaneous nerve transfer in reconstructive brachial plexus surgery. *J Neurosurg* 88:266–271, 1998.

106. Mallet J: [Obstetrical paralysis of the brachial plexus. II. Therapeutics. Treatment of sequelae. Priority for the treatment of the shoulder. Method for the expression of results]. *Rev Chir Orthop Reparatrice Appar Mot* 58:166–168, 1972.
107. Mancias P, Slopis JM, Yeakley JW, et al: Combined brachial plexus injury and root avulsion after complicated delivery. *Muscle Nerve* 17:1237–1238, 1994.
108. McCann ME, Waters P, Goumnerova LC, et al: Self-mutilation in young children following brachial plexus birth injury. *Pain* 110:123–129, 2004.
109. McFarland LV, Raskin M, Daling JR, et al: Erb/Duchenne's palsy: a consequence of fetal macrosomia and method of delivery. *Obstet Gynecol* 68:784–788, 1986.
110. McManus F, Rang M, Chance G, et al: Is cerebral palsy a preventable disease? *Obstet Gynecol* 50:71–77, 1977.
111. McNeely PD, Drake JM: A systematic review of brachial plexus surgery for birth-related brachial plexus injury. *Pediatr Neurosurg* 38:57–62, 2003.
112. Mehta SH, Blackwell SC, Bujold E, et al: What factors are associated with neonatal injury following shoulder dystocia? *J Perinatol* 26:85–88, 2006.
113. Metaizeau JP, Gayet C, Plenat F: [Brachial plexus birth injuries. An experimental study (author's transl).] *Chirurg Pediatr* 20:159–163, 1979.
114. Meyer RD: Treatment of adult and obstetrical brachial plexus injuries. *Orthopedics* 9:899–903, 1986.
115. Michelow B, Clarke H, Curtis C, et al: The natural history of obstetrical brachial plexus palsy. *Plast Reconstr Surg* 93:675–680, 1994.
116. Miller SF, Glasier CM, Griebel ML, et al: Brachial plexopathy in infants after traumatic delivery: evaluation with MR imaging. *Radiology* 189:481–484, 1993.
116a. Millesi H: Surgical management of brachial plexus injuries. *J Hand Surg* 2:367–379, 1977.
116b. Millesi H: Nerve grafting. *Clin Plastic Surg* 11:105–113, 1984.
116c. Millesi H: Brachial plexus injuries. Nerve grafting. *Clin Orthop* 237:36–42, 1988.
117. Mollberg M, Hagberg H, Bager B, et al: High birthweight and shoulder dystocia: the strongest risk factors for obstetrical brachial plexus palsy in a Swedish population-based study. *Acta Obstet Gynecol Scand* 84:654–659, 2005.
118. Morrey BF, Askew LJ, Chao EY: A biomechanical study of normal functional elbow motion. *J Bone Joint Surg Am* 63:872–877, 1981.
119. Moukoko D, Ezaki M, Wilkes D, et al: Posterior shoulder dislocation in infants with neonatal brachial plexus palsy. *J Bone Joint Surg Am* 86-A:787–793, 2004.
120. Mulcahey MJ, Merenda L, Tian F, et al: Computer adaptive test approach to the assessment of children and youth with brachial plexus birth palsy. *Am J Occup Therapy* 67:524–533, 2013.
121. Mulcahey MJ, Kozin S, Merenda L, et al: Evaluation of the box and blocks test, stereognosis and item banks of activity and upper extremity function in youths with brachial plexus birth palsy. *J Pediatr Orthop* 32(Suppl 2):S114–S122, 2012.
122. Nagano A, Tsuyama N, Ochiai N, et al: Direct nerve crossing with the intercostal nerve to treat avulsion injuries of the brachial plexus. *J Hand Surg [Am]* 14:980–985, 1989.
123. Narakas AO: Thought on neurotization or nerve transfers in irreparable nerve lesions. *Clin Plast Surg* 11:153–159, 1963.
124. Narakas AO: Obstetrical brachial plexus injuries. In Lamb D, editor: *The paralysed hand*, Edinburgh, 1987, Churchill Livingstone.
125. Narakas AO: Muscle transpositions in the shoulder and upper arm for sequelae of brachial plexus palsy. *Clin Neurol Neurosurg* 95:S89–S91, 1993.
126. Newman CJ, Morrison L, Lynch B, et al: Outcome of subscapularis muscle release for shoulder contracture secondary to brachial plexus palsy at birth. *J Pediatr Orthop* 26:647–651, 2006.
127. Nikolaou S, Hu L, Tuttle LJ, et al: The contribution of denervated muscle to contractures following neonatal brachial plexus injury: Not just muscle fibrosis. *Muscle Nerve* 2013.
128. Nikolaou S, Peterson E, Kim A, et al: Impaired growth of denervated muscle contributes to contracture formation following neonatal brachial plexus injury. *J Bone Joint Surg Am* 93:461–470, 2011.
129. Noaman HH, Shiha AE, Bahm J: Oberlin's ulnar nerve transfer to the biceps motor nerve in obstetric brachial plexus palsy: indications, and good and bad results. *Microsurgery* 24:182–187, 2004.
130. Ouzounian JG, Korst LM, Phelan JP: Permanent Erb's palsy: a lack of a relationship with obstetrical risk factors. *Am J Perinatol* 15:221–223, 1998.
131. Ozkan T, Okumus A, Aydin A, et al: Brachioradialis transposition for elbow extension in obstetrical brachial plexus palsy. *Tech Hand Up Extrem Surg* 9:60–65, 2005.
132. Pagnotta A, Haerle M, Gilbert A: Long-term results on abduction and external rotation of the shoulder after latissimus dorsi transfer for sequelae of obstetric palsy. *Clin Orthop Relat Res* 426:199–205, 2004.
133. Palmgren T, Peltonen J, Linder T, et al: Sensory evaluation of the hands in children with brachial plexus birth injury. *Dev Med Child Neurol* 49:582–586, 2007.
134. Paradiso G, Granana N, Maza E: Prenatal brachial plexus paralysis. *Neurology* 49:261–262, 1997.
135. Pearl ML: Shoulder problems in children with brachial plexus birth palsy: evaluation and management. *J Am Acad Orthop Surg* 17:242–254, 2009.
136. Pearl ML, Edgerton BW: Glenoid deformity secondary to brachial plexus birth palsy. *J Bone Joint Surg Am* 80:659–667, 1998.
137. Pearl ML, Edgerton BW, Kazimiroff PA, et al: Arthroscopic release and latissimus dorsi transfer for shoulder internal rotation contractures and glenohumeral deformity secondary to brachial plexus birth palsy. *J Bone Joint Surg Am* 88:564–574, 2006.
138. Pearl ML, Edgerton BW, Kon DS, et al: Comparison of arthroscopic findings with magnetic resonance imaging and arthrography in children with glenohumeral deformities secondary to brachial plexus birth palsy. *J Bone Joint Surg Am* 85-A:890–898, 2003.
139. Pedowitz DI, Gibson B, Williams GR, et al: Arthroscopic treatment of posterior glenohumeral joint subluxation resulting from brachial plexus birth palsy. *J Shoulder Elbow Surg* 16:6–13, 2007.
140. Pondaag W, Malessy MJ: Recovery of hand function following nerve grafting and transfer in obstetric brachial plexus lesions. *J Neurosurg* 105:33–40, 2006.
141. Pondaag W, Malessy MJ: The evidence for nerve repair in obstetric brachial plexus palsy revisited. *Biomed Res Int* 2014:434619, 2014.
142. Pondaag W, Malessy MJ, van Dijk JG, et al: Natural history of obstetric brachial plexus palsy: a systematic review. *Dev Med Child Neurol* 46:138–144, 2004.
143. Poyhia TH, Koivikko MP, Peltonen JI, et al: Muscle changes in brachial plexus birth injury with elbow flexion contracture: an MRI study. *Pediatr Radiol* 37:173–179, 2007.
144. Poyhia TH, Lamminen AE, Peltonen JI, et al: Brachial plexus birth injury: US screening for glenohumeral joint instability. *Radiology* 254:253–260, 2010.
145. Poyhia TH, Nietosvaara YA, Remes VM, et al: MRI of rotator cuff muscle atrophy in relation to glenohumeral joint incongruence in brachial plexus birth injury. *Pediatr Radiol* 35:402–409, 2005.
146. Putti V: [Analisi della triada radiosintomatica degli stati di prelussazione.] *Chir Organi Mov* 17:453–459, 1932.
147. Reading BD, Laor T, Salisbury SR, et al: Quantification of humeral head deformity following neonatal brachial plexus palsy. *J Bone Joint Surg Am* 94:e136(131–138), 2012.
148. Rollnik JD, Hierner R, Schubert M, et al: Botulinum toxin treatment of cocontractions after birth-related brachial plexus lesions. *Neurology* 55:112–114, 2000.
149. Rouse DJ, Owen J, Goldenberg RL, et al: The effectiveness and costs of elective cesarean delivery for fetal macrosomia diagnosed by ultrasound. *JAMA* 276:1480–1486, 1996.
150. Ruchelsman DE, Ramos LE, Alfonso I, et al: Outcome following spinal accessory to suprascapular (spinoscapular) nerve transfer in infants with brachial plexus birth injuries. *Hand (NY)* 5:190–194, 2010.
150a. Russo SA, et al: Limited glenohumeral cross-body adduction in children with brachial plexus birth palsy: a contributor to scapular winging. *J Pediatr Orthop* 35(3):240–245, 2015.
151. Russo SA, Kozin SH, Zlotolow DA, et al: Scapulothoracic and glenohumeral contributions to motion in children with brachial plexus birth palsy. *J Shoulder Elbow Surg* 23:327–338, 2014.
152. Sever JW: Obstetric paralysis: Report of eleven hundred cases. *JAMA* 85:1862–1865, 1925.
153. Shah A, Kuo A, Zurakowski D, et al: Use and satisfaction of the Internet in obtaining information on brachial plexus birth palsies and its influence on decision-making. *J Pediatr Orthop* 26:781–784, 2006.
154. Shah AK, Zurakowski D, Jessel RH, et al: Measuring surgeons' treatment preferences and satisfaction with nerve reconstruction techniques for children with unique brachial plexus birth palsies. *Plast Reconstr Surg* 118:967–975, 2006.
155. Sheffler LC, Lattanza L, Sison-Williamson M, et al: Biceps brachii long head overactivity associated with elbow flexion contracture in brachial plexus birth palsy. *J Bone Joint Surg Am* 94:289–297, 2012.
156. Sherburn EW, Kaplan SS, Kaufman BA, et al: Outcome of surgically treated birth-related brachial plexus injuries in twenty cases. *Pediatr Neurosurg* 27:19–27, 1997.
157. Sibinski M, Sherlock DA, Hems TE, et al: Forearm rotational profile in obstetric brachial plexus injury. *J Shoulder Elbow Surg* 16:784–787, 2007.
158. Sibinski M, Synder M: Obstetric brachial plexus palsy—risk factors and predictors. *Ortop Traumatol Rehabil* 9:569–576, 2007.
159. Slooff AC: Obstetric brachial plexus lesions and their neurosurgical treatment. *Clin Neurol Neurosurg* 95:S73–S77, 1993.
160. Smellie W: *A collection of preternatural cases and observations in midwifery*, London, 1764, Wilson & Durham.
161. Smith NC, Rowan P, Benson LJ, et al: Neonatal brachial plexus palsy. Outcome of absent biceps function at three months of age. *J Bone Joint Surg Am* 86-A:2163–2170, 2004.
162. Spellacy WN, Miller S, Winegar A, et al: Macrosomia—maternal characteristics and infant complications. *Obstet Gynecol* 66:158–161, 1985.
163. Spong CY, Beall M, Rodrigues D, et al: An objective definition of shoulder dystocia: prolonged head-to-body delivery intervals and/or the use of ancillary obstetric maneuvers. *Obstet Gynecol* 86:433–436, 1995.

164. Stallings SP, Edwards RK, Johnson JW: Correlation of head-to-body delivery intervals in shoulder dystocia and umbilical artery acidosis. *Am J Obstet Gynecol* 185:268–274, 2001.

164a. Stimson LA: *A treatise on dislocations*, Philadelphia, 1888, Lea Brothers, pp 271–279.

165. Strombeck C, Krumlinde-Sundholm L, Remahl S, et al: Long-term follow-up of children with obstetric brachial plexus palsy I: functional aspects. *Dev Med Child Neurol* 49:204–209, 2007.

166. Strombeck C, Remahl S, Krumlinde-Sundholm L, et al: Long-term follow-up of children with obstetric brachial plexus palsy II: neurophysiological aspects. *Dev Med Child Neurol* 49:204–209, 2007.

166a. Taylor AS: Brachial birth palsy and injuries of similar type in adults. *Surg Gynecol Obstet* 30:494, 1920.

167. Terzis JK, Kokkalis ZT: Elbow flexion after primary reconstruction in obstetric brachial plexus palsy. *J Hand Surg Eur Vol* 34:449–458, 2009.

168. Tse R, Marcus JR, Curtis CG, et al: Suprascapular nerve reconstruction in obstetrical brachial plexus palsy: spinal accessory nerve transfer versus C5 root grafting. *Plast Reconstr Surg* 127:2391–2396, 2011.

169. Urabe F, Matsuishi T, Kojima K, et al: MR imaging of birth brachial palsy in a two-month-old infant. *Brain Dev* 13:130–131, 1991.

170. Vallejo GI, Toh S, Arai H: Results of the latissimus dorsi and teres major tendon transfer on to the rotator cuff for brachial plexus palsy at birth. *Scand J Plast Reconstr Surg Hand Surg* 36:207–211, 2002.

171. van der Sluijs JA, van Ouwerkerk WJ, de Gast A, et al: Treatment of internal rotation contracture of the shoulder in obstetric brachial plexus lesions by subscapular tendon lengthening and open reduction: early results and complications. *J Pediatr Orthop B* 13:218–224, 2004.

172. van Dijk JG, Malessy MJ, Stegeman DF: Why is the electromyogram in obstetric brachial plexus lesions overly optimistic? *Muscle Nerve* 21:260–261, 1998.

173. van Dijk JG, Pondaag W, Malessy MJ: Obstetric lesions of the brachial plexus. *Muscle Nerve* 24:1451–1461, 2001.

174. van Ouwerkerk WJ, van der Sluijs JA, Nollet F, et al: Management of obstetric brachial plexus lesions: state of the art and future developments. *Childs Nerv Syst* 16:638–644, 2000.

175. Vekris MD, Lykissas MG, Beris AE, et al: Management of obstetrical brachial plexus palsy with early plexus microreconstruction and late muscle transfers. *Microsurgery* 28:252–261, 2008.

176. Vekris MD, Pafilas D, Lykissas MG, et al: Correction of elbow flexion contracture in late obstetric brachial plexus palsy through arthrodiatasis of the elbow (Ioannina method). *Tech Hand Up Extrem Surg* 14:14–20, 2010.

177. Vredeveld JW, Blaauw G, Slooff BA, et al: The findings in paediatric obstetric brachial palsy differ from those in older patients: a suggested explanation. *Dev Med Child Neurol* 42:158–161, 2000.

178. Walker AT, Chaloupka JC, de Lotbiniere AC, et al: Detection of nerve rootlet avulsion on CT myelography in patients with birth palsy and brachial plexus injury after trauma. *AJR Am J Roentgenol* 167:1283–1287, 1996.

179. Waters PM: Comparison of the natural history, the outcome of microsurgical repair, and the outcome of operative reconstruction in brachial plexus birth palsy. *J Bone Joint Surg Am* 81:649–659, 1999.

180. Waters PM: Update on management of pediatric brachial plexus palsy. *J Pediatr Orthop* 25:116–126, 2005.

181. Waters PM, Bae DS: Effect of tendon transfers and extraarticular soft-tissue balancing on glenohumeral development in brachial plexus birth palsy. *J Bone Joint Surg Am* 87:320–325, 2005.

182. Waters PM, Bae DS: The effect of derotational humeral osteotomy on global shoulder function in brachial plexus birth palsy. *J Bone Joint Surg Am* 88:1035–1042, 2006.

183. Waters PM, Bae DS: The early effects of tendon transfers and open capsulorrhaphy on glenohumeral deformity in brachial plexus birth palsy. Surgical technique. *J Bone Joint Surg Am* 91(Suppl 2):213–222, 2009.

184. Waters PM, Monica JT, Earp BE, et al: Correlation of radiographic muscle cross-sectional area with glenohumeral deformity in children with brachial plexus birth palsy. *J Bone Joint Surg Am* 91:2367–2375, 2009.

185. Waters PM, Peljovich AE: Shoulder reconstruction in patients with chronic brachial plexus birth palsy. A case control study. *Clin Orthop Relat Res* 364:144–152, 1999.

186. Waters PM, Smith GR, Jaramillo D: Glenohumeral deformity secondary to brachial plexus birth palsy. *J Bone Joint Surg Am* 80:668–677, 1998.

187. Weekley H, Nikolaou S, Hu L, et al: The effects of denervation, reinnervation, and muscle imbalance on functional muscle length and elbow flexion contracture following neonatal brachial plexus injury. *J Orthop Res* 30:1335–1342, 2012.

188. Weizsaecker K, Deaver JE, Cohen WR: Labour characteristics and neonatal Erb's palsy. *Br J Obstet Gynaecol* 114:1003–1009, 2007.

189. White SJ, Blane CE, DiPietro MA, et al: Arthrography in evaluation of birth injuries of the shoulder. *Can Assoc Radiol J* 38:113–115, 1987.

189a. Whitman R: The treatment of congenital and acquired luxations at the shoulder in childhood. *Ann Surg* 42:110–115, 1905.

189b. Wickstrom J, Haslam ET, Hutchinson RH: The surgical management of residual deformities of the shoulder following birth injuries of the brachial plexus. *J Bone Joint Surg Am* 37:27–36, 1955.

190. Wyeth JA, Sharpe W: The field of neurological surgery in a general hospital. *Surg Gynecol Obstet* 24:29–36, 1917.

191. Xu L, Gu Y, Xu J, et al: Contralateral C7 transfer via the prespinal and retropharyngeal route to repair brachial plexus root avulsion: a preliminary report. *Neurosurgery* 63:553–558, 2008.

192. Yilmaz K, Caliskan M, Oge E, et al: Clinical assessment, MRI, and EMG in congenital brachial plexus palsy. *Pediatr Neurol* 21:705–710, 1999.

193. Zancolli EA, Zancolli ER: Reconstructive surgery in brachial plexus sequelae. In Gupta A, Kay S, Scheker L, editors: *The growing hand: diagnosis and management of the upper extremity in children,* London, 2000, Harcourt Limited.

194. Zancolli EA, Zancolli ERJ: Palliative surgical procedures in sequelae of obstetric palsy. *Hand Clin* 4:643–669, 1988.

41

Hand, Wrist, and Forearm Fractures in Children

Donald S. Bae

These videos may be found at *ExpertConsult.com:*

Video 41.1 Closed reduction and percutaneous fixation of a unicondylar fracture

Video 41.2 Open reduction and screw fixation of scaphoid fracture with distal radial bone graft and superficial volar branch of the radial artery vascular pedicle transfer

Video 41.3 Closed reduction and percutaneous pinning of a distal radius fracture

HAND FRACTURES

Children are not small adults. Although many similar treatment principles and techniques are used in all age groups, a number of special considerations are required in the treatment of hand fractures in skeletally immature patients. Examination of the injured hand can be challenging, particularly in an anxious or a nonverbal child. An accurate diagnosis is dependent on the clinical history, careful observation, and skilled physical examination. These challenges are compounded by the smaller size of the affected musculoskeletal structures and the abundant surrounding subcutaneous fat and soft tissue. In addition, the smaller size of the underlying skeletal structures necessitates the use of smaller implants placed with precision during surgical procedures. Although the robust healing potential of skeletal injuries in children reduces the risk of delayed union and nonunion compared with their adult counterparts, it also narrows the window of opportunity to correct deformities using closed means. Much of this robust healing potential arises from the thick and biologically active periosteum, which contributes to appositional bone growth, promotes remodeling, and provides a smooth gliding surface for overlying tendons.

The presence of the physis leads to a unique set of treatment considerations. In many situations, an initial bony deformity will remodel with continued skeletal growth. This remodeling potential is dependent on a number of factors, including the magnitude and pattern of bony deformity, proximity of the injury to the adjacent physis, and amount of remaining skeletal growth. In general, the greatest remodeling potential is seen with displacement in the plane of adjacent joint motion, in close proximity to the physis, and in young children with many years of remaining growth.[19,156] Rotational deformity has little remodeling potential and will persist if not addressed acutely. Similarly, remodeling of radioulnar angulation is limited and is dependent on the amount of adjacent radioulnar joint motion. Efforts to preserve physeal growth may also influence the choice of surgical techniques for operative injuries.

Because children demonstrate varying degrees of compliance following injury or postoperative care, more restrictive immobilization is required to maximize long-term outcomes. Fortunately, the use of longer and more restrictive immobilization following hand fractures in children is not associated with the stiffness seen in adults. Indeed, children are often their own best therapists and quickly resolve issues of stiffness and strength through daily activities of play and sports.

In addition to these considerations, a number of hand injuries are characteristically found in children. Awareness of these injuries and their treatment options is essential for the practicing hand surgeon.

The purpose of this section is to review the epidemiology, pertinent anatomy, and treatment principles for fractures of the child's hand, with particular emphasis on pediatric injuries requiring surgical care.

Epidemiology

Hand fractures are common in children and adolescents. In their analysis of the 1998 National Hospital Ambulatory Medical Care Survey (NHAMCS), Chung and Spilson reported on the epidemiologic findings of hand and forearm fractures in the United States.[39] Based on their four-stage probability model and subsequent extrapolation of the NHAMCS data, an estimated 1,465,874 patients with hand or forearm fractures present to U.S. emergency departments annually. Phalangeal and metacarpal fractures represented 23% and 18% of these cases, respectively. Interestingly, 15% of all metacarpal fractures and 33% of all phalangeal fractures occurred in patients between 0 and 14 years of age. Furthermore, the highest rate of multiple hand fractures was seen in patients between 0 and 4 years of age (29.8%). The calculated incidence of phalangeal fractures in patients 0 to 4 years old was 207.2 per 100,000. The incidence of metacarpal and phalangeal fractures in patients 5 to 14 years old was 100.0 and 184.9 per 100,000, respectively. Although this analysis was limited by the study design and the nature of the NHAMCS database, the results clearly highlight the frequency with which hand fractures occur in the pediatric population.

Feehan and Sheps performed a population-based study evaluating the epidemiology of hand fractures in British Columbia, Canada, from 1996 to 2001.[55] During the 5-year study period, 72,481 fractures were identified, for an overall annual incidence of 3.63 per 1000 across all age groups. The peak incidence for hand fractures was between 10 and 14 years of age (8.69 per

1000). When divided according to gender, the highest incidence was seen in males between 15 and 19 years of age (12.3 per 1000) and females between 10 and 14 years of age (5.3 per 1000). The authors attributed this peak incidence during adolescence to a combination of accelerated skeletal growth and participation in higher risk sporting and recreational activities.[48,49,55]

Over a 6-month period in 2000 at the Pulvertaft Hand Center in Derby, England, 360 children younger than 16 years were seen for hand injuries.[189] Skeletal injuries accounted for 66% of cases, for an annual incidence of 418 per 100,000 children. The peak incidence was in patients between 10 and 16 years of age. Although crushing injuries were the most common mechanism overall, sports-related fractures occurred most commonly in patients older than 10 years. The small finger was most commonly fractured (52%), followed by the thumb (23%). The proximal phalanx was the most frequently injured phalanx (67%). Metacarpal fractures were most commonly diaphyseal, whereas phalangeal fractures typically involved the proximal metaphysis or physis.

Shah and colleagues more recently reported their retrospective analysis of the National Electronic Injury Surveillance System of patients less than 18 years of age treated at U.S. emergency departments from 1990 to 2009.[167] They estimated an incidence of hand injuries at 11.6 per 1000. Approximately one-quarter of all hand injuries consisted of fractures, most commonly affecting patients between 10 and 14 years of age and resulting from recreational and sporting activities.

In addition to the wealth of information on the frequency of hand fractures in children and adolescents, a number of published reports have provided insights into the mechanisms and patterns of injury. Taking these and previous epidemiologic studies together, it is clear that there is a biphasic distribution of hand injuries, with the peak incidences in young toddlers and older adolescents. Bhende and coworkers analyzed 464 children with 477 hand injuries presenting to a level I pediatric emergency department during a 6-month period in 1989.[21] Fractures accounted for 19.3% of all hand injuries, and a bimodal distribution of injuries was seen. Toddlers and younger children presented with lacerations, burns, and fingertip injuries, such as distal phalangeal fractures, as they explored the world around them. Conversely, adolescents tended to present with hand fractures sustained during sporting activities, fights, and self-inflicted trauma.[49] These findings are supported by Liu and associates and Young and colleagues in their separate analyses of children presenting to plastic surgery emergency clinics.[109,212]

Rajesh and associates similarly attempted to characterize the pattern and nature of pediatric hand fractures in their radiographic review of 280 children treated at the Leicester Royal Infirmary in the United Kingdom.[154] Isolated distal phalangeal tuft fractures were most common in the 0- to 4-year-old age group. Distal phalangeal tuft and shaft fractures were most common in 5- to 8-year-old children. Small finger proximal phalangeal fractures were most common in patients 9 to 12 years of age, and small finger metacarpal neck fractures were seen most often in 13- to 16-year-old adolescents (Figure 41.1). Other published reports have also documented a higher frequency of injury to the border digits and to the small finger in particular.[19,77]

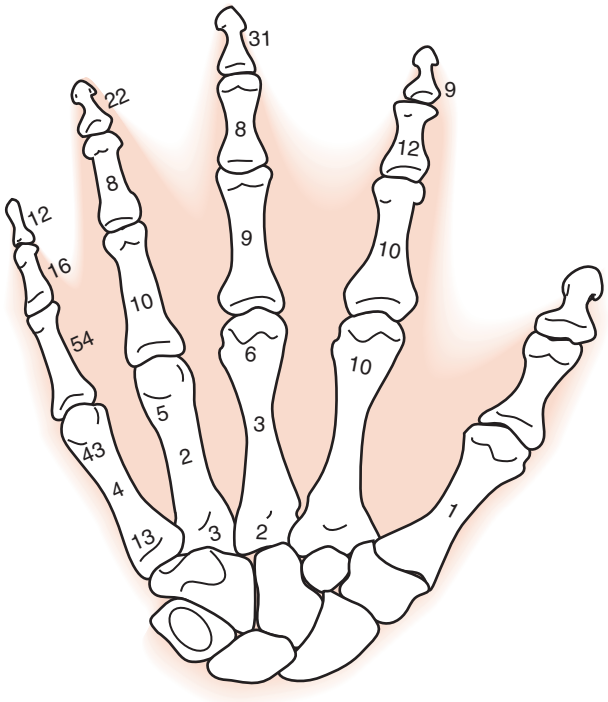

FIGURE 41.1 Schematic diagram depicting the distribution of hand fractures in 280 children younger than 16 years. (From Rajesh A, Basu AK, Vaidhyanath R, et al: Hand fractures: a study of their site and type in childhood. *Clin Radiol* 56:667–669, 2001.)

Approximately one-third of all fractures of the hand propagate through the phalangeal or metacarpal physis.[9,10,77,212] Salter-Harris type II fracture patterns predominate, most commonly of the proximal phalanx.[77,154,161,209,210] Despite the relative frequency with which physeal fractures occur, posttraumatic physeal arrest is an uncommon sequela in isolated closed injuries.

Preoperative Evaluation

Physical examination of a child's injured hand can be challenging, particularly in an anxious, noncompliant, or nonverbal patient. Observation and gentle maneuvers are mandatory to obtain the information needed for an accurate and timely diagnosis. The presence of swelling, ecchymosis, guarded active motion, or soft tissue injury can guide the examiner to the region of the pathologic condition.

The *tenodesis effect*, or gentle pressure applied to the more proximal muscle bellies of the forearm (away from the site of injury), aids in the assessment of both tendon integrity and angular or rotational deformity (Figure 41.2). Assessment of rotational deformity is critical because the deformity exhibits little remodeling and may result in compromised hand function owing to digital overlap or underlap. Malrotation can also be assessed by careful examination of the nail beds of adjacent digits in extension; rotation of greater than 10 degrees out of the plane of adjacent nail plates should alert the examiner to rotational malalignment, although these differences are often subtle and difficult to quantify. Rotational deformity can be better assessed by evaluating digital alignment with attempted finger flexion. In general, the index through small fingers point



FIGURE 41.2 Clinical photograph demonstrating use of the tenodesis effect to identify rotational deformity of the ring finger in the setting of a proximal phalanx fracture. (Courtesy of the Children's Orthopaedic Surgery Foundation.)



FIGURE 41.3 Anteroposterior radiograph of the hand illustrating the phalangeal line test. In the normal hand, the longitudinal axes of the metacarpals and phalanges should align. Angular or translational deviations may be seen in the setting of fractures or dislocations of the hand. (Courtesy of the Children's Orthopaedic Surgery Foundation.)

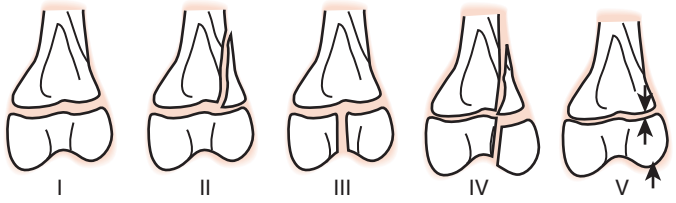

© 2008 COSF, Boston

FIGURE 41.4 Schematic diagram of the Salter-Harris classification of physeal fractures. (McElfresh EC, Dobyns JH: Intra-articular metacarpal head fractures. *J Hand Surg [Am]* 8:383–393, 1983.)

to the scaphoid tubercle in flexion, roughly in parallel alignment; often, patients normally exhibit some degree of digital underlap, such as small finger beneath ring finger. Comparison to the uninjured contralateral hand is valuable in these situations to determine baseline alignment. In young, anxious, or nonverbal patients who are unable to actively flex their digits during physical examination, the tenodesis effect can be used; gentle passive extension of the wrist also allows obligate digital flexion to assess for rotational alignment. Only after all pertinent information has been derived from observation and indirect examination techniques should direct palpation or stress testing be performed.

Sensibility is difficult to elicit in young patients, and threshold testing or two-point discrimination is generally unreliable until children are older than 8 years. In rare situations in which there is concern about an associated digital nerve injury, warm water immersion can be used. The presence of skin wrinkling after several minutes of water immersion implies innervation.

Thorough and directed radiographic evaluation is imperative in the evaluation of a child's injured hand. In general, dedicated anteroposterior (AP), lateral, and oblique radiographs of the injured digit are preferred over hand radiographs, in which overlying structures, projection artifacts, and lack of bony magnification can lead to errors in diagnosis. As part of the systematic evaluation of hand radiographs, the phalangeal line test has been proposed as a means of identifying joint malalignment or bony angulation in younger children whose skeletal structures are not yet ossified (Figure 41.3).[31] When expedited or comprehensive radiographic assessment is needed, fluoroscopy or mini-imaging units may assist in obtaining appropriate views of the injured digit, comparison views of the contralateral hand, or dynamic assessment of bony and articular stability. As ultrasonography becomes increasingly ubiquitous, ultrasound imaging may similarly be used to detect subtle or radiographically occult fractures.[134] The normal sequence of skeletal ossification, as well as common normal radiographic variants (discussed later), should be kept in mind to avoid mistaking these for traumatic injuries.[72,177] Indeed, Chew and Chong previously reported on 204 children referred to a tertiary care center for hand fractures; injuries were misdiagnosed in 16 cases (8%), of which the leading cause was mistaking the epiphyses for fractures.[37]

Among the many proposed classification systems, that of Salter and Harris is most widely used owing to its simplicity and its ability to guide fracture management and prognosticate outcome (Figure 41.4).[161]

PERTINENT ANATOMY

In the skeletally immature hand, the physes of the phalanges lie perpendicular to the long axis of the bones proximally. The metacarpal physes are distal, with the exception of the thumb metacarpal, which is proximal.

The secondary centers of ossification in the epiphyses appear in a timely and orderly fashion. Although there is variation among individuals, the proximal phalangeal epiphyses become radiographically apparent between 10 and 24 months of age, in females before males.[72,177] The epiphyses of the middle and distal phalanges ossify approximately 6 to 8 months later. Conversely, physeal closure proceeds in a distal to proximal direction, typically between the ages of 14 and 16 years. The index through small finger metacarpal epiphyses ossify at 12 to 27 months of age and fuse between 14 and 16 years of age. The thumb metacarpal epiphysis, however, does not typically ossify until 24 to 36 months of age.

Common normal radiographic variants include the appearance of a pseudoepiphysis of the distal thumb metacarpal and the proximal index metacarpal.[75] The pseudoepiphyses become radiographically apparent at an early age, do not contribute to the longitudinal growth of the metacarpal, and typically fuse to the metacarpal diaphysis by the seventh year of life.[75] Other anatomic variants include the double epiphysis, most commonly appearing in the index finger and thumb metacarpals. These physeal variants can be misinterpreted as fractures.

As in other long tubular bones that develop via enchondral ossification, the physis of the phalanges and metacarpals is divided into a number of histologic zones. Proceeding from the epiphysis to the metaphysis, the physis contains a resting zone, proliferative zone, zone of hypertrophy, and zone of provisional calcification. Because most physeal fractures propagate through the zone of hypertrophy without disrupting the resting or proliferative zone, posttraumatic growth disturbance is an uncommon sequela of pediatric hand fractures. In the less common circumstance in which the plane of cleavage traverses the zone of proliferation or the resting zone (e.g., Salter-Harris type III, IV, and V fractures), physeal arrest may occur.[161] As the physis becomes more irregular and calcified as patients approach skeletal maturity, Salter-Harris type III and IV injuries are more likely to occur, mimicking more adult fracture patterns (e.g., Bennett fracture at the base of the thumb metacarpal).

Knowledge of the soft tissue anatomy is critical in understanding common fracture patterns and guiding nonoperative as well as surgical treatment. In the interphalangeal joints, the collateral ligaments arise from the collateral recesses of the phalangeal neck proximally and insert to the epiphysis and metaphysis of the adjacent phalangeal base distally. Conversely, at the metacarpophalangeal (MP) joint, the radial collateral ligament arises from the metacarpal epiphysis proximally and inserts on the proximal phalangeal epiphysis distally; the ulnar collateral ligament originates from both the metacarpal epiphysis and metaphysis and inserts on the proximal phalangeal epiphysis.[23] For these reasons, Salter-Harris III fractures are common about the MP joint but rarely involve interphalangeal joints because the epiphysis is "protected" by the collateral ligaments. Conversely, diaphyseal or Salter-Harris II fractures of the distal phalanx or fractures of the proximal phalangeal head or neck more commonly arise from laterally directed forces on the interphalangeal joints.

Understanding of the tendinous insertions in the hand also helps elucidate fracture patterns and guide treatment. The terminal tendon of the long digital extensor inserts onto the dorsal phalangeal epiphysis, and the flexor digitorum profundus insertion to the index through small fingers spans both the volar epiphysis and metaphysis. This anatomic relationship is particularly relevant in the treatment of distal phalangeal physeal fractures, as described later. In the thumb, the extensor pollicis longus inserts onto the dorsal epiphysis of the distal phalanx, the extensor pollicis brevis inserts onto the epiphysis of the proximal phalanx, and the abductor pollicis longus inserts broadly on both the epiphysis and metaphysis of the thumb metacarpal. As in the digits, the flexor pollicis longus inserts on the metadiaphysis of the distal phalanx.[23]

Historical Review

Most hand fractures in children can be managed nonoperatively on an outpatient basis.[31,59,77,212] Indeed, it has been estimated that only 10% to 20% of pediatric hand fractures require surgical care, and these statistics have been corroborated by contemporary published series.[21]

Hastings and Simmons published a retrospective analysis of 354 hand fractures in skeletally immature patients.[77] Border digits were most commonly fractured, and the metacarpal and proximal phalanx were most commonly affected. Although they found a higher prevalence of physeal fractures than had been reported in previous studies, there were only two cases of growth disturbance, seen in patients with severe crush injuries or infection. Overall results were excellent in most cases, but a number of risk factors were associated with fracture malunion and poor results, including failure to obtain adequate radiographs at the time of injury, false assumptions regarding the remodeling potential of phalangeal fractures, and failure to evaluate clinical deformity (i.e., malrotation). Displaced articular fractures, physeal fractures of the distal phalanx, phalangeal neck fractures, and open fractures were identified as carrying a high risk for suboptimal outcomes in the pediatric population (Box 41.1). Given this information, treatment of these fractures is emphasized in the following sections.

Types of Operations

Distal Phalangeal Fractures

Most distal phalangeal fractures are successfully treated without surgery. Recognition of open fractures and subsequent operative treatment lead to a successful result.

Shaft and Tuft Fractures. Fractures of the distal phalanx typically result from crush injuries in younger patients.[191] In general, patterns of these extraphyseal injuries include transverse, longitudinal split, and comminuted fractures.[99] As expected, these bony injuries are often accompanied by soft tissue avulsions or nail bed lacerations. Treatment is predicated on stabilization of the skeletal injury and appropriate soft tissue injury care, including wound irrigation and débridement, nail plate removal, and nail bed repair.[221,222] Although the majority of

BOX 41.1 High-Risk Pediatric Hand Fractures

Articular fractures, including Salter-Harris type III fractures of the proximal phalanges
- Distal phalangeal physeal fractures (Seymour fractures)
- Phalangeal neck fractures
- Open fractures

distal phalangeal fractures can be treated effectively with splint or cast immobilization following gentle fracture repositioning, surgical stabilization is occasionally needed for widely displaced injuries.[31] In these situations, a single Kirschner wire placed through the digital tip and across the fracture site will suffice. Some have proposed using a hypodermic needle placed under local anesthesia for fracture stabilization.[126]

❖ AUTHOR'S PREFERRED METHOD OF TREATMENT

The majority of extraphyseal distal phalangeal fractures are treated with simple splint or cast immobilization for 4 weeks, with excellent healing and outcomes. Rarely, if complete displacement or translation occurs in transverse fracture patterns, Kirschner wire fixation is used to maintain reduction. A single Kirschner wire is passed in a retrograde fashion through the fingertip, across the fracture, and across the distal interphalangeal (DIP) joint, engaging the head of the middle phalanx. The wire is bent and cut outside the skin and is removed in the office after 4 weeks, followed by range-of-motion exercises and a return to activities as symptoms abate.

Physeal Fractures. Salter-Harris I fractures result in the so-called pseudomallet finger because the distal diaphyseal fragment is volarly displaced, with apex dorsal angulation, by the action of the flexor digitorum profundus.[65] Treatment usually requires extension splinting of the distal phalanx and DIP joint for 4 to 6 weeks.

Seymour fractures are characteristic pediatric injuries of the distal phalangeal physis that merit special attention.[3,166] Typically resulting from crush injuries to the distal phalanx and DIP joint, these are displaced physeal fractures of the distal phalanx accompanied by an overlying nail bed laceration (Figure 41.5). Often there is interposed soft tissue (i.e., germinal matrix) within the displaced physeal fracture. Technically, this is an open physeal fracture; therefore, treatment should consist of nail plate removal, irrigation, and débridement; liberation of any interposed soft tissue; open reduction of the physeal fracture; and meticulous nail bed repair (see Figure 41.5). Dorsal skin incisions from both corners of the dorsal nail fold back toward the DIP joint extension crease elevate the dorsal skin and provide exposure of the germinal matrix and nail bed laceration. The terminal tendon attachment to the dorsal epiphysis must be preserved. Replacement of the trephinated nail plate beneath the dorsal nail fold after nail bed repair often results in sufficient bony stabilization. In cases of excessive instability, transarticular longitudinal pinning of the distal phalanx and DIP joint is used. Krusche-Mandl and colleagues reported results of 24 children treated for Seymour fractures with a mean follow-up of 10 years.[100] With adherence to the above-stated treatment principles, 23 of 24 patients regained full motion, and no infectious complications were noted. Although appropriate and timely treatment results in excellent functional outcomes, failure to attend to these treatment principles and technical steps may lead to late osteomyelitis, physeal arrest, and nail plate deformity (Figure 41.6).[3,65,100]

Salter-Harris III fractures of the dorsal base of the distal phalanx represent the pediatric equivalent of the adult mallet finger (Figure 41.7). Fracture displacement is caused by the proximal pull of the terminal tendon on the epiphyseal fracture fragment. Although minimally displaced or nondisplaced fractures can be treated successfully with extension splinting for 4 to 6 weeks, markedly displaced injuries resulting in volar subluxation of the distal phalanx or articular incongruity unamenable to closed reduction merit surgical consideration. Treatment options include formal open reduction and internal fixation via a dorsal approach (with care taken to preserve terminal tendon attachments to the epiphyseal fragment) or closed reduction and transarticular or extension block pinning.[81]

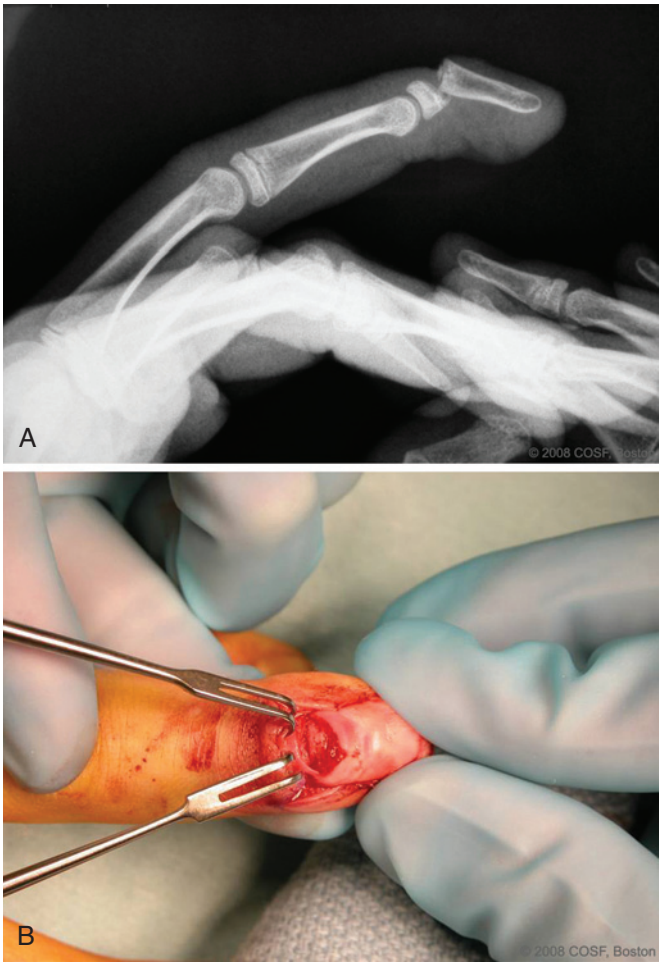

FIGURE 41.5 **A,** Lateral radiograph depicting a displaced physeal fracture of the distal phalanx with an associated nail bed laceration, the so-called Seymour fracture. **B,** Intraoperative photograph following nail plate removal and elevation of the dorsal nail fold. The fracture has been reduced after extrication of interposed germinal matrix, and the cartilaginous physis is visualized. The transverse nail bed laceration can also be seen. (Courtesy of the Children's Orthopaedic Surgery Foundation. See also McQuinn AG, Jaarsma RL: Risk factors for redisplacement of pediatric distal forearm and distal radius fractures. *J Pediatr Orthop* 32:687–692, 2012.)

Rarely, injury to the distal phalangeal physis may result in extrusion of the epiphysis, the so-called epiphyseal dislocation (Figure 41.8).[127] In young children in whom the epiphysis is not yet or incompletely ossified, radiographic findings may be very subtle. For this reason, careful correlation between radiographs and clinical examination is necessary. A heightened suspicion for underlying epiphyseal injury is appropriate when there is a "flake," "crescent," or poorly defined opacity with irregularity or incongruity of the DIP joint. Because the epiphysis typically displaces dorsally, a true lateral radiograph of the digit is needed for diagnosis.

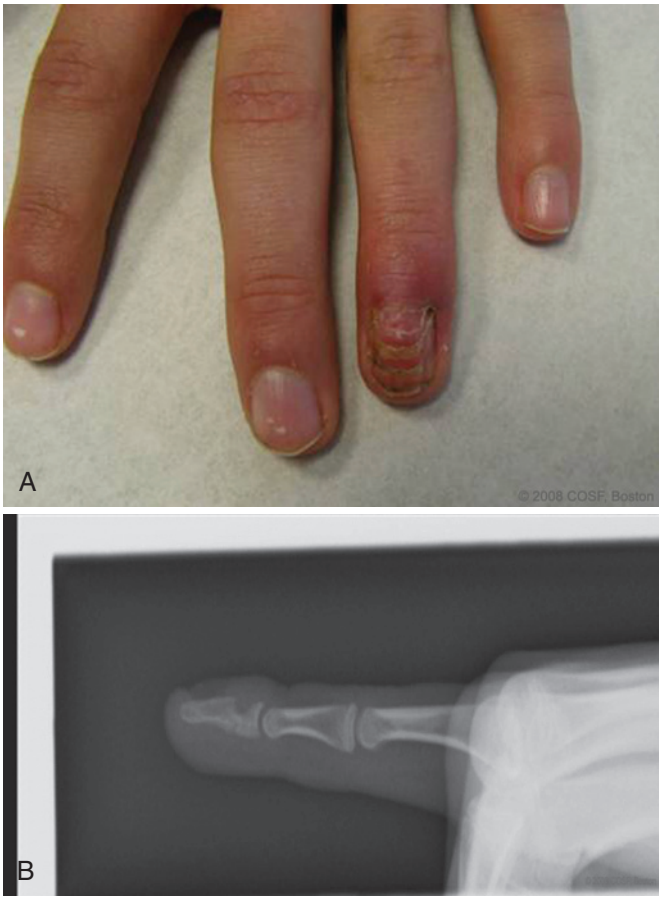

FIGURE 41.6 **A,** Clinical photograph of nail plate deformity following an untreated Seymour fracture. **B,** Lateral radiograph of the same patient depicting premature physeal closure and lytic changes in the metaphysis of the distal phalanx associated with chronic osteomyelitis. (Courtesy of the Children's Orthopaedic Surgery Foundation.)

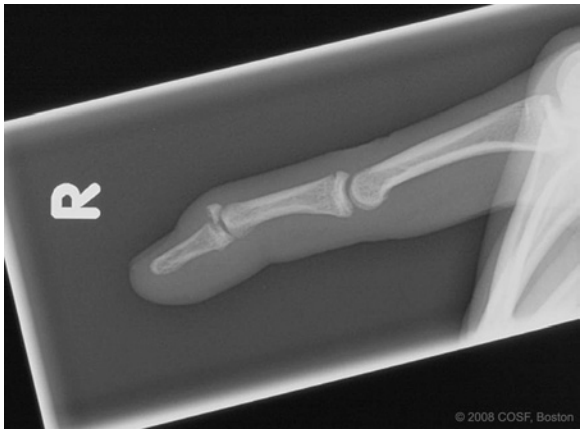

FIGURE 41.7 Lateral radiograph depicting a Salter-Harris III fracture of the distal phalanx, the pediatric equivalent of the adult bony mallet fracture. (Courtesy of the Children's Orthopaedic Surgery Foundation.)

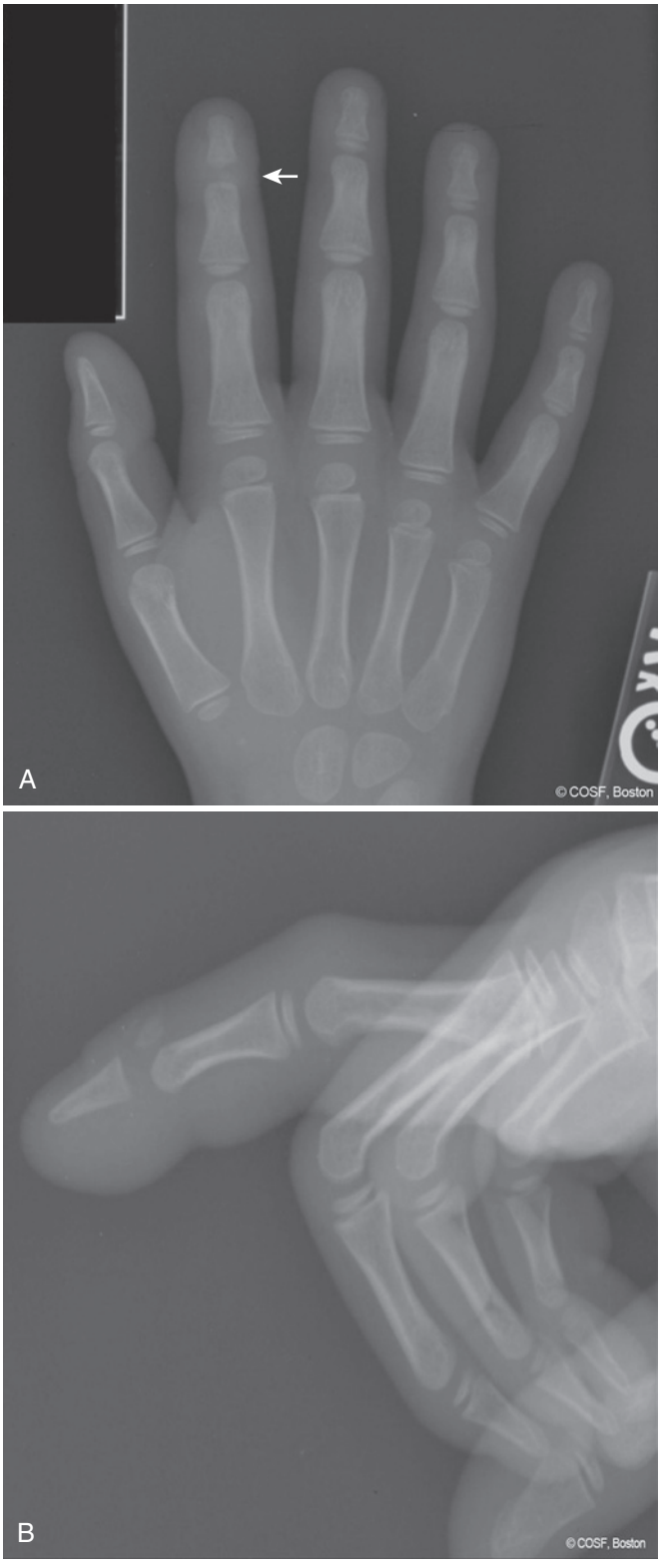

FIGURE 41.8 Anteroposterior **(A)** and lateral **(B)** radiographs of an epiphyseal dislocation. (Courtesy of the Children's Orthopaedic Surgery Foundation.)

❖ AUTHOR'S PREFERRED METHOD OF TREATMENT

Physeal fractures resulting in pseudomallet deformity are treated with closed reduction and immobilization for 4 to 6 weeks. Variations of mallet splinting are viable options in older patients; however, cast immobilization is often needed in the very young to ensure compliance and protection of the injured digit. If an apex dorsal physeal fracture is seen in association with a subungual hematoma, the potential of a Seymour fracture is raised. If there is any question, the nail plate is removed, and appropriate soft tissue repair and bony stabilization are

performed, as described earlier. This is particularly true if a persistent widening of the dorsal phalangeal physis is noted after reduction, suggesting soft tissue interposition. Surgical treatment for dorsal Salter-Harris III fractures of the distal phalanx is reserved for patients with greater than 40% articular surface disruption and volar subluxation of the DIP joint, similar to adult bony mallet injuries. Percutaneous pinning techniques are used when adequate closed reduction can be achieved. Otherwise, an open technique to achieve fracture reduction is necessary.

CRITICAL POINTS *Distal Phalangeal Fractures*

- Most distal phalangeal fractures can be treated nonoperatively with appropriate immobilization and care of associated soft tissue injuries.
- A high index of suspicion is required for Seymour fractures, which should be treated with nail plate removal, fracture débridement and reduction, and nail bed repair.
- Dorsal Salter-Harris III fractures represent the pediatric equivalent of adult bony mallet fractures, with similar treatment principles.

Middle and Proximal Phalangeal Fractures

Fractures of the middle and proximal phalanx are categorized according to their location, pattern, and displacement. Fractures tend to occur at the distal articular surface, diaphysis, physis, or epiphysis. Each has its own set of anatomic and treatment considerations and is discussed separately.

Recognition of and surgery for displaced phalangeal neck and intraarticular fractures reliably result in union and restoration of motion. A delayed presentation complicates surgical management and diminishes outcome.

Articular Fractures of the Phalangeal Head. Articular fractures of the head of the proximal and middle phalanges include unicondylar, bicondylar, and comminuted fracture patterns.[154] As with adult injuries, treatment is predicated on articular congruity and angular or rotational deformity. Nondisplaced injuries can be treated with cast immobilization. In these situations, however, weekly radiographic examinations should be considered to confirm maintenance of reduction and articular congruity.[168,206] In fractures with greater than 5 to 10 degrees of angulation or 1 to 2 mm of articular incongruity, surgical intervention is recommended. Closed or open reduction with smooth Kirschner wire or interfragmentary screw fixation is recommended (Video 41.1). Although closed reduction is desirable, it is imperative to achieve an anatomic reduction to restore articular congruity. In cases in which closed reduction is not feasible, open reduction is performed via a dorsal approach, allowing visualization of the articular surfaces while carefully preserving the collateral ligament and other soft tissue attachments to the condylar fracture fragments to preserve their vascularity. With careful surgical technique, restoration of motion and preservation of joint stability and articular congruity can be expected.[168] Patients and families should be counseled, however, regarding the potential for long-term stiffness and arthrosis, particularly with severely displaced injuries requiring open treatment.[20]

❖ AUTHOR'S PREFERRED METHOD OF TREATMENT

For displaced fractures of the phalangeal head, open reduction and internal fixation using smooth pins (or, less commonly, screws) are performed (Figure 41.9). A dorsal curvilinear incision is centered over the affected interphalangeal joint, with the convexity directed to the side of the fracture. Soft tissue flaps are elevated, preserving the dorsal veins and subcutaneous nerves. An incision between the extensor tendon and lateral bands is made, and the overlying extensor apparatus is carefully retracted. The joint capsule is incised to allow visualization of the fracture line and articular surface. Care is taken to preserve soft tissue attachments to the displaced fracture fragments to maintain vascularity and ligamentous stability. Under direct visualization, the fracture is reduced, and restoration of articular congruity is confirmed. Fixation can then be performed with interfragmentary screws or smooth Kirschner wires or a combination thereof. Two screws or pins are used to provide rotational stability and prevent loss of reduction.[206] Intraoperative fluoroscopy confirms reduction, and the pins are left in a percutaneous location to facilitate subsequent removal. The joint capsule, extensor apparatus, and skin are closed in layers, and the patient is placed in a splint or short-arm hand-based cast. Pins are removed after 3 to 4 weeks, after which time range-of-motion exercises are initiated.

Phalangeal Neck Fractures. Phalangeal neck fractures are characteristic injuries of childhood. They are usually the result of "doorjamb" injuries in which a digit is crushed or trapped in a door and forcefully withdrawn, imparting both extension and rotational forces on the affected digit. Border digits are most commonly affected, and the middle phalanx is injured more frequently than the proximal phalanx. The fracture occurs at the level of the phalangeal neck, and typically the more distal articular segment is displaced into extension, with varying degrees of rotation. Patients present with swelling, tenderness, ecchymosis, and limited interphalangeal joint motion, although the last is often difficult to appreciate in an acutely injured child. A slight angular deformity may be seen.

Careful radiographic evaluation is critical for a timely diagnosis and appropriate treatment.[77] Because the distal fragment typically displaces dorsally, with apex volar angulation, standard AP views of the affected digit often appear benign. A true lateral radiograph of the injured digit is necessary. In addition, in very young patients the phalangeal head remains predominantly cartilaginous, so subtle or seemingly innocuous "bony flecks" should raise the suspicion of a displaced cartilaginous cap or osteochondral fracture. Although the radiographs may appear innocuous, displaced phalangeal neck fractures result in both abnormal digital alignment (in the sagittal plane) and disruption of the normally concave subcondylar fossa. Obliteration of the subcondylar fossa results in a bony block to interphalangeal joint flexion, because the adjacent phalangeal base abuts the bony prominence at the distal end of the proximal fracture fragment.

Al-Qattan's classification of extraarticular phalangeal neck fractures is clinically useful because it can indicate prognosis and guide treatment.[6] Type I fractures are nondisplaced; type II fractures are partially displaced, with some bony or cortical contact; and type III fractures are completely displaced, without bony apposition. Cast immobilization is sufficient in cases of nondisplaced injuries, although serial radiographs are required to confirm maintenance of reduction. Closed reduction and splinting or cast immobilization are often insufficient for type II and III fractures; therefore, surgical treatment in the form of

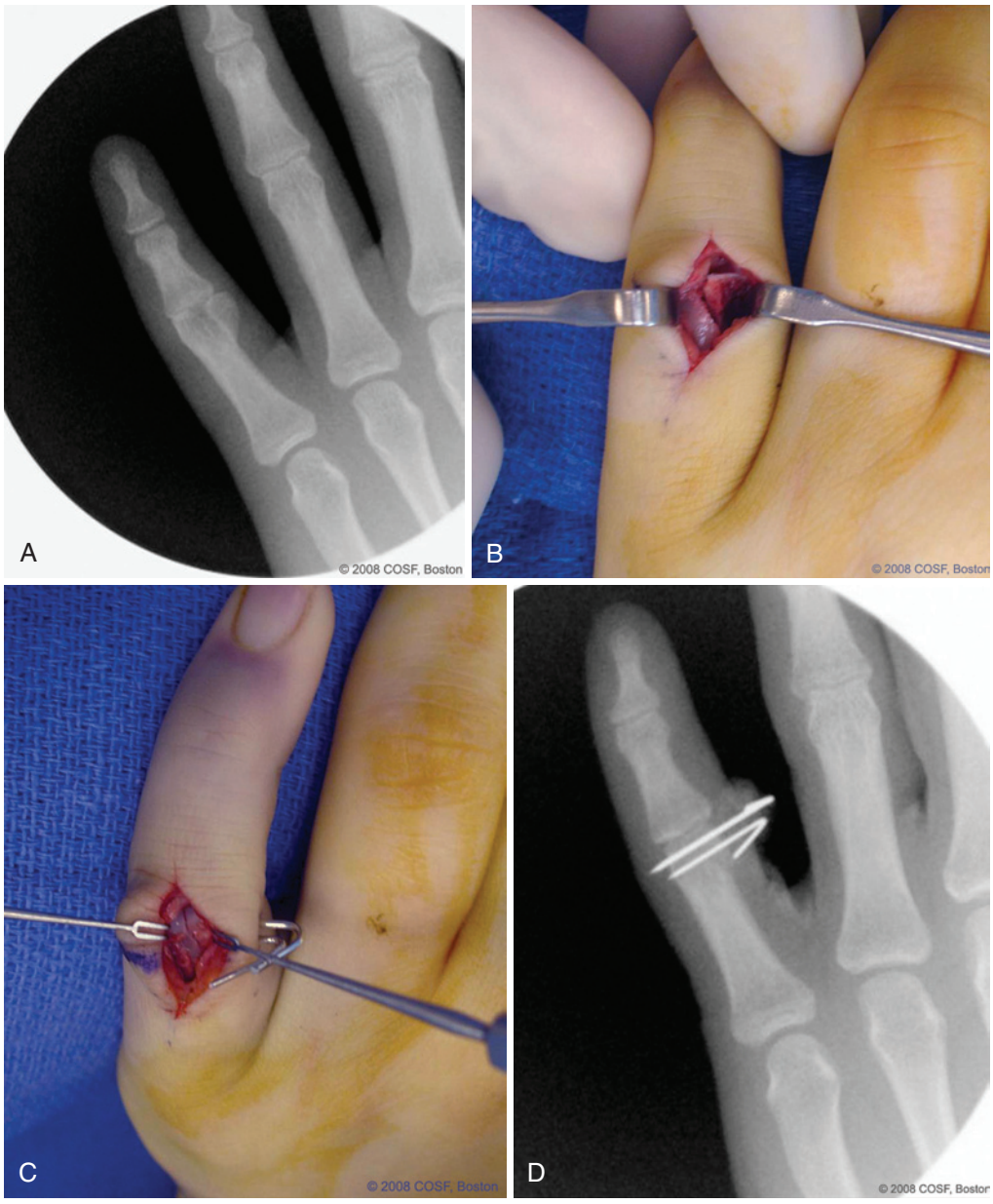

FIGURE 41.9 **A,** Anteroposterior radiograph of the small finger showing a displaced unicondylar fracture in a 14-year-old girl. **B,** Intraoperative photograph depicting the dorsal curvilinear incision, retraction of the extensor apparatus, and exposure of the fracture. The unicondylar fragment is rotated 90 degrees. **C,** Intraoperative photograph after open reduction and pin fixation. **D,** Radiograph showing anatomic reduction and percutaneous pin fixation. (Courtesy of the Children's Orthopaedic Surgery Foundation.)

closed reduction and percutaneous pin fixation is recommended (Figure 41.10). In Al-Qattan's series of 66 patients with 67 phalangeal neck fractures, 13 fractures were nondisplaced and went on to good to excellent results with nonoperative care.[6] Type II fractures accounted for the majority of injuries, and results were highly dependent on treatment. Patients treated with closed or open reduction and Kirschner wire fixation went on to successful bony healing and good to excellent results. Type II injuries treated with closed reduction without surgical stabilization achieved fair to poor results in 66% of cases. Among the seven type III injuries, failure to perform surgical reduction and Kirschner wire fixation uniformly led to fracture nonunion and poor results. Matzon and Cornwall have proposed a treatment algorithm for the care of acute type II phalangeal neck fractures, beginning with minimally invasive interventions and advancing to more involved techniques as needed.[119] In their series of 61 consecutive children, 49 patients were successfully treated with closed manipulation and percutaneous pin fixation, and 12 underwent percutaneous pin-assisted reduction; no children with acute injuries required open reduction. Overall, the vast majority of patients achieved good to excellent results with low complication rates.

Given the fact that these injuries occur in the phalangeal neck and that the physis is located at the proximal phalangeal metaphysis, remodeling potential is limited. There have been only a handful of reported cases of complete skeletal remodeling of phalangeal neck malunions.[40,79,130,149,179] Puckett and associates have previously published a retrospective case series of



FIGURE 41.10 Anteroposterior (AP) **(A)** and lateral **(B)** radiographs of a displaced proximal phalangeal neck fracture of the small finger in a 9-year-old boy. The radiographic findings are subtle on the AP projection, but dorsal displacement is clearly seen on the lateral. **C** and **D,** Postoperative radiographs following closed reduction and percutaneous pin fixation. Note reconstitution of the concave subcondylar fossa, restoring interphalangeal joint flexion. **E,** Follow-up lateral radiograph after bony healing and return of full digital motion. (Courtesy of the Children's Orthopaedic Surgery Foundation.)

eight children with displaced phalangeal neck fracture malunions followed for a mean of 5 years after injury.[153] In this small series of selected, nonconsecutive patients, sagittal plane angulation improved from 31 to 0 degrees, whereas coronal plane alignment changed from 11 to 4 degrees. Although no patients reported functionally limiting loss of motion, two complained of a persistent aesthetic difference in the coronal plane. Although the authors still support surgical reduction and stabilization for acute displaced phalangeal neck fractures, they believe that children may have some remodeling potential of these injuries.

Review of these case reports leads to a number of observations. First, phalangeal neck remodeling may be expected only in very young patients with a considerable amount of growth remaining. Second, sagittal plane deformity has the greatest remodeling potential; coronal plane angulation or bony malrotation will not improve to the same extent. In addition, although radiographic remodeling may be seen and interphalangeal joint motion improved, in some cases interphalangeal joint flexion is only restored to 80 or 90 degrees. Finally, many reported cases involved the middle phalanx, in which more deformity is tolerated due to the relatively smaller amount of DIP joint flexion needed for composite digital flexion and fist formation. Based on these published reports, observation of displaced phalangeal neck fractures should be considered only if there is no rotational or radioulnar deformity, the adjacent interphalangeal joint is congruently reduced, substantial skeletal growth remains, the resultant loss of interphalangeal joint flexion is tolerable without undue functional compromise, and the patient or family is willing to wait months to years for gradual remodeling.[40,153]

In cases of displaced phalangeal neck fractures with incipient malunion that present late, percutaneous pin osteoclasis has been advocated as a way to restore bony alignment, improve interphalangeal joint flexion potential, and minimize the risk of osteonecrosis.[205] The most appropriate patients for percutaneous pin osteoclasis are those with persistent tenderness at the fracture site, a fracture line that is still radiographically apparent, and corresponding interphalangeal joint flexion of less than 90 degrees.

In cases of phalangeal neck malunions, there is a great temptation to perform a corrective osteotomy procedure to restore bony alignment and interphalangeal joint motion. Formal open corrective osteotomy carries the risk of osteonecrosis of the phalangeal head in young patients and is not recommended. In cases of long-standing phalangeal neck fracture malunions, subcondylar fossa reconstruction may be considered.[170,179] Indications include persistent bony malalignment associated with restricted interphalangeal joint motion and functional compromise.[79]

Phalangeal neck fracture nonunions are rare.[4,5,7] Patients will present with complaints of instability, deformity, or stiffness. In the absence of osteonecrosis of the small articular fragment, bone grafting and longitudinal Kirschner wire fixation will allow for healing, though often some residual stiffness remains.

❖ AUTHOR'S PREFERRED METHOD OF TREATMENT

Nondisplaced phalangeal neck fractures can be treated with cast immobilization, but weekly radiographs are required to rule out delayed displacement. In type II or III injuries, closed reduction and percutaneous pinning via cross pins are performed. Patients are casted for 3 to 4 weeks, after which pins are removed and motion is initiated. In the rare situation in which an adequate reduction cannot be obtained with closed techniques, open reduction can be performed via a mid-axial approach, with care taken to preserve the collateral ligament and soft tissue attachments to the articular segment.[6] In fractures with nascent malunion that present late, percutaneous pin osteoclasis is considered if the fracture is still radiographically visible and tenderness to palpation is felt at the fracture site (Figure 41.11).[203] In cases presenting late in which active or passive interphalangeal joint flexion to 90 degrees or more is documented on examination and fluoroscopy, observation is recommended. In established malunions with functionally limiting restrictions in interphalangeal joint flexion, subcondylar fossa reconstruction via a volar or midlateral approach is performed. Rongeurs or burs can be used to remove the bone obliterating the subcondylar fossa. Care must be taken to avoid overzealous resection because the dorsal bony bridge can become quite narrow in cases with considerable dorsal displacement of the articular fragment. Intraoperatively, adequate bony resection is confirmed by passive interphalangeal joint flexion to 90 degrees or more. Early active and passive motion is initiated to maximize the outcome.

Phalangeal Shaft Fractures. Diaphyseal fractures of the phalanges represent approximately two-thirds of phalangeal injuries.[59,77] The most common mechanism is combined bending and torsional forces sustained during falls or sporting activities. Proximal phalangeal shaft fractures usually exhibit apex volar angulation owing to the combined forces of the extensor mechanism on the distal fragment and intrinsic musculature on the proximal fragment. Conversely, fractures of the middle phalanx exhibit either apex palmar or dorsal angulation, depending on the location of the fracture in relationship to the flexor digitorum superficialis insertion. Fractures distal to the flexor digitorum superficialis insertion typically angulate in an apex volar manner, with the extensor mechanism pulling the distal fragment dorsally. Although up to 10 degrees of angulation is acceptable, closed reduction is recommended for greater amounts of angulation or any malrotation resulting in digital overlap or underlap (see Figure 41.2). Al-Qattan and coworkers previously reported on 92 children studied prospectively with proximal phalangeal base fractures.[8] The authors noted excellent outcomes in patients treated with closed reduction with or without percutaneous pinning for cases with greater than 10 degrees of angulation, whereas remodeling was seen in patients with less than 10 degrees of radiographic angulation.

Following closed reduction and cast immobilization, serial clinical and radiographic evaluations are necessary to ensure maintenance of adequate alignment. In patients with irreducible or unstable fractures, surgical treatment via closed or open reduction and smooth pin fixation are recommended. In cases of long oblique fractures, two or more smooth Kirschner wires placed orthogonally to the fracture plane provide both axial and rotational stability. In transverse fractures, oblique cross-pinning may be used, although care should be taken to avoid crossing pins at the fracture site because this results in suboptimal fixation. The end of the pins are bent and trimmed external to the skin and removed after 4 weeks, followed by motion exercises. Boyer and colleagues previously reported a series of 105 patients

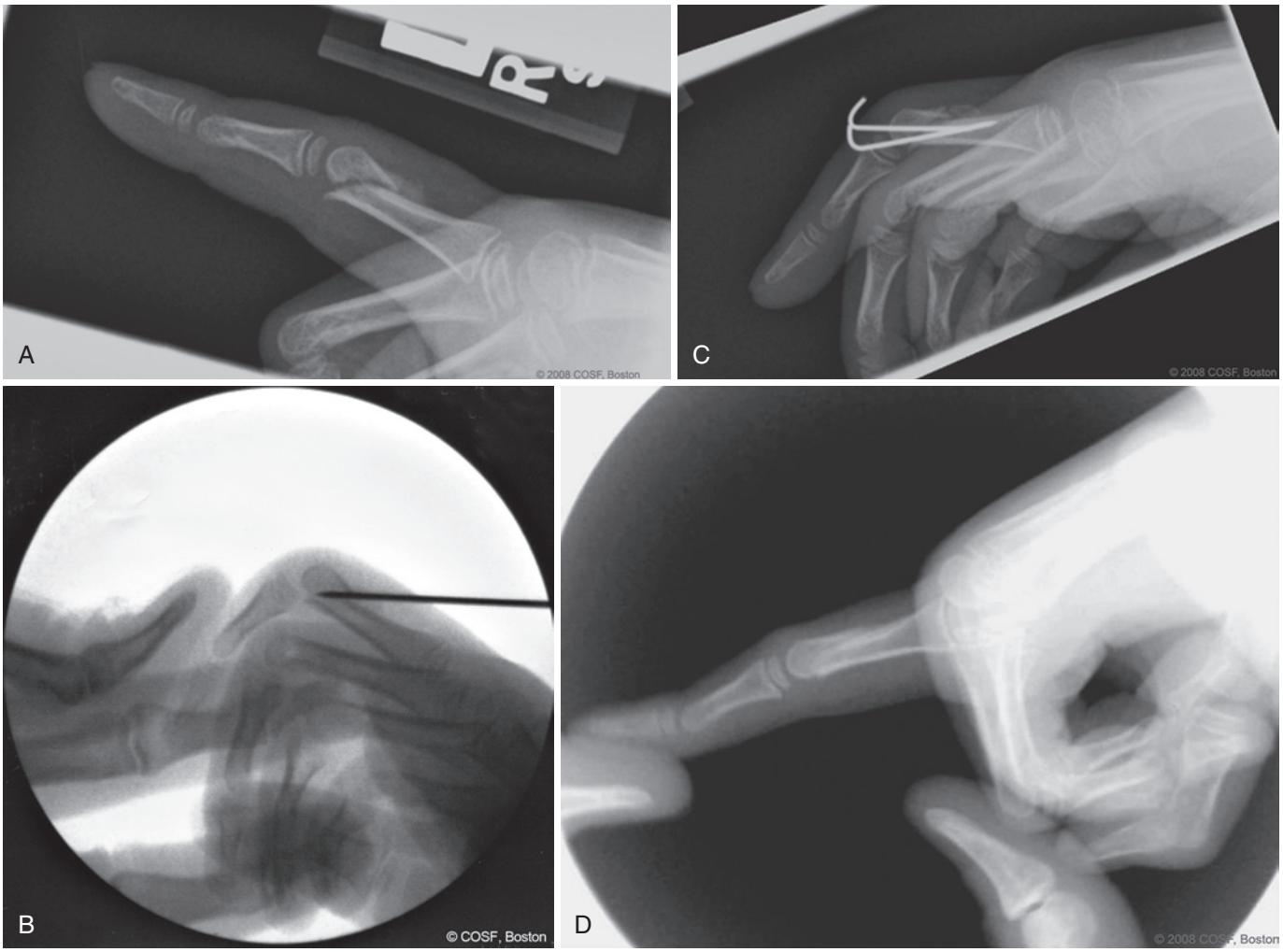

FIGURE 41.11 **A,** Lateral radiograph showing an incipient proximal phalangeal neck malunion, presenting 4 weeks after injury in a 6-year-old patient. Note the formation of fracture callus dorsally, although the fracture line can still be seen. **B,** Intraoperative radiograph depicting percutaneous placement of a smooth pin for osteoclasis and reduction. **C,** Postoperative radiograph following reduction and pin fixation. **D,** Follow-up lateral radiograph demonstrating improved bony alignment, with no evidence of osteonecrosis of the phalangeal head. (Courtesy of the Children's Orthopaedic Surgery Foundation.)

treated with percutaneous pinning for displaced proximal phalanx fractures.[27] In this retrospective cohort, 36 had postoperative stiffness and 31 ultimately underwent therapy to restore motion. Despite this high proportion of patients with stiffness in the initial postoperative period, patients with follow-up for longer than 12 months regained full motion and excellent function.

❖ AUTHOR'S PREFERRED METHOD OF TREATMENT

Closed reduction and cast immobilization are recommended for phalangeal shaft fractures with malrotation or angulation of greater than 10 degrees. Serial radiographs are necessary to confirm maintenance of reduction. Immobilization is discontinued after 3 to 4 weeks, with a gradual return to activity. In cases of fracture instability or inadequate alignment, closed reduction and percutaneous pin fixation are performed (Figure 41.12). Pins are removed at 3 to 4 weeks, followed by range-of-motion exercises. Irreducible fractures require open reduction and pin fixation.

Physeal Fractures. Physeal fractures of the phalanges are common injuries, secondary to combined bending and rotational moments sustained during falls and sporting activities. Patients and families may express anxiety upon learning of the occurrence of a growth plate fracture; however, multiple studies have demonstrated that one-third of all bony injuries of the growing hand involve the physis, and physeal arrest is uncommon.[59,77,145] The proximal phalanx of the small finger is most commonly affected, resulting in the so-called extraoctave fracture (Figure 41.13).[156] The thumb is injured in roughly one-fifth of cases.[145] Physeal fractures of the middle phalanx are considerably less common than those involving the proximal phalanx. Salter-Harris type II patterns predominate owing to the anatomic features of the collateral ligaments described previously.

Closed reduction is recommended for fractures with greater than 10 degrees of angulation and any malrotation, owing to the limited remodeling potential of radioulnar or rotational deformity. During closed reduction maneuvers, flexion of the MP joint assists in stabilizing the proximal fracture fragment by tensioning of the collateral ligaments, and a pen or pencil can be placed in the adjacent web space at the apex of the deformity to serve as a fulcrum during angular correction. Following

closed reduction, both careful assessment of rotational alignment and radiographic confirmation of desired correction are essential for a successful outcome.[77] Cast immobilization in the intrinsic-plus position is required for 3 to 4 weeks, followed by a gradual return to activity. Although splint immobilization and earlier motion have been advocated by some, the risks of noncompliance with removable splint immobilization and the late loss of fracture reduction generally outweigh the benefits of early motion, particularly in young patients in whom posttraumatic stiffness is less common.



FIGURE 41.12 Anteroposterior radiograph of a displaced phalangeal diaphyseal fracture following closed reduction and percutaneous pin fixation. (Courtesy of the Children's Orthopaedic Surgery Foundation.)

In rare cases, these fractures may be unstable. Such fractures tend to be high-energy injuries that disrupt the stabilizing soft tissue envelope. In these cases, closed reduction followed by pin fixation is performed, and the pins are left percutaneous to facilitate removal after 3 to 4 weeks. Smaller wires (ranging from 0.028 to 0.035 inch) and fewer wires are used than in adults.

❖ AUTHOR'S PREFERRED METHOD OF TREATMENT

Closed reduction and cast immobilization are recommended for patients with greater than 10 degrees of angulation or malrotation. Stable fracture reduction is achieved in the majority of cases. Cast immobilization is discontinued after 4 weeks, followed by range-of-motion exercises. Percutaneous pinning is reserved for unstable or irreducible injuries with malrotation or greater than 10 to 15 degrees of angulation. Cast immobilization is discontinued and pins are removed at 3 to 4 weeks, followed by range-of-motion exercises.

Articular Fractures of the Phalangeal Base and Epiphyseal Fractures. Fractures of the phalangeal base with intraarticular extension represent Salter-Harris type III and IV injuries. In cases of articular incongruity, joint instability, or greater than 1 to 2 mm of displacement, closed or open reduction and smooth pin fixation are recommended to restore articular congruity, physeal integrity, and bony alignment. These injuries should be distinguished from volar plate avulsion fractures of the epiphysis. As in adults, small volar plate avulsions can be safely and effectively treated with simple Coban wrapping and "buddy

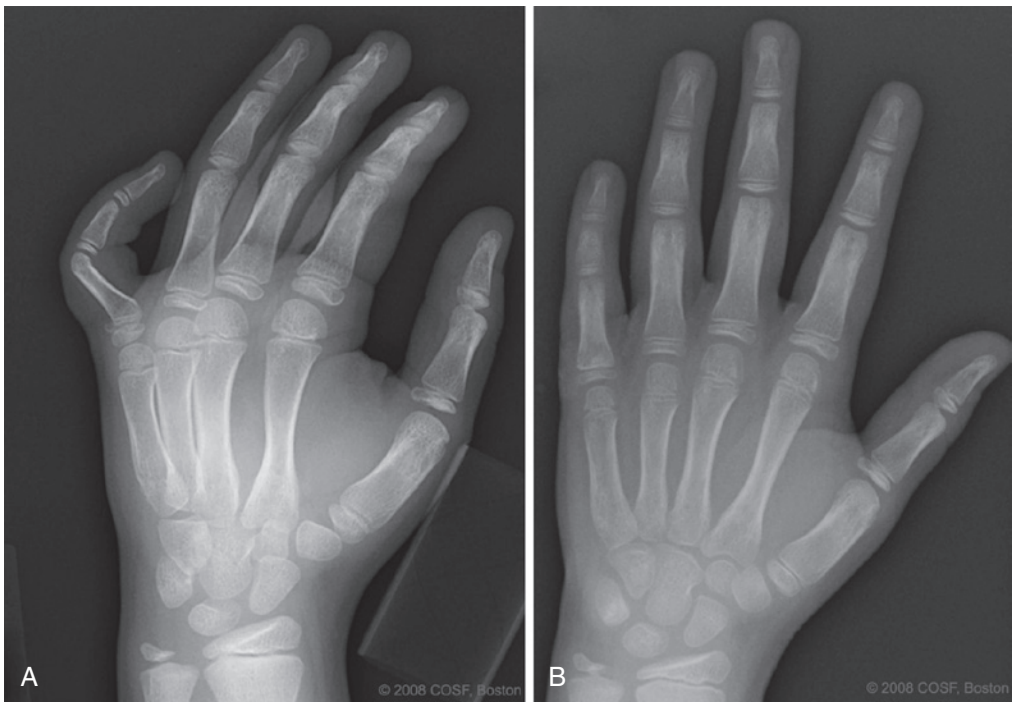

FIGURE 41.13 **A,** Anteroposterior radiograph of an "extraoctave" fracture in a 9-year-old girl. **B,** Radiograph after closed reduction and cast immobilization. Clinical alignment and rotation were restored to normal, with an excellent final outcome. (Courtesy of the Children's Orthopaedic Surgery Foundation.)

taping" with early initiation of motion to avoid stiffness, provided the interphalangeal joint is stable and congruently reduced. In a prior study of 121 proximal interphalangeal joint hyperextension injuries randomized to either buddy taping or aluminum splinting, buddy taping was just as effective as splinting; in general, children had better outcomes than adults.[142]

Comminuted, unstable proximal interphalangeal fracture-dislocations are rare in children. When they do occur, treatment principles are similar to those in adults. Open reduction and internal fixation are recommended to restore joint stability and reconstitute the articular surface. The volar base of the middle phalanx is approached via a volar zigzag incision. The A3-C1 pulleys are elevated in either a radial or an ulnar direction, and flexor tendons are retracted to allow visualization of the joint surface and displaced fracture fragments. Anatomic reduction and restoration of joint congruity are performed, followed by stabilization with size-appropriate smooth pins or screws. Bone grafting may be required to fill any impacted metaphyseal defect. Although early motion is desired, 3 weeks of cast or splint immobilization is often necessary owing to the tenuous fixation achieved and compliance issues in young patients.

❖ AUTHOR'S PREFERRED METHOD OF TREATMENT

Closed or open reduction and internal fixation of displaced Salter-Harris III or IV fractures are performed for cases of articular incongruity, joint instability, or diastasis of greater than 2 mm. Whereas radial and ulnar base fractures may be approached via a dorsal curvilinear incision, proximal interphalangeal fracture-dislocations with volar phalangeal base fractures require a more extensive volar approach to access fracture fragments and restore joint stability. Smooth pin fixation is used, supplemented by cast immobilization. Pins are removed in 4 weeks, followed by range-of-motion exercises.

CRITICAL POINTS *Middle and Proximal Phalangeal Fractures*

- Surgical treatment is recommended for all displaced articular fractures, with care taken to preserve soft tissue attachments and vascularity to the displaced fracture fragment.
- Displaced phalangeal neck fractures are treated with closed reduction and percutaneous pin fixation to avoid posttraumatic interphalangeal joint stiffness.
- Percutaneous pin-assisted osteoclasis is effective in phalangeal neck fractures with persistent tenderness and radiographically visible fracture lines that present late; subcondylar fossa reconstruction may be considered in established malunions with functionally limiting loss of motion.
- Surgical reduction and fixation are recommended for displaced Salter-Harris III and IV fractures to restore articular congruity and joint stability.

Metacarpal Fractures

Treatment principles for metacarpal fractures in children are similar to those in adults. Metacarpal fractures arise from bending forces or axial loads sustained during falls, sporting injuries, or direct blows with a clenched fist. These fractures result in apex dorsal angulation secondary to the intrinsic musculature. Mild to moderate apex dorsal angulation results in little to no compromise of hand function; excessive angulation results in both aesthetic consequences and difficulties with digital extension (i.e., pseudo–claw deformity) or discomfort with forceful grasp. Closed reduction and pin fixation or open reduction of multiple metacarpal fractures results in union and return of function. Open reduction and internal fixation of intraarticular metacarpal head fractures can achieve articular restoration, but stiffness is common.

There is great variation in what is deemed "acceptable" angulation in metacarpal neck and shaft fractures, and each patient merits individualized decision making. Most authorities agree that up to 30 degrees of sagittal plane deformity is acceptable in physeal fractures, particularly in young patients with growth remaining and remodeling potential. Twenty to 45 degrees of apex dorsal angulation is acceptable in metacarpal neck fractures, with greater deformity allowable in the more ulnar digits. Shaft fractures tolerate less angular deformity, so 10 to 15 degrees of angulation is acceptable in the index and long fingers and 30 to 40 degrees in the ring and small fingers. Even mild rotational deformity (>10 degrees) results in digital overlap and functional problems. Malrotation is often undetectable on radiographic evaluation, and the importance of a thorough physical examination cannot be overstated.

In general, metacarpal fractures can be considered according to their anatomic location: epiphyseal, diaphyseal, neck, physeal, and articular fractures.

Epiphyseal Fractures. Fractures of the metacarpal epiphysis are rare and are usually Salter-Harris III or IV fractures.[59,152] These injuries result from axial loads during falls or closed fist injuries. Although nondisplaced injuries may heal satisfactorily with cast immobilization, open reduction and internal fixation are recommended for displaced fractures resulting in articular incongruity.[152] Internal fixation using countersunk interfragmentary screws can be used in older adolescents, as in adults; smooth Kirschner wire fixation is typically used in younger children. This method of fixation provides adequate fracture stability and minimizes the risk of iatrogenic physeal injury. In rare situations, extensive comminution of primarily cartilaginous fragments occurs, and bioabsorbable pin or suture fixation is used. Osteonecrosis has been reported following these severe injuries, and soft tissue attachments to displaced fracture fragments must be preserved during open reduction.[120] Torre has proposed that increased intracapsular pressure secondary to fracture hematoma may play a causative role, but there is little evidence to support this assertion.[184]

❖ AUTHOR'S PREFERRED METHOD OF TREATMENT

Open reduction is performed via a curvilinear dorsal incision. The interval between the extensor tendon and ulnar sagittal band is developed, leaving a cuff of tissue for later sagittal band repair. After dorsal capsulotomy, the fracture hematoma is evacuated, and reduction is performed. Any soft tissue attachments are preserved to maintain vascularity to the displaced fracture fragments. Internal fixation can be performed with smooth pins, screws, or even sutures, depending on the size and integrity of the articular fragments. After adequate stabilization is achieved, the dorsal capsule, sagittal band, and skin are closed. Cast immobilization is instituted for 4 weeks, followed by range-of-motion exercises.

Metacarpal Neck Fractures. Metacarpal neck fractures account for 56 to 70% of all metacarpal fractures in the pediatric and adolescent population.[154] These fractures often result from

closed fist injuries but may also occur after falls and sporting injuries, particularly if the affected hand is stepped on. The small finger is most commonly affected, and the characteristic deformity is apex dorsal angulation with varying degrees of rotation. These fractures usually occur through the distal metaphysis, although physeal involvement is fairly common.[59,77]

Relatively large degrees of apex dorsal angulation are acceptable in ring and small finger metacarpal neck fractures, resulting in minimal impairment owing to the compensatory MP and carpometacarpal (CMC) joint motion. In young children, because the metacarpal physis is distal, remodeling of angular deformity may occur with growth. In general, angulation that is 10 to 30 degrees more than the corresponding range of CMC motion is well tolerated in skeletally immature patients.[99]

Nondisplaced or minimally displaced fractures are effectively treated with cast immobilization for 3 to 4 weeks. Displaced injuries with malrotation or excessive angulation are treated with closed reduction and cast immobilization. Reduction maneuvers are performed under digital or wrist block using local anesthesia or conscious sedation in young patients. Reduction consists of longitudinal traction and correction of the apex dorsal angulation using three-point bending. The *Jahss maneuver* (i.e., flexing the MP joint to 90 degrees and applying a dorsally directed force on the metacarpal head through the flexed digit) is commonly used.[86] The Jahss maneuver also facilitates the correction of rotational malalignment because the MP collateral ligaments are taut in flexion, and torque applied to the flexed digit is imparted to the malrotated distal fracture fragment. Adequate rotational correction is confirmed by restoration of the normal digital cascade.

Traditionally, a cast was used to immobilize the hand in the intrinsic-plus position to avoid extension contractures of the MP joint. Extension of the MP joint often results in loss of reduction, particularly in more displaced injuries. Studies have established, however, that cast immobilization for 4 weeks with the MP joints in extension (the so-called pancake cast) is safe and is not associated with long-term stiffness or MP extension contractures in young adults or children.[181] Indeed, cast application with a three-point bending mold to maintain the desired fracture alignment is easier with the MP joints in extension.

In displaced fractures in which alignment cannot be maintained with closed reduction and cast immobilization, percutaneous pin fixation via either cross-pinning or transmetacarpal pinning techniques is performed. Intramedullary fixation, or "bouquet pinning," has been successful in adults, but these techniques are not commonly used in children owing to the small size of the metacarpal intramedullary canals and the presence of the intervening physis.[61] The Jahss maneuver is particularly helpful for closed reduction and pinning because it allows correction of both the apex dorsal angulation and the rotational alignment and permits pin placement within the collateral recesses without violating the collateral ligament complex. Care to minimize iatrogenic trauma to the metacarpal physis during surgical stabilization is necessary.

Metacarpal neck fractures that present late are common in the pediatric population. Because there is a large amount of compensable angular deformity via MP and CMC motion, usually no intervention is required. Excessive angulation or malrotation, particularly in the index and long finger rays, requires percutaneous pin osteoclasis or formal open reduction and internal fixation. In subacute situations (i.e., <4 weeks from injury, fracture line still visible on radiographs, tenderness still elicited at the fracture site), percutaneous pin osteoclasis can liberate the displaced fracture fragment and allow closed reduction and pin fixation. When percutaneous pin osteoclasis is not possible, open reduction or late corrective osteotomy is considered. As with other displaced physeal fractures with remodeling potential that present late, repeated forceful manipulations are avoided to prevent iatrogenic physeal arrest.

❖ AUTHOR'S PREFERRED METHOD OF TREATMENT

Closed reduction and cast immobilization are used for displaced injuries with excessive angulation or malrotation. In general, 10, 20, 30, and 40 degrees of angulation are acceptable in index, long, ring, and small finger metacarpals, respectively. Casting with the MP joints extended for 3 to 4 weeks is well tolerated and can be used without reservation, given the greater ability to maintain reduction and the infrequency with which long-standing stiffness occurs in young children. In unstable fractures that fail reduction and casting, closed reduction and percutaneous cross-pinning are used. Pins are removed in 3 to 4 weeks, and range-of-motion exercises are then begun.

Metacarpal Shaft Fractures. Metacarpal shaft fractures usually result from torsional or bending mechanisms, yielding spiral or transverse fracture patterns. As in adults, isolated diaphyseal fractures, particularly of the central rays, do not displace considerably owing to the stabilizing forces of the intermetacarpal ligaments and central CMC articulations. Conversely, fractures of the border rays or multiple metacarpal fractures are inherently more unstable and display greater displacement and angulation. Nondisplaced fractures are treated with 3 to 4 weeks of cast immobilization, followed by range-of-motion exercises. Displaced injuries are treated with closed reduction and well-molded cast immobilization in the majority of cases. Serial radiographs during the period of cast immobilization are required to ensure maintenance of reduction as the soft tissue swelling subsides. Four weeks of cast immobilization is sufficient, followed by range-of-motion exercises.

Surgical indications in children are similar to those in adults and include open fractures, multiple fractures, irreducible fractures, and unstable fractures. Additional indications include fractures with extensive soft tissue injury or neurovascular injury that precludes cast immobilization. A host of surgical stabilization options is available for the treatment of metacarpal shaft fractures, including percutaneous pinning, transmetacarpal pinning, interfragmentary screw fixation, plate and screw fixation, intramedullary fixation, and external fixation.[107] Choice of the surgical stabilization technique depends on the fracture pattern and associated soft tissue injury, as well as surgeon preference. In general, the least invasive technique that achieves the desired goals is the best choice. Surgical techniques are similar to those in adults (see Chapter 16), although the presence of the metacarpal physis must be considered during the decision-making process.

❖ AUTHOR'S PREFERRED METHOD OF TREATMENT

Isolated metacarpal shaft fractures are usually stable and are treated with cast immobilization. In cases of unstable fractures or persistent malrotation, closed reduction and percutaneous

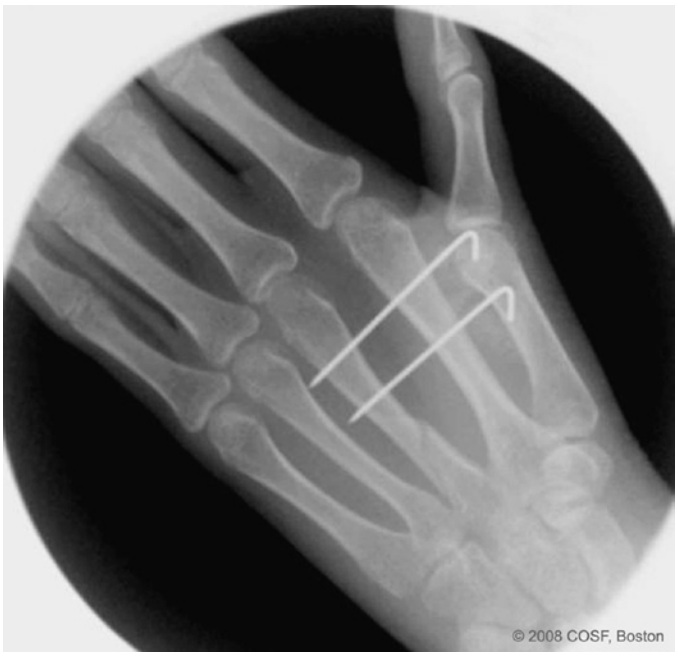

FIGURE 41.14 Postoperative radiograph depicting transmetacarpal pinning of a rotated diaphyseal fracture of the long finger. (Courtesy of the Children's Orthopaedic Surgery Foundation.)

pin fixation via transmetacarpal or cross-pinning techniques are performed (Figure 41.14). Pins are removed at 4 weeks, followed by range-of-motion exercises. In cases of multiple metacarpal fractures, open reduction and internal fixation with interfragmentary compression screws (long oblique fractures) or size-appropriate compression plates (transverse, short oblique, comminuted fractures) are performed via a dorsal approach.

Metacarpal Base Fractures. Metacarpal base fractures account for approximately 13 to 20% of metacarpal fractures in children.[154] The vast majority involve the small finger ray. Rarely, intraarticular extension is possible, with subsequent CMC subluxation or dislocation of the metacarpal shaft (the reverse Bennett fracture equivalent). Clinical evaluation includes a careful assessment of digital rotation, flexion, and extension, as well as the associated soft tissue and neurovascular status. In crush injuries or high-energy trauma, compartment syndrome can occur, and emergent decompression is required. Radiographic evaluation includes AP and lateral radiographs of the affected hand, as well as oblique views to better visualize the border metacarpals.

Nondisplaced or minimally displaced injuries are treated with 3 to 4 weeks of cast immobilization. In displaced injuries, closed reduction is performed under local anesthesia or conscious sedation, with longitudinal traction and volarly directed pressure over the typically dorsal apex of the deformity. Malrotation can be corrected simultaneously by flexing the MP joint of the affected ray and restoring rotational alignment. After cast immobilization, radiographs are necessary to confirm reduction; treatment can then continue as described earlier. In unstable reductions or CMC fracture-dislocations, surgical stabilization is required. If reduction is achieved with closed manipulation, percutaneous pin fixation using transmetacarpal pinning techniques or oblique pins into the proximal fracture fragment or carpus usually suffice. When the fracture is irreducible, formal open reduction is performed via a longitudinal incision, followed by pin fixation. Pins are removed at 4 weeks, and range-of-motion exercises are initiated.

❖ AUTHOR'S PREFERRED METHOD OF TREATMENT

Closed manipulation and casting are mainstays in the treatment of most metacarpal base fractures. Surgical stabilization via percutaneous pinning is used for malrotated, widely displaced, or multiple adjacent metacarpal base fractures. Transmetacarpal pinning or transarticular pinning into the adjacent carpus can be used with little morbidity or concern for long-term arthrosis.

CRITICAL POINTS *Metacarpal Fractures*

- Open reduction and internal fixation are recommended for displaced intraarticular metacarpal head fractures.
- Closed reduction and pin fixation are recommended for unstable or rotationally malaligned metacarpal neck and shaft fractures.
- Given the remodeling potential and compensatory CMC joint motion, as much as 30 degrees of angulation may be acceptable in extraarticular metacarpal fractures.

Thumb Fractures

Phalangeal Fractures. Salter-Harris type III fractures of the thumb proximal phalanx are common injuries in children and represent the pediatric equivalent of "gamekeeper's thumb" in adults. The anatomy of the thumb MP collateral ligament complex explains the pattern of injury encountered. The collateral ligaments insert almost exclusively onto the proximal phalanx epiphysis, and a valgus force results in an avulsion fracture of the ulnar epiphysis rather than a pure ligamentous disruption. In cases of displaced Salter-Harris III fractures of the proximal phalanx of the thumb, surgical treatment is recommended to restore articular congruity and ligamentous MP joint stability.

❖ AUTHOR'S PREFERRED METHOD OF TREATMENT

Surgery is performed under general anesthesia and tourniquet control (Figure 41.15). A dorsal curvilinear incision is made over the thumb MP joint. Subcutaneous dissection is performed in line with the skin incision, identifying and protecting terminal branches of the radial sensory nerve. The adductor aponeurosis is incised along its insertion on the extensor tendon. Because the ulnar collateral ligament is usually intact, the MP joint is exposed through the fracture site, and the collateral ligament is protected. If better visualization of the articular surface is necessary, the dorsal capsule is incised. The fracture is reduced under direct visualization, restoring congruity of the articular surface. Two parallel Kirschner wires are placed into the reduced epiphyseal fragment, across the fracture site, and into the opposite radial cortex. In very young children or in cases of small, predominantly cartilaginous fracture fragments, fixation with only one wire may be feasible. Intraoperative fluoroscopy is used to confirm anatomic reduction and appropriate placement of the wires. Additional sutures can be placed between the ulnar collateral ligament and the underlying periosteum. Wires are bent and cut outside of the skin. Closure is performed in layers,

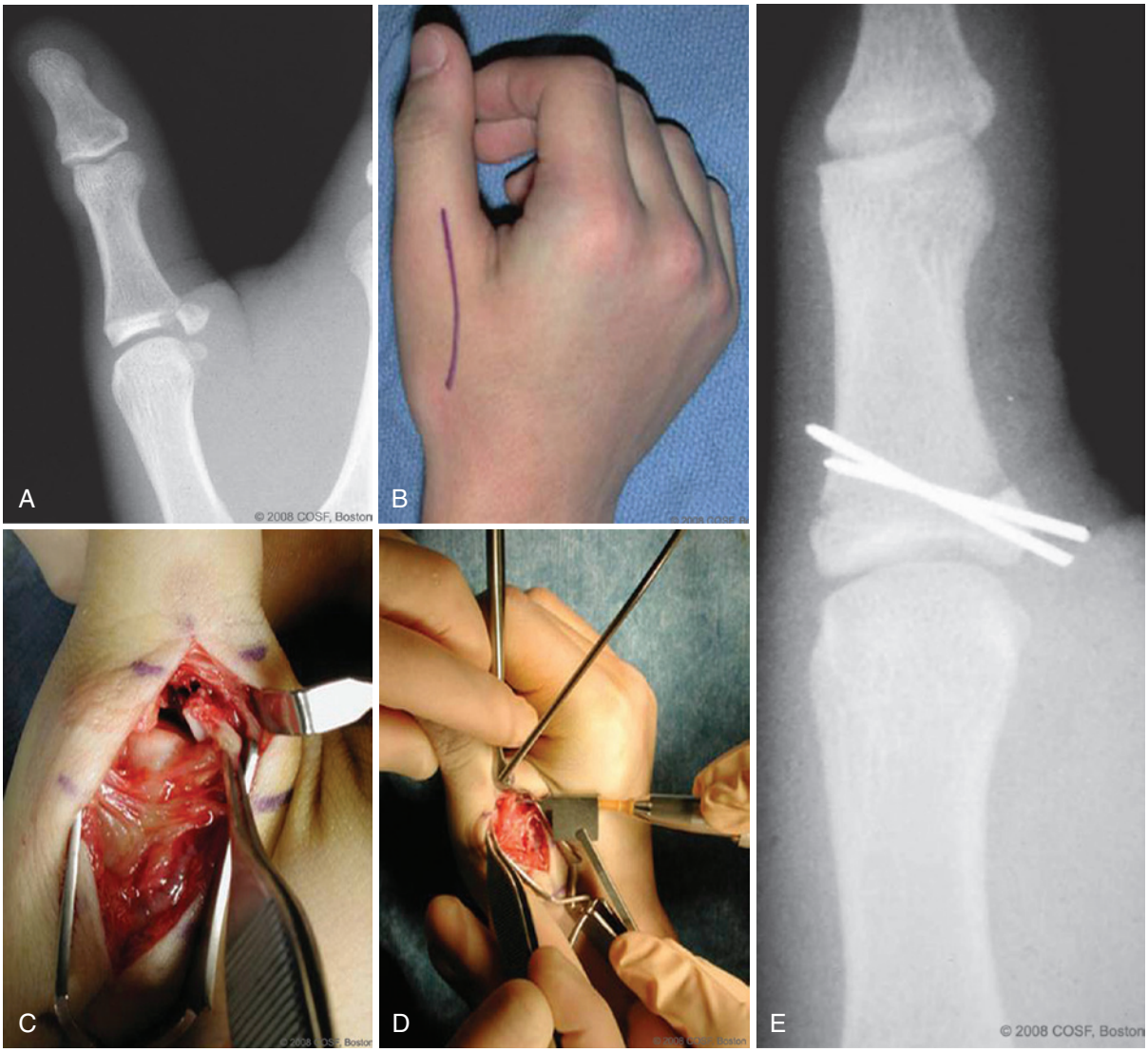

FIGURE 41.15 **A,** Preoperative radiograph illustrating a displaced Salter-Harris III fracture of the proximal phalanx of the thumb, the pediatric "gamekeeper's" injury. **B,** Intraoperative photograph of the dorsal curvilinear incision. **C,** Exposure of the displaced fracture and metacarpophalangeal joint after careful retraction of the extensor apparatus and protection of the radial sensory nerve. Note that the soft tissue attachments to the fracture fragment are preserved. **D,** Fracture reduction and fixation with smooth Kirschner wires. **E,** Postoperative radiograph demonstrating anatomic fracture reduction and restoration of articular congruity. (Courtesy of the Children's Orthopaedic Surgery Foundation.)

with careful reapproximation of the adductor aponeurosis. A thumb spica cast is applied for 4 to 6 weeks, followed by range-of-motion exercises. Formal physical and occupational therapy is usually not required.

Metacarpal Diaphyseal Fractures. Metacarpal diaphyseal fractures of the thumb are treated according to principles similar to those used for fractures of the index through small finger rays.

Base of Thumb Metacarpal Fractures. Base of thumb metacarpal fractures are quite common, typically resulting from falls or sporting injuries. The fracture may be metaphyseal, physeal, epiphyseal, or intraarticular; recent investigations suggest that physeal fractures are most common.[10] Owing to the proximity to the proximal thumb metacarpal physis, these injuries demonstrate tremendous remodeling potential in young children. Impairment of hand function following displaced base of thumb metacarpal injuries is further mitigated by the nearly universal motion of the CMC joint. As a result, as much as 30 degrees of angular deformity is well tolerated, with minimal aesthetic or functional compromise[99] (Figure 41.16). In these situations, thumb spica cast immobilization for 3 to 4 weeks may suffice.

Kozin and Waters have classified base of thumb metacarpal fractures into four types.[98,99] Type A fractures are those in which the fracture line passes between the physis and the junction of the proximal and middle diaphysis. These fractures are transverse or oblique and often amenable to closed reduction and cast immobilization, with excellent functional outcomes.

Type B fractures are Salter-Harris II fractures with an ulnar Thurston-Holland metaphyseal fragment and apex radial angulation. The metacarpal diaphysis is adducted by the pull of the adductor pollicis and displaced proximally by the abductor pollicis longus, thereby effectively narrowing the first web space. Excessive displacement or angulation requires closed reduction

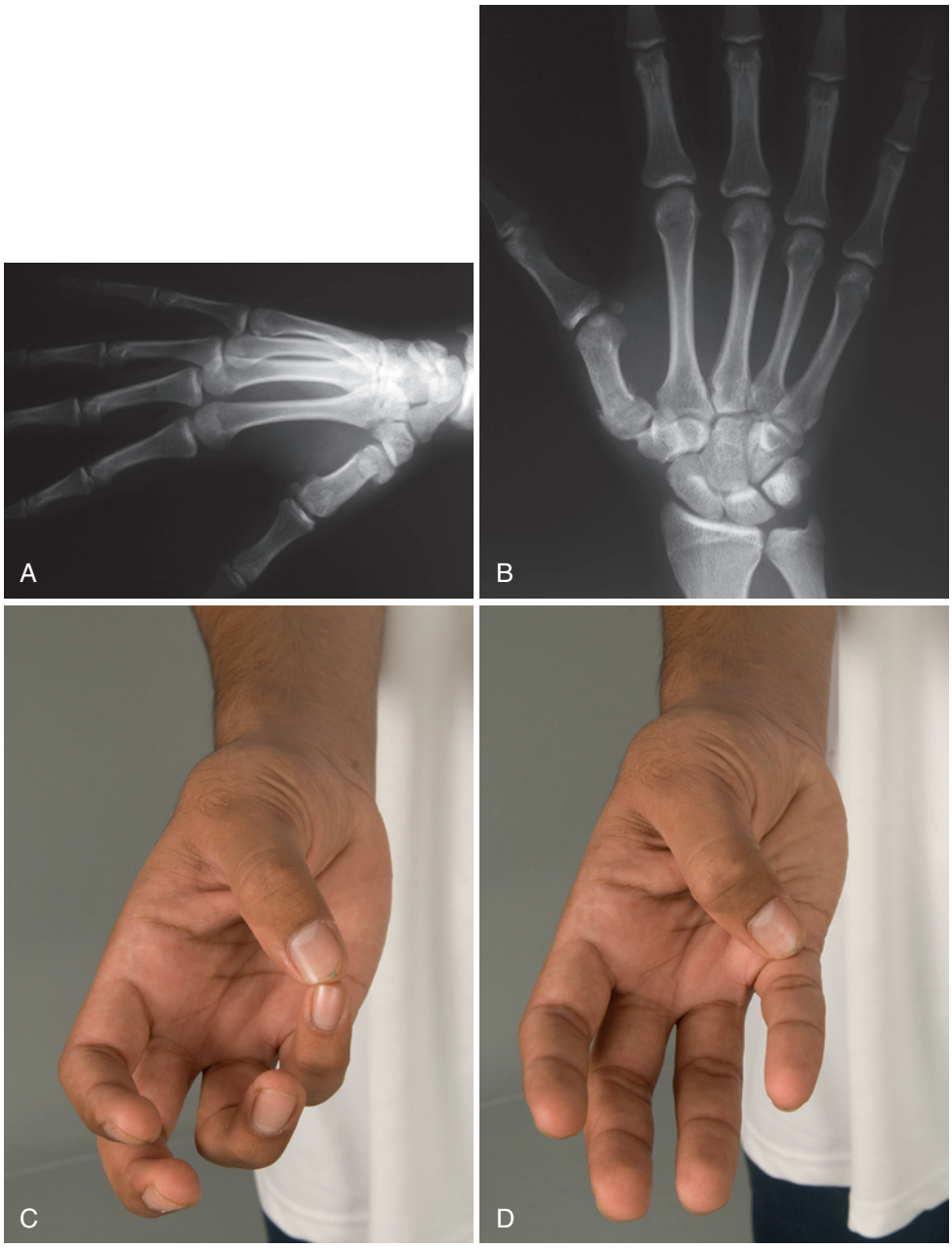

FIGURE 41.16 A 14-year-old boy presents 3 weeks after injury with mild pain and deformity of the base of the right thumb. **A,** Anteroposterior radiograph shows moderately displaced fracture of base of the thumb metacarpal. **B,** Lateral radiograph shows mild angulation. **C,** After splint immobilization of the fracture for an additional 2 weeks, home therapy was instituted. Follow-up thumb motion demonstrates excellent opposition. **D,** Thumb can touch base of small finger. (Courtesy of Shriners Hospital for Children, Philadelphia.)

and cast immobilization to restore bony and physeal alignment. If the reduction is unstable, percutaneous pin fixation into the intact epiphysis or adjacent trapezium is performed.[71] Rarely, open reduction is required when severe soft tissue injury and swelling preclude the ability to manipulate and maintain reduction of the fracture fragments.

Type C fractures are Salter-Harris II injuries with a radial Thurston-Holland fragment and apex ulnar angulation. Severe displacement or angulation requires closed reduction and pinning; however, comminution or soft tissue interposition may prevent bony realignment, necessitating open reduction and pin fixation.

Type D fractures are Salter-Harris III or IV fractures with intraarticular extension. This fracture pattern is the pediatric equivalent of the adult Bennett fracture, and similar treatment principles apply. Closed or open reduction with pin fixation is recommended to restore articular congruity and maintain bony reduction. As in adults, the reduction maneuver consists of longitudinal traction, pronation, and direct pressure applied to the thumb metacarpal base to adduct the thumb ray.

❖ AUTHOR'S PREFERRED METHOD OF TREATMENT

Base of thumb metacarpal fractures are usually treated with closed reduction and short-arm thumb spica casting. Excellent

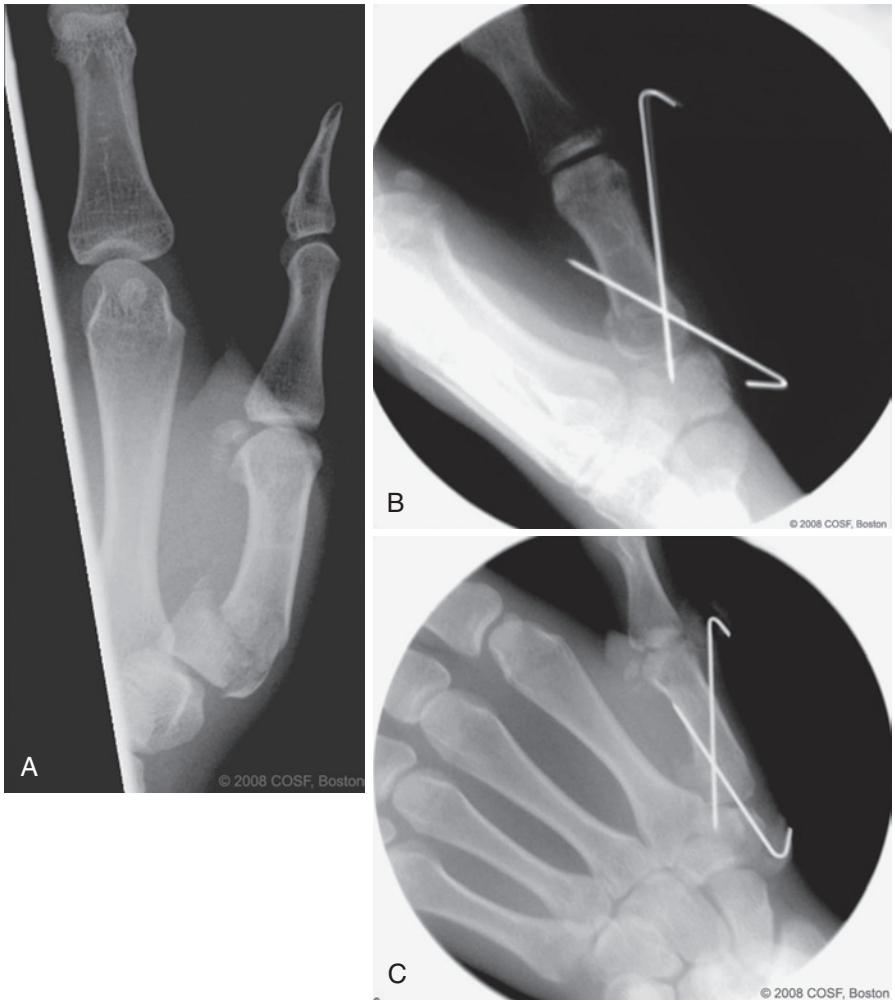

FIGURE 41.17 **A,** Lateral radiograph of a displaced base of thumb metacarpal fracture in a 16-year-old boy sustained in a high-energy motor vehicle collision. Given the fracture displacement and soft tissue swelling, closed reduction and percutaneous pinning were performed. Anteroposterior **(B)** and lateral **(C)** images following reduction and pinning. (Courtesy of the Children's Orthopaedic Surgery Foundation.)

functional outcomes can be anticipated with up to 30 degrees of angulation in skeletally immature patients. In instances of fracture instability or excessive displacement not amenable to closed manipulation, closed or open reduction followed by percutaneous pin fixation is recommended (Figure 41.17). When needed, open reduction is performed via a radial skin incision at the junction of the glabrous and nonglabrous skin, centered at the thumb CMC joint. Subperiosteal dissection allows retraction of the thenar muscles in a volar direction, facilitating fracture exposure. Subsequently, fracture reduction is achieved, and percutaneous pin fixation is performed. An oblique crossed-pin configuration is typically used. I avoid pinning the thumb ray to the index metacarpal across the first web space unless this is necessary to achieve adequate stability.

WRIST FRACTURES

Epidemiology

Although relatively infrequent, scaphoid fractures are the most common carpal bone fractures in children as well as adults, with a peak incidence in the preadolescent and adolescent age group.[132,190,193] The lower incidence of scaphoid fractures in children may be due to the relatively thick cartilaginous cover of the developing ossification center, which protects the scaphoid.[43] Furthermore, the anatomy and ossification pattern affect which regions of the scaphoid are susceptible to injury. The scaphoid ossifies from distal to proximal; this explains the greater frequency of distal pole fractures in young children. Previous studies demonstrated that distal pole scaphoid fractures are most common in children, followed by distal third fractures and waist fractures.[2,43,190] The patterns of scaphoid fractures are changing, however, owing to the greater athletic and functional demands of children, resulting in an increasing frequency of scaphoid waist fractures.[67] In their retrospective analysis of 351 scaphoid fractures in children and adolescents treated from 1995 to 2010, Gholson and colleagues noted that 71% of fractures occurred at the scaphoid waist.[67] Distal and proximal pole fractures accounted for 23% and 6%, respectively, of that cohort. The authors concluded that with changes in activity patterns and patient characteristics, pediatric scaphoid injury patterns are now more similar to those of adults.

Unlike carpal injuries, distal radial fractures are among the most common fractures in children and adolescents, constituting approximately 20% to 35% of pediatric fractures.[16,35,102,209]

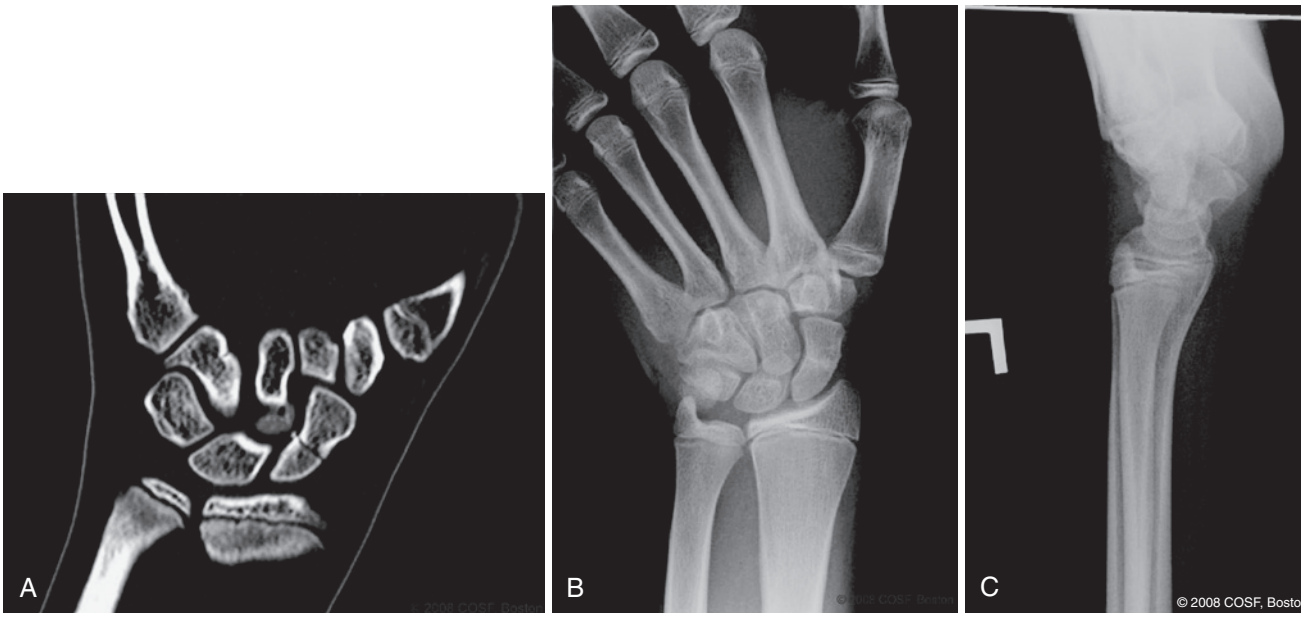

FIGURE 41.18 **A,** Computed tomographic scan of a nondisplaced scaphoid waist fracture in a 14-year-old boy that was not visualized on initial wrist radiographs. **B** and **C,** Follow-up radiographs demonstrating a healed scaphoid fracture after 8 weeks of cast immobilization. (Courtesy of the Children's Orthopaedic Surgery Foundation.)

Similarly, distal radial physeal fractures account for approximately one-third of all physeal fractures, second in frequency only to physeal fractures of the phalanges.[145] These fractures occur most often in patients between the ages of 10 and 14 years, in part due to the increased porosity of the distal radial metaphysis during accelerated skeletal growth. In addition, recent evidence suggests that the incidence of distal radial fractures in pediatric patients may be increasing due to greater sports participation and higher rates of childhood obesity.[96,172] The vast majority of distal radial fractures occurs from a fall onto an outstretched upper limb. The wrist position (extension versus flexion) and amount of force imparted influence the ultimate fracture pattern and displacement.

Preoperative Evaluation

As in adults, fractures of the scaphoid may be subtle in clinical presentation. There may be minimal deformity or swelling, but the presence of focal, reproducible tenderness at the anatomic snuffbox or scaphoid tubercle should alert the examiner to a possible carpal fracture. Axial loading of the thumb metacarpal, loading the scaphoid during forceful pinch, and the scaphoid compression test have also been used to elicit clinical signs of a scaphoid fracture.[188]

A suspected scaphoid fracture requires dedicated radiographic evaluation in addition to standard AP and lateral wrist radiographs. An AP radiograph of the wrist with ulnar deviation and oblique views of the wrist allow better visualization of the scaphoid. A frequently encountered clinical scenario is anatomic snuffbox tenderness and negative plain radiographs, raising the question of an occult scaphoid injury. In these situations, brief immobilization in a thumb spica cast or splint is recommended, followed by repeated clinical and radiographic evaluation in 2 to 3 weeks. If persistent tenderness is noted, advanced imaging with computed tomography (CT) or magnetic resonance imaging (MRI) may confirm or exclude the diagnosis of a scaphoid fracture (Figure 41.18).[52,114,176] Immediate MRI evaluation of all children presenting with snuffbox tenderness and negative radiographs is not recommended; the majority of these injuries are not scaphoid fractures, making such imaging and its associated time and cost unnecessary.[52,87,176]

Similarly, patients with other fractures of the carpus may present with subtle complaints after relatively innocuous traumatic injuries. Careful observation and systematic clinical examination—with specific palpation of each bony structure of the carpus and wrist—should guide the subsequent diagnostic workup and treatment.

Unlike fractures of the carpus, the diagnosis of distal radial fractures is not subtle. Patients present with pain, swelling, and deformity of the affected wrist following trauma, such as a fall onto an outstretched upper limb. Clinical examination of the skin is performed to assess for open injuries. A neurovascular examination is similarly performed to assess for injury or impending compartment syndrome.[200] Compartment syndrome is particularly prevalent in "floating elbow" injuries (Figure 41.19).[159] Plain wrist radiographs usually confirm the diagnosis and guide treatment. A thorough radiographic evaluation should be performed because relatively innocuous findings, such as ulnar styloid fractures or plastic deformation resulting in proximal or distal radioulnar joint disruption, can affect treatment.[105] For example, Galeazzi fracture-dislocations are uncommon in children; instead, distal radial fractures are accompanied by distal ulnar physeal or styloid fractures. Identification of these associated injuries guides decisions regarding both nonoperative and surgical treatment strategies. In general, imaging of the entire forearm, including the elbow, is performed to evaluate for concomitant ipsilateral upper extremity fractures, which may occur in up to 13% of cases.[174]

Distal radial fractures are generally characterized according to anatomic location (metaphysis, physis, epiphysis, intraarticular) and amount of displacement, angulation, and rotation.



FIGURE 41.19 Plain radiograph depicting ipsilateral distal radial and supracondylar humeral fractures, the so-called floating elbow injury. (Courtesy of the Children's Orthopaedic Surgery Foundation.)

Physeal fractures are typically categorized according to the Salter-Harris classification.[161] Salter-Harris type I and II patterns predominate, although Salter-Harris type III and other intraarticular fracture patterns may occur in children.[105] In general, it is important to remember that the metaphyseal Thurston-Holland fragment in type II fractures lies opposite the disruption in the periosteum; this anatomic point assists fracture reduction maneuvers and guides the surgical approach when open operative treatment is necessary.

PERTINENT ANATOMY

Ossification Centers

The radiographic appearance of the carpal centers of ossification occurs in a predictable, ordered sequence.[72,177] The capitate and hamate typically appear at 6 to 8 months of age. The triquetrum ossifies at 2 to 3 years of age, followed by the lunate at 4 years. The scaphoid becomes radiographically apparent at 4 to 5 years of age, followed by the trapezium and trapezoid at 5 years. The pisiform is the last carpal bone to ossify, typically at 6 to 8 years of age.

The scaphoid ossific nucleus appears between age 4 and 5 years.[177] The bony scaphoid forms via enchondral ossification from distal to proximal until the bone is fully ossified, typically by age 14 to 16 years. Multiple ossification centers may appear, and bipartite scaphoids have been described. As discussed earlier, the gradual distal to proximal ossification process may explain the predisposition for distal pole fractures in young children and more adult patterns of scaphoid fractures (waist and proximal pole fractures) in older children and adolescents.

The secondary center of ossification of the distal radial epiphysis becomes radiographically apparent by the first year of life, whereas the distal ulnar epiphysis appears at approximate 6 years of age.[136] The distal ulnar epiphysis often arises from two distinct centers of ossification, giving rise to a bipartite appearance that may be confused with an ulnar styloid fracture. In general, the distal ulnar physis closes at 16 years in females and 17 years in males, with the distal radial physis closing, on average, 6 months later.[72] Knowledge of this timing and the variable patterns of ossification may assist in distinguishing acute skeletal injuries from developmental norms. Although the radiographic appearance of the distal radius and ulna changes with development, similar parameters delineate "normal alignment" in both children and adults. Evaluation of radial inclination, radial length, ulnar variance, and volar tilt is appropriate in all but the youngest patients.

Growth

Because the distal physis contributes approximately 70 to 80% of the longitudinal growth of the radius and 40% of the upper extremity, distal radial fractures have tremendous inherent remodeling potential.[72] Prior investigations confirmed that up to 10 degrees of dorsal volar angulation per year may remodel with continued skeletal growth.[62,83,214,219] As with other fractures of the developing skeleton, remodeling potential is dependent on the amount of skeletal growth remaining, distance from the bony injury to the adjacent physis, magnitude of the deformity, and plane of the deformity. Fractures close to the distal radial physis with mild to moderate angulation in the sagittal plane in younger patients have the greatest remodeling potential. Therefore, in patients younger than 10 to 12 years, 20 to 30 degrees of angulation in the sagittal plane and 50 to 100% translation of the distal radial fracture fragment may remodel with continued skeletal growth.[50,83,201] Radioulnar angulation in the coronal plane is less well tolerated and has less remodeling capacity. Therefore, angulation of more than 10 degrees in the AP plane may not remodel with continued skeletal growth.

Soft Tissue Structures

A number of soft tissue structures impart stability to the wrist and must be considered in the treatment of skeletal injuries. Carpal stability is imparted by both extrinsic and intrinsic ligaments, with anatomic and pathologic considerations similar to those in adults. A discussion of carpal instability due to ligamentous injury is beyond the scope of this chapter; see Chapter 13 for further information. Owing to the relative mechanical strength of these ligaments in relationship to the adjacent bony structures, intrinsic carpal ligamentous injuries are far less common in children than in adults. Furthermore, due to the gradual ossification process of the carpus in skeletally immature patients, the "normal" radiographic parameters used to identify intrinsic ligament disruptions (e.g., scapholunate ligament tears) may not be applicable in younger children.[89]

The triangular fibrocartilage complex (TFCC) refers to a confluence of structures on the ulnar side of the wrist, including the triangular fibrocartilage, dorsal and volar radioulnar ligaments, meniscal homolog, ulnolunate and ulnotriquetral ligaments, and subsheath of the extensor carpi ulnaris tendon.[140]

Functionally, the TFCC provides a smooth articular surface in support of the ulnar carpus and stabilizes the distal radioulnar joint (DRUJ). In ulnar-neutral wrists, approximately 20% of the axial load across the wrist is borne by the ulnar carpus through the TFCC.[139] Small changes in ulnar variance, as might be seen with traumatic or posttraumatic deformity, may result in considerable alterations in loads transmitted across the TFCC and ulnar wrist.

Types of Operations for Wrist Fractures

Scaphoid Fractures

As in adults, treatment of scaphoid fractures in skeletally immature patients is dependent on the fracture location, fracture pattern, and degree of displacement.[39] Distal pole fractures have excellent healing potential owing to the vascularity of the distal pole of the scaphoid and their extraarticular locations. Thumb spica cast immobilization for 4 to 6 weeks is adequate, particularly in cases of incomplete or avulsion injuries (Figure 41.20).

Nondisplaced waist fractures can be treated with cast immobilization, with union rates greater than 90% (see Figure 41.17).[53,67] However, cast immobilization for 2 to 3 months may be required in these situations, owing to the limited and retrograde vascular supply to the scaphoid body, which is the same as in adults.

The optimal type of cast immobilization continues to be debated.[51] Incorporation of the thumb into a spica cast has been advocated by some to eliminate forces across the scaphoid, which may inhibit healing or cause displacement.[29] In addition, immobilization of the elbow eliminates forearm rotation, which has been demonstrated to induce scaphoid fracture motion.[92] Gellman and associates performed a prospective randomized study comparing long-arm versus short-arm thumb spica casting for the treatment of acute nondisplaced scaphoid waist fractures.[66] Patients treated with long-arm casts for the first 6 weeks had a faster time to healing (9.5 versus 12.7 weeks) and lower nonunion and delayed union rates than those treated with short-arm casts alone. Other recent investigations have demonstrated no significant differences in times to union between short-arm and long-arm casts.[11,29] Several biomechanical and clinical studies evaluated the effect of wrist position on scaphoid healing during casting. Arguments have been made for casting with wrist extension, wrist flexion, and radial and ulnar deviation.



FIGURE 41.20 Twelve-year-old boy fell playing ice hockey and complained of right wrist pain. Radiograph revealed a distal pole scaphoid fracture with slight comminution. It was successfully treated with 4 weeks of cast immobilization. (Courtesy of Shriners Hospital for Children, Philadelphia.)

As in adults, there is growing enthusiasm for percutaneous screw fixation for nondisplaced injuries, given contemporary expectations of a faster return to sports and activities in younger patients.[1,28,122,211] It is unclear whether these adult principles apply to the pediatric patient with scaphoid fractures, and there is some evidence that percutaneous screw fixation of nondisplaced injuries in children and adolescents does not decrease the time to union.[67] Discussion of percutaneous screw fixation is beyond the scope of this chapter; however, considerations and surgical techniques are similar to those in adults (see Chapter 18).

In cases of displaced waist fractures or fractures of the proximal pole, surgical treatment with open reduction and internal stabilization is recommended, as in adults. Because these injuries tend to occur in older children and adolescents, the treatment principles and surgical techniques are similar to those in adults. Internal stabilization with smooth Kirschner wires, headed compression screws, or variable-pitch headless compression screws has been used safely and effectively in children.[67]

Scaphoid fracture nonunion does occur in skeletally immature patients, owing either to late presentation or to inadequate immobilization of acute injuries (Figure 41.21).[129,137,202] Indeed, in their retrospective analysis of 351 scaphoid fractures in children and adolescents, Gholson and coworkers noted that 29% of patients presented more than 6 weeks from injury.[67] Typically, patients are older adolescents with waist or proximal pole fractures. Treatment options for established pediatric scaphoid nonunions are quite varied. Historically, cast immobilization has been advocated in injuries that present late.[53,205] Bone grafting via the Matti-Russe technique, Kirschner wire fixation, and compression screw fixation have also been reported, with successful outcomes in the majority of cases, consistent with the published adult literature (Case Study 41.1).[67,129,157,160,182,202] The use of autologous bone graft is common to provide structural support and facilitate healing.

Osteonecrosis of the proximal pole of the scaphoid may occur in children, typically in waist or proximal pole fractures in patients nearing skeletal maturity. Reconstructive procedures using pedicled vascularized bone graft from the distal radius have been recommended in these rare but difficult situations.[44,169,202]

Little is known of the natural history of scaphoid fracture malunions (e.g., humpback deformity) in skeletally immature patients. Although reports of spontaneous correction of secondary carpal instability and remodeling of scaphoid malunions have been published, no definitive statement can be made owing to the infrequency of these situations and the paucity of data available.

CASE STUDY 41.1

A 10-year-old right-handed patient had hurt his left wrist 6 months previously. He complains of persistent pain and decreased range of motion (eFigure 41.1, *A* and *B*). The diagnosis was scaphoid nonunion. The treatment options included a long-arm cast, electrical stimulation, open reduction and vascularized bone grafting, and open reduction and nonvascularized bone grafting. The option of open reduction and nonvascularized bone grafting (eFigure 41.2, *A* to *F*) was performed. Postoperative and 3-month follow-up x-rays are shown (eFigures 41.3, *A* and *B*, and 41.4, *A* and *B*).

Scott H. Kozin



eFIGURE 41.1 **A** and **B**, Radiographs.

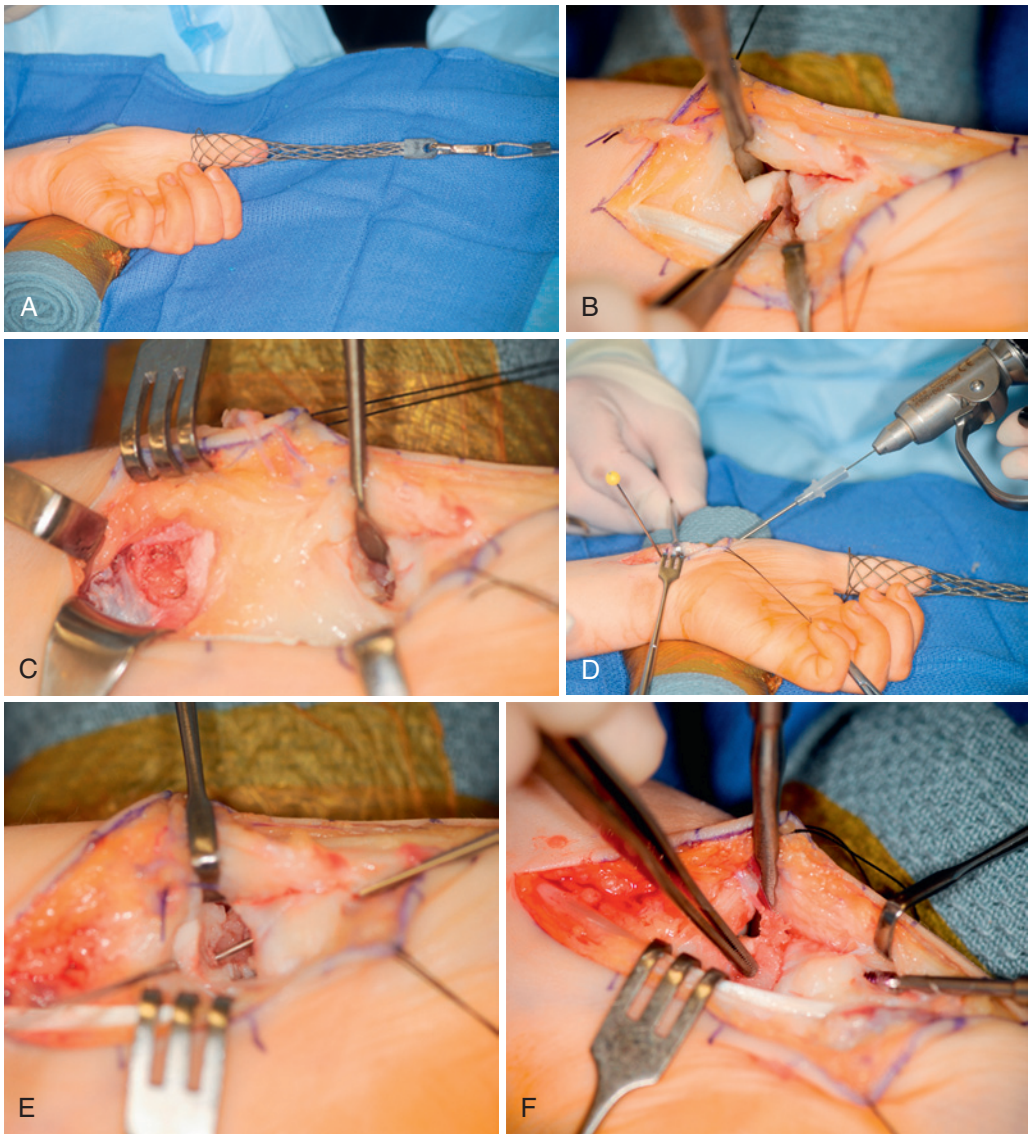

eFIGURE 41.2 **A,** Fingertrap distraction is applied to the thumb to stabilize the wrist and facilitate exposure. **B,** Curettage fracture. **C,** Distal radius bone graft. **D,** Kirschner wire joystick and angiocatheter as drill guide. **E,** Kirschner wire across nonunion site. **F,** Screw insertion and bone graft.

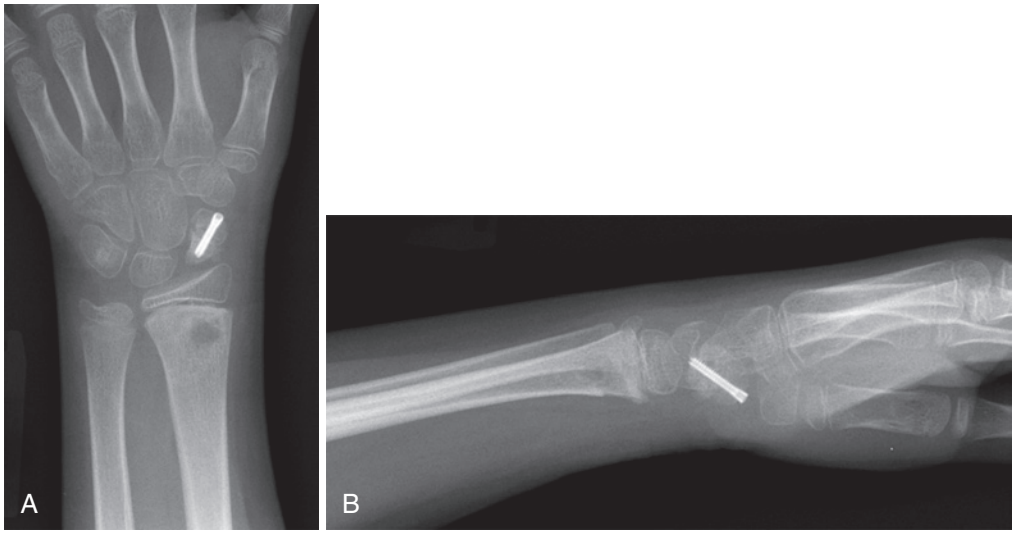

eFIGURE 41.3 **A** and **B**, Postoperative radiographs.

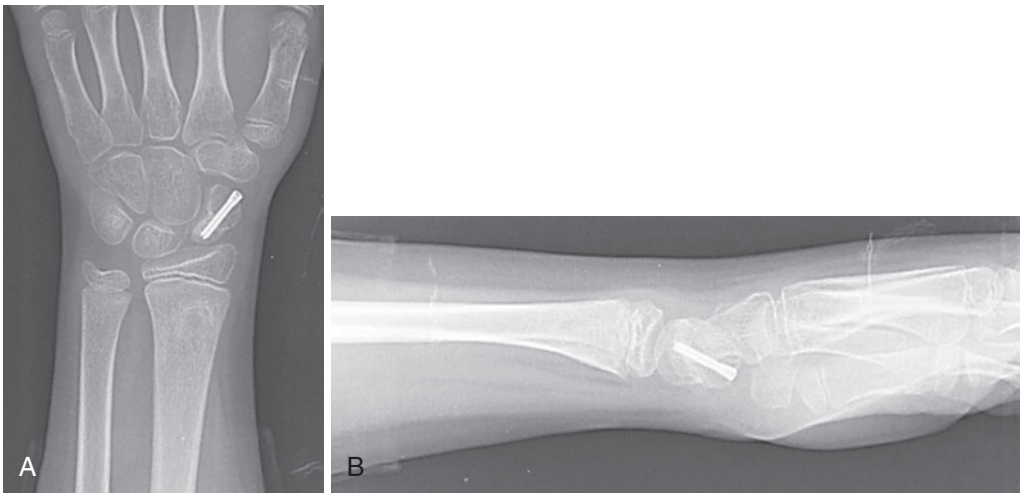

eFIGURE 41.4 **A** and **B**, Radiographs at 3-month follow-up.

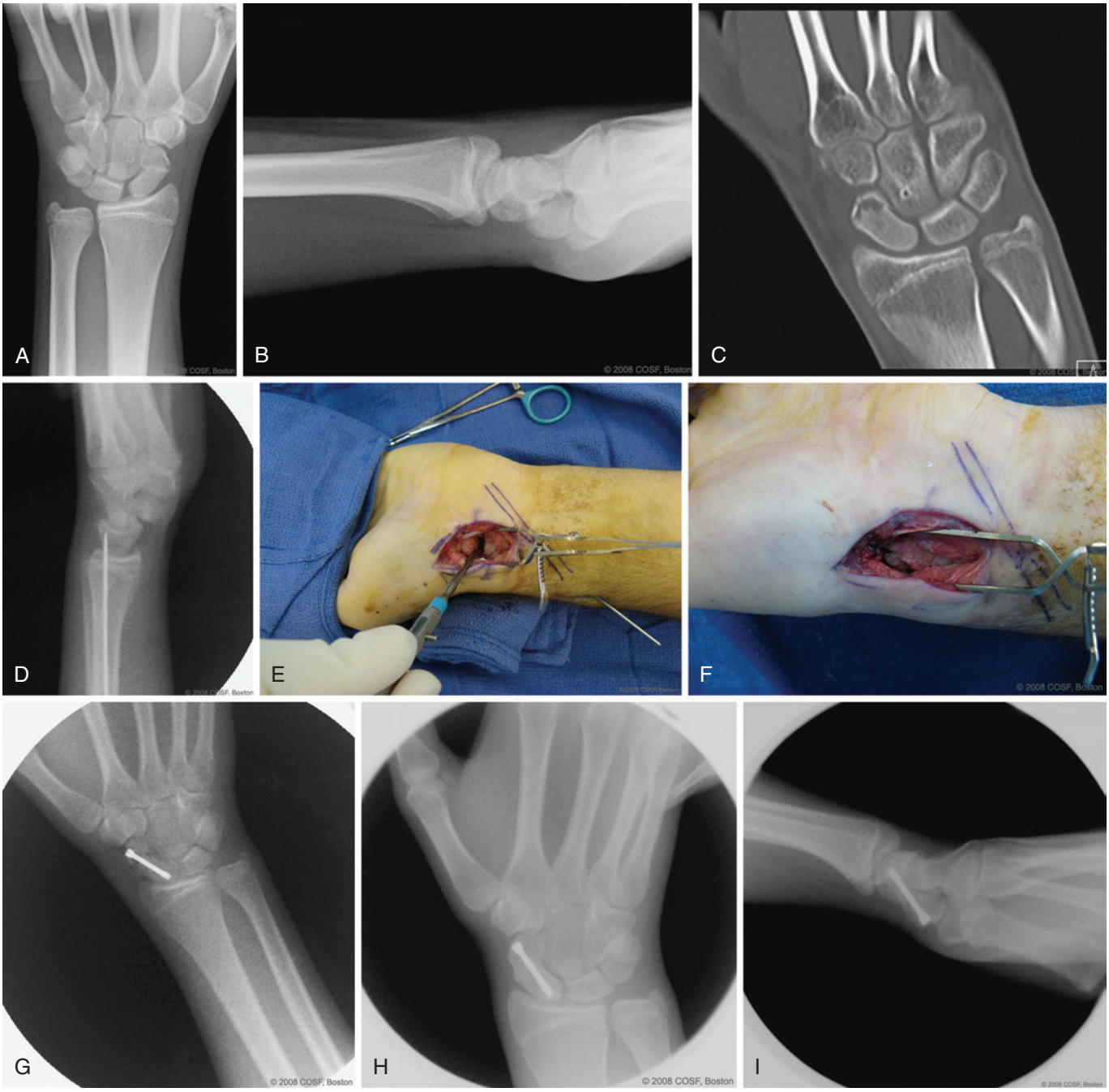

FIGURE 41.21 **A** and **B,** Radiographs of a scaphoid waist fracture nonunion in a skeletally immature patient. Note the increased scapholunate and radiolunate angles on the lateral projection. **C,** Coronal computed tomographic image depicting the nonunion site; the distal fragment is not well visualized due to the "humpback" deformity. **D,** Intraoperative fluoroscopy images depicting radiolunate pinning with the lunate in neutral position. **E,** Intraoperative photograph of the nonunion site. **F,** Intraoperative photograph with tricortical iliac crest bone graft in place. **G,** Intraoperative fluoroscopy image after structural tricortical iliac crest bone grafting and screw fixation. **H** and **I,** Radiographs 2.5 months postoperatively demonstrating bony healing. (Courtesy of the Children's Orthopaedic Surgery Foundation.)

❖ AUTHOR'S PREFERRED METHOD OF TREATMENT

Fractures of the distal pole of the scaphoid are treated with short-arm thumb spica cast immobilization for 4 to 6 weeks, followed by gradual resumption of activities with the return of wrist motion and strength.

Nondisplaced fractures of the scaphoid waist, confirmed by CT scans with reconstructed images in the plane of the scaphoid, are treated with short-arm thumb spica cast immobilization until there is radiographic evidence of healing (see Figure 41.18). Routine CT scans are not performed if there is clinical and radiographic evidence of fracture healing, including bridging trabeculae on multiple radiographic views. In situations in which prolonged cast immobilization is not a viable treatment option (e.g., bilateral upper extremity fractures, high-level athletes), percutaneous screw fixation via a dorsal approach is considered.

Displaced fractures of the scaphoid waist and fractures of the proximal pole are treated with open reduction and internal fixation via standard volar and dorsal approaches, respectively. Internal fixation is performed using a headless, cannulated, variable-pitch compression screw.

Scaphoid nonunions of the waist are treated with open reduction, bone grafting, and internal fixation. In cases of dorsal humpback deformity and dorsal intercalated segment instability, interpositional tricortical iliac crest bone graft is used to restore normal scaphoid architecture and reconstitute carpal alignment. Intraoperative pinning of the radiolunate joint to reduce the lunate out of its dorsiflexed position is often performed, although the pin is removed on completion of the case (see Figure 41.21 and Video 41.2).[183] Provided appropriate alignment and stability are achieved, patients are placed in a short-arm thumb spica cast, followed by wrist immobilization after radiographic evidence of bony healing.[67]

Capitate Fractures

Capitate fractures are rare and typically result from high-energy mechanisms of injury, such as motor vehicle collisions or falls from great heights during sports.[68,143,213] Occasionally, they may be seen in association with a greater-arc perilunate fracture-dislocation injury. Thus, the x-ray should be inspected for concomitant lesser- or greater-arc injuries. Radiographs usually confirm the diagnosis, but advanced imaging studies (e.g., CT, MRI) are helpful to identify fracture displacement and associated wrist pathologic conditions (Figure 41.22).

Treatment is predicated on fracture pattern and displacement. Nondisplaced capitate fractures are effectively managed with cast immobilization. Displaced injuries require open reduction and internal fixation using smooth pins or compression screws. Associated pathologic conditions (e.g., lesser- or greater-arc perilunate fracture-dislocations) should be addressed simultaneously.

Triquetrum Fractures

Although triquetral body fractures are rare and may be seen in the setting of greater-arc perilunate fracture-dislocations, dorsal avulsion fractures do occur, particularly in older adolescents (Figure 41.23). The former require open reduction and internal fixation, but the latter do well with splint or cast immobilization for 3 to 4 weeks until symptoms subside.

Hamate Fractures

Hamate fractures are relatively uncommon in the pediatric population.[154] Fractures of the hamate hook predominate,

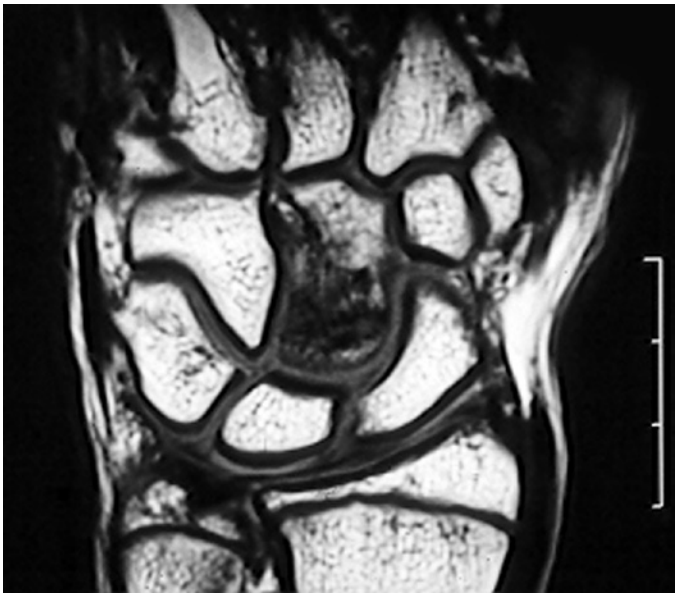

FIGURE 41.22 Thirteen-year-old boy with persistent midcarpal pain after a fall. Magnetic resonance image shows a capitate fracture treated with immobilization. (Courtesy of Shriners Hospital for Children, Philadelphia.)

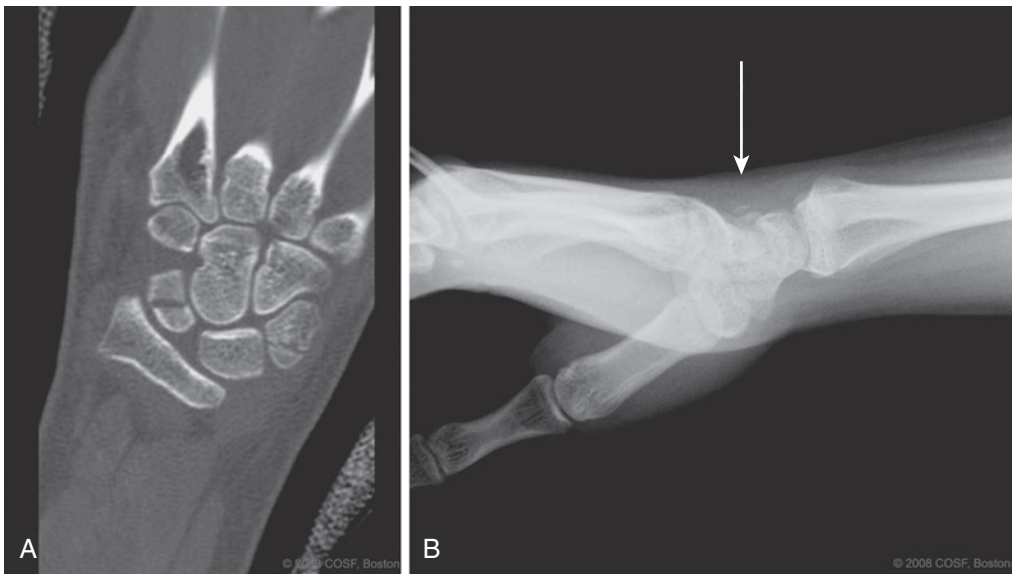

FIGURE 41.23 **A,** Computed tomographic scan depicting a triquetral fracture seen in the setting of a greater arc injury. Also note the scaphoid waist fracture. **B,** Lateral wrist radiograph of a dorsal triquetral avulsion fracture (*arrow*). (Courtesy of the Children's Orthopaedic Surgery Foundation.)

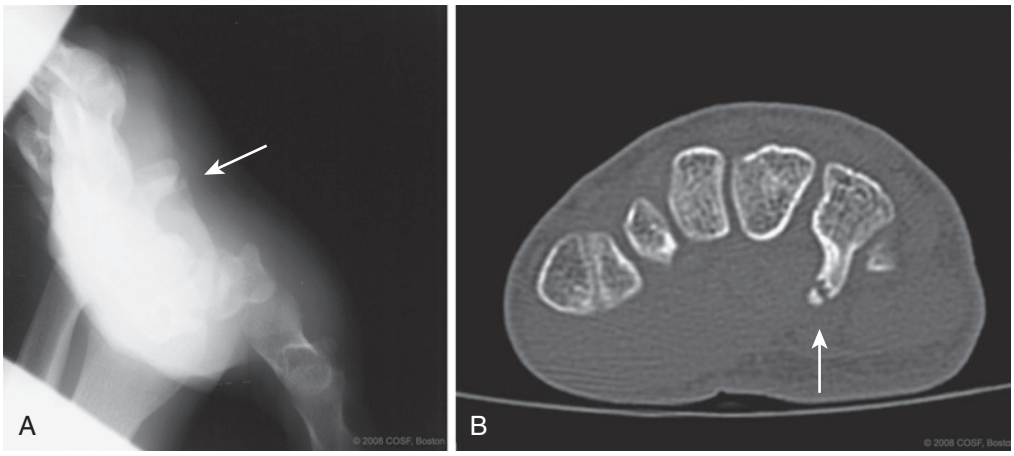

FIGURE 41.24 Carpal tunnel view radiograph **(A)** and CT scan **(B)** of a 14-year-old boy with a hook of hamate fracture (*arrows*). The patient remained symptomatic despite cast immobilization and attempted return to activities. Fracture nonunion was excised via a carpal tunnel incision, resulting in symptomatic relief and return to full activities. (Courtesy of the Children's Orthopaedic Surgery Foundation.)

secondary to a fall. Patients present with point tenderness along the palm and hook of the hamate, along with mild swelling or localized ecchymosis. In acute or chronic cases, patients may complain of paresthesias or weakness in an ulnar nerve distribution or discomfort with small and ring finger flexion, owing to the proximity of the neurovascular and tendinous structures to the hamate hook. Standard radiographs may not delineate the fracture, and the carpal tunnel view may be helpful in suspected cases. CT is becoming the standard of care for the diagnosis of these fractures (Figure 41.24). Although open reduction and internal screw fixation have been advocated by some, short-arm cast immobilization for 4 to 6 weeks often alleviates the symptoms and allows a full return to activities, despite persistence of a radiographic fibrous nonunion. In persistent cases of symptomatic nonunion, fracture fragment excision is performed for relief of symptoms, although athletes should be advised of the possibility of scar irritation or sensitivity. The surgical approach for either fixation or excision is a standard zigzag approach to the Guyon canal or through a carpal tunnel release incision.

Pisiform Fractures

Pisiform fractures are rare and typically result from either a direct blow to the volar ulnar base of the wrist or hyperextension mechanisms (Figure 41.25). Although there is little published information to guide treatment, most patients demonstrate symptomatic relief with cast immobilization for 4 to 6 weeks followed by range-of-motion exercises.[116]

CRITICAL POINTS ***Carpal Fractures***

- The scaphoid is the most commonly fractured carpal bone in children. Distal pole fractures can be treated successfully with cast immobilization. Proximal pole and displaced waist fractures warrant surgical treatment.
- Brief cast or splint immobilization is sufficient for dorsal triquetral fractures.
- Special radiographic imaging is often needed to diagnose hook of hamate fractures. Cast immobilization is recommended acutely. Surgical stabilization or excision may be considered for symptomatic nonunions.

Distal Radial Fractures

Distal radial fractures are characterized by their anatomic location, fracture pattern, and magnitude of displacement, angulation, and rotation. Fractures may involve the distal radial metaphysis or physis. Metaphyseal injuries can be further subdivided into torus, or "buckle," fractures and bicortical fractures. Each fracture pattern has its own set of treatment principles and considerations.

Torus Fractures. In torus fractures of the distal radial metaphysis, cortical failure occurs in compression (Figure 41.26). As a result, these injuries present with minimal deformity and are inherently stable. Brief immobilization with a short-arm cast or a wrist splint for 3 weeks provides adequate symptomatic relief. Multiple randomized prospective trials have demonstrated that true torus fractures can be treated safely and effectively with splint immobilization removed by the parents after 3 weeks, with no need for additional clinical or radiographic follow-up.[46,173,178,194,207,208]

❖ AUTHOR'S PREFERRED METHOD OF TREATMENT

Torus fractures are treated with short-arm splint immobilization for 3 weeks, followed by resumption of activities. Radiographs are not routinely obtained at the time of cast removal owing to the inherent stability of these injuries. Likewise, no follow-up clinical evaluation is necessary after cast immobilization is discontinued.

Bicortical Metaphyseal Fractures. Bicortical fractures of the distal radial metaphysis occur because of bending, rotational, or shear forces imparted on the wrist. Fractures may be transverse, spiral, or oblique and may present with considerable displacement (Figure 41.27). Although bayonet apposition will remodel reliably in young children, fractures with unacceptable angulation or translation are typically treated with closed reduction and cast immobilization.[41] Depending on the patient and care setting, this may involve hematoma block, conscious sedation, or even general anesthesia. Because of the thick periosteum in younger patients, reduction maneuvers consist of exaggeration of the deformity, followed by longitudinal traction and reversal of the mechanism of injury (Figure 41.28). Although the thick, intact periosteum acts as a tension band in

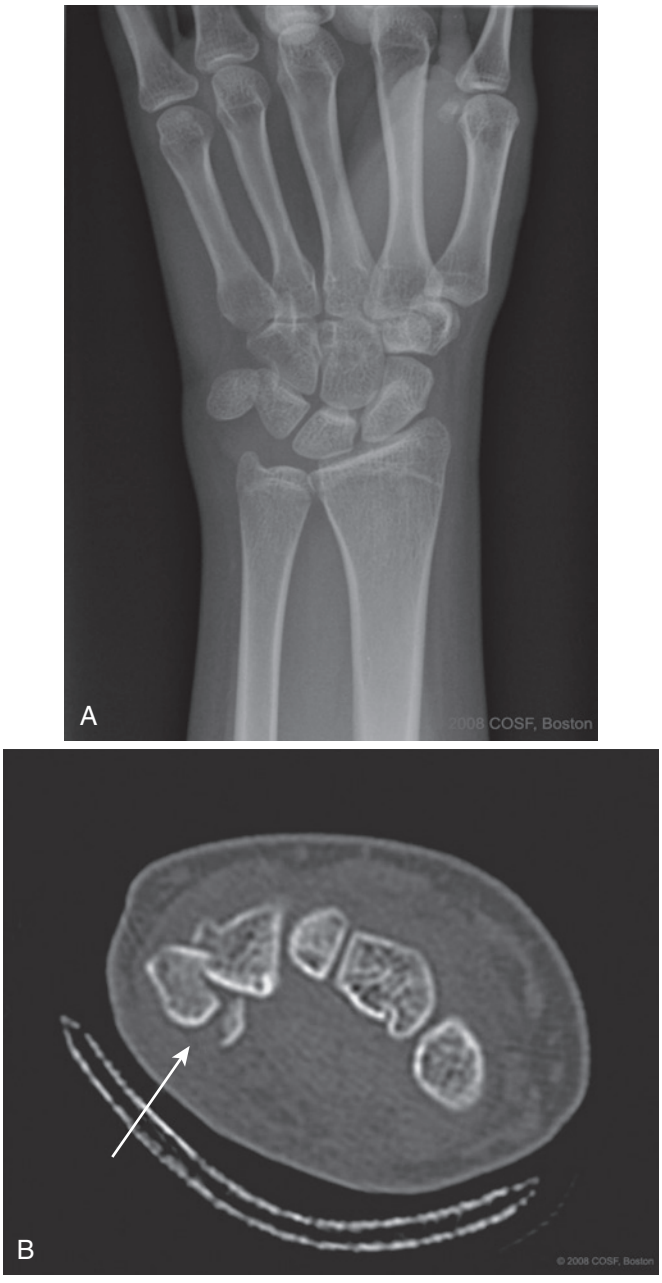

FIGURE 41.25 Radiograph **(A)** and computed tomographic scan **(B)** of a comminuted pisiform fracture in a 15-year-old girl. After 4 weeks of cast immobilization, the patient's symptoms resolved, and she returned to full activities. (Courtesy of the Children's Orthopaedic Surgery Foundation.)

facilitating reduction and conferring stability, if the deformity is not exaggerated first, the intact periosteum limits the ability to restore length or alignment with straight traction alone. Application of a well-molded cast with three-point bending or an appropriate interosseous mold is critical in maintaining reduction and minimizing the risk of late displacement. Excessive wrist flexion should be avoided.[200]

The optimal position of forearm rotation, if a long-arm cast is used, remains controversial. Some advocate pronation, given that pronation may better correct rotational malalignment and maintain fracture reduction in the more common apex volar injury. Others advocate supination to allow improved fracture molding and relaxation of the brachioradialis. Still others advocate immobilization in neutral, citing an improved ability to apply an interosseous mold and theoretically minimize loss of motion at the extremes of forearm rotation.

Two prospective, randomized clinical trials compared the efficacy of short-arm versus long-arm casts in maintaining reduction following closed fracture manipulation.[24,204] Both investigations concluded that short-arm casts are as efficacious in maintaining fracture alignment as long-arm casts; however, careful analysis of the data reveals a number of important points. First, more important than the length of the cast is the quality of fracture reduction and cast molding. Indeed, in one study of 103 patients, the risk for loss of fracture reduction was higher in patients with a cast index greater than 0.7.[204] In addition, fractures that were incompletely reduced (i.e., had residual displacement or angulation following manipulation) were at higher risk for late loss of reduction, a finding that emphasizes the importance of the reduction maneuver over the type of immobilization.[24] Patients with concomitant fractures of the distal ulna were at higher risk for loss of reduction, regardless of the casting technique. Finally, the effect of long-arm casting on the ability to perform activities of daily living should not be dismissed; short-arm casts were associated with fewer days of missed school and less assistance required during daily activities.[204] Subsequent studies and metaanalyses have confirmed these findings.[78]

Despite successful initial closed reduction and cast immobilization, late displacement of fractures is common (Figure 41.29). Although prior published series reported loss of reduction rates of between 10% and 91%, in general, approximately one third of all distal radial fractures requiring reduction will demonstrate late displacement.[56,69,76,117,118,123,128,146,150,218] Factors implicated in the loss of reduction include initial displacement (bayonet apposition, >50% translation, >30 degrees of angulation), isolated distal radial fracture, associated same-level ulnar fracture, inadequate initial closed reduction, poor casting technique, muscle atrophy, and resolution of initial soft tissue swelling while in the cast. It is therefore imperative that serial radiographic evaluations be performed, initially on a weekly basis, to assess bony alignment and rule out loss of reduction.

Efforts have been made to characterize the quality of fracture reduction and casting techniques to predict which injuries might be more prone to late displacement (Figure 41.30). The cast index refers to the ratio between the diameters of the cast at the level of the fracture, as measured on lateral and AP projections.[36,91] Used as a measure of the quality of the cast mold, cast indices greater than 0.7 have been associated with an increased risk of late loss of fracture reduction.[36,204] A gap index has also been proposed to assess the quality of cast molding, as well as excessive cast padding and resolution of soft tissue swelling.[115] The gap index is calculated by dividing the aggregate distance between the skin and cast material by the overall diameter of the cast. If the sum of the gap indices as measured on both AP and lateral radiographs is greater than 0.15, this is associated with a higher risk of loss of fracture reduction, with a sensitivity of 88%. A three-point index has recently been proposed as a more sensitive and specific radiographic measure of cast mold and predictor of late displacement.[85] Axis deviation has also been proposed to assist in risk stratification and is discussed in the following section on forearm diaphyseal fractures.

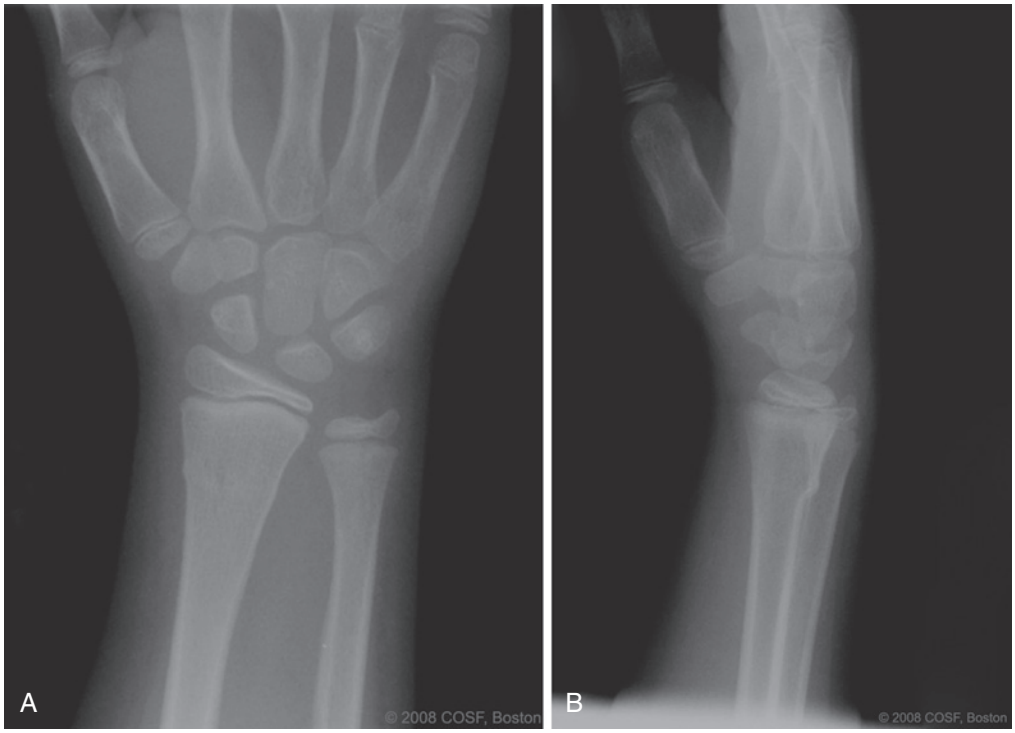

FIGURE 41.26 Anteroposterior **(A)** and lateral **(B)** radiographs of a torus fracture of the distal radius. (Courtesy of the Children's Orthopaedic Surgery Foundation.)

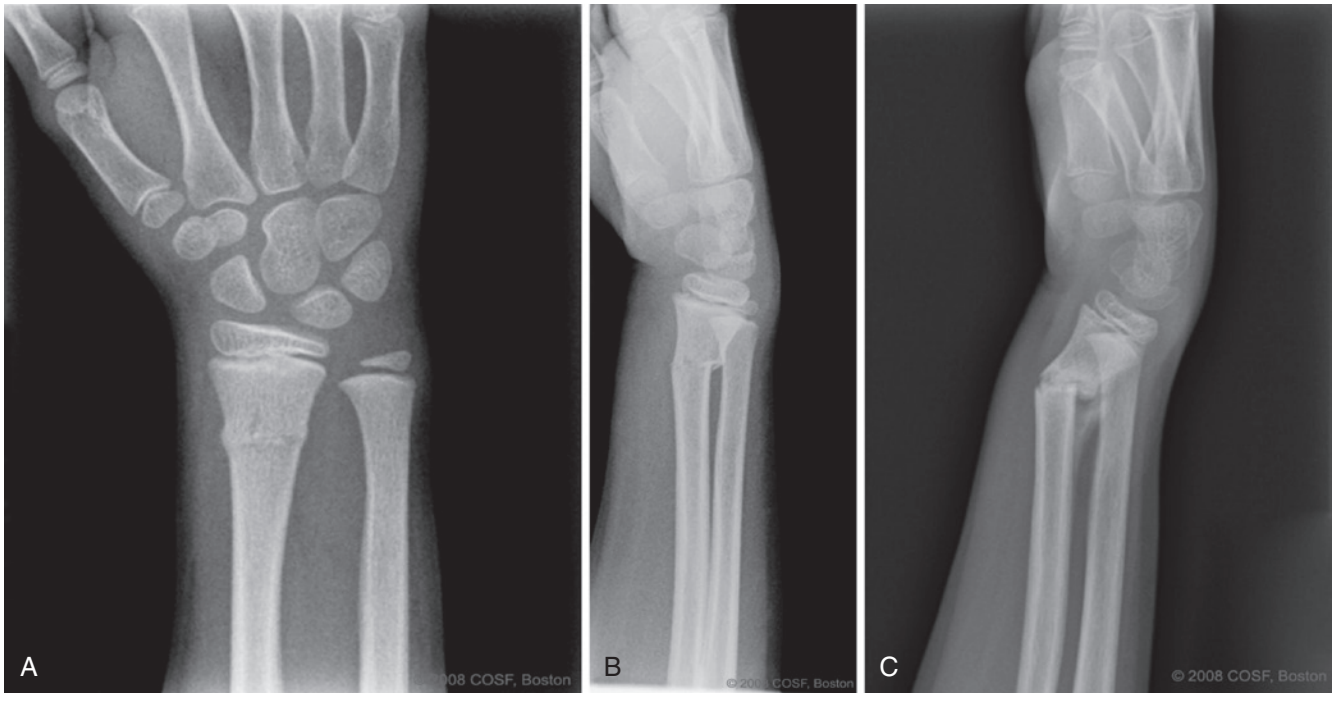

FIGURE 41.27 Anteroposterior **(A)** and lateral **(B)** radiographs of a presumed torus fracture of the distal radius. Note the complete cortical disruption on the lateral view. **C,** Follow-up lateral radiograph taken 3 weeks after injury, demonstrating fracture displacement and 40 degrees of apex volar angulation, consistent with a complete bicortical metaphyseal fracture. (Courtesy of the Children's Orthopaedic Surgery Foundation.)

Owing to the relatively high rate of lost fracture reduction despite initial closed fracture manipulation and cast immobilization, some have questioned whether all fractures deemed to be at risk for late instability should be treated with surgical stabilization.[38,121,128,217] McLauchlan and colleagues performed a prospective, randomized clinical trial of 68 children treated with closed reduction and cast immobilization versus immediate percutaneous pinning.[121] Although loss of reduction occurred in 21% of the casting cohort and in 0% of pinning patients, equivalent clinical outcomes were reported. Miller and

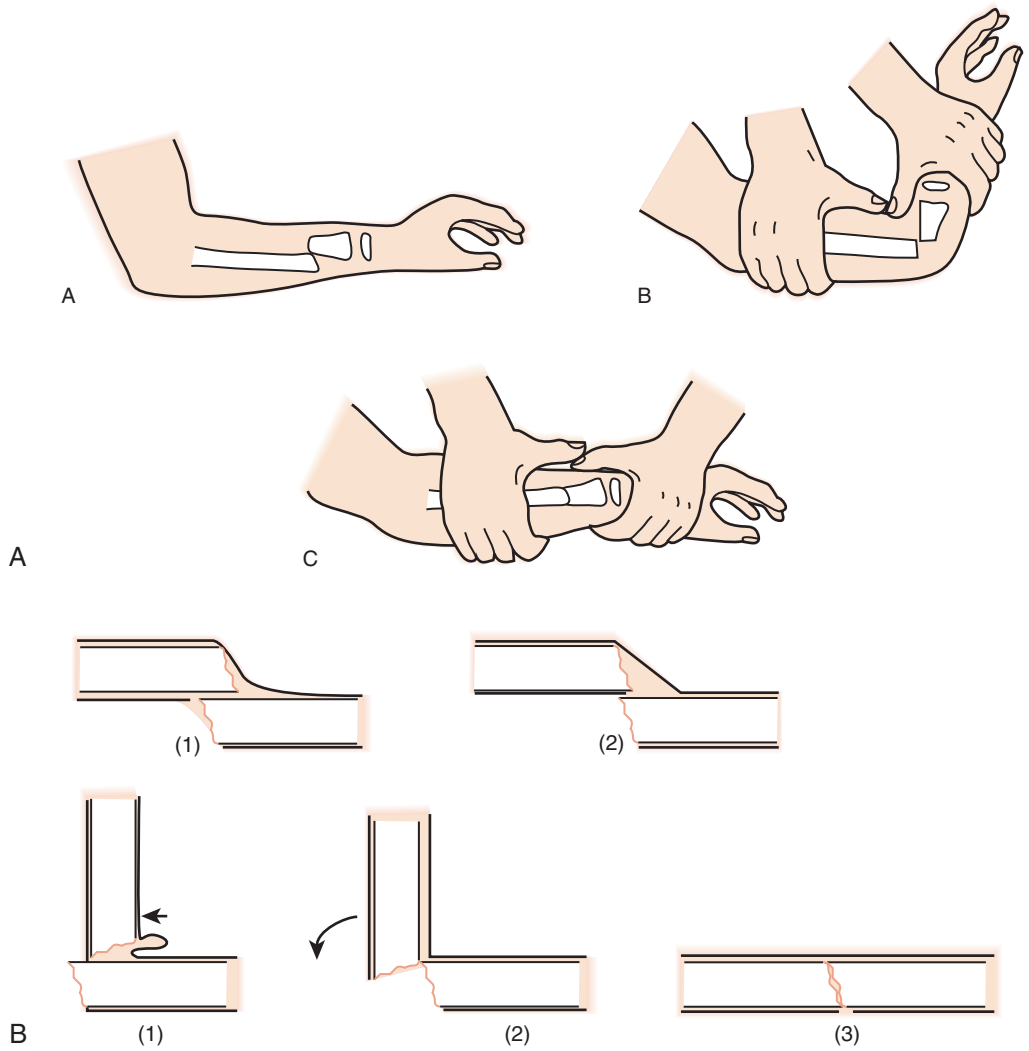

FIGURE 41.28 **A,** Schematic representation of distal radius fracture *(1)* with an intact dorsal periosteum. Longitudinal traction alone *(2)* is insufficient to achieve fracture reduction, given the intact periosteum. **B,** Closed reduction should first begin with exaggeration of the deformity *(1),* followed by longitudinal traction to achieve adequate length *(2).* Following restoration of bony length, a bending moment can be applied to effectuate bony reduction *(3),* with the intact dorsal periosteum conferring additional stability.

associates similarly performed a prospective, randomized trial of closed reduction and cast immobilization versus pin fixation in 34 patients older than 10 years with severely displaced distal radial fractures.[128] Thirty-nine percent of casted patients had loss of reduction requiring remanipulation, and 38% of the pinning cohort had minor pin-related complications, including superficial pin tract infections and superficial radial sensory nerve irritation. Clinical outcomes were equivalent, however, and there was no significant difference in overall cost analysis. Broad treatment recommendations cannot be made based on the limited evidence available. Certainly, when performed with meticulous technique, pinning of severely displaced distal radial fractures is safe and efficacious. However, owing to the frequency of these injuries, the remodeling potential of the distal radius, and equally efficacious results with proper cast immobilization, routine pinning of all displaced pediatric distal radial fractures is not currently recommended.

Indications for surgical treatment of pediatric distal radial fractures include open fractures, unstable or irreducible fractures, floating elbow injuries, and fractures with soft tissue or neurovascular compromise precluding cast immobilization (see Figure 41.29).[38,159,200] Open reduction and surgical stabilization are also indicated in the rare displaced Salter-Harris type III or IV or triplane fractures to reconstitute the articular surface and restore the integrity of the physis. Despite the growing enthusiasm for and experience with open reduction and volar locking plate fixation for displaced extraarticular and intraarticular fractures in adults, the majority of pediatric distal radial fractures can be managed successfully using percutaneously placed pins. Smooth pin fixation is typically performed with an oblique pin directed distal to proximal and radial to ulnar, entering the radial metaphysis proximal to the physis in an effort to avoid iatrogenic injury to the distal radial physis. A second oblique pin or dorsoulnar pin entering between the fourth and fifth extensor compartments can be added to provide additional fracture stability, but this is not always necessary.[106,175] In cases in which adequate fixation cannot be achieved with physis-sparing pinning techniques, transphyseal pinning and intramedullary fixation across the physis into the epiphysis have been reported, with successful outcomes and a low rate of



FIGURE 41.29 Anteroposterior (AP) **(A)** and lateral **(B)** radiographs of a displaced distal radial metaphyseal fracture in an 11-year-old boy. **C** and **D,** Postreduction radiographs demonstrating correction of the initial displacement. Note the mild persistent radioulnar angulation on the AP view and a cast index greater than 0.7. **E,** Follow-up radiograph demonstrating fracture instability. **F** and **G,** Because of progressive fracture instability, the patient underwent closed reduction and percutaneous pin fixation, sparing the distal radial physis. (Courtesy of the Children's Orthopaedic Surgery Foundation.)

complications.[30,80,141,165,217] In addition, intrafocal pinning in the fashion of Kapandji can be used with success.[187] Although external fixation via wrist spanning constructs is an option and has been used with success in children, it is reserved for cases of extensive soft tissue injury (e.g., crush injuries with soft tissue loss) or to supplement comminuted fractures in which adequate internal fixation is not possible.[201]

In fractures of the distal radius at the metaphyseal-diaphyseal junction, pinning techniques are difficult owing to the obliquity with which the pins must be directed to engage the proximal fracture fragment. In these situations, particularly in adolescents with less than 2 years of skeletal growth remaining, formal open reduction and volar plating may be performed with size- and age-appropriate implants, obtaining four cortices of

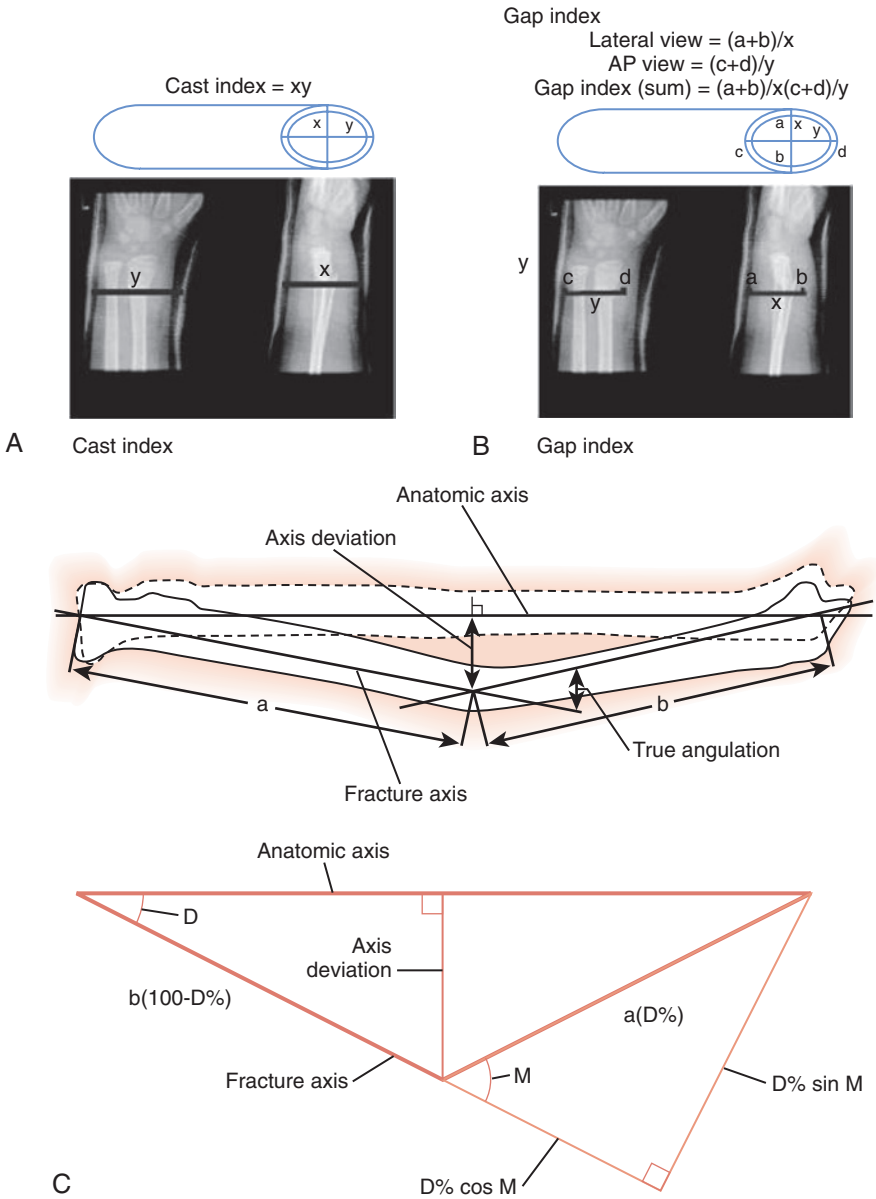

FIGURE 41.30 **A,** Schematic representation of the cast index. **B,** Diagram of the gap index. **C,** Schematic diagram of the calculation of axis deviation. (**A,** Bohm ER, Bubbar V, Yong Hing K, et al: Above and below-the-elbow plaster casts for distal forearm fractures in children: a randomized controlled trial. *J Bone Joint Surg Am* 88:1–8, 2006; Puckett BN, Gaston RG, Peljovich AE, et al: Remodeling potential of phalangeal distal condylar malunions in children. *J Hand Surg [Am]* 37:34–41, 2012. **B,** Iltar S, Alemdaroglu KB, Say F, et al: The value of the three-point index in predicting redisplacement of diaphyseal fractures of the forearm in children. *Bone Joint J* 95B:563–567, 2013. **C,** Russe O: Fracture of the carpal navicular: diagnosis, non-operative treatment, and operative treatment. *J Bone Joint Surg Am* 42:759–768, 1960; Salter RHW: Injuries involving the eiphyseal plate. *J Bone Joint Surg Am* 45:587–622, 1963.)

fixation in the distal fracture fragment while still preserving the distal radial physis (Figure 41.31). In addition, open reduction may be indicated in open fractures and in fractures in which soft tissue interposition precludes the achievement of an acceptable closed reduction. The most common offending structures in apex volar angulated fractures are the volar periosteum and pronator quadratus muscle.

❖ AUTHOR'S PREFERRED METHOD OF TREATMENT

In displaced bicortical metaphyseal fractures of the distal radius, closed reduction and cast immobilization are advocated, typically performed while the patient is under conscious sedation. My preference is to immobilize with long-arm casts to mitigate the motion imparted by forearm rotation. Long-arm casts are also used because a well-molded short-arm cast (cast index <0.7, gap index <0.15) is often difficult to apply, given the soft tissue swelling typical at presentation. Although the position of forearm rotation remains controversial, published information suggests that this position does not affect the final alignment in fractures of the distal radius and ulna metaphysis.[27] I currently use long-arm casts with the forearm in neutral rotation following closed reduction.

Because of the known risk of late displacement, serial radiographs in the cast are obtained at 1 week, 2 weeks, and 4

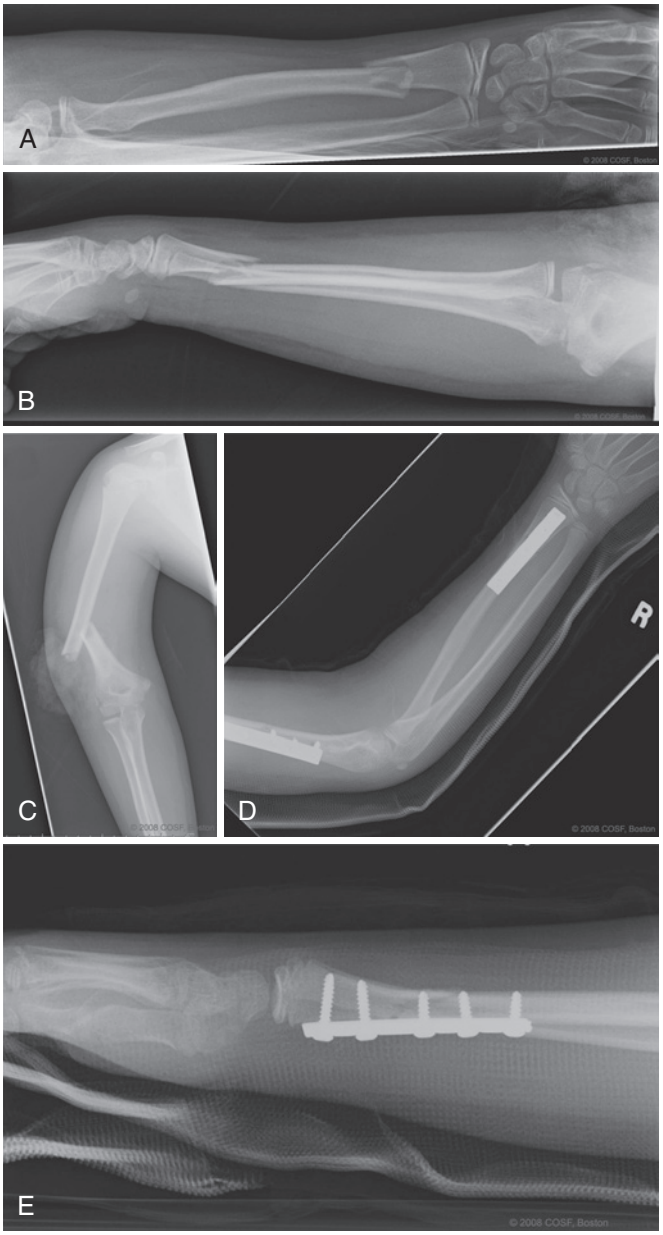

FIGURE 41.31 **A** to **C,** Anteroposterior and lateral radiographs of a distal radial fracture at the metaphyseal-diaphyseal junction in an 11-year-old girl with an ipsilateral open humeral fracture. **D** and **E,** Due to the fracture location, age of the patient, and associated injuries, internal fixation using double-stacked one-third tubular plates was performed in a physis-sparing fashion. (Courtesy of the Children's Orthopaedic Surgery Foundation.)

weeks following fracture manipulation. If adequate alignment is maintained and fracture callus is radiographically apparent, patients are transitioned to a short-arm cast at 4 weeks following the injury. Following 2 weeks of short-arm casting, final radiographs are obtained, and cast immobilization is discontinued.

In cases in which fracture reduction is lost, I prefer to proceed with remanipulation and percutaneous pin fixation (see Figure 41.29). Although prior studies supported the notion that transphyseal pinning can be performed without high risk of physeal injury or growth arrest, I attempt to pin the fracture obliquely in a physis-sparing fashion. With the patient under general anesthesia, the fracture is manipulated and bony alignment is restored. A small 1-cm incision is made along the radial border of the distal radius, roughly at the level of the distal radial physis. Careful blunt dissection in the subcutaneous tissues is performed, and the superficial radial sensory nerve is retracted and protected at all times. Smooth Kirschner wires are passed from the distal fracture fragment just proximal to the physis, traversing the fracture and engaging the far proximal ulnar cortex. A single pin is often sufficient; however, additional pins can be placed for greater stability, taking care to avoid crossing the pins at the fracture site and thus failing to obtain rotational stability. Pins are bent and cut outside the skin in the usual fashion, followed by application of a long-arm cast. The pins are removed in the office at 4 weeks after radiographic confirmation of fracture callus formation, at which time the patient is transitioned to a short-arm cast for an additional 2 weeks.

Physeal Fractures of the Distal Radius. Distal radial physeal fractures represent approximately 20% of all growth plate fractures in children, second in frequency only to those of the phalanges.[145] Remodeling potential, treatment principles, and surgical indications are similar to those for distal radial metaphyseal fractures, with several additional considerations. Specifically, reduction maneuvers should be performed gently, with adequate analgesia or sedation, to avoid iatrogenic physeal injury and growth disturbance of the distal radial physis. Similarly, multiple reduction attempts or repeated late reduction attempts are discouraged to minimize the risk of physeal arrest.[105] If fracture reduction is lost late during the period of cast immobilization, the deformity is often observed for bony remodeling with skeletal growth. If adequate alignment is not achieved, late corrective osteotomies are considered to correct the deformity and avoid secondary carpal instability patterns. Prior studies suggested that fractures with less than 15 degrees of angulation and up to 1 cm of shortening will demonstrate complete remodeling without functional impairment in skeletally immature patients.[36]

The overall risk of physeal arrest after distal radial physeal fracture, even following the foregoing principles, is approximately 4%.[16,32] In displaced distal ulnar physeal fractures, the risk of posttraumatic growth disturbance is higher, approaching 50%.[32,133] Patients and families should be counseled about this risk, and follow-up radiographs are mandatory to assess for physeal arrest.

Distal radial physeal arrest may lead to ulnar overgrowth, abnormal wrist mechanics, ulnocarpal impaction, TFCC tears, and DRUJ instability. In symptomatic patients, surgical treatment options include physeal bar resection, ulnar epiphysiodesis, ulnar shortening osteotomy, corrective radial osteotomy, or combinations thereof, depending on the pattern of arrest, severity of deformity, and amount of remaining skeletal growth (Box 41.2).[84,199]

❖ AUTHOR'S PREFERRED METHOD OF TREATMENT

Displaced fractures of the distal radial physis are initially reduced while the patient is under conscious sedation and then immobilized in a long-arm cast with appropriate three-point molding. Fracture reduction is usually stable and maintained in a cast. Excessive wrist flexion in the cast is avoided to minimize the risk of neurovascular compromise due to swelling in the

BOX 41.2 Physeal Fractures of the Distal Radius

Approximately 4% incidence of posttraumatic distal radial physeal arrest
- Perform closed reduction with adequate sedation or analgesia for displaced injuries
- Avoid late or repeated manipulations
- Surgical treatment recommended for irreducible fractures, open fractures, floating elbow injuries, or neurovascular compromise precluding circumferential cast immobilization

Reconstructive options for posttraumatic distal radial physeal arrest
- Ulnar shortening osteotomy
- Distal ulnar epiphysiodesis
- Corrective distal radial osteotomy
- TFCC repair
- DRUJ stabilization

DRUJ, Distal radioulnar joint; *TFCC*, triangular fibrocartilage complex.

acute fracture setting (Figure 41.32). If late loss of reduction is noted on serial radiographs, the deformity is accepted, and families are counseled regarding remodeling potential. The possibility of corrective osteotomy for persistent malalignment is addressed near skeletal maturity. Repeated forceful manipulations are not attempted. Owing to the risk of physeal arrest, patients with distal radial physeal fracture are reexamined 9 to 12 months after injury with repeat radiographs.

Surgical indications for distal radial physeal fractures include irreducible fractures or fractures associated with soft tissue compromise or neurovascular injury precluding cast immobilization. Closed reduction and pinning techniques are similar to those described for metaphyseal injuries (Video 41.3).

Distal ulnar physeal fractures are often seen in association with distal radial fractures and carry a high risk for subsequent growth arrest (Figure 41.33).[32,133] Although appropriate reduction of the radial fracture usually reduces the ulnar fracture, intervention is recommended for persistent translation greater than 50% or angulation greater than 20 degrees. Failure to obtain a closed reduction is often indicative of soft tissue interposition at the fracture site; in these situations, open reduction and fixation are required. Smooth pin fixation for 4 weeks typically suffices.

The principles for treating distal ulnar styloid fractures are similar to those applicable to adults. Fractures through the base are associated with injury to the TFCC and DRUJ instability. Unstable injuries are best treated with open reduction and internal fixation to avoid late DRUJ instability. These injuries occur in older adolescents, and smooth pinning with tension band fixation is recommended (Figure 41.34).

Physeal arrest is often discovered when a patient presents with persistent ulnar wrist pain in the setting of long-standing distal radial physeal arrest. Surgical intervention is recommended to improve symptoms, correct wrist mechanics, and avoid progressive pain and deformity (see Figure 41.33).[199] The overall goals of surgical reconstruction include (1) restoration of neutral ulnar variance, (2) restoration of volar tilt and at least 10 degrees of radial inclination of the distal radius, (3) repair or débridement of any traumatic TFCC tears, (4) reconstitution of a stable and congruent DRUJ, and (5) prevention of recurrent deformity. Surgical options include wrist arthroscopy and possibly arthroscopic-assisted TFCC repair, ulnar shortening osteotomy to restore neutral ulnar variance, distal ulnar epiphysiodesis to avoid recurrence, and, when appropriate, corrective osteotomies of the distal radius (Figure 41.35). A symptomatic ulnar styloid nonunion or DRUJ instability is treated at the same surgical setting with either ulnar styloid nonunion excision or internal fixation or open reduction of the DRUJ with radioulnar joint ligament reconstruction.

Ulnar osteotomy is performed via a longitudinal ulnar incision between the extensor carpi ulnaris and flexor carpi ulnaris. Parallel oblique osteotomies are created, removing a segment of bone for the desired amount of ulnar shortening. In older children, a specialized ulnar shortening system can be used. Osteotomy is performed at the metaphyseal-diaphyseal junction, which is vascular and increases the healing potential. It is advantageous to apply the desired plate and predrill and tap the screw holes distal to the osteotomy site before creating the osteotomy. Internal fixation is achieved with size-appropriate plates to obtain four to six cortices of fixation distal and proximal to the osteotomy site. In patients with remaining skeletal growth, the distal portion of the ulnar incision is used to expose the distal ulnar physis, and an epiphysiodesis is performed using curets or drill bits. Local bone graft may be placed in the physis to promote bony bar formation. Intraoperative fluoroscopy confirms the restoration of normal ulnar variance. Following ulnar shortening, wrist arthroscopy is often performed. With visualization in the standard 3-4 portal, TFCC débridement or repair is performed using standard techniques. If ulnar styloid nonunion is present, excision (or, less commonly, internal fixation) is performed. Patients are immobilized in long-arm casts (with the forearm supinated after the TFCC is repaired) for 4 weeks, followed by 2 weeks of short-arm casting. Therapy is then initiated.

Postoperative Expectations and Management

Torus fractures reliably heal without functional deficits. Displaced distal radial fractures require reduction and cast immobilization for realignment; healing is generally uneventful. Open reduction for irreducible distal radial fractures results in union and an acceptable outcome.

Excellent functional outcome is expected with adherence to the foregoing principles and meticulous surgical technique. Complications of distal radial and ulnar fractures include fracture malunion, nonunion, synostosis, physeal arrest, and neurovascular compromise.

Owing to the relatively high rate of late fracture displacement following initial closed reduction attempts, distal radial malunions also occur. Given the tremendous remodeling potential of distal radial fractures, observation is recommended for established malunions. In cases of persistent deformity of the distal radius or ulna, corrective osteotomy is performed to restore motion and avoid the risk of secondary carpal instability or arthrosis.[57,151]

Fracture nonunions are rare in children. Nonunion of the distal radius or ulna is due to disruption of the biologic healing potential, which may be seen in open fractures or intrinsic bone pathologic conditions (e.g., neurofibromatosis, congenital pseudarthrosis). In these situations, open reduction and internal fixation with autogenous corticocancellous bone graft or vascularized bone grafts is needed to promote healing and return to function.[17]

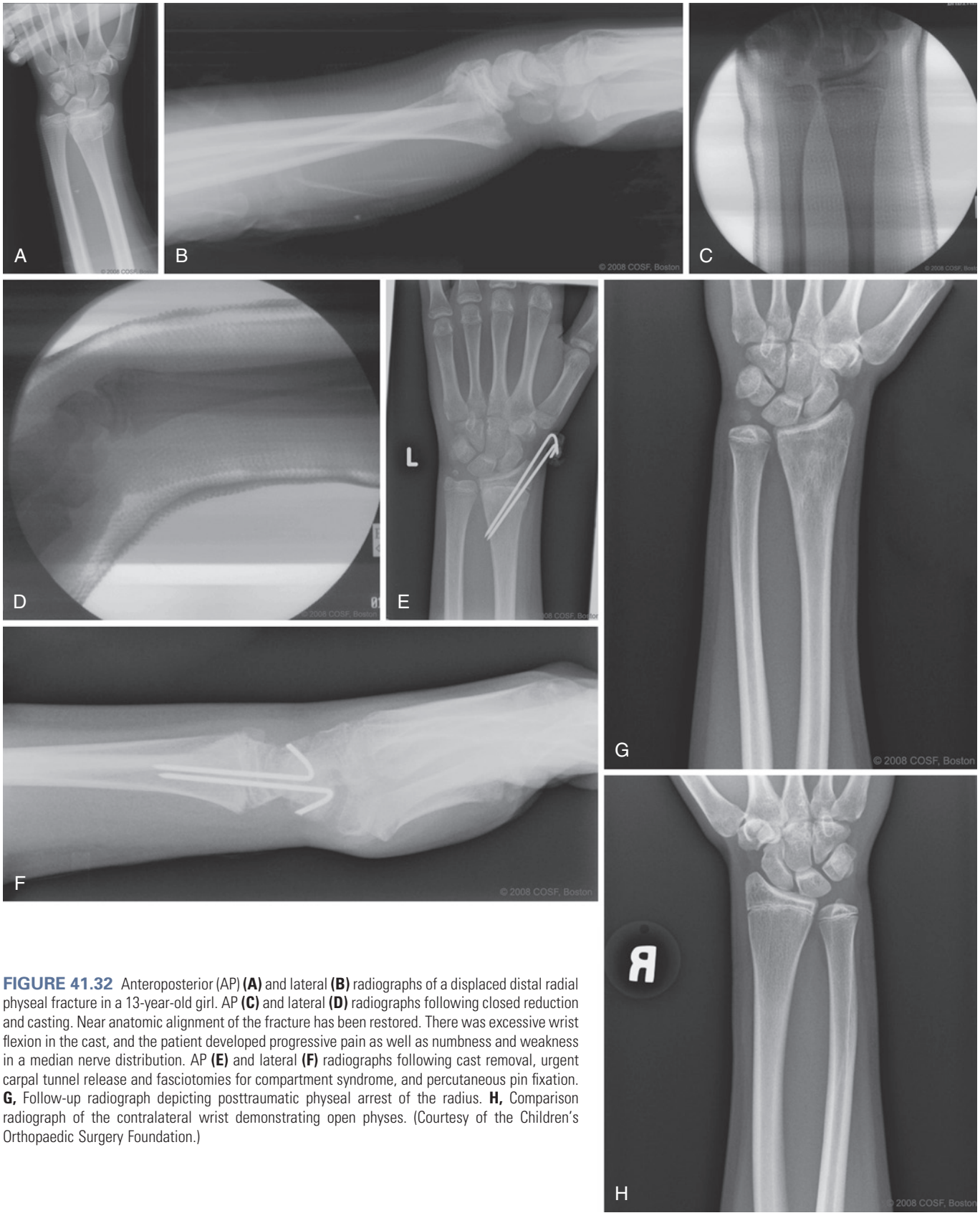

FIGURE 41.32 Anteroposterior (AP) **(A)** and lateral **(B)** radiographs of a displaced distal radial physeal fracture in a 13-year-old girl. AP **(C)** and lateral **(D)** radiographs following closed reduction and casting. Near anatomic alignment of the fracture has been restored. There was excessive wrist flexion in the cast, and the patient developed progressive pain as well as numbness and weakness in a median nerve distribution. AP **(E)** and lateral **(F)** radiographs following cast removal, urgent carpal tunnel release and fasciotomies for compartment syndrome, and percutaneous pin fixation. **G,** Follow-up radiograph depicting posttraumatic physeal arrest of the radius. **H,** Comparison radiograph of the contralateral wrist demonstrating open physes. (Courtesy of the Children's Orthopaedic Surgery Foundation.)

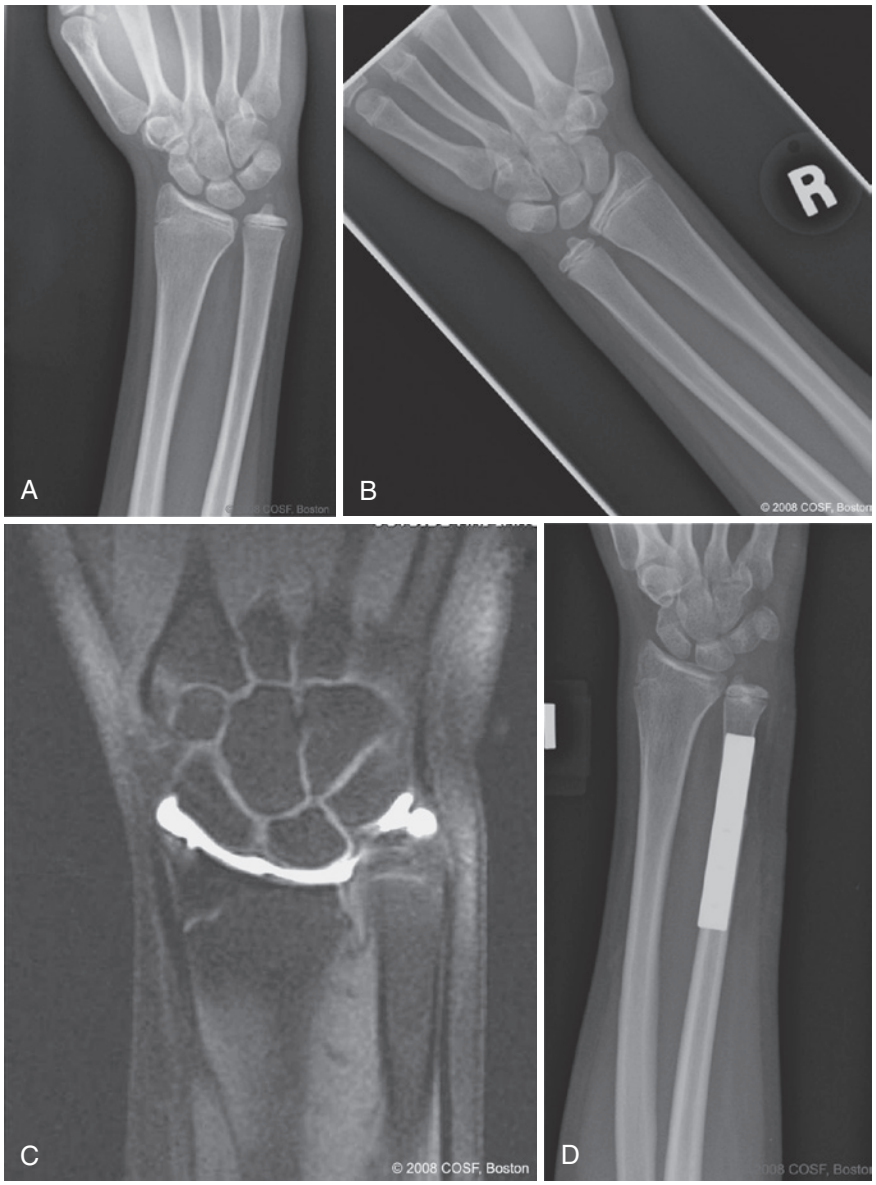

FIGURE 41.33 **A,** Anteroposterior radiograph of a wrist with posttraumatic distal radial growth arrest in a 14-year-old girl 1 year after physeal fracture. Note the premature physeal closure and positive ulnar variance, with subtle cystic changes in the lunate. **B,** Comparison radiograph of the contralateral wrist. **C,** Magnetic resonance imaging-arthrogram consistent with ulnocarpal impaction and a triangular fibrocartilage tear. **D,** Postoperative radiograph following ulnar shortening osteotomy and triangular fibrocartilage complex repair. (Courtesy of the Children's Orthopaedic Surgery Foundation.)

Posttraumatic radioulnar synostosis is uncommon following distal radial and ulnar fractures in children and is commonly associated with TFCC or ulnar styloid pathologic conditions.[13,220] Cross-union is seen, including open fractures or fractures with excessive soft tissue or periosteal stripping of same-level fractures. In established synostosis with functional limitation resulting from loss of forearm rotation, resection with or without soft tissue interposition should be considered.[196]

Physeal arrest occurs in 4% of distal radial physeal fractures and 50% of distal ulnar physeal fractures. Furthermore, there have been case reports of growth arrest after metaphyseal fractures. Monitoring and treatment of posttraumatic physeal arrest should follow the principles and techniques previously described. In cases of established distal radial growth arrest and ulnar overgrowth, corrective osteotomies with or without associated soft tissue procedures can alleviate symptoms due to ulnocarpal impaction, TFCC tears, or DRUJ instability[90,199] (Case Study 41.2). Distraction osteogenesis and physeal bar resection have also been advocated in selected patients.[110,138] Waters and coworkers published their results in 30 adolescents with posttraumatic distal radial growth arrest.[199] Combinations of ulnar shortening osteotomies, ulnar epiphysiodeses, and radial corrective osteotomies were performed to restore normal bony alignment and wrist mechanics. Considerable improvements in wrist motion, pain, and function were noted, with minimal complications.

CASE STUDY 41.2

An 11-year-old right-handed boy had hurt his left wrist 2 years previously while catching a wet Nerf ball. He complains of left wrist prominence (eFigures 41.5 through 41.8). The diagnosis was physeal bar radius with growth arrest and ulnar-positive variance. The treatment options were observation, bar resection, radial lengthening, and ulnar epiphysiodesis. Because of the patient's age and sick physis, the treatment selected was ulnar epiphysiodesis and radial lengthening (eFigure 41.9, *A* to *H*).

Postoperative and 3-month follow-up x-rays are shown (eFigures 41.10, *A* and *B*, and 41.11, *A* and *B*). Clinical photographs are shown in Figure 41.35, *M* and *N*, and eFigure 41.12, *A* and *B*.

Scott H. Kozin

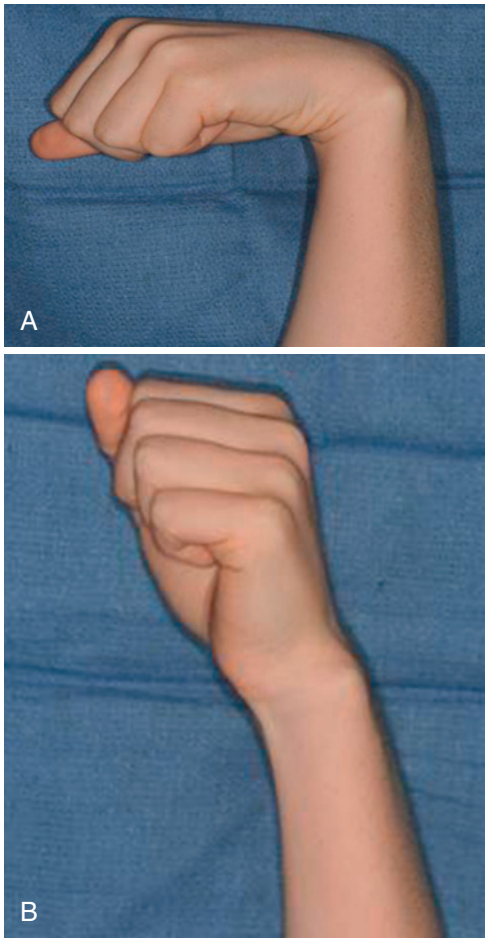

eFIGURE 41.5 **A** and **B**, Range of motion.



eFIGURE 41.6 Dorsal ulnar prominence.



eFIGURE 41.7 Preoperative range of motion.

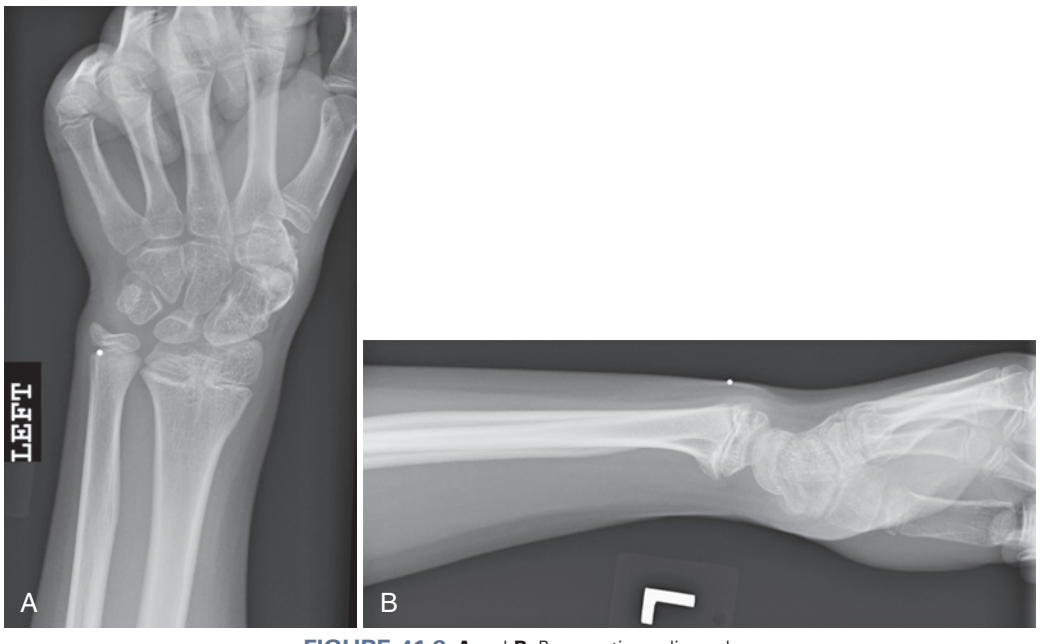

eFIGURE 41.8 **A** and **B,** Preoperative radiographs.



eFIGURE 41.9 Preoperative magnetic resonance imaging.

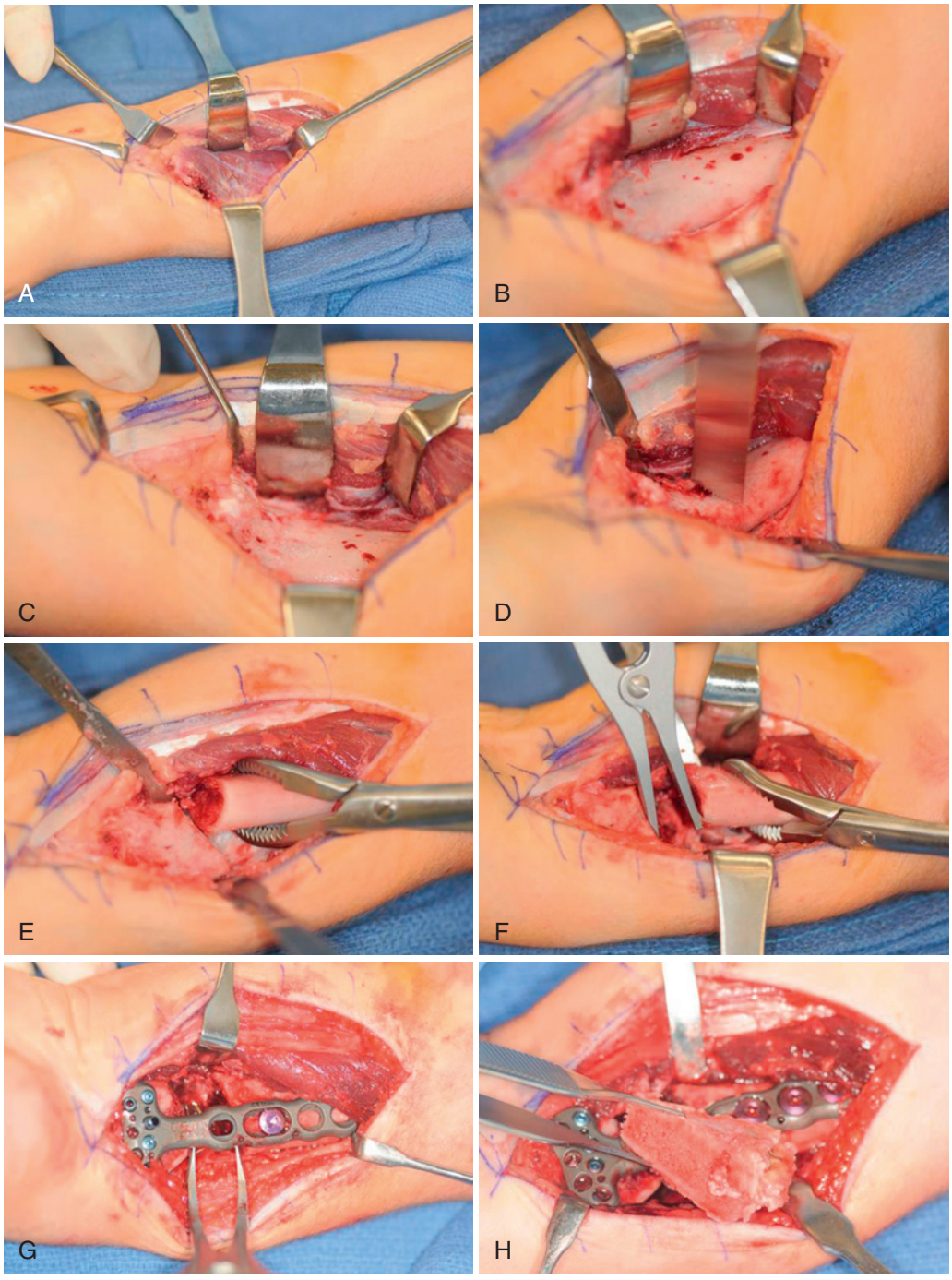

eFIGURE 41.10 **A,** Trans–flexor carpi radialis approach. **B,** Pronator quadratus elevated. **C,** Deformity. **D,** Radial osteotomy. **E,** Osteotomy completed. **F,** Radial lengthening. **G,** Plate fixation. **H,** Tricortical autograft.

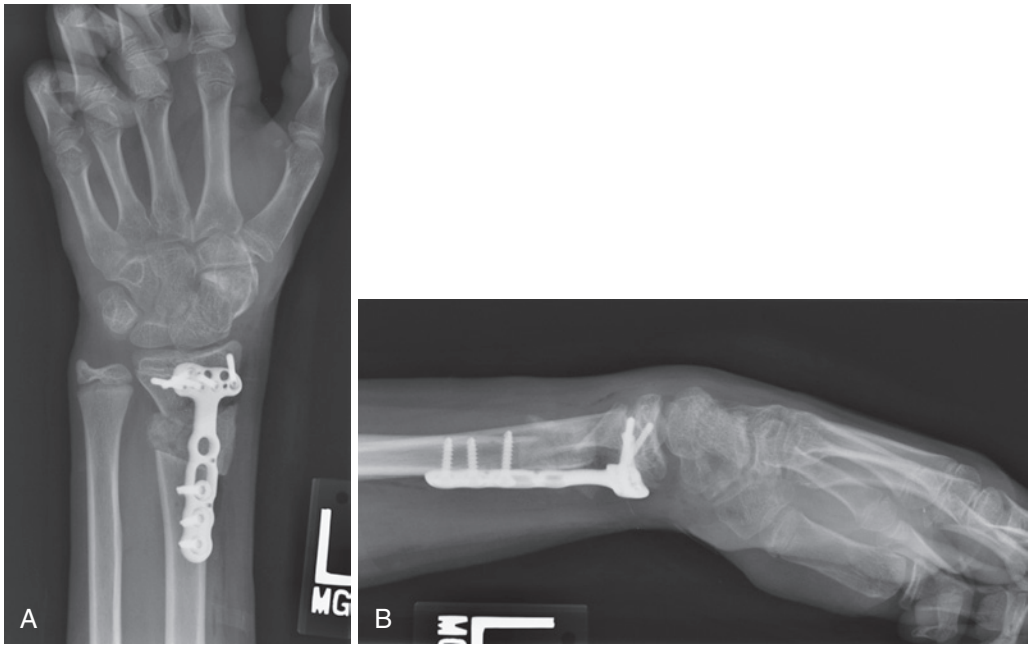

eFIGURE 41.11 **A** and **B,** Postoperative x-rays.

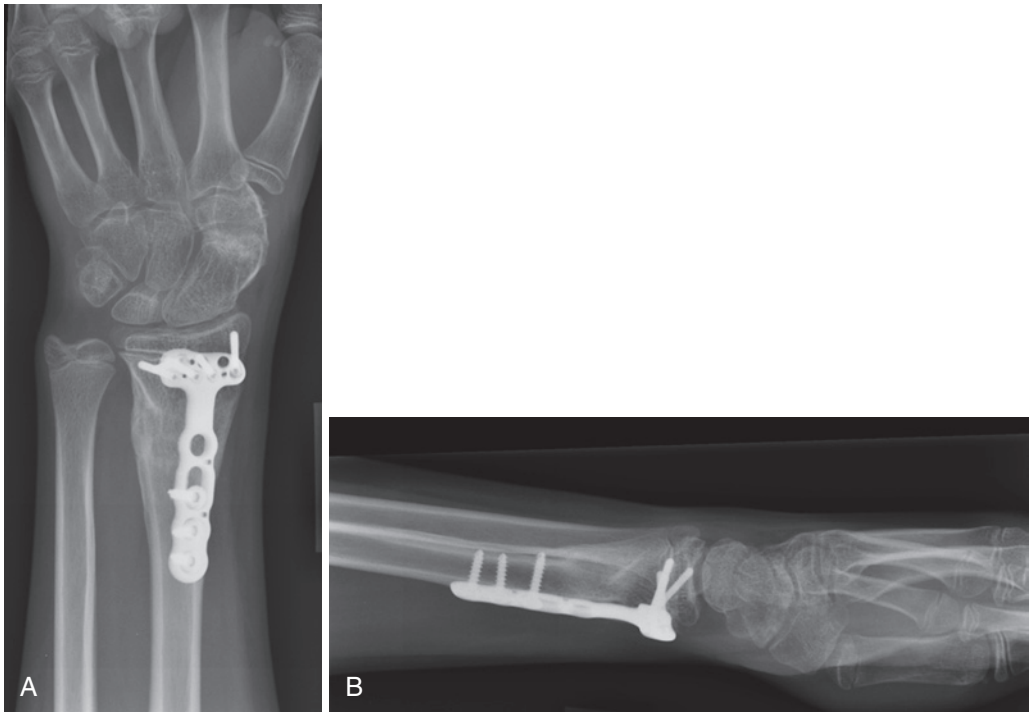

eFIGURE 41.12 **A** and **B,** Radiographs at 3 months following operation.



FIGURE 41.34 **A** and **B,** Preoperative radiographs of a displaced distal radial and ulnar styloid fracture in a 14-year-old girl with open physes. **C** and **D,** Postoperative radiographs after closed reduction and pinning of the radius and open reduction and internal fixation of the ulnar styloid. A tension band technique was performed in the styloid, using smooth pins and figure-of-eight nonabsorbable suture. The pins from the radius have been removed. (Courtesy of the Children's Orthopaedic Surgery Foundation.)

CRITICAL POINTS *Distal Radial Fractures*

- Torus fractures can be safely and effectively treated with brief splint or cast immobilization.
- Late displacement is seen in approximately one third of complete distal radial fractures following closed reduction and cast immobilization.
- Repeated or late reduction attempts are discouraged in displaced distal radial physeal fractures.
- Posttraumatic growth disturbance occurs in approximately 4% of distal radial and 50% of distal ulnar physeal fractures.
- Epiphysiodeses, ulnar shortening osteotomies, radial corrective osteotomies, or TFCC and DRUJ repairs can be performed to treat symptomatic distal radial growth arrest and ulnar overgrowth.

FOREARM DIAPHYSEAL FRACTURES

Forearm fractures are among the most common injuries presenting to orthopedic surgeons and the most common childhood skeletal injury requiring surgical care.[34,39] Despite the frequency with which they occur and the plethora of information available regarding their management, the treatment of forearm fractures remains challenging. There is a range of fracture patterns and presentations, a diversity of nonoperative and surgical techniques, issues of skeletal growth and bony remodeling, and ever-changing patient and family expectations. Furthermore, interpreting the published information regarding treatment and outcomes of forearm diaphyseal fractures is fraught with difficulty. Often, diaphyseal fractures are included with distal metaphyseal fractures of the radius and ulna, which represent a distinct category of clinical injuries, treatment

options, and expected outcomes. Historically, almost all pediatric forearm fractures were treated nonoperatively; however, more recent information regarding functional outcome has challenged the traditional tenets of forearm fracture care. Adding to treatment challenges are the desire for a more expedient return to full activity and expectations of immediate and normal motion and strength. Furthermore, with the advent of new instrumentation and techniques of fracture fixation, surgical treatment options have expanded.

Epidemiology

Forearm fractures are common, occurring in approximately 1 of 100 children each year.[39] When fractures of the distal radius and ulna are considered as a distinct injury, diaphyseal forearm fractures represent the third most common long bone fracture in children, following distal radial and supracondylar humeral fractures.[34] The peak age of incidence is 12 to 14 years. Diaphyseal forearm fractures are the most common open fractures of the upper extremity and represent the most common location of refracture in the pediatric population.[124]

The mechanism of injury is usually a fall onto an outstretched upper limb, imparting both axial loads and rotation or bending forces to the forearm. The position of the limb at the time of injury and the forces applied dictate the pattern of diaphyseal fracture. Radial and ulnar fractures at the same level result from predominantly bending forces, whereas fractures at different levels occur due to rotational forces. Extrapolated further, high-energy torsional mechanisms can cause both

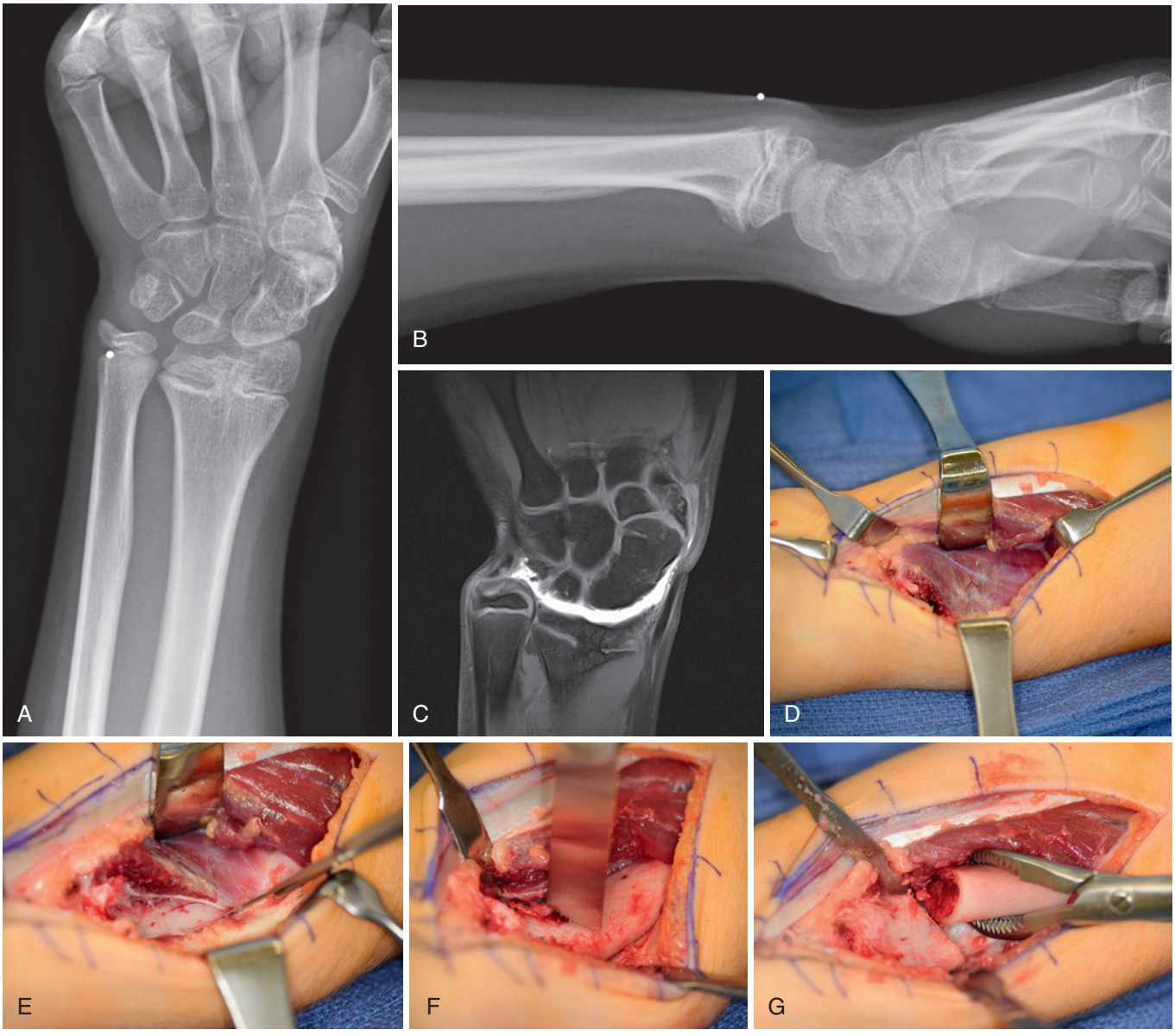

FIGURE 41.35 Eleven-year-old who sustained left wrist injury 2 years ago after catching a wet Nerf football. **A,** Anteroposterior (AP) radiograph reveals shortening of the radius and ulnar positive variance. **B,** Lateral radiograph shows sagittal plane deformity. **C,** Magnetic resonance imaging confirms central bar. **D,** Following ulnar epiphysiodesis, transflexor carpi radialis approach to radius. **E,** Pronator quadratus elevated. **F,** Radial osteotomy. **G,** Osteotomy completed.

Continued



FIGURE 41.35, cont'd **H,** Osteotomy distracted. **I,** Plate and screw fixation. **J,** Iliac crest autograft. **K,** Postoperative AP radiograph after healing. **L,** Lateral radiograph with crossing trabeculae. **M,** Wrist extension. **N,** Wrist flexion. (Courtesy of Shriners Hospital for Children, Philadelphia.)

skeletal injuries and soft tissue disruption of the ligamentous complexes stabilizing the proximal and distal radioulnar joints (e.g., Monteggia and Galeazzi fracture-dislocations).[14,64,131]

Preoperative Evaluation

Patients present with pain, deformity, swelling, and limited forearm motion after a fall onto an outstretched upper limb. Inspection of the overlying skin and soft tissue is mandatory to assess for an open fracture. Furthermore, a thorough neurovascular examination is performed to rule out associated nerve palsies, vascular insufficiency, or impending compartment syndrome.[47,74,113] The wrist and elbow are also carefully assessed for a possible ligamentous injury (e.g., Monteggia fracture-dislocation) or concomitant ipsilateral upper extremity fracture (e.g., floating elbow).[159,174]

Standard AP and lateral radiographs of the forearm, including visualization of the wrist and elbow, are performed in all cases of suspected forearm fracture. The x-rays are evaluated to ensure that there is no disruption of the DRUJ or radiocapitellar articulation. A congruent relationship should exist between the distal radius and ulna on both AP and lateral projections, and the longitudinal axis of the radius should bisect the capitellar ossification center on all views.

Diaphyseal fractures of the forearm are classified according to anatomic location (proximal, middle, or distal third), fracture displacement and angulation, and fracture pattern. In general, three patterns of diaphyseal fractures occur: plastic deformation, greenstick or incomplete fractures, and complete fractures. Each fracture pattern has its own set of treatment considerations.

Plastic deformation, or traumatic bowing, macroscopically presents as bones that are "bent but not broken."[25] Typically, this type of injury occurs during the first decade of life, and there is often little gross deformity, swelling, or ecchymosis and

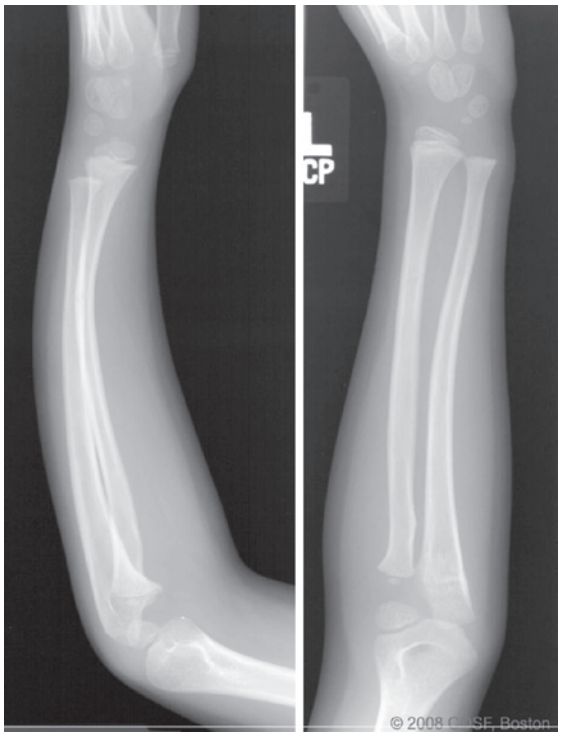

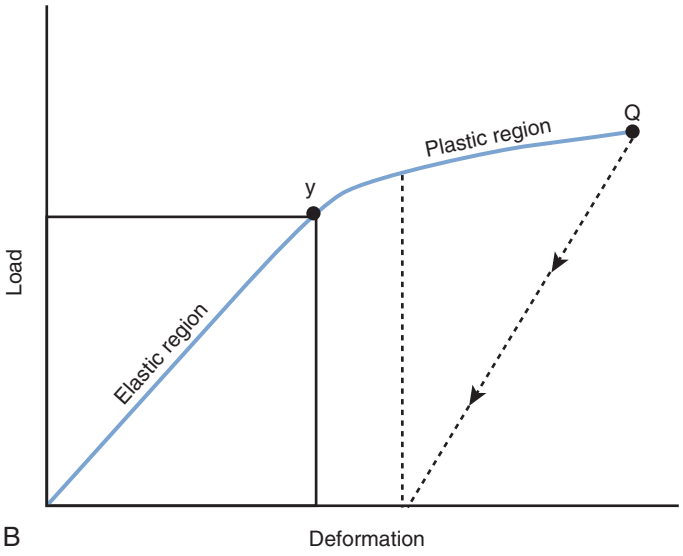

FIGURE 41.36 **A,** Radiographs depicting plastic deformation of the forearm in a 6-year-old boy. **B,** Stress-strain curve depicting the biomechanical mechanism of plastic deformation injuries. The *y* signifies the yield point, and the *Q* denotes the ultimate failure point.

varying degrees of pain and tenderness. Radiographic findings may be subtle, characterized by abnormal curvature of the radial or ulnar shafts in association with narrowing of the interosseous space (Figure 41.36, *A*). Understanding of the normal radiographic appearance of the radius and ulna, particularly the normal radial bow, is imperative in identifying plastic deformation injuries.[58] Histologically, plastic deformation injuries are characterized by slip lines, parallel zones of disruption between bent or wrinkled fiber bundles, and disruption of canaliculi. Biomechanically, plastic deformation injuries occur as the load applied to the bone exceeds the bone's elastic limits but does not exceed its ultimate strength. As a result, the material properties of the bone enter the plastic region of the stress-strain relationship. As the load is withdrawn, plastic deformation results, along with deformity (see Figure 41.36, *B*).[25]

Greenstick fractures represent the intermediate stage of bony failure between plastic deformation and complete fractures (Figure 41.37). Radiographically, one to three cortices may be disrupted on orthogonal views, with the remaining cortices intact or demonstrating traumatic bowing. These injuries result from torsional mechanisms, and the apex of the bony angulation provides insight into the rotational deformity. In general, apex dorsal fractures are caused by hyperpronation and therefore are reduced with forearm supination.[124] Conversely, apex volar fractures are due to hypersupination and are best reduced with pronation. The "rule of thumbs," in which the thumb is rotated toward the apex of the deformity, has been proposed to guide care providers in choosing the appropriate reduction maneuver. For example, in the common apex volar angulated fracture, rotating the thumb imparts pronation of the distal fracture fragment, thus counteracting the hypersupination injury. In situations in which the radius and ulna are fractured at the same level, pure bending is more likely to be the mechanism of injury, and reduction can be achieved with simple three-point molding. Complete fractures involve complete cortical disruption and are akin to their adult counterparts in terms of mechanism of injury, clinical presentation, and radiographic appearance.

Although a number of classification systems exist to describe pediatric forearm fractures, few are practical for guiding treatment or providing prognostic information. For this reason, anatomic descriptions of the fracture location, fracture pattern, degree of angulation and displacement, and associated soft tissue injuries are typically employed. In general, there are two bones (radius, ulna), three levels (proximal, middle, distal), and four fracture patterns (plastic deformation, greenstick, complete, comminuted).[124] Although rotational alignment is important to consider and may affect the ultimate outcome in terms of forearm rotation, malrotation is difficult to quantitate using radiographic indices and may be off by as much as 45 degrees.[42,148]

PERTINENT ANATOMY

The radius is a complex, "S"-shaped bone with approximately 15 degrees of apex ulnar angulation in the region of the radial neck and a gentle bow of 10 degrees of apex radial angulation in the middiaphyseal region.[58] The bicipital tuberosity and radial styloid lie approximately 180 degrees from each other, an important relationship that aids in the assessment of rotational malalignment. The ulna is triangular in cross section and predominantly straight in its longitudinal alignment, with the exception of a mild apex radial bow in the proximal olecranon region. The ulnar styloid and coronoid process lie approximately 180 degrees from each other, likewise aiding in the estimation of rotational deformity. Normal forearm rotation averages 150 to 180 degrees and occurs around an axis between the radial head and distal ulna.

The nutrient artery of the radius enters in the volar proximal half of the radius and travels in a distal ulnar direction.[70] The nutrient artery of the ulna enters in the volar proximal half and courses distally and radially. Awareness of the location of these

nutrient vessels helps avoid misdiagnosing these radiolucencies as fractures.

Soft tissue connections between the radius and ulna impart stability and are implicated in limiting forearm rotation in patients with stiffness despite near-normal radiographic alignment. These connections constitute the ligamentous stabilizers of the distal and proximal radioulnar joints as well as the interosseous ligament (see Chapter 14 for further discussion of these soft tissue restraints and their disorders).

Historical Review

Much of the available literature guiding diaphyseal fracture treatment and anticipated outcomes is based on the desire to promote adequate bony healing and avoid loss of forearm motion or aesthetically displeasing results.[22,82,135,186]

Aesthetic problems following diaphyseal malunion are caused by deformity of the ulna, owing to its subcutaneous location and straight longitudinal shape. Conversely, loss of forearm rotation is a result of a radial malunion, with or without

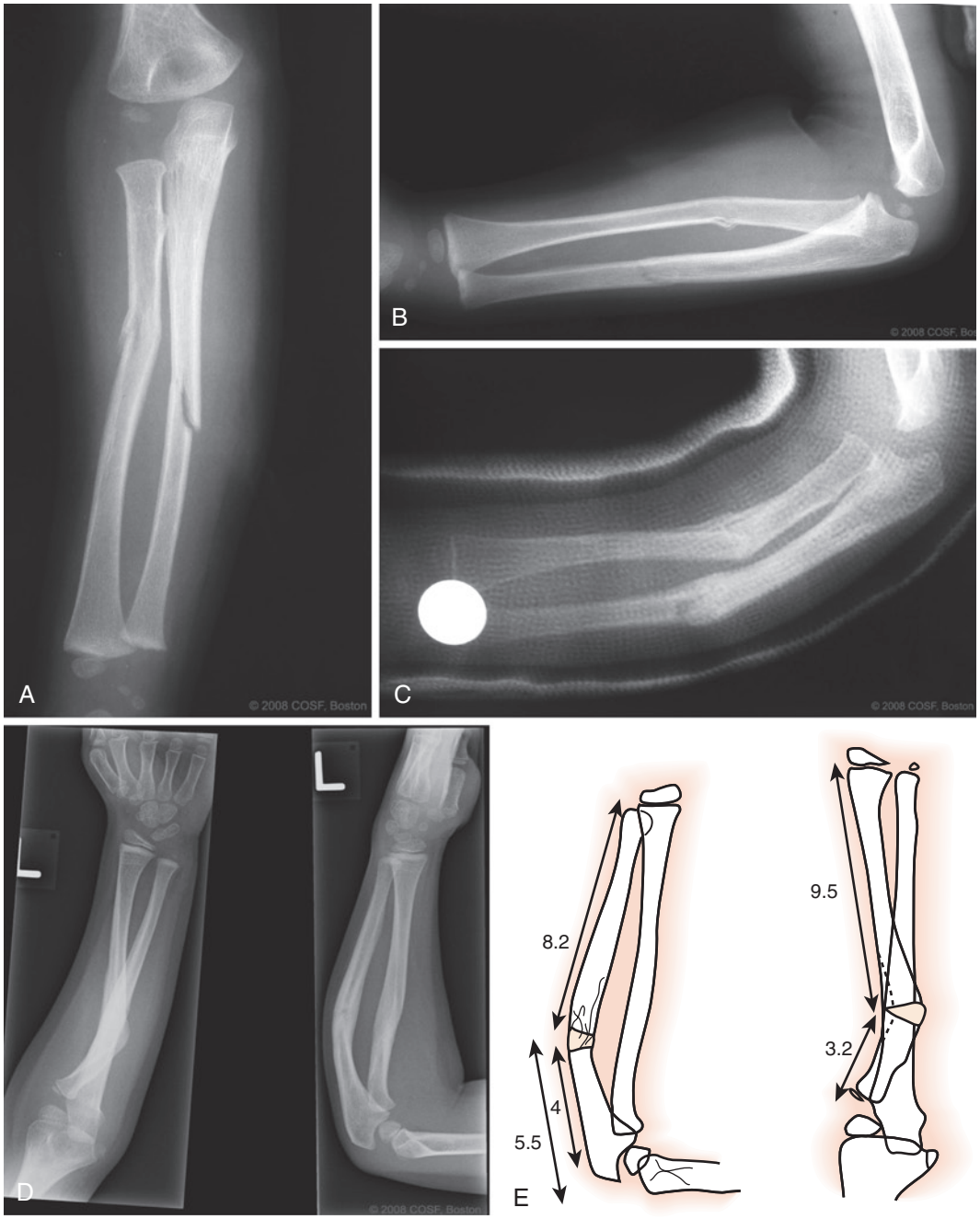

FIGURE 41.37 Initial anteroposterior (AP) **(A)** and lateral **(B)** radiographs of a 7-year-old girl with greenstick fractures of the radius and ulna diaphysis. **C,** Radiograph following closed reduction and cast immobilization. Note the lack of a three-point mold, straight ulnar border, and interosseous mold, resulting in progressive deformity. **D,** AP and lateral radiographs at the time of bony healing, with approximately 45 and 25 degrees of angulation of the radius and ulna, respectively. There was considerable aesthetic deformity and loss of forearm motion. **E,** Preoperative plan depicting closing wedge osteotomies at the apex of the radial and ulnar deformities.

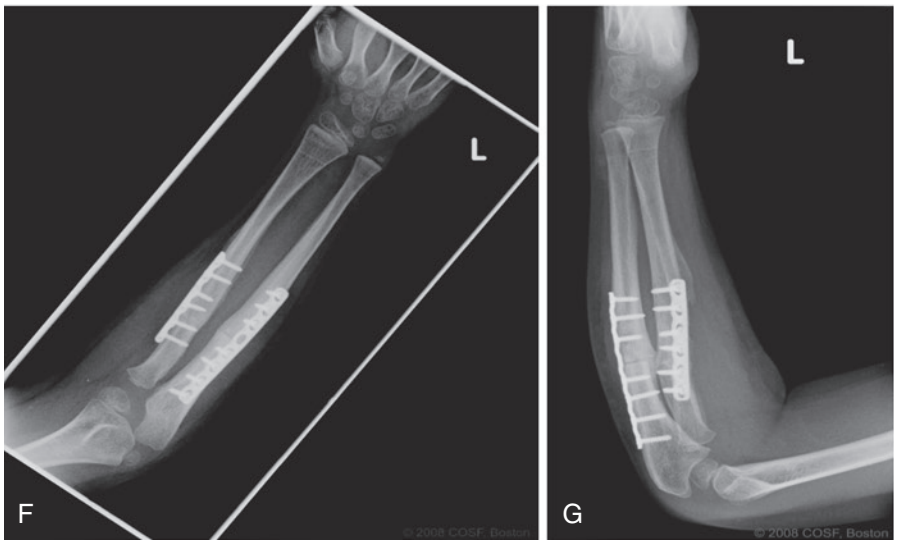

FIGURE 41.37, cont'd AP **(F)** and lateral **(G)** radiographs after corrective osteotomy and internal fixation using 2.4-mm plates. Note the restoration of longitudinal alignment and rotation, with the radial styloid opposite the bicipital tuberosity and the ulnar styloid opposite the coronoid process. (Courtesy of the Children's Orthopaedic Surgery Foundation.)

concomitant ulnar deformity. Although loss of pronation is typically compensated for by shoulder abduction, forearm supination is poorly accommodated owing to the blocking effect of the thorax with attempted shoulder adduction.[148] Multiple published series have demonstrated that diaphyseal fracture malunions contribute to loss of forearm rotation and functional impairment.[45,125,148,186] Cadaveric studies have demonstrated that whereas 10 degrees of angulation results in little if any loss of forearm rotation, greater than 10 degrees of angulation is a considerable impediment to forearm rotation. Recently, it has become increasingly apparent that more proximal forearm deformity imparts greater restrictions in forearm rotation. As a result, less angular or rotational deformity is tolerated in more proximal fractures than in more distal ones.

Rotational deformities, though difficult to quantify by x-ray, cause concomitant loss of forearm rotation.[45,94] For every degree of rotational deformity, 1 to 2 degrees of forearm rotation is lost. In general, ulnar malrotation does not alter the overall arc of forearm rotation but does change the "set point" of forearm motion. Conversely, radial malrotation affects the overall range of forearm supination-pronation. Ultimately, however, clinical outcomes in terms of forearm rotation are not always directly correlated to radiographic alignment.[135]

Adding to the complexity of treating pediatric diaphyseal fractures of the radius and ulna is the potential for bony remodeling with continued skeletal growth. Remodeling occurs as a result of reorientation of the adjacent physis with continued physeal growth; bony lengthening, which reduces the apparent angulation between the proximal and distal diaphyseal segments; and appositional periosteal bone formation at the concavity of the deformity. As with bony remodeling of other long bones, remodeling is greatest in younger patients, with fractures close to the adjacent physis, and with deformity in the plane of adjacent joint motion. In general, up to 20 degrees of diaphyseal angulation can remodel in children younger than 8 years. Beyond the age of 10 years, more than 10 degrees of angulation is unlikely to remodel.

Review of the literature provides guidelines as to how much radiographic deformity will remodel with growth. Up to 1 cm of shortening may be accepted, with little impact on forearm rotation, perhaps due to relaxation of the interosseous membrane.[50,148] Complete or 100% translation reliably remodels in younger patients with fractures of the middle and distal thirds.[42,50,148] Radioulnar angulation or translation is less well tolerated, particularly in older children with less remaining growth, owing to narrowing of the interosseous space and potential bony impingement resulting in loss of forearm rotation. Mehlman and Wall proposed the "20-15-10" rule for determining acceptable angulation in radial and ulnar fractures.[124] Dividing the forearm into thirds, 20, 15, and 10 degrees of angulation may be accepted in the distal, middle, and proximal thirds of the forearm, respectively.

In addition to radiographic parameters of angulation, displacement, and translation, other measurements have been proposed to predict the final position of diaphyseal forearm fractures following reduction and cast immobilization and the ultimate outcome. Younger and associates proposed that axis deviation be used to predict outcomes following forearm diaphyseal fractures and thus guide when closed reduction or surgical intervention is required (see Figure 41.30).[214,215] Axis deviation is defined as the distance between the fractured and anatomic axes of the bone measured at the fracture site, divided by the total length of the bone multiplied by 100. An axis deviation greater than 5 at the time of bony healing (i.e., cast removal) has been correlated with restricted forearm motion even after completion of skeletal growth and bony remodeling. The theoretical advantages of the axis deviation index are that it eliminates the confounding variables of radiographic projection, magnification, and fracture location and does not rely strictly on radiographic angulation or translation to predict functional loss.

Because clinical motion does not directly correlate with radiographic alignment, perhaps a more compelling and relevant question is how much deformity is acceptable for

a reasonable functional outcome. Historically, studies have demonstrated that 10 degrees of angulation, complete translation, and 30 to 45 degrees of malrotation may be well tolerated without functional limitations.[148] These data require careful interpretation, however, and it must be recognized that it is difficult to quantify "reasonable function" in the setting of objective losses in forearm rotation.

Types of Operations for Wrist Fractures

Treatment goals for pediatric radial and ulnar diaphyseal fractures are to achieve bony union while preserving forearm motion and minimizing complications. Although surgical techniques and implants have improved, the importance of skilled closed reduction and artful cast application cannot be overemphasized.

Plastic Deformation

Some authors believe that closed reduction should be attempted for all plastic deformation injuries with more than 20 degrees of angulation in patients older than 4 years, given the limited remodeling potential owing to the fact that the periosteum is not elevated or disrupted and the apex of the deformity and the fracture are often a distance from the adjacent physes.[25,163,197] Prior studies demonstrated that forces as high as 30 kg sustained over several minutes are required to correct traumatic bowing.[163] As a result, controlled three-point bending under general anesthesia or well-administered conscious sedation over a fulcrum (e.g., sandbag or rolled towel) is recommended to achieve correction. Analgesia and sedation options include hematoma block, inhalational anesthesia, and intravenous conscious sedation.

Good casting technique is imperative for maintaining reduction and optimizing outcome. Casts should be applied with a straight ulnar border, interosseous mold, and three-point molding over the apex of the deformity.[91] The resulting cast is often aesthetically displeasing to the patient and family; however, "curved plaster is necessary in order to make a straight limb."[33] With appropriate reduction and casting, up to 85% correction of the deformity can be expected, with minimal long-term restrictions in forearm motion.

In rare situations, a large amount of plastic deformation is not correctable, despite vigorous closed reduction. In these situations, percutaneous pin or drill osteoclasis at the apex of the deformity is performed, followed by correction of longitudinal alignment and appropriate cast immobilization. This technique converts a plastic deformation injury into an incomplete or complete fracture to effectuate reduction.

Greenstick Fractures

Greenstick fractures are effectively treated with closed reduction and well-molded cast immobilization in the majority of cases. Following an analysis of the radiographic findings and understanding of the causative mechanism of injury (e.g., pronation, supination, bending), closed reduction is performed by reversing the rotational deformity, followed by correction of the angulation. An appropriately applied cast with appropriate interosseous and three-point molding is critical in maintaining fracture reduction during bony healing (see Figure 41.37, *C* and *D*). There continues to be controversy regarding the need to complete the greenstick fracture by disrupting the intact cortex at the concavity of the deformity. Proponents of fracture completion cite the theoretical advantages of easier anatomic realignment, lower risk of loss of reduction, and lower refracture rate owing to the exuberant periosteal callus formation that ensues. Opponents cite the greater fracture instability and difficulty in maintaining reduction with fracture completion.

Complete Fractures

In patients with complete fractures of the radius and ulna diaphyses and unacceptable deformity, closed reduction is initially recommended. With adequate analgesia and sedation, closed reduction is performed by first exaggerating the deformity to relax the intact periosteum, applying longitudinal traction, and correcting the rotational malalignment; then the angular deformity is reversed. A long-arm cast with appropriate interosseous and three-point bending mold is applied.

The position of cast immobilization is debated. Although the majority of casts are applied with the elbow flexed 90 degrees, long-arm extension casts have been used with great success in proximal third fractures with apex posterior or apex ulnar angulation (Figure 41.38).[198] If extension casts are used, addition of a thumb spica component and placement of a "D"-ring with neck strap help prevent distal migration of the cast with walking and upright activity.

The optimal position of forearm rotation is even more open to debate, with little published information to provide guidance. Theoretically, fractures of the proximal one-third of the radius may be better immobilized in supination; the distal fragment is rotated into position in relation to the proximal fragment, which is typically supinated by the action of the biceps and supinator muscles. Similarly, middiaphyseal fractures occurring proximal to the insertion of the pronator teres may be better immobilized with the distal segment supinated, again matching rotational alignment. Conversely, fractures distal to the pronator teres insertion on the radius may be best immobilized in neutral rotation or forearm pronation.

Serial radiographs are recommended weekly for the first 2 to 3 weeks to ensure maintenance of reduction and identify unstable fractures. Loss of reduction may be seen in 5 to 25% of fractures and may occur up to 4 weeks after injury. Cast wedging may be considered in patients with loss of reduction and fracture angulation.[162] Provided adequate fracture reduction is maintained, patients can be safely transitioned to short-arm casts at 4 weeks. Short-arm casting is continued until 6 weeks after injury. Some recommend a brief period of splint immobilization after cast removal, and patients and families are counseled about refracture risk and judicious choice of activities.[25,26,164]

Surgical indications for diaphyseal fractures of the forearm include open fractures, soft tissue swelling or neurovascular compromise that precludes circumferential cast immobilization, floating elbow injuries, and irreducible or unstable fractures that fail nonoperative treatment. In addition, refracture is considered a relative indication for surgical stabilization, given the difficulties in achieving and maintaining fracture reduction in these situations. Although there are numerous surgical options, percutaneous pinning techniques are generally insufficient, and external fixation is poorly tolerated (Figure 41.39). As a result, most forearm diaphyseal fractures are currently

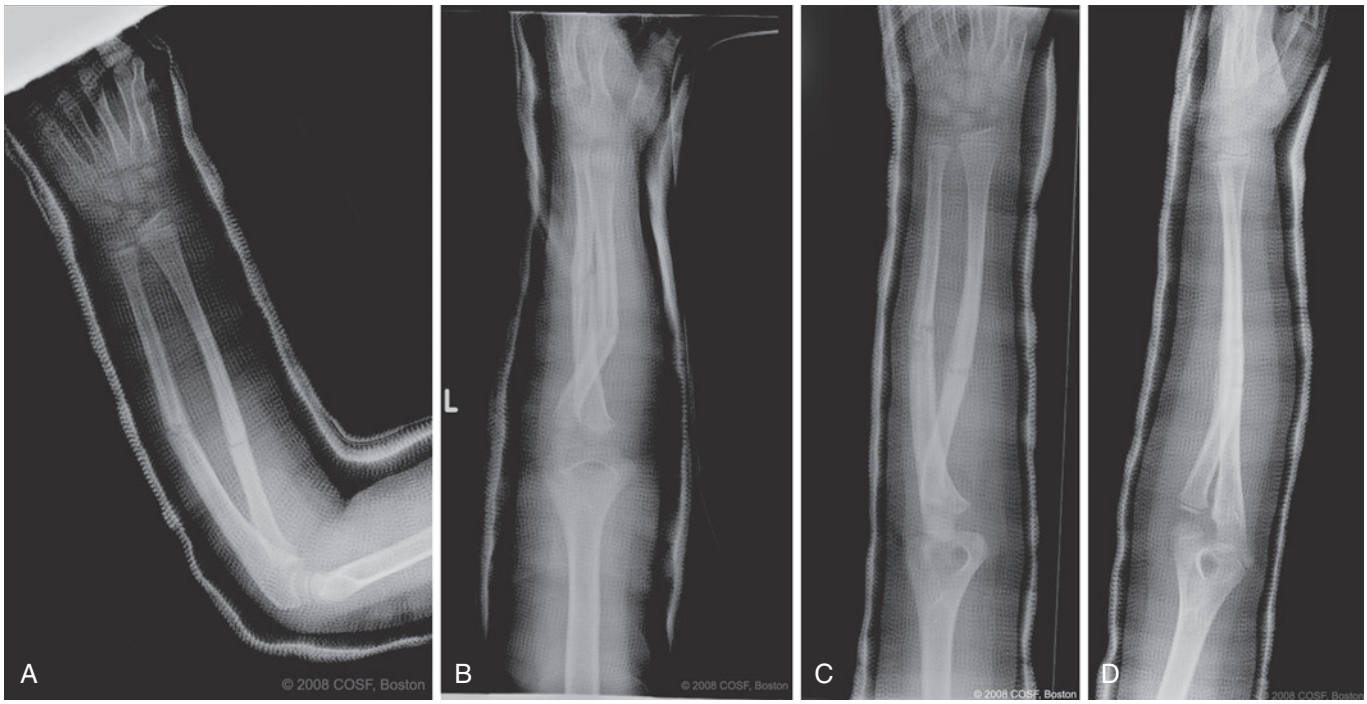

FIGURE 41.38 Anteroposterior **(A)** and lateral **(B)** radiographs of diaphyseal fractures of the radius and ulna in a 6-year-old child. Progressive angulation was noted during cast immobilization, particularly of the radius. **C** and **D,** Improved alignment is noted after extension casting. (Courtesy of the Children's Orthopaedic Surgery Foundation.)

treated with intramedullary fixation or internal fixation with plate and screw constructs.

Intramedullary fixation is well accepted and is becoming the preferred technique for forearm diaphyseal fracture stabilization in children and adolescents. [12,60,104,105,112,192,195,217] Smooth stainless steel Kirschner wires, titanium elastic nails, Rush rods, and Steinmann pins have all been used with reported success, emphasizing the importance of surgical principles over choice of implant. All radial implants can be prebent to facilitate restoration of the normal radial bow. Although length and angular correction is achieved by fracture reduction and intramedullary stabilization, rotational stability is typically conferred by the intact periosteum and surrounding soft tissues. These intramedullary devices are introduced into the intramedullary canal via small incisions and passed across the fracture site after closed reduction or limited open reduction. This technique avoids deep tissue dissection and extensive periosteal stripping, thus preserving the robust biologic healing potential in children and leading to expedient bony healing.

Radial intramedullary implants are typically introduced into the distal metaphysis either just proximal to the Lister tubercle or between the first and second extensor compartments. Ulnar intramedullary devices are introduced in the proximal ulnar metaphysis dorsally or through the olecranon apophysis (Figure 41.40). Maximal stability is achieved if the intramedullary nails are passed to within 1 cm of the far physis. Following intramedullary fixation, implants are typically bent and trimmed close to the cortical margin, with enough implant prominence to facilitate staged removal after bony healing. Less commonly, implants may be bent and cut outside the skin to allow easy removal in the office setting. Early removal of implants left outside the skin may obviate the need for a second anesthetic, but there are greater risks of refracture and superficial or deep pin tract infections. If implants are cut beneath the skin, elective removal is recommended 6 to 12 months after the index procedure.

In young patients, single-bone fixation of both bone fractures has been proposed. After intramedullary nailing of either the ulna (more commonly) or the radius, if acceptable alignment of the other bone is achieved and adequate fracture stability is demonstrated by intraoperative fluoroscopic evaluation of elbow and forearm motion, the remaining bone can be treated with supplemental cast immobilization.[46]

Formal open reduction and internal fixation using plate and screw constructs can also be performed, but this is usually reserved for older adolescents with less than 2 years of remaining skeletal growth (i.e., boys older than 14 and girls older than 12). The surgical technique is similar to that in adults, with several modifications. First, adequate stability may be achieved with four cortices of fixation proximal and distal to the fracture site, particularly if supplemented by postoperative cast immobilization. In addition, given the smaller size of the radius and ulna in children and adolescents, size-appropriate implants (2.4- or 2.7-mm compression plates, one-third tubular plates) should be used. The theoretical advantages of plate and screw fixation include the ability to achieve anatomic reduction and maximize return of full forearm rotation, particularly in older adolescents with little skeletal remodeling potential. Furthermore, given the mechanical stability achieved, early motion can be initiated, perhaps mitigating the soft tissue contractures that may contribute to loss of motion. Disadvantages of plate fixation include the need for more extensive dissection, slower bony healing, and increased scarring.



FIGURE 41.39 **A** and **B,** Preoperative radiographs of diaphyseal radial and ulnar fractures in a 13-year-old boy. **C,** Immediate postoperative radiographs following attempts at percutaneous pin fixation. Note that the pins cross at the fracture site, failing to impart rotational control. **D** and **E,** Final position at the time of bony healing, with a 40-degree angular malunion of the radius. Because of the patient's age and fracture location, little skeletal remodeling is expected. (Courtesy of the Children's Orthopaedic Surgery Foundation.)

The need for implant removal after bony healing remains controversial.[97,103,111,144] Some advocate the routine removal of plate and screw constructs after bony healing of forearm fractures, citing the risks of refracture, growth alteration, metallic allergies, and adverse effects on bone density due to mechanical stress shielding. Others cite the low frequency of symptomatic implants and complication rates of up to 40% as arguments against implant removal from the upper extremity in children.

❖ AUTHOR'S PREFERRED METHOD OF TREATMENT

For children and younger adolescents, intramedullary fixation is performed for open fractures, unstable fractures, floating elbow injuries, and fractures in which circumferential casting is impossible or undesired. General anesthesia and intravenous antibiotics are used. Attention is first turned to the ulna. Fluoroscopy is used to assess the ability to achieve a closed reduction, and the intramedullary canal size is evaluated to ensure use of the proper size of Kirschner wire or titanium elastic nail. The narrowest canal diameter is best seen on the lateral projection of the radius and ulna. If titanium elastic nails are used, the surgeon should recognize that the tips of the nails are typically curved. This curve facilitates intramedullary manipulation and capture of the distal fracture fragment, but it also increases the effective working diameter of the nail.

The ulna is treated first, in part because of the ease of intramedullary rod placement and because restoring ulnar length and alignment improves the alignment of the radius via soft tissue connections. A small stab incision is created over the tip of the olecranon process, just radial to the center of it to account for the apex radial bow of the proximal ulna (Figure 41.40). The triceps is incised in line with the surgical incision, and a drill or smooth wire is used to create a corticotomy for intramedullary rod placement. Care is taken to avoid penetrating the ulnohumeral joint, which typically requires drilling more dorsally than initially anticipated. The appropriately sized implant is then

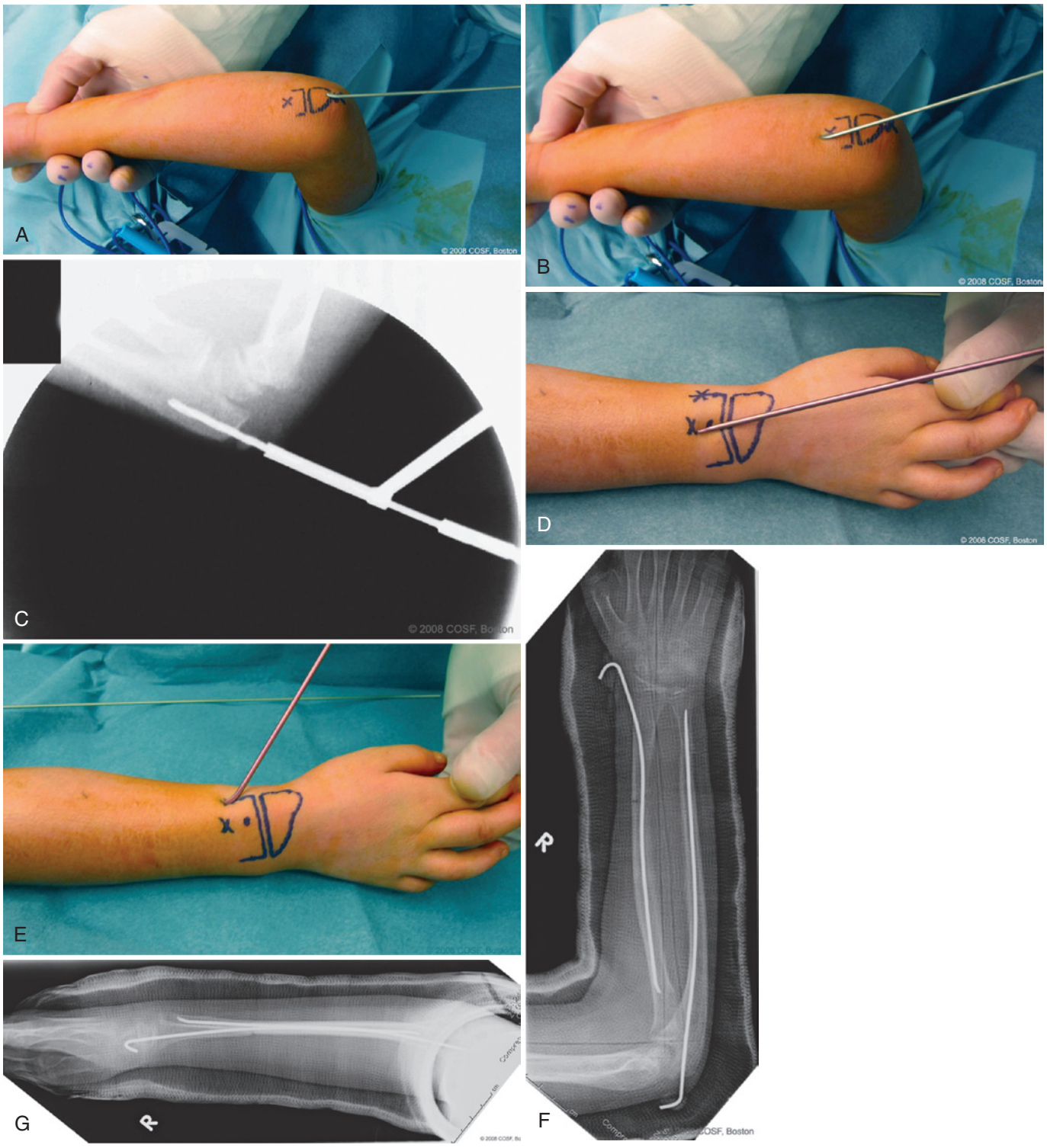

FIGURE 41.40 Technique of intramedullary fixation of diaphyseal fractures of the radius and ulna. The entry point for ulnar intramedullary rods may be through the olecranon apophysis **(A)** or proximal ulnar metaphysis **(B)**, just distal to the olecranon apophysis. **C,** Intraoperative fluoroscopy illustrating creation of the entry site for the ulnar rod. The entry point for the radial rod may be dorsally, just proximal to the Lister tubercle **(D)**, or radially between the first and second extensor compartments **(E)**, just proximal to the radial physis. **F** and **G,** Intraoperative fluoroscopy demonstrating fracture reduction and intramedullary rod placement for a middiaphyseal forearm fracture. (Courtesy of the Children's Orthopaedic Surgery Foundation.)

passed in an antegrade fashion down the canal of the ulna until it reaches the fracture site. The ulna is reduced, and the nail is passed down the canal of the distal fragment. The implant is passed down until the tip of the rod resides 5 to 10 mm from the distal ulnar physis.

Attention is then turned to the radius (see Figure 41.40). I favor a radial entry site between the first and second extensor compartments. A small 2-cm incision is made over the "bare spot" of the dorsal radial metaphysis, just proximal to the distal radial physis. Subcutaneous dissection is performed to identify and retract the superficial sensory branch of the radial nerve. The retinaculum overlying the first dorsal compartment is identified and incised. A small periosteal window is created, and a drill is used to create a corticotomy for nail placement. Creation of an oblique path (distal radial to proximal ulnar) greatly facilitates nail placement. The appropriately sized nail is then precontoured to restore the radial bow and passed up the intramedullary canal in a retrograde manner to the level of the radial fracture. Closed reduction is performed, and the nail is passed into the canal of the proximal radial fracture fragment until the tip lies at the level of the bicipital tuberosity. Multiplanar fluoroscopic images are obtained to confirm the adequacy of reduction, stability, and implant placement.

Multiple forceful attempts at closed reduction and nail passage are discouraged, owing to the risk of increased soft tissue swelling and subsequent compartment syndrome.[112,113,216] If closed reduction and intramedullary nail passage cannot be achieved after several attempts, an open reduction is performed through a small incision centered over the radial fracture, using the brachioradialis–flexor carpi radialis or brachioradialis–pronator teres interval distally or proximally, respectively.

Although the majority of surgeons cut the nails under the skin until elective removal 3 to 6 months postoperatively, I prefer to bend them and leave the rods extending outside the skin.[95] The theoretical risk of soft tissue irritation and infection has not been a considerable problem, given that a sterile bandage is applied and the limb is immobilized with a long-arm cast following surgery. Buried nails result in a small incidence of soft tissue irritation and tendon disruption, particularly if a dorsal entry site is used for the radius. Furthermore, removal of buried rods may not be a trivial procedure.

The cast is bivalved to allow for postoperative swelling, and the intramedullary nails are removed at 4 to 6 weeks in the office or in the operating theater with sedation or brief general anesthesia, followed by an additional 2 weeks of cast immobilization. Although early rod removal theoretically increases the risk of refracture, this has not been a common occurrence, and families are counseled about refracture risk and appropriate activity modification.

In rare situations, particularly in younger children, single-bone fixation may suffice.[60] If the radius assumes an acceptable position after ulnar rod placement, single-bone fixation can be considered. Although alignment may be improved, it is imperative that the stability of the radial reduction be checked with elbow and forearm motion under fluoroscopic visualization. If the radius is unstable, nailing of both bones is performed.

For patients with less than 2 years of skeletal growth remaining, I favor open reduction and internal fixation using plate and screw constructs for middle and proximal third fractures with more than 15 and 10 degrees of angulation, respectively. In adolescent patients, 3.5-mm implants may be too wide or too large for the radius or ulna, so smaller implants are used. Typically, two one-third tubular plates are stacked on each other to increase the bending rigidity. Four to six cortices of fixation are achieved with standard cortical screws; locking screws are rarely needed in this patient population for fractures of the radius and ulnar diaphysis. If adequate stability is achieved, patients are immobilized in a bivalved short-arm cast or splint, and early supervised range of motion is initiated. I do not routinely remove plate and screw constructs after healing is achieved; I believe that the morbidity and risk of plate removal in the upper extremity outweigh the benefits.

Single-Bone Fractures

True single-bone fractures of the radius or ulna (i.e., without associated soft tissue disruption of the distal or proximal radioulnar joints) result from direct blows. Due to the stabilizing effect of the adjacent intact bone, reduction maneuvers are difficult. With fracture displacement and angulation, particularly when the apex of deformity is directed toward the interosseous space, failure to correct the bony alignment may result in loss of forearm rotation due to bony abutment. Reduction maneuvers consisting of longitudinal traction, varus-valgus strain using the intact bone as an indirect means of controlling the distal fracture fragment, and subsequent direct pressure at the fracture site to correct translation have been proposed in these situations.

Open Fractures

Open fractures merit special comment. Several issues distinguish the treatment of these injuries from their closed counterparts. First, open fractures result from higher energy forces with greater periosteal and soft tissue disruption. This leads to greater instability and the need for surgical stabilization. Second, there is a higher incidence of associated neurologic injuries and compartment syndromes with open fractures.[113] Surgical stabilization obviates the need for circumferential cast immobilization and allows care and monitoring of the soft tissues. In addition, when intramedullary fixation is performed, prolonged or repeated forceful attempts to achieve reduction before passage of the intramedullary implant are discouraged to lessen the risk of compartment syndrome.[216] Finally, open fractures carry the inherent risk of soft tissue contamination and subsequent infection. Although the overall rate of infectious complications is low, early and thorough irrigation and débridement are requisite components of open fracture care.[54,171]

Monteggia Fracture-Dislocations

Monteggia fracture-dislocations are fractures of the ulna associated with proximal radioulnar joint dissociation and radiocapitellar dislocation.[14,131] These injuries constitute less than 1% of all pediatric forearm fractures, typically affecting patients between 4 and 10 years of age. The mechanism of injury is classically described as a fall onto an outstretched hand with forced rotation of the forearm.

Acutely, patients present with pain, swelling, deformity, and limitations in elbow motion. A neurovascular examination is critical, as 10 to 20% patients have evidence of a neurologic deficit at presentation, usually involving the posterior interosseous nerve as the radial head commonly dislocates in an

anterior direction. Accurate diagnosis and timely intervention allow reduction and soft tissue healing with excellent functional outcomes. Unfortunately, despite the increased awareness and understanding of Monteggia fracture-dislocations, the initial diagnosis is often missed; late reconstruction is technically challenging, and outcomes are often suboptimal. Therefore, a high index of suspicion is paramount.

The radiocapitellar articulation must be assessed during the radiographic evaluation of any pediatric forearm fracture. Normally, the longitudinal axis of the radius should bisect the capitellar ossification center on all radiographic views. Careful assessment of the radiocapitellar joint is particularly critical during the initial treatment of "isolated" ulnar fractures. Similarly, in cases of presumed isolated radial head dislocations, abnormal ulnar bowing or plastic deformation must be sought.[108] Although congenital radial head dislocations occasionally present as "acute" injuries, the presence of a hypoplastic capitellum and convex radial head usually confirms the diagnosis.

Understanding of the pathoanatomy of Monteggia fracture-dislocations is critical in providing appropriate treatment. In the majority of cases, the annular and quadrate ligaments are disrupted at the proximal radioulnar joint; however, much of the interosseous membrane between the radius and ulna remains intact, as does the TFCC. Anatomic reduction of the ulna, therefore, often restores proximal radioulnar and radiocapitellar joint congruity. For this reason, treatment is predicated on the nature of the ulnar fracture.[155,158] Historically, the Bado classification has been used to describe these injuries, based on the direction of the radial head dislocation and the apex of the associated ulnar fracture.[14] This classification scheme may aid in both describing the pattern of injury and guiding care.

In acute lesions, the method of treatment is determined by the pattern of ulnar fracture (Table 41.1). In patients with plastic deformation, proximal varus buckle, or greenstick fracture of the ulna, closed reduction under general anesthesia is recommended. In these situations, closed reduction of the ulna is typically performed with a combination of longitudinal traction, forearm rotation, and direct pressure applied to the apex of the fracture. The radiocapitellar joint usually reduces spontaneously with this maneuver. The need to apply substantial force to the radial head should raise the suspicion of interposed soft tissue blocking radiocapitellar joint reduction.[180] In the most common Bado type I lesions, for example, the radial head is anteriorly dislocated, and the ulna has apex volar angulation. Correction of the ulnar deformity followed by posteriorly directed pressure on the radial head, elbow flexion, and forearm supination is performed. Typically, the ulnar fracture and radiocapitellar joint are stable after reduction of plastic deformation or incomplete fractures. A well-molded above-elbow cast is then applied for 4 to 6 weeks. After radiographic and clinical healing, range-of-motion exercises are initiated.

In patients with complete transverse or short oblique fractures of the ulna, closed reduction alone can result in loss of reduction in a cast.[155] Therefore, closed reduction and intramedullary fixation of the ulna are recommended to maintain ulnar alignment and radiocapitellar reduction (Figure 41.41). In these cases, an age- and size-appropriate stainless steel Kirschner wire or flexible titanium nail is selected. Via a small longitudinal split in the triceps tendon overlying the olecranon process, this nail is inserted into the intramedullary canal of the ulna and advanced in an antegrade fashion to the fracture site. The ulnar fracture is reduced, and the nail is advanced into the intramedullary canal of the distal fracture fragment, allowing restoration of both ulnar length and alignment. During ulnar reduction and fixation, closed reduction of the radiocapitellar dislocation is also performed. Intraoperative fluoroscopy confirms appropriate ulnar and radiocapitellar reduction. An

TABLE 41.1 Treatment Recommendations Based on the Pattern of Ulnar Deformity for Acute Monteggia Fracture-Dislocations

Pattern of Ulnar Fracture	Recommended Treatment
Plastic deformation	Closed reduction, casting of ulna
Greenstick fracture	Closed reduction, casting of ulna
Complete fracture (transverse, short oblique)	Intramedullary fixation of ulna
Complete fracture (long oblique, comminuted)	Open reduction, plate fixation of ulna

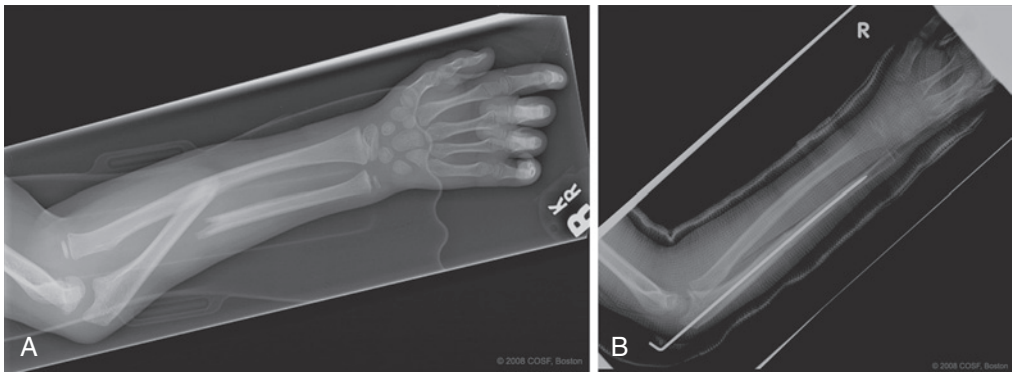

FIGURE 41.41 **A,** Preoperative lateral radiograph of a Monteggia fracture-dislocation in a 7-year-old girl. **B,** Postoperative radiograph following intramedullary fixation of the ulna and closed radiocapitellar reduction. (Courtesy of the Children's Orthopaedic Surgery Foundation.)

above-elbow cast is then applied with the elbow in 90 degrees of flexion and the forearm in supination, which confers additional stability to the radiocapitellar articulation. Cast immobilization and intramedullary fixation are continued for 4 to 6 weeks to allow annular ligament and bony healing. After radiographic confirmation of bony healing, the cast is discontinued, the intramedullary nail is removed, and range-of-motion exercises are begun.

Long oblique or comminuted ulnar fractures cannot be adequately stabilized with intramedullary devices.[155] In these cases, open reduction and internal fixation with plate and screw constructs are necessary, even in young patients with open physes (Figure 41.42). Through a longitudinal incision based on the subcutaneous border of the ulna and centered on the fracture site, reduction is performed, and a one-third tubular or small fragment plate is applied in the standard fashion. Four to six cortices of fixation proximal and distal to the fracture provide adequate stability in pediatric patients. Radiocapitellar joint congruity is achieved during reduction and fixation of the ulna fracture. If closed reduction of the radiocapitellar joint is unattainable, an open reduction may be facilitated by extending the ulnar incision proximally over the posterolateral aspect of the elbow. Cast immobilization for 4 to 6 weeks with the forearm in supination is required following surgery.

Galeazzi Fractures

Galeazzi fractures are fractures of the distal radius associated with DRUJ disruption.[64] Although such injuries are rare in children, Galeazzi equivalents may present with distal ulnar physeal fractures or ulnar styloid avulsions.[73] These injuries result from falls onto an outstretched upper extremity with a combination of axial load and rotational moment. Patients present with pain and restrictions in forearm rotation. Radiographs reveal incongruity of the DRUJ, best seen on a true lateral view of the wrist. Descriptions of Galeazzi fractures are based on the direction of ulnar displacement. However, it is important to remember that the axis of forearm rotation lies from the radial head to the ulnar styloid, and in fact, it is the radius that displaces in relation to the ulna.

Unlike in adults, Galeazzi fracture-dislocations and their equivalents in children can be successfully treated nonoperatively.[73] In general, restoration of anatomic radial alignment using the reduction maneuvers described earlier yields a congruent and stable DRUJ. Closed reduction maneuvers are predicated on the pattern of injury. In situations in which the ulna is dorsally displaced in relation to the radius and there is apex dorsal angulation of the radial fracture, three-point bending combined with forearm supination is the reduction maneuver. Conversely, for apex volar radial fractures in which the ulna is volar, pronation is applied.

If anatomic reduction is achieved, a long-arm cast is applied for 6 weeks, with weekly radiographic evaluation to confirm maintenance of reduction. In cases in which reduction cannot be achieved or in older adolescents with less than 2 years of growth remaining, formal open reduction and internal fixation of the radius with appropriate treatment of the DRUJ dislocation are recommended, as in adults.

Postoperative Expectations and Management

The outcome following a forearm fracture is dependent on the injury and reduction, but adherence to the previously stated principles and techniques results in bony healing and restoration of motion in the majority of patients. Acceptable realignment of the radius and ulna results in union and restoration of forearm motion. Fixation of irreducible, open, or unstable forearm fractures reliably restores anatomy and motion. Monteggia fracture-dislocations require prompt recognition and appropriate treatment for an acceptable outcome.

With careful inspection, some loss of forearm rotation may be observed, even in surgical patients whose radiographs demonstrate anatomic bony alignment.[12,82,135,148,214] Typically, these differences are subtle and are not associated with any complaints or functional limitations.[45,135]

In cases in which the previously stated principles are not followed, fracture malunion may result (see Figure 41.37). Price and colleagues reported on a series of 39 children with malunions following closed treatment of displaced forearm fractures.[148] Average patient age at the time of injury was 9.3 years (range, 1 to 16 years). Average follow-up was 5.7 years, with a minimum 2-year follow-up in all. Malunion was defined as radiographic angulation greater than 10 degrees, greater than 50% displacement, malrotation, or encroachment of the interosseous space. Results were characterized as excellent (no limitations in activity, loss of forearm rotation <10 degrees), good (mild complaints with strenuous physical activity, loss of forearm rotation <30 degrees), fair (mild complaints with activities of daily living, 31- to 90-degree loss of forearm rotation), and poor. Overall, 82% of patients had excellent results, 10% had good results, and 8% had fair results; there were no poor outcomes. All patients were reportedly "satisfied" with

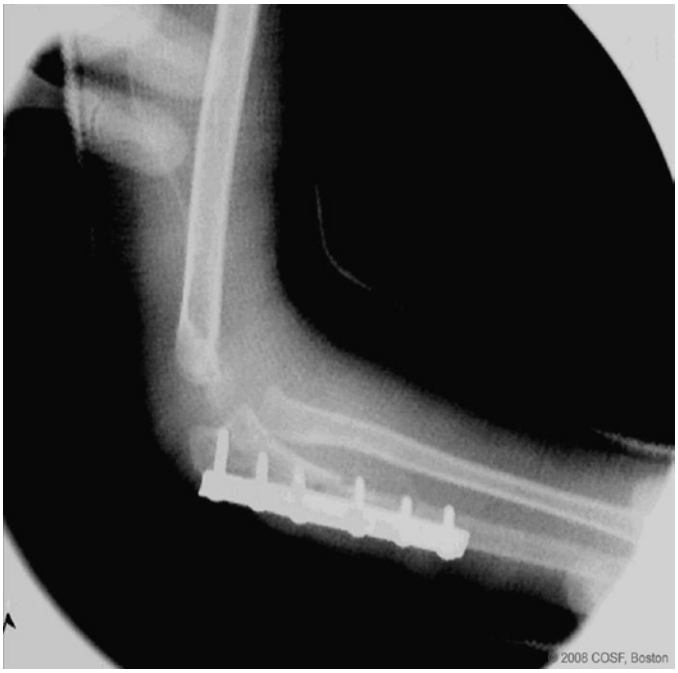

FIGURE 41.42 Postoperative radiograph after open reduction and plate fixation of the ulna and closed radiocapitellar joint reduction in a 4-year-old boy. Plate fixation was necessary to restore ulnar length and alignment owing to the proximal location and comminuted pattern of the ulnar fracture. (Courtesy of the Children's Orthopaedic Surgery Foundation.)

aesthetics and function, regardless of age or radiographic findings, which did not correlate with final clinical motion. Although no correlation was seen between age or fracture displacement and outcome, the authors observed that angulation, shortening, narrowing of the interosseous space, and proximal fracture location were associated with worse functional results. Based on their observations, the authors concluded that up to 10 degrees of angulation, complete translation, complete loss of radial bow, and 45 degrees of malrotation may be well tolerated with minimal aesthetic or functional consequences. Similar findings have been reported by others.[42,45,63]

Malunions that impede functional forearm motion and exceed the amount of deformity that might be anticipated to remodel with remaining growth should be considered for corrective osteotomies (see Figure 41.37).[22,147,186] Closing wedge osteotomies at the apex of the deformity of both the radius and the ulna are recommended to restore a straight ulna and a more normal radial bow. Surgery on the radius and ulna is performed via standard Henry volar and ulnar approaches. The radius is addressed first. After the apex of the deformity is confirmed on intraoperative fluoroscopy, a closing wedge osteotomy is performed sequentially in the radius and ulna. Proximal and distal cuts are made orthogonal to the longitudinal axis of the radius, allowing subsequent rotational correction. Closing wedge osteotomies are preferred because they are technically more reproducible than single-cut oblique osteotomies; they also avoid bony lengthening, which may cause difficulties with internal fixation and alter the proximal and distal radioulnar joints. Plate and screw fixation using size-appropriate implants is preferred, obtaining four to six cortices of fixation in the proximal and distal segments. Rotational alignment is confirmed by the radiographic appearance of the radial styloid and ulnar styloid 180 degrees opposite the bicipital tuberosity and coronoid process, respectively. Long-arm cast immobilization for 4 weeks is followed by 2 weeks of short-arm casting.[147]

Refracture of diaphyseal fractures of the forearm occurs in 4 to 8% of patients; this typically occurs in males more commonly than in females approximately 6 months after the index injury.[18,26,101,185] Patients and families should be counseled about the refracture risk at the time of cast removal, and a transitional period of splint immobilization should be considered to minimize refracture risk. In cases of refracture in which adequate alignment cannot be achieved with closed manipulation, surgical treatment is recommended. Even if intramedullary fixation is to be performed, open reduction and drilling of the intramedullary canal to create an appropriate path for subsequent nail passage are often needed, given the prior fracture callus and healing. In these situations, internal fixation with plate and screw constructs may be used.

Compartment syndrome is a rare but potentially devastating complication of diaphyseal forearm fractures, whether treated nonoperatively or surgically.[74,88,216] Early recognition and prompt treatment with forearm fasciotomies are critical to avoid permanent sequelae.[93] Diagnosis may be difficult, particularly in a young, agitated, or nonverbal child. In addition to the traditional signs of compartment syndrome in adults, a rising analgesic requirement, increasing agitation, and anxiousness are evidence of an impending compartment syndrome.[15,93]

CRITICAL POINTS *Forearm Fractures*

- Adequate sedation or anesthesia and properly molded casts are critical in achieving and maintaining reduction of plastic deformation injuries.
- During intramedullary fixation of open or unstable forearm fractures, multiple forceful attempts at intramedullary nail passage are discouraged to minimize the risk of postoperative compartment syndrome.
- Treatment of Monteggia fracture-dislocations is dictated by the pattern of ulnar fracture.
- Refracture occurs in approximately 5% of children following successful nonoperative treatment of diaphyseal forearm fractures.

For Case Studies, Videos, and more, please visit ExpertConsult.com.

REFERENCES

1. Adolfsson L, Lindau T, Arner M: Acutrak screw fixation versus cast immobilisation for undisplaced scaphoid waist fractures. *J Hand Surg [Br]* 26:192–195, 2001.
2. Ahmed I, Ashton F, Tay WK, et al: The pediatric fracture of the scaphoid in patients aged 13 years and under: an epidemiological study. *J Pediatr Orthop* 34:150–154, 2014.
3. Al-Qattan MM: Extra-articular transverse fractures of the base of the distal phalanx (Seymour's fracture) in children and adults. *J Hand Surg [Br]* 26:201–206, 2001.
4. Al-Qattan MM: Neglected nonunion of phalangeal neck fractures of the thumb in children: the outcome of delayed bone grafting in adulthood. *Ann Plast Surg* 68:276–278, 2012.
5. Al-Qattan MM: Nonunion and avascular necrosis following phalangeal neck fractures in children. *J Hand Surg [Am]* 35:1269–1274, 2010.
6. Al-Qattan MM: Phalangeal neck fractures in children: classification and outcome in 66 cases. *J Hand Surg [Br]* 26:112–121, 2001.
7. Al-Qattan MM, Abou Al-Shaar H, Al Mugaren FM: Nonunion without avascular necrosis of finger phalangeal neck fractures in children: report of 4 cases. *J Hand Surg [Am]* 39:1529–1534, 2014.
8. Al-Qattan MM, Al-Motairi MI, Al-Naeem HA: The diaphysial axis-metacarpal head angle in the management of fractures of the base of the proximal phalanx in children. *J Hand Surg Eur Vol* 38:984–990, 2013.
9. Al-Qattan MM, Al-Zahrani K, Al-Boukai AA: The relative incidence of fractures at the base of the proximal phalanx of the fingers in children. *J Hand Surg Eur Vol* 33:465–468, 2008.
10. Al-Qattan MM, Al-Zahrani K, Al-Boukai AA: The relative incidence of fractures at the base of the proximal phalanx of the thumb in children. *J Hand Surg Eur Vol* 34:110–114, 2009.
11. Alshryda S, Shah A, Odak S, et al: Acute fractures of the scaphoid bone: systematic review and meta-analysis. *Surgeon* 10:218–229, 2012.
12. Amit Y, Salai M, Chechik A, et al: Closing intramedullary nailing for the treatment of diaphyseal forearm fractures in adolescence: a preliminary report. *J Pediatr Orthop* 5:143–146, 1985.
13. Andersson JK, Lindau T, Karlsson J, et al: Distal radio-ulnar joint instability in children and adolescents after wrist trauma. *J Hand Surg Eur Vol* 39:653–661, 2014.
14. Bado JL: The Monteggia lesion. *Clin Orthop Relat Res* 50:71–86, 1967.
15. Bae DS, Kadiyala RK, Waters PM: Acute compartment syndrome in children: contemporary diagnosis, treatment, and outcome. *J Pediatr Orthop* 21:680–688, 2001.
16. Bae DS, Waters PM: Pediatric distal radius fractures and triangular fibrocartilage complex injuries. *Hand Clin* 22:43–53, 2006.
17. Bae DS, Waters PM, Sampson CE: Use of free vascularized fibular graft for congenital ulnar pseudarthrosis: surgical decision making in the growing child. *J Pediatr Orthop* 25:755–762, 2005.
18. Baitner AC, Perry A, Lalonde FD, et al: The healing forearm fracture: a matched comparison of forearm refractures. *J Pediatr Orthop* 27:743–747, 2007.
19. Barton NJ: Fractures of the phalanges of the hand in children. *Hand* 11:134–143, 1979.
20. Bergeron L, Gagnon I, l'Ecuyer C, et al: Treatment outcomes of unstable proximal phalangeal head fractures of the finger in children. *Ann Plast Surg* 54:28–32, 2005.
21. Bhende MS, Dandrea LA, Davis HW: Hand injuries in children presenting to a pediatric emergency department. *Ann Emerg Med* 22:1519–1523, 1993.

22. Blackburn N, Ziv I, Rang M: Correction of the malunited forearm fracture. *Clin Orthop Relat Res* 188:54–57, 1984.
23. Bogumill GP: A morphologic study of the relationship of collateral ligaments to growth plates in the digits. *J Hand Surg [Am]* 8:74–79, 1983.
24. Bohm ER, Bubbar V, Yong Hing K, et al: Above and below-the-elbow plaster casts for distal forearm fractures in children. A randomized controlled trial. *J Bone Joint Surg Am* 88:1–8, 2006.
25. Borden ST: Traumatic bowing of the forearm in children. *J Bone Joint Surg Am* 56:611–616, 1974.
26. Bould M, Bannister GC: Refractures of the radius and ulna in children. *Injury* 30:583–586, 1999.
27. Boyer BA, Overton B, Schrader W, et al: Position of immobilization for pediatric forearm fractures. *J Pediatr Orthop* 22:185–187, 2002.
28. Buijze GA, Doornberg JN, Ham JS, et al: Surgical compared with conservative treatment for acute nondisplaced or minimally displaced scaphoid fractures: a systematic review and meta-analysis of randomized controlled trials. *J Bone Joint Surg Am* 92:1534–1544, 2010.
29. Buijze GA, Goslings JC, Rhemrev SJ, et al: Cast immobilization with and without immobilization of the thumb for nondisplaced and minimally displaced scaphoid waist fractures: a multicenter, randomized, controlled trial. *J Hand Surg [Am]* 39:621–627, 2014.
30. Cai H, Wang Z: Prebending of a titanium elastic intramedullary nail in the treatment of distal radius fractures in children. *Int Surg* 99:269–275, 2014.
31. Campbell RM, Jr: Operative treatment of fractures and dislocations of the hand and wrist region in children. *Orthop Clin North Am* 21:217–243, 1990.
32. Cannata G, De Maio F, Mancini F, et al: Physeal fractures of the distal radius and ulna: long-term prognosis. *J Orthop Trauma* 17:172–179, discussion 179–180, 2003.
33. Charnley J: *The closed treatment of common fractures*, Edinburgh, 1957, Livingstone.
34. Cheng JC, Ng BK, Ying SY, et al: A 10-year study of the changes in the pattern and treatment of 6,493 fractures. *J Pediatr Orthop* 19:344–350, 1999.
35. Cheng JC, Shen WY: Limb fracture pattern in different pediatric age groups: a study of 3,350 children. *J Orthop Trauma* 7:15–22, 1993.
36. Chess DG, Hyndman JC, Leahey JL, et al: Short arm plaster cast for distal pediatric forearm fractures. *J Pediatr Orthop* 14:211–213, 1994.
37. Chew EM, Chong AK: Hand fractures in children: epidemiology and misdiagnosis in a tertiary referral hospital. *J Hand Surg [Am]* 37:1684–1688, 2012.
38. Choi KY, Chan WS, Lam TP, et al: Percutaneous Kirschner-wire pinning for severely displaced distal radial fractures in children. A report of 157 cases. *J Bone Joint Surg Br* 77:797–801, 1995.
39. Chung KC, Spilson SV: The frequency and epidemiology of hand and forearm fractures in the United States. *J Hand Surg [Am]* 26:908–915, 2001.
40. Cornwall R, Waters PM: Remodeling of phalangeal neck fracture malunions in children: case report. *J Hand Surg [Am]* 29:458–461, 2004.
41. Crawford SN, Lee LS, Izuka BH: Closed treatment of overriding distal radial fractures without reduction in children. *J Bone Joint Surg Am* 94:246–252, 2012.
42. Creasman C, Zaleske DJ, Ehrlich MG: Analyzing forearm fractures in children. The more subtle signs of impending problems. *Clin Orthop Relat Res* 188:40–53, 1984.
43. D'Arienzo M: Scaphoid fractures in children. *J Hand Surg [Br]* 27:424–426, 2002.
44. Dailiana ZH, Malizos KN, Zachos V, et al: Vascularized bone grafts from the palmar radius for the treatment of waist nonunions of the scaphoid. *J Hand Surg [Am]* 31:397–404, 2006.
45. Daruwalla JS: A study of radioulnar movements following fractures of the forearm in children. *Clin Orthop Relat Res* 139:114–120, 1979.
46. Davidson JS, Brown DJ, Barnes SN, et al: Simple treatment for torus fractures of the distal radius. *J Bone Joint Surg Br* 83:1173–1175, 2001.
47. Davis DR, Green DP: Forearm fractures in children: pitfalls and complications. *Clin Orthop Relat Res* 120:172–183, 1976.
48. de Jonge JJ, Kingma J, van der Lei B, et al: Fractures of the metacarpals. A retrospective analysis of incidence and aetiology and a review of the English-language literature. *Injury* 25:365–369, 1994.
49. De Jonge JJ, Kingma J, van der Lei B, et al: Phalangeal fractures of the hand. An analysis of gender and age-related incidence and aetiology. *J Hand Surg [Br]* 19:168–170, 1994.
50. Do TT, Strub WM, Foad SL, et al: Reduction versus remodeling in pediatric distal forearm fractures: a preliminary cost analysis. *J Pediatr Orthop B* 12:109–115, 2003.
51. Doornberg JN, Buijze GA, Ham SJ, et al: Nonoperative treatment for acute scaphoid fractures: a systematic review and meta-analysis of randomized controlled trials. *J Trauma* 71:1073–1081, 2011.
52. Dorsay TA, Major NM, Helms CA: Cost-effectiveness of immediate MR imaging versus traditional follow-up for revealing radiographically occult scaphoid fractures. *AJR Am J Roentgenol* 177:1257–1263, 2001.
53. Fabre O, De Boeck H, Haentjens P: Fractures and nonunions of the carpal scaphoid in children. *Acta Orthop Belg* 67:121–125, 2001.
54. Fee NF, Dobranski A, Bisla RS: Gas gangrene complicating open forearm fractures. Report of five cases. *J Bone Joint Surg Am* 59:135–138, 1977.
55. Feehan LM, Sheps SB: Incidence and demographics of hand fractures in British Columbia, Canada: a population-based study. *J Hand Surg [Am]* 31:1068–1074, 2006.
56. Fenton P, Nightingale P, Hodson J, et al: Factors in redisplacement of paediatric distal radius fractures. *J Pediatr Orthop B* 21:127–130, 2012.
57. Fernandez DL: Correction of post-traumatic wrist deformity in adults by osteotomy, bone-grafting, and internal fixation. *J Bone Joint Surg Am* 64:1164–1178, 1982.
58. Firl M, Wunsch L: Measurement of bowing of the radius. *J Bone Joint Surg Br* 86:1047–1049, 2004.
59. Fischer MD, McElfresh EC: Physeal and periphyseal injuries of the hand. Patterns of injury and results of treatment. *Hand Clin* 10:287–301, 1994.
60. Flynn JM, Waters PM: Single-bone fixation of both-bone forearm fractures. *J Pediatr Orthop* 16:655–659, 1996.
61. Foucher G: Bouquet osteosynthesis in metacarpal neck fractures: a series of 66 patients. *J Hand Surg [Am]* 20:S86–S90, 1995.
62. Friberg KS: Remodelling after distal forearm fractures in children. III. Correction of residual angulation in fractures of the radius. *Acta Orthop Scand* 50:741–749, 1979.
63. Fuller DJ, McCullough CJ: Malunited fractures of the forearm in children. *J Bone Joint Surg Br* 64:364–367, 1982.
64. Galeazzi R: Di una particolare syndrome traumatica dello scheletro dell' avambraccio. *Atti Mem Soc Lomb Chir* 2, 1934.
65. Ganayem M, Edelson G: Base of distal phalanx fracture in children: a mallet finger mimic. *J Pediatr Orthop* 25:487–489, 2005.
66. Gellman H, Caputo RJ, Carter V, et al: Comparison of short and long thumb-spica casts for non-displaced fractures of the carpal scaphoid. *J Bone Joint Surg Am* 71:354–357, 1989.
67. Gholson JJ, Bae DS, Zurakowski D, et al: Scaphoid fractures in children and adolescents: contemporary injury patterns and factors influencing time to union. *J Bone Joint Surg Am* 93:1210–1219, 2011.
68. Gibbon WW, Jackson A: An isolated capitate fracture in a 9-year-old boy. *Br J Radiol* 62:487–488, 1989.
69. Gibbons CL, Woods DA, Pailthorpe C, et al: The management of isolated distal radius fractures in children. *J Pediatr Orthop* 14:207–210, 1994.
70. Giebel GD, Meyer C, Koebke J, et al: Arterial supply of forearm bones and its importance for the operative treatment of fractures. *Surg Radiol Anat* 19:149–153, 1997.
71. Greeven AP, Alta TD, Scholtens RE, et al: Closed reduction intermetacarpal Kirschner wire fixation in the treatment of unstable fractures of the base of the first metacarpal. *Injury* 43:246–251, 2012.
72. Gruelick WPS, editor: *Radiographic atlas of skeletal development of the hand and wrist*, ed 2, Palo Alto, CA, 1959, Stanford University Press.
73. Guitton TG, Van Dijk NC, Raaymakers EL, et al: Isolated diaphyseal fractures of the radius in skeletally immature patients. *Hand (N Y)* 5:251–255, 2010.
74. Haasbeek JF, Cole WG: Open fractures of the arm in children. *J Bone Joint Surg Br* 77:576–581, 1995.
75. Haines RW: The pseudoepiphysis of the first metacarpal of man. *J Anat* 117:145–158, 1974.
76. Hang JR, Hutchinson AF, Hau RC: Risk factors associated with loss of position after closed reduction of distal radial fractures in children. *J Pediatr Orthop* 31:501–506, 2011.
77. Hastings H, 2nd, Simmons BP: Hand fractures in children. A statistical analysis. *Clin Orthop Relat Res* 188:120–130, 1984.
78. Hendrickx RP, Campo MM, van Lieshout AP, et al: Above- or below-elbow casts for distal third forearm fractures in children? A meta-analysis of the literature. *Arch Orthop Trauma Surg* 131:1663–1671, 2011.
79. Hennrikus WL, Cohen MR: Complete remodelling of displaced fractures of the neck of the phalanx. *J Bone Joint Surg Br* 85:273–274, 2003.
80. Herrera-Perez M, Alvarez-Alcover H, Pais-Brito JL: Short intramedullary wiring for displaced metaphyseal fractures of the radius in children. *Acta Orthop Belg* 79:150–153, 2013.
81. Hofmeister EP, Mazurek MT, Shin AY, et al: Extension block pinning for large mallet fractures. *J Hand Surg [Am]* 28:453–459, 2003.
82. Holdsworth BJ, Sloan JP: Proximal forearm fractures in children: residual disability. *Injury* 14:174–179, 1982.
83. Houshian S, Holst AK, Larsen MS, et al: Remodeling of Salter-Harris type II epiphyseal plate injury of the distal radius. *J Pediatr Orthop* 24:472–476, 2004.
84. Hove LM, Engesaeter LB: Corrective osteotomies after injuries of the distal radial physis in children. *J Hand Surg [Br]* 22:699–704, 1997.
85. Iltar S, Alemdaroglu KB, Say F, et al: The value of the three-point index in predicting redisplacement of diaphyseal fractures of the forearm in children. *Bone Joint J* 95:563–567, 2013.
86. Jahss S: Fractures of the metacarpals: a new method of reduction and immobilization. *J Bone Joint Surg Am* 20:178–186, 1938.

87. Johnson KJ, Haigh SF, Symonds KE: MRI in the management of scaphoid fractures in skeletally immature patients. *Pediatr Radiol* 30:685–688, 2000.
88. Jones K, Weiner DS: The management of forearm fractures in children: a plea for conservatism. *J Pediatr Orthop* 19:811–815, 1999.
89. Kaawach W, Ecklund K, Di Canzio J, et al: Normal ranges of scapholunate distance in children 6 to 14 years old. *J Pediatr Orthop* 21:464–467, 2001.
90. Kaempf de Oliveira R, Serrano PJ, Badia A, et al: Corrective osteotomy after damage of the distal radial physis in children: surgical technique and results. *Tech Hand Up Extrem Surg* 15:236–242, 2011.
91. Kamat AS, Pierse N, Devane P, et al: Redefining the cast index: the optimum technique to reduce redisplacement in pediatric distal forearm fractures. *J Pediatr Orthop* 32:787–791, 2012.
92. Kaneshiro SA, Failla JM, Tashman S: Scaphoid fracture displacement with forearm rotation in a short-arm thumb spica cast. *J Hand Surg [Am]* 24:984–991, 1999.
93. Kanj WW, Gunderson MA, Carrigan RB, et al: Acute compartment syndrome of the upper extremity in children: diagnosis, management, and outcomes. *J Child Orthop* 7:225–233, 2013.
94. Kasten P, Krefft M, Hesselbach J, et al: How does torsional deformity of the radial shaft influence the rotation of the forearm? A biomechanical study. *J Orthop Trauma* 17:57–60, 2003.
95. Kelly BA, Miller P, Shore BJ, et al: Exposed versus buried intramedullary implants for pediatric forearm fractures: a comparison of complications. *J Pediatr Orthop* 34:749–754, 2014.
96. Khosla S, Melton LJ, 3rd, Dekutoski MB, et al: Incidence of childhood distal forearm fractures over 30 years: a population-based study. *JAMA* 290:1479–1485, 2003.
97. Kim WY, Zenios M, Kumar A, et al: The removal of forearm plates in children. *Injury* 36:1427–1430, 2005.
98. Kozin SH: Fractures and dislocations along the pediatric thumb ray. *Hand Clin* 22:19–29, 2006.
99. Kozin SH, Waters PM: Fractures and dislocations of the hand and carpus in children. In Beaty JH, Kasser JR, editors: *Rockwood and Green's fractures in children*, ed 5, Philadelphia, 2006, Lippincott Williams & Wilkins, pp 257–336.
100. Krusche-Mandl I, Kottstorfer J, Thalhammer G, et al: Seymour fractures: retrospective analysis and therapeutic considerations. *J Hand Surg [Am]* 38:258–264, 2013.
101. Landin LA: Epidemiology of children's fractures. *J Pediatr Orthop B* 6:79–83, 1997.
102. Landin LA: Fracture patterns in children. Analysis of 8,682 fractures with special reference to incidence, etiology and secular changes in a Swedish urban population 1950-1979. *Acta Orthop Scand Suppl* 202:1–109, 1983.
103. Langkamer VG, Ackroyd CE: Removal of forearm plates. A review of the complications. *J Bone Joint Surg Br* 72:601–604, 1990.
104. Lascombes P, Prevot J, Ligier JN, et al: Elastic stable intramedullary nailing in forearm shaft fractures in children: 85 cases. *J Pediatr Orthop* 10:167–171, 1990.
105. Lee BS, Esterhai JL, Jr, Das M: Fracture of the distal radial epiphysis. Characteristics and surgical treatment of premature, post-traumatic epiphyseal closure. *Clin Orthop Relat Res* 185:90–96, 1984.
106. Lenoble E, Dumontier C, Goutallier D, et al: Fracture of the distal radius. A prospective comparison between trans-styloid and Kapandji fixations. *J Bone Joint Surg Br* 77:562–567, 1995.
107. Lieber J, Harter B, Schmid E, et al: Elastic stable intramedullary nailing (ESIN) of pediatric metacarpal fractures: experiences with 66 cases. *Eur J Pediatr Surg* 22:305–310, 2012.
108. Lincoln TL, Mubarak SJ: Isolated traumatic radial-head dislocation. *J Pediatr Orthop* 14:454–457, 1994.
109. Liu EH, Alqahtani S, Alsaaran RN, et al: A prospective study of pediatric hand fractures and review of the literature. *Pediatr Emerg Care* 30:299–304, 2014.
110. Lonjon G, Barthel PY, Ilharreborde B, et al: Bone bridge resection for correction of distal radial deformities after partial growth plate arrest: two cases and surgical technique. *J Hand Surg Eur Vol* 37:170–175, 2012.
111. Lovell ME, Galasko CS, Wright NB: Removal of orthopedic implants in children: morbidity and postoperative radiologic changes. *J Pediatr Orthop B* 8:144–146, 1999.
112. Luhmann SJ, Gordon JE, Schoenecker PL: Intramedullary fixation of unstable both-bone forearm fractures in children. *J Pediatr Orthop* 18:451–456, 1998.
113. Luhmann SJ, Schootman M, Schoenecker PL, et al: Complications and outcomes of open pediatric forearm fractures. *J Pediatr Orthop* 24:1–6, 2004.
114. Mack MG, Keim S, Balzer JO, et al: Clinical impact of MRI in acute wrist fractures. *Eur Radiol* 13:612–617, 2003.
115. Malviya A, Tsintzas D, Mahawar K, et al: Gap index: a good predictor of failure of plaster cast in distal third radius fractures. *J Pediatr Orthop B* 16:48–52, 2007.
116. Mancini F, De Maio F, Ippolito E: Pisiform bone fracture-dislocation and distal radius physeal fracture in two children. *J Pediatr Orthop B* 14:303–306, 2005.
117. Mani GV, Hui PW, Cheng JC: Translation of the radius as a predictor of outcome in distal radial fractures of children. *J Bone Joint Surg Br* 75:808–811, 1993.
118. Marcheix PS, Peyrou P, Longis B, et al: Dorsal distal radius fractures in children: role of plaster in redisplacement of these fractures. *J Pediatr Orthop B* 20:372–375, 2011.
119. Matzon JL, Cornwall R: A stepwise algorithm for surgical treatment of type II displaced pediatric phalangeal neck fractures. *J Hand Surg [Am]* 39:467–473, 2014.
120. McElfresh EC, Dobyns JH: Intra-articular metacarpal head fractures. *J Hand Surg [Am]* 8:383–393, 1983.
121. McLauchlan GJ, Cowan B, Annan IH, et al: Management of completely displaced metaphyseal fractures of the distal radius in children. A prospective, randomised controlled trial. *J Bone Joint Surg Br* 84:413–417, 2002.
122. McQueen MM, Gelbke MK, Wakefield A, et al: Percutaneous screw fixation versus conservative treatment for fractures of the waist of the scaphoid: a prospective randomised study. *J Bone Joint Surg Br* 90:66–71, 2008.
123. McQuinn AG, Jaarsma RL: Risk factors for redisplacement of pediatric distal forearm and distal radius fractures. *J Pediatr Orthop* 32:687–692, 2012.
124. Mehlman CT, Wall EJ: Injuries to the shafts of the radius and ulna. In Beaty JH, Kasser JR, editors: *Rockwood and Green's fractures in children*, Philadelphia, 2006, Lippincott Williams & Wilkins, pp 399–442.
125. Meier R, Prommersberger KJ, Lanz U: Surgical correction of malunited fractures of the forearm in children]. *Z Orthop Ihre Grenzgeb* 141:328–335, 2003.
126. Melone CP, Jr, Grad JB: Primary care of fingernail injuries. *Emerg Med Clin North Am* 3:255–261, 1985.
127. Michelinakis E, Vourexaki H: Displaced epiphyseal plate of the terminal phalanx in a child. *Hand* 12:51–53, 1980.
128. Miller BS, Taylor B, Widmann RF, et al: Cast immobilization versus percutaneous pin fixation of displaced distal radius fractures in children: a prospective, randomized study. *J Pediatr Orthop* 25:490–494, 2005.
129. Mintzer CM, Waters PM: Surgical treatment of pediatric scaphoid fracture nonunions. *J Pediatr Orthop* 19:236–239, 1999.
130. Mintzer CM, Waters PM, Brown DJ: Remodelling of a displaced phalangeal neck fracture. *J Hand Surg [Br]* 19:594–596, 1994.
131. Monteggia G: Lussazioni delle ossa delle extremitata superiori. In Monteggia G, editor: *Instituzioni Chirurgiches*, Milan, Italy, 1814, Maspero.
132. Nafie SA: Fractures of the carpal bones in children. *Injury* 18:117–119, 1987.
133. Nelson OA, Buchanan JR, Harrison CS: Distal ulnar growth arrest. *J Hand Surg [Am]* 9:164–170, 1984.
134. Neri E, Barbi E, Rabach I, et al: Diagnostic accuracy of ultrasonography for hand bony fractures in paediatric patients. *Arch Dis Child* 99:1087–1090, 2014.
135. Nilsson BE, Obrant K: The range of motion following fracture of the shaft of the forearm in children. *Acta Orthop Scand* 48:600–602, 1977.
136. Ogden JA, Beall JK, Conlogue GJ, et al: Radiology of postnatal skeletal development. IV. Distal radius and ulna. *Skeletal Radiol* 6:255–266, 1981.
137. Onuba O, Ireland J: Two cases of nonunion of fractures of the scaphoid in children. *Injury* 15:109–112, 1984.
138. Page WT, Szabo RM: Distraction osteogenesis for correction of distal radius deformity after physeal arrest. *J Hand Surg [Am]* 34:617–626, 2009.
139. Palmer AK, Werner FW: Biomechanics of the distal radioulnar joint. *Clin Orthop Relat Res* 187:26–35, 1984.
140. Palmer AK, Werner FW: The triangular fibrocartilage complex of the wrist–anatomy and function. *J Hand Surg [Am]* 6:153–162, 1981.
141. Parikh SN, Jain VV, Youngquist J: Intrafocal pinning for distal radius metaphyseal fractures in children. *Orthopedics* 36:783–788, 2013.
142. Paschos NK, Abuhemoud K, Gantsos A, et al: Management of proximal interphalangeal joint hyperextension injuries: a randomized controlled trial. *J Hand Surg [Am]* 39:449–454, 2014.
143. Peiro A, Martos F, Mut T, et al: Trans-scaphoid perilunate dislocation in a child. A case report. *Acta Orthop Scand* 52:31–34, 1981.
144. Peterson HA: Metallic implant removal in children. *J Pediatr Orthop* 25:107–115, 2005.
145. Peterson HA, Madhok R, Benson JT, et al: Physeal fractures: Part 1. Epidemiology in Olmsted County, Minnesota, 1979-1988. *J Pediatr Orthop* 14:423–430, 1994.
146. Pretell Mazzini J, Beck N, Brewer J, et al: Distal metaphyseal radius fractures in children following closed reduction and casting: can loss of reduction be predicted? *Int Orthop* 36:1435–1440, 2012.
147. Price CT, Knapp DR: Osteotomy for malunited forearm shaft fractures in children. *J Pediatr Orthop* 26:193–196, 2006.
148. Price CT, Scott DS, Kurzner ME, et al: Malunited forearm fractures in children. *J Pediatr Orthop* 10:705–712, 1990.
149. Pritchett JW: Complete remodelling of displaced fractures of the neck of the phalanx. *J Bone Joint Surg Br* 86:464, author reply 464, 2004.
150. Proctor MT, Moore DJ, Paterson JM: Redisplacement after manipulation of distal radial fractures in children. *J Bone Joint Surg Br* 75:453–454, 1993.
151. Prommersberger KJ, Van Schoonhoven J, Lanz UB: Outcome after corrective osteotomy for malunited fractures of the distal end of the radius. *J Hand Surg [Br]* 27:55–60, 2002.

152. Prosser AJ, Irvine GB: Epiphyseal fracture of the metacarpal head. *Injury* 19:34–35, 1988.
153. Puckett BN, Gaston RG, Peljovich AE, et al: Remodeling potential of phalangeal distal condylar malunions in children. *J Hand Surg [Am]* 37:34–41, 2012.
154. Rajesh A, Basu AK, Vaidhyanath R, et al: Hand fractures: a study of their site and type in childhood. *Clin Radiol* 56:667–669, 2001.
155. Ramski DE, Hennrikus WP, Bae DS, et al: Pediatric Monteggia fractures: a multicenter examination of treatment strategy and early clinical and radiographic results. *J Pediatr Orthop* 35:115–120, 2015.
156. Rang M: *Children's fractures*, ed 2, Philadelphia, 1983, JB Lippincott, pp 221–232.
157. Reigstad O, Thorkildsen R, Grimsgaard C, et al: Excellent results after bone grafting and K-wire fixation for scaphoid nonunion surgery in skeletally immature patients: a midterm follow-up study of 11 adolescents after 6.9 years. *J Orthop Trauma* 27:285–289, 2013.
158. Ring D, Waters PM: Operative fixation of Monteggia fractures in children. *J Bone Joint Surg Br* 78:734–739, 1996.
159. Ring D, Waters PM, Hotchkiss RN, et al: Pediatric floating elbow. *J Pediatr Orthop* 21:456–459, 2001.
160. Russe O: Fracture of the carpal navicular. Diagnosis, non-operative treatment, and operative treatment. *J Bone Joint Surg Am* 42:759–768, 1960.
161. Salter RHW: Injuries involving the eiphyseal plate. *J Bone Joint Surg Am* 45:587–622, 1963.
162. Samora JB, Klingele KE, Beebe AC, et al: Is there still a place for cast wedging in pediatric forearm fractures? *J Pediatr Orthop* 34:246–252, 2014.
163. Sanders WE, Heckman JD: Traumatic plastic deformation of the radius and ulna. A closed method of correction of deformity. *Clin Orthop Relat Res* 188:58–67, 1984.
164. Schwarz N, Pienaar S, Schwarz AF, et al: Refracture of the forearm in children. *J Bone Joint Surg Br* 78:740–744, 1996.
165. Seno N, Hashizume H, Inoue H, et al: Fractures of the base of the middle phalanx of the finger. Classification, management and long-term results. *J Bone Joint Surg Br* 79:758–763, 1997.
166. Seymour N: Juxta-epiphysial fracture of the terminal phalanx of the finger. *J Bone Joint Surg Br* 48:347–349, 1966.
167. Shah SS, Rochette LM, Smith GA: Epidemiology of pediatric hand injuries presenting to United States emergency departments, 1990 to 2009. *J Trauma Acute Care Surg* 72:1688–1694, 2012.
168. Shewring DJ, Miller AC, Ghandour A: Condylar fractures of the proximal and middle phalanges. *J Hand Surg Eur Vol* 40:51–58, 2015.
169. Shin AY, Bishop AT: Vascular anatomy of the distal radius: implications for vascularized bone grafts. *Clin Orthop Relat Res* 383:60–73, 2001.
170. Simmons BP, Peters TT: Subcondylar fossa reconstruction for malunion of fractures of the proximal phalanx in children. *J Hand Surg [Am]* 12:1079–1082, 1987.
171. Skaggs DL, Kautz SM, Kay RM, et al: Effect of delay of surgical treatment on rate of infection in open fractures in children. *J Pediatr Orthop* 20:19–22, 2000.
172. Skaggs DL, Loro ML, Pitukcheewanont P, et al: Increased body weight and decreased radial cross-sectional dimensions in girls with forearm fractures. *J Bone Miner Res* 16:1337–1342, 2001.
173. Solan MC, Rees R, Daly K: Current management of torus fractures of the distal radius. *Injury* 33:503–505, 2002.
174. Stanitski CL, Micheli LJ: Simultaneous ipsilateral fractures of the arm and forearm in children. *Clin Orthop Relat Res* 153:218–222, 1980.
175. Stein AH, Jr, Katz SF: Stabilization of comminuted fractures of the distal inch of the radius: percutaneous pinning. *Clin Orthop Relat Res* 108:174–181, 1975.
176. Stevenson JD, Morley D, Srivastava S, et al: Early CT for suspected occult scaphoid fractures. *J Hand Surg Eur Vol* 37:447–451, 2012.
177. Stuart HC, Pyle SI, Cornoni J, et al: Onsets, completions and spans of ossification in the 29 bonegrowth centers of the hand and wrist. *Pediatrics* 29:237–249, 1962.
178. Symons S, Rowsell M, Bhowal B, et al: Hospital versus home management of children with buckle fractures of the distal radius. A prospective, randomised trial. *J Bone Joint Surg Br* 83:556–560, 2001.
179. Tada K, Ikeda K, Tomita K: Malunion of fractures of the proximal phalangeal neck in children. *Scand J Plast Reconstr Surg Hand Surg* 44:69–71, 2010.
180. Tan JW, Mu MZ, Liao GJ, et al: Pathology of the annular ligament in paediatric Monteggia fractures. *Injury* 39:451–455, 2008.
181. Tavassoli J, Ruland RT, Hogan CJ, et al: Three cast techniques for the treatment of extra-articular metacarpal fractures. Comparison of short-term outcomes and final fracture alignments. *J Bone Joint Surg Am* 87:2196–2201, 2005.
182. Toh S, Miura H, Arai K, et al: Scaphoid fractures in children: problems and treatment. *J Pediatr Orthop* 23:216–221, 2003.
183. Tomaino MM, King J, Pizillo M: Correction of lunate malalignment when bone grafting scaphoid nonunion with humpback deformity: rationale and results of a technique revisited. *J Hand Surg [Am]* 25:322–329, 2000.
184. Torre BA: Epiphyseal injuries in the small joints of the hand. *Hand Clin* 4:113–121, 1988.
185. Tredwell SJ, Van Peteghem K, Clough M: Pattern of forearm fractures in children. *J Pediatr Orthop* 4:604–608, 1984.
186. Trousdale RT, Linscheid RL: Operative treatment of malunited fractures of the forearm. *J Bone Joint Surg Am* 77:894–902, 1995.
187. Trumble TE, Wagner W, Hanel DP, et al: Intrafocal (Kapandji) pinning of distal radius fractures with and without external fixation. *J Hand Surg [Am]* 23:381–394, 1998.
188. Unay K, Gokcen B, Ozkan K, et al: Examination tests predictive of bone injury in patients with clinically suspected occult scaphoid fracture. *Injury* 40:1265–1268, 2009.
189. Vadivelu R, Dias JJ, Burke FD, et al: Hand injuries in children: a prospective study. *J Pediatr Orthop* 26:29–35, 2006.
190. Vahvanen V, Westerlund M: Fracture of the carpal scaphoid in children. A clinical and roentgenological study of 108 cases. *Acta Orthop Scand* 51:909–913, 1980.
191. Valencia J, Leyva F, Gomez-Bajo GJ: Pediatric hand trauma. *Clin Orthop Relat Res* 432:77–86, 2005.
192. Van der Reis WL, Otsuka NY, Moroz P, et al: Intramedullary nailing versus plate fixation for unstable forearm fractures in children. *J Pediatr Orthop* 18:9–13, 1998.
193. Van Tassel DC, Owens BD, Wolf JM: Incidence estimates and demographics of scaphoid fracture in the U.S. population. *J Hand Surg [Am]* 35:1242–1245, 2010.
194. Vernooij CM, Vreeburg ME, Segers MJ, et al: Treatment of torus fractures in the forearm in children using bandage therapy. *J Trauma Acute Care Surg* 72:1093–1097, 2012.
195. Verstreken L, Delronge G, Lamoureux J: Shaft forearm fractures in children: intramedullary nailing with immediate motion: a preliminary report. *J Pediatr Orthop* 8:450–453, 1988.
196. Vince KG, Miller JE: Cross-union complicating fracture of the forearm. Part II: children. *J Bone Joint Surg Am* 69:654–661, 1987.
197. Vorlat P, De Boeck H: Bowing fractures of the forearm in children: a long-term followup. *Clin Orthop Relat Res* 413:233–237, 2003.
198. Walker JL, Rang M: Forearm fractures in children. Cast treatment with the elbow extended. *J Bone Joint Surg Br* 73:299–301, 1991.
199. Waters PM, Bae DS, Montgomery KD: Surgical management of posttraumatic distal radial growth arrest in adolescents. *J Pediatr Orthop* 22:717–724, 2002.
200. Waters PM, Kolettis GJ, Schwend R: Acute median neuropathy following physeal fractures of the distal radius. *J Pediatr Orthop* 14:173–177, 1994.
201. Waters PM, Mih AD: Fractures of the distal radius and ulna. In Beaty JH, Kasser JR, editors: *Rockwood and Green's fractures in children*, Philadelphia, 2006, Lippincott Williams & Wllkins, pp 337–398.
202. Waters PM, Stewart SL: Surgical treatment of nonunion and avascular necrosis of the proximal part of the scaphoid in adolescents. *J Bone Joint Surg Am* 84:915–920, 2002.
203. Waters PM, Taylor BA, Kuo AY: Percutaneous reduction of incipient malunion of phalangeal neck fractures in children. *J Hand Surg [Am]* 29:707–711, 2004.
204. Webb GR, Galpin RD, Armstrong DG: Comparison of short and long arm plaster casts for displaced fractures in the distal third of the forearm in children. *J Bone Joint Surg Am* 88:9–17, 2006.
205. Weber DM, Fricker R, Ramseier LE: Conservative treatment of scaphoid nonunion in children and adolescents. *J Bone Joint Surg Br* 91:1213–1216, 2009.
206. Weiss AP, Hastings H, 2nd: Distal unicondylar fractures of the proximal phalanx. *J Hand Surg [Am]* 18:594–599, 1993.
207. West S, Andrews J, Bebbington A, et al: Buckle fractures of the distal radius are safely treated in a soft bandage: a randomized prospective trial of bandage versus plaster cast. *J Pediatr Orthop* 25:322–325, 2005.
208. Williams KG, Smith G, Luhmann SJ, et al: A randomized controlled trial of cast versus splint for distal radial buckle fracture: an evaluation of satisfaction, convenience, and preference. *Pediatr Emerg Care* 29:555–559, 2013.
209. Worlock P, Stower M: Fracture patterns in Nottingham children. *J Pediatr Orthop* 6:656–660, 1986.
210. Worlock PH, Stower MJ: The incidence and pattern of hand fractures in children. *J Hand Surg [Br]* 11:198–200, 1986.
211. Yip HS, Wu WC, Chang RY, et al: Percutaneous cannulated screw fixation of acute scaphoid waist fracture. *J Hand Surg [Br]* 27:42–46, 2002.
212. Young K, Greenwood A, MacQuillan A, et al: Paediatric hand fractures. *J Hand Surg Eur Vol* 38:898–902, 2013.
213. Young TB: Isolated fracture of the capitate in a 10-year-old boy. *Injury* 17:133–134, 1986.
214. Younger AS, Tredwell SJ, Mackenzie WG: Factors affecting fracture position at cast removal after pediatric forearm fracture. *J Pediatr Orthop* 17:332–336, 1997.
215. Younger AS, Tredwell SJ, Mackenzie WG, et al: Accurate prediction of outcome after pediatric forearm fracture. *J Pediatr Orthop* 14:200–206, 1994.
216. Yuan PS, Pring ME, Gaynor TP, et al: Compartment syndrome following intramedullary fixation of pediatric forearm fractures. *J Pediatr Orthop* 24:370–375, 2004.

217. Yung PS, Lam CY, Ng BK, et al: Percutaneous transphyseal intramedullary Kirschner wire pinning: a safe and effective procedure for treatment of displaced diaphyseal forearm fracture in children. *J Pediatr Orthop* 24:7–12, 2004.
218. Zamzam MM, Khoshhal KI: Displaced fracture of the distal radius in children: factors responsible for redisplacement after closed reduction. *J Bone Joint Surg Br* 87:841–843, 2005.
219. Zimmermann R, Gschwentner M, Pechlaner S, et al: Remodeling capacity and functional outcome of palmarly versus dorsally displaced pediatric radius fractures in the distal one-third. *Arch Orthop Trauma Surg* 124:42–48, 2004.
220. Zoetsch S, Kraus T, Weinberg AM, et al: Fracture of the ulnar styloid process negatively influences the outcome of paediatric fractures of the distal radius. *Acta Orthop Belg* 79:48–53, 2013.
221. Zook EG, Guy RJ, Russell RC: A study of nail bed injuries: causes, treatment, and prognosis. *J Hand Surg [Am]* 9:247–252, 1984.
222. Zook EG, Van Beek AL, Russell RC, et al: Anatomy and physiology of the perionychium: a review of the literature and anatomic study. *J Hand Surg [Am]* 5:528–536, 1980.

42

Replantation

James P. Higgins

No single conceptual development has had an impact on the field of hand surgery as profound as the advent of microsurgical techniques. The ability to repair blood vessels that could not be seen without visual assistance led to an accelerated phase of discovery and innovation that continues to this day. The availability of microsurgical techniques has expanded the extent and type of injuries that can be considered correctable and have made operations for these corrections relatively commonplace.

After the coaptation of blood vessels was first performed by Dr. Alexis Carrell in 1902, modifications followed in techniques for suturing and instrumentation and their applications. The great pioneers of microsurgery developed instrumentation and other techniques that allowed the anastomosis of blood vessels. After the techniques were deemed feasible experimentally, their initial applications were in treatment of the traumatized hand, with replantation being one of the earliest milestones.

In 1962, Malt and McKhann performed the first replantation of a completely severed arm in a 12-year-old boy in Boston.[29] In 1963, Chen and colleagues performed the first successful replantation of an amputated hand in Shanghai, China.[7] In 1968, the first replantation of an individual digit, a thumb, was achieved by Drs. Komatsu and Tamai in Japan. [25] As centers became increasingly more familiar with the technique and as experience around the globe expanded, replantations of increasing complexity were performed. This has led us to the current day, in which the initial procedures for replantation have been adapted, refined, and extended and include repair of distal tip amputations,[38] ectopic banking of amputated parts,[17,21] and, ultimately, vascularized composite allotransplantation.[13,20,23,31]

GENERAL CONSIDERATIONS IN REPLANTATION

Epidemiology

Few studies have evaluated the impact of amputations and replantations on society. A study from Sweden determined the incidence to be 1.9 per 100,000 person-years (males 3.3, females 0.5). Eighty-six percent occurred in males and 9% in children (age 0 to 14 years). The majority occur in males 45 to 54 years of age. Factory workers (26%) and carpenters (14%) were most commonly injured.[3] A large national database study of upper extremity amputation and replantation cases in the United States demonstrated that the patients undergoing replantation were younger (average age 36 years) than those suffering amputation but not undergoing replantation (average age 44 years). Replantation was most often performed in teaching hospitals and larger urban hospitals.[14]

Emergency Management

The patient sustaining an upper extremity amputation should be rapidly and efficiently transported to a specialty center capable of replantation. The patient's candidacy for replantation should be determined after he or she has been assessed in the emergency department. The field trauma care of such a patient should follow the principles of global trauma management. It may be easy to overlook more urgent basic trauma protocols in the setting of the distracting, and sometimes dramatic, appearance of extremity amputations. The ABCs of trauma management should never be neglected.

Specific management of the amputated parts should include collection of all amputated parts in the field, regardless of the degree of contamination or quality of tissue. These parts should be wrapped in a sponge saturated with saline, placed in a plastic bag, and subsequently placed in a bag of ice or on a bed of ice. The goal is to cool the part but avoid freezing of the tissue. The bag should be labeled with the patient's demographic information and transported with the patient to the hospital setting. The amputated stump should be treated with pressure dressings and elevation to control bleeding. Tourniquets should be avoided as well as attempts at ligation of blood vessels in the field, if possible.

In the emergency department, the amputated parts and the amputated stump should be evaluated for the purposes of operative planning and decision making. The patient's limb and amputated parts should be evaluated radiographically. Tetanus prophylaxis should be provided.

Patient Selection

Very few indications or contraindications for replantation are absolute. The most compelling indications for replantation include thumb amputations at any level (Figure 42.1), multiple-digit amputations (Figure 42.2), any amputation in the pediatric population, and amputations through the wrist, forearm,

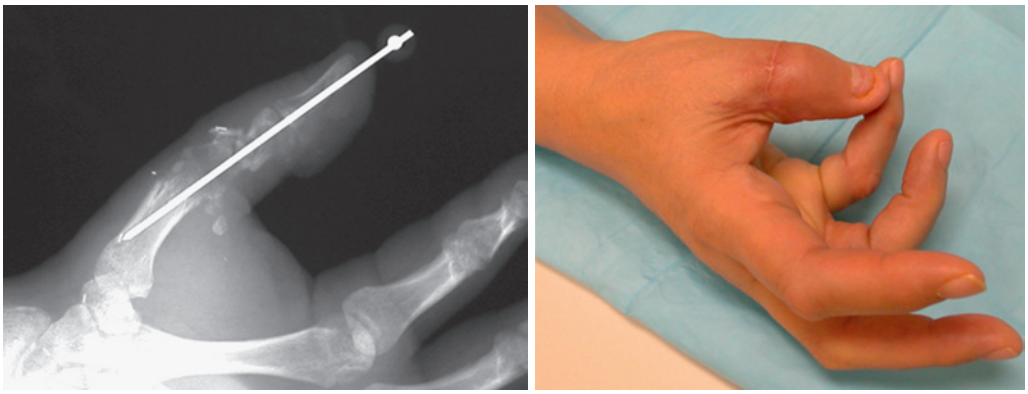

FIGURE 42.1 Example of indication for replantation. This thumb replantation was performed despite extreme comminution and bone loss. Although minimal motion is achieved at the metacarpal or interphalangeal joints, the thumb replantation is a functional success because of the preserved motion at the carpometacarpal joint.

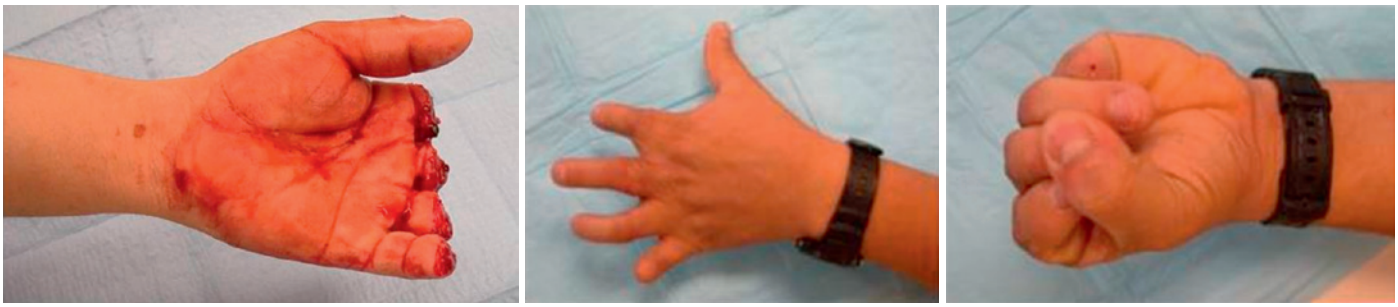

FIGURE 42.2 Example of indication for replantation: multiple-finger amputations. Note the significant shortening of all digits to achieve primary nerve coaptation. Despite the shortened length, the replantation is a functional success.

and elbow. Contraindications for replantation include medical instability that would make lengthy surgical intervention excessively risky. Relative contraindications include single-digit amputations through zone 2 of the flexor tendon sheath, multilevel segmental amputations, and ring finger avulsion amputations. These are felt to be relative contraindications because the procedures are difficult to perform and satisfactory functional results are difficult to achieve. Reports of series of patients in these categories have been published demonstrating surprisingly good results, with authors questioning whether these conditions should be considered relative contraindications.[1,5,6,22,33]

A relative indication for replantation is a single digit distal to the flexor digitorum superficialis insertion. Although the functional loss from such an amputation in a digit other than the thumb is not great, surgical replantation of such an amputated digit can be performed quite speedily and the functional outcomes are good. Lack of involvement of the proximal interphalangeal joint and preservation of the flexor digitorum superficialis insertion will likely provide good proximal interphalangeal motion and an overall satisfying functional result even without significant return of distal interphalangeal flexion. For this reason, amputations at this level are felt to have a more favorable prognosis than those through zone 2 (Figure 42.3).

Special consideration should be given to major replantation cases. Good functional outcomes can be achieved with replantation through the midpalm, wrist, and forearm. The more proximal the amputation, however, the less promising will be the result because of the amount of nerve regeneration needed to achieve protective sensation and the potential for stiffness of the elbow joint; also, myonecrosis may occur in proximal replantation cases with a prolonged ischemia time.

The length of the ischemia time is a much less critical issue in digit-level amputations because muscle sensitive to ischemia is not present. At the level of the midpalm or wrist, the intrinsic muscles may be débrided if injured. If they are uninjured and are left intact despite a prolonged ischemia time, the resultant fibrosis and dysfunction may be manageable. In more proximal injuries, however, the muscle burden of an amputation through the proximal forearm or transhumeral level is quite significant. In these cases, the ischemia time becomes paramount.

Digit replantation is considered feasible if the warm ischemia time is limited to 6 to 12 hours. With a well-preserved, cooled part, cold ischemia can likely be tolerated for up to 24 hours after digital amputation prior to replantation.[28] Sporadic cases of delayed digit replantation have been reported after 33 hours and 94 hours of warm and cold ischemia, respectively.[9,45] Successful hand replantation has been reported in one case after 54 hours of cold ischemia.[42] The limits of tolerated ischemia time in distal amputations are thus poorly defined. Indeed, Lin and colleagues studied ischemia time in 31 cases of hand and finger replantation that exceeded 24 hours and found no correlation between ischemia time and postoperative outcome.[28]

In amputations involving the forearm, even 2 to 3 hours of warm ischemia time can result in substantial muscle necrosis, which can produce a coagulopathy after reperfusion. Venous outflow from the reperfused extremity contains toxic compounds such as oxygen-free radicals that can cause tissue damage and vasospasm. In these cases, cooling the amputated

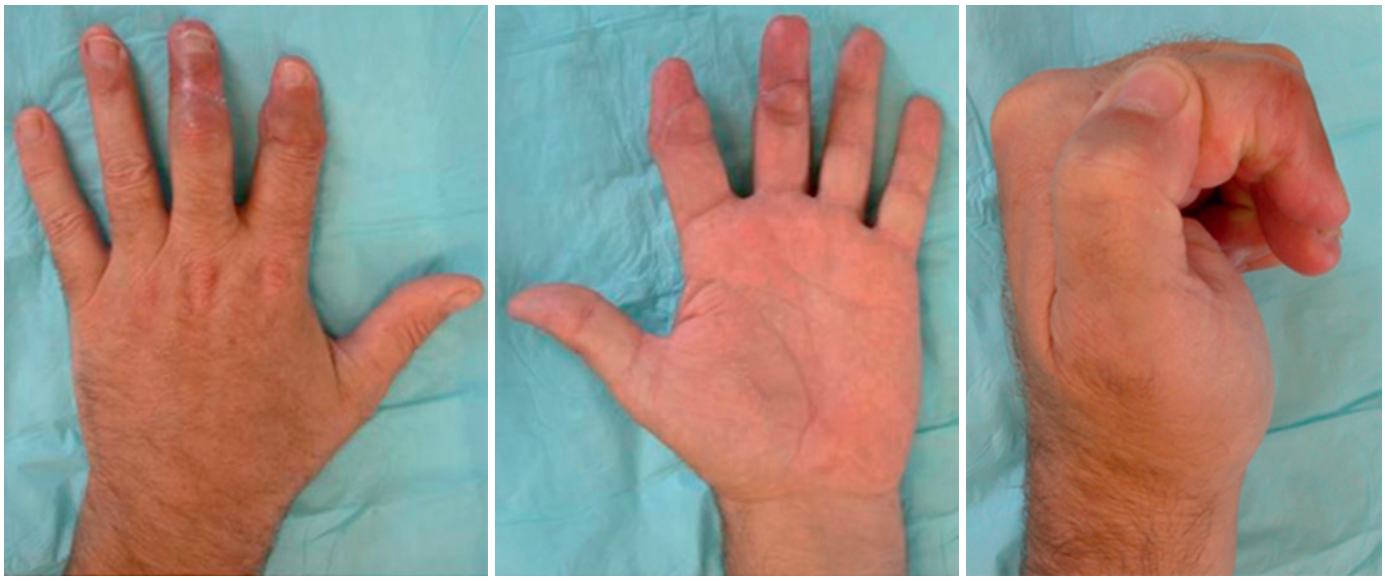

FIGURE 42.3 Example of replantations performed distal to the flexor digitorum superficialis insertion. Despite achieving no significant distal interphalangeal motion, the replantation is a functional success because of the preserved proximal interphalangeal motion.

part (to 4°C) can dramatically prolong the time between injury and successful replantation. Cooling must be performed to the appropriate level because excessive cooling below 4°C can cause formation of intracellular crystals that can cause tissue damage similar to frostbite.

Properly cooled parts have been replanted up to 36 hours after the time of injury; however, the survival rate of an amputated part decreases with the delay to replantation.

It is these considerations of muscle burden, ischemia time, distance of required nerve regeneration, and degree of skeletal injury, as well as the mechanism of injury, that need to be considered in every case of major replantation.

Technical Considerations in Preparing for Replantation

Whether at the digit level or transhumeral level, replantation is best performed with a team effort. The efficiency, speed, and quality of replantation are enhanced using a team approach. Two teams enable simultaneous work on the amputation stump and the amputated parts. In lengthy cases (such as multiple-digit amputations), the team model allows surgeons to work in shifts; each shift of well-rested surgeons works with a fresh perspective and relieves the fatigued surgeons on the shift before them.

This approach should be used as soon as the decision to operate has been made. The amputated parts should be brought to the operating room so that débridement, dissection, and preparation can begin before the patient arrives in the operating room. This will minimize the patient's anesthesia time and allow the surgical team to assess the quality of the part and thus the likelihood of replantation or technical requirements.

INTRAOPERATIVE TECHNIQUE

Preparation of the Amputated Part

The amputated parts are treated with a surgical prep solution and placed on a back table with full sterile technique. Midaxial incisions are made on both the radial and ulnar sides of the digit. The volar and dorsal skin flaps are elevated. The neurovascular bundles are dissected in the radial and ulnar sides and assessed for their quality, caliber, and length. The flexor tendon is prepared with a locking 3-0 suture, with the loose ends protruding through the severed end of the tendon. The extensor tendon is elevated but is not affixed with sutures. The bone is shortened generously to enable primary nerve coaptation. Osseous shortening is preferentially performed from the level of the amputated part so that failure of the replantation would not result in excessive shortening of the amputation stump. If the shortening of the bony structure requires resection back to the adjacent joint, the joint is prepared for arthrodesis by removal of the cartilage and subchondral bone and preparation for a cup-and-cone relationship between the amputated part and the stump.

Anticipated osseous fixation is prepared. This is usually performed with longitudinal nonparallel Kirschner wires driven from proximal to distal in an antegrade fashion through the tip of the digit and then recessed to the level of the proposed osteosynthesis site. Pin balls are applied to the Kirschner wires and protrude through the tip of the digit so that they do not constitute a hazard to the surgeon during the remainder of the operation. The pin balls will later be removed, and the pins driven retrograde to achieve fixation.

We usually remove the nail plate at the time of digit preparation and discard it. This can be helpful if the digit demonstrates venous insufficiency following operation and requires heparin pledget application in the nail bed or leech application. This will avoid the need for nail removal at the bedside in an awake postoperative patient.

An attempt is made to separate the nerves and arteries as minimally as necessary for assessment and preparation. Preserving surrounding subcutaneous tissue may minimize desiccation thoughout the case.

The vessels need to be assessed with a microscope to evaluate the intima in the lumen. Avulsive injuries will often cause

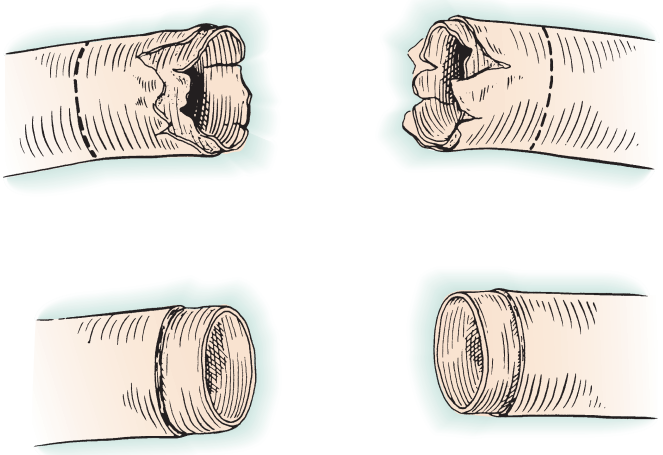

FIGURE 42.4 Damaged microvessels must be sharply incised back to completely normal intima. The intima should be evaluated under magnification through the operating microscope.

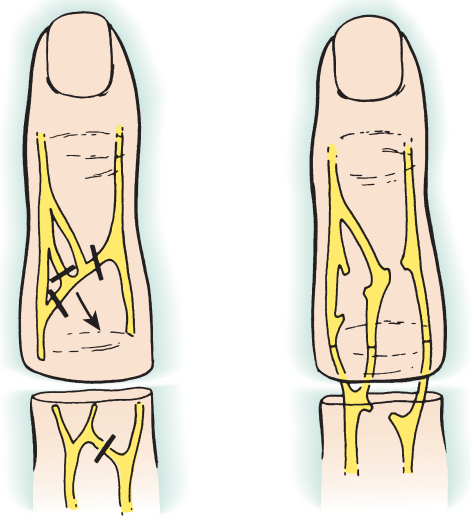

FIGURE 42.5 Vein dissection. The mobilization or harvesting of veins is a useful method of obtaining ease of approximation for vein reconstruction in a complete amputation.

significant dissection of the vessel wall layers or fracturing of the intima near the zone of injury (Figure 42.4). This will require resection of the distal vessel until a normal vessel is observed. If a single arterial reconstruction is being performed, the distal vessel of better quality will be used. This can be performed in a crossover fashion to the contralateral digital artery if length and caliber facilitate it. Additionally, the second distal artery could be considered as a source of venous outflow if no dorsal veins are available, so this vessel should be preserved in the field, and both vessels should be dissected in preparation for replantation.

In the dorsal subcutaneous fat, the veins are assessed. This is also performed with the least amount of initial dissection of the veins possible. The quality and number of available veins are assessed under the microscope.

Preparation of the digit can sometimes be difficult if the surgeon does not have an assistant available. Placement of the longitudinal Kirschner wires can facilitate unassisted dissection. The nonparallel Kirschner wires protruding through the tip of the digit can be held stable with a surgical clamp to prohibit pronation/supination of the part during dissection.

Preparation of the Hand

Information about the osseous level of shortening is shared by the surgical teams. If arthrodesis of either the proximal interphalangeal or distal interphalangeal joint will be performed, the amputation stump is fashioned into a convex cone configuration in preparation for the arthrodesis. If extraarticular fixation is planned, the bone may be prepared so that it is aligned to simplify reduction. The simplest configuration is a transverse osteosynthesis site so that fixation and rotational alignment can most easily be achieved.

The proximal tendon is prepared by retrieving it through the fibroosseous sheath, resecting the edge back to a healthy transverse tenotomy, and preparing it with a 3-0 locking suture similar to the preparation of the distal flexor tendon.

The dorsal extensor tendon is elevated and prepared but does not require presuturing for preparation. The radial and ulnar neurovascular bundles are assessed via radial and ulnar midaxial incisions, and the dorsal skin is elevated with subcutaneous fat for preparation of the veins. A microscope is brought into the field at this point to assess the vessels. Considerations about the quality of the proximal vessels are the same as those described for the distal part. Ultimately, the quality of the proximal artery will be determined by the spurt test, which is performed after the tourniquet is released.

The digital nerves are resected back to a healthy fascicular pattern with great care taken to attempt to achieve primary nerve coaptation after osseous shortening.

Dorsally, the veins are assessed. The proximal veins are usually easier to find and prepare than the distal veins because of their larger caliber. If additional length is needed for vein coaptation, side branches may be ligated to elongate and transpose veins to reach the anastomosis site (Figure 42.5).

It should be noted that the preparation of the amputated part is typically done under tourniquet control. For this reason, all of these processes in preparation of the amputation stump and ultimate replantation should be done as efficiently and rapidly as possible. The surgeon needs to assess, prepare, and plan each sequential phase with a premium placed on speed and a constant awareness of the duration of tourniquet time that has elapsed.

Replantation

Different surgeons favor significant variations in digital replantation technique. There is not a consensus about the "correct" way to perform replantation because there are benefits with many different strategies. Several common concepts are seen in all of the techniques, however.

If multiple digits have been amputated, it is always more efficient to perform the replantations sequentially. For example, the osseous structures in all digits may be addressed and replanted prior to moving forward with the tendinous structures. In this way, structures that are best repaired during tourniquet control can be repaired rapidly digit by digit and structures that are more easily addressed with tourniquet release can also be repaired digit by digit.

Structures that require microscopic procedures are generally repaired last so that the delicate repairs are not damaged by the more disruptive tendon or bone repairs.

The tourniquet time also influences the sequence of events because some procedures may require tourniquet control and others are easily performed without the benefit of a tourniquet.

In our center, we perform digital replantations in the following sequence:

Under tourniquet control we perform osseous fixation, extensor tendon repairs, flexor tendon repairs, digital nerve repairs under the microscope, and dorsal vein repairs under the microscope if time permits.

After tourniquet release we perform any remaining dorsal vein repairs that have not been performed under tourniquet control, arterial repairs under the microscope after adequate inflow has been ensured, and loose approximation of skin.

There are many reported variations in the sequence of the structures repaired in digital replantation. Some surgeons prefer to repair all dorsal structures (extensor tendon and veins) first, followed by all volar structures (flexor tendons, digital nerves, and arteries), for the benefit of positioning efficiency. Other surgeons will purposefully plan the vein repairs last in an effort to achieve arterial inflow first. Surgeons who advocate this technique have reported the benefit of arterial inflow in assessing and locating dorsal veins with the engorgement of venous return. Lastly, some surgeons have advocated repairing flexor tendons before extensor tendons because they feel they are better able to reproduce the position of the replanted digit within the cascade of the hand.

A particular note should be made of the sequence of events for major replantation. When a significant muscle burden exists in the amputated part, the degree of urgency in achieving perfusion is significantly more acute than with a digital replantation. In this case, most surgeons would advocate moving toward arterial repair as quickly as possible. In our center, if we feel that the part was managed with appropriate cooling and has been brought to the operating room with a very short ischemia time, we will perform osseous fixation first in an efficient and rapid manner and then move toward arterial reconstruction. However, if either ischemia time or temperature has been compromised and we feel that there is extreme urgency in achieving revascularization, we will elect to use an artificial arterial shunt. Shunts rapidly achieve distal perfusion by cannulating both the proximal and distal ends of the vessel(s) requiring repair (Figure 42.6). In this setting, a catheter is placed both proximally and distally and is secured, usually with insufflation of balloon cuffs. This can be further secured with an exterior suture ligation of the vessel on top of the shunt to achieve a watertight seal. After arterial inflow is established, the extent of venous bleeding is assessed. A second shunt may be used in the venous system so as to minimize the amount of blood loss. If the muscle burden

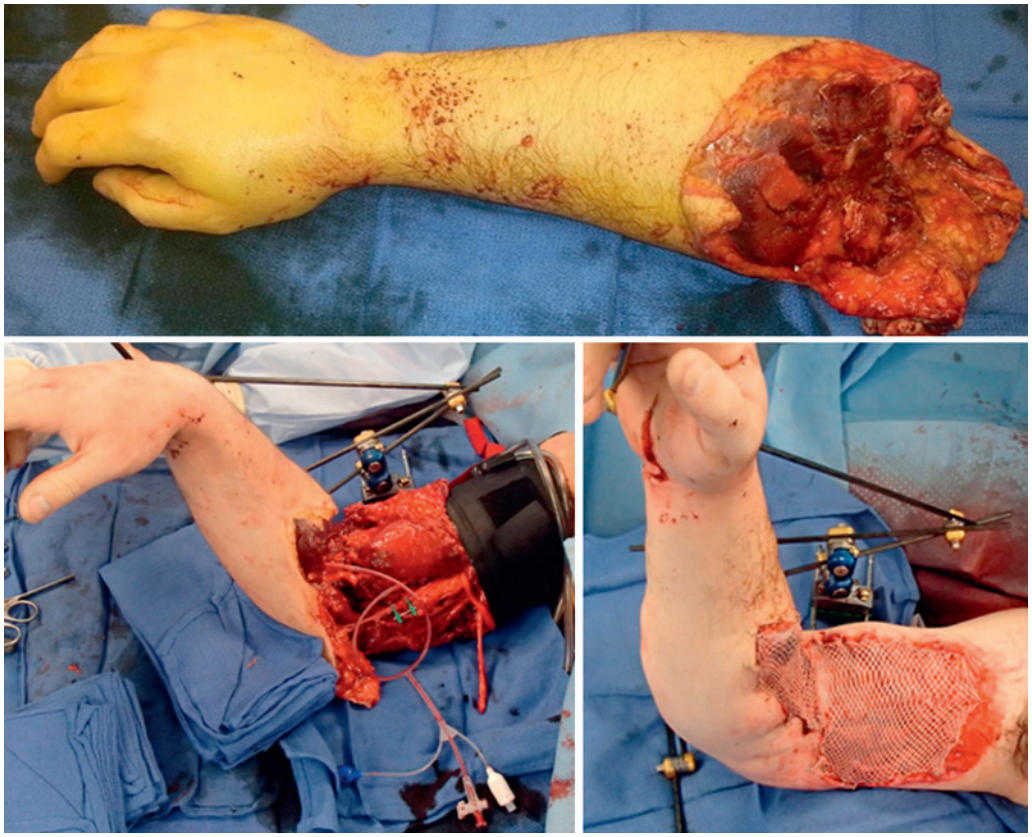

FIGURE 42.6 Example of "major replantation" of amputation through the elbow joint. Due to the significant muscle burden of the amputated part, this arm was replanted with rapid placement of an external fixator followed by the use of an arterial shunt to reperfuse the part. While the shunt was in use, additional steps in the replantation procedure were completed (i.e., repair of tendons and nerves, fasciotomies). Because the sharp amputation preserved much of the elbow joint, skeletal shortening was not favorable. Primary nerve coaptation was achieved with elbow flexion and nerve transposition.

of the amputated part is significant, the anesthesiologist must be prepared to address this with appropriate hydration and fluid cardiovascular monitoring.

We attempt to reperfuse for 20 minutes for every hour of ischemia sustained prior to reperfusion. When this is achieved, one can consider removal of the shunts, exsanguination, and tourniquet application so as to move forward with the rest of the replantation procedure under tourniquet control. Within this time frame, the team may rapidly achieve osseous fixation (typically, plating of the radius, ulna, or humerus or external fixation if there is a significantly complex intraarticular amputation through the elbow). The surgeon may proceed with repair of additional structures such as tendons and nerves with the shunts in place as reperfusion time requires.

Osseous Fixation

At the level of the digit, osseous fixation has often been performed with nonparallel longitudinal Kirschner wires driven retrograde after they had previously been placed in the prepared amputated digit. They can be driven across an osteosynthesis site in a phalanx or across a planned arthrodesis site. Although there is a sense of the need for speed and urgency in these cases, one should always take great care to assess for malrotation or angulation. A successful replantation can be made a functional failure with poor osseous alignment.

Other techniques that have been advocated include interosseous wiring, screw fixation, and plate fixation. Although these techniques provide a more stable construct than longitudinal Kirschner wires, they also require more operative time and, more importantly, more significant osseous exposure. Attempts should be made to minimize soft tissue stripping of the area surrounding the osteosynthesis site. A useful technique that provides stability with minimal stripping is interosseous wire fixation. This is particularly useful when replantation is performed very close to the proximal interphalangeal joint line. Interosseous wire technique, although somewhat more time-consuming than Kirschner wire fixation, can enable the surgeon to avoid hardware crossing the proximal interphalangeal joint.

When performing thumb replantation, the longitudinal Kirschner wire technique may also provide additional benefits. These amputations commonly occur in the region of the metacarpophalangeal joint where the ulnar digital vessels are difficult to visualize with the microscope regardless of hand positioning. In this setting, initial fixation is achieved by driving one of the two prepared Kirschner wires across the osteosynthesis site and leaving the second wire in position at the margin of the osteosynthesis site. This permits the surgeon to temporarily hyperpronate the distal thumb. The surgeon may elect to access the distal ulnar digital artery for primary anastomosis or vein graft distal anastomosis in this position. When this is complete, the thumb may be rotated into anatomic position on the single wire. When rotation is deemed accurate, the perched second wire may be cautiously driven across the osteosynthesis site, completing the fixation and controlling rotation.

Extensor Tendon Repairs

Extensor tendon repairs are rapidly performed with figure-of-eight 3-0 braided permanent sutures. This is usually performed in an attempt to coapt the tendons tightly so as to diminish the degree of extensor lag experienced postoperatively.

Flexor Tendon Repairs

Flexor tendons are repaired using the preaffixed locking sutures. This configuration will leave two 3-0 caliber suture ends protruding through the tenorrhaphy site distally and an additional two suture ends protruding through the tenorrhaphy site proximally. This will result in two knots within the repair site. If the sutures have been tied with this configuration, a two-core suture tendon repair would be achieved. Alternatively, a four-core repair can be achieved by passing the needle from each of the protruding sutures through the opposite tendon with a locking suture technique, returning to the tenorrhaphy site, and completing the suture knots. This results in a four-core, two-knot tendon repair that can be augmented with an epitendinous suture if desired by the surgeon.

Management of the flexor digitorum superficialis tendon in zone 2 replantations is optional. We typically perform digit replantations using FDP tendon repairs only.

Digital Nerve Repairs

Under microscope control, the digital nerves are assessed. We prefer to perform this with the benefit of tourniquet control. The nerves are resected back to healthy fascicles and primarily coapted if possible. Primary coaptation of the nerves is an important benefit of osseous shortening. The functional success of a successfully replanted part will often be determined by the level of sensation that is regained. For this reason, this step should be performed carefully and all attempts should be made to achieve primary nerve repair.

Great emphasis should be given to primary nerve coaptation in the setting of major replantation. At the transhumeral, transelbow, or transforearm level, bony shortening should be pursued if possible to focus on primary nerve coaptation because this will play an even more critical role in the ultimate functional success or failure of the replantation.

Digital Vein Repairs

Venous repair is often the most technically challenging and critical aspect of digital replantation. As many venous anastomoses as possible should be performed in a tension-free manner without the need for interpositional vein grafts. In zone 1 replantations, this is particularly challenging. Finding dorsal veins of reasonable quality may be impossible, and one should consider assessment of the volar pulp for superficial volar veins as well as use of the second digital artery for venous outflow if no distal veins can be located.

CRITICAL POINTS ***Techniques for Locating Distal Veins for Replantation***

- Elevate the fibrofatty tissue deep to the dermis and superficial to the extensor tendon; inspection of this translucent layer against operative lighting allows the surgeon to identify the dorsal veins.
- Perform a dorsal midline longitudinal incision and attempt to visualize the veins while raising the skin flaps in a subdermal plane.
- Perform arterial anastomoses and release the clamps on the arteries prior to performing venous anastomoses; engorgement of dorsal veins will make finding their locations easier.

Arterial Repairs

Even with adequate microscopic investigation of the proximal artery, it can be difficult to determine the adequacy of ultimate inflow from an artery without releasing the tourniquet and checking a spurt test. If the spurt test is inadequate, the artery can be resected proximally to a less damaged vessel. Prior to excessive resection, however, the surgeon should always consider topical vasodilators, including warm saline, papaverine, and lidocaine, to relieve vasospasm and provide an adequate assessment of the inflow capability of the proposed artery.

Primary arterial coaptation can be performed in an anatomic fashion from the proximal-to-distal artery as existed prior to injury, or it can be performed in a "crossover" fashion (i.e., the ulnar digital artery to the digit may be anastomosed to the radial digital artery distally). This technique may be problematic, however, if the patient requires further surgery (i.e., tenolysis) in the future which could interrupt the vascular supply to the finger. Interpositional grafting of the artery reconstruction permits the surgeon to resect out of the zone of injury and perform a tension-free repair. The caliber of the veins on the volar aspect of the distal forearm is a good match for the caliber of the digital arteries. The dorsal hand veins and dorsal forearm veins are usually quite large for this task, as are the greater saphenous or lesser saphenous veins.

When performing an interpositional arterial or venous graft for the artery, it is technically easier to perform the distal anastomosis first. This is a smaller-caliber anastomosis and may have less dissectible length of distal artery and thus less mobility for the distal anastomosis. If performed first, the distal anastomosis may be more freely rotated to access the front and back vessel walls, and the vein graft may also be flipped distally after completing the front wall suturing to access the back vessel wall. Once the distal anastomosis has been performed, the vein graft can be repositioned into its anatomic location and the proximal anastomosis performed with relative ease.

Reperfusion

Prior to releasing the clamps, we will typically apply topical vasodilators, including warm saline, lidocaine, and papaverine, to the arteries and veins. The clamps are released on the artery first. If a vein graft is used, the distal clamps are removed first and the proximal clamps second. This allows rapid passage of the blood through the anastomoses and into the digit. Great vigilance should be used here in preserving a warm and nondesiccated environment for the recovering vessel because it will tend to go into vasospasm if traumatized.

We usually await substantial engorgement of the distal veins prior to releasing the clamps on the venous anastomoses. Venous thrombosis is in part instigated by stasis of blood underneath an area of intimal damage. In this regard, any passage of blood underneath the newly performed anastomoses would best be permitted when there is rapid flow of venous return. With all clamps released, the digit is continually warmed and kept moist. The digital tip is assessed for a Doppler signal as well as color and turgor. It is not uncommon for the digit not to demonstrate a Doppler signal in the operating room, but it will often develop an audible signal while the patient is recovering on the evening following surgery or the following day.

Skin Closure

It is of utmost importance that the skin closure be performed loosely. The dorsal and volar skin can be loosely approximated. With skeletal shortening, this can usually be performed without any difficulty. However, we typically leave the midaxial incisions wide open, even in the setting of exposure of the neurovascular structures. This technique will result in surprisingly successful delayed healing with minimal scarring. The tension provided by skin closure will place undue pressure on arterial and venous repairs in the postoperative period, particularly with postoperative swelling.

POSTOPERATIVE PROTOCOL

There are many postoperative protocols used by replantation surgeons. The frequency and vigilance of postoperative monitoring should depend on the surgeon's threshold for surgical reexploration or alterations in postoperative medical management. The surgeon, patient, and patient's family should have an extensive discussion postoperatively regarding the intraoperative findings, potential postoperative outcomes, and future plans. If the surgeon feels that if a thrombosis develops revision surgery would probably not be successful (because of the condition of the amputated part), the surgeon may elect to minimize postoperative monitoring and discuss the plan for postoperative success or failure quite clearly with the family and the patient. If a thrombosis were to develop and surgical reexploration would not be warranted, hourly vascular assessment would likely not be indicated. On the other hand, if the situation warrants exploration regardless of the difficulty of the initial operation (as with pediatric replantation, major replantation, or multiple-digit replantation), the surgeon may request frequent monitoring postoperatively so that if a thrombosis is detected, emergent reexploration can be performed rapidly and efficiently.

Postoperative adjuvant treatment varies in different centers. Use of topical heat (i.e., warming blanket, heat lamp, and heated room), as well as daily aspirin therapy, is nearly universal. Other antithrombotic medications such as dextran, heparin, or warfarin have not had significant efficacy, and their use is quite variable among replantation surgeons.[2,10,24,32]

Management of a failing replantation depends on the appearance and acuity of the changes seen during postoperative monitoring. If the changes in appearance, Doppler signal, or temperature are subtle and vasospasm is suspected, surgeons may try to control these influences nonsurgically. Indwelling analgesic catheters, release of constructive dressings, environmental warming, and pain control can provide limited improvement if vessel thrombosis has not occurred.

Arterial ischemia due to microvascular thrombosis requires emergent reexploration and revision anastomosis if salvage is to be pursued. Resection of the thrombosed segment and vein grafting of the artery are usually required in this setting.

Venous congestion of a replanted digit may be discovered while arterial inflow is still present. The surgeon may elect to use heparin-soaked pledgets or leeches applied to the nailbed to diminish the venous pressure and maintain arterial patency. The patient and replantation team should anticipate using leeches for several days until the digit establishes new venous

drainage channels. This will require antibiotic therapy to cover *Aeromonas hydrophila*, a gram-negative bacteria that is normal intestinal flora in leeches. Blood transfusions are often needed after lengthy periods of treatment with leeches.

EXPECTED OUTCOMES

Reported survival rates of replanted digits have varied widely from 57 to 90%.[4,15,30,34,43,44] Factors with a negative impact on survival rates include mechanism of amputation (crush injuries faring poorly compared with sharp amputations), patient age, and smoking history. Surgical performance of more than one arterial anastomosis and more than one venous anastomosis also increases survival rates.[27,43,44]

Functional outcomes are most affected by the mechanism of injury (crush injuries faring least well), level of injury, and ischemia time. Replantations within zone 2 of the flexor tendon sheath have been shown to achieve dramatically less range of motion than those performed distal to the flexor digitorum superficialis insertion.[36,41] In a study of more than 400 digital replantations, sensory recovery of 8 mm was reported with replanted sharp amputations and two-point discrimination of 15 mm was reported with replanted crush avulsion injuries.[16] Overall, useful two-point discrimination was achieved in 61% of thumb replantations and 54% of digital replantations.

Functional outcomes as measured by the Disabilities of the Arm, Shoulder, and Hand (DASH) scores have been surprisingly good, with one study reporting average scores of 10 for thumb replantation, 11.2 for single-finger replantation, and 16.1 for multiple amputations where at least one digit was replanted.[11] DASH scores have also been better among replantation patients than amputation patients.[19]

Several studies have attempted to provide objective means of estimating outcomes and approaching the initial decision to pursue limb replantation proximal to the wrist. One large study demonstrated the functional superiority of replanted limbs over prosthetics.[18] Objective sensibility testing, however, was excluded as a measured outcome. Studies have demonstrated that younger age and replantation at more distal levels yielded significantly improved functional scores. The mechanism of injury and ischemic time have also been shown to be strongly predictive of functional outcome.[8,44]

FUTURE DIRECTIONS: VASCULARIZED COMPOSITE TISSUE ALLOTRANSPLANTATION

Since its origins in the 1960s, replantation surgery has been focused on improvement in microsurgical technique, postoperative vascular monitoring technologies, thrombosis prevention and management, and nerve repair/reconstruction and recovery. These improvements have been associated with small gains for a procedure still greatly limited in its reliability and functional results.

Our specialty, which has had astounding growth, is the promising new field of vascularized composite tissue allotransplantation (VCA).[20,23,31] Since the first modern-day hand transplantation in 1998, numerous transplantation teams have been assembled, with over 100 upper extremity transplantations performed in over 70 patients worldwide. Although the field seems similar to that of replantation surgery, the techniques are as distinct as the medical considerations. Because an amputated limb can be replaced with a nontraumatized part without compromised or absent skin/bone/nerve/vessel segments, some of the difficult aspects of replantation surgery that limit functional outcomes can be eliminated.

Many issues have been pivotal in the growth of VCA for hand surgery.[13] The first was the successful control of the immunogenic response to allotransplantation of skin; earlier-generation transplantation immunotherapy protocols had indicated that this was not achievable. The second has been unexpectedly favorable results of sensory and motor nerve recovery in transplantation. It has been confirmed experimentally that a commonly employed immunosuppressive medication, FK-506 (tacrolimus), accelerates nerve regeneration.[26,40] This may have contributed to encouraging reports of motor and sensory recovery of transplanted limbs.

Many centers for upper limb transplantation have been established worldwide. Efforts have been made to provide improved communication and exchange of experience and data among these centers. Scientific societies have been established for the advancement of the field. Despite these collaborations, the functional outcomes and risks of these endeavors remain poorly defined. Centers around the globe are not uniform in their methods of measuring success or their transparency in reporting. Furthermore, the field is so new that only speculative predictions can be made about long-term outcomes and lifetime risks.

In a recent comprehensive review of the worldwide upper extremity transplantation experience to date, Shores and colleagues provided an assessment of mortality rates, limb survival rates, and functional outcomes.[39] The overall limb survival rate is 77.6%. In close assessment of all of the databases, however, it appears that rates of limb loss and/or mortality are especially high in Chinese transplantation centers (7 losses of 15 transplanted limbs). The authors speculate that this is due to lack of patient access to immunosuppressive medications or to noncompliance. They also note that *multisite* transplantations (e.g., of the hand and face or the hand and lower limb) accounted for eight of the limb losses and three of the four reported surgical deaths worldwide in cases involving upper extremity VCA. These two subgroups accounted for 62.5% of the upper limb transplant losses. Excluding these two subgroups, the authors state that in cases of *isolated* upper limb transplantations (i.e., bilateral and unilateral cases without concomitant face or lower limb transplantations) in western Europe, Australia, and the United States, there have been no deaths and the limb survival rate has been 90.5% so far (7 limbs acutely or chronically lost or amputated of 74 transplanted limbs).

Assessment of global functional outcomes is limited by the multitude of grading systems employed by the different centers and the lack of applicability of these measures to hand transplantation. In attempting to correlate these outcome reports, Shores and associates[39] found that patients who had undergone distal forearm level transplantation had the best overall results, with measurable sensory discrimination, some intrinsic motor recovery, and the most rapid recovery times. Patients who had undergone midforearm and proximal forearm level transplantation had little or no intrinsic recovery, had protective and sometimes discriminative sensation, and had weaker overall grip strength. Finally, the smaller cohort of

transhumeral transplanted limb patients has had less return of extrinsic function than the cohort that underwent forearm level transplantation, and they cannot expect intrinsic recovery. Thus, functional results have diminished at more proximal levels, as would be expected. Interpretation of the value of these endeavors is subject to debate. Those in favor of the more proximal transplantations view the outcomes as favorable when compared with prosthetic function, use, and durability and view the functional results as markedly improved over the patient's presurgical state. Critics of proximal transplantation question the risk and benefit balance in light of the speculated long-term risks of immunosuppression.

The evolution of immunosuppressive medication regimens is directed toward the goal of minimizing morbidity. Experimental efforts are focused on achievement of immunotolerance with less medication or no lifelong medication.[12,35,37] If the side effect risk profile of the immunosuppressive medications is minimized, a more widespread acceptance and incorporation of this modality will be likely. The success of these strategies will dictate the pace and success of this field in years to come.

CRITICAL POINTS *Digit Replantation*

- No indication is absolute; the most compelling indications are thumb amputations, pediatric digit amputations, and multiple-digit amputations.
- Surgical preparation of the amputated part should begin in the operating room long before the patient arrives to provide a surgical prognosis, increase efficiency, and limit surgical time and anesthetic risk.
- Osseous shortening should be dictated by the length of nerve defects, with a goal of achieving primary nerve coaptation.
- Arterial repairs should be assessed critically to avoid repairs within the zone of damaged intima; liberal use of vein grafts and possible transposition of vessels (i.e., anastomosis of the proximal ulnar digital artery to the distal radial digital artery) should be considered to obtain optimal results.
- Repairs that require microscope use are generally performed last because of the delicacy of the repairs and the benefit of tourniquet release to assess vascular inflow (spurt test).
- In multiple-digit replantations, repairs are performed in a structure-by-structure sequence, not a digit-by-digit sequence (e.g., osseous fixation is achieved in all digits, followed by tendon repairs in all digits).
- In multiple-digit replantation cases, the quality of amputation stumps and amputated parts may suggest advantages in replanting digits in ectopic positions (i.e., index finger replanted in middle finger position).

CRITICAL POINTS *Major Limb Replantation*

- Operative indications should be assessed rapidly; it is critical to assess the anesthesia risk, amount of blood loss, nerve regeneration potential, and functional deficit with replantation and revision amputation at the level of injury.
- A larger muscle burden makes the ischemia time critical.
- Vascular shunts can be used to rapidly reestablish arterial perfusion and limit ischemia to the distal part.
- Osseous fixation may be attempted before, during, or after temporary shunt reperfusion, depending on the duration of cold or warm ischemia.
- Consider distal compartmental releases if needed in anticipation of swelling after reperfusion.
- Osseous shortening should be dictated by the length of nerve defects, with a goal of achieving primary nerve coaptation.

REFERENCES

1. Adani R, Marcoccio I, Castagnetti C, et al: Long-term results of replantation for complete ring avulsion amputations. *Ann Plast Surg* 51:564–568, 2003.
2. Ashjian P, Chen CM, Pusic A, et al: The effect of postoperative anticoagulation on microvascular thrombosis. *Ann Plast Surg* 59:36–39, 2007.
3. Atroshi I, Rosberg HE: Epidemiology of amputations and severe injuries of the hand. *Hand Clin* 17:343–350, vii, 2001.
4. Boulas HJ: Amputations of the fingers and hand: indications for replantation. *J Am Acad Orthop Surg* 6:100–105, 1998.
5. Brooks D, Buntic RF, Kind GM, et al: Ring avulsion: injury pattern, treatment, and outcome. *Clin Plast Surg* 34:187–195, viii, 2007.
6. Brooks D, Buntic RF, Taylor C: Use of the venous flap for salvage of difficult ring avulsion injuries. *Microsurgery* 28:397–402, 2008.
7. Chen CW, Chien YC, Pao YS: Salvage of the forearm following complete traumatic amputation: report of a case. *Chin Med J (Engl)* 82:633–638, 1963.
8. Chew WY, Tsai TM: Major upper limb replantation. *Hand Clin* 17:395–410, viii, 2001.
9. Chiu HY, Chen MT: Revascularization of digits after thirty-three hours of warm ischemia time: a case report. *J Hand Surg [Am]* 9:63–67, 1984.
10. Conrad MH, Adams WP, Jr: Pharmacologic optimization of microsurgery in the new millennium. *Plast Reconstr Surg* 108:2088–2096, 2001.
11. Dabernig J, Hart AM, Schwabegger AH, et al: Evaluation outcome of replanted digits using the DASH score: review of 38 patients. *Int J Surg* 4:30–36, 2006.
12. Donckier V, Toungouz M, Goldman M: Transplantation tolerance and mixed chimerism: at the frontier of clinical application. *Transpl Int* 14:1–5, 2001.
13. Foroohar A, Elliott RM, Kim TW, et al: The history and evolution of hand transplantation. *Hand Clin* 27:405–409, vii, 2011.
14. Friedrich JB, Poppler LH, Mack CD, et al: Epidemiology of upper extremity replantation surgery in the United States. *J Hand Surg [Am]* 36:1835–1840, 2011.
15. Fufa D, Calfee R, Wall L, et al: Digit replantation: experience of two U.S. academic level-I trauma centers. *J Bone Joint Surg Am* 95:2127–2134, 2013.
16. Glickman LT, Mackinnon SE: Sensory recovery following digital replantation. *Microsurgery* 11:236–242, 1990.
17. Godina M, Bajec J, Baraga A: Salvage of the mutilated upper extremity with temporary ectopic implantation of the undamaged part. *Plast Reconstr Surg* 78: 295–299, 1986.
18. Graham B, Adkins P, Tsai TM, et al: Major replantation versus revision amputation and prosthetic fitting in the upper extremity: a late functional outcomes study. *J Hand Surg [Am]* 23:783–791, 1998.
19. Hattori Y, Doi K, Ikeda K, et al: A retrospective study of functional outcomes after successful replantation versus amputation closure for single fingertip amputations. *J Hand Surg [Am]* 31:811–818, 2006.
20. Hautz T, Engelhardt TO, Weissenbacher A, et al: World experience after more than a decade of clinical hand transplantation: update on the Innsbruck program. *Hand Clin* 27:423–431, viii, 2011.
21. Higgins JP: Ectopic banking of amputated parts: A clinical review. *J Hand Surg [Am]* 36:1868–1876, 2011.
22. Hyza P, Vesely J, Drazan L, et al: Primary vein grafting in treatment of ring avulsion injuries: a 5-year prospective study. *Ann Plast Surg* 59:163–167, 2007.
23. Kaufman CL, Breidenbach W: World experience after more than a decade of clinical hand transplantation: update from the Louisville hand transplant program. *Hand Clin* 27:417–421, 2011.
24. Khouri RK, Cooley BC, Kunselman AR, et al: A prospective study of microvascular free-flap surgery and outcome. *Plast Reconstr Surg* 102:711–721, 1998.
25. Komatsu S, Tamai S: Successful replantation of a completely cut-off thumb: case report. *Plast Reconstr Surg* 42:374–377, 1968.
26. Konofaos P, Terzis JK: FK506 and nerve regeneration: past, present, and future. *J Reconstr Microsurg* 29:141–148, 2013.
27. Lee BI, Chung HY, Kim WK, et al: The effects of the number and ratio of repaired arteries and veins on the survival rate in digital replantation. *Ann Plast Surg* 44:288–294, 2000.
28. Lin CH, Aydyn N, Lin YT, et al: Hand and finger replantation after protracted ischemia (more than 24 hours). *Ann Plast Surg* 64:286–290, 2010.
29. Malt RA, McKhann C: Replantation of severed arms. *JAMA* 189:716–722, 1964.
30. Medling BD, Bueno RA, Jr, Russell RC, et al: Replantation outcomes. *Clin Plast Surg* 34:177–185, vii–viii, 2007.
31. Murphy BD, Zuker RM, Borschel GH: Vascularized composite allotransplantation: an update on medical and surgical progress and remaining challenges. *J Plast Reconstr Aesthet Surg* 66:1449–1455, 2013.
32. Nikolis A, Tahiri Y, St-Supery V, et al: Intravenous heparin use in digital replantation and revascularization: The Quebec Provincial Replantation program experience. *Microsurgery* 31:421–427, 2011.
33. Ozkan O, Ozgentas HE, Safak T, et al: Unique superiority of microsurgical repair technique with its functional and aesthetic outcomes in ring avulsion injuries. *J Plast Reconstr Aesthet Surg* 59:451–459, 2006.

34. Pederson WC: Replantation. *Plast Reconstr Surg* 107:823–841, 2001.
35. Ravindra KV, Xu H, Ildstad ST: Vascularized composite allotransplantation at a crossroad. *Transplant Proc* 43:3501–3503, 2011.
36. Ross DC, Manktelow RT, Wells MT, et al: Tendon function after replantation: prognostic factors and strategies to enhance total active motion. *Ann Plast Surg* 51:141–146, 2003.
37. Schneeberger S, Gorantla VS, Brandacher G, et al: Upper-extremity transplantation using a cell-based protocol to minimize immunosuppression. *Ann Surg* 257:345–351, 2013.
38. Sebastin SJ, Chung KC: A systematic review of the outcomes of replantation of distal digital amputation. *Plast Reconstr Surg* 128:723–737, 2011.
39. Shores JT, Brandacher G, Lee WP: Hand and upper extremity transplantation: an update of outcomes in the worldwide experience. *Plast Reconstr Surg* 135:351e–360e, 2015.
40. Tung TH: Tacrolimus (FK506): safety and applications in reconstructive surgery. *Hand (N Y)* 5:1–8, 2010.
41. Urbaniak JR, Roth JH, Nunley JA, et al: The results of replantation after amputation of a single finger. *J Bone Joint Surg Am* 67:611–619, 1985.
42. VanderWilde RS, Wood MB, Zu ZG: Hand replantation after 54 hours of cold ischemia: a case report. *J Hand Surg [Am]* 17:217–220, 1992.
43. Waikakul S, Sakkarnkosol S, Vanadurongwan V, et al: Results of 1018 digital replantations in 552 patients. *Injury* 31:33–40, 2000.
44. Waikakul S, Vanadurongwan V, Unnanuntana A: Prognostic factors for major limb re-implantation at both immediate and long-term follow-up. *J Bone Joint Surg Br* 80:1024–1030, 1998.
45. Wei FC, Chang YL, Chen HC, et al: Three successful digital replantations in a patient after 84, 86, and 94 hours of cold ischemia time. *Plast Reconstr Surg* 82:346–350, 1988.

43

Mangled Upper Extremity

Jeffrey B. Friedrich and Nicholas B. Vedder

Acknowledgment: We would like to recognize our friend and partner Douglas P. Hanel, MD, who was a coauthor on the 6th edition version of this chapter. His contributions to it, and to hand surgery in general, are innumerable, and we are proud to have him as a partner.

PRINCIPLES

Mangling injuries of the hand and upper extremity are, by definition, devastating injuries that involve multiple critical structures of the fingers, hand, arm, or any combination of the three and nearly always lead to significant disability, both directly and through their psychosocial impact. Such injuries can have a dramatic influence on patients' livelihoods and ability to carry out activities of daily living. Because the forces involved in producing mangling injuries of the upper extremity are often great, serious injury to other organ systems and/or other areas of the body are generally also present and nearly always take precedence over extremity injury management.

CRITICAL POINTS *Goals in Treating Upper Extremity Mangling Injuries*

- Preserve life
- Preserve tissue
- Preserve function
- Reconstruct and restore function of both the extremity and the patient

Mangling injuries generally include all or nearly all of the major functional systems of an extremity, including skin and soft tissue, vascular, nerve, muscle and tendon, bone, and joint (Figure 43.1). It is because of this multisystem injury involving all or nearly all layers of the extremity that ultimate function is so much at risk. Despite the best attempts at reconstruction, a scar will form from the skin down through bone and compromise the function of all structures involved and the extremity overall. Peacock elegantly described this as the "one wound–one scar" concept (Figure 43.2).[82,83]

This variable involvement of multiple tissue layers and critical, interdependent structures and systems and the disabling result of the "one wound–one scar" concept led to the "combined injuries" model described by Büchler and Hastings.[17] The eventual impact of the scarring process must therefore be kept in mind throughout planning and reconstruction. Minimizing the negative effects of this process dictates the following general principles in the management of mangling injuries:

- Complete debridement of devitalized tissue
- Restoration of good vascularity
- Rigid skeletal fixation while minimizing additional soft tissue injury
- Stable, vascularized soft tissue coverage

By following these principles, one can allow early mobilization of the extremity, thereby minimizing the impact of "one wound" scarring and maximizing ultimate motion.

The multisystem nature of mangling injuries demands knowledge and expertise in multiple disciplines related to trauma and reconstruction, including trauma surgery, orthopedic surgery, vascular surgery, and plastic surgery, and often benefits from a multispecialty team approach. Because of the diverse nature of mangling injuries, no two cases are alike; in general, there is no single "preferred approach." Rather, a set of principles is determined to guide the surgeon through the application of multiple approaches and techniques that address each of the involved systems while keeping in mind the impact of various treatment decisions on the comprehensive reconstructive plan and final outcome. Many of the specific operative approaches are detailed elsewhere in this textbook, and therefore this chapter concentrates on principles, judgment, and timing.

What is here is an outgrowth of two chapters in a previous edition of this text, "Open Injuries of the Hand" and "Combined Injuries," to which the authors refer the reader as excellent resources on the topic of mangling injuries of the hand,[14,17] as well as several other excellent reviews.[7,11,41,77,85] Sometimes amputation is the most appropriate treatment, and the choice between amputation, partial amputation, and salvage with reconstruction requires looking into the "crystal ball" that shows 6 to 12 months in the future in an attempt to predict the patient's overall function. Which of the various treatment choices is appropriate? After determining that, then a comprehensive reconstructive plan that includes both short- and long-term objectives must be formulated. Optimal management of a mangled extremity is therefore one of the most challenging aspects of hand surgery; it requires a broad knowledge and facility with various techniques and the judgment and experience to know when and how to apply them. It is a true test of one's mastery of the "art" of hand surgery.

CLASSIFICATION

There have been various attempts by hand and upper extremity surgeons to classify mangling hand injuries, but none of the classification systems is predominant. In 1990, researchers in Seattle published the Mangled Extremity Severity Score (MESS), which used objective criteria to predict lower extremity amputation following trauma.[51] Although attempts have been made

CRITICAL POINTS *Factors Necessary to Optimize Ultimate Function*

- Careful and complete evaluation of the injury in which all functional systems are addressed
- Formulation of a comprehensive reconstructive plan tailored to the patient's needs
- Thorough but careful wound debridement of all devitalized tissue
- Meticulous operative reconstruction, often including secondary procedures
- Restoration of good vascularity
- Rigid skeletal fixation while minimizing additional soft tissue injury
- Stable, vascularized soft tissue coverage
- Comprehensive rehabilitation of the extremity and the patient

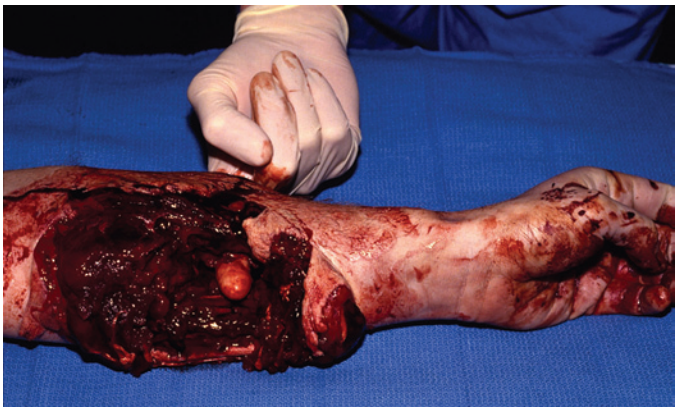

FIGURE 43.1 A mangling injury typically involves all or nearly all of the major functional systems of the extremity, including skin/soft tissue, vascular, nerve, muscle/tendon, bone, and joint.

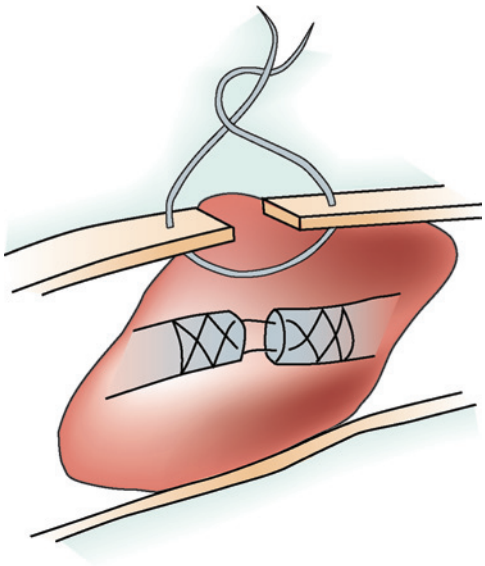

FIGURE 43.2 Classic figure depicting the "one wound–one scar" concept described by Peacock. Despite the best attempts at reconstruction, a scar will form from the skin down to bone and compromise the function of all structures in between and the extremity overall. (Reprinted from Peacock EE, Jr, Van Winkle W, Jr: *Surgery and biology of wound repair*, Philadelphia, 1970, WB Saunders, with permission.)

to apply the MESS to upper extremity mangling injuries, the scoring system in general has not proved helpful in predicting which extremities should be amputated and which should be salvaged.[4,96] One of the reasons why this scoring system is not entirely useful for the upper extremity is that it is not a weight-bearing extremity; therefore, upper extremities with a MESS score of 7 or greater (which in the original study was a predictor for amputation) can often be salvaged and be somewhat useful. Other classification systems, such as the Hand Injury Severity Score (HISS), have emerged, and while they have some utility in predicting time lost from work, they have not been helpful in predicting amputation.[21,107]

MECHANISMS AND PATHOPHYSIOLOGY OF INJURY

A wide variety of mechanisms can produce mangling injuries, including industrial and agricultural machinery, motor vehicles, power tools, explosives, and firearm mechanisms. Most mangling injuries involve some component of a crush injury whereby multiple tissue layers and anatomic systems are injured or destroyed. Certainly, crushing and blast injuries, with their extensive tissue destruction and associated late scarring, are far more difficult to reconstruct and portend a worse outcome than do sharp injuries. As a result of the immediate and delayed tissue necrosis with crushing injuries, the risk for infection is increased, and it often compromises the reconstructive plan. Degloving or avulsion injuries are also frequently mangling in that they involve amputation or partial amputation of one or more critical tissue layers: skin, vessel, nerve, tendon, bone. Abrasion and burn injuries, depending on the extent and depth of involvement, can also be significant components of mangling injuries.

It should be obvious that mangling injuries frequently result in severe wound contamination, depending on the environment and specific mechanism by which they occur. Farming injuries in particular are usually associated with major contamination and require more extensive and often serial debridement and irrigation and special consideration in planning antibiotic management.[36] The combination of a contaminated injury environment with deep, open crushed and devascularized tissue is a dangerous scenario for major life-threatening infection if not recognized and appropriately managed.[75]

A constant element in most mangling injuries is tissue devascularization, which can occur at multiple levels. Crushing, avulsion, degloving, or blast injuries can disrupt major vessels or the branching perforator vessels to muscle and skin, or they can produce endothelial injury that results in thrombosis of large and small vessels, including the microcirculation. Crushing can also cause direct cell disruption and tissue necrosis. Different tissues are more or less susceptible to crushing, with vessels, fat, muscle, and skin being the most severely injured with crushing, in that order. Nerve is unique in that it is often the last structure remaining physically "intact" after a crush or avulsion injury, yet axons themselves are quite susceptible to crushing or stretching, which can lead to a difficult dilemma in distinguishing neurapraxia from axonotmesis in the early stages. Tendon, ligament, and bone tend to be more resistant to crushing/avulsing forces; nevertheless, partial injuries to tendon and ligament can result in significant scarring and functional impairment that

can be minimized only by timely recognition and early and aggressive mobilization.

The metabolic changes after ischemia or traumatic flap elevation are numerous and extreme. Ischemic tissue undergoes a conversion to an anaerobic metabolism with rapid depletion of levels of oxygen, glucose, and adenosine triphosphate, along with a concomitant increase in levels of carbon dioxide and lactic acid. Prostacyclin and thromboxane levels are significantly elevated.[26,50] Associated with the conversion to anaerobic metabolism is the markedly increased production of toxic superoxide radicals.[2,49,50,67] Toxic oxygen radicals can cause direct cytotoxicity, but probably more important, they are a trigger for local acute inflammation, adherence and accumulation of leukocytes, and endothelial injury with the subsequent cellular events leading to microvascular compromise. Levels of the body's key protective enzyme, superoxide dismutase, are decreased in ischemic tissues because the enzyme is consumed when converting superoxide to oxygen in a tissue protective mechanism.[70]

With reperfusion or reoxygenation, toxic metabolites, including superoxide and hydroxyl radicals, are produced, with subsequent tissue injury via two key mechanisms. The first is direct reaction of superoxide radicals with the endothelial membrane, which causes lipid peroxidation, disruption of membrane proteins, increased cell permeability, and consequently, cytoplasmic swelling and dysfunction. The second mechanism is a result of the chemotactic property of oxygen metabolites, primarily superoxide anion, which causes migration of neutrophils into the reperfused area, with the neutrophils actually causing tissue destruction.

There is evidence that a significant proportion of the tissue damage triggered by ischemia frequently may be a consequence of events associated with reperfusion of ischemic tissues (i.e., "reperfusion injury").[101] Rapid intravascular accumulation of neutrophils can lead to progressively decreased perfusion, which may be manifested as the "no-reflow" phenomenon[17,59] or, more precisely, a "diminishing-reflow" phenomenon associated with ischemia and reperfusion.[103] Crushed tissue and traumatically created tissue flaps are a model of "gradient" ischemia in that tissue is progressively ischemic from the base of the normally perfused tissue out toward the ischemic tip with an "ongoing" ischemia-reperfusion injury present. In this setting, too, neutrophil-mediated injury appears to play a major role in tissue necrosis.[102]

There are several mechanisms whereby activated polymorphonuclear neutrophils (PMNs) can cause injury in the setting of ischemia-reperfusion. First, adherent, activated PMNs can cause direct endothelial injury, resulting in the loss of vascular integrity, edema, hemorrhage, and thrombosis (Figure 43.3). Another possible mechanism involves microvascular occlusion and further ischemia resulting from adherence and accumulation of aggregates of PMNs within the vessel lumen. This progressive, inflammatory-mediated injury is largely responsible for the "zone-of-injury" phenomenon associated with mangling injuries; this is another constant element of them.

This concept recognizes that the extent of tissue injury and late scarring associated with a major force often extends well beyond the area of initial injury. The combination of local and regional ischemia, in addition to injury-induced inflammation and the resulting ischemia, extends the zone of tissue necrosis. The extent of the zone-of-injury depends primarily on the force that caused the original injury. This is a critical concept in the management of mangling injuries because it nearly always precludes immediate or one-stage reconstruction and dictates prudent reevaluation and repeat debridement of the wound 24 to 48 h after injury before definitive closure can be considered. The zone-of-injury and related inflammatory responses are also important in planning vascular restoration in the sense that

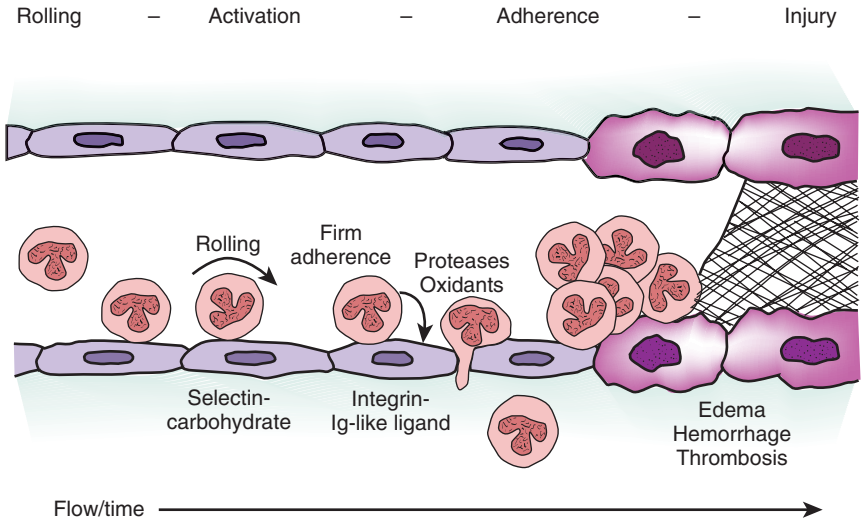

FIGURE 43.3 Diagrammatic representation of the sequential events that occur at a site of neutrophil-mediated microvascular injury. Initial selectin/carbohydrate-mediated rolling along the surface of the endothelium and tethering of neutrophils where local agonists then stimulate integrin-mediated firm adherence lead to neutrophil-mediated endothelial injury with loss of vascular integrity, edema, hemorrhage, and thrombosis. Another mechanism involves microvascular occlusion and further ischemia resulting from adherence and accumulation of aggregates of neutrophils within the vessel lumen. *Ig,* Immunoglobulin. (Reprinted from Vedder NB: Flap physiology. In Mathes SJ, Hentz VR, editors: *Textbook of plastic surgery*, Philadelphia, 2005, Elsevier, © 2003 Nicholas B. Vedder.)

reconstructions performed inside the zone are subject to direct and inflammatory-mediated endothelial injury that can lead to thrombosis of the vascular system.

INITIAL EVALUATION

Because mangling injuries of the hand and upper extremity are often associated with considerable force; it is not uncommon for the patient to have other significant and potentially life-threatening injuries. The mangling extremity injury, although frequently the most obvious, graphic, and visually compelling, rarely leads to loss of life. As always, one must look beyond the obvious extremity injury and evaluate the patient carefully for other serious injuries. The standard Advanced Trauma Life Support approach to any injured patient must be followed, with immediate attention to the airway, breathing, and circulation (ABCs), followed by primary and secondary surveys of the injured patient.[1]

History

As always, the key components of the medical history focus on the "when," "where," and "how."[14] The time of injury is critically important, especially when dealing with devascularizing injuries. Bone, integument, and muscle have, in that order, decreasing tolerances to ischemia, with muscle being able to survive only 4 to 6 h of it, even with the normal tissue cooling that occurs after ischemia.[100] In addition, the longer the duration from the time of injury, the greater the risk for infection, with delays greater than 6 to 12 h precluding primary closure or coverage. If ischemia is present, the temperature of the tissue during the ischemic period is critical inasmuch as extremity tissues devoid of muscle can be successfully revascularized after 12 to 24 h if kept cool. In fact, successful digit replantation has been reported at 94 h.[106]

The "where" of an injury is also important. Farming injuries, for example, tend to be highly contaminated and require more than the usual amount of aggressive debridement, which often precludes primary closure.[75] The presence of caustic industrial chemicals or other contaminated substances can also affect treatment choices. The social and economic aspects of the injury environment must likewise be weighed when planning treatment. A patient living in an area remote from an appropriate medical facility may not be able to follow through with the complex rehabilitation program required for a highly technical reconstruction and may be better served with a more straightforward reconstructive option.

Finally, the "how," or mechanism of injury, can help reveal the force of it and the extent of tissue necrosis or zone-of-injury to anticipate and address during treatment. Sharps injuries tend to involve a limited zone of tissue and are therefore easier to manage, unless the injury is tangential in nature. High-velocity, high-pressure crushing or avulsion injuries have a much broader injury zone and require a modified approach to treatment, which needs to consist of more extensive debridement, thorough evaluation of adjacent tissues, removal of foreign bodies, and assessment for and treatment of compartment syndrome.

The patient's overall health and comorbid conditions must be carefully evaluated in planning any type of complex or lengthy reconstructive procedure. The patient's age and the presence of cardiovascular disease, pulmonary disease, bleeding tendencies, or diabetes can greatly increase the risk for perioperative complications or even mortality; any of these should cause the surgeon to consider simplifying the reconstruction method or at least modifying perioperative treatment plans. Smoking or the use of other vasoactive drugs, such as cocaine, is generally a contraindication to any type of complex microvascular reconstruction.

Perhaps the most important aspect of obtaining a history is determining the patient's functional needs and goals. The age, occupation, socioeconomic environment, and social support systems should all be considered when formulating a treatment plan. Both the risks that the patient is willing to accept and the costs in terms of financial, emotional, and time must be considered. Willingness to endure a protracted reconstructive course and a patient's ability to follow through with the necessary hand therapy are important issues. A self-employed farmer, without workers' compensation insurance, will probably be interested in reconstructive options that offer an expeditious return to work and provide durable function suited for heavy work without multiple complex reconstructive procedures.

An office worker or technology professional may have very different goals and might be more willing and economically able to undergo multiple reconstructive procedures to restore optimal digit function to allow fine manipulation, keyboarding, and other such tasks. Again, the hand surgeon must make decisions based on personal knowledge and experience to try to predict the patient's ultimate function with the available reconstructive options so that the most appropriate option can be selected for that particular patient. Both the patient and the patient's family must be involved in this discussion, although this is often difficult to do when the patient has just suffered a mangling injury, so surgeons frequently must use their best judgment at the time by taking into account all the known variables.

Examination

Because examination of a patient with a severely mangled extremity injury that is wrapped in blood-soaked towels or bandages is often difficult in the emergency department, definitive evaluation often must wait until the operating room. Nevertheless, assessment of injuries to major structures, in particular vascular status, is essential in determining the urgency of definitive treatment and also important in the ability to discuss treatment options and prognosis with the patient and family. Usually, a general assessment of vascular status, sensibility, and muscle–tendon unit function, as well as radiographic evaluation, can and should be done in the emergency department. Preliminary evaluation will also allow adequate preparation of the operating room: microsurgical equipment and supplies, implants and fixation devices, traction and radiographic devices, and other necessities.

The most important system to evaluate is the vascular system of the extremity. Compromised vascularity of the digit or extremity, depending on the duration of devascularization, can dictate whether the digit or limb can be salvaged, whether fasciotomy is required, and the urgency of initiating treatment. Assessment of vascular status is best performed by direct inspection of the patient's affected tissues and comparison to adjacent or similar well-vascularized tissues. Although nail bed capillary refill is traditionally considered a good indicator of peripheral

perfusion, it is in fact a very unreliable indicator of perfusion. A completely devascularized digit can have what appears to be intact capillary refill beneath the nail bed when in actuality stagnant blood is merely being pushed to the sides with compression and then moving back to the center with release of pressure on the nail bed.

A far more reliable area to assess digit perfusion is the dorsal paronychial tissue on the sides of the nail, which should be pink and spongy and have good turgor, compressing with pressure and refilling with release (Figure 43.4). A pink color that returns within 1 to 2 s after the application and release of pressure indicates healthy tissue, whereas a pale color without capillary refill or turgor can represent arterial insufficiency. A dusky color with exceptionally brisk refill can be indicative of venous congestion. Probably the most reliable clinical indicator of tissue vascularity is the color of the blood that oozes from the tissue after sticking it with a needle or scalpel. Bright pink oozing reflects healthy tissue, whereas dark purplish oozing reflects compromised perfusion if it is sluggish or venous insufficiency if it is profuse. Obviously, this should not be performed on the sensate tissue of an awake patient but is often useful in an anesthetized one.

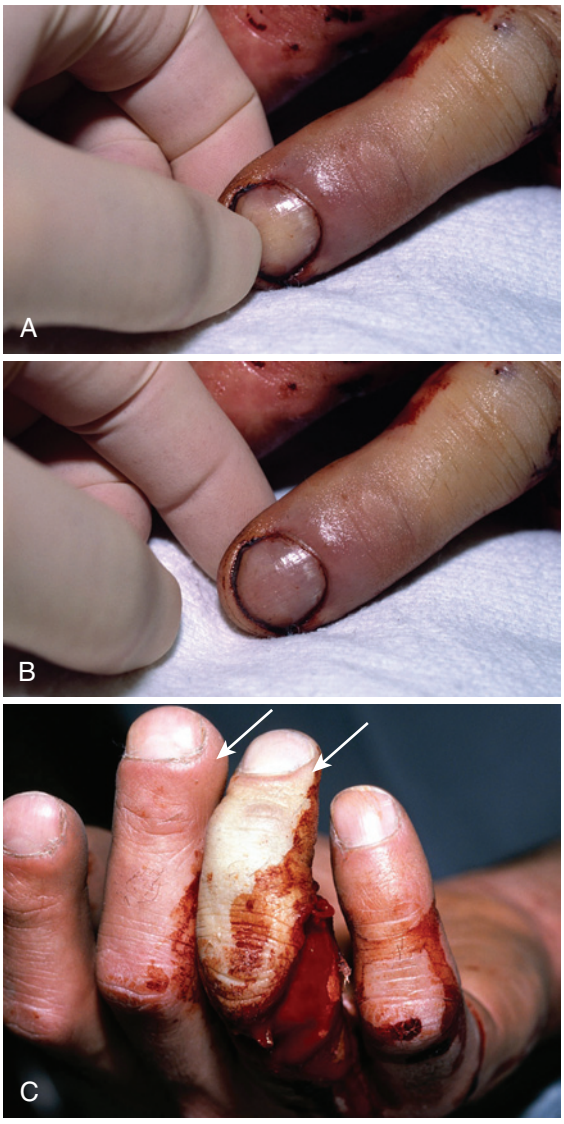

FIGURE 43.4 A completely devascularized digit can have what appears to be intact capillary refill beneath the nail bed when in fact stagnant blood is merely being pushed to the sides with compression **(A)** and then moves back to the center with release of pressure on the nail bed **(B)**. A far more reliable area to assess digit perfusion is the dorsal paronychial tissue on the sides of the nail, which should be pink and spongy and have good turgor, compressing with pressure and refilling with release (long finger, *arrow*), whereas a devascularized digit's paronychial tissue **(C)** will be pale and flat, without turgor (ring finger, *arrow*).

For assessing the status of the major vessels of the upper extremity and even the digital vessels, a handheld Doppler probe is very useful. The standard Allen test, performed by compressing either the radial or the ulnar artery and listening for a signal over the palmar arch or the most distant digital artery, can help determine whether either the radial or ulnar artery has antegrade flow and whether the palmar arch is intact. Angiography has a minimal role in mangling injuries of the forearm, hand, or fingers. In any mangling or crushing injury, a high index of suspicion for compartment syndrome must be maintained.

The diagnosis and treatment of compartment syndrome are covered in Chapter 51, but it is worth reinforcing the importance of recognizing the intense pain of it and, in particular, pain with passive stretch of muscle–tendon units. When suspected, the diagnosis is best confirmed by direct measurement of pressure in the muscle compartment, usually with a handheld device specifically designed for this purpose. The presence of compartment syndrome and attendant tissue ischemia warrants emergency decompression in the operating room.

Although obvious deformity, crepitus, or tenderness on examination can suggest underlying skeletal injury, evaluation of the skeletal system is generally performed radiographically. In most instances, standard plain radiographs are sufficient if care is taken, whenever possible, to ensure that emergency splints or traction devices do not obscure the underlying bones or joints. Sometimes, additional views are needed, including oblique views to assess articular congruity or stress views to evaluate ligament injury (e.g., a clenched fist view to evaluate intercarpal ligamentous integrity). In questionable cases, comparison views with the contralateral extremity, if uninjured, may be necessary.

With most mangling injuries, advanced imaging techniques, such as computed tomography (CT) or magnetic resonance imaging (MRI), are rarely indicated, although at times if the patient is stable, CT scanning of suspected carpal injuries or intraarticular displacement can be useful. If amputated parts are involved and replantation is contemplated, radiographs of the amputated parts should be obtained. Moreover, as always, the joint proximal and the joint distal to the area of injury must be evaluated (Figure 43.5). Ligamentous injuries can be identified by tenderness to palpation or to stress. Stability with the application of stress should also be reevaluated under anesthesia to remove any confounding effect of involuntary muscular splinting.

Evaluation of injury to muscle–tendon units is best performed by having the patient actively flex and extend the digits and wrist. In the presence of pain, and especially with underlying skeletal injury, this examination can be difficult to interpret. For the individual digits, noting aberrations in the normal resting cascade can indicate injury to the underlying flexor muscle–tendon unit. This simple observation can be performed

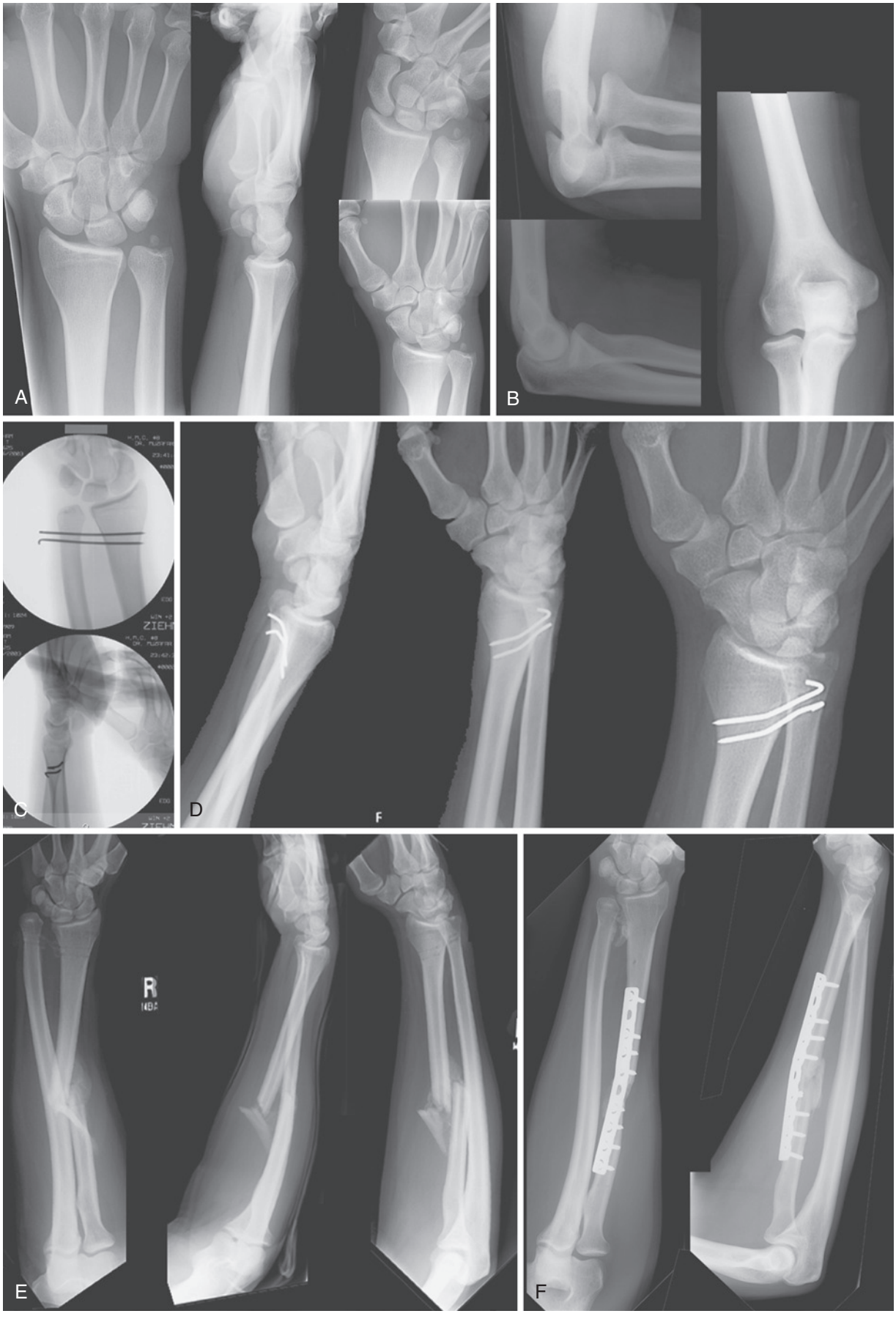

FIGURE 43.5 The importance of obtaining radiographs that include the entire extremity, including a joint above and below the obvious injury, is illustrated in this case of a 22-year-old man who sustained multiple injuries resulting from a motor vehicle accident. **A,** Complaints of wrist pain prompted the radiographs. There is an ulnar styloid fracture and subluxation of the distal radioulnar joint (DRUJ). **B,** Elbow radiographs showed no obvious pathology. **C,** The DRUJ was transfixed with Kirschner wires. **D,** Within 3 weeks the Kirschner wires bent. **E,** The fixation wires were removed, full-length forearm radiographs were obtained, and the culprit—a Galeazzi fracture—was identified. **F,** Restoration of the radius and soft tissue reconstruction of the DRUJ resulted in 80 degrees of pronation and 60 degrees of supination.

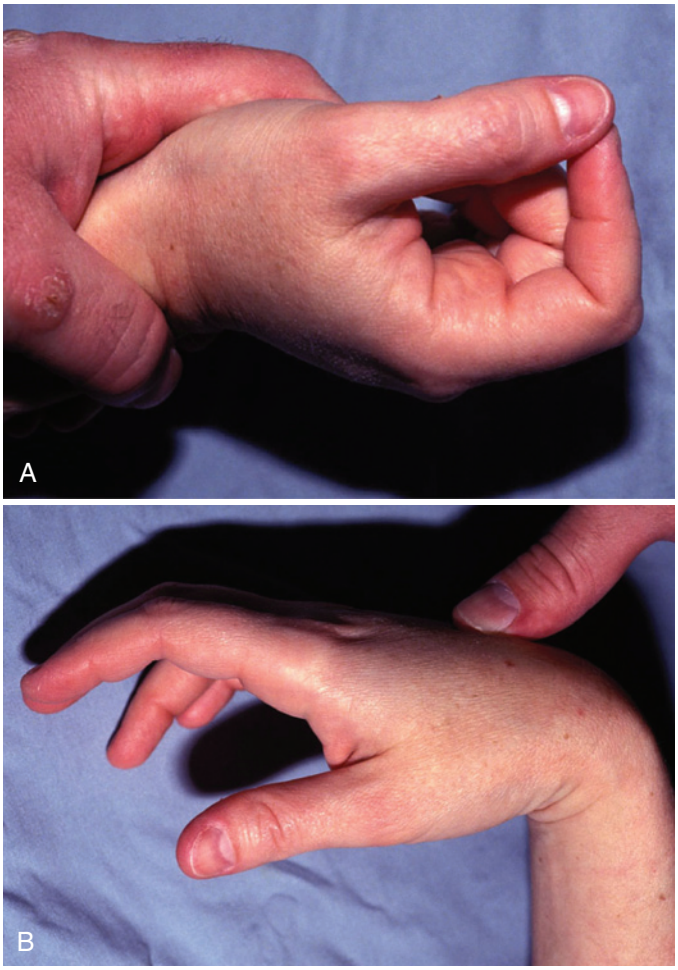

FIGURE 43.6 Evaluation of tendon function by passively extending **(A)** and flexing **(B)** the wrist while observing the normal cascade of digit flexion with wrist extension and digit extension with wrist flexion.

even in a comatose patient, as can evaluation of tendon function by passively flexing and extending the wrist and observing the normal cascade of digit flexion with wrist extension and digit extension with wrist flexion (Figure 43.6). In the end, however, with most mangling injuries, definitive evaluation of tendon injury must wait for careful examination in the operating room.

Nerve injury is evaluated by examining both motor and sensory function. The motor function of the median, radial, and ulnar nerves is assessed by testing both extrinsic and intrinsic muscle function. Three simple maneuvers test motor integrity: (1) resistance to palmar abduction of the thumb reflects median nerve-innervated abductor pollicis brevis function, (2) resistance to flexion of the metacarpophalangeal (MP) joint of the small finger reflects ulnar nerve–innervated flexor digiti quinti function, and (3) resistance to extension of the MP joint of the index finger reflects radial nerve–innervated extensor digitorum communis and extensor indicis proprius function.

Accurate sensory examination is much more difficult, especially in patients with severe injury. By using a light touch and, if questionable, pinprick testing, a reasonable assessment can nevertheless be obtained. If the injury is in the palm or digits, specific attention should be directed to digital nerve function, whereas if the injury is more proximal, attention should be directed to independent areas of sensory function, such as the volar aspect of the index or middle finger, for median nerve function, the volar aspect of the small finger for ulnar nerve function, and the dorsum of the first web space for radial nerve function.

With sharps or penetrating injuries, if you "think the nerve is probably OK," it usually is not. Equivocal results on examination generally indicate an underlying injury that warrants exploration, whereas normal sensory results, with the patient not looking, usually indicate an intact nerve. With blunt or blast injuries, however, nerve contusion and neurapraxia with the nerve in continuity are not uncommon. The threshold of suspicion for exploration of nerves in patients with sharps or penetrating injuries should therefore be much lower than with blunt or blast injuries.

Laboratory studies should be obtained at this time, including a complete blood count with platelets, electrolytes, and any other tests appropriate to the clinical situation (e.g., blood gas analysis, toxicology screen, amylase, and others). In addition, if there has been significant bleeding or considerable bleeding is anticipated during surgery, blood for typing and cross-matching should be obtained at this time.

GOALS OF TREATMENT: BIOMECHANICS OF THE INJURED HAND

In developing a treatment plan for mangling injuries of the hand and upper extremity, the surgeon must keep in mind the seven basic functions of the hand: precision pinch, opposition pinch, key pinch, chuck grip, hook grip, span grasp, and power grasp. Depending on the severity of the injury, some of these functions may not be restored. The basic units that underlie hand function are the following:

1. An opposable thumb
2. The index and long fingers, which serve as the stable fixed unit of the hand for fine manipulation and power pinch
3. The ring and small fingers, which serve as the mobile unit of the hand for grasping functions
4. The wrist (Case Study 43.1)

Restoring these units should therefore be the general goal of reconstruction, with restoration of an opposition digit and a stable opposition post being the bare minimum (reviewed by Moran and Berger[74]). Preservation of length should be a goal, but only functional length should be preserved, not stiff, insensate, potentially painful units with unstable coverage. Durable, stable soft tissue coverage is a necessity, as is at least protective sensation. Without these, chronic breakdown, infection, and failure of the reconstruction can be expected. Not all patients are best served by complex digit reconstruction, especially if the digit is going to be stiff or painful. Sometimes, a prosthesis customized to the patient's occupation is the best option (Figure 43.7). Highly functional, durable mechanical prostheses, as well as advanced myoelectric prostheses, allow excellent return of function and are discussed in Chapter 50.

Amputation/Skeletal Contribution

According to the guidelines of the American Medical Association (AMA) for evaluation of permanent impairment,[25] the thumb accounts for 40% of hand function, the index and

CASE STUDY 43.1

A 57-year-old male was using a chop saw when his left hand became caught in it. The patient presented with the amputated part in saline gauze on ice (eFigure 43.1).

After assessing the patient and speaking with him, he indicates a desire for replantation. Based on the injury pattern, you recommend:

a. Revision amputation through wrist
b. Replantation of thumb/hand part only
c. Replantation of thumb/hand part, plus index finger
d. Replantation of thumb/hand part, plus middle finger

Answer: (d) Replantation of thumb/hand part, plus middle finger

Rationale: While a wrist-level amputation would allow the fastest recovery, it would be functionally limiting. Replantation of the thumb/hand part would not be very functional as the thumb would not have anything against which to pinch/grasp. When choosing between replantation of the index versus middle finger, the middle is typically chosen because the index is considered expendable in multiple-digit replantations.

See postoperative photos and images in eFigure 43.2.

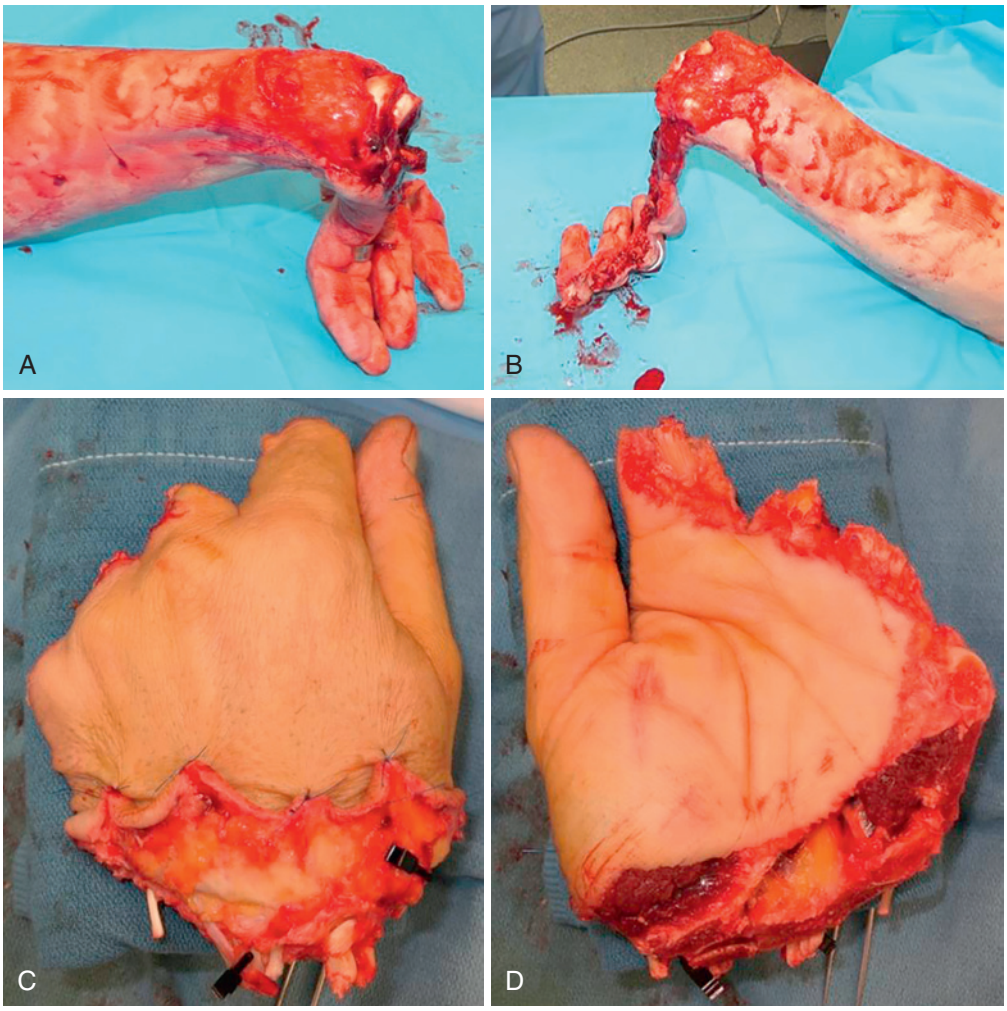

eFIGURE 43.1 **A** through **D,** Amputation injury.

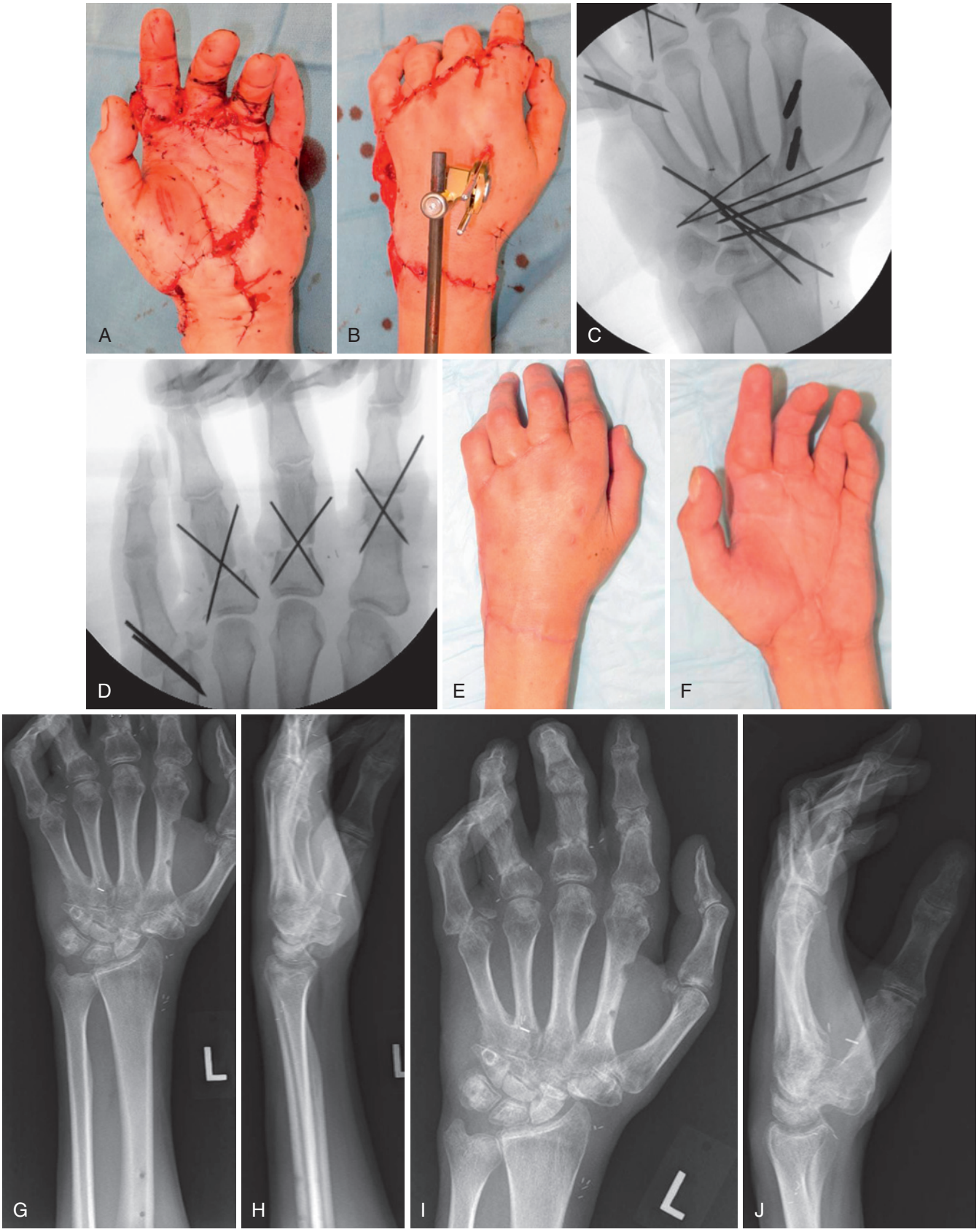

eFIGURE 43.2 **A, B,** Clinical photos immediately following replantation. **C, D,** Immediate postoperative radiographs. **E, F,** Clinical photos following hardware removal. **G** through **J,** Radiographs following hardware removal.

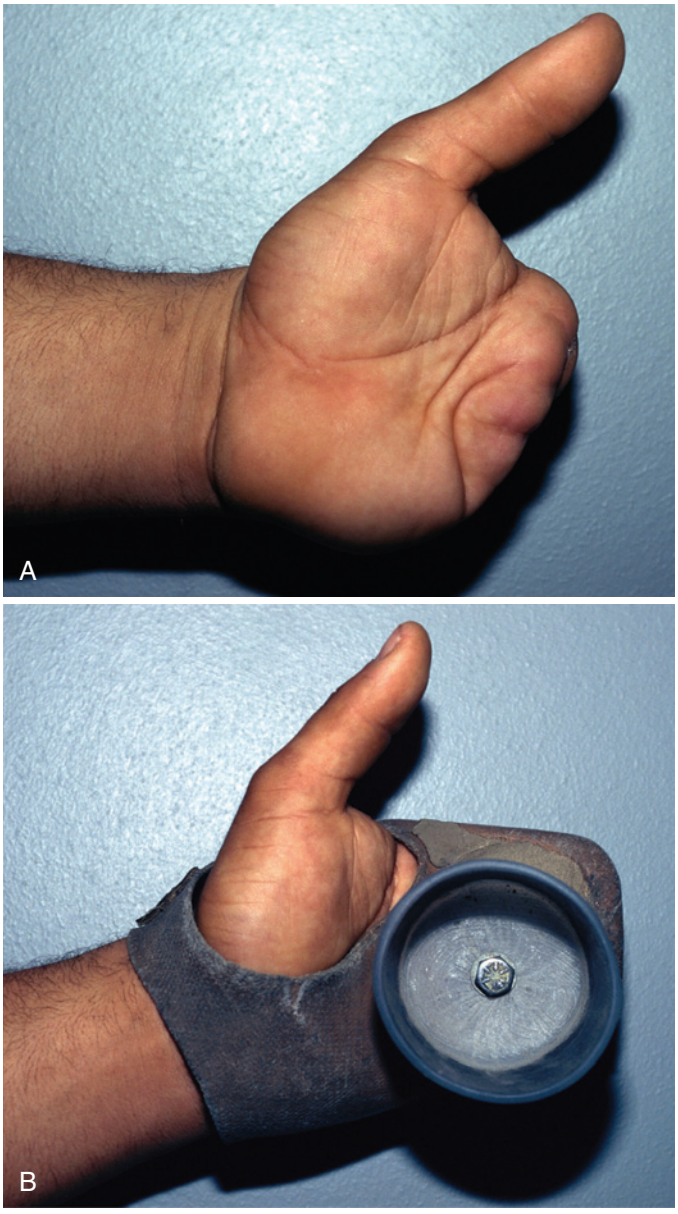

FIGURE 43.7 Sometimes a prosthesis customized to the patient's occupation is the best option, as for this forklift driver.

middle fingers for 20% each, and the ring and small fingers for 10% each. These contributions should be kept in mind when deciding between reconstruction/replantation versus amputation. In the case of mangling injuries, however, these relative contributions do not always apply. For example, with loss of the three central digits, the small finger effectively assumes 50% of hand function.

As discussed previously, surgeons must use their knowledge, experience, and best judgment in an effort to predict a patient's ultimate function with amputation versus reconstruction and with the various reconstructive options. The factors of patient age, health, drug or nicotine use, occupation, and willingness and ability to undergo complex or multistaged reconstructive procedures and rehabilitation must be taken into account. The topics of amputation, replantation, and thumb reconstruction are covered elsewhere in this text, and the reader is referred to these sections for more detailed coverage of the topics.

The thumb is, of course, the most important digit to preserve or reconstruct. The issues related to thumb amputation are discussed in Chapter 48 and vary depending on the level of injury. Interphalangeal (IP) joint motion and the distal phalanx are of relatively lower importance to preserve than multiplanar carpometacarpal (CMC) motion and, to a lesser extent, MP motion.[68] The ability to bring the thumb out of the plane of the hand and into a position of opposition is a key function that must be restored. If the thumb cannot be preserved, consideration should be given to primary pollicization (Case Study 43.2).[54]

The index finger is also important to preserve because of its independent profundus flexion and ability to abduct for precision pinch functions. Without good function and sensibility of the proximal interphalangeal (PIP) joint, however, the index finger is often bypassed in favor of the middle finger because it can be more of a hindrance than help and ray amputation can often improve function by opening the first web space.[30,74,98,108] Amputation at or proximal to the PIP level leaves only the intrinsics for flexion, which is then limited to about 45 degrees. The long and ring fingers are important primarily for grip and grasp functions, although either can take over pinch functions for the radial digits if they are lost. Solitary loss of the ring finger probably results in the least associated functional deficit of all the digits.[98] The small finger, even though it has the least flexion strength, is actually quite important in hand function in that it defines hand width for grip functions, use of tools, and other applications. An important component of this function is the significant CMC motion of the small finger that comes into play with terminal grip.

With amputation at the proximal aspect of the middle phalanx (P2), PIP, or especially the MP level, ray amputation also needs to be considered. Although ray amputation is usually aesthetically preferable to a partial finger amputation, function can suffer. For the index finger, power grip, key pinch, and supination strength are diminished approximately 20%, and pronation strength approximately 50%.[76] There is also a fairly high rate of dysesthesia after ray amputation, thus further arguing against routine ray amputation.

Loss of an isolated digit other than the thumb rarely results in significant compromise of hand function, and as Brown has noted, patient motivation is more important in regaining function than the actual digits lost.[13] Loss of multiple digits, however, is common with mangling injuries and frequently results in significant functional deficits. Maintaining or reconstructing at least the thumb and one opposing digit is a minimum requirement for any type of pinch or grasp. Retaining or reconstructing an additional adjacent digit can nevertheless add significant function by providing lateral stability to the radial digit for power pinch and can allow three-jaw chuck pinch.

Joints

The choice of whether to salvage or fuse a joint is another decision that is often difficult. It is best made by assessing the potential loss of function from a given fusion or set of fusions versus the risk for limited motion, pain, instability, or late arthrosis with reconstruction. Whenever anatomic articular congruity and ligamentous stability can be restored, reconstruction is usually worthwhile. When it cannot be achieved, the potential loss of function needs to be assessed. In general, distal

CASE STUDY 43.2

A 50-year-old male suffered a crush/avulsion injury from industrial machinery to his thumb, index, and middle finger. Initial debridement and index ray amputation were performed (eFigure 43.3).

What is the preferred coverage method for this wound (keeping in mind that a toe transfer may be needed for thumb reconstruction)?

a. Pedicled reversed radial forearm fasciocutaneous flap
b. Groin flap
c. Free radial forearm flap
d. Split thickness skin graft

Answer: (b) Groin flap

Rationale: A split thickness skin graft is not appropriate coverage for the exposed thumb skeleton. While a pedicled or free-radial forearm flap would provide coverage, both of these options would alter the radial artery which is the preferred recipient artery for a toe transfer. Therefore, a groin flap is the preferred coverage type.

See postoperative images in eFigure 43.4.

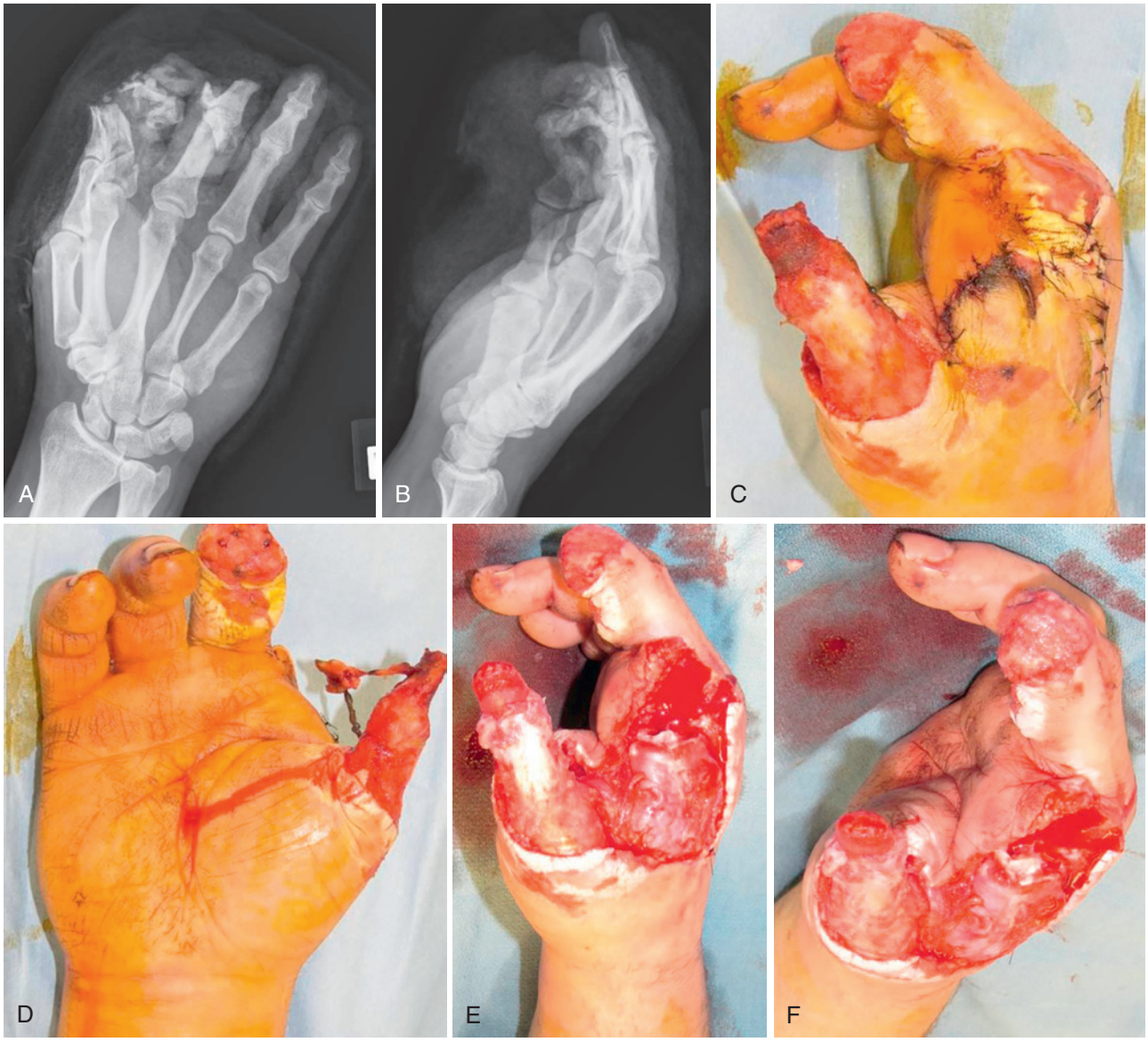

eFIGURE 43.3 Crush/avulsion injury to thumb, index, and middle finger. **A, B,** Radiographs. **C, D,** Clinical photos 48 h after injury (with one debridement). **E, F,** Injury following second debridement.



eFIGURE 43.4 Crush/avulsion injury to thumb, index, and middle finger treated with groin flap. **A,** Following groin flap division. **B, C,** Radiographs. **D, E,** Appearance following multiple groin flap debulkings. **F, G,** Great toe pulp transfer to restore sensibility. **H,** Toe pulp flap inset. **I, J,** Appearance following first web contracture release.

interphalangeal (DIP) fusions of the digits or IP fusion of the thumb is tolerated well with limited loss of function. PIP joint motion is much more important to preserve. Littler and colleagues described the PIP joint as the "functional locus of finger function."[63]

Not only are fingers with fused PIP joints of little use for grip or grasp, but also they frequently get in the way and are easily injured because they do not follow the normal arc of the other fingers. An additional problem, though less so with the index finger, is the quadriga effect, which can occur when profundus excursion is impaired with arthrodesis. Although delayed arthroplasty can be considered, in the presence of combined injuries involving the joint, nerve, and soft tissue, if the PIP joint cannot be primarily reconstructed, serious consideration should be given to amputation, especially of the ulnar two digits.

The MP joint is perhaps the most important joint in terms of function for the index through small fingers in that it contributes 77% of the total arc of finger flexion.[63] Most activities, however, do not require the full arc of MP motion, and in fact as little as 35 degrees of motion can be acceptable if that arc is within the key functional range and the joint is stable.[6] To that end, stable but markedly limited MP motion, even arthrodesis, is far superior to an unstable, painful MP joint (Figure 43.8).

The decision to perform partial or total wrist fusion is seldom made in the acute setting unless there is extensive, nonreconstructible loss of articular surface. Usually, this decision is deferred until late function and pain can be better assessed, at which time elective arthroplasty or arthrodesis can be performed. Studies have shown that as little as 5 to 10 degrees of flexion and 30 to 35 degrees of extension are needed for most activities of daily living.[16,81] When wrist-level amputation is required, preservation of some wrist motion can be incorporated into mechanical prostheses, and preservation of an intact distal radioulnar joint can significantly improve pronation and supination under loading conditions. The functional benefit of preserving the distal radioulnar joint, although attractive in theory, has never been proved in practice.

Tendons

Preservation and reconstruction of skeletal length and joint motion are of little use without a mobile muscle–tendon unit to move it. Because of its complex balanced "shroud" mechanism and limited excursion, the extensor tendon mechanism, especially over the digits, is susceptible to minor changes in length with repair, as well as adhesion formation and underlying skeletal injury.[29] Intrinsic function is also easily compromised in mangling injuries, especially crush and blast injuries with multiple metacarpal fractures.

Fibrosis and contracture leading to significant disability are common. Because of the overlap in function and transmission through the juncturae tendineae, injuries to the extrinsic extensor tendon tend to be more forgiving, especially if a limited number are involved. Although not ideal, complete loss of the extrinsic extensors with associated reconstruction of dorsal soft tissue coverage and the presence of intact intrinsics is tolerated quite well. In this setting, the ensuing deep cicatrix formation allows adequate MP flexion and extension through scar tenodesis. This, combined with intact IP function, results in good overall hand function.[89]

Preserving or reconstructing flexor tendon function in a mangled hand is obviously important but frequently difficult to achieve. It is often difficult to restore independent superficialis and profundus function, and the pulley systems are frequently ruptured. To prevent bowstringing, the A2 and A4 pulleys must be preserved or reconstructed.[48,61] Given the limited tolerances within the flexor pulley system, it is sometimes best to repair only one tendon, usually the profundus tendon, especially if repairing both tendons would lead to adhesions and limited excursion. Two other complications of

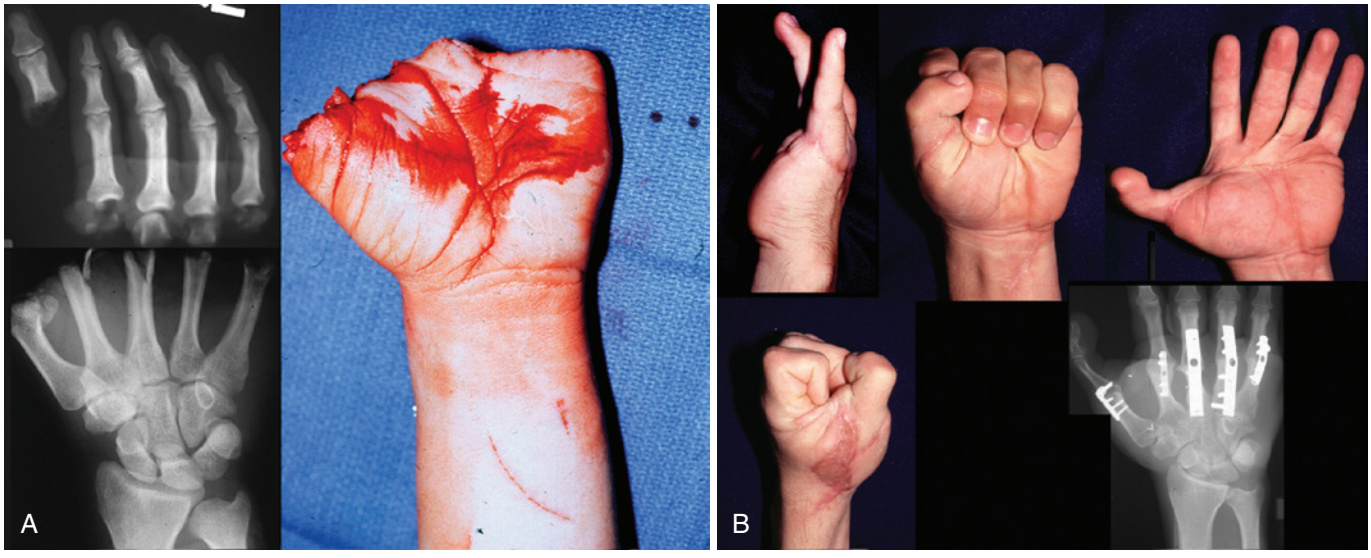

FIGURE 43.8 **A,** Five-digit amputation in an 18-year-old man resulting from a saw accident. **B,** Treatment consisted of primary arthrodesis of the finger metacarpophalangeal joints and replantation of the index, middle, ring, and small fingers. The thumb could not be replanted. Six months after injury, the thumb was reconstructed with a second toe-to-hand transfer. Hand motion is demonstrated a year after the injury.

profundus injury must also be kept in mind and avoided: lumbrical-plus deformity and quadriga.

Lumbrical-plus deformity occurs when a cut and unrepaired profundus retracts, thereby increasing tension on the lumbrical that results in paradoxical extension with digit flexion. This is avoided by either repairing the profundus or, as with amputations, suturing it without tension to the flexor sheath. Quadriga primarily affects the middle through small fingers and is a result of these tendons arising from a common muscle belly. If one profundus becomes adherent in a lengthened position or is repaired with significant shortening, it can prevent full flexion of the remaining digits.

Soft Tissue Coverage and Nerves

Providing durable, stable, pliable soft tissue coverage, with at least a protective sensation in the areas of functional contact, has long been recognized to be the most important factor in determining outcome after mangling injuries.[12,34] Stability of soft tissue coverage is often overlooked in the quest to provide bulk, padding, and durability; it is especially important on the volar aspect of the hand and digits. A bulky, mobile flap subject to shear with a tangential load leads to poor grip function. One can imagine how difficult the simplest of tasks would be if a small water balloon were strapped to one's palm. For this reason, surgeons favor fascia flaps or thin muscle flaps that are skin grafted, as opposed to thick fasciocutaneous or musculocutaneous flaps, especially on potentially friction-dependent, load-bearing surfaces.

Restoring protective sensation (i.e., 7–15-mm two-point discrimination) to the palmar weight-bearing surfaces of the hand is critical. According to the AMA's *Guides to the Evaluation of Permanent Impairment*, greater than 15-mm two-point discrimination is considered functionally insensate.[25] Nerve repair, whether primary or delayed, is an essential component in reconstruction of a mangled hand.

EVOLUTION IN THE TREATMENT OF MANGLING INJURIES

Historically, the primary method of treating mangling injuries has been amputation. Surgeons long ago learned that without effective treatment, devascularized, contaminated, or crushed tissues, along with open fractures, often led to limb- and life-threatening infections; they felt that only with early and thorough debridement plus amputation could such outcomes be avoided. With the advent of antibiotics and advances in anesthesia and surgical care, more aggressive salvage efforts were undertaken. In the 1950s there was a tendency to treat mangling injuries with minimal debridement with the goal of preserving length.

The early enthusiasm for the role of antibiotics for surgical patients was tempered by studies showing failure of antibiotics to significantly alter the rate of postoperative infection.[72] Burke's classic studies finally demonstrated the critical importance of early administration of antibiotics and their significant efficacy when administered before wound inoculation.[20] During the 1970s, the concept of delayed closure to reduce risk of infection was popularized and incorporated into the treatment of mangling upper extremity injuries.[22] In the 1980s, management of mangling injuries became increasingly aggressive and combined thorough debridement with revascularization, early reduction and fixation of fractures, and early vascularized soft tissue coverage with flaps.[5,45]

The identification of and growing experience with reliable axial pedicled flaps and microsurgical free flaps provided a wide range of new opportunities for salvaging mangled extremities (see Chapters 43, 44, and 45). Godina's work showed that with radical debridement and early (i.e., within 72 h) microsurgical soft tissue reconstruction, infection risk, morbidity, and healing time were all dramatically improved.[35] Included in Godina's series and reinforced by other centers was the concept of complete reconstruction in a single emergency setting, including soft tissue reconstruction and free tissue transfer.[62,93] This radical and still controversial approach was viewed as a natural progression in the advances in microvascular surgery used for replantation and the salvage of devascularized tissues (see Chapter 42).

Treatment of the skeletal component of mangling injuries has undergone a parallel evolution over the past several decades. Although the use of external fixation devices remains a mainstay in the treatment of comminuted open fractures, the development of small, strong, low-profile internal fixation devices, when combined with early vascularized soft tissue reconstruction, has revolutionized the treatment of complex open skeletal injuries.[32] Before the advent of modern internal fixation, most complex hand injuries were treated by prolonged immobilization, with the expected results of severe stiffness and tendon adhesions.

Concomitant with the development of early rigid internal fixation was the concept of primary flexor tendon repair and early mobilization popularized by Kleinert and others.[58] Better fracture fixation and early mobilization after tendon repair dramatically improved the outcome of severe hand and upper extremity injuries.

Advances in the treatment of skeletal injuries have prompted independent advances in the repair of vascular and peripheral nerve injuries using microvascular techniques, thereby allowing salvage and reconstruction of mangling injuries that in the past would have certainly resulted in amputation. Taken together, the advances in antibiotics, microsurgery, and skeletal, soft tissue, and nerve reconstruction have dramatically expanded the possibilities of limb salvage. The critical task of the hand surgeon, however, is to know when to use these techniques versus when to choose amputation or partial amputation to achieve the best long-term function for the patient.

RECOMMENDED APPROACH TO TREATMENT

Emergency Treatment

By far the most important aspect of treating a mangling extremity injury is to evaluate the patient and treat other life-threatening injuries before proceeding to evaluation and treatment of the extremity injury. Once the patient has been stabilized and attention can safely be turned to the extremity, the most emergent aspect of treatment is controlling ongoing hemorrhage. This is best done by applying direct pressure to the bleeding area long enough to allow the effects of reflex vasoconstriction and thrombus formation to effectively control the bleeding. Sometimes a compressive dressing held on by an elastic bandage is necessary. In the rare circumstances when

direct pressure is ineffective, it may be necessary to temporarily inflate a proximal blood pressure cuff as a tourniquet until the area of bleeding can be identified and controlled.

It must be kept in mind, however, that tissue distal to the injury may have already been subjected to a period of ischemia and that further complete ischemia will compromise the ability to salvage the limb. Because of the many critical structures running through the extremity, in particular, nerves and arteries, it is important to never blindly clamp bleeding areas and to use clamps only on a specific, well-visualized vessel while being careful to not include any adjacent nerve.

It has been shown that in cases of severe mangling and devascularizing injuries, revascularization before skeletal reconstruction reduces morbidity.[71] If either the brachial artery or both the radial and ulnar arteries are transected or thrombosed, and if extensive skeletal stabilization is going to be required, especially if ischemia has already been present for some time, a vascular shunt should be placed as an initial step.[39,71] This should be done before operative debridement or skeletal fixation to reperfuse the tissues and remove the time pressure so that meticulous debridement and appropriate skeletal fixation and tendon repair can be performed before definitive revascularization.

A standard carotid vascular shunt usually works very well for the brachial, radial, or ulnar arteries. Before inserting the shunt, any thrombus or debris should be removed from the proximal and distal segments with a No. 2 Fogarty catheter to prevent distal embolization after restoration of flow (Figure 43.9). Once the arterial shunt has been connected, it is recommended that the extremity be allowed to bleed so that toxic metabolites do not enter the circulation. In the case of critical ischemia of the upper extremity, 200 cc of bleeding is sufficient to clear the waste products.[78]

As noted earlier, cooling the tissue is the most effective way to prolong the length of time that tissue can be ischemic yet still remain viable. When tissue is amputated, including digits, limbs, or other potentially revascularizable tissue, it should be wrapped in saline-soaked gauze, put in a plastic bag or container, and placed on ice until it can be revascularized. All intact skin bridges should be left intact. There are often critical draining veins within the skin bridge that can provide adequate venous drainage, thereby obviating the need for venous reconstruction at the time of revascularization. In this case, the ischemic digit or limb should simply be wrapped with moist gauze or a moist towel if the patient is not suffering from hypothermia.

Gross skeletal deformity caused by either fracture or dislocation compromises distal circulation and should be reduced, whenever possible. If any flaps of tissue have been traumatically elevated, they should be gently placed back into anatomic position without any tension or kinking to optimize circulation. It is, of course, important to document the results of motor and sensory examination before administering local, regional, or general anesthesia.

With any open wound, the patient's tetanus prophylaxis status should be reviewed and the appropriate prophylaxis given, according to the standard guidelines (Table 43.1).[90] Appropriate intravenous antibiotic prophylaxis should be started at this time. In most instances, a first-generation cephalosporin is adequate because the most common infective organism with open hand injuries is *Staphylococcus aureus*.[27,46,94,95] With agricultural injuries or those that occur at other highly contaminated areas, additional gram-negative coverage should be provided (i.e., an aminoglycoside).

CRITICAL POINTS *Emergency Treatment*

- Evaluate and treat other life-threatening injuries (the trauma "ABCs").
- Control hemorrhage by direct pressure—do not blindly clamp.
- Reduce gross skeletal deformity.
- Administer tetanus prophylaxis and antibiotics.
- For a ischemic major limb, place a temporary vascular shunt.
- Cool devascularized tissue.
- Leave any skin bridges intact.

Operative Treatment

Debridement/Wound Excision

The initial debridement is perhaps the single most important step that determines the functional outcome of mangling injuries. Performing it properly requires experience and judgment. It should therefore not be left to a junior resident to perform. If the initial debridement is inadequate and nonviable tissue is left behind, the result will be infection, further tissue loss, and potential loss of limb or life that might otherwise be prevented. As Pasteur described and as was reinforced by the work of Dellinger and colleagues: "It is the environment, not the bacteria, that determine whether a wound becomes infected."[27] Because there is little in the hand and upper extremity that is not functionally important, some argue for conservative initial debridement so that marginal tissue can "declare itself" over time. We strongly disagree with this approach.

Marginally viable tissue leads to further toxic insult to adjacent tissues, as well as systemic complications. Instead, we favor aggressive debridement of marginally vascularized tissue, especially muscle. The only two exceptions to this approach are (1) if revascularization is going to be performed, final debridement should await definitive revascularization; and (2) in the case of pure skin flaps that are critical for coverage of vital structures, the risk for sepsis by waiting 24 to 48 h for demarcation of viability is small. Nevertheless, if skin does not bleed or oozes only dark blood at the time of initial surgery, it should be debrided. The concept of debridement in the face of mangling injuries should therefore actually be thought of as "wound excision" to create a healthy soft tissue bed for reconstruction.[42]

Unless prolonged muscle ischemia has already occurred, initial debridement is best performed under tourniquet control. This allows safe visualization and preservation of critical structures, specifically major nerves and vessels. Using loupe magnification, all foreign material should be carefully removed, along with clearly devitalized skin, subcutaneous tissue, and muscle. Frayed tendon should be debrided of only loose strands, with any potentially structural portions left intact. Unless clearly destroyed, nerves should be left intact and any foreign material carefully removed. If a major muscle is debrided, one should tag the motor nerve to potentially use later for functional free muscle transfer. The ends of transected major nerves should be tagged with sutures if primary repair is possible or with metal vascular clips if delayed nerve grafting will be necessary; this



FIGURE 43.9 This 24-year-old man sustained a combined complex injury resulting from a rollover motor vehicle crash. In addition to his open fractures were forearm muscle and skin avulsions and transection of the brachial artery. This accident occurred in a rural area, 6 h from the nearest trauma center. The surgeon removed gross debris, reconstructed the artery with a vascular shunt **(A)**, and then transported the patient to our facility. Further treatment consisted of debridement, skeletal fixation, revascularization with vein grafts, and soft tissue reconstruction with a free rectus abdominis muscle flap and split-thickness skin grafts. **B,** These photographs were taken a year after the injury. Forearm rotation is limited to 90 degrees, shared equally by pronation and supination.

TABLE 43.1 Current Guidelines for Tetanus Prophylaxis

General Principles

1. Active immunization against tetanus with tetanus toxoid markedly reduces the incidence of this disease and resulting death.
2. Recommendations for tetanus prophylaxis are based on wound condition, especially its susceptibility to tetanus, and patient's immunization history.
3. Regardless of patient's active immunization status, all wounds should undergo immediate surgical treatment using a meticulous aseptic technique to remove all devitalized tissue and foreign bodies. Consideration should be given to leaving tetanus-prone wounds open. Such care is an essential part of prophylaxis against tetanus.

Warning

4. The only contraindication to tetanus and diphtheria toxoids for a wounded patient is a history of a neurologic or severe hypersensitivity reaction to a previous dose. Local side effects alone do not preclude continued use. If a previous systemic reaction to horse serum is suspected of representing allergic hypersensitivity, immunization should be postponed until appropriate skin testing can be performed. If contraindication to a tetanus toxoid-containing preparation exists, passive immunization against tetanus should be considered for a tetanus-prone wound.

	WOUND CLASSIFICATION	
Clinical Features	**Tetanus-Prone Wounds**	**Nontetanus-Prone Wounds**
Age of wound	>6 h	≤6 h
Configuration	Stellate wound, avulsion	Linear wound, abrasion
Depth	>1 cm	≤1 cm
Mechanism of injury	Missile, crush, burn, frostbite	Sharp surface (e.g., knife, glass)
Signs of infection	Present	Absent
Devitalized tissue		
• Contaminants (e.g., dirt, feces, grass, saliva)	Present	Absent
• Denervated and/or ischemic tissue	Present	Absent

Immunization Schedule

A history of tetanus immunization should be obtained from medical records so that appropriate tetanus prophylaxis can be provided. Individuals with risk factors for inadequate tetanus immunization status (e.g., immigrants, rural or urban poor, elderly without known interval booster shots) should be treated as having unknown status.

	TETANUS-PRONE WOUNDS		NONTETANUS-PRONE WOUNDS	
Adsorbed Tetanus Toxoid History (Doses)	**Tt[a]**	**TIG**	**Tt[a]**	**TIG**
Unknown or <3	Yes	Yes	Yes	No
≥3[b]	No[c]	No	No[d]	No

Disposition

- Each patient should be given an appropriate written record describing the treatment rendered and instructions for follow-up with regard to wound care, drug therapy, immunization status, and potential complications. Arrange for completion of active immunization.
- Every wounded patient should be given a wallet-size card documenting the immunization dosage and date received.

[a]For children younger than 7, diphtheria-pertussis-tetanus (DPT) may be considered.
[b]If only three doses of fluid toxoid have been received previously, a fourth dose, preferably an adsorbed toxoid, should be given.
[c]Yes, if >5 years since the last dose.
[d]Yes, if >10 years since the last dose (more frequent boosters are not needed and can accentuate side effects).
TIG, Tetanus immune globulin (human); *Tt*, tetanus toxoid adsorbed (for adult use).
Modified from Ross SE: *Prophylaxis against tetanus in wound management*, Chicago, 1995, American College of Surgeons Committee on Trauma.

will help in later identification of the nerve ends, either directly or radiographically.

Similarly, the transected ends of major vessels (e.g., the radial, ulnar, anterior interosseous, palmar, or digital arteries) to be repaired should be clamped with spring-loaded microvascular clamps. Smaller branches should be ligated with either suture ties or vascular clips, which we prefer because they are less likely to become a nidus for infection. Nonstructural bone fragments that are not attached to soft tissue should be saved for keying reduction. Attached and potentially viable fragments should be saved, along with structurally important fragments. The remaining bone should undergo curettage to remove contamination and allow anatomic reduction. The wounds should then be irrigated with a gravity-assisted irrigation system if large or with bulb/syringe irrigation if small. The mechanical debridement achieved by scrubbing with a sterile gauze sponge during irrigation is very important.

At this point, the tourniquet should be released and areas of significant bleeding either cauterized or ligated with vascular clips. Any tissues, particularly muscle, that are not pink and bleeding should be debrided down to healthy bleeding tissue. At times it is necessary to reinflate the tourniquet briefly for further debridement. We have not found tissue taken for culture at the time of initial debridement to be of much clinical value.[27]

If the wound is heavily contaminated, or if there are remaining critical areas where viability is not certain, planning for repeat operating room debridement in 24 to 36 h is in order, especially with severe crush injuries.

The debridement phase is when decisions regarding replantation, amputation, partial amputation, or reconstruction must be made, again by looking into the "crystal ball" to predict ultimate function with the various options and relying on the principles described previously for guidance. If amputated tissues have been recovered and on initial inspection are thought to not be appropriate for replantation, they should nevertheless be saved because they could be useful as "spare parts" later in the operation—either as vascularized or nonvascularized grafts: bone, tendon, nerve, or skin.[15] The technical details of various types of amputations are described in Chapter 50.

For the digits, if less than a functional amount of the proximal phalanx remains, we will often perform a ray resection or, in the case of the middle finger, an index-to-middle finger transposition at the time of the initial operation.[43] If the remaining ray will not contribute to function, removal of it can often help in achieving primary soft tissue closure; the skeletal components should be removed, the vascularized soft tissue portions saved, and a "fillet flap" created. This is also the point to pause and plan the reconstruction, both the steps to be performed in the current operation and the type of future operations that may be required. After debridement, reconstruction should then proceed beginning with skeletal reconstruction and working from the base up to the skin.

CRITICAL POINTS *Debridement*

- Excise the wound.
- Perform aggressive debridement of marginally vascularized tissue, especially muscle.
- Save critical structures: nerve, tendon, and arteries.
- Begin with a tourniquet; release and reinflate for further debridement.
- Tag nerves and arteries.
- Save vascularized bone for incorporation; save devascularized bone for keying reduction and then discard.
- Use gravity-assisted lavage with mechanical scrubbing.
- Decide about replantation, amputation, partial amputation, or reconstruction (the "crystal ball").
- Perform amputations as part of debridement; save vascularized soft tissue for coverage/closure.
- Save "spare parts" for later use in primary reconstruction.

Skeletal/Joint Reconstruction

The goal of skeletal reconstruction is to restore length, alignment, and stability, along with anatomically smooth and stable articulations so that the complex flexion and extension units of the forearm and hand can produce the hand's key motor functions outlined previously. This must be achieved while adhering to principles that optimize fracture biology and promote rapid and stable fracture healing. Because the surrounding tissues rapidly become firmer and less pliable in just a matter of days after injury and because tendon gliding and joint motion require early mobilization, the optimal time to achieve anatomic reduction and stable fixation is at the initial operation or, at the very least, within the first week.

Achieving adequately stable fixation to allow early motion is especially important with mangling injuries, when the only chance to overcome the inevitable scar formation around the joints and muscle–tendon units is through early passive and active motion. With the exception of injuries with severe contamination, skeletal fixation is generally best performed during the initial operation. The vascularity of the hand and upper extremity is excellent and allows a far more aggressive fixation approach to be taken than in the lower extremity.

The methods of fixation for humerus, forearm, wrist, hand, and digit fractures and dislocations are adequately covered in other chapters. With open mangling injuries, the wounds often dictate the approach, and every attempt should be made to not create additional, unnecessary soft tissue injury while gaining adequate exposure for fixation. Even with good fracture exposure, intraoperative radiographs or fluoroscopy should always be used to confirm reduction and fixation.

Before proceeding with skeletal fixation, a critical decision must be made as to whether to restore anatomic length or shorten the bone as part of fixation (Case Study 43.3). When concomitant nerve or arterial injury (or both) is present, skeletal shortening can allow debridement and primary repair of nerves or arteries; on the other hand, maintaining length may dictate nerve or vessel grafting with an increased risk for complications from either vascular thrombosis or loss of axonal regeneration across a nerve graft. In the case of severe comminution at the fracture site, shortening can also allow primary bone fixation and thus obviate the need for bone grafting.

Shortening can similarly facilitate tendon repair and soft tissue reconstruction. In general, 1 to 1.5 cm of shortening is tolerated well in the phalanges and metacarpals and up to 4 cm in the forearm without significant loss of function. It must be kept in mind, however, that muscle sarcomeres have a limited capacity to shorten in response to skeletal shortening, and there is a risk for loss of either flexor or extensor function with significant skeletal shortening when tendon shortening is not also part of the repair.[10]

Intraarticular fractures must be assessed to determine whether they are reconstructable or whether primary or secondary fusion is more appropriate. In general, if 50 to 75% of the articular surface remains and is capable of supporting the joint without resulting in bone–bone contact, an attempt should be made at joint salvage. Depressed articular fragments should be elevated and every attempt made to achieve a smooth anatomic surface. If the articular fragments are sufficiently large, small reconstruction screws provide excellent stable fixation.

Frequently, however, multiple Kirschner wires are required for small yet functionally important articular fragments. The mini-condylar plates can be very useful for articular reconstruction.[44,80] If the joint is unstable, an attempt at ligament repair or reconstruction should be made, preferably with adjacent tissue, although sometimes a "spare parts" tendon graft can be used as described in Chapter 6. Joint stabilization can also be facilitated with transarticular Kirschner wires, which are removed after several weeks once the surrounding ligamentous tissues become stable. Carpal fractures and dislocations should be reduced and pinned with multiple Kirschner wires and the ligaments reattached with bone anchors, as described in Chapters 13 and 16.

CASE STUDY 43.3

A 65-year-old man was injured in a motorcycle accident; his left hand was "pinched" off at the metacarpal level by an unknown object (eFigure 43.5).

In this patient, a large portion of the proximal index finger stump is degloved, and there is significant soft tissue loss of that ray. Because of this, you elect to perform immediate ray amputation of the index finger. Following debridement and index amputation, the next step in replantation of the remaining part of the hand should be:

a. Arterial anastomosis
b. Nerve coaptations
c. Tendon repairs
d. Skeletal shortening and fixation

Answer: (d) skeletal shortening and fixation.

Rationale: Unlike more proximal amputations or manglings that result in a dysvascular hand, these distal amputations do not require early circulatory establishment as the amputated part does not contain a significant amount of muscle tissue, which is the most sensitive to the duration of ischemia and releases the most toxins when circulation is reestablished. Therefore, skeletal shortening and stabilization should be performed first, thereby allowing a stable "platform" on which one can later perform tendon repair and microsurgical anastomoses/coaptations.

Postoperative images are shown in eFigure 43.6.

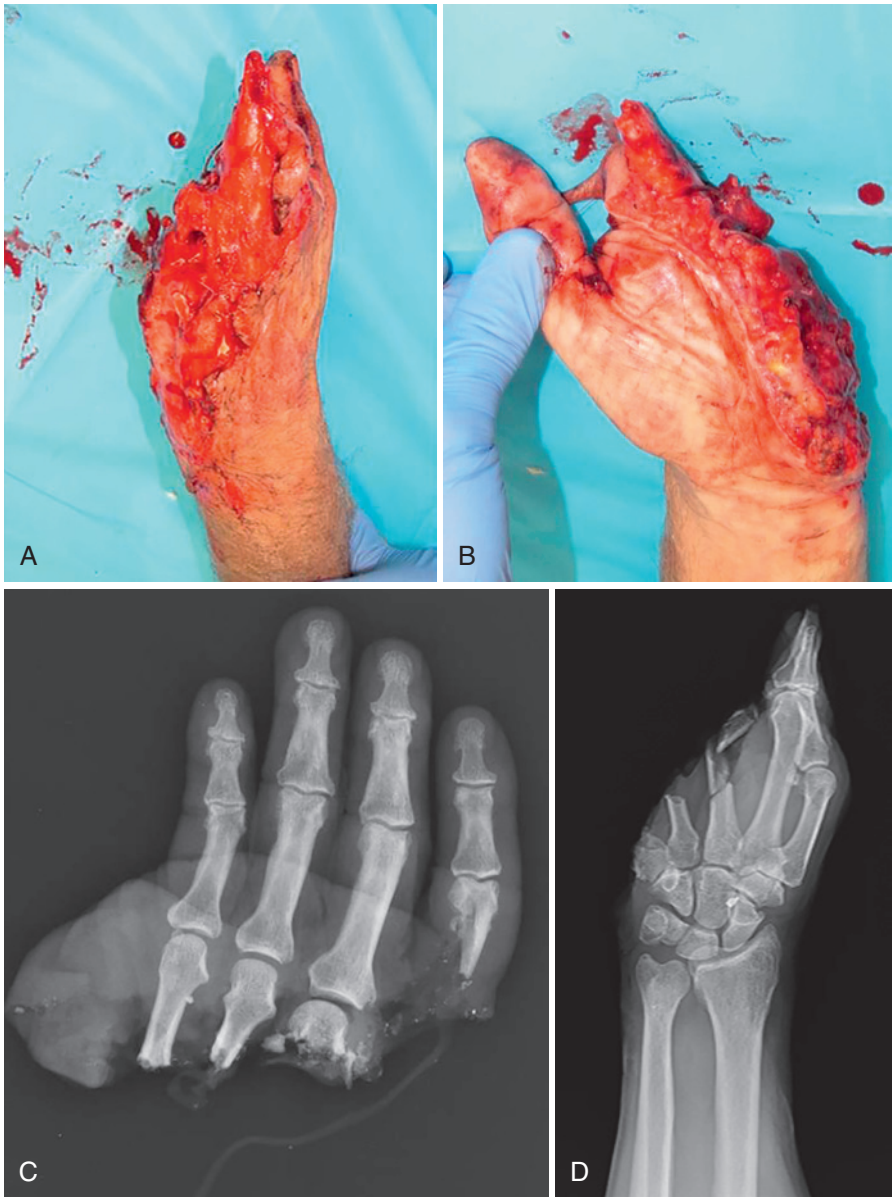

eFIGURE 43.5 Hand pinched at metacarpal level. **A, B,** Clinical photos of injury. **C, D,** Radiographs.



eFIGURE 43.6 Injury at metacarpal level following skeletal shortening and fixation. **A, B,** Early postoperative appearance. **C, D,** Follow-up clinical photos demonstrating viable digits and ongoing wound healing. **E, F,** Radiographs with Kirschner wires. **G,** Radiograph showing removal of Kirschner wires; note significant skeletal shortening.

Fractures of the shaft of the radius or ulna (or both) are best treated with 3.5-mm dynamic compression plates. Fractures of the distal end of the ulna or ulnar styloid associated with instability of the distal radioulnar joint should be treated with Kirschner wire and tension band wire reconstruction as described in Chapter 14. Fractures of the distal end of the radius require first an anatomic reconstruction of the articular surface and then frequently either dorsal or volar buttress plating as described in Chapter 15. When metaphyseal comminution or multiple carpal fractures or dislocations are present, the risk of shortening over time is great. External or internal spanning fixation, from the radius to the second or third metacarpal, can provide excellent stable fixation that will allow early motion and does not carry the infection, tendon adhesion, and other risks associated with the use of an external fixator.[19]

An internal spanning fixation is preferable, with a plate that is left in situ for 3 to 4 months, while the metaphysis and articular surface heal completely (Figure 43.10). This plate can be both applied and removed with minimal soft tissue dissection through only a proximal incision of the radius and a distal incision over the metacarpal. In this way, severe metaphyseal comminution can be reconstructed by ligamentotaxis, with the periosteum left intact and the depressing scenario of "a bag of bones" spilling out onto the operating table avoided. We find that a plating system with locking screws works best for this purpose. It can be inserted through a tunnel between the second and fourth dorsal compartments with the use of three to four locking screws on both the radius and metacarpal. Similarly, it can be removed through fairly small proximal and distal incisions without reopening the entire area.

Whenever possible in such cases, the articular surface should be anatomically reduced by indirect techniques under fluoroscopic guidance. Because of the length and narrowness of the plate, some external support in the form of a cast or rigid splint is required while the plate is in place. This approach provides stability and maintains length better than an external fixator does; is much less cumbersome; and has fewer problems related to pain, irritation, and infection of fixator pins.

Specific treatment of carpal, metacarpal, and phalangeal fractures and dislocations is covered in Chapters 7 and 16. Again, the focus with mangling injuries is to provide sufficiently stable fixation to allow early motion. In the carpus, this is usually achieved with cannulated compression screw fixation and, in the metacarpals and phalanges, with miniplate and screw fixation whenever possible. Kirschner wires, nevertheless, still do have a role, especially in reconstructing articular fragments and with fractures around joints where it is not technically possible to perform fixation with plates and screws.

When Kirschner wires are used and are expected to remain in place beyond 4 weeks, we cut them below the skin's surface and plan to remove them in a small operation at a later stage in an attempt to reduce the complications of pin irritation and infection. In the metacarpals and phalanges, achieving accurate rotational correction is, as always, paramount. Kirschner wires can be helpful in providing provisional fixation so that rotational deformities can be evaluated and corrected before definitive fixation. In cases of severe diaphyseal comminution, cerclage wires can hold the "barrel staves" together and prevent collapse. Kirschner wires should be thought of as "internal splints" rather than rigid fixation. Even crossed wire constructs are unstable to horizontal or rotational deformation. Unless numerous crossed wires are used in a single bone, which carries the risk of tendon, ligament, or soft tissue impingement, rigid stability to allow early motion will be difficult to achieve.

One trick that should be kept in mind with Kirschner wires is to use them as both provisional fixation and as a drill for later screw exchange. In this way, the wires can be placed under fluoroscopic guidance and the resulting fixation checked both clinically and radiographically. The individual Kirschner wires can then be replaced with screws with minimal soft tissue exposure. The diameter of a 0.045-inch Kirschner wire is 1.1 mm, which is the core diameter of a 1.5-mm screw. Similarly, the diameter of a 0.062-inch Kirschner wire is 1.5 mm, which is the core diameter of a 2.0-mm screw.

Like Kirschner wires, external fixation still does have a role in mangling injuries. In some cases it is not possible to achieve rigid internal fixation because of comminution or internal fracture anatomy. In such cases the use of an external fixator either across the wrist (Figure 43.11) or across an MP or IP joint is the best option. The mini-external fixator is also very useful in maintaining the first web space after crushing or mangling injuries to prevent the development of an adduction contracture (Figure 43.12). The tendency for development of an adduction contracture in the presence of a mangling or crushing injury is so strong that either a temporary external fixator construct or pinning across the trapeziometacarpal joint is recommended for most cases. Although distraction lengthening techniques could be used for severe, complex upper extremity injuries, the authors have not found this technique to be of much use for the forearm or hand.

When skeletal defects remain, bone grafting needs to be performed. Unlike the lower extremity, the abundant vascularity of the upper extremity often allows primary bone grafting unless there is significant contamination, poor soft tissue coverage, or compromised adjacent tissue vascularity. We have come to favor cancellous allograft in most cases unless autograft is simple to harvest from adjacent bone such as the radius for wrist or hand defects. If the wound, coverage, or both are deemed unsuitable for primary bone grafting, antibiotic-impregnated polymethyl methacrylate beads or spacers can be used to fill the defect until definitive bone grafting is performed, usually after soft tissues have healed. These beads are available commercially or can be made by mixing 1 g of tobramycin and 1 g of vancomycin with the polymethyl methacrylate and forming small beads on a length of No. 1 or No. 2 braided suture. Alternatively, a custom block can be fashioned to fit the defect and secured as part of the fracture fixation. After wound stabilization and maturation, the spacers are replaced with bone graft (Figure 43.13).

Tendon Repair/Reconstruction

After skeletal stabilization, the next step is tendon repair. Unless the ongoing ischemia is critical, performing tendon repair before vascular repair can reduce the chance of disrupting the vascular repair with the maneuvers involved in repairing the tendons. The details of tendon repair and reconstruction are covered in Chapters 5 and 6. We would like to emphasize that the best outcomes after primary tendon repair occur in the setting of sharp lacerations with minimal soft tissue injury, which is rarely the case with mangling injuries. If primary repair can be performed without significant shortening or

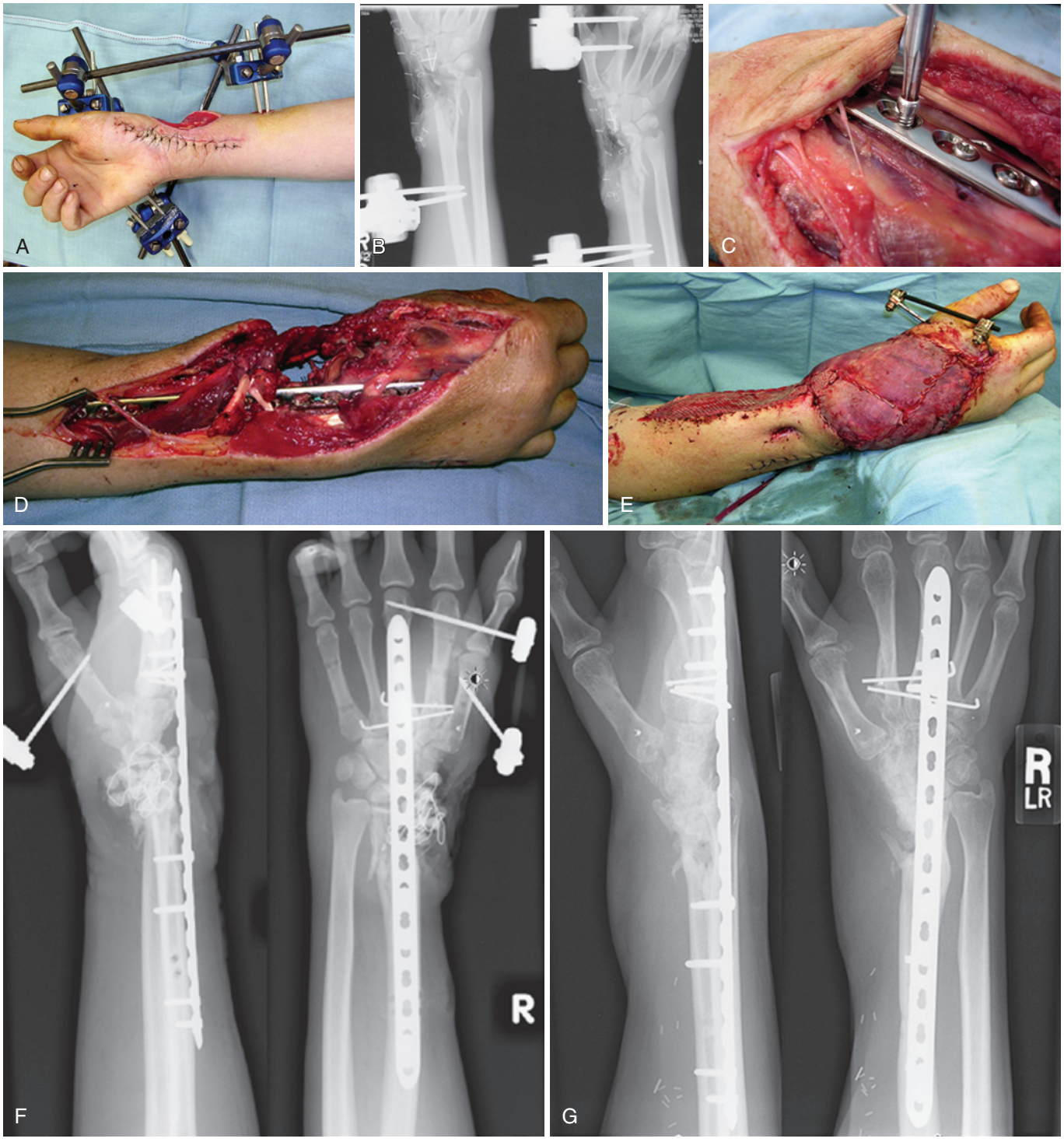

FIGURE 43.10 A rifle injury created this combined complex skeletal and soft tissue injury. **A, B,** Initial treatment consisted of debridement and stabilization with an external fixator before transfer to our facility. **C, D,** Converting the external fixator to a forearm spanning plate with locking screws provided rigid fixation and allowed unimpeded soft tissue reconstruction, including stabilization of the thumb and index carpometacarpal joint dislocations. The bone defect is temporarily filled with polymethyl methacrylate beads impregnated with tobramycin. **E,** The soft tissue defect was reconstructed with the distal three slips of the serratus anterior muscle as a free flap. **F,** Two months after initial reconstruction, the polymethyl methacrylate beads were replaced with allograft cancellous chips milled to fine particles. **G,** Radiographs 6 months after injury demonstrated incorporation of the allograft. The spanning plate was removed 12 to 16 weeks after placement once solid bony healing had occurred.

CRITICAL POINTS *Skeletal Reconstruction*

- Attempt to visualize the fracture with minimal dissection and minimal muscle and periosteal stripping.
- Restore length for optimal function of the muscle–tendon unit or shorten for primary closure and skeletal and nerve repair.
- Perform accurate anatomic reduction with special attention to the articular surfaces.
- Use stable, low-profile, minimally invasive fixation and begin early motion with fracture healing.
- For the radius/ulna, use a 3.5-mm limited-contact dynamic compression (LCDC) plate versus a spanning plate to the second or third metacarpal with locking screws if severe comminution is present.
- For fixation of fractures of the wrist, use compression screws or Kirschner wires, repair or reconstruct ligaments, and stabilize with Kirschner wires.
- For the metacarpals, we prefer miniplate fixation to minimize interference with joints or tendons so that early motion can be achieved.
- Maintain the first web space with an external fixator or thumb CMC pinning.
- For the phalanges, use a miniplate, Kirschner wires, or tension band wiring.
- For skeletal defects, decide between shortening, primary bone grafting, and placement of an antibiotic spacer with delayed bone grafting.



FIGURE 43.11 **A** through **C,** Occasionally it is not possible to achieve rigid internal fixation because of comminution or internal fracture anatomy. In this case, an external fixator across the wrist was used successfully.



FIGURE 43.11, cont'd

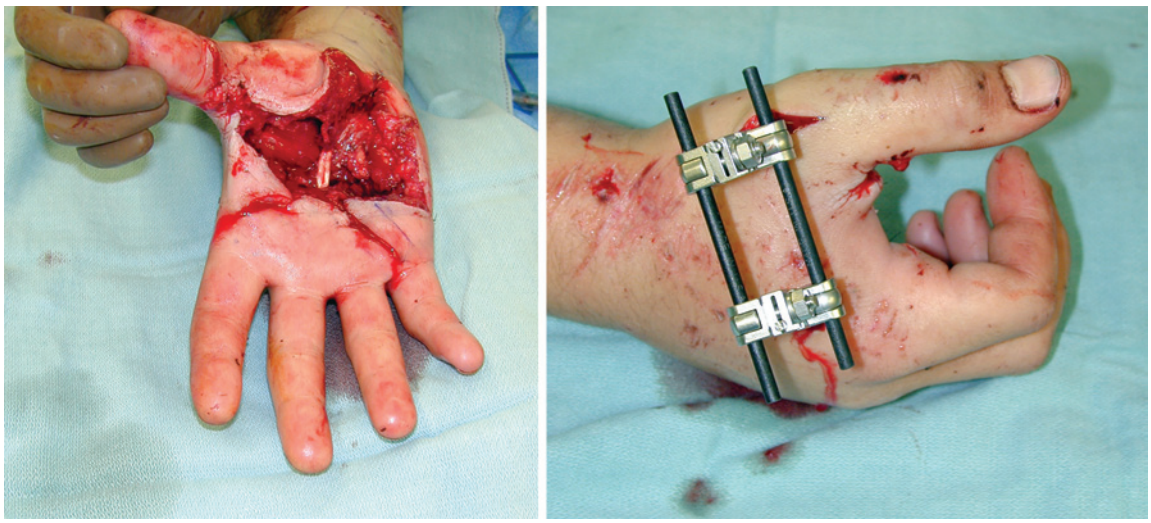

FIGURE 43.12 Use of a mini external fixator to maintain the first web space after a mangling injury to the palm and thenar area.



FIGURE 43.13 **A,** This injury resulted from a rollover car accident. After debridement, skeletal length was restored with a 3.5-mm plate. **B,** A block of polymethyl methacrylate (PMMA) was incorporated into the distal bone defect (*arrow*). Soft tissue coverage was provided with a split latissimus dorsi free flap and skin grafts. Four months after injury, the PMMA block was replaced with an 8-cm allograft fibula bone graft. **C,** Functional result a year after injury.

contracture, the flexor tendons should be repaired with four core sutures to allow early postoperative motion, as well as epitendinous sutures in zone 2.

With mangling injuries in zone 2, we generally repair both the superficialis and profundus tendons. The exception to this is when repair of both tendons compromises gliding through the A2 pulley and results in limited PIP motion. In this situation, we repair only the profundus tendon. If tendons are transected in mangling injuries, the ends are often frayed and have substance missing. Repair may be possible only with concomitant skeletal shortening or with tendon grafting, either acute or delayed. Acute tendon grafting is possible, but it requires an excellent soft tissue bed, stable skeletal fixation, and an intact pulley system so that an immediate passive or active tendon rehabilitation protocol can be started postoperatively.[93] Usually, however, if primary repair cannot be performed, staged tendon grafting should be planned. At the time of definitive soft tissue closure, Silastic tendon spacers should be placed to allow secondary reconstruction. If the critical A2 or A4 flexor pulleys are disrupted, they should be reconstructed with spare parts, tendon, fascia, or a portion of the extensor retinaculum as described in Chapter 43.

Mangling injuries to the extensor tendons, especially on the digits, present some of the greatest challenges for reconstruction. In the digits the extensor tendon mechanism is a finely tuned, balanced "shroud" mechanism with tight tolerances that reacts poorly to injury or adhesions. The lumbrical and interosseous muscles, which comprise the intrinsic extensor mechanism of the hand, are very susceptible to crushing or mangling injuries. In most circumstances, because scarring plus contracture of these intrinsics after injury is the most significant problem, debridement of crushed, devascularized, and severely injured intrinsics is warranted at the time of the initial operation.

With tendon injuries proximal to flexor zone 2 or extensor zone 5, primary tenodesis or tendon transfer should always be kept in mind. Side-to-side tenodesis of either the profundus flexor or extensor tendons proximal to the MP level can restore excellent function. If the flexor pollicis longus can be repaired only with significant shortening and flexion, transfer of the ring superficialis tendon should be considered. Transfer of the superficialis to other profundus tendons should also be considered in similar circumstances. Any late intrinsic deficiency is best treated by delayed intrinsic tendon transfer. Complete destruction of either the flexor or extensor muscle–tendon unit is best treated by delayed tenodesis, tendon transfer, or free muscle transfer reconstruction as described in Chapters 5, 6, and 51.

Vascular Repair/Reconstruction

Optimal revascularization of a mangled extremity is without question the most important aspect of reconstruction. In most cases, to avoid injury to a fragile vascular reconstruction, definitive vascular reconstruction should be deferred until after debridement and skeletal and tendon reconstruction. If, however, major arterial disruption has occurred and rendered the limb ischemic, a temporary vascular shunt should be placed as an initial step, as described previously (see Figure 43.9) (Case Study 43.4). If possible, it is helpful to dissect out the injured vessels, identify the ends, and place microvascular clamps across the ends while still under tourniquet control. The actual vascular reconstruction can then be performed after the tourniquet is released.

CRITICAL POINTS *Tendon Repair/Reconstruction*

- Debride crushed intrinsic muscles to prevent contracture.
- Use four-core locking sutures plus a fine epitendinous suture if zone 2 is involved.
- Repair both the flexor digitorum superficialis and flexor digitorum profundus unless gliding is compromised, in which case repair just the flexor digitorum profundus.
- Repair/reconstruct the A2 and A4 pulleys.
- For tendon rods use two-stage reconstruction if primary repair is not possible.
- Consider primary tenodesis/tendon transfer.
- For late reconstruction, tendon grafting, tendon transfer, tenolysis, and functional free muscle transfer may be needed.

The most important factor in determining success or failure of the vascular reconstruction is ensuring that the vascular anastomosis is performed with uninjured vessel on both sides of the anastomosis and using careful technique, as described in Chapter 60. With mangling injuries, this usually involves trimming the injured vessels back until healthy, uninjured intima can be seen with magnification. Once this is done, it is frequently difficult to achieve a tension-free primary repair. This situation can be addressed several ways.

Sometimes it is possible to ligate and divide small side branches near the ends to allow sufficient mobilization for primary anastomosis. Occasionally, an adjacent joint can be safely flexed to allow a primary repair, especially if flexion is required for concomitant primary nerve repair. This is certainly the case around the elbow, where flexing can often allow primary vascular repair; however, the extended position may be required for a vein graft, only to have it kink and need to be revised when the elbow is flexed for repair of a tendon or nerve. In many cases, however, a reversed vein graft is required.

Just as it is important to perform the microvascular anastomoses outside the injured zone, if a vein graft is required, it is also important to harvest vein from outside the zone-of-injury. Reasonable places to harvest a vein graft from the upper extremity, only if uninjured, include the dorsum of the hand or the dorsal or volar surface of the forearm. Distant sites include the leg (saphenous) or foot. The dorsal veins of the foot are a good source for vein graft with a reasonable size match for reconstructing the digital vessels in the palm or digits. If the palmar arch needs to be reconstructed, it is sometimes possible to find a venous network on the dorsum of the foot that, when reversed, can provide multiple outflow tracts for the common digital vessels (Figure 43.14).[42]

To reconstruct the brachial, radial, or ulnar arteries, the saphenous, lesser saphenous, or cephalic veins are good choices. For all vein grafts it is important to remember that the grafts must be reversed to retain antegrade flow rather than against the venous valves. In some cases when the brachial/radial-ulnar artery bifurcation must be reconstructed, an antegrade bifurcation of a larger vein can be used and the valves released with a valvulotome (Figure 43.15). It is also important to minimize damage to the vein during harvest and to ensure that all small

CASE STUDY 43.4

The arm of a 32-year-old male is caught in a rebar bending machine. He presents with a dysvascular forearm and hand (eFigure 43.7).

The order of initial surgical steps should be the following:

a. Skeletal stabilization, debridement, revascularization
b. Revascularization, debridement, skeletal stabilization
c. Debridement, revascularization, skeletal stabilization

Answer: (c) Debridement, revascularization, skeletal stabilization

Rationale: The key point in the major upper extremity mangling injuries that involve a dysvascular extremity is to establish *temporary* revascularization via a shunt. Debridement should be done first to remove the heavy contamination and nonviable tissue. Shunting should next be done for the brachial artery. Following establishment of temporary circulation, the skeletal stabilization can proceed in a controlled fashion.

Surgical photos are displayed in eFigure 43.8.

Following debridement, vascular reconstruction, and skeletal stabilization, the patient has a large antecubital fossa defect with exposed vascular graft. The most appropriate soft tissue reconstruction is:

a. Split thickness skin graft
b. Negative pressure would treatment until closure
c. Free tissue transfer
d. Groin flap

Answer: (c) Free tissue transfer

Rationale: A skin graft is not optimal coverage over vascular grafts because of the potential for vascular graft rupture. Negative pressure wound therapy can be used over vascular grafts but should not prolong the time for definitive reconstruction. A groin flap would not reach the antecubital fossa. A free tissue transfer is appropriate as it will allow expeditious and stable one-stage soft tissue reconstruction and will provide durable coverage over vascular grafts, nerves, and the joint.

See eFigure 43.9.





eFIGURE 43.7 **A, B,** Dysvascular forearm and hand.

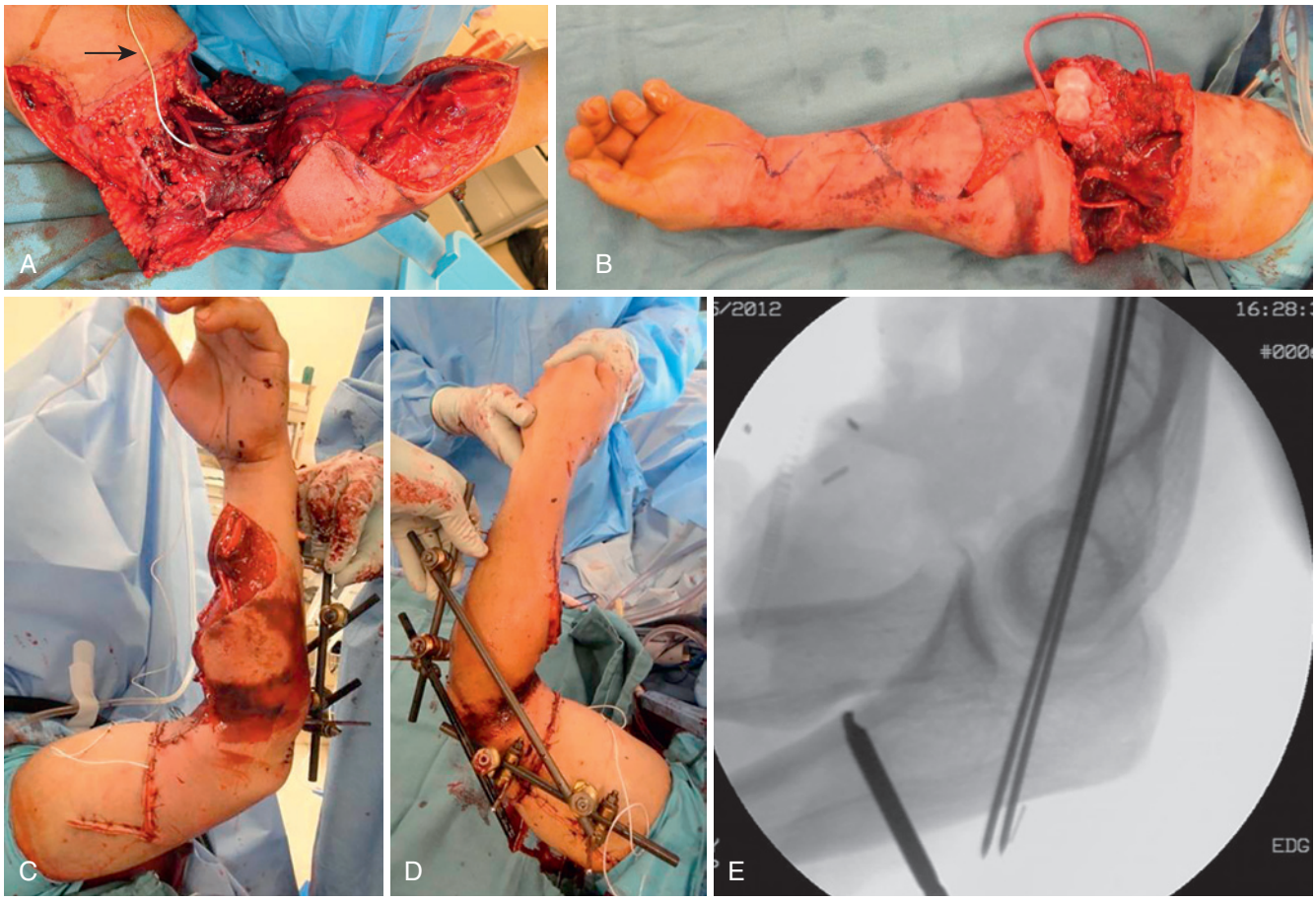

eFIGURE 43.8 Revascularization and skeletal stabilization for dyvascular forearm and hand. **A,** Vascular shunt with incorporated Doppler device (*arrow*). **B,** Shunting prior to skeletal stabilization. **C, D,** Skeletal stabilization with external fixator. **E,** External fixation and ulnohumeral points.



eFIGURE 43.9 Free tissue transfer. **A,** Latissimus dorsi flap on donor site. **B,** Latissimus flap coverage following multiple debridements. **C,** Skin graft over latissimus flap. **D, E,** Surgical results.

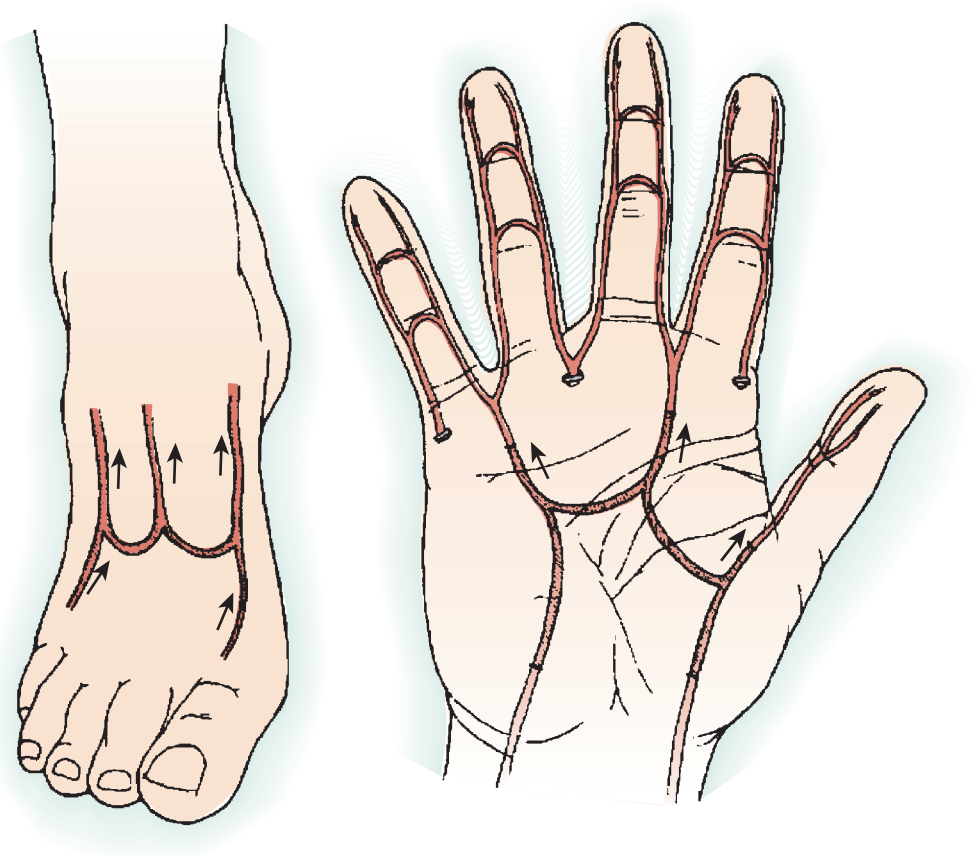

FIGURE 43.14 Venous network on the dorsum of the foot, which when reversed, can provide multiple outflow tracts for the common digital vessels. (Reprinted from Gupta A, Wolff TW: Management of the mangled hand and forearm. *J Am Acad Orthop Surg* 3:226–36, 1995, with permission.)

side branches are ligated either with small hemoclips or with bipolar electrocautery.

Once the vessel ends have been identified, clamped, and trimmed back to healthy tissue, the vessels should be cleared of thrombus proximally and distally. With the major vessels this is usually done with a No. 2 Fogarty catheter or, in the case of digital vessels, by simply milking out the clot and removing it with irrigation and microvascular forceps. The vessels are then irrigated proximally and distally with 10-U/mL heparin in saline solution using a blunt irrigating cannula. If vein graft is to be used, it should first be predilated so that the proper length of vessel can be determined.

One of the most common errors in vein grafting is using too long a piece of vein for the defect, thereby resulting in redundancy, kinking, and thrombosis. Predilation is performed by first reversing the graft and then placing a microvascular clamp on the outflow end of the vessel. The vessel is filled with a heparin–saline solution equivalent to systolic arterial pressure to reproduce the state of the vessel once arterialized. The point of the vein graft that will be used for the proximal anastomosis is cut with microvascular scissors and microvascular anastomosis performed as described in Chapter 60.

With the application of mild tension on both the distal arterial segment and the vein graft to stimulate the state of the vessels under pressure, the point along the vein graft for the distal anastomosis is identified and cut. If a long piece of vein graft is used, it is often helpful to determine the final length by releasing the proximal clamp and allowing the graft to fill with blood under systolic pressure with a distal clamp in place and assume its eventual length. The graft can then be marked and cut to the proper length for the distal anastomosis. The distal anastomosis is performed with double microvascular clamps to take tension off the anastomosis during its creation. The clamps are released and flow established through the anastomoses. Any areas of leakage are addressed with additional sutures at this point and any previously unidentified cut side branches are ligated.

If multiple levels of vascular injury are involved, the proximal reconstruction should be performed first, followed by the more distal ones. In the case of palmar arch or common digital artery injuries, it is not always necessary to reconstruct every common digital vessel because one can adequately perfuse two digits. Reconstructing the common digital artery to the index/middle finger and to the ring/small finger is all that is required, in addition to the thumb, of course. Whether to reconstruct either the radial or the ulnar artery when the other is intact or whether to reconstruct one or both, if both are injured, is a matter of debate.

Some studies have suggested only a 50% patency rate if the other vessel is open and uninjured and that the functional outcome is the same with ligation or repair of a single vessel.[33,52] There is some evidence, however, that with microsurgical repair,

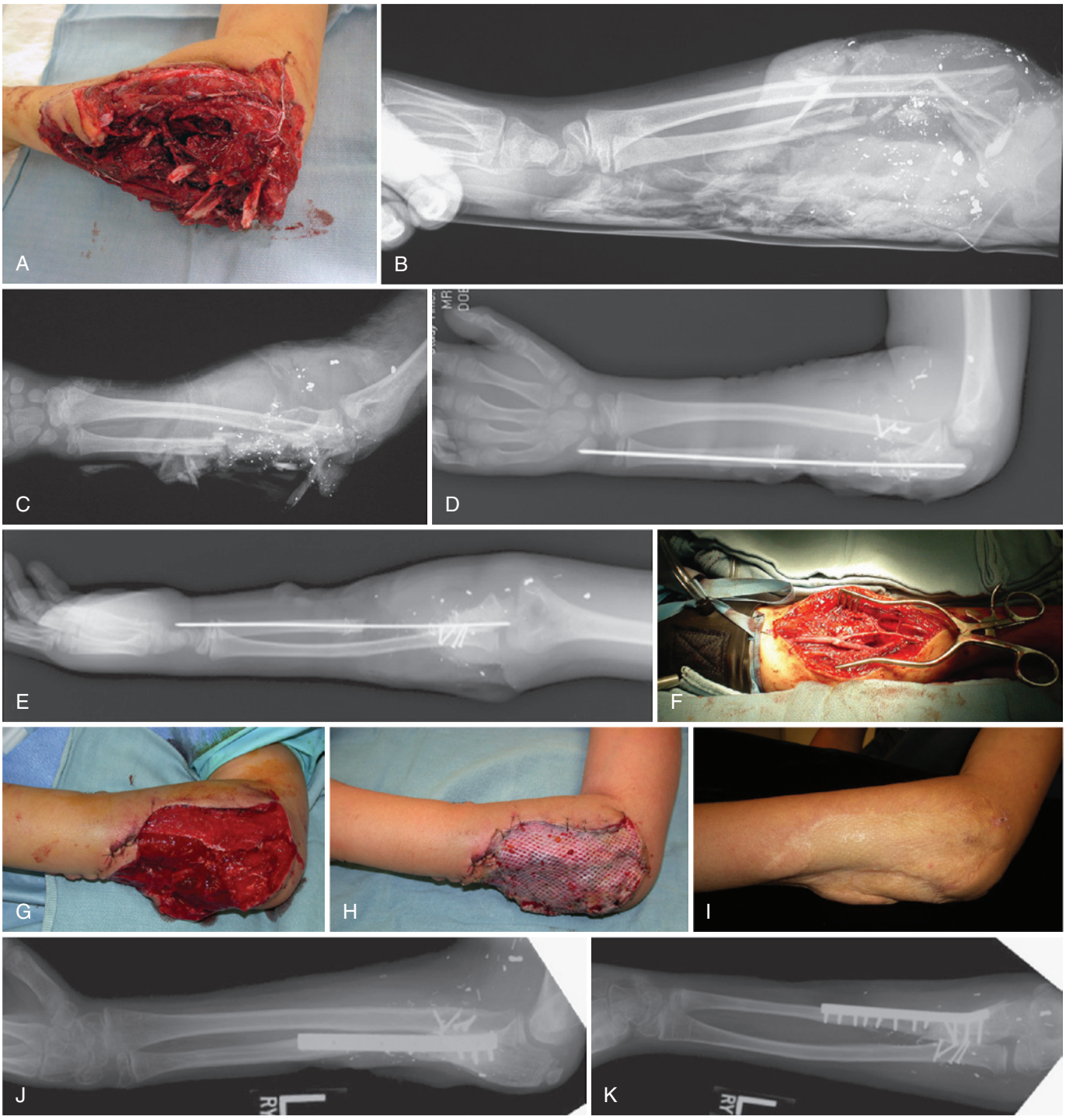

FIGURE 43.15 **A** through **C,** This 10-year-old boy sustained a shotgun wound to his left elbow that resulted in severe soft tissue injury, significant comminuted radius and ulna fractures with bone loss, and devascularization of the forearm with destruction of the brachial/radial-ulnar artery bifurcation. The three major nerves were in continuity, although contused. **D, E,** The wound was thoroughly debrided and provisional fixation achieved with a combination of screws, cerclage wires, and a Steinmann pin through the ulna. **F,** Arterial reconstruction was achieved through a separate anterior approach by using the bifurcation of a large adjacent vein, out of the injury zone, releasing the valves with a valvulotome, and placing it in an antegrade fashion to reconstruct the brachial artery bifurcation. **G, H,** The initially complex wound was treated with negative pressure therapy for a week, which resulted in a wound that could be closed with a simple skin graft. **I,** The resulting soft tissue reconstruction was stable. **J, K,** Skeletal reconstruction was achieved with a combination of an ulna allograft and iliac crest cancellous autograft through a separate approach.

patency rates can be much higher.[91] In the case of most mangling injuries, to maximize flow to all injured tissues through all side branches available and because of the risk for thrombosis in the other vessel, we generally favor reconstructing both the radial and ulnar arteries, if feasible. The same holds true for digital artery injuries.

It is uncommon to require venous reconstruction except in cases in which there is a circumferential or nearly circumferential transection or crush injury to the subcutaneous venous drainage system of either the digit or forearm. In such cases, the same principles that apply to arterial reconstruction also apply to venous reconstruction. Again, the repairs must be performed with an uninjured vessel, and use of a vein graft may be required. Once the arterial and, if necessary, venous reconstructions have been completed, it is important to monitor their patency continuously throughout the remainder of the operation. Should thrombosis occur, it is important to address this quickly before the thrombus propagates distally.

The most common cause of thrombosis in these situations is either technical error in performing the anastomosis or error in judgment with inadequate resection of the damaged vessel. In both cases, reresection of the vessel ends is almost always indicated in revising the anastomosis after thrombectomy. Anticoagulation is generally contraindicated with mangling injuries of the arm and forearm, although it could be considered if injury is confined to the hand or digits. Clinical trials of anticoagulation in microsurgery have failed to demonstrate a consistent benefit.[56,57]

CRITICAL POINTS *Vascular Repair/Reconstruction*

- Perform vascular repair/reconstruction after skeletal and tendon repair unless critical ischemia is present (in which case use a temporary shunt).
- Dissect vessels and use a microvascular clamp under tourniquet control.
- Declot with a Fogarty catheter proximally and distally.
- Trim vessel ends to healthy, uninjured tissue.
- Irrigate and fill with a 10-U/mL heparin solution and then clamp.
- Perform the vascular repair with the microscope, outside the injury zone if possible.
- If there is inadequate length, ligate/divide some side branches, flex the joints, or use a reverse vein graft.
- Perform a vein graft with vein outside the zone-of-injury; predilate and reverse it (valves).
- Repair or reconstruct both the radial and ulnar arteries whenever possible.
- Perform venous reconstruction only if all or nearly all venous outflow is absent.

Nerve Repair/Reconstruction

Nerve repair usually follows skeletal, tendon, and vascular reconstruction in that order because it is less urgent than vascular reconstruction and the delicate techniques involved can easily be compromised by the more aggressive maneuvers involved in skeletal and tendon reconstruction. Again, the details of nerve repair and reconstruction are covered elsewhere (see Chapter 30). As noted previously, it is important to distinguish between neurapraxia, axonotmesis, and neurotmesis in deciding on the appropriate treatment for nerve injury. In nearly all cases involving mangling injuries, if the nerve sheath is in continuity, it is best left alone to see whether function will return later.

In the case of neurotmesis involving the digital nerves or major nerve trunks, primary end-to-end epineural repair should be performed. It is important that the repair be tension-free because a repair under tension leads to nerve ischemia or physical gapping, either of which will impair nerve regeneration. Nerve repair should be performed with the aid of the operating microscope to properly align the major nerve fascicles, to properly place the sutures in the epineurium, and to control the tension when tying the sutures to achieve proper axon-to-axon apposition without bunching. With traumatic nerve transections and especially with crush or avulsion injuries, it is critically important to trim back crushed or injured nerve endings before performing the repair. Again, this is performed with the aid of the operating microscope to determine when soft healthy fascicles have been reached. After trimming, it is sometimes necessary to dissect the nerve proximally and distally, without sacrificing critical side branches, to achieve a tension-free repair.

If primary, tension-free nerve repair cannot be achieved in the acute setting and if the gap is less than 1 to 2 cm, a nerve conduit or decellularized nerve allograft can be used to bridge the gap as described in Chapter 30.[55,66,105] If the remaining gap is longer, however, either delayed nerve grafting or, in the case of a motor–nerve deficit, tendon transfer or nerve transfer should be performed. In nearly all cases, if a functional nerve is to be sacrificed for nerve grafting, we prefer to perform this as a secondary procedure so that healthy nerve endings with soft, viable fascicles can be ensured and the risk of graft loss because of wound contamination and infection is limited.

CRITICAL POINTS *Nerve Repair/Reconstruction*

- Repair or reconstruct nerves as the last step before soft tissue coverage.
- Trim clearly crushed nerve to healthy fascicles.
- Perform epineural repair with the microscope.
- Use the fascicular and surface anatomy for proper alignment.
- Perform a tension-free repair.
- If a nerve gap is present, free the minor branches, flex the joint, use a nerve conduit for a short gap, and use a nerve graft for larger gaps.

Soft Tissue Coverage

Achieving a healed wound with stable, durable coverage and vascularized tissue over critical structures is key. Soft tissue coverage is the last and in many ways the most important step in the treatment of mangling injuries of the upper extremity because it determines the environment in which all other repaired and reconstructed structures will heal and ultimately function. In addition, coverage should be low profile, be supple over mobile areas (e.g., joints and tendons), and have minimal shear characteristics on the volar aspect of the hand and fingers where friction is required for function. Ideally, coverage over the volar tips of the digits should be sensate. Frequently, it is impossible to achieve all these goals with a single reconstruction method, and either some compromise or some combination of methods must be used.

Although achieving early wound closure is desirable to reduce the possibility of infection and optimize healing and



FIGURE 43.16 Use of vascular surgical "vessel loops" in a crisscross fashion with staples along the wound edge to create a "corset" effect that brings the wound together without creating ischemia.

motion, with severe crush or mangling injuries and in particular in the presence of significant contamination, it is often prudent to delay definitive coverage until a stable wound has been achieved. This will sometimes require serial debridements separated by 24 to 48 h. In nearly all cases, however, strive to have definitive coverage by 7 to 10 days even though some smaller, noncritical wound or wounds may remain at that point.

During the intervening period before definitive coverage, it is imperative that the wound and all vital structures remain moist. As swelling develops after injury, there is a clear tendency for wounds to enlarge, thus making closure progressively more difficult. We have found two techniques helpful in controlling this situation. The first involves using rubber bands or vascular surgical "vessel loops" in a crisscross fashion with staples along the wound edge to create a "corset effect" that brings the wound together without creating ischemia (Figure 43.16). This technique also allows a certain degree of limb swelling without creating a compartment syndrome and naturally brings the wound edges together as the swelling diminishes.

The other method uses negative pressure therapy (NPT), an example of which is vacuum-assisted closure (VAC). NPT has a number of salutary effects, including removal of exudate, decrease in edema, closure of dead space, promotion of wound contraction, marsupialization of the wound edges, and promotion of granulation. In essence, it acts as a "mechanical myofibroblast." NPT has revolutionized the approach to soft tissue coverage in complex lower extremity defects in that it allows wounds to contract and granulate to the point where they can be covered with a simple skin graft rather than a complex flap. In the upper extremity, however, because of the importance of maintaining the gliding motion of muscles and tendons, prolonged application of NPT and skin grafting can lead to outcomes inferior to those of early coverage with a supple, vascularized flap.

NPT should never be used to unnecessarily prolong definitive upper extremity soft tissue reconstruction. Nevertheless, it does have an important role in the soft tissue reconstruction of mangled upper extremity injuries. When used judiciously and for limited periods, it can dramatically improve the wound environment and decrease the size requirements for flap coverage.[3,86] The application of NPT has evolved to the current state at which the benefit of immediate soft tissue coverage can be safely postponed. Details on the use of VAC are provided with the device, and because the device can change, the reader is referred to the manufacturer's instructions for details. Trimming the sponge to a size slightly smaller than the wound helps shrink the size of the wound with suction.

Closed NPT should not be used, however, for extremities with severe contamination, infection, or significant bleeding. It should also be used with caution in the setting of vascular repair or reconstruction. Because NPT is a closed system, it is important to change the sponge every 3 to 5 days or more frequently, depending on the level of contamination. In some cases, if the fascial coverage of critical structures is preserved, NPT alone can obliterate dead space and produce a wound that can be skin grafted while preserving vascularized gliding tissue over critical structures (Figure 43.17).

In planning soft tissue reconstruction, it is important to keep in mind the concept of the "reconstructive ladder" as originally described by Mathes and Nahai.[69] This concept implies that the simplest method of coverage appropriate to the situation should be used. We have modified the standard reconstructive ladder to include NPT in the mix. The modified reconstructive ladder generally follows the following progression:

- Primary closure
- Wound contraction ("secondary intention")
- Skin grafting
- NPT
- Flap
- Local
- Distant
- Free

Given the unique functional requirements of the upper extremity, including joint motion and tendon/muscle gliding, the simplest soft tissue reconstruction is not always the most appropriate. The decision often involves making judgments regarding the ultimate functional goals and balancing them with the complexity of the reconstruction required to achieve the goals. If the area in question has exposed "white structures" (i.e., tendon, nerve, bone, or ligament/joint), some form of a vascularized soft tissue reconstruction will be required. If, however, critical functional structures are not involved, a simpler form of reconstruction can be used.

Gottlieb and Krieger have made the point that merely using the simplest reconstruction and moving "up the ladder" when that fails is not appropriate, but rather, riding the "reconstructive *elevator*" up to the most appropriate treatment for the particular condition is what is required.[37] The essential principle is to not merely use the simplest technique possible but to use the simplest technique that will achieve optimum form and function. Do not be afraid to choose a complex reconstruction if it will provide the best result but not every wound requires a free flap.

Whenever possible, primary closure or delayed primary closure (5–7 days after injury) should be performed. In doing so, it is critically important to close the wound loosely so that tension does not lead to ischemia of edges with subsequent dehiscence or ischemia of the underlying structures because of increased compartmental pressure. It is far better to have small gaps that heal secondarily than to have a large dehiscence or, even worse, to induce necrosis in marginally vascularized skin that would otherwise survive, especially in the case of traumatically elevated flaps.

In these situations it is always best to simply lay the skin down and at most tack it in place loosely rather than stretch it



FIGURE 43.17 **A,** A complex crush injury resulted in a severe combined injury that included skin, muscle, and bone. **B,** Complete excisional debridement was performed with removal of all nonviable soft tissue; a "see-through" wound was left that would otherwise require a large flap **(C)**. By preserving and using the forearm fascia, this complex wound could be transformed, with the aid of negative pressure therapy **(D)**, into a wound that could be skin-grafted **(E)** while preserving vascularized gliding tissue over critical structures **(F, G)**.

back to its original position, thereby creating ischemia and necrosis in a large area of the flap, resulting in a defect much greater than one that would be left by simply laying the flap down (Figure 43.18). If the wound edges cannot be closed primarily, it is certainly reasonable to allow the wound to close secondarily by wound contraction if the remaining defect is less than 1 to 2 cm and if there are no vital structures or motion areas (e.g., joints or web spaces) left exposed. Many fingertip injuries and amputations heal best with wound contraction to bring the adjacent, sensate skin together to provide coverage, as opposed to insensate grafts or flaps.

For larger noncritical defects, a skin graft may be required. Skin grafts can consist of autograft (from the patient), allograft (from a human skin bank), or xenograft (usually porcine skin). A xenograft is used primarily as a "biologic dressing" and usually does not revascularize. Allograft can revascularize and "take"; however, it will be rejected after the first week or so. It is useful in promoting vascular ingrowth into a wound bed and preparing the bed for later autografting. If an allograft takes, one can be fairly confident that an autograft will do well and that the wound bed is healthy. Autografts can be either full or split thickness.

Split grafts, because they are thinner and more easily revascularized from the bed, will take better than full-thickness grafts, are more resistant to infection, and will do better in a marginal wound bed. Full-thickness grafts will contract less, be more durable and flexible, and have better sensation. They are therefore preferred for areas prone to shear and load such as the fingertips, palm, web spaces, and areas over joints. Split grafts can be either meshed or unmeshed. Meshed grafts will have fewer problems with seroma, hematoma, and infection and will therefore take better. Their appearance is not as aesthetically pleasing, however. In all cases maintaining contact between the graft and the bed is imperative for inosculation (i.e., ingrowth of vessels into already existing vascular channels) and neovascularization (i.e., new vessel formation) to occur.

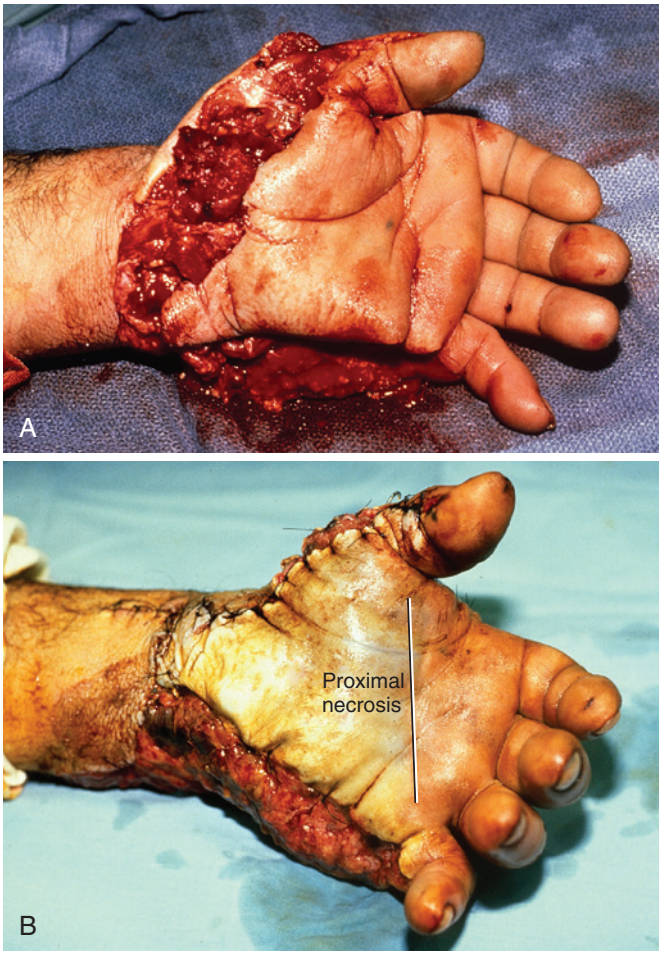

FIGURE 43.18 **A, B,** With traumatically elevated flaps, "lay it, don't stretch it." It is always best to simply lay the skin down and at most tack it in place loosely rather than stretch it back to its original position, thereby creating ischemia and necrosis of a large area of the flap as shown in this case.

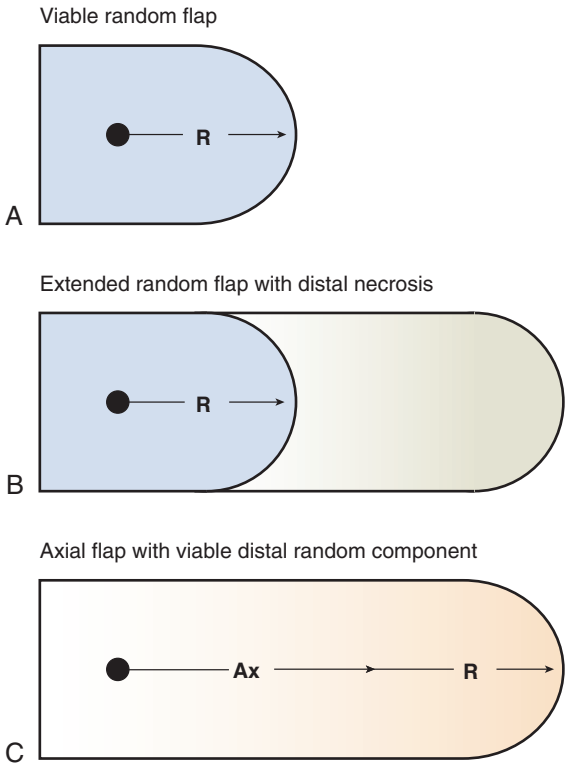

FIGURE 43.19 The importance of axial perfusion of a flap is illustrated. **A,** Reliable perfused area of a flap based on purely random perfusion (R) from the vascular pedicle (*black circle*). **B,** Random flap designed beyond the limits of reliable random perfusion (R), which results in distal flap necrosis. **C,** Benefit of designing a flap based on an axial pedicle. The length of reliable flap perfusion includes the same length of reliable random perfusion (R) plus the length of the axial pedicle (Ax). (Reprinted from Vedder NB: Flap physiology. In Mathes SJ, Hentz VR, editors: *Textbook of plastic surgery*, Philadelphia, 2005, Elsevier, © 2003 Nicholas B. Vedder.)

During the first 24 to 36 h the graft must survive on diffusion, sometimes referred to as "serum imbibition," but without revascularization after that point, the graft will not survive. Anything that disturbs the revascularization process, such as hematoma, infection, or shear, will prevent proper engraftment. The best way to achieve successful engraftment is with a moist, compressive dressing or bolster over the graft to provide both pressure and immobilization. We prefer a first layer of fine-mesh gauze, followed by a layer of gauze soaked in mafenide (Sulfamylon) solution, which has the added benefit of decreasing the local bacterial level and thereby promoting graft take. For split grafts in the extremities, NPT is very effective at optimizing graft–bed contact and graft take.

Donor sites for split grafts include the lateral aspect of the thigh, hip, buttock, scalp, or trunk. The medial aspect of the thigh should be avoided because the skin is much thinner and a full-thickness wound can develop from harvesting skin there. Generally, adults' skin should be harvested at a 0.0010- to 0.0012-inch thickness. Full-thickness skin can be harvested from an elliptic excision in the groin crease, the abdomen, or the hypothenar aspect of the hand, which provides thick, glabrous skin. The volar wrist crease can also be used; however, we avoid it because the resulting scar may be mistaken for a self-inflicted laceration.

For complex wounds, including those with exposed "white structures," wounds over joints or web spaces, or those at risk of compromising function because of scarring or contracture, vascularized soft tissue (i.e., a flap) is required. A flap is simply tissue that contains its own blood supply, as opposed to a graft, which requires revascularization from the bed. Because they remain viable, flaps tend to stay soft and supple while providing vascularity to otherwise devascularized areas. Flaps are mainly classified according to their vascular supply as either random or axial. Flaps that are based on an axial nutrient vascular system will be much more reliable than flaps that are not. Random flaps are those not based on a dominant nutrient vascular system but instead are supplied by flow through the subdermal or subfascial plexus (or both).

As a result, random flaps are much less reliable than axial flaps, and their length is limited to a short distance from the pedicle origin. The portion of an axial flap that extends beyond the axial vessel is random in nature (Figure 43.19). An axial flap that is transplanted from its origin and then connected to a new blood supply elsewhere in the body microsurgically is a free flap. Flaps can then be further classified on the basis of the tissue that they contain (e.g., cutaneous, fascial, fasciocutaneous, muscle, musculocutaneous, osteomusculocutaneous).

In general, random flaps have little role in the reconstruction of mangling injuries to the hand and upper extremities. The exception is the treatment of fingertip or small digit injuries or the treatment of small defects over critical structures such as the median nerve at the wrist or an exposed vascular repair. In most situations, robust and reliable axial flaps from outside the zone-of-injury are required. The various flap choices and the technical details of their transfer are clearly described in Chapters 44 and 45. We will therefore simply point out some of the "workhorse" flaps that are regularly relied on for various areas of the hand and upper extremity in the setting of mangling injuries.

Fingers, Hand, and Wrist. A number of local random and axial flaps are described in Chapters 44 and 45; they are suitable for covering fingertip and finger defects, as well as digit amputation stumps.[34,88] The Moberg advancement flap, cross-finger flap, flag flap, and other axial intrinsic flaps are suitable for isolated digit defects. For severely crushed digits, removing the crushed skeletal component and converting them to a fillet flap can often provide the necessary vascularized tissue for covering critical defects. If multiple digits are involved, sometimes using the Millard "crane principle" and burying the digits in abdominal fat for 2 weeks and then removing them can result in enough vascularized soft tissue coverage to allow skin grafting. This approach is primarily applicable for dorsal defects and not palmar ones with exposed flexor tendon or digital nerves.

For larger defects, a regional or distant axial flap is required. The tubed groin flap is a reliable axial flap that can cover a large defect; it is certainly an upper extremity workhorse flap. In addition to being large and reliable, it contains a thick fatty layer that allows the tendon to glide beneath it and forms an excellent foundation for secondary reconstructions, including tenolysis, tendon transfers, and toe-to-hand transfers. The disadvantage is that unless it is performed as a free flap, which is technically very difficult because of the small pedicle vessel size, it requires that the hand be attached to the groin for at least 2 weeks, which is both awkward and makes effective hand therapy difficult.

The other disadvantage is that it is very thick and bulky and usually requires multiple staged defatting procedures. It can nevertheless produce excellent results (Figure 43.20). Some



FIGURE 43.20 **A** through **G,** Reconstruction of a multidigit degloving injury with a tubed groin flap, including staged syndactyly release.



FIGURE 43.21 **A,** Right hand and forearm of a male in his sixties injured in a log splitter. **B,** Dorsal hand wound following debridement, now with exposed extensor tendons. **C,** Periumbilical perforator flap attached to dorsal hand. **D,** Healed dorsal hand wound.

patients may have had prior groin surgery or pelvic trauma, thereby presenting a contraindication for the groin flap. In this situation, the periumbilical perforator flap as described by O'Shaughnessy is a useful alternative.[79] This flap is based, as the name suggests, on axial vessel(s) near the umbilicus, and a large piece of tissue can be obtained for coverage (Figure 43.21). It does have similar disadvantages to the groin flap in that it requires a second surgery for division and can be bulky.

The other upper extremity workhorse flap is the radial forearm one based on the radial artery and perforating vessels coming up in the septum between the brachioradialis and flexor carpi radialis. Preservation of these perforators during dissection is critical, and dissection must always focus on staying deep, below the artery and its veins. If it is transferred based on reversed flow through the radial artery from the ipsilateral arm, it has the advantage of confining the surgical defect to that one extremity. It is, of course, critical to first confirm that the remaining ulnar artery and the palmar arch are intact by performing an Allen test with a Doppler probe preoperatively. The disadvantage of this flap is that the donor site on the forearm and the palmar arch must not be significantly involved in the zone-of-injury.

When it is taken as a fasciocutaneous flap, unless the cutaneous component is very small, the morbidity of the forearm donor site can be significant, both functionally and aesthetically (Figure 43.22). It is very important to design the flap on the proximal volar aspect of the forearm to allow direct closure over the flexor tendons and skin graft the donor site only over proximal muscle. Because it, like the groin flap, is a fasciocutaneous flap, its bulk can often hinder function and requires defatting. This can also be a significant problem on the palmar aspect of the hand and digits, where firm attachment of the skin to the base is required for grasping and friction-based functions.

For these reasons, we usually transfer the radial forearm flap as a fascia-only flap with skin grafting on the fascia and leave the thick skin and fat layer in the forearm. This provides well-vascularized gliding coverage that is both thin and functional (Figure 43.23). It provides excellent resurfacing for both palmar and dorsal hand and digit defects and can even reach the tips of the fingers (Figure 43.24). The forearm donor defect is then simply a linear scar. The entire width of the forearm fascia can be taken on the radial artery, but even so, there is significant contraction and shrinkage when the flap is finally transferred. If the flap is harvested as fascia only, it is very important to leave the network of small fascial vessels on the surface, as well as a thin stippling of fat, when dissecting the forearm skin and subcutaneous tissue off of the fascia. Even though the flap will usually survive from reversed flow through both the artery and veins, it is beneficial, whenever possible, to microsurgically anastomose an effluent vein from the tip of the flap to a dorsal hand vein. The other reversed-flow flap of the forearm to consider is the posterior interosseous flap, which can also be taken as either a fasciocutaneous or a fascia-only plus skin graft flap. In our experience, this is a much less reliable flap, especially for a mangled extremity.

If a larger piece of fascia is required than can be harvested with the radial forearm flap, the anterolateral thigh fascia free flap, based on the descending branch of the lateral circumflex femoral artery, is an excellent choice (Figure 43.25). It is, of course, transferred as a free flap, usually end-to-side into either the radial or the ulnar artery or end-to-end into the princeps pollicis artery and carries the attendant microsurgical risks. It, too, can be taken as a fasciocutaneous free flap, but the bulk is usually detrimental in the hand and wrist; if used for reconstructing the forearm or elbow region, however, it can provide durable, supple coverage. If harvested as a suprafascial



FIGURE 43.22 **A, B,** The radial forearm fasciocutaneous flap can provide good vascularized coverage of critical defects, although when harvested with the skin, subcutaneous tissue, and fascia, it is usually too bulky for reconstruction of either the palmar or dorsal surfaces of the hand and leaves a morbid "shark bite" defect in the forearm with a skin graft on tendon. For this reason, we now prefer a fascia-only flap with a skin graft for hand and wrist reconstruction. *STSG*, Split-thickness skin graft.

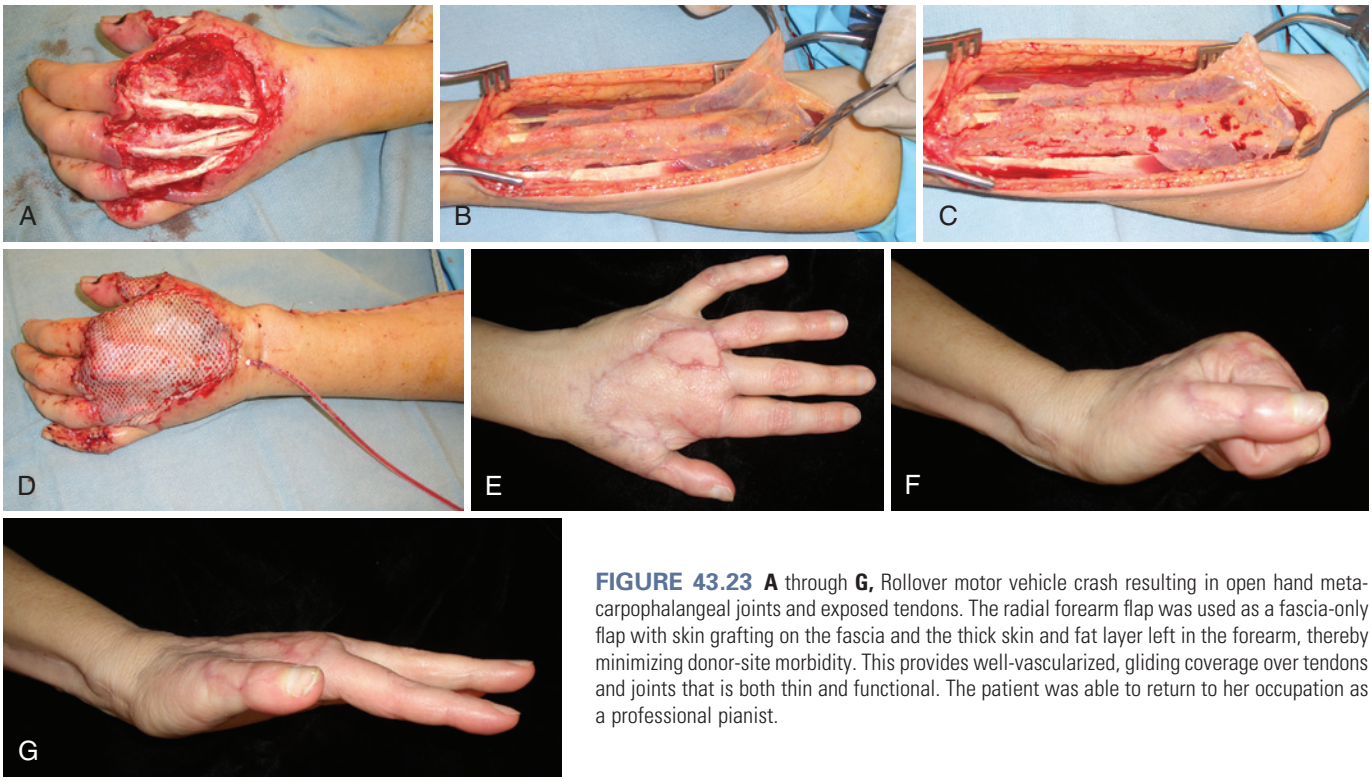

FIGURE 43.23 **A** through **G,** Rollover motor vehicle crash resulting in open hand metacarpophalangeal joints and exposed tendons. The radial forearm flap was used as a fascia-only flap with skin grafting on the fascia and the thick skin and fat layer left in the forearm, thereby minimizing donor-site morbidity. This provides well-vascularized, gliding coverage over tendons and joints that is both thin and functional. The patient was able to return to her occupation as a professional pianist.



FIGURE 43.24 A through **H,** The radial forearm flap as a fascia-only flap with skin grafting can even reach the fingertips, as in this case with these severe deep-contact burns and exposed interphalangeal joints.

perforator free flap, it can be quite thin. In addition, with the thigh fascia preserved, the donor defect is easier to close primarily (Figure 43.26).[60]

The lateral arm free flap, either as a fascia plus skin graft or as a fasciocutaneous flap, can provide more tissue than the radial forearm flap and can be harvested from the zone-of-injury. Like the radial forearm flap, surgery can be confined to one extremity, yet it relies on microsurgery, and the donor defect, even if it can be closed primarily, is very noticeable (Figure 43.27).

Forearm. Forearm defects requiring vascularized coverage generally need a fairly large flap. Although a groin flap can be used, a free flap is usually more appropriate. Many defects can be reconstructed with a free gracilis muscle flap, especially if the muscle fascia is scored, which allows the flap to be spread 8 to 10 cm and also results in a thinner contour (Figure 43.28). For larger defects, generally the latissimus muscle free flap is used. Again, to reduce bulk and minimize donor site morbidity, we use muscle-only flap with a skin graft rather than a fasciocutaneous flap. Even though it is muscle and not fat, it provides good coverage for tendon and joint gliding and is easily reelevated for secondary procedures. If a large cutaneous flap is desired specifically for the purpose of tendon gliding, either an anterolateral thigh suprafascial perforator flap, as described earlier, or a scapular or parascapular fasciocutaneous flap can be used (Figure 43.29). When the defect includes major muscle groups of the forearm (e.g., the flexor or extensor compartments), it is sometimes possible to achieve both coverage and motor reconstruction in a single stage by using an innervated functional free muscle transfer (Figure 43.30).

Elbow and Arm. For defects around the antecubital area, such as exposed vascular or nerve reconstructions, the proximally based brachioradialis muscle flap is an excellent choice with minimal donor morbidity (Figure 43.31). For larger defects around the elbow and even extending to the proximal third of the forearm, the latissimus dorsi muscle can be transferred as a pedicle flap and be skin grafted. By detaching its insertion from the humerus, significant additional length can be achieved; however, it is important to ensure that the proximal pedicle is not stretched or kinked. Although tunneling the flap subcutaneously down the arm has been described, we think that the risk of vascular compromise favors opening the posterior of the arm and skin grafting over the muscle, which can later be revised (Figure 43.32).

Composite flaps and spare parts surgery can also play a role in the soft tissue reconstruction of mangling injuries. Even though an amputated part or segment of tissue may be deemed not replantable or functional, portions of it may still be useful in reconstruction. Any residual nonfunctional proximal phalanx of the index finger can, for example, be transposed

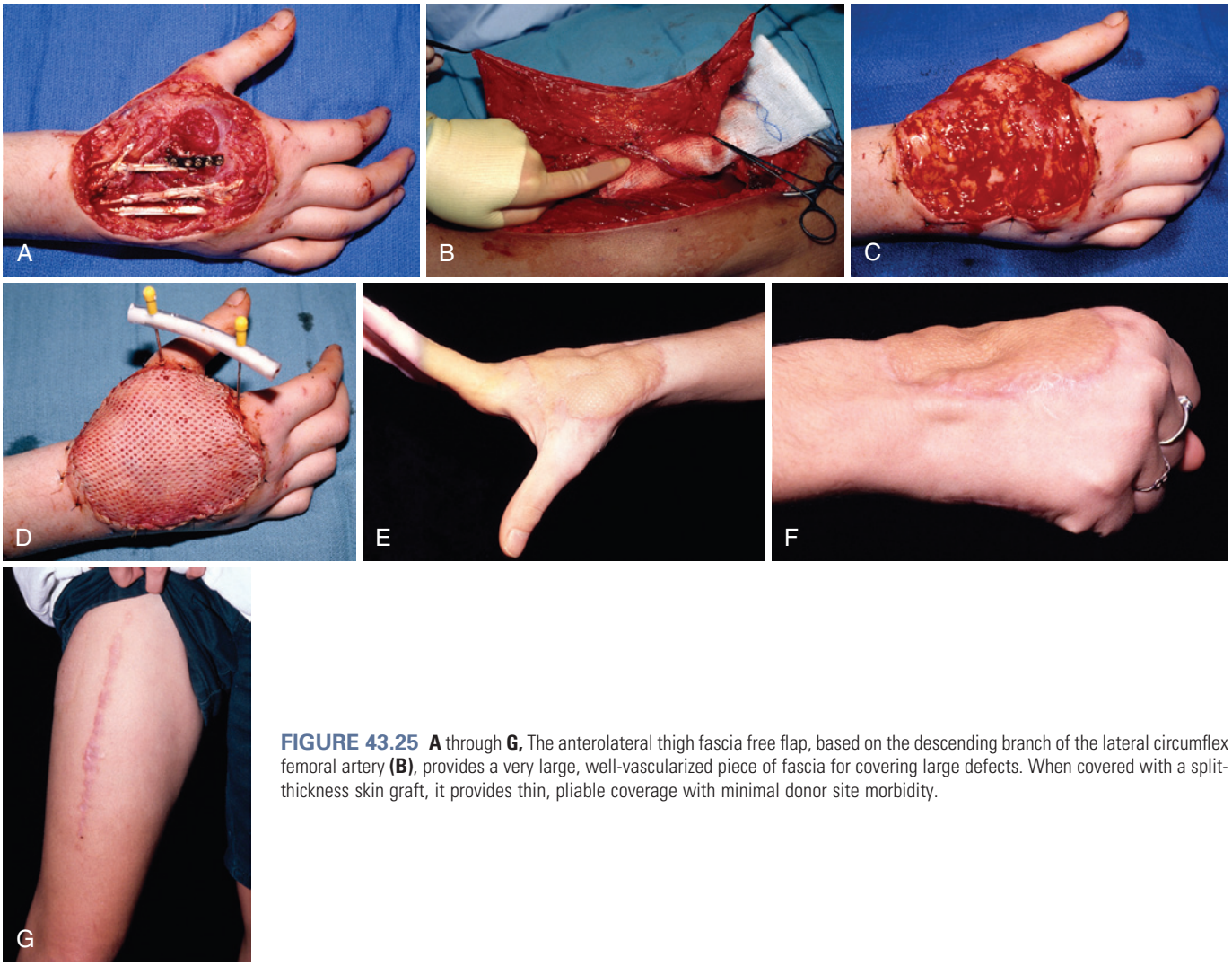

FIGURE 43.25 **A** through **G,** The anterolateral thigh fascia free flap, based on the descending branch of the lateral circumflex femoral artery **(B)**, provides a very large, well-vascularized piece of fascia for covering large defects. When covered with a split-thickness skin graft, it provides thin, pliable coverage with minimal donor site morbidity.

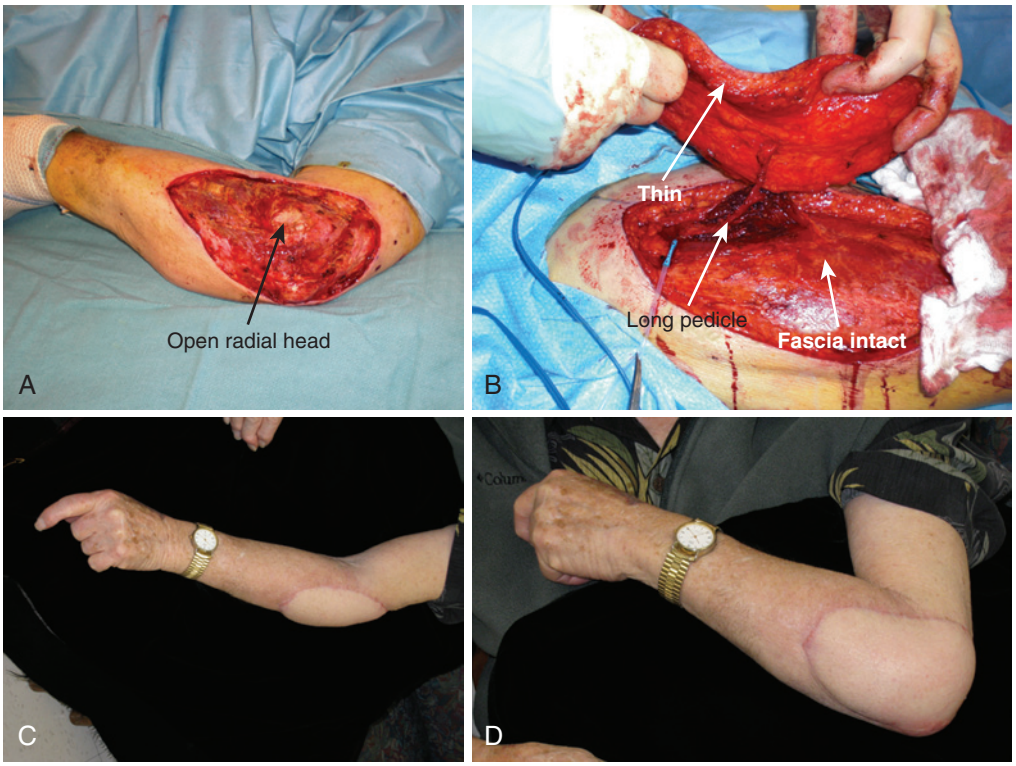

FIGURE 43.26 **A** through **D,** A large soft tissue defect of the elbow region with exposed radial head. The anterolateral thigh flap, when harvested as a suprafascial skin flap, can be quite thin and provides a soft, supple reconstruction with excellent contour while minimizing the donor defect and improving the ability to achieve primary closure.



FIGURE 43.27 **A, B,** A severe mangling injury of the hand and wrist reconstructed with a lateral arm fasciocutaneous free flap. Note the significant donor defect associated with a large lateral arm flap.

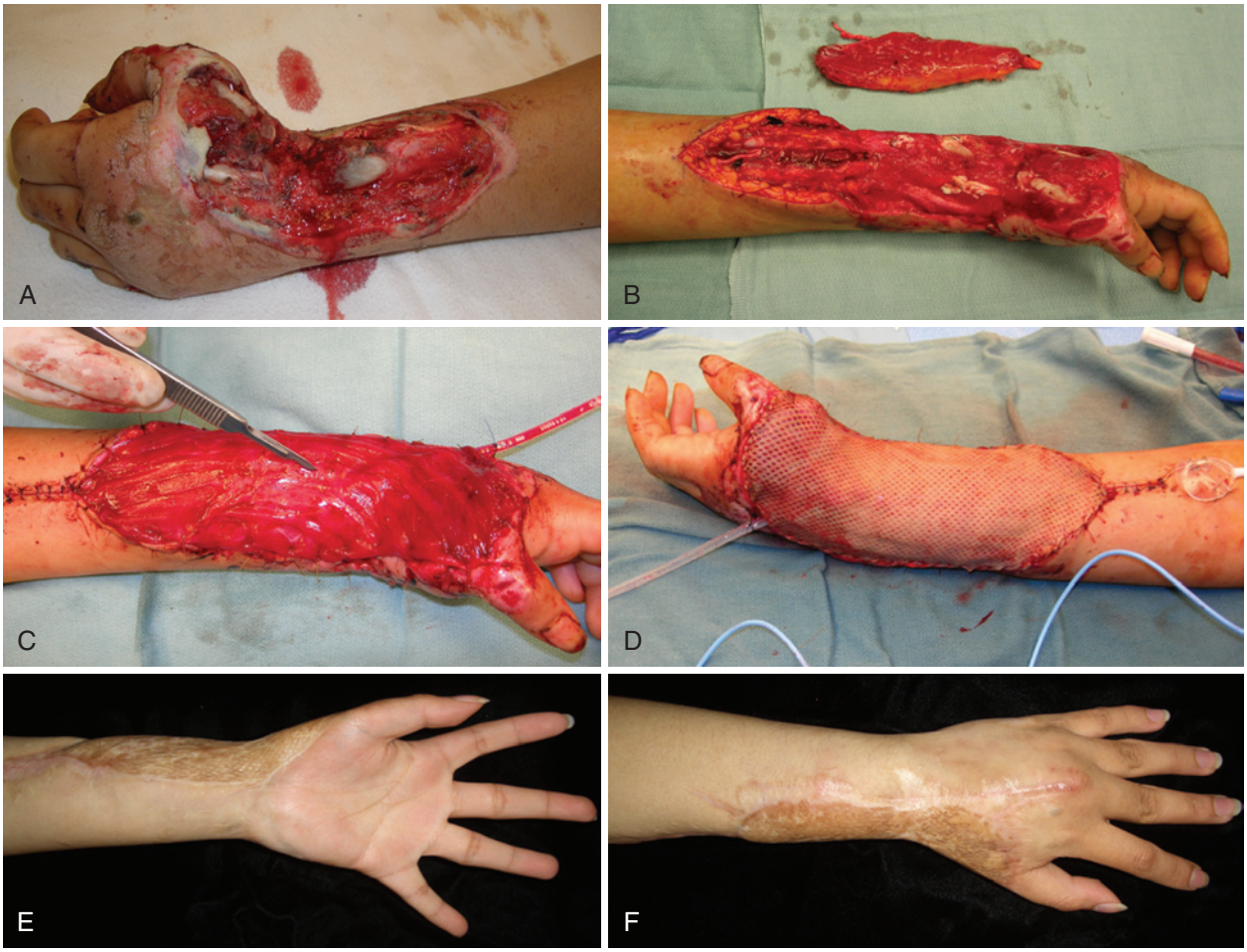

FIGURE 43.28 **A,** Large complex wound of the wrist with exposed metacarpal and radius fracture fixation and loss of the thumb extensors. The free gracilis muscle leaves a minimal donor defect, and although initially small and narrow **(B)**, it can cover a large area if the fascia is multiply scored longitudinally and the muscle gently stretched after insetting it proximally after microvascular anastomoses **(C, D)**. **E, F,** The resulting contour is excellent, and secondary extensor tendon reconstruction can be achieved with a tendon transfer.

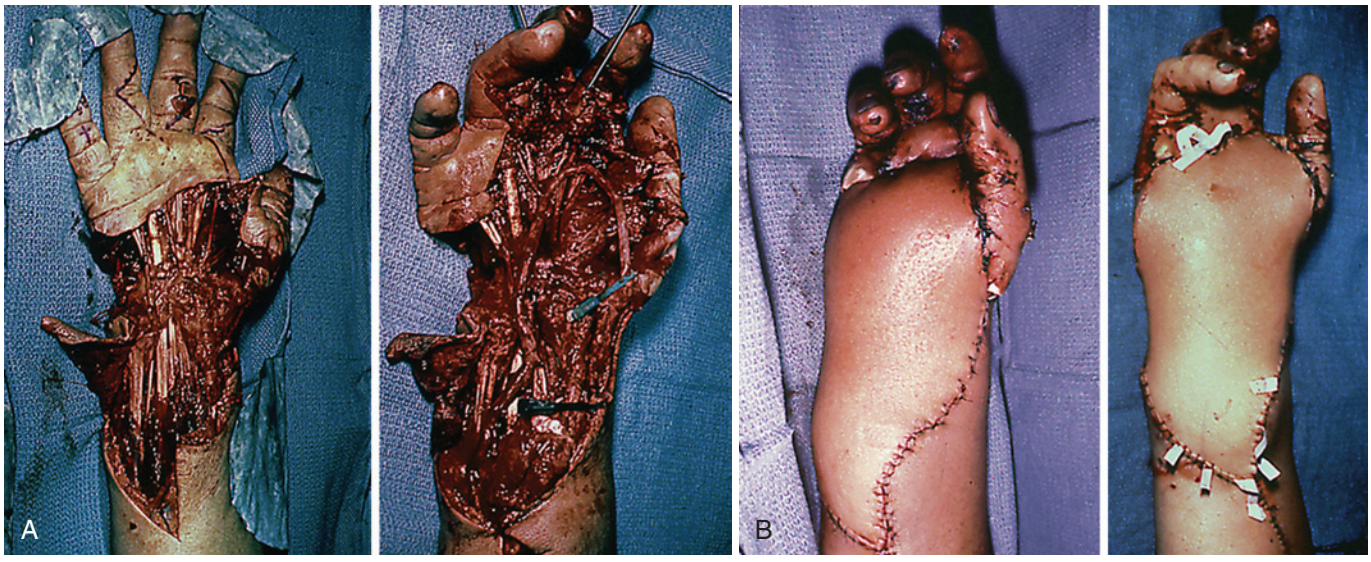

FIGURE 43.29 **A,** This farmer's hand was caught in a fertilizer spreader. Reconstruction consisted of debridement, skeletal stabilization, and soft tissue coverage with a scapular free flap. Note the significant bulk associated with a fasciocutaneous flap **(B)**, which often requires later debulking.

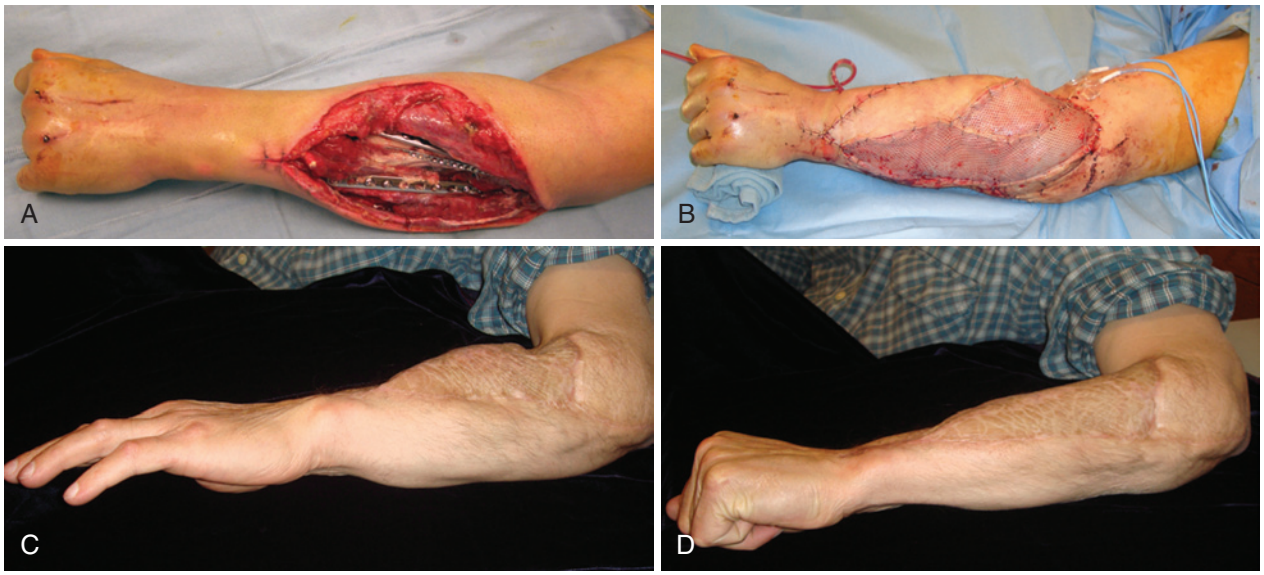

FIGURE 43.30 **A,** After sustaining an explosive injury, this forearm defect included the muscles innervated by the posterior interosseus nerve. **B,** An innervated free gracilis transfer provides both soft tissue coverage and functional motor reconstruction. **C, D,** One year after reconstruction, active finger extension was achieved.

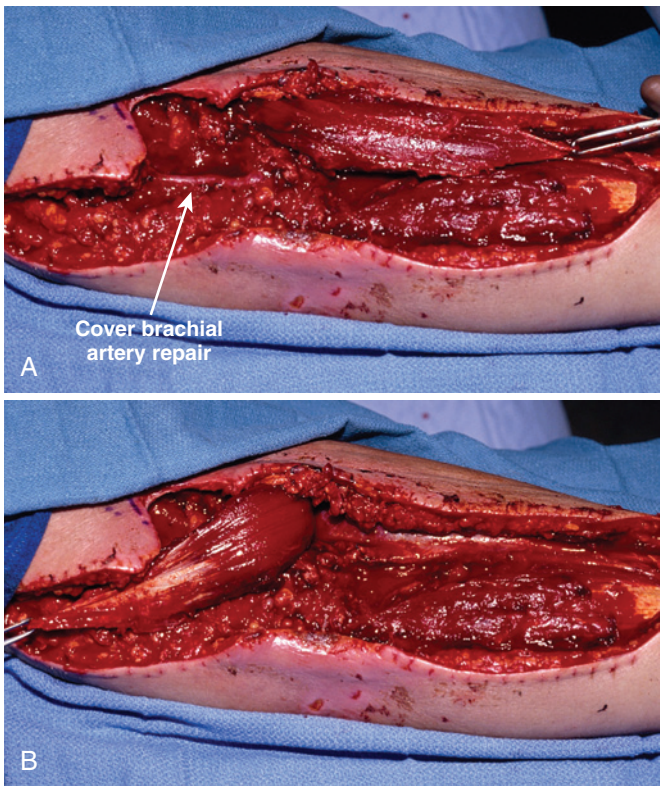

FIGURE 43.31 **A, B,** For defects around the antecubital area, such as exposed vascular or nerve reconstructions, the proximally based brachioradialis muscle flap is an excellent choice with minimal donor morbidity.

to provide additional, sensate length to an injured thumb (Figure 43.33).

The palmar skin of the hand, based on either the radial or ulnar artery, along with either the median or ulnar nerve and its branches, can be used as a vascularized, sensate pedicled flap or free tissue transfer. Spare parts surgery may be one of the very few indications for an "emergency" free flap in the setting of a mangling injury (reviewed by Neumeister and Brown[77]). Similarly, skin or skin and radius bone, based on the radial artery, can be used as a composite flap either as a reversed-flow pedicled flap or as a free tissue transfer. In addition, before discarding amputated tissue, it should always be evaluated for potential use as free graft tissue, either defatted skin, nerve, bone, or tendon.

POSTOPERATIVE MANAGEMENT/ REHABILITATION

Early institution of an appropriate and well-planned therapy and rehabilitation program is critical to achieve an optimal functional outcome. As mentioned previously, injured tissues rapidly become less pliable in just a matter of days after injury; thus, optimizing tendon gliding and joint motion require early, protected mobilization.[23] Edema formation can significantly limit joint mobility, which, if uncorrected, can result in permanent joint contractures. The hand should always be splinted postoperatively in the "safe" position: the MP joints flexed to prevent shortening of the MP collateral ligaments, which can lead to MP extension contracture and the IP joints in extension (Figure 43.34).

Whenever possible, initial skeletal and tendon reconstruction should be performed in a stable enough fashion to allow early mobilization. Conversion to a thermoplastic splint within the first several days after injury can facilitate both wound care and hand therapy. With most mangling injuries, immediate active motion after tendon repair is usually contraindicated, although passive motion can be started immediately. With nerve injuries, blocking splints can be fashioned to prevent tension across the repair while allowing motion in the direction of the nerve. Hypersensitivity is very common after crush and mangling injuries and should be treated by early desensitization therapy.

If a skin graft is used, it is important to prevent motion or shearing beneath the graft for the first 5 to 7 days to allow

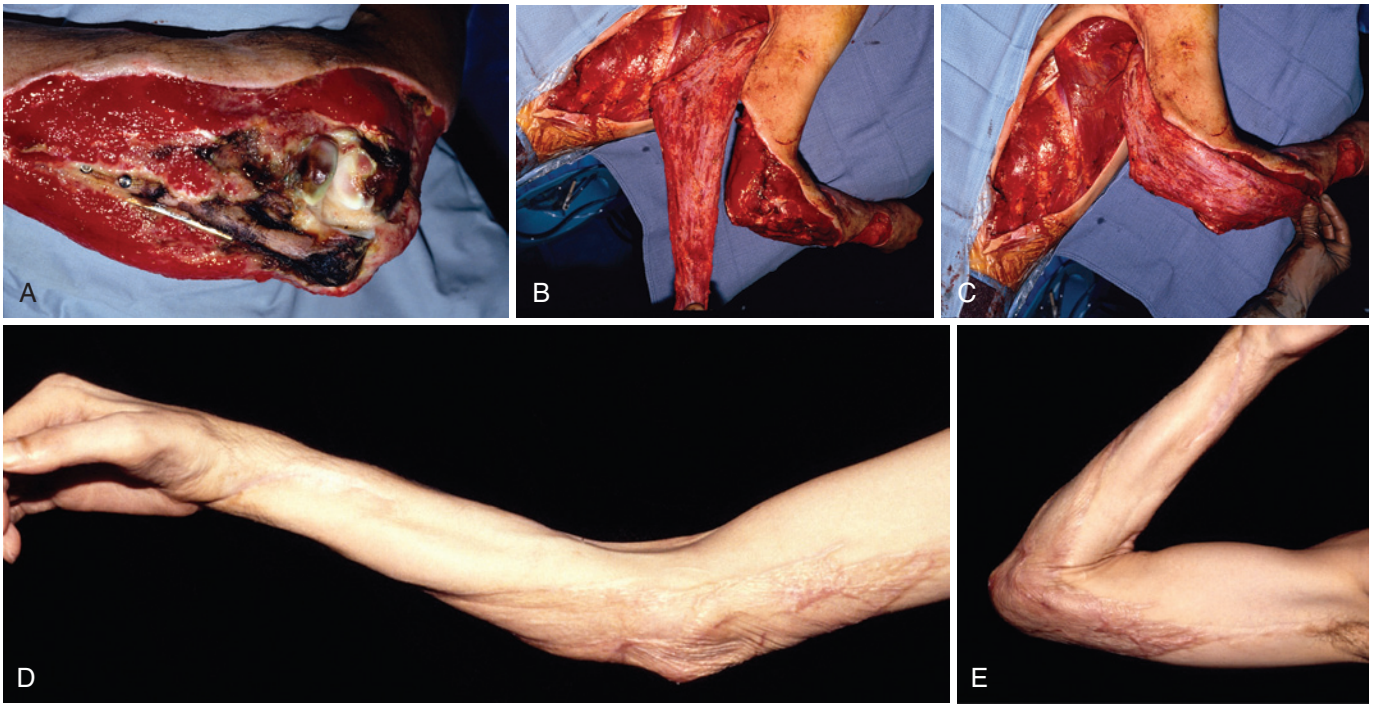

FIGURE 43.32 **A** through **E,** After thorough debridement, the pedicled latissimus dorsi muscle flap can cover large defects around the elbow and even extend to the proximal third of the forearm. By detaching the humeral insertion, significant additional length can be achieved. Then the muscle is skin grafted.

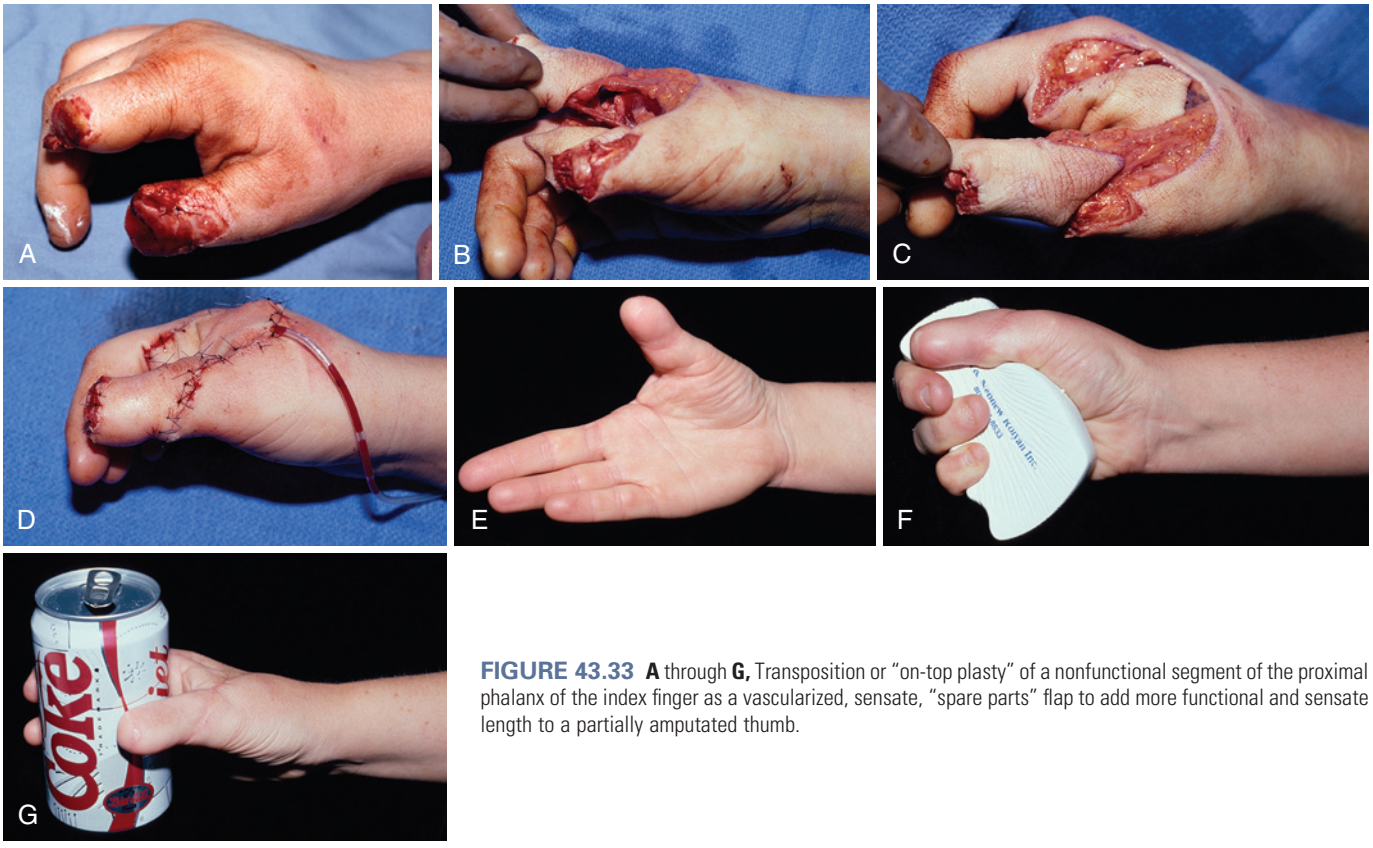

FIGURE 43.33 **A** through **G,** Transposition or "on-top plasty" of a nonfunctional segment of the proximal phalanx of the index finger as a vascularized, sensate, "spare parts" flap to add more functional and sensate length to a partially amputated thumb.

CRITICAL POINTS *Soft Tissue Coverage*

- Coverage over joints and tendons should be adequately vascularized, low profile, and supple.
- Coverage over volar pressure-bearing surfaces should be sensate and have minimal shear characteristics.
- Delay definitive coverage until the wound is stable; repeat debridements if needed.
- Provide definitive coverage by 5 to 10 days; keep the wound moist in the interim.
- Control the size of the wound: vessel loop weave versus NPT.
- Recognize that NPT is contraindicated if infection or bleeding is present.
- Cover "white structures" (i.e., tendon, nerve, bone, or ligament/joint); vascularized soft tissue (flap) is required.
- Do not stretch traumatically elevated flaps to their original position; simply lay them in place.
- For a larger, noncritical defect, use a split-thickness skin graft; use a full-thickness skin graft if area is small, if subject to pressure/shear, or if motion is critical.
- For complex wounds with exposed white structures, use a flap.
- Axial flaps are preferable; include fascia if possible, and consider a fascia-only flap plus a split-thickness skin graft.
- For the fingers, hand, or wrist, use a Moberg, cross-finger, intrinsic, crane, radial forearm, or groin flap.
- For a radial forearm flap, consider a fascia-only plus a split-thickness skin graft; stay deep during dissection and create an effluent venous anastomosis.
- For a groin flap, include sartorius fascia to prevent kinking of the pedicle, protect the lateral femoral cutaneous nerve, delay for 2 weeks, divide/inset at 3 weeks, perform multiple thinning stages, and continue motion to decrease stiffness.
- For the forearm, use a groin, gracilis-free, latissimus-free, lateral arm-free, anterolateral thigh fascia, or suprafascial perforator free flap.
- For the elbow or arm, use a brachioradialis (antecubital defect), latissimus pedicled or free, or suprafascial anterolateral thigh free perforator flap.

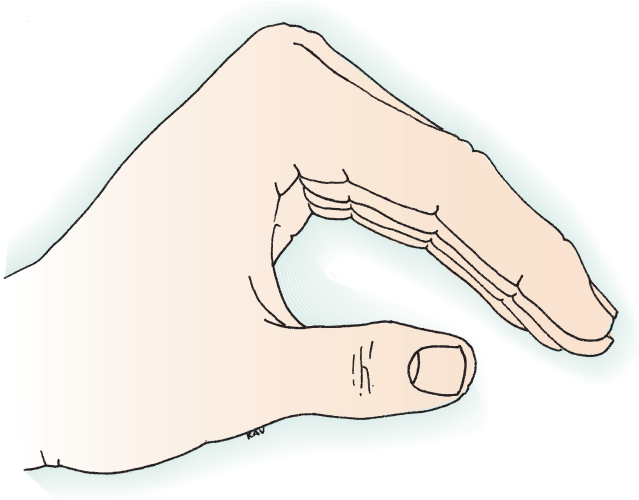

FIGURE 43.34 The hand should always be splinted postoperatively in the "safe" position, with the metacarpophalangeal (MP) joints flexed to prevent shortening of the MP collateral ligaments and subsequent MP extension contracture, and with the interphalangeal joints in extension.

inosculation and take of the graft. Otherwise, liberal washing and soaking of wounds is preferable rather than keeping them wrapped in occlusive dressings where pus can accumulate and an infection can result. The exception to this is NPT, which effectively removes serum and exudate. It should be changed every several days, however.

CRITICAL POINTS *Postoperative Management/ Rehabilitation*

- Splint the wrist in a neutral extended position with MP flexion and IP extension (to minimize contractures and optimize function).
- Prevent early shear of skin grafts/flaps.
- Begin early motion to optimize gliding/motion.
- Control edema.
- Perform desensitization.
- Use goal-based therapy.
- Do not overlook psychosocial issues as well as therapy.

SECONDARY PROCEDURES

Mangling injuries often require secondary reconstructive procedures to achieve optimal form, function, or both. Planning for these secondary reconstructive procedures is best done at the time of the initial operation, again "looking into the crystal ball" and having a vision for the future function of the extremity.[92] The goal of secondary procedures is to improve motion, sensibility, and durability. Some of these procedures have been mentioned previously, including bone grafting, nerve grafting, joint replacement, tenolysis, and release of contractures. Successful secondary reconstruction is predicated on good soft tissue coverage.

In general, secondary procedures should be delayed until the soft tissues have matured and softened, which often takes 3 to 6 months. The exception, however, is bone or nerve grafting, which should be performed early. Some secondary procedures require postoperative immobilization and should be performed first, whereas others require mobilization postoperatively and should therefore be performed at a separate stage. All secondary procedures require stable, soft, and well-vascularized soft tissue coverage; this may require secondary flap reconstruction. In rare cases, tissue expansion techniques can be used.[65] Experience shows, however, that tissue expansion in upper extremity reconstruction is associated with an extremely high complication rate.

If bone grafting is not performed at the initial operation, we perform it as soon as the wounds have healed and crusts have fallen off to minimize the risk for infection, generally at 4 to 6 weeks. As mentioned previously, we favor cancellous allograft in most cases unless autograft is simple to harvest from adjacent bone (e.g., radius for wrist or hand defects). In cases in which tissue vascularity is questionable or with nonunion, cancellous autograft, usually from the iliac crest, is indicated. For defects larger than 6 cm, vascularized bone grafting is indicated. Possible sources for such grafts and techniques are clearly described in Chapter 46 and include fibula, iliac crest, rib, and second metatarsal.

Our preference is a free fibula graft because of its length, minimal morbidity, ease of dissection, and large peroneal vascular pedicle. Structural allograft can also be considered, but

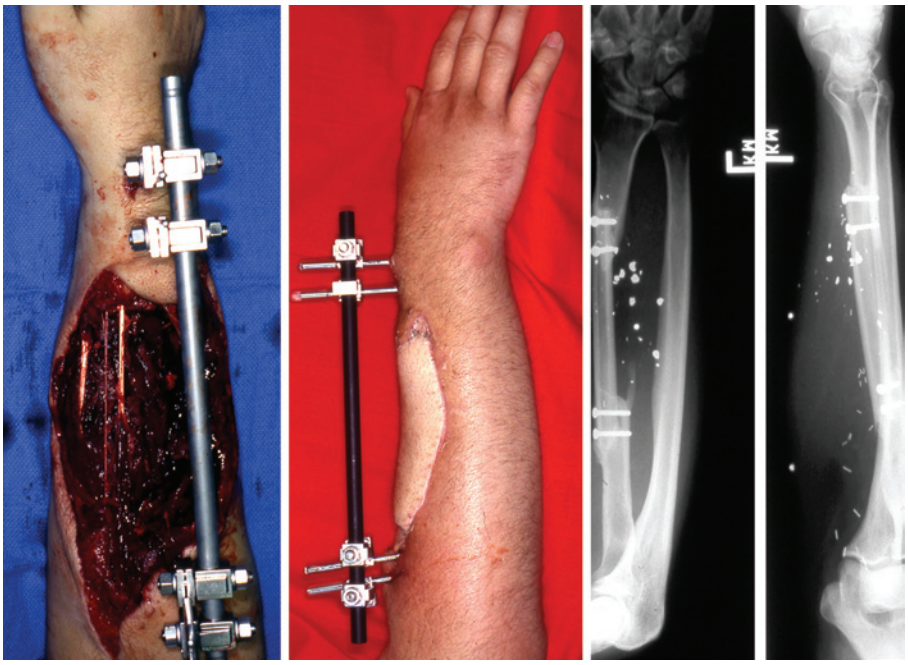

FIGURE 43.35 A close-range gunshot wound resulted in loss of 12 cm of radius, the radial artery, the superficial branch of the radial nerve, and the skin defect shown here. After debridement, the radius was stabilized with an external fixator and the bone and skin defects were reconstructed with an osteocutaneous fibular graft. The radiographs on the right were taken 4 months after reconstruction.

only as a secondary procedure in a mature, well-vascularized tissue bed. With all bone grafting, ensuring adequate soft tissue coverage and tissue vascularity, as well as good postoperative immobilization, is key to achieving bony union (Figure 43.35; see also Figures 43.10 and 43.13).

Corrective osteotomies for functionally significant malunion and the treatment of nonunion should be performed in the initial series of secondary procedures. They usually involve either metacarpal or phalangeal osteotomies to correct digit crossover, distal radius osteotomy to correct dorsal tilt or shortening, or ulnar-shortening osteotomy to correct ulnar impingement.

Nerve grafting for the purpose of restoring motor function should also be performed early because the degree of functional return is inversely related to the delay from the time of injury.[97] Nerve grafting to restore sensory function, however, can be delayed. Again, the techniques for nerve grafting are adequately described in Chapter 30. When nerve grafting is not feasible, a decision must be made as to whether some other form of a sensory or motor reconstruction is required. Again, this depends on the patient's functional needs and a balance between these needs and what can reasonably be expected with additional procedures. For motor reconstruction, tendon transfers should be considered. The indicators and techniques for these are described in Chapters 5 and 6.

When inadequate motor units remain to allow tendon transfer for basic functions, such as composite flexion or extension, functional free muscle transfer using the innervated gracilis muscle should be considered. This is covered in Chapter 51. In areas critical for sensation, specifically the ulnar tip of the radial digit (usually the thumb) and the ulnar tip of the primary opposing ulnar digit (usually the index or middle finger), sensory reconstruction may be required. If sensation is absent and cannot be reconstructed by nerve grafting because of the lack of sensory organelles in the restored soft tissue coverage, transfer of vascularized, innervated glabrous skin can prevent recurrent ulceration and improve tactile-dependent hand function.

The most common indication for sensory reconstruction is when the digit is resurfaced or reconstructed with flap tissue (e.g., a radial forearm or groin flap). If the middle or ring fingers are uninjured, the ulnar pulp can be transferred based on the ulnar digital nerve, artery, and periarterial veins and the donor defect covered with a full-thickness skin graft. Critical to this procedure is ensuring that sufficient perivascular tissue is taken along with the pedicle to allow adequate venous drainage, as well as ensuring that the palmar arch and distal arterial system are intact (Figure 43.36). If pedicled neurovascular island transfer is not possible, a free tissue transfer of the lateral great toe pulp, along with the lateral digital nerve and vessels, can be performed. The technique and dissection are similar to the toe wraparound procedure described in Chapter 47; however, in this case a small 1.5- to 2-cm piece of glabrous skin can be used to allow primary closure of the donor defect (Figure 43.37).

Amputation neuromas are a common and severely disabling complication after a mangling injury. Neuromas are differentiated from normal hypersensitivity after injury by the fact that a symptomatic neuroma is well localized to the nerve stump and does not improve with desensitization therapy, whereas hypersensitivity should improve with desensitization. Treatment involves resecting the neuroma and burying the nerve stump in well-padded, vascularized soft tissue where it will not be subject to pressure irritation.

When the MP or IP joints are destroyed as a result of a mangling injury or when attempts at their initial reconstruction

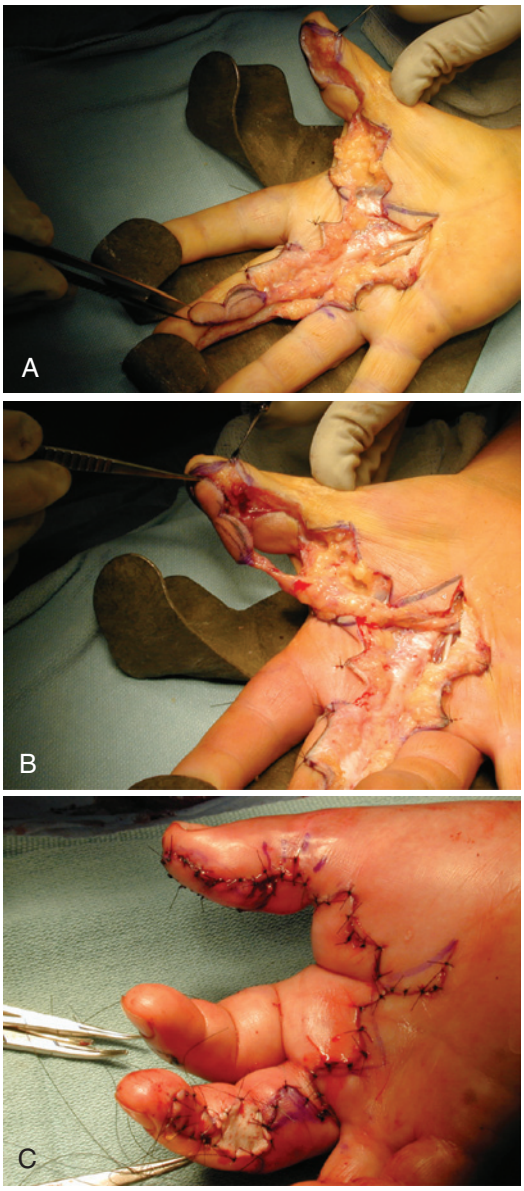

FIGURE 43.36 **A** through **C,** Neurovascular island flap from the ulnar side of the middle finger to the volar surface of the thumb to restore thumb sensation after replantation of an avulsed thumb that had no reconstructible digital nerves. It is critical to ensure that adequate perivascular tissue is taken along with the pedicle to allow venous drainage.

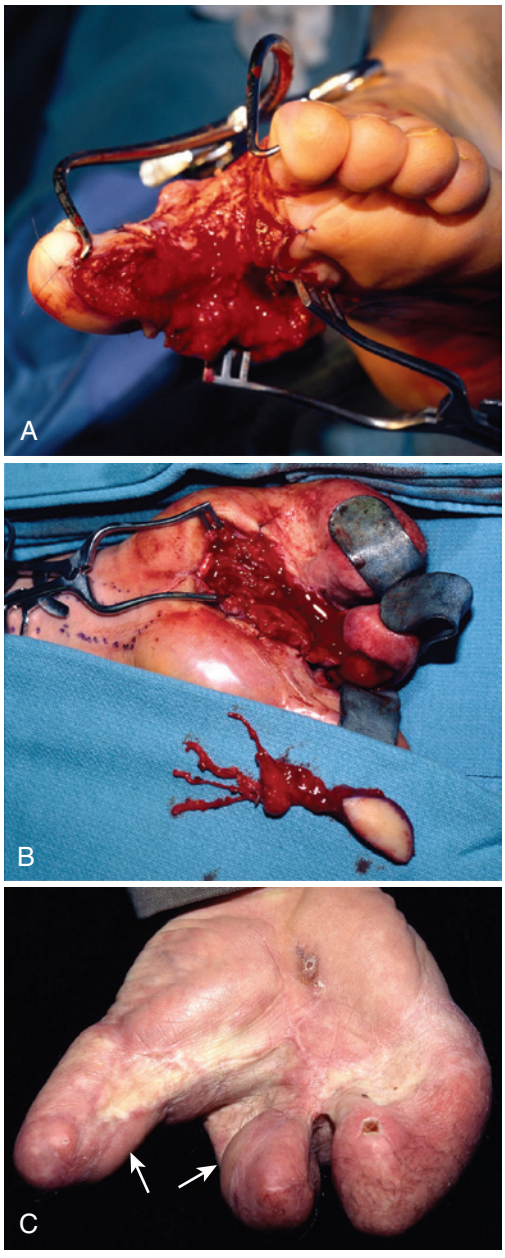

FIGURE 43.37 **A** through **C,** If a pedicled neurovascular island transfer is not possible, a free tissue transfer of the lateral great-toe pulp, along with the lateral digital nerve and vessels, can provide sensate tissue for critical areas of contact. In this case, functional, sensate pinch is achieved between the residual thumb and middle finger with bilateral lateral great-toe pulp neurosensory free flaps (*arrows*).

result in posttraumatic arthrosis, the usual treatment is either arthrodesis or amputation. In rare circumstances, however, when the soft tissue coverage is soft, supple, and well vascularized, arthroplasty can be considered. The indications and procedural details for arthrodesis and arthroplasty are covered in Chapter 12. Posttraumatic arthrosis of the radiocarpal joint, in contrast, especially in patients who use their hands actively, is best treated by wrist arthrodesis, as described in Chapter 12.

Tenolysis, capsulotomy, and contracture release play important roles in secondary reconstruction after a mangling injury.[53,99] Differentiating joint contracture from tendon adhesion is sometimes difficult, and they often occur in concert. Although the lack of active motion relative to available passive motion is a reflection of tendon adhesions, sometimes what appears to be joint contracture with a clear block to passive motion can also be the result of tendon adhesions. Both need to be addressed at the time of secondary surgery. If release will result in a coverage defect that will require either a skin graft or flap reconstruction (if vital structures are left exposed), postoperative immobilization will be required; therefore, the release should be incorporated into the early set of reconstructive procedures. Common areas of contracture after mangling injuries include the MP, IP, and wrist joints, as well as the thumb's CMC joint. For the CMC joint, it is very important to both treat the skin contracture in the underlying adductor muscle contracture and immobilize the joint in both radial and palmar abduction

with either buried Kirschner wires across the CMC joint or a mini-external fixator for a period of at least 6 weeks.

Tenolysis and capsulotomy require early postoperative active and passive mobilization and should therefore be performed only at a separate stage after completing any secondary procedures that require postoperative immobilization and after the overlying soft tissues have matured and softened. There is no fixed time that dictates how long one should wait before performing these procedures; instead, the timing should be dictated solely by the character of the soft tissues. If both flexor and extensor tenolysis and joint releases are required, it is best to begin with the dorsal side first, with aggressive postoperative active and full passive flexion and extension being performed. Release of flexion contractures and flexor tenolysis can then be done at a second stage, again followed by aggressive active and passive flexion and extension and immediate postoperative mobilization. Attempting to address both the dorsal and volar problems in one stage carries a significant risk of disabling postoperative edema, pain that prevents adequate mobilization, recurrent stiffness, and risk of vascular compromise, especially in the digits.

CRITICAL POINTS *Secondary Procedures*

- Procedures requiring immobilization (do first):
  - Bone grafting
  - Corrective osteotomies
  - Joint reconstruction
  - Nerve grafting
  - Sensory reconstruction
  - Tendon transfers
  - Functional muscle transfer
  - Soft tissue reconstruction
  - Toe transfer
- Procedures requiring mobilization (do second):
  - Tenolysis
  - Capsulotomy
  - Contracture releases

COMPLICATIONS

Complications encountered in reconstruction of a mangled extremity are the same as those encountered in the various component parts of the reconstruction: skeletal, vascular, nerve, tendon, and soft tissue. Complications specific to the mangled extremity revolve mostly around failure to recognize and properly address the extent of the zone of tissue injury. Failure to adequately debride devitalized tissue, especially deep muscle, can have devastating consequences, including myoglobinemia, hyperkalemia, necrotizing soft tissue infection, limb loss, generalized sepsis, and death. For this reason, a "second-look" debridement 24 to 48 h after the initial injury, as well as sometimes even a third debridement, is important. Tissue that may not initially appear devitalized can become so as a result of the inflammatory response to injury during this period.

Thrombosis of a vascular reconstruction is another complication that may be related to failure to recognize the zone-of-injury. If soft tissue infection develops, it is important to provide wide, open drainage and debridement to arrest the progression. Even though coverage issues can become a problem, they can always be dealt with later. Osteomyelitis is a challenging complication after a mangling injury and can be due to either inadequate bony debridement at the time of the initial injury, inadequate vascularized soft tissue coverage, percutaneous fixation devices, or fracture motion due to inadequate osteosynthesis. Treatment involves complete debridement of the devitalized, infected bone down to healthy, bleeding bone, along with vascularized soft tissue coverage. Frequently, a temporary spacer consisting of antibiotic-impregnated methyl methacrylate can be placed after debridement and coverage to allow delayed bone grafting.

Other common complications include hypertrophic scarring, joint contractures, tendon adhesions, neuromas, and soft tissue ulcerations, all of which are addressed in the previous section on secondary procedures. In the end, one must recognize that these are very high-risk cases, that complications are not infrequent, and that they need to be anticipated, identified quickly, and treated appropriately before a "snowball effect" develops and leads to a poor outcome.

EXPECTED OUTCOMES

"Expected" outcomes after a mangling injury are very difficult to quantify because no two injuries are the same in terms of their magnitude, location, or involved structures. Although quantitative outcome measurements, such as active range of motion, grip strength, pinch strength, sensibility, and others, are all important components, the most important outcome measure is the degree to which the patient incorporates the reconstructed extremity into daily activities and is able to resume a normal life.[24,47] Important contributors to this outcome include not only biomechanical and sensibility factors but also appearance and psychological factors associated with the mangling injury and the degree to which the patient is able to adjust to its altered function and appearance. Very often the degree of the injury and the functional loss do not correlate with the psychological impact on the patient.

Sometimes injury to a single digit can be more devastating to a patient than a mangling injury involving the entire forearm. Posttraumatic stress disorder has been described for patients after mangling injuries of the upper extremity (reviewed elsewhere[40,73]). This is particularly a problem in work-related injuries, where merely revisiting the site of injury can elicit severe symptoms and be a significant impediment to returning to the job. Enlisting the assistance of rehabilitation psychologists early after an injury is very important when signs of emotional stress are noted. Often more extensive psychological or psychiatric evaluation is needed, and patients may benefit from antidepressant or anxiolytic therapy.

Of all the factors that contribute to the outcome of a mangling injury, the nature and degree of the soft tissue injury have the most impact. The success of skeletal, nerve, tendon, and joint reconstruction all depends on the overlying soft tissue injury and the quality of its reconstruction, as does the final appearance. For this reason, it is critically important to make soft tissue reconstruction a high-priority item in both the initial treatment and secondary reconstruction of mangling injuries.[64]

As noted previously, the success of any reconstruction must be judged against the results of amputation with or without a

prosthetic. A wide array of outcome scores exist for major extremity trauma.[28,31,51,87] There are also a number of outcome scores specifically designed to address the upper extremity, including the Hand Injury Severity Score (HISS); Hand Function Score (HFS); Disabilities of Arm, Shoulder, and Hand (DASH); and the Michigan Hand Questionnaire (MHQ).[21,22,37,104] Although outcome studies of lower-extremity salvage have shown equivocal benefit for complex reconstruction versus amputation and a prosthesis,[8,9] it has long been thought that because of the complex mechanical and sensory functions of the hand, nearly any sensate function is preferable to a prosthesis.[11,18,38,84] This has not been definitively shown, however. As mentioned at the outset of this chapter, no scoring system exists that reliably predicts outcome in a way that allows it to be used as the sole discriminator in choosing salvage versus amputation in the upper extremity. Experience and clinical judgment are still key.

CONCLUSION

Treatment of mangling injuries to the upper extremity is among the most challenging facets of hand surgery. Achieving good outcomes requires intimate knowledge and expertise in all aspects of hand surgery and the ability to evaluate, synthesize, and prioritize a wide variety of treatment options in developing a comprehensive treatment plan that may require multiple staged procedures and rehabilitation protocols over a period of many months. Because the initial operation sets the stage for all that will follow, it is important at that point to be able to look into the crystal ball many months into the future and envision the patient's overall function with various treatment choices to formulate a comprehensive reconstructive plan that achieves both short- and long-term objectives.

Critical aspects of successful reconstruction include complete debridement of devitalized tissue, restoration of good vascularity; early rigid skeletal fixation while minimizing additional tissue injury; and most important, stable, vascularized soft tissue coverage. The important goals of treatment are to preserve life, preserve viable tissue, preserve function, and reconstruct and restore function of the extremity to allow the patient to incorporate the reconstructed extremity into daily life and resume normal activities. Achieving these goals for a patient with a mangling injury is the ultimate challenge for the multidisciplinary reconstructive hand surgeon. It is a true test of one's mastery of the "art" of hand surgery.

For Case Studies, Videos, and more, please visit ExpertConsult.com.

REFERENCES

1. American College of Surgeons: *Advanced trauma life support*, ed 8, 2008. Available from: <http://www.facs.org/trauma/atls/index.html>.
2. Angel MF, Ramasastry SS, Swartz WM, et al: Free radicals: basic concepts concerning their chemistry, pathophysiology, and relevance to plastic surgery. *Plast Reconstr Surg* 79:990–997, 1987.
3. Argenta LC, Morykwas MJ, Marks MW, et al: Vacuum-assisted closure: state of clinic art. *Plast Reconstr Surg* 117(7 Suppl):127S–142S, 2006.
4. Bakker A, Moseley J, Friedrich JB: Vehicle factors and outcomes associated with hand-out-window motor vehicle collisions. *J Trauma Acute Care Surg* 2:687–691, 2013.
5. Beatty ME, Zook EG, Russell RC, et al: Grain auger injuries: the replacement of the corn picker injury? *Plast Reconstr Surg* 69:96–102, 1982.
6. Beckenbaugh RD, Dobyns JH, Linscheid RL, et al: Review and analysis of silicone-rubber metacarpophalangeal implants. *J Bone Joint Surg Am* 58:483–487, 1976.
7. Bernstein ML, Chung KC: Early management of the mangled upper extremity. *Injury* 38(Suppl 5):S3–S7, 2007.
8. Bonanni F, Rhodes M, Lucke JF: The futility of predictive scoring of mangled lower extremities. *J Trauma* 34:99–104, 1993.
9. Bosse MJ, MacKenzie EJ, Kellam JF, et al: An analysis of outcomes of reconstruction or amputation after leg-threatening injuries. *N Engl J Med* 347:1924–1931, 2002.
10. Brand PW, Hollister A: Muscles: the motors of the hand. In *Clinical mechanics of the hand*, St. Louis, 1993, CV Mosby, pp 13–34.
11. Brown HC, Williams HB, Woolhouse FM: Principles of salvage in mutilating hand injuries. *J Trauma* 8:319–332, 1968.
12. Brown JB, Cannon B, Graham B, et al: Restoration of major defects of the arm by combination of plastic, orthopedic and neurologic surgical procedures. *Plast Reconstr Surg* 4:337–340, 1949.
13. Brown PW: Less than ten surgeons with amputated fingers. *J Hand Surg [Am]* 7:31–37, 1982.
14. Brown PW: Open injuries of the hand. In Green DP, Hotchkiss RN, Pederson WC, editors: *Operative hand surgery*, ed 4, Philadelphia, 1998, Churchill Livingstone, pp 1607–1630.
15. Brown RE, Wu TY: Use of "spare parts" in mutilated upper extremity injuries. *Hand Clin* 19:73–87, vi, 2003.
16. Brumfield RH, Champoux JA: A biomechanical study of normal functional wrist motion. *Clin Orthop Relat Res* 187:23–25, 1984.
17. Büchler U, Hastings H, III: Combined injuries. In Green DP, Hotchkiss RN, Pederson WC, editors: *Operative hand surgery*, ed 4, Philadelphia, 1998, Churchill Livingstone, pp 1631–1650.
18. Bueno RA, Jr, Neumeister MW: Outcomes after mutilating hand injuries: review of the literature and recommendations for assessment. *Hand Clin* 19:193–204, 2003.
19. Burke EF, Singer RM: Treatment of comminuted distal radius with the use of an internal distraction plate. *Tech Hand Up Extrem Surg* 2:248–252, 1998.
20. Burke JF: The effective period of preventive antibiotic action in experimental incisions and dermal lesions. *Surg* 50:161–168, 1961.
21. Campbell DA, Kay SP: The hand injury severity scoring system. *J Hand Surg [Br]* 21:295–298, 1996.
22. Campbell DC, 2nd, Bryan RS, Cooney WP, 3rd, et al: Mechanical cornpicker hand injuries. *J Trauma* 19:678–681, 1979.
23. Chan SW, LaStayo P: Hand therapy management following mutilating hand injuries. *Hand Clin* 19:133–148, vii, 2003.
24. Chung KC, Pillsbury MS, Walters MR, et al: Reliability and validity testing of the Michigan Hand Outcomes Questionnaire. *J Hand Surg [Am]* 23:575–587, 1998.
25. Cocchiarella L, Andersson G, editors: *Guides to the evaluation of permanent impairment*, ed 5, Chicago, 2001, American Medical Association Press.
26. Cohen BE, Harmon CS, Phizackerley PJ: Glucose metabolism in experimental skin flaps. *Plast Reconstr Surg* 71:79–86, 1983.
27. Dellinger EP, Miller SD, Wertz MJ, et al: Risk of infection after open fracture of the arm or leg. *Arch Surg* 123:1320–1327, 1988.
28. Dirschl DR, Dahners LE: The mangled extremity: when should it be amputated? *J Am Acad Orthop Surg* 4:182–190, 1996.
29. Duncan RW, Freeland AE, Jabaley ME, et al: Open hand fractures: an analysis of the recovery of active motion and of complications. *J Hand Surg [Am]* 18:387–394, 1993.
30. Dupare J, Alnot J-Y, May P: Single digit amputations. In Campbell DA, Gosse TJ, editors: *Mutilating injuries of the hand*, Edinburgh, 1979, Churchill Livingstone, pp 37–44.
31. Durham RM, Mistry BM, Mazuski JE, et al: Outcome and utility of scoring systems in the management of the mangled extremity. *Am J Surg* 172:569–573, discussion 573–574, 1996.
32. Freeland AE, Lineaweaver WC, Lindley SG: Fracture fixation in the mutilated hand. *Hand Clin* 19:51–61, 2003.
33. Gelberman RH, Nunley JA, Koman LA, et al: The results of radial and ulnar arterial repair in the forearm. Experience in three medical centers. *J Bone Joint Surg Am* 64:383–387, 1982.
34. Giessler GA, Erdmann D, Germann G: Soft tissue coverage in devastating hand injuries. *Hand Clin* 19:63–71, vi, 2003.
35. Godina M: Early microsurgical reconstruction of complex trauma of the extremities. *Plast Reconstr Surg* 78:285–292, 1986.
36. Gorsche TS, Wood MB: Mutilating corn-picker injuries of the hand. *J Hand Surg [Am]* 13:423–427, 1988.
37. Gottlieb LJ, Krieger LM: From the reconstructive ladder to the reconstructive elevator. *Plast Reconstr Surg* 93:1503–1504, 1994.

38. Graham B, Adkins P, Tsai TM, et al: Major replantation versus revision amputation and prosthetic fitting in the upper extremity: a late functional outcomes study. *J Hand Surg [Am]* 23:783–791, 1998.
39. Granchi T, Schmittling Z, Vasquez J, et al: Prolonged use of intraluminal arterial shunts without systemic anticoagulation. *Am J Surg* 180:493–496, discussion 496–497, 2000.
40. Grunert BK, Smith CJ, Devine CA, et al: Early psychological aspects of severe hand injury. *J Hand Surg [Br]* 13:177–180, 1988.
41. Gupta A, Shatford RA, Wolff TW, et al: Treatment of the severely injured upper extremity. *J Bone Joint Surg Am* 81:1628–1651, 1999.
42. Gupta A, Wolff TW: Management of the mangled hand and forearm. *J Am Acad Orthop Surg* 3:226–236, 1995.
43. Hanel DP, Lederman ES: Index transposition after resection of the long finger ray. *J Hand Surg [Am]* 18:271–277, 1993.
44. Hastings H, 2nd: Unstable metacarpal and phalangeal fracture treatment with screws and plates. *Clin Orthop Relat Res* 214:37–52, 1987.
45. Hentz VR, Chase RA: The philosophy of salvage and repair for acute hand injuries. In Wolfort FG, editor: *Acute hand injuries: A multidisciplinary approach*, St. Louis, 1979, CV Mosby.
46. Hoffman RD, Adams BD: Antimicrobial management of mutilating hand injuries. *Hand Clin* 19:33–39, 2003.
47. Hudak PL, Amadio PC, Bombardier C: Development of an upper extremity outcome measure: the DASH (Disabilities of the Arm, Shoulder and Hand) [corrected]. The Upper Extremity Collaborative Group (UECG). *Am J Ind Med* 29:602–608, 1996.
48. Idler RS: Anatomy and biomechanics of the digital flexor tendons. *Hand Clin* 1:3–11, 1985.
49. Im MJ, Manson PN, Bulkley GB, et al: Effects of superoxide dismutase and allopurinol on the survival of acute island skin flaps. *Ann Surg* 201:357–359, 1985.
50. Im MJ, Su CT, Hoopes JE, et al: Skin-flap metabolism in rats: oxygen consumption and lactate production. *Plast Reconstr Surg* 71:685–688, 1983.
51. Johansen K, Daines M, Howey T, et al: Objective criteria accurately predict amputation following lower extremity trauma. *J Trauma* 30:568–572, discussion 572–573, 1990.
52. Johnson M, Ford M, Johansen K: Radial or ulnar artery laceration. Repair or ligate? *Arch Surg* 128:971–974, discussion 974–975, 1993.
53. Jupiter JB, Pess GM, Bour CJ: Results of flexor tendon tenolysis after replantation in the hand. *J Hand Surg [Am]* 14:35–44, 1989.
54. Kaplan I: Primary pollicization of injured index finger following crush injury. *Plast Reconstr Surg* 37:531–535, 1966.
55. Karabekmez FE, Duymaz A, Moran SL: Early clinical outcomes with the use of decellularized nerve allograft for repair of sensory defects within the hand. *Hand (N Y)* 4:245–249, 2009.
56. Khouri RK, Cooley BC, Kunselman AR, et al: A prospective study of microvascular free-flap surgery and outcome. *Plast Reconstr Surg* 102:711–721, 1998.
57. Khouri RK, Sherman R, Buncke HJ, Jr, et al: A phase II trial of intraluminal irrigation with recombinant human tissue factor pathway inhibitor to prevent thrombosis in free flap surgery. *Plast Reconstr Surg* 107:408–415, discussion 416–418, 2001.
58. Kleiner THE, Kutz JE, Ashbell TS, et al: Primary repair of lacerated flexor tendons in "no man's land." *J Bone Joint Surg Am* 49:577, 1967.
59. Kloner RA, Ganote CE, Jennings RB: The no-reflow phenomenon after temporary coronary occlusion in the dog. *J Clin Invest* 54:1496–1508, 1974.
60. Koshima I, Nanba Y, Tsutsui T, et al: New anterolateral thigh perforator flap with a short pedicle for reconstruction of defects in the upper extremities. *Ann Plast Surg* 51:30–36, 2003.
61. Lin GT, Amadio PC, An KN, et al: Functional anatomy of the human digital flexor pulley system. *J Hand Surg [Am]* 14:949–956, 1989.
62. Lister G, Scheker L: Emergency free flaps to the upper extremity. *J Hand Surg [Am]* 13:22–28, 1988.
63. Littler JW, Herndon JH, Thompson JS: Examination of the hand. In Converse JM, Littler JW, editors: *Reconstructive plastic surgery*, Philadelphia, 1977, WB Saunders, p 2973.
64. Lutz BS, Klauke T, Dietrich FE: Late results after microvascular reconstruction of severe crush and avulsion injuries of the upper extremity. *J Reconstr Microsurg* 13:423–429, 1997.
65. Mackinnon SE, Dellon AL: Soft tissue expanders in hand reconstruction. *J Hand Surg [Br]* 12:73–77, 1987.
66. Mackinnon SE, Dellon AL: Clinical nerve reconstruction with a bioabsorbable polyglycolic acid tube. *Plast Reconstr Surg* 85:419–424, 1990.
67. Manson PN, Anthenelli RM, Im MJ, et al: The role of oxygen-free radicals in ischemic tissue injury in island skin flaps. *Ann Surg* 198:87–90, 1983.
68. Matev IB: *Reconstructive surgery of the thumb*, Essex, England, 1983, Pilgrims Press.
69. Mathes SJ, Nahai F: Selection of the muscle and musculocutaneous flap in reconstructive surgery. In Mathes SJ, Nahai F, editors: *Clinical application for muscle and musculocutaneous flaps*, St. Louis, 1982, CV Mosby, pp 3–15.
70. McCord JM: Oxygen-derived free radicals in postischemic tissue injury. *N Engl J Med* 312:159–163, 1985.
71. McHenry TP, Holcomb JB, Aoki N, et al: Fractures with major vascular injuries from gunshot wounds: implications of surgical sequence. *J Trauma* 53:717–721, 2002.
72. McKittrick LS, Wheelock FC, Jr: The routine use of antibiotics in elective abdominal surgery. *Surg Gynecol Obstet* 99:376–377, 1954.
73. Meyer TM: Psychological aspects of mutilating hand injuries. *Hand Clin* 19:41–43, 2003.
74. Moran SL, Berger RA: Biomechanics and hand trauma: what you need. *Hand Clin* 19:17–31, 2003.
75. Moran SL, Strickland J, Shin AY: Upper-extremity mucormycosis infections in immunocompetent patients. *J Hand Surg* 31(7):1201–1205, 2006.
76. Murray JF, Carman W, MacKenzie JK: Transmetacarpal amputation of the index finger: a clinical assessment of hand strength and complications. *J Hand Surg [Am]* 2:471–481, 1977.
77. Neumeister MW, Brown RE: Mutilating hand injuries: principles and management. *Hand Clin* 19:1–15, v, 2003.
78. Nunley JA, Koman LA, Urbaniak JR: Arterial shunting as an adjunct to major limb revascularization. *Ann Surg* 3:271–273, 1981.
79. O'Shaughnessy KD, Rawlani V, Hijjawi JB, et al: Oblique pedicled paraumbilical perforator-based flap for reconstruction of complex proximal and mid-forearm defects: A report of two cases. *J Hand Surg* 35(7):1105–1110, 2010.
80. Ouellette EA, Freeland AE: Use of the minicondylar plate in metacarpal and phalangeal fractures. *Clin Orthop Relat Res* 327:38–46, 1996.
81. Palmer AK, Werner FW, Murphy D, et al: Functional wrist motion: a biomechanical study. *J Hand Surg [Am]* 10:39–46, 1985.
82. Peacock EE, Jr, Van Winkle W, Jr: *Surgery and biology of wound repair*, Philadelphia, 1970, WB Saunders.
83. Peacock EE, Jr, Van Winkle W, Jr: Repair of tendons and restoration of gliding function. In Peacock EE, Jr, Van Winkle W, Jr, editors: *Wound repair*, ed 2, Philadelphia, 1976, WB Saunders, pp 367–370.
84. Peacock K, Tsai TM: Comparison of functional results of replantation versus prosthesis in a patient with bilateral arm amputation. *Clin Orthop Relat Res* 214:153–159, 1987.
85. Pederson WC, Stevanovic M, Zalvras CL, et al: Reconstructive surgery: extensive injuries to the upper limb. In Mathes SJ, Hentz VR, editors: *Plastic surgery*, Philadelphia, 2006, Elsevier, pp 317–349.
86. Pirela-Cruz MA, Machen MS, Esquivel D: Management of large soft-tissue wounds with negative pressure therapy—lessons learned from the war zone. *J Hand Ther* 21:196–202, quiz 203, 2008.
87. Poole GV, Agnew SG, Griswold JA, et al: The mangled lower extremity: can salvage be predicted? *Am Surg* 60:50–55, 1994.
88. Pshenisnov K, Minachenko V, Sidorov V, et al: The use of island and free flaps in crush avulsion and degloving hand injuries. *J Hand Surg [Am]* 19:1032–1037, 1994.
89. Quaba AA, Elliot D, Sommerlad BC: Long-term hand function without long finger extensors: a clinical study. *J Hand Surg [Br]* 13:66–71, 1988.
90. Ross SE: *Prophylaxis against tetanus in wound management*, Chicago, 1995, American College of Surgeons Committee on Trauma.
91. Rothkopf DM, Chu B, Gonzalez F, et al: Radial and ulnar artery repairs: assessing patency rates with color Doppler ultrasonographic imaging. *J Hand Surg [Am]* 18:626–628, 1993.
92. Russell RC, Bueno RA, Jr, Wu TY: Secondary procedures following mutilating hand injuries. *Hand Clin* 19:149–163, 2003.
93. Scheker LR, Langley SJ, Martin DL, et al: Primary extensor tendon reconstruction in dorsal hand defects requiring free flaps. *J Hand Surg [Br]* 18:568–575, 1993.
94. Suprock MD, Hood JM, Lubahn JD: Role of antibiotics in open fractures of the finger. *J Hand Surg [Am]* 15:761–764, 1990.
95. Swanson TV, Szabo RM, Anderson DD: Open hand fractures: prognosis and classification. *J Hand Surg [Am]* 16:101–107, 1991.
96. Togawa S, Yamami N, Nakayama H, et al: The validity of the mangled extremity severity score in the assessment of upper limb injuries. *J Bone Joint Surg Br* 87(11):1516–1519, 2005.
97. Trumble TE: Physiology and repair of peripheral nerves. In Trumble TE, editor: *Principles of hand surgery and hand therapy*, Philadelphia, 2000, WB Saunders, pp 279–296.
98. Tubiana R, Thomine J, Mackin E: Movements of the hand and wrist. In Tubiana R, Thomine J, Mackin E, editors: *Examination of the hand and wrist*, St. Louis, 1996, CV Mosby, pp 40–125.
99. Uhl RL: Salvage of extensor tendon function with tenolysis and joint release. *Hand Clin* 11:461–470, 1995.
100. Urbaniak JR, Seaber AV, Chen LE: Assessment of ischemia and reperfusion injury. *Clin Orthop Relat Res* 334:30–36, 1997.
101. Vedder NB: Flap physiology. In Mathes SJ, Hentz VR, editors: *Textbook of plastic surgery*, Philadelphia, 2006, Elsevier.

102. Vedder NB, Bucky LP, Richey NL, et al: Improved survival rates of random flaps in rabbits with a monoclonal antibody that blocks leukocyte adherence. *Plast Reconstr Surg* 93:1035–1040, 1994.
103. Vedder NB, Winn RK, Rice CL, et al: Inhibition of leukocyte adherence by anti-CD18 monoclonal antibody attenuates reperfusion injury in the rabbit ear. *Proc Natl Acad Sci USA* 87:2643–2646, 1990.
104. Watts AM, Greenstock M, Cole RP: Outcome following the rehabilitation of hand trauma patients. The importance of a subjective functional assessment. *J Hand Surg [Br]* 23:485–489, 1998.
105. Weber RA, Breidenbach WC, Brown RE, et al: A randomized prospective study of polyglycolic acid conduits for digital nerve reconstruction in humans. *Plast Reconstr Surg* 106:1036–1045, discussion 1046–1048, 2000.
106. Wei FC, Chang YL, Chen HC, et al: Three successful digital replantations in a patient after 84, 86, and 94 hours of cold ischemia time. *Plast Reconstr Surg* 82:346–350, 1988.
107. Weinzweig J, Weinzweig N: The "Tic-Tac-Toe" classification system for mutilating injuries of the hand. *Plastic Reconstr Surg* 100(5):1200–1211, 1997.
108. White WL: Why I hate the index finger. *Orthop Rev* 6:23, 1980.

44

Nonmicrosurgical Coverage of the Upper Extremity

William C. Pederson

Acknowledgment: This section on skin grafts was originally a chapter written by Dr. Earl Browne, and much of his writing remains.

SKIN GRAFTING

The skin is the largest organ of the body and serves a number of vital functions. It functions as a semipermeable membrane and a barrier to toxic material and microbes, but it also contributes to homeostasis through temperature regulation and sensibility. This latter function—perception of stimuli—is most important in the hand, especially on the palmar surfaces of the fingers.

All skin is composed of a thick layer of dermis covered by epidermis. The epidermis constitutes only about 5% of the thickness of the skin, and the thickness varies considerably depending on the area of the body.[3] The skin on the palm and back is quite thick, whereas the skin of the inner arms and thighs is relatively thin. The quality of skin depends to a great extent on the epidermal appendages contained in the dermis, which also vary a great deal from area to area. This is especially true for the skin of the palmar and plantar areas, which contains no hair or sebaceous glands but is the almost exclusive domain of the Meissner and Vater-Pacini sensory end organs.[9] It is reasonable to think of the epidermis as the barrier and the dermis as the functional portion of the skin.

One must also consider the hand as an organ and think of the skin as an envelope enclosing a multitude of tendons, nerves, vessels, bones, and joints. For the hand to function properly, this skin envelope must be elastic and nonadherent, contain as many of the appropriate appendages as possible, and be large enough to allow freedom of motion. The palm skin must also be thick enough to withstand the pressure and friction caused by grasp and pinch.

When considering the replacement of hand skin, as is done in skin grafting, one must keep these principles in mind. It is convenient to divide the hand into dorsal and volar surfaces, each having different basic requisites. Dorsal skin must be thinner, more elastic, and loose enough to not restrict flexion and must serve as a barrier to cover tendons and joints. Volar skin must be thicker and tougher while still being loose and elastic enough to allow motion, but above all it must retain its function of sensibility. It is often possible to adequately replace dorsal skin by grafting while this may not be possible with volar skin.

General Considerations in Skin Grafting

Histologic Findings of Skin

Figures 44.1 and 44.2 depict the major differences between dorsal and palmar hand skin. Common to both is the irregularity of the border between the basal layer of the epidermis and the dermis, at the juncture of which are located the dermal papillae and the epidermal rete ridges. Both also contain intraepidermal nerve endings terminating in Merkel cell/neurite complexes and sweat ducts extending out from glands located in the base of the dermis and subcutaneous fat. A network of blood vessels and sensory and autonomic nerve fibers in the dermis is shared by all skin.

Figure 44.1 depicts dorsal hand skin, which is similar to skin found anywhere else on the body. The basal layer of the epidermis is continuous with the hair sheaths and sebaceous glands. Hair follicles lie at different depths and are surrounded by a network of fine nerve endings.

Figure 44.2 depicts the palmar hand skin. The papillae and ridges are deeper and the keratin layer is considerably thicker than in dorsal hand skin. Most significant, however, are the absence of pilosebaceous structures and the presence of specialized encapsulated nerve endings. Meissner corpuscles are present in dermal papillae, and Vater-Pacini corpuscles are present in the deep dermis. These latter structures are also found along nerve trunks, joints, and other areas but exist in the skin almost exclusively in digits and the genital area.

Substitution by Skin Grafts

Because it is similar to the skin of most other areas, dorsal hand skin can usually be adequately replaced by a skin graft. No matter how thick the graft is, however, palmar skin cannot always be fully substituted by ordinary grafts because the special dermal neural mechanoreceptors will be absent. Only glabrous skin will provide these, and, unfortunately, not much of this type of skin is available for grafting.

When a split-thickness graft is removed, healing of the donor area occurs by epithelialization from hair follicles and very little dermal regeneration occurs. The deeper the graft, the better the quality of the skin, but the less there is left behind at the donor site to aid in healing. Also, a deeper graft increases the chance of reinnervation of Merkel complexes and restoration of sensibility in the recipient site.[106] Thick nonglabrous grafts will transfer hair follicles, however, and result in unwanted hair growth if placed on palmar surfaces.[112] In addition to poor

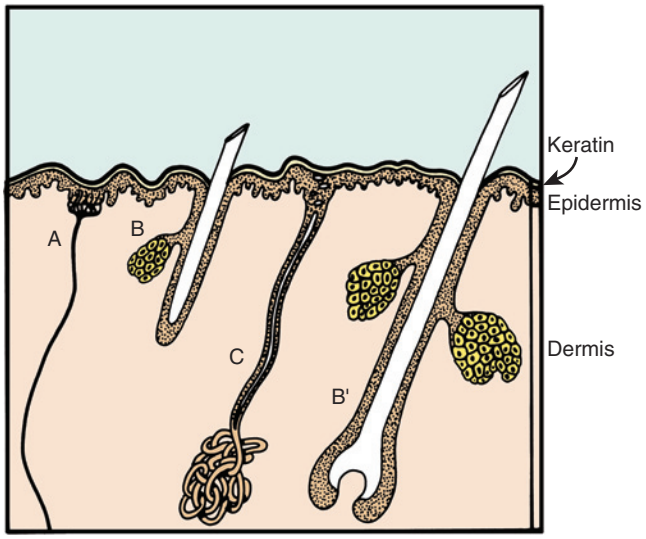

FIGURE 44.1 Dorsal hand skin is similar to skin of the rest of the body in that it has hair and sebaceous glands. **A,** Merkel's cell/neurite complex. **B** and **B′,** Hair follicle and sebaceous apparatus. **C,** Sweat gland.

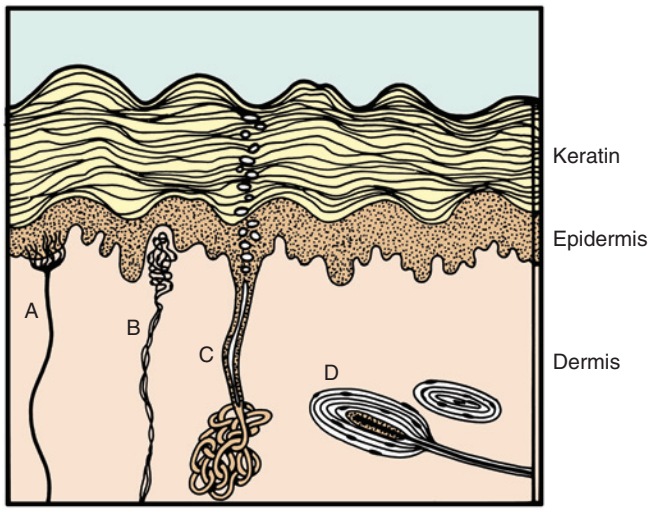

FIGURE 44.2 Palmar hand skin. There are no pilosebaceous structures present. Meissner and pacinian corpuscles exist almost exclusively here. **A,** Meikel cell/neurite complex. **B,** Meissner corpuscle. **C,** Sweat gland. **D,** Vater-Pacini corpuscle.

return of sensibility, grafts on palmar areas do not provide the vascularized subcutaneous tissue necessary to cover tendons and nerves. In general, palmar grafts should be considered a compromise and are usually only indicated in release of flexion contractures in areas not requiring critical sensibility.

Response to Injury

Any injury that results in the loss of a full-thickness segment of skin initiates the process of wound contraction. Although beneficial in helping to minimize defects in other parts of the body, this process of gradual shrinking of the wound edges can be disastrous in hand wounds (Figure 44.3). It appears that fibroblasts migrate into the base of the wound and differentiate into so-called myofibroblasts.[4] These cells have the ability to contract, and the network of these cells and collagen fibers that



FIGURE 44.3 The end result of scar contracture due to severe burn to the hand.

forms in the base of the wound is responsible for pulling the wound edges together. It has been shown that contraction can be temporarily halted by treatment of the wound with smooth muscle relaxants.[74] Once the contraction process has begun, it is not altered to any extent by split-thickness skin grafting.[25]

In a series of experiments by Stone and Madden, wounds in animals were treated with immediate grafting, delayed grafting, and immediate and delayed grafting with splinting.[103] They concluded that immediate grafting with split-thickness skin did not significantly affect wound contraction. However, immediate grafting and splinting with a compressive dressing for 7 days did significantly inhibit wound contraction. On the other hand, delayed grafting had no effect on wound contraction no matter what adjunctive therapy was used. Splinting, although effective with immediate grafting, was ineffective in preventing contraction when used with delayed grafts.

It is generally believed that the condition of the wound is the main determinant in the result of skin grafting. Even full-thickness skin grafts can be found to contract if wound contraction has already begun. Rudolph has found that the application of split-thickness skin does not seem to have as much effect on the differentiation of fibroblasts into myofibroblasts as does a full-thickness graft.[92] He has shown in animal experiments that wounds mature much more rapidly after the application of full-thickness grafts than after split-thickness grafts. The amount of actin and fibronectin found in rat wounds that were allowed to heal secondarily was compared in wounds with split-thickness grafts and those with full-thickness grafts. The thicker the graft, the less matrix protein present, which correlated well with the extent of wound contraction that occurred.[111]

This is important in considering the source of a graft for palmar wounds. The Shriners Burn Institute has compared the results of split-thickness and full-thickness grafts for coverage of deep palmar burns. Normal range of motion was found in over half of the full-thickness group, and only a fourth needed reconstructive procedures. In contrast, normal range of motion was present in only a fourth of the split-thickness group, and two thirds required reconstructive procedures.[97]

Effect of Infection on Wound Healing

A great deal of bacteria is normally present on the skin. It has been estimated that about 1000 organisms per gram of tissue are normally present in hair follicles, crevices, and recesses of the skin. This number of organisms does not seem to have a negative effect on wound healing.[53] However, when contamination of the wound takes place, much higher levels are present. Surface bacteria, which can easily be removed, do not appear to be important in skin grafting if the wound is carefully prepared before surgery. On the other hand, penetration of the bed of the wound is of great significance.[44] It has been established that 10,000 organisms per gram of tissue is a fairly critical level of contamination.[58] Wounds that contain fewer organisms than this do not commonly become infected. In a series of skin grafts applied to contaminated wounds, Krizek and colleagues[53] have shown that no matter what technique was used to prepare the bed of the wound for grafting, a bacterial count of greater than 10,000 organisms resulted in a successful skin graft take of only 19%. If the count was less than 10,000 organisms, however, there was a 94% successful take.

Vascularity of the Wound

After application of a skin graft to the wound, the graft first survives in a precarious fashion, apparently nourished by transudate from the wound. This has been referred to as "plasmatic circulation."[18] It is imperative that the graft become vascularized for ultimate survival, however, and anything that acts as a barrier to this process will cause loss of the graft. The most potent of all barriers is blood, and hematoma will kill a graft even in the absence of infection.

The actual process of vascularization is not altogether clear, but it is certain that this process must begin within a few days if the graft is to survive. It appears that the most important process is the ingrowth of capillary buds into the skin graft from the edges of the wound and, more importantly, from the bed of the wound.[5] For this process to take place, there must be a vascularized bed containing the necessary fine network of capillaries from which budding will take place. Grafts will not take on denuded bone or tendon, and skin grafts are not satisfactory coverage for vital structures.

Timing of Grafting

From the previous discussion, it is obvious that the ideal time for grafting the wound is as soon as it is clean enough and after the fine network of vessels has been established. In this way, contamination of the wound and establishment of a large milieu of myofibroblasts are avoided. In general, immediate débridement and grafting are often possible, and no more than 2 or 3 days should be allowed to pass for the purpose of establishment of a good bed. The principle of allowing a healthy bed of granulation to develop is no longer considered correct, and it should be replaced with the concept of early grafting. The vacuum-assisted wound closure device may be helpful in promoting granulations in severe wounds and may aid in obtaining granulations over tendons and bone,[37] but its use in the hand should be limited to avoid the marked scarring often caused by the device and increasing stiffness.

Bacterial Content Determination. If it appears that the wound may be infected, determination of the bacterial content is necessary. Rather than rely on a wound swab to determine the presence of bacteria, which may yield a false-positive result, it is important to know whether the bed of the wound has become colonized with pathogenic bacteria. A useful method of determining this is by performing a wound biopsy. To do so, the surface of the wound is cleaned to prevent contamination, and a segment of tissue weighing about 1 g is removed. This can be done conveniently with a punch biopsy. A colony-count culture can be obtained from the biopsy material, or a more rapid determination can be made by crushing the tissue and examining it microscopically. It has been said that bacterial presence greater than 1 per high-power field roughly corresponds to a critical level of 10,000 organisms.[58]

Temporary Storage of Skin Grafts. At times the wound may not seem to be ideal to receive a graft because of infection, bleeding, or poor vascularity. It may be convenient to remove skin from the donor site at the time of surgery for wound preparation to avoid another round of anesthesia and operation. In this way, the skin can be stored while the wound is being prepared by dressing changes or periodic bedside débridement to reach an ideal state.

There are very convenient methods for storing such skin grafts if they are removed. One is simply to replace the skin on the donor site from which it was removed. The graft will begin to "take" and will remain well nourished and viable. If this technique is used, it is necessary to remove the graft before significant tensile strength has occurred, which is usually before about 5 or 6 days after harvest. This may be done by injecting a solution of saline and local anesthetic between the graft and the donor site, and the graft can be placed on the recipient site at the bedside.[98]

Another technique is to store the skin graft in tissue culture medium during this interval. A common practice is to wrap the skin graft in a saline-soaked sponge and store it in the refrigerator. This is effective for a few days, but seldom can the graft remain viable for more than a week. It has been shown that by storing the graft in tissue culture medium with various additives, the viability of the graft can be markedly prolonged. Hurst and associates have demonstrated that the use of McCoy 5-A medium containing amino acids and vitamins can allow skin grafts to be stored successfully for up to 30 days.[40] The method of preparing the medium and storage of the grafts is described in detail in their article. This is an excellent method for 10 days to 2 weeks, but after that time the quality of the skin does not seem to be as good as the quality of a freshly harvested graft.

Types of Grafts

The two primary types of skin graft are split-thickness and full-thickness grafts. While other differences were discussed earlier, the main clinical difference in these grafts is in the way in which they are harvested. Split-thickness skin grafts are harvested with a knife or dermatome, and only the superficial layer of the skin is taken. The donor site of a split-thickness graft will heal on its own from propagation of epithelial cells from the deeper skin appendages (hair follicles and sweat glands). Full-thickness grafts are harvested with an incision with a knife and involve taking the entire layer of skin down to the subcutaneous fat. These donor sites must be closed as with an incision; otherwise the patient is left with a wound.

The standard thickness for harvesting split-thickness skin grafts is in the range of 0.015-inch thick. Split-thickness skin

grafts may be taken as either "thin" grafts (0.008 to 0.010 inch) or "thick" grafts (0.016 to 0.020 inch). Thicker split grafts have the theoretical advantage of potentially less contraction, because they contain more dermis. The downside of these types of grafts is that the donor site may have difficulty healing, and this can lead to worse scarring. One prospective study of the differences between standard and "thick" split grafts in the hand found no advantages in terms of range of motion, appearance, or patient satisfaction.[67]

Although it is true that full-thickness grafts afford better protection, hold up better, establish better sensibility, contain more epidermal appendages, and contract less than split-thickness grafts, thick grafts are not always desirable. There are several disadvantages to thick grafts. Full-thickness grafts do not take as readily as split grafts. A full-thickness graft requires a much better bed on which to be placed, and the graft is more prone to infection.

In addition, the availability of skin must be considered. It is not always possible to sacrifice enough skin to afford the luxury of full-thickness grafting, and split-thickness grafts must often be substituted. In general, full-thickness grafts should be used only in situations in which the quality of the skin and the tendency to less contracture are crucial. As a rule, these conditions are necessary only on palmar skin grafts, and the greater level of return of sensibility is an added bonus under these circumstances. Full-thickness grafts have recently been shown to be superior to split-thickness grafts in coverage of palmar wounds extending onto the digits in a large series of children with burns.[13] Dorsal wounds can generally be treated very adequately with intermediate split-thickness grafts.

Skin Substitutes

There have been many attempts in recent years to develop skin substitutes. Autogenous epithelial cells have been cultured and placed on a variety of collagen matrices and used as skin grafts. These have been of great value in the treatment of massive burns, but the take of the graft is not equal to that of standard autografts and the quality is not predictable.[6,117] Cultured epithelial autografts remain extremely expensive and afford very poor coverage, particularly in the hand.

Work continues on the goal of providing skin coverage without the need for a donor site, particularly in terms of reconstruction of the dermal layer.[21,116] Several products now exist that provide a collagen matrix to act as a layer of dermis when placed on a vascularized wound.[27,113] The primary problem with these dermal substitutes is that they generally have to be applied 1 or 2 weeks before coverage with a split-thickness graft to allow for revascularization of the collagen matrix, thus necessitating two operations. Some authors have noted no statistically significant long-term difference in elasticity, scar contracture, and patient satisfaction in patients treated with dermal substitutes plus split-thickness skin grafts versus split-thickness skin grafts alone in the management of donor sites from radial forearm free flaps.[116] It should be noted that the time necessary for rehabilitation of the hand was significantly longer with the dermal substitutes, as the hand had to be immobilized while the dermal autograft became vascularized.

Recent reports have noted that dermal substitutes have few complications when utilized in the upper extremity and obviate the morbidity of a full-thickness skin graft donor site. One fairly large study found that placement of dermal substitute after contracture release was as effective as full-thickness grafting.[30] Other reports of smaller series of patients have shown the utility of this approach to avoid the need for a full-thickness graft in burns and wounds of the upper extremity.[27,49,113] Skin elasticity in patients managed with dermal substitutes and split-thickness skin grafts has been found to be close to normal in objective testing.[79] The issue remains, however, that the application of dermal substitutes in the hand necessitates a period of immobilization while the dermis becomes revascularized, and then a potential second period of immobilization while the split-graft heals. Coupled with the fact that the morbidity of most full-thickness skin graft donor sites is minimal, the utility of these materials in the hand remains in question in my mind.

Skin Thickness

When determining the thickness of a graft to be removed, the skin thickness of the donor area must be considered. Epidermis and dermis vary according to age and sex, as well as location. It is said that the epidermis ranges from 20 to 1400 μm in thickness and the dermis from 400 to 2500 μm.[3] When considering donor sites, however, there is only a practical range of 25 to 80 μm of epidermis and 500 to 1800 μm of dermis. In relation to dermatome settings, these values translate to 0.001 to 0.003 inch of epidermis and 0.020 to 0.070 inch of dermis.

In general, the epidermis is quite thin in infants and reaches a maximum thickness at puberty; it then becomes thinner with age until it is almost as thin in old age as it was during childhood. There is very little difference in epidermal thickness between sexes. The dermis, however, remains relatively thin in youth; it reaches its maximum thickness at about the fourth decade and subsequently becomes thin again in old age. There is a marked difference between sexes, with male dermis being significantly thicker than female dermis.

The skin of the trunk and dorsal and lateral surfaces of the extremities is the thickest. Skin thickness may range from 0.020 to 0.025 inch in a small child to 0.100 inch on the anterior of the abdomen in an adult man. In general, most donor sites cannot be expected to be much thicker than about 0.060 inch in a man and about 0.040 inch in a woman.

Split-Thickness Grafting

Choice of Donor Sites

Removal of a skin graft is a morbid procedure. Although regeneration of the epidermis will occur, it appears that loss of the dermis is irretrievable.[95] The thicker the skin graft, the poorer the quality of the donor site after healing. Therefore, the thickness of the desired graft must, to a certain extent, determine the location of the donor site. The thicker portions of the body, such as the posterolateral aspects of the trunk and thighs, afford the best chance of good healing when a thick graft is desired. The thinner areas, such as the inner aspect of the thigh, are generally unsuitable for donor sites (unless they are absolutely necessary) because of the poor quality of healing of the donor site and the tendency of the skin graft to become hyperpigmented in its new area. So that morbidity and subsequent scarring are prevented, a reasonable guideline for graft thickness is offered in Table 44.1.

The optimal thickness for split-thickness grafts is 0.015 inch in thickness. Thinner grafts of 0.010 to 0.012 inch may be best

TABLE 44.1 Guidelines for Appropriate Thickness of Skin Grafts

Patient	Thickness of Graft
Infants	Never over 0.008 inch
Prepubertal children	If >0.010 inch necessary, remove from lower abdomen or buttocks
Adult males	0.015 inch from thighs, 0.018 inch from abdomen or buttocks
Adult females	Try never to use inner thigh; if >0.015 inch, use lower abdomen
Elderly adults	Treat like children's skin

for wounds where graft survival is at risk. Split grafts greater than 0.018 inch are seldom indicated because of donor site morbidity. If thicker skin is desired, it is best to use a full-thickness graft.

If possible, a graft should be taken from an area that is easy to care for during the healing process. No one likes to have to lie or sit on a donor site, and donor areas that cross intertriginous areas are very unsuitable because of the constant cracking and subsequent drainage with motion of the area. In women and children, it is desirable to remove the graft from the lateral aspect of the upper thigh or buttocks or perhaps the lower portion of the abdomen. These donor sites can be covered by a bathing suit or some other article of clothing. It is important to remember that the thicker the skin graft, the larger the number of hair follicles that are transferred in the graft; thus whenever possible, a relatively hairless area should be selected as a donor site for the hand.[112]

Harvesting Skin Grafts

A very small piece of skin can be removed with a No. 10 knife blade by dissecting superficially just under the surface of the skin. It is convenient to make a very shallow incision in skin that has been distended with intradermal lidocaine before beginning the tangential dissection. In this way the appropriate depth and width of the graft can be selected. The blade is then placed into the depth of the incision, and with a back-and-forth sawing action, parallel to the skin, the desired size of graft can be removed. It is possible to remove a reasonably uniform piece of skin up to about the size of a dime with this technique, but the procedure is difficult for a surgeon without some experience.

A much more satisfactory method of taking a small skin graft is with the Weck-Goulian knife set. There are a number of depth gauges available that can be fitted over the blade (Figure 44.4). These gauges vary in thickness from 0.004 to 0.030 inch. By placing the gauge next to the skin, the appropriate depth and angle of cut are automatically established. Because this instrument tends to take a rather thick graft, I prefer to use the 0.010 guard, avoiding excessive thickness. A strip of skin 2 cm or so in width can easily be removed, and with practice a long strip can be taken. This instrument has the advantage of removing a strip of skin of relatively uniform thickness.

Although it is very convenient to remove a split-thickness skin graft from the upper inner aspect of the forearm because it is in the operative field, this is, in practice, a very poor



FIGURE 44.4 The Weck-Goulian skin graft knife set before assembly. Depth gauges of many thicknesses make it possible to remove a graft of uniform thickness.



FIGURE 44.5 The Padgett gas-turbine driven dermatome. Guards are shown on the lower left with variable openings to control the width of the graft. The blade is seen loaded on the device.

procedure. The skin of the forearm is relatively thin in this area, and often the scar will become hypertrophic. These scars are very obvious to both patients and casual observers, and often women will complain more of the donor site scar than the recipient area scar. It is preferable to remove these grafts from areas of thicker skin, where the scar will not be so readily apparent.

Dermatomes

Padgett Dermatome. The Padgett dermatome is a motorized dermatome (via electricity or nitrogen turbine) and uses a disposable blade that cuts with a very rapid back-and-forth motion. There is a depth gauge on the side of this instrument with which the surgeon can set the desired depth of the graft. Variable-sized plates determine the width of the graft taken (Figure 44.5). After determination of the desired width, the blade is fitted on the machine and the appropriate plate placed over the two screws and screwed down tightly. To put the blade on, it is necessary to first slip the base of the blade under the two projecting metal pieces and snap it down so that the hole in the blade fits onto the projection of the drive shaft. The appropriate graft thickness is selected by moving the blade up and down by using the depth gauge on the side of the machine. The depth of the graft taken is also determined by the pressure applied to the device on the skin and the angle of attack of the blade against the skin.

The skin is surgically prepped and cleansed with saline before taking the graft. The skin should be lubricated so that the dermatome will slide easily and not skip. Either mineral oil or a surgical soap solution can be used for this purpose and is placed both on the skin and on the flat surface of the instrument

that is in contact with the skin. The dermatome is placed flat on the donor site, and traction is held behind the dermatome. It is not necessary to stretch the skin in the direction in which the dermatome will be advanced. It is easy to remove a piece of skin with this dermatome, and very minimal pressure should be exerted on the donor area. A common mistake is to dig the edges of the dermatome into the skin and press too hard, which creates an improper cutting angle. As the dermatome is advanced, the skin may be lifted up to check the thickness, if desired. This is not necessary, however, and in general, a very uniform piece of skin is removed with the Padgett dermatome. This is probably the best instrument to use to take a skin graft if one is not experienced in this area.

Zimmer Air Dermatome. A similar instrument has been produced by Zimmer and is used in the same fashion as the Padgett dermatome. A special disposable blade is made to fit the dermatome and snaps easily onto the reciprocating post. The width gauges are fitted in place and screwed down in the same fashion. The thickness of the graft is adjusted by a gauge on the side of the instrument in the same fashion as the Padgett dermatome, and the technique of skin harvest is identical. One must be careful in the setup of this instrument, however, because it has been reported (and I have personal experience) that this dermatome can cut down to muscle and cause serious injury if it has not been properly set up with the proper blade by the operating room personnel.[66]

Meshed Grafting

At times the condition of the wound cannot be made optimal for grafting. The risk of infection or hematoma may be so great that the chance of survival of a sheet of autograft would be small. In these instances, it is often wise to use a piece of skin that has been "meshed" so that many perforations are present through which blood or exudate can escape. An instrument has been devised that will automatically make these perforations. The skin can be expanded so that the interstices allow drainage and rapidly become epithelialized (Figure 44.6). This method of grafting has wide application in the treatment of burns and large wounds.[64]

It must be remembered, however, that only the portion of the wound that has skin applied to it is being grafted and the interstices of the mesh are left open and allowed to epithelialize. The quality of the graft will not be as good as that of a sheet of skin, and the tendency toward contraction and poor cosmetic results is greater. If meshed grafts of this nature are placed over flexion creases, joint contractures are likely to occur. These factors can be limited somewhat by compression, and it is imperative to treat wounds grafted in this fashion with long-term compression, such as can be obtained by use of a custom-fitted pressure glove.



FIGURE 44.6 A meshed split-thickness graft placed over an innervated gracilis muscle to the forearm.

CRITICAL POINTS *Split-Thickness Skin Grafting*

Indications
- Simple wound with good underlying soft tissue bed
- Marginal wound with plan for more complex reconstruction at a later time

Preoperative Evaluation
- Inspection of wound (for adequate vascularity); possibly, quantitative wound cultures

Pearls
- Avoid a graft that is too thick.
- Small grafts may be taken with a freehand knife or Weck dermatome.
- Mesh or "pie-crust" graft to avoid fluid collection underneath

Technical Points
- Recipient site should be very clean and débrided back to viable tissue everywhere.
- Avoid air or fluid pockets underneath graft (mesh or pie-crust graft).
- Graft must be held in place well to avoid moving against the wound bed.
- Avoid removing the dressing for at least:
  - Three days if there is a question of wound cleanliness
  - Five to 7 days if the wound is very clean
- Place a bolster for graft in a concave surface.

Pitfalls
- Early infection (usually *Streptococcus* or *Pseudomonas*) that destroys the graft
- Early motion that keeps the graft from adhering

Postoperative Care
- Immobilize for at least 2 weeks.
- Change the dressing if signs of drainage, etc., are present.
- Avoid any shearing force on the graft for a minimum of 3 weeks.

Expected Outcomes
- Skin graft will not match surrounding skin in terms of color and texture.
- Split-thickness skin graft should afford stable coverage.
- Donor site morbidity is minimal over the long term; however, donor site scarring can be conspicuous.

Although they were not specifically evaluating hand grafts, el Hadidy and colleagues evaluated the results of meshed versus nonmeshed grafts in burns.[25] As expected, the results of either graft in late excision were significantly worse than the results in early excision, but the meshed grafts contracted more in both groups. In addition, there was a difference in the amount of growth that occurred in the two groups. With early excision, nonmeshed grafts grew back to a size of 91% as compared with 78.5% in the meshed group.

Meshed grafts are often placed on a wound without the graft "expanded," which prevents collection of fluid under the graft

but avoids the necessity for skin to grow over the open interstices. Whereas using a meshed graft in this way inevitably leads to more scarring than using a nonmeshed graft, the functional differences are usually minimal. The advantages of meshing a graft usually outweigh the disadvantages. Nonetheless, split-thickness skin grafts are usually reserved for coverage of the dorsum of the hand, whether meshed or not. When the dorsum of the hand is covered with a muscular or fascial flap, it is certainly acceptable to place an expanded meshed split-thickness graft over the flap. It is sometimes convenient to use a mesh graft as a "temporary" biologic dressing, however, until a later resurfacing procedure can be done as part of the reconstruction.

Preparation of a Meshed Graft. After the graft is taken, it is spread out onto the surface of a plastic carrier, which is provided with the dermatome (Figure 44.7). The "dermacarrier" plastic board has angled troughs cut into it that dictate how much the graft will expand. The various boards are marked and allow expansion from 1.5:1 to 9:1, but sizes larger than 1.5:1 have very large holes that are not practical for hand surgery. Grafts thicker than 0.015 inch in thickness will not feed well into the meshing machine, and thus grafts thicker than this do not mesh well. After the graft has been carefully spread out onto the surface of the carrier, it is fed into the lower end of the machine and run through the mesh by using the hand crank.

It is absolutely critical that the card be fed through the mesher with the grooved side up, however. If the skin is inadvertently placed on the wrong side of the mesh card and passed through the dermatome, the result will be multiple small strands of "linguini" that are unusable.



FIGURE 44.7 A, The mesher device with a "dermacarrier" board in front. **B,** Note oblique troughs in board that control size of mesh of graft.

Full-Thickness Grafts

Full-thickness grafts transfer all the skin appendages and nerve endings except the sweat glands located in the subcutaneous tissue and some of the Vater-Pacini corpuscles of the palmar and plantar skin. This thickness is an advantage for the restoration of sensibility and quality of coverage. These grafts must always be taken from relatively hairless areas to minimize subsequent hair growth in the recipient area. Good donor sites for this type of skin are in the lower and lateral abdominal areas. It is possible to obtain good-quality, relatively hairless skin here, and the area is loose enough to allow a large piece of skin to be removed with no subsequent defect after wound closure. Smaller pieces can be removed from the extremity being operated on, and this is often very convenient inasmuch as the area has been prepared along with the operative site. The medial upper arm offers a good choice for full-thickness grafts from the upper extremity, and large pieces of skin may be taken in older patients. If skin is harvested from the posteromedial aspect of the arm, the scar is usually not objectionable. The volar wrist crease and antecubital fossa are often described as good choices for full-thickness skin grafts, but these areas should be avoided owing to potential scarring. Scars on the volar wrist crease can also be interpreted as a sign of a prior suicide attempt. For coverage of the palmar surface of the fingers, glabrous full-thickness grafts may be taken from the hypothenar eminence. A fairly large graft can be taken from this area with minimal scarring and morbidity. In instances in which sensibility is critical, such as in the fingertips, a fairly large piece of "fingerprint" skin can be obtained from the hypothenar area (Figure 44.8). Small glabrous full-thickness grafts can also be taken from the lateral surface of the great toe. Glabrous full-thickness grafts have the added advantage of transferring skin of a more similar nature, that is, skin containing Meissner corpuscles, thereby potentially restoring better sensibility.

Most full-thickness grafts will be placed on the palmar aspect of the hand; however, the surgeon must remember that there is a marked difference in pigmentation of the palmar skin in black patients, and nonglabrous donor sites should be avoided if possible. In dark-skinned patients, full-thickness grafts for placement on the palmar fingers or in the palm should be taken from the hypothenar area of the hand or from the previously mentioned foot donor sites.

Technique of Obtaining a Full-Thickness Graft

After the appropriate size has been determined, an area for harvest of the full-thickness graft is marked. I prefer to infiltrate underneath this area with plain lidocaine or marcaine, which will elevate the skin somewhat and make harvesting easier (as well as provide some anesthesia in the postoperative period). Local anesthetic with epinephrine should be avoided as this has been reported to cause spasm in the capillary bed of the graft and lead to poor "take" of the graft. An ovoid of skin is excised from the predetermined area with the axis in the direction of minimal tension. The wound is closed in standard fashion. Most donor sites for hand coverage will be small, and primary closure can be performed easily without undermining of the edges.

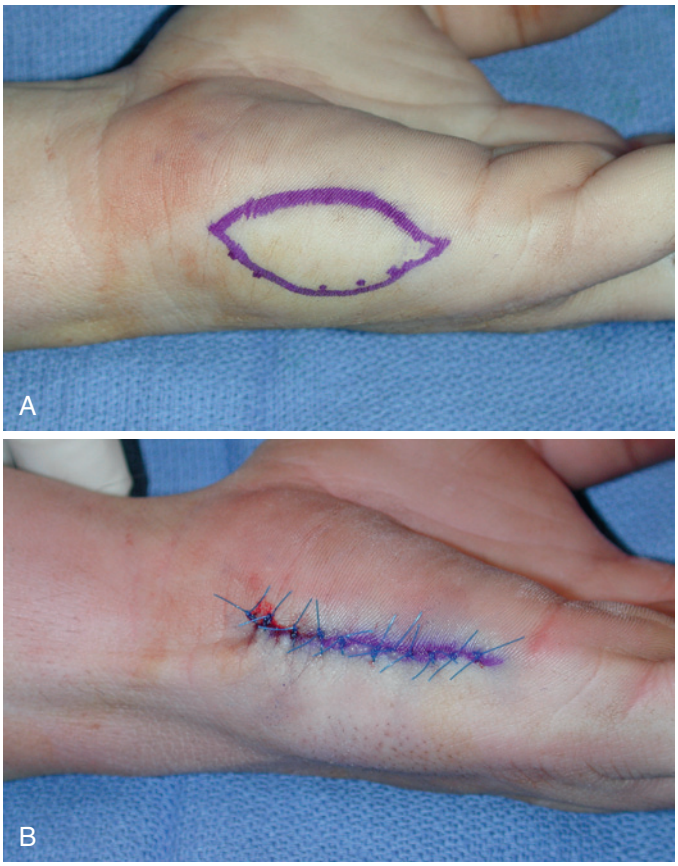

FIGURE 44.8 **A,** Full-thickness skin graft donor site marked on hypothenar area of hand. **B,** Donor site after primary closure, which can usually be performed easily.

Because there will be a moderate amount of tension on the edges, it is probably best to close the wound with buried subdermal sutures and a subcuticular suture to minimize the cross-hatching that might occur with ordinary cutaneous sutures. The wound can be dressed with sterile skin closure strips only.

It is necessary to remove all fat and subcutaneous tissue from the undersurface of the graft because they will otherwise act as a barrier and prevent vascularization. If desired, this can be done at the time of removal of the graft by very carefully excising only the skin and lifting it off its bed of subcutaneous tissue by dissecting sharply with a scalpel in the subdermal plane. The graft can be rolled over a finger as it is taken, and, with appropriate tension, most of the underlying subcutaneous fat can be removed. Once the graft is excised, the remaining subcutaneous tissue is removed. This is easily done by draping the graft around the surgeon's nondominant index finger while holding tension with the ends of the graft in the other fingers. The remaining fatty tissue is removed with a small curved pair of scissors. The normal tendency is to remove portions of the dermis as well, which can actually lead to creating a "thick" split-thickness graft and lead to more contracture. The final result in terms of quality of the graft will be better if the subdermal areolar tissue is left with the graft. The fat can also be removed by placing small mosquito hemostats on the very tips at each end of the graft and draping the skin over a finger or the thumb while keeping tension on both hemostats. If some tension is maintained, it is very easy to snip away the fat in this fashion.

CRITICAL POINTS *Full-Thickness Skin Grafts*

Indications
- Wounds with very good bed in an area where better coverage is desired
- Management of scar contraction in palmar surface

Preoperative Evaluation
- Wound bed vascularity
- Lack of infection in wound bed

Pearls
- Avoid grafts from wrist crease and antecubital fossa.
- Graft from medial upper arm or groin.
- Do not "defat" graft so much that it becomes a split-thickness graft.

Technical Points
- Place lidocaine (without epinephrine) under the skin to be taken first.
- Defat the skin graft as you elevate it.
- Take an ellipse that can be closed primarily at the donor site.
- Suture the graft into the defect exactly, trimming as necessary.
- Avoid straight suture lines along web spaces.
- Use a "tie-over" bolster for almost all full-thickness grafts.
- Leave in place with the extremity immobilized for at least 2 weeks.

Pitfalls
- Infection under grafts
- Motion of graft before revascularization
- Defatting graft too much and making it into a split-thickness graft

Postoperative Care
- Bolster and immobilize the graft for at least 2 weeks.
- Begin motion carefully.
- Consider compression garment/silicone sheeting early to prevent hypertrophy.

Expected Outcomes
- The full-thickness graft should have nearly normal texture and elasticity.
- The color of the full-thickness graft may match the recipient area; however, it may be darkly pigmented if a poor donor site is chosen.
- The donor site morbidity should be minimal because the scar will be a simple straight scar.

Choice of Graft

As previously indicated, a thicker graft contracts less, holds up better, and regains better sensibility than a thinner one. In general, split-thickness grafts should not be used on palmar surfaces of the hand unless there is no other choice or the coverage is considered to be temporary, with secondary resurfacing to be performed at a later date. If split-thickness grafts are to be used, they should be relatively thick and long-term compression with an elastic glove should be used.

Full-thickness grafts are seldom indicated on the dorsal surface of the hand. The need for coverage is not as critical on the dorsum, and split-thickness grafts are generally satisfactory. In addition, the convexity of the dorsum and the subsequent greater tension on the wound edges with motion in the postoperative period appear to allow split grafts to be used with less contraction than would be the case on the concave palmar aspect. The general rule is that a sheet of graft of good-quality skin approximately 0.015 inch thick, if placed on a well-vascularized bed early in the evolution of the wound, will heal

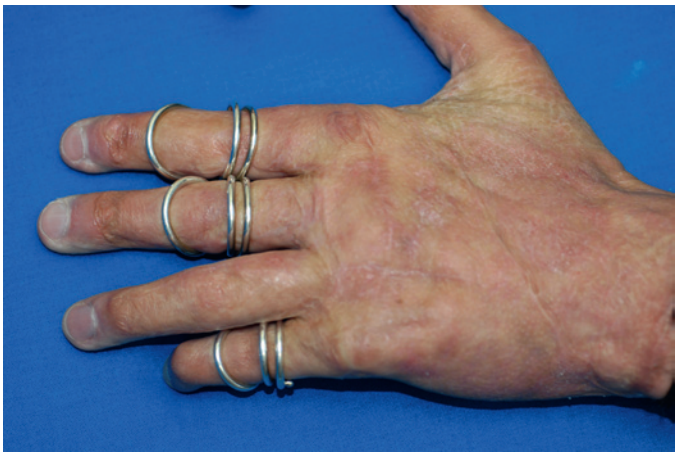

FIGURE 44.9 Hand of a patient who suffered burns of the hands and was treated with excision and primary split-thickness sheet grafting. Note quality of dorsal hand skin after placement of sheet graft.



FIGURE 44.10 Patient after full-thickness skin graft to release first web space contracture. Note "darts" in edges of graft when sewn in to decrease scar contracture along margin of graft.

so well that it is difficult for a casual observer to know that a graft has been done (Figure 44.9). If the bed is not ideal, it makes no difference what kind of graft is used, because the result will always be less than satisfactory. Large areas of bare tendon, bone denuded of periosteum, and nerves and vessels bowstringing in the wound should never be covered with a graft; in such instances, coverage should be obtained by the use of a flap (see later in this chapter). Very small areas of exposed tendon can sometimes be covered successfully with a full-thickness graft if the surrounding bed is good. This is due to the presence of the capillary bed in a full-thickness graft, which will allow vascularization of small areas of graft that are not over areas with adequate vascularity (assuming that the rest of the graft becomes vascularized).

Negative Pressure Wound Therapy

Negative pressure wound management (most usually the VAC device) has become a popular and effective treatment for open wounds.[39,109] It can be used as the sole method for wound closure in certain large wounds of the torso and extremities and has been found to be quite effective as a method of wound management. It has been shown experimentally to increase wound vascularity (possibly as an effect of the polyurethane sponge) and cell proliferation.[80,96] This technique can be easily used in the outpatient setting, and in fact makes it much easier for the patient to manage the wound in this setting. The primary downside of negative pressure wound management is the cost, as the equipment and use of home-health services are quite expensive. Some surgeons question whether this technique is superior to other methods of wound management because high-level evidence studies on it are few.[35,39] Nonetheless, it has some application in the hand and upper extremity. It can be used to prepare a wound bed for skin grafting because it promotes the growth of granulation tissue. It can actually promote granulations over nonvascularized bone and tendon in some instances, but this takes a somewhat lengthy application of the technique. Although it can occasionally be used to great benefit in the arm and forearm, it must be used with care in the hand in my opinion. It is certainly useful as a temporizing measure to manage a wound after or between débridements when preparing the wound for graft or flap coverage. It has been successfully applied to the management of digital pulp defects[2] and is also useful as a dressing if a dermal substitute is being used for wound closure.[57] There has been a report of using the VAC device as a "glove" in hand wounds and allowing motion during healing[78]; however, our experience has been that prolonged application of negative pressure therapy to the hand often leads to marked stiffness. VAC can be used as a very effective bolster for skin grafts (see below); however, it remains a very expensive option in this regard.

Filling the Defect With the Graft

In general, a graft on a convex surface can be placed on the wound with normal tension and held in place in whatever fashion is desired. The convexity will tend to hold the graft in place; by securing the graft to the edges of the defect, the tendency toward shearing will be minimal. One must always remember that the secret to grafting is the amount of dermis that is placed into the wound and that it is a mistake to stretch a graft too tightly for compression of the wound. This will result in thinning of the dermis by stretching, with less net dermis being grafted, which will lead to a poorer result. The graft itself will not cause pressure on the bed inasmuch as any amount of fluid will easily lift the graft up no matter how tightly it is stretched. Compression must come from external dressings. Any blood present under the graft should be irrigated out with saline.

Sheets of skin placed on the hand, whether split thickness or full thickness, should be carefully tailored to the defect. If the margin of the skin graft lies in a line that is likely to cause a scar contracture (particularly in the palm), darts should be made in the hand skin along this line and the graft fitted into these. These small darts break up the scar and can prevent a linear scar contracture from occurring later on (Figure 44.10).

Grafts on the dorsum of the hand may be held in place with sutures or skin staples. Meshed split-thickness grafts are usually easiest to hold down with metal skin staples. After closure is completed, the graft is covered with a compressive dressing and

splint. Meshed grafts should be kept moist and are usually covered with some type of nonadherent gauze that is then covered with moistened gauze. The gauze is soaked with a solution of antibiotic saline that is used for irrigation in the operating room. Many types of nonadherent dressings exist, and most contain some type of petroleum solution that is not water soluble.

Grafts placed on a concave surface must always be held securely in place. They will have a natural tendency to "tent" over the wound and float up off the wound as serum collects under them. One excellent method of preventing this is the use of a bolster or tie-over dressing. In this technique, grafts are placed into the concavity and sutured around the edges with strands of suture that are left long. After the completion of suturing, the graft is covered with some type of nonstick gauze and the concavity filled with wet cotton. The ends of the sutures are tied over the dressing to make a package that will hold the graft in place and prevent shearing, minimize serous accumulation, and optimally cause some pressure on the base of the wound (Figure 44.11). This is an especially good dressing for a full-thickness graft. This bolster dressing can be used anywhere desired, but its use is difficult on a convex surface because the sutures tend to pull the graft up from the edges of the defect. If it is believed that the graft needs to be examined early, rather than tying the sutures, they can be temporarily secured. One way of doing this is by passing the long ends of the thread through a shortened, disposable syringe cylinder and holding them in place in proper tension by then placing the piston back into the syringe cylinder. This allows the threads to be loosened and the dressing removed, replaced, and secured again by the syringe.



FIGURE 44.11 **A,** Finger after scar release and full-thickness skin graft to volar surface. Note irregular contour of graft to avoid scar contracture. **B,** Cotton bolster tied over graft.

A piece of soft foam also can be used as a skin graft dressing. A piece of nonadherent gauze is placed over the graft, a piece of foam is cut large enough to cover the gauze, and the foam is simply stapled down to the skin defect edges. This holds the graft and dressing in place without other sutures or dressings, provides compression and protection from shearing, and is quick and cost effective.

With full-thickness grafts in the hand, we prefer to tailor the graft to fit the defect exactly and then suture the margins in place with running 4-0 chromic sutures. The subgraft area is irrigated with a mixture of thrombin solution and antibiotic solution that is forced out by manual pressure on the graft. A bolster of nonadherent gauze covered with wet cotton balls is placed over the graft and held in place with several polypropylene sutures placed in the surrounding skin and tied over the cotton.

Many surgeons now use vacuum sponge devices to bolster skin grafts.[22] This technique has the advantage of removing exudates from the wound and is very effective in terms of holding the graft down while it is becoming revascularized. This technique has limited application in skin grafts in the hand, with the exception of large wounds.

Postoperative Care

There are two schools of thought in caring for skin grafts. Some surgeons like to look at the grafts within 24 hours so that if a hematoma is present, it can be evacuated. The other group says that doing this might disturb a graft that is getting along well and that a hematoma could be stirred up at that time. In addition, it is almost never possible to put on as good a dressing as the one put on at the time of surgery.

If it is anticipated that hematoma or seroma collection might be a problem, the dressing should be removed at 24 hours and the wound inspected periodically. If fluid collects under the graft, it should be evacuated by stabbing the graft with a No. 11 knife blade and gently rolling the graft with a cotton-tipped applicator to remove the fluid. Care should be taken to roll and not rub, because rubbing can cause shearing of the graft from the bed.

If there is really no reason to suspect that either of these problems will arise, the wound can be monitored just as any other wound would be. As long as there is no drainage, foul smell, fever, or other cause for concern, the splint and dressing can be left undisturbed for 7 to 10 days. After that, the dressing can be removed; and if healing appears to be satisfactory, early guarded motion may begin.

It must be remembered that a skin graft is just like any other wound; that is, there is very little tensile strength present until enough collagen deposition has occurred to cause the wound to be strong. Therefore, even though the graft may be well vascularized at this stage, it will be very prone to injury from shearing forces for another 10 days. If blisters develop, motion should be stopped and the graft adequately protected for a few more days.

Small areas of graft loss of several millimeters in diameter will generally fill in satisfactorily without excessive scarring, especially if compression with a support garment is used. Larger areas of loss should be débrided and regrafted. After the "take" is judged to be satisfactory, the grafts should be kept lubricated with a moisturizing lotion or cream.

Because an open wound continues to contract even after it is covered by a skin graft, there is always the concern of scar contracture limiting motion. The elastic compression garment has been the standard of aftercare of grafts to minimize this effect.[115] The principle of this technique is to provide sufficient compression to exceed capillary pressure to the graft and thus inhibit fibroblasts. To facilitate even pressure, a silicone insert is generally placed over the graft or scar under an elastic glove for the hand. More recently, it has been found that the use of silicone alone will inhibit scar formation, and the effect of mechanical pressure may not be the causative factor.[110] One of the easiest to use is silicone sheeting. Sil-K silicone sheeting (Degania Silicone, Israel) is one of the most applicable types for grafted skin. It is a thin, pliable membrane that can be cut to size and simply taped over the scar. This product, as opposed to gel, stays relatively clean and can be washed and used over and over again. The patient should use this material as much as possible, at the least sleeping every night with it taped in place. If use of silicone sheeting is begun shortly after the skin graft has been judged to have taken well, significant reduction in scarring can be achieved.

Care of the Donor Site

Full-thickness sites require no special care and should be treated like any other wound. Split-thickness grafting, however, is a moderately morbid event, and the patient should be told before grafting that the donor site will probably cause a great deal more discomfort than the grafted area.

A donor site is just like a skinned knee. The sooner it dries out and forms a scab, the quicker it will become asymptomatic. This obviously is a factor of depth inasmuch as a thinner graft will heal much more rapidly than a thick graft. If a thin scab forms on the surface of the donor site, it will generally separate in about 14 days.

There are many of ways of treating donor sites that involve the application of every known kind of dressing or medication. The longer it takes for the wound to become dry and the thicker the resultant eschar, however, the more morbidity the patient will suffer. Whatever technique leads to rapid drying of the donor site will usually result in the best healing. The "old" technique of leaving the donor site totally open probably works the best but can be quite painful in the immediate postoperative period. Many surgeons use an occlusive adherent plastic dressing to cover the split-graft donor site, but this technique suffers from fluid collection under the plastic and an increased risk of infection at the donor site. This approach has the advantage of decreasing pain in the postoperative period, but the benefits are outweighed by the potential problems.

The donor site is covered immediately with a single layer of fine-mesh gauze, which is sprayed with thrombin solution. This is covered with a warm, moistened sponge, which is left until the operation is over. At this time the sponge is removed, with the fine-mesh gauze left in place. There will usually be no further bleeding at this point unless the fine-mesh gauze is removed. The local area is cleansed, and an appropriately sized occlusive plastic dressing placed. The plastic is removed at 2 to 3 days and the fine-mesh gauze left in place to dry onto the wound. This area is dried out by the nursing staff or patient with a bare-bulb light or hair dryer. This approach makes use of the benefit of decreased pain at the donor site from the occlusive dressing for the first couple of days but allows the donor site to dry out before infection can become established. Once the donor site is dry, there is usually very little further pain. The scab formed with the fine-mesh gauze will usually separate in 2 to 3 weeks.

Outpatient Surgery

Traditionally, skin grafts have been done as inpatient procedures, with the patient kept at bed rest to protect the graft from bleeding and shear effect. In this new era of managed care, this will no longer be possible, so ways to perform quicker and less expensive surgery, preferably under local anesthesia, will be desirable.

One approach is to use lateral femoral cutaneous nerve block for anesthesia of the donor site. This nerve passes under the inguinal ligament and provides sensibility to most of the lateral side of the thigh, the perfect donor site. Enough skin can easily be obtained with this block to surface the entire dorsum of the hand. There is some variability in the course of the nerve, but with practice it can almost always be blocked. The usual landmark is two fingertips inferior and two fingertips medial to the anterior superior iliac spine in the average adult. About 10 mL or so of anesthetic should be injected in a fanlike fashion while making sure to place half of it deep to the underlying fascia lata. No infiltration of the skin of the thigh is necessary, which makes harvesting of a large graft much less morbid. Also, if a longer-lasting anesthetic agent is used, the patient has no trouble getting up and walking out.

Although the Unna boot dressing was developed to heal leg ulcers by compression and the drying action of the paste, those same properties make it an ideal support for skin grafts. The Medicopaste bandage (Graham Field, Inc., Hauppauge, NY) can be rolled right over a skin graft to keep it compressed in a bacteriostatic environment. The dressing can be left on for a long time to maintain compression and is, of course, ideal for a graft on an edematous leg because it allows early mobilization. Sanford and Gore, however, have reported the use of this dressing to facilitate outpatient skin grafting of hands.[94] Sixteen burned hands were treated by outpatient débridement, skin grafting, and Unna boot dressing. When the patients returned on the fifth postoperative day, there was 95% "take" of all grafts, with no infections. This allowed the shifting of fairly extensive débridement and skin grafting to the outpatient setting.

Acknowledgment: This section was originally written by Dr. Graham Lister, and much of his contribution remains because of his ability to convey concepts in a clear manner. We also thank Danny Smith, formerly of Louisville and now of Salt Lake City, and Grace von Drasek Ascher, medical illustrator of Louisville Hand Surgery, for their hours of work on the figures in this section of the chapter. The copyright for much of the artwork is held by Louisville Hand Surgery, which we thank for permission to publish it here.

LOCAL AND REGIONAL FLAP COVERAGE OF THE HAND

Because scarring limits the motion that is essential for function in many areas of the upper extremity, every effort must be made to achieve primary wound healing to avoid healing by secondary intention, which involves significant scar formation. Skin defects that are the result of injury or surgery should be closed directly or covered with imported skin. In certain situations, free skin grafts will suffice. In others, free grafts may not "take" or may, by their necessary adhesion to underlying tissue, be unsuitable. "Take" of a skin graft requires that the bed on which it is placed have a blood supply adequate to revascularize the free graft. This blood supply is not present when bare bone, cartilage, or tendon is exposed in the wound. "Take" requires firm adhesion of the graft. This is not acceptable when further surgery is planned beneath the new skin cover (e.g., when tendon grafts will be necessary after an avulsion injury of the dorsum of the hand). It is also not suitable where the firm adhesion of the graft prevents mobility of the skin envelope over underlying structures (e.g., where a graft on a fingertip is adherent to bone). Shear forces applied in daily use will cause intermittent avascularity of the skin and eventual breakdown. A similar mechanism of breakdown may occur when grafts have been placed over the convex aspect of joints. Flexion renders the graft taut and avascular; this situation, along with normal trauma, results in ulceration. To a degree that is inversely proportional to its content of dermis, a free skin graft will contract during the first 6 months after its application; the extent of contraction depends on the location. Thus, on the dorsum of the hand, which is subjected to repeated stretching by normal use, less contracture occurs than on the flexion aspect of a joint. In the latter location, only full-thickness grafts with perfect "take" are suitable. In any circumstances in which free grafts do not provide the best skin, flap coverage is indicated.

Types of Flaps

A *flap* is skin with a varying amount of underlying tissue that is used to cover a defect and that receives its blood supply from a source other than the tissue on which it is laid. The part of the flap that provides the blood supply is termed the *pedicle.* A *graft* is a piece of tissue that does not have an intrinsic blood supply and must be revascularized by the underlying tissue bed. Table 44.2 lists the various flaps discussed in this chapter.

TABLE 44.2 Types of Flaps

Type of Flap	Random Flaps	Axial Flaps
Local	Transposition	Axial flag
		FDMA
		SDMA
	Rhomboid	Reversed dorsal metacarpal
		"V-Y" (Moberg) advancement
		Rectangular advancement
Regional		Cross-finger
		Neurovascular island
		Fillet
		Scapular
		Forearm
		Reversed posterior interosseous artery
		Latissimus
Distant		Groin

FDMA, First dorsal metacarpal artery; *SDMA,* second dorsal metacarpal artery.

Random-Pattern Flaps

The manner in which the skin receives its blood supply has been studied by many anatomists. Lamberty and Cormack[55] described angiotomes in the upper limb, these being areas of skin with a known single arterial supply. The constancy of these arteries has been confirmed by Doppler studies in patients and volunteers. Taylor et al[105] studied the venosomes and reported that venous territories correspond closely to recognized areas of arterial supply. The blood supply of a flap may come not from a single arteriovenous pedicle but from the many minute vessels of the subdermal or subcutaneous plexus. Such a flap is termed a *random-pattern flap.* Although the shape of a random-pattern flap need not be quadrilateral, it is usually conceived as such, and it is raised by incising three of the four sides. The fourth constitutes the pedicle, or base, of the flap. The side opposite the base is called the free margin. Because the adequacy of the subdermal plexus varies from location to location, the area of skin that can be supported by the vessels of the pedicle also varies. As a general rule, a random-pattern flap with a length not exceeding the width of the pedicle—in other words, a rhomboid—is considered to be reliable with respect to blood supply. This is the one-to-one (1:1) rule. It does not always apply, however. For example, it is too cautious for the face (and usually the hand) and too bold for the foot. Observation of this rule and the need to protect the pedicle from undue distortion that would impair blood flow through the subdermal plexus clearly limit the range of applications for the random-pattern flap.

The relatively inadequate blood supply of a random-pattern flap may be enhanced by a "delay" procedure[71] and will often allow a flap larger than the 1:1 rule to be rotated. In a delay procedure, the margins of the flap are incised, but it is not lifted off the underlying tissue and the incisions are sutured. This causes enhancement of the vascularity via the pedicle by interrupting that blood supply to the skin of the flap through the incised margins. The optimal time of delay has been shown to be around 10 days. During that time, both arteries and veins that were random become enlarged and oriented parallel to the axis of the pedicle. They are therefore better able to support the flap when it is transferred.

Axial-Pattern Flaps

When a flap receives its blood supply from a single, constant vessel, it is termed an *axial-pattern flap.* Such a single vessel is materially larger than the vessels of the subdermal plexus. For example, the superficial circumflex iliac artery that supplies the groin flap (see following description) has an average diameter of 2 mm, or five times that of the largest subdermal vessel. Although Poiseuille's law of flow in rigid tubes cannot be applied precisely to blood vessels, it indicates that flow would be approximately 625 times greater through the axial vessel of the groin flap than through a subdermal vessel. The area of skin supplied by such an axial vessel is termed a *vascular territory.*

The area where the vascular territories of two axial pedicles meet is termed a *watershed,* and the small arteries that cross it, *choke vessels*. In these areas, veins have no valves and can be said to allow blood to oscillate between territories. Occlusion of one of the two pedicles results in a shift of the watershed toward the site of occlusion, extending the vascular territory of the other, open pedicle. In raising an axial-pattern flap, it is safe to increase the length of the flap beyond the known vascular territory by the amount that would constitute a random-pattern flap. That is, a safe axial-pattern flap equals the normal vascular territory of the flap with a 1 : 1 extension on the distal portion of the flap.

The vessel of an axial-pattern flap may be purely cutaneous (Figure 44.12, *A*), supplying skin alone and proceeding directly to it. The superficial circumflex iliac artery to the groin flap is such a vessel. In reaching its cutaneous territory, the axial vessel may first supply fascia. In such circumstances, the vessel commonly reaches the fascia by running in an intermuscular septum. Because this is attached to bone, a segment of bone may be taken with skin and be vascularized by the same pedicle. Axial flaps whose vessels first pass through fascia are termed *fasciocutaneous vessels* (see Figure 44.12, *B*). As with the musculocutaneous flap, fascia may be transferred without skin, but not skin without fascia. Such a flap is the lateral arm flap supplied by the posterior radial collateral artery. The axial vessel may first supply muscle (see Figure 44.12, *C*). The secondary vessels to the overlying skin are multiple, so the muscle must be taken with the skin to ensure survival of the skin, but the muscle may be transferred without skin. Such flaps have been called *musculocutaneous, myocutaneous,* and *myodermal flaps.* An example of this type of flap is the latissimus dorsi flap, supplied by the thoracodorsal artery.

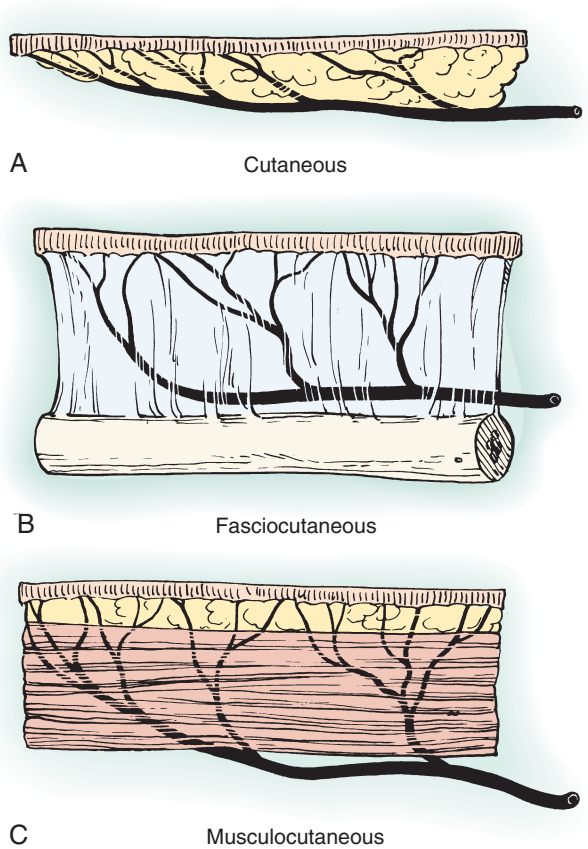

FIGURE 44.12 Axial-pattern flaps are either cutaneous **(A),** fasciocutaneous **(B),** or musculocutaneous **(C),** depending on the source of the major portion of their blood supply. Fasciocutaneous vessels commonly run in intermuscular septa and therefore supply the periosteum of underlying bone. The flap can be taken with a segment of that bone where necessary. (From the Christine Kleinert Institute for Hand and Microsurgery, Inc., with permission.)

Axial-pattern flaps clearly have several advantages over random-pattern flaps. The 1 : 1 ratio can be disregarded in flaps with an axial vessel. Axial-pattern flaps have a blood supply superior to that of random flaps. It has been shown experimentally that axial-pattern flaps resist infection better than do random ones. Because axial flaps can be made longer, they can cover a larger primary defect. In addition, the flap tissue adjacent to the pedicle need not be applied to the defect, permitting much more freedom of movement of the part to which the flap is attached. This bridge segment between the primary and secondary defects may be sutured free edge to free edge, creating a tube that closes off all exposed subcutaneous tissue, or a so-called *tubed pedicle flap*. A further advantage of the axial-pattern flap is that the pedicle can be made much narrower, even to the point of reducing it to the (neuro)arteriovenous bundle itself, in which event it is called an *island pedicle flap*. This permits much more movement of the flap than is possible with a wide skin pedicle. Finally, with the advent of reliable microvascular technology, the pedicle can be divided and anastomosed to vessels adjacent to the primary defect, the so-called *free flap*.

The disadvantage of an axial-pattern flap is that its vascular pedicle must always be preserved at the time of elevation of the flap; at that first stage, it cannot be thinned to the same degree as a random-pattern flap that depends on the subdermal vessels. The vascular advantages of the axial flap are lost if the pedicle is divided in the process of thinning the flap. Indeed, in those instances in which skin from the bridge segment is to be used on an area adjacent to the primary defect, it is prudent to divide the artery in the pedicle 1 week before complete detachment. This constitutes a delay of sorts, as it promotes increased blood flow across the inset wound into the primary defect.

Staging of Flaps

Flaps that come from skin adjacent to the primary defect are called *local flaps* and require only one operative procedure for their completion. Flaps that come from elsewhere on the limb and commonly require two stages are called *regional flaps*. Those from other parts of the body are called *distant flaps*. With the exception of free flaps, all distant flaps require at least two stages for completion. In the first, the flap is raised and applied, attached, or inset. In the second, the pedicle is divided and the free margins inset. In certain instances in which the blood supply is doubtful after division of the pedicle, the final inset may be left until a third stage. This may be necessary if the most distant portion of the divided pedicle has questionable vascularity (as in a pedicled groin flap transfer).

Preparation of the Wound for Flap Transfer

The wound to which a flap is to be applied is called the *primary defect*, or *recipient site*. This may be simply the wound created by trauma or a wound created by excision of a lesion. However, the skin margins are rarely perfect in a traumatic injury, and

generally the wound margins should be excised back to healthy skin prior to flap transfer. Similarly, it is important to recreate the original defect in secondary reconstruction and all scarred skin should be excised so that the flap will be sutured to healthy margins. A pattern of this final primary defect may be taken for future use. This is easily done by marking the margins with ink and taking an imprint of this with a pliable, nonporous material (e.g., a piece of Esmarch bandage), the surface of which has been moistened with alcohol. The wound from which the flap is taken is termed the *secondary defect.* The secondary defect may be closed directly, as in a groin flap, or may require application of a skin graft, as in a cross-finger flap. The region from which a skin graft is taken is called the *donor site.*

Raising a Flap

Between the vascular strata defined earlier—subdermis, subcutaneous tissue, fascia, and muscle—lie relatively avascular planes, the optimal planes of dissection. It is evident that, in order to attain these planes, it is necessary to cut through the vessels of the more superficial strata. Thus, in raising a fascial flap, one must first incise the subdermal and subcutaneous plexus and then the fascia. Only when the surgeon has cut through the peripheral ramifications of the vessels from which the flap obtains its blood supply is he or she in the correct plane. To be one plane too superficial results in division of the vessel, or branches of the vessel, supplying the flap. To be one plane too deep results in a time-consuming, often bloody, and entirely unnecessary struggle.

Applied tension plays a major role in flap dissection. Once the marginal incision has been carried down to the correct plane for dissection, skin hooks or stay sutures are applied to the corners of the flap. Firm upward traction away from the bed displays the plane for dissection. Often this contains only loose areolar tissue that can be stroked away with a knife. Care must be taken not to create a "cave" beneath the flap, that is, a central recess between two marginal pillars of unincised skin, muscle, or fascia. No tension can be applied to the tissues in such a cave, and dissection therein may result in damage to the pedicle. Rather, the marginal pillars are incised progressively in such a way as to avoid caves and permit tension to be applied evenly, thereby protecting the pedicle. Tension on a flap lifts the pedicle off the floor of the secondary defect, on which the knife is dissecting, into the roof formed by the inclined vascular stratum. If dissection proceeds far enough, a point will be reached where the pedicle emerges through the floor to gain the roof. At that point, the surgeon decides whether to proceed. To do so requires dissection of the pedicle. All progress thus far is best made with a scalpel. A scalpel is the instrument of choice both to incise the vascular strata and to dissect the planes, provided that appropriate tension can be applied to the tissues. Cutting with a knife is a result of two opposing forces: the pressure applied to the knife, and the resistance offered by the tissues. The traction applied to a flap produces, and varies, that resistance. It therefore plays a primary role in determining which tissue is cut and which is not. This is why the blade must always be equally sharp, and why the assistant who holds the flap must do so at the same tension first applied by the surgeon. If the assistant cannot do so, the surgeon must apply the necessary tension by grasping and lifting surrounding tissues with dissecting forceps as he or she proceeds.

Scissors provide both the pressure and the resistance required to cut tissue. They are required when the surgeon cannot efficiently control the relationship between tissue tension and knife pressure. When scissors are introduced closed into the tissues and then opened under gentle pressure to clear planes, they can be both precise and innocuous. They create and enter caves, defining structures to be preserved and those to be divided. When scissors are introduced open and then closed to cut, they are less precise than a knife and can do harm in the hands of even the most experienced surgeon. It is therefore important when using scissors that the surgeon sees both surfaces of the tissue to be divided so that he or she is confident what tissues are included between the jaws of the scissors. This often requires that closed-to-open scissor dissection proceed until the instrument can be seen through the tissue to be cut. Such scissor dissection is required as a vascular pedicle is mobilized. Although it has been shown that metal clips are not always secure and that bipolar coagulation may harm the pedicle, both are routinely used in dissecting the pedicle. The clips must be applied with sufficient force to ensure that they will not slip, and the vessel to be clipped should be placed in the middle of the clip, rather than the base (where the clip bends to come together). When dividing small vessels between surgical clips, it is likewise helpful to leave a small amount of tissue surrounding the vessels. This approach gives adequate tissue purchase for the clips so that they do not fall off. The setting on the control box of the coagulator must be of adequate temperature to allow coagulation and sealing of the vessel. The pedicle (i.e., the main vessel) is insulated by holding the branch with a smooth forceps between the pedicle and the point of coagulation.

Local Flaps

Because they have identical or similar qualities to the skin lost, local flaps are the most desirable means of providing cover for a defect. They are, however, severely limited in their availability. This is because there is relatively little skin on the hand and because much of it must remain inviolate to preserve function. The skin of the webs, for example, should never be used for flaps, nor should areas of daily contact. Some skin, such as that of the palm, will not move to the extent necessary for most local flap design. The surgeon must carefully weigh these considerations in selecting a flap. "Lines of maximum extensibility" around which the flap should be planned are selected by pinching the skin. These are the lines along which skin is most available and therefore pinches up more easily. This should be done with the hand in various positions to ensure that function will not be impaired. For example, the skin of the dorsum appears superfluous in extension, but not in flexion.

There are three types of local flaps: transposition, rotation, and advancement. In the advancement flap, the pedicle is that side of the flap opposite the primary defect. In transposition and rotation designs, the flap moves laterally relative to the pedicle to cover the defect. These two differ in that the transposition flap leaves a secondary defect that is closed either directly or by application of new skin cover, whereas the rotation flap leaves no secondary defect, the flap skin being stretched to close the primary defect. This is achieved by differential suturing, in which a slightly smaller amount of the flap edge than of the edge of the bed is included between each two adjacent sutures, thereby advancing the flap. Transposition and

advancement flaps may be random or axial pattern in design. The vascular basis of the axial pattern may be simply a subcutaneous pedicle rich in small vessels or, more reliably, a single known vessel. The advantage of the axial pattern, apart from its potentially larger area and greater reliability owing to superior circulation, is the fact that its pedicle can be reduced to the vessels alone, giving greater mobility. In the advancement flap, the gain is measured in millimeters. In the axial-pattern transposition flap, the gain is limited by the length of pedicle that can be developed. The longer the pedicle, the more the flap becomes a vascular island flap rather than a simple transposition. The distinction between a long axial transposition flap and a vascular island is arbitrary. For the purposes of this chapter, a flap is classified as a vascular island flap when the pedicle is the proper digital artery or larger.

Transposition Flaps

Random-Pattern Flaps

"Z"-Plasty. The "Z"-plasty is one of the simplest forms of random flaps commonly used in hand surgery and is considered a "transposition" flap. The sides of a standard "Z"-plasty should always be of equal length, but the angles vary according to the needs of the situation and the local skin topography. The angles of the design may also differ. As the angles increase, so does the lengthening that occurs along the line of the central limb of the design when the flaps are transposed. The commonly used 60-degree "Z"-plasty theoretically results in 75% lengthening along the line of the central limb (Figure 44.13). The skin that is introduced into the line of the central limb is derived from the transverse axis of that line. Said another way, skin must be available lateral to the central limb before a "Z"-plasty can be used. If sufficient skin is not present for one large "Z"-plasty, multiple "Z"-plasties can be used in series, for the longitudinal gain is aggregate, whereas the transverse loss is not. The following are important points in technique:

1. The angles and limbs should be measured with a ruler and a protractor. When this is not done, mistakes are made, the most common being to cut the angles at 45 degrees when believing them to be 60 degrees.
2. The incisions of the "Z"-plasty should be cut and tested in sequence (Figure 44.14).

First, the central limb and one side limb are incised. The flap created is raised and carried across the central limb with a skin hook. If the side limb cut on the flap can be brought by at least half its length across the central limb, there is sufficient tissue transversely, and the design has been well chosen. If it goes further, a larger "Z"-plasty will work if more lengthening is required. Such a larger design can be made simply by lengthening both initial cuts and testing again. If this first flap can be carried less than halfway across the central limb, the design is too ambitious and must be modified. Because only two limbs have been cut, this modification can be done relatively easily by shortening both the proposed central limb and the as yet uncut second side limb. The excessively long first side limb is simply shortened with one or two stitches.

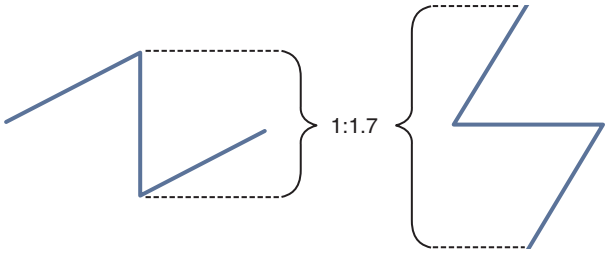

FIGURE 44.13 Standard 60-degree "Z"-plasty. Here all limbs of the "Z"-plasty are of equal length, and the angles between the limbs are 60 degrees. When the flaps are transposed, the lengthening that is achieved along the line of the central limb is 70 to 75% of its original length.

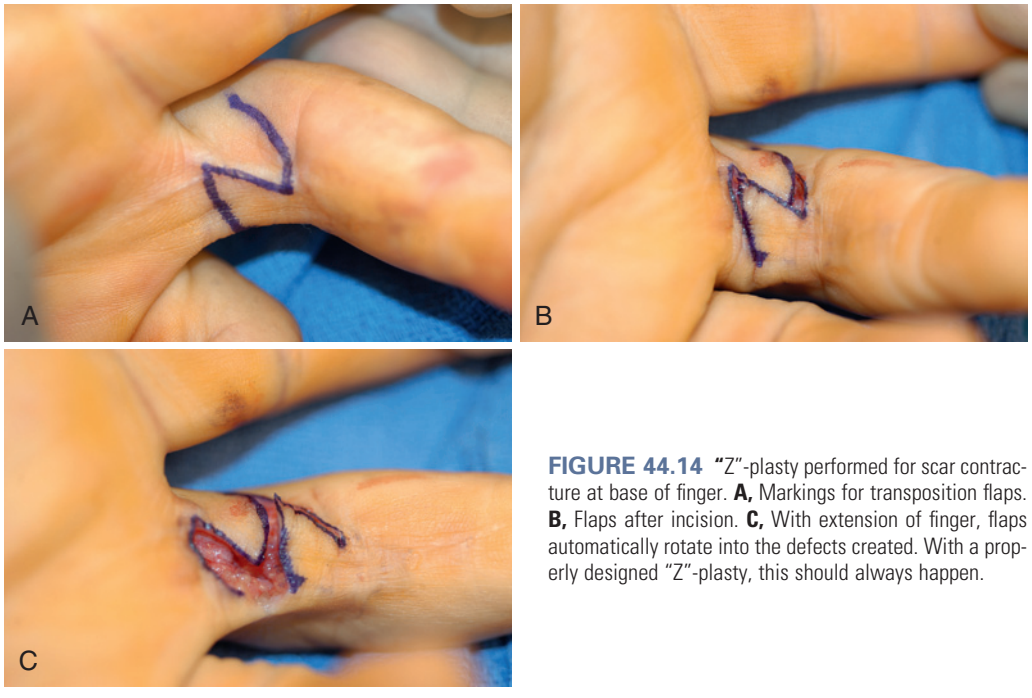

FIGURE 44.14 "Z"-plasty performed for scar contracture at base of finger. **A,** Markings for transposition flaps. **B,** Flaps after incision. **C,** With extension of finger, flaps automatically rotate into the defects created. With a properly designed "Z"-plasty, this should always happen.

CRITICAL POINTS *"Z"-Plasty*

Indications
- Scar contracture, especially on volar surface of fingers
- Minimal web space contracture

Preoperative Evaluation
- Must examine surrounding skin for elasticity and scars
- Generally should not "Z"-plasty grafted skin

Pearls
- Central limb of "Z" goes along line of scar
- Lateral limbs should be designed in areas with loose skin
- Limbs should be 60 degrees to central limb; the tendency is to make them 45 degrees
- Avoid sewing the flaps back where they came from

Technical Points
- Central tight scar should be excised
- Tips of small flaps should not be grasped with forceps
- Base of flap should be thicker than tip when elevating
- Cut only enough skin so that flap will transpose without tension
- Avoid placing sutures in midportion of flap
- Tip suture (half-buried horizontal mattress suture) for tip of flaps
- Only enough sutures to hold flaps in place

Pitfalls
- Poor design
- Flaps with scar at base
- Undermining base of flap so that it is thinner than tip
- Suturing flaps under too much tension

Postoperative Care
- If flaps fit easily, immobilization may not be necessary
- Massage and stretching when healed

Four-Flap "Z"-Plasty. To gain greater lengthening along the central limb, the angles of the "Z"-plasty may be increased. When 120-degree "Z"-plasty flaps are transposed, the resultant central limb lengthening is theoretically 164%. However, flaps with angles much over 60 degrees are difficult to transpose; the pivot points cannot be brought to meet the promontories. This difficulty can be overcome by dividing each flap into two (Figure 44.15). Such four-flap "Z"-plasties are applicable only in very acute contractures, often in the first web. The angle at which the dorsal skin meets the palmar at the web, the ridge angle, must not exceed 30 degrees, or the flaps will not move sufficiently.

Rhomboid Flap. This is a transposition flap designed in the form of a rhomboid, which allows primary closure of the donor site as seen in Figure 44.16. It was described by Limberg in 1963[59] and is a random-pattern flap that is based on assuming that the defect can be imagined in the shape of a rhomboid. It is a parallelogram with two 120-degree angles and two 60-degree angles. All sides of the flap are of equal length, and the flap is designed so that the donor site can be closed primarily. There are theoretically four flaps that can be designed for each defect, and the donor area should be chosen based on skin laxity and resting skin tension lines to allow for closure (Figure 44.17). As with all flaps, knowledge of vascular anatomy can improve viability by basing the flap over a known perforator.

Axial-Pattern Flaps. Vessels that serve to enhance the vascularity of transposition flaps have been isolated at the level of the distal and proximal phalanges. Dorsal digital branches of the digital artery and nerve at the level of the distal phalanx were first described by Holevich.[38] They form the pedicle for dorsolateral flaps transposed to cover digital pulp defects. Pho[85] demonstrated similar vessels arising from the radial digital artery of the thumb and used flaps based on those vessels and the radial

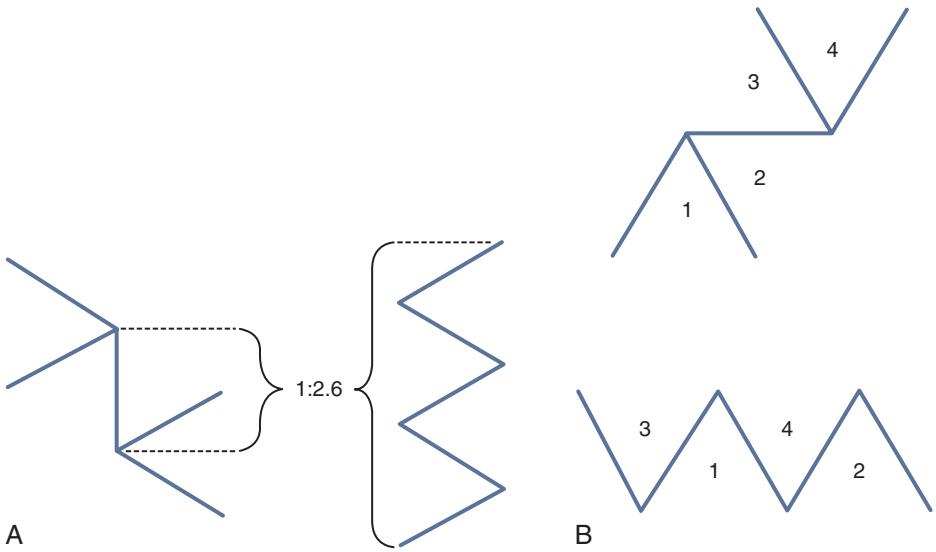

FIGURE 44.15 Four-flap "Z"-plasty. **A,** In the four-flap "Z"-plasty, all measurements are equal, that is, each limb of the design is of equal length but so also are the distances between any two adjacent points in the design. When the flaps are transposed, the two 120-degree angles are closed. As a result, the distance between the points at either end of the initial central limb is some 264% of its original length. **B,** The transposition that is achieved is shown by numbering the flaps. It will be seen that the two 120-degree angles are closed, putting two in the right-hand incision and three in the left-hand incision and interdigitating flaps 1 and 4.

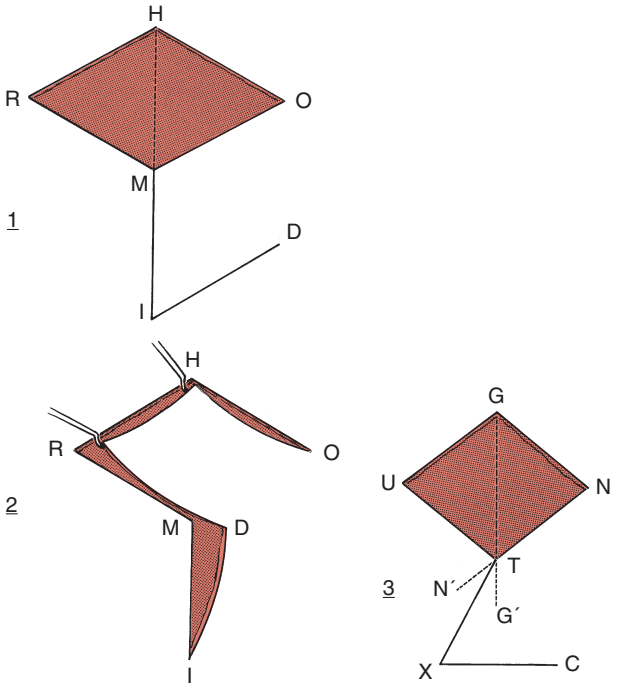

FIGURE 44.16 Rhomboid flap design. *1*, In the Limberg design, all dimensions of the rhomboid that form the primary defect *HOMR* are equal, including the transverse diagonal *HM*. This has been extended by the same length to *I* and the line *ID* drawn parallel to *MO*. *2*, The flap is transposed by moving the pivot point *D* to the promontory *M*. If this can be achieved, the flap will fit. *3*, In the Dufourmentel flap, the transverse diagonal can be of any length. The transverse diagonal *GT* and one of the adjacent sides *NT* are extended to *G′* and *N′*, respectively. The angle that they form is bisected by a line of equal length to one of the sides of the primary defect *TX*. *XC* is then drawn parallel to the longitudinal diameter diagonal *UN*. Transposition is performed by approximating the pivot point *C* to the promontory *T*. (Modified from Lister GD: The theory of the transposition flap and its practical application in the hand. *Clin Plast Surg* 8:115–128, 1981.)

digital nerve and artery to resurface the pulp of the thumb. He states that skin can be taken from the metacarpophalangeal (MP) joint out to within millimeters of the nail fold but advises that a skin bridge be retained until tourniquet release demonstrates satisfactory flow.

These dorsal digital branches allow for advancement of the dorsal finger skin for coverage of defects distal to the proximal interphalangeal (PIP) joints. A flap can be raised by making an incision along the side of the finger (roughly along the midline) back to the MP joint area, at which point the base of the flap is incised as a "V" to allow advancement and closure as a "Y." The skin on one side of the finger is left intact, and the skin is elevated off the dorsal finger at the level of the epitenon. This dorsal skin flap is fed by many dorsal perforators from the digital artery on the side opposite the skin incision. The flap will advance more if the dorsal fibers of the Cleland ligament are released on the side on which the flap is based. This flap has great utility in coverage of small defects over the dorsum of the middle phalanx and distal interphalangeal (DIP) joint and is very reliable. If the base cannot be closed as a "Y," a small skin graft can be placed over the tendon here.

In 1973, both Vilain and Dupuis[114] and Iselin[43] described a "flag" flap raised on the dorsum of the middle phalanx; it was named because the pedicle, narrowed by a generous back-cut, was further mobilized by parallel incisions resembling the pole of a flag. No arterial pedicle was described for this flap; however, it is undoubtedly based on the dorsal branches of the palmar digital arteries.

The skin of the dorsum of the proximal phalanx, especially of the index and middle fingers, has been shown to receive axial flow from the branches of the first and second dorsal metacarpal arteries, vessels that are present in 90% and 97% of hands, respectively. Both of these vessels arise from the radial artery or



FIGURE 44.17 **A,** Basal cell carcinoma of forearm. **B,** After wide local excision, design of two potential rhomboid flaps distally. Note that defect is assumed to be the shape of a rhomboid. **C,** View after flap rotation and primary closure of donor site. Flap was based on more volar surface of arm to potentially allow improved vascularity from perforators.

its communications with the dorsal carpal arch, the posterior interosseous artery, the deep palmar arch, and the ulnar digital artery of the thumb. Stated more simply, both vessels arise from arteries around the base of the second metacarpal. They pursue courses either immediately above or immediately below the fascia of the interosseous muscles. At the web space, the second dorsal metacarpal artery has a constant anastomosis with the palmar metacarpal artery, which is doubly significant in flap design. This communicating vessel must be divided if a longer arc of rotation is to be achieved on a proximally based flap, and it also serves as the axial vessel of reversed dorsal metacarpal flaps.[86] According to the dissections of Johnson and Cohen,[46] the branches of these vessels supply the dorsal skin no further than the PIP joint. The venous drainage of these flaps is excellent, being through either end of the proximal venous arcade, which is of very large caliber. These dorsal vessels form the axial basis of four distinct flaps, the axial flag flap, the first dorsal metacarpal artery (FDMA) flap (or kite flap), the second dorsal metacarpal artery (SDMA) flap, and the reversed dorsal metacarpal flap. Those proximally based on the first dorsal metacarpal artery can readily transfer sensibility by incorporating the branches of the radial nerve to the dorsal skin.

Axial Flag Flap. This simple flap requires no pedicle dissection, for it is based on the web space of the donor finger. The dorsal metacarpal artery has been shown to be reliably present in the second interspace, and less so in the others, but flag flaps can be safely raised from any of the webs (Figure 44.18). Because the pedicle need only be as wide as the vessels, the mobility in this flap is its single major advantage. From the dorsum of the middle finger, for example, it can be rotated to cover the dorsum of either the proximal phalanx of the index finger or the MP joint of either the index or middle finger (Figure 44.19, *A*). It can also, by being passed through the web space, cover the palmar surface of either proximal phalanx of either MP joint (see Figure 44.19, *B*). Before commencing elevation of the flap, the presence of the vessel can be confirmed by Doppler examination. As with the cross-finger flap, the entire skin of the dorsum of the selected proximal phalanx is raised, from midlateral line to midlateral line, and from the proximal extension crease of the PIP joint distally to the level of the free margin of the web proximally. As with all random flaps, the plane of dissection is beneath the subcutaneous vascular stratum, leaving the loose paratenon on the extensor hood. The donor site will usually require a skin graft.

Kite Flap (First Dorsal Metacarpal Artery Flap). This is an island pedicle flap proximally based on the first dorsal metacarpal artery and veins.[28] The skin flap is generally designed on the radial side of the distal portion of the second metacarpal and/or MP joint. With its pedicle fully dissected, it can reach

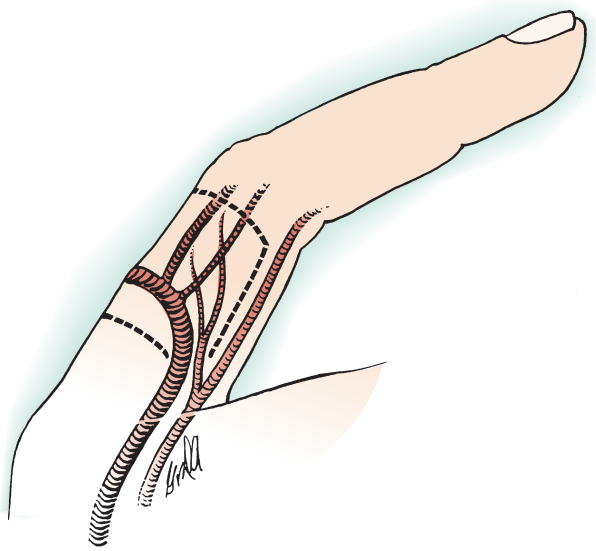

FIGURE 44.18 Axial flag flap. The axial flag flap receives its blood supply from a dorsal digital artery that originates either from the proper digital artery to that finger or from an extension of the dorsal metacarpal artery. Drainage is through the proximal venous arcade to the web space veins. (Modified from Lister GD: The theory of the transposition flap and its practical application in the hand. *Clin Plast Surg* 8:115–128, 1981.)

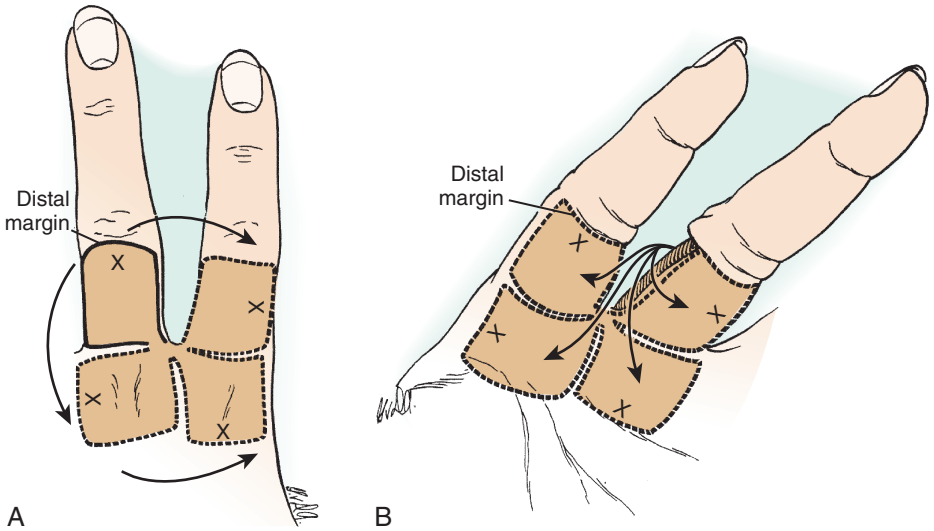

FIGURE 44.19 **A,** An axial flap flap raised on the dorsum of the middle finger can be rotated to cover defects on the proximal phalanx of the index finger or over the metacarpophalangeal (MP) joint of either of those two digits. **B,** By carrying the flap through the web space, it can reach defects on the palmar surface of the MP joint of either the index or middle finger. (Modified from Lister GD: The theory of the transposition flap and its practical application in the hand. *Clin Plast Surg* 8:115–128, 1981.)

the dorsum of the thumb to about the interphalangeal joint. The course of the vessel should be marked with a Doppler ultrasound prior to elevation, but it runs over the first dorsal interosseous muscle from the radial artery as it courses distal to the snuffbox. The flap is elevated from distal to proximal. The skin incision is just deep enough to elevate the skin flaps just above the soft tissues, and a wide swath of tissue is taken along the course of the artery to prevent damage to the draining veins. No effort is made to isolate the vessels in this flap, or they may well be damaged. If a sensory flap is desired, the branch(es) of the superficial radial nerve to this area of skin may be taken with the pedicle. The fascia is carefully lifted off the first dorsal interosseous muscle to near its base to allow rotation of the flap on its pedicle. Once an adequate pedicle has been lifted, the flap can be taken under a skin bridge of the proximal thumb to reach the defect. The donor site requires closure with a skin graft (Figure 44.20).

This flap may be also raised distally based on the perforator near the radial base of the second metacarpal. The arc of rotation of this flap will allow coverage of the index finger to near the DIP joint. The donor site may be closed primarily (in smaller flaps) or with a skin graft.

Second Dorsal Metacarpal Artery Flap. This flap is based on the second dorsal metacarpal artery and venous system in the second interspace. It may be proximally based for coverage of an adjacent dorsal finger or distally based. If it is raised on its proximal pedicle, the rotation point is based near the base of the second metacarpal. The skin off the dorsum of the middle finger proximal phalanx can be raised based on these vessels and transferred to the dorsum of the index MP joint for coverage. The presence of the vessel is confirmed prior to elevation with a Doppler. The dissection proceeds from distal and lateral. The tissue of the second intermetacarpal space is carefully dissected off the interosseous muscle to include the fascia. The dissection is continued proximally, and great care must be taken to prevent damage to the pedicle. The donor site can be closed with a full-thickness skin graft.

The reverse[86] dorsal metacarpal flap is raised in similar fashion but from the dorsal skin of the hand, using the communication between dorsal and palmar metacarpal arteries as the axial vessel. The proximal limit of this flap is the confluence between the extensor indicis proprius and extensor digitorum communis to the middle finger. This flap is raised from proximal to distal and is based over the second intermetacarpal space. Its arc of rotation is generally limited to about the level of the PIP joint based on the pedicle in the second web space. Some have suggested that this flap can be safely transposed more distally; however, the distal end of this flap in this situation tends to be unreliable in our experience. The donor site can sometimes be closed primarily, or it may require a skin graft (Figure 44.21, *A* to *C*).

Digital Artery Island Flaps. The digital artery island flap is based on the radial or ulnar digital artery of the finger. It is a distally based flap and has been used for repair of fingertip injuries.[29] Flow depends on the integrity of the palmar digital arch that lies beneath the palmar plate, and drainage depends on retrograde flow in the fine veins around the artery. It has the advantage of confining the reconstruction to the injured finger: This flap is most useful in the middle or ring fingers, as the digital vessels are codominant in these fingers, and loss of one is unlikely to cause problems with later flow. The index and little fingers, in contrast, may have very small vessels on their radial

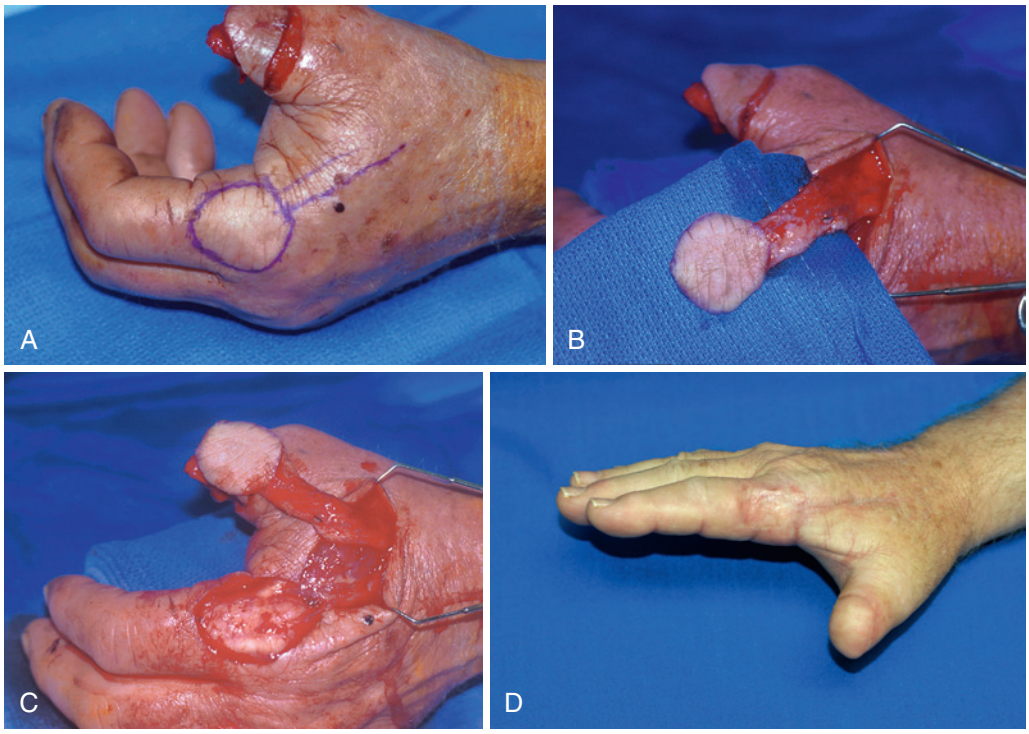

FIGURE 44.20 **A,** Patient with amputation of distal thumb and markings for harvesting a kite flap for coverage. **B,** Flap elevated; note wide margin of tissue taken with vessels. **C,** Showing rotation of flap to defect, flap will be placed under skin bridge. **D,** Hand of patient 6 months after flap transfer showing good stability of flap and healing of skin graft at donor site.

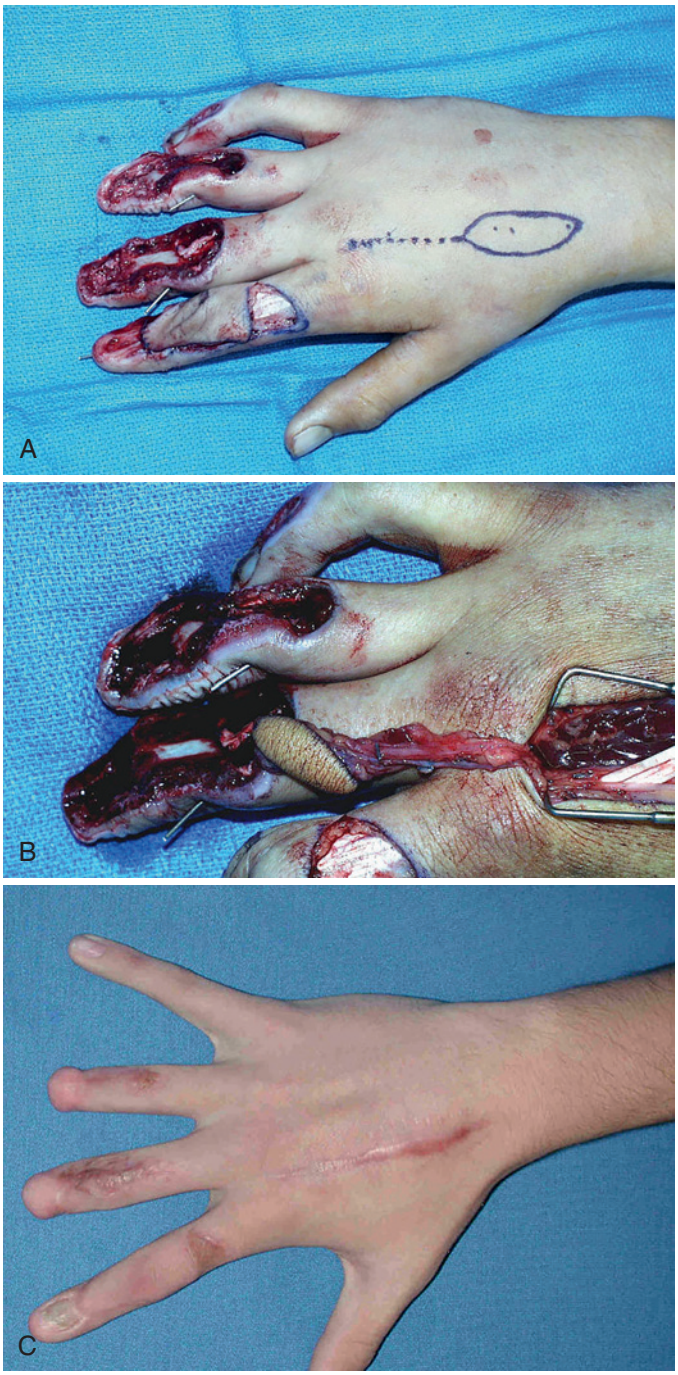

FIGURE 44.21 **A,** Hand with dorsal loss of soft tissue, markings for reverse second dorsal metacarpal artery flap for middle finger. **B,** Flap raised on its vascular pedicle, with rotation point near heads of metacarpals. **C,** Hand after healing, donor site was closed primarily.

and ulnar sides, respectively, which theoretically could lead to problems with cold intolerance after flap harvest.

When used for fingertip coverage, a pattern is made of the defect first and is used to draw an outline of the proposed flap near the base of the involved digit, centered over the digital vascular pedicle. The majority of the flap is taken from the lateral side of the finger, however, to avoid loss of the important palmar skin near the MP joint crease. The anterior border of the flap is incised down to the level of the tendon sheath. The distal portion of the incision is made along the midaxial line. The digital bundle is identified, and the digital vascular pedicle is dissected free from the digital nerve. The veins present the greatest challenge in dissection of this flap, as they are quite small and easily damaged. They may be entwined around the digital nerve and must be carefully removed, using bipolar cautery on a low setting to control branches. The vascular pedicle should not be skeletonized but is rather taken with a small amount of surrounding tissue, again to avoid damaging the veins. This dissection is carried to a level just proximal to the DIP flexion crease, at which level there is usually adequate pedicle to allow easy rotation of the flap to the fingertip defect. The skin incision is carried all the way out to the tip, and the pedicle is carefully placed in this incision. If fascial fibers cause kinking of the pedicle, they must be released, but again, damage to the venous structures in the pedicle must be avoided. The donor site is covered with a small split-thickness skin graft, usually taken from the medial upper arm (Figure 44.22, *A* to *C*).

This flap has several advantages over other pedicle flaps for fingertip coverage: damage is confined to a single finger, the finger may be mobilized sooner, and the cosmetic defect is minimal. We limit its use to the middle and ring fingers for the reasons outlined earlier, however. It provides an excellent option for coverage when one is presented with a significant loss of the palmar pulp of the distal finger.

Advancement Flaps

A simple advancement flap for use in thumb tip amputation was described by Moberg[73] (Figure 44.23), which in fact is a bipedicled flap (based on the two neurovascular bundles of the thumb). This is reserved for amputations through the distal phalanx, because flexion of the interphalangeal joint may be required to assist in closure of the defect. The two parallel incisions to create the flap are made just dorsal to the two neurovascular bundles of the thumb, which are carefully preserved throughout dissection. The flap is elevated from the flexor tendon sheath. Because the bundles are included in the flap, there is theoretically no limit to the length of the flap, but customarily the base is placed at the MP joint skin flexion crease. It is usually best to design the base of the flap with a "V"-shaped incision, which allows the flap to be advanced further and may be closed as a "V-Y" advancement flap (Figure 44.24). Alternatively, a full-thickness graft may be applied to the secondary defect overlying the neurovascular bundles and tendon sheath. This advancement is usually safe in the thumb, for the dorsum is well perfused by dorsal branches from the radial artery. If the base of the flap is too proximal, however, necrosis of a portion of the distal thumb skin can occur. The dorsal neurovascular branches of the digital vessels should be preserved on one or both sides of the flap, which will obviate any vascular problems of the distal dorsal skin. This will decrease the length that the flap can be advanced, however.

A similar procedure has been reported in the finger,[101] but greater care must be exercised here, or loss of the dorsal skin may result. Macht and Watson[63] reported 69 cases with no skin necrosis in either the palmar or dorsal region, two-point discrimination within 2 mm of normal, and a maximum flexion deficit of 5 degrees. However, they emphasized the importance of maintaining the dorsal branches of the proper digital arteries

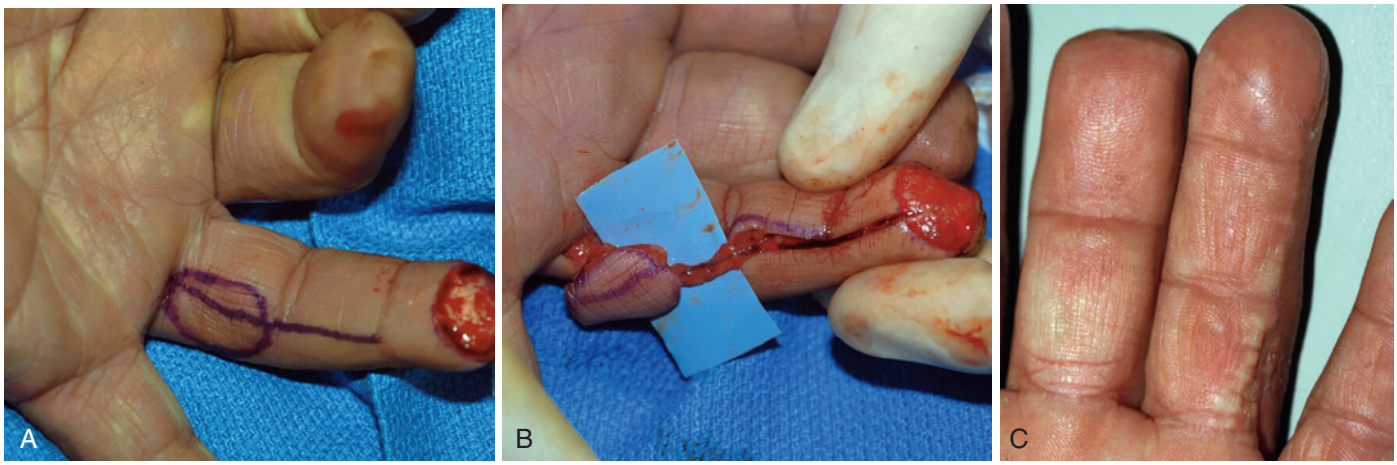

FIGURE 44.22 **A,** Patient with fingertip amputation and reverse digital artery island flap marked over proximal digital vessel. **B,** Flap dissected out on digital vascular bundle. **C,** Flap after healing; donor site was managed with split-thickness skin graft.

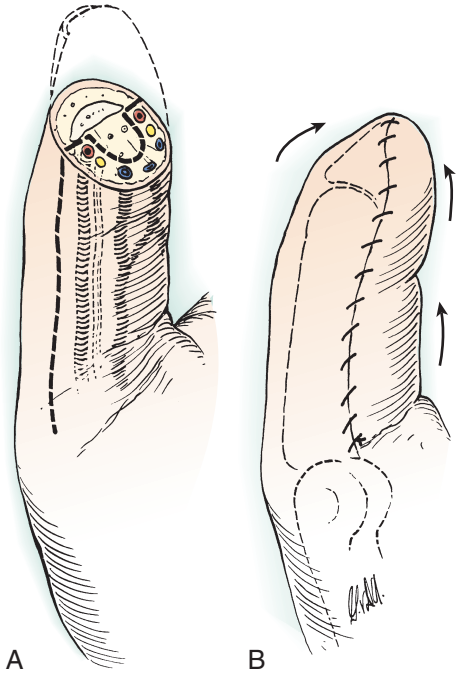

FIGURE 44.23 Moberg advancement flap. **A,** Most useful for amputations distal to the thumb interphalangeal joint, the Moberg advancement flap is composed of the entire palmar skin of the thumb, including the neurovascular bundles. **B,** Flexion of the interphalangeal joint assists in coverage of the defect by the advancement flap. (Modified from Lister GD: The theory of the transposition flap and its practical application in the hand. *Clin Plast Surg* 8:115–128, 1981.)

as noted above. Likewise, the risk of flexion contracture after a volar advancement in the finger is much higher than in the thumb and probably not worth the risk.

"V-Y" Advancement Flap. Commonly used to repair fingertip amputations, the "V-Y" advancement may be a single midline (Atasoy[1]) or double lateral (Kutler[54]) element. Which one is used, and whether the technique is appropriate at all, is determined by examining the primary defect. *It should be stated from the outset that the great majority of fingertip amputations are best managed by allowing secondary healing to occur.* Even if a small portion of the bone is exposed, it can be trimmed back, and wound contracture will close the wound. Allowing secondary healing and wound contraction pulls normal pulp skin into the defect, and is usually superior to a badly scarred tip resulting from ill-advised local flaps. If more tissue has been lost from the palmar than from the dorsal surface, a local palmar flap is unlikely to provide the necessary cover, and a cross-finger or thenar flap may be required. If the loss is equal, or greater on the dorsal aspect, a "V-Y" flap can be used, provided the skin from which it comes is not also damaged.

There are three facts to remember if a "V-Y" flap is to be raised successfully. First, more problems arise through inadequate mobilization than excessive mobilization; the flap should advance easily into position (Figure 44.26). Second, only nerves and vessels need be kept intact. Third, the nerves and vessels in the pulp are slender and elastic and will not resist appreciably the movement of the flap; a corollary of this rule is that any tissue that does offer firm resistance can be divided with impunity. The apex of the "V" in a single midline advancement[107] for most fingertip amputations worthy of reconstruction (i.e., at or distal to the midportion of the nail) should be at the distal digital crease. In the rare case in which length is deemed sufficiently important to justify a "V-Y" advancement in more proximal amputations, the apex can be placed more proximally. The base of the triangle, which lies on the free distal margin, should be as wide as the nail bed but no wider, or the tip will have a flattened appearance. The incisions are made through the skin with a knife, carrying it to bone at either end of the base, where there are periosteal attachments but no vessels. These periosteal attachments should be divided. The deep surface of the flap is freed completely from the underlying tendon sheath as far as its apex. The skin and subcutaneous tissue some 6 or 7 mm on either aspect of the apex are incised down to the sheath. With skin hooks on one lateral margin of the flap distracting the flap away from the digit, the lateral subcutaneous tissues that contain the pedicle of the flap are spread apart with microscissors. Using loupe magnification, any restraining bands are accurately defined and divided, remembering that nerves and vessels will not resist gentle traction.

(An anatomic point should be made here. The veins that accompany the artery of the digital neurovascular bundle are at different levels and of differing, smaller calibers. Therefore, in

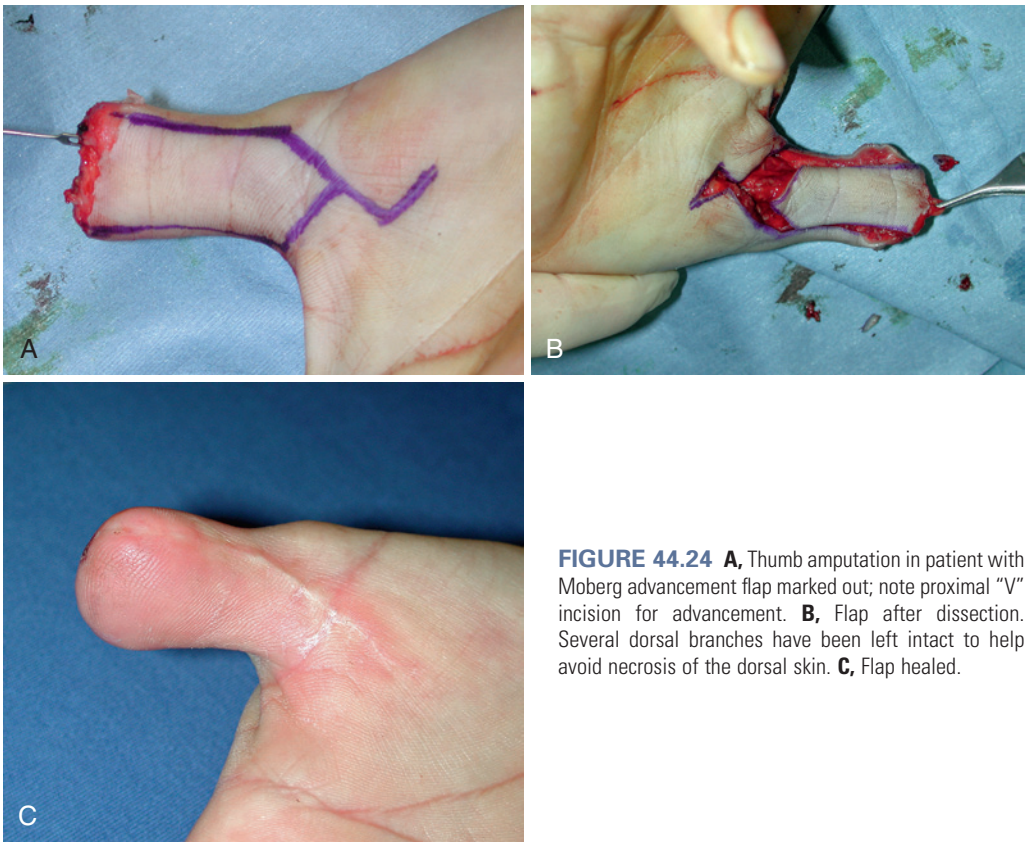

FIGURE 44.24 **A,** Thumb amputation in patient with Moberg advancement flap marked out; note proximal "V" incision for advancement. **B,** Flap after dissection. Several dorsal branches have been left intact to help avoid necrosis of the dorsal skin. **C,** Flap healed.

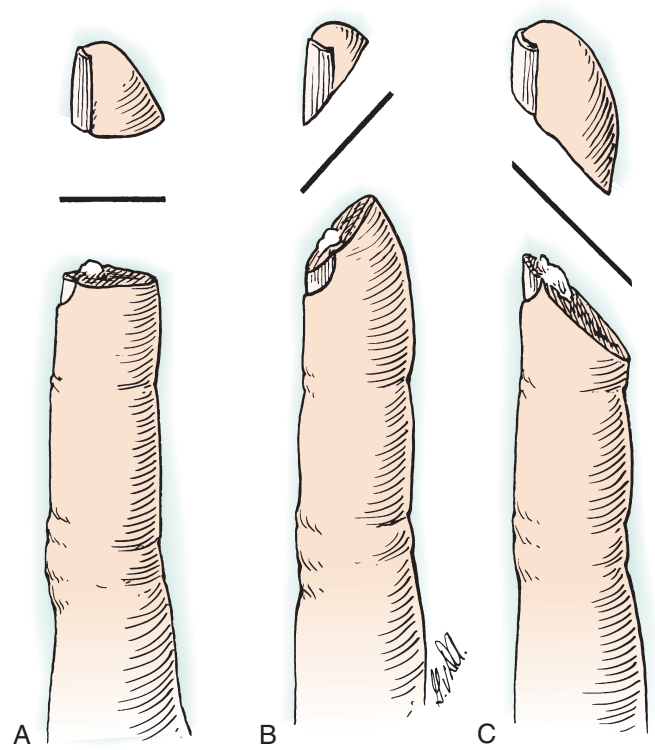

FIGURE 44.25 Suitability for coverage with local flaps is determined by looking at the angle of amputation. Amputations that are transverse **(A)** or have more dorsal loss **(B)** can be treated by local flaps. Where the loss is more palmar **(C)**, palmar flaps have been described (see text) but regional flaps are more reliable. (Modified from Lister GD: The theory of the transposition flap and its practical application in the hand. *Clin Plast Surg* 8:115–128, 1981.)

dissecting a neurovascular bundle for any form of island flap in the digit, no attempt should ever be made to define the artery and nerve independently, for such skeletonization will serve only to damage the veins and thereby seriously impair flap venous drainage.)

The flap should advance easily into place (see Figure 44.26). If it does not, and firm resistance is encountered, one of the fibrous septa must still be intact and must be divided. This process is repeated until the flap moves easily. If the distal end of the flap fails to easily reach the nailbed, it is better to place a small split-thickness skin graft over the raw distal edge of the flap rather than close it too tightly. Closure of the flap is begun at the apex, creating the vertical stem of the "Y" and so advancing the flap. The flap can be inset with the tourniquet inflated, and upon completion and after tourniquet release, color usually returns to the flap. If it does not, time and warmth in the form of hot packs should be permitted to play their valuable role for 20 timed minutes. If there is still inadequate flow, the most distal suture(s) in the vertical limb of the "Y" should be released, which usually produces the desired effect.

The lateral or Kutler[54] "V-Y" advancement flap[99] (Figure 44.27) is raised in identical fashion to the midline "V-Y," with the exception that there is only one neurovascular bundle to be protected in each flap. These flaps tend to lead to a scarred fingertip, however. "V-Y" flaps need not be based on a single known pedicle such as the proper digital artery and nerve. They can be raised on a pedicle of subcutaneous tissue, relying on random vessels contained therein. In such flaps, the pedicle is made as wide as possible. Such "V-Y" flaps have been described for closure of defects and release of contractures. The use of

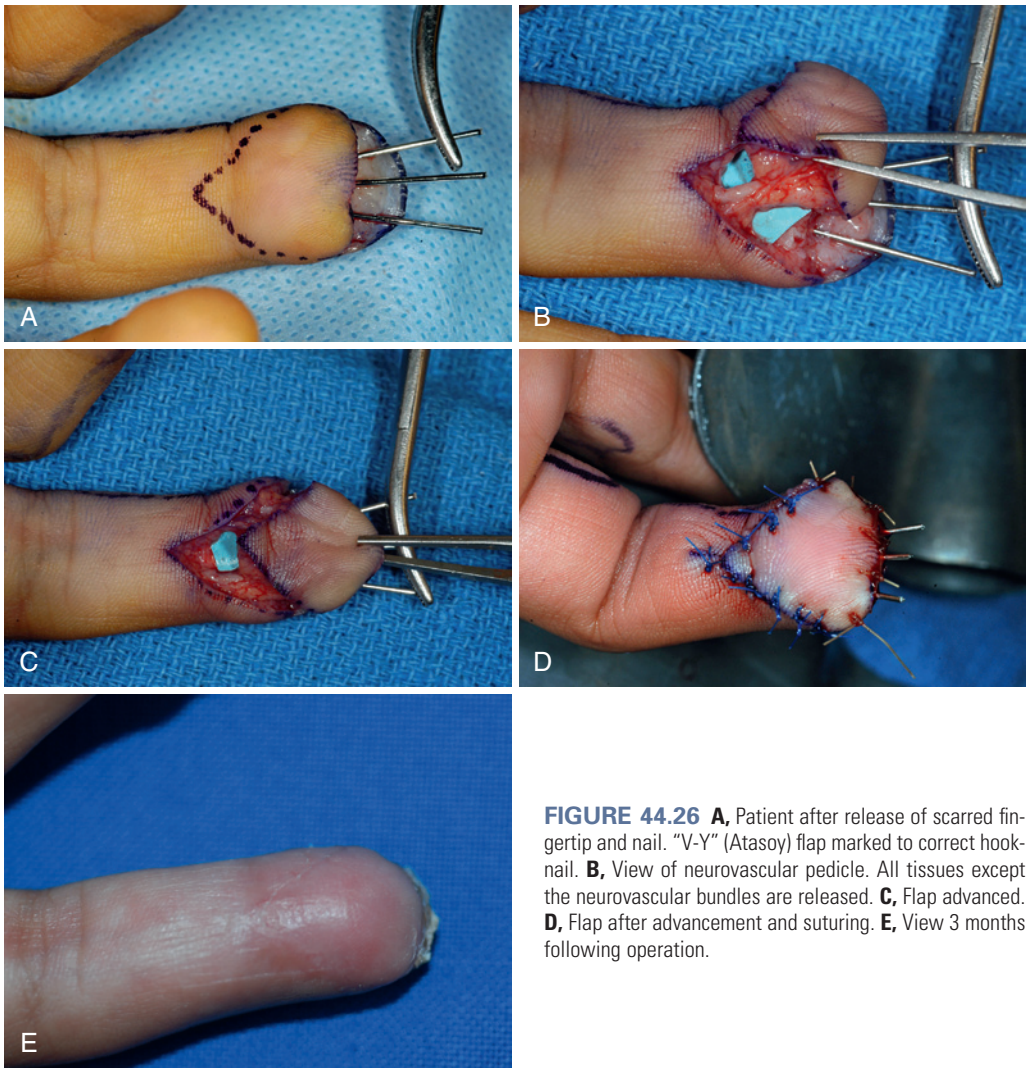

FIGURE 44.26 **A,** Patient after release of scarred fingertip and nail. "V-Y" (Atasoy) flap marked to correct hook-nail. **B,** View of neurovascular pedicle. All tissues except the neurovascular bundles are released. **C,** Flap advanced. **D,** Flap after advancement and suturing. **E,** View 3 months following operation.

lateral "V-Y" flaps should be limited, however, as they lead to significant scarring of the fingertip and are rarely indicated in clinical practice.

Regional Flaps

Regional flaps derive from tissues not immediately adjacent to the primary defect but in its vicinity. Thus most regional flaps in the hand are raised from another part of the hand. They are both random-pattern and axial pattern flaps with respect to their blood supply. In regional flaps, the merit of the axial design is apparent, for all require only one surgical procedure, whereas regional flaps of random design require at least two procedures. At the first operation, the flap is raised and applied to the primary defect. At the second, the pedicle is divided and inset.

Random-Pattern Regional Flaps

The cross-finger and thenar flaps are random-pattern regional flaps. Both are used in the repair of fingertip defects, in particular, those with bone exposed and with more loss of palmar tissue than dorsal tissue. Although the cross-finger flap continues to be used at time, the thenar flap has largely been abandoned in recent years due to problems with flexion contracture of the recipient finger. Fingertip tissue loss is much better managed with secondary healing or a digital artery island flap as described previously.

Cross-Finger Flap. Although the cross-finger flap has several variants that are outlined later, the basic design is for loss of palmar digital tissue and is fashioned on the dorsal aspect of the middle phalanx of the adjacent finger (Figure 44.28). For pulp loss, the middle finger is used for the index finger, but otherwise, the donor finger is the finger radial to the injured one. Flaps to and from the thumb are discussed later. The cross-finger flap can be tailored to fit a pattern of the primary defect. The margin of the defect that is adjacent to the donor finger is designated "the hinge." It corresponds closely to the base of the flap, which is also called a hinge. It is similar to the pivot point of transposition flaps, in that it is a fixed reference around which tissues move. It differs in that it is a line rather than a point. A pattern of the primary defect is made and turned through 180 degrees around the hinge and applied to the dorsum of the donor finger. By adjusting the position of the hinge, the necessary flap can be derived entirely from the skin of the dorsum of the middle phalanx. The flap to be raised is

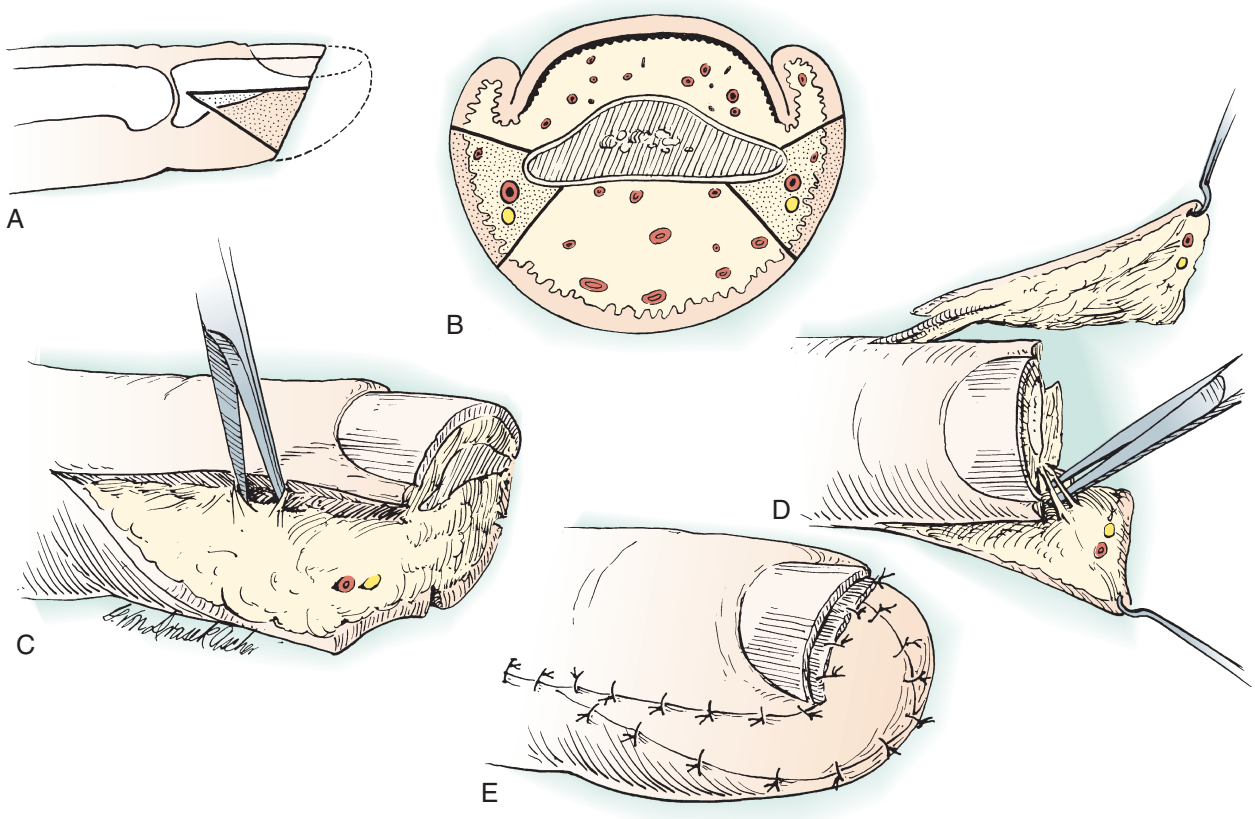

FIGURE 44.27 Kutler double lateral "V-Y" advancements. **A,** The advancement flaps are designed over the neurovascular pedicles and carried right down to bone **(B)**. The fibrous septa are defined and **(C)** divided, permitting free mobilization **(D)** on the neurovascular pedicles alone. The flaps then advance readily to the midline **(E)**. (From the Christine Kleinert Institute for Hand and Microsurgery, Inc., with permission.)

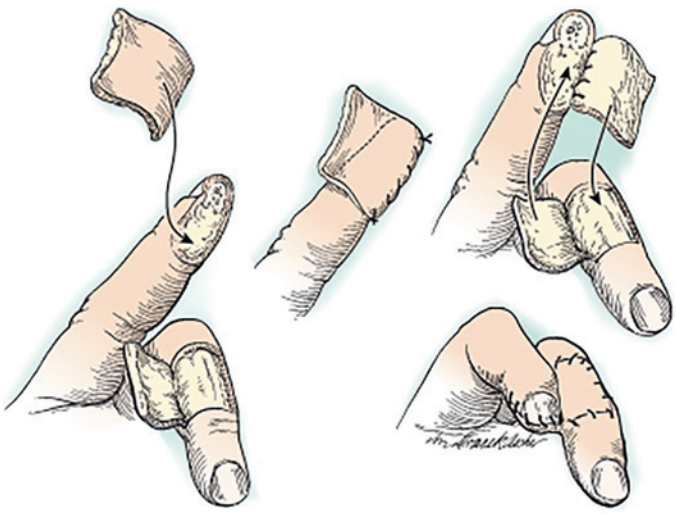

FIGURE 44.28 Cross-finger flap. The flap is raised from the dorsal middle phalanx of the adjacent finger. In this case, a skin graft is tacked to the side of the defect on the finger first, but this is used to close the donor defect. The flap is then sewn in place. (From the Christine Kleinert Institute for Hand and Microsurgery, Inc., with permission.)

outlined to include not only the necessary flap but also all the skin of the dorsum of the middle phalanx, from midlateral line to midlateral line and from the proximal extension crease of the DIP joint to the distal extension crease of the PIP joint. In marking the hinge, one should recall that in all random-pattern flaps, the direction that they face can be altered by extension cuts. Thus, in the cross-finger flap, a proximal transverse incision that extends more palmarly than the distal transverse incision will cause the deep surface of the flap to face proximally; one in which the distal cut extends more palmarly will face distally. The former is more often required, causing the flap to fit well to an amputation stump. The latter is needed only in longer, more palmar defects when considerable flexion of the injured finger is necessary.

The flap margins are incised. Immediately beneath the skin, multiple longitudinal veins are encountered. These are coagulated and cut in order to reach the correct plane, which lies immediately superficial to the extensor tendon. Once the veins are divided, the flap is raised with ease, because only loose areolar tissue lies in the plane of dissection. The flap is hinged away from the donor site and applied to the primary defect to check the fit. If the pedicle is kinked to reach the defect, this can often be eliminated by extending either the proximal or distal transverse cut of the flap. When the flap does not fold easily away from the donor finger, the Cleland ligament may be restraining it. The ligament can be incised to permit easier

folding of the flap. The vessels to the flap penetrate the more superficial part of the ligament and may be damaged unless care is taken to incise it at its depth, against the skeleton.

Once the flap has been raised satisfactorily, a pattern of the full-thickness graft required for the secondary defect is taken. The tourniquet is released at this juncture, and hemostasis is achieved. During this process, the full-thickness graft to cover the secondary defect is obtained. This is commonly taken from the same limb, usually the inner aspect of the upper forearm or arm. This practice is unacceptable in all except perhaps an older working man in whom scars may be of little consequence. In a young patient and, especially, female patient, the infliction of a wound in any of these sites is to be condemned. Rather, the grafts should be taken from over the iliac crest. Skin taken from the groin crease tends to be much darker than the skin on the hand and should be avoided, but skin over the anterior superior iliac spine is generally hairless and a more acceptable color match.

As in all flaps, it is desirable to close all raw surfaces. When one considers the hinge of the cross-finger design, the only free edge to which the skin graft can be sutured is the hinge margin of the primary defect, which is inaccessible after the flap has been sutured in place, lying as it does between the fingers. To overcome this difficulty, the skin graft is first laid on the primary defect, as if it were intended to use it to cover the primary wound rather than the flap already raised. The graft is sutured to the hinge margin of the primary defect. It will be appreciated that there are now two "flaps," the cross-finger and the graft, with contiguous hinges. If both are swung 180 degrees around their hinges, the flap will come to lie on the primary defect and the graft on the secondary defect. One last time, the positioning of the flap is checked. If the flap has been well chosen, any kinks can be eliminated by lengthening the extension cut. The flap can now be inset and sutured into position, trimming as necessary. The skin graft is sutured to the secondary defect. The circulation to the flap should be good, although a little blanching around the margins is common and acceptable. If the flap appears very pale and has been designed and raised correctly, it may be that the recipient finger is extending, thereby exerting undue pressure on the flap and its pedicle. This can be overcome by flexing the recipient finger until circulation returns and then maintaining the position by inserting a suture or Kirschner wire between the fingers, usually transfixing the middle phalanx of the injured finger and the proximal phalanx of the donor. This is rarely necessary.

Reversed Cross-Finger Flap. Primary defects on the dorsum of the finger cannot be covered by a standard dorsal cross-finger flap, as described earlier. They can be treated with a flap taken from the palmar surface, but the skin is rather unsuitable, and the secondary defect would be in a more significant area functionally than the primary defect; this is never a satisfactory solution. In such circumstances, a reversed cross-finger flap should be used. This is designed on the dorsal aspect of the middle phalanx of the adjacent finger, as with the standard flap, the hinge being adjacent to the primary defect. The first step, however, is to raise a full-thickness skin graft from the donor site, commencing the elevation at the hinge and leaving it attached on the opposite margin of the design. This is done at the level of the deep dermis above the layer of subcutaneous veins and below the hair follicles and requires a scalpel. The underlying subcutaneous tissue is raised in the same manner as for the standard cross-finger flap, with its hinge adjacent to the defect. When this flap is swung through 180 degrees around the hinge, its superficial surface lies on the primary defect, and the deep surface becomes superficial. A full-thickness skin graft is harvested and laid on the flap, and both are sutured to the margins of the primary defect. The full-thickness graft previously raised from the donor finger is sutured in place to cover the secondary defect.

Division of Random Regional Flaps. I prefer to divide most regional flaps at between 2 and 3 weeks. The decision whether or not to divide a flap is predicated on the apparent healing of the margins to the defect. If healing appears to be delayed, early division may lead to partial or total loss of the flap. Division is usually performed under local infiltration anesthesia. The pedicle may be inset or not, but the possibility of necrosis exists if too vigorous dissection of the flap is done at this stage. Immediate mobilization is mandatory, and the one benefit of regional over local anesthesia is that the joints can be taken gently through a full range of motion under its protection.

Axial-Pattern Regional Flaps

Regional flaps applicable to the upper extremity that have a known pedicle are the neurovascular island flap, the fillet flap, and those axial cutaneous, fasciocutaneous, and musculocutaneous flaps that may be used in the upper extremity.

Neurovascular Island Flap. The neurovascular island flap (*Littler flap*) has been used historically for reconstruction of the thumb pulp to provide stable and sensate coverage for loss of a significant portion of the touch surface of the thumb. It is described generally as using the ulnar side of the ring finger transferred as a neurovascular island flap to the thumb (Figure 44.29). One has to be sure that the contralateral digital artery is patent to avoid ischemia of the donor finger (Figure 44.30). Although the neurovascular island pedicle flap should be in every hand surgeon's armamentarium, it has little application today. Most significant thumb defects can be managed by other local or regional flaps or vascularized toe pulp transfers. These procedures avoid the donor site problems presented in the finger and provide adequate soft tissue reconstruction, with toe transfers offering the "best" reconstruction of the thumb with little in the way of donor site morbidity. Although one may argue that microvascular toe pulp transfer suffers from the need for microsurgical expertise, the successful dissection, rotation, and tunneling of a neurovascular island flap approaches the difficulty of a microsurgical tissue transfer. The reader is referred to previous editions of this chapter if a complete description of the dissection of this flap is desired.

Fillet Flap. Fillet flaps are developed from a well-vascularized digit that is otherwise worthless due to extensive injury to skeleton, nerves, or tendons and commonly to all three.[14,81] The technique of filleting a finger requires that the skeleton and tendons be removed, preserving all other soft tissues on one or both vascular pedicles. Because the circumference of a finger at the free edge of the web is equal to the distance from the web to a point just proximal to the nail fold, a fillet flap as described here is roughly a square. The difficulties in planning to use such a flap are, first, determining whether or not it can reach the presenting primary defect, and second, incising it to ensure that it does. Measuring the distance from the web of the digit to be



FIGURE 44.29 **A,** Patient with loss of thumb pulp. **B,** View of neurovascular island flap after dissection of pedicle from ulnar side of ring finger into palm. **C,** Flap after passage under palmar skin to reconstruct thumb.

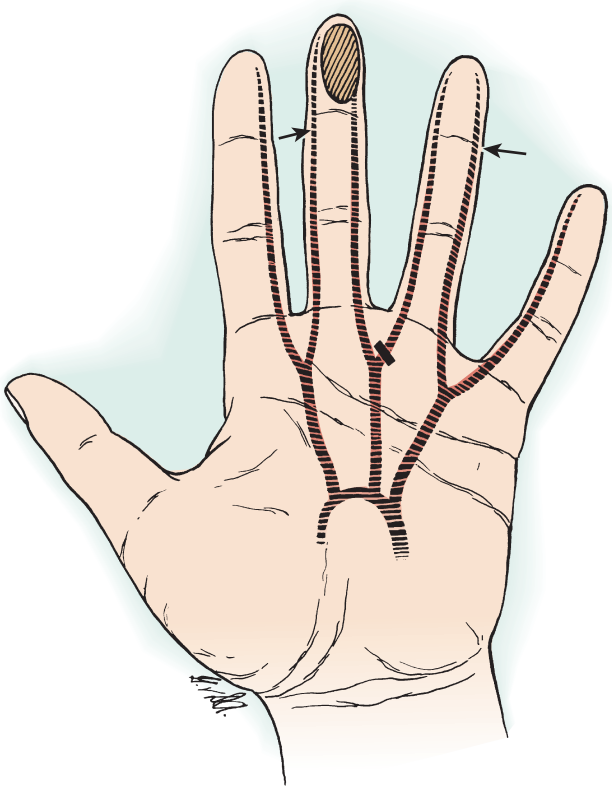

FIGURE 44.30 Neurovascular island flap: preliminary evaluation. It is necessary to ensure by Doppler studies that flow exists not only in the vessel that will supply the flap and in the vessel that will maintain the donor digit after the flap has been raised *(left arrow)* but also in the contralateral digital artery of the adjacent finger *(right arrow)* because the ipsilateral vessel will be divided *(bar)* in mobilizing the pedicle. (From the Christine Kleinert Institute for Hand and Microsurgery, Inc., with permission.)

sacrificed to the nearest point of defect provides only a rough guide, particularly in the secondary situation in which scar in the soft tissues of the digit reduces their elasticity significantly.

In preparing to fillet a finger, the patency or occlusion of the two proper digital vessels is determined. With this knowledge, the surgeon then plans the longitudinal incision in the digit by visualizing how the flap will first open in a lateral direction and then fold over proximally into the defect. For example, if the middle finger is to be filleted for a defect on the dorsum of the hand, the incision in the finger should be on its radial aspect if that defect is predominantly to the ulnar side of the third metacarpal, on the ulnar aspect if the defect is on the radial side. A further consideration when middle or ring fingers are to be sacrificed is whether the adjacent ray (index or small finger, respectively) is to be transposed into the defect left by the ray ablation. If it is, then the fillet flap is best reduced to an island flap by appropriate excision of palmar skin. Although technically more demanding, this gives a more mobile flap and a more pleasing final result. Once these decisions have been made, the appropriate longitudinal incision is made down to the skeleton (Figure 44.31). At its distal end, a circumferential incision is made around the finger at a point 5 mm proximal to the nail fold. This means discarding the pulp tissue, because its bulk makes it a rather unsatisfactory cover for its new location. At the proximal end of the longitudinal incision, its continuation depends on whether the metacarpal of the digit is to be resected and an adjacent digit transposed. If the metacarpal is not to be resected, a transverse incision is made over the dorsum of the finger so as to create a hinge along the side of the finger opposite the incision. All dorsal veins are ligated with the exception of the end of the proximal venous arcade that corresponds to the hinge. This single vein alone gives excellent venous drainage. If

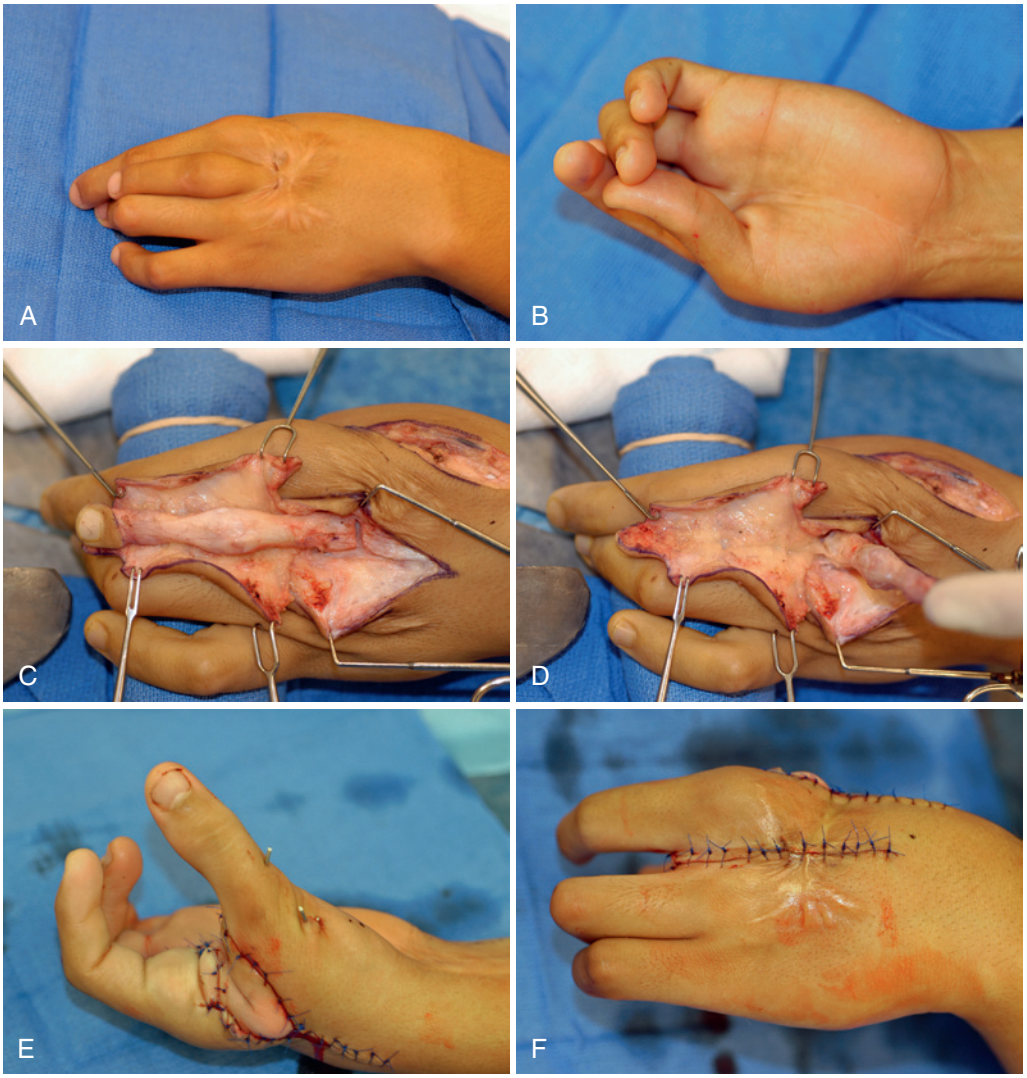

FIGURE 44.31 **A,** View of patient's hand 1 year after gunshot wound through hand with loss of metacarpal length and soft tissue deficit. **B,** Palmar view; note first web space contracture. **C,** Middle finger being dissected for use as fillet flap for first web space release; skin has been dissected off of tendons and bones. **D,** View of skin with bone retracted out of the way. **E,** Thumb after release and rotation of fillet flap through the palm as an island flap. **F,** Donor site after resection of metacarpal and closure.

there is intention to transpose a digit, thereby making the fillet an island flap, the incision is again circumferential at the level of the proximal digital crease, that is, at the free margin of the web. A further incision is made in a zigzag manner proximally into the palm, through which the necessary neurovascular bundle is dissected. This is always done before the skeleton is removed, as dissection of supported tissues is easier. To remove the digital skeleton, skin hooks are applied to the margins of the longitudinal incision distally, and the soft tissues are peeled off the underlying extensor tendon, bone, and flexor tendon sheath. The deep branches and tributaries of the vessels are ligated as this is done. The flap can now be opened and folded onto the primary defect. The necessary movement of the flap is more readily obtained if the injury to the donor digit is fresh and if the fillet has been raised as an island. Now, for the first time, the surgeon can really judge whether the flap will fit the primary defect. If it is too small, other solutions must be added. If it is too large, but the defect is deep, the excess should not be discarded; rather, it should be deepithelialized and turned in to fill the depths of the wound. If the hole in the depths of the wound is caused by a segmental bony defect, a portion of phalanx can be taken as a vascularized bone graft with the fillet flap.

Axial Cutaneous Flap

The scapular flap,[23] commonly used as a free flap, can reach the upper extremity as an island and can be used after the release of burn contractures of the axilla. This flap has some utility in reconstruction of the scarred axilla, but it suffers from the potential to be bulky when placed in this position. This can be obviated by making sure the fascia of the flap is tacked deep into the axilla and can also be improved by later thinning of the flap. The scapular flap will cover the superior shoulder as well if taken as a long "parascapular" flap. It has little value as a pedicle flap in coverage of the elbow and lower arm because the pedicle is not lengthy and the flap will not reach these areas. For a description of this flap, see Chapter 45 on free tissue transfer.

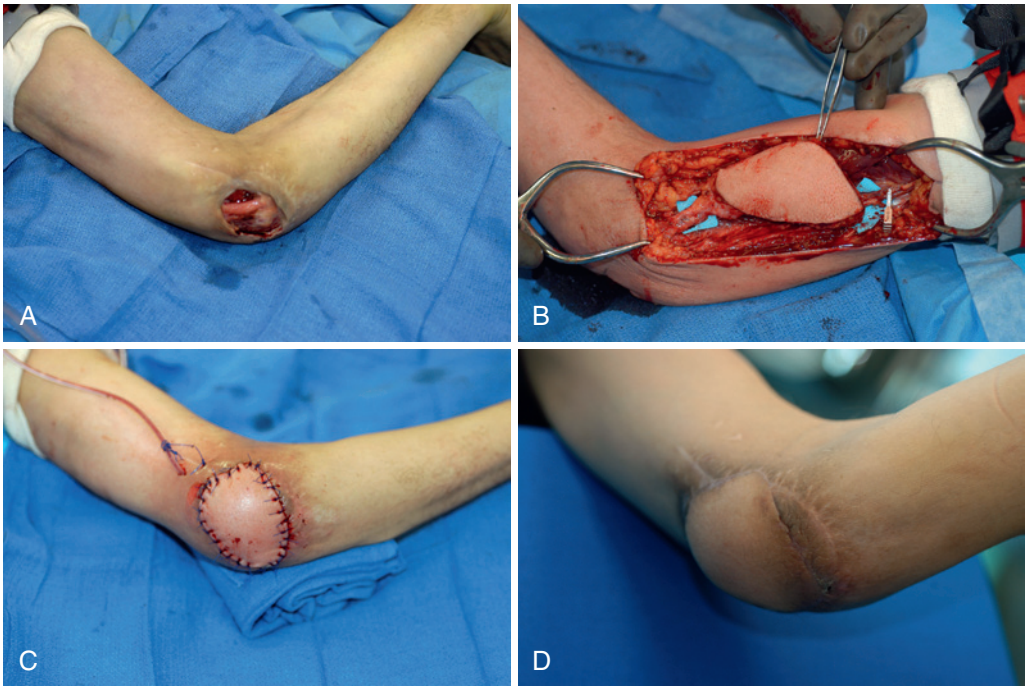

FIGURE 44.32 **A,** View of recurrent elbow wound in patient after radial forearm flap for coverage. **B,** Lateral arm flap dissected on distal vessels (radial recurrent). **C,** Flap after transposition from lateral arm to medial elbow. **D,** Flap healed at 6 months.

Fasciocutaneous Flap

Regional fasciocutaneous flaps have been described from the forearm to the periolecranon region and from the medial arm for release of axillary and elbow burn contractures. However, the major fasciocutaneous flaps of the upper extremity are the lateral arm flap; the radial artery forearm, or "Chinese," flap; the ulnar artery flap; and the posterior interosseous artery flap.[118] The lateral arm flap is primarily used as a free flap for hand coverage, but a small area of the elbow can be covered by a distally based flap (Figure 44.32). This procedure may leave an unsightly scar and also lead to numbness in the proximal forearm. By contrast, the reversed radial artery flap, with its potential area of much of the forearm skin and a pedicle located at the anatomic snuffbox, is capable of covering almost any defect in the hand.[102]

Radial Artery Forearm Flap

The radial forearm flap represents one of the best flaps for coverage of hand defects. Based on its distal pedicle, it can cover nearly any wound of the hand and can import a variety of tissues, including skin, fascia, tendon, and bone. It has been called a "reconstructive chameleon" because of its versatility.[51] It can also be based proximally and used for elbow coverage. The two primary disadvantages of this flap are the necessity for harvesting the radial artery and the poor cosmesis of the donor site, particularly in younger patients. One study noted that the radial artery was the dominant vessel to the hand in 12%,[73] and acute ischemia and cold intolerance have been reported. The absolute need for reconstruction of the radial artery after harvest is not known, although some have suggested that this may decrease the incidence of cold intolerance. In personal experience with several hundred radial forearm flaps (both pedicled and free), I have seen only two patients who required vein grafting of the radial artery who had a normal Allen test preoperatively. This experience is borne out by several studies, with one group noting that while flow to the hand was initially decreased, this improved over time to normal levels via the remaining circulation of the ulnar artery.[42] Although functional problems are minimal, the cosmesis of the donor site remains problematic. The donor site usually requires skin grafting, and it remains ugly, particularly in younger patients. Proposals to improve cosmesis include suturing the superficialis muscle over the flexor carpi radialis tendon to improve skin graft "take" and various local flaps to avoid the need of a skin graft.[52] In many instances, the cosmetic defect can be minimized by taking a fasciosubcutaneous flap only. This modification will be discussed below.

The radial artery (Figure 44.33) pursues a relatively superficial course in the forearm from its source at the division of the brachial artery to the point where it passes deep to the tendon of the abductor pollicis longus to reach the anatomic snuffbox. In the proximal forearm, it lies on the superficial surface of the pronator teres, just beneath the anterior margin of the muscle belly of the brachioradialis. Leaving the pronator teres, it comes to lie in turn on the radial head of the flexor digitorum superficialis and the flexor pollicis longus, here being palpable through the skin. Throughout its course, the artery gives branches to a plexus of vessels in the overlying deep fascia, and this plexus supplies the skin of the anterior and radiodorsal surfaces of the forearm. By means of similar fascial branches it also supplies the periosteum of the distal half of the radius between the insertions of pronator teres and brachioradialis. This allows construction of osteocutaneous flaps if so desired. The artery is accompanied by two or more venae comitantes. The multiple anastomoses between these veins permit reversal of flow in the venae comitantes without valvular obstruction.

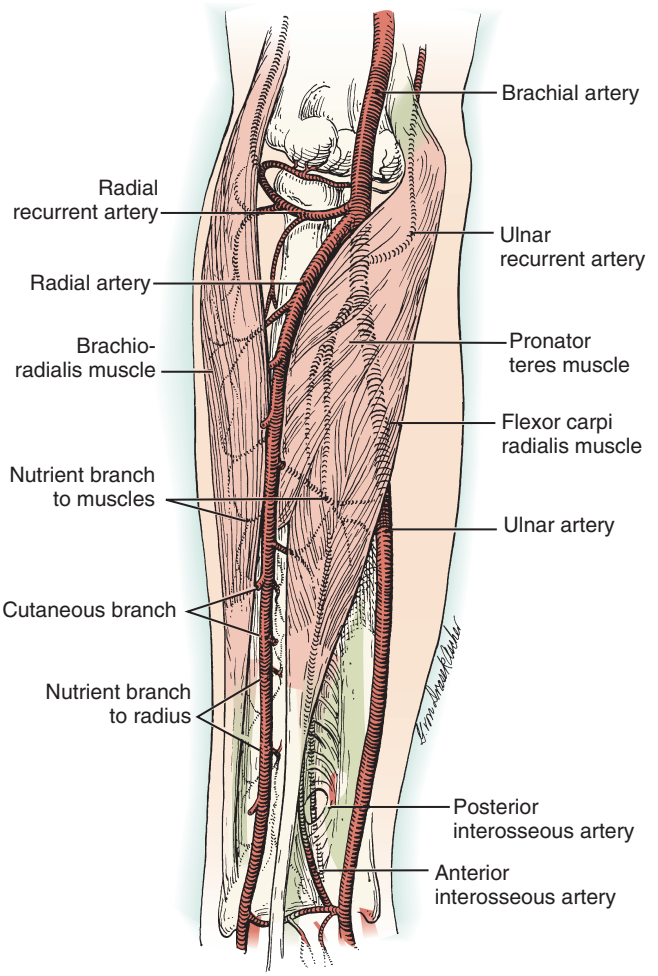

FIGURE 44.33 The course of the radial artery is superficial throughout much of the forearm, lying just beneath the margin of the brachioradialis on the pronator teres and the flexor digitorum superficialis. The cutaneous branches supply the overlying skin and nutrient branches of the radius. (From the Christine Kleinert Institute for Hand and Microsurgery, Inc., with permission.)

Thus the artery and veins can be divided proximally, and no venous engorgement will result (valvulotomy has been described to enhance flow[82]). The minimal precaution that should be taken before raising a forearm flap is a timed Allen test to ensure that flow is present and adequate through both vessels. Conversely, a "dynamic" Doppler examination can be done with the arch identified with the Doppler pencil and flow through the ulnar artery confirmed by digital pressure on the radial artery at the wrist.

The course of the radial artery is mapped out with a Doppler study and marked on the skin, as is the course of the major veins in the region of the flap. Using a soft inelastic material, the distance from the radial styloid to the closest margin of the primary defect is measured and transposed to the forearm to determine the location of the distal edge of the flap outline. I prefer to leave approximately 1 inch of pedicle in-site proximal to the volar wrist crease. I believe that this allows improved backflow to the flap via the multiple vascular interconnections around the wrist. The pattern of the primary defect is drawn out proximal to this point, remembering to place the proximal pattern to the distal flap, because the flap will be reversed on its pedicle. The margins of the flap are incised. A straight incision is extended distally from the flap margin over the course of the radial artery. The skin margins adjacent to the flap are elevated from the underlying deep fascia. I prefer to begin the dissection along the ulnar border of the flap and to continue all the way under the vessels prior to beginning the radial-side dissection. Once the skin has been elevated for 1 cm or so from the flap margin, the deep fascia is incised all around the flap, thereby gaining the plane of dissection. The flap is now raised by dissecting in the loose areolar tissue beneath the deep fascia. In larger flaps, some intermuscular deep extensions may be encountered, which should be incised. In the pedicle forearm flap described here, it is less likely that the secondary defect will lie distally over the wrist tendons than when it is used as a free flap. Nonetheless, whenever a tendon is encountered in elevating the flap, care must be taken to preserve the overlying epitenon. Once the flap has been raised across the flexor carpi radialis from the ulnar margin, traction reveals the radial artery and its venae comitantes (Figure 44.34). Multiple small branches to the muscles must be divided as the dissection proceeds from the ulnar side. Once the underside of the pedicle is freed up, the radial dissection is begun. From proximal to distal, the fascia and septum are carefully dissected off the brachioradialis muscle and tendon. Great care must be taken here to avoid dividing the perforators to the skin as they run along the brachioradialis. While both the aforementioned muscles are retracted away from each other, the lateral intermuscular septum in which the artery runs is incised parallel and deep to the radial artery. The pedicle is now dissected distally, and the entire pedicle with its surrounding fascia should be taken together. No attempt should be made to separate the veins from the radial artery. The radial artery can now be ligated proximally and the flap transposed to the primary defect (see Figure 44.34, *B* to *E*), passing it through a tunnel beneath intervening intact skin. Some surgeons prefer to make an incision and resuture this after passing the flap, but if the tunnel is made at least two to three fingerbreadths wide, most flaps will pass without difficulty.

Once the flap is in place, the previously proximal radial artery in the flap, now distal, can be anastomosed either immediately or at a later procedure to supply more distal tissues, such as a devascularized finger or a toe transfer.[65] The forearm flap can be used for forearm defects, provided that their location is appropriate. In such cases, one or more superficial veins can be rejoined proximally to make venous drainage more efficient. The quality of circulation in the hand can be evaluated once the flap is raised and the tourniquet let down. If it is necessary to reconstruct the radial artery, the gap between the end of the radial artery proximally and the radial artery at the pivot point adjacent to the snuffbox is measured. A vein graft of that length is harvested from the cephalic vein and interposed end to end proximally and end to side distally, using standard microsurgical techniques.

The secondary skin defect is closed with a split-thickness skin graft. Generally, take of the graft is improved if the tendon of the flexor carpi radialis tendon is covered with some of the flexor pollicis longus and/or superficialis muscle bellies, as noted above. This is cosmetically unsightly, but it rarely if ever causes the problems of distal edema that were feared when this flap was first used. The poor appearance of the secondary defect can be eliminated by raising the flap as fascia alone. In this

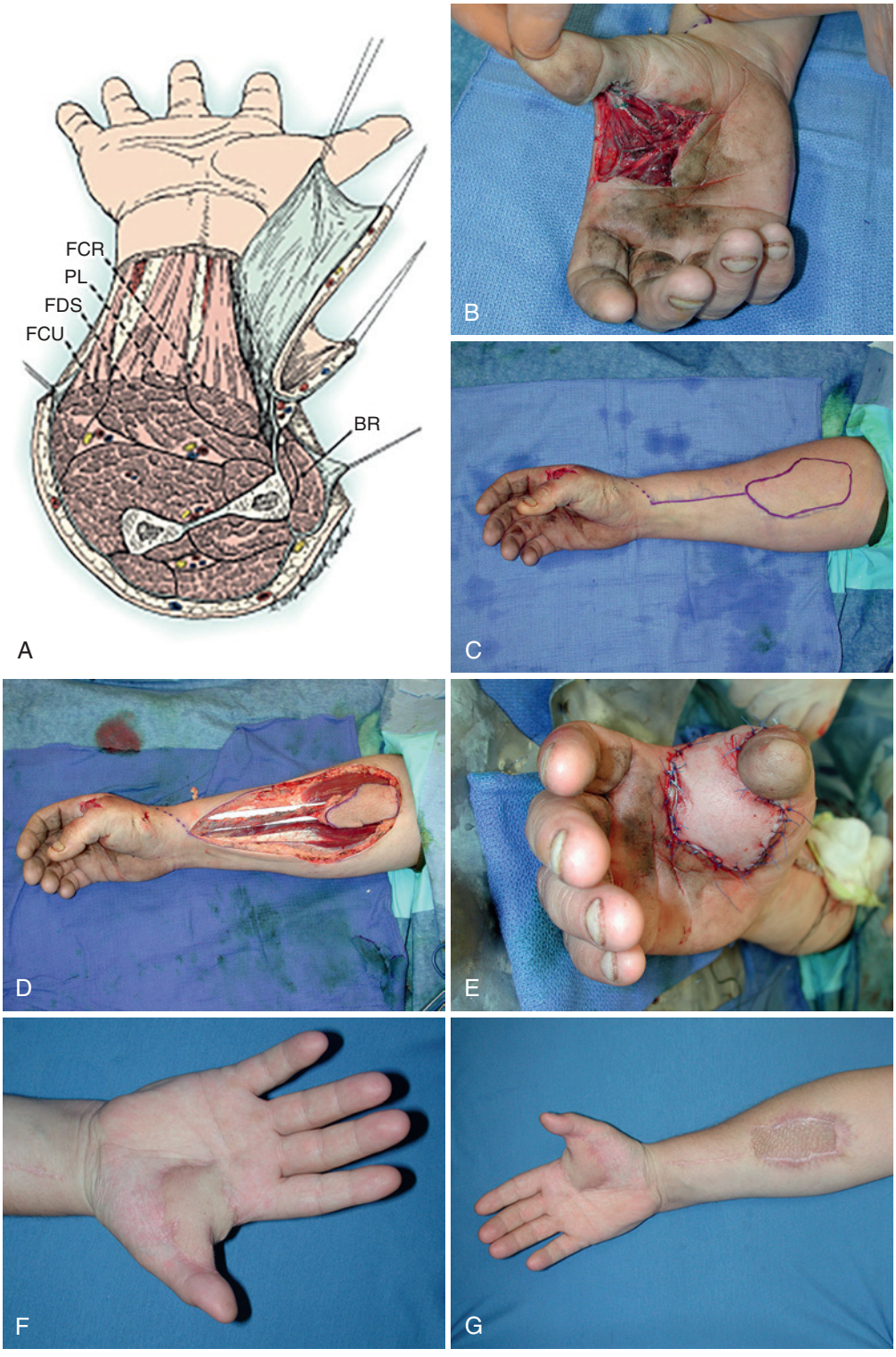

FIGURE 44.34 Radial forearm flap. **A,** Diagram of dissection of radial forearm flap with forearm skin based on radial artery. **B,** Hand of patient after débridement of gunshot wound to first web space. **C,** Markings for harvest of distally based pedicled radial forearm flap for coverage. Note pivot point 2 cm proximal to wrist crease. **D,** Flap after elevation with pedicle. **E,** Inset of flap into palm. **F,** Flap at 8 months. Patient has undergone defatting and "Z"-plasty of margins of flap. **G,** Donor site. Portions of the skin graft have been excised and the margins advanced at the time of defatting of the flap in the palm. *BR*, Brachioradialis; *FCR*, flexor carpi radialis; *FCU*, flexor carpi ulnaris; *FDS*, flexor digitorum superficialis; *PL*, palmaris longus.

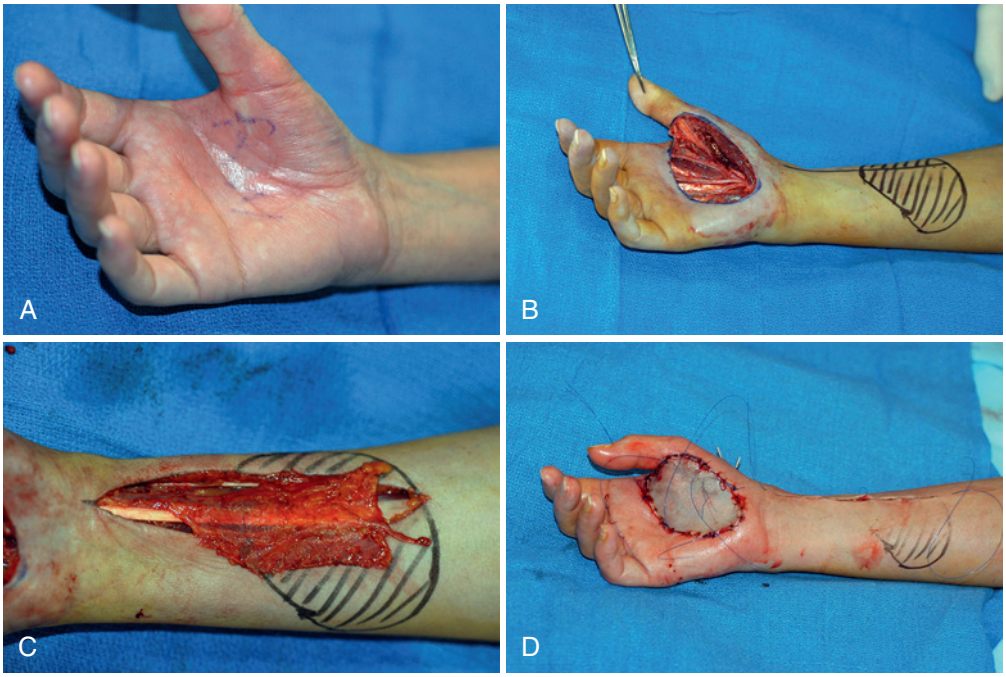

FIGURE 44.35 Radial forearm fascial flap. **A,** Palm of patient with soft tissue sarcoma following irradiation prior to resection. **B,** View of hand after resection and markings for harvest of a distally based radial forearm fascial flap. **C,** Flap elevated with pedicle. **D,** Rotated into palm and covered with a split-thickness skin graft.

instance, the fascia is raised alone without the overlying skin. The area of fascia necessary to cover the soft tissue defect is marked on the forearm, adequately proximal to allow rotation of the pedicle (Figure 44.35). The skin is elevated off the fascia in the manner of a full-thickness graft, but care must be taken to avoid damage to the underlying fascia. Once the skin is elevated, the dissection deep to the fascia proceeds as described earlier for the standard radial forearm fasciocutaneous flap (see Figure 44.35, *C*). The radial artery with its fascia is then rotated into the defect. The fascia is usually covered with a full-thickness skin graft. This type of flap affords appropriately durable and thin coverage of the hand and avoids the need for skin grafting of the donor site. Although there has been some question about the efficacy of graft take over fascial flaps, my experience and that from reported series have been reasonable.

The radial forearm flap can also be used for coverage of the elbow as a proximally based pedicled flap. It offers excellent thin, stable coverage of elbow defects at the expense of a potentially noncosmetic donor site. The dissection is similar to that for distally based flaps, but the flap is based on the distal forearm and the pedicle is dissected proximal to its branching from the brachial artery and divided distally (Figure 44.36).

Ulnar Artery Forearm Flap

Like the radial artery flap, the ulnar artery flap can be based proximally to cover defects around the elbow[45] or distally for hand cover. First described in 1984,[62] it has gained less popularity than the radial artery forearm flap, despite offering the advantages of less hairy skin and a less obvious secondary defect, which, having more muscle and less tendon, should take skin grafts more readily. The donor site of this flap can often be closed primarily, particularly in older patients who may have excess skin on the ulnar border of the forearm. This flap is particularly useful in the management of distressing chemotherapy burns to the dorsal hands in elderly women. In this group of patients, a large flap can be taken to cover the dorsal hand with primary closure of the donor site in most instances. This flap may also be used as a free flap to the hand in appropriate circumstances.

Dissection is similar to the radial artery forearm flap, except that the vascular septum from artery to skin lies between the flexor carpi ulnaris and flexor digitorum muscles and that care must be taken not to harm the ulnar nerve lying immediately deep to the vessel. If taken very proximally on the arm, the septum can be tenuous, with very small perforators, but the flap is very reliable in my experience. Owing to the proximity of the dissection to the ulnar nerve (and possibly devascularization of the nerve with flap harvest), most patients experience a period of ulnar nerve dysesthesia postoperatively. This generally resolves in a few months.

Reversed Posterior Interosseous Artery Flap

In 1986, the anatomic basis[84] and clinical application[120] of a flap based on the posterior interosseous artery (PIA) were first reported. Initially used as a proximally based flap to cover the elbow, its popularity has increased since the description of more detailed anatomy became available and also because of its use as a reversed flap.[12,104]

The PIA arises in the anterior compartment from the common interosseous artery, which also gives rise to the anterior vessel. The PIA immediately passes dorsally through the interosseous membrane some 6 cm distal to the lateral epicondyle, emerging just below the distal edge of the supinator. Throughout its course, it lies between the extensor carpi ulnaris and the extensor digiti minimi, initially lying on the abductor pollicis longus muscle belly in close approximation to the

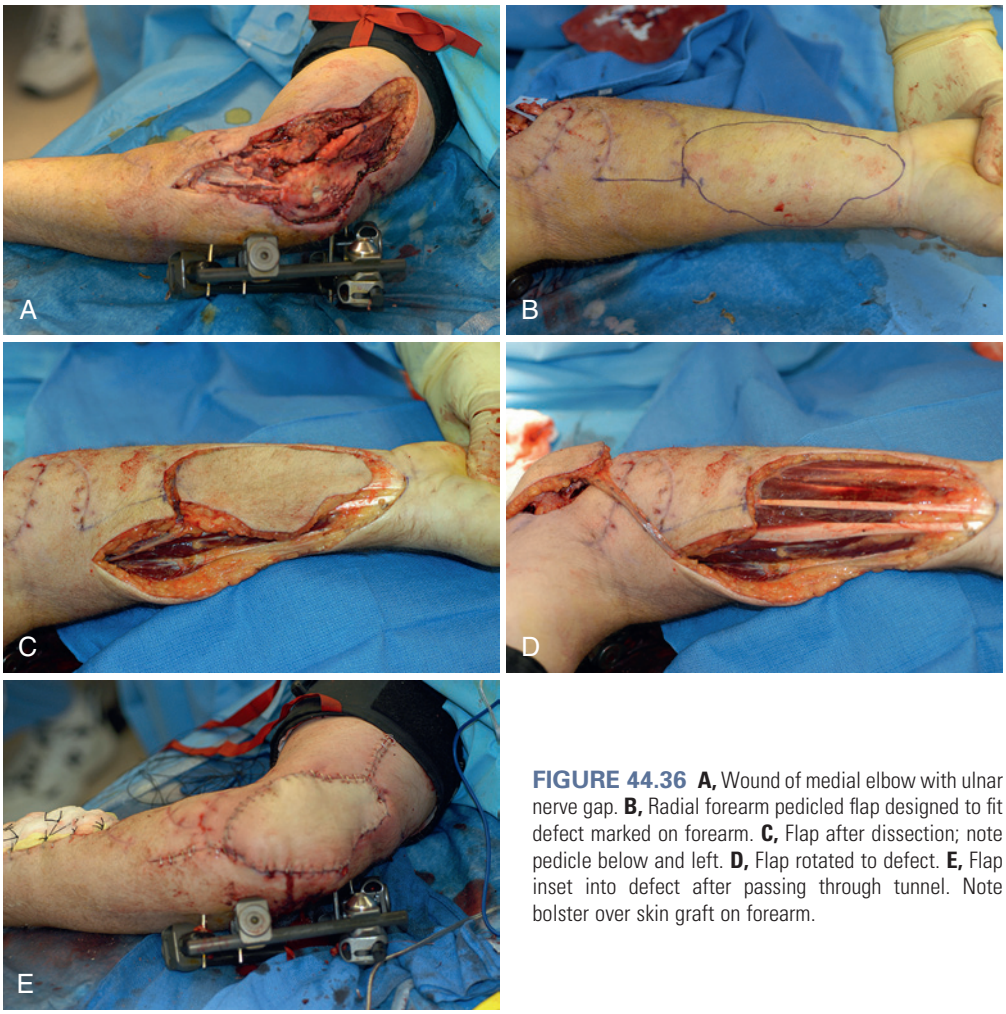

FIGURE 44.36 **A,** Wound of medial elbow with ulnar nerve gap. **B,** Radial forearm pedicled flap designed to fit defect marked on forearm. **C,** Flap after dissection; note pedicle below and left. **D,** Flap rotated to defect. **E,** Flap inset into defect after passing through tunnel. Note bolster over skin graft on forearm.

CRITICAL POINTS *Radial Forearm Flap*

Indications
- Wounds of dorsal hand, forearm, or elbow
- For acute coverage of trauma or tumor resection

Preoperative Evaluation
- Allen test and Doppler examination to ascertain adequacy of ulnar artery flow to hand
- Forearm skin without injury or scar (where flap is to be designed)

Pearls
- For distally based flaps, design pedicle to allow room for rotation
- Dissect pedicle out as a unit, without separation of artery and veins
- Begin dissection on ulnar side of flap

Technical Points
- Take skin, subcutaneous tissue, and fascia off muscle
- Great care must be taken to elevate flap off of brachioradialis tendon to avoid injury to perforators
- Identify and protect radial nerve under brachioradialis and distally
- Avoid separation of artery and venae comitantes
- With exposure of flexor carpi radialis tendon, suture superficialis muscle over this to improve skin graft take at donor site
- Avoid kinking pedicle with distal rotation
- If tunneling flap under intact skin bridge, make sure this is very loose

Pitfalls
- Elevating fascia with perforators away from skin when dissecting over brachioradialis tendon
- Kinking pedicle with distal rotation
- Loss of skin graft at donor site due to flexor carpi radialis and brachioradialis tendon exposure

Postoperative Care
- Immobilize wrist, MP joint, and PIP joint for 2 to 3 weeks for skin graft to take
- Motion may begin after graft has taken

Expected Outcomes
- The radial forearm flap supplies excellent supple skin to the hand with a good color match
- There should be little functional problems from the donor site of this flap over the long term
- The cosmetic aspect of the donor site may present problems in younger patients and women
- Minor revision (defatting) of the flap may be necessary in the future, but this is not always necessary

posterior interosseous nerve. Some 2 cm proximal to the ulnar styloid, it has an anastomosis with the anterior interosseous artery, and it then passes on to the dorsum of the carpus, where it anastomoses with branches of the radial artery. Throughout its course, the PIA gives septocutaneous perforators that supply the skin over the dorsum of the forearm.

To raise the flap, a line is first drawn from the lateral epicondyle to the distal radioulnar joint. A point on this line 2 cm proximal to the ulnar styloid is marked, which represents the pivot point of the distally based flap. Measurements are taken from this point to the proximal and distal edges of the primary defect. These represent the distances from the pivot point along the line initially drawn at which the distal and proximal margins of the flap outline, respectively, are marked (Figure 44.37). The radial margin of the flap and a distal extension to the distal radioulnar joint are incised. The distal extension can be made 1 cm radial to the previously made surface marking of the PIA. The flap is raised, and the fascia over the extensor digiti minimi is incised 5 mm radial to the thick fascial septum. While retracting the muscle radially, the posterior interosseous artery, its branches, and the anastomosis to the anterior interosseous artery distally are dissected, taking care to preserve the perforating vessels to the skin. Provided no anomalies are encountered, a similar skin and fascial incision is now made on the ulnar aspect over the extensor carpi ulnaris, which is again mobilized by division of the muscular branches of the PIA. Most authors suggest keeping a segment of dorsal forearm fascia intact with the septal vessels distally, which may contain veins to improve venous outflow in the distally based flap (see Figure 44.37, *C*). The relationship of the motor branch of the extensor carpi ulnaris to the PIA and its most proximal relevant perforator (MPRP) must now be inspected, for if it passes superficial to the PIA and the MPRP is the major septocutaneous perforator, which it may be, the surgeon may decide to divide and repair



FIGURE 44.37 Posterior interosseous flap. **A,** Hand after explosive injury to first web space. **B,** Markings of posterior interosseous flap. Perforators and posterior interosseous artery have been located and confirmed with a Doppler probe. **C,** Flap after elevation. Note posterior interosseous pedicle to the left. *Arrow* points to posterior interosseous nerve, which can be entwined with perforators if the flap is taken too proximally. **D,** Flap rotated to recipient site. **E,** Flap after insetting. Donor site was closed with split-thickness skin graft. **F,** View of hand 6 months following operation. **G,** Donor site at 6 months.

the nerve in that circumstance. This anatomy is one of the primary factors that mitigate against the choice of this flap, in my mind. The potential morbidity of dividing and repairing the posterior interosseous nerve in a flap that often has questionable viability makes this flap often less than an ideal choice. Once the pedicle and flap have been fully mobilized so that they are attached only by the proximal and distal vascular connections, there is merit in placing a microvascular clamp on the PIA proximal to the MPRP and releasing the tourniquet. If flow is good, ligation can replace the clamp, and the flap can be turned into place on the hand.

The reach of the flap has not been clearly defined. It can certainly reach the first web space and the MP joints. Büchler and Frey[8] have taken the flap to the PIP joint, but they reported a 21% incidence of partial necrosis. Although statistical analysis of their results indicated that this necrosis was not related to pedicle length, this incidence of partial flap loss is higher than that encountered in other series, with only one case of remediable venous congestion out of 32 flaps performed. Nonetheless, this flap remains somewhat problematic in most hands, regardless of the length of the pedicle. Despite enthusiasm for this flap, Brunelli reported a 14% incidence of at least partial necrosis of 113 posterior interosseous flaps.[7] Another more recent report found anatomic variations in 24% of 88 flaps elevated, which led to inability to harvest the flap in 5 patients (6% of cases).[19] This same group noted variable degrees of flap necrosis in 13% of cases. For these reasons, this flap should not be attempted without knowledge of both the anatomy (and its variations) and an acceptance of a rather high rate of either partial or complete flap failure.

Musculocutaneous Flap

The blood supply of muscles has been classified into five types[69]:

Type I. One vascular pedicle, e.g., tensor fascia lata
Type II. One dominant plus other minor, e.g., gracilis
Type III. Two dominant, e.g., gluteus maximus
Type IV. Several, equal, segmental, e.g., sartorius
Type V. One dominant plus peripheral, e.g., latissimus dorsi

In types I, II, and V, one so-called dominant pedicle is capable of supporting the entire muscle if the others are ligated. Theoretically, therefore, any muscle in the upper extremity that belongs to one of these three types can be transposed on its pedicle. Several have been described: latissimus dorsi to the shoulder and upper arm; deltoid to the shoulder; brachioradialis, extensor carpi radialis longus, and flexor carpi ulnaris to the elbow; flexor digitorum superficialis to the antecubital fossa; extensor carpi ulnaris and flexor digitorum profundus to the proximal ulna; pronator quadratus and abductor digiti minimi[90] to the wrist; and the first dorsal interosseous to the first metacarpal and to the third metacarpal. Because the majority of these lie beneath a well-vascularized deep fascia, most have been used as muscle flaps to which split-thickness skin grafts have been applied. These flaps have limited value, for they all eliminate a functioning motor. Furthermore, their contour is good only when the defect has a volume similar to that of the muscle belly. The function of the transposed muscle can be preserved where necessary,[68] provided the correct tension is maintained. The fascia overlying a muscle, if it is thick, has a rich plexus supplied through vessels of the intermuscular septa. In the absence of a direct axial cutaneous vessel, that plexus supplies the overlying skin, which is therefore best raised as a fasciocutaneous flap, leaving the muscle in place. Where the fascia is thin or absent, the supply to the skin comes more from small branches that perforate the muscle; such vessels supply the skin over the latissimus dorsi. In this case, the muscle and the skin overlying it can be moved efficiently as a block to provide skin cover and, where needed, function. Whether the cover achieved is better when the muscle alone is moved and then skin grafted, or when a musculocutaneous flap is used, is still a matter of debate, but most feel today that musculocutaneous flaps are generally too bulky.

Two muscles in the type V classification have been used in this manner to the upper extremity, the pectoralis major and latissimus dorsi. As with other type V muscles, the main vascular pedicle of the pectoralis major, the pectoral branch of the acromiothoracic axis supplemented by the lateral thoracic artery,[88] enters close to its insertion. There are numerous small vessels entering the periphery or origin of the muscle, notably from the internal mammary artery. Unlike all the regional axial muscle flaps listed earlier, the pectoralis is left attached at its insertion and released from its origin. It can be split longitudinally to cover two adjacent defects. The pectoralis muscle without skin (and it may be used with the addition of the pectoralis minor) has long been used for restoration of elbow flexion lost as a result of nerve injury[15] or arthrogryposis. With an island of overlying skin, it has been used as an axial regional flap for reconstruction of the axilla and shoulder. However, the secondary defect, even when it can be closed directly, is entirely unacceptable to women and largely so to men. Because all primary defects in the upper extremity that can be reached by the pectoralis can be covered with ease and with a much more acceptable donor site by the latissimus dorsi flap, the latter is preferred in virtually all cases.

Latissimus Dorsi Flap. The wide arc of rotation around its pedicle makes the latissimus currently popular for reconstruction of the breast, the abdominal wall, the head and neck, and the shoulder.[24,72] The diameter of the artery (1 to 2.5 mm) and the length of the pedicle (11 cm) has made it the most robust and therefore popular tissue for free transfer, especially to the extremities. Functional transposition of the latissimus dorsi to restore lost biceps function has been known to the orthopedic surgeon for over 30 years.[121] Its use to restore both function and skin cover[56] and to restore cover alone is a more recent development.

The latissimus dorsi arises from the lower six thoracic vertebrae, from the thoracolumbar fascia, and from the posterior part of the iliac crest. From this extensive origin the muscle fibers converge to wrap around the lower border of the teres major and end in a quadrilateral tendon that inserts into the intertubercular sulcus of the humerus. Together with the teres major, it forms the posterior axillary fold. Furnas and Furnas[32] reported one patient in whom the lower part of the muscle was absent, but its anterior border felt quite normal preoperatively. Its main blood supply derives from the vessel popularly known as the thoracodorsal artery, which is the continuation of the subscapular artery after it gives off its circumflex scapular branch some 2 cm distal to its origin from the axillary artery. The thoracodorsal artery gives a variable number of branches to the chest wall, notably one to the serratus anterior, before reaching its hilum on the latissimus dorsi some 11 cm from the

axillary artery. Immediately distal to the hilum, the artery divides into two branches in most patients. The upper branch runs parallel to and 3.5 cm from the upper margin of the muscle; the lateral branch runs parallel to and 2.1 cm from the lateral margin of the muscle. This arrangement permits the surgeon to split the muscle longitudinally when a narrow flap is required. One might suppose that absence of the artery would preclude use of the latissimus dorsi flap; however, this need was disputed in the belief that previous injury to the vessel served as a delay. Certainly, if the serratus branch remains intact, it has been shown that collateral circulation is established and the flap can be safely transposed. This would, however, severely limit the reach of the flap when it is taken to the arm and carries the risk of kinking the pedicle. The muscle can also be used in "reverse," based on the vessels of the T9, T10, and T11 intercostal spaces, but rarely in this fashion for coverage of the upper extremity. Any significant defect of the upper arm and elbow can be covered with a pedicle latissimus dorsi flap (Figure 44.38), and it has been transferred successfully to the forearm.

When the latissimus dorsi is to be transposed to a defect in the upper extremity, the involved limb, together with the entire ipsilateral hemithorax and distally to the iliac crest, is prepared and draped. The axilla can be displayed by wrapping the forearm with soft padding and then applying upward traction with the help of an assistant. Some have advocated placing the arm on a Mayo stand or the equivalent in a fixed position, but I have seen cases of injury to the brachial plexus from prolonged placement in this position. I prefer to avoid placing the arm in a fixed abducted position and simply have an assistant hold the arm abducted with periodic relaxation of the patient's shoulder (and the assistant). A zigzag incision is made in the axilla, avoiding the hair-bearing area, extending down along the anterior border of the muscle. Through this incision, the anterior border of the latissimus is located and sharply freed up. Once the anterior border is freed up, the submuscular dissection is done easily in the areolar plane next to the chest wall. The thoracodorsal vessel can best be found where it approaches the muscular hilum. This is approximately at the nipple line in a man or a child. With good retraction and light, the vessel can be traced proximally, identifying first the serratus branch and then the circumflex scapular artery. These are ligated and divided. If they are not, they tether and kink the pedicle after transposition. The most proximal extent of the dissection constitutes the pivot point or axis of the flap.



FIGURE 44.38 **A,** Elbow of patient with wound dehiscence after total-elbow arthroplasty. **B,** Latissimus dorsi muscle pedicled to cover elbow. This will be covered with a split-thickness skin graft.

At this juncture, the distance from this pivot point to the proximal margin of the defect in the limb is measured and transposed to the anterior border of the latissimus dorsi previously marked. This second point represents the proximal edge of the proposed flap. Using a pattern of the primary defect, the flap can now be marked out over the posterolateral thorax. The anterior margin is incised, and the anterior border of the latissimus is elevated with the overlying skin. The inferior border of the flap can now be raised by incising through skin, subcutaneous tissue, and muscle, using cutting cautery for all but the skin. The distal and medial muscle may also be divided using one of the gastrointestinal anastomotic stapling devices (Endo GIA, Covidien-Medtronic, Minneapolis, MN), which places a line of small hemostatic staples and divides the muscle between these two rows. The use of this instrument can make the dissection very rapid. Once the inferior and medial muscle is divided, the latissimus dorsi can be swung away and posterior from the trunk, permitting a clear view of the vascular tree of the thoracodorsal artery. Where a narrow flap is all that is needed, the lateral branch is located, and the posterior border of the flap is incised as was the inferior border, while carefully avoiding that lateral branch. The upper branch (situated also medial and posterior) is ligated and divided. The thoracodorsal artery is now dissected off the latissimus dorsi, working from the axilla distally as far as possible without injury to it or its muscular branches. The proximal margin of the flap can be incised in a similar manner to the inferior (or distal) and posterior, while retracting the pedicle anteriorly and so protecting it from harm. Raising the flap in this manner rather than taking the whole muscle, as was done in the past, yields a flap tailored exactly to the primary defect. In particular, it avoids both a bulky proximal portion to the flap and the difficult task of separating the latissimus dorsi from the teres major. The bulk proximally was not only unsightly but also difficult to fit into the upper arm. This is particularly so in the common circumstance in which the flap is to be passed beneath an intact skin bridge. The flap can now be passed to the primary defect and sutured in place. The secondary defect is always closed directly, for a skin graft in this location presents many difficulties in terms of graft take and wound care. Seroma formation is common, and prolonged suction drainage is indicated.[87] More tissue is available for superior to inferior closure than in the line of the trunk; therefore, small defects are best closed transversely. No significant loss of function has been shown following use of the latissimus dorsi.[93]

CRITICAL POINTS *Latissimus Dorsi Pedicled Flap*

Indications
- Coverage of upper arm, elbow, proximal forearm
- Functional reconstruction of elbow flexion or extension

Preoperative Evaluation
- Presence and function of latissimus (especially for functional reconstruction)
- Absence of scars in axilla (axillary dissection, mastectomy, thoracotomy)

Pearls
- May take skin paddle for coverage or place skin graft over muscle
- If not needed for functional coverage, should cut thoracodorsal nerve to prevent muscle from pulling loose with movement
- Artery and vein in pedicle should be left together in areolar tissue to avoid kinking of vein
- Should divide tendon from humerus to obtain the most length
- Distal muscle may not be viable, especially if overstretched

Technical Points
- Elevate skin from muscle with knife or cautery
- Identify pedicle running under proximal portion of muscle
- Deep surface can usually be elevated with finger dissection
- Divide distal muscle with cautery once pedicle is identified
- Dissect pedicle carefully with muscle flipped over
- Should ligate or clip the large paraspinous perforators (not cautery)
- Once pedicle is identified and isolated, can divide muscle proximally
- If taken under an intact skin bridge to defect, tunnel must be adequate to prevent pressure on muscle
- Avoid suturing the muscle too tightly distally

Pitfalls
- Damage to pedicle during dissection
- Passing the muscle under a skin bridge that is too tight
- Suturing the muscle under too much tension

Postoperative Care
- Large drains in donor site for 5 to 7 days (seromas common)
- Immobilize shoulder and elbow for 2 to 3 weeks
- Begin gradual mobilization

Expected Outcome
- The patient should have excellent tissue reconstruction with the muscle
- There should be little in the way of donor site morbidity
- The rate of seroma formation is high and requires aspiration in the office on occasion
- There will occasionally be some tightness from the scar and numbness of the anterior chest wall

Distant Flaps

Distant flaps come from body parts outside of the upper extremity. Both random-pattern and axial-pattern varieties exist. All distant flaps require a period of attachment between the operated limb and the donor part. They therefore all require at least two stages: attachment and division. When the blood supply to a random-pattern flap is doubtful, preliminary delay and later inset operations may be necessary, making four operations in total. Distant random-pattern flaps were formerly the routine method of providing skin cover to the hand where free grafts would not suffice,[11] but the necessary hospitalization time was long and the outcome unpredictable. When these factors (i.e., attachment, multiple stages, prolonged hospital stay, and doubtful result) are considered together, it is readily understood why the random-pattern distant flap has been largely superseded by the axial-pattern distant flap and it, in turn, by free microvascular flap transfer. There are, however, still indications for the use of both types of conventional distant flaps. The axial flaps all have defined territories based on pedicles that run in the vascular strata previously defined. The need to ensure that the vessel is included in the flap restricts the surgeon's ability to invade its vascular territory too boldly in trying to harvest a flap for a small defect, and the license to thin an axial flap is strictly controlled by the need to preserve the nutrient vascular plane. It follows that for small defects or for ones requiring thin skin, distant axial flaps, either conventional or by free transfer, are unsuitable. Normally, local or regional flaps satisfy the need, but where they are not suitable or available, distant random-pattern flaps are still required. Such a circumstance may arise in loss of palmar skin, circumferential avulsion of soft tissue from the thumb, and small but significant defects (e.g., when bone is exposed on the dorsum of the thumb) in a hand already extensively injured.

Conventional distant axial flaps are indicated in quite different circumstances. They are the most reliable form of coverage when microsurgical expertise is not available. When it is, free flap transfer is the method of choice, not only because it eliminates the problems of attachment and multiple procedures detailed above but also because it ensures a permanent, vigorous blood supply to the injured area. It may be difficult, however, to transfer much spare soft tissue with a free flap. Thus, if it is intended at a later stage to transfer the index finger by pollicization or toes from the foot to restore an amputated thumb or fingers, a conventional axial-pattern flap should be used for skin cover. Its tube pedicle can provide the additional skin necessary to cover the proximal portion of the later digital transfer. The presence of such additional skin allows a minimum of skin to be taken from the foot, so that closure there can be achieved entirely with local skin, a desirable objective. In the case of toe transfer, the use of a conventional flap has the additional benefit over free flap transfer of preserving the vessels of the hand untouched for the later anastomosis to those of the toe. As experience in microvascular surgery increases, this consideration becomes less valid.

Random-Pattern Distant Flaps

As the blood supply of the random-pattern flap derives from the subdermal or subcutaneous plexus, it can be raised at any site on the body. This apparent freedom is severely restricted by considerations of suitability, availability, positioning, and appearance. To give extreme examples, scalp skin is not suitable, penile skin is not available, leg skin would not be comfortable, and neck skin is not cosmetically acceptable. Indeed, when all factors are weighed, few donor sites remain. In the male patient, any site on the torso or the other uninjured arm may be used if no better alternative is available. In the female, only the inguinal region, where the defect can be closed directly and concealed beneath a two-piece swimsuit, is universally acceptable. In practice, this means that random-pattern flaps are rarely used in females, except to transfer thin skin from the region of the iliac crest. In some instances, this type of flap may be indicated

despite the donor site and circulatory difficulties. These would include suture of cutaneous nerves in the flap to branches of the radial nerve in the defect to reinnervate a thumb reconstruction, the use of double flaps to cover both dorsal and palmar wounds and to create a new first web,[114] and the use of several interdigitating flaps to resurface multiple finger injuries.

With the advent of regional axial-pattern flaps (i.e., the radial forearm flap) and the availability of the axial groin flap, there is in fact little application for these flaps today. The donor defects are generally quite ugly, particularly from the chest, even in male patients who usually find these sites marginally acceptable. For these reasons, we feel that these are generally not only a secondary choice for coverage but should be considered as a last resort.

Axial-Pattern Distant Flaps

Groin Flap. The groin flap is an axial-pattern flap of the cutaneous variety (Figure 44.39). Its axial vessel is the superficial circumflex iliac artery, which is a relatively constant vessel, being present in 96% of a series of angiograms.[48] The vessel arises from the femoral artery in the femoral triangle, which forms a vascular "hub," for the pedicles of several flaps converge here. The superficial circumflex iliac artery emerges from the triangle by passing over the medial border of the sartorius immediately after giving off a deep muscular branch. Initially below the deep fascia, the vessel emerges through that fascia as it crosses the sartorius. It passes laterally, parallel to and some 2 cm below the inguinal ligament. At a point below the anterior superior iliac spine, the vessel divides and supplies the skin immediately below the iliac crest. The vascular territory of the superficial circumflex iliac artery therefore ends at some point lateral to the anterior superior iliac spine. Common wisdom and practical experience dictate that the flap can safely be extended beyond the spine by a distance at least equal to the width of the flap. The venous drainage, which is as important as the arterial supply, and lymphatic outflow of the flap have both been studied in detail.[16,83] The report by Penteado[83] gives details of venous variations in the femoral triangle that are important to the microsurgeon; a surgeon intent on using the flap as an axial pedicle need only know that all drainage of this region is to the femoral triangle and therefore will lie within the pedicle. Commonly, no reinnervation of the flap is attempted, but Joshi[47] pointed out that the lateral cutaneous branch of the subcostal or 12th thoracic nerve consistently crosses the iliac crest 5 cm posterior to the anterior superior iliac spine. This can be dissected, divided, and sutured to any available cutaneous nerve ending in the hand. The groin flap can provide skin cover for any defect on any aspect of the hand or of the forearm in its distal two thirds. It can safely be made wide enough to replace massive loss, with the only drawback being that the widest secondary defect that can be readily closed directly is about 12 cm. For defects on both aspects of the hand, the flap can be split longitudinally or used in conjunction with a hypogastric flap, a tensor fascia lata musculocutaneous flap, or a contralateral groin flap. Where a relatively large block of bone is required in the hand in the depths of a soft tissue defect, the iliac crest immediately beneath the flap can be taken as a vascularized composite extension,[10,89] although the bone taken with the superficial circumflex iliac artery does not have as good a blood supply as when taken on the deep circumflex iliac artery.

In planning the groin flap, a pattern of the primary defect should be made first. It is next decided from which direction the flap should approach the defect. For example, for defects primarily on the dorsal aspect of the wrist, the flap pedicle could lie to either the radial or the ulnar side. Time should be taken with this decision, for the obvious choice is not always the correct one. Factors to be considered are the precise location of the defect, the resulting configuration of the tube pedicle, the freedom of pronation and supination of the forearm, and the patient's comfort and exercise postoperatively. The major fact to be appreciated with respect to the configuration of the pedicle *is that it will do well if it is stretched gently and will do poorly if it is kinked*; flaps always perfuse more satisfactorily on a convex surface than on a concave one. To take another example, a defect on the dorsal aspect of the hand extending on

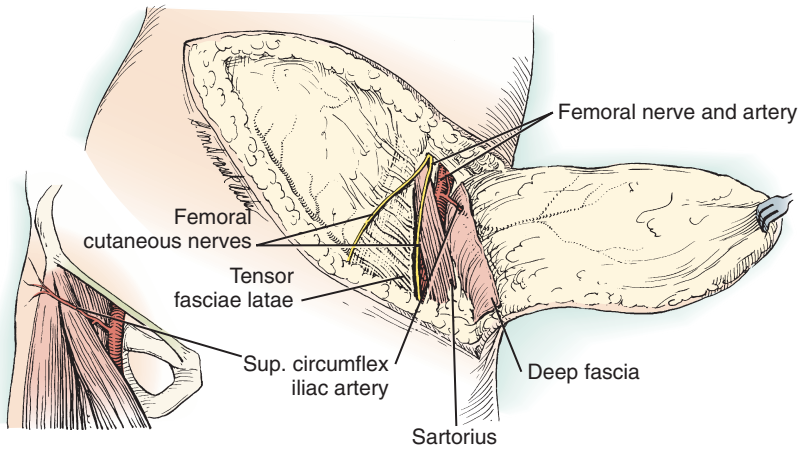

FIGURE 44.39 Groin flap. The groin flap is based on the superficial circumflex iliac artery, which runs parallel to and approximately 1 inch inferior to the inguinal ligament. It emerges through the deep fascia as it crosses the sartorius and breaks up into branches at the level of the anterior superior iliac spine. When the flap is raised, the lateral femoral cutaneous nerve should be preserved or, in certain instances (see text), divided and repaired. The fascia that is divided at the lateral margin of the sartorius can be seen. (From the Christine Kleinert Institute for Hand and Microsurgery, Inc., with permission.)

to the radial border might be best approached by a pedicle around the ulnar border, for full pronation and supination would place little stress on the suture line and would not kink the pedicle. The previously prepared pattern can be extended with a portion to represent the pedicle so that various approaches and positions can be tested. Once the approach and eventual position have been chosen, that edge of the primary defect that will be closest to the pedicle will be known. The original pattern should be laid on the skin immediately below and behind the anterior superior iliac spine, for the more medial, inguinal portion of the flap will largely be used to construct the tube.

A few words about constructing the tube are appropriate at this juncture. Two extreme possibilities should be considered. If a flap is not tubed at all, its distal and lateral margins can be made to fit precisely to the primary defect. The other margin of the defect, adjacent to the pedicle, has to be left unsutured, but the eventual contour of the flap to the hand is excellent, without revision. At the other extreme, if the flap is raised as a rectangle and tubed throughout its length, it could cover a circular defect, but it would approach the defect perpendicularly and would be most difficult to inset after division. Because the first (untubed) flap is unacceptable because of the open wound, poor flap fixation to the defect margins, and difficulties with postoperative exercise, and the latter is unacceptable because of contour, a compromise must be sought. The distal margin of the flap is cut to conform to the edge of the distal half of the defect. When this design is tubed, the distal few centimeters of the lateral edges of the flap come to meet the edge of the proximal half of the defect. After division of the flap, there will be too much skin at the proximal margin, which will require excision as dog-ears at the time of division or at a later stage. The surgeon's ability to tube the groin flap depends on the width of the flap, but also on its thickness. Because its axial vessel emerges through the deep fascia, the flap cannot be thinned appreciably in the part to be tubed, except at the margins. Thus, in choosing the width of the flap, the surgeon must pay heed not only to the width of the primary defect but also to the weight-height ratio of the patient. If this is high, the flap will be thick and must therefore be wide. Skin grafts may be necessary to close the secondary defect, but it is best to do everything to avoid having to skin graft the donor site. It is difficult to get a graft to take in this location, and it leaves a significant soft tissue defect in the side.

Once all these factors have been considered and the patient is prepared and draped, the midline of the flap is drawn out 2 cm (or two fingerbreadths) inferior and parallel to the inguinal ligament. In children, this vessel can be located by measuring below the inguinal ligament by a distance equal to the breadth of the child's index and middle fingers. In most patients, the circumflex iliac artery can be identified in approximately the midanterior thigh with a pencil Doppler, which aids in centering the flap. The elected width of pedicle to be tubed is measured out as far as the anterior superior iliac spine, and the distal, lateral margin of the flap is made to conform to the distal half of the pattern of the primary defect. The part of the flap to cover the primary defect can be wider than the pedicle. There must be a limit to the extent by which it can be wider, but this is not a problem in normal practice. The entire margin of the flap is incised down to the superficial surface of the deep fascia. The distal edge of the flap is placed under tension, and the subcutaneous plane is developed with a knife as far as the anterior superior iliac spine, making sure not to create a cave beneath the midportion of the flap. At this point, the flap is laid in a cephalad direction, and retraction is applied to the inferior incision. The deep fascia is incised at the level of this inferior incision and retracted toward the abdomen to reveal the sartorius, the tensor fascia lata lateral to it, and the intervening intermuscular septum. While the surgeon maintains traction on the flap cephalad and away from the thigh, the deep fascia is divided in the line of the fibers of the sartorius from inferior to superior and, at its lateral border, just medial to the septum between the tensor and sartorius. As this incision in the deep fascia proceeds, the subcutaneous plane previously developed laterally is advanced to meet it. The superficial circumflex iliac artery will be seen in the deep fascia as it is lifted from the sartorius. Incision of the fascia proceeds cephalad beyond the artery as far as the origin of the sartorius from the anterior superior iliac spine. Here the flap is drawn in the opposite direction, caudally, to facilitate dissection of the upper margin. The upper incision, if carried down to the external oblique aponeurosis, will, in the majority of cases, divide the superficial inferior epigastric artery. The flap is retracted caudally off the aponeurosis until the level of the anterior superior iliac spine is reached. The incision previously made in the sartorius fascia is located and turned medially to free the deep fascia of the thigh from the inguinal ligament. In the course of this incision, the lateral cutaneous nerve of the thigh will be encountered. Care must be taken not to injure this, for meralgia paresthetica may result.[75] Although this nerve usually passes deep to the vessel of the flap, in which case it can be freed by dissection, on occasion, it or one of its usual two branches may be superficial and is therefore more likely to be injured and also more likely to kink the vessel of the flap. Any such branches superficial to the artery are divided, placed deep to the vessel, and repaired. All fascial incisions are now completed.

It should be noted that it is possible to raise a groin flap without ever dividing either the fascia or the vessel. However, the consequences may be dire, for the superficial circumflex iliac artery is tethered by the intact fascia. The relaxed and redirected flap pulls on the vessel and may kink it severely (Figure 44.40). Herein lies the explanation for necrotic edges on otherwise well-designed and well-executed groin flaps. The fascia must *always* be incised.

Applying upward traction to the flap, the fascia is dissected from the underlying fibers of the sartorius, paying heed to the vessels, which can sometimes be seen through the elevated fascia. In preparing a pedicled groin flap, dissection can cease at the medial border of the sartorius (Figure 44.41, *B*). In dissecting for free tissue transfer, or where the flap is to be taken to the opposite hand, the pedicle is dissected further, using scissors and forceps. The main hazard is the muscular branch of the superficial circumflex iliac artery. This is isolated by retracting the sartorius laterally with instruments on either side of the pedicle, caudad and cephalad. Once dissected free under loupe magnification, the muscular branch is divided. The pedicle can then be freed as far as its origin.

The flap can now be thinned. This is done by having an assistant hold the flap vertically with hooks or stay sutures and proceeding with curved tenotomy scissors and forceps. Using the scissors with the concave surface uppermost, the surgeon

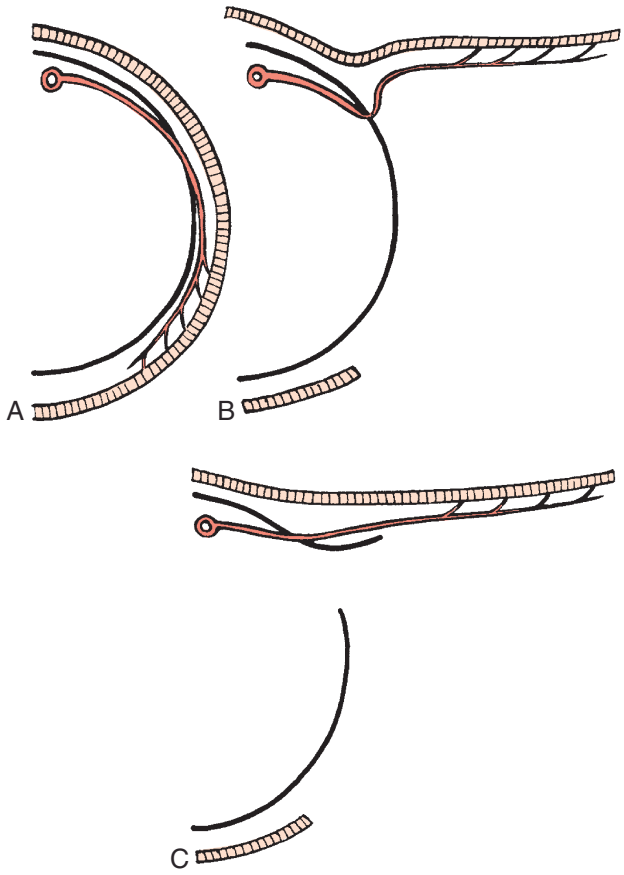

FIGURE 44.40 **A,** In cross-sectional diagram, the course of the superficial circumflex iliac artery is shown. The *black line* represents the deep fascia, and it can be seen that the superficial circumflex iliac artery pierces that fascia. **B,** If the flap is raised without dividing the fascia, the vessel is restrained and kinked by that deep fascia, reducing significantly the blood flow to the flap. **C,** If the fascia is divided, as recommended, at the lateral margin of the sartorius, this kink in the vessel is eliminated.

can thin the flap quite radically at the margins by trimming away fat. In the midline of the flap, the surgeon must be more cautious, or the pedicle may be damaged. Lobules of fat can be lifted with forceps and trimmed away, between periphery and midline, but the deep fascia that has been lifted *must not be transgressed*. Therefore, any fat that lies between it and the skin must be left alone. If there is a significant amount, it makes the tube necessarily bulky.

Closure begins at the lateral end of the secondary defect. It may be difficult, *but the surgeon should not undermine the margins in an attempt to facilitate closure*. Such action only increases the area of the potential dead space and does little to relax the skin. Instead, the surgeon should flex the thigh, take up a heavy suture, and proceed with the knowledge that closure is always possible if the defect was 12 cm or less when first outlined (see Figure 44.41, *C*). (The tension created will inevitably result in postoperative inflammation along the closure. Do not remove sutures for an inflamed wound. To do so would open the entire cavity created by the closure. If this then becomes infected, as is almost inevitable, one has created a disaster akin to a bedsore.) Closure of the secondary defect could continue medially all the way to the pedicle. However, a more comfortable closure is achieved if, in the last few centimeters, the flap is resutured from whence it came. Where these three suture lines meet, the tubing of the flap commences. This should be easily achieved, provided the width has been well tailored to the thickness. If it has not, further marginal thinning should be done. The tube is closed with interrupted sutures. The closure continues until the portion of flap remaining open for the defect is clearly too small. That is, the tube is closed too far. The reason for this is that once the flap is sutured to the hand, it is simple to release sutures from the tube but very awkward to insert them. The limb is now brought to the flap, the planned posture adopted, any minor adjustments made, and the flap sutured in place. It is good to commence this at the center point of the distal margin of the flap and then proceed progressively around both margins alternately toward the pedicle. In this way, little or no distortion is applied to the flap. With each stitch, the skin of the flap is stretched slightly to reproduce tension similar to that present in the margin of the defect. Whether or not this has been done correctly can be determined by looking at the wound edges between each stitch: neither should sit above the other.

On completion of application of the flap, the involved limb is immobilized. It has been suggested that this be done with external fixation between the iliac crest and the radius,[77] but this is not necessary and is disadvantageous if it limits motion of the hand throughout the period of flap attachment. Temporary control can be achieved by placing rolled bandages between the limb and the torso and then strapping the arm in place with tape from the abdomen, around the arm, to the back. The intent of this strapping is to control the arm in such a way that the flap is not kinked; indeed, it is held under gentle traction.

Care must be taken that the flap is not disrupted during recovery from anesthesia. Aside from the surgeon being present during this critical phase, another useful maneuver is to have the anesthesiologist do a brachial block just before awakening the patient. This minimizes stress on (and possible disruption of) the flap suture line during the occasionally turbulent immediate postanesthetic phase. It may be best to perform the block prior to placing the flap so that the arm may be properly abducted to allow the anesthesiologist access to the axilla.

Once the patient has fully recovered from anesthesia, on the first or second postoperative day, all restraints are removed, and the patient is placed in charge of his or her own flap. Clear instructions are given to maintain a little traction and avoid kinking the flap. The patient is shown how to exercise all joints. By depressing the shoulder and carrying the hand toward the umbilicus, the elbow can be flexed to 90 degrees. By elevating the shoulder and carrying the hand toward the knee, it can be fully extended. Taking excess flap to allow tubing of the flap will allow the patient more motion and hopefully prevent stiffness (Figure 44.42). Full pronation and supination, flexion and extension of the wrist, and motion of all the digital joints can be attained, and should be, every waking hour. It is in this respect that the axial flap with its tube pedicle is incontestably superior to even the best-designed random-pattern flap. Patients can be dressed soon after surgery by wearing either jeans or trousers with a pocket removed and a fastening incorporated in the waistband above the pocket.

The groin flap can be used in young children with no increased incidence of flap avulsion during the postoperative period. Unless unforeseen circumstances are encountered, the

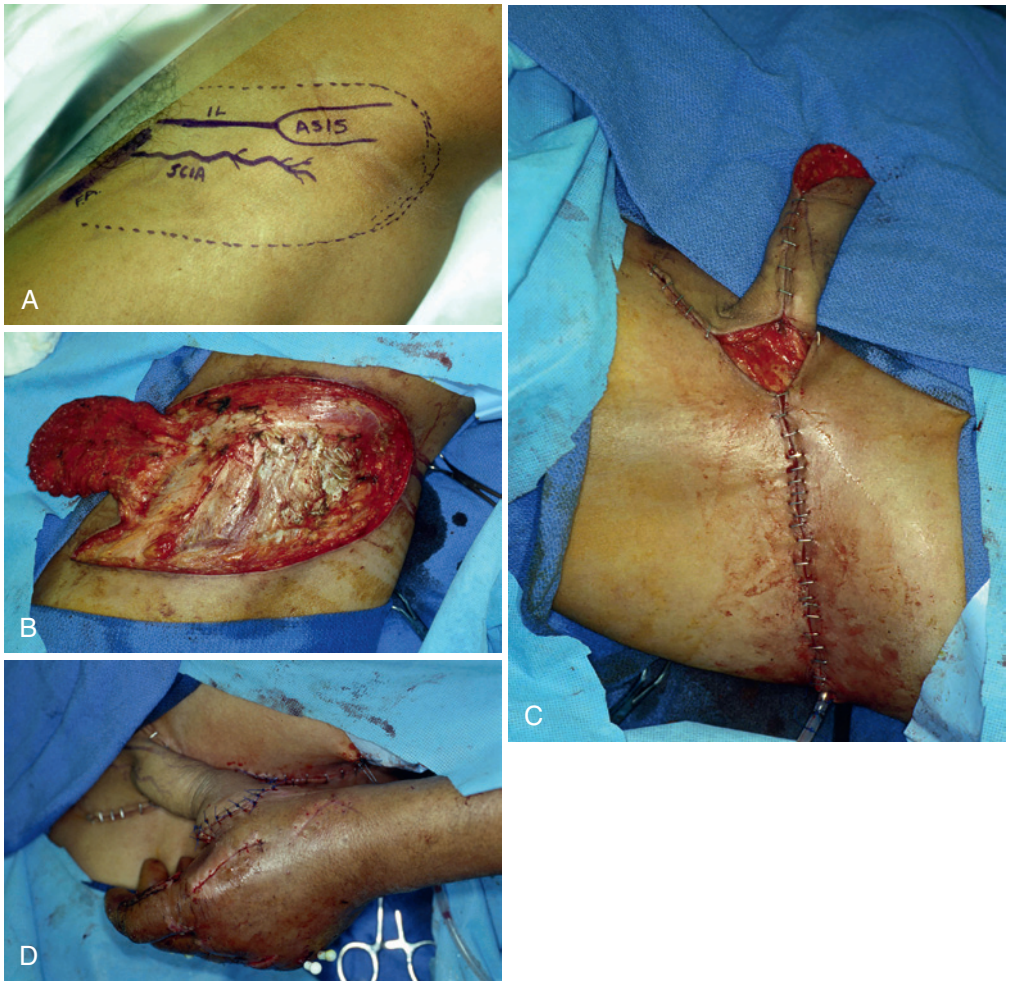

FIGURE 44.41 **A,** Markings for elevation of a pedicled groin flap. The center of the flap is located approximately two fingerbreadths below the inguinal ligament and the pedicle can be located here with a pencil Doppler. **B,** Flap after elevation. The dissection becomes suprafascial at the lateral border of the sartorius to avoid damage to the pedicle. **C,** The donor site has been closed primarily, and the flap has been tubed. This is done prior to inset. **D,** The flap after insetting on the hand.



FIGURE 44.42 Pedicled groin flap with long tubed section. This is ideal in order to allow for motion of the arm and forearm.

complete survival of the groin flap can be predicted with sufficient confidence that the practiced exponent should not hesitate to undertake extensive reconstruction in the bed of the primary defect, including joint replacement and tendon grafts.

Problems with circulation are understandably more likely to arise after division of the pedicle, for the flap, previously nourished by an axial vessel, is now dependent on flow across the lines of attachment. The optimal time at which to perform the division varies considerably, as shown by fluorescein studies.[70] The first requirement for safe division is perfect healing of the line of attachment. The second requirement is that the line of attachment be long when compared with the area of flap skin required on the hand. This is not so, for example, when much or all of the tubed pedicle is required for later use. Division of such a flap should be preceded by a delay procedure. The third requirement is that the surrounding skin of the limb be supple and unscarred. If all these requirements are met, the flap can be safely divided at 3 weeks and inset. If these criteria are not met, then one or more of the following steps should be taken. First, wait. No harm comes from a longer attachment. Second, test the flow. This is done by placing a rubber tourniquet around the tube pedicle and testing whether flow to the flap remains good. Flow can be assessed by the use of systemic fluorescein or by injecting atropine into the flap and measuring the time until the onset of visual disturbance. It may also be assessed by the simple clinical test of sticking a needle into the flap or observing whether reactive hyperemia develops in the flap after 20 minutes

of occlusion. Third, if the flap is divided, and bleeding from the flap on the hand is poor, do not inset it, but simply wrap the hand and return 1 week later, at which time any nonviable portion of the flap can be débrided and the flap inset. Fourth, and this is our routine practice when the tube pedicle is needed to cover a later digital transfer, perform a delay procedure. This is done under local anesthetic and consists of making an incision halfway around the tube pedicle, through which all deep soft tissue in the tube is divided. The wound is closed and the flap divided completely and with confidence 1 week later.

CRITICAL POINTS *Pedicled Groin Flap*

Indications
- Wounds of hand and/or forearm
- Especially when later toe transfers are to be considered

Preoperative Evaluation
- Absence of scars in groin in area of flap to be raised
- Doppler superficial circumflex iliac artery 2 cm below inguinal ligament

Pearls
- Center flap over Dopplered vessel (2 cm below inguinal ligament)
- Make flap longer than needed to allow some elbow/shoulder motion
- Tube excess flap at base
- Suture flap into as broad an area as possible of the wound to increase revascularization

Technical Points
- Begin dissection laterally; stay out of deep iliac fat
- Once over muscles, stay right on muscle
- Vessel may often be identified in depths of flap visually
- Take fascia of sartorius to avoid damage to vessel
- Stop dissection just at medial edge of sartorius
- May safely thin fat from margins of flap
- Close donor site securely *prior* to insetting flap into defect (flex hip)

Pitfalls
- Damaging vessel with elevation (dissection is too superficial)
- Making flap too small (no pedicle for tubing)
- Dehiscence of flap from wound in recovery room
- Dehiscence/infection of donor site

Postoperative Care
- Carefully protect flap until patient is fully awake, to avoid dehiscence
- Suture hand to abdominal wall with large suture
- Strap arm around torso
- May remove protection once patient is fully awake
- Encourage as much motion of elbow and shoulder as possible
- May divide flap in 3 to 4 weeks
- Must have healing of margins of flap to defect of hand
- May perform delay procedure of flap prior to division
- At time of division, if proximal flap (at site of division) is dusky, do not attempt closure (débride nonviable tissue after demarcation and close)

❖ AUTHOR'S PREFERRED METHOD OF TREATMENT: Defects of the Hand and Forearm

Most experienced reconstructive surgeons feel that definitive skin cover at the time of injury is preferable to delayed closure, provided only that débridement is adequate. As is evident from the earlier account of local, regional, and distant flaps, all with both random and axial designs, we have a rich storehouse from which to select that skin cover. If one has microsurgical training, to that store must be added all the free tissue transfers described elsewhere in this book. However, for younger surgeons, these riches may be a source of confusion, causing them to make less than the best choice or, worse, to disregard or remain ignorant of the older techniques in favor of the more complex and more expensive, but more exciting, free skin transfers. In an attempt to offer guidance, we approach the matter of skin cover not from the viewpoint used throughout this chapter (namely, which flaps are available) but rather by the nature of the presenting skin defect (Table 44.3). We have assumed in all that

TABLE 44.3 Author's Preferred Methods for Specific Situations

Region	Palmar Injury	Dorsal Injury, Larger Defects
Distal to PIP joint	Loss more dorsal: "V-Y" advancement	Reversed cross-finger
	Loss more palmar: middle or ring finger–digital artery island flap	Dorsal skin "V-Y" advancement
	<40 years of age	
	Cross-finger	
	Digital artery island	
	>40 years of age	
	Not important: revise amputation	
PIP joint	Cross-finger	Reversed cross-finger
Proximal phalanx	Small defect: transposition from lateral aspect	Reversed cross-finger
	Large defect	
	Palmar alone: cross-finger	
	Plus lateral	
	Index or middle finger: axial flag	
	Ring or small finger: vascular island	
MP joint	Index or middle finger: axial flag	Index or middle finger: axial flag
	Ring or small finger: vascular island	Ring or small finger: vascular island
Metacarpus or several fingers syndactylized	Worthless digit: fillet	Worthless digit: fillet
	Small defect:	
	Vascular island	
	SDMA	
	Large defect (free lateral arm)	Free lateral arm
	Forearm fascia plus skin graft	Anterolateral thigh free flap
Thumb	Loss more dorsal: "V-Y" advancement	FDMA from index
	More palmar:	Forearm (preferably PIA)
	<2/3 pulp: Moberg	
	>2/3 pulp	
	Neurovascular island from toe	
	No donor digit, no microsurgical skills	
	FDMA or SDMA	

FDMA, First dorsal metacarpal artery; *MP*, metacarpophalangeal; *PIA*, posterior interosseous artery; *PIP*, proximal interphalangeal; *SDMA*, second dorsal metacarpal artery.

follows that the possibility of a free skin graft has been weighed and rejected. We look at defects on the fingers separately from those on the thumb, and palmar defects apart from dorsal defects. Dorsal defects can be subdivided further into small and large defects. All small dorsal defects we manage by transposition or rotation flaps taken from either the adjacent dorsal skin or the lateral aspect of the fingers. Wounds over the distal dorsal finger can be usually managed by advancement of the dorsal finger skin as noted above.

Palmar defects distal to the PIP joint are most commonly fingertip injuries.[41] The great majority of these injuries can be managed by allowing secondary healing; however, in such injuries in which more skin is lost dorsally or the amputation is transverse, a "V-Y" advancement flap (Atasoy) may be indicated. When more is lost from the palmar surface, a regional flap is required. In patients who have sustained an injury to the middle or ring finger, the digital artery island flap is the best option. With injury to the index or little fingers, one of the other regional flaps should be selected. A cross-finger flap may be the best option in this circumstance. In those older than 40 years, if the digit is of considerable functional importance, for example, the thumb or a finger where others have been lost, a neurovascular island flap may be justified, with a microvascular toe pulp transfer the preferred choice. When the digit is of less importance, we explain the thoughts outlined earlier to the patient and recommend revision of the amputation. If he or she balks, we proceed as if the patient were younger than 40 years, knowing that he or she understands the potential problems. On the dorsal aspect of the finger distally, if the defect is sufficiently large that we cannot use a local flap, a reversed cross-finger flap is indicated. Defects around the PIP joint we cover with cross-finger flaps, a conventional flap for the palmar surface and a reversed flap for the dorsal surface.

Small defects on the palmar aspect of the proximal phalanx, as are produced in releasing burn contractures, require transposition flaps from the lateral or dorsal aspect of the finger, as described by Green and Dominguez[34] and by Harrison and Morris,[36] respectively. Larger defects that are confined strictly to the palmar surface can be covered with an extended cross-finger flap. For defects that extend onto the lateral aspect to any great extent, we find it difficult to use a conventional cross-finger flap for cover and fear problems with kinking of the pedicle. In such circumstances, the axial flag flap is ideal for defects on the index and middle fingers. However, the vessel of the flag flap is not always reliable in the third and fourth web spaces. We listen for it there with a Doppler. If a vessel cannot be heard, we take a vascular island from the adjacent digit, as described by Rose.[91] For dorsal defects over the proximal phalanx, we prefer an axial flag flap in those digits with a demonstrable vessel, for the quality of the skin is identical to that lost. In others, the reversed cross-finger flap is adequate.

Palmar defects around the MP joint, as with palmar-lateral defects of the proximal phalanx, do well with an axial flag flap, taking care to ensure that the injury did not damage the pedicle. When the vessel cannot be heard, we employ a vascular island. Dorsal defects should be treated similarly. Thus, for example, for full-thickness loss over the middle MP joint, we might use an axial flag from the proximal phalanx of the index finger; for loss over that of the ring finger, an SDMA flap or a vascular island from the small finger might be used.

Injuries over the metacarpus are to the palm or dorsum of the hand. Although skin loss from several adjacent digits over the proximal phalanx can usually be covered by multiple local and regional flaps, on occasion this is not possible, and they should be considered as one large defect and managed as if at the metacarpus. The defects on the digits are temporarily covered by suturing their adjacent margins, thereby creating a syndactyly, which is later divided. Small defects in the palm can be covered with an SDMA flap or a vascular island. This may be in the form of a fillet flap when a vascularized digit is deemed of no functional value. This solution is also applicable to dorsal defects, a situation most commonly encountered in gunshot wounds. For larger defects on either aspect of the metacarpus, we use a free lateral arm flap: fasciocutaneous when its subcutaneous layer is not too thick; fascial when it is. If microsurgical expertise is not available, a pedicled fascial radial forearm flap (covered with a nonmeshed split skin graft or full-thickness skin graft) can be used for palmar defects.[26] For most defects of this location and size, we adopt a reversed radial forearm flap, using the fascia alone or an ulnar artery flap when the cosmetic defect of a fasciocutaneous flap would be distressing. For dorsal defects of the metacarpus, a forearm flap is similarly appropriate, the reversed posterior interosseous artery flap being preferred to the radial artery flap, provided that the vessel is present. For coverage of larger wounds in the hand, and in the absence of microsurgical skills, we believe that the groin flap remains an excellent choice for skin cover. This flap has none of the potential cosmetic and vascular problems that exist with the forearm flap. In practice, however, the groin flap is especially useful for those circumstances in which later microsurgical reconstruction is planned and we know that the skin of the tube will be needed to give additional cover, for example, a later toe transfer.

For dorsal defects on the thumb, we raise an FDMA (Kite) flap from the dorsal aspect of the proximal phalanx of the index finger. When that is not available owing to the extent of injury, we use a reversed PIA flap; if no vessel can be found, we use a radial forearm skin or fascial flap. Tip amputations in the thumb with more loss dorsally require a "V-Y" advancement. Those with loss that is more palmar but is less than two thirds of the pulp are ideal for a Moberg advancement or some variant thereof. When the entire pulp is lost, we replace it with a neurovascular island flap, preferably as a microvascular transfer from the toe. Today, we would rarely perform a pedicled neurovascular island flap from another finger. If no donor digit is available, usually when an island transfer is judged unsuitable for a particular patient, an FDMA or SDMA flap must be used.

Circumferential degloving injuries of the thumb require immediate cover with either a pedicled axial groin flap or an immediate great toe wraparound flap. We usually will perform a groin flap prior to any type of toe transfer, to avoid having to take too much skin from the foot. Toe-to-hand transfer and pollicization both require more skin than that needed simply to cover the primary defect on the thumb. Degloving of a single finger, in the presence of other normal digits, requires amputation; a ray amputation is needed when the degloving involves the proximal phalanx. When several digits have been degloved, we cover them all with a tube pedicle groin flap or pedicled radial forearm flap. Thereafter, for short stumps, we remove the

skin of the flap and skin graft the soft tissue over the stumps. In longer fingers, we leave the flap in place and the digits are used as a mitten. These can be separated only if the blood supply is improved. We have done this by transferring a neurovascular island, either from the foot or from the thumb, if an arteriogram shows the presence of two sufficiently long digital vessels in that digit.

For defects of the wrist, forearm, and elbow, we prefer free tissue transfers, because the patient is not immobilized and a permanent pedicle is provided to the skin cover.[31] We use the lateral arm flap for small defects, the anterolateral thigh[119] or scapular flap for medium ones, and the tailored latissimus flap or anterolateral thigh flap for large ones.[33] When these are not indicated or available, the groin flap can reach defects of both dorsal and palmar aspects as far proximally as the midpoint of the forearm. The pedicled latissimus dorsi flap can reach the elbow with ease and the forearm with difficulty. Defects of the proximal half of the forearm, where no local flaps suffice, can be covered with a pedicled rectus abdominis muscle flap, or, better, an anterolateral thigh fasciocutaneous flap or latissimus dorsi free muscle flap.

The first web space is the remaining specialized region worthy of mention. Contracture here is common, both of congenital and traumatic origin, and the solutions are numerous.[61] We release relatively long yet tight first web contractures, which are composed of normal skin, with a simple 60-degree "Z"-plasty or some variant thereof. When the web is shorter and the tight web margin produces an acute ridge angle, a four-flap "Z"-plasty works well. In other circumstances, when the skin is scarred or the adduction contracture is severe, skin must be brought into the web space by transposition from the dorsum of the thumb or index finger or by rotation from the dorsum of the hand. When these do not suffice or the donor sites are themselves scarred, other skin must be used. It is important that this skin be as thin as possible, for it is pointless to dig a hole, the web space, and promptly fill it with a fat flap. The lateral arm free flap is the best choice to fill a severely scarred first web. The lateral arm flap placed in the first web space can be small enough to primarily close the donor site and fits the defect after release of the web space well, and vascular access for anastomosis is easily obtained with the radial artery and cephalic vein in the snuffbox. If microsurgical skills are not available, then the posterior interosseous or radial forearm fasciocutaneous flaps can be used, donor site issues notwithstanding.

Chemotherapeutic Extravasation Skin Loss

The injury that created the primary defect is of significance mainly when its nature makes it difficult or impossible to define the extent of eventual skin loss. One instance of clinical significance is the chemical injury resulting from extravasation of chemotherapeutic agents, of which the most common is doxorubicin hydrochloride (Adriamycin). Identification of the agent in the tissues has been the subject of some debate.[17,20] However, all are agreed that wide excision of all potentially damaged tissues should be undertaken. A period of observation before applying definitive skin cover has been recommended.[60] The cover eventually chosen should be robust. In this situation, we prefer the ulnar forearm flap for the reasons outlined earlier. If this is unavailable, free tissue transfer is probably the procedure of choice.

Postoperative Care

Postoperative care is directed toward the comfort of both patient and flap and is the responsibility of a team of trained, trusted nurses. The comfort of the patient is pursued through the usual channels and should not be neglected because of concern for the flap. It is important that the patient be up and about as soon as possible, preferably starting on the first postoperative day. All joints are mobilized. Comfort of the flap is achieved mainly by avoiding kinks in its pedicle if the patient has been treated with a pedicled groin flap. This is ensured by correct positioning of the involved upper limb and of the patient. Once the correct position is attained, other patient positions that similarly avoid kinking should also be sought. If conscious, the patient is shown which part of the flap to inspect for kinking and which positions are acceptable. The earlier the patient takes charge of the flap, the better. If the patient is not conscious, the position must be maintained by strapping. Skin-to-skin contact produces maceration and the chance of consequent infection. Therefore, padding is used to ensure that all skin surfaces are exposed to air. A routine of wound cleansing is established, using hydrogen peroxide followed by a thin smear of antibiotic ointment. This routine has many benefits. It eliminates a nutritious medium for bacteria. It ensures that color assessment is neither obscured by blood staining nor impaired by vivid contrast within the observer's visual field. It permits assessment of the rate of bleeding from the wound, in itself a valuable index of venous insufficiency. Finally, it has an inestimable effect on the morale of the patient who can see the wound.

Flap Failure

Flaps fail for a number of reasons, some of which are still debated.[50,100] Therefore, having made the patient and the flap comfortable, the nurse observes the flap regularly to ensure its continued good health. There are several steps in this process.

1. *Observe the color of the flap.* Difficult to learn and impossible to convey adequately, color assessment remains a mainstay of care. The lighting must always be good. The observer can start by neutralizing his or her color perception by looking for 10 seconds at an area of normal skin, similar to the flap. He or she then assesses the flap. The random-pattern and axial-pattern flaps differ in their color. A healthy random-pattern flap is pink. If arterial supply is inadequate, it becomes pale with a faint blue-gray tinge. If venous drainage is occluded, it is first an angry red and then progressively purple-red and purple-blue. The axial-pattern flap, especially the groin flap, is pale to a degree that makes the novice nervous. It is not a pure white, as can be detected by comparing it with a sheet of white paper, but rather a very pale pink. Changes in a failing flap are much more rapid and dramatic in the random than in the axial pattern. Within 48 hours, the failed portion of a random-pattern flap becomes cyanosed and then blistered, and the margin between the part that will fail and that which will survive is represented by a clear line. The sick axial flap at first assumes a waxy pallor, white tinged with yellow or brown, that differs from its healthy pink pallor by a margin so subtle that only the experienced are pessimistic. The failed

margin then becomes indurated and may blister, but doubts concerning the extent of loss persist for as long as a week.

2. *Observe the refill after blanching by fingertip pressure or by running a blunt point across the flap*. If refill after blanching is slow and the flap is pale, arterial insufficiency is the likely cause. Very slow refill may be seen in a flap with no flow whatsoever, owing to the movement of stagnant blood by surrounding tissue pressures. If it is too swift and the flap has a bluish hue, venous outflow is impaired. This may be caused by kinking and should be corrected. Kinking of a flap pedicle is similar to strangulation of bowel. In both cases, the pressure is not high enough initially to occlude the arterial flow, but it impedes the venous drainage. The occluded area therefore becomes engorged, and tissue tension rises to a point at which arterial inflow is finally arrested and the tissue dies in engorgement.[108]
3. *Measure the temperature of the flap.* This may be done with the dorsum of the middle phalanx of the observer, comparing the flap with tissue adjacent both to the pedicle and to the primary defect. A marked difference is a significant index of impaired flow. When there is little or no difference, it cannot be concluded that the flap is undoubtedly well, however, for the warmth may be largely or entirely transmitted from the underlying bed.
4. *Stick the flap and adjacent tissue with an 18-gauge needle or a No. 11 scalpel blade*. Take care to go to the same depth, and observe the bleeding. Although this cannot be done repeatedly, it is permissible when the first three clinical tests leave serious doubt. A healthy flap should yield blood of the same color as the control and should bleed just a little longer. If no bleeding occurs or does so only briefly, arterial inflow is inadequate. If the blood is darker and bleeding persists much longer, there is venous congestion. For the same reason, persistent bleeding from the marginal wounds of a flap indicates venous inadequacy.

Many more complex tests of flap viability have been introduced. They fall into three broad categories: detection of an alteration in local tissue constituent, observation of the presence in the flap of systemically administered agents, and monitoring of pulsatile flow within the flap. These generally have little application in pedicled flaps, as problems with pedicled flaps are more usually due to poor design that is not amenable to surgical intervention. Although a pedicle flap can certainly undergo kinking or can be sutured in so that flow is compromised, these problems are usually apparent very early on and can be addressed. In most cases, however, there is little need to monitor pedicled flaps; they will either survive or they will not, primarily depending on the appropriateness of their design. A few problems can be seen later on, however, and their management is discussed in the following.

Salvage of a Failing Flap

What actions can be taken to salvage a failing flap?

1. *Seek and eliminate any kinks in the pedicle.* Multiple small kinks produce an accordion-like appearance and are equally as harmful as one large obstruction. Flaps do best if they lie on a convex surface and are gently stretched, thereby eliminating all possible occlusion and reducing edema to a minimum. This should be explained to the patient at an early stage so that he or she can take care of the flap in the case of pedicled flaps.
2. *Check the patient's general condition.* Hypotension, cardiopulmonary impairment, or a low circulating volume as revealed by urinary output may all affect oxygenation of the flap. Cold extremities may be caused by circumstances as grave as advanced shock or as simple as a low room temperature. Both should be evaluated and corrected.
3. *Look for signs of hematoma and evacuate if found.* Whenever the possibility of hematoma exists, the surgeon should have inserted a drain underneath the flap. Ensure that it is functioning. If no drain is present, the flap is swollen and discolored, there is persistent serosanguineous oozing from the flap wounds, and edema is revealed by pitting on pressure, a hematoma is likely. This has been shown to cause loss of a flap, but it can be saved by evacuation of the hematoma.[76] The use of a Penrose or a small, flat Silastic drain often allows expression of the hematoma via the drain site at the bedside (if it has not been sutured too tightly), which can improve a potentially bad situation. If the hematoma is larger, it should be evacuated in the operating room as a formal procedure.
4. *Look for unduly tight stitches and release them.* This should be done only by the operating surgeon, for only he or she knows their significance.
5. *Reposition the patient.* Determine in particular whether elevation or dependency of the limb improves the flow. If it does, make the patient comfortable in this new position.

There are as many publications in the literature concerning methods of enhancing flap survival as there are of monitoring it, possibly more. They appear to be equally fruitless. Once again, they fall into three main categories: alteration of the environment, physical applications, and administration of drugs. In the end, the surgeon is left with the knowledge that the only way to ensure that a flap will survive is to follow simple rules: assess the primary defect carefully, select the correct flap for that defect and execute it properly, and train nurses who can be trusted to protect and care for the work.

REFERENCES

1. Atasoy E, Ioakimidis E, Kasdan ML, et al: Reconstruction of the amputated finger tip with a triangular volar flap. A new surgical procedure. *J Bone Joint Surg Am* 52:921–926, 1970.
2. Attar KH, Imran D, Iyer S: Vacuum-assisted closure (VAC) therapy in the management of digital pulp defects. *Acta Chir Plast* 49(3):75–76, 2007.
3. Barker DE: Skin thickness in the human. *Plast Reconstr Surg* 7(2):115–116, 1951.
4. Baur PS, Larson DL, Stacey TR: The observation of myofibroblasts in hypertrophic scars. *Surg Gynecol Obstet* 141(1):22–26, 1975.
5. Birch J, Branemark PI: The vascularization of a free full thickness skin graft. I. A vital microscopic study. *Scand J Plast Reconstr Surg* 3(1):1–10, 1969.
6. Boyce ST, Goretsky MJ, Greenhalgh DG, et al: Comparative assessment of cultured skin substitutes and native skin autograft for treatment of full-thickness burns. *Ann Surg* 222(6):743–752, 1995.
7. Brunelli F, Giele H, Perrotta R: Reverse posterior interosseous flap based on an exteriorized pedicle to cover digital skin defects. *J Hand Surg [Br]* 25(3):296–299, 2000.
8. Buchler U, Frey H-P: Retrograde posterior interosseous flap. *J Hand Surg [Am]* 16:283–292, 1991.
9. Bunyan AR, Mathur BS: Medium thickness plantar skin graft for the management of digital and palmar flexion contractures. *Burns* 26(6):575–580, 2000.

10. Button M, Stone EJ: Segmental bony reconstruction of the thumb by composite groin flap: A case report. *J Hand Surg [Am]* 5:488–491, 1980.
11. Cannon B, Trott AW: Expeditious use of direct flaps in extremity repairs. *Plast Reconstr Surg* 4:415–419, 1949.
12. Cavadas PC, Ibanez J, Landin L, et al: Use of the reversed posterior interosseous flap in staged reconstruction of mutilating hand injuries before toe transfers. *Plast Reconstr Surg* 122(6):1823–1826, 2008.
13. Chandrasegaram MD, Harvey J: Full-thickness vs split-skin grafting in pediatric hand burns—a 10-year review of 174 cases. *J Burn Care Res* 30(5):867–871, 2009.
14. Chase RA: Belaboring a principle. *Ann Plast Surg* 11:255–260, 1983.
15. Clark JM: Reconstruction of biceps brachii by pectoral muscle transplantation. *Br J Surg* 34:180–182, 1946.
16. Clodius L, Smith PJ, Bruna J, et al: The lymphatics of the groin flap. *Ann Plast Surg* 9:447–458, 1982.
17. Cohen FJ, Manganaro J, Bezozo RC: Identification of involved tissue during surgical treatment of doxorubicin-induced extravasation necrosis. *J Hand Surg [Am]* 8:43–45, 1983.
18. Converse JM, Uhlschmid GK, Ballantyne DL, Jr: Plasmatic circulation in skin grafts. The phase of serum imbibition. *Plast Reconstr Surg* 43(5):495–499, 1969.
19. Costa H, Gracia ML, Vranchx J, et al: The posterior interosseous flap: a review of 81 clinical cases and 100 anatomical dissections—assessment of its indications in reconstruction of hand defects. *Br J Plast Surg* 54(1):28–33, 2001.
20. Cuono CB: Doxorubicin-induced extravasation necrosis. *J Hand Surg [Am]* 8:497–498, 1983.
21. Dantzer E, Braye FM: Reconstructive surgery using an artificial dermis (Integra): results with 39 grafts. *Br J Plast Surg* 54(8):659–664, 2001.
22. DeFranzo AJ, Marks MW, Argenta LC, et al: Vacuum-assisted closure for the treatment of degloving injuries. *Plast Reconstr Surg* 104(7):2145–2148, 1999.
23. Dos Santos LF: The vascular anatomy and dissection of the free scapular flap. *Plast Reconstr Surg* 73:599–603, 1984.
24. Dowden RV, McGraw JB: Muscle flap reconstruction of shoulder defects. *J Hand Surg [Am]* 5:382–390, 1980.
25. El Hadidy M, Tesauro P, Cavallini M, et al: Contraction and growth of deep burn wounds covered by non-meshed and meshed split thickness skin grafts in humans. *Burns* 20(3):226–228, 1994.
26. Engelhardt TO, Rieger UM, Schwabegger AH, et al: Functional resurfacing of the palm: flap selection based on defect analysis. *Microsurgery* 32(2):158–166, 2012.
27. Eo S, Cho S, Shin H, et al: The utility of Alloderm in hand resurfacing. *J Plast Reconstr Aesthet Surg* 63(1):e41–e43, 2010.
28. Foucher G, Braun JB: A new island flap transfer from the dorsum of the index to the thumb. *Plast Reconstr Surg* 63:344–349, 1979.
29. Foucher G, Khouri RK: Digital reconstruction with island flaps. *Clin Plast Surg* 24(1):1–32, 1997.
30. Frame JD, Still J, Lakhel-LeCoadou A, et al: Use of dermal regeneration template in contracture release procedures: a multicenter evaluation. *Plast Reconstr Surg* 113(5):1330–1338, 2004.
31. Friedrich JB, Pederson WC, Bishop AT, et al: New workhorse flaps in hand reconstruction. *Hand (N Y)* 7(1):45–54, 2012.
32. Furnas DW, Furnas H: Absence of the lower part of the latissimus dorsi muscle: An important anatomical variation. *Ann Plast Surg* 10:70–71, 1983.
33. Giessler GA, Schmidt AB, Germann G, et al: The role of fabricated chimeric free flaps in reconstruction of devastating hand and forearm injuries. *J Reconstr Microsurg* 27(9):567–573, 2011.
34. Green DP, Dominguez OJ: A transpositional skin flap for release of volar contractures of a finger at the MP joint. *Plast Reconstr Surg* 64:516–520, 1979.
35. Gregor S, Maegele M, Sauerland S, et al: Negative pressure wound therapy: a vacuum of evidence? *Arch Surg* 143(2):189–196, 2008.
36. Harrison SH, Morris A: Dupuytren's contracture: The dorsal transposition flap. *Hand* 7:145–149, 1975.
37. Herscovici D, Jr, Sanders RW, Scaduto JM, et al: Vacuum-assisted wound closure (VAC therapy) for the management of patients with high-energy soft tissue injuries. *J Orthop Trauma* 17(10):683–688, 2003.
38. Holevich J: A new method of restoring sensibility to the thumb. *J Bone Joint Surg Br* 45:496–502, 1963.
39. Hunter JE, Teot L, Horch R, et al: Evidence-based medicine: vacuum-assisted closure in wound care management. *Int Wound J* 4(3):256–269, 2007.
40. Hurst LN, Brown DH, Murray KA: Prolonged life and improved quality for stored skin grafts. *Plast Reconstr Surg* 73(1):105–110, 1984.
41. Idler R, Strickland JW: Management of soft tissue injuries to the fingertip. *Orthop Rev* 11:25–39, 1982.
42. Iida Y, Numata T, Shiba K, et al: Hemodynamic changes of the hand after radial forearm flap harvesting. *Ann Plast Surg* 49(2):156–160, 2002.
43. Iselin F: The flag flap. *Plast Reconstr Surg* 52:374–377, 1973.
44. Jackson DM, Stone PA: Tangential excision and grafting of burns. The method, and a report of 50 consecutive cases. *Br J Plast Surg* 25(4):416–426, 1972.
45. Jawad AS, Harrison DH: The island sensate ulnar artery flap for reconstruction around the elbow. *Br J Plast Surg* 43(695):698, 1990.
46. Johnson MK, Cohen MJ: *The hand atlas*, Springfield, Ill., 1975, Charles C Thomas.
47. Joshi BB: Neural repair for sensory restoration in a groin flap. *Hand* 9:221–225, 1977.
48. Katai K, Kido M, Numaguchi Y: Angiography of the iliofemoral arteriovenous system supplying free groin flaps and free hypogastric flaps. *Plast Reconstr Surg* 63:671–679, 1979.
49. Katrana F, Kostopoulos E, Delia G, et al: Reanimation of thumb extension after upper extremity degloving injury treated with Integra. *J Hand Surg Eur Vol* 33(6): 800–802, 2008.
50. Kerrigan CL: Skin flap failure: pathophysiology. *Plast Reconstr Surg* 72:766–774, 1983.
51. Khouri RK: The radial forearm flap: a reconstructive chameleon. *J Reconstr Microsurg* 10(6):403–404, 1994.
52. Kolker AR, Coombs CJ, Meara JG: A method for minimizing donor site complications of the radial forearm flap. *Ann Plast Surg* 45(3):329–331, 2000.
53. Krizek TJ, Robson MC, Kho E: Bacterial growth and skin graft survival. *Surg Forum* 18:518–519, 1967.
54. Kutler WA: A new method for finger tip amputation. *JAMA* 133:129, 1947.
55. Lamberty BGH, Cormack GC: The forearm angiotomes. *Br J Plast Surg* 35:420–429, 1982.
56. Landra AP: The latissimus dorsi musculocutaneous flap used to resurface a defect on the upper arm and restore extension to the elbow. *Br J Plast Surg* 32:275–277, 1979.
57. Leffler M, Horch RE, Dragu A, et al: The use of the artificial dermis (Integra) in combination with vacuum assisted closure for reconstruction of an extensive burn scar—a case report. *J Plast Reconstr Aesthet Surg* 63(1):e32–e35, 2010.
58. Levine NS, Lindberg RB, Mason AD, Jr, et al: The quantitative swab culture and smear: A quick, simple method for determining the number of viable aerobic bacteria on open wounds. *J Trauma* 16(2):89–94, 1976.
59. Limberg AA: Design of local flaps. In Gibson T, editor: *Modern trends in plastic surgery*, ed 2, London, 1966, Butterworths.
60. Linder RM, Upton J, Osteen R: Management of extensive doxorubicin hydrochloride extravasation injuries. *J Hand Surg [Am]* 8:32–38, 1983.
61. Lister GD, Milward TM: Skin contracture of the first web space. In *Trans Sixth Intl Congress Plast Reconstr Surg*, Paris, 1976, pp 594–604.
62. Lovie MJ, Duncan GM, Glasson DW: The ulnar artery forearm free flap. *Br J Plast Surg* 37:486–492, 1984.
63. Macht SD, Watson HK: The Moberg volar advancement flap for digital reconstruction. *J Hand Surg [Am]* 5:372–376, 1980.
64. MacMillan BG: The use of mesh grafting in treating burns. *Surg Clin North Am* 50(6):1347–1359, 1970.
65. Mahoney J, Naiberg J: Toe transfer to the vessels of the reversed forearm flap. *J Hand Surg [Am]* 12:62–65, 1987.
66. Manders EK, Melitz C, Artim LS: Danger of using a Padgett dermatome blade in Zimmer dermatome. *Plast Reconstr Surg* 105(4):1581–1582, 2000.
67. Mann R, Gibran NS, Engrav LH, et al: Prospective trial of thick vs standard split-thickness skin grafts in burns of the hand. *J Burn Care Rehabil* 22(6):390–392, 2001.
68. Mathes SJ, Nahai F: Muscle flap transposition with function preservation: Technical and clinical considerations. *Plast Reconstr Surg* 66:242–249, 1980.
69. Mathes SJ, Nahai F: Classification of the vascular anatomy of muscles: Experimental and clinical correlation. *Plast Reconstr Surg* 67:177–187, 1981.
70. McGrath MH, Adelberg D, Finseth F: The intravenous fluorescein test: Use in timing of groin flap division. *J Hand Surg [Am]* 4:19–22, 1979.
71. McGregor IA: *Fundamental techniques of plastic surgery*, ed 7, Edinburgh, 1980, Churchill Livingstone.
72. Mendelson BC, Masson JK: Treatment of chronic radiation injury over the shoulder with a latissimus dorsi myocutaneous flap. *Plast Reconstr Surg* 60:681–691, 1977.
73. Moberg E: Aspects of sensation in reconstructive surgery of the upper extremity. *J Bone Joint Surg Am* 46:817–825, 1964.
74. Morton D, Jr, Madden JW, Peacock EE, Jr: Effect of a local smooth muscle antagonist on wound contraction. *Surg Forum* 23(0):511–512, 1972.
75. Moscona AR, Hirshowitz B: Meralgia paresthetica as a complication of the groin flap. *Ann Plast Surg* 4:161–163, 1980.
76. Mulliken JB, Healey NA: Pathogenesis of skin flap necrosis from an underlying hematoma. *Plast Reconstr Surg* 63:540–546, 1979.
77. Nappi JF, Drabyn GA: External fixation for pedicle-flap immobilization: A new method providing limited motion. *Plast Reconstr Surg* 72:243–245, 1983.
78. Ng R, Sebastin SJ, Tihonovs A, et al: Hand in glove–VAC dressing with active mobilisation. *J Plast Reconstr Aesthet Surg* 59(9):1011–1013, 2006.
79. Nguyen DQ, Potokar TS, Price P: An objective long-term evaluation of Integra (a dermal skin substitute) and split thickness skin grafts, in acute burns and reconstructive surgery. *Burns* 36(1):23–28, 2010.

80. Orgill DP, Manders EK, Sumpio BE, et al: The mechanisms of action of vacuum assisted closure: more to learn. *Surgery* 146(1):40–51, 2009.
81. Peacock EE: Reconstruction of the hand by the local transfer of composite tissue island flaps. *Plast Reconstr Surg* 25:298–311, 1960.
82. Pederson WC, Eades E, Occhialini A, et al: The distally-based radial forearm free flap with valvulotomy of the cephalic vein; a preliminary report. *Br J Plast Surg* 43:140–144, 1990.
83. Penteado CV: Venous drainage of the groin flap. *Plast Reconstr Surg* 71:678–682, 1983.
84. Penteado CV, Masquelat AC, Chevrel JP: The anatomic basis of the fasciocutaneous flap of the posterior interosseous artery. *Surg Radiol Anat* 8:209–215, 1986.
85. Pho RWH: Local composite neurovascular island flap for skin cover in pulp loss of the thumb. *J Hand Surg [Am]* 4:11–15, 1979.
86. Quaba AA, Davison PM: The distally-based dorsal hand flap. *Br J Plast Surg* 43:28–39, 1990.
87. Reddick LP: Seroma after latissimus dorsi myocutaneous flap for breast reconstruction (letter). *Plast Reconstr Surg* 85:826, 1990.
88. Reid DAC, Taylor GI: The vascular territory of the acromiothoracic axis. *Br J Plast Surg* 37:194–212, 1984.
89. Reinisch JF, Winters R, Puckett CL: The use of the osteocutaneous groin flap in gunshot wounds of the hand. *J Hand Surg [Am]* 9:12–17, 1984.
90. Reisman NR, Dellon AL: The abductor digiti minimi muscle flap: A salvage technique for palmar wrist pain. *Plast Reconstr Surg* 72:859–863, 1983.
91. Rose EH: Local arterialized island flap coverage of difficult hand defects preserving donor digit sensibility. *Plast Reconstr Surg* 72:848–857, 1983.
92. Rudolph R: Inhibition of myofibroblasts by skin grafts. *Plast Reconstr Surg* 63(4):473–480, 1979.
93. Russell R, Pribaz JJ, Zook E, et al: Functional evaluation of latissimus dorsi donor site. *Plast Reconstr Surg* 78(3):336–344, 1986.
94. Sanford S, Gore D: Unna's boot dressings facilitate outpatient skin grafting of hands. *J Burn Care Rehabil* 17(4):323–326, 1996.
95. Sawhney CP, Subbaraju GV, Chakravarti RN: Healing of donor sites of split skin grafts. An experimental study in pigs. *Br J Plast Surg* 22(4):359–364, 1969.
96. Scherer SS, Pietramaggiori G, Mathews JC, et al: The mechanism of action of the vacuum-assisted closure device. *Plast Reconstr Surg* 122(3):786–797, 2008.
97. Schwanholt C, Greenhalgh DG, Warden GD: A comparison of full-thickness versus split-thickness autografts for the coverage of deep palm burns in the very young pediatric patient. *J Burn Care Rehabil* 14(1):29–33, 1993.
98. Shepard GH: The storage of split-skin grafts on their donor sites. Clinical and experimental study. *Plast Reconstr Surg* 49(2):115–122, 1972.
99. Shepard GH: The use of lateral V-Y advancement flaps for fingertip reconstruction. *J Hand Surg [Am]* 8:254–259, 1983.
100. Sloan GM, Reinisch JF: Flap physiology and the prediction of flap viability. *Hand Clin* 1:609–620, 1985.
101. Snow JW: Use of a volar flap for repair of fingertip amputations. A primary report. *Plast Reconstr Surg* 40:163–168, 1967.
102. Soutar DS, Tanner NSB: The radial forearm flap in the management of soft tissue injuries of the hand. *Br J Plast Surg* 37:18–26, 1984.
103. Stone PA, Madden JW: Effect of primary and delayed split skin grafting on wound contraction. *Surg Forum* 25(0):41–44, 1974.
104. Tan O: Reverse posterior interosseous flap in childhood: a reliable alternative for complex hand defects. *Ann Plast Surg* 60(6):618–622, 2008.
105. Taylor GI, Caddy CM, Watterson PA, et al: The venous territories (venosomes) of the human body: Experimental study and clinical implications. *Plast Reconstr Surg* 86:185–213, 1990.
106. Terzis JK: Functional aspects of reinnervation of free skin grafts. *Plast Reconstr Surg* 58(2):142–156, 1976.
107. Tranquilli-Leali E: Ricostruzione dell'apice delle falangi ungueali mediante autoplastica volare peduncolata per scorrimento. *Infort Traum Lavoro* 1:186–193, 1935.
108. Tsuzuki K, Yanai A, Tange I, et al: The influence of congestion and ischemia on survival of an experimental vascular pedicle island flap. *Plast Reconstr Surg* 84:789–793, 1989.
109. Ubbink DT, Westerbos SJ, Nelson EA, et al: A systematic review of topical negative pressure therapy for acute and chronic wounds. *Br J Surg* 95(6):685–692, 2008.
110. Van den Kerchhove E, Boeckx W, Kochuyt A: Silicone patches as a supplement for pressure therapy to control hypertrophic scarring. *J Burn Care Rehabil* 12(4): 361–369, 1991.
111. Vande Berg JS, Rudolph R: Immunohistochemistry of fibronectin and actin in ungrafted wounds and wounds covered with full- and split-thickness skin grafts. *Plast Reconstr Surg* 91(4):684–692, 1993.
112. Vecchione TR: Hair growth as a late sequela in skin grafts from the groin. *Br J Plast Surg* 30(1):52–53, 1977.
113. Verolino P, Casoli V, Masia D, et al: A skin substitute (Integra) in a successful delayed reconstruction of a severe injured hand. *Burns* 34(2):284–287, 2008.
114. Vilain R, Dupuis JF: Use of the flag flap for coverage of a small area on a finger or the palm. 20 years experience. *Plast Reconstr Surg* 51:397–401, 1973.
115. Ward RS: Pressure therapy for the control of hypertrophic scar formation after burn injury. A history and review. *J Burn Care Rehabil* 12(3):257–262, 1991.
116. Wax MK, Winslow CP, Andersen PE: Use of allogenic dermis for radial forearm free flap donor site coverage. *J Otolaryngol* 31(6):341–345, 2002.
117. Williamson JS, Snelling CF, Clugston P, et al: Cultured epithelial autograft: five years of clinical experience with twenty-eight patients. *J Trauma* 39(2):309–319, 1995.
118. Yang G: Forearm free skin flap transplantation. *Natl Med J China* 61:139, 1981.
119. Yildirim S, Taylan G, Eker G, et al: Free flap choice for soft tissue reconstruction of the severely damaged upper extremity. *J Reconstr Microsurg* 22(8):599–609, 2006.
120. Zancolli EA, Angrigianni C: Colgafo dorsal de antebrazo (en "isla" con pedianco de vasos interoseos postemomes). *Rev Asoc Arg Ortop Traumatos* 51:161–168, 1986.
121. Zancolli EA, Mitre H: Latissimus dorsi transfer to restore elbow flexion. *J Bone Joint Surg Am* 55:1265–1275, 1973.

45

Free Flaps to the Hand and Upper Extremity

Neil F. Jones and Graham D. Lister

In contradistinction to a split-thickness or full-thickness skin graft, a flap receives its blood supply independent from the underlying bed on which it is laid. An *axial-pattern flap* derives its circulation through an inflow artery and an outflow vein, which is termed the *vascular pedicle*. When this pedicle of an axial-pattern flap is divided, the flap becomes a *free flap*. Alternative terms include *microsurgical free flap*, *microvascular flap*, and *free tissue transfer*. A free flap is any segment of skin, fascia, muscle, or bone, or composite combination of some of these tissues, that is completely detached from its donor site and transferred to a distant site and for which the blood supply is immediately restored by microvascular anastomoses of its inflow artery and outflow vein to recipient blood vessels in the vicinity of the defect. More than 40 years ago, the first successful free tissue transfers[26] were allied to a new understanding of the axial pattern of certain vascular territories. Published review articles have since attested to the rapid and continuing growth in the number and variety of such free tissue transfers, throughout the body and specifically to the upper extremity.[31,33,94,102]

INDICATIONS

The general indications for flap coverage (see Chapter 44) are (1) a defect with exposed joint cartilage, bone devoid of periosteum, or tendon devoid of paratenon that cannot support the neovascularization of a skin graft and (2) a defect at any specific location in which a skin graft might be subject to exposure and repeated ulceration or might impair later reconstruction.

But why use a free flap, which is the most complex technique in the reconstructive hierarchy? Local or regional flaps to the hand have a distinct advantage in that they provide skin of similar color, texture, and thickness and do not require a donor defect elsewhere in the body. However, they are limited in their size and availability. The larger the primary defect created by injury or excision, the less local skin remains to provide flap coverage. Even when the area is large enough, the thickness required to fill a defect is often lacking. Furthermore, raising a local flap inflicts additional injury on the traumatized limb. The resultant compound wound may impair hand function more than the initial defect.

If not local flaps, are there disadvantages to distant pedicle flaps? Distant pedicle flaps (e.g., the groin flap) can provide sufficient tissue for all but the most massive defects. However, circumferential defects are difficult to cover; the hand must be dependent during attachment; positioning may be uncomfortable; lack of exercise may result in more joint stiffness; the flap may be avulsed by a young or an uncooperative patient; and the thickness of the tube presents a later problem of inset and contour. Most importantly, a pedicled flap is no longer supported by its vascular pedicle after division, and the flap becomes something of a parasite, obtaining nutrition from the underlying scarred bed. In contrast, a free flap has a permanent vascular pedicle. Although the contention that a flap brings a new blood supply to relatively avascular tissue is fallacious, certainly at the time the flap is applied and probably in the long term, there is merit in the fact that it will not place additional vascular demands on the area of the defect, further compromising the limb. There is a strong similarity between tissues adjacent to a major wound and those that have been irradiated. The advantage of a "permanent pedicle, blood-carrying flap" in coverage of radiation ulcers was shown many years ago.

Free flaps offer an attractive alternative to the limitations of conventional techniques of skin coverage. They are now available in virtually any size and thickness and may be cut to fit the defect with incomparable precision. They permit elevation of the limb and early mobilization and are relatively unaffected by random movement in the infant or disoriented patient.

CONTRAINDICATIONS

Free tissue transfer in its early years was a lengthy, unpredictable undertaking. In one series of over 500 cases performed in Ljubljana between 1976 and 1983, only 12 of the first 100 free flap procedures took less than 6 hours to complete.[41] By contrast, 92 of the last 100 were finished in less than 6 hours, 24 of them in less than 4 hours. The failure rate in the first 100 was 26% and in the last 100, 4%. Similar survival rates have been reported from other centers. Free tissue transfer is now a relatively rapid and highly reliable procedure when performed by an experienced team.

Free flaps are equally successful in both pediatric and elderly patients.[54,108,125] The youngest patient on whom the authors have performed a free tissue transfer was 9 months of age; the oldest, 87 years. Both have done well, with no complications attributable to their ages. There were only 2 failures in a recent series of 433 free tissue transfers in children, a success rate of 99.8%.[125]

Inadequate Débridement

Free flaps will not help heal unsuitable wounds. Adequate débridement and preparation are mandatory (see later). In an emergency situation, especially in crush injuries, the wound may be so ill defined that radical débridement might needlessly destroy vital structures that otherwise may potentially survive

and continue to function. In these circumstances, débridement of unquestionably dead and contaminated tissue should be followed by the application of wet dressings or, perhaps better, copious application of a petrolatum-based ointment such as Neosporin or, more recently, application of a vacuum-assisted closure (VAC) dressing. At a second look within 72 hours, it may be possible to create a clean wound by further débridement, to which an "early" flap can be applied. If doubt remains much beyond 72 hours and further serial débridements are necessary, the chance of infection beneath the flap rises 12-fold.[41] Split-thickness skin grafts should therefore be employed wherever possible after the final débridement, and secondary flap reconstruction is left until the wounds have healed.

The alternative to this approach provides the rationale for an "emergency free flap."[18,41,55,78,104] The initial injury or subsequent débridement may expose vital tissues that will not (or should not) support a skin graft: bare bone, cartilage, ligament or tendon, and exposed vessels or nerves. A flap will therefore be required at some stage. Even with the wettest of wet dressings, exposed bone and tendon continue to desiccate and die and eventually have to be excised. It follows, therefore, that with exposure of such important but poorly vascularized structures, emergency or early flap coverage is mandatory to preserve function. Radical débridement with emergency free flap coverage has become accepted for both upper and lower extremity traumatic wounds; similarly, early free flap coverage of high-voltage electrical burn injuries is becoming the accepted standard of care.[102]

Although early flap coverage of traumatic wounds of the extremities has been advocated within 72 hours of injury, a recent systematic review of timing of upper extremity free flap reconstruction found no significant association between timing of reconstruction and rates of flap loss, infection, or bony nonunion.[50] However, early reconstruction seemed to decrease the length of hospital stay and limit associated medical costs.

Poor Limb Function

Free tissue transfer should not be used to salvage a limb with insufficient potential for eventual function. Such function can only be attained by an acceptably sensate hand with mobile joints controlled by sufficient musculotendinous units. In complex injuries, the potential salvage of a limb can often be assessed only by an experienced hand surgeon; one must weigh the benefits of the three options of primary amputation, radical débridement and emergency free flap coverage, or serial débridements and secondary free flap coverage.

CLASSIFICATION OF FREE FLAPS

The recognition that theoretically any vascular territory or angiosome could be transferred on its axial pedicle, led to a renaissance in studies on the vascular anatomy of the skin and underlying muscles[118] and the development of a wide armamentarium of potential free flap donor sites. Only those flaps that have stood the test of time or are currently evolving as potential free flaps for use in the upper extremity are included in Table 45.1. The customary division of axial-pattern flaps into cutaneous, fasciocutaneous, and musculocutaneous flaps has been outlined in Chapter 44 and is reiterated here for convenience.

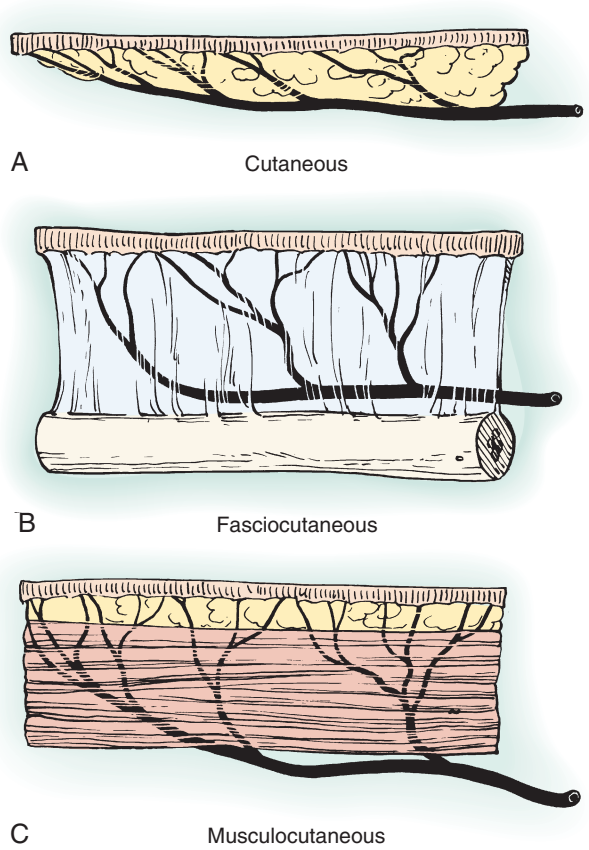

FIGURE 45.1 Axial-pattern flaps are either cutaneous **(A),** fasciocutaneous **(B),** or musculocutaneous **(C),** depending on the source of the major portion of the blood supply. Fasciocutaneous vessels commonly run in intermuscular septa and therefore supply the periosteum of underlying bone. The flap can be taken with a segment of that bone when necessary. (From the Christine M. Kleinert Institute for Hand and Microsurgery, with permission.)

Cutaneous Flaps

The vessel of an axial flap may be purely cutaneous (Figure 45.1, *A*), proceeding directly to and supplying skin alone. Free flaps based on these cutaneous vessels are termed *free cutaneous flaps* or *free skin flaps*. Typical free cutaneous flaps used for reconstruction of the upper extremity include the dorsalis pedis flap,[84,100,138] the groin flap,[22,48,54] and the first web space neurosensory flap.[82,86]

Fasciocutaneous Flaps

The axial vessel may first supply fascia before reaching its cutaneous territory (see Figure 45.1, *B*). The vessels commonly reach the fascia by running in an intermuscular septum. Because the septum is attached to bone, a segment of bone may be taken as a composite flap with the overlying skin and be vascularized by the same pedicle, for example, the fibular osteocutaneous flap. Axial flaps whose vessels first pass along the fascia are termed *fasciocutaneous flaps*. Just as with a musculocutaneous flap, fascia may be transferred alone without the overlying skin,[14,32] but skin cannot be transferred without the underlying fascia.

Typical fasciocutaneous flaps used for coverage of the upper extremity include the radial forearm flap,[51,64,87,112,134] ulnar forearm flap,[21] and lateral arm flap.[66,67,124] Pure fascial flaps

TABLE 45.1 Common Free Flap Donor Sites

Classification	Flap	Artery	Composite Tissues	References
Cutaneous				
	Dorsalis pedis	Anterior tibial–dorsalis pedis artery	Bone: second metatarsal Tendon: extensor tendons Sensory: superficial peroneal nerve	84, 92, 100, 138
	Groin	Superficial circumflex iliac artery Deep circumflex iliac artery	Bone: iliac crest	22, 48, 54, 110
	Scapular	Transverse branch of circumflex scapular artery		25, 39, 46
	Parascapular	Descending branch of circumflex scapular artery	Bone: lateral border of scapula	13, 89, 114
	Anterolateral thigh	Descending branch of lateral circumflex femoral artery	Sensory: lateral cutaneous nerve of thigh	4, 59, 73, 113, 127, 129
	First web space/toe pulp	Dorsalis pedis artery/first dorsal metatarsal artery	Sensory: fibular digital nerve to great toe; tibial digital nerve to second toe; deep peroneal nerve	12, 45, 72, 76, 82, 86
Fascial/fasciocutaneous	Radial forearm	Radial artery	Bone: radius Tendon: palmaris longus Sensory: medial and lateral antebrachial cutaneous nerves	6, 51, 64, 87, 93, 112, 121
	Ulnar forearm	Ulnar artery	Sensory: medial and lateral antebrachial cutaneous nerves	21
	Posterior interosseous	Posterior interosseous artery		15, 109
	Lateral arm	Posterior radial collateral artery	Bone: humerus Tendon: triceps Sensory: posterior cutaneous nerve of arm	66, 67, 124, 136
	Fibular osteocutaneous	Peroneal artery	Bone: fibula	128
	Medial plantar	Medial plantar artery		85, 90
	Temporoparietal	Superficial temporal artery		52, 53, 126
Musculocutaneous	Gracilis	Medial circumflex femoral artery		61
	Latissimus dorsi	Thoracodorsal artery		19, 42, 43, 75
	Rectus abdominis	Deep inferior epigastric artery		95, 96, 98, 117
	Serratus anterior	Thoracodorsal artery	Bone: rib	10, 49
Omentum	Right gastroepiploic artery			58, 105

include the radial forearm fascial flap, lateral arm fascial flap,[136] scapular fascial flap,[27] dorsal thoracic fascial flap,[70] serratus fascial flap,[11,32] and temporoparietal fascial flap.[8,126]

Muscle and Musculocutaneous Flaps

The axial vessel may first supply muscle (see Figure 45.1, *C*) with multiple secondary perforators supplying the overlying skin. The muscle must be harvested with the skin to ensure survival of the overlying skin, but the muscle may be transferred itself without the overlying skin and covered with a split-thickness skin graft. Flaps containing muscle and skin are termed *musculocutaneous flaps* or *myocutaneous flaps*, whereas transfer of the muscle alone is referred to as a *free muscle flap*. Useful muscle and musculocutaneous flaps for reconstruction of the upper extremity include the latissimus dorsi,[43] serratus anterior,[10] rectus abdominis,[95,96,98] and gracilis muscles.[61] In certain cases, free muscle flaps can be reinnervated by coaptation of the motor nerve to a recipient motor nerve in the forearm to restore otherwise irretrievable motor function.

Perforator Flaps

More recently, *perforator flaps*[103] have been developed in which a specific muscle perforator is dissected in continuity between the overlying skin and the main axial vessels, so that the skin component of a musculocutaneous flap can be transferred without the bulk of the underlying muscle; the base is only the single muscle perforator.[2,19,25,56,65,73-75,135] There are two options for dissection of perforator flaps and their anastomoses to recipient vessels. The skin flap can be harvested based on an individual perforator or multiple perforators that remain in continuity with the axial vessels to provide a long pedicle that can be anastomosed to recipient vessels of a similar caliber. Alternatively, the same skin flap can be harvested based only on a single perforator without dissecting the vessels of the main pedicle more proximally; this obviously simplifies the dissection and shortens the time necessary for it. However, anastomosis of these smaller-diameter vessels in the shorter pedicle may require *supermicrosurgical techniques*. Perforator flaps include the thoracodorsal artery perforator (TDAP) flap,[2,19,65,75,135] circumflex

scapular artery perforator flap,[25] superficial circumflex iliac artery perforator (SCIP) flap,[56,74] and anterolateral thigh perforator flap.[73]

Composite Flaps

Vascularized bone grafts and vascularized nerve grafts can also be transferred on their vascular pedicle (see Chapter 46). Apart from these "pure" tissue flaps, composite transfers usually containing two tissue components have been described: skin-bone (osteocutaneous),[91,128] skin-nerve (neurosensory),[82,84,86,92] and skin-tendon (tendocutaneous).[99,104,107,119] These composite flaps have very specific indications: osteocutaneous flaps such as the fibular osteocutaneous flap[128] and the deep circumflex iliac artery osteocutaneous flap[91,118] may be indicated for reconstruction of combined bone and soft tissue defects of the upper extremity; the radial forearm flap with the palmaris longus tendon[51,99] and the dorsalis pedis flap with vascularized long extensor tendons[104] may occasionally be indicated for reconstruction of a combined skin and extensor tendon defect due to a dorsal degloving injury of the hand; and neurosensory flaps[82,84,86] may be specifically indicated for restoring sensation to an important tactile area of the hand (the nerve within the flap itself can be used as a vascularized nerve graft and possibly provide more rapid return of sensation in the distal extremity).

Venous Flaps

Venous flaps[16,34,38,123] and *arterialized venous flaps*[30] have provoked sporadic interest during the past decade. In a pure venous perfusion flap, a small flap of skin and subcutaneous tissue containing a superficial vein that projects a few millimeters both proximally and distally beyond the flap is harvested from the flexor surface of the distal forearm. The flap is then reversed and can be used for simultaneous coverage of a defect over the dorsal aspect of the fingers or hand as well as for restoration of venous outflow by anastomosis of both the proximal and distal ends of the vein to a vein proximal and distal to the defect.[16,34,38,123]

There are two types of arterialized venous flaps.[30] In the first type, the flap inflow vein is anastomosed to a digital artery and the outflow vein is anastomosed to a vein proximal to the defect, in essence creating an arteriovenous fistula. The second type of arterialized venous flap can be used for simultaneous coverage of a defect over the palmar surface of a digit as well as for restoration of a segmental defect in the digital artery, by anastomosis of both the proximal and distal ends of the vein to the digital artery to create a *flow-through flap*. Clinically, arterialized venous flaps have better survival rates than pure venous perfusion flaps. The largest successfully surviving venous perfusion flap measured 10 × 8 cm, so it is unlikely that these flaps survive purely as a composite graft. Until the hemodynamics are more fully understood, pure venous flaps should only be considered for coverage of small dorsal or palmar defects of the fingers requiring simultaneous restoration of venous outflow or arterial inflow.

PREOPERATIVE ASSESSMENT AND PREPARATION

Complete examination of any limb on which surgery is being considered is mandatory. Where free tissue transfer is proposed, particular attention should be paid to the wound itself, the bony skeleton, the vascular anatomy, and any structures that may require simultaneous repair or reconstruction.

Tissue Defect

Preliminary examination of the wound should be directed toward those factors that will influence flap selection: size, depth, and special needs. In the fresh wound, the area may have been reduced somewhat by approximation, but the surgeon should remember two facts. First, one of the major benefits of importing additional tissue is that tension, with all its adverse effects of delayed wound healing, edema, and limitation of early motion, can be eliminated completely. Second, depending on the flap selected, additional area is required to accommodate the bulk of the flap itself. This bulk has its merits, because it serves to fill dead spaces in the wound. In the old wound that is to be excised, the full extent of excision should ideally include all scar tissue, with the incision being made in adjacent normal tissue throughout. If this is impractical (e.g., in extensive healed burns), the excision should include not only ulcerated skin but all the skin that is immobile due to fixation to deep tissues. It should be recognized that the size of flap required will be considerably larger than the area of skin excised, because of scar contracture affecting the surrounding tissues. For this reason, as emphasized below, the final pattern for the flap should not be made until after wound excision. In those cases in which some scar tissue has to remain on the limb, the surgeon must realize that its lack of elasticity may prevent closure of contiguous incisions, such as that over the pedicle and make allowances for that fact by planning for "pseudopods" on the flap to close such extensile incisions (Figure 45.2).

Radiographs and Computed Tomography, Magnetic Resonance Imaging, and Bone Scans

The bony skeleton should be fully evaluated by radiography and, if necessary, computed tomography (CT). Rigid fixation is an essential prerequisite, not only because a rigid skeleton supports the soft tissue reconstruction but also because motion at unstable fractures creates a dead space in which infection can develop. In chronic wounds, the presence and extent of any osteomyelitis can be assessed by four-phase technetium-99m bone scanning and indium-111–labeled leukocytes or magnetic resonance imaging (MRI) with gadolinium enhancement.

Angiography

The vascular anatomy of the limb should be evaluated by the surgeon by palpation of the brachial, radial, and ulnar pulses and also by using a handheld Doppler pencil probe, making sure to determine the direction of flow and any possible occlusion in the radioulnar arch system by selective occlusion. Blood flow distal to the wound in the recently injured limb should be assessed both before surgery and after fixation of any fractures. If blood flow is deemed to be inadequate, revascularization should be considered, either by means of an interposition vein graft or a flow-through flap,[18,132] such as the radial artery of the radial forearm flap.[9,93] For old injuries, information regarding the vascular anatomy should be obtained by noninvasive vascular studies and transfemoral angiography. Whereas some concerns have been expressed in the past regarding the possible adverse effect of angiographic dye injection in the days immediately preceding free tissue transfer, the authors have routinely

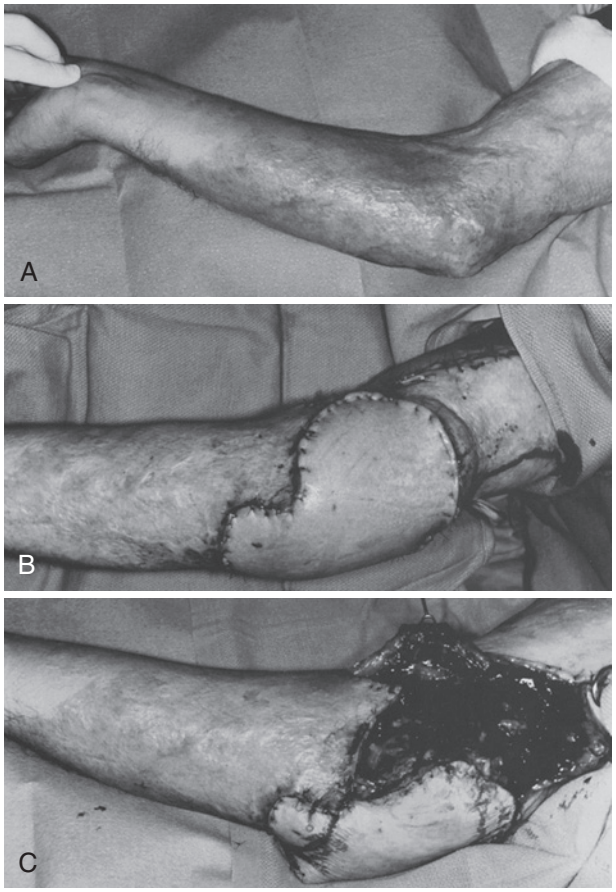

FIGURE 45.2 **A,** This patient had suffered 40% burns and required replacement of the skin over the extensor surface of the elbow together with excision of heterotopic bone. **B,** A free groin flap was harvested and inset into the defect. Although the extensile incision to dissect the recipient vessels had to be made in scar tissue, no "pseudopod" of the flap had been planned to relieve tension over the pedicle. The crease just proximal to the flap above the Penrose drain bodes ill for later circulation. **C,** The flap subsequently developed venous engorgement, and extensive hematoma beneath the congested flap was found on exploration.

obtained such studies during the 48 hours before surgery without adverse effect. The newer noninvasive techniques of magnetic resonance angiography and computed tomographic angiography may eventually supersede the need for invasive angiography of the recipient limb. Angiography of the flap donor site is not necessary, except possibly for some partial and total toe transfers. Instead the surgeon should examine all potential flap donor sites to ensure that there are no previous scars that might compromise harvesting the flap.

Preparation of the Patient for the Operating Room

As with all free tissue transfers, the patient should be brought to the operating room well perfused. To this end, the patient should be kept warm during the night preoperatively, and intravenous fluids should be commenced at midnight at a rate that ensures a urinary output of more than 100 mL/hour in the adult patient at the beginning of surgery. The operating room must be kept at a temperature above 70° F. Some surgeons use aspirin or heparin on a routine prophylactic basis, but this is not our custom.

The use of two surgical teams, one to harvest the flap and the other to prepare the recipient site, is common practice and provides the opportunity for the shared experience of two microsurgeons. However, the anecdotal experience of several microsurgeons suggests that little or no time is saved by using two teams and the incidence of complications may be somewhat higher than when one microsurgeon carries the responsibility for the entire procedure.

OPERATIVE TECHNIQUE

Wound Débridement

A wound that is to be covered by a free flap should lie over a stable skeleton. It should not contain any tissue that remains contaminated or has a compromised blood supply. The defect should present as flat a bed as possible for application of the flap. These prerequisites are achieved by rigid fixation and radical débridement (Figure 45.3). Such débridement may be performed with confidence only in the knowledge that good soft tissue cover is available. Similarities to tumor surgery exist in that resection of a malignant tumor with adequate clear margins is best achieved by the surgeon who knows he or she can close the resulting defect. As with cancer ablation, radical débridement demands incision through normal tissue. This should be done under tourniquet control; otherwise, the bleeding from muscle and viable soft tissue will conceal the lack of bleeding from tissues that are not viable. If a major vessel has to be repaired, tissues distal to the arterial injury will be better perfused after the vascular repair, and therefore débridement should be performed after reperfusion.

In severe limb trauma, adequate bone shortening can sometimes facilitate approximation of muscle and soft tissue, as in macroreplantation. In these cases, débridement must precede the arterial anastomosis. Those tissues that remain viable can be demonstrated by cannulating the distal end of the vessel to be repaired and perfusing the ischemic part with heparinized saline. Weeping of this fluid will indicate potential viability; absence of this weeping fluid indicates inevitable ischemia.

When immediate flap coverage is planned,[18,41,55,78,102,104] contaminated bone can be retained; it is scrubbed vigorously, and burrs and a rongeur are used to remove contamination. Even free fragments can be similarly treated and used as bone grafts, but only if they are rigidly fixed and are covered with well-vascularized soft tissue. In late cases, in which osteomyelitis has developed, two criteria are used for assessing bone viability. The *paprika sign* denotes the punctate bleeding that occurs when cortical bone has been burred back to the level at which there is adequate perfusion. The presence of adherent periosteum is usually indicative of viable bone, and therefore bone should be resected through adjacent adherent periosteum.

CRITICAL POINTS *Wound Débridement*

- The wound should be débrided in a manner similar to that of a "tumor resection."
- All foreign material must be removed.
- All nonviable tissue must be removed.
  - Neurovascular structures should be spared.
  - Débride back to bleeding tissue.
  - Remaining muscle should contract with stimulation.
- The extent of débridement should not be predicated on size.
  - A free flap can cover almost any defect in the hand or arm.

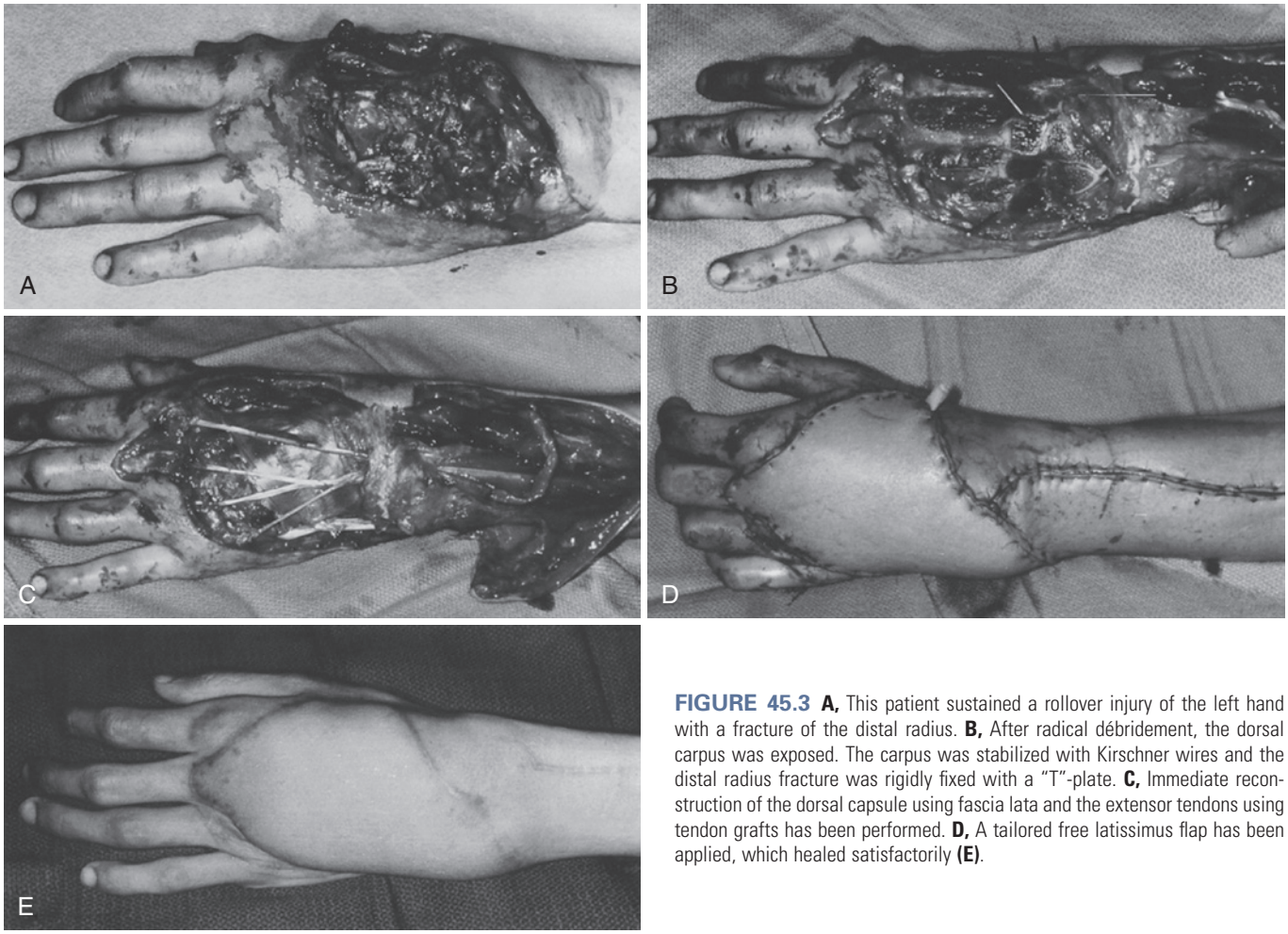

FIGURE 45.3 **A,** This patient sustained a rollover injury of the left hand with a fracture of the distal radius. **B,** After radical débridement, the dorsal carpus was exposed. The carpus was stabilized with Kirschner wires and the distal radius fracture was rigidly fixed with a "T"-plate. **C,** Immediate reconstruction of the dorsal capsule using fascia lata and the extensor tendons using tendon grafts has been performed. **D,** A tailored free latissimus flap has been applied, which healed satisfactorily **(E)**.

All marginally viable skin should be removed with the exception of highly specialized areas such as the fingertip or palm. If marginal tissue is retained, such skin may harbor infection and will certainly heal with profuse scarring. When débridement appears adequate, tissue samples are taken from several points in the wound for rapid gram-stained smear and quantitative cultures. Such tissue samples are only necessary in open wounds and where there has been previous infection. Samples are taken from tissues that are considered clinically to be noninfected at the completion of adequate débridement and therefore are indicative of inadequate débridement; they also identify the probable organism in the event of later infection.

After débridement, the wound may be uneven. Additional excision of vital but nonessential tissue is justified to create a flat wound surface. Close contact between flap and bed is thus assured, and dead spaces are eliminated that could later become the sites of infection or fibrosis. The only exceptions to the rule of radical débridement are longitudinal vital structures that carry the promise of function: intact tendons or nerves and major patent arteries. These should be retained and cleaned with the help of magnification.

Skeletal Stabilization

Once débridement is complete, rigid skeletal fixation should be applied. Compression plates are preferred for the radius and ulna, low-profile miniplates for the metacarpals, and type A intraosseous wiring or 90-90 intraosseous wiring for the phalanges. External fixation is employed for bony segmental defects. Small defects can be reconstructed primarily with cancellous bone grafts, whereas large defects can be obliterated either with the muscle component of the free flap or a temporary antibiotic-impregnated methylmethacrylate spacer, pending later definitive bony reconstruction.

After radical débridement of chronic osteomyelitis, secondary cancellous bone grafting should be delayed until 6 weeks after application of the flap, provided that soft tissue healing is uneventful.

Skin Pattern

The skin margins should be freshened and made even by excising any redundant promontories and peninsulas of no functional importance. A pattern of the defect is taken using any suitable material, such as a piece of an Esmarch bandage that has been moistened with alcohol (see Figure 45.9, *C*) or the paper of a glove wrapper.

Recipient Vessels

An additional incision will invariably be required to expose the recipient vessels. In the extremities, closure of the wound over the free flap pedicle may cause impairment of flow to the flap.

If this possibility has not been anticipated and a tongue or "pseudopod" of flap has not been incorporated, it may become necessary to apply a split-thickness skin graft over the pedicle. In situations in which no extension of the flap is planned, a zigzag incision is used to expose the recipient vessels, with a 60-degree angle between each limb. This not only improves exposure but also permits closure of the wound as a series of "V-Y" advancements, thus increasing the circumference of the limb and avoiding any possibility of vascular compromise of the flap.

With the use of loupe magnification, the recipient vessels are dissected in a preliminary manner, meaning that the vessels are exposed but are not prepared definitively for the microvascular anastomoses. This is for two reasons: the precise location of the anastomoses can only be determined with the flap sutured in place, and dissection is best achieved under relatively higher magnification under the operating microscope.

Avoiding the Zone of Injury

The key to dissection of the recipient vessels is that exploration should proceed from normal tissue toward the wound, not in the more obvious centrifugal fashion, working outward from the wound. This is especially true in reconstruction of chronic wounds, because the inflammation and subsequent fibrosis that follows the original injury spreads farthest from the wound along the vascular planes. If the surgeon dissects outward from the wound, stopping when the vessels clearly improve, the point at which one stops will be closer to the wound than if one dissects toward the wound, stopping when the vessels clearly deteriorate. The distance between these two stopping points may be small, but it is highly significant. Because the vessels still contain scar that is scarcely evident to the examiner, it makes them friable and inelastic, which causes problems in performing the anastomoses, and also the vessels may fail to dilate in response to increased flow, which is especially significant in the venous outflow of a free flap.

If prior examination has shown that only one artery to the limb is patent, that artery should be inspected with particular care for the presence of (1) large and expendable side branches to which an end-to-end anastomosis could be performed and (2) atherosclerosis. The latter may be seen as irregular, transverse striations on the vessel or felt as unusual hardness in the vessel wall detected with the touch of either the gloved finger or a jeweler's forceps. If atherosclerosis is detected in a single artery extremity in which an end-to-side anastomosis would normally be the technique of choice, the surgeon may elect to perform two end-to-end anastomoses by resecting a segment of the vessel and incorporating a "T"-junction in the flap pedicle (see Figure 45.19, *C*).[79]

Pedicle Length and Accessibility

As a final step, the length of vascular pedicle required should be measured between the point selected for the anastomoses and the closest margin of the defect. This should be done before the precise location of the flap on the donor site has been drawn and dissection of its pedicle completed. Pedicle length can be increased by extending the dissection of the pedicle farther than is customary, often with increasing difficulty. In some flaps, the pedicle can be lengthened relatively, by moving the skin pattern of the flap further away from the vascular pedicle but keeping the majority of the skin paddle within the vascular territory.

If the pedicle of the selected flap is not long enough, three solutions exist. First, choose a different flap. Second, harvest a vein graft. Third, create a temporary arteriovenous fistula using an interposition vein graft between the recipient artery and vein or create a recipient shunt by anastomosing a long length of a recipient vein end-to-side into the recipient artery. However, a recipient shunt should only be considered when the recipient vein is situated away from the recipient artery, continues distally into the limb away from the wound, and remains unscarred and of good caliber. This last solution is attractive not only when the selected flap pedicle is going to be too short, but also when the selected recipient artery is relatively deep and inaccessible and when there are two experienced microsurgical teams. When the intended end-to-side arterial anastomosis is deep and somewhat inaccessible, the additional presence of the flap in the way will make it even more difficult to see and do. Use of a temporary arteriovenous or recipient shunt can improve visibility and move the two end-to-end anastomoses of the flap to a more accessible location. When there are two teams, the team dissecting the recipient site will always complete its task before the team raising the flap. The whole operation will be accelerated if the recipient team performs the more time-consuming end-to-side anastomosis of the interposition vein graft or recipient vein to the recipient artery.

Harvesting the Flap

With knowledge of the anatomy of the selected flap, a template of the defect can be positioned on the skin in such a way as to optimize the desired thickness of the flap and the necessary pedicle length. It is usually prudent to maximize the length of pedicle because the microsurgical anastomoses can be moved more proximally away from the wound. A loose pedicle will also facilitate end-to-side anastomoses. Only one flap margin should be incised initially, with an extension over the presumed course of the pedicle. The vascular pedicle can be visualized and dissected through this incision. In those rare cases in which the pedicle is found to be anomalous or absent, this initial incision can be closed without compromising the circulation to the skin.

Between the vascular strata (the subcutaneous tissue, fascia, and muscle) lie planes that are relatively avascular. It is in these planes that the flap should be elevated. To reach these planes, it is necessary to cut through the vessels of the more superficial strata. For example, in harvesting a fascial flap, the surgeon must first incise the subdermal and subcutaneous plexus and then the fascia and elevate the fascial flap in the plane beneath the fascia but superficial to the muscle. To be one plane too superficial would result in division of the vessel supplying the flap. To be one plane too deep would result in a time-consuming, often bloody dissection.

Application of tension plays a major role in flap dissection. Once the marginal incision has been carried down to the correct plane for dissection, skin hooks should be applied to the corners of the flap. Firm upward traction away from the bed will display the plane for dissection. Often this plane only contains loose areolar tissue that can be stroked away with a knife. Tension on the flap lifts the pedicle off the floor of the secondary defect, on which the knife is dissecting, into the roof containing the vascular plexus. Care must be taken not to create a "cave" beneath

the flap, that is, a central recess between areas of unincised skin, muscle, or fascia. When closed scissors are introduced into the tissues and then opened under gentle pressure to clear planes, they can be both precise and innocuous. They create and enter "caves," defining structures to be preserved and those to be divided. When scissors are introduced open and closed to cut, they are less precise. It is therefore important when using scissors that the surgeon see both aspects of the structure to be divided so as to be confident about which tissues have been included between the jaws of the scissors.

Dissection of the Pedicle

Unrecognized damage to the vascular pedicle during dissection is one of the major causes of postoperative complications after free tissue transfer, often resulting in poor perfusion to the flap or culminating in thrombosis at the anastomosis. Any problem in the entire vascular tree either affecting arterial inflow or venous outflow may eventually result in anastomotic thrombosis. Meticulous dissection of the pedicle therefore plays a paramount role in achieving a successful outcome. Hemostasis must be perfect during dissection of any flap, because it is hazardous to achieve once the anastomoses have been completed. Although it has been shown that metal clips are not secure and that bipolar coagulation may harm the pedicle, both the clips and coagulation are routinely employed in dissecting the pedicle. The clips must be applied with sufficient force to ensure that they will not slip. If bipolar coagulation is being used, the pedicle should be insulated by using smooth forceps to hold the side branch between the pedicle and the point of coagulation.

On completion of the dissection of the pedicle, the flap should be allowed to perfuse after bathing the pedicle with either 2% lidocaine (Xylocaine) or papaverine, before dividing the pedicle and transferring the flap to the recipient site.

Flap Insetting

The flap is placed into the defect; check to see that the end of the pedicle comes to lie approximately at the predicted site of the anastomoses. The flap can either be sutured into place definitively or temporarily stapled into position. With definitive insetting, the completed anastomoses will be less likely to be at risk during final wound closure. Furthermore, the edema that will inevitably occur in the flap after reperfusion will be controlled and should not produce such swelling as to make complete closure of the flap impossible.

Once the flap is in place, the microscope is introduced, the pedicle is approximated to the recipient vessels, and the site of the anastomoses is selected. If the venous repair lies at some distance from the arterial repair, this is the stage when the surgeon can most safely separate the vein and artery within the pedicle. The recipient vessels should be dissected circumferentially over a sufficient distance to allow easy rotation to bring their back walls forward. When an end-to-end anastomosis is to be performed, the recipient vessel should only be dissected over a length necessary to accommodate a microsurgical approximator clamp. The techniques of microvascular anastomosis are described in the Classic chapter, Principles of Microvascular Surgery, available on ExpertConsult.com.

Both the arterial and venous anastomoses should be performed before removing the clamps from either vessel. The more difficult anastomosis is performed first.

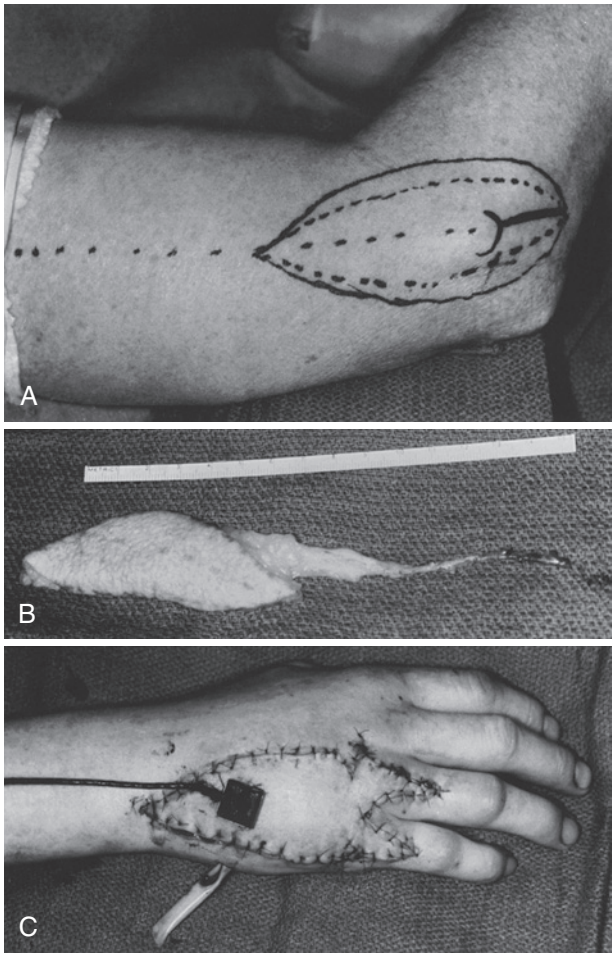

FIGURE 45.4 Lateral arm flap. **A,** The deltoid tubercle and the lateral epicondyle have been marked and joined with a *dotted line* that traverses the figure from left to right. The skin incision is marked with a *dotted line,* and the intended inclusion of the fascia is marked with a *solid line.* **B,** The distal location of the flap provides a long pedicle. **C,** The lateral arm flap has been inset to cover the ulnar aspect of the dorsal hand and also the proximal portions of the ring and small fingers. The anastomosis to the ulnar artery was performed proximal to the wrist.

If a monitor such as a photoplethysmograph, laser Doppler, or tissue oximeter is to be used, the sterile probe should be sutured to the flap and connected before the microsurgical clamps are removed (Figure 45.4). In this way, reperfusion of the flap can be charted, as can any changes that occur during wound closure.[62,115,116] If there is any persistent accumulation of blood in the wound that cannot be controlled, usually from scar or bone, a drain or drains should be inserted (see Figures 45.3, *D,* and 45.4, *C*). Suction can be applied but only very carefully, because however far from the pedicle the drain lies, the two may come together with disastrous consequences.

Dressings

No dressings should be applied to the flap surface; it is best for the flap to be easily observable at all times. The incisions can be covered with Neosporin ointment and a thin strip of nonadherent gauze. To protect the limb during sleep, a splint should be applied, leaving a generous window for inspection. A surgical glove is turned inside out to close the fingers and is packed with gauze sponges. The glove is laid over the flap, cast padding is

applied to the whole limb including the glove, and a plaster of Paris splint is made. Once the cast is dry, the prominence created by the packed glove is removed with a saw, rather as if one were opening a boiled egg, and the glove is removed, so that the flap is protected yet always visible.

POSTOPERATIVE CARE AND MONITORING

Patient Care

Postoperative care should be directed toward the comfort of both patient and flap and should be the responsibility of a team of trained, trusted nurses. The comfort of the patient is pursued through the usual channels and should not be neglected because of concern for the flap. It is important that the patient be up and about as soon as possible, preferably starting on the first postoperative day. All joints not included in the cast should be mobilized.

Several different anticoagulants such as intravenous dextran 40, intravenous heparin, subcutaneous low-dose heparin, and oral low-dose aspirin are used prophylactically by many surgeons to prevent thrombosis of the microsurgical anastomoses. There are no prospective controlled trials to confirm the efficacy of any of these anticoagulant regimens, and occasionally their disadvantages outweigh the theoretical benefits. One of the authors (NFJ) uses a 40-mL bolus of dextran 40 just before release of the microsurgical clamps followed by a continuous intravenous infusion of 25 mL of dextran 40 per hour for 5 days (based on an adult patient who weighs 70 kg) together with aspirin, 81 mg orally daily. The other author (GDL) does not use any anticoagulant therapy after routine free tissue transfer.

Routine wound cleansing should be accomplished using hydrogen peroxide followed by a thin smear of antibiotic ointment. This routine has many benefits: it eliminates a nutritious inoculum for bacteria; it ensures that color assessment is neither obscured by blood staining nor impaired by vivid contrast within the observer's visual field; it permits assessment of the rate of bleeding from the wound, in itself a valuable index of venous insufficiency; and it has an inestimable effect on the morale of the patient who can see the healing wound.

Flap Monitoring

The nurse should observe the flap regularly, usually every hour for the first 48 hours, to ensure its continued viability. Clinical evaluation of the flap is based on several criteria.

Color

Although difficult to learn and impossible to convey adequately, color assessment still remains the mainstay of clinical evaluation. The lighting must obviously be good. The observer's color perception can be neutralized by first looking at an area of normal skin for 10 seconds and then looking at the flap and comparing the colors.

A healthy free flap, especially a groin flap, is pale to a degree that makes the novice nervous. It is not pure white, when one compares it with a sheet of white paper, but rather it is a very pale pink. If arterial inflow is inadequate, a flap will become paler, with a faint blue-gray tinge. If venous drainage is compromised, the flap will at first become an angry red color and then progressively purple-red and purple-blue (Figure 45.5, *A*). The unperfused free flap at first assumes a waxy pallor, that is, white tinged with yellow or brown, which differs from its healthy pink pallor by a margin so subtle that only the experienced are pessimistic. The margins of the failing flap then become indurated and may blister, but doubts concerning the extent of loss may persist for several days.



FIGURE 45.5 **A,** This lateral arm flap on the ulnar aspect of the hand is clearly experiencing serious venous embarrassment, with significant discoloration of the proximal end of the flap, which is to the left. **B,** Exploration revealed thrombosis of the outflow vein of the flap. **C,** Thrombectomy resulted in salvage of the entire flap.

Capillary Refill

Capillary refill may be assessed after blanching by fingertip pressure or by running a blunt point across the flap. If the refill after blanching is very slow and the flap is pale, arterial insufficiency is the likely cause. If capillary refill is too swift and the flap has a bluish hue, venous outflow is impaired. Little stock can be placed on this test in isolation because entirely stagnant blood will move around in the tissues in response to pressure, although more slowly than one would see in a healthy flap.

Bleeding

Although the color and capillary refill of a flap can be assessed on a regular protocol, bleeding from the flap should only be evaluated if there is any suspicion of impending compromise to the perfusion of the flap. The flap and adjacent tissue can be punctured with an 18-gauge needle or a No. 11 scalpel blade and the resultant bleeding compared. A healthy flap should produce bright red blood of the same color as the control and should bleed just a little longer. If no bleeding occurs or if the flap only bleeds very briefly, arterial inflow is inadequate. If the blood is dark red or purple and bleeding persists much longer, venous congestion should be suspected. Persistent dark red bleeding from around the margins of a swollen flap is almost pathognomonic of venous occlusion.

Other Monitoring Techniques

Many techniques for postoperative monitoring of free tissue transfers have been developed and evaluated in experimental free flap models. Several of these techniques have been used in large clinical series.[29,60,62,68,69,111,115,116] There have been no prospective clinical trials of any monitoring technique, and there is still no consensus as to which will eventually become the standard accepted method.[5,23,62]

An ideal monitoring technique should provide a continuous recording of flap perfusion or flap metabolism, with immediate detection of arterial or venous occlusion. It is important that the criteria indicative of arterial or venous occlusion be easily interpreted by nursing personnel or junior medical staff. Finally, an ideal system should allow monitoring of both visible and "buried" types of free tissue transfers.[5,23,62]

Several techniques are currently used:

- Photoplethysmography
- Differential surface temperature monitoring[69]
- Doppler surface monitoring[80,111]
- Laser Doppler monitoring[60]
- Implantable Doppler probes[29,80,115,116]
- Implantable pH electrodes
- Implantable oxygen electrodes
- Pulse oximetry[63]
- Tissue oximetry[68,80]

Photoplethysmography has been shown to indicate early signs of compromised flap perfusion owing to excessive tension during skin closure. Photoplethysmographic waveforms can even be transmitted by telephone to a remote monitoring station to allow the surgeon at home to interpret any abnormal waveforms, so that the nursing personnel can be advised whether the waveform is normal or whether the flap should undergo reexploration. Tissue oximetry based on near-infrared spectroscopy is showing promise in providing continuous postoperative monitoring of tissue oxygen saturation in free flaps.[68]

A surface temperature probe can be used to compare the relative difference in temperature between the flap and a second control temperature probe on adjacent normal skin. Differential surface temperature monitoring has been evaluated retrospectively in a large series of 600 free tissue transfers.[69] A difference between the differential surface temperature measurements at two points in time of greater than 1.8°C has been shown to be diagnostic of arterial or venous occlusion.

The characteristic arterial pulsation of either a free skin flap or a free muscle flap resurfaced with a split-thickness skin graft can be heard with a handheld pencil 8-MHz Doppler probe.[111] The best arterial Doppler signal on the surface of the flap is marked by a suture and the arterial signal monitored both during closure and every hour postoperatively for the first 48 hours. Augmentation of the venous "hum" can also be produced by compression of the flap tissue, thereby confirming the patency of venous outflow. The laser Doppler flowmeter[60] has been used for postoperative monitoring of free skin flaps and musculocutaneous flaps and free muscle flaps resurfaced with split-thickness skin grafts.

An implantable 20-MHz ultrasonic Doppler probe can be used for continuous monitoring of the patency of the arterial anastomosis and will provide instantaneous detection of an arterial occlusion.[29,116] However, this technology also requires further refinement, both with regard to positioning the probe either on the artery or the vein and recognition of a venous occlusion.[115]

Paradoxically, because of the ever-increasing success rates of free tissue transfers, it will become more and more difficult to document scientifically the value of any postoperative monitoring technique. One of the authors (NFJ) uses Doppler surface monitoring of the arterial pulsation with a handheld Doppler probe every hour for postoperative monitoring of free skin, muscle, and osteocutaneous flaps and a pulse oximeter for postoperative monitoring of toe-to-hand transfers.[63] An audible alarm can be set to detect the lowest acceptable level of oxygen saturation or the loss of the arterial pulse rate, and this obviously reduces the frequency of nursing vigilance. Loss of the arterial pulse is indicative of arterial occlusion in a toe transfer, whereas an oxygen saturation level falling below 90% is suggestive of venous occlusion.

SAVING THE FAILING FREE FLAP

What actions can be taken to salvage a failing free flap?

1. The patient's general condition (e.g., hypotension, cardiopulmonary impairment, or a low circulating volume, manifested by a low urinary output) may all adversely affect oxygenation of the flap. A cold vasoconstricted extremity may be due to circumstances as grave as advanced shock or as simple as a low room temperature. Both should be evaluated and corrected.
2. Look for any unduly tight dressings or sutures. Remove the splint and all the dressings down to the flap. Cut any tight sutures.
3. Reposition the patient's arm; in particular, determine if elevation or dependency of the arm improves flap perfusion. If it does, make the patient comfortable in this new position.
4. Look for signs of hematoma and evacuate the hematoma. If the flap is swollen or edematous and discolored and there is persistent serosanguineous fluid oozing from the flap margins, a hematoma should be strongly suspected. A flap hematoma may cause loss of a flap; its evacuation may salvage the flap. A few sutures along the flap margin opposite the entrance of the vascular pedicle into the flap should be cut immediately. This may allow some dissipation of the pressure induced by the hematoma, but formal evacuation of the hematoma should be done in the operating room as soon as possible after the hematoma is detected (see Figure 45.2, *C*).

Exploration in the Operating Room

If none of these maneuvers rapidly improves the appearance of the flap, the patient should be returned to the operating room immediately for exploration of the pedicle; if this is done quickly, it can be very successful (see Figure 45.5). The situation is almost always worse than it appears. Chen and colleagues reported a 9.9% reexploration rate in 1142 free flaps and an overall salvage rate of 63.7%. Of the failing flaps, 96% presented within 72 hours and 85% of them could be salvaged.[17]

1. Initially, only the incision that provides access to the pedicle is reopened. If all the sutures around the flap are removed, the edematous flap will be very difficult to control during inspection of the pedicle and it will be impossible to replace

the flap back into the primary defect with the precision achieved in the first surgery.
2. Any hematoma should be gently removed with warm irrigation and the gloved finger. Suction should only be used with extreme care.
3. The pedicle and recipient vessels proximal to the anastomoses should be examined for obvious kinks, occlusions, or thrombosis. The point of occlusion in a vein will usually be obvious, the upstream segment being turgid and the downstream segment collapsed. Arterial occlusion is usually less evident and can be detected by lack of a pulse on palpation or with a sterile Doppler probe. Testing of arterial flow by the "milking" or "sweeping" test should not be done until a microsurgical clamp has been placed across the artery downstream distal to a side branch through which emboli, which would otherwise wash into the flap microcirculation, can be safely diverted. After placement of the clamp, the side branch can be opened to determine the presence or absence of flow across the anastomosis.
4. Do not hesitate to open an anastomosis between clamps to assess flow and if necessary redo the anastomosis. If a clot is present in a patient with a normal clotting mechanism, remember that blood flow only stops if arterial inflow is poor, if "runoff" through the flap is impeded, or if the anastomosis is technically imperfect. If the anastomosis looks good, inspect the downstream segment for an unrecognized injury to the pedicle. If none is found and inflow through the recipient artery is strong, excise the anastomosis and do it again. There is usually enough redundancy in the recipient artery and arterial pedicle to allow a second end-to-end anastomosis. If not, a short interposition vein graft may be necessary. Revision of an end-to-side anastomosis is more difficult unless a "T"-graft[40,79] has been used or can be harvested. With a "T"-graft, three cuts and three anastomoses can save the situation.
5. Do not hesitate to excise a redundant segment and perform another anastomosis.
6. The patient should be kept in the operating room for a period of time after reexploration and revision of the anastomoses to ensure that further thrombosis does not occur.

Other Salvage Techniques

There are as many publications in the literature concerning experimental methods of enhancing flap survival as there are of monitoring, possibly more, but there are no prospective clinical trials documenting the efficacy of any pharmacologic agent to enhance flap survival. However, medicinal leeches and various thrombolytic agents may play an occasional role in the salvage of a failing free flap, either as an adjunct intraoperatively, during reexploration of the microsurgical anastomoses, or if the patient or the flap is not deemed suitable for surgical reexploration.

Leeches

It is well established that leeches can be used to salvage a failing replanted digit if venous outflow is compromised or if a suitable vein is not available for anastomosis. In an extension of this technique, leeches have been used to relieve venous congestion in pedicled flaps and free flaps.[7,28,131] The success of flap salvage after leech therapy has been reported to be as high as 60 to 70%. Just as in the replant situation, there is one report of a successful free flap performed with only an arterial anastomosis in which leeches provided venous drainage of the flap for 8 days until neovascularization was reestablished.

Hirudo medicinalis may ingest an amount of blood almost 10 times its own weight; however, the therapeutic effect of leeches is not due to the volume of blood ingested but due to continued bleeding from the bite after detachment of the leech. Several pharmacologically active substances are secreted by the leech, including hyaluronidase, an antihistamine, a vasodilator, and hirudin, which is the most potent natural anticoagulant known. Hirudin is a 65-amino acid polypeptide with a molecular weight of 9000 daltons and inhibits the conversion of fibrin to fibrinogen.

The most significant risk of leech therapy is infection[28] with *Aeromonas hydrophila*, which may cause a major necrotizing soft tissue or muscle infection with an incidence estimated at between 7 and 20%. Consequently, it may be prudent not to use leeches for a failing free muscle flap. *A. hydrophila* infections may be prevented or treated secondarily with a second- or third-generation cephalosporin or an aminoglycoside antibiotic. The second major risk of prolonged leech therapy is blood loss and the eventual need for blood transfusion. Leeches must also be prevented from "wandering" or attaching to normal better perfused tissues.

Thrombolytic Agents

Several thrombolytic agents have been used for the treatment of various arterial and venous thromboses, including myocardial infarction, pulmonary embolism, deep venous thrombosis, and thrombotic-embolic problems in the upper and lower extremities. However, there are only a few reports of thrombolytic therapy for salvage of a failing free flap.[3,20,24,37,77,83,97,106]

Heparin may prevent anastomotic thrombosis by blocking the conversion of prothrombin to thrombin and by decreasing platelet adhesiveness. Systemic intravenous infusion of heparin is sometimes used by some microsurgeons to prevent thrombosis of the arterial and venous anastomoses in replanted or revascularized digits, especially when these injuries have been associated with a crushing mechanism or after repeated revision of the anastomoses. However, systemic heparin may be complicated by bleeding and the development of hematomas. Local infusion of heparin through a tiny silicone catheter inserted into one of the venae comitantes of a free gracilis muscle flap was successful in preventing thrombosis of a revised end-to-side anastomosis of the other vena comitans. Heparin was infused at a rate of 250 U/hour for 6 days, and the flap was successfully salvaged after revision venous anastomosis was performed without inducing systemic anticoagulation.[83]

Streptokinase is an enzyme isolated from group C β-hemolytic streptococci that converts plasminogen into the enzyme plasmin, which in turn sequentially degrades fibrin in a thrombus. Successful salvage of a failing free flap due to either arterial or venous thrombosis has been reported, either by infusion of streptokinase into the totally isolated free flap[97] or by selective arterial infusion of streptokinase into the flap by direct arterial puncture proximal to the arterial anastomosis using a fine 30-gauge needle.[77] By avoiding return of streptokinase to the systemic circulation, very high doses of intraarterial streptokinase infusion can be used, up to 60,000 U in 1 hour.

Urokinase is a naturally occurring enzyme derived from human kidney cells and probably has significant advantages over streptokinase.[106] Unlike streptokinase, urokinase does not cause allergic reactions and can be used at very high concentrations with less risk of hemorrhage and without inactivating plasminogen. One of the authors (NFJ) has successfully salvaged two radial forearm flaps and one toe transfer that were failing due to venous thrombosis or combined arterial and venous thromboses by expedient reexploration and intraarterial infusion of urokinase into the recipient artery proximal to the arterial anastomosis. Serletti and associates[106] reported the successful salvage of five free flaps that were failing due to thrombosis of the venous anastomosis by infusion of 250,000 U of urokinase over 30 minutes through a 25-gauge catheter inserted into the recipient artery proximal to the arterial anastomosis.

There are two case reports of the use of an intravenous infusion of tissue plasminogen activator (t-PA)[37] in conjunction with an intravenous infusion of heparin to successfully salvage a free flap compromised by a presumed arterial thrombosis. The optimal dose of t-PA to achieve therapeutic thrombolysis has not been determined. Intravenous infusion of t-PA was begun at 12 mg/hour but was discontinued after 15 minutes because of hemorrhage from the flap donor site.

In summary, reexploration of the microsurgical anastomoses is the best solution to salvage a failing free flap, but leeches and the newer thrombolytic agents[20] may occasionally be indicated either before reexploration or in conjunction with surgical reexploration.

CRITICAL POINTS *The Failing Free Flap*

Nonoperative Measures

- Check the volume status of the patient, oxygenation, hematocrit.
- Release or remove constricting dressings.
- Reposition the patient's arm (up or down).
- Release sutures at the margin of the flap to release pressure and/or hematoma.

Operative Measures

- Return to the operating room for exploration.
  - Remove any hematoma.
  - Check the status of the vessels (e.g., for clotting or kinking).
  - Open the vessel between clamps (avoid distal embolization of clot).
  - Revise the anastomosis.
  - Add a vein graft if necessary.
  - Observe the flap closely in the operating room after revision for re-thrombosis.

Other Measures

- Use leeches for venous congestion (but not instead of returning to the operating room for revision of the thrombosed anastomosis).
- Anticoagulation (heparin)
- Thrombolytic agents
  - Streptokinase/urokinase/t-PA for disseminated thrombosis

INFECTION

Should infection develop beneath a flap, it should be treated just like any wound infection. In a patient who is not compromised systemically, infection invariably means that débridement of the original wound has been inadequate or perfusion to part of the flap has failed. Antibiotics may be used as a supplement, but expeditious surgical exploration is the best guarantee of flap survival. If exploration is delayed, thrombosis of the pedicle may result in complete loss of the flap. The flap should be elevated on the side opposite to the pedicle and reflected to the extent necessary to reveal the source of infection. If the source is an infected hematoma, evacuation with subsequent catheter irrigation for 2 days should suffice. Any suspicious areas of infection in the bed or in the flap itself should be radically débrided, followed once again by catheter irrigation for 2 days.

SPECIFIC FREE FLAPS

Lateral Arm Flap

First described by Song and associates, the lateral arm flap and its vascular anatomy were popularized by Katsaros and colleagues.[66,67] In many respects, it is ideal for upper extremity reconstruction because it can be harvested from the same limb using the same tourniquet.[124] The flap can be made as small as 10 cm^2 (Figure 45.6 and see Figure 45.4) and as large as virtually the entire circumference of the upper arm or extended onto the proximal forearm. It is thin and pliable and can be innervated. A segment of vascularized humerus (up to 10 cm long and 25% [1.5 cm] of the circumference) can also be harvested with the flap,[124] as can a vascularized segment of triceps tendon.[136]

For special contouring, the flap can be divided along the midline of its long axis or transversely from side to side, provided that the lateral intermuscular septum is preserved. This permits the proximal and distal portions to be laid side by side to cover a wider defect or to be placed on both sides of a hand that has sustained a major penetrating wound or requires coverage of both the palmar and dorsal aspects of the thumb/index finger web space (Figure 45.7). One drawback, which precludes its use in some young female patients, is that the donor site scar is very noticeable, whether it is closed directly or with a skin graft. Another is that the flap may be bulky: in one series of lateral arm flaps used for reconstruction of the upper extremity, 50% were considered bulky by the surgeon and required defatting.[44] These two disadvantages of the lateral arm skin flap can potentially be avoided by harvesting only lateral arm fascia[136] and covering this lateral arm fascial flap with a split-thickness or full-thickness skin graft.

Anatomy

The arterial supply to the lateral arm flap is the posterior radial collateral artery, one of the two terminal branches of the profunda brachii artery. The profunda brachii arises from the brachial artery in the distal axilla and accompanies the radial nerve in the spiral groove until both penetrate the lateral intermuscular septum, just distal to the deltoid insertion. Here the artery divides, with the anterior radial collateral artery continuing with the radial nerve anterior to the brachioradialis origin from the humerus and the posterior radial collateral artery passing posterior to the origin of the lateral intermuscular septum. The vessel becomes closer to the humerus and supplies bone via the overlying periosteum as it proceeds down to the lateral epicondyle, to which it is adherent.

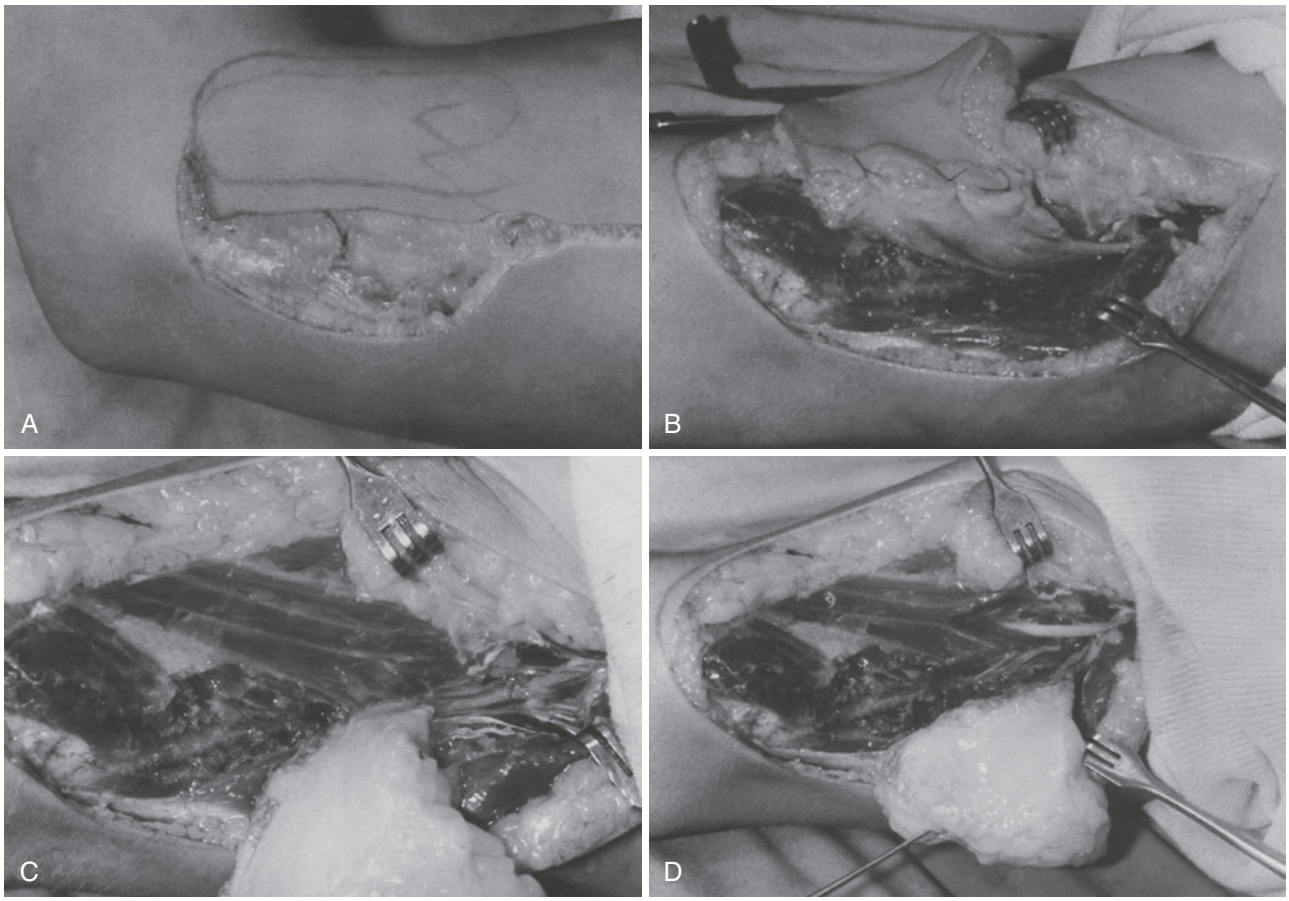

FIGURE 45.6 Lateral arm flap dissection. **A,** The posterior incision has been made, and the fascia overlying the triceps is seen. This must be divided to gain access to the correct plane for further dissection. **B,** The dissection has been completed to the point of releasing the lateral intermuscular septum from the underlying bone. The humerus can be seen in the distal third of the wound with the muscles of the mobile wad anteriorly and the triceps posteriorly. The sutures between the fascia and the skin prevent any shearing force from developing between these tissues. **C,** On a close-up view, the humerus is seen more clearly. The oozing is from the muscular branches that have been divided. The more proximal course of the pedicle is seen to the right of the incision. **D,** The pedicle has been dissected more proximally, and the radial nerve is now clearly seen as the white structure passing forward between the brachialis and the brachioradialis.

Between the point at which it leaves the radial nerve and the lateral epicondyle, the posterior radial collateral artery provides branches to bone, to muscles in both anterior and posterior compartments, and to the fascia and overlying skin. The main branches to fascia and skin therefore arise between these two points, which roughly demarcate the lower half of a line between the deltoid tubercle and the epicondyle.

The posterior radial collateral artery anastomoses distally with a rich vascular plexus composed of the olecranon anastomosis and branches of the radial recurrent artery, so that the territory of the lateral arm flap can be extended up to 12 cm distal to the lateral epicondyle onto the proximal forearm. Alternatively, only the proximal forearm skin can be harvested, thereby increasing the length of the posterior radial collateral artery pedicle.

The artery of the flap is usually accompanied by two venae comitantes and by two nerves, the posterior cutaneous nerve of the arm and forearm and both branches of the radial nerve. The posterior cutaneous nerve of the arm can be used to innervate the flap, whereas the posterior cutaneous nerve of the forearm should be preserved but can be harvested with the flap as a vascularized nerve graft. If the flap is designed on its distal skin territory as the lateral arm/proximal forearm flap, the posterior nerve of the forearm is used to innervate the flap.

Operative Technique

A sterile tourniquet is applied high on the upper arm after preparation up to the axilla. A line marking the lateral intermuscular septum is drawn from the deltoid tubercle to the lateral epicondyle and defines the midline axis of the flap (see Figure 45.4, *A*). The flap template is laid over this line marking the septum and in most instances, should be centered over the distal half of the line, although if a longer pedicle is required, the template can be moved more distally until it is centered over the epicondyle. If more skin cover over the pedicle is desired, the template should be moved proximally.

The skin is incised around the posterior margin of the flap and the incision extended proximally along the axial line as far as the deltoid tubercle. The incision is carried down to fascia. The posterior margin of the incision is elevated with skin hooks and the dissection continued posteriorly, superficial to the fascia until the midline of the triceps tendon is reached. The

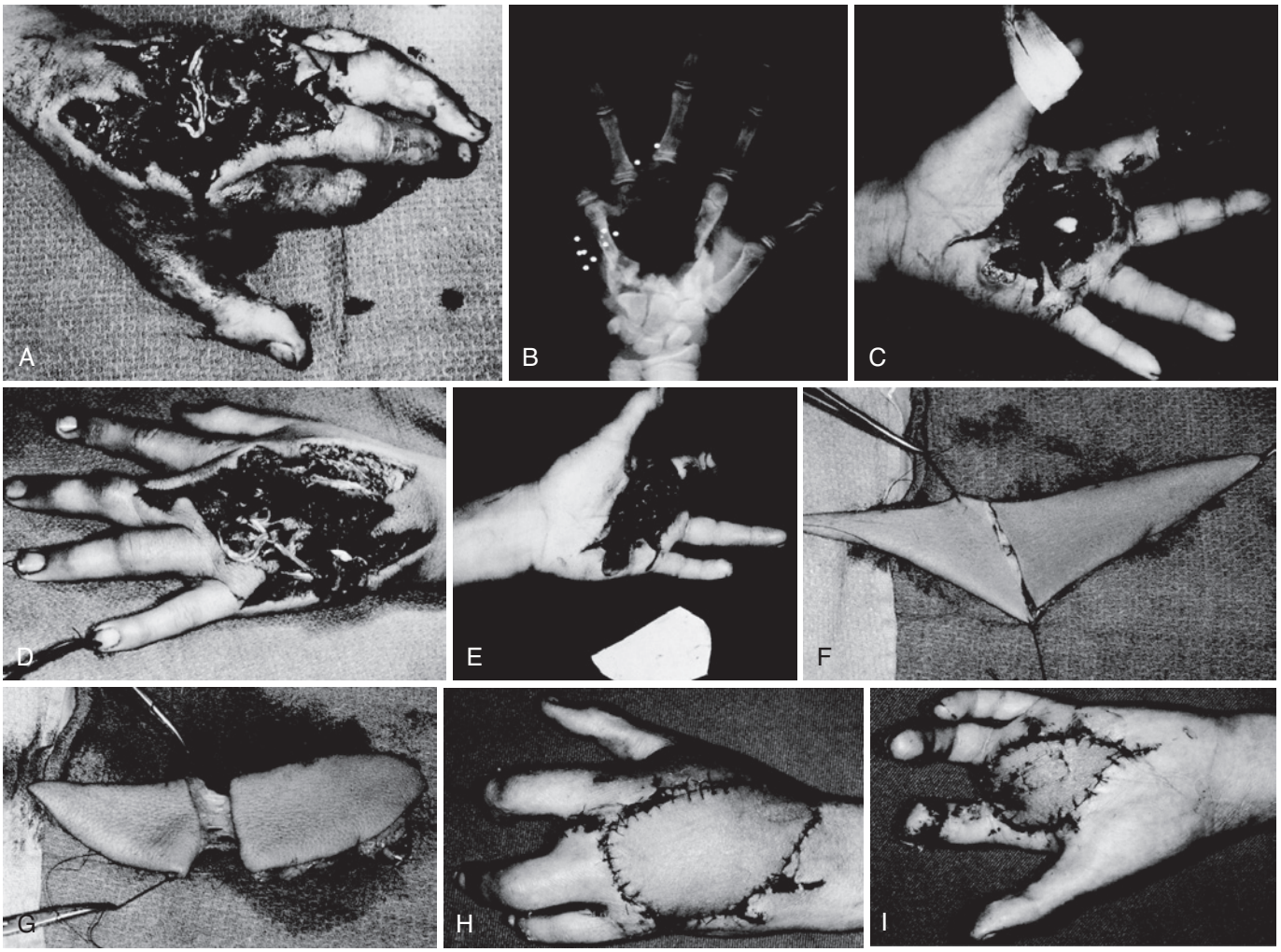

FIGURE 45.7 Lateral arm flap. **A,** This 14-year-old right-handed youth sustained a close-range shotgun injury to his left hand. **B,** Radiographs show significant metacarpal loss. Distraction displayed the **(C)** palmar and **(D)** dorsal defects. The middle finger was nonviable and had no metacarpal and was therefore amputated. The index finger was transposed into the position of the middle finger metacarpal. Length was restored by inserting the middle phalanx from the middle finger as an intercalated bone graft. The bony defect in the ring metacarpal was restored by using the proximal phalanx from the middle finger in a similar fashion. Significant palmar and dorsal defects remained. **E** and **F,** Templates were taken and placed end to end in designing a lateral arm flap taken from the same arm. **G,** After the lateral arm flap was raised, it was divided transversely through skin and subcutaneous tissue down to the level of the intermuscular septum containing the pedicle. The vessels of the flap were anastomosed to the radial artery and cephalic vein, placing the proximal portion of the flap on the dorsal defect and the distal portion of the flap on the palmar defect. The intervening pedicle was accommodated between the heads of the ring finger and now translocated index finger. **H** and **I,** Complete viability of the flap 14 days postoperatively when the patient started on a passive and active exercise program.

fascial vessels can be clearly seen running over the tendon (see Figure 45.6, *B*). The fascia is incised along the midline of the tendon and elevated from the tendon and muscle by dissecting in an anterior direction with the fascia elevated under some tension, at the same time retracting the triceps muscle in a posteromedial direction. The fascia and skin can be sutured to one another using the long ends of the ties as stay sutures. The dissection proceeds easily, with few if any small vessels to cauterize, until the septum is reached, at which point the pedicle vessels will be seen with muscular branches diving into the triceps. The posterior-to-anterior dissection is completed at this point.

The anterior margin of the flap and the underlying fascia over the brachialis and brachioradialis muscles should now be incised. The fascia here is more flimsy than that posteriorly but can be readily defined and managed in precisely the same way as previously described for the posterior portion of the flap, dissecting this time in a posterior direction beneath the fascia until the muscular vessels are encountered. The distal margin of the flap should now be raised, dissecting right up against the aponeurosis of the extensor origin in a proximal direction until the epicondyle is reached. The fascia here is very ill defined. There is no need, however, to incise the aponeurosis as one is tempted to do, only a need to dissect hard against it up to the epicondyle.

After raising all three margins, the flap can be elevated away from the lateral humerus. The assistant should retract the anterior and posterior muscle bellies away from the septum. With

traction applied to the flap in an upward direction with the nondominant hand, the surgeon should now elevate the septum from the periosteum of the humerus with a knife or bipolar cautery, taking care to ensure that all periosteal and muscular branches are cauterized. Although initially difficult, the further proximal one proceeds, the more easily the flap is raised (see Figure 45.6, *C* and *D*).

When the radial nerve is first seen leaving the field anteriorly between the brachialis and brachioradialis muscles, those vessels passing forward with the nerve should be ligated. The dissection is continued as far proximally as necessary to achieve a pedicle length of approximately 6 cm (see Figure 45.6, *D*). The two posterior cutaneous nerves will be encountered here: the deeper posterior cutaneous nerve of the forearm can be dissected out of the septum to avoid anesthesia in the forearm; the more superficial posterior cutaneous nerve of the arm can be divided high and later used to innervate the flap. The more proximal the dissection proceeds, the more difficult it becomes, because one is now pursuing the profunda brachii in the spiral groove beneath the lateral head of the triceps. This requires strong retraction with heavy rakes. A further impediment is the overlying tourniquet, but to release it at this stage will only make the situation worse. If necessary, an additional 6 to 8 cm of pedicle length can be gained by splitting the lateral and long heads of the triceps to expose the entire length of the profunda brachii vessels in the spiral groove. A tunnel can be developed beneath the lateral head of the triceps, and either the flap can be delivered proximally through this tunnel or the pedicle can be divided and the pedicle vessels delivered distally. This extended pedicle also increases the mean diameter of the artery from 1.5 mm up to 2.45 mm.

The authors adopt the convention of placing metal clips on the veins and silk ligatures on the artery, thus avoiding any potential confusion later. After dissection of a free tissue transfer has been completed, it is customary to release the tourniquet to reperfuse the flap before dividing the pedicle, but the lateral arm flap is an exception. It is completely reliable and the inevitable bleeding from adjacent muscles will obscure the important step of dividing the pedicle at its highest point.

The secondary defect can be closed directly if the flap is less than 6 to 8 cm wide, but otherwise a split-thickness skin graft is applied with confident expectation of full take, because the bed is well vascularized. The only complications associated with the harvest of a lateral arm flap are permanent hypoesthesias in the distribution of the posterior cutaneous nerve of the forearm if it is divided and temporary radial nerve palsy. The authors have never encountered this serious problem in their practice, but it has been reported after an Esmarch bandage was used as a tourniquet or when careful monitoring of cuff pressure was not followed.[44] A study of donor-site morbidity and aesthetic outcomes revealed that 90% of patients had decreased sensation after harvest of a lateral arm flap, but 85% of patients would still choose a lateral arm flap again.[71]

CRITICAL POINTS *Lateral Arm Flap*

Indications
- Soft tissue defects of the hand (smaller areas)
- Defects of the first web space

Preoperative Evaluation
- Doppler examination of the pedicle

Pearls
- A sterile tourniquet is placed as high as possible.
- The flap axis is a line from the deltoid tubercle to the lateral epicondyle.
- Avoid damage to the radial nerve during pedicle dissection.

Technical Points
- Begin dissection posteriorly on the skin.
- Elevate the skin and fascia toward bone.
- Elevate the anterior skin and fascia.
- Dissect the pedicle off the humerus in a distal-to-proximal direction.
- The artery can be quite small; the vein is fragile.
- Beware of the radial nerve running with the pedicle proximally.
- It may be necessary to remove the tourniquet to get added length on the pedicle as it spirals around the humerus.

Pitfalls
- Elevating skin and fascia without vessels
- Injury to radial nerve

Donor Site Management
- Small defects (<7 cm) can be closed primarily.
- Defects of 7 cm or larger will need skin grafting.

Radial Forearm Flap

The radial forearm flap[35,87,112,134] certainly offers unrivaled quality of thin, mobile skin, similar in its characteristics to the skin over the dorsum of the hand. Most dorsal and palmar defects of the hand can be covered by a pedicled reverse radial forearm flap[81] (see Chapter 44), but occasionally the size and shape of the defect may necessitate using a free radial forearm flap either from the contralateral forearm (Figure 45.8) or even from the ipsilateral forearm.[64] In any of these variations, the radial forearm flap depends on the availability of good flow through the ulnar artery and the palmar arches into the digital vessels. The radial artery may occasionally be the only patent vessel to the hand when there has been a penetrating or crushing injury to the forearm or palmar surface of the hand. Even when this is not the case, the radial artery has been shown to be the dominant artery in 12% of hands. Harvesting a radial forearm flap may potentially result in acute ischemia of the hand or postoperative symptoms of cold intolerance. However, digital temperature and Doppler flow studies have shown that loss of the radial artery does not cause any significant compromise to the circulation of the hand. Therefore, most surgeons no longer reconstruct the radial artery with a reversed interposition vein graft. The appearance of the donor defect, which has to be skin grafted, remains the major drawback of this flap for some surgeons.

Anatomy

The radial artery pursues a relatively superficial course down the forearm, from its origin at the bifurcation of the brachial artery to just distal to the radial styloid, where it passes deep to the abductor pollicis longus and extensor pollicis brevis tendons through the anatomic snuffbox. In the proximal forearm, it lies on the superficial surface of the pronator teres, just beneath the medial margin of the brachioradialis muscle. More distally, it comes to lie in turn on the radial head of the flexor digitorum

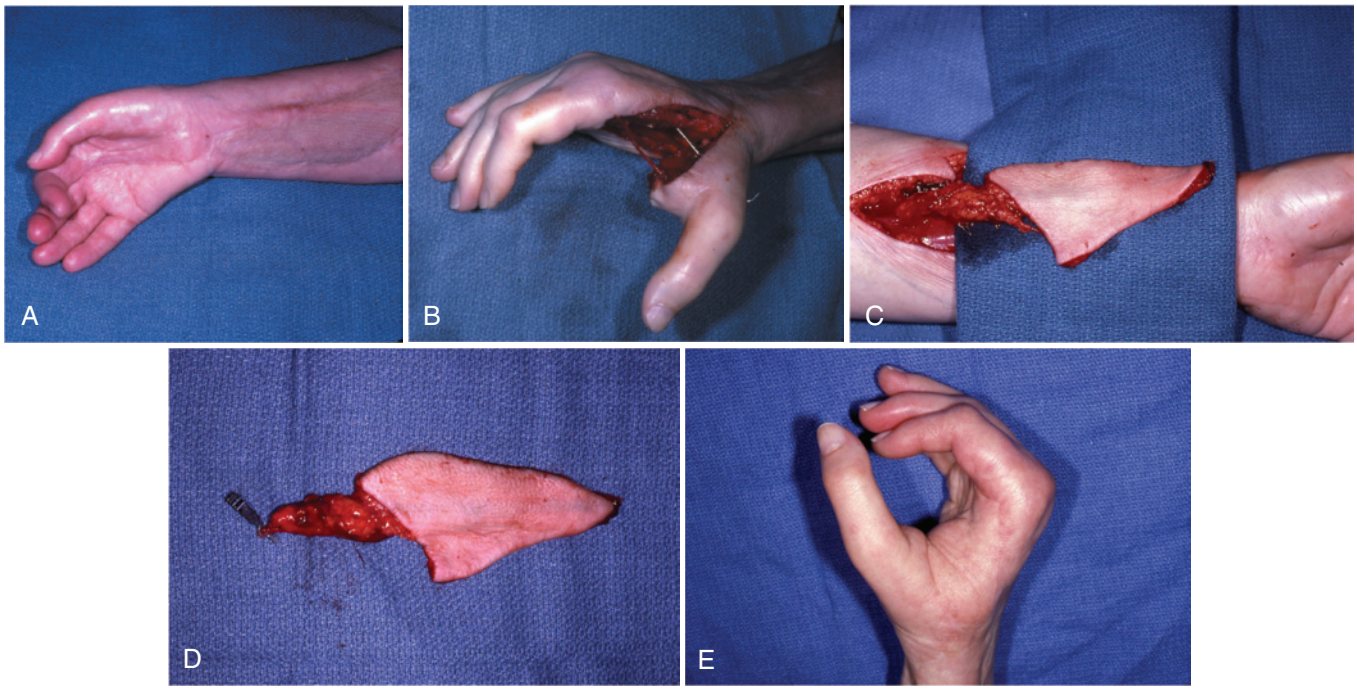

FIGURE 45.8 Radial forearm flap. **A,** This woman sustained a severe crushing injury of her right dominant forearm which required fasciotomies and vein graft revascularization. **B,** She later developed a severe adduction contracture of the thumb/index finger web space which necessitated a radical release of the first web space. **C** and **D,** A reverse radial forearm flap was not an option for coverage of the radical web space release, because the forearm had been previously skin grafted and the radial artery reconstructed with a vein graft. Therefore a contralateral left radial forearm flap was harvested. **E,** This provided thin pliable skin for the widened thumb/index finger web space.

superficialis and flexor pollicis longus, where it is palpable through the skin. The artery is accompanied by two venae comitantes.

Throughout its course, the artery gives off branches to a plexus of vessels in the overlying deep fascia, which supplies the skin of the anterior and radiodorsal surfaces of the forearm. Similarly, deep fascial branches also supply the periosteum of the distal half of the radius between the insertions of the pronator teres and brachioradialis. This allows a segment of vascularized bone to be harvested from the radius up to 10 cm in length and up to 30% of the cross-sectional area of the radius as an osteocutaneous flap.[35]

The minimal precaution that should be taken before raising a forearm flap is an Allen test to ensure that flow will be adequate through the remaining ulnar artery. Noninvasive vascular studies to determine arterial dominance are probably unnecessary.

Operative Technique

The course of the radial artery should be mapped out with a Doppler probe and marked on the skin, as should the course of the largest superficial vein in the forearm proximal to the flap (Figure 45.9, *C*).

The pattern of the defect is placed on the forearm with the marked course of the radial artery close to the radial border of the template. The radial artery should not be used as the midaxis of the flap; otherwise, if the flap extends around the radial border of the forearm, the skin-grafted defect becomes much more noticeable.[64] The flap is usually designed over the middle or distal third of the forearm. However, if the radial artery is to be used in a "flow-through" situation to reconstruct an associated arterial defect in the wound (see Figure 45.9),[9,93] the length of radial artery required proximal and distal to the flap to restore arterial inflow to the distal limb will predetermine the proximal-distal location of the flap on the forearm.

If pedicle length is not a consideration, the flap can be raised with its distal margin 3 to 5 cm proximal to the wrist crease. This avoids skin grafting over the more distal flexor tendons, especially the flexor carpi radialis, and the chances of the skin graft not taking over this critical area are reduced.

The radial margin of the flap is incised as well as a short longitudinal incision extending distally from the flap margin over the course of the radial artery. In elevating the radial skin margin from the underlying deep fascia, the cephalic vein should be identified and preserved, because very occasionally it may be needed to reconstruct the radial artery. Great care should be taken to preserve branches of the superficial radial nerve. Once the skin has been elevated for about 1 cm from the flap margin, the deep fascia should be incised to enter the plane of dissection radial to the radial artery pedicle.

The distal, ulnar, and proximal margins of the flap are now incised and the deep fascia can be sutured to the skin at several points around the flap to prevent shearing between the two during elevation of the flap. If the ends of these sutures are left long, they can be grasped with hemostats to provide the necessary tension during dissection. The flap is now raised by dissecting in the loose areolar tissue beneath the deep fascia in an ulnar-to-radial direction. Wherever a tendon is encountered in elevating the flap, care must be taken to preserve the overlying paratenon.

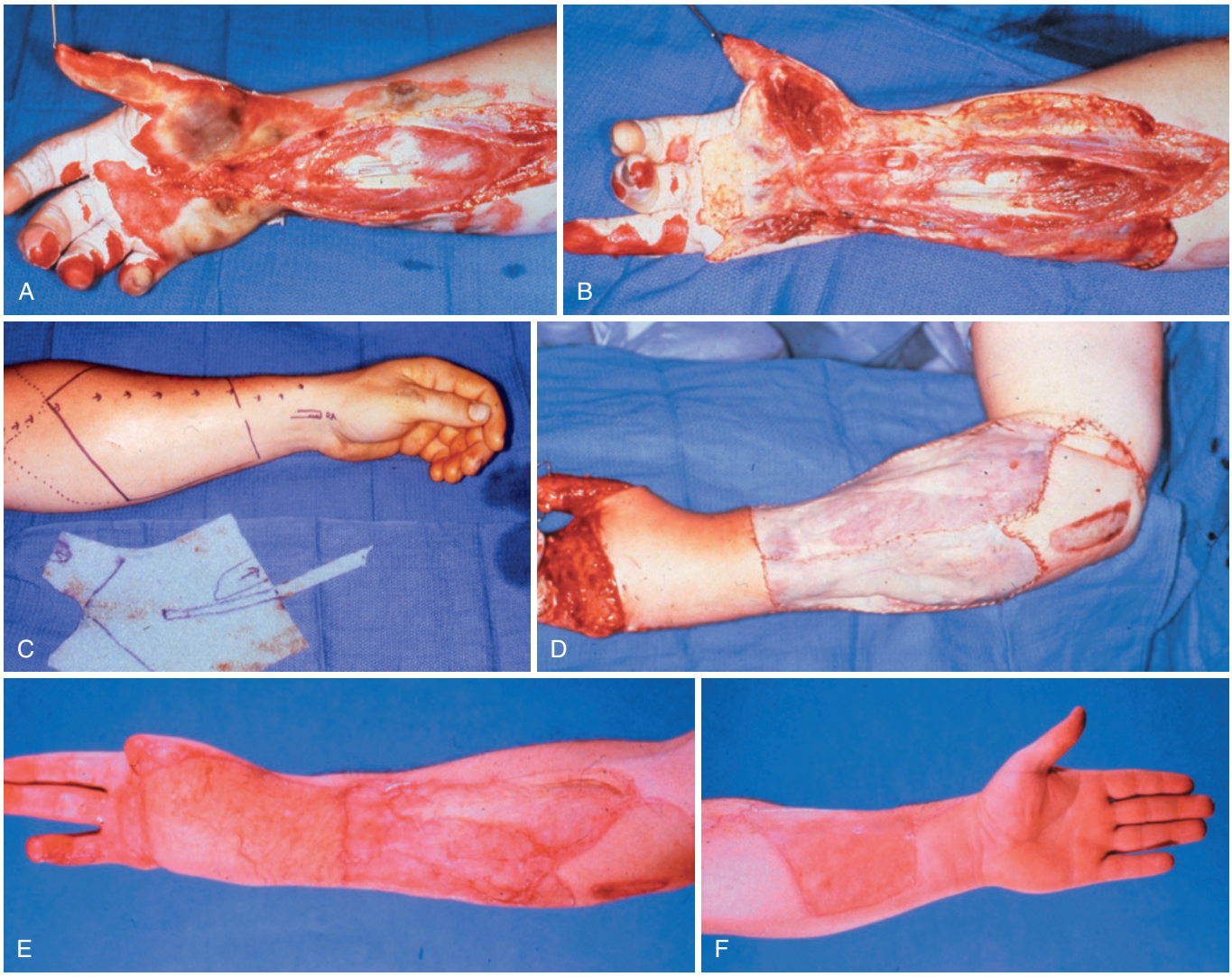

FIGURE 45.9 Radial forearm flap. **A,** This extensive thermal crush injury of the right hand required extensive débridement **(B)** with excision of the thrombosed ulnar artery, the small finger, the flexor retinaculum, and the distal portion of the flexor carpi ulnaris. Circulation to the digits was deemed to be marginal. **C,** A contralateral left radial forearm flap was designed based on the radial artery and the cephalic vein. The flap was to be applied in retrograde fashion to provide not only cover for the structures of the carpal tunnel but also to restore blood flow to the superficial palmar arch from the proximal ulnar artery. Fascial extensions of the radial forearm flap to be used to cover the palm of the hand are shown by the *dotted outline*. A pattern has been taken with plastic foam. **D,** The appearance immediately after application of the radial forearm flap, the skin grafts, and a transposition flap of the flexor carpi ulnaris. **E,** The result before thumb reconstruction. **F,** The defect of the donor forearm covered with a split-thickness skin graft. (From Chick LR, Lister GD, Sowder L: Early free-flap coverage of electrical and thermal burns, *Plast Reconstr Surg* 89:1013–1019, 1992, with permission.)

Once the flap has been raised from the ulnar margin across to the flexor carpi radialis tendon, traction on this muscle in an ulnar direction will reveal the radial artery and its venae comitantes. Similarly, dissection from the radial margin of the flap will reveal the vessels as the fascia is lifted from the brachioradialis. This muscle conceals the artery beneath its anterior border, the more so the farther proximal the dissection. Strong traction on the brachioradialis in a radial direction and dissection hard against the muscle and tendon are required. Distally, the two venae comitantes are ligated and divided. The radial artery is also divided between a ligature proximally and a microvascular clamp distally. Working from the radial and ulnar aspects, the lateral intermuscular septum containing the radial artery and venae comitantes can be visualized at all times and the portion of the septum passing inferiorly from the artery down to the flexor pollicis longus and radius can be divided to allow elevation of the vascular pedicle in continuity with the overlying flap. Small perforating vessels passing downward to supply the radius and flexor pollicis longus muscle can be coagulated. Dissection now progresses in a distal-to-proximal direction, and the vascular pedicle is elevated in the plane between the flexor carpi radialis and brachioradialis muscles. A longitudinal or gently curving incision proximal to the skin flap allows elevation of the proximal radial artery and any subcutaneous veins, if necessary, all the way to the bifurcation of the brachial artery just distal to the antecubital fossa. Usually, the two venae comitantes drain via a communicating branch into the superficial venous system so that a single large cubital vein can be

used as the proximal venous anastomosis.[120] The tourniquet is deflated, and this should reveal immediate reperfusion of the flap and the hand.

The microvascular clamp is removed from the distal stump of the radial artery, and this allows subjective evaluation of retrograde flow from the radial artery provided by inflow through the ulnar artery and palmar arches. If this flow is adequate, the distal radial artery is ligated. The proximal radial artery and venae comitantes or superficial vein are ligated and divided in the antecubital fossa, and the flap is transferred to the recipient defect.

The radial artery is reconstructed only if there is poor retrograde flow through the distal stump of the radial artery after release of the tourniquet. If this is necessary, either the cephalic vein, if it has not been incorporated in the flap, or the greater saphenous vein can be harvested, reversed, and used as an interposition vein graft with two end-to-end anastomoses to the proximal and distal ends of the radial artery. If bone has been taken from the radius in its distal third for a radial forearm osteocutaneous flap, contour can be restored by transposing the pronator quadratus muscle on the anterior interosseous vascular pedicle. The strength of the radius can be augmented by prophylactic anterior plating of the radius from proximal to distal of the bony defect. Any exposure of the flexor carpi radialis tendon is covered by imbrication of the flexor digitorum superficialis muscle. The margins of the flap donor defect are sutured to the underlying muscles to provide a shallow contour over which a nonmeshed split-thickness skin graft is placed (see Figure 45.9, *F*).[6,64,121] Some surgeons believe the donor defect to be cosmetically unsightly, but most patients are not embarrassed by the appearance of the forearm in long-term follow-up. To improve the "take" of a split-thickness skin graft over the donor site, a suprafascial radial forearm flap can be harvested above the level of the deep fascia, with only a cuff of fascia around the radial artery. The appearance of the donor defect can also be potentially eliminated by raising a radial forearm fascial flap with fascia alone (Figure 45.10).[14,36,51] However, a potential disadvantage is that split-thickness skin grafts may not "take" completely over a fascial flap and the fascial flap may not be sufficiently robust to provide coverage of the primary defect.

CRITICAL POINTS *Radial Forearm Free Flap*

Indications
- Soft tissue defect of hand and wrist
- May provide fascia, skin, tendon, and bone if needed
- Wound with need for distal revascularization (flow-through flap)

Preoperative Evaluation
- Allen test for patency and adequacy of ulnar artery inflow to hand
- Scars on forearm from prior injury or surgery

Pearls
- "Best" flap to place on hand but donor site may be cosmetically ugly
- May use as fascia-only flap to avoid skin graft on forearm

Technical Points
- Design the flap 3 to 5 cm proximal to wrist if possible.
- Do not center the flap on the radial artery, but make the radial artery the radial border of the flap.
- Dissect the pedicle as a "unit"; do not divide the veins from the artery.
- Preserve the cephalic vein; avoid damage to the superficial branch of the radial nerve.
- The palmaris longus may be included in the flap if vascularized tendon reconstruction is required.

Pitfalls
- Damage to superficial branch of radial nerve
- Inadvertent division of the septum between the skin and vascular pedicle, when dissecting from radial side

Donor Site Management
- All but very small flaps will require skin grafting.
- The flexor carpi radialis tendon may be covered by imbrication of the superficialis muscle "up and over."
- A nonmeshed split-thickness graft is fine; the donor site is somewhat better with a full-thickness graft.
- Use a splint until the graft has taken.

Scapular Flap

Anatomy

The scapular flap, a cutaneous flap, is based on the vascular territory of the cutaneous branch of the circumflex scapular artery.[39,46] The circumflex scapular artery is the first branch of the subscapular artery, arising 2 cm from the origin of the subscapular artery from the axillary artery. The external diameter of the circumflex scapular artery is 1.72 mm. The circumflex scapular artery passes posteriorly through the triangular space between the long head of the triceps laterally, the teres major inferiorly, and the subscapularis medially and superiorly. It then divides into a number of branches deep to the teres minor. The cutaneous branch continues posteriorly between the teres minor above and the teres major below. It turns sharply medially over the lateral border of the scapula and divides into two branches: one branch runs transversely, superficial to the deep fascia overlying the teres minor and the infraspinatus, and the other branch runs obliquely downward parallel to the lateral border of the scapula. Flaps based on the transverse branch of the circumflex scapular artery have by convention been described as scapular flaps, whereas those based on the descending branch are described as parascapular flaps (Figure 45.11, *B*).[89] A thin circumflex scapular artery perforator flap based on a perforator vessel arising within 1.5 cm of the bifurcation of the circumflex scapular artery has recently been described.[25]

Injection studies have shown that the vascular territory includes all of the skin inferior to the scapular spine, extending medially toward the spine and laterally over the deltoid. The lateral border of the scapula can be harvested with either the scapular or parascapular flaps as a vascularized bone graft[114] and could potentially be considered as an option for simultaneous reconstruction of a combined dorsal hand defect and an underlying metacarpal bony defect. A combined scapular osteocutaneous flap and latissimus dorsi flap can also be harvested on their common vascular pedicle.

Operative Technique

The patient is placed in the lateral position with padding beneath the opposite axilla. The arm that is uppermost should be prepared and draped with a stockinette, so that the arm can be abducted as required. With the arm abducted, the triangular space through which the pedicle passes can be convincingly

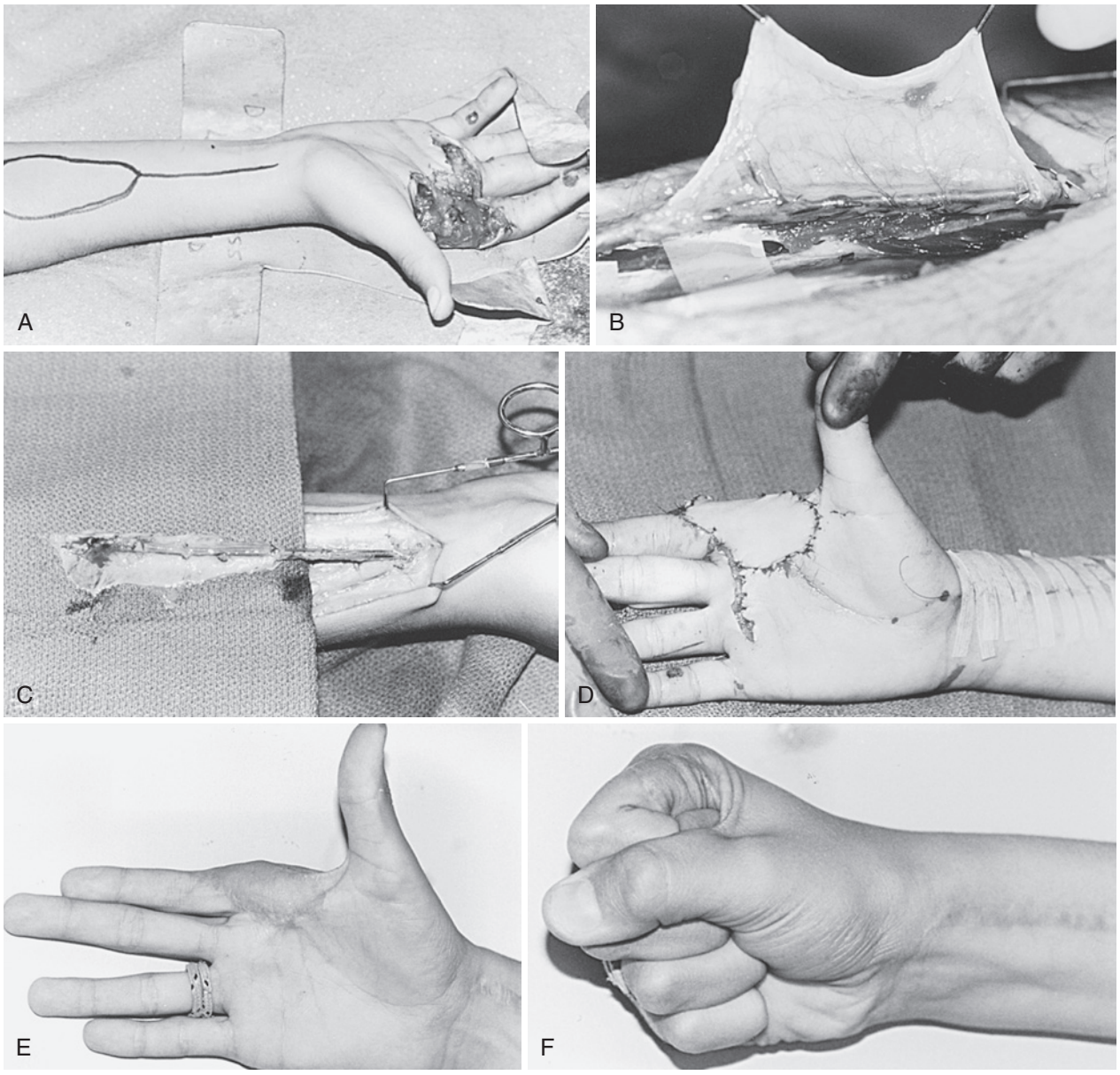

FIGURE 45.10 Reverse radial forearm fascial flap. **A,** Palmar defect from a shotgun injury with the area of fascia to be harvested outlined on the forearm. **B,** Fascia elevated off the muscle. Note the rich vascularity of the fascia. **C,** The fascia with its radial artery pedicle after harvest. **D,** Fascia placed in the palmar defect and covered with a full-thickness skin graft. **E** and **F,** Late result with stable coverage and good motion. Note the forearm scar from primary closure of the donor site.

palpated by gripping the posterior axillary fold between the finger and thumb (see Figure 45.11, *A*). The defect into which the thumb intrudes is formed by the teres major, the deltoid, and the combined scapula and teres minor.

A sterile Doppler probe may be used to trace the cutaneous vessels across the back, and the axis of the transverse and descending branches should be drawn. The flap template should now be placed over either axis, taking into account the orientation of the pedicle to the primary defect and the laxity of the skin with regard to primary closure. A transverse scapular flap may extend medially as far as the spine and can be extended farther across the midline or laterally over the deltoid if required. Scapular and parascapular flaps should not be designed as more than 10 cm wide, because such width would make it impossible to directly close the secondary defect, and this is not a good site for a skin graft.

The margins of the flap are incised down to the thick fascia overlying the infraspinatus. The plane superficial to this deep fascia is well defined and relatively avascular. The flap can be swiftly raised proceeding from medial to lateral for a scapular flap or from inferior to superior for a parascapular flap. As the triangular space is approached, the cutaneous branch of the circumflex scapular artery can be displayed by transilluminating the flap. The triangular space should be approached by splitting the aponeurotic teres minor away from the muscular teres major. As dissection proceeds into the space, the surgeon should be very careful because there are several large, short, and comparatively fragile branches that supply the muscles and



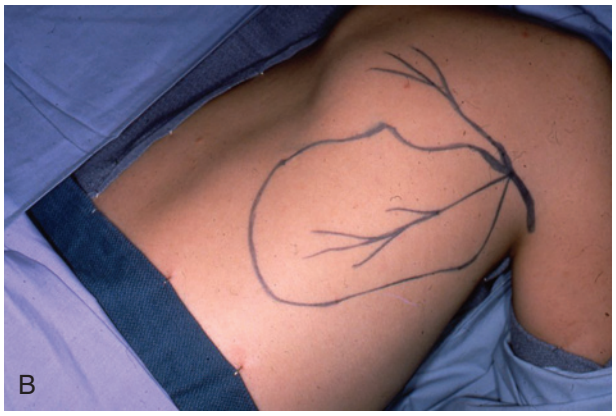

FIGURE 45.11 Scapular flap. **A,** Using the finger and thumb to grip the posterior axillary fold, the triangular space is readily detected lying between the triceps (T), the teres minor (TMn), and the teres major. **B,** A pencil Doppler probe can be used to trace the transverse and descending branches of the circumflex scapular artery. In this patient, a parascapular flap is to be harvested based on the descending branch of the circumflex scapular artery.

CRITICAL POINTS *Scapular Flap*

Indications
- Moderately sized soft tissue defects of upper extremity (Figure 45.12)
- Defects with short segmental bone loss (using vascularized lateral border of scapula)

Preoperative Evaluation
- Perform Doppler imaging of the pedicle as it exits the triangular space.
- Mark the lateral border of the scapula, teres major, and teres minor.

Pearls
- A very large "parascapular" flap can be harvested to cover very large defects.

Technical Points
- Flaps should be designed over a vessel defined by Doppler imaging.
- Do not design flaps wider than 10 cm because this is a difficult area for a split-thickness skin graft to take.
- Raise the skin with fascia from medial to lateral (scapular flap) or inferior to superior (parascapular flap).
- Watch for multiple branches from the pedicle to muscles and lateral scapula in the triangular space.
- The pedicle can be lengthened by dissecting subscapular vessels up to axillary vessels.

Pitfalls
- Dissection should proceed with caution when one is approaching the triangular space.

Donor Site Management
- Limit the flap width to 10 cm and close primarily over drains.
- Skin grafting of this donor site is unwise.

lateral border of the scapula. The assistant should apply traction to the borders of the space, so that the surgeon can visualize and ligate these branches.

To obtain the longest possible pedicle, the incision should be extended into the axilla. The thoracodorsal artery should be located on the undersurface of the latissimus dorsi muscle and traced proximally so that the "T"-bifurcation of the subscapular artery into the thoracodorsal and circumflex scapular arteries can be completely defined. Either the circumflex scapular artery can be divided just distal to the thoracodorsal artery, or the subscapular artery can be divided just below its origin from the axillary artery, thereby incorporating the "T"-junction that will facilitate two end-to-end anastomoses rather than an end-to-side anastomosis using the circumflex scapular artery. A pedicle some 15 cm in length from the axillary artery to the flap can be achieved.

After completion of the dissection, the secondary defect can be closed primarily. This should be done with strong sutures because dehiscence can occur with abduction of the shoulder. After harvest of a parascapular flap, 45% of patients complained of sensory abnormalities, but 100% said they would choose a parascapular flap again.[71]

A "fascial" version of the scapular flap has been described with the advantages that its width can be greater than 10 cm and that the donor scar is less likely to widen and become hypertrophic.[27,70] Strictly speaking, this scapular fascial flap should probably be termed a subcutaneous flap or adipofascial flap. If the surgeon has decided that a fascial flap is the optimal flap, the scapular fascial flap may be a better selection in men in order to avoid the potential alopecia seen after harvesting a temporoparietal fascial flap, but it requires a change from the lateral position to the supine position during surgery.

Groin Flap

Anatomy

The groin flap (Figure 45.13, *A*) is an axial-pattern cutaneous flap. Its axial vessel is the superficial circumflex iliac artery,[110] which is a relatively constant vessel, present in 96% of a series of angiograms. The vessel arises from the femoral artery in the femoral triangle, which forms a vascular "hub"[118] for the axes of several flaps that converge in this location (Figure 45.14).

The superficial circumflex iliac artery emerges from the femoral triangle by passing over the medial border of the sartorius immediately after giving off a deep muscular branch. Initially below the deep fascia, the vessel emerges upward through the fascia as it crosses the sartorius. It passes laterally, parallel to, and 2 cm below the inguinal ligament (see Figure 45.13, *A*).[22,48,54] At a point below the anterior superior iliac spine, the vessel divides and supplies the skin immediately below the iliac crest. The vascular territory of the superficial circumflex

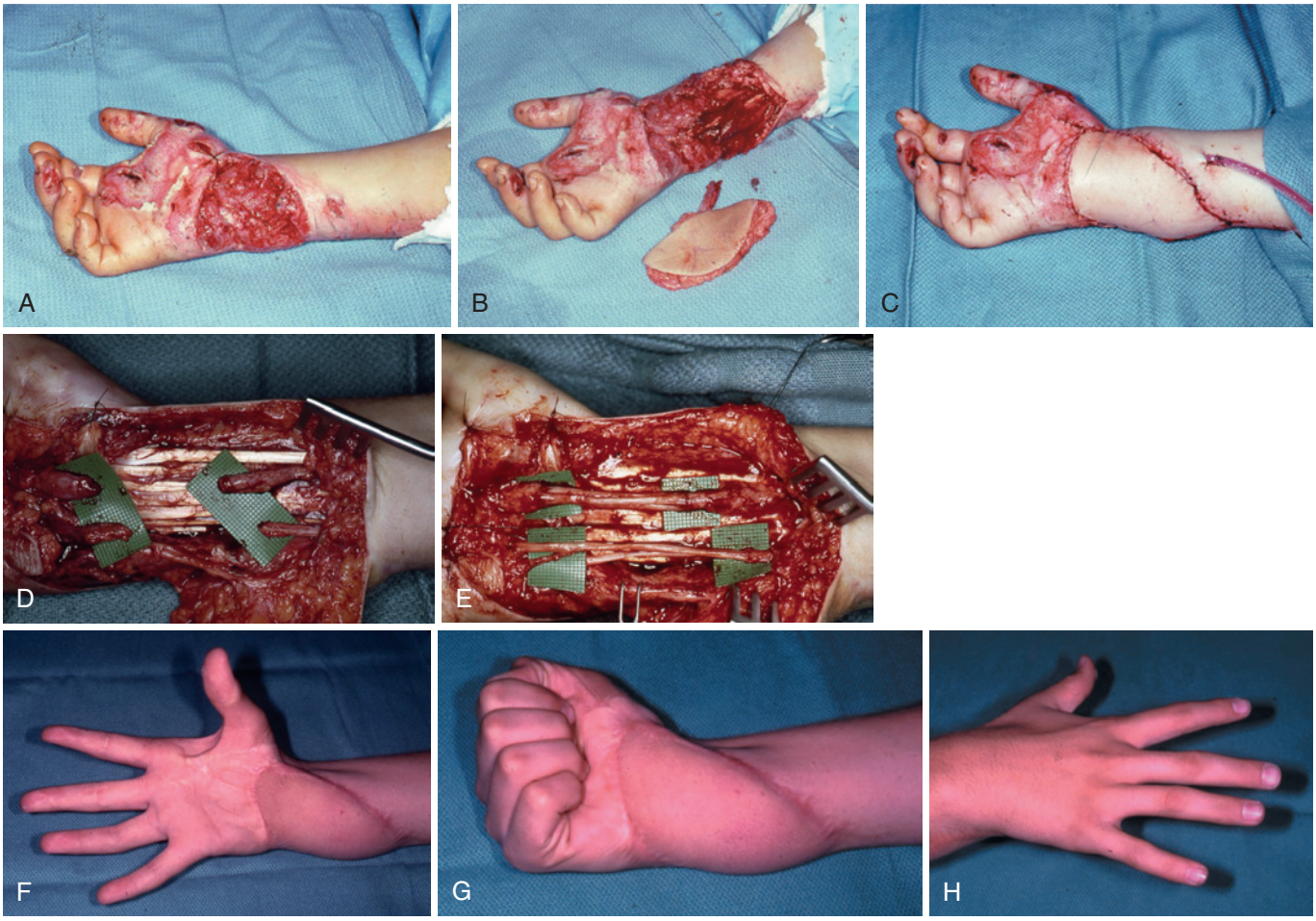

FIGURE 45.12 Scapular flap. **A,** This 5-year-old boy sustained a degloving injury of the palmar aspect of his right wrist with segmental defects of both the median and ulnar nerves and several flexor tendons, when he was thrown out of a car. **B** and **C,** After serial débridements, the flexor tendons were reconstructed and the soft tissue defect covered with a free scapular flap, with end-to-end anastomosis of the circumflex scapular artery to the already transected distal ulnar artery. **D** and **E,** Three months later, the flap was re-elevated and the segmental defects of the median and ulnar nerves were reconstructed with sural nerve grafts. At 9 years after operation, without any tenolyses or tendon transfers, the patient has regained excellent palmar abduction of the thumb **(F)** and full flexion **(G)** and extension of the fingers without any clawing **(H)**. The flap developed some hypertrophy of the subcutaneous fat as the patient went through puberty and would benefit from minor debulking.

iliac artery ends at some point lateral to the anterior superior iliac spine. Practical experience has demonstrated that the flap can be safely extended beyond the anterior superior iliac spine by a distance at least equal to the width of the flap.

The venous drainage, which is as important as the arterial supply, and the lymphatic outflow of the flap have both been studied in detail. Variations in venous anatomy in the femoral triangle are important to the microsurgeon. Usually, the groin flap is not reinnervated, but the lateral cutaneous branch of the subcostal or 12th thoracic nerve consistently crosses the iliac crest 5 cm posterior to the anterior superior iliac spine. This nerve could potentially be dissected, divided, and sutured to any available cutaneous nerve in the hand. If a relatively large block of bone is required in the hand in association with a soft tissue defect, a segment of vascularized bone can be taken from the iliac crest immediately beneath the flap (see Figure 45.13, *B*).[91]

The groin flap can be designed up to 12 cm wide and still allow primary closure of the donor defect (Figure 45.15, *D*). Because the donor site scar can be readily hidden, it is an ideal flap for use in young women when aesthetic considerations are important. It requires a more demanding dissection compared with most other free flaps, but the free groin flap has been advocated in children for repair of congenital differences, tumor resection, and trauma repair. Despite a higher reexploration rate of 24%, there were only 2 failures in a series of 33 children.[54]

Operative Technique. The midline axis of the flap should be drawn 2 cm inferior and parallel to the inguinal ligament (see also Chapter 44). A planning template of the defect should be laid on the skin immediately below the anterior superior iliac spine. This allows for a relatively long vascular pedicle by incorporating the more medial inguinal dissection (see Figure 45.13, *C*). The lower margin of the flap is incised down to the superficial surface of the deep fascia. The deep fascia should be incised and retracted proximally to reveal the sartorius, the tensor fasciae latae lateral to it, and the intervening intermuscular septum. While maintaining traction on the flap superiorly

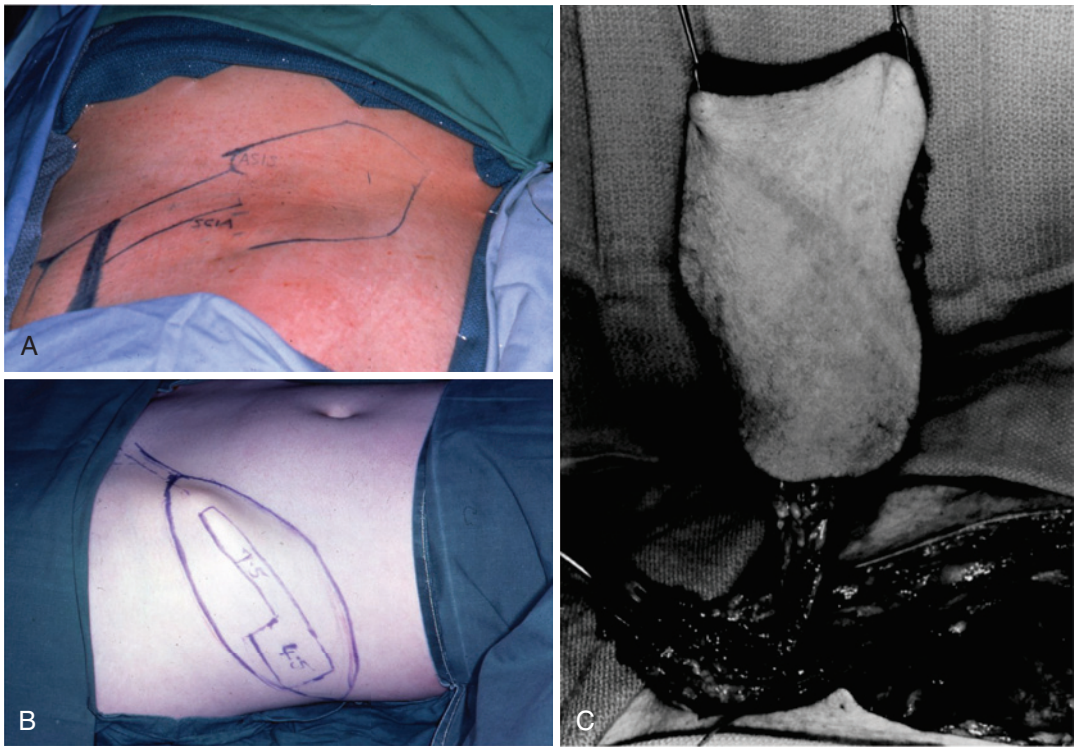

FIGURE 45.13 Groin flap. **A,** The superficial circumflex iliac artery pedicle of a free groin flap lies 2 cm below and parallel to the inguinal ligament passing from the pubic tubercle to the anterior superior iliac spine. **B,** Vascularized bone from the iliac crest can be incorporated into a free groin flap, but is better based on the deep circumflex iliac artery rather than the superficial circumflex iliac artery. **C,** The long pedicle that can be achieved in harvesting a free groin flap is demonstrated.

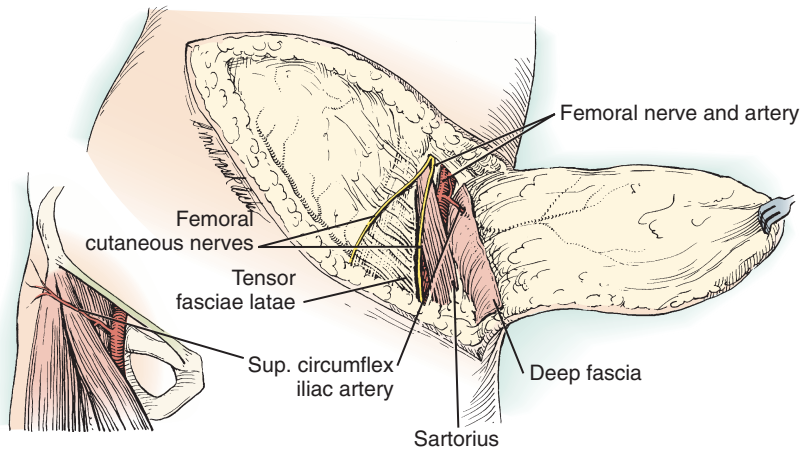

FIGURE 45.14 Groin flap. The groin flap is based on the superficial circumflex iliac artery, which runs parallel to and approximately 1 inch inferior to the inguinal ligament. It emerges through the deep fascia as it crosses the sartorius and breaks up into branches at the level of the anterior superior iliac spine. When the flap is raised, the lateral femoral cutaneous nerve should be preserved or, in certain instances (see text), divided and repaired. The fascia that is divided at the lateral margin of the sartorius can be seen. (From the Christine M. Kleinert Institute for Hand and Microsurgery, with permission.)

and away from the thigh, the deep fascia should be divided in a superior direction in the line of the fibers of the sartorius and at its lateral border just medial to the intermuscular septum.

The superficial circumflex iliac artery will be seen in the deep fascia as it is lifted from the sartorius. Incision of the fascia proceeds beyond the artery as far as the origin of the sartorius from the anterior superior iliac spine. Once it has been confirmed that the vessel is present, the remainder of the incision outlining the upper margin of the flap is made. As the upper incision is carried down to the external oblique aponeurosis, a significant artery passing superiorly will be encountered in the majority of cases. This should not cause alarm, because this is the superficial inferior epigastric artery, which must be divided. Furthermore, division of the superficial inferior epigastric

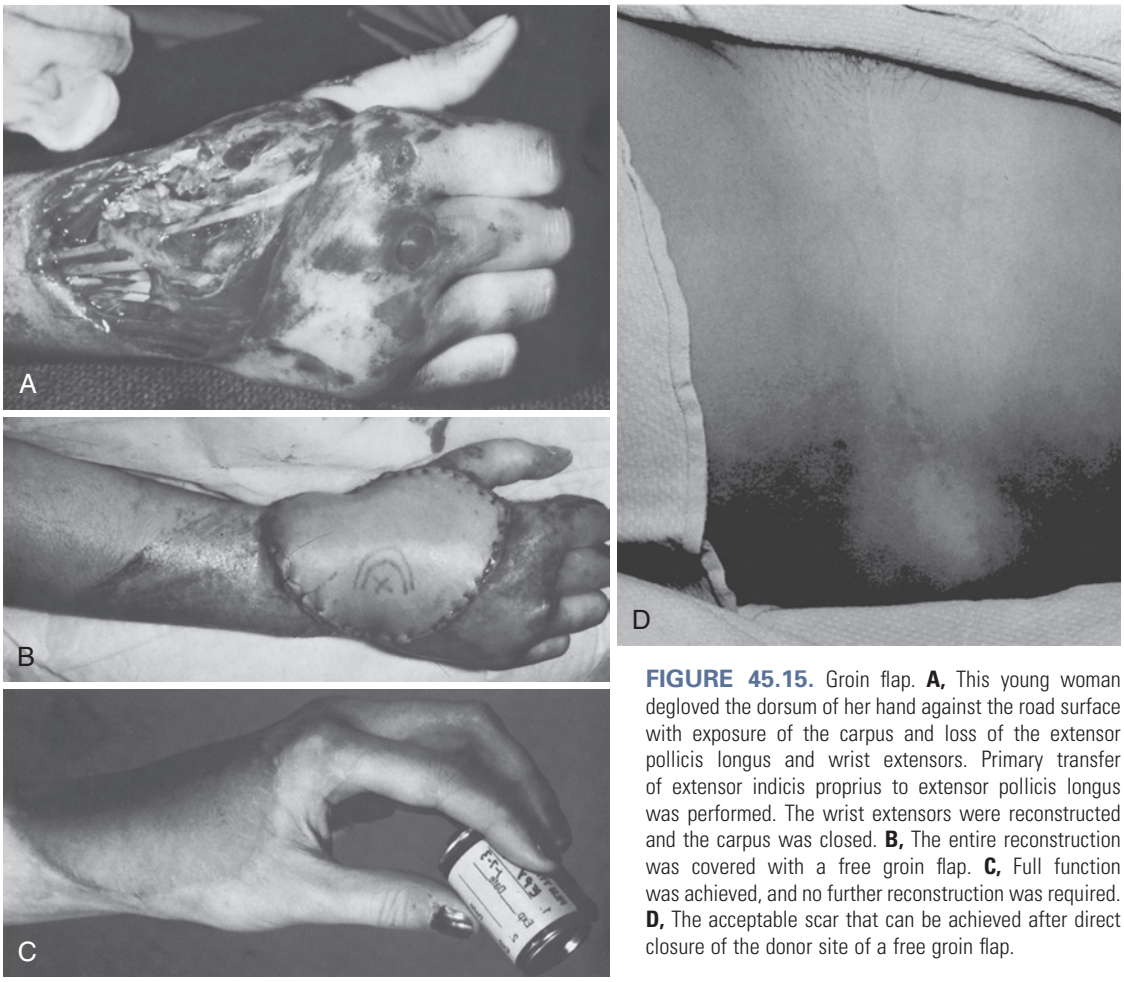

FIGURE 45.15. Groin flap. **A,** This young woman degloved the dorsum of her hand against the road surface with exposure of the carpus and loss of the extensor pollicis longus and wrist extensors. Primary transfer of extensor indicis proprius to extensor pollicis longus was performed. The wrist extensors were reconstructed and the carpus was closed. **B,** The entire reconstruction was covered with a free groin flap. **C,** Full function was achieved, and no further reconstruction was required. **D,** The acceptable scar that can be achieved after direct closure of the donor site of a free groin flap.

artery indicates that the level of dissection is in the correct plane.

The flap is retracted inferiorly off the external oblique aponeurosis until the level of the anterior superior iliac spine is reached. The incision made previously in the sartorius fascia is located and turned medially to free the deep fascia of the thigh from the inguinal ligament. In the course of this incision, the lateral cutaneous nerve of the thigh will be encountered. Care must be taken not to injure this nerve; otherwise, *meralgia paresthetica* may result. Whereas the nerve usually passes deep to the flap vessels and can be freed by dissection, on occasion it or one of its usual two branches may be superficial to the vessels. In this situation, the vascular pedicle should be dissected medially, divided, and passed beneath the nerve.

By applying upward traction to the flap, the fascia can be dissected off the underlying fibers of the sartorius muscle as far as its medial border, paying careful attention to the vessel, which can usually be seen passing down through the superficial fascia to lie on the muscle itself. The main hazard to further dissection of the pedicle is the muscular branch of the superficial circumflex iliac artery. This should be isolated by retracting the sartorius laterally with instruments on either side of the pedicle, superiorly and inferiorly. Once the muscular branch has been dissected free under loupe magnification, it can be divided. The superficial circumflex iliac artery can be mobilized all the way to its origin from the femoral artery. If the vessel is of small caliber, a cuff of the femoral artery can be taken. This is especially advantageous if an end-to-side anastomosis is to be performed. The venous drainage of the flap will be encountered as the medial border of the flap is incised. All veins emerging from the flap should be preserved and traced medially. They will usually join before draining into the termination of the long saphenous vein, providing at most two veins, of suitable caliber, for anastomosis.

The flap can now be thinned by having an assistant hold the flap vertically with hooks or stay sutures and the surgeon using forceps and curved tenotomy scissors with their concave surface uppermost. The flap can be thinned quite radically at the margins by trimming away fat. In the middle of the flap, the surgeon must be more cautious; otherwise, the pedicle may be damaged. Lobules of fat between the flap margins and midline can be lifted with the pickups and trimmed away. The deep fascia that has been lifted must not be transgressed; any fat that lies between it and the skin must be left alone.

Closure should commence at the lateral end of the donor defect. It may be difficult, but the surgeon should not undermine the margins in an attempt to facilitate closure. This only increases the area of potential dead space and does little to relax the skin. Rather, the surgeon should flex the thigh and use heavy sutures, knowing that primary closure is always possible if the width of the flap was less than 12 cm when first outlined. The tension created will inevitably result in postoperative

inflammation along the suture line. Even if this inflammation becomes pronounced, do not remove sutures! To do so would open the entire cavity, and if the cavity becomes infected, as would almost be inevitable, one has created a disaster similar to a pressure sore.

More recently, the superficial circumflex iliac artery perforator (SCIP) flap has evolved from the conventional free groin flap.[56,74] The potential advantages of this flap are possible thinning of the flap by primary defatting, harvesting of a purely adipofascial flap, and minimal concealment of the donor site. However, the disadvantages are the dissection of a smaller perforator and supermicrosurgical anastomosis of vessels less than 1 mm in diameter.

A similar perforator flap may be designed and harvested on the superficial inferior epigastric artery system (SIEA).[88]

Anterolateral Thigh Flap

Anatomy

After the vascular anatomy of the anterolateral thigh (ALT) flap was first described by Baek[4] in 1983 and Song in 1984,[113] it has been increasingly used over the past decade for microsurgical reconstruction in Asia[73,129] but has not really achieved the same popularity in North America and Europe.[1,59,127] A large skin island over the anterior and lateral aspect of the thigh can be harvested supplied by either the septocutaneous or musculocutaneous perforators of the descending branch of the lateral circumflex femoral artery.[133] The lateral femoral circumflex artery is a branch of the profunda femoris artery and passes downward between the rectus femoris and vastus lateralis muscles. Xu and colleagues[133] reported that the perforators to the skin passed through the vastus lateralis muscle, and Wei and associates[129] found that 87% of the skin perforators were musculocutaneous and only 13% were septocutaneous in a study of 672 anterolateral thigh flaps. The continuation of the descending branch can be used as a flow-through artery for simultaneous revascularization of the forearm or hand.[55] Fascia lata can be harvested with the flap for tendon or ligament reconstruction, and a portion of the vastus lateralis muscle can be harvested to fill any dead space. Potentially, this flap can be harvested as a sensate flap by including the lateral femoral cutaneous nerve of the thigh.

Operative Technique

The flap is designed over a line drawn between the anterior superior iliac spine and the midpoint of the lateral border of the patella with the patient in a supine position.[101] The main cutaneous perforators are detected with a pencil Doppler probe and are centered primarily within a 3- to 5-cm radius of the midpoint of this longitudinal axis and 1.5 cm lateral to this line[137] (Figure 45.16, *C*). The descending branch of the lateral circumflex femoral artery passes downward in the fascia between the rectus femoris and the vastus lateralis muscles. The medial margin of the skin flap is incised down through the deep fascia overlying the rectus femoris muscle. The flap is elevated posteriorly in the subfascial plane until the intermuscular space between the rectus femoris and vastus lateralis muscles is exposed. If septocutaneous perforators from the lateral circumflex femoral artery are seen, the lateral border of the flap is incised, the flap is elevated in an anterior direction toward the intermuscular septum, and the flap is harvested as a septocutaneous flap. However, if septocutaneous perforators are absent, the flap is harvested with a small cuff of vastus lateralis muscle as a musculocutaneous flap or as a perforator flap by intramuscular dissection of the musculocutaneous perforators.[73] After the perforators have been dissected and included, the descending branch of the lateral circumflex femoral artery is ligated distally and the pedicle elevated in a distal-to-proximal direction up to the ascending branch. If more pedicle length is required, the pedicle can be dissected further up to the profunda femoris artery. Either the descending branch of the lateral circumflex femoral artery or the lateral circumflex femoral artery itself may serve as the vascular pedicle with a length of 8 to 12 cm.

The main advantage of the anterolateral thigh flap is that the patient does not need to be turned in a lateral position as might be the case with harvesting a latissimus dorsi or scapular flap. Specifically for upper extremity reconstruction, the anterolateral thigh flap can be radically thinned to a thickness of 2 to 4 mm (see Figure 45.16).[1,73,127,129] Extra fascia can be harvested to wrap around exposed tendons. The anterolateral thigh flap has numerous advantages compared with other free flaps for upper extremity reconstruction: a large skin paddle of up to 20 × 15 cm even for thinned flaps; a long vascular pedicle; the possibility of restoring sensation by incorporating the lateral femoral cutaneous nerve; harvesting part of the vastus lateralis muscle to fill any dead space; the ability to harvest the flap simultaneously in a supine position; and minimal morbidity at the donor site because the donor site can be closed directly if the width does not exceed 6 to 8 cm (otherwise, a split-thickness skin graft is necessary). Potential disadvantages of the anterolateral thigh flap include a lateral thigh scar, especially if a skin graft has to be used (this may preclude its use in women); hairiness of the lateral thigh skin in men; decreased sensation over the lateral thigh; and variability of the vascular anatomy. In a study of 220 patients undergoing anterolateral thigh flap transfer, Hanasono and colleagues[47] found a low incidence of wound-healing problems, but 84% of patients had numbness in the lateral femoral cutaneous nerve distribution. Even though 37% of patients had a significant amount of vastus lateralis muscle harvested as part of the flap, all patients returned to their preoperative level of activity. Klinkenberg and associates[71] found altered sensation in 90% of patients after harvesting an anterolateral thigh flap compared with 45% of patients after harvesting a parascapular flap. Only 75% of patients said they would choose an anterolateral thigh flap again, compared with 100% of patients who said they would choose a parascapular flap again. However, it is likely that in the future, the anterolateral thigh flap may become one of the top choices for reconstruction of extensive defects of the upper extremity.

Latissimus Dorsi Muscle and Musculocutaneous Flaps

The latissimus dorsi was first described as an axial-pattern regional flap for breast reconstruction by Tansini in 1906. It was used only sporadically until Olivari reintroduced it for coverage of radiation defects of the anterior chest wall in 1976. The muscle is supplied primarily by the thoracodorsal artery from which perforators pass through the muscle to supply the overlying skin as a musculocutaneous flap (Figure 45.17, *B*). The diameter of the thoracodorsal artery (1 to 2.5 mm) and the



FIGURE 45.16 Anterolateral thigh flap. **A** and **B,** After serial radical débridements and amputation of the index and middle fingers for severe necrotizing fasciitis following a spider bite, soft tissue coverage of both the dorsal and palmar aspects of the left hand was required. **C,** Most of the septocutaneous perforators of the descending branch of the lateral circumflex femoral artery lie within 3 to 5 cm of the midpoint of the axis of the flap, which lies between the anterior superior iliac spine and the midpoint of the lateral border of the patella. **D,** This flap may be thinned to a thickness of 2 to 4 mm away from the vascular pedicle. **E,** Intraoperative appearance of the thinned anterolateral thigh flap. The flap can be monitored postoperatively by surface Doppler monitoring of a perforator marked by the suture. **F** and **G,** Two years following operation, the anterolateral thigh flap provides thin supple coverage of the palmar and dorsal aspects of the hand and maintains the web space between the thumb and ring finger.

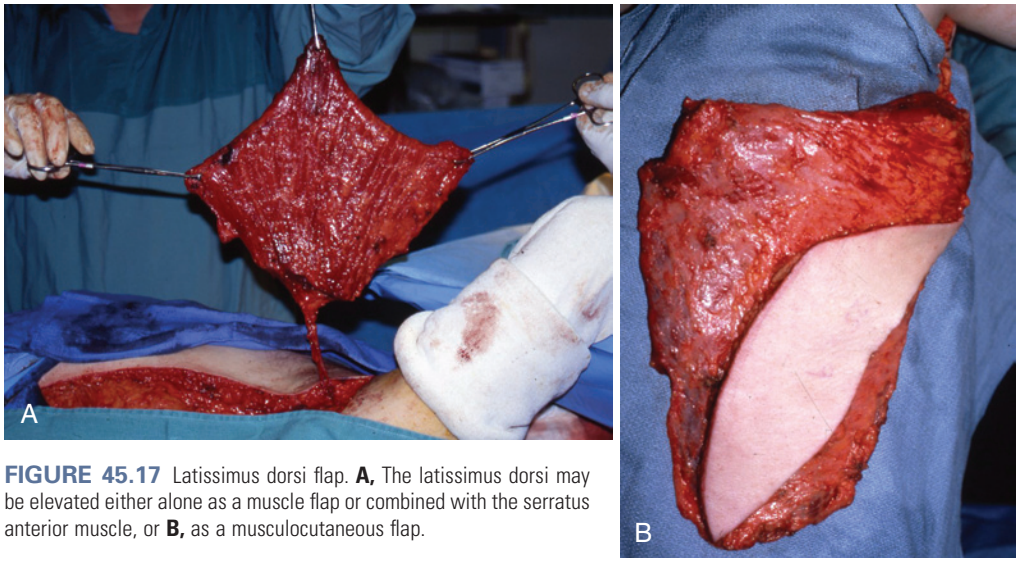

FIGURE 45.17 Latissimus dorsi flap. **A,** The latissimus dorsi may be elevated either alone as a muscle flap or combined with the serratus anterior muscle, or **B,** as a musculocutaneous flap.

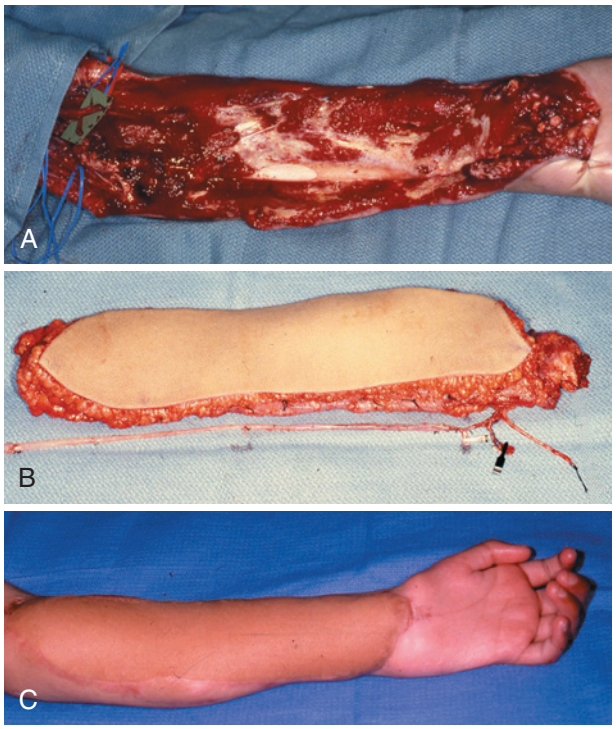

FIGURE 45.18 Latissimus dorsi musculocutaneous flap. **A,** This 9-year-old girl sustained a degloving injury of the entire volar forearm, including the median and ulnar nerves, the radial and ulnar arteries, and all of the flexor musculature. **B,** A very large contralateral right latissimus dorsi musculocutaneous flap was harvested with dissection of the vascular pedicle all the way to the origin of the subscapular artery from the axillary artery. A long interpositional vein graft was anastomosed end-to-end to the circumflex scapular artery. The subscapular artery was anastomosed end-to-end to the stump of the radial artery at the elbow, and the interpositional vein graft was anastomosed end-to-end to the distal ulnar artery to augment the vascular supply to the hand. The thoracodorsal nerve was coapted to the stump of the anterior interosseous nerve, and the distal latissimus muscle fascia was sutured to the flexor digitorum profundus tendons at the wrist to act as a functioning free muscle transfer, as well as to provide soft tissue coverage of the forearm. **C,** The latissimus dorsi musculocutaneous flap provides a very satisfactory appearance of the reconstructed forearm 1 year postoperatively.

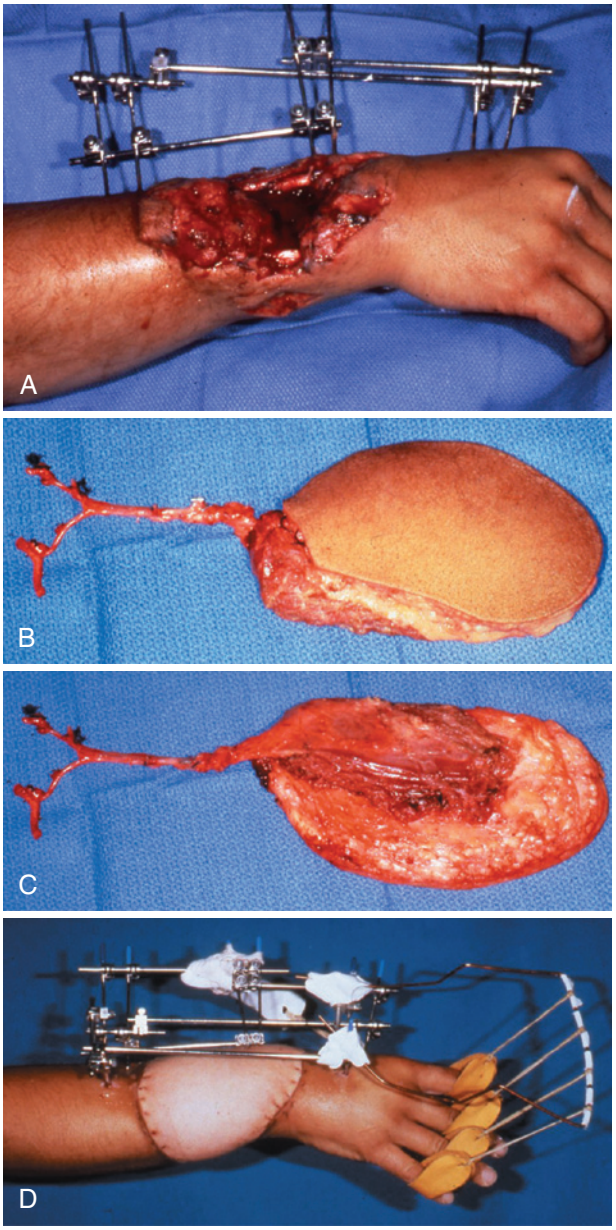

FIGURE 45.19 Tailored latissimus dorsi musculocutaneous flap. **A,** Radical débridement and external fixation of a high-velocity gunshot wound. **B,** The long pedicle and limited bulk of the tailored latissimus dorsi musculocutaneous flap is displayed. **C,** The small portion of latissimus muscle required to vascularize this musculocutaneous flap is demonstrated. The "T"-segment obtained by harvesting both the subscapular and the circumflex scapular arteries in continuity with the thoracodorsal artery can be seen to the left side of the figures. **D,** The tailored latissimus dorsi musculocutaneous flap has been anastomosed to the ulnar artery in the midforearm. An extension outrigger has been fitted to allow immediate motion. (**B** and **C** from Lister GD, Arnez AO: The anterior T and Y grafts. *Plast Reconstr Surg* 88:319–322, 1991, with permission.)

length of the pedicle (11 to 16 cm) have made it the most robust and, therefore, popular flap for free tissue transfer, especially to the extremities (Figures 45.18 and 45.19).[31]

Harvested as a free muscle flap (Figure 45.20 and see Figure 45.17, *A*),[43] the latissimus has the advantages of its easy draping into the interstices of a complex convoluted wound and of easy closure of the donor defect. Minor disadvantages include the appearance of the split-thickness skin graft on the muscle and the decreased perfusion in the most distal part of the muscle. The musculocutaneous flap has the advantages of appearance and excellent flow (see Figure 45.18). If the defect contains deep isolated pockets, these can be filled with a combined serratus anterior and latissimus dorsi muscle flap (Figure 45.21).[49]

Anatomy

The latissimus dorsi muscle arises from the lower six thoracic vertebrae, from the thoracolumbar fascia, and from the posterior iliac crest. From this extensive origin the muscle fibers converge to wrap around the lower border of the teres major and end in a quadrilateral tendon that inserts into the intertubercular sulcus of the humerus. Together with the teres major it forms the posterior axillary fold.

The blood supply of the muscle is supplied primarily by the thoracodorsal artery, which is the continuation of the subscapular artery after it gives off its circumflex scapular branch some 2 cm distal to its origin from the axillary artery. The



FIGURE 45.20 Latissimus dorsi muscle flap. **A,** This 62-year-old woman sustained a severe crushing-degloving injury to her left wrist and hand with multiple carpal and metacarpal fractures in a rollover accident. After Kirschner wire fixation of the fractures, she unfortunately developed secondary fungal infection of the dorsal soft tissues and was advised to undergo a below-elbow amputation. **B,** Radical débridement of the infected skin and soft tissues all the way down to the dorsal aspect of the carpus and metacarpals, but with preservation of some of the extensor tendons. **C** and **D,** The entire defect was covered immediately with a free latissimus dorsi muscle flap and a nonmeshed split-thickness skin graft. **E,** Two years later, the patient has maintained a sensate functional hand with satisfactory appearance of the forearm, wrist, and hand.

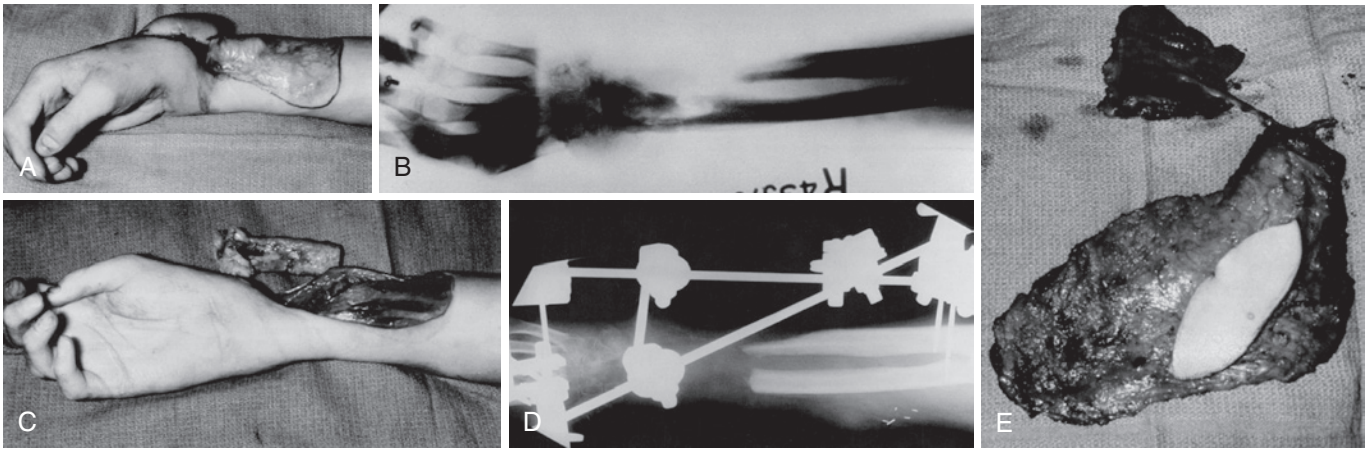

FIGURE 45.21 Combined latissimus dorsi and serratus anterior muscle flaps. **A,** This patient, who had sustained a crushing injury, had previously been treated with a skin graft and a pedicled groin flap and now presents with a sinus discharging pus. **B,** A radiograph reveals absence of the distal ulna and osteomyelitis of the distal radius. **C,** Radical débridement, including the portion of the radius that did not have adherent periosteum, has been performed. **D,** An external fixator has been applied. **E,** A combined latissimus dorsi and serratus anterior muscle flap has been harvested. The serratus anterior was placed into the defect created by excision of the radius, and the latissimus covered the remaining defect. Six weeks later, when there was no evidence of recurrent infection, a vascularized fibular bone graft was used to reconstruct the distal radius.

thoracodorsal artery provides a variable number of branches to the chest wall, notably one to the serratus anterior muscle, before reaching the hilum of the latissimus dorsi muscle some 11 cm from the axillary artery (Figure 45.22). Immediately distal to the hilum the artery divides into two branches in 94% of specimens.[122] The upper branch runs parallel to, and 3.5 cm from, the upper margin of the muscle; the lateral branch runs parallel to, and 2.1 cm from, the lateral margin of the muscle. This arrangement allows the surgeon to split the muscle longitudinally as a hemi–latissimus muscle flap when a narrow flap is required,[122] with the additional advantage of preserving the thoracodorsal nerve innervation to the remaining muscle.

Preoperatively, it may be of some benefit to have the patient abduct the arm against resistance so that four or five points can be tattooed along the posterior axillary fold with methylene blue and a hypodermic needle.

Operative Technique

The patient should be placed in the lateral position with padding beneath the torso sufficient to protect circulation to the

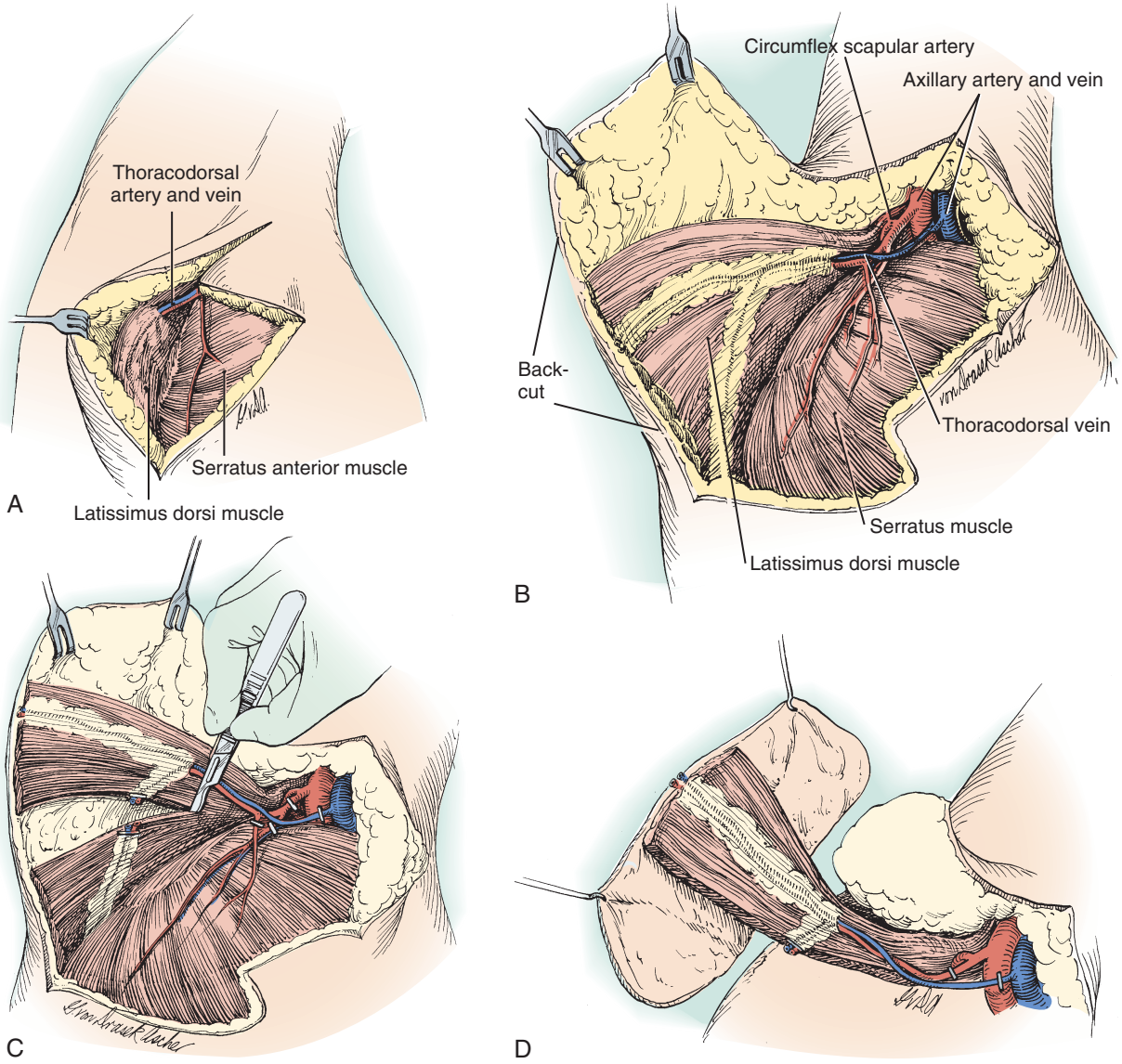

FIGURE 45.22 The vascular pedicle of the latissimus dorsi flap is displayed here in the course of its dissection. The subscapular artery arises from the axillary artery and soon gives off the circumflex scapular, which passes between the teres major and the latissimus dorsi. **A,** The next branch to arise is that to the serratus. The thoracodorsal artery passes beneath the epimysium of the latissimus dorsi and there divides into two branches. The upper branch runs parallel to and 3.5 cm from the upper margin of the muscle, and the lateral branch runs parallel to and 2.1 cm from the lateral margin of the muscle. **B,** The first, distal cut of the flap has been made through skin and muscle. **C,** The lateral or anterior portion of the muscle is being used alone in designing this small flap. The posterior, or upper, branch of the thoracodorsal has therefore been divided, and the muscle is split either with a knife, as shown here, or better with cutting diathermy through both muscle and skin as required. **D,** The proximal margin of the flap has been divided here through skin and will be divided through muscle just proximal to the point at which the thoracodorsal artery passes beneath the epimysium of the latissimus dorsi. In this way, a thin, well-tailored latissimus dorsi is created. (The clips shown here on the artery and vein of the pedicle would not, of course, be applied in using the latissimus as a regional flap.) (Modified from Godina M: The tailored latissimus dorsi flap. *Plast Reconstr Surg* 80(2):304–306, 1987.)

contralateral arm on the operating table. Easy exposure to the axilla is provided by wrapping the forearm with soft padding and then applying upward traction to a ceiling fixture to achieve 100 degrees of abduction. A similar position can be achieved, although less satisfactorily, by taping the forearm to a sterile Mayo stand. In either case there is considerable danger of a brachial plexus neurapraxia with consequent paresis. Checking the radial pulse regularly is no guarantee that all is well. This complication can only be avoided by a strict practice of returning the arm to the patient's side for 5 minutes every hour, a practice that should be monitored by the anesthesiologist.

An inverted "L"-shaped incision should be made skirting the axillary hair-bearing area and extending down toward the previously tattooed points marking the posterior axillary fold. Through this incision, the anterior border of the latissimus is located and everted using retractors or heavy stay sutures placed in the muscle margin.

The thoracodorsal pedicle can best be found where it approaches the muscular hilum. This is approximately at the nipple line in the male or the child. With good retraction and light, the vessel can be traced proximally, identifying first the serratus branch, a branch to the teres major, and then the circumflex scapular artery. These should be ligated and divided.

With a template of the primary defect, the cutaneous component of the flap can be marked out over the posterolateral thorax, distal to the level of the hilum, which has already been identified. The flap template can be designed either anteriorly or posteriorly with respect to the anterior border of the muscle. Placing the skin pattern more posteriorly gives more muscle to fold into a deep defect, whereas moving the skin pattern anteriorly, relative to the muscle, produces a thinner flap.[42] The flap margins are incised and extended down to the underlying muscle with cutting diathermy. Depending on the requirements for extra muscle anterior or posterior to the skin flap, either the anterior or posterior margins of the incision will need to be elevated off the latissimus dorsi muscle. After the anterior border of the muscle is elevated off the underlying serratus anterior muscle, the entire muscle and skin flap are dissected in an anterior-to-posterior direction. Care should be taken to ligate any large secondary perforators entering the muscle posteriorly. The requisite amount of muscle is cut with the diathermy and the flap swung superiorly away from the trunk to allow clear definition of the proximal thoracodorsal artery. Careful isolation of the thoracodorsal artery and its two venae comitantes up to their origin from the subscapular artery and vein completes the axillary dissection (see Figure 45.17, *A* and *B*).

If an end-to-side anastomosis is to be performed or if the flap is being transferred into an atherosclerotic vessel or into a single-vessel limb, it may be advantageous to take the subscapular artery and as much as needed of the circumflex scapular artery as a "T"-segment (see Figure 45.19, *B* and *C*). By interposing the subscapular-circumflex scapular portion of the "T"-segment into the atherosclerotic vessel, a difficult end-to-side anastomosis is avoided. By saving the "T"-segment of the subscapular/thoracodorsal/circumflex scapular arteries and performing the end-to-side anastomosis using the thoracodorsal artery, the "T"-segment can later be used to salvage the end-to-side anastomosis should it be required.[79]

"Tailored" Latissimus Dorsi Musculocutaneous Flap and Thoracodorsal Artery Perforator Flap

If only a narrow flap is needed, the lateral branch of the thoracodorsal artery should be located and the anterior and inferior borders of the flap carefully incised, avoiding the lateral branch. The medial branch should be ligated and divided and the thoracodorsal artery dissected off the latissimus dorsi, working from the axilla as far distally as possible. The pedicle can be lengthened by dividing muscular branches that turn in a proximal direction toward the axilla within the muscle. The proximal margin of the flap can be incised while the pedicle is retracted anteriorly to protect it. Raising the flap in this manner, rather than taking the whole muscle as in the past, provides a flap tailored exactly to the primary defect (see Figure 45.19).[42] Use of the tailored flap avoids the bulky proximal portion of the latissimus muscle that is inevitable when the whole muscle is taken.

Recently, Angrigiani and colleagues[2] have described harvesting the latissimus dorsi skin flap without the underlying muscle based on a single muscle perforator. The thoracodorsal artery perforator (TDAP) flap may be designed either vertically, based on a proximal perforator of the descending branch of the thoracodorsal artery,[19] or transversely, based on perforators from both the descending and transverse branches of the thoracodorsal artery.[75] TDAP flaps based on multiple perforators (identified with a handheld Doppler probe) are more reliable than flaps based on a single perforator.[65,135]

CRITICAL POINTS *Latissimus Dorsi Muscle Flap*

Indications
- Large and small defects of the hand and arm
- Complex defects requiring more tissue
- Untidy wounds after débridement or management of osteomyelitis

Preoperative Evaluation
- Presence of scars or a prior mastectomy with axillary dissection may contraindicate use (pedicle may have been damaged or ligated).

Pearls
- "Best" free flap for most surgeons
- May take a portion of the muscle or "tailor" flap to defect

Technical Points
- Approach muscle from the anterior border first.
- Elevate the muscle and identify the pedicle with the descending branch to the serratus anterior.
- Once the pedicle has been identified, elevate the muscle off the chest wall.
- Once an adequate portion of the muscle is elevated, divide it distally and medially and continue the dissection from distal to proximal.
- Carefully dissect the pedicle in the axilla.
- Abduction of the arm helps with pedicle dissection.
- The pedicle may include the subscapular artery up to the axillary artery.

Pitfalls
- Damage to the pedicle may occur during dissection.
- Do not divide any branch until the main pedicle is identified proximally.
- Seromas may occur at the donor site.

Donor Site Management
- Primary closure is performed over drains.
- Leave drains in for 10 to 14 days to prevent seromas.
- Morbidity from loss of muscle is minimal.

The donor defect should always be closed directly, because a skin graft in this location presents a very difficult nursing problem. Large defects may require transposition of loose tissue from the waistline anteriorly, using a rhomboid design (see Chapter 44). Suction drains should be left for several days because this donor site is associated with a higher incidence of seroma formation. No significant loss of function has been shown after harvesting the latissimus dorsi.

Serratus Anterior Muscle Flap

The serratus anterior free muscle flap was popularized by Buncke as the flap of choice for small to moderate-sized soft tissue defects in the upper extremity.[10] It is a remarkably reliable free muscle flap because of its consistent long vascular pedicle and large-diameter vessels and is associated with minimal donor site morbidity.

Anatomy

The serratus anterior muscle arises from the first nine ribs medial to the anterior axillary line and inserts into the medial border of the scapula. The lower three slips of the muscle arising from the seventh, eighth, and ninth ribs are supplied by a large branch of the thoracodorsal artery, whereas the upper six slips are supplied by branches of the lateral thoracic artery (Figure 45.23, *A*). The dual vascular supply allows elevation of the lower three slips of the muscle with simultaneous preservation of the vascular supply to the upper two thirds of the muscle. If necessary, a very long vascular pedicle, up to 15 cm in length, can be obtained by dividing the thoracodorsal artery and vein distal to the origin of the branch to the serratus muscle and elevating the thoracodorsal pedicle all the way up to its origin from the subscapular artery and vein, just as in the dissection of the latissimus dorsi vascular pedicle (see Figure 45.23, *B*). The serratus muscle is innervated by the long thoracic nerve that lies directly anterior to the vascular pedicle on the chest wall. Under magnification, the branches of the long thoracic nerve to the lower three slips of muscle can be dissected. This ability to separate the motor innervation and blood supply to the lower three slips of the serratus muscle while still preserving the motor nerve and blood supply to the upper six slips minimizes the morbidity of harvesting the entire serratus muscle. In a series of 100 consecutive serratus anterior free muscle flap transfers, winging of the scapula did not occur and all patients retained full range of motion of the shoulder. Occasionally, this separate motor nerve to the lower three slips can be reinnervated as a functional free muscle transfer for functional restoration of thenar muscle loss.

Operative Technique

The patient is placed in the lateral position with the arm included in the operative field. Through a long midaxillary incision, the anterior border of the latissimus dorsi muscle can be elevated and retracted to reveal the thoracodorsal vessel pedicle and its branch to the serratus muscle. The small branches to the upper six muscle slips can be divided, but all branches to the lower three slips are preserved. With the use of loupe magnification, the nerve branches to the lower three slips are carefully divided from the main branch of the long thoracic nerve. Starting inferiorly and working in a superior direction, the lower three slips of the serratus muscle are divided at their origin from the seventh, eighth, and ninth ribs and elevated in the loose areolar plane between the muscle and the chest wall, taking care not to penetrate the intercostal muscles and pleura. Posteriorly, the insertions of the three slips into the scapula are divided. This allows the vascular pedicle to be lifted off the upper six slips of the muscle, and the pedicle can then be easily mobilized up to its origin from the thoracodorsal artery and vein. If a long vascular pedicle is not required, the muscle is allowed to perfuse and then the pedicle is divided just distal to its origin from the thoracodorsal vessels. If a longer vascular pedicle is required, the thoracodorsal vessels are divided distal to the origin of the serratus vessels and the entire thoracodorsal-subscapular system is dissected up to its origin from the axillary artery and vein (see Figure 45.23, *B*). If the serratus muscle is also to be used as a functioning free muscle transfer, interfascicular dissection will allow the branches to the lower three slips to be split off from the main long thoracic nerve for several centimeters as a separate group fascicle.

Hemostasis is achieved over the lower chest wall. The distal stump of the lower three slips of the serratus muscle attached to the angle of the scapula can be resutured to the remaining upper six slips of the serratus muscle and the incision closed directly over a suction drain.

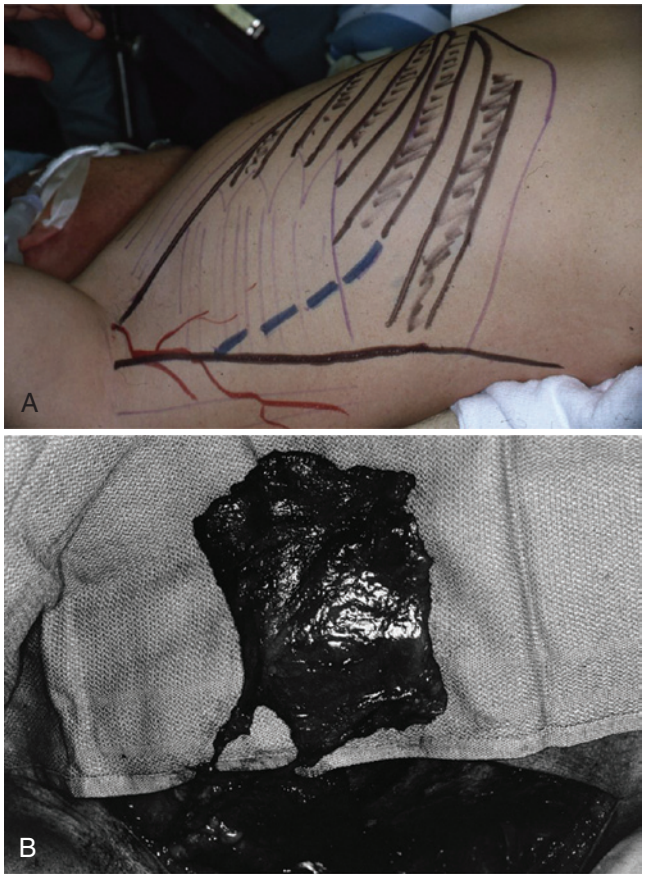

FIGURE 45.23 Serratus anterior muscle flap. **A,** Preoperative marking of the midaxillary incision used to harvest a right serratus anterior muscle flap. The descending serratus branch from the thoracodorsal artery passes anteriorly down to supply the lower three slips of the muscle. **B,** This small muscle flap can be isolated on a very long vascular pedicle by dividing the thoracodorsal artery and vein distal to the origin of the serratus branch and mobilizing the thoracodorsal artery and vein all the way proximally to their origin from the subscapular artery and vein.

Rectus Abdominis Muscle Flap

The rectus abdominis muscle flap is a distant second choice for coverage of large soft tissue defects of the upper extremity after the optimal choice of the latissimus dorsi muscle flap.[95,96,98] The rectus abdominis muscle is long and thin and can therefore be considered for coverage of longitudinal defects of the dorsal or palmar surfaces of the forearm and wrist and may be spiraled in "barber pole" fashion around the radial or ulnar borders of the forearm.

Anatomy

The rectus abdominis muscle has two vascular pedicles: the superior epigastric artery and the deep inferior epigastric artery arising from the external iliac artery. As a free flap for upper extremity reconstruction, it is isolated on the inferior pedicle, the deep inferior epigastric artery, and two accompanying venae comitantes.[117] The vascular anatomy is very reliable with a pedicle length of 5 to 7 cm and an arterial diameter of approximately 2.5 mm.

Operative Technique

The muscle can be harvested through a paramedian or transverse Pfannenstiel abdominal incision. A longitudinal or transverse ellipse of overlying skin perfused by musculocutaneous perforators can be incorporated in a rectus abdominis musculocutaneous flap, and this has become the optimal choice for microsurgical breast reconstruction. However, for upper extremity reconstruction, the rectus abdominis is usually harvested as a muscle flap and resurfaced with a split-thickness skin graft. One advantage of the rectus abdominis muscle flap is that it can be harvested with the patient in a supine position, compared with the lateral position used for harvesting a contralateral latissimus dorsi muscle flap. Relative disadvantages include the shorter length of the vascular pedicle and the possibility of abdominal bulging or even herniation of the lower abdomen after harvest of the rectus muscle.

An intriguing potential spin-off is the use of a flap of posterior rectus sheath and peritoneum supplied by the deep inferior epigastric vessels to provide a gliding peritoneal surface for coverage of exposed extensor tendons in dorsal hand degloving injuries.

Massive defects of the upper extremity have been reconstructed using a combination latissimus dorsi and rectus abdominis musculocutaneous flap based on the intact vascular pedicle of the thoracodorsal vessels and microsurgical anastomoses of the deep inferior epigastric vessels to the radial or ulnar arteries at the wrist.

Temporoparietal Fascial Flap

The ultrathin and highly vascular tissue of the temporoparietal fascia is ideal for coverage of small defects of the hand and wrist[8,14,52,53,126] when a skin graft would be preferable to a bulky flap but the recipient bed is poorly vascularized, as in circumstances where periosteum has been stripped to expose bone or where tendons have been denuded of paratenon.

Anatomy

The temporoparietal fascia is the superior extension of the submuscular aponeurotic system, which supports the muscles of facial expression. It is located between the scalp and the fascia overlying the temporalis muscle and is supplied by the superficial temporal artery and vein, which emerge from beneath the parotid gland in front of the ear to pass superiorly into the temporal and parietal scalp (Figure 45.24, *A*).[126] The superficial temporal artery measures 1.8 to 2.2 mm in diameter in front of the ear and provides a pedicle length of 4 to 5 cm. The superficial temporal vein lies posterior and superficial to the artery

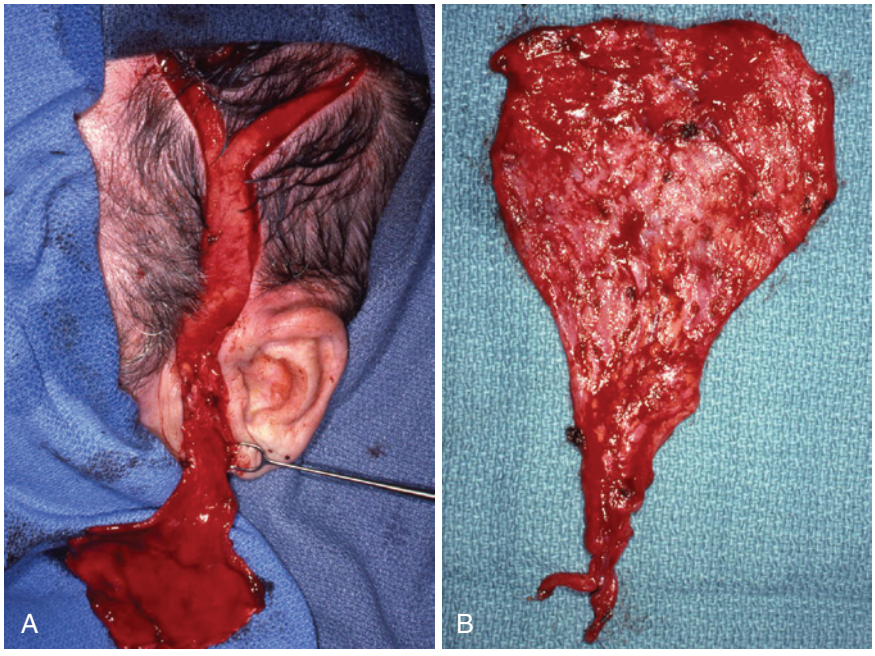

FIGURE 45.24 Temporoparietal fascial flap. **A,** The temporoparietal fascia can be harvested through a preauricular incision extending up into the temporal hair-bearing scalp as a "Y"- or "T"-shaped extension. **B,** This thin fascial sheet can be used to wrap around exposed tendons to preserve their gliding and can then be covered either primarily or secondarily with a split-thickness or full-thickness skin graft.

and gives off multiple branches to the subcutaneous tissue of the scalp. Most temporoparietal fascial flaps have not exceeded 13 cm in length and 9 cm in width (see Figure 45.24, *B*). The superficial and deep fascias investing the temporalis muscle are vascularized by the deep middle temporal branch of the superficial temporal artery, and consequently this fascia can also be transferred together with the temporoparietal fascia to provide a "double" fascial flap[53] that can be used to "sandwich" exposed flexor or extensor tendons and preserve gliding.[8]

The auriculotemporal nerve follows the course of the superficial temporal vessels and is divided during flap dissection. A segment of the outer table of the skull vascularized by the temporoparietal fascia has been reported for craniofacial reconstruction, but vascularized bone transfer to the hand using the temporoparietal fascial flap has not been described.

Operative Technique

The patient is positioned supine with the head turned to the side. The contralateral side of the head is used to allow simultaneous donor and recipient site dissection (two-team approach). The vascular axis of the superficial temporal artery is determined either by palpation or by using a pencil Doppler probe. A 1- to 1.5-cm strip of scalp is shaved over this vascular axis beginning just above the ear. Narrow temporoparietal flaps can be harvested through this single incision, but for larger flaps an inverted "L"-shaped or a "T"-shaped extension may be required within the hair-bearing scalp skin (see Figure 45.24, *A*). The preauricular part of the incision extends down to the earlobe. The temporoparietal fascia can also be harvested endoscopically. The superficial temporal artery and vein are identified in front of the ear and traced in a superior direction. The vessels are quite fragile, and great care must be taken to use bipolar coagulation of all the small branches. Scalp flaps are elevated in the plane between the subcutaneous tissue and the temporoparietal fascia. The proper plane is sometimes difficult to find, but the hair follicles should be kept in the subcutaneous tissue of the elevated scalp flaps. Dissection continues anteriorly and posteriorly from the incision but should not be extended too far anteriorly from the axis of the superficial temporal artery because of injury to the frontal branch of the facial nerve. The superficial temporal vessels lie above or within the fascia, whereas the motor branches of the facial nerve lie below the fascia. A nerve stimulator may be helpful in identifying these facial nerve branches at the level of the zygoma and lateral orbital rim. The template of the recipient defect is either centered over the axis of the superficial temporal vessels or positioned a little more posteriorly, again to avoid damage to the frontal branches of the facial nerve. The superior and posterior margins of the outlined fascial flap are incised to enter the loose areolar plane between the temporoparietal fascia and the fascia overlying the temporalis muscle. The anterior margin of the flap is incised in a distal-to-proximal direction up to the point where the frontal branch of the superficial temporal artery passes anteriorly to the forehead. After division of this branch, further dissection proceeds just anterior to the superficial temporal vessels to taper the pedicle down to the axial vessels at the top of the ear. The temporoparietal fascial flap is now completely isolated as an island based on the vascular pedicle in front of the ear. Additional length to the vascular pedicle can be obtained by more proximal dissection, but this may be both tedious and bloody because of large branches from the artery and vein. After ligation of the superficial temporal artery and vein, the fascia is transferred to the hand and covered with either a split-thickness or full-thickness skin graft.

After hemostasis of the scalp incision has been achieved, the incision is closed over a small suction drain. The preauricular incision is closed with fine 5-0 nylon sutures, and these are removed within 5 days to prevent conspicuous scarring. The temporoparietal fascia probably produces one of the most inconspicuous donor sites of any free flap, but alopecia may sometimes occur. Patients may occasionally have diminished sensibility within the distribution of the auriculotemporal nerve, but this is usually not painful.

CRITICAL POINTS *Temporoparietal Fascial Flap*

Indications
- Need for thin soft tissue coverage in hand
- Potential need for "gliding" surface over tendons

Preoperative Evaluation
- Doppler examination/palpation of superficial temporal artery

Pearls
- Very thin flap for reconstruction, particularly on the dorsal hand over and around the extensor tendons

Technical Points
- This tissue lies directly underneath the hair follicles, and getting in the right plane can be difficult.
- Elevate scalp carefully off fascia; beware of vein branches into scalp.
- Superficial and deep fascia may be taken.
- Artery and vein are small and fragile.
- Avoid deep dissection proximally in the parotid to prevent damage to the facial nerve!

Pitfalls
- Alopecia common, particularly around incision
- Damage to thin-walled veins when elevating flap

Donor Site Management
- Close primarily over drain.

Sensory Flaps From the First Web Space of the Foot

Either the great toe or the second toe can be transferred for reconstruction of the thumb or fingers (see Chapter 47), but for reconstruction of digital pulp defects or crucial areas of the hand that require sensation, there is unanimity regarding the appropriate donor site, namely, the first web space of the foot. Depending on the requirements of the primary defect, this flap may vary from a single pulp alone[12,45,72,76] to the fibular aspect of the great toe together with all or part of the nail combined with the tibial aspect of the second toe.[82,86] Such sensory flaps can be used to reconstruct critical areas of the hand, including pulp defects of the thumb and fingers, pulp defects of adjacent digits, and the thumb/index finger web space. Reconstructed digits in the hand develop a sensory threshold similar to the contralateral donor toe with an average static two-point

discrimination of 3 to 7 mm[45] and an average moving two-point discrimination of 6 to 8 mm.[72]

Anatomy

All the tissues in the first web space of the foot are supplied by the lateral digital artery to the great toe and the medial digital artery to the second toe, which arise from a variable "arterial complex" in the web space. This arterial complex receives its blood supply from two sources: the first dorsal metatarsal artery, arising from the dorsalis pedis artery, and the first plantar metatarsal artery, arising from the plantar arch (Figure 45.25, *A*). This first plantar metatarsal artery is supplied not only by the posterior tibial artery but also by the dorsalis pedis artery through a deep communicating branch that passes downward through the first intermetatarsal space at the point where the first dorsal metatarsal artery arises from the dorsalis pedis artery. The two feeding arteries and the two digital arteries have a varying relationship in the first web space, hence the term "arterial complex".

The nerve supply to the first web space likewise comes from two sources: (1) the lateral digital nerve to the great toe and the medial digital nerve to the second toe, both originating from the first common plantar digital nerve, and (2) the deep peroneal nerve dorsally (see Figure 45.25, *B*).

Operative Technique

The fibular aspect of the great toe provides an ideal donor site because its structure is identical to that of the pulp of an important digit, such as an avulsed thumb (Figure 45.26). Preparation for harvest commences with examination of the foot with a pencil Doppler probe to identify the presence and course of the first dorsal metatarsal artery as it originates from the dorsalis pedis artery to pass distally. It is possible to make some estimate of the depth of the vessel by angling the probe in different directions. Detection of a pulse suggests that the vessel lies superficial in its most common location along the dorsal surface of the interosseous muscle.

The venous drainage on the dorsum of the foot should be mapped out before exsanguinating the limb and inflating the tourniquet (see Figure 45.25, *A*). There are two venous systems on the dorsum of the foot. One drains the medial aspect of the great toe and metatarsal region and lies superficial to the second, larger system, which forms an arch extending from side to side across the dorsum of the foot and drains into the greater saphenous vein. The deeper system is less pronounced on inspection but clearly has veins of larger caliber and should be selected for harvest.

An incision should be marked out on the dorsum of the foot overlying the first intermetatarsal space to provide access to the most promising vein and should pass distally to reach the outline of the flap, which should be marked on the fibular aspect of the great toe. A second incision extends proximally on the plantar surface of the foot between the weight-bearing areas of the first and second metatarsal heads.

Only the distal portion of both dorsal and plantar incisions should be opened initially and should be sufficient to dissect the contents of the first web space. Although there are some fibrous septa in the web, the tissues are relatively loose. The most distal structure of importance in the web is likely to be the arterial complex. Loupe magnification and delicate scissor dissection are required immediately. As soon as an artery is encountered (and it may lie as far as 1 cm proximal to the free margin of the web), it should be dissected distally into both the great toe and second toe and proximally onto the dorsal and plantar aspects, until all the ramifications of the "arterial complex" are displayed and understood. If the dorsal artery

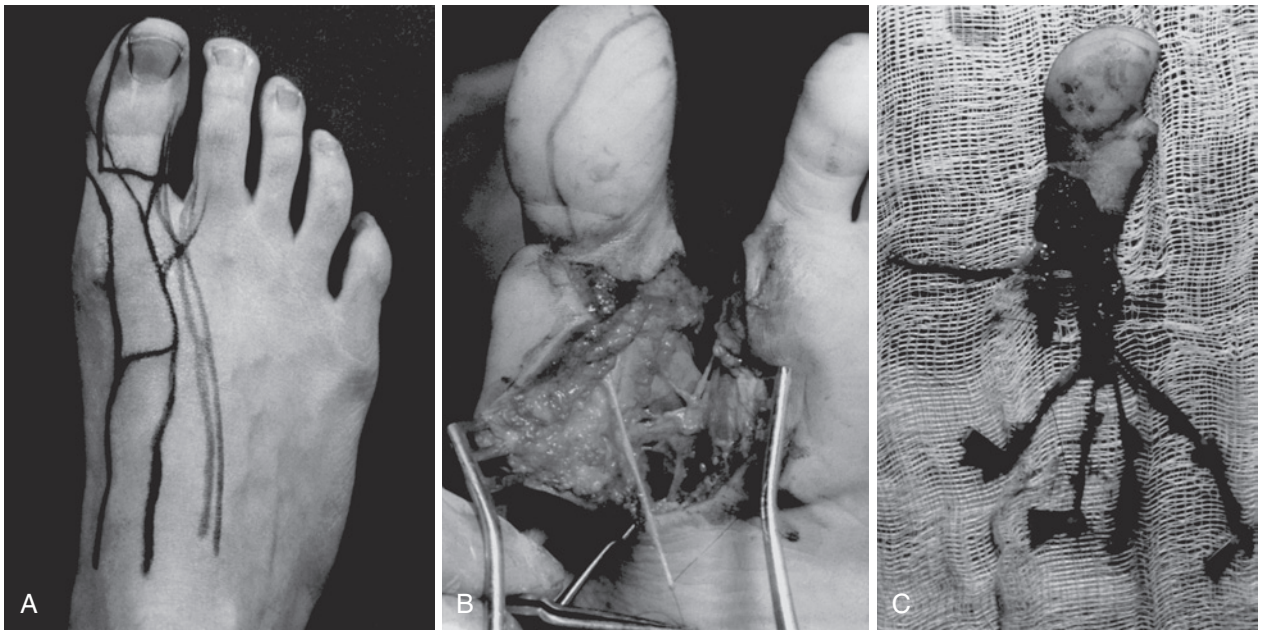

FIGURE 45.25 Sensory flap from the first web space of the foot. **A,** Using a pencil Doppler probe, the first dorsal metatarsal artery has been marked *(double pale line).* The major veins have been marked after temporary elevation of the tourniquet *(dark lines).* **B,** Dissection of the first web space. The plantar digital nerve to the fibular aspect of the great toe has been divided and marked with a suture. **C,** After dissection, the veins and first dorsal metatarsal artery are marked with microvascular clamps.



FIGURE 45.26 Sensory flap from the first web space of the foot. **A** and **B,** Palmar and dorsal views of the defect resulting from avulsion of the pulp of the dominant thumb. **C,** The partial toe flap designed on the fibular aspect of the left great toe. **D** and **E,** Postoperative result.

appears large and seems to communicate with the first dorsal metatarsal artery, it should be chosen because it provides a longer pedicle. The dorsal incision is extended proximally and the medial flap reflected until a suitable vein is located over the first metatarsal. The vein does not need to be dissected distally all the way to the flap, because it will probably have several fragile tributaries. Instead, the medial dorsal flap, which will remain on the foot, should be dissected off the venous system on the dorsum of the great toe. A monobloc of subcutaneous tissue between the toe flap and the selected proximal vein can be defined by cutting down onto the extensor tendons on either side of the venous pedicle and elevating it by bipolar dissection directly off the extensor tendons. This relatively bulky tissue will be readily accommodated by the loose skin of the thumb/index finger web space. The vein is dissected proximally, until sufficient length is obtained to reach a recipient vein of satisfactory caliber in the hand.

The first dorsal metatarsal artery is dissected in a distal-to-proximal direction from its initial identification in the web space to its origin from the dorsalis pedis artery.[130] The deep communicating branch from the dorsalis pedis artery to the plantar arch should be ligated and divided. Dissection of the dorsalis pedis artery is continued as far proximally as is necessary to reach the site of arterial anastomosis in the hand, which is usually a branch of the radial artery just distal to the anatomic snuffbox at the base of the index and middle finger metacarpals. The dorsalis pedis artery passes beneath the extensor hallucis brevis tendon, which courses from proximal lateral to distal medial and can either be preserved or divided to improve access. In circumstances in which the first dorsal metatarsal artery is judged to be too small or absent, the surgeon will have to decide whether to dissect the shorter first plantar metatarsal artery to the great toe/second toe web space and whether, if necessary, to elongate this plantar pedicle by harvesting an interposition graft, either an arterial graft from the subscapular, superficial temporal, or interosseous systems[40,79] or a venous graft from the saphenous system.

During this dissection of artery and vein, the surgeon will encounter the deep peroneal nerve, which lies just superficial to the artery. The branch of the deep peroneal nerve passing to the great toe should be dissected proximally, splitting it away from the other branches and transecting it with sufficient length so that it can be coapted to the "unsatisfied" radial digital nerve of the thumb ("unsatisfied" because the lateral digital nerve of the great toe will be coapted to the more important ulnar digital nerve of the thumb).

The plantar incision should be opened, and surgical access can be facilitated by externally rotating the patient's hip and flexing the knee and tilting the table as far toward the operative side as necessary to afford a comfortable view of the operative field. Initially, the incision should be made just long enough to obtain the necessary length of the lateral digital nerve of the

great toe; the length required should have been first determined from dissection of the ulnar digital nerve in the thumb. In contrast to the artery and vein, the lateral digital nerve should be as short as possible to allow early return of sensibility. Once sufficient nerve has been exposed, the lateral digital nerve should be mobilized as far distally as the proximal edge of the flap. The nerve should be gently separated proximally from the common digital nerve to obtain the required length, while the medial and lateral digital nerves are retracted apart with nerve hooks (see Figure 45.25, *B*).

The pulp flap, which has been left undisturbed throughout the previous dissection, can now be elevated. If pulp alone is to be taken, the pattern should be outlined almost to the lateral eponychial fold, leaving a rim of only 1 to 2 mm. The dorsal and plantar margins of the flap should be incised directly down to the underlying distal phalanx. The already dissected digital artery, vein, and digital and peroneal nerves should be retracted away from the skeleton with vessel loops, so that the flap can be elevated from proximal to distal beneath these protected structures, using bipolar cautery to raise the flap directly off the underlying bone and lateral collateral ligament of the interphalangeal joint.

If the nail plate is to be incorporated with the pulp flap, the dorsal cortex of the distal phalanx beneath the nail should also be harvested by making a coronal cut, which avoids the vessels passing through the rima ungulae, the aperture that lies between the neck of the phalanx and the lateral collateral ligament. Access for this cut is made through the distal part of both the plantar and dorsal incisions.

CRITICAL POINTS *First Web Space and Toe Pulp Flaps*

Indications
- Loss of thumb or digital pulp
- Reconstruction of sensation in other complex reconstructions

Preoperative Evaluation
- Pencil Doppler examination of great toe/second toe web space
- Mark superficial veins on the foot before tourniquet elevation.

Pearls
- Use the fibular aspect of the great toe for thumb pulp.
- Inspect the vascular anatomy distally in the web space first.

Technical Points
- Dissection may be done in a distal-to-proximal direction, or vice versa.
- The artery is deep to the veins in the first web space.
- Proper digital arteries may branch proximal to the web.
- Dissection of vessels in the web space must be done very carefully to avoid damage and/or later spasm.
- Base the flap on the dorsal arterial system (first dorsal metatarsal artery) if available.
- The flap may need to be based on the first plantar metatarsal artery system if the dorsal artery is small, and this may require vein grafting to reach recipient vessels.

Donor Site Management
- Close the dorsal foot incision.
- Use a split-thickness skin graft for the toe donor site with a bolster dressing.
- Place the foot in a walking cast with a toe pad for protection.

The most distal attachment of the flap should be left attached, the tourniquet is released, and reperfusion is confirmed without the risk of torsion of the pedicle, which might occur if the flap were totally detached. Once satisfactory perfusion to the flap is confirmed, the artery and vein can be ligated and the flap transferred to the hand (see Figures 45.25, *C* and 45.26). Closure is achieved by suturing the access incisions and applying a split-thickness skin graft to the secondary defect. If the graft is secured in place with a bolster dressing, the patient can ambulate on the first postoperative day. A walking cast is desirable to ensure undisturbed healing of the foot.

❖ AUTHORS' PREFERRED METHOD: Flap Selection

Soft Tissue Defects Alone

The selection of local, regional, distant, or free flaps for coverage of specific defects of the upper extremity has been detailed in Chapter 44. In choosing a specific free flap, the following factors should be considered: the health, comfort, and cosmetic demands of the patient; the size, thickness, and special needs of the defect; and the skill and experience of the surgeon. Patients with respiratory problems require full lung expansion after long surgical procedures. Therefore, latissimus dorsi or scapular flaps from the chest wall should probably be avoided in these circumstances. In a patient with an upper extremity wound who has suffered multiple traumas, other injuries may dictate a period of prolonged bed rest. Flaps from the back might create a nursing problem. In these patients, the radial forearm flap[51,64,87,112] may be an appropriate substitute for medium-sized defects. Female patients in particular are likely to be distressed enough by the primary wound without adding a disfiguring scar on the upper arm or forearm or over the scapula. Although attempts have been made to improve the secondary donor defect of such flaps by prior tissue expansion, the free groin flap[22,48,54] remains the optimal choice where cosmesis is a consideration (see Figure 45.15, *D*).

Large defects involving the entire anterior or posterior surface of the forearm, wrist, and hand require a latissimus dorsi flap harvested either as a musculocutaneous flap, a muscle flap resurfaced with a split-thickness skin graft,[31,43] or an anterolateral thigh flap.[1,59,73,127,129] An alternative option may be omentum harvested through a conventional laparotomy or a laparoscopy and covered with a split-thickness skin graft.[58,105]

Medium-sized defects can be covered with either the "tailored" latissimus dorsi musculocutaneous flap or TDAP flap,[2,19,42,75] the scapular flap,[39,46,89] or the anterolateral thigh flap.[1,59,73,127,129] The "tailored" latissimus dorsi flap or TDAP flap offers a long pedicle without the disadvantage of the bulky proximal portion of the muscle close to its insertion (see Figure 45.19). The scapular flap[39,46,89] offers remarkably tough skin with no underlying muscle (see Figure 45.12). This flap is therefore well suited for large dorsal or palmar defects of the hand and wrist,[13] except in the overweight patient, where such a flap would be very thick.

Small defects for which no local flap is available or suitable can often be covered with either a lateral arm free flap[66,67,124] or a fascial flap. The lateral arm flap can be made small enough to provide coverage of one phalanx in a single finger (see Figure 45.4). It can also be contoured to be thick in a slim patient or thin in an obese patient. Thickness is achieved by harvesting a larger area of fascia than of skin and folding the fascia into the

primary defect; thinness is achieved by taking fascia alone without skin[136] and later applying a split-thickness skin graft.

Free fascial flaps[14,32] based on the temporoparietal fascia,[8,52,53,126] radial forearm fascia,[36,51] dorsal thoracic fascia,[27,70] and serratus fascia[11] can also provide coverage of small defects in the hand and fingers. These free fascial flaps can be covered by a split-thickness skin graft primarily, but skin graft "take" may be better if the skin graft is applied a few days later. Free fascial flaps have also been advocated for coverage of small wounds with exposed flexor or extensor tendons or even to wrap around the tendons to maintain their gliding function and prevent their adherence to exposed bone.

Composite Defects

Traumatic injuries and surgically created defects of the upper extremity frequently involve the underlying tendons, sensory nerves, and bony skeleton. Even though one-stage reconstruction of all the tissue components of a composite defect would be ideal, composite reconstruction of associated defects of bone, tendon, artery, and nerve is indicated only occasionally.[78,104]

In the future, it may become possible to prefabricate composite flaps having the exact requirements of each tissue component required to reconstruct a specific defect.

Bone

Vascularized bone can be included in an overlying free flap as an osteocutaneous flap, as with the iliac crest with the groin flap,[91] the lateral border of the scapula with the scapular flap,[114] a rib with the serratus anterior muscle flap,[57] the radius with the radial forearm flap,[35] the second metatarsal with the dorsalis pedis flap,[91] the humerus with the lateral arm flap,[124] and the fibula with the fibular osteocutaneous flap.[128] Small bone defects can be reconstructed with conventional nonvascularized bone graft, either as a corticocancellous block for structure or as cancellous chips. This can be performed primarily at the same time as free flap coverage of the defect or secondarily once the soft tissues have healed. Large segmental defects of the humerus, radius, and ulna or composite soft tissue and bony defects are best reconstructed with the fibular osteocutaneous flap.[128] See also Chapter 46.

Tendon

Vascularized tendon grafts can be transferred with the dorsalis pedis flap[84,107] or the radial forearm flap.[51,99] Such tendocutaneous flaps may occasionally be indicated for one-stage reconstruction of a degloving injury of the dorsum of the hand with loss of skin and extensor tendons. The donor defect in the foot is troublesome after harvest of a dorsalis pedis flap. There is also no evidence that extensor tendon function is any better than with conventional tendon grafting as a secondary procedure beneath a healed skin flap.

Artery

Arterial reconstruction in the upper limb can also be performed using the same arterial system that supplies the free flap. Thus the subscapular arterial system has been used to restore arterial continuity via the circumflex scapular branch, while the thoracodorsal branch supplies the overlying latissimus flap. The distal end of the inflow artery to a flap can also be anastomosed to a distal artery in the limb as a "flow-through" flap to restore flow to the distal limb. The radial artery of a contralateral radial forearm flap has been used in such a "flow-through" fashion to replace segmental defects of the radial or ulnar arteries and so restore flow to the hand.[9,93] Similarly, the continuation of the posterior radial collateral artery supplying a lateral arm flap to cover a defect over the anatomic snuffbox and first metacarpal can be anastomosed to a digital artery to restore flow to the thumb. The descending branch of the lateral circumflex femoral artery of an anterolateral thigh flap,[55] the peroneal artery of a fibular osteocutaneous flap, the medial plantar artery flap,[132] and a flap harvested from the amputated upper extremity have also been reported as "flow-through" flaps.

Sensation

Modest sensibility can be restored to some free flaps by coapting the sensory nerve of the flap, such as the superficial peroneal nerve of the dorsalis pedis flap,[84,92,100] the posterior cutaneous nerve of the arm of the lateral arm flap,[66] the medial or lateral antebrachial cutaneous nerves of the radial forearm flap, and the T12 branch of the groin flap to a sensory nerve in the vicinity of the defect. No such donor sensory nerves exist for scapular or latissimus flaps.

However, for restoration of critical sensation in the thumb or fingertips, a free neurovascular flap from the fibular aspect of the great toe or the tibial aspect of the second toe is the optimal choice (see Figure 45.26).[12,45,72,76,82,86]

CONCLUSION

The practicing hand surgeon should have a limited repertoire of highly reliable free flaps that can be used to reconstruct the majority of defects encountered in the upper extremity. The lateral arm flap or various fascial flaps can be used for reconstruction of small defects; the scapular, tailored latissimus, or radial forearm flaps for medium-sized defects; and the latissimus muscle flap, anterolateral thigh flap, or omental flap for large defects. The free groin flap or superficial circumflex iliac artery perforator flap, although more difficult to dissect, should be considered if cosmesis of the donor site is especially important. A contralateral radial forearm flap is especially indicated for coverage of the forearm or wrist if simultaneous revascularization of a segmental radial or ulnar arterial injury is also required. The fibular osteocutaneous flap is the optimal choice for composite reconstruction of associated bone and soft tissue defects involving the humerus, radius, and ulna. Finally, the fibular aspect of the great toe, the tibial aspect of the second toe, or the entire first web space flap is the preferred sensory flap for reconstruction of the thumb or finger pulp or for restoration of critical areas of sensibility in the hand.

REFERENCES

1. Adani R, Tarallo L, Marcoccio I, et al: Hand reconstruction using the thin anterolateral thigh flap. *Plast Reconstr Surg* 116:467–473, 2005.
2. Angrigiani C, Grilli D, Siebert J: Latissimus dorsi musculocutaneous flap without muscle. *Plast Reconstr Surg* 96:1608–1615, 1995.
3. Askari M, Fisher C, Weniger FG, et al: Anticoagulation in microsurgery: a review. *J Hand Surg [Am]* 31:836–846, 2006.
4. Baek S: Two new cutaneous free flaps: The medial and lateral thigh flaps. *Plast Reconstr Surg* 71:354–365, 1983.
5. Bakri K, Moran SL: Monitoring for upper-extremity free flaps and replantations. *J Hand Surg [Am]* 33:1905–1908, 2008.

6. Bardsley AF, Soutar DS, Elliot D, et al: Reducing morbidity in the radial forearm flap donor site. *Plast Reconstr Surg* 86:287–292, 1990.
7. Batchelor AGG, Davison P, Sully L: The salvage of congested skin flaps by the application of leeches. *Br J Plast Surg* 37:358, 1984.
8. Biswas G, Lohani I, Chari PS: The sandwich temporoparietal free fascial flap for tendon gliding. *Plast Reconstr Surg* 108:1639–1645, 2001.
9. Brandt K, Khouri RK, Upton J: Free flaps as flow-through vascular conduits for simultaneous coverage and revascularization of the hand or digit. *Plast Reconstr Surg* 98:321–327, 1996.
10. Brody GA, Buncke HJ, Alpert BS, et al: Serratus anterior muscle transplantation for treatment of soft tissue defects in the hand. *J Hand Surg [Am]* 15:322–327, 1990.
11. Buehler MJ, Pacelli L, Wilson KM: Serratus fascia "sandwich" free-tissue transfer for complex dorsal hand and wrist avulsion injuries. *J Reconstr Microsurg* 15:315–320, 1999.
12. Buncke HJ, Rose AH: Free toe-to-fingertip neurovascular flaps. *Plast Reconstr Surg* 63:607, 1979.
13. Burns JT, Schlafy B: Use of the parascapular flap in hand reconstruction. *J Hand Surg [Am]* 11:872, 1986.
14. Carty MJ, Taghinia A, Upton J: Fascial flap reconstruction of the hand: a single surgeon's 30-year experience. *Plast Reconstr Surg* 125:953–962, 2010.
15. Chen HC, Tang YB, Chuang D, et al: Microvascular free posterior interosseous flap and a comparison with the pedicled posterior interosseous flap. *Ann Plast Surg* 36:542–550, 1996.
16. Chen HC, Tang YB, Noordhoff MS: Four types of venous flaps for wound coverage: A clinical appraisal. *J Trauma* 31:1286–1293, 1991.
17. Chen KT, Mardini S, Chuang DC, et al: Timing of presentation of the first signs of vascular compromise dictates the salvage outcome of free flap transfers. *Plast Reconstr Surg* 120:187–195, 2007.
18. Chen SHT, Wei FC, Chen HC, et al: Emergency free-flap transfer for reconstruction of acute complex extremity wounds. *Plast Reconstr Surg* 89:882–888, 1992.
19. Chen SL, Chen TM, Wang HJ: Free thoracodorsal artery perforator flap in extremity reconstruction: 12 cases. *Br J Plast Surg* 57:525–530, 2004.
20. Cheng HT, Lin FY, Chang SC: Free-flap salvage by thrombolytic agents? An evidence-based systemic analysis. *Plast Reconstr Surg* 129:766e–767e, 2012.
21. Christie DRH, Duncan GM, Glasson DW: The ulnar artery free flap: The first 7 years. *Plast Reconstr Surg* 93:547–551, 1994.
22. Chuang DC, Jeng SF, Chen HT, et al: Experience of 73 free groin flaps. *Br J Plast Surg* 45:81–85, 1992.
23. Chae MP, Rozen WH, Whitaker IS, et al: Current evidence for postoperative monitoring of microvascular free flaps: a systematic review. *Ann Plast Surg* 74:621–632, 2015.
24. Conrad MH, Adams WP, Jr: Pharmacologic optimization of microsurgery in the new millennium. *Plast Reconstr Surg* 108:2088–2096, 2001.
25. Dabernig J, Sorensen K, Shaw-Dunn J, et al: The thin circumflex scapular artery perforator flap. *J Plast Reconstr Aesthet Surg* 60:1082–1096, 2007.
26. Daniel RK, Taylor GI: Distant transfer of an island flap by microvascular anastomoses. *Plast Reconstr Surg* 52:111–117, 1973.
27. Datiashvili RO, Yueh JH: Management of complicated wounds of the extremities with scapular fascial free flaps. *J Reconstr Microsurg* 28:521–528, 2012.
28. de Chalain TMB: Exploring the use of the medicinal leech: A clinical risk-benefit analysis. *J Reconstr Microsurg* 12:165–172, 1996.
29. de la Torre J, Hedden W, Grant JH, III, et al: Retrospective review of the internal Doppler probe for intra- and postoperative microvascular surveillance. *J Reconstr Microsurg* 19:287–289, 2003.
30. De Lorenzi F, van der Hulst RR, den Dunnen WF, et al: Arterialized venous free flaps for soft-tissue reconstruction of digits: A 40-case series. *J Reconstr Microsurg* 18:569–577, 2002.
31. Derderian CA, Olivier WA, Baux G, et al: Microvascular free-tissue transfer for traumatic defects of the upper extremity: a 25-year experience. *J Reconstr Microsurg* 19:455–462, 2003.
32. Flügel A, Kehrer A, Heitmann C, et al: Coverage of soft-tissue defects of the hand with free fascial flaps. *Microsurgery* 25:47–53, 2005.
33. Foo IT, Malata CM, Kay SP: Free tissue transfers to the upper limb. *J Hand Surg [Br]* 18:279–284, 1993.
34. Foucher G, Norris RW: The venous dorsal digital island flap or the "neutral" flap. *Br J Plast Surg* 41:337, 1988.
35. Foucher G, Van Genechten F, Merle N, et al: A compound radial artery forearm flap in hand surgery: An original modification of the Chinese forearm flap. *Br J Plast Surg* 37:139–148, 1984.
36. Friedrich J, Vedder N: The use of radial forearm fascia flaps in upper extremity reconstruction. *Hand* 2:51–83, 2007.
37. Fudem GM, Walton RL: Microvascular thrombolysis to salvage a free flap using human recombinant tissue plasminogen activator. *J Reconstr Microsurg* 5:231–234, 1989.
38. Fukui A, Inada Y, Maeda M, et al: Pedicled and "flow-through'' venous flaps: Clinical applications. *J Reconstr Microsurg* 5:235–243, 1989.
39. Gilbert A, Teot L: The free scapular flap. *Plast Reconstr Surg* 69:601–604, 1982.
40. Godina M: Arterial autografts in microvascular surgery. *Plast Reconstr Surg* 78:293–294, 1986.
41. Godina M: Early microsurgical reconstruction of complex trauma of the extremities. *Plast Reconstr Surg* 78:285–292, 1986.
42. Godina M: The tailored latissimus dorsi free flap. *Plast Reconstr Surg* 80:304–306, 1987.
43. Gordon L, Buncke HJ, Alpert BS: Free latissimus dorsi muscle flap with split-thickness skin graft cover: A report of 16 cases. *Plast Reconstr Surg* 70:173–178, 1982.
44. Graham B, Adkins P, Scheker LR: Complications and morbidity of the donor and recipient sites in 123 lateral arm flaps. *J Hand Surg [Br]* 17:189–192, 1992.
45. Gu JX, Pan JB, Liu HJ, et al: Aesthetic and sensory reconstruction of finger pulp defects using free toe flaps. *Aesthetic Plast Surg* 38(1):156–163, 2014.
46. Hamilton SGL, Morrison WA: The scapular free flap. *Br J Plast Surg* 35:2–7, 1982.
47. Hanasono MM, Skoracki RJ, Yu P: A prospective study of donor-site morbidity after anterolateral thigh fasciocutaneous and myocutaneous free flap harvest in 220 patients. *Plast Reconstr Surg* 125:209–214, 2010.
48. Harii K, Ohmori K, Torii S, et al: Free groin skin flaps. *Br J Plast Surg* 28:225–237, 1975.
49. Harii K, Yamanda A, Ishihara K, et al: A free transfer of both latissimus dorsi and serratus anterior flaps with thoracodorsal vessel anastomoses. *Plast Reconstr Surg* 70:620–629, 1982.
50. Harrison BL, Lakhiani C, Lee MR, et al: Timing of traumatic upper extremity free flap reconstruction: a systematic review and progress report. *Plast Reconstr Surg* 132:591–596, 2013.
51. Hentz VR, Pearl RM, Grossman JAI, et al: The radial forearm flap: A versatile source of composite tissue. *Ann Plast Surg* 19:485–498, 1987.
52. Hing DN, Buncke HJ, Alpert BS: Use of the temporoparietal free fascial flap in the upper extremity. *Plast Reconstr Surg* 81:534–544, 1988.
53. Hirase Y, Kojima T: Use of the double-layered free temporal fascia flap for upper extremity coverage. *J Hand Surg [Am]* 19:864–870, 1994.
54. Hough M, Fenn C, Kay SP: The use of free groin flaps in children. *Plast Reconstr Surg* 113:1161–1166, 2004.
55. Hsu CC, Lin YT, Lin Ch, et al: Immediate emergency free anterolateral thigh flap transfer for the mutilated upper extremity. *Plast Reconstr Surg* 123:1739–1747, 2009.
56. Hsu WM, Chao WN, Yang C, et al: Evolution of the free groin flap: the superficial circumflex iliac artery perforator flap. *Plast Reconstr Surg* 119:1491–1498, 2007.
57. Hui KC, Zhang F, Lineaweaver WC, et al: Serratus anterior–rib composite flap: Anatomic studies and clinical application to hand reconstruction. *Ann Plast Surg* 42:132–136, 1999.
58. Iglesias M, Butrón P, León-López DA, et al: Soft tissue reconstruction with omental free flap in complex upper extremity injuries: report of 13 cases. *Microsurgery* 34(6):425–433, 2014.
59. Javaid M, Cormack GC: Anterolateral thigh free flap for complex soft tissue hand reconstructions. *J Hand Surg [Br]* 28:21–27, 2003.
60. Jenkins SD, Sepka RS, Barwick WJ: Routine use of laser Doppler flowmetry for monitoring autologous tissue transplants. *Ann Plast Surg* 21:423–426, 1988.
61. Jones JW, Thorvaldsson S: Simplified gracilis harvesting. *Plast Reconstr Surg* 85:829–830, 1990.
62. Jones NF: Intraoperative and postoperative monitoring of microsurgical free tissue transfers. *Clin Plast Surg* 19:783–797, 1992.
63. Jones NF, Gupta R: Postoperative monitoring of pediatric toe-to-hand transfers with differential pulse oximetry. *J Hand Surg [Am]* 26:525–529, 2001.
64. Jones NF, Jarrahy R, Kaufman MR: Pedicled and free radial forearm flaps for reconstruction of the elbow, wrist, and hand. *Plast Reconstr Surg* 121:887–898, 2008.
65. Karaaltin MV, Erdem A, Kuvat S, et al: Comparison of clinical outcomes between single- and multiple-perforator-based free thoracodorsal artery perforator flaps: clinical experience in 87 patients. *Plast Reconstr Surg* 128:158e–165e, 2011.
66. Katsaros J, Schusterman M, Beppu M, et al: The lateral upper arm flap: Anatomy and clinical applications. *Ann Plast Surg* 12:489–500, 1984.
67. Katsaros J, Tan E, Zoltie N, et al: The use of the lateral arm flap in upper limb surgery. *J Hand Surg [Am]* 16:598–604, 1991.
68. Keller A: Noninvasive tissue oximetry for flap monitoring: an initial study. *J Reconstr Microsurg* 23:189–197, 2007.
69. Khouri RA, Shaw WW: Monitoring of free flaps with surface temperature recordings: Is it reliable? *Plast Reconstr Surg* 89:495–502, 1992.
70. Kim PS, Gottlieb JR, Harris GD, et al: The dorsal thoracic fascia: anatomic significance with clinical applications in reconstructive microsurgery. *Plast Reconstr Surg* 79:72, 1987.
71. Klinkenberg M, Fischer S, Behr B, et al: Comparison of donor-site morbidity and satisfaction between anterolateral thigh and parascapular free flaps in the same patient. *J Reconstr Microsurg* 29:537–544, 2013.

72. Koshima I, Inagawa K, Urushibara K, et al: Fingertip reconstructions using partial-toe transfers. *Plast Reconstr Surg* 105:1666–1674, 2000.
73. Koshima I, Nanba Y, Tsutsui T, et al: New anterolateral thigh perforator flap with a short pedicle for reconstruction of defects in the upper extremities. *Ann Plast Surg* 51:30–36, 2003.
74. Koshima I, Nanba Y, Tsutsui T, et al: Superficial circumflex iliac artery perforator flap for reconstruction of limb defects. *Plast Reconstr Surg* 113:233–240, 2004.
75. Lee SH, Mun GH: Transverse thoracodorsal artery perforator flaps: experience with 31 free flaps. *J Plast Reconstr Aesthet Surg* 61:380–381, 2008.
76. Lin CH, Lin YT, Sassu P, et al: Functional assessment of the reconstructed fingertips after free toe pulp transfer. *Plast Reconstr Surg* 120:1315–1321, 2007.
77. Lipton HA, Jupiter JB: Streptokinase salvage of a free-tissue transfer: Case report and review of literature. *Plast Reconstr Surg* 79:977–981, 1987.
78. Lister G, Scheker L: Emergency free flaps to the upper extremity. *J Hand Surg [Am]* 13:22–28, 1988.
79. Lister GD, Arnez AO: The anterior T and Y grafts. *Plast Reconstr Surg* 88:319–322, 1991.
80. Lohman RF, Langevin CJ, Bozkurt M, et al: A prospective analysis of free flap monitoring techniques: physical examination, external Doppler, implantable Doppler, and tissue oximetry. *J Reconstr Microsurg* 29:51–56, 2013.
81. Lu K, Zhong D, Chen B, et al: The clinical application of the reversed forearm island flap. *Chin J Surg* 20:695–697, 1982.
82. May JW, Chait LA, Cohen BE, et al: Free neurovascular flap from the first web of the foot in hand reconstruction. *J Hand Surg [Am]* 2:387–393, 1977.
83. May JW, Rothkopf DM: Salvage of a failing microvascular free muscle flap by direct continuous intravascular infusion of heparin: A case report. *Plast Reconstr Surg* 83:1045–1048, 1989.
84. McCraw JB: On the transfer of a free dorsalis pedis sensory flap to the hand. *Plast Reconstr Surg* 59:738–739, 1977.
85. Morrison WA, Crabb DM, O'Brien B, et al: The instep of the foot as a fasciocutaneous island and as a free flap for heel defects. *Plast Reconstr Surg* 72:56–63, 1983.
86. Morrison WA, O'Brien BM, MacLeod AM, et al: Neurovascular free flaps from the foot for innervation of the hand. *J Hand Surg [Am]* 4:235–242, 1978.
87. Muhlbauer W, Herndl E, Stock W: The forearm flap. *Plast Reconstr Surg* 70:336–342, 1982.
88. Nasir S, Aydin MA: Upper extremity reconstruction using free SCIA/SIEA flap. *Microsurgery* 30:37–42, 2010.
89. Nassif TM, Vidal L, Bovet JL, et al: The parascapular flap: A new cutaneous microsurgical free flap. *Plast Reconstr Surg* 69:591–600, 1982.
90. Ninkovic M, Wechselberger G, Schwabegger A, et al: The instep free flap to resurface palmar defects of the hand. *Plast Reconstr Surg* 97:1489–1493, 1996.
91. O'Brien BM, Morrison WA, Dooley BJ: Microvascular osteocutaneous transfer using the groin flap and iliac crest and the dorsalis pedis flap and second metatarsal. *Br J Plast Surg* 32:188–206, 1979.
92. Ohmori K, Harii K: Free dorsalis pedis sensory flap to the hand, with microneurovascular anastomoses. *Plast Reconstr Surg* 58:546–554, 1976.
93. Partecke BD, Buck-Gramcko D: Free forearm flap for reconstruction of soft tissue defects concurrent with improved peripheral circulation. *J Reconstr Microsurg* 1:1–6, 1984.
94. Pederson WC: Upper extremity microsurgery. *Plast Reconstr Surg* 107:1524–1536, 2001.
95. Pennington DG, Lai MF, Pelly AD: The rectus abdominis myocutaneous free flap. *Br J Plast Surg* 33:277–282, 1980.
96. Press BHJ, Chiu DTW, Cunningham BL: The rectus abdominis muscle in difficult problems of hand soft tissue reconstruction. *Br J Plast Surg* 43:419–425, 1990.
97. Puckett CL, Misholy H, Reinisch JF: The effects of streptokinase on ischemic flaps. *J Hand Surg [Am]* 8:101–104, 1983.
98. Rao VK, Baertsch A: Microvascular reconstruction of the upper extremity with the rectus abdominis muscle. *Microsurgery* 15:746–750, 1994.
99. Reid C, Moss L: One-stage flap repair with vascularized tendon grafts in a dorsal hand injury using the Chinese forearm flap. *Br J Plast Surg* 36:473, 1983.
100. Robinson DW: Microsurgical transfer of the dorsalis pedis neurovascular island flap. *Br J Plast Surg* 29:209–213, 1976.
101. Saint-Cyr M, Oni G, Lee M, et al: Simple approach to harvest of the anterolateral thigh flap. *Plast Reconstr Surg* 129:207–211, 2012.
102. Sauerbier M, Ofer N, Germann G, et al: Microvascular reconstruction in burn and electrical burn injuries of the severely traumatized upper extremity. *Plast Reconstr Surg* 119:605–615, 2007.
103. Sauerbier M, Unglaub F: Perforator flaps in the upper extremity. *Clin Plast Surg* 37:667–676, 2010.
104. Scheker LR, Ahmed O: Radical debridement, free flap coverage, and immediate reconstruction of the upper extremity. *Hand Clin* 23:23–36, 2007.
105. Seitz IA, Williams CS, Wiedrich TA, et al: Omental free-tissue transfer for coverage of complex upper extremity and hand defects: the forgotten flap. *Hand (N Y)* 4:397–405, 2009.
106. Serletti JM, Moran SL, Orlando GS, et al: Urokinase protocol for free-flap salvage following prolonged venous thrombosis. *Plast Reconstr Surg* 102:1947–1953, 1998.
107. Shen Z: Vascularized tendon grafting from the dorsum of the foot: A functional anatomic study and clinical experience. *J Reconstr Microsurg* 5:90, 1989.
108. Shestak KC, Jones NF: Microsurgical free tissue transfer in the elderly patient. *Plast Reconstr Surg* 88:259, 1991.
109. Shibata M, Iwabuchi Y, Kubota S, et al: Comparison of free and reversed pedicled posterior interosseous cutaneous flaps. *Plast Reconstr Surg* 99:791–802, 1997.
110. Smith PJ, Foley B, McGregor IA, et al: The anatomical basis of the groin flap. *Plast Reconstr Surg* 49:41–47, 1972.
111. Solomon GA, Yaremchuk MJ, Manson PN: Doppler ultrasound surface monitoring of both arterial and venous flow in clinical free tissue transfers. *J Reconstr Microsurg* 3:39–41, 1986.
112. Song R, Gao Y, Song Y, et al: The forearm flap. *Clin Plast Surg* 91:21–26, 1982.
113. Song YG, Chen GZ, Song YL: The free thigh flap: A new free flap concept based on the septocutaneous artery. *Br J Plast Surg* 37:149–159, 1984.
114. Swartz WM, Banis JC, Newton ED, et al: The osteocutaneous scapular flap for mandibular and maxillary reconstruction. *Plast Reconstr Surg* 77:530–545, 1986.
115. Swartz WM, Izquierdo R, Miller MJ: Implantable venous Doppler microvascular monitoring: Laboratory investigation and clinical results. *Plast Reconstr Surg* 93:152–163, 1994.
116. Swartz WM, Jones NF, Cherup LL, et al: Direct monitoring of microvascular anastomoses with the 20 MHz ultrasonic Doppler probe: An experimental and clinical study. *Plast Reconstr Surg* 81:149–158, 1988.
117. Taylor GI, Corlett RJ, Boyd JB: The versatile deep inferior epigastric (inferior rectus abdominis) flap. *Br J Plast Surg* 37:330, 1984.
118. Taylor GI, Palmer JH: The vascular territories (angiosomes) of the body: Experimental study and clinical application. *Br J Plast Surg* 40:113, 1987.
119. Taylor GI, Townsend P: Composite free flap and tendon transfer: An anatomical study and a clinical technique. *Br J Plast Surg* 32:170–183, 1979.
120. Thoma A, Archibald S, Jackson S, et al: Surgical patterns of venous drainage of the free forearm flap in head and neck reconstruction. *Plast Reconstr Surg* 93:54–59, 1994.
121. Timmons MJ, Missotten FE, Poole MD, et al: Complications of radial forearm flap donor sites. *Br J Plast Surg* 39:176–178, 1986.
122. Tobin GR, Schusterman M, Peterson GH, et al: The intramuscular neurovascular anatomy of the latissimus dorsi muscle: The basis for splitting the flap. *Plast Reconstr Surg* 67:637–641, 1981.
123. Tsai SM, Matiko JD, Breidenbach W, et al: Venous flaps in digital revascularization and replantation. *J Reconstr Microsurg* 3:113, 1987.
124. Ulusal BG, Lin YT, Ulusal AE, et al: Free lateral arm flap for 1-stage reconstruction of soft tissue and composite defects of the hand: A retrospective analysis of 118 cases. *Ann Plast Surg* 58:173–178, 2007.
125. Upton J, Guo L: Pediatric free tissue transfer: a 29-year experience with 433 transfers. *Plast Reconstr Surg* 121:1725–1737, 2008.
126. Upton J, Rogers C, Durham-Smith G, et al: Clinical applications of free temporoparietal flaps in hand reconstruction. *J Hand Surg [Am]* 11:475–483, 1986.
127. Wang HT, Fletcher JW, Erdmann D, et al: Use of the anterolateral thigh free flap for upper-extremity reconstruction. *J Hand Surg [Am]* 30:859–864, 2005.
128. Wei FC, Chen HC, Chuang CC, et al: Fibular osteoseptocutaneous flap: Anatomic study and clinical application. *Plast Reconstr Surg* 78:191–199, 1986.
129. Wei FC, Jain V, Celik N, et al: Have we found an ideal soft-tissue flap? An experience with 672 anterolateral thigh flaps. *Plast Reconstr Surg* 109:2219–2226, 2002.
130. Wei FC, Silverman RT, Hsu WM: Retrograde dissection of the vascular pedicle in toe harvest. *Plast Reconstr Surg* 96:1211–1214, 1995.
131. Wells MD, Manktelow RT, Boyd JB, et al: The medical leech: An old treatment revisited. *Microsurgery* 14:183–186, 1993.
132. Wong SS, Wang ML, Su MS, et al: Free medialis pedis flap as a coverage and flow-through flap in hand and digit reconstruction. *J Trauma* 47:738–743, 1999.
133. Xu DC, Zhong SZ, Kong JM, et al: Applied anatomy of the anterolateral femoral flap. *Plast Reconstr Surg* 82:305–310, 1988.
134. Yang G, Chen B, Gao Y: Forearm free skin flap transplantation. *Natl Med J China* 61:139–142, 1981.
135. Yang LC, Wang XC, Bentz ML, et al: Clinical application of the thoracodorsal artery perforator flaps. *J Plast Reconstr Aesthet Surg* 66:193–200, 2013.
136. Yousif NJ, Warren R, Matloub HS, et al: The lateral arm fascial free flap: Its anatomy and use in reconstruction. *Plast Reconstr Surg* 86:1138–1145, discussion 1146–1147, 1990.
137. Yu P, Youssef A: Efficacy of the handheld Doppler in preoperative identification of the cutaneous perforators in the anterolateral thigh flap. *Plast Reconstr Surg* 118:928–933, 2006.
138. Zuker RM, Manktelow RT: The dorsalis pedis free flap; technique of elevation, foot closure, and flap application. *Plast Reconstr Surg* 77:93–104, 1986.

46

Vascularized Bone Grafting

Allen T. Bishop and Alexander Y. Shin

Bone grafts have been used since the first decade of the twentieth century to fuse joints and repair defects. The desirability of a living bone graft was recognized by several early investigators who used pedicled fibular grafts for tibial defects as early as 1905.[59] The concept of pedicle grafting has been widely applied since that time, using rib, clavicular, iliac crest, scapular, radial, greater and lesser trochanter, medial femoral condylar, pisiform, second metacarpal, and humeral grafts.

The microsurgical transfer of autogenous living bone awaited the development of techniques and instruments for microvascular anastomosis. With appropriate microsurgical instruments and techniques, development of free vascularized bone flaps was rapid. This included the first free bone transfer, of an osteocutaneous composite rib flap,[91] followed with use of rib, fibula, and iliac crest transfers. The fibula remains the mainstay for most large extremity defect reconstructions. Many variations have been described that allow tailoring of the graft to meet specific needs, including reconstruction of combined bone and soft tissue loss in one setting. In recent years, smaller bone grafts, as well as periosteal and osteochondral free flaps, have provided additional choices better suited for some specific applications than the fibula, rib, or iliac crest.

GENERAL CONSIDERATIONS IN VASCULARIZED BONE GRAFTING

Pedicle Flap Versus Free Flap

Vascularized bone grafts allow living bone tissue to be transplanted to an adjacent or remote location and survive by maintenance or restoration of blood flow. Free vascularized bone grafts require microvascular anastomoses to a recipient site artery and vein, whereas pedicle grafts are moved with their blood supply undisturbed to an adjacent area. Pedicle flaps may have orthograde or retrograde flow through a distally based pedicle with satisfactory results.

Biology of Conventional Bone Grafts

A bone graft obtained without a blood supply is termed a *conventional graft*. It may be obtained from the patient (autograft), another individual (allograft), or another species (xenograft). Cancellous conventional autografts are commonly used to encourage healing of fractures, arthrodeses, or allograft/host junctions in reconstructive surgery. Structural autografts are used to span significant defects in the axial or appendicular skeleton. Autografts are superior, in general, to allogeneic or xenogeneic material.

For most bone defects of less than 6 cm with a well-vascularized bed, adequate soft tissue cover, and absence of infection, a conventional cancellous or corticocancellous autograft is generally recommended. Cancellous bone has greater inductive capacity than cortical bone and should be used unless mechanical stability is required.

The process of bone graft incorporation is by *creeping substitution*, a process of gradual vascular ingrowth, resorption, and replacement of necrotic bone. Creeping substitution results in rapid revascularization of small cancellous grafts but is slow and incomplete in cortical bone. As much as 40 to 50% of lamellar bone remains necrotic, and the revascularization process that does occur causes significant mechanical weakening because of resorption of necrotic bone. Large structural allografts, like autografts, must also be replaced by living bone. Despite the reduction in immunogenicity resulting from cryopreservation, they invoke a local and systemic immune response that diminishes the stimulus of new bone formation and are replaced more slowly and less completely than similar grafts of autograft bone. This effect may be diminished by freezing, freeze drying, irradiating, or decalcifying the bone, or eliminated with the use of immunosuppressive drugs. Conventional (nonvascularized) bone grafts of all types have substantial problems with fatigue fracture, even years after the surgical procedure. Successful grafting requires a well-vascularized bed, adequate immobilization, and protection from excessive stress by rigid internal fixation.

Biology of Vascularized Bone Grafts

Unlike conventional bone grafts, vascularized bone remains alive and dynamic in its new site. Viable bone does not undergo creeping substitution; thus, significant osteopenia does not occur. The result is improved strength, healing, and stress responsiveness as compared with nonvascularized conventional bone grafts. The incidence of stress fracture is lower than in massive structural autografts or allografts. Further, union is more rapid, and bone hypertrophy in response to applied stress may occur with time.[24] Bone healing is more likely in difficult circumstances, including scarred or irradiated beds, or in avascular bone. Vascularized grafts have superior material properties. These include strength, toughness, and an elastic modulus two to four times greater than these factors in conventional structural grafts.

The ability of vascularized grafts to adapt to applied stress by hypertrophy is a frequently observed phenomenon. Hypertrophy does not invariably occur, however. It is less likely when the graft is significantly stress-shielded by extensive internal fixation, or in the absence of weight bearing.[24] Other important factors include age, extent of bone vascularity, and the source of the bone graft. The fibula is more likely to undergo hypertrophy than the iliac crest or rib.

Other Advantages of Vascularized Bone Grafts

In addition to superior cell survival, maintained circulation, and useful mechanical properties, vascularized grafts have other significant advantages over conventional grafts. These include the possibilities of restoring longitudinal growth by inclusion of the growth plate, revascularizing adjacent necrotic bone, improving local blood flow in scarred soft tissue beds, and reconstructing composite tissue loss in one procedure by inclusion of skin, muscle, tendon, nerve, and other tissues with the bone graft.

INDICATIONS FOR VASCULARIZED BONE GRAFTING

Based on the information reported above, it would seem that vascularized autografts would be ideal for grafting under most circumstances. Their use as free tissue transfers is technically demanding, however, and pedicle grafts are often more limited in location, dimension, pedicle length, and, hence, indications. Prolonged operative times and extensive dissection increase the risk of complications, and donor site morbidity may be significant. For bone defects under 6 to 8 cm with normal soft tissues, conventional techniques remain the method of choice under many circumstances.

Segmental Bone Loss

Vascularized transfer is indicated in segmental bone defects larger than 6 to 8 cm that are due to tumor resection, traumatic bone loss, osteomyelitis, or infected nonunion.[149]

Biologic Failure

The use of vascularized grafts in smaller defects is reasonable in cases where "biologic failure" of bone healing is likely or has already occurred. Examples include persistent nonunion after conventional graft treatment, poorly vascularized bone and/or surrounding soft tissue, avascular necrosis of bone, and congenital pseudarthrosis. Other indications include composite tissue loss requiring composite bone/soft tissue flap reconstruction, joint arthrodesis in exceptional circumstances, and a need for longitudinal bone growth requiring physeal transfer.

Avascular Necrosis of Bone

Vascularized grafts have been used to treat osteonecrosis in many areas, including the femoral head, scaphoid, talus, and lunate. Experimental models of avascular necrosis have demonstrated that vascularized bone or arteriovenous pedicle grafts can be used to repair necrotic bone by neovascularization and new bone formation extending from the vascularized graft into the damaged area.[131,151] In the clinical setting, symptomatic improvement and direct evidence of revascularization on imaging studies have been reported in these locations. Vascularized bone or corticoperiosteal flaps also optimally treat nonunions of long bones due to osteoradionecrosis.

Complex Tissue Loss

Many vascularized bone flaps may be harvested to include other tissues. Examples include osteomuscular or osteocutaneous fibular flaps, composite groin flaps including skin and/or muscle, and scapular flaps based on the thoracodorsal pedicle that may include skin and serratus anterior or latissimus dorsi muscle (Figure 46.1). Flow-through fibular flaps permit simultaneous transfer of a second free flap, allowing simultaneous coverage of large soft tissue defects in a single stage. The unique ability of free tissue transfer to solve complex tissue defect problems with a single-stage reconstruction makes them highly desirable in these difficult circumstances.

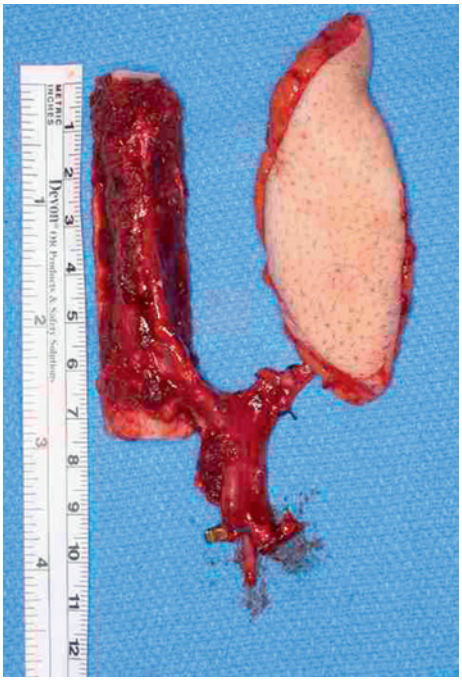

Figure 46.1 Osteocutaneous fibula. The fibula may be harvested as a composite flap including skin for coverage or monitoring purposes.

Physeal Arrest

Transfer of vascularized epiphyses may allow continued growth of a limb.[60] This is currently practical only for fibular grafts with inclusion of the entire proximal fibula, or with toe flaps including bone or joint.

Osteomyelitis

Infections represent a particularly difficult problem. Application of systemic or local antibiotics and aggressive débridement of necrotic bone and soft tissue must be carried out until the infection is deemed inactive or eradicated. Criteria commonly used to determine inactive sepsis include an absence of sinus tracts, negative bacterial cultures, a negative C-reactive protein level, and a sedimentation rate of less than 15 mm/hour, maintained for at least 1 month.[96] When strict criteria for determining quiescence are used, recurrent infection will occur infrequently.

Carpal Defects or Disorders

Vascularized bone or osteochondral flaps may be applied to defects of the carpal and hand to aid or accelerate fracture healing or replace deficient bone. However, they have most widely been indicated for revascularization of ischemic bone. The most common instances are scaphoid fractures resulting in

proximal pole avascular necrosis, osteonecrosis of the lunate (Kienböck disease), or osteonecrosis of the scaphoid (Preiser disease). They are also indicated when previous conventional surgery has failed or is deemed likely to fail. Bone-only flaps must be used with some caution once subchondral fracture results in damage to the articular surface, or in very small or fragmented scaphoid proximal fragments. In such instances, partial replacement of both deficient bone and a damaged or nonfunctional articular surface has been recently demonstrated in scaphoid nonunions with small or fragmented proximal segments[11] and in avascular necrosis of the lunate.[12] In both circumstances, replacing the proximal half of the lunate or scaphoid to include the radial articular surface may prove to be a viable technique.

VASCULARIZED BONE GRAFT SELECTION

Selection of the optimal donor for a vascularized bone graft depends on consideration of a number of factors, including whether material taken from the donor site will match not only the size and shape of the defect but also its material properties. Other considerations include the proximity to the donor area, adequacy of the vascular pedicle for microvascular anastomosis at the recipient site, and donor site morbidity. The most important source of vascularized grafts for large upper extremity bone defects (>6–8 cm) is the fibula. Historically, the iliac crest has been used as well, but its membranous nature, curved shape, and relatively weak mechanical properties make it a secondary consideration in most such instances. Smaller defects, particularly in the hand and wrist, continue to benefit from vascularized bone flaps, as well. Distal radius pedicle grafts taken from either the dorsal or palmar surface have been extensively used for carpal nonunion or avascular necrosis based on well-defined anatomy and flap design. In recent years, the medial femoral condyle (MFC) flap variants, including bone,[18,29,68] periosteum,[25,36,114] and articular cartilage,[12,55] are finding increasing favor in difficult clinical situations. Corticoperiosteal flaps are superior to other methods in treating failed reconstructions and radiation-induced pathologic fractures of the clavicle.[36] The healing rate and time to union are significantly better in scaphoid nonunions with humpback deformity and dorsal intercalated segmental instability carpal collapse, when treated with a large MFC graft.[18] Previously unsalvageable lunates, with damaged proximal articular surfaces, may also be reconstructed with osteoarticular MFC segments.[12] Additional options may include pedicled flaps from the pisiform,[21,53] metacarpal head,[109] proximal second metacarpal metaphysis,[120] and ulnar or radial diaphysis.[46] Free microsurgical transfer is also possible from the iliac crest[106] and rib.[78]

Preoperative Planning

Recipient Site

Preoperative planning is vital for successful free tissue transfer. The bony, vascular, and soft tissue anatomy of a particular recipient site must be considered, along with factors related to the bone defect itself. For example, the length and location of the bone defect, infection status, amount of soft tissue loss or scarring, and condition of recipient vessels must be determined. The method of bone fixation should be planned in advance. If osteomyelitis is present, extensive débridement of all devitalized bone and adequate preliminary soft tissue coverage are prerequisites before vascularized grafting is considered.

The adequacy of recipient vessels is a paramount consideration. Clinical examination of pulses and the Allen test may be all that is required in nontraumatic cases. In many instances of traumatic or postirradiation bone deficiency, the extent of soft tissue injury extends well proximal and distal to the level of bony abnormality. Within the reactive zone, a patent vessel may be prone to spasm as well as friability due to surrounding scar or granulation tissue. This will render any anastomosis potentially flawed. In such situations, planning an anastomosis proximal or distal to the zone of injury is necessary. This may be performed with a sufficiently large flap or long pedicle, or at times by the use of vein grafts. Arteriography of the recipient site should be performed if there is any preoperative concern. This is most common in trauma indications, where vascular damage is likely. The probable need for vein grafting may be determined by preoperative arteriography, and by consideration of known factors such as pedicle length and distance of bone from available recipient vessels.

Vein grafting may be done as conventional arterial and venous interposition grafts, or by fabrication of a temporary arteriovenous fistula. In the latter circumstance, a reversed saphenous vein graft is anastomosed end to side to the recipient artery and end to end to the vein. End-to-side arterial anastomoses may have a higher patency rate in free tissue transfer and preserve distal circulation. The shunt is allowed to perfuse while the donor tissue is harvested.

The vascularized graft can be placed in either an orthograde or retrograde flow position, as dictated by the position of the best vascular anastomosis. A retrograde position has no effect on patency or rate of union.[23] Bony stabilization is performed, followed by vascular anastomosis. Use of stable internal fixation provides results superior to those of minimal internal or external fixation.[48,54] Plates spanning the entire reconstruction, or intramedullary fixation, are optimal. Stabilization may include the use of intercalary allografts.[14,17,82,103] In the upper limb, this is most generally considered for humeral shaft and shoulder arthrodesis reconstructions.[112] Addition of supplemental cancellous graft at junction sites increases the primary healing rate.

Donor Site

Selection of the best donor site is based on a consideration of the recipient site requirements and the characteristics of available donors. Larger defects in the upper limb are generally best reconstructed with fibular flaps, but smaller defects and bone with impaired vascularity or failure to heal with conventional methods may heal with smaller vascularized bone, corticoperiosteal, or osteocartilaginous flaps.

The donor site should be examined for evidence of previous injury or surgery, and an adequate history should be obtained to rule out systemic disease or local closed injury possibly affecting the surgical plan. A vascular examination should be performed, including peripheral arterial pulses. In the case of fibular harvest, vascular anomalies are rare, and adequate perfusion of the foot following harvest has been demonstrated to be nearly normal in most cases. We do not routinely perform angiography unless the examination suggests possible problems. Less invasive methods, such as computed tomography (CT)

scanning or magnetic resonance angiography, are proving to be of value.

Postoperative Monitoring

Thrombosis of the vascular pedicle in a vascularized bone graft results in conditions less favorable for vascular invasion and the usual process of bone graft incorporation than a conventional bone graft. Monitoring of graft viability in the immediate postoperative period is therefore desirable. A variety of methods have been used to assess viability on an intermittent basis, for the purposes of planning subsequent treatment and anticipating outcome. These include selective angiography, monitoring of healing and hypertrophy with serial radiographs, bone biopsy or observation of bleeding on subsequent surgery, or early 99m technetium bone scans, generally in the first postoperative week, as well as use of Doppler ultrasound scanning or single photon emission computed tomography scans.

Intermittent monitoring methods, however, will not detect acute thrombosis. Continuous monitoring is possible with the use of a surface or implantable laser Doppler velocimeter or a thermocouple probe, or, most practically, monitoring of a skin paddle serving as a "buoy flap." Detection of thrombosis allows revision of the anastomosis and salvage of a significant number of failing free tissue transfers.

Buoy Flap

By far the most feasible and easily interpreted continual monitor is a fasciocutaneous buoy flap. It enables direct observation of the transferred tissue, allowing immediate return to the operating room if loosening of the dressing, altering of the limb position, or trial of anticoagulation does not reverse the observed changes in 1 to 2 hours.[153] Cutaneous island monitoring is possible with most vascularized bone flaps, including the most common fibular, iliac crest, medial femoral condylar, and 1,2 intercompartmental supraretinacular artery (1,2 ICSRA) flaps.

Implanted Laser or Ultrasonic Probes

Although measurement of blood flow in an imbedded free flap is difficult, special probes have been used effectively for at least 48 hours postoperatively. In Schuurman's study of free fibular transfer, an occlusion rate of 10%, with 50% successful salvage, was seen with use of a laser Doppler probe.[121] A miniature Doppler ultrasonic probe is also available, designed to be secured to the outflow vein of the flap via a silicone rubber cuff.[132] The device was successful in salvaging 20 instances of thrombosis or spasm in 16 of 135 consecutive free flaps.[76]

Arteriogram

Arteriography allows assessment of bone viability at a single point in time. Angiography performed 6 to 8 weeks after surgery if positive is suggestive of likely clinical progress.

Bone Scan

Experimentally, positive bone scans correlate with vessel patency when done before the end of the first week, prior to the onset of creeping repair in both vascularized and nonvascularized autografts[122] (Figure 46.2). Use of dynamic imaging provides a more accurate, even semiquantitative, linear relationship between scan values and bone blood flow.

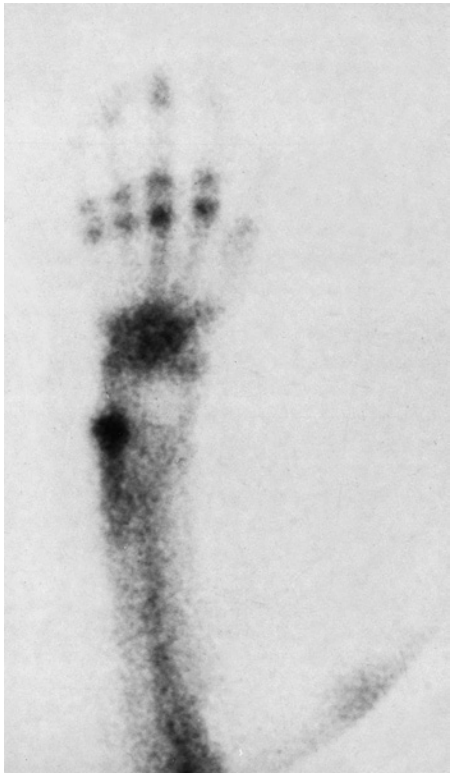

Figure 46.2 Bone scan 4 days following operation demonstrates excellent uptake in a fibular graft placed in the radius.

Bone scans obtained in the first 1 to 2 weeks following flap transfer have been demonstrably useful in clinical and experimental studies, correlating well with preserved circulation and clinical outcome.[158] In these studies, patients with a "hot" postoperative radionuclide were more likely to have a successful clinical outcome than those with negative or equivocal scans. In one series, only one of seven patients with poor scans healed primarily, and two cases (almost 30%) resulted in frank failure, necessitating removal of the transferred bone.[158]

COMPLICATIONS OF VASCULARIZED BONE GRAFTS

Impaired Vascularity

Vessel thrombosis occurs in a small percentage of free tissue transfers. If thrombosis occurs in a bone flap, it is likely that the surrounding cuff of necrotic soft tissue may impede neovascularization. Experimentally, the viability of thrombosed vascularized bone grafts is significantly less than that of conventional nonvascularized grafts as quantified by measurements of bone blood flow, new bone formation, and osteocyte counts.[125] Thus, the process of creeping substitution of necrotic bone is likely less extensive in failed vascularized grafts than in conventional grafts.

Delayed Union: Need for Secondary Bone Graft

Secondary bone grafting will be necessary in a substantial number of patients treated with structural vascularized bone grafts of the long bones. Primary healing occurs in roughly 68%

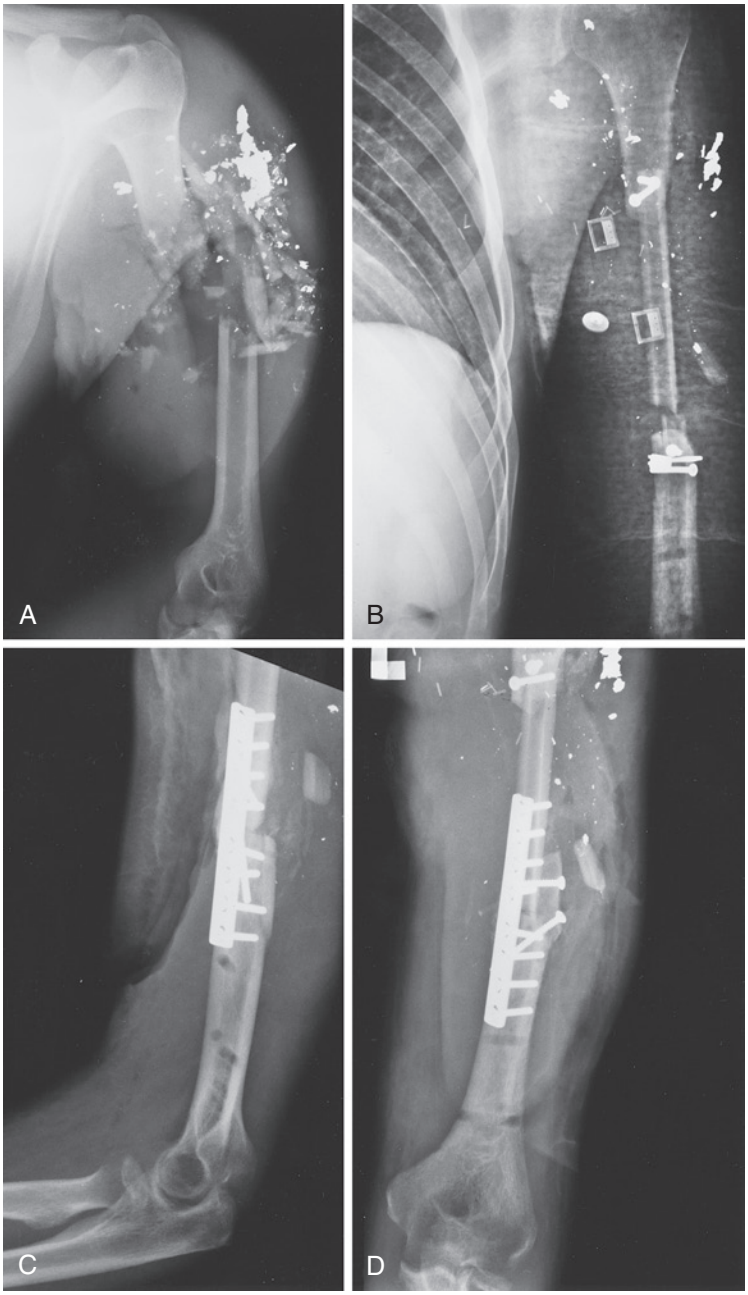

Figure 46.3 Gunshot wound in a 23-year-old man. **A,** Fragmentation of the humeral diaphysis before débridement. A large anterior wound was closed with a pedicled latissimus dorsi flap placed as an elbow flexorplasty to replace the missing biceps. **B,** A simultaneous fibular graft reconstructed the bone defect. A stress fracture occurred shortly after removal of a bridging external fixator several months later. **C** and **D,** Supplemental onlay bone grafting a plate fixation allowed healing of the fibula.

of vascularized fibular grafts, with poorer results in some locations and with a diagnosis of osteomyelitis.[48] Most that do not heal primarily will benefit from a secondary bone graft. Because the mean time to healing is 6 months for fibular grafts and 7 months for iliac crest grafts, timing of a secondary graft is generally somewhat longer, frequently at or before 12 months following the vascularized graft. A largely cancellous autograft at the ununited junction is usually sufficient. Problems associated with insufficient internal fixation may require revision at that time.

Stress Fracture

Stress fracture of a structural graft spanning a segmental defect may occur in both the upper and lower extremities (Figure 46.3, *A* to *D*).[112,135] Minami reported an incidence of 12 fractures occurring in 10 of 53 vascularized fibular transplant patients (23%).[98] Rigid stability provided by spanning plates or allograft replacement with intramedullary fixation on only fibular grafts results in a lower incidence of fracture.[112] Healing of stress fractures may occur with immobilization, provided the graft has adequate vascularity. Rapid formation of callus at the

fracture site and hypertrophy of the bone is observed thereafter, although displacement is common and requires stabilization.

The time of fracture occurrence may be significant because most occur within the first year after grafting. Fractures occurring in this time period generally have adequate circulation, as demonstrated by postoperative bone scanning[48] but have had insufficient time to undergo hypertrophy. Late fractures are uncommon and are associated with negative or equivocal bone scans. Most stress fractures occur through the transferred bone, rather than at its junctions.

When the fracture occurs in adults, union is often relatively easily obtained. Nondisplaced upper extremity fractures will heal in a cast alone, whereas displaced fractures require internal or external fixation with or without bone grafting.[48,98] A vascularized graft should be protected against fatigue fracture during the first year, allowing a gradual increase in mechanical loading, which enhances remodeling and hypertrophy.[24]

SPECIFIC VASCULARIZED GRAFTS: LONG BONE RECONSTRUCTION

Vascularized Fibular Grafts

ANATOMY

The fibula is the most used vascularized bone graft because its structure and shape are appropriate for diaphyseal locations. A long, straight segment of 26 to 30 cm in length may frequently be harvested, and osteosynthesis securely obtained to the recipient bone.

The blood supply to the fibula, as in other long bones, is derived normally from a nutrient artery via radially oriented branches, which penetrate the cortex and anastomose with the periosteal vessels. The source of the nutrient blood supply is a branch of the peroneal artery, generally entering the bone in its middle third. The resulting blood flow is centrifugal from medulla to cortex. This arrangement is the norm for the fibula, which has a single nutrient vessel entering its middle third from the peroneal artery. Additional periosteal branches from the peroneal and anterior tibial arteries also supply the diaphysis.

The proximal epiphysis is supplied by an arcade of vessels, including the lateral inferior genicular vessels and a recurrent branch from the anterior tibial artery.[61] Although some recommend use of the genicular blood supply, recent studies support the use of the anterior tibial vessels, which will also support the proximal two thirds of the diaphysis via the periosteal supply.[61] Such a pedicle supplies adequate vascularity to provide either longitudinal growth in children or viable articular cartilage for joint reconstruction. Although the genicular pedicle will provide periosteal blood flow, the peroneal vessels must be separately identified and supply the fibular shaft.

Transfer of a fasciocutaneous skin paddle of up to 10 by 20 cm is made possible by a series of fasciocutaneous or myocutaneous perforators from the peroneal artery, which typically pierces the soleus muscle adjacent to the lateral intermuscular septum (Figure 46.4). The location of the perforators may be determined in the operating room prior to skin incision by use of a Doppler ultrasound stethoscope. Osteomuscular flaps, including the flexor hallucis longus muscle and portions of the soleus or peroneal muscles, may also be raised using the same peroneal artery pedicle.

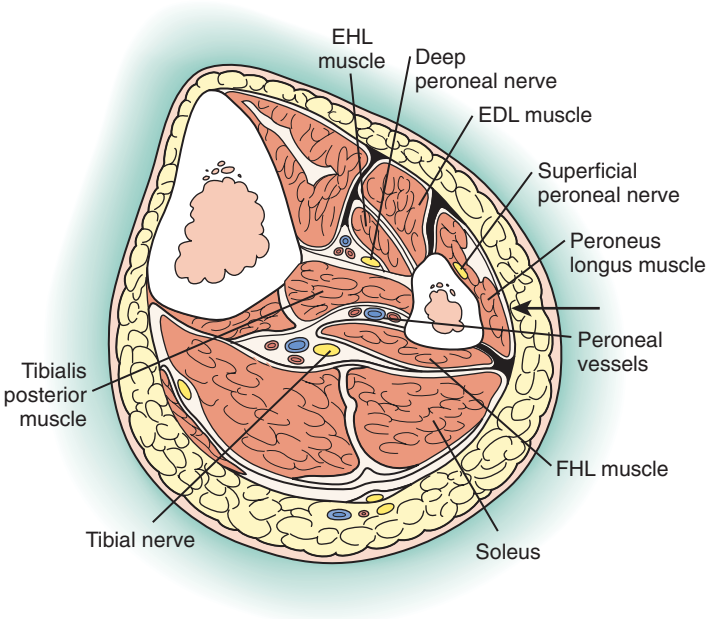

Figure 46.4 Harvest of a fibular free bone graft is performed from a lateral approach. The initial dissection is between the peroneus longus and the soleus. In this middle-third cross-sectional view, the peroneal vessels lie between the flexor hallucis longus and the tibialis posterior muscles. *EDL,* Extensor digitorum longus; *EHL,* extensor hallucis longus; *FHL,* flexor hallucis longus.

The peroneal pedicle has a length of 6 to 8 cm and an arterial diameter of 1.5 to 3 mm. Two venae comitantes lie on either side of the artery. Variations in the vascular anatomy of the leg are infrequent and include unusual deviations in the course of the peroneal vessels or its prominent contribution to the blood supply of the foot.

Technique

Osseous Fibular Flap. Two methods of fibular harvest have been described, including the original posterior approach developed by Taylor,[136] and the preferred lateral approach of Gilbert,[41] described below with some modifications. Exposure must protect the peroneal vessels, which lie between the tibialis posterior and flexor hallucis muscles (see Figure 46.4).

The patient is positioned supine, with a small sandbag beneath the ipsilateral buttock and another secured to the table near its foot to allow the patient's foot to rest securely with the knee flexed. The entire leg is draped free. Next, a pneumatic tourniquet is inflated. The fibula is measured, and its middle third identified. An incision is made directly along the fibular longitudinal axis laterally, extending through skin and subcutaneous tissue (Figure 46.5, *A*). The anterior border of a skin flap is incised at this step. This exposes the broad tendon of the peroneus longus, which is easily identified. A fat stripe posterior to the tendon identifies the interval between the peroneus longus muscle and the soleus muscle. This interval is developed with blunt dissection, beginning in the middle third of the bone (see Figure 46.5, *B*).The cutaneous vascular perforators supplying the skin may be visualized at this point passing either through the lateral intermuscular septum or, more commonly, through the adjacent anterior centimeter of the soleus. As the soleus is reflected posteriorly, one can identify the flexor hallucis

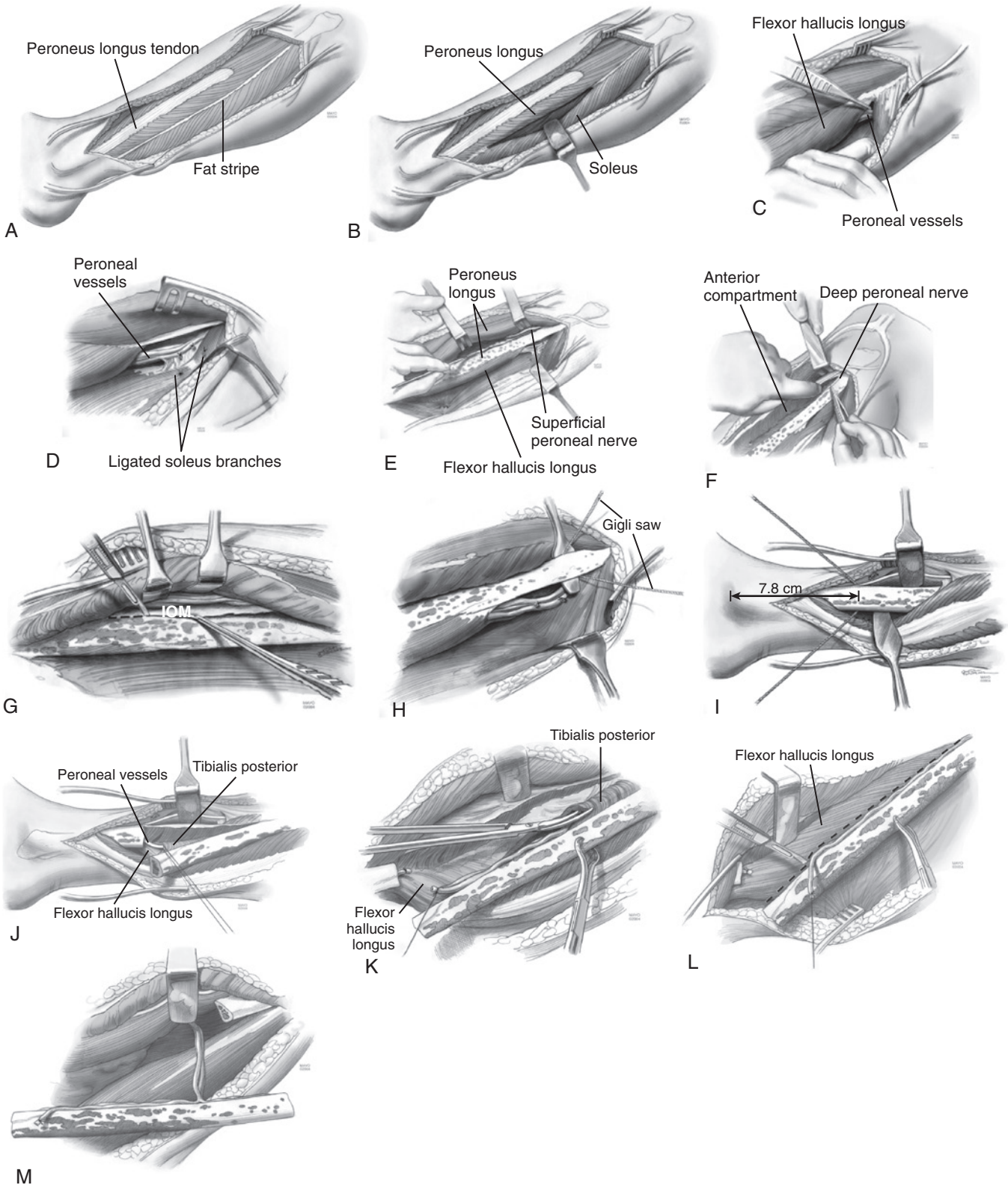

Figure 46.5 Technique of fibula harvest. See description in text. **A,** The *fat stripe* dorsal (posterior) to the peroneus longus tendon marks the plane of the initial dissection. **B,** Open the soleus/peroneus longus interval at midtibia. **C,** Follow the flexor hallucis longus (FHL) muscle on posterior surface of fibula to its proximal origin. The peroneal vessels will then be visualized passing anterior to the muscle. **D,** Ligate any muscular branches to the soleus, and complete the dissection of the soleus from the fibular neck. **E,** Dissect the lateral compartment muscles from the fibula, beginning *subperiosteally* proximally until the superficial peroneal nerve is identified and protected. Dissection proceeds above the periosteum distally. **F,** The deep peroneal nerve is identified, and the anterior compartment muscles are dissected from the fibula in a similar fashion. **G,** The interosseous membrane is divided from the anterior aspect. The tibialis posterior muscle is then visible. **H,** The proximal fibular cut is made, protecting the peroneal vessels and nerve. **I,** The distal fibular cut is made, preserving 7 to 8 cm of distal fibula. **J,** The peroneal vessels are visualized and ligated distally, located between the FHL and the tibialis posterior. **K,** The tibialis posterior muscle is divided from distal to proximal, exposing the peroneal vessels. It is necessary to identify and ligate multiple muscular branches. **L,** The FHL muscle is next removed from the fibula. **M,** The fibula is isolated on its proximal peroneal vessel pedicle.

muscle belly covering the posterior surface of the bone and obscuring the peroneal vessels from view.

The flexor hallucis longus muscle (FHL) origin lies well distal to the fibular neck. Proximal to the muscle, the peroneal vessels are identified as they pass deep to the FHL origin (see Figure 46.5, *C*). The vessels should be mobilized carefully from the posterior surface of the fibula, to prevent their inadvertent injury when the bone is divided.

Dissection is continued progressively proximally, elevating the soleus tendon of origin from its fibular attachment. Muscular branches of the peroneal vessels to the soleus will be visualized during the dissection and should be ligated and divided unless a composite osteomuscular flap with the soleus is desired (see Figure 46.5, *D*). The soleus is completely detached from the proximal fibula.

Next, the lateral compartment muscles are elevated from the fibula. Proximally, this must be done subperiosteally to avoid injury to the peroneal nerve. The nerve must be visualized and protected at this proximal level, lying directly on the bone of the fibular neck and proximal diaphysis. As the muscle is elevated in a distal direction, the superficial branch of the nerve lies further from the bone, and an extraperiosteal dissection plane will better preserve the bone blood supply. This dissection should leave small occasional wisps of muscle rather than a large muscular cuff on the bone surface because this will form a necrotic barrier to revascularization should the anastomosis fail (see Figure 46.5, *E*).

The anterior compartment is elevated similarly. Again, care is needed proximally to protect the deep branch of the peroneal nerve (see Figure 46.5, *F*). The anterior tibial artery will be identified, as will the interosseous membrane at the conclusion of this dissection. Depending upon ease of visibility, the interosseous membrane may be divided at this point (see Figure 46.5, *G*), or the bone divided proximally and distally first. Bone division is carried out with a Gigli saw, protecting neurovascular structures with careful circumferential retraction and blunt passage of the saw cable (see Figure 46.5, *H*). The middle third of the bone, at a minimum, must be raised to preserve the nutrient artery supply. Harvesting more of the proximal third will improve visualization of the peroneal artery pedicle at the conclusion of the graft elevation. Although the entire proximal fibula may be harvested if articular surface or physis is required, 7 to 8 cm of the distal fibula should be preserved to prevent valgus instability of the ankle (see Figure 46.5, *I*). In children, a distal tibiofibular syndesmotic fusion is necessary with an iliac crest interposition graft and screws to prevent ankle instability (see Figure 46.6). Fusion is not necessary in adults.

After the interosseous membrane and bone are divided, the peroneal artery is identified at the distal osteotomy and ligated (see Figure 46.5, *J*). A long suture tag is left on the proximal stump to facilitate proximal dissection of the vessel. Dissection proceeds from distal to proximal. Viewing the fibula from a dorsal direction, the muscle of the tibialis posterior muscle is now exposed after division of the interosseous membrane. The tibialis posterior muscle and posterior fascia must be divided to expose the peroneal vessels (see Figure 46.5, *K*). The muscle is teased away carefully first, ligating muscular perforators as they are encountered. A tissue plane is identified just anterior to the ligated peroneal vessel. This is the posterior fascia of the tibialis posterior, which is next divided to expose the artery. The dissection must be meticulous to identify and ligate multiple muscular perforators and protect the underlying vessels.

At this point, only the vascular pedicle and the FHL muscle belly remain attached to the bone. The FHL tendon may be divided at this point if the muscle is to be included with the fibula as an osteomuscular flap. In most cases, it is not, and the FHL is carefully incised at its fibular origin, protecting the peroneal vessels at all times (see Figure 46.5, *L*). Additional perforators will frequently require ligation.

Finally, the peroneal pedicle is dissected as far proximally as possible. Separation of the artery and venae comitantes from each other is desirable at this time. At this point, they form the sole remaining attachment of the fibula (see Figure 46.5, *M*). The tourniquet is released, and the bone is allowed to perfuse while careful hemostasis is obtained in the leg. The artery and veins are ligated proximally and divided to detach the flap. Two suction drains are placed, one between FHL and the soleus, and another subcutaneously. The FHL is loosely repaired to the peroneal muscle with a running absorbable suture. The skin is closed in layers.

Fibula With Skin Flap. Osteocutaneous flaps are often advocated because the skin serves as a visible and immediate monitor of peroneal vascular patency. At times, the skin is needed to enable wound closure without tension and provide coverage for the underlying fibula and vascular reconstruction. Inclusion of skin is made possible by several fasciocutaneous perforators from the peroneal artery, which supplies the skin at intervals, particularly along the middle third of the bone. If a cutaneous flap is elevated with bone, the locations of the major fasciocutaneous perforators are identified with a Doppler ultrasound stethoscope prior to tourniquet elevation because their exact position and number vary considerably between individuals. They may be readily identified midlaterally by an audible pulse using the probe, near the soleus/peroneal junction (lateral intermuscular septum). Alternatively, the exact placement of the skin island can be determined by visualization of the vessels directly after the anterior incision is made. The dissection proceeds exactly as for a conventional fibular graft, except that the peroneus-soleus interval is left undisturbed in the middle and distal thirds until the peroneal vessels are exposed anteriorly (after fibular osteotomies, and division of the tibialis posterior). Isolation of the perforating vessels is performed by division of the posterior skin flap at this point, and their mobilization back to the peroneal vessels. To avoid problems with excessively tight skin closure and compartment syndrome, the donor site at the skin paddle area should be closed by a split-thickness skin graft, unless a very small buoy flap only is taken.

Fibula With Physis. Inclusion of the proximal growth plate to allow for growth of the transferred bone is a reasonable procedure when no other options exist. In a leg with normal vascular anatomy, current opinion favors the use of the anterior tibial vascular pedicle, which will support the fibular head and neck with a nutrient vessel supply, and a periosteal supply to the diaphysis. The technique of harvest is well described by Innocenti.[61] It is most used in the upper limb for restoration of growth following resection of the distal radius in children,[3,60] but is also useful with resection of the proximal humerus[92] or distal ulna.[3]

A longitudinal incision centered between the tibialis anterior and extensor digitorum longus is prolonged proximally,

following the biceps femoris muscle. Dissection in the intermuscular plane between these two muscles, starting distally, exposes the tibialis anterior neurovascular bundle and preserves the delicate network of periosteal vessels supplying the diaphysis. During proximal dissection, many motor branches of the peroneal nerve cross the operating field, and they must be carefully preserved.

The common peroneal nerve is identified and protected at the level of the fibular neck. The origins of the extensor digitorum longus and peroneal muscles are incised and reflected laterally and inferiorly 2 cm distal to the proximal fibular tip, leaving a muscular cuff surrounding the fibular epiphysis. Once the vessels are isolated, the fibular head is released by division of the biceps femoris tendon and iliotibial band attachments and release of the lateral collateral ligament and tibiofibular joint capsule. The anterior tibial vessels may be ligated at their origin to complete the harvest.

Fibula With Muscle. The fibula may be harvested with inclusion of the lateral portion of soleus and/or the flexor hallucis muscle. The FHL provides only enough muscle to cover the distal fibular segment. It is easily harvested by dividing its distal tendon rather than by separating the FHL from the fibula at its origin.

A larger muscle, sufficient to obliterate dead space or provide coverage, may be preferred. In this instance, use of the lateral portion of the soleus is appropriate. This is also easily accomplished by sparing the soleus muscular branch(es) visualized during exposure of the peroneal pedicle early in the dissection, as described previously. Once one or more of the muscular branches is identified and spared, the dissection proceeds unchanged until the end of the elevation, when the soleus is divided longitudinally in its midsubstance. The tibialis posterior artery and tibial nerve are carefully protected during this process.

Double-Barrel Flap. Strength can be improved particularly for femoral applications, or two segments can be separated sufficiently to allow simultaneous reconstruction of the radius and ulna, by use of a *double-barrel graft*. Following harvest, the free fibula graft is osteotomized at its midpoint, the surgeon having first gently elevated and separated the peroneal vessels from the bone at the osteotomy point. This produces two vascularized bone grafts that require only one set of anastomoses. This folded fibula provides twice the cross-sectional area of a single fibula transfer when placed in a single bone. For forearm use, resection of a short intercalary segment of fibula will increase the separation of the proximal and distal segments of bone without tension on the spanning vascular bundle for reconstruction of both forearm bones. An effort should be made to ensure that one of the segments is vascularized by both a periosteal and an endosteal blood supply including the nutrient vessel. In most cases, this will be the proximal segment; the distal segment will therefore be vascularized by periosteal vessels alone.

Fibular Graft Complications

Donor site complications are unusual and mostly transient. A review of 132 free fibular grafts from the Mayo Clinic demonstrated donor site problems in 10 patients (8%).[48] These included transient peroneal nerve palsy (in five patients), FHL contracture (in three patients), stress fracture of the ipsilateral tibia (in one patient), and compartment syndrome (in one patient). Closure after harvest of an osteocutaneous fibula should include use of a split-thickness skin graft to minimize the risk of compartment syndrome postoperatively.



Figure 46.6 Fusion of the distal tibiofibular interval prevents the development of valgus instability of the ankle in children.

In children, valgus deformity of the ankle may occur unless a distal tibiofibular fusion is performed proximal to the physis (Figure 46.6). No similar sequelae have been seen at the knee when the fibular head is harvested for articular surface or physis.

Donor site morbidity, studied by Youdas and Wood[155] at two time points postoperatively, manifested itself as minimal alterations in knee and ankle-foot motion with gait analysis at less than 10 months postoperatively. After 10 months, no significant gait abnormalities were discernible, although impaired strength of ankle inverters and everters persisted.

Iliac Crest Flap

Although widely used in past decades, the iliac crest flap has been less commonly used in recent years, particularly in the upper limb. This is due to the development of alternative sources of smaller bone grafts, such as the medial femoral condyle, and the preferential use of fibular flaps in long bone reconstruction. Additional factors are its curved shape and relatively weak material properties when compared with the fibula. The donor scar is well hidden, however, and it can include a very large cutaneous component, permitting simultaneous reconstruction of large soft tissue defects. Its principal advantages are its largely cancellous nature and the large amount of soft tissue that may be raised with bone as a combined osteomusculocutaneous flap. The advantages of the osteocutaneous groin flap include (1) its use in supplying vascularized bone to what is frequently a poor recipient bed for a bone graft, (2) its

use in reconstruction of both soft tissue and bony defects simultaneously, and (3) the fact that it can be used in facilities without the capability for microvascular surgery when used as a pedicle flap for the upper extremity. As such, it remains a valuable reconstructive option in selected circumstances. Smaller grafts may certainly be taken. Excellent clinical outcomes have been reported for reconstruction of both scaphoid nonunions and Kienböck disease, for example.[2,38]

ANATOMY

The iliac crest receives a dual blood supply from the superficial circumflex iliac artery (SCIA) and deep circumflex iliac artery (DCIA). Of the two, the DCIA system is most important.[117,137] Musculocutaneous perforators penetrating the abdominal wall 1 cm proximal to the iliac crest provide its nutrition. The skin paddle is less reliable than a standard groin flap, and its size, when based on the DCIA, is quite variable, ranging from 7 by 10 to 15 by 30 cm.[137] Enhanced skin survival may result from "supercharging" its blood supply using both SCIA and DCIA vessels. An osteomuscular flap may also be raised, including a portion of the adjacent internal oblique muscle or transversalis muscle based on the ascending branch of the DCIA.

The DCIA arises from the external iliac artery 1 cm proximal to the inguinal ligament. Several branches supply the internal oblique and iliacus muscles, as well as the lateral femoral circumflex vessels. The DCIA courses obliquely cephalad and laterally between extraperitoneal fat and the transversus muscle, until it reaches the anterior superior iliac spine. At this level, it pierces the transversus muscle to run between it and the internal oblique muscle along the inner lip of the iliac crest adjacent to the iliacus muscle. At its origin, the artery has a mean diameter of 2.78 mm, and the vena comitans, 3.6 mm.[57]

Although the entire crest may be harvested, the practical limit of length is 10 cm as a vascularized graft because of its curved shape. It is relatively less well suited for diaphyseal reconstruction than the fibula because remodeling for tolerance of weight bearing is prolonged. Further, osteosynthesis is difficult and weak.

Technique

The patient is positioned supine. The patient is draped to the midline anteriorly, costal margin proximally, and as far posteriorly as possible. The leg is draped free to facilitate hip flexion for wound closure. The skin flap is marked, its axis along the inner margin of the iliac crest, centered at a point 4 to 8 cm posterior to the anterior superior iliac spine (ASIS).[137] The pubic tubercle, ASIS, femoral pulse, and iliac crest are marked. The skin flap is incised along its medial margin, extending it medially along the inguinal ligament and obliquely inferiorly along the femoral pulse. Just proximal to the inguinal ligament, the external oblique is incised, exposing the inguinal canal contents. These are secured and retracted medially with an elastic cord. The floor of the canal (internal oblique and transversalis fascia) is incised to visualize the DCIA and accompanying veins. After identifying their origin, they are traced laterally toward the ASIS, and ligation of multiple small branches, as well as the large ascending branch, is performed. The lateral femoral cutaneous nerve is identified and spared if it lies below the vessels. It will occasionally pass superficially and must then be divided for later repair. The external and internal oblique and transversus muscles are sectioned 2 cm medial to the iliac crest insertion to preserve the skin blood supply. At this point, the vessels are not visualized. Finally, the lateral skin incision is made and the tensor fascia femoris and gluteal vessels are dissected extraperiosteally from the outer table of the ilium. The ilium is osteotomized and the pedicle divided to complete the harvest. Closure is important to prevent herniation, first approximating the transversalis to the iliacus fascia, and then the internal and external oblique to the gluteus and tensor fascia femoris. It may be necessary to attach the abdominal wall muscles to the bone via suture holes or bone anchors. Skin closure is facilitated by hip flexion.

Iliac Crest Complications

Complications related to the iliac crest include incisional hernias and partial loss of the cutaneous portion of the composite flaps. The surgical approach to the vascular pedicle is through the inguinal canal; this approach raises the risk of an abdominal hernia.

Results: Large Segmental Bone Loss

Fibula Donor Results

The authors' review of 478 vascularized fibular grafts performed for all indications demonstrated the rate of primary union healing (without secondary bone grafting) to be 68%, with ultimate healing after supplemental bone grafting to occur in 82% of cases.* Healing, as well as hypertrophy, depends on a number of variables, including patient age, weight-bearing location, type of graft used, method of fixation, and vascular status of the graft. Hypertrophy, when it occurs, is seen by an average of 13.5 months postoperatively.[24] It occurs primarily in young individuals (age < 20 years) and is more common in the lower extremity when stresses of weight bearing are not shielded by rigid fixation spanning the fibular graft (Figure 46.7, *A* to *C*). Fibulas are more likely to hypertrophy than other grafts. Improving the biomechanics of the reconstruction will improve results. Options include simultaneous use of a size-matched cryopreserved structural allograft with either an onlay or an intramedullary fibula[34,103,112] or internal fixation spanning the entire reconstruction (plate or intramedullary rod).

Iliac Crest Donor Results

Vascularized iliac crest grafting is subject to higher rates of complications with lower overall success when compared with the fibula.[42,115,118,119,127,150] A summary of 97 flaps in the six reports cited reveals an average time to union of 7 months, with prolonged protected weight bearing (mean, 18 months). The overall frank failure rate was somewhat higher than with fibular grafts, with eventual union in 67% (38% requiring secondary bone grafting). Most authors are dissatisfied with the skin flap, noting a frequent tendency for necrosis of a part or all of the soft tissue.[5] Suggested solutions include use of an osteomuscular flap without skin, with inclusion of the internal oblique muscle, or improving skin perfusion with a double pedicle of both the DCIA and SCIA.[115] Revision of the anastomosis is more commonly required than for fibular grafts.

*See references 1, 15, 16, 26, 37, 43, 47, 49, 69, 70, 85, 95, 97, 100, 104, 105, 108, 126, 127, 130, 133, 138, 141, 142, 144.

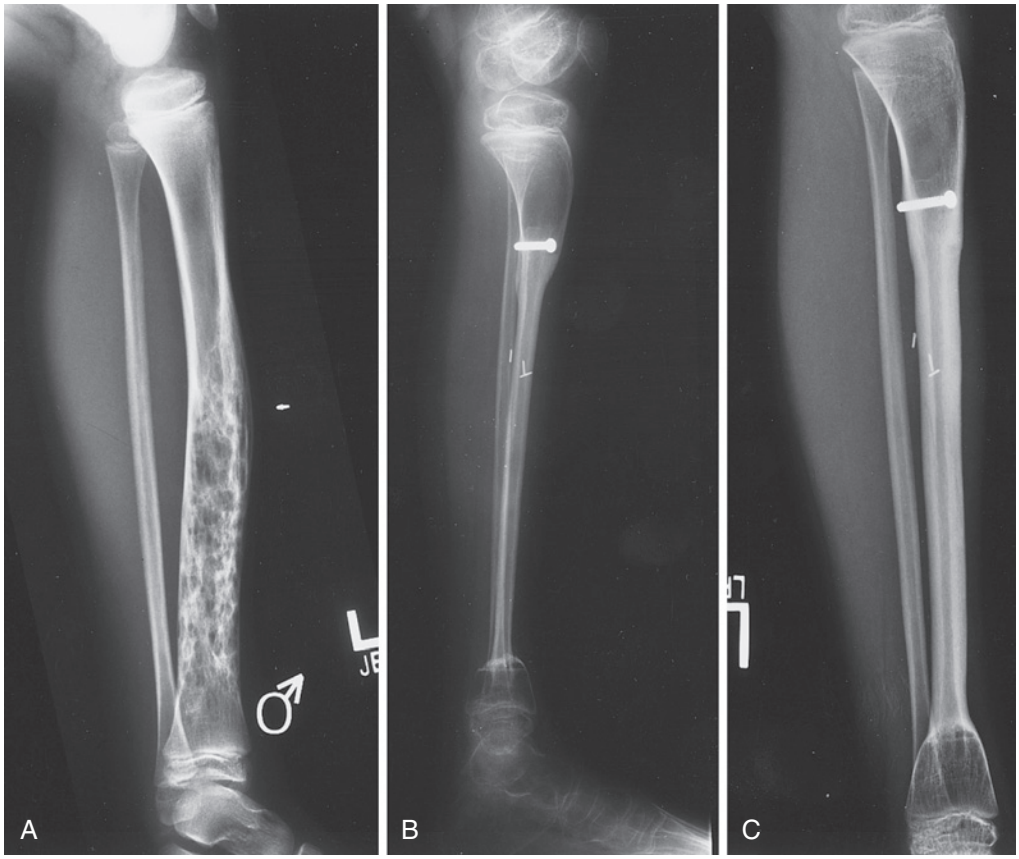

Figure 46.7 Resection of an adamantinoma of the tibia in an 8-year-old boy. **A,** Postoperative lateral radiograph. **B,** Successful union was seen at 4 months postoperatively. **C,** Hypertrophy of the vascularized fibular graft is obvious in this view taken 23 months following operation.

Fibular and Iliac Crest Grafts in the Upper Extremity

A review of fibula and iliac crest grafts for large upper extremity defects in 21 cases included graft placement in the humerus in 11 patients, radius in 5 patients, ulna in 3 patients, and clavicle in 2 patients.[148] Overall, primary bone union occurred in 15 patients (71.4%), and eventual union was achieved in 17 patients (81%). The most favorable results were achieved in cases of forearm bone reconstruction (100% union). Clavicle nonunions and shoulder fusions with vascularized bone carry a worse prognosis. Failure to correct deformed clavicular nonunions may result in brachial plexus compression as well as shoulder girdle weakness and pain. The use of the medial femoral condylar corticoperiosteal graft, combined with conventional graft and internal fixation, provides superior results for difficult clavicle nonunions (see Figure 46.11, *D*).[36] Results for shoulder fusion can be improved with improved stability using allograft proximal humerus/fibula composite grafts with rigid internal fixation (Figure 46.8),[112] although satisfactory results with the fibula alone have also been reported. Segmental loss of the humerus requires careful technique and planning to avoid prolonged healing and stress fracture. Use of a bridging plate and/or frozen allograft structural segment in addition to the fibula is to be recommended (Figure 46.9). In the forearm, radius reconstruction for sarcoma or aggressive benign tumors has provided acceptable healing and function. The average time

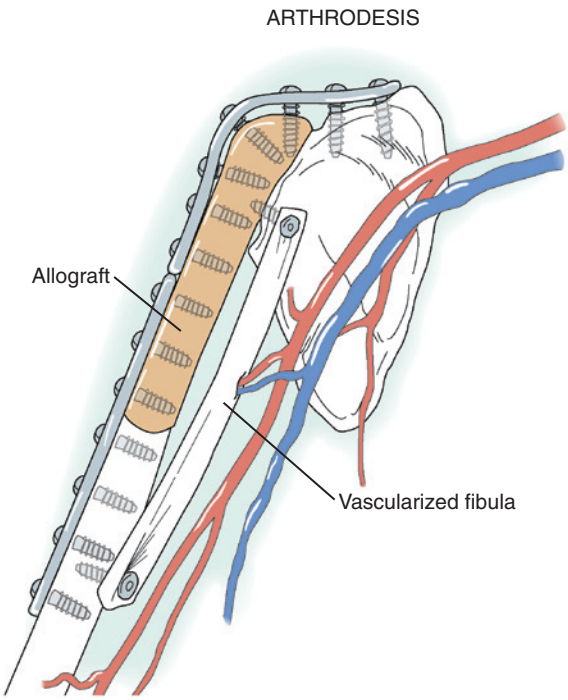

Figure 46.8 Arthrodesis of the shoulder using frozen allograft, vascularized fibular strut, and internal fixation.



Figure 46.9 Vascularized fibula as intercalary graft following tumor resection in humeral diaphysis. A spanning plate minimizes risks of nonunion and fibular stress fracture.

to union for all locations is approximately 6 months, without significant difference based on anatomic location.[48]

Results by Diagnosis

The results of reconstruction of large defects with vascularized bone grafting differ significantly by diagnosis. A history of infection had the least favorable results overall. In a large series of 160 vascularized grafts, defects with infection had a primary union rate of 49% and an overall union rate of 77%. Reconstructions when no infection was present had a primary union rate of 69%, with 84% ultimate success after a secondary graft.[48]

Grafting for Defects Caused by Tumor Excision. Vascularized grafts are useful in limb salvage surgery of aggressive upper extremity tumors, including benign lesions such as giant cell tumor and aneurysmal bone cyst as well as primary bone malignant tumors (Figure 46.10, *A* to *C*). Many patients will receive preoperative and postoperative chemotherapy and/or radiotherapy, with their associated morbidities. Postoperative chemotherapy or radiotherapy increases the incidence of stress fracture and delays healing in experimental models, although most clinical cases eventually heal, often without surgery. Han reported successful union in 81% of 69 tumor patients in 1992,[48] and even more favorable results are seen in more recent studies.[19]

There is also a proven role for fibular grafts in correcting nonunion at the host-allograft junction following tumor reconstruction with conventional frozen allograft diaphyseal segments. A review of 33 patients treated with fibular onlay graft

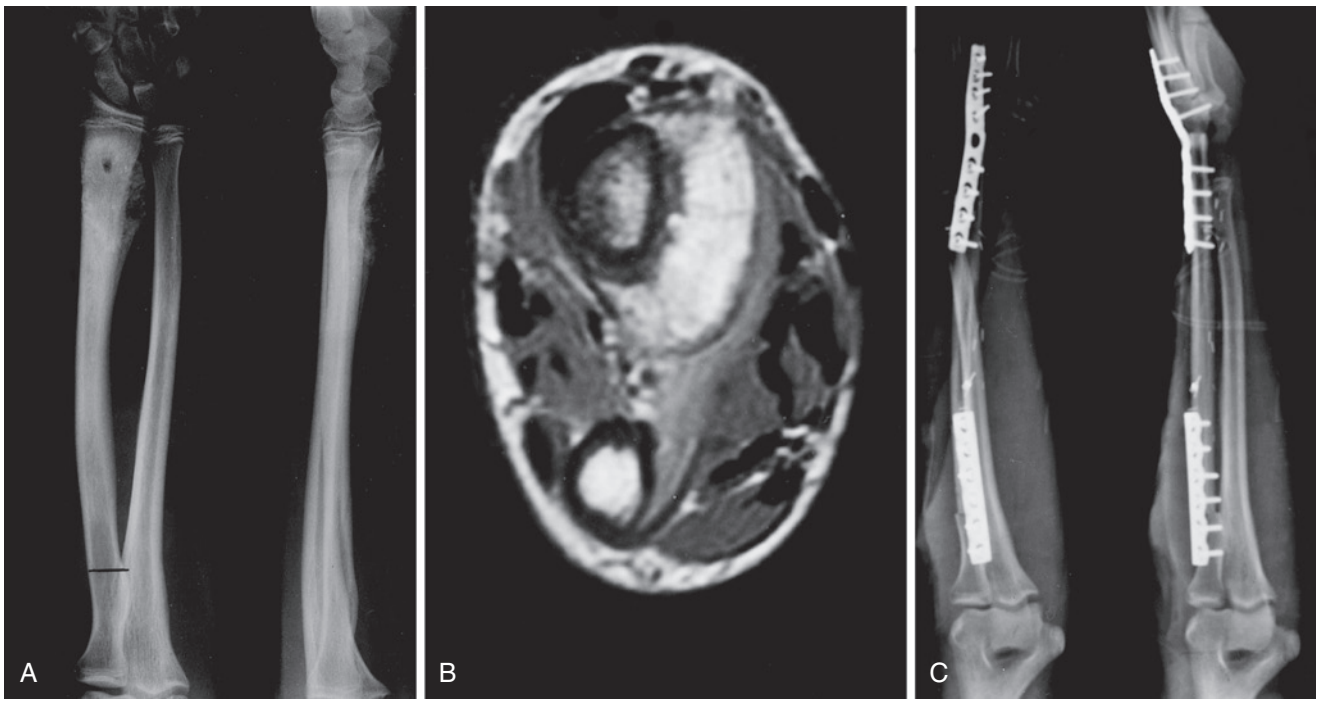

Figure 46.10 Osteogenic sarcoma of the distal radius, with diaphyseal medullary extension in a 14-year-old boy. **A,** Preoperative radiographs. **B,** Preoperative magnetic resonance imaging demonstrating a large soft tissue extension on the palmar surface of the radius. **C,** Immediate postoperative radiographs. Most of the radius has been excised and reconstructed with a vascularized free fibular graft, including a wrist arthrodesis distally.

salvage of allograft reconstruction failures resulted in successful salvage in 23, with 7 failures resulting in 5 amputations.[35] Pathologic fracture due to tumor invasion is also effectively treated by fibular flaps.[35]

Radiation necrosis of bone is a not-infrequent complication of radiotherapy for soft tissue and bone malignant tumors. This is a progressive fibrotic problem, which requires efforts to improve local blood flow. Fractures occur years later (mean, 111 months in one study[31]). Spanning the area of necrosis and fracture with vascularized onlay bone grafts provided healing in 16 of 18 cases in this series.

Grafting in Cases of Infection. The results are less satisfactory for patients who had had the reconstruction for bone loss due to osteomyelitis.[48] Experience with infected pseudarthrosis with segmental osseous defect, treated by débridement and microvascular bone transfer, has demonstrated an increased potential for a number of complications. These include recurrent infection, occasionally leading to amputation,[5] and nonunion. It is critical that vascularized bone transfer be delayed until sepsis is inactive. Criteria used for determining inactive sepsis include absence of sinus tracts, negative bacterial cultures, negative C-reactive protein levels, and a sedimentation rate of less than 15 mm/hour, maintained for at least 1 month following the last clinical evidence of infection.[96] Recurrent infection was seen after vascularized bone grafting in 16% of osteomyelitis patients in the large Mayo Clinic series.[48]

In the forearm, infected nonunions may not respond to conventional treatment. Dell reported success with the use of vascularized fibular grafts and conversion to a one-bone forearm after failure of as many as six procedures.[26] The fibula was fixed to the ulna proximally and the radius distally with internal fixation, and this was supplemented with an external fixator in three of the four patients. All wounds healed and all bone junctures healed, with one requiring supplemental cancellous grafting.

Grafting Following Trauma. The prognosis is better for traumatic nonunion without infection. Union rates are typically greater than 90% when patients requiring supplemental grafting are included.[48] Although some have reported poorer union rates for trauma than for tumor indications, trauma cases had the highest union rate overall in Han's series (primary union, 76%; overall, 92%).[48] Residual limb shortening and other problems are common, occurring more frequently in patients with scarred and relatively avascular soft tissues surrounding the long bone defects.

Grafting for Congenital Pseudarthrosis of the Forearm. The use of vascularized grafts for congenital tibial pseudarthrosis has been shown to be demonstrably superior to conventional methods, including bone graft, electrical stimulation, corticoperiosteal graft, or osteotomy of the involved bone.[98,108,142,144] Vascularized grafts have been used successfully in pseudarthrosis of the forearm as well. In the forearm, creation of a one-bone forearm may be reasonable, especially if conventional bone grafting has failed. Wide resection of associated neurofibromatosis is required. With this initial resection and a vascularized graft, good results may be anticipated.

Grafting for Epiphyseal Transfer and Growth. The superiority of vascularized growth plate transfer over nonvascularized transfer for physeal replacement has been well documented in experimental models.[7,10,154] Clinically, nearly normal longitudinal growth following digit replantation or toe transfer in children has been well documented.[73] The application of epiphyseal transfers to problems such as radial club hand and physeal arrest of long bones is currently showing substantial promise. Long-term longitudinal growth has been seen in 12 children with proximal humerus or distal radius epiphyseal reconstruction using the fibula, averaging more than 1 cm/year.

VASCULARIZED GRAFTS: SMALL BONE AND PERIOSTEAL FLAPS

Indications for Grafting in the Carpus

Grafting for Fracture of the Scaphoid

The scaphoid is the most frequently fractured carpal bone. With prompt appropriate diagnosis and treatment, over 90% will unite. Unfortunately, failure to diagnose acute injury or to surgically treat displaced scaphoid fractures increases the risk of nonunion substantially. The development of scaphoid foreshortening and associated carpal instability with elapsed time contributes to the risk of nonunion. In addition, the fracture may disrupt the proximal pole blood supply, particularly in proximal third fractures, resulting in avascular necrosis of the proximal fragment.

Many scaphoid fractures that fail to heal with inlay or wedge conventional grafts have impaired vascularity as a contributing factor, as demonstrated by sclerosis of the proximal pole on x-ray and MRI studies and absence of punctate bleeding at the time of surgery.[45] The risk is further increased in smokers. The use of conventional grafts, such as the Matti-Russe volar inlay graft, may be contraindicated in the presence of an avascular fragment.[45]

Vascularized bone grafts have been proposed as appropriate methods to increase the rate and frequency of healing in fractures with a poor prognosis. As early as 1965, Roy-Camille used the palmar tubercle of the scaphoid based on an abductor pollicis brevis muscle pedicle for this problem.[113] In recent years, palmar distal radius grafts,[77,87] dorsal radius grafts,[123,157] second metacarpal base grafts,[120] free medial femoral condylar grafts,[29,66] and free iliac grafts[106] have demonstrated improved results as compared with conventional grafts in difficult circumstances. These include displaced acute fractures with small proximal fragments or bone deficiency requiring grafting, failed conventional grafts, and nonunions associated with avascular necrosis.[124,131] Alternatively, inlay or wedge bone grafting coupled with vascular bundle implantation may be considered.[33,66] Vascularized grafts are also indicated in avascular necrosis of the entire scaphoid, prior to bone collapse and fragmentation.[102]

Grafting for Kienböck Disease

Treatment of Kienböck's disease remains controversial, with a large number of treatment options available. These include mechanical unloading and revascularization procedures. Examples of the former include joint leveling, angular radius osteotomy, capitate shortening and intercarpal fusions. Arteriovenous pedicles,[56,151] and vascularized bone grafts[6,101] are examples of the latter. In addition, salvage procedures for advanced changes with arthrosis may be necessary, including proximal row carpectomy or complete wrist arthrodesis.

Experimental studies have demonstrated the ability of vascularized bone grafts to revascularize ischemic bone.[139,140] The main function of the procedure appears to be the provision of vessels into avascular bone. The use of vascularized bone to both revascularize necrotic lunate cancellous bone and, if necessary, restore its dimensions once collapse begins is an attractive alternative to joint leveling and other load-altering options.

Medial Femoral Condyle Grafts

The medial femoral condyle flap was described originally as a corticoperiosteal flap for local use.[52] Its potential as a free corticoperiosteal flap was soon demonstrated and applied to upper limb defects.[30,36] Periosteal flaps in general have been demonstrated experimentally to produce predictable new bone formation, and a variety of other donor sites have been identified, including the clavicle, fibula, ilium, humerus, and tibia. In the upper extremity, thin corticoperiosteal grafts and small periosteal bone grafts harvested from the supracondylar region of the femur have proven to be of great use, based on either the descending genicular or medial superior genicular vessels (Figure 46.11, *A*). This graft is elastic and readily conforms to small tubular bones. Originally described as a pedicle flap, it has been successfully used as a free tissue transfer for clavicular, humeral, and forearm applications, including pathologic fractures from radiation necrosis and other recalcitrant nonunions.[30,36]

This versatile graft may also be harvested as a vascularized bone graft[28,29,66] and as an osteoarticular flap with bone and patellar facet cartilage for resurfacing of small damaged joints.[11,55] The ability to include substantial skin further enhances its versatility. At present, its value has been well demonstrated as a periosteal flap to induce healing in ununited fractures in the clavicle, humerus, and forearm without large gaps, and has been used similarly at allograft junction nonunions.[30,36,71] As a bone-only flap, it has been most widely used in scaphoid nonunion, but it has been applied to treat talus avascular necrosis and small defects in the metacarpals.[116,147] It is certain that the indications for this versatile flap will broaden in the near future.

ANATOMY OF THE MEDIAL FEMORAL CONDYLE

Corticoperiosteal, bone, and osteocartilaginous flaps with or without an accompanying skin island may be obtained from the medial femoral condylar and supracondylar region in a rather straightforward manner.[30] In most knees, a dual blood supply is demonstrable, including the descending genicular vessels and the medial superior genicular vessels. A segment of vascularized distal femoral metaphyseal bone 6 to 8 cm in length may be harvested from the medial femoral condyle for use in smaller

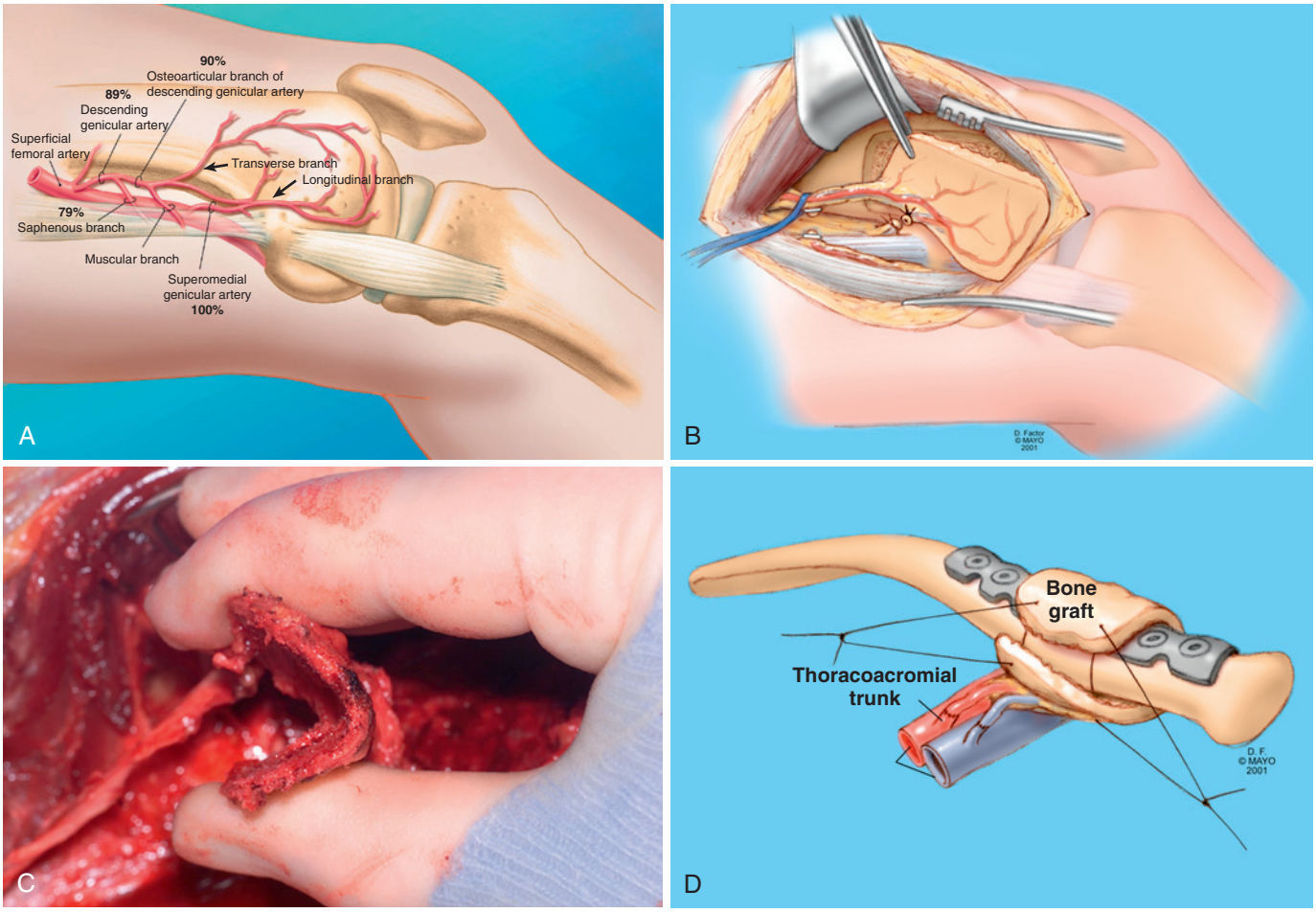

Figure 46.11 Corticoperiosteal flap (medial femoral condyle). **A,** The blood supply of the medial femoral condyle is provided by both the descending and superior medial genicular vessels. **B,** The corticoperiosteal flap elevated from medial femoral condyle. **C,** The flap is sufficiently flexible to wrap around small tubular bones. **D,** Flap wrapped around clavicle with vascular connections to thoracoacromial trunk.

defects, as well as corticoperiosteal flaps generally measuring 5 by 7 cm (see Figure 46.11, *C*).

As originally described,[52] the vascular supply to the surface of the distal medial femoral metaphysis is provided by two vessels in most individuals. Since the anatomy of the region was originally described, further details have been added. The two arteries supplying the medial distal femur are the descending genicular vessel, present in 89% of 20 adult knee specimens in a recent study,[152] and the superomedial genicular vessel, which is constantly present (see Figure 46.11, *A*).[81] The descending genicular vessel arises from the superficial femoral artery and vein proximal to the adductor hiatus at a mean distance of 13.7 mm proximal to the joint line (see Figure 46.11, *B*). The artery has a mean diameter of 1.5 mm and is the dominant vessel in 89% of the specimens studied by Yamamoto and colleagues.[152] When absent or small in size, the medial superior genicular vessel is invariably of sufficient size and length to serve as the vascular supply for an MFC flap.

The descending genicular vessels separate into osteoarticular and saphenous branches at an average distance of 11 cm proximal to the femorotibial joint. The osteoarticular branch supplies several small branches to the posterior border of the vastus medialis, which lies immediately anterior to it in the distal thigh. It is joined by the medial superior genicular vessel just proximal to the posterior aspect of the medial femoral condyle to supply the periosteum and bone of the medial distal femoral metaphysis. Together they form a nearly circular pattern of vessels lying on the bone just proximal to the knee joint capsule and medial collateral ligament origin. They form a nearly circular pattern on the surface of the medial femoral metaphysis. These osteoarticular vessels supplied an average of 30 perforators into the bone, with the largest number located in the distal posterior quadrant of the condylar surface (Figure 46.12, *A*).[152] They penetrated the cancellous bone to an average depth of 13 mm, supporting the use of the MFC as an ideal periosteal and bone flap. The branching pattern of the conjoined medial and descending genicular vessels was further described by Hugon and associates.[58] It separates into two main branches: an upper transverse branch and a central longitudinal artery. The former runs anteriorly to the patellar facet, and the latter toward the tibial joint line. The vessels are connected by an arcuate anastomotic vessel forming the previously described circular appearance easily seen on first inspection of the bone surface. The longitudinal vessel is used for harvest of vascularized bone, and the upper transverse vessel is required if an osteoarticular graft including patellar facet cartilage is to be used.

The safe dimensions of bone that may be harvested depend primarily on the location of the metaphyseal/diaphyseal junction. It is imperative that the bone graft not extend beyond the thin metaphyseal bone if weakening of the femur and potential disastrous femoral fracture is to be avoided. This complication is rare but has occurred when an overzealous graft is taken. This is due to the open-section effect that markedly weakens tubular diaphyseal bone when resected at this level. Thus, even though some proximal perforators may be identified as much as 13 cm proximal to the joint line,[62] no attempt should be made to harvest bone at this level. It is unlikely that grafts longer than 6 to 7 cm may be safely taken, based on the authors' experience, but the length most importantly should be based on preoperative or fluoroscopic findings at surgery, so as to not violate the

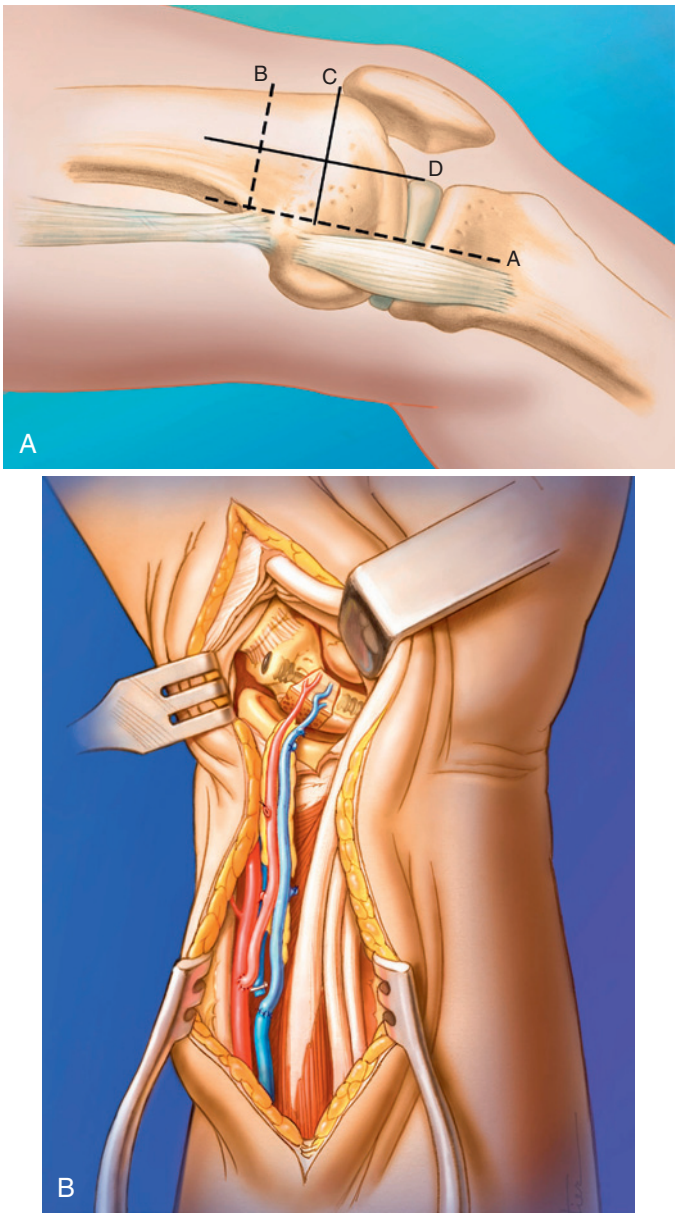

Figure 46.12 Use of a free vascularized wedge graft from the medial femoral condyle to treat a scaphoid nonunion. **A,** Borders of the medial femoral graft. The site is defined posteriorly by the hamstring and medial collateral ligament insertions *(A),* proximally by the insertion of the hamstring *(B),* distally by the proximal pole of the patella *(C),* and anteriorly by the anterior horn of the medial meniscus *(D).* The preferred site for graft harvest is from the distal posterior quadrant. **B,** The graft is placed from a Russe approach as a wedge graft to restore scaphoid length and is fixed with a scaphoid screw. Vascular connections are an end-to-side anastomosis to the radial artery in the forearm and an end-to-end venous anastomosis to a vena comitans or cephalic vein.

robust proximal diaphyseal cortex. No complications were seen in 10 patients who had undergone medial femoral condyle free flap procedures and were followed more than a year postoperatively with CT scans.[110] The average bone harvested per procedure was 16.1 cm^3 (range, 2 to 34 cm^3), representing an average condylar volume of 9% (range, 1% to 18%). The depth of the graft ranged from 4 to 6 mm in this study, and the longest graft harvested measured 7 cm in length. We have routinely used grafts as deep as 15 mm without problems when the other dimensions are similar or smaller. Because only minimal bone

regeneration was seen in Rao's study, one cannot expect the defect to fill in spontaneously. We routinely fill the MFC bone flap harvest site with bone substitute to facilitate remodeling for this reason.[110]

Inclusion of a skin island is advocated by some for monitoring flap viability and can also be used for soft tissue cover if needed. Use of the saphenous branch will require a long proximal pedicle if it is to be included with the descending genicular vessel because it arises approximately 2 cm distal to the descending genicular artery origin.[152] An additional distinct, reliable, further distal, descending genicular cutaneous branch can be found at condyle level, capable of supporting skin, as well.[63] This vessel provides an average perfusion area of 70 cm^2 centered over the medial knee. The saphenous artery branch was reported to support an average perfusion area of 361 cm^2 along the medial aspect of the distal thigh and proximal leg. Perforators may be identified by direct visualization at the time of flap exposure.

Inclusion of patellar facet cartilage is desirable when reconstructing damaged or missing joint surfaces, most commonly in fragmented small proximal scaphoid pole fractures and the proximal (radial) articular surface of the lunate in Kienböck disease. The bone is harvested from the medial trochlea, ideally slightly distal to the most proximal cartilage border.[58] This area has little or no patellar contact, but serves as a pulley for the medial aspect of the quadriceps tendon during knee flexion. Harvest of bone no larger than 7 to 8 mm in lateral/medial width and 10 to 12 mm in proximal/distal length has been recommended, based on limited data.[58]

Surgical Technique

Flap Exposure and Pedicle Dissection. The patient is positioned supine on the operating table. A sandbag taped to the table distal to the foot allows the knee to rest in 90 degrees of flexion. The limb is elevated but not exsanguinated prior to tourniquet elevation to more easily visualize the periosteal vessels. Once the tourniquet is elevated, the surgical approach for any of the medial femoral condyle flap variants (bone, corticoperiosteal, or osteochondral) is made along the posterior border of the vastus medialis muscle. The skin incision may be longitudinal for bone-only flaps, but may best curve in a convex-posterior direction for osteochondral flap harvest or to more safely identify skin perforators if a buoy flap is to be included. This incision is thus directed from posterior/proximal at the Hunter canal toward the medial border of the patella and again posteriorly to the joint line. The proximal border of the skin incision will overlie the adductor magnus and sartorius in the distal medial thigh.[66,81] By retracting the vastus medialis anteriorly and the sartorius muscle posteriorly, the descending genicular vessels and superomedial genicular vessels are visualized in the floor of the vastus compartment and behind the proximal medial condyle, respectively. They are generally closely applied to the vastus muscle to several muscular perforators that must be ligated and divided. As the vessels approach the femoral metaphysis, they follow its contour to lie more superficially, requiring attention of the surgeon in this area. At this level, they are joined by the medial superior genicular vessels, which follow the posterior surface of the femur toward their popliteal origin. They must be visualized and assessed for their diameter relative to the descending genicular pedicle. In 10% of cases, they will be larger and likely a superior pedicle. They are best found just anterior to the adductor longus tendon, by incising the thin fascial layer at its anterior surface to expose the posterior surface of the distal femur. A distal-first approach is often to be preferred, initially exposing the medial femoral metaphysis and the superficial and prominent periosteal vessels. This is easily done by following and mobilizing the posterior border of the quadriceps musculotendinous junction. Once the quadriceps tendon and distal vastus medialis muscle are mobilized and retracted anteriorly, the face of the medial femoral condyle is immediately exposed and the periosteal vessels identified, forming a robust, arching arcade on the surface of the medial femoral condyle (see Figure 46.11, *A*). A natural plane of dissection lies immediately superficial to the vessels, allowing their rapid more proximal exposure. As described previously, both the medial superior and descending genicular branches must be identified at the proximal condyle and a decision made regarding selection of the best vessels for microvascular anastomoses. Cutaneous branches are sought if a buoy flap is to be used, and muscular branches of the descending genicular ligated. It may be followed proximally to its superficial femoral origin some 13 cm above the joint line to maximize vessel diameter or to include a saphenous branch–based skin island. Shorter pedicles may be used with pedicle vessels of a smaller diameter. Similarly, the medial superior vessels may be followed toward the popliteal vessels with somewhat greater difficulty. Multiple bone and muscular branches will be encountered and require ligation. During this exposure process, the vessels are bathed with papaverine or other vasodilators. Care is taken to maintain the patient's core temperature to help minimize intraoperative vasospasm.

Medial Femoral Condyle Corticoperiosteal Flap Harvest. With the pedicles mobilized and the medial femoral condyle exposed, a corticoperiosteal graft is outlined to include the large arcuate vessels that follow the margins of the condyle. Distally and posteriorly, care must be taken to avoid injury of the medial collateral ligament. The superior margin is the reflection of the knee joint capsule at the medial patellar facet. Proximally, the change in cortical thickness at the diaphyseal-metaphyseal margin limits elevation. The periosteum, together with fragments of the underlying outer cortex, is elevated with the accompanying vessels, with a dimension of generally no more than 5 by 7 cm (see Figure 46.11, *C*). This is done by incising the margins and using a small osteotome to alternately cut, then pry, the periosteum from the underlying femur. Note that one should include fragments of the underlying thin cortex. Once elevated, the corticoperiosteal graft should be pliable (see Figure 46.11, *D*), enabling it to be wrapped around the small-diameter diaphysis of the clavicle, radius, or ulna, or to conform to the shape of a larger bone. Once elevated, the pedicle previously dissected as described above is ligated and divided.

At the recipient site, the corticoperiosteal flap may be wrapped around the nonunion site of the clavicle, radius, or ulna and secured with heavy nonabsorbable suture (see Figure 46.11, *D*). When applied as a patch over larger bones, suture anchors are a typical alternative. Microvascular anastomoses are performed to adjacent vessels. An end-to-end anastomosis of both vessels to the thoracoacromial trunk vessels is preferred for the clavicle, and end-to-side arterial anastomoses to the radial or ulnar artery in the forearm. Vessel patency and a bleeding flap surface confirm a successful transfer. A skin buoy flap

can be transferred for continuous monitoring if desired as described previously.

Medial Femoral Condyle Vascularized Bone Graft Harvest. Harvest of the MFC graft should be from the same side as the upper limb recipient, unless there is a compelling reason not to do so. This is potentially important because any donor site discomfort requiring support with a cane or crutch requires use of the opposite hand. Although significant temporary pain is uncommon, it is impossible to predict whether it will occur prior to surgery. With the pedicles mobilized and the medial femoral condyle exposed, the bone graft site is determined by visual inspection of the condyle. For scaphoid nonunions with a humpback deformity, the graft dimensions are generally 10 to 12 mm in proximal and distal length, and 10 mm in anterior and posterior width and depth. As described previously, the optimal location for the graft is the distal posterior quadrant of the condyle (see Figure 46.12, *A*). The graft is outlined in this area centered over the longitudinal branch of the conjoined medial genicular vessels. It is necessary to free the longitudinal branch proximal to the flap from the underlying periosteum. We prefer to do this using a microbipolar cautery and a small scalpel blade, elevating the pedicle by dissection 1 to 2 mm to either side of the vessels and gently dissecting beneath them with the aid of a small-diameter vessel loop. Multiple small periosteal vessels can be seen and dealt with in this fashion with the microbipolar cautery at a distance far enough from the pedicle so as not to endanger it. Once the pedicle is entirely freed to the desired position of the bone graft, the graft is outlined to the desired depth with a microsagittal saw along all four borders. Next, a small wedge of bone is removed to one side of the flap (Figure 46.13). This allows access to the deep surface of the graft with a small osteotome. It is used with a prying motion to complete the elevation of the graft from below. Attempts to free the graft in any other way risk fracture and separation of the cortex from the underlying cancellous bone. The excavated cavity may be filled with a bone substitute if desired prior to layered wound closure. Note that the graft must not extend into the thick cortex at the diaphyseal/metaphyseal junction. Such extension risks the possibility of a femoral fracture. Generally, the maximal length obtainable is no more than 6 to 7 cm. The graft is placed into the scaphoid as an interposition graft through a volar (Russe) incision in the floor of the flexor carpi radialis tendon sheath and is fixed with a cannulated scaphoid screw. Vascular repairs are end to side to the radial artery and end to end to a vena comitans (see Figure 46.12, *B*).

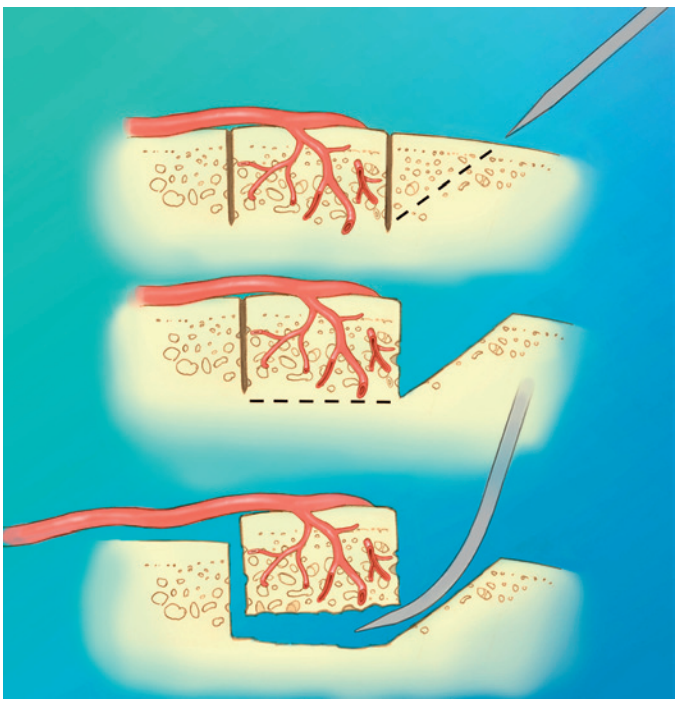

Figure 46.13 Technique of medial femoral condyle bone graft elevation. Removal of a small wedge of bone adjacent to the bone flap permits its elevation without risk of fracture or separation of the cortical from the cancellous bone. (By permission of Mayo Foundation for Medical Education and Research. All rights reserved.)

Medial Femoral Condyle Osteochondral Graft Harvest. As stated previously, the common genicular artery and venae comitantes divide into two major periosteal vascular branches at the level of the condylar flare. The transverse branch courses 90 degrees anteriorly from the main pedicle and its longitudinal branch continuation. The transverse branch is directed toward the medial trochlea. It is followed to the proximal knee capsule, which is opened to visualize the trochlea and clearly see the multiple nutrient branches supplying bone and cartilage in this region. Their position marks the target area for harvest. A margin of bone and periosteum bordering the articular cartilage that includes these nutrient branches must be included with the flap. Before the graft is elevated, however, the transverse branch vessels proximal to the graft are mobilized to the proximal condyle as described for MFC bone graft harvest, completing the pedicle exposure. The pedicle vessels are bathed in papaverine or another vasodilator thereafter. In elevating the graft, it is important to minimize its dimensions because of potential donor site morbidity. Some form of preoperative or intraoperative modeling is helpful in this regard. One method described by Burger is the intraoperative molding of methyl methacrylate to the donor site defect.[11] A maximal suggested size is 8 by 12 mm.[58] Either small, sharp osteotomes or a microsagittal saw is used to elevate the bone.

Medial Femoral Condyle Graft Aftercare

All patients will experience discomfort at the donor site postoperatively. In the case of bone and corticoperiosteal flaps, the discomfort is caused primarily by motion of the soft tissues over the extraarticular area of the bone graft harvest. Weight bearing is not painful, but knee flexion and extension may be uncomfortable for up to 6 weeks. Patients begin immediate weight bearing without restrictions on the same day as surgery, although a knee immobilizer is provided for intermittent use at the patient's discretion. The patient is instructed in knee flexion and extension exercises and advised to increase activity as discomfort permits, without specific restrictions.

Donor Site Complications

All clinical reports in the literature to date describe donor site complications to be few and transient. All patients will have medial distal thigh discomfort as described previously. Suture intolerance, seroma, and numbness in the saphenous territory are occasionally seen and have been reported to be transient.[111] The saphenous nerve is vulnerable to injury and must be protected. Only a handful of osteochondral grafts have been

reported in the literature. Although there is certainly potential for patellofemoral problems, care regarding size and location of the graft should make this an uncommon problem. No published reports of femoral fracture have been published, and CT analysis of donor site morphologic characteristics postoperatively has failed to demonstrate any bony concerns.[110] Unpublished cases of femoral fracture have occurred, however, and remain a significant risk if graft harvest extends into the metaphyseal/diaphyseal junction. Safe dimensions of metaphyseal-only bone harvest are as yet not firmly established. Prudence is recommended. Rao found a graft volume of 16.1 cm^3 (range, 2 to 34 cm^3), representing an average condylar volume of 9% (range, 1% to 18%), to be safe.[110]

Radius Pedicle Grafts

Pedicled bone grafts from both the palmar and dorsal radius are widely used for treatment of carpal avascular necrosis and nonunion. These grafts are relatively easily harvested through the same operative field used for carpal exposure, based on arteriovenous pedicles whose position relative to anatomic landmarks (extensor retinaculum and dorsal compartments dorsally, and pronator quadratus palmarly) is constant.

Dorsal Radius Grafts

The blood supply to the distal dorsal radius is robust and constant, provided by a series of longitudinal vessels originating from the radial artery or anterior interosseous vessels that demonstrate consistent spatial relationships to surrounding anatomic landmarks and distal anastomotic vascular connections. The anatomy of the extraosseous and interosseous vascular supply of the distal radius has been described in some detail, including the design of several reverse-flow pedicle grafts applicable to the carpus.[123] Their location allows vascularized bone grafting for Kienböck disease or scaphoid nonunion with minimal if any additional morbidity. Blood flow is provided by a reverse-flow mechanism in both the artery and the venae comitantes (analogous to the radial forearm flap), with demonstrable preservation of flow possible by inclusion of cutaneous islands whether based on the radial artery or posterior division of the anterior interosseous artery. Experimental studies in the canine distal radius have demonstrated that similar reverse-flow pedicle bone grafts have measurable flow immediately after elevation, and marked hyperemia when reevaluated 2 weeks later.[139,140]

DORSAL RADIUS ANATOMY

Four extraosseous vessels contribute nutrient vessels to the distal radius and ulna. They demonstrate consistent spatial relationships to surrounding anatomic landmarks, and supply bone with predictable groups of nutrient arteries (Figure 46.14, *A*). The anterior interosseous artery divides into anterior and posterior divisions proximal to the distal radioulnar joint. The posterior divisions, together with the radial artery, are the primary sources of orthograde blood flow to the dorsal distal radius. The vessels also supply nutrition to soft tissues, making possible fabrication of composite pedicle flaps that include the posterior interosseous nerve, skin, and muscle.[157]

The four vessels supplying nutrient arteries to the dorsal radius are best described by their relationships to the extensor compartments of the wrist and the extensor retinaculum. Two of the vessels are superficial in location, lying on the dorsal surface of the extensor retinaculum between the first and second, and second and third dorsal compartments. At these locations, the retinaculum is adherent to an underlying bony tubercle separating the respective compartments, allowing nutrient vessels to penetrate bone. Because of the location of these arteries, they have been named the 1,2 and 2,3 intercompartmental supraretinacular arteries (1,2 and 2,3 ICSRAs) (see Figure 46.14, *A*).[123]

Two deep vessels also provide nutrient vessels to the dorsal distal radius. They lie on the surface of the radius within the fourth and fifth dorsal compartments. They are consequently named the fourth and fifth extensor compartment arteries (see Figure 46.14).[123]

1,2 Intercompartmental Supraretinacular Artery. The 1,2 ICSRA originates from the radial artery approximately 5 cm proximal to the radiocarpal joint, passing beneath the brachioradialis muscle and tendon to lie on the dorsal surface of the extensor retinaculum (see Figure 14.14, *A*). Distally, the artery enters the anatomic snuffbox to anastomose with the radial artery and/or the radiocarpal arch. Like the other vessels described below, it runs with two venae comitantes and has a distal anastomotic connection, in this case to the radial artery in the anatomic snuffbox. It provides nutrient vessels to the radius through the small tubercle to which the retinaculum attaches between the first and second dorsal compartments. Thus, elevation of the vessel with the underlying bone and ligation of the proximal origin result in creation of a retrograde-flow pedicled vascularized bone flap. The distal anastomotic connection or termination of the 1,2 ICSRA is the "ascending irrigating branch" described by Zaidenberg, used for scaphoid nonunion.[157] Its position superficial to the retinaculum and directly on the bony tubercle between the first and second extensor compartments makes its dissection and use as a vascularized pedicled graft to the scaphoid fairly straightforward. However, its arc of rotation is short, and its nutrient artery branches are small in number and caliber.

2,3 Intercompartmental Supraretinacular Artery. The 2,3 ICSRA originates from the posterior division of the anterior interosseous artery and runs superficial to the extensor retinaculum directly on the dorsal radial tubercle (Lister tubercle) between the second and third dorsal compartments, with a distal anastomotic connection most usually with the dorsal intercarpal arch (see Figure 46.14, *A*). As it passes over the dorsal radial tubercle of the radius, it reliably provides several nutrient branches, allowing it to be used as a retrograde pedicled flap, as well (see Figure 46.14, A). As the pedicle overlies the wrist joint capsule, however, it and the bone graft must be mobilized prior to inspection of the carpus. The more marginally located 1,2 ICSRA and fifth extensor compartment artery (ECA) pedicles are more attractive because they do not have this same issue. We do not routinely use this graft source for this reason.

Fourth Extensor Compartment Artery. The fourth ECA lies directly adjacent to the posterior interosseous nerve on the surface of the radius. It is found within the radial aspect of the floor of the fourth extensor compartment below the extensor digitorum communis tendons (see Figure 46.14, *A*). In some instances, it may lie within the 3,4 intercompartmental septum. It originates from the posterior division of the anterior

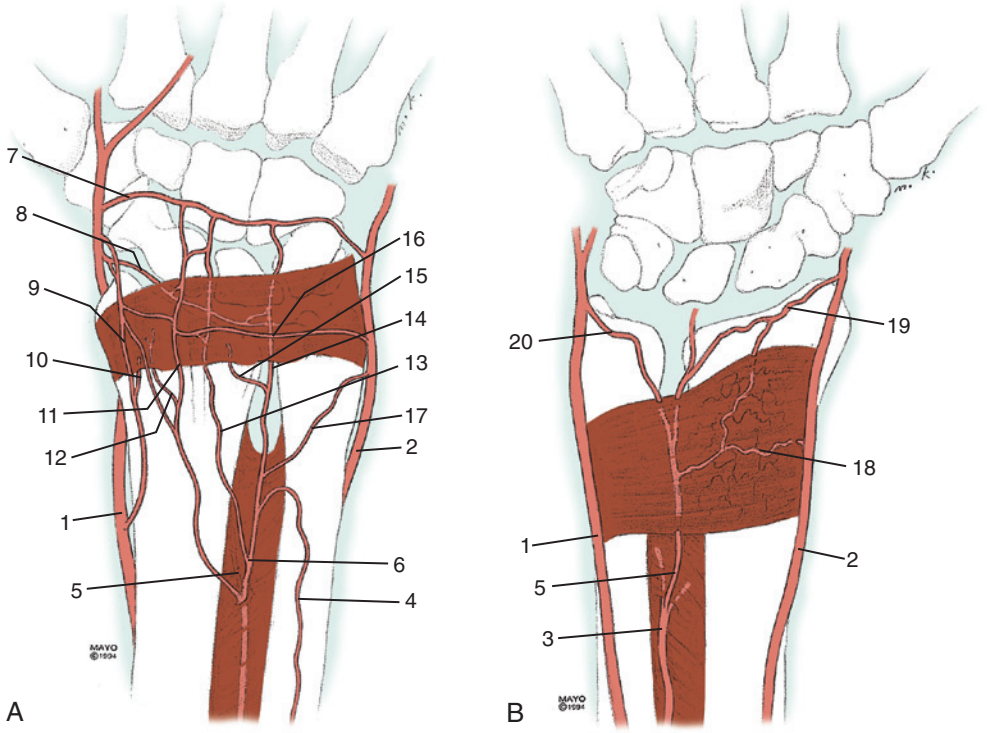

Figure 46.14 Vascular anatomy of the distal radius. **A,** Dorsal radius blood supply. Two superficial vessels lie on the surface of the extensor retinaculum (the 1,2 intercompartmental supraretinacular artery [ICSRA; 9] and the 2,3 ICSRA [11]). Two deep vessels lie directly on the radius beneath the tendons of the fourth extensor compartment (13) and the fifth extensor compartment (14). **B,** The palmar blood supply is provided by two arches connecting the anterior interosseous vessels and the radial artery (palmar carpal arch [19] and palmar metaphyseal arch [18]). 1, radial artery; 2, ulnar artery; 3, anterior interosseous artery; 4, posterior interosseous artery; 5, anterior division of anterior interosseous artery; 6, posterior division of anterior interosseous artery; 7, dorsal intercarpal arch; 8, dorsal radiocarpal arch; 9, 1,2 ICSRA; 10, second compartment branch of 1,2 ICSRA; 11, 2,3 ICSRA; 12, second compartment branch of 2,3 ICSRA; 13, fourth extensor compartment artery (ECA); 14, fifth ECA; 15, fourth compartment branch of fifth ECA; 16, dorsal supraretinacular arch; 17, oblique dorsal artery of the distal ulna; 18, palmar metaphyseal arch; 19, radial portion of palmar radiocarpal arch; 20, ulnar portion of palmar radiocarpal arch. (By permission of Mayo Foundation for Medical Education and Research. All rights reserved.)

interosseous artery, with a distal anastomotic connection to the dorsal intercarpal arch. It is the source of numerous nutrient vessels to the floor of the fourth compartment.

Fifth Extensor Compartment Artery. The fifth ECA is generally the largest of all the dorsal vessels and is located in the radial floor of the fifth extensor compartment, or at times partially in the intercompartmental septum between the fourth and fifth compartments (see Figure 46.14, *A*).[123] Its origin and distal anastomotic connections are the same as those of the fourth ECA. It generally overlies the distal radioulnar joint and most frequently has no nutrient branches to the radius. It is quite useful, however, as a large conduit of retrograde flow from the intercarpal arch. Ligation of the posterior division of the anterior interosseous artery proximally allows this blood flow to turn and flow in an antegrade direction through the fourth ECA, creating a vascularized bone graft with a long pedicle and a wide arc of coverage that can reach anywhere in the carpus.

Specific Dorsal Radius Pedicle Grafts. Although reverse-flow pedicle grafts may be taken based on any of the four dorsal vessels described above, the two grafts that are most practical in clinical application are the 1,2 ICSRA graft used for scaphoid nonunions and the 5 plus 4 ECA graft, which may be placed within a necrotic lunate in Kienböck disease.[18,101,123] The 5 plus 4 ECA graft may reach anywhere in the carpus and has been used for a number of purposes, including avascular necrosis (AVN) of the capitate.[50]

1,2 Intercompartmental Supraretinacular Artery Graft. Grafts based on a retrograde 1,2 ICSRA pedicle were originally described by Zaidenberg for scaphoid nonunion.[157] Because the vessel lies superficial to the extensor retinaculum, it is easily visible after retraction of the skin and subcutaneous tissue. It is useful only for scaphoid nonunions because it cannot reach other carpal bones because of its limited arc of rotation.[123]

Harvest technique. The extremity is elevated for exsanguination, and a tourniquet is inflated. Use of an Esmarch bandage before tourniquet elevation will make vessel visualization more difficult. The bone graft donor site and scaphoid are exposed through a gently curvilinear dorsoradial incision paralleling the course of the extensor pollicis longus tendon (Figure 46.15, *A*). Branches of the superficial radial nerve are identified and protected. Once the subcutaneous tissues are gently raised from the retinaculum, the 1,2 ICSRA and venae comitantes are visualized on the surface of the extensor retinaculum. They are dissected carefully toward their distal anastomosis with the radial artery and venae comitantes in the floor of the anatomic snuffbox. A vessel loop is placed around the distally based pedicle to protect it during later dissection. Next, the first and second dorsal compartments are opened at the graft elevation site to create a cuff

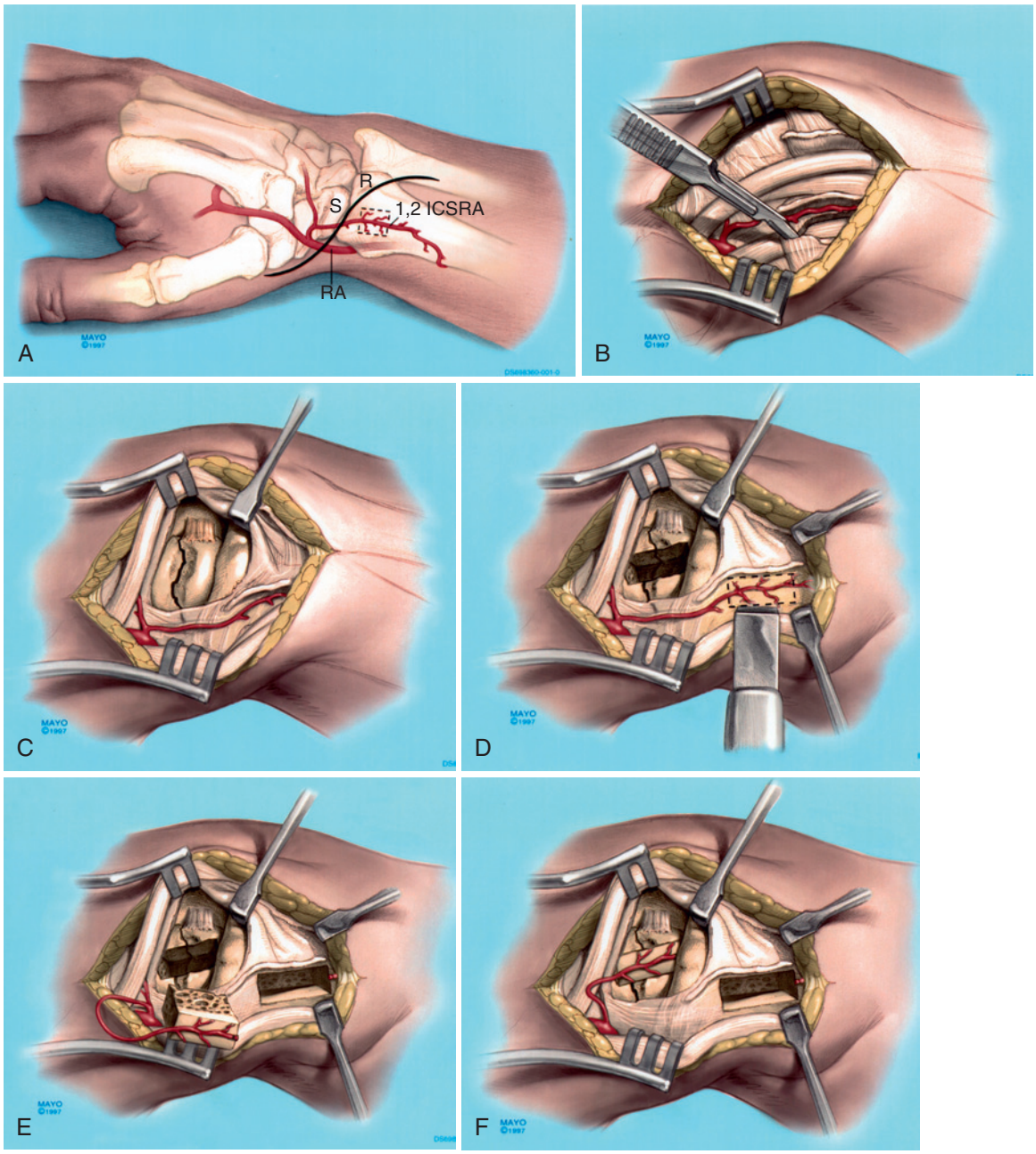

Figure 46.15 Treatment of scaphoid nonunion with a 1,2 intercompartmental supraretinacular artery (ICSRA) pedicle bone graft. **A,** A curvilinear dorsal radial incision is used for exposure of the scaphoid and the 1,2 ICSRA. **B,** The 1,2 ICSRA is identified on the surface of the extensor retinaculum. The first and second dorsal compartments are opened on either side of the vessels. **C,** The scaphoid nonunion is visualized after the vessel is identified and protected. **D,** A trough for a dorsal inlay graft has been prepared, spanning the nonunion. A distal radius graft including the 1,2 ICSRA is outlined. **E,** The graft is raised and transposed to the nonunion site. **F,** The graft is placed as a dorsal inlay. *R*, Radius; *RA*, radial artery; *S*, scaphoid. (By permission of Mayo Foundation for Medical Education and Research. All rights reserved.)

of retinaculum containing the vessels and their nutrient branches (see Figure 46.15, *B*). The center of the graft should be 1.5 cm proximal to the radiocarpal joint to include the nutrient vessels.

Scaphoid preparation. Before the graft is elevated, a transverse dorsoradial capsulotomy is made to expose the nonunion site (see Fig 46.15, *C*). In most cases, this will be a proximal pole fracture in which a dorsal inlay graft is most appropriate. If this is the case, a 2- to 3-mm bur or small, sharp osteotomes are used to prepare a slot to receive the bone graft, curetting any fibrous tissue from the nonunion site (see Figure 46.15, *D*). The slot will span the nonunion, unless the proximal pole fragment is very small, in which case the graft is shaped to lie within the concavity of the proximal pole fragment and slot into the distal fragment. Alternatively, a wedge graft may be used to expand the scaphoid length through the radial approach. In some cases, a limited radial styloidectomy may improve exposure, but it is not generally necessary. For either method, the size and orientation of the bone graft are carefully determined prior to graft elevation.

Placement of the dorsal inlay graft. Most of the cases in which vascularized grafts have been used have been proximal pole nonunions. In these cases, the use of a dorsal inlay graft is generally appropriate, allowing the graft to bridge the nonunion, facilitating stability and early union.

Preparation of the nonunion site should be performed following pedicle dissection but prior to graft elevation, as described previously. Careful inspection of the midcarpal and radiocarpal joint surfaces of the scaphoid is mandatory to prevent articular surface injury during creation of the trough. If the proximal pole fragment is very small, the bone graft is placed within it rather than fitted into a dorsal slot. The graft is removed from the radius, outlining the desired shape using small, sharp osteotomes and protecting the distally based pedicle. The proximal origin of the 1,2 ICSRA may be ligated or cauterized with a bipolar forceps. The graft is pried from the metaphyseal bone using an osteotome placed in the proximal cut at the desired depth (≈1 cm) (see Figure 46.15, *E*). Prior to placement of the graft, the scaphoid is stabilized with a cannulated scaphoid screw placed antegrade from the proximal pole. The graft is placed and carefully reshaped as needed so that it can be placed snugly in the slot with sufficient press-fit interference to maintain stability (see Figure 46.15, *F*).

Once the scaphoid is prepared, a graft of appropriate dimension, including the vessels and cuff of retinaculum between the first and second compartments, is raised. The location of harvest is positioned to include the nutrient vessels, centered a mean 15 mm from the radiocarpal joint margin.[123] The 1,2 ICSRA pedicle is ligated proximal to the graft. Next, the vessels are meticulously dissected subperiosteally distal to the graft to separate them from the radial styloid and joint capsule. To improve the arc of rotation, the pedicle may be dissected to its distal radial artery anastomosis. With the vessels mobilized, the graft is carefully separated from the radius with sharp osteotomes. The cancellous bone is fragile, requiring attention to detail to prevent its fracture as the graft is levered out from the radius. The graft is transposed beneath the radial wrist extensor tendons to reach the nonunion site, where it is gently impacted into position. When used as a dorsal inlay graft, the vessels and cortical bone are positioned on the dorsal surface of the scaphoid. For use as a wedge graft, the cortical bone is positioned palmarly.

5 plus 4 Extensor Compartment Artery Graft. A fourth compartment artery graft based on retrograde flow from the intercarpal arch may also be useful in Kienböck disease.[101] Its arc of rotation consistently reaches the lunate, and the nutrient arteries are numerous and large. The fourth ECA vessel is quite small distal to the radiocarpal joint in many patients. As a result, in most cases we now prefer to use the fifth ECA as the source of retrograde blood flow, with antegrade flow to the fourth compartment vessel nutrient branches via their common origin (Figure 46.16). The large diameter of the fifth ECA provides optimal blood flow to the bone graft, and straightening of the "Y"-bifurcation creates a very long pedicle twice the length of each vessel. This allows it to reach anywhere in the carpus, while easily protecting it from injury during wrist capsulotomy and carpal bone exposure due to its ulnar location. In nearly every wrist studied by Sheetz, the fifth ECA had no nutrient branches to bone.[123]

Harvest technique for the 5 plus 4 extensor compartment artery graft. Bone graft harvest requires identification of the fifth ECA by opening the fifth dorsal compartment (see Figure 46.16, *A* to *F*). A dorsal wrist incision is made to expose the extensor retinaculum. A single retinacular flap is created for wrist capsule exposure, radially based, with its initial opening directly overlying the fifth compartment (see Figure 46.16, *A*). The fifth ECA and accompanying veins are easily visualized on the radial aspect of the compartment with retraction of the extensor digiti minimi tendon, lying adjacent to the septum separating the fourth and fifth compartments and occasionally lying within the septum. Its distal anastomotic connections must be meticulously protected. The artery is traced proximally from the intercarpal arch to its origin from the anterior interosseous artery. During this mobilization, the oblique dorsal artery to the distal ulna and the communicating branch with the posterior interosseous artery must be ligated and divided. Proximal to the distal radioulnar joint, the origin of the fourth ECA should be identified for inclusion with the distally based fifth ECA pedicle (see Figure 46.16, *B*). At this point, the vascular pedicle overlying the joint capsule is protected with a vessel loop and an arthrotomy made to expose the carpal pathologic condition. Once the need for a graft is verified, a bone graft is elevated overlying the fourth ECA, including its nutrient artery branches, which enter the cortex a mean 11 mm proximal to the joint (see Figure 46.16, *C*). This creates a lengthy pedicle with retrograde flow from the fifth ECA, continuing in an orthograde fashion into the fourth ECA. The bone graft is then raised.

Graft Insetting for the Lunate. Once the graft is elevated and retracted distal to the lunate on its pedicle, a capsulotomy is performed to expose the joint using Berger's dorsal ligament-sparing approach[4] (see Figure 46.16, *C*). The lunate is inspected. If it is not fragmented, vascularized bone grafting is feasible. Necrotic bone is removed with the aid of direct inspection and an image intensifier, leaving a shell of intact cartilage and subchondral bone through a dorsal opening. This opening is placed to avoid injury to the dorsal scapholunate or lunotriquetral ligaments. The lunate may be expanded gently to normal dimensions if it has collapsed using a small elevator (see Figure 46.16, *D*). The bone graft is placed into the lunate, orienting the pedicle vertically and the cortical surface on which it lies arranged to serve as a proximodistally oriented strut to maintain lunate height during revascularization (see Figure 46.16, *E* and *F*). No internal fixation is necessary provided the lunate is not fractured and the graft is carefully shaped and impacted into the bone.

Palmar Radius Pedicle Grafts

ANATOMY

Palmar radius grafts have been described based on a pronator quadratus pedicle (palmar metaphyseal arch) or palmar radiocarpal arch.[9,87] We have found the pronator flap to have essentially no significant nutrient blood supply to the radius and cannot recommend this flap. The palmar radiocarpal arch, however, has anastomotic connections to the ulnar artery, radial artery, and anterior division of the anterior interosseous artery (see Figure 46.14, *B*).

Harvest of Palmar Radius Bone Grafts to Reach Either the Scaphoid or the Lunate. If inflow is based on the anterior interosseous

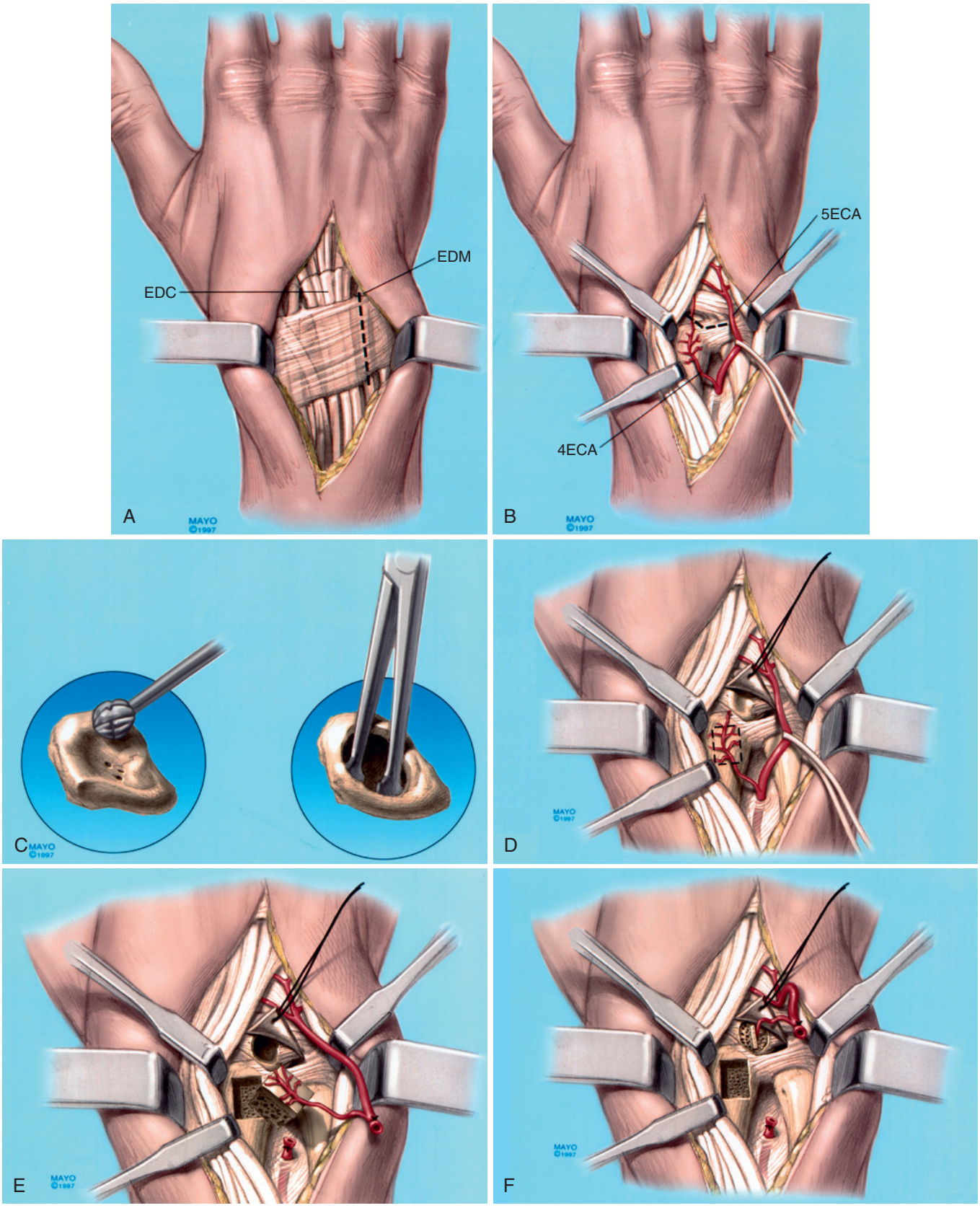

Figure 46.16 Vascularized graft for Kienbock disease using the 5 plus 4 extensor compartment artery (ECA) pedicle graft. **A,** The fifth ECA is exposed by opening the fifth extensor compartment. **B,** The fifth ECA is traced proximally to its origin from the posterior division of the anterior interosseous artery. A radial based retinacular flap exposes the fourth compartment tendons, which are retracted radially to expose the fourth ECA. A ligament sparing capsulotomy is performed, protecting the fifth ECA and exposing the lunate. **C,** The lunate necrotic bone is removed with a burr and expanded. **D,** The site of the bone graft including the fourth ECA. **E,** The graft is elevated, providing retrograde blood flow through the fifth ECA into the fourth ECA with attached radius bone. **F,** The graft is inserted vertically into the lunate. *EDC,* Extensor digitorum communis; *EDM,* extensor digiti minimi. (By permission of Mayo Foundation for Medical Education and Research. All rights reserved.)

artery, the graft must be harvested from the radialmost aspect of the palmar radius to provide an adequate pedicle to reach the lunate. When a radial-based pedicle supplied by the palmar radiocarpal branch of the radial artery is used, the bone is harvested from the ulnarmost aspect of the palmar distal radius for placement in the scaphoid.[123]

Although the location of the graft places the palmar radiocarpal ligaments and articular surfaces at risk, there is a robust supply of nutrient vessels to the radius from the palmar radiocarpal arch.[123] Graft placement also requires a palmar carpal exposure, of necessity through important radiocarpal ligaments. This limits exposure and may risk radiocarpal instability postoperatively. The pedicle is short, requiring careful dissection and accurate placement of the graft harvest if the carpal nonunion or AVN site is to be reached and reconstructed. Nevertheless, excellent clinical results have been reported with this flap.[22,44,89]

Technique. An extensile exposure is recommended to the palmar distal radius in the interval between the radial artery and flexor carpi radialis.[87] For scaphoid placement, the scaphoid is first exposed and prepared through a standard Russe approach. The graft is raised by incising the distal 1 cm of the pronator quadratus and elevating a 1 cm–wide cuff of tissue from the ulnar aspect of the radius, to include a bone graft directly adjacent to the sigmoid notch and lunate facet of the distal radius. At the ulnar border of the graft, contributions to the radiocarpal arch from the anterior interosseous and ulnar arteries are ligated and divided. The pedicle is progressively raised from the radius, and the graft rotated into the prepared scaphoid. For lunate placement, the graft is placed radially and distally, with the base of the pedicle at the ulnar border of the radius to provide inflow from the anterior interosseous and ulnar arteries.

Results. The proximity of the graft to articular surfaces and radiocarpal ligaments requires great care in graft elevation and harvest. Despite these difficulties, Mathoulin has reported excellent results for both scaphoid nonunion and Kienböck disease with palmar radius pedicle graft. He reported union in 96% of 112 scaphoid nonunion cases and healing in 17 of 22 patients with Kienböck disease.[86] Another recent report found a healing rate of only 73%[65]; only two of the cases were proximal pole fractures with avascular necrosis, and neither united. Complications were many, including two articular radius fractures occurring during graft harvest. Five patients had subsequent surgeries, including four proximal row carpectomies and one conventional bone graft.[65]

OTHER VASCULARIZED GRAFTS

Rib

The rib, although used in early reports,[91] has not been widely used for upper extremity reconstruction because of its membranous, weak structure and curved shape. When based on its anterior internal mammary or supracostal arterial blood supply, only periosteal vessels are supplied.[51] The posterior rib graft, which includes its nutrient artery, requires ligation of the dorsal branch of the posterior intercostal artery. Another alternative, however, is the use of an osteomuscular composite graft including one or more lower slips of the serratus anterior, which provide a periosteal supply to the ribs. Provided nonadjacent ribs are selected, a double-rib graft may be used for long bone reconstruction. This prevents chest wall instability and allows stable reconstruction and soft tissue coverage in cases of segmental bone loss as an alternative to the fibula. Because the entire thoracodorsal system may be included, composite flaps including the latissimus dorsi, scapular, and parascapular skin are also possible on a single vascular pedicle (Figure 46.17, *A* to *D*).[83] It may also be used as a pedicle graft for clavicular reconstruction.

Scapula

Scapular free flaps may be based on the lateral border (lateral scapular osteocutaneous flap) or on the medial ridge of the scapula. The lateral scapular flap is based on the circumflex scapular circulation and is usually taken as a composite flap. The dissection requires division of the teres major and minor, resulting in some shoulder impairment. The medial flap, based on the same pedicle, depends on the periosteal blood supply for bone nutrition. No donor site morbidity has been reported, although scapular winging from division of the serratus anterior is a likely potential problem. The utility of the flaps as composite flaps in the hand and forearm has been well demonstrated.

Humerus

Portions of the humeral diaphysis can be taken at the lateral intermuscular septum as part of an osteocutaneous lateral arm flap.[72] Periosteal flaps may also be raised from the humerus.[128]

Pisiform

The pisiform receives its blood supply from the ulnar artery via its deep volar and dorsal carpal branches.[94] The dorsal carpal branch is the major vessel, with at least two descending branches entering the proximal tip of the bone. This allows elevation of a pedicled pisiform graft, which may be used to replace the lunate,[32] or, when placed as a decorticated graft with the lunate, to revascularize it.[6] A recent series of 21 Kienböck disease patients treated with lunate excision and pisiform replacement reported preservation of preoperative ranges of motion and high patient satisfaction with wrist function. Over the longer term, however, carpal collapse and resultant osteoarthritis were seen in 50% of the patients.[21]

Second Metacarpal

A small amount of bone may be raised as a vascularized graft from the first or second metacarpal, based on the first dorsal metacarpal artery. The second metacarpal may be harvested entirely for skeletal thumb reconstruction associated with destruction of the index finger, or partially as an elective procedure for carpal pathologic conditions. The arc of rotation allows transposition within the radial side of the hand, for applications in the thumb and carpus.[109] Dorsal proximal metaphyseal grafts have been used successfully for scaphoid nonunions and Kienböck disease.[120,156]

Manufactured Bone Grafts

Another future possibility is the creation of pedicled vascularized bone grafts in desired shapes. This has been demonstrated in the laboratory by implantation of vascular bundles into bone fragments or demineralized bone matrix.[99,151] When

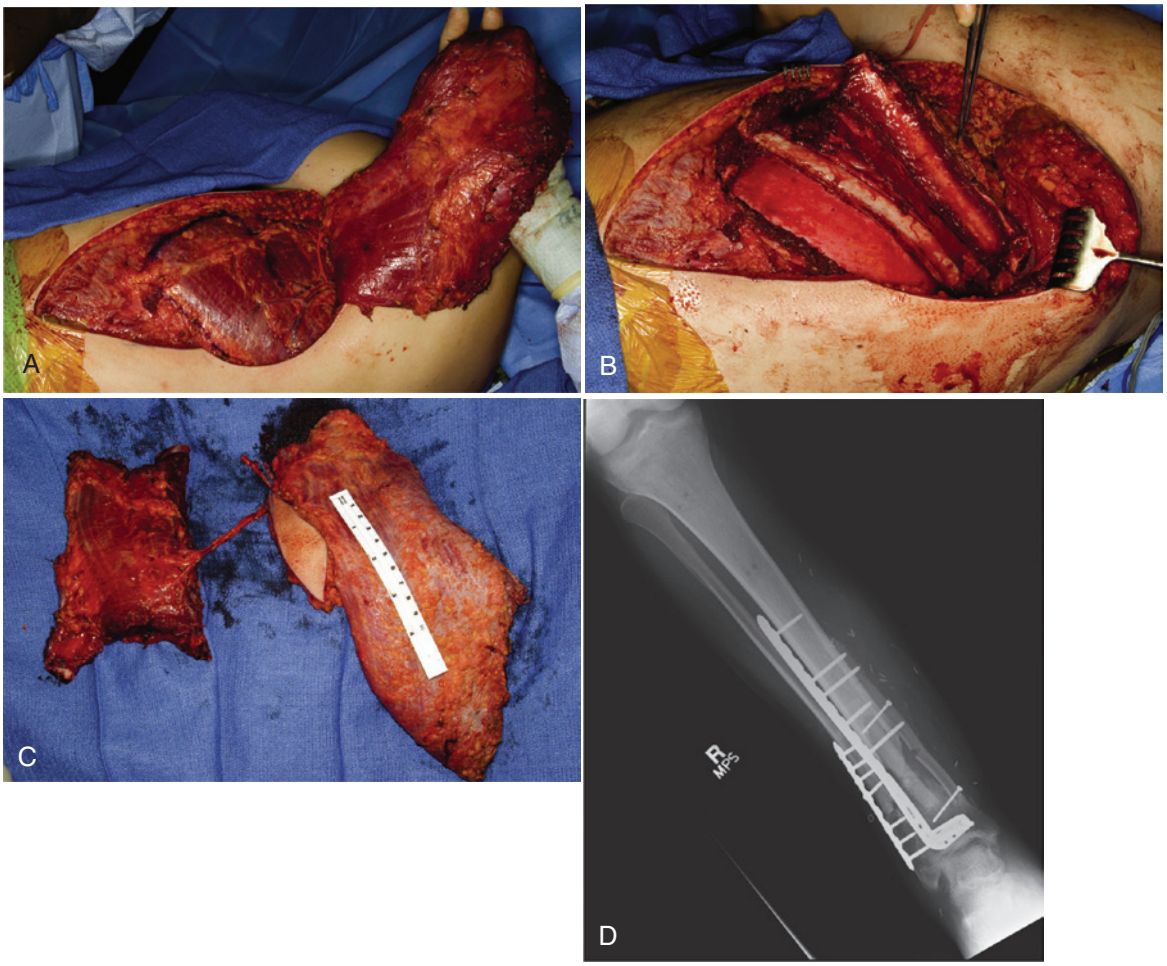

Figure 46.17 A composite rib–serratus anterior–latissimus dorsi osteomuscular flap. **A,** The latissimus dorsi has been elevated, and the inferior portion of the serratus identified for elevation, to include two nonadjacent ribs. **B,** Inferior surface of rib/serratus flap, with one intact rib spanning the donor site. **C,** The composite rib/serratus and latissimus dorsi flap based on a common thoracodorsal artery and vein pedicle. **D,** Flap transferred to reconstruct a combined bone and soft tissue defect with ankle arthrodesis. Similar methods are useful in the upper extremity.

arteriovenous pedicles are enclosed in titanium or hydroxyapatite or polyethylene chambers, or wrapped with vascularized periosteum in vivo, bone formation and remodeling occur in the shape of the chamber, along with microangiographic evidence of a sprouting vascular network that may occur only 4 weeks later.[99] Similarly, Khouri has demonstrated the ability to transform muscle into bone of any desired shape using silicone rubber molds containing the recently purified osteoinductive factor osteogenin, when coated with demineralized bone matrix.[75] These findings support the concept of creating a preformed vascularized bone graft to reconstruct segmental bone defects.[99] Demonstration of clinical applicability remains to be performed.

Allogeneic Bone Grafts

The ability to safely restore viability of cryopreserved structural allografts or maintain long-term viability of allogeneic transplanted bone would be an important advance in reconstructive surgery that might in the future obviate other means of long bone reconstruction. Expendable autogenous sources for large vascularized bone segments are limited, primarily to the fibula and iliac crest. Both are generally poor structural replacements for missing metaphyseal or diaphyseal bone, particularly in the humerus, femur, and tibia, due to gross size mismatch. In these locations, load sharing by rigid internal fixation, external fixators, or allograft plus autograft composites, or a protracted period of no weight bearing and/or bracing, is necessary if the risk of stress fracture is to be minimized.[48] An ideal replacement for such large-segment bone and joint defects would be a living bone and/or joint allogeneic transplant, or a "revitalized" cryopreserved allograft revascularized and repopulated with living bone. Not only would such allogeneic bone match the dimensions and structural property of the missing tissue, but it would also have the same enhanced healing and remodeling potential as a vascularized autogenous bone graft. Survival of musculoskeletal allotransplants at present requires long-term immunosuppression, with a significant risk of opportunistic infections, malignant disease, and organ toxicity that is difficult to justify in transplantations not critical to preserve life. It is not surprising, therefore, that living musculoskeletal allografts have been seldom used clinically, and that late failure due to rejection or infection has been the rule.[27]

Characterization of the immune response to vascularized bone allografts may subsequently allow more specific modification of the host response and/or graft tissue. The use of surgical angiogenesis to revitalize cryopreserved allograft bone[90,146] or replace allogeneic circulation of living allotransplanted bone with recipient-derived autogenous vessels[40,79,80,107,112,145] is an alternative to conventional immune modulation that may provide a new source for living bone in future clinical practice.

Recipient Site

Clavicle

Although most clavicular fracture nonunions are successfully treated with conventional grafting and plate fixation, at times, bone loss, infection, or irradiation-induced pathologic fracture makes union challenging.[36] Partial excision of the clavicle, often advocated in this situation, may result in persisting pain, weakness, sensation of instability, and brachial plexopathy. Because of the thin soft tissue envelope covering the clavicle, bulky bone and/or soft tissue reconstruction is preferentially avoided. Several methods of surgical reconstruction have been described. In cases involving failed prior plating or infection, conventional nonvascularized iliac tricortical bone grafting may not be successful, especially if a significant defect remains in the clavicle. Microvascular fibular transfer combined with autografting has been reported as an appropriate treatment option for difficult nonunions associated with previously irradiated long bones[31]; a high failure rate for the clavicular site has been shown, however. Other biologic options include the vascularized transfer of a rib as a composite flap, including the serratus anterior and/or latissimus dorsi, or the use of free corticoperiosteal grafts to envelop and revitalize the nonunion site.[36]

Because of their osteogenic capability, vascularized periosteal grafts have considerable potential for the reconstruction of bone defects. The transfer of free vascularized corticoperiosteal bone flaps seems to be ideally suited for radiation-induced fractures or chronic nonunions of the clavicle without substantial bone loss but with a poor chance of healing on their own. Successful use of periosteal flaps from the medial femoral condyle has been reported, with much higher success rates than other methods.[36] The flap is thin and can be shaped according to the reconstructive requirements without compromising its blood supply. It can be wrapped around the clavicle without visible bulk, thereby avoiding further stress on the previously irradiated overlying skin. Rapid subperiosteal new bone and improved local blood flow both serve to correct many of the changes attributed to radiation necrosis of bone. Although microvascular expertise is necessary, flap exposure and elevation are straightforward. The dual blood supply from the medial superior and descending genicular vessels enables identification of vessels of sufficient diameter and pedicle length for reliable microsurgical anastomoses. Improved healing over other methods has been demonstrated.[36]

Vascular connections are most easily accomplished by direct end-to-end anastomoses to the thoracoacromial trunk artery and cephalic vein. A corticoperiosteal flap raised from the medial femoral condyle will envelop at least three quarters of the bone circumference and span the nonunion site, leaving sufficient room for plate-and-screw stabilization on the remaining exposed bone surface. Additional cancellous bone graft may be used beneath the periosteal flap.

Shoulder and Humerus

Proximal humerus resections are reconstructive challenges, particularly when tumor resection results in loss of the rotator cuff and/or deltoid tissue. Preservation of glenohumeral joint function may be possible with fibular free flaps, including the femoral head with its suspension from the scapula and the reattachment of these muscles. A vascularized fibular flap including the fibular head and physis has the potential to provide longitudinal growth as well as partial joint function, an important consideration in children. Deficient soft tissue in adults favors a glenohumeral arthrodesis, providing the patient with very satisfactory upper limb function.[143] Arthrodesis after segmental resection of the proximal humerus is best accomplished with an allograft/fibula construct, in the authors' experience[112] (see Figure 46.8), placing the fibula obliquely from interior glenoid to humerus. Fixation with lag screws proximally and distally requires a shoulder spica cast for stabilization, which is unnecessary with plate-and-screw fixation.

When a fibular segment is used for humeral shaft reconstruction, stability is also an important issue. Bone fixation of a fibular graft is best performed with plate-and-screw fixation, with a long compression plate spanning the humeral defect. The graft may be placed as an interposition graft in the defect, doweled into the proximal and distal humerus when possible (see Figure 46.9).[112] Alternatively, reconstruction with an allograft interposition graft and an onlay fibula spanning the reconstructed segment provides enhanced stability. Vascular anastomoses are straightforward because the brachial vessels lie adjacent to the bone. End-to-side anastomosis to the brachial artery and end-to-end repair to the cephalic vein or a brachial vena comitans is preferred in most cases.

Forearm

Bone stabilization with rigid internal fixation is relatively easily obtained. In cases of massive bone loss of both forearm bones, creating a one-bone forearm may be the best solution, placing the fibula between the proximal ulna and distal radius. Alternatively, both bones may be reconstructed with a double-barrel graft or dual fibular grafts. Positioning of the fibula may be either orthograde or retrograde, depending on the optimal location for vessel approximation. Fixation with dual plating at either end is reasonable. Vascular anastomoses to radial or ulnar vessels are easily performed, usually as end-to-side arterial anastomoses. The venae comitantes or superficial (cephalic or basilic) veins are satisfactory for end-to-end anastomosis. A long-arm cast is maintained until radiographic signs of union occur.

Reconstruction of the radius alone, commonly for giant cell tumor, is also successfully accomplished with fibular grafts. If the distal radius must be resected, one has the alternative of performing a wrist arthrodesis or attempting to spare some carpal motion. In the latter case, in which the incorporation of the proximal fibular head and its articular cartilage is needed, use of the anterior tibial artery pedicle rather than a peroneal artery pedicle is required to maintain circulation to the head and neck of the fibula.[61] The procedure is technically more difficult, and results in carpal subluxation and arthritic changes in a substantial number of cases (5 of 12 patients in a recent series).[20] Alternatively, it is the authors' preference to use a fibular diaphyseal segment (the peroneal pedicle). Either a

complete wrist arthrodesis with a standard arthrodesis plate is performed or a procedure is done with fusion to the scaphoid and lunate only, permitting some midcarpal mobility.[64] Most commonly in these cases, the ulna is intact, and a bridging plate is not necessary. Two shorter proximal and distal plates are used instead.

Recalcitrant forearm nonunions with minimal bone loss are successfully treated with corticoperiosteal flap envelopment, as described above for the clavicle.[25]

Wrist and Hand

Vascularized bone grafts have demonstrated their utility in the treatment of carpal pathologic conditions. These include difficult scaphoid nonunions of the proximal pole or associated with avascular necrosis and bone loss producing a humpback deformity. The grafts have also been effective in the treatment of Kienböck disease. Pedicled grafts from the adjacent dorsal or palmar radius, pisiform, ulna, or metacarpals have been described and used for this purpose. Pedicled grafts allow harvest of the vascularized bone graft and preparation of the recipient site through a single incision. Increasingly, free microvascular bone flaps, most commonly from the medial femoral condyle, are demonstrating their usefulness, as well.[66] Because the exposure must not damage the vascular pedicle or its anastomotic connections, pedicle preparation precedes preparation of the recipient site. Free bone flap vascular anastomoses may be made to the radial artery from end to side. Graft placement and stabilization are carefully planned in advance. Recent evidence suggests that local pedicle flaps are appropriate in scaphoid nonunion with or without avascular necrosis, so long as the scaphoid dimensions and carpal alignment remain normal.[18] A humpback deformity with carpal collapse requires a substantial interposition graft. Although it may indeed be possible to use a larger distal radius graft to correct the deformity and resultant carpal instability,[44] the authors favor a stronger, larger graft from the medial femoral condyle. An injury with small proximal pole fragments, particularly when fragmented or shell-like, or an irreparable lunate articular cartilage injury has been treated with a salvage procedure. New developments using osteoarticular flaps from the distal femur appear promising. They enable partial replacement of the proximal aspect of either bone, including the articular cartilage and strong subchondral bone, with a radius of curvature closely matched to that of the normal contours.[58]

Results

Scaphoid

Vascularized bone grafting has been applied to the scaphoid in an effort to improve the results of treatment of nonunion. Roy-Camille used the palmar tubercle of the scaphoid on an abductor pollicis brevis pedicle in 1965.[113] Grafts from the palmar distal radius based on a pronator quadratus pedicle resulted in successful treatment of 13 nonunions in two series,[9,74] and palmar grafts based on the palmar radiocarpal arch have been similarly effective in cases with AVN.[88] Zaidenberg reported successful results with a dorsal reverse-flow pedicle graft from the distal radius in 11 cases,[157] using the vessel subsequently described as the 1,2 ICSRA.[123] Our initial experience was similar, with successful healing in 15 patients with established scaphoid nonunions.[87] The time to union averaged 11.1 weeks (range, 5.5–16 weeks), judged by bridging trabeculae on CT scans. The experience with vascularized bone grafting of the scaphoid has not been uniformly successful, however. Although many authors report rates of healing of over 90%, others have demonstrated healing rates of 27 to 80%.[8,18,39,129] Variations in type and length of internal fixation, numbers of individuals with documented AVN, and other variables certainly may affect the results. A metaanalysis of scaphoid nonunions has demonstrated that vascularized bone grafts provide better union rates overall in scaphoids with avascular necrosis, and a trend to better results than conventional grafts in patients who have failed previous surgery.[93]

Role of Internal Fixation. Supplemental internal fixation is necessary for scaphoid nonunions, even with the use of vascularized grafts. In most cases, a scaphoid screw may be safely placed without jeopardy to the pedicle. Kirschner wires are required at times when insufficient bone is available to allow screw purchase. A recent metaanalysis of scaphoid nonunion literature has demonstrated that Kirschner wire fixation results in higher rates of pseudarthrosis than does the use of screws.[93] This has also been our experience.[18] The authors' preferred method (discussed previously) is placement of the screw in an antegrade direction prior to graft placement. A recent review of 50 such cases demonstrated the method to be inappropriate in cases where the proximal pole was fragmented.[18]

1,2 Intercompartmental Supraretinacular Artery Inlay Graft. Chances of successful union using a 1,2 ICSRA pedicled graft placed as a dorsal inlay graft were only 50% when associated with carpal collapse and a humpback deformity combined with an avascular proximal pole. We now reserve the use of this graft for proximal pole nonunions without significant scaphoid deformity and shortening because the graft is generally too small and perhaps too weak to provide the large interposition wedge generally required to restore scaphoid length.[18,84] With this more limited set of indications, we continue to find the 1,2 ICSRA graft useful and appropriate.

Medial Femoral Condyle Bone Flap. Wedge grafts that enhance vascularity are important for successful healing when AVN is combined with humpback deformity and carpal collapse. These may be conventional iliac crest grafts combined with an arteriovenous pedicle,[33,84] or large vascularized grafts placed to lengthen the scaphoid (Figure 46.18, *A* to *H*).[66,81] Both methods result in reliable scaphoid healing, although the healing time for conventional wedge graft with avascular bundle implantation is twice as long.[66] We now favor the use of large vascularized interposition grafts from the medial femoral condyle when both humpback deformity and avascular necrosis are present. An additional indication for the use of the MFC flap is a foreshortened scaphoid with a failed prior bone grafting procedure.

Medial Femoral Condyle Osteochondral Flap. When the authors analyzed the reasons behind the failure of vascularized grafting for scaphoid nonunion, we found fragmentation of the proximal pole or a very small, shell-like proximal fragment to be less likely to heal than scaphoids with more proximal bone stock. Prior use of large-diameter scaphoid screws played a role in this process, leaving little bone for fixation.[67] In these instances, it may be preferable to consider the use of a free osteochondral graft to replace the proximal scaphoid, as recently described by Burger.[11] Because the scapholunate ligament is generally not reconstructed, Burger's technique of sparing the distal

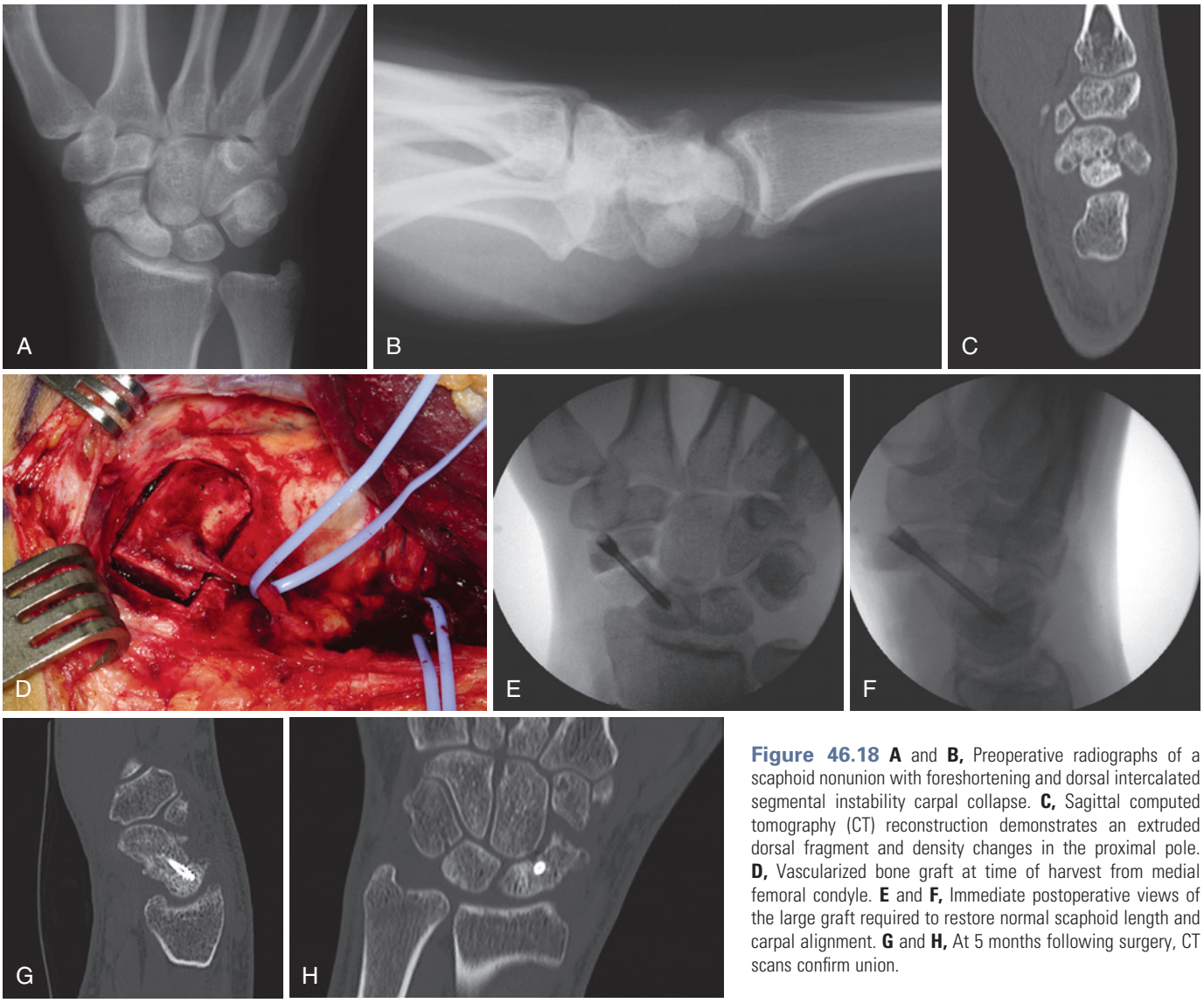

Figure 46.18 **A** and **B,** Preoperative radiographs of a scaphoid nonunion with foreshortening and dorsal intercalated segmental instability carpal collapse. **C,** Sagittal computed tomography (CT) reconstruction demonstrates an extruded dorsal fragment and density changes in the proximal pole. **D,** Vascularized bone graft at time of harvest from medial femoral condyle. **E** and **F,** Immediate postoperative views of the large graft required to restore normal scaphoid length and carpal alignment. **G** and **H,** At 5 months following surgery, CT scans confirm union.

(capitate) articular surface and thus some of the dorsal and palmar scapholunate ligament may be important for long-term success of such a procedure. Alternatively, it may be that a large "overstuffed" osteochondral graft may provide stability that is adequate to prevent carpal collapse (Figure 46.19, *A* and *B*).[13]

Lunate Graft in Kienböck Disease

Vascularized grafts in general have demonstrated satisfactory clinical results in Kienböck disease, with excellent pain relief and improvement in range of motion and strength. Radiograph progression of lunate and carpal height collapse occurred in 0 to 15% of patients in three recent studies[6,101,134] and radiographic or MRI evidence of revascularization may be minimal for an extended period of time.[101] Vascularized grafts may be especially useful in cases of ulnar-positive or neutral Kienböck disease, when joint leveling is contraindicated to avoid ulnar impaction syndrome. The lunate may be expanded with the graft, resulting in improvement of the lunate index and carpal height ratio postoperatively in stage IIIA disease. Use of the graft is questionable with displaced coronal fractures of the lunate, due to the unreliable healing of such fractures; in cases with marked carpal collapse; which may progress radiographically with osteoarthritic changes or fragmentation of the lunate[134]; and when the articular surfaces are damaged. Protection during early healing is necessary to prevent lunate collapse with revascularization.

Twenty-six Kienböck patients treated with a 5 plus 4 extensor compartment artery dorsal radius pedicle graft were followed for a mean of 31 months in one study; grip strength improved (from 50 to 89% of the opposite side), as did motion.[101] Fully 92% of patients reported improvement in pain, with 85% having satisfactory results overall. MRI data demonstrated some progressive signs of revascularization with time, but months to years were often required. Wrists with evidence of lunate revascularization generally fared better than those without MRI findings of improvement.

Advanced changes resulting in destruction of the articular surfaces of the lunate have generally been an indication for a salvage procedure. Recently, the osteochondral flap has been used for replacement of the majority of the lunate, including

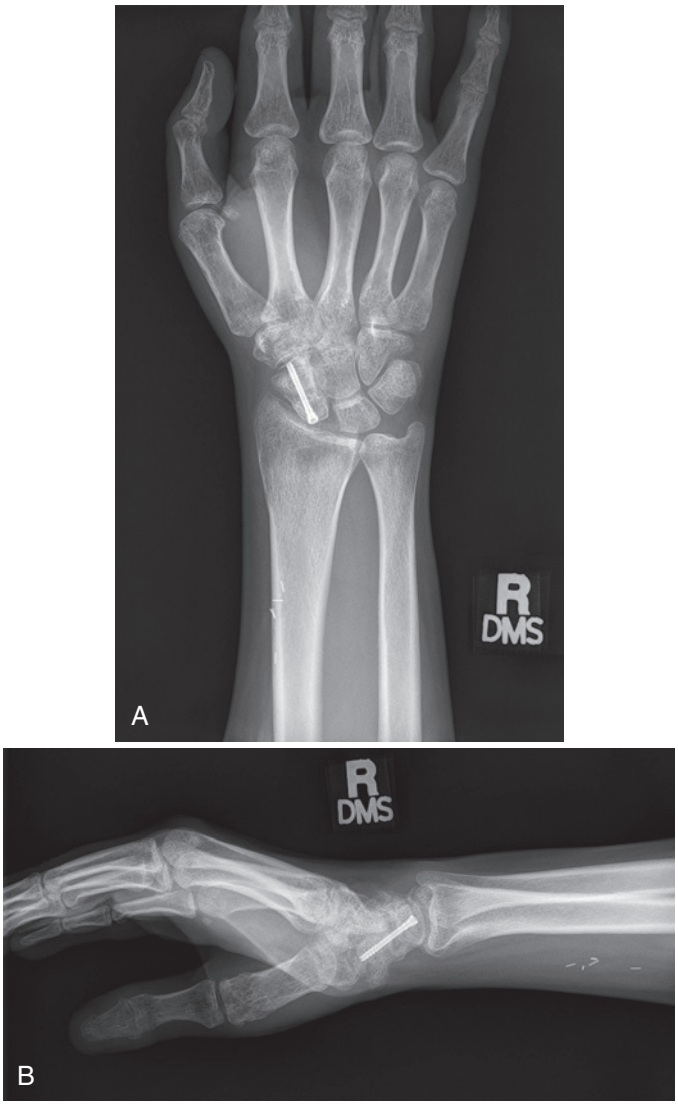

Figure 46.19 Replacement of the proximal scaphoid with a free medial femoral condyle osteochondral flap 6 months following operation.

the proximal joint surface. Generally, only the distal (capitate) surface of the lunate is preserved for function. All but 1 patient had had a good clinical result, and the radiographic changes demonstrated either no further collapse or improvement in lunate and carpal height over time (in 14 of 16 patients). Thus, the use of small osteochondral grafts in the near future may be expected to become more generally used, with the potential to provide improved clinical outcomes for this challenging clinical problem.

SUMMARY

Vascularized bone grafting is indicated in the upper extremity following segmental bone loss of greater than 6 cm as a result of trauma, infection, or tumor resection. Grafting is also indicated in smaller long bone defects in the presence of radionecrosis, failed prior graft, scarred beds, or the need for composite tissue reconstruction. Currently, restoration of growth by inclusion of the epiphysis is possible, as well. Primary sources of vascularized bone for long bone reconstruction include the fibula and iliac crest. In cases with minimal bone loss but with recalcitrant nonunion due to scarring, prior infection, or irradiation-induced damage, free corticoperiosteal flaps that envelop the bone permit revascularization and healing.

In the wrist, vascularized grafts have proven value in scaphoid fracture and nonunion, as well as in carpal avascular necrosis (Preiser disease, Kienböck disease, capitate AVN). For carpal indications, the primary options currently considered are reverse-flow pedicle grafts from the dorsal distal radius, and both bone-only and osteoarticular flaps from the medial femoral condyle. We now reserve 1,2 ICSRA pedicle grafts for scaphoid nonunions with minimal displacement, and 5 plus 4 ECA grafts for patients with Kienböck disease without collapse or injury to the articular surfaces. MFC grafting is now the procedure of choice for scaphoid nonunions when the unfavorable combination of humpback deformity and proximal pole AVN is present, or when a prior operation has failed with bone loss and/or avascular necrosis. Osteochondral flaps for fragmented and very small proximal pole scaphoid nonunions may prove to be a useful option for common salvage procedures, but data are limited at present. Similarly, lunates with extruded fragments, damaged articular surfaces, and extensive collapse that currently cannot be healed may prove to be best treated with osteochondral flap replacement.

REFERENCES

1. Aberg M, Rydholm A, Holmberg J, et al: Reconstruction with a free vascularized fibular graft for malignant bone tumor. *Acta Orthop Scand* 59(4):430–437, 1988.
2. Arora R, Lutz M, Deml C, et al: Long-term subjective and radiological outcome after reconstruction of Kienbock's disease stage 3 treated by a free vascularized iliac bone graft. *J Hand Surg [Am]* 33(2):175–181, 2008.
3. Bae DS, Waters PM, Sampson CE: Use of free vascularized fibular graft for congenital ulnar pseudarthrosis: surgical decision making in the growing child. *J Pediatr Orthop* 25(6):755–762, 2005.
4. Berger RA, Bishop AT, Bettinger PC: New dorsal capsulotomy for the surgical exposure of the wrist. *Ann Plast Surg* 35(1):54–59, 1995.
5. Bishop AT, Wood MB, Sheetz KK: Arthrodesis of the ankle with a free vascularized autogenous bone graft. Reconstruction of segmental loss of bone secondary to osteomyelitis, tumor, or trauma. *J Bone Joint Surg Am* 77(12):1867–1875, 1995.
6. Bochud RC, Buchler U: Kienbock's disease, early stage 3: height reconstruction and core revascularization of the lunate. *J Hand Surg [Br]* 19(4):466–478, 1994.
7. Bowen V: Experimental free vascularized epiphyseal transplants. *Orthopedics* 9(6):893–898, 1986.
8. Boyer MI, von Schroeder HP, Axelrod TS: Scaphoid nonunion with avascular necrosis of the proximal pole. Treatment with a vascularized bone graft from the dorsum of the distal radius. *J Hand Surg [Br]* 23(5):686–690, 1998.
9. Braun RM: Proximal pedicle bone grafting in the forearm and proximal carpal row. *Orthop Trans* 7(1):35, 1983.
10. Brown K, Marie P, Lysakowski T, et al: Epiphyseal growth after free fibular transfer with and without microvascular anastomosis: experimental study in the dog. *J Bone Joint Surg Br* 65:493–501, 1983.
11. Burger HK, Windhofer C, Gaggl AJ, et al: Vascularized medial femoral trochlea osteocartilaginous flap reconstruction of proximal pole scaphoid nonunions. *J Hand Surg [Am]* 38(4):690–700, 2013.
12. Burger HK, Windhofer C, Gaggl AJ, et al: Vascularized medial femoral trochlea osteochondral flap reconstruction of advanced Kienbock disease. *J Hand Surg [Am]* 39(7):1313–1322, 2014.
13. Capito AE, Higgins JP: Scaphoid overstuffing: the effects of the dimensions of scaphoid reconstruction on scapholunate alignment. *J Hand Surg [Am]* 38(12): 2419–2425, 2013.
14. Ceruso M, Taddei F, Bigazzi P, et al: Vascularised fibula graft inlaid in a massive bone allograft: considerations on the bio-mechanical behaviour of the combined graft in segmental bone reconstructions after sarcoma resection. *Injury* 39 (Suppl 3):S68–S74, 2008.
15. Chacha P, Ahmad M, Daruwalla JS: Vascular pedicle graft of the ipsilateral fibula for nonunion of the tibia with a large defect. *J Bone Joint Surg Br* 63:244–253, 1981.

16. Chacha PB: Vascularised pedicular bone grafts. *Int Orthop* 8(2):117–138, 1984.
17. Chang DW, Weber KL: Segmental femur reconstruction using an intercalary allograft with an intramedullary vascularized fibula bone flap. *J Reconstr Microsurg* 20(3):195–199, 2004.
18. Chang MA, Bishop AT, Moran SL, et al: The outcomes and complications of 1,2-intercompartmental supraretinacular artery pedicled vascularized bone grafting of scaphoid nonunions. *J Hand Surg [Am]* 31(3):387–396, 2006.
19. Chen CM, Disa JJ, Lee H-Y, et al: Reconstruction of extremity long bone defects after sarcoma resection with vascularized fibula flaps: a 10-year review. *Plast Reconstr Surg* 119(3):915–924, discussion 925–926, 2007.
20. Chung DW, Han CS, Lee JH, et al: Outcomes of wrist arthroplasty using a free vascularized fibular head graft for Enneking stage II giant cell tumors of the distal radius. *Microsurgery* 33(2):112–118, 2013.
21. Daecke W, Lorenz S, Wieloch P, et al: Lunate resection and vascularized os pisiform transfer in Kienbock's disease: an average of 10 years of follow-up study after Saffar's procedure. *J Hand Surg [Am]* 30(4):677–684, 2005.
22. Dailiana ZH, Malizos KN, Zachos V, et al: Vascularized bone grafts from the palmar radius for the treatment of waist nonunions of the scaphoid. *J Hand Surg [Am]* 31(3):397–404, 2006.
23. de Boer HH: *Vascularized fibular transfer*, Leiden, the Netherlands, 1988, University of Leiden.
24. de Boer HH, Wood MB: Bone changes in the vascularized fibular graft. *J Bone Joint Surg Br* 71(3):374–378, 1989.
25. De Smet L: Treatment of non-union of forearm bones with a free vascularised corticoperiosteal flap from the medial femoral condyle. *Acta Orthop Belg* 75(5): 611–615, 2009.
26. Dell PC, Sheppard JE: Vascularized bone grafts in the treatment of infected forearm nonunions. *J Hand Surg [Am]* 9(5):653–658, 1984.
27. Diefenbeck M, Nerlich A, Schneeberger S, et al: Allograft vasculopathy after allogeneic vascularized knee transplantation. *Transplant Int* 24(1):e1–e5, 2011.
28. Doi K, Hattori Y: Vascularized bone graft from the supracondylar region of the femur. *Microsurgery* 29(5):379–384, 2009.
29. Doi K, Oda T, Soo-Heong T, et al: Free vascularized bone graft for nonunion of the scaphoid. *J Hand Surg [Am]* 25(3):507–519, 2000.
30. Doi K, Sakai K: Vascularized periosteal bone graft from the supracondylar region of the femur. *Microsurgery* 15(5):305–315, 1994.
31. Duffy GP, Wood MB, Rock MG, et al: Vascularized free fibular transfer combined with autografting for the management of fracture nonunions associated with radiation therapy. *J Bone Joint Surg Am* 82(4):544–554, 2000.
32. Erbs G, Bohm E: Long-term results of pisiform bone transposition in lunate necrosis. *Handchir Mikrochir Plast Chir* 16(2):85–89, 1984.
33. Fernandez DL, Eggli S: Non-union of the scaphoid. Revascularization of the proximal pole with implantation of a vascular bundle and bone-grafting [see comments]. *J Bone Joint Surg Am* 77(6):883–893, 1995.
34. Friedrich JB, Moran SL, Bishop AT, et al: Free vascularized fibular graft salvage of complications of long-bone allograft after tumor reconstruction. *J Bone Joint Surg Am* 90(1):93–100, 2008.
35. Friedrich JB, Moran SL, Bishop AT, et al: Vascularized fibula flap onlay for salvage of pathologic fracture of the long bones. *Plast Reconstr Surg* 121(6):2001–2009, 2008.
36. Fuchs B, Steinmann SP, Bishop AT: Free vascularized corticoperiosteal bone graft for the treatment of persistent nonunion of the clavicle. *J Shoulder Elbow Surg* 14(3):264–268, 2005.
37. Fujimaki A, Suda H: Experimental study and clinical observations on hypertrophy of vascularized bone grafts. *Microsurgery* 15(10):726–732, 1994.
38. Gabl M, Pechlaner S, Zimmermann R: Free vascularized iliac bone graft for the treatment of scaphoid nonunion with avascular proximal fragment. *Oper* 21(4–5): 386–395, 2009.
39. Gabl M, Reinhart C, Lutz M, et al: Vascularized bone graft from the iliac crest for the treatment of nonunion of the proximal part of the scaphoid with an avascular fragment. *J Bone Joint Surg* 81(10):1414–1428, 1999.
40. Giessler GA, Zobitz M, Friedrich PF, et al: Host-derived neoangiogenesis with short-term immunosuppression allows incorporation and remodeling of vascularized diaphyseal allogeneic rabbit femur transplants. *J Orthop Res* 27(6):763–770, 2009.
41. Gilbert A: Vascularized transfer of the fibular shaft. *Int J Microsurg* 1:100–102, 1979.
42. Gilbert A: Free vascularized bone grafts. *Int Surg* 66(1):27–31, 1981.
43. Gordon L, Chin EJ: The treatment of infected non-unions and segmental defects of the tibia with staged microvascular muscle transplantation and bone-grafting. *J Bone Joint Surg Am* 70:377–386, 1988.
44. Gras M, Mathoulin C: Vascularized bone graft pedicled on the volar carpal artery from the volar distal radius as primary procedure for scaphoid non-union. *Orthop Traumatol Surg Res* 97(8):800–806, 2011.
45. Green DP: The effect of avascular necrosis on Russe bone grafting for scaphoid nonunion. *J Hand Surg [Am]* 10(5):597–605, 1985.
46. Guimberteau JC, Panconi B: Recalcitrant non-union of the scaphoid treated with a vascularized bone graft based on the ulnar artery. *J Bone Joint Surg Am* 72(1): 88–97, 1990.
47. Guo F, Ding BF: Vascularized free fibular transfer in the treatment of bone tumors. *Arch Orthop Traumat Surg* 98:209–215, 1981.
48. Han CS, Wood MB, Bishop AT, et al: Vascularized bone transfer. *J Bone Joint Surg Am* 74(10):1441–1449, 1992.
49. Harrison DH: The osteocutaneous free fibular graft. *J Bone Joint Surg Br* 68:804–807, 1986.
50. Hattori Y, Doi K, Sakamoto S, et al: Vascularized pedicled bone graft for avascular necrosis of the capitate: case report. *J Hand Surg [Am]* 34(7):1303–1307, 2009.
51. Hendel PM, Hattner RS, Rodrigo J, et al: The functional vascular anatomy of the rib. *Plast Reconstr Surg* 70:578–587, 1982.
52. Hertel R, Masquelet AC: The reverse flow medial knee osteoperiosteal flap for skeletal reconstruction of the leg. Description and anatomical basis. *Surg Radiol Anat* 11(4):257–262, 1989.
53. Heymans R, Adelmann E, Koebke J: Anatomical bases of the pediculated pisiform transplant and the intercarpal fusion by Graner in Kienbock's disease. *Surg Radiol Anat* 14(3):195–201, 1992.
54. Hierner R, Stock W, Wood MB, et al: Vascularized fibula transfer. A review. *Unfallchirurg* 95(3):152–159, 1992.
55. Higgins JP, Burger HK: Osteochondral flaps from the distal femur: expanding applications, harvest sites, and indications. *J Reconstr Microsurg* 30(7):483–490, 2014.
56. Hori Y, Tamai S, Okuda H, et al: Blood vessel transplantation to bone. *J Hand Surg [Am]* 4(1):23–33, 1979.
57. Huang GK, Liu ZZ, Shen YL, et al: Microvascular free transfer of iliac bone based on the deep circumflex iliac vessels. *J Microsurg* 2:113–120, 1980.
58. Hugon S, Koninckx A, Barbier O: Vascularized osteochondral graft from the medial femoral trochlea: anatomical study and clinical perspectives. *Surg Radiol Anat* 32(9):817–825, 2010.
59. Huntington TW: Use of a segment of fibula to supply a defect in the tibia. *Ann Surg* 41:249–251, 1905.
60. Innocenti M, Delcroix L, Manfrini M, et al: Vascularized proximal fibular epiphyseal transfer for distal radial reconstruction. *J Bone Joint Surg Am* 86(7):1504–1511, 2004.
61. Innocenti M, Delcroix L, Manfrini M, et al: Vascularized proximal fibular epiphyseal transfer for distal radial reconstruction. *J Bone Joint Surg Am* 87(Suppl 1 Pt 2):237–246, 2005.
62. Iorio ML, Masden DL, Higgins JP: The limits of medial femoral condyle corticoperiosteal flaps. *J Hand Surg [Am]* 36(10):1592–1596, 2011.
63. Iorio ML, Masden DL, Higgins JP: Cutaneous angiosome territory of the medial femoral condyle osteocutaneous flap. *J Hand Surg [Am]* 37(5):1033–1041, 2012.
64. Jaminet P, Rahmanian-Schwarz A, Pfau M, et al: Fibulo-scapho-lunate arthrodesis after resection of the distal radius for giant-cell tumor of the bone. *Microsurgery* 32(6):458–462, 2012.
65. Jessu M, Wavreille G, Strouk G, et al: Scaphoid nonunions treated by Kuhlmann's vascularized bone graft: radiographic outcomes and complications. *Chir Main* 27(2–3):87–96, 2008.
66. Jones DB, Jr, Burger H, Bishop AT, et al: Treatment of scaphoid waist nonunions with an avascular proximal pole and carpal collapse. A comparison of two vascularized bone grafts. *J Bone Joint Surg Am* 90(12):2616–2625, 2008.
67. Jones DB, Jr, Burger H, Bishop AT, et al: Treatment of scaphoid waist nonunions with an avascular proximal pole and carpal collapse. Surgical technique. *J Bone Joint Surg Am* 91(Suppl 2):169–183, 2009.
68. Jones DB, Jr, Moran SL, Bishop AT, et al: Free-vascularized medial femoral condyle bone transfer in the treatment of scaphoid nonunions. *Plast Reconstr Surg* 125(4):1176–1184, 2010.
69. Judet H, Judet J, Gilbert A: Vascular microsurgery in orthopaedics. *Int Orthop* 5(2):61–68, 1981.
70. Jupiter JB, Bour CJ, May JWJ: The reconstruction of defects in the femoral shaft with vascularized transfers of fibula bone. *J Bone Joint Surg Am* 69:365–374, 1987.
71. Kakar S, Duymaz A, Steinmann S, et al: Vascularized medial femoral condyle corticoperiosteal flaps for the treatment of recalcitrant humeral nonunions. *Microsurgery* 31(2):85–92, 2011.
72. Katsaros J, Schusterman M, Beppu M, et al: The lateral upper arm flap: anatomy and clinical applications. *Ann Plast Surg* 12(6):489–500, 1984.
73. Katz D, Gilbert A, Teot L: Growth potential of vascularized epiphyseal bone transplants. Experimental and clinical study. *Ann Chir Main* 4(3):249–258, 1985.
74. Kawai H, Yamamoto K: Pronator quadratus pedicled bone graft for old scaphoid fractures. *J Bone Joint Surg Br* 70(5):829–831, 1988.
75. Khouri RK, Koudsi B, Reddi H: Tissue transformation into bone in vivo. A potential practical application. *JAMA* 266(14):1953–1955, 1991.
76. Kind GM, Buntic RF, Buncke GM, et al: The effect of an implantable Doppler probe on the salvage of microvascular tissue transplants. *Plast Reconstr Surg* 101(5): 1268–1273, discussion 1274–1275, 1998.

77. Kuhlmann JN, Mimoun M, Boabighi A, et al: Vascularized bone graft pedicled on the volar carpal artery for non-union of the scaphoid. *J Hand Surg [Br]* 12(2):203–210, 1987.
78. Lanzetta M: Scaphoid reconstruction by a free vascularized osteochondral graft from the rib: a case report. *Microsurgery* 29(5):420–424, 2009.
79. Larsen M, Friedrich PF, Bishop AT: A modified vascularized whole knee joint allotransplantation model in the rat. *Microsurgery* 30(7):557–564, 2010.
80. Larsen M, Willems WF, Pelzer M, et al: Fibroblast growth factor-2 and vascular endothelial growth factor mediated augmentation of angiogenesis and bone formation in vascularized bone allotransplants. *Microsurgery* 34(4):301–307, 2014.
81. Larson AN, Bishop AT, Shin AY: Free medial femoral condyle bone grafting for scaphoid nonunions with humpback deformity and proximal pole avascular necrosis. *Tech Hand Up Extrem Surg* 11(4):246–258, 2007.
82. Li J, Wang Z, Pei G-X, et al: Biological reconstruction using massive bone allograft with intramedullary vascularized fibular flap after intercalary resection of humeral malignancy. *J Surg Oncol* 104(3):244–249, 2011.
83. Lin N, Ye Z, Li W: Long-term result of fibula grafting for reconstruction of the distal radius after giant cell tumor excision. *Zhonghua Wai Ke Za Zhi* 47(14):1079–1082, 2009.
84. Masden DL, Iorio ML, Higgins JP: Comparison of the osseous characteristics of medial femoral condyle and fibula flaps. *J Hand Surg Eur Vol* 38(4):437–439, 2013.
85. Mathoulin C, Gilbert A, Azze RG: Congenital pseudarthrosis of the forearm: treatment of six cases with vascularized fibular graft and a review of the literature. *Microsurgery* 14(4):252–259, 1993.
86. Mathoulin C, Gras M, Roukos S: Vascularized bone grafting from the volar distal radius for carpal bones reconstruction. *Chir Main* 29(Suppl 1):S65–S76, 2010.
87. Mathoulin C, Haerle M: Vascularized bone graft from the palmar carpal artery for treatment of scaphoid nonunion. *J Hand Surg [Br]* 23(3):318–323, 1998.
88. Mathoulin C, Haerle M, Vandeputte G: Vascularized bone graft in carpal bone reconstruction. *Ann Chir Plast Esthet* 50(1):43–48, 2005.
89. Mathoulin C, Wahegaonkar AL: Revascularization of the lunate by a volar vascularized bone graft and an osteotomy of the radius in treatment of the Kienbock's disease. *Microsurgery* 29(5):373–378, 2009.
90. Mattar T, Friedrich PF, Bishop AT: Effect of rhBMP-2 and VEGF in a vascularized bone allotransplant experimental model based on surgical neoangiogenesis. *J Orthop Res* 31(4):561–566, 2013.
91. McKee DM, editor: *Microvascular rib transplantation in reconstruction of the mandible. Presented at the Annual meeting of the American Society of Plastic and Reconstructive Surgeons*, Montreal, Canada, 1971.
92. Medrykowski F, Barbary S, Gibert N, et al: Vascularized proximal fibular epiphyseal transfer: two cases. *Orthop Traumatol Surg Res* 98(6):728–732, 2012.
93. Merrell GA, Wolfe SW, Slade JF, 3rd.: Treatment of scaphoid nonunions: quantitative meta-analysis of the literature. *J Hand Surg [Am]* 27(4):685–691, 2002.
94. Mestdagh H, Houcke M, Mairesse JL, et al: Vascular anatomy of the pisiformis bone. *Ann Chir Main* 3(2):145–148, 1984.
95. Metaizeau JP, Olive D: Conservative treatment of malignant bone tumors by vascularized bone grafts (letter). *Presse Med* 12(15):960–961, 1983.
96. Minami A, Kaneda K, Itoga H: Treatment of infected segmental defect of long bone with vascularized bone transfer. *J Reconstr Microsurg* 8(2):75–82, 1992.
97. Minami A, Kaneda K, Itoga H, et al: Free vascularized fibular grafts. *J Reconstr Microsurg* 5:37–43, 1989.
98. Minami A, Kimura T, Matsumoto O, et al: Fracture through united vascularized bone grafts. *J Reconstr Microsurg* 9(3):227–232, 1993.
99. Mizumoto S, Inada Y, Weiland AJ: Fabrication of vascularized bone grafts using ceramic chambers. *J Reconstr Microsurg* 9(6):441–449, 1993.
100. Moore JB, Mazur JM, Zehr D, et al: A biomechanical comparison of vascularized and conventional autogenous bone grafts. *Plast Reconstr Surg* 73(3):382–386, 1984.
101. Moran SL, Cooney WP, Berger RA, et al: The use of the 4 + 5 extensor compartmental vascularized bone graft for the treatment of Kienbock's disease. *J Hand Surg [Am]* 30(1):50–58, 2005.
102. Moran SL, Cooney WP, Shin AY: The use of vascularized grafts from the distal radius for the treatment of Preiser's disease. *J Hand Surg [Am]* 31(5):705–710, 2006.
103. Moran SL, Shin AY, Bishop AT: The use of massive bone allograft with intramedullary free fibular flap for limb salvage in a pediatric and adolescent population. *Plast Reconstr Surg* 118(2):413–419, 2006.
104. Nonnenmacher J, Bahm J, Laforest P, et al: Aneurysmal cyst of the proximal radius: resection and free vascularized fibular bone graft. *Microsurgery* 14(4):280–284, 1993.
105. Okada T, Tsukada S, Obara K, et al: Free vascularized fibular graft for replacement of the radius after excision of giant cell tumor: case report. *J Microsurg* 3(1):48–53, 1981.
106. Pechlaner S, Hussl H, Kunzel KH: Alternative surgical method in pseudarthroses of the scaphoid bone. Prospective study. *Handchir Mikrochir Plast Chir* 19(6):302–305, 1987.
107. Pelzer M, Larsen M, Chung Y-G, et al: Short-term immunosuppression and surgical neoangiogenesis with host vessels maintains long-term viability of vascularized bone allografts. *J Orthop Res* 25(3):370–377, 2007.
108. Pho RW, Levack B, Satku K, et al: Free vascularized fibula graft in the treatment of congenital pseudarthrosis of the tibia. *J Bone Joint Surg Br* 67:64–70, 1985.
109. Pierer G, Steffen J, Hoflehner H: The vascular blood supply of the second metacarpal bone: anatomic basis for a new vascularized bone graft in hand surgery. An anatomical study in cadavers. *Surg Radiol Anat* 14(2):103–112, 1992.
110. Rao SS, Sexton CC, Higgins JP: Medial femoral condyle flap donor-site morbidity: a radiographic assessment. *Plast Reconstr Surg* 131(3):357e–362e, 2013.
111. Rodriguez-Vegas JM, Delgado-Serrano PJ: Corticoperiosteal flap in the treatment of nonunions and small bone gaps: technical details and expanding possibilities. *J Plast Reconstr Aesthet Surg* 64(4):515–527, 2011.
112. Rose PS, Shin AY, Bishop AT, et al: Vascularized free fibula transfer for oncologic reconstruction of the humerus. *Clin Orthop Relat Res* 438:80–84, 2005.
113. Roy-Camille R: Fractures et pseudarthroses du scaphoide moyen utilisation d'un gretion pedicule. *Actual Chir Ortho R Poincare* 4:197–214, 1965.
114. Sakai K, Doi K, Kawai S: Free vascularized thin corticoperiosteal graft. [see comment]. *Plast Reconstr Surg* 87(2):290–298, 1991.
115. Salibian AH, Anzel SH, Salyer WA: Transfer of vascularized grafts of iliac bone to the extremities. *J Bone Joint Surg Am* 69:1319–1327, 1987.
116. Sammer DM, Bishop AT, Shin AY: Vascularized medial femoral condyle graft for thumb metacarpal reconstruction: case report. *J Hand Surg [Am]* 34(4):715–718, 2009.
117. Sanders R, Mayou BJ: A new vascularized bone graft transferred by microvascular anastomosis as a free flap. *Br J Surg* 66(11):787–788, 1979.
118. Santoni-Rugiu P: Review of 33 free groin flaps in the repair of complicated defects of the lower limb. *Ann Plast Surg* 9:10–17, 1982.
119. Satoh T, Tsuchiya M, Kobayashi M, et al: Experience with free composite tissue transplantation based on the deep circumflex iliac vessels. *J Microsurg* 3:77–84, 1981.
120. Sawaizumi T, Nanno M, Ito H: Vascularized second metacarpal-base bone graft in scaphoid non-union by the palmar approach. *J Reconstr Microsurg* 19(2):99–106, 2003.
121. Schuurman HH, Bos KE, VanNus YH: Laser doppler bone probe in vascularized fibula transfers: A preliminary report. *Microsurgery* 8:186–189, 1987.
122. Shaffer JW, Field GA, Wilber RG, et al: Experimental vascularized bone grafts: histopathologic correlations with postoperative bone scan: the risk of false-positive results. *J Orthop Res* 5(3):311–319, 1987.
123. Sheetz KK, Bishop AT, Berger RA: The arterial blood supply of the distal radius and ulna and its potential use in vascularized pedicled bone grafts. *J Hand Surg [Am]* 20(6):902–914, 1995.
124. Shin AY, Bishop AT: Vascularized bone grafts for scaphoid nonunions and Kienbock's disease. *Orthop Clin North Am* 32(2):263–277, viii, 2001.
125. Siegert JJ, Wood MB: Thrombosed vascularized bone graft: viability compared with a conventional bone graft. *J Reconstr Microsurg* 3(2):99–103, 1987.
126. Solonen KA: Free vascularized bone graft in the treatment of pseudarthrosis. *Int Orthop* 6(1):9–13, 1982.
127. Sowa DT, Weiland AJ: Clinical applications of vascularized bone autografts. *Orthop Clin North Am* 18(2):257–273, 1987.
128. Stock W, Hierner R, Wolf K: Vascularized periosteal transplant. A review of a new therapeutic possibility. *Handchir Mikrochir Plast Chir* 23(3):149–156, 1991.
129. Straw RG, Davis TR, Dias JJ: Scaphoid nonunion: treatment with a pedicled vascularized bone graft based on the 1,2 intercompartmental supraretinacular branch of the radial artery. *J Hand Surg [Br]* 27(5):413, 2002.
130. Sumiura S: Free vascularized fibula graft applied to anterior body fusion of the cervical spine—clinical and experimental study. *J Jpn Orthop Assoc* 63(4):308–319, 1989.
131. Sunagawa T, Bishop AT, Muramatsu K: Role of conventional and vascularized bone grafts in scaphoid nonunion with avascular necrosis: a canine experimental study. *J Hand Surg [Am]* 25(5):849–859, 2000.
132. Swartz WM, Izquierdo R, Miller MJ: Implantable venous Doppler microvascular monitoring: laboratory investigation and clinical results. *Plast Reconstr Surg* 93(1):152–163, 1994.
133. Takami H, Doi K, Takahashi S, et al: Reconstruction of a large tibial defect with a free vascularized fibular graft. *Arch Orthop Trauma Surg* 102:203–205, 1984.
134. Tamai S, Yajima H, Ono H: Revascularization procedures in the treatment of Kienbock's disease. *Hand Clin* 9(3):455–466, 1993.
135. Taylor GI: The current status of free vascularized bone grafts. *Clin Plast Surg* 10(1):185–209, 1983.
136. Taylor GI, Miller GDH, Ham FJ: The free vascularized bone graft. A clinical extension of microvascular techniques. *Plast Reconstr Surg* 55:533–534, 1975.
137. Taylor GI, Townsend P, Corlett R: Superiority of the deep circumflex iliac vessels as the supply for free groin flaps. *Plast Reconstr Surg* 64(5):595–604, 1979.

138. Tsai TM, Bennett DL, Pederson WC, et al: Complications and vascular salvage of free-tissue transfers to the extremities. *Plast Reconstr Surg* 82(6):1022–1026, 1988.
139. Tu YK, Bishop AT, Kato T, et al: Experimental carpal reverse-flow pedicle vascularized bone grafts. Part I: the anatomical basis of vascularized pedicle bone grafts based on the canine distal radius and ulna. *J Hand Surg [Am]* 25(1):34–45, 2000.
140. Tu YK, Bishop AT, Kato T, et al: Experimental carpal reverse-flow pedicle vascularized bone grafts. Part II: bone blood flow measurement by radioactive-labeled microspheres in a canine model. *J Hand Surg [Am]* 25(1):46–54, 2000.
141. Twisk R, Pavlov PW, Sonneveld J: Reconstruction of bone and soft tissue defects with free fibula transfer. *Ann Plast Surg* 21(6):555–558, 1988.
142. Usami F, Iketani M, Hirukaa M, et al: Treatment of congenital pseudarthrosis of the tibia by a free vascularized fibular graft: Case report. *J Microsurg* 3:40–47, 1981.
143. Viehweger E, Gonzalez JF, Launay F, et al: Shoulder arthrodesis with vascularized fibular graft after tumor resection of the proximal humerus. *Rev Chir Orthop Reparatrice Appar Mot* 91(6):523–529, 2005.
144. Weiland AJ: Vascularized bone transfers. *AAOS Instr Course Lect* 33:446–460, 1984.
145. Willems WF, Larsen M, Friedrich PF, et al: Cell lineage in vascularized bone transplantation. *Microsurgery* 34(1):37–43, 2014.
146. Willems WF, Larsen M, Giusti G, et al: Revascularization and bone remodeling of frozen allografts stimulated by intramedullary sustained delivery of FGF-2 and VEGF. *J Orthop Res* 29(9):1431–1436, 2011.
147. Wong VW, Higgins JP, Katz RD: Functional reconstruction of subtotal thumb metacarpal defect with a vascularized medial femoral condyle flap: case report. *J Hand Surg [Am]* 39(10):2005–2008, 2014.
148. Wood MB: Upper extremity reconstruction by vascularized bone transfers: results and complications. *J Hand Surg [Am]* 12(3):422–427, 1987.
149. Wood MB, Bishop AT: Massive bone defects of the upper limb: reconstruction by vascularized bone transfer. *Hand Clin* 23(1):49–56, 2007.
150. Wood MB, Cooney WP, 3rd, Irons GB, Jr: Skeletal reconstruction by vascularized bone transfer: indications and results. *Mayo Clin Proc* 60(11):729–734, 1985.
151. Yajima H, Tamai S, Mizumoto S, et al: Experimental study on secondary living bone graft—method of creating new donor by vascular bundle implantation to isolated bone. *J Jpn Orthop Assoc* 63(5):539–548, 1989.
152. Yamamoto H, Jones DB, Jr, Moran SL, et al: The arterial anatomy of the medial femoral condyle and its clinical implications. *J Hand S Eur* 35(7):569–574, 2010.
153. Yoshimura M, Shimamura K, Iwai Y, et al: Free vascularized fibular transplant. *J Bone Joint Surg Am* 65:1295–1301, 1983.
154. Yoshizaki K: Experimental study of vascularized fibular grafting including the epiphyseal growth plate–autogenous orthotopic grafting. *J Jpn Orthop Assoc* 58(8):813–828, 1984.
155. Youdas JW, Wood MB, Cahalan TD, et al: A quantitative analysis of donor site morbidity after vascularized fibula transfer. *J Orthop Res* 6(5):621–629, 1988.
156. Yuceturk A, Isiklar ZU, Tuncay C, et al: Treatment of scaphoid nonunions with a vascularized bone graft based on the first dorsal metacarpal artery. *J Hand Surg [Br]* 22(3):425–427, 1997.
157. Zaidenberg C, Siebert JW, Angrigiani C: A new vascularized bone graft for scaphoid nonunion. *J Hand Surg [Am]* 16(3):474–478, 1991.
158. Zinberg EM, Wood MB, Brown ML: Vascularized bone transfer: evaluation of viability by postoperative bone scan. *J Reconstr Microsurg* 2(1):13–19, 1985.

47

Toe-to-Hand Transplantation

Fu-Chan Wei and Nidal F. AlDeek

The first report on a toe-to-hand transfer ever done to a human goes back in time to the 19th century when Nicoladoni described staged, pedicled toe-to-hand transfer over a four-week period. Davis was the first to combine staged transfer with microsurgical anastomosis of the dorsalis pedis artery; however, the credit for the first, one-stage toe transplantation to the thumb actually goes to Yang who transplanted the second toe in 1966.[1] Cobbett, on the other hand, transferred the great toe to the thumb for the first time in 1968.[14] After that, many clinical reports using various forms of toe transfer ensued during the 1970s and 1980s reflecting the intimate relationship between toe transfer and advances in microsurgery.[19,22,24,29,30,35,39,65,82–85,93,95,101,104,113,114] Nowadays, toe transplantation is the only safe and reliable procedure that replaces "like with like" in cases of missing or lost thumb and/or fingers.

For thumb reconstruction, either functional or aesthetic, toe transfer is a widely accepted option; in contrast, for finger reconstruction, toe transplantation has been somewhat controversial. It is getting more acceptance now because patients have become better informed and more demanding, and colleagues have accumulated additional experience.[19,48,69,88,93,95,101,104,114] Not surprisingly, digital and thumb amputations have a profound impact on quality of life, psychosocial functioning, and the ability of the patient to return to work.[64,88] Such an impact is expected to have a debilitating effect when mutilating injuries involve multiple digits. Therefore, "like-with-like" reconstruction using feet as donor sites is a good alternative to restore function and appearance after digital amputations.

In comparison to the results obtained with prostheses or some conventional techniques,[4] microsurgical toe transfer is the only procedure that provides functioning digits with sensitivity[39,91,102]; and in contrast to hand transplantation, toe transfer does not involve lifelong immunosuppressant administration. Plus, satisfactory hand function and patients' approval are still achievable.[32,47,49] Reports on the use of toe transplantation for finger replacement include multiple-digit reconstruction with bilateral toe transplantation,[82,104,105] combined transplantation of the second and third toes,[100] combined transplantation of the third and fourth toes,[82,106] single transplantation of the third toe,[101,108] and other toe combinations transplanted as one unit.[8]

Microsurgical restoration of distal digit function with partial toe transfer was first suggested in 1979 by Buncke and Rose,[3] who used pulp neurosensory free flaps for finger reconstruction. During the past 10 years more attention has been focused on this complex anatomic region, and various surgical procedures have been described and refined for distal digit reconstruction, including vascularized nail grafts,[39] toe hemipulp free flaps,[60] lesser toe wraparound procedures,[44,53,96] and partial transplantation of a lesser toe[21] or a great toe.[112] This brief review leaves no doubt that microsurgical toe transplantation has revolutionized hand reconstruction and that its role will continue to expand.

This chapter focuses on toe-to-finger reconstruction but also covers many aspects of thumb reconstruction and some topics about congenital hand reconstruction.

GENERAL CONSIDERATIONS

Although technically feasible, not every patient who experiences digit amputation is a candidate for microsurgical toe-to-hand transplantation. In selecting the right patients for this type of surgery, a multifactorial assessment, which has to be thorough and complete, should be conducted focusing on amputation level, number of digits involved, patient's age and parents' motivation (in the pediatric population), and patient's needs and motivations (in the adult population). For instance, a distal amputation of one digit might be psychologically more important and meaningful to one patient than a metacarpal hand deformity is to another, even though a higher functional deficit is present in the latter patient. Moreover, although it may seem counterintuitive, a single-finger amputation distal to the proximal interphalangeal (PIP) joint constitutes one of the best indications for toe transfer because of the excellent functional results that can be achieved; whereas, a single-finger amputation proximal to this joint is probably best addressed with ray amputation.[19] The patient's overall general health, medical problems, and associated injuries should be considered as well.

Age deserves special discussion; although advanced age is not an absolute contraindication to toe transplantation, functional requirements in the hand are lower in elderly patients. Furthermore, a higher risk of medical complications and less sensory recovery can be expected at an advanced age.[17] In contrast to elderly patients, infants appear to benefit significantly from toe transplantation, as remarkable gains in function, sensation, and ability to perform daily activities with high psychological satisfaction of the growing children and their parents are achievable[39,40]; however, performing toe-to-hand transplantation in children younger than two can be technically challenging.[39] Occupation, hand dominance, and activity levels are all important factors for adults. Surgical indications may also differ from country to country, based on the level of worker's compensation coverage, job opportunities, and cultural demands.[79]

The location and number of missing digits are important for establishing reconstructive priorities.[99] Radial pulp defects in the index and middle finger and the ulnar aspect of the thumb are more important for fine pinch and the handling of small objects.[35] With multiple-digit amputation, reconstruction should encompass at least two adjacent fingers to enhance stability and strength and to provide tripod pinch to ensure that the thumb is functional. The radial digits (index and middle) are more important for patients with occupations that require fine manipulation, whereas the ulnar digits (ring and middle) are more necessary for work that requires a powerful grasp.[97,102]

When toe-to-hand transplantation is being considered as a reconstructive option, donor site morbidity should be extensively discussed with the patient and relatives. Although foot function for most ambulatory activities is not restricted after the resection of one or two toes, it might be limited to some degree for specific activities (e.g., certain sports). Moreover, when both feet are used for transfer, the dominant foot, which generally is the right, should be given preference in terms of the least donor site morbidity. For instance, if a great toe and combined second and third toes are considered, the right foot is chosen to be the donor for combined second and third toes given the fact that donor site deficit will be less than that following the loss of the hallux. Foot cosmesis should not be overlooked and can be important in some cultures and in young patients. Finally, for surgeons involved in hand reconstruction, experience and familiarity with the various toe transplantation techniques are a must in order to avoid failures and complications and to offer their patients the optimal result.

Initial Care and Preoperative Evaluation

Digit replantation, including use of the distal parts, remains the best option for the management of acute traumatic amputations. This is a reliable procedure that should be attempted whenever indicated and possible.[6,28] Toe transplantation for digit reconstruction must be considered from the time of initial injury; however, and when practical, it should be discussed with the patient and relatives as an option for future reconstruction, even before replantation. This is particularly true for patients with multiple-digit amputations and when conditions for replantation are not ideal (e.g., severe crushing or avulsion injuries).[80] If replantation fails or is not feasible, toe transplantation for reconstruction should be planned during the initial care period. Bone, tendon, and neurovascular bundle length must be preserved after debridement of all nonviable tissue and provision of adequate soft tissue coverage (Figure 47.1).[66,90] The length of all anatomic structures retained in the stump is likely to determine the type of toe transplantation and its functional and aesthetic outcome. Moreover, preservation of stump length reduces the likelihood of requiring nerve or tendon grafts, and vein grafts for vascular anastomoses, during finger reconstruction, thus avoiding extensive dissection in the donor foot.

Bone and Joint

It is a common mistake to excessively shorten the digital skeleton to achieve direct or primary closure of the wound with local flaps. For skeletal fixation with toe-to-hand transplantation, bone stumps as short as 5 mm can be used for intraosseous wiring.[115] It is therefore recommended that bone length be

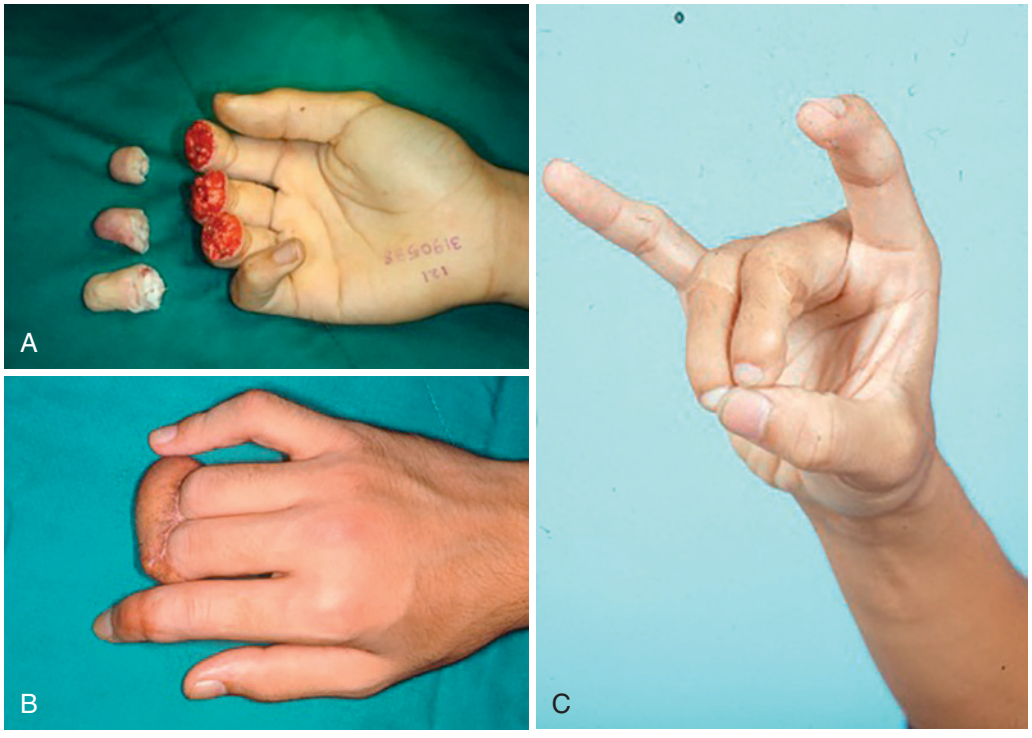

FIGURE 47.1 **A**, Distal amputation of the index, middle, and ring fingers. **B**, Only the index finger was successfully replanted, and the middle and ring finger stumps were covered with a pedicled groin flap after debridement and preservation of the fingers' skeleton, tendons, and neurovascular bundle length. **C**, Final result showing pinch function after reconstruction involving bilateral partial second-toe simultaneous transplantation.

preserved to the extent that complete soft tissue coverage is still possible. Every effort should be made to maintain functioning joints or the cartilage surface with the articular capsule. The transferred toe can be harvested through disarticulation, and the joint capsule can be directly repaired with the recipient finger to achieve good functional results, particularly in thumb reconstruction.[78] Metacarpal stumps can be augmented to the desired length with a nonvascularized bone block,[100] thus avoiding proximal transmetatarsal osteotomies during toe transfer and preserving metatarsal length, which minimizes donor foot morbidity.

Tendons

Preservation of the extensor mechanism in the finger is important for maintenance of balance between the intrinsic and extrinsic systems involved in extension. For distal amputations, the extensor apparatus should be left in situ on the digital stump, and the intrinsic insertions on the proximal phalanx should be preserved. For more proximal amputations at the metacarpophalangeal (MP) joint level, retention of the extensor hood is necessary for the same reason.[66,90] Conservative debridement of flexor tendon length is important in distal digit amputations because functional results are better when the insertion of the flexor digitorum superficialis (FDS) is present. For more proximal amputations, the finger flexors must be left in situ, although they might be shortened for future tendon repair in zone 3. By preserving the flexor tendons in place, it is possible to maintain the integrity of and space within the pulley system, which is vital for future function, especially the A2 and A4 pulleys.

Vessels

The digital arteries and veins are seldom intact after crushing or avulsion injuries. Every effort should be made to retain the arteries' length in nonreplantable digit amputations because these can be used as recipient vessels for toe transplantation in the future. The ulnar digital artery in particular is larger than its counterpart in the radial side of the fingers. The veins are less of a concern, given that a rich venous network on the dorsum of the hand is usually present.

Nerves

To prevent the development of neuromas in amputation stumps, proximal resection of the digital nerves has been advocated.[37] When toe-to-hand transplantation is considered for future reconstruction, however, the nerves' length must be preserved because recovery of sensation is faster when neurorrhaphies are performed closer to the transferred toe.

Skin

Instead of using local or regional flaps to cover the wound, soft tissue augmentation with a pedicle groin flap is a better alternative. The use of local flaps may increase morbidity, create additional deformity, and impede functional rehabilitation.[23] The redundant skin provided by a groin flap may later prove useful for covering the transferred toe (see Figure 47.1, *C*). It can also be used to protect the pedicle, create an adequate web space, and decrease scarring. Moreover, when there is enough skin available on the recipient finger (or hand), it is possible to minimize the amount of skin included during toe transfer, thus facilitating primary closure of the foot incision and enhancing donor site appearance.[21]

In some circumstances it may be possible to overcome hand skin deficiency in a single stage if additional tissue is taken from the foot along with the toe. Although readily available, the dorsalis pedis fasciocutaneous flap is not recommended because of donor site morbidity; however, a fasciosubcutaneous flap (excluding skin) based on the dorsalis pedis or metatarsal arteries, followed by a skin graft, has been reported to lead to good success.[20]

Primary Versus Secondary Toe-to-Hand Transplantation

Toe-to-hand transplantation can be performed either primarily or secondarily. Primary reconstruction refers to transfer in the setting of an open wound. Secondary reconstruction refers to transfer after definitive wound closure is achieved. Acute, subacute, and chronic are confusing terms and of no clinical relevance to toe-to-hand surgery. It is important, however, to emphasize that in primary transfer adequate debridement should be achieved and associated injuries should be managed before toe-to-hand transplantation is performed. Moreover, primary toe-to-hand transfer may not be suitable for nonreplantable finger amputations in children due to the potential risk of loss of the transferred toe; however, further studies are needed.[57] Nevertheless, parents should be made aware of such a possibility and stump closure should not compromise future toe-to-hand transfer.

From the standpoint of functional outcome, primary transfer maybe more beneficial compared to secondary transfer. A retrospective study of 31 primary and 144 secondary toe-to-hand procedures showed a survival rate of 96.9% in primary and 96.5% in secondary transplants. There was no statistical difference between the two groups in terms of intraoperative anastomotic revision, reexploration, complications, and secondary procedures.[116] Similar results were reported in a study by Woo and associates, who also noted a 30% reduction in convalescent time and a greater likelihood of patients returning to their original jobs after immediate reconstruction.[112] Early transfer may also result in better sensory recovery than delayed transfer.[11]

Primary toe-to-hand transplantation can be performed safely either for functional or aesthetic restoration whether a single or multiple toes are involved. Compared with secondary procedures, it reduces hospital stay, restores hand function, and the patient's body image in less time. In some cases, primary transfer may also be technically easier because dissection of the neurovascular bundles is not impeded by fibrosis or scar adhesion. It is recommended in highly motivated, well-informed patients in good physical condition and when wounds are clearly demarcated and clean (Figure 47.2).[72,112,116] It is also recommended in the setting of multiple-extremity injury when spare parts are available. Woo and associates found that patient satisfaction with the aesthetic appearance is less in primary versus secondary transfer.[112] Some surgeons therefore recommend delayed transfer in all cases to give the patient time to understand the extent of the hand deficit, appreciate the need for the procedure, and accept the reconstructive limitations and possible donor site morbidity.[19] In our opinion, however, the benefits of immediate transfer far outweigh these considerations.







FIGURE 47.2 **A**, Amputation of the index, middle, and ring fingers seven days after debridement in a patient who sustained a severe crushing injury. The finger stumps are prepared for primary reconstruction by toe transplantation. **B, C**, After using two second toes for index and middle finger reconstruction, full active extension and flexion are possible.

RECONSTRUCTIVE OPTIONS

Thumb Amputation

Although a thumb amputated at the interphalangeal (IP) joint level can still perform its basic functions, fine manipulation ability and hand appearance are compromised. Therefore, when replantation is not possible, toe transplantation should always be offered as a reconstructive option, even at a distal level. The thumb can be reconstructed with either the great toe or a lesser toe. Transfer of the great toe can include the entire toe or modified transfers such as the great-toe wraparound flap, trimmed great toe, twisted toe, and many others. The methods of thumb reconstruction should be individualized, taking into consideration the functional and cosmetic needs of the patient as well as donor site morbidity. In general, thumbs reconstructed with the great toe and its variants have a better functional and aesthetic result than those reconstructed with lesser toes.

In cases of thumb amputation between the IP joint and metacarpal head, the functional outcome is significantly affected by the level of amputation and thenar musculature status. Amputations proximal to the metacarpophalangeal joint inevitably result in destruction of the thenar musculature and secondary loss of opposition. Opposable tripod pinch is one of the essential goals in toe-to-thumb reconstruction, which is usually achieved by pronation osteosynthesis in the setting of loss of the muscles of opposition. However, Lin and associates recommended primary opponensplasty in toe transfers to provide active restoration of opposition and better restoration of tripod pinch.[57]

In cases of thumb amputation at the metacarpal level, the toe alone is inadequate to restore normal function. Although a larger flap from the foot, which includes the toe and metatarsal bone, is feasible, donor site morbidity can be quite high. Separate thumb ray reconstruction using osteoplastic techniques should be performed first, followed by second-stage toe transfer.[56]

Reconstruction of Single-Finger Amputation

Just as replantation of single-digit amputations has been a matter of debate for many years, single-digit reconstruction with toe transplantation remains controversial. Because the functional deficit in the hand is minimal when only one finger is missing, some authors believe that sacrificing a toe for finger reconstruction (other than the thumb) is not justified, especially in the nondominant hand.[34,36,79] However, when optimal reconstruction is desired, finger reconstruction with like-tissue transplantation from the foot usually offers satisfactory results, particularly in distal finger amputations.[98,103]

Reconstruction of Distal Digit Amputation

The distal end of a digit is most frequently injured. It is defined as the end portion of the digit distal to the insertion of the flexor pollicis longus in the thumb or the flexor digitorum superficialis (FDS) in the finger.[21,103] The highest density of innervation in the body surface is contained in the finger pulp; thus, it is considered the "end organ of touch." Specialized components of the distal digit include a sensate glabrous pulp and stable adherent nail. Glabrous skin characteristics allow resistance to wear and tear and provide a nonslippery surface for grasping. Attachment of the pulp skin to the underlying distal phalanx by a network of septa prevents excessive skin gliding and shearing, which is essential for strong pinching. The fatty tissue arrangement between the septa allows the pulp to conform to the shape of objects during pinch and grasp. The nail plays a major role in tactile sensibility of the pulp and in tip pinch, and it is an important aesthetic component, especially in women and in some cultures. None of these characteristics can be replicated by local or regional flaps, such as the cross-finger flap or

thenar flap, explaining their limitations and inferiority compared with tissue transferred from the toe.

The ideal reconstruction in this part of the finger maintains digit length with adequate soft tissue padding, provides near-normal sensation, and results in recovery of nail function. Reconstructive options using partial toe transplantation in distal defects include a combination of different portions of the nail, pulp, and distal phalanx from the great or lesser toes. Depending on the defect, vascularized nail grafts,[46,67] onychocutaneous flaps,[44,45] wraparound flaps,[53,96] pulp and hemipulp flaps,[16,60,71] and partial lesser toe transplantation[21,98,103] can be selected for reconstruction (Figure 47.3).

Amputations between the base of the distal phalanx and the middle of the middle phalanx require partial toe transfer with inclusion of the distal interphalangeal (DIP) joint and the flexor and long extensor tendons.[21] Modern jobs and hobbies often demand the presence of all digits (e.g., using a computer keyboard, playing a musical instrument). When indicated, this is the amputation level for which the most rewarding results are obtained with toe-to-finger transplantation (see Figure 47.1).

Reconstruction of Proximal Digit Amputation

Finger amputation between the FDS insertion and the web space (i.e., base of the proximal phalanx) presents a more controversial indication for reconstruction with lesser toes because a shorter finger might result. If the finger amputation has occurred distal to the middle of the proximal phalanx, the second or third total toe (with the PIP joint) may be long enough to achieve adequate function and aesthetic results in some patients (see Figure 47.2, *B*). Because of the resulting

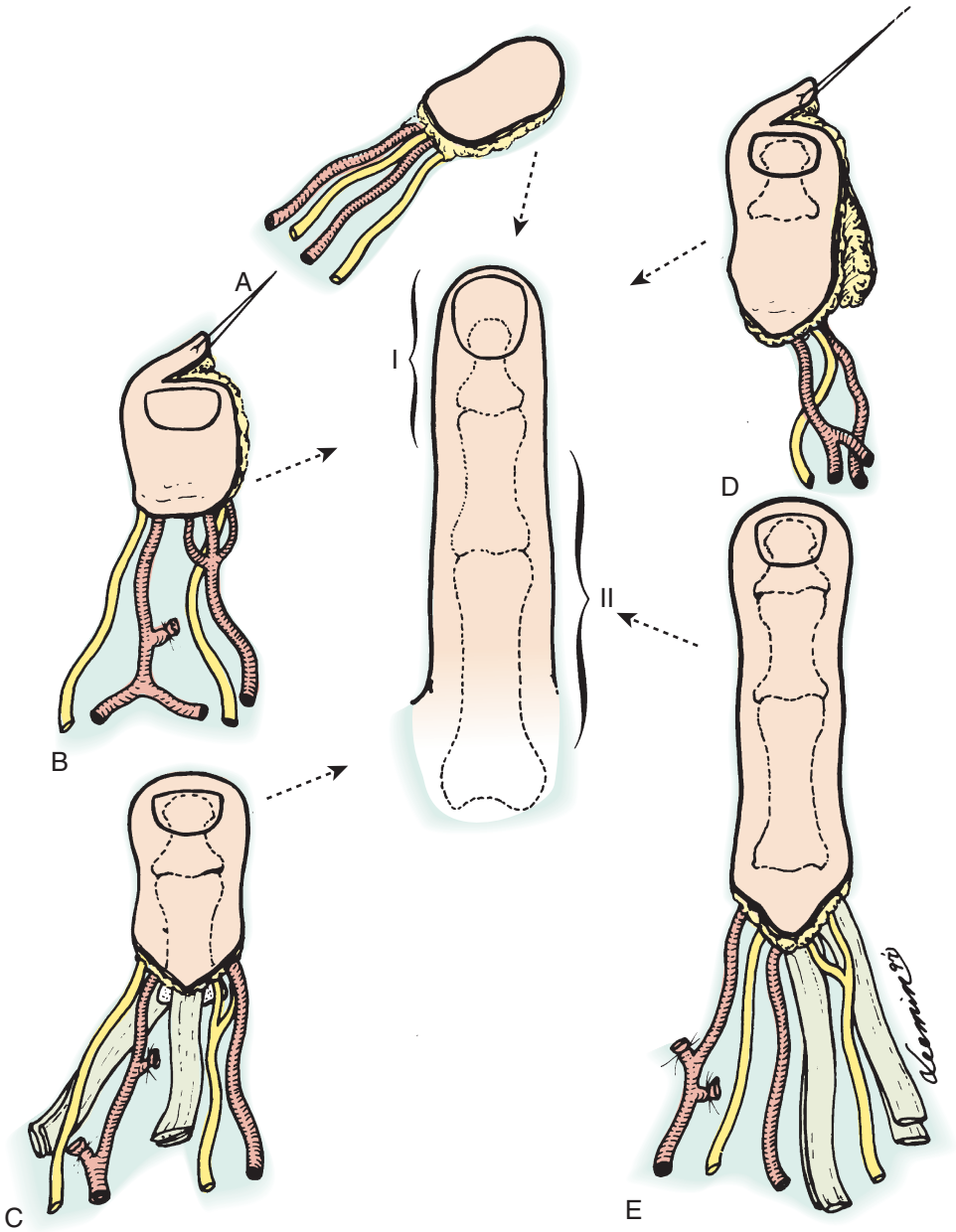

FIGURE 47.3 Single-finger amputation levels and reconstructive options with toe-to-finger transplantation. A pulp toe flap (**A**), vascularized nail graft (**B**), partial lesser toe flap (**C**), or wraparound lesser toe flap (**D**) can be used for distal finger amputation (*I*). Total lesser toe transplantation (**E**) is used for proximal finger amputation (*II*).

length discrepancy with the remaining fingers, more proximal amputations in a single finger might not be suitable for reconstruction with total toe transplantation, and ray amputation could yield more acceptable results.[19] Nevertheless, a functional finger with a suboptimal but acceptable appearance can be achieved with highly motivated patients.

Reconstruction of Multiple-Digit Amputation in the Nonmetacarpal Hand

Reconstruction of Multiple Digits in Distal Amputation

The same principles described for single-digit distal amputation apply to the reconstruction of two or more fingers with distal amputation. Priority should be given to reconstruction of the index and middle fingers because they play a more important role in global hand function, specifically in fine manipulation.[98]

Reconstruction of Multiple Digits in Proximal Amputation

For proximal amputation of two or more fingers, the main purpose of reconstruction is to provide improved prehension ability. It is therefore recommended that reconstruction of at least two fingers be considered.[97,99] The advantages of this approach are provision of a useful tripod pinch, stronger hook grip, lateral stability, and handling precision (Figure 47.4). Reconstructive options for adjacent finger amputations include two separate lesser-toe transplantations or a combined second- and third-toe (or third- and fourth-toe) transplantation on a single vascular pedicle. For two adjacent fingers amputation proximal to the web space, reconstruction with combined second- and third-toe transplantation is a better choice, not only because it reconstructs the web but also because it limits donor morbidity to a single foot and requires only one pair of anastomoses (Figure 47.5). In amputations distal to the web space, combined toe transplantation may create a syndactylous appearance, so two separate toes (e.g., bilateral second toes) may be preferable.[100,104,105]

Recently, Lin and colleagues described the use of split second- and third-toe transplantation in situations in which the web space was preserved but bilateral second-toe transplantation was undesirable owing to harvesting of the great toe.[54] For experienced surgeons, this approach may combine the best of both options in these special situations. An additional consideration, when considering tandem second- and third-toe transplantation for reconstruction of two adjacent digits, is the length of the remaining fingers. As a general rule, the remaining fingers have to be shorter than the tip of the normal little finger; otherwise, the transplanted unit cannot simulate the pinch point and grasp arch of full-length fingers.[83,100]

In cases with an intact articular surface on the metacarpal, the tandem toes can be disarticulated at the metatarsophalangeal joint, and the joint capsule and ligaments are circularly divided and used for reconstruction of the MP joint (i.e., composite joint reconstruction). If the metacarpal articular surface has been damaged or is absent, transmetatarsal toe transplantation is performed.

Reconstruction of Multiple Digits at Various Amputation Levels

It is not uncommon for a reconstructive surgeon to be confronted with the scenario of multiple-digit amputations. It becomes difficult to provide a treatment algorithm because these injuries have a wide array of combinations. The same principles apply here as in other digital reconstructions with toe

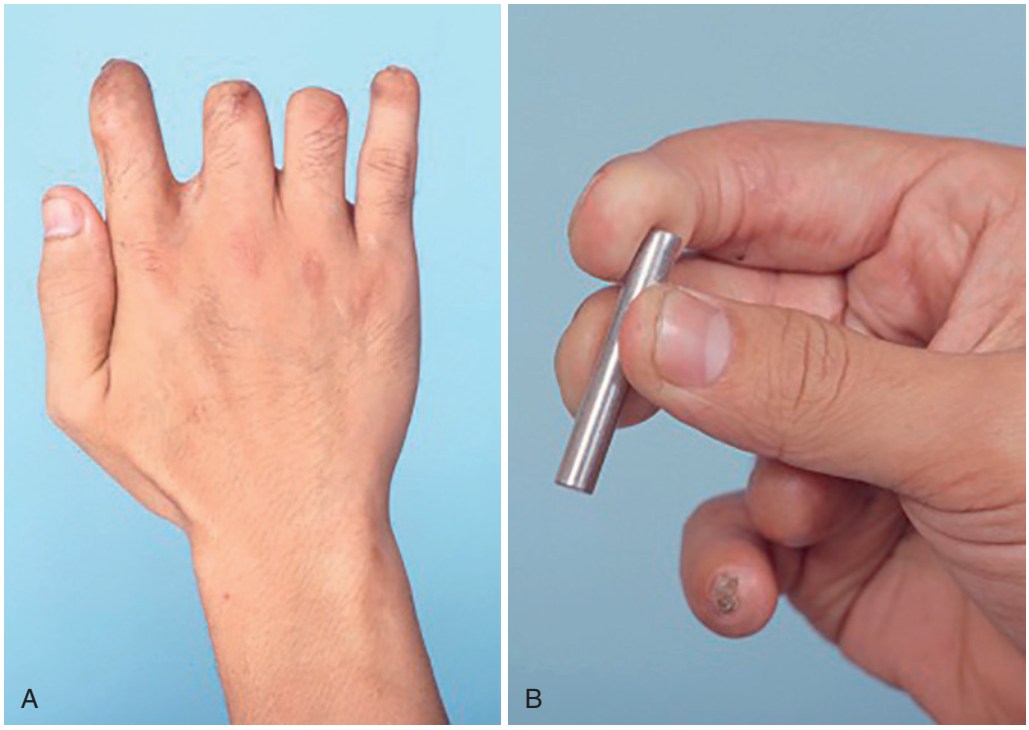

FIGURE 47.4 **A, B**, With multiple-digit amputation, it is best to aim at reconstructing at least two adjacent fingers to provide useful tripod pinch, stronger hook grip, lateral stability, and handling precision.

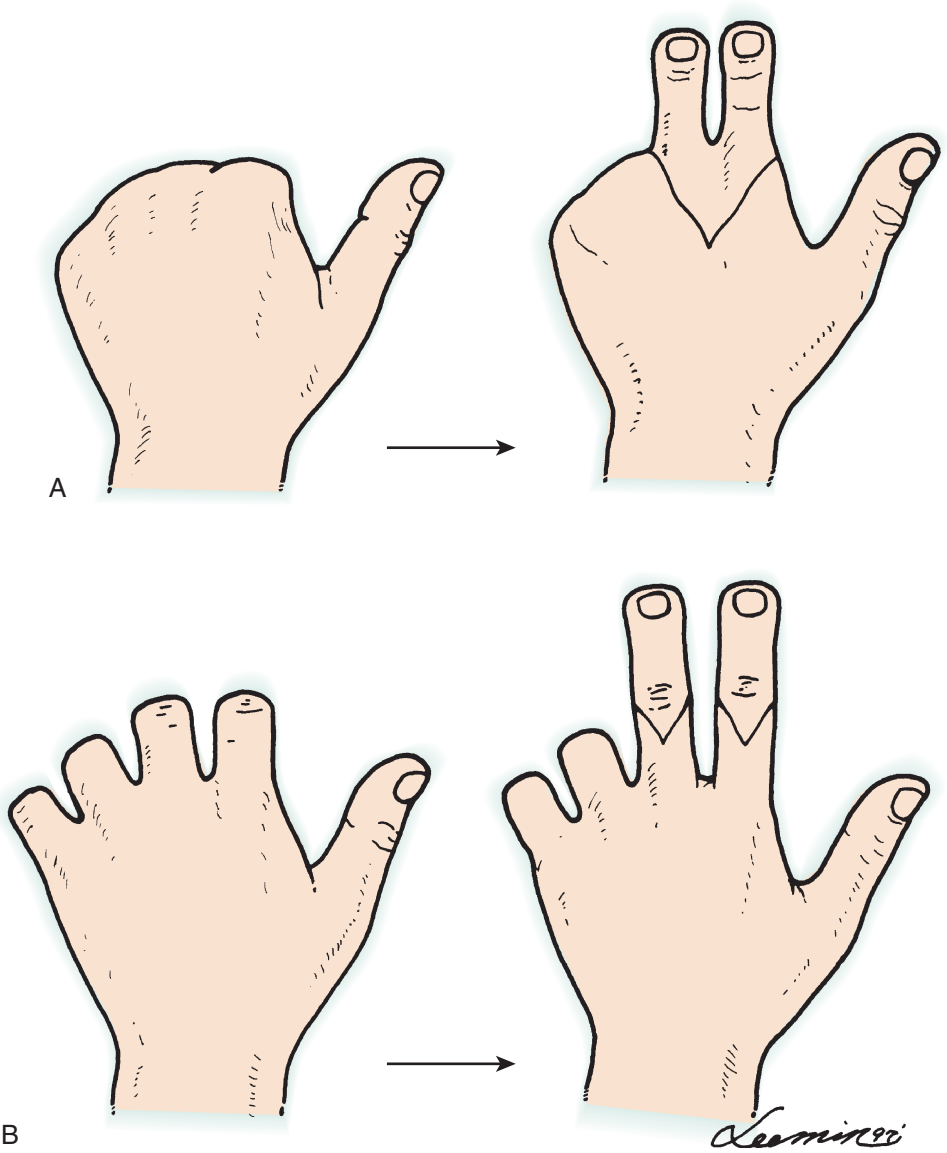

FIGURE 47.5 In digit amputation proximal to the web spaces, combined second- and third-toe transplantation is advocated (**A**), whereas in digit amputation distal to the web spaces, bilateral second-toe transplantation in one stage is preferable (**B**).

transfers. The proportional length of the fingers should not be disregarded as even minimal shortening of one finger draws attention to the others and gives a disfigured appearance. Therefore, the reconstructive surgeon should feel free to use whatever is available to achieve the aforementioned goals of digital reconstruction. A combination of toe transfer, ray amputation, and lengthening procedures may be necessary. To simplify management, the hand is converted into an acceptable one (Del Pinal classification) by means of toe transfer to the distally amputated finger and ray amputation to the proximally amputated finger with great effort to provide three functioning fingers whenever possible.[18,19]

Reconstruction of the Metacarpal Hand

A more severe functional deficit and deformity are present when mutilating hand injuries involve all digits at a proximal level, with or without thumb amputation—a condition referred to as metacarpal hand.[93] The senior author (F-C.W.) and his colleagues have proposed a practical classification of metacarpal hands and defined specific reconstructive options for toe transplantation (Tables 47.1 and 47.2).[61,63,102,104,105] This classification divides the metacarpal hand into two types for reconstructive purposes.

In type I, amputation has occurred in all fingers proximal to the middle of the proximal phalanx, and the thumb is either intact or amputated distal to the IP joint (considered the minimum functional length required for precise prehension). In type II, amputation of all fingers is proximal to the middle of the proximal phalanx, with thumb amputation proximal to the IP joint. For the type I metacarpal hand, it is recommended that at least two adjacent digits be replaced. Depending on the finger amputation level relative to the MP joint (subtypes IA, IB, and IC), bilateral lesser toes or combined second- and third-toe transplantation can be used for reconstruction. For the type II metacarpal hand, a systematic strategy must be followed for the selection of donor toes and reconstructive stages.

TABLE 47.1 Type I Metacarpal Hand

Subtype	Level of Thumb Amputation	Level of Finger Amputation	Recommendations
IA	Intact or distal to IP joint	Distal to MP joint	Bilateral second toes for amputations distal to web space Combined second and third toes for amputations proximal to web space (transproximal phalanx transfer)
IB	Intact or distal to IP joint	Through MP joint with intact metacarpal articular surface	Combined second and third toes (composite joint transfer)
IC	Intact or distal to IP joint	Through MP joint with damaged metacarpal articular surface or transmetacarpal amputation	Combined second and third toes (transmetatarsal transfer)

IP, Interphalangeal; *MP,* metacarpophalangeal.

TABLE 47.2 Type II Metacarpal Hand

Subtype	Level of Thumb Amputation	Level of Finger Amputation	Recommendations
IIA	Distal to metacarpal neck	Four fingers at any level proximal to middle of proximal phalanx	Whole or trimmed great-toe transfer (transproximal phalanx transfer)
IIB	Proximal to metacarpal neck with adequate thenar muscle function	Four fingers at any level proximal to middle of proximal phalanx	Preliminary distraction lengthening or interpositional bone graft, followed by whole or trimmed great-toe transfer *or* Transmetatarsal second-toe transfer
IIC	Any level with inadequate thenar musculature	Four fingers at any level proximal to middle of proximal phalanx	Thumb reconstruction in a second stage after finger reconstruction *and* Tendon transfer to restore opposition
IID	Any level with damaged carpometacarpal joint	Four fingers at any level proximal to middle of proximal phalanx	Same as for IIA and IIB, but aiming at reconstruction of an immobile thumb post

If thenar muscle function is adequate (subtypes IIA and IIB), simultaneous reconstruction of the thumb and two adjacent fingers in one stage is preferable (Figure 47.6). If thenar muscle function is inadequate (subtype IIC), a staged reconstruction is appropriate; the fingers are reconstructed first, and a prosthetic thumb post is used temporarily to assist in determining the length and position of the transferred toe for thumb reconstruction during the second stage (Figure 47.7). Even more complex are conditions in which both hands are involved because the selection of donor toes should take into account functional impairment and deformity of the feet.[102,105]

In the bilateral type II metacarpal hand, the dominant hand can be reconstructed with three toes to achieve tripod pinch, and the nondominant hand can be reconstructed with two toes to provide key or pulp-to-pulp pinch.[61,63,81] The five toes harvested can be the right second and third toes and the left great, third, and fourth toes, sparing the second toe for foot balance.[81] Our experience has revealed good functional recovery of the hands and no significant donor site morbidity with such an approach (Figure 47.8).

Congenital and Traumatic Loss of Digits in a Pediatric Hand

O'Brien and colleagues described the first toe-to-hand transfer for a congenital hand anomaly in 1978 and several series on different hand malformations, including but not limited to, thumb hypoplasia, adactylous hand, symbrachydactyly, and so on.[42,59,73,75,86,87]

For traumatic amputation of fingers in the pediatric population, management is similar to what has been described thus far. Replantation should always be attempted even in single-digit amputation. In nonreplantable digit(s), toe-to-hand transfer should be discussed with the parents extensively, and this complex procedure is clearly indicated even in the setting of a single-digit amputation. However, timing is affected by the child's age (two years old) and primary transfer is usually avoided in children younger than this.

For congenital absence of fingers, constriction ring syndrome is the ideal indication because the joints, muscles, and tendons proximal to the amputation site are typically present and normal. However, aplastic or hypoplastic conditions, including symbrachydactyly, have also been addressed successfully with toe transfers (Figure 47.9).[24,73] Thumb hypoplasia, in particular, remains controversial because many surgeons believe that results obtained by pollicization are better than toe transfers.[24] Reconstruction of the adactylous hand is usually a staged procedure; although reconstructing the thumb is suggested for the first stage followed by ulnar digit reconstruction in the second stage, it can be done in reverse order.[87]

Technical considerations in congenital reconstructions are similar to those outlined elsewhere in this chapter with a few notable exceptions. Although Lister described performing a successful transfer as early as 6 months to a year old, toe transfer should usually not be attempted until the patient is around two when the vessels are of adequate caliber for microvascular anastomosis. Another consideration regarding timing is the

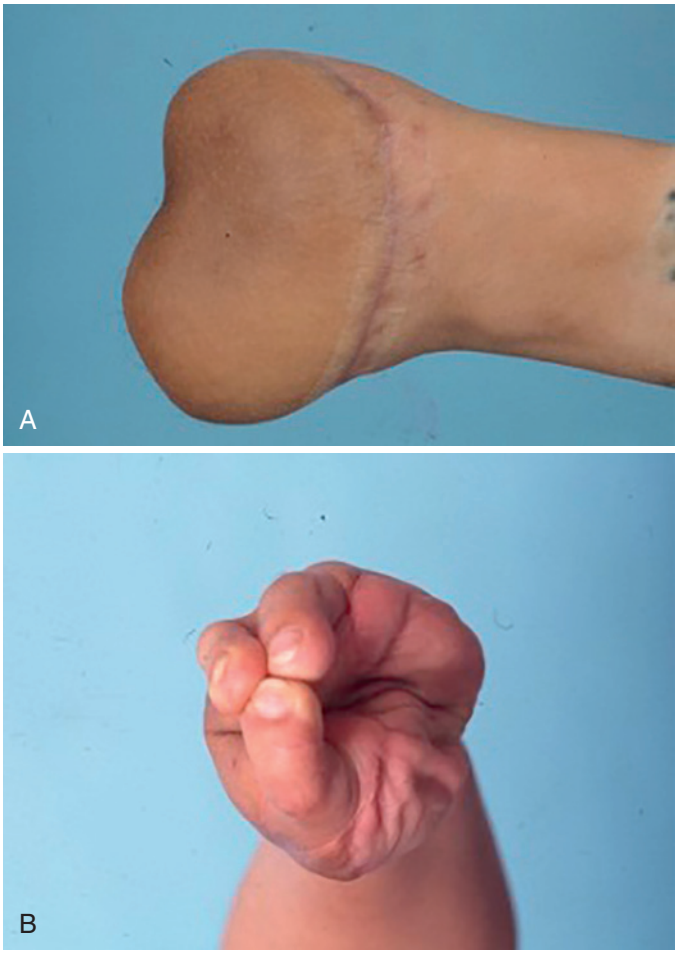

FIGURE 47.6 **A**, Metacarpal hand subtype IIB: amputation of the thumb and all fingers proximal to the metacarpophalangeal joint with good thenar muscle function. **B**, Tripod pinch after reconstruction of the thumb by trimmed great-toe transplantation and reconstruction of the two radial fingers by combined transplantation of the second and third toes from the contralateral foot.

unilateral type of the anomaly. It is best to treat children with unilateral malformations early before adaptive patterns are developed and the use of the abnormal hand is superseded by the normal hand. This situation does not occur in children with bilateral deficiencies.

In aplastic cases, the recipient vessels, nerves, and tendons must be identified before toe harvesting. The toes themselves also may be abnormal in patients with congenital hand abnormalities. As with adults, the first dorsal metatarsal artery (FDMA) is usually dominant and provides the pedicle for the flap. When multiple digits are required, flaps combining two or three toes can be transferred based on the plantar arch. Bony fixation must preserve the epiphyseal plates. Recipient tendons in the aplastic hand may be absent, and primary tendon transfers may be required.[39]

Success rates as high as 96% have been reported. Sensory recovery is usually quite good, with moving two-point discrimination of 5 mm in the series of studies of Foucher and coworkers.[24] However, the most commonly encountered problem is the unpredictable range of motion of the transplanted toe. Transferred toes usually have minimal active DIP motion, an extension deficit at the PIP joint, and a fixed-flexion deformity. Foucher and colleagues reported on 58 children with 65

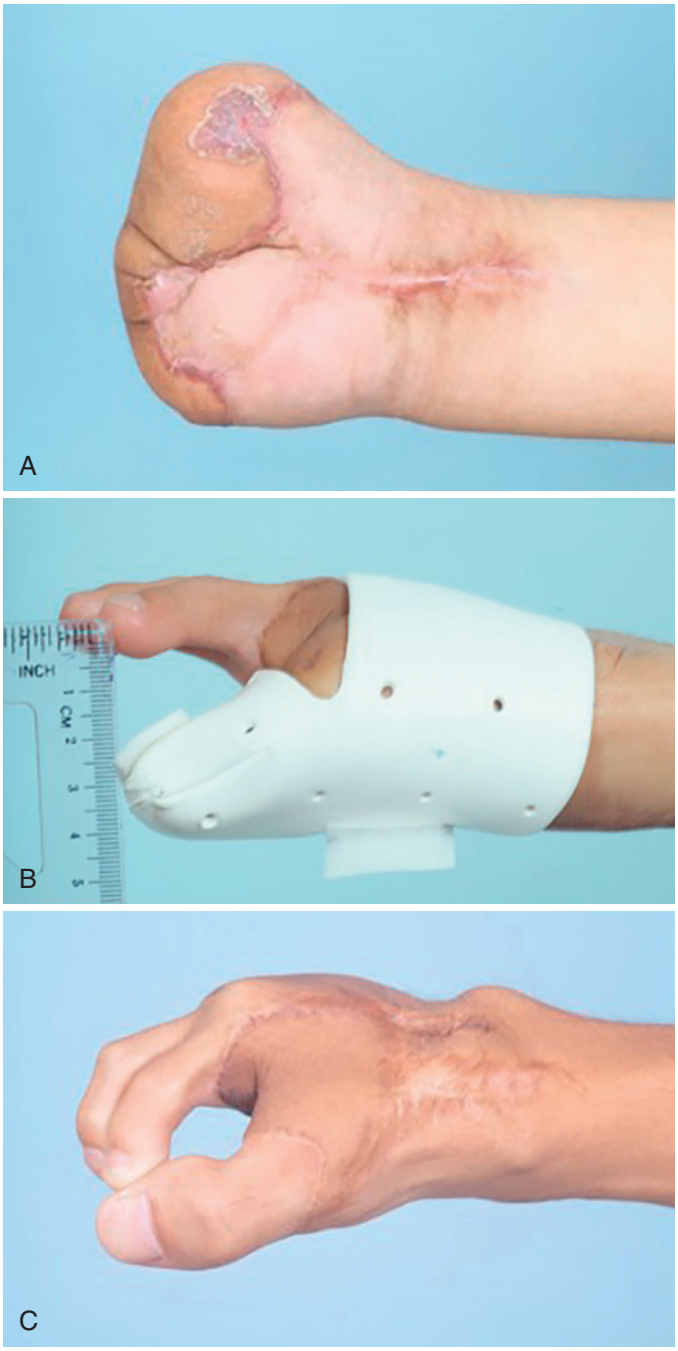

FIGURE 47.7 **A**, Metacarpal hand subtype IIC. **B**, After reconstruction of two adjacent fingers with combined second- and third-toe transplantation, a post is used to enhance pinch function of the transplanted unit and to determine the future position of the toe that will be used for thumb reconstruction. **C**, Eight months after thumb reconstruction by total great-toe transplantation, the patient has a stable pinch function.

toe-to-hand transfers with a mean active range of motion of 38 degrees and a mean extension lag of 25 degrees.[24] Nevertheless, children appear to incorporate the transferred toe into their hand function quite well. Growth of the transferred toe is 60 to 100% of the normal toe.[22,42]

Anatomy for Toe Dissection

Most surgical procedures involved in partial or total toe transplantation use the arterial pedicle to the great and second toe.

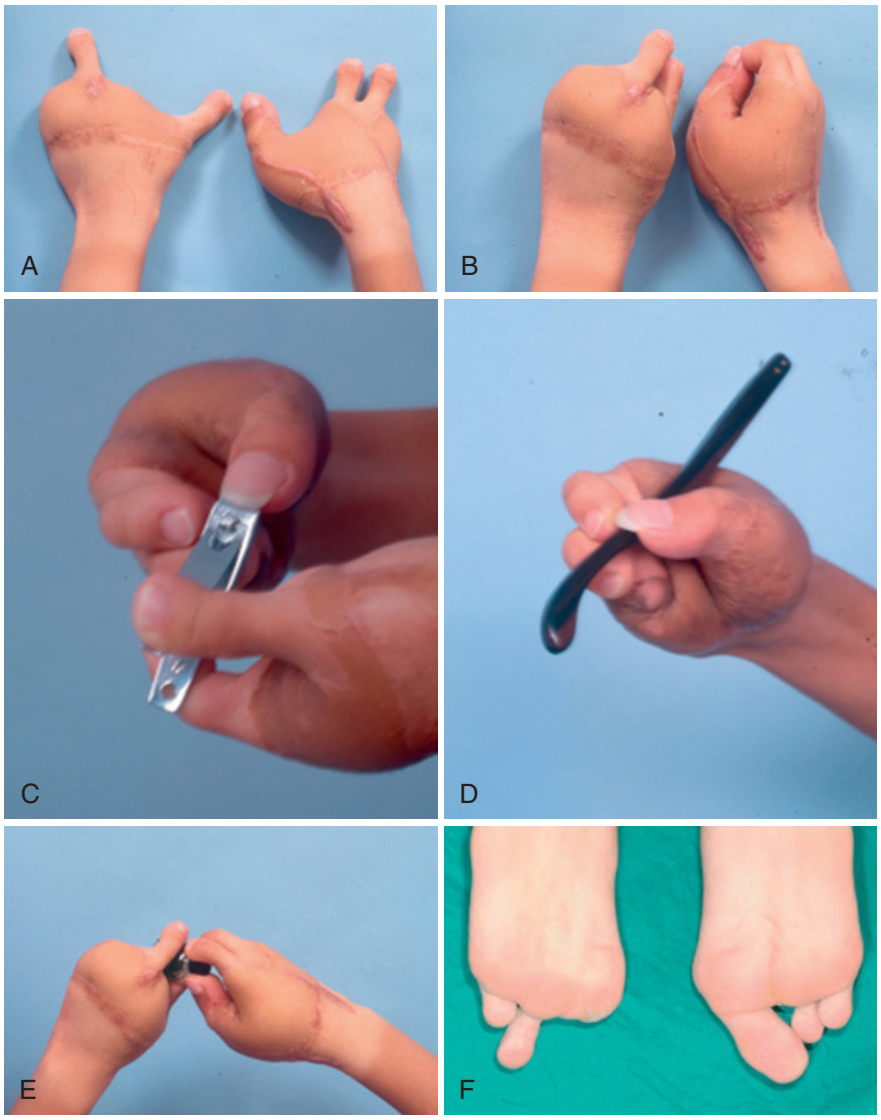

FIGURE 47.8 **A** through **E**, Bilateral metacarpal hand type IIB reconstructed with a total of five toe transplantations to provide tripod pinch for the dominant right hand and pulp-to-pulp pinch for the nondominant left hand. **F**, The donor feet have no callus formations, which is evidence of good maintenance of the original weight-bearing areas.

Several authors have proposed various classifications of the vascular anatomy in the first metatarsal space.[30] All of them describe anatomic variations in the origin of the FDMA; in the relationship between the FDMA and the interosseous muscle; and intermetatarsal ligament, FDMA diameter, and branching patterns. These descriptions have created an image of a complex and highly variable network of vessels in the first–second metatarsal interspace, making the vascular anatomy difficult to understand.

Classically, with most surgical techniques, vascular dissection begins proximally in the dorsum of the foot to identify and follow the course of the dorsalis pedis artery and its continuity as the FDMA. In the senior author's experience, the FDMA was the dominant artery in approximately 70% of cases, the first plantar metatarsal artery (FPMA) was dominant in 20% of cases, and both arteries had the same caliber in the remaining 10% (Figure 47.10). (Notably, the pattern of dominance is asymmetric between the two feet in approximately 20% of people.[77]) In the presence of a plantar-dominant arterial system, dissection of the dorsal aspect in the first metatarsal space needs to include only one superficial vein, and there is no need to deepen the dissection, which might damage the foot and is a waste of time.

It is easier to harvest the great or second toe (or any of the various flaps in this anatomic region) by identifying the dominant vascular pattern in the first web space at the beginning of the dissection and proceeding with dissection of the artery in a retrograde fashion.[107] Dissection always starts in the dorsal aspect of the first web space. The junction of the lateral digital artery of the great toe and the medial digital artery of the second toe, arising from the FDMA, is identified over the intermetatarsal ligament (Figure 47.11). Further dissection of the pedicle is then proximally carried out 2 to 3 cm from this junction. If a dorsal-dominant system is present, retrograde dissection of the FDMA is facilitated by early ligation of the smaller plantar vessel, and the FDMA is isolated proximally. In most cases the



FIGURE 47.9 **A**, Symbrachydactyly of the left hand in a 3-year-old boy. The patient has nearly complete absence of all digits of the hand with the exception of a rudimentary fifth finger. The thenar muscles are hypoplastic but maintain some function. **B**, The second toe was transferred from the right foot, which required concurrent release of syndactyly. (There was a congenital absence of toes on the left foot, necessitating use of the right foot as the donor.) **C**, The harvested toe based on the first dorsal metatarsal artery. The upper arrow indicates the vein, the middle arrow the artery, and the lower arrow the nerve. **D, E**, Ten years after the procedure the patient demonstrates good function. Although he cannot achieve pulp-to-pulp pinch owing to thenar hypoplasia and poor interphalangeal joint motion, he has excellent span and a useful grip.

artery is superficial to the muscle; however, it may also be localized within or deep in the interosseous muscle. If both vessels have a similar caliber, dissection of the FDMA is preferable because it is much easier and more straightforward.[107] If a plantar-dominant system is noted and the FDMA is either absent or very small, the dissection is continued later during the plantar dissection.

The FPMA is usually isolated up to the middle of the metatarsal shaft on the plantar surface. At this point, the union between the FPMA and the dorsalis pedis artery is located at the proximal communicating artery (or deep perforator). If a longer arterial pedicle is required, dissection of the communicating branch in continuity with the dorsalis pedis artery may be too tedious and destructive to the foot. Thus, it is advisable to divide the FPMA and use a vein graft for the vascular anastomosis.

Retrograde dissection is particularly helpful in partial toe transplantation for distal digit reconstruction when only a short pedicle is needed because proximal dissection of the vascular pedicle will not be necessary. In addition, retrograde dissection is helpful in pediatric toe dissection because donor vessel diameter is the most important factor after recipient vessel availability. Therefore, if the FDMA is found to have adequate diameter, dissection proceeds more proximally; otherwise, the

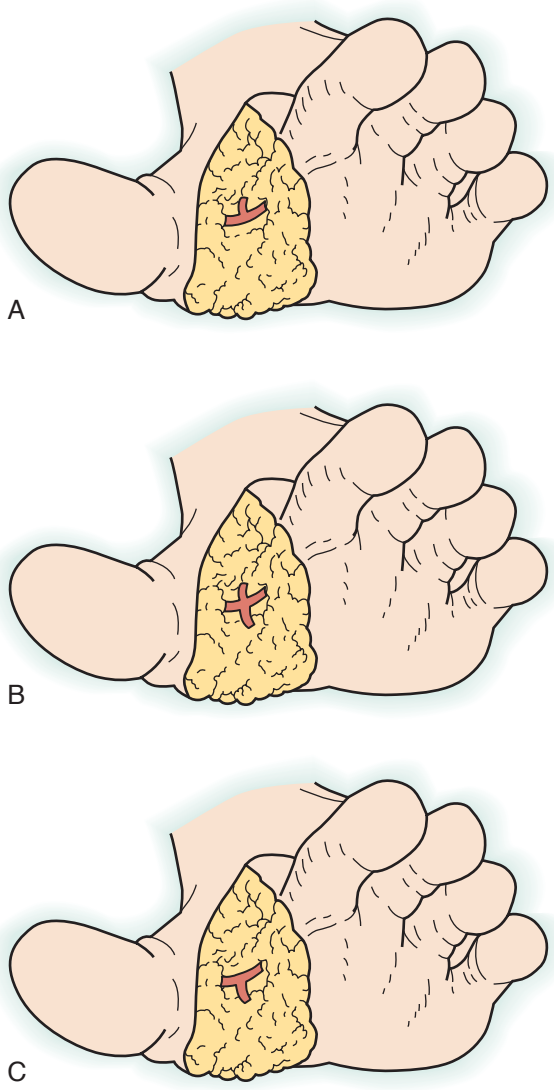

FIGURE 47.10 Retrograde dissection of the first web space in the foot. **A**, In approximately 70% of dissections, the first dorsal metatarsal artery (FDMA) is the larger (dominant) vessel and gives origin to the dorsal proper digital arteries to the great toe and the second toe. **B**, In 10% of cases, the FDMA and first plantar metatarsal artery (FPMA) have the same caliber. **C**, In 20% of cases, the FPMA is the dominant vessel.

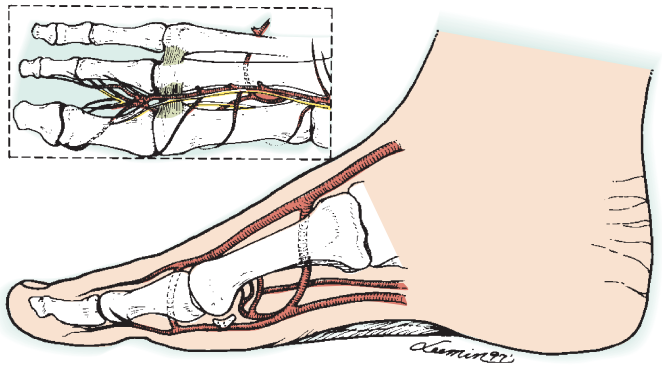

FIGURE 47.11 Anatomic relationship between the first dorsal metatarsal artery over the intermetatarsal ligament and the first plantar metatarsal artery. Communicating branches are present in the web space distally and in the base between the first and second metatarsal bones (also known as the deep perforator or proximal communicating artery).

FPMA is chosen and no time is wasted.[107] Moreover, routine preoperative angiography of the donor foot is not required when this approach is used to harvest any toe or flap based on the arterial system of the first metatarsal space.[107]

SURGICAL TECHNIQUES

Total or Trimmed Transplantation of the Great Toe

Indications

Total transfer of the great toe is selected for thumb reconstruction when the amputation level is at either the proximal phalanx or metacarpal level. It aims to provide a new thumb with a better range of motion and a broader pulp surface for a more powerful pinch. However, it is often too large to simulate the normal thumb on the opposite side. The great-toe wraparound technique was developed by Morrison using the great toenail, skin envelope, and conventional bone graft to circumvent the size problem.[68] Although it yields a nice looking thumb, it does not provide a mobile IP joint. Trimmed transplantation of the great toe combines the advantages of total transfer and the great-toe wraparound technique.[93,94] It is indicated when there is an unacceptable size difference between the thumb on the normal opposite side and the great toe to be harvested, especially when a mobile IP joint is desirable. It is worth mentioning that with the trimmed great-toe technique a reduction of 18 degrees in IP joint motion is expected, which does not seem to affect pulp-to-pulp pinch prehension.[95]

❖ AUTHORS' PREFERRED METHOD OF TREATMENT

The great toe usually looks portlier than the thumb, with wider transverse and anteroposterior diameters. The discrepancy involves bone as well as soft tissue elements (Figure 47.12, *A*). To assess the size discrepancy between the great toe and the normal thumb, the circumferences of the great toe and the normal thumb are measured at three points: the nail eponychium, the widest point (corresponding to the IP joint), and the middle of the proximal phalanx. The thumb measurements are transposed to their corresponding points on the great toe. An additional 2 to 3 mm is added to each measurement to allow direct closure without tension. The residual medial skin strip usually measures 0.5 to 0.8 cm wide, which represents the difference between the toe and thumb circumferences. This should be tapered to a point around the tip of the toe, leaving 2 mm of nail fold to facilitate skin closure. The proximal skin incision is determined by the level of thumb amputation and is usually marked in a circular or "V" shape (Figure 47.12, *B*). Although it is possible to trim the nail together with the underlying nail bed, this is not recommended because the nail fold may become deformed.

The procedure starts by identifying one sizable vein and the dominant arterial supply in the first web space. The vascular pedicle is dissected in a retrograde fashion to the desired length and diameter. Branches of the deep peroneal nerves are preserved. The extensor tendon is then dissected on the dorsal side, and the neurovascular bundle and flexor tendon are isolated on the plantar side. Care is taken to place the incision on the plantar aspect, lateral to the head of the first metatarsal, to prevent a scar over the weight-bearing area.

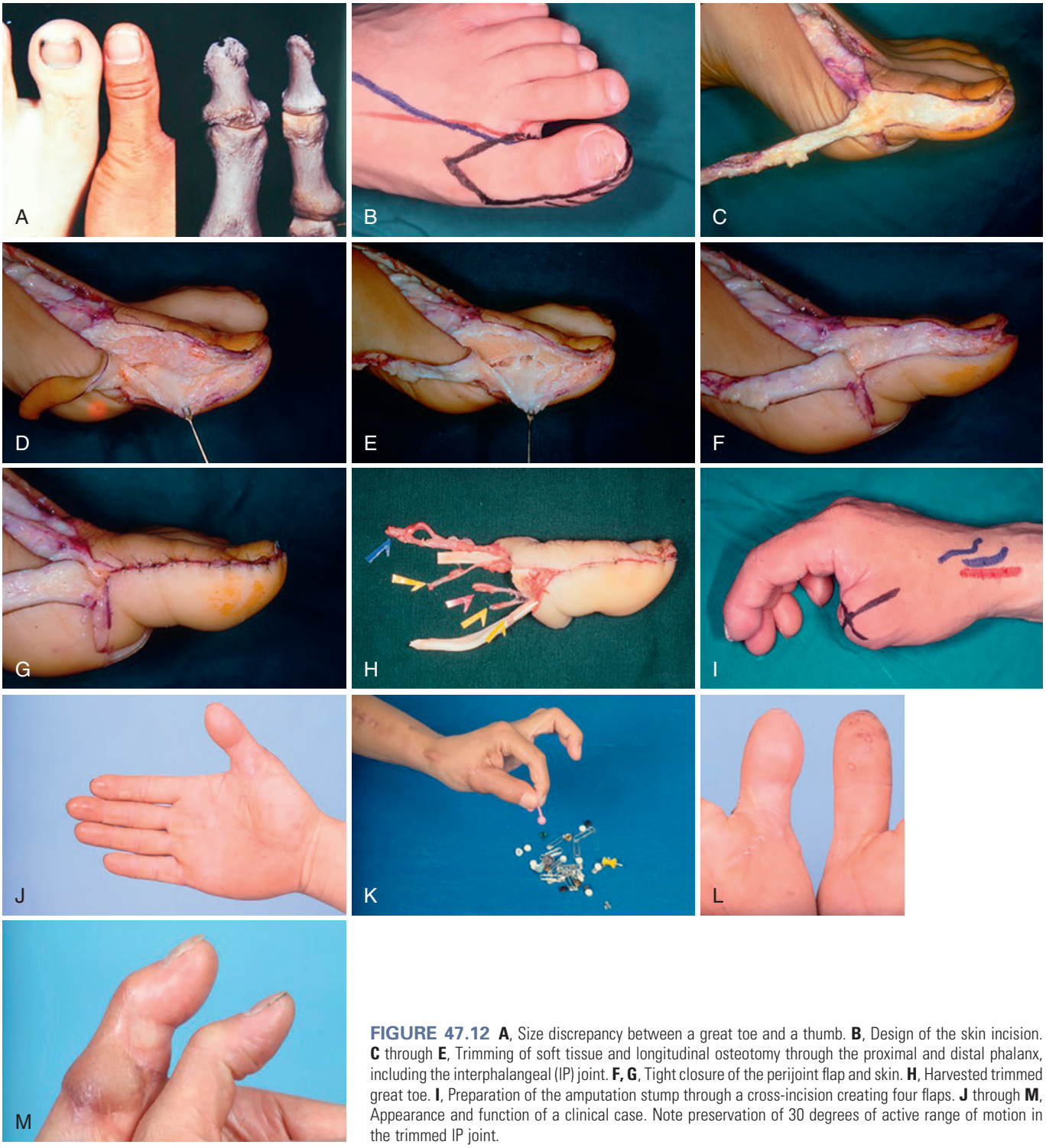

FIGURE 47.12 **A**, Size discrepancy between a great toe and a thumb. **B**, Design of the skin incision. **C** through **E**, Trimming of soft tissue and longitudinal osteotomy through the proximal and distal phalanx, including the interphalangeal (IP) joint. **F, G**, Tight closure of the perijoint flap and skin. **H**, Harvested trimmed great toe. **I**, Preparation of the amputation stump through a cross-incision creating four flaps. **J** through **M**, Appearance and function of a clinical case. Note preservation of 30 degrees of active range of motion in the trimmed IP joint.

Next, the medial skin strip is incised and elevated from distal to proximal. The incision is deepened to the periosteum at the tip of the distal phalanx (Figure 47.12, *C*) but remains superficial to the medial collateral ligament on the medial surface of the IP joint. The second incision is made all the way through the periosteum. The collateral ligament, joint capsule, and periosteum are elevated as a plantar-based single, thick, strong composite soft tissue envelope, which we have designated a "perijoint flap." This subperiosteal (perijoint flap) elevation is continued along the hemicircumference to the middle of the plantar surfaces of both the proximal and distal phalanges (Figure 47.12, *D*). A longitudinal osteotomy (Figure 47.12, *E*) is then performed with an oscillating saw while carefully protecting the neurovascular bundle. This removes a 4- to 6-mm width of the medial joint prominence, along with a 2- to 4-mm width of the phalangeal shafts.

A smooth contour of the osteotomy edges is obtained using a high-speed bur. The hemicircumferential composite perijoint

flap is redraped and the redundant portion is trimmed, followed by repair under proper tension with interrupted sutures using nonabsorbable material. The repair should be tight enough to maintain joint stability (Figure 47.12, *F*). The medial skin incision is also approximated with interrupted sutures (Figure 47.12, *G*). Care should be taken to prevent injury to the nail bed or matrix because this can result in a deformed nail. Finally, the proximal phalanx is osteotomized, preserving at least 1 cm of the base of the proximal phalanx and leaving the great toe attached only by its vascular pedicle. After removal of the tourniquet, the transplant is allowed to perfuse for at least 20 minutes before proceeding with transplantation (Figure 47.12, *H*). The donor site is closed primarily. The osteotomy edges are smoothed and the remaining proximal portion of the medial skin flap of the great toe can be used to assist tension-free closure, if required.

The amputated stump is prepared through a cross-incision creating four flaps (Figure 47.12, *I*). These flaps are mobilized to prepare the bone, extensor and flexor tendons, and digital nerves. They also allow smooth closure of the skin between the recipient site and transplanted toe for a better appearance of the reconstructed thumb. The recipient artery can be the common digital artery (our first choice), the princeps pollicis artery, or the radial artery in the anatomic snuffbox. The bone, extensor and flexor tendons, recipient artery, vein, and nerves are prepared at the recipient site in the usual manner.

Flap insetting and repair of tendons and neurovascular bundles are performed as described in other sections of this text. When closing the wound defect, preservation of skeletal length and good skin coverage are important. In transplantation of the great toe, it is advisable to preserve at least 1 cm of the proximal phalanx to maintain foot span for a better appearance and to preserve push-off function of the donor foot. Skin grafting of the donor site should be avoided. With adequate planning, rarely should there be a problem achieving tension-free closure of the wound in the foot. No drains are required at the donor site.

Partial or Total Transplantation of the Second Toe

Indications

In adults, although selection of the second toe for thumb reconstruction may be controversial,[53,92] use of the second toe for finger reconstruction is a well-accepted procedure. However, thumb amputation proximal to the carpometacarpal (CMC) joint may, in particular, benefit from a second-toe transfer that provides valuable length up to the proximal metatarsal bone compared to the proximal phalanx with great-toe transfer. For pediatric patients, second-toe transfer is usually preferred for both thumb and finger amputations.[41] Partial transplantation of the second toe is used for digit amputations distal to the insertion of the superficial flexor tendon (Figure 47.13),[21,98,103] whereas total transplantation is used for the reconstruction of more proximal finger amputations (Figure 47.14).[26,44]

Flap Design and Elevation

Most surgical techniques designed to harvest the second toe use a combined dorsal and plantar approach.[53] Foucher and Norris suggested harvesting the second toe alone from a dorsal approach to avoid incision and dissection of the fibrofatty tissue in the plantar surface and to allow faster recovery and early walking.[27] In addition, the blood supply to the second toe is theoretically improved because the first- and second-dorsal metatarsal arteries and the plantar arteries are included in a vascular network. Access to the plantar structures from the dorsal approach is facilitated by removing the second metatarsal bone.

For less experienced surgeons, this technique can be more difficult than a combined dorsal and plantar approach and may entail excessive manipulation of the vessels, which might increase the risk of pedicle injury and postoperative vascular complications. Furthermore, resection of the second metatarsal is not necessary in many cases, and the plantar skin flap usually included in the transferred toe is often needed to provide glabrous skin on the volar aspect and to cover the pedicle in the recipient's hand. For these reasons, we prefer the combined approach.

❖ AUTHORS' PREFERRED METHOD OF TREATMENT

The length of the second toe to be harvested is determined before surgery and depends on the level of finger amputation and radiographic findings. Two microsurgical teams work simultaneously to reduce surgical time. The exact lengths of the tendons, nerves, and vascular pedicle in the toe are assessed intraoperatively before dividing them. The dorsal and plantar skin flaps are designed in a "V" shape to ensure primary wound closure without tension. The vertex of the "V"-shaped skin incision is marked 5 to 10 mm proximal to the osteotomy site on the dorsal and plantar aspects of the toe, and the two divergent points of the "V" flap are marked at the midpoint of the first and second web space. The incision is extended proximally in a lazy "S" course for exposure of the vessels and nerves. On the plantar surface, this incision is always made in a vertical direction, and the weight-bearing surface is avoided.

The skin in the dorsal flap is incised and elevated superficially to protect the dorsal veins. Only one sizable vein, usually in the first metatarsal space, is selected and dissected proximally. The dissection continues in the first web space where the dominant arterial pattern is identified and dissected in a retrograde direction (see "Anatomy for Toe Dissection" section). All fatty tissue is carefully removed from the nerves and vessels and the transmetatarsal ligament is then divided. In a dorsal-dominant arterial system, the FDMA is dissected proximally until an adequate length is obtained. If a plantar-dominant system is present, dissection on the dorsal surface is necessary only for the vein; the FPMA is isolated afterward. All small veins and arteries in the second metatarsal space are divided. Branches of the superficial peroneal nerve in the first and second metatarsal space are dissected and used together with the proper digital nerves only when sensory recipient nerves are available; otherwise, just the digital nerves are used for sensory recovery of the transplanted toe. The extensor retinaculum is opened and the extensor digitorum longus and brevis tendons are isolated and followed distally.

The skin flap on the plantar aspect is raised to the base of the proximal phalanx with only 2 to 3 mm of subcutaneous tissue left attached to the dermis. All fibrofatty tissue between the plantar skin and neurovascular bundles is discarded to minimize anteroposterior bulkiness and maximize joint motion in the reconstructed finger. The proper digital nerves are

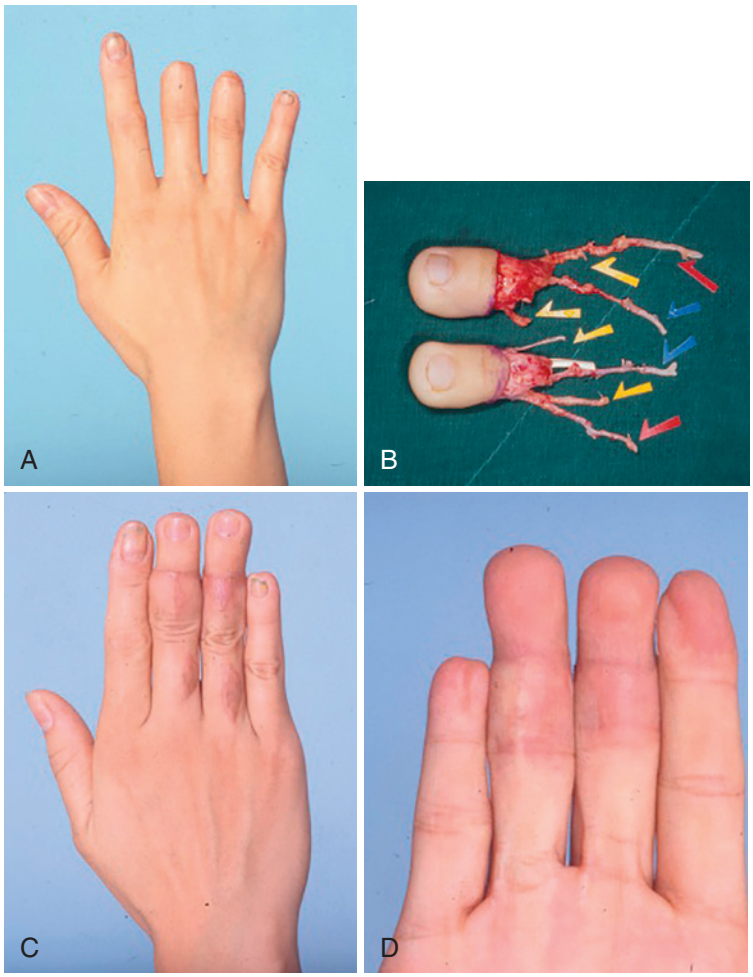

FIGURE 47.13 **A**, Amputation of the middle and ring fingers distal to the insertion of the superficialis flexor tendon. **B**, Bilateral second toes harvested with an osteotomy at the middle of the middle phalanx level. **C, D**, Results three months after reconstruction.

identified distally in the web space, close to the proper digital plantar arteries, on the medial and lateral aspects. Both plantar nerves are dissected proximally up to their union with the respective common digital nerves, which also contain the proper digital nerves to the great and third toes. When a long digital nerve is required, the common digital nerve can be internally neurolysed for several centimeters to extend the length of the proper digital nerve to be harvested. Next, the flexor tendon sheath is approached and opened vertically to expose the short- and long-flexor tendons.

To facilitate tailoring and insetting of the toe, it is advisable to extend the dissection for several millimeters distal to the osteotomy site. This allows skeletonization of the artery and nerves and removal of all fibrofatty tissue, especially what is between the skin and the flexor tendon in the plantar aspect.[94] These refinements are more meaningful in partial transplantation of the second toe, which is associated with a higher incidence of vasospasm. Often the vessels need to be tunneled under the skin proximally, and fixation of the partial toe transfer is critical for a good cosmetic and functional result.[21]

Once all the anatomic structures have been isolated and the required length has been determined, the nerves are divided and marked with 6-0 nylon. The flexor tendons are pulled out and cut. In total transplantation of the second toe, the proximal phalanx is cut at the proper level; alternatively, the metatarsophalangeal joint may be disarticulated and the proximal phalanx shortened to the length needed in the reconstructed finger (see Figure 47.13). In partial transplantation, the veins, nerves, and tendons are dissected distal to the PIP joint, and the middle phalanx is osteotomized in a dorsal-to-plantar direction; otherwise, the distal toe is disarticulated at the PIP joint (see Figure 47.14, *B*). The tourniquet is then released, and the toe is allowed to reperfuse for at least 20 minutes before dividing the main artery and vein.

The donor site in the foot should be closed primarily without tension. It is not necessary to repair the intermetatarsal ligament, and no drains are needed. In unusual cases in which primary closure is difficult, metatarsophalangeal joint disarticulation or transverse metatarsal amputation should be performed. Skin grafting of the donor site should be avoided to prevent foot morbidity and deformity.

Wraparound Flap of the Second Toe

Indications

Despite the fact that the great-toe wraparound flap was initially described for thumb reconstruction,[68] this flap also can be used for other injured fingers. Wraparound flaps can be elevated

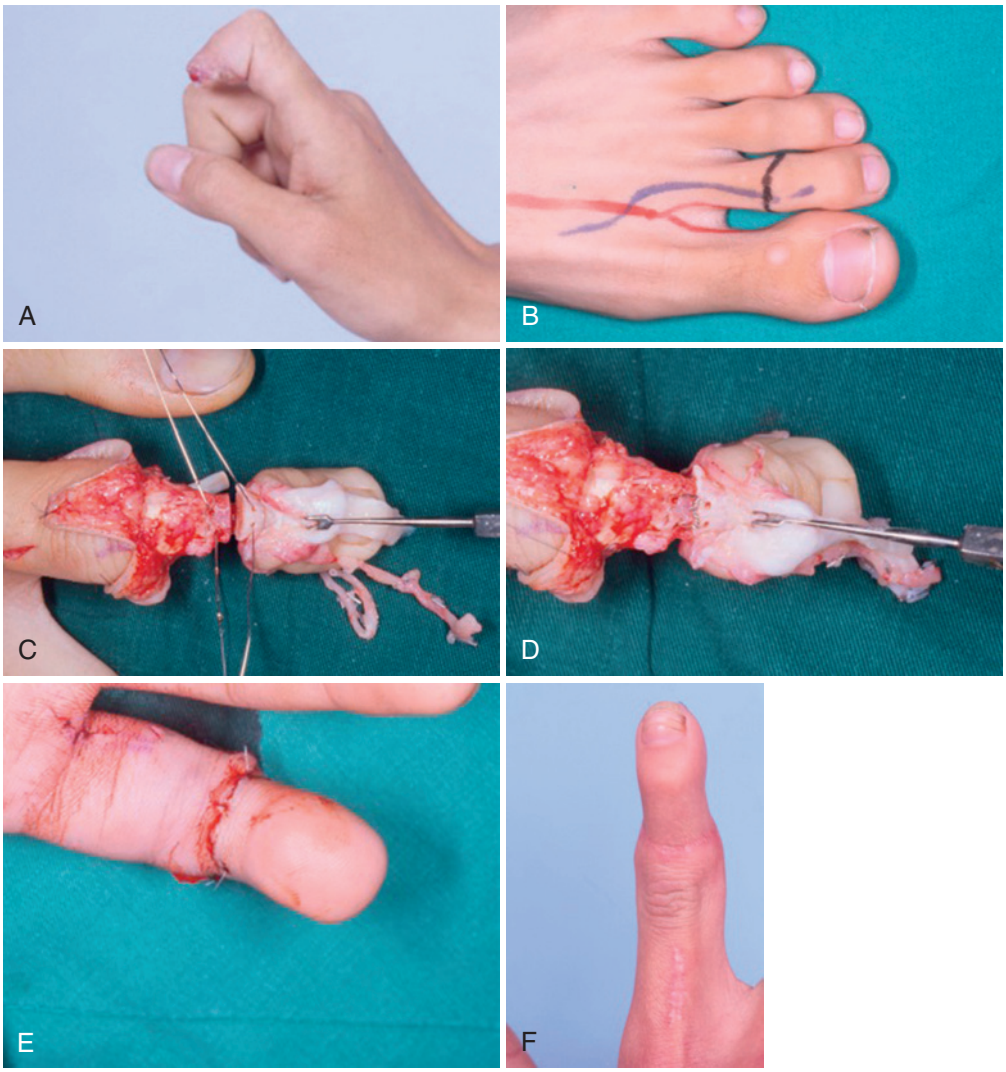

FIGURE 47.14 **A**, Distal amputation of the index finger. **B**, Planned disarticulation of the second toe at the proximal interphalangeal joint in preparation for partial second-toe transfer. **C**, **D**, Osteosynthesis of the partial 2nd toe after shortening the middle phalanx. **E, F**, Immediately after surgery and months later, respectively.

from a lesser toe as well. The senior author advocates the second-toe wraparound flap for finger reconstruction because the size usually matches the distal digit better, especially the toenail.[96] However, it can also be used for thumb reconstruction (although the nail size may be different), particularly for patients who will not accept or cannot tolerate partial loss of the great toe.

The second-toe wraparound flap is indicated for the reconstruction of a circumferential or dorsal hemicircumferential loss of skin and nail that is localized distal to the proximal portion of the middle phalanx with intact skeleton, tendons, and PIP joint (Figure 47.15).[96] No tendons are harvested with the second-toe wraparound flap, but the distal phalanx is always included to prevent swiveling, instability, and bone resorption of the reconstructed finger.

Flap Design

The second-toe wraparound flap can be adapted for either foot depending on the nail configuration, size of the defect, previous surgery or injury to the foot, and patient preference. The object of the incisions in the hand and foot is to avoid scars on the radial aspect of the index, middle, and ring fingers and on the ulnar aspect of the thumb and little fingers. Proximally, the dorsal and plantar skin incisions are usually outlined in a circular or "V" shape.

The same guidelines described for harvest of the second toe are used to dissect the wraparound flap but with an emphasis on skeletonization of the neurovascular bundle. The distal phalanx of the second toe is always included, and the tendons are cut close to their insertion. The remaining portion of the toe is disarticulated at the metatarsophalangeal joint to close the wound and provide an aesthetic appearance.

Pulp and Web Space Neurosensory Flaps

Indications

Pulp-free flaps from the great toe or second toe are appropriate for large finger pulp defects that cannot be covered with local



FIGURE 47.15 **A**, After an avulsion injury of the ring and little fingers, there is circumferential loss of skin and nails with an intact skeleton, tendons, and proximal interphalangeal joint. **B, C**, Results six months after reconstruction with bilateral second-toe wraparound flaps.

or regional flaps (Figure 47.16), or when the use of such flaps may create unacceptable donor site morbidity or restrict global function of an already compromised hand. Although local flaps have many indications for repairing pulp defects, under certain conditions they may be inconvenient because of limited mobility, size, position, and time of immobilization. In addition, the anatomic features of the pulp cannot be imitated by other tissue; specialized skin with rich sensory innervation is unique to the fingers and palm, and, ideally, any defect in these surfaces should be repaired with "like tissue."[2,16,25,41,44,60,68]

Pulp flaps are also a good choice when sensory recovery is essential for proper hand function and protection. Although pulp-free flaps are best to use for thumb reconstruction, they also are useful for other finger defects in patients with special jobs or hobbies that require critical sensation in all fingers (e.g., artist, musician).[55]

In cases where regenerating axons are too far from the injured surface or local sensory neurotization cannot reliably be expected, pulp flaps are an excellent alternative. In addition, they may be utilized to replace skin grafts or local flaps previously used for pulp reconstruction that resulted in an unstable or painful scar.[103]

The neurosensory first web space free flap is an alternative option. A good indication for this flap would be a soft tissue defect in one finger (Figure 47.17). It is also appropriate when thin, glabrous soft tissue is needed, as in the palm with minimal subcutaneous tissue.[3,23,33,41,51,65] A flap extending to the tip of the great and second toes can be as wide as 7.3 cm and as long as 14 cm (Figure 47.18). Adjacent fingers with contiguous defects in the pulp or in the proximal ventral aspect can be reconstructed with one first-web neurosensory flap and a temporary syndactyly, which is divided later.

The first web receives its blood supply from the distal communicating artery that connects the FDMA and FPMA. If the design of the flap includes an extension to the lateral aspect of the great toe or the medial aspect of the second toe, the respective digital arteries should be included in the pedicle dissection. Innervation of the dorsal aspect is provided mainly by the deep peroneal nerve and, to a lesser extent, the superficial peroneal nerves. However, when a wider flap with extension to the pulp of the great or second toe is desired, the respective common digital nerves in the plantar aspect also should be included.

Flap Design and Elevation

Pulp Flap. The great toe is selected more often than the second toe as a donor source of pulp flaps for the following reasons: the great toe has better superficial sensation than the second toe (two-point discrimination, 7-18 mm vs. 10-25 mm)[2]; more donor tissue can be obtained from the great toe; and it is possible to directly close the donor defect, speeding recovery and resulting in less morbidity.

The flap can be designed on the lateral aspect of the pulp in the great toe or the medial hemipulp in the second toe and extended to the first web space proximally, depending on the size of the defect in the recipient finger. The deep peroneal nerve supplies these surfaces, and its sensory innervation overlaps with that of the corresponding proper digital nerves; thus, two nerves always need to be included with a hemipulp flap from either of these two toes. The skin incisions are outlined according to a template of the recipient site defect or a drawing of the finger defect on the surgeon's corresponding finger to compare with the patient's toe. Outlining the incision for dissection of the pedicle follows the course of the proper digital artery to the great or second toe in continuity with the FDMA and FPMA in the first web space.

During elevation of the flap, special care should be taken to dissect all superficial veins on the lateral and dorsal surface of the great toe in continuity with one sizable vein. Next, the dominant artery to the great and second toes is localized in the first web space and dissected in a retrograde fashion. All small

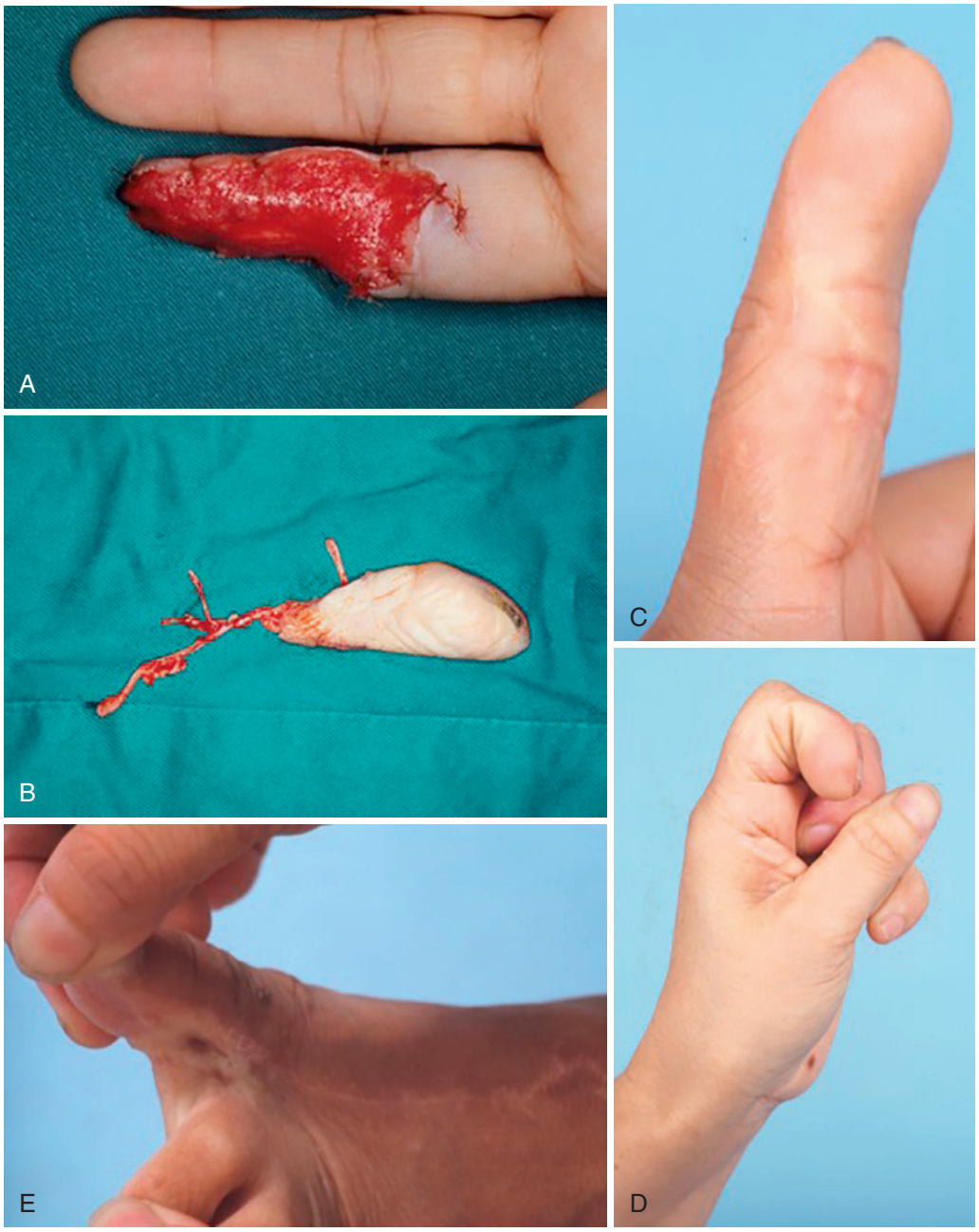

FIGURE 47.16 **A**, Avulsion injury of the index finger involving skin and subcutaneous tissue in the palmar aspect. **B**, Hemipulp free flap from the great toe. **C, D**, Final results showing full flexion and extension of the reconstructed finger. **E**, Donor site appearance after primary closure.

arterial branches must be skeletonized (see Figure 47.16, *B*) to facilitate passage of the vessels in the subcutaneous tissue during insetting of the flap.

When primary closure of the defect is not possible, a split-thickness skin graft (usually from the instep area) is required to close the donor site defect. Because delayed healing of the toe can prolong foot recovery and affect walking, skin grafting of the donor site should be performed with the utmost care.

First Web Space Neurocutaneous Flap. The flap is outlined according to the size of the defect in the hand. The posterior border of the flap is incised first, and the incision is extended in a lazy "S" fashion over the dorsal surface between the first and second metatarsals to the level of the metatarsal head. After isolating one sizable vein draining the flap, the artery is dissected distally over the intermetatarsal ligament. When the FDMA is dominant, retrograde dissection of this artery in continuity with the dorsalis pedis artery is straightforward. The deep peroneal nerve lies beside the artery along its course, under the extensor retinaculum proximally. The rest of the island flap is readily dissected. If the FDMA is very small or absent, elevation of the island flap starts on the plantar aspect of the web space where the FPMA is localized. From this point, the artery is dissected in a retrograde fashion until the desired length is

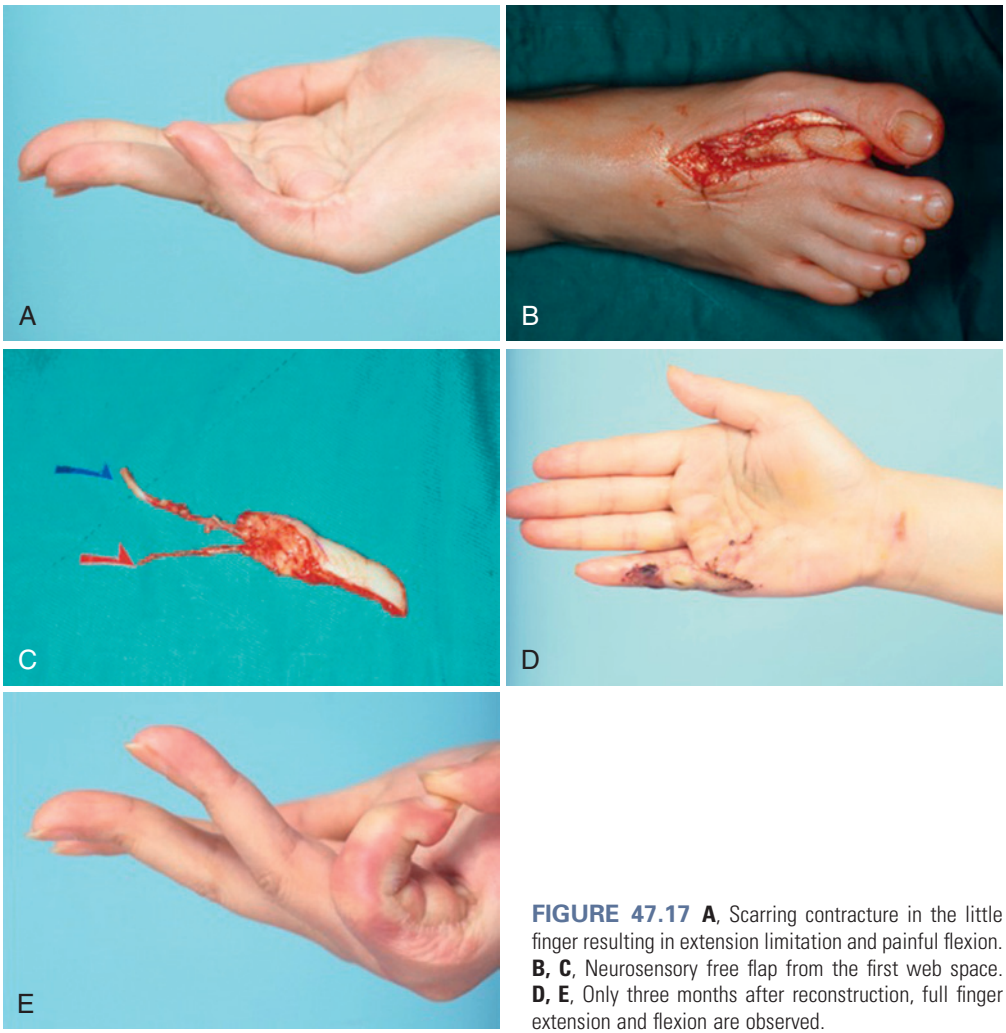

FIGURE 47.17 **A**, Scarring contracture in the little finger resulting in extension limitation and painful flexion. **B, C**, Neurosensory free flap from the first web space. **D, E**, Only three months after reconstruction, full finger extension and flexion are observed.



FIGURE 47.18 A large neurosensory skin flap harvested from the first web space can include the lateral aspect of the great toe and the medial aspect of the second toe.

obtained; if the vessel is too short, a vein graft can be used for the vascular anastomosis.[107] There is no need to abandon the procedure if the FDMA is not present. A split-thickness skin graft is used to close the donor site and is sutured in place with a tie-over dressing.

Vascularized Nail Graft

Indications

Microvascular nail transplantation is performed to ensure adequate blood inflow to the nail bed.[46,67,76] In contrast to nonvascularized nail grafts, these usually "take" better and provide adequate function and a superior aesthetic appearance. Vascularized nail grafts may be used for fingertip injuries involving the nail bed or for nail reconstruction after tumor excision. They are also a good option for replacement of nail deformities that are painful or aesthetically unacceptable to the patient (e.g., posttraumatic hook nail deformity). In most instances there is damage or loss of adjacent tissue such as the eponychial fold, pulp, and skeleton (Figure 47.19).

Technically, it is easier to transfer the whole second or third toe distal to the middle of the middle phalanx instead of trying to use nail segments with small flaps that may compromise venous outflow.[44] Whenever a larger amount of soft tissue is included with the transplanted toenail, a variable amount of normal tissue might need to be removed in the recipient finger for proper insetting.[21]

Flap Design and Elevation

The great toe usually matches the thumbnail better and may be trimmed to fit fingernails as well. Still, it is used infrequently



FIGURE 47.19 **A**, Middle and ring fingertip amputation covered with a pedicled flap. The patient's major complaint was anesthesia and nail absence in the middle finger. **B** through **D**, Results after nail reconstruction of the middle finger with partial second-toe transplantation, including the whole of the distal phalanx. Comparative views with the other intact digits are presented. **E**, Radiograph showing fixation in the middle phalanx with intraosseous wiring.

because of the secondary deformity created in the donor foot. Although the second toenail is somewhat smaller than a fingernail and has a squared shape, it looks similar to the finger counterparts, and the resultant donor defect in the foot is minor.[76] The design of the dorsal skin flap, including the toenail, should incorporate the small veins on the dorsal surface of the toe. Usually the dorsal skin flap extends from the eponychial fold up to the IP joint in the great toe and to the PIP joint in the second toe. The entire width of the nail, including both lateral eponychial folds, is harvested. The size of the pulp tissue taken is determined by the size of the defect in the finger pulp. However, for inclusion of the dorsal proper digital artery, more than half of the pulp on the medial side of the second toe (or the lateral side of the great toe) must be harvested with the vascularized nail graft. If the entire distal segment of the finger needs reconstruction, a second-toe wraparound flap is a better option (see earlier description). The proper digital nerve is included to restore nail sensation and function.

Dissection of the artery is similar to the technique described previously in the "Anatomy for Toe Dissection" section. It is

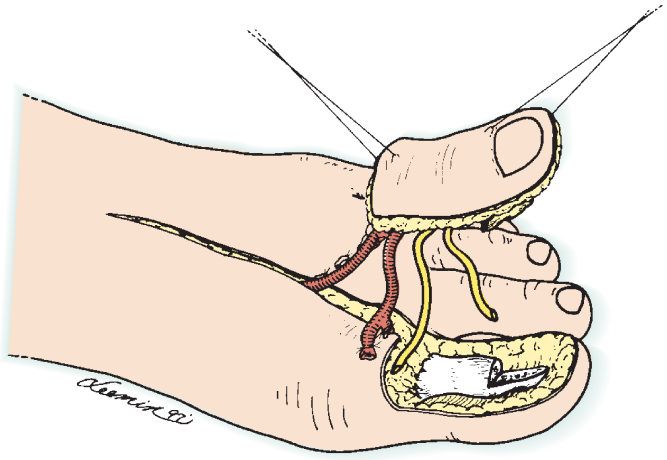

FIGURE 47.20 Vascularized nail transfer from the great toe. The nail bed is harvested through a transverse osteotomy in the distal phalanx.

important to emphasize that the small veins on the dorsal surface of the distal toe should be carefully dissected in continuity with one sizable vein tributary of the saphenous venous system to ensure dependable venous return.

After raising the dorsal flap, the extensor tendons are exposed and divided close to their insertion. Next, the nail is harvested together with the entire distal half or dorsal distal half of the distal phalanx by a transverse osteotomy of the great toe (Figure 47.20), or by including the entire distal phalanx or the entire dorsal half of the distal phalanx after DIP joint disarticulation in the second toe (authors' preferred method). In either case, the periosteum should be left attached to the nail and the skeleton exposed after reflecting the pulp flap from the distal phalanx on the plantar surface. Before doing the osteotomy, the artery, vein, and nerves in the pedicle should be protected from potential injury.

Morrison described technical modifications in which the width of the great toenail is decreased by trimming the lateral edges of the nail matrix.[67] In the great toe, the donor site defect can be closed with a cross-toe skin flap, which is divided two weeks later. In second- or third-toe vascularized nail grafts, proximal metatarsophalangeal disarticulation is favored because of the possibility of direct closure and the better appearance of the donor site. Nevertheless, if the patient's desire is to preserve the remaining toe, cross-toe skin flaps from the adjacent toe can be used to close the defect. Whenever a cross-toe flap is planned, the risk of complications and potential morbidity should be considered.

Transplantation of the Third Toe

Indications

Single transplantation of the third toe to the hand is indicated when (1) the second toe is not available or is not suitable for transfer because of previous injury, surgery, or deformity; (2) the second toe is on the same foot from which the great toe was removed (usually for thumb reconstruction in bilateral metacarpal hands) and the second toe is therefore spared for gait; and (3) the third toe provides a better size match for finger reconstruction than the second toe.[108]

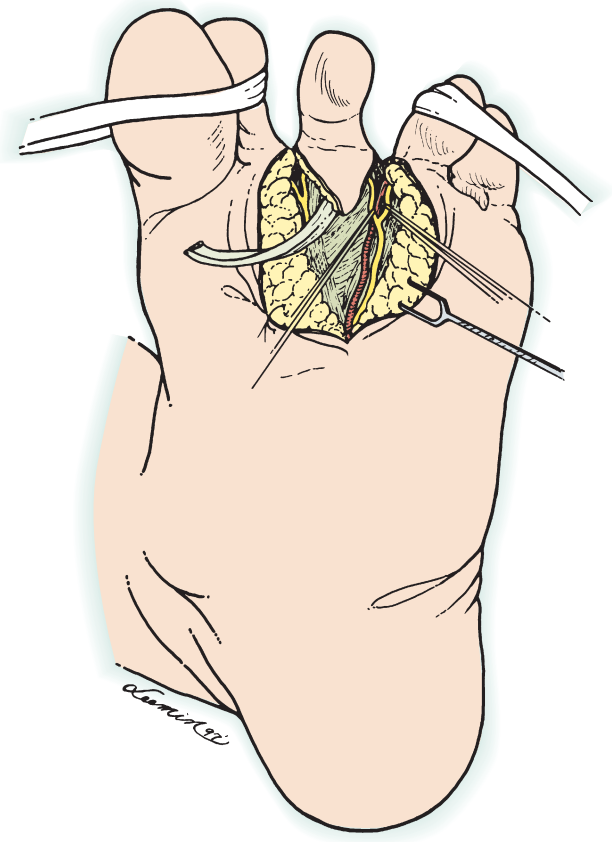

FIGURE 47.21 Dissection of the third toe depicting the third common plantar digital artery and nerve in the plantar surface.

❖ AUTHORS' PREFERRED METHOD OF TREATMENT

Preoperative planning and the operative technique are similar to that for transplantation of the second toe. The third toe receives its blood supply from the second and third dorsal metatarsal arteries and the second and third plantar metatarsal arteries. Because the majority of patients undergoing transplantation of the third toe have already had or will undergo transplantation of the great or second toe, the second metatarsal pedicle is either not available or must be preserved for subsequent transfer of the great or second toe. Therefore, transfer of the third toe is usually based on the third common plantar digital artery (Figure 47.21).[108] Although this artery might be small, it is usually larger than the second or third dorsal metatarsal arteries. It is simpler and quicker to proceed directly to dissection of the plantar vascular pedicle and, if necessary, to use a vein graft for the vascular anastomosis. In most cases, however, the pedicle is long enough to reach the proper digital artery in the proximal phalanx. The donor site is closed in the same way as described for the second toe.

Combined Transplantation of the Second and Third Toes

Indications

Combined transplantation of the second and third toes is indicated for reconstruction of two adjacent fingers after traumatic amputation proximal to the digital webs.[100] With this approach, tripod pinch function, hook–grip capability, and greater lateral

stability are the result.[83,94,99,100] Additional advantages of combined transplantation of the second and third toes over bilateral transplantation of both second toes include the following:

- Only a single set of recipient vessels is required—a potentially significant advantage for severely injured hands
- Less operative time is required
- Potential morbidity in the donor site is limited to one foot, thus allowing earlier postoperative ambulation

Nevertheless, because of its length limitation, a combined transplant cannot be expected to accurately simulate the functional capabilities of full-length fingers, particularly in point pinch and arch of grasp (Figure 47.22). Optimal function is attained when the reconstructed fingers and the remaining fingers are relatively uniform in length, with the distal tip of the normal little finger used as a guide.[100] If the remaining digits extend beyond this point, tandem transplantation of the second and third toes will take less time and contribute less to smooth prehension.

The level of digit amputation is used to determine the osteotomy level of the second and third toes. If 5 to 6 mm of length is present in the proximal phalanx of the fingers, the toe osteotomy should be at the proximal phalanx. The toes are harvested through metatarsophalangeal joint disarticulation (see Figure 47.22, *C*); the bases of the proximal phalanges are shortened during toe insetting, and the periosteum is elevated to the osteotomy level. During subperiosteal dissection and osteotomy of the phalanx, all anatomic structures in the toe must be protected from injury, and excessive manipulation of the neurovascular pedicle should be avoided. Active range of motion in the MP joint of the reconstructed fingers will be similar to that observed in intact MP joints.[100]

If the cartilage surface in the metacarpal heads and the joint capsule and ligaments are intact, the tandem toes are transplanted together with the respective metatarsophalangeal joint capsule and ligaments for composite joint repair in the hand. In this case, active range of motion averaging 52 degrees (range, 30-80 degrees) can be expected.[91] In addition, when the toes are disarticulated at the metatarsophalangeal joint, the metatarsal heads and arch are preserved in the donor foot, which is important for an even weight-bearing surface and prevention of a "scissors deformity" in the donor foot.[100]

In a more proximal transmetacarpal amputation, both toes can be harvested with a transmetatarsal osteotomy. It was previously suggested that the bony arch be reconstructed with a nonvascularized bone graft after transmetatarsal amputation of both toes.[100] However, this approach is no longer recommended because no functional difference was found in a recent biomechanical gait analysis (unpublished) or in our clinical observations when no bone grafts were used to reconstruct the metatarsal defect.

❖ AUTHORS' PREFERRED METHOD OF TREATMENT

Formerly, radial digit amputations were reconstructed by using combined transplantation of the second and third toes from the contralateral foot, whereas the ipsilateral toes were used for the reconstruction of ulnar digit amputations, with the aim of placing the longer second toe in a more acceptable central position.[83,100] Nowadays, when only one second- and third-toe combination is needed, we always harvest the tandem toes from the left foot because more demand is placed on the right foot in daily ambulatory activities. The right foot is selected only when the left foot is not suitable, such as when the great toe from the same foot has been or will be used for thumb reconstruction in multiple toe transplantation cases (see Figure 47.7). Skeletal length in the digits can be adjusted by the level of osteotomy in

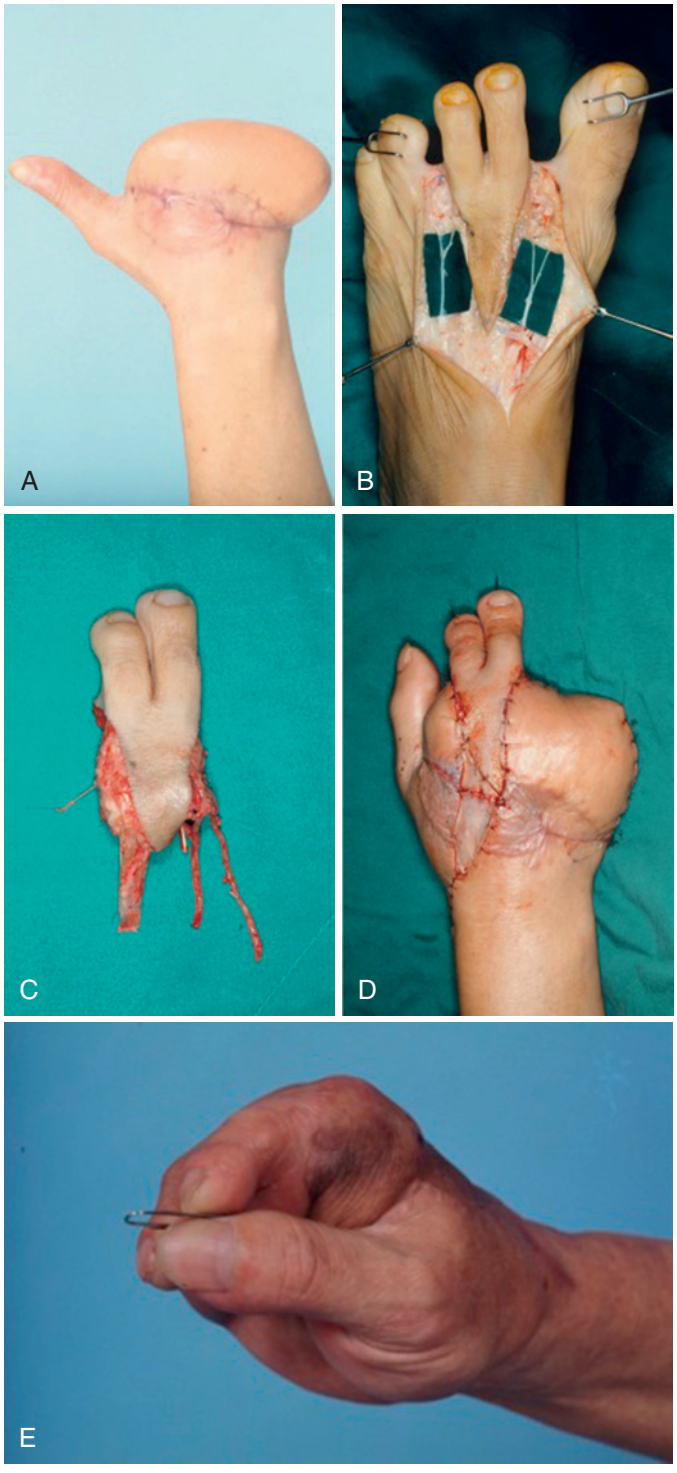

FIGURE 47.22 **A**, Metacarpal hand subtype IB. **B**, Dissection of branches of the superficial peroneal nerve in the first and third metatarsal spaces. The width of the "V"-shaped dorsal skin flap should not extend beyond the midpoint in the first web and the third web. **C**, Tandem second and third toes disarticulated in the metatarsophalangeal joint. **D**, Immediate result after inset of the transplanted unit for reconstruction of the radial fingers. **E**, Fourteen months after reconstruction, tripod pinch is adequate.

the proximal phalanges or metacarpals and the toe phalanges or metatarsals.

Skin flaps with a "V" shape are outlined on the dorsal and plantar aspects of the second and third toes. The skin incisions should not extend beyond the midpoint of the first and third web space in the foot (see Figure 47.22, *B*). By including narrow skin flaps with the toes, it is always possible to close the donor site directly without tension.

Dissection of the flap starts on the dorsal aspect of the foot, with isolation of one donor vein going to the saphenous venous system connecting all draining small veins from the second and third toes. Then the first web space is dissected to identify the dominant vascular pattern to the second toe (see "Anatomy for Toe Dissection" section). The branches of the superficial peroneal nerve to the second and third toes are dissected free (see Figure 47.22, *B*). After isolating the vessels and nerves on the dorsal surface, the extensor tendons to the second and third toes are raised and cut. To preserve the vessels communicating between these two toes, it is advisable to avoid excessive manipulation of the soft tissue connections in the second web space, especially when the bone is dissected distal to the metatarsophalangeal joint.

Next, the plantar skin flap is raised to the base of the proximal phalanx in both toes, and all fibrofatty tissue under the skin and over the plantar neurovascular bundles is carefully removed. The following three nerves are identified on this surface and included in the surgical unit:

- The proper digital nerve to the second toe, which is found in the medial aspect of the second toe
- The second common digital nerve to the second and third toes, which is located between the two toes
- The proper digital nerve to the third toe, which is in the lateral aspect of the third toe

The senior author and his colleagues assessed the arterial blood supply in 57 combined transplantations of the second and third toes in 54 consecutive cases.[13] Reexploration secondary to arterial insufficiency (i.e., vasospasm or thrombosis) was required in almost 20% of cases after revascularization using the dominant artery. Therefore, our current tendency is to preserve the second and third common plantar digital arteries and use one of these two vessels for a second arterial anastomosis, especially when arterial perfusion to the third toe is uncertain.

The osteotomy site is exposed in both toes, and all anatomic structures except the main vascular pedicle are divided and dissected a few millimeters distal to the osteotomies. The two phalanges are cut or disarticulated, and the tandem toes are allowed to reperfuse for at least 20 minutes before being transplanted. The incisions should always be closed without tension. Skin grafting on the donor site is unacceptable and can lead to severe complications in the foot.

Combined Third and Fourth Transplantation

Indications

The indications for combined third- and fourth-toe transplantation are similar to combined second- and third-toe transplantation in purpose (i.e., to establish tripod chuck pinch in the metacarpal hand with multiple-finger amputation that is proximal to the digital web); however, this combined transfer is an alternative to the combined second- and third-toe transfer and appropriate when the second toe is spared either for gait or for thumb reconstruction (i.e., in proximal thumb amputation). Another indication is when the second toe is not available or is unsuitable because of previous surgery, injury, or deformity.[82]

❖ AUTHORS' PREFERRED METHOD OF TREATMENT

The combined third and fourth toe is harvested in a similar manner to the combined second and third toe except for the following. Skin incisions are begun in the second and fourth web spaces, converging proximally to the shape of a "V" skin flap. Although the plantar system is more constant than the dorsal system, dissection starts dorsally in the second web space to identify the junction of the lateral digital artery of the second toe and the medial digital artery of the third toe. Once identified, the vessel is traced proximally to assess the second dorsal metatarsal artery. If present and of adequate caliber, further dissection to the level of the arcuate artery or the dorsalis pedis artery is done based on pedicle length requirements. If the second plantar metatarsal artery is absent or of inadequate caliber, dissection starts plantarward to identify the second or third plantar metatarsal artery.

In case of a previous injury to the second toe or when subsequent ipsilateral second-toe transfer is planned, the third plantar metatarsal artery is preferred. It is advisable in this transfer to include a "lifeboat" vessel, which is the fourth plantar metatarsal artery, because perfusion across the third web space based on a single pedicle is uncertain. All plantar metatarsal arteries are dissected no further than the level of the midtarsal shaft to minimize damage to the foot. The senior author advises that two arterial anastomoses be performed for safety; however, the decision should be made intraoperatively when any sign of arterial insufficiency is present.[10,82]

Combined Triple-Toe Transplantations

Triple-toe transplantation from the same foot, such as combined second, third, and fourth toes or combined third, fourth, and fifth toes, has been reported in the literature as case studies and mainly for the reconstruction of a bilateral metacarpal hand.[8] For these extreme transfers, the patient's level of motivation and job requirements must be carefully considered because the donor site can be problematic. Foot deformity is very conspicuous, but functional impairment is not significant when these combined toes are removed properly.

Recipient Site Preparation

A surgical approach with one team preparing the recipient site and another harvesting the toe provides several advantages:

- The proper length of all anatomic structures included in any flap from the foot can be verified before being divided.
- There is no need for extensive dissection of the foot, resulting in less morbidity in the donor site.
- Operative and anesthetic times are considerably reduced, leading to less fatigue for the patient and surgeons.

Routinely, the recipient site is prepared under a bloodless field with conventional tourniquet control, and the dissection is performed with the aid of loupe magnification.

Skin Incisions

The amputation stump is always cross-incised to create four skin flaps for exposure of the bone, tendons, and distal nerves.

The skin flaps are sufficiently undermined, and the redundant fatty tissue is properly trimmed to obtain thin skin flaps with wide mobility over the stump skeleton (see Figure 47.14, *A*). Flexibility in mobilizing the skin flaps off the underlying structures is very important for shaping them to fit smoothly with the triangular skin flaps of the toe during insetting.[94] The recipient artery can be identified by using a separate incision on the ulnar side of the proximal phalanx or distal palm, especially in distal finger reconstruction, or by extending the stump incisions proximally to this area. A separate incision in the snuffbox is usually made if the radial artery is selected. This incision must be connected with the digital stump through a wide subcutaneous tunnel to allow passage of the donor vessels without compression; otherwise, it is better to open the skin between the two incisions.

Bone and Joint Preparation

Periosteal dissection should be minimal to expose the fixation site in the recipient bone. The bony surface of the stump is smoothed to provide good contact and stability, which are essential for adequate bone union (Figure 47.23). Whenever it is going to be repaired, the joint capsule and ligaments must be carefully dissected while exposing the cartilage surface.

Tendon and Pulley Preparation

Usually the extensor tendon is located close to the bony stump, and every effort should be made not to detach it (especially in distal finger reconstruction) because extensor mechanism integrity is essential for finger function. The flexor tendons have various locations in distal and proximal finger amputations, and the pulley system must be preserved while exposing the tendon. To achieve a functional result, it is critical to have good tendon excursion, so all tendon adhesions should be removed at this stage if necessary.

Most tendons can be repaired at the midpalm level, with enough distance left from the tenorrhaphy site to the A1 pulley for smooth excursion. In distal finger reconstruction, the insertion of the FDS must be carefully exposed, together with the flexor digitorum profundus (FDP) over the middle phalanx shaft level. It is seldom necessary to repair the flexor tendon at the wrist level. If no flexor tendons are available, the FDS tendon from the adjacent finger can be transferred first.



FIGURE 47.23 Recipient site preparation. The distal end of the bone is regularized to attain stability and good bone contact with the transplanted toe.

Nerve Preparation

The proper or common digital nerves, in most cases, are close to the edge of the stump of distal finger amputation, and these are used for neurorrhaphy with the transferred toe. In deciding the proper site for neurorrhaphy in a normal or relatively normal recipient nerve, the appearance of the fascicles under the microscope is a good guide. More proximal recipient nerves in the palm, including the palmar cutaneous branch of the median nerve and dorsal sensory branches of the ulnar nerve, may be selected if the distal nerves have been avulsed. Nerve transfers from the ulnar side of the long or ring finger, or sensory branches of the superficial radial nerve on the dorsum of the hand, may be used as well.

Vessel (Artery and Vein) Preparation

The proper digital arteries at the proximal phalanx level can be used for anastomosis in distal finger reconstruction. Because of its larger size, the proper digital artery on the ulnar side is selected more often than the proper digital artery on the radial side. Common digital arteries in the palm are a good option for more proximal amputations, provided the arterial arch in the hand was not involved in the initial injury. The recipient arteries should be meticulously dissected and the adventitial layer stripped off to avoid postoperative vasospasm. If these vessels are too small for vascular anastomosis, it is advisable to select a larger artery (e.g., the radial artery in the anatomic snuffbox or the princeps pollicis artery). Vein grafts should be considered, if the donor artery is short (e.g., in a plantar-dominant system) or if the proximal arteries are required for anastomosis, rather than struggling to increase the length of the donor artery in the foot or anastomose the vessels under tension.

One vein is generally dissected on the dorsal aspect of the hand and used as a recipient vessel. More proximal veins can easily be mobilized when these are not found distally.

Toe Fixation Technique

Usually, the following sequence is suggested for insetting the transplanted toe.

Skeletal Fixation

In toe-to-hand transplantation, intraosseous wires, Kirschner wires, and rigid fixation systems have been used for bone fixation.[26,84,85,115] In addition, an intramedullary bone peg can be used in combination with wires.[52] Parallel or coronal and sagittal intraosseous wiring is used frequently. In the experience of Yim and the senior author with parallel intraosseous wiring in 68 toe-to-hand transplants in 47 patients, an overall nonunion rate of 1.5% was observed after a mean follow-up of 30

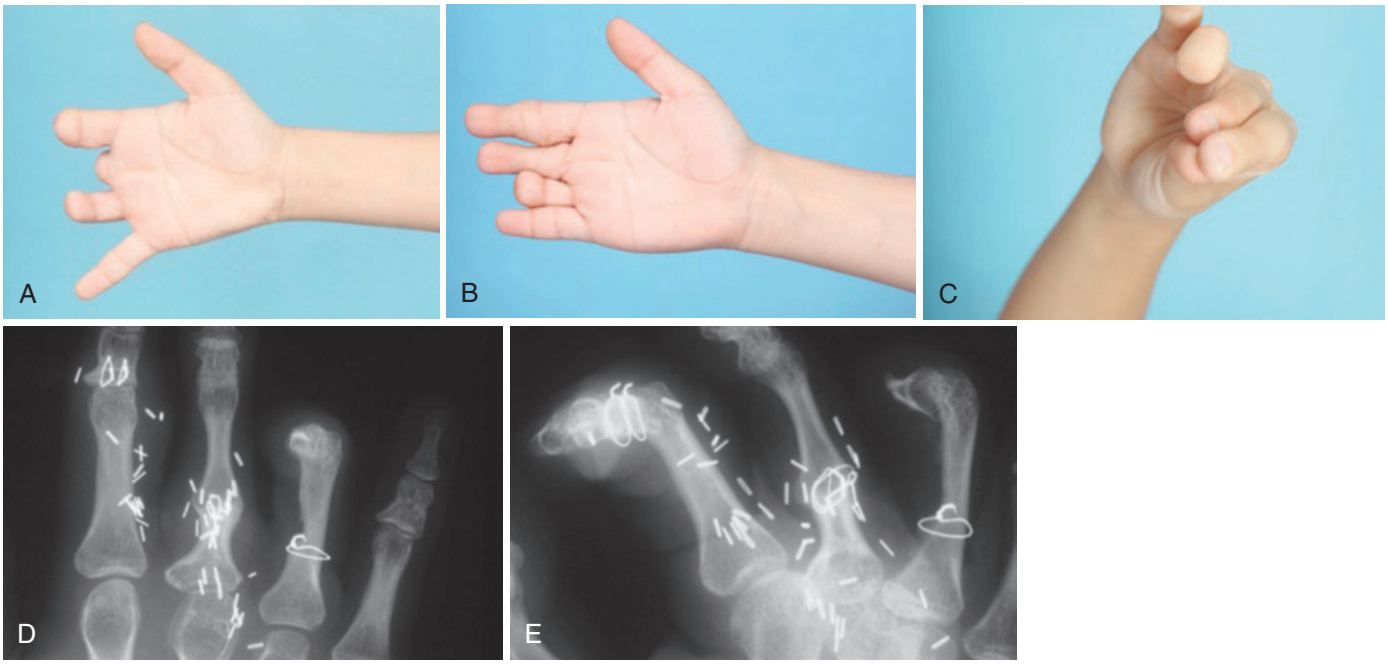

FIGURE 47.24 **A**, Multiple-digit amputation. **B, C**, Adequate tripod pinch after index finger reconstruction by partial second-toe transplantation and middle finger reconstruction by total second-toe transplantation. **D, E**, Radiographs with the index finger under extension and flexion eight months after surgery. In the index finger, 3 mm of proximal bone in the middle phalanx was used to fix the toe and preserve the proximal joint.

months.[115] Some of the advantages of this technique include the following:

- Stability is provided for early mobilization, thus preventing tendon adhesions and improving the overall range of motion in the reconstructed digit (Figure 47.24).
- Any slight angulation and malrotation can be corrected with appropriate splints during the early postoperative period (Figure 47.25).
- It is a simple, quick, and inexpensive method.
- It can be applied to a stump of phalanx as short as 5 mm (see Figure 47.24, *D*) so that the intact proximal joint can be preserved.

For intraosseous wiring, 2 mm of healthy bone between the holes and the bony edge in the skeleton stump is enough for bone healing. Two parallel 1-mm holes are made through both cortices in the distal part of the bony stump in a dorsal-to-volar direction. After placing the toe in its proper position, the angle and rotation of the toe are determined, and two parallel holes are drilled in the toe's phalanx. Next, 2-0 (28-gauge) stainless steel wires are introduced through the corresponding holes and twisted while the position of the toe is carefully adjusted. The wire ends must be placed away from the gliding extensor tendon to avoid tethering.

For composite joint repair, the volar plate and collateral ligaments of the toe are attached to the corresponding structures on the finger with nonabsorbable sutures.[78] The volar plate has to be repaired with proper tension to prevent postoperative hyperextension of the joint. This technique has been used primarily with combined transplantation of the second and third toes.[78]

Tendon Repair

After fixing the bone, the extensor tendon is repaired. It is sutured with the PIP and MP joints in full extension to minimize flexion deformity. The extensor longus tendon of the toe is sutured to the extensor of the finger using the weaving method with nonabsorbable sutures. Next, the long flexor tendon of the toe is sutured to the proximal FDP tendon stump as follows. In distal finger amputations, the FDP is repaired only to provide stability in power pinch because the insertion of the FDS is intact. So, when the proximal FDP stump is located distal to the FDS insertion, it is directly repaired; however, if the FDP stump is not present distally, the flexor tendon of the toe can be sutured to the distal portion of the FDS insertion. On the other hand, in proximal finger amputations, only the FDP is repaired, usually in zone 3, to prevent entrapment of the tenorrhaphy site by the remaining pulleys during tendon excursion. The tension between both tendons should be adjusted so that the finger forms a natural cascade with the other digits. We recommend tight extensor tendon repair and night splint application with the finger in full extension for at least a year to minimize claw deformity.[21,94]

From experience with second-toe transfer, PIP joint extensor lag is a common problem that limits the joint's range of motion.[9] At our institute, we studied the anatomy of the extensor mechanism of the lesser toe and found that the central slip of it has two different arrangements: either attenuated (type I lesser toe) or distinct central slip (type II lesser toe). In type I toes, traction on the extensor digitorum brevis and longus did not correct the extensor lag. The extension lag decreased when the metatarsophalangeal joint was flexed passively or when both extrinsic and

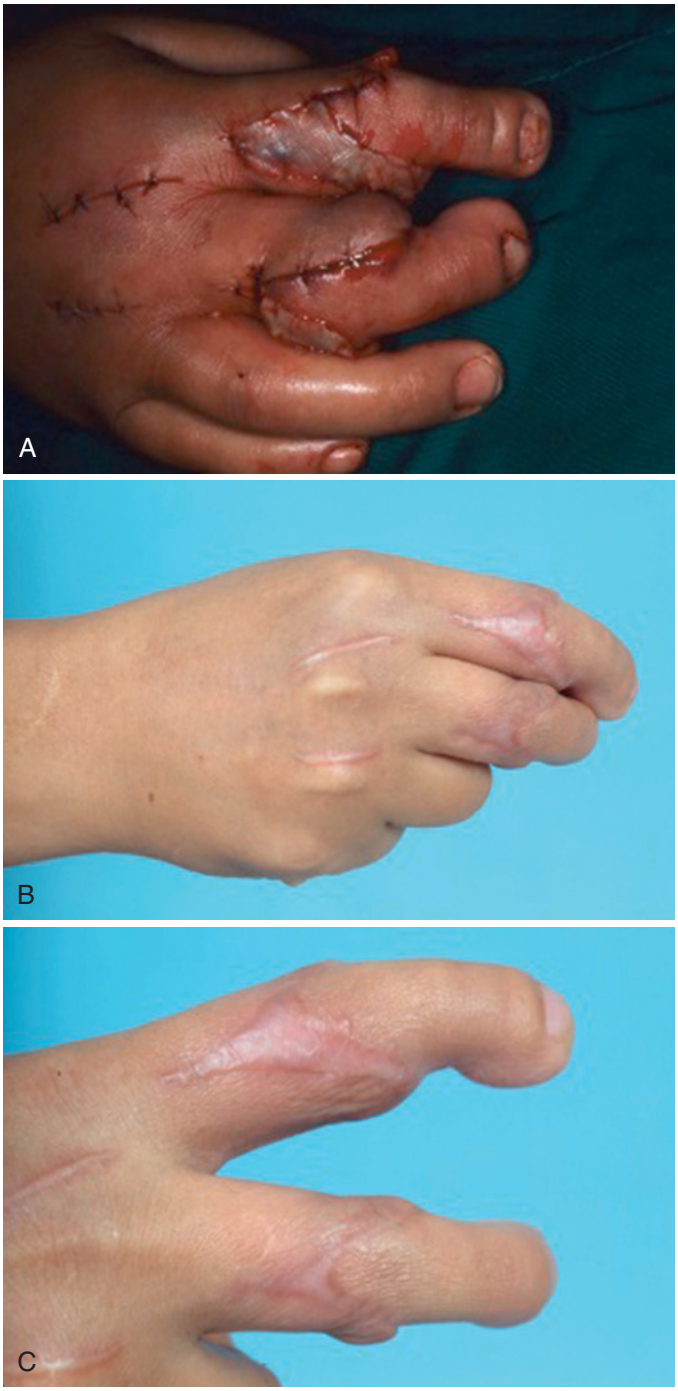

FIGURE 47.25 **A**, Bilateral second-toe transplantation. Immediately after surgery, significant rotation of the toe to long finger is observed. **B**, **C,** After rehabilitation therapy good alignment of the transferred toe has been achieved.

intrinsic tendons were pulled simultaneously. In type II toes, a full extension of the proximal interphalangeal joint was achieved when the extensor tendons were pulled with or without pulling the intrinsic tendons.

Using this information, an algorithm was constructed for a series of nine patients: (1) in a type I toe with sufficient recipient lateral bands, a centralization procedure was carried out; (2) when the lateral bands were insufficient, a modified Stack procedure was carried out. In type II toes, a tight repair of the corresponding extensor tendons was performed. The study demonstrated a total range of motion of 53.9 degrees (mean flexion, 72.2 degrees) that approximated 81.1% of the pretransfer passive range of motion at the toe proximal interphalangeal joint. These preliminary results are encouraging for wider application in lesser toe transfers.[50]

Nerve Repair

The nerves are coapted in an end-to-end fashion with 10-0 nylon. Usually only the proper digital nerves are repaired; however, if enough recipient nerves are available, the deep and superficial peroneal nerves can be individually repaired. When only one digital nerve is available proximally, various toe nerves can be sutured together with this nerve, with priority given to the proper digital nerves.

Skin Closure

The skin is adjusted and temporarily closed after ending the neurorrhaphies and before performing the vascular anastomoses. This minimizes swelling and tension during wound closure immediately after reperfusion. The four skin flaps built in the recipient stump are tailored and interposed with the triangular flaps of the transferred toe to create a smooth surface. Inadequate skin coverage in toe transplantation is a major cause of complications. Conversely, a "cobra deformity" may result when redundant skin is left at the junction between the transplanted toe and the digit, and excessive fatty tissue is a common cause of a bulbous appearance with unpleasant results.[94]

Vascular Anastomoses

The arterial anastomosis is performed first. Once completed, the venous return should be observed for several minutes. Whenever the blood outflow proves to be insufficient, the arterial anastomosis and the entire course of the vessel must be reassessed. If perfusion of the toe is suspected (e.g., into the third toe in combined transplantation of the second and third toes), a second artery can be used for anastomosis.[10]

The remaining wounds in the finger are closed, and the vein anastomosis is completed through a separate incision in the dorsum of the hand. If there is some tension while closing the skin, it is advisable to partially close the wound and use skin grafts to cover the remaining raw surface; with adequate preoperative planning, however, tension on the skin during closure is uncommon. Small silastic drains can be used to prevent hematoma accumulation, although contact of the drain with the vascular anastomoses must be avoided.

POSTOPERATIVE MANAGEMENT

The patient is hospitalized an average of five days in the microsurgery intensive care unit, where specially trained nurses can closely monitor the transplanted toe and the patient's general condition. No splints are used; rather, the proximal portion of the palm and wrist is gently wrapped with the fingers uncovered for continuous observation. The hand and forearm are kept slightly elevated atop a smooth support to reduce edema formation. Bulky dressings are not recommended because blood clots may be retained around the wounds, and dressing removal could induce vasospasm. Also, bulky dressings make it impossible to start early postoperative rehabilitation.

Beginning directly after surgery, aspirin (325 mg/d) is administered for two weeks to reduce the risk of platelet aggregation. Dextran was popularly used in the past as a rheologic agent but has lately lost favor because of its risk of systemic complications. When used, a typical dosage is an initial bolus of 100 mL of dextran 40 (low molecular weight) administered intravenously 10 minutes before completion of the arterial anastomosis, followed by a continuous infusion (25 mL/h) during the next 4 to 5 days. Likewise, heparin may be given at the time of the anastomoses and as an intravenous drip postoperatively, but it can cause a hematoma or other bleeding problems that may compromise the final outcome.

Our routine is to avoid dextran and heparin except in cases in which significant trouble was encountered during the anastomoses. Prophylactic antibiotics (cephalosporins) are used in toe transplantation. In prolonged surgical cases or potentially contaminated wounds, gentamicin is added initially, and the antibiotics are subsequently adjusted according to bacterial sensitivity in the event of an infection.

Vascular conditions in the toe are subjectively monitored by direct observation of skin color, turgor, and capillary refill; they are objectively monitored by measurement of the toe's surface temperature in comparison to the adjacent normal finger and opposite hand. In addition, arterial patency is assessed periodically by Doppler ultrasound. Another informative modality is differential pulse oximetry, in which pulse oximeter probes are placed on the transferred toe and another "control" digit; an irregular or lost waveform may signify arterial thrombosis, whereas desaturation is correlated with venous occlusion.[38]

The donor foot is gently covered with nitrofurazone (Furacin)-impregnated gauze over the wound and a light fluff dressing. No splints are used on the donor foot. Two days later the foot is uncovered, and no further dressings are used.

COMPLICATIONS

Vascular Complications

Vasospasm is probably the most commonly encountered complication in toe surgery; it most often occurs during the first three postoperative days. Therefore, vigilant observation and swift intervention are essential for a successful outcome. The smaller the vessel's caliber, the higher the chances are to develop vasospasm; thus, this complication is most likely encountered in distal-digit reconstruction with partial toe transplantation. Vasospasm can affect the flap pedicle, the recipient vessels, or both; because "prevention is the best medicine," precipitating factors should be avoided. These include consumption of caffeinated beverages or chocolate, smoking, cold room temperatures, and/or excessive manipulation of the hand. Prevention necessitates optimal systemic blood pressure throughout the surgery, adequate fluid therapy, and constant analgesia. Furthermore, dissection should be meticulous and bloodless with gentle handling of the delicate vessels, and recipient vessels located away from the zone of injury should always be chosen.

If vasospasm occurs, the following measures can be taken: warm the patient, lower the hand below heart level, and release some skin sutures. Additionally, 2 to 4% lidocaine can be intermittently instilled over the partially opened wounds. However, if no circulation is restored after observation for a reasonable time (1 h), prompt reexploration in the operating room is mandatory.

During reexploration, the hematoma is evacuated, if there is any, and the adventitia is excised. If a constricting adventitial layer or band is found, the vasospasm may be relieved by releasing or removing this. Instillation of 4% lidocaine or papaverine also may be helpful. However, in intractable vasospasm, the spasmodic vessel has to be excised and replaced with a vein graft or a flow-through venous flap.

Similarly, in the case of recipient vessel spasm, vessels at a proximal level and of a larger caliber are used with a vein graft or a flow-through venous flap. The vascular anastomosis is always checked in "takebacks" for thrombosis and revised in cases of thrombus or excised and vein grafted. If preserved, the second or third plantar metatarsal arteries can be used for a second arterial anastomosis in combined second- and third-toe transfer, provided the arterial insufficiency is secondary to inadequate proximal inflow.[10]

Venous thrombosis is uncommon and is usually related to compression of the vein as a result of inaccurate insetting or hematoma accumulation. In the majority of cases, it is possible to salvage the transplanted toe after reexploration.[10,115] However, 3.5% of cases still end in failure.[94,117] The need for reexploration and the possibility of failure must be extensively discussed with and understood by the patient and relatives before surgery, as for any other microsurgical procedure.

If failure occurs, the senior author believes that another toe transfer is possible; however, this transfer should not be done immediately. Instead, a complete evaluation of possible reasons for failure and a thorough discussion with the patient and family should precede the second surgery, and enough time to recover from the failed procedure should be given to the patient and the surgeon.

In planning for toe transfer after a failed initial attempt, and if the second toe was harvested the first time, a second toe or a great toe from the contralateral foot is usually excised. On the other hand, if the great toe was harvested in the initial surgery, the second toe from the contralateral foot should be used to minimize gait disturbance. When patients refuse a second transfer attempt, a salvage procedure with a groin flap,[70] for example, could be proposed, especially if the compromised toe is a great toe.

Other Complications

Skin coverage and wound-healing problems are probably the most common complications in toe-to-hand transplantation. Often these problems are secondary to partial necrosis of the thin skin flaps raised in the toe or at the recipient site, particularly when a groin flap was previously used. When the subjacent tendons and nerves are exposed, immediate action should be taken to provide soft tissue coverage and prevent desiccation of these structures and subsequent sequelae.

SECONDARY PROCEDURES

According to various authors, secondary procedures may be required in 20 to 70% of cases after toe-to-hand transplantation, particularly when the function or aesthetics of the transferred toe falls short of expectations.[13,15,26,31,58,85,101,112,113,116]

In a study of 133 toe-to-hand transplantations in our unit, secondary procedures for functional improvement were necessary in 19 transfers (14.3%) after an average time of 8.8 months.[116] The incidence of secondary procedures on tendon, bone, joints, and soft tissues was 9.0%, 1.5%, 2.3%, and 3.8%, respectively. Tenolysis was the secondary procedure most commonly performed (6.8%), followed by arthrodesis (3.0%) and web space deepening (3.0%). In our experience, secondary procedures yield satisfactory results, particularly flexor tendon tenolysis.

Other secondary procedures are sometimes required after toe-to-hand transplantation. These include tendon and nerve grafts, tenorrhaphies, tendon transfers, osteotomies, and capsulotomies. In addition, small revisions are used for aesthetic improvement after toe-to-finger reconstruction. Pulp-plasties are minor procedures performed under local anesthesia and are used to improve bulbous-appearing reconstructed fingers.[94,109] Scar revisions and "Z"-plasties in the junction between the transplanted toe and the recipient finger are used to correct soft tissue irregularities that result from inadequate tailoring and adjustment of the skin during toe insetting.[94]

DONOR SITE MORBIDITY AND GAIT ANALYSIS

Foot deformity is more evident after resection of the great toe or combined second and third toes than after removal of the second toe alone. Besides the alteration in appearance, a few complications, including hypertrophic scarring and partial skin necrosis, may be observed in the donor foot. Both are usually related to the elevation of very thin flaps to dissect the proximal pedicle in the dorsum of the foot and excessive tension during wound closure because of inadequate surgical planning.

Recently, biomechanical function of the foot before and after harvesting the second toe and combined second and third toes was evaluated at our institution (unpublished study). In 36 patients who experienced removal of the second toe, gait and force plate foot pressure analyses were performed during stance and walking. The results showed slightly increased loading on the first toe during stance, with the third toe becoming unloaded and the first metatarsal more loaded during walking. However, pre- and postoperative comparative results were not statistically significant.

Foot kinetics before and 6 months after combined second- and third-toe transfer were also assessed in 17 patients. The analysis revealed no significant change in gait parameters such as walking velocity, cadence, step length and width, duration of stance phase, and percentage of single- and double-limb support phases. Similar to second-toe harvesting, it was found that excising of the combined second and third toes slightly unloaded the metatarsal region and increased the load on the big toe and, to a lesser extent, the heel; this was seen as adequate compensation for the simultaneous loss of the two toes. Clinically, there were no significant complaints from the patients. It was concluded that transplantation of the second toe or combined second and third toes is associated with minimal biomechanical foot changes and problems. These findings were supported by a study using the Lower Limb Function Questionnaire, in which toe transfer patients had statistically identical scores as normal controls.[13]

Therefore, there should be no hesitation in using this surgical procedure for finger reconstruction in properly selected patients, provided the previously mentioned precautions related to toe harvesting and postoperative care of the donor site are definitely followed.

REHABILITATION

Rehabilitation after toe-to-hand transplantation is aimed at improving motor capability and sensory function of the transplanted toe.[7,62]

Motor Rehabilitation

Early controlled motor rehabilitation not only prevents joint stiffness and tendon adhesion but also enhances coordination and dexterity of the reconstructed hand. The rehabilitation program developed in our unit consists of these five stages starting on the first postoperative day.

1. *Protective stage (days 1-3).* Psychological support is provided to the patient, who is hospitalized in the microsurgery intensive care unit for observation of toe viability. During this stage, interaction between the patient and the hand therapist is established.
2. *Early mobilization stage (day 4-week 4).* Rehabilitation is directed at preventing excessive swelling and joint stiffness. From day 4-week 2 forward, the hand is kept about one foot higher than the heart level. On day 4, gentle passive range-of-motion exercises of the joints are commenced by individually moving each joint about 15 degrees. Special care is taken not to compromise the viability of the transferred toe while performing the exercises. In the subsequent weeks the controlled passive movement of all joints both proximal and distal to the osteosynthesis site is increased gradually but should not interfere with bone union. A light-pressure tubular bandage with the fingertips exposed is also applied at this time, and the patient is taught to perform gentle massage. A protective splint is provided between exercises. As a general rule, the splint should be placed in a position that prevents stress on the repaired tendons or neurovascular structures.
3. *Active motion stage (weeks 5-6).* Gentle active exercise is added to the passive exercises, and the splint is changed to a dynamic one, if necessary. During week 6, once the tendons have healed, blocking flexion and extension exercises are initiated. Compression bandages are used to help reduce edema and minimize scar formation. Ultrasound and scar massage are employed to produce a softer scar and increase the range of motion.
4. *Activities of daily living training stage (weeks 7-8).* Tasks are given that require training to strengthen muscle power and improve the joint's range of motion. According to patient capabilities, various tasks that simulate daily manual activities are assigned.
5. *Prevocational training stage (week 8 and beyond).* Vocational activities are designed to further improve muscle strength and hand dexterity and coordination. To prevent a claw deformity, the patient is encouraged to use nighttime extension splints for at least a year. The patient is encouraged to resume normal activities with the reconstructed hand and periodically attend interactive group sessions with other

patients who have received toe-to-hand transplants. Individual psychological therapy is appropriate only if required.

Sensory Rehabilitation

It is difficult to achieve functional sensory recovery after toe-to-hand transplantation without sensory rehabilitation.[17,62] Sensory reeducation is directed at helping the patient interpret the altered sensory impulses reaching the brain from peripheral nerves. This does not make axons grow faster or cause receptors to form, but it uses higher cortical functions (e.g., concentration, learning, and memory) to maximize the sensory function provided by the regenerated nerves.

The program of sensory reeducation is divided into early and delayed stages. In the early stage, reeducation focuses on facilitating the perception of touch submodalities with correct localization. Training is initiated when the patient can perceive vibrations from a tuning fork of 30 cycles per second with the reconstructed fingertip.

Late-phase sensory reeducation focuses on size and shape discrimination and object identification. This program is begun after the recovery of touch sensation. It consists of touching several objects with different textures, sizes, and shapes, the nature of which the patient attempts to appreciate with the tip of the transplanted toe instead of the adjacent normal finger's surface. It can be implemented as a home rehabilitation program, often leading to significant improvement in the final result.

In a study of sensory recovery after toe-to-hand transplantation, the senior author and his colleagues found a good relationship between the Meissner corpuscle number and two-point discrimination.[91]

Donor Site Rehabilitation

The patient is allowed to walk a few steps on the heel of the donor foot after week 2. It must be emphasized that any contact with the anterior plantar weight-bearing surface should be avoided during this recovery period. The sutures in the donor foot should not be removed earlier than week 3 after the operation. After week 4, the patient is allowed to walk with a normal gait.

OUTCOME

High success rates of more than 97%, as reported in our study series of 1841 transfers over 22 years (1985-2007), and as comparable results have been reported by our colleagues,[19,24,113] is expected in toe-to-hand surgery nowadays. Therefore, the focus currently should be on achieving near-normal function and acceptable appearance. As a result, and despite careful planning and patient selection and use of refined techniques, touch-up procedures (e.g., minor pulp-plasties and tenolyses) are still commonly performed in a second stage to enhance appearance and function, respectively. Other secondary procedures that may be needed, to a lesser degree, include flap thinning, web space deepening, scar revision, extensor tendon tightening, and arthrodesis.[89,94,109,113,116]

Sensory recovery in the transferred toe is generally adequate enough to allow the patient to have better use of the reconstructed hand compared with hand use before toe-to-hand surgery, especially in thumb reconstruction cases.[13] Delayed sensory reeducation provided for toe transplantation within a few months of toe transfer has been shown to play a key role in better sensory recovery and overall integration into the body.[11] Numerically speaking, static two-point discrimination as low as 8 mm[111,113] and moving two-point discrimination in the range of 3 to 10 mm have been reported.[32,33,43,44] Pulp pinch and sensory threshold have been studied, too, and found to be normal in reconstructed fingers.

Range-of-motion and strength recovery are still less than those of a normal finger but remain within a functional range.[29] An average range of motion of 25 degrees and 29 degrees is expected at the MP joint and PIP joint, respectively, after great toe-to-thumb transplantation.[35] In toe-to-finger transplantation, an average total range of motion of 50 to 60 degrees is expected for the PIP and DIP joints.[108,110] A slight extensor lag is common at the DIP joint; however, transfers to the distal finger typically regain nearly normal motion at the otherwise intact MP and PIP joints. Pinch strength can be restored up to 75% of the contralateral hand, and grip strength can be restored from approximately 70% of the contralateral hand when performing an immediate second-toe transfer and up to 90% with osteoonychocutaneous techniques.[13,48,49]

Compared with patients who do not undergo thumb reconstruction, toe transfer restores objective and subjective hand functioning. Thus, although normal sensation and motion are not typically achieved, toe transfer can restore function and appearance to near-normal levels.[13]

Outcomes of great toe-to-thumb transfer versus thumb replantation were also compared, and no statistically significant difference was shown except for IP motion, which was slightly better in the toe transfer group.[74] Outcomes of great-toe transfer by various techniques have been investigated in a recent systematic review of the literature. The study failed to identify any differences by technique, largely due to the heterogeneity of current data.[88]

As for integration into the body, the transplanted toe is perceived as a finger within 6 months of surgery.[12] This observation is consistent with functional MRI studies showing that motor and sensory tasks involving the transplanted toe evoke enhanced activation and cortical recruitment in the hand area of the primary sensorimotor cortex.[5] This may also be related to the observation that phantom finger phenomena are often ameliorated or eliminated after toe transfer.[12]

CONCLUSION

Between January 1985 and December 2012, a total of 2083 toes were transplanted for 1871 patients at our institution (Table 47.3): 45% (941 of 2083) were second-toe transfers, 11.5% (241 of 2083) were great-toe transfers, and 10% (209 of 2083) were combined second- and third-toe transfers. Other forms of toe transfer, including sensory pulp flaps constituted 33.5% (480 of 2083). The success rate in this series was 98%. Functional recovery, as assessed by sensation and pinch strength, was good, and patient satisfaction was high. From this experience, the authors conclude that toe-to-hand transplantation is reliable and useful for the reconstruction of missing thumbs and fingers. It replaces "like with like" that other reconstructive techniques cannot achieve. However, optimal functional and aesthetic results can be obtained only through strict adherence to the following

TABLE 47.3 Transplantations at Chang Gung Memorial Hospital

January 1985–December 2012

Type of Toe Transplant	Number of Toes
Second toe	941
Great toe	241
Combined second and third toes	209
Glabrous skin/pulp	188
Wraparound (great or lesser toes)	114
Vascularized joint	127
Third toe	44
Fourth toe	4
Combined third and fourth toes	3
Total	2083

principles: (1) proper initial management of all injured structures, (2) adequate preoperative planning, (3) selection of the appropriate transfer technique, (4) meticulous execution of the transfer, (5) thorough motor and sensory rehabilitation, and (6) performance of appropriate revision procedures.

REFERENCES

1. American Replantation Mission to China: Replantation surgery in China. *Plast Reconstr Surg* 52:476–489, 1973.
2. Buncke HJ, Buncke GM: Free pulp transfer. In Foucher G, editor: *Fingertip and nailbed injuries*, New York, 1991, Churchill Livingstone, pp 92–97.
3. Buncke HJ, Rose EH: Free toe-to-fingertip neurovascular flaps. *Plast Reconstr Surg* 63:607–612, 1979.
4. Bunnell S: The management of the nonfunctional hand: reconstruction vs. prosthesis. *Artif Limbs* 4:76–102, 1957.
5. Chen CJ, Liu HL, Wei FC, et al: Functional MR imaging of the human sensorimotor cortex after toe-to-finger transplantation. *AJNR Am J Neuroradio* l27:1617–1621, 2006.
6. Chen CT, Wei FC, Chen HC, et al: Distal phalanx replantation. *Microsurgery* 15:77–82, 1994.
7. Chen HC, Tang YB, Chen SHT, et al: Improving the result of vascularized joint transfer in hand joints: two-stage reconstruction with two periods of rehabilitation. *Tech Hand Upper Extremity Surg* 2:262–268, 1998.
8. Chen HC, Tang YB, Wei FC, et al: Finger reconstruction with triple toe transfer from the same foot for a patient with a special job and previous foot trauma. *Ann Plast Surg* 27:272–277, 1991.
9. Chen SHT, Wei FC, Chen HC: Vascularized toe joint transplantation. *Hand Clin* 15:613–628, 1999.
10. Cheng MH, Wei FC, Santamaria E, et al: Single versus double arterial anastomoses in combined second- and third-toe transplantation. *Plast Reconstr Surg* 102:2408–2412, 1998.
11. Chu NS, Wei FC: Recovery of sensation and somatosensory evoked potentials following toe-to-digit transplantation in man. *Muscle Nerve* 18:859–866, 1995.
12. Chu NS, Wei FC: Peripheral recovery and central response following toe-to-finger transplantation. *Suppl Clin Neurophysiol* 59:317–320, 2006.
13. Chung K, Wei FC: An outcome study of thumb reconstruction using microvascular toe transfer. *J Hand Surg [Am]* 25:651–658, 2000.
14. Cobbett JR: Free digital transfer: report of a case of transfer of a great toe to replace an amputated thumb. *J Bone Joint Surg Br* 51:677–679, 1969.
15. Coskunfirat OK, Wei FC, Lin CH, et al: Simultaneous double second toe transfer for reconstruction of adjacent fingers. *Plast Reconstr Surg* 115:1064–1069, 2005.
16. Deglise B, Botta Y: Microsurgical free toe pulp transfer for digital reconstruction. *Ann Plast Surg* 26:341–346, 1991.
17. Dellon AL: Sensory recovery in replanted digits and transplanted toes: a review. *J Reconstr Microsurg* 2:123–129, 1986.
18. delPñal F, Herrero F, García-Bernal FJ, et al: Minimizing impairment in laborers with finger losses distal to the proximal interphalangeal joint by second toe transfer. *Plast Reconstr Surg* 116:1000–1012, 2003.
19. del Piñal F: The indications for toe transfer after "minor" finger injuries. *J Hand Surg [Br]* 29:120–129, 2004.
20. del Piñal F, García-Bernal FJ, Delgado J, et al: Overcoming soft-tissue deficiency in toe-to-hand transfer using a dorsalis pedis fasciosubcutaneous toe free flap: surgical technique. *J Hand Surg [Am]* 30:111–119, 2005.
21. El-Gammal TA, Wei FC: Microvascular reconstruction of the distal digits by partial toe transfer. *Clin Plast Surg* 24:49–55, 1997.
22. El-Gammal TA, Wei FC: Microvascular toe transfer in children. Part B: The traumatic deficit. In Scheker KS, editor: *Growing hand*, London, 1999, Harcourt, pp 1000–1008.
23. Foucher G: Discussion in: Resurfacing of thumb-pulp loss with a heterodigital neurovascular island flap using a nerve disconnection/reconnection technique. *J Reconstr Microsurg* 13:122–123, 1997.
24. Foucher G, Medina J, Navarro R, et al: Toe transfer in congenital hand malformations. *J Reconstr Microsurg* 17:1–7, 2001.
25. Foucher G, Merle M, Maneaud M, et al: Microsurgical free partial toe transfer in hand reconstruction: a report of 12 cases. *Plast Reconstr Surg* 65:616–627, 1980.
26. Foucher G, Moss AL: Microvascular second toe to finger transfer: a statistical analysis of 55 transfers. *Br J Plast Surg* 44:87–90, 1991.
27. Foucher G, Norris RW: The dorsal approach in harvesting the second toe. *J Reconstr Microsurg* 4:185–187, 1988.
28. Foucher G, Norris RW: Distal and very distal digital replantation. *Br J Plast Surg* 45:199–203, 1992.
29. Frykman GK, O'Brien BM, Morrison WA, et al: Functional evaluation of the hand and foot after one-stage toe-to-hand transfer. *J Hand Surg [Am]* 11:9–17, 1986.
30. Gordon L: Toe-to-thumb transplantation. In Green DP, editor: *Operative hand surgery*, New York, 1993, Churchill Livingstone, pp 1253–1282.
31. Gordon L, Leitner DW, Buncke HJ, et al: Hand reconstruction for multiple amputation by double microsurgical toe transplantation. *J Hand Surg [Am]* 10:218–225, 1985.
32. Gülgönen A, Gudemez E: Toe-to-hand transfers: more than 20 years follow-up of five post-traumatic cases. *J Hand Surg [Br]* 31:2–8, 2006.
33. Halbert CF, Wei FC: Neurosensory free flaps. *Hand Clin* 13:251–261, 1997.
34. Harvey FJ, Harvey PM: A critical review of the results of primary finger and thumb amputation. *Hand* 6:157–162, 1974.
35. Henry SL, Wei FC: Thumb reconstruction with toe transfer. *J Hand Microsurg* 2(2):72–78, 2010.
36. Hentz VR: Reconstruction of individual digits. *Hand Clin* 1:335–339, 1985.
37. Herndon JH: Neuromas. In Green DP, editor: *Operative hand surgery*, ed 3, New York, 1993, Churchill Livingstone, pp 1387–1400.
38. Jones NF, Gupta R: Postoperative monitoring of pediatric toe-to-hand transfers with differential pulse oximetry. *J Hand Surg [Am]* 26:525–529, 2001.
39. Jones NF, Hansen SL, Bates SJ: Toe-to-hand transfers for congenital anomalies of the hand. *Hand Clin* 23:129–136, 2007.
40. Kaplan JD, Jones NF: Outcome measures of microsurgical toe transfers for reconstruction of congenital and traumatic hand anomalies. *J Pediatr Orthop* 34(3):362–368, 2014.
41. Kato H, Ogino T, Minami A, et al: Restoration of sensibility in fingers repaired with free sensory flaps from the toe. *J Hand Surg [Am]* 14:49–54, 1989.
42. Kay SP, Wiberg M: Toe to hand transfer in children. Part 1. Technical aspects. *J Hand Surg [Br]* 21:723–734, 1996.
43. Kimura N, Saitoh M: Recovery of disused replanted digits by second toe hemipulp flap transfer. *Plast Reconstr Surg* 117:507–513, 2006.
44. Koshima I, Eoh H, Moriguchi T, et al: Sixty cases of partial or total toe transfer for repair of finger losses. *Plast Reconstr Surg* 92:1331–1338, 1993.
45. Koshima I, Moriguchi T, Soeda S, et al: Free thin-osteo-onychocutaneous flaps from the big toe for reconstruction of the distal phalanx of the fingers. *Br J Plast Surg* 45:1–5, 1992.
46. Koshima I, Soeda S, Dakase T, et al: Free vascularized nail grafts. *J Hand Surg [Am]* 13:29–32, 1988.
47. Kotkansalo T, Vilkki SK, Elo P: The functional results of post-traumatic metacarpal hand reconstruction with microvascular toe transfers. *J Hand Surg Eur Vol* 34(6): 730–742, 2009.
48. Kotkansalo T, Vilkki S, Elo P, et al: Long-term functional results of microvascular toe-to-thumb reconstruction. *J Hand Surg Eur Vol* 36(3):194–204, 2011.
49. Kotkansalo T, Vilkki S, Elo P: Long-term results of finger reconstruction with microvascular toe transfers after trauma. *J Plast Reconstr Aesthet Surg* 64(10): 1291–1299, 2011.
50. Lam WL, Waughlock N, Hsu CC, et al: Improving the extensor lag and range of motion following free vascularized joint transfer to the proximal interphalangeal joint: Part 2. A clinical series. *Plast Reconstr Surg* 132(2):271e–280e, 2013.
51. Lee WPA, May JW, Jr: Neurosensory free flaps to the hand: indications and donor selection. *Hand Clin* 8:465–477, 1992.
52. Leung PC: Use of an intramedullary bone peg in digital replantation, revascularization and toe-transfers. *J Hand Surg [Am]* 6:281–284, 1981.

53. Leung PC: Thumb reconstruction using second-toe transfer. *Hand Clin* 1:285–295, 1985.
54. Lin CH, Hu TL, Lin CH: Split second- and third-toe transplantation in mutilating-hand-injury reconstruction. *Ann Plast Surg* 60:267–271, 2008.
55. Lin CH, Lin YT, Sassu P, et al: Functional assessment of the reconstructed fingertips after free toe pulp transfer. *Plast Reconstr Surg* 120:1315–1321, 2007.
56. Lin CH, Mardini S, Lin YT, et al: Osteoplastic thumb ray restoration with or without secondary toe transfer for reconstruction of opposable basic hand function. *Plast Reconstr Surg* 121:1288–1297, 2008.
57. Lin CH, Lo S, Lin CH, et al: Opponensplasty provides predictable opposable tripod pinch in toe transfer for proximal thumb ray defect reconstruction. *Plast Reconstr Surg* 130(6):810e–818e, 2012.
58. Lister GD, Kalismann M, Tsai TM: Reconstruction of the hand with free microneurovascular toe-to-hand transfer: experience with 54 toe transfers. *Plast Reconstr Surg* 71:372–384, 1983.
59. Lister G: Microsurgical transfer of the second toe for congenital deficiency of the thumb. *Plast Reconstr Surg* 82:658–665, 1988.
60. Logan A, Elliot D, Foucher G: Free toe pulp transfer to restore traumatic digital pulp loss. *Br J Plast Surg* 38:497–500, 1985.
61. Lutz BS, Wei FC, Chen SHT, et al: Functional reconstruction of metacarpal hand with multiple toe transplantations. *Tech Hand Upper Extrem Surg* 3:37–43, 1999.
62. Ma HS, El-Gammal TA, Wei FC: Current concepts of toe-to-hand transfer: surgery and rehabilitation. *J Hand Ther* 9:41–46, 1996.
63. Mardini S, Wei FC: Unilateral and bilateral metacarpal hand injuries: classification and treatment guidelines. *Plast Reconstr Surg* 113:1756–1759, 2004.
64. Matsuzaki H, Narisawa H, Miwa H, et al: Predicting functional recovery and return to work after mutilating hand injuries: usefulness of Campbell's Hand Injury Severity Score. *J Hand Surg [Am]* 34(5):880–885, 2009.
65. May JJ, Chait LA, Cohen BE, et al: Free neurovascular flap from the first web of the foot in hand reconstruction. *J Hand Surg [Am]* 2:387–396, 1977.
66. McKee NH: Amputation stump management and function preservation. In McCarthy JG, editor: *Plastic surgery*, Philadelphia, 1990, WB Saunders, pp 4329–4343.
67. Morrison WA: Microvascular nail transfer. *Hand Clin* 6:69–76, 1990.
68. Morrison WA, O'Brien BM, MacLeod AM: Thumb reconstruction with a free neurovascular wrap-around flap from the big toe. *J Hand Surg [Am]* 5:575–583, 1980.
69. Ohmori K, Harii K: Transplantation of a toe to an amputated finger. *Hand* 7:134–138, 1975.
70. Ozkan O, Chen HC, Mardini S, et al: Principles for the management of toe-to-hand transfer in reexploration: toe salvage with a tubed groin flap in the last step. *Microsurgery* 26(2):100–105, 2006.
71. Ratcliffe RJ, McGrouther DA: Free toe pulp transfer in thumb reconstruction: experience in the West of Scotland Regional Plastic Surgery Unit. *J Hand Surg [Br]* 16:165–168, 1991.
72. Ray EC, Sherman R, Stevanovic M: Immediate reconstruction of a nonreplantable thumb amputation by great toe transfer. *Plast Reconstr Surg* 123(1):259–267, 2009.
73. Richardson PW, Johnstone BR, Coombs CJ: Toe-to-hand transfer in symbrachydactyly. *Hand Surg* 9:11–18, 2004.
74. Rosson GD, Buncke GM, Buncke HJ: Great toe transplant versus thumb replant for isolated thumb amputation: critical analysis of functional outcome. *Microsurgery* 28:598–605, 2008.
75. Schenker M, Wiberg M, Kay SP, et al: Precision grip function after free toe transfer in children with hypoplastic digits. *J Plast Reconstr Aesthet Surg* 60:13–23, 2007.
76. Shibata M, Seki T, Yoshizu T, et al: Microsurgical toenail transfer to the hand. *Plast Reconstr Surg* 88:102–110, 1991.
77. Spanio S, Wei FC, Coskunfirat OK, et al: Symmetry of vascular pedicle anatomy in the first web space of the foot related to toe harvest: clinical observations in 85 simultaneous bilateral second-toe transfer patients. *Plast Reconstr Surg* 115:1325–1327, 2005.
78. Strauch RJ, Wei FC, Chen SHT: Composite finger metacarpophalangeal joint reconstruction in combined second and third free toe-to-hand transfers. *J Hand Surg [Am]* 18:972–977, 1993.
79. Swanson AB: Levels of amputation of fingers and hand: considerations for treatment. *Surg Clin North Am* 44:1115–1126, 1964.
80. Tamai S: Twenty years' experience of limb replantation: review of 293 upper extremity replants. *J Hand Surg [Am]* 7:549–556, 1982.
81. Tan BK, Wei FC, Lutz BS, et al: Strategies in multiple toe transplantation for bilateral type II metacarpal hand reconstruction. *Hand Clin* 15:607–612, 1999.
82. Tan BK, Wei FC, Chang KJ, et al: Combined third and fourth toe transplantation. *Hand Clin* 15:589–596, 1999.
83. Tsai TM, Jupiter JB, Wolff TW, et al: Reconstruction of severe transmetacarpal mutilating hand injuries by combined second and third toe transfer. *J Hand Surg [Am]* 6:319–328, 1981.
84. Urbaniak JR: Wrap-around procedure for thumb reconstruction. *Hand Clin* 1:259–269, 1985.
85. Valauri FA, Buncke HJ: Thumb and finger reconstruction by toe-to-hand transfer. *Hand Clin* 8:551–574, 1992.
86. Van Holder C, Giele H, Gilbert A: Double second toe transfer in congenital hand anomalies. *J Hand Surg [Br]* 24:471–475, 1999.
87. Vilkki S: Advances in microsurgical reconstruction of the congenitally adactylous hand. *Clin Orthop Relat Res* 314:45–48, 1995.
88. Waljee JF, Chung KC: Toe-to-hand transfer: evolving indications and relevant outcomes. *J Hand Surg [Am]* 38(7):1431–1434, 2013.
89. Wallace CG, Wei FC: Further aesthetic refinement for great toe transfers. *J Plast Reconstr Aesthet Surg* 2008.
90. Wei FC: Tissue preservation in hand injury—the first step to toe-to-hand transplantation. *Plast Reconstr Surg* 102:2497–2501, 1998.
91. Wei FC, Carver N, Lee YS, et al: Sensory recovery and Meissner corpuscle number after toe-to-hand transplantation. *Plast Reconstr Surg* 105:2405–2411, 2000.
92. Wei FC, Chen HC, Chuang CC, et al: Microsurgical thumb reconstruction with toe transfer: selection of various techniques. *Plast Reconstr Surg* 93:345–351, 1994.
93. Wei FC, Chen HC, Chuang CC, et al: Simultaneous multiple toe transfers in hand reconstruction. *Plast Reconstr Surg* 81:366–377, 1988.
94. Wei FC, Chen HC, Chuang DC, et al: Aesthetic refinements in toe-to-hand transfer surgery. *Plast Reconstr Surg* 98:485–490, 1996.
95. Wei FC, Chen HC, Chuang DCC, et al: Reconstruction of the thumb with a trimmed great toe transfer technique. *Plast Reconstr Surg* 52:506–513, 1988.
96. Wei FC, Chen HC, Chuang DCC, et al: Second toe wrap-around flap. *Plast Reconstr Surg* 88:837–843, 1991.
97. Wei FC, Coessens B, Ganos D: Multiple microsurgical toe-to-hand transfer in the reconstruction of the severely mutilated hand: a series of 59 cases. *Ann Chir Main Memb Super* 16:177–187, 1992.
98. Wei FC, Colony LH: Microsurgical restoration of distal digital function. *Clin Plast Surg* 16:443–455, 1989.
99. Wei FC, Colony LH: Microsurgical reconstruction of opposable digits in mutilating hand injuries. *Clin Plast Surg* 16:491–504, 1989.
100. Wei FC, Colony LH, Chen HC, et al: Combined second and third toe transfer. *Plast Reconstr Surg* 84:651–661, 1989.
101. Wei FC, Coskunfirat K, Lin CH, et al: Isolated third toe transfer: indications, technique, and reliability. *Plast Reconstr Surg* 115:1314–1321, 2005.
102. Wei FC, El-Gammal TA, Lin CH, et al: Metacarpal hand: classification and guidelines for microsurgical reconstruction with toe transfers. *Plast Reconstr Surg* 99:122–128, 1997.
103. Wei FC, Epstein MD, Chen HC, et al: Microsurgical reconstruction of distal digits following mutilating hand injuries: results in 121 patients. *Br J Plast Surg* 46:181–186, 1993.
104. Wei FC, Jain V, Chen SHT: Toe-to-hand transplantation. *Hand Clin* 19:165–175, 2003.
105. Wei FC, Lutz BS, Cheng SL, et al: Reconstruction of bilateral metacarpal hands with multiple toe transplantations. *Plast Reconstr Surg* 104:1698–1704, 1999.
106. Wei FC, Mardini S: Reevaluation of the technique of toe-to-hand transfer for traumatic digital amputations in children and adolescents. *Plast Reconstr Surg* 112:1870–1874, 2003.
107. Wei FC, Silverman TS, Hsu WM: Retrograde dissection of the vascular pedicle in toe harvest. *Plast Reconstr Surg* 96:1211–1214, 1995.
108. Wei FC, Yim KK: Single third-toe transfer in hand reconstruction. *J Hand Surg [Am]* 20:388–394, 1995.
109. Wei FC, Yim KK: Pulp plasty after toe-to-hand transplantation. *Plast Reconstr Surg* 96:661–666, 1995.
110. Whitworth IH, Pickford MA: The first toe-to-hand transfer: a 30-year follow-up. *J Hand Surg [Br]* 25:608–610, 2000.
111. Woo SH, Kim JS, Seul JH: Immediate toe-to-hand transfer in acute hand injuries: overall results, compared with results for elective cases. *Plast Reconstr Surg* 113:882–892, 2004.
112. Woo SH, Lee GJ, Kim KC, et al: Immediate partial great toe transfer for the reconstruction of composite defects of the distal thumb. *Plast Reconstr Surg* 117:1906–1915, 2006.
113. Woo SH, Lee GJ, Kim KC, et al: Cosmetic reconstruction of distal finger absence with partial second toe transfer. *J Plast Reconstr Aesthetic Surg* 59:317–324, 2006.
114. Yang D, Yudog G: Thumb reconstruction utilizing second toe transplantation by microvascular anastomosis—report of 78 cases. *Chin Med J* 92:295–301, 1979.
115. Yim KK, Wei FC: Intraosseous wiring in toe-to-hand transplantation. *Ann Plast Surg* 35:66–69, 1995.
116. Yim KK, Wei FC: Secondary procedures to improve function after toe-to-hand transfers. *Br J Plast Surg* 48:487–491, 1995.
117. Yim KK, Wei FC, Lin CH: A comparison between primary and secondary toe-to-hand transplantation. *Plast Reconstr Surg* 114:107–112, 2004.

48

Thumb Reconstruction

Kodi Azari

Acknowledgments: The author wishes to recognize the work of previous authors Dr. William Kleinman, Dr. James Strickland, Dr. Neil Salyapongse, and W. P. Andrew Lee for their contributions to Green's Operative Hand Surgery *and this chapter.*

> *The hand without a thumb is at worst nothing but an animated fish-slice, and at best a pair of forceps whose points don't meet properly.*
>
> ***—John Napier***[95]

Despite a long-standing recognition of the uniquely human way of using the hand, anthropologists have only recently defined the significance of the structure of the human hand that allows us to forgo an arboreal lifestyle in pursuit of vocations ranging from computer programmer to auto mechanic to surgeon. Their findings focus in large part on the anatomic features allowing three "grips" that differentiate the human hand from that of other hominids. These grips—the pad to side, three-jawed chuck, and five-jawed cradle-chuck—are possible due to the structure of the human thumb. As described by Napier, the absence of the thumb, whether due to failure of formation or loss from trauma, significantly impairs hand function.[95] In previous editions of this textbook, Drs. Kleinman and Strickland provided an excellent summary of 125 years of efforts by hand surgeons to preserve and, if necessary, reconstruct thumb function. As they predicted, many of these creative techniques have given way to the demonstrated success of microsurgery, including improved initial thumb salvage via replantation and reconstruction using free toe transfer. Unchanged from their writings is the dictum that, for a willing and motivated patient, "reconstruction of an opposable thumb should be attempted whenever possible by using whatever technical pathways are available to the surgeon."

With a few notable exceptions, techniques used to reconstruct the thumb after trauma are not unique to this digit. Skin grafts, local or regional flaps, free tissue transfer, and distraction and lengthening are all discussed at length in their respective chapters. A brief review of the evolution of thumb reconstruction outside of microsurgical techniques is provided to give the reader some perspective on the breadth of procedures developed. After this, we place the available procedures within a framework to help guide the clinician when planning thumb reconstruction. Apart from advances in microsurgery and refinements in toe transfer techniques, few changes in the procedures used for thumb salvage and reconstruction have taken place. Given this, we describe procedures unique to thumb reconstruction in detail, with attention to both preoperative planning and postoperative care.

HISTORICAL REVIEW

Although technical advances have led to changes in surgical methods, the general surgical philosophies of thumb reconstruction have remained relatively constant since their inception. In the latter part of the 19th and early 20th centuries, two distinct surgical philosophies evolved: (1) optimization of remaining function via local thumb phalangization after partial amputation, essentially a deepening of the first web space, as first described by Huguier[53]; and (2) distant pedicle flap attachment with delayed secondary detachment, first described in 1897 by Nicoladoni.[96,97] The principle of phalangization continued to evolve throughout the 20th century as techniques such as the "Z"-plasty, four-flap "Z"-plasty,[7] dorsal rotational flap,[9] and metacarpal lengthening[77] were used to provide additional web span and depth. Nicoladoni's staged great toe–to–thumb transfer and the delayed pedicle finger transfers of Luksch[75] are clearly mirrored in our current microvascular toe-to-thumb and occasional finger-to-thumb transfers.

Also during the late 19th century, the groundwork for the development of the neurovascular island flap was laid.[28] In addition to its role in plastic surgery and craniofacial reconstruction,[19] this work would become the basis for the third persistent theme in thumb reconstruction: Gosset's revolutionary concept of transfer of a digit on its own neurovascular pedicle.[40,41] In introducing this technique, Gosset not only revolutionized contemporary traumatic thumb reconstruction but also pioneered the seminal principles of reconstruction for a congenitally absent thumb. His initial recommendations involved simple lateral displacement of the index ray without bone shortening. Subsequently modified to include metacarpal recession and rotation, intrinsic muscle transfers, and skin flaps specially designed to produce a wide first web space free of scar,[12] pollicization via nonmicrovascular transfer of the long,[47,80] ring,[16,112] and little[60] fingers remains one of the mainstays of thumb reconstruction.

The fourth pathway to thumb reconstruction consisted of osteoplastic thumb creation.[99,100] Used extensively before World War II, osteoplastic reconstruction was performed in either one or two stages. The first step involved attaching the injured thumb stump to a random tubed pedicle of vascularized skin and subcutaneous tissue from the abdomen or groin; an iliac crest corticocancellous bone graft could be inserted and fixed

to the residual thumb either at a second stage (division of the tubed pedicle) or during primary formation of the pedicle. As recently as 1955, advances in osteoplastic thumb reconstruction were reported, with Moberg's introduction of the "island pedicle" transfer of vascularized, sensible cornified skin from an uninjured portion of the hand to restore stereognosis to the tactile portion of the osteoplastic thumb.[90] This technique has been widely practiced and remains a fundamental approach in complex thumb reconstruction after trauma.[19]

GENERAL CONSIDERATIONS

An ideal reconstruction of the thumb would replace "like with like," restoring both function and appearance. Replantation has demonstrated great success, in that it restores the actual lost thumb and often yields excellent functional outcomes.[61,65,125] When replantation is not possible or fails, the surgeon must re-create the likeness of the thumb. Deconstructing the ideal thumb function into its basic elements can assist the surgeon in choosing a reconstructive technique to provide an optimal outcome. Although authors differ in the specific breakdown of thumb requirements, two broad categories must be addressed: sensation and opposition. Sensation can be further divided into freedom from pain and adequate sensibility to interact with, or at least protect itself from, the environment. Opposition, the hallmark of "thumbness," necessitates length, stability, strength, and mobility.[15,18,49,130] The exact importance of each of these factors varies, depending on the individual needs of the patient: a jeweler who seeks sensibility and mobility may require different management than a manual laborer who may sacrifice mobility for stability and power.

For a patient to consistently use a reconstructed thumb, it must have painless stable skin coverage, be durable enough for normal use, and have at least protective, if not normal, sensation. Thus, regardless of the level of amputation and planned thumb length after salvage or reconstruction, every attempt should be made to restore at least an acceptable level of sensory cognition.[15,18,49,62,67,73,106,130] Procedures should be selected to provide a predictably satisfactory level of tactile perception and stereognosis. Failure to achieve this quality was the most consistent reason for patients' thumb disuse after many early reconstructive techniques (despite the fact that other functional requirements may have been met by the procedures). The use of neurovascular island pedicle techniques, sensory-innervated cross-finger flaps, and other methods of transferring innervated skin have greatly enhanced the ability to restore sensation when carrying out thumb salvage after trauma or to address congenital disorders.

First among the components of opposition is length; amputations that deprive the thumb of the distal phalanx or occur just proximal to the interphalangeal (IP) joint may not require reconstruction.[14,62,106,107] Loss at or more proximal to the shaft of the proximal phalanx, however, usually leaves a stump inadequate for pinch and grasp functions.[117] To oppose the remaining digits, a thumb of sufficient length must be antiposed (abducted, slightly extended, and pronated).[126] Whereas thumb IP flexion results in slight pronation of the distal phalanx,[49] normal motion at the metacarpophalangeal (MP) or IP joints is not mandatory. In contrast, active thumb function depends on preserving a full arc of circumduction at the carpometacarpal (CMC) joint.[15,46] If a substantial range of CMC motion cannot be attained, an essentially sensate prosthesis may be created by arthrodesing the thumb in nearly full abduction-opposition (40 degrees of abduction, 15 degrees of extension, 120 degrees of metacarpal pronation),[62] so that other mobile digits can be flexed to meet it. Thus, strength and mobility that more closely approximate normal thumb opposition may be sacrificed to provide a stable, if immobile, post for resistance during pinch and grasp.

Additional considerations when counseling a patient on the options for thumb reconstruction include the patient's age, sex, occupational demands, hand dominance, and subjective needs. Once the patient has expressed an interest in a restorative or reconstructive effort, an open and honest dialogue between the patient (and/or family) and surgeon is necessary before any final decision can be made. Rehabilitation after any reconstructive procedure is critical to obtaining a successful outcome; the patient must be motivated and should fully understand that his or her efforts during therapy will be as important as the surgery (if not more so) in regaining a functional thumb.

THUMB RECONSTRUCTION AFTER PARTIAL OR COMPLETE TRAUMATIC LOSS

Thumb function after amputation depends primarily on the remaining elements. Consequently, most algorithms for thumb reconstruction begin by stratifying the injury by level of loss.* Division of the thumb into functional levels varies slightly from one author to the next[49,67]; however, when approaching the reconstructive needs of the thumb, we prefer to stratify thumb defects after the style of Lister, as follows[67]:

1. Acceptable length with poor soft tissue coverage. These injuries are typically tip or pulp amputations that leave adequate length, functional thenar musculature, and basal joint mobility for opposition. Additional requirements for these injuries focus on sensibility or sensitivity and durability of skin coverage.
2. Subtotal amputation with questionable remaining length. This group encompasses the widest range of needs, from injuries requiring only soft tissue coverage to those demanding reconstruction analogous to total amputations. Choice of procedure is determined chiefly by the patient's perceived needs.
3. Total amputation with preservation of the basal joint. Although intrinsic thumb function is lost to varying degrees, the foremost requirement of amputations at this level is restoration of length. The extent of remaining intrinsic function, as well as the chosen reconstructive technique, determines how the new thumb is motored.
4. Total amputation with loss of the basal joint. Provision of length is critical, but functional opposition becomes more difficult. Either a substitute for the basal joint must be provided in the reconstruction, or the thumb must be arthrodesed in antiposition.

The following sections present our rationale for this division, define the differing reconstructive needs at each of these levels, and describe in detail the surgical options available.

*See references 11, 13, 15, 44, 49, 61, 63-65, 67, 68, 76, 88, 125, 130, 134.

Acceptable Length With Poor Soft Tissue Coverage

Even complete amputation of the thumb at the level of the IP joint, when treated with appropriate revision amputation, rarely results in significant functional deficit.[38] Therefore, this level has been described as the "compensated amputation zone."[30] If the skeletal and soft tissues have suffered damage sufficient to make restoration of a stable, sensate thumb tip unlikely, completion amputation and closure may provide a more immediate and equally functional outcome.[31] In this setting, it is important that closure be carried out using sound amputation principles, including avoidance of boxy stump edges and proximal resection of the digital nerves.[31,84] If these techniques are properly carried out, a good stump in the distal third of the thumb can function well with almost no functional disability.[106]

A broad spectrum of injury exists short of complete amputation or unsalvageable trauma to the distal thumb. Goals of treatment include restoration of skeletal stability; coverage of the thumb with durable, painless skin; and restoration of adequate sensory perception. The specific procedures used to accomplish these goals vary, depending on the amount and depth of tissue loss. An attempt should be made to salvage all viable tissues consistent with these objectives. Although injuries to the palmar pad of the distal phalanx of the thumb can be managed by the same coverage techniques applicable to fingertip injuries, the approach may be somewhat different as one strives to preserve length.[50,107,112,121,124]

The choice of reconstructive procedure for soft tissue deficits over the distal thumb depends primarily on the size of the defect. When the loss of skin and subcutaneous tissue from the terminal aspect of the distal phalanx is small (typically <1 cm^2) and no exposed bone is present, reasonable treatment options include allowing spontaneous healing by secondary intention, free skin grafts,[120] lateral triangular advancement flaps,[39,66] "V-Y" advancement flaps (Figure 48.1),[3,34,66] and a variety of other techniques.[52,54-56,58,101,104] For these small defects, we prefer conservative, open treatment to allow the wound to heal through secondary intention. The advantage of spontaneous healing is more favorable wound contraction, which results in a minimal defect with nearly normal sensation preserved.[62] At the time of presentation, patients undergoing conservative treatment should have the wound cleansed and covered with a nonadherent dressing. The initial dressing is removed at 24 to 48 hours, and daily dressing changes are performed thereafter until the wound has completely closed. Patients should be counseled that a few weeks may elapse before the thumb tip has healed.

Loss of greater than 50% of the distal portion of the thumb pad, tendon denuded of sheath and soft tissue coverage, and bone stripped of its periosteum may jeopardize not only the function of the injured thumb but also the preservation of thumb length. Under these circumstances, more complex reconstructive procedures such as palmar advancement flaps, cross-finger flaps, and neurovascular island or radial sensory-innervated cross-finger flaps may be warranted. Each of these techniques is considered in detail in the following sections.

Palmar Advancement Flap

Originally described by Moberg,[91] the palmar advancement flap provides a good reconstructive option for loss of greater than



FIGURE 48.1 "V-Y" palmar advancement flap. **A,** Distal thumb amputation with exposed distal phalanx. **B,** Advancement of flap to cover the defect. Note that the apex of the "V" does not cross the interphalangeal crease in order to avoid flexion contracture of the IP joint. **C** and **D,** Results 3 months after surgery.

half of the distal thumb pad.[62] It has the advantage of bringing well-innervated sensate palmar thumb skin distally to resurface the pad lesion, thereby restoring nearly normal sensory perception with durable skin and subcutaneous tissue. Resurfacing of the thumb tip is accomplished by advancement of a palmar flap containing the neurovascular structures, with or without proximal skin release and interpositional grafting.[59,86,91,105] This flap has proved most useful in covering defects ranging from slightly greater than 1 cm to "quarter sized,"[59] or as large as 2 cm.[105] The thumb is uniquely suited for this flap because the thumb IP joint can be flexed as much as 45 degrees to provide sufficient advancement of the flap. Although some authors believe this degree of flexion does not result in long-term flexion deformity,[59,105] in our practice, we have found that it does. Additionally, we have found that advancement of the flap by more than 1.5 cm is facilitated by a proximal transverse releasing incision,[2] which can decrease the need for acute IP flexion and increase the amount of tissue that can be mobilized. Although the defect created by the releasing incision can be left to heal by secondary intention, coverage with a full-thickness skin graft provides a closed wound and decreases wound contraction. The proximal flap can also be advanced by a "V-Y" technique in which the proximal incision is designed as a "V" rather than perpendicular to the thumb.

Palmar Advancement Flap Without Proximal Releasing Incision

This technique is best for terminal distal phalangeal pad defects 1.5 cm or less in length. Under tourniquet control, necrotic and ragged bone is trimmed from the distal phalanx, and thorough soft tissue débridement is carried out (Figure 48.2, *A*). Midaxial incisions are made over the radial and ulnar sides of the thumb and extended proximally from the lesion to the proximal thumb crease. Placement of the incisions across the dorsal apices of the flexion creases facilitates dissection dorsal to the neurovascular bundles. The palmar flap is carefully dissected from the underlying flexor tendon sheath; the flap should include subcutaneous tissue and both neurovascular bundles (see Figure 48.2, *B*). The mobility of the flap is tested by distal traction to determine whether any additional soft tissue undermining or releases are necessary. If tension is too great, the midaxial incisions can be extended proximally onto the thenar eminence. The MP and IP joints of the thumb are flexed 30 to 45 degrees. The distal edge of the flap is sutured to the remaining nail, nail bed, or terminal skin remnant, and radial and ulnar sutures are used to complete skin closure (see Figure 48.2, *C*). Figure 48.2, *E* to *G*, shows a clinical example of the palmar advancement flap without a proximal incision in a patient who suffered a distal thumb amputation during an altercation.

Palmar Advancement Flap With Proximal Releasing Incision

Use of a proximal releasing incision allows the palmar advancement flap to cover defects up to 2.5 cm long. As in the case of a palmar flap without a releasing incision, appropriate bone and soft tissue débridement should be carried out under tourniquet hemostasis (Figure 48.3, *A*). Dissection begins at the radial and ulnar edges of the wound via midaxial incisions. How far proximal these midaxial incisions are carried depends on the method chosen to close or cover the wound created by the relaxing incision. If the necessary advancement is only slightly greater than that achievable without a relaxing incision, options such as ending each incision as a "Z"-plasty over the thenar eminence or creating a "V-Y" advancement flap just proximal to the proximal thumb crease may allow primary closure of all wounds. More often, however, when significant advancement is required, the midaxial incisions should be carried to the level of the proximal third of the proximal phalanx. At this point, a transverse incision should be used to connect the proximal ends of the incisions. The neurovascular bundles must be identified, protected, and carefully mobilized (see Figure 48.3, *B*). It is more convenient and simpler to raise the flap in a distal-to-proximal direction, maintaining a plane of dissection just superficial to the flexor sheath. On reaching the proximal portions of the midaxial incisions, the flap consists of skin, subcutaneous tissue, and both neurovascular bundles. This "islandized" flap can be advanced to the thumb tip and sutured into place (see Figure 48.3, *C*). As when insetting the standard palmar advancement flap, it may be necessary to flex both the IP and MP joints to relieve tension on the closure. The resulting gap between the proximal end of the flap and the proximal releasing incision is covered with a full-thickness skin graft harvested from the medial arm (preferred), hypothenar eminence, antecubital fossa, or groin (see Figure 48.3, *D*).

At the conclusion of either palmar advancement flap, a dressing consisting of antibiotic ointment, nonadherent gauze, fluffed cotton gauze, and a thumb spica splint is applied. Care should be taken in shaping the thumb spica to maintain the flexion applied to achieve a tension-free closure. The splint and dressings are removed to allow inspection of the flap and skin grafts (if used) after 7 to 10 days. Thereafter, a removable Orthoplast thumb spica splint is applied to prevent overextension of the thumb. After 3 weeks, the patient begins active range-of-motion exercises; if necessary to regain full extension, dynamic splinting can begin at around 4 weeks.

CRITICAL POINTS *Palmar Advancement Flap*

Indications

- Palmar thumb pad defects greater than 1 cm but less than 2 cm long
- Exposed distal phalanx devoid of periosteum

Technical Points

- Perform thorough débridement of the defect.
- Incise skin in the midaxial line beginning at the wound and extending proximally on the radial and ulnar aspects of the thumb up to the proximal thumb crease.
- Dissect the flap, containing the subcutaneous tissue and both neurovascular bundles, from the flexor sheath.
- Test tension on the flap by providing distal traction.
- If additional length is necessary, extend incisions or dissection onto the thenar eminence.
- Flex thumb MP and IP joints to 30 to 45 degrees.
- Suture the distal flap to the remaining nail, nail bed, or skin.
- Apply nonadherent dressing and a thumb spica splint.

Postoperative Care

- Inspect the wound at 7 to 10 days.
- Switch to a thermoplastic thumb spica splint.
- Begin active range-of-motion exercises at 3 weeks.
- If necessary to achieve IP joint extension, dynamic splinting can start at 3 to 4 weeks.

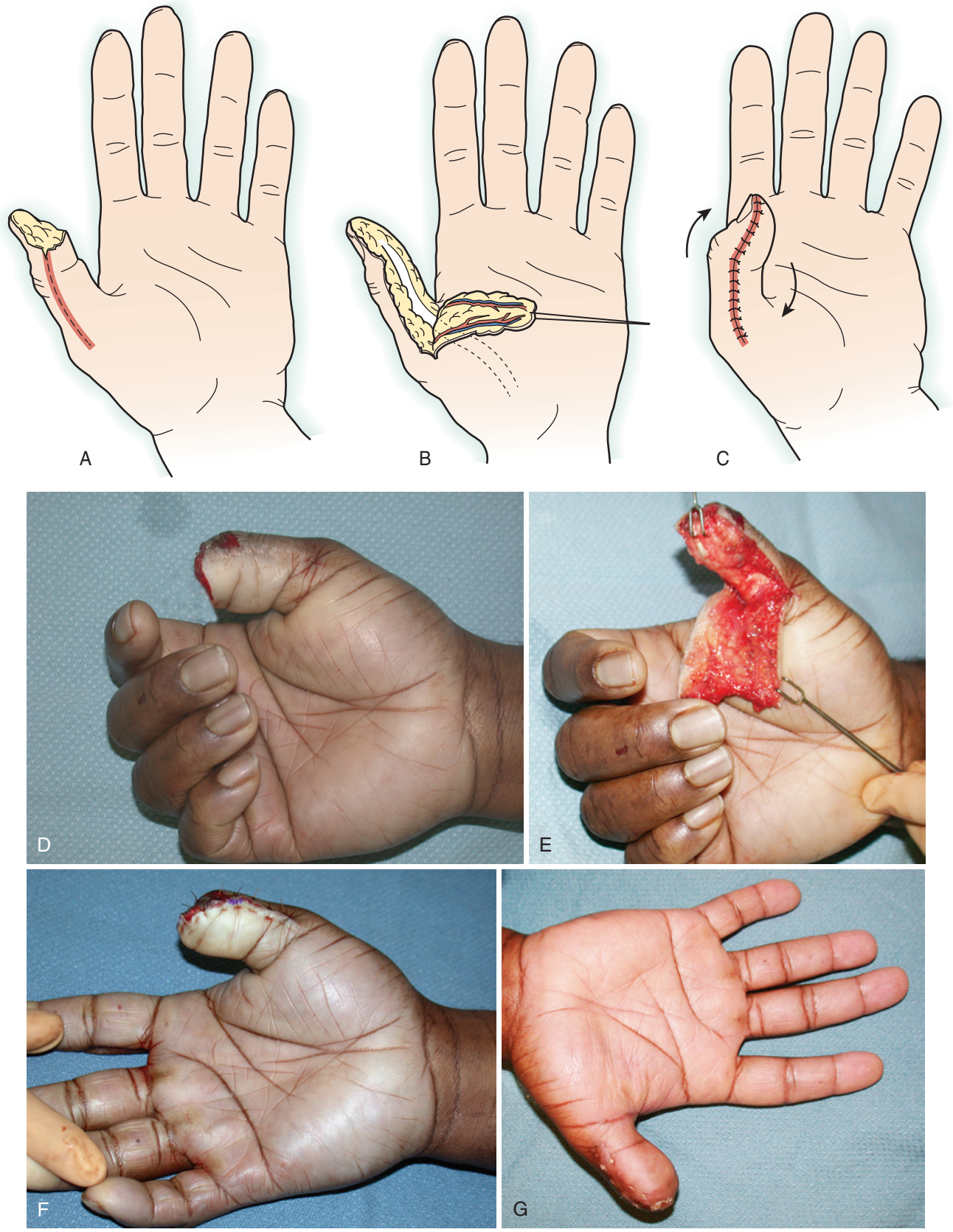

FIGURE 48.2 Palmar advancement flap without a proximal incision. **A,** Defect representing 50% of the tactile thumb pad. **B,** Proximal reflection of the advancement flap containing neurovascular bundles to expose the sheath of the flexor pollicis longus. **C,** Advancement and closure of the flap with flexion of the metacarpophalangeal and interphalangeal joints. **D** to **G,** Clinical example of a patient who suffered a distal thumb amputation when it was bitten off during an altercation. (Modified from Keim HA, Grantham SA: Volar-flap advancement for thumb and finger-tip injuries. *Clin Orthop* 66:109–112, 1969; and Posner MA, Smith RI: The advancement pedicle flap for thumb injuries. *J Bone Joint Surg Am* 53:1618–1621, 1971.)

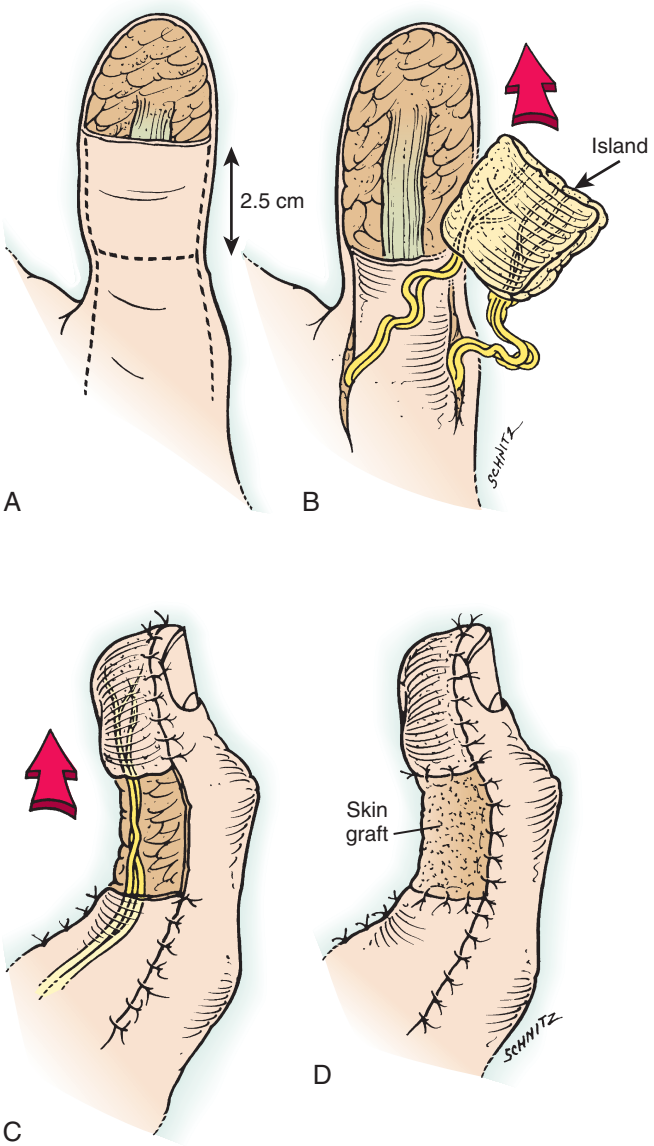

FIGURE 48.3 Palmar advancement flap with a proximal releasing incision. **A,** A 2.5-cm defect of the distal phalangeal thumb pulp and outlines of incisions for the advancement flap. **B,** Elevation of the flap and mobilization of the neurovascular bundles through the proximal incision. **C,** Advancement of the flap to close the defect. **D,** Free skin graft coverage of the proximal donor area. (Modified from Vilain R, Michon J: *Plastic surgery of the hand and pulp,* New York, 1979, Masson.)

Although these flaps are used primarily in acute situations, they can also be employed for thumb resurfacing at a later time when inadequate coverage exists.[86,91,103] Choosing the appropriate wound for reconstruction with these flaps provides the best chance for a successful outcome. The required advancement should not exceed 2.5 cm and should include, if at the upper end of this distance, plans for a proximal releasing incision. Despite the excellent dorsal vascularity of the thumb, it is possible to induce ischemia in the ungual area, particularly in smokers; therefore, it is advisable to avoid dissecting the pedicle too far. Other risks worth mentioning during preoperative counseling include sloughing of bits of bone or nail during the immediate postoperative period[59] and the possibility of flexion contractures of the IP joints.

CRITICAL POINTS *Palmar Advancement Flap With Proximal Releasing Incision*

Indication

- Same as for the standard palmar advancement flap, with defects greater than 2 cm and less than 2.5 cm long.

Technical Points

- Perform thorough débridement of the defect.
- Incise the skin in a midaxial line beginning at the wound and extending proximally on the radial and ulnar aspects of the thumb up to the proximal third of the proximal phalanx.
- Connect the midaxial incisions via a transverse palmar incision.
- Identify and mobilize the neurovascular bundles.
- Dissect the flap, containing the subcutaneous tissue and both neurovascular bundles, from the flexor sheath.
- Test tension on the flap by providing distal traction.
- If additional length is necessary, extend incisions or dissection onto the thenar eminence.
- Flex thumb MP and IP joints to 30 to 45 degrees.
- Suture the distal flap to the remaining nail, nail bed, or skin.
- Apply a full-thickness skin graft to the proximal thumb flap harvest site.
- Apply nonadherent dressing and a thumb spica splint.

Postoperative Care

- Inspect the wound at 7 to 10 days.
- Switch to a thermoplastic thumb spica splint.
- Begin active range-of-motion exercises at 3 weeks.
- If necessary to achieve extension, dynamic splinting can start at 3 to 4 weeks.

Heterodigital Flap Reconstruction

Loss of the entire palmar surface of the thumb distal phalanx presents a wound too great to be covered with a palmar advancement flap. Simple skin grafting may preserve length, but it does not restore durable, painless skin. Initially developed for coverage of exposed tendon or bone and for loss of a significant amount of skin and subcutaneous tissue from the palmar surface of the fingers,[43] a cross-finger flap designed from the dorsal proximal phalanx of the index finger often provides excellent coverage of these lesions, with satisfactory skin and subcutaneous tissue and adequate recovery of sensation.[26,29,62,82,106,115,123] This flap, and its innervated variations, substitutes a delayed skin flap from an adjacent digit for flaps historically based on cross-arm, thoracic (Figure 48.4), or abdominal donor sites. The reliability and ease of performance of these flaps have made them the mainstay for larger tissue losses in the distal third of the thumb, despite the development of numerous more elaborate techniques, including transfer of the tip of the fifth finger,[123] free toe pulp transfers,[108,118] a one-stage advancement–rotational flap combination,[52,56] "kite" or "flag" flaps from the index finger,[33,54,114] a dorsal flap based on the first web space,[79] or a flap hinged on the ulnar side of the thumb and rotated distally, as popularized by Brunelli[10] (Figure 48.5).

Occasionally, irreparable damage to the digital nerves of the thumb, resulting in permanent sensory loss in the palmar tactile pad, accompanies soft tissue loss in the distal third of the thumb. A patient with this wound may suffer substantial disability

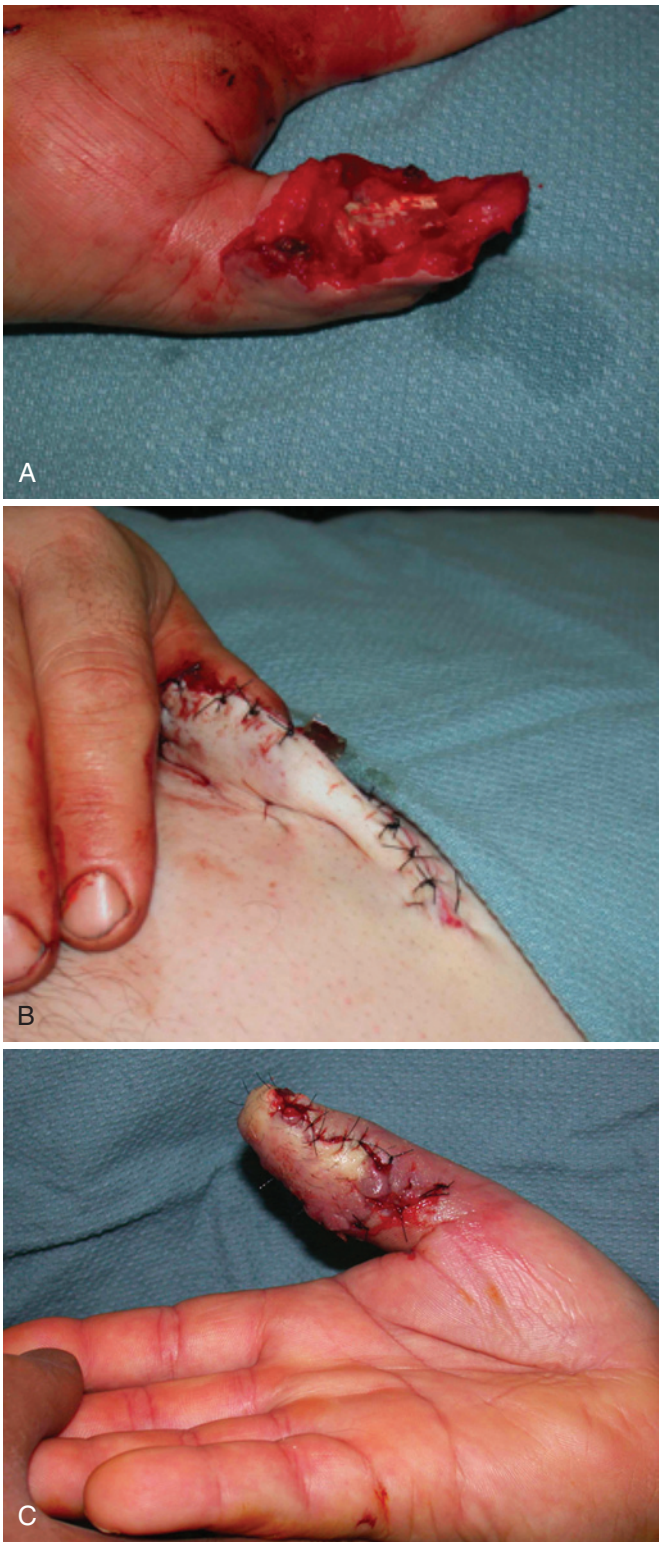

FIGURE 48.4 A thoracoepigastric flap is shown here for historical purposes because much better reconstructive options exist. **A,** Large volar thumb defect sustained from a table saw. **B,** After débridement, the thumb defect is secured to a random-pattern thoracoepigastric flap. **C,** Division of the flap 3 weeks later.

owing to impairment of pinch and grasp function. Under these circumstances, it may be appropriate to use a neurovascular island pedicle transfer, as first suggested by Moberg[91] and Littler.[72] This technique is very demanding, however, and the quality of sensory return has been challenged.[93]

Cross-Finger Flap to the Thumb

Under tourniquet hemostasis, acute wounds should be thoroughly débrided and the wound margins excised. Some attempt to convert the lesion into a square or rectangular defect may facilitate flap design and inset; however, this should not take precedence over preservation of viable palmar skin, especially along the radial aspect of the thumb, which represents the most distal aspect of the cross-finger flap. Blotting the wound with a sterile piece of paper produces a template corresponding in size to the defect. This template can be cut from the paper and traced onto the dorsal radial aspect of the index finger after adducting the thumb against the side of the index finger to determine the appropriate level for the base of the flap (Figure 48.6, *A*). Because of the unique rotational motion of the thumb, the base of the flap originates palmar to the midaxial line of the index finger and extends across the dorsum of the proximal phalanx as far as the defect size requires. A slightly oblique configuration of the donor flap aids in positioning it against the pad lesion.

Incisions are made along the proximal, ulnar, and distal borders of the flap through the skin and subcutaneous tissue down to the level of the paratenon. The flap is raised in an ulnar-to-radial direction in the plane just superficial to the extensor paratenon. As dissection proceeds radially toward the base of the flap, the cutaneous ligaments of Cleland must be incised to increase mobility of the flap. Dorsal veins running in the subcutaneous tissue can be divided with bipolar cautery, but small veins in the radial corner of the flap should be preserved to ensure its viability (see Figure 48.6, *B*). On completion of dissection, the tourniquet is deflated, and hemostasis is achieved using bipolar cautery.

A full-thickness skin graft is patterned slightly larger than the donor defect and harvested from the ipsilateral medial arm (preferred), antecubital fossa, or groin. The graft excess is applied to the base of the flap as it spans the space between the apposed thumb and index finger. Inset of the flap to the proximal, radial, and distal thumb wound is performed using fine (5-0) nonabsorbable monofilament sutures. The skin graft is applied to the donor defect and sutured in place with fine (5-0) plain gut suture. The inset of the skin graft is completed by suturing to the ulnar aspect of the thumb defect, thereby creating a closed wound (see Figure 48.6, *C* and *D*). The skin graft and flap should be covered with antibiotic ointment, a nonadherent dressing, followed by cotton gauze. The gauze overlying the skin graft should be conformed to the wound to serve as a bolster. These dressings are held in place by rolled cotton gauze, and the thumb and index finger are immobilized in a palmar splint extending across the hand and wrist.

Motion is permitted in the ulnar three fingers to prevent stiffness, and a dressing change at 5 to 7 days is used to assess the viability of the flap and the "take" of the graft. The flap can be safely divided after 14 to 21 days. Some recommend elevation of the wound edges and inset of the flap, as well as closure of the index donor site during division of the flap. Although this is possible, the wounds will heal just as effectively by secondary intention, without the risk of constricting either finger by attempting inset and closure. Daily dressing changes to the divided flap wounds are performed until complete closure has occurred. Active and passive range-of-motion exercises are begun immediately after division of the flap.



FIGURE 48.5 Brunelli flap reconstruction of the dorsal thumb. **A,** Squamous cell carcinoma of the nail bed. **B,** Total excision of the nail complex and distal phalanx dorsal cortex with clear surgical margins. **C,** Marking of the flap and the course of the dorsal ulnar artery of the thumb pedicle. **D,** Elevation and rotation of the flap. **E,** Flap inset and closure of the donor site with a rotation flap. **F,** Results 6 weeks after surgery.

Satisfactory sensory return has been reported in several long-term studies of cross-finger flap performance.[103] The technique is reliable and well tolerated by patients and provides sufficient padding for long-term heavy thumb use (eFigure 48.1). Disadvantages and complications include a potentially unsightly defect over the dorsum of the index finger, which may be particularly annoying to children and women, and some occasional problems with digital joint stiffness or thumb web contracture.

Innervated Cross-Finger Flap

Protective sensation and two-point discrimination return most predictably after cross-finger flaps in patients younger than 20 years; in patients older than 40, nearly half fail to regain protective sensation. In an attempt to improve on these outcomes, large cross-finger pedicle flaps that carry a sensory branch of the radial nerve have been described.[6,37,88,110,131] With the exception of the axial, bipedicled neurovascular island flap developed by Paneva-Holevich and Holevich,[102] each of these flaps differs from a traditional cross-finger flap primarily in that additional dissection over the first web space is used to facilitate inclusion and transposition of a dorsal sensory branch of the radial nerve.[6,37] Walker and colleagues[131] determined that the ultimate sensibility of these flaps is a mixture of the median and radial nerves, and Hastings[48] described a "dual innervated cross-finger" or island flap that coapts the dorsal sensory branch of the index radial digital nerve to the ulnar digital nerve of the thumb in an effort to improve cortical recognition of the flap as a thumb. Other variations have also been described,[23,51,88,110] and though it is rarely required, the procedure has a definite place among the reconstructive options for restoring thumb sensibility.

CRITICAL POINTS *Cross-Finger Flap*

Indication

- Loss of the entire palmar surface of the thumb distal to the IP joint

Technical Points

- Thoroughly débride the wound.
- Blot the wound with sterile paper to form a template.
- Align the thumb with the radial aspect of the index finger to determine the level for the base of the flap.
- Trace the template onto the dorsal index finger.
- Incise the proximal, ulnar, and distal borders of the flap.
- Preserve the small veins in the radial corner of the flap.
- Raise the flap in a plane just superficial to the extensor paratenon.
- On the radial aspect of the flap, divide the Cleland ligaments to increase mobility of the flap.
- Deflate the tourniquet and achieve hemostasis before flap inset.
- Inset the flap along the proximal, radial, and distal margins of the wound.
- Harvest a full-thickness skin graft (medial arm) and inset this in the donor site using 5-0 plain gut sutures.
- Apply antibiotic ointment and a nonadherent gauze dressing to the flap and graft.
- Immobilize the thumb and index finger via a palmar splint crossing the hand and wrist.

Postoperative Care

- Inspect the wound in 5 to 7 days.
- Divide the base of the flap at 10 to 14 days.
- Allow the divided bridge to heal by secondary intention.
- Begin active range-of-motion exercises immediately after flap division.

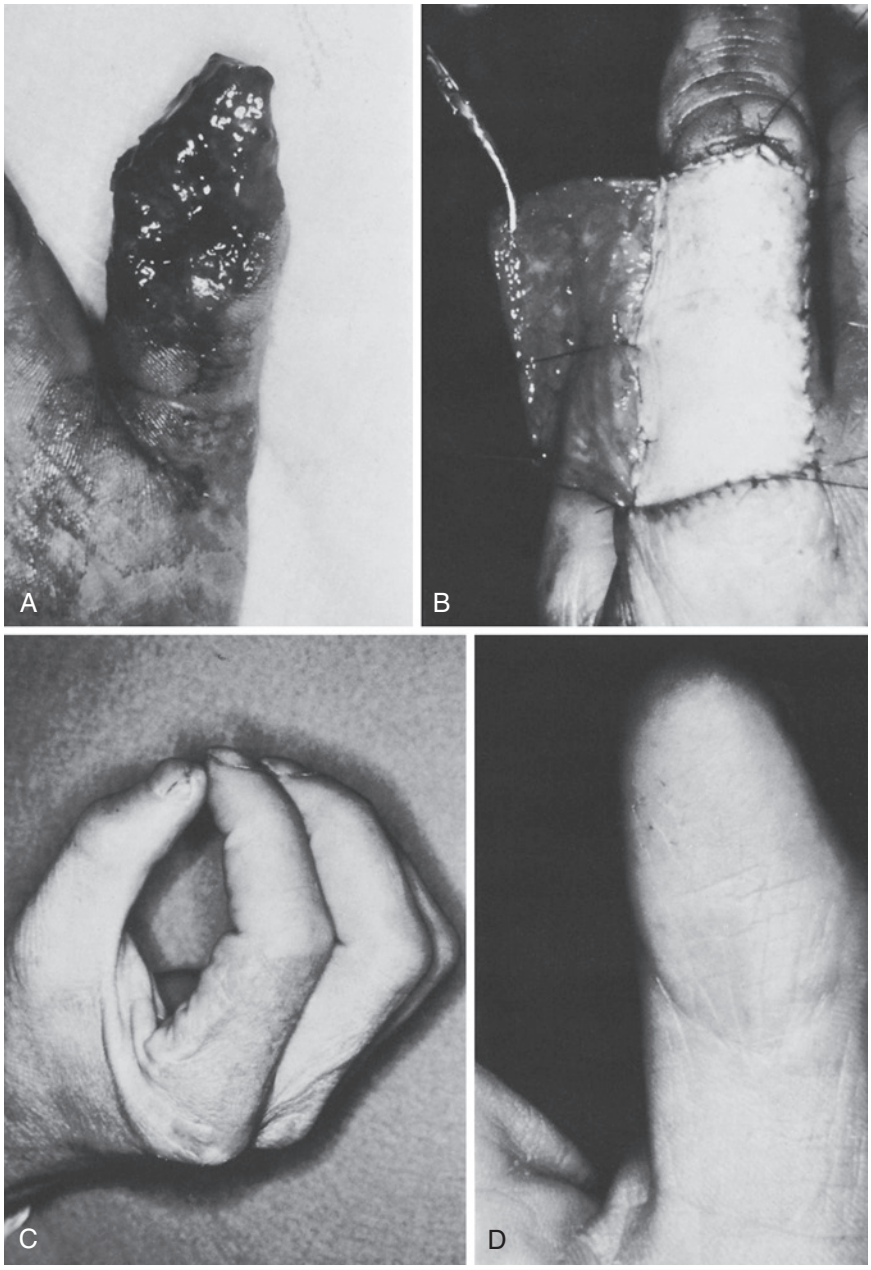

eFIGURE 48.1 Cross-finger flap coverage of a large thumb defect. **A,** Large avulsion defect involving the entire palmar aspect of the distal phalanx of the thumb. **B,** Large cross-finger flap designed from the dorsum of the proximal phalanx of the index finger. The donor site has already been covered with a skin graft. **C,** Appearance of the thumb and donor defect at 3 months. **D,** Cosmetic appearance of the thumb pad at 3 months, with satisfactory sensation and durable coverage. (From Strickland JW: Restoration of thumb function following partial or total amputation. In Hunter JM, Schneider LH, Mackin EJ, et al, editors: *Rehabilitation of the hand*, St Louis, 1978, CV Mosby.)

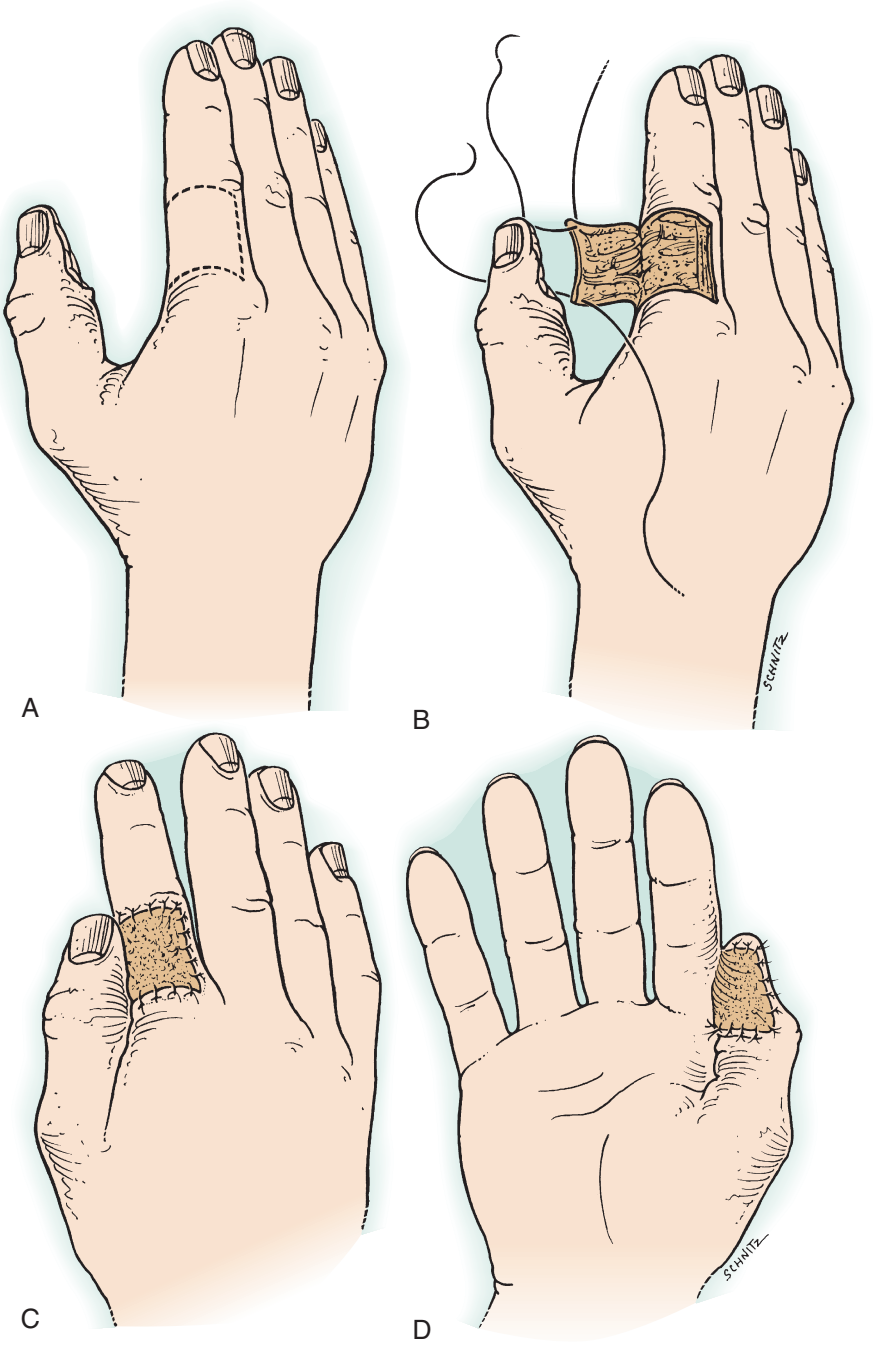

FIGURE 48.6 Cross-finger flap from the index finger to the thumb. **A,** Large defect involving most of the distal pulp of the thumb, and outline of the cross-finger flap on the proximal phalanx of the index finger. **B,** Placement of the flap on the thumb defect. **C** and **D,** Position of the thumb and cross-finger flap with a free graft covering the donor defect.

Radial-Innervated Cross-Finger Flap. After appropriate débridement under tourniquet hemostasis, a pattern matching the size of the acute defect or the defect to be created to provide sensory restoration to the denervated thumb is created. Markings for the size and location of the cross-finger flap are carried out in a manner identical to that described for the noninnervated cross-finger flap. If necessary, the flap can be extended over the MP joint for the resurfacing of larger defects. Beginning at the midpoint of the proximal transverse outline of the flap, an oblique incision extends proximally over the dorsal ulnar border of the first web space to a level several centimeters proximal to the midportion of the thumb web (Figure 48.7, *A*). A large dorsal sensory branch of the radial nerve may be identified on the muscle fascia in the proximal portion of this incision and traced distally into the proximal margin of the flap. Complete mobilization of the nerve from the proximal edge of the flap to the base of the web space incision is necessary to prevent undue tension on the nerve after transposition. Small branches of the nerve encountered during mobilization should be divided.

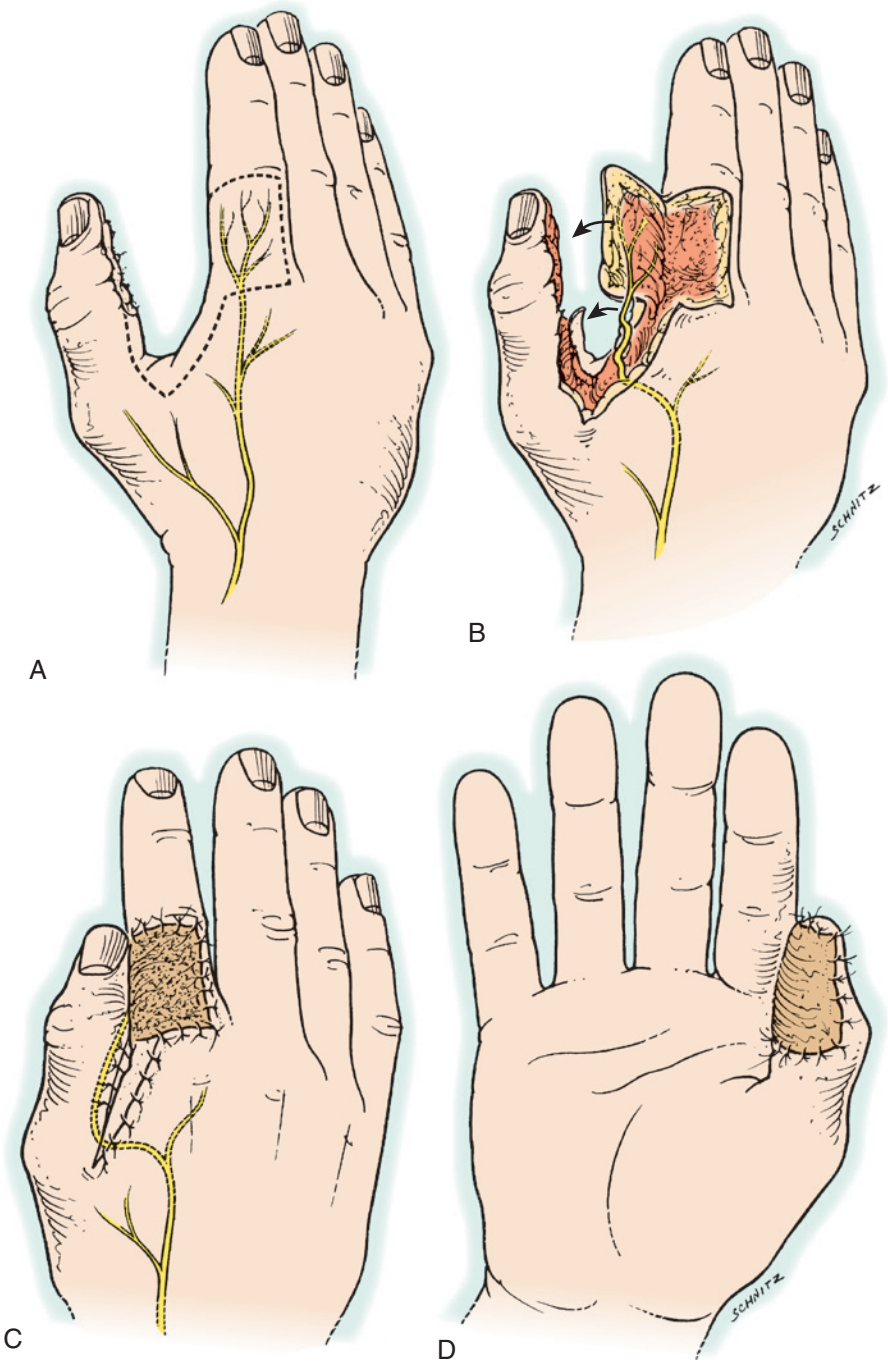

FIGURE 48.7 Sensory radial nerve–innervated cross-finger flap. **A,** Outline of the cross-finger flap with dorsal web incisions connecting to the thumb defect. The incision is made dorsal and proximal to the thumb web to prevent a subsequent scar contracture. The position of the dorsal sensory radial nerve is depicted. **B,** Reflection of the flap after dissection of the nerve branch. **C** and **D,** Position of the thumb and transferred flap, with closure of incisions and free graft coverage of the donor defect.

Once the radial sensory branch has been mobilized, the cross-finger flap is incised and elevated, as for a standard cross-finger flap. A solitary but significant difference from the standard flap is that care must be taken when incising the proximal transverse border of the flap to avoid injury to the radial sensory branch as it enters the flap. When the flap has been mobilized to its base, the thumb is brought along the side of the index finger to check the positioning of the flap into the recipient defect (see Figure 48.7, *B*).

A connecting incision is made along the midaxial ulnar border of the thumb and carried proximally to the previous oblique incision extending from the flap. At the time of flap attachment, the nerve is carefully transposed from the dorsum of the index ray to the ulnar thumb incision after undermining has provided a satisfactory trough in which it can lie without tension. Suturing of the ulnar thumb incision and the connecting dorsal radial index incision secures the position of the nerve, and the defect over the dorsum of the proximal phalanx is

covered with a full-thickness skin graft. As in the standard cross-finger flap, enough graft is harvested to provide coverage of the exposed pedicle by suturing into the free ulnar edge of the thumb defect (see Figure 48.7, *C* and *D*).

A dressing and splint identical to that described for the standard cross-finger flap are applied. Flap monitoring and division are also as described earlier. In addition to active and passive motion rehabilitation, a protocol of gradually increasing pressure stimuli is added, with the goal of increasing appropriate cortical recognition of the transferred flap. Risks inherent in using the innervated cross-finger flap include those related to damage to the mobilized branch of the radial sensory nerve secondary to undue tension or manipulation. Sensory return may be only protective, and the patient may continue to interpret thumb sensation as that of the dorsal index finger. Nonetheless, the radial-innervated cross-finger flap is a useful procedure when one is faced with irreparable sensory damage to the thumb and no other source is available for reconstruction (eFigure 48.2).

CRITICAL POINTS *Radial-Innervated Cross-Finger Flap*

Indications

- Similar to those for the cross-finger flap
- Damage to the terminal digital nerve with tissue loss, as for the standard cross-finger flap

Technical Points

- Débride, create a template, and outline the flap, as for the standard cross-finger flap.
- Incise the skin obliquely, beginning at the midportion of the proximal flap incision and extending along the ulnar border of the first web space.
- Stop the incision a few centimeters proximal to the midportion of the thumb web.
- Bluntly dissect a branch of the radial sensory nerve, typically found running deep on the muscle fascia.
- Trace the nerve up to the flap.
- Dissect the flap as for the standard cross-finger flap, taking care not to divide the nerve as it enters the flap.
- Incise from the proximal margin of the thumb wound along the radial aspect of the first web space.
- Stop this incision at the proximal end of the incision used to identify the radial sensory nerve branch.
- Deflate the tourniquet and achieve hemostasis.
- Bluntly dissect and elevate the radial sensory nerve branch.
- During inset of the flap, transpose the nerve to the incision created on the ulnar aspect of the thumb.
- Harvest a graft large enough to allow coverage of the harvest site as well as the nerve pedicle at the proximal flap inset.

Postoperative Care

- Same as for the standard cross-finger flap

Dual Innervated Cross-Finger Flap. Under tourniquet hemostasis, thumb débridement, pattern creation, and flap design are carried out as described for the standard cross-finger flap. An incision is made from the proximal aspect of the flap along the radial aspect of the index metacarpal to the recess between the base of the index metacarpal and the extensor pollicis longus. A second incision is extended distally along the dorsal ulnar aspect of the thumb metacarpal to the MP joint and the more distal thumb defect just palmar to the midaxial line (Figure 48.8, *A*).

Flap elevation is initiated along the distal and ulnar incisions on the index finger. As the incision is carried down to the level of the paratenon, small veins are divided with bipolar electrocautery. The flap is elevated in a dorsal-to-palmar direction while preserving the paratenon of the extensor mechanism and including all neurovascular structures within the flap. Along the incision coursing proximal over the index metacarpal, flaps are elevated superficial to the neurovascular structures. No attempt is made to separately dissect out the two to four terminal branches of the dorsal sensory radial nerve to the dorsal index finger. The subcutaneous tissue surrounding the dorsal sensory radial nerve contains veins and, in most instances, the first dorsal intermetacarpal artery; a narrow 0.5- to 1-cm-wide strip of this subcutaneous tissue should be raised down to the level of the investing muscle fascia to incorporate these nerve branches and, if the flap is to be transferred as an island pedicle, the artery and veins (see Figure 48.8, *B*). If an island flap is planned, the first dorsal intermetacarpal artery should be identified proximally before raising the subcutaneous portion of the flap to ensure that it is contained in the pedicle. Although, as stated by Foucher,[33] the artery most often runs superficial to the fascia, it may run deep to the fascia in 15% of cases or consist of two vessels, one superficial and one deep, in 10%.[48] At the level of the MP joint, the dorsal branch from the index radial digital nerve (median nerve distribution) is identified and dissected back to its origin. The connecting incision to the thumb is completed, and the ulnar digital nerve amputation stump proximal to the thumb defect is identified.

Transposition of the flap with the dorsal sensory radial nerve branches is accomplished as described earlier, and the inset begins radially (see Figure 48.8, *C* and *D*). Before completion of the proximal and distal inset, neurorrhaphy of the palmar ulnar digital nerve of the thumb to the more distal dorsal sensory nerve branch of the transposed flap is accomplished under the operating microscope (eFigure 48.3). The connecting incisions are closed, and skin grafts are applied to the donor area.

Postoperative care, flap division, and rehabilitation are identical to these steps for the radial-innervated cross-finger flap previously described.

First Dorsal Metacarpal Artery Island Flap

The first dorsal metacarpal artery (FDMA) flap was popularized as a pure island flap (kite flap) by Foucher in 1979.[34] In many ways, this flap is similar in design to the radial-innervated cross-finger flap. However, it is transferred as a pure island flap carrying the FDMA, subcutaneous veins, and branches of the radial sensory nerve in a single stage, thus eliminating the need for prolonged immobilization and potential long-term stiffness. The FDMA island flap can reach the volar and dorsal aspects of the distal thumb and is considered a versatile workhorse flap for innervated distal thumb soft tissue coverage.

As with the other described procedures, the operation begins with appropriate débridement. Then a pattern matching the size of the defect is drawn on the dorsum of the index finger

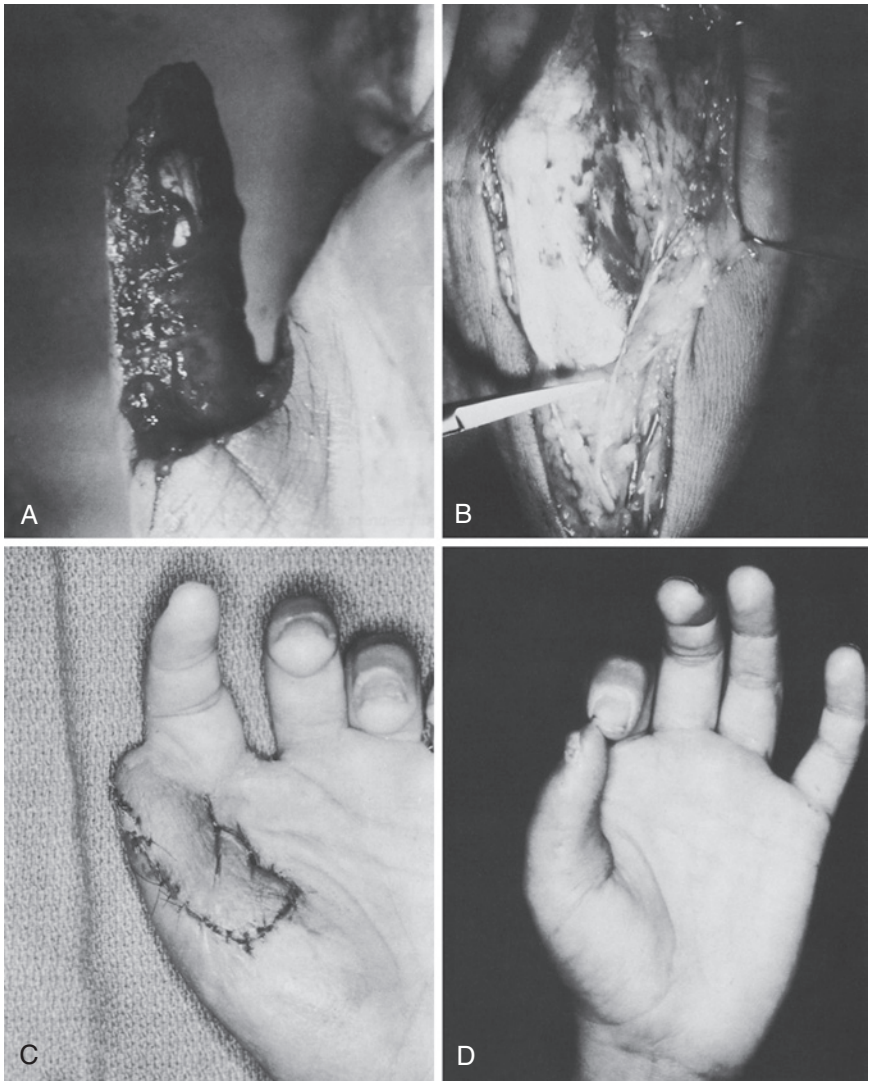

eFIGURE 48.2 Large sensory radial nerve–innervated cross-finger flap. **A,** Avulsion of the entire palmar thumb after forceful removal of a circumferential pipe. **B,** Use of a large sensory-innervated cross-finger flap from the index finger and second metacarpal. Scissors indicate the nerve branch within the flap. **C,** Appearance of the flap on the palmar aspect of the thumb at the time of detachment (3 weeks). **D,** Appearance of the thumb, with satisfactory motion and sensation, at 9 months. (From Strickland JW: Restoration of thumb function following partial or total amputation. In Hunter JM, Schneider LH, Mackin E, et al, editors: *Rehabilitation of the hand*, St Louis, 1984, CV Mosby.)

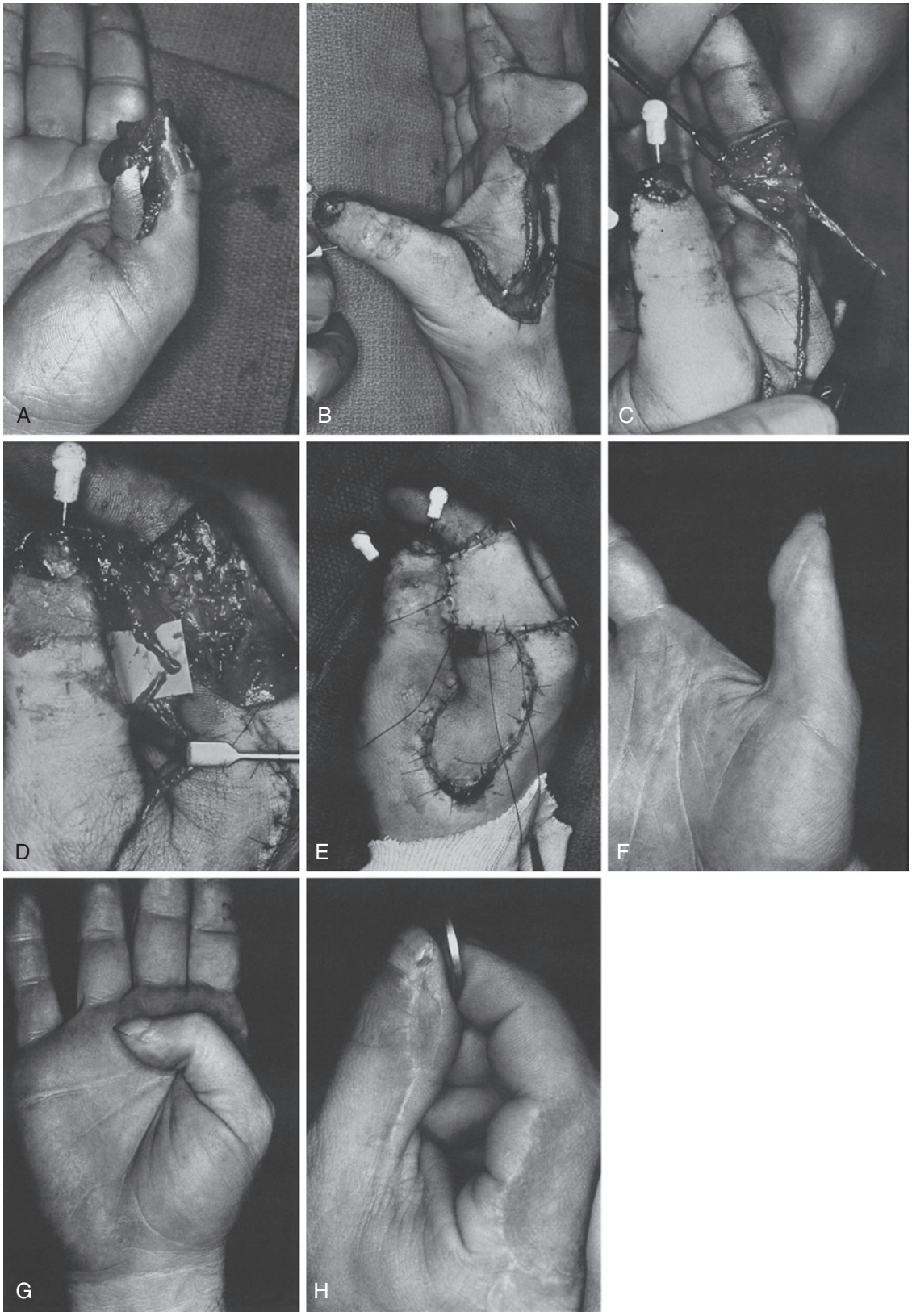

eFIGURE 48.3 Use of the dual innervated cross-finger flap. **A,** Crush amputation of the pulp and nail bed of the thumb distal phalanx with a proximal phalangeal fracture. **B,** Dissection of the dorsal sensory radial nerve branches along with the surrounding soft tissues to be transposed to the thumb. **C,** The dorsal branch of the index radial digital nerve provides ample pedicle for microneurorrhaphy to the thumb ulnar digital nerve after transposition of the cross-finger flap. **D,** Microneurorrhaphy of the index dorsal branch of the radial digital nerve to the ulnar digital nerve of the thumb. With a short regeneration distance, sensory return is rapid, predictable, and cortically perceived as the thumb. **E,** A thick split-thickness skin graft is applied to both the donor area and the intervening pedicle between the index finger and the thumb. **F** to **H,** Final appearance and function of the resurfaced thumb.

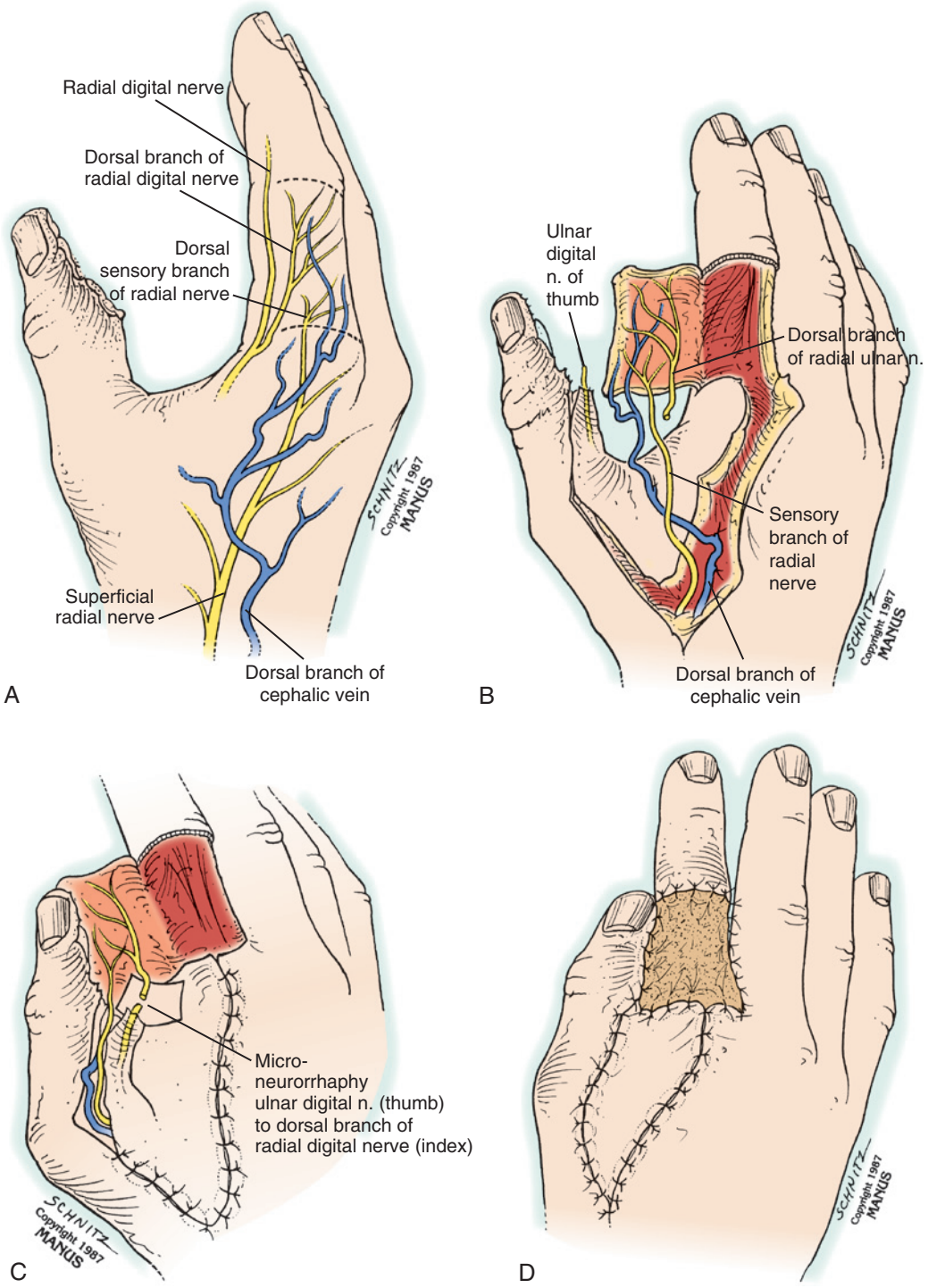

FIGURE 48.8 Dual innervated cross-finger flap. **A,** The dorsal sensory branch of the index radial digital nerve predictably innervates the distal dorsal aspect of the index proximal phalanx. **B,** Elevation of an index-to-thumb cross-finger flap with joining incisions for transposition of the dorsal sensory branch of the radial nerve. **C,** Microneurorrhaphy of the thumb ulnar digital nerve to the dorsal branch of the index radial digital nerve. **D,** Appearance of the flap at closure. (From Hastings H, 2nd: Dual innervated index to thumb cross finger or island flap reconstruction. *Microsurgery* 8:168–172, 1987.)

proximal phalanx (Figure 48.9). To avoid scar contracture, the proximal limit of the flap is the MP joint, and the distal limit is the proximal IP joint. The course of the FDMA is mapped with the aid of a handheld pencil Doppler from the radial aspect of the index MP joint to its proximal pivot point, located at the juncture of the proximal first and second metacarpals. Under tourniquet hemostasis, the flap is elevated in the loose areolar plane above the extensor tendon paratenon. Dissection generally moves from distal to proximal and from the ulnar to the radial side. Extreme care must be taken at the radial border of the MP joint because this is where the FDMA enters the flap's subcutaneous network.



FIGURE 48.9 Sensate first dorsal metacarpal artery (FDMA) flap. **A,** Thumb amputation following débridement. **B,** Skin markings indicating the course of the FDMA, outlined such that the skin of the metacarpophalangeal joint is preserved. **C,** The flap is raised proceeding from distal to proximal and ulnar to radial. Care is taken to leave the extensor tendon paratenon intact to ensure skin graft "take." The flap pedicle contains the fascia of the first dorsal interosseous muscle, two large dorsal veins, the FDMA, and radial sensory nerve branches. **D** to **F,** Results 2 months after surgery. **G,** The preferred alternate teardrop-shaped skin incision.

At the level of the MP joint, a teardrop-shaped incision (preferably) (see Figure 48.9, *G*) or a lazy-"S" proximal incision is made, and the skin is elevated in the deep dermal plane superficial to the adipose tissues. The pedicle is dissected by incising the interosseous fascia at the radial edge of the muscle and second metacarpal periosteum at the ulnar edge. The deep periosteal incision is carried radially and deep to the muscle fascia. The dorsal veins and sensory branches of the radial nerve that typically enter the flap over the ulnar border of the MP joint are included in the pedicle. The pedicle is dissected back to the pivot point at the juncture of the first and second metacarpals.

The tourniquet is released, and the vascularity of the flap is assessed. Once viability is assured, the flap is passed to the defect through a subcutaneous tunnel and sutured. In our experience, we have found that the subcutaneous tunnel is often too narrow and must be opened to avoid unnecessary tension on the flap. The teardrop flap design allows a tension-free closure in this instance and is recommended. The index finger dorsal donor site defect is covered with a full-thickness skin graft obtained from the medial arm. The skin graft is covered with a nonadherent dressing and moist gauze; a bulky dressing is applied to the entire hand. The dressing over the distal tip of the thumb should be opened to expose the most distal portion of the flap and allow monitoring of viability. A full dressing change is carried out at 7 to 10 days, and motion is permitted.

Potential complications include flap vascular compromise and index finger donor site morbidity, such as stiffness, cold intolerance, hypertrophic scarring, and neuroma.

Neurovascular Island Pedicle Flap

Although developed before the innervated cross-finger flap, the neurovascular island pedicle flap now plays a smaller role in the armamentarium of hand surgeons. This stems not only from the greater technical difficulty of the procedure but also from the need to sacrifice palmar sensation along the ulnar aspect of another digit. As a result, important preoperative considerations include selection of a donor digit and determination of

the amount of digital skin and subcutaneous tissue to be brought with the pedicle. The main factor in choosing the donor digit is the status of the median nerve; if median nerve function is intact, the ulnar aspect of the long finger provides a long neurovascular pedicle that can facilitate transposition of the flap. In the absence of median nerve function, an ulnar-innervated digit must be chosen; under these circumstances, the ulnar aspect of the ring finger may serve as a donor.

In either setting, the ulnar aspects of the digits do not participate in pinch, making the sacrifice of tactile surface an acceptable deficit. In general, the size of the flap should correspond to the deficit created by adequate débridement of the scarred and insensate tissue along the thumb defect; occasionally, it may be reasonable to use an "extended" neurovascular island transfer that consists of almost the entire ulnar palmar half of the donor digit to provide the widest possible areas of sensory restoration.[93,109,119,129] Thompson[128] emphasized that it is not necessary to apply the flap to the absolute tip of the thumb unless it is required for soft tissue coverage and that the position should favor the ulnar side of the thumb.

Variations have involved attempts to improve innervation, as well as the creative use of extended flaps. Some authors have advocated suturing the divided proper digital nerve of the neurovascular island pedicle flap to the distal stump of a previously severed thumb digital nerve to improve sensation and help prevent neuromas.[1] Chen and Noordhoff[20] reported one case in which the entire distal phalanx of the thumb was resurfaced with twin neurovascular island flaps taken from the ulnar and radial sides of the middle and ring fingers.

Before beginning, it is necessary to determine the size of the thumb defect to be resurfaced; this measurement mandates the size of the flap. Because most clinical conditions warrant the use of an extended flap involving the entire length of a donor digit, this technique is described here (Figure 48.10, *A*).

Under tourniquet hemostasis, the flap is outlined on the ulnar aspect of the donor digit; it extends from well out on the pad of the distal phalanx along the midline of the palmar aspect of the digit and terminates just short of the proximal digital crease. Small darts are created at the IP creases, and the flap extends posteriorly beyond the midlateral line to the dorsal aspect of the digit. A midlateral proximal continuation is used to connect the digital incision with a series of palmar zigzag incisions. A paper template with the exact size and configuration of the flap is used to outline the recipient area on the palmar aspect of the thumb. A proximal connection into the palm is also provided in this area to facilitate passage of the flap. Under magnification, the dissection begins in the palm, and the neurovascular bundle to the web space is identified. The digital artery to the radial side of the adjacent finger is identified and ligated well distal to the arterial bifurcation. The digital nerves to the adjacent sides of the long and ring fingers are carefully teased apart well into the midpalm. The artery and nerve to the ulnar side of the donor finger have now been isolated as far as the base of the finger and are dissected distally into the island flap. Incisions are made about the entire periphery of the flap, and dissection is performed distally and carefully continued in a proximal direction while incorporating skin, subcutaneous tissue, and the neurovascular bundle, which should be protected by the surrounding soft tissue. The flap is freed on its neurovascular pedicle to the level of the midpalm. Small vascular branches are transected during this dissection using bipolar electrocautery.

Skin and scar tissue within the previously outlined recipient site on the thumb are excised, and a bridge between the proximal thumb incision and the proximal end of the palmar incision is carefully undermined in an area just deep to the palmar aponeurosis (see Figure 48.10, *B*). A suture placed in the distal end of the island pedicle flap is used to gently pull the flap from the palmar wound into the thumb wound, with great care taken not to damage or twist the pedicle (see Figure 48.10, *C*). It is important to create some redundancy of the pedicle and a generous subcutaneous pocket to prevent tension and ensure flap survival.

The transferred flap is loosely tagged in place in the recipient defect, and the tourniquet is released. Any bleeders are ligated, and the vascularity of the flap is assessed. Completion of flap suture and repair of the palmar and proximal digital wounds are carried out at this time. A full-thickness skin graft taken from the medial arm (or groin) is sutured into the donor defect (see Figure 48.10, *D*).

The skin graft is covered with a nonadherent dressing and moist gauze; a compressive dressing is applied to the entire hand. The dressing over the distal tip of the thumb should be opened to expose the most distal portion of the flap and allow monitoring of viability. A full dressing change is carried out at 7 to 10 days, and motion is permitted at 3 to 4 weeks.

Potential complications include partial or complete flap necrosis, failure of the graft, or stiffness of the donor finger. Obviously, the loss of sensate skin in the donor finger is considerable; however, when the indications are appropriate, the restoration of good palmar sensory skin to the critical tactile pad of the thumb is functionally justified. Few adults will convert sensory recognition of the transferred flap to that of the thumb.[93]

Summary: Reconstruction of Soft Tissue Defects of the Thumb

The primary goal in treating tissue loss of a thumb of adequate length is to provide or improve skin coverage while optimizing the chance for the return of satisfactory sensation without pain. Although providing additional length is not necessary at this level, techniques directed at preserving stump length or covering significant palmar soft tissue losses may be useful. The choice of procedure is dictated primarily by the size of the defect. For defects less than 1 cm^2, healing by secondary intention provides adequate coverage, with no additional donor wound. For defects less than 2.5 cm long, the palmar advancement flaps offer excellent coverage with minimal morbidity and no need for sensory cortical reorganization. Larger lesions may require one of the heterodigital flaps. Circumferential soft tissue loss with preservation of the underlying skeletal and tendinous structures often requires reconstruction using local and regional flaps for hand coverage (see Chapter 44). A secondary but important consideration is the extent of nerve damage. Radial sensory-innervated cross-finger flaps and neurovascular island pedicle flaps are occasionally used for acute thumb injuries with loss of skin, subcutaneous tissue, and one or both digital nerves. Although these procedures result in varying degrees of impairment to their respective donor areas and often involve some difficulty in terms of patients' cortical interpretation, they

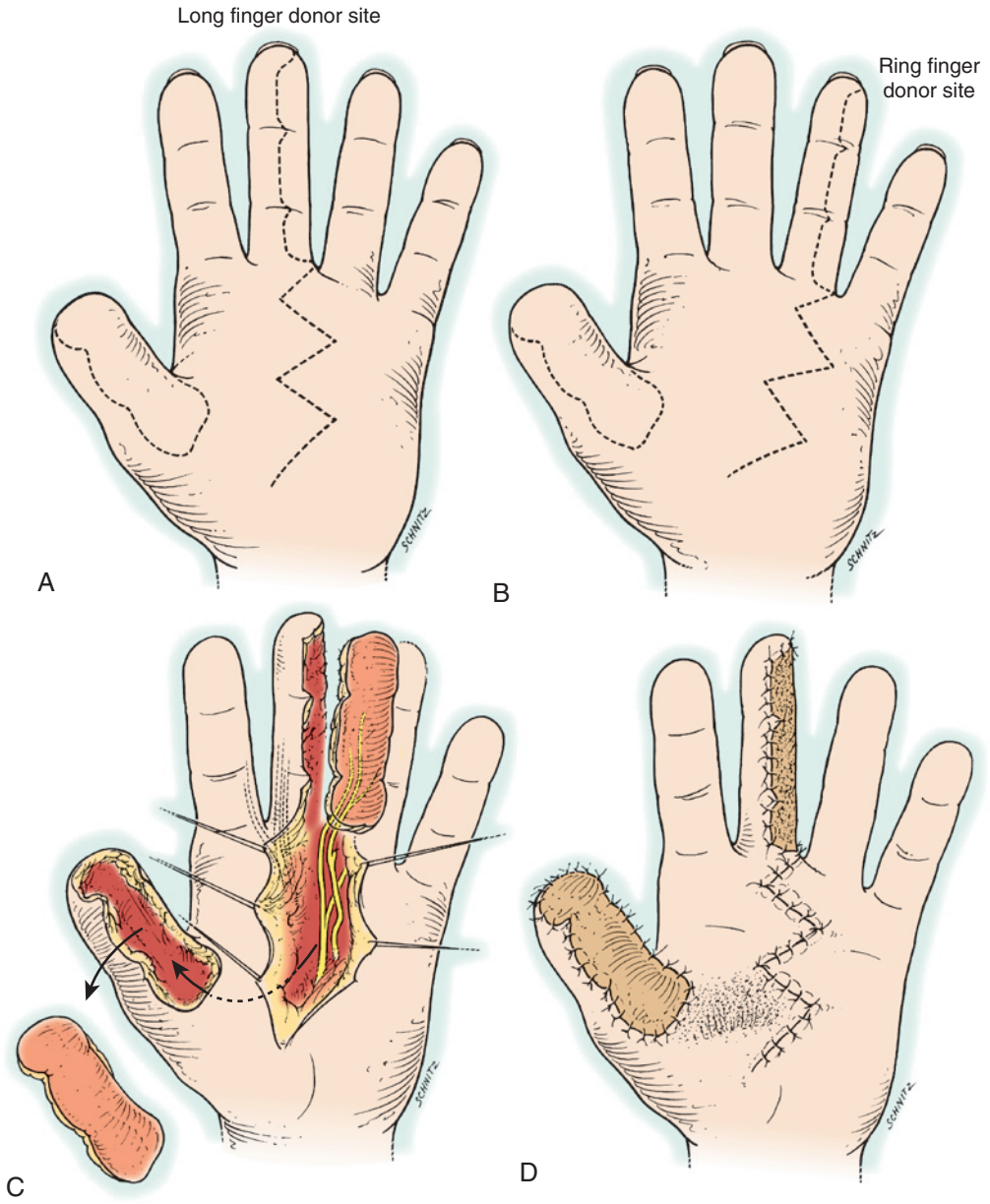

FIGURE 48.10 Neurovascular island transfer from either the long finger or the ring finger to provide sensate coverage of the thumb. **A,** Neurovascular island flap using the ulnar side of the long finger. An extended island flap is designed with an identical defect patterned over the palmar aspect of the thumb. **B,** Use of the ulnar aspect of the ring finger, which is designed and transferred in a similar manner. **C,** Mobilization of the island flap on its neurovascular pedicle, and preparation of the recipient bed on the thumb. Note the areas of undermining required between the palmar and thumb incisions (*dotted arrow*). **D,** Completed transfer of the neurovascular island flap with a free graft on the donor area of the long finger. Care must be taken to avoid a longitudinal scar along the palmar aspect of the donor finger. (Modified from Reid DAC: Reconstruction of the mutilated hand. In Rob C, Smith R, Pulvertaft RG, editors: *Operative surgery: the hand*, ed 3, London, 1977, Butterworth.)

are time-honored methods of improving function in certain cases of devastating palmar thumb loss and are best used as secondary restorative methods.

Subtotal Amputation With Questionable Remaining Length

Amputations of primarily the palmar soft tissues can be managed as described in the preceding section; however, if the tissue loss extends to the bony structures, the presence of a thumb of adequate length for opposition becomes questionable. Although the provision of extra thumb length can be performed in the setting of acute injury,[127] the surgeon is more commonly presented with a patient who has already undergone completion amputation and now seeks advice regarding reconstructive options. Under these circumstances, it is imperative that the choice of reconstruction, ranging from none to microvascular toe transfer, be carefully tailored to the patient's needs. Minimal bone loss, up to the level of the thumb IP joint, is unlikely to significantly impair function. In contrast, loss of length proximal to the midportion of the proximal phalanx decreases the hand span, making it difficult to grasp large objects and causing problems with dexterous pinch. After amputation at this level, most thumbs retain acceptable CMC rotation and an adequate thumb–index finger cleft. Functional

CRITICAL POINTS *Neurovascular Island Pedicle Flap*

Indications

- Extensive loss of the palmar thumb pulp
- Loss of terminal digital nerve innervation, particularly of the ulnar thumb

Technical Points

- Choose a donor digit based on remaining intact innervation: either the ulnar long finger (median nerve intact) or the ulnar ring finger (ulnar nerve intact).
- Determine the size of the defect to be resurfaced and create a template.
- Outline the template on the ulnar aspect of the donor digit, extending from the distal palmar pad to just short of the proximal digital crease.
- Center the template such that the donor flap begins at the midpalmar aspect of the digit and extends onto the dorsum of the donor digit.
- Add small darts to the flap design at the IP creases.
- Connect the proximal flap via an incision along the midlateral aspect of the digit to a series of zigzag incisions on the palm.
- Create the palmar thumb defect to fit the flap design.
- Extend the recipient site via an incision into the palm in a similar fashion to the donor digit extension, leaving a skin bridge of 1 to 2 cm between the donor zigzag incision and the thumb proximal incision.
- Identify the common digital artery and nerve to the donor web space.
- Ligate the proper digital artery to the adjacent (nondonor) finger's radial aspect at least 5 to 10 mm away from the bifurcation.
- Tease apart the common digital nerve into the proximal palm, separating the donor ulnar nerve from the adjacent radial sensory branch.
- Dissect the donor artery and nerve to the base of the flap.
- Incise the margins of the flap.
- Raise the flap, including skin, subcutaneous tissue, and the neurovascular bundle.
- Undermine the skin bridge between the two proximal extending incisions just deep to the palmar aponeurosis.
- Place a suture in the distal flap and pass this through the tunnel into the thumb defect wound.
- Gently pull the flap through into the thumb defect.
- Tag the flap in place and release the tourniquet.
- Achieve hemostasis.
- Inset the flap with fine, nonabsorbable sutures.
- Harvest a full-thickness skin graft and inset this into the donor defect using fine chromic sutures.
- Apply a nonadherent dressing and moist gauze; leave the thumb tip of the dressing open to facilitate monitoring of the flap.
- Apply a volar resting splint from fingertip to distal forearm and a gentle compressive dressing.

Postoperative Care

- Inspect the flap and graft at 7 to 10 days.
- Begin active range-of-motion exercises at 3 to 4 weeks.

Expected Outcomes

- Improved padding and sensibility of the thumb
- Potential scarring in thumb and palm
- Potential stiffness of the donor finger

requirements at this level therefore include added length; preservation of sensibility, mobility, and stability; and a pain-free thumb.

When unsalvageable thumbs are amputated near the distal portion of the proximal phalanx, satisfactory function can usually be achieved by procedures designed to deepen the first web space and create a widened thumb–index finger interval. These procedures have been called phalangization, and they use methods that deepen the interdigital cleft so that the first metacarpal and remaining proximal phalanx are relatively lengthened.[9,29,70,87,94,98] This can be accomplished by simple scar-lengthening techniques; local, regional, or distal pedicle flaps; or, when necessary, free tissue transfer. The indications for these techniques vary according to residual thumb length, amount of first web contracture, mobility of the first metacarpal, and condition of the web space skin and muscle.[9,69,87,94] Apart from their use in thumb reconstruction, these techniques also prove useful when contracture of the first web space occurs after thumb reconstruction by another procedure, such as free toe transfer.

"Z"-Plasty Procedures

"Z"-plasty techniques are designed to lengthen the distance between the apices of the "Z" at the cost of narrowing the distance between the endpoints of the "Z." The simple and four-flap "Z"-plasties take advantage of both actions to increase the thumb–index finger span and simultaneously deepen the first web space. Prerequisites for effective web space deepening via "Z"-plasty include the following: (1) at least half the proximal phalanx remains, (2) the skin is minimally scarred, (3) the first metacarpal is mobile, and (4) there is minimal muscle contracture. The following sections discuss the concepts of "Z"-plasty, including proper flap design, mobilization, and repositioning as applied to the first web space.

Simple "Z"-Plasty of the Thumb Web. Under tourniquet hemostasis, the central limb of the planned "Z" is marked on the distal ridge of the first web space, extending from the proximal digital crease of the thumb to approximately 1 cm proximal to the proximal digital crease of the index finger, at a point that corresponds with the radial confluence of the proximal and middle palmar creases. Using these landmarks as guidelines decreases the likelihood of extending the flap onto the ulnar thumb or radial index finger. Oblique proximal palmar and distal dorsal limbs oriented at 60-degree angles to the central limb are designed, with their length corresponding to the length of the central limb. Local scar, previous incisions, or possible approaches for other reconstructive procedures may result in the need to reverse the direction of the two oblique limbs (proximal dorsal and distal palmar). Either combination seems to work satisfactorily (Figure 48.11, *A*), but the combination of proximal palmar and distal dorsal parallels the interthenar crease and affords excellent cosmesis to the closure.

After incising the skin, dissection is carried down to the level of the muscle fascia. The flaps are carefully undermined just superficial to the muscle fascia to avoid vascular compromise. Care should be taken during dissection to avoid injuring (if present) a distal arterial connection between the indicis radialis and princeps pollicis vessels. Deepening of the web space is facilitated by incision of the fascia over the first dorsal interosseous muscle and partial division of its distal mass (see Figure 48.11, *B*). Abducting the thumb tends to begin transposing the flaps; as the span between the thumb and index finger increases, the distance across the web space, from dorsal to palmar, decreases. This decrease is compensated for by recession of the first dorsal interosseous muscle. Once the flaps are reversed and sutured in place, the result is an increased web span and deepened web space (see Figures 48.11, *C* and eFigure 48.4).

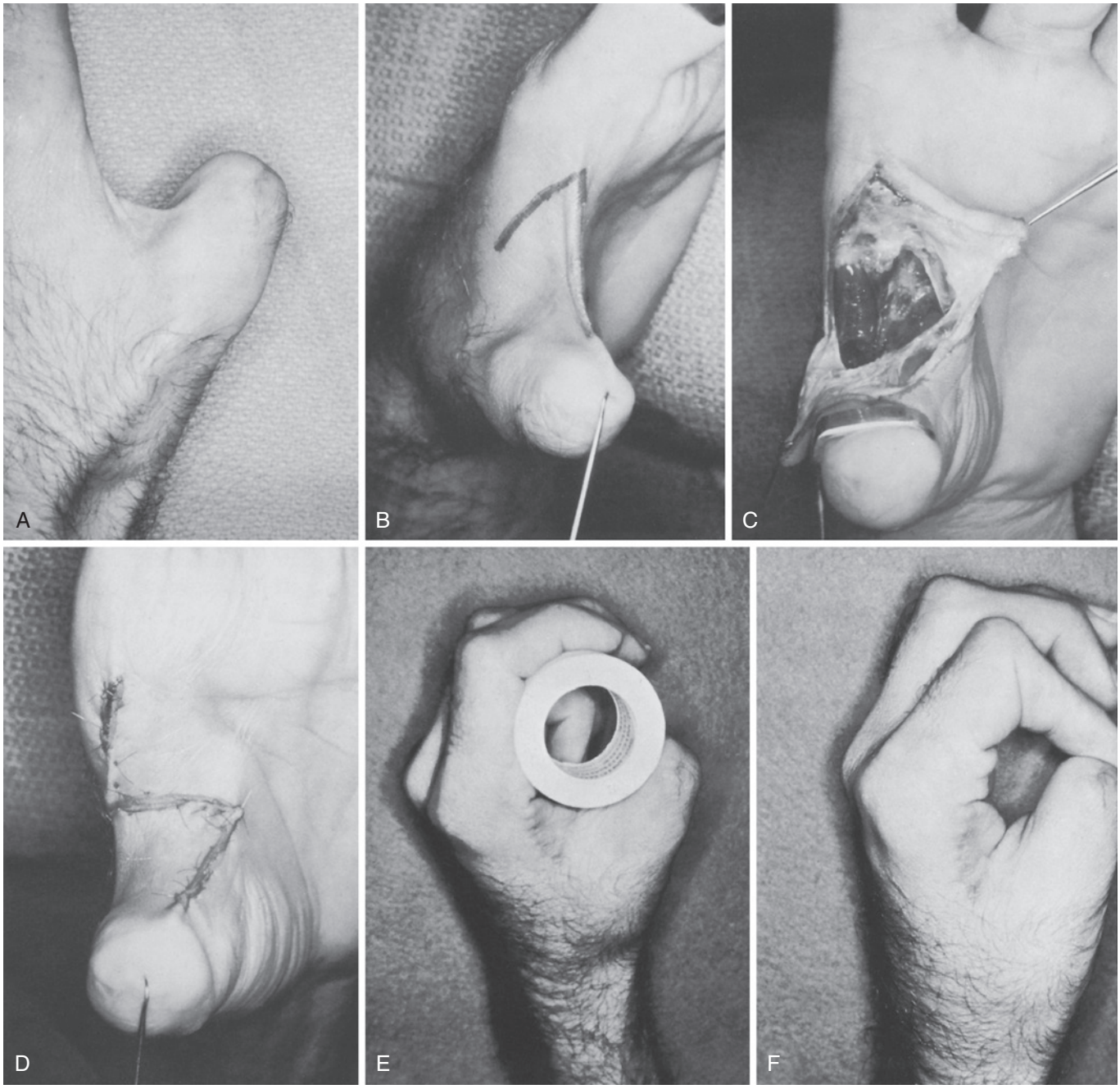

eFIGURE 48.4 Simple "Z"-plasty of the thumb web. **A,** Limited thumb–index finger cleft following amputation through the midproximal phalanx. **B,** Design of the "Z"-plasty. **C,** Reflection of flaps with partial recession of the first web musculature. **D,** Appearance of the "Z"-plasty after reversal and suture of flaps. **E** and **F,** Effective deepening of the thumb web 3 months postoperatively. (From Strickland JW: Restoration of thumb function following partial or total amputation. In Hunter JM, Schneider LH, Mackin E, et al, editors: *Rehabilitation of the hand*, St. Louis, 1984, CV Mosby.)

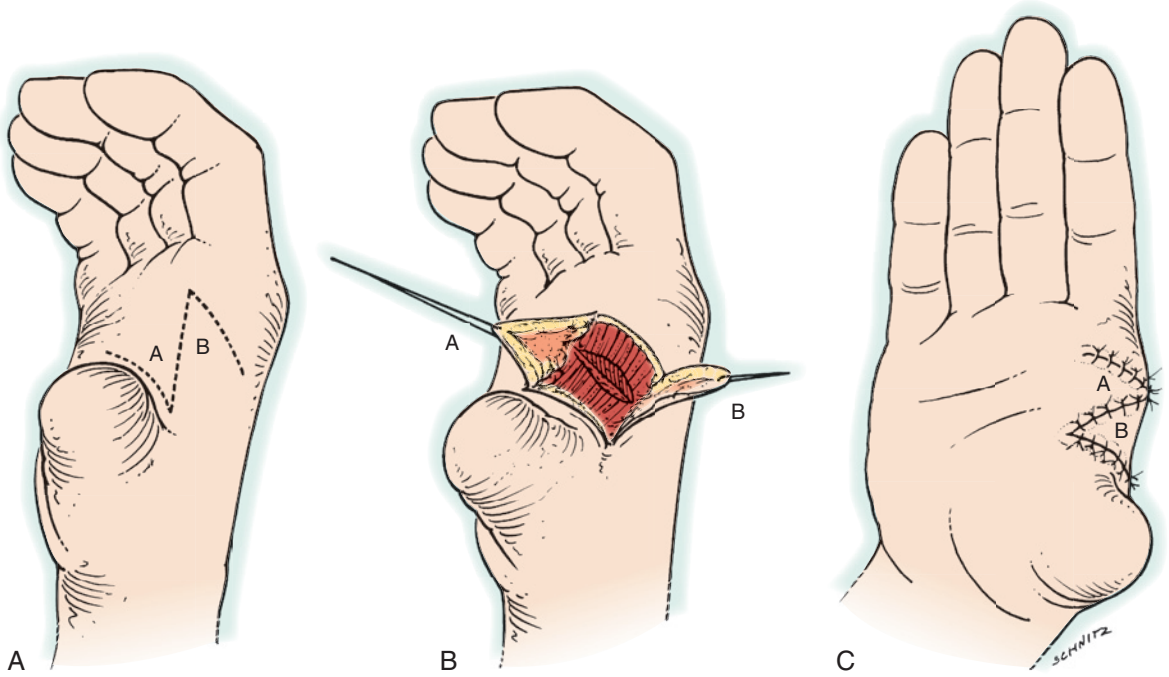

FIGURE 48.11 Simple "Z"-plasty of the thumb web. **A,** Design of the "Z"-plasty. The preferred angles are approximately 60 degrees. **B,** Flaps reflected with partial recession of the web space musculature. **C,** Appearance of the flaps after reversal and suture. Comer sutures are preferred in the tips of the flaps.

Four-Flap "Z"-Plasty of the Thumb Web. Under tourniquet hemostasis, the central limb of the "Z"-plasty is drawn on the distal edge of the thumb web ridge, as described for the simple "Z"-plasty. Proximal palmar and distal dorsal limbs at angles varying from 90 to 120 degrees relative to the central limb are made, with their lengths equaling that of the longitudinal incision. The angles formed by these three limbs are bisected by oblique lines, equal in length to the prior limbs, extending from their apices and yielding four angles ranging from 45 to 60 degrees (Figures 48-12, *A* to *C*, and 48.13, *A*). The flaps are reflected on their bases by gentle undermining, and a small recession of the thumb web musculature can be carried out to provide additional depth.

The flaps are transposed so that the common border of the two middle flaps previously formed by the central limb now lies against the proximal and distal incision sites (see Figure 48.12, *D* and *E*). The proximal palmar and distal dorsal flaps are rotated to the midline, and their medial edges, previously formed by the oblique bisecting incisions, are joined. The flaps are sutured in place without tension. Completion of flap transposition should result in a substantial increase in web depth (see Figures 48.12, *F*, and 48.13, *B*).

At the conclusion of the procedure, the wound is dressed with nonadherent gauze and a compressive dressing consisting of adequate gauze to maintain the expanded web space is applied. The wound is examined at 10 to 14 days, at which time the bulky dressing is exchanged for a static, custom-fitted splint. Therapy consisting of active and passive range of motion begins after this initial dressing change; the patient continues to wear the web spacer splint when not performing range-of-motion exercises. The patient is gradually weaned from the splint over the next few weeks, based on his or her individual progress in therapy.

CRITICAL POINTS *Four-Flap "Z"-Plasty*

Indications

- Amputation near the midportion of the proximal phalanx
- Minimal scarring of the first web skin
- Absence of first web muscle contracture
- Mobile first metacarpal

Technical Points

- Mark the central limb of the planned "Z" on the distal ridge of the first web space, beginning at the proximal digital crease of the thumb and extending to 1 cm proximal to the proximal digital crease of the index finger.
- Design the proximal palmar and distal dorsal limbs at an angle between 90 and 120 degrees relative to the central limb; the combined length of these limbs should equal the length of the central limb.
- Add two more limbs, each equal in length to the proximal and distal limbs, and each positioned to bisect the angle between the proximal or distal limbs and the central limb.
- Incise the skin along the markings, and gently undermine the flaps.
- If necessary, incise the musculature to deepen the web space.
- Transpose the flaps so that the common border of the central flaps (the central limb) lies against the proximal and distal incision sites.
- Transpose the proximal palmar and distal dorsal flaps so that their medial edges (previously the bisecting limbs) are joined.
- Inset the flaps with fine, nonabsorbable suture.
- Apply nonadherent gauze and a gentle compressive dressing.

Postoperative Care

- Examine the wound at 10 to 14 days.
- Switch to a thermoplastic splint to maintain the web space.
- Begin active and passive range-of-motion exercises immediately after the first dressing change.
- Wean the patient from the web spacer splint over the course of a few weeks.

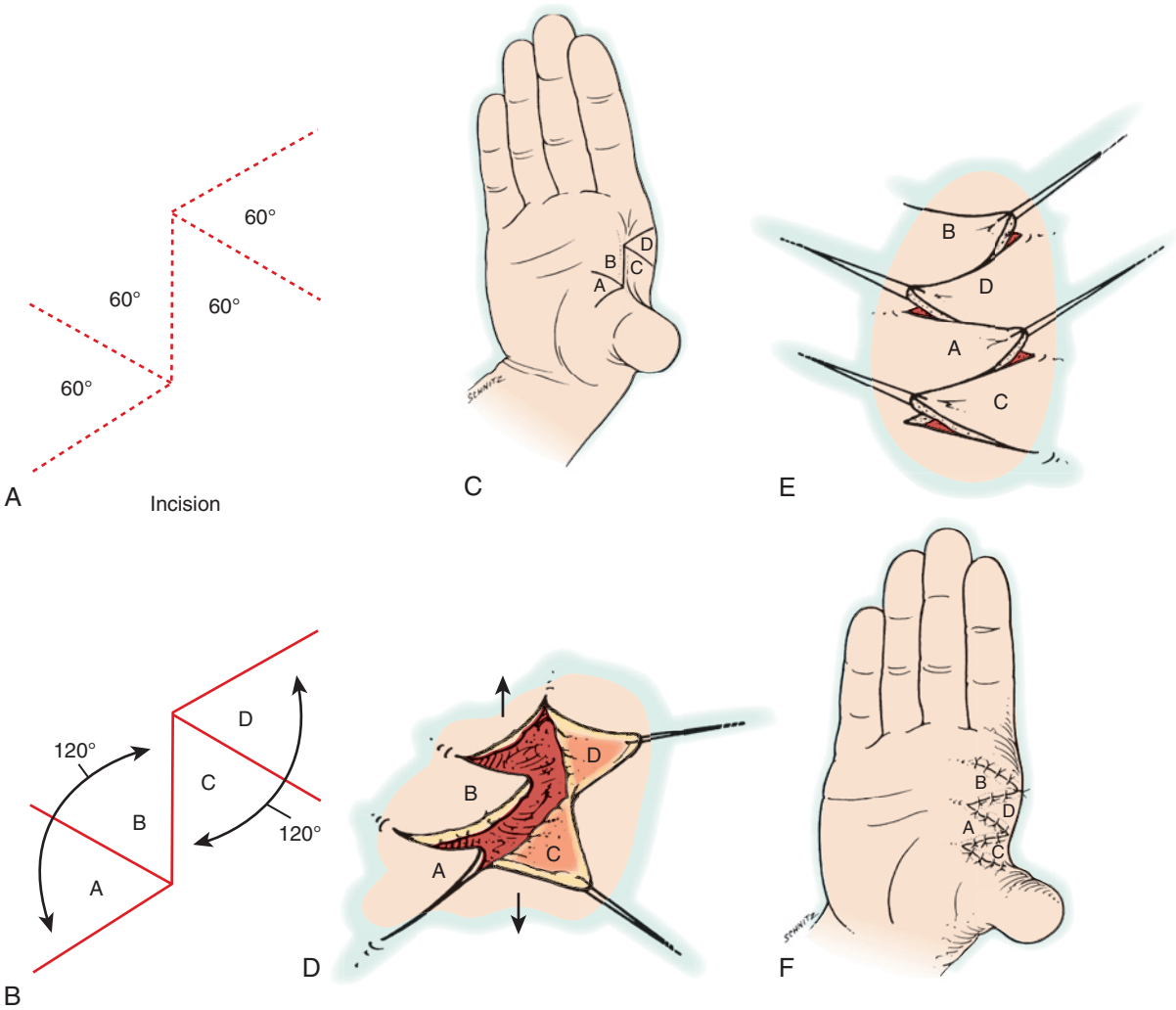

FIGURE 48.12 Four-flap "Z"-plasty of the thumb web. **A** and **B,** Two 120-degree-angle opposing incisions are bisected to form four 60-degree flaps. **C,** Design of the flaps in the first web space. **D,** Incision, elevation, and undermining of the flaps. **E,** Flap position after interposition. **F,** Appearance of the thumb web after interposition of the flaps. (Modified from Broadbent TR, Woolf RM: Thumb reconstruction with contiguous skin-bone pedicle graft. *Plast Reconstr Surg* 26:494–499, 1960.)

These simple skin mobilization techniques, occasionally combined with short distal muscle recession, can provide reliable deepening of the thumb web and relative lengthening of the shortened thumb. When measured, the gain in depth varies from 1.5 to 2 cm, which should result in an improved ability to grasp large objects. The main potential complication with these techniques is necrosis, either partial or complete, of the flaps; the risk can be minimized with careful planning and dissection of the flaps.

Dorsal Rotational Flap

When at least half the proximal phalanx of the thumb remains but extensive scarring of the first web skin or an adduction contracture of the first metacarpal exists, "Z"-plasty techniques are no longer useful. To phalangize the residual thumb stump, sequential division of all restraining skin, muscle, scar, and capsular adhesions may be necessary. Such extensive mobilization is likely to result in a significant skin deficit over the first web. Several dorsal rotational flap techniques have proved effective in deepening the first web space and mobilizing and resurfacing the metacarpal-phalanx unit.[9,32,103,116,120] Advantages of web space coverage by a dorsal rotational flap include excellent skin quality and sensory perception in the web.

Phalangization of the First Metacarpal With Dorsal Rotational Flap Coverage. With the use of tourniquet anesthesia, a continuous linear dorsal and palmar incision is carried through the first web, beginning dorsally at the level of the trapeziometacarpal joint and extending along the ulnar border of the first metacarpal to the first MP joint, where it passes through the thumb web and continues volarly into the palm at the base of the thenar eminence (Figure 48.14).

Sharp dissection is continued just ulnar to the extensor pollicis longus. With careful technique to protect sensory branches of the radial nerve, the origin of the first dorsal interosseous muscle is stripped from the metacarpal; alternatively, if the muscle is scarred or fibrotic, it is divided. The radial artery must be identified as it dips between the two heads of the first dorsal interosseous muscle just beyond the trapeziometacarpal joint. By following the artery distally, the princeps pollicis artery can be identified and protected as the border of the adductor

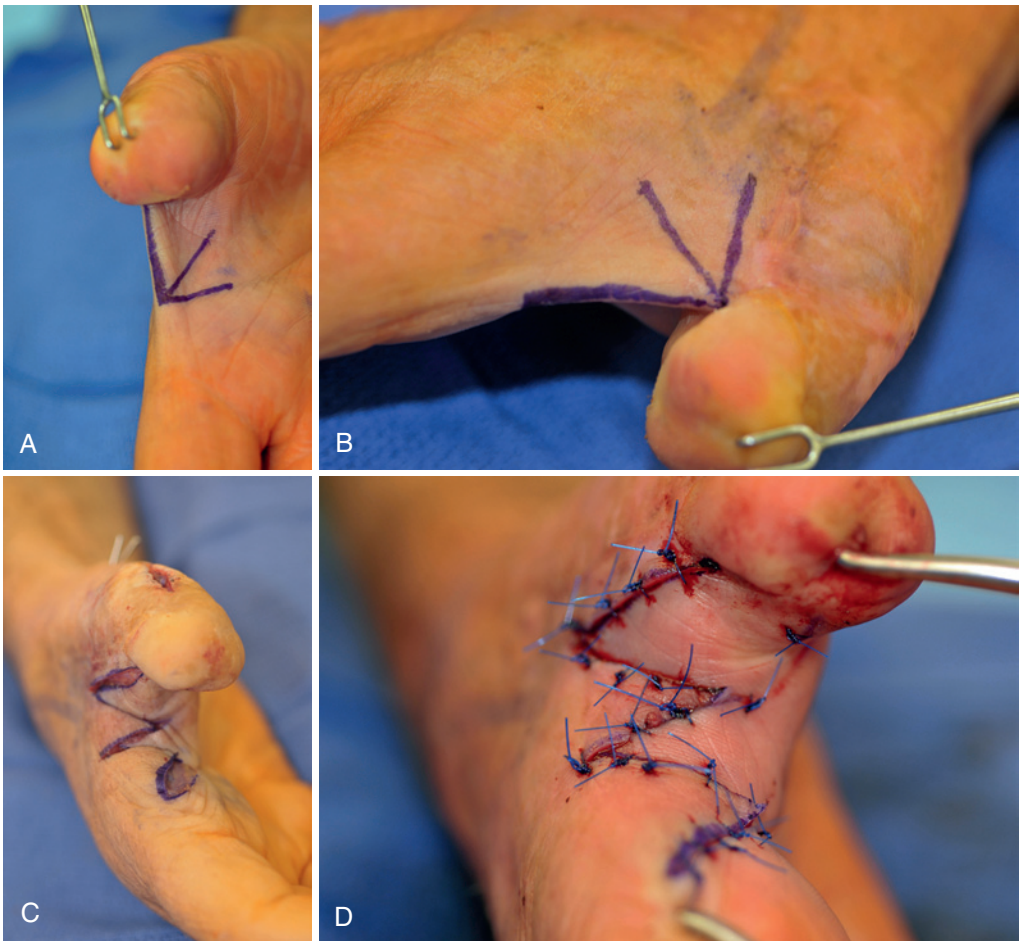

FIGURE 48.13 Four-flap "Z"-plasty of the thumb web. **A,** Design of the flaps (see also Figure 48.12). **B,** Appearance of the thumb web immediately after transposition and suture of the flaps.

pollicis is defined. Both the oblique and transverse heads of the adductor are divided, and by gentle abduction traction on the first metacarpal, the adequacy of mobilization of the first ray can be evaluated. Stripping of the opponens pollicis muscle may be required to mobilize a severely contracted first metacarpal. In some cases, muscle release does not result in complete mobilization of the first metacarpal, and release of the CMC joint capsule or occasionally trapezial excision may be necessary. The capsule of the trapeziometacarpal joint is opened transversely through a palmar incision, and a similar capsulectomy on the dorsal ulnar side of the joint is sometimes used. The mobilized thumb is stabilized in the corrected position by transfixing the first and second metacarpals through their proximal segments with two nonparallel Kirschner wires (see Figure 48.14, *D*) or with an external fixator (Figure 48.15). The tourniquet is released at this point; all brisk bleeding vessels are controlled, and the vascularity of the thumb is confirmed before reinflation. Trial rotation of a paper pattern placed over the dorsum of the hand can help determine the proper size and configuration of the flap. The incision is continued from the ulnar aspect of the first web dorsally across the radial aspect of the MP joint of the index finger and onto the dorsum of the proximal phalanx of that digit. It is brought proximally over the dorsum of the hand to approximately the base of the fourth metacarpal; the exact configuration can best be determined by the paper pattern technique just described (see Figure 48.14, *B* and *C*). The dorsal flap is dissected free from the peritenon overlying the extensors of the fingers, and although there is minimal interference with the dorsal veins of the hand, a few sizable veins should be ligated distally and brought with the flap (see Figure 48.14, *C*). Gentle undermining is carried out, and an occasional additional dorsal ulnar skin release may be necessary to bring the flap into the proper position to cover the defect. The flap is sutured in place, and the resulting triangular defect over the dorsal radial aspect of the hand is covered with either a dissected, nearly full-thickness graft from the groin or a split-thickness graft taken with a dermatome (see Figure 48.14, *D*).

Nonadherent gauze and a saline-moistened cotton dressing are used over the graft. Kirschner wires are bent and trimmed, and a compressive dressing is applied to the hand, wrist, and forearm. The flap and grafts are first checked at 7 to 10 days, and the sutures are removed at 2 weeks. Active and passive therapy for digital mobilization begins at 2 to 3 weeks; during this initial rehabilitation, a custom-made first web splint is worn to maintain the web space. The pins are removed at 4 to 6 weeks, after which the patient is gradually weaned from continuous use of the web splint. Continual monitoring of the status of the web space is necessary for 1 year, and night

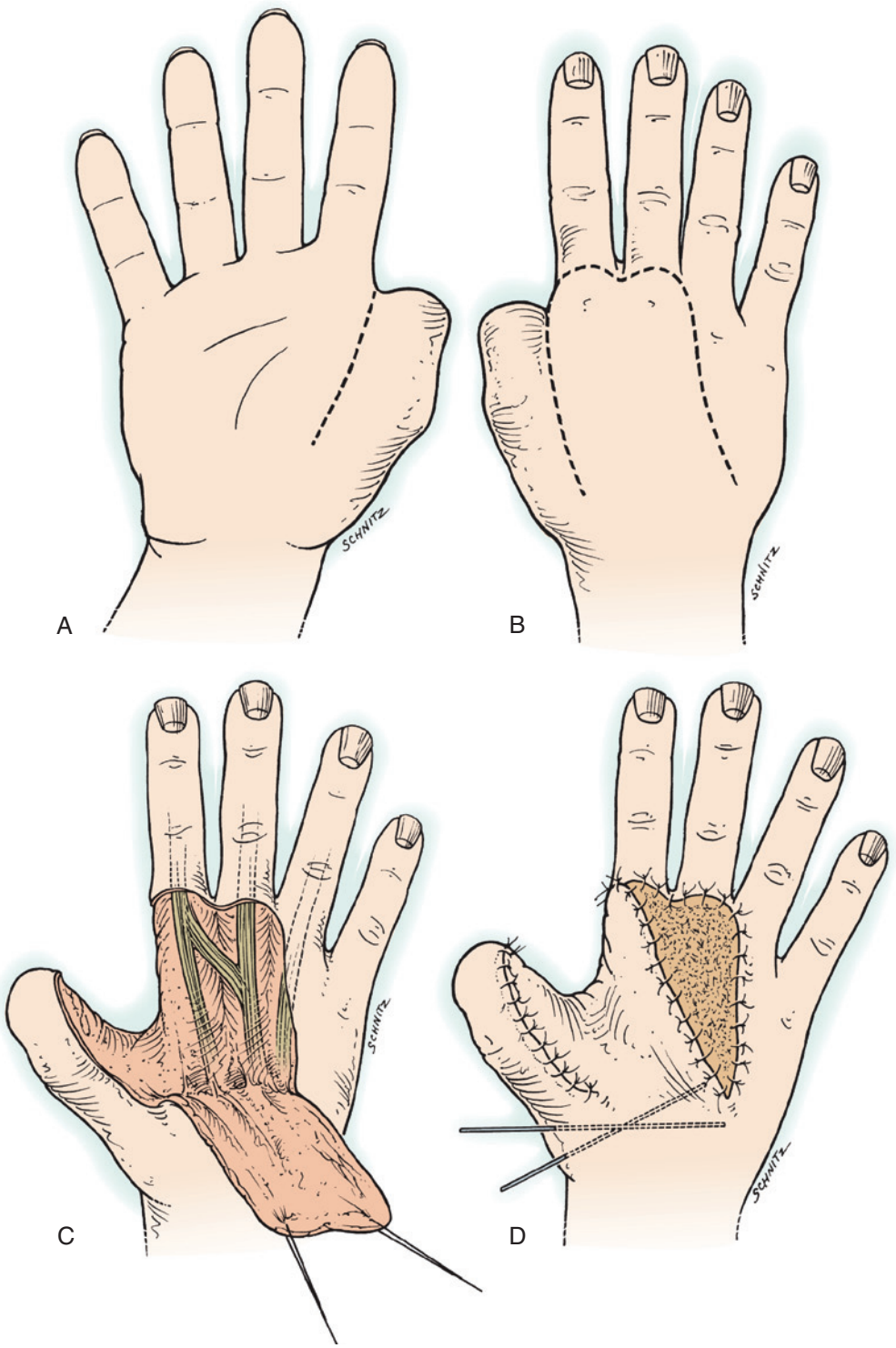

FIGURE 48.14 Release of adduction contracture of the first web space with dorsal rotational flap coverage. **A,** The palmar web-dividing incision is a continuous linear incision from the first web space to the thenar crease, paralleling the medial margin of the thenar musculature. **B,** Linear incision over the dorsum of the first web with approximate outline of the dorsal rotational flap. **C,** First web defect after division of restraining skin, soft tissue, and muscle with abduction of the first metacarpal. Elevation of the dorsal rotational flap down to the peritenon overlying the extensor tendons is complete. **D,** Appearance of the first web after coverage with the dorsal rotational flap. Kirschner wires hold the thumb in abduction during healing, and a free skin graft is used to cover the donor defect. (Modified from Brown PW: Adduction-flexion contracture of the thumb: correction with dorsal rotation flap and release of contracture. *Clin Orthop Relat Res* 88:161–168, 1972.)

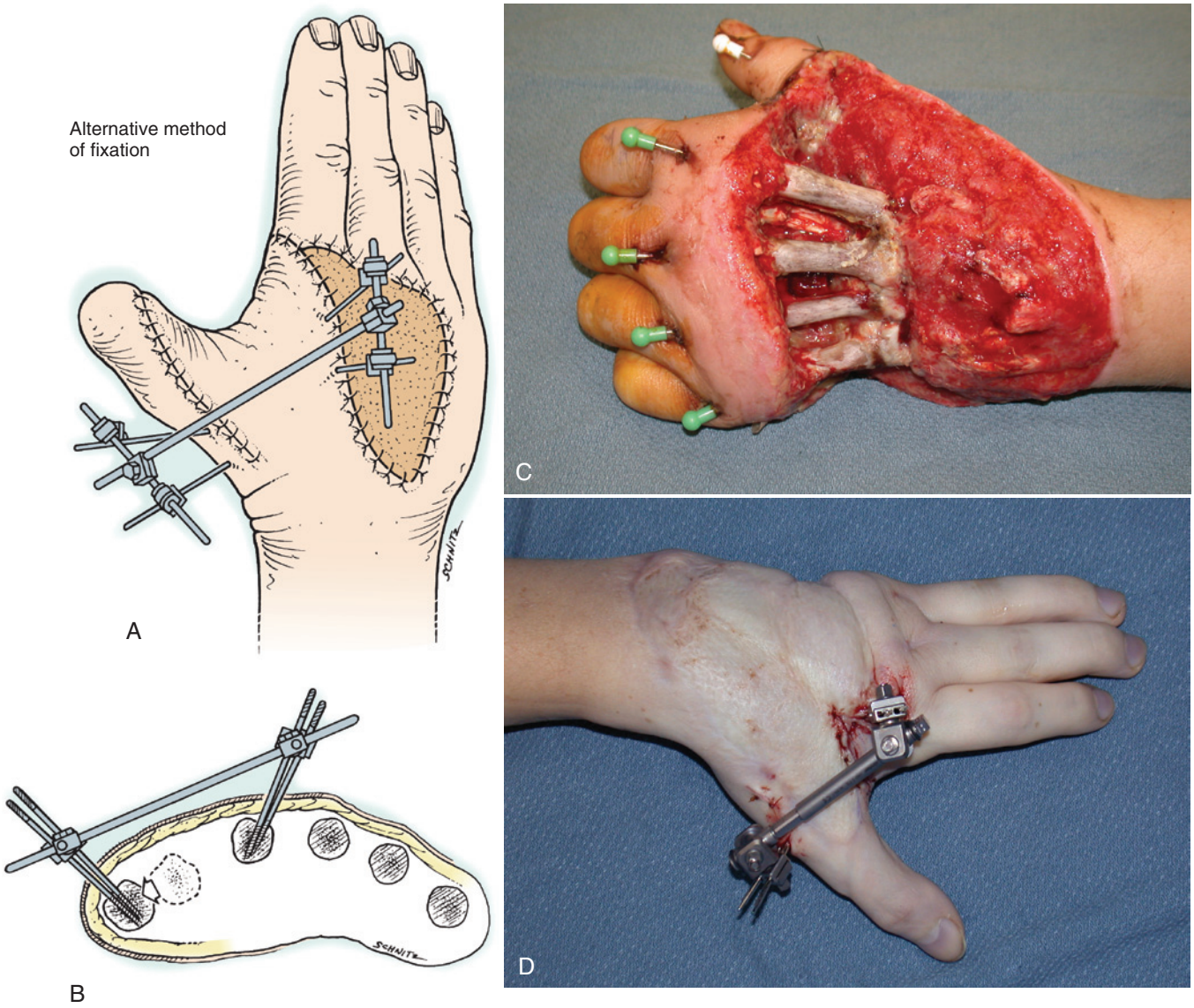

FIGURE 48.15 Alternative method of fixation of the first and second metacarpals after first web space deepening. The use of a mini–external fixator is depicted. **A,** Purchase pins in the lateral aspect of the first metacarpal and dorsum of the second metacarpal, with a transfixing bar used to stabilize and maintain the web. **B,** Transverse section to depict the position of the fixator pins in the metacarpals. **C,** Alternatively, a mini–distraction device can be applied and gradually distracted, as in this case, in which the mutilated hand was reconstructed with a rectus free flap, adductor release, and first web space distraction. **D,** Application of mini–distraction device.

splinting with a web spacer may be necessary throughout that period.

Long-standing severe adduction contracture of the first metacarpal is a crippling deformity, particularly when a portion of the distal thumb has been lost. Surgical release of the deformity is accomplished by meticulous sequential division of all contracting elements, which results in a substantial skin and soft tissue deficit. This defect can be well covered by a rotational flap from the dorsum of the hand (eFigure 48.5).

Potential complications include hematoma formation, flap loss, graft failure, or recurrent adduction contracture. If the surgical procedure is carried out carefully, with attention to technical detail, and if proper postoperative care is given, the incidence of these problems should be minimal. Additional reconstructive procedures such as tendon transfers may be necessary to further enhance thumb function; however, restoration of the web space and improvement in thumb posture alone should have a profoundly favorable influence on hand performance.

Regional and Distant Flaps

Just as damage to the first web skin and muscle contractures render the simple "Z"-plasty inadequate for thumb phalangization, damage to the skin overlying the dorsum of the hand removes the possibility of deepening the web space with a dorsal rotational flap. In this setting, a remote pedicle source must be sought to provide quality coverage after releasing procedures. A variety of regional and distant flaps have been employed to cover defects on the hand, and these flaps may serve equally well to release contractures of the first web space and provide greater hand span. Because the locations and techniques for elevating these flaps are described in detail in other chapters, they are

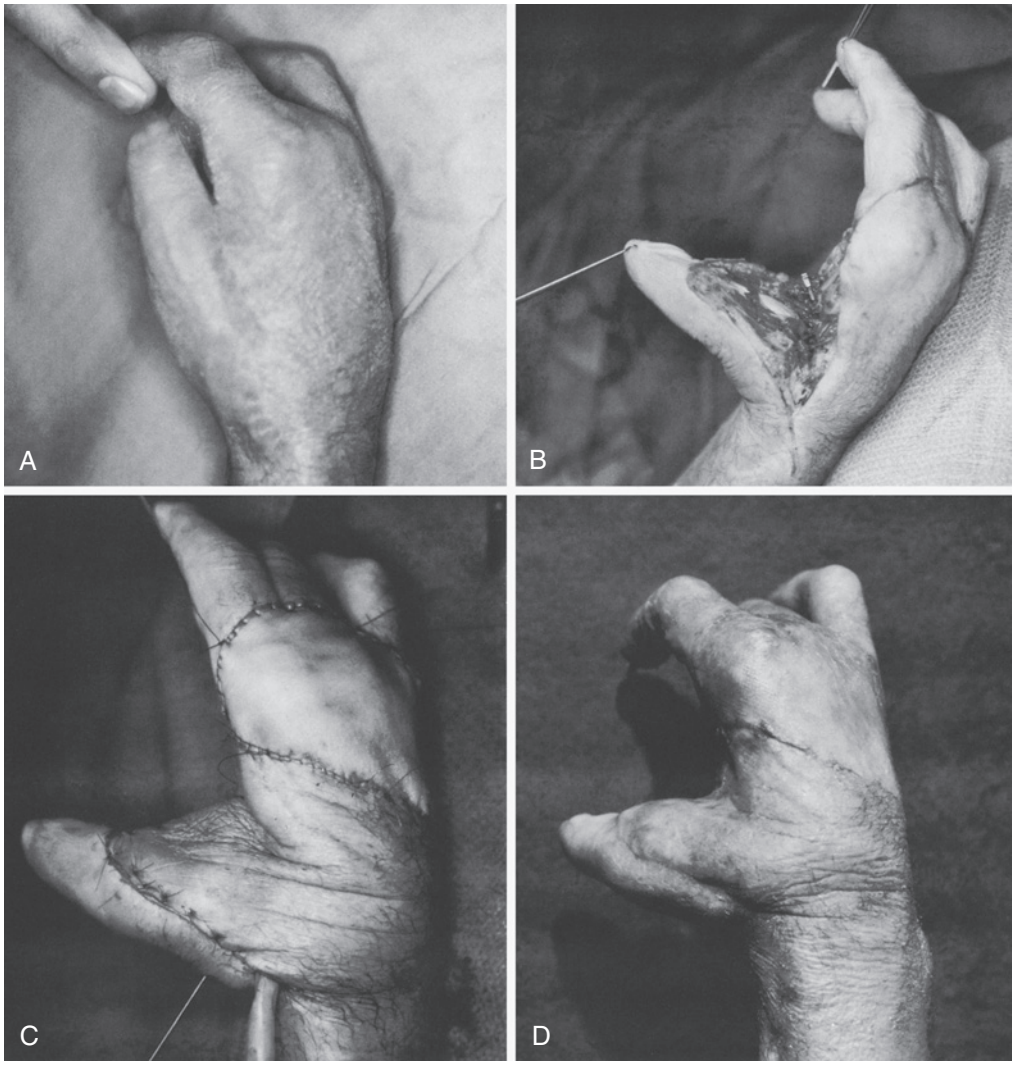

eFIGURE 48.5 Phalangization of a severely contracted first metacarpal with a dorsal rotational flap. **A,** Severe, long-standing adduction contracture of the thumb after amputation through the proximal phalanx. **B,** Appearance of the thumb web after release of skin, soft tissue, web space musculature, and the basal thumb joint. **C,** Coverage of the thumb web with a large dorsal rotational flap. **D,** Appearance of the thumb web at 3 months.

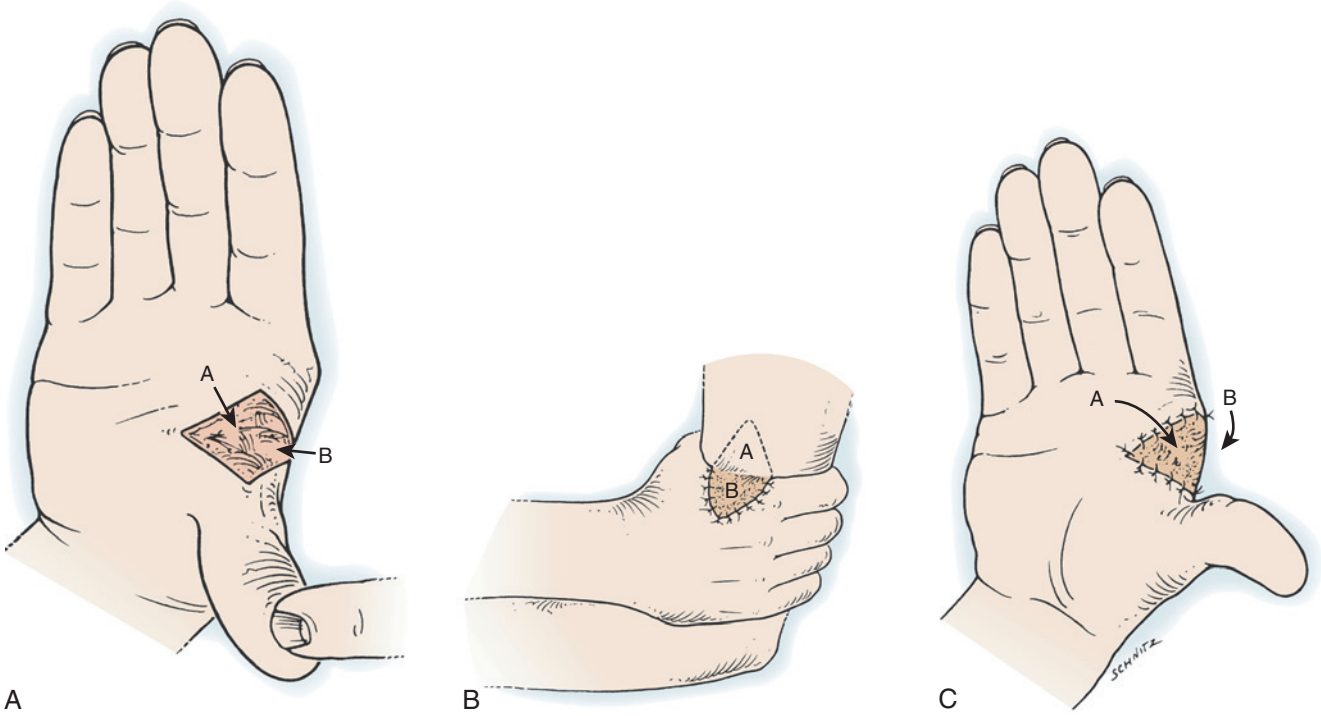

FIGURE 48.16 Cross-arm flap coverage of a deepened thumb web. **A,** Diagram of web space deepening after skin division and muscle recession. **B,** Position of the hand with the triangular distal (cross-arm) flap *B* sutured into the dorsal thumb web defect. An outline of the proximal triangular flap *A* that will be used for palmar web coverage is shown. **C,** Appearance of completed web space reconstruction after transfer of palmar flap *A* at the second-stage operation 3 weeks later.

mentioned only briefly here. The distally based radial forearm flap[29] and posterior interosseous flap[25] are both capable of reaching the first web space and providing excellent soft tissue coverage to allow web space deepening and expansion. When trauma to the arm has rendered both of these regional flaps unusable, free tissue transfer either alone, as in the lateral arm flap,[111] or as an adjunct to free toe transfer can be used to augment the first web space.

Although seldom used owing to the awkwardness of positioning and the inconvenience of even simple activities such as donning a shirt, distant pedicled flaps, such as the groin flap, pectoral flap, or cross-arm flap,[94,122] can provide excellent resurfacing of the first web space. Unlike the groin and pectoral flaps, the limited size of the cross-arm flap makes it less useful for general hand wound coverage; however, the flap can provide thin, supple skin for web space resurfacing, and the contour of the arm is excellent for maintaining the web space while the pedicle is being vascularized.[94] The medial aspect of the arm bears the thinnest skin and a thin subcutaneous layer, making it the preferred donor site for the flap. Given its potential use in phalangization and web space creation, we include a description of the cross-arm flap technique here.

First Web Space Deepening With Cross-Arm Flap Coverage. Release of the first web space is carried out in a manner identical to that described for the dorsal rotational flap (Figure 48.16, *A*; see also Figure 48.14). The abducted position of the thumb is maintained by Kirschner wires crossed between the bases of the first and second metacarpals or by an external fixator. The hand is brought into place against the opposite arm in such a manner that the ulnar border of the hand rests against the anterior medial surface of the forearm, with the thumb comfortably placed around the inner aspect of the upper arm. Patterns are used to design a proximally based triangular flap for resurfacing the dorsal half of the divided web space (Figure 48.16, *B*). The flap is meticulously elevated, including skin and subcutaneous tissue, and temporary split-thickness skin coverage is placed on the arm and palmar hand defects. Moist cotton stent dressings over the graft are important, and the position of the arm is maintained by a plaster Velpeau dressing. At 2 to 3 weeks the patient is returned to the operating room, and a corresponding triangular flap is designed proximally; this is dissected out and turned into the palmar defect after the free graft is excised. Defatting of the flap is not usually necessary, and excellent restoration of the web space can be achieved in this manner (see Figure 48.16, *C*). A bulky dressing to maintain the web space is applied and changed at 7 to 10 days. Suture removal and web space splinting with a custom-fit spacer are performed at 2 weeks. Rehabilitation and pin removal occur on the same schedule as for the dorsal rotational flap. Likewise, monitoring for web space contracture may be necessary for up to 1 year, and night splinting with the web spacer may be required.

The cross-arm flap can provide excellent coverage after release of the first web space in patients with thumb amputation through the middle third of the first ray. The procedure restores excellent skin and subcutaneous tissue both palmarly and dorsally, without the need to use the frequently compromised dorsal hand skin. A disadvantage is the resulting defect on the opposite arm, and although this procedure can generally maintain the hand in a position of function, upper limb function is limited during the period of obligatory immobilization.

Nonetheless, it has proved to be an effective technique for web space widening and deepening and relative thumb lengthening in certain cases where microvascular free tissue transfer is not available.

Subtotal amputations at or proximal to the midportion of the proximal phalanx are unlikely to achieve adequate length solely through phalangization procedures. At this level, the reconstructive options overlap with techniques used to provide an opposable thumb in the setting of total amputation with preservation of the basal joint.

Total Amputation With Preservation of the Basal Joint

Although not the only possible reconstruction at this level, the reliability of free toe transfer procedures, the availability of microsurgical instrumentation, and the familiarity of most hand surgeons with the techniques make free toe transfer the optimal choice for these amputations. Either great toe or second toe transfer is often an excellent restorative option that can provide the necessary length, mobility, and sensibility for a functional thumb. Given the excellent outcomes with free toe transfer (see Chapter 44),[22,132,133] the majority of patients seeking thumb reconstruction who require additional length are candidates for these procedures. There may be occasional patients who are unwilling to accept the cosmetic alteration of the foot or for whom athletic performance may be compromised after sacrifice of a toe. Alternative methods include metacarpal distraction or lengthening techniques, osteoplastic reconstruction, and pollicization of an injured or partially amputated digit.[85] Distraction osteogenesis, as discussed elsewhere, may be useful when the amputation has spared a substantial amount of the first metacarpal. Under optimal conditions, progressive metacarpal distraction can safely result in 3 to 4 cm of additional length for patients with traumatic thumb amputation. Although distraction can add length, motoring of the digit depends on the residual function of the intrinsic muscles of the thumb. With increasingly proximal amputations, motor function may need to be provided through tendon transfers.

Osteoplastic Reconstruction

Osteoplastic reconstruction, or thumb reconstruction by means of a bone graft covered with a pedicled flap, was first attempted by Nicoladoni in 1897.[96] Early reports of successful thumb reconstruction using bone graft and tubed pedicle techniques made this the preferred method of thumb reconstruction during the first half of the 20th century[27,42,96]; however, results were plagued by the inability to provide adequate sensory perception to the reconstructed thumb and significant resorption of the bone graft inside the pedicle. Moberg[89] and Littler[71] improved sensation by suggesting that a neurovascular island pedicle transfer become part of osteoplastic reconstruction of the thumb, and the use of large, extraperiosteal, tricortical iliac crest grafts may have reduced the extent of bone resorption.[67,92] Although toe-to-thumb transfer procedures have largely supplanted osteoplastic reconstruction, it may still prove useful when there is good basal joint motion, the fingers are normal or too badly damaged for transfer, and toe transfers or lengthening techniques are not appropriate.[68]

Variations on the osteoplastic theme include the Gillies "cocked-hat" flap, which uses local tissue to cover the bone graft (Figure 48.17), and composite flaps based on the pedicled radial forearm flap.[5,8,17,24,78,135] Biemer and Stock[5] described a one-stage total thumb reconstruction using a composite flap containing skin and subcutaneous tissue, a segment of radial bone, a length of the lateral cutaneous nerve of the forearm, and two veins. The elevated flap is turned 180 degrees, and the radial bone is fixed to the first metacarpal. The digital nerves of the thumb are sutured to the nerves in the flap, and vein anastomosis is optional. Foucher's technique varies, in that it restores sensation by means of a neurovascular island pedicle flap.[35]

Two-Stage Osteoplastic Reconstruction of the Thumb

Stage 1. In the first stage (Figure 48.18, *A* to *D*), a groin flap that includes the superficial circumflex iliac artery is patterned and raised on the same side as the hand whose thumb is to be reconstructed (see Chapter 44). The flap should have a width of 7.5 cm and a minimum length of 12 cm, with its free end positioned over the lateral prominence of the underlying iliac crest. A large extraperiosteal tricortical bone graft is taken from the iliac crest; the graft should be 7 to 8 mm thick, 5 to 6 cm long, and 1.5 cm wide (see Figure 48.18, *B*).

Under tourniquet hemostasis, adequate débridement of scar, skin, and any necrotic bone from the distal metacarpal is carried out. A cuff of viable skin over the first metacarpal should be reflected to increase the vascular contact area of the flap. A small curet is used to fashion a hole in the medullary canal of the metacarpal, and the bone graft is shaped with a motorized bur to produce a stout cortical stem 2 cm long. The graft is inserted and secured in the metacarpal so that its flattened raw edge is facing the index finger in opposition with the first metacarpal (see Figure 48.18, *C*). Lister[67] has suggested that the fit of the graft peg into the metacarpal should be tight enough to enable lifting of the arm by the graft after insertion; however, fixation is typically secured by longitudinally or obliquely placed pins. The distal tip of the graft is shaped with a rongeur to remove any sharp edges and approximate the length of the IP joint of the normal thumb.

The substantial amount of subcutaneous fat present in most groin flaps necessitates defatting of the distal tip of the flap before inset. After careful removal of an adequate amount of fat, the flap is tubed along most of its length. The donor defect is undermined and closed without excessive tension, and the bone graft is inserted into the tube with the suture line coming to lie palmarly in preparation for insertion of the neurovascular island flap during the second stage. The free end of the pedicle is sutured to the expanded metacarpal skin defect (see Figure 48.18, *D*). Care is taken to avoid tension, twisting, or "kinking" of the pedicle, and a low-suction drain is placed in the groin wound for 24 to 48 hours. A soft Velpeau-type restraining dressing is used to comfortably immobilize the arm. Throughout the period of neovascularization of the flap, the patient is instructed to move the untethered fingers and wrist through a full range of motion. The debate over how long to wait before pedicle division and performance of the second stage ranges from just over 8 days (provided an ischemic preconditioning protocol has been followed)[21] to 4 weeks.[113] Useful methods to assess the readiness of the flap for division include fluorescein testing[83] and laser Doppler flowmetry.[21] Whichever testing modality is used, if flap viability is still questionable at 10 to 14 days, partial division of the flap and ligation of the superficial circumflex iliac artery can be performed with the patient under local

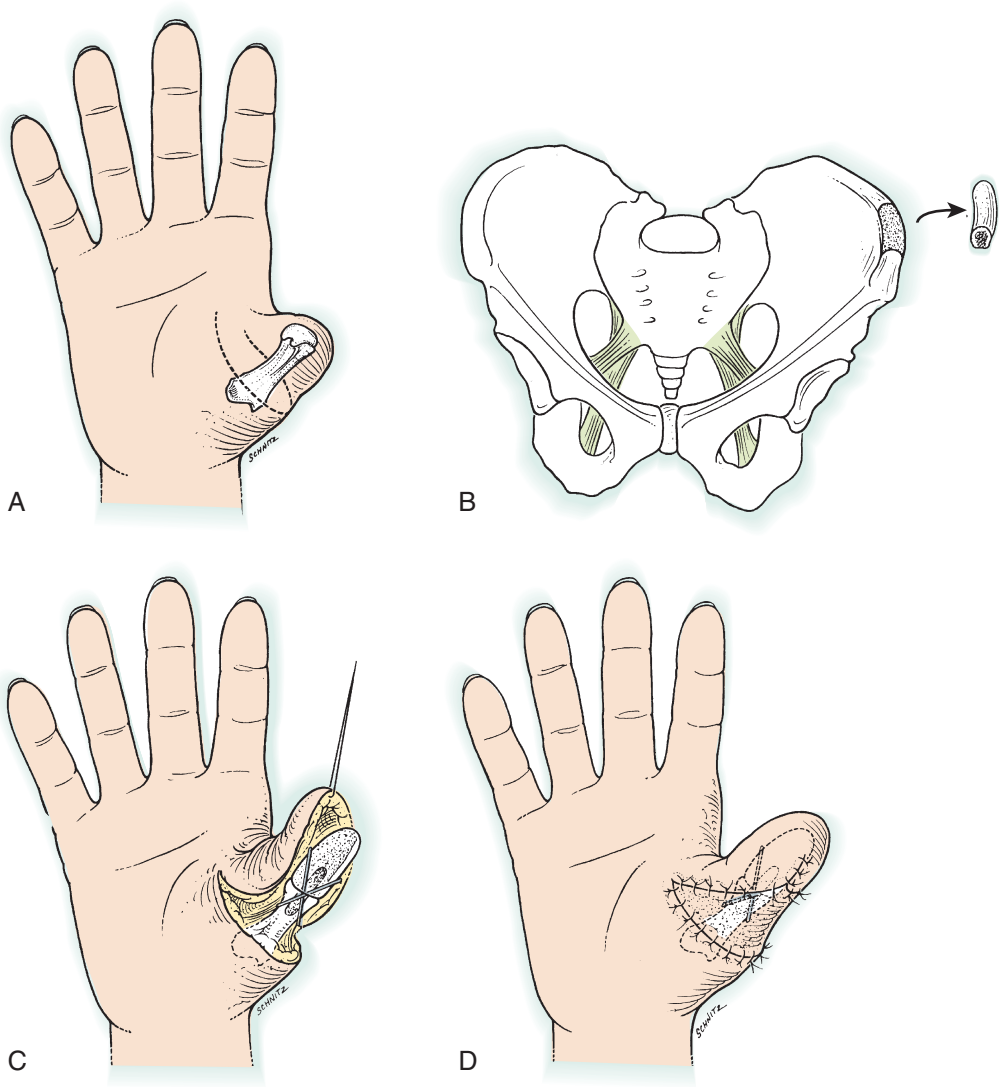

FIGURE 48.17 Gillies "cocked-hat" flap. **A,** Outline of the incisions around the base of the thenar eminence. **B,** Tricorticocancellous iliac bone graft to elongate the first metacarpal. **C,** The flap is reflected, and the graft is held in place with crossed Kirschner wire fixation. The graft may be stemmed for insertion into the metacarpal, or a cortical peg may be used to bridge the graft-metacarpal interval, as shown here. **D,** The flap brought back to cover the bone graft. A free skin graft covers the thumb defect. (Modified from Reid DAC: Reconstruction of the mutilated hand. In Rob C, Smith R, Pulvertaft RG, editors: *Operative surgery: the hand*, ed 3, London, 1977, Butterworth.)

anesthesia to effect a "delay" of the flap and improve its vascularity.

Stage 2. At the time of complete tube release, whether at the initial assessment or after the partial delay procedure, an extended neurovascular island flap is raised from the ulnar aspect of the long finger and dissected well into the palm as described earlier (see Figure 48.18, *E* to *H*). When re-creating the defect into which the flap will be placed, the surgeon should extend the defect over the distal aspect of the bone graft and dissect down to the raw bone on the palmar side of the graft (see Figure 48.18, *F* and *G*). Passage, inset, and donor site closure are identical to the techniques used for the standard neurovascular island flap (see Figure 48.18, *H*).

A plaster-reinforced compressive dressing is used postoperatively for 7 to 10 days, and cast immobilization is continued until bony union is complete at 6 to 8 weeks. Gradually increasing use of the reconstructed thumb is then permitted.

Although rarely necessary, this type of thumb reconstruction is fairly rapid and does not require the use of other digits or toes (eFigure 48.6). Its disadvantages lie in the obligatory insult to the long finger and the tendency to continue to perceive the reconstructed thumb unit as the long finger, although this may be a less bothersome phenomenon with the passage of time. The potential complications are numerous and include partial necrosis of the groin flap, loss of blood supply or diminished sensory perception in the neurovascular island flap, failure of the free graft to the long finger, and nonunion or resorption of the bone graft.

Composite Radial Forearm Island Flap

This procedure has the advantage of providing a well-vascularized skin and bone flap and, with the addition of an extended neurovascular island pedicle flap, avoiding the staging necessitated by conventional osteoplastic methods. Preoperative

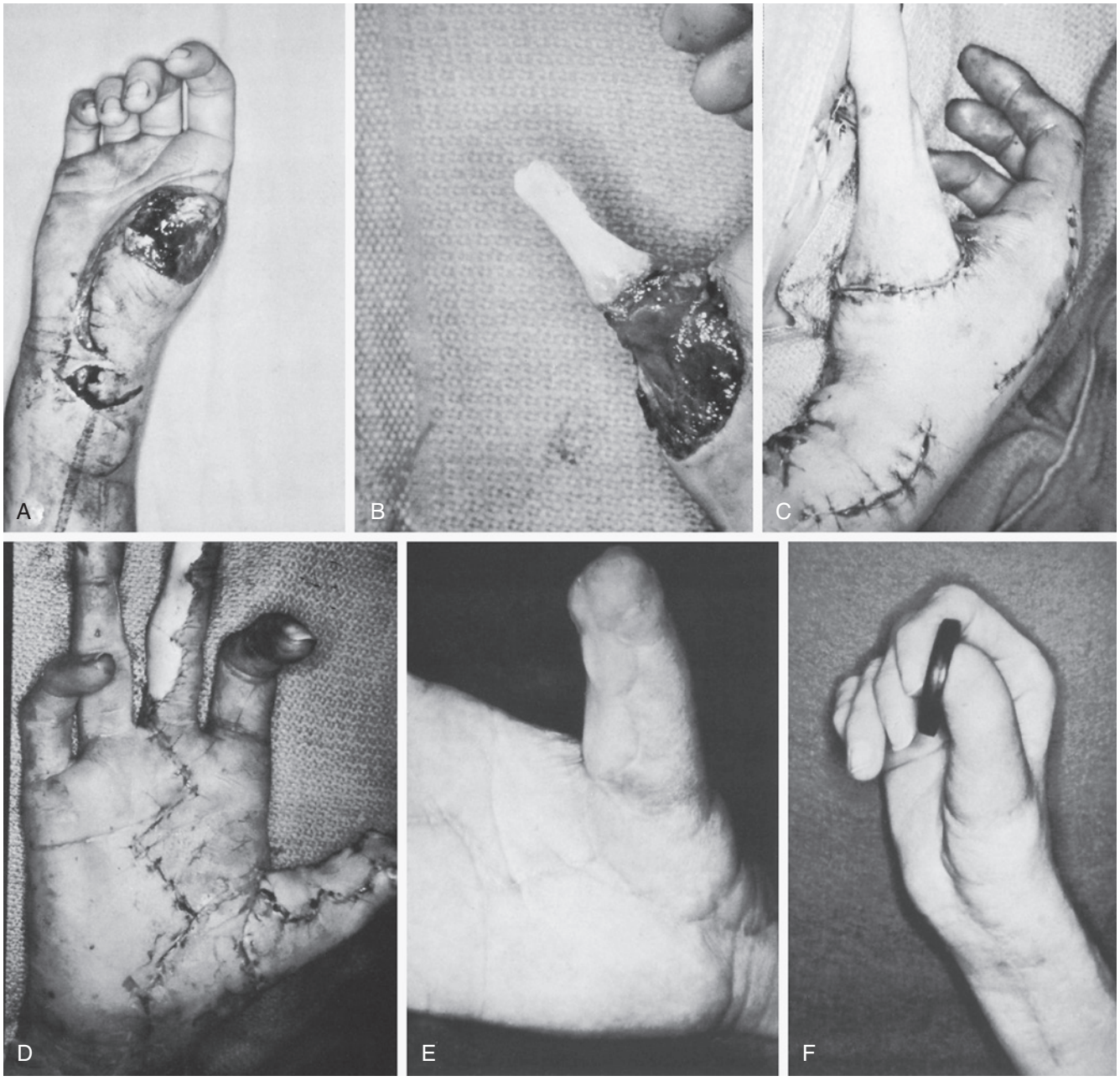

eFIGURE 48.6 Osteoplastic reconstruction of an amputated thumb. **A,** Traumatic amputation of the thumb through the first metacarpal. **B,** Bone graft using the preserved proximal phalanx of the amputated thumb. **C,** Application of a thin, tubed upper abdominal pedicle flap. **D,** Transfer of an extended neurovascular island pedicle flap from the ulnar aspect of the long finger at the time of pedicle flap detachment. **E** and **F,** Appearance of the thumb unit at 9 months, with satisfactory pinch and grasp functions. (From Strickland JW: Restoration of thumb function following partial or total amputation. In Hunter JM, Schneider LH, Mackin EJ, et al, editors: *Rehabilitation of the hand*, St. Louis, 1978, CV Mosby.)

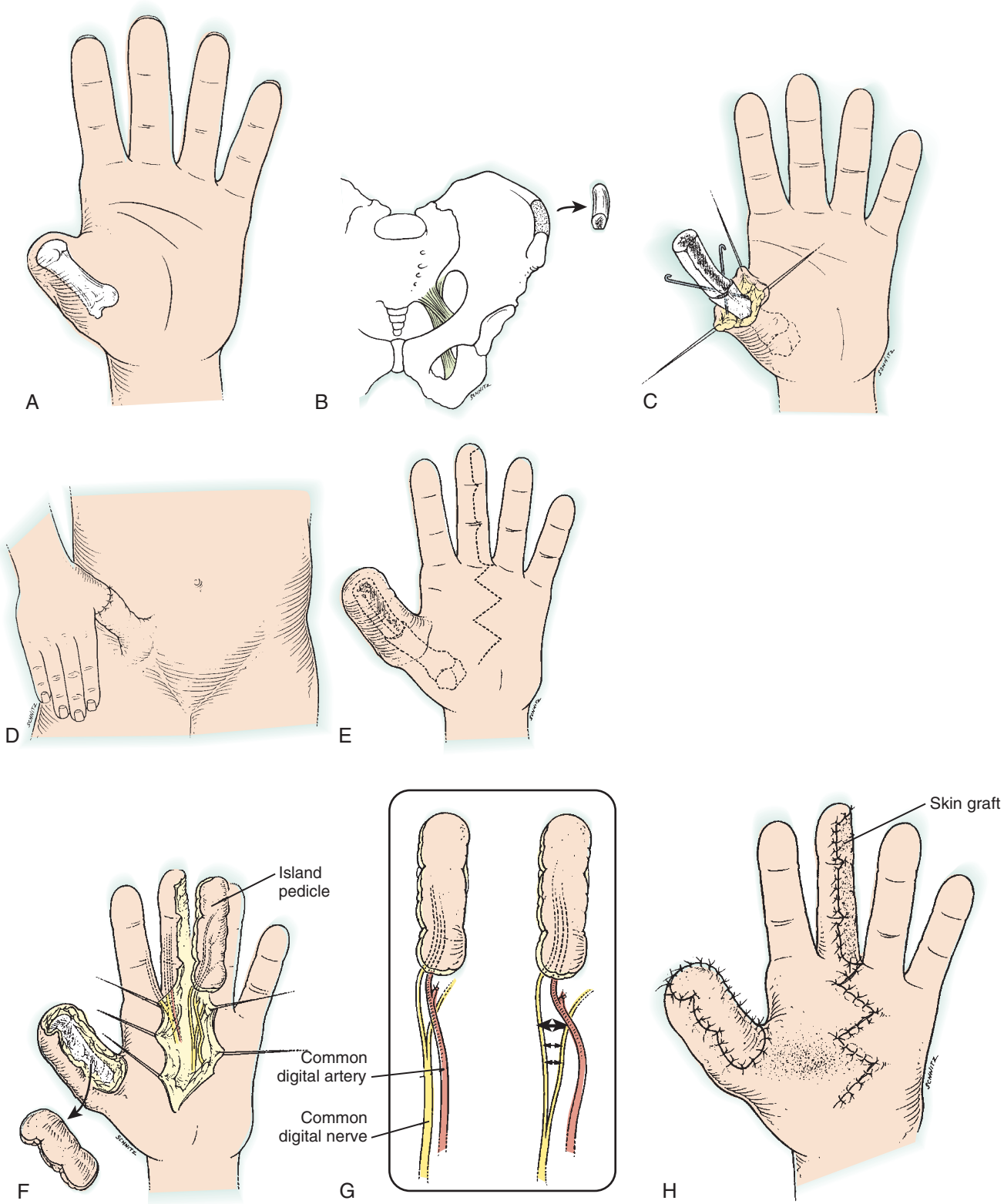

FIGURE 48.18 Osteoplastic reconstruction of the thumb. **A,** Thumb amputation through the metacarpophalangeal joint. **B,** Site of removal of extraperiosteal tricorticocancellous iliac crest bone graft. **C,** Preparation of the recipient site with insertion of the iliac crest graft into the first metacarpal, shown here with Kirschner wire fixation. **D,** Bone graft coverage with a tubed groin flap. **E,** Incisions for the use of an extended neurovascular island pedicle flap to provide vascularized and innervated skin on the palmar aspect of the reconstructed thumb. **F,** Transfer of the neurovascular island flap to the palmar thumb defect at the time of flap detachment. **G,** Severance of the digital artery to the opposite web and careful intraneural separation of the common digital nerve in preparation for tension-free transfer of the neurovascular island flap. **H,** Completion of neurovascular island transfer with a free skin graft to the donor defect in the long finger. (Modified from Simonetta C: Reconstruction of the thumb by tube pedicle, bone graft and island flap. In Reid DA, Gosset J, editors: *Mutilating injuries of the hand*, New York, 1979, Churchill Livingstone.)

requirements are those of the standard radial forearm flap (see Chapter 44), including a patent ulnar artery and palmar arch. The finding of a predominantly radial blood supply or the absence of an ulnar artery precludes the use of this procedure.

The flap is designed from the palmar and radiodorsal aspect of the forearm, beginning several centimeters proximal to the radial styloid. It should be 7 to 8 cm long and 6 to 7 cm wide (Figure 48.19, *A*). After preparation of the distal thumb stump, the flap, including the radial artery and its venae comitantes, is carefully raised. Great care is taken not to damage the cutaneous branches of the radial nerve or the blood supply to the radius just proximal to the styloid process. One or more small branches from the radial artery should be identified entering the pronator quadratus muscle and extending down to the periosteum of the radius. These vessels must be protected, which often necessitates leaving a small amount of muscle attached to the radius. A bone flap measuring from 2 to 4 cm is patterned on the lateral side of the radius and designed to include the perforating branches from the radial artery. The bone is osteotomized with either powered or conventional bone instruments, taking care to protect the radial artery and perforating vessels. After ligating the radial vessels proximally, the entire flap is mobilized as a composite unit to the level of the anatomic snuffbox. The abductor pollicis longus and extensor pollicis brevis tendons are freed proximally by releasing the distal portion of the first dorsal compartment. The composite bone-skin preparation is passed in a palmar-to-dorsal direction beneath the skin and over the abductor pollicis longus, extensor pollicis brevis, and extensor pollicis longus. Whichever way the pedicle is taken, however, one must be mindful to prevent kinking of the vascular bundle. The flap is passed under the skin bridge of the first web space to the level of the distal thumb wound. Connecting incisions are often used if scar tissue makes this passage difficult. The segment of bone is secured to the metacarpal with its cancellous raw edge facing the index finger and the first metacarpal in opposition. Fixation is secured by longitudinal or obliquely placed pins or by the use of a small plate. Distal shaping and trimming of the graft ensure a smooth configuration. The forearm skin now provides coverage in a nearly circumferential fashion around the graft and the distal aspect of the remaining metacarpal or proximal phalangeal bone (see Figure 48.19, *B*).

At this point, an extended neurovascular island pedicle flap taken from the ulnar side of either the long or ring finger can be placed on the palmar aspect of the bone graft to provide sensory perception and complete the reconstruction (see Figure 48.19, *D*). A split-thickness skin graft taken from the opposite anterior thigh is used to close the forearm donor area after adjacent muscle has been mobilized over the defect created by the removal of radial bone. The tourniquet should be released before application of a dressing to ensure a sufficient blood supply to both flaps, and exploration of the vascular pedicle must be carried out if any problems exist.

A plaster-reinforced compressive dressing is applied over the forearm; however, the dressing should be loose around the wrist and hand, and sufficient portions of both flaps are left exposed to allow continuous monitoring of their vascularity. A dressing change is carried out at 1 week, and a plaster short-arm thumb spica cast is applied at 2 weeks and continued for 6 weeks. Additional immobilization may be necessary, depending on bone healing.

Advantages of the composite radial forearm island flap include the elimination of staging and the excellent vascularity achieved with both flaps, which helps minimize the possibility of flap failure. Because the bone segment is vascularized, this technique should theoretically prevent bone resorption, which is probably the most significant disadvantage of osteoplastic thumb reconstruction. Bone grafts (even vascularized ones) placed out in "space" and not spanning a gap often show some resorption of the distal portion over time, however.

Disadvantages of the procedure include a considerable cosmetic defect created in the area of forearm flap harvest and the possibility of distal radius fracture. The risk of fracture can be decreased by making the initial osteotomies on the radius at a sharp angle, creating a "canoe-shaped" graft. This avoids the stress risers associated with osteotomies performed at right angles and may help prevent fractures at these sites. Although no microvascular anastomoses are required, the dissection must be carried out under loupe magnification to ensure that no damage occurs to the radial artery or its venae comitantes and to maintain the vascular supply to the bone graft. When carried out correctly, this procedure seems to be the most effective means of osteoplastic thumb restoration (eFigures 48.7).

Pollicization of an Injured Digit

Not infrequently, injuries that result in loss of the thumb also cause partial destruction or amputation of adjacent digits. This creates the possibility for transfer of an injured digit or distal metacarpal to the base of the proximal phalanx of the thumb or to the first metacarpal to restore length and sensory perception.[18,19,45,57,81,109,123] The most common digital injuries associated with thumb loss are partial or complete amputation of the index finger or index and long fingers. This creates an ideal situation for pollicization of the index or long finger stump to the thumb remnant. This procedure not only adds length to the thumb but also widens and deepens the first web space by providing a ray resection of the second metacarpal.

When both the thumb and the index finger have been lost and the long finger has been damaged or partially amputated, transposition of the stump of the long finger can be carried out by techniques almost identical to those described for pollicization of the index stump. Occasionally, satisfactory index function is preserved with damage to or amputation of the long finger, thus making it the best candidate for transposition. Although transfer of an injured ring or small finger may occasionally be indicated, concomitant damage to the index and long fingers makes them much more frequent candidates for transfer, and the techniques described here are limited to these two digits.

Pollicization of an Index or Long Finger Stump. Under tourniquet hemostasis, an incision is designed circumferentially around the base of the index finger, at about the level of the MP joint, to join as a "V" over the dorsal hand proximal to the midportion of the second metacarpal. An incision originating from the tip of the "V" curves transversely to the ulnar aspect of the first metacarpal. This creates a flap that can be used to cover the new first web (Figure 48.20).

Skin flaps are carefully raised, with the initial dissection carried out palmarly. Under magnification, the digital nerve to

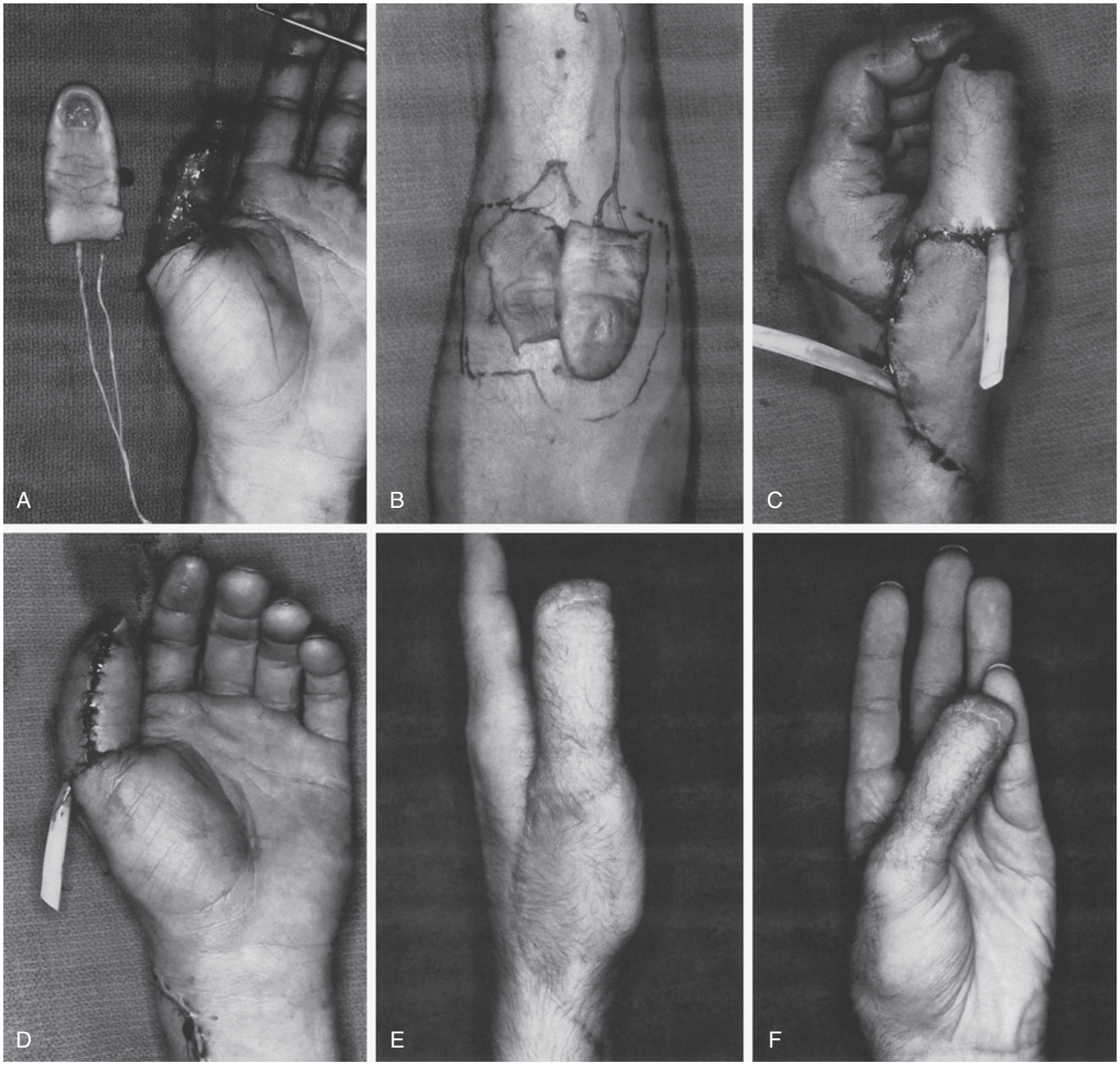

eFIGURE 48.7 Coverage of a degloved thumb with a patterned radial artery forearm flap. **A,** This thumb was totally degloved from the metacarpophalangeal joint distally, including skin and digital nerves. **B,** The avulsed skin was used as a pattern for the radial artery forearm flap. Note the oversizing of the skin pattern to ensure adequate coverage. **C** and **D,** The thumb immediately after completion of radial forearm flap coverage. **E,** Appearance of the thumb at 3 months. **F,** The reconstructed thumb demonstrating pinch to the small finger. Sensation can be enhanced with a dual innervated cross-finger flap or an extended neurovascular island pedicle flap. (Courtesy of Hill Hastings II, MD.)

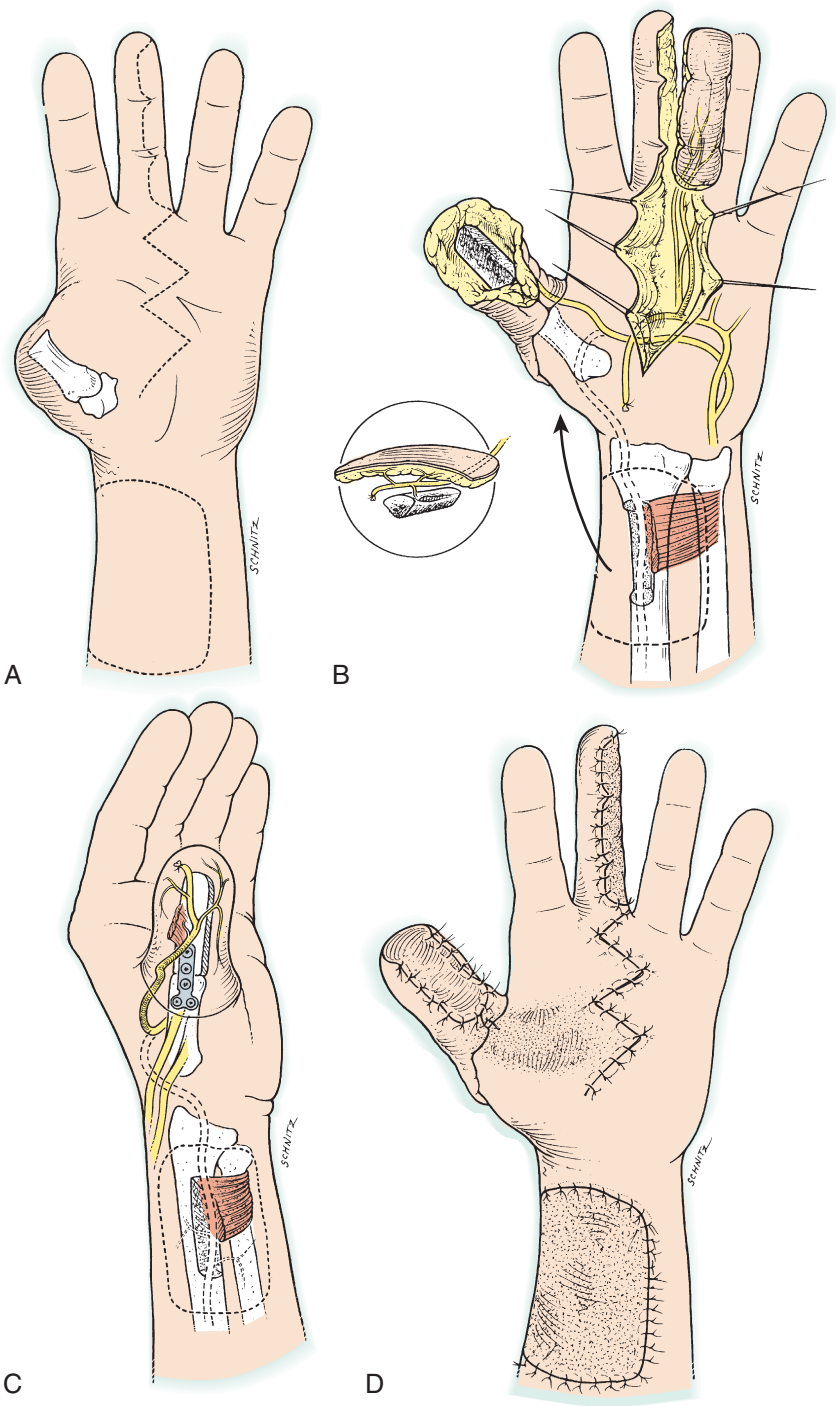

FIGURE 48.19 Composite radial forearm island flap. **A,** Incisions used for thumb reconstruction entailing a composite radial forearm island flap and neurovascular island flap taken from the ulnar side of the long finger. The radial flap is approximately 7 by 7 cm and is raised from the distal volar lateral forearm. **B,** Elevation of the flap together with a segment of the distal radius, with careful preservation of radial artery communications between the skin and the bone graft (*inset*). The artery is ligated proximally, and the flap is tunneled under the first dorsal compartment. The positions of the bone graft and the flap are shown. The neurovascular island pedicle flap is raised in preparation for palmar resurfacing of the reconstructed thumb. **C,** Dorsal appearance of the composite radial forearm flap and bone graft in position; a small "T"-plate is used for fixation. Note the position of the radial artery. **D,** Completion of the thumb reconstruction, with skin grafts used to cover the radial side of the long finger and the volar forearm. (Modified from Foucher G, Van Genechten M, Merle M, et al: Single stage thumb reconstruction by a composite forearm island flap. *J Hand Surg [Br]* 9:245–248, 1984.)

CRITICAL POINTS *Composite Radial Forearm Island Flap*

Indications

- Indications are few, given the success of toe-to-thumb microvascular transfer.
- Loss of the thumb at the mid to proximal metacarpal level
- Intact remaining digits, making sacrifice for pollicization less desirable
- Patency of the ulnar artery and superficial palmar arch

Technical Points

- Design a flap 7 to 8 cm long and 6 to 7 cm wide over the volar, radiodorsal aspect of the forearm.
- Débride the distal thumb stump.
- Raise the flap as for a standard, distally based radial forearm flap.
- As dissection approaches the radial styloid, identify a branch of the radial artery coursing to or through the pronator quadratus and the underlying radius periosteum.
- Osteotomize a corticocancellous bone graft 2 to 4 cm long and 1.5 cm wide, including the entry point of the feeding vessel from the radial artery.
- Ligate the radial vessels proximally, and elevate the composite flap to the level of the anatomic snuffbox.
- Incise the distal portion of the first dorsal extensor compartment to release the abductor pollicis longus and extensor pollicis brevis tendons.
- Pass the composite flap over the abductor pollicis longus, extensor pollicis brevis, and extensor pollicis longus tendons and under the overlying skin bridge into the dorsal aspect of the thumb wound.
- Avoid kinking or twisting of the pedicle during passage; if passage is difficult, create connecting incisions in the skin to facilitate passage.
- Orient the cancellous portion of the osseous part of the flap so that it faces the index finger, with the residual thumb metacarpal in opposition.
- Secure the bone portion of the flap to the thumb metacarpal using a small plate or Kirschner wires.
- Harvest a neurovascular island pedicle flap and transpose to the palmar aspect of the composite flap in the standard fashion.
- Release the tourniquet, achieve hemostasis, and inspect the transferred flaps for viability.
- Inset the flaps using fine, nonabsorbable suture.
- Harvest a split-thickness graft and inset this in the radial forearm harvest site.
- Harvest a full-thickness skin graft and inset this in the neurovascular island flap defect.
- Apply nonadherent gauze, a gentle compressive dressing, and a volar resting splint.

Postoperative Care

- Inspect the flaps at 1 week.
- Apply a short-arm thumb spica cast after the initial dressing change.
- Continue cast immobilization for 6 weeks (possibly longer, depending on bone healing).
- On cessation of casting, begin active and passive range-of-motion exercises.

Expected Outcomes

- Improved length and function of the thumb
- Adequate padding and sensation (with a neurovascular island flap)
- No motion in the thumb
- Potential donor site problems (skin graft "take," fracture of the radius, unattractive scar on the forearm)

the radial side of the index finger is identified, together with the radial digital artery. The flexor tendons are identified, and the neurovascular bundle to the index and long fingers is delineated. Careful dissection isolates the digital artery to the radial side of the long finger, which is clamped and ligated well beyond the bifurcation of the common digital artery. Under magnification, the digital nerves to the adjacent sides of the index and long fingers are carefully teased apart, well back into the palm (see Figure 48.20, *B* and *D*).

By alternating dissection from the palm to the dorsum, the second intermetacarpal space is developed beginning in the web and proceeding proximally. The transverse intermetacarpal ligament is divided, and the interossei in the cleft are separated down to the proximal part of the intermetacarpal interval by blunt dissection. Flexor and extensor tendons are left undisturbed.

The index metacarpal is now completely exposed subperiosteally, and a reciprocating saw is used to divide it obliquely at its base. The amount of additional metacarpal to be removed depends on the exact level of thumb loss, but this is usually just proximal to the metacarpal neck for amputations at the MP joint level. The stump to be pollicized should now be quite mobile, attached only by its two neurovascular pedicles and the flexor and extensor tendons.

At this point, the thumb stump is prepared by removing all scarred bone and cartilage. At the time of transposition, a small bone peg may be fashioned from the removed section of the second metacarpal and used to traverse the bony juncture (see Figure 48.20, *E*). The limiting factor in the transfer is the length of the neurovascular pedicles, and great care must be taken to avoid putting these structures under tension. Obliquely placed Kirschner wires or a small compression plate is used to secure fixation of the transferred digit (see Figure 48.20, *F*). The tourniquet is released to ensure hemostasis and the vascularity of the transferred digital stump. Skin defects are closed by transposing the lateral flap into the cleft created by transposition (Figure 48.21; see Figures 48.20, *G* and *H*).

Postoperatively, the hand is kept in a large plaster-reinforced compressive dressing for 2 weeks, and a plaster cast is continued until bony union occurs. A lightweight splint that will maintain the web space should be worn at least intermittently for several additional months.

In the setting of a functional index finger, pollicization of a long finger stump differs slightly from the technique of index transfer. Dorsal incisions are similar, but the palm is approached through an additional zigzag incision (Figure 48.22, *A* and *B*). Through the palmar incision, the digital arterial bifurcations are identified, and the proper digital arteries to the ulnar side of the index finger and the radial side of the ring finger are exposed and carefully ligated and divided well away from the bifurcations (see Figure 48.22, *C*). The common digital nerves are carefully separated from each other well back into the palm. Dissection, exposure, and division of the third metacarpal proceed as for the index technique (see Figure 48.22, *D*). Transfer of the digit differs, in that after ensuring that the neurovascular bundles have been mobilized well into the palm, a subcutaneous tunnel is made to the distal aspect of the first metacarpal, which has been cleared of scar tissue and trimmed to strong, well-vascularized bone. The isolated middle finger stump is passed through the tunnel, and additional tailoring of

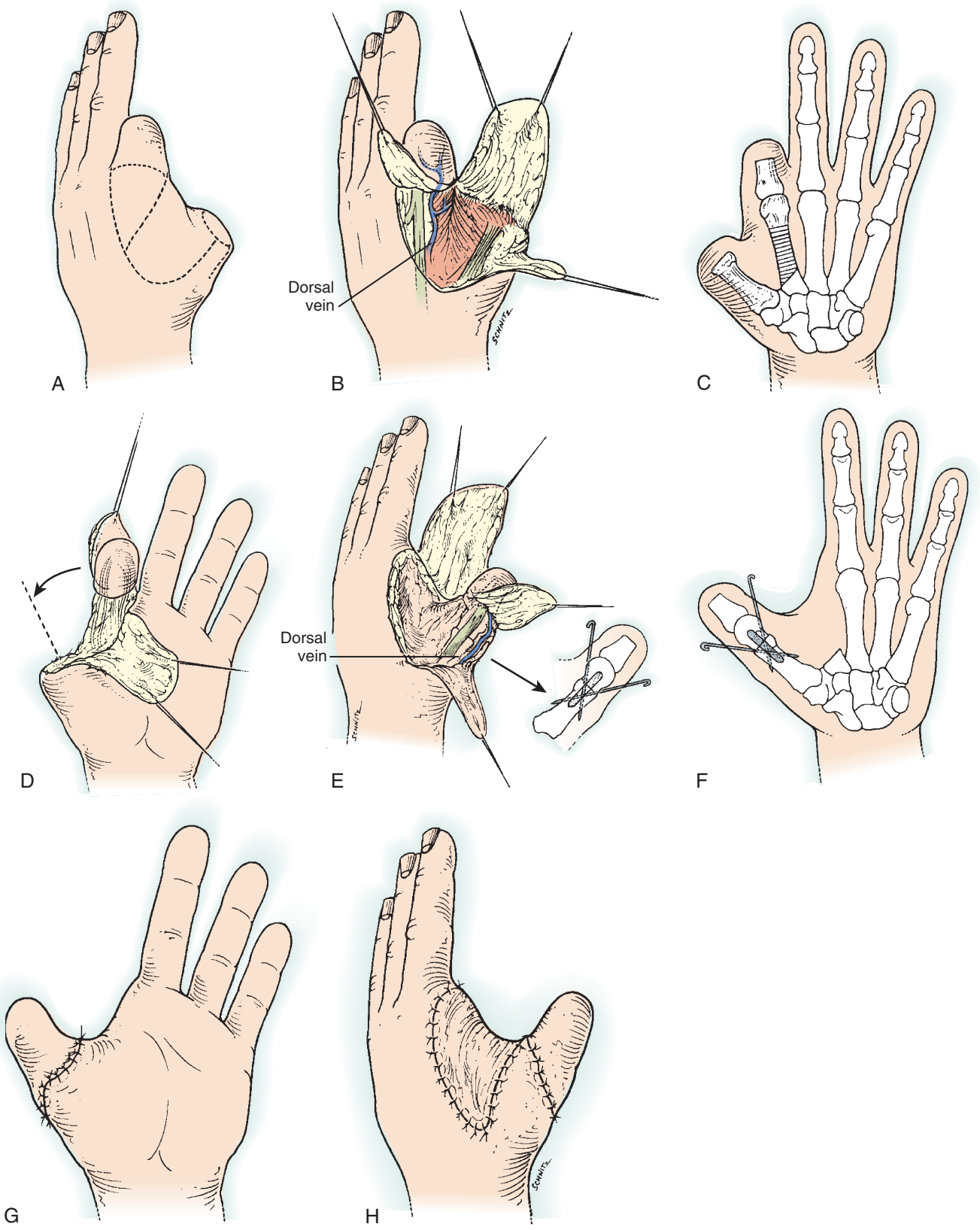

FIGURE 48.20 Pollicization of an index finger stump. **A,** Incisions used for index stump transposition. **B,** Elevation of flaps and mobilization of the second ray. A dorsal vein is identified. **C,** Diagram depicting the areas of the second metacarpal to be divided and excised (*stripes*) before transfer of the distal metacarpal and proximal phalangeal stump. **D,** The palmar flap with intact neurovascular bundles and flexor tendons following division of the radial digital artery to the long finger. **E,** Transfer of the index stump to the first metacarpal, again with preservation of a dorsal vein. Fixation by means of a bone peg and crossed Kirschner wires is shown. **F,** First and second metacarpal fixation with proximal deletion of the second metacarpal. **G,** Wound closure on the palmar surface of the transposed index stump. **H,** Use of the palmar flap to create a thumb–long finger cleft. (From Reid DAC: Reconstruction of the mutilated hand. In Rob C, Smith R, Pulvertaft RG, editors: *Operative surgery: the hand*, ed 3, London, 1977, Butterworth.)

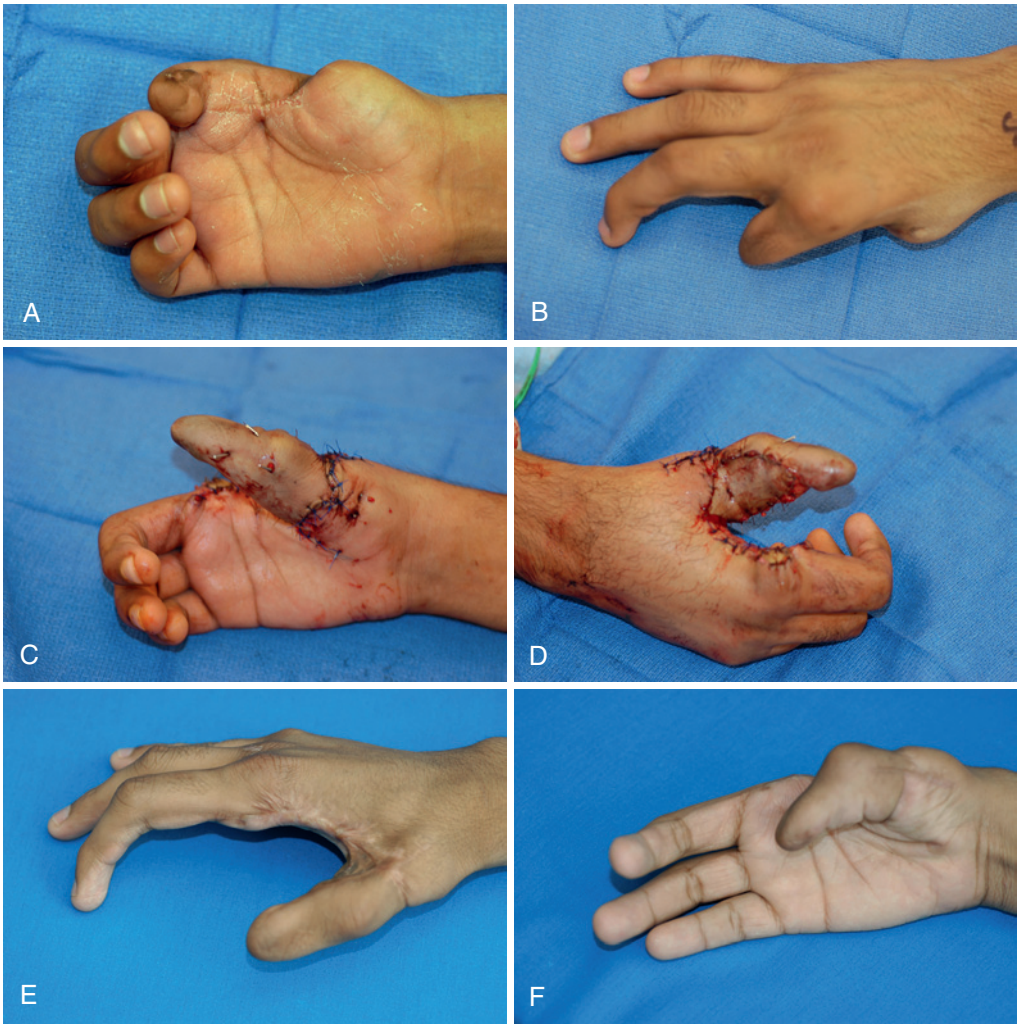

FIGURE 48.21 Pollicization of a second metacarpal stump. **A,** Old amputations of the thumb and index finger through the metacarpophalangeal joints. **B,** Incisions outlined for pollicization of the index stump to the first metacarpal. **C,** Appearance of the transferred index metacarpal at 6 months. **D,** Restoration of pinch and grasp after transfer.

the bone ends is required to ensure proper positioning of the pollicized stump. At this point, it may be possible to identify the stump of the extensor pollicis longus, free it from its scar tissue, and trim it to good tendon tissue. Tendon repair to the extensor tendon of the transferred long finger stump can be completed under appropriate tension. Closure of the donor defect is accomplished by approximating the index and ring fingers by suturing their opposing deep transverse metacarpal (intervolar plate) ligaments, and closure of the palmar wound and web space is carried out (see Figure 48.22, *E*).

These techniques that entail transferring stumps of injured index or long fingers to create additional thumb length are perhaps the most practical and efficient of all the thumb reconstructive techniques. They use functionless and sometimes obstructing parts that, by virtue of their excellent sensibility, can substantially improve function in their new position. Potential complications include partial or complete necrosis of the transferred part, nonunion of the bony juncture, and flap or graft necrosis. With careful planning, precise surgical technique, and appropriate postoperative care, these procedures should have a high degree of predictability and patient acceptance, despite the fact that the cosmetic appearance of the reconstructed thumb may be somewhat bulbous.

Total Loss With Destruction of the Basal Joint

Amputations up to, but not including, the basal joint of the thumb can be successfully reconstructed with either free toe transfer or pollicization as described in the previous section. Loss of the basal joint of the thumb, however, leaves the surgeon with the unattractive option of a thumb arthrodesed in opposition (such as might be achieved through an osteoplastic technique), pollicization, or free transfer of an injured digit from the opposite hand.[4] The chief advantage of pollicization and free digit transfers is that the hyperextended MP joint can substitute for the lost basal joint of the thumb.

Pollicization of either a normal index or ring finger has emerged as the most popular technique, and each has its advocates. Littler[74] has championed index pollicization on the grounds that it is technically simpler, provides restoration of excellent thumb function and sensation, and is cosmetically pleasing. Others have suggested that the index finger is too long and that its deletion deprives the hand of the most important

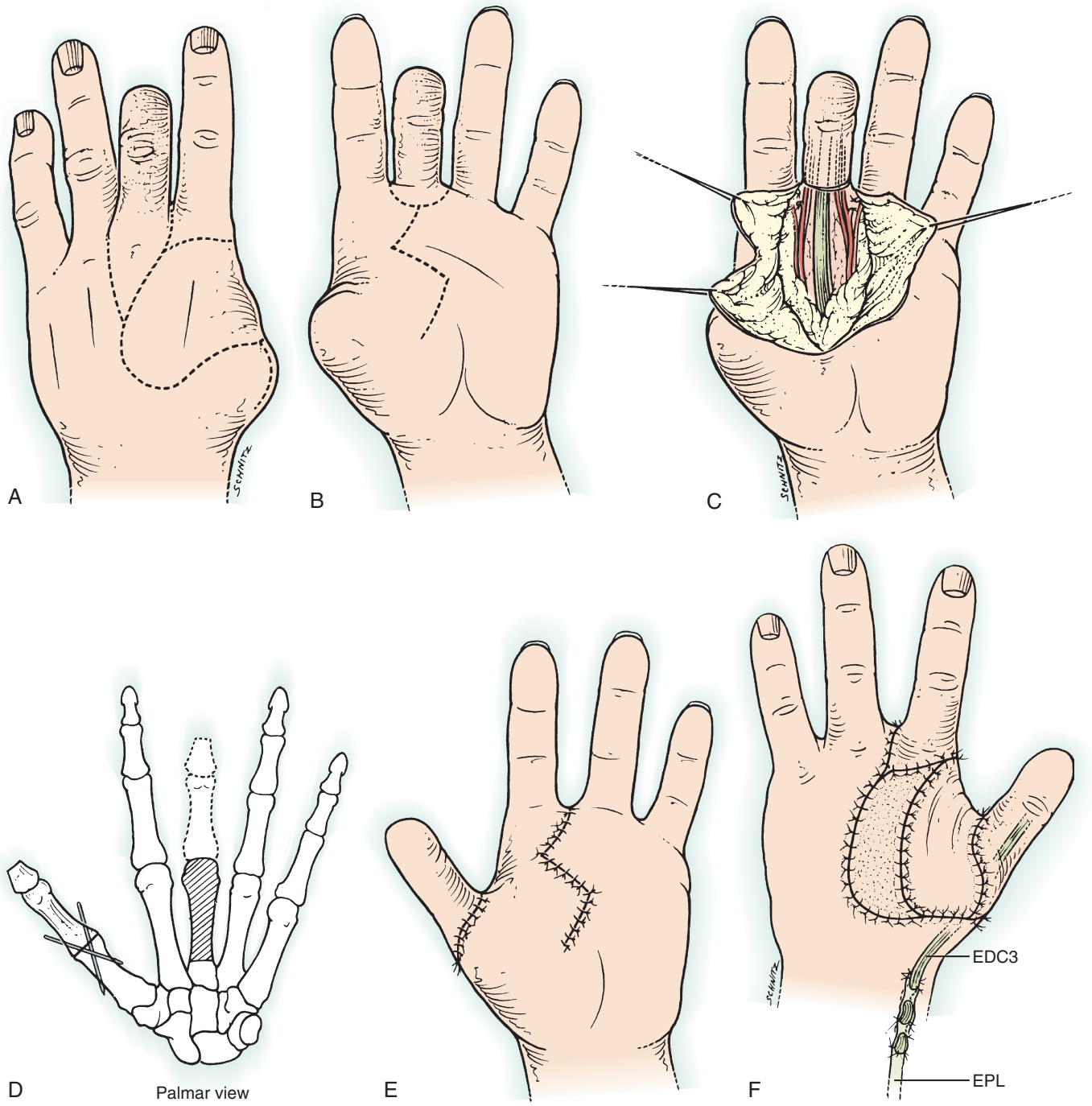

FIGURE 48.22 Pollicization of the stump of the long finger. **A,** Dorsal incision creating a dorsal lateral flap for thumb web coverage. **B,** Palmar incisions. **C,** Palmar dissection showing isolation and ligation of the ulnar digital artery to the index finger and the radial digital artery to the ring finger. **D,** Diagram of bone transfer using phalangeal bone from the long finger stump and ray excision of the third metacarpal (*stripes*). **E,** Closure of the palmar wound after completion of pollicization. **F,** Dorsal wounds after completion of web space reconstruction using the dorsal flap with free skin graft coverage of the donor defect proximal to the index finger. Suture of the extensor pollicis longus (EPL) to the extensor digitorum communis of the long finger (EDC3) is shown. (Modified from Reid DAC: Reconstruction of the mutilated hand. In Rob C, Smith R, Pulvertaft RG, editors: *Operative surgery: the hand*, ed 3, London, 1977, Butterworth.)

prehensile digit.[16,36] They prefer ring finger transfer to the thumb position because there is a minimal sacrifice of normal hand function, and excellent cosmetic and functional recovery can be achieved. Regardless of the digit transposed, pollicization as described for congenital thumb deformities (see Chapter 44) may allow restoration of not only the basal joint but also the motors lost due to injury to the thumb intrinsics.

CONCLUSION

Restoration of a functional thumb after injury remains one of the chief responsibilities of the hand surgeon. Restoration attempts should begin at the time of injury with adequate débridement and coverage of small injuries and, in the case of more significant amputations, attempts at replantation. When

CRITICAL POINTS *Pollicization of an Index Finger Stump*

Indications

- Loss of the thumb at or near the MP level
- Partial amputation of the index finger

Technical Points

- Incise circumferentially around the palmar base of the index finger near the MP joint.
- Extend this incision dorsally as a "V" proximal to the midportion of the second metacarpal.
- Incise from the tip of this dorsal "V" transversely toward the ulnar aspect of the thumb metacarpal and distally along the ulnar aspect of the thumb metacarpal.
- Raise the dorsal flaps to the level of the MP, taking care to leave at least one dorsal vein to the stump intact.
- Identify the radial digital nerve and artery and flexor tendons to the index finger.
- Identify the radial digital artery to the long finger, and ligate it well away from the bifurcation of the common digital artery.
- Tease apart the digital nerves to the ulnar index finger and radial long finger into the palm.
- Alternate between palmar and dorsal dissection to separate the second intermetacarpal space; sharply divide the transverse intermetacarpal ligament, and bluntly separate the interossei.
- Expose the second metacarpal subperiosteally.
- Obliquely osteotomize the second metacarpal at its base.
- Resect an appropriate amount of metacarpal, based on the required thumb length (amputations at the MP level typically require metacarpal just proximal to the neck).
- Remove scarred bone and cartilage from the thumb stump.
- Transfer and fix the index stump to the residual thumb metacarpal; before performing osteosynthesis with a compression plate or crossed Kirschner wires, pronate the transferred index finger to align its palmar surface with the palmar surface of the residual thumb.
- Release the tourniquet, and achieve hemostasis.
- Transfer the lateral flap into the new web defect.
- Inset flaps with fine, nonabsorbable sutures.
- Dress the area with nonadherent gauze, a compressive dressing, and a splint.

Postoperative Care

- Inspect the wound at 10 to 14 days.
- Apply a short-arm thumb spica–style cast; maintain the cast until bony union occurs.
- After cessation of casting, a thermoplastic web spacer splint should be worn and then weaned over several months.
- Begin active and passive range-of-motion exercises immediately after removal of the cast.

Expected Outcomes

- Improved function in the hand
- Deepening of the first web space with ray resection of the second metacarpal, and better span of the hand
- Minimal morbidity from loss of the index finger

loss is limited to the soft tissue of the tip, a multitude of local flaps have been used successfully to reconstruct the defect. We have detailed the most commonly used and reliable techniques, although many others have been reported. Intermediate levels of loss may be treated with phalangization, but as more surgeons become facile with microsurgical procedures, free toe transfer will become the most attractive option. With destruction including the basal joint, pollicization of another digit remains the best method of restoring thumb function. Although the procedure offered to the patient may be governed by these guidelines, a successful reconstruction is one that provides adequate function for the patient with an acceptable loss from the chosen donor site.

For Case Studies, Videos, and more, please visit ExpertConsult.com.

REFERENCES

1. Adani R, et al: The heterodigital reversed flow neurovascular island flap for fingertip injuries. *J Hand Surg [Br]* 24:431–436, 1999.
2. Alnot JY, Monod A: [Bipedicled rectangular palmar sliding flap in distal tissue loss of the fingers]. *Ann Chir Main* 7:151–157, 1988.
3. Atasoy E, et al: Reconstruction of the amputated fingertip with a triangular volar flap: a new surgical procedure. *J Bone Joint Surg Am* 52:921–926, 1970.
4. Bartlett SP, Moses MH, May JW, Jr: Thumb reconstruction by free microvascular transfer of an injured index finger. *Plast Reconstr Surg* 77:660–663, 1986.
5. Biemer E, Stock W: Total thumb reconstruction: a one-stage reconstruction using an osteo-cutaneous forearm flap. *Br J Plast Surg* 36:52–55, 1983.
6. Bralliar F, Horner RL: Sensory cross-finger pedicle graft. *J Bone Joint Surg Am* 51:1264–1268, 1969.
7. Broadbent T, Woolf R: Thumb reconstruction with contiguous skin-bone pedicle graft. *Plast Reconstr Surg* 26:494–499, 1960.
8. Brotherston TM, Banerjee A, Lamberty BG: Digital reconstruction using the distally based osteofasciocutaneous radial forearm flap. *J Hand Surg [Br]* 12:93–95, 1987.
9. Brown PW: Adduction-flexion contracture of the thumb: correction with dorsal rotation flap and release of contracture. *Clin Orthop Relat Res* 88:161–168, 1972.
10. Brunelli F, et al: Arterial anatomy and clinical application of the dorsoulnar flap of the thumb. *J Hand Surg [Am]* 24:803–811, 1999.
11. Buchler U, Phelps DB, Boswick JA: Digital replantation: guidelines for selection and management. *Rocky Mt Med J* 74:17–22, 1977.
12. Buck-Gramcko D: Pollicization of the index finger: method and results in aplasia and hypoplasia of the thumb. *J Bone Joint Surg Am* 53:1605–1617, 1971.
13. Buckley PD, Smith P, 3rd, Dell PC: Thumb amputation: a review of reconstructive alternatives. *Microsurgery* 8:140–145, 1987.
14. Bunnell S: Physiological reconstruction of a thumb after total loss. *Surg Gynecol Obstet* 52:245–248, 1931.
15. Bunnell S: Reconstruction of the thumb. *Am J Surg* 95:168–172, 1958.
16. Butler B, Jr: Ring-finger pollicization, with transplantation of nail bed and matrix on a volar flap. *J Bone Joint Surg Am* 46:1069–1076, 1964.
17. Chacha B, Soin K, Tan KC: One stage reconstruction of intercalated defect of the thumb using the osteocutaneous radial forearm flap. *J Hand Surg [Br]* 12:86–92, 1987.
18. Chase R, et al: In thumb repair, is length most crucial? *Mod Med* 20:75–79, 1973.
19. Chase RA: An alternate to pollicization in subtotal thumb reconstruction. *Plast Reconstr Surg* 44:421–430, 1969.
20. Chen H, Noordhoff S: Coverage of the degloved thumb with twin neurovascular island flaps: a case report. *Br J Plast Surg* 39:255–256, 1986.
21. Cheng MH, et al: Combined ischemic preconditioning and laser Doppler measurement for early division of pedicled groin flap. *J Trauma* 47:89–95, 1999.
22. Chung KC, Wei FC: An outcome study of thumb reconstruction using microvascular toe transfer. *J Hand Surg [Am]* 25:651–658, 2000.
23. Cohen BE, Cronin ED: An innervated cross-finger flap for fingertip reconstruction. *Plast Reconstr Surg* 72:688–697, 1983.
24. Coleman DA, Urbaniak JR: Osteocutaneous flaps for thumb and digit reconstruction in unique situations. *Hand Clin* 1:717–728, 1985.
25. Costa H, Smith R, McGrouther DA: Thumb reconstruction by the posterior interosseous osteocutaneous flap. *Br J Plast Surg* 41:228–233, 1988.

CASE STUDY 48.1

A 36-year-old migrant farm worker had a thumb amputation at the interphalangeal joint (eFigure 48.8).

Question: What procedure would improve hand function with the least amount of "down time"?

Answer: Four-flap "Z"-plasty first web space deepening increases the thumb index span with minimal down time.

Question: Which procedure will provide the best reconstructive option for this patient?

Answer: Toe-to-hand microvascular transfer is the gold standard reconstructive procedure for this injury because it will afford the best cosmesis, sensation, and functionality.

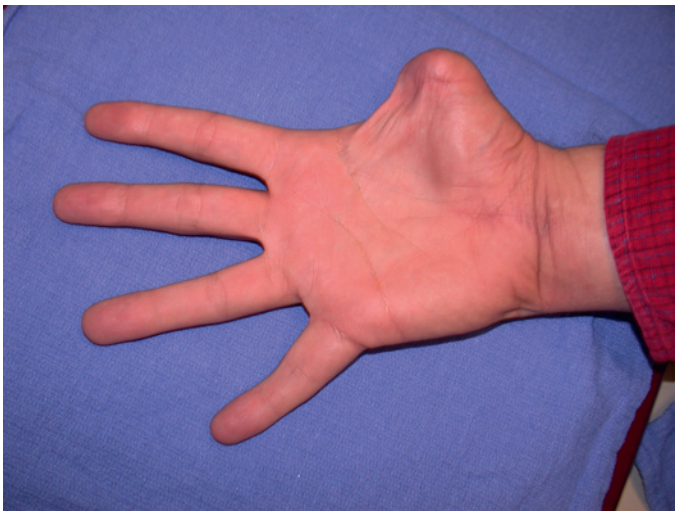

eFIGURE 48.8

CASE STUDY 48.2

A 26-year-old graduate student suffered a bicycle chain injury resulting in a 3.5-cm volar thumb open wound with exposed tendon and distal phalanx (eFigure 48.9).

Question: The patient does not want scars on any other part of his hand. Is the Moberg palmar advancement flap an option for this patient?

Answer: No, the defect is too large to be reconstructed by the palmar advancement flaps. The indications for the Moberg palmar advancement flaps are defects of 1 to 2 cm for the standard flap and 2 to 2.5 cm for the palmar advancement flap with proximal releasing incisions.



eFIGURE 48.9

CASE STUDY 48.3

A 42-year-old carpenter with an amputation his dominant thumb at the metacarpal level presents to your emergency department (eFigure 48.10). The amputated segment is mutilated and not replantable. You discuss reconstructive options with the patient, and he prefers microvascular toe transfer.

Question: What procedure will be helpful prior to toe transfer in this patient?

Answer: This patient has a large soft tissue defect that must be reconstructed prior to toe transfer. The best reconstructive option for this defect is a reversed radial forearm flap; it will bring a robust artery and veins (radial artery and venae comitantes) into the region and greatly simplify the toe transfer.

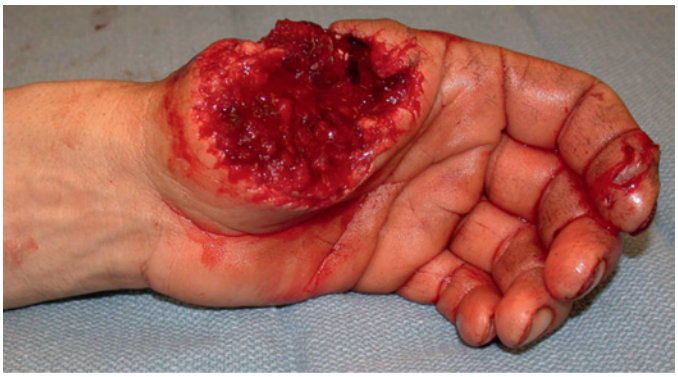

eFIGURE 48.10

CASE STUDY 48.4

A 40-year-old mechanic has suffered a nonreplantable thumb avulsion injury at the level of the proximal phalanx (eFigure 48.11). You discuss reconstructive options, and he is not amenable to sacrificing a toe.

Question: What are some of the options for thumb reconstruction?

Answer: Any of the osteoplastic thumb reconstruction methods can be used as long as they can provide sufficient soft tissue to cover the exposed tissues. Therefore, the Gilles "cocked-hat" flap is not an option. In this instance, a composite reversed radial forearm island flap was used (eFigure 48.12).



eFIGURE 48.11



eFIGURE 48.12

26. Curtis RM: Cross-finger pedicle flap in hand surgery. *Ann Surg* 145:650–655, 1957.
27. Dongyue Y, Yudong G: Thumb reconstruction utilizing second toe transplantation by microvascular anastomosis: report of 78 cases. *Chin Med J (Engl)* 92:295–309, 1979.
28. Dunham T: A method for obtaining a skin flap from the scalp and a permanent buried vascular pedicle for covering defects of the face. *Ann Surg* 17:677–699, 1893.
29. Eaton CJ, Lister GD: Treatment of skin and soft-tissue loss of the thumb. *Hand Clin* 8:71–97, 1992.
30. Elsahy NI: Replantation of a completely amputated distal segment of a thumb: case report. *Plast Reconstr Surg* 59:579–581, 1977.
31. Flatt A: *The care of minor hand injuries*, St Louis, 1963, CV Mosby.
32. Flatt AE, Wood VE: Multiple dorsal rotation flaps from the hand for thumb web contractures. *Plast Reconstr Surg* 45:258–262, 1970.
33. Foucher G: The kite flap. In Tubiana R, editor: *The hand*, Philadelphia, 1985, WB Saunders.
34. Foucher G, Braun JB: A new island flap transfer from the dorsum of the index to the thumb. *Plast Reconstr Surg* 63:344–349, 1979.
35. Foucher G, et al: Single stage thumb reconstruction by a composite forearm island flap. *J Hand Surg [Br]* 9:245–248, 1984.
36. Garcia-Velasco J: Thumb reconstruction using the ring finger. *Br J Plast Surg* 26:406–407, 1973.
37. Gaul JS, Jr: Radial-innervated cross-finger flap from index to provide sensory pulp to injured thumb. *J Bone Joint Surg Am* 51:1257–1263, 1969.
38. Goldner RD, et al: One hundred eleven thumb amputations: replantation vs revision. *Microsurgery* 11:243–250, 1990.
39. Gordon L, et al: Free microvascular transfer of second toe ray and serratus anterior muscle for management of thumb loss at the carpometacarpal joint level. *J Hand Surg [Am]* 9:642–644, 1984.
40. Gosset J: La pollicisation de l'index (technique chirurgicale). *J Chir* 65:403, 1949.
41. Gosset J: Reconstruction of the amputated thumb. In Reid D, Gosset J, editors: *Mutilating injuries of the hand*, New York, 1979, Churchill Livingstone.
42. Greeley P: Reconstruction of the thumb. *Ann Surg* 124:60–70, 1946.
43. Gurdin M, Pangman WJ: The repair of surface defects of fingers by trans-digital flaps [1946]. *Plast Reconstr Surg* 5:368–371, 1950.
44. Hamilton RB, et al: Survival factors in replantation and revascularization of the amputated thumb: 10 years' experience. *Scand J Plast Reconstr Surg* 18:163–173, 1984.
45. Harkins PD, Rafety JE: Digital transposition in the injured hand. *J Bone Joint Surg Am* 54:1064–1069, 1972.
46. Harrison S: Restoration of muscle balance in pollicization. *Plast Reconstr Surg* 34:236–246, 1964.
47. Harrison S: Pollicization in children. *Hand* 3:204, 1971.
48. Hastings H, 2nd: Dual innervated index to thumb cross finger or island flap reconstruction. *Microsurgery* 8:168–172, 1987.
49. Hentz VR: Conventional techniques for thumb reconstruction. *Clin Orthop Relat Res* 195:129–143, 1985.
50. Hirasawa Y, Katsumi Y, Tokioka T: Evaluation of sensibility after sensory reconstruction of the thumb. *J Bone Joint Surg Br* 67:814–819, 1985.
51. Holevich J: A new method of restoring sensibility to the thumb. *J Bone Joint Surg Br* 45:496–502, 1963.
52. Hueston J: Local flap repair of fingertip injuries. *Plast Reconstr Surg* 37:349–350, 1966.
53. Huguier P: Replacement du pouce par son metacarpien, par l'angrandissement du premier espace interosseoux. *Arch Gen Med* 1:78, 1874.
54. Iselin F: The flag flap. *Plast Reconstr Surg* 52:374–377, 1973.
55. Jeffs JV, Kemble JV: The cone flap for resurfacing reconstructing partial digits. *Br J Plast Surg* 26:163–166, 1973.
56. Joshi BB: One-stage repair for distal amputation of the thumb. *Plast Reconstr Surg* 45:613–615, 1970.
57. Kaplan I, Plaschkes J: One-stage pollicisation of little finger. *Br J Plast Surg* 13:272–276, 1960.
58. Kartchinov KD: Reconstruction and sensitization of the amputated thumb. *J Hand Surg [Am]* 9:478–484, 1984.
59. Keim HA, Grantham SA: Volar-flap advancement for thumb and finger-tip injuries. *Clin Orthop Relat Res* 66:109–112, 1969.
60. Kelleher JC, Sullivan JG: Thumb reconstruction by fifth digit transposition. *Plast Reconstr Surg Transplant Bull* 21:470–478, 1958.
61. Kleinert HE, et al: Digital replantation: selection, technique, and results. *Orthop Clin North Am* 8:309–318, 1977.
62. Kleinman W, Strickland J: Thumb reconstruction. In Green D, Hotchkiss R, Pederson W, editors: *Green's operative hand surgery*, ed 4, New York, 1999, Churchill Livingstone.
63. Kleinman WB: Management of thumb hypoplasia. *Hand Clin* 6:617–641, 1990.
64. Koman LA, Poehling GG, Price JL, Jr: Thumb reconstruction: an algorithm. *Orthopedics* 9:873–878, 1986.
65. Komatsu S, Tamai S: Successful replantation of a completely cut-off thumb. *Plast Reconstr Surg* 42:374–377, 1968.
66. Kutler W: A new method for fingertip amputation. *JAMA* 133:29–30, 1947.
67. Lister G: The choice of procedure following thumb amputation. *Clin Orthop Relat Res* 195:45–51, 1985.
68. Lister G: Reconstruction of the hypoplastic thumb. *Clin Orthop Relat Res* 195:52–65, 1985.
69. Littler J: Subtotal reconstruction of the thumb [1946]. *Plast Reconstr Surg* 10:215–226, 1952.
70. Littler J: The neurovascular pedicle method of digital transposition for reconstruction of the thumb [1946]. *Plast Reconstr Surg* 12:303–319, 1953.
71. Littler J: The prevention and correction of adduction contracture of the thumb. *Clin Orthop Relat Res* 13:182–192, 1959.
72. Littler J: *Neurovascular skin island transfers in reconstructive hand surgery*, Edinburgh, 1960, E&S Livingstone.
73. Littler J: On making a thumb: one hundred years of surgical effort. *J Hand Surg [Am]* 1:35–51, 1976.
74. Littler J: Reconstruction of the thumb in traumatic loss. In Coverse J, editor: *Reconstructive plastic surgery*, Philadelphia, 1977, WB Saunders.
75. Luksch I: Uber eine nene Methode zum Ersatz des verlorenen Daumens. *Verh Dtsch Gest Chir* 32:221, 1903.
76. Manktelow RT, McKee NH: Digital replantation: a functional assessment. *Can J Surg* 22:47–53, 1979.
77. Matev IB: Thumb reconstruction through metacarpal bone lengthening. *J Hand Surg [Am]* 5:482–487, 1980.
78. Matti BA, Quaba A, Page RE: Partial thumb reconstruction using the proximal skin paddle radial artery island flap. *J Hand Surg [Br]* 11:35–39, 1986.
79. May JW, Jr, Bartlett SP: Great toe-to-hand free tissue transfer for thumb reconstruction. *Hand Clin* 1:271–284, 1985.
80. May JW, Jr, Smith RJ, Peimer CA: Toe-to-hand free tissue transfer for thumb construction with multiple digit aplasia. *Plast Reconstr Surg* 67:205–213, 1981.
81. May JW, Jr, et al: Thumb reconstruction in the burned hand by advancement pollicization of the second ray remnant. *J Hand Surg [Am]* 9:484–489, 1984.
82. McFarlane R: The treatment of major skin loss in the thumb. In Stack H, Bolton H, editors: *The second hand club*, London, 1975, British Society for Surgery of the Hand.
83. McGrath MH, Adelberg D, Finseth F: The intravenous fluorescein test: use in timing of groin flap division. *J Hand Surg [Am]* 4:19–22, 1979.
84. Metcalf W: Salvage of the injured distal phalanx: plan of care and analysis of 369 cases. *Clin Orthop Relat Res* 13:114–123, 1959.
85. Michon J, et al: Functional comparison between pollicization and toe-to-hand transfer for thumb reconstruction. *J Reconstr Microsurg* 1:103–112, 1984.
86. Millender LH, Albin RE, Nalebuff EA: Delayed volar advancement flap for thumb tip injuries. *Plast Reconstr Surg* 52:635–639, 1973.
87. Minkow FV, Stein F: Phalangization of the thumb. *J Trauma* 13:648–655, 1973.
88. Miura T: Thumb reconstruction using radial-innervated cross-finger pedicle graft. *J Bone Joint Surg Am* 55:563–569, 1973.
89. Moberg E: Discussion of paper by Brooks D: Nerve grafting in orthopaedic surgery. *J Bone Joint Surg Am* 37:305, 1955.
90. Moberg E: The place of nerve-grafting in orthopedic surgery. *J Bone Joint Surg Am* 37:305, 1955.
91. Moberg E: Aspects of sensation in reconstructive surgery of the upper extremity. *J Bone Joint Surg Am* 46:817–825, 1964.
92. Morgan LR, Stein F: Method for a rapid and good thumb reconstruction. *Plast Reconstr Surg* 50:131–133, 1972.
93. Murray JF, Ord JV, Gavelin GE: The neurovascular island pedicle flap: an assessment of late results in sixteen cases. *J Bone Joint Surg Am* 49:1285–1297, 1967.
94. Mutz S: Thumb web contracture. *Hand* 4:236–246, 1972.
95. Napier J: *Hands*, Princeton, NJ, 1993, Princeton University Press.
96. Nicoladoni C: Daumenplastik. *Wien Klin Wochenschr* 10:663–670, 1897.
97. Nicoladoni C: Daumenplastik fund organischer Ersatz der Fingerspitze Anticheiroplastik und Daktyloplastik. *Arch Klin Chir* 61:606–614, 1900.
98. O'Brien B, Brennen M, MacLeod A: Microvascular free toe transfer. *Clin Plast Surg* 5:223–237, 1978.
99. O'Brien BM, et al: Hallux-to-hand transfer. *Hand* 7:128–133, 1975.
100. O'Brien BM, et al: Microvascular great toe transfer for congenital absence of the thumb. *Hand* 10:113–124, 1978.
101. Orticochea M: Reconstruction of the thumb using two flaps from the same hand. *Br J Plast Surg* 24:345–350, 1971.
102. Paneva-Holevich E, Holevich Y: Further experience with the bipedicled neurovascular island flap in thumb reconstruction. *J Hand Surg [Am]* 16:594–597, 1991.
103. Peacock E: Reconstruction of the thumb. In Flynn JE, editor: *Hand surgery*, Baltimore, 1966, Williams & Wilkins.
104. Pho RW: Local composite neurovascular island flap for skin cover in pulp loss of the thumb. *J Hand Surg [Am]* 4:11–15, 1979.

105. Posner MA, Smith RJ: The advancement pedicle flap for thumb injuries. *J Bone Joint Surg Am* 53:1618–1621, 1971.
106. Pringle RG: Amputations of the thumb: a study of techniques of repair and residual disability. *Injury* 3:211–217, 1972.
107. Ratcliffe RJ, McGrouther DA: Free toe pulp transfer in thumb reconstruction: experience in the West of Scotland Regional Plastic Surgery Unit. *J Hand Surg [Br]* 16:165–168, 1991.
108. Ratliff AH: Amputations of the distal part of the thumb. *Hand* 4:190–193, 1972.
109. Reid D: Pollicization: an appraisal. *Hand* 1:27–31, 1969.
110. Rybka FJ, Pratt FE: Thumb reconstruction with a sensory flap from the dorsum of the index finger. *Plast Reconstr Surg* 64:141–144, 1979.
111. Scheker LR, Lister GD, Wolff TW: The lateral arm free flap in releasing severe contracture of the first web space. *J Hand Surg [Br]* 13:146–150, 1988.
112. Serafin D, Kutz JE, Kleinert HE: Replantation of a completely amputated distal thumb without venous anastomosis: case report. *Plast Reconstr Surg* 52:579–582, 1973.
113. Simonetta C: Reconstruction of the thumb by tube pedicle, bone graft, and island flap. In Reid D, Gosset J, editors: *Mutilating injuries of the hand*, New York, 1979, Churchill Livingstone.
114. Small JO, Brennen MD: The first dorsal metacarpal artery neurovascular island flap. *J Hand Surg [Br]* 13:136–145, 1988.
115. Smith RC, Furnas DW: The hand sandwich: adjacent flaps from opposing body surfaces. *Plast Reconstr Surg* 57:351–354, 1976.
116. Spinner M: Fashioned transpositional flap for soft tissue adduction contracture of the thumb. *Plast Reconstr Surg* 44:345–348, 1969.
117. Stefani AE, Kelly AP, Jr: Reconstruction of the thumb: a one-stage procedure. *Br J Plast Surg* 15:289–292, 1962.
118. Stern PJ: Free neurovascular cutaneous toe pulp transfer for thumb reconstruction. *Microsurgery* 8:158–161, 1987.
119. Storvik HM: The extended neurovascular island flap in thumb reconstruction. *Scand J Plast Reconstr Surg* 7:147–149, 1973.
120. Strauch B: Dorsal thumb flap for release of adduction contracture of the first web space. *Bull Hosp Joint Dis* 36:34–39, 1975.
121. Strickland J: Restoration of thumb function following partial or total amputation. In Schneider L, Mackin E, Bell J, editors: *Rehabilitation of the hand*, St Louis, 1978, CV Mosby.
122. Strickland J: Reconstruction of the contracted first web space. In Strickland J, Steichen J, editors: *Difficult problems in hand surgery*, St Louis, 1982, CV Mosby.
123. Strickland J: Restoration of thumb function following partial or total amputation. In Hunter J, et al, editors: *Rehabilitation of the hand*, St Louis, 1984, CV Mosby.
124. Tajima T: Treatment of open crushing type of industrial injuries of the hand and forearm: degloving, open circumferential, heat-press, and nail-bed injuries. *J Trauma* 14:995–1011, 1974.
125. Tamai S: Digit replantation: analysis of 163 replantations in an 11 year period. *Clin Plast Surg* 5:195–209, 1978.
126. Tanzer RC, Littler JW: Reconstruction of the thumb by transposition of an adjacent digit [1946]. *Plast Reconstr Surg* 3:533–547, 1948.
127. Thomas BP, Tsai TM: Primary reconstruction of a degloved hand using multiple toe transfers on a single pedicle and a reversed radial artery flap. *J Reconstr Microsurg* 20:3–6, 2004.
128. Thompson J: Reconstruction of the insensate thumb by neurovascular island transfer. *Hand Clin* 8:99–105, 1992.
129. Tubiana R: Phalangization of the metacarpals. In Reid D, Gosset J, editors: *Mutilating injuries of the hand*, New York, 1979, Churchill Livingstone.
130. Tubiana R, Duparc J: Restoration of sensibility in the hand by neurovascular skin island transfer. *J Bone Joint Surg Br* 43:474–480, 1961.
131. Walker MA, Hurley CB, May JW, Jr: Radial nerve cross-finger flap differential nerve contribution in thumb reconstruction. *J Hand Surg [Am]* 11:881–887, 1986.
132. Wei FC, et al: Reconstruction of the thumb with a trimmed-toe transfer technique. *Plast Reconstr Surg* 82:506–515, 1988.
133. Wei FC, et al: Combined second and third toe transfer. *Plast Reconstr Surg* 84:651–661, 1989.
134. Wei JN, Wang SH, Li YN: Reconstruction of the thumb. *Clin Orthop Relat Res* 215:24–31, 1987.
135. Wendt JR: Transplantation of an osteoarthrotendinous allograft with autogenous soft-tissue coverage for thumb reconstruction. *Plast Reconstr Surg* 88:713–717, 1991.

49

Digital Amputations

Sanjeev Kakar

Acknowledgment: I would like to acknowledge the contributions of Dean S. Louis, Mark Bagg, Brian T. Carlsen, and, in particular, Peter J. L. Jebson.

These videos may be found at *ExpertConsult.com:*

49.1 Flexor digitorum superficialis tenodesis for proximal phalangeal amputation. View at 4 weeks following revision amputation through the proximal phalanges of the index, long, and ring fingers. To increase metacarpophalangeal flexion, the flexor digitorum superficialis tendon was tenodesed to the proximal phalanx.

The most common cause of an amputated finger or thumb is accidental traumatic injury. In other cases, digital amputation may be necessary because of congenital deformity or acquired pathologic conditions (e.g., malignant tumors or chronic infection). Other indications may arise as sequelae of trauma, such as stiffness or debilitating pain, or revision surgery may be needed to improve the fit of a prosthesis. Amputations may occasionally be self-inflicted because of a psychological disturbance or in an attempt to defraud an insurance company.[20] Return of function is the primary consideration after an amputation; for this reason, the surgeon should be aware of the patient's occupation and vocations. The surgeon should express empathy and gauge the patient's emotional response following the amputation. Failure to appreciate the patient's attitude and ability to adjust to the injury may compromise an otherwise successful operative procedure.

As surgeons, we tend to be much influenced by the experience of mentors early in our careers, and later, our own expanding experience is helpful. We hold fast to methods that prove satisfactory in our hands and quickly seek alternatives to procedures that yield unsatisfactory outcomes. The numerous articles referenced in this chapter attest to the reasoned contributions of many authors who treat seemingly similar amputation situations by widely disparate methods. For some surgeons, the more technically demanding procedures have great appeal. Others prefer the simplest yet most effective procedure, such as shortening of bone followed by primary closure, or healing by secondary intention. There is clearly no gold standard technique for every clinical scenario.

The *goals* of amputation surgery in the upper extremity should be (1) preservation of functional length, (2) provision of durable skin coverage, (3) preservation of useful sensibility, (4) avoidance of symptomatic neuromas, (5) prevention of adjacent joint contractures, (6) prevention of morbidity, so that the patient has the fewest complications possible, (7) allowance of early prosthetic fitting when applicable, and (8) allowance of early return to work, play, and activities of daily living.

Any amputation in a child, whose ultimate role in life is yet undefined, should be approached with a conservative attitude. Late reconstruction is generally preferable to any early radical ablative procedure. Adults with well-defined functional roles may be better served by a more definitive approach that will accelerate their functional rehabilitation.

At times, deciding whether to perform limb salvage or amputation may be difficult. Consultation with an experienced and knowledgeable colleague is helpful and should always be documented in the patient's medical record. It will reassure the patient and family and will be helpful should medicolegal matters ensue. Photographs of the injured extremity before amputation are useful to document the severity of the injury. Although replantation or attempted salvage of a severely traumatized limb is an option at times, it may be more of a technical triumph than a procedure done in the patient's best interests. The enthusiasm for the successful technical accomplishment of replanting an amputated finger part versus closure and early rehabilitation has been dampened by poor patient outcomes at a greater financial cost, including lost wages and the cost of hospitalization and therapy. Cold intolerance can be a substantial problem for patients following an amputation, but the symptoms tend to improve over time.[28]

CRITICAL POINTS *Principles of Amputation Surgery*

- Maintain length
- Restore sensation
- Provide stable soft tissue coverage
- Prevent symptomatic neuromas
- Prevent adjacent joint contractures
- Allow early prosthetic fitting when applicable
- Allow early return to activities of daily living

DIGITAL TIP AMPUTATIONS

An amputation of the fingertip is the most common type of amputation seen in the upper extremity and at the same time provokes the greatest controversy because of the multitude of treatment options. Multiple techniques have been developed to advance local skin or transfer soft tissue to ensure coverage of an area where bone is exposed. The surgeon, in consultation with each patient, must choose the type of coverage that appears to be most appropriate for that individual's needs and within the technical abilities of the surgeon. Regardless of choice of treatment, the goals of preserving functional length and restoring adequate sensibility remain constant. When one is comparing the various treatment options available or looking for guidance, the injury zone classification systems of Hirase,[69] Allen,[3] and Tamai[139] provide a useful frame of reference (Figure 49.1).

Digital Tip Amputations With Skin or Pulp Loss Only

When the digital tip is amputated, the geometry of the defect dictates the various treatment possibilities. The loss may be transverse or oblique, with more volar skin loss than dorsal skin loss, or the reverse may be true. Some slicing amputations may result in skin loss primarily from the ulnar or radial side of the digit and may spare the distal tip.

Nonmicrosurgical Reattachment or Composite Graft

If the amputated part is available and not highly contaminated, it may be cleansed and reattached as a "biologic cover." This is an effective approach in children with injuries distal to the distal interphalangeal (DIP) joint in which the tip is defatted and repaired to the stump without microsurgery. If there is bony involvement, stability may be afforded by repair of the amputated tip with absorbable sutures, Kirschner wires, or an 18-gauge needle. The nail plate is removed and the nail plate repaired.[92] Timing of repair is crucial. Moiemen and Elliot noted that those repaired within 5 hours after injury had a 61% survival rate compared with none after this time point.[109] The tip may become necrotic but should be left in situ as long as there is no developing infection because the tissue acts as a biologic dressing. Similar success has not been noted within adults.[93] Heistein and Cook[67a] reported on 53 patients who underwent composite tissue grafting of injuries distal to the DIP joint. The success rate was 43% for injuries between the DIP joint and the eponychium and 58% for injuries distal to the eponychium. Factors linked to suboptimal results were smoking, age older than 18 years, alcohol use, presence of diabetes, and crush injury. In an effort to improve survival, Chen and colleagues[31a] reported on a technique whereby the distal amputated tip was defatted and deepithelialized and the bone excised in patients who sustained either a crush or sharp transection injury. The survival rate was higher than 93% with an average two-point discrimination of 6.3 mm after 6 months. Over 90% of patients were happy with the cosmetic appearance and 86% were able to use the finger normally at work.

Dressing Changes and Healing by Secondary Intention

Healing by secondary intention with dressing changes is one of the best options for a tip amputation without exposed bone. This technique is especially applicable when the amputated part is unavailable or cannot be used. This technique is simple, inexpensive, and effective, regardless of patient age (Figure 49.2).[3,21,38,41,45,71,74,95] Healing by secondary intention is most

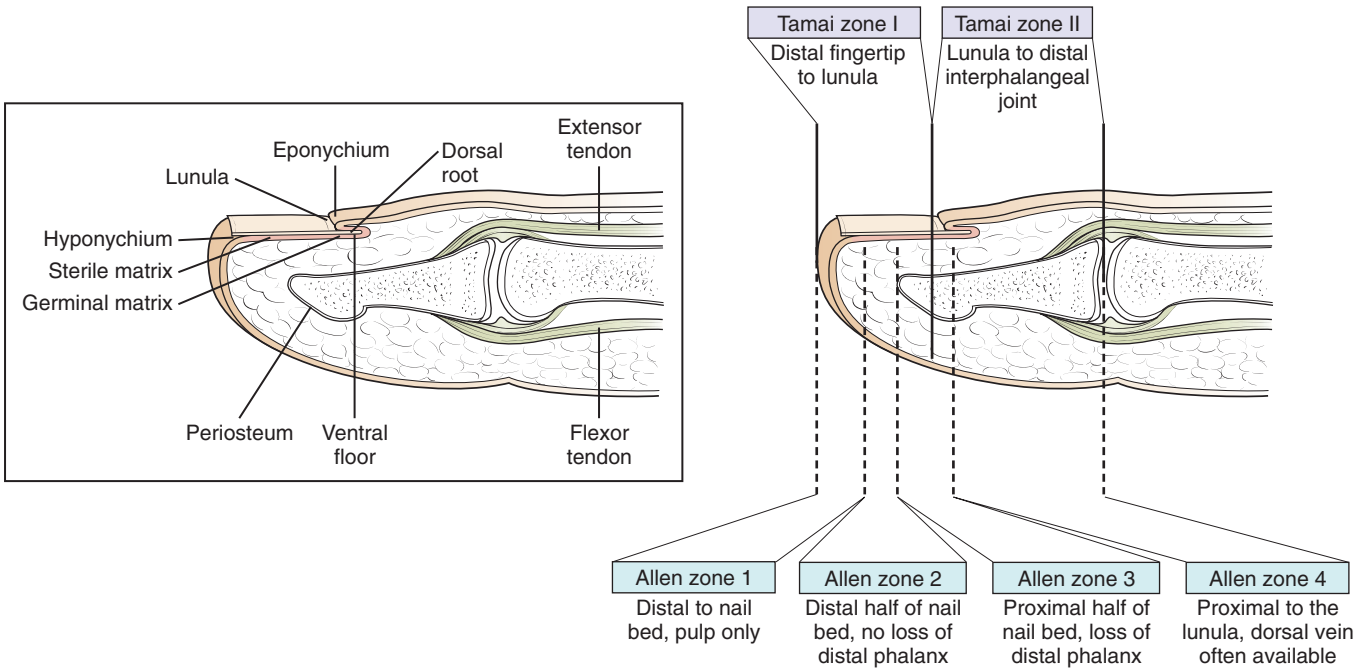

FIGURE 49.1 Illustration demonstrating the anatomy of the distal finger and nail bed and the Tamai and Allen classifications for distal amputations of the fingertip. The *line* through the lunula represents the divisions between Tamai zones I and II. (Redrawn from Figure 1, page 757, Lee DH, Mignemi ME, Crosby SN: Fingertip injuries: an update on management. *J Am Acad Orthop Surg* 21(12):756–766, 2013. (Obtaining perm from: JAAOS)



FIGURE 49.2 Seventy-four-year-old woman who sustained a degloving injury to the thumb tip that was treated with MIST treatment and dressing changes. Note the excellent aesthetic result. **A-C,** Degloving injury to thumb. Note the loss of palmar tissue. **D-E,** Aesthetic result of the thumb after nonoperative treatment.

applicable for wounds with skin loss of 1.5 cm or less; healing will occur by reepithelialization over 3 to 4 weeks with return of normal sensation and two-point discrimination. Indeed, recovery of sensation tends to be better than with other forms of surgical reconstruction. Dressing changes can also be used to treat wounds where there is additional loss of subcutaneous tissue of similar size, but it may take 1 to 2 months to heal by secondary intention. The patient performs daily dressing changes and local wound care. Protective splinting may be used to protect the healing wound. Patients can be referred to hand therapists within the first few days after injury to use modalities such as MIST ultrasound therapy (Celleration, Inc., Eden Prairie, MN) to encourage granulation tissue formation. Ultrasound works by reducing the bacterial load and promoting tissue regeneration by increasing angiogenesis, release of growth factors, and collagen deposition.[81] Patients are encouraged to work on the range of motion to avoid joint stiffness and/or contractures.

Bojsen-Moller and colleagues reviewed a series of 134 digital tip injuries in 110 patients who were treated by dressing changes, shortening of the digit, or skin grafting.[19] They observed that nonoperative treatment was almost always uncomplicated, whereas in some of the surgical cases, there were complications such as infection or graft failure that actually prolonged treatment. In addition, there was no significant difference in time off work between the treatment groups. The authors concluded that management of an amputation by shortening and primary closure was inferior to skin grafting or dressing changes. Allen[3] reported on 46 patients with 49 fingertip injuries from the lunula and distal phalanx. If the distal phalanx was exposed it was trimmed back to allow soft tissue to cover it. Forty-five patients thought their results were very good or good, 3 thought they were acceptable, and 1 deemed the result as poor. Four of the 49 injuries required secondary surgery, 3 for nail growth problems and 1 because of lack of soft tissue coverage. The average two-point discrimination was 6 mm, and the average time off work ranged from 18 to 26 days. None of the patients had any joint stiffness, although 50% did experience cold intolerance, which was marked in 10%. Weichman and colleagues[149] compared the outcomes of patients with fingertip injuries treated nonoperatively with those treated operatively (nail removal, revision amputation, or grafting with full-thickness grafts or local flaps, such as the "V-Y" advancement, cross-finger, thenar, or first dorsal metacarpal flap). Those who had surgery had larger wounds (3.3 cm versus 1.75 cm), volar oblique lacerations (50% versus 9%), exposed bone (81% versus 35%), and a distal phalanx fracture (81% versus 47%). The authors found that patients requiring operative treatments had

more time off work (4.3 weeks compared with 2.9 weeks), which is likely related to the extent of injury.

Primary Closure

Primary closure may be performed if the repair is without tension at the wound edges. Often this can be difficult because there tends to be a lack of sufficient mobile dermis for a tension-free primary repair. Primary closure, when possible, was shown in the series by Holm and Zachariae to give results equivalent to conservative healing by secondary intention.[71] However, in the series reported by Sturman and Duran,[136] 51% of the patients complained of tenderness and had some disability. Shortening of the bone may allow primary closure; however, the surgeon needs to perform traction neurectomies to prevent a symptomatic neuroma. A nail bed ablation is performed if the injury is at or through the lunula. The entire germinal and sterile matrix is excised, which requires scraping the dorsal cortex of the distal phalanx with a curette and excising the tissue on the undersurface of the proximal nail fold and in the paronychial folds. The patient needs to be informed of the potential risk of a neuroma and a nail horn at the time of closure because these entities can become symptomatic several months after the procedure.

Split-Thickness Grafting

Split-thickness skin grafting has been a popular method for coverage of the exposed pulp when there is a well-vascularized recipient bed.[59,111] Split-thickness grafts contract more than full-thickness grafts and are limited by the fact they cannot be placed directly onto bone or tendon devoid of its paratenon.[92] In a study by Holm and Zachariae, only 56% of the patients who had undergone skin grafting considered their results to be good after 5 years of follow-up, compared with 90% of patients treated conservatively with a wound that was permitted to heal by secondary intention.[71] The most important complaints after skin grafting were induration and fissuring of the skin and reduced sensibility in the area of the graft, as well as complaints about the donor site. Cold sensitivity was present in 39% of the patients treated conservatively and in 33% of those who received a split-thickness skin graft. Hypoesthesia was present in 26% of those treated conservatively and in 67% of those who were treated with a skin graft. The authors concluded that split-thickness skin grafting offered no advantages for fingertip coverage.

Sturman and Duran monitored 235 patients with a fingertip amputation for a minimum of 1 year and reported their late outcomes.[136] Of the patients who had split-thickness skin grafts, 70% reported tenderness in the area of the graft, and in 41%, the tenderness was considered to be marked. Cold sensitivity was present in 49% of the patients who had split-thickness skin grafts, including 27 of the 53 who had thumb or index tip amputations. Fifty-nine percent of the latter group avoided the injured digit when the pickup test was administered. Thirty-two percent of them noted diminished touch sensibility. The average two-point discrimination measured was 5 mm, considerably greater than the normal 2 mm.

Digital Tip Amputations With Exposed Bone

When bone is exposed, the question becomes whether length should be preserved (necessitating coverage of the site) or whether sacrifice of length is justifiable. An important variable is the extent of nail matrix injury. The development of a hooked nail is avoided by careful attention to wound closure and avoidance of the loss of bony support for the nail bed. Closure of a fingertip amputation by pulling the nail bed over the distal phalanx should be avoided. If a satisfactory amount of distal phalanx is absent, the nail bed must be trimmed back to the same level at the end of the bone so that it does not curve over the end of the bone and subsequently lead to the development of a hooked nail. A nail bed ablation is performed if the injury is at or through the lunula. Given that the primary aim is to restore function to the injured individual, some wounds with minimal exposed bone may be converted to wounds with no bone exposed by rongeuring followed by closure. My preference for closure is to use absorbable 3-0 suture to avoid the need for suture removal because often sutures may be covered with thick eschar and painful to remove. Alternatively, the wound may be left to heal by secondary intention, ensuring that the nail bed is supported by underlying bone. Antibiotics are not routinely prescribed if there has been adequate wound débridement without gross contamination. Patients are seen after 1 to 2 weeks and are sent to occupational therapy to work on edema control and range of motion. Tip desensitization is started once the wound is healed and stable. Many of these injuries are work related, and most manual workers are able to return to duty without restrictions by 6 to 8 weeks after injury.

If there is no possibility of direct closure of the wound, bony coverage may be accomplished by one of several described techniques, each with its own merits and limitations.

Semiocclusive Dressings

Studies have demonstrated successful treatment with the use of an occlusive dressing.[43,70] The dressing should be applied within a few days of the injury. Self-adhesive OpSite or Flexifix film (Smith and Nephew, London, UK) is used. The dressing is changed weekly until epithelialization has been completed. Hoigne and associates reported on a series of 17 patients with an exposed distal phalanx; patient satisfaction was good with regeneration of approximately 90% of the original soft tissue volume with an average two-point discrimination of 4 mm.[70] The average duration of dressing use was 6.5 weeks. There were no cases of bone regeneration or infection. Complications included a single case of a nail horn and posttraumatic neuroma.

Bilayer Matrix Wound Dressing

The Integra Bilayer Matrix Wound Dressing (BMWD) (Integra Life Sciences, Plainsboro, NJ) is an acceptable alternative to flap coverage. The graft consists of an acellular dermal matrix composed of bovine collagen covered by a silicone layer. It is designed to act as a skin regeneration scaffold that allows the host's cells to grow into the dermal template. They can be placed directly onto bone or tendon once the wound bed is clean and devoid of contamination. It can be sutured in place and its "take" encouraged with bolster or negative pressure dressings. The graft is normally applied as part of a two-stage procedure in which autologous skin graft is applied 3 to 4 weeks after matrix application. Taras and coworkers used two-stage grafting in digital injuries with exposed bone, joint, tendon, or hardware in 21 digits.[142] The area of Integra application ranged from 1 to 12 cm^2. Twenty of 21 digits demonstrated complete



FIGURE 49.3 Treatment of a patient with a ring avulsion injury with Integra and skin grafting. **A,** Ring avulsion injury, palmar view. **B,** Ring avulsion injury, dorsal view. **C,** Application of Integra. **D,** Granulating wound after Integra placement. **E,** Granulating bed for skin graft. Palmar **(F)** and dorsal **(G)** appearance of small finger.

incorporation of the dermal matrix, and following skin grafting, 16 of 20 digits demonstrated complete incorporation. Single-stage use avoids the morbidity of skin grafting and is the same as healing by secondary intention because the healing process relies on both wound contraction and reepithelialization. In a series of nine patients with an average defect of 2.3 cm^2 (range, 1 to 3.2 cm^2), Jacoby and colleagues[75a] demonstrated high patient satisfaction, with a mean static two-point discrimination of 9.6 mm (4.6 mm for the opposite unaffected finger). One patient developed an early infection, followed by a hook nail deformity 18 months after treatment. There were no other complications. The Integra BMWD is more expensive than a semiocclusive dressing or healing by secondary intention. However, the graft may be placed directly on bone, preserving critical length and obviating the need for flap coverage with the associated inconvenience and morbidity (Figure 49.3).

Atasoy-Kleinert Volar "V-Y" Flap

In 1970, Atasoy and associates described a triangular volar "V-Y" advancement flap (Figure 49.4) for reconstruction of the distal pad with preservation of length when bone is exposed.[6] It is indicated for dorsal oblique or transverse distal fingertip amputations beyond the midpart of the nail. The flap is contraindicated in injuries in which there is an oblique amputation with more palmar skin loss than dorsal skin loss and in situations in which there is extensive skin loss as a result of the injury.

Digital anesthesia is administered before preparation of the wound. After surgical preparation of the hand, a Tourni-Cot

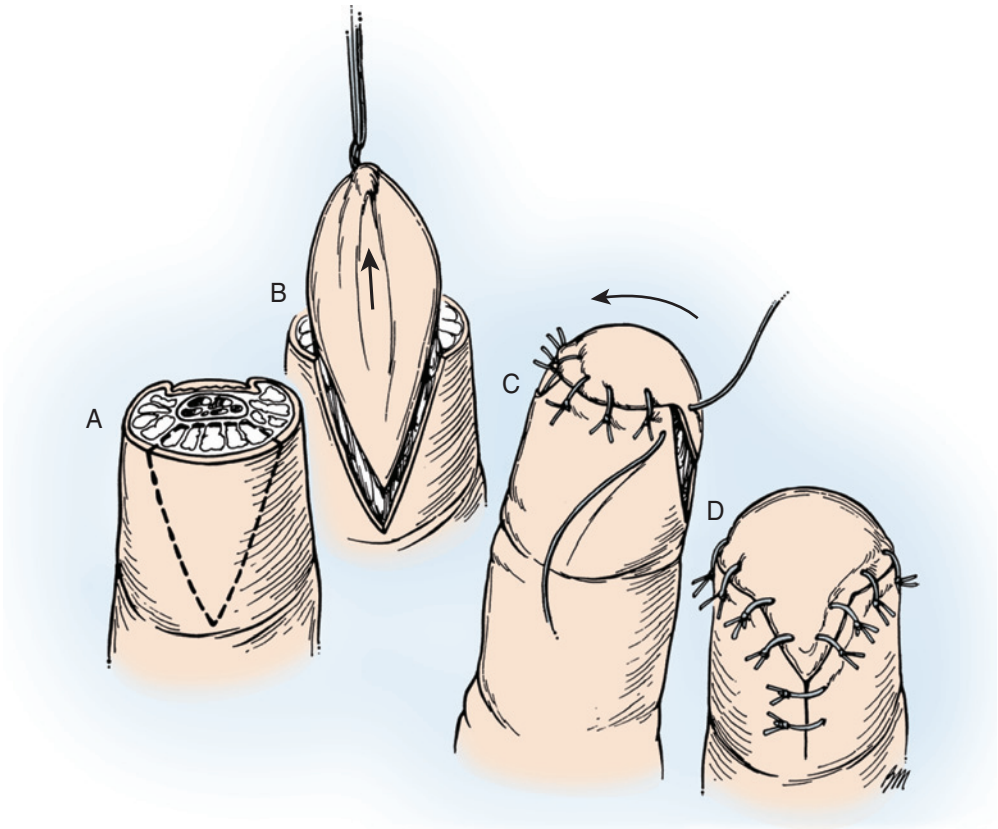

FIGURE 49.4 The Atasoy-Kleinert volar "V-Y" technique is applicable to distal tip injuries with bone exposed and when the distal injury is either transverse or oblique and sloping in a dorsal proximal–to–volar distal direction. In injuries with more volar pad loss, there is usually insufficient skin for this technique to be used. **A,** Marking of the flap. Note that the apex is at the DIPJ crease. **B,** Raising and advancement of the skin flap distally. **C,** Closure of the flap from distal to proximal. Take care to ensure the flap is not overly tight. **D,** Closure of V-Y. (Copyright Elizabeth Martin.)

(Mar-Med, Grand Rapids, MI) is used to exsanguinate the digit and simultaneously provide tourniquet ischemia. Alternatively, the finger is elevated and a Penrose drain tied at the base of the digit. A pattern may be made to cover the dimensions of the defect and then transposed proximally to the cut edge of the skin that is to be advanced. The base of the triangle will be the distal cut edge, and an appropriate triangle of skin is made according to the pattern, with the apex of the triangle being at the DIP flexion crease. The two sides of the triangle should be at least 1.5 times the length of the desired advancement. Only the full thickness of the skin is cut. The digital nerves and blood vessels of the flap are preserved. Its blood supply is from the small arterial branches of the digital arteries distal to the trifurcation of the digital nerves. Separation between the flexor sheath and subcutaneous tissue is performed by dividing the fibrous septae that anchor the subcutaneous tissue to the bone, which facilitates advancement of the flap distally. The skin of the flap must be connected to the subcutaneous tissue to maintain its viability. The base of the triangle is carefully contoured and sutured to the nail bed or remaining nail, and the resulting "V" incision on the palmar aspect of the digit is closed, thus converting it to a "Y" (see Figure 49.4). The Tourni-Cot or Penrose drain is removed prior to flap insetting to ensure its viability. The flap can be adequately mobilized up to 1 cm and if necessary defatted to facilitate tension-free skin closure. Postoperative management consists of sterile dressings over the surgical sites that allow early motion of all adjacent joints. Active motion and digital usage are advanced as healing ensues over the next few weeks.

In their initial report, Atasoy and associates stated that 56 of 61 patients available for follow-up had normal sensation and motion.[6] However, a follow-up study conducted by Frandsen found hypoesthesia or dysesthesia in 7 of 10 patients with triangular volar flaps.[51] Four of the 10 patients had subjective complaints of cold intolerance, and 5 of the patients also had difficulty grasping objects. Conolly and Goulston had unsatisfying results in 4 of 7 patients treated by this technique.[38] The results were deemed unsatisfactory because of persistent paresthesias or impaired sensibility. Tupper and Miller reported diminished sensibility in all 16 of their patients.[144] Eight of their patients reported hypersensitivity, particularly cold intolerance.

Kutler Lateral "V-Y" Flaps

Kutler described the use of "V-Y" advancement flaps for digital tip injuries (Figure 49.5).[87] The technique involves advancing two triangular flaps from lateral positions to cover the tip of the digit.

Preparation of the digit is similar to that used in the Atasoy technique. The tip of the digit is débrided as necessary. Two triangular flaps are developed from the midlateral aspect of each side of the digit, and the incisions are made just down through the dermis. The subcutaneous tissue is similarly mobilized from the phalanx on a deep plane by dividing the fibrous

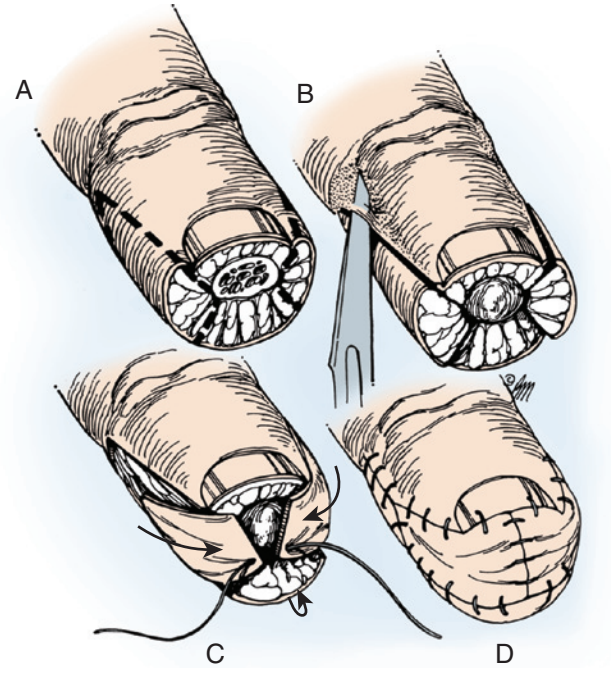

FIGURE 49.5 **A,** Triangular flaps are marked, centered over the midlateral aspect of the finger. **B,** The skin is incised and fibrous septa divided, allowing mobilization of the flaps distally. **C,** Distal advancement of the flaps. **D,** The wounds are closed from distal to proximal.

septae. Both triangles are advanced to the midline distally and sutured together. The "V" apex of the triangle is closed in a "Y" fashion, and the surrounding edges and nail bed, or nail, are carefully sutured to the distal edges of the advanced flaps (see Figure 49.5). This flap can only be advanced up to 3 to 4 mm. Haddad reported on a series of 20 patients treated with this technique and stated that slight skin necrosis occurred at the edges if the flaps were too large.[64] Subjective evaluation in a series of 22 patients was reported by Freiberg and Manktelow, who noted mild hypersensitivity and numbness in 7 of 22 patients.[52] Frandsen reported a follow-up study of 14 patients who underwent Kutler's technique and found subjective complaints of coldness in 8 patients (57%), tenderness on percussion in 10 (71%), difficulty in grasping small objects in 6 (43%), and slight hypoesthesia or dysesthesia in 10 (71%) when objectively measured.[51] Patients also reported an average time off work of 61 days.

Shepard reported excellent results with a modification of Kutler's technique in 28 traumatic amputations and 9 reconstructive procedures by dividing the dorsal pedicle and advancing the flap 10 to 14 mm. The nerves, vessels, and subcutaneous tissues are preserved under the palmar skin incision.[129] The dorsal incision is made down to bone and the fibrous septa divided. On the palmar side, the skin is incised only and the flap advanced distally. He suggested that the Kutler technique is most applicable to oblique palmar and transversely oriented amputations.[129]

Given the limited advancement of the Kutler lateral "V-Y" flaps, others have described modifications by either raising the triangular flap on its neurovascular pedicle[18] or extending the flap to the proximal interphalangeal (PIP) joint crease to increase its size and ability to advance distally.[88,131] The flap could be advanced up to 2 cm, although patients were at risk of cold intolerance (49%), numbness (78%), PIP joint flexion contractures (17%), and DIP joint flexion contractures (22%).[131] These "V-Y" advancement flaps are at risk of necrosis if tension-free closure is not achieved. The tension placed on them at closure could cause a hook nail deformity because it pulls the nail bed palmarly and could also cause diminished sensation due to tension on the digital nerves and its branches.[140] This may be overcome by allowing the proximal wounds to heal by secondary intention or treating them with bilayer matrix wound dressings, thereby avoiding tension of the wounds distally.

Volar Flap Advancement

Moberg is credited with the technique of volar flap advancement for coverage of thumb tip amputations.[82] The flap is a bipedicled, axial-pattern, cutaneous advancement flap. Snow advocated the technique for fingertip amputations when length is to be maintained.[134] Advancing volar skin on its neurovascular pedicle provides the dermis with sensibility without losing length. Arons has modified this with the addition of a terminal dermal graft for padding, and sometimes a skin graft may be added at the base of the digit to gain length.[5]

Regional anesthesia is obtained, the limb is exsanguinated with an Esmarch bandage, and a pneumatic tourniquet is inflated. The distal tip is appropriately débrided, and midaxial incisions just dorsal to the flexion crease at each of the interphalangeal (IP) joints are made on both sides of the digit. The flap is completely separated from the underlying flexor tendon sheath, advanced to the distal tip, and sutured to the nail bed and the adjacent sides of the digit. The tip of the flap may need to be shaped to fit the distal defect. The lateral portions of the skin are sutured in place.

This method is more appropriate for the thumb (Figure 49.6) than for the fingers because of the more mobile skin of the thumb and the decreased likelihood of subsequent flexion contracture. However, in both the thumb and fingers, flap advancement is limited to 1 cm. Reported complications are fixed flexion deformity of the IP joints and skin necrosis on the dorsum of the finger. The studies of Caplan and coworkers,[26] Leffert and associates,[94] and Armenta and Lehrman[4] suggest that the blood supply to the flexor tendon apparatus must be compromised for this flap to be used. Although I do not know of any reports of tendon nutritional complications after the use of this technique, such complications could theoretically be a disadvantage of this method.

Cross-Finger Pedicle Flap

The cross-finger pedicle flap technique, first described by Gurdin and Pangman in 1950, has found acceptance when other techniques for local flap coverage are not possible and in those situations in which it is deemed important to maintain length.[63] Examples of such circumstances are distal amputations of the index finger or thumb and situations in which multiple digits are injured and maintenance of length in the remaining injured tips is critical.[22] The flap, however, is associated with stiffness postoperatively and is considered contraindicated in patients with preexisting arthritis or in patients over the age of 50 years. Paterson noted an increased incidence of stiffness in patients older than 41 years.[117]

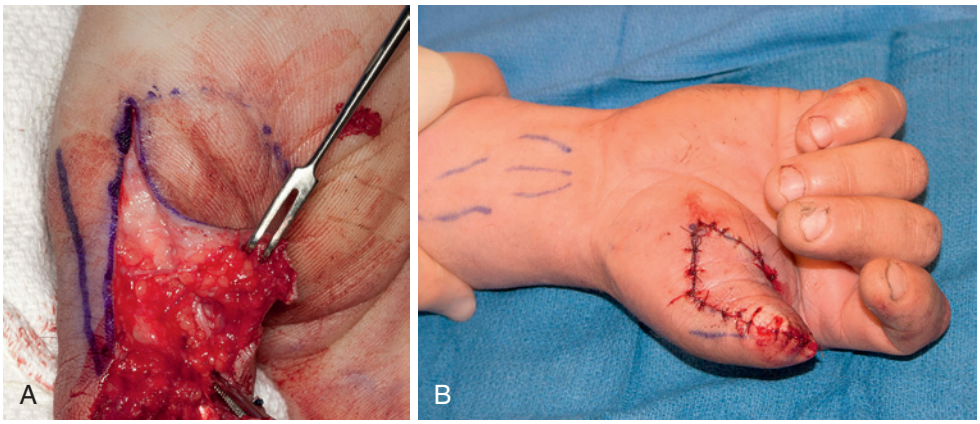

FIGURE 49.6 Patient with traumatic amputation of thumb with advancement flap to preserve as much length as possible. **A,** Raising flap from distal to proximal with neurovascular bundle within volar flap to maintain viability. **B,** Bony coverage by volar lap advancement.

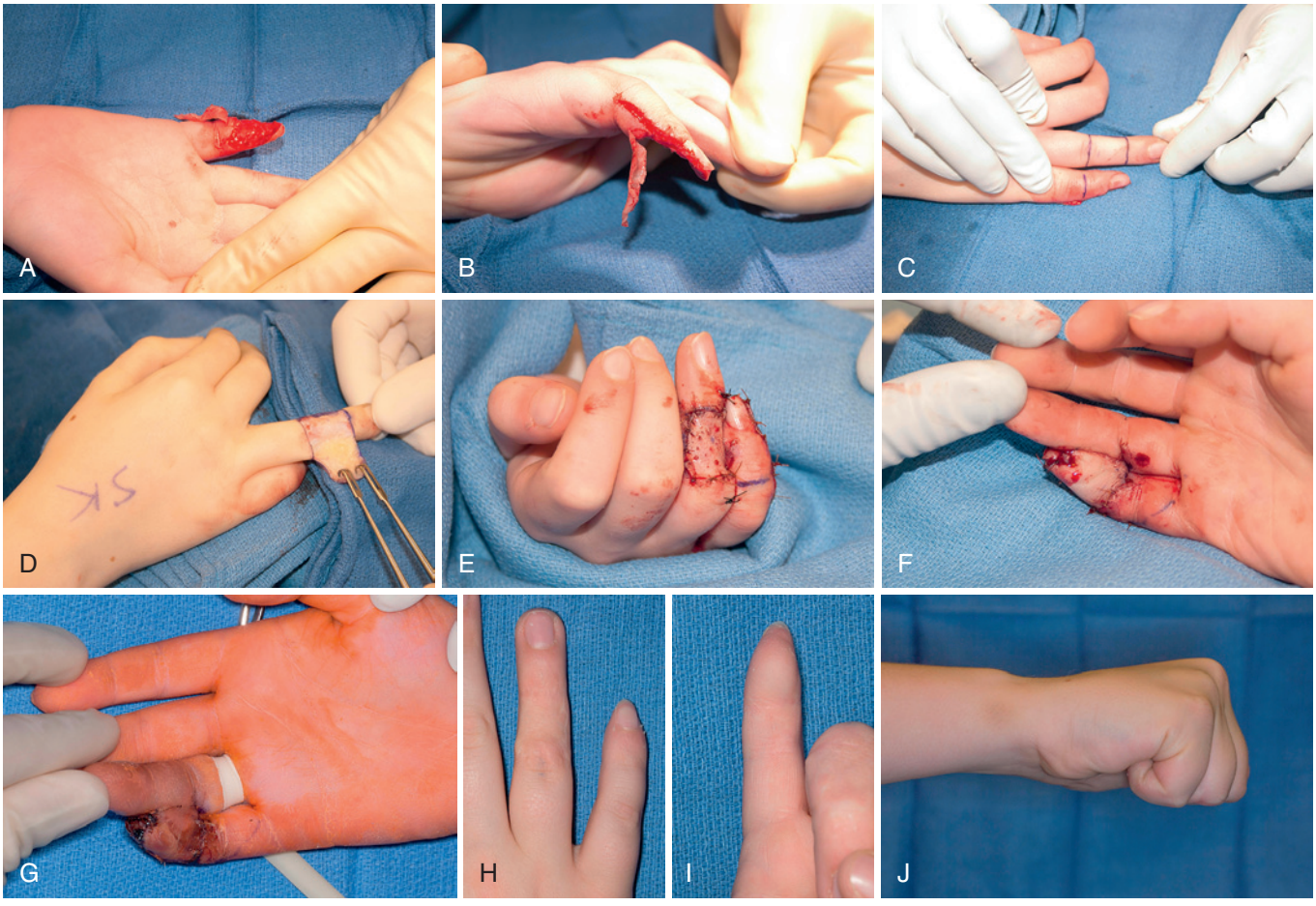

FIGURE 49.7 Cross-finger flap for loss of palmar skin to small finger. **A,** Tip degloving injury. **B,** Lateral view of degloving injury. **C,** Marking out flap on dorsum of ring finger. **D,** Raising cross-finger flap, staying above the paratenon. **E,** Full-thickness skin graft to donor site ring finger. **F,** Insetting of cross-finger flap palmarly. **G,** Penrose drain occluding blood supply from ring finger to flap demonstrating that flap has developed its own blood supply from small finger and is ready for division. **H,** Note aesthetic appearance of donor from ring finger. **I,** Aesthetic appearance of cross-finger flap. **J,** Full range of motion.

The flap provides coverage for an oblique volar defect of the pulp region or for extensive soft tissue loss on the volar fingertip with exposed bone and tendon. The example shown in Figure 49.7 in which the adjacent digit is used as a donor and the flap is laterally based is a common application of this technique. A piece of an Esmarch bandage is used to template the defect and to design the flap. It is important to make a template rather than estimate the flap size. I prefer to cut the template 2 mm larger around its three sides to ensure tension-free insetting of the flap.

Once the template has been made, the donor site is outlined with a marking pen. With careful tissue handling, the flap is reflected with preservation of its venous drainage at the base of the flap. The dissection is carried down to the plane between the paratenon of the extensor mechanism and the subcutaneous fat. Three of the four available margins of the flap are sutured in place on the recipient site. The fourth margin is sewn down at the time of flap detachment and closure. A full-thickness skin graft from the ipsilateral antecubital region or medial forearm is used to cover the defect on the extensor surface of the donor digit. Skin without hair is used because this can be a cosmetic concern, especially if the digits are hairless. To avoid undue tension on the vascular pedicle of the flap, the two fingers may be sewn together or a transdigital Kirschner wire placed. A bulky soft dressing may be reinforced with a plaster splint. At 3 weeks postoperatively, a Penrose drain is placed around the base of the donor digit to assess whether the flap is being perfused from the recipient finger. If so, the flap is detached and inset into the recipient site. Cohen and Cronin modified the technique to include a dorsal sensory branch of the digital nerve that is coapted to the recipient digital nerve at the time of flap division.[36] They reported an average two-point discrimination of 4.8 mm in 88% of the patients in their series.

After detachment of the flap, motion of the digits is encouraged to mobilize all the adjacent joints. Follow-up studies by Sturman and Duran,[136] Kleinert and associates,[84] and Johnson and Iverson[77] have indicated that the return of sensibility to cross-finger flaps as measured by two-point discrimination tests shows excellent reinnervation in the majority of these flaps with progressive improvement occurring with time. Lassner and colleagues[89] reported an average sensibility of 3.6 mm and cold intolerance in 6 of their 15 patients with a bilaterally innervated sensory flap.

Thenar Flap

In 1926, Gatewood described the technique of a thenar flap for coverage of digital tip injuries with exposed bone.[54] This was subsequently expanded on by Flatt[49] in 1957 and modified by Smith and Albin[132] with a technique that they describe as a thenar "H"-flap.

The indications for the random-pattern thenar flap are similar to those for a cross-finger flap, namely, when preservation of length is important and other techniques are not applicable. The flap has been advocated for use only in the index and long fingers and in younger patients without any preexisting arthritis or joint injury. The proposed advantages are (1) better skin color and texture match, (2) abundance of subcutaneous tissues, and (3) return of some sensibility. To avoid permanent joint stiffness or unsightly scarring in the donor area, one must keep in mind the three cardinal technical principles outlined by Melone and colleagues[103]: (1) Design the flap near the metacarpophalangeal (MP) crease of the thumb and avoid the midpalmar area; (2) fully flex the MP joint with whatever amount of flexion is required in the IP joints of the recipient finger; and (3) detach the pedicle 10 to 14 days postoperatively and begin immediate active range-of-motion exercises.

Thenar "H"-Flap. Figure 49.8 shows the thenar "H"-flap as described by Smith and Albin.[132] The area of contact of the injured digital tip with the thenar eminence is outlined. An "H" is drawn on the skin approximately 20% wider than the defect.

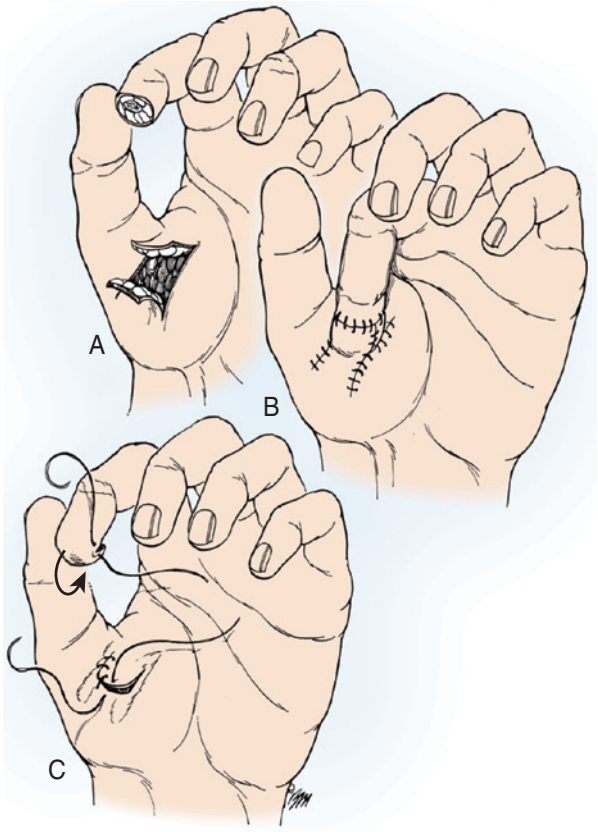

FIGURE 49.8 **A** to **C,** The thenar "H"-flap as described by Smith and Albin. (Copyright Elizabeth Martin. See also Smith RJ, Albin R: Thenar "H-flap" for fingertip injuries. *J Trauma* 16:778–781, 1976.)

The transverse limb of the incision is made at the most distal contact point of the fingertip with the thenar eminence (see Figure 49.8, *A*). Square proximal and distal flaps are elevated, including the subcutaneous tissue. The proximal flap is sutured to the fingertip, and the distal flap is sutured to the proximal margin of the defect on the volar side of the injured finger (see Figure 49.8, *B*). The proximal flap is advanced distally and the distal flap advanced proximally to close the donor defect. A soft dressing is applied, and 2 weeks later the flap is detached. The fingertip is closed with the proximal flap, and the distal flap is advanced into the thenar defect (see Figure 49.8, *C*). This closes the donor site primarily and avoids the potential problem of an unsightly scar in the thenar eminence.

An alternative technique is to elevate a proximally based flap and suture it to the injured tip in a fashion similar to that just described but to use a full-thickness or split-thickness skin graft or Limberg-type flap for the thenar defect when the flap is divided and inset.[49,54]

Satisfactory outcomes with the thenar flap have been reported in several clinical series.[11,48,103] Porter compared the results of 56 pedicle flaps with 44 free grafts.[120] He found sensibility was better in cross-finger and thenar flaps and that these flaps resulted in excellent cosmesis. Porter also concluded that full-thickness grafts were superior to split-thickness skin grafts. In terms of subjective and objective sensibility evaluation, of the five methods evaluated in his study, the results were superior with the thenar and cross-finger flaps.

Island Flaps

A number of elegant and ingeniously conceived island flaps have been described for coverage of fingertip amputations.[1,2,50,68,85,154] These consist of flaps raised on their neurovascular pedicle, and advantages include the avoidance of prolonged digital immobilization in an awkward position, single-stage reconstruction permitting early rehabilitation, introduction of an independent blood supply to provide a good soft tissue bed for nerve grafting or repair, satisfactory restoration of a well-padded sensate digital pulp, the potential for a composite tissue transfer, a wide selection of donor sites, and a greater arc of rotation for mobilization of the flap over longer distances. These include homodigital and heterodigital island flaps and can be anterogradely or retrogradely based.[72,80] However, island flaps are more technically demanding and are associated with complications such as flap failure, joint contracture, and cold intolerance.[155] In addition, they have not proved to be more advantageous than simpler methods of achieving coverage of a fingertip amputation. The use of an island flap may be beneficial in select cases, and the reader is referred to comprehensive review articles to become familiar with the indications and surgical techniques.[50,140]

Free Flaps

With advances in microsurgery, free tissue transfer has been used to treat complex digital defects, including medial arm free flaps, anterolateral thigh flaps, wraparound toe flaps, and arterialized venous flaps.[32,34,76,83] These can be complicated by their bulky appearance, necessitating revision surgery, donor site morbidity, and unpredictable survival rates. A fasciocutaneous free flap based on the superficial palmar branch of the radial artery has been reported for medium-to-large volar soft tissue defects, including the fingertip region.[75] The use of a free thenar flap has also been reported by Kamei and Sassu and associates.[79,126] Coverage of complex digital defects using a proximal first dorsal metacarpal artery free flap was recently described in 10 patients.[73] The proximal first dorsal metacarpal artery flap is particularly applicable when the defect is large or when scars or injuries prevent the use of a pedicled homodigital or heterodigital flap. Ulnar artery free flaps have been described for managing complex digital defects because they are thin, have aesthetic and textural characteristics similar to those of the finger, and tend to be free of hair. Given that they require harvesting of a major artery, ulnar artery perforator free flaps have been developed to treat such defects. These can be either proximally or distally based.[100,138] Zheng and colleagues[156] described the use of a distal ulnar artery perforator bilobed free flap in the treatment of 15 patients with complex digital defects. Citing the advantages of having a cosmetic appearance similar to that of digital skin, the presence of the donor and recipient sites within the same surgical field, preservation of the main trunk of the ulnar artery, having a size similar to that of the proper digital artery, containing both the accompanying and superficial veins, and allowing sensation via the medial cutaneous nerve of the forearm or dorsal sensory branch of the ulnar nerve, the authors reported satisfactory outcomes in 14 of 15 patients (1 patient had partial flap necrosis) with good digit range of motion and two-point discrimination ranging from 6 to 11 mm.

❖ AUTHOR'S PREFERRED METHOD OF TREATMENT: Digital Tip Amputation

I prefer to treat all digital tip injuries without exposed bone nonoperatively, with dressing changes or ultrasonic MIST therapy to allow healing by secondary intention. Educating the patient and the family with photographs from previous cases has proven to be invaluable. The analogy that the injury looks "like a dog's dinner" and that it will heal, with pictures from similar case examples, allows one to gain the trust of the patient and help the patient engage with therapy.

In single-digit injuries with a small protruding portion of the distal phalanx, I will trim the bone back and allow healing by secondary intention. For larger defects with more exposed bone, I prefer the "V-Y" advancement flap for dorsal oblique or transversely oriented fingertip amputations. For volar oblique wounds, I use bilayer matrix wound dressings followed by a skin graft when appropriate. I tend not to favor the thenar flap for concern of developing IP joint stiffness but may consider it in young patients with index or long fingertip amputations. If the defect is large, I use a cross-finger flap. If the defect also involves a large portion of the volar tissues, I use a neurovascular island flap, although I have become more and more impressed with the results obtained with bilayer matrix wound dressings and have been increasing their indications in my practice.

AMPUTATIONS FROM THE DISTAL INTERPHALANGEAL TO THE METACARPOPHALANGEAL JOINT (EXCLUDING THE THUMB)

Distal Interphalangeal Joint Disarticulation

My preferred method of management for an amputation through the DIP joint or just distal with loss of flexor digitorum profundus (FDP) function is skeletal shortening and primary closure. I preserve the FDP attachment when possible to maintain some length, IP joint flexion, and pinch stability (Figure 49.9). If the insertion of the FDP is not salvageable, I pull the tendon as far distal as possible and transect it under tension. Whitaker and colleagues presented experimental and clinical data suggesting that there was less inflammation if the articular surface of the middle phalanx was preserved.[150] However, I believe that the shape and contour of the amputation stump should be fashioned to resemble the normal distal phalangeal tuft. This is accomplished by rongeuring off the volar and lateral condylar prominences. The digital nerves should be dissected and cut under tension to allow them to retract away from the cutaneous scar into an area where the inevitable neuromas will not become symptomatic. The flexor and extensor tendons should be inspected and their cleanliness established; they should not be sutured to each other. This inevitably limits the excursion of both and compromise function of the remaining digits. Wang and associates[147a] reported on the outcomes of revision amputation at or distal to the DIP joint and noted that the average arc of motion of the PIP joint was 94 degrees; 24% of patients experienced cold intolerance; most patients had normal sensibility with a mean two-point discrimination of 5.6 mm; and the return to work averaged 7 weeks after surgery.

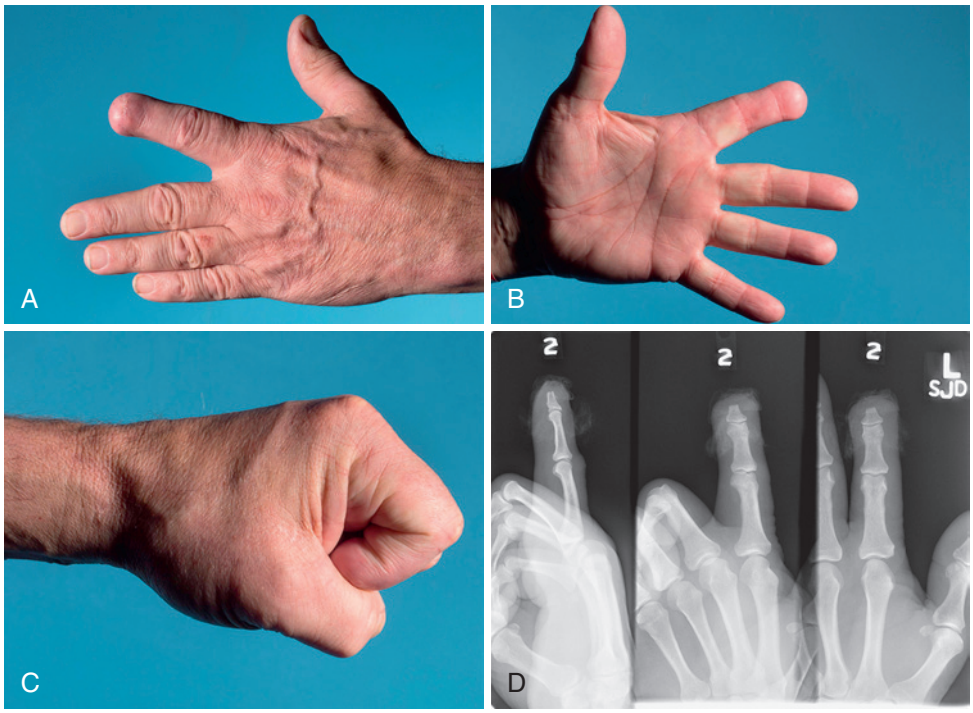

FIGURE 49.9 Amputation of the distal phalanx with preservation of the flexor digitorum profundus attachment and concurrent nail bed ablation. Patient has maintained a degree of function at the distal interphalangeal joint. **A,** Dorsal view of index finger with nail bed ablation. **B,** Palmar view with volar flap closure. **C,** Flexion of distal interphalangeal joint to aid in grip. **D,** Postoperative radiographs showing preservation of flexor digitorum profundus attachment.

Complications of Digital Amputation: The Lumbrical-Plus Finger

Distal release of the FDP tendon to the index finger may lead to a "lumbrical-plus" deformity. As the independent FDP and its lumbrical move proximally, tension increases in the lumbrical tendon and its contribution to the intrinsic extensor of the PIP joint. As active flexion of the digit is attempted, further proximal migration of the lumbrical may put sufficient tension on this lateral band to cause paradoxic extension of the PIP joint. Sectioning the lumbrical tendon allows the superficialis to regain control of the PIP joint and may alleviate the problem. In my experience, this rarely occurs, and sectioning of the lumbrical is unnecessary at the time of the amputation.

Amputation Through the Middle Phalanx

If amputation has occurred proximal to the DIP joint of the index finger, most patients will transfer pinching and picking up of small objects to the tip of the long finger (Figure 49.10). Therefore, efforts to preserve index finger length by flap coverage may be necessary. Preserving length in other digits may also be important in certain occupations such as a professional musician or one who uses a computer keyboard and mouse. For injuries in which preserving length is not feasible, the bone should be shortened sufficiently to allow primary coverage with available skin without tension (Figure 49.11). The flexor digitorum superficialis (FDS) insertion should be preserved because the middle phalangeal segment will be able to participate effectively in grasping activities; PIP flexion is always limited, however, if the middle phalanx stump is short. If amputation has occurred proximal to the insertion of the superficialis or if the tendon has been transected, there will be no active flexion of the remaining middle phalanx; therefore, preservation of the middle phalanx is more of a cosmetic issue and less of a functional consideration (Figure 49.12).

The amputation is designed as a "fish-mouth" incision with equal palmar and dorsal skin flaps (Figure 49.13). Alternatively, the incision can be fashioned with a larger palmar skin flap to ensure that the thicker palmar skin covers the tip surface. Regional or digital anesthesia can be used for this procedure. Limb exsanguination is performed by arm elevation and compression of the brachial artery for cases of infection or tumor. Otherwise, the arm is elevated and exsanguinated using an Esmarch bandage. The skin is incised and the extensor tendon cut. On the palmar surface, the neurovascular bundles are identified and the digital vessels isolated and cauterized. The digital nerves are dissected proximally and cut under tension so they retract proximally. The FDP tendon is cut under tension. The insertion of the FDS tendon is protected as much as possible and the osteotomy of the middle phalanx planned a few millimeters proximal to the level of the skin incision to ensure tension-free closure. The phalanx is cut using a reciprocating saw and the ends are smoothed with a rasp. If a disarticulation is to be performed, the articular cartilage is left intact but the volar and lateral condyles are trimmed with a rongeur to decrease stump protuberance. The tourniquet is deflated, hemostasis is obtained, and the wounds are closed with a 4-0 nonabsorbable suture. A soft dressing is applied and range-of-motion exercises are encouraged. Sutures are removed at 2 weeks or once the wounds have healed. Edema control and desensitization exercises are initiated.

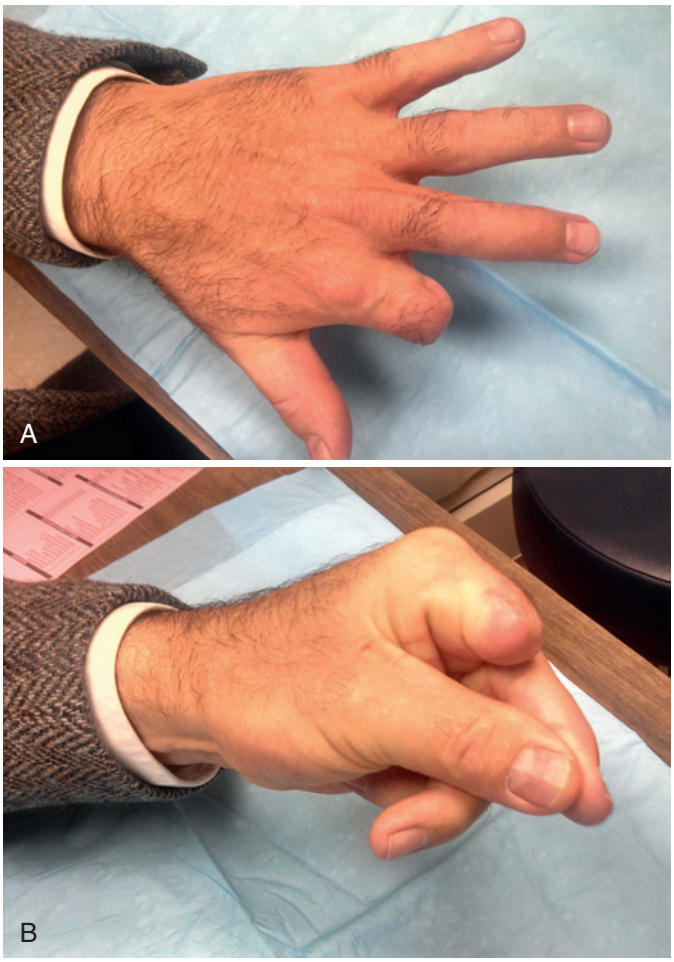

FIGURE 49.10 In a patient with an amputation proximal to the distal interphalangeal joint of the index finger, pinch will virtually always be transferred to the long fingertip. **A,** Dorsal view showing amputation through proximal phalanx. **B,** Lateral view highlighting patient transferring pinch to the long finger. (Courtesy of P. L. Jebson.)

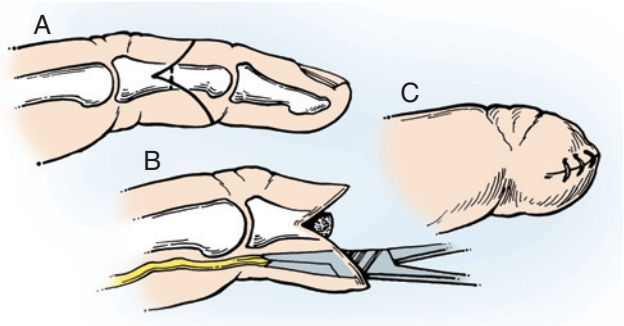

FIGURE 49.11 Use of volar and dorsal skin flaps for coverage when a distal amputation in the finger, that is, distal to the metacarpophalangeal joint, is indicated. Volar flap coverage is considered preferable because of its greater sensibility. This technique is also applicable when primary closure is desired by means of bone shortening. The digital nerve is sectioned after distal traction to allow the inevitable neuroma to form at a location proximal to the cutaneous scar. **A,** Fish-mouth incision. **B,** Traction neurectomy. **C,** Closure of incision. (Copyright Elizabeth Martin.)

Amputations Through the Proximal Interphalangeal Joint

Amputations through the PIP joint should be carried out in a manner similar to those through the DIP joint, with denuding of articular cartilage, shaping of the condyles of the proximal phalanx, and coverage with local skin.



FIGURE 49.12 Note the amputation proximal to the insertion of the superficialis through the base of the middle phalanx. Although no flexion control of the middle phalangeal remnant is possible, the length preserved with such an amputation may be helpful in preventing small objects from falling through the hand.

Amputation Through the Proximal Phalanx

If an amputation has occurred proximal to the PIP joint, the remaining proximal segment is under motor control of the intrinsic muscles and the extensor digitorum communis. This provides active MP joint flexion of approximately 45 degrees. The remaining segment will participate in gripping and help keep small objects in the palm. To improve flexion at the MP joint, tenodesis of the FDS tendon to the end of the proximal phalanx can be performed. Kirschner wire holes are made through the distal end of the proximal phalanx and the FDS tendon is sutured at its resting length to the phalanx, which provides almost 90 degrees of flexion with grasp (Figures 49.14 and 49.15).

If the amputation has occurred near or at the MP joint level, particularly in the long and ring fingers, functional problems such as dropping small objects through the defect will result, and further consideration of prosthetic replacement or a proximal ray amputation should be contemplated. If the amputation involves the index finger, immediate ray amputation should be considered.

RAY AMPUTATIONS

A ray amputation involves excision of a digit from its metacarpal base. Indications include trauma, tumor resection, infection, failed replantation, debilitating Dupuytren disease, and macrodactyly.[30] When considering a ray amputation, it is important to think about its effects on overall hand function because the amputation will affect the three functional units—namely, (1) an opposable thumb, (2) the index and long fingers

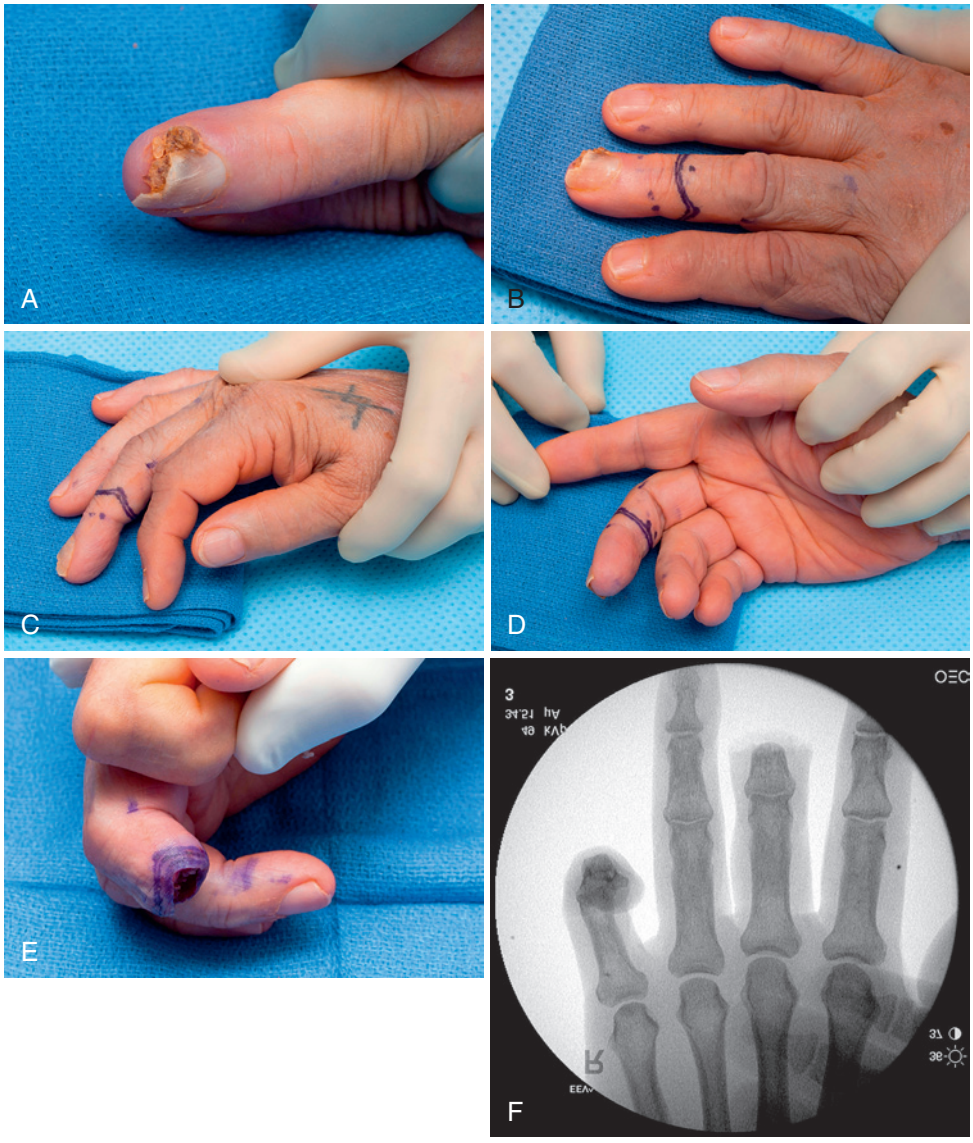

FIGURE 49.13 **A,** A 75-year-old woman with squamous cell carcinoma of the fingertip. Magnetic resonance imaging of the finger demonstrated increased edema within the distal phalanx, and therefore an amputation through the middle phalanx with clean margins was performed. **B** to **D,** Fish-mouth insertion. **E** and **F,** View following amputation through the middle phalanx.

CRITICAL POINTS *Digital Amputation Levels*

- Amputations through the DIP joint are managed by skeletal shortening and primary closure.
- If the FDP attachment and, thus, DIP joint flexion are intact, length should be maintained with flap coverage to preserve joint motion and stability.
- In amputations through the middle phalanx, bone should be shortened to allow primary coverage by available skin without tension. If possible, the amputation level should be distal to the FDS insertion.
- Amputations through the PIP joint are managed like those through the DIP joint.
- If amputation through the proximal phalanx is near the PIP joint, some useful gripping function is preserved and can be enhanced with FDS tenodesis.
- If amputation is near or at the MP joint, ray amputation should be considered.

for pinch, and (3) the ring and small fingers for grip.[110] It can narrow the palm span by 10%, with a resultant decrease in grip strength.[102] However, the narrower palm must be weighed against other impairments related to the space created by the missing digit, especially for the central digits, because small objects may fall through this area. Ray amputation may be indicated at the time of initial trauma, but in most instances, it is performed as an elective procedure secondary to functional impairment or unremitting pain. In most injuries, the principle of saving all viable tissue should be followed. Tissue that may appear at first glance to be of little functional benefit may serve as a good source of material for subsequent reconstruction (e.g., bone graft).[31]

Peimer and colleagues[117a] conducted a retrospective review of 12 patients who underwent primary ray amputations (within 2 weeks) and 13 patients who had secondary ray amputations for either traumatic or oncologic reasons. They noted that patients who underwent primary ray resection had better

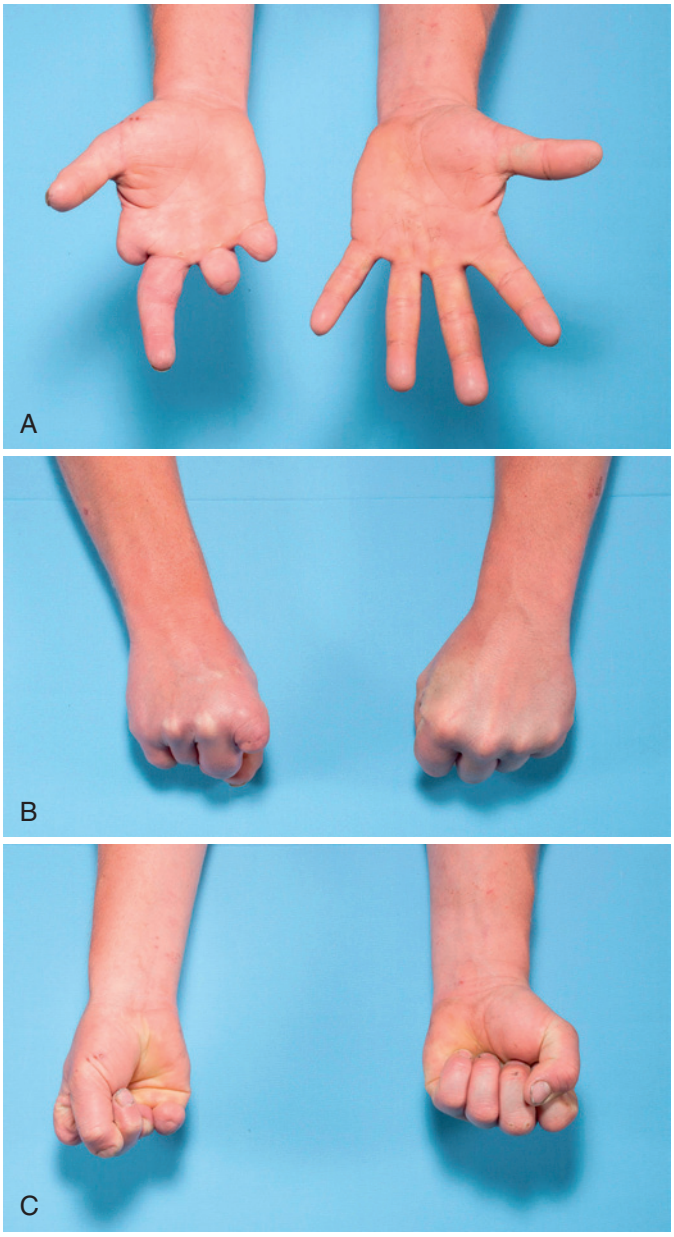

FIGURE 49.14 Twenty-six-year-old male following replantation of right long finger and FDS tenodesis to ring and small finger proximal phalanges. **A,** Palmar view of hand with full extension of ring and small fingers at metacarpophalangeal joint. Dorsal **(B)** and palmar **(C)** views of hand showing good flexion at the metacarpophalangeal joint of the ring and small fingers, which provided the patient with the ability to grasp and function as a manual laborer.

strength and dexterity and had to take less time off work. On average, patients lost 28% of grip strength, 26% of opposition, and 13% of key pinch strength. The vast majority of patients, excluding those involved in workers compensation or litigation cases, were satisfied with the functional outcome, with most returning to the preinjury occupation. Melikyan and colleagues[102] reported on 20 patients at an average of 32 months following surgery. Grip strength decreased by 27% and three-point pinch by 22%. Patients who had an amputation of border digits recovered better than those who had amputation of the central digits, with the latter group having impaired manual dexterity.

Index Finger Ray Amputation

Murray and colleagues reviewed 41 patients who underwent index finger transmetacarpal amputation (13 patients at the level of and 28 patients proximal to the metacarpal head). They reported a 20% reduction in power grip, key pinch, and supination strength.[113] Pronation strength, which is a measure of grasp stability, decreased by 50% owing to the narrowing of the palm. With loss of the index finger, the pronosupination fulcrum is decreased by 25%, resulting in a loss of stability and a mechanical disadvantage for forearm rotation (Figure 49.16).[110] There was no significant difference in strength between those who had proximal or distal amputations. Patients noted that the overall hand function had improved, despite the loss in strength, because of the ability to maintain thumb prehension. Cold intolerance was the most common persistent symptom (35 of 41 patients). Fifty-nine percent of patients had suboptimal results owing to hyperesthesia in the thumb/long finger web space. This was secondary to excessive mobilization of the index finger radial digital nerve during the amputation process and interfered with hand function in 37% of patients.[113] Fisher and Goldner[46] reported a similar complication in five patients; it appeared 6 to 8 weeks after surgery. Although this problem may resolve with secondary surgery, the symptoms may recur over time. In the series of Murray and associates, 34 patients underwent elective ray amputations. Twenty-one complained of pain in the stump before the transmetacarpal amputation, and only 3 experienced complete relief after the procedure. This information is important when advising a patient preoperatively about the possibility of *persistent postoperative neuroma-like symptoms*. Ay and Akinci[9] described a technique of primary transposition of the index finger digital nerves into the interossei to decrease neuroma formation. After amputation of the digit, the radial and ulnar digital nerves are mobilized in a proximal direction and inserted within the interossei of the long finger.

In an effort to restore strength to the long finger, several tendon transfers have been described, including transfer of the first dorsal interosseous muscle to the second dorsal interosseous tendon or extensor hood, the extensor indicis proprius to the long finger extensor, or the FDS to the proximal phalanx of the long finger. Of the more commonly performed transfers, Murray and associates[113] found no differences in key pinch strength in patients who had or had not undergone transfer of the first to the second dorsal interosseous tendon. In 11 of 28 cases in which the second dorsal interosseous tendon was augmented by transfer of either the first dorsal interosseous tendon or one of the long flexor tendons of the index finger, there was an intrinsic-plus deformity evident on clinical examination. From these data it would appear that procedures designed to augment the second dorsal interosseous tendon are unnecessary and may lead to additional complications.

Germann and colleagues[55] reported on 120 patients with ray amputations (42 of the index finger). The majority of patients noted minimal functional deficits in performing activities of daily living. There was no significant loss of strength compared with patients who had undergone an amputation through the middle phalanx with respect to tip, key, and palmar pinch and sustained grip. Unlike those who had undergone digital amputation, 90% of patients with a ray amputation were happy

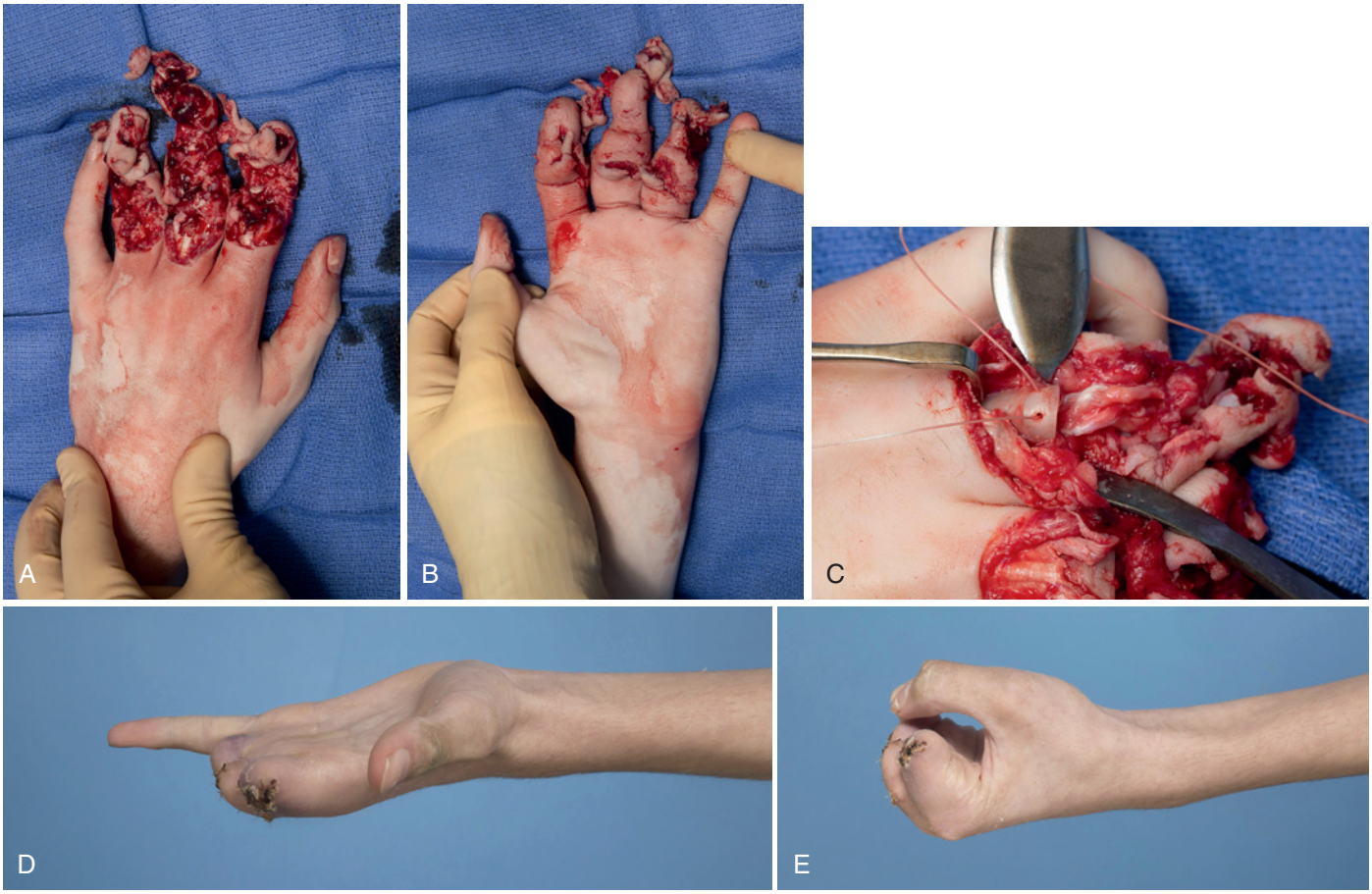

FIGURE 49.15 This patient sustained a punch press injury with proximal phalangeal amputations of his index, long, and ring fingers. Flexor digitorum superficialis tenodesis was performed to improve flexion of the proximal phalanges, and fillet flaps were used from the palmar skin for wound coverage. **A,** Dorsal view. **B,** Palmar view. **C,** Flexor digitorum superficialis tenodesis to proximal phalanx through drill holes at the end of the bone. The underlying flexor digitorum superficialis tendon will be sutured to the end of the distal phalanx. **D,** Full extension of metacarpophalangeal joint. **E,** Note that with the flexor digitorum superficialis tenodesis, patient was able to achieve nearly 90 degrees of flexion at the metacarpophalangeal joint. Patient will be fitted with a body-powered M-finger (see hand prosthetics section).

with the cosmetic appearance. Similar results were reported by Melikyan and associates[102] in an evaluation of ray amputations. Eight of the 20 patients underwent index finger ray amputation. Grip strength was decreased by a mean of 19% compared with the contralateral hand. Interestingly, 6 of 8 patients learned to transfer manual dexterity precision skills (commonly performed between the thumb and index finger) to the long finger without difficulty, presumably because of the unrestricted first web space. Many cases of ray amputation are performed following trauma. Puhaindran and coworkers[122] reported on the outcomes of single-ray amputation (7 of the index finger, 5 of the long finger, 6 of the ring finger, and 7 of the small finger) for tumors of the hand that included soft tissue malignant tumors, metastases, giant cell tumors of bone, and primary bone sarcomas. Ten patients underwent postoperative radiation treatment (2 for positive margins and 8 for close margins). None of the patients had local recurrences. Patients who received preoperative radiotherapy had a decrease in functional outcomes and grip strength that averaged 66% compared with the contralateral hand.

❖ AUTHOR'S PREFERRED METHOD OF TREATMENT: Index Finger Ray Amputation

For trauma cases, transmetacarpal amputation is not performed in the acute setting unless there is injury proximal to the MP joint. In cases of multiple-digit injuries, it is especially important to preserve as much finger length as possible. For ray amputation, regional anesthesia is preferred. For cases of infection or tumor, limb exsanguination is performed by arm elevation and compression of the brachial artery. Otherwise, the arm is elevated and exsanguinated using an Esmarch bandage. A proximally based "V" incision is fashioned on the volar surface at the midproximal phalangeal level of the index finger. Dorsally, this is joined by a "Y"-shaped incision with proximal extension over the index metacarpal (Figure 49.17, *A*). The longitudinal dorsal incision is made through the subcutaneous tissue, and the veins are ligated as necessary. If indicated, dorsal sensory branches of the superficial radial nerve should be divided under tension to allow proximal retraction. The extensor digitorum communis and extensor indicis proprius tendons

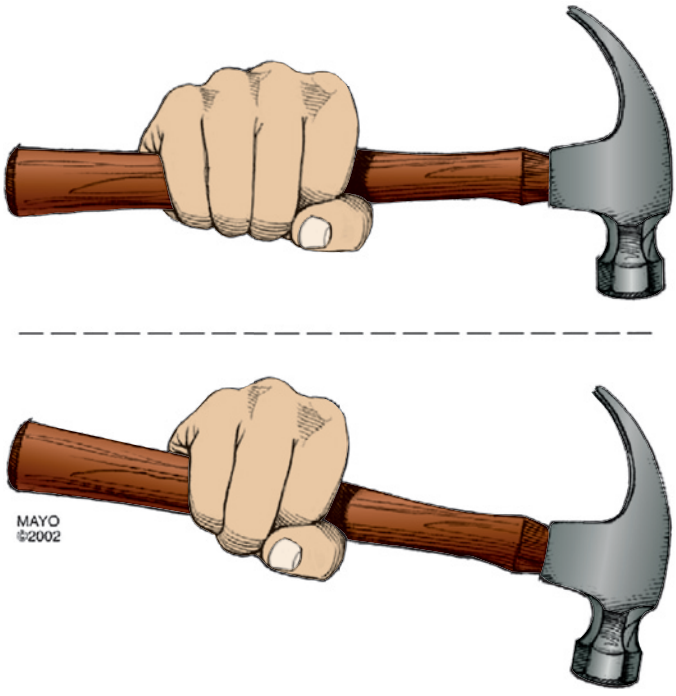

FIGURE 49.16 Loss of a ray decreases the span of the palm and has a negative effect on pronosupination strength. (Modified from Moran SL, Berger RA: Biomechanics and hand trauma: what you need. *Hand Clin* 19:17–31, 2003, Figure 11, p 23. Used with permission of Mayo Foundation for Medical Education and Research. All rights reserved.)

are divided at the level of the second metacarpal base and reflected distally to expose the underlying periosteum. The dorsal periosteum is sharply incised, and a subperiosteal sleeve is raised. The index finger metacarpal is transected via a reciprocating saw distal to the insertion of the extensor carpi radialis longus tendon (maintaining wrist strength), with care taken to protect the underlying radial artery as it passes beneath the base of the metacarpal (see Figure 49.17, *B*). A rasp is used to address any rough edges of the transected metacarpal base. Dissection is carried around the distal circular portion of the incision. The first dorsal interosseous tendon and lumbrical muscle to the radial side of the index finger are divided. One next proceeds around the palmar aspect of the finger, and the neurovascular bundles to the index finger are identified. Care must be taken to identify and protect the radial digital nerve to the long finger and its accompanying digital artery. The vessels to the index finger are ligated and the digital nerves dissected distally into the middle phalangeal segment and divided. The flexor tendons are transected under tension to promote retraction into the palm. The tendon of the first palmar interosseous tendon is also divided.

The volar plate, deep transverse intermetacarpal ligament (DTIL), and proximal portion of the flexor tendon sheath are sharply incised, permitting delivery of the amputated digit. The distal end of the digital nerves that have intentionally been transected in the finger are now carefully dissected proximally, with their connections with the palmar skin left undisturbed (see Figure 49.17, *C*). The distal ends are transposed proximally into the interosseous space between the first and second dorsal interossei to provide protection from external compression (see Figure 49.17, *D*). Alternatively, the nerves may be coapted. The tourniquet is deflated, hemostasis is obtained, and the periosteal sleeve is closed. The skin flaps are trimmed, inset, and closed with interrupted sutures. A well-padded soft dressing is applied, and early motion is encouraged. Strengthening is started at 6 weeks following operation. Patients should be followed to ensure an uneventful recovery because complications such as neuroma formation and carpal tunnel syndrome may occur. The latter may occur as a result of proximal migration of the transected flexor tendons into the carpal canal.

Long Finger Ray Amputation

Given its central location, the long finger plays an important role in hand function, especially in lateral pinch, chuck pinch, and power grip.[110,135] Any loss of length distal to the PIP joint can lead to small objects falling between the gap of the index finger and ring finger[53] (Figure 49.18) and a loss of three-point chuck pinch. Angular deformity of the index finger can occur when the amputation is at the level of the MP joint.[29] Key pinch strength is diminished because the origin of the adductor pollicis muscle is removed from the long finger metacarpal. One of the main complications following central ray deletion is scissoring of the adjacent index and ring fingers due to instability of the DTIL and altered intrinsic muscle function. Given this, two techniques of long finger ray amputation have been popularized, namely, repair or reconstruction of the DTIL and ray transposition.

Long Finger Ray Amputation Without Transposition

Melikyan and colleagues reported on the outcomes of patients who underwent central ray amputation compared with those who underwent border digit ray amputation.[102] Amputations were performed through the base of the metacarpal, and the DTIL was closed for central deletion cases. Compared with patients who underwent border digit deletion, those who underwent long finger ray amputation had weaker three-point pinch, decreased manual dexterity, and weakness in torque power and work output of up to 38% compared with the contralateral hand. The authors did not find any cases of gapping or scissoring by primarily repairing the DTIL (Figure 49.19). One of the concerns with imbrication of the DTIL when the metacarpal base of the long finger is left in situ is the scissoring that may develop as the metacarpal heads of the index finger and ring finger are drawn together. This was highlighted by Steichen and Idler,[135] who stated that the procedure may be better suited for ring finger ray amputation because in the ring finger, the metacarpal is thinner and gap closure is more readily achieved due to the mobility of the fifth carpometacarpal (CMC) joint; in the long finger, the metacarpal is wider and the index finger CMC joint stiffer. Nonetheless, in their report of 13 patients (4 of whom had long finger surgery and 9 of whom had ring finger surgery), satisfactory functional and cosmetic results were noted in all but 1 patient, who complained of continued palmar tenderness and narrowing of the palm. For cases in which the DTIL is absent or deficient, Gong and coworkers[56] described a technique of reconstructing the dorsal transverse intermetacarpal ligament using a free tendon graft. Following metacarpal base osteotomy, a free tendon graft (either a graft from the amputated digit or an autograft) is looped around the index and ring finger metacarpal necks and sutured to itself and

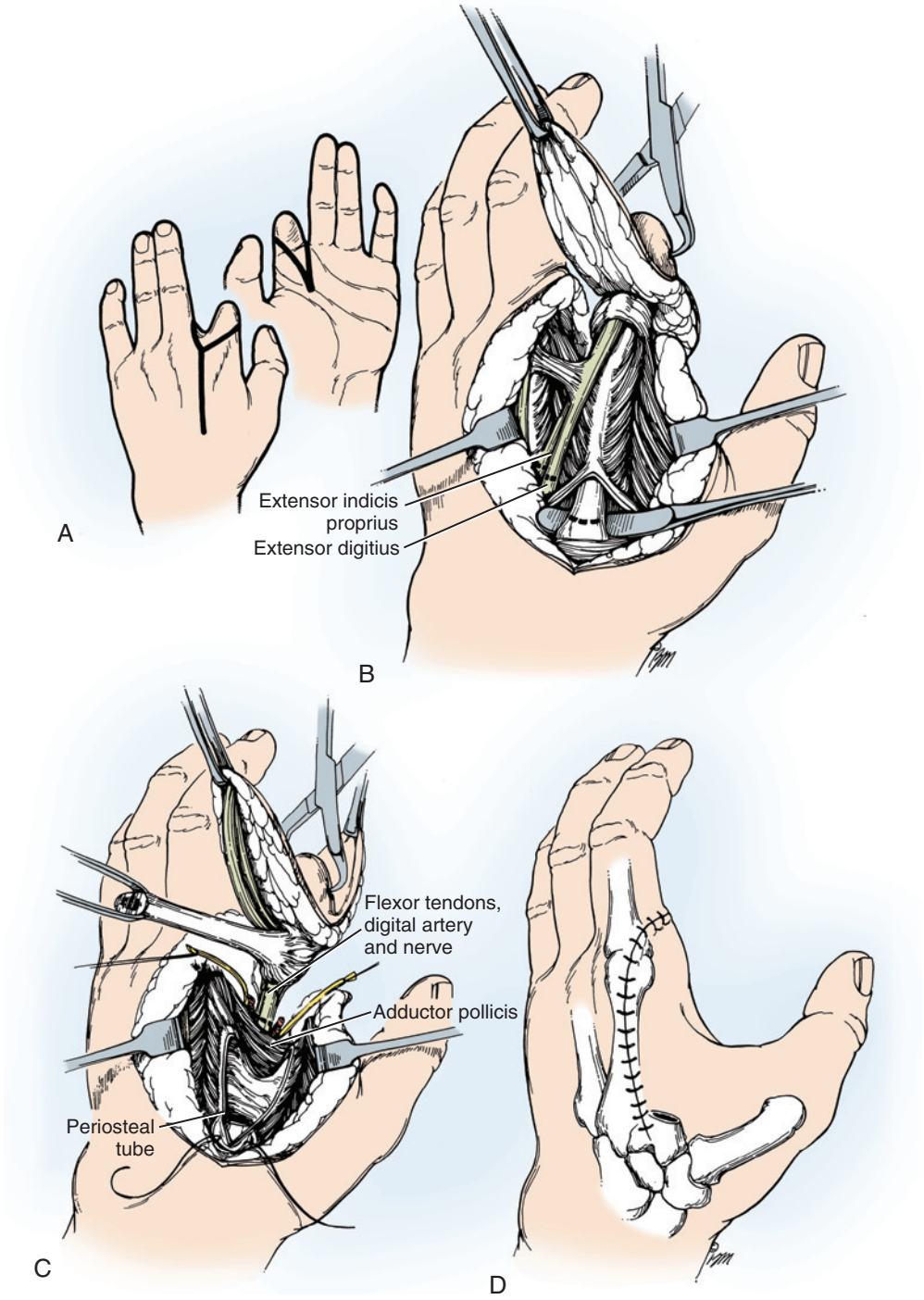

FIGURE 49.17 **A** to **D,** Technique of index finger ray amputation. After the appropriate skin flaps are raised, dissection proceeds from dorsal to volar. After division of the extensor digitorum communis and extensor indicis proprius, the index finger metacarpal is transected at its flare, distal to the extensor carpi radialis longus insertion. Following division of the lumbrical, dissection proceeds volarly where the neurovascular bundles are identified. The digital nerves are transposed into the interosseous space to prevent the formation of a symptomatic neuroma.

to the adjacent periosteum (Figure 49.20). An alternative method of fixation would be to use biotenodesis screws within the index finger and ring finger metacarpal necks.

To draw the index and ring fingers closer together, Iselin and Peze[73a] described a technique whereby a closing wedge osteotomy of the capitate (distally based wedge with apex proximal) is performed after long finger ray amputation. The operation was performed in 12 patients, and the authors reported satisfactory closure of the gap between the index finger and ring finger with soft tissue repair; patients were satisfied with the functional and aesthetic results. Alternatively, Lyall and Elliot[97a] described a technique whereby the entire middle finger ray is amputated at the CMC joint. Care must be taken to protect the underlying motor branch of the ulnar nerve. Subperiosteal

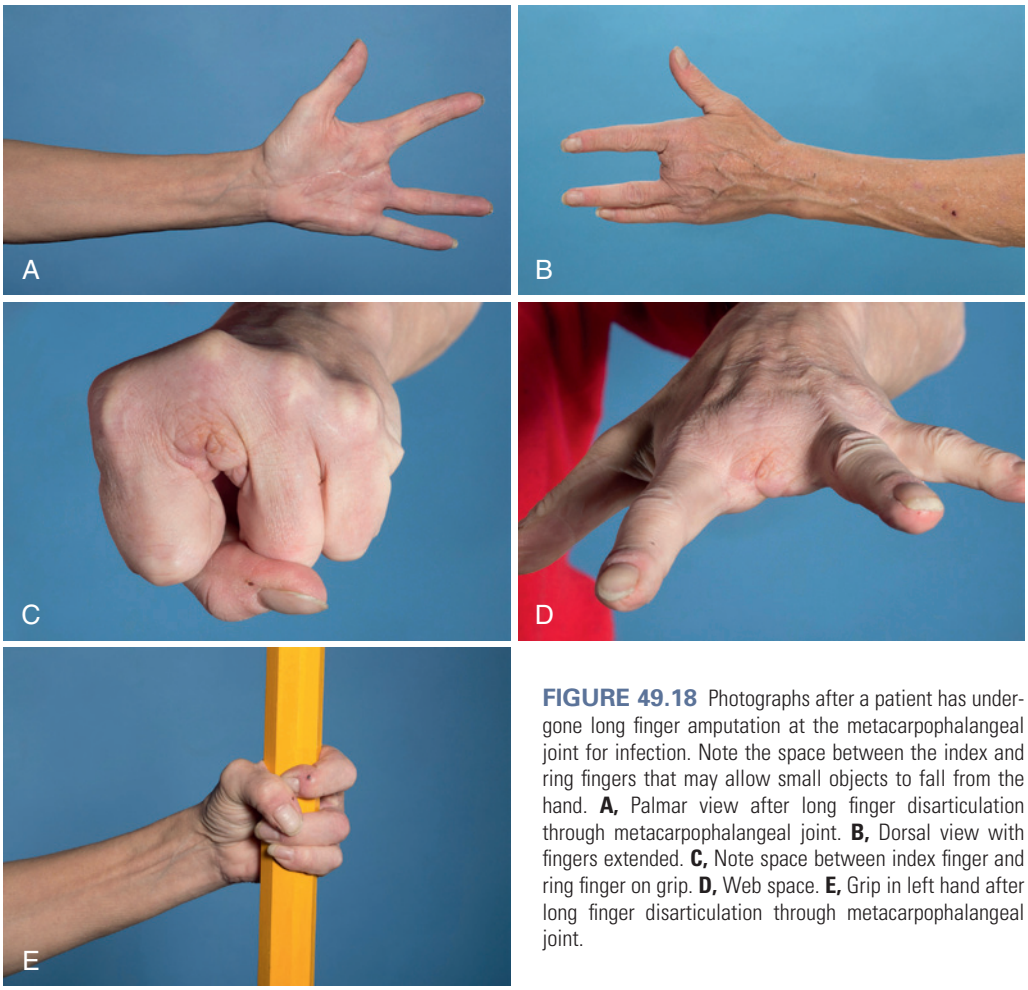

FIGURE 49.18 Photographs after a patient has undergone long finger amputation at the metacarpophalangeal joint for infection. Note the space between the index and ring fingers that may allow small objects to fall from the hand. **A,** Palmar view after long finger disarticulation through metacarpophalangeal joint. **B,** Dorsal view with fingers extended. **C,** Note space between index finger and ring finger on grip. **D,** Web space. **E,** Grip in left hand after long finger disarticulation through metacarpophalangeal joint.

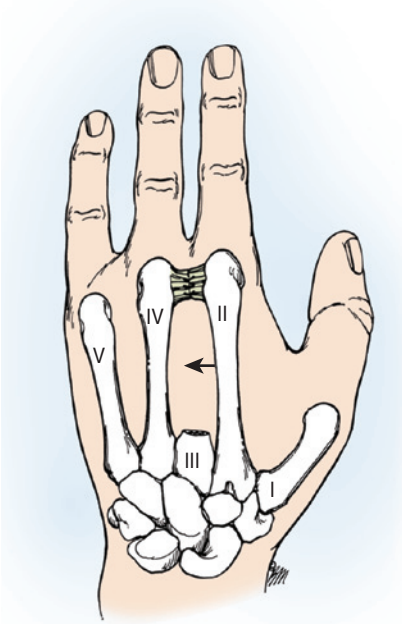

FIGURE 49.19 Long finger ray amputation with repair of the deep transverse intermetacarpal ligament. This may be provisionally stabilized by a transverse intermetacarpal Kirschner wire during the healing process. The *arrow* indicates how the index and ring finger metacarpals are drawn together, obliterating the space left after long finger deletion.

dissection of the extensor carpi radialis brevis from the dorsal aspect of the long finger metacarpal base is necessary to preserve its function. Reconstruction of the hand involves closing the gap between the index finger and ring finger metacarpals while avoiding angulation and malrotation. From proximal to distal, sutures are placed between the periosteum/muscles of the index finger and ring finger metacarpals, followed by their respective sagittal bands and DTIL (having excised the palmar plate of the long finger MP joint, which can act as a barrier to preventing closure of the dead space). Dorsal skin excision or dermadesis helps to further support the reconstruction. A palmar "V" flap of excess skin is excised.

❖ AUTHOR'S PREFERRED METHOD OF TREATMENT: Long Finger Ray Amputation Without Ray Transposition

After satisfactory regional or general anesthesia, the limb is exsanguinated and a tourniquet is applied. A dorsal incision is made and extended along the shaft of the long finger ray (Figure 49.21). The distal ends of the incision are carried over the proximal phalangeal skin to preserve sufficient skin for closure of the commissure between the index and ring fingers. This technical point is important when performing ray amputations of the middle two rays to preserve skin and prevent iatrogenic web contracture. Alternatively, a web-saving incision that

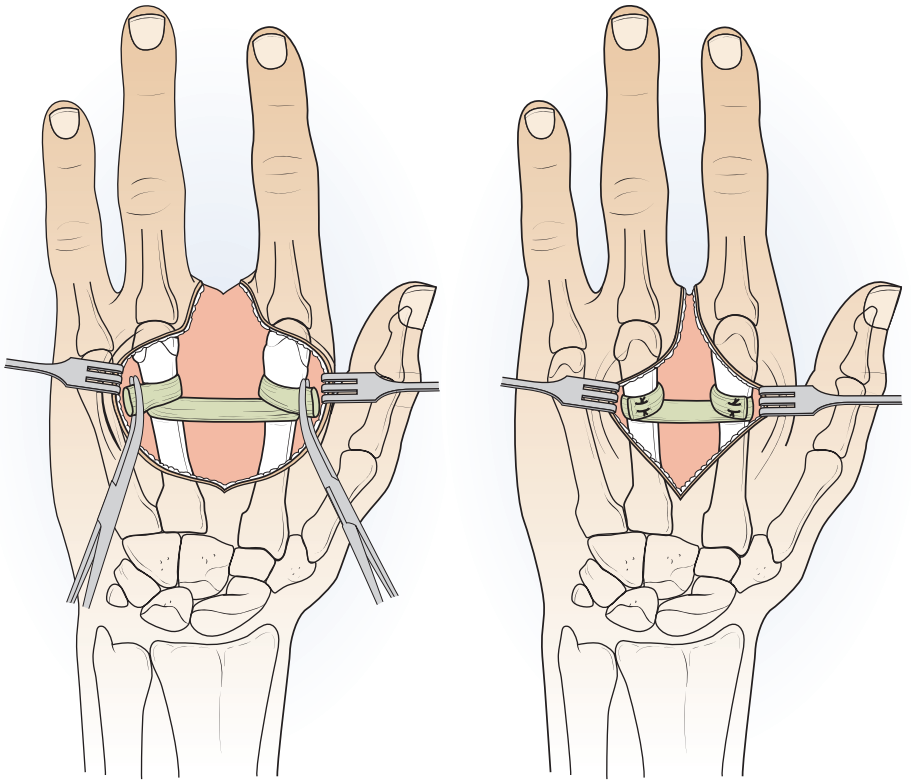

FIGURE 49.20 Reconstruction of dorsal transverse intermetacarpal ligament between index and ring finger metacarpals after central ray deletion. (From Gong HS, Shin SI, Baek GH: Creation of a "dorsal transverse intermetacarpal ligament" to prevent scissoring deformity in central ray amputation. *J Hand Surg Eur Vol* 33:163–165, 2008.)

avoids placing the scar in the new web space can be used (Figure 49.22).

The extensor digitorum communis tendon to the long finger is divided proximally. The long finger metacarpal is osteotomized at its base distal to the extensor carpi radialis brevis insertion after subperiosteal dissection has been carried out and the intrinsic muscles reflected. The second dorsal interosseous, lumbrical, and third dorsal interosseous tendons are divided. The DTIL is identified as it lies between the palmar lumbrical and dorsal interossei. A continuous band is created by leaving the volar plate in situ as the metacarpal is released from its volar capsule and adjacent interossei. Palmar dissection is carried out in a fashion similar to the procedure for the index finger, and the blood vessels are ligated and the digital nerves transected as far proximally as possible. The flexor tendons are divided and allowed to retract proximally. The digital nerves of the long finger are buried deep in the muscles of the second and third intermetacarpal spaces or can be sutured together in an end-to-end manner.[58] Wound closure is critically important in order to try to prevent malrotation and scissoring of the index and ring fingers. The ring finger and index finger metacarpals are compressed together to close the space created by central ray deletion. The DTIL is imbricated in a pants-over-vest configuration with 3-0 nonabsorbable sutures. This should be performed tightly because the repair will stretch. In cases where the intermetacarpal ligaments are absent or insufficient, free tendon grafts may be used to prevent scissoring.[56] The palmar skin is closed and scissoring of the digits checked via wrist tenodesis. The dorsal structures are next closed, including the periosteum/muscles of the index and ring finger metacarpals, followed by their sagittal bands and the dorsal skin. Attention should be paid to dorsal skin closure because dorsal skin dermadesis can exacerbate any malrotation caused by gap closure after central ray deletion. The hand is inspected by passive range of motion of the fingers and wrist tenodesis to check for rotational deformity. The commissure is fashioned to reflect a dorsal-volar slope of the web skin between the index and ring fingers. Temporary Kirschner wires can be placed from the index to ring finger metacarpals. A splint is applied, and early digit range of motion is encouraged. The Kirschner wires are removed after 4 to 6 weeks, and active and active-assisted range-of-motion exercises are begun. Strengthening is delayed until palmar tenderness has resolved.

Long Finger Ray Amputation With Transposition

Despite technical advancements, acute long finger ray resection with repair of the DTIL may still cause malrotation and scissoring of neighboring digits. To avoid the subsequent loss of three-point chuck pinch and the functional impairment that may ensue, transposition of the index finger to the long finger has been advocated.[29,65] The advantage of index finger ray transposition is that it gives immediate closure of the intervening space when the long finger ray is removed and allows the surgeon to control rotation at the osteotomy site.

Colen and coworkers[37] reported on the functional outcomes after ray transposition for central digital loss. Eleven patients had an index finger transfer for long finger deletion and 8 had a small finger transposition for ring finger amputation. Total grip was 80% compared with the contralateral hand, with greater digit range of motion, pinch, and grip strength in those



FIGURE 49.21 Long finger ray depletion without ray transposition. **A,** Dorsal longitudinal incision. **B,** Palmar "V" incision. **C,** Exposure of the long finger metacarpal with proximal division of its extensor tendon. **D,** Palmar exposure. **E,** Long finger deletion. **F,** Palmar closure. **G,** Note the rotational alignment of the digits after closure of the space between the ring and index finger. **H,** Dorsal wound. **I,** Intraoperative fluoroscopic images. **J, K,** Functional result. (Reprinted from Diaz-Garcia RJ, Haase SC: Upper limb amputations and prosthetics. In Arnold-Peter C, editor: *Textbook of Hand and Upper Extremity Surgery*, Chicago, 2013, American Society for Surgery of the Hand, Figure 6, p 1471. With permission from American Society for Surgery of the Hand.)

who underwent small finger to ring finger transfer than in those who underwent index finger to long finger transfer. Posner[120a] reported on a series of 14 patients who underwent 9 index finger and 5 small finger transpositions. In 13 of 14 patients, the step-cut osteotomy had healed by 9.5 weeks. There were no instances of malrotation, and all patients were happy with the prehension function and cosmetic result. Hanel and Lederman[65] treated 10 patients with index finger to long finger ray transposition. Rigid internal fixation was used, and patients were mobilized immediately. The authors reported a union rate

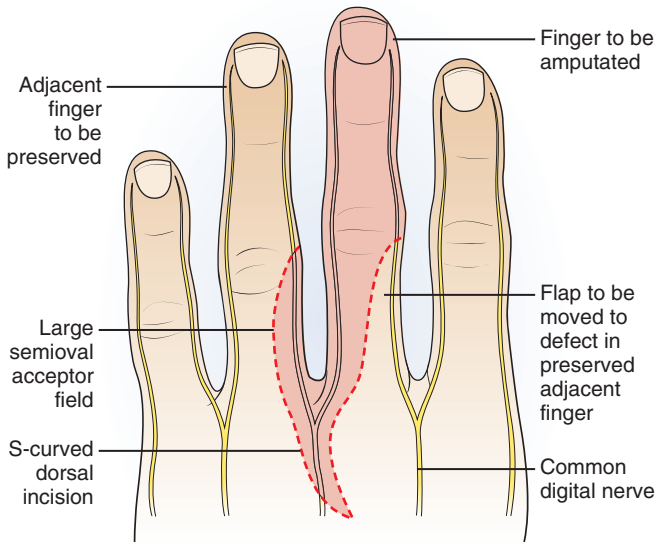

FIGURE 49.22 An incision is made to preserve the web space with amputation of the long or ring finger ray with its digital nerves (*shaded*), with preservation of the adjacent digital nerves of the transposed ray (*unshaded*).



FIGURE 49.23 This radiograph demonstrates a nonunion of index finger to long finger ray transposition. The osteotomy site in the long finger metacarpal was made too far distally. If ray transposition of the index finger is done, it is important to perform the osteotomy at the metacarpal base; this leads to a lower nonunion rate.

of 100%, no loss of range of motion, and no cases of malrotation. The average strength of grip and pinch was 65 and 78%, respectively, compared with the contralateral hand. The size of the web space in the reconstructed hand was within 2 mm of the uninjured hand. Six patients involved in workers' compensation cases returned to the same occupation. Patients were uniformly pleased with the hand function and aesthetic results. Carroll[29] also reported his results in 20 cases in which the entire index metacarpal was transposed to the base of the capitate and an arthrodesis was performed between the base of the index metacarpal and the capitate after the transposition. He noted no difference between this procedure and transposition to the base of the long finger metacarpal but preferred osteotomy at the base of the index metacarpal and osteosynthesis of the transposed metacarpal shaft to the base of the third metacarpal.

Complications of ray transposition include malunion, nonunion (Figure 49.23), and stiffness of the transposed digit related to extensor tendon adherence at the osteotomy site. In addition, the transfer results in a large first web space and removes the necessary relationship between the thumb and the index finger for precision pinch.

❖ AUTHOR'S PREFERRED METHOD OF TREATMENT: Long Finger Ray Amputation With Ray Transposition

After satisfactory regional or general anesthesia, the limb is exsanguinated and the tourniquet inflated. A dorsal incision is made extending along the shaft of the long finger ray (Figure 49.24, *A*). The distal ends of the incision are carried out over the proximal phalangeal skin to preserve sufficient skin for closure of the commissure between the index and ring fingers. Alternatively, a web-saving incision that avoids placing the scar in the new web space can be used (see Figure 49.22).

After the dorsal skin is incised, the extensor digitorum communis tendon to the long finger is divided proximally and reflected distally. Subperiosteal dissection is performed to expose the long finger metacarpal and maintain the origin of the adductor pollicis muscle. Many methods of osteosynthesis have been described, including Kirschner wires and rigid internal fixation. With the advent of locking technology, my preference is the use of rigid fixation with plates and screws. The plate is placed onto the proximal aspect of the metacarpal and aligned along its shaft. A mark is placed on the metacarpal at a point that ensures a minimum of three screw holes proximally. The plate is removed and a transverse osteotomy made at the marked area, which tends to lie at the metadiaphyseal junction and is distal to the extensor carpi radialis brevis insertion (see Figure 49.24, *B*). Attention focuses palmarly, whereby the flexor tendons of the long finger are sharply divided under tension and retracted proximally. The digital arteries are ligated and the radial and ulnar digital nerves are sutured in an end-to-end manner.[58] As the long finger is excised, care is taken to identify and preserve the DTIL (see Figure 49.24, *C*).

Through the same incision, the index finger metacarpal is exposed and a transverse osteotomy performed at the proximal metadiaphyseal flare (see Figure 49.24, *D*). To aid in the mobilization of the index finger metacarpal, the first palmar and second dorsal interossei are resected. The "T"-plate is applied to the long finger metacarpal base and secured proximally. The index finger metacarpal shaft is transposed onto the recipient site of the long finger metacarpal base. The overall alignment of the digit as well as its height in relation to the ring finger metacarpal is checked and adjusted before rigid osteosynthesis is performed. Bone graft from the excised long finger metacarpal can be used at the osteotomy site. After fixation, the periosteal sleeve containing the origin of the adductor pollicis is

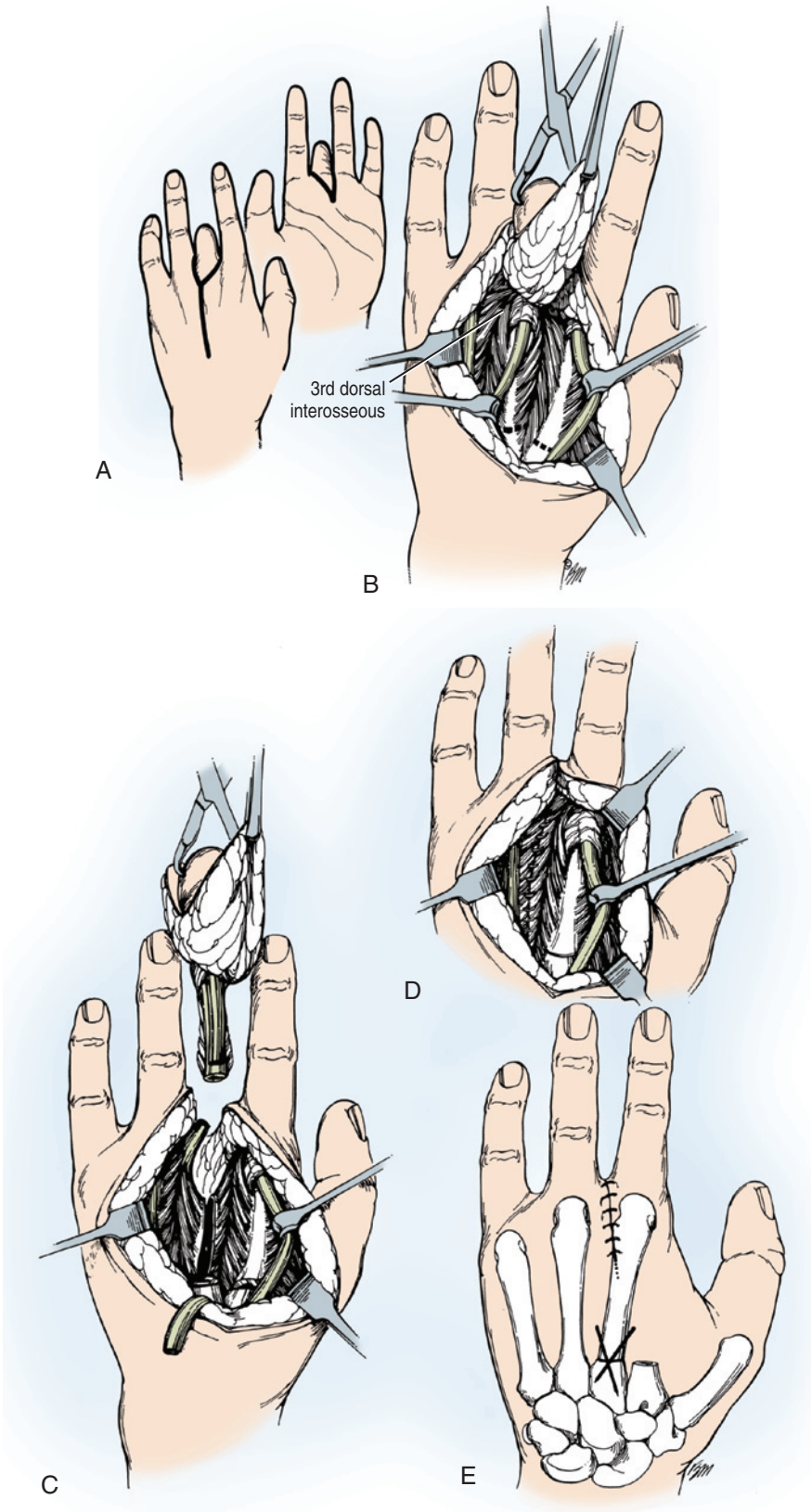

FIGURE 49.24 **A** to **E,** Diagram detailing index finger ray transposition to the base of the long finger metacarpal.

reattached to the index finger metacarpal in its newly transposed position. The DTIL between the index finger and ring finger is securely repaired in a pants-over-vest configuration with 3-0 nonabsorbable sutures. The alignment of the digits is rechecked through both passive range of motion and wrist tenodesis. To aid with abduction of the transposed digit, the third dorsal interosseous tendon is sutured to the distal end of the first palmar interosseous tendon. After hemostasis is obtained, the dorsal fascia and skin are closed. The commissure is fashioned to reflect a dorsal-volar slope of the web skin between the index and ring fingers. Patients are immobilized in an intrinsic-plus splint for up to 4 to 6 to weeks (depending on the method of fixation) to ensure healing of the osteotomy. The PIP joints are left free for active motion (Figure 49.25). If an extensor lag develops at the long finger MP joint, a dynamic extension splint is used.[65]

RING FINGER RAY AMPUTATION

Along with the long finger, the ring finger plays an important role in forming the keystone of the palmar arch, and, together with the small finger, it plays an important role in power grip. On its own, it plays a minimal role in precision pinch and grip and is considered by some to be the least important digit with respect to hand function.[143] Despite this, ring finger ray resection can have negative effects on hand function. Nuzumlali and colleagues[115a] compared patients who underwent amputation (through the proximal phalanx) with those who underwent ray resection for ring finger avulsion injuries at the PIP joint. Compared with the amputation cohort, key and chuck pinch strengths were substantially decreased in the ray resection patients; this finding suggests that ray resection be avoided in patients requiring key and chuck pinch in their occupations. In addition, central ray deletion can have a negative impact on manual dexterity.[102]

As with the long finger, two techniques of ring finger ray amputation have been described, namely, performing the procedure with bony transposition or without it.

Ring Finger Ray Amputation Without Transposition

In the ring finger, unlike in the index finger and long finger, there is 15 to 30 degrees of mobility between the ring and small finger metacarpal bases and the hamate at the carpometacarpal joint. The ring finger and small metacarpal bases also share a common articulation with the hamate. It is therefore possible for the base of the fifth metacarpal to slide radially if the entire

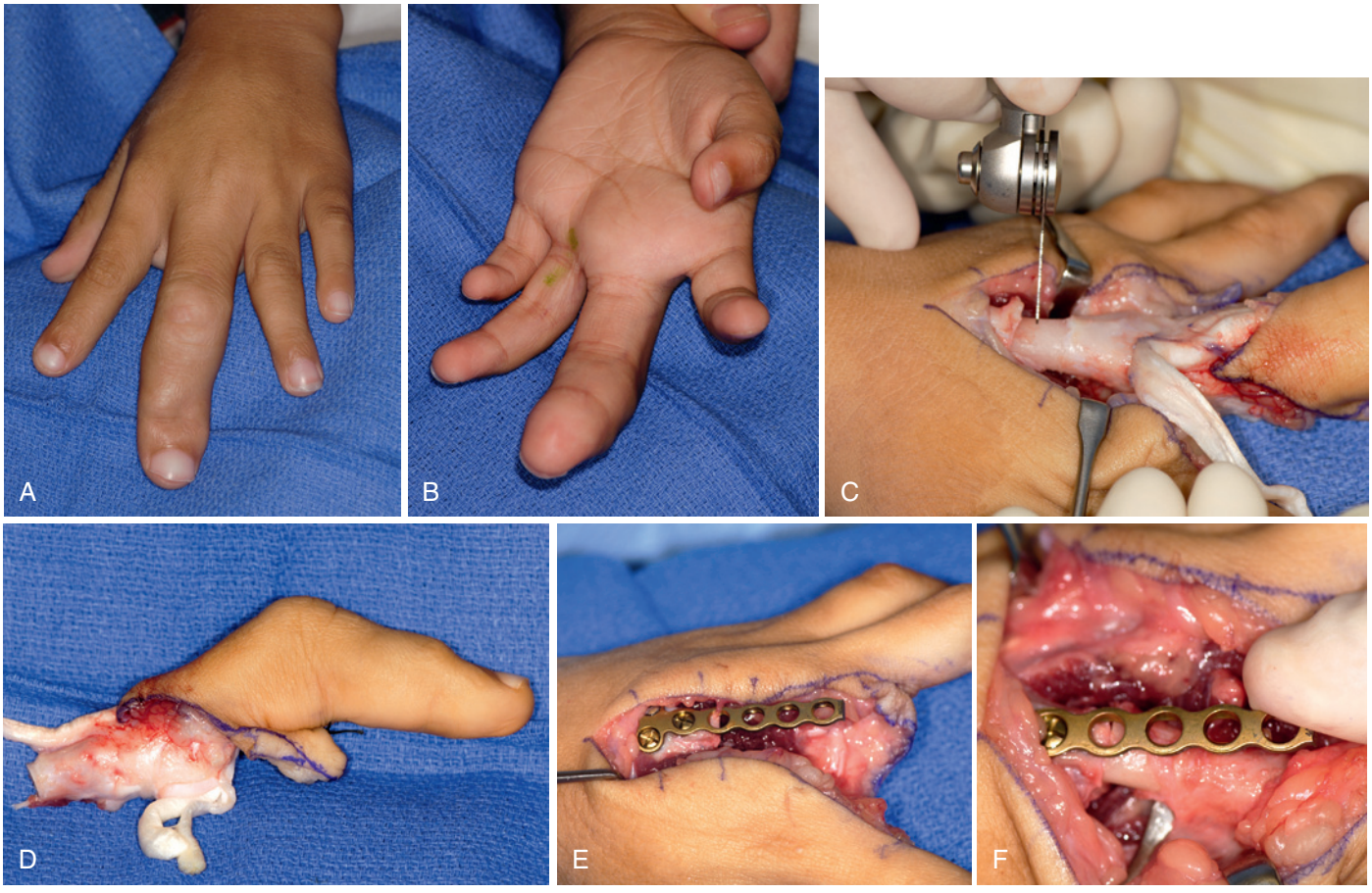

FIGURE 49.25 A 4-year-old boy with isolated left long finger macrodactyly treated with early ray resection and index finger transposition. **A,** Preoperative dorsal view. **B,** Preoperative palmar view. **C,** Long finger metacarpal osteotomy. **D,** Amputated long finger macrodactyly. **E,** "T"-plate and screw fixation at the long finger metacarpal base in preparation for index finger transposition. Note a minimum of six cortices proximally. **F,** Index finger transposed to long metacarpal.



FIGURE 49.25, cont'd **G,** Digital rotation checked before final fixation. **H,** Volar wound closure. **I,** Dorsal wound closure. **J,** Anteroposterior postoperative radiographs. **K,** Lateral postoperative radiograph. **L,** Functional use of transposed index finger into daily activity. (Courtesy of Scott Kozin, Shriners Hospital for Children, Philadelphia.)

metacarpal shaft of the fourth metacarpal is excised. This possibility is enhanced by the anatomic lack of tendinous attachments to the base of the fourth metacarpal, unlike in the remaining metacarpals in the hand. This concept was borne out by the results of Steichen and Idler,[135] who reported on patients who underwent central ray resection without transposition. Given the mobility of the fifth CMC joint and the narrower diameter of the fourth metacarpal, they noted that it was relatively easy to close the intermetacarpal space between the long finger and small finger compared with the space between the index finger and ring finger after long finger deletion. Cosmetic and functional results were satisfactory in 12 of 13 patients.

Transmetacarpal ray resection of the ring finger can leave an open space between the long finger and small finger because the remaining metacarpal base prevents convergence of the two digits. This can be avoided by complete ray deletion, but complete deletion can lead to a loss of small finger abduction and possible scissoring due to forced convergence of fifth toward the center.[91]

❖ AUTHOR'S PREFERRED METHOD OF TREATMENT: Ring Finger Ray Amputation Without Transposition

A racket-shaped incision is created distally over the proximal phalanx or its remnant (Figure 49.26). A proximal longitudinal incision is made over the fourth metacarpal, continuous with the racket incision. Alternatively, a web-saving incision that avoids placing the scar in the new web space can be designed (see Figure 49.22). The incision is carried down through the subcutaneous tissue, beginning dorsally. The dorsal veins are preserved when possible. The extensor digitorum communis tendon to the ring finger ray is transected proximally and the tendon is reflected distally. An incision is made through the periosteum down to the metacarpal shaft. Subperiosteal dissection is carried out, and the base of the metacarpal is identified at its articulation with the hamate. The dorsal CMC ligaments are incised; subsequently, by detaching the articulation and performing palmar flexion of the metacarpal, the volar CMC ligaments may be divided. Care must be taken to avoid damage to



FIGURE 49.26 Diagram showing racket-based incision for performing a ring finger ray resection. (Copyright Elizabeth Martin.)

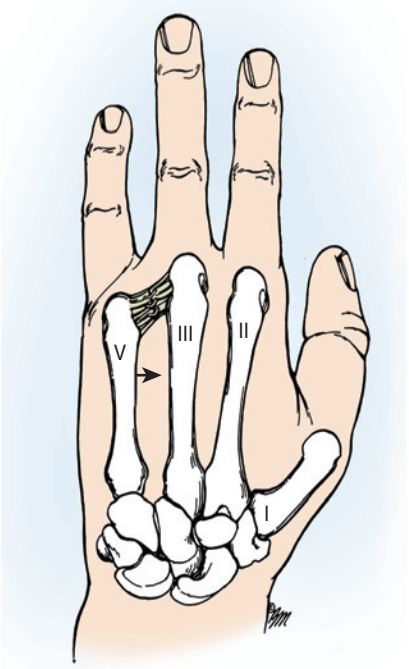

FIGURE 49.27 Suture of the deep intervolar plate ligaments with subsequent migration of the fifth metacarpal base radially across the hamate during complete ring finger ray amputation. The *arrow* indicates how the small finger metacarpal can slide on its hamate articulation toward the long finger metacarpal.

the underlying ulnar nerve and artery. The metacarpal base is elevated, and further dissection frees the metacarpal from its underlying bed. The lumbrical, second volar, and fourth dorsal interosseous tendons are divided. Dissection is carried out around the volar aspect of the amputation site, the digital vessels are identified and ligated, and the digital nerves are transected under tension at their most proximal portion. The flexor tendons are sharply divided under traction after incision of the palmar fascia. The DTIL is identified and appropriately transected close to the volar plate with careful preservation of the digital nerves. The palmar fascial attachments are incised, and the ray is removed.

As with the long finger, attention must be paid to wound closure to prevent malrotation and scissoring of the long and small fingers. The small finger is compressed to the long finger along its articulation with the hamate. The DTIL is imbricated in a pants-over-vest configuration with 3-0 nonabsorbable sutures (Figure 49.27). This should be done tightly because the repair will stretch. The digital nerves are either transposed dorsally into the interosseous space or sutured together in an end-to-end manner.[58] The palmar skin is closed and scissoring of the digits checked via wrist tenodesis. The dorsal structures are next closed. Skin dermadesis can exacerbate any malrotation caused by gap closure after ring finger ray deletion. The hand is inspected by passive range of motion of the fingers and wrist tenodesis to check for rotational deformity. Temporary transverse Kirschner wires can be placed between the long finger and small finger metacarpals. A splint is applied, and early digit range of motion is initiated. The Kirschner wires are removed after 4 to 6 weeks. Patients work on regaining active range of motion before strengthening is initiated (Figure 49.28).



FIGURE 49.28 Radial migration of the base of the small finger along the hamate after ring finger deletion.

Ring Finger Ray Amputation With Transposition of the Fifth Metacarpal

Given the risk of possible convergence of the long finger and small finger after ring finger ray resection,[37] as well as the risk of impaired mobility and the possibility of objects falling

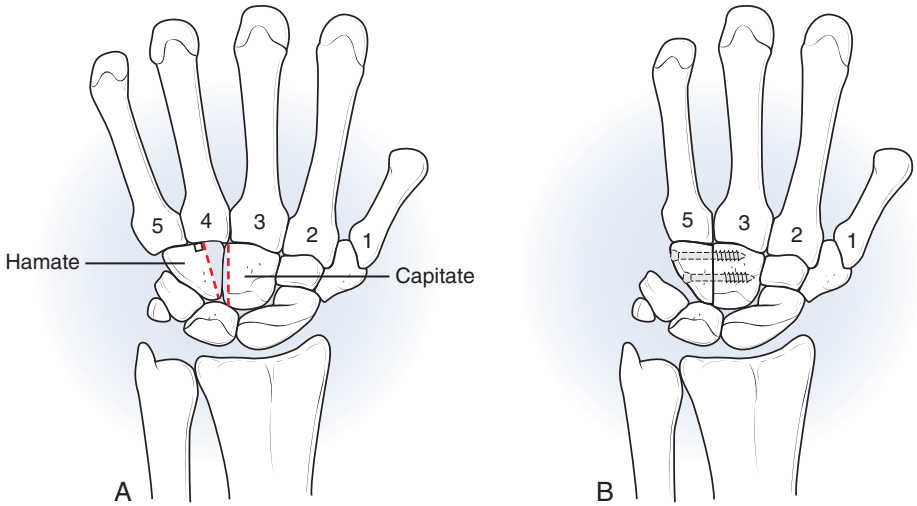

FIGURE 49.29 **A,** Osteotomy of the ulnar aspect of the capitate and radial side of the hamate. **B,** Capitohamate arthrodesis. The *red dotted line* indicates the margins of the osteotomy. (**B,** Redrawn from Le Viet D, Dailiana ZH: Third and fourth finger ray amputations by intracarpal osteotomy. *Tech Hand Up Extrem Surg* 3:110–115, 1999.)

through the space between the third and fifth rays, there are advocates for transposition of the small finger to the ring finger. Le Viet[90] described a technique that involved complete ring finger ray resection, an intracarpal wedge-shaped osteotomy, and a capitohamate arthrodesis for small finger translocation[90,91] (Figure 49.29). He proposed four main advantages: (1) convergence between the small finger and long finger is avoided, (2) the integrity of the ulnar side of the hand is maintained, (3) the fifth CMC joint is preserved, and (4) the action of the interossei is unchanged. In a series of 17 patients, 14 were satisfied with preservation of motion at the CMC joint. Complications included transient wrist pain that subsided after 6 weeks, 1 pseudoarthrosis, 1 transient case of carpal tunnel syndrome, and 7 cases of malrotation. The author acknowledged that there is a learning curve with this technique. Others have reported more favorable results and state that the technique is easier than metacarpal osteotomy.[42,97] Another concern of small finger transposition is that the finger will be shorter than the ring finger. To mitigate this issue, Posner[120a] described a step-cut osteotomy to add height to the small finger as it is transposed to the base of the ring finger metacarpal. The small finger metacarpal is cut at a more proximal level than the ring finger metacarpal and as such, can lengthen the small finger by 1.5 cm at the time of transposition (Figure 49.30). This lessened the discrepancy in length between the long finger and transposed small finger and resulted in satisfactory hand function and cosmesis.

❖ AUTHOR'S PREFERRED METHOD OF TREATMENT: Ring Finger Ray Amputation With Small Finger Ray Transposition

The technique is similar to that for index transposition to the long finger as previously described. A racket incision is made around the proximal phalangeal remnant of the ring finger (see Figure 49.26). The incision is extended dorsally between the ring finger and small finger metacarpals. Care is taken to identify and protect the dorsal sensory branches of the ulnar nerve as well as the extensor digitorum communis to the small finger, which may be small and mistaken for a junctura tendinum. The extensor digitorum communis tendon to the ring finger is transected proximally and reflected distally. After subperiosteal dissection, a transverse osteotomy is made through the metaphyseal flare with an oscillating saw. The metacarpal is freed distally, and the lumbrical and second volar and fourth dorsal interosseous tendons are divided. The volar extent of the dissection is carried out by identifying the neurovascular bundles, ligating the digital vessels, and transecting the digital nerves at the most proximal level possible under tension. The palmar fascia, flexor sheath, and flexor tendons are divided. The DTILs are identified and transected and the ray is excised. Dissection is carried out in subperiosteal fashion to allow an osteotomy through the base of the fifth metacarpal just distal to its metaphyseal flare. To enable transposition of the small finger, the origin of the fourth dorsal interosseous tendon is released from the fifth metacarpal.

The small finger metacarpal shaft is transposed onto the recipient site of the ring finger metacarpal base. The overall alignment of the digit in relation to the long finger metacarpal is checked and adjusted as needed before osteosynthesis is performed. Bone stabilization can be performed with a "T"-plate (the preferred technique, as discussed earlier) or two crossed Kirschner wires (Figure 49.31). Bone graft from the excised ring finger metacarpal can be used at the osteotomy site. The DTIL is imbricated in a pants-over-vest configuration with 3-0 nonabsorbable sutures (see Figure 49.27). This should be performed tightly because the repair will stretch. The digital nerves are either transposed dorsally into the interosseous space or sutured together in an end-to-end manner.[58] The wounds are closed in routine fashion, with care taken to fashion the interdigital commissure appropriately. Dry sterile dressings are applied after the tourniquet has been deflated. Postoperative management is similar to that described for long finger ray amputation with index finger transposition. Patients are immobilized in an intrinsic-plus splint for up to 4 to 6 weeks (depending on the method of fixation) to ensure healing of the osteotomy. The PIP joints are left free for active motion.

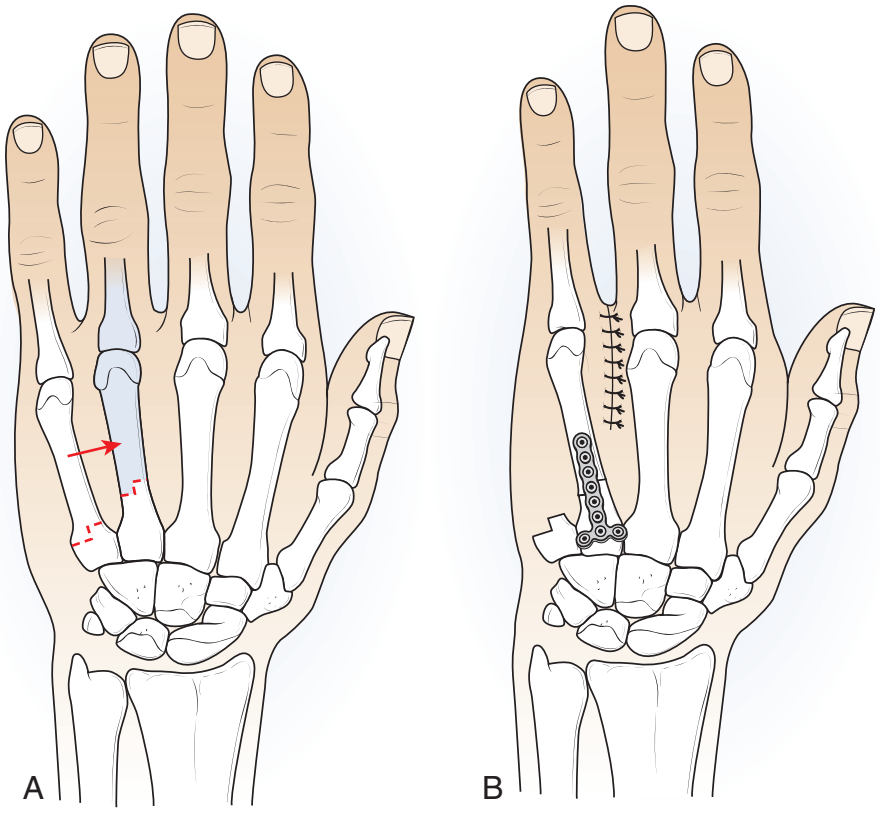

FIGURE 49.30 **A** and **B,** Step-cut osteotomy through the base ring finger metacarpal followed by transposition of the small finger. Note the approximation of the transposed small finger to the length of the amputated ring finger. The *red arrow* indicates the digit to be amputated, and the *red dotted line* indicates the level of the step-cut osteotomies within the ring and small finger metacarpals to ensure satisfactory length of the transposed digit.

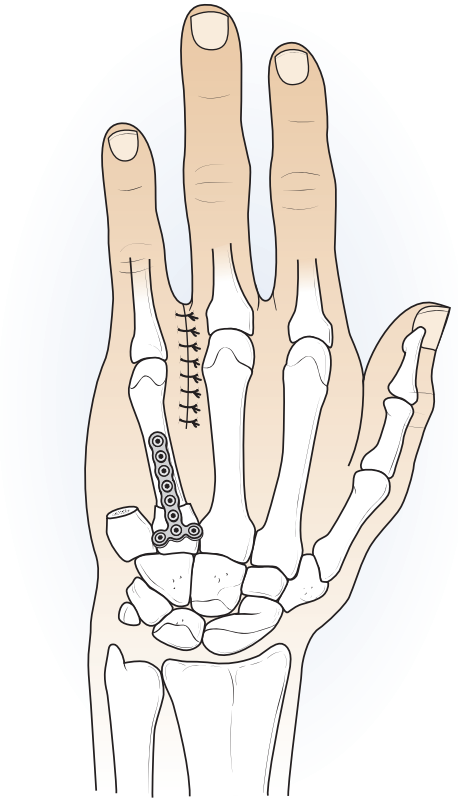

FIGURE 49.31 Small to ring finger transposition. Note osteosynthesis with two crossed Kirschner wires.

SMALL FINGER RAY AMPUTATION

The small finger plays an important role in digitopalmar grip because of the mobility of its CMC joint and the action of the hypothenar muscles.[110] It also increases the span of the hand for grasp owing to its abduction moment. These two facts have led some to believe that the small finger has the most functional value after the thumb.[143]

❖ AUTHOR'S PREFERRED METHOD OF TREATMENT: Small Finger Ray Amputation

For small finger ray amputation (Figure 49.32), a dorsal incision is fashioned over the small finger metacarpal and curved around the base of the proximal phalanx. Care is taken to ensure that the incision is not placed directly over the ulnar border of the hand to prevent scar sensitivity. After the dorsal skin is incised, care is taken to identify and protect the dorsal sensory branches of the ulnar nerve, which lie within the subcutaneous tissue. The extensor digitorum communis and extensor digiti minimi tendons to the small finger are transected proximally and reflected distally. Subperiosteal dissection is carried out around the base of the metacarpal, and an osteotomy is performed with a reciprocating saw at its metaphyseal flare, with care taken to protect the insertions of the extensor carpi ulnaris and flexor carpi ulnaris tendons (Figure 49.33). The metacarpal is reflected distally, and the conjoined tendon of the abductor digiti minimi and flexor digiti minimi is divided distally, as well as the third volar interosseous and lumbrical tendons. Attention is next diverted to the palmar side. The digital vessels are ligated and

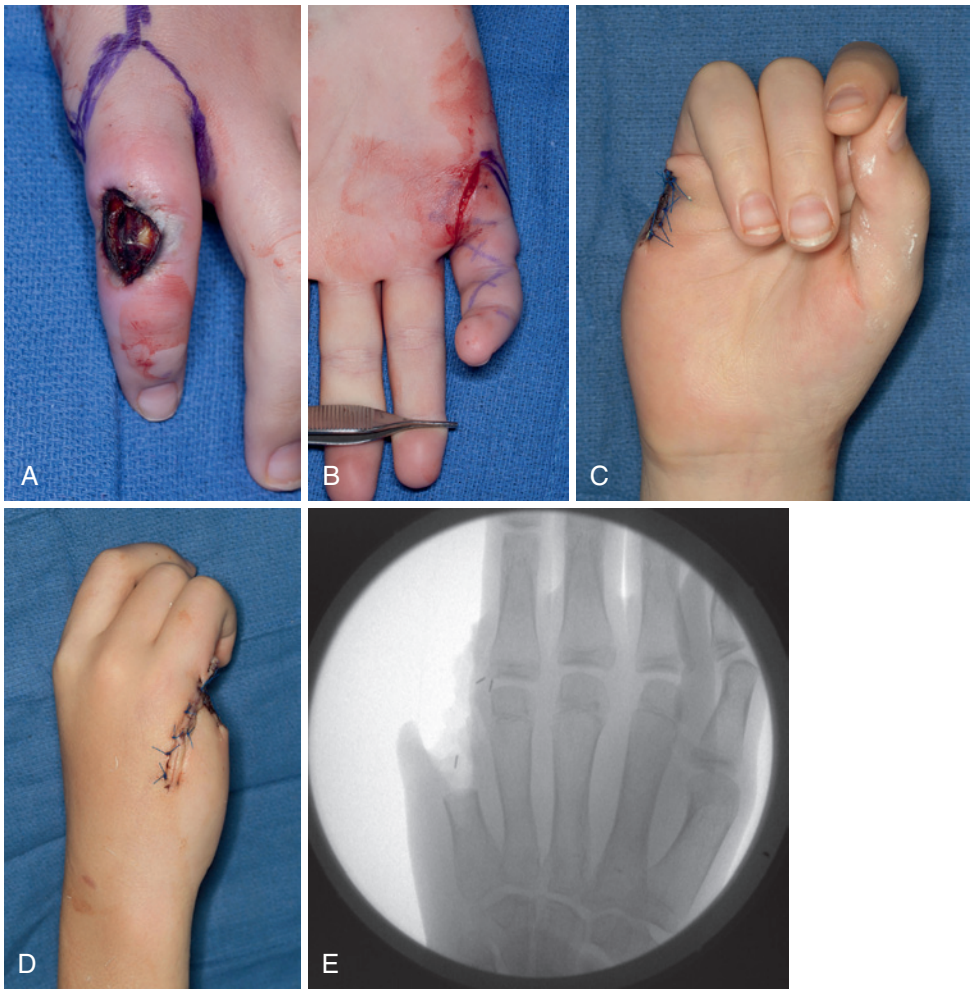

FIGURE 49.32 A 13-year-old boy with acute lymphocytic leukemia who underwent small finger ray amputation for rapidly disseminating mucormycosis infection from the small finger. **A,** Necrotic mucormycosis infection. **B,** Palmar incision. **C,** Postoperative volar view. **D,** Postoperative dorsal view. **E,** Postoperative fluoroscopic view.

the digital nerves divided proximally in the wound. They can either be transposed later into the interosseous space to protect them from direct trauma or sutured directly to each other in an end-to-end manner. The extrinsic flexor tendons are transected under tension, and the DTIL is transected between the ring and small fingers. The hypothenar muscles are not sutured to the fourth interossei and are used to fill the remaining defect, providing satisfactory cushioning to the digital nerves and ulnar side of the hand. It is not advisable to reattach the hypothenar muscles to the tendon of the fourth dorsal interosseous, because this is unnecessary and the results are unpredictable. The tourniquet is deflated, hemostasis is obtained, and the skin incision is closed. The hand is placed into a bulky dressing, and the patient is encouraged to begin early active range-of-motion exercises for all remaining digits.

CRITICAL POINTS *Ray Amputations*

- Although single-ray amputation of the index, long, ring, or small finger affects the biomechanics of the hand, it does not result in substantial loss of hand function.
- An acute ray amputation following trauma should be performed sparingly because most ray amputations are performed as secondary procedures.
- Ray amputations can improve the appearance of the hand.
- Skin incisions should be planned to prevent a web space contracture.
- Ray resections without transposition are preferred to avoid complications such as nonunion and to minimize postoperative immobilization.
- Vigilance during soft tissue closure is necessary to avoid scissoring of the neighboring.
- Amputation of the small finger ray requires preservation of the metacarpal base to protect the insertion of the flexor and extensor carpi ulnaris tendons.

MULTIPLE-DIGIT AMPUTATIONS

Amputations that involved multiple digits may be needed following mechanical trauma, infection, hypothermia, or vascular disturbances. The incidence is about 3 to 6 times greater in men than in women and is 4.9 times greater in left-handed than in right-handed individuals.[8,35,141] The basic principle in such situations is to save all viable tissue by whatever means appropriate and to preserve the tissue for possible reconstruction at a later date.[31] Amputation of the thumb is associated with substantial disability because the thumb provides over 40% of the function in the hand. Thus, all attempts are made to replant or salvage the thumb. If the thumb is deemed nonreplantable, Soucacos

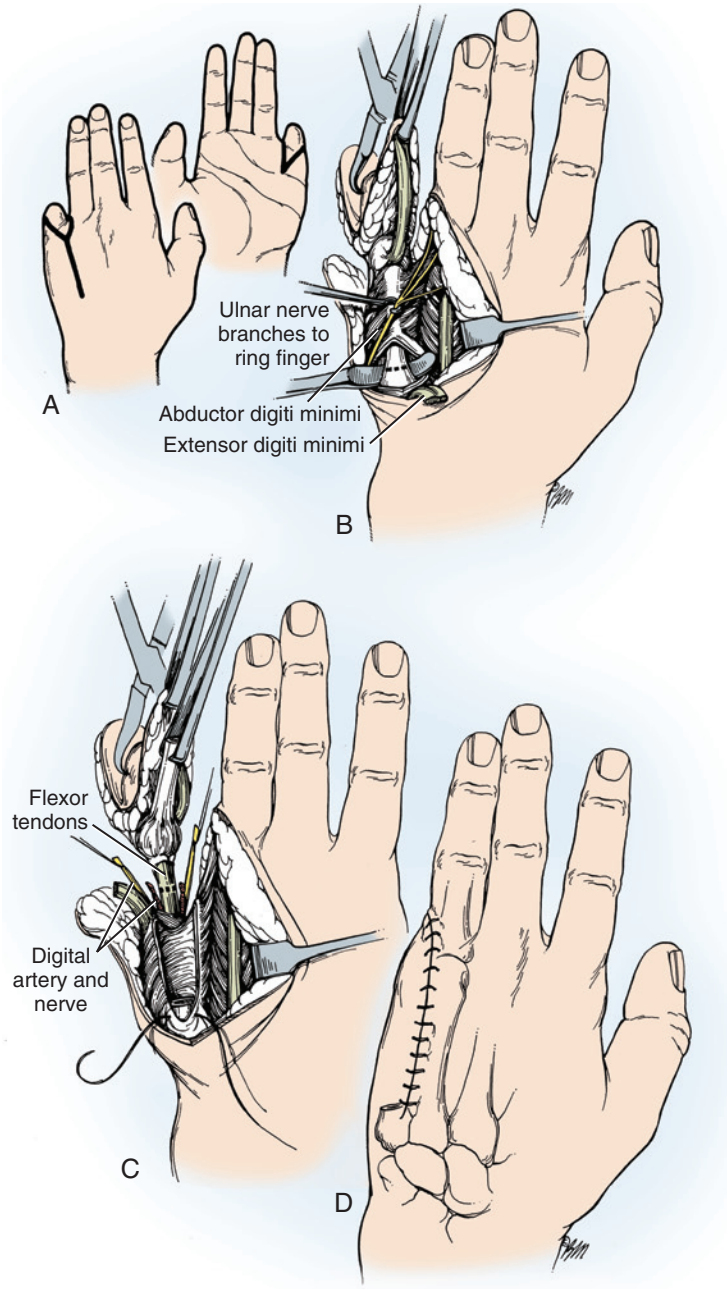

FIGURE 49.33 Ray amputation of the small finger is accomplished by transection of the metacarpal at its base, with the hypothenar muscles preserved to serve as an ulnar pad for the hand. **A,** Preoperative skin markings. **B,** Planned osteotomy site of the small finger metacarpal base, distal to the flexor carpi ulnaris and the extensor carpi ulnaris insertions. **C,** Removal of small finger metacarpal. **D,** Wound closure. (Copyright Elizabeth Martin.)

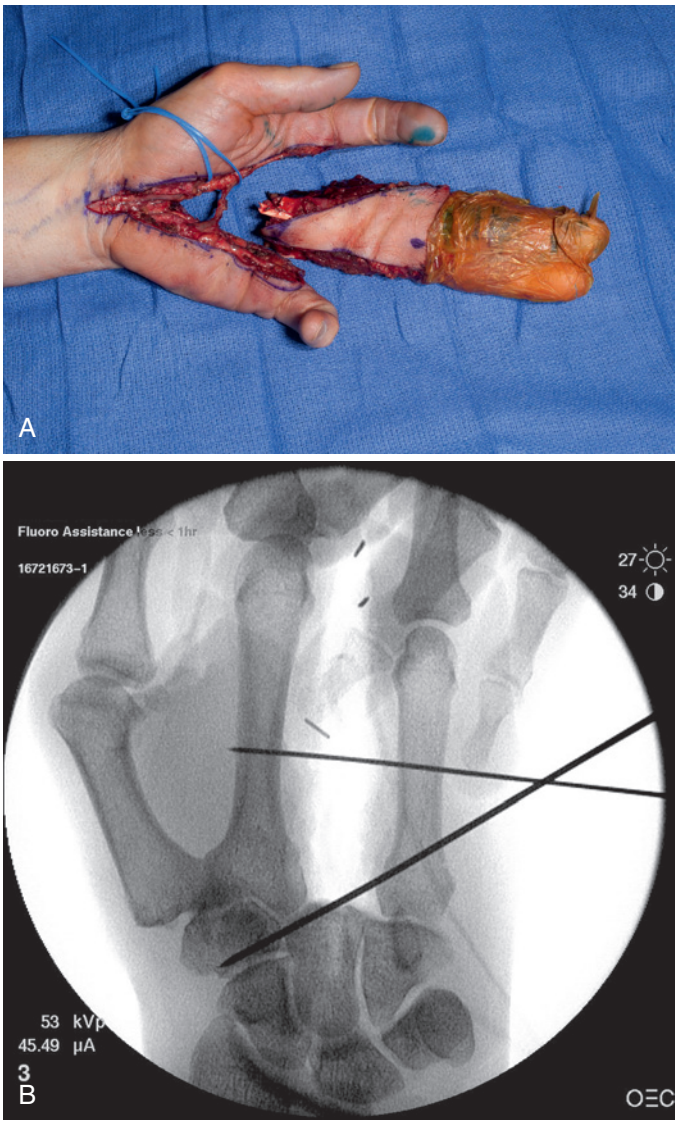

FIGURE 49.34 Long and ring finger ray amputation in a 59-year-old patient with soft tissue sarcoma of the hand. **A,** Palmar view of long and ring finger ray amputation with maintenance of the superficial palmar arch. **B,** Radialization of the small finger metacarpal on its articulation with the hamate.

and colleagues[134a] advocated transpositional digital microsurgery, in which the least damaged digit is replanted to the injured thumb. Preservation of a sensate thumb and another digit allows basic opposition pinch, and the addition of a third digit further improves chuck pinch, hook grip, and power grasp.[33,110,125] This concept was emphasized by Rose and Buncke[125] when they performed selective replantation in four patients with multiple-digit amputations. The least traumatized digits were replanted to the more ulnar metacarpal rays, and this resulted in a wider hand span for grasp, improved precision handling, and better chuck pinch. Additional digits may be added by microvascular toe transfer.[57,148] Gordon and coworkers[57] reported on double microsurgical toe transfers for reconstruction of the thumb and an ulnar ray or, when the thumb was present, two-finger reconstructions with bilateral second toe transfers. Patients reported improvement in hand function, with an average of more than 9 pounds of pinch using the transplanted toes. None of the patients reported difficulties with activities of daily living, although the majority did experience symptoms of cold intolerance.

Partial hand amputations may be necessary for the treatment of malignant tumors[106] (Figure 49.34). The tumor surgeon must balance the importance of obtaining negative surgical margins, which is associated with improved survival rates, and the preservation of critical structures that are important for hand function. Puhaindran and Athanasian and colleagues[121-123] reported on eight patients with soft tissue sarcomas of the hand who underwent partial hand resection followed by postoperative radiotherapy. Six of the eight patients were disease-free and had

a mean Musculoskeletal Tumor Society score of 26 (range, 19 to 29). (The score is based on a functional outcome scoring system of 0 to 5 points for six domains: pain, function, emotion, hand positioning, dexterity, and lifting ability. The higher the score, the better the function.) Patients who had undergone double-ray amputations (index finger and long finger or ring finger and small finger) had lower functional outcome scores. In their series of double-ray amputations, four of five patients with high-grade soft tissue sarcomas of the hand were disease-free and the mean grip strength was 24% of the contralateral hand. Notwithstanding this weakness, patients maintained good key, tip, and tripod pinch when the deep motor branch of the ulnar nerve was preserved.

CRITICAL POINTS *Multiple-Digit Amputations*

- Early surgical management in the mutilated hand involves sharp débridement of contaminated tissue, maintenance of as much digit length as possible, and preservation of all viable tissue for later reconstruction.
- All attempts should be made to preserve thumb function.
- Preservation of an additional digit will result in basic opposition pinch, and the addition of a third digit will improve chuck pinch, hook grip, and power grasp.

AMPUTATIONS THROUGH THE CARPUS

Amputations through the carpus require special consideration. Coverage may be possible with local or distant skin, but the intrinsic musculature is absent (Figure 49.35) and the patient is incapable of pinching and grasping. Preservation of the distal radioulnar joint (DRUJ) and the triangular fibrocartilage complex (TFCC) maintains forearm rotation. One of the concerns about keeping the carpus is the added length to the arm following prosthetic fitting. This may initially create a dilemma for both the patient and surgeon. More proximal amputation and fitting with a conventional prosthesis are alternative considerations, especially in terms of early functional rehabilitation. However, at the time of the initial traumatic event, the injured patient is incapable of making a decision such as this. Therefore, it is preferable to save what is salvageable and allow time for the patient to make a decision after having an opportunity to evaluate the alternatives. In addition, the preservation of some wrist movement is beneficial as the patient hooks objects between the forearm and carpus.

WRIST DISARTICULATION

As with a transcarpal amputation, one of the main advantages of a wrist disarticulation is preservation of the DRUJ and forearm rotation. Preserving the length of the forearm and the metaphyseal flare of the distal radius aids in prosthetic suspension. Despite these advantages, prosthetists argue that fitting may be more challenging than for transradial amputees because conventional prostheses may be too long, the prominence of the radial and ulnar styloids can lead to pressure necrosis, and myoelectric fitting is more difficult. This was highlighted by Wright and colleagues[153] in their review of prosthetic usage in patients with upper extremity amputations. The authors found a 94% utilization rate in patients with a below-elbow amputation compared with only 54% in those with a wrist disarticulation. One of the main reasons for the lower utilization rate could be the added length of the forearm in patients with a wrist disarticulation who can use the stump for object manipulation. In addition, by maintaining its sensibility, the stump may be more useful than an insensate prosthesis. Other factors linked to poor utilization of prosthetics include the type of device, late fitting, the cost of repairs, and the perceived limited functionality of the device.[7,16,40]

With improvements in prosthetic technology, preoperative consultation with the local prosthetist regarding the preferred level may be worthwhile. Hand transplantation is an option in the future and should be a part of the decision as to whether to shorten the residual limb to accommodate a prosthesis. Whenever possible, the patient, after weighing all of the medical information, should have the final decision about choosing a long transradial amputation or a wrist disarticulation.

❖ AUTHOR'S PREFERRED METHOD OF TREATMENT: Wrist Disarticulation

After satisfactory regional or general anesthesia, the limb is exsanguinated using an Esmarch wrap and the tourniquet inflated. If the surgical indication is infection or tumor, the arm is elevated and drained using gravity exsanguination and digital occlusion of the brachial artery. If possible, skin flaps are marked and raised at a level distal to the DRUJ such that the palmar flap is longer and the dorsal flap shorter for closure over the amputation stump (Figure 49.36). Once the skin has been incised, flaps are raised in a proximal direction and all veins ligated (Figure 49.37). My preference is to start on the dorsal surface and identify all the appropriate nerves, vessels, and tendons. The superficial branch of the radial nerve and the dorsal sensory branch of the ulnar nerve are dissected and divided under traction. Care is taken to ensure that they adequately retract in a proximal direction away from the amputation stump to minimize the chance of symptomatic neuroma. The posterior interosseous neurovascular bundle is identified and divided using electrocautery. The extensor tendons are divided at their resting physiologic tension and fixed to the distal radius. This has two main purposes: (1) Contraction of the extensor muscles can be used to drive a myoelectric prosthesis, and (2) the tendons are readily accessible if the patient becomes a candidate for hand transplantation. Attention then focuses on the palmar surface, where the medial antebrachial cutaneous, median, and ulnar nerves and the anterior interosseous neurovascular bundles are divided in a similar manner. An alternative method was described by Louis and colleagues,[95] whereby a separate longitudinal incision was made between the pronator teres and brachioradialis just distal to the elbow flexion crease to doubly ligate the median, ulnar, and superficial radial nerves at this region. This causes a neuroma-in-continuity to form at this site, and these neuromas are buried beneath the proximal muscles, where they are less likely to be symptomatic. The authors noted they did not find it necessary to ligate the antebrachial cutaneous nerves in the proximal forearm. The radial, ulnar, and median arteries (when present) are doubly ligated proximal to the wrist. After transection of the vessels, flexor tendons are secured to the distal radius in a fashion similar to that for the extensor tendons. Wrist disarticulation is performed through a transverse dorsal incision of the radiocarpal joint that gives visual access to the radiocarpal joint. By identifying and

CASE STUDY 49.1

A 15-year-old right-hand-dominant boy sustains a table saw injury to his left hand at school. Examination demonstrates dorsal degloving injuries to the index, long, and ring fingers through the proximal phalanges, with bone loss (eFigures 49.1 to 49.4).

Given the extent of the injury and the fact that the digits are not replantable, the patient is taken to the operating room emergently for revision amputation of the injured digits and wound closure using the palmar skin to maintain proximal phalangeal length. To improve flexion of the preserved metacarpophalangeal joints, the flexor digitorum superficialis tendons of the injured digits are tenodesed to the proximal phalanx (eFigures 49.5 to 49.8).

The patient's wounds heal without complications (eFigure 49.9 and Video 49.1). The treatment options now are observation (the thumb and small finger and span of the hand have been retained), prosthetic fitting, or toe-to-hand transfer.

The patient elects to use a prosthesis, and he meets with the prosthetist within 4 weeks of amputation for early fitting. He is fitted with iLimb digits (eFigure 49.10) to enable a full hand grasp around power tools and prevent toggling.

In addition, he receives a passive mechanical device for heavy-duty use (eFigure 49.11) and a passive silicone partial hand device to use in social settings (eFigure 49.12).



eFIGURE 49.1 Dorsal finger injury.



eFIGURE 49.2 Palmar finger injury.



eFIGURE 49.3 Preoperative anteroposterior hand and wrist radiograph.



eFIGURE 49.4 Preoperative oblique hand and wrist radiograph.

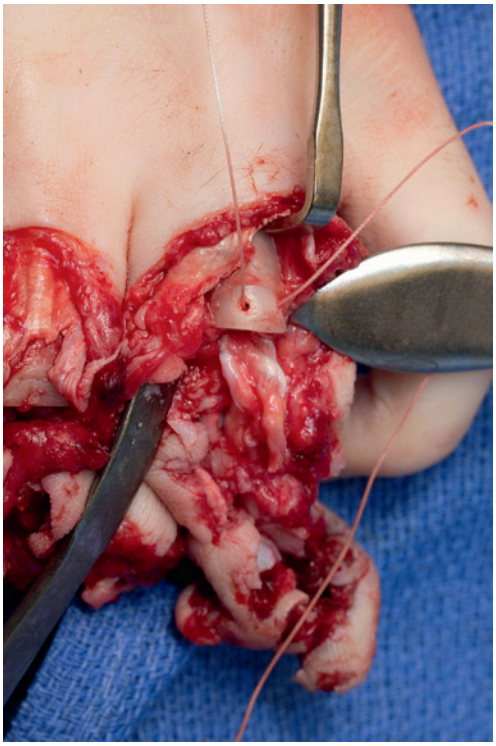

eFIGURE 49.5 Intraoperative view demonstrating drill holes through the proximal phalanx to tenodese the flexor digitorum superficialis tendon.

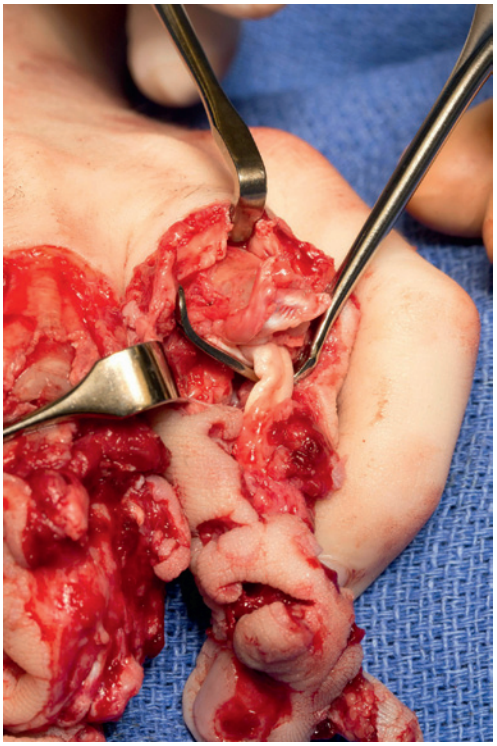

eFIGURE 49.6 Flexor digitorum superficialis tenodesis to proximal phalanx. The underlying flexor digitorum profundus tendon was transected under tension to permit proximal retraction.



eFIGURE 49.7 Intraoperative anteroposterior hand fluoroscopic image.

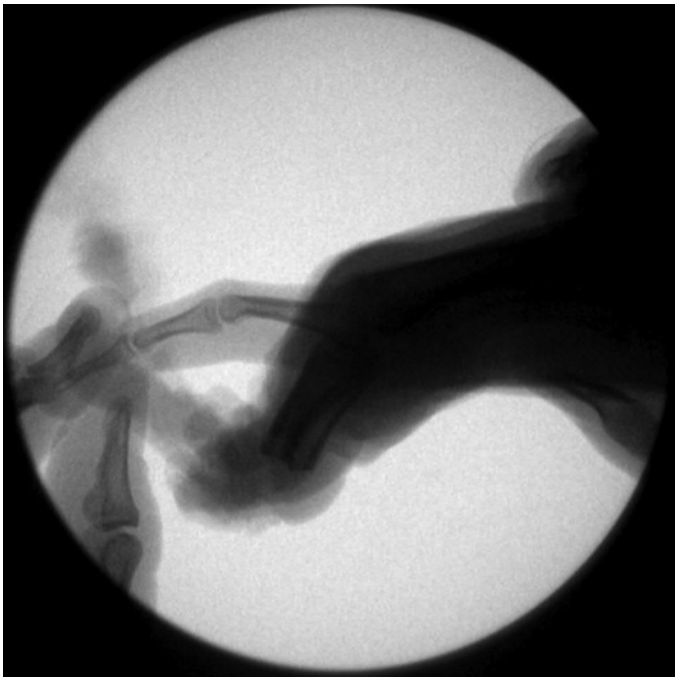

eFIGURE 49.8 Intraoperative lateral hand fluoroscopic image showing flexion of the proximal phalanx after tenodesis.



eFIGURE 49.9 Postoperative healing wounds.



eFIGURE 49.10 iLIMB digits.



eFIGURE 49.11 Mechanical passive device.



eFIGURE 49.12 An example of a partial hand silicone prosthesis. Note the aesthetic appearance.



FIGURE 49.35 Patient suffered a traumatic left midcarpal amputation **(A** and **B)**. After revision amputation **(C** and **D)** with local wound closure, patient was fitted with a myoelectric prosthesis with good function **(E** to **G)**. (Courtesy of Brian Carlsen and David Dennison, Mayo Clinic, Rochester, MN.)

protecting the distal radioulnar ligaments as well as the TFCC, the radiocarpal and ulnocarpal ligaments are divided, allowing amputation of the hand with the carpus. The prominent ulnar and radial styloid processes must be rounded off with a rasp to ensure they do not cause pressure necrosis at the wound edges. The skin flaps are fashioned to eliminate redundancy. The tourniquet is deflated, hemostasis is obtained, and the subcutaneous tissue and skin are closed in layers. A suction drain is used as necessary. A soft dressing is applied with compression in a distal-to-proximal direction to prevent edema. The patient is seen at 2 weeks following operation for suture removal and referral to the amputation team for prosthetic fitting.

HAND PROSTHETICS

Improvement of hand function after multiple-digital amputation can be provided by modern-day prosthetics. Early prosthetic fitting of the upper extremity amputee has many advocates. Biddiss and Chau[17] noted that when fitted within 6 months of an amputation, patients were 16 times more likely

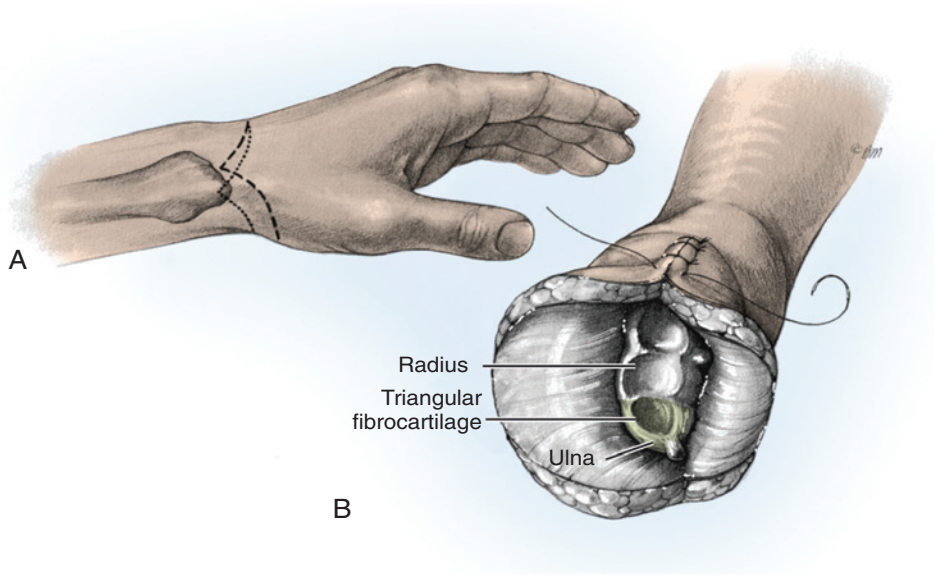

FIGURE 49.36 Wrist disarticulation. With modern prosthetic techniques, this is a very functional level of amputation. Care must be taken in the course of the operation to preserve the distal radioulnar joint ligaments and the triangular fibrocartilage complex to maintain distal radioulnar joint stability. **A,** Skin markings demonstrating fishmouth incision. **B,** Wrist disarticulation.

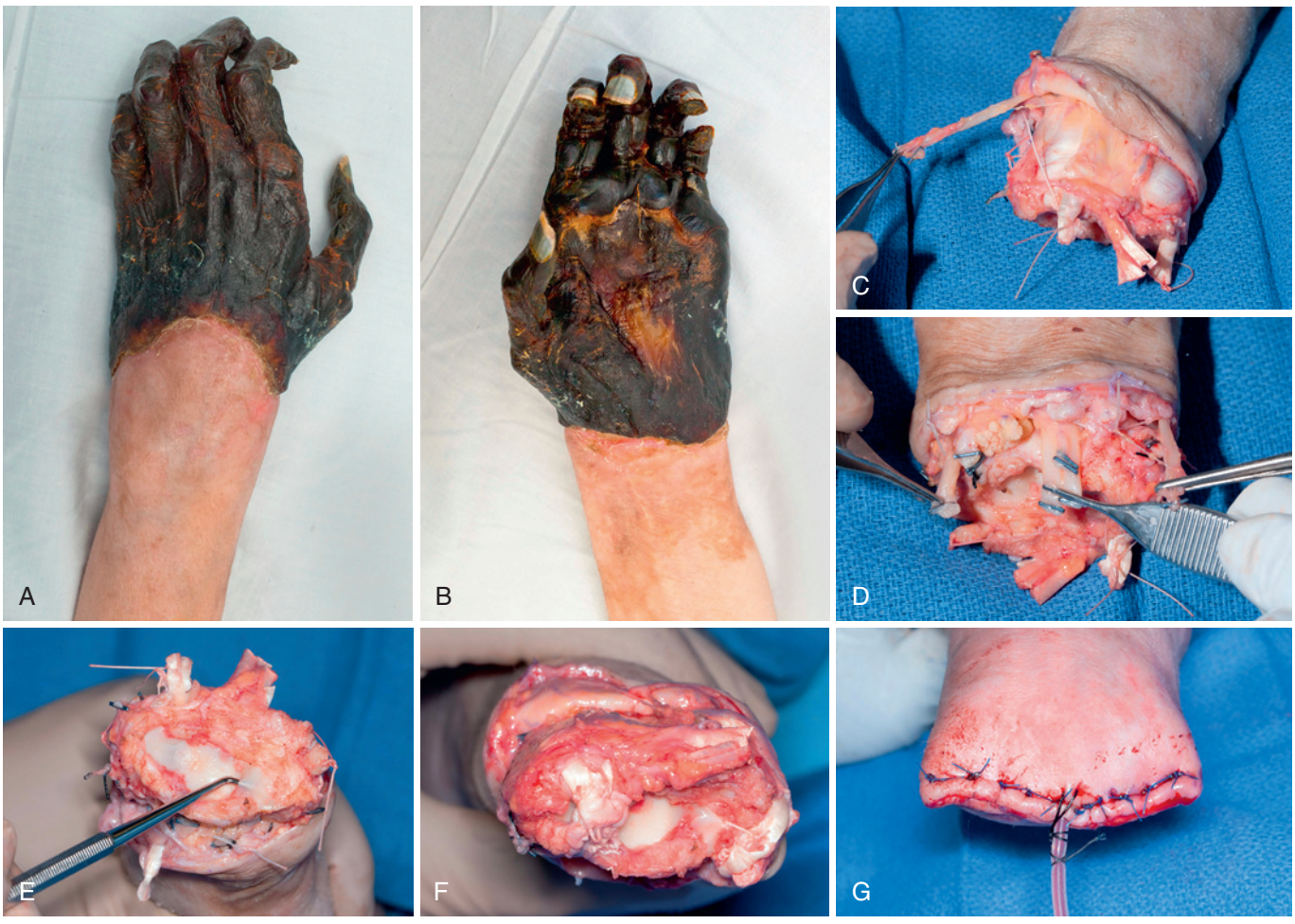

FIGURE 49.37 Patient undergoing a wrist disarticulation for necrosis secondary to septic shock. **A,** Preoperative hand necrosis from septic shock, dorsal view. **B,** Preoperative hand necrosis from septic shock, palmar view. **C,** Dorsal skin flap reflected proximally and dorsal sensory branch of the radial nerve identified. **D,** Identification of lateral antebrachial cutaneous nerve and bifid median and ulnar nerve before they are cut under tension. **E,** Preservation of triangular fibrocartilage complex. **F,** Tethering of the flexor and extensor tendons to the distal radius. **G,** Stump closure.

to continue using the prosthesis. In contrast to patients with lower extremity amputations, in whom vascular insufficiency and problems with wound healing are major concerns, most upper extremity amputees have excellent vascularity in the amputation stumps and are much less prone to wound breakdown and other wound-healing complications. The major advantage of the application of modified upper extremity prostheses in the early postsurgical period is the early performance of bimanual activities. In addition, early prosthetic fitting allows for patient education in prosthetic use during the wound-healing phase and thus shortens the period of morbidity and hastens functional rehabilitation. Prosthetic fitting improves patients' ability to perform many activities of daily living, such as hygiene and dressing, and enhances their self-esteem.

When deciding on the type of prosthesis, the use of a trial device can help determine whether it will meet the needs and expectations of the patient. Factored into the decision are variables such as age, gender, profession, patient motivation, and unilateral versus bilateral involvement. The level of amputation plays an important role in prosthetic fitting. The thumb, for example, affects 40% of hand function, and any type of device should afford length, stability, and opposition.[145] Preserved sensation is an important determinant of thumb function because a partially amputated thumb with preserved sensory function may be more useful than one that is insensate but of normal length. A custom-made thumb prosthesis may restore length but can impede function due to a lack of sensation, especially when the other digits have been treated with a prosthesis. In these cases, procedures such as distraction osteogenesis, web space deepening, pollicization, or microsurgical toe transfer may be more beneficial in providing a functional thumb.[114,118]

Types of Prostheses

There are four main types of partial hand prostheses: *passive devices, opposition posts, body-powered designs,* and *externally powered designs*. Passive devices are high-definition silicone prostheses that provide the most aesthetically pleasing appearance of the hand and thereby have an important psychological benefit for the patient's body image. The color tone and skin creases are matched with those of the recipient's hand (Figure 49.38). A nail is applied to the digital prosthesis. The prosthesis can be designed to fit all levels of injury from the fingertip to a complete hand. In addition to improving the overall appearance of the hand, this passive prosthesis can protect areas of hypersensitivity and also serve as a post for stability with other functioning digits.

Opposition posts are used in patients who are missing a thumb but have all the other digits. They add length and can help hold objects with the remaining functioning digits. Most are rigid, but advancements in the development of articulating hinges have allowed the joints to be manually positioned for task-specific activities.

Body-powered prostheses use movement from a more proximal joint to drive distal function by means of a harness and cables. They claim improved sensory feedback from the cable system and tend to be relatively durable, yet are limited with respect to their range of motion and prehensile strength. Traditional body-powered prostheses had a terminal hook voluntary opening or closing device (Figure 49.39); newer examples include the X-finger (Didrick Medical, Naples, FL) and M-finger

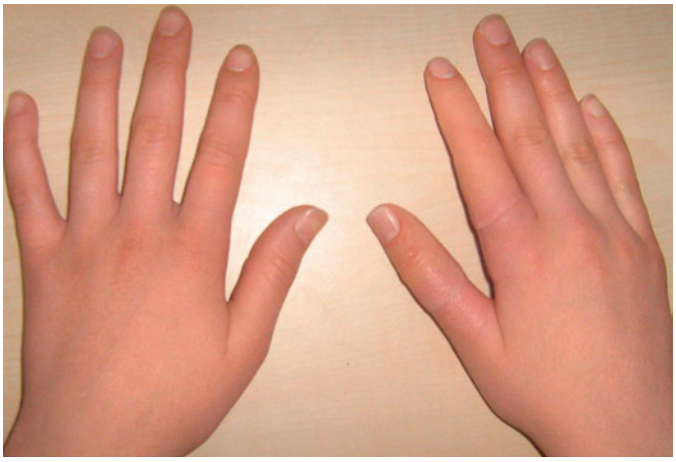

FIGURE 49.38 Silicone prosthetic replacement of amputated right thumb and index finger. Note the aesthetic appearance compared with the other digits. (Used with permission of Aydin C, Nemli SK, Yilmaz H: Esthetic, functional and prosthetic outcomes with implant-retained finger prostheses. *Prosthet Orthot Int* 37(2):167–174, 2013, Figure 3A, p 172. With permission from Sage.)



FIGURE 49.39 Body-powered prosthetic hook terminal device.

(Liberating Technologies, Holliston, MA) (Figure 49.40, *A* and *B*). The latter uses a cable system where wrist flexion causes prosthetic finger flexion at the MP and PIP joints (the DIP joint is fixed). For patients with partial digital amputation, power from the native MP joint can drive prosthetic PIP joint flexion by means of a cable from the dorsal side of the MP joint to the volar side of the prosthetic PIP joint. As such, this prosthesis allows for independent finger motion to improve the dexterity of the hand.

With advancements in modern-day biomaterials and engineering, there have been considerable improvements in *externally powered prostheses* for the hand.[157] The devices are now lighter, more functional, and more durable than ever before. The prosthetic hands have mobile joints and individually powered fingers that can perform power gripping, tip and key pinching, and three-point chuck gripping. They currently fall into two main categories: *single-grasp, three-digit hands* and

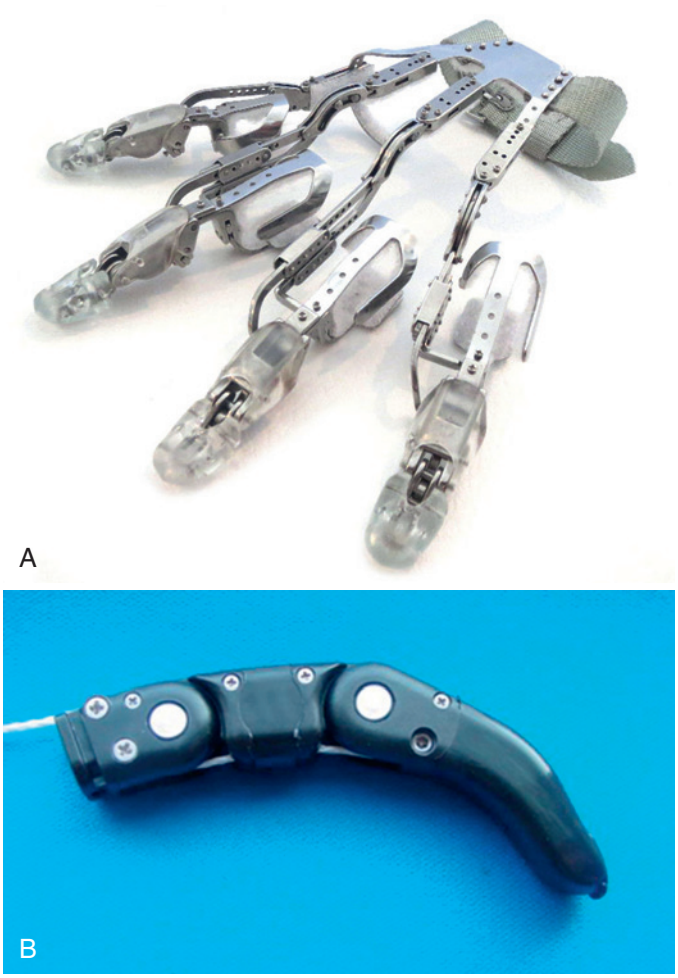

FIGURE 49.40 **A,** Use of the X-finger for partial digital amputations. **B,** The M-finger uses a cable device system where wrist motion causes flexion of the prosthetic finger. (**A,** Courtesy of Dan Didrick, Didrick Medical, Inc. **B,** Reprinted, with permission, from Liberating Technologies.)

multigrasp anthropomorphic hands (Figure 49.41 and Tables 49.1 and 49.2).[15] Although the former are often easier to control, lighter in weight, and more affordable than their more advanced counterparts, they are also more limited in function because they are able to form only a single, rigid grasp. Examples of the multigrasp anthropomorphic hands include the iLIMB (Touch Bionics, Mansfield, MA) and the Michelangelo hand (Ottobock, Minneapolis, MN). The iLIMB has a thumb and independently powered fingers. The thumb must be positioned manually to the required position. The Michelangelo hand is similar to the iLIMB prosthetic hand, except that it has its own independently powered thumb, obviating the need for manual positioning. The Contineo MultiGrasp hand (Orthocare Innovations, Oklahoma City, OK) was developed in the Revolutionizing Prosthetics program of the Defense Advanced Research Projects Agency and offers powered thumb abduction and adduction. More recently, a research team at the Mayo Clinic in Rochester, MN, has been working with collaborators in Italy and Arizona to transform a robotic Softhand from a heavy, wall-powered, tethered device to a lighter, battery-powered device that weighs about as much as commercially available prosthetic arms. The SoftHand prosthetic component (SoftHand Pro) (Figure 49.42) is portable, compatible, and patient friendly. The long-term objectives of this study are to design and build a low-cost, high-performance prosthetic hand that will allow patients who have undergone amputation to perform a wider range of daily tasks than they currently are able to with commercially available prostheses. Early evaluation of the SoftHand Pro shows that it holds great promise. Current multifunctional prosthetic hands are not robust enough to withstand the functional demands of many users and are often prohibitively expensive. The SoftHand Pro attempts to address some of these issues with innovative solutions. Stein and Walley compared patients who had undergone amputation of one upper extremity limb and were using a body-powered cable hook device, a myoelectric hand, and a normal remaining hand. Patients with the hook device tended to wear the prosthesis longer (14 hours versus 9.6 hours) and could complete functional tasks twice as fast as patients with a myoelectric hand. Despite this, patients with myoelectric devices preferred the function, range of motion, and aesthetic appearance to those of conventional body-powered prostheses.

Myoelectric fingers, such as the ProDigits (Optimus Prosthetics, Columbus, OH), Vincent fingers (Vincent Systems, Karlsruhe, Germany), and iLIMB (Figure 49.43), have a power supply and a series of linked motors and struts that drive finger motion. For cosmesis, the myoelectric fingers can be covered with a material that resembles natural skin (Livingskin, Touch Bionics, Hilliard, OH). They can be driven by myoelectric activity via surface electrodes placed on the remaining musculature. These myoelectric control sites can be within the hand or forearm. Commonly used muscles of the hand include the thenar, hypothenar, and dorsal interossei; there is the advantage of allowing individual finger function independent of wrist motion.[145] In the absence of a myoelectric signal, small switches can be incorporated within the device to activate the digit. Because each finger is self-contained, a variety of digital amputations can be accommodated, and the device can provide up to 30 pounds of grip strength, as compared with 8 pounds with the body-powered devices. Despite these advantages, the motors and batteries add weight and cost to the device. To improve the ability of the prosthesis to perform the ever-increasing complexity of hand movements, the number of myoelectric sensor points needs to increase.[157] To accomplish this goal, one can reroute selected transected nerves (that may go on to form neuromas) to provide signals to nonfunctional muscles. This targeted reinnervation causes the muscle to act as a biologic amplifier of residual nerve signals and, therefore, to develop proprioception from the transferred nerve with the overlying skin acquiring its sensory territory. These areas can produce surface myoelectric impulses used to control prosthetic devices. For example, a muscle signal using the ulnar nerve transfer site can be used to control finger motion within the prosthetic hand.[112,128,157] Targeted reinnervation for motor control is called *targeted muscle reinnervation* and tends to be used in patients with more proximal amputations, such as for shoulder disarticulation and at the transhumeral level.[27]

Another area of research for prosthetic control has focused on the use of direct brain wave control.[39] Cerebral control of a prosthetic device has the major advantage of being independent of the peripheral nervous system within the residual limb, which may be damaged or nonfunctioning. Da Paz and Braga[39]



FIGURE 49.41 Types of myoelectric hands. **A,** Vincent hand (Vincent Systems, Karlsruhe, Germany). **B,** iLimb hand by Touch Bionics (Hilliard, OH). **C,** iLimb Pulse (Touch Bionics). **D,** Bebionic hand (RSL Steeper, Leeds, UK). **E,** Bebionic hand version 2 (RSL Steeper). **F,** Michelangelo hand (Ottobock, Minneapolis, MN). All hands are shown without a cosmetic glove. (Used with permission from Belter JT, Segil JL, Dollar AM, et al: Mechanical design and performance specifications of anthropomorphic prosthetic hands: a review. *J Rehabil Res Dev* 50(5):599–618, 2013, Figure 1.)

used functional magnetic resonance images of the brain to study the relationship between cerebral activation and control of a myoelectric prosthetic hand. They noted similar activation in the areas of the brain that controlled prosthetic and contralateral hand function, suggesting that it may be possible to control myoelectric devices through cortical regulation.

Hopper and colleagues[71a] studied the use of digital prostheses in workers' compensation cases and noted that 28% of patients did not use or seldom used the prosthesis (low use) and only 24% used it for more than 4 hours a day (high use). Those in the former group included male patients, patients with stump complications such as cold intolerance, patients with hypersensitivity and pain, and patients with amputations at the more distal digital level. Those with a ring finger or thumb prosthesis reported the least use. Patients who tended to wear the prosthesis were workers who did not do manual labor and had either an index finger or a small finger injury. Women were more likely to continue wearing the prosthesis than men over the long term. Lifchez and coworkers[94b] noticed an improvement in hand function in patients with multiple-digit amputations who used their prostheses. Ten patients who had undergone amputation of two or more fingers proximal to the DIP joint were given a series of hand function tests. Patients reported using their prostheses on an average of 4.3 days a week for over 7 hours a day. Five of the nine employed patients returned to their preinjury occupations. When patients used the device, they had increased tip pinch, lateral pinch, and grip strength and better function in activities of daily living. Burger and colleagues[24] investigated whether patients with a partial hand amputation were able to return to their previous occupations and whether they used their silicone prostheses. The index finger was most commonly affected, and most fingers were amputated through the middle phalanx or PIP joint. Less than 50% of patients were able to return to the same job. Those involved in nonmanual labor and those who had undergone amputation of only one finger had a better chance of keeping the same job. None of the patients with amputation of three or more fingers were able to keep their previous jobs. The greatest loss and functional impairment were caused by partial or complete thumb amputation. Less than a third of patients used the prosthesis at work, and, on average, they wore it 5.3 hours a day (women tended to wear it longer than men, for 7 hours versus 3.5 hours). Loss of tip sensibility while using the prosthesis was the main cause for lack of usage at work.

TABLE 49.1 Published General Characteristics of Commercial Prosthetic Hands

Hand	Developer	Weight (g)	Overall Size	Number of Joints	Degrees of Freedom	Number of Actuators	Actuation Method	Joint Coupling Method	Adaptive Grip
SensorHand (2011) [8-9]	Ottobock	350-500	Glove sizes 7-8 1/4*	2	1	1	DC motor	Fixed pinch	No
Vincent Hand (2010) [10]	Vincent Systems	–	–	11	6	6	DC motor-worm gear	Linkage spanning MCP to PIP	Yes†
iLimb (2009) [11]	Touch Bionics	450-615	180-182 mm long, 80-75 mm wide, 35-41 mm thick	11	6	5	DC motor-worm gear	Tendon linking MCP to PIP	Yes†
iLimb Pulse (2010) [11]	Touch Bionics	460-465	180-182 mm long, 80-75 mm wide, 35-45 mm thick	11	6	5	DC motor-worm gear	Tendon linking MCP to PIP	Yes†
Bebionic (2011) [12]	RSL Steeper	495-539	198 mm long, 90 mm wide, 50 mm thick	11	6	5	DC motor-lead screw	Linkage spanning MCP to PIP	Yes†
Bebionic v2 (2011) [12]	RSL Steeper	495-539	190-200 mm long, 84-92 mm wide, 50 mm thick	11	6	5	DC motor-lead screw	Linkage spanning MCP to PIP	Yes†
Michelangelo (2012) [13]	Ottobock	≈420	–	6	2	2	–	Cam design with links to all fingers	No

*Ottobock glove sizes measured in inches from base of palm to tip of middle finger.
†Adaptive grip accomplished through electronic torque control; others from adaptive mechanical coupling.
DC, Direct current; *MCP*, metacarpophalangeal; *PIP*, proximal interphalangeal.
Used with permission from Belter JT, Segil JL, Dollar AM, et al: Mechanical design and performance specifications of anthropomorphic prosthetic hands: a review. *J Rehabil Res Dev* 50(5):599–618, 2013.

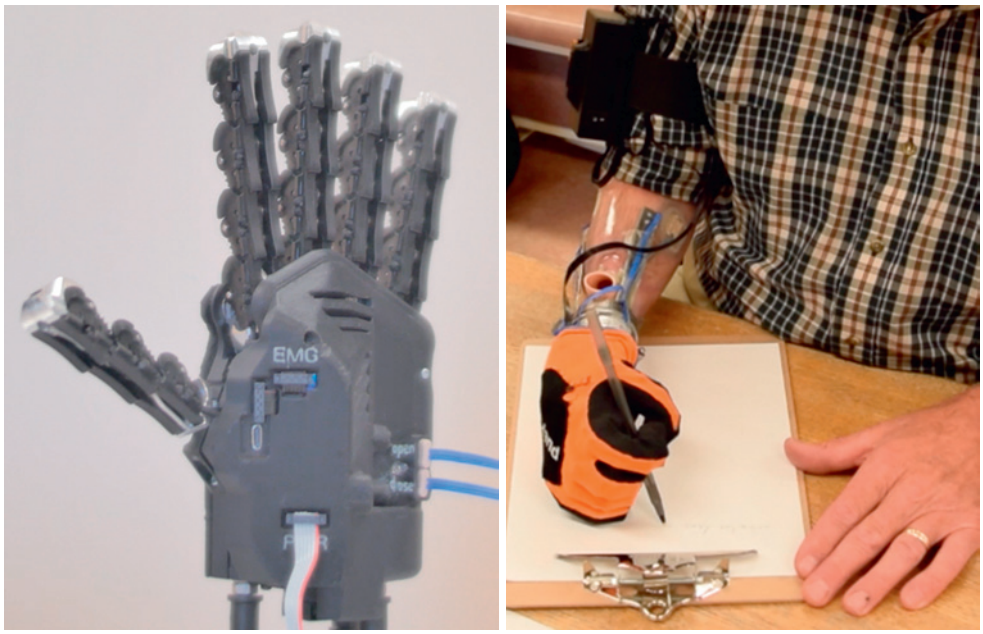

FIGURE 49.42 Example of the SoftHand prosthetic component. (Courtesy of Karen Andrews, Ryan Breighner, Kristin Zhao, Mayo Clinic, Rochester, MN.)

TABLE 49.2 Published Grip and Kinematic Characteristics of Commercial Prosthetic Hands

	GRIP FORCE			RANGE OF MOTION						GRASP TYPE	
Hand	Precision Grasp (N)	Power Grasp (N)	Lateral Pinch (N)	MCP Joints (??)	PIP Joints (??)	DIP Joints (??)	Thumb Flexion (??)	Thumb Circumduction (??)	Thumb Circumduction Axis	Finger/Grasp Speed	Achievable Grasps
SensorHand (2011) [8-9]	NA	100	NA	0-70*	NA	NA	0-70*	NA	None	Up to 300 mm/s at tip	Power
Vincent Hand (2010) [10]	–	–	–	0-90*	0-100*	NA	–	–	Parallel with wrist axis	–	Power, precision, lateral, hook, finger-point
iLimb (2009) [11]	10.8	–	17-19.6	0-90*	0-90*	~20	0-60*	0-95*	Parallel with wrist axis	200 mm/s	Power, precision, lateral, hook, finger-point
iLimb Pulse (2010) [11]	–	136	–	0-90*	0-90*	~20	0-60*	0-95*	Parallel with wrist axis	1.2 s (power grasp)	Power, precision, lateral, hook, finger-point
Bebionic (2011) [12]	34 (tripod)	75	15	0-90	10-90	~20	–	0-68	Parallel with wrist axis	1.9 s (power grasp), 0.8 s (tripod grasp), 1.5-1.7 s (key grasp)	Power, precision, lateral, hook, finger-point
Bebionic v2 (2011) [12]	34 (tripod)	75	15	0-90*	0-90*	~20	–	0-68	Parallel with wrist axis	0.9 s (power grasp), 0.4 s (tripod grasp), 0.9 s (key grasp)	Power, precision, lateral, hook, finger-point
Michelangelo (2012) [13]	70	NA	60	0-35*	NA	NA	–	–	Compound axis	–	Opposition, lateral, and neutral mode

*Estimated based on images and videos.

DIP, Distal interphalangeal; *MCP*, metacarpophalangeal; *N*, newtons; *NA*, not applicable; *PIP*, proximal interphalangeal; *??*, degrees.

Used with permission from Belter JT, Segil JL, Dollar AM, et al: Mechanical design and performance specifications of anthropomorphic prosthetic hands: a review. *J Rehabil Res Dev* 50(5):599–618, 2013.



FIGURE 49.43 A 28-year-old patient who underwent revision amputations of his digits for frostbite. On the left hand **(A** to **D)**, he has been fitted with the iLIMB myoelectrically controlled prosthetic device, which allows complete grasp, precision pinch, and up to 12 different grip patterns. The ideal level for use of this partial hand prosthesis is at the metacarpophalangeal joint or more proximally through the palm to allow for room for the iLIMB digits to be mounted at the amputation site and provide function and an acceptable aesthetic appearance. The device is controlled by two surface-mounted electrodes next to the skin, inside the prosthetic socket. The patient is retaught to activate the muscles with proportional control, to make the hand open and close at the desired speed and with the intended force. On the right side **(E** to **G)**, the amputated digits had greater residual length; if an iLIMB prosthesis had fit, it would have made the fingers excessively long, so that it would have been difficult for the patient to touch his digits to the thumb and have good grasp function. As a result, he was fitted with a passive prosthetic device. The passive digits are positioned manually to help enable full passive grasp or thumb-to-forefinger prehension. The patient opens and closes the device using the proximal phalanges inside it. The wrist strap holds the prosthesis in place and allows the user to lift heavy objects. (Courtesy of Brandon Sampson.)

One of the main problems with modern-day prosthetics is that they do not provide sensory feedback to the user. In addition, the socket can lead to skin breakdown, excessive sweating, and restriction of movement.[78] In an effort to mitigate this problem, *osseointegrated prostheses* have been devised with varied success.[78,96,99] This involves a two-stage procedure in which an implant is placed into a bony stump, followed by attachment of a prosthesis (Figure 49.44). Advocates argue that tactile perception is improved and socket problems are fewer. Lundborg and colleagues[96] reported on three patients who underwent placement of a titanium-based osseointegrated prosthesis for traumatic amputation at the thumb MP joint. After 3 months, they noted that the fixture was stable enough within the proximal phalanx to allow attachment of the thumb prosthesis. They noted no signs of implant loosening and postulated that the improvement in tactile discrimination was secondary to transfer of pressure to the endosteal nerves within the bone. Similar results were reported by Manurangsee and colleagues[99] in the treatment of index and long finger amputations at the base of the proximal phalanges but with bone of at least 1.5 cm in length remaining to accommodate the implant. All patients reported improvements in grip strength, hand function, and deep sensation, with minimal wound complications. In trying to decide which patients may benefit from this treatment modality, Jönsson and associates[77] highlighted four main criteria: (1) The bone quality and length of the stump were sufficient to accommodate the implant; (2) the patient could not be fitted with a standard prosthesis or had a history of socket complications; (3) the patient did not have a history of immunosuppression; and (4) the patient was highly motivated. The authors reported on 10 thumbs and 1 partial hand reconstruction. Overall, patients reported improvements in function and quality of life. Complications included one infection that required removal of the implant and two loose implants.



FIGURE 49.44 This figure shows the concept of an osseointegrated prosthesis. (Reprinted from Manurangsee P, Isariyawut C, Chatuthong V, et al: Osseointegrated finger prosthesis: an alternative method for finger reconstruction. *J Hand Surg [Am]* 25:86–92, 2000, Figure 1C, p 88.)

CRITICAL POINTS *Hand Prostheses*

- Early prosthetic fitting (within 30 days) is recommended with the aid of a multidisciplinary team to improve acceptance and use.
- When deciding on the type of prosthesis, patient-specific variables need to be considered and more than one type of device may be necessary to meet patient needs.
- With improvements in technology, modern-day prosthetics have the potential to be as functional as the digit that was amputated.
- Development of a prosthesis with improved sensory feedback may increase rates of adoption.

REHABILITATION PROCESS OF THE HAND AMPUTEE

Successful rehabilitation of the amputee requires the input of a comprehensive multidisciplinary team. The members of the team should include the surgeon to provide surgical expertise, occupational therapist to provide rehabilitation, prosthetist to fabricate upper extremity devices, psychiatrist for psychological support, and pain management specialists to administer the appropriate analgesia; equally as important are other upper extremity amputees, who can provide camaraderie. A support network of amputees is vitally important for the recently injured patient undergoing various psychological stressors that can lead to low self-esteem, disability, denial, and a low rate of prosthetic use.[7,16,17,153] The Amputee Coalition of America provides important information and support.

The rehabilitation process has four stages that may overlap to ensure maximum recovery of the patient. These include the *postsurgical stage, preprosthetic training stage, basic prosthetic stage,* and *advanced functional training stage*. The goal is to provide the patient with the necessary physical and psychological skills to meet functional goals and requirements.[124,133] Many of these principles have come from the experiences gained through the management and rehabilitation of patients in the Veterans Affairs Agency and the Defense Advanced Research Projects Agency.

The *acute postsurgical phase* lasts from the time of surgery until all wounds have healed. During this period, emphasis is placed on achieving a stable wound, edema control, desensitization, scar management, and pain control. Depending on the nature of the wound, serial débridement may be needed if the wound has been heavily contaminated or has substantial tissue damage. Once the wound has been definitively closed, occupational therapists focus on controlling edema by using distal-to-proximal compression wrapping followed by silicone sleeves that provide continuous compression and also aid in minimizing scar formation.[124,133] These dressings also help with the desensitization process, which advances to massage and the use of texture devices as the scar matures. During this time, the therapist also works on the range of motion of adjacent joints to minimize the development of joint contractures. Training in activities of daily living such as feeding and hygiene is encouraged by means of custom adaptive aids as needed. During this period, patients can have residual or phantom limb pain. In a study by Jensen and colleagues,[76a] 57% of patients had stump pain 8 days after surgery, and it lasted for up to 2 years in 21% of patients. Involvement of a pain specialist may be necessary if symptoms do not resolve within the first few weeks after surgery. Within the immediate postoperative period, a patient-controlled analgesia pump can be used or an indwelling catheter can be placed. As medications are weaned, the patient can be given long-acting opioids and then transitioned to short-acting medications, such as short-acting opioids, nonsteroidal antiinflammatory medications, anticonvulsants, or tricyclic antidepressants. Other modalities such as transcutaneous electrical nerve stimulation (TENS) and thermal treatments can improve pain control because they have a synergistic effect with other pharmacologic and psychological interventions.[108]

The provision of psychological support, through work with trained psychologists and psychiatrists as well as family members, is started early in the rehabilitation process to ease patient fears and promote independence. These issues are gaining increasing scrutiny because early therapeutic regimens can reduce medical bills, disability payments, loss of income, and mental health costs. Psychological stress can be triggered by the sudden and unexpected nature of the injury, the alien hospital environment, fear of loss of bodily function, helplessness, and humiliation.[108] Early in the recovery process, many patients experience symptoms suggestive of posttraumatic stress disorder. Grunert and colleagues[62] showed that up to 94% of patients suffered from flashbacks, nightmares, poor concentration, cosmetic concerns, and the fear of death within 2 months of their injuries. Given that these symptoms can persist for up to 6 months after injury,[61] patients, as well as family members, require psychological support as early as 3 days after injury, and it may continue throughout the rehabilitation. The hand surgeon can play an important role in the promotion of a healthy adjustment to the injury because he or she is often the

first health care professional involved with the patient.[105] A positive preoperative and postoperative relationship with the surgeon can result in improved patient compliance, satisfaction, and recovery.[104]

Psychological adjustment during recovery from devastating hand injuries has three interlinked phases.[14,60] *Functional acceptance* is the process whereby the patient comes to terms with his or her altered form. This is dependent on several factors, such as the patient's motivation, nature of the injury, and type of functional disability. The next phase is acceptance of the *aesthetic appearance* of the hand and is affected by age, gender, underlying personality, and perception of how others see the hand. Early involvement with prosthetists can be important in improving the patient's cosmetic concerns following a mutilating hand injury. The final stage of adjustment is related to the *emotional acceptance of the injury*. This is characterized as the time necessary for the patient to accept the loss of a finger, hand, or other body part. This stage has a variable length related to numerous prognostic factors such as occupation, personal and family relationships, feeling of self-guilt as a cause of the injury, previous history of mental health issues, whether the injury is work related, severity of the injury, and whether there has been early or delayed psychological therapeutic intervention.[60]

Therapeutic modalities include pharmacotherapy such as tricyclic antidepressants, monoamine oxidase and selective serotonin reuptake inhibitors, and psychotherapy. The latter includes cognitive behavioral therapy (e.g., systematic desensitization, graded exposure) and management of life skills, such as relaxation therapy, anger control, and cognitive restructuring to address pain, anxiety, and depression.[105] Weis and colleagues[149a] investigated the efficacy of imaginal exposure, a form of cognitive behavioral therapy, when given early (within 30 to 60 days) or later (after more than 120 days) following a severe work-related injury. The authors noted that the therapy had a beneficial effect on symptom reduction in the early treatment group, so that fewer therapeutic sessions were required than in the group for whom treatment was delayed. Eighty-three percent of patients were able to return to work after 6 months. Despite receiving psychological therapy, the remaining 17% who did not return to work still cited psychological distress rather than physical disability as the main reason for not returning.

During the 2 to 3 weeks after definitive surgical management, the *preprosthetic phase* occurs, in which time is spent readying the patient to accept a prosthesis. This coincides with the "golden window" for upper limb prosthetic fitting during the first 30 days after amputation.[98a] Forty-seven patients underwent immediate, early, or late postoperative fitting after upper extremity amputation. Those fitted within 30 days of amputation had a 93% rehabilitation success rate and a 100% return to work rate within 4 months after injury compared with a successful rehabilitation rate of only 42% and a return to work rate of only 15% in those fitted with a prosthesis after 30 days from injury. During this period, changes in limb volume and sensitivity will occur, and the occupational therapist will work on range-of-motion and physical conditioning of the injured limb. Psychological support is ongoing and adapted to meet the changing demands of the patient.[133] This may include interaction with other amputee patients as well as participation in occupation-based activities. Change of hand dominance training may be introduced in patients with substantial mutilating hand trauma. Given the limitation of fine motor skills with the available prosthetics, patients learn to use the contralateral uninjured hand independently.

If a patient is to be fitted with a myoelectric prosthesis, the patient begins electrode site identification and training. The goals during this phase are to teach the patient how to effectively contract the residual limb muscles to activate a basic myoelectric device. Forearm flexors control closing and pronation of the prosthesis, and extensors control its supination and opening movements.

Patients gradually advance into the *prosthetic training stage* of rehabilitation. The goal during this phase is to ensure that the prosthesis becomes an integral part of the patient's life as the patient learns the actions required for prosthetic control and incorporates the device into activities of daily living. Each patient trains with a variety of prostheses to determine which is the best fit. A patient often chooses different prostheses to match particular tasks at hand. Patients are also taught principles of skin care to avoid breakdown.

The final stage of the rehabilitation process is the *advanced prosthetic training stage*. Patients learn efficient prosthetic use as therapy is tailored to meet specific needs. They are challenged through a series of tasks that require precise motor control, such as using a tool, musical instrument, or cooking utensil. This training enhances knowledge about the prosthetic components, limb care, and how to don and doff the prosthesis. Furthermore, postural and strengthening programs emphasizing educational awareness of altered body patterns will prevent overuse injuries.[27,133] Ultimately, the patient selects the myoelectric or body-powered prosthesis as the preferred prosthesis. Advanced training guides the patient to facilitate selection via operation and control of the prosthesis to engage in complex tasks.

CRITICAL POINTS *Rehabilitation*

- Successful rehabilitation starts from the time of injury and requires a multidisciplinary team.
- Rehabilitation extends through a four-stage process: postsurgical stage, preprosthetic training stage, basic prosthetic stage, and advanced functional training stage.
- Most patients experience signs and symptoms of psychological trauma that need to be addressed for them to return to their job, family, and society.

PAIN MANAGEMENT AFTER AMPUTATIONS

Despite the surgeon's expertise, 7 to 49% of patients will develop residual pain in the limb after an upper extremity amputation.[119] This pain can have a deleterious effect on recovery and function, including causing difficulties with prosthetic training, depression, reduced likelihood of employment, and overall disability.[66] The two types of pain commonly seen after an upper extremity amputation are phantom limb pain and residual limb pain. *Phantom limb pain* is pain felt in the amputated limb, whereas *residual limb pain* is pain felt in the remaining proximal body part.[133] After an amputation, patients may develop the non-painful phenomenon of *phantom limb sensation* because they feel that the amputated part is still present. The mechanism for this bothersome phenomenon is ill-defined, but fortunately, it resolves gradually over time.

An early approach to pain management may prevent long-term impairment of function.[151] The treating surgeon should begin pain management immediately with either postoperative patient-controlled analgesia or long-acting opioids. Involvement of a pain specialist is required to facilitate the prescribing of short-acting narcotics and anticonvulsants. Nonpharmacologic therapies such as thermal treatments, massage, or TENS are synergistic to pharmacologic measures. Psychological support is equally as important to address any developing issues such as low self-esteem, concerns about disability, and denial.

Desensitization is recognized as an effective way to decrease pain following amputation. The physiologic basis for dysesthesias and their response to desensitization techniques is not entirely understood. Sica and associates[130] demonstrated that the amplitude of the cortical-evoked response of the contralateral somatosensory cortex was diminished in patients with partial limb amputations.[130] Interestingly, they found an increase in amplitude of the evoked response in the proper area corresponding to the uninjured limb on the same side as the partial amputation. These data suggest that the cerebral cortex adapts when its peripheral afferents are interrupted. Exactly how this information relates to dysesthesias after amputation is unclear. Empirically, desensitization techniques appear effective because of this adaptability of the central nervous system to repetitive stimuli. Several techniques of desensitization have been suggested, but most are related to early return to functional activities as advocated by Fisher and Boswick[47] or intensive supervised programs of progressive resensitization to textures and objects.[12] On many occasions, patients are unable to visit regularly with a hand therapist. Given this dilemma, it is important to review a home program of desensitization. Patients and their family members are shown how to rub and tap the fingertip against various smooth and rough surfaces, such as sandpaper and cloth, for a minimum of 6 weeks. The patient is educated on the importance of participating in the home program and routine visits with a hand therapist to prevent the functional consequences and limitations of the hypersensitive part.

Optimizing the care of the patient with a major limb loss requires a comprehensive multidisciplinary approach, including the help of a pain management specialist. Residual limb pain and phantom limb pain occur in 56 to 85% of amputees and have a considerably negative impact on long-term functional outcomes.[86,152] Hanley and colleagues[66] reported on the incidence of chronic pain in 104 patients with upper limb amputations at 6 months after surgery. They noted residual limb pain in 71% and phantom limb pain in 79% of their patients. Interestingly, the patients also complained of pain in the back (52%), neck (43%), and uninjured contralateral arm (33%). Men reported a greater amount of neck, phantom limb, and residual limb pain, and those who used a prosthesis were significantly more likely to have phantom limb pain ($p < .05$). Patients who complained of pain in the nonamputated limb reported a high level of disability and days off work. Overall, 90% of patients experienced at least one type of postamputation pain. This study serves as an important reminder to the surgeon to actively address these issues, either by himself or herself or with the help of a multidisciplinary team.

Phantom limb pain remains a persistent and poorly understood problem that is extremely difficult to treat. Montoya and colleagues[109a] studied cortical regulation in healthy controls, patients with a congenital upper limb amputation, and traumatic amputees. The authors noted that traumatic amputees who had symptoms of phantom limb pain demonstrated reorganization of their sensory and motor cortical maps compared with the other patients. Li and associates[94a] noted that digital amputation caused changes with synaptic transmission within the anterior cingulate cortex, a region that relays pain within the central nervous system, as possibly contributing to phantom limb pain. Jensen and colleagues[76a] noted that the presence of preoperative limb pain plays a role in the development of phantom limb pain immediately after surgery. Fifty-eight patients who primarily underwent elective lower limb amputations for peripheral vascular disease were interviewed preoperatively and postoperatively about their stump and phantom limb pain. The incidence of residual limb stump pain was 57% at 8 days, 22% at 6 months, and 21% by 2 years following amputation. The incidence of phantom limb pain was much higher (72% at 8 days, 65% at 6 months, and 50% at 2 years) in patients who had preoperative pain. Lambert and coworkers[87a] conducted a prospective randomized trial comparing preoperative epidural medications (bupivacaine and diamorphine) with intraoperative perineural analgesia (bupivacaine) of 30 patients undergoing lower limb amputations. The authors noted that at 3 days following amputation, there was a significant reduction in stump pain in the epidural group but no real differences in phantom limb pain with either regimen. Aggressive pain management with multimodal pharmacologic management in conjunction with integrative and alternative measures such as biofeedback, hypnosis, relaxation techniques, or acupuncture may contribute to a successful outcome.[116]

Neuromas

A peripheral nerve injured during amputation will attempt to regenerate. Regeneration is initiated by axonal growth (sprouting) from the proximal nerve end. There are a host of neurotrophic factors that are released to stimulate the repair process, including substance P, calcitonin gene-related peptide, and fibroblast growth factors.[23] Because there is no end organ present, a neuroma will form (Figure 49.45). Even when repair is possible, some regenerating axons can grow outside the repair site and become symptomatic. The overall incidence of neuroma formation following amputation varies from 2.7 to 30%.[47,115,137,146] Most neuromas are asymptomatic. Only 3 to 5% become symptomatic; they can be frustrating for the patient and the surgeon, resulting in dissatisfaction and disability.

Patients tend to present with a history of trauma from a sharp, crushing, or stretch injury. Symptoms include hypersensitivity and an aching or throbbing pain. The pain may or may not localize to a single peripheral nerve distribution. The diagnosis is made clinically, with patients usually having a positive Tinel sign over a localized site yielding lancinating pain. Selective local anesthetic injections can be used to facilitate the diagnosis. Complete symptom relief after the injection will help the patient to realize the area of numbness that will develop after neuroma excision, transposition, or grafting. Initial management requires nonoperative measures, such as scar massage, desensitization, and TENS. Oral medications, including opioids, nonsteroidal antiinflammatory medications, antidepressants, anticonvulsants, and topical analgesics, have had varied success. There are many surgical techniques for symptomatic neuroma,

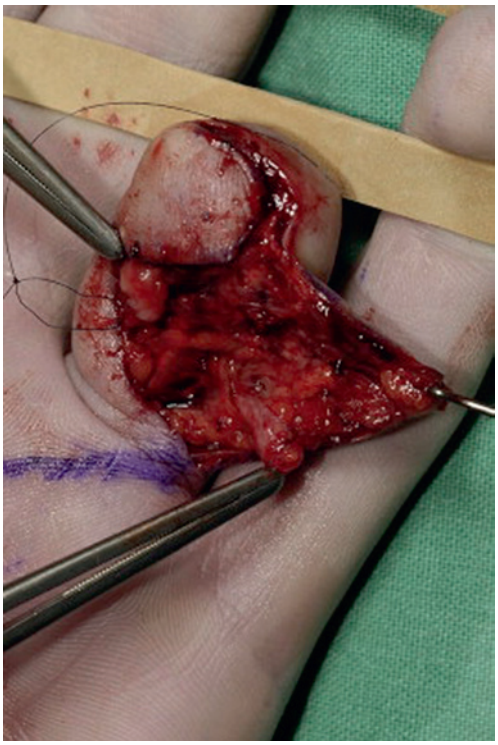

FIGURE 49.45 A digital nerve neuroma after an amputation. (Used from Van der Avoort DJJC, Hovius SER, Selles RW, et al: The incidence of symptomatic neuroma in amputation and neurorrhaphy patients. *J Plast Reconstr Aesthet Surg* 66:1330–1334, 2013, Figure 1.)

and they should be considered in patients refractory to nonoperative treatment who have had a positive response to a local anesthetic injection and symptom resolution. In patients whose pain is not aligned with the anatomic distribution of a nerve, caution is necessary when considering surgery, because these patients may have secondary gain issues or an underlying psychological pathologic condition. Surgical treatment of neuromas is centered around four main options: (1) neuroma resection; (2) primary microsurgical end-to-end coaptation or coaptation using a vein graft or neural tube; (3) containment of the neuroma, including translocation into muscle or bone; and (4) nerve translocation.[10,13,23,25,44,58,67,98,101,107,147] The preferred technique is impossible to determine due to the lack of prospective randomized comparative studies. My preference for the management of symptomatic digital nerve neuromas is to relocate them proximally into tissues outside the zone of injury, such as the interosseous muscle (Figure 49.46 and Table 49.3), or to suture them directly to each other.

CRITICAL POINTS *Postamputation Pain Management*

- Dysesthetic amputation stumps occur even with careful tissue management, especially with distal digital injuries.
- Desensitization programs may improve outcomes in digital amputations.
- Aggressive preoperative and postoperative pain management by a pain specialist may reduce the incidence of phantom pain.
- Amputation neuromas are often identified by clinical examination. The results of treatment vary, and the definitive technique remains elusive.

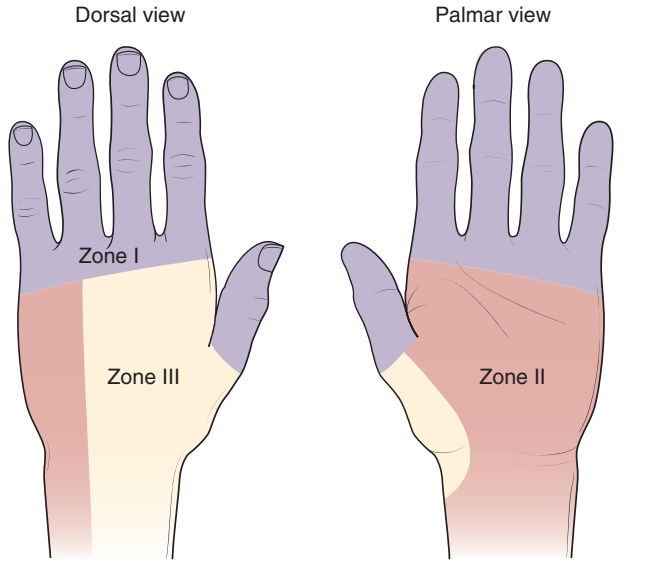

FIGURE 49.46 For preoperative planning in nerve relocation, the hand and distal forearm can be divided into three zones. (Redrawn from Atherton DD, Leong JC, Anand P, et al: Relocation of painful end neuromas and scarred nerves from the zone II territory of the hand. *J Hand Surg Eur Vol* 32(1):39, 2007; with permission.)

TABLE 49.3 Neuromas of the Hand and Wrist and Treatment Options Based on Location

Zone	Nerves Involved	Relocation Options
I	Digital nerves	Proximal phalanx or metacarpal
II	Common digital nerves Palmar cutaneous branches of median and ulnar nerves Dorsal sensory branch of ulnar nerve	Pronator quadratus
III	Superficial branch of radial nerve Lateral antebrachial cutaneous nerve Medial and posterior cutaneous nerves	Brachioradialis or other muscles of forearm

Adapted from Atherton DD, Leong JC, Anand P, et al: Relocation of painful end neuromas and scarred nerves from the zone II territory of the hand. *J Hand Surg Eur Vol* 32(1):39, 2007, with permission.

For Case Studies, Videos, and more, please visit ExpertConsult.com.

REFERENCES

1. Adani R, Busa R, Pancaldi G, et al: Reverse neurovascular homodigital island flap. *Ann Plast Surg* 35:77–82, 1995.
2. Adani R, Busa R, Scagni R, et al: The heterodigital reversed flow neurovascular island flap for fingertip injuries. *J Hand Surg [Br]* 24:431–436, 1999.
3. Allen MJ: Conservative management of fingertip injuries in adults. *Hand* 12:257–265, 1980.
4. Armenta E, Lehrman A: The vincula to the flexor tendons of the hand. *Ar J Hand Surg Am* 5:127–133, 1980.
5. Arons MS: A fingertip reconstruction with a palmar advancement flap and free dermal graft: a report of six cases. *J Hand Surg [Am]* 10:230–233, 1985.
6. Atasoy E, Loakimidis E, Kasdan ML, et al: Reconstruction of the amputated fingertip with a triangular volar flap: a new surgical procedure. *J Bone Joint Surg Am* 52:921–926, 1970.

7. Atkins DJ, Heard DC, Donovan WH: Epidemiologic overview of individuals with upper limb loss and their reported research priorities. *J Prosthet Orthot* 8:2–11, 1996.
8. Atroshi I, Roseberg HE: Epidemiology of amputations and severe injuries of the hand. *Hand Clin* 17:343–350, 2001.
9. Ay S, Akinci M: Primary transposition of digital nerves into muscle in second ray amputation: a possible answer for neuroma formation. *Tech Hand Up Extrem Surg* 7:114–118, 2003.
10. Balcin H, Erba P, Wettstein R, et al: A comparative study of two methods of surgical treatment for painful neuroma. *J Bone Joint Surg Br* 6:803–808, 2009.
11. Barbato BD, Guelmi K, Romano SJ, et al: Thenar flap rehabilitated: a review of 20 cases. *Ann Plast Surg* 37:135–359, 1996.
12. Barber L: Desensitization of the traumatized hand. In Hunter JM, Schneider LC, Mackin EJ, editors: *Rehabilitation of the hand*, St. Louis, 1984, Mosby.
13. Battiston B, Tos P, Conforti LG, et al: Alternative techniques for peripheral nerve repair: conduits and end-to-side neurorrhaphy. *Acta Neurochir Suppl* 100:43–50, 2007.
14. Beasley RW: Surgery of hand and finger amputations. *Orthop Clin North Am* 12:763–803, 1981.
15. Belter JT, Segil JL, Dollar AM, et al: Mechanical design and performance specifications of anthropomorphic prosthetic hands: A review. *J Rehabil Res Dev* 50: 599–618, 2013.
16. Biddiss E, Beaton D, Chau T: Consumer design priorities for upper limb prosthetics. *Disabil Rehabil Assist Technol* 2:346–357, 2007.
17. Biddiss EA, Chau TT: Multivariate prediction of upper limb prosthesis acceptance or rejection. *Disabil Rehabil Assist Technol* 3:181–192, 2008.
18. Biddulph SL: The neurovascular flap in fingertip injuries. *Hand* 11:59–63, 1979.
19. Bojsen-Moller J, Pers M, Schmidt A: Fingertip injuries: late results. *Acta Chir Scand* 122:177–183, 1961.
20. Bonte W: Self-mutilation and private accident insurance. *J Forensic Sci* 28:70–82, 1983.
21. Bossley CJ: Conservative treatment of digit amputations. *N Z Med J* 82:279–386, 1975.
22. Boyes JH: *Bunnell's surgery of the hand*, Philadelphia, 1970, JB Lippincott.
23. Brogan DM, Kakar S: Management of neuromas of the upper extremity. *Hand Clin* 29:409–420, 2013.
24. Burger H, Maver T, Marincek C: Partial hand amputation and work. *Disabil Rehabil* 29:1317–1321, 2007.
25. Calcagnotto GN, Braga Silva J: The treatment of digital nerve defects by the technique of vein conduit with nerve segment. A randomized prospective study. *Chir Main* 34:126–130, 2006.
26. Caplan HS, Hunter JM, Merklin RJ: Intrinsic vascularization of flexor tendons. In *AAOS Symposium on Tendon Surgery in the Hand*, St. Louis, 1975, CV Mosby, p 48.
27. Carlsen BT, Prigge P, Peterson J: Upper extremity limb loss: functional restoration from prosthesis and targeted reinnervation to transplantation. *J Hand Ther* 27: 106–113, 2014.
28. Carlsson IK, Dahlin LB: Self-reported cold sensitivity in patients with traumatic hand injuries or hand-arm vibration syndrome—an eight year follow-up. *BMC Musculoskelet Disord* 15:83–91, 2014.
29. Carroll RE: Transposition of the index finger to replace the middle finger. *Clin Orthop Relat Res* 15:27–34, 1950.
30. Cerrato F, Eberlin KR, Waters P, et al: Presentation and treatment of macrodactyly in children. *J Hand Surg [Am]* 38:2112–2123, 2013.
31. Chase RA: The damaged index digit, a source of components to restore the crippled hand. *J Bone Joint Surg Am* 50:1152–1166, 1968.

31a. Chen SY, Wang CH, Fu JP, et al: Composite grafting for traumatic fingertip amputation in adults: technique reinforcement and experience in 31 digits. *J Trauma* 70(1):148–153, 2011.

32. Cheng G, Fang G, Hou S, et al: Aesthetic reconstruction of thumb or finger partial defect with trimmed toe-flap transfer. *Microsurgery* 27:74–83, 2007.
33. Cheng TJ, Cheng NC, Tang YB: Restoration of basic hand function by double transpositional digital replantation in five-digit amputations. *J Reconstr Microsurg* 20:201–205, 2004.
34. Chi Z, Gao W, Yan H, et al: Reconstruction of totally degloved fingers with a spiraled parallelogram medial arm free flap. *J Hand Surg [Am]* 37:1042–1050, 2012.
35. Chow SP, Ng C: Hand function after digital amputation. *J Hand Surg [Br]* 18:125–128, 1993.
36. Cohen BE, Cronin ED: An innervated cross-finer flap for fingertip reconstruction. *Plast Reconstr Surg* 72:688–697, 1983.
37. Colen L, Bunkis J, Gordon L, et al: Functional assessment of ray transfer for central digital loss. *J Hand Surg [Am]* 10:232–237, 1985.
38. Conolly WB, Goulston E: Problems of digital amputations: a clinical review of 260 patients and 301 amputations. *Aust N Z J Surg* 43:118–123, 1973.
39. da Paz J, et al: Brain activation in a myoelectric prosthetic hand: the role of the brain in the rehabilitation of amputees. *J Pediatr Orthop* 27:947–951, 2007.
40. Dakpa R, Heger H: Prosthetic management and training of adult upper limb amputees. *Curr Orthop Relat Res* 11:193–202, 1997.
41. Das SK, Brown HG: Management of lost fingertips in children. *Hand* 10:16–27, 1978.
42. de Boer A, Robinson PH: Ray transposition by intercarpal osteotomy after loss of the fourth digit. *J Hand Surg [Am]* 14(2 Pt 2):379–381, 1989.
43. De Boer P, Collinson PO: The use of sulphadiazine occlusive dressing for finger-tip injuries. *J Bone Joint Surg Br* 63:545–547, 1981.
44. Dellon AL, Mackinnon SE: Treatment of the painful neuroma by neuroma resection and muscle implantation. *Plast Reconstr Surg* 3:427–438, 1986.
45. Douglas BS: Conservative management of guillotine amputation of the finger in children. *Aust Paediatr J* 8:86, 1972.
46. Fisher EG, Goldner JL: Index ray deletion—complications and sequel. *J Bone Joint Surg Am* 54:898, 1972.
47. Fisher GT, Boswick JA: Neuroma formation following digital amputations. *J Trauma* 23:136–142, 1983.
48. Fitoussi F, Ghorbani A, Jehanno P, et al: Thenar flap for severe fingertip injuries in children. *J Hand Surg [Br]* 29:108–112, 2004.
49. Flatt AE: The thenar flap. *J Bone Joint Surg Br* 39:80–85, 1957.
50. Foucher G, Khouri RK: Digital reconstruction with island flaps. *Clin Plast Surg* 24:1–32, 1997.
51. Frandsen PA: A V-Y plasty as treatment of fingertip amputations. *Acta Orthop Scand* 49:256–259, 1978.
52. Freiberg A, Manktelow R: The Kutler repair of fingertip amputations. *Plast Reconstr Surg* 50:371–375, 1972.
53. Furlong R: *Injuries of the hand*, Boston, 1957, Little, Brown.
54. Gatewood A: A plastic repair of finger defects without hospitalization. *JAMA* 87:1479, 1926.
55. Germann G, Karle B, Bickert B: Ray amputations–preferable to dgital amputations? An analysis of function and quality of life. *J Hand Surg Eur Vol* 22:53, 1997.
56. Gong HS, Shin SI, Baek GH: Creation of a "dorsal transverse intermetacarpal ligament" to prevent scissoring deformity in central ray amputation. *J Hand Surg Eur Vol* 33:163–165, 2008.
57. Gordon L, Leitner DW, Bunche HJ, et al: Hand reconstruction for multiple amputations by double microsurgical toe transplantation. *J Hand Surg [Am]* 10:218–225, 1985.
58. Gorkisch K, Boese-Landgraf J, Vaubel E: Treatment and prevention of amputation neuromas in hand surgery. *Plast Reconstr Surg* 73:293–299, 1984.
59. Grabb WC, Dingman RO: The common fingertip injury. *Mich Med* 63:565–567, 1964.
60. Grob M, Papadopulos NA, Zimmermann A, et al: The psychological impact of severe hand injury. *J Hand Surg Eur Vol* 33:358–362, 2008.
61. Grunert BK, Hargarten SW, Matloub HS, et al: Predictive value of psychological screening in acute hand injuries. *J Hand Surg [Am]* 17:196–199, 1992.
62. Grunert BK, Smith CJ, Devine CA, et al: Early psychological aspects of severe hand injury. *J Hand Surg [Br]* 13:177–180, 1988.
63. Gurdin M, Pangman WJ: The repair of surface deficits of fingers by transdigital flaps. *Plast Reconstr Surg* 5:368–371, 1950.
64. Haddad RJ: The Kutler repair of fingertip amputation. *South Med J* 61:1264–1267, 1968.
65. Hanel DP, Lederman ES: Index transposition after resection of the long finger ray. *J Hand Surg [Am]* 18:271–277, 1993.
66. Hanley MA, Ehde DM, Jensen M, et al: Chronic pain associated with upper-limb loss. *Am J Phys Med Rehabil* 88:742–751, 2009.
67. Hazari A, Elliot D: Treatment of end-neuromas, neuromas-incontinuity and scarred nerves of the digits by proximal relocation. *J Hand Surg [Br]* 4:338–350, 2004.

67a. Heistein JB, Cook PA: Factors affecting composite graft survival in digit tip amputations. *Ann Plast Surg* 50(3):299–303, 2003.

68. Henry M, Stutz C: Homodigital antegrade-flow neurovascular pedicle flaps for sensate reconstruction of fingertip amputation injuries. *J Hand Surg [Am]* 31: 1220–1225, 2006.
69. Hirase Y: Salvage of fingertip amputated at nail level. New surgical principles and treatments. *Ann Plast Surg* 38:151–157, 1997.
70. Hoigne D, Hug U, Schurch M, et al: Semi-occlusive dressing for the treatment of fingertip amputations with exposed bone: quantity and quality of soft-tissue regeneration. *J Hand Surg Eur Vol* 39:505–509, 2013.
71. Holm A, Zachariae L: Fingertip lesions: an evaluation of conservative treatment versus free skin grafting. *Acta Orthop Scand* 45:382, 1974.

71a. Hopper RA, Griffiths S, Murray J, et al: Factors influencing use of digital prostheses in workers' compensation recipients. *J Hand Surg [Am]* 25(1):80–85, 2000.

72. Hrabowski M, Kloeters O, Germann G: Reverse homodigital dorsoradial flap for thumb soft tissue reconstruction: surgical technique. *J Hand Surg [Am]* 35:659–662, 2010.
73. Hyza P, Kubek T, Vesely J, et al: The proximal first dorsal metacarpal artery free flap for reconstruction of complex digital defects. *J Hand Surg Eur Vol* 2013 38e:399–404, 2013.

73a. Iselin F, Peze W: Ray centralization without bone fixation for amputation of the middle finger. *J Hand Surg [Br]* 13(1):97–99, 1988.
74. Illingworth CM: Trapped fingers and amputated finger tips in children. *J Pediatr Surg* 9:853–858, 1974.
75. Iwuagwu FC, Orkar SK, Siddiqui A: Reconstruction of volar skin and soft tissue defects of the digits inclusing the pulp. Experience with the free SUPBRA flap. *J Plast Reconstr Aesthet Surg* 68(1):26–34, 2015.
75a. Jacoby SM, Bachoura A, Chen NC, et al: One-stage coverage for fingertip injuries. *Hand* 8:291–295, 2013.
76. Javaid M, Cormack GC: Anterolateral thigh free flap for complex soft tissue hand reconstructions. *J Hand Surg [Br]* 28:21–27, 2003.
76a. Jensen TS, Krebs B, Nielsen J, et al: Immediate and long-term phantom limb pain in amputees: incidence, clinical characteristics and relationship to pre-amputation limb pain. *Pain* 21(3):267–278, 1985.
77. Johnson RK, Iverson RE: Cross finger pedicle flaps in the hand. *J Bone Joint Surg Am* 53:913–919, 1971.
78. Jönsson S, Caine-Winterberger K, Brånemark R: Osseointegration amputation prostheses on the upper limbs: methods, prosthetics and rehabilitation. *Prosthet Orthot Int* 35:190–200, 2011.
79. Kamei K, Ide Y, Kimura T: A new free thenar flap. *Plast Reconstr Surg* 82:1380–1384, 1993.
80. Katz RD: The anterograde homodigital neurovascular island flap. *J Hand Surg [Am]* 38:1226–1233, 2013.
81. Kavos SJ, Liedl DA, Boon AJ, et al: Expedited wound healing with noncontact, low-frequency ultrasound therapy in chronic wounds: a retrospective analysis. *Adv Skin Wound Care* 21:416–423, 2008.
82. Keim HA, Grantham SA: Volar flap advancement for thumb and fingertip injuries. *Clin Orthop Relat Res* 66:109–112, 1969.
83. Khouri RK, Diehl GJ: Salvage in a case of ring avulsion injury with an immediate second-toe wrap-around flap. *J Hand Surg [Am]* 17:714–718, 1992.
84. Kleinert HE, McAlister CG, MacDonald CJ, et al: A critical evaluation of cross finger flaps. *J Trauma* 14:756–766, 1974.
85. Kojima T, Tsuchida Y, Hirase Y, et al: Reverse vascular pedicle digital island flap. *Br J Plast Surg* 43:290–295, 1990.
86. Kooijman CM, Dijkstra PU, Geertzen JH, et al: Phantom pain and phantom sensations in upper limb amputees: an epidemiological study. *Pain* 87:33–41, 2000.
87. Kutler W: A method for the repair of finger amputation. *Ohio State Med J* 40:120, 1944.
87a. Lambert AW, Dashfield AK, Cosgrove C, et al: Randomized prospective study comparing preoperative epidural and intraoperative perineural analgesia for the prevention of postoperative stump and phantom limb pain following major amputation. *Reg Anesth Pain Med* 26(4):316–321, 2001.
88. Lanzetta M, Mastropasqua B, Chollet A, et al: Versatility of the homodigital triangular neurovascular island flap in fingertip reconstruction. *J Hand Surg [Br]* 20: 824–829, 1995.
89. Lassner F, Becker M, Berger A, et al: Sensory reconstruction of the fingertip using the bilaterally innervated sensory cross finger flap. *Plast Reconstr Surg* 109(3):988–993, 2002.
90. Le Viet D: Translocation of the fifth finger by intracarpal osteotomy. *Ann Plast Surg* 17:228–238, 1986.
91. Le Viet D, Dailiana ZH: Third and fourth finger ray amputations by intracarpal osteotomy. *Tech Hand Up Extrem Surg* 3:110–115, 1999.
92. Lee DH, Mignemi ME, Crosby SN: Fingertip injuries: An update on management. *J Am Acad Orthop Surg* 21:756–766, 2013.
93. Lee PK, Ahn ST, Lim P: Replantation of fingertip amputation by using the pocket principle in adults. *Plast Reconstr Surg* 103:1428–1435, 1999.
94. Leffert RD, Weiss C, Athanasoulis CA: The vincula—with particular reference to their vessels and nerves. *J Bone Joint Surg Am* 56:1191–1198, 1974.
94a. Li J, Wu M, Zhuo M, et al: Alteration of neuronal activity after digit amputation in rat anterior cingulate cortex. *Int J Physiol Pathophysiol Pharmacol* 5(1):43–51, 2013.
94b. Lifchez SD, Marchant-Hanson J, Matloub HS, et al: Functional improvement with digital prosthesis use after multiple digit amputations. *J Hand Surg [Am]* 30(4): 790–794, 2005.
95. Louis DS, Palmer AK, Burney RE: Open treatment of digital tip injuries. *JAMA* 244:697–698, 1980.
96. Lundborg G, Brånemark PI, Rosén B: Osseointegrated thumb prostheses: a concept for fixation of digit prosthetic devices. *J Hand Surg [Am]* 21:216–221, 1996.
97. Luppino T, Vaccari A, Stefanini T, et al: Transposition of the 5th to the 4th ray by osteotomy of the hamate. *Ital J Orthop Traumatol* 11:61–65, 1985.
97a. Lyall H, Elliot D: Total middle ray amputation. *J Hand Surg [Br]* 21(5):675–680, 1996.
98. Mackinnon SE: Wandering nerve graft technique for management of the recalcitrant painful neuroma in the hand: a case report. *Microsurgery* 9:95–102, 1988.
98a. Malone JM, Fleming LL, Roberson J, et al: Immediate, early, and late postsurgical management of upper-limb amputation. *J Rehabil Res Dev* 21(1):33–41, 1984.
99. Manurangsee P, Isariyawut C, Chatuthong V, et al: Osseointegrated finger prosthesis: An alternative method for finger reconstruction. *J Hand Surg [Am]* 25:86–92, 2000.
100. Mathy JA, Moaveni Z, Tan ST: Perforator anatomy of the ulnar forearm fasciocutaneous flap. *J Plast Reconstr Aesthet Surg* 65:1076–1082, 2012.
101. Meek MF: A randomized prospective study of polyglycolic acid conduits for digital nerve reconstruction in humans. *Plast Reconstr Surg* 4:1087–1088, 2001.
102. Melikyan EY, Beg MS, Woodbridge S, et al: The functional results of ray amputation. *Hand Surg* 8:47–51, 2003.
103. Melone CP, Beasley RW, Carstens HJ: The thenar flap: an analysis of its use in 150 cases. *J Hand Surg [Am]* 7:291–297, 1982.
104. Mendelson RL, Burech JG, Polack EP, et al: The psychological impact of traumatic amputations. A team approach: physician, therapist, and psychologist. *Hand Clin* 2:577–583, 1986.
105. Meyer TM: Psychological aspects of mutilating hand injuries. *Hand Clin* 19:41–49, 2003.
106. Miller SJ, Rayan GM: Triple central ray amputation for clear cell sarcoma of the hand. *Am J Orthop* 29:226–228, 2000.
107. Millesi H: Bridging defects: autologous nerve grafts. *Acta Neurochir Suppl* 100:37–38, 2007.
108. Mohta M, Sethi AK, Tyagi A, et al: Psychological care in trauma patients. *Injury* 34:17–25, 2003.
109. Moiemen NS, Elliot D: Composite graft replacement of digital tips. A study in children. *J Hand Surg [Br]* 22:346–352, 1997.
109a. Montoya P, Ritter K, Huse E, et al: The cortical somatotopic map and phantom phenomena in subjects with congenital limb atrophy and traumatic amputees with phantom limb pain. *Eur J Neurosci* 10(3):1095–1102, 1998.
110. Moran SL, Berger RA: Biomechanics and hand trauma: what you need. *Hand Clin* 19:17–31, 2003.
111. Moynihan FJ: Long term results of split-skin grafting in finger-tip injuries. *BMJ* 2:802–805, 1961.
112. Mulliken GH, Musallam S, Andersen RA: Decoding trajectories from posterior parietal cortex ensembles. *J Neurosci* 28:12913–12926, 2008.
113. Murray JF, Carman W, MacKenzie JK: Transmetacarpal amputation of the index finger: a clinical assessment of hand strength and complications. *J Hand Surg [Am]* 2:471–481, 1977.
114. Muzaffar AR, Chao JJ, Friedrich JB: Posttraumatic thumb reconstruction. *Plast Reconstr Surg* 116:103e–122e, 2005.
115. Nelson AW: The painful neuroma: the regenerating axon versus the epineural sheath. *J Surg Res* 23:215–221, 1977.
115a. Nuzumlali E, Orhun E, Oztürk K, et al: Results of ray resection and amputation for ring avulsion injuries at the proximal interphalangeal joint. *J Hand Surg [Br]* 28(6):578–581, 2003.
116. Pasquina PF, Bryant PR, Huang ME, et al: Advances in amputee care. *Arch Phys Med Rehabil* 87(3 Suppl 1):S34–S43, 2006.
117. Paterson P, Titley OG, Nancarrow JD: Donor finger morbidity in cross finger flaps. *Injury* 31:215, 2000.
117a. Peimer CA, Wheeler DR, Barret A, et al: Hand function following single ray amputation. *J Hand Surg [Am]* 24:1245–1248, 1999.
118. Pet MA, Ko JH, Vedder NB: Reconstruction of the traumatized thumb. *Plast Reconstr Surg* 134:1235–1245, 2014.
119. Pinzur MS, Angelats J, Light TR, et al: Functional outcome following traumatic upper limb amputation and prosthetic limb fitting. *J Hand Surg [Am]* 19:836–839, 1994.
120. Porter RW: Functional assessment of transplanted skin in volar defects of the digits: a comparison between free grafts and flaps. *J Bone Joint Surg Am* 50:956–963, 1968.
120a. Posner MA: Ray transposition for central digital loss. *J Hand Surg [Am]* 4:242–257, 1979.
121. Puhaindran ME, Athanasian EA: Double ray amputation for tumors of the hand. *Clin Orthop Relat Res* 468:2976–2979, 2010.
122. Puhaindran ME, Healey JH, Athanasian EA: Single ray amputation for tumors of the hand. *Clin Orthop Relat Res* 468:1390–1395, 2010.
123. Puhaindran ME, Steensma MR, Athanasian EA: Partial hand preservation for large soft tissue sarcomas of the hand. *J Hand Surg [Am]* 35:291–295, 2010.
124. Resnik L, Meucci MR, Lieberman-Klinger S, et al: Advanced upper limb prosthetic devices: implications for upper limb prosthetic rehabilitation. *Arch Phys Med Rehabil* 93:710–717, 2012.
125. Rose EH, Buncke HJ: Selective finger transposition and primary metacarpal ray resection in multi-digit amputations of the hand. *J Hand Surg [Am]* 8:178–182, 1983.
126. Sassu P, Lin CH, Lin YT, et al: Fourteen cases of free thenar flap: a rare indication in digital reconstruction. *Ann Plast Surg* 60:260–266, 2008.
127. Schenck RR, Cheema TA: Hypothenar skin grafts for finger-tip reconstruction. *J Hand Surg [Am]* 9:750–753, 1984.

128. Sensinger JW, Lock BA, Kuiken TA: Adaptive pattern recognition of myoelectric signals: exploration of conceptual framework and practical algorithms. *IEEE Trans Neural Syst Rehabil Eng* 17:270–278, 2009.
129. Shepard GH: The use of lateral V-Y advancement flaps for fingertip reconstruction. *J Hand Surg [Am]* 8:254–259, 1983.
130. Sica REP, Sanz OP, Cohen LG, et al: Changes in the N1-P1 component of the somatosensory cortical evoked response in patients with partial limb amputation. *Electromyogr Clin Neurophysiol* 24:415–427, 1984.
131. Smith KL, Elliot D: The extended Segmuller flap. *Plast Reconstr Surg* 105:1334–1346, 2000.
132. Smith RJ, Albin R: Thenar "H-flap" for fingertip injuries. *J Trauma* 16:778–781, 1976.
133. Smurr LM, Gulick K, Yancosek K, et al: Managing the upper extremity amputee: a protocol for success. *J Hand Ther* 21:160–176, 2008.
134. Snow JW: The use of a volar flap for repair of fingertip amputations: a preliminary report. *Plast Reconstr Surg* 40:163–168, 1967.
134a. Soucacos PN, Beris AE, Malizos KN, et al: Transpositional microsurgery in multiple digital amputations. *Microsurgery* 15(7):469–473, 1994.
135. Steichen JB, Idler RS: Results of central ray resection without bony transposition. *J Hand Surg [Am]* 11:466–474, 1986.
136. Sturman MJ, Duran RJ: The late results of fingertip injuries. *J Bone Joint Surg Am* 45:289–298, 1963.
137. Sullivan DJ: Results of digital neurorrhaphy in adults. *J Hand Surg [Br]* 1:41–44, 1985.
138. Sun C, Hou ZD, Wang B, et al: An anatomical study on the characteristics of cutaneous branches-chain perforator flap with ulnar artery pedicle. *Plast Reconstr Surg* 131:329–336, 2013.
139. Tamai S: Twenty years' experience of limb replantation: review of 293 upper extremity replants. *J Hand Surg [Am]* 7:549–556, 1982.
140. Tang JB, Elliot D, Adani R, et al: Repair and reconstruction of thumb and fingertip injuries: a global view. *Clin Plast Surg* 41:325–359, 2014.
141. Taras JS, Behrman MJ, Degnan GG: Left-hand dominance and hand trauma. *J Hand Surg [Am]* 20:1043–1046, 1995.
142. Taras JS, Sapienza A, Roach JB, et al: Acellular dermal regeneration template for soft tissue reconstruction of the digits. *J Hand Surg [Am]* 35:415–421, 2010.
143. Tubiana R, Thomine J, Mackin E: Movements of the hand and wrist. In Tubiana RTJ, Mackin E, editors: *Examination of the hand and wrist*, St. Louis, 1996, Mosby, pp 40–125.
144. Tupper J, Miller G: Sensitivity following volar V-Y plasty for fingertip amputations. *J Hand Surg [Br]* 10:183–184, 1985.
145. Uellendahl JE, Uellendahl EN: Experience fitting partial hand prostheses with externally powered fingers. In Parenti-Castelli V, Troncossi M, editors: *Grasping the future: advances in powered upper limb prosthetics*, Oak Park, IL, 2012, Bentham Science, pp 15–27.
146. Van der Avoort DJJC, Hovius SER, Selles RW, et al: The incidence of symptomatic neuroma in amputation and neurorrhaphy patients. *J Plast Reconstr Aesthet Surg* 66:1330–1334, 2013.
147. Vernadakis AJ, Koch H, Mackinnon SE: Management of neuromas. *Clin Plast Surg* 2:247–268, 2003.
147a. Wang K, Sears ED, Shauver MJ, et al: A systematic review of outcomes of revision amputation treatment for fingertip amputations. *Hand* 8(2):139–145, 2013.
148. Wei FC, Chen HC, Chuang CC, et al: Simultaneous multiple toe transfers in hand reconstruction. *Plast Reconstr Surg* 81:366–377, 1988.
149. Weichman KE, Wilson SC, Samra F, et al: Treatment and outcomes of fingertip injuries at a large metropolitan public hospital. *Plast Reconstr Surg* 131:107–112, 2013.
149a. Weis JM, Grunert BK, Christianson HF: Early versus delayed imaginal exposure for the treatment of posttraumatic stress disorder following accidental upper extremity injury. *Hand* 7(2):127–133, 2012.
150. Whitaker LA, Graham WP, 2nd, Riser WH, et al: Retaining the articular cartilage in finger joint amputations. *Plast Reconstr Surg* 49:542–547, 1972.
151. Wilson RL, Carter-Wilson MS: Rehabilitation after amputations in the hand. *Orthop Clin North Am* 14:851–872, 1983.
152. Woodhouse A: Phantom limb pain. *Clin Exp Pharmacol Physiol* 32:132–134, 2005.
153. Wright TW, Hagen AD, Wood MB: Prosthetic usage in major upper extremity amputations. *J Hand Surg [Am]* 20:619–622, 1995.
154. Yazar M, Aydin A, Yazar SK, et al: Sensory recovery of the reverse homodigital island flap in fingertip reconstruction: a review of 66 cases. *Acta Orthop Traumatol Turc* 44:345–351, 2010.
155. Yildirim S, Avci G, Akan M, et al: Complication of the reverse homodigital island flap in fingertip reconstruction. *Ann Plast Surg* 48:586–592, 2002.
156. Zheng DW, Li ZC, Sun F, et al: Use of a distal ulnar artery perforator-based bilobed free flap for repairing complex digital defects. *J Hand Surg [Am]* 39:2235–2242, 2014.
157. Zlotolow DA, Kozin SH: Advances in upper extremity prosthetics. *Hand Clin* 28: 587–593, 2012.

Major Limb Amputations and Prosthetics

Rafael J. Diaz-Garcia and Paul S. Cederna

Amputation of the upper extremity takes its toll on both the patient and surgeon. The patient is devastated at the prospect of life with a disability and laments the potential loss of the independence we all take for granted. For the surgeon, the toll is much less, but feelings of sympathy and regret remain, as we wish we had another option. Nonetheless, it is important that surgeons who care for patients with hand and upper extremity injuries have an appreciation of the finer points of amputations. In addition, they should have a comfortable understanding of the treatment goals in postoperative rehabilitation and restoration of upper extremity function to maximize outcomes.

MAJOR LIMB AMPUTATIONS

Although the amputation of a digit is by far more common, major upper extremity amputations account for up to 25% of all amputations.[3-5,15] In the United States alone, approximately 41,000 people underwent transradial amputations in 2005. This prevalence has risen from previous estimates because of improved trauma and critical care medicine, which is preserving the life of severely injured patients; it is likely to continue to rise due to an aging population of patients with a higher incidence of diabetes and vascular disease. The effects of an upper extremity amputation are significant and greatly impact the quality of life. Up to a third of patients who undergo amputation of an upper extremity require a change in occupation, and almost two thirds discontinue vocations and hobbies as a consequence of the amputation.[43,48]

The technical principles of upper extremity amputations are fairly consistent, regardless of the indication for surgery or level of amputation:

- Preservation of functional residual limb length
- Durable coverage of the residual limb to allow for long-term prosthetic use
- Prevention of symptomatic neuromas
- Prevention of adjacent joint contractures
- Early prosthetic fitting (golden period)

Indications

Unlike in the lower extremity, the majority of upper extremity amputations are performed as treatment for acute trauma.[5,44] In Scandinavia, up to 90% of upper extremity amputations are trauma related.[2] Amputations may be performed acutely when the hand surgeon believes that the functional potential of the salvaged limb would be substantially worse than that of a prosthetic limb. At times, the surgeon will elect to perform multiple operative procedures in an attempt to salvage a hand or extremity but is unsuccessful in these attempts. Such attempts to salvage a severely damaged limb may even be detrimental to the health of the patient. In these cases, there is often severe and unreconstructible damage to the neurovascular supply of the extremity or severe injuries to the skeleton, either of which may make meaningful recovery nearly impossible.

Major upper extremity amputations may also be required following burns or infections or as treatment for malignant disease. Up to 26% of electrocution injuries require some form of major amputation.[16] Deep thermal burns result in amputations approximately 3.8% of the time, usually because of nonviable tissues, but at times for control of burn wound sepsis[41] (Figure 50.1). Most infections can be managed with antibiotics and surgical débridement, but some require amputation. For instance, invasive fungal infections such as mucormycosis almost uniformly require amputation; the mortality rate in this patient population may be as high as 92%.[17,30] Advances in radiation therapy, chemotherapy, and limb salvage surgical techniques have considerably reduced the need for upper extremity amputation in sarcoma patients over the past 40 years, but radical amputation remains a mainstay of treatment for recurrent disease or large tumors.[37,46]

Wrist Disarticulation and Transradial Amputation

After decades of research, the optimal level of amputation for patients who require removal of the hand remains controversial.[44] Wrist disarticulation preserves limb length, providing an arm with a longer lever for prosthetic control. In addition, the longer residual limb preserves the distal radioulnar joint, resulting in better pronation and supination.[42] The metaphyseal flare of the distal radius also provides a contour that aids in suspension of a terminal device (Figure 50.2). However, the benefits of a wrist disarticulation come at a cost. The prominence of the styloids of the distal radius and ulna can become pressure points, leading to breakdown of the residual limb within the socket. The additional residual limb length in a wrist disarticulation also can create limb-length discrepancies when a prosthesis is worn. In fact, a myoelectric terminal device may add several centimeters to the length of the residual limb, accentuating the limb-length discrepancy seen in patients who have undergone wrist disarticulation.[33] This not only presents an aesthetic concern but also makes it more difficult for a patient to reach the anatomic midline because greater shoulder abduction and scapular retraction are required to do so. For these reasons, patients with wrist disarticulations are more likely to abandon their prostheses than transradial amputees.[6,48] Ideally, the patient is afforded the opportunity to have a preoperative consultation with a physiatrist and a prosthetist so that he or she may make an educated choice between a wrist disarticulation

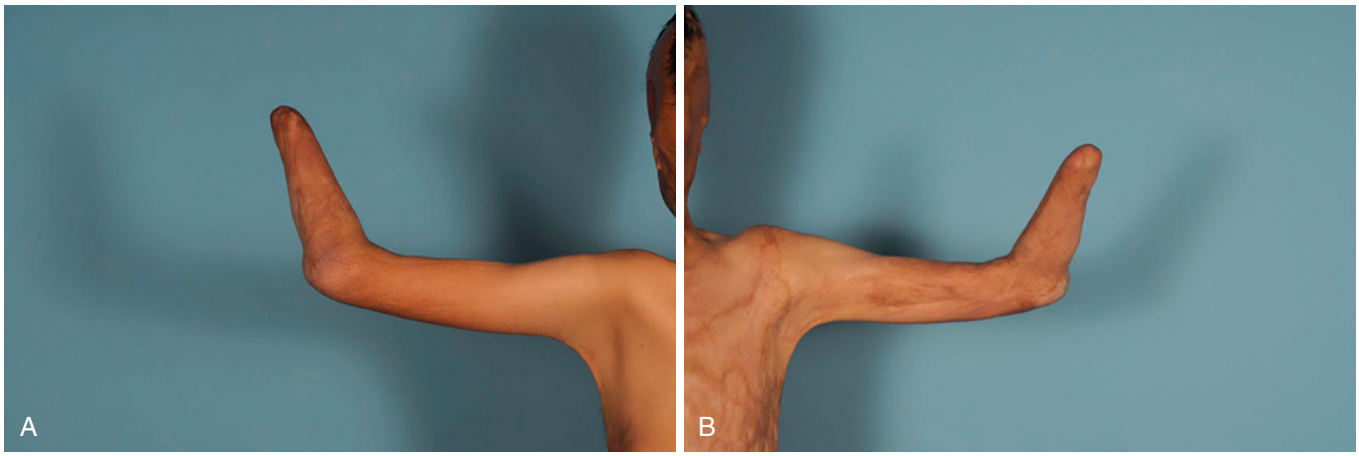

FIGURE 50.1 **A, B,** Thirty-four-year-old gentleman suffering more than 50% total body surface area burns to the head, trunk, and upper extremities, requiring bilateral transradial amputations.



FIGURE 50.2 The increased width provided by the metaphysis of the distal radius allows for easier prosthetic suspension with a wrist disarticulation in comparison with a transradial amputation.

and a transradial amputation. Given the usual indications, however, this is unfortunately rarely the case. Amputation 8 to 10 cm proximal to the ulnar styloid provides the greatest variety of prosthetic options for functional restoration of the extremity.[24,43] This preserves adequate pronation and supination and a reasonable lever arm for prosthetic control during flexion of the elbow. One form of amputation is not ideal for all patients, however, making the preoperative consultation critically important in the process. Patients who perform heavy labor frequently prefer a wrist disarticulation owing to the increased durability of a body-powered prosthetic, the increased lever arm length, and the preserved distal radioulnar joint.

As the transradial amputation becomes more proximal and approaches the elbow, the anticipated pronation and supination decrease. In fact, there is minimal pronation and supination once half of the initial forearm length is removed. Yet, preserving at least 5 cm of the ulna is sufficient for successful prosthetic fitting.[34] Once the level of amputation moves proximally above the elbow, the dramatic increase in the amount of work required to function with the prosthesis greatly increases the likelihood of abandonment.[6] Preserving the elbow joint should remain a high priority, even when complex reconstructive efforts such as free flaps are required to maintain this articulation.

❖ AUTHORS' PREFERRED METHOD OF TREATMENT: Transradial Amputation

The skin incisions are designed with equal-length flaps along the volar and dorsal aspects of the forearm, in what is often referred to as a fish-mouth pattern. The incisions are designed so that the osteotomies in the radius and ulna will lie at least 1 to 2 cm proximal to the level of the skin incision (Figure 50.3). The arm is exsanguinated, and tourniquet control is used for hemostasis. The skin and subcutaneous tissues are elevated off of the underlying antebrachial fascia proximally past the level of the proposed osteotomies. The antebrachial fascia is incised at the level of the skin incision, and all of the neurovascular structures are individually identified. The radial and ulnar arteries are ligated with suture ties or vascular clips, and the interosseous vessels are cauterized. The nerves are dissected proximally and divided to ensure that they are positioned proximal to the level of the osteotomy. The flexor and extensor musculature is divided 1 cm distal to the level of the osteotomy. The periosteum is incised and a small cuff is elevated proximally. An oscillating saw is used to make the bony cuts, and edges are smoothed with a rasp. A myodesis is performed, first with the deeper muscle bellies fixed firmly to the underlying skeleton to establish durable bony coverage and to prevent bursitis from excessive excursion. The superficial musculature is then sutured in agonist/antagonist pairing over the end of the osteotomies to complete the myodesis. Care is taken to re-create physiologic tension to superficial muscle units to maximize postoperative contractions. The force of these contractions may ultimately be used to provide efferent motor control of a myoelectric prosthesis. The wound is closed in layers, and a bulky compressive dressing is applied.

Elbow Disarticulation and Transhumeral Amputation

Loss of the elbow joint has a significant adverse functional impact on the residual limb and greatly diminishes a patient's adaptation to meaningful use of a prosthesis. In these more proximal amputations, the elbow must be replaced with a

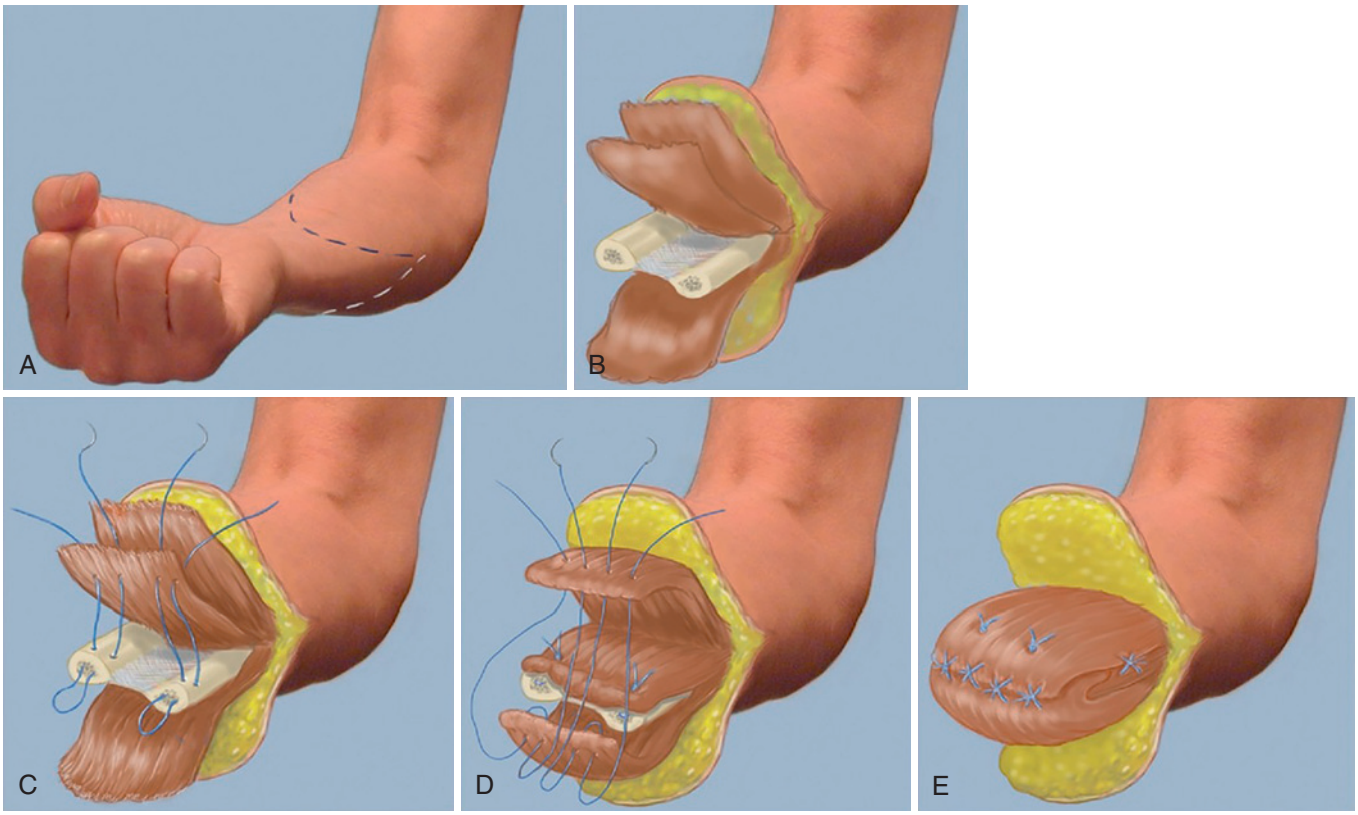

FIGURE 50.3 Artist's rendition of a planned, elective transradial amputation. **A,** A fish-mouth incision is designed 1 to 2 cm distal to the level of the planned osteotomies, which are usually 8 cm from the ulnar styloid. **B,** Soft tissues are elevated and osteotomies completed with an oscillating saw. **C,** A myodesis is completed with the deep musculature to the bone. **D** and **E,** Superficial musculature is sutured in agonist/antagonist pairing over top, trying to re-create physiologic tension. (From Marchessault JA, McKay PL, Hammert WC: Management of upper limb amputations. *J Hand Surg [Am]* 36(10):1718–1726, 2011.)

prosthetic component, which adds a substantial amount of weight and limits the utility of these devices. In addition, with above-the-elbow prostheses, more energy is required to perform daily functions, and thus, transhumeral amputees are more likely to abandon their prosthetics than their transradial counterparts.[6]

The discussion regarding elbow disarticulation versus transhumeral amputation is similar to the previous discussion regarding wrist disarticulation versus transradial amputation. There are advocates for both surgical approaches because each has its benefits and drawbacks. Preservation of the distal humerus conserves the flare of the condyles, which not only aid in the suspension of the device but also allow for transmission of rotation. These benefits come at a fairly high price, however. When an elbow disarticulation is performed, the greater length of the residual upper arm creates a limb-length discrepancy, which is particularly problematic when a patient uses a prosthetic device with an elbow articulation. In these situations, it is more difficult for the patient to reach the anatomic midline, and the asymmetry with the unaffected arm is fairly noticeable, unaesthetic, and functionally limiting.

❖ AUTHORS' PREFERRED METHOD OF TREATMENT: Transhumeral Amputation

It is our preference to perform a transhumeral amputation rather than an elbow disarticulation because the benefits of the latter seem fairly minor. The exception is in the pediatric patient, where there is a high incidence of bony overgrowth following transhumeral amputation through the metaphysis, which ultimately may require surgical revision.[1] A sterile tourniquet is used to limit blood loss and facilitate identification of key structures in a bloodless field. After exsanguination, anterior and posterior flaps are designed 2 cm distal from the level of the planned osteotomy. Ideally, the osteotomy is planned 10 cm proximal to the olecranon tip to maximize prosthetic options. The brachial artery is securely ligated with a suture ligature, and the radial, median, and ulnar nerves are dissected proximally and divided to ensure that they are positioned proximal to the level of the osteotomy. The osteotomy is performed with an oscillating saw, and any bony edges are carefully rasped so they are smooth. The tourniquet is removed and hemostasis ensured. It is possible to perform an angulation osteotomy of the distal humerus to provide rotational control of the prosthesis.[28,32] This operation would only be performed, however, if there were extensive preoperative discussions with the physiatrist and prosthetist and it was determined that this would provide the optimal functional rehabilitation for the patient. This is not done routinely in all patients because it can create a pressure point in the residual limb. If it is planned, the amputation is performed more distally to account for the limb length lost with the angulation osteotomy. A myodesis is performed by securing the musculature from the anterior compartment to the

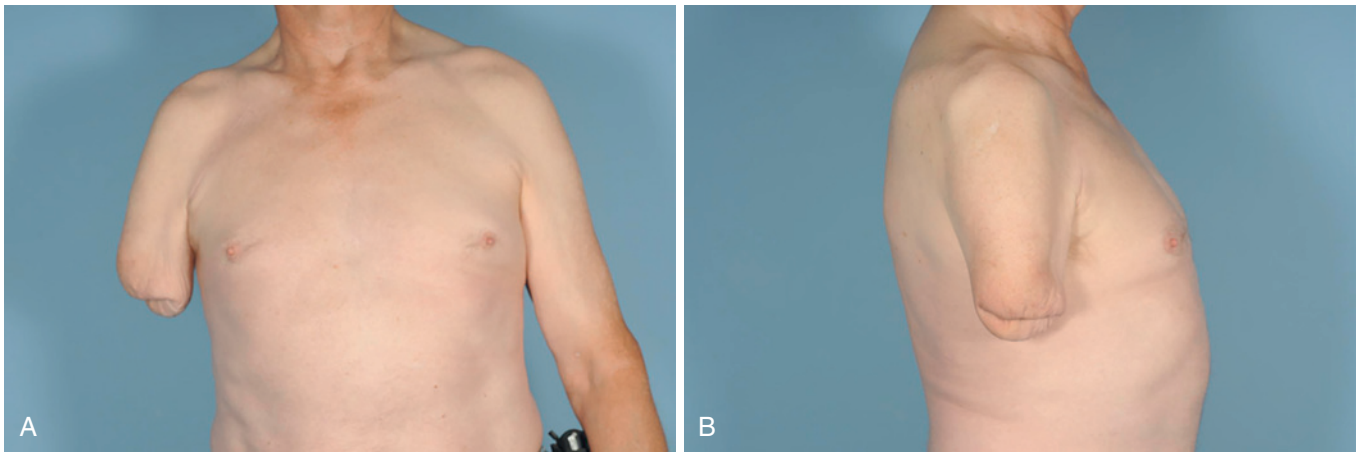

FIGURE 50.4 Elderly patient with transhumeral amputation, with no interest in prosthetic rehabilitation. **A,** Frontal view. **B,** Lateral view.

posterior compartment to cover the distal humeral edge. Unlike in transradial amputations, a closed suction drain is placed to avoid fluid collections. The skin is closed in layers, and a bulky compressive dressing is applied (Figure 50.4).

Interscapulothoracic Amputation

Interscapulothoracic (forequarter) amputation is the most radical and, luckily, least frequent amputation in surgical practice. This disfiguring procedure requires disarticulation of the entire shoulder girdle from the thoracic cavity. Although initially described in the setting of trauma in 1808, the surgical technique has not evolved much over two centuries because of the rarity of the procedure.[18] Its main clinical role today is as a last resort in the treatment of aggressive malignant disease. The use of forequarter amputation has continued to decline from 32% in the 1970s to 5% in a current series because of advances in radiation therapy, chemotherapy, and limb salvage surgical techniques.[37,46] Because most of these amputations are done for aggressive malignant conditions, the outcomes are generally poor. Over a 12-year span at a major orthopedic oncology center, the overall survival rate at 1 year was 42% and by 2 years, it was less than 20%.[37]

Planning the closure of the eventual defect is important because the amputation cannot proceed any more proximally if there is tension on the skin (Figure 50.5). This is particularly true in cases of recurrent sarcoma, where radiation damage to the surrounding tissues may present a dilemma and create additional challenges for soft tissue coverage. If the area of skin resection or previous irradiation will likely result in too much tension at the suture line, the surgeon should plan to fillet the forearm and use it as a fasciocutaneous free flap based on the brachial artery.[19,49]

❖ AUTHORS' PREFERRED METHOD OF TREATMENT: Forequarter Amputation

The patient is placed in the lateral decubitus position, with all pressure points appropriately padded. Like most amputations, previous scars or recurrent malignant disease may affect the ultimate incision design. The classic design is an ellipse at the base of the shoulder and around the scapula, with a cephalad extension along the clavicle up to the sternocleidomastoid muscle to obtain proximal control of the subclavian vessels (Figure 50.6). The anterior portion of the incision is an extension of the deltopectoral groove inferiorly, and the posterior portion crosses the acromion and runs along the medial border of the protracted scapula. The natural skin redundancy over the retracted scapula is preserved to facilitate tension-free closure.

The operation is started anteriorly, exposing the entire clavicle by releasing the muscular attachments with electrocautery. An osteotomy is completed just lateral to the origin of the sternocleidomastoid with a Cobb elevator protecting the underlying vascular structures. The osteotomy provides excellent exposure of the subclavian artery and vein, which are divided and suture ligated. If a free flap is planned for coverage, vascular control is maintained with a combination of vessel loops and atraumatic vessel clamps to preserve the vasculature for microvascular transfer. Once control of the major vessels is obtained, the pectoralis major tendon is divided and retracted medially. The origins of the coracobrachialis and short head of the biceps are dissected off of the coracoid along with the insertion of the pectoralis minor. The transverse cervical and suprascapular arteries are ligated as they cross the surgical field. If the patient is younger than 50 years of age, the major branches of the brachial plexus should be cut and implanted into the pectoralis major and serratus anterior to allow for the possibility of targeted muscle reinnervation for prosthetic control (see Frontiers in Prosthetic Rehabilitation).

Attention is then directed posteriorly, where the incision is made along the medial border of the scapula, dissecting toward the muscular insertion of the rhomboids. As the muscle fascia is incised, the shoulder is flexed and adducted to bring the scapula off of the thorax. If one does not have sufficient help in the operating room, a hydraulic arm holder can be of great assistance. All of the muscular attachments are released superiorly and medially off of the scapula, leaving only the serratus anterior and latissimus dorsi muscles as attachments to the specimen. These tendons are divided, and the specimen is passed off for pathologic study. The skin is closed in a layered fashion over drains.

CURRENT PROSTHETIC REHABILITATION

The loss of an upper extremity is devastating, and current prosthetic options cannot adequately replace all the functions of the



FIGURE 50.5 **A,** Traumatic injury of the right upper extremity with multilevel injury made operative salvage futile. **B,** Axillary wound showing large brachial plexus nerve gaps secondary to avulsion injury. **C,** Radiographs illustrate the large segmental loss of proximal humerus. **D** and **E,** Final closure of amputation site with Jackson-Pratt drains in place.

human hand. Modern devices do not have ample degrees of freedom and lack sufficient sensory feedback. Every activity requires visual cues for direction because there is minimal tactile feedback from the terminal device. Thus, the upper extremity amputee must expend more energy—both physical and cognitive—to perform activities of daily living. The ultimate postoperative goal is for patients to regain functional independence and be able to participate in the vocational and recreational activities they enjoyed prior to surgery. However, as mentioned previously, 33% of patients require a change in occupation and 58% discontinue recreational activities.[43,48]

There are a multitude of factors that influence prosthetic rehabilitation, including the level of amputation, comorbidities, range of motion, strength, patient goals and preferences, and health insurance coverage. The level of amputation probably has the greatest impact on prosthetic rehabilitation because it determines (1) the functions that need to be replaced, (2) the length of the residual limb needed to provide stability and control of the terminal device, and (3) the prosthetic components that will be required to reestablish function. There are a wide variety of rehabilitative choices when developing a restorative plan after upper extremity loss, from passive cosmetic devices to futuristic robotic units with multiple degrees of freedom. Comprehensive coverage of all the options is beyond the scope of this chapter. We hope to provide you with a basic understanding of prosthetic rehabilitation and how it pertains to the hand surgeon, however.

Rehabilitation After Upper Extremity Amputation

Ideally, prosthetic rehabilitation commences before the major limb amputation even takes place. The patient should meet with a physiatrist prior to surgery, and there should be collaboration between the surgeon and physiatrist to create a rehabilitation care plan. The level of amputation should be discussed, focusing on the impact the various levels of amputation will have on functional outcome, prosthetic restoration, and rehabilitation. The physiatrist can also provide counseling and patient references that may better prepare the patient for the limb loss. Obviously, because most amputations of the upper extremity result from trauma, this is not a possibility in many cases. However, when possible, this is greatly beneficial to all patients physically and psychologically.

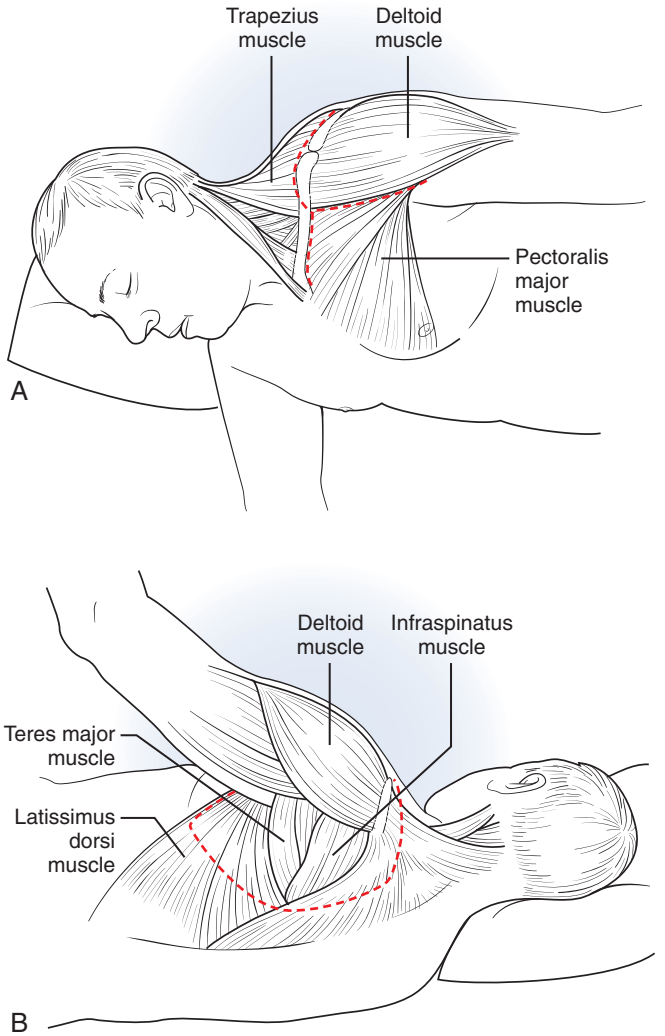

FIGURE 50.6 Anterior **(A)** and posterior **(B)** incision design for elective interscapulothoracic amputation. This allows for proximal access to the subclavian vessels and sufficient soft tissue for closure of the amputation site. (Redrawn with permission from Qadir R, Sidhu S, Romine L, et al: Interscapulothoracic [forequarter] amputation for malignant tumors involving the upper extremity: surgical technique and case series. *J Shoulder Elbow Surg* 23(6):e127–e133, 2014.)

If there are no contraindications, range-of-motion exercises of the residual limb should be initiated soon after surgery. Occupational therapy can provide gentle range of motion of the surgical limb and training in using the noninvolved arm for feeding, dressing, and self-care. The occupational therapist can also provide thermoplastic extensions for the residual limb, which can assist the patient in performing some bimanual skills before the permanent prosthesis can be fitted. In this early postoperative period, graded compression of the residual limb will help create a well-shaped recipient for the socket liner. Good pain control is of utmost importance; ongoing pain will delay recovery and participation in rehabilitation.

Barring any wound healing issues, a provisional prosthesis should be fitted as soon as possible. After upper extremity amputation, patients immediately begin using compensatory movements to be more functional, some of which persist even after completion of rehabilitation.[12] Motivation and interest peak early after limb loss; this is the optimal time to fit the patient for the prosthesis and begin rehabilitation, before the patient has adapted to life without the extremity. The first month after amputation is often referred to as *Malone's "golden period."* The successful rehabilitation rate drops to 42% for patients fitted after the initial 30 days postoperatively.[27] The main purpose of the provisional prosthesis is to acclimate the patient to the use of a prosthesis, hopefully providing a positive experience. As edema resolves, a final prosthesis can be designed and fitted; patients who undergo this step within 6 months are 16 times more likely to use the prosthesis over the long term.[7] It is critically important that the patient undergo counseling regarding all of the various types of terminal devices, including their capabilities and functionality, so the patient can select the device best suited to his or her needs. Even with good education and fitting, however, many patients ultimately abandon the prosthesis because of discomfort, lack of functional gains, appearance or weight of the device, lack of sensory feedback, short battery life, and financial constraints. A review of the literature shows that rejection rates are greater for passive-power prostheses, and approximately 20% of adults with amputations abandon all prosthetics and routinely use no terminal device.[8]

PROSTHETIC COMPONENTS AND OPTIONS

Prosthetic Designs

Upper extremity prostheses can be categorized in a variety of ways. The most obvious categorization is by level of amputation. As the amputation becomes more proximal, it is more difficult to suspend the prosthesis without the use of a harness and more functions need to be replaced with either locking or powered joints. For an individual patient, prostheses are best categorized by their source of power, whether passive, body-powered, externally powered, or hybrid. The *passive prosthesis* is considered a cosmetic terminal device because that is the use for which it is most commonly selected. Passive prostheses are usually lightweight and appear lifelike if fitted with a cosmetic silicone glove. Interestingly, they can also be quite functional, providing the ability to stabilize objects or having recreation-specific designs.

Body-powered prostheses are the most commonly prescribed prostheses in the upper extremity. They are lightweight and much less expensive than externally powered devices, particularly for transhumeral amputees. They harness scapular and humeral motion, and because they work through a relatively simple system of metal cables, joint locks, and rubber bands, they are durable and require very little maintenance. These qualities make them attractive to manual laborers, who are more likely to have suffered a traumatic amputation (Figure 50.7). Unfortunately, they do appear to be "mechanical" devices, have a bare hook, and are not aesthetically pleasing to some patients.

Although the designs of body-powered devices have not changed much in a century, *externally powered prostheses* have undergone extensive research and development. Early designs used pneumatics and hydraulics, but current myoelectric prosthetics are run by battery-powered motors housed in the artificial limb itself. Surface electromyographic electrodes detect electrical activity in the superficial musculature of the residual limb, allowing the patient to open and close the terminal device



FIGURE 50.7 A body-powered hook terminal device is durable and requires very little maintenance; it is therefore attractive to manual laborers. (Courtesy of Advanced Arm Dynamics, with permission.)



FIGURE 50.8 The new Michelangelo Hand from Otto Bock has multiple specific grip functions for mastering tasks such as gripping a key or holding a pen, enabling it to function more like a human hand. (Courtesy of Advanced Arm Dynamics, with permission.)

by activation of agonist and antagonist muscle groups. Externally powered prostheses have greater prehension strength (>30 pounds of pinch) than body-powered devices, which usually close on the basis of a series of rubber bands (Figure 50.8). However, each additional function greatly increases the cost of the device, its weight, and its required maintenance. Prototypes tested by the Department of Defense for transhumeral amputees cost upward of $100,000.

Once the patient is proficient in the use of the provisional prosthesis, the limb size and shape have stabilized, and the functional needs have been determined, decisions about the definitive restoration can be made. As stated previously, some patients may need more than one device to achieve their goals. Although the final prescription is an individualized decision, there are some general trends. *Myoelectric devices* are preferred for most transradial amputees due to their improved cosmesis, pinch strength, and anatomic suspension. *Hybrid prostheses* are usually preferred for proximal amputations, including transhumeral amputations and shoulder disarticulations (Figure 50.9). This is due to the lack of sufficient and distinct proximal muscle signals to power a complete myoelectric device. However, passive and body-powered devices can be fashioned for any level of amputation, the latter being the device of choice for the manual laborer because of its durability.



FIGURE 50.9 Transhumeral amputees can have reasonable function with the use of a hybrid prosthesis. (Courtesy of Advanced Arm Dynamics, with permission.)

Sockets and Suspension Systems

The socket is the very foundation of the prosthetic restoration. It must be comfortable to wear, or the patient is sure to discontinue its use. A test socket is created during the initial fitting of the provisional prosthesis. Based on patient feedback, a customized permanent socket is constructed out of carbon fiber and Kevlar to fit the final prosthesis. Sockets may be self-suspended or require a harness. Self-suspended sockets have an intimate fit that has direct translation of motion from the residual limb to the socket and, in turn, the prosthesis. Conversely, non–self-suspended sockets are easier to don but require a highly visible harness that is less cosmetically appealing. The harness is necessary in more proximal amputations, such as in a transhumeral amputee. As the prosthesis becomes heavier, it becomes more important to suspend the weight from the harness to prevent excessive force on the end of the residual limb. Suspension depends not only on the level of amputation but also on the control method for the prosthetic joints. For instance, a body-powered prosthesis requires an external suspension system to harness the scapular motion and translate it down the cable to a terminal device.

FRONTIERS IN PROSTHETIC REHABILITATION

In recent years, there has been an increase in awareness of the limitations of current prosthetic designs, as wounded servicepeople have attempted to reintegrate into society after limb loss. This awareness has resulted in significant increases in research funding and scientific discovery in the field. Although advances have been made, limitations abound, with upper extremity

prosthetic users uniformly dissatisfied with the prehensile function of the available terminal devices. There is insufficient control of multiple degrees of freedom and a lack of sensory feedback from the prosthetic devices, both of which are key in optimizing functional recovery following limb loss. Unfortunately, these problems are accentuated in patients with more proximal amputations because loss of the elbow joint decreases the muscles available for prosthetic control. Current and future researchers hope to address these shortcomings and create prosthetic devices with more degrees of freedom, better sensory feedback capabilities, and more intuitive control strategies.

Improved Prosthetic Control

In an attempt to create the ideal prosthetic that will provide the optimal functional recovery following limb loss, the largest obstacles stem from the lack of control and true sensory feedback. The perfect mechanical extremity would be useless if the patient were not able to control it consistently and precisely. Without proprioception and tactile feedback, there is a significant cognitive burden in doing everyday tasks because visual cues must be used for every act. An ideal control system would not only provide that crucial feedback to the user but also allow for simultaneous motion at multiple joints with volitional control. A high-fidelity neural-machine interface, both for motor control and for sensory feedback, is the ultimate goal. In attempting to reach this goal, three research paradigms have been developed to record high-fidelity signals for volitional control of a robotic extremity: (1) targeted-muscle reinnervation, (2) peripheral nerve interfaces, and (3) central nervous system interfaces.

Targeted-muscle reinnervation (TMR) is a creative and innovative approach to providing efferent motor signals for prosthetic control by innervating muscle territories (myosites) in proximal amputees. In conventional myoelectric devices, patients with transradial amputations will use their innervated wrist flexors and extensors to control the terminal device. In a more proximal amputation, however, there are minimal residual innervated muscles to provide an electromyographic signal for prosthetic control; in a transhumeral amputation or shoulder disarticulation, there are no innervated wrist flexors or extensors to provide myoelectric signals for control of prosthetic hand function. In these circumstances, there is limited ability to control hand function and elbow function simultaneously. Dumanian and colleagues have led a team at Northwestern University to create a solution for this problem with TMR. Target proximal muscles are denervated and then provided an alternative signal with nerve transfers.[13,14,20-22] The reinnervated muscles serve as biologic amplifiers of the previously lost motor commands. The muscle contractions are detected by surface electromyographic electrodes, which provide the appropriate control signals for the myoelectric prosthesis.

TMR patients have had great clinical success, though the number of patients remains small. They have demonstrated a seven-fold increase in efficiency in completing tasks with their prostheses, so that proximal amputees are able to control their devices at multiple articulations simultaneously.[11,14,20] Patients report that the control is more natural and intuitive, reducing the amount of necessary training. Recently, an in vivo regenerative peripheral nerve interface has been developed as a microscopic version of TMR. Nerve endings are implanted into muscle grafts with an applied electrode and wrapped in a bioelectric insulator, providing signal amplification with long-term stability and durability.[23,39] This interface strategy can be employed at the nerve fascicle level, providing the potential for higher-fidelity independent motor control of numerous joints simultaneously.

The peripheral nerve interface research and development community has spent a substantial amount of time and resources creating new, innovative, and highly technically advanced interface designs for providing improved motor control of prosthetic devices. These interfaces have been developed and refined in many different configurations and out of many different materials to record efferent motor action potentials from peripheral nerves in the residual limb. One of the peripheral nerve interface strategies uses *cuff electrodes*, implanted extraneural electrodes that surround the nerve and record action potentials from several fascicles within the nerve.[31,45] Cuff electrodes have been shown to be safe and effective for up to 3 years in humans, but they have limitations in selectivity. The small-amplitude neural signals can be difficult to isolate from adjacent muscle contractions or from adjacent fascicles, which may be providing different volitional control signals (i.e., index finger flexion versus middle finger flexion) within the same nerve.[36] Intraneural electrodes, such as intrafascicular electrodes and rigid multielectrode arrays, are placed within the peripheral nerve with direct axonal contact.[10,29] (Figure 50.10). This increased contact area with the axons improves the selectivity of the individual signals. However, the location of intraneural electrodes within the peripheral nerve leads to progressive fibrosis over time owing to (1) the initial procedure to place the electrode within the nerve, (2) foreign body reaction, and (3) micromotion. Scarring in the nerve causes progressive axonal damage, axonal pruning, and biofouling of the electrode, which ultimately results in loss of the signal.

The central nervous system has also been an attractive site for capturing motor commands and providing sensory



FIGURE 50.10 The Utah multielectrode array has become a benchmark for multichannel, high-density neural recordings, and is one of the peripheral nerve interfaces being used for prosthetic control. (Courtesy of Blackrock Microsystems, with permission.)

feedback to patients with limb loss or spinal cord injuries. Brain signals can be captured with electroencephalograms (EEGs) on the scalp or electrocorticograms (ECoGs) in the brain, and that electrical activity can be used to direct the motions of a robotic limb. There are significant limitations, however. EEG signals represent a large number of neurons, rather than individual cells, so there are limits in the resolution of the signal.[9,47] This makes it difficult to code movement for volitional intent consistently. Because the ECoG signals are derived directly from the motor cortex, they are more specific and have much better signal resolution, but gaining access requires a craniotomy, placing a foreign body on the surface of the brain, or penetrating the brain with an electrical probe. These implants have a limited functional life for reasons similar to those of intraneural electrodes; ECoG arrays lose fidelity and signal strength over time because of the fibrosis at the cortex/electrode contact area.[36] Nevertheless, there has been success in animals, who were able to execute complex tasks with these implanted interfaces, and some success in achieving control of a prosthetic limb with ECoG electrodes in humans.[9] These central nervous system interfaces are unlikely to be the answer in patients with upper extremity amputations but will undoubtedly serve a purpose among the spinal cord injury population.

Improved Prosthetic Design

The past 20 years has seen amazing advancements in the field of robotics. Although the advancements realized in robotic design and functionality have been astounding, the progress seen in prosthetic rehabilitation has been less dramatic. Functional gains in prosthetic limbs must be balanced with the added weight and size that comes with these designs. Furthermore, the average amputee lacks the means to pay for the complex robotic devices available at the cutting edge of the field. Nevertheless, prosthetic terminal devices are constantly being improved for the purposes of providing enhanced function in patients suffering from limb loss.

Sockets and liners provide a critical interface between the prosthetic device and the residual limb. Not only must they allow for the transfer of work from the organic structures to the mechanical structure, but they also must remain comfortable to allow the patient to use them over a full day. New materials are always under development in the hopes of greater durability and less weight. Polymers will continue to be developed with greater strength and pliability. *Computer-aided design and computer-aided manufacture* (CAD/CAM) has recently become an area of increased interest in prosthetics. Custom-fitted devices can be designed and produced more quickly and at a fraction of the usual cost.[40] Northwestern University's Prosthetics-Orthotics Center is at the forefront of the CAD/CAM movement with their "Squirt Shape" technique.[38] On the design side, they are using new technology such as the Inspeck 3D Mega Capturor optical system and ShapeMaker software. The former can digitize complex shapes such as residual limbs with the aid of up to 7,800,000 sampled points from a single camera, and the latter creates three-dimensional models that can be digitally modified to relieve pressure in a sensitive area by applying it in a more tolerant location. On the manufacturing side, they use a deposition modeler, which can extrude hundreds of layers of plastic, thermally bonded together, in any complex three-dimensional shape, including prosthetic sockets. Fabrication is totally automated, and thus, a finished product can be produced in less than an hour with a dollar's worth of raw materials. One can envision that centralized prosthetic centers could easily provide sockets and liners for patients with decreased fabrication errors and inconsistencies on a large scale. This is a dramatic shift from the current state of prosthetic rehabilitation, which is more art than science and is taught in an apprenticeship model.

Actuators convert available potential energy to actual work, and, much like batteries, are valued in terms of their power density. Engineered actuators are much more efficient than human muscle, yet have higher expectations still given the limited space for stored energy. The current gold standard is the brushless DC motor, which requires less maintenance and delivers a higher-powered output at a smaller size than its predecessors. Electromagnetic motors waste significant energy in the speeding up and slowing down with each movement, however. Potential alternatives are under development, such as mesofluidic actuation, which uses pressurized fluid for the creation of force and has a much greater power density than conventional electric motors. Although traditional hydraulics have lost their mechanical advantage when miniaturized, researchers have linked antagonistic joint movements and recently patented a fully mesofluidic actuated digit.[25,26] Another potential solution to the energy lost with brushless motors is *cobotics*. In cobotic actuation, a central electromagnetic motor spins continuously and has multiple outputs, which can actuate motion individually or in unison.[35] This would be ideal for the complex, multidimensional motions that the upper extremity must perform at multiple joints to have more naturalistic movements. Cobots preserve the energy lost in stopping/starting conventional electric motors, but current advances in development have yet to produce a cobot small enough to become a component of a terminal prosthetic device.

SUMMARY

A major amputation of an upper extremity can be severely disabling. The human hand is a true marvel that engineers have been trying to re-create since the Industrial Revolution. Our hands not only play a role in our ability to perform our daily activities but are also integral in how we communicate with others and how we view our own humanity. Early prosthetic rehabilitation is critical in maximizing patient outcomes; significant evidence demonstrates that delays in prosthetic rehabilitation lead to a greater likelihood of prosthetic abandonment over the long term. Current upper extremity prosthetic options have significant limitations, but they can often result in a patient's return to a fulfilling life at work and play.

The field of prosthetics and biomechanical engineering has seen a surge in interest and research funding in parallel to the surge of young men and women with limb loss returning from overseas conflicts. Lighter materials, smaller and faster processors, and newer batteries have contributed positively to the functional recovery of this patient population over the past decade. Significant challenges remain, however, because new devices are prohibitively expensive and still fail to provide the necessary haptic feedback for optimal functional restoration. Neural-machine interfaces are an exciting area of research and development but require much more study prior to integration

into clinical practice. Surely, the next decade will be an exciting time in the field of prosthetics and neural engineering, and one hopes that over time, the loss of a limb will become more of a hurdle than a disability.

For Case Studies, Videos, and more, please visit ExpertConsult.com.

REFERENCES

1. Aitken GT: Surgical amputation in children. *J Bone Joint Surg Am* 45:1735–1741, 1963.
2. Anderson-Ranberg F, Ebskov B: Major upper extremity amputation in Denmark. *Acta Orthop Scand* 59(3):321–322, 1988.
3. Atroshi I, Rosberg HE: Epidemiology of amputations and severe injuries of the hand. *Hand Clin* 17(3):343–350, vii, 2001.
4. Barmparas G, Inaba K, Teixeira PG, et al: Epidemiology of post-traumatic limb amputation: a National Trauma Databank analysis. *Am Surg* 76(11):1214–1222, 2010.
5. Baumgartner RF: The surgery of arm and forearm amputations. *Orthop Clin North Am* 12(4):805–817, 1981.
6. Biddiss E, Chau T: Upper-limb prosthetics: critical factors in device abandonment. *Am J Phys Med Rehabil* 86(12):977–987, 2007.
7. Biddiss EA, Chau TT: Multivariate prediction of upper limb prosthesis acceptance or rejection. *Disabil Rehabil Assist Technol* 3(4):181–192, 2008.
8. Biddiss EA, Chau TT: Upper limb prosthesis use and abandonment: a survey of the last 25 years. *Prosthet Orthot Int* 31(3):236–257, 2007.
9. Birbaumer N: Breaking the silence: brain-computer interfaces (BCI) for communication and motor control. *Psychophysiology* 43(6):517–532, 2006.
10. Branner A, Stein RB, Fernandez E, et al: Long-term stimulation and recording with a penetrating microelectrode array in cat sciatic nerve. *IEEE Trans Biomed Eng* 51(1):146–157, 2004.
11. Bueno RA, Jr, French B, Cooney D, et al: Targeted muscle reinnervation of a muscle-free flap for improved prosthetic control in a shoulder amputee: case report. *J Hand Surg [Am]* 36(5):890–893, 2011.
12. Carey SL, Jason Highsmith M, Maitland ME, et al: Compensatory movements of transradial prosthesis users during common tasks. *Clin Biomech (Bristol, Avon)* 23(9):1128–1135, 2008.
13. Cheesborough JE, Souza JM, Dumanian GA, et al: Targeted muscle reinnervation in the initial management of traumatic upper extremity amputation injury. *Hand* 9(2):253–257, 2014.
14. Dumanian GA, Ko JH, O'Shaughnessy KD, et al: Targeted reinnervation for transhumeral amputees: current surgical technique and update on results. *Plast Reconstr Surg* 124(3):863–869, 2009.
15. Freeland AE, Psonak R: Traumatic below-elbow amputations. *Orthopedics* 30(2): 120–126, 2007.
16. Haberal M: Electrical burns: a five-year experience: 1985 Evans lecture. *J Trauma* 26(2):103–109, 1986.
17. Jones NF, Shin EK, Eo S, et al: Successful salvage of mucormycosis infection of the forearm and osteomyelitis of the ulna. *Hand* 3(4):332–336, 2008.
18. Keevil JJ: Ralph Cuming and the interscapulo-thoracic amputation in 1808. *J R Nav Med Serv* 36(2):63–72, 1950.
19. Koulaxouzidis G, Simunovic F, Stark GB: Shoulder silhouette and axilla reconstruction with free composite elbow tissue transfer following interscapulothoracic amputation. *J Plast Reconstr Aesthet Surg* 67(1):81–86, 2014.
20. Kuiken T, Miller L, Lipschutz R, et al: Prosthetic command signals following targeted hyper-reinnervation nerve transfer surgery. *Conf Proc IEEE Eng Med Biol Soc* 7: 7652–7655, 2005.
21. Kuiken TA, Dumanian GA, Lipschutz RD, et al: The use of targeted muscle reinnervation for improved myoelectric prosthesis control in a bilateral shoulder disarticulation amputee. *Prosthet Orthot Int* 28(3):245–253, 2004.
22. Kuiken TA, Miller LA, Lipschutz RD, et al: Targeted reinnervation for enhanced prosthetic arm function in a woman with a proximal amputation: a case study. *Lancet* 369(9559):371–380, 2007.
23. Kung TA, Langhals NB, Martin DC, et al: Regenerative peripheral nerve interface viability and signal transduction with an implanted electrode. *Plast Reconstr Surg* 133(6):1380–1394, 2014.
24. Lake C, Dodson R: Progressive upper limb prosthetics. *Phys Med Rehabil Clin N Am* 17(1):49–72, 2006.
25. Lind RF, Jansen JF, Love LJ, *Inventors. Mesofluidic controlled robotic or prosthetic finger.* 2012.
26. Love LJ, Lind RF, Jansen JF: Mesofluidic actuation for articulated finger and hand prosthetics. In *Proceedings of the 2009 IEEE/RSJ International Conference on Intelligent Robots and Systems*, St. Louis, MO, 2009, IEEE Press, pp 2586–2591.
27. Malone JM, Fleming LL, Roberson J, et al: Immediate, early, and late postsurgical management of upper-limb amputation. *J Rehabil Res Dev* 21(1):33–41, 1984.
28. Marquardt E, Neff G: The angulation osteotomy of above-elbow stumps. *Clin Orthop Relat Res* 104:232–238, 1974.
29. Micera S, Navarro X, Carpaneto J, et al: On the use of longitudinal intrafascicular peripheral interfaces for the control of cybernetic hand prostheses in amputees. *IEEE Trans Neural Syst Rehabil Eng* 16(5):453–472, 2008.
30. Mitchell TA, Hardin MO, Murray CK, et al: Mucormycosis attributed mortality: A seven-year review of surgical and medical management. *Burns* 40(8):1689–1695, 2014.
31. Navarro X, Krueger TB, Lago N, et al: A critical review of interfaces with the peripheral nervous system for the control of neuroprostheses and hybrid bionic systems. *J Peripher Nerv Syst* 10(3):229–258, 2005.
32. Neusel E, Traub M, Blasius K, et al: Results of humeral stump angulation osteotomy. *Arch Orthop Trauma Surg* 116(5):263–265, 1997.
33. Northmore-Ball MD, Heger H, Hunter GA: The below-elbow myo-electric prosthesis. A comparison of the Otto Bock myo-electric prosthesis with the hook and functional hand. *J Bone Joint Surg Br* 62(3):363–367, 1980.
34. Owens P, Ouellette EA: Wrist disarticulation and transradial amputation: surgical management. In Smith DG, Michael JW, Bowker JH, editors: *Atlas of amputations and limb deficiencies: surgical, prosthetic, and rehabilitation principles*, ed 3, Rosemont, IL, 2004, American Academy of Orthopedic Surgeons, pp 219–222.
35. Peshkin MA, Colgate JE, Wannasuphoprasit W, et al: Cobot architecture. *IEEE Trans Robot Autom* 17(4):377–390, 2001.
36. Polasek KH, Hoyen HA, Keith MW, et al: Stimulation stability and selectivity of chronically implanted multicontact nerve cuff electrodes in the human upper extremity. *IEEE Trans Neural Syst Rehabil Eng* 17(5):428–437, 2009.
37. Puhaindran ME, Chou J, Forsberg JA, et al: Major upper-limb amputations for malignant tumors. *J Hand Surg [Am]* 37(6):1235–1241, 2012.
38. Rapid Prototyping Lab:rp.lab@northwestern.edu.
39. Sando IC, French ZP, Hassett CA, et al: Lasting quality of regenerative peripheral nerve interface signals throughout a fatigue protocol. *Plast Reconstr Surg* 134 (4 Suppl 1):41–42, 2014.
40. Smith DG, Burgess EM: The use of CAD/CAM technology in prosthetics and orthotics: current clinical models and a view to the future. *J Rehabil Res Dev* 38(3):327–334, 2001.
41. Tarim A, Ezer A: Electrical burn is still a major risk factor for amputations. *Burns* 39(2):354–357, 2013.
42. Taylor CL: The biomechanics of control in upper-extremity prostheses. *Artif Limbs* 2(3):4–25, 1955.
43. Tintle SM, Baechler MF, Nanos GP, 3rd, et al: Traumatic and trauma-related amputations: Part II: Upper extremity and future directions. *J Bone Joint Surg Am* 92(18): 2934–2945, 2010.
44. Tooms RE: Amputation surgery in the upper extremity. *Orthop Clin North Am* 3(2): 383–395, 1972.
45. Upshaw B, Sinkjaer T: Digital signal processing algorithms for the detection of afferent nerve activity recorded from cuff electrodes. *IEEE Trans Rehabil Eng* 6(2): 172–181, 1998.
46. Williard WC, Collin C, Casper ES, et al: The changing role of amputation for soft tissue sarcoma of the extremity in adults. *Surg Gynecol Obstet* 175(5):389–396, 1992.
47. Wolpaw JR, Birbaumer N, McFarland DJ, et al: Brain-computer interfaces for communication and control. *Clin Neurophysiol* 113(6):767–791, 2002.
48. Wright TW, Hagen AD, Wood MB: Prosthetic usage in major upper extremity amputations. *J Hand Surg [Am]* 20(4):619–622, 1995.
49. Zachary LS, Gottlieb LJ, Simon M, et al: Forequarter amputation wound coverage with an ipsilateral, lymphedematous, circumferential forearm fasciocutaneous free flap in patients undergoing palliative shoulder-girdle tumor resection. *J Reconstr Microsurg* 9(2):103–107, 1993.

CASE STUDY 50.1

JD is a 38-year-old right-handed woman with a history of mantle irradiation for Hodgkin lymphoma and previous papillary thyroid carcinoma. She presents with paresthesias in the two right ulnar digits and axillary discomfort. The workup done outside the hospital, which includes an axillary lymph node biopsy, has not led to a diagnosis.

The examination reveals a thin woman who appears to be well. She has mild weakness of digital abduction and key pinch in comparison with the contralateral, nondominant side. An exquisitely tender mass is present in the axilla.

What is the differential diagnosis of an isolated axillary mass?

ANS:

Adenitis	Cat-scratch disease	Metastatic cancer
Aneurysm of artery	Cystic hygroma	Sarcoma
Arteriovenous malformation	Hidradenitis	Schwannoma
Accessory breast tissue	Lymphangitis	Tuberculosis
Breast cancer	Lymphoma	

Magnetic resonance imaging studies (MRIs) are shown in eFigure 50.1. Biopsy guided by computed tomography shows histologic findings of a high-grade spindle cell tumor with fasciculating patterns.

The tumor board consensus for diagnosis is a radiation-induced malignant peripheral nerve sheath tumor.

What is the treatment of choice for this type of tumor?

ANS: As for most sarcomas, the mainstay of treatment for malignant peripheral nerve sheath tumors is surgical resection with negative margins. Irradiation is often added preoperatively to make limb salvage more technically feasible. Chemotherapy is added for large, deep, and high-grade tumors, as well as for those with evidence of metastases.

The patient undergoes 11 courses of radiation therapy and 2 courses of chemotherapy with doxorubicin, ifosfamide, and mesna. A repeat MRI shows interval growth. The tumor board recommends interscapulothoracic amputation.

The surgical procedure is demonstrated in eFigure 50.2.

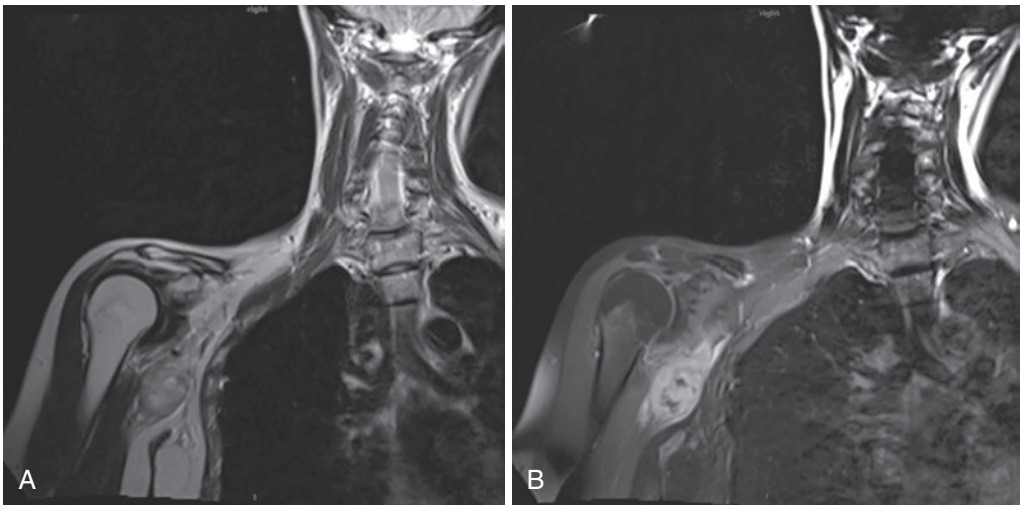

eFigure 50.1 **A** and **B,** Magnetic resonance images.

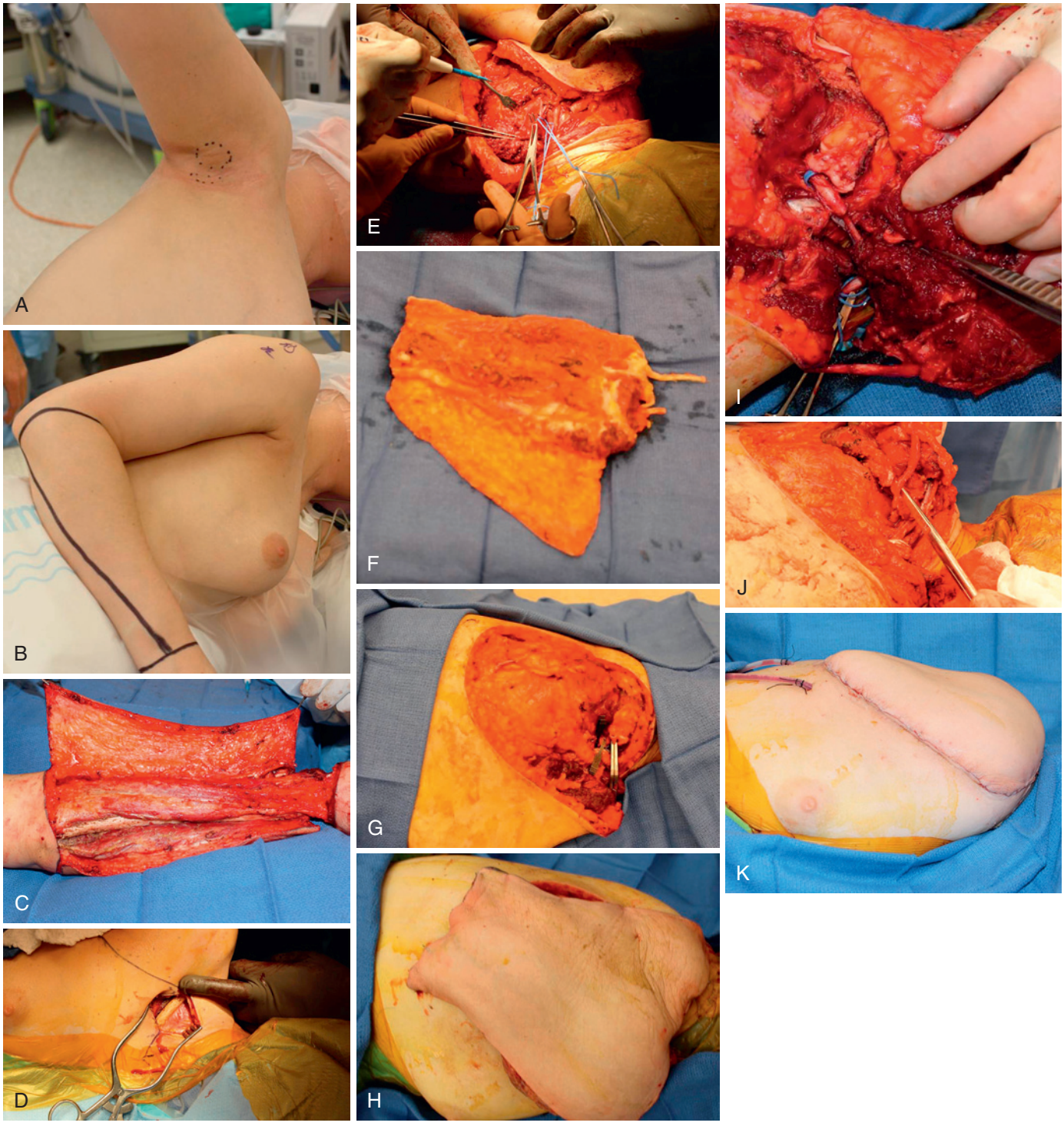

eFigure 50.2 Procedure for interscapulothoracic amputation. **A** and **B,** Preoperative markings. **C,** Fillet-of-forearm free flap. **D,** Exposure of clavicle. **E,** Isolation and control of subclavian vessels. **F** and **G,** Flap and recipient vessels. **H** and **I,** Flap after revascularization. **J,** Neurorrhaphy of cords to peripheral nerves for targeted-muscle reinnervation of flap. **K,** Closure.

CASE STUDY 50.2

AM is a 67-year-old right-handed, critically ill man who developed ischemia of the left hand secondary to a thrombosed radial artery resulting from an arterial line and vasopressors. The patient underwent radial artery thrombectomy, carpal tunnel release, and hand fasciotomies. Intrinsic muscles appeared nonviable. Continued vasopressor usage led to gangrene of all digits and the distal palm, even with Doppler signals in palmar arches (eFigure 50.3).

What level of amputation would provide the most prosthetic options?

ANS: The patient could undergo a wrist disarticulation or a transradial amputation. The former preserves the distal radioulnar joint and maximum pronation and supination, and the latter offers the most options for prosthetic rehabilitation. The ideal level of amputation is 8 to 10 cm proximal from the styloids.

The surgical procedure is shown in eFigure 50.4.



eFigure 50.3 Gangrene of all digits and distal palm.

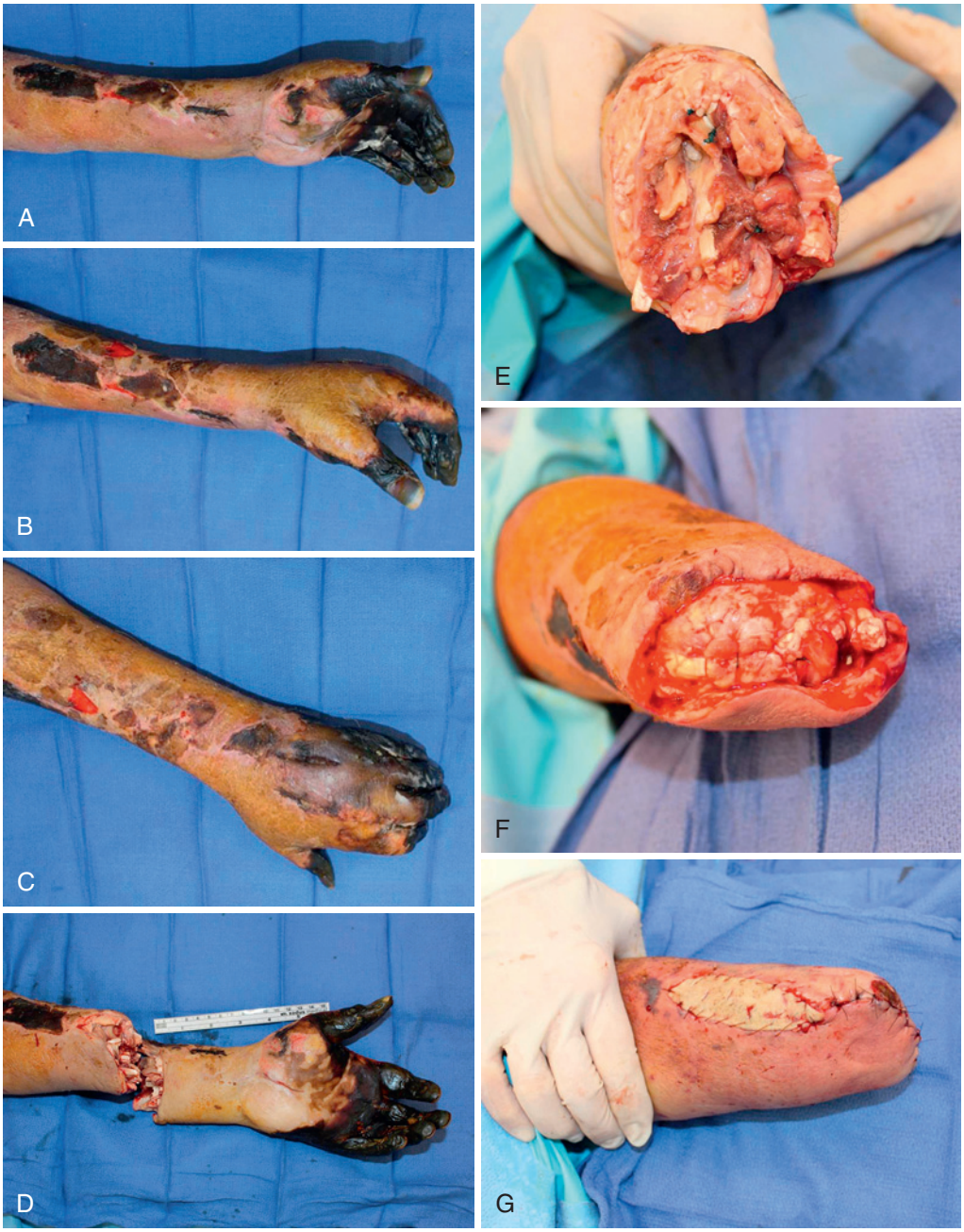

eFigure 50.4 **A** to **C,** Incision design. **D,** Osteotomies 1 to 2 cm proximal to incision line. **E,** Deep muscle myodesis. **F,** Superficial muscle myoplasty. **G,** "Spare parts" full-thickness skin graft.

51

Compartment Syndrome and Volkmann Ischemic Contracture

Milan V. Stevanovic and Frances Sharpe

Acknowledgment: The authors gratefully acknowledge the contributions of Dr. Ayan Gulgonen and Dr. Kagan Ozer, who wrote the chapter on compartment syndrome that appears in the sixth edition of Green's Operative Hand Surgery.

These videos may be found at *ExpertConsult.com:*

51.1 Surgical technique of upper extremity fasciotomy, cadaver demonstration.

51.2 Ten-year follow-up on flexor origin slide for "moderate"-type Volkmann contracture.

51.3 Eighteen-month follow-up on functional free muscle transfer for finger flexion for "severe"-type Volkmann contracture.

COMPARTMENT SYNDROME

Acute compartment syndrome (ACS) of the extremity is a diagnosis requiring emergent surgical intervention. It is characterized by sustained elevation of tissue pressure within an osseofascial or fascial compartment that exceeds tissue perfusion pressure. This results in local circulatory impairment, ischemia, cellular anoxia, and ultimately tissue death. ACS represents the acute phase of the injury during which time surgical intervention can reduce the extent of irreversible muscle injury. Timely diagnosis and treatment are critical in reducing the extent of permanent changes within muscle and nerve tissue. Even with emergent treatment, there may be permanent disability in the affected extremity and a subsequent need for additional surgery, including amputation.[22] Volkmann ischemic contracture represents the late sequelae of compartment syndrome. This disorder has a spectrum of fixed muscle contractures and muscular and neurologic impairments. Numerous authors have contributed to our understanding and treatment of this condition. Table 51.1 summarizes some of the historical events in the recognition of this entity, its etiology, its pathologic findings, and its sequelae.

Types of Compartment Syndromes

Acute Compartment Syndrome

Acute compartment syndrome (ACS) occurs when tissue pressures rise high enough within an osseofascial compartment to cause tissue ischemia. The resultant tissue injury can range from reversible muscle swelling to permanent tissue necrosis depending on the magnitude and duration of tissue pressure elevation. When pathologic tissue pressure elevation has been present for less than 4 hours, ACS is in the early stage[39]; when pathologic tissue pressure elevation has been present for more than 4 hours, ACS is in the late stage.

Impending Compartment Syndrome

Impending compartment syndrome represents a clinical setting in which a compartment syndrome is at risk of developing; however, tissue pressure is not yet sufficiently elevated to cause muscle ischemia. Clinical scenarios in which this may occur include limb reperfusion after prolonged ischemia, posttraumatic swelling of a limb, or high-energy injuries.

Exercise-Induced or Exertional Compartment Syndrome

Exercise-induced compartment syndrome is a reversible tissue ischemia due to a noncompliant fascial compartment that is unable to accommodate muscle expansion occurring during exercise. It has been described in both the upper and lower extremities and is different from ACS in that the symptoms are reversible after cessation of exercise. Emergent surgery is not usually indicated.[10,90] Both traditional fasciotomy and endoscopically assisted fasciotomy have been used to treat exercise-induced compartment syndrome.

Crush Injury or Crush Syndrome

Crush injury is the external compression of an extremity, as might occur in a building collapse or construction injury or in an obtunded patient who lays on an extremity for a prolonged period. The compression of the extremity leads to muscle ischemia and reperfusion injury as the compression is relieved. This process of events can lead to compartment syndrome. *Crush syndrome* is a localized crush injury with systemic manifestations. Reperfusion of the affected extremity can rapidly release muscle breakdown products into the system, which can lead to renal failure or death.[13]

Neonatal Compartment Syndrome and Neonatal Volkmann Contracture

Both neonatal compartment syndrome and neonatal Volkmann contracture have been reported. Awareness of this diagnosis is important because early recognition and treatment can improve the functional outcome and growth in neonatal compartment syndrome. In addition to swelling of the forearm, there is often a characteristic skin lesion on the proximal lateral arm, known as the *sentinel lesion of neonatal compartment syndrome*.[66]

TABLE 51.1 Events in the Recognition and Understanding of Compartment Syndrome

Author and Year	Development
Volkmann, 1881[87a]	First thorough description of this entity with attribution of the cause to muscle ischemia
Leser, 1884[41a]	Animal investigations; concluded that the pathologic findings were a result of oxygen deprivation
Hildebrand, 1890[45a]	First to use the term *Volkmann's contracture*; now sometimes referred to as *Volkmann-Leser contracture*
Bardenhauer, 1906[4a]	Release of internal pressure through a forearm fasciotomy to treat an impending Volkmann contracture
Brooks, 1922, 1925[9a,9b]; Jepson, 1926[45a]	Animal model used to reproduce compartment syndrome through vascular occlusion; muscle necrosis could be prevented by surgical decompression of the muscle compartment
Griffiths, 1940[35a]	Emphasized arterial injury and reflex spasm of the collateral vessels as the sole source of muscle ischemia; minimized the role of tight external dressings as the cause of muscle ischemia
Seddon, 1956[74] and 1964[73]	Described the pattern of muscle infarction common in compartment syndrome (ellipsoid infarct) and treatment with infarct excision; also highlighted the importance of ischemic injury to nerves
Holden, 1975, 1979[41b,42]	Reestablished both intrinsic and extrinsic causes of muscle ischemia; distinguished two patterns of injury leading to muscle ischemia: Type 1: Arterial insult proximal to the site of ischemia Type 2: Elevated intrinsic pressure within the compartment from either internal or external sources
Matsen, 1975[57]	Unified concept of compartment syndrome
Whitesides, 1975[89]	Tissue pressures as a determinant of the need for fasciotomy

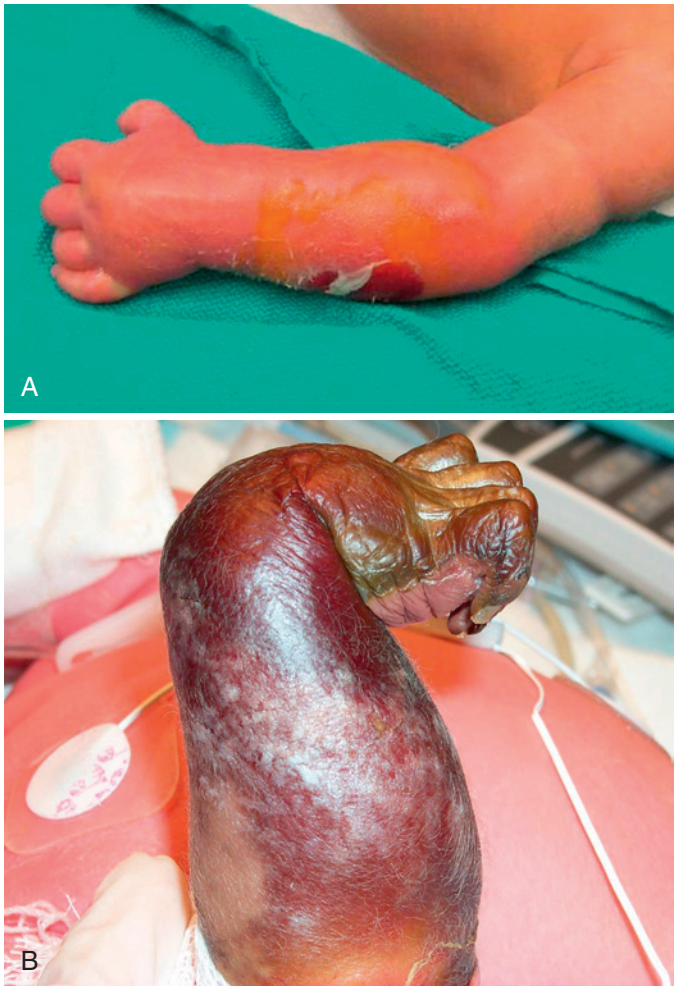

FIGURE 51.1 A, Neonatal compartment syndrome. Note the hallmark sentinel lesion at the lateral proximal forearm. **B,** Neonatal Volkmann contracture. The entire forearm is necrotic. This patient underwent amputation at the proximal forearm. (**A,** See Ragland RI, Moukoko D, Ezaki M, et al: Forearm compartment syndrome in the newborn: report of 24 cases. *J Hand Surg [Am]* 30(5):997–1003, 2005.)

Established neonatal Volkmann contracture cannot be improved by early intervention; however, awareness of this diagnosis can aid in counseling of the family and treatment of the patient (Figure 51.1, *A* and *B*).

Volkmann Ischemic Contracture

Volkmann ischemic contracture is the end result of prolonged ischemia, is associated with irreversible tissue necrosis, and has a spectrum of presentations.

Etiologic Findings and Incidence

Compartment syndrome in the upper extremity is most commonly associated with trauma. A variety of conditions and injuries can lead to ACS. These include fractures, penetrating trauma, closed soft tissue injuries, infection, animal and insect bites, extravasation injuries, ischemia-reperfusion injury, external compression by tight dressings or casts, burns, or crush injuries. Compartment syndrome in the absence of fracture should raise concern about an underlying bleeding disorder (Figure 51.2).

The incidence of upper extremity compartment syndrome is difficult to determine. The estimated incidence in pediatric upper extremity fractures is approximately 1%.[36] In a large series of trauma patients, the incidence of fasciotomy associated with all upper extremity traumas was 0.41%. Branco and colleagues[9] noted a decreasing incidence of the need for surgical fasciotomy over a 10-year period, despite stable injury severity scores, with the overall incidence for upper and lower extremity trauma decreasing from 3.2 to 0.7%. They suggested a possible explanation for the declining incidence as the diminished use of crystalloid for fluid resuscitation and the use of mannitol to decrease extracellular fluid volume. Fasciotomy rates associated with traumatic arterial injury ranged from 6.7 to 16%.[30,83]

Historically, ACS of the upper extremity in the pediatric population was most commonly reported in association with supracondylar humerus fractures. Likely, this was related to the historical treatment methods of casting with the elbow in a position of hyperflexion. Currently, pediatric fracture patterns most associated with forearm compartment syndrome are both-bone forearm fractures and supracondylar humerus fractures associated with distal radius fractures (i.e., floating elbow



FIGURE 51.2 This 4-year-old presented with hand and forearm swelling after minor trauma. Other areas of bruising were noted. After workup, the child was found to have hemophilia A. He underwent fasciotomy of his hand and forearm. **A,** Swelling of the hand and forearm. **B,** After dorsal fasciotomy of the hand and volar extended carpal tunnel release and forearm fasciotomy. **C,** Bruising of the periorbital region.

injury).[6,36,46,93] In adults, the most common upper extremity fractures associated with compartment syndrome are distal radius fractures and both-bone forearm fractures.[25,46]

Compartment syndrome is more prevalent in males younger than 35 years of age, penetrating trauma, open fractures, elbow dislocations, and vascular injuries.[9,25,58] The need for surgical fasciotomy increases dramatically when vascular injury is present.[22,30] Compartment syndrome in the hand is most commonly associated with intravenous injections.[63]

Pathophysiologic Findings

The pathophysiology of ACS is complex. Several theories and models have been developed. The common prerequisite is a soft tissue structure (usually fascia) that prevents muscle expansion when the muscle is exposed to increased fluid volume. In all cases, the final common pathway is cellular anoxia.

Matsen presented a "unified concept" of compartment syndrome that incorporates several mechanisms of vascular compromise all leading to cellular injury.[57] Increased compartmental pressure occurring from either internal injury (edema, reperfusion, or bleeding) or external injury (tight cast or dressing, pressure garment) causes a decreased perfusion gradient between arteriole and venous pressures and a resultant decrease in local tissue perfusion. Decreased tissue perfusion results in further tissue insult, increased capillary leakage, and further increase in intracompartmental pressure. This causes a vicious cycle of increasing cellular ischemia leading to further capillary leakage and swelling and increasing compartment pressures (Figure 51.3).

Ongoing ischemia eventually leads to cell death and lysis of the myocyte. Degradative enzymes are activated and released into the interstitial tissues, causing further tissue necrosis. The extent of muscle injury depends on the duration of ischemia and the metabolic rate of the tissue. Prolonged ischemia can ultimately lead to liquefactive necrosis of the muscle compartment.

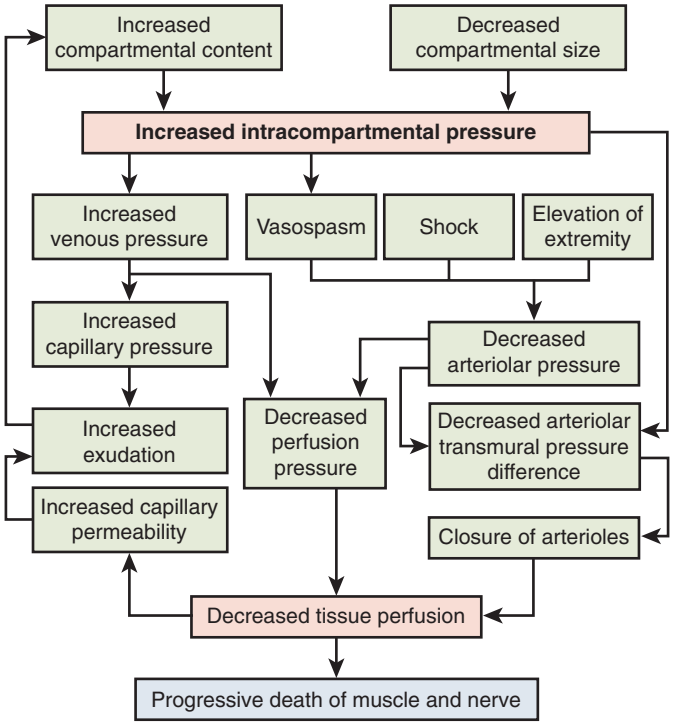

FIGURE 51.3 Schematic representation of factors contributing to the vicious cycle of compartment syndrome, based on the descriptions of Holden and the proposed unified concept theory of Matsen. (See Holden C: The pathology and prevention of Volkmann's ischaemic contracture. *J Bone Joint Surg Br* 61(3):296–300, 1979; and Matsen FA, 3rd: Compartmental syndrome: a unified concept. *Clin Orthop Relat Res* 113:8–14, 1975.)

Diagnosis

Diagnosis of Acute Compartment Syndrome

The diagnosis of ACS is principally based on clinical examination. Maintenance of a high index of suspicion, particularly in the setting of at-risk injuries and conditions, aids in the prompt recognition and treatment of this condition.

Although compartment syndrome is frequently associated with fractures, many other causes can also lead to ACS. Causes are commonly separated into intrinsic causes (typically, bleeding or swelling into a compartment) and extrinsic causes (applied external pressure preventing a compartment from expanding) (Box 51.1). The physician must keep this in mind because ACS not associated with fracture frequently has a delayed diagnosis and worse clinical outcomes.[43,65]

BOX 51.1 Injuries That May Lead to Compartment Syndrome

Intrinsic Injuries

High-energy fracture, usually in young male (open fractures more at risk than closed fractures)

Fracture in child

- Supracondylar fracture of humerus, especially one associated with distal radius fracture[6,44a]
- Both-bone forearm fractures (intramedullary nailing of pediatric both-bone and radial head fractures is associated with difficult reduction and prolonged tourniquet times[93])

Fracture in adult

- Distal radius fracture
- Upper extremity fractures associated with vascular injury
- Soft tissue trauma without fracture
- Blunt trauma without fracture or skin violation)

Penetrating trauma (usually from bleeding into otherwise closed compartment)

Vascular injury

- Trauma
- Iatrogenic procedures, such as venipuncture or arterial blood draw
- Reperfusion after prolonged ischemia
- Prophylactic fasciotomy should be considered after vascular repair[28,30]

Burns

- Edema associated with burn injury
- Electrical burns associated with deep muscle damage and edema
- Systemic inflammation and fluid resuscitation
- Burn eschar causes an extrinsic compression

Animal and insect bites (e.g., Crotalidae [pit viper] snakebite)

- Treatment of impending compartment syndrome from snakebite should be with antivenin
- (Crofab [ovine]; Antivenin Crotalidae Polyvalent ACP [equine])
- Rarely requires surgical decompression

Intravenous fluid extravasation (hypertonic fluids such as intravenous contrast material)

- Intraoperative fluid extravasation, particularly in patients where the arm position does not allow easy visualization of the extremity, and when infusion pumps are used[4b]

Infection

Bleeding disorders

- Coagulation disorders (e.g., von Willebrand hemophilia)
- Anticoagulation therapy
- Spontaneous bleeding may occur with no trauma or minor trauma

Extrinsic Injuries

Compressive casts or dressings

Burn eschar (circumferential inelastic eschar)

- Important to release fingers with dermotomies if burn involves the hand

Crush injury

- In obtunded patient during drug or alcohol overdose
- Resulting from coma, seizure, or hypoglycemic episode
- Building collapse
- Intraoperative positioning (prone or lateral positioning with poorly positioned axillary or chest roll causing axillary artery occlusion; also seen in the lower extremity with prolonged lithotomy position)

The timing of presentation can vary from within the first few hours of injury to several days following injury.[70,76]

The hallmarks of diagnosis of ACS have classically been described as the six *P*s of compartment syndrome (Table 51.2): pain, pressure, paresthesias, pallor, paresis, and pulselessness. Some authors have added or substituted poikilothermia of the extremity as one of the *P*s. This use of the term *poikilothermia* is not completely accurate but indicates that the affected extremity is cool relative to body temperature. In most series, pain has been the earliest and most reliable finding. However, pain peaks at 2 to 6 hours of ischemia and then gradually subsides as muscle necrosis progresses and nerve function becomes impaired. Therefore, patients with a late presentation of or late diagnosis of compartment syndrome have less pain than those with an earlier presentation.

It has been suggested that in pediatric patients, "it's the *A*s, not the *P*s" that signal ACS.[49] These *A*s are an increasing requirement for analgesia, the presence of anxiety (or restlessness), and the presence of agitation (or crying).[3,49] Children are unable to articulate the feeling of paresthesias, and sensibility testing is unreliable.

Certain conditions can make the clinical diagnosis of ACS challenging. Altered levels of consciousness as can occur in head trauma, a medically induced coma, or obtundation from other causes can obscure the normal pain response that is one of the early signs of compartment syndrome. Similarly, distracting pain from polytrauma, neurologic injury in the affected limb, and/or regional anesthetic blockade can mask the signs and symptoms of compartment syndrome. Diagnosis is also more

TABLE 51.2 Diagnostic Findings in Compartment Syndrome

Sign or Symptom	Description
Pain	Described as deep, constant, often poorly localized pain that is disproportionate to the physical findings; often poorly responsive to analgesics Pain is accentuated with passive stretching of the involved compartment. Although this is the most consistent and reliable finding, cases of "silent" compartment syndrome of the lower extremity have been reported (Badhe) and likely also occur in the upper extremity. Pain usually peaks at around 2 to 6 hours of ischemia and then subsides. Patients who present late with acute compartment syndrome may not report as much pain.
Pressure	Affected compartment(s) are firm and noncompressible; often described as "rock hard"
Paresthesias	Numbness or "pins-and-needles" sensation in the cutaneous distribution of the nerves that traverse the affected compartment
Pallor	Usually pale, but the extremity may also appear blotchy and often cool (see poikilothermia)
Paralysis	Late and unreliable finding. Muscle paralysis may be pain related. When true paralysis is present, this is a poor prognosticator for recovery.
Pulseless	Also usually a late finding and poor prognosticator for recovery

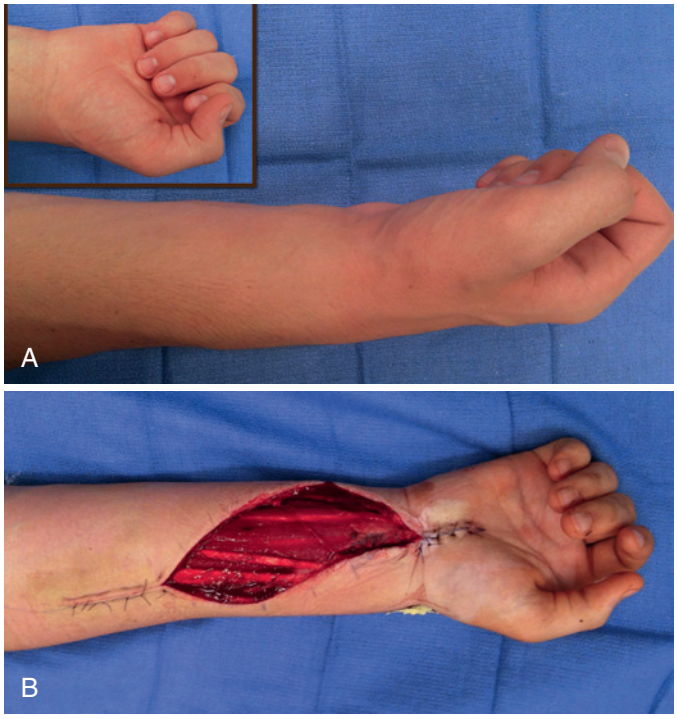

FIGURE 51.4 Localized compartment syndrome. This 16-year-old boy sustained a coronoid process fracture and a mildly angulated distal radius fracture through an old fracture malunion. He had pain and localized swelling at the distal forearm and subjective numbness in the median and ulnar distributions in the hand. His fingers were clenched and his thumb was flexed. He had pain with passive extension of the fingers. He underwent extended carpal tunnel release and fasciotomy. Compartment swelling was localized to the distal forearm. The proximal incision was closed at the time of primary surgery. Delayed primary wound closure was done after 4 days. **A,** Localized forearm swelling and clenched posture of the fingers and thumb. **B,** On postoperative day 2, persistent swelling of distal forearm musculature is present.

TABLE 51.3 Measurement of Compartment Pressures

Aspect of Measurement	Considerations
Patient position	Supine Measured extremity should be at heart level Measurements in uncooperative patients and children should be made with the patient sedated or in the operating room with the patient sedated
Needle	18-g straight, side-port, slit catheter, or wick
Transducer	Handheld digital (Stryker pressure transducer) Arterial line monitor
Needle placement	Perpendicular to muscle belly Several readings at multiple depths Near fracture site (see Figure 51.4, localized compartment) Near area of maximum tension
Threshold pressure	30 to 40 mm Hg Within 30 mm Hg of diastolic blood pressure or mean arterial pressure
Contraindications to measuring compartmental pressure	Underlying neurovascular structures at risk Coagulopathy Diffuse cellulitis

difficult in children and infants who may have difficulty in cooperating with examination, are nonverbal, or are apprehensive and crying. Also, the thicker layer of subcutaneous fat in children may contribute to a false sense of a soft compartment on palpation, further complicating the diagnosis. Diagnosis or exclusion of compartment syndrome on clinical grounds alone is often impossible.

If the clinician is uncertain of the diagnosis based on equivocal physical findings, compartment pressure can be measured (Figure 51.4 and Table 51.3). Several different methods can be used. Continuous pressure measurements can be obtained with a wick catheter or connection to a continuous pressure monitor.[59,89] Typically, the newer digital devices are used to assess or monitor the compartment.[7,21,38] These devices are sensitive to patient motion and should not supplant repeat clinical examinations. Although controversial, the thresholds/indications for fasciotomy are an absolute pressure greater than 30 to 40 mm Hg or pressures within 30 mm Hg of either the diastolic blood pressure or the mean arterial pressure.[79]

Although pulse oximetry of the affected extremity has not been found to be useful,[19,56] near-infrared spectroscopy (NIRS) may prove to be useful in the early diagnosis and monitoring of an impending compartment syndrome. This technique was proposed as a method of monitoring for compartment syndrome as early as 2001,[33] but it has not been widely adopted because of its cost and problems with availability of sensors and equipment. NIRS is noninvasive and capable of measuring the oxygenation state of at-risk tissues and may gain wider use in the future. NIRS is limited by the depth of tissue penetration (2 to 3 cm) and the presence of hematoma within the compartment.[20]

In these questionable clinical situations, the safer intervention is to perform a fasciotomy. Bulging of the muscle compartment and clinical softening of the extremity at the time of fasciotomy confirms the diagnosis.

Diagnosis of Exertional Compartment Syndrome

Chronic exertional compartment syndrome of the upper extremity has been described in the flexor compartment of the forearm and in the anconeus muscle; in the hand, it has been described specifically in the adductor of the thumb.[2,8,35,51,78,80,81] Patients with chronic exertional compartment syndrome typically complain of pain that starts as a dull ache within the first 30 minutes after starting an activity. Burning, cramping, or aching pain progresses as the activity is continued. The pain escalates to a level of discomfort where the patient can no longer continue or where it adversely affects the patient's performance. Activities associated with exertional compartment syndrome of the upper extremity include sports such as rowing, bicycle riding, or motorcycle riding or repeated episodes of manual labor requiring a prolonged grip or pinch. The pain and tissue firmness resolve spontaneously with cessation of the activities. Diagnostic studies have principally involved measurement of compartment pressures before, during, and after exercise.[8,10,84] More recently, magnetic resonance imaging has been used before and after exercise as a diagnostic tool. A signal change in

T2 imaging in an isolated fascial compartment associated with activity supports the diagnosis of exercise-induced compartment syndrome.[53]

PERTINENT ANATOMY

The compartments of the upper extremity are listed in Table 51.4. Any of these anatomic spaces can be affected by tissue pressure elevation. Although elevated tissue pressures are most commonly seen in osseofascial spaces, other tissue structures provide a rigid barrier that does not expand sufficiently to accommodate swelling. In the upper extremity, the fascial components and the skin can act as barriers that require decompression at the time of surgery.

Treatment

The goal of treatment is to prevent tissue necrosis, avert neurovascular compromise, and avoid permanent functional deficits. These devastating complications can be minimized or avoided with early recognition and prompt intervention.

The first step in treatment is to remove all possible extrinsic causes of pressure, including circumferential dressings, cast padding, and casts. Casts have been shown to restrict compartment expansion by 40%. Release of a cast and subsequent spreading reduces pressure elevation by 40 to 60% depending on the presence of dry or wet blood on the cast padding.[32] The limb should be elevated only to heart level. Although limb elevation may decrease swelling, it can also reduce perfusion to the affected limb, risking exacerbation of tissue ischemia.

A history of bleeding disorders or use of anticoagulation therapy should be obtained from the patient or family member. Laboratory analysis should include a complete blood count, prothrombin time, and partial thromboplastin time. If there is a suspicion of a bleeding disorder, a hematologist should be involved in the evaluation and treatment of the patient. Urinalysis for myoglobin, serum electrolytes, creatinine, and myoglobin should be obtained in the setting of prolonged ischemia, crush injury, or ischemia-reperfusion injury. Medical management of shock, hypoxia, metabolic acidosis, and electrolyte imbalance should be addressed immediately. Supportive care with vigorous hydration, correction of metabolic function, and treatment of hyperkalemia is necessary to prevent sequelae such as renal failure, shock, hypothermia, cardiac arrhythmias, or cardiac failure. Supportive care should be initiated in the emergency room but should not delay surgical treatment.

Hypertonic mannitol has been used to lower intracranial pressure. The use of mannitol in decreasing extremity swelling has been described in animal models and limited case studies. It has not gained widespread use for treatment of impending or acute compartment syndrome. Nonetheless, it has been hypothesized that the use of mannitol may have played a role in the decreased incidence of compartment syndrome in trauma patients at a single medical center over a 10-year time period.[9] Hypertonic mannitol has been found to decrease endothelial swelling and may help reduce muscle necrosis in its function as an oxygen-free radical scavenger.[62] In one clinical report, patients were given a 100-mL bolus of 20% mannitol, followed by an infusion of 10 g/hour for 6 to 24 hours.[11]

Emergent surgical decompression (fasciotomy, or release of the fascia overlying the affected compartments) performed as quickly and safely as possible is needed for ACS. Fasciotomy

TABLE 51.4 Compartments of the Upper Extremity

Compartments			Contents
Arm	Anterior		Biceps and brachialis muscles, brachial artery, and median nerve
	Posterior		Triceps muscle and ulnar and radial nerves
	Deltoid	Not technically a separate compartment but has a thick epimysium that may require decompression	
Forearm	Volar	Superficial	Flexor carpi radialis, palmaris longus, pronator teres, flexor carpi ulnaris, and flexor digitorum superficialis muscles
		Deep	Flexor digitorum profundus, flexor pollicis longus, pronator quadratus muscles,* and anterior interosseous nerve and artery
	Dorsal	Mobile wad	Brachioradialis, extensor carpi radialis longus, and extensor carpi radialis brevis muscles
		Extensor	Extensor digitorum communis, extensor carpi ulnaris, extensor pollicis longus, abductor pollicis longus, extensor pollicis brevis, and supinator muscles,† and posterior interosseous nerve
		Anconeus*	Anconeus
Hand	Thenar		Abductor pollicis brevis, opponens pollicis, and flexor pollicis brevis muscles
	Hypothenar		Abductor digiti minimi, flexor digiti minimi, and opponens digiti minimi muscles
	Adductor pollicis		Adductor pollicis muscle (two heads)
	Dorsal interossei (4)		Each is a separate compartment
	Volar interossei (3)		Each is a separate compartment
Fingers‡			

*Reported isolated involvement in exertional compartment syndrome.
†The supinator muscle is not typically a component of the extensor compartment, but decompression can be done through the brachioradialis/extensor carpi radialis longus interval.
‡Compression of the neurovascular structures by rigid Cleland and Grayson ligaments can lead to skin necrosis and/or loss of the finger.

within the first 8 hours after diagnosis is associated with a lower risk of permanent functional impairment. Release of the epimysium surrounding the muscle may also be necessary. Necrotic tissue should be excised because it may become a nidus for infection or lead to subsequent fibrosis and contracture. Questionable tissue should be left in place for a second look at a later date. Late fibrosis of necrotic muscle can lead to compression of the adjacent nerves and further impair extremity function. Other concomitant procedures may be indicated based on the cause of the compartment syndrome, including fracture reduction and stabilization, vascular repair, and nerve exploration if indicated. Nerve repair or grafting should be performed at the time of definitive wound closure.

Late or delayed diagnosis increases the risk for severe complications, including infection, neurologic injury, need for amputation, and death. In the past, concerns about an increased risk of infection have led some authors to recommend not performing a fasciotomy after 24 hours has elapsed since the onset of symptoms. We do not feel this risk outweighs potential benefits and no longer consider this a contraindication for surgery. Currently, there are more options for wound management and antibiotic therapy. Removal of necrotic muscle can decrease the severity of subsequent muscle fibrosis and joint contracture. Débridement of nonviable muscle improves the environment for the neurovascular structures and may allow early functional reconstruction of the lost muscle(s) by means of tendon transfers or free functional muscle transfers (FFMTs).

In addition, the length of time that elevated pressure sufficient to cause tissue necrosis has been present is often unclear, and some muscle preservation may be facilitated with late fasciotomy. In some cases, good results in children have been reported following fasciotomy as late as 72 hours after the injury (within the acute swelling phase).[29] Dramatic, essentially full, recovery has been reported following compartment syndrome of the lower leg in children after delayed presentation.[15]

Surgical Procedure

Indications. The indications for surgical fasciotomy are described previously. Our preference is to manage questionable cases of impending compartment syndrome with surgical decompression, provided the patient is stable enough for the procedure. Prophylactic fasciotomies should be performed following vascular repair/reconstruction where ischemia time exceeds 3 hours.[28] Shorter periods of ischemia do not eliminate the risk of developing compartment syndrome, and careful monitoring is necessary after vascular surgery.

Contraindications. Contraindications to fasciotomy are few. Coagulopathy should be corrected prior to surgical intervention. Plasma, factor, or platelet transfusion may be necessary to optimize the patient for surgery. Intubated patients who are not stable for surgery should be considered for a bedside fasciotomy using local anesthesia and sedation.[26]

❖ AUTHOR'S PREFERRED METHOD OF TREATMENT

The surgical incision for the upper extremity is extensile from the brachium to the carpal tunnel. The extent of the release performed is tailored to the clinical and intraoperative findings. Release of the dorsal forearm and compartments of the hand requires separate incisions when indicated. A separate incision for a dermotomy of each of the fingers may also be added to prevent skin necrosis and loss of the fingers.

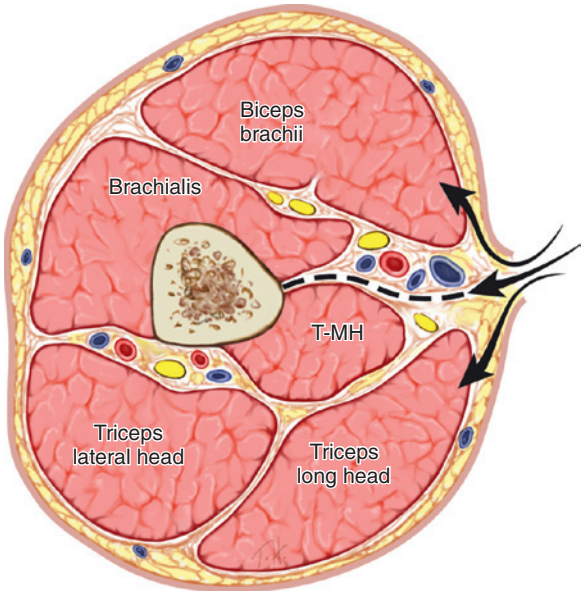

FIGURE 51.5 Cross section of the midarm with *arrows* showing the plane of dissection for decompression of the anterior and posterior compartments. Alternatively, separate anterior and posterior incisions can be used. *T-MH,* Triceps, medial head.

Release of the Compartments of the Arm. The anterior and posterior compartments of the arm can be decompressed through a single medial incision. This allows access to the neurovascular structures of the arm, the medial fascia of the biceps and brachialis in the anterior compartment, and the fascia of the triceps. Excision of the medial intermuscular septum will provide additional decompression of both compartments (Figure 51.5). The incision can be easily extended to the elbow crease and incorporated with the incision for decompression of the forearm. This also allows release of the lacertus fibrosus and access to the brachial artery. When there is no anticipated need to evaluate the brachial artery or to decompress the forearm compartments, fasciotomies can be performed through separate anterior and posterior midline incisions to decompress the flexor and extensor compartments, respectively.

Release of the Compartments of the Forearm. Several skin incisions have been described for the forearm. Because the surgical incisions are long and extensile, almost any incision can be used to decompress the forearm compartments (Figure 51.6). Because the incisions are left open, we prefer an incision that minimizes exposure of neurovascular structures and can be extended in a proximal direction into the medial arm and in a distal direction into the carpal tunnel (see Figure 51.6, *A* and *B*). Once the skin incision has been made, the antebrachial fascia is incised longitudinally from the lacertus fibrosus to the wrist flexion crease. This decompresses the superficial flexor compartment. The deep flexor compartment is most easily and safely exposed through the ulnar side of the forearm.[69] We begin at the mid to distal forearm and identify the interval between the flexor carpi ulnaris and flexor digitorum superficialis. The flexor digitorum profundus and flexor pollicis longus fascias are exposed and released through this interval (Figure 51.7). This is the most important component of this procedure because the

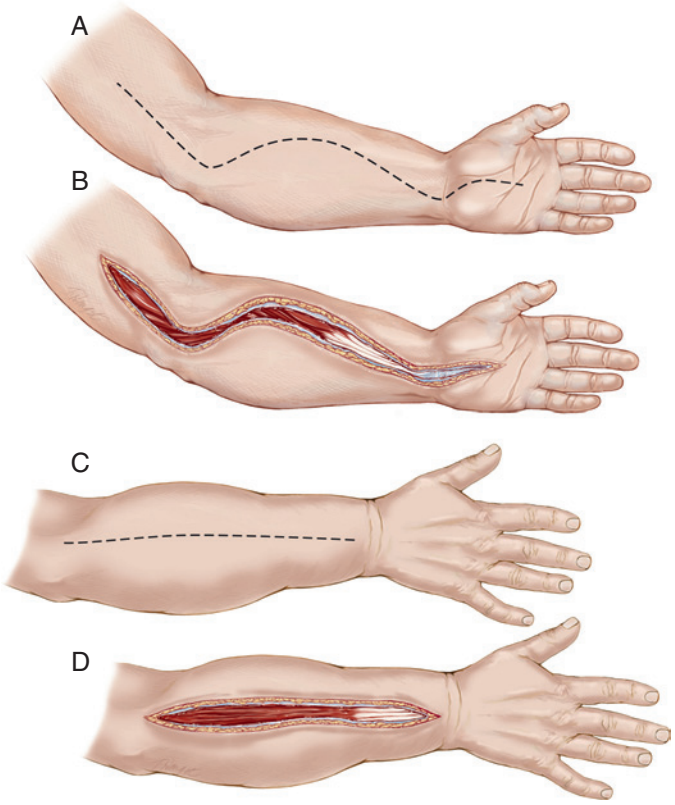

FIGURE 51.6 Extensile incision for decompression of the forearm: The incision can be extended proximally to decompress the arm and distally into the carpal tunnel. **A,** Line of skin incision for volar release. **B,** Volar incision opened from the midarm to the carpal tunnel. **C,** Line of the dorsal incision. **D,** Dorsal incision opened and fascia released.

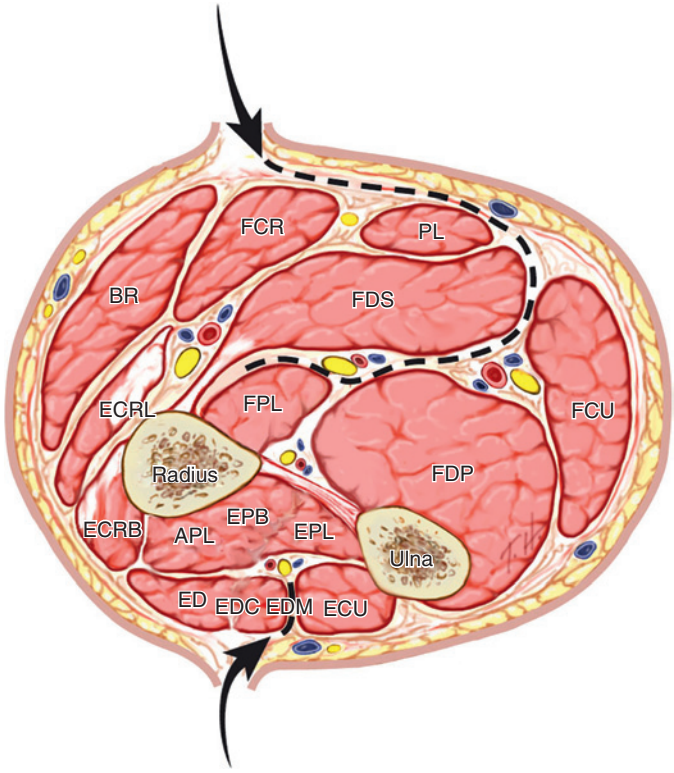

FIGURE 51.7 Cross section of the midforearm with *arrows* showing the plane of dissection for decompression of the superficial and deep flexor compartments of the volar forearm and the dorsal forearm. *APL,* Abductor pollicis longus; *BR,* brachioradialis; *ECRB,* extensor carpi radialis brevis; *ECRL,* extensor carpi radialis longus; *ECU,* extensor carpi ulnaris; *ED, EDC,* extensor digitorum communis; *EDM,* extensor digiti minimi; *EPB,* extensor pollicis brevis; *EPL,* extensor pollicis longus; *FCR,* flexor carpi radialis; *FCU,* flexor carpi ulnaris; *FDP,* flexor digitorum profundus; *FDS,* flexor digitorum superficialis; *FPL,* flexor pollicis longus; *PL,* palmaris longus.

deep flexor compartment is usually the one first and most affected by increased compartmental pressure. Through the same interval, the fascia overlying the pronator quadratus is released.

During the dissection, if the muscles appear pale after release of the fascia, additional release of the epimysium of the pale muscle should be performed. For these muscles, if the epimysium is not released, reperfusion injury will lead to additional swelling within the muscle and further muscle damage.

Clinical evaluation of the remaining tension in the dorsal forearm compartment and/or hand should be done to determine whether additional release of the extensor and hand compartments should be added.

The extensor compartments are released through a midline longitudinal dorsal incision extending from the lateral epicondyle to the distal radioulnar joint. This will allow release of the mobile wad and the extensor compartment (Figure 51.8 and see Figure 51.6, *C* and *D*).

Release of the Compartments of the Hand. The hand has 10 separate compartments. It is rarely necessary to release all 10 compartments, and intraoperative assessment and/or measurement of compartment pressures should be used to determine the extent of release needed (Figures 51.9 and 51.10).

Volar Release. Decompression should start with an extended carpal tunnel release. Carpal tunnel release will usually adequately release the Guyon canal without division of the volar carpal ligament (roof of the Guyon canal) and directly decompress the ulnar neurovascular structures. The carpal tunnel incision can be extended to the second volar web space. In the distal portion of the incision, the volar fascia of the adductor pollicis muscle can be released. Also, the fascia extending from the long finger metacarpal to the palmar fascia (separating the deep radial and ulnar midpalmar spaces) can be released. This will help decompress the volar interosseous muscles. The thenar and hypothenar muscles are decompressed through separate incisions as needed.

Dorsal Release. The dorsal interosseous muscles (and volar interosseous muscles) are decompressed through dorsal incisions between the second and third metacarpals and fourth and fifth metacarpals. The first dorsal interosseous muscle is decompressed through an incision placed in the first dorsal web space. The dorsal fascia of the adductor pollicis can also be released through this incision (see Figure 51.9).

Release of the Fingers. Tense swollen fingers can result in skin and subcutaneous tissue necrosis. The tight fibers of Cleland and Grayson ligaments can compress and obstruct the digital arteries. Dermotomy of all involved fingers reduces the risk of necrosis of the skin and possible loss of a digit. Dermotomies should be done in the midaxial plane to prevent subsequent contracture. When possible, the dermotomy should be performed on the side that will cause the least amount of scar irritation. The preferred locations for finger and thumb dermotomies are shown in Figure 51.9, *A* and *B*.

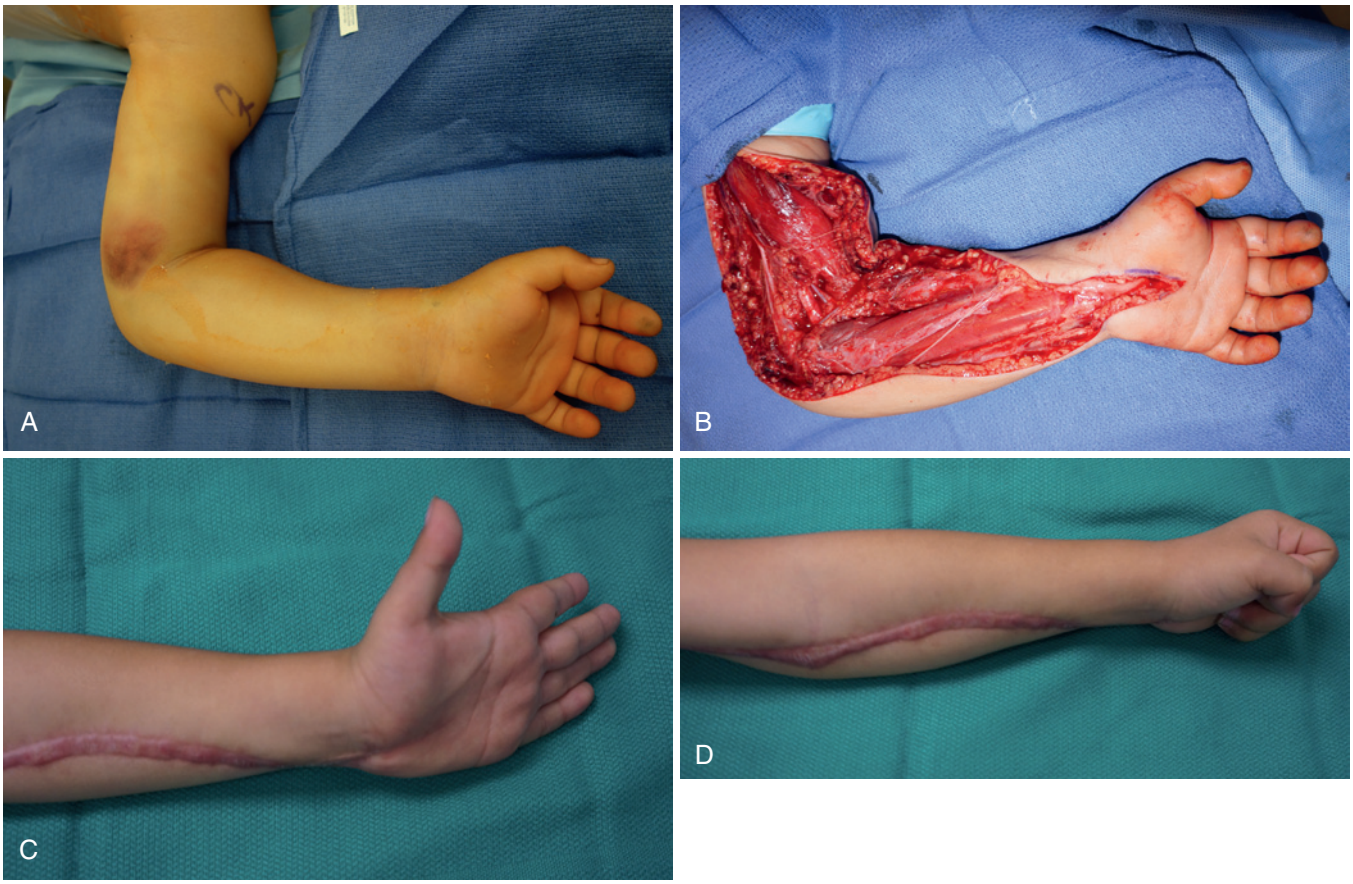

FIGURE 51.8 This 5-year-old patient sustained a type 3 100% displaced supracondylar humerus fracture that was treated with closed reduction and pinning. Approximately 6 hours after surgery, the patient had increased pain and analgesia requirements. On examination, the compartments were tense and swollen. He was taken emergently for fasciotomy of the arm and forearm. **A,** Appearance of the arm after closed reduction and pinning after patient returned to the operating room. **B,** Fasciotomy of the arm and forearm. **C,** Final finger and wrist extension after 6 months. **D,** Final finger flexion after 6 months.

See Case Study 51.1 and Video 51.1 for further information on compartment release of the arm, forearm, and hand.

Postoperative Management

All surgical incisions are left open. We prefer not to use retention sutures. Even if there is minimal swelling of the muscle(s) during the primary release, muscle swelling will usually increase after perfusion has improved. If nerves and arteries are not exposed, a negative-pressure wound dressing (e.g., VAC, Kinetic Concepts, Inc., San Antonio, TX) can be used. We use lower pressures for the negative pressure dressing than in other wounds, usually just enough to maintain good seal on the dressing. If nerves or arteries are exposed, we prefer to use a moist gauze dressing. Dressing changes should be done in the operating room at 24 to 48 hours. Partial delayed primary wound closure can be performed at that time if swelling has decreased and/or to provide coverage over open neurovascular structures. Definitive delayed primary wound closure should be performed only after swelling has decreased. Some cases will require repeat débridement of necrotic tissue. Split-thickness skin grafting for closure is necessary in many patients. Younger patients with high-energy or crush injuries are more likely to require split-thickness skin grafting at 48 hours.[25] In our practice, we prefer to manage the wound until swelling decreases sufficiently to allow delayed primary wound closure if possible, which may require 7 to 10 days. In the hand, only the incision for the carpal tunnel release should be considered for delayed primary wound closure. The other palmar and dorsal incisions as well as the dermotomy incisions will heal quickly by secondary intention. If the skin cannot be closed without tension, split-thickness skin grafting with or without dermal substitutes such as Integra (Integra, Plainsboro, NJ) should be used.

Therapy should be started immediately following surgery to promote maximum active and passive range of motion of the fingers. Splinting should be done for soft tissue stabilization and/or for treatment of other associated injuries. Cessation of therapy during healing of skin grafts may be necessary, but therapy should be resumed as soon as tissue healing allows. Once the soft tissues are adequately healed, nighttime splinting is continued to prevent contractures of the wrist and fingers. Splinting is continued until scars and soft tissues are mature and supple.

Outcomes and Expectations

Outcomes following fasciotomy depend on the duration and severity of the compartment pressure elevation and the resultant extent of muscle necrosis. Early prompt fasciotomy within the first 4 hours usually results in minimal sequelae. Delayed management results in muscle fibrosis and contracture that varies with the extent of muscle necrosis and nerve

CASE STUDY 51.1 Compartment Syndrome of the Upper Extremity

Surgical Approach to Treatment

All or portions of this approach can be used, depending on the clinical setting. The approach is extensile from the arm to the distal forearm, and separate incisions are required to release the extensor compartment (when indicated). Multiple incisions are used to release the compartments of the hand.

Fasciotomy of the Upper Extremity

Incisions are designed to provide the most coverage of neurovascular structures (at the time of later closure). Linear incisions across flexion creases are avoided. After the skin incision, the antebrachial fascia is released, allowing assessment of the superficial flexor compartment. The interval between the flexor digitorum superficialis and flexor carpi ulnaris is opened to provide access to the deep flexor compartment of the forearm.

After release of the flexor compartments, muscles are inspected and epimysiotomies are performed for tense or dysvascular muscles. Once the flexor compartments are released, the extensor compartment is assessed. If tense, this is released through a dorsal midline incision.

Release at the elbow requires division of the lacertus fibrosus with exploration of the median nerve and brachial artery. Fasciotomies in the hand are performed through a carpal tunnel release, release of the thenar and hypothenar eminences, and dorsal incisions for the release of the interosseous muscles.

Decompression of the fingers may be necessary to prevent digital loss. This is performed through midlateral incisions, avoiding pinching surfaces, including the radial border of the thumb, ulnar borders of the index and long fingers, and radial borders of the ring and small fingers.

The Cleland ligaments are released when necessary to decompress the digital arteries (see Video 51.1).

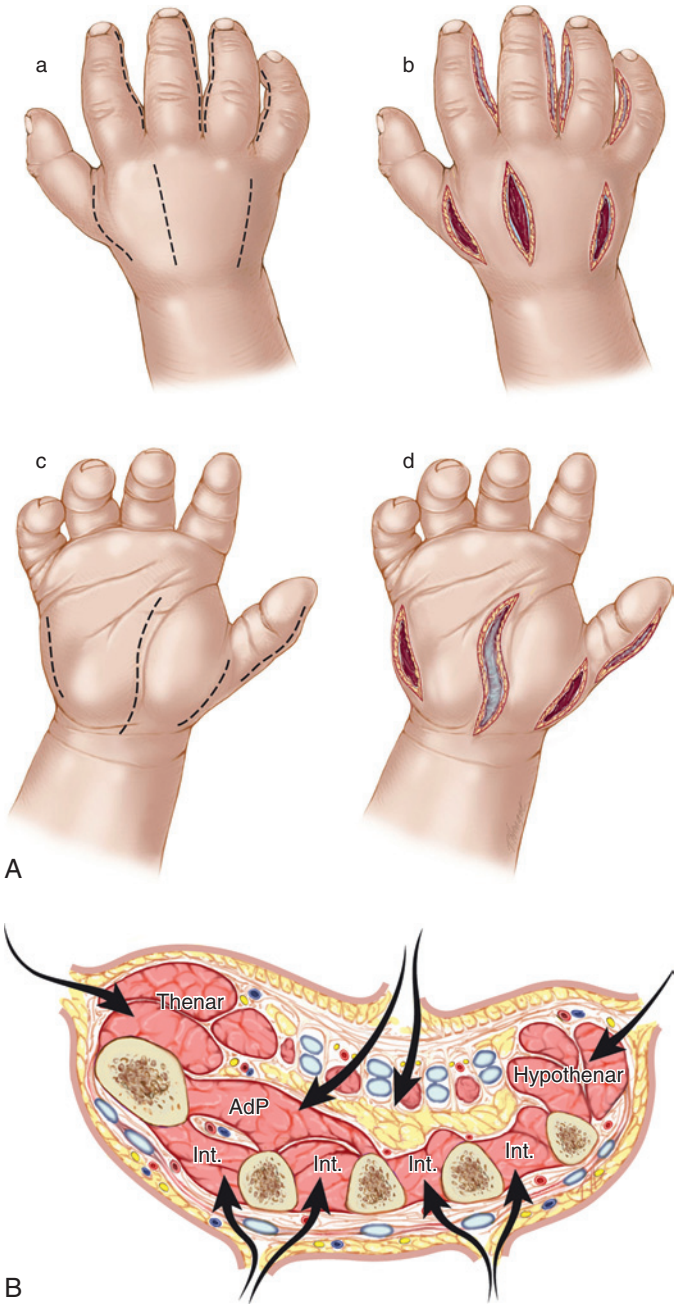

FIGURE 51.9 **A,** Incisions for decompression of the hand. **B,** Cross section of the midhand showing planes of dissection for surgical decompression. *AdP,* Adductor pollicis; *Int.,* interosseous muscles.

CRITICAL POINTS *Compartment Syndrome*

Diagnosis
- Diagnosis is usually a clinical one
- Pain is out of proportion to clinical findings
- Pain with passive motion
- Firm, "rock hard" compartment
- Objective findings include elevated compartment pressures and 30 to 40 mm Hg or within 30 mm of diastolic blood pressure or mean arterial pressure

Management
- Correct any underlying coagulopathy
- Perform emergent fasciotomy
- Perform vascular repair or reconstruction when indicated
- Treat associated injuries
- Repeat surgical débridement
- Close the wound with delayed primary closure, split-thickness skin graft, or flap
- Perform early reconstruction when indicated with tendon transfer or functional muscle transfer

Arm Management
- Anterior and posterior compartments
- Medial incision to decompress both compartments
- Deltoid may require epimysiotomy

Forearm Management
- Deep volar, superficial volar, and extensor compartments
- Deep compartment must be released
- Best decompressed through the interval between the flexor carpi ulnaris and the ulnar side of the flexor digitorum superficialis
- Extensor compartment may soften with release of volar compartments but requires separate assessment and release if indicated

Hand Management
- Ten separate compartments
- Start with extended carpal tunnel release
- Release additional compartments as necessary

Finger Management
- Tense, swollen fingers can result in digital necrosis
- Midlateral dermotomies are performed dorsal to the neurovascular bundles

Pitfalls
- Failure to diagnose in a timely manner
- Failure to adequately release compartments
- Inadequate excision of necrotic tissue leading to scarring and fibrosis around nerves

involvement. Secondary surgery is usually necessary to improve the outcome of these delayed cases.

Outcomes following fasciotomy for chronic exertional compartment syndrome are good. Preoperative symptoms of pain related to activity resolve, and 90% of patients are able to return to sports or other activities.[10,31,41,88,91]

Complications of compartment syndrome and its treatment are common. In a metaanalysis, Kalyani and colleagues reported a complication rate of 42% (18 of 43 patients).[46] Duckworth and associates reported a complication rate of 32% (29 of 99 patients). The most common complication was a neurologic deficit. Other complications included contracture, reflex sympathetic dystrophy, gangrene, muscle weakness, fracture nonunion, and soft tissue tethering associated with skin grafting.[25]

VOLKMANN CONTRACTURE

Volkmann ischemic contracture is the end result of prolonged ischemia and associated with irreversible tissue necrosis. Established Volkmann contracture has a much different presentation than ACS. It has a broad clinical spectrum, based on the extent of muscle necrosis and degree of nerve injury. Unlike ACS, patients with an ischemic contracture do not have pain but rather have deformity and dysfunction resulting from the

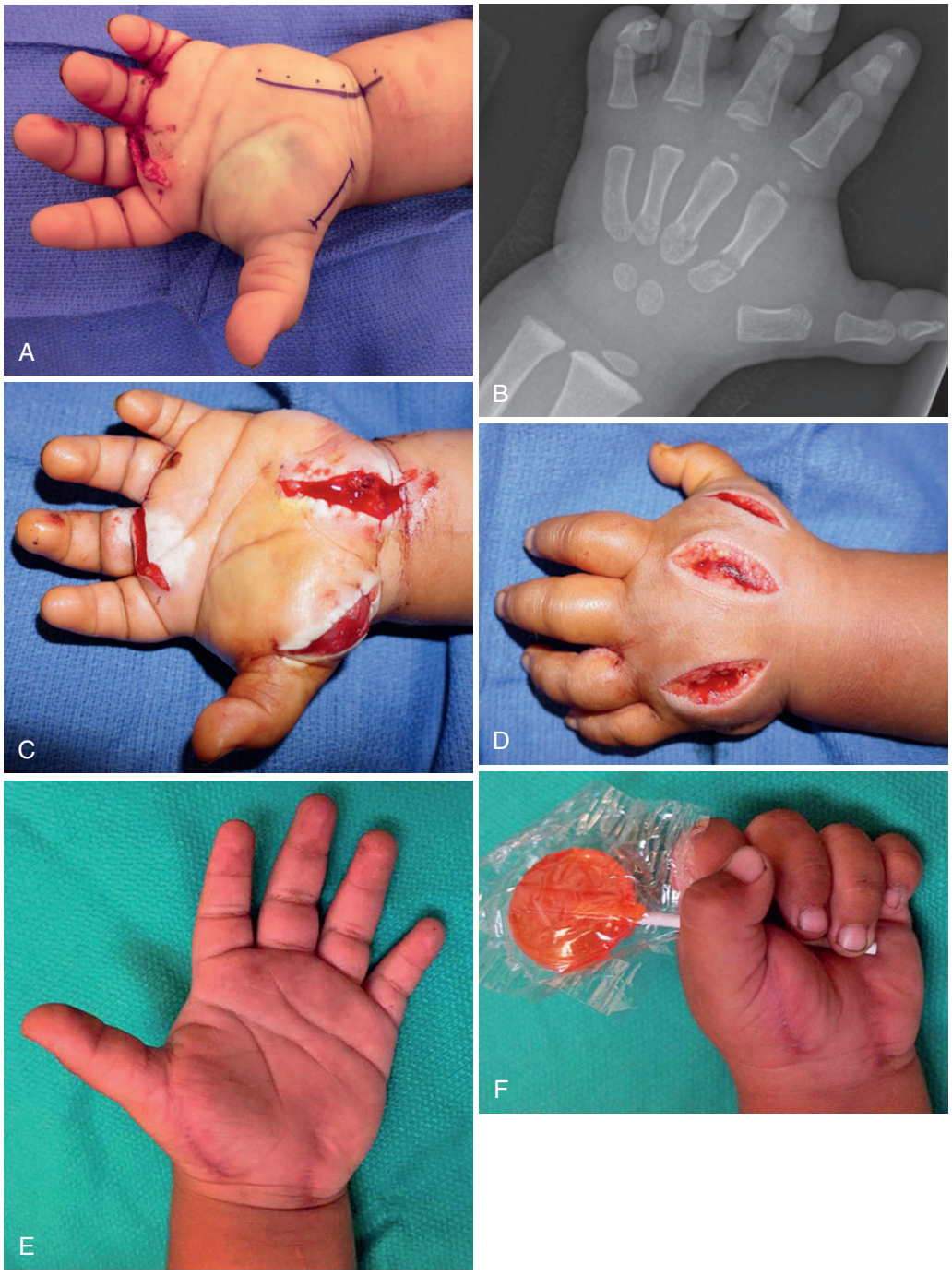

FIGURE 51.10 A 2-year-old sustained a crush injury to his left hand, with fractures of the second to fourth metacarpal bases and an open wound at the volar metacarpal heads. He presented with a tense swollen hand. He was taken emergently for fasciotomies of the hand and underwent percutaneous pinning of the displaced metacarpal base fractures. **A,** Appearance of the hand at presentation. **B,** Metacarpal base fractures, 100% displaced in the sagittal plane. **C,** Fasciotomies of the volar hand. **D,** Fasciotomies of the dorsal hand. **E,** Final extension at 9 months following injury. **F,** Final flexion at 9 months following injury.

ischemic event and subsequent muscle scarring and fibrosis. Nerve dysfunction can occur either from the initial trauma or subsequent ischemic insult or secondary to the fibrosis around the nerves. The muscle fibrosis and neurologic deficits lead to deformity of the joints distal to the site of ischemia. The deformity is progressive over the ensuing weeks to months. In children, an untreated deformity will progress until skeletal maturity because the ischemic muscles are unable to elongate during limb growth. Even when the contractures are treated, the affected extremity is shortened due to the tethering across the physis.

Classification

Several classification systems have been described for Volkmann contracture of the forearm. Most are based on the extent of muscle involvement and the severity of the clinical disability. The classification systems can be useful in guiding treatment plans for functional reconstruction. Most authors recognize the

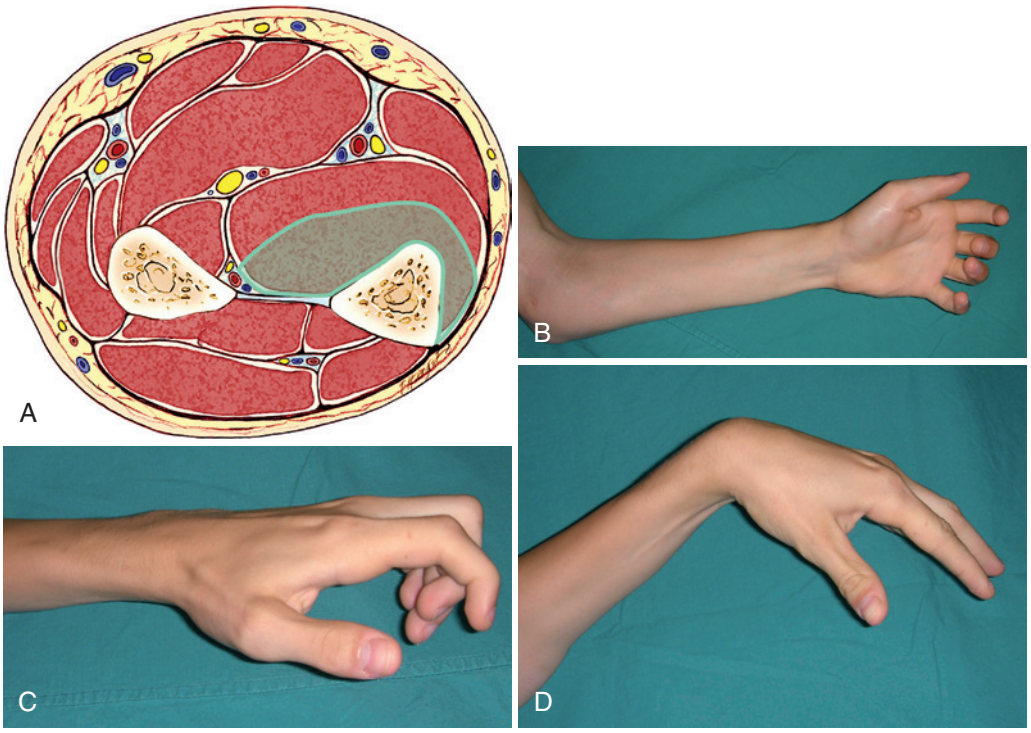

FIGURE 51.11 **A,** Cross-sectional representation of a mild Volkmann contracture (according to Tsuge classification) at the midforearm level. **B,** Volar clinical appearance of mild Volkmann contracture. **C,** Lateral view appearance of mild Volkmann contracture. **D,** Mild contracture allows for full extension of the fingers when the wrist is positioned in volar flexion.

TABLE 51.5 Tsuge Classification for Volkmann Contracture of the Forearm

Type	Findings	Treatment Options
Mild	Localized Volkmann contracture Usually involves principally the deep flexor compartment (flexor digitorum profundus of long and ring fingers most affected) Little or no nerve involvement	Nonsurgical treatment Stretching Splinting Must be maintained through skeletal maturity Surgical treatment Selective fractional lengthening Selective flexor origin slide
Moderate	Most or all of flexor digitorum profundus and flexor pollicis longus Partial flexor digitorum superficialis Neurologic impairment present Sensory in median nerve more than ulnar nerve	Surgical treatment Flexor origin slide Fractional lengthening Shortening of forearm Proximal row carpectomy
Severe	All of flexor compartment Varying involvement of extensor compartment Severe neurologic deficits, including sensory deficits and intrinsic dysfunction	Surgical treatment Tendon transfer Functional free muscle transfer Both may need to be performed Both may require adjunctive flexor slide, infarct excision, and/or contracture release Nerve reconstruction frequently necessary

tremendous variability of the clinical presentations and the subsequent limitations of the classification systems.[73,85,86,94]

The most commonly used, and our preferred, classification system is that proposed by Tsuge.[85] Established Volkmann contracture was divided into mild, moderate, and severe types, according to the extent of muscle involvement (Figures 51.11 through 51.13 and Table 51.5). Tsuge's category of severe contractures included cases of moderate tissue necrosis that were exacerbated by fixed joint contractures, a scarred soft tissue envelope, or failed surgeries.

Within each classification type, there is a broad range of clinical presentations. The heterogeneity of presentation makes it difficult to apply a specific treatment based solely on the classification system. The variability also confounds meaningful outcome and comparison studies.

Treatment

There is a limited role for the nonoperative treatment of established contracture. There may be some benefit from therapy to stretch and splint mild contractures. In children, splinting is

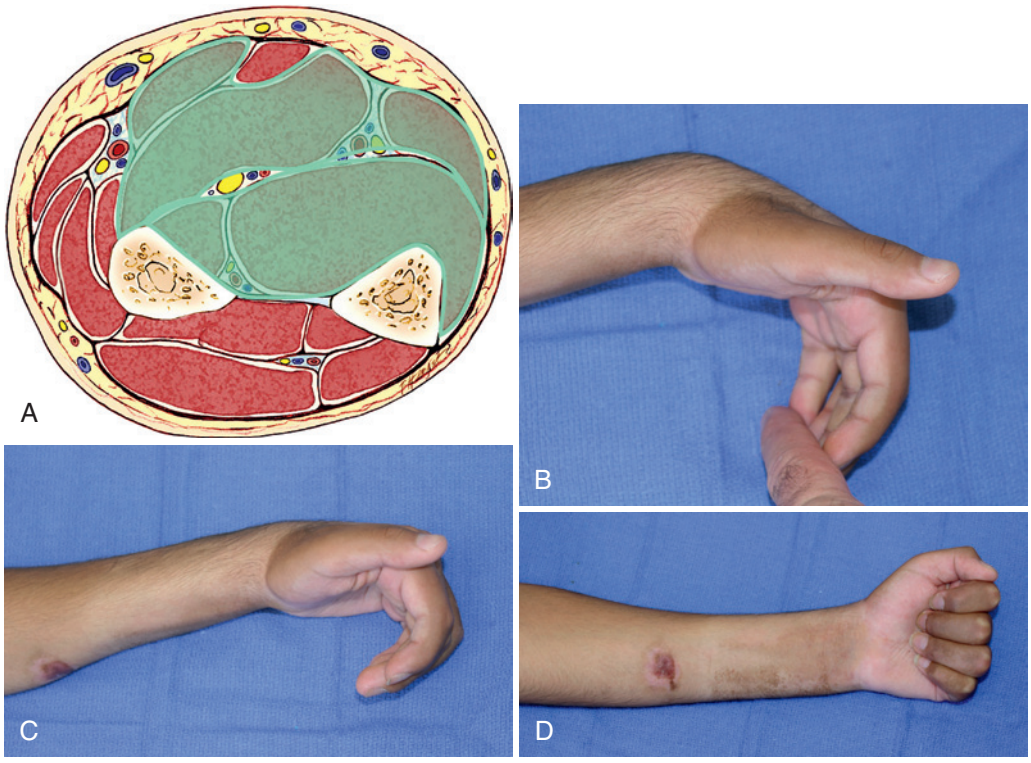

FIGURE 51.12 **A,** Cross-sectional representation of moderate Volkmann contracture (according to Tsuge classification) at the midforearm level. **B,** Patient with Tsuge moderate Volkmann contracture. With the wrist in a position of volar flexion, the fingers cannot be brought into full passive extension. **C,** Finger flexion contracture is worsened by the wrist being brought into a neutral position. **D,** Patient demonstrates full active finger flexion.

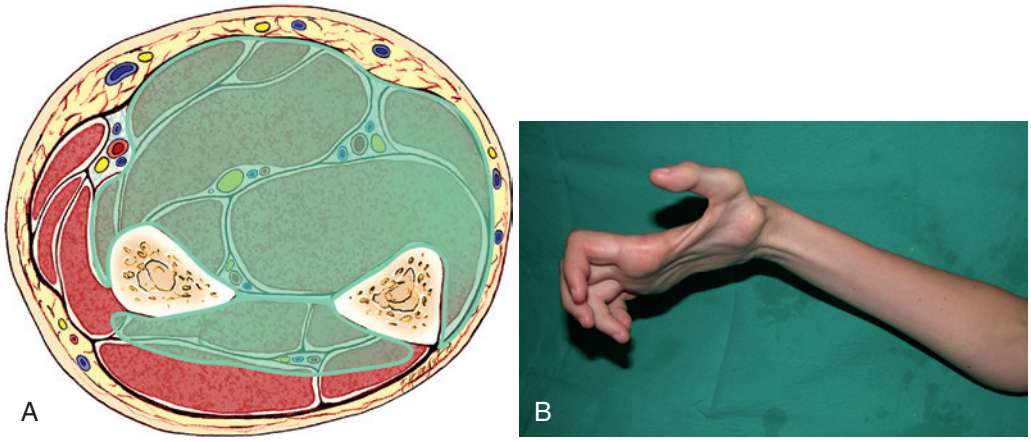

FIGURE 51.13 **A,** Cross-sectional representation of severe Volkmann contracture (according to Tsuge classification) at the midforearm level. **B,** Patient with severe contracture with extensive intrinsic wasting secondary to neurologic involvement at the forearm.

continued until skeletal maturity. Moderate and severe contractures are usually recalcitrant to therapy.

Operative Treatment

A variety of surgical techniques have been proposed, including bony and soft tissue management (Table 51.6).

Bone Procedures. Skeletal shortening or fusions are frequently performed in conjunction with some of the soft tissue procedures listed in Table 51.6. Shortening procedures include shortening osteotomy of the radius and ulna[68] and proximal row carpectomy.[34] These procedures have been used to match the skeletal length to the shortened fibrotic muscle. One concern with bone procedures is that the principal contracture is within the flexor compartment. Shortening the forearm indiscriminately lengthens the muscle resting length of both the flexor and extensor muscles, neglecting the predominant involvement of the contracture within the flexor compartment muscles. Shortening procedures raise additional concerns in children because the forearm is already shortened by the initial ischemic insult to the bone and growth plates.

Bony reconstructive procedures are useful for residual problems related to nerve dysfunction or for long-standing contractures not amenable to additional soft tissue release. Options include wrist fusion, trapeziometacarpal joint fusion, or thumb metacarpophalangeal joint fusion. Severe progressive finger deformities can also be managed with arthrodesis in a more

TABLE 51.6 Surgical Options for Management of Volkmann Ischemic Contracture of the Forearm

LATE MANAGEMENT OF COMPARTMENT SYNDROME; SURGICAL OPTIONS FOR THE FOREARM

Operation	Authors	Advantages	Disadvantages
Bone			
Proximal row carpectomy	Zancolli, 1979[94] Goldner, 1975[34]	Addresses wrist flexion contracture without causing additional scarring in the forearm	(1) Nonselective shortening of both extensors and flexors (2) Limb is already shortened from ischemic insult
Diaphyseal shortening	Rolands, 1905[68] Domanasiewicz, 2008[24a] Pavanini, 1975[64a]	Satisfactory correction of contracture Does not preclude other procedures	(1) Nonselective shortening of both extensors and flexors (2) Limb is already shortened from ischemic insult (3) High nonunion and refracture rate reported
Arthrodesis	Botte, 1998[8] Goldner, 1975[34]	Wrist: Maintains wrist in physiologic position; if additional tendon transfers are needed, if wrist is fused, one less donor muscle is needed and wrist extensor muscles are available as donors for finger function PIP: Fingers maintained in a more functional position; may be only option to correct intrinsic imbalance	Wrist: (1) Loss of tenodesis effect of wrist position (2) Decreased grip strength (3) Loss of motion PIP: (1) Loss of finger flexion (2) Resultant loss of grip strength
Soft Tissue			
Fractional or tendon "Z"-lengthening	Goldner, 1975[34]	Straightforward surgical release of flexion contracture	(1) Loss of active flexion (2) More disruption of muscle resting length and loss of flexion strength
Infarct excision with tendon reconstruction/ transfer	Seddon, 1964,[73] Seddon, 1956[74] Tsuge, 1975[85]	Tsuge advocated infarct excision for mild contractures with involvement of only one or two fingers	(1) Late infarct excision creates more scarring around nerves (2) Deficit created from scar excision is replaced with more scar tissue later
Flexor-pronator slide	Page, 1923[64] Scaglietti, 1957[72] Gosset, 1956[34a] Sharma, 2012[75]	Allows greatest correction of flexion contracture with least impact on muscle resting length	(1) Will not fully correct finger flexion contracture that is not passively correctable in maximal wrist flexion (2) Wide surgical dissection with potential injury to CIA/PIA
Functional free muscle transfer	Zuker, 1989,[96] Zuker, 2007[98] Manktelow, 1978[55a] Manktelow, 1989[55b] Doi, 1993[24]	Only procedure that can restore function for severe contracture according to Tsuge classification	(1) Difficult microsurgical procedure requiring an experienced team (2) Failure can only be remedied with a second functional free muscle transfer

functional position. These procedures are ideally done after skeletal maturity but may need to be performed earlier if there is progressive deformity. In these cases, we attempt to fuse the joint and preserve the growth plate (i.e., chondrodesis).

Soft Tissue Procedures. Soft tissue procedures include excision of the infarcted muscle, fractional or "Z"-lengthening of the affected muscles, muscle sliding operations (flexor origin muscle slide), neurolysis, tendon transfers, and functional free-tissue transfers, as well as combinations of these procedures.[16,17,27,34,37,45,50,52,67,73,74,82,85,86,96,98] Excision of scarred fibrotic nerves without distal function followed by nerve grafting has been described to try and establish some protective sensation in the hand.[44] Fixed contractures of the joints can be addressed with soft tissue release, including capsulectomy and collateral ligament recession or excision, depending on the joints involved.

❖ AUTHORS' PREFERRED METHODS OF TREATMENT

Our preferred methods of treatment depend on the general classification of severity of contracture, individualized to the patient presentation.

Mild (Localized) Type (Deep Flexor Compartment Without Neurologic Deficit). For mild contractures that have failed to respond to nonsurgical management, our preferred treatment is a muscle sliding operation initially described by Page and subsequently endorsed by several others.[52,61,64,72-75,85] We have found this procedure effective as long as good active finger flexion is present. We do not combine this procedure with infarct excision, nor have we found it necessary to release the distal insertion of the pronator teres to correct pronation contracture.[52,85]

A limited flexor slide may be done for mild deformity, affecting only a portion of the flexor digitorum profundus. Because the flexor digitorum profundus originates solely from the ulna, the flexor pronator mass does not have to be released from the medial epicondyle and the ulnar nerve does not have to be transposed. This limited approach reduces potential scarring and vascular compromise to the remaining muscles and nerves in the flexor compartment.

Moderate Type (Deep and Superficial Flexor Compartment With Neurologic Deficit). For moderate deformity, we prefer a flexor muscle origin slide to correct the tightness of the flexors, provided that there is still adequate remaining strength in the

flexors. Because neurologic impairment is characteristic of the moderate injury, we combine the flexor slide with neurolysis of both the median and ulnar nerves. A separate incision to release the carpal tunnel may also be needed. Depending on the functional deficits, tendon transfer can be combined with flexor origin slide, either as a staged or simultaneous procedure.

Reconstruction of Thumb Function. Our preferred transfer for thumb flexion is to transfer the brachioradialis or extensor carpi radialis longus to the flexor pollicis longus. The extensor indicis proprius can be used for thumb opposition at a later date.

Reconstruction of Finger Flexion. When the finger flexors are very weak or absent, an FFMT may produce a better functional result than a tendon transfer. However, if an FFMT is not an option, tendon transfers may be considered depending on the availability of donors. The best option is transfer of the extensor carpi radialis longus to the flexor digitorum profundus because this transfer is synergistic and easy to relearn. Other lesser options include the biceps brachii elongated with graft, the brachioradialis, the extensor carpi ulnaris, and the extensor indicis proprius. Many of these secondary options do not have sufficient excursion to match the flexor muscles, but in the absence of other options, they can provide some improvement in grasp. Lastly, if there is minimal involvement of the flexor digitorum superficialis muscle, this muscle can be used as a donor to the flexor digitorum profundus

Nerve Reconstruction. When sensory impairment is severe and there has been no recovery, the nerve should be carefully evaluated at surgery. A densely scarred atrophic nerve or avascular nerve requires resection back to fascicles that appear healthy followed by sural nerve grafting to restore protective sensation to the hand (Figure 51.14).

Severe Type (Superficial and Deep Flexor Compartments, Extensor Compartment, and Severe Neurologic Deficits). Severe contractures are best treated with FFMTs.[16,18,24,45,50,92,95,96] The donor vessels are usually either the radial or anterior interosseous artery for an end-to-end anastomosis or the brachial artery for an end-to-side procedure. The donor motor nerve is the anterior interosseous nerve, which should be resected back to fascicles that appear healthy. Our preference for the donor muscle is the gracilis. For severe contractures with extensive involvement of both flexor and extensor compartments, a double free muscle transfer should be considered. Tendon transfer, nerve graft reconstruction, and late osseous reconstructive procedures may improve final functional outcomes.

Surgical Techniques

Flexor Pronator Slide. Both volar and ulnar incisions have been described for the surgical approach for a flexor pronator slide.[64,85] We favor the incision and technique initially described by Page[64] with minor modifications (Figure 51.15). The surgical incision begins on the medial distal arm and continues along the ulnar border of the forearm all the way to the wrist. The ulnar nerve is identified and mobilized for several centimeters proximal and distal to the medial epicondyle, including proximal release at the arcade of Struthers. Approximately 4 to 6 cm of intermuscular septum between the brachialis and triceps is excised to prevent kinking of the ulnar nerve after transposition. The flexor pronator mass is elevated off of the medial epicondyle, taking care to preserve the medial collateral ligament and elbow joint capsule. Inadvertent disruption of the joint capsule is repaired. The origins of the flexor carpi ulnaris,

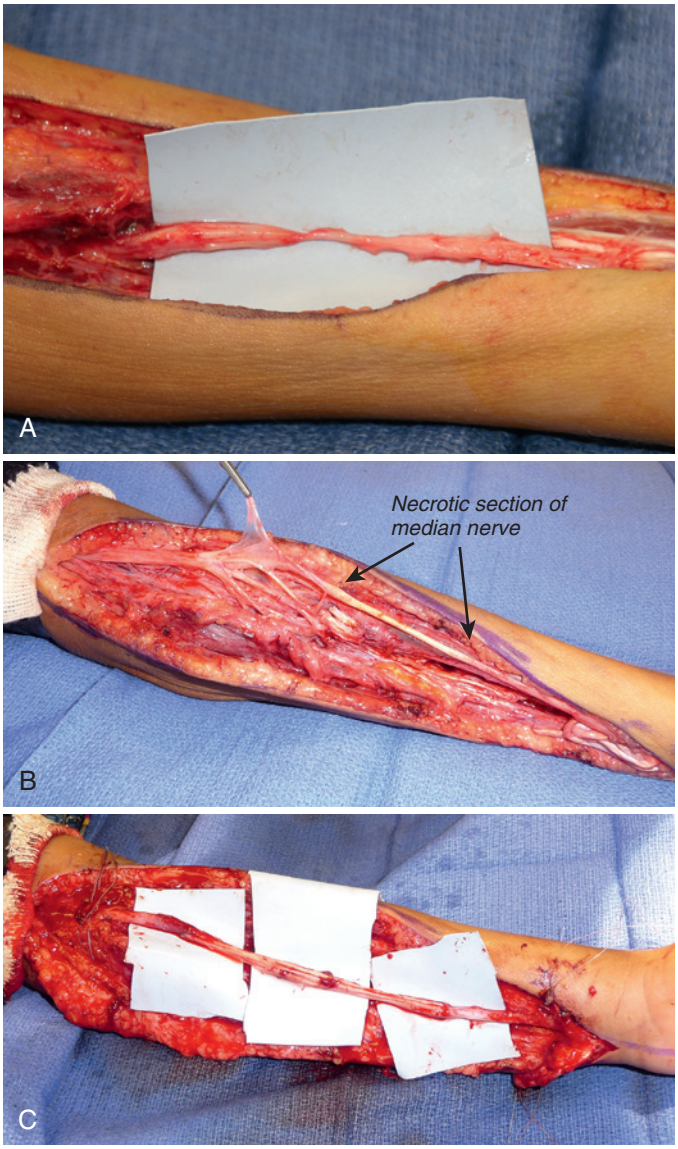

FIGURE 51.14 **A,** Scarred nerve. **B,** Avascular nerve. **C,** Reconstructed nerve.

flexor digitorum profundus, and flexor digitorum superficialis are mobilized off of the ulna and interosseous membrane. The dissection is carried out above the periosteum toward the radius. The common interosseous artery arises as a branch of the ulnar artery and must be protected. This artery crosses the flexor digitorum profundus, where it bifurcates into the anterior and posterior interosseous arteries (see Figure 51.15, *C*). The posterior interosseous artery enters the posterior compartment at the proximal edge of the interosseous membrane. Because the posterior interosseous artery is the dominant blood supply to the extensor compartment, protection of this branch is mandatory.

Continuing the dissection toward the radius, the origin of the flexor pollicis longus is released from proximal to distal. Special attention is needed in this area to protect the anterior interosseous nerve. Throughout the procedure, the wrist and fingers are manipulated to check whether the contracture is improving and to help determine whether there are still areas of tightness within the muscle origin. The dissection must

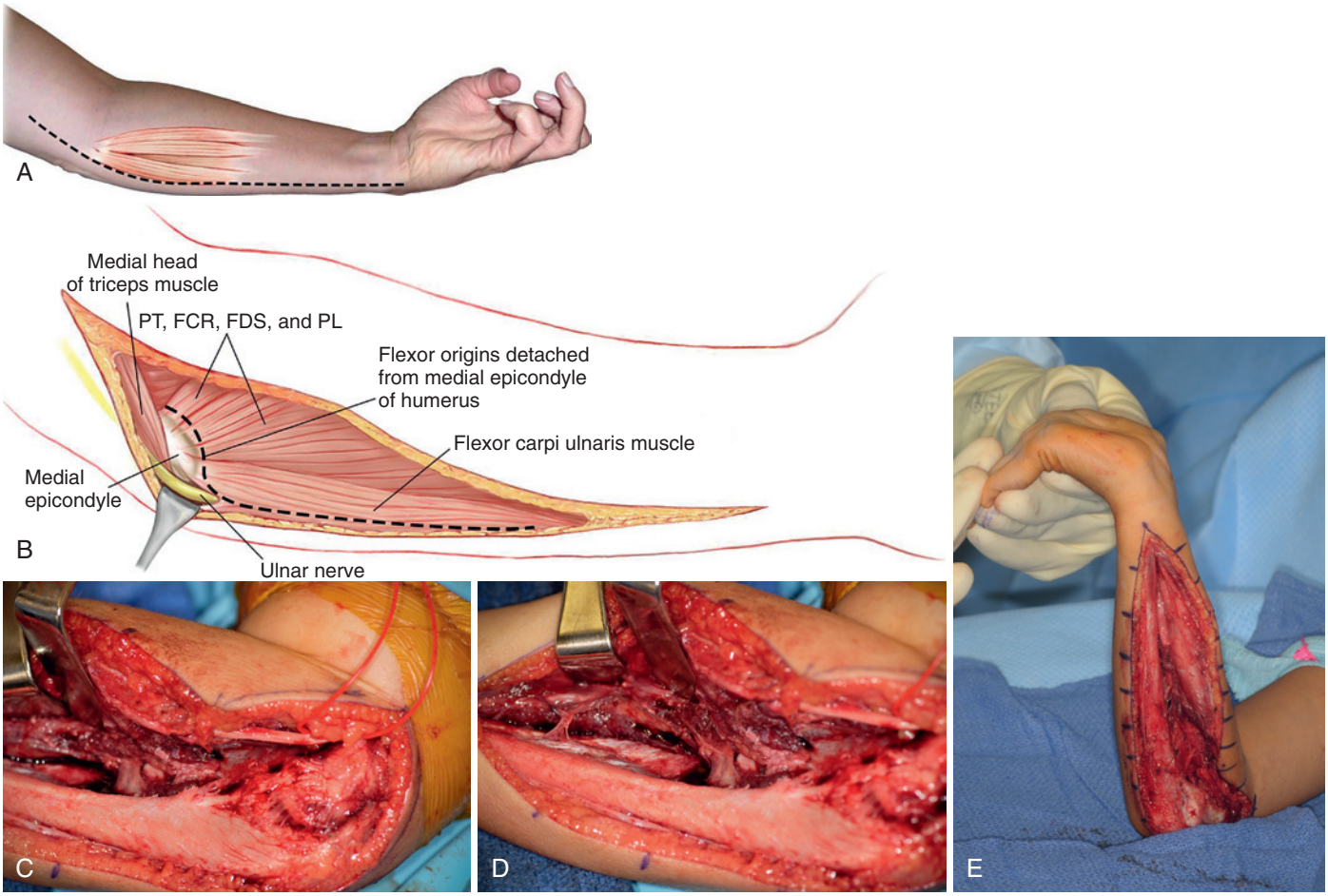

FIGURE 51.15 **A,** Diagram of surgical incision for flexor origin slide. **B,** Schematic diagram of deeper layer of dissection for flexor origin slide. **C,** Ulnar incision with ulnar nerve identified and mobilized. Flexor pronator mass elevated from the medial epicondyle with preservation of the medial collateral ligament and elbow joint capsule. **D,** Dissection proceeds in a radial direction with protection of the interosseous arteries. **E,** Complete release heralded by full finger wrist extension with the wrist held in extension. *FCR*, Flexor carpi radialis; *FDS*, flexor digitorum superficialis; *PL*, palmaris longus; *PT*, pronator teres.

often be carried down to the level of the wrist to release adhesions between the flexor tendons and pronator quadratus before full correction is achieved. If necessary, the carpal tunnel should be opened and tendon adhesions released in this area. It has been our experience that the lacertus fibrosus and superficial fascia around the antecubital fossa are often tight and are contributing to the residual elbow flexion contracture. The fascia can also tether the superficial flexors of the wrist and fingers, contributing to incomplete correction of the wrist and fingers with the muscle sliding only. Release of this fascia helps correct the deformity and also prevents median nerve compression between the heads of the pronator teres. Slight undercorrection, which can be addressed by postoperative splinting and rehabilitation, may decrease the reduction in muscle power resulting from the muscle slide. When a pronation contracture is present and has not been corrected by the release of the flexor-pronator origin, we release the pronator quadratus from the distal ulna. Even with a complete release of both the pronators and the volar distal radioulnar joint capsule, complete correction of the pronation deformity may not be possible due to fibrosis and contracture of the interosseous membrane. At the completion of the muscle slide, the ulnar nerve is transposed to an anterior subcutaneous position. The hand is casted in a position of forearm supination with the wrist and fingers in full extension. Immobilization is continued for a period of 6 weeks to allow the flexor pronator to heal adequately to its new origin (Figure 51.16 and Case Study 51.2).

Restoration of Extrinsic Flexor Function. For moderate contractures, a muscle slide may leave adequate flexor muscle function. Commonly, flexor strength and excursion are weakened and can benefit from flexor reconstruction. The options for tendon transfer depend on the extent of muscle necrosis in the forearm. Donor muscles from the extensor compartment can be used to reconstruct finger flexion and thumb flexion and opposition. Our preferred transfers are transfer of the extensor carpi radialis longus through the interosseous membrane to the flexor digitorum profundus, transfer of the brachioradialis to the flexor pollicis longus, and transfer of the extensor indicis proprius to restore opposition of the thumb.

Secondary options may be available in the flexor compartment when there is involvement of the deep flexor compartment only. A transfer of the flexor digitorum superficialis to the

CASE STUDY 51.2 Moderate Volkmann Contracture

A 15-year-old right hand dominant football player sustained a minimally displaced but angulated left both-bone forearm fracture. The fracture was treated in a long-arm cast with extreme molding at the midforearm. When the cast was removed at 6 weeks, the patient was noted to have a flexion contracture of the thumb and fingers. The fingers could be extended only with maximum wrist flexion. He could actively flex his fingers into a full fist. The patient was seen in the hand surgery department at 9 months after injury (eFigure 51.1).

At 9 months following injury, the patient underwent a flexor origin slide. A cast was applied with the wrist, fingers, and thumb in maximum extension for 6 weeks after surgery. At the time of cast removal, the patient was seen in therapy. A nighttime extension splint was made and recommended for use for 1 year after surgery. (The patient reported that he used this splint only for a few weeks.)

At 10 years of follow-up, the patient is working in light construction and builds motorcycles.

He feels happy with the outcome and grip strength, although he reports occasional fatigue in the forearm with prolonged use (eFigure 51.2 and Video 51.2).

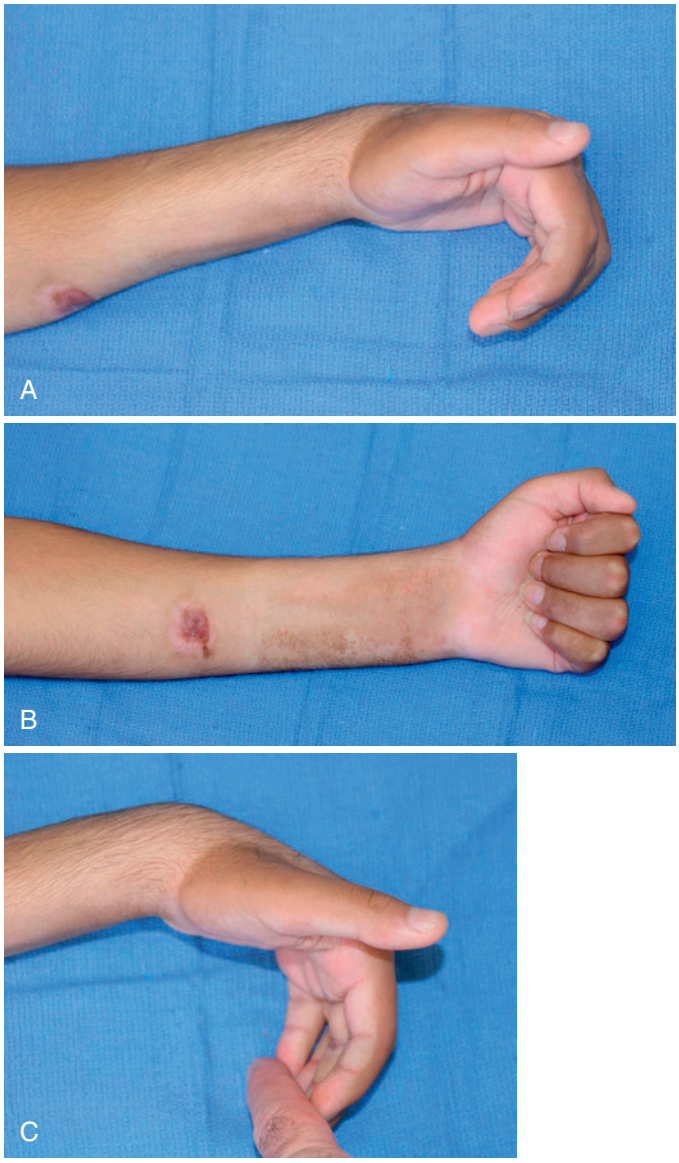

eFIGURE 51.1 Moderate Volkmann contracture. **A** and **B,** Presentation at 9 months following injury. **C,** Intraoperative passive extension.

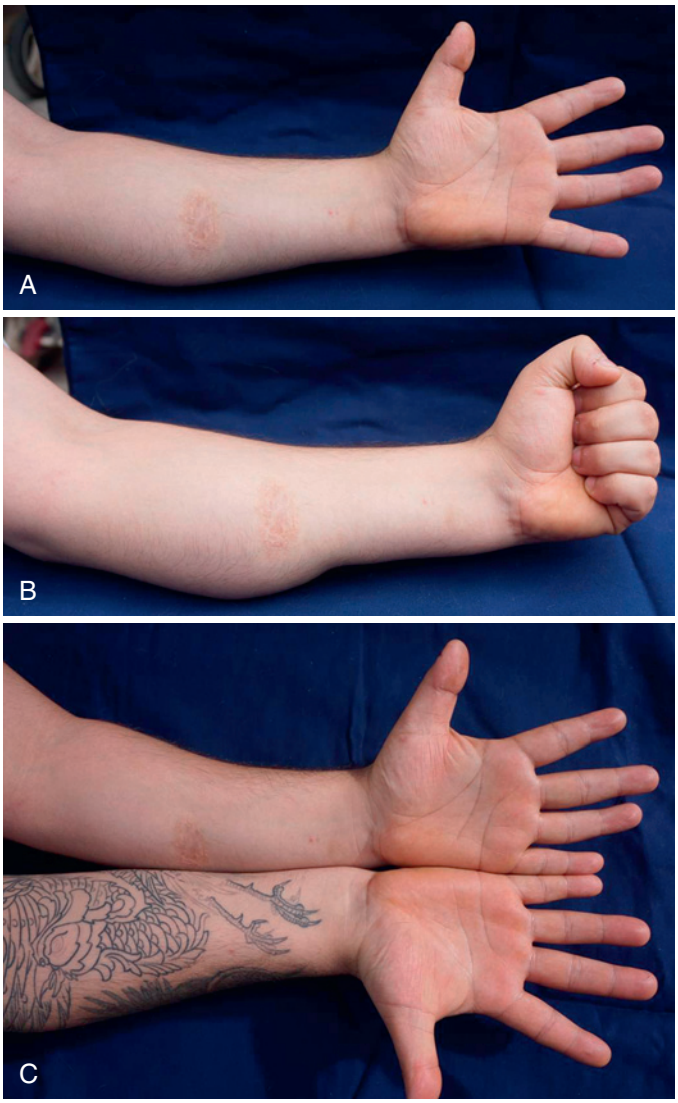

eFIGURE 51.2 Ten-year follow-up after flexor origin slide. **A,** Full finger extension with wrist in full extension; slight thumb interphalangeal flexion. **B,** Full thumb and finger flexion with grip strength 85% of contralateral side. **C,** Mild shortening of the affected forearm.

CRITICAL POINTS *Flexor Pronator Slide for Volkmann Contracture*

Preoperative Planning

- Indications include mild and moderate contractures of the forearm muscles
- Special evaluations include clinical examination of flexor muscle strength and preoperative magnetic resonance angiogram or arteriogram when indicated for previous vascular injury or by an abnormal vascular examination
- Bipolar cautery is useful for this procedure

Surgical Technique

- Incision from ulnar side from middle third to distal third junction of the arm, following the course of the ulnar nerve and continuing along the border of the forearm to the wrist flexion crease (extensile ulnar approach)
- Mobilize and transpose the ulnar nerve
- Release the flexor-pronator origin off of the medial epicondyle, preserving the medial collateral ligament and joint capsule
- Release the origins of the flexor carpi ulnaris, flexor digitorum profundus, flexor digitorum superficialis, and flexor pollicis longus from the ulna and intermuscular septum, working from proximal to distal and ulnar to radial
- Identify and protect the common interosseous artery and its division into the anterior and posterior interosseous arteries
- Frequently passively extend the wrist and fingers to identify structures that remain tight; the release is complete when full passive wrist and finger extension is achieved
- A separate release of the carpal tunnel and release of tendon adhesions in this area may be necessary if complete slide fails to achieve full extension
- Residual pronation contracture is addressed by release of the pronator quadratus from its ulnar origin and release of the volar dorsal radioulnar joint capsule; complete correction may not be possible due to interosseous membrane tightness
- A large drain is placed below the flexor pronator mass (it is removed on the first postoperative day)
- No fascial closure; skin and subcutaneous tissue only are closed

Postoperative Care

- Immobilization in long-arm cast with the elbow at 90 degrees and the forearm in supination; the wrist and fingers are in full extension, and the thumb is in abduction and extension; the initial cast should be bivalved if swelling is a concern
- Duration of immobilization is 2 to 3 weeks in a long-arm cast; convert to short-arm cast with wrist and finger extension and thumb abduction-extension for an additional 3 to 4 weeks (full 6 weeks postoperatively)
- Rehabilitation: Begin elbow motion and nerve gliding at time of conversion from long-arm cast to short-arm cast; begin wrist and finger range-of-motion exercises with therapy guidance at time of cast removal; strengthening may begin as tolerated starting at 6 weeks; custom thermoplast orthosis at night until skeletal maturity
- Activities: The patient may return to sports when adequate strength and motion allow participation in the sport of choice; we encourage swimming activities to develop strength and motion

flexor digitorum profundus will provide the patient with good flexor strength and sufficient excursion to achieve functional grasp. Also, the flexor carpi radialis and flexor carpi ulnaris may be spared and available as donor muscles for transfers. Neither of these muscles has excursion matching that of the flexor digitorum muscles.

When the extensor compartment has been compromised by the ischemic event, the muscles are not available for transfer. For these patients, the only option for functional reconstruction remains an FFMT.

CRITICAL POINTS *Tendon Transfer for Finger and Thumb Flexion*

Preoperative Planning

- Careful preoperative clinical assessment of available donor muscle strength

Surgical Technique

- Extensor carpi radialis longus to flexor digitorum profundus, brachioradialis to flexor pollicis longus, or extensor indicis proprius to radial side of the thumb metacarpal
- The extensor carpi radialis longus is harvested from the radial base of the index metacarpal through a longitudinal incision.
- The harvest incision of the extensor carpi radialis longus is extended or a separate proximal incision is made at the junction of the middle third and distal third of the forearm to create a tunnel through the interosseous membrane.
- The brachioradialis is exposed through the same incision used to expose the extensor carpi radialis longus proximally. The brachioradialis must be freed from the forearm fascial attachments to improve excursion.
- The extensor indicis proprius is exposed through a separate incision at the metacarpophalangeal and mobilized proximally.
- A volar incision is made at the distal third of the volar forearm to identify and mobilize the flexor digitorum profundus tendons. The flexor pollicis longus is identified through the same incision. The flexor digitorum superficialis tendons are excised. The flexor digitorum profundus tendons are sutured together as a single tendon unit.
- The extensor carpi radialis longus is transferred through the interosseous membrane; the opening created in the interosseous membrane must be sufficient in size to prevent constriction of the transferred muscle-tendon unit.
- The extensor carpi radialis longus is woven into the flexor digitorum profundus tendons using a weave technique.
- The tenorrhaphy is placed under sufficient tension to restore the resting cascade of the fingers but still allow full passive extension of the fingers with the wrist in neutral position.
- The brachioradialis to flexor pollicis longus transfer is completed in a similar manner.
- The extensor indicis proprius is mobilized proximally, then passed through a subcutaneous tunnel around the ulnar side of the wrist. An ulnar-sided incision around the level of the pisiform is made to retrieve the extensor indicis proprius and to create a subcutaneous tunnel from the ulnar wrist to the radial side of the thumb metacarpal neck.
- The extensor indicis proprius is secured to the radial side of the thumb metacarpal neck with the thumb in a position of abduction and pronation, as described by Burkhalter.[12]

Postoperative Care

- Immobilization is in a splint or cast: Dorsal block with wrist at 30 degrees of flexion, metacarpophalangeals at 70+ degrees of flexion, thumb in abduction and pronation with interphalangeal joint in neutral
- The duration of immobilization is 4 weeks, during which time the patient is instructed in passive range-of-motion exercises
- At 4 weeks, a thermoplast splint may be worn full time and place-and-hold exercises may begin.
- At 6 weeks, the transition is made to nighttime use of the splint only.
- Rehabilitation with place-and-hold exercises beginning at 4 weeks; passive extension after 6 weeks
- Activities: The patient may return to sports when there is adequate strength and motion to participate in the sport of choice; minimum of 6 months after tendon transfer



FIGURE 51.16 This 42-year-old woman sustained an isolated brachial artery laceration and had a dysvascular forearm and hand. She underwent repair of the artery. She presented 1 year after injury with inability to straighten her fingers with the wrist in a neutral position (Holden type 1 contracture). **A,** Finger extension with the wrist in neutral. Flexor pollicis longus is spared. **B,** Finger extension with the wrist in neutral. **C,** Finger flexion. **D,** Flexor origin slide with release of flexor pronator mass and flexor digitorum profundus. The ulnar nerve is transposed anteriorly. The wrist and fingers are extended throughout the procedure until full extension of the fingers is achieved with the wrist in full extension. **E,** Finger flexion at 6 months. **F,** Finger and wrist extension at 6 months.

Restoration of Extrinsic Flexor Function: Free Functional Muscle Transfer. Functional reconstruction following Volkmann ischemic contracture was the first clinical application of FFMT. Several different donor muscles have been used to restore finger flexion, including the pectoralis major (lateral portion), medial gastrocnemius, latissimus dorsi, and gracilis. When using the latissimus dorsi muscle, we place the caudad portion of the muscle as the origin on the medial epicondyle and use the tendinous portion to attach to the profundus tendons. The gracilis (and also latissimus) has independent neuromuscular territories that can be separated and used to restore independent thumb and finger flexion. If the latissimus dorsi is being used for functional reconstruction and independent neuromuscular territories are needed, the latissimus cannot be reversed. The tendinous insertion of the latissimus dorsi should become the neoorigin of the forearm flexors, and the muscle should be separated distally to reconstruct finger and thumb flexion independently.

Our preferred muscle for reconstruction is the gracilis, due to its size match, excursion, and power. Specific points related to FFMT in the setting of Volkmann ischemic contracture are highlighted here.

Prior to FFMT, procedues may be necessary to prepare the recipient site. Excision of the infarcted muscle is not necessary

because the tendons are released distal to the area of muscle infarct. However, fixed contractures and tendon adhesions distal to the planned tenorraphy site need to be addressed.

The median and ulnar nerves (if clinically impaired) are explored. Areas of necrotic or constricted nerve are excised and grafted using a sural nerve graft. If both the median and ulnar nerves are affected over a long distance and there is not enough sural nerve graft, the median nerve should have priority of reconstruction using autogenous graft. Ulnar nerve reconstruction can be performed or augmented with nerve allograft if necessary. We prioritize median nerve function because of the importance of radial-sided sensation for pinch as well as the higher likelihood of recovery in both sensory and motor function.[14,47,48,60] In our experience, the median nerve is more frequently and more severely affected, likely due to its anatomic location.

At the time of FFMT, surgical incisions are planned to provide the best soft tissue coverage over the transferred muscle and tenorraphy site. The recipient site should be prepared *before* the donor muscle is harvested. A two-team approach is frequently used, but division of the donor tendon insertion should not be completed until the recipient vessels and motor nerve are identified. This is particularly important when using an FFMT for reconstruction in patients with Volkmann contracture. In these cases, it is often necessary to obtain intraoperative frozen sections to identify healthy fascicles of the recipient motor nerve. In addition, the vascular anastomosis should be performed proximal to the ischemic tissue bed. Even though an adequate arterial inflow may be found within the reconstruction site, the venous outflow is unreliable. The vascular pedicle and recipient nerve should be mobilized as much as possible to obtain sufficient length for proper positioning of the transplanted muscle.

The vascular anastomosis is completed first, and the muscle is allowed to perfuse for 10 to 15 minutes until the venous outflow does not appear overly dark. The anastomosis is completed as quickly as possible to minimize permanent ischemic changes to the muscle. Irreversible muscle loss increases with time in a nonlinear relationship.[5] It is our experience that if the muscle ischemia time exceeds 2 hours, the muscle will likely survive but the function will never be good. If the cause of the prolonged ischemia time can be identified (ususally, compromised venous outflow leading to reperfusion problems) and rectified (e.g., vein grafting to different recipient vessels), the surgeon can consider harvesting a different donor muscle at the same procedure.

The muscle is secured to its new origin site on the medial epicondyle using nonabsorbable suture. The origin may be secured to the periosteum and surrounding fascia. Bone tunnels or suture anchors can also be used. The muscle neoorigin should be spread out as much as possible. The tendons of the flexor digitorum superficialis are excised from the musculotendinous junction to the wrist flexion crease. The wrist and fingers are flexed so that after transection, the cut ends of the flexor digitorum superficialis will be distal to the carpal canal. The flexor digitorum profundus is divided just distal to the musculotendinous junction. The tendons are sutured side to side, with tensioning of the position to re-create the normal cascade of the fingers (Figure 51.17). When traction is applied to the sutured tendons, the fingers should all touch the midpalmar crease. The flexor pollicis longus tendon is transected distal to its musculotendinous junction. Traction is applied along the tendon to ensure proper tendon gliding. Flexor pollicis longus function is reconstucted separately using a tendon transfer if available (either the brachioradialis or extensor carpi radialis longus). If these muscles are not functional, independent flexor pollicis longus function can be restored by using the separate neuromuscular territories of the gracilis muscle to allow independent finger and thumb flexion. The transferred muscle is stretched to restore its resting length, and the site for the distal tenorraphy is marked with the wrist and fingers in full extension. The neurorraphy is completed last; its site is placed as close as possible to the transplanted muscle. Wound closure should be performed with attention to avoiding compression of the vascular pedicles. Tight skin closures should be avoided at all costs because a compartment-like syndrome or venous outflow obstruction can occur when the reperfused muscle swells following the surgery.

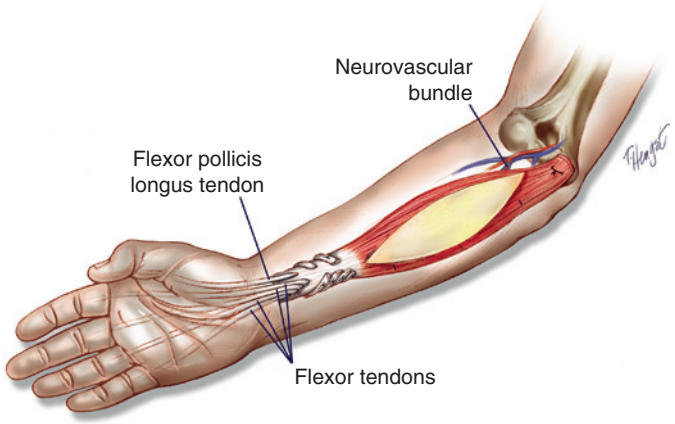

FIGURE 51.17 Schematic drawing of gracilis muscle used for free functional muscle transfer for reconstruction of finger flexion.

Transfer of Gracilis Muscle. The gracilis muscle is usually harvested with the patient supine in a frogleg position. Either the ipsilateral or contralateral gracilis can be used for finger flexor reconstruction because the recipient vascular pedicle and obturator nerve have sufficient length to accommodate the distance to the recipient site. Technique highlights are listed in the critical points box.

Outcomes

Outcomes following Volkmann contracture in the upper extremity are difficult to assess. Studies are limited by the small numbers of patients, the great variability in the initial presentations, the varied surgical techniques used, and the difficulty in tracking patients over the long term as they grow to skeletal maturity. Ultee and Hovius attempted to provide some information regarding outcomes.[87] They found that all patients who had developed the contracture during childhood had a relatively shortened extremity. Substantial improvements in hand function were noted in patients who underwent FFMT. Tendon lengthening alone often resulted in recurrence of contracture. Finally, in patients who had sufficient remaining muscle, procedures that combined infarct excision, tenolysis, neurolysis, and tendon transfer produced good hand function.[87] Sundararaj and Mani noted improvement in sensory function in conjunction with neurolysis.[82]

CRITICAL POINTS *Free Functional Muscle Transfer for Finger Flexion*

Preoperative Planning

- Indications are no active finger flexion and no available tendon transfers
- Microsurgical instrumentation and magnification are required

Surgical Technique

Preparation of the Donor Site

- Extensile surgical incision along the forearm
- Excision of necrotic and/or fibrotic muscle may not be necessary after division of the flexor tendons
- Neurolysis of the median and ulnar nerves
- Nerve reconstruction when indicated using sural nerve autograft
- Identification and preparation of the recipient nerve: recipient nerve options are the anterior interosseous nerve and the median nerve; recipient artery and vein options are the anterior interosseous artery (end-to-end), radial artery (end-to-end), ulnar artery (end-to-end), and brachial artery (end-to-side)

Harvest of the Gracilis

- Frog position of the leg; a sandbag can be used to help positioning
- Mark the axis of dissection of the gracilis from the pubic tubercle to the tendon insertion of the pes anserinus
- A distal incision is made and the tendon of the gracilis is identified between the sartorius and the semitendinosus
- Tension applied to the distal tendon will help identify the axis of the muscle
- A skin paddle is incorporated into the surgical incision
- Dissection is carried down to the fascia; the gracilis is harvested within its fascial sheath (Figure 51.18); a wide harvest of fascia is taken anterior to the gracilis
- The resting length of the gracilis is marked with the hip in full abduction and the knee in full extension; marking sutures are placed at 5-cm intervals
- Dissection is best completed from distal to proximal and from posterior to anterior
- The tendon is released distally
- The muscle origin is divided after the neurovascular pedicle is mobilized and isolated
- The dominant vascular pedicle enters the muscle proximally on the anterior deep surface; the vascular pedicle arises from the profunda femoral artery; the obturator nerve enters the muscle proximal to the dominant pedicle; the nerve is stimulated to ensure that it produces a muscle contraction
- The nerve is divided and the vascular pedicle is ligated *only* after the recipient site is ready

Muscle Transfer

- Arterial and venous anastomosis first; allow muscle to perfuse for 10 minutes
- Establish and secure new muscle origin at the medial epicondyle; reset the muscle resting length; the resting length is reset with the wrist and fingers in full extension
- Use a weave to secure the gracilis tendon to the flexor digitorum profundus and flexor pollicis longus; although the resting length is set with the wrist and fingers in extension, once that has been established, the repair is performed with the wrist and fingers in flexion to minimize tension at the repair site; flexor pollicis longus function is reconstructed with a tendon transfer (extensor carpi radialis longus or brachioradialis); alternatively, the separate neuromuscular territory of the gracilis can be used to create separate functional reconstruction for thumb flexion; this requires two motor donor nerves
- Neurorraphy is completed last; the neurorraphy is completed close to the transplanted muscle

Postoperative Care

- Immobilization is with a long-arm splint followed by a long-arm cast, with the elbow at 90 degrees of flexion, wrist at 30 degrees of flexion, and metacarpophalangeals at 90 degrees of flexion; the thumb is in palmar abduction and interphalangeal flexion
- Duration of immobilization is 4 to 6 weeks
- Rehabilitation: After cast removal, gentle passive range of motion; more firm passive motion may start at 3 months; muscle stimulation may also start at 3 months; light and progressive strengthening after onset of muscle reinnervation
- Activities: The patient should not participate in sports until at least 1 year after reinnervation, and then only when he or she has adequate strength and motion to participate in sport of choice

Outcomes of Flexor Origin Slide. Since the original description of this procedure by Page in 1923, there have been few reports about it.[27,72,75,85] The most detailed report of outcomes for this procedure was published by Sharma and colleagues, who reported on patients with moderate Volkmann contracture with no fixed joint contractures, noting improvements in dexterity, sensibility, ability to flex and extend the fingers, and grip strength. In 15 of 19 patients, dexterity scores were in the good range. In 14 of 19, grip strength was in the good range and reached 20 to 87% of that of the contralateral hand (average, 75%). The authors attribute their good outcomes to careful patient selection and emphasis on postoperative therapy.[75]

In our experience, substantial functional improvement of mild and moderate contractures can result following flexor muscle slide and nerve reconstruction when indicated. Normal function is not anticipated, but a hand with protective sensation and functional grasp can often be achieved.

A flexor origin slide for severe contractures can improve passive finger and wrist motion and is useful as a first stage of treatment before functional reconstruction with tendon transfer or FFMT (Figure 51.19 and Case Study 51.3). All of these procedures have better outcomes in patients with preserved hand intrinsic function.

Outcomes of Free Functional Muscle Transfer. Since the first case report of an FFMT for reconstruction of finger flexion, several other case reports and small series have been reported. Zuker and colleagues reported on a series of FFMTs performed in 1991 for seven patients using a gracilis donor muscle. All patients achieved less than 2 cm of pulp to palm grip. Grip strength was approximately 25% of the contralateral side. All patients achieved a functional nondominant hand.[97] In 2011, they reported on a modification in their technique to provide independent thumb flexion by separating the fascicles of the obturator nerve and using two donor nerves, providing separate innervation to the neuromuscular territories of the gracilis muscle.[97] Krimmer and associates used the gracilis muscle in 15 patients with the primary indication being Volkmann contracture. Reinnervation occurred in 13 of 15 muscles. Ten patients achieved full active motion.[50] Liu and coworkers used the medial gastrocnemius muscle in 20 patients, reporting electromyographic activity at 6 to 20 months. Functional outcomes were reported as satisfactory, but the clinical pictures suggest

CASE STUDY 51.3 **Severe Volkmann Contracture**

A 5-year-old boy developed a severe Volkmann contracture after a supracondylar humerus fracture. One year later the patient underwent a flexor origin slide to reduce the contracture at the wrist and fingers. At 2 years following injury, he underwent a free functional muscle transfer to restore finger and thumb flexion. Nerve grafting of the median nerve was performed at the same time (see Figure 51.19 and Video 51.3).

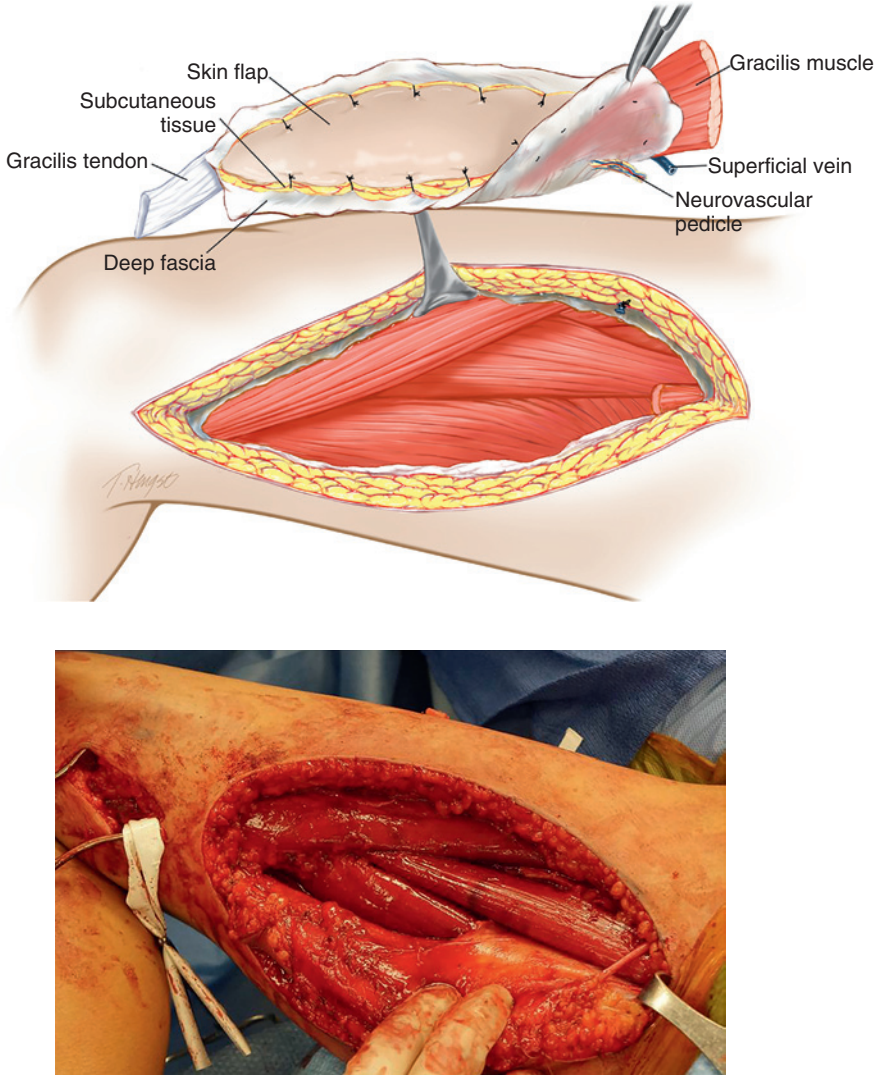

FIGURE 51.18 Dissection of gracilis.

incomplete finger flexion, likely related to the short excursion of the muscle.[55]

Restoration of Intrinsic Function After Volkmann Contracture of the Forearm

Nerve Dysfunction Associated With Forearm Compartment Syndrome. Intrinsic dysfunction in the setting of a Volkmann ischemic contracture of the forearm results from nerve ischemia in the forearm. Intrinsic dysfunction remains an extremely difficult problem to address both operatively and nonoperatively. Nerve reconstruction is performed when there is absent sensory and motor function or a clearly necrotic nerve is identified at the time of exploration. Some recovery of sensation can be expected. Motor recovery is less predictable. There are few available tendon transfers for functional restoration because donor tendons are often necessary for extrinsic flexor reconstruction. If protective sensation is not improved with neurolysis or nerve reconstruction, nerve transfer from the dorsal sensory branch of the radial nerve to the ulnar digital nerve of the thumb and radial digital nerve of the index finger should be considered for restoration of sensate pinch. Also, if ulnar nerve function is intact, transfer of the common digital nerve to the fourth web space to the radial digital nerve of the index finger and ulnar digital nerve of the thumb is another option for sensory restoration for pinch.

Volkmann Contracture of the Hand

Volkmann contracture isolated to the hand is much less common than contracture in the forearm. Little is written about this problem, and treatment options are limited. Volkmann contracture of the hand commonly involves contracture of the first web space with the inability to open the thumb for grasp. The fingers assume variable degrees of the intrinsic-plus posture, with metacarpophalangeal joint flexion and proximal interphalangeal joint extension secondary to ischemia within the interosseous muscles. In combination with the thumb deformity, the hand cannot be opened sufficiently to grasp even medium-sized objects (Figure 51.20).

The first web space contracture is addressed with excision of the first dorsal interosseous muscle and the fibrotic portion of the adductor pollicis. Options to maintain the web space include placement of a bone block from the iliac crest between the thumb and index metacarpal shafts, or fusion of the

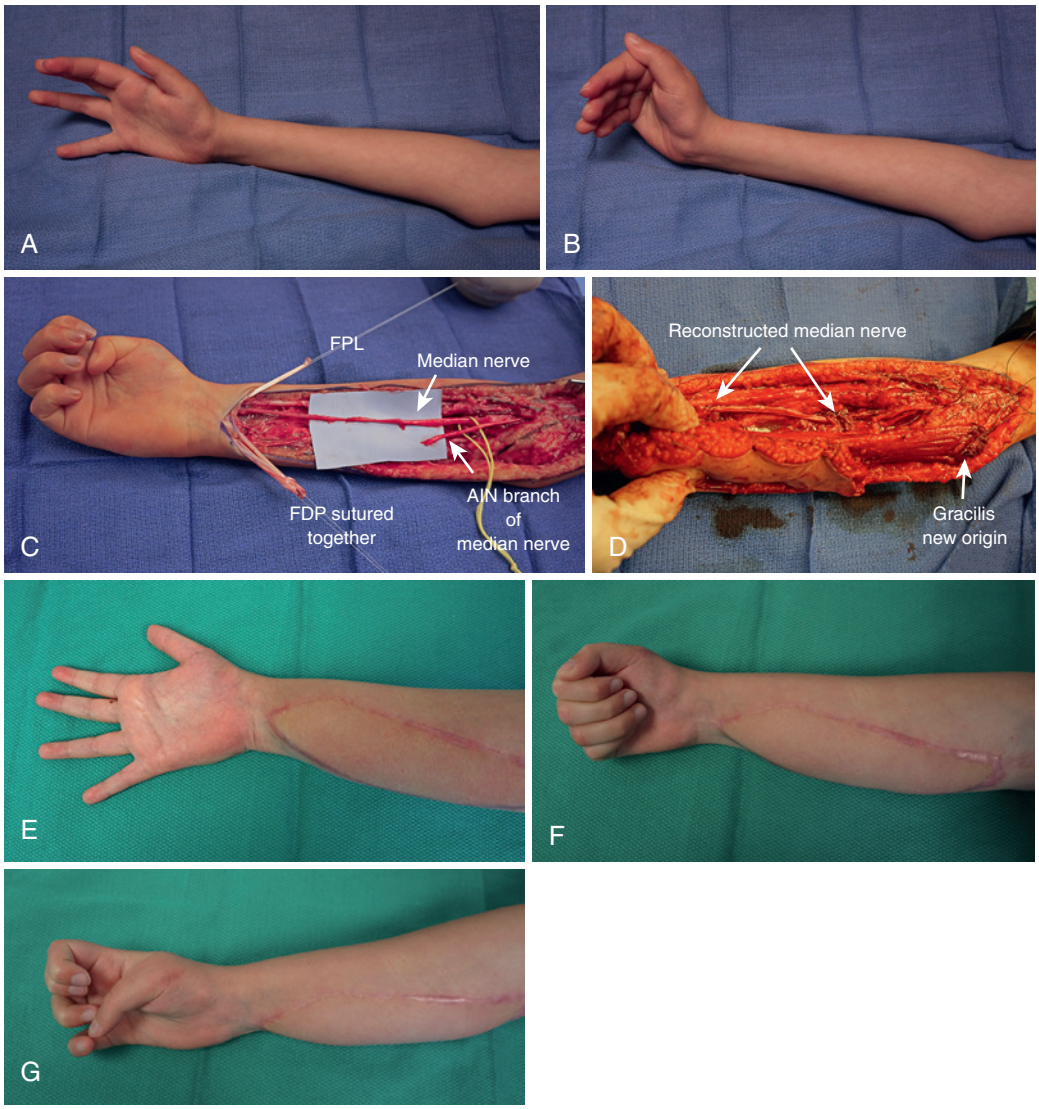

FIGURE 51.19 This 5-year-old boy developed a Volkmann contracture after sustaining a supracondylar humerus fracture. One year after his initial injury, he underwent a flexor origin slide to reduce wrist and finger flexion contractures. One year later he underwent a free functional muscle transfer of the gracilis for restoration of finger flexion. The extensor carpi radialis longus was transferred to restore flexor pollicis longus function. An opponensplasty was performed 9 months later using the extensor indicis proprius. **A,** Preoperative extension 1 year after flexor origin slide. **B,** Preoperative flexion. **C,** Necrotic flexor muscles have been partially resected. The flexor digitorum profundus tendons are sutured together distally. The flexor pollicis longus tendon has been independently separated. The median nerve has been dissected. The anterior interosseous nerve (AIN) branch has been isolated for neurorrhaphy to the nerve to the gracilis. **D,** Insetting of functional free gracilis muscle. The median nerve has been reconstructed with a sural nerve graft over a 7-cm segment. **E,** Finger and wrist extension at 1 year after functional free gracilis transfer and median nerve reconstruction. **F,** Finger and thumb flexion at 1 year after his last surgery. **G,** Opposition to small finger at 1 year. See Video 51.3. *AIN,* Anterior interosseous nerve; *FDP,* flexor digitorum profundus; *FPL*, flexor pollicis longus.

trapeziometacarpal joint. If skin is deficient, these procedures may require augmentation with a four-flap "Z"-plasty, pedicled rotational flap, or even free tissue transfer. Our preferred technique would be dependent upon the extent of contracture. The choice of free tissue transfer would depend on the body habitus of the patient, but a posterior interosseous forearm rotational flap or a free lateral arm flap would be our first choice. Sacrifice of the index finger with a ray resection may be a good alternative for some patients, particularly those with substantial dysfunction of the index finger. This provides an adequate web space for grasp, removes the need for tissue transfer, and allows the resected index metacarpal to be used as a bone block between the first and third metacarpals to maintain the web space.

Intrinsic tightness of the fingers clinically presents as a metacarpophalangeal joint flexion and interphalangeal joint extension. Intrinsic tightness can sometimes be distinguished from joint contracture by performing an intrinsic tightness test.

Milder cases of intrinsic contracture can be addressed with excision of portions of the oblique and lateral bands at the level of the distal third of the proximal phalanx.[40,54,77] Fixed joint contractures are addressed with concomitant capsulectomy and collateral ligament releases as needed. Intrinsic muscle sliding procedures have been described but have limited indications

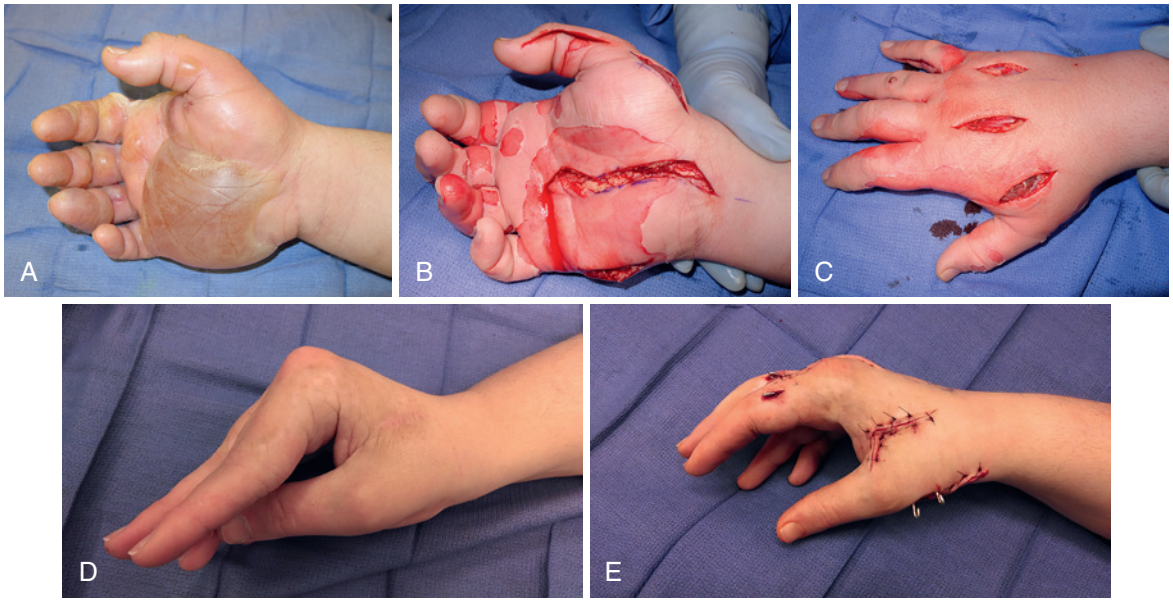

FIGURE 51.20 A 38-year-old diabetic presented to the orthopedic department more than 24 hours after lying on his hand for an unknown period of time during a diabetic coma. **A,** Appearance of the hand at time of presentation. **B,** Fasciotomy performed immediately after presentation, volar incisions. **C,** Fasciotomy performed immediately after presentation, dorsal incisions. **D,** Volkmann contracture of the hand developed despite release. **E,** First web space release with excision of fibrotic muscles and release of the intrinsics to the index and long fingers at the level of the metacarpophalangeal joint.

with severe contractures. These muscle sliding procedures have better outcomes with some underlying intrinsic muscle function preservation. Tenolysis of the flexor and extensor tendons and release of the intrinsic muscles at their insertion may be necessary to treat severe contractures. Despite these extensive releases, overcorrection of the contracture is not typically seen.

There is a limited role for tendon transfers in treatment of these deformities. Tendon transfers such as the flexor digitorum superficialis (ring finger) or extensor indicis proprius for reconstruction of opposition may improve function after addressing the contracture.

Complications

Complications can be seen with any surgical procedures. Specific complications related to surgery for Volkmann contracture are listed below.

Complications of Tendon Transfer. The most difficult aspect of performing a tendon transfer is establishing the appropriate tension of the transfer. Overtensioning or undertensioning can limit the functional outcome. Incorrect tensioning can be addressed with secondary surgery to tighten or loosen the transfer.

Complications of Flexor Origin Slide. Hematoma formation and wound dehiscence are potential complications. The use of a drain and judicious closure will minimize these complications. Sharma and Swamy reported on 19 patients with two events of wound dehiscence that healed by secondary intention.[75]

Complications of Functional Free Muscle Transfer. FFMT is a complex procedure associated with multiple potential complications, which can be divided into acute and long-term complications and also into those at donor sites and those at recipient sites.

Acute complications at the recipient site include flap loss, partial flap loss (either skin paddle or partial muscle loss),

CRITICAL POINTS *Late Management of Volkmann Contracture*

Pitfalls and Their Prevention

- Distinguishing Volkmann contracture from pseudo–Volkmann contracture is important:
  Historical features may favor one diagnosis over the other; clinical findings of nerve involvement are less likely in pseudo–Volkmann contracture; magnetic resonance imaging will not show ischemic muscle changes in pseudo–Volkmann contracture
- Failure to address severe muscle necrosis with wide excision of necrotic or fibrotic muscle may result in nerve ischemia and contracture: When necrotic and/or fibrotic muscle is identified, early excision of it and reconstruction of the compartment with healthy soft tissue will limit scarring and ischemia of the nerves
- Progressive or recurrent deformity during growth: regardless of the treatment provided this will occur. Night splinting should be continued through skeletal maturity
- Flexor-pronator slide: (1) Incomplete correction at the time of surgery will not improve postoperatively with therapy; obtain maximum correction during surgery; (2) injury to the common interosseous artery (which supplies the dorsal forearm compartment) can be prevented by careful dissection, especially in the proximal third of the forearm
- Free functional muscle transfer: (1) With prolonged surgical ischemia (>2 hours), even if the muscle survives, muscle function will likely be poor; consider a second muscle transfer; (2) therapy that is too aggressive during the early stage of healing can lead to rupture of muscle fibers; use gentle rehabilitation for the first 6 months following FFMT

Common Complications

- If the deformity recurs after a soft tissue procedure, arthrodesis of the wrist may be necessary and may need to be combined with proximal row carpectomy
- Inadequate active range of motion or strength after flexor origin slide may need to be managed with FFMT

hematoma, and infection. *Long-term complications at the recipient site* include scarring and tendon adhesions requiring revision surgery, attenuation at the tendon repair site, and inadequate recovery of muscle power for the desired level of function. In pediatric patients, the bone growth may be more rapid than the transferred muscle growth, which can lead to joint contracture.

Acute complications at the donor site include hematoma or seroma formation. The latissimus dorsi donor site is frequently complicated by seroma formation. Quilting and use of fibrin sealant at the donor site may reduce this complication.[4] Drains are a prerequisite to lessen this complication and should be retained until the patient is ambulating and drain output is less than 25 mL in 24 hours. Several authors have reported transient peroneal or sciatic nerve palsy related to intraoperative positioning.[1,23] *Long-term donor site complications* include painful unsightly scarring, donor site pain or dysesthesia, and functional losses. Russell and colleagues investigated changes in shoulder girdle function following latissimus dorsi harvest, noting a 5% to 10% decrease in shoulder girdle strength.[71] Deutinger and colleagues measured a decrease in adductor strength of 11% following harvest of the gracilis muscle.[23] Despite the measured decrease in muscle strength, the relative weakness is rarely noted by the patient, and therefore this possibility is not a contraindication for donor selection.

For Case Studies, Videos, and more, please visit ExpertConsult.com.

REFERENCES

1. Addosooki AI, Doi K, Hattori Y: Technique of harvesting the gracilis for free functioning muscle transplantation. *Tech Hand Up Extrem Surg* 10(4):245–251, 2006.
2. Allen M, Barnes M: Chronic compartment syndrome of the flexor muscles in the forearm: a case report. *J Hand Surg [Br]* 14(1):47–48, 1989.
3. Bae D, Kadiyala R, Waters P: Acute compartment syndrome in children: contemporary diagnosis, treatment, and outcome. *J Pediatr Orthop* 21(5):680–688, 2001.
4. Bailey SH, Oni G, Guevara R, et al: Latissimus dorsi donor-site morbidity: the combination of quilting and fibrin sealant reduce length of drain placement and seroma rate. *Ann Plast Surg* 68(6):555–558, 2012.

4a. Bardenheuer L: Die entstehung und behandlung der ischaemishen muskelkontractur und gangran. *Dtsch Z Chir* 108:44, 1911.

4b. Bebawy JF, Gupta DK, Koht A: Compartment syndrome caused by a properly functioning infusion pump. *J Clin Anesth* 23(2):134–136, 2011.

5. Becker MH, Wermter TB, Brenner B, et al: Comparison of clinical performance, histology and single-fiber contractility in free neurovascular muscle flaps. *J Reconstr Microsurg* 16(7):525–534, 2000.
6. Blakemore L, Cooperman D, Thompson G, et al: Compartment syndrome in ipsilateral humerus and forearm fractures in children. *Clin Orthop Relat Res* 376:32–38, 2000.
7. Boody AR, Wongworawat MD: Accuracy in the measurement of compartment pressures: a comparison of three commonly used devices. *J Bone Joint Surg Am* 87(11):2415–2422, 2005.
8. Botte MJ, Fronek J, Pedowitz RA, et al: Exertional compartment syndrome of the upper extremity. *Hand Clin* 14(3):477–482, 1998.
9. Branco BC, Inaba K, Barmparas G, et al: Incidence and predictors for the need for fasciotomy after extremity trauma: a 10-year review in a mature level I trauma centre. *Injury* 42(10):1157–1163, 2011.

9a. Brooks B: Pathologic changes in muscle as a result of disturbances of circulation. *Arch Surg* 5:188–216, 1922.

9b. Brooks B: New methods for study of the diseases of the circulation of the extremities. *J Bone Joint Surg Am* 7:316–318, 1925.

10. Brown JS, Wheeler PC, Boyd KT, et al: Chronic exertional compartment syndrome of the forearm: a case series of 12 patients treated with fasciotomy. *J Hand Surg Eur Vol* 36(5):413–419, 2011.
11. Buchbinder D, Karmody AM, Leather RP, et al: Hypertonic mannitol: its use in the prevention of revascularization syndrome after acute arterial ischemia. *Arch Surg* 116(4):414–421, 1981.
12. Burkhalter W, Christensen RC, Brown P: Extensor indicis proprius opponensplasty. *J Bone Joint Surg Am* 55(4):725–732, 1973.
13. Bywaters EG: 50 years on: the crush syndrome. *BMJ* 301(6766):1412–1415, 1990.
14. Cho MS, Rinker BD, Weber RV, et al: Functional outcome following nerve repair in the upper extremity using processed nerve allograft. *J Hand Surg [Am]* 37(11):2340–2349, 2012.
15. Choi PD, Melikian R, Skaggs DL: Risk factors for vascular repair and compartment syndrome in the pulseless supracondylar humerus fracture in children. *J Pediatr Orthop* 30(1):50–56, 2010.
16. Chuang D-C: Functioning free-muscle transplantation for the upper extremity. *Hand Clin* 13(2):279–289, 1997.
17. Chuang D-C, Carver N, Wei F-C: A new strategy to prevent the sequelae of severe Volkmann's ischemia. *Plast Reconstr Surg* 98(6):1023–1031, 1996.
18. Chuang DC, Carver N, Wei FC: A new strategy to prevent the sequelae of severe Volkmann's ischemia. *Plast Reconstr Surg* 98(6):1023–1031, 1996.
19. Clay NR, Dent CM: Limitations of pulse oximetry to assess limb vascularity. *J Bone Joint Surg Br* 73(2):344, 1991.
20. Cole AL, Herman RA, Jr, Heimlich JB, et al: Ability of near infrared spectroscopy to measure oxygenation in isolated upper extremity muscle compartments. *J Hand Surg [Am]* 37(2):297–302, 2012.
21. Collinge C, Kuper M: Comparison of three methods for measuring intracompartmental pressure in injured limbs of trauma patients. *J Orthop Trauma* 24(6):364–368, 2010.
22. Dente CJ, Feliciano DV, Rozycki GS, et al: A review of upper extremity fasciotomies in a level I trauma center. *Am Surg* 70(12):1088–1093, 2004.
23. Deutinger M, Kuzbari R, Paternostro-Sluga T, et al: Donor-site morbidity of the gracilis flap. *Plast Reconstr Surg* 95(7):1240–1244, 1995.
24. Doi K, Sakai K, Ihara K, et al: Reinnervated free muscle transplantation for extremity reconstruction. *Plast Reconstr Surg* 91(5):872–883, 1993.

24a. Domanasiewicz A, et al: Modified Colzi method in the management of established Volkmann contracture—the experience of Trzebnica Limb Replantation Center (preliminary report). *Ortop Traumatol Rehabil* 10(1):12–25, 2008.

25. Duckworth AD, Mitchell SE, Molyneux SG, et al: Acute compartment syndrome of the forearm. *J Bone Joint Surg Am* 94(10):e63, 2012.
26. Ebraheim NA, Abdelgawad AA, Ebraheim MA, et al: Bedside fasciotomy under local anesthesia for acute compartment syndrome: a feasible and reliable procedure in selected cases. *J Orthop Traumatol* 13(3):153–157, 2012.
27. Eichler G, Lipscomb P: The changing treatment of Volkmann's ischemic contractures from 1955-1965 at the Mayo Clinic. *Clin Orthop Relat Res* 50:215–223, 1967.
28. Farber A, Tan TW, Hamburg NM, et al: Early fasciotomy in patients with extremity vascular injury is associated with decreased risk of adverse limb outcomes: a review of the National Trauma Data Bank. *Injury* 43(9):1486–1491, 2012.
29. Flynn J, Bashyal RK, Yeger-McKeever M, et al: Acute traumatic compartment syndrome of the leg in children: diagnosis and outcome. *J Bone Joint Surg Am* 93: 937–941, 2011.
30. Franz RW, Skytta CK, Shah KJ, et al: A five-year review of management of upper-extremity arterial injuries at an urban level I trauma center. *Ann Vasc Surg* 26(5): 655–664, 2012.
31. Garcia-Mata S: Chronic exertional compartment syndrome of the forearm in adolescents. *J Pediatr Orthop* 33(8):832–837, 2013.
32. Garfin SR, Mubarak SJ, Evans KL, et al: Quantification of intracompartmental pressure and volume under plaster casts. *J Bone Joint Surg Am* 63(3):449–453, 1981.
33. Garr JL, Gentilello LM, Cole PA, et al: Monitoring for compartmental syndrome using near-infrared spectroscopy: a noninvasive, continuous, transcutaneous monitoring technique. *J Trauma* 46(4):613–616, 1999.
34. Goldner J: Volkmann's ischemic contracture. In Flynn J, editor: *Hand surgery*, New York, 1975, Williams & Wilkins, pp 599–618.

34a. Gosset J: [Surgical desinsertion of the anterior long muscles of the forearm in the treatment of contractures and ischemic retraction]. *J Chir* 72(5):487–494, 1956.

35. Goubier J, Saillant G: Chronic compartment syndrome of the forearm in competitive motor cyclists: a report of two cases. *Br J Sports Med* 37:452–454, 2003.

35a. Griffiths D: Volkmann's ischaemic contracture. *Br J Surg* 28:239–260, 1940.

36. Grottkau B, Epps H, Di Scala C: Compartment syndrome in children and adolescents. *J Pediatr Surg* 40(4):678–682, 2005.
37. Gulgonen A: Invited Review Article: Surgery for Volkmann's ischaemic contracture. *J Hand Surg [Br]* 26(4):283–296, 2001.
38. Hammerberg EM, Whitesides TE, Jr, Seiler JG, 3rd: The reliability of measurement of tissue pressure in compartment syndrome. *J Orthop Trauma* 26(1):24–31, 2012.
39. Hargens A, Schmidt D, Evans K, et al: Quantitation of skeletal muscle necrosis in a model compartment syndrome. *J Bone Joint Surg Am* 63(4):631–636, 1981.
40. Harris C, Jr, Riordan DC: Intrinsic contracture in the hand and its surgical treatment. *J Bone Joint Surg Am* 36:10–18, 1954.

41. Harrison JW, Thomas P, Aster A, et al: Chronic exertional compartment syndrome of the forearm in elite rowers: a technique for mini-open fasciotomy and a report of six cases. *Hand* 8(4):450–453, 2013.
41a. Hill RL, Brooks B: Volkmann's ischemic contracture in hemophilia. *Ann Surg* 103(3):444–449, 1936.
41b. Holden C: Compartmental syndromes following trauma. *Clin Orthop Rel Res* 113:95–102, 1975.
42. Holden C: The pathology and prevention of Volkann's ischaemic contracture. *J Bone Joint Surg Br* 61(3):296–300, 1979.
43. Hope M, McQueen M: Acute compartment syndrome in the absence of fracture. *J Orthop Trauma* 18(4):220–224, 2004.
44. Hovius S, Ultee J: Volkmann's ischemic contracture. prevention and treatment. *Hand Clin* 16(4):647–657, 2000.
44a. Hwang R, Bas de Witte P, Ring D: Compartment syndrome associated with distal radial fracture and ipsilateral elbow injury. *J Bone Joint Surg Am* 91:642–645, 2009.
45. Ikuta Y, Kubo T, Tsuge K: Free muscle transplantation by microsurgical technique to treat severe Volkmann's contracture. *Plast Reconstr Surg* 58(4):407–411, 1976.
45a. Jepson P: Ischaemic contracture. Experimental study. *Ann Surg* 84(6):785–793, 1926.
46. Kalyani B, Fisher B, Roberts C, et al: Compartment syndrome of the forearm: a systematic review. *J Hand Surg [Am]* 36:535–543, 2011.
47. Kim DH, Han K, Tiel RL, et al: Surgical outcomes of 654 ulnar nerve lesions. *J Neurosurg* 98(5):993–1004, 2003.
48. Kim DH, Kam AC, Chandika P, et al: Surgical management and outcomes in patients with median nerve lesions. *J Neurosurg* 95(4):584–594, 2001.
49. Kozin S: *Supracondylar elbow fractures, in ASSH specialty day 2012. Make my day in hand surgery*, San Francisco, 2012, American Society for Surgery of the Hand.
50. Krimmer H, Hahn P, Lanz U: Free gracilis muscle transplantation for hand reconstruction. *Clin Orthop Relat Res* 314:13–18, 1995.
51. Kumar PR, Jenkins JP, Hodgson SP: Bilateral chronic exertional compartment syndrome of the dorsal part of the forearm: the role of magnetic resonance imaging in diagnosis: a case report. *J Bone Joint Surg Am* 85:1557–1559, 2003.
52. Lanz U, Felderhoff J: Ischaemische kontrakturen an unterarm und hand. *Handchir Mikrochir Plast Chir* 32:6–25, 2000.
53. Lee CH, Lee KH, Lee SH, et al: Chronic exertional compartment syndrome in adductor pollicis muscle: case report. *J Hand Surg [Am]* 37(11):2310–2312, 2012.
54. Littler JW: The finger extensor system. Some approaches to the correction of its disabilities. *Orthop Clin North Am* 17(3):483–492, 1986.
55. Liu XY, Ge BF, Win YM, et al: Free medial gastrocnemius myocutaneous flap transfer with neurovascular anastomosis to treat Volkmann's contracture of the forearm. *Br J Plast Surg* 45(1):6–8, 1992.
55a. Manktelow R, McKee N: Free muscle transplantation to provide active finger flexion. *J Hand Surg [Am]* 3(5):416–426, 1978.
55b. Manktelow R, Zucker R: The principles of functioning muscle transplantation: applications to the upper arm. *Ann Plast Surg* 22(4):275–282, 1989.
56. Mars M, Hadley GP: Failure of pulse oximetry in the assessment of raised limb intracompartmental pressure. *Injury* 25(6):379–381, 1994.
57. Matsen FA, 3rd: Compartmental syndrome. A unified concept. *Clin Orthop Relat Res* 113:8–14, 1975.
58. McQueen M, Gaston P, Court-Brown C: Acute compartment syndrome. Who is at risk? *J Bone Joint Surg Br* 82:200–203, 2000.
59. Mubarak SJ, Carroll NC: Volkmann's contracture in children: aetiology and prevention. *J Bone Joint Surg Br* 61:285–293, 1979.
60. Murovic JA: Upper-extremity peripheral nerve injuries: a Louisiana State University Health Sciences Center literature review with comparison of the operative outcomes of 1837 Louisiana State University Health Sciences Center median, radial, and ulnar nerve lesions. *Neurosurgery* 65(4 Suppl):89, 2009.
61. Nisbet NW: Volkmann's ischaemic contracture benefited by muscle slide operation. *J Bone Joint Surg Br* 34(2):245–247, 1952.
62. Oredsson S, Plate G, Qvarfordt P: The effect of mannitol on reperfusion injury and postischaemic compartment pressure in skeletal muscle. *Eur J Vasc Surg* 8(3):326–331, 1994.
63. Ouellette E, Kelly R: Compartment syndromes of the hand. *J Bone Joint Surg Am* 78(10):1515–1522, 1996.
64. Page C: An operation for the relief of flexion-contracture in the forearm. *J Bone Joint Surg Am* 3:233–234, 1923.
64a. Pavanini G, Volpe A: [Diaphysary resection using Colzi's method in the treatment of Volkmann's syndrome]. *Clin Ortop* 26:287–292, 1975.
65. Prasarn ML, Ouellette EA: Acute compartment syndrome of the upper extremity. *J Am Acad Orthop Surg* 19(1):49–58, 2011.
66. Ragland RI, Moukoko D, Ezaki M, et al: Forearm compartment syndrome in the newborn: report of 24 cases. *J Hand Surg [Am]* 30(5):997–1003, 2005.
67. Reigstad A, Hellum C: Volkmann's ischaemic contracture of the forearm. *Injury* 12(2):148–150, 1981.
68. Rolands R, Lond M: A case of Volkmann's contracture treated by shortening of the radius and ulna. *Lancet* 2:1168–1171, 1905.
69. Ronel D, Mtui E, Nolan W, III: Forearm compartment syndrome: analysis of surgical approaches to the deep space. *Plast Reconstr Surg* 114(3):697–705, 2004.
70. Royle SG: Compartment syndrome following forearm fracture in children. *Injury* 21(2):73–76, 1990.
71. Russell RC, Pribaz J, Zook EG, et al: Functional evaluation of latissimus dorsi donor site. *Plast Reconstr Surg* 78(3):336–344, 1986.
72. Scaglietti O: Chirurgische behandlung der volkmannschen paralyse. *Verh Dtsch Orthop Ges* 45:219, 1957.
73. Seddon H: Volkmann's ischaemia. *Br Med J* 1(5398):1587–1592, 1964.
74. Seddon HJ: Volkmann's contracture: treatment by excision of the infarct. *J Bone Joint Surg Br* 38:152–174, 1956.
75. Sharma P, Swamy MK: Results of the Max Page muscle sliding operation for the treatment of Volkmann's ischemic contracture of the forearm. *J Orthop Traumatol* 13(4):189–196, 2012.
76. Simpson NS, Jupiter JB: Delayed onset of forearm compartment syndrome: a complication of distal radius fracture in young adults. *J Orthop Trauma* 9(5):411–418, 1995.
77. Smith RJ: Balance and kinetics of the fingers under normal and pathological conditions. *Clin Orthop Relat Res* 104:92–111, 1974.
78. Soderberg TA: Bilateral chronic compartment syndrome in the forearm and the hand. *J Bone Joint Surg Br* 78(5):780–782, 1996.
79. Staudt JM, Smeulders MJ, van der Horst CM: Normal compartment pressures of the lower leg in children. *J Bone Joint Surg Br* 90(2):215–219, 2008.
80. Steinmann SP, Bishop AT: Chronic anconeus compartment syndrome: A case report. *J Hand Surg [Am]* 25(5):959–961, 2000.
81. Summerfield SL, Folberg CR, Weiss AP: Compartment syndrome of the pronator quadratus: a case report. *J Hand Surg [Am]* 22(2):266–268, 1997.
82. Sundararaj GD, Mani K: Management of Volkmann's ischaemic contracture of the upper limb. *J Hand Surg [Br]* 10(3):401–403, 1985.
83. Tan TW, Joglar FL, Hamburg NM, et al: Limb outcome and mortality in lower and upper extremity arterial injury: a comparison using the National Trauma Data Bank. *Vasc Endovascular Surg* 45(7):592–597, 2011.
84. Tiidus PM: Is intramuscular pressure a valid diagnostic criterion for chronic exertional compartment syndrome? *Clin J Sport Med* 24(1):87–88, 2014.
85. Tsuge K: Treatment of established Volkmann's contracture. *J Bone Joint Surg Am* 57(7):925–929, 1975.
86. Tsuge K: Management of established Volkmann's contracture. In Green D, editor: *Green's operative hand surgery*, ed 4, Philadelphia, 1999, Churchill Livingstone, pp 592–603.
87. Ultee J, Hovius SE: Functional results after treatment of Volkmann's ischemic contracture: a long-term followup study. *Clin Orthop Relat Res* 431:42–49, 2005.
87a. Volkmann R: Die ischaemischen muskellaehmungen und kontrakturen. *Centrabl f Chir* 51:801, 1881.
88. Waterman BR, Laughlin M, Kilcoyne K, et al: Surgical treatment of chronic exertional compartment syndrome of the leg: failure rates and postoperative disability in an active patient population. *J Bone Joint Surg Am* 95(7):592–596, 2013.
89. Whitesides T, Haney T, Mounoto K: Tissue pressure measurments as a determinant for the need of fasciotomy. *Clin Orthop Relat Res* 113:43, 1975.
90. Wilder R, Magrum E: Exertional compartment syndrome. *Clin Sports Med* 29:429–435, 2010.
91. Winkes MB, Luiten EJ, van Zoest WJ, et al: Long-term results of surgical decompression of chronic exertional compartment syndrome of the forearm in motocross racers. *Am J Sports Med* 40(2):452–458, 2012.
92. Xing-yan L, Bao-feng G, Yi-Min W, et al: Free medial gasrocnemius myocutaneous flap transfer with neurovascular anastomosis to treat Volkmann's contracture of the forearm. *Br J Plast Surg* 45:6–8, 1992.
93. Yuan P, Pring M, Gaynor T, et al: Compartment syndrome following intramedullary fixation of pediatric forearm fractures. *J Pediatr Orthop* 24(4):370–375, 2004.
94. Zancolli E: Classification of established Volkmann's ischemic contracture and the program for its treatment. In Zancolli E, editor: *Structural and dynamic bases of hand surgery*, Philadelphia, 1979, JB Lippincott.
95. Zuker R, Egerszegi E, Manktelow R, et al: Volkmann's ischemic contracture in children: the results of free vascularized muscle transplantation. *Microsurgery* 12:341–345, 1991.
96. Zuker RM: Volkmann's ischemic contracture. *Clin Plast Surg* 16(3):537–545, 1989.
97. Zuker RM, Bezuhly M, Manktelow RT: Selective fascicular coaptation of free functioning gracilis transfer for restoration of independent thumb and finger flexion following Volkmann ischemic contracture. *J Reconstr Microsurg* 27(7):439–444, 2011.
98. Zuker RM, Manktelow RT: Functioning free muscle transfers. *Hand Clin* 23(1):57–72, 2007.

52

Management of Venomous Injuries

Vidal Haddad, Jr., and Trajano Sardenberg

Many venomous animals can cause injuries to humans. The injuries are induced by substances called toxins that are produced or stored in the body of these animals and inoculated (i.e., injected) into victims by their venom apparatus, as seen in snakes, spiders, and scorpions.[3,9,11] Toxins can also cause lesions from contact when the animal is handled or crushed, as happens with some species of beetles.[9,26,40] In this situation, they are called poisonous animals, as they do not cause active envenomation.

Toxins can interact and cause lesions in the tissues, organs, and systems of other animals. The mixture of toxins in a venomous animal represents its venom, and venomous animals use the toxins or venom as a defense against predators and to obtain food. The effects are variable, but mainly the blood, nervous system, and tissue at the inoculation site are affected (e.g., hemolytic, neurotoxic, and necrotic effects). Some envenomations cause minimal local manifestations because of their mainly neurotoxic and hemolytic actions. However, coagulant/anticoagulant and proteolytic venom fractions can cause severe necrosis, which facilitates significant secondary bacterial infection. Such lesions can be classified into two types according to the depth of action: (1) surface (or cutaneous) lesions are the result of contact with irritating substances from certain invertebrate species, whereas (2) inoculation lesions occur when venom is injected deep into the dermis and subcutaneous tissue and causes variable degrees of skin necrosis. Some necroses are superficial, as with cnidarians (jellyfish), whereas others are deep and severe, as caused by snakes and some spiders.[3]

Many conditions can lead to human envenomation in the extremities, especially in the lower and upper limbs. One profile for bites by snakes includes male farmers working outside without foot or leg protection. Envenomation often occurs in the hands because of their exploratory function, especially in children. Adult hand injuries occur mainly to farmers and fishermen as a result of the characteristics of their work. Academically, hand envenomation can also be characterized according to animal groups, but the groups will always possess venom with coagulant and proteolytic actions that cause superficial or deep tissue necrosis.

THE MAIN GROUPS OF VENOMOUS ANIMALS ASSOCIATED WITH HAND ENVENOMATION WITH LOCAL MANIFESTATIONS

Caterpillars

Envenomation by caterpillars is the most common of all injuries by venomous animals around the world. Caterpillars of the Saturniidae and Megalopygidae families cause the majority of injuries, and their hollow bristles contain toxins capable of provoking intense pain and a mild inflammatory reaction at the point of contact (Figure 52.1).[6,9,19,26] As a rule, the pain is out of proportion to the mild erythema and edema observed. Occasionally, local superficial necrosis occurs. The injury can be treated by a regional anesthetic block to control the pain. There are no later sequelae as a result of this type of envenomation.

Spiders

Most spider bites cause minimal local and systemic effects in humans, with variable pain intensity and healing without sequelae; the only treatment necessary for these injuries is analgesia and hygienic measures at the bite site.[35,37,52,58,60] Spider bites that cause systemic complications and risk to life, such as in bites by *Latrodectus* (the black widow), *Atrax* (the funnel web spider), and *Phoneutria* (the banana spider), do not cause significant manifestations at the bite site. A spider associated with severe local effects, including marked tissue necrosis, is the cosmopolitan brown "recluse" spider (genus *Loxosceles*) that lives in some regions of Africa; the North, Central, and South Americas; Australia; and some places in Asia and Europe.[14,19,33,36,45,61,63–65] *Loxosceles* spiders often live in home environments, mainly in dark places, and can bite when crushed against a victim's body. The incidence of arm and hand spider bites is about 15% to30%, and they can cause severe functional problems and long periods of incapacity; these are important injuries that specialists in upper-extremity surgery should become familiar with.[12,34,42,45,57]

Brown recluse spider venom is a mix of proteins. The most important fraction is sphingomyelinase D, which causes skin necrosis, vasculitis, and hemolysis.[14,15,19,33,36,45,47,61,62,63,65] There are two classic manifestations: cutaneous loxoscelism and viscerocutaneous loxoscelism. The initial bite may be minimally painful and go unnoticed. In 2 to 6 h a burning pain arises along with local erythema and blanching of the skin with eventual cyanosis and edema. Occasionally, hemorrhagic blisters develop. In 3 to 7 days necrosis is evident (Figure 52.2).[7,9,10,14,26,38,41,44,55,56] If skin lesions are absent after 2 to 3 days, soft tissue necrosis is unlikely.[33,55] Systemic alterations, if they occur, will be present within 24 to 72 h after the bite and include fever, arthralgias, vomiting, hemolysis, petechiae, and urticaria, with disseminated intravascular coagulation and renal failure being at the severe end of the spectrum.[10,33,44,52,55]

The gold standard for diagnosis is capture and identification of the spider, a situation that rarely occurs and unfortunately leaves clinical diagnosis as the most important method.[7,9,10,14,18,26,38,41,44,48,49,55,56,66] We must remember that the

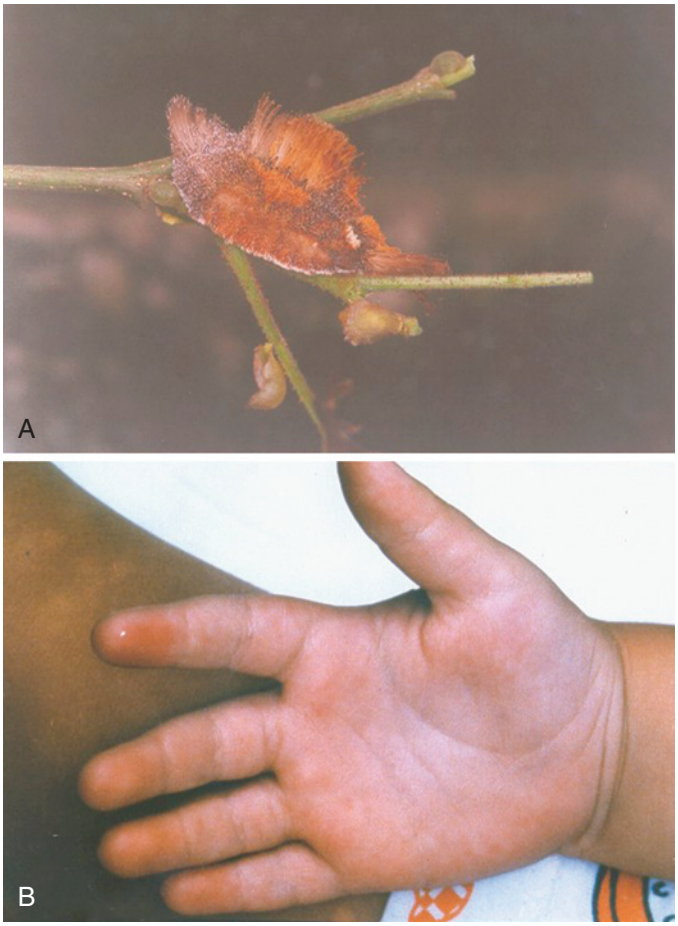

FIGURE 52.1 Caterpillar of the Megalopygidae family **(A)** and injuries in a child **(B)**. The pain was intense, but local inflammation was discrete. (Photographs courtesy of Vidal Haddad, Jr.)



FIGURE 52.2 **A,** *Loxosceles,* the brown recluse spider. **B,** The venom of this spider has a potent necrotic effect. Considerable necrosis occurred in the fifth finger of a woman after a brown spider bite (she saw the spider). (**A,** Photograph courtesy of Vidal Haddad, Jr.; **B,** photograph courtesy of Dr. Jefferson Braga Silva, Brazil.)

clinical appearance of the necrotic injury in the skin is not specific to the bite of spiders and may be caused by several medical conditions, such as erysipelas, cellulitis, necrotizing fasciitis, and fungal and bacterial infections, as well as other animal envenomations.[8,10,67] Serologic diagnosis is currently in the experimental stage.[20,39,59]

There is no standard treatment for spider bites.[17,54,60] Skin integrity should be maintained to prevent infection and local circulation preserved,[54] specifically with hand lesions, to maintain articular mobility and skin sensitivity. The initial phases of treatment should include rest, cold packs, elevation of the limb, intensive cleaning, tetanus prophylaxis, systemic analgesics, and gentle passive and active articular mobilization.[55,60] Moderate or severe bites (with significant necrosis) are treated with antibiotics (e.g., dapsone), corticosteroids, surgical excision, and antivenin.[10,33,51,60,61] Dapsone is an antibiotic from the sulfone group with antimicrobial and antiinflammatory properties; it is commonly used for leprosy and many inflammatory skin diseases.[69,72] Use of dapsone is based on its capacity to block the diapedesis of neutrophils. Dapsone is used in later phases (48 h after envenomation) and the recommended dose is 100 to 300 mg/d.[69] There are no conclusive studies of the efficacy of dapsone or corticosteroids for spider bites, however.[5,7,9,10,14,16,26,38,41,44,55,56,70] Antibiotics are only used in the presence of secondary infection of necrotic lesions.

Antivenin is routinely used in Brazil, and studies have shown that it can prevent necrosis when used in the first 12 h after envenomation.[33,44,55] Unfortunately, this medication is not presently available in the United States. Surgical treatment includes debridement and excision of necrotic tissue and coverage with grafts or flaps once viable tissue is reached. The question involves the time to initiate intervention because necrosis can be active for up to 2 to 8 weeks after the bite. Rees and coauthors reported that late surgery gave better results in their study series.[53] Clinical experience indicates that management consisting of debridement, hygiene measures, and waiting for stabilization of the tissue necrosis is prudent initial treatment.[4,10,17,33,53,55,61,68,71]

Snakes

The most important envenomations by snakes are from the Elapidae and Viperidae families. Bites by the Elapidae family cause discrete skin manifestations, mainly as a result of their neurotoxic and myolytic effects. The snakes include the African and Asian cobras, the African green and black mambas, the American coral snake, the Australian Elapidae snakes, the taipans, and brown snakes. Envenomation can be very severe, and patients sustaining significant envenomation should be identified early. The typical facial symptom is called "drunken face" because of eyelid ptosis, and this should not be confused with other situations such as myasthenia gravis or alcoholic intoxication. Muscular paralysis is the main clinical effect of the bites.



FIGURE 52.3 **A,** *Crotalus durissus*, the South American rattlesnake of the Viperidae family. The venom is mainly neurotoxic, but it can cause skin necrosis. **B,** The Viperidae rattlesnake family causes extremely severe necrosis of the skin and deep structures in humans. This snake is a spotted jararaca (*Bothrops matogrossensis*). (Photographs courtesy of Vidal Haddad, Jr.)



FIGURE 52.4 Edema and erythema are the early signs after the bite of a Viperidae snake. The edema is sometimes so pronounced that it causes compression and ischemia in hand structures. (Photograph courtesy of João Luiz Costa Cardoso, Butantan Institute, São Paulo, Brazil.)

Envenomation by the Viperidae induces necrosis of the skin and deep structures. Snakes in this family are found around the world; the most common associated with human bites are the European and Asiatic vipers and the African vipers such as the Gaboon viper (*Bitis gabonica*), the puff adder (*Bitis arietans*), and the saw-scaled viper (*Echis carinatus*). In the New World, necrotic and inflammatory lesions can be associated with *Lachesis* (bushmasters) and *Agkistrodon* (the North American cottonmouth and copperhead), but mainly with snakes of the *Crotalus* (rattlesnakes) and *Bothrops* genera, which are very common in Central and South America (Figure 52.3). The venom of all these snakes can induce intense inflammation, edema, and necrosis at the bite site (Figure 52.4).[8,9,26,50]

The intensity of the necrosis caused by envenomation is variable and modulated by the capacity of the venom fractions to destroy tissue. Bites inoculate venom into subcutaneous tissue or muscle, and bite marks may be invisible. Edema at the site of injury occurs very early and can be extremely intense; pain is proportional to the edema. When present, the coagulant and anticoagulant factors in venom cause local and systemic effects, and they can affect systemic coagulation and induce hemorrhage. Skin blisters are common (Figure 52.5).

Large areas of necrosis and inflammation can simulate erysipelas and cellulitis. These findings can also occur in the presence of a secondary bacterial infection, a common complication

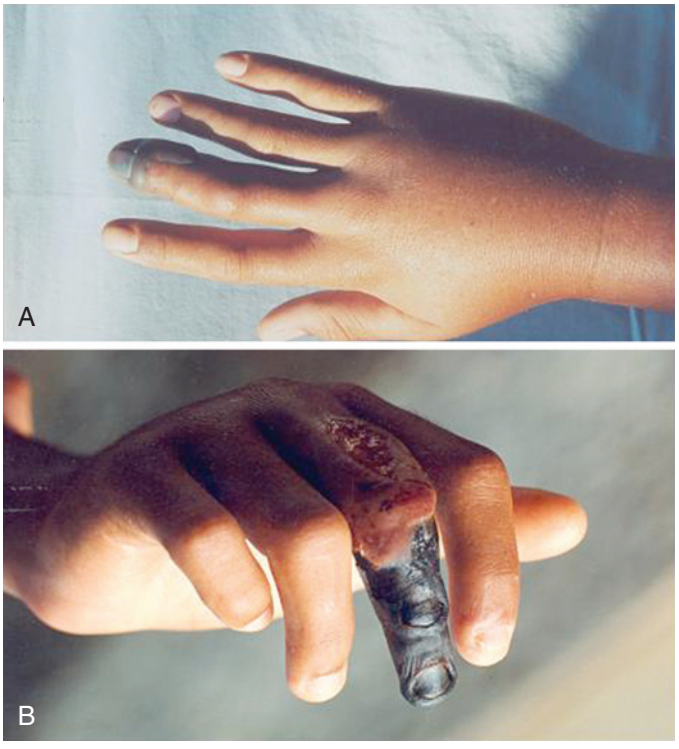

FIGURE 52.5 **A,** Hemorrhagic bullae and edema with necrosis are common complications of Viperidae bites. The ischemia and necrosis can be severe. **B,** Snakebites in the extremities are potentially severe because of their terminal circulation. Necrosis and amputation of the fingers can occur, especially in patients who do not begin treatment soon enough. (Photographs courtesy of João Luiz Costa Cardoso, Butantan Institute, São Paulo, Brazil.)



FIGURE 52.6 The severe inflammation and necrosis in this patient was aggravated by secondary bacterial infection. There is risk for compartment syndrome. (Photograph courtesy of João Luiz Costa Cardoso, Butantan Institute, São Paulo, Brazil.)

in envenomations that leads to extension of necrosis and ulcers at the bite site (Figure 52.6). Abscess formation can be seen at the bite site as well and is usually caused by gram-negative and anaerobic bacilli. Occasionally, amputation of the compromised extremity is necessary because of necrosis and infection. This is common in fingers and is due to the compromise of their circulation, and the necrosis can extend proximally to muscles, tendons, and bones.[8,50]

A rare but very severe complication is compartment syndrome, which is an increase in pressure in a closed compartment that results in abnormal neuromuscular function because of compression of muscles, nerves, and vessels. This syndrome is a result of necrosis and inflammation and is most commonly found in the fingers, legs, and dorsal and ventral regions of the forearm. The most valuable signs and symptoms to help in the diagnosis of compartment syndrome is pain that is not proportional to the edema and limitations in neuromuscular action. The gold standard in the United States for evaluation of this syndrome is measurement of compartment pressure. Systemic hypotension may be present in patients with normal peripheral pulses. Treatment of compartment syndrome consists of fasciotomy, which is more effective when performed early.

Antivenin (specific for various genera) is the only worthwhile treatment, but it has little effect on local complications. The primary antivenin used in the United States today is CroFab®, a sheep-derived antivenin that was approved for use by the U.S. Food and Drug Administration in October 2000 and is marketed by Savage Laboratories. It consists of purified Fab immunoglobulin fragments obtained from sheep immunized with the venom of the western diamondback, eastern diamondback, and Mojave rattlesnakes and the cottonmouth or water moccasin.

❖ AUTHORS' PREFERRED METHOD OF TREATMENT OF SNAKEBITE

Pit viper bites differ from other compartment syndromes in that the venom is injected directly into the skin and subcutaneous tissue with immediate resultant tissue edema, ecchymosis, and rapid swelling. The venom may or may not be injected into a closed compartment, but it usually is. The severe swelling of the skin and soft tissues outside a compartment can be of such a degree that the circulation will be impaired, particularly with bites on the digits of the hand. When a snakebite victim in whom the tissues of the envenomated extremity have the appearance of an impaired blood supply or compartment syndrome, or both, is first seen, the patient is prepared for surgery. This is regardless of whether antivenin was or is being administered; however, surgery is started only after blood coagulation studies have been completed.

The skin and subcutaneous swelling can be so great that the blood supply is impaired, which may result in subsequent tissue loss. If such swelling is noted, fasciotomy of the underlying compartment as described earlier is done at the same time, without measuring compartment pressures. If the swelling is severe enough to necessitate a dermotomy, the fascia has been penetrated and intracompartmental swelling is present. Failure to release skin that is too tight and is compromising local blood flow can lead to significant tissue loss in the hand, which may necessitate later replacement. Local tissue necrosis at the site of the fang marks is debrided, but no other debridement is done at this time.

If after a snakebite no clinical evidence of impending tissue loss secondary to severe swelling exists and there is no clinical evidence of a compartment syndrome, no surgery is performed. As emphasized previously, the pain and degree of swelling after a pit viper bite can make the clinical diagnosis of compartment syndrome a difficult one and may necessitate continuous intracompartmental pressure monitoring. The guidelines for decompression of the soft tissues outside a compartment are nebulous and based on past experience; however, the question of whether a closed compartment needs to be opened should be settled by measuring compartment pressure.

Cnidarians (Jellyfish, Portuguese Man o' War, Anemones, Corals)

These marine animals have a round structure with several tentacles that have defensive cells called *cnidoblasts*; they contain nematocysts—the organelles that can fire a thin tube filled with neurotoxic and necrotizing venom (Figure 52.7). One tentacle has millions of these small structures and can cause significant envenomation in humans. A typical sting from a cnidarian causes immediate intense pain on contact with the animal, even

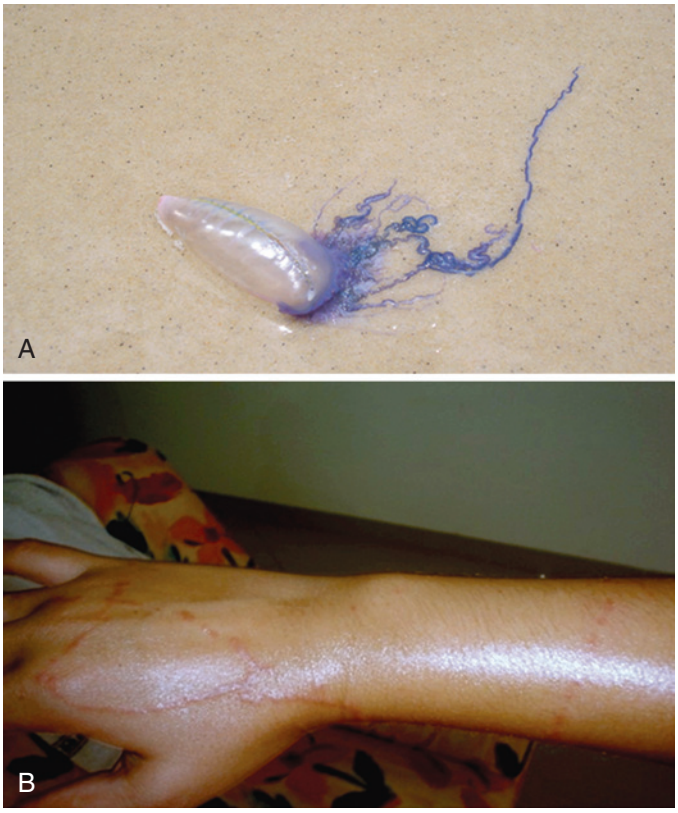

FIGURE 52.7 **A,** The Portuguese man o' war (PMW; *Physalia phisalis*) is a cnidarian that causes human injuries all around the world. **B,** Typical lesions caused by PMW. The superficial necrosis has linear aspect, like rosary beads. The pain is very severe and lesions occur soon after contact, even when the patient is still in the water. (**A,** Courtesy of Ana M. de Cerqueira, Rio de Janeiro, Brazil; **B,** courtesy of Lucia Fransozo, São Paulo State, Brazil).

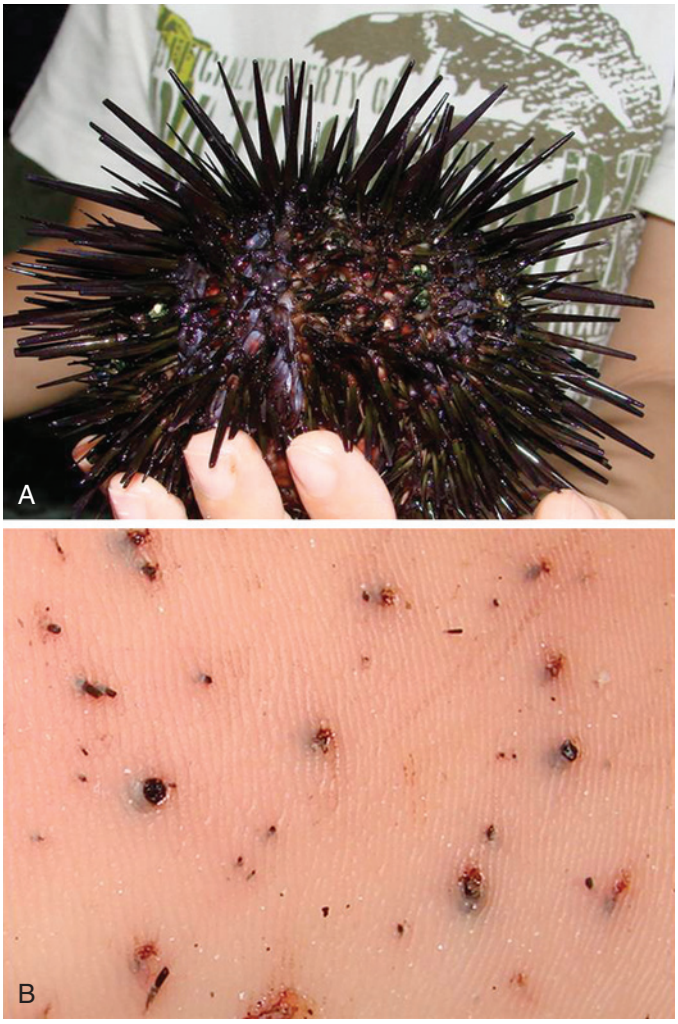

FIGURE 52.8 Black sea urchin **(A)** and spines in the skin of a victim **(B)**. Early extraction of the spines is very important to prevent complications such as bacterial infections and foreign body granulomas.

while in the water. There is also the instant appearance of erythematous crossing linear plaques reproducing the shape of the tentacles.[9,22–24,26,27,32] These lesions can become vesiculobullous. There are reports of vascular spasm and digit necrosis after unidentified jellyfish stings.[13]

Jellyfish "burn" (an incorrect term because it is not a real burn but an envenomation) should be treated at the time of the incident with ice-water compresses (avoid freshwater, which triggers more nematocysts by osmosis) and bathed with vinegar hopefully to stabilize nematocyst firing. In the hospital, analgesia is important for pain control.[9,22–24,26,27,32]

Sea Urchins

Sea urchins and some species of starfish can cause lesions in humans from their spines. The body spines are composed of calcium carbonate and can be venomous.[46] Spines left in the wound can provoke a foreign body reaction and bacterial infection.[31] Therefore, early spine extraction through an elliptical incision at the point of contact (spines are visible in most situations) is very important. The use of hot water has been described, as has hot candle wax, vinegar, and urine; however, these are only measures for controlling the pain from injuries caused by venomous sea urchins. In most cases the problem is resolved by early spine extraction or later extraction in the presence of a foreign body reaction (Figure 52.8). The recommended action is total spine extraction with large-caliber needles[31] or through an elliptical incision under magnification.

Venomous Fish

The severe pharmacologic action of all fish venoms is similar: intense pain as a result of neurotoxicity together with variable skin necrosis, depending on venom intensity and the common secondary infection. The most venomous fish include the Scorpaenidae family: the stonefish (*Synanceia* genus), the scorpionfish (*Scorpaena* genus), and the lionfish (*Pterois* genus) (Figure 52.9). Marine and freshwater stingrays and catfish are important venomous fish as well.[9,23,25–30,50]

Hand envenomation from marine and freshwater catfish is common, and bacterial infections and retention of stinger fragments can lead to severe complications, such as osteomyelitis, and the need for ray amputation (Figures 52.10 and 52.11; Case Study 52.1). The most common organisms causing these infections are *Edwardsiella tarda*, *Vibrio* species, and *Aeromonas hydrophila*. Antibiotics recommended for the initial phases of



FIGURE 52.9 **A,** The lionfish is a fish of the Scorpaenidae family and is the most venomous fish in the world. Even so, it is sold as an aquarium fish worldwide, increasing the risk for serious accidents. **B,** Note the edema and erythema caused by a puncture from the dorsal fin ray of a lionfish. The pain is very severe, and there are no specific measures for treating this kind of injury. (Photographs courtesy of Vidal Haddad, Jr.)



FIGURE 52.11 **A,** Early laceration in the hand of an amateur fisherman caused by a catfish. The pain was excruciating and persisted for about 24 h. **B,** Radiologic examination of the patient's hand showing a common complication from catfish injury: a broken stinger fragment. Apart from envenomation, a fragment in the wound can cause additional inflammation and secondary infections. (Photographs courtesy of Vidal Haddad, Jr.)



FIGURE 52.10 Marine and freshwater catfish have three serrated stingers that can cause perforations, lacerations, and inflammatory phenomena in humans. It is not uncommon to find secondary infections and broken stingers in wounds. (Photograph courtesy of Vidal Haddad, Jr.)

envenomation are aminoglycosides or ciprofloxacin, but aggressive debridement is the most effective measure when infection is already established.[2,21,29,43]

Stingrays cause severe envenomation by puncturing the victim with their bony caudal stinger or stingers and introducing venom. The pain is intense, and necrosis tends to become established within 24 h after injury. Initial management consists of submersion of the affected part in hot water (104°F), which denatures the proteins in the venom. Pain will recur if the extremity is removed from the water too soon. Care must be taken to make sure that the water is not too hot and that the limb is not left in too long to avoid burns. If the wound persists, ulcers can be extensive and are slow to heal (Figure 52.12).

Injury by stingrays can be confused with various diseases that cause ulcers in the lower limbs, such as a tropical ulcer, pyoderma gangrenosum, sickle cell anemia, and ulcers associated with venous stasis and bullous erysipelas. Nonvenomous fish can cause severe trauma, including lacerations and bacterial infections. Sharks, barracudas, and moray eels can inflict this kind of hand injury (Figure 52.13).

Immersing the compromised part in tolerably hot water is important in the initial phase of any venomous fish incident; this causes vasodilation and counteracts the vasoconstriction provoked by the venom.[1] Resulting tissue necrosis may well lead to the need for coverage with surgical flaps or skin grafting.

CASE STUDY 52.1

A female, 42 years old, was wounded in the third finger of the right hand by a catfish (see eFigure 52.1) when she was taking the fish off the hook. The patient presented intense pain, edema, and erythema for almost 6 hours. She used alcohol on the wound without relief of the pain. After three days, there were still local erythema and edema (see eFigure 52.2), without fever or purulent discharge in the orifice of entry of the sting.

Points of discussion include:

- Absence of infection (which is very common): without fever or malaise.
- Edema and erythema without pain: absence of envenomation (lasts about 1 day).
- Is there a foreign body?

After viewing eFigure 52.3, what is your option of treatment in this case?

a. Antibiotic therapy
b. Immersion in hot water
c. Surgical intervention
d. Observation

ANS: c, Surgical intervention

Now see eFigure 52.4. Injuries by catfish are the most common envenomation caused by fish in marine or freshwater environments (about 80%). Initially: intense pain is caused by the venom. Treatment: hot water (vasodilatation). Complications: bacterial and fungal infections and retention of fragments of the stinger; it should receive the attention of a hand surgeon.



eFIGURE 52.1 Marine catfish. Note the three stingers (1 dorsal and 2 pectoral). (Photographs courtesy of Vidal Haddad, Jr.)

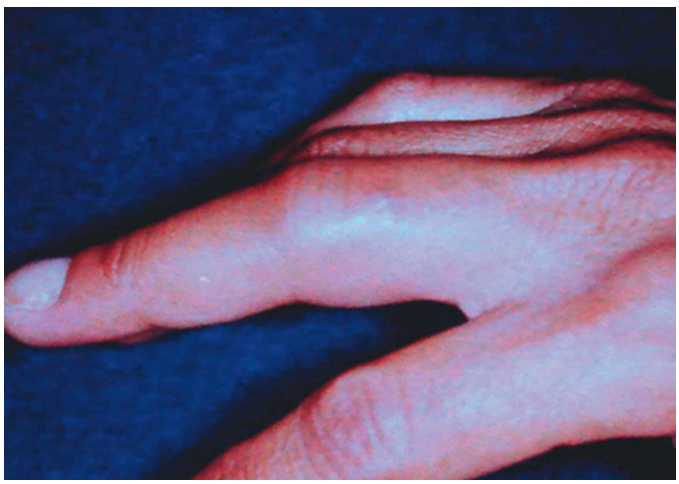

eFIGURE 52.2 The case patient: nodule and inflammation after 3 days. (Photographs courtesy of Vidal Haddad, Jr.)

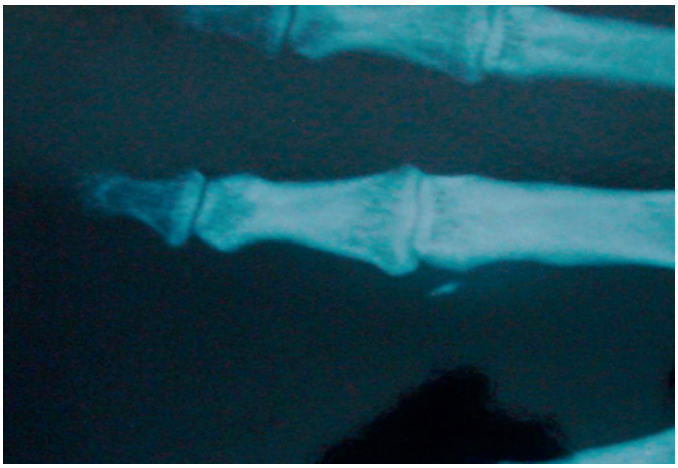

eFIGURE 52.3 Radiological exam: fragment of the stinger. (Photographs courtesy of Vidal Haddad, Jr.)

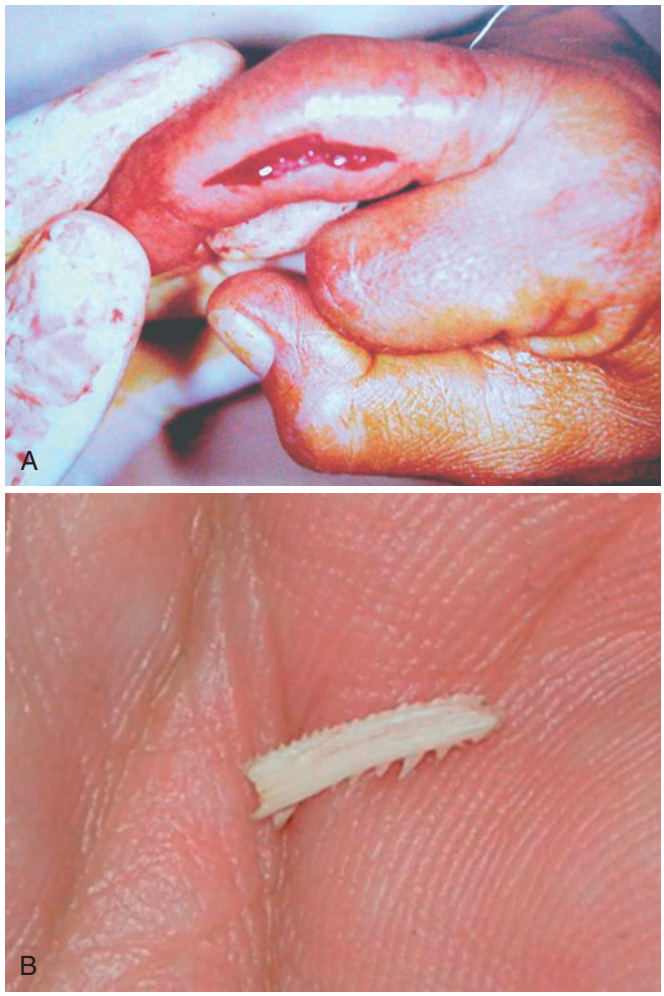

eFIGURE 52.4 **A,** Extraction of the fragment by surgical intervention. **B,** Detail of the fragment of the stinger. (Photographs courtesy of Vidal Haddad, Jr.)



FIGURE 52.12 Laceration in a fisherman's hand (at 30 days) caused by the sting of a marine stingray. Note the mild necrosis. In the initial phase, pain and edema were intense. *Right,* A marine stingray (*Rhinoptera bonasus*) associated with envenomation in fishermen. (Photographs courtesy of Vidal Haddad, Jr.)

CRITICAL POINTS *Venomous Injuries of the Hand*

General
- Envenomation often occurs in the hands because of their exploratory function, especially in children.
- There are no significant sequelae from the majority of envenomations by animals such as caterpillars, bees, jellyfish, and others.

Spiders
- Brown recluse spider bites can cause skin necrosis.
- Initial treatment should include rest, cold packs, elevation of the limb, intensive cleaning, tetanus prophylaxis, systemic analgesics, and gently passive and active articular mobilization.
- Moderate and severe bites are treated with antibiotics (e.g., dapsone) and corticosteroids and often surgical excision.
- The skin necrosis can be active for up to 2 to 8 weeks after the bite; extensive debridement, or flaps or skin grafting (or both) should be delayed until after week 6 to 8 of the necrosis.

Snakes
- Envenomation by snakes of the Viperidae family causes skin and deep necrosis.
- The tissue necrosis is variable and modulated by the capacity of the venom fractions to destroy tissue; the necrosis can extend to muscles, tendons, and bones.
- Large areas of necrosis and inflammation can occur, as well as abscesses caused by gram-negative and anaerobic bacilli.
- Amputation of the compromised part may be necessary as a result of necrosis and infection, especially in fingers because of poor terminal circulation.
- Antivenin (specific for various genera) is the only worthwhile treatment, but it has little effect on local complications.
- A rare but very severe complication is compartment syndrome. Treatment is by fasciotomy, which should be done early.

Cnidarians (Jellyfish)
- Treatment at time of the accident includes water compresses and bathing the part with vinegar, which may stabilize nematocyst firing.
- Avoid freshwater, which triggers more nematocysts by osmosis.

Sea Urchins
- The spines must be extracted early to prevent inflammation and infection at the puncture sites, especially to prevent foreign-body granulomas, which must be extracted by surgery.

Venomous Fish
- Immersing the compromised part in extremely, but tolerably, hot water (104°F) is important in the initial phase of any venomous fish incident; this causes vasodilation and counteracts the vasoconstriction induced by the venom.
- Chronic ulcers are candidates for surgical flaps or skin grafting.
- Bacterial infections and retention of stinger fragments are common and can cause severe complications such as osteomyelitis.

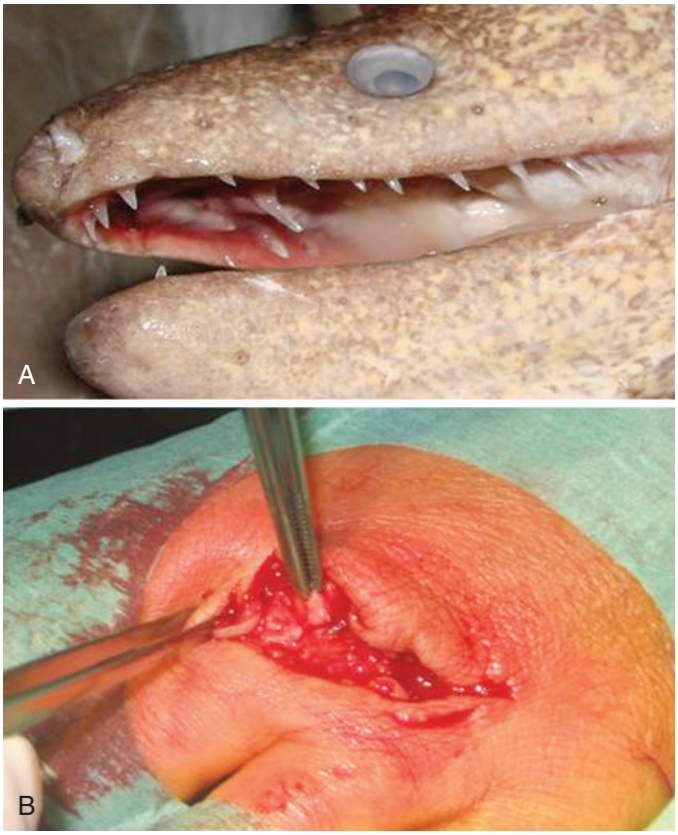

FIGURE 52.13 **A,** *Muraena helena*, a species of moray eel associated with human injuries. They are not aggressive but can occasionally bite. **B,** The lesions caused by moray eels lacerate and result in tissue loss. There is current evidence that their saliva contains toxins associated with the disproportionate pain observed in patients after bites. (**A,** Courtesy of Vidal Haddad, Jr.; **B,** courtesy of João Pedro Barreiros, Azores, Portugal.)

EXPECTED OUTCOMES

- There are no later problems from the majority of envenomations by animals. In this category we can include caterpillars, bees, jellyfish, and others.
- The question about the treatment of brown spider bites involves the time of intervention because necrosis can be active for up to 2 to 8 weeks after the bite. Late surgery gave better results in one series.
- The intensity of necrosis after envenomation by snakebites is variable and modulated by the capacity of the venom fractions to destroy tissue. Extensive necrosis and inflammation can simulate erysipelas and cellulitis and can even be present when secondary bacterial infection occurs; this is a common complication in envenomation that leads to extension of the necrosis and ulcers at the bite site. Abscess formation can be seen at the bite site and is caused by gram-negative and anaerobic bacilli. Occasionally, amputation of the compromised part is necessary as a result of necrosis and infection. This is common for fingers because of their terminal circulation. The necrosis can extend to muscles, tendons, and bones.
- In most cases of injury caused by sea urchin spines, the problem is early spine extraction or late extraction in the presence of nodules caused by reaction to a foreign body.
- Hand envenomation by marine and freshwater catfish is common, and bacterial infections and retention of stinger fragments can cause severe complications, such as osteomyelitis, and the need for ray amputation.

For Case Studies, Videos, and more, please visit ExpertConsult.com.

REFERENCES

1. Atkinson PRT, Boyle A, Hartin D, et al: *Is hot water an effective treatment for marine envenomation?* Clinical evidence. Available at: emj.bmj.com.
2. Baack BR, Kucan JO, Zook EG, et al: Hand infections secondary to catfish spines: case reports and literature review. *J Trauma* 31:1432–1436, 1991.
3. Brazilian Health Office: *Handbook of diagnosis and treatment of accidents caused by venomous animals*, Brasília, Ministério da Saúde, 1997, Fundação Nacional de Saúde.
4. Breiner MJ: Surgical treatment of envenomation injuries. *Top Emerg Med* 22:74–76, 2000.
5. Bryant S, Pittman L: Dapsone use in *Loxosceles reclusa* envenomation: is there an indication? *Am J Emerg Med* 21:89–90, 2003.
6. Cardoso AEC, Haddad V, Jr: Injuries caused by Lepidoptera (caterpillars and moths). *An Bras Dermatol* 80:571–578, 2005.
7. Cardoso JLC, França FOS, Eickstedt VRD, et al: Loxoscelism: a study of 242 cases (1980–1984). (Loxoscelismo: estudo de 242 casos (1980–1984). *Rev Soc Bras Toxicol* 1:58–60, 1988.
8. Cardoso JLC, França FOS, Wen HF, et al: Randomized comparative trial of three antivenoms in the treatment of envenoming by lance-headed vipers (*Bothrops jararaca*) in São Paulo, Brazil. *Q J Med* 86:315–325, 1993.
9. Cardoso JLC, França FOS, Wen FH, et al: *Animais peçonhentos no Brasil: biologia, clínica e terapêutica (Venomous animals in Brazil: biology, clinic aspects and therapeutic of the injuries)*, São Paulo, Brazil, 2003, Sarvier.
10. Da Silva PH, Silveira RB, Appel MH, et al: Brown spider and loxoscelism. *Toxicon* 44:693–709, 2004.
11. Davidovici BB, Halevy S: Is capturing spider essential for diagnosis of spider bite? A clinical perspective. *J Am Acad Dermatol* 58:349–350, 2008.
12. Delozier JB, Reaves L, King LE, et al: Brown recluse bites of upper extremity. *South Med J* 81:181–184, 1988.
13. Drury JK, Noonan JD, Pollock JG, et al: Jellyfish sting with serious hand complications. *Injury* 12:66–68, 2004.
14. Dyachenko P, Ziv M, Rozenman D: Epidemiological and clinical manifestations of patients hospitalized with brown recluse spider bite. *J Eur Acad Dermatol Venereol* 20:1121–1125, 2006.
15. Elston DM, Eggers JS, Schmidt WE, et al: Histological findings after brown recluse spider envenomation. *Am J Dermatol* 22:242–246, 2000.
16. Elston DM, Miller SD, Young RJ, III, et al: Comparison of colchicine, dapsone, triamcinolone, and diphenhydramine therapy for the treatment of brown recluse spider envenomation. *Arch Dermatol* 141:595–597, 2005.
17. Farace F, Lissia M, Mele A, et al: Local cutaneous arachnidism: a report of three cases and their management. *J Plast Aesthet Surg* 59:197–201, 2006.
18. Farbat DW: Arachnidism. *Top Emerg Med* 22:1–5, 2000.
19. Goddard J: *Arthropods of medical importance*, Boca Raton, FL, 1993, CRC Press.
20. Gomez HF, Krywko DM, Stoecker WV: A new assay for the detection of Loxosceles species (brown recluse) spider venom. *Ann Emerg Med* 39:469–474, 2002.
21. Grenga TE: Catfish spine envenomation of the hand. *J Hand Surg [Am]* 14:1035–1036, 1989.
22. Haddad V, Jr: *Therapeutical, clinical and epidemiological evaluation of accidents provoked by marine venomous animals in Southeast of Brazil (Avaliação epidemiológica, clínica e terapêutica de acidentes provocados por animais peçonhentos marinhos na região Sudeste do Brasil)*, PhD thesis, São Paulo, Brazil, 1999, São Paulo Federal University.
23. Haddad V, Jr: *Atlas of dangerous aquatic animals of Brazil: A medical guide to identification and treatment (Atlas de animais aquáticos perigosos do Brasil: guia médico de identificação e tratamento)*, São Paulo, Brazil, 2000, Editora Roca, p 145.
24. Haddad V, Jr: Aquatic animals of medical importance (Animais aquáticos de importância médica). *Rev Soc Bras Med Trop* 36:591–597, 2003.
25. Haddad V, Jr: Cutaneous infections and injuries caused by traumatic and venomous animals which occurred in domestic and commercial aquariums in Brazil: a study of 18 cases and an overview of the theme. *An Bras Dermatol* 79:157–167, 2004.
26. Haddad V, Jr, Cardoso JLC: Dermatoses provocadas por animais venenosos. *An Bras Dermatol* 74:441–447, 1999.
27. Haddad V, Jr, Cardoso JLC, França FOS, et al: Injuries caused by cnidarians: clinical and therapeutical aspects (Acidentes provocados por celenterados: aspectos clínicos e terapêuticos). *An Bras Dermatol* 72:206–210, 1997.
28. Haddad V, Jr, Garrone Neto D, Paula Neto JB, et al: Freshwater stingrays: study of epidemiologic, clinic and therapeutic aspects based in 84 envenomings in humans and some enzymatic activities of the venom. *Toxicon* 43:287–294, 2004.

29. Haddad V, Jr, Martins IA: Frequency and gravity of human envenomations caused by marine catfish (suborder Siluroidei): a clinical and epidemiological study. *Toxicon* 47:838–843, 2006.
30. Haddad V, Jr, Martins IA, Makyama HM: Injuries caused by scorpionfishes (*Scorpaena plumieri* Bloch, 1789 and *Scorpaena brasiliensis* Cuvier, 1829) in the Southwestern Atlantic Ocean (Brazilian coast): epidemiologic, clinic and therapeutic aspects of 23 stings in humans. *Toxicon* 42:79–83, 2003.
31. Haddad V, Jr, Novaes SPMS, Miot HA, et al: Accidents caused by sea urchins—the efficacy of precocious removal of the spines in the prevention of complications. *An Bras Dermatol* 77:123–128, 2002.
32. Haddad V, Jr, Silveira FL, Cardoso JLC, et al: A report of 49 cases of cnidarian envenoming from southeastern Brazilian coastal waters. *Toxicon* 40:1445–1450, 2002.
33. Hogan CJ, Barbaro KC, Winkel K: Loxoscelism: old obstacles, new directions. *Ann Emerg Med* 44:608–624, 2004.
34. Isbister GK: Prospective cohort study of definite spider bites in Australian children. *J Paediatr Child Health* 40:360–364, 2004.
35. Isbsiter GK, Gray MR: A prospective study of 750 definite spider bites, with expert spider identification. *Q J Med* 95:723–731, 2002.
36. Isbister GK, White J: Clinical consequences of spider bites: recent advances in our understanding. *Toxicon* 43:477–492, 2004.
37. Isbister GK, Whyte IM: Suspected white-tail spider bite and necrotic ulcers. *Intern Med J* 34:38–44, 2004.
38. King LE, Rees RS: Dapsone treatment of a brown recluse spider bite. *JAMA* 250:648, 1983.
39. Krywko DM, Gomez HF: Detection of *Loxosceles* species venom in dermal lesions: a comparison of 4 venom recovery methods. *Ann Emerg Med* 39:475–480, 2002.
40. Lehman CF, Pipkin JL, Ressmann AC: Blister beetle dermatitis. *Arch Dermatol* 71:36, 1955.
41. Lucas MS: Spiders in Brazil. *Toxicon* 26:759–772, 1988.
42. Málaque CRSA, Castro-Valencia JE, Cardoso JLC, et al: Clinical and epidemiological features of definitive and presumed loxoscelism in São Paulo, Brazil. *Rev Inst Med Trop Sao Paulo* 44:139–143, 2002.
43. Mann JW, III, Werntz JR: Catfish stings to the hand. *J Hand Surg [Am]* 16:318–321, 1991.
44. Ministério da Saúde do Brasil: Araneísmo. In *Manual de diagnóstico e tratamento de acidentes por animais peçonhentos*, Brasilia, 2001, Fundação Nacional de Saúde, pp 45–58.
45. Mold JW, Thompson DM: Management of brown recluse spider bites in primary care. *J Am Board Fam Pract* 17:347–352, 2004.
46. Nassab R, Rayatt S, Peart F: The management of hand injuries caused by sea urchin spines. *J Hand Surg [Br]* 30:423–433, 2005.
47. Ospedal KZ, Apeel MH, Fillus Neto J, et al: Histopathological findings in rabbits after experimental acute exposure to the *Loxosceles intermedia* (brown spider) venom. *Int J Pathol* 84:287–294, 2002.
48. Osterhoudt KC: Diagnosis of brown recluse spider bite in absence of spiders. *Clin Pediatr (Phila)* 43:407–408, 2004.
49. Osterhoudt KC, Zaoutis T, Zorc JJ: Lyme disease masquerading as brown recluse spider bite. *Ann Emerg Med* 39:558–561, 2002.
50. Paula Neto JB, Ribeiro RSP, Luz JA, et al: Clinical and epidemiological characteristics of injuries caused by venomous snakes observed at the Hospital for Tropical Diseases of Araguaína, Tocantins State, Brazil, from 1995 to 2000. *J Venom Anim Toxins Incl Trop Dis* 11:422–432, 2005.
51. Pauli I, Puka J, Gubert IC, et al: The efficacy of antivenom in loxoscelism treatment. *Toxicon* 48:123–137, 2006.
52. Pommier P, Rollard C, de Haro L: Morsures d'araignées: les aranéismes d'importance médicale. *Press Med* 34:49–56, 2005.
53. Rees RS, Altenbern DP, Lynch JB, et al: A comparison of early surgical excision versus dapsone and delayed surgical excision. *Ann Surg* 202:659–663, 1985.
54. Rhoads J: Epidemiology of the brown recluse spider bite. *J Am Acad Nurse Pract* 19:79–85, 2007.
55. Sams HH, Dunnick CA, Smith ML, et al: Necrotic arachnidism. *J Am Acad Dermatol* 44:561–573, 2001.
56. Sams HH, Hearth SB, Long LL, et al: Nineteen documented cases of *Loxosceles reclusa* envenomation. *J Am Acad Dermatol* 44:603–608, 2001.
57. Sezerino UM, Zannin M, Coelho LK, et al: Clinical and epidemiological study of *Loxosceles* spider envenoming in Santa Catarina, Brazil. *Trans R Soc Trop Med Hyg* 92:546–548, 1998.
58. Steen CJ, Carbonaro PA, Shwartz RA: Arthropods in dermatology. *J Am Acad Dermatol* 50:819–842, 2004.
59. Stoecker WV, Green JA, Gomez HF: Diagnosis of loxoscelism in a child confirmed with an enzyme-linked immunosorbent assay and noninvasive tissue sampling. *J Am Acad Dermatol* 55:888–890, 2006.
60. Swanson DL, Vetter RS: Medical progress: bites of brown spiders and suspected necrotic arachnidism. *N Engl J Med* 352:700–707, 2005.
61. Swanson DL, Vetter RS: Loxoscelism. *Clin Dermatol* 24:213–221, 2006.
62. Tombourgi DV, Pedrosa MFF, van den Berg C, et al: Molecular cloning, expression, function, and immunoreactivities of members of a gene family of sphingomyelinases from *Loxosceles* venom glands. *Mol Immunol* 41:831–840, 2004.
63. Tambourgi DV, Gonçalves-de-Andrade RM, Berg CW: Loxoscelism: from basic research to the proposal of new therapies. *Toxicon* 56:1113–1119, 2010.
64. Vetter RS, Cushing PE, Crawford RL, et al: Diagnoses of brown recluse spider bites (loxoscelism) greatly outnumber actual verifications of the spider in four western American states. *Toxicon* 42:413–418, 2003.
65. Vetter RS, Isbister GK: Do hobo spider bites cause dermonecrotic injuries? *Ann Emerg Med* 44:605–607, 2004.
66. Vetter RS, Swanson DL: Of spiders and zebras: publication of inadequately documented loxoscelism case reports. *J Am Acad Dermatol* 56:1063–1064, 2007.
67. Vetter RS: Spider envenomation in North America. *Crit Care Nurs N Am* 25:205–223, 2013.
68. Wendell RP: Brown recluse spiders: a review to help guide physicians in nonendemic areas. *South Med J* 96:486–490, 2003.
69. Wolf R, Tüzün B, Tüzün Y: Dapsone: unapproved uses or indications. *Clin Dermatol* 18:37–53, 2000.
70. Wright SW, Wrenn KD, Murray L, et al: Clinical presentation and outcome of brown recluse spider bite. *Ann Emerg Med* 30:28–32, 1997.
71. Zeglin D: Brown recluse spider bites—managing the effects, which can include necrotic arachnidism and loxoscelism. *Am J Nurs* 105:64–68, 2005.
72. Zhu YI, Stiller MJ: Dapsone and sulfones in dermatology: overview and update. *J Am Acad Dermatol* 45:420–434, 2001.

A Practical Guide for Complex Regional Pain Syndrome in the Acute Stage and Late Stage

L. Andrew Koman, Beth Paterson Smith, and Thomas L. Smith

The classification of abnormal, posttraumatic pain is complicated and encompassed in the term *complex regional pain syndrome* (CRPS).[135] The term *reflex sympathetic dystrophy* (RSD), a descriptor of posttraumatic pain, is established in the lay, medical, and legal literature despite the absence of defined pathophysiologic findings and consistent clinical symptoms and signs. RSD is a condition considered to be present in a subset of patients contained within the broader category of CRPS. Even with introduction of the name CRPS, much of the contemporary literature uses RSD, algodystrophy, and other descriptors. The purpose of this chapter is to present diagnostic criteria that define clinical subtypes of CRPS and to provide a practical approach for treatment in the acute and chronic stages of this dynamic process.

GENERAL CONSIDERATIONS IN COMPLEX REGIONAL PAIN SYNDROME

Clinical Definitions

The diagnosis of CRPS is contingent on the presence of regional pain combined with autonomic dysfunction, atrophy, and functional impairment (Figure 53.1 and Box 53.1) affecting musculoskeletal, neural, and vascular structures.[32] Type 1, or "classic," RSD is not associated with an identifiable peripheral nerve injury. Type 1 CRPS is initiated by trauma and is often associated with swelling as a result of dependency, extensive trauma, or a cast or bandage that was quite tight. Type 2 is associated with an identifiable peripheral nerve injury (causalgia). Type 3 includes nontraumatic causes producing extremity pain such as myofascial syndrome (Table 53.1).[39] The type 3 category of CRPS is controversial; however, its use expands the concept to include all extremity pain pathologic conditions. This chapter discusses only CRPS type 1 and type 2.

Budapest Criteria

The International Association for the Study of Pain (ISAP) recommended and endorsed specific diagnostic criteria based upon a consensus process conducted through a "by invitation only" workshop held in the fall of 2003 (Box 53.2). Subsequent internal and external validation studies and modifications of decision rules support a sensitivity of 0.70 and a specificity of 0.94. While not perfect, with a tendency toward overdiagnosis, these criteria are clinically superior to previous criteria but subject to observer variability (Box 53.3).[57]

The distinction "major nerve damage" is confusing as a discriminator for type 2 versus type 1 CRPS, and injury to an identifiable named nerve is appropriate to designate a diagnosis as type 2. Historically, causalgia was associated with an injury to a "major" mixed motor and sensory nerve (e.g., the median or sciatic nerve).

Neuropathic pain is defined as pain initiated or caused by a primary lesion or lesions or dysfunction of the peripheral nervous system or central nervous system (CNS). *Nociceptive pain* results from damage to tissues as a result of thermal, mechanical, chemical, or other irritants. Neuropathic pain may be associated with CRPS type 2, or it may be considered a distinct entity, depending on its source (Table 53.2). Mononeuropathy, if symptoms and signs extend beyond the nerve distribution, may constitute CRPS type 2.

The diagnosis of CRPS is based on the patient's history and physical examination and relies on the intuition, experience, and clinical judgment of the physician.

Diagnostic criteria based upon consensus recommendations are a valuable but not an infallible tool that aids the diagnosis.

Although attempts have been made to establish these diagnostic tools, serum biomarkers or laboratory findings cannot be used to make the diagnosis of CRPS.[1,2,56,66,94] Early recognition along with prompt treatment of CRPS is important to minimize permanent loss of function. However, despite prompt recognition and treatment, patients with CRPS may experience permanent impairment and disability.[17] Many patients also face loss or suspension of work, changes in occupation, and psychological disorders.[42]

CRPS may include sympathetically maintained pain (SMP) or sympathetically independent pain (SIP). These terms recognize the dynamic nature of dystrophic responses and stress the value of reliable and consistent clinical observations and descriptions. The diagnosis of SMP is based on pain relief with sympatholytic medications or sympathetic blocks[109,110]; however, SMP may become SIP over time. Objective and reproducible methods to assess pain, quantify trophic changes, define autonomic dysfunction, and measure functional impairment are important to provide consistent treatment regimens and reliably assess outcomes.[77,78]

Historical Review

- Ambrose Paré, 16th century: Charles IX experienced burning pain after phlebotomy
- Percivall Pott, 1771: described pain after nerve injury

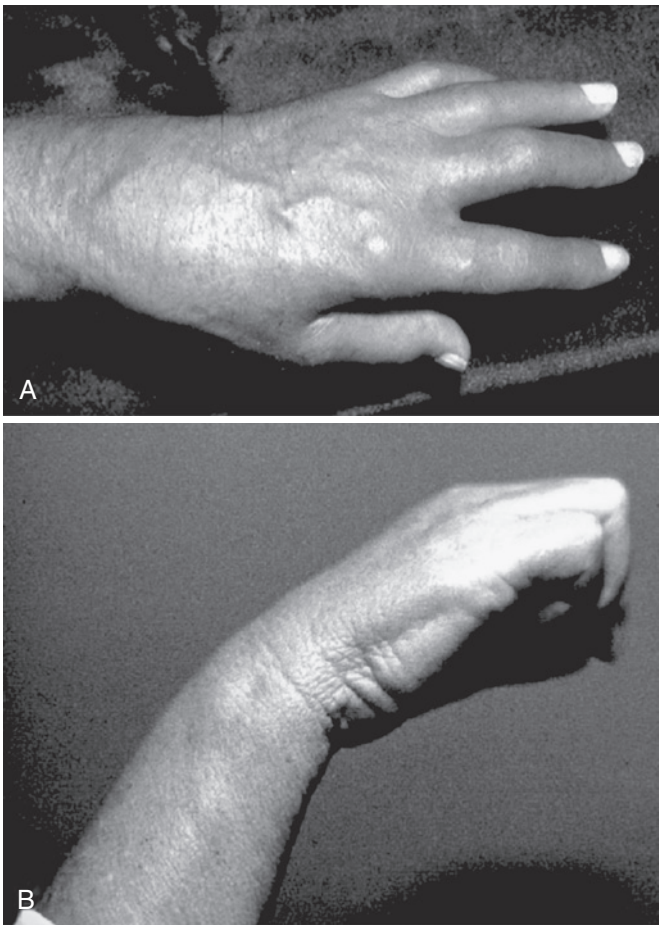

FIGURE 53.1 **A,** Hand of a patient with complex regional pain syndrom (CRPS) showing swelling and autonomic dysfunction. **B,** Hand and forearm of a patient with CRPS showing trophic changes and arthrofibrosis.

BOX 53.1 Synonyms for Complex Regional Pain Syndrome

Acute atrophy of bone
Algodystrophy
Algoneurodystrophy
Causalgia state/syndrome
Chronic traumatic edema
Major causalgia
Major traumatic dystrophy
Mimocausalgia
Minor causalgia
Minor traumatic dystrophy
Neurodystrophy
Neurovascular dystrophy
Osteoneurodystrophy
Pain dysfunction syndrome
Painful posttraumatic osteoporosis
Peripheral trophoneurosis
Postinfarctional sclerodactyly
Posttraumatic pain syndrome
Posttraumatic sympathetic dystrophy
Posttraumatic vasomotor abnormality
Posttraumatic vasomotor instability
Reflex nervous dystrophy
Reflex neurovascular dystrophy
Reflex sympathetic dystrophy
Shoulder-hand-finger syndrome
Shoulder-hand syndrome
Sudeck atrophy
Sympathalgia
Sympathetic algodystrophy
Sympathetic-mediated pain
Sympathetic neurovascular dystrophy
Sympathetic overdrive syndrome
Transient osteoporosis
Traumatic angiospasm

- Silas Weir Mitchell, 1864: description of causalgia
- Sudek, 1900: bone demineralization associated with posttraumatic pain
- Leriche, 1916: posttraumatic "burning" pain
- Evan, 1947, and Bonica, 1973; term *reflex sympathetic dystrophy*
- Proceedings of the VI Congress on Pain, 1991: introduced the term *complex regional pain syndrome*
- Budapest criteria, 2007: diagnostic criteria based on symptoms and signs with improved specificity

Physiology of Pain

Normally, pain is perceived only in the presence of actual or impending cellular tissue damage; persistent pain is pathologic in the absence of continued trauma. Painful peripheral nociceptive experiences that include cellular damage produce secondary inflammation by activating and sensitizing polymodal low-threshold mechanoreceptors and nociceptor afferent neurons, which produce, in theory, ectopic chemosensitivity to α-adrenergic agonists.[28] This information is relayed via the process of *transduction* through small myelinated (Aδ), large myelinated (Aβ), and small unmyelinated (C) afferent fibers to the dorsal horn of the spinal cord, where *sensitization* of wide–dynamic range (WDR) neurons contributes to central nociceptive discharge (Figure 53.2, *A*).[28] Within the dorsal horn, excitatory amino acids serve as the principal neurotransmitters. Transmitters include *N*-glutamate, aspartate, α-amino-3-hydroxy-5-methyl-4-isoxazopropionic acid (AMPA), *N*-methyl-D-aspartate (NMDA), and substance P. Of these, the NMDA receptor-transmitter interaction produces long-lasting potentials, is refractory to stimulation, and is theorized to play an

TABLE 53.1 Types of Complex Regional Pain Syndromes

Type	Description
Type 1	Reflex sympathetic dystrophy (pain, functional impairment, autonomic dysfunction, dystrophic changes without clinical peripheral nerve lesion/injury)
Type 2	Causalgia (pain, functional impairment, autonomic dysfunction, dystrophic changes with a diagnosable peripheral nerve injury)
Type 3*	Other pain dysfunction problems (e.g., myofascial pain)

*Not discussed in this chapter.

BOX 53.2 International Association for the Study of Pain Budapest Diagnostic Criteria for Complex Regional Pain Syndrome (CRPS)*

1. The presence of an initiating noxious event, or a cause if immobilization†
2. Continuing pain, allodynia, or hyperalgesia in which the pain is disproportionate to any known inciting event
3. Evidence at some time of edema, changes in skin blood flow, or abnormal sudomotor activity in the region of pain (can be a sign or symptom)
4. This diagnosis is excluded by the existence of other conditions that would otherwise account for the degree of pain and dysfunction

*If seen without "major nerve damage," diagnose CRPS I; if seen in the presence of "major nerve damage," diagnose CRPS II.
†Not required for diagnosis; 5% to 10% of patients will not have this.

BOX 53.3 Proposed Refinement of Original Budapest Clinical Diagnostic Criteria for Complex Regional Pain Syndrome

1. Continuing pain that is disproportionate to any inciting event
2. Must report at least one symptom in *three of the four* following categories:
   - *Sensory:* report of hyperesthesia and/or allodynia
   - *Vasomotor:* reports of temperature asymmetry and/or skin color changes and/or skin color asymmetry
   - *Sudomotor/edema:* reports of edema and/or sweating changes and/or sweating asymmetry
   - *Motor/trophic:* reports of decreased range of motion and/or motor dysfunction (weaknesses, tremor, dystonia) and/or trophic changes (hair, nails, skin)
3. Must display at least one sign at time of evaluation in *two or more* of the following categories:
   - *Sensory:* evidence of hyperalgesia (to pinprick) and/or allodynia (to light touch and/or deep somatic pressure and/or joint movement)
   - *Vasomotor:* evidence of temperature asymmetry and/or skin color changes and/or asymmetry
   - *Sudomotor/edema:* evidence of edema and/or sweating changes and/or sweating asymmetry
   - *Motor/trophic:* evidence of decreased range of motion and/or motor dysfunction (weakness, tremor, systonia) and/or trophic changes (hair, nails, skin)
4. There is no other diagnosis that better explains the signs and symptoms

Harden RN, Bruehl S, Stanton-Hicks M, et al: Proposed new diagnostic criteria for complex regional pain syndrome. *Pain Med* 8(4):326–331, 2007; Harden RN, Bruehl S, Perez RS, et al: Validation of proposed diagnostic criteria for complex regional pain syndrome. *Pain* 150:268–274, 2010.

TABLE 53.2 Terms Used in Complex Regional Pain Syndrome

Term	Definition
Pain	Unpleasant perception associated with actual or potential cellular damage
Analgesia	Absence of pain in response to an insult that should produce pain
Neuropathic pain	Pain initiated or produced by a primary lesion or lesions or dysfunction of the peripheral or central nervous system
Nociception	Response to an unpleasant (noxious) stimulus that produces pain in humans under normal circumstances because of thermal, mechanical, chemical, or other irritants of nonneural tissues
Allodynia	Pain in a specific dermatomal or autonomous distribution associated with light touch to the skin; a stimulus that is not normally painful
Hyperalgesia	Increased sensitivity to stimulation (includes allodynia and hyperesthesia)
Hyperesthesia	Increased sensitivity to simulation (pain on response to a mild nonnoxious stimulus)
Sympathetic pain	Pain in the presence of or associated with overaction of sympathetic fibers; by definition, the pain is relieved by sympatholytic interventions
Hypoesthesia	Decreased sensitivity to stimulation
Hyperpathia	Abnormally painful reaction to a stimulus
Dysesthesia	An unpleasant abnormal sensation
Paresthesia	An abnormal sensation

From Gracely R, Price D, Roberts W, et al: Quantitative sensory testing in patients with complex regional pain syndrome (CRPS) I and II. In Janig W, Stanton-Hicks M, editors: *Reflex sympathetic dystrophy: a reappraisal*, vol 6, Progress in pain research and management, Seattle, 1996, International Association for the Study of Pain, pp 151–170.

important role in CRPS types 1 and 2. Nociceptive input is modulated via descending pathways, and both peripheral and central factors are required for the perception of pain (see Figure 53.2, *B*). Pain intensity is determined by the magnitude and extent of the initiating/ongoing event, afferent input, efferent modulation, and CNS interpretation. Conscious appreciation of nociceptive (painful) experiences is dependent on a complex interplay of afferent and efferent information modulated and balanced by physiologic adaptations. Vasomotor disturbances may result from a variety of mechanisms, including antidromic vasodilation, vasoparalytic dilation, normal somatosensory reflexes, and denervation super sensitivity.[28] Responses to nociceptive stimuli can vary significantly among individuals. The presence of nociceptive-induced inappropriate transmitter-receptor activity can affect peripheral microcirculatory control and, thereby, result in impaired nutritive blood flow[76,106,113] and may sensitize CNS pathways.[10,11,26,28,29,88,97,103]

Perception of Pain

By definition, CRPS does not exist in the absence of pain. Peripheral injury stimulates endogenous inflammatory mediators via nociceptive pathways. Repetitive trauma/injury may alter protective responses by producing earlier activation through sensitization. In addition to providing central input, local nociceptors initiate the direct release of peptides and neurotransmitters, control the inflammatory process, and promote tissue repair. Pain requires cognitive recognition.

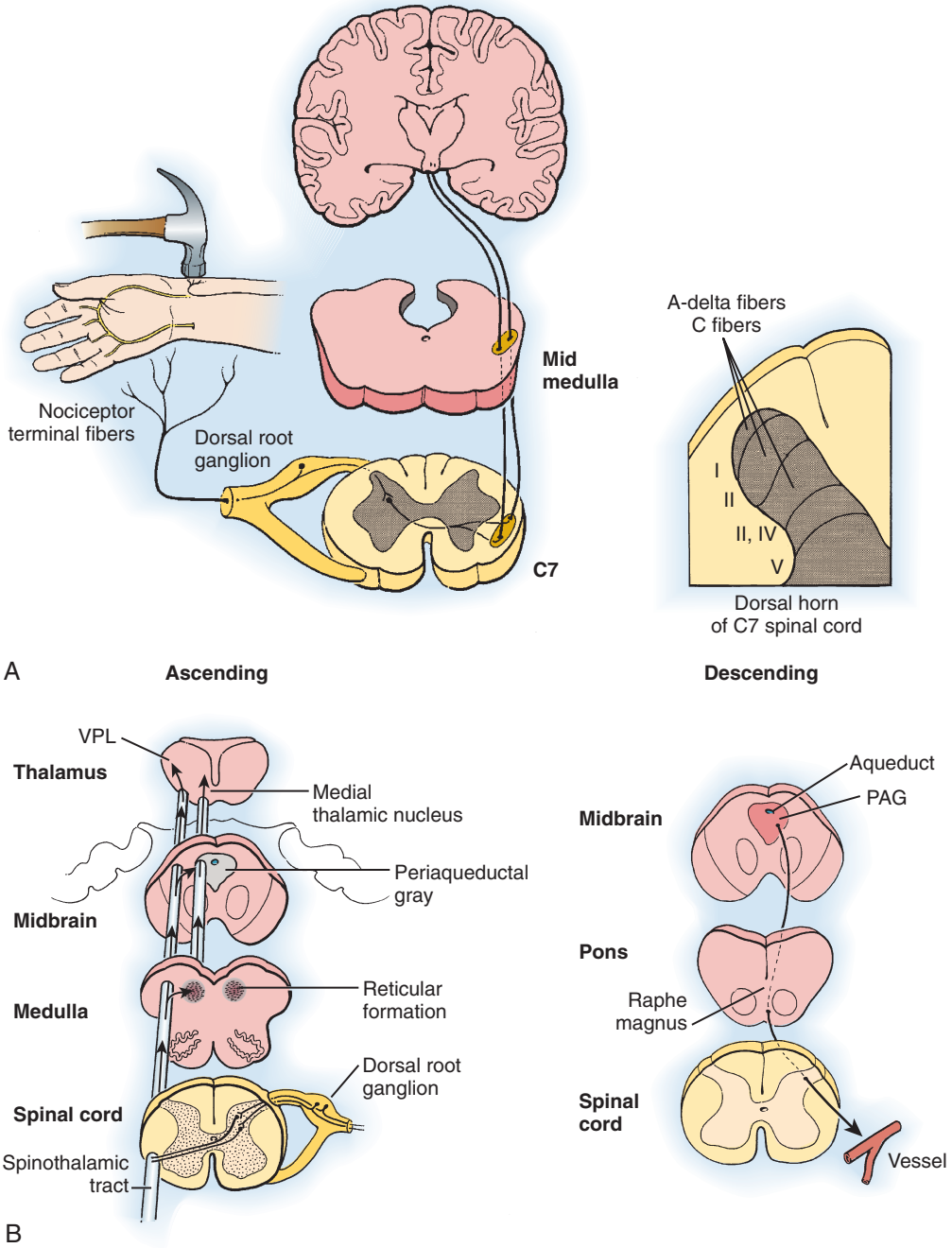

FIGURE 53.2 **A,** Abnormal central nervous system modulation of afferent sensory stimuli may contribute to the development of a dystrophic response after an injury that produces a peripheral nociceptive focus or "trigger." **B,** Ascending and descending pathways in the spinal cord and brain. *PAG*, Periaqueductal gray matter; *VPL*, ventral posterolateral nucleus. (From Koman LA, editor: *Bowman Gray orthopaedic manual*, Winston-Salem, NC, 1996, Orthopaedic Press.)

Pain Mediators and Receptor Control

A variety of nonneurogenic and neurogenic mediators participate in the transmission of information interpreted as pain. Nonneurogenic mediators include bradykinin, serotonin, histamine, acetylcholine, prostaglandins E_1 and E_2, and leukotrienes. Neurogenic mediators, which are biologically active peptides produced by primary afferent neurons, potentiate or inhibit nociceptive information. These mediators include substance P, vasoactive intestinal peptide, calcitonin gene–related peptide, gastrin-releasing peptide, dynorphin, enkephalin, galanin, somatostatin, cholecystokinin, γ-aminobutyric acid, dopamine, and glycine.

The role of α-adrenergic receptors and local blood flow in sympathetically maintained complex regional pain states is well documented,[31,60,109,111] and relief of pain after intravenous phentolamine, a mixed α_1- and α_2-antagonist, is considered pathognomonic for SMP (CRPS type 1).[109,110] Abnormal regulation of adrenoreceptor function or modulation (or both) in neural and

vascular structures is the major common control pathway supporting the concept that RSD (SMP) is a *receptor disease*.[36,109] Presynaptic and postsynaptic receptors are involved and affect nociceptive foci, blood flow, nutritional perfusion, and peripheral nerve excitability.[14,80,113] The pathologic mechanisms involved in the compromise of extremity blood flow and neural control include: (1) abnormal neurotransmitter release secondary to nociceptive foci, (2) abnormal receptor distribution, and (3) alterations in receptor sensitivity (e.g., upregulation or downregulation).

Gate Theory of Pain

The "gate theory" is an appropriate aid in the conceptualization of pain. The theory assumes that a finite amount of information can be received at the spinal cord or cortical level. The "gate" is the dorsal horn of the spinal cord. Thus, painful information displaced or modified by less noxious input cannot be processed through the gate. Although as yet unproven, certain general principles relating to pain processing can be conceptualized by using this theory.

Acute Versus Chronic Pain

Acute pain is initiated during tissue injury or destruction, and the presence of acute pain may be beneficial or harmful. Beneficial effects include physiologic responses for maintenance of blood pressure, cardiac output, intravascular volume, and appropriate homeostasis. Acute pain warns the host of danger, prevents inappropriate motion of an injured extremity, and may diminish additional harm from repetitive injury. Persistence of pain beyond the need for protective action is unpleasant and may induce hypertension, tachycardia, coagulopathy, hyperglycemia, anxiety, fear, and chronic pain. Chronic pain that occurs in the absence of ongoing tissue destruction or that provides an inappropriate reflection of the intensity, magnitude, or duration of the tissue damage/compromise is pathologic. Although the pathophysiology of chronic pain is incompletely understood, the following processes can contribute to its establishment: persistent mechanical irritation of peripheral neural structures, incomplete regeneration of peripheral nerves, abnormal neurotransmitter activity, nutritional deprivation secondary to abnormal arteriovenous shunting, and central imprinting.

After trauma or surgery, a transient period of dystrophic extremity function is normal. However, it is abnormal for hyperpathia (heightened pain for a given stimulus), allodynia (painful responses to normally nonpainful stimuli), vasomotor disturbances, and functional deficiencies to persist. If untreated, these conditions may progress to permanent compromise of the extremity. Posttraumatic alterations in extremity physiology follow a variable time course. Consequently, abnormal prolongation of these otherwise normal responses is pathologic, and over time, irreversible changes in anatomic structures or physiologic processes may occur (Figure 53.3). Therefore, *CRPS may be considered an abnormally severe or prolonged manifestation of a normal postinjury response.* Abnormally prolonged dystrophic events may damage or compromise the arteriovenous shunt mechanism,[77-79,106] produce arthrofibrosis,[77,78] cause excessive osteopenia,[16] alter neuroreceptor function,[109] or result in central pain imprinting or any combination of these sequelae.

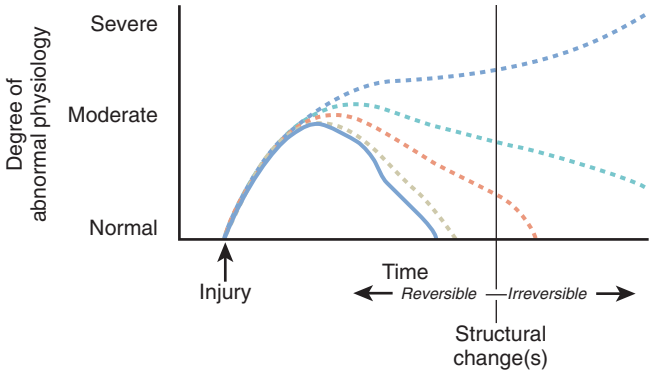

FIGURE 53.3 Abnormal physiologic events after trauma are "normal"; the majority of patients (*solid line*) recover spontaneously from the trauma. Abnormal prolongation of the intensity of these events and dystrophic pain of varying magnitude and duration (*broken lines*) are pathologic. Irreversible changes may occur and convert sympathetically maintained pain to sympathetically independent pain. (From Koman LA, editor: *Bowman Gray orthopaedic manual*, Winston-Salem, NC, 1996, Orthopaedic Press.)

Demographics of Complex Regional Pain Syndrome

In 2003, the incidence of CRPS in Olmsted County, Minnesota, was 5.46 per 100,000 person-years, with four times as many female as male patients.[119] From the electronic medical records of more than 600,000 patients listed in the Dutch Health Care System, the overall incidence rate of CRPS in the Netherlands was higher at 26.2 per 100,000 person-years, with females affected three times more often than males.[25] The mean age at onset was 46 years in the Minnesota study and 53 years in the Dutch study.[25,119] However, CRPS can also develop in children and adolescents.[147] The upper extremity is involved more frequently than the lower extremity, and fracture was the most common precipitating event.[25] The incidence of cigarette smoking is higher in RSD patients, and cigarette smoking is statistically linked to RSD.[4] Data suggesting a possible familial or genetic predisposition to RSD have also been presented but have not been confirmed.[47] A predisposition to CRPS type 1 has been suggested on the involved side of hemiplegic patients.[48] Eighty percent of patients in whom RSD was diagnosed within 1 year of injury will improve significantly,[77,78] and it is reported that 50% of patients with untreated symptoms lasting longer than 1 year will have profound residual impairment.[143]

Fracture of the distal end of the radius and ulna is one of the most *common* injuries associated with CRPS, and it complicates postinjury recovery in a measurable percentage of patients.[17] The natural history of CRPS after distal radius fractures includes finger stiffness or "poor function" at 3 months after injury and correlates with residual RSD at 10 years.[35] CRPS is more likely to occur after distal radius fractures in patients with tight casts[34] or after a nociceptive or neuropathic event such as compression of the median nerve, overdistraction, instability of the distal radioulnar joint, or ulnar fracture. Dystrophic pain after surgical release of the carpal tunnel is commonly encountered in referral centers.[77,78]

Common nerve injuries occurring during operative procedures that may precipitate CRPS include (1) injury to the palmar cutaneous branch of the median nerve during carpal tunnel surgery, (2) damage to the superficial branch of the

radial nerve during surgical approaches to the first and second dorsal compartments for tenosynovitis, and (3) trauma to the dorsal branch of the ulnar nerve during a surgical approach to the distal ulna.[77,78] The reports that CRPS may produce devastating consequences in association with simultaneous median nerve decompression at the wrist and partial palmar fasciectomy for Dupuytren contracture are not correct, and it may be performed safely.[84]

Psychological Factors and Effects

CRPS is not a psychogenic condition. Extensive reviews of the existing literature do not support a psychological causation or an associated personality disorder. However, chronic pain is known to play a role in psychological well-being, with 58% of 283 consecutive patients admitted to pain centers, regardless of cause, fulfilling the criteria for personality disorders.[37,140] Dependent, passive-aggressive, and histrionic personality disorders are common in those with chronic pain and are seen in patients with CRPS. Behavioral responses that reduce extremity use exacerbate edema and atrophy.

Psychological Problems Mimicking Complex Regional Pain Syndrome

The differential diagnosis of CRPS includes some psychological conditions, including conversion disorders and clenched fist syndromes.[48,132] A patient with SHAFT (sad, hostile, anxious, frustrated, and tenacious) syndrome is difficult to discern from a patient with CRPS without active suspicion.[46] A history of multiple operations, absence of consistent clinical findings, multiple treating physicians, a myriad of medications, psychiatric treatment, absence from work, disproportionate self-characterization and verbalization of symptoms, crying from pain, and a family history of disability are common factors. Misdiagnosis associated with abnormal postures is documented. Dysfunctional postures are defined, such as holding an upper extremity in a fixed posture. The typical posture of the hand of a patient with CRPS includes metacarpophalangeal (MP) and proximal interphalangeal (PIP) joint extension. MP and PIP joint flexion (clenched) is uncharacteristic of CRPS, and in such cases an alternative diagnosis is probable. Similarly, mild to moderate swelling is common; massive swelling or edema is rare, and alternative explanations (e.g., factitious symptoms) should be ruled out. Lack of objective findings (e.g., trophic changes, edema, osteopenia, radiographic or fixed contractures) suggests that other conditions are responsible for the symptoms.

Symptoms and Signs

The *pain* associated with CRPS is seen in a variety of clinical manifestations (see Table 53.3). The pain may be described as burning, throbbing, pressing, cutting, searing, shooting, or aching (or any combination of these descriptors). *Hyperalgesia*, or the perception of pain greater than would be expected, may be primary and affect the area of injury or secondary and affect nontraumatized surrounding areas or the entire limb. Identification of the zone of primary pain may aid in the localization of a *nociceptive* focus; however, diagnosis of the etiologic trigger event may not be possible until successful sympatholytic management of the secondary hyperalgesia is complete. *Allodynia*, or perception of pain initiated by normally innocuous stimuli, is a characteristic of sympathetically maintained CRPS. *Hyperpathia*, or pain produced by painful stimuli that appears with a delay, outlasts the initiating stimulus, and spreads beyond the normal neural distribution, is encountered frequently. It is important to differentiate *spontaneous pain* from stimulus-evoked pain. Difficulty sleeping because of burning pain is common and may be an early portent of progressive symptoms and signs.

Quantifying subjective complaints of pain with the use of standardized and validated instruments or questionnaires allows an objective analysis of symptoms.[77,78] Useful instruments to evaluate symptoms and health status include the visual analog scale (VAS) for pain,[96] the 36-item health status questionnaire (SF-36),[144] the McGill Short Form Pain Questionnaire,[96] and self-administered questionnaires designed to assess upper extremity symptoms/function.[13,83] The self-administered questionnaire used for assessment of the severity of symptoms and functional status for patients with carpal tunnel syndrome is applicable to dystrophic states caused by carpal tunnel surgery or injury to the median nerve at the wrist and allows the examiner to graphically follow the patient's health-related quality of life (Figure 53.4).[77,78,83] Cold intolerance, or pain on exposure to cold, may be analyzed by the McCabe Cold Sensitivity Severity Scale.[93] The importance of standardized physiologic testing and instruments is supported by the lack of reproducibility of isolated clinical evaluations. However, the use of published criteria and scoring systems for CRPS may be helpful.[44] The Budapest criteria facilitate the process.[57]

Trophic changes—stiffness; edema; osteopenia; atrophy of the hair, nails, or skin; hypertrophy of the skin (or hyperkeratosis); or any combination of these changes—may be present in patients with CRPS (see Figure 53.1). Changes in the skin, hair, or nails are seen within 10 days of onset in 30% of extremities with CRPS type 1 (RSD).[12] Despite treatment that reduces pain, cold intolerance, pain after use of the affected extremity, joint stiffness, nail and hair growth abnormalities, sensory disturbances, loss of finger extension/flexion, decreased grip strength, and shoulder stiffness are frequent and may persist.[150] Osteopenia is common, involves both cortical and cancellous (trabecular) bone, and requires significant demineralization for visualization on plain radiographs (Figure 53.5).[16] Objective analysis of bone demineralization requires dual-photon absorptiometry or quantitative scintigraphy.[7,16] Stiffness and atrophy of joints, muscles, and tendons may become apparent during endurance testing.[77,78] Movement disorders and dystonic posturing may also occur.[20]

Autonomic Function

The *autonomic nervous system* controls microvascular perfusion and sweat gland activity. Abnormalities in autonomic or vasomotor control, or in both, are seen during the course of CRPS in most patients, and loss of thermoregulatory control is common.[22,136] Affected extremities (hands) may be either "*hot*" or "*cold*," and significant differences in digital temperatures occur between the affected and unaffected extremities in 80% of patients.[12] Abnormalities in thermoregulation/vasomotion usually occur[76-78,105,106] and may vary depending on progression in the clinical stages of CRPS.[80] Autonomic control may be evaluated by assessment of total digital blood flow, which consists of both thermoregulatory and nutritional components,

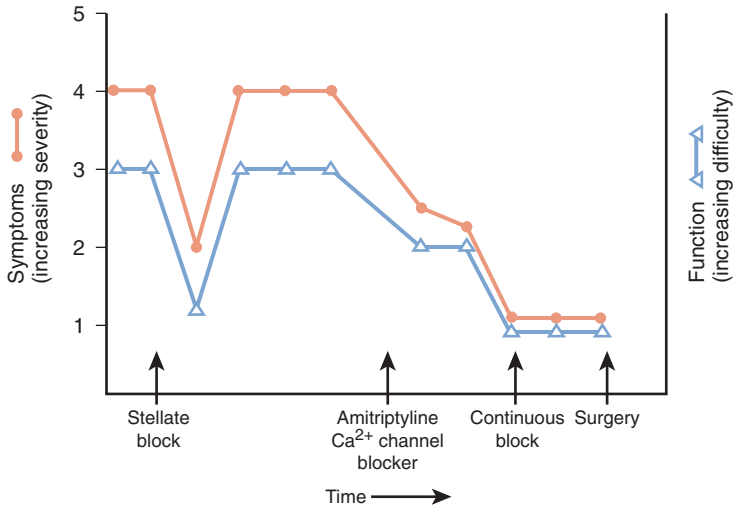

FIGURE 53.4 Symptoms and function in a dystrophic patient after carpal tunnel surgery may be monitored objectively with appropriate instruments. The self-administered carpal tunnel questionnaire contains 11 questions on hand/wrist symptoms and 8 questions on hand/wrist function; symptoms are rated numerically from none (1) to severe (5), and function is rated from no difficulty (1) to cannot do at all (5). A numerical score that reflects symptoms and function can be monitored over time, and the effects of intervention can be analyzed objectively. (From Koman LA, editor: *Bowman Gray orthopaedic manual*, Winston-Salem, NC, 1996, Orthopaedic Press.)



FIGURE 53.5 Plain radiograph of a patient with type 1 complex regional pain syndrome after fracture of the distal ends of the radius and ulna. The fracture line is visible. There is diffuse osteopenia in addition to juxtacortical demineralization and subchondral erosions and cysts. (From Koman LA, editor: *Bowman Gray orthopaedic manual*, Winston-Salem, NC, 1996, Orthopaedic Press.)

and by analysis of sudomotor activity—sweating and piloerection. A detailed history will reveal symptoms of autonomic dysfunction in 80% of patients.[12] Symptoms include abnormal sweating (excessive sweating or anhidrosis), vasomotor alterations, and heat or cold sensitivity (or both) (heat or cold intolerance). Vasomotor changes may be described as a reddish or bluish discoloration of the extremity either at rest or, more commonly, with the limb dependent. Evidence of autonomic dysfunction can be detected in 98% or more of patients by using sophisticated technology during the painful stages of CRPS.[77,78,80,106] Digital perfusion and its components can be analyzed by digital temperature measurements, laser Doppler fluxmetry, plethysmography, and vital capillaroscopy.[76-78] Sweating may be analyzed by resting sweat output, the quantitative sudomotor axon reflex test (QSART),[85] changes in galvanic skin response,[85] or asymmetry of somatosensory evoked potentials in the affected and contralateral extremities.

Sympathetic nervous system function, as reflected in laser Doppler fingertip blood flow and the vasoconstriction response to deep inspiration, varies by stage. Stage 1 patients exhibit increased blood flow but an unchanged vasoconstriction response, whereas stage 2 patients demonstrate decreased blood flow and stronger vasoconstriction.[62]

Functional impairment may be analyzed by using standardized assessments of hand function, such as the Moberg pickup test.[99] In addition, quantitative evaluation of extremity function before, during, and after stress with computerized equipment may detect subtle functional changes reflecting stiffness or atrophy. Thus, the use of standardized tests and various computerized systems can document functional impairment that may be difficult to quantify by traditional methods. The use of grip meters may be problematic. The utilization of standardized templates facilitates evaluation and documentation (Tables 53.3 and 53.4).

Physical Examination

The clinical characteristics of CRPS are related to altered extremity physiology. The magnitude of symptoms and signs is a reflection of the initiating event, postinjury response, inherent patient adaptability, interventional modalities, and time. The classic dystrophic progression from acute (<3 months) to dystrophic (3 to 6 months) to chronic (>6 months) occurs infrequently because of individual variability and the effects of

TABLE 53.3 Rating Subjective Symptoms According to the Budapest Criteria

Budapest Criterion	0, None	1, Mild	2, Moderate	3, Severe	4, Very Severe
Symptoms					
Pain					
Swelling					
Weakness					
Deformity					
Discoloration					
Cold sensitivity					
Radiculopathy					
Dystonia (movement)					
Pain					
Pain "out of proportion"					
Sensory: hyperesthesia					
Sensory: hyperpathia					
Sensory: allodynia					
Vasomotor Function					
Temperature asymmetry					
Skin color changes					
Skin color asymmetry					
Pseudomotor Function					
Edema					
Sweating changes					
Sweating asymmetry					
Other					
Motor or Trophic Abnormality					
Stiffness					
Decreased range of motion					
Trophic changes					
Weakness					
Tremor					
Dystonia					
Functional impairment					

partial treatment. Patients with CRPS who are evaluated for a painful, hot, swollen, stiff hand are easily recognizable; however, the precipitating nociceptive trigger (e.g., contusion of the superficial radial nerve) may not be identified until the SMP is managed and the dystrophic manifestations are treated. Once allodynia and hyperpathia are alleviated, careful examination may delineate an underlying disorder that may be amenable to treatment.[77,78] Partially treated CRPS or variants of CRPS may be subtly manifested and can be labeled "poor results" or "noncompliant patients." In the postoperative or posttraumatic period, unusual swelling, stiffness, pain, and restlessness may represent a dystrophic response.

The physical examination of suspected CRPS patients should include a neurologic assessment and evaluation of the cervical and thoracic spine. The presence of cervical disease (either diskogenic or degenerative) may exacerbate CRPS, a form of "double-crush syndrome." Preexisting or acquired thoracic outlet or distant compression neuropathies may represent a "triple or more" crush syndrome. Cervical spine and shoulder range of motion should be recorded, and the brachial plexus should be evaluated. The arm should be assessed to rule out evidence of vascular or neurologic compression within the thoracic outlet. An adhesive capsulitis, or "shoulder-hand syndrome," is a frequent sequela that may be overlooked unless the shoulder is examined. Hypersensitivity, vascular adequacy, edema, sensibility, joint range of motion, motor function, grip, pinch, fibrosis, sweating, and vasomotor tone of the entire extremity must be evaluated. Grip is frequently abnormal and should be assessed carefully. Currently, there are no objective laboratory tests to aid in the diagnosis of CRPS.[32]

Mechanical Nociceptive Focus

Identification of nociceptive foci, which include peripheral nerve lesions and mechanical derangements, is important.

TABLE 53.4 Template for Evaluating Clinical Signs and Radiographic Signs of Complex Regional Pain Syndrome

Signs		0, None	1, Mild	2, Moderate	3, Severe	4, Very Severe
Clinical Signs						
Skin	Mottled Cyanotic					
Skin temperature	Cool Warm Dry Overly moist					
Skin texture	Smooth Nonelastic					
Atrophy	Pulp Skin					
Joint	Stiffness Decreased passive range of motion					
Nail changes						
Hair growth	Decreased Increased					
Contracture joints						
Radiographic Signs						
Trophic bone changes						
Bone scan						
Sensory	Allodynia					
Dexterity						
Strength	Grip Dynamometer					

Evaluation before and after sympatholytic intervention may delineate "trigger events" that might have initiated or propagated the dystrophic symptoms.[77,78] Nociceptor input may be associated with SMP or SIP. However, early diagnosis plus prompt surgical correction of SMP associated with peripheral nerve injury is an effective management approach.

Diagnostic Testing

Pain Threshold Evaluation

Standardized evaluations and tests provide reproducible and objective information with regard to pain-pressure thresholds. Rubber-tipped algometers, dolorimetry, monofilaments, computer-controlled stimuli, or evaluations of thermal pain thresholds may be used to provide a quantitative measure of hyperpathia or allodynia. For example, perception of pain from a 2.83 Von Frey monofilament (normally not painful) in a specified area or dermatomal distribution defines the extent of allodynia. Success or failure of treatment can be assessed by repeated pain threshold evaluations. Monofilaments provide the most practical method for assessing and monitoring allodynia and hyperesthesia. Von Frey monofilaments are available in pocket kits, are inexpensive, and provide useful bedside sensibility and pain threshold data. Decreased pain after the use of a same-size or larger monofilament documents improvement, whereas persistent pain from the same-size or a smaller-diameter monofilament suggests ineffective management.

Radiography

Regional osteopenia can be seen on plain radiographs in approximately 80% of extremities affected by CRPS.[16,43,79] Significantly decreased mineralization is necessary for changes to be visualized on standard anteroposterior and lateral radiographs (see Figure 53.5). Classic Sudeck atrophy includes diffuse osteopenia with juxtacortical demineralization and subchondral erosions or cysts. Five radiographic patterns of resorption have been described: (1) irregular resorption of trabecular bone in the metaphysis creating a patchy appearance, (2) subperiosteal bone resorption, (3) intracortical bone resorption, (4) endosteal bone resorption, and (5) surface erosions in subchondral and juxtachondral bone.[43] Although osteopenia is easily visualized in metaphyseal areas, recent data confirm that the density of cortical and cancellous bone is affected equally in patients with CRPS.[7,16]

Functional Magnetic Resonance Imaging

In the future, functional magnetic resonance imaging may be valuable in evaluating the pathophysiology associated with CRPS and in monitoring patients' responses to interventions. Abnormalities in the size of the cortical representations of the affected hand on the primary and secondary somatosensory cortices have been reported, and "patterns of cortical reorganization in the primary somatosensory cortex seem to parallel impaired tactile discrimination."[104]

Bone Scan (Scintigraphy)

Three-phase technetium 99m bone scanning (TPBS) is performed commonly and has assumed a significant role in the diagnosis of RSD.[79,149] With TPBS, the first, or "dynamic," phase lasts 2 to 3 minutes and provides an assessment of digital perfusion; the second phase, or "blood pool image" or "tissue phase," allows an assessment of total perfusion over a 3- to 5-minute period; and the third phase, a standard bone scan, evaluates uptake of radiotracer in bony structures (Figure 53.6). In patients with CRPS, the use of a forearm or arm tourniquet or blood pressure cuff may affect accumulation of radiotracer in the hands or digits during phases I and II. Traditionally, scans have been considered "positive" if asymmetric flow is noted in phases I, II, or III.[79] However, more recent reports suggest that the diagnostic yield of phase III alone equals the diagnostic yield of the three-phase scan (Figure 53.7).[146] Mackinnon and Holder have stated that a "strictly interpreted" phase III scan with "diffuse increased tracer uptake in the delayed image is diagnostic for RSD."[59] Although a positive phase III scan provides specific corroboration of the clinical diagnosis of CRPS, the sensitivity of scintigraphy is insufficient to provide standalone criteria, and, therefore, it should be used to corroborate clinical suspicion. In the majority of studies, a "positive" scan has high specificity but poor sensitivity.[77-79,146] Quantitative scintigraphy provides useful physiologic data, allows quantitative assessment of regional bone loss associated with complex regional pain,[16] and adds useful diagnostic information.[3,15,77,78,118] However, bone scan data do not correlate with symptoms, do not provide prognostic information, and are unable to aid in the prediction of which interventional approaches might be successful.[77,78]

In the majority of patients, the abnormal bone turnover reflected in the TPBS is diffuse throughout the hand and wrist. The segmental distribution of RSD isolated to a digit, a single ray, or multiple rays can be evaluated by a bone scan to delineate the affected areas (Figure 53.8). Although TPBS is used frequently, there is no evidence to support (1) diagnostic accuracy

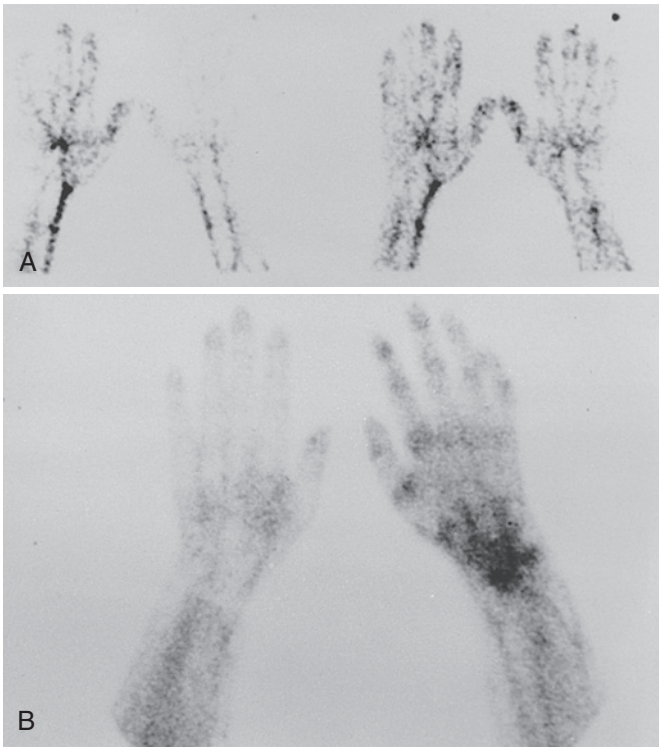

FIGURE 53.6 Three-phase bone scans. **A,** Phase I, a "dynamic phase," evaluates vascular perfusion by visual or quantitative analysis or by uptake of radiotracer after an intravenous injection. Each image represents a 3- to 5-second interval and allows assessment of flow dynamics. **B,** Phase II, a "blood pool" image, documents total tissue uptake of tracer during the first 3 to 5 minutes after injection. Phase III is a conventional bone scan (see Figure 53.7). (From Koman LA, editor: *Bowman Gray orthopaedic manual*, Winston-Salem, NC, 1996, Orthopaedic Press.)



FIGURE 53.7 Abnormal (phase III) bone scan demonstrating increased periarticular uptake throughout the hand. This is a scan of the patient whose radiograph is seen in Figure 53.6. Notice the increased radiolucency at the fracture site. (From Koman LA, editor: *Bowman Gray orthopaedic manual*, Winston-Salem, NC, 1996, Orthopaedic Press.)

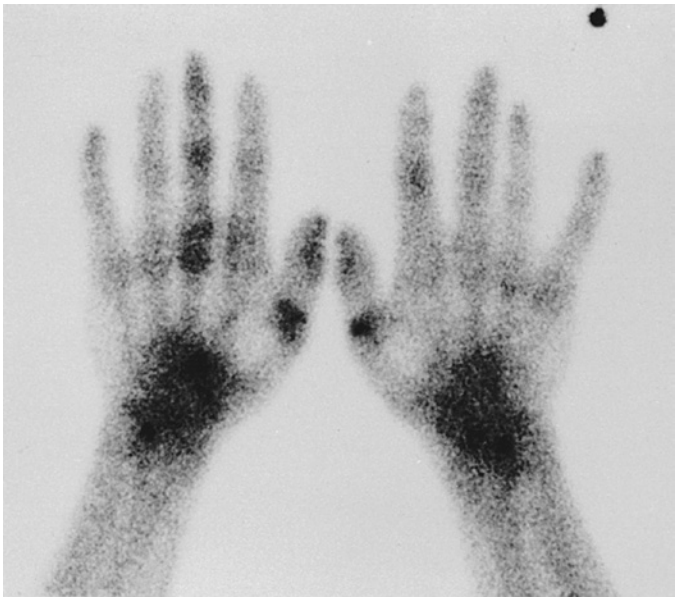

FIGURE 53.8 Segmental periarticular uptake confined to a digit in a bone scan of a patient with complex regional pain syndrome isolated to the long finger. (From Koman LA, editor: *Bowman Gray orthopaedic manual*, Winston-Salem, NC, 1996, Orthopaedic Press.)

in variant, partially treated, or late-stage CRPS[58]; (2) prognostic data that predict outcome[77,78]; or (3) value in determining management decisions.[58,77,78]

At this time, a "positive" phase III bone scan is not a prerequisite for the diagnosis of CRPS or SMP.[81] Bone scans do not correlate with traditional staging criteria for RSD, are not part of the diagnosis of SMP or CRPS,[81] do not predict recovery, and will not predict the potential for response to treatment.[77,78,146] However, the presence of a positive phase III bone scan provides objective support for the clinical diagnosis of CRPS.

Evaluation of Autonomic Control

Autonomic function controls sweating and microvascular perfusion. Evaluation of sympathetic control or, more specifically, the sympathetic dysfunction associated with characteristic pain from CRPS provides objective and sensitive methods to corroborate the clinical suspicion of CRPS.[134]

Regulation of Microvascular Flow

Under normal conditions, total digital blood flow is composed of 80 to 95% thermoregulatory flow and 5 to 20% nutritional flow; the distribution of nutritional versus thermoregulatory flow is governed by complex factors that control arteriovenous shunting.[33,76,105] Abnormal autonomic control of microvascular perfusion in patients with CRPS is reflected, in part, by ischemia secondary to inappropriate arteriovenous shunting and decreased nutritional flow.[64,76-78,80,92,105] The importance of nutritional flow in the pathogenesis of CRPS is supported by the segmental distribution of trophic events, the rapidity of action of successful sympatholytic interventions, and the similarity of pain patterns in patients with contrasting clinical findings. Abnormal arteriovenous shunting in bone has been documented in patients with CRPS. Nutritional deprivation may exist in both a "warm, swollen" hand with high total flow and a "cold, stiff" hand with low total flow. The common underlying finding in both clinical situations is nutritional deprivation resulting from inappropriate arteriovenous shunting (Figure 53.9). Pain relief in CRPS is not dependent on peripheral vasodilation (thermoregulatory flow) after spinal cord stimulation, thus suggesting the importance of nutritional flow.[69] In addition, there is growing evidence that physiologic subgrouping of CRPS patients, in contradistinction to staging based on timing, is important. For example, "warm" CRPS responds differently to intervention than "cold" CRPS does.

Total digital flow—both the thermoregulatory and nutritional components—may be analyzed by digital temperature measurements, laser Doppler fluxmetry, and vital capillaroscopy. *The use of a stressor to perturb physiologic homeostasis, by*

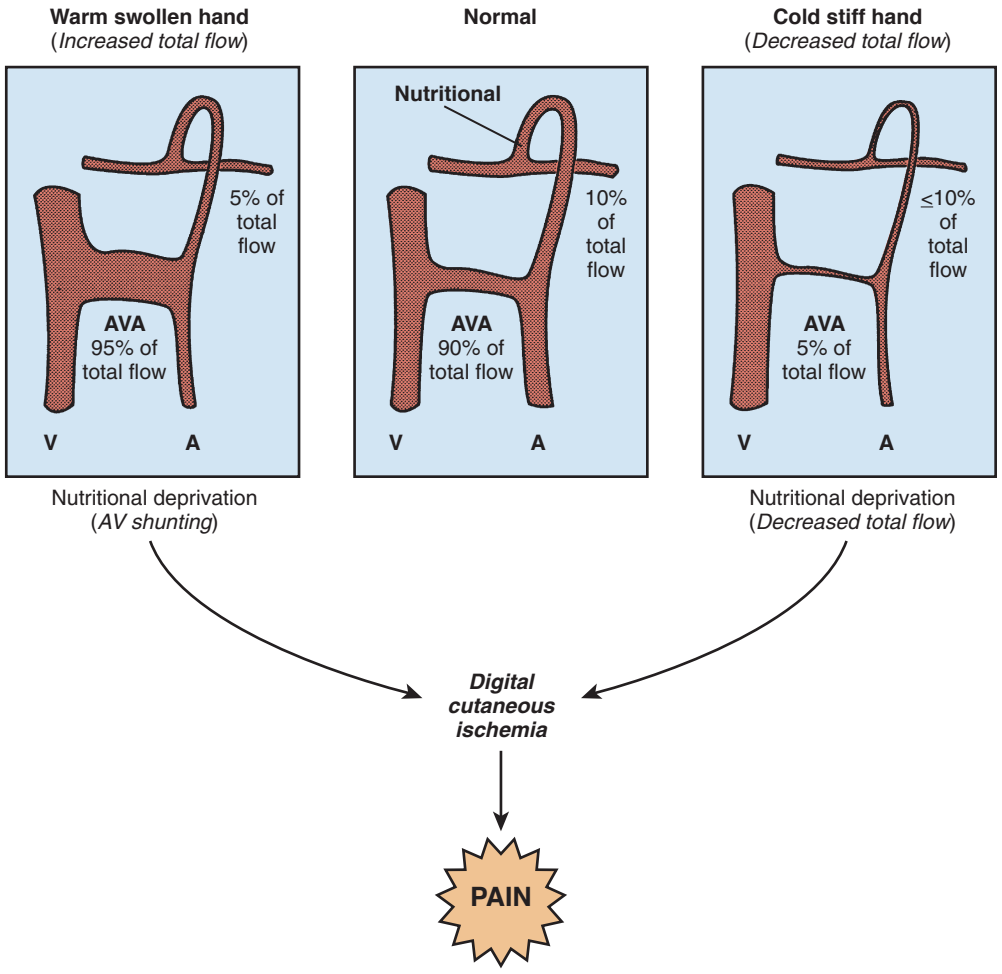

FIGURE 53.9 In a warm, swollen hand with increased total digital blood flow and in a cold, stiff hand with decreased digital flow, abnormal arteriovenous (AV) control through an arteriovenous anastomosis (AVA) may produce or contribute to abnormally decreased nutritional blood flow and pain. (From Koman LA, editor: *Bowman Gray orthopaedic manual*, Winston-Salem, NC, 1996, Orthopaedic Press.)

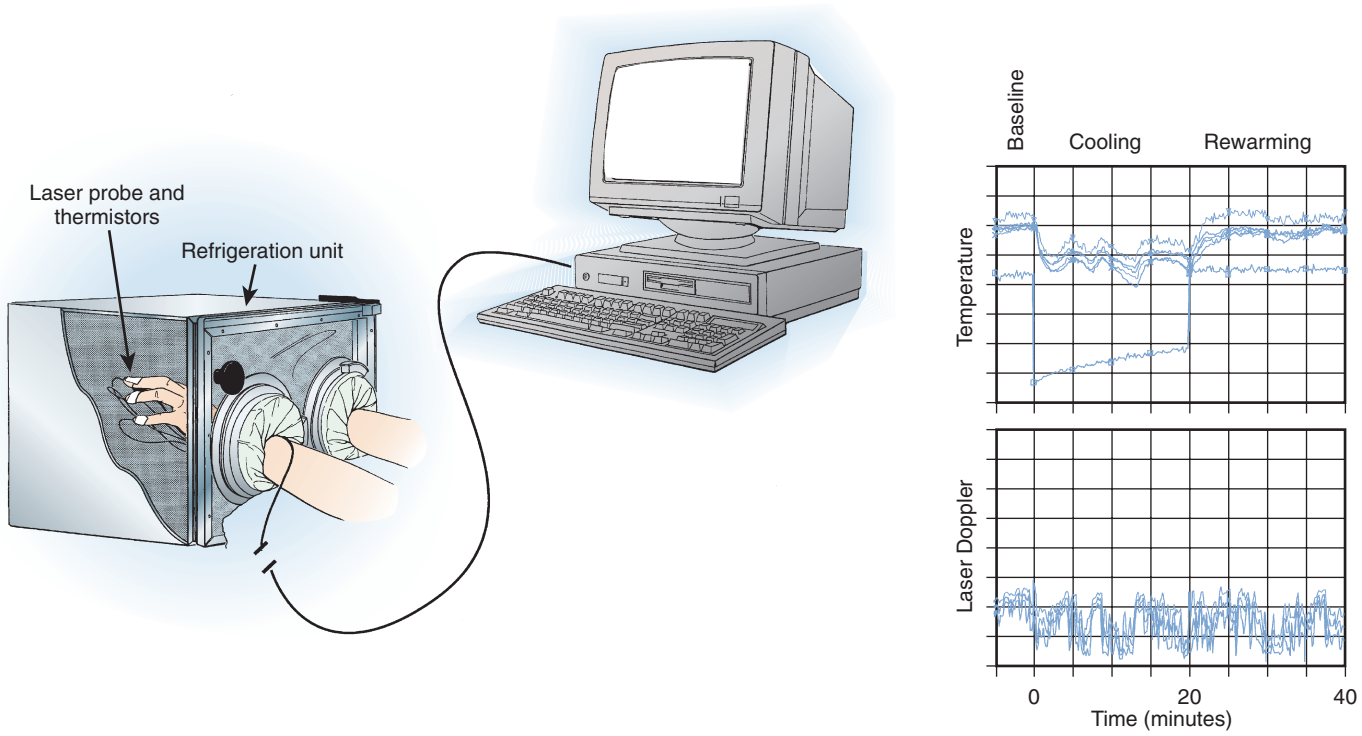

FIGURE 53.10 Digital microvascular physiology can be evaluated by using an isolated cold stress test combining digital temperature and laser Doppler fluxmetry measurements. Digital temperatures are monitored with thermistors attached to each digit of both extremities. Microvascular cutaneous perfusion is assessed with a laser Doppler probe attached to one digit of each extremity. Digital temperature and laser Doppler fluxmetry measurements are sampled with the use of custom computer software, and the results of the test are plotted for analysis. (From Koman LA, editor: *Bowman Gray orthopaedic manual*, Winston-Salem, NC, 1996, Orthopaedic Press.)

thermal, emotional, or ischemic methods, is necessary to obtain reproducible information, to evaluate dynamic response patterns over time, and to maximize sensitivity (Figure 53.10).[76,105] A technique that combines a stressor with a measurement technique is isolated cold stress testing.[76,105] In this procedure, total digital blood flow and microvascular perfusion may be evaluated by monitoring digital temperature and laser Doppler fluxmetry before, during, and after controlled thermal stress.[76] The heterogeneity of digital microvascular perfusion may be analyzed by laser Doppler techniques and is reflected in average pulp temperature readings. Nutritional flow may be measured directly by vital capillaroscopy (Figure 53.11).[76,113] Analysis of temperature, laser Doppler fluxmetry, microvascular perfusion, and nutritional flow permits an objective determination of autonomic vasomotor stability, as well as physiologic staging of autonomic sympathetic performance, defines the adequacy of nutritional flow, and provides an assessment of the effects of interventions.[76,78,85] For example, the effectiveness of sympathetic blockade may be assessed by analysis of digital temperature and microvascular perfusion during the application of a physiologic stress (Figure 53.12). Laser Doppler perfusion imaging provides an assessment of microvascular perfusion over a 12- × 12-cm area and may be used to evaluate the effects of sympathetic blockade on skin blood flow.[126]

Sudomotor Function

Sudomotor activity may be assessed by cumulative unstimulated resting sweat output, QSART,[85] galvanic skin response, combined temperature and peripheral autonomic surface potential reflex response,[75] and analysis of sympathetic skin response evoked by activation of sympathetic unmyelinated efferent fibers.[121] These techniques can be used to obtain quantitative measurements of sweat function, which can then be contrasted to contralateral or ipsilateral areas or normal controls (or both). When combined with microvascular perfusion indices of temperature or laser Doppler fluxmetry, these data supplement the clinical examination, document autonomic dysfunction, and provide objective evidence of the effects of intervention.[76,85]

Diagnostic Regional and Sympathetic Blockade

CRPS may be sympathetically maintained (SMP) or sympathetically independent (SIP). Relief after sympatholytic interventions defines SMP.[108,109] Pain relief after the administration of parenteral, oral, or topical pharmacologic preparations or after neural blockade confirms the influence of the sympathetic nervous system and supports receptor-mediated abnormalities.[108,109] Pain relief after an intravenous injection of phentolamine (a mixed α_1- and α_2-adrenergic blocking agent) is considered presumptive evidence of SMP,[109] or it may be considered diagnostic of SMP.[108] Phentolamine testing is compromised unless the drug is administered in conjunction with placebo injections.[109,110] Intravenous phentolamine may produce profound transient side effects, including headache and hypotension. Unlike other pharmacologic end-organ blockers (e.g., bretylium), phentolamine has no therapeutic indications and is used only as a diagnostic modality. Recent data indicate that adequate sympathetic blockade does not consistently correlate

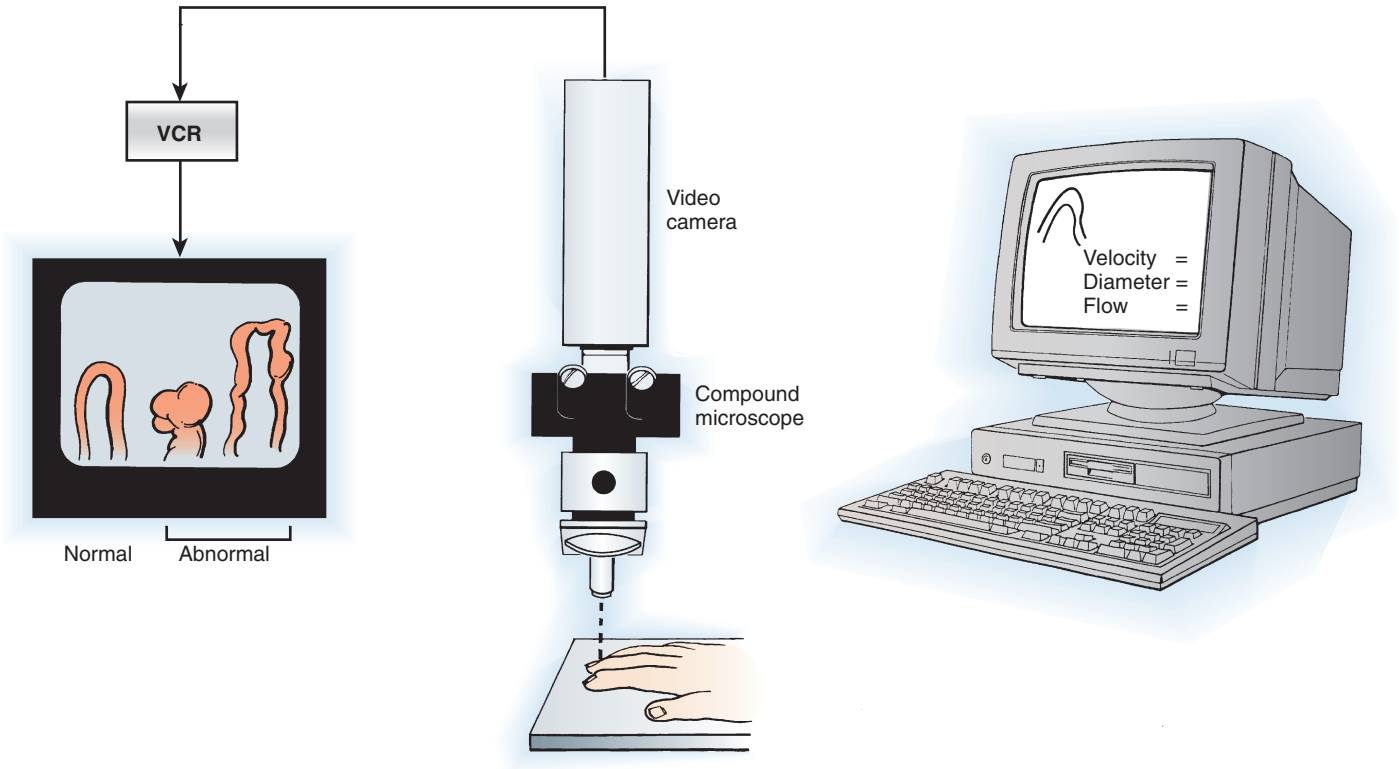

FIGURE 53.11 Nutritional capillaries may be visualized directly through a compound microscope, which provides visualization of red blood cell motion within the capillaries and permits the identification of normal and abnormal capillary morphology. Videotape analysis facilitates quantitation of the diameter of the capillaries and velocity of flow within the ascending and descending capillary loop. Abnormal morphology diagnostic of collagen vascular disease can be observed. *VCR,* Videocassette recorder. (From Koman LA, editor: *Bowman Gray orthopaedic manual*, Winston-Salem, NC, 1996, Orthopaedic Press.)

with the extent of pain relief and that the duration and density of the block may alter the clinical response.[137] The role of SMP may be evaluated by nerve blocks of the stellate ganglion, epidural space, brachial plexus, or peripheral nerves.[77,78] Diagnostic blocks are usually obtained with short-acting or intermediate-acting local anesthetics (e.g., lidocaine). Stellate ganglion blocks may be performed by injections administered at the transverse process of C6 (Chassaignac tubercle) or by a medial approach at C7. Injections of the stellate ganglion or sympathetic trunk that are adequate to induce sympatholysis are dependent on variations in patient anatomy, the presence or absence of scarring in or around the sympathetic chain, drug diffusion characteristics, and the ability and skill of the injector. Therefore, adequate interpretation of results requires verification of sympatholysis, which can be accomplished by the observation of indirect signs such as Horner syndrome, nasal congestion, or facial anhidrosis or by direct evidence of sympathetic nerve block such as an increase in temperature (≥3°C), venous engorgement of the hand veins, dry skin, changes in skin color, and characteristic laser Doppler changes.[77,78,90,106] Indirect "signs" of blockade are mediated by preganglionic fibers and can occur without sympathetic blockade. Consequently, it is imperative to have objective evidence of blockade before dismissing patients or declaring them to have SIP. Effective stellate ganglion blocks, even when administered by experienced anesthesiologists, occur in only 70 to 75% of cases. Therefore, objective determination of the adequacy/effectiveness of autonomic blockade is important. Furthermore, a patient who does not respond favorably to peripheral sympathetic blockade may achieve symptomatic relief with a continuous sympathetic block or from epidural blockade.[21]

Thermography

Thermographic techniques provide a large quantity of temperature data, allow comparison of both upper extremities, and permit rapid repeated measurements over time. However, peer-reviewed data do not support the use of thermography as a superior alternative to other conventional diagnostic modalities.[8] Recent data suggest that higher temperatures indicated by thermography do not correlate with skin surface flow in RSD[92] and that the use of temperature alone cannot distinguish RSD from "chronic upper limb pain." Thermographic data must be interpreted strictly to be effective. Misleading color-coded asymmetry patterns may be created by inappropriate sensitivity settings; that is, settings should exceed 0.5°C to 1.0°C per color band.[124] Repeated measurements over time from the same subject or subjects are reproducible and consistent, reflect skin blood flow, and correlate with symptoms in a variety of painful pathologic entities.[124] The use of a stressor strengthens thermographic data, which are a reflection of total skin blood flow,[52,76,105] and significantly improves the predictive and diagnostic value of telethermography.[52]

Endurance Testing

Objective evaluation of extremity function can be accomplished by using standardized tests and computerized analysis systems.

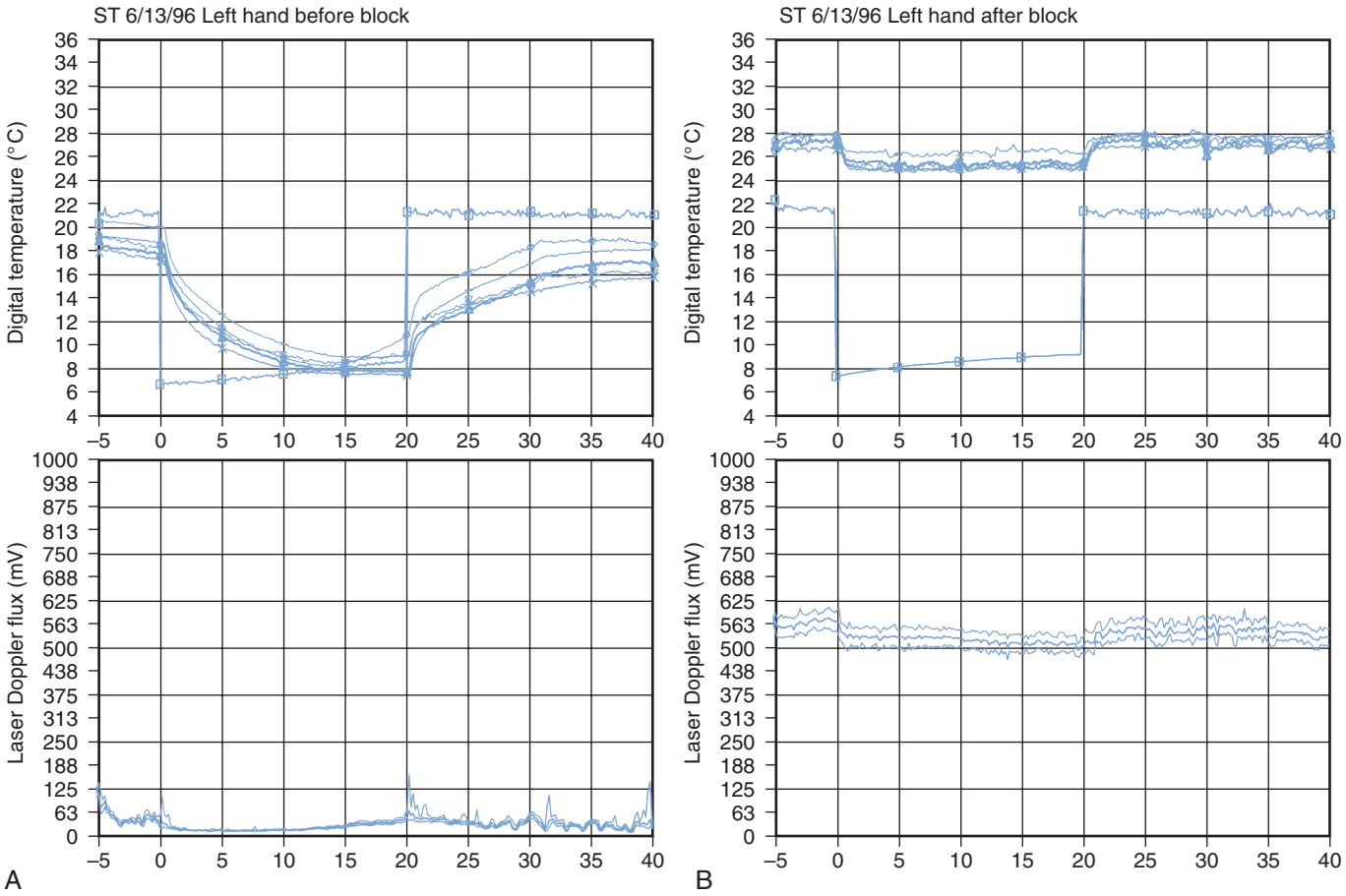

FIGURE 53.12 Laser Doppler fluxmetry in a patient with clinical RSD before **(A)** and after **(B)** sympathetic blockade. The temperature of all five fingers of the left hand and the environmental temperature (indicated by *squares*) are plotted in the upper portion of the graphs. Laser Doppler measurements were monitored with a probe placed on the left ring finger. Baseline temperatures and laser Doppler measurements were taken for 5 minutes. For the cooling phase, the hands were inserted into the refrigeration unit for 20 minutes. After cooling, the hands were removed from the unit and allowed to rewarm at room temperature for 20 minutes. After sympathetic blockade, digital temperatures were increased markedly during all phases of the testing procedure. The amplitude of laser Doppler flux was increased after the block, thus confirming modulation of sympathetic input (chemical sympathectomy). (From Koman LA, editor: *Bowman Gray orthopaedic manual*, Winston-Salem, NC, 1996, Orthopaedic Press.)

These evaluations document overall functional capacity, verify gross and fine motor skills, and quantitate strength and endurance. Repeating these measures over time provides a sensitive and reproducible methodology that is capable of delineating subtle functional deficits, documenting the effects of intervention (management), and defining the magnitude of permanent impairment.[77,78]

Staging

As a practical guide to treatment, the concept of "acute stage" and "late-stage" CRPS may be helpful. The length of acute CRPS is variable and affected by the injury, patient coping mechanisms, and treatment. The acute stage encompasses treatment from onset to the development of atrophy and fixed contracture. Treatment of the acute stage is designed to alleviate pain, decrease abnormal arteriovenous shunting, manage edema, and correct nociceptive and/or neuropathic abnormalities. Management of late-stage patients is divided into (1) pain palliation using chronic medications (e.g., ketamine) or peripheral nerve or centrally implanted devices (e.g., dorsal column stimulators) and (2) correction of the fixed deformity or contracture.

Treatment

Patients with CRPS may have SMP or SIP. In general, patients with the latter have a poorer prognosis, do not respond as well to sympatholytic modalities, and may be more likely to progress to chronic pain and disability. The diagnosis of sympathetically independent CRPS should be reserved for patients:

1. Who have the clinical symptoms and signs of CRPS, that is, pain, atrophy, autonomic dysfunction, and functional impairment, and do not experience pain relief after sympatholytic intervention
2. With CRPS that was initially relieved by sympatholytic intervention that is no longer effective

If a nociceptive (dystrophic) focus, or trigger area, is identifiable, direct treatment of the abnormality may provide significant pain relief and reduce the need for prolonged use of medication. After a favorable response to oral sympatholytics, it may be possible to identify a specific cutaneous nerve injury, correct this underlying mechanical nerve problem, facilitate recovery, and improve functional outcome. By definition, patients with CRPS type 2 (causalgia) have an identifiable or documented peripheral nerve injury. Surgical interventions that

correct nerve damage or protect the nerve may decrease the incidence of nociceptive foci, lessen symptoms, and enhance function. Similarly, patients with CRPS type 1 (classic RSD) may have a nonneural or mechanical nociceptive focus, which if corrected will facilitate recovery of the extremity.

The choice of intervention may be influenced by physiologic staging, which in turn facilitates the selection of appropriate pharmacologic agents. The goal should be to correct the pathophysiologic manifestations of CRPS. Before selection of treatment, clinical or laboratory testing should be performed to determine (1) the extent of sympathetic tone (increased, normal, or decreased), (2) the presence or absence of edema, (3) the amount of total digital flow (elevated, normal, or decreased), and (4) the status of nutritional flow (decreased or normal).

If sympathetic tone is increased (based on clinical judgment or objective testing), sympatholytic medications aimed at correction of neural or vascular adrenergic tone should be used. On occasion, the only manifestation of abnormal tone may be inappropriate arteriovenous shunting with decreased nutritional flow. Edema should be managed with physical modalities or specific pharmacologic treatment. Estimates of total blood flow and the components of flow may also guide treatment decisions. In summary, *treatment of CRPS is complex and may involve simultaneous or sequential use of multiple treatment modalities.*

Multidisciplinary Approach to Management

Although CRPS can be managed effectively by a single physician, a multidisciplinary team approach is often advisable to optimize patient outcomes. Input from a surgeon, primary care practitioner, psychologist, hand therapist, case worker, or psychiatrist (or any combination of these professionals) is often beneficial. Inclusion of a rehabilitation specialist, case worker, or workers' compensation coordinator may also be beneficial. The lead member of the team is determined by the circumstances of the pain process. For example, management of the acute phase of CRPS type 2 after a distal radius fracture and median nerve injury is often best coordinated by a hand surgeon. Under other circumstances, a primary care physician, anesthesiologist, or psychologist might be the most appropriate individual to coordinate care (e.g., in a patient with CRPS type 1 and persistent symptoms after more than a year of active treatment). Pain clinics are a valuable resource and should be incorporated into management plans. However, they should not be used as a patient "dumping ground." Continued involvement of the initial treating physician throughout the process optimizes patient management. After the dystrophic process is quiescent, one or more mechanical foci may be evident that would not be apparent to an isolated practitioner. A physician who understands the injury process and is knowledgeable about the diagnosis and management of upper extremity disorders should be involved in the ongoing management of the patient.

Pharmacologic Interventions

On the basis of empirical, theoretical, and documented modes of action, a variety of oral, topical, and parenteral pharmacologic interventions are and have been used to treat CRPS.[82] Theoretical mechanisms of drugs that control pain associated with dystrophic or causalgic responses include membrane stabilization (e.g., anticonvulsants, local anesthetics), competitive inhibition of the neurotransmitter receptor blockade (e.g., terazosin), blockade of the end-organ effects of sympathetic stimulation (e.g., nifedipine), and desensitization of central pain-signaling neurons (e.g., α_1- and α_2-blocking agents). Some of these drugs may exhibit more than one mode of action. Few of the drugs used in the management of CRPS are listed for "pain management" in the accompanying package insert approved by the U.S. Food and Drug Administration (FDA). Rather, their use is based largely on empirical data and assessment of the risk-benefit ratio. *Before using the drugs discussed in this chapter, each practitioner should be familiar with the pharmacology, side effects, potential complications, indications, and contraindications for each* (see accompanying tables).

Vitamin C

Although the mechanism is unknown, four randomized controlled trials support the efficacy of 500 mg of vitamin C as a preventive intervention to decrease CRPS after trauma or surgery. The relative risk after treatment with 500 mg or more of vitamin C daily after surgery or injury is 0.22.[125]

Oral and Topical Medications

Antidepressants

Antidepressants are frequently used in the management of chronic pain, although there is no clear evidence that they are effective,[32] and the evidence that is available is anecdotal.[114] Antidepressants have been used in patients with CRPS because they have been shown to effectively relieve pain in those with diabetic neuropathy and postherpetic neuralgia.[20] Originally, antidepressants were used empirically to relieve posttraumatic depression; however, they also provide analgesia and modulate sympathetic hyperactivity in the peripheral nervous system and CNS.[24,86,145] Antidepressants used for CRPS include tricyclic antidepressants, tetracyclic antidepressants, atypical antidepressants, and selective serotonin reuptake inhibitors.

Tricyclic antidepressants have been in use since the early 1960s and are some of the most common agents used for the management of CRPS. A decrease in SMP is based on the drugs' interference with postganglionic reuptake of amines, downregulation and desensitization of presynaptic α_2 and serotonergic receptors, and reduction of the synthesis and release of norepinephrine. The variation in the biogenic amines in these antidepressants produces differential receptor affinity and accounts for the differences in clinical response. This explains why one antidepressant may prove efficacious in one patient and not in another. The most commonly used tricyclic antidepressants include imipramine, amitriptyline, doxepin, desipramine, nortriptyline, and protriptyline (Table 53.5).[24]

Drug selection should be individualized to account for potential side effects, drug interactions, comorbid conditions, previous response to the drug, and patient age. The most common side effects of tricyclic antidepressants are anticholinergic, cardiovascular, and CNS effects (see Table 53.5). Long-term treatment with these drugs is tolerated; however, abrupt drug discontinuation should be avoided because of the potential adverse side effects. Chronic treatment with this class of drugs requires physician monitoring.

The *tetracyclic antidepressant* maprotiline (Ludiomil) is pharmacologically similar to imipramine and blocks the

TABLE 53.5 Antidepressants Used in Pain Management

Drug	Mechanism of Action: Action	Mechanism of Action: Efficacy	Dosage (Range)	Common Side Effects: Anticholinergic Effects	Seizures	Orthostatic Hypotension	Conduction Abnormalities	Sedation
Tricyclic Antidepressants								
Imipramine (Tofranil, SK-Pramine)	Blocks reuptake of amines Serotonin Norepinephrine	 ++++ ++	50-75 mg (50-300 mg)	+++	+++	++++	++++	++
Amitriptyline	Blocks reuptake of amines Serotonin Norepinephrine	 ++++ ++	25-75 mg (50-300 mg)	++++	+++	+++	++++	++++
Doxepin (Sinequan, Adapin)	Blocks reuptake of amines Serotonin Norepinephrine	 +++ ++	50-75 mg (50-300 mg)	+++	+++	++	++	++++
Desipramine (Norpramin, Pertofrane)	Blocks reuptake of amines Serotonin Norepinephrine	 +++ ++	50-75 mg (50-300 mg)	+++	++	+++	+++	++
Nortriptyline (Aventyl, Pamelor)	Blocks reuptake of amines Serotonin Norepinephrine	 +++ +++	25-50 mg (50-150 mg)	+++	++	+	+++	+++
Protriptyline (Vivactil)	Blocks reuptake of amines Serotonin Norepinephrine	 +++ ++++	10-20 mg (15-60 mg)	+++	++	++	++++	+
Tetracyclic Antidepressants								
Maprotiline (Ludiomil)	Blocks reuptake of amines Serotonin Norepinephrine	 + ++	50-75 mg (50-225 mg)	+++	++++	++	+++	+++
Atypical Antidepressants								
Trazodone (Desyrel)	Blocks reuptake of amines Serotonin Norepinephrine	 +++ ±	50-150 mg (50-600 mg)	+	++	+++	+	+++

++++, Marked; +++, moderate; ++, minimal; +, none.
From Koman LA, editor: *Bowman Gray orthopaedic manual*, Winston-Salem, NC, 1996, Orthopaedic Press.

reuptake of norepinephrine more than that of serotonin. The anticholinergic properties of this drug are significant and may complicate its use (see Table 53.5).

Trazodone (Desyrel), an *atypical antidepressant*, can be used to treat CRPS. Its mechanism of action includes preferential blocking of the reuptake of serotonin and binding to adrenergic (α_1 and α_2) receptors. Once-per-day dosing is possible; however, the effects of β-adrenergic blockade are often difficult to tolerate and include tremor, hypertension, bradycardia, dizziness, and sedation.

The use of *selective serotonin reuptake inhibitors*, or second-generation antidepressants, has increased significantly over the past decade. These drugs include fluvoxamine (Luvox), paroxetine (Paxil), fluoxetine (Prozac), and sertraline (Zoloft) (Table 53.6).[98,139] Selective serotonin reuptake inhibitors bind preferentially to the presynaptic serotonin carrier in the CNS and thereby inhibit reuptake of serotonin. Side effects, which may be significant, tend to diminish after 1 to 2 weeks. Even though the efficacy of the selective serotonin reuptake inhibitors used for treating chronic pain is not well defined, these agents are used frequently for that purpose. Selective serotonin reuptake inhibitors are commonly prescribed in conjunction with low-dose tricyclic antidepressants; the use of both drugs has a synergistic effect in many patients. Tricyclic antidepressants produce the most pronounced sympatholytic effects and should be used before or in addition to selective serotonin reuptake inhibitors.

TABLE 53.6 Selective Serotonin Reuptake Inhibitors Used in Management of Complex Regional Pain Syndrome

	Fluvoxamine (Luvox)	Fluoxetine (Prozac)	Paroxetine (Paxil)	Sertraline (Zoloft)
Blocks presynaptic serotonin reuptake	Moderate serotonin affinity	Minimal serotonin affinity	Pronounced serotonin affinity	Moderate serotonin affinity
Dosage	Start at 50 mg/day; increase to 100-300 mg/day	20-80 mg/day	Initially 20 mg/day Average, 20-50 mg/day (titrate to effect)	Initially 50 mg/day Average, 50-100 mg/day (titrate to effect)
Common side effects	CNS: headaches, sleep disorders GI: nausea	CNS: headaches, sleep disorders, agitation GI: nausea Other: chills, weight loss	CNS: asthenia, sleep disorders GI: nausea Other: male sexual dysfunction	CNS: agitation, sleep disorders, headaches GI: nausea Other: male sexual dysfunction

CNS, Central nervous system; *GI*, gastrointestinal.
From Koman LA, editor: *Bowman Gray orthopaedic manual*, Winston-Salem, NC, 1996, Orthopaedic Press.

TABLE 53.7 Anticonvulsants Used in Management of Complex Regional Pain Syndrome

	Phenytoin (Dilantin)	Carbamazepine (Tegretol)	Valproic Acid/Valproate (Depakene)	Gabapentin (Neurontin)
Starting dose (maximum dose)	100 mg tid (up to 400 mg/day)	100 mg bid (1200 mg/day)	250 mg qid (3000 mg/day)	600-800 mg tid (2400 mg/day)
Mechanism of action	Membrane stabilization	Blocks sodium influx across cell membranes	Stimulates GABA production	Unknown; assumed to be GABA related
Gastrointestinal side effects	Nausea, vomiting, constipation, hepatitis, liver damage	Nausea, vomiting, jaundice (hepatocellular, cholestatic)	Nausea, vomiting	Anorexia, flatulence
Hematologic side effects	Thrombocytopenia, leukopenia, megaloblastic anemia	Aplastic anemia, agranulocytosis, thrombocytopenia	Thrombocytopenia, anemias, clotting disorders	Purpura
CNS side effects	Nystagmus, ataxia, dizziness, convulsion	Dizziness, drowsiness, ataxia	Sedation, tremor, hallucinations, headache	Somnolence, dizziness, ataxia
Other side effects	Rashes	Rashes, epidermal neurolysis, congestive heart failure	Hepatic failure, dysmenorrhea, pancreatitis	Fatigue, hypertension
Contraindications	Liver disease, pregnancy	Bone marrow depression, simultaneous monoamine oxidase inhibitors	Liver disease, pregnancy	Care must be taken in patients with renal disease

GABA, γ-Aminobutyric acid.
From Koman LA, editor: *Bowman Gray orthopaedic manual*, Winston-Salem, NC, 1996, Orthopaedic Press.

Anticonvulsants

Anticonvulsants were first used to treat hyperpathic pain and later to treat CRPS.[95] Although their mechanism of action is unknown, it is postulated that these compounds stabilize excitable nerve membranes, limit neuronal hyperexcitability, and inhibit transsynaptic neuronal impulses in the CNS.[86] Anticonvulsants are often used in combination with other medications (e.g., tricyclic antidepressants). Phenytoin (Dilantin), carbamazepine (Tegretol), valproic acid (Depakene), and gabapentin (Neurontin) are the most commonly used anticonvulsants in managing CRPS (Table 53.7).

Membrane-Stabilizing Agents

The oral use of local anesthetics provides a new approach to the management of CRPS. Local anesthetics selectively depress neuronal activity within the spinal cord, decrease C fiber polysynaptic conduction, reduce alpha motor neuron reflexes, and diminish noxious thermal and chemical reflexes.[24] However, the exact mechanism by which local anesthetics reduce pain is unclear. The development of oral membrane-stabilizing agents was based on the observation that lidocaine, when used intravenously, provided relief from chronic pain. Tocainide (Tonocard) and mexiletine (Mexitil) are available as oral medications (Table 53.8). Unfortunately, side effects with tocainide are common (40% to 80% of patients experience adverse effects) and include serious idiosyncratic reactions such as interstitial pneumonitis, psychosis, encephalopathy, neutropenia, lupus-like syndrome, agranulocytosis, anemia, hepatitis, and convulsions. Mexiletine is less commonly associated with severe complications, but known drug reactions associated with its use include lupus-like syndrome, abnormal liver function, blood dyscrasias, and impotence. Therefore, the use of these drugs in patients with CRPS is limited to severe or refractory cases.

Adrenergic Compounds

The role of α-adrenergic receptors and transmitters is well documented in CRPS with SMP (Table 53.9).[6,24] Adrenergic agents useful in the management or diagnosis (or both) of SMP

TABLE 53.8 Comparative Characteristics of Intravenous and Oral Local Anesthetic Agents Used for Chronic Pain: Membrane-Stabilizing Agents

	Lidocaine	Mexiletine (Mexitil)	Tocainide (Tonocard)
Dosage	3 mg/kg (range, 2-6 mg/kg). Test dose over period of 20-30 minutes	10 mg/kg/day	20 mg/kg/day
Cardiovascular side effects	Bradycardia, hypotension	Palpitations, chest pain, syncope	Hypotension, ventricular arrhythmias
Central nervous system side effects	Dizziness, nervousness, apprehension, euphoria	Dizziness, tremor, headache	Dizziness uncommon: encephalopathy and psychosis
Other side effects		Nausea, vomiting	Blood dyscrasias, pulmonary fibrosis, nausea, rashes
Contraindications		Cardiogenic shock, second- or third-degree atrioventricular block (if no pacemaker)	Second- or third-degree atrioventricular block in the absence of a pacemaker, heart failure

From Koman LA, editor: *Bowman Gray orthopaedic manual*, Winston-Salem, NC, 1996, Orthopaedic Press.

TABLE 53.9 Adrenergic Agents Used in Management of Complex Regional Pain Syndrome

	Phentolamine (Regitine)	Phenoxybenzamine (Dibenzyline)	Prazosin (Minipress)	Terazosin (Hytrin)	Clonidine (Catapres)
Administration and dosage	IV infusion: 25-30 mg/100 mL saline in 20 minutes	PO: 5-120 mg/day	PO: 1 mg once at bedtime up to tid	PO: 1 mg qid	Topical, intrathecal, or PO: 1 mg/hour by patch weekly; 1 mg PO tid initially
Action/mechanism	Postsynaptic α_1-antagonist Presynaptic α_2-antagonist	Postsynaptic α_1-antagonist Presynaptic α_2-antagonist $\alpha_1 > \alpha_2$	Postsynaptic α_1-antagonist	Postsynaptic α_1-antagonist	Presynaptic α_2-agonist
Side effects	Hypotension, cardiac arrhythmias, weakness, nausea, dysrhythmias	Orthostatic hypotension	Orthostatic hypotension	Orthostatic hypotension	Dry mouth, drowsiness

From Koman LA, editor: *Bowman Gray orthopaedic manual*, Winston-Salem, NC, 1996, Orthopaedic Press.

and variant forms of CRPS include α_1-antagonists, α_2-antagonists, combined α_1- and α_2-antagonists, and α_2-agonists (see Table 53.9).[6,63,108,109]

Phentolamine (Regitine), first introduced as a diagnostic test for RSD, produces nonselective, competitive α-adrenergic blockade by affecting postsynaptic α_1 receptors and presynaptic α_2 receptors.[6,108,109] Theoretically, the resulting chemical sympathectomy induces peripheral vasodilation, increases nutritional blood flow, and decreases non–microvascular-mediated adrenergic sensitization. Decreased pain or pain relief after intravenous phentolamine (25 to 30 mg) is pathognomonic for adrenergically driven SMP.[109] Patients with a positive response to intravenous phentolamine are likely to respond to other forms of sympatholytic intervention. The use of phentolamine as a definitive test for CRPS is hindered by the presence of false-negative results and the absence of placebo controls.[107]

Nonselective oral adrenergic medications include phenoxybenzamine (Dibenzyline), which is an irreversible postsynaptic α_1-antagonist and a presynaptic α_2-antagonist. Unfortunately, the drug is poorly tolerated by many patients; however, the pain relief that it provides may be dramatic. Prazosin (Minipress) and terazosin (Hytrin) block postsynaptic α_1 receptors selectively without significantly affecting presynaptic α_2 receptors and may diminish symptoms such as allodynia and vasospasm.[128]

α_2-Adrenergic agonists may also be effective. Clonidine (Catapres), a selective presynaptic α_2-agonist in the CNS, is used clinically in three divided doses or as a continuous transcutaneous patch. In patients with edema and hyperalgesia, dramatic improvement may result from α_2-agonist stimulation (Table 53.10).[24]

Calcium Channel Blockers

Calcium channel blockers have been demonstrated to decrease symptoms in selected patients with CRPS (Table 53.11). Although their mechanism of action in the treatment of CRPS is unclear, calcium channel blockers decrease sympathetic tone by preventing release of calcium after stimulation of adrenergic receptors. Nifedipine (Adalat, Procardia) and amlodipine (Norvasc) are the most commonly used.[24] By inhibiting extracellular calcium passage through L-channels in the vascular smooth muscle membrane, the effects of adrenergic agents are blocked and vasoconstriction is diminished. Use of these drugs often results in significant diminution of pain, which may correlate with increased nutritional perfusion and decreased abnormal arteriovenous shunting.[76,77,109,110]

Corticosteroids

High success rates have been reported with the use of corticosteroids for the management of CRPS.[20,32,114] The exact

TABLE 53.10 Parenteral Medications Used in Management of Complex Regional Pain Syndrome

	Methods of Administration and Usual Dosage	Mechanism of Action	Major Short-Term Disadvantage or Side Effects	Contraindications
Bretylium	IV regional: 100-200 mg	Norepinephrine-reuptake-blocking agent; depletion of terminal vesicle of norepinephrine		No longer available
Clonidine	Continuous epidural: 10-40 mg/hour	Diminishes regional sympathetic outflow by direct action at the spinal cord (see Table 53.9)	Hypotension, transient sedation (see Table 53.9)	Advanced renal insufficiency, first-degree atrioventricular block, concurrent agonists or α-antagonist (see Table 53.9)
Phentolamine	IV injection: 5-15 mg	α-Adrenergic blocker	Hypotension	Coronary artery disease
Cortisone	IV injection: 5-15 mg	α-Adrenergic blocker	Hypotension	Coronary artery disease
Reserpine	IV injection: no longer available in the United States	Norepinephrine inhibitor	Orthostatic hypotension	Depression

TABLE 53.11 Calcium Channel Blockers and Corticosteroids Used in Management of Complex Regional Pain Syndrome

	Nifedipine (Adalat, Procardia)	Amlodipine (Norvasc)	Corticosteroid
Dosage	10-30 mg PO tid or 30-90 mg qid sustained	2.5-5 mg/day	10 mg/day PO
Mechanism of action	Blockade of calcium channels on vascular smooth muscle cells	Blockade of calcium channels on vascular smooth muscle cells	Decreases inflammation, unknown
Common side effects	Headaches, peripheral edema, postural hypotension	Headaches, postural hypotension	Multiple, including edema, circulatory problems, paresis, dermatologic effects, cataracts

From Koman LA, editor: *Bowman Gray orthopaedic manual*, Winston-Salem, NC, 1996, Orthopaedic Press.

mechanism of action of these agents in dystrophic pain has not been elucidated, although they are believed to stabilize membranes. A high starting dose (e.g., 60 mg of prednisone) rapidly tapered over a period of 5 to 10 days is commonly used. Long-term use of low doses (2 to 5 mg) is also advocated.[49] The use of corticosteroids remains controversial because of their potential side effects, complications, and variable benefits. Side effects include adenohypophyseal suppression, hirsutism, and abnormal fat deposition. Complications include avascular necrosis of osseous structures (i.e., the femoral head). Corticosteroids have also been infused regionally in a Hannington-Kiff protocol as an intravenous bolus distal to a proximal tourniquet.[55]

Neuromuscular Blocking Agents

Botulinum A and B toxins have been used for the management of acute and chronic pain. These agents are injected into muscle or skin with reported relief of muscle spasm, dystonia, and skin hypersensitivity through incompletely delineated mechanisms that include inhibition of substance P and decreased muscle overactivity.[5,18,73,74,116,117]

Bisphosphonates

Bisphosphonates have been shown to be effective for CRPS in multiple clinical trials.[114,141] A variety of bisphosphonate compounds and routes of administration have been used, including intravenous clodronate and alendronate.[39,114] The mechanism of action of this class of drugs is to decrease inflammation and provide analgesia by preventing bone resorption.[20,114] Clodronate has been shown to act on inflammatory mediators, including interleukin-1, interleukin-6, lactic acid, and tumor necrosis factor-α.[114] The analgesia produced by bisphosphonates is attributed to modulation of inflammatory cytokines and systemic factors such as prostaglandin E_2 and subsequent nociceptor desensitization. However, to date, no studies have compared the efficacy of the different bisphosphonate compounds.[114]

Calcitonin

Salmon calcitonin (Miacalcin) delivered either by intramuscular injection or intranasal spray has been used for CRPS (Table 53.12).[32] Several studies evaluating the pain relief provided by calcitonin have shown that it is superior to placebo for the relief of CRPS pain. However, the degree of pain relief is probably similar to that associated with therapies such as a combination of physical therapy and analgesics.

Ketamine

Ketamine, an NMDA receptor antagonist, has been studied in animal models of pain (see Table 53.9).[9,32,45,102,115,122] Ketamine is believed to have a peripheral effect on opioid, sodium, and potassium channels.[41] Pain relief, improved mobility, and a reduction in autonomic symptoms are reported after intravenously infused ketamine.[32] However, the use of intravenous ketamine is associated with a high incidence of side effects. Intravenous ketamine must be administered by appropriately credentialed professionals with access to patient monitoring

TABLE 53.12 Other Medications

	Mechanism of Action	Dosage	Common Side Effects
Salmon calcitonin (Miacalcin)	Decreased bone resorption	200 IU by nasal spray	Rhinitis, fatigue, back pain, hypertension, epistaxis, hepatitis, headache, depression, possible allergies
Bisphosphonates: alendronate (Fosamax)	Decreased bone resorption Decreased serum Ca^{2+}	800 mg bid PO 300 mg IV for 2-5 days for problems	Abdominal cramping, exacerbation of kidney problems
Dissociative anesthetics: ketamine hydrochloride (Ketalar)	Anesthetic NMDA receptor blocker (blocks Na^+/K^+ channels	2 mg/kg (IV), 2-3 mg/kg (IM), topical	Severe physiologic reactions, respiratory depression, must be administered by an anesthesiologist with monitoring
Vitamin C	Unknown	500 mg/day PO	Minimal

From Koman LA, editor: *Bowman Gray orthopaedic manual*, Winston-Salem, NC, 1996, Orthopaedic Press.

and resuscitation equipment. Ketamine gel has also been used in a limited number of patients to treat neuropathic pain.[32]

Free Radical Scavengers

Free radical scavengers have been proposed to treat CRPS type 1 based on the assumption that an exaggerated inflammatory response to injury produces toxic oxygen-free radicals that cause pain.[32] Dimethyl sulfoxide (DMSO): 50% concentration showed favorable results in a randomized controlled trial in "warm" CRPS type 1 and *N*-acetylcysteine (NAC) in "cold" CRPS. Both groups—DMSO and NAC—were more effective if patients were treated early.[101] DMSO has not been approved by the FDA for use in human patients.

Other Treatments

Other additional oral and topical medications used to treat CRPS include capsaicin,[129] transdermal nitroglycerin,[61] and prostaglandin E_1 ointment.[91] Ketanserin, a selective S_2 serotonergic antagonist, has been documented to provide relief of RSD pain in a double-blind, placebo-controlled crossover study.[54] However, further clinical trials with these medications are necessary to determine their safety and efficacy in patients with CRPS.

Some of the newer proposed treatments of CRPS include thalidomide (Thalomid), which is believed to affect cytokines that might play a role in CRPS.[114] Several drugs that have been used successfully to manage neuropathic pain have also been suggested for use in CRPS patients.[114] An example is tramadol (Ultram), which has a dual action on μ-opioid receptors and serotonin/norepinephrine reuptake.[114] Intrathecal baclofen has been used to treat CRPS patients with dystonia.[20]

Parenteral Medications

Intravenous Regional Infusion

Infusion of drugs into an isolated extremity for analgesia was described by Bier in 1908, and intravenous drug infusion for dystrophic pain was used first in the 1970s by Hannington-Kiff.[55] The latter's protocol, with or without minor modifications, is still used by many anesthesiologists and pain specialists to deliver intravenous drugs to patients with CRPS. The most common pharmacologic agents used with this technique are bretylium tosylate and corticosteroids (see Table 53.10).[32,38,55,60,65] Tourniquet-induced analgesia may be involved in the short-term pain relief observed after the Hannington-Kiff protocol. Although guanethidine was used in the past, evidence suggests that when compared with placebo, it does not produce any decrease in pain.[20,39] Guanethidine and reserpine are no longer available commercially in the United States and, in general, are not indicated clinically in the management of CRPS type 1 or 2. The use of intravenous corticosteroids in the management of CRPS is not supported by any controlled clinical trials. Bretylium tosylate (Bretylol) is the only drug approved and labeled by the FDA as an intravenous competitive blocking agent. Bretylium produces a transient release of norepinephrine from postganglionic sympathetic nerve endings, followed by blockade of norepinephrine uptake. It is well tolerated and appears to be effective in selected patients.[38,60] Bretylium or corticosteroids may be used in conjunction with regional anesthesia for surgical procedures in patients requiring reconstructive procedures or to facilitate mobilization of stiff joints by manipulation under anesthesia.[142] In rare cases, lasting relief may be obtained after a single intravenous infusion of a sympatholytic drug or corticosteroid; however, in many cases, sequential blocks (three to five) are required. Intravenous regional droperidol, an α-adrenergic antagonist, has been evaluated in a double-blind, placebo-controlled crossover study.[72] Effectiveness of intravenous ketorolac and lidocaine has been reported.[131] Intravenous regional phenoxybenzamine "appeared" to produce long-term relief in five patients.[89]

Diagnostic Intravenous Infusion

Intravenous infusions are used for diagnostic purposes; there are no current treatment programs that involve the use of such infusions.[127] Intravenous phentolamine is used to determine the presence of α-adrenergically mediated sympathetic pain,[6] and intravenous lidocaine may be used to assess the potential efficacy of oral membrane-stabilizing agents.[24]

Epidural Agents

Epidural corticosteroids and clonidine have been used and may provide relief in selected patients.[31,111]

Percutaneous Neural or Ganglionic Blockade

Neural blockade of the stellate ganglion, brachial plexus, or spinal cord/nerve roots is effective in relieving CRPS in some cases (see the earlier section "Diagnostic Regional and Sympathetic Blockade"). A series of blocks performed at 3- to 14-day intervals is often necessary to achieve adequate sustained relief.

Continuous Autonomic Blockade

The use of prolonged blockade or continuous sympathetic blockade (or both) for the management of chronic pain has been established. Sympathetic blockade may be achieved by continuous infusion of a local anesthetic over the area of the stellate ganglion or paravertebral ganglia, along the brachial plexus, or within the epidural space. Specific blocks include anterior scalene, axillary, and brachial (Figure 53.13). Epidural blocks have been used successfully in the lower extremity and provide an alternative method to achieve sympathetic blockade in the upper extremity.[21] Blocks should be performed by experienced physicians with access to resuscitation equipment and ventilatory support. Epidural blocks may be effective in patients who demonstrate no improvement after peripheral sympathetic blockade,[21] and brachial plexus blocks may provide relief in patients unresponsive to stellate ganglion blocks.[30] Complications include complete or temporary motor and sensory blockade, which may compromise respiration, as well as bleeding, and nerve irritation.

Biofeedback and Acupuncture

Self-hypnosis or biofeedback (or both) may be useful in the management of properly selected patients.[40,51] Acupuncture (using electrodes or transdermal needles, or both) has also been advocated for the management of CRPS.[81] These techniques should be used judiciously.

Implantable Devices

Peripheral Nerve Implants

Implantable electrical stimulators have been placed on painful peripheral nerves throughout the nervous system. These include stimulators for gray matter, the dorsal column, the spinal cord, and peripheral nerves. Currently available devices allow various options, including placement of multiple electrodes on peripheral nerves, use of long-lasting implantable pulse generators, and use of remote programming. Single peripheral nerve stimulation can result in pain relief, improve sleep, decrease the use of addictive pain medication, and improve health-related quality of life.[23]

Implantable Spinal Cord Stimulation

Spinal cord stimulation (SCS) in selected patients relieves pain, improves the health-related quality of life, and is more effective and less expensive than standard treatment.[71,138] Selected patients who respond to a trial of SCS are candidates for SCS.[100] Analysis of spinal cord stimulators at 5 years after a randomized controlled trial documented a high complication rate in the implant group and results similar to physical therapy alone for pain relief and other measures.[70] Despite diminishing effectiveness over time, 98% of the SCS group would repeat the procedure.[70] Because of the invasive nature of SCS, it should not be used early in the treatment protocol; however, SCS is a potential intervention that can be used after careful patient selection.[20]

Central Nervous System Ablative Techniques

CRPS has been treated by bilateral anterior cingulotomy with only short-term palliation.[120]

Level of Evidence for Treatment of Complex Regional Pain Syndrome

A review of the randomized placebo-controlled trials on the treatment of CRPS type 1 identified 26 studies, 18 randomized, placebo-controlled trials, and 8 randomized, actively controlled trials.[39] Based on this review, there is limited to no evidence for the efficacy of sympathetic blocks (stellate ganglion or regional intravenous sympathetic blocks), free radical scavenging, prednisolone treatment, acupuncture, or manual lymph drainage.[39] However, promising results were observed with drugs regulating calcium[39,114] and qigong.[39] Vitamin C was identified as being useful in preventing CRPS type 1 after distal radius fractures (see Table 53.12). Authors have attributed the lack of high-quality evidence for the efficacy of lumbar sympathetic blocks, intravenous regional blocks, and stellate ganglion blocks to studies with small sample sizes, lack of control treatment groups, inadequate methodology to rate the response to interventions, and lack of data on the duration of response.[100] The only pharmacologic intervention that has been shown to be effective in multiple controlled trials is treatment with bisphosphonates.[114]

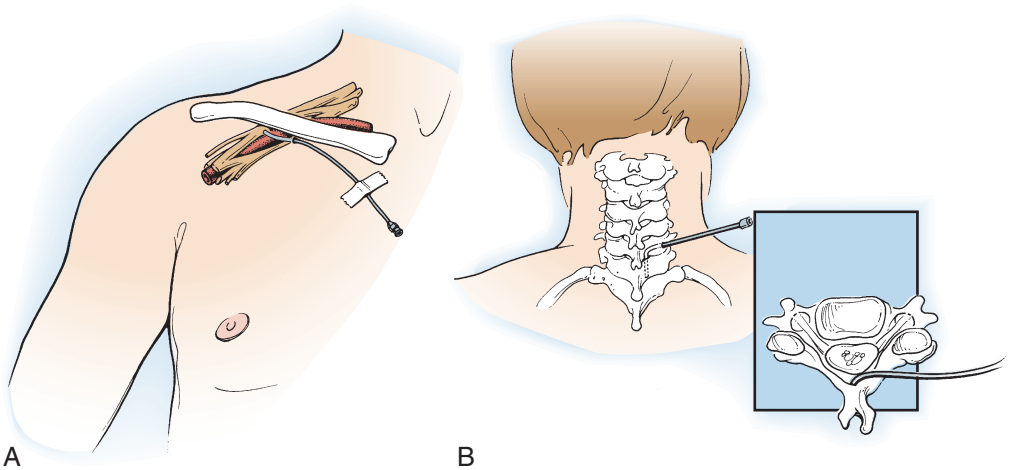

FIGURE 53.13 Placement for continuous blockade with a brachial plexus catheter **(A)** and continuous cervical epidural blockade **(B)**. In both cases a small Silastic catheter is introduced percutaneously and continuous blocking agents or other medications are infused via a pump mechanism. (From Koman LA, Pochling GG: Reflex sympathetic dystrophy. In Gelberman RH, editor: *Operative nerve repair and reconstruction*, Philadelphia, 1990, Lippincott, pp 1497–1524.)

❖ AUTHORS' PREFERRED METHOD OF EVALUATION AND TREATMENT

The manifestation of CRPS is quite variable, and the classic finding of a mildly to moderately swollen, painful hand is not always present. Difficulty sleeping and burning pain may be harbingers of escalating symptoms and signs. Commonly, the patient's condition is thought to represent a "poor" result after surgery or minor trauma. However, examination reveals subtle, yet retrospectively more obvious, symptoms and signs of a dystrophic process. The time course of CRPS may vary considerably, with mild symptoms preventing recovery without pathognomonic findings. Variability in the course of the syndrome is common. Many patients with undiagnosed CRPS recover spontaneously; others "smolder" in the early stage of CRPS for prolonged periods. Occasionally, within a short period patients progress rapidly from painful extremities that are hot and swollen to painful, cold, and stiff extremities and then to stiff and painless extremities. CRPS can affect a single digit, an isolated peripheral nerve distribution, or an entire limb. *Early diagnosis is aided by a high index of suspicion and the recognition that CRPS can occur after any traumatic event.*

Diagnosis

Because successful treatment of CRPS is positively influenced by the rapidity of diagnosis and treatment, early clinical recognition of this syndrome is crucial. A dystrophic process should be considered in all patients experiencing pain that is out of proportion to the traumatic or surgical insult and that is inappropriately influencing function or outcome. High-risk groups for CRPS include patients who sustain peripheral nerve injury, distal radius and ulna fractures, or crushing trauma; however, CRPS may affect any person with an injury. In the postoperative period, painful and excessive swelling combined with vasoconstriction or vasodilation suggests CRPS. The diagnosis of CRPS is clinical, and symptoms must include pain, trophic changes, autonomic dysfunction, and functional deficits. If a diagnosis of CRPS is suspected, instruments to quantitate pain (e.g., McGill Short Form Pain Questionnaire and VAS for pain),[96] overall symptoms and function (e.g., self-administered carpal tunnel questionnaire),[83] and Disabilities of the Arm, Shoulder, and Hand (DASH)[13] are administered. Objective measures of hyperpathia/allodynia are preferred, if possible, and responses to measured stimuli such as monofilament testing are quantifiable. Edema is estimated or measured by volumetric analysis. Function is assessed by questionnaires or verified by standardized methods (or both) (e.g., grip, pinch, Moberg pickup test, computerized instrumentation). The use of standard instruments, appropriate questionnaires, and reproducible objective tests assists in confirming the diagnosis and aids in monitoring the efficacy of interventions.

Physiologic staging of autonomic function is determined by analysis of temperature and laser Doppler fluxmetry before, during, and after a cold stress.[76,105] Nutritional capillary perfusion is assessed by vital capillaroscopy. Temperature and laser Doppler fluxmetry data provide reproducible and sensitive information that can give an estimate of physiologic function, document pathophysiology, and guide treatment decisions. Although not used routinely, phase III bone scans provide confirmative information when combined with clinical prerequisites. Intravenous phentolamine, stellate ganglion blocks, epidural injections, and somatic nerve blocks are used to verify the presence of SMP and predict the efficacy of oral sympatholytic drugs. The location of any identifiable nociceptive foci can be identified after the use of oral or parenteral sympatholytic medications.

Multidisciplinary Team Approach

Our management protocol involves a pain control clinic, as well as anesthesiologists, psychologists, case workers, and therapists. In acute, active phases of the dystrophic process, diagnostic testing and treatment decisions are coordinated through our offices in concert with a hand therapist and case manager. Direct referrals for specific evaluations or treatments are made as needed. If blocks are required, referral is made to an anesthesiologist-directed pain clinic in which resuscitative equipment and skilled personnel are available to perform invasive interventions. The choice of intervention is discussed with the physician administering the block or blocks, and follow-up is coordinated in both offices. In more chronic cases, patients are referred for either primary management or consultation, depending on the circumstances.

Hand Therapy

The use of physical therapy in the management of CRPS is well supported.[53,77,78] Therapeutic regimens should address treatment of the entire limb. For example, restricted shoulder motion resulting from secondary adhesive capsulitis is often insidious in onset and debilitating over time. Therefore, maintenance (or restoration) of shoulder motion is necessary to optimize recovery and may have a profoundly positive impact on health-related quality of life. If present, limited elbow motion may also be debilitating. Joints in close proximity to the area of trauma and the small joints of the hand and wrist are most frequently involved with arthrofibrosis and resultant restricted hand and wrist range of motion. Prevention of arthrofibrosis is important because once it is established, it is difficult to manage. Although physical therapy modalities alone may provide dramatic improvement, many patients require concomitant pharmacologic intervention and adaptive therapies[77,78] or surgery (or both).[53] *The mainstay of therapy should include active and passive joint range of motion, including stress-loading activities, transcutaneous electrical nerve stimulation (TENS) desensitization techniques, or sensory reeducation, or any combination of these therapies.*

Adaptive Modalities

Adaptive therapeutic modalities include TENS techniques, contrast baths, continuous passive motion, intermittent positive pressure with pneumatic pumps, and hydrotherapy.[112] TENS units are theorized to decrease pain by blocking nociceptive input and have been shown to increase extremity blood flow.[112]

Patient Expectations

Nonoperative treatments are a valuable adjunct in the management of CRPS; however, patient tolerance of these treatments differs. Expectations regarding the events taking place during traditional therapeutic modalities, the physiologic consequences of these interventions, and the time course until recovery should be discussed in detail with patients before treatment is initiated.

Details of the type of therapy to be used, such as active range of motion, splinting, or contrast baths, should be outlined. In addition, possible adverse effects, such as swelling and transiently increased pain, should be discussed and the variability in the potential responses detailed. Possible adjustments to the treatment regimen, including the addition of blocks and oral medications, and the side effects/consequences of these treatments should be discussed before treatments are initiated.

❖ AUTHORS' PREFERRED METHOD OF TREATMENT: Oral Medications

Drug selection should be based on physiologic staging of the CRPS and should address the symptoms. In patients with SMP, an estimate of total flow, nutritional flow, edema, and reported symptoms may guide the decision-making process. Combination drug treatment is used frequently, often in conjunction with hand therapy (i.e., stress loading), adaptive therapy, and TENS. Various combinations of drugs may be used; two drugs from separate classes are often more effective than two drugs from one class. For example, patients with SMP, high total blood flow, and nutritional shunting without edema may be given amitriptyline and phenytoin in combination with a stress-loading program. If treatment is successful, total flow will be decreased by minimizing arteriovenous shunting, nutritional flow will increase, and pain will be relieved.

In patients with pain associated with a cold, stiff, atrophic hand, evaluations usually indicate compromised nutritional flow. The use of a calcium channel blocker combined with a serotonin reuptake inhibitor should increase nutritional flow and thereby relieve the symptoms. TENS may also increase nutritional flow by inhibiting smaller nociceptive fibers.[112] Hyperalgesia with significant edema is managed initially by transdermal clonidine in conjunction with a tricyclic antidepressant or a serotonin reuptake inhibitor (or both). Corticosteroids are seldom used because of fear of avascular necrosis. Patients should be monitored carefully with the use of objective data (e.g., pain scales, functional instruments, physiologic testing) when possible. In the absence of clinical improvement, oral medications should be altered or augmented by parenteral interventions.

Treatment Expectations and Complications

The natural history and potential side effects associated with oral medications should be outlined before initiation of the treatment. The fact that drugs prescribed for CRPS are often used for "off-label" indications should be mentioned, and the potential side effects of each drug should be discussed. It is helpful to emphasize to patients that certain classes of drugs are not always used for the package insert indications. Because side effects of drugs are dose related, patients should understand that the doses used for managing the symptoms of CRPS are often less than the doses that are commonly prescribed for other conditions. It should be explained that several drugs used to manage the pain associated with CRPS were originally developed to treat psychological issues or seizures. For example, when using an antidepressant or antipsychotic medicine, it is prudent to tell patients that you are not prescribing the drug because they have psychological issues or because they are having seizures. Instead, you are prescribing the drug because of its effects on the nervous system that facilitate pain management. For phenytoin (Dilantin), patients should be informed that short-term use does not cause gingival hypertrophy.

Expected Outcomes of Drug Therapy

The expected outcomes of drug therapy are relief of pain, decreased swelling, and diminished hypersensitivity to touch.

Drug therapy is frequently combined with other therapies because drugs often provide incomplete relief without additional interventions in 80% of patients.

❖ AUTHORS' PREFERRED METHOD OF TREATMENT: Parenteral Medications

The administration of intravenous medications via variations of the Hannington-Kiff technique or serial stellate ganglion blocks should be guided by controlled protocols, and their continuation should be based on documented and progressive improvement in pain management. We prefer continuous autonomic blocks (e.g., epidural blocks) for 3 to 7 days. The effectiveness of the block may be verified by stress testing after 24 to 36 hours of blockade. It is important to monitor the patient closely by objective criteria, and courses of "blocks" should be based on the attainment of prospective goals within a predetermined time frame.

We have found continuous autonomic blockade to be efficacious in selected patients; it may attenuate the dystrophic process, thereby allowing identification of a nociceptive focus. Furthermore, its use for 3 to 5 days may alleviate symptoms, may allow the patient to return to a satisfactory functional level, or may prevent recurrence or exacerbation of pain after surgical intervention. Biofeedback may be used in conjunction with psychological support in selected patients who demonstrate appropriate psychological profiles established by objective testing (e.g., Minnesota Multiphasic Personality Inventory).

Treatment Expectations and Complications

Parenteral interventions are administered primarily by anesthesiologists. Nevertheless, providing patients with a description of the procedures used to administer parenteral drugs and an explanation of the expected outcomes is helpful. We advise patients that although serial blocks may result in transient benefits, the cumulative effects of repeated serial blocks or continuous blocks may decrease pain in 50% to 80% of patients. The major common side effects of parenteral interventions are pain associated with injection of the drug and bruising at the injection site. Patients should also be informed that a small percentage of patients will have increased symptoms after blocks.

Expectations for Parenteral Treatment

Few patients are affected negatively after parenteral interventions (<5%). Eighty percent of patients experience at least a 50% or greater decrease in pain and other symptoms. Pain during drug injection and injection site tenderness are common.

Surgical and Ablative Therapies

Chemical Sympathectomy

Chemical sympathectomy achieved by the injection of phenol or other agents along the sympathetic trunk provides clinical efficacy in selected patients. For this procedure, diluted phenol (3-7%) is injected into the nerve or ganglia with computed

tomography being used for needle localization. This allows a reversible axonotmesis with recovery in 3 to 6 months. Theoretically, chemical sympathectomy produces pain relief without complete transection of the nerves and diminishes the possibility of delayed hypersensitivity from receptor upregulation. The use of peripheral sympathectomy to increase perfusion after arterectomy, including resection of sympathetic fibers on peripheral blood vessels, was first described by Leriche.[66] Although resection of major blood vessels is not recommended for CRPS, the role of sympathectomy continues to be evaluated and has been reported anecdotally as being effective.

Surgical Sympathectomy

Surgical sympathectomy has been reserved for patients with refractory CRPS because the results are variable. Short-term effectiveness is common, and success after sympathectomy has been reported after failure of other treatment modalities. Successful surgical sympathectomy requires complete sympathetic denervation of the appropriate limb fibers from the stellate ganglion to T2 and T3. Thoracoscopic ganglionectomy is currently being used with satisfactory sympathectomy success rates[123]; however, the effects of proximal sympathectomy on distal sympathetic tone (as reflected by increased blood flow) are transient and last from 6 to 24 weeks. The cause of the loss of efficacy is postulated to be secondary to upregulation of distal receptors, which may produce supersensitivity to circulating or endogenous catecholamines and prompt recurrence of symptoms. However, in some patients, the pain relief after sympathectomy is sufficient to break the dystrophic cycle, and the improvement persists. Patients occasionally experience an increase in pain and symptoms after sympathectomy. Therefore, temporary (3- to 6-month) chemical sympathectomy of the autonomic sympathetic nervous system may be preferable to transection of neural structures. When chemical sympathectomy is used, nerve regeneration will occur and receptor upregulation either does not take place or is diminished. Radiofrequency ablation of the cervicothoracic ganglion has also been recommended.[148] Recently, intrathecal or epidural administration of drugs such as clonidine has been advanced.[111]

Surgical Outcomes and Complications

Deterioration in the patient's condition after surgery occurs infrequently in patients who have responded positively to preoperative sympathetic blocks. In addition, patients benefit from appropriate sympatholysis initiated during the postoperative period to control symptoms. Exacerbation of symptoms occurs transiently in 50% of patients; however, few patients (<5%) continue to experience these symptoms 3 months after surgery. A 50% or greater decrease in pain and other symptoms is observed in 75 to 80% of patients if (1) nociceptive or neuropathic foci are appropriately identified and (2) perioperative sympatholytic management techniques are used. *These observations can be extrapolated to all surgical interventions used in CRPS patients except dorsal column stimulation.*

Summary of the Role of Sympathectomy

Critical analysis of the peer-reviewed literature to assess the effects of both chemical and surgical sympathectomy for neuropathic pain concluded that this clinical practice "is based on poor quality evidence, uncontrolled studies, and personal experience. Furthermore, complications of the procedure may be significant…"[87,130] and "denervation super-sensitivity of blood vessels and intense vasomotion may be associated with recurrence of pain."[12,100] These findings are in agreement with observations by the authors, although some investigators report success with stellate ganglion ablation.[68]

Management of the Neural Dystrophic Focus

If a nociceptive (dystrophic) focus, or trigger area, is identifiable, direct treatment of the abnormality may provide significant pain relief. Nociceptive foci, identifiable in less than 50% of patients, may be mechanical or neural. If diagnosed, the underlying focus may be managed by conventional procedures after maximal pharmacologic control is achieved. If symptoms persist, surgical correction of the defect/deformity may be helpful. The most common neural diagnoses contributing to CRPS are neuroma, neuroma-in-continuity, and secondary compression neuropathies.

Diagnosis and Management of Structural Neural Problems

Neuromas develop in 30 to 40% of patients with significant nerve injuries and may precipitate a dystrophic response, complicate clinical management, and interfere with health-related quality of life. A partial nerve injury, when complicated by a neuroma-in-continuity, is characterized by allodynia, hyperpathia, and vasomotor abnormalities; sudomotor changes are common and cold sensitivity may be significant. Compression neuropathies are frequently seen in patients with CRPS[50,77,78] and may either be the precipitating causal event or occur secondarily. Most frequently, the median nerve is involved within the carpal canal; involvement at the elbow is less frequent. The ulnar nerve at the cubital tunnel or within the wrist may also be involved. The posterior interosseous branch of the radial nerve may be compressed above or within the supinator (radial tunnel syndrome).

Physical examination after sympatholytic intervention may be required to verify the clinical suspicion of neuroma, neuroma-in-continuity, or compression neuropathy. Local anesthesia of the suspected nerve proximal to the suspected injury may be helpful and provides confirmation of clinical suspicion.

Surgical Management of Neural Injury in Complex Regional Pain Syndrome

Surgery on neural structures compromised by neuromas, neuroma-in-continuity, or compression is indicated if symptoms persist after nonoperative modalities, including sympatholytic medications, and if the symptoms can be controlled medically in the perioperative period. An acute dystrophic flare-up of quiescent CRPS is possible in the postoperative period; however, exacerbation of symptoms may be managed effectively with oral medications or a continuous block. Surgical options include neurolysis, neurorrhaphy, or neural relocation. Environmental modification is also an option as is a combination of surgical procedures and environmental modification.

If a neural insult is identified and is correctable surgically, the nerve is explored via an extensile incision. All adhesions are released, and the nerve is evaluated under magnification, with an operating microscope if necessary. The appropriate treatment option depends on the clinical findings, the location and

type of nerve (i.e., motor, sensory, or mixed), the preoperative nerve function, the location of the injury, the quality of the neural bed and its environment, and the general needs and condition of the patient. With a complete nerve transection or a neuroma-in-continuity, the following general principles apply:

- Avoid tension on the repair site or sites by performing nerve grafts from the sural nerve or, for small nerves, a branch of the medial or lateral antebrachial cutaneous nerve.
- Manage adhesions between the skin and nerve by "Z"-plasty local flaps or distant flaps.
- If excessive scarring or adhesions develop, modify the neural bed with the use of autologous fat, rotational muscle flaps, pedicled muscle or fascial flaps, free muscle transfer, autologous or allograft venous wraps, or nerve conduits.[67]
- Minimize internal neurolysis.
- Include sympatholytic intervention (e.g., continuous autonomic blockade), pharmacologic palliation, physical therapy, and early active and passive range of motion in the postoperative care.
- Establish hemostasis to prevent hematoma formation.
- Avoid constrictive postoperative dressings.

For the treatment of compression neuropathy, the dystrophic response is managed by sympatholytic medications or autonomic blockade, or both, and the nerve is evaluated clinically. If symptoms are sufficient to justify intervention, location of the compression neuropathy is confirmed by peripheral nerve conduction velocities or interstitial pressure measurements. Complete release of the involved nerve is important. If there is damage to the neural bed or the neural bed is compromised, modification of the neural environment is appropriate. The patient may be treated postoperatively with appropriate sympatholytic oral medications or continuous autonomic blockade (or both) to minimize postoperative pain and prevent a dystrophic flare-up. Postoperative management of CRPS patients is dependent on the type of surgical procedure. However, sympatholytic intervention with parenteral or oral agents is important, and exacerbation of symptoms is rare. Patients should expect prolonged rehabilitation, continued use of oral nonnarcotic agents for 3 to 6 months, and residual disability. For example, surgical release of the intrinsics by myotomy or tenotomy of the MP or PIP joints will decrease "stiffness" but will not restore full range of motion (50% improvement is average).

❖ AUTHORS' PREFERRED METHOD OF TREATMENT: Common Nerve–Related Complex Regional Pain Syndrome

Surgical Technique for the Management of Injury to the Superficial Branch of the Radial Nerve Complicated by Complex Regional Pain Syndrome

The superficial radial nerve may be injured traumatically or during surgical release of the first or second dorsal compartment of the wrist. Options for treatment include proximal transection of the nerve in normal tissue beneath the brachioradialis muscle, exploration with neurolysis, or repair.

The nerve should be approached through an extensile incision that incorporates the previous scar, if necessary. The nerve may be adherent to the tendons, the tendon sheath, or overlying skin; regional fat necrosis is common. To facilitate dissection, the nerve should be identified proximally and distally in an unoperated or uninjured area while working toward the area of injury. While working from normal to abnormal tissue, the nerve is isolated to expose existing lesions. A decision is then made regarding management of the injury. If repair is selected, microscopic dissection plus repair of injured fascicles is performed end to end or with a nerve graft. If the nerve is to be transected, it may be resected to a level of surrounding normal tissue or relocated to an unscarred area (Figure 53.14). Either a sural nerve or a forearm nerve is harvested from a separate incision to accomplish nerve grafting. Based on experience in six patients with injured superficial radial nerves and CRPS, our preference is to use the sural nerve to avoid a potential nociceptive focus in the same extremity. During preoperative assessment, donor nerves may be blocked proximally so that the patient appreciates the degree of potential numbness in the donor nerve field that will be experienced after the surgery. The sural nerve is harvested through a separate lateral incision in

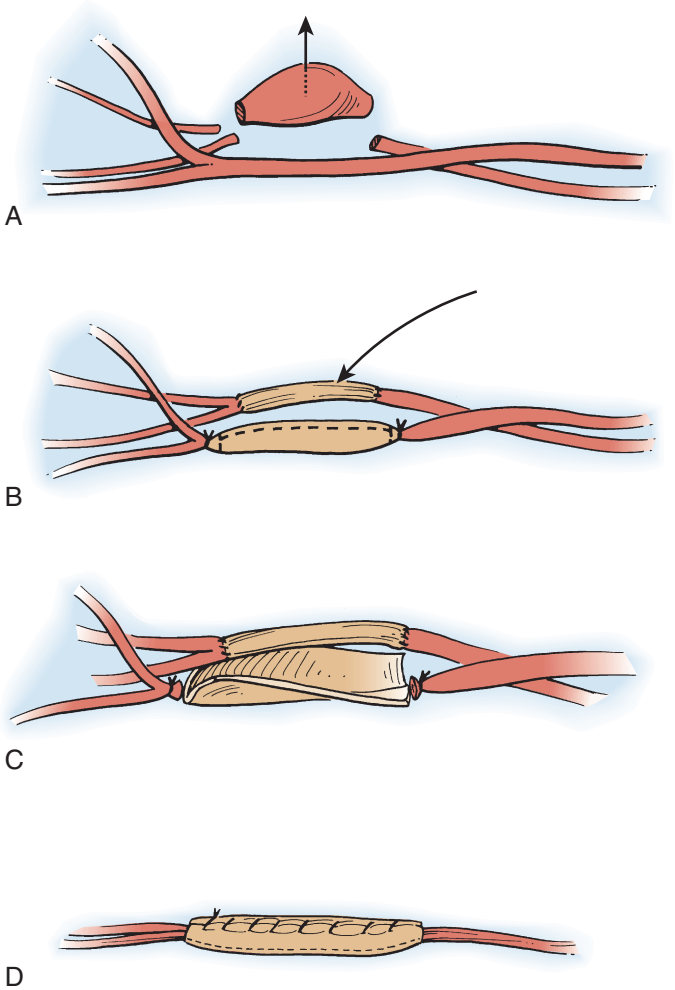

FIGURE 53.14 Authors' preferred treatment of a neuroma of the superficial branch of the radial nerve. **A,** Resection of the neuroma. **B,** Repair with a sural nerve graft and ligation of the cephalic vein. **C,** Longitudinal split in the resected segment of vein. **D,** Cephalic vein wrapped loosely around the nerve repair. (From Koman LA, editor: *Bowman Gray orthopaedic manual*, Winston-Salem, NC, 1996, Orthopaedic Press.)

the leg. The grafting is then completed with 8-0 or 9-0 nonabsorbable suture under the operating microscope.

Excessive scar-related attachment of the nerve to underlying tendon structures or to overlying skin requires environmental modification. Although this may be achieved by a variety of means, we prefer covering the nerve with a section of the adjacent cephalic vein or harvesting a separate vein from the leg or arm. Alternatives include nerve conduit grafts, local or free fat grafts, and free muscle transfer.[67] After repair, the tourniquet is deflated, bleeding is controlled, and a drain is placed to prevent hematoma formation. Subcutaneous tissue is closed with absorbable suture, and the skin is approximated with nonabsorbable suture or staples, or both. Postoperative reactivation of the dystrophic process is a major concern, but it may be minimized by maintaining a continuous autonomic blockade for 3 to 5 days after surgery.

CRITICAL POINTS *Management of Patients With a Painful Median Nerve and Complex Regional Pain Syndrome*

Indications
- Quiescent or stable sympathetically maintained CRPS with mechanical pain
- Previous neurolysis with scar and decreased nerve mobility

Preoperative Evaluation
- Demonstrate painful nerve gliding.
- Evaluate peripheral nerve conduction velocities.
- Do not perform surgery unless sympatholytic intervention reduces the pain significantly.

Pearl
- Have an anesthesiologist perform a continuous autonomic block before surgery for intraoperative and postoperative pain management (2 to 5 days).

Technical Points
- Perform an extensile neurolysis.
- Excise any synovitis, if present.
- Mobilize the nerve.
- Cover the nerve with fat, a muscle flap, vein, synthetic conduit, or free tissue transfer.

Pitfalls
- Failure to confirm potential control of postoperative pain with oral or parenteral drugs or continuous field or nerve blocks
- Incomplete mobilization of the involved nerve
- Inadequate interposition of soft tissue or other material between skin-nerve and nerve-tendon interfaces

Postoperative Care
- Initiate early range-of-motion exercises of the fingers and wrist.
- Maintain adequate pain management for 3 to 7 days with parenteral or oral agents, or both.
- Note that continuous blocks are helpful for pain relief. Allow unrestricted motion when the patient is comfortable.

❖ AUTHORS' PREFERRED METHOD OF TREATMENT: Revision of Carpal Tunnel Surgery

Persistent mechanical pain associated with dystrophic symptoms after release of the transverse carpal ligament or neurolysis of the median nerve is a difficult problem. The nociceptive focus may result from internal or external scarring, neuroma-in-continuity, or transection of a nerve branch (e.g., the palmar cutaneous branch of the median nerve). When SMP is associated with a demonstrable peripheral nerve lesion, surgical intervention/correction of the underlying lesion may provide significant palliation. If external adhesions or mechanical problems are contributing to the nociceptive focus, environmental modification may be necessary.

The nerve is approached through an extensile excision and identified proximally and distally in "normal" tissue. The nerve is then traced distally to the "takeoff" of the palmar cutaneous branch, which is dissected separately and protected unless already damaged. Dissection in a distal to proximal direction is performed while avoiding injury to the nerve branches. The entire nerve from the distal portion of the forearm in normal tissue to the terminal proper and common digital nerves and motor branches should be identified. The superficial palmar arch should be identified and protected. Internal neurolysis should be avoided, if possible. If a *neuroma* or *neuroma-in-continuity* is encountered, it may be dissected under the operating microscope and either repaired or grafted, and placed in a protected environment. All sensory branches and recurrent motor branches are identified.

If there is significant scarring between the nerve and the surrounding subcutaneous tissue, tendons, skin, or synovium, the neural environment should be modified. Options include placing a local or distal autologous flap, using local pedicle muscle flaps (e.g., abductor digiti quinti, palmaris brevis, pronator quadratus), using forearm fascia, transferring distal free tissue (i.e., fascia, omentum, muscle), or wrapping the scarred nerve with an autologous or allograft vein, usually the saphenous vein (Figure 53.15). If venous wrapping is selected, either autogenous saphenous vein or allograft may be wrapped directly around the median nerve with a space left through which the palmar cutaneous branch can exit (Figure 53.16).[67] The palmar cutaneous branch, if scarred or injured, may be wrapped separately with a small vein from the forearm, or an allograft may be placed around the nerve. If autologous vein is used, it can be wrapped around the nerve in "barber pole" fashion. The saphenous vein is seldom large enough to fold around the median nerve itself but will wrap easily around the branches. The graft should be sutured proximally and distally with a 5-0 or 6-0 nonreactive suture. *Chromic suture should be avoided because chemicals released from the suture can create a nociceptive neural focus.*

Injury to the palmar cutaneous branch of the median nerve is common. If this branch is injured, the branch may be resected and moved to an unscarred area or repaired by using end-to-end anastomoses or an interposition nerve graft. For grafting, we prefer, when possible, to use a short branch of the medial or lateral antebrachial cutaneous nerve. This graft may be harvested through a separate oblique incision in the forearm. Nerve repair is accomplished under the operating microscope with 9-0 to 10-0 nonabsorbable suture on 75- to 130-μm needles.

Before completion of the procedure, the tourniquet is released, bleeding is controlled, and a suction drain is placed. Postoperatively, the limb is protected from pain and dystrophic flare-up by the use of continuous autonomic blockade. Motion of the affected extremity is initiated in a controlled active

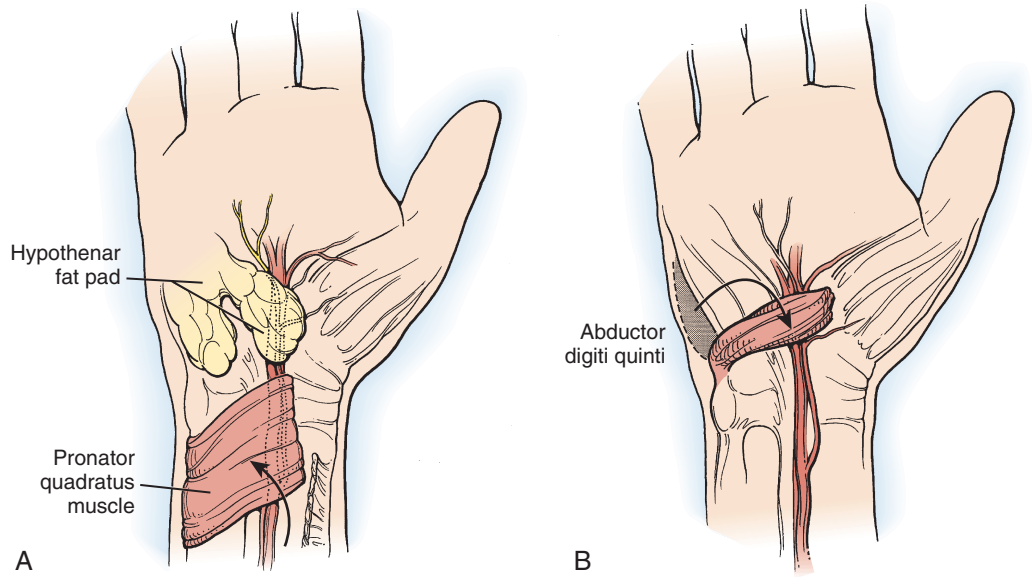

FIGURE 53.15 Options for modifying the environment surrounding an injured median nerve at the wrist include transposition of **(A)** pedicled hypothenar fat, the pronator quadratus muscle, or **(B)** the abductor digiti quinti muscle. (From Koman LA, editor: *Bowman Gray orthopaedic manual*, Winston-Salem, NC, 1996, Orthopaedic Press.)

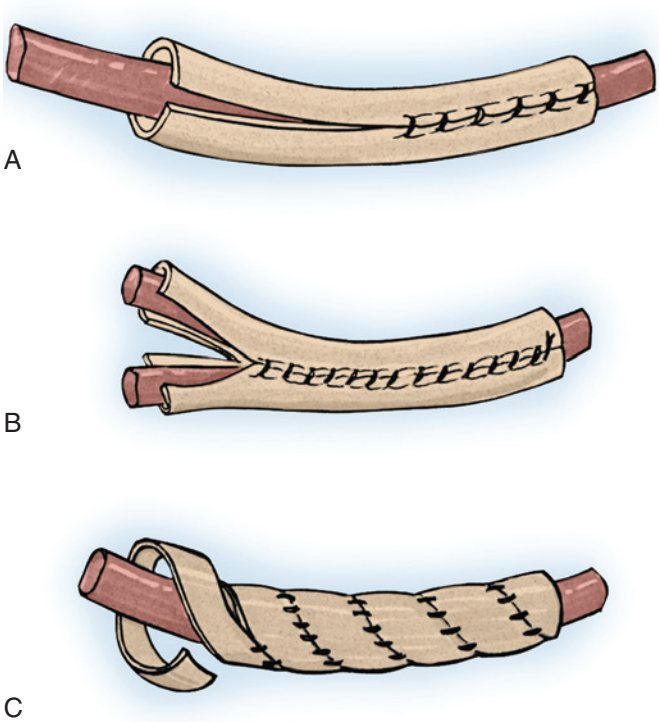

FIGURE 53.16 Alternative methods of covering a nerve with an autologous vein. **A,** The vein is split and sewn together around the nerve. **B,** If the vein is large enough, branches may be managed by a second longitudinal slit in the nerve, which is closed to form two sleeves. **C,** For a larger nerve, the vein may be "wrapped" in barber pole fashion. (From Koman LA, editor: *Bowman Gray orthopaedic manual*, Winston-Salem, NC, 1996, Orthopaedic Press.)

therapy program or by using continuous passive motion over the 3- to 5-day period of hospitalization for the continuous blockade.

❖ AUTHORS' PREFERRED METHOD OF TREATMENT: Metacarpophalangeal and Proximal Interphalangeal Joint Contractures (Late-Stage Treatment)

Surgical management of any chronic deformity that may occur after CRPS is possible and appropriate. However, reexacerbation of a dystrophic response is a potential risk with any surgical intervention for these deformities. This risk is minimized by attention to the principles discussed in this chapter. Perioperative pain control with continuous epidural or peripheral catheters is prudent and should be maintained for 3 to 5 days after surgery. Alternatively, continuous field block catheters may be used for pain control.

Surgical correction of secondary joint deformities from arthrofibrosis may be necessary after CRPS. Fixed contractures of the MP joints in extension and the PIP joints in flexion or extension are common. In addition, the shoulder, elbow, and wrist may have restricted motion.

Early management of CRPS will diminish the development of contractures; manipulation under sympatholytic blockade has been advocated to prevent such contractures. However, disuse and segmental ischemia of the extremity may produce arthrofibrosis despite active intervention. Surgery on contracted joints should not be initiated until maximal nonoperative improvement has been achieved. In general, the waiting period should be a minimum of 3 to 6 months after successful elimination of the active dystrophic pain. This policy is in contradistinction to early intervention for identifiable peripheral nerve injuries, which should be dealt with as soon as it is safe in terms of dystrophic symptoms.

When nonoperative improvement has reached a plateau, and symptoms warrant intervention, release of the MP or PIP joints

(or both) can be achieved. Indications for surgery are joint pain without diffuse dystrophic symptoms and arthrofibrosis that interferes with functioning. Persistence of MP and PIP joint contractures is devastating because it prevents adequate hand function and interferes with the health-related quality of life. If necessary, all four MP joints and all four PIP joints can be released in a single operation. It is important for the patient and physician to understand that this is a salvage procedure and that improvement in gross hand function, reduction in pain, and improved quality of activity are both the long-term and the short-term goals; restoration of full flexion or extension, or both, is not a reasonable goal or expectation. Surgery is performed to allow the hand to achieve improved function, to facilitate MP joint motion, and to make active grasp and release less cumbersome and painful. The range of motion achieved intraoperatively rarely persists postoperatively.

Operative Technique

After placement of an epidural or brachial plexus catheter, adequate surgical anesthesia is obtained. The MP and PIP joints are approached through oblique dorsal incisions. The extent of adhesions in the extensor mechanism and the degree of arthrofibrosis are identified. Major findings in the MP joint in the presence of an extension deformity include contracture and thickening of the collateral ligaments, adhesions of the volar plate and metacarpal neck, dorsal capsular tightness, and intrinsic muscle contracture. PIP joint motion is limited by contracture of the extensor mechanism, as well as by the collateral ligaments and volar plate adherence. Tendon-splitting incisions are avoided by approaching the MP joints from the radial side and moving the extensor tendon ulnarly. The joint capsule is opened and the collateral ligament identified. Frequently, erosions are present beneath the collateral ligament, which is invariably hypertrophied and contracted. The true and accessory collateral ligaments are released from the metacarpal head on the radial and ulnar sides; a small elevator is used to mobilize the volar plate without detaching it from the phalanx. Transection of the volar plate is rarely necessary. After release of the collateral ligaments and freeing of the volar plate, the MP joints should move from neutral to greater than 90 degrees of flexion without subluxation (Figure 53.17).

If necessary, the PIP joint is approached through a dorsal incision. Tendon splitting is avoided with the extensor mechanism retracted after releasing both transverse retinacular ligaments. The lateral band and central slip may be moved radially or ulnarly to allow ready access to the joint. The joint is dissected, the collateral ligaments are released, and the volar plate is freed (see Figure 53.17).

The intrinsics are tested after sequential release of the MP and PIP joints. If an intrinsic contracture exists, intrinsic release is performed. Once these procedures are completed, all these joints should move through a satisfactory range of motion of 170 degrees or greater, and the joints should be stable. If stability is in question, the MP joint is pinned in full flexion and the PIP joint in 35 to 45 degrees of flexion. Continuous passive motion or an active and passive range-of-motion program is used postoperatively.

The results of MP joint release are gratifying, and usually 80% to 90% of the intraoperatively achieved range of motion is maintained. However, release of the PIP joint is less satisfactory. Although patients report significant symptomatic relief and improved health-related quality of life, joint range of motion averages approximately 50% of that observed intraoperatively.

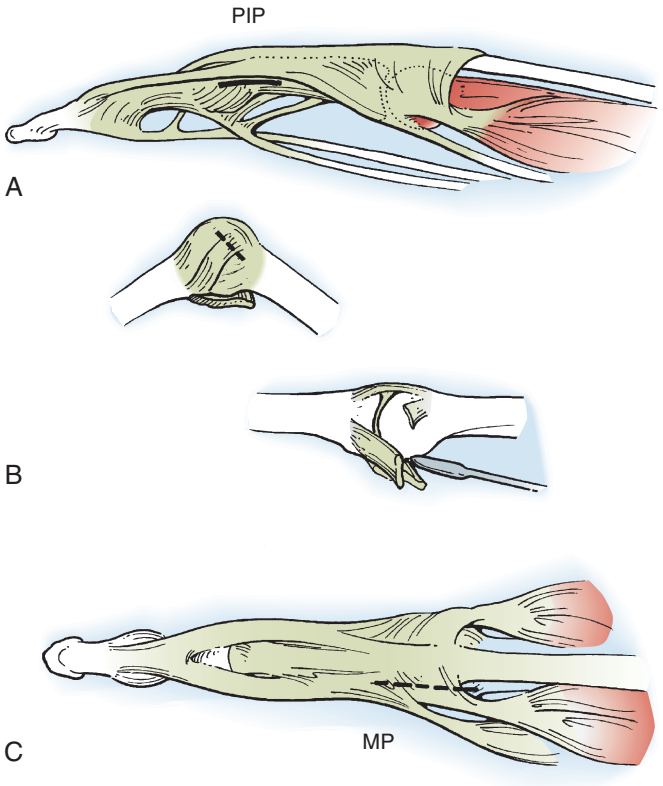

FIGURE 53.17 Release of the metacarpophalangeal (MP) and proximal interphalangeal (PIP) joints. **A,** Through an oblique dorsal incision, the PIP joint is exposed by elevating the extensor mechanism after release of the transverse retinacular ligament. **B,** The capsule is incised and the collateral ligament released. Dorsal adhesions may require lysis. **C,** The MP joint is approached by incising a portion of the sagittal bone, reflecting the extensor tendon ulnarly, and incising the capsule. The collateral ligaments are then released. (From Koman LA, editor: *Bowman Gray orthopaedic manual*, Winston-Salem, NC, 1996, Orthopaedic Press.)

Amputation

Amputation is reported as a course of last resort in a small number of patients with CRPS. Indications for amputation of the affected limb are recurrent infection and massive edema, as well as improvement in function; however, even after amputation, patients are rarely symptom free, prosthesis use is rare, recurrence of CRPS is frequent,[19,27] and psychosocial dysfunction persists.[133]

If necessary, amputation of limbs affected by CRPS requires perioperative sympatholytic treatment with oral medications and sympathetic blockade. Immediate prosthetic fitting is advisable and psychological support is helpful.

REFERENCES

1. Alexander GM, Peterlin BL, Perreault MJ, et al: Changes in plasma cytokines and their soluble receptors in complex regional pain syndrome. *J Pain* 1:10–20, 2012.
2. Alexander GM, Reichenberger E, Peterlin BL, et al: Plasma amino acids changes in complex regional pain syndrome. *Pain Res Treat* 2013:742407, 2013.

3. AlSharif A, Akel AY, Sheikh-Ali RF, et al: Is there a correlation between symptoms and bone scintigraphic findings in patients with complex regional pain syndrome? *Ann Nucl Med* 26(8):665–669, 2012.
4. An HS, Hawthorne KB, Jackson WT: Reflex sympathetic dystrophy and cigarette smoking. *J Hand Surg [Am]* 13:470–472, 1988.
5. Argoff CE: A focused review on the use of botulinum toxins for neuropathic pain. *Clin J Pain* 18(6 Suppl):S177–S181, 2002.
6. Arner S: Intravenous phentolamine test: diagnostic and prognostic use in reflex sympathetic dystrophy. *Pain* 46(1):17–22, 1991.
7. Atkins R, Tindale W, Bickerstaff D, et al: Quantitative bone scintigraphy in reflex sympathetic dystrophy. *Br J Rheumatol* 32:41–45, 1993.
8. Awerbuch MS: Thermography—its current diagnostic status in musculoskeletal medicine. *Med J Aust* 154:441–444, 1991.
9. Azari P, Lindsay DR, Briones D, et al: Efficacy and safety of ketamine in patients with complex regional pain syndrome: a systematic review. *CNS Drugs* 26(3):215–228, 2012.
10. Bank PJ, Peper CL, Marinus J, et al: Motor dysfunction of complex regional pain syndrome is related to impaired central processing of proprioceptive information. *J Pain* 14(11):1460–1474, 2013.
11. Barad MJ, Ueno T, Younger J, et al: Complex regional pain syndrome is associated with structural abnormalities in pain-related regions of the human brain. *J Pain* 15(2):197–203, 2014.
12. Baron R, Maier C: Reflex sympathetic dystrophy: skin blood flow, sympathetic vasoconstrictor reflexes and pain before and after surgical sympathectomy. *Pain* 67:317–326, 1996.
13. Beaton DE, Katz JN, Fossel AH, et al: Measuring the whole or the parts? Validity, reliability, and responsiveness of the Disabilities of the Arm, Shoulder and Hand outcome measure in different regions of the upper extremity. *J Hand Ther* 14(2):128–146, 2001.
14. Bej M, Schwartzman R: Abnormalities of cutaneous blood flow regulation in patients with reflex sympathetic dystrophy as measured by laser Doppler fluxmetry. *Arch Neurol* 48(September):912–915, 1991.
15. Bernateck M, Karst M, Gratz KF, et al: The first scintigraphic detection of tumor necrosis factor-alpha in patients with complex regional pain syndrome type 1. *Anesth Analg* 110(1):211–215, 2010.
16. Bickerstaff DR, Charlesworth D, Kanis JA: Changes in cortical and trabecular bone in algodystrophy. *Br J Rheumatol* 32:46–51, 1993.
17. Bickerstaff DR, Kanis JA: Algodystrophy: An under-recognized complication of minor trauma. *Br J Rheumatol* 33:240–248, 1994.
18. Birthi P, Sloan P, Salles S: Subcutaneous botulinum toxin A for the treatment of refractory complex regional pain syndrome. *PM R* 4(6):446–449, 2012.
19. Bodde MI, Dijkstra PU, den Dunnen WF, et al: Therapy-resistant complex regional pain syndrome type I: to amputate or not? *J Bone Joint Surg Am* 93(19):1799–1805, 2011.
20. Cepeda MS, Lau J, Carr DB: Defining the therapeutic role of local anesthetic sympathetic blockade in complex regional pain syndrome: a narrative and systematic review. *Clin J Pain* 18(4):216–233, 2002.
21. Cicala RS, Jones JW, Westbrook LL: Causalgic pain responding to epidural but not to sympathetic nerve blockade. *Anesth Analg* 70:218–219, 1990.
22. Cooke ED, Ward C: Vicious circles in reflex sympathetic dystrophy—a hypothesis: discussion paper. *J R Soc Med* 83(2):96–99, 1990.
23. Cooney WP: Electrical stimulation and the treatment of complex regional pain syndromes of the upper extremity. *Hand Clin* 13(3):519–526, 1997.
24. Czop C, Smith TL, Koman LA: The pharmacologic approach to the painful hand. *Hand Clin* 12(4):633–642, 1996.
25. de Mos M, de Bruijn AG, Huygen FJ, et al: The incidence of complex regional pain syndrome: a population-based study. *Pain* 129(1–2):12–20, 2007.
26. Di PF, McAuley JH, Parkitny L, et al: Primary motor cortex function in complex regional pain syndrome: a systematic review and meta-analysis. *J Pain* 14(11): 1270–1288, 2013.
27. Dielissen PW, Claassen ATPM, Veldman PHJM, et al: Amputation for reflex sympathetic dystrophy. *J Bone Joint Surg Br* 77:270–273, 1995.
28. Dotson RM: Causalgia—reflex sympathetic dystrophy—sympathetically maintained pain: myth and reality. *Muscle Nerve* 16:1049–1055, 1993.
29. Drummond PD: A possible role of the locus coeruleus in complex regional pain syndrome. *Front Integr Neurosci* 6:104, 2012.
30. Durrani Z, Winnie AP: Diagnostic and therapeutic brachial plexus block for RSD unresponsive to stellate ganglion block. *Anesth Analg* 74:S1–S368, 1992.
31. Eisenach J, Rauck R, Buzzanell C, et al: Epidural clonidine analgesia for intractable cancer pain: phase 1. *Anesthesiology* 71:647–652, 1989.
32. Eisenberg E, Geller R, Brill S: Pharmacotherapy options for complex regional pain syndrome. *Expert Rev Neurother* 7(5):521–531, 2007.
33. Fagrell B: *Microcirculation of the skin*, ed 2, Orlando, FL, 1984, Academic Press.
34. Field J, Protheroe DL, Atkins RM: Algodystrophy after Colles fractures is associated with secondary tightness of casts. *J Bone Joint Surg Br* 76:901–905, 1994.
35. Field J, Warwick D, Bannister GC: Features of algodystrophy ten years after Colles' fracture. *J Hand Surg [Br]* 17:318–320, 1992.
36. Figuerola ML, Levin G, Bertotti A, et al: Normal sympathetic nervous system response in reflex sympathetic dystrophy. *Funct Neurol* 17(2):77–81, 2002.
37. Fishbain DA, Goldberg M, Meagher BR, et al: Male and female chronic pain patients categorized by DSM-III psychiatric diagnostic criteria. *Pain* 26:181–197, 1986.
38. Ford SR, Forrest WH, Eltherington L: The treatment of reflex sympathetic dystrophy with intravenous regional bretylium. *Anesthesiology* 68:137–140, 1988.
39. Forouzanfar T, Koke AJ, van KM, et al: Treatment of complex regional pain syndrome type I. *Eur J Pain* 6(2):105–122, 2002.
40. Gainer MJ: Hypnotherapy for reflex sympathetic dystrophy. *Am J Clin Hypn* 34(4):227–232, 1992.
41. Gammaitoni A, Gallagher RM, Welz-Bosna M: Topical ketamine gel: possible role in treating neuropathic pain. *Pain Med* 1(1):97–100, 2000.
42. Geertzen JH, Dijkstra PU, Groothoff JW, et al: Reflex sympathetic dystrophy of the upper extremity—a 5.5-year follow-up. Part II. Social life events, general health and changes in occupation. *Acta Orthop Scand Suppl* 279:19–23, 1998.
43. Genant H, Kozin F, Bekerman C, et al: The reflex sympathetic dystrophy syndrome. *Diagn Radiol* 117:21–32, 1975.
44. Gibbons JJ, Wilson PR: RSD score: criteria for the diagnosis of reflex sympathetic dystrophy and causalgia. *Clin J Pain* 8(3):260–263, 1992.
45. Goldberg ME, Torjman MC, Schwartzman RJ, et al: Pharmacodynamic profiles of ketamine (R)- and (S)- with 5-day inpatient infusion for the treatment of complex regional pain syndrome. *Pain Physician* 13(4):379–387, 2010.
46. Graham WP, III, Shearer AW, Mackay DR, et al: SHAFT syndrome revisited. *Ann Plast Surg* 42(4):411–416, 1999.
47. Greipp ME, Thomas AF: Familial occurrences of reflex sympathetic dystrophy. *Clin J Pain* 7:48, 1991.
48. Greyson ND, Tepperman PS: Three-phase bone studies in hemiplegia with reflex sympathetic dystrophy and the effect of disuse. *J Nucl Med* 25:423–429, 1984.
49. Grundberg A: Reflex sympathetic dystrophy: treatment with long-acting intramuscular corticosteroids. *J Hand Surg [Am]* 21(4):667–670, 1996.
50. Grundberg AB, Reagan D: Compression syndromes in reflex sympathetic dystrophy. *J Hand Surg [Am]* 16:731–736, 1991.
51. Grunert BK, Devine CA, Sanger JR, et al: Thermal self-regulation for pain control in reflex sympathetic dystrophy syndrome. *J Hand Surg [Am]* 15:615–618, 1990.
52. Gulevich SJ, Conwell TD, Lane J, et al: Stress infrared telethermography is useful in the diagnosis of complex regional pain syndrome, type I (formerly reflex sympathetic dystrophy). *Clin J Pain* 13:50–59, 1997.
53. Haines BL: Rehabilitation of the painful upper extremity. *Hand Clin* 12(4):801–816, 1996.
54. Hanna MH, Peat SJ: Ketanserin in reflex sympathetic dystrophy. A double-blind placebo controlled cross-over trial. *Pain* 38:145–150, 1989.
55. Hannington-Kiff JG: Pharmacological target blocks in hand surgery and rehabilitation. *J Hand Surg [Br]* 9(1):29–36, 1984.
56. Harden RN: Cytokine imbalance/activity as a unifying hypothesis for the pathogenesis and pathophysiology of Complex Regional Pain Syndrome? *Pain* 152(2): 247–248, 2011.
57. Harden RN, Bruehl S, Stanton-Hicks M, et al: Proposed new diagnostic criteria for complex regional pain syndrome. *Pain Med* 8(4):326–331, 2007.

57a. Harden RN, Bruehl S, Perez RS, et al: Validation of proposed diagnostic criteria for complex regional pain syndrome. *Pain* 150:268–274, 2010.

58. Hoffman J, Phillips W, Blum M, et al: Effect of sympathetic block demonstrated by triple-phase bone scan. *J Hand Surg [Am]* 18(5):860–864, 1993.
59. Holder LE, Mackinnon SE: Reflex sympathetic dystrophy in the hands: clinical and scintigraphic criteria. *Radiology* 152:517–522, 1984.
60. Hord AH, Rooks M, Stephens B, et al: Intravenous regional bretylium and lidocaine for treatment of reflex sympathetic dystrophy: a randomized, double-blind study. *Anesth Analg* 74(821):818–821, 1992.
61. Hyland WT: Treating reflex sympathetic dystrophy with transdermal nitroglycerin. *Plast Reconstr Surg* 83:195, 1989.
62. Ide J, Yamaga M, Kitamura T, et al: Quantitative evaluation of sympathetic nervous system dysfunction in patients with reflex sympathetic dystrophy. *J Hand Surg [Br]* 22(1):102–106, 1997.
63. Inchiosa MA, Jr: Phenoxybenzamine in complex regional pain syndrome: potential role and novel mechanisms. *Anesthesiol Res Pract* 2013:978615, 2013.
64. Irazuzta J, Berde C, Sethna N: Laser Doppler measurements of skin blood flow before, during, and after lumbar sympathetic blockade in children and young adults with reflex sympathetic dystrophy syndrome. *J Clin Monit* 8(1):16–19, 1992.
65. Jadad A, Carroll D, Glynn C, et al: Intravenous regional sympathetic blockade for pain relief in reflex sympathetic dystrophy: a systematic review and a rondomized, double-blind crossover study. *J Pain Symptom Manage* 10(1):13–20, 1995.
66. Jin EH, Zhang E, Ko Y, et al: Genome-wide expression profiling of complex regional pain syndrome. *PLoS ONE* 8(11):e79435, 2013.

67. Jones NF: Treatment of chronic pain by "wrapping" intact nerves with pedicle and free flaps. *Hand Clin* 12(4):765–772, 1996.
68. Kastler A, Aubry S, Sailley N, et al: CT-guided stellate ganglion blockade vs. radiofrequency neurolysis in the management of refractory type I complex regional pain syndrome of the upper limb. *Eur Radiol* 23(5):1316–1322, 2013.
69. Kemler MA, Barendse GA, van Kleef M, et al: Pain relief in complex regional pain syndrome due to spinal cord stimulation does not depend on vasodilation. *Anesthesiology* 92(6):1653–1660, 2000.
70. Kemler MA, de Vet HC, Barendse GA, et al: Effect of spinal cord stimulation for chronic complex regional pain syndrome Type I: five-year final follow-up of patients in a randomized controlled trial. *J Neurosurg* 108(2):292–298, 2008.
71. Kemler MA, Furnee CA: Economic evaluation of spinal cord stimulation for chronic reflex sympathetic dystrophy. *Neurology* 59(8):1203–1209, 2002.
72. Kettler RE, Abram SE: Intravenous regional droperidol in the management of reflex sympathetic dystrophy: A double-blind, placebo-controlled, crossover study. *Anesthesiology* 69:933–936, 1988.
73. Kharkar S, Ambady P, Venkatesh Y, et al: Intramuscular botulinum toxin in complex regional pain syndrome: case series and literature review. *Pain Physician* 14(5): 419–424, 2011.
74. Kharkar S, Ambady P, Yedatore V, et al: Intramuscular botulinum toxin A (BtxA) in complex regional pain syndrome. *Pain Physician* 14(3):311–316, 2011.
75. Knezevic W, Bajada S: Peripheral autonomic surface potential: A quantitative technique for recording autonomic neural function in man. *Clin Exp Neurol* 21:201–210, 1985.
76. Koman LA, Smith BP, Smith TL: Stress testing in the evaluation of upper-extremity perfusion. *Hand Clin* 9(1):59–83, 1993.
77. Koman LA, Smith TL, Poehling GG, et al: Reflex sympathetic dystrophy. *Curr Opin Orthop* 4(IV):85–88, 1993.
78. Koman LA, Smith TL, Smith BP, et al: The painful hand. *Hand Clin* 12(4):757–764, 1996.
79. Kozin F, Soin J, Ryan L, et al: Bone scintigraphy in the reflex sympathetic dystrophy syndrome. *Radiology* 138:437–443, 1981.
80. Kurvers HAJ, Jacobs M, Beuk R, et al: Reflex sympathetic dystrophy: Evolution of microcirculatory disturbances in time. *Pain* 60:333–340, 1995.
81. Lee M, Ernst M: The sympatholytic effect of acupuncture as evidenced by thermography: a preliminary report. *Orthop Rev* 12:67, 1983.
82. Lee SK, Yang DS, Lee JW, et al: Four treatment strategies for complex regional pain syndrome type 1. *Orthopedics* 35(6):e834–e842, 2012.
83. Levine D, Simmons B, Koris M, et al: A self-administered questionnaire for the assessment of severity of symptoms and functional status in carpal tunnel syndrome. *J Bone Joint Surg Am* 75:1585–1592, 1993.
84. Lilly SI, Stern PJ: Simultaneous carpal tunnel release and Dupuytren's fasciectomy. *J Hand Surg [Am]* 35(5):754–759, 2010.
85. Low PA, Amadio PC, Wilson P, et al: Laboratory findings in reflex sympathetic dystrophy: a preliminary report. *Clin J Pain* 10(3):235–239, 1994.
86. Magni G: The use of antidepressants in the treatment of chronic pain. *Drugs* 42(5):730–748, 1991.
87. Mailis A, Furlan A: Sympathectomy for neuropathic pain. *Cochrane Database Syst Rev* (2):CD002918, 2003.
88. Maleki J, LeBel AA, Bennett GJ, et al: Patterns of spread in complex regional pain syndrome, type I (reflex sympathetic dystrophy). *Pain* 88(3):259–266, 2000.
89. Malik VK, Inchiosa MA, Jr, Mustafa K, et al: Intravenous regional phenoxybenzamine in the treatment of reflex sympathetic dystrophy. *Anesthesiology* 88(3):823–827, 1998.
90. Malmqvist ELA, Bengtsson M, Sorensen J: Efficacy of stellate ganglion block: A clinical study with Bupivacaine. *Reg Anesth* 17:340–347, 1992.
91. Mashimo T, Tomi K, Pak M, et al: Relief of causalgia with prostaglandin E_1 ointment. *Anesth Analg* 72:700–701, 1991.
92. Matsumura H, Jimbo Y, Watanabe K: Haemodynamic changes in early phase reflex sympathetic dystrophy. *Scand J Plast Reconstr Hand Surg* 30:133–138, 1996.
93. McCabe SJ, Mizgala C, Glickman L: The measurement of cold sensitivity of the hand. *J Hand Surg [Am]* 16:1037–1040, 1991.
94. Meissner A, van der Plas AA, van Dasselaar NT, et al: 1H-NMR metabolic profiling of cerebrospinal fluid in patients with complex regional pain syndrome-related dystonia. *Pain* 155(1):190–196, 2014.
95. Mellick G, Mellicy L: Gabapentin in the management of reflex sympathetic dystrophy. *J Pain Symptom Manage* 10(4):265–266, 1995.
96. Melzack R: The McGill pain questionnaire: major properties and scoring methods. *Pain* 1:277–299, 1975.
97. Mercier C, Leonard G: Interactions between pain and the motor cortex: insights from research on phantom limb pain and complex regional pain syndrome. *Physiother Can* 63(3):305–314, 2011.
98. Mitchell SW: *Injuries of nerves and their consequences*. Philadelphia, 1872, JB Lippincott; The Classics of Neurology & Neurosurgery Library.
99. Moberg E: Objective methods for determining the functional value of sensibility in the hand. *J Bone Joint Surg Br* 40(3):454–476, 1958.
100. Nelson DV, Stacey BR: Interventional therapies in the management of complex regional pain syndrome. *Clin J Pain* 22(5):438–442, 2006.
101. Perez RS, Zuurmond WW, Bezemer PD, et al: The treatment of complex regional pain syndrome type I with free radical scavengers: a randomized controlled study. *Pain* 102(3):297–307, 2003.
102. Pickering AE, McCabe CS: Prolonged ketamine infusion as a therapy for complex regional pain syndrome: synergism with antagonism? *Br J Clin Pharmacol* 77(2): 233–238, 2014.
103. Pleger B, Draganski B, Schwenkreis P, et al: Complex regional pain syndrome type I affects brain structure in prefrontal and motor cortex. *PLoS ONE* 9(1):e85372, 2014.
104. Pleger B, Ragert P, Schwenkreis P, et al: Patterns of cortical reorganization parallel impaired tactile discrimination and pain intensity in complex regional pain syndrome. *Neuroimage* 32(2):503–510, 2006.
105. Pollock FE, Jr, Koman LA, Smith BP, et al: Measurement of hand microvascular blood flow with isolated cold stress testing and laser Doppler fluxmetry. *J Hand Surg [Am]* 18(1):143–150, 1993.
106. Pollock FE, Jr, Koman LA, Smith BP, et al: Patterns of microvascular response associated with reflex sympathetic dystrophy of the hand and wrist. *J Hand Surg [Am]* 18(5):847–852, 1993.
107. Price DD, Gracely RH, Bennett GJ: The challenge and the problem of placebo in assessment of sympathetically maintained pain. *Pain Res Manag* 6:173–189, 1996.
108. Raja S, Davis K, Campbell J: The adrenergic pharmacology of sympathetically-maintained pain. *J Reconstr Microsurg* 8(1):63–69, 1992.
109. Raja SN, Treede RD, Davis KD, et al: Systemic alpha-adrenergic blockade with phentolamine: a diagnostic test for sympathetically maintained pain. *Anesthesiology* 74(4):691–698, 1991.
110. Raja SN, Turnquist JL, Meleka S, et al: Monitoring adequacy of alpha-adrenoceptor blockade following systemic phentolamine administration. *Pain* 64:197–204, 1996.
111. Rauck RL, Eisenach JC, Jackson K, et al: Epidural clonidine treatment for refractory reflex sympathetic dystrophy. *Anesthesiology* 79(6):1163–1169, 1993.
112. Richlin DM, Carron H, Rowlingson JC, et al: Reflex sympathetic dystrophy: Successful treatment by transcutaneous nerve stimulation. *J Pediatr* 93:84–85, 1978.
113. Rosen L, Ostergren J, Fagrell B, et al: Skin microvascular circulation in the sympathetic dystrophies evaluated by videophotometric capillaroscopy and laser Doppler fluxmetry. *Eur J Clin Invest* 18:305–308, 1988.
114. Rowbotham MC: Pharmacologic management of complex regional pain syndrome. *Clin J Pain* 22(5):425–429, 2006.
115. Sabia M, Hirsh RA, Torjman MC, et al: Advances in translational neuropathic research: example of enantioselective pharmacokinetic-pharmacodynamic modeling of ketamine-induced pain relief in complex regional pain syndrome. *Curr Pain Headache Rep* 15(3):207–214, 2011.
116. Safarpour D, Jabbari B: Botulinum toxin A (Botox) for treatment of proximal myofascial pain in complex regional pain syndrome: two cases. *Pain Med* 11(9): 1415–1418, 2010.
117. Safarpour D, Salardini A, Richardson D, et al: Botulinum toxin A for treatment of allodynia of complex regional pain syndrome: a pilot study. *Pain Med* 11(9):1411–1414, 2010.
118. Sampath S, Mittal BR, Arun S, et al: Usefulness of asymmetry score on quantitative three-phase bone scintigraphy in the evaluation of complex regional pain syndrome. *Indian J Nucl Med* 28(1):11–16, 2013.
119. Sandroni P, Benrud-Larson LM, McClelland RL, et al: Complex regional pain syndrome type I: incidence and prevalence in Olmsted county, a population-based study. *Pain* 103(1–2):199–207, 2003.
120. Santo JL, Arias LM, Barolat G, et al: Bilateral cingulumotomy in the treatment of reflex sympathetic dystrophy. *Pain* 41(1):55–59, 1990.
121. Sato J, Perl E: Adrenergic excitation of cutaneous pain receptors induced by peripheral nerve injury. *Science* 251:1608–1610, 1991.
122. Schilder JC, Sigtermans MJ, Schouten AC, et al: Pain relief is associated with improvement in motor function in complex regional pain syndrome type 1: secondary analysis of a placebo-controlled study on the effects of ketamine. *J Pain* 14(11):1514–1521, 2013.
123. Sharony R, Saute M, Uretzky G: Video assisted thoracic surgery: our experience with 102 patients. *J Cardiovasc Surg* 35:173–176, 1994.
124. Sherman RA, Barja RH, Bruno GM: Thermographic correlates of chronic pain: Analysis of 125 patients incorporating evaluations by a blind panel. *Arch Phys Med Rehabil* 68:273–279, 1987.
125. Shibuya N, Humphers JM, Agarwal MR, et al: Efficacy and safety of high-dose vitamin C on complex regional pain syndrome in extremity trauma and surgery—systematic review and meta-analysis. *J Foot Ankle Surg* 52(1):62–66, 2013.
126. Sorensen J, Bengtsson M, Malmqvist ELA, et al: Laser Doppler perfusion imager (LDPI) for the assessment of skin blood flow changes following sympathetic blocks. *Acta Anaesthesiol Scand* 40:1145–1148, 1996.

127. Stanton TR, Wand BM, Carr DB, et al: Local anaesthetic sympathetic blockade for complex regional pain syndrome. *Cochrane Database Syst Rev* (8):CD004598, 2013.
128. Stevens DS, Robins VF, Price HM: Treatment of sympathetically maintained pain with terazosin. *Reg Anesth* 18:318–321, 1993.
129. Stewart M, Morling JR: Oral vasodilators for primary Raynaud's phenomenon. *Cochrane Database Syst Rev* (7):CD006687, 2012.
130. Straube S, Derry S, Moore RA, et al: Cervico-thoracic or lumbar sympathectomy for neuropathic pain and complex regional pain syndrome. *Cochrane Database Syst Rev* (9):CD002918, 2013.
131. Suresh S, Wheeler M, Patel A: Case series: IV regional anesthesia with ketorolac and lidocaine: is it effective for the management of complex regional pain syndrome 1 in children and adolescents? *Anesth Analg* 96(3):694–695, 2003.
132. Swift DW, Walker SE: The clenched fist syndrome. A psychiatric syndrome mimicking reflex sympathetic dystrophy. *Arthritis Rheum* 38(1):57–60, 1995.
133. Szeinberg-Arazi D, Heim M, Nadvorna H, et al: A functional and psychosocial assessment of patients with post-Sudeck atrophy amputation. *Arch Phys Med Rehabil* 74(4):416–418, 1993.
134. Taneyama C, Yokota S, Goto H: Patients with complex regional pain syndrome type 1: fractal dynamics of heart rate variability and baroreflex evaluations. *Clin J Pain* 29(11):962–966, 2013.
135. Task Force on Taxonomy of the International Association for the Study of Pain: *Classification of chronic pain: descriptions of chronic pain syndromes and definitions of pain terms*, Seattle, WA, 1994, IASP Press.
136. Terkelsen AJ, Molgaard H, Hansen J, et al: Heart rate variability in complex regional pain syndrome during rest and mental and orthostatic stress. *Anesthesiology* 116(1):133–146, 2012.
137. Treede R, Davis K, Campbell J, et al: The plasticity of cutaneous hyperalgesia during sympathetic ganglion blockade in patients with neuropathic pain. *Brain* 115:607–621, 1992.
138. Van Buyten JP, Smet I, Liem L, et al: Stimulation of dorsal root ganglia for the management of complex regional pain syndrome: a prospective case series. *Pain Pract* 15:208–216, 2015.
139. van Harten J: Clinical pharmacokinetics of selective serotonin reuptake inhibitors. *Clin Pharmacokinet* 24(3):203–220, 1993.
140. van Velzen GA, Perez RS, van Gestel MA, et al: Health-related quality of life in 975 patients with complex regional pain syndrome type 1. *Pain* 155(3):629–634, 2014.
141. Varenna M, Adami S, Rossini M, et al: Treatment of complex regional pain syndrome type I with neridronate: a randomized, double-blind, placebo-controlled study. *Rheumatology (Oxford)* 52(3):534–542, 2013.
142. Varitimidis SE, Papatheodorou LK, Dailiana ZH, et al: Complex regional pain syndrome type I as a consequence of trauma or surgery to upper extremity: management with intravenous regional anaesthesia, using lidocaine and methylprednisolone. *J Hand Surg Eur Vol* 36(9):771–777, 2011.
143. Veldman PHJM, Reynen H, Arntz I, et al: Signs and symptoms of reflex sympathetic dystrophy: prospective study of 829 patients. *Lancet North Am Ed* 342:1012–1016, 1993.
144. Ware JE, Jr, Sherbourne CD: The MOS 36-item short-form health survey (SF-36) I. Conceptual framework and item selection. *Med Care* 30(6):473–481, 1992.
145. Watson CPN: Antidepressant drugs as adjuvant analgesics. *J Pain Symptom Manage* 9(6):392–405, 1994.
146. Werner R, Davidoff G, Jackson D, et al: Factors affecting the sensitivity and specificity of the three-phase technetium bone scan in the diagnosis of reflex sympathetic dystrophy syndrome in the upper extremity. *J Hand Surg [Am]* 14(3):520–523, 1989.
147. Wilder RT, Berde CB, Wolohan M, et al: Reflex sympathetic dystrophy in children: clinical characteristics and follow-up of seventy patients. *J Bone Joint Surg Am* 74:910–919, 1992.
148. Wilkinson HA: Radiofrequency percutaneous upper-thoracic sympathectomy. *N Engl J Med* 311(1):34–36, 1984.
149. Zyluk A: The usefulness of quantitative evaluation of three-phase scintigraphy in the diagnosis of post-traumatic reflex sympathetic dystrophy. *J Hand Surg [Br]* 24(1):16–21, 1999.
150. Zyluk A: The sequelae of reflex sympathetic dystrophy. *J Hand Surg [Br]* 26(2):151–154, 2001.

54

Factitious Disorders

Dean S. Louis and Morton L. Kasdan

Occasionally, a patient will have symptoms or physical findings that do not coincide with recognizable disease patterns. The symptoms may be out of proportion to the physical findings, or the physical findings may not make sense based on the historical record or when compared with our previous experience. When this happens, the examining physician should consider the possibility that the patient's agenda may be something other than wellness.[3,8,13,15,18]

A variety of terms have been used to describe these findings, including *malingering*, *factitious disorders*, and *conversion reactions*.[2,7,9,20,29,30] These are only a few of the various and often confusing designations that apply and that the hand and upper extremity surgeon must recognize. The complexities of the psychiatric diagnoses are not pertinent here but are referenced elsewhere.[8,16,20]

The majority of the diagnoses that we have seen fit into one of the major categories just listed. There are some recognizable patterns of clinical findings that should instantly alert the evaluating physician. Current psychiatric thought in this area has been summarized by LoPiccolo and colleagues[16] as follows: "While malingering[12] represents a *conscious* intent to deceive for the purpose of obtaining an easily identifiable goal (secondary gain), it should not be confused with factitious disorders. Factitious disorder is also defined as an *intentional* production of symptoms, but differs from malingering in that it is always considered pathological, and in that its goal is an internal rather than an external incentive, i.e., to assume the sick role."[4,20] Previous thought had denied attribution to personal motivation and referred to unconscious mechanisms to explain the observed behavior. Both malingering[12] and factitious disorders may be detected by either direct observation of situational behavior or by videotaped surveillance. The former would occur when an individual was observed in the workplace, social environment, or inpatient facility by staff to be performing contrary to any self-described limitations. Secondary surveillance involves direct videotaping from a concealed location of the individual performing a task or tasks that the individual claims to be unable to do because of a specific condition (examples would involve observed gripping or fine motor skills when the individual denies being able to do them). Although malingering and factitious disorders are "first cousins," they have a major difference. A malingerer is *feigning* illness, whereas a person with a factitious disorder is *causing* illness.

RECOGNIZABLE FACTITIOUS DISORDERS

Factitious Lymphedema

Patients with factitious lymphedema[10,17,19,23,26,27] usually have a history of the mysterious appearance of painless swelling of the limb and denial of any knowledge of the cause of the problem. It is usually attributed to occupational activities. The site of the edema is at a defined point anywhere from the shoulder distally (Figure 54.1). It is probable that the condition formerly called Secretan's disease was a form of factitious lymphedema.[11]

Once it is recognized, treatment may be effective. Hospitalization of the patient and controlled elevation will result in a rapid decrease in the edema. If it persists with constant elevation, late night rounds may reveal a tourniquet somewhere about the limb. An alternative outpatient technique is the application of a shoulder spica cast. Psychiatric or psychological consideration, or both, should be sought. There is no indication for surgical intervention.

Factitious Ulceration

Patients with factitious ulceration usually have a history of trivial trauma, with lesions subsequently developing that will not heal (Figure 54.2). The easiest way to confirm that the lesion is factitious is to cover the area with a cast so that the patient cannot manipulate the wound.[22] Healing under such circumstances helps confirm the diagnosis. Be aware that even with the application of a cast, some patients may still attempt to aggravate the wound with something as simple as a wire hanger.

Dysfunctional Postures

There are a host of nonfunctional hand postures that patients assume.[6,17] They have some common characteristics and are usually associated with a claimed inability to use the hand (Figures 54.3 to 54.5). In the classic position of the clenched fist,[25] the ulnar three digits are held in a flexed position while the thumb and index fingers are fully mobile and functional. There are many variations on this theme, including but not limited to an adducted thumb, extension of the digits, and combinations of all possible positions.

We are aware of a case in which the examining physician was sued for performing a vigorous passive examination that the patient claimed hurt her and worsened her condition. In such circumstances, it may be prudent for the physician to merely



FIGURE 54.1 Thirty-seven-year-old woman with a history of mysterious swelling of her left hand. There is an obvious area of tourniquet compression just distal to the elbow flexion crease. This was the initial manifestation of a long-involved and convoluted series of events that ended with severe flexion contracture of all fingers.

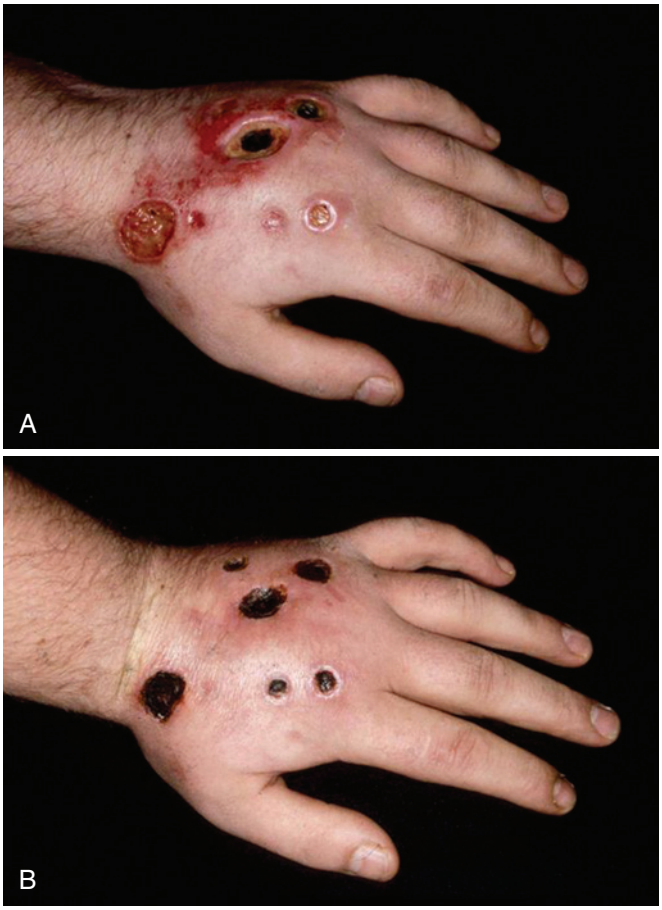

FIGURE 54.2 **A,** This young man sustained a trivial injury to the dorsum of his hand while at work. There was no break in the skin initially. While recovering from the initial condition, multiple circular areas resembling burns appeared as noted here. **B,** It was presumed that the areas seen in the previous picture represented self-inflicted cigarette burns. A cast was applied for 2 weeks and the wounds healed as seen here. After cast removal, an exacerbation of the wounds occurred.

observe and record active motion when patients say that they cannot move from a certain position.

DIFFERENTIAL DIAGNOSIS OF FACTITIOUS DISORDERS

There are many clinical patterns that may be factitious,[1] but those illustrated here are the most common ones observed in two separate practices over a 30-year period. The assumption inherent in this chapter is that all recognized medical conditions have been excluded and that the evaluating physician is now trying to figure out what is really going on. Recognition of the entities mentioned will make them a part of "recognized medical conditions."

Recognizing Factitious Illness and Avoiding *Mistaken* Diagnoses

There are several warning signs of factitious illness seen by a hand surgeon. Such signs may include

- Seeking treatment at many health facilities without a clear diagnosis after multiple tests and operations
- Severe symptoms that are not consistent with what seems to be a minor incident or injury
- Multiple wounds or scars
- Symptoms, such as swelling or stiffness, that are reported to be changing and worsening without apparent cause
- A desire and willingness for further testing and treatment that has little, if any, justification

Factitious illness is frequently underdiagnosed, misdiagnosed, and therefore incorrectly treated. Because of the patient's role and psychological condition, factitious illness is seldom suspected at the onset of care unless the treating physician is aware of such patterns and includes this condition as a possibility. Factitious illness is also difficult to prove because concealment and denial by the patient are central to the condition itself. Not surprisingly, treatment of a variety of conditions, *except* factitious illness, often begins and compounds the disorder, thereby creating new problems. The most common misdiagnosis is complex regional pain syndrome (CRPS) type 1 (see Chapter 53), or reflex sympathetic dystrophy.[28] Once labeled as having CRPS, the patient often proceeds through multiple levels of the health care system—from primary care physicians to advanced surgical specialties. Patients who indeed have a factitious condition (psychologically needing to be ill) begin to accept the fact that they have a real disease. Multiple stellate ganglion blocks, surgical nerve decompression, and intensive physical therapy are often undertaken over a period of months or years with no improvement and the usual



FIGURE 54.3 This woman, with an initial diagnosis of factitious lymphedema, as seen in Figure 54.1, was lost to follow-up for 6 months and returned with the classic posture of a clenched fist with severe excoriation of the palmar skin. The flexion deformities became permanent with fixed flexion contracture.



FIGURE 54.4 When first seen in June 1995, this 23-year-old man claimed that he had been injured in 1994 when a heavy object struck the dorsum of his right hand. At the time of his evaluation, he held his right upper extremity in a fixed posture and claimed that he was unable to use the right upper extremity for anything. Reflex sympathetic dystrophy had been diagnosed, and he had undergone multiple blocks and insertion of a dorsal column stimulator. Bilateral radiographs documented symmetric and normal mineralization of the bones. Video surveillance clearly revealed full active and strenuous use of the entire upper extremity. The grand jury returned a true bill of indictment for felony fraud. He pleaded guilty to a lesser charge of making a false sworn statement.

consequence of intensifying and solidifying the psychological disorder.

Because these patients accept and expect to be ill and disabled, the misapplication of treatment of CRPS results in the nocebo effect.[5,11,14,24] In contradistinction to the placebo effect, the patient's symptoms actually *worsen* with treatment despite the lack of noxious side effects of the various treatments and interventions, however misguided. Despite these dismal results, these patients are surprisingly willing to undergo further testing, imaging, and treatments. This feature of factitious illness adds weight to the imperative for proper diagnosis as early as possible.

MANAGEMENT OF PATIENTS WITH FACTITIOUS DISORDERS

There are neither easy solutions nor uniformly applicable paradigms for dealing with these difficult patients. Most patients with factitious disorders have a need to be injured or disabled, usually without seeking financial gain. Instead, they may have personality disorders or be seeking attention from a parent, spouse, or family member. Others may have a more obvious source of financial gain if disabled.

It is the hand surgeon's responsibility to recognize these patterns of factitious disease and refer or suggest referral for psychiatric evaluation, if possible. The act of referral itself is a delicate matter that requires a level of trust and frequently family support. This is not always the case. Unfortunately, family members are often unwittingly enabling and abetting the factitious illness and are hostile to the suggestion that there is not an operation or test that will cure the problem. Nonetheless, if possible, it is best to refer these patients to a psychiatrist who is willing to help them. Unfortunately, not all psychiatrists are willing to accept these patients, and finding sympathetic treatment may be extremely difficult.[7,8]

Editor's note (DPG): Some readers may think it inappropriate to have a chapter on factitious disorders in a book on operative surgery. Everyone would agree that the patients described in this brief chapter are clearly those in whom we should want to avoid operative intervention, but an accurate diagnosis in such patients is not always clearly apparent and virtually never easy to prove. It is precisely because these patients do constitute a pitfall for the unsuspecting hand surgeon that the editors deemed it necessary to include the chapter.



FIGURE 54.5 When first seen in 1989, this 53-year-old man claimed that he did not have good use of his left hand. He was a diabetic and was noted to have diffuse neuropathy. The patient had a full range of active motion but would immediately return his hand to the stiff, extended position. The significance of the black glove that he wore at each visit was not clear. He was drawing disability benefits.

REFERENCES

1. Al-Qattan MM: Factitious disorders of the upper limb in Saudi Arabia. *J Hand Surg [Br]* 26:414–421, 2001.
2. American Psychiatric Association: *Diagnostic and statistical manual of mental disorders*, ed 4, Washington, DC, 2000, American Psychiatric Association.
3. Barsky AJ: Forgetting, fabricating, and telescoping. *Arch Intern Med* 162:981–984, 2002.
4. Bellamy R: Compensation neurosis. *Clin Orthop Relat Res* 336:94–106, 1997.
5. Benson H: The nocebo effect: history and physiology. *Prev Med* 26:612–615, 1997.
6. Dobyns JH: Pain dysfunction syndrome. In Gelberman R, editor: *Operative nerve repair*, Philadelphia, 1991, JB Lippincott, pp 1489–1494.
7. Feldman MD, Eisendrath SJ: *The spectrum of factitious disorders*, Washington, DC, 1996, American Psychiatric Press.
8. Feldman MD, Ford CV: *Patient or pretender*, New York, 1994, John Wiley & Sons.
9. Fliece H, Scholler G, Rose R, et al: Factitious disorders and pathological self-harm in a hospital population. An interdisciplinary challenge. *Gen Hosp Psychiatry* 24:164–171, 2002.
10. Grunert BK, Sanger JR, Matloub HS, et al: Classification system for factitious syndromes in the hand with implications for treatment. *J Hand Surg [Am]* 16:1027–1030, 1991.
11. Hahn RA: The nocebo phenomenon: concept, evidence, and implications for public health. *Prev Med* 26:607–611, 1997.
12. Hall HV, Pritchard DA: *Detecting malingering and deception*, Boca Raton, FL, 1996, St. Lucie Press.
13. Hardie TJ, Reed A: Pseudologic fantastica, factitious disorder, and impostership: a deception syndrome. *Med Sci Law* 38:198–201, 1998.
14. Kasdan ML, Lewis K, Bruner A, et al: The nocebo effect: do no harm. *J South Orthop Assoc* 8:108–113, 1999.
15. Lazare A: Conversion symptoms. *N Engl J Med* 305:745–748, 1981.
16. LoPiccolo CJ, Goodkin K, Baldewicz TT: Current issues in the diagnosis and management of malingering. *Ann Med* 31:166–174, 1999.
17. Louis DS: Recognizable dysfunction syndromes. *Hand Clin* 9:213–220, 1993.
18. Louis DS, Jebson PJL: Factitious disorders. *Tech Hand Up Extrem Surg* 2:88–93, 1998.
19. Louis DS, Lamp MK, Greene TL: The upper extremity and psychiatric illness. *J Hand Surg [Am]* 10:687–693, 1985.
20. McDermitt BE, Feldman MD: Malingering in the medical setting. *Psychiatr Clin North Am* 30:645–662, 2007.
21. Deleted in review.
22. Phelps DB, Buchler U, Boswick JA: The diagnosis of factitious ulcer of the hand: a case report. *J Hand Surg [Am]* 2:105–108, 1977.
23. Reading G: Secretan's syndrome: hard edema of the dorsum of the hand. *Plast Reconstr Surg* 65:182–187, 1980.
24. Schweiger A, Parducci A: Nocebo: the psychologic induction of pain. *Pavlov J Biol Sci* 16:140–145, 1981.
25. Simmons BP, Vasile RG: The clenched fist syndrome. *J Hand Surg [Am]* 5:420–427, 1980.
26. Smith RJ: Factitious lymphedema of the hand. *J Bone Joint Surg Am* 57:89–94, 1975.
27. Storm S, Weiss MD: Self-inflicted tourniquet paralysis mimicking acute demyelinating polyneuropathy. *Muscle Nerve* 27:631–635, 2003.
28. Stutts JT, Kasdan ML, Hickey SE, et al: Reflex sympathetic dystrophy misdiagnosis in patients with dysfunctional postures of the upper extremity. *J Hand Surg [Am]* 25:1152–1156, 2000.
29. Turner J, Reid S: Munchausen's syndrome. *Lancet* 359:346–349, 2002.
30. Ziegler FJ, Imboden JB: Contemporary conversion reactions. *Arch Gen Psychiatry* 6:279–287, 1962.

55

Rheumatoid Arthritis and Other Connective Tissue Diseases

Paul Feldon, Andrew L. Terrono, Edward A. Nalebuff, and Lewis H. Millender

Acknowledgments: The authors would like to acknowledge Stuart J. Schneller, MD, and John A. Foote, Jr., for their help in revising the chapter's manuscript.

These videos may be found at *ExpertConsult.com:*
55.1 Metacarpophalangeal arthroplasty in rheumatoid arthritis.

Reconstructive hand surgery has been established as an effective component in the overall management program of a patient with rheumatoid arthritis. However, it should be understood that hand reconstruction does not restore normal function to rheumatoid hands. Pain may be alleviated, severe deformity prevented or corrected, and appearance and function improved, but motion and dexterity still will be limited, and weakness will remain a significant disability.[129] Because of the difficulty in consistently restoring or improving function, careful judgment must be used when recommending reconstructive surgery. Fortunately, disease-modifying medical therapy has decreased the need for reconstructive hand and upper extremity surgery. Nonetheless, the skilled hand surgeon should have a working knowledge of rheumatoid hand and wrist deformities and their treatment.

The purpose of this chapter is to describe the surgical techniques used to correct rheumatoid hand deformities. However, an understanding of these techniques is only one requirement—the surgeon must also appreciate the natural history of the disease and its deformities. In addition, he or she must understand the functional needs and limitations of each patient to make appropriate judgments regarding the indicators for surgical treatment.[22] By working closely with the rheumatologist; orthopedic surgeon; and physical, occupational, and hand therapists, the hand surgeon will have a better understanding of an overall treatment program and thereby provide the best care possible for these patients.

SURGICAL CONSIDERATIONS IN THE ARTHRITIC PATIENT

The care of a hand affected by rheumatoid arthritis differs in many respects from that of a hand affected by trauma. In a rheumatoid patient, an ongoing process of joint and tendon destruction can persist for many years. Involvement of one joint affects adjacent joints. Involvement of neighboring joints or recurrent disease can nullify the effects of previous surgery. The manifestations of the disease vary for each patient. Cooperation between the rheumatologist and the surgeon is essential to provide appropriate surgical recommendations for each individual.[62,117]

Rheumatoid arthritis is a systemic condition that affects synovial tissue. All deformities, joint destruction, and pathologic anatomy that occur in patients with rheumatoid arthritis are the result of the way in which the diseased and hypertrophied synovial tissue alters its surroundings. Rheumatoid synovium destroys articular cartilage by a poorly understood enzymatic reaction, invades subchondral bone, and stretches the soft tissues that support the involved joint. It also surrounds and invades the flexor and extensor tendons. The result is disruption of the normal architecture of the hand and wrist and loss of the normal delicate balance of flexor and extensor forces across adjacent joints of the hand–wrist unit. Nearly all the surgical procedures performed on the rheumatoid hand and wrist fall into one of five groups: synovectomy, tenosynovectomy, tendon surgery, arthroplasty, and arthrodesis.

Judgment regarding the type and timing of surgical procedures for reconstructing the rheumatoid hand and wrist requires experience. An individual treatment plan must be formulated for each patient based on the status of the hand and the patient's needs, as well as the surgeon's expertise and experience. The presence of deformity is not, in and of itself, an indication for surgery because many patients maintain good function despite significant deformity. We believe that reconstructive rheumatoid hand surgery is not for the physician who occasionally performs hand surgery.[29,119]

Good rapport with the patient is essential because the reconstructive program usually spans many months and often years. The patient's disease pattern affects the surgical approach in rheumatoid reconstruction. In general, synovectomy is indicated for patients with mild disease controlled by drugs who experience persistent synovitis in one or two joints. However, synovectomies are contraindicated in patients with rapidly progressive joint disease. In these patients, frequent observation is required so that reconstructive surgery can be performed before the development of severe deformities. Early tenosynovectomy may be required for patients with progressive disease to prevent tendon rupture. With the advent of antitumor necrosis factor (anti-TNF) therapy, communication between the rheumatologist and hand surgeon is especially important for patients with aggressive disease. Before embarking on surgical treatment, an optimal medical regimen should be established.

Better results are possible when reconstruction is performed before severe fixed contractures occur and before significant subluxation or dislocation develops. After the capsule and supporting ligamentous structures have stretched, the lack of adequate soft tissue support makes maintenance of joint alignment and function more difficult. Caution must be used when considering reconstructive surgery for patients with mild deformities who are basically healthy and active but are frustrated because of general loss of function. They want to pursue their avocations or sports activities but may not have the strength or endurance to do so. Hand surgery cannot restore full function in these patients and may weaken the hand even further; therefore, it is not indicated because it would not produce the desired or expected end result. Such patients need to understand their disease and modify their activities. A hand therapist can be helpful in this situation.

Hand surgery can also lead to disappointing results in patients with significant destruction of multiple joints but who have minimal pain and function relatively well despite their disease. Unless surgery can provide either significant pain relief or a dramatic change in function, the patient's expectations for reconstructive surgery may not be fulfilled. Patients' expectations should match the surgeon's goals and anticipated results. They must know that some deformity, especially at the metacarpophalangeal (MP) joints, is likely to recur after surgery. There is no substitute for in-depth preoperative discussion between the surgeon and patient.[24]

MEDICAL CONSIDERATIONS IN THE RHEUMATOID PATIENT

Certain factors should be considered in rheumatoid patients scheduled for hand surgery. A careful evaluation prior to the scheduled surgery will alert the surgeon to these, and appropriate consultations can be obtained ahead of time if needed.[112]

Cervical spine involvement may be subtle. However, with the increased use of brachial plexus block technique, and options for general anesthesia, which minimize cervical manipulation in rheumatoid patients with limited cervical extension (i.e., laryngeal mask airway, video scope, or fiber-optic scope intubation), formal preoperative evaluation of the cervical spine rarely is necessary unless symptoms are present. If the patient has a history of numbness or paresthesias with cervical motion, imaging studies and neurological consultation should be obtained preoperatively.

Temporomandibular joint involvement may compromise intubation, and the anesthesiologist should be aware of this so that adequate plans can be made for nasotracheal or fiber-optic intubation if necessary. Pulmonary involvement can result from the disease itself (i.e., pulmonary rheumatoid nodules or interstitial fibrosis) or as a consequence of antirheumatic therapy. Felty syndrome (splenomegaly and neutropenia), although rare, can cause a profound decrease in the white blood cell count and thereby increase susceptibility to infection.

Drug therapy must be taken into account when planning surgery.[48] The medications currently used to treat patients with rheumatoid arthritis include nonsteroidal antiinflammatory drugs (NSAIDs), such as ibuprofen, naproxen, diclofenac, piroxicam, and etodolac; corticosteroids; nonbiologic disease-modifying antirheumatic drugs (DMARDs), such as methotrexate, leflunomide (Arava), sulfasalazine (Azulfidine), and hydroxychloroquine (Plaquenil); and biologic DMARDs. The latter interferes with the action of tumor necrosis factor (TNF-α), interleukin 1 or 6 (IL-1, IL-6), and T-cell costimulation or depletes B lymphocytes such as infliximab (Remicade), etanercept (Enbrel), adalimumab (Humira), anakinra (Kineret), tocilizumab (Actemra), abatacept (Orencia), and rituximab (Rituxan). Systemic corticosteroids and penicillamine can delay wound healing. Methotrexate can affect liver function, which may affect the choice of anesthesia.

There have been conflicting reports on infection rates in patients taking methotrexate who undergo surgery for rheumatoid arthritis.[18,44,54,115] We have not noticed an increased incidence of infection in patients undergoing reconstructive hand surgery, however, and the recent literature supports continuing the use of methotrexate during the perioperative period.

Some studies have reported twice the infection rate in rheumatoid patients taking biologic DMARDs and undergoing major joint arthroplasty compared to osteoarthritic patients who are not taking these medications. In spite of this, the overall postoperative infection rates remain low, in the 1 to 2% range. Again, we have not had an increase in infection rate in our rheumatoid patients undergoing hand and wrist reconstruction, the majority of who are taking DMARDs.

Detailed discussions and recommendations regarding withholding and restarting various antirheumatoid medications in the perioperative period are available in the literature. While specific recommendations may vary, we have found the following general guidelines for the length of time to withhold various medications preoperatively useful:

- ASA: 5 to 7 days
- NSAIDs: 3 half-lives (varies with each drug)
- Methotrexate and hydroxychloroquine: do not withhold
- Cyclophosphamide, azathioprine, sulfasalazine: several days
- Leflunomide (Arava): 2 weeks
- Biologic DMARDs: two treatment cycles

However, it is important to consult with the patient's rheumatologist before making a final decision. Postoperatively, we take the precaution of withholding biologic DMARDs until wound healing is complete (2–3 weeks) and all temporary pins placed during surgery have been removed.

STAGING HAND SURGERY

One of the difficult tasks in rheumatoid surgery is formulation of a plan for systematic reconstruction of the hand. Although there are no hard-and-fast rules, some general principles can be outlined. The priorities for hand surgery in rheumatoid patients are to (1) alleviate pain, (2) improve function, (3) retard progression of the disease and/or prevent loss of function, and (4) improve appearance. Appropriate decisions are made more easily if each of these priorities is considered for each patient. Relief of pain is the foremost goal. The indications for surgery to relieve pain are clear and predictable; fusions and arthroplasties accomplish this goal.

Pain may be the most important factor in determining a rheumatoid patient's ability to work. Many with severe deformities can work because they are able to adapt to their functional limitations. In contrast, patients with much less deformity but with significant pain are less able to continue gainful

employment. A painful wrist or thumb usually takes precedence over dislocated MP joints of the fingers. Acute carpal tunnel syndrome or proliferative dorsal tenosynovitis with a single-tendon rupture is allocated high priority to prevent permanent loss of median nerve function or more tendon ruptures.

Loss of function is not synonymous with deformity, and careful evaluation and discussion are needed before any surgery to improve function is undertaken. Patients with adequate function, despite deformity, may not benefit from surgery. Carpal tunnel syndrome can be aggravated by any surgical procedure in the hand. Therefore, carpal tunnel release should be considered before or in conjunction with other surgical procedures on the volar aspect of the wrist.

Each joint must be evaluated both individually (Table 55.1) and as part of the whole hand. We usually correct MP joint deformities before treating proximal interphalangeal (PIP) joint ones.[86,95] An exception to this approach is a severe boutonnière deformity, which should be corrected before or at the same time as the MP joint because a severe flexion deformity at the PIP joint compromises the result of the MP joint surgery. Conversely, an extension deformity of the PIP joint concentrates flexion at the MP joint and enhances MP motion. Therefore, extension deformities at the PIP joint can be corrected at a later time.

PIP joint deformity is often the result of a primary MP joint deformity. Treating the MP joints first may simplify treatment of the PIP joints. Just restoring MP joint alignment and motion can provide significant improvement in hand function, even with imperfect PIP joint function. The converse is not necessarily true; reasonable PIP joint motion does little to improve hand function if the MP joints remain fixed in flexion (Figure 55.1).[77]

If extensor tendon reconstruction is required in addition to MP joint surgery, we reconstruct the MP joints before the extensor tendons are treated. This facilitates postoperative rehabilitation because MP extension can be provided with a dynamic splint. Extensor tendon reconstruction can be done at a second stage without compromising the previous MP joint surgery.

Most patients have bilateral hand problems that require surgical treatment. We encourage the patient to help us decide on which hand to operate first. During the rehabilitation period, the nonoperated hand must perform additional work, and this can induce a flare of synovitis. It may be prudent to operate on the less-involved hand first, especially with an apprehensive patient. This approach can prevent progressive deformity, provide a better overall result, and allow the patient to assess the potential benefits of further reconstruction.

We prefer to perform preventive surgery, such as synovectomy, dorsal tenosynovectomy, and even median nerve decompression, before considering reconstructive surgery. It is best to begin a reconstructive program with surgical procedures that are predictable in their outcome and effect and to progress in stages to procedures that are less predictable. Thus, procedures such as thumb MP joint fusion, distal interphalangeal (DIP) fusion in the fingers, and wrist fusion can be performed first, followed by distal ulnar excision and MP joint arthroplasty.

The effect of proximal joint function on the wrist and hand must be considered in preoperative planning. Shoulder or elbow reconstruction (or both), if indicated, should be done before hand reconstruction so that rehabilitation of the hand after surgery is not impeded by more proximal problems. The proximal and distal joints must be evaluated before any surgery because they can affect the type of surgery to be performed. If elbow flexion is limited, for example, the ability of the hand to get to the mouth may be compromised if the wrist is corrected into a more extended position. Therefore, the wrist should be fused in a neutral or slightly flexed position, or elbow flexion should be increased.

Occasionally, it is necessary to consider hand deformities and upper extremity limitations in view of the patient's lower extremity problems. If a painful or deformed hand prevents the use of ambulatory aids, such as crutches or walkers, it may be necessary to perform upper extremity surgery before lower extremity surgery. In general, patients with a rheumatoid wrist problem require fusion to allow the use of ambulatory aids.

TABLE 55.1 Stages of Rheumatoid Joint Involvement

Stage	Description
1	Synovitis without deformity
2	Synovitis with a passively correctable deformity
3	Fixed deformity without joint changes
4	Articular destruction

OTHER CONNECTIVE TISSUE DISEASES (RHEUMATOID VARIANTS)

Psoriatic arthritis, systemic lupus erythematosus (SLE), and scleroderma are three uncommon arthritic diseases that superficially resemble rheumatoid arthritis, but they are different and may require an unusual surgical approach. These diseases frequently involve the hand and wrist and thus are significant to the hand surgeon. Each of these diseases has distinct features affecting the types of deformities seen and the treatments needed to adequately care for the patients. The specifics of the surgical techniques are discussed in the corresponding section on rheumatoid arthritis.

Psoriatic Arthritis

Psoriatic arthritis is a rheumatoid variant that is classified as one of the seronegative spondyloarthropathies, along with Reiter's syndrome, ankylosing spondylitis, and the arthritis of inflammatory bowel disease. The classic finding in psoriasis is a scaly, erythematous rash. Approximately 5% of patients with psoriasis have some type of inflammatory arthritis. The skin lesions precede the arthritis-associated changes in most cases, but in 15 to 20% of patients the skin lesions develop after the onset of arthritis. This rash may be extensive or localized to small patches on the scalp, face, or extremities. Direct skin involvement can occur on the hand and complicates surgical treatment because of the enhanced risk for infection.

Staphylococcus aureus has been cultured from psoriatic skin. The psoriatic rash improves with ultraviolet light, which is one of the main treatments of this condition. Because the skin condition often improves during the summer, this factor should be taken into account when scheduling elective surgery on a hand with a significant psoriatic rash.[7] The diagnosis of psoriasis can

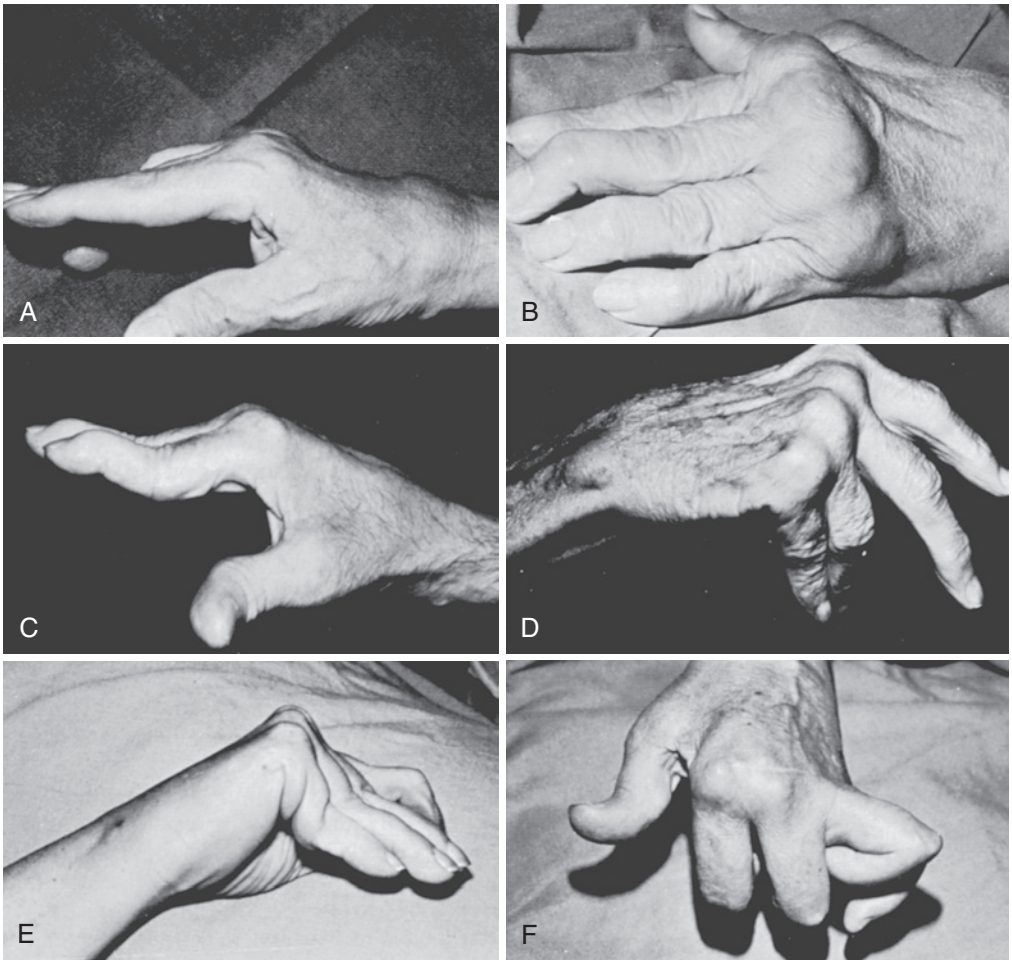

FIGURE 55.1 Examples of stages of rheumatoid hand deformities. **A,** Stage 1: early metacarpophalangeal (MP) joint synovitis without deformity. Note the early dorsal tenosynovitis. **B,** Stage 2: moderate MP joint synovitis without dislocation of the MP joints and without marked bone destruction. **C,** Stage 2: early MP joint subluxation with a swan neck deformity. Both these deformities are correctable passively, and there is no cartilage or bone destruction. The patient is a candidate for intrinsic release, synovectomy, and extensor tendon relocation. **D,** Stage 3: classic example of MP joint dislocation without proximal interphalangeal (PIP) joint involvement. Note the absence of wrist joint subluxation and minimal subluxation of the distal end of the ulna. Extensor tendon function is intact. **E,** Stage 3: fixed dislocation of the MP joints with a secondary swan neck deformity. Note the mallet deformity of the distal interphalangeal joint in the index finger. **F,** Stage 4: severe hand deformity with fixed dislocation of the MP joints and fixed-flexion contractures of the PIP joints. The patient had previously undergone synovectomy. Salvage surgery includes PIP joint arthrodeses and MP joint arthroplasties. (From Millender LH, Nalebuff EA: Evaluation and treatment of early rheumatoid hand involvement. *Orthop Clin North Am* 6:697–708, 1975, with permission.)

also be made by characteristic changes in the nails. It has been stated that 80% of patients with psoriasis have nail changes, but this finding is present in just 15% of those with arthritic involvement. Psoriasis of the nails alone without overt evidence of cutaneous disease is infrequent. The most common nail finding is pitting, which represents involvement of the proximal matrix. Other nail findings include leukonychia and crumbling nails.

The pattern of joint involvement in psoriatic arthritis varies widely: 95% of such patients have peripheral joint involvement; 25% have a polyarthritis similar to rheumatoid arthritis; and 5% have classic DIP joint disease with erosion of the terminal phalanges, DIP joint destruction, nail pitting, and onycholysis. Osteolysis is common, with destruction of bone and ultimate widening of the joint spaces. Bone proliferates along the margins of the bone on the distal side of the joint. The proximal bone tapers and, when associated with distal bone changes, leads to a "pencil-in-cup" appearance.

Osteolysis most commonly affects the DIP joints but can involve all the finger joints and result in digital shortening. In its full-blown stage, these patients have arthritis mutilans. Because of collapse of the digits, the condition has been called "opera-glass hand."[91] Collapse of the fingers can also occur in rheumatoid patients but is more frequently seen in those with psoriatic arthritis. Although osteolysis is the most frequent radiographic finding in a psoriatic hand, spontaneous ankylosis can also occur. In digits with spontaneous or surgical fusion, digital length is maintained.[91] It is common for the distal joints to fuse spontaneously, but this can also occur at the PIP level. Most patients with hand involvement have combinations of osteolytic and fused joints. In our experience, ankylosis of the digital MP joints does not occur. Inflammation of the periosteum, tendons, and tendon insertions may be a factor in the fusiform swelling of digits in this disease—the so-called sausage swelling or psoriatic dactylitis with significant soft tissue

swelling around the joints. Radiographs readily show the periarticular soft tissue enlargement that explains the clinical appearance. Fusiform swelling of the digits is best treated by medical means.

Psoriatic arthritis causes hand deformities similar to those seen in rheumatoid arthritis, with several typical differences, including psoriatic skin lesions. There is a much lower incidence of tenosynovitis and tendon rupture than noted for rheumatoid arthritis.[132] Therefore, tenosynovectomy and other tendon surgery are uncommon in patients with psoriatic arthritis. The subcutaneous nodules associated with rheumatoid arthritis are not found in this condition. Unlike rheumatoid disease, which tends to be symmetric, patients with psoriatic arthritis usually have asymmetric involvement of the hands. This asymmetry is also present within the hand, with apparently unaffected digits adjacent to involved fingers that are short or demonstrate significant deformity.

Although individual patients can have both osteolysis and ankylosis, one of these characteristics is usually more prominent than the other, thus making it possible to categorize patients into various groups, which helps determine treatment choices. We now use a modification of the Moll and Wright classification, which is based directly on the radiographic and clinical changes seen in these hands. In psoriatic arthritis there can be (1) spontaneous fusions that maintain digital length, (2) osteolysis with bone loss, or (3) joint stiffness with rheumatoid arthritis–like deformities. It is important to stress that the degree of bone loss can vary from mild to extensive. Spontaneous ankylosis can also involve single or multiple joints.[7,90]

Digital Deformity

The most common deformities seen in a psoriatic hand are flexion deformities of the PIP joints without the corresponding distal joint hyperextension characteristic of the boutonnière deformity.[106,132] As a consequence of the flexed PIP joint, the MP joints are often hyperextended and ultimately become stiff. Severe fixed-flexion deformities are best treated by fusion rather than arthroplasty. Swan neck deformities, which are common in rheumatoid arthritis, occur occasionally in psoriatic arthritis but often result from a distal joint mallet deformity rather than originating at the PIP level.

In contrast to rheumatoid arthritis, patients with psoriatic arthritis tend to have MP joint extension contractures rather than flexion contractures. Postoperative motion after MP arthroplasty may be limited in comparison to that usually obtained for rheumatoid patients. If arthroplasties are performed, more bone should be resected to allow adequate space for the implant. Experience with MP arthroplasties has found that the risk for infection is higher in this group.[74] Fixed-flexion deformities of the MP joints appear in patients with stiff or extended PIP joints. These patients have difficulty grasping large objects because of the limited MP extension frequently associated with a contracted thumb web space.

The DIP joints are involved frequently but rarely need treatment because they tend to fuse spontaneously. Arthritis mutilans, which results in severe loss of bone stock with collapse and shortening of the digit, is not uncommon and must be treated early and aggressively by joint fusions and bone grafting to restore digital length (Figure 55.2).[106]

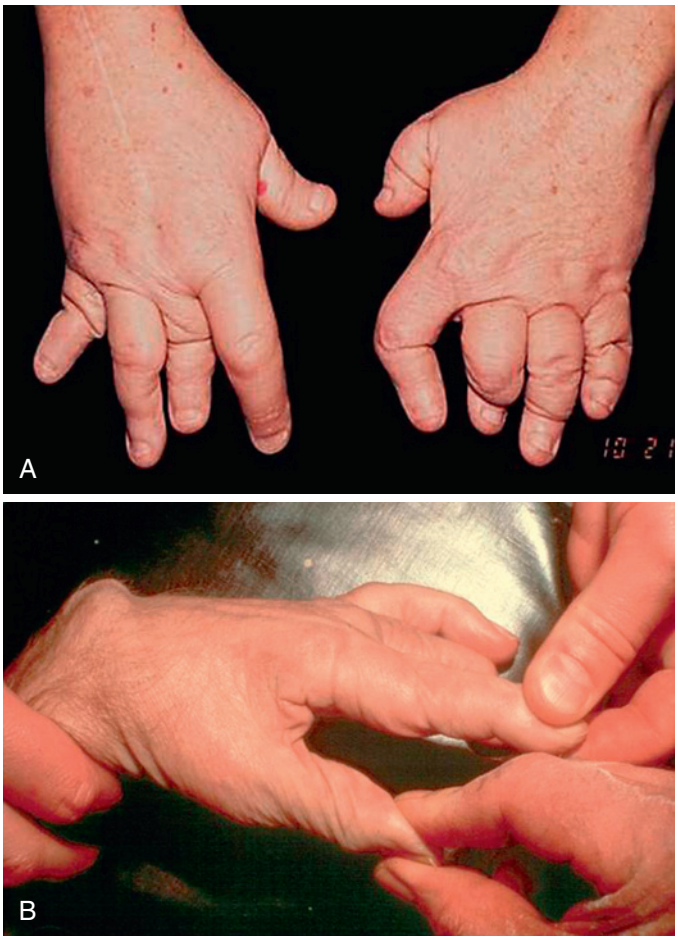

FIGURE 55.2 **A,** Arthritis mutilans with typical "opera-glass" hand deformities. **B,** Traction on the collapsed digits restores the soft tissue envelope to length. This allows restoration of pinch function by fusion of the affected joints using bone graft.

Thumb Deformity

Each of the three thumb joints can be involved in psoriatic arthritis. As noted for rheumatoid arthritis, the most common deformity includes MP joint flexion and interphalangeal (IP) joint hyperextension. Hyperextension deformities of the MP joint are rare in this group. Stiffness at the carpometacarpal (CMC) joint level does develop in these patients and greatly reduces thumb function. Surgical procedures should include MP or IP fusion, or fusion of both joints. It is advisable to pronate the thumb as part of the fusion to improve thumb–index finger pinch. At the basal joint, to restore or maintain thumb motion, we prefer resection arthroplasty with ligament suspension,[13] as used for osteoarthritis.[90]

Wrist Deformity

Wrist involvement is common in psoriatic arthritis.[132] Presently, we limit wrist surgery in patients with psoriatic arthritis to fusion and excision of the distal ulna.[92] The techniques are the same as those used for rheumatoid arthritis. Spontaneous intercarpal fusion can alleviate the need for additional wrist surgery if the alignment is good and motion is not painful. We do not recommend wrist arthroplasty for patients with psoriatic arthritis.

Systemic Lupus Erythematosus

SLE is a multisystem disease with frequent joint and hand involvement. It can involve many major organs of the body such as the heart, lungs, and kidneys.[107] Pericarditis is the most common heart problem, and pleuritis affects pulmonary function. It has been reported that 50% of lupus patients have clinical manifestations of renal disease. Skin lesions occur in 85% of them, with a typical erythematous blush in the butterfly area on the cheeks and across the bridge of the nose often being noted after sun exposure. Another common rash is an erythematous maculopapular eruption on the fingers and palm that also can occur after sun exposure.[107]

Systemic lupus erythematosus is frequently diagnosed initially as rheumatoid arthritis or "nonspecific" arthritis.[107] In children, the most common initial diagnosis is rheumatic fever. At present, the generally accepted means of diagnosing SLE is based on the American Rheumatism Association's preliminary criteria. A patient needs to have 4 of 14 criteria, either simultaneously or serially, to make the diagnosis of SLE. Some of them are LE cells, arthritis, Raynaud's disease, facial erythema, pleuritis, pericarditis, and uremia.[107]

Lupus patients are predominantly young women, with a female-to-male ratio of 9:1.[107] This condition is more common in black women than in white women, with an average age at onset of between 15 and 25 years.[107] Hand involvement can include symmetric joint swelling, tenderness, pain with motion, and morning stiffness. Raynaud's disease is common. Joint deformities are the most predominant hand manifestation of SLE. Although the deformities can appear similar to those seen in rheumatoid arthritis, ligamentous and volar plate laxity, as well as tendon subluxation leading to joint imbalance, are the hallmarks of this disease rather than joint destruction.[30]

The joint deformities occur without the erosive destruction of the articular cartilage seen in other forms of arthritis. The wrist, digits, and thumb are the most frequent sites of involvement, and the ankles, elbows, and shoulders are least often affected.[30] The deformities occur without the erosive destruction of the articular cartilage seen in other forms of arthritis. Radiographs show deformity, but with normal-appearing joint spaces (Figure 55.3). Tenosynovitis can occur and may be present without joint involvement.

Patients with SLE are best managed by a team approach. They may have serious medical problems that take priority over hand and wrist deformities. A rheumatologist or internist should carry out the medical treatment of this condition. Patients without major organ involvement are usually treated symptomatically with NSAIDs.[107] In more serious cases, corticosteroids are indicated. With regard to specific wrist and hand involvement, a cooperative effort between a hand therapist and surgeon is ideal.

The initial treatment of passively correctable deformities, which are the hallmark of SLE, is best handled by exercises and splinting. We do not believe that the common deformities of SLE will be permanently corrected by these methods, but it is possible to maintain function for an extended period, thereby delaying surgery. Patients can be taught to stretch tight ulnar intrinsics caused by digital ulnar deviation at the MP joint level. Wrist splints are helpful to maintain wrist alignment. Resting splints at night are useful to keep the fingers in proper alignment at the MP joint level. For passively correctable swan neck deformities of the fingers, patients can wear Silver Ring or Oval-8® splints, which resemble jewelry and are well accepted by patients. Commercially available LMB Wire-Foam™ and Soft-Core Foam™ splints are useful for early boutonnière deformities. The risk of "conservative" nonoperative treatment may be progression to fixed deformities that alter the treatment options for the surgeon. Therefore, the surgeon's role is to determine when it is appropriate to modify the course of the disease by surgical intervention.



FIGURE 55.3 Lupus causes deformities similar to those seen in rheumatoid arthritis but without joint destruction. Note the ulnar deviation and volar subluxation of the metacarpophalangeal joints, the secondary radial deviation of the metacarpals, and the scapholunate dissociation in the absence of joint space narrowing, periarticular erosions, and cyst formation.

Wrist Deformity

Deformities can often be corrected passively, but attempts to reconstruct the deformities by soft tissue procedures are associated with a frustratingly high recurrence rate. Thus, arthroplasties or fusions, or both, may be necessary, even though the joints have been preserved and look uninvolved on radiographs. Surgery in lupus patients should be performed before fixed deformities occur. With regard to the wrist, the most useful surgical procedures are limited to total wrist fusions. For complete wrist dislocations, total wrist fusion is the procedure of choice.[92] For ulnar translocation of the carpus, wrist realignment should be performed along with either radiolunate or radiocarpal fusion to maintain midcarpal motion.[92] In our opinion there is no place for arthroplasty in the lupus wrist. Total wrist replacement is not advisable because stability and soft tissue balance are so critical to success. The lax ligaments characteristic of lupus do not provide the essential support to

prevent recurrent deformity. Realignment of the wrist reduces the risk for secondary finger deformities. However, most of the deformities at the MP joint level are primary as a result of soft tissue changes at the local level.

A common wrist problem is carpal supination, which results in prominence of the distal end of the ulna. In addition to being unsightly, causing pain, and restricting wrist rotation, it can cause attrition extensor tendon ruptures.[30,89] Dorsal wrist tenosynovitis is uncommon in SLE. When tendon ruptures do occur, they are generally the result of attrition. A Darrach procedure is useful in lupus. Stabilization of the remaining ulna with a portion of the extensor carpi ulnaris (ECU) tendon or the ulnar carpal ligaments should be performed to prevent dorsal migration.[64] It is important to bevel the dorsal lip of the resected ulna to minimize subsequent attrition tendon ruptures over a sharp bone edge.

Digital Deformity

The characteristic finger deformity at the MP joint is ulnar deviation and volar subluxation.[30,89] The patients demonstrate excellent finger flexion with loss of active extension while maintaining passive extension. With time, they gradually lose passive extension. The sequence of pathologic findings is as follows: subluxation of the extensor tendon ulnar to the metacarpal head occurs and, as this support is diminished, the proximal phalanx subluxes volarly. The joint capsule becomes thinned, and a defect in the dorsal capsule occurs. With increasing ulnar deviation, the ulnar intrinsic muscle shortens, with subsequent hyperextension deformity at the PIP level. At first, the deformity is passively correctable, but gradually this mobility is lost. Despite the MP deformity becoming fixed, the articular cartilage is preserved.

In a previous review of this subject, we noted that soft tissue realignment of the extensor tendons did not maintain correction in 21 of 30 digits.[30,89] In each of these fingers, the deformity recurred and often became fixed. Swanson arthroplasties were performed either for fixed-MP joint deformities or for digits in which soft tissue correction had failed. We concluded that arthroplasty with a silicone implant was indicated even though the metacarpal head was intact, with normal-appearing articular cartilage.[30,89] Zancolli reported success in maintaining MP joint alignment in patients with rheumatoid arthritis by attaching the extensor tendon to the proximal phalanx, which minimized recurrent tendon subluxation.[141] Wood and associates, using the same technique, corrected recurrent extensor tendon subluxation in a large group of patients that included two with SLE.[140]

❖ AUTHORS' PREFERRED METHOD OF TREATMENT

We have attempted to restore MP alignment and function by soft tissue surgery, including extensor tendon relocation and tenodesis. In patients with full passive correction, we approach the joint dorsally. A central defect in the joint capsule is repaired, and the extensor tendon is relocated to the dorsum of the joint directly on the bone, as described by Wood and associates.[140] As part of the soft tissue rebalancing, the contracted ulnar sagittal fibers are released and the radial sagittal fibers are reefed in an attempt to rebalance support of the extensor tendon directly over the joint. The aim is to restore full MP extension when direct traction is applied to the extensor tendon.

Although the ulnar intrinsic was released completely in many patients, there have been complications later. In a few fingers, we noted late radial deviation with tightness of the radial intrinsic. For this reason, we now believe that complete ulnar intrinsic release is not without risk and prefer, instead, to step-cut and lengthen the ulnar intrinsic. We believe that the intrinsic transfers that are useful in correcting severe ulnar deviation in rheumatoid arthritis are particularly dangerous in SLE. All the soft tissue surgery that we perform is designed to restore alignment and balance to the joint. It may be foolhardy to think that restoration of local anatomy can withstand the tissue changes in SLE. We believe, however, that the deformities can be corrected and the need for joint replacement thereby delayed or avoided. These same soft tissue repairs are indicated for patients with fixed-MP joint deformities requiring prosthetic replacement.

Prolonged postoperative splinting is required after MP surgery regardless of whether implants are used. The joints are held in good alignment for 6 weeks before motion is initiated. Once MP motion is begun, the fingers are splinted together as a unit to maintain alignment and concentrate flexion at the MP level. Dynamic splinting is also used to support extension and maintain digital alignment during the early healing stage.

Occasionally, we have treated SLE patients who also demonstrate excessive finger MP joint hyperextension. In this situation, the "lasso procedure" described by Zancolli for ulnar nerve palsy[141] is combined with dorsal soft tissue balancing. In this procedure, the sublimis tendon is detached from its insertion and passed around the A1 pulley to restrain MP joint hyperextension.

Proximal Interphalangeal Joint Deformity

Finger IP joints can have hyperextension, flexion, or lateral deformities that occur as a result of stretching of the supporting tendons, collateral ligaments, and volar plate mechanism. With mild and early deformities, the soft tissue procedures useful for rheumatoid arthritis can be carried out. Unfortunately, these deformities frequently become severe and fixed, thus making arthrodesis the treatment of choice. Restoration of IP alignment, even by fusion, is essential if the MP joint corrections are to be maintained long term.

Thumb Deformity

The thumb is commonly involved in SLE. It is often the first place where hand deformities occur.[30,89] A frequent primary manifestation is lateral subluxation of the distal joint. However, the distal joint deformity can be a secondary response to primary deformity at the MP level. With MP joint hyperextension, the distal joint rapidly assumes a flexed position, whereas the reverse occurs with MP flexion deformities.[85] The treatment of choice is surgical fusion, which restores thumb stability and function. In addition, correction of the IP joint deformity decreases the chance of reciprocal deformity at the more proximal MP joint.[85]

The thumb MP joint can also be the primary site of deformity. Subluxation of the extensor tendons is common in SLE, and the thumb is no exception. As extensor pollicis longus (EPL) support diminishes, the MP joint assumes a flexed position.[85] Lateral instability can also occur in long-standing cases as a result of laxity of the collateral ligaments. Initially, passive

correction is possible, but later the deformity becomes fixed. As a response to the severe flexion, the metacarpal assumes an abducted position and the distal joint hyperextends, thereby producing the typical type I thumb deformity.[85]

❖ AUTHORS' PREFERRED METHOD OF TREATMENT

If passive MP joint extension is possible, there are two surgical approaches that we have found useful: EPL rerouting[85] and MP joint arthrodesis. EPL rerouting is preferred if the thumb IP joint requires fusion to provide stability. This procedure restores active MP extension while maintaining mobility, thereby relieving some strain on the CMC joint. However, certain modifications are in order, including reefing the collateral ligaments for lateral support and postoperative splinting for 6 weeks. Temporary Kirschner wire fixation is important to maintain the corrected position. Joints in SLE patients ordinarily do not get stiff after immobilization. The typical range of postoperative flexion is about 40 degrees and is usually achieved even with 6 weeks of immobilization.

When the flexed MP joint cannot be passively corrected or is hyperextended or if the CMC and IP joints are good, arthrodesis is the procedure of choice. The joint should be fixed in 15 to 20 degrees of flexion. Arthroplasty of the MP joint with a flexible implant might be considered, but experience with this approach in SLE patients has not been as successful as in those with rheumatoid arthritis. SLE patients tend to regain excessive motion and fracture the prosthesis, with recurrent deformity. If both the MP and IP joints are fused, it is imperative that motion at the thumb CMC joint be maintained.

Primary subluxation or dislocation of the thumb CMC joint also occurs in lupus. If the MP and IP joints are well aligned and stable, fusion of the CMC joint can be performed to provide general improvement in thumb alignment and function.[30,89] It is important to stabilize the CMC joint with the metacarpal in a slightly abducted position. However, excessive metacarpal abduction must be avoided because it may lead to excessive MP joint flexion and dislocation, with a further reduction in thumb function. A prosthetic replacement is not indicated.

An alternative to CMC fusion is soft tissue stabilization, which is essential if the MP and IP joints are fused. Realignment of the metacarpal with the flexor carpi radialis (FCR) tendon is effective in maintaining stability with[10] or without[31] resection arthroplasty. Temporary Kirschner wire fixation can be used.

Scleroderma

Scleroderma (systemic sclerosis) is a generalized disease with involvement of the skin, gastrointestinal tract, kidneys, lungs, heart, and often the hands. It is more frequent in females than males. Although the etiology of this condition is unknown, it is thought to be a disorder of small blood vessels and connective tissues that leads to fibrosis. Fibrosis of the skin affects primarily the face and hands; it alters the patient's appearance and leads to severe finger deformities and subsequent loss of hand function. The facial involvement contracts the skin around the mouth, thereby reducing the patient's ability to open the mouth. Scleroderma patients tend to look alike.

A common early manifestation is Raynaud's phenomenon, with intermittent vasospasm and reduced digital circulation. During these episodes, the fingers become white, then turn blue and finally reddish. The reduced digital circulation can lead to skin ulcers, gangrene of the fingertips, and ultimately digital amputations. The acronym CREST has been used to describe the common features of systemic sclerosis: calcinosis, Raynaud's phenomenon, esophageal dysfunction, sclerodactyly, and telangiectasia. The term *overlap syndrome* is used for scleroderma patients with associated findings characteristic of lupus, dermatomyositis, or rheumatoid arthritis.

There are two forms of systemic sclerosis: (1) a type with limited and localized skin involvement and (2) a more common diffuse type. Patients with the diffuse type more frequently exhibit finger joint contractures and digital deformities. Subcutaneous or intracutaneous calcinosis can occur within a single digit and cause painful hard areas at the fingertip, or it may be widespread within the hand and arm. The skin can break down over these areas and discharge a white toothpaste-like or chalky material. The term *sclerodactyly* is used to describe the appearance of the fingers, which become slender with thin, shiny, and sclerotic skin.

Digital Deformity

The deformity patterns seen in scleroderma are diverse, but certain combinations are common. The most frequent deformity is the progressive development of PIP flexion contractures (Figure 55.4). The patients gradually lose the ability to actively extend the PIP joints, and then flexion contractures develop and become severe and fixed. The extensor mechanism over the joints thins and ultimately ruptures. The skin blanches and eventually breaks down, thereby exposing the underlying tendon or the open joint. The danger of joint infection or osteomyelitis is real. Therefore, keeping areas of skin breakdown clean before surgical correction is critical. As increasing flexion of the PIP joint develops, patients compensate by hyperextension at the MP joint level. Initially, the MP joints maintain active flexion, but over time, the collateral ligaments, joint capsule, and overlying skin contract and severely limit MP joint flexion.

The development of PIP joint hyperextension is also encountered in scleroderma but is infrequent. This deformity is secondary to the development of MP joint subluxation in flexion, similar to patients with rheumatoid arthritis. The prominent metacarpal head can erode the overlying skin. The skin and muscles of the first web space often shorten, and a contracture



FIGURE 55.4 Scleroderma typically causes severe proximal interphalangeal joint contractures that result in compensatory hyperextension of the metacarpophalangeal joints.

develops. This reduces thumb mobility and diminishes the ability to grasp large objects between the thumb and index finger.

Surgery on a scleroderma patient's hand is usually performed to improve function and relieve pain. It is unlikely that splinting and exercises can stop progression of the deformity. Scleroderma poses distinct problems for the hand surgeon. The deformities encountered are similar to those seen in rheumatoid arthritis; however, the altered circulation and skin changes associated with this disease adversely affect surgical options and treatment. Wound healing is compromised, and surgical exposure is limited because of the tight skin and poor circulation, thus complicating the surgery options.

❖ AUTHORS' PREFERRED METHOD OF TREATMENT

Increasing deformity with loss of function, the development of skin breakdown, and extrusion of calcific material are frequent indications for surgical consultation. The most common indications for surgery are vascular insufficiency with digital ulceration, calcinosis, and finger and thumb deformities.

Ulceration

Ulceration at the tips of fingers is the result of poor circulation and may be extremely painful. The ulceration is often slow to heal. Skin breakdown at the PIP or MP level results from a combination of decreased circulation and pressure from underlying bone prominence secondary to the joint deformity. Such open wounds can progress to deep infection, but with splinting and good wound care they often heal. They require frequent dressing changes, occasional debridement, and protective splinting. Range-of-motion exercises should be curtailed to protect the underlying joint because the risk for joint sepsis or osteomyelitis is real.

At the fingertips, the underlying phalangeal tufts can be resorbed, and if gangrene ultimately develops, autoamputation can occur or surgical amputation will be needed. These ulcerations are best treated with local topical antibiotics such as silver sulfadiazine. Wound cultures usually reveal *S. aureus*, and appropriate antibiotics are used if an infection is present. Resection of a bony prominence or joint fusion may be the only way to heal open wounds over the MP or PIP joints. With patience, however, many open areas heal spontaneously and therefore should be treated conservatively initially.

Calcinosis

Calcinosis can be intracutaneous or subcutaneous. According to Jones and associates, its frequency is 15% in the diffuse type of scleroderma and 44% in the limited cutaneous variety.[57] Calcium deposits can occur within a single digit or be widespread throughout the hand. They cause symptoms when close to the surface and result in local skin breakdown. The deposits are quite firm and produce tender areas in finger pulp that interfere with the patient's ability to pick up objects. They can spontaneously extrude calcific material, which can be removed surgically from the distal pulp. In areas with digital nerves in close proximity, only limited removal is carried out. Usually, a curet is used rather than a scalpel. This is a particularly common approach in the thumb.

Irrigation with saline solution is also used to safely remove as much material as possible. Occasionally, after removing the calcium deposits the fingertips are left open to allow spontaneous healing rather than placing sutures through compromised skin. In most cases, partial removal or debulking may be enough to relieve the patient's symptoms.[57] Isolated calcific masses in the forearm can be surgically excised without any risk for circulatory or nerve problems.

Deformity of Digital Joints

Surgery at the DIP joints usually consists of either amputation or fusion. Amputation may be required if gangrene, osteomyelitis of the distal phalanx, or a septic DIP joint develops. Such surgery is best done under regional anesthesia with release of the tourniquet before closure to check for adequate circulation. The skin flaps are closed loosely to avoid any compromise of the skin. However, any surgery at the distal level is risky as a result of diminished circulation. Therefore, the surgeon must proceed cautiously because of the possibility of postoperative gangrene and subsequent amputation.

The Proximal Interphalangeal Joint

At the PIP joint level, the most common deformity is fixed flexion. Skin blanching or breakdown is frequently present, along with exposure of the extensor mechanism. In late cases, there may be complete sloughing of the extensor mechanism and exposure of the PIP joint. Hand function decreases as the fixed-flexion deformity increases. To improve grasp, patients compensate with MP joint hyperextension, which itself becomes fixed unless an attempt is made to maintain motion. The circulation at the PIP level is better than in the distal part of the finger. Thus, it is possible to operate with less risk at the PIP joint, even with infected or exposed joints.

In our opinion, fusion is the procedure of choice for the common fixed-PIP joint flexion contracture. The bone resection as part of the fusion procedure, combined with skin resection, makes it possible to achieve primary healing. The overall functional result of a PIP joint fusion is determined in large part by the range of motion of the MP joints. With good MP function, the PIP joints can be fused in less flexion. If MP motion is reduced, it should be regained surgically by either capsulotomy or arthroplasty before proceeding with PIP joint fusion. With severe flexion contractures, there may be an intraoperative circulatory problem as the digit is straightened. In this situation, it may be necessary to either accept less correction than usual[57] or perform digital sympathectomy to improve the circulation and preserve the correction. Sympathectomy is not usually performed at the same time.

Some surgeons have reported using Swanson flexible implant arthroplasties at the PIP joint level. However, the ultimate gain in motion in reported cases has been small.[98] In addition, the amount of bone resection required for insertion of the implant can lead to considerable digital shortening. This approach is not recommended.

The Metacarpophalangeal Joint

At the MP level, the circulation approaches normal levels. The area is warm to palpation, and therefore the surgeon has the ability to carry out more extensive surgery with normal wound healing. However, tight skin poses a significant problem when one tries to achieve additional flexion. Although it is possible to insert flexible prosthetic implants at this level, the risks are

increased over resection arthroplasty, which can also restore satisfactory motion. With shortened dorsal skin and fixed MP hyperextension, however, the situation changes. When faced with this dilemma, the surgeon can safely approach the metacarpal heads using a palmar approach and carry out wide resection of the metacarpal heads to restore flexion.

For patients with fixed-MP hyperextension and severe fixed-flexion of the PIP joints, it is imperative that the PIP flexion contractures be corrected by fusion before restoring MP flexion by resecting the metacarpal heads through a volar incision. We have noted considerable remodeling of the metacarpal heads after resection, which makes this technique a viable alternative to implant surgery for some patients. In patients with MP flexion deformities, a standard dorsal approach is used.

First Web Contracture

Another area treated surgically in patients with scleroderma is a tight first web space between the thumb and index finger. Opening the space and releasing the tight deeper structure may require release of the adductor attachment to the thumb and the addition of a skin graft. Selected fusion of the IP or MP joint of the thumb is also helpful when thumb deformities reduce the ability to achieve adequate thumb–index finger pinch. In some patients, resection of the trapezium may be required to restore thumb metacarpal abduction.

Vascular Insufficiency

Surgical approaches to improve digital circulation have focused on attempts to decrease the sympathetic innervation of the digital vessels. Several authors, including Flatt,[39] have described various techniques to strip the adventitia of the common digital arteries in the palm. Each of the techniques has resulted in temporary improvement in digital blood flow, with increases in skin temperature and improvement in the healing of fingertip ulcers. Jones and coworkers investigated digital circulation in scleroderma patients by several methods, including digital plethysmography, cold stress testing, and intraarterial digital subtraction angiography.[58] Cold stress testing involves measurement of digital temperature, pulse volume readings, or laser Doppler flow values of the digits before and during exposure of the hands to a cold environment and during subsequent rewarming.

At surgery, the entire superficial palmar arch is inspected to look for segmental occlusions and determine the need for interposition vein grafts. The surgeon also inspects for constrictive fibrous tissue around the small vessels that can be excised. Jones and colleagues call this surgical approach "decompressive arteriolysis." Unfortunately, patients undergoing these various techniques often continue to have pain, and recurrent ulceration develops within 2 years. However, it is an exciting new approach to the management of diminished distal circulation in patients. For further information, please see Chapter 60.

RHEUMATOID NODULOSIS

Subcutaneous nodules are common in patients with rheumatoid arthritis and are seen occasionally in those with SLE. These nodules occur frequently in the olecranon areas (Figure 55.5) and on the extensor surfaces of the forearms. They can be tender and a source of discomfort to the patient if they are large. The nodules can develop on the dorsal aspect of the hand (see Figure 55.5, *A*), where they are unsightly, or on the palmar surface of the digits, where they may interfere with hand function because of pressure sensitivity or compression of digital nerves. They can cause erosion of the overlying skin and can form a draining sinus from necrosis of the central core of the nodule. Nodules that form in subcutaneous areas on the volar surface of the digits can interfere with function because pressure during grip or pinch causes discomfort.

Symptomatic nodules can be resected. Meticulous hemostasis should be obtained, particularly in the region of the olecranon. The use of a drain (brought through normal skin) usually prevents or minimizes the postoperative formation of hematoma or seroma. On the palmar surface of the digits, care must be taken to protect underlying structures, particularly the neurovascular bundles, and to maintain sufficient skin to allow primary closure. If the wound cannot be closed, skin grafts should be used.

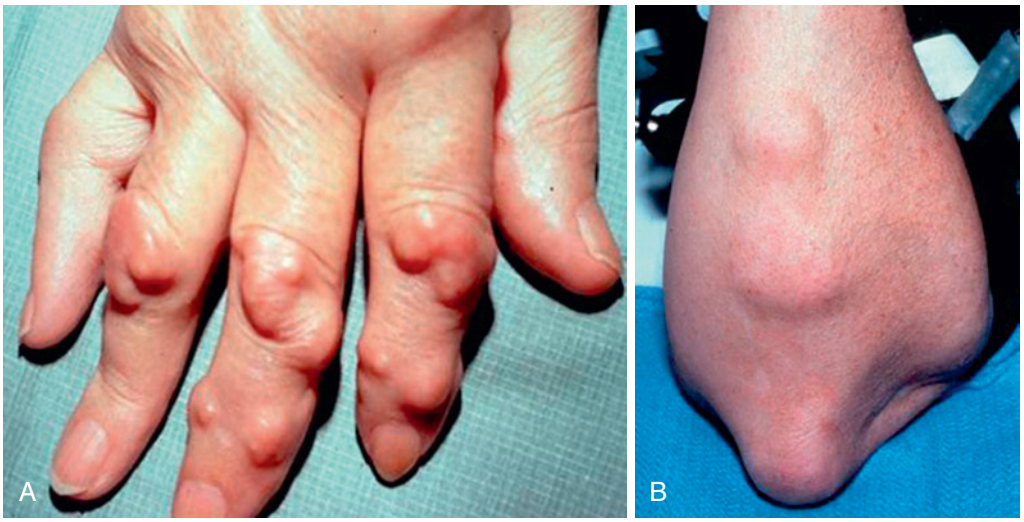

FIGURE 55.5 **A,** Rheumatoid nodulosis on the fingers' dorsal aspects. **B,** Rheumatoid nodules on the posterior aspect of the forearm and in the olecranon region can cause considerable discomfort. Resection of these nodules is accomplished through longitudinal incisions.

Rheumatoid nodulosis has been described as a separate clinical entity (rheumatoid variant); it is characterized by multiple subcutaneous nodules, usually on the hands, and is associated with intermittent polyarthralgia, absent or minimal joint involvement, subchondral cystic radiolucencies, and positive rheumatoid factor. Involvement of the hands by prominent subcutaneous nodules, often in clusters, can be extensive. When unsightly, resection of multiple nodules can dramatically improve the hand's appearance. There is some tendency for these nodules to recur after excision.[40,69]

RHEUMATOID ARTHRITIS

Tenosynovitis

Rheumatoid arthritis is a disease of the synovium. The synovium-lined sheaths that surround many of the tendons about the hand and wrist can be affected by proliferative synovitis in the same way as the synovium-lined joint spaces. Tendon sheath involvement is common and may occur months before the symptoms of intraarticular disease are noted.[97]

The three common sites of tendon sheath involvement are (1) the dorsal aspect of the wrist, (2) the volar aspect of the wrist, and (3) the volar aspect of the digits (Figure 55.6). Rheumatoid tenosynovitis can cause pain, dysfunction of tendons, and ultimately tendon rupture after invasion of tendons by the proliferating synovium. Treatment can relieve the pain and, if instituted before secondary changes in the surrounding structures and before tendon ruptures have occurred, can prevent both deformity and loss of function. For this reason, dorsal, volar, and digital tenosynovectomies are often the first surgical procedures indicated for rheumatoid patients.[97] Of patients with tenosynovitis, 50 to 70% have been found to have infiltration of the tendon by proliferative tenosynovium at the time of prophylactic tenosynovectomy.[73]

ANATOMY OF THE TENDONS AND TENDON SHEATH

On the dorsal aspect of the wrist, the deep fascia thickens to form a band approximately 3 cm in width. This dorsal retinaculum functions as a pulley for the extensor tendons that run in compartments directly beneath it. Six separate compartments are formed by vertical septa that run from the volar surface of the retinaculum to the dorsal surface of the radius and ulna; they are referred to numerically:

1. Contains the most radial tendons, abductor pollicis longus (APL) and extensor pollicis brevis (EPB)
2. Contains the extensor carpi radialis longus (ECRL) and extensor carpi radialis brevis (ECRB) tendons
3. Contains the EPL tendon
4. Contains the extensor digitorum communis (EDC) and the extensor indicis proprius (EIP) tendons
5. Contains the extensor digiti quinti (EDQ) tendon
6. Contains the ECU tendon

Each of the tendons within these compartments is surrounded by tenosynovium, which begins just proximal to the proximal edge of the retinaculum and continues distally to the level of the metacarpal bases. The tendons distal to this area are covered by paratenon rather than by tenosynovium.

On the volar aspect of the wrist, the flexor tendons of the fingers and thumb and the median nerve pass into the hand under the transverse carpal ligament (flexor retinaculum). This thick ligament extends across the volar aspect of the carpus attached to four "pillars"—the trapezium and the scaphoid on the radial side of the wrist and the hamate hook and pisiform on the ulnar side—to form the roof of the carpal canal. Just before the finger flexors enter the carpal canal, a common sheath of tenosynovium surrounds them. The flexor pollicis longus (FPL) tendon runs in a separate tendon sheath.

The tendon sheaths of the index, middle, and ring fingers extend from midpalm to the DIP joints. The sheaths of the thumb and little finger continue proximally into the carpal

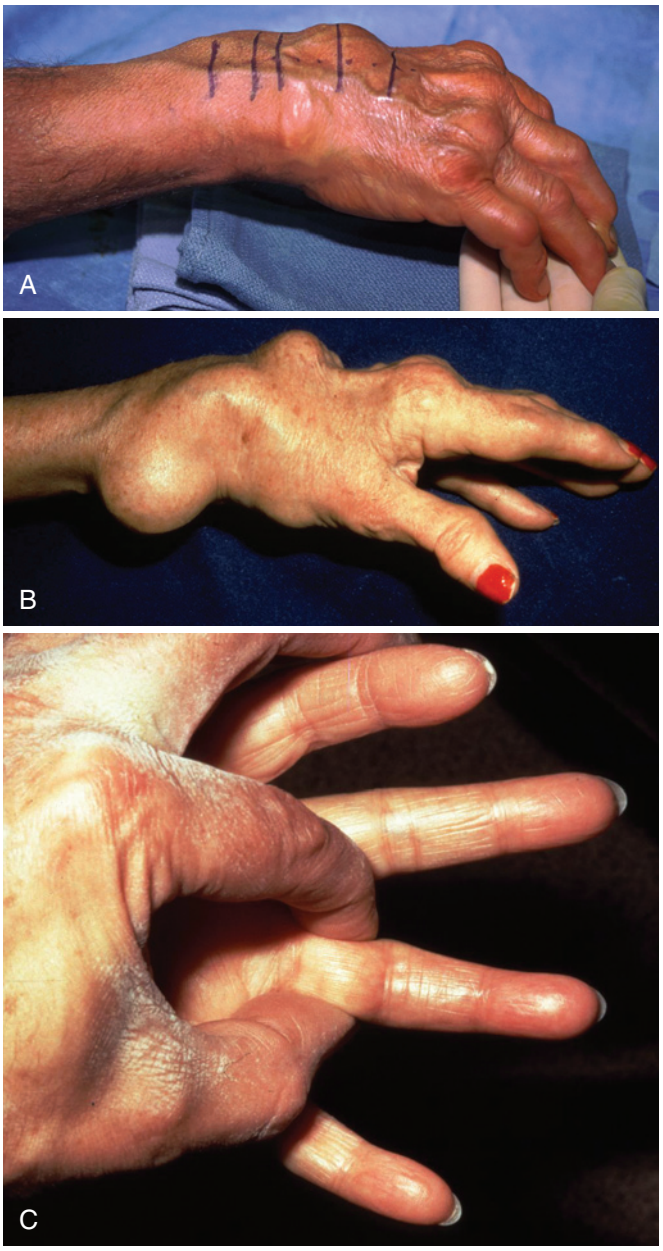

FIGURE 55.6 Examples of dorsal (extensor) and flexor tenosynovitis. **A,** Dorsal tenosynovitis affecting only the extensor digitorum communis compartment. **B,** More extensive dorsal tenosynovitis affecting multiple extensor tendon compartments. Note the bulging along the course of the abductor pollicis longus and extensor pollicis brevis, extensor pollicis longus, and common digital extensors. **C,** Digital flexor tenosynovitis manifested as volar fullness over the proximal phalanges. (From Millender LH, Nalebuff EA: Evaluation and treatment of early rheumatoid hand involvement. *Orthop Clin North Am* 6:697–708, 1975, with permission.)

tunnel. The flexor tendons within the digits are enclosed in a snug fibroosseous canal lined with synovium.

Dorsal (Extensor) Tenosynovitis in the Wrist

Dorsal tenosynovitis is characterized by swelling on the dorsal aspect of the wrist. It may be subtle or massive and may involve one tendon, a combination of tendons, or all the tendons in the dorsal compartments. Because the dorsal skin of the wrist and hand is thin and displaced easily as tenosynovium proliferates, dorsal tenosynovitis is usually obvious and may be the first sign of rheumatoid arthritis. Isolated dorsal tenosynovitis is painless. Patients tend to ignore the swelling, and tendon rupture with loss of active extension can be the first manifestation of the condition. When patients with dorsal tenosynovitis complain of pain, one must look for involvement of the radiocarpal or radioulnar joints.

Although early in the disease the synovial tissue remains thin and distends the sheath with fluid, as the disease progresses, this tissue thickens and takes on a more solid appearance, similar to that found within joints affected by advanced rheumatoid arthritis. Small fibrinoid "rice bodies" occasionally fill the tendon sheaths. The hypertrophic synovium adheres to tendon surfaces and may eventually invade the tendon substance and result in weakening and, not infrequently, rupture of the tendon. Occasionally, rheumatoid nodules are found within the tendon substance.

Spontaneous or drug-induced remission of early dorsal tenosynovitis can occur. Rest or local injection of a steroid solution, or both, may also result in remission. However, if the proliferative synovitis progresses, remission becomes unlikely. The dorsal tenosynovitis becomes unsightly, and the risk for tendon rupture increases. For this reason, early dorsal tenosynovectomy is recommended (i.e., if there is no improvement after 4 to 6 months of appropriate medical management). Although the appearance of the tendons within the compartments affected by tenosynovitis may be poor (as evidenced by fraying), tendon rupture rarely occurs after dorsal tenosynovectomy is performed.[73,110]

❖ AUTHORS' PREFERRED METHOD OF TREATMENT: Dorsal Tenosynovectomy

A straight (preferred) or gently curved longitudinal incision is made over the dorsal aspect of the wrist just to the ulnar side of the midline (Figure 55.7). Full-thickness skin flaps, including the subcutaneous tissue, are reflected to expose the underlying extensor retinaculum and deep fascia. The superficial branches of the ulnar and radial nerves remain in the subcutaneous tissue of the flaps and thus are protected. Longitudinal veins are preserved if possible, but transverse communicating veins are divided. The fourth compartment is opened in a "Z" manner. The terminal branch of the posterior interosseous nerve on the radial side of the floor of the fourth compartment can be

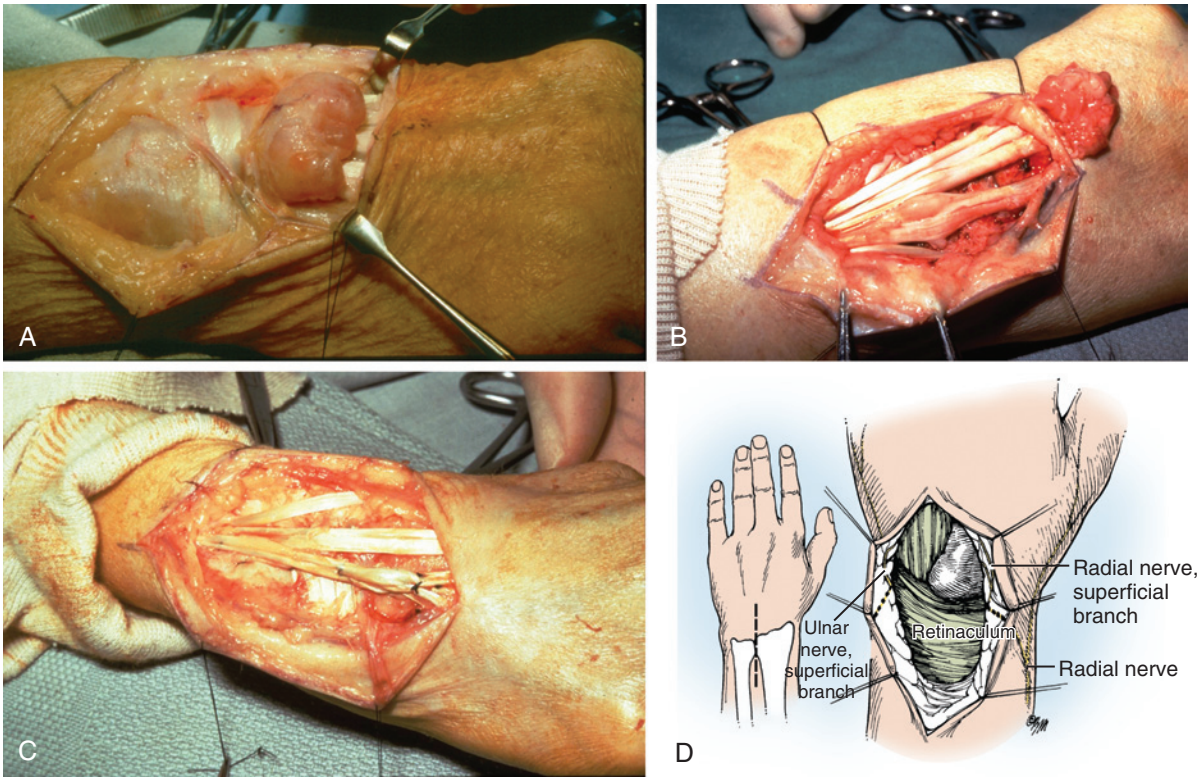

FIGURE 55.7 Surgical technique of dorsal tenosynovectomy. **A,** A straight dorsal incision has been made. The extensor retinaculum and the bulging dorsal tenosynovitis are seen. **B,** The retinaculum has been incised in the midline and reflected radially and ulnarward. Tenosynovitis is seen surrounding the extensor tendons. Dorsal tenosynovectomy and retinacular relocation have been completed. The dorsal retinaculum has been placed deep to the extensor tendons. **C,** Capsular closure is completed and tendon transfer is performed. Note the extensor carpi ulnaris relocation using a portion of the dorsal retinaculum. **D,** Exposure for dorsal tenosynovectomy. We prefer a straight rather than a slightly curved incision (as shown). Note the superficial branches of the radial and ulnar nerves protected in skin flaps. (**A-C,** From Millender LH, Nalebuff EA: Preventative surgery: tenosynovectomy and synovectomy. *Orthop Clin North Am* 6:765–792, 1975, with permission; **D,** copyright © Elizabeth Martin.)

resected to partially denervate the wrist joint. The septum between the third and fourth compartments is opened and the EPL tendon is identified and protected. The vertical septum between each compartment is divided. The radial flap of retinaculum is hinged on the septum between either the second and third compartments or the first and second compartments (if the second compartment requires tenosynovectomy). The ulnar flap of retinaculum is hinged on the septum between the fourth and fifth compartments.

The first dorsal compartment is not opened unless it is involved significantly. Hypertrophic synovium is removed from each extensor tendon sheath in a systematic manner. A limited dorsal tenosynovectomy can be done through a single compartment incision (e.g., the fourth) if indicated. In this case, the fourth compartment is opened in the same Z manner, but not extended radially or ulnarly. The posterior interosseous nerve is resected as just described. The tenosynovium is dissected from the extensor tendons with small scissors or with a rongeur.

As much of the diseased tenosynovium is removed as possible, although it is sometimes necessary to leave material that is densely adhered to the extensor tendon's surface. Frayed areas of the tendons are repaired with absorbable suture. If an area of tendon appears so attenuated or frayed so that tendon rupture seems imminent, the tendon at risk can be sutured to an adjacent extensor tendon above and below the area of damage, or the frayed and attenuated areas can be imbricated. If extensive tendon infiltration is found, similar infiltration may be present in other areas or on the contralateral side, and early surgery in these areas should be considered to prevent rupture.

After complete tenosynovectomy has been performed, the wrist joint is evaluated. If synovitis is present, the joint is opened and wrist synovectomy is performed with a small curved rongeur. The dorsal aspects of the ulna and radius are examined, and any bone spicules, which might cause attrition ruptures, are removed with a rongeur. The distal ulna is resected if it is dislocated and prominent dorsally. This is discussed in greater detail in the section on the distal radioulnar joint (DRUJ).[53]

The dorsal retinaculum is passed deep into the extensor tendons and sutured in place to provide a smooth gliding surface beneath them. If bowstringing is anticipated as a potential problem (e.g., in a patient with good wrist extension), half of the retinaculum may be retained over the tendons (Figure 55.8). The ECU tendon may be stabilized in a dorsal position with a narrow segment of the retinaculum.

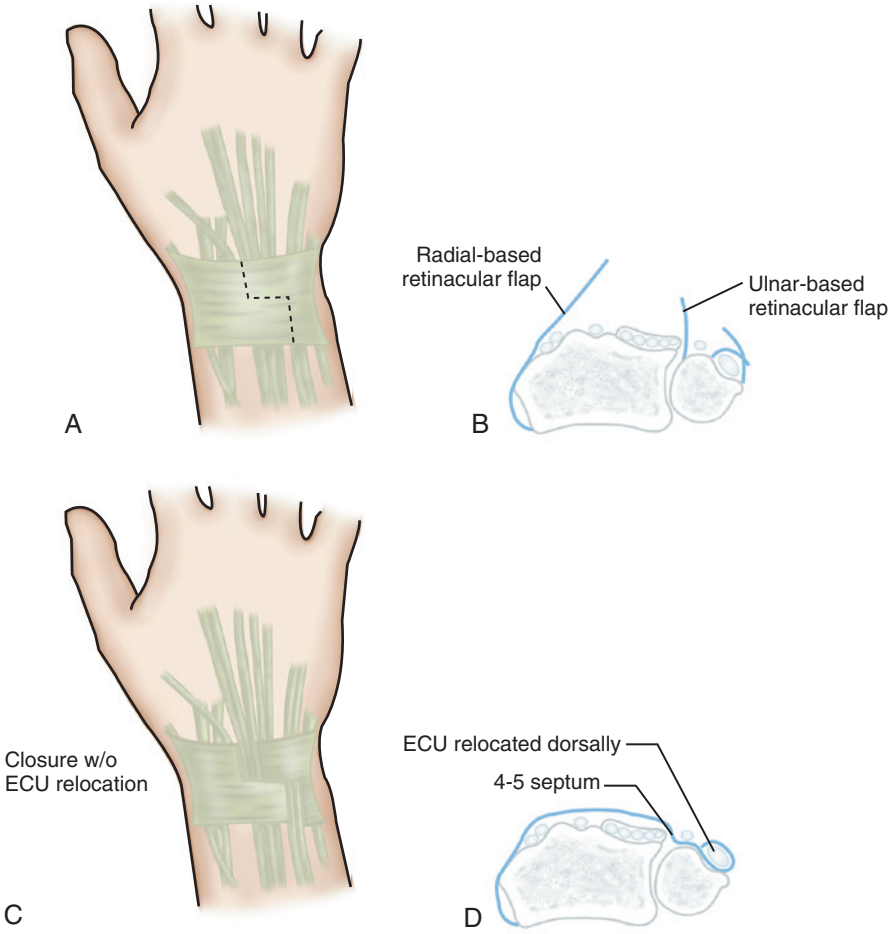

FIGURE 55.8 Illustration of the basic operative technique. **A,** The retinaculum is opened in a "Z" fashion. **B,** Usually, the radial-based retinacular flap is hinged on the 1-2 septum and the ulnar flap on the 4-5 septum. The fifth compartment is opened as needed. **C,** The retinaculum is usually closed in a lengthened position. If needed, one flap can be placed under the tendons. **D,** Also if needed, the ulnar flap, which is hinged on the 4-5 septum, can be looped under the extensor carpi ulnaris (ECU). The synovial side of the retinaculum is placed against the ECU. (**A-C,** From Slutsky DJ: *The principles and practice of wrist surgery*, Philadelphia, 2010, Elsevier. **D,** copyright Elizabeth Martin.)

The tourniquet can be released and bleeding controlled before final closure. If the tourniquet is released and bleeding is minimal, no drain is necessary. However, a small Penrose or suction drain prevents hematoma formation if the tourniquet is not released. The hand and wrist are immobilized in a bulky conforming dressing and a volar plaster splint. The wrist is held in neutral with the MP joints in extension. The IP joints are left free. The drain is removed 24 to 36 h after surgery. Dorsal tenosynovectomy can be performed in conjunction with other procedures such as thumb fusion, volar synovectomy, or finger tenosynovectomy.

Postoperative Management. Hand motion is started 24 to 48 h after surgery. Active extension and flexion exercises are emphasized. Motion usually returns rapidly, but in a patient with a low pain threshold, formal hand therapy may be required. The MP joint should be splinted in extension to prevent extensor lag until active extension is possible. The wrist is supported with a volar splint for 2 weeks after the procedure.

When patients have difficulty regaining active MP joint extension, taping the fingers with the PIP and DIP joints in flexion during active extension exercise is helpful in improving joint movement. All the extensor power is concentrated at the MP joint level, and extensor tendon excursion is increased over the areas of surgery (Figure 55.9).

Complications. Complications after dorsal tenosynovectomy are infrequent. The most serious complication is skin necrosis or sloughing. When this occurs, the extensor tendons are exposed and are at risk for rupture or scarring. Hematoma formation under the thin dorsal flaps of rheumatoid patients (especially those taking corticosteroids) is the most frequent cause of delayed skin healing. Special care must be taken to prevent hematoma formation. The skin is closed without tension, and a drain should be used routinely. The proximal and distal ends of the wound can be left open if necessary to avoid hematoma formation. A layered closure to cover the tendons with subcutaneous tissue can sometimes be done. Occasionally, it is useful to put the extensor retinaculum over the tendons to protect them if skin breakdown occurs. Sutures should not be removed prematurely. If skin sloughing occurs, the wound can be treated by debridement and skin coverage. The MP joints are splinted in extension until the wound has healed by secondary intention in 2 to 3 weeks.

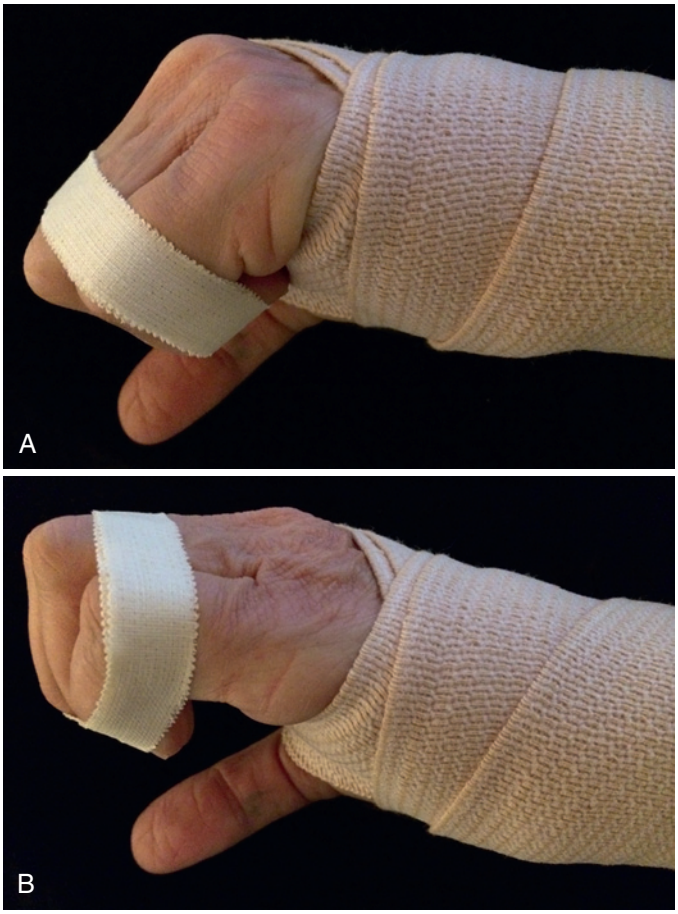

FIGURE 55.9 Postoperative metacarpophalangeal (MP) joint exercises can be done with the proximal interphalangeal and dorsal interphalangeal joints taped in flexion. This maximizes extensor tendon excursion as the MP joint moves from flexion **(A)** to extension **(B)**.

Occasionally, postoperative adhesions may result in either an extensor lag of the MP joints or loss of active finger flexion. Hand therapy is adjusted to emphasize flexion or extension as necessary. If pain or flexor weakness prevents flexion, passive flexion exercises and dynamic flexion splints can be added. If a significant extensor lag develops, a dynamic dorsal extension splint is used. Loss of motion after dorsal tenosynovectomy occurs more often in patients whose tendons are found to be in poor condition at the time of surgery, in patients with multiple joint involvement, and in those with low pain tolerance. Tenolysis after dorsal tenosynovectomy is rarely necessary. However, if significant impairment of function persists after 6 months of therapy, tenolysis should be considered.

Flexor Tenosynovitis in the Wrist

Although swelling on the dorsal aspect of the wrist is often prominent because of thin skin in the area, hypertrophic synovitis on the volar aspect of the wrist may not be obvious. However, proliferative synovitis of the flexor tendon sheaths occurs commonly and affects the anatomic structures. Compression of the median nerve can occur and cause symptoms of carpal tunnel syndrome. Restriction of the free-gliding motion of the flexor tendons results in impaired active and passive motion of the fingers.

As in extensor compartment tenosynovitis, flexor tenosynovitis eventually destroys the tendons' outer surfaces. The tendons adhere to one another, and as synovial tissue invades the tendon substance, ruptures can occur. There may occasionally be complete destruction of the flexor tendons within the confines of the carpal canal.

Even though rheumatoid flexor tenosynovitis may respond temporarily to local corticosteroid injection, we believe that early surgical decompression of the carpal canal combined with flexor tenosynovectomy is indicated to prevent permanent damage to the median nerve. Flexor tenosynovectomy with decompression of the nerve prevents permanent pain, numbness, thenar muscle loss, and spontaneous rupture, as well as preserves independent tendon-gliding function.

❖ AUTHORS' PREFERRED METHOD OF TREATMENT: Flexor Tenosynovectomy

An incision is made in the midpalm, parallel to the thenar crease, and extended proximally while curving ulnarward at the wrist (Figure 55.10). The incision is extended 4 to 5 cm above

CRITICAL POINTS *Dorsal Tenosynovectomy*

Indications

- Persistent dorsal tenosynovitis after 4 to 6 months of appropriate medical management.
- Extensor tendon rupture.

Pearl

- Tape the IP joints in flexion for postoperative exercise if the patient has difficulty regaining active MCP extension.

Technical Points

- Use a straight midline incision.
- Make transverse incisions distal and proximal to the retinaculum.
- Use a longitudinal incision volar to the sixth compartment.
- Elevate the radially based retinacular flap by dividing the septa between compartments.
- If tenosynovitis is limited to a single compartment, use a longitudinal incision for limited tenosynovectomy.
- Remove the tenosynovium from each tendon.
- Repair a frayed tendon or suture a tendon at risk for rupture to an adjacent tendon.
- Remove any tenosynovium infiltrating the tendon substance and repair.
- Perform synovectomy of the wrist joint if necessary.
- Perform a distal ulnar resection if necessary.
- Transpose the retinaculum beneath tendons; split transversely, transpose half, and reattach the left half dorsal to preserve function.
- Stabilize the ECU in a dorsal position with a retinacular flap if necessary.
- Close the skin over a drain.

Postoperative Care

- Splint with the wrist in neutral and the MP joints in extension.
- Leave IP joints free and start finger motion within 24 h.
- Use a wrist splint for 2 weeks after the patient is able to maintain active MP extension.

the wrist in a zigzag manner. Care should be taken to protect the palmar cutaneous branch of the median nerve at the level of the wrist flexion crease. The deep fascia is divided to expose the median nerve. The palmar fascia is incised and separated from the superficial surface of the transverse carpal ligament, which is divided to open the carpal canal.

The median nerve is freed from adherent synovial tissue. The motor branch of the median nerve is identified and traced into the thenar musculature. If compression of this branch by the fascia of the thenar muscles has occurred, the fascia is divided. The hypertrophic tenosynovium surrounding the flexor tendons is excised, and areas of tendon fraying are repaired as described for the extensor tendons. Occasionally, unsuspected ruptures of the deep flexor tendons may be discovered at this time. Therefore, it is critical that the function of the flexor tendons be known before surgery. If the flexor tendons are functioning by pulling through scar tissue, complete removal of all diseased tissue is not done. Careful dissection is required when performing an extensive flexor tenosynovectomy, and thought must be given to the consequences of separating each of the deep flexor tendons out of the mass of tenosynovium binding them together. It may be more prudent to separate the superficial flexor tendons and leave the deep flexor ones in situ; that is, do not separate the flexor digitorum profundus (FDP) into its four component tendons but merely separate them en masse from their scarred bed.

After tenosynovectomy is performed, the floor of the carpal canal is inspected and palpated. Any exposed bone spicules, particularly over the volar surface of the scaphoid bone, are removed with a rongeur because they can result in tendon rupture by attrition. Exposed bone surfaces are covered by mobilizing and suturing local soft tissue.[68] Ertel and colleagues described a volar rotation flap to close the defect if primary closure is not possible (Figure 55.11).[35]

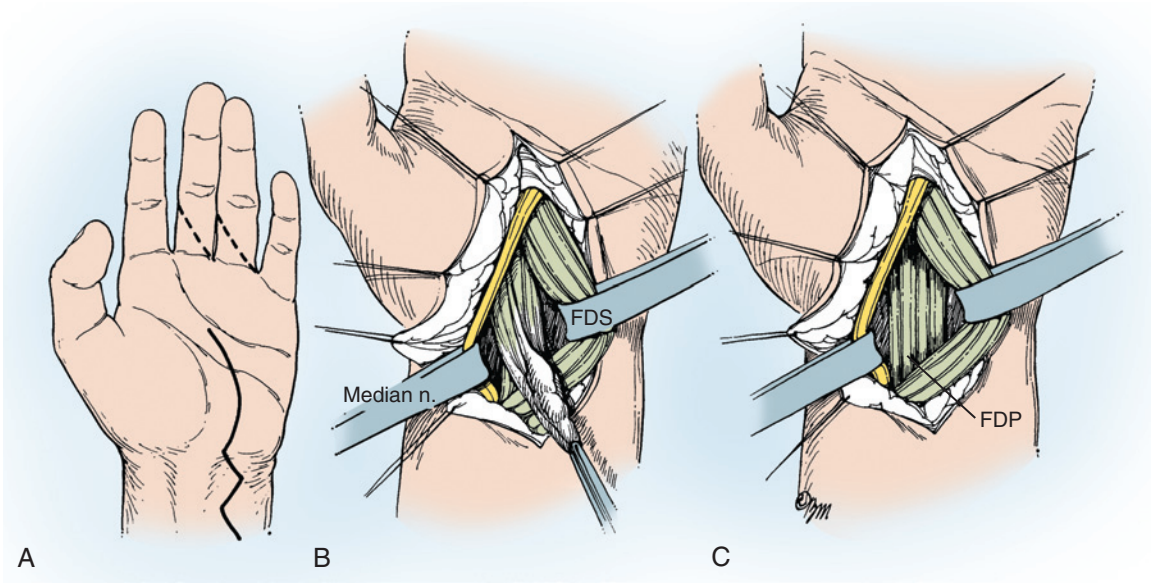

FIGURE 55.10 A-C, Surgical technique of wrist flexor tenosynovectomy; incisions for wrist, palm, and digital flexor are shown. The flexor tendons are exposed at the wrist and elevated into the wound. The median nerve is retracted with a Penrose drain. The flexor tenosynovium is excised from the flexor tendons. *FDP*, Flexor digitorum profundus; *FDS*, flexor digitorum superficialis. (Copyright Elizabeth Martin.)

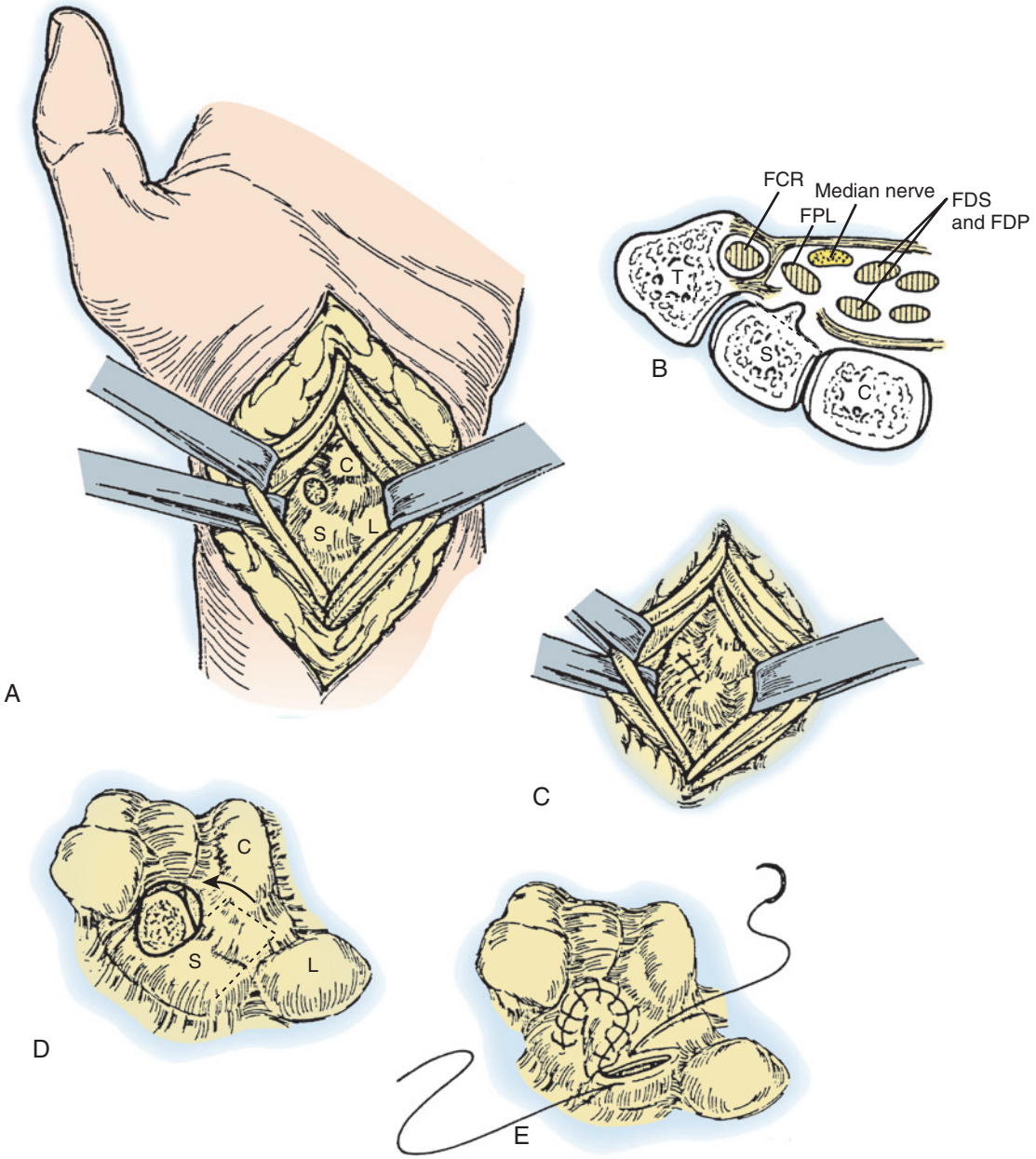

FIGURE 55.11 A scaphoid osteophyte can erode through the volar wrist capsule **(A)** and result in the "Mannerfelt lesion." **B,** Attrition rupture of the flexor pollicis longus (FPL) tendon. During volar tenosynovectomy, the osteophyte is resected and the defect in the capsule is closed either primarily **(C)** or with local rotation flaps of the wrist capsule **(D, E)**. *C,* Capitate; *FCR*, flexor carpi radialis; *FDP*, flexor digitorum profundus; *FDS*, flexor digitorum superficialis; *L,* lunate; *S,* scaphoid. (Copyright Elizabeth Martin.)

CRITICAL POINTS *Volar Tenosynovectomy*

Indications

- Symptoms or signs of median nerve compression.
- Persistent tenosynovitis after injection/medical management.
- Flexor tendon rupture.

Pearls

- If multiple FDP tendon ruptures are found at the time of surgery, do not perform individual tenosynovectomies but leave the FDP mass intact.
- If "catching" is found when testing for tendon excursion after tenosynovectomy, check for flexor tendon nodules in the digits and palm.

Technical Points

- Make an incision from midpalm (parallel to the thenar crease) to 4 to 5 cm proximal to the wrist flexion crease.
- Protect the palmar cutaneous nerve.
- Expose and protect the median nerve in the forearm.
- Divide the volar fascia and transverse carpal ligament longitudinally under direct vision.
- Perform tenosynovectomy.
- Inspect the floor of the carpal canal, debride any scaphoid osteophytes, and cover with a soft tissue rotation flap if present.
- Check for free tendon excursion.

Postoperative Care

- Splint the wrist in neutral.
- Start immediate active finger motion.

Traction is applied to the flexor tendons to check finger motion. Smooth motion of the fingers and thumb should be present. Catching signals the presence of tendon nodules in the palm or digits. If smooth motion of the tendons is not present, the involved tendon must be explored as far distally as necessary to remove the nodules. After removal of the nodules, the defect in the tendon is repaired with interrupted fine sutures.

Flexor Tenosynovitis in the Digits

As described previously, the fibroosseous canal is lined by synovium. This canal is not distensible, and even mild synovial hypertrophy can affect finger function significantly. Discrete rheumatoid nodules can form in one or both flexor tendons within the sheath. Such nodules may occur at different levels. The size of these nodules and their relationship to the annular pulleys determine the degree of finger dysfunction.

Several clinical patterns of rheumatoid "trigger finger" can occur and are based on the size and location of the nodules. Small, localized areas of disease cause catching of the tendons during flexion. This resembles the triggering that occurs in nonrheumatoid stenosing tenosynovitis. Flexor tendon nodules in the distal aspect of the palm can cause the finger to lock as it is flexed. A nodule in the FDP tendon in the region of the A2 pulley over the proximal phalanx can cause the finger to lock in extension.

Generalized tenosynovitis within the fibroosseous canal can result in palpable swelling on the volar aspect of the digit and limit motion. Usually, active motion is more restricted than passive motion. This loss of finger motion can result in stiffness of the IP joints as the periarticular soft tissue structures contract. As the IP joints become stiff, making a diagnosis becomes more difficult because one cannot tell whether the lack of finger motion is due to joint stiffness or restricted excursion of the flexor tendons. Prolonged flexor tenosynovitis within the fibroosseous canal can ultimately result in tendon rupture. Flexor tenosynovectomy and excision of flexor tendon nodules are indicated regardless of the type of tenosynovitis or triggering present.

❖ AUTHORS' PREFERRED METHOD OF TREATMENT: Digital Tenosynovectomy

We explore the flexor tendon sheaths of rheumatoid patients with digital tenosynovitis through zigzag incisions on the volar aspect of the digits (Figure 55.12). Such incisions can be extended proximally or distally to provide additional exposure if necessary. If multiple fingers are involved, a single transverse incision across the distal part of the palm can be used to expose the proximal portions of the flexor tendon sheaths. The diseased tenosynovium surrounding the tendon is excised. However, *the annular pulleys are preserved to prevent bowstringing of the flexor tendons.* The pulleys can be narrowed if necessary, but as much pulley as possible needs to be preserved.

Nodules within the flexor tendons are excised and the defects are closed with fine sutures. After complete tenosynovectomy and nodule excision have been performed, traction is applied to the flexor tendons to confirm smooth gliding. Occasionally, another nodule is present at a different level within the fibroosseous canal and is revealed only after the obvious nodule is excised and flexor tendon excursion is tested. If passive flexion of the finger is greater than the flexion obtained by traction applied to the tendon, additional tenosynovectomy is necessary. The objective of flexor tenosynovectomy is to make active and passive finger flexion equal. Gentle manipulation of stiff joints can be performed to restore passive joint motion at this time.

One surgical solution is to excise one slip of the flexor digitorum superficialis (FDS) tendon to decompress the fibroosseous canal. Although we do not use this method routinely, we prefer it to resecting excessive amounts of annular pulley to allow free excursion of the tendons. The entire FDS tendon may be excised if it is severely diseased and prevents complete "pull-through" of the FDP tendon.

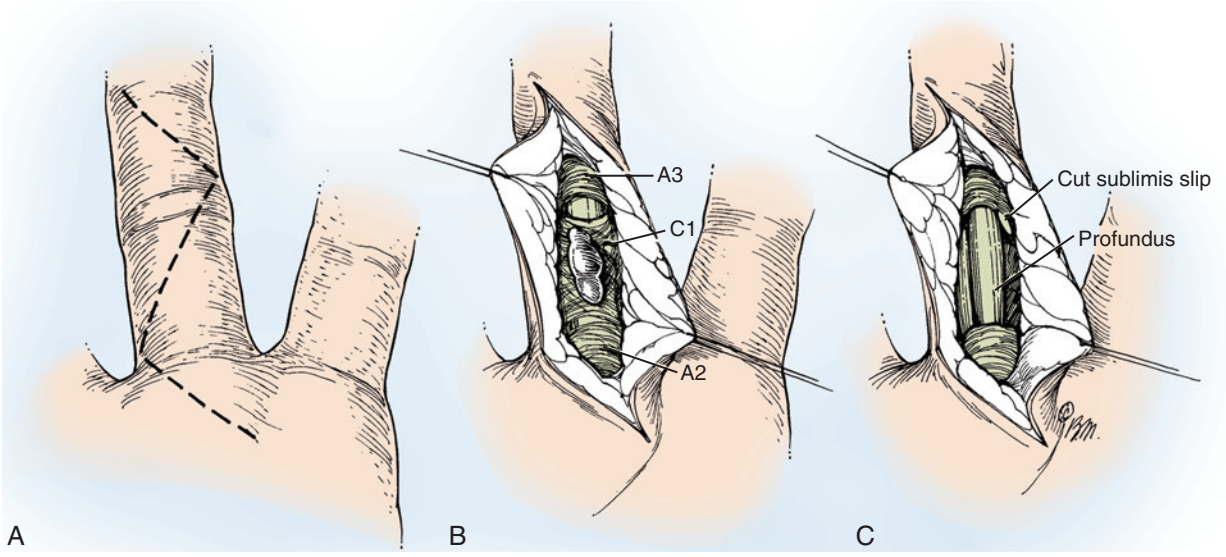

FIGURE 55.12 Digital flexor tenosynovectomy. **A,** The tendon sheath is approached through an extensile zigzag incision. **B,** Note the annular pulleys; the synovium usually bulges through the thin cruciate pulleys. As much annular pulley as possible is preserved when tenosynovectomy is performed. **C,** Half the superficialis tendon can be excised to allow free excursion of the remaining tendons without compromising annular pulley function. (Copyright Elizabeth Martin.)

Postoperatively, finger motion is started early, usually the day after surgery. The patient is taught to stabilize each joint of the operated on finger in sequence to exercise the superficial and deep flexor tendons independently; this thereby avoids adhesions between the two tendons.

Tendon Ruptures

Tendon ruptures in the hand are common in rheumatoid arthritis; the cause and location of them vary. Attrition ruptures occur as the tendon moves across bone roughened or eroded by chronic synovitis. Attrition ruptures of the extensor tendons occur most frequently either at the distal end of the ulna or at Lister's tubercle, which acts as a bony pulley for the EPL tendon. Attrition ruptures of flexor tendons occur on the volar aspect of the wrist where they contact the scaphoid. Tendon ruptures also can be caused by direct tendon invasion of rheumatoid tenosynovium, which erodes and weakens the tendon, or by ischemic necrosis from a diminished blood supply caused by pressure from proliferative synovium under the dorsal retinaculum, transverse carpal ligament, or flexor tendon pulleys.[68,79,130]

The treatment options for rheumatoid patients with tendon ruptures are fusions of various joints and tendon transfers. There are differences between tendon transfers performed in rheumatoid and nonrheumatoid patients. For a rheumatoid patient, (1) the joints to be moved by the transfer may be stiff or unstable; (2) the bed through which the transfer passes may be scarred or irregular and compromise tendon excursion; (3) the tendons to be transferred may have been weakened; and (4) if the wrist, MP, or PIP joints (or any combination of the three) are stiff or deformed, the tenodesis effect of wrist motion or the complementary motion of the MP and PIP joints cannot be relied on to enhance the performance of the transferred tendons. These factors must be considered carefully when planning tendon transfers to reconstruct rheumatoid tendon ruptures.

Diagnosis

Extensor Tendon Ruptures. Although the correct diagnosis of tendon rupture is not usually difficult to make, it requires both an observant patient and an informed physician. The sine qua non of tendon rupture is the *sudden loss of finger extension or flexion*. Tendon ruptures are generally painless and commonly follow trivial hand use or activity. Rheumatoid patients who become accustomed to frequent variations and limitations of hand function are likely to delay medical attention unless the functional loss after rupture of a tendon is obvious to them or is quite significant. Isolated ruptures of the EDQ or EPL may cause only limited functional loss and therefore go unrecognized or be overshadowed by more significant deformities.

The factors leading to rupture of a single tendon, unless corrected, are often responsible for subsequent ruptures with more significant functional loss. Frequently, after a rupture of the extensor tendon of the little finger, the ring finger extensor ruptures, followed by the long finger extensor, and so on (Figure 55.13). This occurs as the remaining intact tendons shift ulnarward and become abraded over the roughened edges of the distal ulna. Thus, the usual progression of extensor tendon ruptures is in a radial direction, with the index finger being the last one affected. In our experience, multiple extensor tendon ruptures (especially those that occur in rapid succession) are the result of attrition as the tendons wear against a bone spicule on the ulnar aspect of the wrist.

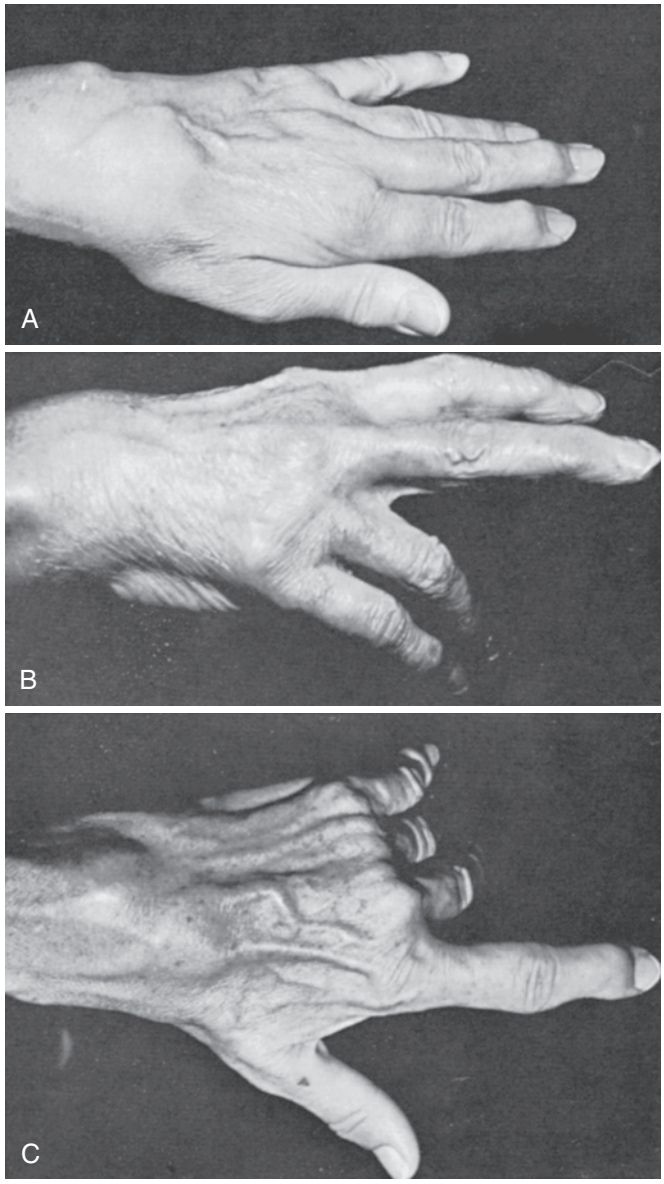

FIGURE 55.13 Examples of extensor tendon ruptures. **A,** Dorsal tenosynovitis and single rupture of the extensor digitorum communis (EDC) tendon to the ring finger. Note the minimal lag associated with a single rupture. **B,** Double rupture of the EDC to the ring and little fingers. When two tendons rupture, there is an appreciable extension lag and the disability becomes obvious. **C,** Triple rupture involving the long, ring, and little fingers. (From Millender LH, Nalebuff EA: Preventative surgery: tenosynovectomy and synovectomy. *Orthop Clin North Am* 6:765–792, 1975, with permission.)

Although sudden loss of extension of the little, ring, and middle fingers is most likely the result of multiple extensor tendon ruptures, three other conditions occur in rheumatoid arthritis that can mimic tendon rupture and should be excluded before surgery is performed to restore extensor power to the fingers. The most common of these conditions is MP joint dislocation, which results in a flexed and ulnar-deviated position of the finger. The lack of passive MP joint extension and the presence of palpable or visible extensor tendons on the dorsal aspect of the hand make the differential diagnosis

between MP joint dislocation and extensor tendon rupture straightforward. The second condition to be excluded is displacement of the extensor tendons into the valleys between the metacarpal heads. When such displacement occurs, extensor force is lost because the tendons now lie volar to the axes of motion of the MP joints. With this condition, the posture of the fingers is similar to the posture that occurs in patients with multiple extensor tendon ruptures.

Differentiation between extensor tendon rupture and displacement of the tendons between the metacarpal heads can sometimes be made if the patient is able to maintain MP joint extension actively after the joints are extended passively. This is not always the case, however, and occasionally it is necessary to explore the tendons at the level of the wrist at the time of MP arthroplasty to verify their continuity. Treatment of subluxation of the extensor tendons consists of relocation over the MP joints with or without MP joint arthroplasty.

The least common but most difficult condition to diagnose among those simulating multiple extensor tendon rupture is paralysis of the common extensor muscle secondary to posterior interosseous nerve compression as a result of elbow synovitis.[75] Several subtle differences allow tendon rupture to be differentiated from muscle paralysis. Patients with posterior interosseous nerve compression usually demonstrate some radial deviation of the wrist because of paralysis of the ECU muscle, in addition to the absence of active finger extension. Soft tissue fullness around the elbow signals proliferative synovitis of the radiohumeral and ulnohumeral joints, which can result in compression of the posterior interosseous nerve. In patients with posterior interosseous nerve compression, the extensors of the middle and ring fingers may be weaker than those of the index and small fingers. Thus, there is a greater extensor lag of the middle and ring fingers than of the index and little fingers.

In contrast, in rheumatoid attrition ruptures, the ring and little finger extensors are involved first. The best diagnostic test is the presence or absence of MP joint extension as the wrist is flexed. A positive "tenodesis effect" is found in the paralytic condition because the extensor tendons are in continuity. With tendon rupture, flexion of the wrist generally has no effect on finger extension because the extensor tendons are not in continuity. In addition, patients with multiple extensor tendon ruptures usually have dorsal tenosynovitis or a prominent distal ulna, which predisposes them to extensor tendon rupture, whereas patients with posterior interosseous nerve compression may have no such findings about the wrist.

Flexor Tendon Ruptures. Flexor tenosynovitis is not uncommon in rheumatoid arthritis. Although carpal tunnel syndrome is the most common manifestation of flexor tenosynovitis at the wrist, weakness, loss of dexterity of the hand, local or radiating pain, and discomfort with hand use can occur. Tendon gliding becomes restricted, and progressive loss of active finger flexion ensues. A discrepancy between active and passive finger flexion is characteristic of rheumatoid flexor tenosynovitis. Triggering, locking, loss of the normal finger cascade, and loss of active flexion can occur, particularly with tenosynovitis in the palm or in the fibroosseous canals. Joint stiffness makes concomitant flexor tenosynovitis more difficult to detect. Flexor tendon ruptures occur but are much less common than extensor tendon ruptures.

The presence of inflammatory flexor tenosynovitis adversely affects the outcome of reconstructive surgery. That is, there is less restoration of function after a tendon transfer done for a rupture caused by inflammatory synovitis than after one performed for an attrition rupture. The most common flexor tendon to rupture is the FPL. Patients with this rupture lose active flexion of the IP joint of the thumb. It occurs when the tendon is eroded by a volar osteophyte on the scaphoid that penetrates the volar wrist capsule and is known as the "Mannerfelt lesion."[68] The diagnosis of FPL rupture is not difficult unless there is a fixed-hyperextension deformity or stiffness of the IP joint.

An isolated rupture of the FDP tendon results in an inability to flex the DIP joint actively. A condition that mimics FDP tendon rupture and in fact is a precursor to such a rupture is a rheumatoid nodule in the tendon within the fibroosseous canal of the finger. The nodule restricts profundus excursion, and there is loss of active flexion of the DIP joint. This condition was discussed earlier.

Rupture of both the superficial and deep flexor tendons causes such obvious functional loss that the diagnosis is straightforward. The patient lacks active PIP and DIP joint motion and can flex the finger only at the MP joint. Of course, passive finger motion must be present to conclude that both tendons are ruptured.

After a flexor tendon rupture is recognized, the site of rupture must be determined. Flexor tendon ruptures can occur at the wrist, in the palm, and within the finger. Palpation for fullness (or lack thereof) within the finger can be useful in this regard. Ultimately, surgical exploration is often necessary to determine the exact site of a rupture.

Treatment of Extensor Tendon Ruptures

Rupture of the Extensor Pollicis Longus. Rupture of the EPL is common in rheumatoid arthritis (Figure 55.14).[64] Functional loss varies, depending on the functional capacity of the EPB and the status of the thumb joints. Although spontaneous rupture of the EPL can cause a "droop" or incomplete extension of the IP joint of the thumb, more commonly the patient maintains the ability to extend this joint despite the rupture. IP joint extension is a shared function of the EPL and the intrinsic



FIGURE 55.14 Extensor pollicis longus tendon rupture. Note that the major deformity is loss of metacarpophalangeal joint extension. The interphalangeal joint can be extended by intact intrinsic tendons, as seen in this patient.

muscles of the thumb. The intrinsics alone can extend this joint to neutral; the EPL is necessary for IP joint hyperextension. A patient with rupture of the EPL loses extension of the MP joint because the EPB is not strong enough to extend this joint by itself. Occasionally, no deformity occurs at either the MP or IP joint level, and the diagnosis is often missed unless a specific test for tendon function is done by asking the patient to extend the thumb with the palm resting on a flat surface while the examiner palpates the tendon of the EPL at the wrist.

If the tendon is ruptured and functional loss or deformity is significant, EPL function should be restored. The options available include end-to-end repair, tendon grafting, or tendon transfer. Although a tendon rupture can occasionally be repaired by an end-to-end technique, this is an exception and should not be expected. In general, tendon grafts through areas of rheumatoid tissue tend to become adherent. However, a graft used to repair an EPL rupture can function satisfactorily. The power and long excursion of the thumb flexor overcome the adhesions that form on the dorsum. The proximal motor must not be scarred or contracted for this to be effective, and for this reason, we prefer tendon transfers for the treatment of EPL rupture. The two most commonly used tendons for transfer are the EIP and ECRL. We prefer to use the EIP because (1) it can be taken from the index finger at the MP joint level without interfering with index finger's function and (2) in our experience the patient does not lose independent extension of the index finger as a result of this transfer.[80]

❖ AUTHORS' PREFERRED METHOD OF TREATMENT

The EIP tendon is identified at the level of the MP joint; it is usually the most ulnar of the two tendons, but it can be the most radial. The easiest way to differentiate between the two is to identify the most distal muscle belly, which is the EIP. It is withdrawn at the wrist through a second transverse incision and passed subcutaneously into the thumb. In the past, we did an end-to-end or weaving connection of the transferred tendon with the distal stump of the EPL. This was always tedious, and adjustment to the proper tension was difficult once the tendon was sutured. Now we pass the tendon directly to the MP joint level and weave it into the extensor mechanism. A temporary suture is used to judge tension. With the correct tension, the thumb remains in extension when the wrist is flexed.

With the wrist extended, passive flexion of the thumb to the little finger pulp should be possible. Weaving of the tendon through the extensor mechanism results in a strong connection and allows the initiation of motion with confidence after 4 to 5 weeks of immobilization. The result of a properly performed tendon transfer to restore EPL function is usually excellent. If necessary, dorsal tenosynovectomy and excision of a prominent, dorsally displaced distal ulna are performed at the same time as the EIP transfer.

Rupture of the Finger Extensors

Single Tendon Ruptures

Although single tendon ruptures can involve any finger, the little finger is affected most often (Table 55.2). The patient demonstrates incomplete extension of the finger at the MP joint level. The amount of extensor lag depends on whether both the EDQ and the EDC tendons are ruptured. With an isolated EDQ rupture, MP joint extension may lag only 30 to 40 degrees. The contribution of the EDC to extension of the little finger is tested by holding the index, middle, and ring finger MP joints in flexion and asking the patient to extend the little finger. An increased extensor lag demonstrates loss of the contribution to extension provided by the EDC. Because of the danger of additional ruptures that can complicate treatment, patients with a single tendon rupture are advised to undergo early surgical reconstruction. Surgical treatment of an isolated rupture of any one finger extensor is relatively easy, and the functional result is usually excellent (Figure 55.15).[73,96]

TABLE 55.2 Treatment Options for Extensor Tendon Ruptures

Type of Rupture	Treatment
Ruptures—all	Dorsal tenosynovectomy Removal of bone spikes Retinacular relocation to cover bone Ulnar head resection as needed
Single rupture	Primary repair Adjacent suture Intercalated graft
Double rupture (EDC of long, ring, and small fingers, EDQ)	As for single rupture plus EIP transfer
Triple rupture	As for double rupture plus FDS_{mid} through the interosseous muscle or around the side Wrist extensor, especially if wrist fusion is present EPL if MP fusion is present
Quadruple rupture	As for triple rupture plus another FDS

EDC, Extensor digitorum communis; *EDQ*, extensor digiti quinti; *EIP*, extensor indicis proprius; *EPL*, extensor pollicis longus; *FDS*, flexor digitorum superficialis, *MP*, metacarpophalangeal.

Operative Technique

Occasionally, end-to-end repair of a ruptured extensor tendon is feasible. With this technique, the MP joints are extended to allow direct repair of the ruptured tendons. The adjacent intact tendons look too long and the fingers are out of sequence, which should be expected, when the repair is completed. The posture of the hand improves 7 to 10 days after surgery as the proximal part of the repaired muscle–tendon unit stretches out. The wrist is splinted in extension to allow the MP joints to flex slightly.

If direct repair is not possible, we prefer to suture the distal tendon stump to an adjacent extensor tendon. Dorsal tenosynovectomy and removal of any bone spicules from the distal end of the ulna (or ulnar head resection) should be done at the same time to eliminate the cause of rupture. The dorsal retinaculum should be transferred deep into the extensor tendons to provide a bed for gliding if bone is exposed. This is done before the tendons are reconstructed. Partial transfer of the retinaculum is described in the section on tenosynovectomy.

Suturing to adjacent tendon is particularly easy for an isolated rupture of the middle or ring finger. For example, the distal end of the EDC tendon to the little finger or the EDQ is woven through the EDC of the ring finger and sutured.

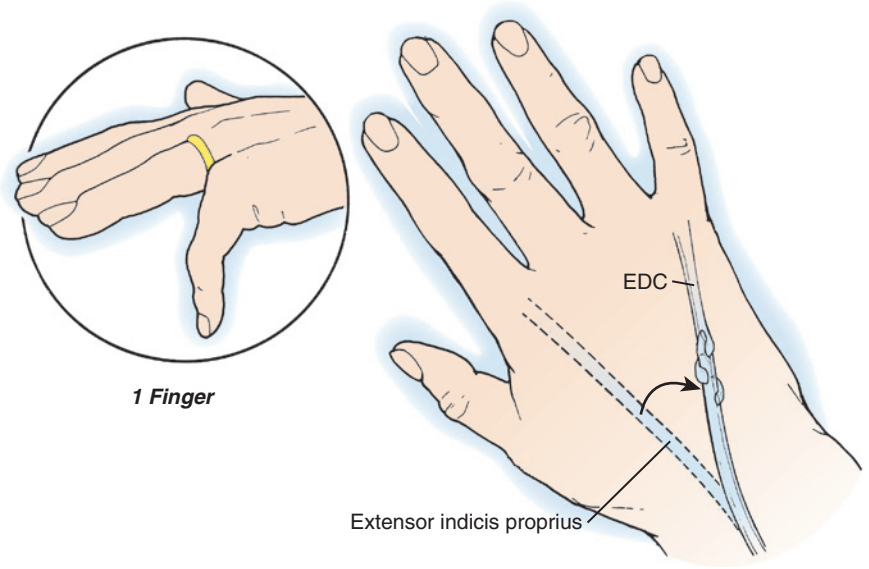

FIGURE 55.15 The extensor indicis proprius tendon is transected over the metacarpophalangeal joint and transferred to the stump of the extensor digiti communis (EDC; little finger) tendon. (From Williamson SC, Feldon P: Extensor tendon ruptures in rheumatoid arthritis. *Hand Clin* 11:449–459, 1995, with permission.)

Similarly, the distal end of the ring finger EDC can be transferred to the long finger EDC. If there has not been major loss of tendon substance, an end-to-end repair can be done. Nonabsorbable suture material is used, and tension is determined by restoring the appropriate extensor stance (in sequence) to the fingers. The tension must be sufficiently tight so that when the wrist is flexed moderately, the fingers are maintained in complete extension and, when the wrist is extended moderately, the MP joints flex only 20 to 30 degrees.

The use of intravenous regional anesthesia or local anesthesia with sedation ("MAC") simplifies the task of judging proper tension. After tendon suturing has been completed, the tourniquet can be released. When voluntary muscle control is regained, the patient is asked to extend the fingers. If there is a lag in extension, tendon tension can be corrected at this time. Skin closure is done under local infiltration anesthesia if this technique is used.[73] If the tourniquet is not released, a drain is used to prevent a subcutaneous hematoma.

Multiple Ruptures of the Extensor Tendons

As additional tendons rupture, surgical treatment becomes more complicated. With double ruptures of the long and ring finger extensors, it is still possible to use the adjacent suture technique; the stump of the ring finger tendon is attached to the little finger tendon, and the stump of the long finger tendon is attached to the index finger tendon. If the EDC to the little finger is not present, the ring finger tendon stump can be sutured to the EDQ.[138]

Options and Techniques for Extensor Tendon Reconstruction

Ring and Little Finger Ruptures

Double ruptures more frequently involve the ring and little fingers (Figure 55.16). Although the adjacent suture technique can be done in some of these patients by connecting both distal tendon stumps to the long finger tendon, there can be difficulty with the little finger. The distal tendon stump of this finger may be so short that it cannot reach the ring finger tendon without resulting in excessive abduction of the little finger. In this situation, a different method is required, and we use the EIP as a tendon transfer. Other tendon transfers, such as the ECU, have been advocated to restore extension in this situation. However, this wrist extensor is very important in maintaining wrist alignment and power, and we believe that it is best left in its normal position. In addition, it does not have the same excursion as the finger extensors, and its use results in lack of either full flexion or extension of the little finger. We have occasionally used the ECRB tendon as a transfer, with satisfactory but not excellent results.

When the extensor tendons of the ring and little fingers rupture (the so-called double rupture), MP joint extension can be restored with two tendon transfers: the EIP to the little finger and the distal stump of the ring finger to the intact common extensor tendon of the long finger.

Rupture of More Than Three Extensor Tendons

As additional extensor tendons rupture, restoring finger extension becomes more difficult. With three or four extensor tendons gone, the adjacent suture technique combined with EIP transfer is no longer sufficient to restore extensor power. A donor tendon for transfer that has a strong motor, is expendable, and has the necessary length to reach the distal tendon stump just proximal to the MP joints is needed. The superficial flexor tendons meet these criteria.[96] The FDS transfer was advocated first by Boyes[11a] for radial nerve palsy. He showed that patients learned to use a former finger flexor as an extensor.

With his technique, the transferred tendon was brought through a wide opening in the interosseous membrane to provide a direct route to the site of connection. We prefer this routing of the tendon transfer through the interosseous membrane for patients who have no scarring in the region of the

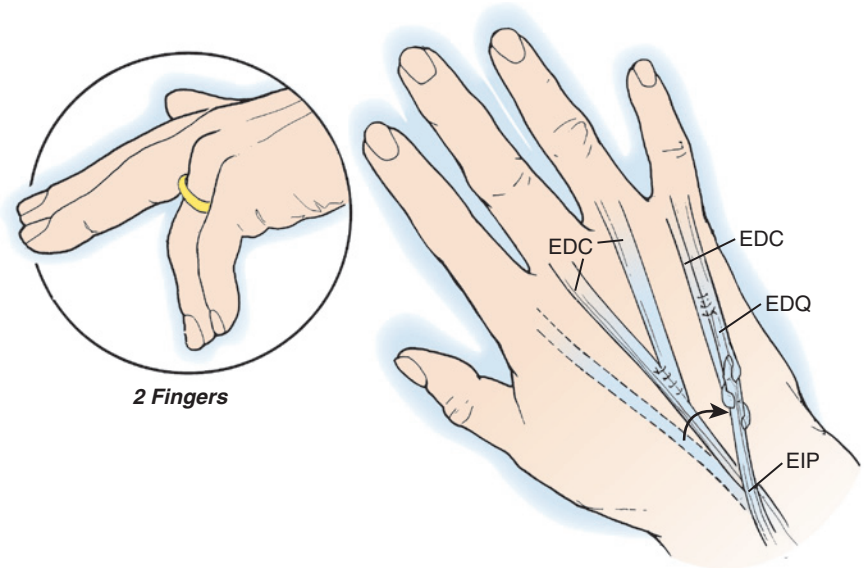

FIGURE 55.16 The extensor digitorum communis (EDC; ring finger) tendon stump is sutured end to side or woven into the EDC (long finger) tendon, and the extensor indicis proprius (EIP) tendon is transferred to the EDC (little finger) or extensor digiti quinti (EDQ) tendon stumps, or to both. (From Williamson SC, Feldon P: Extensor tendon ruptures in rheumatoid arthritis. *Hand Clin* 11:449–459, 1995, with permission.)

distal forearm or wrist. This more direct route of the sublimis tendon provides optimal function of the transfer. A window large enough to allow the muscle belly of the superficialis, rather than just the tendon alone, to be passed into and through the membrane should be made in the interosseous membrane. This helps preserve maximal excursion of the tendon after transfer (see Chapter 31 for details of the Boyes transfer through the interosseous membrane).

We have modified the Boyes technique for patients with scarring in the dorsal wrist area either from previous surgical procedures or from long-standing tendon ruptures. In these patients, we use the long finger FDS instead of the ring finger sublimis tendon as a motor to avoid a decrease in grasp power, and we route the tendon subcutaneously around the radial aspect of the forearm rather than going through the interosseous membrane and the area of scarring. This direction of pull was chosen to eliminate the risk of pulling the fingers into increased ulnar deviation (Figure 55.17).

The transfer is performed through three incisions. A small transverse incision is made in the distal palmar crease, and the tendon is divided after applying proximal traction. This provides enough length to reach the MP joints. A second incision is made on the volar aspect of the forearm. It should be placed ulnar to the midline so that the final transfer passes deep to the skin incision and thus minimizes tendon adherence. The third incision is made on the dorsal aspect of the hand, where the transfer is attached to the extensor mechanism of the ring and little fingers. Usually, we suture the middle finger tendon to the adjacent index finger tendon. Care must be taken to route the transferred tendon deep into the superficial radial nerve. Otherwise, symptomatic compression of the nerve can occur as a result of the tendon passing over the nerve.

With quadruple tendon ruptures, two superficial flexor tendon transfers are used: one to restore extension of the index and middle fingers and the other to restore ring and little finger extension (Figure 55.18). Again, the judgment of tension is critical. The transfer should be tight enough to have a tenodesis effect, as described previously. There is a tendency for the transfer to stretch postoperatively because of the strong flexor pull.

We have used the FDS transfer in patients who had previously undergone wrist fusion. The large excursion of the FDS allows the patients to achieve satisfactory extension of the fingers without the benefit of any tenodesis effect. For patients with multiple tendon ruptures and advanced disease of the thumb MP joint, this joint can be fused and the EPL used as a tendon transfer to the finger extensors.

We have found that primary intercalated or "bridge" grafts can be useful, particularly for triple tendon ruptures. The palmaris longus tendon or, if the wrist is fused, one of the wrist extensors can be used for the graft.[82] The dorsal wrist incision is extended proximally, and the proximal stumps of the ruptured extensor tendons are located and dissected free from scar and adherent soft tissue. The tendon in the best condition is selected for the motor if satisfactory excursion is available. The bridge graft is inserted between the proximal and distal tendon ends by using an interweaving technique. The graft should be put in tightly because the muscle will gradually stretch postoperatively. Bora and associates reported excellent results (MP joint motion, 10–75 degrees) in a long-term follow-up study in which the palmaris longus was used as a "loop" tendon graft to bridge the extensor tendon defect after multiple tendon ruptures (Figure 55.19).[10]

Tendon Transfers for Patients With Fused Wrists

For patients with fused wrists, the wrist motors can be used to restore finger extension. Although the excursion of these muscles is limited, many patients have limited MP joint motion and transfer of a tendon with less than optimal excursion may be sufficient. The wrist extensors are valueless with the wrist fused and can be used to extend the fingers without diminishing

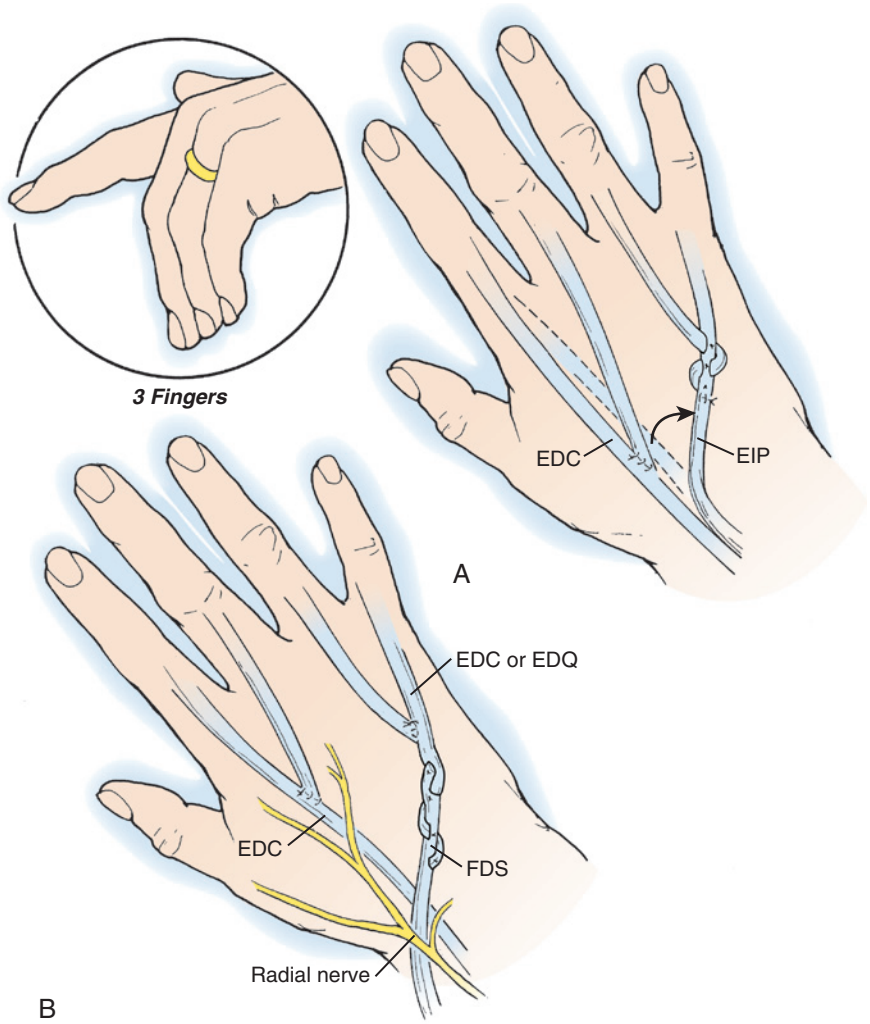

FIGURE 55.17 **A,** The extensor digitorum communis (EDC; long finger) tendon stump is sutured end to side to the EDC (index finger) tendon, and the extensor indicis proprius (EIP) tendon is transferred to the stumps of the ring and little finger EDC tendons. **B,** If the EIP tendon cannot be used for transfer, the flexor digitorum superficialis (FDS; middle finger) tendon is transferred to the stumps of the little and ring finger EDC tendons. Note that the FDS is passed beneath the superficial radial nerve. The EDC (long finger) is sutured side to side to the EIP or EDC (index finger) tendon stump. *EDQ,* Extensor digiti quinti. (From Williamson SC, Feldon P: Extensor tendon ruptures in rheumatoid arthritis. *Hand Clin* 11:449–459, 1995, with permission.)

the power of finger flexion that results when a FDS transfer is performed. We have used both wrist extensors and flexors to restore finger extension in this situation. The wrist extensors may be of sufficient length for transfer if they are dissected from their insertions on the bases of the metacarpals and the wrist unit is shortened slightly when the radiocarpal joint is prepared for fusion. The wrist flexors are frequently not long enough to reach the ruptured tendon ends, and a supplementary tendon graft is needed. When performing a wrist fusion that is to be followed later by a second-stage tendon transfer for multiple extensor tendon rupture, one or more silicone-rubber rods can be inserted at the time of wrist fusion. This makes the second-stage tendon graft procedure easier and minimizes the risk for postoperative adhesions.

Multiple Ruptures With Metacarpophalangeal Joint Disease

The not infrequent situation of multiple extensor tendon ruptures with associated MP joint disease warrants attention. We do not try to restore finger extension by tendon transfer before restoring joint motion. Unless the MP joints can be extended passively, any transfer will become adherent; thus, a staged reconstruction is usually necessary. Initially, MP arthroplasty is performed. Postoperatively, dynamic splinting is a substitute for the absent extensor tendons. At the second stage, appropriate transfers are done to provide active extensor power. With experience, it is possible to combine the MP joint arthroplasty with a tendon transfer in a single operative procedure.

The arthroplasty is done in routine fashion, after which an FDS tendon is brought around the forearm and sutured to the extensor mechanism at the arthroplasty site. The postoperative management of patients with combined arthroplasty and tendon transfers is geared toward protecting the tendon transfer. Therefore, active motion is delayed for 3 weeks, and restoration of complete active motion is not expected in such cases. The results of a combined procedure fall short when compared with an arthroplasty in the presence of normal tendons or with a tendon transfer in the presence of minimally involved joints.

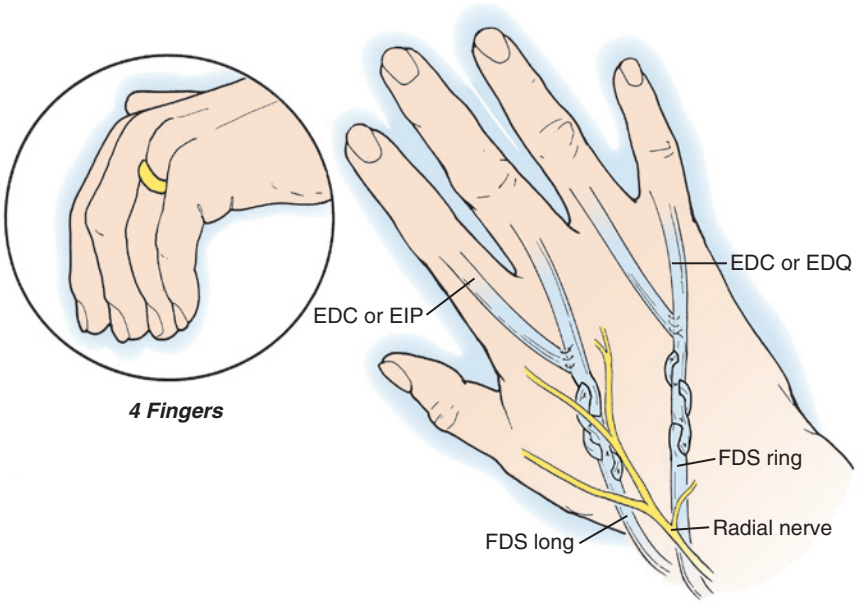

FIGURE 55.18 The donor flexor digitorum superficialis (FDS; ring finger) tendon is passed around the radial aspect of the forearm and transferred to the little and ring finger extensor digitorum communis (EDC) tendon stumps. The FDS (long finger) is transferred to the index and long finger EDC tendon stumps. *EDQ*, Extensor digiti quinti; *EIP*, extensor indicis proprius. (From Williamson SC, Feldon P: Extensor tendon ruptures in rheumatoid arthritis. *Hand Clin* 11:449–459, 1995, with permission.)

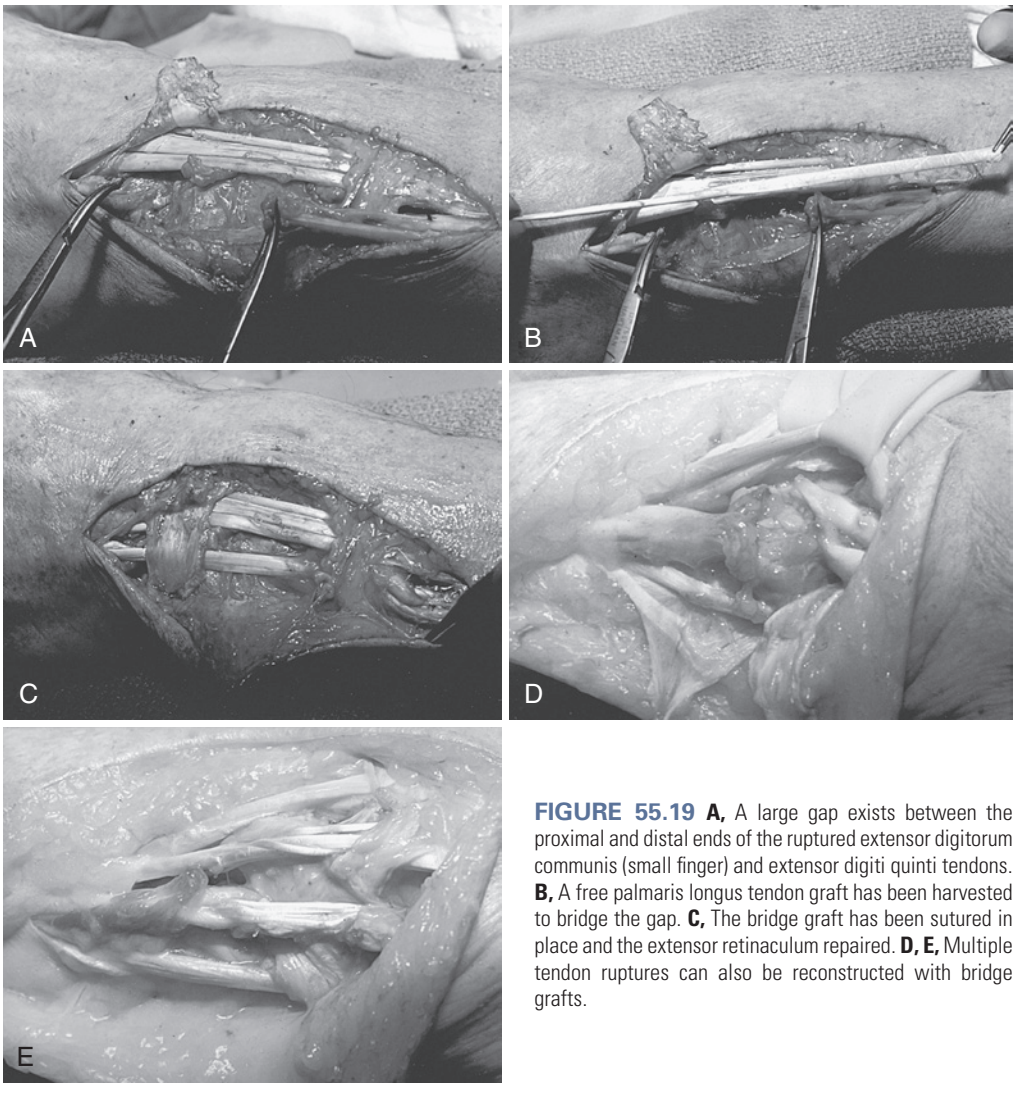

FIGURE 55.19 **A,** A large gap exists between the proximal and distal ends of the ruptured extensor digitorum communis (small finger) and extensor digiti quinti tendons. **B,** A free palmaris longus tendon graft has been harvested to bridge the gap. **C,** The bridge graft has been sutured in place and the extensor retinaculum repaired. **D, E,** Multiple tendon ruptures can also be reconstructed with bridge grafts.

Treatment of Flexor Tendon Ruptures

Rupture of the Flexor Pollicis Longus. The most common flexor tendon to rupture in patients with rheumatoid arthritis is the FPL. It is usually secondary to attrition at the level of the carpal scaphoid bone and has been referred to as the Mannerfelt lesion.[68] The functional loss is variable. If the patient has a good IP joint, the loss is apparent. If the MP joint has significant involvement or is fused, the loss of any IP joint motion results in substantial functional loss. Either terminal joint stability or restoration of active motion must be provided. Even if the IP joint is fused to provide stable pinch, the volar aspect of the wrist still must be explored. The bone spicule that has disrupted the FPL affects the tendons of the index finger next and must be removed. One of our patients was found to have ruptures of both the superficial and deep flexor tendons of the index and middle fingers, in addition to the thumb flexor.

Operative Technique. The volar aspect of the palm and wrist is exposed through a curved incision along the thenar crease and is extended proximally in a zigzag manner (Figure 55.20). The bone spicule on the ulnar aspect of the scaphoid bone, which protrudes into the radial side of the carpal canal, is removed, and the exposed bone is covered by mobilizing adjacent soft tissue. Attention is then directed toward restoration of tendon function. Surgical choices include the use of a bridge graft, a standard tendon graft, or a tendon transfer. If both tendon ends can be identified at the wrist level, we prefer to insert a short bridge graft. The palmaris longus is suitable for this, but if it is not present, a slip of the FCR or one of the multiple slips of the APL can be used. If suturing at the level of the rupture is difficult because of its location in the carpal tunnel, incisions can be made at the level of the MP joint and distal forearm and the graft passed across the tunnel and sutured distal and proximal to it. If the distal tendon stump cannot be brought into the wrist incision, we either use a full-length tendon graft or transfer a superficial flexor tendon. The preference is to use the superficial flexor of the long finger as the motor because it is longer and avoids compromising the grip function of the ring and little fingers.

The superficial flexor is detached in the distal part of the palm and sutured to the volar aspect of the distal phalanx of the thumb with a suture passed through the distal phalanx and tied over a button on the dorsal aspect of the nail plate. A soft rubber catheter or a tendon passer is used to bring the tendon through the sheath and pulley mechanism. The stump of the FPL is elevated, and the underlying cortex is roughened before final attachment of the graft or transfer. Carpal tunnel release and flexor tenosynovectomy are usually performed at the same time. The thumb and wrist are immobilized in moderate flexion for 3 weeks, after which active motion is started. If the carpal tunnel was opened to perform tendon reconstruction, the wrist is positioned in neutral for 3 weeks to prevent flexor tendon bowstringing.

Rupture of the Flexor Digitorum Profundus. Rupture of one or more of the deep flexor tendons is not uncommon. If a patient with these ruptures can maintain superficial flexor function (both range of motion and strength), functional loss is minimal. The treatment should match the degree of functional loss. If the distal tendon stump becomes adherent, the patient may lose active flexion but may maintain enough stability of the DIP joint to preclude the need for surgical stabilization.

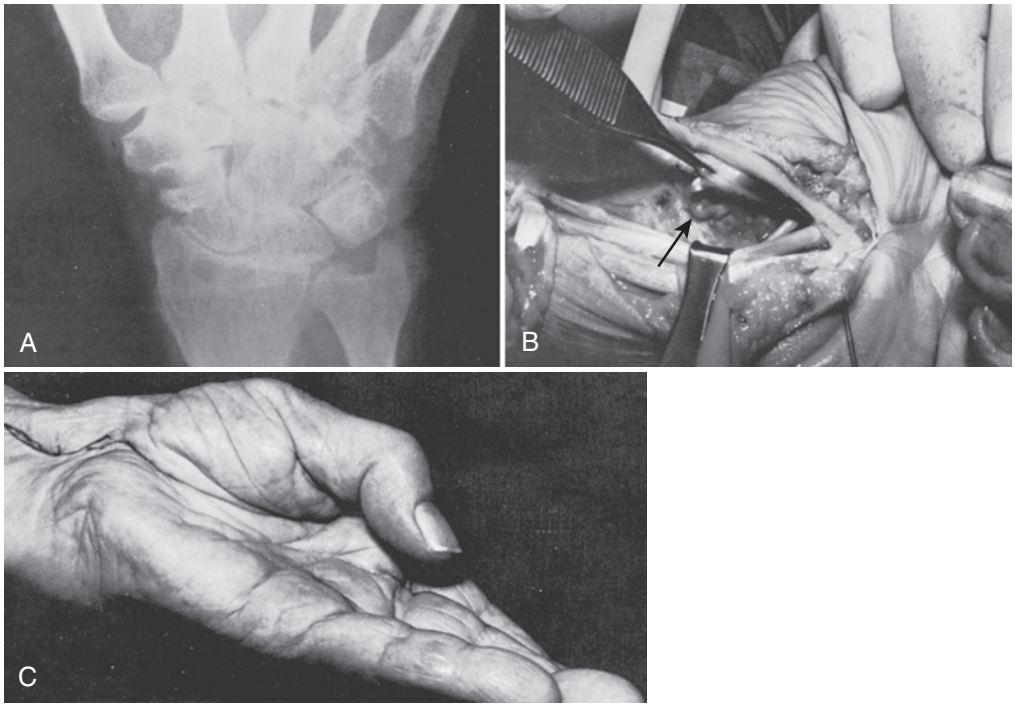

FIGURE 55.20 **A,** Radiograph of a patient with a ruptured flexor pollicis longus (FPL) tendon. Note the osteophyte of the scaphoid, which caused an attrition rupture of the FPL. **B,** Another patient with a ruptured FPL tendon. The flexor tendons are exposed, and the ruptured one is held with forceps. Synovium from the scaphotrapezial joint can be seen (*arrow*). A sharp spur on the scaphoid can be palpated adjacent to this capsular tear. Note the ruptured proximal tendon and intact finger flexors. **C,** Range of motion of the interphalangeal joint of the thumb 4 months postoperatively. (From Nalebuff EA: Reconstructive surgery and rehabilitation of the hand. In Kelly WN, Harris ED, Ruddy S, et al., editors: *Textbook of rheumatology*, ed 2, Philadelphia, 1985, WB Saunders, pp 1818–1826, with permission.)

The most important factor determining the type of treatment is the level of tendon rupture. Flexor tendon ruptures can occur within the finger, at the palm, or at the wrist. The palm is the easiest level at which function can be restored. Ruptures in the palm may be less obvious if the ruptured tendon adheres to the adjacent flexors. This obscures the diagnosis inasmuch as DIP joint flexion is possible with the finger extended and the flexor mass pulls on the distal tendon end through scar tissue; however, this is not so when the finger is flexed actively or passively at the PIP joint. This situation can be confused with a flexor tendon nodule that blocks active excursion of the profundus tendon. Clues to the proper diagnosis include the lack of a palpable nodule and an alteration in resting finger posture, with the finger assuming a more extended position than the adjacent fingers.

Flexor tendon ruptures at the palm and wrist levels are best treated by suturing the distal tendon ends to the adjacent intact tendon, although small bridge grafts can be used at the wrist level. Suturing to adjacent tendon cannot be done if the rupture occurs within the fibroosseous canal. In this case, surgery is performed only to remove diseased synovium from the intact superficial flexor, which is now vital to finger function. Caution should be used when considering staged flexor tendon reconstruction of the FDP through an intact FDS. The results with this technique have not been good. If the DIP joint hyperextends, we prefer to stabilize the DIP joint rather than consider a flexor tendon graft through an intact FDS tendon.

Rupture of the Flexor Digitorum Superficialis. Loss of FDS function alone causes no obvious functional loss. In fact, as described previously in the section on tenosynovitis, we occasionally resect half of the FDS to restore proper function of the deep flexor tendon. The diagnosis of FDS rupture can be made only by careful examination. The treatment should not jeopardize existing tendon function; however, suturing to adjacent tendons within the palm or the wrist is feasible. A tenosynovectomy should be performed to protect the FDP tendons.

Rupture of Both Superficial and Deep Finger Flexor Tendons. The loss of both flexor tendons of a finger results in obvious and significant functional loss: the finger "sticks out" from the other fingers and thereby "gets in the way." Restoration of active finger flexion is a goal that is not always possible to achieve. For this reason, it is far better to be aware of early nodular tenosynovitis and to perform a prophylactic tenosynovectomy before tendon rupture occurs. If ruptures have occurred at the wrist, function can be restored by suturing to adjacent tendons or by a bridge graft of the FDP tendon with the suture lines placed proximal and distal to the carpal tunnel area. It is not necessary to reconstruct FDS tendon ruptures at the wrist. Therefore, an intact portion of it can be used for bridge grafts to reconstruct ruptured FDP tendons. If the rupture is in the palm and the distal tendon stump is long enough, adjacent suturing to an FDP tendon is the best option. If not, transfer of an FDS to the distal profundus stump can be done.

Within the fibroosseous canal, the same problem encountered in tendon laceration at this level exists, except that the situation is worse. The disease is not localized, and the dissection needed for exposure leaves a very poor bed for tendon grafting. In addition, the adjacent joints may have restricted or painful motion (or both). In our experience, free-flexor tendon grafts have not produced good results in patients with rheumatoid arthritis. Occasionally, if no other alternative is available, we perform a staged-flexor tendon reconstruction using a silicone-rubber tendon rod, particularly for younger patients who have minimal joint involvement. The technique is essentially the same as described for posttraumatic flexor tendon reconstruction.

Finally, because of advanced age, poor status of the IP joints, or generalized disease, the wisest choice for some patients in whom both flexor tendons have ruptured within the finger is to fuse both the PIP and DIP joints in a functional position. In this way, satisfactory function can be restored and pain diminished. Suturing the proximal flexor tendon stumps to the base of the proximal phalanx may augment MP flexor strength if there is free excursion of the flexor tendon proximal to the rupture. Of course, this is a last resort, but it should be considered as a method to handle this complicated problem with selected patients.

THE WRIST

The wrist is the "cornerstone" of the hand. A painful, unstable, and deformed wrist impairs hand function regardless of the status of the fingers. In addition, wrist deformity is a major cause of finger deformity, and unless wrist alignment is preserved or restored, correcting finger deformities is difficult if not impossible. An understanding of the pathophysiology of rheumatoid wrist disease is necessary to appreciate the effects of wrist involvement on hand function and finger deformity.

Natural History of Rheumatoid Wrist Involvement

Rheumatoid synovitis follows predictable patterns. In the wrist, the ulnar styloid, the ulnar head, and the midportion of the scaphoid are frequently the earliest to be involved by rheumatoid synovitis. Progressive synovial proliferation in these areas leads to the various patterns of wrist deformity.

In the ulnar compartment, synovitis stretches the ulnar carpal ligamentous complex and may result in changes that Backdahl called the "caput ulna syndrome."[5] This syndrome is the result of destruction of the ligamentous complex, including the triangular fibrocartilage complex, which allows dorsal prominence of the distal ulna, possible supination of the carpus on the hand, and volar subluxation of the ECU. The caput ulna syndrome (seen in up to one-third of rheumatoid patients undergoing hand surgery) can result in significant disability. Patients with this syndrome complain of weakness and pain that are aggravated by forearm rotation. Examination of the wrist reveals prominence of the distal ulna, instability of the DRUJ, limited wrist dorsiflexion, and supination of the carpus on the forearm. As the ECU tendon subluxates volarward, normal function of this tendon is diminished, thereby allowing the wrist to deviate radially and setting the stage for attrition ruptures of the ulnar extensor tendons.

Radiocarpal involvement by proliferative synovitis begins beneath the radioscaphocapitate ligament in the region of the deep volar radiocarpal ligament. Destruction of these ligaments combined with intercarpal ligament damage eventually results in instability of the scaphoid. In this condition, the scaphoid assumes a volar-flexed (vertical) position. There is secondary loss of carpal height and radial rotation of the carpus and metacarpals on the radius.



FIGURE 55.21 This patient had failed metacarpophalangeal (MP) arthroplasties with fractured implants secondary to a fixed-radial deviation deformity of the wrist. This is treated by correction of the wrist deformity and subsequent revision MP arthroplasties. When performing revision MP arthroplasty, the procedure is identical to the initial technique—there are no shortcuts.

The combination of rotatory subluxation of the scaphoid, volar subluxation of the ulnar carpus, and dorsal subluxation of the distal ulna produces relative supination of the wrist in relation to the distal forearm. This common pattern of wrist collapse results in imbalance of the extensor tendons, radial shift of the metacarpals, and ulnar deviation of the fingers.[123] This deformity is thought to be one of the important factors initiating ulnar deviation of the MP joints, as well as recurrence of ulnar deviation after MP joint arthroplasty (Figure 55.21).[113] An untreated, end-stage rheumatoid wrist is dislocated volarward with complete destruction of the carpal bones and complete dissociation of the radioulnar joint. Early surgical treatment can prevent this severe pattern of destruction.

Operative Treatment for Rheumatoid Radiocarpal and Radioulnar Joint Deformities

Surgical procedures for the radiocarpal and radioulnar joints are either preventive or reconstructive. Preventive procedures include synovectomy of the radioulnar and radiocarpal joints, balancing of the wrist extensors, and tenosynovectomy. Reconstructive surgery includes distal ulnar excision, reconstruction of the ulnocarpal ligamentous complex, radiocarpal joint arthroplasty, partial wrist fusion, and total wrist arthrodesis.[66,67,71,92,104]

Synovectomy of the Radiocarpal and Radioulnar Joints

Indications. The indications for wrist joint synovectomy have never been clearly established. No studies have conclusively demonstrated that synovectomy changes the natural course of rheumatoid disease. In addition, because the wrist is a multiarticulated complex joint, total synovectomy is impossible. The indicators used for diagnosing wrist synovectomy vary among hand surgeons. Some have recommended a several-month trial period of conservative therapy before synovectomy. Flatt advocated early synovectomy because of the rapid joint destruction that can occur when active synovitis does not respond to medical therapy.[34] Hindley and Stanley found relative sparing of the midcarpal joint and suggested that early synovectomy may prevent progression.[47] We and others[125] have found that synovectomy can provide significant pain relief, even in patients with advanced disease. Synovectomy in some cases can thus be an alternative to wrist salvage.

We used wrist synovectomy in a small group of patients with persistent, painful wrist synovitis, and minimal-to-moderate radiographic involvement. Many authors, including Brumfield and colleagues,[15] found consistent and dramatic relief for pain and varying loss of wrist motion after wrist synovectomy in long-term follow-up reviews. Grip strength was found to be adequate, not weaker, after synovectomy.

We have found that synovectomy can relieve pain despite moderate destruction of the radiocarpal joint (based on radiographs). Thus, if a patient has clinical evidence of radiocarpal synovitis and other wrist surgery is being done, we include wrist synovectomy combined with denervation even when the radiographs show relatively advanced destructive changes.

Adolfsson and Frisen performed a limited series of arthroscopic dorsal wrist synovectomies with good short-term results.[2] Although we have done only a small series using this technique, early results are encouraging. We have found little morbidity and more rapid recovery after this procedure than after open wrist synovectomy. Synovectomy of the wrist may also be more effective and durable in the era of biologics and disease-modifying agents.

Operative Technique: Dorsal Approach for Synovectomy. The wrist is exposed with a straight, longitudinal incision as described for dorsal tenosynovectomy (Figure 55.22). The terminal branch of the posterior interosseous nerve can be found consistently on the floor of the fourth dorsal compartment, deep in the extensor tendons. This is an articular branch that innervates the wrist joint. It can be resected to partially denervate the wrist joint for pain relief.[16,28,135]

A transverse or "U"-shaped incision is made in the wrist capsule, and a distally based flap is elevated to expose the wrist and intercarpal joints. The distally based capsular flap allows the wrist capsule to be reefed easily to stabilize the joint by limiting flexion. Synovium is usually seen bulging from the proximal and distal carpal rows. Traction applied to the hand distracts the joints and allows synovectomy to be performed with a small rongeur. A small, blunt periosteal elevator can be used to provide better exposure within the joint. Periarticular erosions are treated by curettage. Synovium is removed from the area between the triquetrum and the fibrocartilage.

The DRUJ is exposed through a longitudinal incision proximal to the triangular fibrocartilage. The forearm is rotated to provide exposure as the synovectomy is performed. Bone spurs are removed from the distal end of the ulna, and again, periarticular erosions are treated by curettage. After the synovectomy is completed, the capsular incisions are closed with interrupted

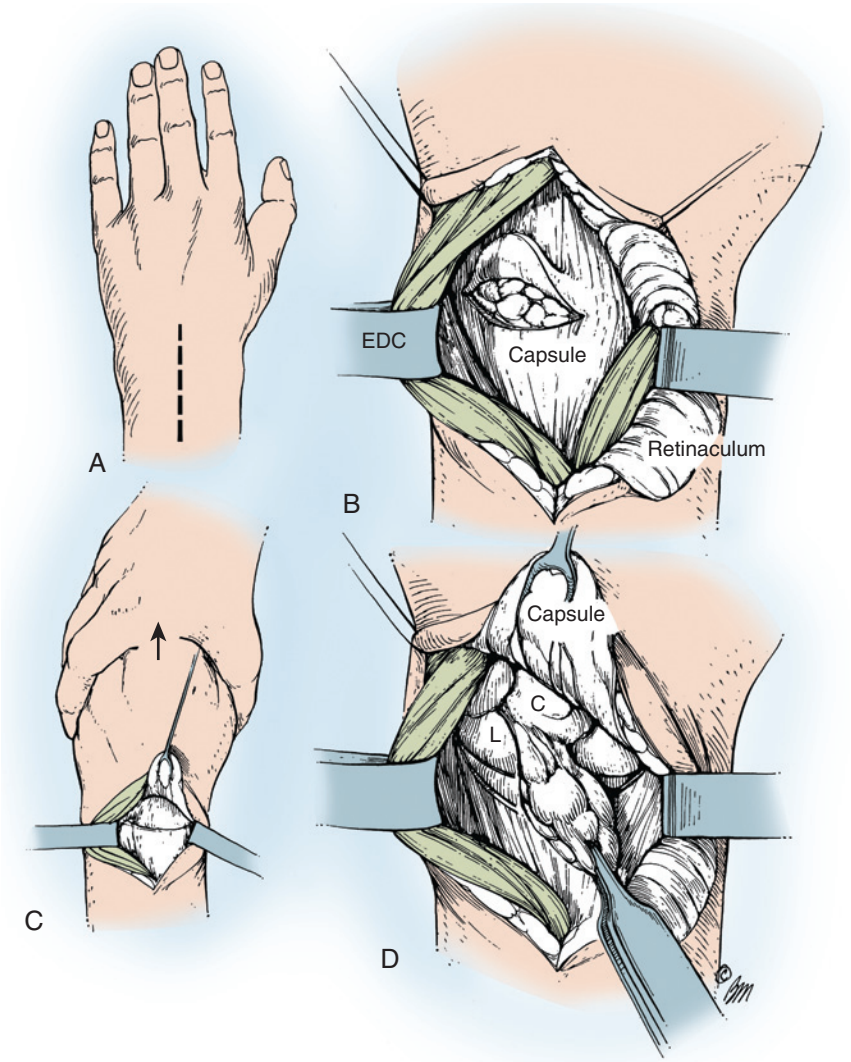

FIGURE 55.22 Technique for wrist joint synovectomy. **A,** The extensor tendons are exposed. A dorsal tenosynovectomy is performed. **B,** The extensor tendons are retracted and the wrist capsule is exposed. **C,** A transverse capsule incision exposes the underlying synovium. **D,** The proximal and distal carpal rows are exposed, and synovectomy is performed with a rongeur. The capsular flaps are preserved for closure. *C,* Capitate; *EDC,* extensor digitorum communis; *L,* lunate. (Copyright Elizabeth Martin.)

nonabsorbable sutures. Closure is performed with the forearm in supination to minimize the tendency for the ulna to subluxate and to allow tighter closure of the DRUJ capsule. Tendon rebalancing, dorsal tenosynovectomy, and relocation of the dorsal retinaculum are performed if necessary. The tourniquet may be released at this point and hemostasis obtained. If the tourniquet is not released, a drain is placed in the subcutaneous area before skin closure.

A bulky compression dressing is applied. The wrist is splinted in neutral, and the forearm is held in full supination with a sugar tong splint. The drain is removed in 24 h. Forearm supination is maintained for approximately 3 weeks, at which time the splints are removed and both forearm and wrist range-of-motion exercises are started.

The length of postoperative splinting depends on the extent of wrist ligament laxity present preoperatively and the degree of ligament disruption found at the time of surgery. The greater the laxity, the longer the wrist needs to be splinted postoperatively. Splinting for 4 to 6 weeks may be necessary to allow enough capsular healing to provide stability. We have found that the optimal range of motion after surgery is 30 to 40 degrees each of flexion and extension.

Operative Technique: Volar Wrist Synovectomy. Volar wrist synovectomy can be done when flexor tenosynovectomy is indicated. Volar wrist synovectomy, in conjunction with wrist flexor tenosynovectomy to prevent destruction of the deep volar ligaments and secondary rotation of the scaphoid, has been advocated by some.

When present, volar wrist synovitis is manifested by bulging of the volar capsule. The skin incision described for volar tenosynovectomy is used; that is, a transverse incision is made over the bulging volar wrist capsule. Traction is applied to the hand, and synovium is removed from the volar portion of the wrist with a rongeur. The capsule is closed with interrupted nonabsorbable sutures. Postoperative management is the same as that described for dorsal tenosynovectomy.

Distal Ulnar Excision and DRUJ Complex Reconstruction

Involvement of the DRUJ is a common cause of disability in a rheumatoid wrist. For this reason, distal ulnar excision and reconstruction of the triangular fibrocartilage are performed frequently in wrists affected by rheumatoid arthritis.

Distal ulnar excision was described first by Smith-Peterson in 1943 for rheumatoid arthritis. It remains our procedure of choice because it is reliable and allows adequate exposure to perform synovectomy of the DRUJ and to reconstruct the triangular fibrocartilage complex.[70] Swanson described distal ulnar excision and replacement with a silicone-rubber implant.[116a] We no longer use this implant because of problems with bone resorption beneath the implant collar, fracture of the implant stem, dislocation of the implant, and particulate synovitis. The importance of soft tissue reconstruction to correct supination of the carpus and subluxation of the distal ulna has been emphasized by many authors.[5] Total loss of the triangular fibrocartilage ligamentous complex complicates correction of the supination of the carpus on the distal end of the forearm and the dorsal prominence of the ulna. Distal ulnar excision for symptoms of the caput ulna syndrome is usually performed in conjunction with dorsal tenosynovectomy and tendon transfer for ruptured extensor tendons or in conjunction with wrist joint synovectomy or wrist joint reconstruction.

Other surgical techniques are available to reconstruct a DRUJ destroyed by the rheumatoid process, such as the Sauvé-Kapandji procedure in which the distal ulna is fused to the sigmoid notch of the radius with resection of a segment of ulna to allow rotation of the forearm.[131] Taleisnik believes that the Sauvé-Kapandji procedure is indicated for younger patients with painful DRUJ dysfunction because it provides stable fixation of the ulnar head, preserves ulnocarpal support, restores forearm rotation, and results in a better cosmetic appearance than does distal ulnar resection.[123] He prefers the Sauvé-Kapandji procedure to distal ulnar resection for patients with impending ulnar translocation not severe enough to warrant radiolunate fusion. In our experience, the Sauvé-Kapandji procedure does not prevent or correct ulnar translocation in a rheumatoid patient.

We prefer radiocarpal fusion for patients with established or impending ulnar translocation of the carpus.[21] In patients with juvenile rheumatoid arthritis who have had spontaneous fusion of the DRUJ, segmental osteotomy of the ulna similar to that done in the Sauvé-Kapandji procedure can be used to restore partial forearm rotation. Recently, we have used variations of partial distal ulna resection (hemiresection/interposition and matched distal ulna resection) for rheumatoid patients with good results.[3,6,84]

Operative Technique: Distal Ulnar Excision and DRUJ Reconstruction. The surgical principles of distal ulnar excision are important and include the following: (1) limited resection of the distal end of the ulna (2 cm or less) to minimize instability of the remaining ulna, (2) synovectomy of the DRUJ, (3) correction of carpal supination by suturing the remnant of the triangular fibrocartilage complex to the dorsal ulnar corner of the radius, and (4) reconstruction of the dorsal capsule and extensor retinaculum with volar-to-dorsal relocation of the ECU if it is subluxated.

The wrist joint is approached through the dorsal longitudinal wrist incision described previously. The extensor retinaculum is opened. It is usually thin or adherent (or both) over the capsule of the distal ulna, which makes separation of these two layers difficult. Identification of the volarly subluxed ECU may also be difficult. The tendon usually can be palpated on the ulnar aspect of the wrist. Frequently, tenosynovium is noted bulging in the region of the sixth dorsal compartment. Occasionally, the entire sixth compartment sheath is destroyed and the tendon is frayed or ruptured. If the ECU has subluxated volarward, it is released and replaced dorsal to the axis of wrist flexion. It can be held in place with a sling of tissue fashioned from the extensor retinaculum.

A longitudinal capsular incision is made over the distal ulna. The capsule and triangular fibrocartilage are reflected from the ulna and preserved. The periosteum of the ulna is elevated, and small bone retractors are placed around the distal ulna, which can be sectioned with a bone cutter, an osteotome, or a power saw. A towel clip is used to apply traction to the bone fragment when the soft tissue attachments are divided. Approximately 2 cm of bone is resected. If excessive bone is removed, stability of the distal ulna may become a problem. The dorsal edge of it should be beveled and smoothed to minimize the risk of postoperative attrition ruptures of the extensor tendons.

After the bone is removed, complete synovectomy of the DRUJ is performed. Although the triangular fibrocartilage often is destroyed, it should be protected during the synovectomy if it is present. Reconstruction of the soft tissue support for both the DRUJ and the radiocarpal joint is important to correct carpal supination and to stabilize the distal ulna. If the triangular fibrocartilage and radioulnar ligamentous complex are present, they are sutured tightly to the dorsal and ulnar aspect of the radius.

Various methods have been used to stabilize the distal ulna after resection of the ulnar head. Blatt and Ashworth incised the volar capsule to form a distally based flap.[9] The flap is brought dorsally and fixed to the ulna to reconstitute the ligament (Figure 55.23).

Linscheid and Dobyns used a different method.[66] A distally based strip of the ECU tendon is detached, woven through the ulnar collateral ligament and any remnants of the triangular fibrocartilage, and sutured to the radius (Figure 55.24). The dorsal radioulnar capsule is closed tightly, with imbrication of the tissues when necessary. This is facilitated by supinating the wrist to relocate the DRUJ. After this, the extensor retinaculum is relocated deep in the tendons. The position of the ECU tendon is corrected if necessary.

Another method uses a distally based slip of ECU tendon.[64] The tendon slip is passed through the distal end of the ulna, through a hole made in the dorsal cortex of the ulna, and is then sutured back onto itself (Figure 55.25).

Ruby and colleagues described transferring the origin of the pronator quadratus to the dorsal aspect of the ulna and placing the muscle belly between the radius and ulna to stabilize the distal ulna after resection of its head.[109] Their long-term results were satisfactory, but their study did not include rheumatoid patients. More recently this has been described by Bain and colleagues in combination with hemiresection arthroplasty.[6]

A Penrose or suction drain can be placed if the tourniquet is not released. A bulky hand dressing is applied with the wrist and fingers splinted in extension and the forearm in supination. The dressing is changed in 24 h, at which time the drain is

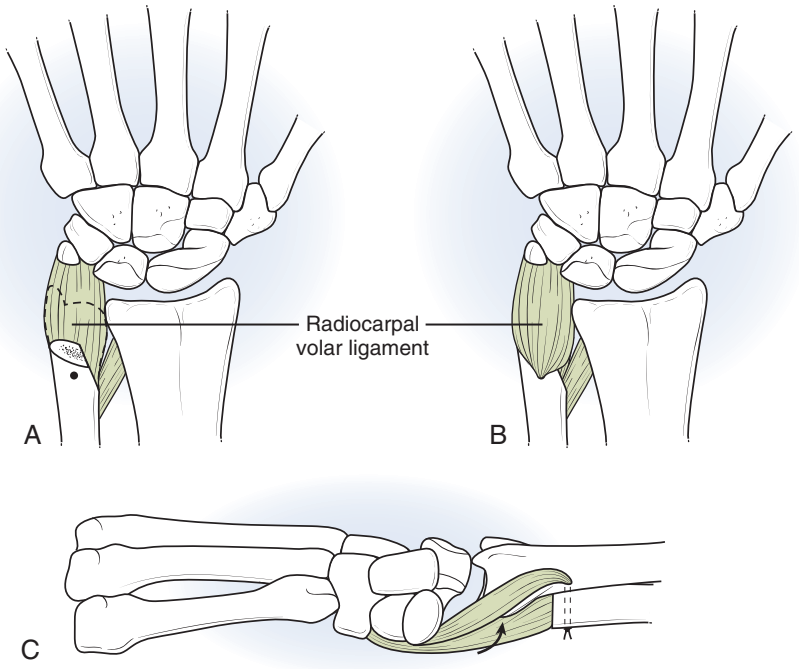

FIGURE 55.23 Stabilization of the distal end of the ulna with a flap of volar capsule. **A,** After distal ulnar excision and synovectomy are completed, a distally based flap of volar capsule is reflected. **B,** The free proximal end is brought dorsalward and sutured to the dorsal cortex of the ulna through drill holes. The flap acts as a volar restraining ligament to prevent dorsal subluxation of the distal ulna. **C,** Volar flap sutured over the dorsal cortex of the distal ulna. (Copyright Elizabeth Martin.)

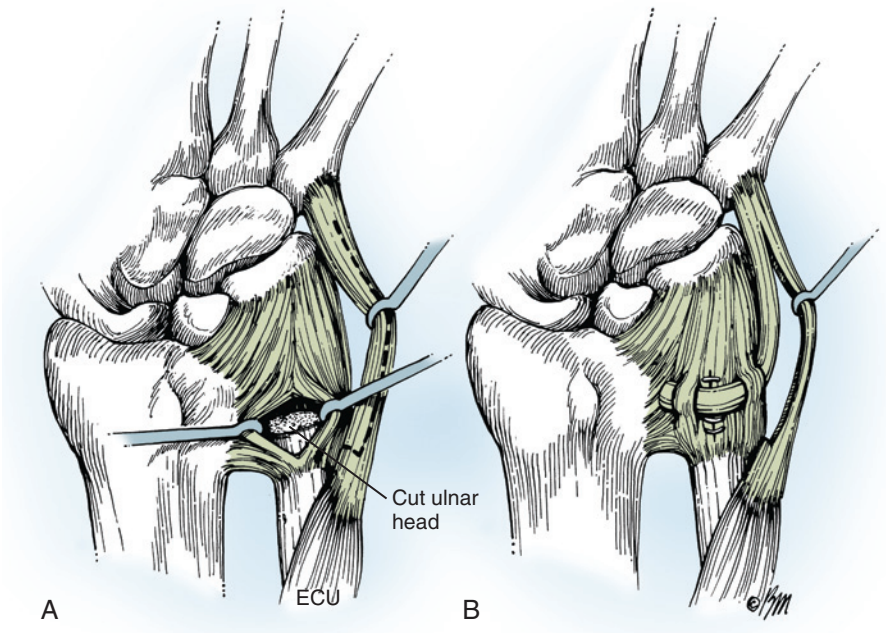

FIGURE 55.24 Reconstruction of the distal radioulnar joint (DRUJ) after synovectomy and distal ulna excision. **A,** The dorsal capsule of the DRUJ is opened longitudinally, a synovectomy is performed, and the distal end of the ulna is excised. (The slip of tendon to be stripped from the extensor carpi ulnaris [ECU] is shown by the *dashed line*.) **B,** A strip of ECU is mobilized, passed through the ulnar aspect of the joint capsule and across the joint's dorsal aspect and sutured to the dorsal capsule over the radius to correct the supination deformity. The radioulnar joint capsule is imbricated to correct the dorsal subluxation of the distal ulna. The dorsal retinaculum can be used to further reinforce the radioulnar joint capsule. The dorsal edge of the distal ulna should be beveled and smoothed to avoid postoperative attrition ruptures. (Copyright Elizabeth Martin.)

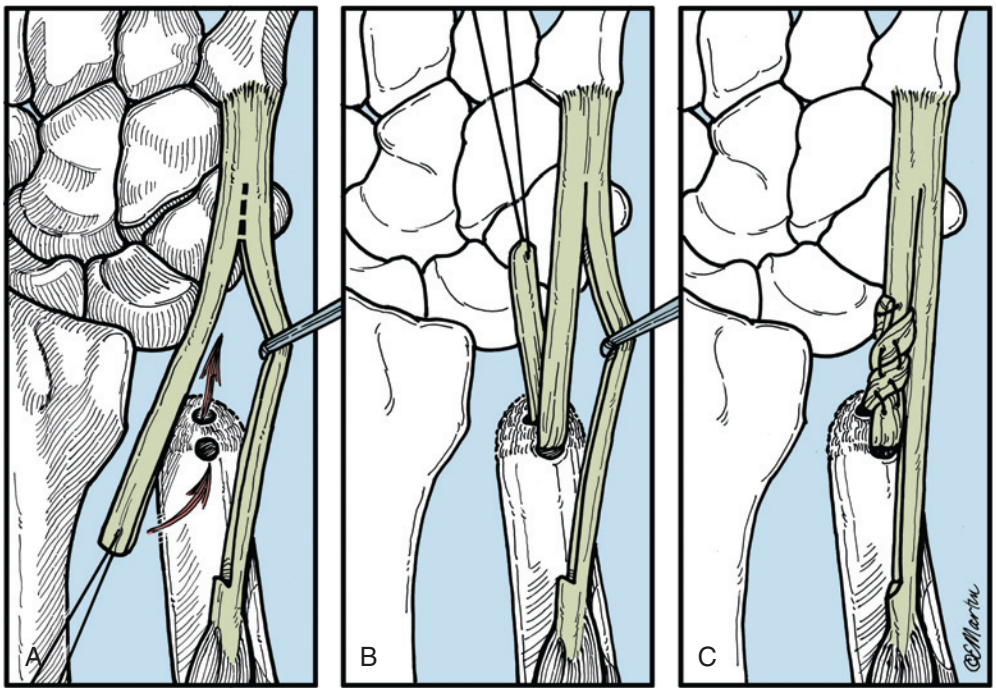

FIGURE 55.25 **A,** The distal end of the ulna has been exposed subperiosteally and osteotomized just proximal to the sigmoid notch. **B,** The extensor carpi ulnaris has been identified and split in half longitudinally from the musculotendinous junction to its insertion at the base of the fifth metacarpal. Half of the tendon is then harvested as a distally based slip. **C,** The proximal portion of the slip is passed through a previously drilled hole in the dorsal distal cortex of the ulna and brought out through the intramedullary cavity. The volar cortex is not violated. The free end of the distally based slip is woven about itself and then sutured under maximal tension to keep the ulna and wrist reduced. (From O'Donovan TM, Ruby LK: The distal radioulnar joint in rheumatoid arthritis. *Hand Clin* 5:249–256, 1989, with permission.)

removed. Finger motion is begun immediately. When the fingers are not being exercised, they are splinted in extension until the patient is able to actively extend them.

If the preoperative deformity or instability was minimal and if a satisfactory ligamentous reconstruction and tight capsular closure were possible at surgery, short-arm splints provide adequate immobilization postoperatively. Occasionally, a sugar tong splint to limit forearm motion is useful for pain relief during the first few days after surgery. Gentle forearm motion is allowed gradually as postoperative pain and swelling decrease. However, if the soft tissue closure is suboptimal, the forearm should be maintained in *supination* with a long-arm splint or cast for at least 3 to 4 weeks to allow soft tissue healing before starting forearm motion exercises. It is not uncommon to have mild crepitus or a click during forearm rotation for the first few weeks after motion is started. This usually diminishes gradually and resolves entirely after several months. It is helpful to warn the patient of this possibility before surgery.

Complications of Ulnar Head Excision. The most frequent complication after distal ulnar excision is painful forearm rotation. This often responds to prolonged splinting and a gentle motion exercise program under the direction of a therapist. No surgery is indicated for 3 to 4 months unless a definite cause of the symptoms is evident. If the symptoms do not abate after several months and the distal ulna is found to be unstable on examination, a soft tissue stabilization procedure using the ECU to reinforce the DRUJ joint capsule can be considered.

We have noted several extensor tendon ruptures after distal ulnar resection in rheumatoid patients. These occurred from

CRITICAL POINTS *Distal Ulnar Resection*

Indications
- Painful synovitis
- Painful/limited DRUJ range of motion
- Extensor tendon attrition rupture

Pearls
- Use a sugar tong splint postoperatively, if necessary, to control pain.
- Click and crepitus are not uncommon for several weeks after surgery but usually resolve spontaneously after several months.

Technical Points
- Use a dorsal longitudinal incision.
- Release and relocate the ECU tendon if subluxated volarward.
- Perform limited resection of the distal ulna (2 cm or less) through a longitudinal capsulotomy.
- Perform synovectomy.
- Bevel the dorsal edge of the ulna to minimize the risk for postoperative tendon rupture.
- Taper the end of the ulna to a smooth "bullet" shape.
- Correct carpal supination by suturing the remnant of the triangular fibrocartilage complex/volar capsule to the dorsal edge of the radius.
- Stabilize the ulna with a tendon slip/pronator quadratus if necessary.
- Reconstruct the dorsal capsule to stabilize and pad the distal ulnar stump.
- Close the skin over a drain.

Postoperative Care
- Apply a short-arm splint for 2 to 3 weeks.
- Allow gentle forearm rotation, as tolerated, and increase forearm motion exercises after 3 weeks.

attrition by the sharp edge of the distal ulnar shaft. We now bevel the dorsal edge of the distal ulna at the osteotomy site and use local tissues to provide a soft tissue layer over the distal end of the ulna after ulnar head resection.

Tendon Transfers to Restore Wrist Balance

A frequent wrist imbalance in rheumatoid arthritis is supination and ulnar translocation of the carpus on the radius. As stated previously, this deformity is associated with the caput ulna syndrome and rotator instability of the carpus. In caput ulna syndrome with volar subluxation or dislocation of the ECU tendon, there is unopposed radial deviation of the carpus from the pull of the radial wrist extensors. This is exacerbated if there is a concomitant intercarpal dissociation with a collapse deformity of the scaphoid.

Clayton advocated correcting wrist imbalance by transferring the ECRL to the ECU in patients who cannot actively deviate the wrist ulnarly.[11,25,52] We have used this transfer in patients with radial deviation of the wrist that is correctable passively. The procedure should be considered in conjunction with wrist joint synovectomy, dorsal tenosynovectomy, and distal ulnar excision. However, indications for this procedure are limited because most of our patients already have advanced wrist involvement with fixed deformity. In these advanced cases, correction requires major reconstructive surgery (wrist fusion).

Preoperatively, to evaluate whether the relocated ECU will function, we place the forearm in supination and evaluate wrist extension. If the ECU functions as an extensor in this position, it will function appropriately in the relocated position. If not, ECRL transfer is indicated.

Operative Technique for ECRL Transfer

After dorsal tenosynovectomy, distal ulnar excision, and ligamentous reconstruction are performed, the ECRL is divided at the base of the second metacarpal. This can be done through either a separate small incision or the primary surgical incision. The tendon is rerouted dorsal to the finger extensors and sutured into the repositioned ECU tendon. At the completion of the transfer, the wrist should be able maintain a neutral position in the coronal plane (radial and ulnar deviation). The wrist is splinted in the corrected position for 4 weeks before beginning exercises.

Extensor Carpi Ulnaris Tendon

Operative Technique for Repositioning. During any surgical procedure on the dorsal aspect of the wrist, the ECU tendon should be released from its volarly subluxated position and repositioned in its normal dorsal position. If the extensor retinaculum has been reflected radially, a strip of this retinaculum can be split and looped around the ECU to hold the tendon dorsal to the axis of wrist flexion. Alternatively, when the retinaculum has been reflected radially and ulnarward, the ulnar portion can be placed deep to the ECU and used as a sling to hold the tendon in the corrected position. If there is a tendency for the tendon to subluxate, it can be sutured to the capsule over the dorsal aspect of the carpus.

Reconstruction of the Radiocarpal Joint

The indications for reconstruction of the radiocarpal joint by either arthrodesis or arthroplasty include deformity and instability that interfere with function, persistent pain unresponsive to conservative therapy, and progressive destruction of the joint seen on radiographic examination.

Historically, arthrodesis has been the reconstructive procedure of choice for the rheumatoid wrist.[93] In 1971, Mannerfelt and Malmsten described the use of a Rush rod that was introduced into the third metacarpal and driven across the radius to obviate the need for external fixation.[67] In 1973, we reported a modification of the techniques described by Mannerfelt for 60 patients who underwent wrist fusion.[61,71] All the patients had relief of pain and improved hand function. Although wrist fusion diminishes pain, wrist motion is lost, which is in itself a disability, especially in patients with stiffness of the opposite wrist.[51]

In the mid-1970s, Swanson developed a silicone-rubber wrist arthroplasty for reconstruction of the rheumatoid wrist. In 1980, we reported early results with 35 Silastic® wrist implant arthroplasties. In 1986, we reviewed the long-term follow-up (average, 5 years) of 71 patients who had undergone wrist arthroplasty with the implants. We found a fracture rate of 20% and a failure rate of 25% when fractures and revisions for pain and recurrent deformity were combined.[12] Subsequent studies by have corroborated these results. Although silicone synovitis has been noted after the use of some silicone-rubber implants in the hand and wrist, this condition did not occur in our series of wrist arthroplasties. Based on experience and these reports, we have abandoned the use of this procedure.

Total wrist arthroplasties have been used with inconsistent results.[26,133] We feel that the potential benefits still are outweighed by the risks and therefore continue to manage painful, destroyed rheumatoid wrists using other methods.

Choice of Operation for the Rheumatoid Wrist

Because of the increased number of surgical options now available for the reconstruction of joints affected by rheumatoid arthritis, preoperative clinical assessment must be done carefully. After evaluation, a considered recommendation for treatment can be made. Patient education, nonoperative treatment (including splinting and the judicious use of steroid injections), and hand therapy with modification of wrist use patterns are all important.[105]

Distal ulnar excision alone may be indicated in a patient whose symptoms are limited to the radioulnar joint and whose radiocarpal joint is stable and functional, even when the radiocarpal joint shows significant destruction on radiographs.[42,43] Distal ulna excision combined with radiocarpal synovectomy can be performed when there is mild-to-moderate loss of articular cartilage from the radiocarpal joint or early erosive changes within the carpus.

We have found that synovectomy alone can slow or even prevent progression in some cases. When soft tissue procedures or limited bone procedures are not appropriate, the decision to perform a total wrist arthrodesis or an arthroplasty must be made. We favor radiocarpal fusions for patients with destruction limited to the radiocarpal joints and/or early collapse patterns of the wrist and whose midcarpal joints are preserved. We advise total wrist fusion in patients who have significant wrist deformity or instability, advanced joint destruction, poor wrist extensor function, or poor bone stock.

Partial Wrist Fusion

Partial wrist fusion has applications in rheumatoid as well as in nonrheumatoid wrist disease.[21,66,92] Limited wrist fusion is useful in rheumatoid patients whose disease has destroyed the radiocarpal joints but has left the midcarpal joints relatively unaffected. Taleisnik demonstrated the paucity of ligaments in the midcarpal region of the wrist.[122] Because the synovium is concentrated in areas with abundant ligaments, the midcarpal area is the last to become involved and is frequently preserved even when the radiocarpal joint is not.

The earliest wrist changes in a rheumatoid patient occur as the volar ligaments stabilizing the proximal row are lost, which results in vertical rotation of the scaphoid and the lunate, ulnar translocation of the lunate, or both. These changes can be arrested in their early stages before progressive collapse and joint destruction occur by fusion of the lunate or scaphoid (or both) to the radius. Of course, a destroyed radiocarpal joint can be salvaged by this fusion as well.[6,66,81,92,103,128] Limited arthrodesis of the involved joints combined with synovectomy of the less involved joints may relieve pain yet preserve 25 to 50% of wrist motion (Figure 55.26).

Operative Technique for Partial Wrist Arthrodesis. The wrist is exposed as described previously for synovectomy. The proximal and midcarpal rows are identified, and a synovectomy is performed with a small rongeur. Articular cartilage is removed from the joints selected for limited fusion. Cancellous bone is exposed by removing or "fish-scaling" the subchondral plate. The contours of the individual carpal bones are preserved to allow apposition of the prepared surfaces. It is important to preserve the overall dimensions of the carpus; that is, the carpal bones should not be "collapsed" onto one another after the cartilage and subchondral plate are removed. Rather, the resulting space should be filled with bone graft. When a proximal row fusion is performed, we usually fuse the radius, scaphoid, and lunate bones. If the articular surface of the scaphoid is preserved, the fusion may be limited to the radiolunate articulation alone, as reported by Chamay and colleagues[18] and by Linscheid and Dobyns.[66] If a midcarpal fusion is necessary, we include all the joints surrounding the capitate.

Autogenous bone graft is used to supplement the fusion site. Cancellous bone is packed between the individual bones to be fused. The distal ulna can be used as bone graft if distal ulnar excision has been performed. Alternatively, bone may be harvested from the distal radius either by removing Lister's tubercle or by making a small window in the distal radius. We prefer internal fixation with multiple 0.045-inch smooth Kirschner wires for the midcarpal joints and small cannulated screws (Acutrak, Herbert-Whipple, or ASIF system) for the radiocarpal joints. Kirschner wires can be cut beneath the skin or left protruding through it. Compression staples can also be used.

Postoperatively, the wrist is immobilized in a short-arm cast for 4 to 6 weeks, at which time the Kirschner wires are removed. Immobilization in a cast is necessary for an additional 3 to 4 weeks until there is evidence of solid fusion on radiographs. We expect to retain 25 to 50% of normal wrist motion after limited wrist arthrodesis.

Taleisnik described partial wrist fusion combined with carpal bone implant arthroplasty in selected rheumatoid patients with radiocarpal destruction or ulnar translocation and an unsatisfactory midcarpal articular surface of either the capitate or the scaphoid.[122] If the articular surface of the capitate head has been eroded, he excises the proximal pole of the capitate and replaces it with either a condylar implant (e.g., a pyrocarbon button with stem) or a soft tissue spacer (e.g., a rolled-up length of tendon graft—"anchovy"). If the articular surface of the scaphoid is unsatisfactory but the capitolunate articulation has been preserved, he fuses the lunate to the radius and replaces the scaphoid with an implant. In both procedures, the radiocarpal joint

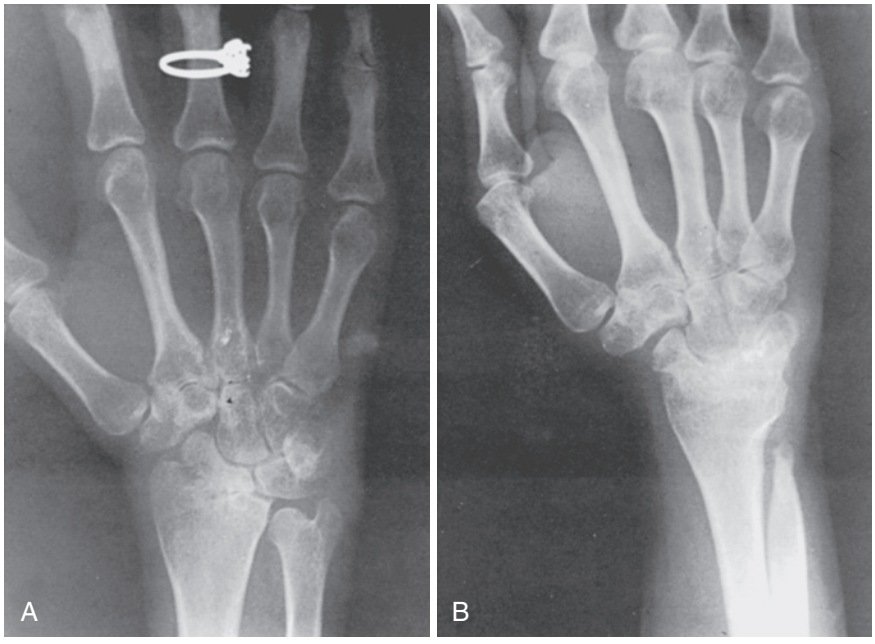

FIGURE 55.26 Partial wrist fusion. **A,** Isolated destruction of the radiocarpal joint and ulnar translocation of the carpus with preservation of the midcarpal joints. **B,** Correction of wrist alignment with preservation of some wrist motion by partial wrist fusion (radius-scaphoid-lunate).

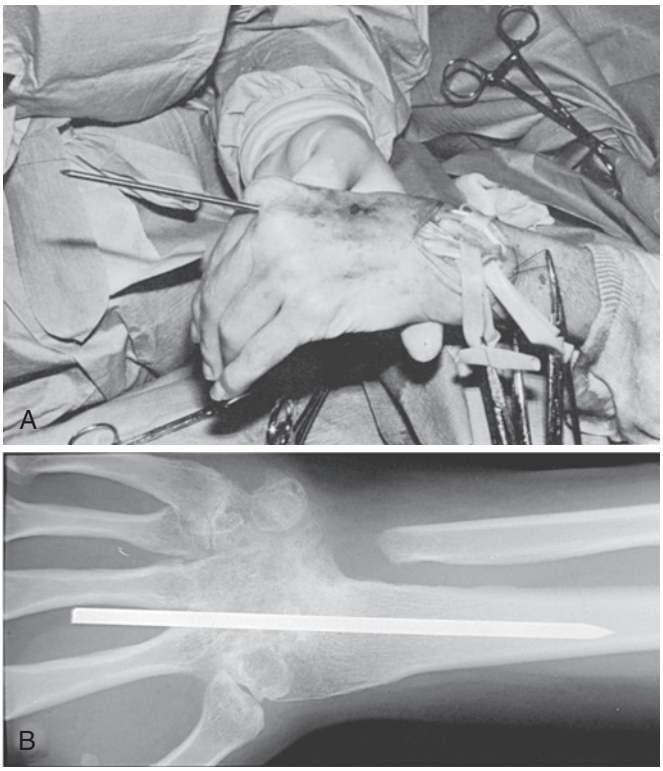

FIGURE 55.27 Technique for wrist arthrodesis. **A,** A Steinmann pin is driven into the radius and countersunk between the second and third metacarpals. **B,** Postoperative radiographic appearance. (From Millender LH, Nalebuff EA: Reconstructive surgery in the rheumatoid hand. *Orthop Clin North Am* 6:709–732, 1975, with permission.)

is stabilized and midcarpal motion is maintained. We have found very few indications for this procedure in our practice.

Operative Technique for Wrist Arthrodesis. The wrist is exposed through a dorsal longitudinal incision (Figure 55.27) similar to that for the wrist procedures described previously.[72] A dorsal tenosynovectomy and associated procedures are performed. The radiocarpal joint is exposed by elevating a distally based flap of the wrist capsule. The distal ulna is exposed and excised as described previously. The radioulnar capsule and triangular fibrocartilage are preserved for closure later. With traction and moderate flexion, synovectomy of the radiocarpal joint is performed. The capsule is released from the radial styloid while avoiding the APL and EPB tendons located in the first dorsal compartment. The cartilage and sclerotic bone are removed from the distal radius and proximal carpal row with a rongeur to provide proper alignment. The amount of bone resected is determined by the degree of deformity and subluxation.

In the standard procedure, the medullary canal of the radius is perforated with a pointed awl to provide a channel for the Steinmann pin to be used for internal fixation.[61] The pin is tapped through the carpus and exits between the second and third or between the third and fourth metacarpals, depending on the alignment between the carpus and radius. The pin should exit between the MP joints. After this step, the pin is tapped with a mallet retrogradely into the previously prepared channel in the radius and countersunk approximately 2 cm proximal to the level of the MP joints. Cutting the pointed end of the pin with a sterile bolt cutter minimizes the risk of penetrating the cortex as the pin is advanced by tapping it with a mallet. Power should not be used to insert the pin into the radius because of the increased chance of penetrating or fracturing the cortex. Bone chips from the resected segment of the ulna are packed into the radiocarpal joint before the carpus is impacted against the radius. One or two small staples or an obliquely placed Kirschner wire can be used to provide additional fixation of the radiocarpal joint if necessary. The Kirschner wire generally has to be removed later; the staples can remain in place permanently.

If there is severe loss of carpal bone stock, a Steinmann pin is introduced into the third metacarpal to provide stability. If the MP joints are dislocated and MP joint arthroplasties are indicated, the rod can be drilled through the distal end of the metacarpal and countersunk proximally, and an MP joint arthroplasty can be performed subsequently. If MP joint arthroplasty is not indicated, the Steinmann pin is introduced into the third metacarpal through a hole in the cortex made just proximal to the collateral ligament. This avoids passing the pin through the interosseous muscles and through the MP joint. Leaving the rod buried in the metacarpal has not caused problems.

This method requires that the wrist be fused in a neutral position; that is, the metacarpal is aligned with the radius. We have found that this is an excellent wrist position for most rheumatoid patients and have used this method for patients requiring bilateral wrist fusions. The position of the wrist can be varied only 5 to 10 degrees by adjusting the direction of the pin as it is driven into the radius. The position of the wrist cannot be altered after the rod has been inserted. The single rod, albeit large in diameter, does not provide secure rotatory stability of the carpus to the distal radius.

Feldon's Two-Pin Modification. Feldon uses a modification of the technique described earlier for wrist fusion in both rheumatoid and nonrheumatoid patients. The wrist is prepared as described previously. Instead of using a single large Steinmann pin, two relatively thin (3/32- to 7/64-inch diameter) pins are inserted through the second and third web spaces between the metacarpal bones, across the carpus, and into the medullary canal of the radius. This results in a "stacked-pin" effect in the radius that provides rotational stability, as well as anteroposterior and lateral stability, without the need for supplementary internal fixation (Figure 55.28). The pins are thin enough that they can be bent slightly after insertion into the radius to allow final correction and adjustment of wrist position. Thus, if slightly more dorsiflexion is desired after the rods are in place, the wrist is gently manipulated into the correct position. The use of thinner Steinmann pins minimizes the potential for compression of the intrinsic muscles of the hand (interossei) by a large rod.

Care must be taken to insert the pins through the dorsal portion of the web space to avoid potential damage to the neurovascular structures in the palm. It is sometimes helpful to make a small window in the dorsal cortex of the distal radius. This allows the pins to be guided into the medullary canal of the radius under direct vision. The pins may lie dorsal to the capitate bone because of the configuration of the wrist; this is not of concern (see Figure 55.29, *B*). An additional cancellous bone graft can be harvested from the distal radius as well. The pins are cut short beneath the skin in the web spaces and

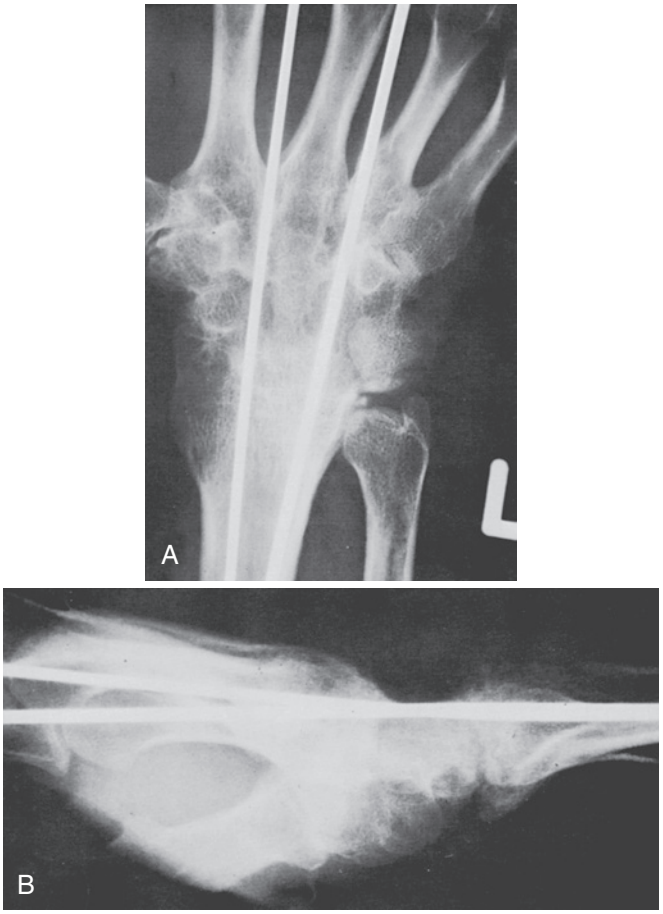

FIGURE 55.28 Wrist fusion using dual Steinmann pins for internal fixation. **A,** Solid fusion was obtained with the wrist in slight ulnar deviation. **B,** The wrist is in slight extension. The pins are positioned on the dorsal aspect of the wrist to minimize the risk for damage to the soft tissue structures in the palm and to facilitate placement of the pins in the medullary canal of the radius. Note that the Steinmann pins may be dorsal to the fused carpus.

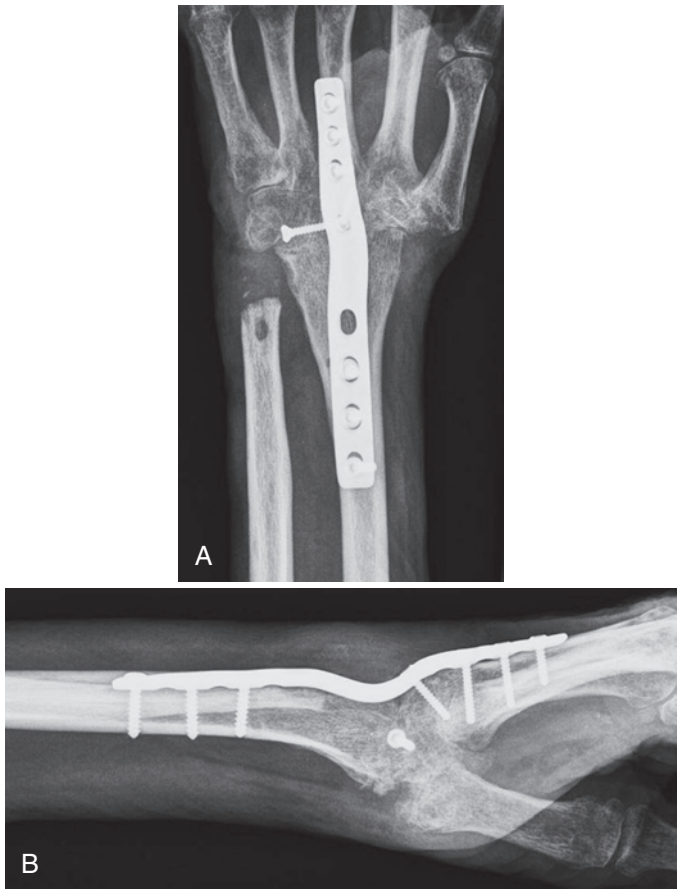

FIGURE 55.29 Fusion of rheumatoid wrist using a wrist fusion plate. The distal ulna has been stabilized with a distally based slip of the extensor carpi ulnaris tendon after resection of the ulnar head. **A,** Posteroanterior view. **B,** Lateral view.

removed after solid bone union has occurred, usually between 4 and 6 months postoperatively, or if they become symptomatic. However, the pins have been left in situ for many years without adverse effect. The pins are removed under local anesthesia by making a vertical incision in the web space and grasping the end with a 10- to 12-inch "diamond jaw" needle holder.

Solid union has been obtained in more than 30 patients over the past several years. This technique has been used in rheumatoid patients even when carpal bone stock has been minimal. Advantages of this method include ease of hardware insertion and removal, the ability to adjust the position of the wrist at the time of surgery in both the anteroposterior and lateral planes, and stable fixation even with suboptimal bone stock. Recently, we have been using ASIF wrist fusion plates with good results for rheumatoid patients with good bone stock (Figure 55.29).

Tourniquet release, drainage, and closure are performed as described previously. A bulky dressing and a sugar tong or long-arm splint are used until the first dressing change. After this, only a short-arm cast or a splint is necessary if the internal fixation is stable and the soft tissue reconstruction of the DRUJ allows early forearm rotation. The forearm is held in supination for 2 to 3 weeks if this joint must be protected. Short-arm cast or splint immobilization facilitates early motion of the elbow and shoulder, as well as the forearm, and is much easier for patients to tolerate. The patient may walk with platform crutches 7 to 10 days after wrist fusion.

When the single Steinmann pin technique is used, the pin is not removed unless it causes discomfort or migrates. The pin rarely migrates distally enough to penetrate the skin. Should this occur, it is removed and supplementary external fixation is used if appropriate. Reintroduction of a pin that has come through the skin should be avoided because of the risk for infection.

Combined Wrist Arthrodesis and MP Joint Arthroplasty

It is not unusual for a patient with severe rheumatoid arthritis to require both wrist fusion and reconstruction of the MP joints (Figure 55.30). Ordinarily, this would necessitate two separate surgical procedures. However, we have performed both procedures during one operation.[76,122] Such a combined procedure is indicated for patients with painful wrists (but without significant wrist deformity) who are appropriate candidates for MP joint arthroplasty. The single, definite contraindication to this combined procedure is a severely deformed or dislocated wrist that would require extensive exposure to correct the radiocarpal alignment.

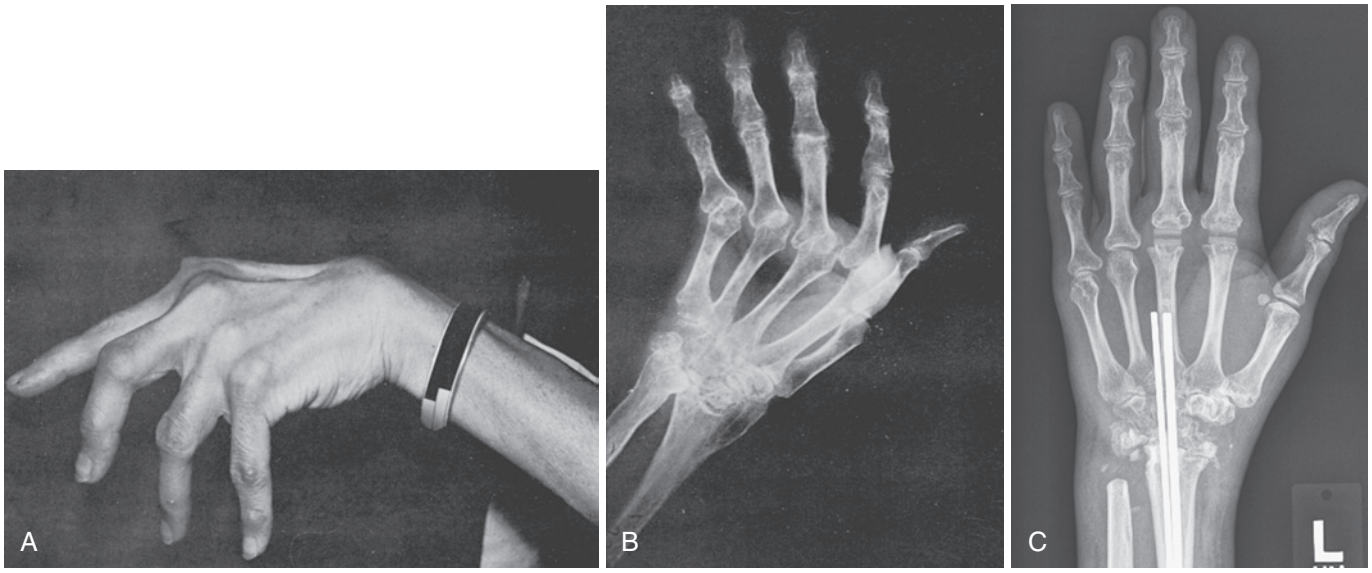

FIGURE 55.30 Wrist fusion combined with metacarpophalangeal (MP) joint arthroplasty. **A,** Photograph of patient with a painful wrist and dislocated MP joints. **B,** Radiograph demonstrating the destroyed wrist joint and dislocated MP joints. **C,** Radiographic appearance after arthroplasty. Note how far the Steinmann pin has been countersunk into the third metacarpal.

A less extensive exposure, without dislocation of the radiocarpal joint, can be used to prepare the wrist for fusion. This allows the MP joint arthroplasty to be performed with minimal chance of excessive postoperative edema and its attendant risk of skin sloughing and other complications. The procedure is a modification of the technique for wrist arthrodesis described earlier.

Complications of Wrist Fusion

In our experience, pseudarthrosis occurs infrequently in rheumatoid patients, is usually asymptomatic, and rarely requires further treatment. Other complications occur rarely but include deep wound infection, superficial skin necrosis, transient median nerve or superficial radial nerve compression, fracture of the healed fusion, and pin migration.

THE METACARPOPHALANGEAL JOINTS

The MP joint is the key joint for function of the fingers. Rheumatoid destruction of it results in severe deformity and functional loss. The MP joints are condylar and allow motion in two separate planes. Because of this anatomic configuration, their inherent stability is less than that of the IP joints, and they are therefore more vulnerable to the deforming forces present in rheumatoid arthritis.

The causes of deformity of the MP joints have been the subject of much debate. There are multiple factors leading to the classic ulnar drift and volar dislocation seen in rheumatoid patients. An understanding of the various factors leading to these deformities is important for the surgeon dealing with these problems.[88,90]

Etiology of Rheumatoid MP Joint Deformities

The deforming forces begin as proliferative synovitis stretches the capsule and ligamentous structures. In the MP joints, this proliferation occurs in the recess between the metacarpal head and attachment of the collateral ligament and results in destruction of the collateral ligaments. Flatt believes that loosening of the ligaments markedly decreases the stability of the joint and is one of the early factors leading to progressive deformity.[38] The normal MP joint is stable in full flexion, with little lateral motion possible in this position. However, in a rheumatoid patient, the flexed MP joint can often be deviated 45 degrees. The following factors affect the altered MP joint and ultimately result in volar subluxation or dislocation and ulnar deviation: wrist deformity, flexor and extensor tendon forces, intrinsic muscle imbalance, and the forces of gravity and pinch.

Shapiro showed that wrist collapse leads to radial deviation of the metacarpals and, subsequently, to an increased tendency for ulnar deviation of the MP joints affected by the rheumatoid process.[113] This is an expansion of the intercalary collapse theory of Spoor and Landsmeer.[114a]

The extrinsic extensor and flexor tendons also affect ulnar drift. In the rheumatoid hand, the extensor tendons are often shifted or even dislocated ulnarward. Selective stretching of the radial-side transverse lamina (sagittal band) fibers by synovial proliferation and the normal ulnar shift of the extensor tendons during MP flexion as the fourth and fifth metacarpal bones descend (which may be increased in patients with rheumatoid arthritis because of laxity of the fourth and fifth CMC joints) contribute to this ulnar subluxation.

Flexor tendon forces also contribute to MP joint deformity.[114] Flatt demonstrated that during pinch there are palmar and ulnar forces in the index and long fingers and a palmar force at the MP joint level in all four fingers.[38] Stretching of the collateral ligaments of the MP joints, which support the flexor tendon sheath, allows a volar and ulnar shift of the A2 pulley mechanism, which can increase the tendency toward MP joint deformity significantly. The anatomic configuration of the joint and the forces of the intrinsic mechanism contribute to the tendency toward ulnar deviation.

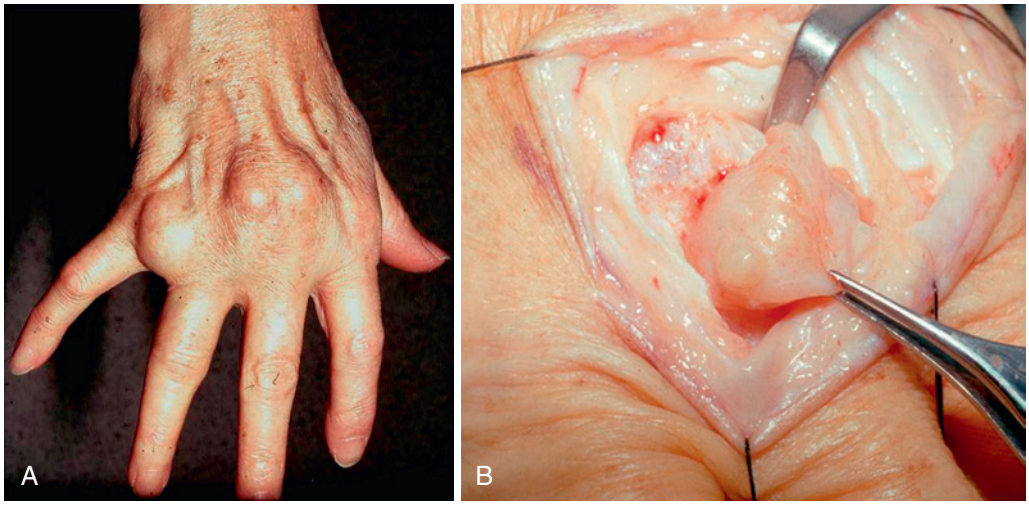

FIGURE 55.31 **A,** Metacarpophalangeal (MP) joint synovitis affecting the long and ring fingers. **B,** Proliferative synovium is excised via MP joint arthrotomy.

Indications for Operative Treatment of MPJoint

Operative procedures for the MP joint are either preventive or reconstructive. The only potentially prophylactic procedure is synovectomy (Figure 55.31). Reconstructive procedures include surgical reconstruction of the soft tissue and various types of arthroplasties.

Synovectomy

The indications for either synovectomy alone or synovectomy with soft tissue reconstruction are difficult to define because no study has shown definitively that these procedures affect the natural course of the disease. Although synovectomy is considered by some to arrest local disease or to slow progression of the disease and allow erosive lesions to heal, recurrence is always possible. Recurrent synovitis may take place as early as several months or as late as many years after the procedure. It is impossible to predetermine patients in whom recurrence is likely to develop. In addition, 30 to 50% of patients with rheumatoid arthritis will have spontaneous remission, thus making it difficult to evaluate the effectiveness of any preventive surgery.[34] Because of the inconclusive results after synovectomy, most rheumatologists and surgeons today take a conservative attitude toward synovectomy of the MP joints.

Synovectomy is indicated for the infrequent patient with persistent MP joint synovitis, minimal radiographic changes, and minimal if any evidence of deformity. Intermittent, painful synovitis (i.e., infrequent) is an additional indication for synovectomy. Before considering synovectomy, the patient must have undergone an adequate trial of conservative therapy, which includes systemic medication, splinting, and up to three local intraarticular corticosteroid injections.

We consider a 6- to 9-month period of conservative therapy necessary before performing synovectomy. Within this period, some patients being considered for the procedure will have a medical remission, and unnecessary surgery can be avoided. Others undergoing conservative therapy will show rapid joint destruction, so these patients would not have good results from synovectomy. The third group of patients undergoing conservative therapy will continue to have persistent localized synovitis with minimal, if any, deformity and minimal radiographic changes. These patients, we anticipate, will benefit on a long-term basis from synovectomy.

Combined Synovectomy and Soft Tissue Reconstruction

Our indications for combined synovectomy and soft tissue reconstruction to correct deformity are limited because the persistence of multiple deforming forces and progression of the disease frequently result in recurrence. Synovectomy with soft tissue reconstruction is considered in a patient who is a candidate for synovectomy but who also has early volar subluxation and ulnar drift. If the disease appears to be progressing slowly and the patient is young, soft tissue reconstruction may slow recurrence of the deformity. Occasionally, a patient is initially seen with an inability to extend the MP joint actively because of complete dislocation of the extensor tendons but has the ability to maintain active extension if the MP joints are extended passively. Extensor tendon relocation with synovectomy is indicated for this patient. We have found that soft tissue surgery alone is indicated infrequently.[45]

Contraindications to MP Joint Surgery

There is a group of patients for whom surgery should not be suggested. Even though these patients have definite subluxation, ulnar drift, advanced radiographic changes, and a weakened grip, they are usually free of pain and have good hand function. Although MP joint deformity is present, surgery will not increase joint function and would probably weaken their grip, especially in those with good PIP joint function. Such patients are best treated with night splints and evaluation every 3 to 4 months. If they maintain satisfactory function, observation should be continued. If they show progressive deformity and dysfunction, they will become candidates for operative treatment.

Operative Techniques for MP Joint

Synovectomy

MP joint synovectomy on multiple joints is performed through a transverse incision centered over the dorsal aspect of the joint.

Synovectomy for a single joint can be performed through a longitudinal incision located just ulnar to it. A longitudinal incision is also used when multiple procedures are being performed in one finger to decrease the risk for excessive swelling. The initial skin incision must not be too deep to avoid damage to the extensor tendons that lie immediately beneath the skin. The dorsal veins and nerves are located within fat pads in the interdigital spaces. These structures must be protected because injury to them can result in painful neuromas or dysesthesias or increase the risk for postoperative swelling (or both), with resultant adherence of the extensor mechanism.[72]

The mechanism is exposed, and the areolar tissue overlying the sagittal bands is separated so that the degree of extensor tendon subluxation to the joint's ulnar side can be determined. In early cases, there is minimal subluxation of the tendon and no significant intrinsic tightness. We prefer to expose the joint by making an incision through the ulnar-side sagittal band, volar to and parallel with the extensor tendon; others enter the joint from the radial side. For patients without extensor tendon subluxation, Swanson described splitting the extensor mechanism in the middorsal line to avoid damaging either the radial or the ulnar sagittal bands. Intrinsic release is performed at this stage, if necessary (see later).

The extensor mechanism is separated from the underlying capsule with small, blunt-tipped scissors. This dissection is often difficult because the capsule has been thinned and disrupted by proliferating synovium that has herniated dorsally or because the capsule is scarred and adhers to the extensor mechanism. The transverse orientation of the fibers of the sagittal bands serves as a guide to the plane between the capsule and the extensor mechanism, which is retracted radially and the joint capsule is incised transversely. Bulging synovium is excised by sharp dissection or with a small rongeur. Traction applied to the finger allows easier access to the volar pouch. Synovectomy of the recess between the collateral ligament and metacarpal neck is performed with a small pituitary rongeur or a curet. Cystic areas of the metacarpal head undergo curettage.

After completing the synovectomy, the extensor mechanism is repositioned. If it subluxates ulnarward, it must be secured as described previously. No attempt is made to close the dorsal capsule. The wound is closed over a Penrose or suction drain placed in the subcutaneous area, and a bulky conforming dressing is applied. Active motion is begun 1 to 2 days postoperatively, and a program of dynamic splinting similar to that after MP joint arthroplasty is maintained for 4 weeks.

Intrinsic Release

Intrinsic release is usually performed in conjunction with MP joint synovectomy or arthroplasty, but it can be performed as an independent procedure in one or more fingers (Figure 55.32).[45] Either a transverse or a longitudinal incision can be used. After the dorsal neurovascular structures have been mobilized and the extensor mechanism has been identified, areolar tissue is freed from the entire ulnar side of the mechanism. The sagittal, transverse, and oblique fibers of the intrinsic mechanism are identified. A longitudinal incision is made in the sagittal band adjacent to the extensor tendon. A curved hemostat is passed beneath the transverse and oblique fibers and exits around the thickened portion of the oblique fibers. These structures are divided, and a section of the oblique fibers can be excised. If release of the bony attachment is required to obtain adequate position of the MP joint, the proximal portion of the tendon is grasped with a clamp, and the tendon attachment into the proximal phalanx is sectioned with scissors.

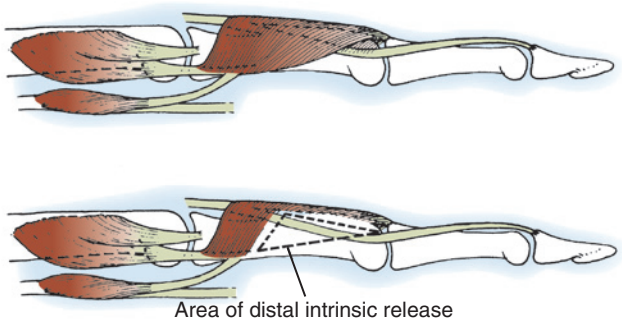

FIGURE 55.32 Technique for ulnar intrinsic release. The ulnar intrinsic tendon is exposed, and a triangular section of the extensor hood, including the lateral band, is resected.

In the small finger, the abductor digiti quinti is a strong, ulnar-deforming muscle that must be released. A blunt retractor is used to hold the skin and subcutaneous tissue out of the way. The fascial sheath is incised to expose the hypothenar muscles. The abductor digiti quinti is separated from the flexor digiti quinti and selectively sectioned at its musculotendinous junction. The ulnar neurovascular bundle lies just volar to these muscles and must be protected. Flatt emphasized the importance of releasing only the abductor digiti quinti without sacrificing the flexor digiti quinti. He showed that releasing the flexor digiti quinti results in limited MP joint flexion and increased weakness.[33]

Harris and Riordan described an alternative method of releasing tight intrinsics. After the intrinsic mechanism is exposed, a triangular portion of the oblique fibers is excised.[45] With this method, the transverse fibers, which act as a yoke to flex the MP joints, are left intact. However, this method does not release the bone insertion and may not provide adequate correction in some patients.

Flatt described a modified intrinsic release that he uses for early subluxation of the MP joint or for persistent flexion contracture. He releases the portion of the transverse fibers that aids flexion of the MP joint.[33] If tightness persists after this release, the bone attachment of the intrinsic tendon is released as well.

Crossed Intrinsic Transfer

The crossed intrinsic transfer is an additional method to restore finger alignment and prevent recurrent ulnar drift. In principle, the intrinsics are released from the ulnar sides of the index, long, and ring fingers and transferred to the radial aspect of the adjacent fingers to provide additional radial stability. We do not use this procedure frequently. Oster and colleagues found that it can provide effective long-term correction of ulnar drift.[99] In a subsequent follow-up study, El-Gammal and Blair found a decrease in active range of motion of the MP joint after 5 years.[32]

Crossed intrinsic transfer is performed in conjunction with MP joint synovectomy and soft tissue reconstruction. The intrinsic tendons of the index, long, and ring fingers are exposed

as described previously. In Straub's method, the tendon is released from the extensor mechanism over the midportion of the proximal phalanx and dissected proximal to its musculotendinous junction. The bony attachment is released from the base of the proximal phalanx to allow free excursion of the muscle–tendon unit. Each tendon is transferred to the radial intrinsic mechanism of the adjacent finger. The tendon is woven into the lateral band and sutured.

Flatt and associates believe that the intrinsic transfer performed as described here may cause a swan neck deformity. They suture the intrinsic tendon to the radial collateral ligament of the adjacent finger rather than weaving the tendon into the lateral band of the adjacent finger.[33]

In the Flatt method, the intrinsic tendons are exposed and released as described earlier. The extensor expansion is opened on the radial side to expose the collateral ligament. The intrinsic tendon is sutured to the radial collateral ligament at its phalangeal attachment with several interrupted 4-0 sutures. The tension at which the attachment is made is correct if complete finger alignment is restored at the completion of the repair. The finger is splinted for 3 weeks before beginning exercises. A dynamic splint is then applied and used for an additional 3 weeks.

Extensor Tendon Relocation

Realignment of an ulnarly dislocated extensor tendon is necessary to correct deformity, restore extension, and prevent recurrent dislocation. The degree of extensor tendon subluxation varies from minimal to complete dislocation with the tendon fixed within the intermetacarpal valley. Several different operative techniques have been described to centralize the extensor tendon.

Longitudinal incisions are used when only one or two fingers are to be done. If all four fingers are to be done, adequate exposure can be achieved through a transverse incision. The subluxated extensor tendon is identified, and the sagittal fibers along its ulnar side are incised. A hemostat is placed beneath the transverse and oblique fibers of the intrinsic tendon on the ulnar side, and an intrinsic release is performed. The extensor tendon is dissected free and relocated over the dorsal aspect of the MP joint. The tendon can be maintained in the relocated position by one of three methods. The simplest, but least effective, method is to reef the stretched radial sagittal fibers. After the tendon has been relocated, the lax fibers are imbricated with absorbable 4-0 suture. We use this procedure when there is no tendency for the tendon to resubluxate. If, however, there is a tendency for radial deviation of the wrist, which increases the tendency for ulnar subluxation of the tendon, more secure fixation of the tendon must be obtained.

An effective method is described by Harrison. A 4-cm slip of extensor tendon, 5 mm wide, is detached proximally and freed distally to the distal portion of the MP joint. This slip is passed through a hole drilled into the dorsal cortex at the base of the proximal phalanx.[46] Zancolli described a method for rebalancing and stabilizing the extensor mechanism by attaching the extensor tendon to the proximal phalanx through drill holes.[141]

We have had good results with direct attachment of the extensor tendon to the proximal phalanx. The attachment is made by either suturing the tendon to the joint capsule just proximal to the base of the proximal phalanx or attaching the tendon directly to the dorsal aspect of the proximal phalanx with a suture passed through drill holes in the proximal phalanx or a small bone anchor using absorbable sutures (Figure 55.33).



FIGURE 55.33 Ulnarly subluxated extensor tendons of the index and long fingers have been relocated by using small bone suture anchors to attach the extensor tendons directly to the proximal phalange, just distal to the metacarpophalangeal joint.

Postoperative Management of Soft Tissue Procedures

At the completion of the surgical procedure, a bulky conforming dressing is used to immobilize the hand with the MP joints in extension and correct alignment. The drain placed in the subcutaneous area is removed on the first postoperative day. Exercises for PIP joint motion, supervised by a hand therapist if necessary, are started immediately, and the MP joints are splinted in extension and slight radial deviation for 4 to 6 weeks. A "resting" splint is used at night for 3 months to maintain finger position. Long-term splinting and carefully supervised therapy are important in preventing recurrence of the deformity.

MP Joint Arthroplasty in Rheumatoid Arthritis

In the late 1950s and early 1960s, several authors described techniques to correct the deformities of arthritic MP joints. The procedures included joint resection and interposition of soft tissues between the metacarpal and proximal phalanx. Despite improved digital alignment and moderate motion from these resection arthroplasties, the results were unpredictable and recurrent deformities were common.

Swanson, in the mid-1960s, devised a flexible hinge implant to improve the reliability of the resection/interposition arthroplasty. The silicone-rubber implant was designed to function as an internal splint that would maintain alignment and stimulate a capsular response termed *encapsulation*.[116] The flexible stem of the implant was allowed to glide in the medullary canal. The combination of the implant and scar tissue provides joint stability and alignment while allowing a reasonable arc of motion. Swanson called his implant a "load-distributing flexible hinge." That silicone implant is composed of a high-molecular-weight, crosslinked silicone elastomer. In 1975, an improved silicone elastomer with a fourfold increase in tear propagation strength was made available for use. The most recent modifications have

further increased fatigue/crack growth resistance and have been used since 1986. The result was a resection arthroplasty with a painless and functional arc of motion that was much more reliable and predictable than a resection arthroplasty alone.

Flexible-hinge arthroplasty has remained the most accepted and widely performed technique for the treatment of severely involved MP joints in rheumatoid arthritis. However, strict attention to technical detail is necessary for this operation to succeed. Recently, new implant designs have sought to replicate the anatomy of the MP joint to preserve function and improve on the limitations of silicone arthroplasty.

Indications

The goals for implant arthroplasty of the MP joint are relief of pain, correction of deformity, and improvement in function and appearance. Implant arthroplasty should fulfill the following criteria: restoration of functional range of motion, adequate stability, resistance to lateral and rotational forces, biologic compatibility, adequate material properties, and the opportunity for satisfactory soft tissue reconstruction.

The typical patient with rheumatoid arthritis has a combination of MP joint ulnar deviation and volar subluxation deformity, pain from synovitis, deformities at other joints, and grasp weakness. MP joint arthroplasty can improve the patient's function by correcting deformity, as well as relieving pain and improving appearance. Combined or staged procedures (or both) may be necessary (Figure 55.34).

Initially, MP joint reconstructive surgery was advocated only for patients with severe deformity and limited function. This standard has been modified with increased confidence in the outcomes of arthroplasty. Current trends favor surgery in less deformed hands for the following reasons: (1) less bone is resected in patients with mild deformity than in those with severe deformity; and (2) soft tissues (e.g., the capsule and collateral ligaments) are better preserved, which ultimately facilitates soft tissue reconstruction. Nevertheless, silicone MP joint arthroplasty is not indicated for mild deformities. Likewise, radiographic deformity alone is not a sufficient indication for MP joint reconstruction. Realistic goals and expectations by both the patient and the surgeon are necessary ingredients for a successful outcome in MP joint surgery.

Contraindications

Active infection is a contraindication to MP arthroplasty. A previous MP joint infection is a relative contraindication to implant surgery. The surgeon should give consideration to the duration of the infection and the pathogens involved. Bone loss and soft tissue problems after an adequately treated infection may preclude arthroplasty. Other general contraindications include inadequate skin coverage, compromised neurovascular status, insufficient bone stock, and an irreparable musculotendinous system.

Patients with severe, progressive rheumatoid arthritis (arthritis mutilans) may have inadequate bone to support or receive the implant. Typically, the phalanges and metacarpals of patients with juvenile rheumatoid arthritis have very small intramedullary canals that may make it impossible to insert even the smallest implant. In such cases, simple resection arthroplasty should be considered to realign the digits. Extensor tendon dysfunction must be considered but it is not a contraindication to MP joint

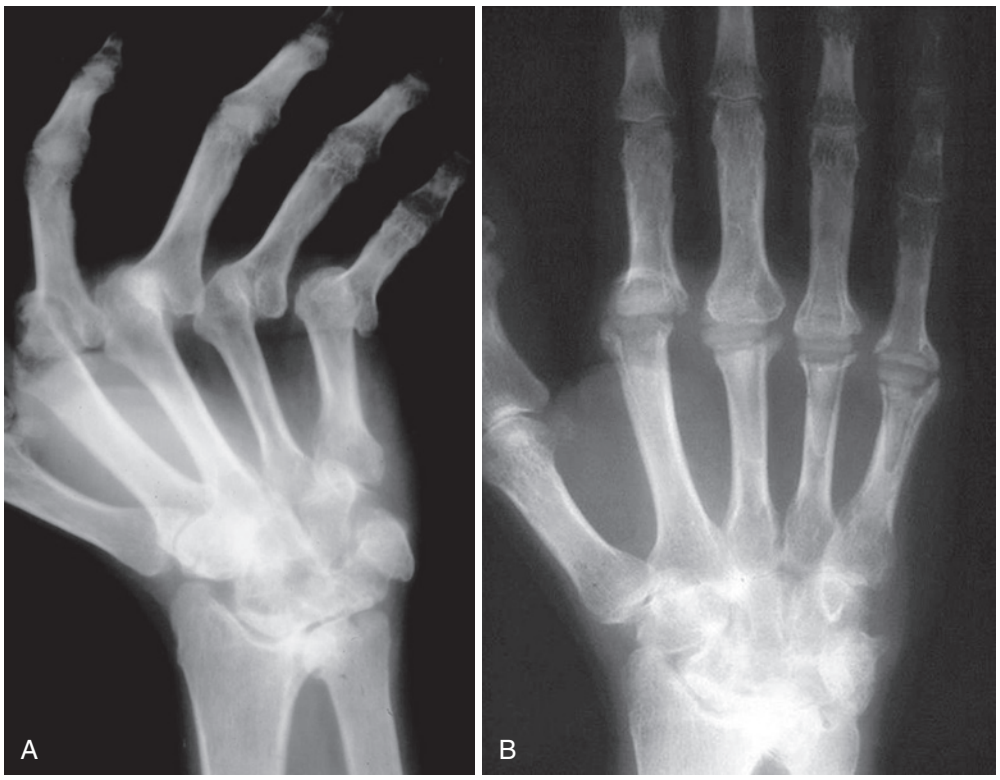

FIGURE 55.34 **A,** Radial deviation of the wrist should be addressed prior to metacarpophalangeal (MP) joint arthroplasty. **B,** In this patient with a painless and supple wrist in spite of degenerative changes on radiograph, the compensatory radial deviation deformity corrected spontaneously after MP joint arthroplasties corrected ulnar deviation of the fingers.

arthroplasty. MP joint arthroplasty and extensor tendon reconstruction can be done as either a combined procedure or in stages.[77]

Patients with multiple deformities from rheumatoid arthritis may require a staged reconstruction.[77] Wrist deformity and pain must be considered when planning MP joint surgery. We have found that many of our patients with ulnar deviation deformities of the MP joints compensate (involuntarily) by radially deviating their wrists to help align their fingers with the forearm. This occurs in patients with supple, painless wrists in spite of moderately severe radiograph changes at the radiocarpal and/or midcarpal joints. In these patients, the radial deviation deformity corrects automatically after the MP joint alignment is improved by arthroplasty (see Figure 55.34). However, a fixed radial deviation deformity of the wrist can lead to recurrent ulnar deviation of the fingers after arthroplasty (see Figure 55.21); if there is significant wrist pain, hand function may still be limited even after successful MP joint reconstruction. Therefore, the wrist problem should be addressed before or in conjunction with MP joint reconstruction.

Arthroplasty Options

Many implants have been used over the past 30 years in an attempt to achieve pain-free, well-functioning MP joints. Such implants can be categorized into one of three design types: metal-hinged prostheses (Flatt), flexible implant (Swanson), and third-generation prostheses. The first hinged prostheses used for MP joint arthroplasty were simple metal uniaxis hinges. Evolution of this type resulted in multiaxis hinges with combinations of metal, ceramic, and polymer components. Despite early promising results, recurrent deformity, dislocation, and loosening plagued these designs in the longer term.

Flexible silicone implants have been the most extensively used and studied and currently remain the implant of choice. Despite their limitations, they are relatively easy to implant, can be revised without undue difficulty, and are reasonable in cost. The newer designs of silicone implants (e.g., NeuFlex® and SBI) have more cube-shaped barrels that better approximate the shape of a normal MP joint and are available in both straight and preflexed configurations. These are now preferrable to the older Swanson design.[36,101,136]

The group of third-generation prostheses includes surface replacement and hybrids of hinged and flexible ones. The most recently studied is the pyrolytic carbon MP implant. They have an articulating, unconstrained design with a hemispheric head and grooved, offset stems to re-create the bony anatomy. The material is made of an isotropic carbon coating over a graphite substrate and has wear properties similar to those of ceramic. The designs were developed to provide greater strength and durability.

At this time we believe that there are limited indications for surface replacement MP arthroplasty of any type in rheumatoid patients because the outcomes have been variable with high rates of subsidence in patients, and complication and revision rates higher than those for silicone MP joint arthroplasty.[100]

Surgical Technique

Flexible Implant Arthroplasty. There are three major design choices in flexible implant arthroplasty: the original Swanson design (Wright Medical), the Small Bone Innovations (SBI) flexible implant, and the NeuFlex (DePuy) implants. The surgical technique for each of the designs is essentially identical. A single longitudinal incision can be used when the surgery is confined to a single digit.

When two or more arthroplasties are done simultaneously, a single transverse skin incision is made over the affected MP joints. With multiple joint implantations, surgery is started on the index finger and proceeds sequentially to the little finger. In patients with rheumatoid arthritis, the skin is often thin and care should be taken to avoid damage to the underlying veins, superficial nerves, and extensor tendons. The skin is retracted with sutures, and the extensor mechanism of each digit is exposed by blunt dissection. It is usually necessary to divide the junctura between the index and middle fingers and to separate the conjoint tendon going to the ring and little fingers.

Attenuation of the radial sagittal band fibers and ulnar translocation of the extensor tendons are common. The tendons and extensor mechanism are elevated from the underlying joint capsule after the ulnar side of the extensor tendon is identified and freed. Release of the shortened ulnar sagittal band is often required to mobilize the extensor tendon. We prefer to approach the joint from the ulnar side to release the fibers (Figure 55.35). A longitudinal incision is made between the volar edge of the extensor tendon and the sagittal fibers. Adherences between the extensor tendon and the underlying joint capsule are freed, and the tendon is retracted to the radial side to expose the MP joint capsule.

The ulnar intrinsic tendon is identified and released in most cases (Figure 55.36). Passing a right-angled clamp around the tendon will help isolate it and protect the neurovascular bundle volar to it. It is tagged with a suture if a crossed intrinsic transfer or lengthening is planned. Release of the ulnar intrinsic can help correct ulnar deviation of the finger. If the intrinsic is not contributing to the deformity at the MP (or the PIP) joint, we do not divide it.

A longitudinal midline incision is made through the joint capsule, and the exposed synovium is removed. The collateral ligaments usually need to be released to correct the deformity

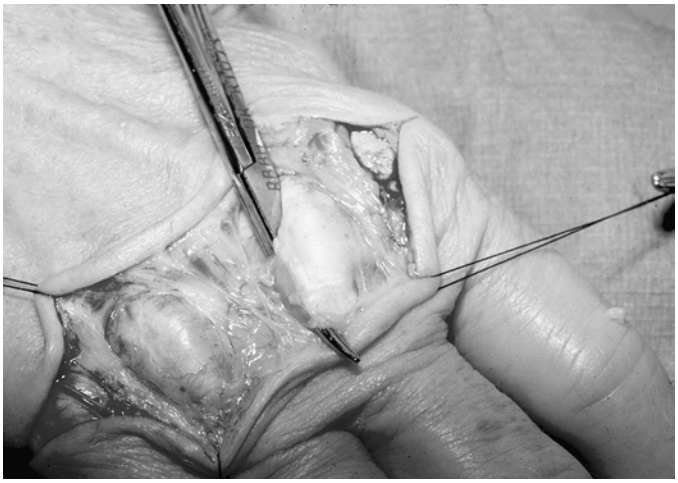

FIGURE 55.35 A transverse incision is used to expose the metacarpophalangeal joints. The superficial nerves and veins that run between the metacarpal heads are preserved. The ulnar sagittal band is identified with a hemostat and then released with a transverse incision parallel to the extensor tendon.



FIGURE 55.36 The ulnar intrinsic is identified in the hemostat (*arrow*) and relaxed to correct the significant ulnar deviation of the metacarpophalangeal joint.



FIGURE 55.38 This preoperative radiograph demonstrates dorsal erosion of the proximal phalanx of the index finger (*arrow*). This should be recognized preoperatively to avoid perforation of the proximal phalanx or excessive bone resection of the metacarpal (or both).

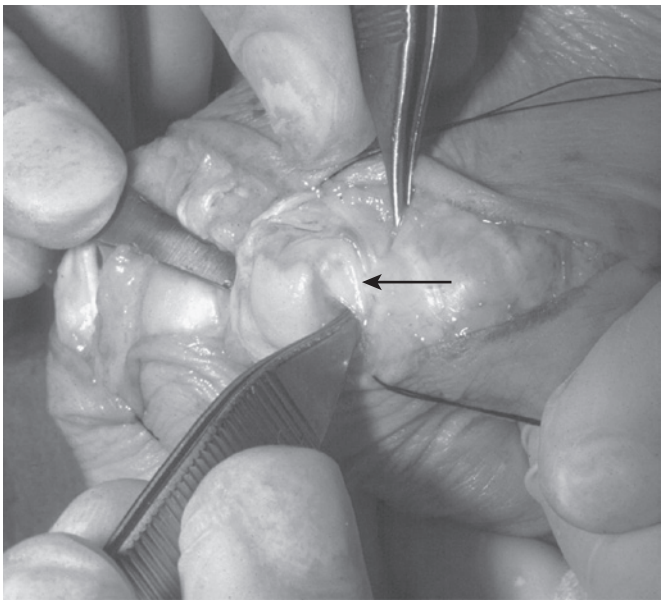

FIGURE 55.37 The capsule has been incised and the metacarpophalangeal joint flexed. The collateral ligament can then be identified and released, if necessary, from the metacarpal neck (*arrow*).

or allow access to the joint, or both. However, if there is minimal deformity and the collateral ligaments are competent, release of the ligaments may not be necessary.

A knife blade is placed in the collateral ligament sulcus at the metacarpal neck and swung dorsalward along the neck to detach the origin of the collateral ligament while preserving its distal attachment to the proximal phalanx. Flexion of the joint facilitates this step (Figure 55.37). Preservation of the radial collateral ligament is especially important for reconstructing the joint. Reattachment of this ligament allows correction of the ulnar deviation deformity and provides resistance to the lateral forces generated during pinch.

Before the metacarpal head is resected, the configuration of the base of the proximal phalanx should be checked. If dorsal erosion has occurred, the base of the proximal phalanx is squared by resecting bone from the volar portion of the base of the phalanx (Figure 55.38). In this case, less of the metacarpal head will be resected. If the proximal phalanx is not checked first, too large a space for the implant can result after bone has been resected from both sides of the joint to provide flush surfaces for the barrel of the implant to rest against. If the preoperative radiographs are unclear, a small portion of the metacarpal head can be removed to allow visualization of the joint before the entire metacarpal head is resected.

The metacarpal head can now be resected. The periosteum is incised transversely at the proposed resection site on the dorsal aspect of the metacarpal neck. The periosteum is left intact proximally to provide tissue for reattachment of the collateral ligament and capsule (Figure 55.39). With the blade of a small oscillating saw oriented perpendicular to the shaft, the metacarpal head is resected level with the origin of the collateral ligaments. This is best done with the joint flexed and a flat elevator placed on the volar surface of the metacarpal for support. The synovectomy can now be completed and the amount of space available for the implant checked by applying distal traction to the finger. If there is not enough space to accommodate the implant, more of the metacarpal head is resected. It is better to err on the side of too little initial bone resection than too much.

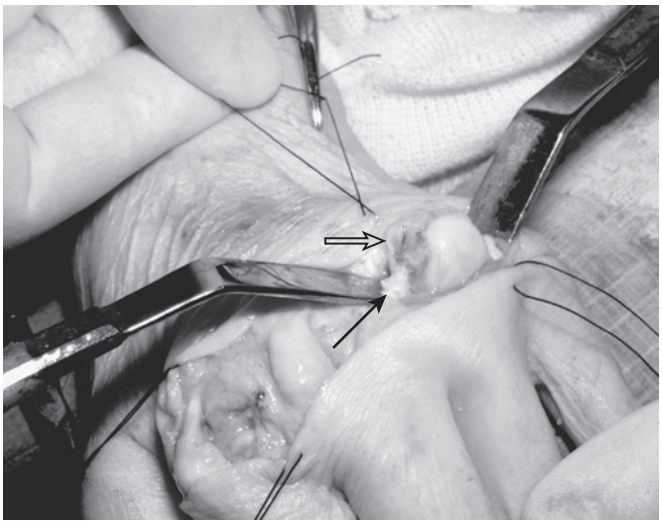

FIGURE 55.39 After the collateral is released (*closed arrow*), the periosteum is stripped proximally (*open arrow*) to provide tissue for repair of the collateral ligament when needed.



FIGURE 55.41 A trial implant is in place, and adequate space for the implant is demonstrated.

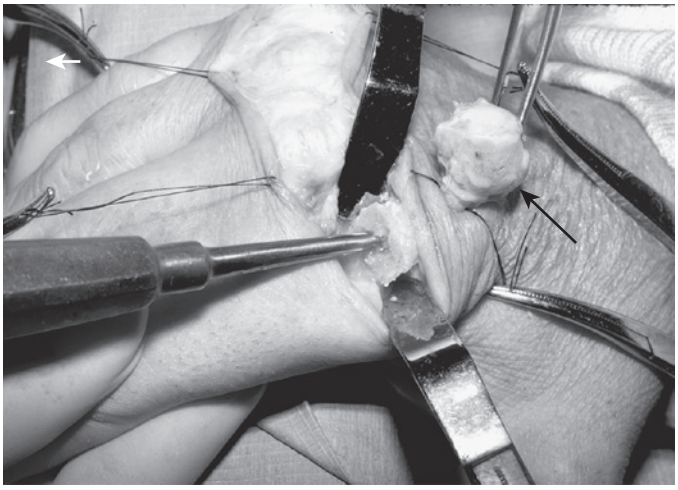

FIGURE 55.40 The metacarpal head has been removed (*arrow*) perpendicular to the metacarpal, and the medullary canal is perforated with an awl.

Flexion of the joint exposes the base of the proximal phalanx. The base is brought dorsal to the metacarpal. Resection or release of the volar plate may be necessary to allow adequate exposure and alignment of the proximal phalanx. This may also gain additional space for the implant after bone resection and preclude the need for additional bone removal. Care is taken to avoid injury to the flexor tendons while releasing the volar plate. A limited flexor tenosynovectomy can be performed at this time if needed, and flexor tendon excursion can be checked.

The base of the proximal phalanx should be exposed completely. An oscillating saw or rongeur is used to provide a base flush with the proximal phalanx. Usually only the joint margins or, if necessary, a thin portion of the subchondral bone needs be removed.

After bone removal is completed, a pointed awl is introduced into the medullary canals of the proximal phalanx and metacarpal (Figure 55.40). The phalanx is prepared first because it usually determines the size of the implant to be used. This prevents overreaming of the metacarpal. The exception to this is in the fourth (ring finger) metacarpal. The canal of it is generally narrower than that of the ring finger and is prepared first to avoid overreaming the proximal phalanx. Rasps are used to shape a rectangular opening in the proximal phalanx, which helps resist rotation of the implant stem. Power burs with a blunt leading tip can be helpful when the diaphysis is constricted. For the index and long fingers, the rectangular opening should be angled so that it is slightly more dorsal on the ulnar side. This will supinate the fingers slightly, which facilitates opposition to the thumb and thereby chuck pinch. In the other fingers, the rectangular opening is made parallel to the volar surface of the proximal phalanx. Preparation of the metacarpal is similar, with the rectangular opening being parallel to the bone's volar surface.

At this point it is essential to confirm that there is sufficient space for insertion of the implant. A 1-cm space is ideal and usually allows placement of the implant without buckling (Figure 55.41). If the space is too small, insertion of the implant will be difficult and subluxation can occur and result in limited joint motion or recurrent deformity (or both). The space can be increased by several methods: release or resection of the ulnar intrinsic and capsule, release or resection of the volar plate, and resection of additional bone.

The joint is now ready for insertion of the implant and soft tissue reconstruction. A 2-0 absorbable suture is woven into the radial collateral ligament at the base of the proximal phalanx for the index and middle fingers. Traction applied to the suture after placement deviates the proximal phalanx radialward if the suture has been properly placed (Figure 55.42). The collateral ligament need not be repaired for the ring and little fingers unless necessary to correct finger alignment. The radial collateral ligament of the index and middle fingers is generally sutured to the periosteal sleeve on the dorsal and radial aspect of the metacarpal. The ligament can be reattached through drill

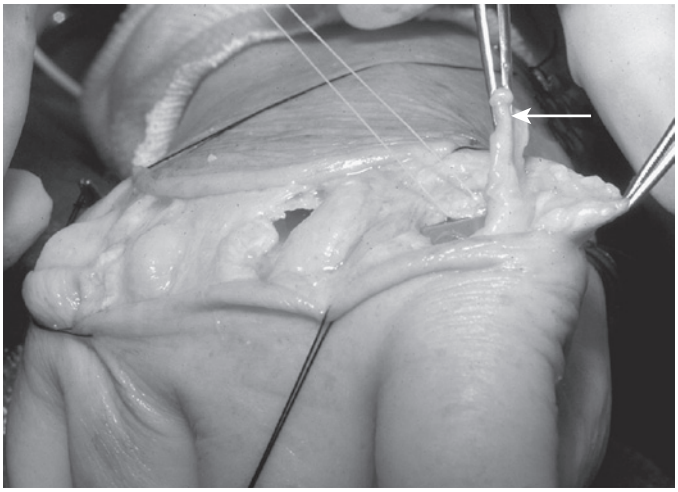

FIGURE 55.42 The radial collateral ligament is held in forceps (*arrow*) and prepared for repair in slight overcorrection.

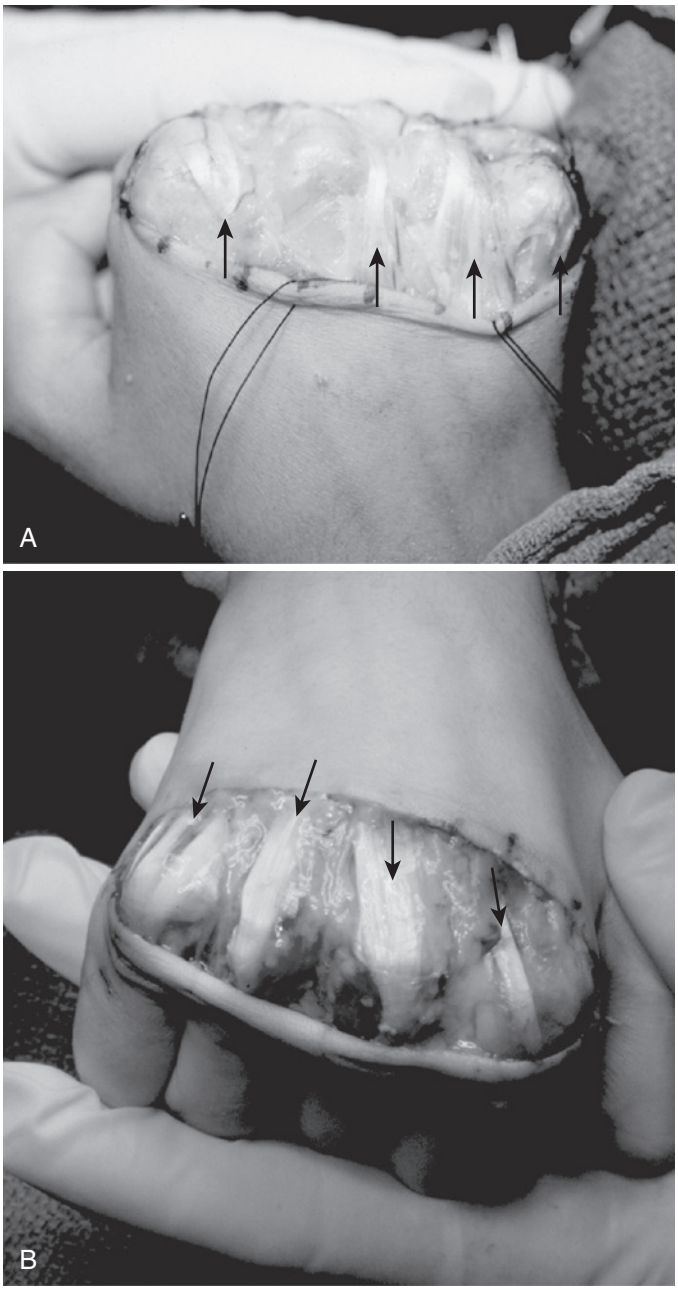

FIGURE 55.43 Example of extensor tenodesis. **A,** The extensor tendons are ulnarly subluxated (*arrows*). **B,** Tenodesis of the tendon to the proximal phalanx has been performed. With full metacarpophalangeal flexion, the extensor tendons remain centralized (*arrows*).

holes on the dorsal/radial edge of the metacarpal if insufficient periosteum is present. The suture is not tied until after the implant is in place. If the radial collateral ligament is so attenuated that it cannot be reattached, the volar plate can be used to reconstruct the ligament.[60]

The implant is inserted with smooth forceps to minimize injury to its surface. Implant insertion is done with the metacarpal and the proximal phalanx positioned at right angles to one another. Generally, the metacarpal stem is inserted first. The central portion of the implant is held with a smooth instrument while the phalanx stem is inserted. The joint is extended to seat the implant. The surgeon should check to be sure that both stems of the implant are in their respective medullary canals. If the implant buckles with the joint extended or dislocates with the joint flexed, there is not enough space and either a soft tissue release or additional bone resection must be done.

The finger is held in extension and slight radial deviation while the collateral ligament suture is tied with sufficient tension to maintain the joint in 5 to 10 degrees of radial deviation. Redundant capsule is trimmed, and the capsule is closed to cover the implant. Capsular closure helps protect against dislocation of the implant and speeds the encapsulation process. If doing multiple implants, the most radial finger is done first and the more ulnar digits aligned to it. Our technique of MP joint arthroplasty is demonstrated in Video 55.1.

Extensor Tendon Centralization. Laxity of the radial sagittal fibers with ulnar displacement of the extensor tendon after insertion of the implant typically requires reinforcement of the radial side. If there is mild subluxation, placement of several 4-0 absorbable mattress sutures shortens the radial sagittal fibers and brings the extensor tendon into a centralized position. If the tendon is dislocated or does not stay centralized during passive MP joint flexion, a more formal centralization procedure is necessary, as described previously. Once all implants are in place, the previously divided tendon junctura can be repaired, if necessary, to help prevent tendon subluxation (Figure 55.43).

At the conclusion of the procedure, the fingers should align in slight radial deviation. Passive MP joint flexion of 70 to 80 degrees should be possible without capsular suture failure or extensor subluxation. The skin edges are closed with 5-0 nylon sutures. In most cases, with careful attention to hemostasis, the skin is closed with the tourniquet still inflated. A drain placed in the subcutaneous space helps prevent postoperative hematoma formation. A well-padded hand dressing is applied with the MP joints supported as follows: the position of immobilization of the MP joints is determined by their preoperative position. If the major problem was ulnar deviation or subluxation without fixed flexion, the fingers are placed in a functional position with the MP joints slightly flexed. If the patient had severe MP joint flexion deformity preoperatively with weak or absent extension, the MP joints are splinted in extension. This may result in interphalangeal flexion because of tight flexor tendons

but usually corrects as the soft tissues stretch over time. Each finger is maintained in slight radial deviation with tape supporting the ulnar side of the proximal phalanx to protect against ulnar deviation. The wrist is supported in slight extension and neutral deviation by a plaster splint that also supports the MP joints in the desired position. The PIP joints are usually left free.

Technical Points. An alternative approach to exposure of the joint is through the stretched radial sagittal fibers. This method requires shortening of the radial sagittal fibers once the implant is in place.

Consideration of release of the ulnar intrinsic tendon should be based on the amount of deformity present and the finger involved. Specifically, the ulnar intrinsic provides a supination force for the index finger and is helpful in pinch. Therefore, it can be left intact when the deformity is mild and correctable without release. The final decision for release of the ulnar intrinsic can be made after resecting the metacarpal head in patients with mild deformity. If the MP joint deformity cannot be corrected completely, the intrinsic should be released.

Intrinsic release may also correct a concomitant swan neck deformity by decreasing the extensor force to the PIP joint. However, intrinsic division reduces the patient's ability to spread the fingers in a normal fashion after the arthroplasty. Lengthening of the intrinsic tendon is an alternative to complete division. This should diminish the deforming force while preserving some ulnar intrinsic function. Keeping the intrinsics intact should also be considered for patients with significant laxity (e.g., those with SLE). Complete ulnar intrinsic release in such patients may result in a radial deviation deformity after reconstruction.

Inadequate bone resection or soft tissue release can result in not enough space for placement of the implant, causing implant fracture or limited motion, or both. Dislocation of the implant can occur if too much bone is resected or if there is inadequate soft tissue release. Sharp bone edges must be smoothed to prevent injury to the implant.

Perforation of the dorsal or volar aspect of the proximal phalanx can occur during preparation for the distal stem. Typically, an unrecognized deformity of the base of the proximal phalanx leads to perforation. This is not usually a problem if the stem is redirected distal to the perforation.

Rehabilitation

Most MP joint reconstructions are now performed on an outpatient basis. We recommend that the dressing be changed and the drain removed in 1 to 2 days. A static splint to maintain the MP joint in the corrected position (nearly full extension and slight radial deviation) is applied and supplemented with soft tape to keep the fingers in proper alignment. It is clear, however, that a single postoperative protocol does not work for all patients who have undergone MP arthroplasty. A splinting and exercise program for each patient needs to be specifically designed around that person's preoperative deformity and the condition of the soft tissues at surgery.

The initial Swanson protocol used a dynamic splint with slings under the proximal segments of the fingers to maintain MP joint extension and slight radial deviation. We found that this method often resulted in limited flexion of the ring and little fingers and modified it by leaving the slings off these fingers (Figure 55.44). Now we use low-profile custom volar splints to support the MP joint in nearly full extension for 6 weeks; a lip on the ulnar side controls radial deviation. Generally, the PIP joints are left free and motion of them is encouraged. The splint is removed for range-of-motion exercises several times daily. If the PIP joints are supple, splinting them in extension during the MP joint exercises facilitates obtaining MP joint flexion. Careful postoperative monitoring is necessary to be sure that the reconstructed joints are responding as



FIGURE 55.44 **A,** A low-profile dynamic extensor splint can be used to support the metacarpophalangeal (MP) joints in extension while allowing active flexion. **B, C,** A short-arm cast extended distally to support the MP joints in extension is an alternative to dynamic splinting in selected patients. Note the use of tape to maintain MP joint alignment.

desired. The protocol should be changed as necessary to accommodate the patient's progress.

Currently, for most patients we use a short-arm cast extended distally to support the MP joints in about 30 degrees of extension and leave the IP joints free for 4 to 6 weeks after removal of the sutures. For patients with severe preoperative flexion deformities, the MP joints are held in full extension for 4 to 6 weeks. Gradual mobilization is started after the cast is removed, and a period of dynamic splinting may be helpful after the cast is discontinued. Use of a static splint to maintain the corrected position at night for 3 months is recommended.

The need to customize postoperative splinting and therapy for each patient by taking into account the nature of the disease (e.g., rheumatoid, psoriatic, lupus) and the severity of the deformity before arthroplasty, as well as the condition of the soft tissues and flexor and extensor tendons, cannot be emphasized enough. For example, patients with supple PIP joints tend to flex these joints rather than the reconstructed MP joints during grasp. For these patients, postoperative MP joint flexion can be maximized by having them exercise while wearing finger splints that limit PIP joint motion (Figure 55.45). Careful planning and close follow-up maximize hand function after MP joint arthroplasty.

Complications

Complications associated with MP joint arthroplasty include recurrent ulnar deviation, extensor lag, limited MP joint flexion, implant fracture, infection, and silicone-induced particulate synovitis.[41] Most patients have some recurrent ulnar deviation and loss of MP joint extension over time. Bieber and colleagues reported on 210 Swanson-design MP implants.[8] These patients were monitored for an average of 5.3 years. At the initial postoperative evaluation, ulnar drift improved from the preoperative average of 25 degrees to <5 degrees. The preoperative average extension deficit decreased from 56 to 10 degrees, whereas the average range of motion increased from 17 to 51 degrees. At long-term postoperative evaluation, the average ulnar drift had increased to 12 degrees, the average extension deficit had increased to 22 degrees, and the average range of motion had decreased to 39 degrees.

In another long-term follow-up study, Kirschenbaum and coworkers reported on a series of 144 arthroplasties at an average of 8.5 years after surgery.[59] They found an average recurrence of 7 degrees of ulnar deviation, improvement in mean extension to a range of 7 to 19 degrees, and a mean range of flexion from 56 to 66 degrees. At the time of the last follow-up, motion of the MP joints had not deteriorated significantly. However, range of motion alone is not the only determinant of success or failure of MP arthroplasty in any given patient.

Reported fracture rates for all designs of MP silicone implants range from 1 to 26%. When earlier (less tear-resistant) designs are excluded, the incidence of implant fracture varied from 0.9 to 10%. The studies of Bieber and associates and Kirschenbaum and coworkers found fracture rates of 0% and 10%, respectively, for the Swanson design.[8,59]

Encapsulation of the implant tends to maintain a functional joint even with implant fracture. However, with a significant increase in ulnar deviation or shortening of a finger, implant failure should be suspected and can be confirmed with radiographs of the hand. Burgess and coauthors reported the

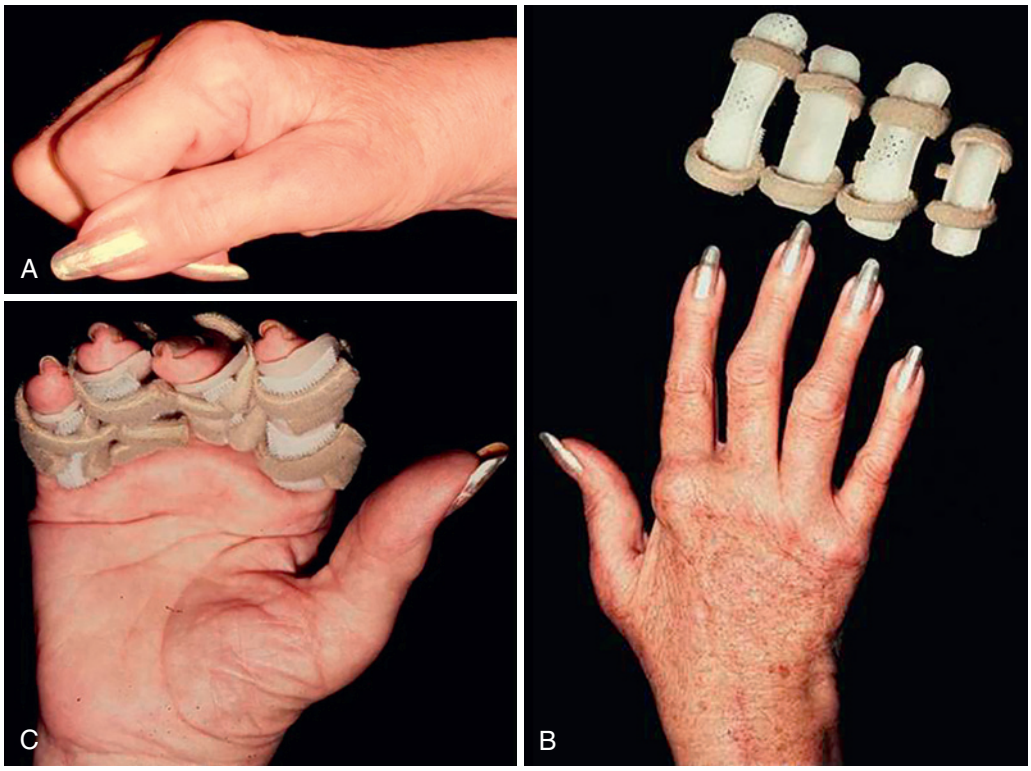

FIGURE 55.45 **A,** Supple proximal interphalangeal joints allow grasp with minimal metacarpophalangeal (MP) joint flexion. **B, C,** In patients with good interphalangeal (IP) joint flexion, MP joint motion after arthroplasty can be maximized by using splints to keep the IP joints in extension during postoperative exercises.

results of their series of MP arthroplasty revisions, which demonstrated satisfactory clinical, if not optimal, objective outcomes.[17]

Titanium grommets have been used to protect the stems of the implant against the bone edges and may decrease implant fracture rates.[78] Schmidt and associates evaluated the effect of grommet use in 151 Silastic MP arthroplasties.[111] There were no significant differences in clinical outcomes with respect to swelling, correction of ulnar deviation, range of active movement, and grip strength. However, the use of grommets slightly reduced reactive osteolysis, protected the spacers from breakage, and slightly decreased the amount of pain with only a few additional complications in the midterm 3.9-year follow-up. The favorable bone response and better bone preservation at the metaphysis with use of grommets, as described by Swanson, were not seen. As such, the main advantage seems to be prevention of implant fracture. Insertion and fitting of grommets, however, add to the complexity of the procedure. We limit their use to cases with previous implant fracture or when the resected bone edges are particularly sharp.

Infections around implants are rare, and rates of deep infection requiring excision of the implant have varied from 1.6 to 9%. Removal of the implant with a short period of antibiotic coverage generally controls the problem. We do not usually reinsert an implant after an MP joint infection has been brought under control. By removing the implant, the operation is converted to a "resection" arthroplasty. Range of motion is reduced, but pain is eliminated and digital alignment can be maintained by splinting for 6 weeks.

Outcomes

In patients with rheumatoid arthritis, the ability to correlate clinical and radiographic parameters to subjective patient interpretation of outcome is difficult, if not impossible. Patient satisfaction and radiographic parameters have not shown significant correlations. The results of MP joint arthroplasties are as varied as the patients undergoing them. Chung and colleagues reviewed all published series of the Swanson MP joint arthroplasty used for the treatment of rheumatoid deformity.[23] Based on these authors' findings, use of the Swanson implant has been shown to effectively correct ulnar drift deformity and improve the appearance of the rheumatoid hand. Several major research design deficiencies hindered analysis, including unclear overall design, lack of uniform outcome measurements, confounding patient characteristics and clinical factors, and varying follow-up intervals.

One of the most important considerations in MP joint arthroplasty is restoration of function. The literature indicates that the expected active range of motion is 40 to 50 degrees (with passive motion typically being greater) after uncomplicated arthroplasty. After implant arthroplasty, the functional arc usually is shifted to greater extension, which is generally advantageous for hand function.[23,139] Postoperative range of motion is influenced by many factors, including the type of arthritis, the condition of adjacent joints, the controlling tendons, and the tissue elasticity of the patient.

Hume and colleagues reported that a functional arc between 33 and 73 degrees is necessary for most activities of daily living.[49] It is important to understand that range of motion alone may not be the ultimate determinant of the outcome of MP joint implant arthroplasty. Despite good motion, hand function can be compromised if finger stiffness or poor position limits grasp or pinch. Rothwell and associates, in a prospective study, showed improvement in standardized hand function tests.[108] In the final analysis, patient satisfaction may be related most to pain relief and improved appearance at moderate-term follow-up.

Quantitative assessment of hand function related to activities of daily living may be a more meaningful outcome measure than recording range of motion, correction of deformity, strength, and radiographic changes. Rothwell's study included the evaluation of hand function after Silastic MP arthroplasties with the Baltimore quantitative test of upper extremity function.[108] The results demonstrated that MP arthroplasty significantly improved hand function within 6 weeks and the benefits were maintained up to 4 years. Most improvement occurred in functions requiring pinch, span, or hook grip. The authors attributed this to correction of ulnar drift, stabilization of the fingers for pinch grip, and the change in arc of MP joint motion, which restored the ability to open the hand for grasp. The gains in hand function should continue provided that there is no further deterioration in thumb or wrist function. The patients in whom scores declined between 1 year and 3 to 4 years also showed significant deterioration of the shoulder or elbow, which affects ultimate hand function.

In our practice it is common for patients with bilateral hand deformities to request MP joint arthroplasties in the second hand. *To us, this is the best test of patient satisfaction with the operation.*

THE PROXIMAL INTERPHALANGEAL JOINTS

Synovectomy

Although synovectomy is performed infrequently at the wrist and MP joints for the reasons discussed previously, the indications for synovectomy of the PIP joint are broader. Progressive PIP joint synovitis that stretches the extensor mechanism results in a boutonnière deformity that is difficult to reconstruct. The outcome of PIP joint arthroplasty is less reliable than MP joint arthroplasty, and PIP joint fusions are more disabling. For these reasons, preservation of PIP joint function is important. In addition, the PIP joint is more stable than the MP joint, and recurrent deformity after synovectomy is less common than after MP joint synovectomy. PIP joint synovectomy is associated with relatively little morbidity.[4,137]

Operative Technique

The joint is exposed through a slightly curved incision on the dorsal aspect of the finger (Figure 55.46). The extensor mechanism is uncovered while preserving the longitudinal dorsal veins. The joint is exposed through a longitudinal incision splitting the central slip or through an incision between the lateral band and the central tendon. The location of the capsulotomy is determined by the site of bulging synovium. Hypertrophic synovium is removed by sharp dissection or with a small rongeur. Gentle distal traction of the finger and flexion of the joint facilitate the synovectomy.

Occasionally, the synovium bulges laterally. In this case, incising the transverse retinacular ligament and reflecting the lateral band dorsally expose the synovium bulging through the

CRITICAL POINTS *Metacarpophalangeal Joint Arthroplasty*

Indications

- Painful or deformed MP joints from arthritis (rheumatoid, osteoarthritis, posttraumatic)

Pearls

- Correct the wrist deformity before MP arthroplasty.
- Reconstruct the radial collateral ligament with slight overcorrection of the deformity.
- Begin supervised hand therapy postoperatively.

Technical Points

- Use a longitudinal incision for a single implant and a transverse one for multiple implants.
- Preserve longitudinal veins and sensory nerve branches.
- Divide the ulnar sagittal band.
- Release the ulnar intrinsic if necessary.
- Reflect the extensor tendon radialward; preserve the joint capsule.
- Divide the collateral ligaments at the metacarpal neck; preserve insertion of the radial collateral ligament on the proximal phalanx.
- Resect the metacarpal head.
- Perform synovectomy.
- Release the volar plate if necessary.
- Prepare the medullary canals (proximal phalanx first except for the fourth metacarpal).
- Size the implant.
- Preplace suture in the radial collateral ligament.
- Insert the implant; it should not buckle or dislocate.
- Repair the radial collateral ligament and joint capsule.
- Centralize the extensor tendon.
- Check the flexor tendon.
- Close over a drain.

Postoperative Care

- Splint with MP joint in maximum extension and slight radial deviation; prevent ring finger and little finger MP hyperextension.
- Use a dynamic splint or cast with the IP joints free for 4 to 6 weeks.

accessory collateral ligament. A longitudinal incision volar to the collateral ligament allows the synovectomy to be performed without injuring the ligament and facilitates removal of synovium from the volar pouch.

The extensor mechanism is repaired with absorbable 4-0 suture. A conforming hand dressing is applied with the PIP joint positioned in extension. Postoperatively, early motion is begun to preserve PIP joint function. Active flexion and extension are started 1 to 2 days after surgery. The joint is splinted in extension, except during exercise periods, for 2 weeks.

FINGER DEFORMITIES

Two finger deformities commonly occur in rheumatoid arthritis: the so-called swan neck and boutonnière. The former is characterized by PIP joint hyperextension with DIP joint flexion, and the latter is the reverse deformity. Neither the swan neck nor the boutonnière deformity is unique to rheumatoid arthritis. Rather, they represent the end result of muscle and tendon imbalance caused by rheumatoid disease. Thus, we

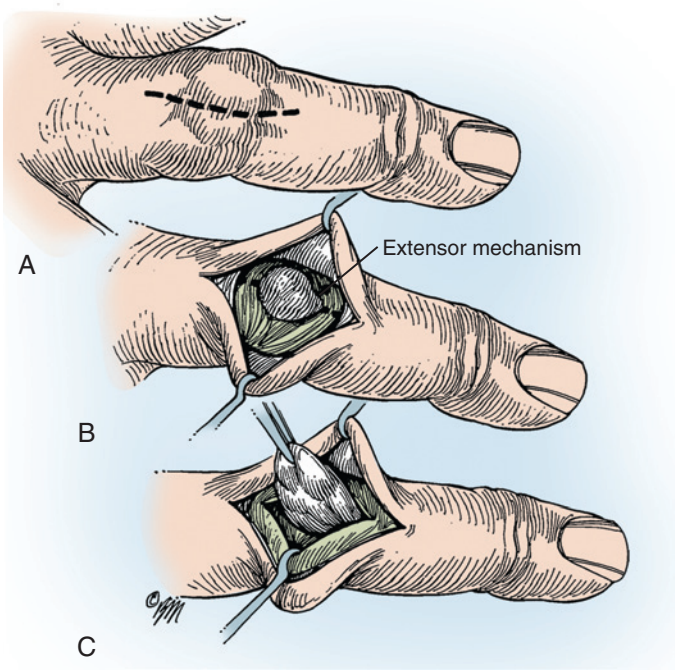

FIGURE 55.46 A-C, Technique for proximal interphalanageal joint synovectomy. Exposure of the extensor mechanism demonstrates proliferative synovium bulging between the lateral bands and central slip. A longitudinal incision through the stretched extensor mechanism exposes the synovium, which is excised sharply. (Copyright Elizabeth Martin.)

occasionally see patients who have both deformities in adjacent fingers of the same hand. Many factors cause the deformities and contribute to the degree of functional loss that they produce. The following subsections discuss the variety of operations recommended to correct these deformities and the diversity of opinion regarding treatment.

Swan Neck Deformity

Although all swan neck deformities have a superficial resemblance to one another, they vary considerably. Careful determination of the type of deformity present is essential for proper selection of treatment. The significant functional loss associated with this deformity is related directly to the loss of motion at the PIP joint, which ranges from no loss to partial loss to almost complete loss of flexion. Patients with almost complete loss of PIP joint flexion can be subdivided further into those with and those without preservation of joint space by radiographic examination. The deformities are classified into one of four types, depending on PIP joint mobility and the condition of the joint surfaces, as shown in Tables 55.3 through 55.5. This classification serves as the basis for treatment of fingers with swan neck deformities.[87,94,95]

Type I: PIP Joints Flexible in All Positions

Some rheumatoid patients with swan neck deformities demonstrate hyperextension of the PIP joint with DIP joint flexion yet maintain the ability to flex the PIP joint completely. The deformity can originate at either the DIP or the PIP joint. At the DIP joint it starts with stretching or rupture of the terminal extensor tendon attachment, which results in the so-called mallet deformity. Imbalance of the extensor mechanism secondary to DIP

TABLE 55.3 Classification System for Finger Swan Neck Deformities

Type	Characteristics
I	Full range of motion No intrinsic tightness No functional limitations
II	Intrinsic tightness Limited PIP motion and an extended MP joint with ulnar deviation corrected
III	Stiff PIP in all positions of the MP joint Radiograph good
IV	Severe arthritic changes

MP, Metacarpophalangeal; *PIP*, proximal interphalangeal.

TABLE 55.4 Treatment Options for Swan Neck Deformity of Fingers

Type	MP Joint	PIP Joint	DIP Joint
I		Splint Dermadesis FDS sling Littler ORL reconstruction	Fusion
II	Intrinsic release	As for type I	Fusion
III	As for type II MP joint reconstruction as needed	As for type II PIP joint manipulation Skin release Lateral band mobilization Check flexor tendons	Fusion
IV	As for type III	As for type III Arthroplasty Fusion	Fusion

FDS, Flexor digitorum sublimis; *MP*, metacarpophalangeal; *ORL*, oblique retinacular ligament. *PIP*, proximal interphalangeal.

joint flexion coupled with laxity of the volar plate of the PIP joint allows the PIP joint to assume a posture of hyperextension. In patients with early deformity, this progression can be observed. However, in patients with an established deformity, the sequence of events described can be inferred if the DIP joint deformity is more severe than the PIP joint hyperextension.

For other patients, the deformity may originate at the PIP joint as synovitis stretches out the volar capsule or if rupture of the superficial flexor tendon removes the force restraining PIP joint hyperextension. In these cases, DIP joint flexion is secondary. Swan neck deformity originating at the DIP or the PIP joint is classified as type I if full passive motion of the PIP joint is maintained. These patients have only a small functional loss related to the limitation of DIP joint extension and usually do not have associated MP joint disease.

Treatment of patients with type I swan neck deformity is directed at preventing or limiting the PIP joint hyperextension, restoring DIP joint extension, or both. Use of a Silver Ring splint can be helpful in correcting PIP hyperextension while allowing motion (Figure 55.47).[87] Several surgical procedures can be considered, including DIP joint fusion, dermadesis (i.e., volar to the PIP joint), flexor tenodesis of the PIP joint, and reconstruction of the retinacular ligament.

DIP Joint Fusion. Although correction of the flexion deformity of the DIP joint to restore balance to the finger can be obtained by reattaching the extensor mechanism to reestablish active control of the joint, the reconstructed tendon is subject to the same rheumatoid changes that led to the deformity in the first place. In addition, secondary arthritic changes within the joint may make attempts to restore motion unwise. An alternative treatment is to fuse the DIP joint.[19] We prefer this approach, particularly when the mallet deformity is primary.

We use a dorsal curved skin incision or a "Y" incision. The extensor mechanism is divided transversely. The joint is flexed, and the collateral ligaments are divided to improve exposure. The articular cartilage is removed, and the bone ends are shaped to provide good bone contact. Either a small headless screw or one or more Kirschner wires can be used for internal fixation. We prefer screw fixation unless the medullary canals are too small to accommodate it.

TABLE 55.5 Soft Tissue Procedures for Rheumatoid Swan Neck Deformity of Finger

Technique	Indications	Contraindications	Complications
Intrinsic release	Positive intrinsic tightness test		
Manipulation of the PIP joint	Stiff joint with acceptable articular surfaces	Excessive force required	Injury to the extensor mechanism Boutonnière deformity Loss of motion in the postoperative period
Skin release	Blanching of the skin with full PIP joint flexion		
Sublimis tenodesis Littler oblique retinacular ligament reconstruction	PIP hyperextension that interferes with flexion; may be combined with any of the others	Mild PIP deformity with severe mallet deformity (treat with DIP fusion)	Flexion contracture
Lateral band mobilization	Stiff joint with acceptable articular surfaces, not amenable to manipulation	Bone loss, instability, painful degeneration	Boutonnière deformity Loss of motion in the postoperative period
Flexor tendon exploration and tenolysis	Active motion limited		

DIP, Dorsal interphalangeal; *PIP*, proximal interphalangeal.

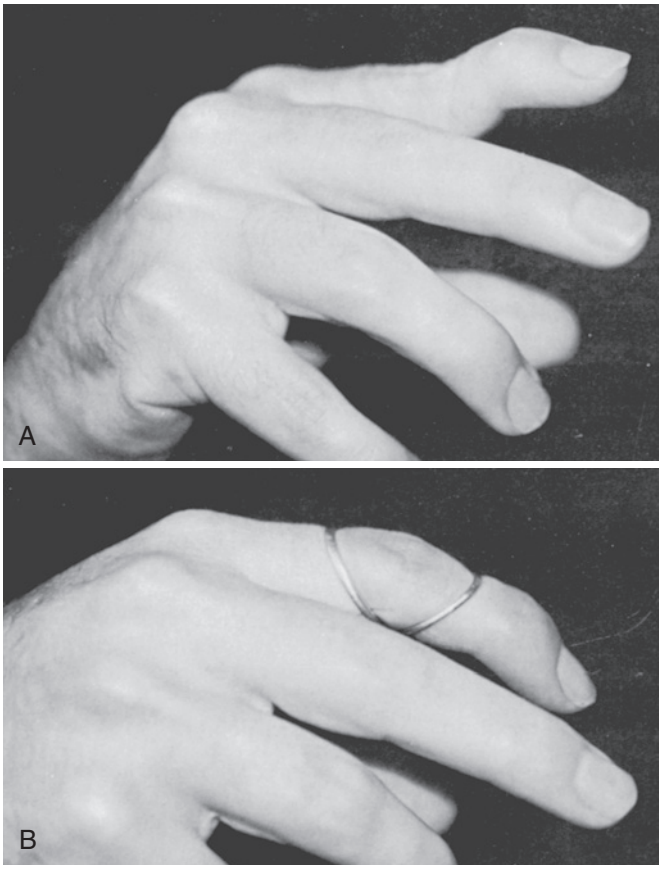

FIGURE 55.47 A mild, supple swan neck deformity **(A)** can be corrected with the Silver Ring splint **(B)**.

An Acutrak small joint fusion screw, Acutrak II microscrew, Herbert screw, Herbert-Whipple screw, or a similar headless screw system can be used for internal fixation of DIP joint fusions.[37] These provide rigid internal fixation and do not need to be removed after the fusion heals. Intramedullary placement ensures the preferred straight position of the joint. The relatively rigid fixation provided by the screw device precludes the need for prolonged postoperative splinting—2 to 3 weeks is sufficient.

The screw systems have several disadvantages, however. If a screw is inserted incorrectly, the threads can damage the germinal matrix of the nail and result in nail plate deformity. The distal phalanx must be large enough to accept the trailing threads of the screw. If using a Herbert-type screw, fixation can be lost if the leading screw threads extend beyond the isthmus of the middle phalanx and toggle in the soft bone of the metaphysis. For that reason, we prefer a continuously threaded design and have used these screws more and more frequently. The results are positive when attention is paid to the technical details of inserting the screws (Figure 55.48).

If a longitudinal Kirschner wire is used for internal fixation, we use the following technique. To be certain that the wire is introduced into the medullary canal of the middle phalanx, predrill a small hole in the middle phalanx into the canal. Then pass a slightly larger wire distally through the distal phalanx. This wire should emerge from the pulp just volar to the nail bed; it is then passed retrograde across the joint into the

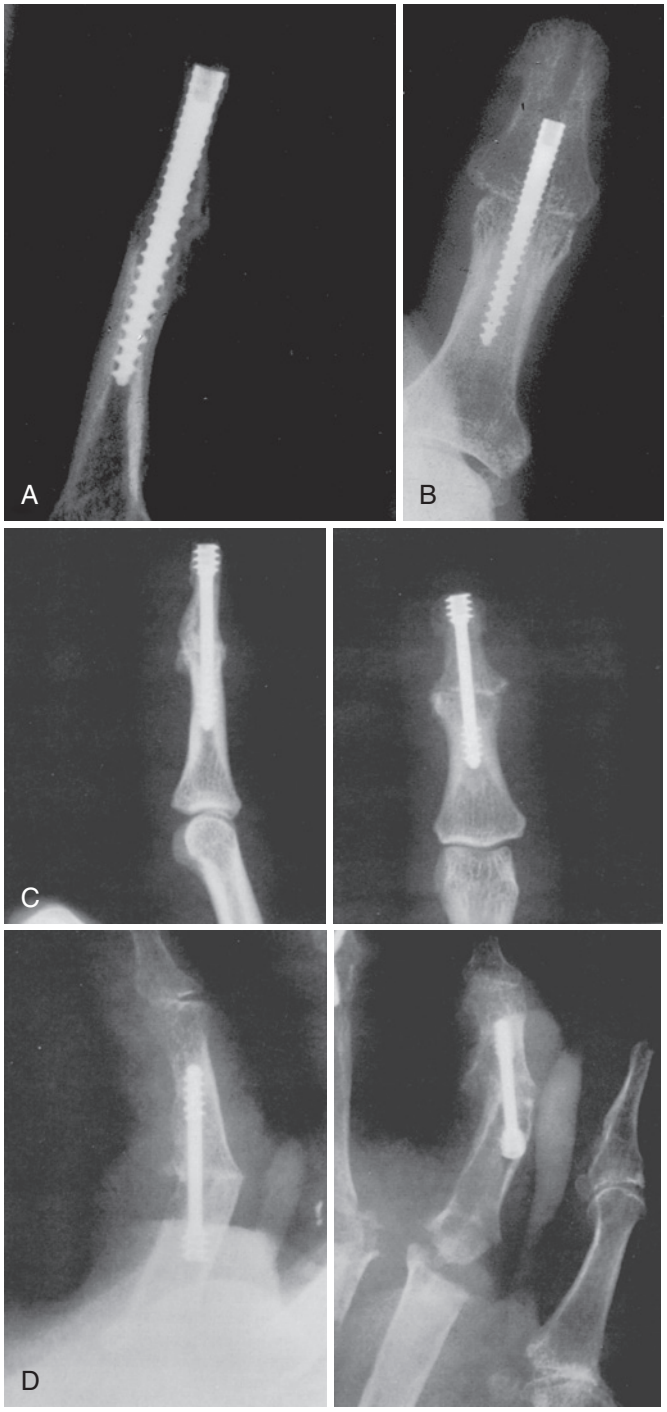

FIGURE 55.48 Self-compressing screws provide excellent internal fixation for the fusion of small joints in rheumatoid patients. The Acutrak small joint fusion system has been used to fuse the dorsal interphalangeal (DIP) joint of a finger **(A)** and the interphalangeal (IP) joint of a thumb **(B)**. **C, D,** Herbert screws can be used for both DIP and proximal interphalangeal (PIP) joints in the fingers and for the thumb IP joint. The leading threads of a screw used to stabilize the DIP joint fusion should extend only into the isthmus of the middle phalanx to avoid loss of fixation from toggling of the screw in the softer bone of the metaphysis. Metacarpophalangeal joint arthroplasties do not preclude the use of Herbert screws for PIP joint fusion in a rheumatoid patient.

predrilled hole in the middle phalanx. Care should be taken to not drill the Kirschner wire too far proximally to avoid damage to the PIP joint. The minimum pin size that should be used is 0.045 inch.

The DIP joint is fixed in neutral position (full extension), which is the preferred position for correction of the swan neck deformity. The Kirschner wire can be either cut off just below the skin or left exposed. If the wire is left exposed, removal after fusion is easy and the risk for pin tract infection is minimized. However, the finger cannot be immersed in water and the protruding pin must be covered to prevent injury to the patient and others. Burying the pin under the skin allows washing of the hand but increases the risk for skin irritation, skin breakdown, and subsequent infection.

Generally, we use only one longitudinal Kirschner wire for DIP joint fusion. However, if necessary, an obliquely placed wire is added to control rotation. To facilitate fusion, it is common to add bone grafts to the fusion site. These grafts are essential for patients with extensive erosive changes and significant loss of bone substance.[59] The metacarpal heads removed for implant arthroplasty provide a good source of local bone graft material. External support with a small aluminum splint is advisable for the first 4 to 6 weeks after fusion.

If the pin has been buried, it can be removed in the office after the fusion has healed entirely. Local anesthetic can be injected directly into the skin and subcutaneous tissue overlying the pin or a digital block can be given. A stab wound is made over it, and the pin is extracted with a needle holder. Occasionally, the pin may migrate proximally so that it is completely or almost completely buried in bone. This requires more extensive dissection to locate and remove the pin and should therefore be done in the operating room under optimal conditions that allow removal of some bone from the distal phalanx to expose the end of the pin.

Operative Technique for DIP Joint Fusion With a Screw. Before beginning this procedure, the lateral radiograph of the finger should be checked to be sure that the width of the medullary canal of the distal phalanx is sufficient to accept a screw. The DIP joint is exposed and its surfaces are prepared as described previously. The medullary canal of the middle phalanx is located with a Kirschner wire. The canal is prepared with either a larger Kirschner wire or the appropriate drill/reamer, depending on the type of screw system selected. A Kirschner wire is inserted through the base of the distal phalanx into the medullary canal. The wire is driven distally and exits on the tip of the finger just below the hyponychium. A transverse stab wound is made where the Kirschner wire exits. The wire is withdrawn, and the appropriate drill/tap is inserted through the stab wound into the tuft of the distal phalanx, and advanced proximally until it emerges at the base of the phalanx.

Next, the appropriate length of screw is inserted and advanced until it emerges at the base of the distal phalanx. The screw tip is aligned with the hole in the middle phalanx under direct vision and then advanced with the fusion surfaces held tightly together. The trailing threads of the screw are recessed into the tuft. If a Herbert-type screw is used and is too long, there may be a sudden loss of fixation as the leading thread passes through the isthmus into the softer and wider portion of the phalanx. Rotatory stability can be augmented by inserting a 0.028- or 0.035-inch Kirschner wire parallel to the screw. Intraoperative radiographs are obtained to confirm proper placement and screw length.

Dermadesis. Dermadesis is an operative approach that is rarely used for patients with type I swan neck deformities.[95] This procedure attempts to prevent PIP joint hyperextension by creating a skin shortage volarly. An elliptic wedge of skin (4–5 mm at its widest point) is removed from the volar aspect of the PIP joint. Care is taken to preserve the venous network just under the skin and to not open or disturb the underlying flexor tendon sheath. The skin is closed with the PIP joint in flexion. This technique is helpful only in mild cases and usually fails unless it is done in conjunction with other procedures (e.g., DIP joint fusion). When the PIP joint hyperextension is primary, we prefer to use a stronger checkrein against hyperextension. Our procedure of choice is flexor tendon tenodesis using one slip of the FDS.

Flexor Tendon Tenodesis ("Sublimis Sling"). Patients with PIP joint hyperextension maintain full passive motion but, as the hyperextension increases, begin to have difficulty initiating active flexion. These patients require restoration of strong volar support to the joint. We prefer the use of FDS tenodesis to prevent PIP joint hyperextension.[20]

A volar zigzag incision is made over the PIP joint to expose the flexor tendon sheath. The thin portions of the sheath on either side of the A3 pulley are excised while preserving the pulley. The flexor tendons are exposed, and care is taken to avoid injury to the vincula passing between the FDS and FDP tendons. One slip of the FDS is divided approximately 1.5 cm proximal to the joint. This portion is separated from its corresponding slip but is left attached distally. With the joint in 20 to 30 degrees of flexion, the detached slip is fixed proximally to act as a checkrein against extension. The proximal attachment can be made directly into the bone by using a bone anchor or pull-out wire, or it can be made at the thickened margin of the flexor tendon sheath (distal edge of the A2 pulley) with sutures (Figure 55.49).

We have found that the easiest technique is to use a small bone anchor with a 2-0 or 3-0 suture to attach the tendon

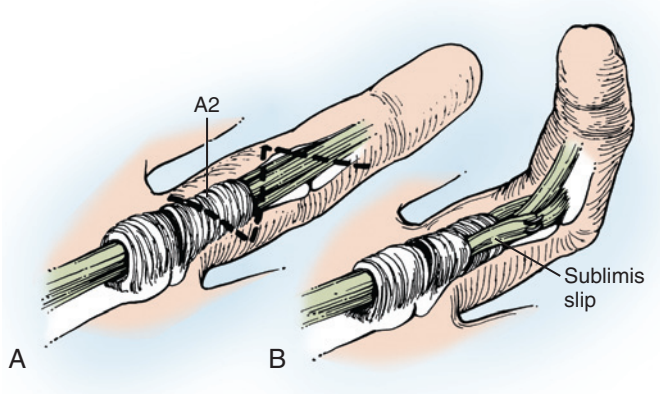

FIGURE 55.49 One technique for superficialis tenodesis to correct swan neck deformity. **A,** Zigzag incision used to expose the flexor tendon sheath. The incision should be extended far enough proximally to expose the A2 pulley. Tenosynovectomy is performed if necessary. **B,** A slip of flexor digitorum superficialis (sublimis) is sectioned proximally, passed through a slit in the A2 pulley, and sutured back on itself. (Copyright Elizabeth Martin.)

directly to the bone. To attach the tendon slip to the sheath, a transverse slit is made in the distal portion of the A2 pulley; the detached tendon slip is then passed through the pulley and sutured back onto itself. With both methods, the goal is to create a slight flexion contracture of the PIP joint. For greater purchase, the tendon slip can be attached through or adjacent to the A1 pulley in the distal part of the palm. Postoperatively, the joint is splinted in flexion at 30 degrees. We start flexion at 3 weeks to maintain PIP joint function but block hyperextension for at least 6 weeks.

A modified technique divides the FDS tendon more proximally with a distal palm incision. The FDS slip is then passed around the A1 pulley to prevent PIP joint hyperextension. This is simpler and faster and avoids an incision in the digit.

Retinacular Ligament Reconstruction. Littler devised a clever technique to prevent hyperextension while restoring DIP joint extension by reconstructing an oblique retinacular ligament with the ulnar lateral band.[126] In this procedure, the ulnar lateral band is freed from the extensor mechanism proximally but left attached distally. It is passed volar to Cleland's fibers to bring it volar to the axis of PIP joint motion. We pass the tendon slip to the opposite side of the finger and suture it to the fibrous tendon sheath under enough tension to restore DIP joint extension and prevent PIP hyperextension. In theory, this approach should solve both the DIP and PIP joint problems simultaneously. However, in a rheumatoid patient who has a primary mallet deformity with destruction of the terminal tendon, no amount of tension applied to the relocated lateral band can restore DIP joint extension. Thus, the net result of this procedure is restriction of PIP joint hyperextension. For patients with rheumatoid arthritis, it is an alternative to dermadesis or flexor tenodesis.

Type II: Limited PIP Joint Flexion in Certain Positions

Some rheumatoid patients with swan neck deformities have restriction of finger flexion only in certain positions. The deformity may appear similar to the type I deformity; however, on examination, PIP joint flexion is influenced by the position of the MP joint. With the MP joint extended and neutral in the anteroposterior plane, passive PIP joint flexion is limited. If the MP joint is allowed to flex or turn ulnarward, PIP joint flexion is increased. In such cases the swan neck deformity is secondary to MP joint involvement.

As the MP joints deviate and subluxate and the intrinsics become tight, a secondary swan neck deformity develops as the result of muscular imbalance. Initially, it is supple in most positions and becomes stiff only when the MP joint is in extension and the intrinsics are tightened further. Ultimately, however, the PIP joint becomes stiff regardless of the position of the MP joint. In these patients it is not sufficient to restrict PIP joint hyperextension. The intrinsic tightness must be relieved. Any MP joint disorder that initiates or aggravates the finger's muscular imbalance (i.e., subluxation or deviation) must also be corrected. This is accomplished by intrinsic release in patients with minimally involved MP joints and by combined MP joint arthroplasty and intrinsic release in the others.

Intrinsic Release. Intrinsic muscle release is performed through a dorsal ulnar longitudinal incision over the proximal phalanx, as described earlier. After release, PIP joint flexion with the MP joint extended or radially deviated should be improved. Intrinsic release can be combined with DIP or PIP joint procedures (or both) to restore balance.

In patients with an associated MP joint disease, MP joint alignment is corrected by implant arthroplasty. Although MP joint arthroplasty (Swanson) with resection of the metacarpal heads does lengthen the intrinsic tendon, we prefer to resect the ulnar intrinsic tendon as well to reduce the risk for recurrent intrinsic tightness and ulnar drift of the fingers.

Type III: Limited PIP Joint Flexion in All Positions

For patients with the type I and II deformities described earlier, there is only slight-to-moderate functional loss despite the finger deformity. However, patients with marked reduction of PIP joint motion in any position (type III) have significant loss of hand function because the ability to grasp objects is greatly reduced. Although it might seem logical to assume that patients with stiff swan neck deformities have advanced intraarticular changes that require either fusion to bring the finger into a functional position or arthroplasty to restore active motion, radiographic examination often reveals well-preserved joint spaces. In these cases, the structures that restrict passive motion include the extensor mechanism, the collateral ligaments, and the skin. The first step in surgical reconstruction of a stiff swan neck deformity is restoration of passive PIP joint motion. The procedures that we use to restore passive motion include joint manipulation, skin release, and lateral band mobilization. Correction of the deformity is delayed until passive motion is restored.

PIP Joint Manipulation. In patients with stiff swan neck deformities, the soft tissues have contracted about the joint. However, with the patient under anesthesia, it is sometimes possible to obtain 80 to 90 degrees of PIP joint flexion by gentle manipulation. PIP joint manipulation is rarely performed alone; it is usually done in conjunction with intrinsic release, MP arthroplasty, or flexor tenosynovectomy. If the joint is splinted in the flexed position, the tight soft tissues will stretch. After several weeks, the passive motion obtained by manipulation and splinting can be maintained as active motion, provided that the flexor tendons have not become adherent.

When done in conjunction with MP arthroplasty, temporary Kirschner wire fixation is used to hold the PIP joint in flexion. This concentrates the postoperative exercises on MP joint motion. After 10 days, the pins are removed and therapy is directed toward increasing PIP joint motion by using an extension block splint to prevent full extension of the joints. As stated previously, this method has restored 80 to 90 degrees of PIP joint flexion in joints that had been stiff.

When PIP joint manipulation is performed in conjunction with flexor tenosynovectomy, the joints are not pinned but are splinted in the flexed position postoperatively. Usually, after 24 to 48 h of splinting, therapy can be initiated with extension block splints. Therapy includes active PIP range-of-motion exercises with careful splinting in flexion between exercise periods. Initially, exercises are done for 5 minutes, 4 to 6 times daily, and increased as pain and endurance allow. Splinting is continued for 2 to 4 weeks, depending on the range of motion obtained. If an extensor lag of the PIP joint develops, extension splinting may be necessary.

Skin Release. The dorsal skin may limit the amount of passive flexion that can be achieved by manipulation. At some point

during the manipulation of long-standing fixed deformities into flexion, the dorsal skin blanches. If it is not relieved, skin necrosis occurs directly over the joint.

Dorsal skin tension can be minimized with an oblique incision just distal to the PIP joint, which allows skin edges to spread. The defect created is the result of skin contracture (not loss) and closes gradually in 2 to 3 weeks. Although initially we used skin grafts to cover these defects, satisfactory healing by secondary intention has convinced us that grafts are not needed. In fact, leaving this portion of the wound open allows drainage and reduces postoperative swelling and pain. It is important that the skin be released distal to the joint so that the extensor mechanism overlying the joint is covered (Figure 55.50).

Certain precautions must be observed when joint manipulation is performed. Minimal force should be used to bring the PIP joint into flexion; the soft tissues should stretch, not rupture. Fracture of osteopenic bone must be avoided. Therefore, if manipulation is difficult, we proceed to soft tissue release. The procedure used most often is lateral band mobilization.

Lateral Band Mobilization. With established swan neck deformities, the lateral bands are displaced dorsally. Their normal volar shift is lost, and the finger has limited flexion. We have found that freeing the lateral bands from the central slip with two parallel longitudinal incisions in the extensor mechanism allows the joint to be manipulated gently into full flexion without releasing the collateral ligaments or lengthening the central slip (Figure 55.51). Full passive flexion can often be achieved using this method. When the procedure is performed under local anesthesia, shifting of the lateral bands volarward on flexion, and relocation of them dorsally on extension, can be observed during active motion.

When this procedure was first used for stiff swan neck deformities in 1962, the greatest problem was loss of flexion after skin closure. Once the skin was sutured, the passive and active motion achieved by lateral band mobilization was lost. If the skin was allowed to heal before active motion was started, the amount of flexion obtained in the operating room was seldom maintained. We now use a curved dorsal incision with a short

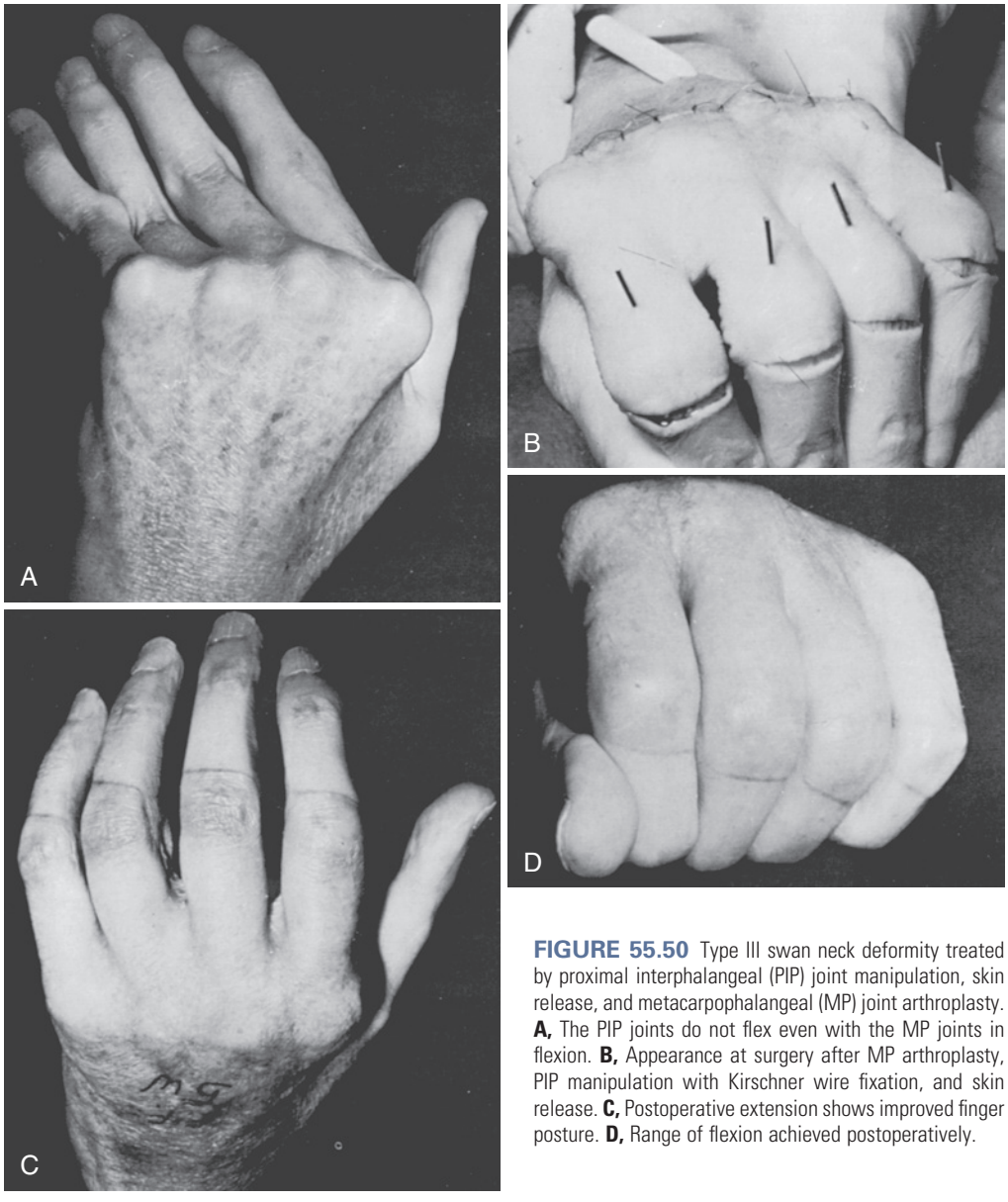

FIGURE 55.50 Type III swan neck deformity treated by proximal interphalangeal (PIP) joint manipulation, skin release, and metacarpophalangeal (MP) joint arthroplasty. **A,** The PIP joints do not flex even with the MP joints in flexion. **B,** Appearance at surgery after MP arthroplasty, PIP manipulation with Kirschner wire fixation, and skin release. **C,** Postoperative extension shows improved finger posture. **D,** Range of flexion achieved postoperatively.

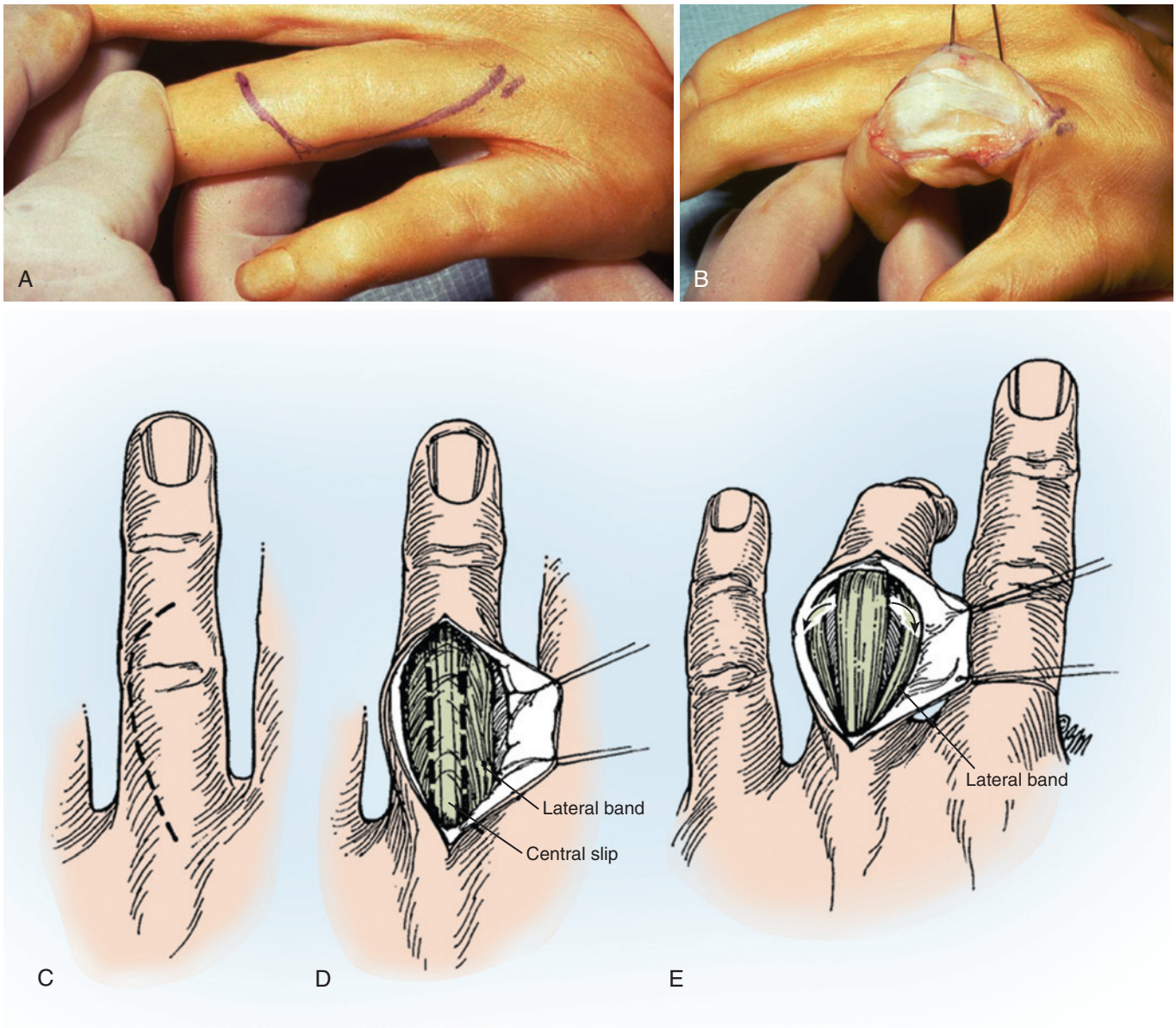

FIGURE 55.51 Type III swan neck deformity treated by lateral band mobilization. **A,** Incision used to expose the extensor mechanism over the proximal interphalangeal (PIP) joint. **B,** Parallel incisions separate the lateral bands from the central slip. Note the flexion obtained after manipulation of the PIP joint and volar shift of the lateral bands. **C-E,** Drawings of the technique for lateral band mobilization. (**C-E,** Copyright Elizabeth Martin.)

oblique limb across the middle segment. The proximal portion of the incision is closed with the finger held in flexion. The distal third of the incision is generally left open. The finger is splinted in flexion for 3 to 5 days to stretch the contracted collateral ligaments. Occasionally, however, it is necessary to release these ligaments, as well as lengthen the central slip with a step-cut. A dorsal extension block splint is used to prevent full extension of the PIP joints.[42,87]

Flexor Tenosynovitis and PIP Joint Stiffness

The flexor tendons must also be considered and assessed if optimal results are to be obtained from the procedures described earlier. Flexor tenosynovitis and secondary flexor tendon adherence are integral etiologic factors of stiff PIP joints and must be understood to provide adequate treatment. Flexor tenosynovitis or adhesions that limit active PIP joint flexion can result in stiff PIP joints. Conversely, stiff PIP joints can result in adherence of the flexor tendons. In either case, flexor tenosynovectomy or tenolysis must be a consideration in any treatment aimed at restoration of PIP joint motion.

Adhesions or rupture of the flexors obviate any passive motion gained by procedures directed at the extensor mechanism or the soft tissues surrounding the joint. However, preoperative assessment of flexor tendon function is limited if stiff joints are present. For this reason, we now determine the status of the flexor tendons in the operating room. If intravenous regional or local anesthesia has been used for either manipulation or lateral band mobilization, the tourniquet is released and the patient is asked to flex the fingers after muscle control has returned.

If active motion is not nearly equal to passive motion, anesthesia is reinstituted and the flexor tendons are explored. Tendon adhesions are released, and rheumatoid nodules within the tendon are removed. If regional block anesthesia has been used, the flexor tendons are exposed in the palm and traction is applied to test excursion. Occasionally, extensive flexor tenosynovectomy is required to improve flexor tendon excursion. Postoperatively, supervised splinting and active exercises are important in maintaining the motion ability gained at the time of surgery (see later).

Type IV: Stiff PIP Joints With Poor Radiographic Appearance

Patients with stiff PIP joints and radiographic evidence of advanced intraarticular changes require some type of salvage procedure, either fusion or arthroplasty. Factors that must be considered in deciding between procedures to use include the fingers involved, the status of adjacent joints, the status of supporting ligamentous structures, and the status of the flexor tendons. We tend to prefer fusion in the index finger, where lateral stability is particularly important. The status of adjacent joints is also essential. If the MP joints require arthroplasty, we favor fusion at the PIP joint level; however, experience shows that arthroplasty can be performed at both levels with good results. Although Adamson and colleagues reported less than optimal results with PIP arthroplasty in patients with inflammatory arthritis, their study combined the results of treating both boutonnière and swan neck deformities.[1] We believe that arthroplasty plays a limited role in the treatment of flexion boutonnière deformities because the extensor tendon is often compromised. With swan neck deformities, PIP arthroplasty works well as long as hyperextension is corrected; sublimis tenodesis can be performed at the same time if necessary. Inadequate lateral ligamentous support or associated flexor tendon ruptures, or both, are also relative indications for fusion.

PIP Joint Fusion for Swan Neck Deformity. After making a longitudinal skin incision, the extensor mechanism is split at the midline and the collateral ligaments are detached from the proximal phalanx. The joint is flexed to expose the articular surfaces, which are prepared for fusion by removing the articular cartilage and softening the subchondral bone with cup and cone reamers. Internal fixation can be achieved with crossed Kirschner wires, a tension band wire, or headless screws if the bone stock is adequate and the medullary canal is wide enough (see Figure 55.48).[63] A precise technique is needed to attain the desired angle of fusion if a screw is used. The position of fusion selected depends on the finger involved and the gender of the patient.

In general, the index finger PIP joint is fused in less flexion than the middle finger. The degree of flexion is greater in the ring and little fingers to facilitate grip. The amount of flexion chosen ranges from 25 to 45 degrees. When appearance is more important than strong grasp, less flexion than the so-called functional position is used. The patient's requirements must be discussed and determined preoperatively. It is helpful to have a small sterile goniometer on the instrument table because it is sometimes difficult to visually judge the angle of flexion of the PIP joint accurately. Usually, the joint is flexed more than anticipated. Measurement of the angle of flexion after the first pin is inserted allows easy correction before inserting the final pins.

PIP Joint Arthroplasty. Proximal interphalangeal silicone arthroplasty was originally used in 1966 in conjunction with silicone implants for the MP joints in rheumatoid arthritis.[118] Over the years the indicators have changed, and we now find the procedure most useful with degenerative arthritis and certain cases of traumatic arthritis.

Swanson's single-piece polymeric silicone spacer has been the arthroplasty implant of choice for several decades. The flexible silicone spacer was designed to facilitate the development of a fibrous capsule that would provide a pain-free and functional PIP joint.[65,121] The dorsal hinge design, as well as intramedullary stem pistoning, was thought to increase "in-plane" functional motion; however, only modest improvements in flexion arcs have been reported.[118] Other silicone implants include those made by DePuy and SBI (Figure 55.52). Although the material properties are essentially the same, the design features are slightly different. Both SBI and DePuy PIP implants have a more volar hinge, which may allow improved flexion arcs without volar impingement.

Even though silicone implant arthroplasty has been used clinically with success, complications occur and include hinge failure, angular deformities, bone erosion, and particulate synovitis.[118] Failure to replicate normal PIP motion may be a primary contributing factor to hinge joint implant failures. Recently, surface replacement arthroplasty of the PIP joint has been developed to improve joint biomechanics. These implants are designed to mimic the physiologic articulation of the PIP joints to restore normal motion based on a virtual axis rather than a fixed axis.[65,83] Minimal bone resection, preservation of the collateral ligaments, and implant design also may have a theoretic

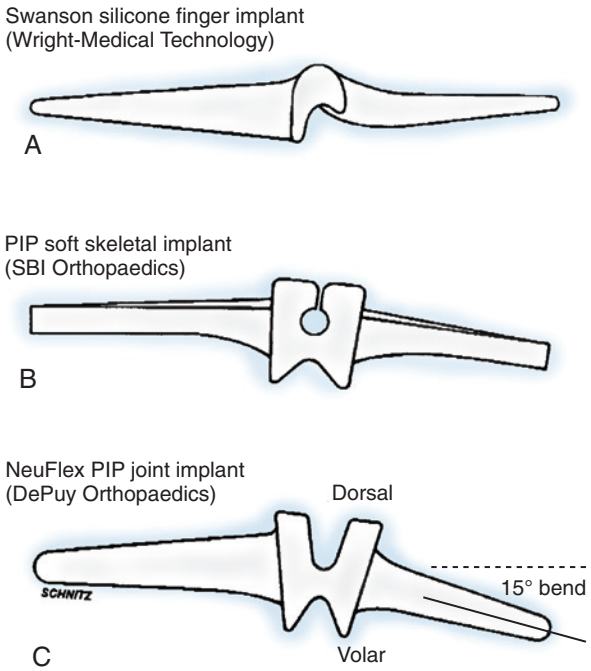

FIGURE 55.52 Silicone proximal interphalangeal (PIP) implants. **A,** Swanson silicone finger implants (Wright Medical Technology, Arlington, TN). **B,** PIP soft skeletal implant (Small Bone Innovations). **C,** NeuFlex PIP joint implant (DePuy Orthopaedics, Warsaw, IN). (From Kobayashi K, Terrono AL: Proximal interphalangeal joint arthroplasty of the hand. *J Hand Surg Am* 3:219–226, 2003, © 2003 by the American Society for Surgery of the Hand. Used with permission.)

advantage in improving "out-of-plane" stability when considering PIP joint arthroplasties on the hand's radial side; this is particularly so with the index finger, which must be able to resist the forces generated during pinch. Current surface replacement arthroplasty designs include an SBI metal-polyethylene prosthesis and a pyrolytic carbon prosthesis made by Ascension Orthopedics in Austin, TX (Figure 55.53).[14] However, the use of these implants for rheumatoid patients has been limited and outcomes have been variable.[14,27,55,134]

Indications. Arthroplasty of the PIP joint is primarily used for patients who have persistent pain that has been refractory to several months of intensive nonoperative therapy, including NSAIDs, occasional cortisone injections, temporary splinting, and carefully prescribed hand therapy focusing on modification of activity (no range of motion). If PIP motion is greater than 70 degrees or if the patient can touch the finger to the palm, we recommend PIP arthroplasty cautiously unless pain is an overriding factor.

The best candidate for PIP joint arthroplasty is a patient who has a painful PIP joint from degenerative or posttraumatic arthritis in one of the ulnar three digits and nearly full extension and limited (20–40 degrees) flexion. When there is good bone stock, minimal deformity, and a preserved extensor and flexor mechanism, the prognosis for eliminating pain and improving motion is good.

PIP arthroplasty is not usually recommended in painless conditions, especially if MP and DIP joint motion is good. However, occasionally patients with a single long, ring, or little finger that is stiff in an extended position are candidates for the procedure, even though the amount of flexion attained may be less than optimal. Silicone-rubber implants generally do not stand up to the repeated stress of pinch and are therefore not recommended for the index finger.

PIP joint arthroplasty is often unsuccessful in patients with severe rheumatoid involvement, particularly those with advanced boutonnière deformities. The results with swan neck deformities are much better. Combining PIP joint arthroplasty with MP joint arthroplasty, either as a combined procedure or in two stages, is not usually successful. We recommend PIP joint fusions combined with MP joint arthroplasty for combined involvement. However, in the unusual case of an isolated painful digit with little deformity, preserved bone stock, and functional extensor and flexor mechanisms, PIP arthroplasty may be appropriate.

Contraindications. The worst results after PIP joint arthroplasty have been in patients who have had PIP joint infections or previous failed attempts at tenolysis. The surgery generally fails because of recurrent scar formation. Massive bone loss, severe deformity, and repeated surgery, including initial extensive open reductions, are relative contraindications to the procedure, and arthrodesis should be considered in these cases.

We are cautious in recommending PIP arthroplasty for digits with significant fixed-flexion contractions in the range of 50 degrees or greater. In these cases, one must remove excessive bone to insert the implant, and extensive reconstruction of the extensor mechanism with prolonged postoperative splinting is required. The results after these procedures are not usually good. When surgery is indicated in such situations, it may be preferable to consider arthrodesis in a more functional position.

In general, we recommend PIP arthrodesis for the index finger because flexion is not as crucial, strong pinch is necessary, and lateral deviation occurs after PIP arthroplasty (Figure 55.54).[118] Volar plate arthroplasty may be a reasonable option for the radial digits given the lateral stability that can be obtained with this procedure. However, we would not absolutely exclude implant arthroplasty in the index finger PIP joint in certain cases.

Surgical Approaches. PIP arthroplasty can be done through either a dorsal or a volar approach. The original dorsal approach has some specific indications and advantages. It is useful if there is a significant flexion contracture that must be corrected or if reconstruction or tenolysis of the extensor mechanism is needed. With this approach, the extensor mechanism must be handled carefully, reattached, and then protected during the rehabilitation phase.

The volar approach spares the extensor mechanism, and for that reason it is now the preferred approach for patients with degenerative arthritis. It is simple and provides excellent exposure without interfering with the extensor mechanism. Swan



FIGURE 55.53 Surface replacement implants. **A,** SR PIP Implant System (Small Bone Innovations). **B,** Ascension PIP PyroCarbon Total Joint (Ascension Orthopedics, Austin, TX).

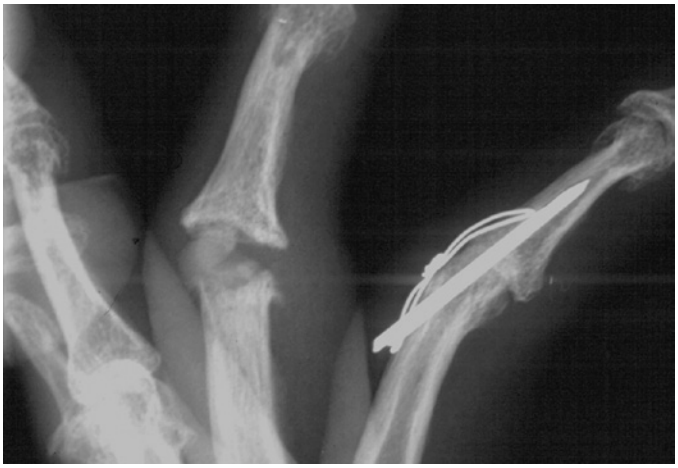

FIGURE 55.54 Status after arthrodesis of the index finger and arthroplasty of the middle finger proximal interphalangeal joint.

neck deformities can be corrected by repairing or reconstructing the volar plate. If flexor tendon adhesions are an additional issue, a volar approach allows easy access for tenolysis (Figure 55.55). However, this approach puts the digital nerves and vessels at risk and requires strict attention to orientation of the joint to ensure that the bone cuts are made appropriately and that the implant is inserted correctly.

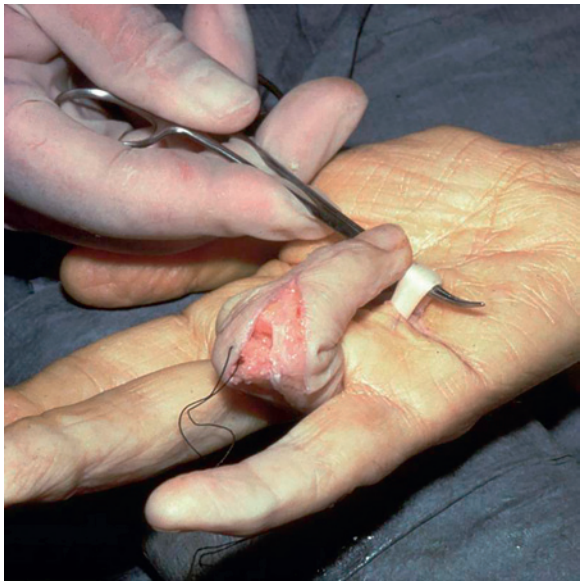

FIGURE 55.55 Flexor tendons can be assessed for adhesions by making a small incision at the proximal border of the A1 pulley. (From Kobayashi K, Terrono AL: Proximal interphalangeal joint arthroplasty of the hand. *J Hand Surg Am* 3:219–226, 2003, © 2003 by the American Society for Surgery of the Hand. Used with permission.)

Dorsal approach. A slightly curved dorsal incision is made to expose the extensor apparatus of the PIP joint. A midline incision is made through the extensor mechanism while protecting the insertion of the central slip. If adjustments in length are necessary to address boutonnière deformities, a distally based flap can be created. Alternatively, an incision can be made between the central slip and one of the lateral bands. The collateral ligaments can be released to allow adequate exposure of joint surfaces (Figure 55.56), which are prepared for arthroplasty with careful attention to preserving collateral ligament integrity. The head of the proximal phalanx is resected.

Preparation of the middle phalanx can be the most difficult part of the procedure depending on the amount of deformity at the base. When there are erosions with large lateral ridges on the sides of the middle phalanx, the ridges must be removed to prepare a flat surface to seat the implant. To do so, the assistant lifts the base and supports the phalanx while the surgeon carefully detaches the collateral ligament from the ridges, while being careful to not completely detach the entire ligament from the middle phalanx. A rongeur is used to remove the ridge. The medullary canals of the proximal and middle phalanges are opened with an awl and reamed to fit the selected size of implant by using the broaches supplied with each of the implant instrument sets. Occasionally, a high-speed bur with a blunt leading tip is used to shape the canal.

Trial components are inserted to assess motion and stability. It is sometimes necessary to repair the collateral ligaments to bone if laxity is present. The implant is inserted with the joint

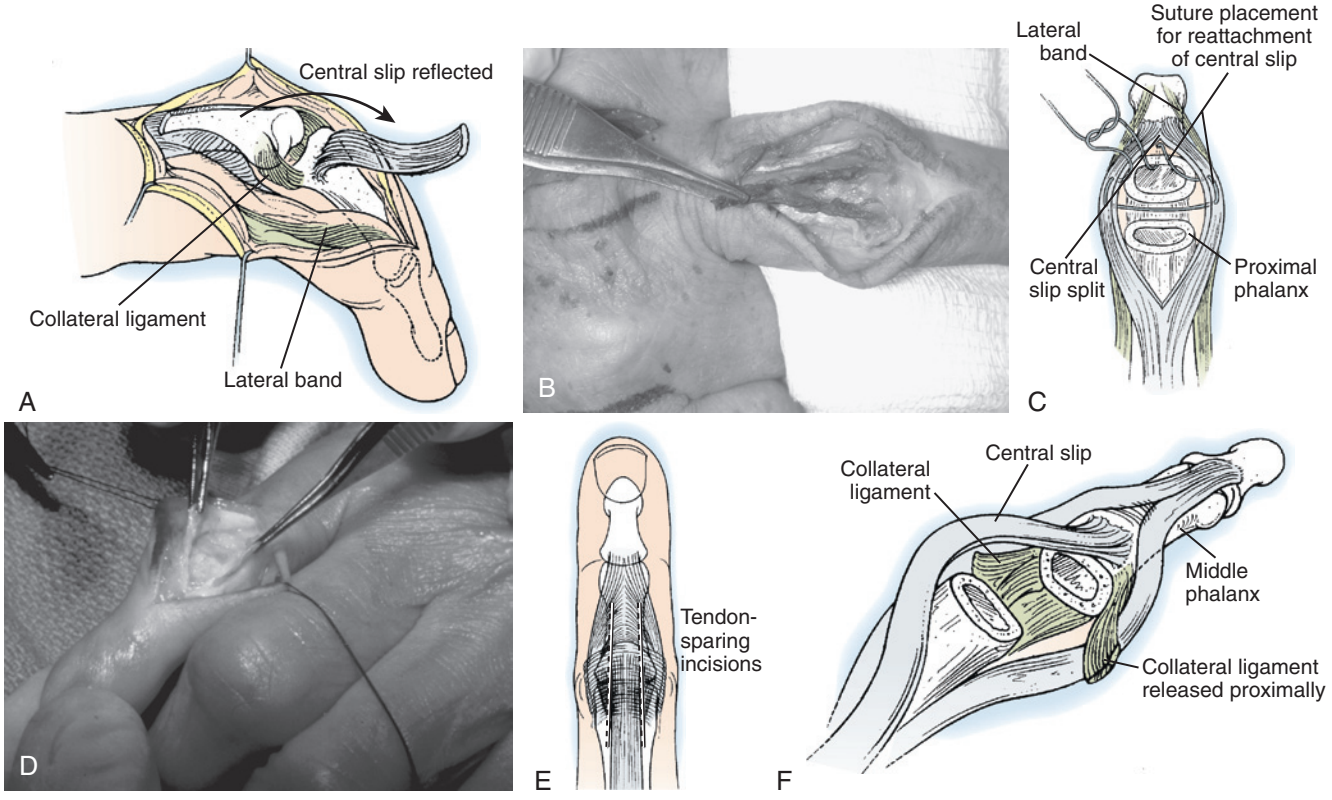

FIGURE 55.56 Dorsal approach to proximal interphalangeal arthroplasty. **A, B,** Distally based extensor flap technique. **C, D,** Central slip-splitting technique. **E, F,** Central tendon-sparing technique. (From Kobayashi K, Terrono AL: Proximal interphalangeal joint arthroplasty of the hand. *J Hand Surg Am* 3:219–226, 2003, © 2003 by the American Society for Surgery of the Hand. Used with permission.)

hyperflexed; it should be stable in the extended position. If the implant dislocates, buckles, or cannot be inserted, the space for it is usually too small and more bone must be resected. The extensor mechanism is repaired with either interrupted mattress sutures or a running suture. A monofilament absorbable suture is preferable for this but nonabsorbable sutures can be used.

The flexor tendon must be assessed if full active flexion was not present preoperatively. A trigger-finger incision can be used, and traction can be placed on the tendons to ensure full flexion. Alternatively, if local or intravenous regional anesthesia has been used, the tourniquet can be deflated and active flexion checked.

Volar approach. A generous volar zigzag incision centered over the PIP joint is made. The neurovascular structures are mobilized and protected. A 2- to 3-cm flap of volar pulley that includes the A3 pulley and a small portion of A2 and A4 is raised. This exposes the volar plate, which is detached from its membranous proximal origin and the accessory collateral ligaments; however, it is left widely attached to the base of the middle phalanx for later reconstruction. Penrose drains can be placed to retract each flexor tendon on either side of the joint. The joint is then carefully dislocated by hyperextension ("shotgun"), and the joint surfaces are prepared as described for the dorsal approach (Figure 55.57). Care must be taken to protect the attachment of the central slip, as well as to orient the bone cuts and insert the implant properly.

Closure is done by reattaching the volar plate to soft tissue or bone if necessary. If reattaching to bone, two drill holes are made in the base of the proximal phalanx. The suture should be placed before insertion of the implant. The flexor sheath can be used to reinforce the volar plate by placing it deep into the tendons, but it is generally placed in its anatomic position or excised. The tourniquet is deflated, and meticulous hemostasis is obtained because a postoperative hematoma or excessive swelling can jeopardize an early exercise program. A bulky dressing is applied with a volar splint holding the digits in extension.

Rehabilitation. If the condition of the extensor tendon is satisfactory, motion is started on the day of or day after the procedure regardless of the approach used. This can be modified if the extensor mechanism has been reconstructed. The dressing is changed 1 to 3 days after surgery. Rehabilitation protocols for dorsal approaches focus on maintaining the integrity of the extensor apparatus and prevention of adhesions. Early protected active PIP flexion and independent DIP flexion minimizes adhesions of the extensor apparatus.

Usually, the PIP joint is maintained in a neutral position (full extension) in between exercise periods and at night. A light dynamic extension splint can be used after the sutures are removed. If a significant extension deformity was present preoperatively, the patient is instructed to tape the finger in maximum flexion during the day and release the tape hourly for extension exercises. If the volar approach was used, active flexion and extension can be started immediately, usually with an extension block splint to maintain the PIP joint in 15 to 20 degrees of flexion for the first 2 weeks to protect the volar plate and prevent a hyperextension deformity.

Supervised hand therapy is generally prescribed, and the protocol is customized for each patient based on the preoperative deformity, the condition of the soft tissues, and the type of approach used. This therapy is continued for 4 to 6 weeks. Night or resting splints (or both) are used for protection after dynamic splinting is discontinued.

Outcomes. A large series of Swanson silicone PIP arthroplasties demonstrated an average range of motion of 45 to 60 degrees with approximately 70% of patients achieving more than 40 degrees.[118] Better results are obtained in patients with degenerative and posttraumatic arthritis. Our results for silicone PIP implant arthroplasty are similar to those reported in

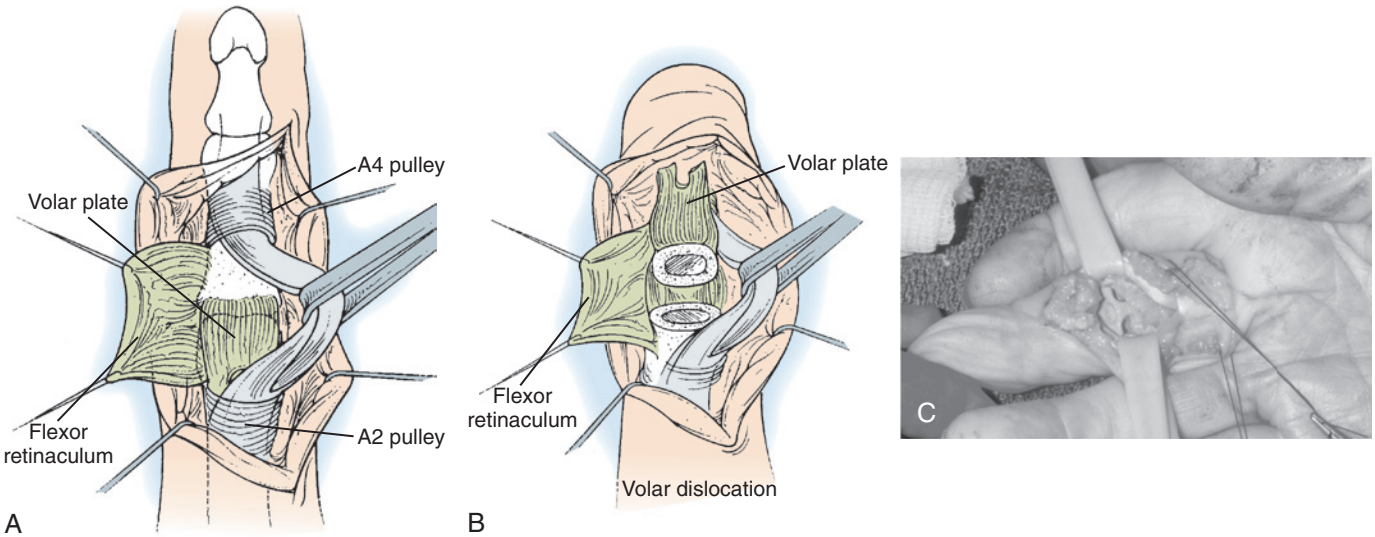

FIGURE 55.57 Volar approach to proximal interphalangeal (PIP) arthroplasty. **A,** An incision centered over the volar PIP joint exposes the volar plate, which is detached from the proximal phalanx. **B,** The flexor tendons are retracted with a Penrose drain to permit dislocation and preparation of the joint surfaces. **C,** Trial implant inserted to assess stability, appropriate size, and motion. (From Kobayashi K, Terrono AL: Proximal interphalangeal joint arthroplasty of the hand. *J Hand Surg Am* 3:219–226, 2003, © 2003 by the American Society for Surgery of the Hand. Used with permission.)

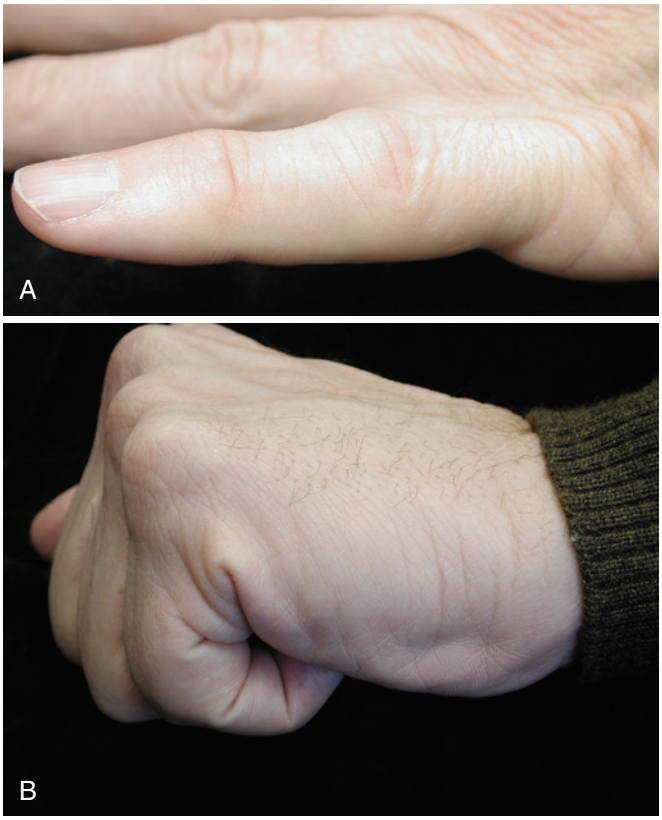

FIGURE 55.58 Seven-year follow-up of left little finger proximal interphalangeal arthroplasty demonstrating excellent extension **(A)** and flexion **(B)**, which is possible with proper patient selection, precise surgical technique, and supervised rehabilitation. (From Kobayashi K, Terrono AL: Proximal interphalangeal joint arthroplasty of the hand. *J Hand Surg Am* 3:219–226, 2003, © 2003 by the American Society for Surgery of the Hand. Used with permission.)

the literature, with excellent pain relief, good motion, and stability. No fractures, dislocations, or infections have occurred. In our series, patients with posttraumatic arthritis demonstrated an average range of motion of 48 degrees without deterioration or pain at an average follow-up of 7 years (Figure 55.58). Iselin and Conti reported on 238 Swanson implants of the PIP joint between 1970 and 1990 and noted an average range of motion of −20 degrees of extension to 80 degrees of flexion (long, ring, and little fingers).[50] These authors concluded that results obtained at 12 months were likely to remain the same at 12 years.

The incidence of infection and dislocation in a large series was approximately 0.4%.[118] The implant fracture rate was about 6%, with an overall revision rate of 10%. Reports of bone resorption vary from 1.2 to 35% and may vary with the length of follow-up and person evaluating the radiographs. Foliart reviewed all the literature (70 articles, 15,556 small joint implants) pertaining to complications associated with silicone finger implants and reported very low complication rates.[41] Implant fracture and bone changes occurred in 2% and 4% of patients, respectively. Particulate synovitis and particle wear lymphadenopathy were noted in less than 1%.[41]

Little information is available for semiconstrained surface replacement PIP arthroplasty. In 2001, Johnstone reported his experience with 20 surface replacement PIP arthroplasty implants (CoCr/polyethylene), used primarily for osteoarthritis and posttraumatic pain.[56] The average follow-up was 14.6 months (range, 2–34 months). All patients noted pain reduction, with 90% reporting excellent pain relief. No patient lost movement, and 70% of them demonstrated an average arc of motion of 73 degrees. Poor results were associated with high levels of early postoperative pain and noncompliance with hand therapy.

CRITICAL POINTS *Proximal Interphalangeal Joint Arthroplasty*

Indications
- Persistent PIP joint pain.
- Swan neck deformity with joint destruction.

Contraindications
- Infection.
- Bone loss.
- Unstable joint.
- Severe flexion deformity.

Pearls
- Do not overbroach; stability provided by the implant will be lost.
- Splint the DIP joint in extension postoperatively to concentrate motion at the PIP joint.

Technical Points
- Use a dorsal approach if the extensor tendon requires reconstruction (i.e., boutonnière deformity).
- Use a volar approach if the extensor tendon is normal.
- Make a volar zigzag incision centered on the PIP joint.
- Mobilize and protect the neurovascular bundles.
- Open the A3 pulley and retract the flexor tendons.
- Detach the volar plate proximally.
- Detach the collateral ligaments from the proximal phalanx (if necessary).
- Perform synovectomy/debridement.
- Resect the condyle of the proximal phalanx perpendicular to the long axis.
- Square off the base of the middle phalanx.
- Broach the middle phalanx first, slightly dorsal to center.
- A rectangular broach provides stability and rotational alignment.
- Broach the proximal phalanx.
- Insert a trial implant; it should fit flush against the bone and extend just beyond the medial/lateral cortices.
- The implant should not buckle or dislocate.
- Check flexor tendon excursion (make a separate incision in the palm if necessary).
- Preplace a suture in the volar plate.
- Insert implant and then repair the volar plate if necessary.

Postoperative Care
- Splint for several days, then start active flexion/extension based on the condition of the extensor mechanism.
- Use an extension block splint that includes the adjacent digit or digits for 4 to 6 weeks when the volar approach is used.
- Buddy strap for 3 months.

Boutonnière Deformity

Boutonnière deformity occurs frequently in patients with rheumatoid arthritis. Like the swan neck deformity, it is not specific to this disease and represents an alteration in muscle and tendon

balance. The deformity has three components: flexion of the PIP joint, hyperextension of the DIP joint, and hyperextension of the MP joint. Although the swan neck deformity in a rheumatoid patient can originate at any of the finger joints, the boutonnière deformity begins with flexion of the PIP joint. Changes in the adjacent joints are secondary.

Synovial proliferation within the PIP joints stretches the extensor mechanism. As a result, the central slip is unable to maintain full extension of the joint. The lateral bands displace volarward and become fixed in this position. Shortening of the oblique retinacular ligaments results in hyperextension and limited active flexion of the DIP joint. As the flexion deformity of the PIP joint increases, the patient compensates by hyperextending the MP joint. When seen early, the deformities are correctable passively. Later, with fibrosis and contracture of the capsular tissues, the deformity becomes fixed. Functional loss as a result of the boutonnière deformity may remain minimal until the late stages. For this reason, the treatment of early boutonnière deformity should be simple and involve minimal risk.

Salvage surgery (fusion or arthroplasty) should be performed only for severe fixed deformities. Our operative approach to rheumatoid boutonnière deformities depends on the degree of severity. We classify boutonnière deformities as mild, moderate, or severe on the basis of the degree of flexion of the PIP joint, the presence of passive correctability of this joint, and the status of the PIP joint surfaces. This classification helps direct the type of treatment to use (Table 55.6).

Stage I: Mild Boutonnière Deformity

In the early stages of the boutonnière deformity, there is only a slight lag (10–15 degrees) in PIP joint extension. There may be active synovitis of the joint. The DIP joint may or may not be slightly hyperextended. The MP joint is usually normal during this early stage. The extensor lag of the PIP joint can be corrected passively; however, when such correction is done, there is limited flexion of the DIP joint. Flexion of the DIP joint improves as the PIP joint is flexed. The patient's functional loss is related as much to the lack of full DIP joint flexion as to the lack of PIP extension, but functional impairment is minimal at this stage.

Any operative treatment of this mild boutonnière deformity should not jeopardize existing function. We treat a mild deformity by extensor tenotomy to improve DIP joint flexion.[29] Dynamic splinting to extend the PIP joint is used postoperatively to restore the balance of the finger. This method does not risk loss of PIP joint flexion. If active PIP joint synovitis is present, we consider either local corticosteroid injection or synovectomy in a treatment plan.

Extensor Tenotomy. For this, we make a longitudinal incision over the dorsal aspect of the middle phalanx (Figure 55.59). The extensor mechanism is divided obliquely to allow the DIP joint to flex. The oblique tenotomy allows the tendon to be sutured

TABLE 55.6 Treatment Options for Boutonnière Deformity of Finger

Stage	PIP Joint	DIP Joint
I—Mild	Dynamic splinting Injection vs. synovectomy	Extensor tenotomy
II—Moderate	Correct any wrist flexion first Extensor reconstruction	Extensor tenotomy
III—Severe	Fusion (standard) Arthroplasty	Extensor tenotomy

DIP, Dorsal interphalangeal; *PIP,* proximal interphalangeal.

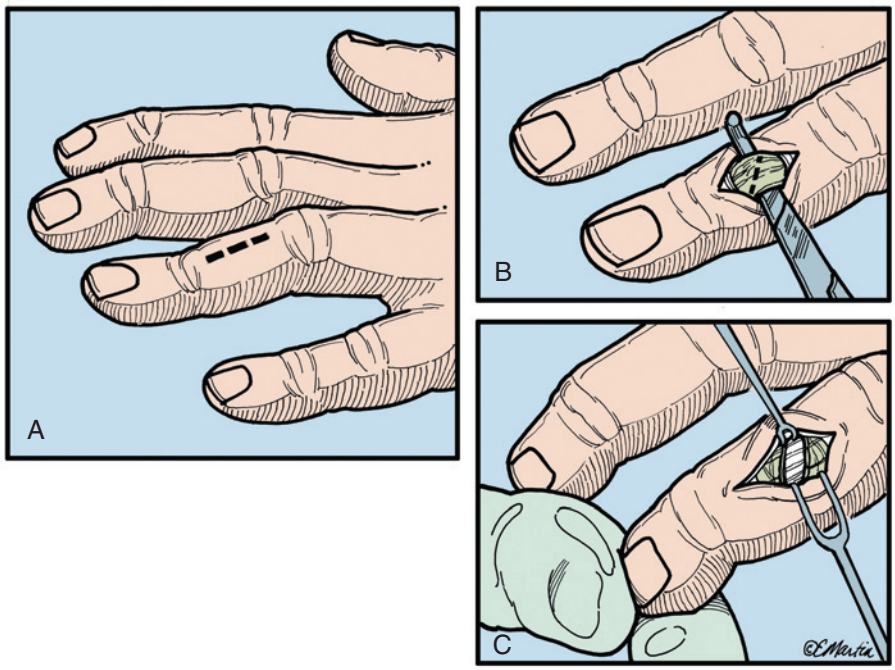

FIGURE 55.59 Technique of extensor tenotomy for a mild boutonnière deformity. **A,** Preoperative deformity of the ring finger. **B,** The extensor mechanism is isolated over the middle phalanx through a longitudinal incision. **C,** Tenotomy of the extensor mechanism can be performed transversely or obliquely, as shown. Note the flexion of the distal joint after tenotomy. (Copyright Elizabeth Martin.)

in the lengthened position and provides more tendon surface area for healing. Postoperatively, there may be a slight "droop" of the DIP joint, but a significant mallet deformity does not usually develop. This procedure is based on the concept that the oblique retinacular ligament acts to extend the DIP joint. However, the dorsal support provided by the extensor mechanism and joint capsule most likely plays a role in maintaining the normal posture of the joint.

It is preferable to perform extensor tenotomy under local anesthesia because this allows the alteration in finger stance as well as finger function to be observed at the time of surgery. Recently we have done these in the office using a percutaneous technique with a No. 18 needle. Any residual extensor lag of the DIP joint is treated with a brief period of postoperative external splinting, which generally corrects the problem. If the deformity is not corrected or if it progresses, the DIP joint can be fused in extension. For most patients, we do not splint the DIP joint postoperatively but encourage active flexion with the PIP joint supported by a dynamic extension splint. This is important in restoring proper balance between the two joints.

Stage II: Moderate Boutonnière Deformity

Loss of finger function becomes more significant as the flexion deformity of the PIP joint reaches 30 to 40 degrees. Patients usually compensate for this by hyperextending the MP joint. Although there are significant difficulties involved in reconstruction of a fixed moderate boutonnière deformity, we have found that satisfactory correction of the deformity with preservation of active PIP joint flexion can be achieved. All the procedures described for correcting an established boutonnière deformity attempt to restore extensor power to the PIP joint with local tissue. This is done by shortening the central slip and bringing the lateral bands dorsally. We believe that it is important to combine this procedure with extensor tendon tenotomy at the DIP joint. Unless this is done, there is a risk of restoring PIP extension but markedly limiting DIP flexion.

We recommend reconstruction of the extensor mechanism in patients with moderate progressive deformity if several criteria are met: good dorsal skin, relatively smooth joint surfaces, intact and functioning flexor tendons, and, of course, passive correctability of the PIP joint. We prefer to reconstruct the PIP joint extensor mechanism before or at the same time as MP joint arthroplasty because any residual flexion deformity at the PIP joint has an adverse effect on achieving MP joint flexion after arthroplasty.

Reconstruction of the Extensor Mechanism. A dorsal longitudinal curved incision is made over the PIP joint (Figure 55.60). A laterally based skin and subcutaneous flap is elevated to expose the extensor mechanism. This places the skin incision away from the site of the extensor tendon repair. The central slip is divided distally while leaving a cuff of tendon attached to the base of the middle phalanx and separated from the lateral bands proximally. Inspection of the undersurface of the central slip shows the changes that have occurred from gradual stretching. Approximately ½-inch (6 mm) of the central slip is excised. The remaining portion is reattached to the cuff of the central slip insertion, which was left intact at the base of the middle phalanx, with nonabsorbable sutures.

Two longitudinal relaxing incisions are made just volar to the lateral bands. The incisions divide the transverse retinacular

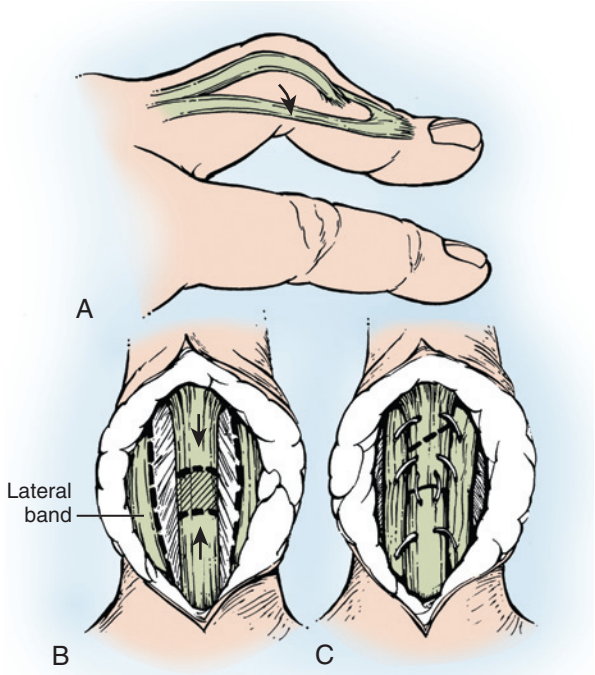

FIGURE 55.60 Reconstruction of the extensor mechanism for a boutonnière deformity. **A,** The fixed-volar position of the lateral band (*arrow*). **B,** Lateral bands mobilized. The portion of the central slip to be excised is shaded. **C,** The central slip is sutured in a shortened position, and the lateral bands are brought dorsalward and sutured to the central slip. (Copyright Elizabeth Martin.)

ligaments and allow the lateral bands to be brought dorsally. The lateral bands are sutured either to the central slip or to each other. The posture of the finger should be corrected now. However, there is usually increased resistance to passive DIP joint flexion, or even to hyperextension of this joint. The extensor mechanism overlying the middle phalanx is divided obliquely through the distal portion of the incision to allow the DIP joint to flex. This procedure allows all extensor mechanism force to be concentrated at the PIP joint level.

Adjustment of the tension of the central slip is very important. It should be possible to flex the PIP joint passively 70 or 80 degrees after the central slip has been reattached. The strong flexors act to increase the range of flexion after postoperative splinting has been discontinued.

A Kirschner wire is placed across the PIP joint to maintain full extension during the early postoperative period. The DIP joint is left free, and active motion of this joint is allowed. After 2 to 3 weeks, the wire is removed and the joint is protected for several weeks with a light dynamic extension splint during the day and a padded aluminum extension splint at night.

The postoperative program can be modified according to the finger involved and the amount of PIP joint flexion possible after the Kirschner wire is removed. If several fingers are reconstructed simultaneously, we remove the wire from the little finger first. For this finger we accept less correction of PIP joint extension to ensure maximal flexion. The reverse is true for the index finger, in which loss of some flexion is less significant.

If necessary, reconstruction of a moderate boutonnière deformity can be performed on all four fingers at the same time. In most patients, however, the criteria necessary for this

operation are present in only one or two fingers. Limiting the reconstruction to these fingers simplifies the operation, as well as the postoperative splinting and exercise program.

Stage III: Severe Boutonnière Deformity

In time, a boutonnière deformity progresses to the point where the PIP joint can no longer be extended passively. No attempt should be made to restore extensor mechanism function unless the joint can be extended passively without excessive force. In this case, restoration of passive motion by dynamic splinting or serial plaster casting is attempted. Occasionally, soft tissue release (i.e., dividing the transverse retinacular ligaments and the accessory collateral ligaments) is necessary to restore passive extension. This is combined with reconstruction of the extensor mechanism. Such extensive surgery is not often indicated.

In severe deformities with poor joint surfaces, the alternative treatment is fusion or arthroplasty. Fusion is the standard method used to correct severe fixed-flexion deformities in rheumatoid patients. It is used for those with finger extension that is so restricted that they are unable to grasp moderate-sized to large objects.

The position of PIP fusion is chosen so that a "functional" position of the involved finger is achieved. In the index or middle finger, loss of full flexion is not critical. In patients with severe bilateral boutonnière deformities, we have performed multiple fusions on one hand while leaving those on the other side untreated to maintain the ability to grasp small objects. However, the loss of PIP joint flexion after fusion is compensated, in part, by the gains in MP joint flexion.

PIP Joint Fusion. Technically, it is easier to perform PIP joint fusion to correct a fixed-flexion deformity than to correct a swan neck deformity because of the surplus skin on the dorsal aspect of the finger and the compression of the bone ends that occurs as the joint is straightened. We use a longitudinal curved incision over the PIP joint. The extensor mechanism is often nonexistent. The collateral ligaments are divided at their origin on the proximal phalanx. With the finger in maximal flexion, the distal end of the proximal phalanx is cut at a slight angle, directed volarly, and removed. The articular cartilage is removed from the base of the middle phalanx, and the subchondral bone is softened with a rongeur. As the finger is straightened, the bone ends are compressed. Bone grafts are not usually needed because of the excellent bone contact.

The position of fusion that we choose varies with the finger involved. We prefer 25 degrees of flexion for the index finger and gradually increase it to 45 degrees for the little finger. As mentioned previously, confirmation of the desired angle of fusion with a sterile goniometer is suggested. A Kirschner wire is passed longitudinally across the joint (Figure 55.61) and is supplemented by an obliquely placed wire. Wires can be cut off

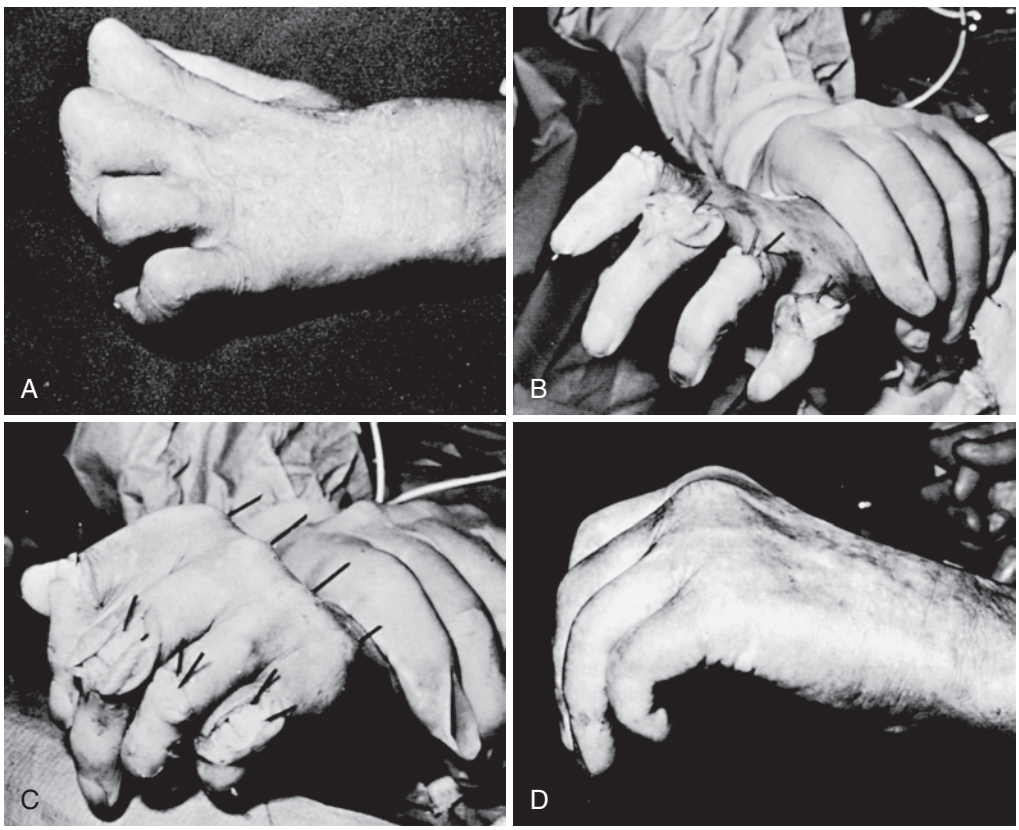

FIGURE 55.61 Severe boutonnière deformities treated by proximal interphalangeal (PIP) fusion. **A,** Severe fixed-flexion contractures of the PIP joints with the metacarpophalangeal (MP) joints fixed in extension. **B,** The degree of flexion for fusion increases from the index to the little finger. **C,** MP joints manipulated into flexion and held with Kirschner wires. **D,** Postoperatively, finger position is improved, and grasp of moderate-sized objects is possible. (From Nalebuff EA, Millender LH: Surgical treatment of the boutonnière deformity in rheumatoid arthritis. *Orthop Clin North Am* 6:753–763, 1985, with permission.)

flush to the bone and left in place permanently or left protruding through the skin to facilitate removal after fusion has occurred. A headless fusion screw can be used as described previously for internal fixation (see Figure 55.48).[37] External splints are used for the first 4 to 6 weeks until the fusion has started to consolidate. If the MP joints were fixed in hyperextension preoperatively, they are brought into flexion by manipulation, soft tissue release, or arthroplasty.

PIP Joint Arthroplasty. PIP joint arthroplasty using a silicone implant is an alternative method for treating a fixed rheumatoid boutonnière deformity. Because the goal of this procedure is to maintain motion, the extensor mechanism must be reconstructed as part of it. This is done by reattaching the central slip to the base of the middle phalanx. Relocation of the lateral bands dorsally is often also required to direct all the extensor force to the PIP joint.

This approach is particularly appropriate for patients whose deformity involves the ring and little fingers and whose MP joints are flexible because preservation of PIP motion in these fingers enhances the ability to grasp. However, we believe that it is not indicated for a severely flexed PIP joint because of the necessity of resecting excessive bone to provide enough space for the implant. PIP joint arthroplasty is discussed in more detail elsewhere in this text.

THUMB DEFORMITIES

Pathophysiology

The original classification of thumb deformities suggested by Nalebuff included four groups.[85] This classification has been revised to include a fifth and a sixth group. Type I deformity (boutonnière) is the most common, and type III deformity (swan neck) is the second most common. Type IV deformity is seen occasionally, and types II and V are rarer. Type VI is joint destruction and collapse associated with arthritis mutilans (Table 55.7). Surgical treatment must be individualized for each patient and each joint and includes synovectomy, tenodesis, tendon transfer, arthrodesis, and arthroplasty.

Type I Thumb (Boutonnière) Deformity

A type I deformity is characterized by MP joint flexion and distal joint hyperextension. It is usually initiated by proliferative MP joint synovitis, which bulges dorsally and results in attenuation of the EPB tendon insertion, stretching of the extensor hood, and displacement of the EPL tendon ulnarward and volarly. The collateral ligaments are stretched, and intraarticular joint destruction occurs to varying degrees. This loss of dorsal support results in proximal phalanx subluxation on the metacarpal and concomitant IP joint hyperextension from the altered pull of both intrinsic muscles and the EPL. The first metacarpal becomes radially abducted to compensate for MP flexion. The hyperextension of the IP joint and the flexion of the MP joint are accentuated when pinch forces are applied to the thumb and, with time, may become fixed. This particular deformity can be described as an "extrinsic-minus" deformity. Rupture of the EPL at the wrist level can therefore result in a similar deformity.

Distal joint hyperextension can be the primary disturbance, with MP joint flexion being secondary, although this is less common. This may be a result of attenuation of the volar plate of the IP joint because of synovitis or rupture of the FPL tendon, which generally occurs in the carpal tunnel. In these patients, IP hyperextension is greater than MP flexion. Metacarpal radial abduction is not usually a significant component because the MP flexion is less. Thus, when faced with a patient with a type I deformity, it is necessary to evaluate the MP and IP joints, as well as the individual flexor and extensor tendons that control them.

In the early stage, both MP and IP joint deformities are correctable passively (Figure 55.62); however, over time, fixed deformities develop, first of the MP joint alone and later of both the MP and IP joints.

Indications for Operative Treatment

There are three clinical stages in the development of type I deformity (Table 55.8). Each requires a different type of surgical

TABLE 55.7 Rheumatoid Thumb Deformities

Type	CMC Joint	MP Joint	IP Joint
I (boutonnière)	Not involved	Flexed	Hyperextended
I—Early	Not involved	Passively correctable	Passively correctable
I—Moderate	Not involved	Fixed contracture	Passively correctable
I—Severe	Not involved	Fixed contracture	Fixed contracture
II (uncommon)	CMC flexed and adducted	Flexed	Hyperextended
III (swan neck)	CMC subluxated, flexed, and adducted	Hyperextended	Flexed
III—Early	Minimal deformity	Passively correctable	
III—Moderate	CMC subluxated	Passively correctable	
III—Severe	CMC dislocated	Fixed contracture	
IV (gamekeeper's)	CMC not subluxated, flexed, and adducted	First degree, radially deviated, UCL unstable	Not involved
V	May or may not be involved	First degree, hyperextended, volar plate unstable	Not involved
VI (arthritis mutilans)	Bone loss at any level	Bone loss at any level	Bone loss at any level

CMC, Carpometacarpal; *IP,* interphalangeal; *MP,* metacarpophalangeal; *UCL,* ulnar collateral ligament.

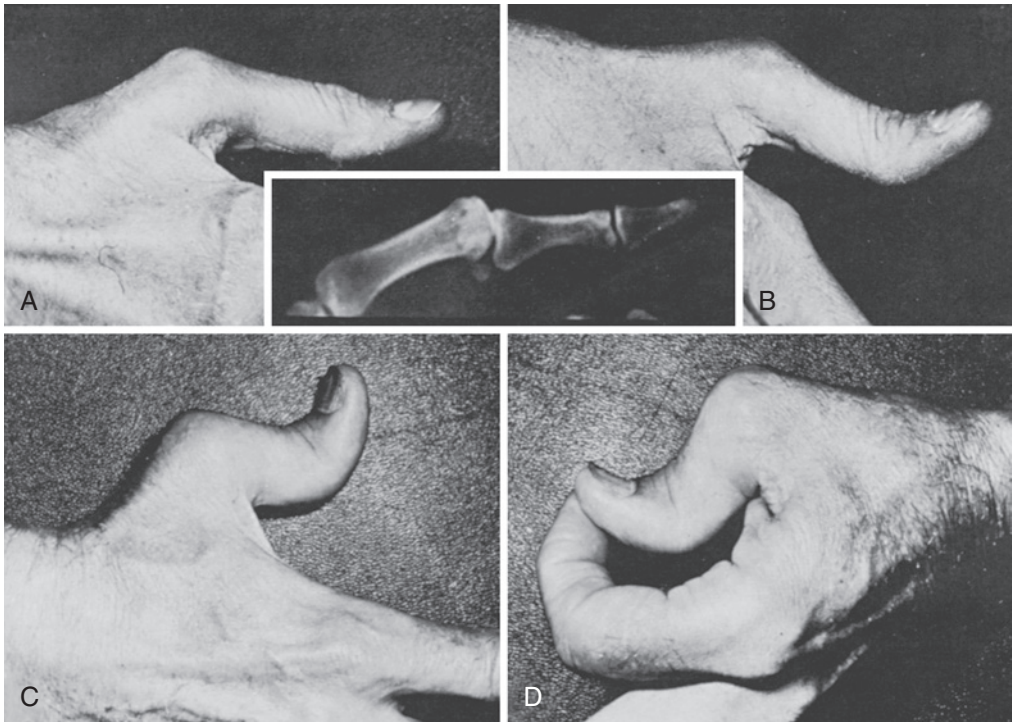

FIGURE 55.62 Type I thumb deformity. **A,** Synovitis of the metacarpophalangeal (MP) joint stretches the extensor mechanism and results in MP joint extension lag. Initially, the interphalangeal (IP) joint is not involved. **B,** MP joint subluxation with IP joint hyperextension. As the disease progresses, there is MP joint involvement with cartilage loss and early subluxation. **C,** Advanced type I deformity with fixed MP and IP joint deformities. **D,** Pinch aggravates the collapse deformity.

TABLE 55.8 Treatment Options for Type I Thumb (Boutonnière) Deformity

Stage	MP Joint	IP Joint
Early	Synovectomy EPL rerouting	Synovectomy Restore FPL function Flexor tenodesis
Moderate	Fusion Arthroplasty	Joint release
Advanced	Arthroplasty	Fusion Joint release

EPL, Extensor pollicis longus; *FPL,* flexor pollicis longus; *IP,* interphalangeal; *MP,* metacarpophalangeal.

treatment. In the early stages, there is MP joint flexion with IP joint hyperextension, but both joints are correctable passively. Surgical treatment at this stage includes synovectomy of the MP joint and reconstruction of the extensor mechanism. The original reconstruction of the extensor mechanism as described by Nalebuff is an EPL-rerouting procedure in which the long extensor tendon is rerouted through the dorsal capsule of the joint to provide additional extensor force at this level.[85] When this procedure is done, the intrinsic muscles of the thumb act as extensor forces for the distal joint. Synovectomy alone has not been shown to significantly alter the natural history of the disease, and synovitis recurs in 6 to 13% of patients after MP joint synovectomy. EPL rerouting corrects the MP joint deformity and helps prevent further collapse of the IP joint, but a review of this procedure by Terrono and colleagues revealed a high late recurrence rate; however, this procedure does improve function during that period.[124]

In the second stage, a fixed MP joint is present with or without intraarticular joint destruction. The IP joint deformity is correctable passively. Most patients are seen at this stage. Arthrodesis is recommended for the MP joint if it is totally destroyed and the two adjacent joints are minimally involved. However, if destructive changes are likely to develop at one of the adjacent (i.e., CMC or IP) joints, CMC joint arthroplasty or MP arthroplasty combined with EPL rerouting must be considered. Correction of the deformity at the second stage helps prevent the third stage from developing.

The third and most difficult stage consists of both a fixed MP joint flexion deformity and a fixed IP joint hyperextension deformity. Treatment is dependent on the status of each of the two joints. If the IP joint is not destroyed and can be released by a dorsal capsulotomy, some degree of IP joint motion can be preserved. However, the deformity usually recurs after release of the IP joint.

If the deformity is too severe, IP joint arthrodesis is indicated. MP joint surgery depends on the severity of the deformity, the status of the articular surfaces, and the surgery indicated for the IP joint. If the IP joint has been fused, it is best to try to preserve MP joint motion either with synovectomy and EPL rerouting or with silicone implant arthroplasty (Figure 55.63). However, in severely deformed or destroyed joints, combined MP and IP joint fusions are sometimes indicated. Although Ratliff stated that he had never found an indication for arthrodesis of both these joints,[102] others believe that this is

indicated occasionally. If the MP joint is only moderately stiff and has a salvageable joint surface, intrinsic muscle and ligament release with reconstruction of the extensor mechanism is indicated.

Type II Thumb Deformity

Type II deformity, which is seen rarely, is a combination of types I and III deformities. It consists of MP joint flexion with IP joint hyperextension and an associated subluxation or dislocation of the CMC joint. Treatment of this deformity is similar to that for types I and III deformities.

Type III Thumb (Swan Neck) Deformity

The second most common thumb deformity is type III, or swan neck deformity. It is characterized by MP joint hyperextension, IP joint flexion, and metacarpal adduction.[85] This deformity results from disease at the level of the CMC joint. Synovitis and erosion of the articular surfaces and capsular distention allow dorsal and radial subluxation of the CMC joint as the thumb is used for grasp. Repeated use can result in complete dislocation of this joint. As the joint subluxates, abduction forces are reduced and adduction contracture of the metacarpal develops (Figure 55.64).

Hyperextension of the MP joint develops secondary to the metacarpal adduction contracture if the volar plate is lax. As the patient attempts to open the first web space to grasp, the fixed-CMC joint deformity prevents metacarpal abduction and extension. The extension forces are transmitted to the MP joint, which results in hyperextension of it. Such patients can grasp moderate-sized objects only by hyperextending the MP joint.

Indications for Operative Treatment

Patients with type III deformities are also seen in three general stages (Table 55.9). In the first, a painful CMC joint, weak pinch, and various degrees of radiographic joint destruction are seen. At this stage there is minimal subluxation, minimal deformity, and no secondary MP joint involvement. Surgical treatment is indicated only for persistent pain after proper conservative therapy has failed. Such therapy consists of an adequate trial of systemic medications, 2 to 4 months of splinting, and occasional corticosteroid injections. The recommended surgical treatment is hemiarthroplasty. We no longer use implant arthroplasty at the thumb base but instead perform resection arthroplasty with ligament reconstruction and tendon interposition.[13]

Patients in the second stage show varying degrees of CMC joint deformity and mild, passively correctable MP joint hyperextension (Figure 55.65). Unless the pain is significant, these patients function quite well except for weakness of pinch. The recommended treatment of a CMC joint with mild MP joint deformity is resection arthroplasty and ligament reconstruction,[10] combined with volar tenodesis or sesamoidesis[127] of the MP joint. MP joint fusion is performed for advanced deformity or joint destruction or in patients with marked hyperextension but limited MP flexion.

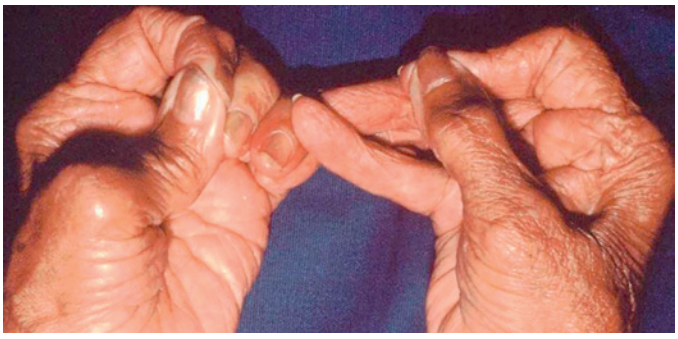

FIGURE 55.63 Type I thumb with impaired pinch function (*left*) is improved by interphalangeal joint fusion and extensor pollicis longus rerouting (*right*).

TABLE 55.9 Treatment Options for Type III (Swan Neck) Deformity

Stage	CMC Joint	MP Joint
Early	Resection arthroplasty, LRTI	None
Moderate	Resection arthroplasty, LRTI	Fusion Volar restraint
Advanced	Resection arthroplasty, LRTI Release contracture	Fusion

CMC, Carpometacarpal; *LRTI*, ligament reconstruction tendon interposition arthroplasty; *MP,* metacarpophalangeal.

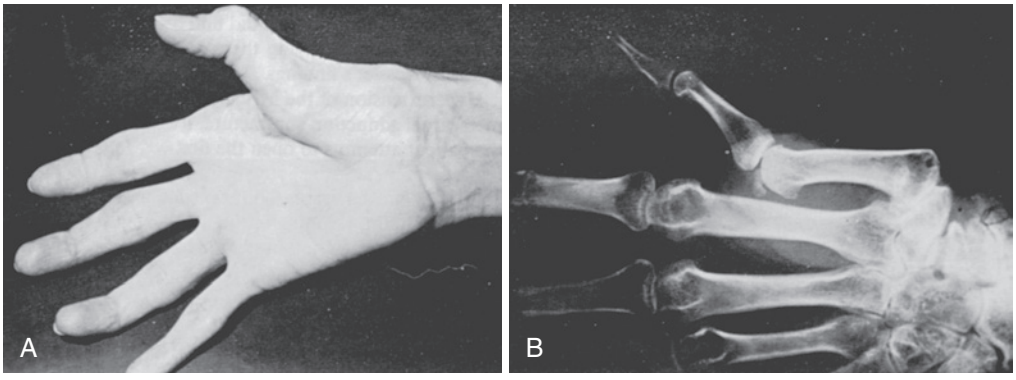

FIGURE 55.64 Type III thumb deformity. **A,** Clinical appearance with carpometacarpal (CMC) joint subluxation, thumb metacarpal adduction, and secondary metacarpophalangeal joint hyperextension. **B,** Radiograph demonstrating CMC joint destruction with erosion of the trapezium and metacarpal subluxation.

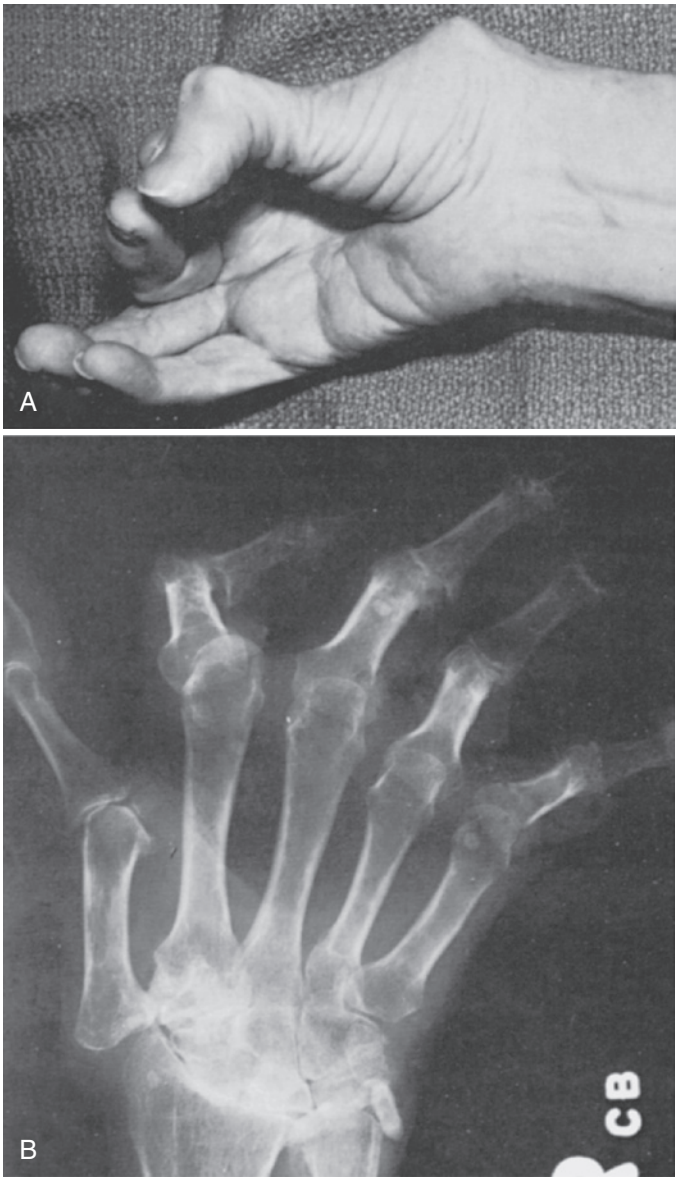

FIGURE 55.65 Advanced rheumatoid thumb deformity. **A,** Dislocated carpometacarpal joint with an adduction deformity of the metacarpal and hyperextension deformity of the metacarpophalangeal (MP) joint. **B,** Radiograph of the hand. Note the collapse deformity of the wrist, dislocation of the MP joints, and lateral dislocation of the index proximal interphalangeal joint. (From Nalebuff EA: Reconstructive surgery and rehabilitation of the hand. In Kelly WN, Harris ED, Ruddy S, et al., editors: *Textbook of rheumatology*, ed 2, Philadelphia, 1985, WB Saunders, pp 1818–1826, with permission.)

Advanced type III deformity includes complete CMC joint dislocation with a fixed-adduction contracture and a fixed-hyperextension deformity of the MP joint. These patients have significant disability as a result of the contracted first web space, which prevents grasp of moderate-sized objects. The zigzag collapse deformity precludes adequate pinch. CMC resection arthroplasty with ligament reconstruction and MP joint fusion is helpful in restoring function to these patients. MP arthroplasty is not performed for hyperextension deformity of the thumb. In a patient with SLE, CMC joint fusion should be done because of increased ligamentous laxity.

TABLE 55.10 Treatment Options for Type IV (Gamekeeper's) Thumb Deformity

Stage	MP Joint
Early	Synovectomy Reconstruction of the collateral ligament
Moderate	As for early (rare) Fusion Adductor fascia release
Advanced	Fusion Adductor fascia release

MP, Metacarpophalangeal.

Type IV Thumb (Gamekeeper's) Deformity

Type IV deformity is characterized by a radial deviation deformity of the MP joint with secondary adduction of the thumb metacarpal. This occurs as synovitis of the MP joint stretches the ulnar collateral ligament, thereby resulting in lateral instability of this joint. Secondarily, an adduction contracture of the thumb develops. In some cases, shortening and contracture of the adductor fascia similar to that seen in type III deformity can occur. The important aspect of type IV deformity is that there is no primary CMC joint disease; therefore, treatment is directed toward the MP joint.

Indications for Operative Treatment

For early deformity, MP joint synovectomy and collateral ligament reconstruction are performed (Table 55.10). In advanced cases, MP joint arthrodesis is done. If the metacarpal remains adducted after the fusion is completed, soft tissue release is added. After the MP joint is stabilized, the thenar muscles function to abduct and oppose the entire thumb ray more effectively and to prevent further adduction of the thumb metacarpal.

Type V Thumb Deformity

Type V thumb deformity results from stretching of the volar plate of the MP joint. It hyperextends, with secondary flexion of the IP joint as tension on the flexor tendon increases. In contrast to a type III deformity, the first metacarpal does not assume an adducted position.

Surgical treatment of a type V thumb deformity is simple; the MP joint is stabilized in flexion by volar capsulodesis, sesamoidesis, or fusion.

Thumb Deformities Secondary to Joint Destruction

These deformities are usually the result of the bone destruction and resorption associated with arthritis mutilans. In advanced cases they cause severe loss of hand function and disability.[91]

Operative Treatment Indications for Severe Joint Destruction and Arthritis Mutilans

Arthrodesis is the usual procedure of choice for severely affected joints. In patients with arthritis mutilans, arthrodesis should be performed early before marked bone resorption occurs. When arthritis mutilans has resulted in marked bone loss, bone grafts are required to restore or maintain length and to allow fusion to occur.[91]

Operative Techniques for Thumb Reconstruction

Surgery is based on which joint is involved. The classification of deformity by type improves the surgeon's understanding of the problem but is not important in the overall treatment chosen.

Interphalangeal Joint. Surgical techniques used for reconstruction of the IP joint are synovectomy, extensor tendon release (for fixed-hyperextension deformities), and arthrodesis of the IP joint.

Synovectomy. Synovectomy of the IP joint can be performed through a dorsal curved, a longitudinal, or a Y incision centered over the IP joint. Another incision that has been used is a longitudinal zigzag one centered over the IP joint. This protects the terminal branches of the dorsal sensory nerve. After the skin flaps are elevated, the proliferative synovium can be removed from either side of the joint with a small rongeur. A small portion of the extensor mechanism can be detached from the base of the distal phalanx which, combined with traction on the phalanx, allows easier access to the joint.

After IP joint synovectomy, the joint is splinted in extension for a few days before beginning exercises. It should be splinted between exercise periods for 2 weeks to prevent an extensor lag from developing.

IP Joint Release. This procedure is performed in conjunction with MP joint fusion or arthroplasty for a moderately severe type I deformity. The skin incision used is critical because the dorsal skin is contracted and thereby limits the amount of flexion that can be obtained. The usual approach involves a lateral incision on either side of the joint. Tenolysis of the extensor mechanism is performed. The dorsal capsule is incised by sliding the blade volar to the extensor mechanism and then rotating it 90 degrees. The dorsal portion of the collateral ligament is released through each incision, and the joint is manipulated into flexion. Usually, it can be held in 25 to 30 degrees of flexion without placing the dorsal skin under undue tension.

Alternatively, a "Z"-plasty can be used. A longitudinal incision is made over the midportion of the joint, which provides excellent exposure. The release is performed as described earlier. After the Kirschner wire has been inserted, the incision is converted into a Z-plasty. There is rarely sufficient skin to close the incision completely, and a portion of the wound is left partially open over the proximal phalanx. This epithelializes within 10 to 12 days, after which time the Kirschner wire is removed and exercises are initiated. For several days after the wire is removed, the joint is protected with a plaster or aluminum splint. Occasionally, an extensor lag develops; in such cases, the joint should be splinted in extension to allow the extensor mechanism to contract. After these procedures 10 to 25 degrees of active joint flexion can be expected; a large range of flexion is never obtained and the deformity often recurs.[124]

IP Joint Arthrodesis. This procedure was described earlier.

Metacarpophalangeal Joint. Operative procedures for a rheumatoid MP joint include synovectomy, synovectomy with reconstruction of the extensor mechanism, volar release in conjunction with reconstruction of the extensor mechanism for fixed-flexion deformities, arthroplasty, and arthrodesis.[46]

Synovectomy. A slightly curved, dorsal, longitudinal incision 3 to 4 cm in length is made over the MP joint. Radial and ulnar flaps are reflected to expose the extensor mechanism. The sensory branches of the radial nerve must be protected. The joint is exposed by a longitudinal incision between the EPL and EPB tendons, which are reflected ulnarward and radially, respectively. The synovium bulges dorsally, often having ruptured through the joint capsule. A synovectomy is performed with a small rongeur.

Traction applied to the joint gives additional exposure. Synovium should be removed carefully from the recesses on either side of the attachment of the collateral ligament to the metacarpal head. Synovitis in this area causes early bone erosions that can be seen radiographically. A small curet is helpful when entering the tight space between the ligament and the metacarpal head. After synovectomy is completed, the extensor mechanism is closed and tightened. The joint is splinted in extension to prevent a flexion deformity. Splinting is continued for 12 to 14 days before beginning exercises. In the thumb, MP joint stability is more important than motion; therefore, allow time for adequate soft tissue healing before motion is started.

MP Joint Synovectomy With Extensor Mechanism Reconstruction. These procedures are indicated for early type I deformity in which the joint is preserved and subluxation is correctable passively (Figure 55.66). Several different methods have been described, and in each the extensor mechanism is exposed as described for synovectomy. The EPL and EPB tendons are identified. The EPB is usually attenuated, and the EPL is often displaced ulnarly and volarly.

To perform the EPL rerouting described by Terrono and colleagues,[120,124] the interval between the EPL and the EPB is identified. The EPL is transected over the proximal third of the proximal phalanx and freed proximally. The attenuated EPB tendon is dissected from the base of the proximal phalanx and detached from the extensor hood. The joint is approached through a transverse incision in the thin portion of the capsule while leaving the thickened portion attached to the base of the proximal phalanx. A transverse incision is made in this thicker capsule distal to the joint, through which the EPL tendon is passed and pulled back over itself. Complete synovectomy of the joint is performed. With the joint held in full extension, the tendon is sutured tightly to itself or attached directly to bone with suture anchors or with sutures placed through drill holes. In a modified technique, the EPL tendon is transected more proximally and the EPB tendon sutured to the EPL stump to improve IP joint extension. An oblique Kirschner wire is used to hold the MP joint in extension. The thumb is splinted with the IP joint in extension.

IP joint flexion and extension exercises are started in a few days. The IP joint is protected in extension when not being exercised to prevent an extensor lag. The Kirschner wire across the MP joint is removed after 4 weeks. However, the MP joint is splinted in extension for an additional 1 to 2 weeks to allow complete healing of soft tissue. All splinting is discontinued 6 weeks after surgery.

MP Joint Ligament Reconstruction for Type IV Deformity. The skin incision described earlier is used. The interval between the EPL and EPB tendons is opened, and the EPL and dorsal expansion of the adductor pollicis are reflected ulnarward. The stretched ulnar collateral ligament is identified. This ligament is detached from the proximal phalanx or metacarpal, whichever end is more attenuated, and synovectomy of the joint performed. The attenuated portion of the collateral ligament is excised. The end of the collateral ligament is attached to bone

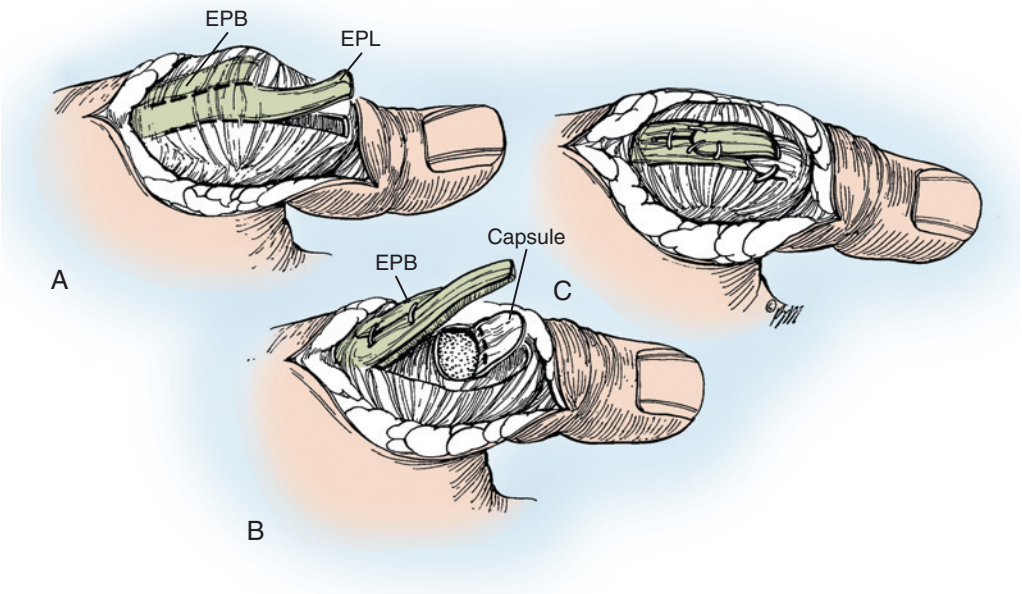

FIGURE 55.66 Extensor pollicis longus (EPL) rerouting for an early type I deformity. **A,** In the standard method of EPL rerouting, the tendon is transected between the metacarpophalangeal (MP) and interphalangeal joints and elevated proximally. **B,** With Nalebuff's modified technique, the EPL is transected more proximally and the distal stump is sutured to the extensor pollicis brevis (EPB) tendon. **C,** The proximal stump is passed through the MP joint capsule and sutured back onto itself in both methods. (Copyright Elizabeth Martin.)

with a pull-out suture or suture anchor. The adductor tendon is detached from the base of the proximal phalanx and advanced distally. Postoperative management is similar to that for the EPL-rerouting procedure.

Procedures for Fixed MP Joint Contractures. The procedures performed for fixed MP joint contractures are soft tissue release with extensor reconstruction (in mild-to-moderate cases) and arthroplasty or arthrodesis (for severe contractures with extensive cartilage loss). If the deformity is in the range of 25 to 35 degrees and the MP joint cartilage is involved minimally, soft tissue release may be preferable to arthroplasty or arthrodesis.

Arthrodesis of IP and MP joints without severe deformity or bone loss. Generally, the IP joint is fused in full extension or in very slight flexion. If necessary, also rotate the IP joint into slight pronation, particularly if the CMC joint is compromised. The technique is similar to that described for PIP joint fusion. A 0.045- or 0.062-inch guidewire is passed distally through the medullary canal of the distal phalanx to exit at the tip, just volar to the nail plate. The exit position of the wire on the fingertip is important. Placement too dorsal will damage the nail bed. With the joint held in the selected position, a self-compressing fusion screw is inserted in a distal-to-proximal direction through a small stab wound just below the nail at the level of the guidewire. A longitudinal or crossed Kirschner wire can also be used for internal fixation. The size of the wire is determined by the softness of the bone and the size of the medullary canal.

Several techniques for MP fusion are available. The MP joint is approached and prepared essentially as described earlier. In one technique, the joint is transfixed with two crossed Kirschner wires. Although the wires can be passed retrograde, they are inserted most easily directly across the joint from a dorsal approach and ulnarward on the metacarpal to dorsal and radial on the proximal phalanx, and vice versa. The wires should be directed so that they do not exit on the volar surface of the thumb, thereby putting the flexor tendon or digital nerves (or both) at risk. A single or dual parallel screws can be used for internal fixation of MP joint fusions.

Alternatively, a tension band technique can be used. It provides a more stable construct than Kirschner wires do, as well as earlier function and minimal immobilization. However, the tension band technique is more demanding (Figure 55.67), and the wires and pins frequently need to be removed after the fusion heals. The MP joint can be fused in 15 to 25 degrees of flexion. Slight pronation may facilitate pinch if the CMC joint is unstable, and the MP joint should be fused in more flexion, up to 25 degrees. It is advisable to measure the position of fusion accurately with a sterile goniometer before the final internal fixation devices are inserted. Intraoperative radiographs are also helpful in confirming the appropriate alignment for fusion.

If after obtaining stable fixation the position varies from that described earlier and is considered suboptimal, the joint can be bent into a better position if only one small-diameter Kirschner wire has been inserted. The second wire is inserted after the position is corrected.

Athrodesis for arthritis mutilans. Loss of bone stock is the major factor that makes fusion in rheumatoid patients difficult. The amount of loss ranges from thinned cortices and absent medullary cancellous bone to severe bone resorption with shortening, as seen in arthritis mutilans.[91,127] Joint exposure may be difficult because of the deformity or subluxation, and the soft, thin bone may not hold Kirschner wires well. In general, the technique is similar to that used for fusing any rheumatoid joint. However, certain points should be emphasized. Excellent exposure is mandatory. If "pencil-in-cup" deformities are present at the IP or MP joints, the bones are exposed by excising the capsule from the rim of the bone and the volar plate from

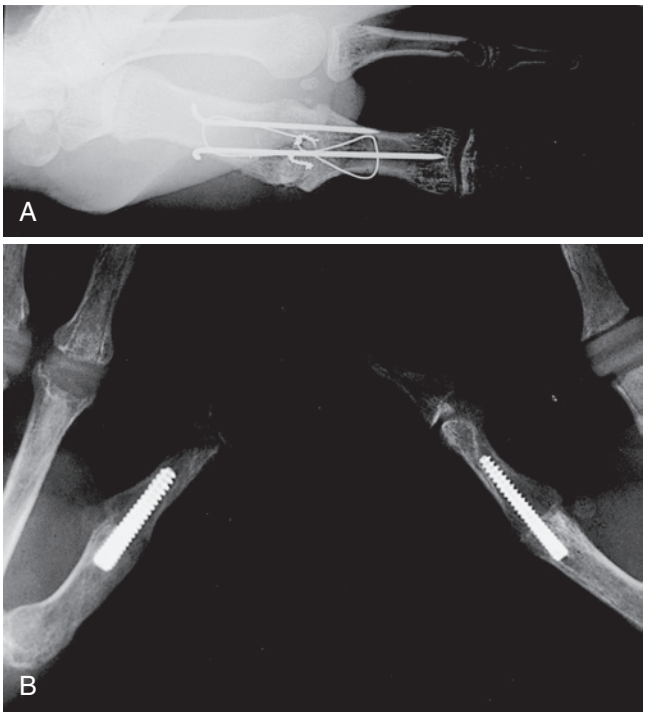

FIGURE 55.67 **A,** Thumb metacarpophalangeal (MP) joint fusion using the tension band technique. **B,** The left thumb MP joint was fused with a standard Acutrak screw, and the right thumb MP joint was fused with a Mini-Acutrak screw. Both fusions healed completely in 6 weeks.

the undersurface of the phalanx, then cut the cartilaginous and cortical rim transversely to obtain a flat surface.

After this has been accomplished, the joints can be apposed. However, adequate bone stock must be present. If bone stock is insufficient, cancellous bone from other areas (e.g., resected metacarpal heads) is helpful to fill the gap and increase stability. If the metacarpal heads from arthroplasty are devoid of cancellous bone, the cortical bone is crushed and used to fill the cavity. Wires are inserted as described earlier. A second longitudinal or crossed Kirschner wire may be needed for the IP joint.

Bone grafts are important in cases of arthritis mutilans. Shortening is accepted if the joints have fused spontaneously. However, iliac bone blocks are often needed to restore length and to obtain fusion (Figure 55.68).[91] The joints are exposed and prepared as described earlier. A bone block from the iliac crest or distal radius is fashioned, wedged into place, and fixed with longitudinal Kirschner wires. Cancellous bone is packed into the remaining space. These fusions are technically difficult and require 4 to 5 months of immobilization postoperatively.

Trapeziometacarpal joint anthroplasty. We now use the trapezium resection and tendon suspension/interposition method—that is, ligament reconstruction with tendon interposition (LRTI)—described by Burton and Pellegrini.[13] The APL should be advanced to ensure adequate postoperative abduction power. MP joint hyperextension or instability must be corrected at the same time, usually by arthrodesis. IP joint arthrodesis can also be performed at the same time if indicated.

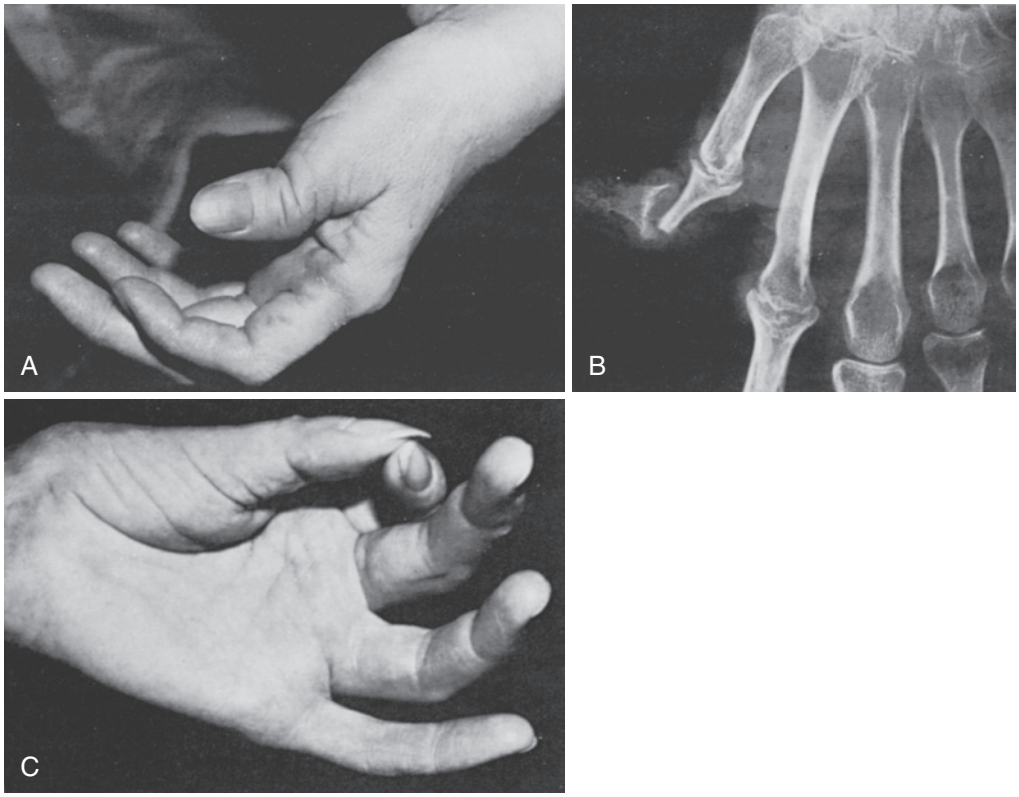

FIGURE 55.68 Unstable distal joint of the thumb fused with a bone graft. **A,** Clinical appearance of the thumb with collapse of the interphalangeal joint. **B,** Radiograph showing significant absorption of the distal end of the proximal phalanx. **C,** Note the stable pulp pinch between the lengthened thumb and index finger. The distal joint is fused in slight flexion. (From Nalebuff EA: Reconstructive surgery and rehabilitation of the hand. In Kelly WN, Harris ED, Ruddy S, et al., editors: *Textbook of rheumatology*, ed 2, Philadelphia, 1985, WB Saunders, pp 1818–1826. Used with permission.)

For Case Studies, Videos, and more, please visit ExpertConsult.com.

REFERENCES

1. Adamson GJ, Gellman H, Brumfield RH, Jr, et al: Flexible implant arthroplasty of the proximal interphalangeal joint in patients with systemic inflammatory arthritis. *J Hand Surg [Am]* 19:378–384, 1994.
2. Adolfsson L, Frisen M: Arthroscopic synovectomy of the rheumatoid wrist: a 3.8-year followup. *J Hand Surg [Br]* 22:711–713, 1997.
3. Ahmed SK, Cheung JP, Fung BK, et al: Long term results of matched hemiresection interposition arthroplasty for DRUJ arthritis in rheumatoid patients. *Hand Surg* 16:119–125, 2011.
4. Ansell BM, Harrison SH, Little H, et al: Synovectomy of the proximal interphalangeal joints. *Br J Plast Surg* 23:380–385, 1970.
5. Backdahl M: The caput ulnae syndrome in rheumatoid arthritis: a study of the morphology, abnormal anatomy, and clinical picture. *Acta Rheumatol Scand* 5:1–75, 1963.
6. Bain GI, Ondimu P, Hallam P, et al: Radioscapholunate arthrodesis—a prospective study. *Hand Surg* 14:73–82, 2009.
7. Belsky MR, Feldon P, Millender LH, et al: Hand involvement in psoriatic arthritis. *J Hand Surg [Am]* 7:203–207, 1982.
8. Bieber EJ, Weiland AJ, Volenec-Dowling S: Silicone-rubber implant arthroplasty of the metacarpophalangeal joints for rheumatoid arthritis. *J Bone Joint Surg Am* 68:206–209, 1986.
9. Blatt G, Ashworth CR: Volar capsule transfer for stabilization following resection of the distal end of the ulna. *Orthop Trans* 3:13–14, 1979.
10. Bora FW, Osterman AL, Thomas VJ, et al: The treatment of ruptures of multiple extensor tendons at the wrist level by a free tendon graft in the rheumatoid patient. *J Hand Surg [Am]* 12:1038–1040, 1987.
11. Boyce T, Youm Y, Sprague BL, et al: Clinical and experimental studies on the effect of extensor carpi radialis longus transfer in the rheumatoid hand. *J Hand Surg [Am]* 3:390–393, 1978.

11a. Boyes J: Tendon transfer for radial palsy. *Bull Hosp Joint Dis* 21:97, 1960.

12. Brase DW, Millender LM: Failure of silicone rubber wrist arthroplasty in rheumatoid arthritis. *J Hand Surg* 11:175–183, 1986.
13. Burton RI, Pellegrini VD, Jr: Surgical management of basal joint arthritis of the thumb: II. Ligament reconstruction with tendon interposition arthroplasty. *J Hand Surg [Am]* 11:324–332, 1986.
14. Bravo CJ, Rizzo M, Hormel KB, et al: Pyrolytic carbon proximal interphalangeal joint arthroplasty: results with minimum two-year follow-up evaluation. *J Hand Surg [Am]* 32:1–11, 2007.
15. Brumfield R, Jr, Kuschner S, Gellman H, et al: Results of dorsal wrist synovectomies in the rheumatoid hand. *J Hand Surg [Am]* 15:733–735, 1990.
16. Buck-Gramcko D: Denervation of the wrist joint. *J Hand Surg [Am]* 2:54–61, 1977.
17. Burgess SD, Kono M, Stern PJ: Results of metacarpophalangeal joint surgery in rheumatoid patients following previous silicone arthroplasty. *J Hand Surg [Am]* 32:1506–1512, 2007.
18. Carpenter MT, West SG, Vogelgesang SA, et al: Postoperative joint infections in rheumatoid arthritis patients on methotrexate therapy. *Orthopedics* 19:207–210, 1996.
19. Carroll RE, Hill NA: Small joint arthrodesis in hand reconstruction. *J Bone Joint Surg Am* 51:1219–1221, 1969.
20. Catalano LW, Skarparis AC, Glickel SZ, et al: Treatment of chronic, traumatic hyperextension deformities of the proximal interphalangeal joint with flexor digitorum superficialis tenodesis. *J Hand Surg [Am]* 28:448–452, 2003.
21. Chamay A, Della Santa D, Vilaseca A: Radiolunate arthrodesis, factor of stability for the rheumatoid wrist. *Ann Chir Main* 2:5–17, 1983.
22. Chung KC, Kotsis SV, Kim HM, et al: Reasons why rheumatoid arthritis patients seek surgical treatment for hand deformities. *J Hand Surg [Am]* 31:289–294, 2006.
23. Chung KC, Kowalski CP, Myra KH, et al: Patient outcomes following Swanson Silastic metacarpophalangeal joint arthroplasty in the rheumatoid hand: a systematic overview. *J Rheumatol* 27:1395–1402, 2000.
24. Chung KC, Pushman AG: Current concepts in the management of the rheumatoid hand. *J Hand Surg [Am]* 36:736–747, 2011.
25. Clayton ML, Ferlic DC: Tendon transfer for radial rotation of the wrist in rheumatoid arthritis. *Clin Orthop Relat Res* 100:176–185, 1974.
26. Cooney W, Manuel J, Froelich J, et al: Total wrist replacement: a retrospective comparative study. *J Wrist Surg* 1:165–172, 2012.
27. Daecke W, Kaszap B, Martini AK, et al: A prospective, randomized comparison of 3 types of proximal interphalangeal arthroplasty. *J Hand Surg* 37A:1770–1779, 2012.
28. Dellon AL: Partial wrist denervation: resection of the distal posterior interosseous nerve. *J Hand Surg [Am]* 10:527–533, 1985.
29. Dolphin JA: Extensor tenotomy for chronic boutonnière deformity of the finger: report of two cases. *J Bone Joint Surg Am* 47:161–164, 1965.
30. Dray G, Millender LH, Nalebuff EA, et al: The surgical treatment of hand deformities in systemic lupus erythematosus. *J Hand Surg [Am]* 6:339–345, 1981.
31. Eaton RG, Littler JW: Ligament reconstruction for the painful thumb carpometacarpal joint. *J Bone Joint Surg Am* 55:1655–1666, 1973.
32. El-Gammal TA, Blair WF: Motion after metacarpophalangeal joint reconstruction in rheuamtoid disease. *J Hand Surg [Am]* 18:504–511, 1993.
33. Ellison MR, Flatt AE, Kelly KJ: Ulnar drift of the fingers in rheumatoid disease: treatment by crossed intrinsic tendon transfer. *J Bone Joint Surg Am* 53:1061–1082, 1971.
34. Ellison MR, Kelly KJ, Flatt AE: The results of surgical synovectomy of the digital joints in rheumatoid disease. *J Bone Joint Surg Am* 53:1041–1060, 1971.
35. Ertel AN, Millender LH, Nalebuff EA, et al: Flexor tendon ruptures in patients with rheumatoid arthritis. *J Hand Surg [Am]* 13:860–866, 1988.
36. Escott BG, Ronald K, Judd MGP, et al: NeuFlex and Swanson metacarpophalangeal implants for rheumatoid arthritis: prospective randomized, controlled clinical trial. *J Hand Surg* 35A:44–51, 2010.
37. Faithfull DK, Herbert TJ: Small joint fusions of the hand using the Herbert bone screw. *J Hand Surg [Br]* 9:167–168, 1984.
38. Flatt AE: Some pathomechanics of ulnar drift. *Plast Reconstr Surg* 37:295–303, 1966.
39. Flatt AE: Digital artery sympathectomy. *J Hand Surg [Am]* 5:550–556, 1980.
40. Fleischer A, McGrath MH: Rheumatoid nodulosis of the hand. *J Hand Surg [Am]* 9:404–411, 1984.
41. Foliart DE: Swanson silicone finger joint implants: a review of the literature regarding long-term complications. *J Hand Surg [Am]* 20:445–449, 1995.
42. Gainor BJ, Hummel GL: Correction of rheumatoid swan-neck deformity by lateral band mobilization. *J Hand Surg [Am]* 10:370–376, 1985.
43. Gainor BJ, Schaberg J: The rheumatoid wrist after resection of the distal ulna. *J Hand Surg [Am]* 10:837–844, 1985.
44. Goodman SM, Paget S: Perioperative drug safety in patients with rheumatoid arthritis. *Rheum Dis Clin North Am* 38:747–759, 2012.
45. Harris C, Jr, Riordan DC: Intrinsic contracture in the hand and its surgical treatment. *J Bone Joint Surg Am* 36:10–20, 1954.
46. Harrison SH: Reconstruction arthroplasty of the metacarpophalangeal joint using the extensor loop operation. *Br J Plast Surg* 24:307–309, 1971.
47. Hindley CJ, Stanley JK: The rheumatoid wrist: patterns of disease progression. *J Hand Surg [Br]* 16:275–279, 1991.
48. Howe CR, Gardner GC, Kadel NJ: Perioperative medication management for the patient with rheumatoid arthritis. *J Am Acad Orthop Surg* 14:544–551, 2006.
49. Hume MC, Gellman H, McKellop H, et al: Functional range of motion of the joints of the hand. *J Hand Surg [Am]* 15:240–243, 1990.
50. Iselin F, Conti E: Long-term results of proximal interphalangeal joint resection arthroplasties with a silicone implant. *J Hand Surg [Am]* 20:S95–S97, 1995.
51. Ishikawa H, Murasawa A, Nakazono K: Long-term follow-up study of radiocarpal arthrodesis for the rheumatoid wrist. *J Hand Surg [Am]* 30:658–666, 2005.
52. Ito J, Koshino T, Okamoto R, et al: Radiologic evaluation of the rheumatoid hand after synovectomy and extensor carpi radialis longus transfer to extensor carpi ulnaris. *J Hand Surg [Am]* 28:585–590, 2003.
53. Jain A, Ball C, Freidin AJ, et al: Effects of extensor synovectomy and excision of the distal ulna in rheumatoid arthritis on long-term function. *J Hand Surg [Am]* 35:1442–1448, 2010.
54. Jain A, Witbreuk M, Ball C, et al: Influence of steroids and methotrexate on wound complications after elective rheumatoid hand and wrist surgery. *J Hand Surg [Am]* 27:449–455, 2002.
55. Jennings CD, Livingstone DP: Surface replacement arthroplasty of the proximal interphalangeal joint using the PIP-SRA implant: results, complications, and revisions. *J Hand Surg* 33A:1565.e1–1565.e11, 2008.
56. Johnstone BR: Proximal interphalangeal joint surface replacement arthroplasty. *Hand Surg* 6:1–11, 2001.
57. Jones NF, Imbriblia JE, Steen VD, et al: Surgery for scleroderma of the hand. *J Hand Surg [Am]* 12:391–400, 1987.
58. Jones NF, Raynor SC, Medsger TA: Microsurgical revascularization of the hand in scleroderma. *Br J Plast Surg* 40:264–269, 1987.
59. Kirschenbaum D, Schneider LS, Adams DC, et al: Arthroplasty of the metacarpophalangeal joints with the use of silicone-rubber implants in patients who have rheumatoid arthritis: long-term results. *J Bone Joint Surg Am* 75:3–12, 1993.
60. Kleinert HE, Sunil TM: Use of volar plate for reconstructing the radial collateral ligament after metacarpophalangeal arthroplasty of fingers in rheumatoid arthritis: surgical technique. *J Hand Surg [Am]* 30:390–393, 2005.
61. Kluge S, Schindele S, Henkel T, et al: The modified Clayton-Mannerfelt arthrodesis of the wrist in rheumatoid arthritis: operative technique and report on 93 cases. *J Hand Surg [Am]* 38:999–1005, 2013.
62. Larsen A, Dale K, Eek M, et al: Radiographic evaluation of rheumatoid arthritis by standard reference films. *Acta Radiol Diagn (Stockh)* 18:481–491, 1977.

63. Leibovic SJ: Arthrodesis of the interphalangeal joints with headless compression screws. *J Hand Surg [Am]* 32:1113–1119, 2007.
64. Leslie BM, Carlson G, Ruby LK: Results of extensor carpi ulnaris tenodesis in the rheumatoid wrist undergoing a distal ulnar excision. *J Hand Surg [Am]* 15:547–551, 1990.
65. Linscheid RL: Implant arthroplasty of the hand: retrospective and prospective considerations. *J Hand Surg [Am]* 25:796–816, 2000.
66. Linscheid RL, Dobyns JH: Radiolunate arthrodesis. *J Hand Surg [Am]* 10:821–829, 1985.
67. Mannerfelt LG, Malmsten M: Arthrodesis of the wrist in rheumatoid arthritis: a technique without external fixation. *Scand J Plast Reconstr Surg* 5:124–130, 1971.
68. Mannerfelt LG, Norman O: Attrition ruptures of flexor tendons in rheumatoid arthritis caused by bony spurs in the carpal tunnel: a clinical and radiological study. *J Bone Joint Surg Br* 51:270–277, 1969.
69. McGrath MH, Fleischer A: The subcutaneous rheumatoid nodule. *Hand Clin* 5:127–133, 1989.
70. Mikic ZD, Helal B: The value of the Darrach procedure in the surgical treatment of rheumatoid arthritis. *Clin Orthop Relat Res* 127:175–185, 1977.
71. Millender LH, Nalebuff EA: Metacarpophalangeal joint arthroplasty utilizing the silicone rubber prosthesis. *Orthop Clin North Am* 4:349–371, 1973.
72. Millender LH, Nalebuff EA: Arthrodesis of the rheumatoid wrist: an evaluation of sixty patients and a description of a different surgical technique. *J Bone Joint Surg Am* 55:1026–1034, 1973.
73. Millender LH, Nalebuff EA, Albin R, et al: Dorsal tenosynovectomy and tendon transfer in the rheumatoid hand. *J Bone Joint Surg Am* 56:601–610, 1974.
74. Millender LH, Nalebuff EA, Hawkins RB, et al: Infection after silicone prosthetic arthroplasty in the hand. *J Bone Joint Surg Am* 57:825–829, 1975.
75. Millender LH, Nalebuff EA, Holdsworth DE: Posterior interosseous nerve syndrome secondary to rheumatoid synovitis. *J Bone Joint Surg Am* 55:753–757, 1973.
76. Millender LH, Philips C: Combined wrist arthrodesis and metacarpophalangeal joint arthroplasty in rheumatoid arthritis. *Orthopedics* 1:43–48, 1978.
77. Miller-Breslow A, Millender LH, Feldon PG: Treatment considerations in the complicated rheumatoid hand. *Hand Clin* 5:279–289, 1989.
78. Minamikawa Y, Peimer CA, Ogawa R, et al: In vivo experimental analysis of silicone implants used with titanium grommets. *J Hand Surg [Am]* 19:567–574, 1994.
79. Moore JR, Weiland AJ, Valdata L: Tendon ruptures in the rheumatoid hand: analysis of treatment and functional results in 60 patients. *J Hand Surg [Am]* 12:9–14, 1987.
80. Moore JR, Weiland AJ, Valdata L: Independent index extension after extensor indicis proprius transfer. *J Hand Surg [Am]* 12:232–236, 1987.
81. Motomiya M, Iwasaki N, Minami A, et al: Clinical and radiological results of radiolunate arthrodesis for rheumatoid arthritis: 22 wrists followed for an average of 7 years. *J Hand Surg Am Aug* 38:1484–1491, 2013.
82. Mountney J, Blundell CM, McArthur P, et al: Free tendon interposition grafting for the repair of ruptured extensor tendons in the rheumatoid hand: a clinical and biomechanical assessment. *J Hand Surg [Br]* 23:662–665, 1998.
83. Murray P: Surface replacement arthroplasty of the proximal interphalangeal joint. *J Hand Surg [Am]* 32:899–904, 2007.
84. Murray PM: Current concepts in the treatment of rheumatoid arthritis of the distal radioulnar joint. *Hand Clin* 27:49–55, 2011.
85. Nalebuff EA: Diagnosis, classification and management of rheumatoid thumb deformities. *Bull Hosp Jt Dis* 29:119–137, 1968.
86. Nalebuff EA: Metacarpophalangeal surgery in rheumatoid arthritis. *Surg Clin North Am* 49:823–832, 1969.
87. Nalebuff EA: The rheumatoid swan-neck deformity. *Hand Clin* 5:203–214, 1989.
88. Nalebuff EA: Factors influencing the results of implant surgery in the rheumatoid hand. *J Hand Surg [Br]* 15:395–403, 1990.
89. Nalebuff EA: Surgery of systemic lupus erythematous arthritis of the hand. *Hand Clin* 12:591–602, 1996.
90. Nalebuff EA: Surgery of psoriatic arthritis of the hand. *Hand Clin* 12:603–614, 1996.
91. Nalebuff EA, Garrett J: Opera-glass hand in rheumatoid arthritis. *J Hand Surg [Am]* 1:210–220, 1976.
92. Nalebuff EA, Garrod KJ: Present approach to the severely involved rheumatoid wrist. *Orthop Clin North Am* 15:369–380, 1984.
93. Nalebuff EA, Millender LH: Arthrodesis of the rheumatoid wrist: functional evaluation of a modified technique. *Orthop Rev* 1:13–18, 1972.
94. Nalebuff EA, Millender LH: Surgical treatment of the swan-neck deformity in rheumatoid arthritis. *Orthop Clin North Am* 6:733–752, 1975.
95. Nalebuff EA, Millender LH: Surgical treatment of the boutonnière deformity in rheumatoid arthritis. *Orthop Clin North Am* 6:753–763, 1975.
96. Nalebuff EA, Patel MR: Flexor digitorum sublimis transfer for multiple extensor tendon ruptures in rheumatoid arthritis. *Plast Reconstr Surg* 52:530–533, 1973.
97. Nalebuff EA, Potter TA: Rheumatoid involvement of tendon and tendon sheaths in the hand. *Clin Orthop Relat Res* 59:147–159, 1968.
98. Norris RW, Brown HG: The proximal interphalangeal joint in systemic sclerosis and its surgical management. *Br J Plast Surg* 38:526–531, 1985.
99. Oster LH, Blair WF, Steyers CM, et al: Crossed intrinsic transfer. *J Hand Surg [Am]* 14:963–971, 1989.
100. Parker WL, Rizzo M, Moran SL, et al: Preliminary results of nonconstrained pyrolytic carbon arthroplasty for metacarpophalangeal joint arthritis. *J Hand Surg [Am]* 32:1496–1505, 2007.
101. Parkkila T, Belt EA, Hakala M, et al: Comparison of Swanson and Sutter metacarpophalangeal arthroplasties in patients with rheumatoid arthritis: a prospective and randomized trial. *J Hand Surg* 30A:1276–1281, 2005.
102. Ratliff AHC: Deformities of the thumb in rheumatoid arthritis. *Hand* 3:138–143, 1971.
103. Raven EE, Ottink KD, Doets KC: Radiolunate and radioscapholunate arthrodeses as treatments for rheumatoid and psoriatic arthritis: long-term follow-up. *J Hand Surg [Am]* 37:55–62, 2012.
104. Rayan GM, Brentlinger A, Purnell D, et al: Functional assessment of bilateral wrist arthrodeses. *J Hand Surg [Am]* 12:1020–1024, 1987.
105. Rizzo M, Cooney WP: Current concepts and treatment for the rheumatoid wrist. *Hand Clin* 27:57–72, 2011.
106. Rose JH, Belsky MR: Psoriatic arthritis in the hand. *Hand Clin* 5:137–144, 1989.
107. Rothfield N: Clinical features of systemic lupus erythematosus. In Kelly WN, Harris ED, Ruddy S, et al, editors: *Textbook of rheumatology*, ed 2, Philadelphia, 1985, WB Saunders, pp 1106–1132.
108. Rothwell AG, Cragg KJ, O'Neill LB: Hand function following Silastic arthroplasty of the metacarpophalangeal joints in the rheumatoid hand. *J Hand Surg [Br]* 22:90–93, 1997.
109. Ruby LK, Ferenz CF, Dell PC: The pronator quadratus interposition transfer: an adjunct to resection arthroplasty of the distal radioulnar joint. *J Hand Surg [Am]* 21:60–65, 1996.
110. Ryu J, Saito S, Honda T, et al: Risk factors and prophylactic tenosynovectomy for extensor tendon ruptures in the rheumatoid hand. *J Hand Surg [Br]* 23:658–661, 1998.
111. Schmidt K, Willburger R, Ossowski A, et al: The effect of the additional use of grommets in silicone implant arthroplasty of the metacarpophalangeal joints. *J Hand Surg [Br]* 24:561–564, 1999.
112. Schneller S: Medical considerations and perioperative care for rheumatoid surgery. *Hand Clin* 5:115–126, 1989.
113. Shapiro JS: The etiology of ulnar drift: a new factor. *J Bone Joint Surg Am* 50:634, 1968.
114. Smith EM, Juvinall RC, Bender LF, et al: Flexor forces and rheumatoid metacarpophalangeal deformities: clinical implications. *JAMA* 198:130–134, 1966.
114a. Spoor C, Landsmeer JMF: Analysis of the zigzag movement of the human finger under influence of the extensor digitorum tendon and the deep flexor tendon. *J Biomechanics* 9:561–566, 1976.
115. Suzuki M, Nishida K, Soen S, et al: Risk of postoperative complications in rheumatoid arthritis relevant to treatment with biologic agents: a report from the Committee on Arthritis of the Japanese Orthopaedic Association. *J Orthop Sci* 16:778–784, 2011.
116. Swanson AB: Finger joint replacement by silicone rubber implants and the concept of implant fixation by encapsulation. *Ann Rheum Dis* 28(Suppl):47–55, 1969.
116a. Swanson AB: Implant arthroplasty for disabilities of the distal radioulnar joint. *Orthop Clin North Am* 4:373–382, 1973.
117. Swanson AB, de Groot Swanson G: Pathogenesis and pathomechanics of the rheumatoid deformities in the hand and wrist. *Orthop Clin North Am* 4:1039–1056, 1973.
118. Swanson AB, Maupin BK, Gajjar NV, et al: Flexible implant arthroplasty in the proximal interphalangeal joint of the hand. *J Hand Surg [Am]* 10:796–805, 1985.
119. Stanley JK: Soft tissue surgery in rheumatoid arthritis of the hand. *Clin Orthop Relat Res* 366:78–90, 1999.
120. Stein AB, Terrono AL: The rheumatoid thumb. *Hand Clin* 12:541–550, 1996.
121. Takigawa S, Meletiou S, Sauerbier M, et al: Long-term assessment of Swanson implant arthroplasty in the proximal interphalangeal joint of the hand. *J Hand Surg [Am]* 29:785–795, 2004.
122. Taleisnik J: Combined radiocarpal arthrodesis and midcarpal (lunocapitate) arthroplasty for treatment of rheumatoid arthritis. *J Hand Surg [Am]* 12:1–8, 1987.
123. Taleisnik J: Rheumatoid arthritis of the wrist. *Hand Clin* 5:257–278, 1989.
124. Terrono A, Millender L, Nalebuff E: Boutonnière rheumatoid thumb deformity. *J Hand Surg [Am]* 15:999–1003, 1990.
125. Thirupathi RG, Ferlic DC, Clayton ML: Dorsal wrist synovectomy in rheumatoid arthritis—a long-term study. *J Hand Surg [Am]* 8:848–856, 1983.
126. Thompson JS, Littler JW, Upton J: The spiral oblique retinacular ligament (SORL). *J Hand Surg [Am]* 3:482–487, 1978.
127. Tonkin MA, Beard AJ, Kemp SJ, et al: Sesamoid arthrodesis for hyperextension of the thumb metacarpal joint. *J Hand Surg [Am]* 20:334–338, 1995.
128. Trieb K, Machacek P, Hofstaetter SG, et al: Radio-lunate arthrodesis in rheumatoid arthritis: outcome and techniques. *Arch Orthop Trauma Surg* 133:729–734, 2013.

129. van Lankveld W, van't Pad BP, van der Schaaf D, et al: Evaluating hand surgery in patients with rheumatoid arthritis: short-term effect on dexterity and pain and its relationship with patient satisfaction. *J Hand Surg [Am]* 25:921–929, 2000.
130. Vaughan-Jackson OJ: Rupture of extensor tendons by attrition at the inferior radioulnar joint: report of two cases. *J Bone Joint Surg Br* 30:528–530, 1948.
131. Vincent KA, Szabo RM, Agee JM: The Sauvé-Kapandji procedure for the reconstruction of the rheumatoid distal radioulnar joint. *J Hand Surg [Am]* 18:978–983, 1993.
132. Walton RL, Brown RE, Giansiracusa DF: Psoriatic arthritis mutilans: digital distraction lengthening: pathophysiologic and current therapeutic review. *J Hand Surg [Am]* 13:510–514, 1988.
133. Ward CM, Kuhl T, Adams BD: Five- to ten-year outcomes of the Universal total wrist arthroplasty in patients with rheumatoid arthritis. *J Bone Joint Surg Am* 93:914–919, 2011.
134. Watts AC, Hearnden AJ, Trail IA, et al: Pyrocarbon proximal interphalangeal joint arthroplasty: minimum two-year follow-up. *J Hand Surg* 37A:882–888, 2012.
135. Weinstein LP, Berger RA: Analgesic benefit, functional outcome, and patient satisfaction after partial wrist denervation. *J Hand Surg [Am]* 27:833–839, 2002.
136. Weiss AC, Moore DC, Infantolino C, et al: Metacarpophalangeal joint mechanics after 3 different silicone arthroplasties. *J Hand Surg* 30A:796–803, 2004.
137. Wilde AH, Sawmiller SR: Synovectomy of the proximal interphalangeal joint in rheumatoid arthritis. *J Bone Joint Surg Am* 56:71–78, 1974.
138. Williamson SC, Feldon P: Extensor tendon ruptures in rheumatoid arthritis. *Hand Clin* 11:449–459, 1995.
139. Wilson YG, Sykes PJ, Niranjan NS: Long-term follow-up of Swanson's Silastic arthroplasty of the metacarpophalangeal joints in rheumatoid arthritis. *J Hand Surg [Br]* 18:81–91, 1993.
140. Wood VE, Ichtertz DR, Yahiku H: Soft tissue metacarpophalangeal reconstruction for treatment of rheumatoid hand deformity. *J Hand Surg [Am]* 14:163–174, 1989.
141. Zancolli EA: Claw-hand caused by paralysis of the intrinsic muscles: a simple surgical procedure for its correction. *J Bone Joint Surg Am* 39:1076–1080, 1957.

56

Tendinopathy

Scott W. Wolfe

Acknowledgment: I would like to thank Dr. Avrum Froimson for his superb and comprehensive chapter "Tenosynovitis" that appeared in several previous editions of this book and constituted the framework from which this chapter was written.

These videos may be found at *ExpertConsult.com:*
Video 56.1 Percutaneous trigger finger release.
Video 56.2 Dynamic ultrasound. *(Copyright © Mukund Patel, MD.)*

Tendinopathy is a term used to encompass painful conditions affecting the tendons of the wrist and hand and is perhaps the most common reason for a visit to a hand surgeon. Tendinopathy includes conditions such as tendon entrapment and stenosis (e.g., trigger finger, de Quervain disease), as well as inflammatory conditions (*tenosynovitis*). Strictly defined, *tenosynovitis* refers to inflammation of the synovial lining of a tendon sheath and is abundantly demonstrated by the diffuse, invasive synovitis associated with rheumatoid arthritis (RA) or other inflammatory arthropathies. Such proliferative tenosynovitis is relatively uncommon, is erosive, is not restricted to the retinacular thickenings of the tendon sheath, and may lead to tendon rupture. Other causes of inflammatory or proliferative tenosynovitis include deposition diseases such as amyloidosis, crystalline tendinopathy (e.g., calcific tenosynovitis or gout), and septic tenosynovitis, including bacterial, mycobacterial, and viral agents.

A far more common condition than proliferative tenosynovitis is *tendon entrapment* or *stenosing tendovaginitis*,[13] caused by narrowing or stenosis of a tendon's retinacular sheath. The two most common conditions are *trigger finger* and *de Quervain disease*. Because there is a paucity of inflammatory tissue associated with tendon entrapment,[36] the term *tenosynovitis*, when used to describe these conditions, is misleading and inaccurate from an etiologic perspective. Tendon entrapment occurs about the narrow fibroosseous canals that provide fulcrums for acute angulation of the digital and wrist tendons. Repeated motion of a tendon through such a narrow passageway can cause hypertrophy and fibrosis of the retinacular sheath[34] that results in an impediment to gliding, edema, and, ultimately, catching or locking of the tendon on either side of the sheath. Rarely, these conditions may be initiated by direct trauma. Tendon entrapment is initially characterized by local pain, swelling, and crepitus. Over time, the affected retinacular sheath responds by thickening (up to three times its normal diameter) and undergoes fibrocartilaginous metaplasia.[97] Pathologic examination rarely demonstrates hypertrophied synovium but rather thickening, nodularity, and attritional changes within the tendon, accompanied by gross thickening of the overlying sheath. These conditions as a group respond well in the early phase to conservative measures such as ice, splinting, and rest. Recalcitrant cases respond well to one or more corticosteroid injections. Surgical release of the retinacular sheath is definitive treatment because recurrence is rare.

PROLIFERATIVE TENOSYNOVITIS

Rheumatoid Arthritis

It has been estimated that tenosynovitis of the hand and wrist will develop in 64 to 95% of patients with RA.[9] The process may begin within the synovial lining of the tendon sheath, or it may invade the tendon from involvement of a contiguous joint. Rheumatoid tenosynovitis produces relatively painless bulky swelling along the entire extent of the synovial sheath and is most noticeable at the retinacular boundaries. Because of the thin, expansile dorsal skin of the hand, the disease may be quite prominent dorsally and produce noticeable swelling from the distal retinaculum to the metacarpal bases. The process can easily be differentiated from common wrist tumors such as ganglia or lipomas by the mobility of the mass with the extensor tendons and the tendency of the mass to bunch (the characteristic *tuck sign*) at the retinacular edge with active digital extension.[9] Tenosynovitis of RA is most common on the ulnar border of the wrist over the distal radioulnar joint and most frequently involves the fourth, fifth, and sixth dorsal compartments.

On the flexor surface, the earliest signs of considerable flexor tenosynovitis may be painful paresthesias caused by median nerve entrapment beneath the unyielding transverse carpal ligament. With time, palmar nodularity along the flexor tendons, crepitus, and frank triggering will develop in more than a third of patients with RA. Fusiform swelling of one or more digital flexor sheaths may cause a substantial impediment to flexion, pain, and stiffness mimicking rheumatoid arthropathy of the interphalangeal (IP) joints. Rarely, a finger may trigger in RA from entrapment of the profundus tendon by synovitis at the superficialis decussation (Camper chiasm). Helal described the cardinal sign of this syndrome as an inability to flex the distal interphalangeal (DIP) joint when the proximal interphalangeal (PIP) joint was held passively by the examiner in full flexion.[53]

For a more detailed discussion of rheumatoid tenosynovitis and the medical and surgical treatment options, the reader is referred to Chapter 55.

Crystalline Tendinopathy

Gout

Precipitation of crystalline material within the confines of an enclosed space (joint or tenosynovial space) incites an acute, fulminant inflammatory reaction marked by intense swelling, erythema, and pain. Gout is a disorder of urate metabolism in which the overproduction of uric acid causes hyperuricemia and hyperuricosuria.[25]

Gout affects over 6 million individuals in the United States and the incidence is reported to be rising.[21] The low solubility of monosodium urate is responsible for its crystallization and deposition in peripheral sites, including subcutaneous, intraarticular, and tenosynovial locations. Attempted phagocytosis by peripheral leukocytes releases lysosomal enzymes that produce an intense inflammatory synovitis. If left unchecked, the disease results in the formation of gouty *tophi*, which are large, lobulated subcutaneous deposits of monosodium urate crystals commonly seen in the pinna of the ear and the great toe.[107] Deposition in the hand occurs relatively late in the disease and is uncommon with good medical management.[79] Radiographic manifestations of gouty arthritis may precede symptoms in up to 25% of patients and precedes deposition of gouty tophi in up to 42%.[6] Gouty arthritis is manifested by acute and rapidly escalating joint pain over the first 24 hours, followed by spontaneous resolution over the next week to 10 days. Medical control of the disease is the mainstay of treatment. Gouty tenosynovitis in the hand can be present without visible tophi or previous involvement of the upper extremity. Often called "the great imitator," gout may masquerade as septic arthritis, RA, or neoplasm, and the diagnosis is often delayed by weeks or months. Initial signs of flexor tendon involvement include marked pain, erythema, acute swelling, and warmth suggestive of acute suppurative tenosynovitis.[1,11,43,79] Gouty flexor tenosynovitis within the carpal tunnel can compromise the median nerve and result in acute carpal tunnel syndrome.[43,79] In unsuspected cases, an intense exudative inflammatory reaction can occur after carpal tunnel release that mimics infection but responds well to antiinflammatory medications and uricosuric agents.[43] Gout can rarely coexist with RA, but it is perhaps more frequently misdiagnosed as RA because of its proliferative synovitis[1] and because 10% to 20% of patients with RA have elevated uric acid levels.[107]

Because hyperuricemia can be found in 5 to 7% of adult men, a diagnosis of gout should not be based on laboratory values alone. The combination of joint or tenosynovial aspiration, gram-stained smear results, and examination under polarized light is 85% sensitive for the diagnosis of gout and may be helpful in differentiating acute gouty tenosynovitis from RA or infection. Suspected pathologic material must be transported to the laboratory in ethanol rather than formalin to prevent degradation of the monosodium urate crystals. Compensated polarized light microscopy will demonstrate negatively birefringent (urate) crystals within the granuloma and histologic features otherwise typical of RA.

Other sites of gouty tenosynovial involvement in the hand include the extensor tendons at the dorsal retinaculum, a localized painful mass in the midpalm, and tophi over the dorsal aspect of the IP or metacarpophalangeal (MP) joints. Neglected cases can proceed to intratendinous infiltration,[1] flexion contractures,[107] tendon rupture,[79] and skin ulceration in extreme cases. Acute attacks are generally well handled by the administration of colchicine and antiinflammatory agents. Prophylactic perioperative treatment is recommended to reduce the chance of a postoperative flare-up.[79]

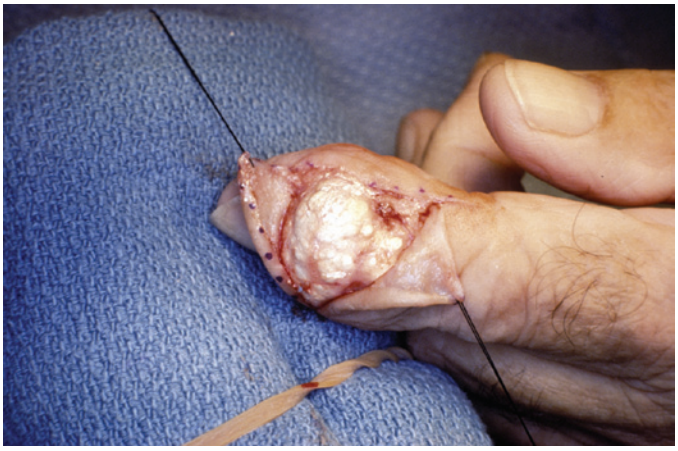

FIGURE 56.1 Excision of gouty tophus involving the extensor tendons and distal interphalangeal joint. Meticulous skin flap handling is necessary to avoid skin sloughing and wound breakdown.

Indications for operative management include synovectomy for restoration of mobility, tendon transfers for tendon rupture, decompression for median nerve compression, and removal of painful or disfiguring tophi to prevent skin breakdown and infection (Figure 56.1). When excising gouty tophi, care should be taken not to devascularize involved or compromised skin. Skin grafts are rarely necessary for coverage. Curettage is useful for bony involvement, and extensive stripping of periosteum is avoided. No attempt should be made to completely eradicate a tophus if excision would damage vital neurovascular structures or impair function. Bulky compression dressings are recommended to reduce dead space. Recurrence is rare after subtotal excision of gouty tophi and ample medical management.[107]

Calcific Tendinitis

An acute, intensely painful synovitis can accompany the release of calcium salts into the intrasynovial space in joints or tenosynovial sheaths and can resemble an infectious process.[18,80] The disease is not unlike the deposition of calcium about major joints in the body, as exemplified by calcific bursitis of the hip, knee, shoulder, and elbow. Hypercalcemia is neither necessary nor sufficient to produce ectopic calcifications, and elevated laboratory values and systemic signs are characteristically lacking.

The cause of calcific tendinitis of the hand and wrist is unknown. Neither trauma nor repetitive use can be implicated, and the disorder occurs more commonly in men (40 to 60 years of age) than women (5:1) and rarely in children.[50,75] The most common site is the flexor carpi ulnaris (FCU), although any of the flexors or extensors of the wrist may be afflicted. Histologic studies of crystalline material collected at surgery may demonstrate hydroxyapatite, which may induce the acute inflammatory reaction. As in other types of inflammatory synovitis, carpal tunnel syndrome has been reported to result from acute calcific tenosynovitis about the flexor tendons.[84]

The patient may present for treatment of a "septic" tendon or joint but demonstrates a striking lack of systemic findings.[18] The patient seldom has a history of penetrating trauma or previous infection. Although erythema is present, the pattern differs from that seen in cellulitis in that it seldom streaks proximally. The area of acute inflammation is typically more confined and localized. Radiographs should be carefully scrutinized for "fluffy" calcification in the area of symptoms or small soft tissue calcium deposits (Figure 56.2, *A* and *B*). Patients may recall similar events in the past. The diagnosis is frequently delayed, presumably because of confusion with infection.[80]

Treatment with oral nonsteroidal antiinflammatory agents for 5 to 7 days is usually successful. Symptoms often subside within 24 hours. For patients who may not take these agents, a prepackaged tapered methylprednisolone oral dose pack (Medrol Dosepak) can be used. Splinting the afflicted joint may also lessen the pain. Although direct aspiration and injection of corticosteroids with lidocaine can be performed, this is seldom needed. Follow-up radiographs will generally show complete disappearance of small deposits in 2 to 4 weeks. Resistant or chronic cases with large calcific deposits may require surgical excision, but this is an exception. Incision of the affected tendon will allow extrusion of the material, which resembles "toothpaste."[18]

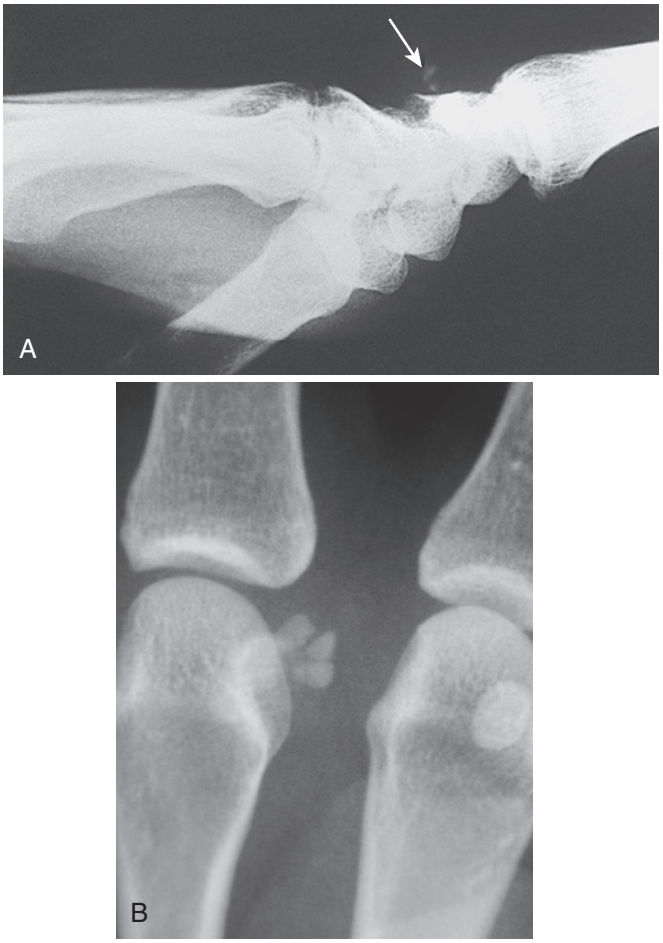

FIGURE 56.2 **A,** A small calcific deposit within the extensor carpi ulnaris tendon sheath (*arrow*) explained the extreme pain and loss of motion experienced by this 28-year-old businessman. **B,** Fluffy calcifications at the level of the A1 pulley appeared 1 week after the onset of excruciating pain along the flexor sheath that mimicked acute septic flexor tenosynovitis in this 38-year-old woman with no history of penetrating trauma. The symptoms resolved with antiinflammatory agents and splinting.

Other Crystalline Tendinopathies

Pseudogout. Rarely, calcium pyrophosphate dihydrate (CPPD, or pseudogout) can precipitate within the carpal tunnel and cause an acute fulminant inflammatory tenosynovitis with resultant carpal tunnel syndrome.[11,22] Radiographs may reveal fluffy soft tissue calcifications within the carpal tunnel and often show calcifications within the triangular fibrocartilage complex (TFCC). Pathologic examination reveals rhomboid-shaped crystals with faintly positive birefringence under polarized light.

Hydroxyapatite Deposition. Deposition of hydroxyapatite has also been reported to cause an acute carpal tunnel syndrome that is recalcitrant to antiinflammatory agents and rest.[114] Both conditions are best treated by early decompression and excision of the crystalline material.

Amyloid Deposition

Amyloidosis is a condition resulting from the deposition of a low-molecular-weight serum protein, β_2-microglobulin, in the bones and soft tissues. Excess protein accumulation can result from a rare primary enzymatic defect (Meretoja syndrome)[93] but more commonly occurs in patients with renal failure who are undergoing peritoneal dialysis or hemodialysis. The protein is not filtered by standard dialysis membranes, and the severity of the disease is proportional to the age at initiation of hemodialysis and the duration of treatment.

Hand involvement in amyloidosis is usually characterized by cystic lesions in the carpal bones and destructive arthropathy involving the wrist and IP joints. Thick, plaquelike accumulations along the flexor tendons can cause trigger fingers, carpal tunnel syndrome, flexion contractures, and tendon rupture, usually without signs of inflammation. In a patient undergoing renal dialysis, paresthesias in the median nerve distribution and diminished active motion are strongly suggestive of amyloid deposition within the carpal canal. Surgical decompression along with débridement and complete removal of amyloid "tenosynovium" is effective in relieving symptoms, which usually do not recur (Figure 56.3). Trigger fingers should be



FIGURE 56.3 The more extended operative exposure required for amyloid-induced carpal tunnel syndrome. Note the extensive hypertrophied synovium excised from around the flexor tendons.

approached through standard incisions in the midpalm, and complete tenosynovectomy and division of the A1 pulley should be performed. Digital tenosynovitis may be excised through Bruner incisions, with retention of all other annular pulleys.

Ochronosis

Alkaptonuria is an extremely rare autosomal recessive defect of tryptophan metabolism caused by a deficiency in the enzyme homogentisic acid oxidase. As a result, unmetabolized homogentisic acid is excreted in urine and deposited in the joints and soft tissues (ochronosis). The protein deposits have a characteristic dark pigmentation that causes darkened urine and deep staining of collagenous tissue. Joint deposition or accumulation in the intervertebral disk can lead to severe destructive arthropathy. The protein may be deposited within tendons[70] and has been demonstrated to cause stenosing tenosynovitis. Seradge reported a case involving multiple digits of both hands that was unresponsive to corticosteroid injection. Surgical release of the A1 pulley was successful at eliminating the symptoms.[102]

Septic Tenosynovitis

Acute suppurative flexor tenosynovitis is covered in Chapter 3.

Chronic Tenosynovitis

Certain indolent infections can be manifested as subacute tenosynovitis and must be included in the differential diagnosis. Such infections include tuberculosis,[15] atypical *Mycobacterium* infection,[62] gonococcal tenosynovitis, and fungal infections. These chronic infections are discussed in detail in Chapter 3.

Sarcoid

On occasion, sarcoidosis can be manifested as digital flexor tenosynovitis and must be included in the differential diagnosis of isolated, inflammatory tenosynovitis.[38,74] Sarcoidosis is a systemic, immune-mediated granulomatous disease that primarily affects the lungs, spleen, and lymph nodes but may be manifested as bone, joint, or tenosynovial involvement in approximately 25% of patients. Radiographs of affected hands typically reveal well-defined cystic granulomatous lesions in the phalanges. The causative agent that triggers sarcoidosis has not been identified. Its progression is variable, with spontaneous regression in some but progression to a chronic fibrotic state in others.[35] The disease is more common in women than men and affects blacks 10 times more frequently than whites in the United States. Sarcoidosis may precipitate secondary gout because of an overproduction of purines in the proliferative granulomas. Treatment includes surgical tenosynovectomy and systemic corticosteroids.[74] Histopathologic examination of the excised material demonstrates noncaseating granulomas, as well as epithelioid and multinucleated giant cells.

Tendon Entrapment

Tendon entrapment (formerly known as *stenosing tenosynovitis*) refers to mechanical impingement of a tendon in the hand or wrist caused by narrowing of its retinacular sheath. Unfortunately, tenosynovitis is generally very broadly defined and has been used to describe a heterogeneous collection of vague aching conditions of the upper extremity. *Tendovaginitis* (Latin for "tendon sheath" and Greek for "inflammation") may be a more precise term than *tenosynovitis* to describe the thickened retinacular sheath that characterizes these conditions. In 1952, Burman[13] tried to clarify the definition as follows: "Tendovaginitis is not tenosynovitis. Before there is stenosing tendovaginitis, there must be nonstenosing tendovaginitis. It takes time to make a sheath stenotic. The latter is reversible, the former is not." As the term *tendovaginitis* is considered archaic, this group of conditions is best simply described as *tendon entrapment*.

Histologic Findings

The most common types of tendon entrapments are de Quervain disease and trigger digits, although the process has been reported to affect each of the tendons of the hand and wrist. Inflammation has been cited as the common denominator of a number of affectations of the upper extremity, including de Quervain disease, trigger digits, and carpal tunnel syndrome. In patients without a known history of inflammatory disease, several studies have failed to detect acute or chronic inflammatory cells in tenosynovial biopsy samples taken from patients undergoing carpal tunnel release.[40,58,100] Similarly, in Fahey and Bollinger's pathologic analysis of synovium from adults and children who underwent trigger release, synovial proliferation was uncommon (one case), and pathologic findings of degeneration, vascular proliferation, and cartilage formation were limited to the retinacular sheath.[34] Similar histologic analysis of tissue removed during tenolysis for de Quervain disease or stenosis of the flexor carpi radialis (FCR) tendon documented perisynovial fibrous tissue and endothelial proliferation with a paucity of inflammatory tissue. The lack of pronounced inflammatory findings within the tenosynovium and the demonstration of fibrotic thickening in the retinacular ligament prompted Garsten in 1951 to coin the term *peritendinitis stenosans* and to suggest that the conditions may be related more to intrinsic anatomic and degenerative changes than to occupational factors.[41]

Causative Factors

Although the cause of tendon entrapment is disputed, certain epidemiologic factors are apparent. These conditions tend to cluster in certain patients, with coexistence of carpal tunnel syndrome, trigger digits, de Quervain disease, epicondylitis, and subacromial bursitis implicating a more systemic yet undefined predisposition.[44,85] A recent study demonstrated a three-fold incidence of carpal tunnel syndrome in patients with multiple trigger digits.[117] Each condition is far more common in women than men,[85,87,116] and the peak incidence of trigger digits averaged 55 to 60 years of age in several series.[34] The age distribution of trigger digits has not changed appreciably in more recent series despite an increase in the use of computer keyboards, personal digital assistants, and other "repetitive" tools and tasks in younger individuals.[85,87,97] Bunnell proposed anatomic factors to explain the pronounced difference in prevalence among men and women.[12] Degenerative factors may have an etiologic role in the development of flexor tendon entrapment of the digits, as evidenced by the increased incidence of these disorders in the dominant hand.[85,87,97] Several studies point to a relationship between activities that require exertion of pressure in the palm while performing forceful grip or repetitive digital flexion, such as arc welding, use of heavy shears, or constant handheld tool

work.[13,34] Forceful use is unlikely to be the sole etiologic factor, however, as evidenced by the strikingly low incidence in males and athletes and an age distribution that peaks in the sixth decade. Trezies and colleagues demonstrated no significant difference between the occupational distribution of patients with trigger digits and that of the general population.[111] A recent systematic review of 179 studies could find no causal link between de Quervain disease and occupational risk factors.[104] Other anatomic and intrinsic factors undoubtedly contribute to a predisposition for the development of tendon entrapment in the hand and wrist.

Trigger Digits

Tendon entrapment of the fingers and thumb is one of the most common causes of hand pain and disability. The condition causes painful catching or popping of the involved flexor tendon as the patient flexes and extends the digits. On occasion, the digit will lock in flexion and require passive manipulation of the digit into extension. Rarely, a digit may be locked in extension. Over time, guarding and reluctance on the part of patients to fully range the digit can lead to secondary flexion contractures at the PIP joint.

Pathologic Findings

Twenty-two extrinsic tendons cross the wrist and provide a unique combination of power and dexterity in the hand. Each tendon passes through a series of tight fibroosseous canals designed to optimize the balance between motion and production of force by maintaining the tendon in close apposition to the joint or joints that it controls. Division, attenuation, or rupture of a critical retinacular ligament, or *pulley*, will allow the tendon to drift away from the joint's center of rotation and consequently increase its moment arm for production of force and lead to tendon imbalance and flexion contracture. Pulley disruption also effectively lengthens the tendon and limits its excursion.

The phenomenon of trigger finger is due to mechanical impingement of the digital flexor tendons as they pass through a narrowed retinacular pulley at the level of the metacarpal head.[85,87,97] Proximal phalangeal flexion, particularly with power grip, causes high angular loads at the distal edge of the first annular (A1) pulley. Hueston and Wilson suggested that "bunching" of the interwoven tendon fibers occurs, akin to the effect of pulling a multifilament strand through the eye of a needle[55]; this may be responsible for the reactive intratendinous swelling sometimes noted at surgery.[34] The most remarkable pathologic changes are seen in the pulley itself, which demonstrates gross hypertrophy, described by Bunnell as a "whitish, cicatricial collar-like thickening."[12] Microscopic examination demonstrates degeneration, cyst formation, fiber splitting, and lymphocytic or plasma cell infiltration.[34] Ultrastructural studies comparing normal and trigger A1 pulleys have demonstrated the presence of chondrocytes in the normal innermost, or *friction*, layer of normal A1 pulleys and chondrocyte proliferation and the presence of type III collagen in pathologic pulleys.[97] It is thought that the A1 pulley and the corresponding surface of the flexor tendon undergo fibrocartilaginous metaplasia under the influence of repetitive, compressive loads. A recent study by Miyamoto and colleagues in which a specialized ultrasonographic compression technique was used documented increases in both stiffness and thickness of the A1 pulley in patients with symptomatic triggering; notably, corticosteroid injection reversed these changes within 3 weeks of injection.[76]

Demographics

The most common form of trigger finger is the primary type, which is found predominantly in otherwise healthy middle-aged women with a frequency of two to six times that seen in men.[34,85,87,71] Involvement of several fingers is not unusual; in patients with multiple trigger digits, the most commonly affected digit is the thumb, followed by the ring, long, little, and index fingers.[34] Secondary trigger finger can be seen in patients with diabetes, gout, renal disease, RA, and other rheumatic diseases and is associated with a worse prognosis after conservative or surgical management.[20,44,103] The lifetime incidence of trigger digits has been reported to be 2.2% in nondiabetic adults older than 30 years and up to 10% in patients with insulin-dependent diabetes mellitus.[103]

Although the flexor tendon sheath is constricted at the MP joint, the patient or examining physician often localizes the phenomenon incorrectly to the PIP joint. A locked trigger digit can lead to an incorrect diagnosis of dislocation, Dupuytren disease, and even focal dystonia or hysteria. A locked trigger digit can be confused with so-called *true locking* of the MP joint (see Chapter 8). Except for rare instances of locking caused by a tumor of the tendon or sheath, a loose body in the MP joint, anomalies of the sesamoids, or entrapment of an intrinsic tendon on an irregularity of the metacarpal head,[89] the diagnosis should be straightforward and can be confirmed with a simple lidocaine injection into the flexor sheath to unlock the digit. On occasion, de Quervain disease[115] and tendon entrapment of the extensor pollicis longus (EPL) have been demonstrated to cause triggering of the thumb and may lead to an error in diagnosis. Rarely, localized enlargement of the flexor digitorum profundus can trigger at a stenotic A3 pulley and lead to persistence of symptoms after routine surgical incision of the A1 pulley. Up to a quarter of trigger digits in patients with RA may be due to profundus entrapment by synovitis at the superficialis decussation.

Classification

Attempts have been made to classify triggering, but in one such report by Newport and colleagues,[85] no correlation was found between their grading scheme and outcome after injection therapy. I believe that some type of simple classification is useful if for no other purpose than to provide the clinician with a way to record notes in the patient's chart for retrospective review. Several authors have used a scheme such as the following, originally proposed by Quinnell[90] and modified by David Green (Green DP, personal communication, 1997):[31,48,83,87]

- Grade 1 (pretriggering)—Pain; history of catching, but not demonstrable on physical examination; tenderness over the A1 pulley
- Grade II (active)—Demonstrable catching, but the patient can actively extend the digit
- Grade III (passive)—Demonstrable catching requiring passive extension (grade IIIA) or inability to actively flex (grade IIIB)
- Grade IV (contracture)—Demonstrable catching with a fixed flexion contracture of the PIP joint

Treatment

Nonoperative Management. Most primary trigger digits in adults can be successfully treated nonsurgically with corticosteroid injection or splinting. Early series recommended surgical treatment as straightforward and highly effective and regarded prolonged conservative treatment as "unreliable and expensive."[34] Subsequent follow-up series documented poor results in 7 to 9% of patients after surgical treatment, with complications including reflex sympathetic dystrophy, infection, persistent triggering, stiffness, and nerve injury. More recent reports continue to document infrequent but serious complications, including nerve transection, infection, incisional pain, flexion deformity, pulley rupture, flexor tendon bowstringing, and recurrence.[19,44,52,83,85] The small but finite risk for complications from open trigger release warrants an initial attempt at splinting or corticosteroid injection, or both.

The popularity of corticosteroid injection has waxed and waned over the years. In primary trigger finger and thumb, corticosteroid injection has a highly satisfactory rate of success, particularly in nondiabetic patients with involvement of a single digit, a discrete palpable nodule, and a short duration of symptoms (Table 56.1). Although several authors have demonstrated that improvement after injection is less likely in diabetic patients than in nondiabetic patients, the treatment is not ineffective in diabetic patients, and it is associated with a low complication rate. Rarely, tendon ruptures have been reported after corticosteroid injection, and the cause is difficult to discern. In one case, the flexor pollicis longus (FPL) ruptured in a 62-year-old patient who was opening a file drawer 4 years after two corticosteroid injections for trigger thumb.[109] In a second case, both the superficialis and profundus tendons ruptured in a 77-year-old patient approximately a year after two steroid injections with triamcinolone acetonide (40 mg/mL).[37] In a recently reported case, Gyuricza and colleagues described rupture of multiple flexor tendon pulleys and severe bowstringing after a series of corticosteroid injections for trigger finger.[47] Even though a causative link between a particular corticosteroid preparation and tendon or pulley rupture cannot be made, all authors recommend that intratendinous injection be avoided given the known attritional effects of corticosteroids on collagen. No other serious complications of this technique have been reported. A transient rise in blood and urine glucose levels is common in diabetics,[44] and these patients should be advised that this is likely to occur. Because of the theoretical chance of inhibition of wound healing, it is prudent to wait at least 6 weeks after corticosteroid injection before consideration of open surgical release.

In a novel evidence-based study of cost-effectiveness, Kerrigan and Stanwix investigated five strategies of treatment ranging from one or two corticosteroid injections, followed by surgical release, to immediate open or percutaneous release. They concluded that the strategy of two corticosteroid injections followed by surgery in nonresponders was the least costly algorithm and was 250 to 340% less expensive than immediate surgical release.[59]

Technique of Corticosteroid Injection. There are many different techniques for injection of trigger fingers, but the following is my preferred method. A 3-mL syringe is loaded with 0.9 mL of plain lidocaine (no epinephrine) and 0.1 mL of sodium bicarbonate. Sodium bicarbonate, in a 1:10 mixture, neutralizes the acidity of lidocaine and effectively reduces the pain of injection. (Bupivacaine [Marcaine] should not be used

TABLE 56.1 Outcomes of Steroid Injection for Trigger Digits

Author	Year	Cortisone Preparation	Findings	Number of Digits	Notes
Kolind-Sorensen[61]	1970	Hydrocortisone	67% success overall; 78% for "primary" trigger digits	106	Only 50% success rate with trigger digits secondary to rheumatoid arthritis, diabetes
Lapidus and Guidotti[64]	1972	Methylprednisolone	"Uniformly good results"	41	Follow-up unspecified
Rhoades et al[91]	1984	Methylprednisolone	72% resolution overall; 93% resolution if <4 months	53	Favorable prognosis: single digit, short duration
Freiberg et al[39]	1989	Triamcinolone acetonide	79% resolution overall: 93% for "nodular," 48% for "diffuse"	101	Improved prognosis: nodular vs. diffuse type, shorter duration of symptoms
Marks and Gunther[71]	1989	Triamcinolone acetonide	Single injection: 84% Two injections: 91%	108	Average 44-month follow-up; better outcomes in female patients
Newport et al[85]	1990	Betamethasone sodium phosphate	One to three injections: 77%	338	Favorable prognosis: single digit, <6 months' duration; trigger grade had no effect on outcome
Griggs et al[44]	1995	Betamethasone sodium phosphate	50% success in diabetics: 72% for NIDDM, 44% for IDDM	121	Incidence of multiple trigger digits and failure of injection statistically increased in IDDM population
Murphy et al[82]	1995	Betamethasone sodium phosphate	64% resolution in steroid group, 20% placebo response	24	Sheath distention alone unsuccessful
Stahl et al[103]	1997	Methylprednisolone	Diabetics: 49%	60	Diabetics: higher incidence of diffuse type, multiple digits; 7% complication rate in diabetics
			Nondiabetics: 76%	60	
Ring et al[92]	2008	Triamcinolone vs. dexamethasone	6 weeks: 63%, 3 months 66% 6 weeks: 38%, 3 months: 71%	84 PRCT	Significant improved satisfaction in triamcinolone group at 6 weeks, not sustained at 3 months.

IDDM, Insulin-dependent diabetes mellitus; *NIDDM*, non–insulin-dependent diabetes mellitus; *PRCT*, prospective randomized controlled trial.

when mixing with bicarbonate because precipitation may occur.) One milliliter of soluble corticosteroid solution is added to the mixture; I prefer betamethasone sodium phosphate or acetate, but other preparations such as dexamethasone or triamcinolone hexacetonide are equally satisfactory. A short 25- or 27-gauge needle is applied to the syringe. The hand is prepared with a povidone-iodine or alcohol solution and the digits slightly hyperextended. The metacarpal head is palpated, and the skin sprayed with ethyl chloride solution for a few seconds as a local refrigerant/anesthetic. The needle is introduced through the frosted skin and directly into the flexor tendon over the metacarpal head (Figure 56.4). Needle placement can be confirmed if necessary by disengaging the syringe from the needle and asking the patient to bend the digit gently; however, injection studies have demonstrated similar outcomes in patients with extrasynovial injection of corticosteroid.[57] Light pressure is applied to the plunger while simultaneously withdrawing the needle slowly. When the needle tip emerges from the tendon substance, dramatic relief of resistance is felt, and a fluid wave may be palpated throughout the tendon sheath proximal and distal to the injection site. Generally, no more than 1 to 2 mL of the solution can be injected. The needle is withdrawn and slight digital pressure applied. As an alternative to midline injection, Carlson and Curtis prefer a midaxial injection site at the level of the midproximal phalanx.[17]

Splinting. For those who decline injection, some consideration should be given to splinting the involved digit. To test the efficacy of simple splinting for trigger digits, Patel and Bassini compared the outcomes of splinting the MP joint in 15 degrees of flexion with a single injection of betamethasone.[87] At a 1-year follow-up, 66% of all digits splinted were symptom free versus 84% of the injected digits. The authors concluded that splinting is an efficacious alternative for patients who are reluctant to consider corticosteroid injection. Rodgers and associates demonstrated 55% resolution of early trigger digits in 31 workers after splinting the DIP joint in full extension for 6 weeks.[94] They proposed that limitation of profundus gliding, decreased differential gliding of the flexor tendons within the sheath, decreased overall use of the digit, or a combination of these factors were responsible for resolution of the symptoms in this manual laborer population.

Surgical Treatment

PERTINENT ANATOMY

The flexor digitorum profundus and superficialis tendons enter a narrow fibroosseous tunnel formed by a groove in the palmar surface of the metacarpal neck and the annular ligament. Doyle and Blythe demonstrated that the flexor sheath in the finger is a double-walled, hollow, synovial-lined, connective tissue tube that encloses the flexor tendons.[28,29] These authors identified four annular and three cruciform pulleys (Figure 56.5). The annular pulleys are thick and rigid. The second pulley (A2), attached to the proximal phalanx, and the fourth pulley (A4) are the most important functionally. It has been shown experimentally that section of only the first annular pulley (A1), as done for surgical release of trigger finger or thumb, produces no loss of flexor function. However, division of both the A1 and A2 pulleys causes substantial postoperative bowstringing and limitation of full active flexion to the distal palmar crease.

The FPL passes through a narrow tunnel formed by the grooved palmar surface of the first metacarpal neck and the transverse fibers of the annular ligament of the flexor sheath (Figure 56.6). The thumb is enclosed in a similar double-layered synovial sheath, and its pulley system consists of one oblique and two annular pulleys.[29] The first annular pulley is 7 to 9 mm wide and located palmar to the MP joint. Embedded on either side of the capsule of the MP joint is a sesamoid bone into which a tendon of one head of the flexor pollicis brevis inserts. This locale is the narrowest point in the FPL sheath and the point at which the constriction develops. Overlying the proximal phalanx is a second pulley that has variably been described as oblique[29] or transverse[7] but is critically important to prevent bowstringing of the FPL. The pulley is 9 to 11 mm wide and is continuous with a slip of the tendon of insertion of the

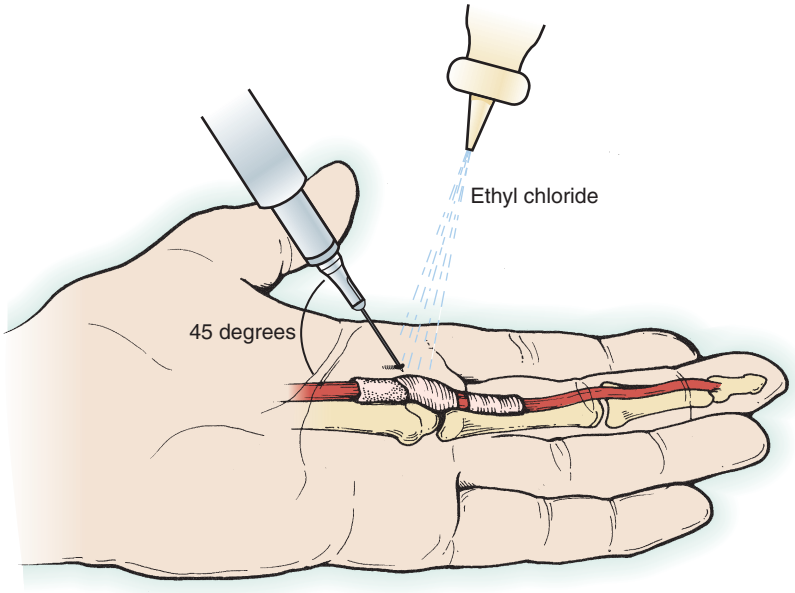

FIGURE 56.4 The author's preferred technique of trigger finger injection (see text).

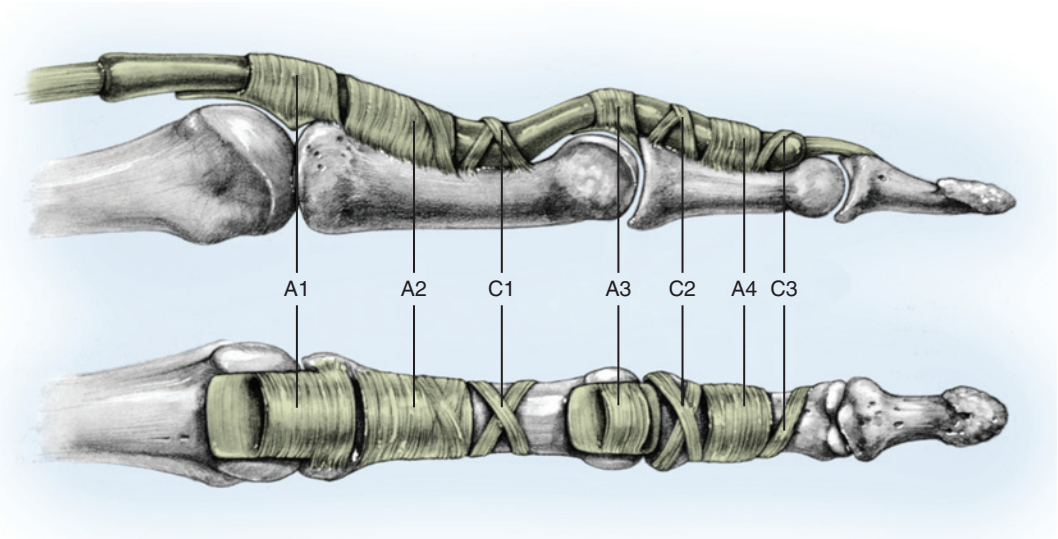

FIGURE 56.5 Doyle and Blythe have identified four annular and three cruciform pulleys in the fingers. (Adapted from Doyle JR, Blythe W: The finger flexor tendon sheath and pulleys: anatomy and reconstruction. In *AAOS Symposium on Tendon Surgery in the Hand*, St. Louis, 1975, CV Mosby, pp 81–87, with permission. Redrawn by Elizabeth Martin.)

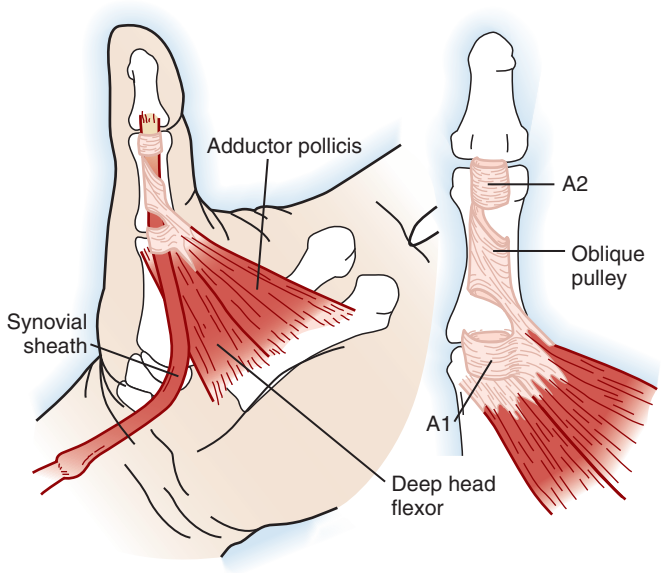

FIGURE 56.6 The flexor pollicis longus passes beneath a similar system of pulleys. Note the important *oblique* pulley just distal to the first annular pulley. (Adapted from Doyle JR, Blythe W: Anatomy of the flexor tendon sheath and pulleys of the thumb. *J Hand Surg [Am]* 2:149–151, 1977, with permission.)

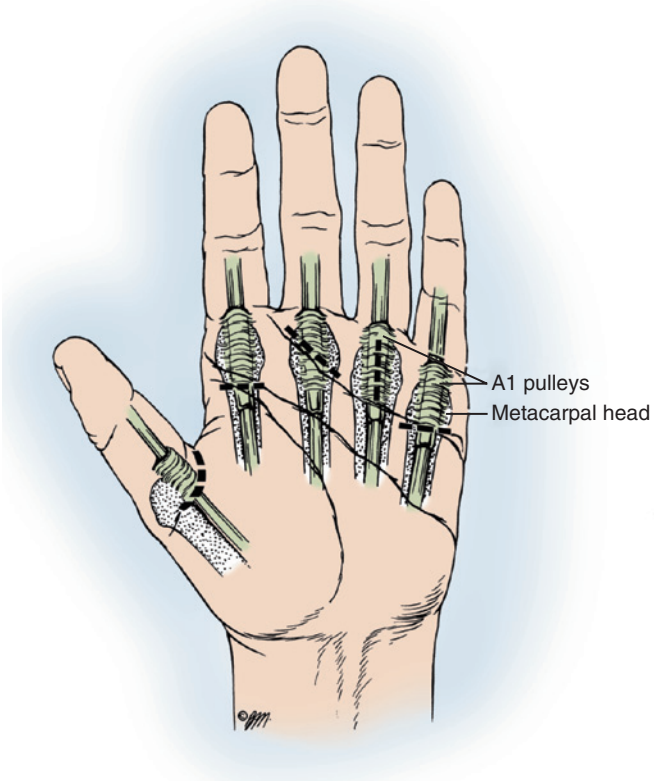

FIGURE 56.7 Incisions for release of trigger fingers and thumb. The leading edge of the A1 pulley is identified on the middle digit. Typical transverse incisions are demonstrated on the thumb, index, and small digits. Oblique and longitudinal incisions are illustrated on the long and ring digits. (Copyright © Elizabeth Martin.)

adductor pollicis and courses in an ulnar-proximal to radial-distal direction. The oblique pulley must be preserved during trigger thumb release. Bayat and colleagues have called our attention to considerable variability of the thumb pulley system, with three distinct types of "Av" pulleys located between the oblique and first annular pulleys.[7] The exact significance of the Av pulley and consequences of sectioning have not been elucidated; consequently, it is recommended that these fibers are left intact. The second annular pulley overlies the volar plate of the IP joint, just proximal to the insertion of the FPL on the distal phalanx.

Topographic Anatomy and Skin Incisions. The proximal edge of the first annular pulley roughly coincides with the distal palmar crease in the fourth and fifth rays and the proximal palmar crease in the index finger and is halfway between the two creases in the middle finger (Figure 56.7). An anatomic study of 256 cadaveric digits demonstrated that the palmar-digital skin crease lies midway between the proximal edge of the A1 pulley and the PIP flexion crease, thus allowing the examiner

to precisely identify the A1 pulley's leading edge.[118] This study has practical surgical implications; with surprising accuracy, the surgeon can topographically identify the leading edge of the A1 pulley by first measuring the distance between the PIP flexion crease and the palmar-digital crease and then measuring the same distance proximally from the palmar-digital crease. The proximal edge of the FPL sheath annulus is directly deep to the MP flexion crease of the thumb and lies directly over the volar plate.

Short transverse incisions placed adjacent to the proximal or distal palmar crease—or for the middle finger, halfway between the two creases—thus provide excellent exposure of the A1 pulley to be divided. This site also positions the healed incision away from the underlying bony prominence of the metacarpal head, thereby lessening direct pressure on the scar in grasping spherical or cylindrical objects. Longitudinal incisions are favored by several authors because this extensile approach allows rapid and safe visualization of a longer segment of the flexor tendon and the leading edge of the A2 pulley.[105] It is important to avoid crossing the palmar or digital creases with a longitudinal incision to prevent a painful scar contracture. In either approach, the location of the digital nerves and arteries that closely parallel each flexor sheath in the fingers must be understood and the bundles protected. In particular, the radial digital nerve of the thumb is vulnerable because it lies quite close to the deep layer of dermis at the flexion crease and will be lacerated if the initial incision is carried too deeply.[19] The same nerve can also be injured by blind scissors dissection more proximally where it crosses the thumb flexor sheath diagonally (Figure 56.8).

Operative Technique of Open Trigger Digit Release. A padded pneumatic forearm tourniquet is applied to the awake patient, and 3 to 5 mL of 1% lidocaine (neutralized with sodium bicarbonate in a 10:1 lidocaine:bicarbonate solution) anesthetic is used to infiltrate the skin overlying the A1 pulley. It is not generally necessary to fill the flexor tendon sheath with anesthetic. The distance between the palmar-digital crease and the PIP crease is measured, and the leading edge of the A1 pulley is identified by the technique of Wilhelmi and associates,[118] as described above. A 1- to 1.5-cm transverse, oblique, or longitudinal incision is made directly over the involved A1 pulley as dictated by local skin creases. In the thumb, the flexor pollicis tendon is approached through a 1.5-cm transverse incision in the MP flexion crease. Immediately after the skin has been incised, blunt dissection is used to spread the subcutaneous tissues and the palmar fascia to expose the flexor sheath. The digital nerves and vessels are retracted with small right-angled retractors and are not subjected to extensive dissection. The proximal edge of the thickened flexor sheath (proximal side of the A1 pulley) is identified, and a scalpel blade is used to divide the entire A1 pulley under direct vision (Figure 56.9). Anatomic studies have demonstrated apparent continuity between the first and second annular pulleys in up to 40 to 60% of digits. Care is taken to avoid division of the A2 pulley and consequent bowstringing, although it has been demonstrated that up to 25% of either end of the A2 pulley can be divided without any detrimental mechanical effect on digital flexion. In the thumb, care is taken to preserve the oblique pulley in its entirety to prevent bowstringing. After release, the patient is asked to actively move the digit to confirm complete relief of the triggering. Meticulous hemostasis is obtained via electrocautery, and the wound is closed with one or two monofilament sutures.

A small hand dressing is applied, with all digits left free, and motion is encouraged on the day of surgery. The patient is counseled to use the hand for light activities, and supervised hand therapy is usually necessary only for patients with preoperative fixed flexion contractures. Sutures may be removed 7 to

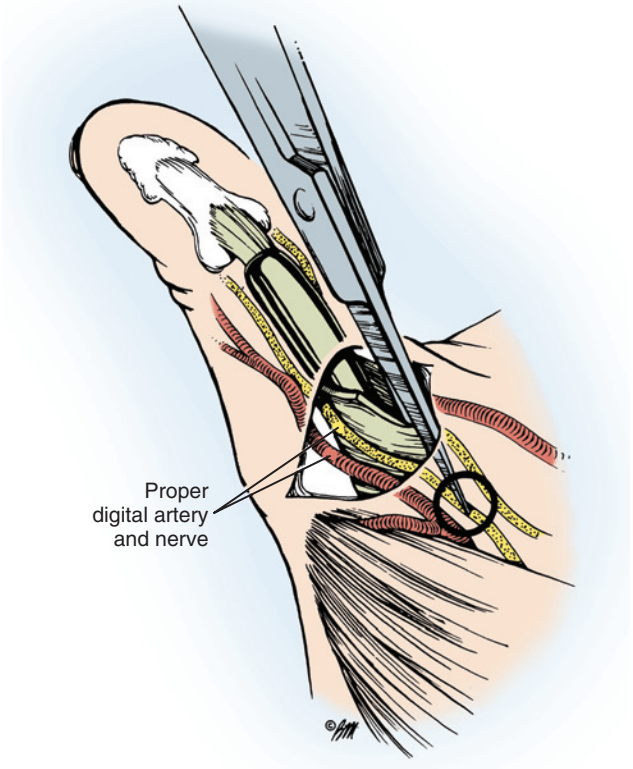

FIGURE 56.8 The digital nerves are vulnerable to injury if the skin incision is deepened too quickly or if a knife or scissors are inserted too far proximally without visualizing the nerves (*circle*). (Copyright © Elizabeth Martin.)

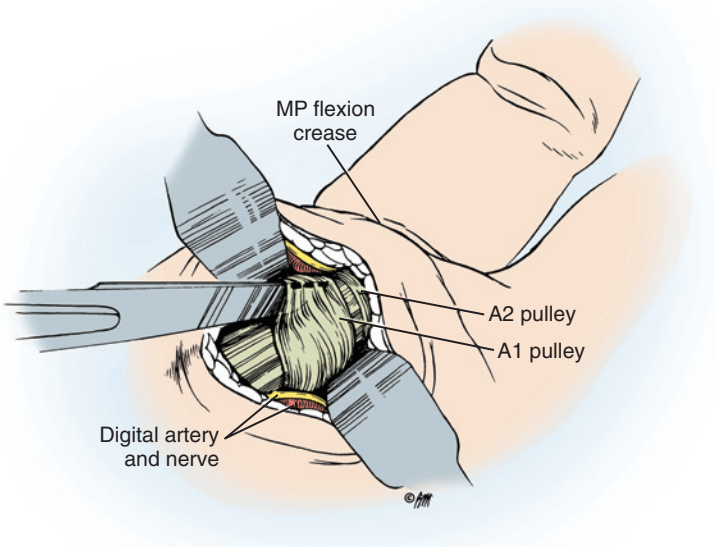

FIGURE 56.9 A No. 11 knife blade is used to divide the first annular pulley to relieve triggering in the finger. *MP,* Metacarpophalangeal. (Copyright © Elizabeth Martin.)

10 days postoperatively. Most patients can resume full hand use within 3 to 4 weeks of surgery.

CRITICAL POINTS *Open Trigger Finger Release*

- For the index through small digits, measure the distance between the palmar digital and PIP flexion creases, and measure this distance again proximal to the palmar-digital crease to identify the leading edge of the A1 pulley.
- Make a transverse, oblique, or longitudinal incision directly over the A1 pulley.
- Do not cross flexion creases with a longitudinal incision.
- Spread down to the flexor sheath; retract the neurovascular bundles.
- Sharply divide the A1 pulley fibers to expose the flexor tendons.
- Preserve the A2 pulley in the fingers; preserve the oblique fibers in the thumb.
- Confirm complete release by active flexion.
- Use a small conforming bandage and advise immediate motion. Perform early therapy for fixed flexion contractures.

Percutaneous Trigger Finger Release (Video 56.1). Open surgical release of trigger digits is not without complication; in fact, some authors report a dissatisfaction rate as high as 26%.[110] Percutaneous trigger release has been reported by several authors to be a safe alternative to traditional open methods using a variety of instruments (Table 56.2).[31,67,69,108] Reported results have been encouraging, with success rates of 74 to 94% at medium-term follow-up and few reported complications. Incomplete relief of triggering has been reported in a higher percentage of patients with grade 4 trigger digits and fixed flexion contractures[48] and in those undergoing hemodialysis.[83] All authors agree that practice on cadaveric hands is recommended before attempting the procedure in patients.

This procedure is done in the office.[31,88] The palm and affected digit are prepared with antiseptic solution and the digit exposed with a fenestrated drape. The MP joints are hyperextended over a rolled towel to displace the neurovascular structures dorsally. The A1 pulley is palpated directly over the metacarpal head. Ethyl chloride is sprayed by an assistant as a topical anesthetic, and the skin and flexor tendon sheath are

TABLE 56.2 Percutaneous Trigger Finger Release

Author	Year	Number of Digits	FINDINGS		Follow-up (months)	Notes
			Instrument	Success Rate		
Lorthioir[67]	1958	52	Custom "tenotome"	100%		Longitudinal tendon scoring well tolerated
Tanaka et al[108]	1990	210	4-mm scalpel blade	74%	24	29% poor results in fingers; best results in thumbs
Eastwood et al[31]	1992	35	21-gauge needle	94%	13	1 repeat release; discouraged for thumbs
Lyu[69]	1992	63	Custom hook device	88%	11	11% conversion to open release; no complications
Stothard and Kumar[106]	1994	18	18-gauge needle	94%		One recurrence; several patients with temporary flexion contractures; superficial tendon scoring
Pope and Wolfe[88]	1995	25 (cadaveric)	19-gauge needle	90%	N/A	Superficial scoring of tendon; not recommended for the thumb or index finger because of the proximity of digital nerves
	1995	13	19-gauge needle	100%	N/A	5 of 13 pulleys incompletely divided distally; active trigger necessary to confirm release
Bain et al[5]	1995 (cadaveric)		14-gauge angiocatheter	68% for digits, 58% for thumb	N/A	Five missed releases; not recommended for the thumb or little finger
Nagoshi et al[83]	1997	67	18-gauge needle	78% idiopathic, 62% hemodialysis	9	Active triggering necessary at the time of release; higher grades and digits locked in extension do less well with the percutaneous method
Cihantimur et al[23]	1998	34	16-gauge angiocatheter	100%	12	No complications
Bain and Wallwork[5a]	1999	31	14-gauge angiocatheter	97%	2	Active triggering at the time of release; not recommended for locked digits, tenosynovitis
Dunn and Pess[30]	1999	52 (cadaveric)	Custom push knife	98%	N/A	No nerve or vessel injury; complete release
		26	19-gauge needle	38%		Superficial scoring of tendons
Ha et al[48]	2001	185	Custom hooked blade	94%	12	No complications; effective for locked digits
Guler et al[46]	2013	87	18-gauge needle	98% open 97% percutaneous	23	5.7% digital nerve injury in percutaneous group

N/A, Not available.

infiltrated with 1 to 2 mL of neutralized 1% lidocaine solution using a 27-gauge needle. A 19-gauge needle is placed percutaneously through the annular pulley, and placement within the flexor tendon is confirmed by asking the patient to slightly flex the digit (Figure 56.10). The needle is withdrawn slowly and rotated to align the bevel of the needle along the longitudinal axis of the tendon. A sweeping motion is used to score and section the A1 pulley proximal and distal to the site. Disappearance of a grating sensation indicates complete sectioning of the annulus. The needle is withdrawn and the patient is asked to flex and extend the digit several times. On occasion, a second needle stick is necessary to complete the release. An adhesive bandage is applied, and the patient is instructed to use the hand for activities as tolerated. Patients should be advised to expect a mild to moderate degree of discomfort for several days; ice and antiinflammatory agents are helpful in the immediate 48 to 72 hours postoperatively.

CRITICAL POINTS *Percutaneous Trigger Finger Release*

- Release is indicated for recalcitrant digits that have failed one or two corticosteroid injections.
- Actively triggering digits may be candidates for percutaneous release.
- A 19-gauge needle is used according to the technique of Eastwood and colleagues.[31]
- Do not use for the thumb and index finger because of the proximity of crossing nerves.
- Hyperextend the digit over a rolled towel at the MP joint to retract the nerves.
- Insert the needle into the tendon; confirm placement by active tendon motion.
- Withdraw the needle slowly out of the tendon.
- Rotate the needle to align the bevel with the tendon; sweep back and forth with the tip.
- One or two needle placements may be necessary to complete division of the pulley.
- Confirm complete release by active flexion of the digit.

❖ AUTHOR'S PREFERRED METHOD OF TREATMENT

All patients with trigger digits are offered one to two trials of corticosteroid injection. Patients with trigger digits secondary to RA or diabetes are counseled about the reduced success rate with this form of treatment and are not generally offered a second attempt at injection. Resistant primary trigger digits that actively trigger (grade II or III) at the time of the office visit may be considered for percutaneous release; active triggering is necessary at the time of release to confirm complete sectioning of the annular pulley. The technique is not used in the index finger and thumb or for digits with PIP joint contractures. Open release is performed through a 1-cm longitudinal or oblique incision placed in the skin lines and directly over the A1 pulley. The thumb is released through a 1.5-cm transverse incision at the level of the MP flexion crease.

Complications

There have been no reported nerve or vascular complications with steroid injection or percutaneous trigger finger release in

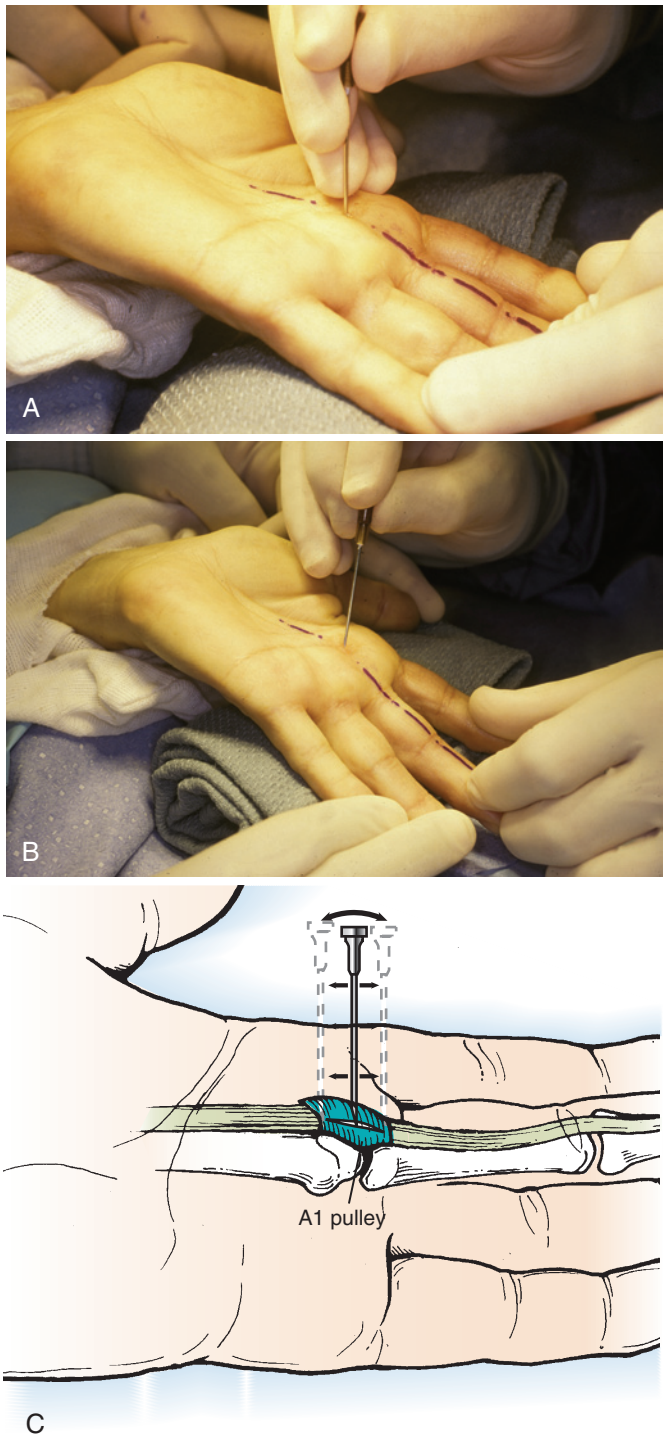

FIGURE 56.10 **A,** Percutaneous release of a long finger A1 pulley. The metacarpophalangeal joint is hyperextended and a 19-gauge needle inserted just distal to the palmar crease. The bevel of the needle is oriented longitudinally with the tendon. The skin markings indicate the path of the flexor tendons. **B,** The needle is stabilized and the pulley is released in a proximal to distal direction. Elimination of a grating sensation as the pulley is cut indicates completion of the release. **C,** A proximal to distal sweeping motion of the needle is used to lyse the annular pulley. (**A** and **B,** From Pope DF, Wolfe SW: Safety and efficacy of percutaneous trigger finger release. *J Hand Surg [Am]* 20:280–283, 1995, with permission.)

the index through small fingers. Authors have identified digital nerve injury of up to 5.7% following percutaneous trigger thumb release[46] because of the crossing radial digital nerve. Hence, the release is not advised in affected thumbs. There is a finite rate of incomplete release or recurrence following percutaneous trigger release; open release is indicated in persistently symptomatic patients.

Reported rates of complication following open trigger release range widely from 3 to 31%,[10,119] depending in large part on the definition of "complication" and the severity of the adverse events noted. In a retrospective study of 1598 patients at a single institution, 5% of operated digits had an adverse event, and less than 1% required additional surgery. The majority of adverse events were wound-related problems, surgical site tenderness, or digital stiffness requiring therapy, and complications were higher among patients with diabetes mellitus.[10] Chronically locked trigger digits may require hand therapy and dynamic splinting to overcome PIP joint flexion contractures. Digital nerve injury is an infrequent but serious complication of trigger release by the open method.[31] Prompt exploration and repair or reconstruction is indicated. Rarely, persistence or recurrence requiring reoperation has been reported.[112] Inadvertent sectioning of all or a portion of the A2 pulley can cause bowstringing with resultant loss of full finger flexion.[47] If bowstringing does not resolve, pulley reconstruction with a tendon graft may be required (see Chapter 6).

Congenital Trigger Thumb

When a child is seen with a thumb locked in flexion, a variety of diagnoses must be entertained, including congenital clasped thumb, absent or aberrant extensor tendons, arthrogryposis, or spasticity (see Chapter 37). The most common cause of abnormal thumb posturing in flexion or extension is termed *congenital trigger thumb*, although the digit is rarely seen to trigger or catch as occurs in the adult equivalent.[26] Pathologic specimens document more frequent thickening and synovial proliferative changes in the tendon itself rather than in the annular sheath, as opposed to adult cases, which show characteristic thickening and degeneration within the tendon pulley.[34] A frequent pathologic finding at surgery is nodular thickening in the tendon, referred to as a Notta node after the individual who reportedly first described the trigger phenomenon in 1850 (Figure 56.11). The eponymous designation is not entirely appropriate (or accurate), as Alphonse Notta described the nodular palmar thickening of trigger finger in four adult patients and did not actually visualize the tendon in these cases.[24] The node of Notta can be palpated just proximal to the proximal border of the A1 pulley, confirming the diagnosis.

Although the condition is rare, the true incidence of trigger thumb is unknown. Among all children seen at a major pediatric hospital, the condition was diagnosed in 0.05%.[42] Whether the condition is truly congenital or acquired is of some controversy because it is rarely diagnosed at birth.[26,27,81] Some authors contend that the condition is overlooked until at least 6 months of age because of characteristic flexion posturing of the thumb in newborns. Of 70 congenital trigger digits treated by De Smet and colleagues, only 3 were reported by the parents as being present at birth and only 9 before the age of 6 months.[26] In two prospective series involving a total of 8746 newborns, no trigger thumbs were demonstrated in the nursery, and the authors



FIGURE 56.11 Inspection of the flexor pollicis longus after release of the first annular pulley reveals the characteristic "Notta node" (*arrow*) seen in congenital trigger thumbs.

contended that the condition is acquired rather than congenital.[78,95] Within a cohort of 78 children treated surgically for trigger thumb, none was initially seen before 3 months of age.[95] Current consensus favors the acquired versus congenital disorder. The condition has a bilateral incidence of 25% to 33%,[27,34,42] and no association with specific congenital anomalies has been demonstrated.[42] Trigger thumbs have been reported in monozygotic twins,[34] thus raising the question of a genetic predisposition.

Treatment

Early authors found conservative measures such as observation and splinting to be "uniformly unsuccessful"[34] and perhaps causative of deleterious MP hyperextension deformities or fixed IP contractures. A later study of 26 trigger thumbs diagnosed in early infancy by Dinham and Meggitt documented a 31% rate of spontaneous resolution.[27] In children aged 6 to 30 months at diagnosis, however, the same authors cited a recovery rate of just 12% after a 6-month observation period. Ger and coworkers reported no spontaneous resolution in 19 trigger thumbs diagnosed in children younger than 6 months of age and monitored for an average of 44 months.[42] Similarly, Wood and Sicilia found no spontaneous resolution in 37 digits monitored for an average of 9 months.[120] Baek and colleagues recently demonstrated a 63% spontaneous resolution rate in a cohort of 71 thumbs monitored for a longer period averaging 48 months.[4] Splinting is difficult to maintain, particularly in infants and toddlers. It is unlikely that a period of observation, with or without stretching or splinting, will result in any permanent deficit or flexion contracture. If the triggering or deformity does not resolve, surgical release can be performed before the age of 5 years to prevent permanent contracture of the IP joint.

Surgical Technique. The procedure is generally performed under a general anesthetic, supplemented with local lidocaine (see the section on Trigger Thumb, Chapter 37, for operative details). A well-padded tourniquet is applied to the arm, and the arm is exsanguinated with an Esmarch bandage. A small transverse incision is made over the palpable nodule at the MP flexion crease. Blunt dissection is performed to identify both digital nerves, which lie immediately beneath the skin at this

level. Right-angled retractors are used to retract the neurovascular bundles, and the transverse retinacular A1 pulley is divided to expose the flexor tendon and associated nodule. The oblique fibers of the retinacular pulley system are carefully preserved.[7,29] No attempt is made to excise or reduce the tendon nodule. The flexor tendon should be lifted out of the wound with a blunt instrument to ensure unrestricted range of thumb motion.

Outcomes of surgical release for congenital trigger thumb have been excellent, with no reports of recurrence and few complications.[42] McAdams and associates performed a long-term study of 21 patients for an average of 15 years and demonstrated minor deficits in IP extension in 23% of their patients but no functional deficit.[72] Longitudinal incisions in a third of their patients resulted in unsatisfactory scarring and contracture. The authors underscored the importance of a transverse incision and careful preservation of the oblique pulley fibers to prevent alterations in tendon mechanics and the development of a flexion contracture.

Trigger Digits in Childhood

Rarely, triggering can occur in other digits in childhood.[16,34] Surgical release of the A1 pulley is not as universally successful as it is with childhood trigger thumbs, thus suggesting a different cause of the condition. In a series of 16 children with 18 trigger digits, Cardon and colleagues demonstrated resolution of triggering in only 10 after division of the A1 pulley alone. In 6 others, abnormalities of the flexor digitorum superficialis decussation necessitated excision of one or both of its slips.[16] The authors recommended the use of an extensile approach to the flexor tendons so that additional surgery can be performed if division of the A1 pulley does not resolve the triggering (see section on Trigger Thumb, Chapter 37, for operative details). Children with storage diseases, such as Hurler syndrome, can acquire trigger digits and carpal tunnel syndrome as a result of abnormal collections of mucopolysaccharide within and around the flexor tendons. Surgical decompression has been demonstrated to be successful in improving hand function.[16,113] Seiler and Kerwin reported trigger finger in an adolescent secondary to a painless calcific nodule in the substance of the flexor profundus tendon.[101]

De Quervain Disease

There are six separate compartments under the dorsal carpal ligament, each lined with a separate synovial sheath membrane. The first of these, which is over the styloid process of the radius, contains the abductor pollicis longus (APL) and extensor pollicis brevis (EPB) tendons. These tendons pass through an unyielding osteoligamentous tunnel formed by a shallow groove in the radial styloid process, covered by a tough overlying roof composed of the transverse fibers of the dorsal ligament, and bordered by vertical septa between the retinaculum and radius. This fibrous tunnel is about 2 cm long, but the synovial sheath extends from each musculotendinous junction proximally to the tendon insertions well beyond the tunnel itself.

Tendon entrapment of the first dorsal compartment of the wrist is a common cause of pain and disability of the wrist and hand. Fritz de Quervain has been credited with the description, in 1895, of a specific entity involving the APL and EPB tendons at the radial styloid process. A similar entity had been reported in the 1893 edition of *Gray's Anatomy* and named "washerwoman's sprain." The process is attributed to activities requiring frequent abduction of the thumb and simultaneous ulnar deviation at the wrist. Tension on the tendons of the first dorsal compartment, if sustained and repeated, is said to produce friction at the rigid retinacular sheath, with subsequent swelling or narrowing of the fibroosseous canal. Acute angulation of the tendons at the retinaculum occurs with wrist extension, and increased anatomic angulation of the tendons in women was suggested by Bunnell to help explain their markedly increased prevalence of the disease.[12] Aberrant tendons and variations in anatomy of the tendons and their sheaths have been thought by several authors to contribute to the process and help explain the poor response to conservative treatment in certain individuals.

The diagnosis is usually made without difficulty after eliciting a complaint of several weeks or months of pain localized to the radial side of the wrist and aggravated by movement of the thumb. The average age in most series is in the fifth and sixth decades, and the syndrome may be up to six times more common in women.[116] The disease also peaks among recent postpartum and lactating females.[3] Findings of local tenderness and swelling 1 to 2 cm proximal to the radial styloid and knife-like pain when the thumb is clasped in the palm and the wrist forced into ulnar deviation (*Eichhoff maneuver*)[32] are diagnostic of the disease. Harry Finklestein subsequently described the pathognomonic examination maneuver that bears his name: "On grasping the patient's thumb and quickly abducting the hand ulnarward, the pain over the styloid tip is excruciating."[36] Both tests should be performed in patients with suspected de Quervain disease.

de Quervain disease must be differentiated from the less common condition of *intersection syndrome*, in which pain, swelling, and, in severe cases, crepitus are found over the second dorsal compartment tendons more proximally. The condition has also been confused with trigger thumb,[36] and this may be related to the presence of a separate fibroosseous tunnel and "pseudotriggering" of the EPB tendon.[115] de Quervain disease should also be differentiated by radiography and physical examination from arthritis of the thumb carpometacarpal (CMC) or scaphotrapezial-trapezoid joints (or both), although these lesions may coexist because of their similar demographics. Radiographic study also excludes scaphoid fracture and arthrosis involving the radiocarpal or intercarpal joints. Occasionally, radiographs show localized osteopenia or spurring at the radial styloid (Figure 56.12). Advanced imaging modalities are rarely helpful for diagnosis.

Treatment

Nonoperative Treatment. In acute cases, some success has been reported after immobilization in a cast or splint with the wrist gently extended and the thumb abducted, but in my experience, symptoms tend to recur shortly after removal of the cast when the inciting activity is resumed. In a prospective study, splint immobilization alone led to a 70% failure rate in 37 wrists and was shown to provide no additional benefit when combined with corticosteroid injection of the first dorsal compartment sheath.[116]

As with trigger digits, corticosteroid injection was initially discouraged as ineffective but later hailed as a successful form of treatment of de Quervain disease. Success with corticosteroid



FIGURE 56.12 Anteroposterior radiographs of the wrist in a patient with de Quervain disease occasionally reveal localized osteopenia or a small spur (*arrow*).



FIGURE 56.13 **A** and **B,** Local complications from the use of corticosteroid injections for the treatment of de Quervain disease. Although successfully relieved of pain, both patients had localized capillary fragility and recurrent transient hemangioma-like lesions at the site of injection.

injection has been reported in 50 to 80% of patients after one to two injections,[116] and it is particularly effective in relatively acute cases. Injection is less effective in patients with diabetes.

In de Quervain disease of pregnancy and lactation, nonoperative treatment is highly effective, and the condition tends to resolve after cessation of lactation.[3] In a comparative study of splinting and corticosteroid injection, Avci and coworkers demonstrated complete resolution of pain and a negative Finkelstein test result after injection of methylprednisolone in nine patients, whereas all patients in the splinted group continued to report pain during the treatment period. Eight of the nine patients in the latter group experienced complete resolution 2 to 6 weeks after cessation of lactation.[3]

Technique of Injection. The radial styloid area is prepared with antiseptic solution. A number of corticosteroid preparations are available and differ predominantly in their solubility and thus their duration of action. Less soluble preparations may contribute to a higher incidence of local complications, including depigmentation,[66] subcutaneous atrophy, and fat necrosis (Figure 56.13). Therefore, in this very superficial location, I prefer a water-soluble preparation of 2 to 4 mg of dexamethasone or 6 mg of betamethasone mixed with 1 mL of 1% lidocaine (no epinephrine). The anesthetic effect of lidocaine allows confirmation of correct needle placement and diagnosis by immediate, temporary relief of discomfort.

The first dorsal compartment tendons can easily be palpated as the patient abducts and extends the thumb. While ethyl chloride is sprayed as a local refrigerant, the examiner's gloved index finger and thumb bracket the tendons at a level 1 cm proximal to the radial styloid, which serves to steady the patient's wrist and localize the injection site. A short 25- or 27-gauge needle is introduced into the tendon sheath, and resistance may be felt as the injection is attempted. The needle is slowly backed out of the tendon while pressure is maintained on the plunger, and a fluid wave should be palpable proximal and distal to the injection site as the APL sheath fills. A portion of the solution should be redirected slightly dorsal (ulnar) to the first site in an attempt to infiltrate a possible separate EPB sheath.[65] In a study in which radiopaque dye was mixed with a corticosteroid and injected into the first dorsal compartment, 13 of 19 wrists failed to demonstrate dye filling the EPB subsheath, thus suggesting that it is technically more difficult to successfully administer the medication to the EPB compartment.[121] The accuracy of EPB injection may be improved by palpating the tendons at the tip of the radial styloid while the patient flexes and extends the thumb MP joint. Should the injection fail to relieve symptoms, a second injection may be performed 4 to 6 weeks after the first; however, repeated ongoing injections are not indicated and may be detrimental to local tissues (see Figure 56.13).

Surgical Treatment

PERTINENT ANATOMY

Although early anatomic textbooks showed one long thumb abductor tendon accompanying one extensor brevis tendon passing through a single first dorsal compartment as the normal

anatomy, modern anatomic and surgical studies have shown that this is not usually the case. In most reports, less than 20% of patients exhibit the so-called normal anatomy.[56]

In fact, the first dorsal compartment of the wrist is probably the site of the most numerous variations in tendon structure in the upper limb. Failure to recognize these variations can cause persistence or recurrence of pain because of incomplete surgical release of the tendon sheath.

The EPB is a phylogenetically young structure found only in humans and gorillas as a separate muscle distinct from the thumb abductor. The muscle is always thinner than and courses dorsal to the abductor and is absent in 5 to 7% of people. The larger APL usually has two and sometimes three or more tendinous slips inserting variously into the base of the first metacarpal, trapezium, volar carpal ligament, opponens pollicis, or abductor pollicis brevis.

In 24 to 37% of specimens in anatomic studies, the first compartment was found to be subdivided by a longitudinal ridge and septum into two distinct fibroosseous tunnels, the ulnar one for the EPB and the radial tunnel containing one or more slips of the APL.[65] A third deep tunnel containing an anomalous tendon has also been reported. The reported incidence of separate compartments at surgery is higher than that seen in anatomic specimens in several series,[98,116] which raises the possibility that septation of the EPB increases the probability that nonsurgical treatment will fail. Harvey and associates reported success with one or two corticosteroid injections in 80% of patients and found separate compartments for the APL and EPB in 10 of 11 wrists that failed injection and required surgical release.[51] As noted in various published reports of operative findings, either one of the subdivisions, or both, of the first dorsal compartment may be stenotic. The *EPB entrapment test* was reported to be 81% sensitive in its ability to identify the presence of a septated EPB compartment in patients who had failed corticosteroid treatment and required surgery. The test is a two-part test in which the patient is asked to forcibly (1) extend the MP joint or (2) abduct the CMC joint against resistance from the examiner.[2] Pain during the MP joint portion of the test is said to be a positive predictor of a separate compartment for the EPB tendon.

The anatomic relationship of the radial artery and nerve to this compartment must be understood to prevent injury to these structures during surgical release of the tendons (Figure 56.14). The radial artery passes diagonally across the anatomic snuffbox from the volar aspect of the wrist to the dorsum of the web space deep to the thumb abductor and both extensors. It is separated from the first compartment sheath by enough areolar tissue that it need not be exposed during the dissection. However, two or three terminal divisions of the radial sensory nerve lie immediately superficial to the first dorsal compartment and must be identified and protected during the surgical procedure.

❖ AUTHOR'S PREFERRED METHOD

The procedure is usually performed with only local infiltration of anesthesia. A pneumatic tourniquet around the forearm is well tolerated for the short duration of the procedure, and a bloodless surgical field is essential for identification of the radial sensory branches, as well as the anatomic variations discussed earlier.

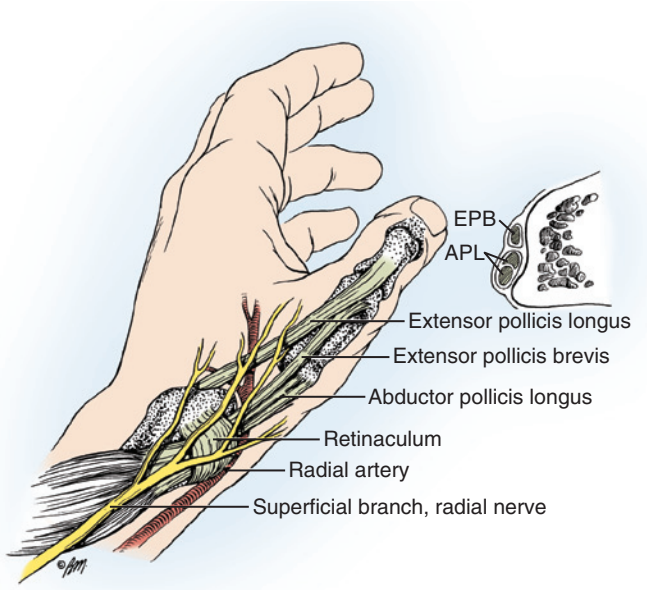

FIGURE 56.14 Anatomic relationships in the first dorsal compartment. *APL,* Abductor pollicis longus; *EPB,* extensor pollicis brevis. (Copyright © Elizabeth Martin.)

A 2-cm transverse skin incision is made over the first dorsal compartment about 1 cm proximal to the tip of the radial styloid process (Figure 56.15). Care is taken to identify and gently retract the one to three radial sensory branches that cross the compartment obliquely by using gentle, blunt longitudinal dissection as soon as the deepest dermal layer of skin has been incised. A common technical error is to transversely incise the subcutaneous fat with the skin knife, which may injure a superficial nerve branch. As an alternative, one can make a longitudinal skin incision, which may pose less risk to the nerve. The exposed annular ligament covering the compartment is sharply incised with a scalpel.

CRITICAL POINTS *De Quervain Release*

- A positive response to a diagnostic injection should precede the decision for surgery.
- Use a transverse incision; protect the numerous superficial sensory nerves.
- Incise the sheath on its dorsal margin to prevent tendon subluxation.
- Identify both tendons; inspect for the EPB subsheath; and excise the septa.
- Ask the patient to voluntarily move the thumb to confirm release.

Complete excision of the entire sheath should be avoided because this has occasionally been associated with painful palmar subluxation of the tendons postoperatively. Burton and Littler recommended incising the sheath on its most dorsal margin and leaving a flap of palmar sheath to prevent subluxation.[14] A thorough exploration for separate compartments must be performed, with complete division of all intervening septa and identification of each tendon slip. Unusually thick septa can be excised entirely. If the tenosynovial tissue is thick and opaque, surgical debulking is performed. The tendons are lifted by hook or blunt retractors out of the tunnel to ensure

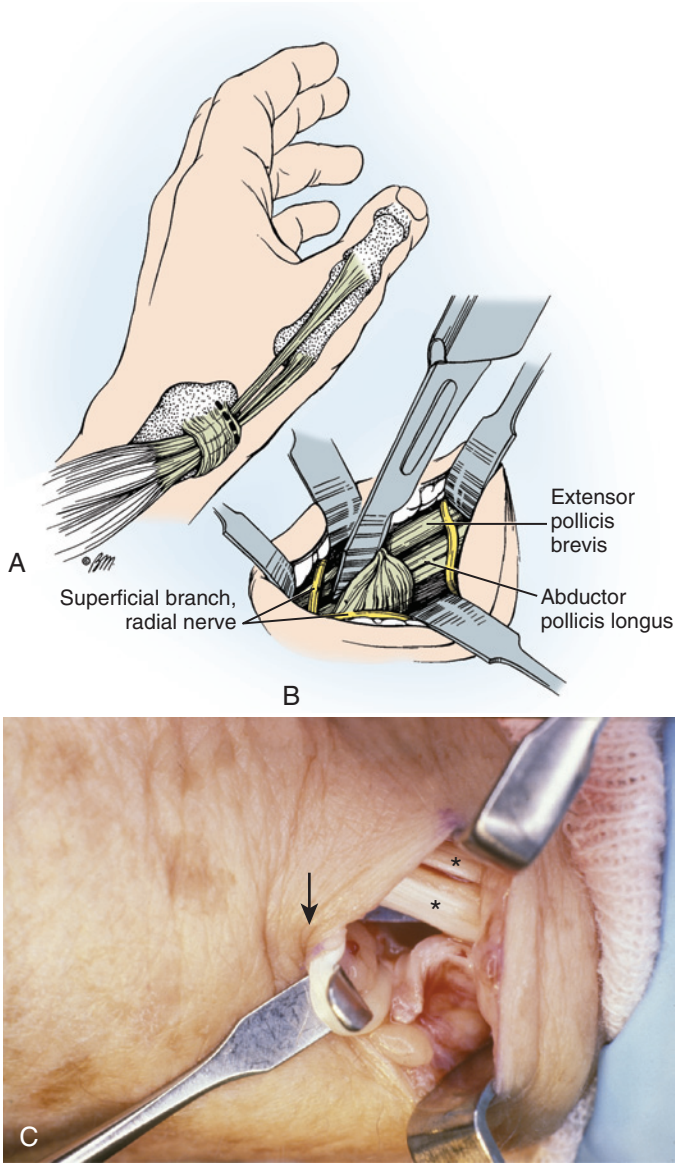

FIGURE 56.15 Release for de Quervain disease. **A,** The first dorsal compartment is approached by a short transverse skin incision. **B,** The annular ligament is incised with a scalpel from the snuffbox to the musculotendinous junctions. **C,** Surgical demonstration of a separate compartment for the extensor pollicis brevis (*arrow*) after release of the abductor pollicis longus (*asterisks*). (**A** and **B,** Copyright © Elizabeth Martin.)

complete decompression from the musculotendinous junction of the EPB to the radial styloid. The tendons are replaced and the patient is asked to move the thumb to demonstrate free and independent movement of the long abductor and short extensor. It is imperative that the separate tendon of the EPB be specifically identified by demonstrating passive extension of the thumb MP joint with gentle retraction on the tendon.

Hemostasis is established with electrocautery after release of the tourniquet, and the skin is closed with an intradermal absorbable monofilament suture and adhesive glue. A soft bulky dressing is applied and thumb motion is encouraged in the immediate postoperative period. If it is thought that the released tendons are unstable after release, a palmar thumb spica splint may be applied with the wrist in 20 degrees of extension for 10 to 14 days, although this is rarely necessary. Thereafter, the patient may begin to resume use of the thumb and wrist as tolerated. Supervised hand therapy is rarely necessary. Localized soreness may persist for 4 to 6 weeks postoperatively and generally responds to wound massage and light use of the hand. It is advised to avoid heavy mechanical activities for the initial 4 to 6 weeks.

Complications

Not infrequently, extravasation of injected corticosteroid into superficial tissues can cause subcutaneous atrophy, fat necrosis, depigmentation, or any combination of these complications (see Figure 56.13).[66,98,99] Darker-skinned individuals are particularly prone to this occurrence, and all patients should be counseled before injection concerning the 5 to 10% risk for this complication. In my experience, these adverse effects have usually resolved within a year, but persistent symptoms can be severe enough to warrant transposition of healthy skin or fat grafts to the area. Though decidedly uncommon, corticosteroid injection can lead to tendon rupture: one case report describes the rupture of both the APL and the EPB following repeated corticosteroid injections for de Quervain disease.[86]

The most serious complication of this operation follows iatrogenic injury to a superficial sensory branch of the radial nerve and the subsequent formation of a painful neuroma. Overly vigorous retraction of a radial nerve branch without apparent injury may cause a painful neuroma-in-continuity. Injuries to this vulnerable nerve can result in excruciating, disabling symptoms that dwarf the initial symptoms in severity. Management of an inadvertently lacerated radial sensory nerve is a controversial subject. Some authors advise resection of the lacerated nerve to put the resultant neuroma well proximal to the operative scar, where it will be less exposed to repeated contusion. However, because I have not been entirely satisfied with the persistent pain of those who have undergone proximal transposition of painful forearm neuromas, I agree with those who advocate immediate nerve reapproximation using microsurgical technique to reduce the likelihood of neuroma formation and minimize hypoesthesia in the thumb and index finger. (For a more detailed discussion of this complication, the reader is referred to Chapter 320.)

Incomplete relief of pain after release of the first dorsal compartment is not uncommon. Associated diagnoses, including painful CMC and IP joint arthritis or instability, are common and may be confirmed with a diagnostic lidocaine injection into the suspected area. If documentation of specific identification and release of both the EPB and APL tendons in the operative report is lacking, some consideration should be given to ultrasound or magnetic resonance imaging to establish adequacy of release. Reexploration for an unreleased septated compartment of the extensor brevis may be required, and a preoperative lidocaine challenge into this compartment can be helpful in predicting the outcome of reexploration. Hypertrophic or painful longitudinal scars may be modified by "Z"-plasty. For the rare patient with painful palmar or dorsal subluxation of the tendons after release, pulley reconstruction with a slip of extensor retinaculum, a distally based slip of the brachioradialis,[73] or a strip of the second dorsal compartment retinaculum has been described.

OTHER STENOTIC CONDITIONS OF TENDONS AT THE WRIST

ANATOMY

The second compartment contains the two radial wrist extensors, the extensor carpi radialis longus and brevis, respectively. The third compartment contains the EPL tendon, which angulates acutely around the Lister tubercle en route to the distal phalanx of the thumb. Four slips of the extensor digitorum communis tendon and the single extensor indicis proprius tendon compose the fourth compartment. The fifth and sixth compartments each contain a single tendon: the extensor digiti minimi and the extensor carpi ulnaris (ECU) tendons. The floor of the ECU tendon sheath is quite thick and forms an important structural component of the TFCC that aids in stabilization of the distal radioulnar joint. Although each of the dorsal extensor compartments may be involved in tendon entrapment, the most commonly involved are the first and sixth compartments.

Intersection Syndrome

Pain and swelling about the muscle bellies of the APL and EPB are characteristic of intersection syndrome. This area, which lies about 4 cm proximal to the wrist joint, may show increased swelling of a normally prominent area (Figure 56.16) and, in severe cases, redness and crepitus. There is controversy as to the precise site of the syndrome: whether it occurs at the intersection between the muscle bellies of the APL and EPB and the radial wrist extensor tendons, or whether it involves only the tendons of the second dorsal compartment. The finding of a positive Finklestein test in patients with this condition and ultrasound reports of peritendinous fluid collection about the first dorsal compartment tendons at their intersection with the wrist extensors support the former. In 13 operative cases, Grundberg and Reagan demonstrated histologic evidence of acute and chronic synovitis about the tendons of the second dorsal compartment.[45]

The syndrome, like other stenotic conditions about the hand and wrist, has been associated with activities requiring frequent or repetitive motions of the wrist. Though rare, it is most often seen in athletes, particularly those involved in sports such as rowing, cycling, and weightlifting. Initial nonoperative treatment consists of eliminating the inciting activity, taking nonsteroidal antiinflammatory agents, and wearing a thermoplastic molded wrist splint in 15 degrees of extension for 2 to 3 weeks. Incorporating the thumb into the splint may provide more rapid relief by immobilizing the first dorsal compartment tendons. In refractory cases, steroid injection into the area of maximal tenderness usually relieves symptoms. The majority of patients remain permanently asymptomatic with nonoperative treatment.

For those with persistent pain, Grundberg and Reagan suggested a longitudinal incision to approach the radial wrist extensors that begins at the wrist and extends proximal to the swollen area.[45] After incising the deep fascia, release of the second dorsal compartment demonstrates the area of pathologic structures (Figure 56.17). The tendons are elevated and inspected, and no attempt is made to close the retinaculum. The wrist is splinted in neutral to slight extension for 10 days postoperatively, and patients are advised to use the hand and wrist as tolerated thereafter. Although bowstringing of the extensor

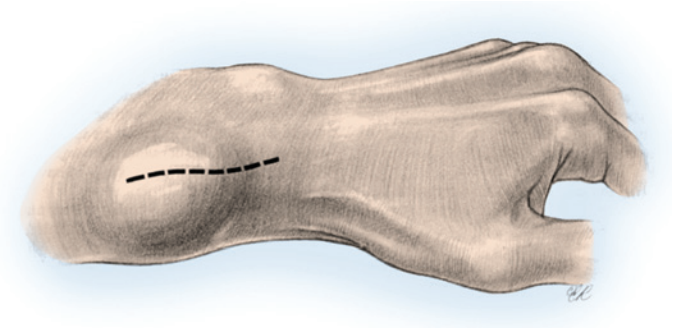

FIGURE 56.16 A patient with intersection syndrome has swelling in the area where the abductor pollicis longus and extensor pollicis brevis cross the common radial wrist extensors. The *dashed line* indicates the location of the surgical incision. (Adapted from Grundberg AB, Reagan DS: Pathologic anatomy of the forearm: intersection syndrome. *J Hand Surg [Am]* 10:299–302, 1985, with permission. Redrawn by Elizabeth Martin.)

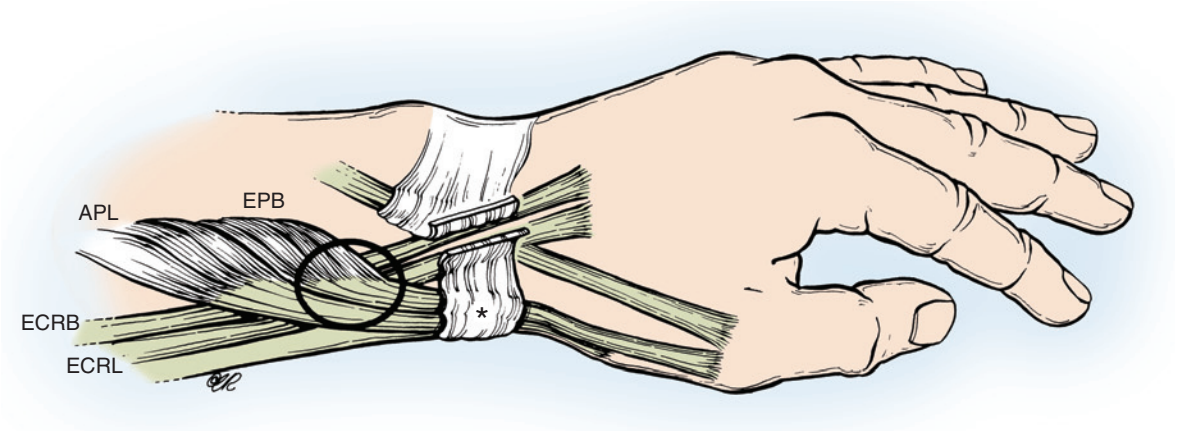

FIGURE 56.17 The *circled area* shows where the extensor pollicis brevis (EPB) and abductor pollicis longus (APL) cross the common radial wrist extensors. The location of the first dorsal compartment where de Quervain disease occurs is indicated with an *asterisk*. The second dorsal compartment has been released in the manner recommended for the treatment of intersection syndrome. *ECRB,* Extensor carpi radialis brevis; *ECRL,* extensor carpi radialis longus. (Copyright © Elizabeth Martin.)

tendons is a theoretical problem after incising the dorsal retinaculum, Grundberg and Reagan did not report any symptomatic bowstringing in their series.

Extensor Pollicis Longus Entrapment

Tendon entrapment of the EPL occurs rarely but requires early diagnosis and urgent operative treatment to prevent tendon rupture, a complication that is seldom seen in de Quervain disease, trigger finger, or trigger thumb. The condition is recognized by pain, swelling, tenderness, and often crepitus on the dorsum of the distal end of the radius at the Lister tubercle, around which the long thumb extensor tendon angulates as it courses to its insertion on the thumb. Passive or active flexion of the thumb IP joint is associated with pain at the level of the Lister tubercle, and triggering has been reported.[63] The tendon has a separate synovial sheath–lined tunnel beneath the extensor retinaculum that may be compromised by blunt trauma or a Colles' fracture. Rupture of the tendon has been reported and occurs most commonly in association with initially undisplaced distal radial fractures. Its tendency to rupture in these circumstances may be secondary to the local ischemia produced by increased pressure or hematoma within a relatively unyielding fibroosseous canal. Microvascular studies have demonstrated a watershed zone in proximity to the Lister tubercle wherein the tendon is entirely dependent on synovial fluid for its nutrition[33] and that may be vulnerable to ischemic rupture after local trauma. A recent report suggests an incidence as high as 5% in patients with nondisplaced distal radius fractures treated with immobilization.[96] The tendon is also exquisitely sensitive in this location to prominent screws and pegs inserted from the palmar approach during fixation of distal radius fractures, and special care should be taken to avoid violation of the dorsal cortex by hardware and consequent tendon rupture (see Chapter 15).

Operative treatment of EPL tendon entrapment is recommended to prevent attritional rupture of the tendon. The tendon is exposed through a 2-cm dorsal incision centered over the Lister tubercle. Care is taken to avoid injury to small branches of the radial sensory nerve. The third dorsal compartment is identified and incised completely, and the tendon is elevated from its bed and transposed radial to the tubercle. Any osteophytes within the tunnel may be débrided and the tunnel closed to prevent the EPL from returning to its groove (Figure 56.18). The skin is closed with a single subcuticular suture, and postoperative splinting is not necessary. Unrestricted use of the hand and wrist is permitted as tolerated.

Stenosis of the Fourth and Fifth Extensor Compartments

Although common in patients with RA, primary symptomatic stenosis of the fourth and fifth extensor compartments is extremely rare. The condition most commonly affects the extensor digitorum communis tendons to the index and small digits because these tendons angulate more acutely at the distal edge of the retinacular sheath. Isolated extensor indicis proprius tenosynovitis has been reported and is attributed to the presence of the distal extensor indicis proprius muscle belly within the retinacular sheath. The process may be initiated after a Colles' fracture and has also been thought to be due to increased demands on the extensor tendons secondary to loss of wrist flexion. Clinical findings demonstrate tenderness and swelling

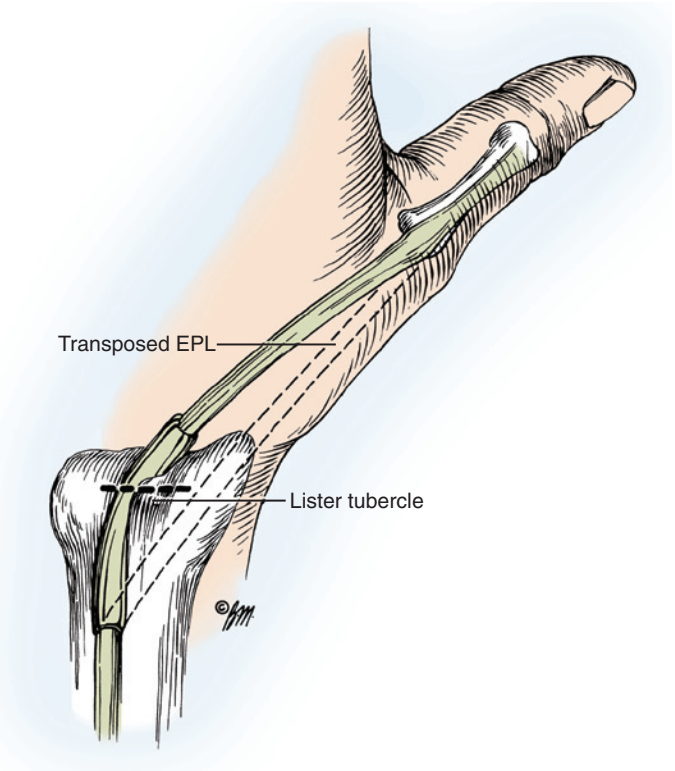

FIGURE 56.18 The extensor pollicis longus (EPL) tendon is rerouted superficially radial to the Lister tubercle (*dashed lines*) to relieve tenosynovitis. (Copyright © Elizabeth Martin.)

over the affected compartment. With the wrist flexed, pain may be elicited at the involved retinacular sheath by attempted MP extension against resistance. Pathologic findings show thickening of the tendon sheath, tight stenosis, and sparse inflammatory tissue. Duplicate tendons or anomalous muscle bellies should be suspected in a patient who does not respond to the usual conservative modalities of rest, ice, antiinflammatory medications, or corticosteroid injection.[54]

Extensor Carpi Ulnaris Tendinitis

Reactive tendinitis of the ECU is the second most common pattern of tendinopathy in the wrist and must be included in the differential diagnosis of ulnar-sided wrist pain. The ECU tendon occupies a narrow subsheath within the sixth dorsal compartment, and its relative position changes with rotation of the forearm. The tendon assumes a linear path in pronation but angulates approximately 30 degrees around the ulnar styloid to reach the fifth metacarpal base in full supination. Tendinitis may be initiated by a twisting injury or overuse, followed within 24 to 48 hours by increasing pain and swelling. Nocturnal pain is frequent and occasionally severe enough to interfere with sleep. Dysesthesias along the course of the overlying dorsal sensory branch of the ulnar nerve are frequent findings. Because the floor of the ECU tendon sheath is an important stabilizer of the TFCC, the process may be difficult to differentiate from traumatic disruption of the TFCC (see Chapter 14).

Pain is generally poorly localized by the patient and frequently felt to be deep within the joint. Pain is increased with all motions of the wrist, and extension/ulnar deviation against applied resistance is a useful provocative diagnostic maneuver.

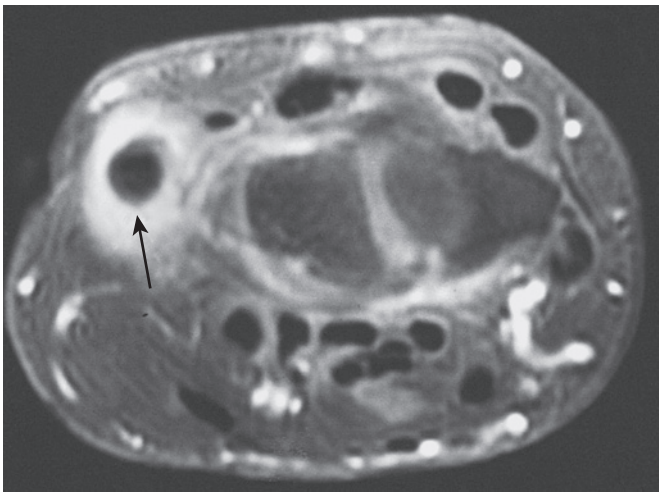

FIGURE 56.19 Magnetic resonance image of the wrist demonstrating abundant tenosynovial thickening and a halo of edema surrounding the extensor carpi ulnaris tendon (*arrow*).

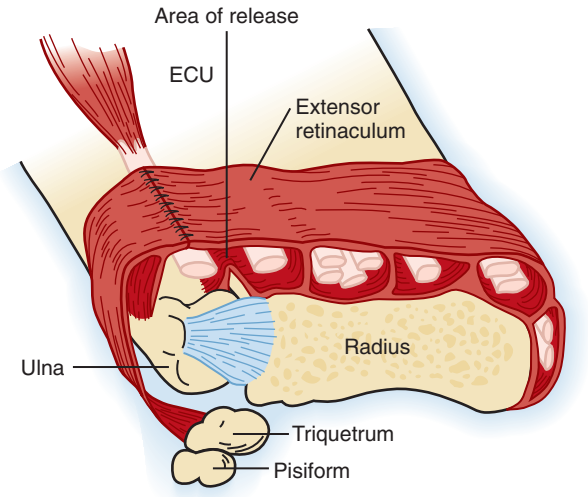

FIGURE 56.20 Technique of release of the intervening septum between the fifth and sixth dorsal compartments combined with retinacular repair for the treatment of tendinopathy of the extensor carpi ulnaris (ECU) tendon. (Redrawn with permission, from Hajj AA, Wood MB: Stenosing tenosynovitis of the extensor carpi ulnaris. *J Hand Surg [Am]* 11:519–520, 1986.)

Crepitus may be palpable within the swollen ECU sheath (Figure 56.19). The condition may coexist with tendon entrapment of other wrist compartments, an anomalous accessory tendon slip of the ECU, TFCC tears, ulnar styloid nonunion, distal radioulnar degenerative disease, and lunotriquetral ligament injury. Rarely, complete rupture of the tendon has been reported, usually following one or more corticosteroid injections[77]; repair with an intercalated tendon graft is recommended in active patients to restore its stabilizing effect on the TFCC and to maintain wrist balance and strength.

Instability of the tendon may coexist with tendon entrapment or may be isolated and symptomatic enough to warrant operative reconstruction. It is important to differentiate acute instability from the more chronic overuse tendinopathy, as treatment options differ. In athletes, ECU instability is usually heralded by an acute episode of moderate to severe pain during a forceful supinated activity; a frequent example is the upper hand of a two-handed backhand tennis swing.[77] ECU instability may be elicited by palpating the tendon while the patient actively rotates the extended wrist from full pronation to full supination. The tendon may subluxate, occasionally with an audible snap, as the supinated wrist is brought from extension into ulnar deviation and flexion. Magnetic resonance imaging (MRI) may be helpful to identify tendon subluxation and to differentiate it from peritendinous synovitis, longitudinal splitting of the tendon substance, a shallow ECU groove on the distal ulna, or anomalous extensor tendon anatomy. Dynamic ultrasonography is a valuable adjunct to clinical examination in patients with suspected ECU subluxation.[77] Both MRI and ultrasound should be performed in full supination and in pronation.

Transient but complete relief of discomfort after filling the ECU sheath with lidocaine confirms the diagnosis of ECU tendinitis and helps differentiate the process from intraarticular pathologic conditions. Conservative treatment with ice, extension splinting or casting, and antiinflammatory agents generally provides relief of symptoms. Corticosteroid injection is helpful when splinting and antiinflammatory medications have failed. On occasion, recalcitrant cases require surgical release or reconstruction of the stenotic retinacular subsheath. Among operative cases, splitting or fraying of the ECU tendon is frequently observed.

Surgical Treatment

Operative treatment of ECU tendinitis without instability involves complete incision of the fibroosseous canal of the sixth dorsal compartment through a 3-cm curvilinear incision over the distal radioulnar joint that parallels the course of the underlying ulnar sensory nerve. Care must be taken to identify and protect subcutaneous nerve branches with vessel loops throughout the procedure. Controversy exists about whether retinacular repair (see Chapter 14) is necessary to prevent postoperative instability, but several authors have reported no postoperative ECU instability after complete release without repair of the retinaculum.[13,60] Hajj and Wood demonstrated success with a technique in which the septum between the fifth and sixth compartments was excised through an open incision of the ECU retinaculum, followed by complete repair of the retinaculum to prevent potential instability (Figure 56.20 and Case Study 56.1).[49] Operative reconstructive options for athletic patients with disabling instability of the ECU are discussed further in Chapter 14.

Flexor Carpi Radialis Tendinitis

The sharp angulation of the FCR tendon across the ridge of the trapezium and the tight fibrous canal through which it runs on its course to the base of the index metacarpal make this tendon prone to stenotic tendinopathy. The multiplicity of other diagnoses in the immediate vicinity of the tendon, including ganglion cysts, basal joint degenerative disease, scaphoid fractures and nonunions, and de Quervain disease, may lead to misdiagnosis and prolong the treatment of this condition.

ANATOMY

On the flexor surface, the radial and ulnar wrist flexors span the carpal tunnel, and each enters a short tenosynovial sheath

CASE STUDY 56.1 Tendinopathy

A 17-year-old female high school hockey star presented with ulnar-sided right wrist pain. She had felt a "snap" during a slap shot 6 months earlier. The patient attempted rest and splinting for several months. After a 3-month course of therapy, she was unable to return to play. She reported minimal discomfort with daily, school, or other recreational activities. There had been no improvement with cortisone injection. The patient was referred for definitive treatment.

Physical examination showed tenderness to ECU without snapping, laxness but no gross instability of the dorsal radioulnar joint; pain with resisted supination and ulnar deviation; and ulnar impaction positive in full supination.

Radiographs (eFigure 56.1)

What is your working diagnosis?

A. Ulnar impaction syndrome
B. Kienbock disease
C. Tear of the triangular fibrocartilage complex
D. Extensor carpi ulnaris instability
E. Radioulnar instability

What additional workup should be completed?

A. Bone scan
B. Computed tomography in three positions of rotation
C. Magnetic resonance imaging
D. Bilateral pronated grip films
E. Dynamic ultrasound

(Video 56.2)

What is the diagnosis?

A. Ulnar impaction syndrome
B. Kienböck disease
C. Tear of the triangular fibrocartilage complex
D. Extensor carpi ulnaris instability
E. Radioulnar instability

What are the treatment recommendations?

A. Ulnar-shortening osteotomy
B. Radial-shortening osteotomy
C. Arthroscopic repair of the triangular fibrocartilage complex
D. Extensor carpi ulnaris stabilization
E. Tendon graft ligament reconstruction of the dorsal radioulnar ligament

Surgical Procedure

Through a 5-cm dorsoulnar incision, the retinaculum is incised and reflected radialward (eFigure 56.2, *arrows*) to expose the extensor carpi ulnaris (ECU) subsheath (*asterisk*) and ulna. A Bennett retractor is placed in the interosseous space. The *arrow* in eFigure 56.3 demonstrates the ECU groove (not deepened). Drill holes are made on the ulnar side, and multiple suture anchors are placed. The ECU subsheath is imbricated and tied down. As shown in eFigure 56.4, the sheath has been successfully imbricated. The retinacular flap is securely repaired. The patient was treated with a long-arm cast for 4 weeks, a short-arm cast for 4 weeks, and a splint and range-of-motion exercises for 4 weeks. The patient successfully returned to playing hockey in her senior year (eFigure 56.5).

MacLennan AJ, Nemechek NM, Waitayawinyu BS, et al: Diagnosis and anatomic reconstruction of extensor carpi ulnaris subluxation. *J Hand Surg [Am]* 33(1):59–64, 2008.

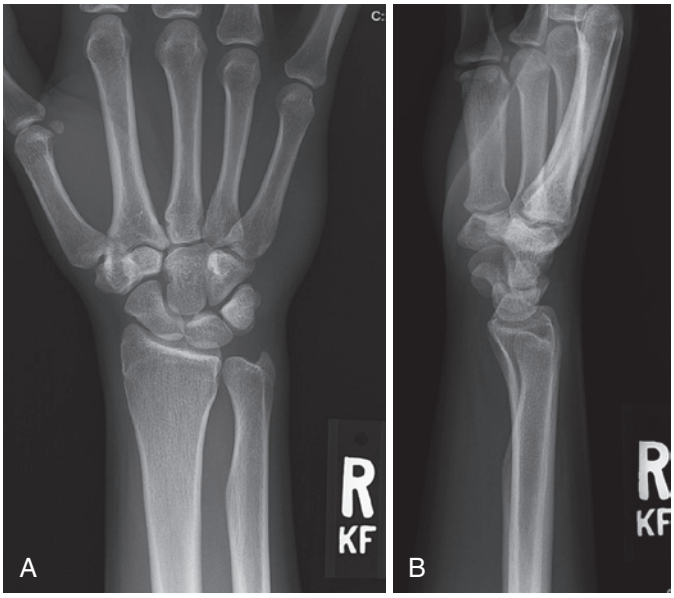

eFIGURE 56.1

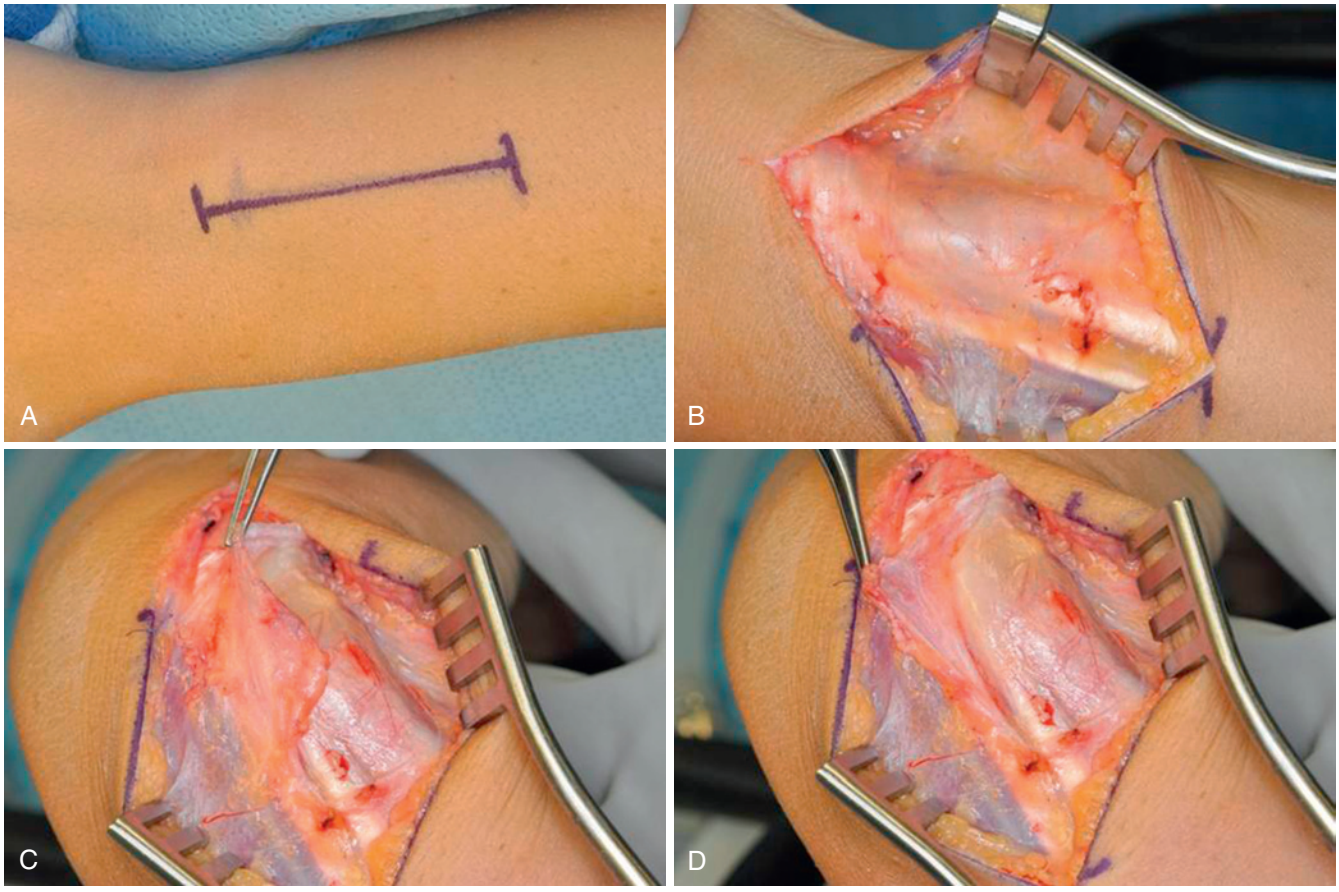

eFIGURE 56.2

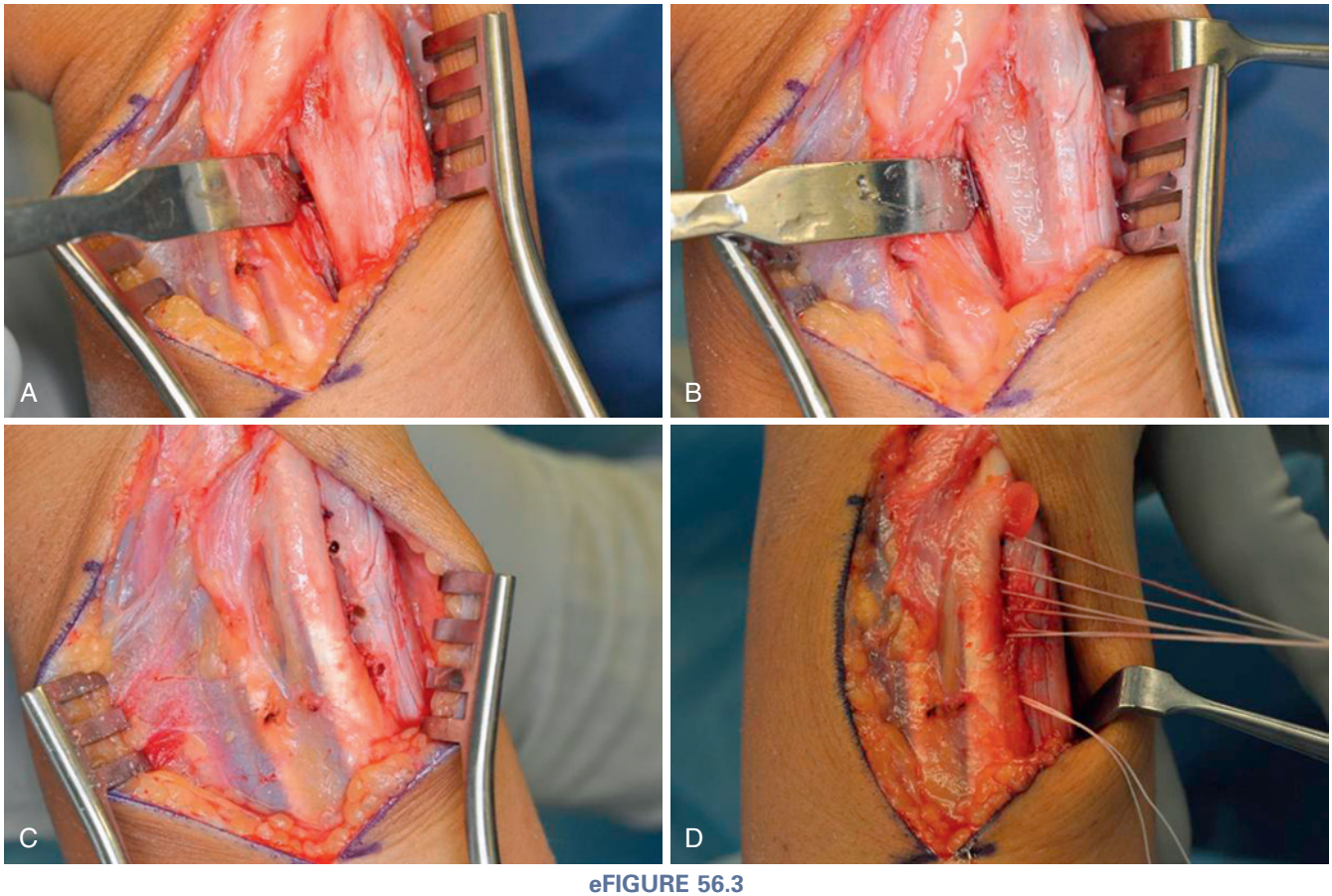

eFIGURE 56.3

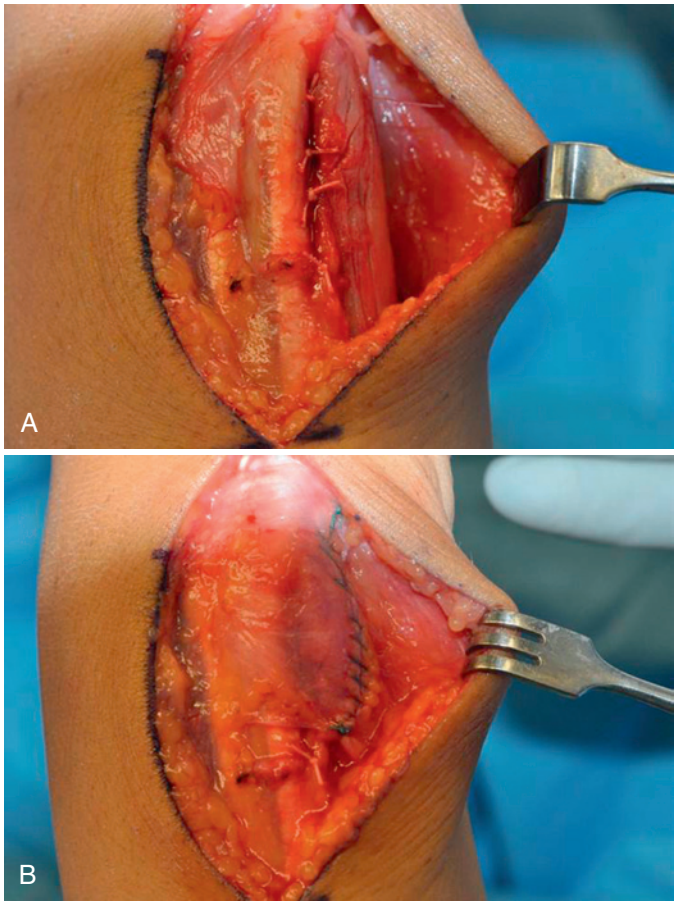

eFIGURE 56.4



eFIGURE 56.5 At 8 months' follow-up.

where it crosses the wrist joint. The musculotendinous junction of the FCR tendon is located approximately 8 cm proximal to the wrist crease, and the tendon is surrounded by a thin paratenon. The tendon becomes invested by antebrachial fascia as it approaches the wrist crease and is completely lined by a true synovial sheath from the level of the trapezial crest to the metacarpal insertion distally.[8] Bishop and colleagues demonstrated that the tendon is nearly encircled by the tubercle of the trapezium, which constitutes between 61 and 80% of the wall of the tunnel.[8] Within this tunnel, these authors found the tendon to occupy 90% of the available cross-sectional area. The authors propose that the tendon's narrow fibrous sheath and the rigid anchoring of the tendon to the wall of the trapezium make it vulnerable to both primary tendon entrapment and secondary injury in association with traumatic or degenerative lesions of the trapezium.

The condition typically affects persons in their fifth decade and is more often diagnosed in women. The process does not appear to have a predilection for the dominant hand. Most cases develop insidiously, and a history of repetitive flexion/extension of the wrist or blunt trauma is rarely elicited. Low and Hales reported a 25% incidence of FCR tendinopathy following trapezial excision and APL suspensionplasty, attributed to the passage of the APL slip around the FCR tendon.[68] I have seen a low incidence of FCR tendinitis following the use of half of the FCR tendon for basal joint arthroplasty and now prefer to use the entire tendon.

Pain is most pronounced at the palmar wrist crease over the scaphoid tubercle. Increased pain with resisted wrist flexion and radial deviation is pathognomonic of the process. Localized swelling may be evident, and a ganglion may overlie the tendon. Radiographs may identify trapezial degenerative disease, and the neighboring degenerative process may be responsible for attrition and fraying of the FCR within the adjacent tendon sheath. Successful relief of pain after injection of lidocaine and/or corticosteroid into the offending sheath helps to confirm the diagnosis.

Treatment

Nonoperative Treatment. As for other stenotic conditions of the wrist tendons, nonoperative treatment is attempted initially, with a period of splinting, ice, and antiinflammatory agents. Corticosteroid injection provides relief in cases not associated with neighboring degenerative disease or bone spurs. Chronic cases may lead to tendon fraying and rupture. Paradoxically, however, FCR rupture is characteristically associated with complete cessation of pain, and operative repair is not generally warranted. In my experience, some restitution of FCR continuity secondary to pseudotendon formation occurs over the 6- to 12-month period after FCR rupture. Operative release is occasionally indicated in active patients who are recalcitrant to splinting and corticosteroid injection.

Operative Technique. Exposure of the tendon is performed through a 3- to 4-cm hockey-stick incision centered over the scaphoid tubercle. Care must be taken to avoid injury to the nearby palmar cutaneous branch of the median nerve, as well as the thenar branches of the radial sensory and lateral antebrachial cutaneous nerves. Limited elevation of the thenar muscles can be performed for exposure. The sheath is opened proximal to the fibrous tunnel and dissection is carried distally to a point just beyond the trapezial tubercle. The tendon should be elevated and inspected, with frayed or degenerated fibers excised. If the trapezial groove has rough, sharp edges or osteophytes, limited débridement with a small rongeur should be performed. No attempt is made to approximate the sheath, and the wound is closed with a subcuticular suture. A light, conforming dressing is applied, and gradually increasing activity is encouraged within days of surgery.

On occasion, a chronically scarred or degenerated FCR tendon must be surgically excised to relieve chronic pain. This procedure should be reserved for patients who have failed a comprehensive course of nonoperative treatment. I use an ultrasound-guided corticosteroid injection to ensure precise localization and confirm at least short-term relief prior to consideration of excision. Relief following excision is generally immediate and profound. I have identified no deficits of motion or function following FCR tendon excision.

For Case Studies, Videos, and more, please visit ExpertConsult.com.

REFERENCES

1. Abrahamsson SO: Gouty tenosynovitis simulating an infection. A case report. *Acta Orthop Scand* 58(3):282–283, 1987.
2. Alexander RD, Catalano LW, Barron OA, et al: The extensor pollicis brevis entrapment test in the treatment of de Quervain's disease. *J Hand Surg [Am]* 5:813–816, 2002.
3. Avci S, Yilmaz C, Sayli U: Comparison of nonsurgical treatment measures for de Quervain's disease of pregnancy and lactation. *J Hand Surg [Am]* 27(2):322–324, 2002.
4. Baek GH, Kim JH, Chung MS, et al: The natural history of pediatric trigger thumb. *J Bone Joint Surg Am* 90(5):980–985, 2008.
5. Bain GI, Turnbull J, Charles MN, et al: Percutaneous A1 pulley release: a cadaveric study. *J Hand Surg [Am]* 20:781–784, 1995.

5a. Bain GI, Wallwork NA: Percutaneous A1 pulley release: a clinical study. *Hand Surg* 4(1):45–50, 1999.

6. Barthelemy CR, Nakayama DA, Carrera GF, et al: Gouty arthritis: a prospective radiographic evaluation of sixty patients. *Skeletal Radiol* 11(1):1–8, 1984.
7. Bayat A, Shaaban H, Giakas G, et al: The pulley system of the thumb: anatomic and biomechanical study. *J Hand Surg [Am]* 27(4):628–635, 2002.
8. Bishop AT, Gabel G, Carmichael SW: Flexor carpi radialis tendinitis. Part I: Operative anatomy. *J Bone Joint Surg Am* 76(7):1009–1014, 1994.
9. Brown FE, Brown M: Long-term results after tenosynovectomy to treat the rheumatoid hand. *J Hand Surg [Am]* 13:704–708, 1988.
10. Bruijnzeel H, Neuhaus V, Fostvedt S, et al: Adverse events of open A1 pulley release for idiopathic trigger finger. *J Hand Surg [Am]* 37(8):1650–1656, 2012.
11. Bullocks JM, Downey CR, Gibler DP, et al: Crystal deposition disease masquerading as proliferative tenosynovitis and its associated sequelae. *Ann Plast Surg* 62(2):128–133, 2009.
12. Bunnell S: *Injuries of the hand: surgery of the hand*, Philadelphia, 1944, J.B. Lippincott, pp 496–499.
13. Burman M: Stenosing tendovaginitis of the dorsal and volar compartments of the wrist. *Arch Surg* 65:752–762, 1952.
14. Burton RI, Littler JW: Tendon entrapment syndrome of first extensor compartment (deQuervain's disorder). *Curr Probl Surg* 12:32–34, 1975.
15. Bush DC, Schneider LH: Tuberculosis of the hand and wrist. *J Hand Surg [Am]* 9(3):391–398, 1984.
16. Cardon LJ, Ezaki M, Carter PR: Trigger finger in children. *J Hand Surg [Am]* 24(6):1156–1161, 1999.
17. Carlson CS, Jr, Curtis RM: Steroid injection for flexor tenosynovitis. *J Hand Surg [Am]* 9(2):286–287, 1984.
18. Carroll RE, Sinton W: Acute calcium deposits in the hand. *JAMA* 130:422–426, 1955.
19. Carrozzella J, Stern PJ, Von Kuster LC: Transection of radial digital nerve of the thumb during trigger release. *J Hand Surg [Am]* 14:198–200, 1989.
20. Chammas M, Bousquet P, Renard E, et al: Dupuytren's disease, carpal tunnel syndrome, trigger finger, and diabetes mellitus. *J Hand Surg [Am]* 20(1):109–114, 1995.

21. Chimenti PC, Hammert WC: Medical management of acute gout. *J Hand Surg [Am]* 37(10):2160–2164, 2012.
22. Chiu KY, Wong WB, Choi CH, et al: Acute carpal tunnel syndrome caused by pseudogout. *J Hand Surg [Am]* 17:299–302, 1992.
23. Cihantimur B, Akin S, Ozcan M: Percutaneous treatment of trigger finger: 34 fingers followed 0.5-2 years. *Acta Orthop Scand* 69:167–168, 1998.
24. Clapham PJ, Chung KC: A historical perspective of the Notta's node in trigger fingers. *J Hand Surg [Am]* 34(8):1518–1522, 2009.
25. Darmawan J, Valkenburg HA, Muirden KD, et al: The epidemiology of gout and hyperuricemia in a rural population of Java. *J Rheumatol* 19(10):1595–1599, 1992.
26. De Smet L, Steenwerckx A, Van Ransbeeck H: The so-called congenital trigger digit: further experience. *Acta Orthop Belg* 64(3):306–308, 1998.
27. Dinham JM, Meggitt BF: Trigger thumbs in children. A review of the natural history and indications for treatment in 105 patients. *J Bone Joint Surg Br* 56:153, 1974.
28. Doyle JR, Blythe W: *The finger flexor tendon sheath and pulleys: anatomy and reconstruction. AAOS symposium on tendon surgery in the hand*, St. Louis, 1975, C.V. Mosby, pp 81–87.
29. Doyle JR, Blythe W: Anatomy of the flexor tendon sheath and pulleys of the thumb. *J Hand Surg [Am]* 2:149–151, 1977.
30. Dunn MJ, Pess GM: Percutaneous trigger finger release: a comparison of a new push knife and a 19-gauge needle in a cadaveric model. *J Hand Surg [Am]* 24: 860–865, 1999.
31. Eastwood DM, Gupta KJ, Johnson DP: Percutaneous release of the trigger finger: an office procedure. *J Hand Surg [Am]* 17(1):114–117, 1992.
32. Eichhoff E: Zur pathogenese der tendovaginitis stenosans. *Bruns Beitrage zur Klinischen Chirurgie* 136:746–755, 1927.
33. Engkvist O, Lundborg G: Rupture of the extensor pollicis longus tendon after fracture of the lower end of the radius—a clinical and microangiographic study. *Hand* 1:76–86, 1979.
34. Fahey JJ, Bollinger JA: Trigger-finger in adults and children. *J Bone Joint Surg Am* 36(6):1200–1218, 1954.
35. Fanburg BL: Sarcoidosis. In Bennett JC, Plum F, editors: *Cecil's textbook of medicine*, ed 20, Philadelphia, 1996, W.B. Saunders, pp 431–436.
36. Finklestein H: Stenosing tendovaginitis at the radial styloid process. *J Bone Joint Surg Am* 12:509–540, 1930.
37. Fitzgerald BT, Hofmeister EP, Fan RA, et al: Delayed flexor digitorum superficialis and profundus ruptures in a trigger finger after a steroid injection: a case report. *J Hand Surg [Am]* 30(3):479–482, 2005.
38. Fodor L, Bota IO, Fodor M, et al: Sarcoid flexor tenosynovitis as a single early manifestation of the disease. *J Plast Reconstr Aesthet Surg* 65(8):e217–e219, 2012.
39. Freiberg A, Mulholland RS, Levine R: Nonoperative treatment of trigger fingers and thumbs. *J Hand Surg [Am]* 14:553–558, 1989.
40. Fuchs PC, Nathan PA, Myers LD: Synovial histology in carpal tunnel syndrome. *J Hand Surg [Am]* 16(4):753–758, 1991.
41. Garsten P: Stenosis of the extensor carpi ulnaris tendon sheath. *Acta Chir Scand* 101:85–90, 1951.
42. Ger E, Kupcha P, Ger D: The management of trigger thumb in children. *J Hand Surg [Am]* 16(5):944–947, 1991.
43. Graff SN, Seiler JG, Jupiter JB: Acute gout after carpal tunnel release. *J Hand Surg [Am]* 17(6):1031–1032, 1992.
44. Griggs SM, Weiss AP, Lane LB, et al: Treatment of trigger finger in patients with diabetes mellitus. *J Hand Surg [Am]* 20:787–789, 1995.
45. Grundberg AB, Reagan DS: Pathologic anatomy of the forearm: intersection syndrome. *J Hand Surg [Am]* 10(2):299–302, 1985.
46. Guler F, Kose O, Ercan EC, et al: Open versus percutaneous release for the treatment of trigger thumb. *Orthopedics* 36(10):e1290–e1294, 2013.
47. Gyuricza C, Umoh E, Wolfe SW: Multiple pulley rupture following corticosteroid injection for trigger digit: a case report. *J Hand Surg [Am]* 34:1444–1448, 2009.
48. Ha KI, Park MJ, Ha CW: Percutaneous release of trigger digits. *J Bone Joint Surg Br* 83(1):75–77, 2001.
49. Hajj AA, Wood MB: Stenosing tenosynovitis of the extensor carpi ulnaris. *J Hand Surg [Am]* 11(4):519–520, 1986.
50. Hansen U, Battista V: Pediatric trigger finger from calcific tendonitis. *J Hand Surg [Am]* 32(10):1558–1559, 2007.
51. Harvey FJ, Harvey PM, Horsley MW: De Quervain's disease: surgical or nonsurgical treatment. *J Hand Surg [Am]* 15(1):83–87, 1990.
52. Heithoff SJ, Millender LH, Helman J: Bowstringing as a complication of trigger finger release. *J Hand Surg [Am]* 13(4):567–570, 1988.
53. Helal B: Distal profundus entrapment in rheumatoid disease. *Hand* 2:48–51, 1970.
54. Hooper G, McMaster MJ: Stenosing tenovaginitis affecting the tendon of extensor digiti minimi at the wrist. *Hand* 11(3):299–301, 1979.
55. Hueston JT, Wilson WF: The aetiology of trigger finger. *Hand* 4(3):257–260, 1972.
56. Jackson WT, Viegas SF, Coon TM, et al: Anatomical variations in the first extensor compartment of the wrist. A clinical and anatomical study. *J Bone Joint Surg Am* 68:923–926, 1986.
57. Kazuki K, Egi T, Okada M, et al: Clinical outcome of extrasynovial steroid injection for trigger finger. *Hand Surg* 11(1–2):1–4, 2006.
58. Kerr CD, Sybert DR, Albarracin NS: An analysis of the flexor synovium in idiopathic carpal tunnel syndrome: report of 625 cases. *J Hand Surg [Am]* 17(6):1028–1030, 1992.
59. Kerrigan CL, Stanwix MG: Using evidence to minimize the cost of trigger finger care. *J Hand Surg [Am]* 34(6):997–1005, 2009.
60. Kip PC, Peimer CA: Release of the sixth dorsal compartment. *J Hand Surg [Am]* 19:599–601, 1994.
61. Kolind-Sorensen V: Treatment of trigger fingers. *Acta Orthop Scand* 41:428–432, 1970.
62. Kozin SH, Bishop AT: Atypical Mycobacterium infections of the upper extremity. *J Hand Surg [Am]* 19(3):480–487, 1994.
63. Lanzetta M, Howard M, Conolly WB: Post-traumatic triggering of extensor pollicis longus at the dorsal radial tubercle. *J Hand Surg [Br]* 20(3):398–401, 1995.
64. Lapidus PW, Guidotti FP: Stenosing tenovaginitis of the wrist and fingers. *Clin Orthop Relat Res* 83:87–90, 1972.
65. Leslie BM, Ericson WB, Jr, Morehead JR: Incidence of a septum within the first dorsal compartment of the wrist. *J Hand Surg [Am]* 15(1):88–91, 1990.
66. Liang J, McElroy K: Hypopigmentation after triamcinolone injection for de Quervain tenosynovitis. *Am J Phys Med Rehabil* 92(7):639, 2013.
67. Lorthioir J: Surgical treatment of trigger-finger by a subcutaneous method. *J Bone Joint Surg Am* 40:793–795, 1958.
68. Low TH, Hales PF: High incidence and treatment of flexor carpi radialis tendinitis after trapeziectomy and abductor pollicis longus suspensionplasty for basal joint arthritis. *J Hand Surg Eur Vol* 39:838–844, 2014.
69. Lyu SR: Closed division of the flexor tendon sheath for trigger finger. *J Bone Joint Surg Br* 74(3):418–420, 1992.
70. MacKenzie CR, Major P, Hunter T: Tendon involvement in a case of ochronosis. *J Rheumatol* 9(4):634–636, 1982.
71. Marks MR, Gunther SF: Efficacy of cortisone injection in treatment of trigger fingers and thumbs. *J Hand Surg [Am]* 14(4):722–727, 1989.
72. McAdams TR, Moneim MS, Omer GE, Jr: Long-term follow-up of surgical release of the A(1) pulley in childhood trigger thumb. *J Pediatr Orthop* 22(1):41–43, 2002.
73. McMahon M, Craig SM, Posner MA: Tendon subluxation after de Quervain's release: treatment by brachioradialis tendon flap. *J Hand Surg [Am]* 16(1):30–32, 1991.
74. Merle M, Bour C, Foucher G, et al: Sarcoid tenosynovitis in the hand. A case report and literature review. *J Hand Surg [Br]* 11(2):281–286, 1986.
75. Millon SJ, Bush DC, Harrington TM: Acute calcific tendinitis in a child: a case report. *J Hand Surg [Am]* 18(4):592–593, 1993.
76. Miyamoto H, Miura T, Isayama H, et al: Stiffness of the first annular pulley in normal and trigger fingers. *J Hand Surg [Am]* 36(9):1486–1491, 2011.
77. Montalvan B, Parier J, Brasseur JL, et al: Extensor carpi ulnaris injuries in tennis players: a study of 28 cases. *Br J Sports Med* 40(5):424–429, 2006.
78. Moon WN, Suh SW, Kim IC: Trigger digits in children. *J Hand Surg [Br]* 26(1):11–12, 2001.
79. Moore JR, Weiland AJ: Gouty tenosynovitis in the hand. *J Hand Surg [Am]* 10(2):291–295, 1985.
80. Moyer RA, Bush DC, Harrington TM: Acute calcific tendinitis of the hand and wrist: A report of 12 cases and a review of the literature. *J Rheumatol* 16:198–202, 1989.
81. Mulpruek P, Prichasuk S, Orapin S: Trigger finger in children. *J Pediatr Orthop* 18(2):239–241, 1998.
82. Murphy D, Failla JM, Koniuch MP: Steroid versus placebo injection for trigger finger. *J Hand Surg [Am]* 20:628–631, 1995.
83. Nagoshi M, Hashizume H, Nishida K, et al: Percutaneous release for trigger finger in idiopathic and hemodialysis patients. *Acta Med Okayama* 51(3):155–158, 1997.
84. Nakamichi K, Tachibana S, Tamai K: Carpal tunnel syndrome caused by a mass of calcium phosphate. *J Hand Surg [Am]* 19(1):111–113, 1994.
85. Newport ML, Lane LB, Stuchin SA: Treatment of trigger finger by steroid injection. *J Hand Surg [Am]* 15(5):748–750, 1990.
86. Nguyen ML, Jones NF: Rupture of both the abductor pollicis longus and extensor pollicis brevis tendons after steroid injection for de quervain tenosynovitis. *Plast Reconstr Surg* 129(5):883e–886e, 2012.
87. Patel MR, Bassini L: Trigger fingers and thumb: when to splint, inject, or operate. *J Hand Surg [Am]* 17(1):110–113, 1992.
88. Pope DF, Wolfe SW: Safety and efficacy of percutaneous trigger finger release. *J Hand Surg [Am]* 20(2):280–283, 1995.
89. Posner MA, Langa V, Green SM: The locked metacarpophalangeal joint: Diagnosis and treatment. *J Hand Surg [Am]* 11:249–253, 1986.
90. Quinnell RC: Conservative management of trigger finger. *Practitioner* 224(1340): 187–190, 1980.
91. Rhoades CE, Gelberman RH, Manjarris JF: Stenosing tenosynovitis of the fingers and thumb. *Clin Orthop Relat Res* 190:236–238, 1984.

92. Ring D, Lozano-Calderon S, Shin R, et al: A prospective randomized controlled trial of injection of dexamethasone versus triamcinolone for idiopathic trigger finger. *J Hand Surg [Am]* 33(4):516–522, 2008.
93. Rintala AE, Alanko A, Makinen J, et al: Primary hereditary systemic amyloidosis (Meretoja's syndrome): clinical features and treatment by plastic surgery. *Scand J Plast Reconstr Surg Hand Surg* 22(2):141–145, 1988.
94. Rodgers JA, McCarthy JA, Tiedeman JJ: Functional distal interphalangeal joint splinting for trigger finger in laborers: a review and cadaver investigation. *Orthopedics* 21(3):305–309, discussion 309–310, 1998.
95. Rodgers WB, Waters PM: Incidence of trigger digits in newborns. *J Hand Surg [Am]* 19(3):364–368, 1994.
96. Roth KM, Blazar PE, Earp BE, et al: Incidence of extensor pollicis longus tendon rupture after nondisplaced distal radius fractures. *J Hand Surg [Am]* 37(5):942–947, 2012.
97. Sampson SP, Badalamente MA, Hurst LC, et al: Pathobiology of the human A1 pulley in trigger finger. *J Hand Surg [Am]* 16(4):714–721, 1991.
98. Sampson SP, Wisch D, Badalamente MA: Complications of conservative and surgical treatment of de Quervain's disease and trigger fingers. *Hand Clin* 10(1):73–82, 1994.
99. Saour S, Dhillon BS, Ho-Asjoe M, et al: Ascending hypopigmentation of the forearm following injection of triamcinolone. *J Plast Reconstr Aesthet Surg* 62(12): e597–e598, 2009.
100. Schuind F, Ventura M, Pasteels JL: Idiopathic carpal tunnel syndrome: histologic study of flexor tendon synovium. *J Hand Surg [Am]* 15(3):497–503, 1990.
101. Seiler JG3, Kerwin GA: Adolescent trigger finger secondary to post-traumatic chronic calcific tendinitis. *J Hand Surg [Am]* 20(3):425–427, 1995.
102. Seradge H: Ochronotic stenosing flexor tenosynovitis—case report. *J Hand Surg [Am]* 6(4):359–360, 1981.
103. Stahl S, Kanter Y, Karnielli E: Outcome of trigger finger treatment in diabetes. *J Diabetes Complications* 11(5):287–290, 1997.
104. Stahl S, Vida D, Meisner C, et al: Systematic review and meta-analysis on the work-related cause of de Quervain tenosynovitis: a critical appraisal of its recognition as an occupational disease. *Plast Reconstr Surg* 132(6):1479–1491, 2013.
105. Stefanich RJ, Peimer CA: Longitudinal incision for trigger finger release. *J Hand Surg [Am]* 14(2 Pt 1):316–317, 1989.
106. Stothard J, Kumar A: A safe percutaneous procedure for trigger finger release. *J R Coll Surg Edinb* 39:116–117, 1994.
107. Straub LR, Smith JW, Carpenter GK, Jr, et al: The surgery of gout in the upper extremity. *J Bone Joint Surg Am* 43:731–752, 1961.
108. Tanaka J, Muraji M, Negoro H, et al: Subcutaneous release of trigger thumb and fingers in 210 fingers [see comments]. *J Hand Surg [Br]* 15(4):463–465, 1990.
109. Taras JS, Iiams GJ, Gibbons M, et al: Flexor pollicis longus rupture in a trigger thumb: A case report. *J Hand Surg [Am]* 20:276–277, 1995.
110. Thorpe AP: Results of surgery for trigger finger. *J Hand Surg [Br]* 13(2):199–201, 1988.
111. Trezies AJ, Lyons AR, Fielding K, et al: Is occupation an aetiological factor in the development of trigger finger? *J Hand Surg [Br]* 23(4):539–540, 1998.
112. Turowski GA, Zdankiewicz PD, Thomson JG: The results of surgical treatment of trigger finger. *J Hand Surg [Am]* 22(1):145–149, 1997.
113. Van Heest AE, House J, Krivit W, et al: Surgical treatment of carpal tunnel syndrome and trigger digits in children with mucopolysaccharide storage disorders. *J Hand Surg [Am]* 23(2):236–243, 1998.
114. Verfaillie S, DeSmet L, Leemans A, et al: Acute carpal tunnel syndrome caused by hydroxyapatite crystals: A case report. *J Hand Surg [Am]* 21(3):360–362, 1996.
115. Viegas SF: Trigger thumb of de Quervain's disease. *J Hand Surg [Am]* 11(2):235–237, 1986.
116. Weiss AP, Akelman E, Tabatabai M: Treatment of de Quervain's disease. *J Hand Surg [Am]* 19(4):595–598, 1994.
117. Wessel LE, Fufa DT, Boyer MI, et al: Epidemiology of carpal tunnel syndrome in patients with single versus multiple trigger digits. *J Hand Surg [Am]* 38(1):49–55, 2013.
118. Wilhelmi BJ, Snyder N4, Verbesey JE, et al: Trigger finger release with hand surface landmark ratios: an anatomic and clinical study. *Plast Reconstr Surg* 108(4):908–915, 2001.
119. Will R, Lubahn J: Complications of open trigger finger release. *J Hand Surg [Am]* 35(4):594–596, 2010.
120. Wood VE, Sicilia M: Congenital trigger digit. *Clin Orthop Relat Res* 285:205–209, 1992.
121. Zingas C, Failla JM, Van Holsbeeck M: Injection accuracy and clinical relief of de Quervain's tendinitis. *J Hand Surg [Am]* 23(1):89–96, 1998.

57

Burned Hand

Günter Germann and Manuel Hrabowski

Hands are involved in more than 80% of all severe burns.[114] Each hand represents less than 3% of the total body surface area, but nonetheless, the American Burn Association categorizes burns of the hand as major injuries.[88] Even small burns of the hand may result in severely limited function. When burns of the hand occur as part of a major thermal injury, treatment of the hand receives high priority because the patient's ability to perform useful work after recovery is to a great degree determined by residual hand function. The functional importance of the hand cannot be overemphasized inasmuch as severe hand burns may leave individuals unable to work or even care for themselves. The hand plays a crucial role in the evaluation of our environment ("get a grip on a problem"), in communication with others, in sending and receiving emotional signals, and in sexuality and is frequently a mirror image of our mental state.[139,143]

Burns on the hand frequently have devastating consequences in terms of functional outcome and also aesthetic appearance. Although burned areas of the trunk or lower extremity can easily be hidden under clothing, burned hands are readily visible. Social and professional reintegration of the patient may be delayed because of the psychological stigma that is caused by the visible mutilation. For these reasons, burned hands deserve to be treated with excellent conservative and surgical techniques to achieve not only the best function but also the best possible aesthetic result. The statement of Guy Foucher that "hand surgery is also aesthetic surgery" has never been truer than in the treatment of burned hands. The functional importance of the hand gives it top priority in modern treatment concepts. The most important treatment principles include early initiation of physical therapy; the use of splinting,[133] passive motion movements, and topical treatment; and, when indicated, the use of excision and grafting. A multidisciplinary team, including plastic surgeons, physical and occupational therapists, and psychologists, should be involved from the day of admission to ensure the best quality of care.[78,148]

EPIDEMIOLOGIC FINDINGS

It is estimated that about 1% of the population in Western countries will have a burn injury each year, approximately a quarter of which will require medical care.[13,113] This makes thermal injury the most frequently reported accident. The workplace, however, accounts only for less than a third of burn unit admissions and fire-related deaths. The upper extremity is the most common anatomic area burned, involved in up to 89% of burns.[13,50] The two main reasons for this frequent involvement are the protective reflex with which patients try to guard their faces and the fact that the hand in most instances is exposed without any form of protection. The dorsum of the hand is predominantly involved in flame or explosion injuries, whereas injuries to the palm are more frequently found with chemical exposure, friction burns, or high-voltage injuries. Thermal energy may be transmitted directly by contact with a hot object or liquid. More commonly, however, energy is transmitted indirectly, as when escaping gas from an oven ignites.[50]

ANATOMY

The skin and soft tissues of the hand demonstrate some unique properties. The dorsal skin is thin and very flexible and lies on a rather thin subcutaneous layer of fatty tissue. This structure provides little mechanical protection but allows maximum tendon excursion and joint mobility without the necessity for excess skin. The wrinkles over the metacarpophalangeal (MP), proximal interphalangeal (PIP), and distal interphalangeal (DIP) joints deepen with finger extension and stretch with flexion. Similar movements are facilitated by longitudinal creases in the web space. The dorsal skin contains large superficial veins, hair follicles, and sebaceous glands, but contains no sweat glands. The skin is especially thin over the PIP joints, where the extensor tendons are at risk. Attenuation or rupture of the central slip with PIP joint exposure is one of the most frequently encountered complications after deep dorsal burns. The underlying cause of many functional disturbances following burns is disruption of the coordinated interplay of extrinsic and intrinsic muscles, tendons, and joints.

The palmar skin shows similarities to the plantar skin of the weight-bearing portion of the foot. The thick subcutaneous fatty layer has a honeycomb-like structure that has shock-absorbing properties and provides grip stability by means of numerous fibrous septa that connect the skin with the deep fascia. Thick epidermal layers are found in the areas of greatest mechanical stress. In the finger, the Cleland ligament (dorsal to the neurovascular bundle) and Grayson ligament (palmar to the neurovascular bundle) provide stability.

PATHOPHYSIOLOGY

The anatomic properties described previously can lead to severe direct thermal effects in the hand that are not seen elsewhere in the body.[122] Blood vessels, tendons, and joints are situated just beneath the skin surface over the dorsum of the fingers, making these structures extremely susceptible to the effects of thermal energy. The cylindrical form of the fingers, with their ligaments

limiting swelling and changes in volume of the fingers after thermal injury, can lead to dermal compartment syndromes in the event of deep dermal circumferential burn injury.[122]

The severity of a thermal injury depends on the amount of transferred energy, which is correlated with the duration of exposure and the temperature of the heat source. Longer exposure to lower temperatures has the same pathophysiologic consequences as short exposure to high temperatures. The character of the skin at the site of injury also determines the depth of the injury. The palmar skin, for example, can withstand greater thermal energy than the dorsal skin can. The heat leads to coagulation of blood vessels, denaturation of proteins, and an increase in capillary permeability (*capillary leak*). This phenomenon divides the burn wound into a zone of necrosis, a zone of stasis, and a zone of impaired circulation.[55] Insufficient primary treatment (i.e., no escharotomy if indicated or insufficient fluid replacement) may convert the zone of stasis into a zone of necrosis (*afterburn*) (Figure 57.1).

Intravascular fluid shifts into the interstitial space and causes a protein-rich edema. Burns of more than 20% of the body surface area lead to a generalized edema in which swelling of the skin and subcutaneous tissue is also encountered in nonburned areas. Edema causes several pathologic effects by increasing intercellular pressure and decreasing circulation. In the intrinsic musculature of the hand, this may lead to a compartment syndrome requiring fasciotomy. Intracellular edema results from disruption of the sodium pump and subsequent entry of sodium and water into the cell.[88] In the hand, persistent interstitial edema that has not resolved after 72 hours may lead to subcutaneous fibrosis with subsequent stiffness of the joints.

Blisters are the cutaneous equivalent of the accumulation of intercellular edema. The blister fluid is rich in proteins and inflammatory cytokines, leukotrienes, and prostaglandins, in addition to multiple growth factors such as angiogenic factors[99] and platelet-derived growth factor, interleukin-6 (IL-6) and IL-8, and transforming growth factor-α.[52,88,98,105,107] Fluid losses through blistering may be considerable in major burns because the ability of the epidermis to limit loss of water vapor is unbalanced, but this does not play a role in isolated hand burns.

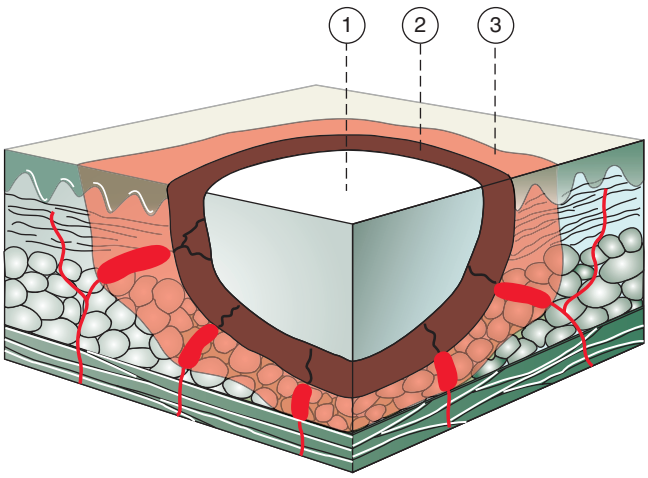

FIGURE 57.1 Model of burn wound pathophysiology. The zone of stasis may convert to a zone of necrosis if insufficient fluid resuscitation is administered.

Blisters are found in partial-thickness (second-degree) burns and superficial dermal (second-degree) burns and less frequently in deep dermal (third-degree) burns.

ACUTE HAND BURNS

Treatment Goals

Any burn injury, even if considered minimal in extent, can still be catastrophic if the hand burns are severe enough to result in deformities that render the individual unable to perform personal daily functions. One of the major basic principles of management of injuries to the skin and subcutaneous tissue of the hand is to achieve wound healing as rapidly as possible. It is equally important to avoid complications that may extend the magnitude of the injury.[50,142] The basic considerations in treating a burned hand can be divided into treatment goals and treatment principles. The most important treatment goals can be defined as follows:

1. Avoid any additional injury or increase in the depth of the burn (do no harm).
2. Achieve early wound closure.
3. Maintain active and passive range of motion.
4. Prevent infection or loss of soft tissue coverage.
5. Initiate early functional rehabilitation.

Treatment should always focus on these goals while taking into consideration the individual circumstances of the patient, which may lead to a shift in priorities.[54,88] To achieve these goals, the following basic treatment principles should be followed (Figure 57.2):

1. Evaluate the size and depth of the burn.
2. Perform escharotomy if indicated.[116]
3. Apply proper wound care and dressings.
4. Make a decision about conservative or operative treatment.
5. Initiate early hand therapy and splinting.
6. Manage the burn surgically (removal of eschar, transplantation of skin grafts, flap coverage if necessary)
7. Begin early postoperative physical therapy.
8. Provide functional rehabilitation.
9. Perform secondary and tertiary corrections if necessary.

Initial Evaluation and Management

A careful and comprehensive history of the injury is of great diagnostic value and prognostic importance and may provide important information for necessary decisions about treatment. After the history, a thorough physical examination should define the extent and probable depth of the burn, the presence and severity of associated injuries, and the general health of the patient. Physical diagnosis of the depth of burn is initially difficult even with years of experience, but knowledge of the mechanism and circumstances can help in indicating the amount of thermal energy conveyed to the tissue.[130]

All injuries should be documented carefully to create a solid foundation for further decisions and a baseline for follow-up and evaluation of outcome during the treatment course. Photographic documentation is highly recommended, especially in view of potential medicolegal issues.[56] The status of perfusion, capillary refill, skin color, and other characteristics has to be documented to facilitate decisions about escharotomy, compartment release, or acute eschar excision.

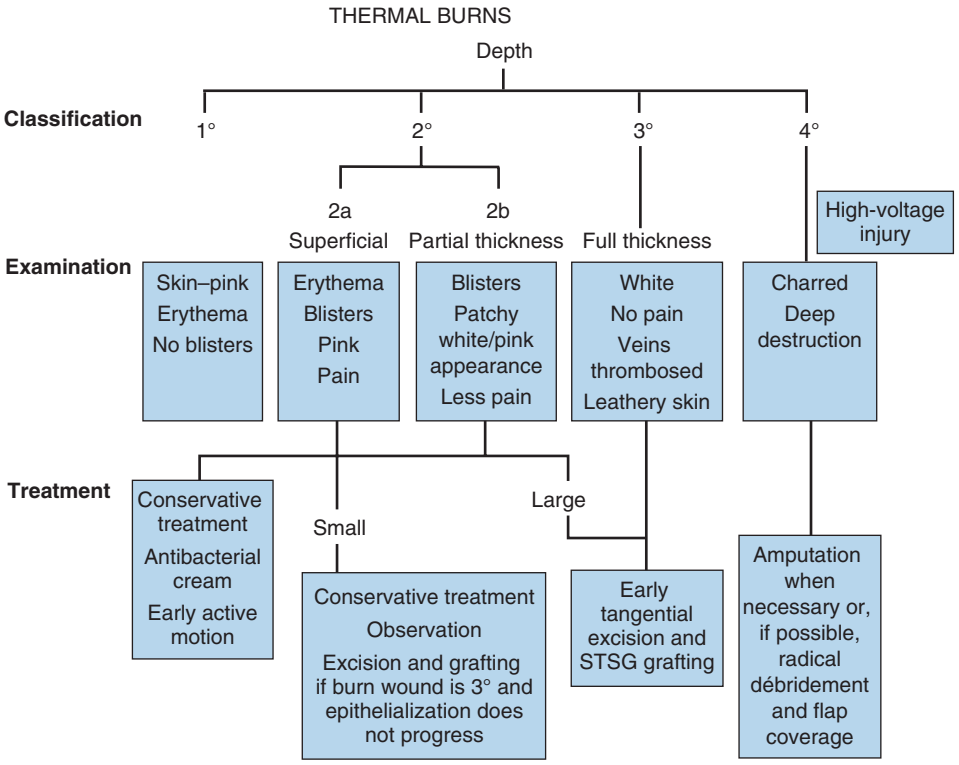

FIGURE 57.2 Decision algorithm for the treatment of cutaneous burns. *STSG,* Split-thickness skin graft. (With permission from Germann G, Sherman R, Levin SL: *Decision making in reconstructive surgery on the upper extremity,* New York, 1999, Springer-Verlag.)

BOX 57.1 Postburn Hand Deformities

First web adduction contractures
Web space contractures
Dorsal skin contractures
Digital flexion contractures
Boutonnière deformity
Dorsal skin deficiency
Digital loss secondary to ischemia
Median and ulnar nerve compression syndrome

Classification of Burns

The cause of the burns can be considered the most useful predictive factor with regard to the prognosis for healing. Scalds usually result in a mixed-depth pattern of injury and frequently involve the palms. Especially in younger patients, scald burns demonstrate a high capacity for spontaneous healing. A more aggressive approach is indicated in elderly individuals with thinner skin. Flame burns are the most serious types of burns, with the notable exception of high-voltage injuries. Flame burns are usually deep partial-thickness or full-thickness burns and often require surgical treatment.[46,130]

Treatment of burns is dictated by the severity of the injury, and severity is determined by the level of thermal energy transmitted to the tissue. Burn wounds have been classified in many ways, although the most common is an anatomic classification based on the depth of the damage (Box 57.1).

Superficial, first-degree burns are characterized by an erythematous epidermis without blistering and are moderately painful. The clinical appearance is similar to sunburn. First-degree burns are those in which cell damage occurs without cell death. These injuries require only symptomatic care, principally directed at relieving pain, which is usually achieved by the application of cooling lotions and pain relievers. They will heal without scarring, usually in 2 to 3 days, and with good return of function.

Superficial partial-thickness second-degree burns destroy the epidermis and some elements of the basal epidermal regenerating layers of the dermis. They are considered to be the most painful type in the immediate posttrauma period because sensitive nerve endings are not damaged. They have the potential to heal by virtue of regeneration from the living epidermal elements remaining in the dermis (sweat or sebaceous glands and hair follicles).[31,98,130] Regeneration, however, may be quite prolonged, depending on the depth of the injury. In second-degree injuries, the resulting scar formation is directly dependent on the depth of injury, and the quality of the regenerated skin is inversely proportional: the deeper the burn, the poorer the quality of the regenerated skin (Figure 57.3).

Deep partial-thickness second-degree burns appear as a moist mottled surface that may be pale or erythematous, depending on the depth of the burn. These wounds typically blanch with pressure and refill on release. Nerve endings are still present in the vital layers, and thus these burns can be quite painful. The skin still bleeds after a needle prick (Figure 57.4).

Full-thickness third-degree burns are characterized by the death of all germinal epidermal elements. The wound extends below the level of the dermis. The skin has a leathery unyielding appearance and is pale to brown in color. The nerve endings are destroyed, so the pain may not be significant. Because all the dermal appendages, as well as the overlying epidermis, are



FIGURE 57.3 Superficial-thickness second-degree burn with blister formation.



FIGURE 57.4 Deep partial-thickness second-degree burn of the palm. The burn will heal spontaneously because of the healing capacity of the palmar skin.

destroyed, these wounds cannot heal by epithelial regeneration and thus are not self-healing.

A *fourth-degree injury* involves necrosis of deeper structures such as tendons and bone[50,130] and is usually found only after contact burns or high-voltage injuries (Figure 57.5).

Determination of Burn Depth

Clinical assessment has not been usurped by modern technology in the evaluation of burn depth. Evaluation is based on the clinical appearance, testing of residual sensibility, pinprick testing for bleeding, and evaluation of capillary refill.[60] These findings are correlated with classification of the burn. Modern devices such as laser Doppler imaging, high-resolution ultrasound studies, and spectrometric analysis are interesting adjunctive techniques but have not improved clinical assessment in hand burns.[155]



FIGURE 57.5 Deep partial-thickness and full-thickness third-degree burns of the forearm. These burns will require excision and grafting.

Control of Edema

Initial delivery of first aid to an individual with a hand burn includes immediate cooling of the wound by rinsing with cold tap water within the first 30 minutes of injury.[116] Cold packs or crushed ice may cause additional harm by decreasing the tissue temperature too much. There is good evidence that the immediate application of cooling to a burn wound will reduce subsequent edema formation and may decrease the actual depth of injury by reducing the zone of stasis.[122,125] A positive side effect is reduction of pain by cooling the burn wound. Another major defense against edema in the early management of acute hand burns is proper positioning of the hand. Strict elevation of the burned hand above the level of the heart of the patient is recommended. This elevation must be maintained continuously during the early postburn period.[130]

Escharotomy

The most important principle in the initial management of a burned upper extremity is maintenance of perfusion, which is ensured by adequate fluid resuscitation to maintain circulating volume and removal of any mechanical obstruction to the flow of fluid in the extremity. The tourniquet effect of an unyielding circumferential burn eschar may worsen the situation of edema following a burn, and the potential for circulation insufficiency is great, especially with deep partial-thickness or full-thickness circumferential burns. The initial therapy for these burn injuries of the upper extremity should therefore be directed toward releasing subdermal tissue pressure and maintenance of the circulation.[112,116,120,142]

Escharotomy for tight constricting burns was first described by Fabry of Hilden in 1607. The need for escharotomy is relatively common in the treatment of circumferential full-thickness burn injuries and has been recommended frequently for some years, especially over the last 3 decades.[116,120,142,158]

Indications for escharotomy include pain, resistance to passive extension of the fingers, and disappearance of capillary refill in the nail beds. The forearm and hand feel tense to palpation. Doppler measurement of digital or superficial palmar arch pulses may also help, but by the time that the radial or

ulnar pulses disappear, tissue ischemia is well advanced.[133] Measurement of subcutaneous pressure with Wick catheters has been recommended by several authors.[1] Escharotomy is indicated when intracompartmental tissue pressure is greater than 30 mm Hg on two separate readings. However, the clinical experience of the surgeon is the most important factor in making the decision to perform an escharotomy.

The surgeon should carefully plan surgical escharotomy incisions with the aim of releasing areas of circulatory restriction and restoring adequate flow while avoiding injuries to underlying structures such as nerves or vessels. Escharotomies can be carried out either with the use of electrocautery or by scalpel. A radial full-thickness incision to decompress the hand and arm should be performed as the first step because there is no risk of any injury to one of the peripheral sensory nerves except the superficial branch of the radial nerve. The length of the incision depends on the size of the constricting eschar. The maximum length of the incision should extend on an axis from the tip of the acromion to the lateral edge of the antecubital flexion crease up to the radial aspect of the distal flexion crease of the wrist.[120,116] If necessary, medial ulnar escharotomy can be added. The incision line should be drawn from the axilla, to the medial aspect of the antecubital flexion crease, to the ulnar aspect of the distal flexion crease of the wrist.

In patients with tight circumferential burn eschar of the fingers, digital escharotomies should be performed. The ulnar incision can be continued along the hypothenar eminence to the midlateral line of the ulnar border of the little finger. The radial escharotomy incision line can be extended along the radial aspect of the thenar eminence and the midlateral aspect of the thumb. The index, long, and ring fingers can be decompressed with similar midlateral incisions on the ulnar aspect of each finger. If the blood supply is not restored adequately with these incisions, the opposite side of each digit can be released in similar fashion by performing bilateral digital escharotomies. Decompression (fasciotomy) of the dorsal interossei should be performed in hands with significant edema and diminished flexion. Small vertical escharotomy incisions are made on the dorsum of the hand between the metacarpals.[112,116] Salisbury and coworkers were able to show in a randomized trial that there was an almost threefold increase in the number of fingers that could be salvaged by extended digital escharotomy (Figure 57.6, *A* to *C*).[128]

Wang and associates have pointed out the importance of intrinsic muscle decompression to overcome ischemic contracture of the hands. It is therefore vitally important with deep burns in the upper extremity to detect possible muscle ischemia to prevent the loss of fingers or the thumb because of secondary vascular compromise. If there is significant subfascial edema, escharotomy can be combined with fasciotomy.[106,112,158,166] The early signs of ischemic necrosis of the intrinsic muscles are hyperextension of the fingers at the MP joint with flexion of the interphalangeal joints.

Splinting

Without appropriate early splinting and positioning, a typical intrinsic-minus posture develops in a severely burned hand that is initially in large part due to swelling of the hand. The injured hand takes the characteristic position of wrist flexion, hyperextension of the MP joints, and flexion of the interphalangeal joints. The thumb usually adducts toward the palm with the interphalangeal joint hyperextended.[13,32,50,64,71,78,135,148] In a short period, edema, inflammation, and immobility are being replaced by scarring and fibrosis, which result in deformities not correctable without surgical intervention. Scar contractures across the dorsum of the hand further accentuate extension of the MP joints and lead to the so-called *claw deformity* that is typical of neglected burns of the hand.

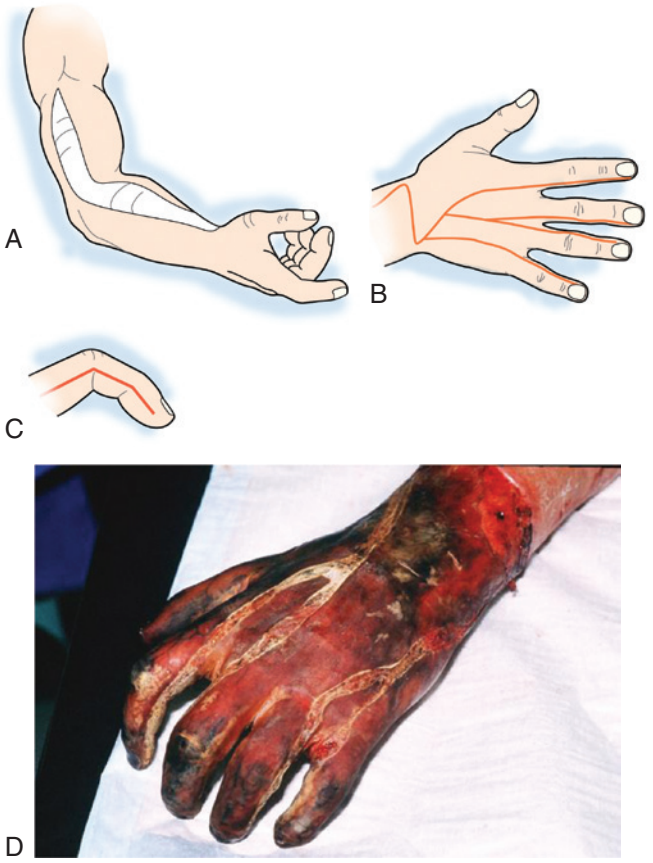

FIGURE 57.6 **A,** Schematic illustration of escharotomy incisions in the upper extremity. **B,** Escharotomy incisions in the dorsum of the hand. **C,** Clinical situation after escharotomy of the dorsum of the hand. **D,** Escharotomy incisions in the digits, midlateral view.

The anticlaw position is essential to prevent permanent contracture deformities. To maintain this position, the hand should be splinted immediately in the so-called *position of safety* (intrinsic-plus position; Figure 57.7). In this position, the MP joints are fully flexed and the interphalangeal joints are essentially fully extended. The first web space is maximally abducted. This position keeps the ligaments of the digital joints in the best tension to prevent shrinking of these ligaments. With the burned hand in this position, the dorsal skin is stretched somewhat tightly across the metacarpals and there is little room for excessive edema formation. The so-called *position of function* with all digital joints slightly flexed should be avoided at all times because this position will inevitably lead to contractures. The elbow should be kept in an extended position because flexion contractures are the most frequent deformities. Care must be taken, however, to keep the elbow moving, for a permanent contracture in the fully extended position is much more

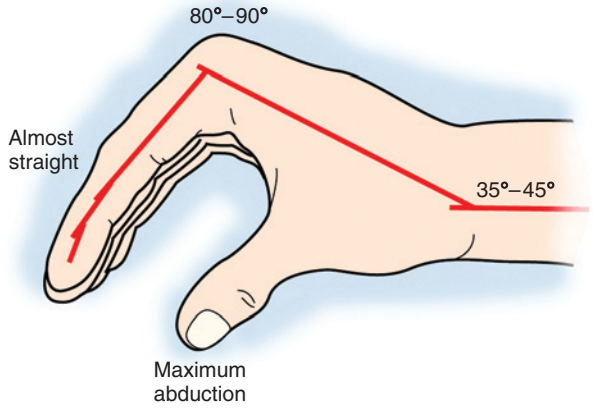

FIGURE 57.7 Ideal splinting position for the hand.

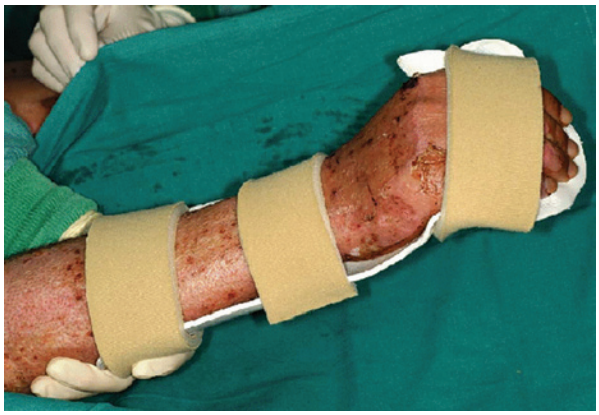

FIGURE 57.8 Custom-made thermoplastic splint in the intrinsic-plus position.

of a functional problem than is a contracture in a flexed position. The shoulder is best positioned in abduction to prevent axillary contractures.

Hand splints should be applied on the day of injury. Customized splints made of thermoplastic material are most effective and can be adjusted to every clinical situation. Whether one chooses to initiate early motion or maintain the hand relatively immobilized for a longer period depends principally on the condition of the skin over the PIP joints. Here the skin is very thin, and deep burns over this area frequently lead to disruption of the central extensor mechanism over the PIP joint and development of the so-called *boutonnière deformity*. If the burn over the PIP joint is fairly superficial, early active flexion and extension exercises of these joints can be initiated. However, if the skin over the PIP joint appears to be more deeply burned, it is best to maintain the joints splinted in nearly full extension. The use of Kirschner wires has been advocated to maintain the PIP joints in extension with deep dorsal burns, but we have seen more problems (such as pin tract infections and joint stiffness) than detectable benefits, so this technique is used only on rare occasions (Figure 57.8).

Local Wound Care

Local care of the burn wound depends on the depth of the injury, the injury pattern, and the general condition of the patient. The decision-making process is illustrated in Figure 57.2. Basic wound care includes débridement, daily cleaning, prevention of infection with topical agents, and wound dressings.[82,130,133,135]

In a partial-thickness second-degree burn, spontaneous healing can be expected within 7 to 14 days, depending on the size of deeper areas. The burn wound should be débrided of all contamination.[133] Areas of peeled skin also need to be removed. Treatment of blisters remains controversial. Small intact blisters less than 1 cm in diameter can be left intact and the wound allowed to heal spontaneously. It has previously been proposed that larger blisters should be left intact as a biologic dressing because they may protect against infection.[54] However, the fluid of burn blisters was found to be rich in prostaglandins and other proinflammatory cytokines, such as IL-6 and IL-8,[52,105,107] that may propagate the burn wound injury and increase the zone of necrosis.[107] The current recommendation for larger blisters is aspiration of the fluid, removal by incision, or débridement of the blisters.[129] Dressings can then be applied directly to the burn wound.

The principle of moist wound healing is applied for spontaneously healing burns. The burn wound should be cleaned daily either in a hydrotherapy tank or under filtered tap water. This is followed by the application of an antibacterial cream. The cutaneous immune response of the individual against bacteria is compromised during the edema phase of the burn wound. Administration of antibacterial creams during this period can prevent sequelae such as streptococcal cellulitis or erysipelas of the burned hand.[54]

With superficial thermal injury, agents such as water-soluble bacitracin can alternatively be used. A deeper partial-thickness burn wound should be dressed with a topical antibacterial agent that has more penetrating capability, such as silver sulfadiazine. Unless the thermal injuries to the hand are associated with large surface areas, systemic antibiotics are not indicated. Vaseline gauze strips and elastic netting are generally used to hold the dressing in place and to provide a custom fit with the opportunity for maximum movement of the extremity. The fingertips should remain visible in the dressings to allow observation of their color and vascularity. Siliconized gauze can alternatively be applied.[82,109]

As the superficially burned areas begin to epithelialize, care must be taken to avoid shearing of the new epithelium with dressing changes or exercise. Bland ointments or creams such as vitamin A and D ointment are helpful to prevent dehydration of the new epithelium. These new epithelial surfaces will require some maturation before sebaceous and sweat gland function recovers.

In recent years, some simpler techniques of burn care have been introduced that involve less work and are less time consuming. The simplest treatment of these types of burns is a large surgical glove filled with silver sulfadiazine cream. The patient slips his hand into the glove, which is then fixed with a bandage at the wrist level. Some patients feel uncomfortable in the rather tight-fitting glove, but for many patients this technique provides a simple, inexpensive solution that is also applicable in developing countries. Harrison and Parkhouse described the use of silicone oil in a glove for the same purpose.[50] In patients who cannot tolerate the tight-fitting glove, the extremely large Gore-Tex glove provides a useful alternative (Figure 57.9). The glove can be left on for several days; however, daily dressing changes are easy and almost painless with both techniques.[70]

The Biobrane glove provides an excellent alternative to the techniques just described. The biohybrid membrane of knitted nylon, silicone mesh, and peptides from porcine proteins is perfectly fitted to the hand and then sealed. It is semipermeable, and small amounts of wound fluid can evaporate through the membrane. Larger fluid collections have to be evacuated through little puncture holes in the material. The glove remains on the wound until the surface is epithelialized and then automatically peels off. Because the glove is transparent, changes in the wound can be observed through the membrane. Dressing changes are not necessary, so the primary high cost of the glove is equalized over time, especially since only limited nursing care is required. The major disadvantage of this method is that the initial wound assessment has to be correct because only wounds of superficial thickness will heal spontaneously under the glove. However, our experience has shown that in cases in which patches of deeper burns are detected, the glove can be removed and treatment in these areas can be directed toward surgical intervention (Figure 57.10, *A* to *C*). Similar techniques can be applied with polyurethane films such as OpSite or Omniderm or with polyacrylic mesh (SurfaSoft).[70,82] Many authors claim that film dressings lead to superior results in superficial burns; however, gauze dressings can provide the same effect, provided that the moist environment of the wound is maintained. Most recently, the new epithelial substitute Suprathel, a cellulose material, has been used for second-degree burns with excellent results.[151]



FIGURE 57.9 Gore-Tex glove filled with silver sulfadiazine for conservative treatment of a superficial partial-thickness second-degree burn.

Excision and Grafting

Deep dermal and full-thickness burns of the hand are best treated by early excision and grafting. It is usually accepted that the burn wound is uninfected and suitable for primary surgical treatment within the first 5 days. If this initial ideal period is missed, a delay of 3 weeks before surgery is thought to be best because of the increased risk for graft loss secondary to infection and excessive bleeding from the inflamed bed of the eschar.[7,13,31,112,133]

Tangential excision is the preferred surgical procedure for hand burns. It involves shaving of the burned skin in thin layers until brisk capillary bleeding is encountered. A typical instrument used for the hand is the Goulian/Weck knife, which



FIGURE 57.10 **A,** Biobrane glove fitted to a superficially burned hand. **B** to **D,** Excellent cosmetic and functional result after spontaneous healing.

consists of a single-edged razor blade with a guard. Layers of devitalized tissue can be removed until healthy tissue is encountered. It is very important to not leave residual devitalized tissue because this might prevent adequate take of skin grafts, promote wound infection, and delay the process of recovery. Reddish areas of fat are considered to represent the zone of stasis and should be excised. No matter how deep the burn is, salvage of the paratenon of the extensor tendons and the fine layer of areolar tissue above the joint capsules is essential to facilitate skin graft take. After excision of the eschar, sponges soaked with epinephrine are applied to reduce bleeding. The most crucial area is the dorsal skin over the PIP and MP joints. Failure of skin graft take in these areas almost inevitably leads to exposure of the joint, with the consequence of joint infection and cartilage erosion and resulting joint stiffness.

Débridement can also be performed under tourniquet control, especially if the hands are involved in a major burn. This makes assessment of the wound a little more difficult and requires more surgical experience, but it may reduce blood loss. Our procedure includes wrapping the hand with epinephrine-soaked sponges and tight elastic bandaging before releasing the tourniquet and leaving the bandages in place for approximately 20 minutes. Most capillary bleeding has usually stopped by this time; however, meticulous further hemostasis is still necessary.

After bleeding is controlled, skin grafts are transplanted. Resurfacing the wound with split-thickness grafts is considered the "gold standard" in most cases.[7,79,89,100] There is still ongoing debate about whether the grafts should be meshed or unmeshed. Many authors claim that sheet grafts provide a superior aesthetic appearance when compared with mesh grafts. It is said that they produce less scar tissue than mesh grafts do and usually provide a more functional result (Figure 57.11, *A* to *C*). Meshed grafts have the advantage of facilitating drainage of wound fluid, blood, and bacteria through the holes in the mesh. They generally have a higher overall "take" rate in critical wound beds when there is some remaining bleeding or patches of questionable viability.[84] The main disadvantage is the high rate of scar contracture that frequently leads to major functional disturbances. The mesh-graft expansion ratio used in burned hands should not exceed 1.5 : 1 (Figure 57.12). There are studies showing no significant difference in aesthetic appearance and function between sheet or meshed split-thickness skin grafts after 12 months, however. In patients with major burns involving the rest of the body, skin grafts may be in short supply and meshed grafts have to be selected for coverage.[89,100,128,133] Our recommendation for the choice of graft depends on the availability of skin graft donor sites and the general condition of the patient. If sufficient donor sites are present, split-thickness sheet grafts are the first choice. In patients with limited graft availability, meshed grafts have to be used. In rare cases with isolated hand burns, split-thickness skin grafts may be harvested a little thicker. This will result in more supple skin with fewer contractures and better functional results.

Full-thickness skin grafts have no indication in acute burns, except in children.[93,114,115] Their take rate depends too much on a perfect wound bed, perfect hemostasis, and the ability to provide a perfect tie-over dressing. With the significant risk for graft loss, full-thickness grafts are generally reserved for secondary corrections.

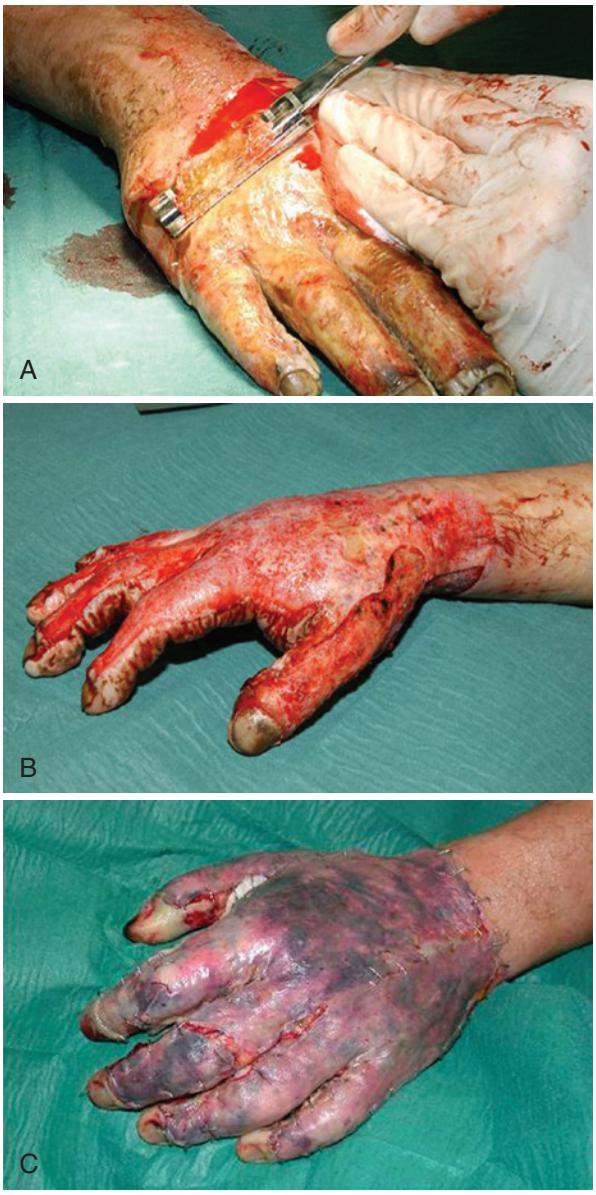

FIGURE 57.11 **A,** Tangential excision of a deep partial-thickness burn on the dorsum of the hand. **B,** Sheet graft transplantation to the excised areas. **C,** Short-term postoperative result after sheet graft transplantation.

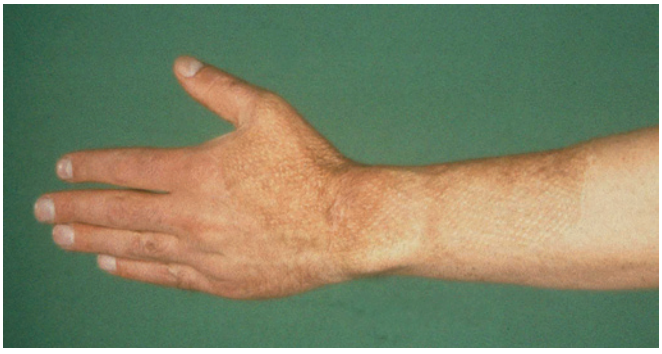

FIGURE 57.12 Cosmetic result of a meshed skin graft transplant on the hand.

The graft is held in place with either single interrupted stitches or a running stitch (4-0 or 5-0), and metal skin staples are a good choice on larger grafts. Care should be taken to create smooth transitions between the grafts and the edges of the remaining skin. The wound is dressed with Vaseline gauze or siliconized gauze. Cotton balls are placed over the gauze for a bolster tie-over dressing. Experimental data suggest that skin graft take is best when pressure of 30 mm Hg is exerted evenly over the wound. Clinical experience has shown that a conventional bolster tie-over dressing reaches this goal. A rather new technique to enhance skin graft take is the application of vacuum pressure to the wound. This has been shown to yield very good results in skin grafting of chronic wounds, but it is technically very difficult to apply this technique to a burned hand. The first results with vacuum gloves have been reported, but larger series are still lacking.[65,101]

In full-thickness burns of the upper extremity and involvement of a large surface area of the entire body, epifascial excision may be indicated. The skin envelope may be reconstructed with meshed skin grafts in these cases, but this will most likely result in severe postburn contractures. Artificial dermal equivalents such as Integra, AlloDerm, Dermacell, or Matriderm[28,29,51,85] can be used in these circumstances. Use of one of these materials may result in a more pliable skin envelope with less need for corrective surgeries later (Figure 57.13, *A* to *C*).

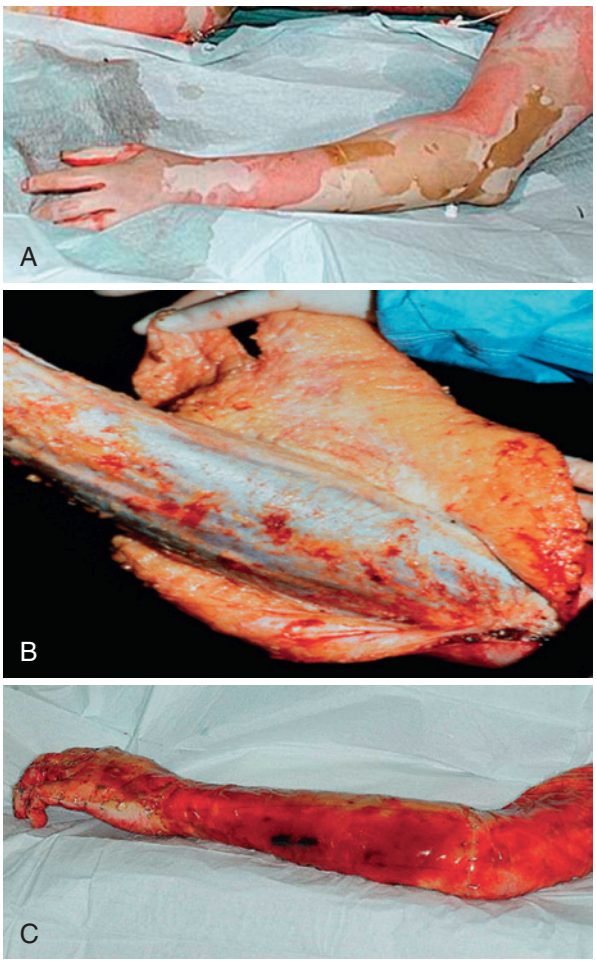

FIGURE 57.13 **A,** Deep full-thickness burn on the left upper extremity. **B,** Epifascial excision of a severe full-thickness burn on the left upper extremity. **C,** Application of Integra to the extremity.

Dressings are left in place for 5 days. Skin graft take can be assessed by then, and decisions for further wound care can be made. If the wound becomes odiferous, the dressing can be changed earlier to avoid graft loss through infection. If the wound is found to be clean with satisfying graft take, no particular treatment is indicated. Only Vaseline or any similar basic cream is administered to keep the graft moist and supple. If traces of infection such as suppuration or colored crusts are found, all debris has to be removed carefully, and the wound rinsed with an antiseptic solution such as chlorhexidine (Hibiclens) or polyhexanide (Lavasept). All skin graft areas that seem to be nonviable have to be removed. The wound is redressed with gauze and an antiseptic cream such as mafenide acetate (Sulfamylon) or silver sulfadiazine (Silvadene).[50,55,82] Dressing changes are performed daily until the wound does not show any signs of infection. With this technique, many "endangered" grafts may be salvaged.

Special emphasis has to be given to postoperative splinting and physical therapy. Splints are an integral part of the postoperative treatment plan. After grafting, the hands are immobilized for 5 days until graft take is secured. Passive physical therapy is then initiated to prevent and reduce stiffening of the joints. Minor graft loss has to be accepted if joint mobility can be maintained. Even in situations in which graft take over the PIP joints is not guaranteed, mobility of the remaining joints has priority. Active range of motion is initiated as soon as the patient is awake and conscious.

In rare cases, tangential excision does not suffice. With full-thickness injuries the skin damage may reach down to the paratenon and tendons, and the metacarpal bones or joints may be exposed. In these cases primary flap coverage is indicated. The choice of flaps depends on donor site availability and the ideal tissue for the particular situation. In younger females and children, a conventional groin flap still may be the prime choice. This donor site can easily be hidden, the skin is supple, and immobilization of the shoulder is usually well tolerated. A drawback of this flap is that four to five procedures are required to achieve a definitive result. However, in patients with thick subcutaneous fatty layers, the flap may be too thick and yield aesthetically unsatisfying results.

In most situations when the general condition of the patient allows more sophisticated procedures, the flap can be tailored to the individual need of the patient (i.e., free flaps, pedicled forearm flaps, or intrinsic hand flaps).[11,22,128] Fascial flaps have proved to be very helpful for coverage of dorsal hand defects when cutaneous flaps would yield flaps that are too thick.[31,35,118] They provide stable but supple tissue; secondary reconstructive procedures can be performed under these flaps; and the aesthetic results after grafting the fascia with split-thickness skin grafts are pleasing. Temporoparietal fascia, serratus fascia, or anterolateral thigh fascia flaps are the most frequently used. They seldom require secondary debulking (Figure 57.14, *A* and *B*).[35,36,66,131]

In situations in which large flaps are required, the latissimus dorsi flap, the anterolateral thigh flap, or a cutaneous flap from the subscapular system would be the primary choice.[92,94] These flaps are rarely indicated for flame burns but are more frequently used for chemical burns, contact burns, or high-voltage injuries (see later). Secondary revisions of these flaps are frequently required.



FIGURE 57.14 **A,** Deep contact burn on both hands with exposed proximal interphalangeal joints after failed skin grafts. **B,** Result after the application of free serratus fascia flaps to both hands with skin grafts.

The principles of physical therapy are the same for a flap-covered hand as for a grafted hand. After 5 days, flap healing is usually secured, and passive exercises can be initiated.

Skin grafting is rarely necessary with palmar burns because of the enormous capacity for spontaneous healing from the many glabrous skin appendages. This is the reason why thick split-thickness skin grafts are seldom required. Flap coverage may be needed more frequently with deep palmar burns. In our practice, fascial flaps offer the best solution for this problem. The stability of the tissue is sufficient, and there is almost no shearing within the flap to diminish the quality of grip. Deep sensation is reported to return within 12 to 15 months.

In children, Pensler and colleagues found no significant difference in the number of operative procedures with either full-thickness or split-thickness grafts. They claim that split-thickness skin grafts have less tendency toward hyperpigmentation, thereby leading to superior cosmetic results, are more expeditious to harvest, and preserve donor sites for future reconstruction.[114] In contrast, Pham and coauthors consider full-thickness skin grafts as a first choice for deep palm burn injuries in children.[115]

Complications

Complications after isolated hand burns are rare and can usually be avoided by proper treatment. They are more frequent with major burns in which the immune response of the patient is severely suppressed and the patient remains in a catabolic state for a considerable period. Three types of complications can jeopardize the treatment result: secondary infection, graft loss, and early hypergranulation.

Secondary Infection

Secondary infection can be a major problem in hand burn injuries. Two areas of the hand are extremely susceptible to secondary infection.[130,133] The thin skin overlying the dorsum of the PIP joints makes the tendons likely to be injured or can result in an open joint. A decreased blood supply may also increase susceptibility to infection with secondary joint involvement (Figure 57.15, *A* to *D*). The nail bed is the other area that is particularly susceptible to injuries. Despite its high vascularity, the nail bed is readily exposed to thermal injury and to secondary trauma and infection.

Infected areas are treated with the local application of antibacterial creams or ointments (see above). Systemic antibiotic therapy is rarely indicated and should be used only when clinical signs of cellulitis or ascending lymphangitis are seen. The hand is cleaned and rinsed daily and then antibacterial agents are applied.

Graft Loss

The loss of skin grafts can have several underlying causes:

- Insufficient débridement with residual layers of nonvital tissue
- Bleeding of the wound bed with hematoma under the graft
- Imperfectly fitting tie-over dressing
- Secondary infection of the wound bed

In the event of graft loss or nonviable grafts, the wound has to be débrided surgically. All nonviable skin must be removed, and the wound bed has to be débrided until healthy bleeding is encountered; meticulous hemostasis is mandatory to prevent further graft loss. Regrafting can be performed in the same session if there is minimal drainage and hemostasis is adequate. If the wound is seriously infected, the viability of the deeper layers is questionable, or if the wound is bleeding too much because of inflammation, it is best to treat the wound for several days with local care and delay secondary regrafting to avoid additional graft loss.

Early Hypergranulation

Early hypergranulation occurs between nonepithelialized areas of mesh grafts or the borders of sheet grafts. It is rarely encountered in large surface area burns because the immune response of patients with these injuries is usually severely impaired. Surgical removal of these hypergranulated areas is not recommended, because it will cause profuse bleeding. Dressing the wound with steroid-containing gauze (Corticotulle) has proved to be extremely useful. Several days of treatment generally suffice until the wound has reepithelialized. Early treatment with pressure gloves and silicone sheets is mandatory in these patients.

POSTBURN DEFORMITIES

Even if in the initial phase of acute hand burn injury all treatment measures have been executed properly, postburn deformities still occur and are the most common causes of skin contracture in the hand.[12,16,33,47,71,73,90,119] Postburn scarring and



FIGURE 57.15 **A,** Typical exposure of the proximal interphalangeal joint after a deep partial-thickness second-degree burn and graft loss. **B,** Design of a reversed dorsal metacarpal artery (DMCA) flap based on the second DMCA. **C,** Flap raised on its pedicle. The pivot point is in the web space. **D,** Flap after 5 days. Flap perfusion is excellent, and a skin graft is needed for reconstruction of the donor site.

contractures affect the function as well as the aesthetic appearance of the hand and remain the most frustrating late complication of a hand burn. If contractures or scarring affect the dominant hand, as they do on most occasions, the vocation and thereby the economic status of the patient suffer. Proper management of these deformities is thus highly desirable. A classification of postburn deformities has been proposed by Achauer.[1]

A. Claw deformity
   1. Complete
   2. Incomplete
B. Palmar contracture
C. Web space deformity
   1. Web space contracture
   2. Adduction contracture
   3. Syndactylism
D. Hypertrophic scar and contracture bands
E. Amputation deformity
F. Nail bed deformity
G. Elbow
   1. Flexion contracture
   2. Deep burn with extensive tissue loss
   3. Heterotopic ossification
H. Axilla

Scars can also be assessed with scoring systems such as the Vancouver Scar Score,[8] which allows classification of the scar based on the variable clinical picture.

Prevention

It is well accepted that the best therapy for burn wound contractures is prevention. Prasad and colleagues suggest that comprehensive treatment efforts have led to a significant reduction in the development of burn scar contractures.[119] It appears that factors such as improved burn wound management, liberal use of positioning, improved splinting, early maintenance of range of motion, and exercise programs have contributed to this success.[119] A decrease in the need for late reconstructive surgical procedures is reflected in the literature over the last 35 years. Dobbs and Curreri reported a serious contracture rate of 27% in 681 adult burn patients.[25] Pegg and coauthors reported on 411 patients with a 7.8% incidence of burn scar contractures,[113] and Kraemer and associates noted only a 3.7% rate of reconstructive procedures 9 years after burn scar release in a population of 839 adults and children with burn injury.[71] These data suggest that improved treatment protocols and splinting for prolonged periods are reducing the need for readmission for reconstructive procedures.

Treatment

Postburn deformities are usually related to the initial soft tissue deficit. Contractures can be caused by spontaneous healing of deeper burns (i.e., the burn wound itself) or more frequently by the inevitable contracture of transplanted split-thickness skin grafts. This phenomenon occurs more extensively in the acute burn situation and is less pronounced in elective situations. The clinical impression that secondary split-thickness grafts contract more in burn wound releases than in other posttrauma situations is shared by many authors; however, scientific evidence of this tendency is rare. Release of contractures may be accomplished by various patterns of "Z"-plasties,[40,47,73,128,144] but skin grafting or flap coverage is frequently required.

Full-thickness skin grafts play an important role in these secondary corrections because they are more similar to normal skin than split-thickness grafts in texture, color, and resilience. However, full-thickness grafts take less readily than do split-thickness grafts and may suffer the setback of limited availability in patients with larger burns.[59,89,90,93,171] The latter problem, in some situations, may be solved by preexpansion of the donor sites.[10] Full-thickness grafts have less tendency for contraction because there is an inverse relationship between thickness of the dermis and graft contraction.[59,63]

Before surgically addressing the problem, a thorough analysis is mandatory. Several questions have to be answered:

1. What is the nature of the contracture or the limiting scarring?
2. Are there any underlying joint problems (e.g., shrinking of the ligaments or capsules, cartilage destruction)?
3. Are soft tissue procedures sufficient?
4. Which type of coverage is adequate after contracture release?
5. Where should the skin grafts or flaps be harvested?

Only after these questions have been answered can a surgical plan be designed. The most disturbing functional problems are usually addressed first; however, the patient may perceive aesthetic deformities as the more urgent problem. Decision-making algorithms are presented in Figures 57.16 and 57.17.

Nail Bed Deformities

Dorsal scarring over the DIP joint leads to distortion of the eponychial fold, retraction of the eponychium, and proximal nail exposure. In cases involving only skin tightness without severe retraction of the nail fold, skin release and skin grafting may be sufficient.

When reconstruction of the nail fold is required or skin grafts are not appropriate, proximally based lateral skin flaps are recommended. The donor site of these narrow flaps can generally be closed primarily, and the resulting tip deformity evens out over time (Figure 57.18).[1,2]

Claw Deformities

Claw deformities may be difficult to correct (Figure 57.19). They usually consist of hyperextended MP joints with flexion contracture of the PIP joints. In contrast to Achauer's classification, we prefer to divide claw deformities into (1) long-standing fixed deformities with ligament shrinkage and (2) cutaneous deformities in which simple release of the skin contracture solves the joint position problem.

The first group requires arthrolysis, either from the dorsum or in rare cases from the palmar aspect of the joint. Both approaches to the joint can usually be performed from the dorsal skin incision. These situations generally require some sort of flap coverage because the extensive dissection has eliminated all tissue layers where skin graft take is likely. The same holds true for situations in which the extensor tendon apparatus is exposed and stable soft tissue coverage is required. As mentioned previously, the choice of flaps depends on the individual profile of the patient and ranges from regional flaps such as the radial forearm flap to distant flaps (groin flap) and microvascular flaps.[3,5,11,23,26,33,38,44,49,66,73,91,96,118,132,138,152]

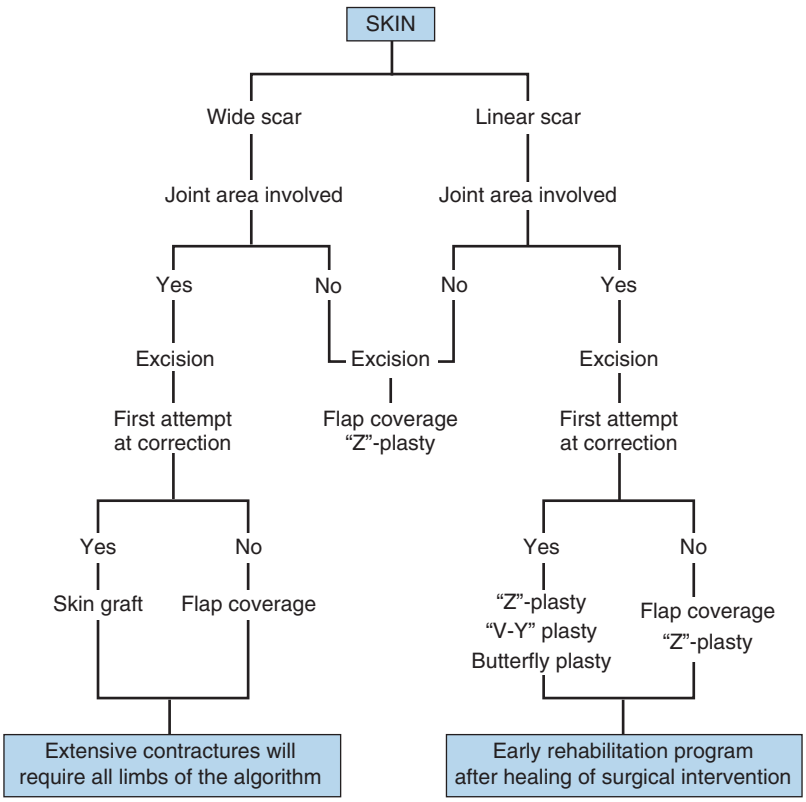

FIGURE 57.16 Decision-making algorithm for skin contractures. (With permission from Germann G, Sherman R, Levin SL: *Decision making in reconstructive surgery on the upper extremity*, New York, 1999, Springer-Verlag.)

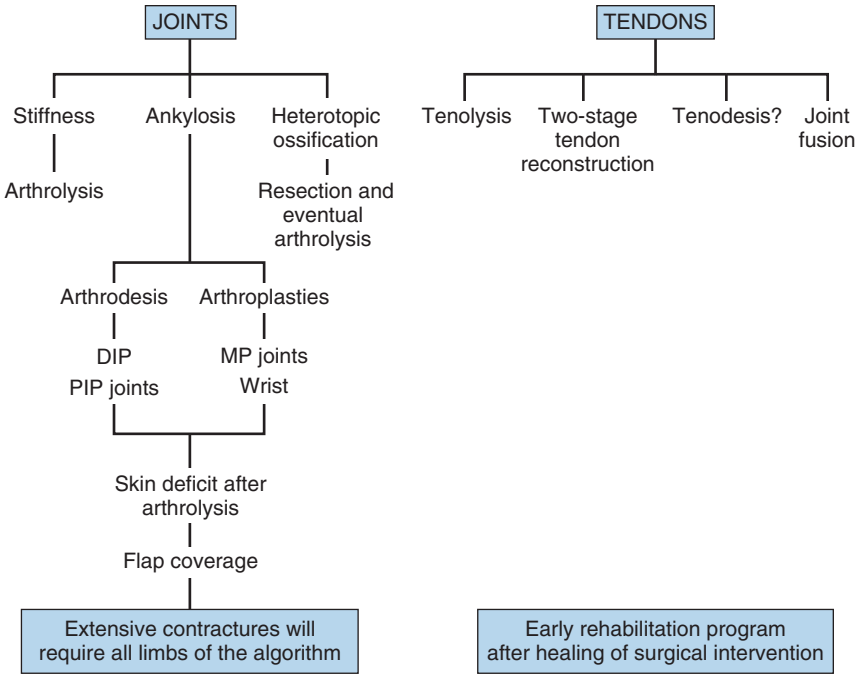

FIGURE 57.17 Decision-making algorithm for joint contractures. *DIP,* Dorsal interphalangeal; *MP,* metacarpophalangeal; *PIP,* proximal interphalangeal. (With permission from Germann G, Sherman R, Levin SL: *Decision making in reconstructive surgery on the upper extremity,* New York, 1999, Springer-Verlag.)

Full-thickness skin grafts are preferred when skin grafts will suffice for skin reconstruction. Only in cases of limited availability, as when other important areas require full-thickness skin grafts (e.g., eyelids, lips), are split-thickness grafts used.

Temporary fixation with Kirschner wires is indicated only in joints in which "elastic" resistance remains after release of the skin and ligaments and the patient will probably not be able to mobilize sufficient strength to overcome this resistance.[137,141]

The same holds true for the PIP joint in claw deformities. In most cases there will remain palmar tissue deficit that requires either full-thickness skin grafting or flap coverage after release. Local intrinsic hand flaps are generally limited in these hands, so distant flaps or free tissue transfers are frequently indicated because the problem is usually encountered in more than one digit.

Web Space Syndactyly and Interdigital Contractures

There are two mechanisms in burn injuries of the hand that cause interdigital fusion (i.e., syndactyly). Adjacent burned digits may be allowed to fuse together during the healing process, and granulation or contractures of the digital skin could allow distal migration of the web. Contracture of the second, third, and fourth web spaces usually occurs along the dorsal margin of the web. Numerous methods that generally involve local flaps and grafts have been developed to improve this surgically. They usually consist of variations of "Z"-plasty, such as three-, four-, or five-flap ("V-M") "Z"-plasty.[144,145] The most important step in correcting these deformities is to reconstruct the natural slope of the web space, from proximally dorsal to distally palmar. This re-creates the natural appearance of the web and the natural motion pattern of the dorsal skin creases (Figure 57.20).

In cases in which any type of "Z"-plasty cannot provide sufficient skin, patches of full-thickness skin grafts are used. To achieve a satisfying take rate, the wound bed must be dry, all cavities of the wound surface have to be filled with Vaseline gauze, and the tie-over bolsters are meticulously applied. Mancoll and associates reported the long-term follow-up of various techniques used to surgically correct interdigital contractures. Although all techniques using skin grafts or local flaps showed a high recurrence rate, "Z"-plasties alone had the lowest recurrence rate.[90] With all techniques, care should be taken during these procedures to avoid damage to the neurovascular bundles in the web space.[4,9,16]

Contractures of the Thumb

Contractures of the first web space are usually the result not only of hypertrophic scarring or skin shortage in the web but also shrinking of the adductor muscle, fascia, and possibly the basal joint capsule. First web space contractures limit movement of the thumb at the trapeziometacarpal joint, affecting both grasp and pinch.[16] They can be treated by release of all structures involved and soft tissue reconstruction with skin grafts or any type of suitable flap (Figure 57.21, *A* to *C*). Our experience has shown that in most cases at least the adductor muscle is involved, so division of the muscle is an integral part of the contracture release.

Contractures of the first web space can be released with a variety of techniques, including "Z"-plasties, four-flap "Z"-plasties, local rotation flaps, and full-thickness or split-thickness skin grafts. Distant or free microvascular flaps will be required infrequently.[5,58,91,111,152] The technique of simple 60-degree "Z"-plasty gives the greatest increase in length and depth of the web space. A four-flap "Z"-plasty with a 90-degree flap on each end

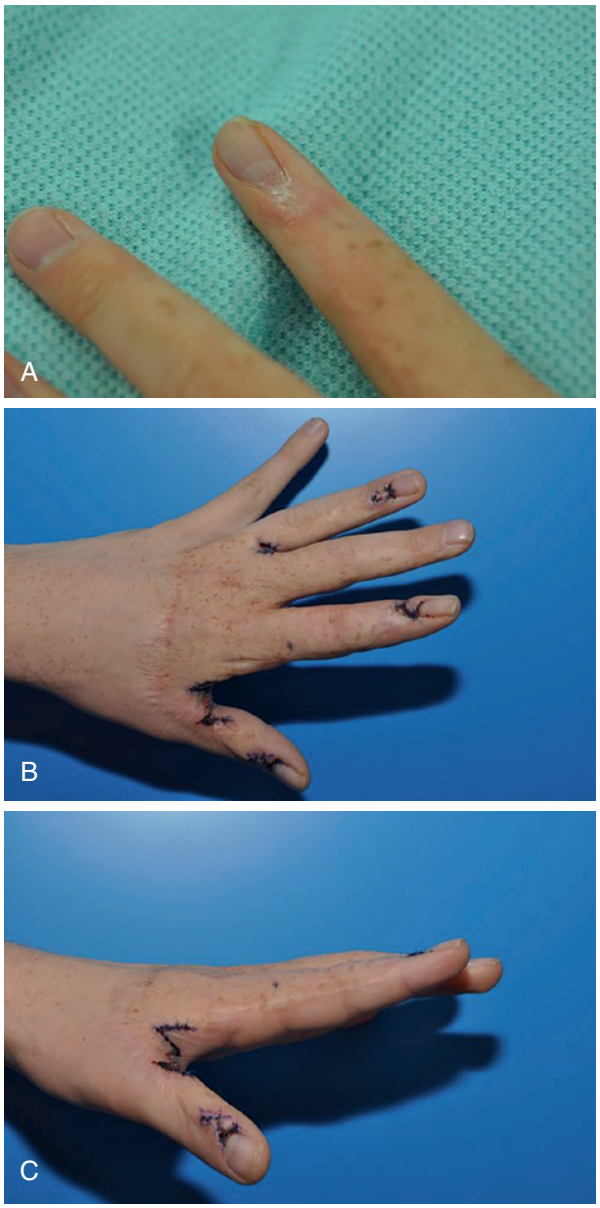

FIGURE 57.18 **A,** Typical nail bed deformity with tissue deficit over the proximal matrix. **B,** Correction of the tissue deficit with local pedicled flaps. Creation of a new nail fold is not possible. **C,** Simultaneous correction of the first web space with "Z"-plasties.



FIGURE 57.19 Bilateral claw deformity.

of the central incision and each of these flaps divided into two 45-degree flaps will provide a smoother contour than the standard "Z"-plasty does. In addition, other types of rotation flaps have been described by many authors.[33,39,112]

Although the most common contracture of the thumb is an adduction deformity, other anatomic deformities are also seen. Less frequently, the thumb metacarpal may be contracted in opposition and extension as a result of bands of dorsal hypertrophic scars between the distal radius and first metacarpal, or in flexion as a result of palmar scarring producing flexion of the interphalangeal or MP joint.[137] Correction of these contractures requires surgical release, sometimes combined with wider burn scar excision, followed by appropriate soft tissue coverage (Figure 57.22, *A* to *C*).[1,93,128,135,137,145] Fusion may be necessary in selected cases.

Digital Flexion Contracture

Release of flexion contracture of the digits and palm is one of the most commonly performed procedures in patients with burn injuries.[47] The skin of the palmar surface of the hand is specialized because of its unique functional requirements. It is hairless, thick, and sturdy and has relatively nonelastic skin designed to withstand the heavy demands of daily work. It is the best tactile organ with optimal sensitivity and is rich in sweat glands to provide the moisture essential for sure grasp and touch. The fundamental principle of reconstruction is to replace the lost tissue with similar tissue. Because of the unique similarities in characteristics, plantar skin is an excellent donor area for skin grafting of the palmar aspect of the digits and hand. The similarities between palmar and plantar skin have been described by many authors.[10,18,47,59,79,100,103,146,164,171] Histologically, both types of skin have a thick epidermal layer with a well-defined stratum lucidum and solid stratum corneum. The connective tissue of the dermis in both is less elastic and more compact than dermis elsewhere to provide stability against pressure and shearing forces. Both are hairless and lack sebaceous glands and melanocytes. They have numerous pacinian corpuscles for optimal sensibility and abundant sweat glands to provide moisture. The sweat glands produce multicentric epithelial budding, and this leads to rapid and good-quality healing of the plantar area.

Le Worthy first reported split-thickness plantar skin grafting.[79] Webster and Zoltie and colleagues used full-thickness plantar skin grafts from the plantar instep area,[164,171] and more recently Tanabe and coworkers described the use of plantar dermal grafts for reconstruction of palmar skin defects of the digits and hand.[146] Hyperpigmentation, scarring, and recurrence of contracture are the common problems encountered with traditional skin grafts on the palm. Skin grafts from the plantar area of the foot are probably better because they have few pigment cells and tend to contract less because of less elasticity and more compact connective tissue in the dermis. Good cosmetic and functional results were obtained at both the donor and recipient sites.[100,103,146]

Postburn flexion contractures of the fingers functionally impair the digits and restrict the functional capability of the entire hand. They have been classified by Kurtzman and Stern[73,74]:

Type I: Skin only, MP joint in passive flexion, PIP joint able to be fully extended

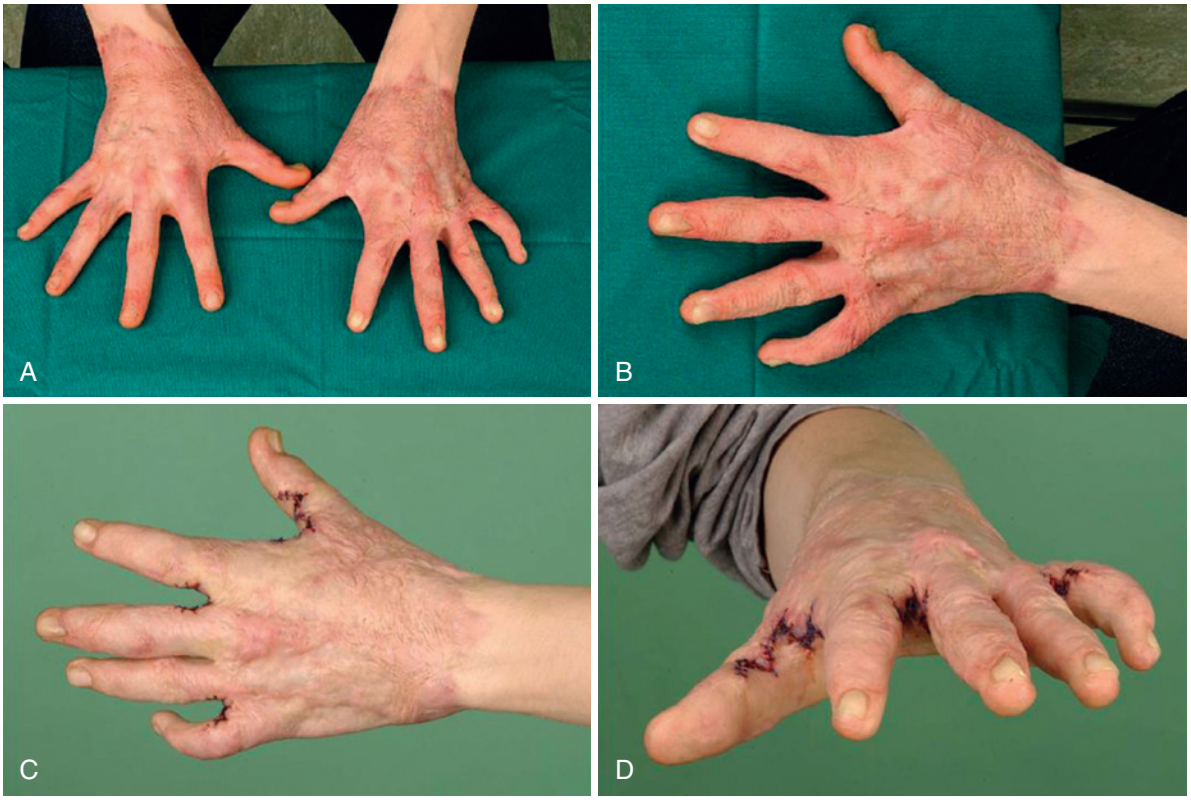

FIGURE 57.20 **A** to **D,** Web space contracture.

Type II: Palmar capsular structures—MP joint in passive flexion, no passive extension of the PIP joint possible

Type III: Soft tissue, joint structures—fixed PIP joint regardless of MP position

The skin shortage between the palmar digital and DIP skin creases limits extension of the PIP joint. This deformity can be corrected by releasing the contracted structures and replacing the palmar skin deficiency.[1] Whenever possible, we attempt to achieve the treatment goal with modified "Z"-plasties and prefer full-thickness skin grafts if the "Z"-plasty is not sufficient.

Type II deformities frequently require release of the volar plate and division of the checkreins to free the joint. Flap coverage can be indicated in these cases when the joint capsule or flexor tendons are exposed.

Type III deformities are fixed with joint irregularities and frequent cartilage destruction. These patients are often best served by joint fusion despite available complex soft tissue reconstructive procedures.

Boutonnière Deformity

A postburn boutonnière deformity is a multifaceted disorder, and the damaged central slip of the extensor apparatus is only one facet of the problem. Deep dermal and full-thickness burns of the dorsum of the PIP joint are a potential cause of the development of a boutonnière deformity. These burns damage the central slip of the extensor apparatus over the PIP joint initially or during the healing phase. When this occurs, the lateral bands slide below the axis of rotation of the PIP joint. As a result, the lateral bands become PIP joint flexors rather than extensors, and thus the PIP joint is flexed up to 90 degrees and unable to actively extend. Absence of the central slip creates a loss of restraint of the extensor mechanism that allows this system to move proximally. This results in excessive pull on the DIP joint through the lateral bands and subsequent hyperextension at the DIP joint.

Such postburn boutonnière deformities are a challenge to surgeons and call for a comprehensive approach. Surgical management is extremely difficult, and the results of the various operations are unpredictable. First of all, it is necessary to eliminate the related contractures of all hand joints and restore the passive movements of the PIP joint by preparatory operations, and distraction devices set the stage for successful tenoplasty.[45] A variety of tenoplasty techniques are described in the literature. It has been proposed that the lateral bands be shifted to the dorsum of the finger and be sutured together or that a figure-of-eight tenoplasty be created.[75,129,136] Other authors perform a tenoplasty with transected lateral bands.[11] More widespread is a technique in which the tendon transplant is pulled through a hole in the base of the middle phalanx to connect it with the lateral bands or with the central slip over the proximal phalanx.[75] Although methods vary, the results are frequently unsatisfactory. Consequently, PIP joint fusion or finger amputation is common, and many authors believe that arthrodesis is more effective than tenoplasty.[43,129,136] By shortening the finger with an arthrodesis, no additional coverage is usually necessary and healing time is often shorter than with tendon reconstruction.

Contractures of the Dorsum of the Hand

The initial thermal injury to the hand is almost always limited to the skin alone, and the underlying tendons and joints are usually spared. Therefore, dorsal contracture is the most

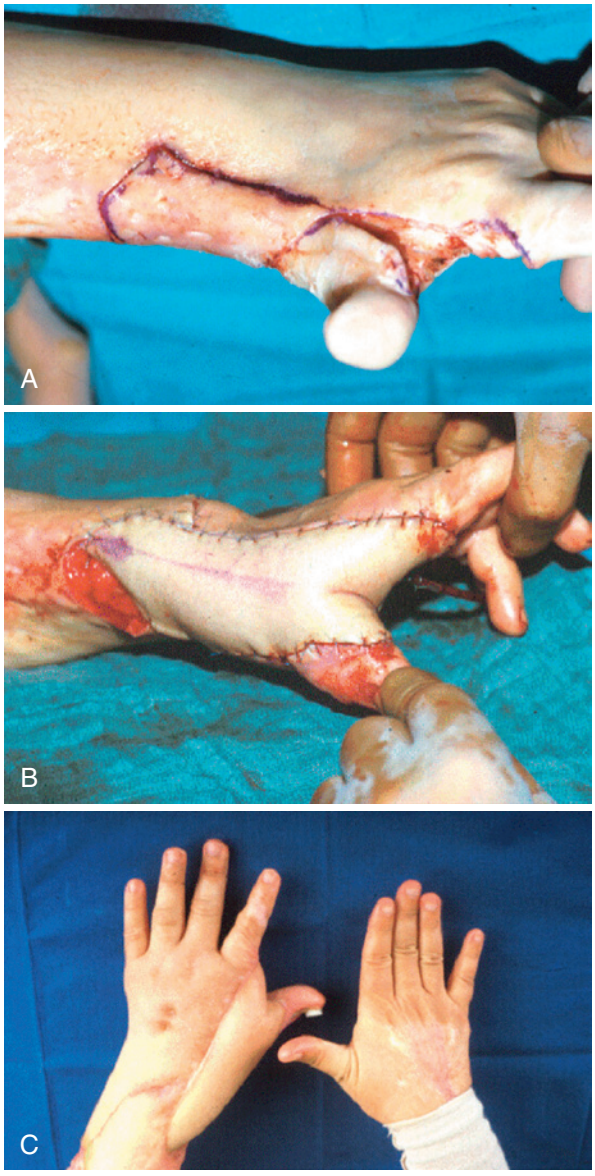

FIGURE 57.21 **A,** Severe contracture of the first web space. **B,** After release of the contracture, a posterior interosseous flap is rotated into the resulting defect. **C,** Long-term result.

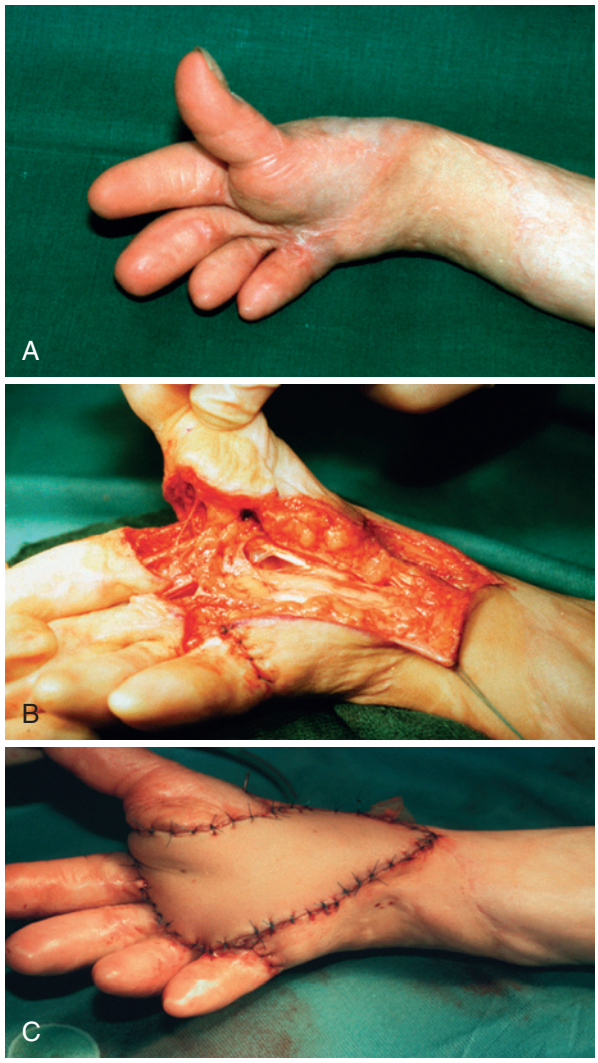

FIGURE 57.22 **A,** Severe adduction contracture of the palm of a 10-year-old child. **B,** Resulting defect after release of the contracture. **C,** Reconstruction with a free parascapular free flap.

common problem encountered after hand burns. This deformity, which generally occurs after skin grafting, may be due to unsatisfactory skin coverage, partial graft loss as a result of wound infection, or inadequate exercise and splinting in the antideformity position.[13,19] This results in a feeling of tightness, MP joint hyperextension, and limitation of finger flexion.[13,19]

Correction consists of complete excision of the contracted tissues and mobilization of all adjacent joints. Full-thickness skin grafts are the primary choice for reconstruction. Resurfacing the dorsum of a hand with full-thickness skin grafts requires a considerable amount of skin, however, which frequently may not be available. Thick split-thickness skin grafts may be a reasonable alternative. A simple solution is to use the crane principle. Subcutaneous tissue can be carried on a skin flap placed temporarily over a wound defect. The skin flap, along with a thin layer of subcutaneous tissue, is later returned to the donor site *while* leaving a layer of subcutaneous tissue, suitable for skin grafting, over the original defect.[98]

Whenever there is doubt about the wound bed and the graft take rate, flaps should be considered.[5,22,23,110,149] In addition to all types of skin flaps, fascial flaps have proved to be excellently suited because they provide thin, stable, and supple coverage that requires only split-thickness skin grafting.[118] To avoid any graft loss, hemostasis should be meticulous. If oozing persists at the time of scar excision and fascial flap placement, secondary grafting should be considered. This can be done as a secondary bedside procedure 2 to 3 days postoperatively, with the skin graft harvested at the time of flap transfer (Figure 57.23, *A* and *B*).[35,66]

Volume Deficiencies and Contour Irregularities

Major volume deficiencies and contour irregularities require complex reconstructive procedures. In many cases, however, dorsal contractures and atrophy of the subcutaneous tissues lead to minor volume deficiencies and contour deformities. These minimal deformities are difficult to correct. An excellent

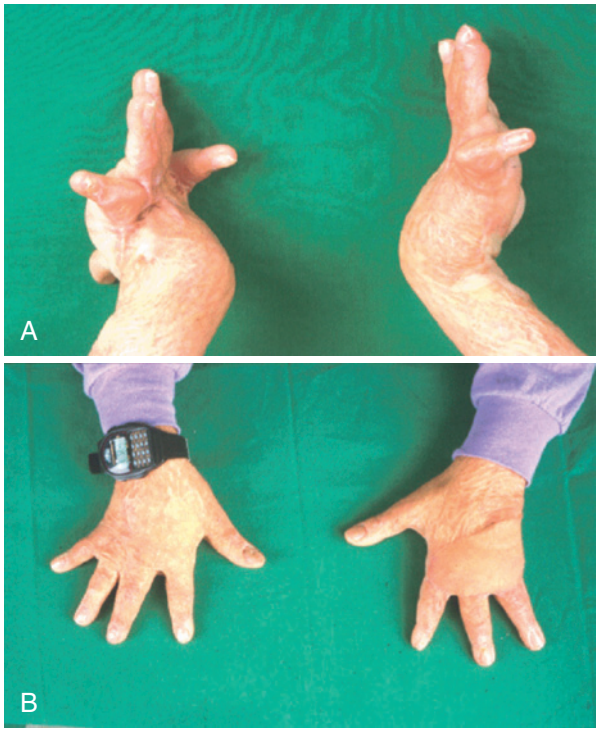

FIGURE 57.23 **A,** Severe bilateral contractions of the dorsum of the hand. **B,** Long-term result after release and reconstruction of the right hand with full-thickness skin grafts and use of a conventional groin flap on the left hand.

alternative for these types of deformities is the lipofilling technique.

The technique is usually used in aesthetic and reconstructive procedures to treat volume deficiencies after deep inferior epigastric perforator flap reconstruction or to fill wrinkles in facial rejuvenation. The fat is applied in a "microdrop technique" to achieve a maximal take rate of the transplanted fat. The transplanted fat creates a new tissue layer between contracted scars and the suprafascial plane. This makes the scars softer and more pliable. The method is increasingly used in our department with excellent results.

With this technique, a permanent take rate of up to 70% can be achieved. Multiple procedures may be required (Figure 57.24, *A* and *B*).

Amputation Deformity

Patients with significant burns of the hand and digital involvement are always at risk for vascular compromise of the digits. Early escharotomy to preserve the intrinsic muscles of the hand and improve the circulation in digits is crucial. Despite these procedures, some patients face partial or total amputation of the digits. Such losses both distort the aesthetic appearance of the hand and severely affect its function.

Salisbury pointed out that it might be inappropriate to concentrate multiple surgical efforts on one finger if a patient has other extensive problems. Amputation might rapidly relieve the problems of "hooking" or chronic pain in these cases. The overall goal is to do only the operations necessary to rehabilitate the patient.[128]

Reconstruction of the digits usually concentrates on restoration of a three-point grip involving the thumb and predominantly the index finger. The thumb accounts for approximately 40% of hand function, which is why its reconstruction is a primary concern in rehabilitation of a burned hand with multiple digital loss. Any reconstructive procedure in a burned hand is surgically more difficult than in other posttraumatic situations.

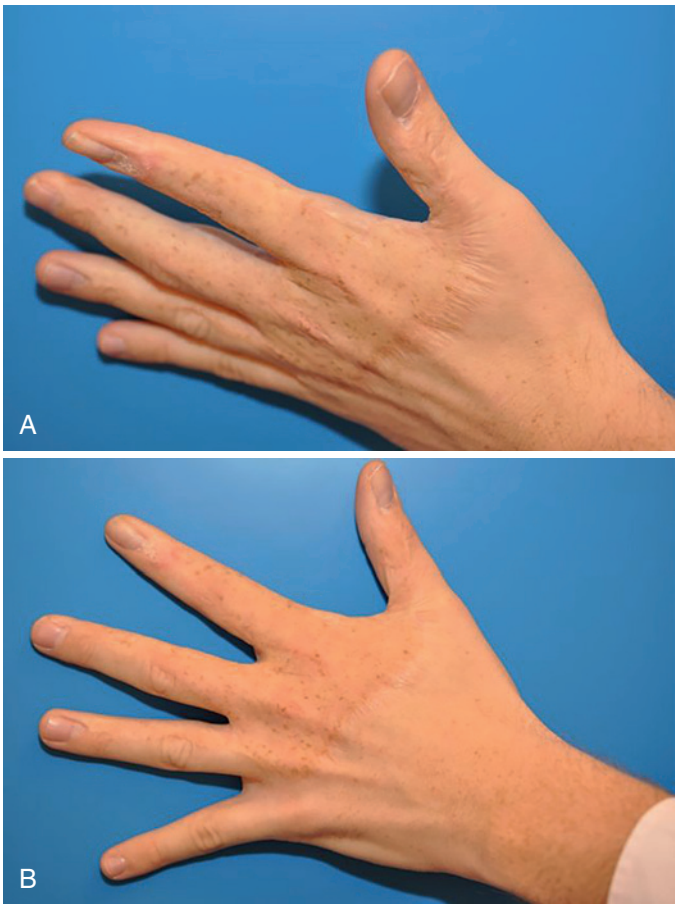

FIGURE 57.24 **A,** Significant volume deficiency in the intertendinous spaces. **B,** Marked improvement after one session of lipofilling.

Thumb Reconstruction. In thumb reconstruction, the adequacy of soft tissue coverage must first be assessed. If soft tissue coverage is not adequate, flap coverage of the area of the first metacarpal and web space should be undertaken as an initial stage. Adequate length, mobility, stability, and sensation, as well as aesthetics, are the goals of functional thumb reconstruction.[83,84,153]

With thumb loss distal to the interphalangeal joint, function remains good. Frequently, simple deepening of the web space by "Z"-plasties yields sufficient additional length for the thumb. When the proximal phalanx becomes foreshortened, function progressively diminishes. In such deformities, pollicization or transfer of partial digits is very useful and should be considered when the thumb does not have sufficient length to oppose the remaining digits. Littler addressed the issue of thumb reconstruction in patients with multiple digital amputations by performing first-to-second metacarpal transfer via a vascularized osteocutaneous transfer.[84,159] In these patients, two functionless digits are combined to make a functional thumb. This procedure both lengthens the thumb and creates a newly developed first web space, which allows pinch.[84] Although Littler's patients

were not burn victims, other surgeons have applied this approach to thumb reconstruction in cases of burn injuries to the hand with digital amputations.[159]

Toe-to-thumb transfer is an alternative for thumb reconstruction,[53,58,153] especially in cases in which no digits are available for pollicization. In a severely burned patient with large total body area burns, most toes and fingers will be damaged, so pollicization may be a more viable solution.

In some cases, such as electrical injuries with complete loss of the thumb, toe-to-thumb transfer is a better choice. Frequently, soft tissue shortage is encountered, so procedures such as groin flaps or free tissue transfers are necessary as a first stage to provide a sufficient soft tissue envelope for the transplanted toe. Technical difficulties of toe transfer in burn patients are many and include dissection in heavily scarred tissue, shortage of large-caliber cutaneous veins, and tight surrounding tissues with a risk for compression of the vascular pedicle after toe transfer.

Modified toe transfers such as en bloc transfer of the second and third toes to facilitate a three-point grip or additional transfers to the fourth or fifth rays may be indicated in severe cases to provide grip in the dominant hand. Whenever possible, local finger transpositions or partial finger transpositions should be performed to use any available intrinsic "spare parts."



FIGURE 57.25 **A** and **B,** Elbow release.

Elbow Contractures

Elbow contractures are divided according to the structures involved into intraarticular and extraarticular types involving skin, musculotendinous units, and the joint capsule. Most contractures are extraarticular flexion contractures. Correction can usually be achieved with all of the measures described earlier (see Figure 57.16). Contraction bands can be released with any type of suitable "Z"-plasty. Thick split-thickness skin grafts can be used to resurface the volar aspect of the elbow if no vital structures are exposed. The combination of artificial dermis equivalents such as Integra, AlloDerm, or Dermacell with split-thickness skin grafts has also yielded favorable results.[21,28,29,51] With deeper defects after release, flap coverage may be indicated. The spectrum of flaps ranges from local and regional flaps to more sophisticated free flaps, depending on the availability of surrounding tissue. Most commonly used are[11,68,131]:

- Antegrade forearm flaps
- Posterior interosseous transposition flaps[3]
- Recurrent radial collateral artery flaps
- Inner upper arm fasciocutaneous flaps
- Scapular free flaps
- Parascapular free flaps
- Anterolateral thigh free flaps
- Fascial free flaps (temporoparietal, serratus)

Physical therapy is initiated as soon as graft take is guaranteed or secure healing of the flap is confirmed (Figure 57.25).

Heterotopic Ossification. In severely burned patients, the incidence of heterotopic bone formation is estimated to be 2%.[31] The incidence is higher with massive full-thickness burns and in elbows that have to be immobilized for a prolonged period. Radiographs are recommended before any contracture release of the elbow to rule out heterotopic ossification. Bone formation is usually found posteriorly and medially and occasionally leads to ulnar nerve entrapment. There are several reports about reduction of bone formation after hip surgery with the use of nonsteroidal antiinflammatory drugs; however, data are sparse in the burn literature, and prophylactic use of such drugs is not applicable. The same holds true for protocols using bisphosphonates.[34,124]

Early excision is indicated only when severe impairment of active motion is caused by the newly formed bone. Otherwise, it is recommended that one wait until the bone has matured, usually after 12 to 18 months. Maturity can be confirmed by serial x-rays. The surgical approach is through a posteromedial incision. Care has to be taken to not injure the ulnar nerve (which is generally released as part of the procedure) and to avoid resection of the stabilizing medial collateral ligament complex. An arthrotomy should be part of the procedure to release any intraarticular adhesions. Physical therapy is of utmost importance and should be initiated after 2 days if the wound is stable. Continuous passive motion in the postoperative period has proved to be useful in our practice in these cases.

Axillary Contractures

Axillary contractures are divided into three groups[73,147]:

- Type I patterns involve either the posterior (IA) or, in the majority of cases, the anterior axillary fold (IB).
- Type II contractures involve both axillary folds, with an island of intact skin in the axillary dome.
- Type III contractures involve all structures in the axilla, including the skin of the dome.

Contraction bands in both axillary folds are usually addressed by variations of the "Z"-plasty if sufficient local tissue is available. In type II patterns, sequential operations are recommended because vascularization of the flaps may be jeopardized by a bilateral approach. Release has to be performed to the underlying fascia of the latissimus or the pectoralis muscle to prevent early recurrence.

In type III patterns, skin grafting is correlated with an extremely high incidence of recurrence. In this frequently

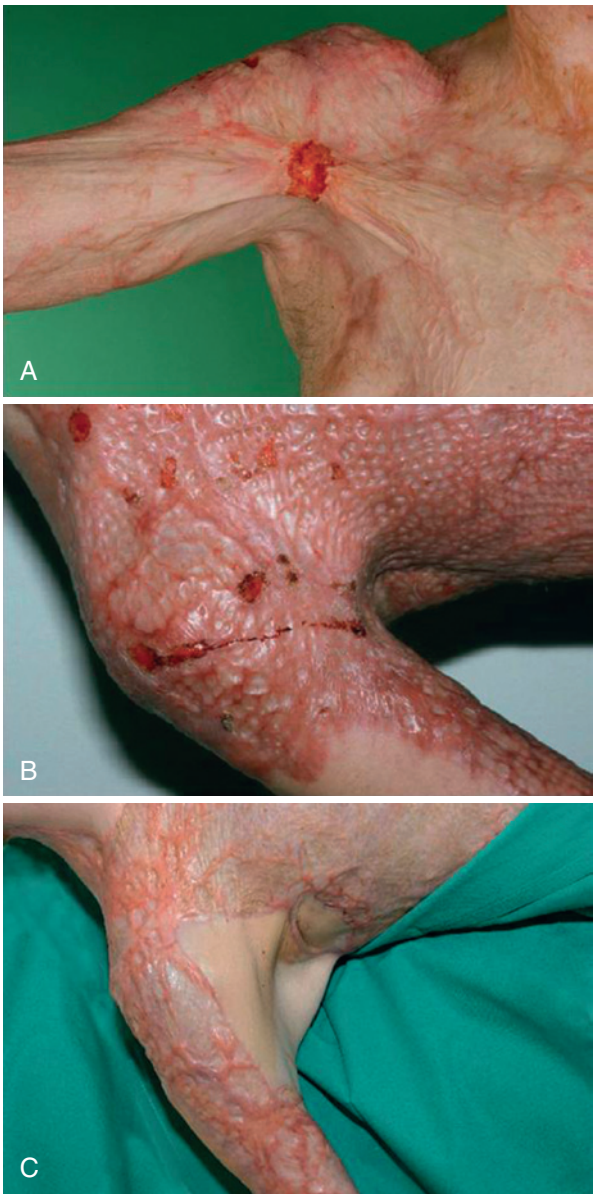

FIGURE 57.26 **A** and **B,** Type II axillary contracture, anteroposterior view. **C,** Contracture release with an anterolateral thigh free flap. A perfect contour with almost free range of motion was achieved.

uneven area, skin graft take can be poor, and secondary healing promotes further recontraction. The same holds true for transplantation of dermis equivalents. Flap reconstruction has proved to be very helpful in these cases. Regional flaps such as the pedicled scapular, parascapular, latissimus dorsi, or regional perforator flaps are preferred when available. In severe cases in which no regional options exist, one should not hesitate to choose the option of a microsurgical free flap. The spectrum of flaps is identical to those listed earlier for elbow release with the exception of fascial flaps, which require skin graft coverage and thus are not desirable in axillary release (Figure 57.26).

RECONSTRUCTIVE TOOLS

Most "Z"-plasties and their modifications, as well as most regional or microvascular flaps, are described elsewhere. However, some flaps have proved to be very useful and are discussed in this chapter.[95,156]

A number of distant pedicle flaps are available for hand coverage. The choice of flap depends on the type of soft tissue coverage required, as well as the experience of the surgeon involved. The entire armamentarium of flaps can be used in burn reconstruction. The spectrum ranges from simple distant flaps such as the random abdominal wall flap to regional pedicled flaps such as the groin flap or the tensor fasciae latae flap. The cross-arm flap has also been used for acute coverage of burned hands[13] but has generally been abandoned because of its unsightly donor site and the necessary immobilization of both extremities. Some of the more commonly used flaps are described in the following sections.

Random Abdominal Wall Flap

The random abdominal wall flap has the advantage of simplicity in that no knowledge of specific vascular anatomy is necessary to perform the procedure. The flap is suitable for coverage of the entire hand and fingers. A disadvantage is that the covered hand is inaccessible for inspection. In the event that the patient becomes febrile, operative exploration may be necessary to rule out infection. A second disadvantage is that the transplanted skin retains the fat cell characteristics of abdominal skin; an increase in body weight will result in thickening of the transposed abdominal skin, as well as increased abdominal girth. Finally, the immobility of the hand while in the abdominal tissue pocket results in joint stiffness at the hand, elbow, and shoulder, and the donor site is highly unaesthetic.[117]

Groin Flap

One of the most important distant flaps is the groin flap.[40,41] Since the pedicled groin flap was first described by McGregor and Jackson in 1972[96] and the free groin flap was first applied clinically by Daniel and Taylor in 1973,[26] the free groin flap has become a well-accepted and widely used method for the reconstruction of many types of defects.[22,24,80,96] The groin flap is a particularly useful flap in burn reconstruction because the groin is usually spared even in large body surface area burns. Use of the groin flap for acute coverage of burned hands has been described earlier in detail.[5,22,41,46,132,170]

The specific advantages of a free groin flap are as follows: large size of the flap, direct closure of the donor defect in most cases, scar situated in an area that is usually hidden, and reliability of the blood supply.[41] The blood supply to the flap consists of the superficial epigastric artery or the superficial circumflex iliac artery (or both) and their branches. These two arteries constitute a subcutaneous vascular network to give the flap adequate blood supply. This method, when compared with the pedicled groin flap, is more convenient for the patient, hospitalization time is shorter, and cost is lower. The free groin flap has been used less frequently as other donor sites have emerged because of problems with frequent anatomic variations in the pedicle, limited length and inconsistent caliber of the vascular pedicle, and excessive bulk in obese patients.[41,48,49,132,170]

Tensor Fasciae Latae Flap

The tensor fasciae latae flap is based on the tensor fasciae latae muscle and can be considered a second line of defense in reconstruction of a burned hand. A fasciocutaneous territory three

to four times larger than the muscle can reliably be elevated for a total flap size of up to 15 by 14 cm. The anterior aspect of the flap is defined as a line running from the anterior superior iliac spine to the lateral tibial condyle. The distal margin is a point approximately 8 cm superior to the knee. The posterior border runs along a line drawn from the greater trochanter to the head of the fibula.[92,138] The vascular pedicle, located 6 to 10 cm below the anterior superior iliac spine, is the axis of rotation and allows coverage of defects of the groin, sacrum, lower part of the abdomen, or hand.[66,92,94] Use of the tensor fasciae latae flap as a pedicled flap for hand coverage allows some shoulder and elbow motion before division of the pedicle. A disadvantage of this flap in burn patients is the need to place operative incisions on the lateral aspect of the thigh, normally a prime donor site for split-thickness autografts.

Forearm Flaps

Forearm flaps are distally based on either the ulnar or the radial artery or their perforating vessels; they provide thin, tailored flap coverage and allow the upper extremity to be appropriately elevated during the initial phase of healing. Forearm flaps may be raised either as a fascial flap alone on the ulnar or radial artery or as a fasciocutaneous flap.[44,119] The fascia alone provides a supple layer of subcutaneous tissue that is readily grafted with split skin. The forearm skin is relatively thin and provides acceptable coverage for the dorsum of the hand, although it leaves a more obvious donor defect. Nevertheless, with reversed-flow forearm flaps, the donor defects are placed proximally over muscle bellies rather than over tendons close to the wrist, and donor morbidity in general is low. Very large flaps can be raised if necessary. It is essential to ensure the presence and viability of the palmar arch before embarking on one of these flaps. Generally, the venae comitantes provide adequate venous drainage, and it has not been found necessary to anastomose additional superficial veins.[38,40,61]

Anterolateral Thigh Flaps

Anterolateral thigh fasciocutaneous flaps can be used for defects involving an extremely large skin territory on the dorsum of the hand when extensor tendons are exposed. The vascular supply is based on the lateral circumflex femoral artery. The donor site can be closed directly, with a low morbidity rate. Some patients suffer from temporary numbness at the donor site, but this generally disappears after 6 months. Satisfactory functional and cosmetic results are usually obtained at 1 year postoperatively. Free anterolateral thigh flaps can be thinned as necessary to achieve optimal contouring. In experienced hands, the mean operative time required for anterolateral thigh flap transfers is less than that required for other free flaps.[110]

Lateral Arm Flap

The lateral arm fasciocutaneous flap is raised on the lateral aspect of the upper part of the arm, just above the lateral epicondyle of the humerus, and its vascular basis is the posterior branch of the radial collateral artery and its venae comitantes. The advantage of this flap is that it provides a good tissue match and contour in the forearm and hand. Another advantage of this flap is that it can be taken from the injured arm in some cases via a single operative field. The donor site can generally be closed primarily. When placed on a flap surface, the flap may be bulky and secondary contouring by liposuction or excision may be necessary. Its short pedicle length may require an interposition vein graft for tension-free anastomosis.[110]

Free Serratus Fascial Flap

With this flap, coverage of exposed functional structures such as tendons, bones, vessels, or nerves at the dorsal and palmar sides of the hand can be achieved. This flap is thin and provides supple tissue to allow adequate range of motion and satisfying aesthetic results.[35,36,131]

ELECTRICAL INJURY

Epidemiologic Findings

Injuries caused by electric current are seen infrequently and account for less than 3% of all admissions to specialized burn units in industrialized countries. Two thirds of all injuries are low-voltage injuries. The victims of major electrical trauma are characteristically young, previously healthy men and adolescents. The upper extremity is involved in 75% to 88% of all electrical injuries.[14] Patient profiles reflect the risk for occupational exposure, with a third of all accidents occurring through contact with power lines and another third sustained in construction work.[62] Amputation rates range between 40% and 70%,[52] and the mortality rate ranges from 8% to 14%. The hospital stay is usually prolonged.[62] Five years after trauma, more than 50% of patients still suffer from neurologic problems. In cases of occupational accidents, permanent disability has been noted in 85% of all patients sustaining a high-voltage injury.[154]

Properties of Electricity and Pathophysiologic Conditions

The history of electrical injuries starts with the invention of the electric incandescent lamp by Thomas Alva Edison in 1879 and the death of a theater carpenter in Lyon, France, in the same year, who was killed by an alternating current of 250 V.[62] To understand the pattern of injuries it is helpful to consider the physical properties of electric current.

The quantity of charge in a wire is expressed in amperes (André M. Ampère, French physicist, 1775-1836); one unit is defined as a flow of 6.2×10^{18} electrons per second. The potential difference between two points in a conductor characterizes the electromotive force and is defined in volts (Alessandro Volta, Italian physicist, 1745-1827). Resistance describes the opposition to electron flow and is caused by collisions of current-carrying charged particles. Resistance is directly proportional to the length of the conductor and inversely proportional to its cross-sectional area and depends on the material of the conductor. Resistance is measured in ohms (Georg S. Ohm, German physicist, 1789-1854).

Today, distribution of electrical energy is mainly through alternating current. The motion of the electric charge is periodically reversed. The frequency of this change per cycle is defined as frequency in hertz (Heinrich Rudolph Hertz, German physicist, 1857-1894). The voltage used in households and most industrial fields ranges from 110 to 380 V, depending on the country. Cross-country power lines carry 38,000 V, and most train power lines carry 15,000 V with 16 Hz. Direct current is used only for specialized applications, such as subway train networks.

The three units of current are related by *Ohm's law*. It states that resistance equals the ratio of electromotive force and current in amperes:

$$R = \frac{V}{I}$$

Another important equation is *Joule's law*, which describes the heat production in an electric circuit. The heat in centigrade can be calculated as

$$H = 0.24\, I^2 \times R \times t \text{ (duration in seconds)}$$

The extent of tissue damage is determined by the current, voltage, duration of contact, tissue resistance, and pathway of flow through the body. Alternating current is more dangerous than direct current with respect to cardiac function. One milliampere to 2 mA causes a tingling sensation, and muscular contraction is seen at between 8 and 12 mA. A current of more than 20 mA may exceed the "let-go threshold" because of tetanic contractions caused by the alternating current, which can be strong enough to cause joint dislocations and even fractures. One hundred milliamperes can lead to ventricular fibrillation when flowing from the hand to the foot, with the same current passing through the brain, immediately rendering the victim unconscious.[150]

Tissue resistance is a decisive factor for the extent of damage. The skin demonstrates values between 5000 and 50,000 Ω/cm^2. The glabrous skin of the palm and feet may have a resistance of 2 million Ω, which can be reduced 1000-fold in the presence of moisture. When skin resistance is low, the direct cutaneous effect is also low, but a high-energy current flows through the deeper tissues. When skin resistance is high, low energy flows through deeper tissues, but the skin manifestation of the burn is significant. The amount of heat generated by the flow of the current is also proportional to the resistance of the tissue, which is also determined by the conducting properties and the cross-sectional area.

There are three current theories about the mechanism through which tissue damage is inflicted.

The first theory is that largest current densities (A/cm^2) are passed through nerves and arteries, followed by muscle, skin, and bone. Muscle with the largest cross-sectional area passes the largest portion, although the resistance is relatively low. Regions with a small cross-sectional area such as the elbow or wrist demonstrate high resistance, which leads, according to Joule's law, to extraproportional generation of heat. These areas are called "choke points."[144] This hypothesis is supported by experimental data from Hunt and colleagues, who showed in rats that the individual conducting properties of tissues are less significant than the resistance related to the cross-sectional area.[62,77]

The second theory is that current causes formation of pores or defects in the cell membrane that lead to severe cell damage and death (*electroporation*). Lee and Kolodney demonstrated that nonthermal electrical forces cause defects in the cell membrane, preferably in the largest cell populations such as neurons or myocytes.[77] The lesions can be found scattered throughout the muscle (*skipping lesions*). This would explain a portion of the myolysis and persistent neurologic deficits.[27,168,169]

The third theory is based on progressive constant release of arachidonic acid metabolites such as thromboxane from disrupted cells. Robson and associates postulated that this will disturb the balance in prostaglandin E_2 and $E_{2\alpha}$.[126]

An ongoing discussion circles around the question of whether there is progressive tissue damage or whether the extent of damage is determined primarily at the moment of trauma. Experimental data by Zelt and colleagues support the occurrence of a definitive extent of damage at the time of the injury,[169] thus suggesting that in the clinical situation the surgeon may be able to determine the true extent of the damage.

Many surgeons strongly oppose these data based on their clinical experience. They frequently encounter progressive damage (i.e., necrotic muscle in serial débridements) in places where healthy muscle has been seen 2 days before. Damage to the vascular intima and media may lead to delayed occlusion with progressive damage, a theory supported by local ischemia induced by the release of thromboxane metabolites.[126] The truth most likely lies somewhere in between, but burn surgeons agree that assessment of tissue damage after high-voltage injuries always poses a challenge, even for experienced surgeons.

Mechanism and Classification

Although as described earlier many factors determine the extent of tissue damage in electrical injuries, they have been divided for clinical purposes into low-voltage injuries (<1000 V) and high-voltage injuries (>1000 V).

- Low-voltage injuries
  - Flash burns
  - Direct contact burns
    - Cutaneous burns
    - Muscle contractures
    - Cardiac involvement
      - Arrhythmias, ventricular and atrial fibrillation
      - ST-T changes
- High-voltage injuries
  - Flash burns
  - Arcing burns
  - Direct contact burns
    - Cutaneous burns
    - Muscle contractures, fractures, dislocations
    - Tissue destruction
      - Muscle, nerve, vessel, bone, or tendon destruction
    - Cardiac involvement
      - Arrhythmias, ventricular and atrial fibrillation
      - Elevated isoenzymes
      - Electrocardiographic changes

Arcing occurs between objects of opposite charge and does not require direct contact. It is estimated that approximately 10,000 V can bridge a distance of 1 cm. Although voltage drops immediately after skin contact, temperatures from 3000°C to 5000°C develop for milliseconds, which is enough to inflict severe cutaneous destruction. Direct contact with high-tension lines frequently exceeds the "let-go" threshold, and the victim suffers continuous flow of current through the body. Flash burns are principally flame burns with ignition of the clothing and follow the same pathophysiologic principles as thermal burns.

Clinical Manifestations

High-voltage injuries are often life-threatening because of the combination of deep tissue destruction and large surface

cutaneous burns. The clinical manifestations are related to exposure to the current, the pathway through the body, and the patient's premorbid medical status. The majority of injuries involve the hands. Contact burns are localized, deep, depressed, sometimes blistered, and frequently charred, with surrounding redness and swelling.

Arcing occurs across flexor surfaces and typically involves the distal part of the forearm, the antecubital fossa, and the axilla.[14] High-tension injuries are devastating injuries that are usually associated with an entrance wound and one or more exit wounds at the points where the current enters and exits the body.[54,57] High-tension injuries have a high incidence of compartment syndrome. The main source of damage in tissues by the electric current is conversion of the electrical energy into heat.[37] The heat generated by the electrical injury causes coagulation necrosis of the tissues involved. As explained earlier, the muscles with the largest cross-sectional areas suffer the greatest energy load. The rich vascular network also conveys thermal energy. It is therefore assumed today that bony necrosis is not caused by the poor conducting properties of bone with high resistance but by the extremely heated muscle environment.[37] Similarly, intravascular thrombosis can be quite extensive[57,77] and lead to occlusion of major vessels. The extent of cutaneous damage is correlated with the resistance of the skin (see earlier). The upper extremity is frequently initially seen in a fixed flexion contracture position, indicative of severe muscle contraction and necrosis, and often with a compartment syndrome. The loss of intracellular proteins (such as myoglobin) into the circulation because of rhabdomyolysis is responsible for myoglobinuria, which may obstruct the renal collecting system and potentially lead to renal failure (Figure 57.27).



FIGURE 57.27 Clinical situation after a high-voltage injury with flow of current through the upper extremity.

Because peripheral nerves are very sensitive to electrical forces, even minor electrical trauma may cause temporary nerve dysfunction. Symptoms of anesthesia, paresthesia, or dysesthesia may occur.

Other clinically significant features of electrical injury include refractory cardiac arrhythmias, spinal fractures as a result of tetanic muscular contraction, other fractures and dislocations, derangements in serum electrolytes, and blast trauma.[57] Any coexisting injuries must be diagnosed, assessed, and managed.

Treatment

General Management

Patient evaluation and resuscitation should proceed simultaneously. Stabilization of vital signs is necessary, and monitoring should include a urinary catheter, central venous access, and invasive hemodynamic monitoring if indicated. Fluid requirements are significantly higher than with pure cutaneous burns, and care must be taken not to underestimate the amount of fluid necessary to maintain a urinary output that should be at least 2 mL/kg/hr. With severe muscle destruction, the clinical picture of a "crush syndrome" is seen. Our experience has shown that with high-voltage injuries, the amount of crystalloid required is 2.5 to 3 times more than that required with similar surface flame burns.[4,27] Some authors have recommended alkalinization of the urine to improve clearance of hemoglobin and myoglobin from the renal tubuli,[4,86] whereas others have used resuscitation with high-volume lactated Ringer solution alone.[86,87] Levels of creatine kinase are indicative of the extent of muscle destruction but are not clearly correlated. Low or normal levels, however, indicate only that there is little or no dead muscle tissue.

Once the patient is stabilized, a detailed history is essential, followed by a thorough physical examination for skeletal, neurologic, and intraabdominal injuries. If there is concern about cardiac injury as indicated by electrocardiographic abnormalities on admission, continuous cardiac monitoring, daily 12-lead electrocardiograms, and cardiac isoenzyme analyses are performed to assess direct myocardial damage. Tetanus prophylaxis and antibiotics protecting against clostridial infection should be given.

Surgical Management

Once the patient is stabilized, treatment is directed toward preservation of function, prevention of infection, débridement of clearly necrotic parts, and resurfacing of defects. Wounds over vital structures such as arteries, nerves, tendons, and bone take first priority.[14,22]

Tissue decompression techniques are central to the successful initial treatment of electrical injuries to the upper extremity.[27] Standard escharotomies as described earlier should be combined with fasciotomies. Both escharotomies and fasciotomies should decompress the digits, carpal tunnel, and Guyon canal.[116] All compartments should be addressed both dorsally and palmarly, and the muscle compartments in the hand should be adequately decompressed within 6 to 8 hours of injury.[27] It has to be emphasized that division of the epimysium is also sometimes necessary. The need for this is based on clinical assessment. Measurements of intracompartmental pressure may be a useful adjunct, but symptoms such as swelling, pain

on passive motion, and firmness are usually sufficient for diagnosis. Skin burns should be incorporated into incision lines. Although escharotomies can be performed at the bedside, fasciotomies should be performed in the operating room and have to be considered emergency measures that can make the difference between amputation or limb salvage. Temporary coverage is recommended until conditions for definitive coverage are reached.

Radical débridement of nonviable tissue should be performed as soon as the patient is stabilized. Regardless of the initial technique, a second-look operation to reinspect tissues and to débride additional necrotic tissue should be undertaken every 48 hours until only viable tissue remains.[27] After each débridement, allografts or topical antimicrobial agents are applied to the wounds. Splints are essential between surgeries to reduce pain, maintain the position of function, prevent tendon rupture, and protect vascular perfusion.

Assessment of tissue viability can be performed by

- Clinical evaluation (muscle color, contractile response)
- Scintigraphy with technetium 99m pyrophosphate
- Magnetic resonance imaging (MRI) with contrast enhancement
- Sequential histologic sections
- Perfusion with nitroblue tetrazolium

Most surgeons rely on their clinical experience, which can be misleading. To date, however, good clinical judgment of tissue viability has not been surpassed by imaging techniques, of which scintigraphy is probably the most useful. Although muscle is generously débrided, tendons and nerves are resected only if they are clearly necrotic. If viability is questionable, early flap coverage may salvage the structures. If essential vessels are occluded, vein graft reconstruction can be performed if placed under well-vascularized tissue coverage.[167] Excision plus grafting of damaged arteries, especially at the wrist level, has been described for the salvage of extremities.[167] Whether more aggressive surgical reconstruction may prove to be beneficial in long-term patient outcomes remains controversial.[27]

Once viability of the remaining tissue is established, skin grafts, local skin or fasciocutaneous flaps, or microvascular free flaps may be used to close the wound and salvage the injured extremity. The method of resurfacing is dependent on the tissue exposed, with split-skin grafts suitable for muscle and local, pedicled, and free flaps suitable for the coverage of nerves, patent arteries, tendons, and bone. Chick and coauthors reported promising results with radical débridement and free flap coverage within 3 days based on their experience with other extremity trauma.[22] Many authors have also applied microvascular techniques to the salvage of limb and function in severe electrical injuries (Figure 57.28).[38,61,131,134]

On occasion, the tissue destruction in a limb is so extensive that limb salvage would jeopardize the patient's life. In these cases, patient survival and functional outcome are best optimized by proximal limb amputation early in the course of treatment (life over limb). The threshold for this decision has moved more toward amputation in recent years. Today, use of microvascular free tissue transfer techniques has added much to limb salvage,[38,131,164] although somewhat higher complication rates have been reported in this group of patients.[11,165] All reconstructive techniques described earlier and in other sections of this volume can be applied to patients with electrical burns. Selection of the technique depends on the size of the defect, the availability of flaps, and the condition of the patient.

Complications

Early complications include vascular occlusion, wound infection caused by residual nonvital tissue, systemic sepsis, multiorgan failure, and failure of reconstructive procedures with subsequent limb amputation.

Late sequelae include cataract formation, peripheral neuropathies, pulmonary dysfunction, cerebral hemorrhage, and muscle fibrosis.[27]

Rehabilitation

In view of the devastating nature of these injuries, rehabilitation is an essential part of the treatment regimen. Despite all efforts, many patients are left with permanent disabilities and are not able to return to their original occupations. Besides all conservative measures such as splinting, continuous passive motion, lymph drainage, compression therapy, prosthetic fitting, and intensive physical therapy, operative procedures such as tendon transfers to restore muscle function, transfer of innervated muscles, and toe transfer for missing thumbs are also an integral part of the rehabilitation program.

CHEMICAL BURNS

Chemical burns are unique injuries that need specialized knowledge and management principles to obtain a satisfactory outcome. The literature about therapy for chemical burns is relatively sparse; however, chemical burns are common problems, especially for hand surgeons. Many chemicals are widespread in common household and industrial use. Products containing chemicals capable of causing a cutaneous injury number more than 25,000.[25] More than 60% of admissions to the hospital because of chemical injury are due to work-related injuries.[102,123] The upper extremity is one of the most commonly injured parts of the body, specifically the digits. Chemical burns involve an average total body surface area of 19.5%. Prolonged hospitalization with poor wound healing is the rule.[15]

As with thermal burns, the damage caused by chemical burns of the hand is usually limited to the skin. The major difference, however, is that some chemical agents may continue to be active at the site and continue to destroy tissues.[30] Ongoing tissue destruction will occur for as long as the chemical remains active and in contact with the skin. The level of injury depends on the area exposed to the chemicals, the nature and concentration of the noxious agent, the volume of substance contacting the skin, the local characteristics of the skin, and the duration of contact with the chemical.[15,123] The duration of contact of the noxious agent with the skin is the major determinant of the severity of chemical injury.[117] Most chemical injuries are the result of contact of the individual with either acidic or alkaline agents.[15,72]

Acid burns are classically described as hydroscopic in nature and gain access through the protective stratum corneum. Cellular dehydration occurs, as well as destruction of cell membranes and liquefaction necrosis. The reactions are progressive unless lavage or neutralization therapy is used to chemically bind, inactivate, or remove the offending agent. The depth of tissue damage is limited by the buffering capacity for acids

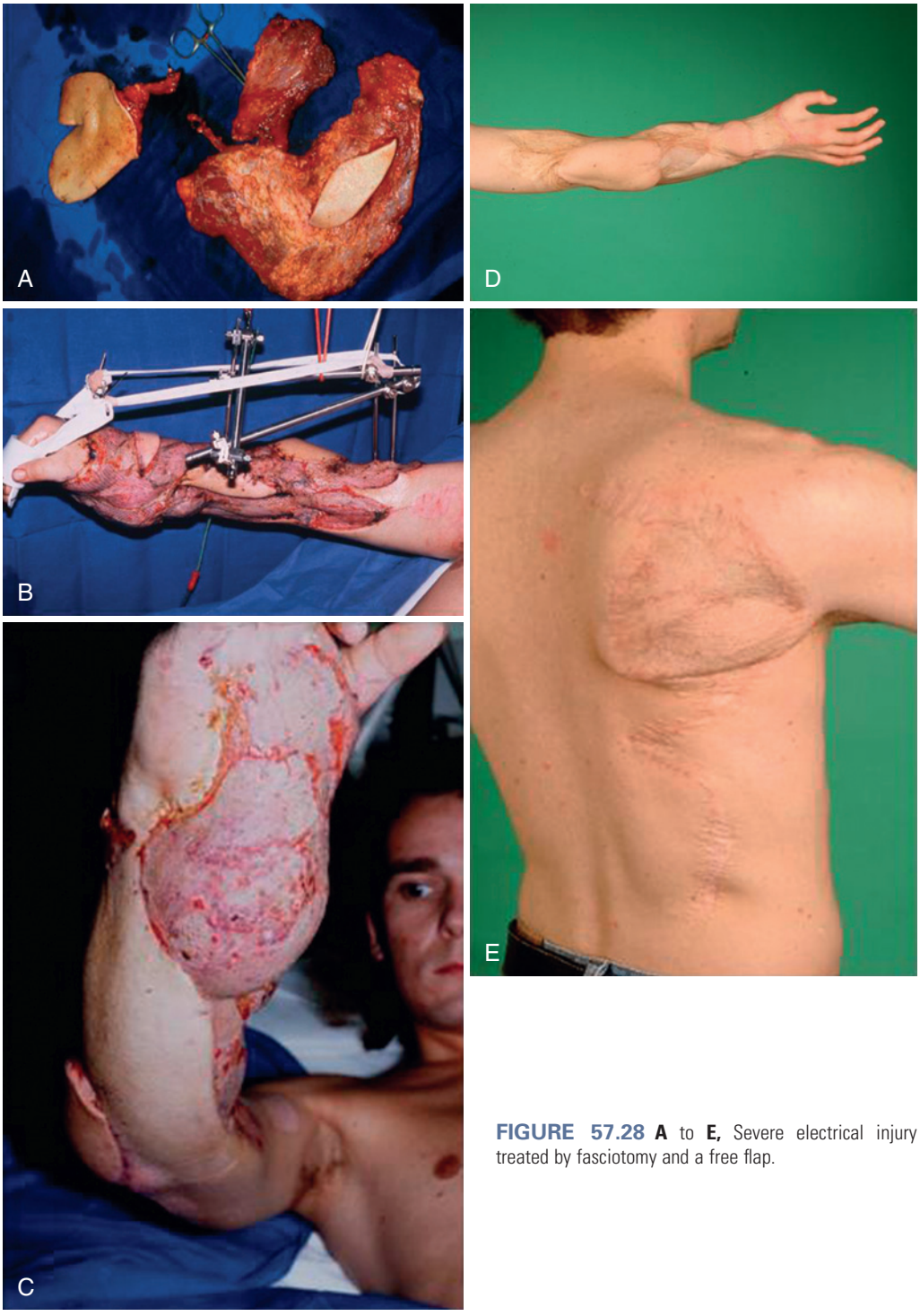

FIGURE 57.28 A to **E,** Severe electrical injury treated by fasciotomy and a free flap.

contained in the injured tissue. Alkali burns are clinically more latent than acid burns. Alkaline albuminates combine with tissue elements to form fatty soaps. These hydroscopic reactions may continue for days with extensive destruction of tissue.[15] This tissue injury is commonly known as *liquefaction necrosis*. It allows a deeper injury than occurs with acid burns as a result of a continued basic wound milieu produced by the alkaline injury. Because damaged tissue has a limited capacity to buffer alkalis, there is further penetration of the lipophilic alkali, which results in deeper injury.

Management

Chemical burns of the upper extremity do not present any special management problems that have not already been discussed under thermal or electrical injuries. The same careful attention must be given to elevation, immobilization, tetanus immunization, and monitoring of pulses (Figure 57.29).

There is no question about the first step of treatment. The essential activity in the initial care is to stop the burning process. Immediately after contact with either acid or alkali, removal of the patient from the offending chemical agent should be

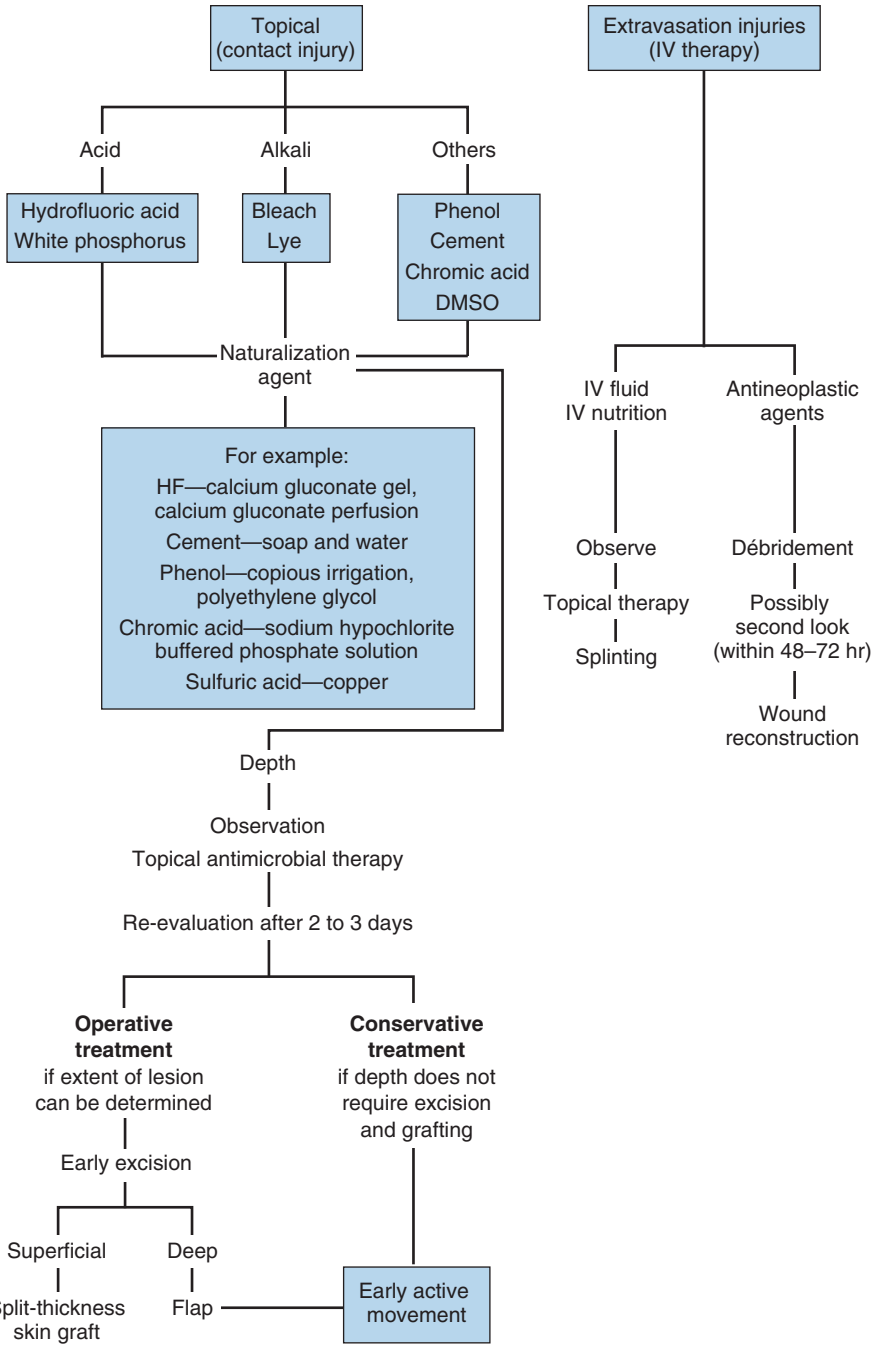

FIGURE 57.29 Decision-making algorithm for chemical burns. *DMSO*, Dimethyl sulfoxide; *HF*, hydrofluoric acid; *IV*, intravenous.

performed and all affected clothing should be removed. The initial goal in the treatment of chemical injuries is immediate dilution or, better, neutralization of the chemical agent. Lavage that is not thorough enough enhances absorption of the agent. Water is the appropriate emergency treatment of most chemical contact spills. Water lavage lasting 1 to 2 hours is recommended for acid burns and longer for alkali burns.[27] Water lavage facilitates dilution of the chemical agent away from the victim, thereby decreasing the chemical load to the skin. In addition, water lavage decreases the rate of the chemical reaction and tissue metabolism and contributes to restoration of normal skin pH.[123] Both animal studies and human experience confirm the essential fact that copious and continuous water irrigation immediately after chemical exposure is critical to limiting the injury process.[117] A delay of just 15 minutes after contact with a chemical agent may allow the epidermis to be destroyed.

Once the agent has been clearly established, neutralizing substances can be added.[54] Skin pH measurements with litmus paper give a rough guide to neutralization of the surface skin but do not provide an accurate estimate of the pH of deeper tissues, where the damage may be ongoing. Pain may also be a useful guide but is not completely reliable because some chemicals, such as phenols, demyelinate nerves and make the wound anesthetic.[123]

After adequate removal of the chemical from the injured part, the damaged skin must be protected from infection. Nonviable tissue, blisters, and bullae should be débrided because they may contain residual concentrations of the chemical agent. Topical antibacterial agents should be applied. Partial-thickness chemical burns are generally managed conservatively with dressing changes. Patients with deep partial-thickness burns of the hands should be hospitalized and the injured skin excised and grafted early in a fashion similar to that outlined for thermal injuries.[15] Deeper injuries may require local or even microvascular flap coverage (Figure 57.30).

Persistent chemical contact beneath the nail bed can be difficult to treat as a result of the lack of access to water because of the overlying nail. Partial or even complete removal of the nail may be necessary for adequate water irrigation.

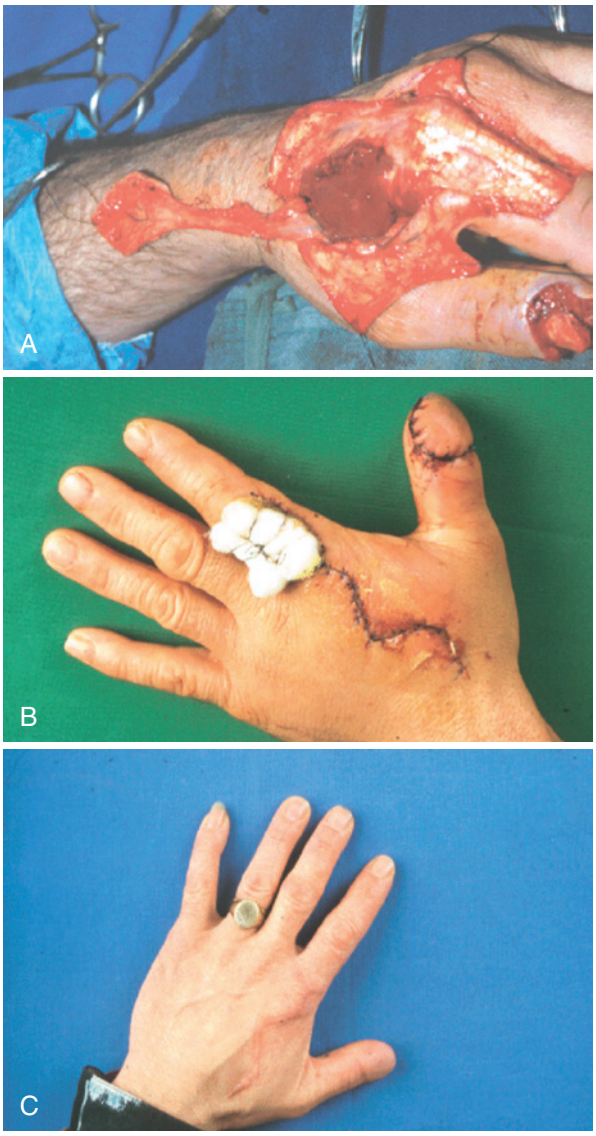

FIGURE 57.30 **A,** Hydrofluoric acid burn of the tip of the thumb with loss of the nail. The area is débrided, and a "kite flap" (first dorsal metacarpal artery flap) has been raised. The artery is clearly visible in the pedicle, which includes the fascia of the interosseous muscle. **B,** The flap has securely healed in place. A full-thickness skin graft was applied to the donor site. **C,** Very appealing aesthetic result.

As in thermal injuries, the fascial compartments of the upper extremity are at risk for the development of edema. Because the magnitude of a chemical injury can often be underdiagnosed in the early hours, compartment syndromes may be missed in their initial stages unless careful surveillance of the patient's neurovascular status is carried out. Consequently, surgical release of the fascial compartments is performed in standard fashion and treated as for open burn areas.[123]

There are several specific exceptions, however, to the rule of copious water dilution for chemical injuries that deserve mention.

Phenol

Phenol was historically used as an antiseptic. Its use was limited by the occurrence of cutaneous irritation and systemic symptoms (phenol marasmus). Today, phenol has wide application in industrial substances, such as cleaning agents, cosmetics, plastics, and explosives.

Phenol is not water soluble, and specific therapy is required. Phenol should be removed from the skin with glycerol or polyethylene glycol.

Hydrofluoric Acid

Hydrofluoric acid is a common industrial chemical. It penetrates the skin, especially areas not protected by the stratum corneum such as the nail bed, and causes severe pain. Treatment consists of immediate water lavage followed by specific fluoride-binding therapies. Traditionally, magnesium sulfate solutions have been used with limited success. More recent therapies include subdermal injections around the lesions of 10% calcium gluconate.

Cement Burns

Cement burns are traditionally considered alkali burns because the lime (calcium oxide) component of cement has a pH as high as 12.9. There is usually no initial pain, so the injury remains unrecognized and untreated for hours. The final result is generally manifested as a full-thickness injury that is very slow to heal.

White Phosphorus

Phosphorus is highly fat soluble. Absorption of this chemical is enhanced by oils used topically and should be avoided. Therapy consists of water lavage followed by identification and excision of any remaining particles. A dilute solution of copper sulfate (0.05% to 1%) is helpful in identifying phosphorus particles (Table 57.1).

FROSTBITE INJURIES

Frostbite is an injury that results from exposure to temperatures that are low enough to cause crystal formation in the exposed tissue. There is risk for tissue exposed to temperatures below 2° C.[17,127] Frostbite can develop after exposure to these low temperatures for more than 1 hour.[64] This usually happens when protection from the environment is insufficient.[155] The severity of a frostbite depends on numerous factors besides the ambient temperature, such as wind velocity (wind chill factor), altitude, duration of exposure, wetness of the tissue, the patient's vascular status, and previous exposure to cold injury.[17]

TABLE 57.1 Common Chemical Agents and Their Characteristics in Causing Tissue Damage

Agent	Commercial Use	Characteristics of Damage	Treatment
Phenol	Cleaning agents, cosmetics, plastics	Protein denaturation, rapid absorption	Water irrigation, cover with oil, no alcohol
Phosphorus (white)	—	Highly fat soluble	Water irrigation, excision
Lyes	Cement, oven cleaners	Liquefaction necrosis, fulminant initial response, saponification of fats, dehydration of other cells	Water irrigation
Hydrofluoric acid	Rust removers	Painful, deep ulcerations below a tough coagulum	Local infiltration of calcium gluconates
Hydrochloric acid	Pool cleaners	Shallow ulcers form with a coagulated eschar and base	Water irrigation, magnesium oxide, soaps
Muriatic acid	Toilet bowl cleaners	Hard eschar with an indolent ulcer	Water irrigation
Sodium hypochloride	Bleach	Coagulation of proteins	Water irrigation

Adapted from Bentivegna PE, Deane LM: Chemical burns of the upper extremity. *Hand Clin* 6:253–259, 1990; and Reilly DA, Garner WL: Management of chemical injuries to the upper extremity. *Hand Clin* 16:215–224, 2000.

A variety of classification systems have been developed to describe frostbite injuries. Traditionally, cold injuries have been classified into four degrees[17,67,69,133]:

First degree (superficial skin): Erythema, edema, and hyperemia develop in the injured areas; blisters and tissue loss do not occur.

Second degree (full-thickness skin): Erythema, vesicle formation, and superficial skin sloughing occur; no deeper necrosis develops.

Third degree (full-thickness and subcutaneous tissue): Local edema and grayish blue discoloration occur and are followed by skin loss down to the subcutaneous level.

Fourth degree: Deep cyanosis without the development of vesiculation or local edema is observed. There is necrosis of the subcutis or deeper tissues down to muscle, tendon, and bone.

Currently, a more clinically useful classification system considers frostbite injuries as superficial or deep.[155] This classification system is useful because it has prognostic implications and defines frostbite through its fluctuating clinical course. Superficial frostbite results in minimal, if any, tissue loss. In contrast, deep frostbite injuries result in significant tissue loss.[133]

Outdoor winter activities such as downhill skiing, cross-country skiing, or other sporting activities[98] and mountaineering make cold injury a common clinical problem. Inadequate clothing or prolonged exposure because of alcohol abuse,[17] psychiatric disorders, or accidents[67] might lead to these injuries. The fingers, toes, nose, and ears are most commonly involved.

Pathophysiologic Findings

In cold-exposed areas, the blood becomes viscous and the circulation in the capillaries slows. Vessel damage leads to fluid extravasation and blistering. Thrombosis may occur in the terminal arterioles. Although cellular dehydration and enzymatic damage undoubtedly contribute to the necrosis of frozen tissue, peripheral circulatory failure may play the major role in determining the extent of the eventual tissue loss.[139,140] Venules clot with thrombi within the first 10 minutes after warming. Within 1 hour, most of the capillaries are thrombosed and blood flow is short-circuited from the arterial to the venous circulation via arteriovenous communications. Thus, while blood may continue to flow through the larger arterioles and venules, the tissues are not nourished.[139] Two different theories on the pathogenesis of frostbite are discussed:

1. Cold injury directly damages the tissue cells.[99]
2. Cold produces injury to the endothelial lining of small blood vessels with a consequent increase in capillary permeability, loss of fluid from the circulation, and intravascular cellular aggregation in the injured area. The clumping of red blood cells causes occlusion of small blood vessels with resulting tissue ischemia and necrosis.[163]

Diagnosis

Both the history and physical examination are important in assessing the depth and degree of frostbite injury. The severity is proportional to both the temperature and the duration of exposure and depends on the amount of heat lost from tissues.[133]

Various imaging techniques have been used in an attempt to more accurately predict the extent and severity of frostbite injury. Plain radiographs are of no value in determining the ultimate level of demarcation.[133] Technetium 99m bone scanning has become the standard imaging study used within the first several days to assess tissue perfusion and viability.[42] Such scans allow evaluation of the microcirculation of both soft tissue and bone.[133] Cauchy and colleagues found a strong correlation between positive uptake and eventual healing. They showed that technetium 99m bone scanning in the first few days after frostbite injury indicates the level of amputation in severe frostbite in more than 84% of cases.[20]

Barker and coworkers compared MRI and magnetic resonance angiography (MRA) with bone scanning for the evaluation of frostbite injuries.[6] MRI and MRA directly image occluded vessels and surrounding tissues. Both define the extent of tissue ischemia well before clinical signs of necrosis. T2-weighted images show increased signal intensity in muscles after the disruption of cell membranes, as well as an increased content of extracellular water, an indicator of cell death. The major disadvantage of MRI and MRA is their high cost in comparison with bone scans.[6]

Treatment

Management of acute frostbite is carried out in accordance with the guidelines popularized by Mills (Box 57.2).[99]

Early treatment includes a thorough assessment of the patient's general condition and stabilization of other disorders in a routine system of priorities. Normal body temperature is restored by provision of a warm environment and oral or intravenous administration of warm liquids.

Immediate local treatment consists of rewarming the frozen extremity in warm water (40°C to 44°C).[53,99] This emergency treatment is widely accepted as the single most important step in the salvage of tissue and limb function, followed by elevation and splinting of the extremity.[121] Tetanus prophylaxis and appropriate analgesia are given, and some consider antibiotic prophylaxis for the first several days.[17,133] Local treatment concepts of the affected areas vary. Some reports consider early débridement of all blisters to be adequate,[17] whereas other authors favor débridement of only ruptured blisters.[97]

No adjuvant intervention but hydrotherapy (daily for 30 to 45 minutes at 40°C) reliably improves revascularization of the affected tissues after cold injury.[53] Heparinization has been used to prevent intravascular thrombosis, but the results have been inconclusive.[97] Hyperbaric oxygen was successfully used in exemplary cases.[76,160] Pentoxifylline shows some beneficial effects in animal models[121] but has not become a generally accepted therapeutic agent. Inhibitors of prostaglandin synthesis and inhibitors of free radicals such as superoxide dismutase may be promising agents in the future.[17,67]

Surgical management leans toward the conservative. The principle of early excision and grafting is not applied to frostbite injuries because determination of tissue damage is extremely difficult and a high capacity for spontaneous healing under the eschar is frequently observed. During the first 9 to 15 days, seriously frostbitten skin forms a black, hard, leathery eschar.[133] Over time the eschar separates, with relatively healthy underlying skin frequently being revealed. Some patients will not heal and instead proceed to complete mummification within 3 to 6 weeks.[104,108] Once mummification of the involved extremity has taken place, reconstructive or ablative options are to be considered. Primary amputation of an affected digital part is often the most expeditious and least morbid method of restoring function to the remaining digit or hand.[155]

When more extensive upper extremity frostbite injuries are encountered, skin grafts, local rotation flaps, and staged pedicled grafts have been the mainstay of reconstructive techniques. With the advent of microsurgical tissue transfer, surgical options for reconstruction of the extremity, including restoration of grip function, have been significantly broadened. Although the functional results have improved by virtue of thin tissue transfer, aesthetic restoration still remains a challenge.[155]

BOX 57.2 Management of Acute Frostbite

- Restoration of core body heat
- Rapid rewarming of the frozen extremity in a water bath at 40°C to 44°C
- Sedation or analgesia, or both
- Triple-phase technetium 99m bone scan
- Tetanus prophylaxis
- Open dressing
- Oral ibuprofen
- Antibiotics for confirmed infections
- Physical therapy
- Amputation or surgical débridement only after clear demarcation

REHABILITATION

As in all hand surgery cases, planned rehabilitation with intensive physical and occupational therapy is an essential prerequisite for the best possible results. In general terms, active movement is encouraged from the earliest time after thermal injury. Immediately after contracture release, splinting is of the utmost importance. The joints can be immobilized in ideal positions (Figure 57.31), or a dynamic splint can be applied to encourage active motion after surgical corrections[78] (Figure 57.32). Psychological support is mandatory.[157]

The first few months after a burn are characterized by a period of scar hypertrophy.[111] Scars become thick, red, and tight, and they limit range of motion. The patient needs to overcome this tightness with active range-of-motion exercises of all joints every day. An important adjunct to scar management is custom-fitted elastic pressure garments. Linares and coworkers provided interesting details about the history of pressure treatment.[81,162] The first reference was written by Johnson in 1678, who himself referred to the work of Ambroise Paré from the 16th century. The first full description dates back to Petz in 1790. Nason observed in 1942 that the ischemia produced by pressure stops the formation of hypertrophic scarring. The ideal pressure for these garments ranges from 15 to 40 mm Hg.

Pressure therapy should be initiated as early as 2 weeks after grafting. The pressure garments should be worn 23 hours a day for the initial period of approximately 6 months for burns with a prolonged healing time or burns that have required skin grafting.[133,135] Subsequent pressure garment use is individualized depending on scar quality and response. The exact mechanism by which pressure garments alter scar formation is not yet clear[106,161]; however, they improve the quality of scars in terms of both texture and color in the long term (Figure 57.33). Special spacers may be placed in the web spaces to minimize the problem of compromised web spaces by burn scar contractures.[1]



FIGURE 57.31 Adjustable splint after release of an axillary contracture.

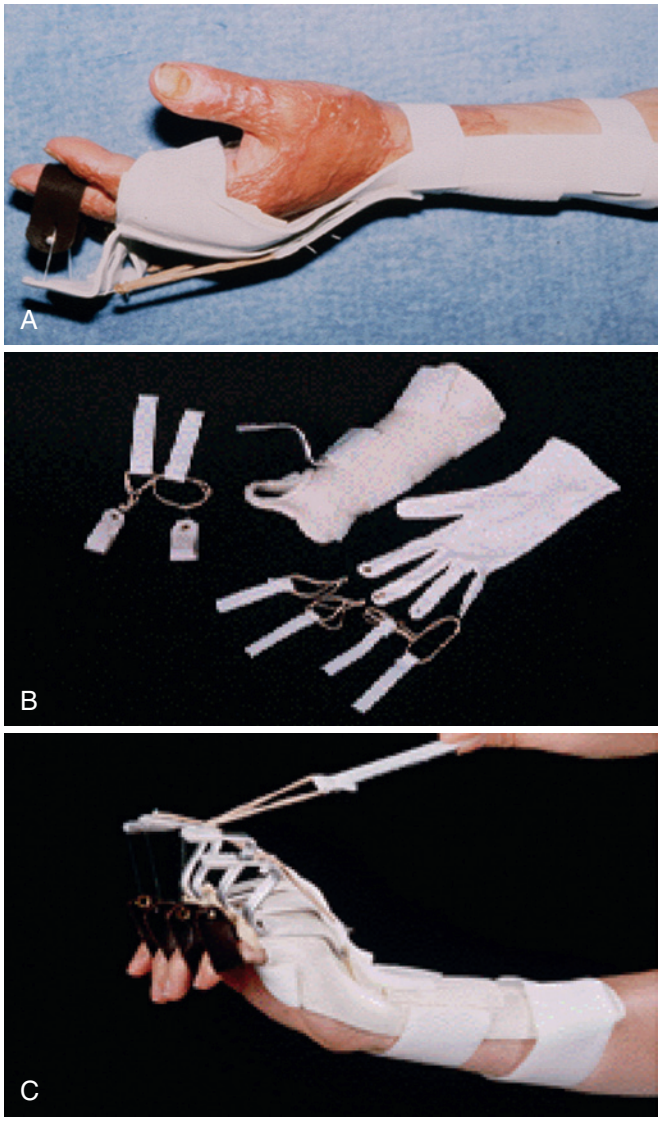

FIGURE 57.32 **A** to **C,** Active dynamic extension splint after release of the extensor tendons.



FIGURE 57.33 Custom-fitted pressure gloves after a skin graft.

Silicone sheets have proved to be useful on the dorsum of fingers and web spaces if placed under the pressure garment gloves. Coban wrapping is useful in controlling edema.[154] Hand therapy continues until function returns to normal or treatment is no longer demonstrating improvement. A maintenance hand therapy program should then be continued.[133,135]

CRITICAL POINTS *Hand Burns*

Management of Hand Burns
- Avoid any additional injury or an increase in the depth of burn (do no harm)
- Achieve early wound closure
- Maintain active and passive range of motion
- Prevent infection or loss of soft tissue coverage
- Start early functional rehabilitation

Basic Treatment Principles of Hand Burns
- Evaluation of size and depth
- Escharotomy if indicated
- Application of proper wound care and dressings
- Decision about operative or conservative treatment
- Initiation of early hand therapy, including splinting

Surgical Management
- Removal of eschar
- Meticulous hemostasis
- Transplantation of skin grafts
- Sheet grafts preferable
- Flap coverage if necessary
- Early postoperative physical therapy
- Functional rehabilitation

Causes of Skin Graft Loss
- Insufficient débridement with remaining nonviable layers of burned tissue
- Hematoma formation under the graft
- Imperfectly fitting tie-over dressing
- Secondary infection of the burn wound

Commonly Used Flaps
- Random abdominal wall flap
- Groin flap
- Anterior lateral thigh flap
- Free fascia flaps (serratus, temporoparietal fascia)
- Lateral arm flap
- Scapula flap

Expected Functional Outcome
- Satisfying aesthetic result
- Function that allows return to work or activities of daily living
- Stable coverage of joint surfaces
- Minimal development of residual contractures
- Low incidence of secondary corrections

REFERENCES

1. Achauer BM: *Management of the burned patient*, East Norwalk, CT, 1987, Appleton & Lange.
2. Acikel C, Peker F, Yuksel F, et al: Bilateral side finger transposition flaps in the treatment of chronic postburn flexion contractures of the fingers. *Ann Plast Surg* 49:344–349, 2002.
3. Agir H, Sen C, Alagoz S, et al: Distally based posterior interosseous flap: primary role in soft-tissue reconstruction of the hand. *Ann Plast Surg* 59:291–296, 2007.
4. Arturson G, Hedlund A: Primary treatment of 50 patients with high-tension electrical injuries. I. Fluid resuscitation. *Scand J Plast Reconstr Surg* 18:111–118, 1984.

5. Barillo D, Arabitg R, Cancio L, et al: Distant pedicle flaps for soft tissue coverage of severely burned hands: an old idea revisited. *Burns* 27:613–619, 2001.
6. Barker JR, Haws MJ, Brown RE, et al: Magnetic resonance imaging of severe frostbite injuries. *Ann Plast Surg* 38:275–279, 1997.
7. Baruchin AM, Scharf S, Baruchin O, et al: Resurfacing of fingertip following deep burns: the hypothenar skin graft. *Burns* 31:243–244, 2005.
8. Baryza MJ, Baryza GA: The Vancouver Scar Scale: an administration tool and its interrater reliability. *J Burn Care Rehabil* 16:535–538, 1995.
9. Bhattacharya S: Avoiding unfavorable results in postburn contracture hand. *Indian J Plast Surg* 46:434–444, 2013.
10. Bauer BS, Vicari F, Richard ME, et al: Expanded full-thickness skin grafts in children: case selection, planning, and management. *Plast Reconstr Surg* 92:59–69, 1993.
11. Baumeister S, Germann G, Giessler G, et al: Reconstruction of burned extremities by free flap transplantation. *Chirurg* 75:568–578, 2004.
12. Beasley RW: Secondary repair of burned hands. *Clin Plast Surg* 8:141–148, 1981.
13. Belliappa PP, McCabe SJ: The burned hand. *Hand Clin* 9:313–324, 1993.
14. Benmeir P, Lusthaus S, Ad-El D, et al: Very deep burns of the hand due to low voltage electrical laboratory equipment: a potential hazard for scientists. *Burns* 19:450–451, 1993.
15. Bentivegna PE, Deane LM: Chemical burns of the upper extremity. *Hand Clin* 6:253–259, 1990.
16. Bhattacharya S, Bhatnagar SK, Pandey SD, et al: Management of burn contractures of the first web space of the hand. *Burns* 18:54–57, 1992.
17. Britt LD, Dascombe WH, Rodriguez A: New horizons in management of hypothermia and frostbite injury. *Surg Clin North Am* 71:345–370, 1991.
18. Bunyan AR, Mathur BS: Medium thickness plantar skin graft for the management of digital and palmar flexion contractures. *Burns* 26:575–580, 2000.
19. Burm JS, Oh SJ: Fist position for skin grafting on the dorsal hand: II. Clinical use in deep burns and burn scar contractures. *Plast Reconstr Surg* 105:581–588, 2000.
20. Cauchy E, Marsigny B, Allamel G, et al: The value of technetium 99 scintigraphy in the prognosis of amputation in severe frostbite injuries of the extremities: a retrospective study of 92 severe frostbite injuries. *J Hand Surg [Am]* 25:969–978, 2000.
21. Chen SG, Tzeng YS, Wang CH: Treatment of severe burn with Dermacell®, an acellular dermal matrix. *Int J Burns Trauma* 2:105–109, 2012.
22. Chick L, Lister GD, Sowder L: Early free flap coverage of electrical and thermal burns. *Plast Reconstr Surg* 89:1013–1021, 1992.
23. Chow T, Bilos Z, Hui P, et al: The groin flap in reparative surgery of the hand. *Plast Reconstr Surg* 77:421–425, 1986.
24. Chuang D, Jeng S, Chen H, et al: Experience of 73 free groin flaps. *Br J Plast Surg* 45:81–85, 1992.
25. Curreri PW, Asch MJ, Pruitt BA: The treatment of chemical burns: specialized diagnostic, therapeutic, and prognostic considerations. *J Trauma* 10:634–642, 1970.
26. Daniel R, Taylor G: Distant transfer of an island flap by microvascular anastomoses. *Plast Reconstr Surg* 52:111–122, 1973.
27. Danielson JR, Capelli-Schellpfeffer M, Lee RC: Upper extremity electrical injury. *Hand Clin* 16:225–234, 2000.
28. Danin A, Georgescu G, Touze AL, et al: Assessment of burned hands reconstructed with Integra® by ultrasonography and elastometry. *Burns* 38:998–1004, 2012.
29. Dantzer E, Queruel P, Salinier L, et al: Integra, a new surgical alternative for the treatment of massive burns. Clinical evaluation of acute and reconstructive surgery: 39 cases. *Ann Chir Plast Esthet* 46:173–189, 2001.
30. Davidson DC: Treatment of acid and alkali burns: an experimental study. *Ann Surg* 85:481–489, 1927.
31. Demir E, Rahnama R, Gazyakan E, et al: Burned palm reconstruction. Current concepts regarding grafting techniques, sensibility and hand function. *Chirurg* 77:367–375, 2006.
32. Dobbs ER, Curreri PW: Burns: analysis of result of physical therapy in 681 patients. *J Trauma* 12:242–248, 1972.
33. Eski M, Nisanci M, Sengezer M: Correction of thumb deformities after burn: versatility of first dorsal metacarpal artery flap. *Burns* 33:65–71, 2007.
34. Evans EB: Heterotopic bone formation in thermal burns. *Clin Orthop Relat Res* 263:94–101, 1991.
35. Fassio E, Laulan J, Aboumoussa J, et al: Serratus anterior free fascial flap for dorsal hand coverage. *Ann Plast Surg* 43:77–82, 1999.
36. Flugel A, Heitmann C, Kehrer A, et al: Defect coverage of the hand with the free serratus fascial flap. *Handchir Mikrochir Plast Chir* 37:186–192, 2005.
37. Garcia-Sanchez V, Gomez Morell P: Electric burns: high and low tension injuries. *Burns* 25:357–360, 1998.
38. Giessler GA, Erdmann D, Germann G: Soft tissue coverage in devastating hand injuries. *Hand Clin* 19:63–71, 2003.
39. Gümüs N, Yilmaz S: Management of scar contractures using Z advancement rotation flap. *Burns* 38:988–994, 2012.
40. Grabb WC: Basic techniques of plastic surgery. In Grabb WC, Smith JW, editors: *Plastic surgery*, ed 3, Boston, 1979, Little Brown.
41. Graf P, Biemer E: Morbidity of the groin flap transfer: are we getting something for nothing? *Br J Plast Surg* 45:86–88, 1992.
42. Greenwald D, Cooper B, Gottlieb LL: An algorithm for early aggressive treatment of frostbite with limb salvage directed by triple-phase scanning. *Plast Reconstr Surg* 102:1069–1074, 1998.
43. Grishkevich V: Surgical treatment of postburn boutonniere deformity. *Plast Reconstr Surg* 97:126–132, 1996.
44. Grobbelaar AO, Harrison DH: The distally based ulnar artery island flap in hand reconstruction. *J Hand Surg [Br]* 22:204–211, 1997.
45. Groenevelt F, Schoorl R: Reconstructive surgery of the post-burn boutonnière deformity. *J Hand Surg [Br]* 11:23–30, 1986.
46. Grotting J, Walkinshaw M: The early use of free flaps in burns. *Ann Plast Surg* 15:127–131, 1985.
47. Gulgonen A, Ozer K: The correction of postburn contractures of the second through fourth web spaces. *J Hand Surg [Am]* 32:556–564, 2007.
48. Hanumadass M, Kagan R, Matsuda T: Early coverage of deep hand burns with groin flaps. *J Trauma* 27:109–114, 1987.
49. Harii K, Ohmori K, Torii S, et al: Free groin skin flaps. *Br J Plast Surg* 28:225–237, 1975.
50. Harrison DH, Parkhouse N: Experience with upper extremity burns. The Mount Vermont experience. *Hand Clin* 6:191–209, 1990.
51. Haslik W, Kamolz LP, Nathschlager G, et al: First experiences with the collagen-elastin matrix Matriderm as a dermal substitute in severe burn injuries of the hand. *Burns* 33:364–368, 2007.
52. Heggers JP, Ko F, Robson MC, et al: Evaluation of burn blister fluid. *Plast Reconstr Surg* 65:798–804, 1989.
53. Heggers JP, McCauley RL, Phillips LG, et al: Cold-induced injury: frostbite. In Herndon DN, editor: *Total burn care*, London, 1996, WB Saunders, pp 408–414.
54. Hentz VR: Burns of the hand: thermal, chemical, and electrical. *Emerg Med Clin North Am* 3:391–403, 1985.
55. Herruzo-Cabrera R, Garcia-Torres V, Rey-Calero J, et al: Evaluation of the penetration strength, bactericidal efficacy and spectrum of action of several antimicrobial creams against isolated microorganisms in a burn centre. *Burns* 18:39–44, 1992.
56. Hop MJ, Moues CM, Bogomolova K, et al: Photographic assessment of burn size and depth: reliability and validity. *J Wound Care* 144:148–152, 2014.
57. Hunt JT, Mason AD, Masterson TS, et al: The pathophysiology of acute electric injuries. *J Trauma* 16:335–340, 1976.
58. Isik S, Er E, Uygur F, et al: Repair of thumb abduction contracture by microsurgical transfer of partial toe. *Burns* 28:486–489, 2002.
59. Iwuagwu FC, Wilson D, Bailie F: The use of skin grafts in postburn contracture release: a 10 year review. *Plast Reconstr Surg* 103:1198–1204, 1999.
60. Jackson DM: The diagnosis for the depth of burning. *Br J Surg* 40:588–596, 1953.
61. Jenkins AM, Pegg SP: Island flaps in the primary reconstruction of electrical burns. *Burns* 13:236–240, 1987.
62. Jex-Blake AJ: Death by electric currents and by lightning. *Br Med J* 1:425–430, 1913.
63. Johnson TM, Ratner D, Nelson BR: Soft tissue reconstruction with skin grafting. *J Am Acad Dermatol* 27:151–165, 1992.
64. Kaine EC, Fidler P, Schulz J, et al: "Roll-bar" for protective posture splint limits potential trauma to dorsal hand grafts. *J Burn Care Res* 29:204–207, 2008.
65. Kamolz LP, Andel H, Haslik W, et al: Use of subatmospheric pressure therapy to prevent burn wound progression in human: first experiences. *Burns* 30:253–258, 2004.
66. Kimura N: A microdissected thin tensor fasciae latae perforator flap. *Plast Reconstr Surg* 109:69–77, 2002.
67. Kiris T, Gorgulu A, Unal F, et al: Superoxide dismutase activity and the effect of *N*-methyl-aspartate antagonists on lipid peroxidation in the early phase of cold injury. *Res Exp Med* 198:341–347, 1999.
68. Knize DM: Cold injury. In McCarthy JG, editor: *Reconstructive plastic surgery*, Philadelphia, 1977, WB Saunders, pp 516–530.
69. Knize DM, Weatherly-White RCA, Paton BC, et al: Prognostic factors in the management of frostbite. *J Trauma* 9:749–759, 1969.
70. Kok K, Georgeu GA, Wilson VY: The Acticoat glove: an effective dressing for the completely burnt hand: how we do it. *Burns* 32:487–489, 2006.
71. Kraemer MD, Jones T, Deitch EA: Burn contractures: incidence, predisposing factors and results of surgical therapy. *J Burn Care Rehabil* 9:261–265, 1988.
72. Kumar P, Chirayl PT: Helium vapour injury: a case report. *Burns* 25:265–268, 1999.
73. Kurtzman LC, Stern PJ: Upper extremity burn contractures. *Hand Clin* 6:261–279, 1990.
74. Kurtzman LC, Stern PJ, Yakuboff KP: Reconstruction of the burned thumb. *Hand Clin* 8:107–119, 1992.
75. Larson DL, Wolfold BH, Evans EB, et al: Repair of the boutonniere deformity of the burned hand. *J Trauma* 10:481–487, 1970.

76. Ledingham I: Some clinical and experimental applications of high pressure oxygen. *Proc R Soc Med* 56:999–1002, 1963.
77. Lee RC, Kolodney MS: Electrical injury mechanisms: dynamics of the thermal response. *Plast Reconstr Surg* 80:663–671, 1987.
78. Leman CJ: Splints and accessories following burn reconstruction. *Clin Plast Surg* 19:721–731, 1992.
79. Le Worthy GW: Sole skin as a donor site to replace palmar skin. *Plast Reconstr Surg* 32:30–38, 1963.
80. Li Y, Wang J, Lu Y, et al: Resurfacing deep wound of upper extremities with pedicled groin flaps. *Burns* 26:283–288, 2000.
81. Linares HA, Larson DL, Willis-Galstaun BA: Historical notes on the use of pressure in the treatment of hypertrophic scars or keloids. *Burns* 19:17–21, 1993.
82. Lionelli GT, Lawrence WT: Wound dressings. *Surg Clin North Am* 83:617–638, 2003.
83. Lister G: The choice of procedure following thumb amputation. *Clin Orthop Relat Res* 195:45–58, 1985.
84. Littler JW: The neurovascular pedicle method of digital transposition for reconstruction of the thumb. *Plast Reconstr Surg* 12:303–319, 1953.
85. Logsetty S, Heimbach DM: Modern techniques for wound coverage of the thermally injured upper extremity. *Hand Clin* 16:205–214, 2000.
86. Luce EA: Electrical burns. *Clin Plast Surg* 27:133–143, 2000.
87. Luce EA, Gottlieb SE: "True" high-tension electrical injuries. *Ann Plast Surg* 12:321–326, 1984.
88. Lund T, Onarheim H, Reed RK: Pathogenesis of edema formation in burn injuries. *World J Surg* 16:2–9, 1992.
89. MacMillan BG: The use of mesh grafting in treating burns. *Surg Clin North Am* 50:1347–1359, 1970.
90. Mancoll JS, Mlakar JM, McCauley RL, et al: Burn web space contractures: are they just a bad penny? *Proc Am Burn Assoc* 28:111, 1996.
91. Mast B, Newton E: Aggressive use of free flaps in children for burn scar contractures and other soft-tissue deficits. *Ann Plast Surg* 36:569–575, 1996.
92. Mathes S, Nahai F: *Clinical atlas of muscle and musculocutaneous flaps*, St. Louis, 1979, Mosby.
93. McCauley RL: Reconstruction of the pediatric burned hand. *Hand Clin* 16:249–259, 2000.
94. McCraw JB, Arnold PG: *McCraw and Arnold's atlas of muscle and musculocutaneous flaps*, Norfolk, VA, 1986, Hampton Press.
95. McGregor IA: *Fundamental techniques of plastic surgery and their surgical applications*, ed 8, Edinburgh, 1989, Churchill Livingstone, pp 39–63.
96. McGregor IA, Jackson IT: The groin flap. *Br J Plast Surg* 25:3–16, 1972.
97. Meryman TH: Tissue freezing and local cold injury. *Physiol Rev* 37:233–251, 1957.
98. Millard DR: The crane principle for the transport of subcutaneous tissue. *Plast Reconstr Surg* 43:451–462, 1969.
99. Mills WJ, Jr: Frostbite: a method of management including rapid thawing. *Northwest Med* 65:119–125, 1966.
100. Milner CS: Thirkannad S: Resurfacing glabrous skin defects in the hand: the thenar base donor site. *Tech Hand Up Extrem Surg* 18(2):89–91, 2014.
101. Molnar JA, Simpson JL, Voignier DM, et al: Management of an acute thermal injury with subatmospheric pressure. *J Burns Wounds* 4:e5, 2005.
102. Murray JF: Cold, chemical, and irradiation injuries. In McCarthy JG, editor: *Plastic surgery*, Philadelphia, 1990, WB Saunders, pp 5431–5436.
103. Nakamura K, Namba K, Tsuchida H: A retrospective study of split-thickness plantar skin grafts to resurface the palm. *Ann Plast Surg* 12:508–513, 1984.
104. Nissen ER, Melchert PJ, Lewis EJ: A case of bullous frostbite following recreational snow-mobiling. *Cutis* 63:21–23, 1999.
105. Nissen NN, Gamelli RL, Polverini PJ, et al: Differential angiogenic and proliferative activity of surgical and burn wound fluids. *J Trauma* 54:1205–1211, 2003.
106. O'Brien KA, Weinstock-Zlotnick G, Hunter H, et al: Comparison of positive pressure gloves on hand function in adults with burns. *J Burn Care Rest* 27:339–344, 2006.
107. Ono I, Gunji H, Zhang JZ, et al: A study of cytokines in burn blister fluid related to wound healing. *Burns* 21:352–355, 1995.
108. Orr KD, Fainer DC: Cold injuries in Korea during winter 1949-1951. *Medicine (Baltimore)* 31:177–220, 1952.
109. Osti E: Cutaneous burns treated with hydrogel (Burnshield) and a semipermeable adhesive film. *Arch Surg* 141:39–42, 2006.
110. Pan CH, Chuang SS, Yang JY: Thirty-eight free fasciocutaneous flap transfers in acute burned-hand injuries. *Burns* 33:230–235, 2007.
111. Parry SW: Reconstruction of the burned hand. *Clin Plast Surg* 16:577–586, 1989.
112. Pegg SP: Escharotomy in burns. *Ann Acad Med Singapore* 21:682–684, 1992.
113. Pegg SP, Gregory JJ, Hogan PG, et al: Epidemiological pattern of adult burn injuries. *Burns* 5:326–334, 1979.
114. Pensler JM, Steward R, Lewis SR, et al: Reconstruction of the burned palm: full-thickness versus split-thickness skin grafts: long term follow up. *Plast Reconstr Surg* 81:46–49, 1988.
115. Pham TN, Hanley C, Palmieri T, et al: Results of early excision and full-thickness grafting of deep palm burns in children. *J Burn Care Rehabil* 22:54–57, 2001.
116. Piccolo NS, Piccolo MS, Piccolo PD, et al: Escharotomies, fasciotomies and carpal tunnel release in burn patients: review of the literature and presentation of an algorithm for surgical decision making. *Handchir Mikrochir Plast Chir* 39:161–167, 2007.
117. Pradier JP, Oberlin C, Bey E: Acute deep hand burns covered by a pocket flap-graft: long-term outcome based on nine cases. *J Burns Wounds* 6:e1, 2007.
118. Prakash V, Mishra LK, Mantri R: Management of deep palmar burns with reverse prefabricated radial fascial flaps. *Plast Reconstr Surg* 115:1220–1221, 2005.
119. Prasad JK, Bowden ML, Thomson PD: A review of the reconstructive surgery needs of 3167 survivors of burn injury. *Burns* 17:302–305, 1991.
120. Pruitt BA, Jr, Dowling JA, Moncrief JA: Escharotomy in early burn care. *Arch Surg* 96:502–507, 1968.
121. Purkayastha SS, Roy A, Chauhan SK, et al: Efficacy of pentoxifylline with aspirin in the treatment of frostbite in rats. *Indian J Med Res* 107:239–245, 1998.
122. Raine TJ, Heggers JP, Robson MC, et al: Cooling the burn wound to maintain microcirculation. *J Trauma* 21:394–397, 1981.
123. Reilly DA, Garner WL: Management of chemical injuries to the upper extremity. *Hand Clin* 16:215–224, 2000.
124. Richards AM, Klaassen MF: Heterotopic ossification after severe burns: a report of three cases and review of the literature. *Burns* 23:64–68, 1997.
125. Robson MC, Del Beccaro EJ, Heggers JP: The effect of prostaglandins on the dermal microcirculation after burning, and the inhibition of the effect by specific pharmacological agents. *Plast Reconstr Surg* 63:781–787, 1979.
126. Robson MC, Murphy RC, Heggers JP: A new explanation for the progressive tissue loss in electrical injuries. *Plast Reconstr Surg* 73:431–437, 1984.
127. Robson MC, Smith DJ: Cold injuries. In McCarthy JG, editor: *Plastic surgery*, Philadelphia, 1990, WB Saunders, pp 849–866.
128. Salisbury RE: Reconstruction of the burned hand. *Clin Plast Surg* 27:65–69, 2000.
129. Salisbury RE, Bevin AG: Boutonniere deformity. In *Atlas of reconstructive burn surgery*, Philadelphia, 1981, WB Saunders, pp 164–167.
130. Salisbury RE, Levine NS: The early management of upper extremity thermal injury. In Salisbury RE, Pruitt B, editors: *Burns of the upper extremity*, Philadelphia, 1976, WB Saunders, pp 36–46.
131. Sauerbier M, Ofer N, Germann G, et al: Microvascular reconstruction in burn and electrical burn injuries of the severely traumatized upper extremity. *Plast Reconstr Surg* 119:605–615, 2007.
132. Schlenker J, Averill R: The illiofemoral (groin) flap for hand and forearm coverage. *Orthop Rev* 9:57–61, 1980.
133. Sheridan RL, Hurly J, Smith MA, et al: The acutely burned hand: management and outcome based on a ten-year experience with 1047 acute hand burns. *J Trauma* 8:406–411, 1995.
134. Silverberg B, Banis JC, Verdi GD, et al: Microvascular reconstruction after electrical injury. *J Trauma* 26:128–133, 1986.
135. Smith MA, Munster AM, Spence RJ: Burns of the hand and the upper limb: a review. *Burns* 24:493–505, 1998.
136. Souter WA: The problem of boutonniere deformity. *Clin Orthop Relat Res* 104:116–133, 1974.
137. Stern PJ, Neale HW, Carter W, et al: Classification and management of burned thumb contractures in children. *Burns* 11:168–174, 1985.
138. Strauch B, Vasconez L, Hall-Findley E, editors: *Grabb's encyclopedia of flaps* (vol II), Upper extremities, Boston, 1990, Little Brown.
139. Su CW, Lohman R, Gottlieb LJ: Frostbite of the upper extremity. *Hand Clin* 16:235–247, 2000.
140. Sumner DS, Simmonds RC, La Munyon TK, et al: Peripheral blood flow in experimental frostbite. *Ann Surg* 171:116–123, 1970.
141. Sungur N, Ulusoy MG, Boyacgil S, et al: Kirschner-wire fixation for postburn flexion contracture deformity and consequences on articular surface. *Ann Plast Surg* 56:128–132, 2006.
142. Tambuscio A, Governa M, Caputo G, et al: Deep burn of the hands: early surgical treatment avoids the need for late revisions? *Burns* 32:1000–1004, 2006.
143. Tan O, Atik B, Dogan A, et al: Postoperative dynamic extension splinting compared with fixation with Kirschner wires and static splinting in contractures of burned hands: a comparative study of 57 cases in 9 years. *Scand J Plast Reconstr Surg Hand Surg* 41:197–202, 2007.
144. Tan O, Atik B, Ergen D: A new method in the treatment of postburn scar contractures: double opposing V-Y-Z plasty. *Burns* 32:499–503, 2006.
145. Tan O, Ergen D, Bayindir O: Winged groin flap for web space reconstruction. *Burns* 32:660–661, 2006.
146. Tanabe H, Aoyagi A, Tai Y, et al: Reconstruction for plantar skin defects of the digits and using plantar dermal grafting. *Plast Reconstr Surg* 101:992–998, 1998.
147. Tanaka A, Hatoko M, Tada H, et al: An evaluation of functional improvement following surgical corrections of severe burn scar contracture in the axilla. *Burns* 29:153–157, 2003.

148. Tilley W, McMahon S, Shukalak B: Rehabilitation of the burned upper extremity. *Hand Clin* 16:303–318, 2000.
149. Tourabi K, Moussaoui A, Ribaq Y, et al: Utility of the hypogastric flap in the treatment of burns to the dorsum of the hand. *Ann Burns Fire Disasters* 30:144–145, 2010.
150. Tropea BI, Lee RC: Thermal injury kinetics in electrical trauma. *J Biomech Eng* 114:241–250, 1992.
151. Uhlig C, Rapp M, Dittel KK: New strategies for the treatment of thermally injured hands with regard to the epithelial substitute Suprathel. *Handchir Mikrochir Plast Chir* 39:314–319, 2007.
152. Ulkur E, Uygur F, Karagoz H, et al: Use of free dorsoulnar perforator flap in the treatment of postburn contractures of the fingers. *Burns* 32:770–775, 2006.
153. Valauri FA, Buncke HJ: Thumb reconstruction: great toe transfer. *Clin Plast Surg* 16:475–489, 1989.
154. Vimont AB, Rich WB: *Edison Electrical Institute Safety and Industrial Health Committee summary report: Nonfatal contact electric shock and burn accidents*, Washington, DC, 1977, Edison Electric Institute.
155. Vogel JE, Dellon AL: Frostbite injuries of the hand. *Clin Plast Surg* 16:565–576, 1989.
156. Wallace AF: *The progress of plastic surgery: an introductory history*, Oxford, 1982, Willem A. Meeuws, pp 133–141.
157. Wallis H, Renneberg B, Ripper S, et al: Emotional distress and psychosocial resources in patients recovering from severe burn injury. *J Burn Care Res* 27:734–741, 2006.
158. Wang XW, Sang HH, Davies JW, et al: Role of escharotomy and fasciotomy as a first aid measure in the early treatment of an electrically burned arm and wrist. *Burns* 11:419–422, 1985.
159. Ward JW, Penler JM, Parry SW: Pollicization for thumb reconstruction in severe pediatric hand burns. *Plast Reconstr Surg* 76:927–932, 1985.
160. Ward MP, Garnham JR, Simpson BRJ, et al: Frostbite: general observations and report of cases treated by hyperbaric oxygen. *Proc R Soc Med* 61:787–789, 1968.
161. Ward RS: Pressure therapy for the control of hypertrophic scar formation after burn injury. A history and review. *J Burn Care Rehabil* 12:257–262, 1991.
162. Waxman K, Lefcourt N, Achauer B: Heated laser Doppler flow measurements to determine depth of burn injury. *Am J Surg* 157:541–543, 1989.
163. Weatherly-White RCA, Sjostrom B, Paton BC: Experimental studies in cold injury. II. The pathogenesis of frostbite. *J Surg Res* 4:17–22, 1964.
164. Webster JP: Skin grafts for hairless areas of the hands and feet. *Plast Reconstr Surg* 15:83–101, 1955.
165. Windhofer C, Gruber S, Hofer E, et al: Free flap survival despite severe anemia after fourth degree hand burn. *Burns* 32:261–265, 2006.
166. Wong L, Spence RJ: Escharotomy and fasciotomy of the burned upper extremity. *Hand Clin* 16:165–174, 2000.
167. Xue-Wei W, Jia-Ning W, Yung-Hua S, et al: Early vascular grafting to prevent upper extremity necrosis after electrical burns. *Burns* 8:303–312, 1981.
168. Zachary LM, Lee RC, Gottlieb LJ: Evolving clinical and scientific concepts of upper extremity electrical trauma. *Hand Clin* 6:243–252, 1990.
169. Zelt RG, Daniel RK, Ballard PA, et al: High-voltage electrical injury: chronic wound evolution. *Plast Reconstr Surg* 82:1027–1041, 1988.
170. Zhu S, Lu S, Chen J: Free inguinal skin flap transfer: report of 19 cases. *Chin J Surg* 17:163–166, 1979.
171. Zoltie N, Verlende P, Logan A: Full thickness grafts taken from the plantar instep for syndactyly release. *J Hand Surg [Br]* 14:202–203, 1989.

58

Skin Tumors of the Hand and Upper Extremity

David T. Netscher

ANATOMY AND CLINICAL EXAMINATION

Skin is made up of the epidermis, dermis, and subcutaneous layers (Figure 58.1). The epidermis possesses the following appendages:[7,8]

- Eccrine glands
- Apocrine glands
- Sebaceous glands
- Hair follicles
- Nails***

Glands and hair follicles arise as "down growths" from the epidermis and project into the dermis. The two types of sweat glands are the eccrine and apocrine. Eccrine glands exist all over the skin. They start as a coil in the dermis and open onto the skin's surface and secrete clear, watery fluid. The apocrine glands are large sweat glands that open into hair follicles, to which they are attached, but rarely directly, to the skin's surface. They are also coiled tubular glands found mainly in the axilla that do not develop fully until puberty. Secretion is evoked in response to stress, pain, and fright. Sebaceous glands are found all over the body, except the palms and soles of the feet. They have no lumen, are multilobulated, appearing as a pouch hanging on the side of the hair follicle, and secrete a fatty sebum.

The dermis is divided into two parts: (1) papillary and (2) reticular. The papillary dermis lies up against the epidermis, and papillae project up into it so that the alternating areas of epidermis, which drop down into it, are called "rete pegs." It is these pegs that help resist shear disruption between the dermal and epidermal layers. The reticular dermis is deeper, made of coarser bundles of connective tissue fibers, and extends to the subcutaneous layer; it contains:

- Connective tissue fibers—collagen, elastin, and reticulin
- Cellular elements—migratory cells (leukocytes, histiocytes) and fixed cells (fibroblasts, mast)
- Blood vessels
- Nerves and specialized nerve endings
- Smooth muscle
- Lymphatics
- Ground substance

The epidermis is superficial to the basal lamina and is comprised histologically of four cell layers (five layers in the palm) (Figure 58.2), as follows:

1. The basal layer (stratum basale) consists of a single layer of columnar cells that stain deeply basophilic. At haphazard intervals between these basal cells are melanocytes—clear cells with small nuclei. Melanin is produced through the conversion of tyrosine to dopa, facilitated by the enzyme tyrosinase. Melanocytes can multiply and form nests in the deep epidermis and even spread into the subadjacent dermis, where they lose the ability to synthesize melanin but retain the melanin-storing property and remain pigmented. These intradermal clusters are called "nevus cells" and give the appearance of nevi. Melanocytes are actually dendritic cells that connect to each other over distances. They are derived from the neural crest. Merkel cells, like melanocytes, are nonkeratinocyte intraepidermal cells. They also occur in the basal cell layer and are associated with sensory axons for slow-adapting mechanoreceptors and pressure sensors. They are found in hair follicles as well.
2. The malpighian (or prickle cell) layer (i.e., stratum spinosum) is made up of cells connected to each other by intracellular bridges, so artifactually (during tissue processing) give the spiny, or prickle, appearance of this layer.
3. The granular layer (stratum granulosum) is made up of a few layers of diamond-shaped cells filled with basophilic granules (keratohyalin).
4. The horny layer (stratum corneum) has cells with no nuclei, and they are continuously shed from the surface.
5. In the palm only, the clear layer (stratum lucidum) gives a translucent appearance to the skin. It is composed of up to five layers of "dead" keratinocytes; this layer is situated between the stratum granulosum and the stratum corneum. Cells are filled with eleidin, an intermediate form of keratin.

There is a normal progression of maturation from deep to superficial layers of the epidermis.

In epidermal cancers, this natural progressive maturation is lost and becomes disorderly and finally totally anaplastic.[27,54] The relative invasiveness of such cancers is also seen first by invasion deep into the basement membrane, then by depth of invasion, next entering the papillary dermis, and on into the deeper reticular dermis. Thus, carcinoma in situ is a true cancer that is disorganized in its progressive epidermal cell maturation but nonetheless has not invaded through the basement membrane of the dermis.

Originally, Clark's levels were applied descriptively to the depth of melanoma invasion into the papillary dermis, reticular dermis, and on into subcutaneous sites. However, Breslow's levels of actual millimeter thickness of invasion have been found to be more accurate prognostically.[54] In the subungual regions, rete pegs and papillary dermis are less well defined, and

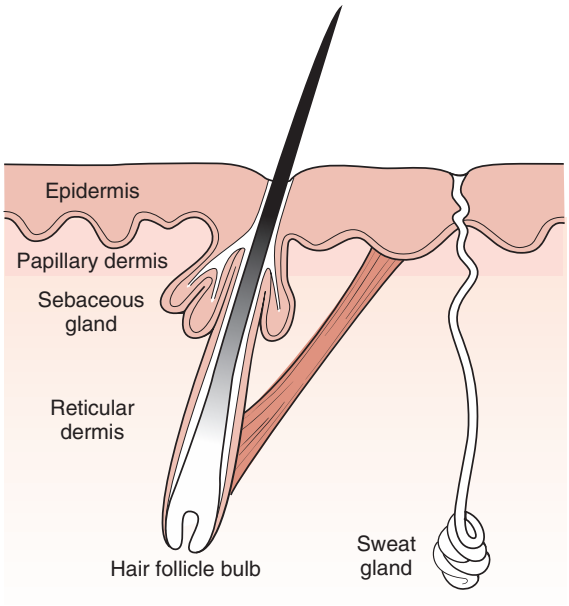

BENIGN	MALIGNANT	
Verrucae	Bowen squamous cell carcinoma	Epidermal
Seborrheic keratosis	Basal cell carcinoma Merkel	Epidermal
Actinic keratosis		Epidermal
Lentigines	Melanoma	Epidermal
Nevus		Epidermal
Inclusion and keratinous cysts		Dermal
Dermatofibroma		Dermal
Eccrine poroma	Sweat gland cancers	Dermal
	Sarcoma	Dermal

FIGURE 58.1 Layers of skin that include adnexal structures and the origin of benign and malignant tumors.

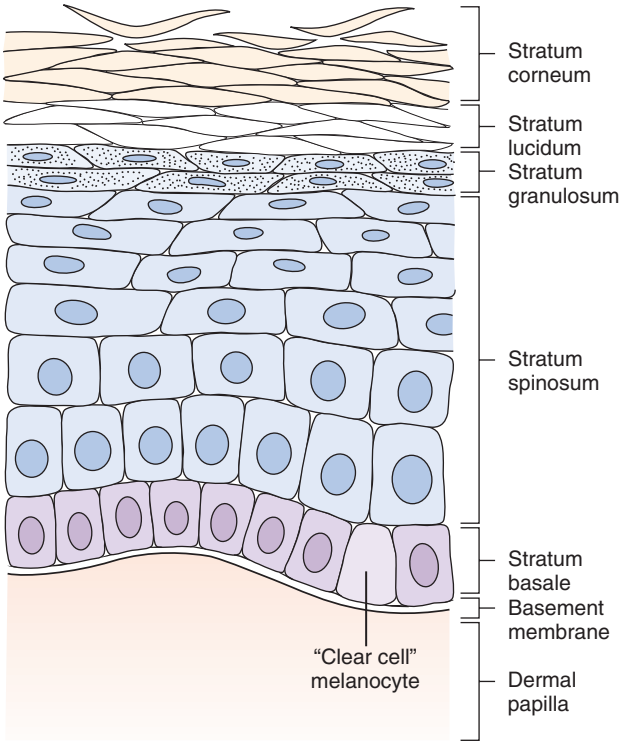

FIGURE 58.2 Cellular layers of the epidermis.

there is also no subcutaneous fat, which means that the distance of tumor penetration between epidermis and periosteum is very small. In this region especially, the Clark and Breslow measurements cannot be used as an effective treatment guide.[54]

Benign and malignant skin tumors thus may arise from epithelial elements (in which case malignancies are termed *carcinoma*) of the epidermis, as well as from the adnexae in the dermis (i.e., hair follicles and sweat glands) (see Figure 58.1). Basal cell carcinoma (BCC) is derived from the basal cell layer of the epidermis and squamous cell carcinoma (SCC) comes from the more superficial keratinocytes.

Epithelial cysts within the dermis may be a result of implantation into the dermis (epidermal inclusion cyst), from blocked gland ducts (pilosebaceous cysts), and/or from hair follicles (trichilemmal cysts). Connective tissue tumors (malignant forms are termed *sarcomas*) may arise from the fibrous tissue of the dermis, such as dermatofibromas and the rarer dermatofibrosarcoma protuberans. Nerve-ending tumors and those relative to blood vessels also occur in the dermis (e.g., neurofibroma, glomus, Merkel cell). Hemangiomas and capillary stains and vascular malformations are discussed elsewhere in this book.

Having an understanding of skin anatomy and tumor location is helpful in arriving at a clinical diagnosis.[46] Intraepidermal lesions may be plaquelike but are not elevated into papules or nodules (the hallmark of intradermal lesions). Junctional (between dermis and epidermis) lesions are also not elevated, as is the case with a junctional nevus—a flat pigmented lesion. Dermatofibromas and the more vertically invasive nodular melanomas, in contrast, are elevated into a nodule. Melanomas are pigmented (though not always) because their cell of origin is the melanocyte, which produces melanin. However, melanocytes also do pass melanin into adjacent basal and spongy cells, so both BCCs and SCCs may be pigmented.

Epidermal lesions often have an "irritated" surface that may be ulcerative or thickened. Hyperkeratosis is a thickening of the stratum corneum, leading to an exuberant, flaking, and cracked appearance of the skin as in actinic keratosis and verrucae (or warts).[46] In acanthosis, there is a thickening of the stratum spinosum; it gives the skin a leathery, folded appearance and, if it is pigmented, is called *acanthosis nigricans*. This may occur in simple obesity but can be a marker for internal malignancy. Hyperkeratosis may be so pronounced as to become heaped up to form a cutaneous horn. It is most commonly associated with

actinic keratosis but may have an underlying SCC or keratoacanthoma. Similarly, greasy scaling lesions, which have a "pasted on" appearance, are typical of seborrheic keratosis.

In contradistinction, dermal lesions form a papule or nodule. A dermal inclusion cyst retains its attachment to the overlying epidermis (i.e., a punctum) and a dermatofibroma arises in the superficial dermal layers, so the overlying epidermis adheres to the deeper lesion.[46] In fact, there may be an overlying pressure necrosis from a dermatofibroma, leading to an almost pathognomonic feature of central umbilication. The nodule in dermatofibroma is hard, but a nodular nevus is soft and indents with the back end of a cotton-tipped applicator.[46]

The lesions of the deeper dermis will not have an overlying epidermal adherence. Lesions that are deeply attached will be nonmobile. Physicians should always clinically assess skin cancers for deep fixation and lack of deep mobility because these imply a deep invasion.

Regional clinical evaluation of lymph node drainage basins for malignant lesions is also important, and one must have an understanding of this anatomy,[63] including the superficial and deep lymphatics. Superficial lymphatics from the ulnar side of the hand may drain first into the supratrochlear nodes just proximal to the medial epicondyle, but most pass directly up to the axilla. Superficial radial lymphatics ascend to the deltopectoral glands and then on to the subclavicular axillary nodes.

Deep lymphatic vessels accompany the deep blood vessels (e.g., radial, ulnar, anterior and posterior interosseous), along which there may be lymph glands. Most pass up to the lateral axillary nodes. Thus, it is necessary to examine the forearm, epitrochlear, supratrochlear, and deltopectoral regions, as well as the axilla (i.e., medial, lateral, and apex) and supraclavicular lymph node drainage basins. When planning so-called "prophylactic" lymph node biopsy in the absence of palpable glands, physicians cannot rely on a seemingly logical ascent of lymph drainage up the extremity to the axilla, but must assess for the "sentinel" node that can be at any one of these potential sites.

DIAGNOSTIC PROCEDURES AND NONSURGICAL TREATMENT

Most cutaneous lesions do not require special imaging unless, for example, there is a large, deeply invasive skin cancer; in that case, magnetic resonance imaging (MRI) may be helpful in planning resection.

For small lesions, one may proceed directly to an excisional biopsy. However, many small lesions are noncancerous or only minimally invasive, so various diagnostic and/or treatment options are available. Once again, understanding the depth of cutaneous involvement is an important guide. Many epidermal lesions can be treated by shaving or curettage. Where indicated, one of these methods has an advantage over elliptical excision because the deeper dermal layers are not violated, and there is less likelihood of adverse scarring. This is, perhaps, not as critical in the hand as on more cosmetically important areas such as the face. Appropriate nonsurgical treatments may be as follows:

- *Patient surveillance*—Total lesion ablation may not be feasible. Periodic clinical examination and follow-up photographs may detect malignant transformation. This course can be chosen when total excision of a large congenital nevus is impractical, when a patient has multiple dysplastic nevi, or for diffuse syndromal conditions with a high risk of development of cutaneous malignancy (e.g., xeroderma pigmentosum, basal cell nevus syndrome).
- *Topical medications*—Diffusely spread conditions with malignant potential can be treated with topically applied 5-fluorouracil (5-FU) (Figure 58.3). However, Bowen lesions and superficial BCCs or SCCs cannot be treated with 5-FU. Verrucae can be treated by topical application of podophyllin or keratolytic agents (e.g., salicylic acid). A 5% imiquimod cream (Aldera, Graceway Pharmaceuticals, Bristol, TN) is approved for treatment of superficial BCCs; it should be applied 5 to 7 times per week for up to 12 weeks. Incomplete data are available for its use for Bowen disease, SCC, or lentigo maligna melanoma.
- *Curettage*—A 5-mm curet is most commonly used, and curettage is performed after adequate local anesthesia. It yields material for histologic examination but does not allow assessment of tumor margins. Curettage permits safe removal of superficial lesions with minimal scarring and is amenable for actinic, seborrheic keratoses, and verruca vulgaris. It is an excellent treatment for subungual verrucae, leaving almost no residual nail deformity. Remove the nail plate in order to identify a deep curettage cleavage plane using loupe magnification (Figure 58.4).
- *Cryosurgery*—Intense cold is applied and all cells within the freezing wave are killed. Liquid nitrogen can remove warts, superficial keratoses, and actinic lentigines. It must be used with caution where there are adjacent peripheral nerves, such as on the volar finger and olecranon, as permanent freeze damage to the nerve can occur. Also, destruction to critical paronychial and nail bed structures can occur at the fingertip. Aesthetic results are otherwise usually excellent, but cryosurgery must be used with caution in dark-skinned patients because hypopigmentation may result. It causes little pain and rarely requires anesthesia. For the procedure, a cotton-tipped applicator is used, with cotton teased out and tapered. As liquid nitrogen runs down the applicator,



FIGURE 58.3 Topical application of 5-FU can be used to treat a variety of superficial epidermal lesions.



FIGURE 58.4 **A,** Periungual verruca vulgaris on two fingers. **B,** The lesions here have been curettaged after nail plate removal. Reepitheliazation and normal nail growth will follow because the full-thickness epidermis has not been breached.

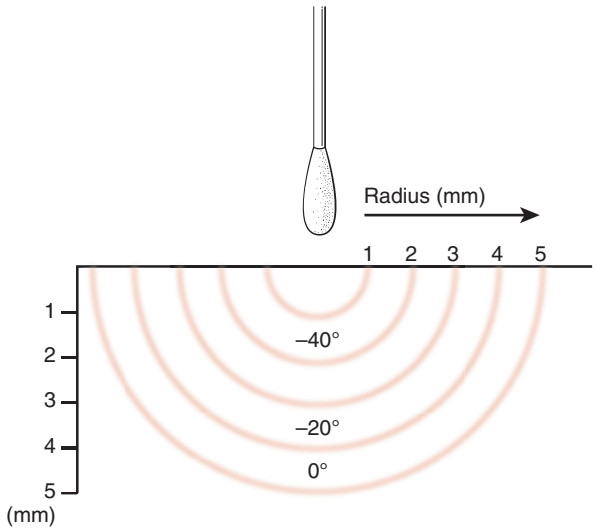

FIGURE 58.5 Diagrammatic representation of cryotherapy with cotton-tipped applicator dipped in liquid nitrogen.

skin at its tip turns white and the ice front spreads outward (Figure 58.5). Application should cease when visible freezing extends just beyond the lesion.

- *Electrosurgery*—Electrical energy is converted to heat by tissue resistance. An office hyfrecator is a good electrosurgical instrument and can be used to destroy seborrheic keratoses, skin tags, lentigines, and spider nevi.
- *Electrodesiccation and curettage*—A curet is used to scrape the lesion down to dermis. Scraping is then paused to use a hyfrecator. This causes electrocoagulation (electrodesiccation) of the raw surgical surface. The process is usually repeated three times or until the surgeon is comfortable with the margins. The technique's effective use depends on clinical experience but has advantages: (1) good cosmetic results, (2) rapid recognition of a recurrence because the lesion is not obscured by a wound closure or flap, and (3) a straightforward office procedure. It can be used for multiple superficial lesions that would otherwise be difficult or tedious to treat with multiple excisions. It is useful for seborrheic keratoses and viral warts but also has been used for multiple superficial BCCs, keratoacanthoma, and Bowen disease. For larger lesions, sometimes scarring can be obvious.

Before ablative surgery, a histologic diagnosis should always be obtained using the following as needed. In some cases, the biopsy process actually may be the curative treatment for smaller lesions.

- *Shave biopsy*—This may totally excise the lesion and be curative or just serve as a diagnostic biopsy. Lesion elevation by the mechanical effects of a wheal of local anesthetic and pinching between thumb and index finger above the plain of the surrounding tissue enables a full-thickness shave biopsy down to dermis. This can be done with a scalpel or a razor blade (Figure 58.6). Shave biopsies are not suitable for neoplasms that clinically appear to infiltrate dermis and generally not for pigmented lesions with a suspicion for melanoma.
- *Punch biopsy*—This may be incisional or excisional, if the lesion is small enough for the punch to fit around. Variable-sized cutting punches are available from 1.5 to 6 mm (4 mm is the most frequently used). Local anesthetic is first injected. When the circular punch incision reaches subcutaneous fat, the punch is removed. The small cylinder of tissue is then lifted and its base transected at the level of the subcutaneous tissue with small iris scissors (Figure 58.7). Sutures are generally not used. Sampling error is minimized by careful choice of the site to be biopsied.
- *Elliptical incisional or excisional biopsy*—If the lesion is too large to make an excisional biopsy impractical, incisional biopsy with a margin of adjacent normal skin is performed. Provided that subsequent excision is performed in a timely manner for histologically proven malignant conditions, prior incisional biopsy does not alter the natural history of melanoma and other cutaneous malignancies. Incisional biopsies should be done longitudinally so that the resulting scar, which may need to be excised later, does not compromise subsequent excision of a potential malignancy.
- *Elliptical excision*—This is usually designed in the line of least skin tension to facilitate linear closure. If the line of least skin tension is difficult to assess, simply excise around the lesion perimeter with appropriate margins and the wound will gape into an ellipse, indicating skin tension; then simply excise the "dog ears" (Figure 58.8).
- *Subungual lesions and longitudinal melanonychia*—Remove the nail plate and perform either incisional or excisional longitudinal removal depending on the ability to finely repair the nail bed in a tension-free manner after lateral undermining.

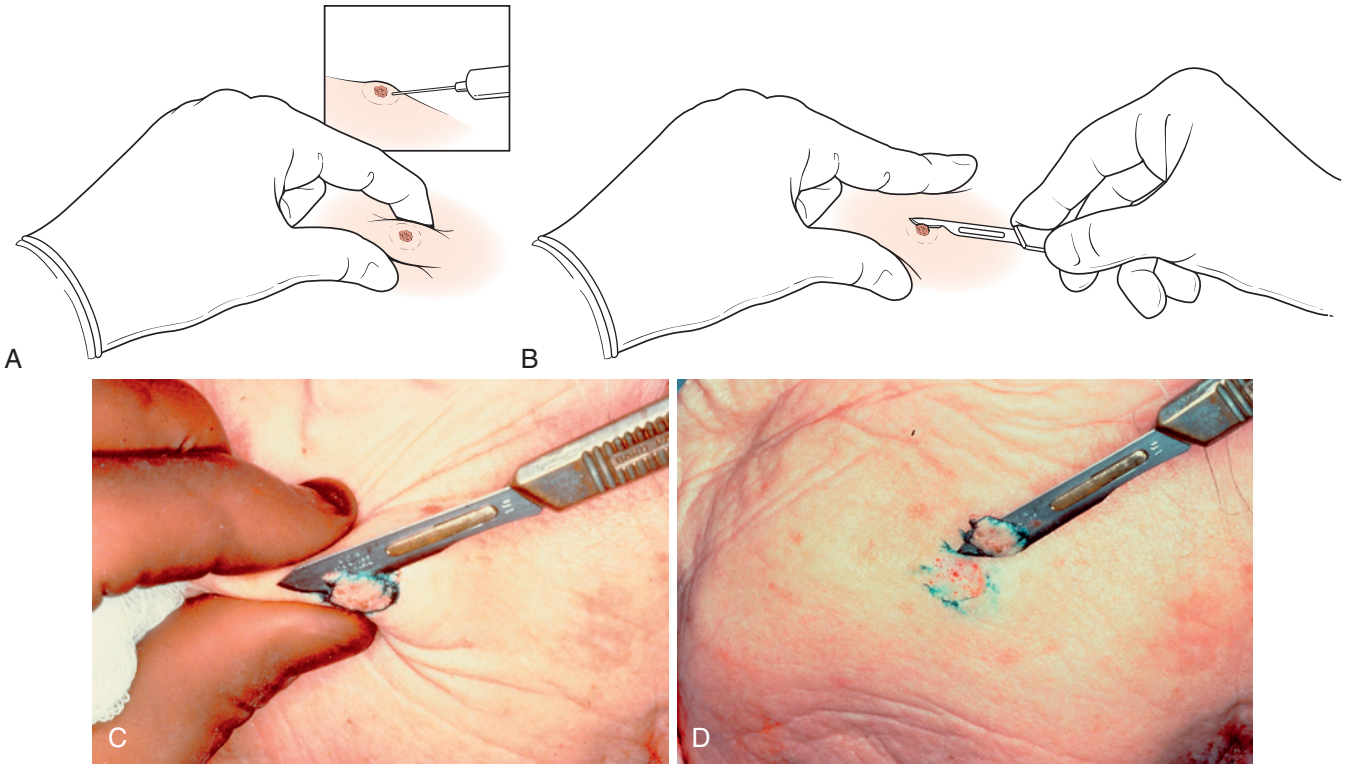

FIGURE 58.6 **A, B,** Diagrammatic illustration of shave biopsy. The lesion is plumped up first by local anesthetic infiltration and then by pinching the skin between the index finger and thumb. Tangential excision of the lesion is thus facilitated. **C, D,** Clinical demonstration of shave biopsy.

SURGICAL LESION EXCISION

Such excisions range from simple elliptical ones and tumor closure, through excision with frozen section assessment of margins, to Mohs micrographic surgery. If the lesion is small and there is abundant surrounding tissue laxity, then excision and linear closure may be permissible. If permanent sections reveal a persistent tumor, then reexcision of the scar is a simple matter. However, if a surgeon is planning a complex wound closure by tissue rearrangement or flap coverage, or if the lesion has complex invasion or is difficult to evaluate clinically by inspection and palpation (e.g., recurrence or certain infiltrative lesions), then intraoperative frozen section analysis of tumor margins is wise or resort to Mohs micrographic surgery.

When performing a simple tumor excision under local anesthesia, first determine tumor extent by loupe magnification inspection and palpation; mark the tumor margin together with the anticipated excision margin. Do this before local anesthetic infiltration because the presence of anesthesia distorts the tissues (Figure 58.9).

Mohs micrographic surgery[27,46,47,52,54,63] is generally reserved for certain widespread lesions with margins that are difficult to interpret clinically and where optimum conservation of uninvolved tissue is necessary such as with diffuse Bowen lesions (Figure 58.10). In contrast to the conventional bread-loafed sectioning of the excised specimen, Mohs surgery involves tangential layered excisions and creating maps of the residual tumor for further excision until the whole lesion is excised. It is applicable to recurrent carcinomas, high-risk squamous carcinomas, tumors with ill-defined clinical margins (e.g., dermatofibrosarcoma protuberans), and in areas where maximal conservation of tissue is required to preserve function.

EPIDERMAL LESIONS

Warts

Verruca vulgaris (wart) is caused by the human papilloma virus (HPV) and is transmissible by direct contact or autoinoculation.[1,25,46] Histologically, physicians see hyperkeratosis (i.e., thickening of the stratum corneum), acanthosis (i.e., thickening of the epidermis), and parakeratosis. The characteristic lesion is a well-demarcated, raised, and rough cauliflower-like lesion. The less frequent plane wart (verruca plana) is flat. Verrucae are common on the hand and fingers and may occur in periungual and subungual locations. Warts may be isolated lesions or groups of them that combine to form plaques.

Most warts spontaneously regress in two years. However, in immunocompromised patients they can reach especially large sizes and take longer to resolve. A variety of treatment options are available, all of which result in about a 70 to 85% cure rate. Most commonly the wart is first pared down and then a topical keratolytic agent is applied. Salicylic acid solution in collodium is the most frequently used topical agent. Treatment with an emery board has been recommended and various other topical applications, which may need to be repeated, have been used, including imiquimod, 5-FU, and cryotherapy. Silver duct tape (not clear tape) has an unknown mechanism of action. It is applied for 7 days, then the lesion is debrided with a pumice stone. This kind of treatment generally is repeated.[19]

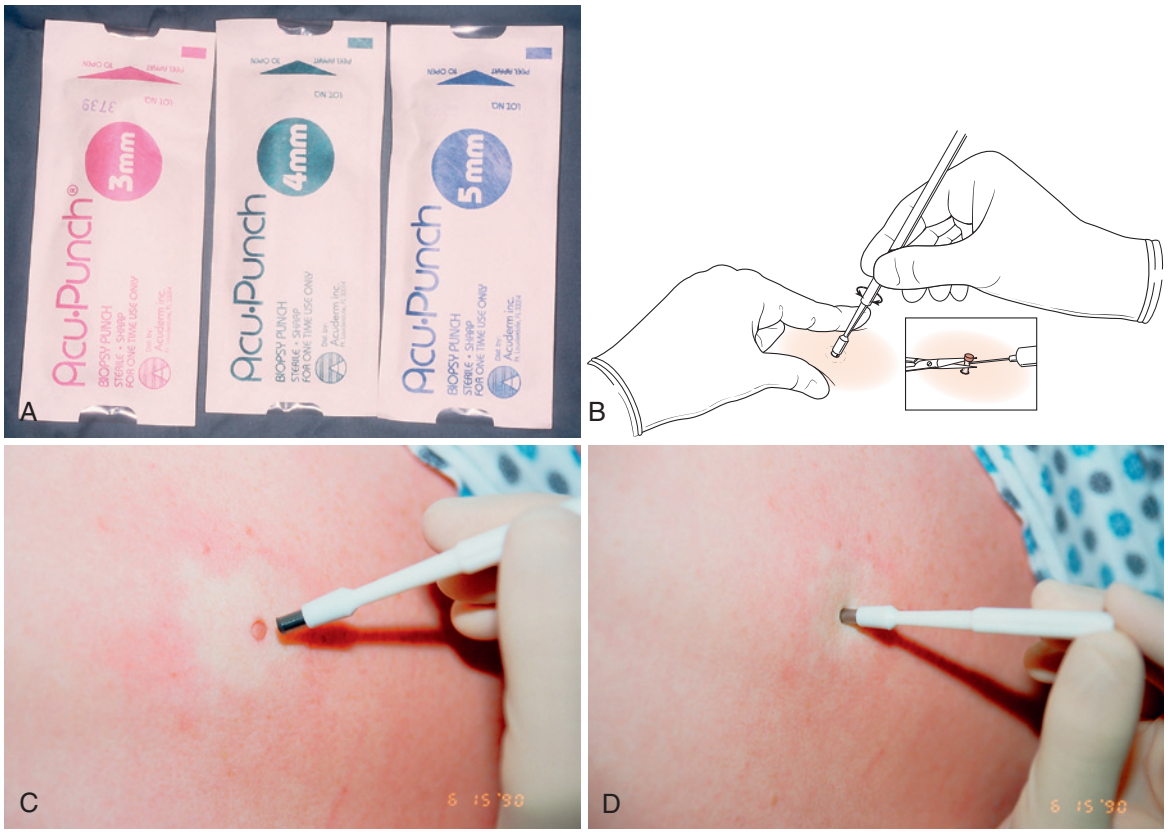

FIGURE 58.7 **A,** Different size punches (3 mm, 4 mm, 5 mm). **B,** Illustration that shows how the cutting punch creates a cylinder of tissue that can then be lifted up and cut loose. **C, D,** The core of tissue can be lifted up by fine forceps or by piercing it with the tip of a hypodermic needle.

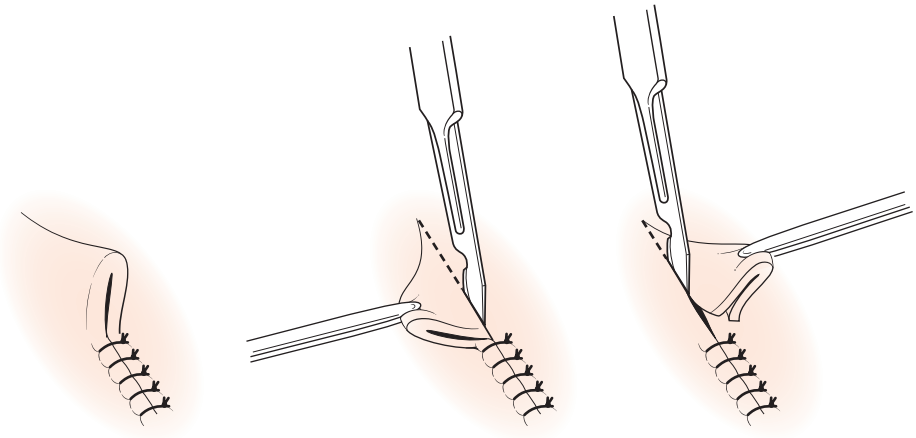

FIGURE 58.8 Method of "dog-ear" excision following elliptical excision of a lesion.



FIGURE 58.9 **A,** The margin around a pigmented lentigo maligna lesion is marked prior to infiltration of local anesthetic. **B,** Resulting soft tissue wound. **C,** If clear clinical margins are ensured, a flap reconstruction may possibly be performed; this shows the outline of a Limberg transposition flap. **D-H,** However, always select the simplest and most effective method of wound closure. Wound edge undermining reveals that the wound can be closed directly. Subcuticular wound closure is performed after deep dermal closure, and dog-ear excision; the wound is supported by adhesive strips. Final outcome is shown in **H**.

My preferred treatment is to shave the wart down to the level of the surrounding epidermis. A discrete edge is then viewed with magnification loupes and the entire wart is sharply curetted from the surrounding normal epidermis. Because this is an entirely epidermal lesion (i.e., the basal epidermal layer is not involved), reepithelialization occurs rapidly. This is an excellent way of treating periungual and subungual warts, resulting in a low risk of residual nail or perionychial deformity.

Seborrheic Keratosis

These lesions are more common in middle-aged and elderly patients. Lesions are usually centrally located, thus are more frequently seen on the upper arm and chest than on the hands. The depth of pigmentation is related to the amount of sun exposure. Occasionally, they mimic melanoma and require diagnostic biopsy. Seborrheic keratoses are benign flat lesions that take on a characteristic greasy scale and appear to have been "stuck" onto the skin's surface (Figure 58.11). Because they are entirely epidermal lesions, treatment takes advantage of their superficiality and includes curettage, shave biopsy, or application of liquid nitrogen. Given that these treatments do not invade the dermis, the potential for scarring is minimal.

Sweat Glands

Eccrine poroma is a sweat gland lesion.[26] Because it arises from the eccrine duct within the epidermis, not in the deeper dermal region, it is truly an epidermal lesion. The lesion presents as a moist and red papule with a surrounding collarette and occasionally may be mistaken for a pyogenic granuloma. Eccrine poroma is said to be more common on the soles and the palms and may be totally epidermal, or it may straddle both dermis and epidermis. Malignant change is unusual. Treatment is surgical excision. Multiple palm and sole lesions may occur in the uncommon genetic hidrotic ectodermal dysplasia syndrome.



FIGURE 58.10 **A, B,** Bowen carcinoma. It is difficult to define the tumor margins by clinical inspection. Mohs surgery is performed **(C, D)** and skin grafting done **(E),** with the long-term outcome shown in **F** and **G**.

PIGMENTED EPIDERMAL LESIONS

Pigmented Macules

Lentigines are benign pigmented macules with increased melanocytic activity.[46,55] Unlike freckles, they do not fade in the absence of sun exposure. A simple lentigo (lentigo simplex) appears during childhood, is usually less than 5 mm in diameter, and may occur on both sites sun-exposed and those not exposed to sun. Solar lentigo is also called *senile lentigo* and is common on the forearm and dorsum of the hand at sun-exposed areas. There is associated solar damage in the dermis, as can be seen by histologic solar elastosis. Their incidence increases with age and may resemble melanoma; thus, diagnostic biopsy may be required. Otherwise, specific treatment is unnecessary, though laser therapy may be helpful if the patient is bothered by cosmesis.

Melanocytes

Melanocytic nevus is a benign proliferation of melanocytes. Nevi, or simple moles, are the most common tumors in humans. Few are present at birth but begin to appear soon after, reaching their greatest incidence in young adults.

Junctional nevi have nevus cells confined to the dermoepidermal junction, and intradermal nevi have these nests in the dermis alone. Most nevi in younger patients are junctional and flat. In adults, most are intradermal and elevated. Compound

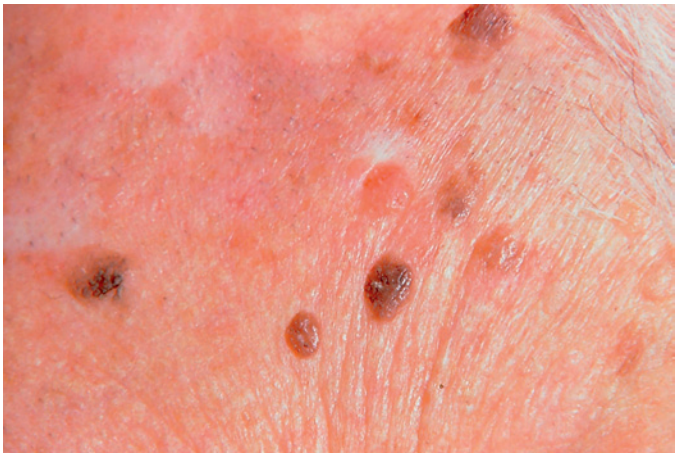

FIGURE 58.11 Characteristic appearance of seborrheic keratoses on dorsum of the hand.

nevi have nevus cells at both locations. It is the junctional component of both junctional and compound nevi that can, more rarely, transform into malignant melanoma; however, most melanomas do not arise out of preexisting nevi. Unlike melanocytes in the basal layer of the epidermis, nevus cells do not have dendritic processes (except in a blue nevus).

Melanocytic nevi may be either acquired or congenital. The latter are classified according to size (e.g., small, medium, or giant), and the former are classified according to pathologic findings (e.g., common mole, Spitz, blue, and atypical/dysplastic).

Moles

Most common moles (nevi) do not require any specific treatment unless malignant transformation is suggested by enlargement, darkening pigmentation, or ulceration—"ABCD": asymmetry, border irregularity, color variation, diameter greater than 6 mm. Palmar nevi were thought to be prone to malignant transformation, but this view has changed. Incidences of palmar nevi occur in 13% of whites and 29% of blacks, making routine excision of nevi in these locations both impractical and unnecessary.

Giant hairy congenital nevi occur most often on the face and bathing trunk area but can occur on the upper extremity (Figure 58.12). It is unclear what the precise risk is for malignancy developing in giant congenital nevi. A systematic review suggests a range of 0 to 9%.[46] The highest risk of malignant transformation with these lesions is actually during childhood and prepuberty, unlike the general incidence of melanoma, which is after puberty. Smaller congenital nevi are generally excised. However, excision of larger nevi may be less practical and require use of skin expansion, flaps, or skin grafting to close large wounds. Where excision is not feasible, periodic cancer surveillance and biopsy of suspicious areas must be done.

Benign Juvenile Melanoma

With spindle (or Spitz) nevus, which has also been called benign juvenile melanoma, the incidence of malignant transformation is no greater than with other compound nevi. The color ranges from pink to purplish-red, and the minority are darkly pigmented. Treatment is total excision.

Blue Nevus

This contains dermal melanocytes that produce melanin, and unlike the intradermal nevus, these melanocytes also have dendritic processes. Dermal melanin scatters shorter wavelengths of light, producing a blue color. It is more commonly found on the dorsum of the hand as a solitary lesion and arises in adolescence or early adulthood. Malignant degeneration is unusual.

Dysplastic Nevus Syndrome

This occurs in both sporadic and familial forms (Figure 58.13). There are multiple atypical nevi varying from 10 to more than 100, occurring mostly on the upper trunk. Lesions are often greater than 1 cm in diameter with irregular and variegated colors. Microscopic appearance is characteristic with large, atypical melanocytes that are spindle or epithelioid in type. The papillary dermis shows fibroplasia. It is impractical to excise all the lesions. Excision of a representative lesion can confirm a pathologic diagnosis. Such patients must be carefully observed and suspicious lesions excised.

Acral nevi (nevi occurring on the thickened palmar skin) can have histologic findings that may mimic dysplastic nevi.

Longitudinal Melanonychia

This term refers to the dark streaking of the nail caused by melanin deposits in the nail plate. Acral nevi that involve the nail matrix can present in this way. In dark-skinned patients, longitudinal melanonychia is common and is simply caused by increased melanin production by normal melanocytes. A longitudinal full-thickness nail bed biopsy is required for a suspicious lesion after removal of the nail plate and repair of the hyponychial nail fold and nail bed. Suspicious new lesions for potential melanoma include those in older patients (50–70 years), a longitudinal band >3 mm in width, change in lesion color and size, involvement of a single digit, nail dystrophy, and extension to the periungual skin (Hutchinson sign) (Figure 58.14).

DERMAL LESIONS

Such lesions are often elevated to be classified as macules or papules and nodules.[25,43] The following list describes some.

- *Dermatofibroma* (histiocytoma) is a fibrous tumor that involves the dermis. They most frequently occur on the extremities. It is usually solitary, slow growing, and firm and attached to overlying skin but freely mobile in relation to deeper subcutaneous tissues. They may have a depressed central "umbilication." Occasionally, dermatofibroma may be dark brown and be clinically confused with malignant melanomas. When indicated, simple excision can be done (Figure 58.15).
- *Digital fibrokeratoma* (acral fibrokeratoma) usually occurs on the acral surfaces of the hands. They are characteristically a hornlike projection with a raised collar of skin at the base. The overlying epidermis is hyperkeratotic and the dermis demonstrates increased fibrosis. They may mimic fibromas, eccrine poromas, and pyogenic granuloma. Treatment is by excision, though reappearance may occur.
- *Epidermal inclusion cysts* arise from occluded pilosebaceous follicles, with some arising from traumatic displacement of

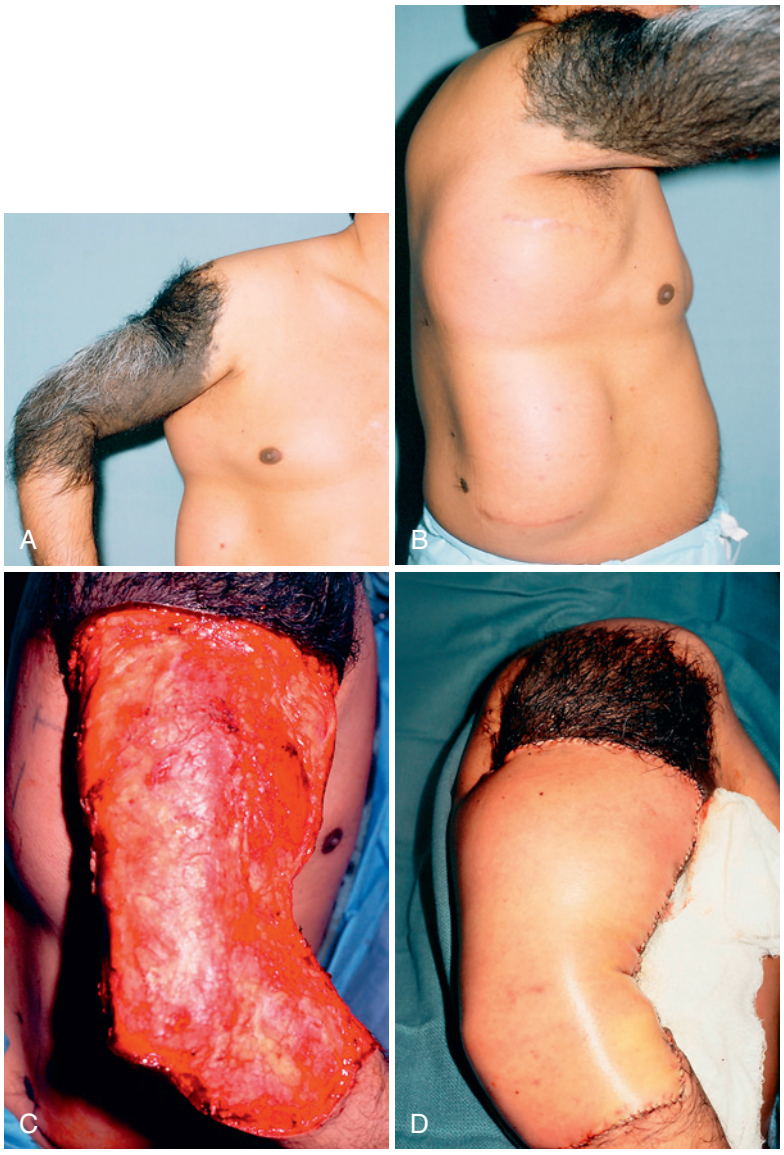

FIGURE 58.12 **A,** Arm giant hairy nevus. **B,** Large tissue expanders have been placed in the lateral chest wall. **C,** Most of the lesion is able to be excised at the first stage and a large wraparound chest wall pedicle flap is used for reconstruction **(D)**.

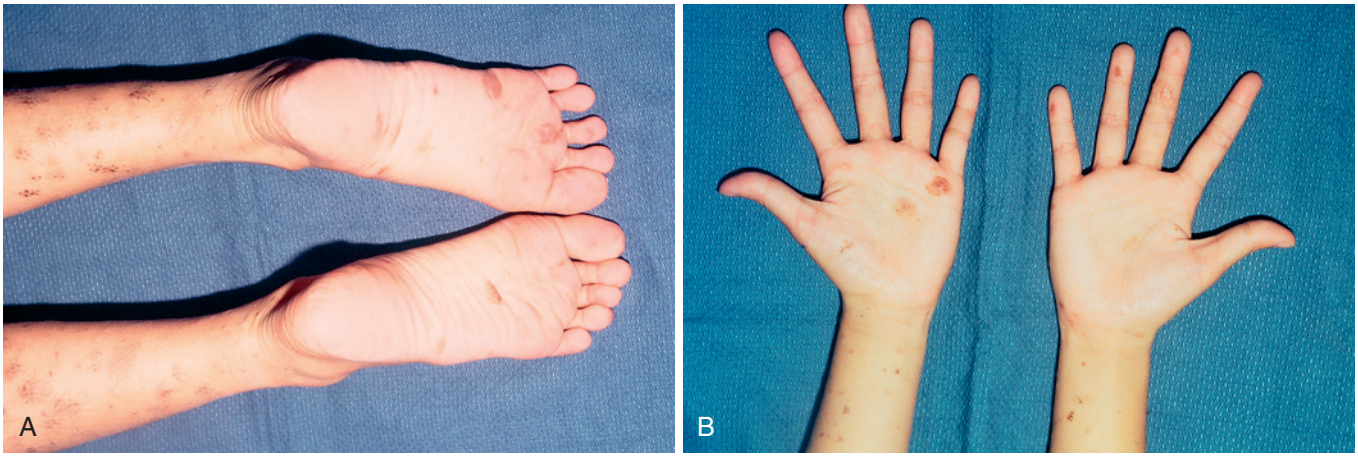

FIGURE 58.13 **A, B,** Child with multiple dysplastic nevi on trunk and upper and lower extremities, including plantar and palmar surfaces (acral nevi).



FIGURE 58.14 **A,** Nail has become completely involved by dark pigmentation. **B,** Nail plate has been removed to reveal germinal matrix nail bed pigmentation. Biopsy showed cellular atypia but no invasive melanoma. This was treated by nail bed surgical ablation and full-thickness skin grafting. **C,** Subungual melanoma showing Hutchinson sign with pigmentation encroaching on the proximal eponychium.

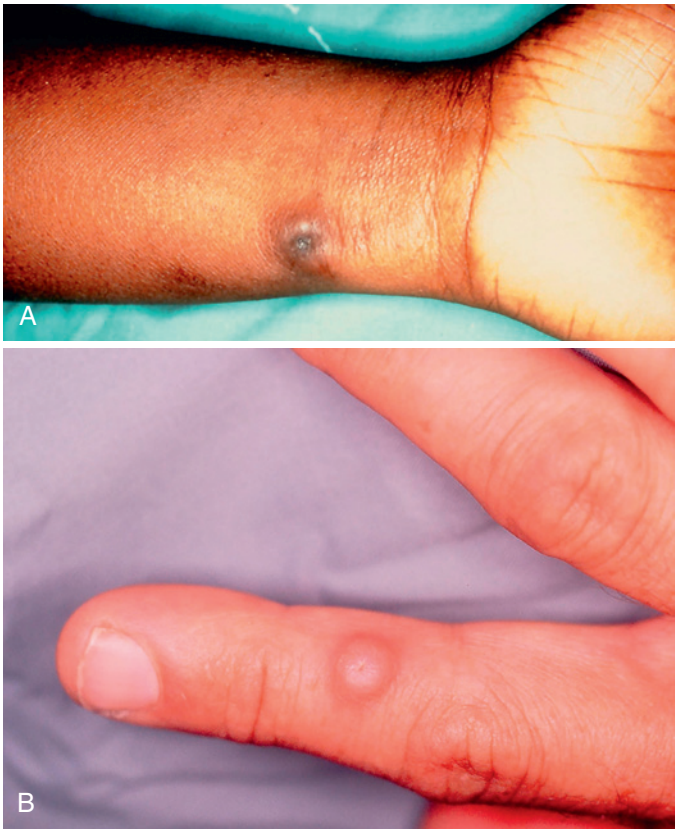

FIGURE 58.15 **A,** Dark-colored dermatofibroma showing central "umbilication." **B,** Finger dermatofibroma.

epidermal cells into the dermis (Figure 58.16). The skin is elevated over the underlying lesion and adherent to it. Central keratin-filled punctum may be seen. They are asymptomatic but may become secondarily infected. The preferred treatment is excision to include the entire epidermal lining.

- *Pilomatricoma* (or calcifying epithelioma of Malherbe) occurs as a solitary tumor in the upper extremities of children and young adults (Figure 58.17, *A, B*). It is usually a nondescript small dermal nodule (0.5-cm diameter), and the foci of calcification are seen histologically. Treatment consists of surgical excision
- *Neurofibroma* may occur as an isolated dermal lesion or as part of a more diffuse neurofibromatosis (Figure 58.17, *C–E*)
- *Infantile digital fibromatosis* occurs at the tips of the fingers (but not the thumb). These may be single or multiple, as "kissing" lesions on adjacent digits (Figure 58.18). They may cause functional deformity. Histologically, there are characteristic eosinophilic cytoplasmic inclusion bodies. Wide excision is required to minimize return but risk of recurrence is high.

NONHEMANGIOMATOUS VASCULAR LESIONS

These lesions can be excised; smaller ones can be destroyed with electrosurgery, laser, or silver nitrate cautery; descriptions follow. Incompletely removed lesions may reoccur.

- *Telangiectasias* are fine linear vessels on the skin's surface. They are common and may be normal, occurring especially

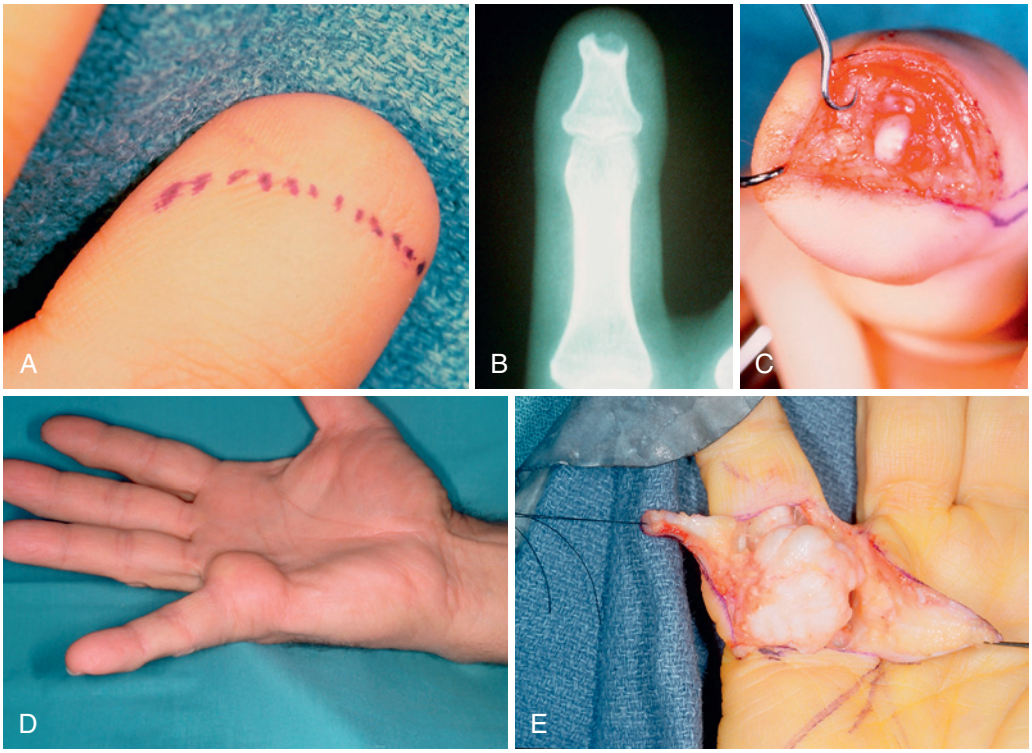

FIGURE 58.16 **A,** Patient who had prior fingertip traumatic amputation now presents with an apical finger mass. **B,** Radiograph shows pressure indentation of the distal phalanx. **C,** Fingertip inclusion cyst is excised. **D, E,** Palmar finger inclusion cyst.

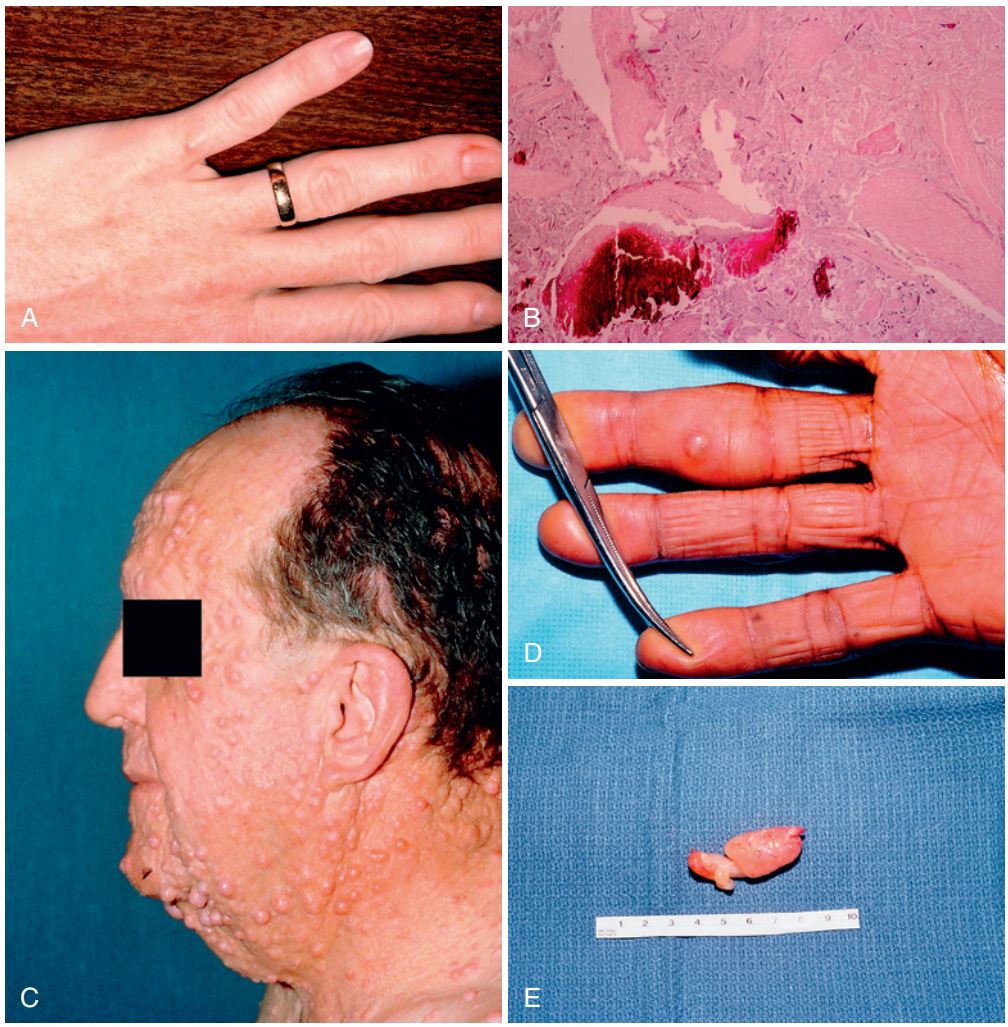

FIGURE 58.17 **A,** Small, slightly tender, and erythematous lesion over dorsum of proximal phalanx of little finger. **B,** Characteristic calcification of pilomatricoma is seen histologically. **C,** Patient with neurofibromatosis. **D, E,** Patient has a simple tender digital neurofibroma which is excised.



FIGURE 58.18 A, Characteristic appearance of "kissing" lesions of infantile digital fibromas. **B, C,** Treated by wide excision and flap or full-thickness skin graft wound coverage. **D,** Pathognomonic histology shows intracytoplasmic eosinophilic inclusion bodies.

in the elderly on sun-damaged skin. Their significance may lie in their association with other diseases such as collagen vascular disorders.

- *Pyogenic granuloma*[65] is a proliferation of capillaries arising at the site of prior trauma, often is relatively trivial. An associated infection may occur, but the condition is not an infectious process. Pyogenic granulomas have a friable surface and bleed easily (Figure 58.19). They occur most frequently on distal extremities, probably because of minor trauma at the sites. Spontaneous resolution is unusual.

PREMALIGNANT, SKIN CANCER ASSOCIATED, AND INDETERMINATE BEHAVIOR LESIONS

Cutaneous Horns

These arise from underlying epidermal lesions, most commonly actinic keratoses (Figure 58.20).[34,46] They are not premalignant, but as many as 10% have underlying squamous cell carcinomas, and extremely rarely a BCC. Numerous other lesions may give rise to cutaneous horn outgrowth (e.g., keratoacanthoma, sebaceous adenoma, seborrheic keratosis, and verruca). Because of the possibility of malignancy, biopsy is required together with excision of a 1 to 2 mm margin of normal skin. Subsequent treatment then depends on the underlying lesion.

Porokeratosis

These lesions are characterized by a surrounding sharply raised keratotic and horny rim.[1,36] Histologically, there is a rim of parakeratosis and often have an autosomal-dominant inheritance. About 13% transform into squamous cell carcinomas. There are several subtypes, including a Mibelli with raised plaques (Figure 58.21), disseminated superficial actinic (DSAP), linear, and punctate. All may occur on the hand and upper extremity. Because of their association with premalignancy, treatment modalities include cryosurgery, topical 5-fluorouracil, or imiquimod.

Keratoacanthoma

This is a benign, self-limited epithelial tumor, usually occurring on sun-exposed, hair-bearing skin.[25,46,58] It closely resembles squamous cell carcinoma, both clinically and histologically. A firm, erythematous papule appears initially and rapidly enlarges up to 2 cm or more in diameter over several weeks. The characteristic central crater of the lesion is filled with a keratinous plug (Figure 58.22).

Large lesions, even though indurated, are often freely moveable over the underlying structures. Common for such lesions, a regressive phase begins, the central plug is expelled, and the lesion heals spontaneously with a scar. It is believed to arise from proliferation of pilar epithelium. The evolution and regression of the lesions are felt to be related to the hair cycle. Treatment is generally complete excision, especially when the lesion is first recognized and small. Some prefer to call this lesion SCC keratoacanthoma type; thus, for this reason as well, surgical excision is the preferred treatment even though metastases are rare.

Keratoacanthomas may have an aggressive course with metastasis and cannot be distinguished from SCC under such circumstances. The cause, however, for confusion may be an initial mistake in diagnosis, and the histopathologic interpretation of keratoacanthoma may be problematic.

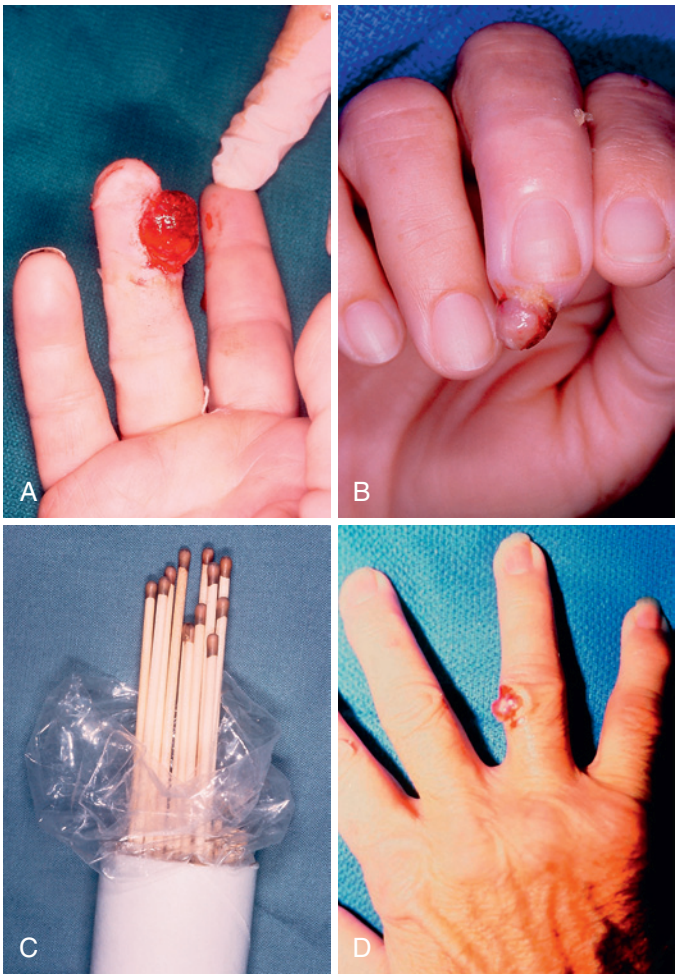

FIGURE 58.19 **A, B,** Pyogenic granulomas are common on the fingers. They have friable surfaces that bleed on contact. **C, D,** Silver nitrate sticks may be used to treat smaller lesions.

Distal Digital Keratoacanthoma

This is a rare, destructive form of keratoacanthoma of the distal subungual tissue.[5] As such, it does not occur in hair-bearing skin. Like a true keratoacanthoma, it does exhibit very rapid



FIGURE 58.21 Extremity porokeratosis of Mibelli.

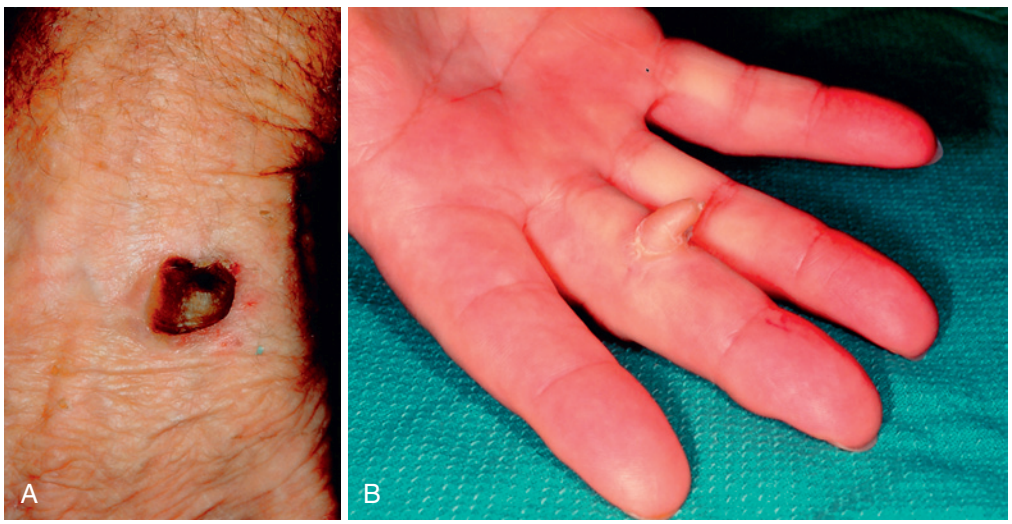

FIGURE 58.20 **A, B,** Examples of cutaneous horns on the hand and finger.

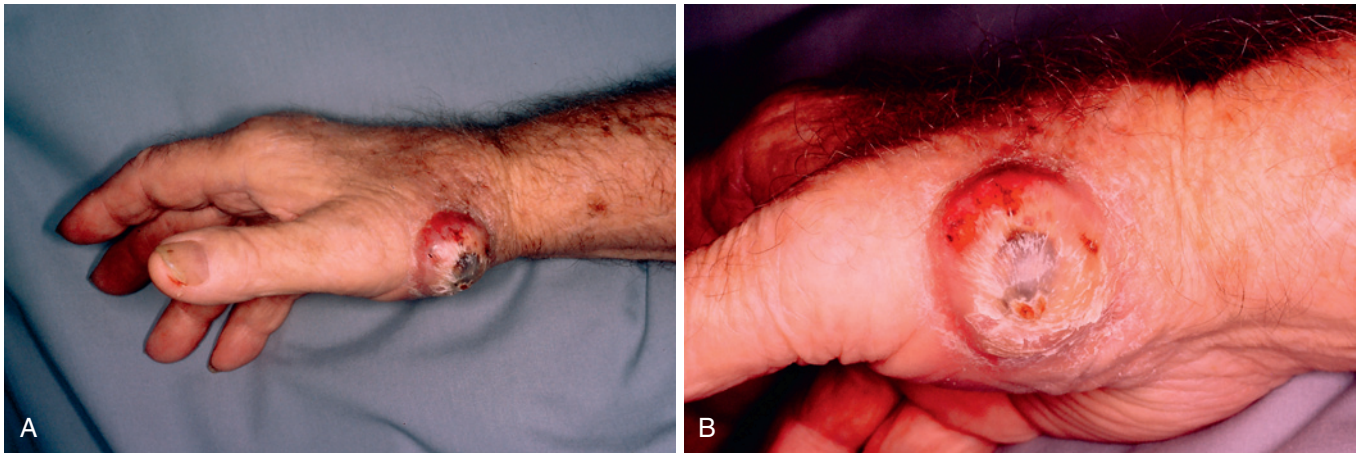

FIGURE 58.22 **A, B,** Keratoacanthoma at dorsal base of thumb. It shows the characteristic central keratinous plug.

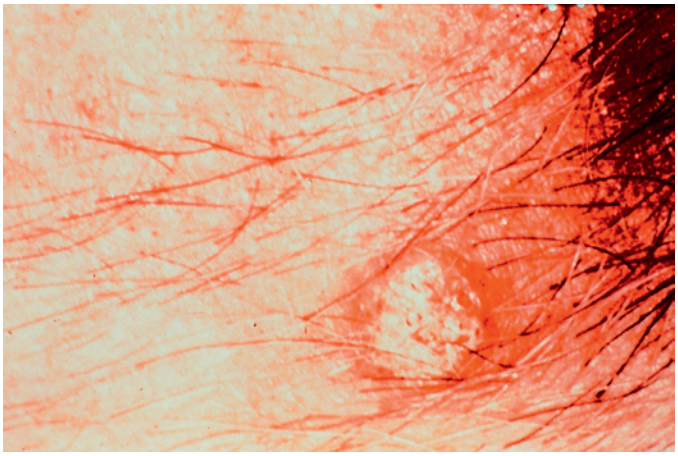

FIGURE 58.23 Scaly lesion of actinic keratosis.

growth. It causes nail bed distortion and may even result in bone destruction. Spontaneous regression has been reported, but it is probably a low-grade carcinoma. If one cannot conclusively rule out SCC, distal digital amputation is warranted.

Actinic Keratosis

The most frequently occurring premalignant cutaneous condition is actinic keratosis[15,42]; it is also called solar or senile keratosis. Lesions are rough and scaly with an erythematous border (Figure 58.23). Histology shows hyperkeratosis and areas of parakeratosis. The granular layer of the epidermis is usually absent, and there is an atypical cellular pattern. The basement membrane is thickened but intact. They occur in genetically susceptible people—for example, frequently older males of Celtic heritage—and a history of sun-exposed sites (e.g., hands and forearms). They must be differentiated from chronic eczema, psoriasis, and Bowen disease. Estimates suggest that invasive SCC develops in fewer than 10% of patients with actinic keratosis.

For individual lesions, treatment may involve cryotherapy and electrodesiccation with curettage. In situations of severe sun damage and multiple areas of actinic keratoses, topical treatments spread over a wider area are more suitable. These may include 5-fluorouracil, dermabrasion, trichloroacetic acid chemical peel, and photodynamic therapies. Lesions resistant to treatment with 5-FU may contain foci of invasive SCC.

Arsenical Keratosis

This occurs secondary to exposure to inorganic arsenic compounds either through ingestion or contact in the agricultural industry.[42] It usually manifests on the arms and soles of the feet and is rarely seen in the United States.

Bowen Disease

An intraepidermal SCC (or carcinoma in situ), Bowen disease[29,42] may become invasive after many years in fewer than 10% of the population. Squamous cell carcinoma arising from Bowen disease is more aggressive than carcinoma arising from actinic keratosis, and metastases develop in up to one-third of patients. Chronic sun exposure is etiologically related.

Lesions are irregular plaques with thickened and hyperkeratotic surfaces (Figure 58.24) and are usually erythematous. They must be differentiated from psoriasis, eczema, verruca, chronic fungal infections (especially when involving the perionychium), actinic keratosis, and superficial BCC. Surgical excision with a margin of normal tissue is the most effective treatment.

Mohs micrographic surgical techniques may be helpful because the clinical boundary of the lesion may be difficult to define. Because of deep follicular involvement, curettage and topical applications (e.g., 5-FU) may be less effective. Distal digital lesions (Figure 58.25) with significant nail distortion may be treated best by fingertip amputations. Large surface-area wounds remaining after lesion excision may be most effectively treated by skin grafting.

SYNDROMAL CONDITIONS ASSOCIATED WITH SKIN CANCERS

Gorlin Syndrome

Basal cell nevus syndrome[42,50] is also called Gorlin syndrome (Figure 58.26). Typical nevi are reddish-brown, papular, and may number up to many thousands that appear after puberty. Lesions may become invasive BCCs. Patients also have a characteristic facies, palmar, and plantar pits; brachymetacarpia;

and occasional neurologic abnormalities (e.g., mental impairment and medulloblastoma).

Xeroderma Pigmentosum

This is a genodermatosis that is an autosomal recessive defect in which the DNA repair mechanism for ultraviolent (UV) light damage is impaired. Skin and eyes are intolerant to UV light.[42] With sunlight exposure, an exaggerated sunburn reaction occurs; that is, the skin thickens and there is subcutaneous atrophy. The prognosis is dismal. Sun protective clothing is required, as well as avoidance of UV exposure. Patients develop multiple malignant epithelial tumors and melanomas during the first decade of life (Figure 58.27).

Other unusual conditions include Bazex syndrome, which is inherited as an X-linked dominant trait and results in multiple BCCs, hypotrichosis, and hypohidrosis. Haber's syndrome is a familial variant of Bowen's lesions, generally appearing in the covered areas of the body.



FIGURE 58.24 Palmar Bowen carcinoma.

BASAL CELL CARCINOMA

Although BCC is the most commonly occurring skin cancer, it is relatively rare on some anatomic sites (e.g., the hand).[45] Squamous cell carcinoma (SCC) is much more common than BCC at this site. BCC arises without a precursor lesion and is locally aggressive and recurrent; however, metastasis is rare. BCCs arise from the basal layer of the epidermis and from pilosebaceous adnexae. The characteristic cell has a large basophilic nucleus with minimal cytoplasm. Tumor cells at the periphery of any nest of cells are oriented with long axes perpendicular to the nest, giving a "picket fence" appearance. In the so-called morpheaform cancer, there is significant dermal collagen that compresses tumor cells into cords.

Differential diagnosis includes factitious ulceration, eczema, actinic keratosis, psoriasis, and fungal infection. Nodular pigmented basal cell carcinoma may mimic melanoma in appearance, but still behaves clinically as a well-circumscribed nodular BCC.

BCCs are distinguished primarily as circumscribed and diffuse lesions.[28,59] Nodular and circumscribed lesions generally are less virulent, and Jacobs et al were the first to differentiate

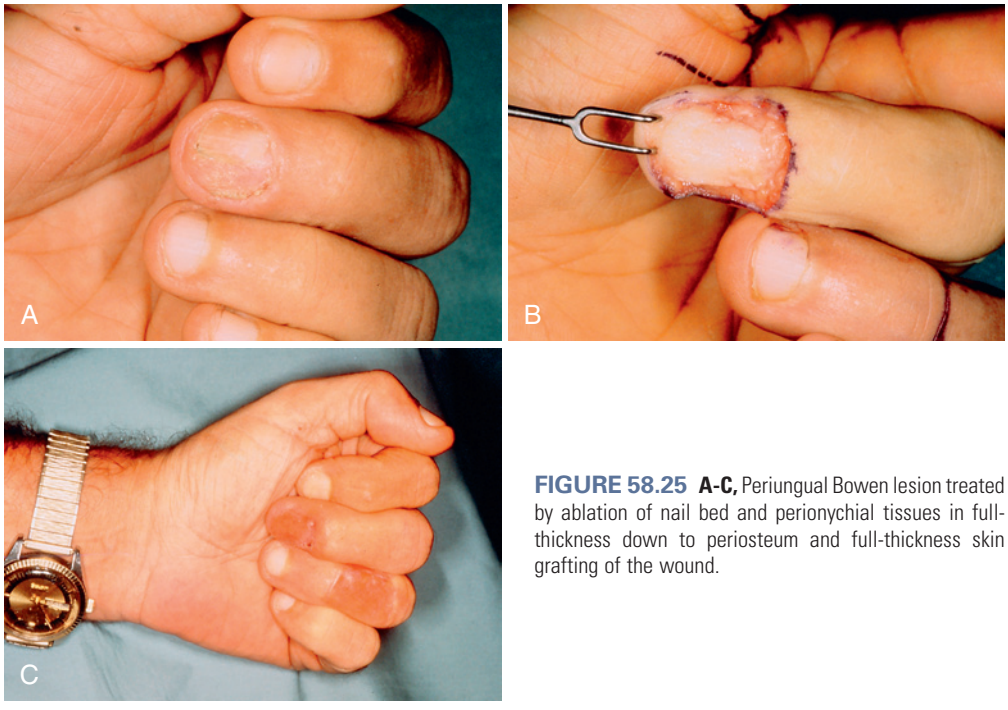

FIGURE 58.25 **A-C,** Periungual Bowen lesion treated by ablation of nail bed and perionychial tissues in full-thickness down to periosteum and full-thickness skin grafting of the wound.



FIGURE 58.26 **A, B,** Characteristic facial appearance of a patient with Gorlin syndrome.

TABLE 58.1 Classification of Basal Cell Carcinoma

Circumscribed	Diffuse
Nodular	Superficial spreading
Nodular ulcerative	Morpheaform (sclerosing)
Adenoid	Infiltrating
Cystic	Eccrine and apocrine epithelioma
Fibroepithelioma of Pinkus	

tumor type and tumor behavior (Figure 58.28). Within the two groups, circumscribed and diffuse, BCC in turn is classified according to degree of differentiation and depth of invasion, which is clinically noted with fixation to deeper structures.

Classification of BCCs

Nodular and ulcerative are the most common types of BCC (Table 58.1). Of the diffuse types, superficial spreading characteristically may occur on the trunk and upper extremities (Figure 58.29). Overall, this type of spreading is the next most common form of BCC.

Solid (Nodular) BCC

This is the most common form of basal cell carcinoma. It may ulcerate, which is called nodular ulcerative. It is dome-shaped with well-defined borders, is often a pink-red papule, and has a "pearly" appearance with telangiectasias. Although nodular BCCs may be histologically poorly differentiated, their growth pattern is circumscribed.

Adenoid BCC

This type of basal cell carcinoma has strands of tumor islands that resemble tubular structures surrounded by myxoid stroma.

Cystic BCC

This type of basal cell carcinoma has spaces in the tumor island secondary to degeneration of tumor cells. When "adenoid" areas are also present, the lesion is called "adenoid cystic." These large lacunae have a distinct macroscopic appearance, and cysts may rupture, allowing fluid to reach the lesion's surface (see Figure 58.28).

Diffuse basal cell carcinomas have a higher recurrence rate than circumscribed lesions because they extend insidiously into the dermis beyond the clinically visible or palpable border.

Superficial BCC

This type of basal cell carcinoma has been called multicentric because discrete foci seem to be present. However, three-dimensional histological reconstruction reveals that the apparent multiple foci are actually connected. This BCC is not easily treated and has a higher recurrence rate because of its extension beyond clinically apparent borders. Superficial BCC is scaly, crusted, erythematous, and level with the skin's surface. It may be ringed by a raised "pearly" border that slowly expands. Confusion with eczema, actinic keratosis, psoriasis, and fungal infection may occur.

Morpheaform (Sclerosing) BCC

This is quite rare on the hand but more common on the face. It is a firm plaque surrounded by "scar" tissue, and lateral spread has been reported as much as 7 mm beyond the clinically apparent tumor border.[56] Dense, fibrous stroma precludes treatment by curettage.

Treatment of BCC

Curettage and electrodessication is the most common method of treating BCC but is reserved for primary lesions less than 1 cm in diameter. Hand extremity lesions are amenable to this form of treatment. Well-defined lesions can also be treated by



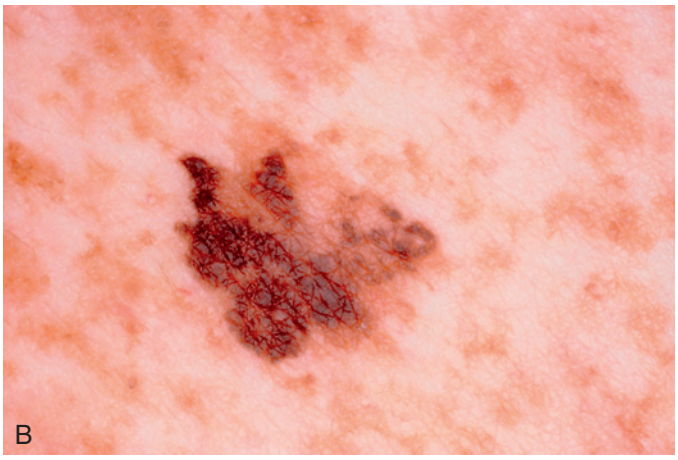

FIGURE 58.27 **A, B,** Patient with xeroderma pigmentosum has developed melanoma.

cryosurgery.[32] A potential risk is neuropathy due to uncontrolled depth of freeze, so this form of treatment should be avoided on digits and around the ulnar nerve at the elbow.

Although cure rate for curettage and electrodesiccation, and for cryosurgery for small lesions, has been reported to be as high as 97%, an inherent disadvantage is lack of microscopic verification of complete tumor removal.[64,31] Surgical excision offers a greater than 90% cure rate[27,44] (Figure 58.30). Loupe magnification allows more accurate visual assessment of tumor borders. Mark out the tumor borders before local anesthetic injection to avoid tumor distortion.

A 2-mm surgical margin may be sufficient for a less than 1 cm diameter nodular lesion. However, for lesions up to 2 cm, a 3 to 5 mm margin is more appropriate and should extend deep into subcutaneous fat. Lesions greater than 2 cm and those with aggressive growth patterns (e.g., morpheaform and superficial "multicentric" BCC) may require resection margins of 10 mm (where practically possible),[16,40] but this should be reserved for larger and infiltrative lesions.

Frozen sections of tumor margins is expensive and not recommended for every suspected BCC. If microscopic margins are found to be involved on permanent pathologic assessment, reexcision will not affect the likelihood of cure. However, for the higher risk lesions already discussed, frozen sections of margins are recommended and even a potential recourse to Mohs micrographic surgery. If flap reconstruction is planned, always ensure that margins are uninvolved by tumor, either through frozen section or while awaiting the results of a permanent section; meanwhile maintain a moist dressing (Figure 58.31).

Therapeutic topical 5-FU or imiquimod does not offer an acceptable cure rate for treatment of BCC.[35]

SQUAMOUS CELL CARCINOMA

Squamous cell carcinoma does have premalignant precursors (e.g., actinic keratosis), as well as the in situ variant (Bowen disease).[2] SCCs may also arise de novo, are more aggressive than BCCs, and metastasize more frequently. Fair skin, previous history of sunburns, blue eyes, and blond or red hair increase the risk of SCC. Additionally, immunocompromised patients, especially those with renal and heart transplants, are 65% more likely to develop SCC. These patients may also have multiple and more aggressively behaving squamous cell carcinomas (Figure 58.32).

Unlike BCC, where tumor type is the principle prognosticator for treatment, the following are more important factors influencing the prognosis of SCC[10,23,24,41,44,54]:

- *Broader grades of differentiation*—These are graded 1 through 4 based on the ratio of differentiated to undifferentiated cells. Grades 3 and 4 (50% and 75% of undifferentiated cells, respectively) are twice as likely to recur and three times more likely to metastasize than grades 1 and 2.
- *Location*—Example: paronychial SCC has a high incidence of local recurrence but a low metastatic rate.
- *Tumor size*—T1 indicates lesion size less than 2 cm, T2 is 2 to 4 cm, and T3 is greater than 4 cm. SCCs of a size greater than 2 cm are twice as likely to recur and three times as likely to metastasize than tumors less than 2 cm.
- *Tumor depth*—Some physicians feel this to be the most important factor determining whether SCC will metastasize. SCCs more than 4 mm deep or extending into the subcutaneous tissue (Clark level 5) are the most likely to recur and metastasize.
- *Perineural invasion*—This is a poor prognostic sign for both recurrence and metastasis and indicates a need for postexcision radiation therapy. There is a rate of 47% recurrence, 35% metastasis to regional nodes, and 15% distant metastasis. Perineural invasion is often asymptomatic but may be associated with pain.

Thus, high-risk lesions are those that show rapid growth of greater than 2 cm; have depth of invasion on biopsy of 2 mm or more, or at least Clark level 4; have poor histologic differentiation; and show perineural invasion. Low-risk SCCs can be treated by cryotherapy, electrodesiccation and curettage, photodynamic therapy, or excision. The margin of excision for



FIGURE 58.28 Clinically different basal cell carcinoma subtypes: **A,** pigmented; **B,** superficial ulcerative; **C,** adenoid cystic; **D,** superficial spreading; and **E,** sclerosing (morpheaform).



FIGURE 58-29 **A-D,** Superficial spreading basal cell carcinoma of forearm is excised and then treated with fasciocutaneous bilobed transposition flap; there is a good final healed outcome following frozen section confirmation of clear margins intraoperatively.

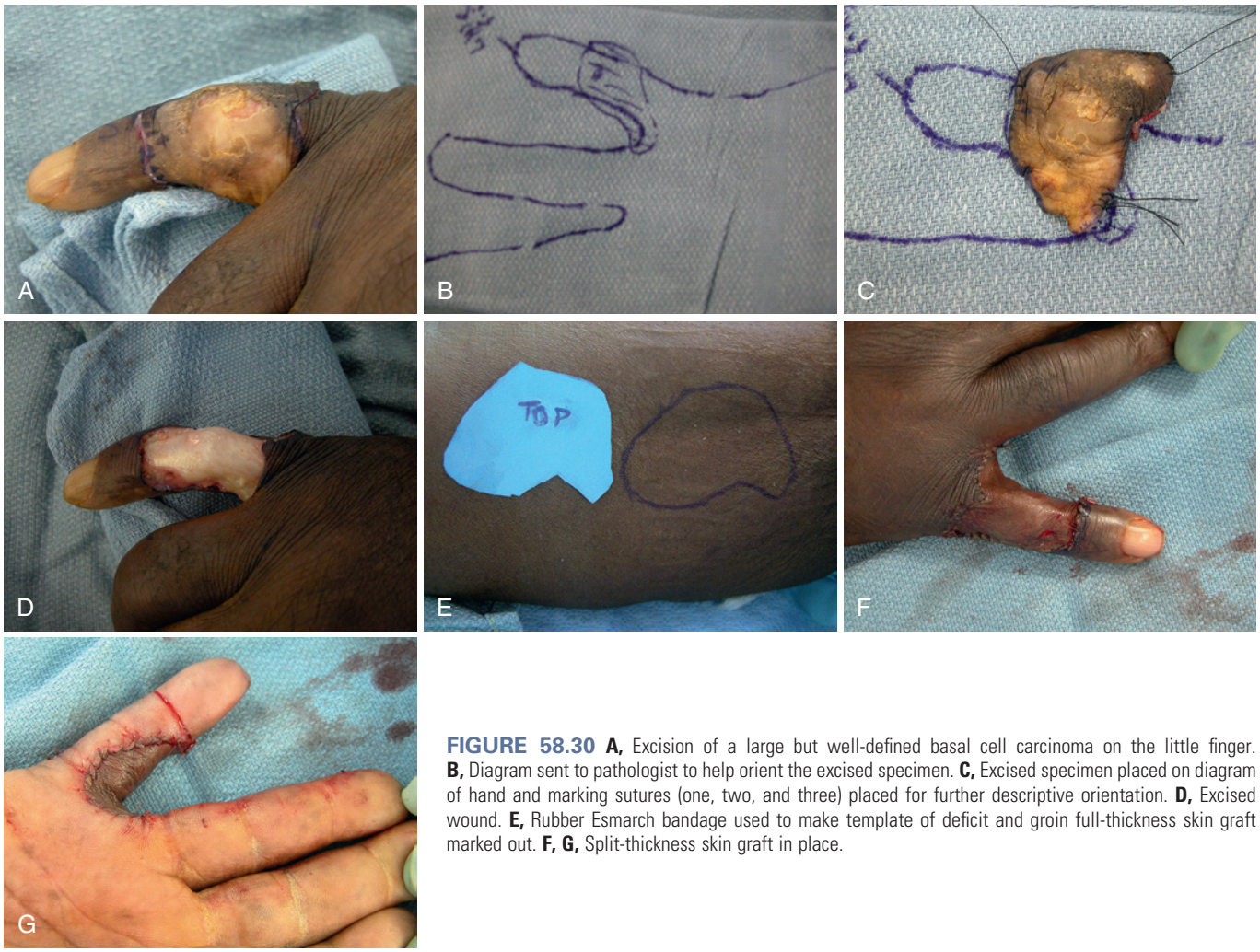

FIGURE 58.30 A, Excision of a large but well-defined basal cell carcinoma on the little finger. **B,** Diagram sent to pathologist to help orient the excised specimen. **C,** Excised specimen placed on diagram of hand and marking sutures (one, two, and three) placed for further descriptive orientation. **D,** Excised wound. **E,** Rubber Esmarch bandage used to make template of deficit and groin full-thickness skin graft marked out. **F, G,** Split-thickness skin graft in place.

low-risk lesions is 4 mm, and for high-risk SCCs it is at least 6 mm and down into subcutaneous fat or even to fascia (Figure 58.33).

Cure rates for surgery are about 92%. Mohs micrographic surgery may be indicated for the more high-risk lesions, especially for recurrent tumors, perineural invasion, poorly differentiated and deeply penetrating tumors, and in areas where tissue conservation is desired (e.g., on fingers).

Resulting excisional wounds may be able to be closed directly, but larger wounds can be covered with a skin graft. Local rotation flaps may be used; however, before realigning tissues the surgeon must be certain of free resection margins, either by frozen section or awaiting permanent section results. Amputation may be required to control aggressive tumors (Figure 58.34). Once again, periungual invasive SCC lesions may be confused with fungal infection, eczema, or Bowen disease (Figure 58.35).[37]

It is estimated that 2 to 5% of SCCs metastasize to axillary nodes. Elective node dissection or sentinel lymph node biopsy (SLNB) has not been shown to be of advantage in treating squamous cell carcinomas unless nodes are actually clinically enlarged because of the relatively low incidence of lymph node metastasis.[51] SCCs are slower to invade deeper tissues than are cutaneous malignant melanomas. Superficial dermis and epidermis are devoid of lymphatic drainage, making SCC less likely to spread via lymphatics. SLNB is under investigation for high-risk squamous cell carcinoma. If there are axillary node metastases, 5-year survival drops to 40%.

MELANOMA

There are several malignant melanoma morphologic subtypes. For cutaneous lesions thought to be melanoma, one may use the ABCDE acronym—asymmetric, border irregularity, color variation, diameter greater than 6 mm, evolving or changing—as a diagnostic guide (Figure 58.36). However, nodular melanomas grow vertically and may be greater than 6 mm and melanomas may be amelanotic.[17,21,22]

Such melanomas are subdivided into those with more rapid radial growth (i.e., lentigo maligna, superficial spreading, acral lentiginous) and those with a relative absence of radial growth with prominent vertical growth (nodular melanoma) (Figure 58.37). Vertical growth determines tumor depth and ultimate prognosis.

Clark's levels of invasion recognized the prognostic importance of vertical melanoma growth but was descriptive with



FIGURE 58.31 **A-D**, Open wound initially treated with moist dressings. Bilobed flaps may be very useful on the upper extremity because they can be transposed across the webspace. In addition, tissue can be taken from areas (i.e., those easily closed) of tissue laxity to areas where there is less laxity. This flap incidentally is also centered over the first dorsal metacarpal artery, thus ensuring good blood supply.

regard to invasion into the papillary dermis, reticular dermis, and finally into subcutaneous fat. We now use Breslow's millimeter depth of invasion thickness, which is measured from the epidermal basement membrane to the deepest melanoma tumor cells. Depth of invasion is difficult to accurately quantitate for subungual melanoma because the epidermal nail bed is compressed tightly against the dorsal periosteum of the distal phalanx.

Morphologic subtypes of melanoma, including superficial spreading, lentigo maligna (solar), acral lentiginous, subungual, nodular, amelanotic, and desmoplastic, are described next.

Superficial spreading melanoma makes up 70% of melanomas. Of all of them, it is the most likely to arise within or contiguous to a melanocytic nevus. There is a long, horizontal growth phase (6 months to 6 years) before vertical growth occurs; thus, these lesions have a better prognosis. Metastatic spread correlates with vertical invasion and rarely occurs during the early radial growth phase.

Lentigo maligna (solar) melanoma accounts for 4 to 10% of all melanomas. It is associated with elderly patients' long-term sun exposure. Thus, it occurs in the same areas affected by actinic keratoses, especially on the extensor aspect of the forearm. In situ melanoma is called lentigo maligna (sometimes Hutchinson's freckle). It is a flat macule that has a horizontal growth phase that lasts 1 to 2 decades. Once a vertical growth phase occurs and the dermis is invaded (often apparent clinically by papules in the lesion), the invasive melanoma is then called lentigo maligna melanoma. Histologic determination of margins may be difficult and often it is advisable to excise the lesion with at least 5-mm margins and await permanent histologic section confirmation before definitively closing the wound with a skin graft or flap.

Acral lentiginous melanoma makes up 2 to 8% of cutaneous malignant melanomas and occurs on the palmar surface and nail apparatus; it is not associated with sun exposure. This is the most common type of melanoma in people in whom melanoma is generally uncommon (i.e., African Americans, Asians, Hispanics). It has a long horizontal growth phase before vertical growth occurs. Diagnosis is often delayed because the lesions occur in areas not frequently examined clinically.

Subungual melanoma most commonly affects the thumb in the upper extremity. It may be mistaken for a subungual hematoma. Formal biopsy is required for a pigmented nail lesion that has persisted for more than 2 months.

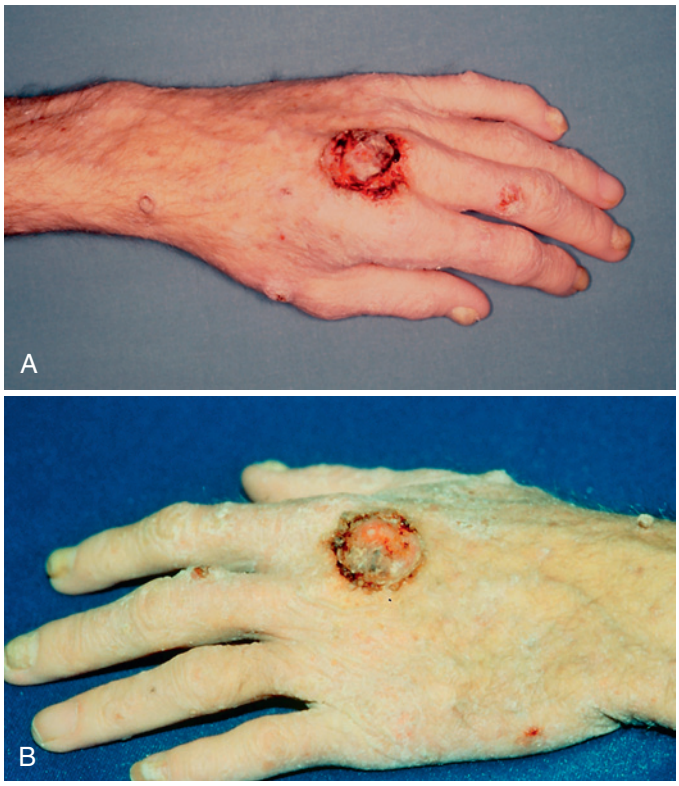

FIGURE 58.32 **A, B,** Renal transplant patient has multiple upper extremity squamous cell carcinoma.

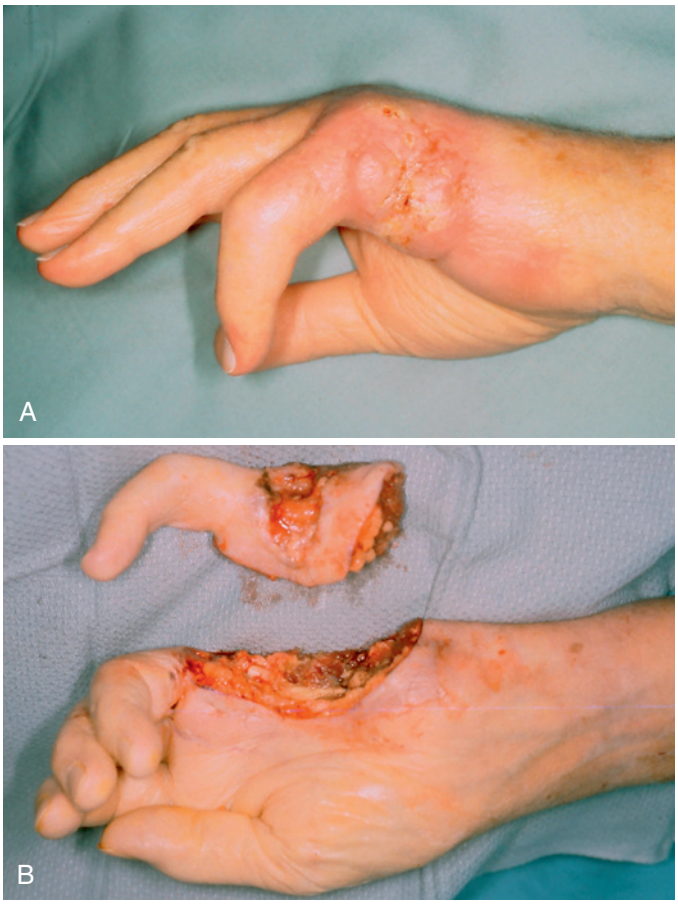

FIGURE 58.34 **A, B,** Squamous cell carcinoma invasive into bone and joint is best treated by digital ray amputation.

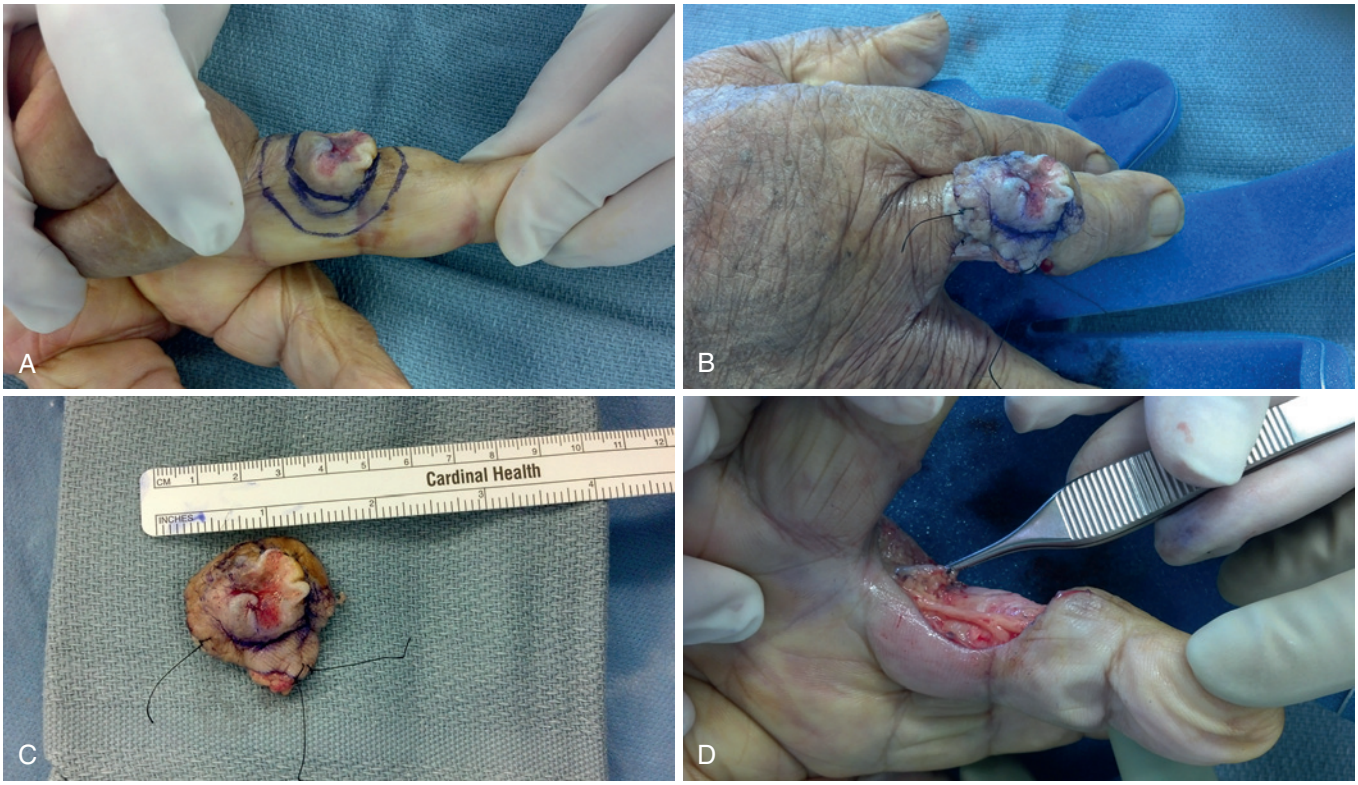

FIGURE 58.33 **A,** Digital squamous cell carcinoma is deeply adherent and measured. **B,** Excised lesion is orientated in situ and marking sutures are placed. **C,** Excised specimen showing marking orientation sutures. **D,** Resulting wound with exposed digital nerve.

Nodular melanoma accounts for 2 to 20% of melanomas. It is frequently thick at the time of diagnosis and thus has an increased metastatic potential. It generally arises de novo.

Amelanotic melanoma lesions may be gray or pink and devoid of dark pigmentation. They are a diagnostic challenge and can be mistaken for intradermal nevus or nodular BCC.

Desmoplastic melanoma occasionally may affect the hands. Histologically, it is similar to lentigo malignant melanoma but has a fibroblastic reaction in the dermis and neural invasion. Mean thickness at the time of initial clinical detection is 4.3 mm, but survival is more favorable for this tumor type than for other melanomas of equivalent thickness (5-year survival of 63% versus 48%).



FIGURE 58.35 Periungual squamous cell carcinoma.

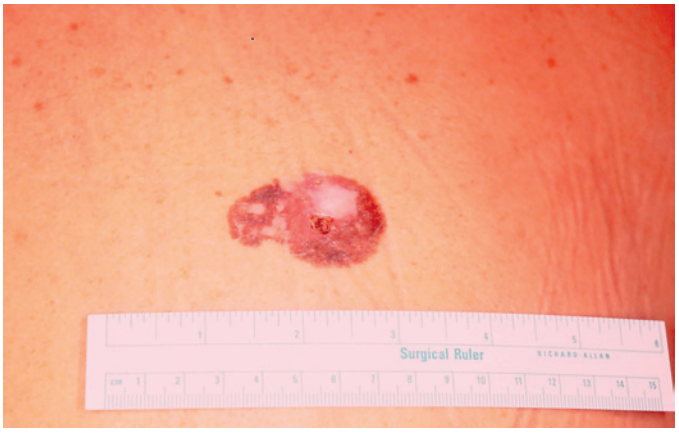

FIGURE 58.36 Superficial spreading melanoma showing irregular borders and variable pigmentation.

Prognosis and Staging

Independent prognostic indicators for patient survival with melanoma are Breslow thickness, macroscopic or microscopic ulceration, and lymph node involvement (determined by SLNB). Morphologic type, corrected for thickness, does not influence survival. Potential prognostic correlations exist for gender, mitotic rate, and truncal versus limb location (with the latter being more favorable).

Staging is determined by tumor size; regional lymph node metastases by the presence of micro- or macrometastases; by number of nodes involved; and, finally, by three subgroups of distant metastases—skin and soft tissue (best prognosis), lung, and other visceral metastases (worst prognosis) (Table 58.2). Elevated lactate dehydrogenase in any of the first metastatic subgroups upstages to the last subgroup.[3,20]

Laboratory investigations are unnecessary for early cutaneous melanoma (<1 mm thickness) in the absence of signs and symptoms to suggest metastatic disease. For larger melanomas, there are no uniform recommended initial staging evaluations, but these may include chest radiograph, blood count, liver function tests, and computed tomography (CT) scans. Positron emission tomography (PET) and CTs help identify developing metastases and facilitate decisions for surgical resection. Patients with melanoma possibly may be best evaluated in a multispecialty melanoma clinic.

Local Surgical Excisional Treatment

The Breslow depth classification assists in determining tumor excision margins.[4,20,44,61] In the 1980s, safety margins of 5 cm, independent of tumor thickness, were standard. Recommended excisional margins, based on Breslow tumor thickness, now are the following:

- In situ—2 to 5 mm (5-year survival, 95–100%)
- <1 mm—1 cm (5-year survival, 95–100%)
- 1 to 2 mm—1 to 2 cm (5-year survival, 80–96%)
- 2 to 4 mm—2 to 3 cm (5-year survival, 60–75%)
- >4 mm—3 cm (5-year survival, 50%)

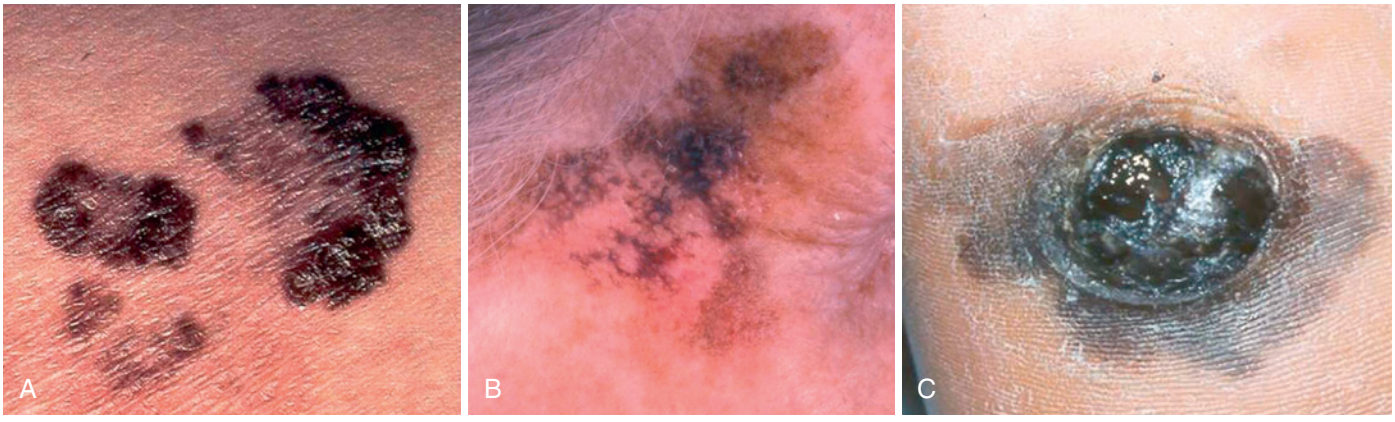

FIGURE 58.37 Different melanoma subtypes: **A,** Superficial spreading; **B,** lentigo maligna; and **C,** nodular.

TABLE 58.2 Tumor Staging

Tumor, Node, and Metastatic	Description*
Primary Tumor	
xT	Primary tumor cannot be assessed (e.g., shave biopsy or regressed melanoma)
T0	Primary tumor
Tis	Melanoma in situ
T1	Melanoma ≤1.0 mm
T2	1.01–2.0 mm
T3	2.01–4.0 mm
T4	>4.0 mm
Regional Lymph Nodes	
N0	No regional metastases
NX	Patients in whom regional nodes cannot be assessed (previously removed)
N1	1 metastatic node: (1) micrometastasis, (2) micrometastases
N2	2–3 metastatic c nodes: (1) micrometastasis, (2) macrometastases, (3) satellite and in-transit metastases without metastatic nodes
N3	4 or more metastatic nodes, or matted nodes, or satellite/in-transit metastases with metastatic nodes
Distant Metastatic	
M0	No detectable evidence of metastases
Mx	Presence or absence of metastases cannot be assessed
M1a	Metastases to skin, subcutaneous tissue, or distant lymph nodes
M1b	Metastases to lung
M1c	Metastases to all other visceral sites

*Presence of ulceration as determined by histopathology designates a tumor as Tb in contrast to a nonulcerated melanoma (Ta) and results in upstaging by one substage compared with nonulcerative melanoma.

Obviously, these measurements apply only to the peripheral margin because it is impossible to obtain equivalent deep margins on the hand. For in situ lesions, surgeons can excise through subcutaneous fat; however, for all other melanomas, extend the depth of excision to the hand's paratenon on the dorsum and to the forearm's fascia. Obviously, for deeper histological tumor extension, a more radical excision on the deep surface is required.

Subungual melanoma of an in situ type can be treated by surgical excision of the entire nail bed and paronychial region, and then covered with a full-thickness skin graft directly on the periosteum.[62] Invasive subungual melanoma is treated by amputation proximal to the next joint. Thus, if the distal phalanx is involved, amputate proximal to the IP joint of the thumb or the DIP joint of a finger. If a tumor extends to the middle phalanx, amputate proximal to the PIP joint. For functional reasons, a ray amputation may be the most appropriate.

Evaluation of Lymphatic Basins

Lymph node dissection is performed if there are palpable nodes that are histologically proven to be involved with metastatic melanoma.[11,38,39,44,48,49] This will probably not effect a cure, but it minimizes the morbidity of progressive malignancy in the axilla with tumor ulceration, pain from nerve plexus invasion, and lymphedema (Figure 58.38).

A randomized trial showed that SLNB patients who had a positive sentinel node and went on to complete lymph node dissection had an improved survival rate over those who had clinical observation and then only dissection when nodes were detected.[39] Sentinel lymph node biopsy is recommended for all lesions greater than 1-mm thickness in the absence of clinically palpable nodes.

SLNB is used to stage melanoma patients who are clinically node-negative (Figure 58.39). Lymph node staging is used to detect micrometastases for cutaneous melanoma with a Breslow tumor thickness of greater than 1 mm and for tumors of less than 1 mm if nonetheless of a Clark level 4 or 5. Thin melanomas of less than 1 mm account for about 70% of new cases, and SLNB generally is not recommended because the rate of micrometastases to nodes is less than 2%. For intermediate-thickness lesions, detection of micrometastasis by SLNB is the most important prognostic factor. However, it remains unclear, except for one study,[18,39] whether SLNB and subsequent radical axillary lymphadenectomy for positive nodes actually prolongs survival.

Isosulfan vital blue dye injection is done 10 minutes before surgical preparation of the patient. The use of both radiocolloid and mapping intraoperatively with a sterile gamma probe, combined with the blue dye injection, increases sentinel lymph node detection rates to more than 99% compared with 87% when only blue dye is used.[48] The morbidity associated with SLNB is obviously far less than with elective lymph node dissection (ELND), so formal node dissection can be targeted at specific patients who have a positive sentinel node biopsy (see Figure 58.39).

LESS COMMON MALIGNANT TUMORS

Merkel Cell (Neuroendocrine) Carcinoma

Merkel cells are in the basal layer of the epidermis and are associated with slow-adapting, pressure-sensitive sentry nerve endings. Merkel cell carcinoma[57,60] is a rapidly growing, painless and nontender intracutaneous nodule that can grow to as large as 5 cm in diameter. Treatment requires wide surgical excision and sometimes even amputation with regional lymphadenectomy. Some physicians recommend postoperative irradiation as well as chemotherapy. Local recurrence, distant metastases, and lymph node metastases are common (Figure 58.40).

Lymphangiosarcoma (Stewart-Treves Syndrome)

Lymphangiosarcoma[14,33,66] is a rare tumor that occurs in the upper extremity of patients with chronic lymphedema for more than 10 years following mastectomy with axillary lymph node dissection and irradiation. Initially, the tumor may not be obvious clinically and may appear simply as a bruise or as multiple purple skin papules; after that the tumor develops rapidly. Following biopsy confirmation, life-saving amputation in

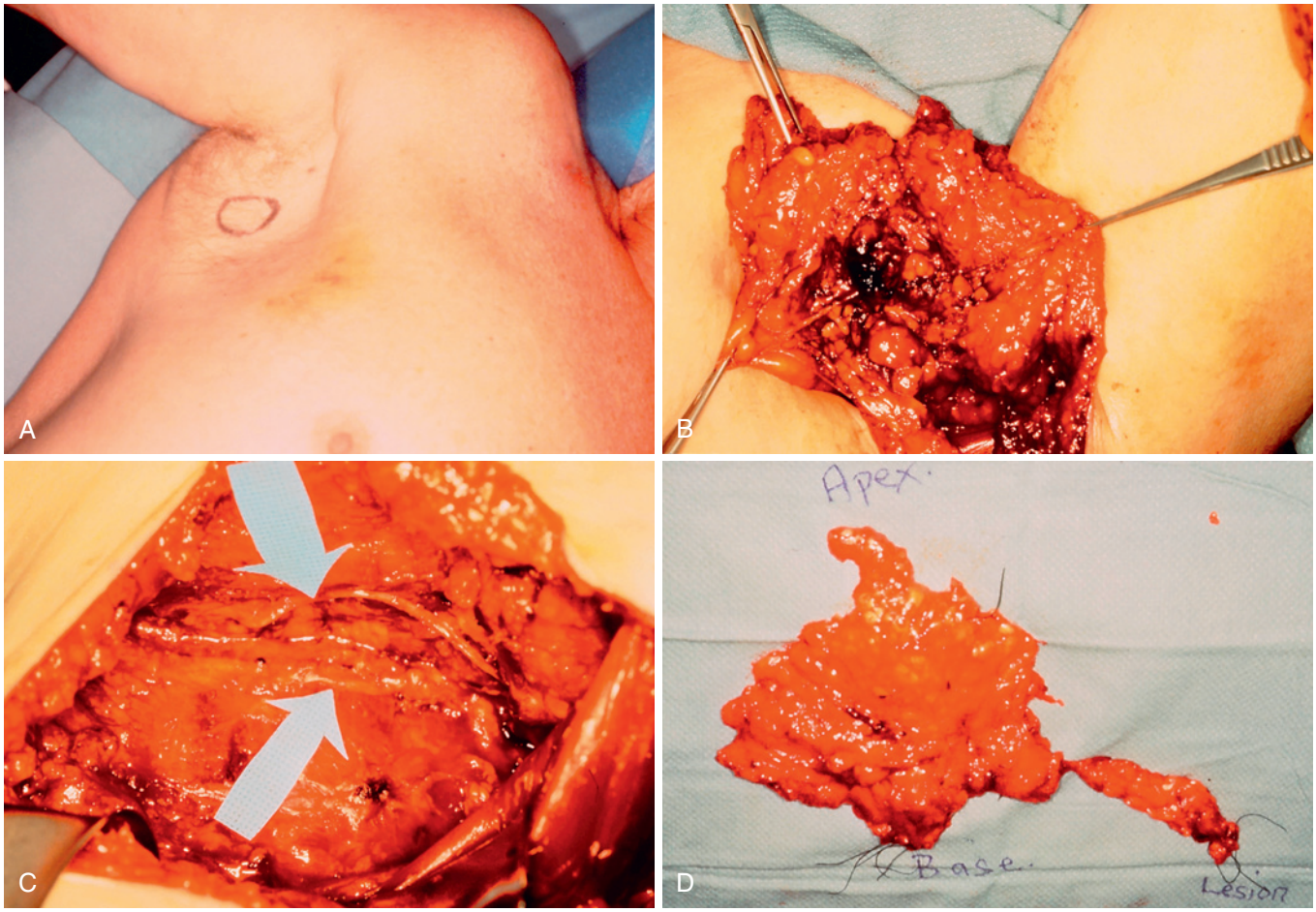

FIGURE 58.38 **A,** Patient with upper extremity melanoma and palpable axillary lymph node. **B,** Melanoma pigmentation is seen macroscopically in the involved node. **C,** Axillary dissection clearing all the way to the apical nodes (*arrows* point to axillary vessels and laterally to thoracodorsal nerve). **D,** Glandular axillary tissue removed as a single specimen (sutures oriented to the axillary specimen).

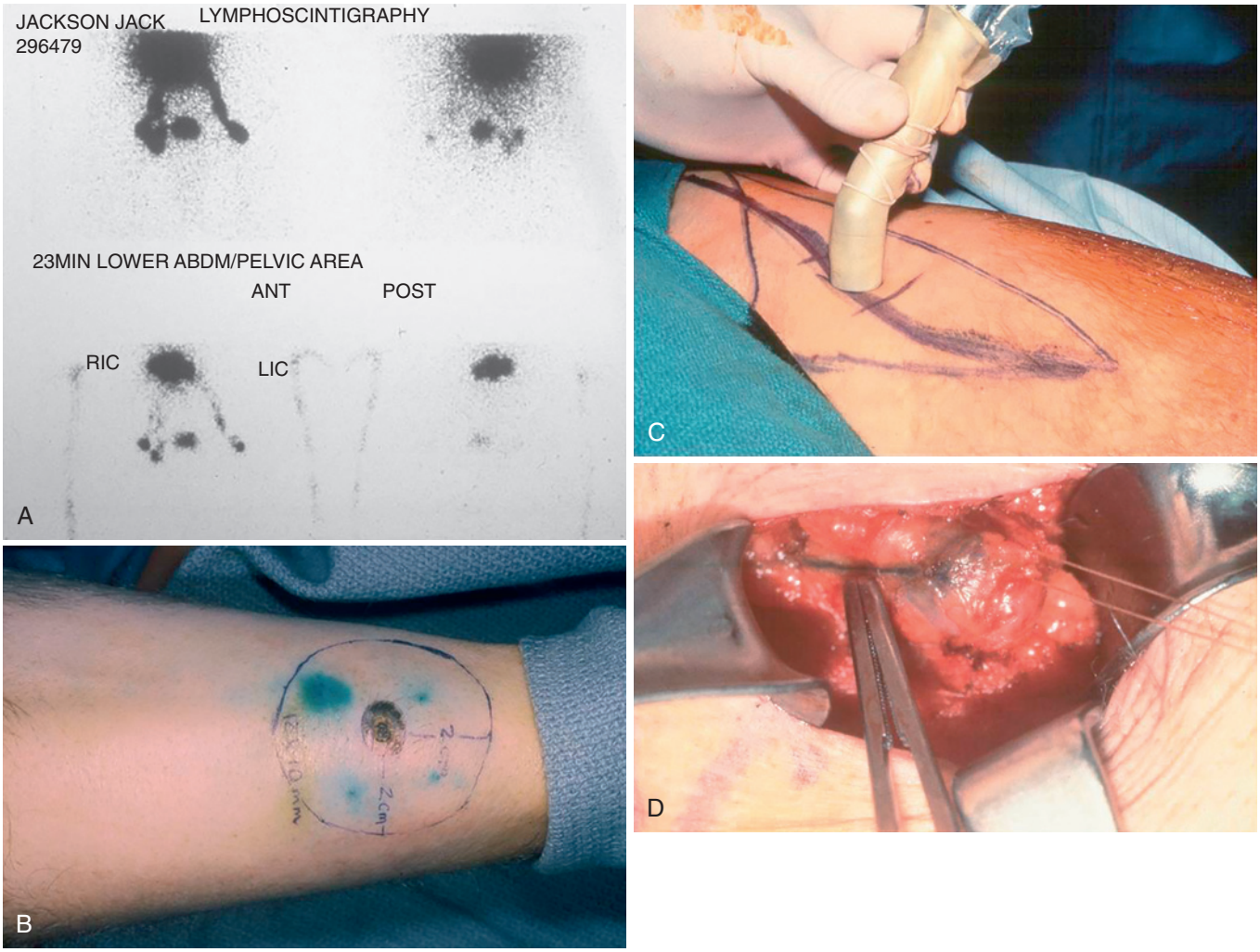

FIGURE 58.39 **A, B,** Sentinel lymph node mapping can be performed and facilitated by both intralesional injection of a vital dye and radiocolloid. **C,** A sterile probe detects the node with the highest radioactivity count. **D,** The sentinel node also takes up the vital dye stain.

conjunction with adjuvant chemotherapy is the preferred treatment.

Sweat Gland Tumors

Even so-called benign sweat gland tumors have a tendency to recur locally, and benign tumors may transform into a malignancy over time.[12,13] Treatment of the benign tumors must include excising a margin of surrounding normal tissue. Examples are eccrine poroma, chondroid syringoma, and eccrine spiradenoma. Tumors occur most commonly on the palm because this is where there is the highest concentration of sweat glands.

Malignant varieties of sweat gland tumors do occur but are rare, so there are no clear treatment guidelines. They develop painful ulceration, are locally invasive, and spread to lymph nodes and distant metastatic sites. Wide local excision is necessary as well as SLNB, with some recommending prophylactic regional lymph node dissection.

Human Immunodeficiency Virus

Patients with human immunodeficiency virus (HIV) have a higher risk of skin cancer, especially with a known viral etiology (e.g., Kaposi sarcoma)[6] (Figure 58.41). There is also a higher incidence of nonmelanoma skin cancers with a two-fold higher risk of BCC in HIV-infected Caucasian males, and a 2.6-fold higher risk of SCC in HIV-infected individuals irrespective of gender.[30] HIV virus levels and antiretroviral therapy are not related to this higher risk. Melanoma may also occur at higher rates among HIV patients.

Dermatofibrosarcoma Protuberans

This is a locally invasive fibrosarcoma of the dermis (Figure 58.42) that has poorly defined clinical margins.[9,53] Treatment is wide resection followed by appropriate wound closure, most often with a skin graft. This is because the widely resected tumor often precludes direct wound closure and local flaps may be ill-advised unless the surgeon is certain of the clear clinical margins.

Metastatic Tumors

Tumors rarely metastasize from other sites to soft tissues or bones of the fingers or hand; however, always biopsy suspicious lesions (Figure 58.43).

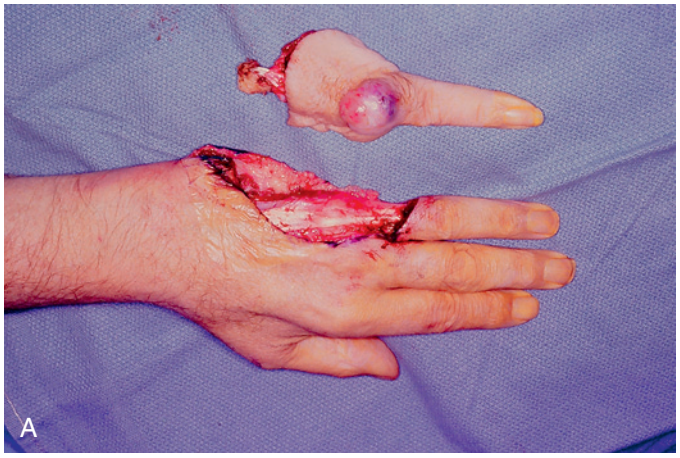

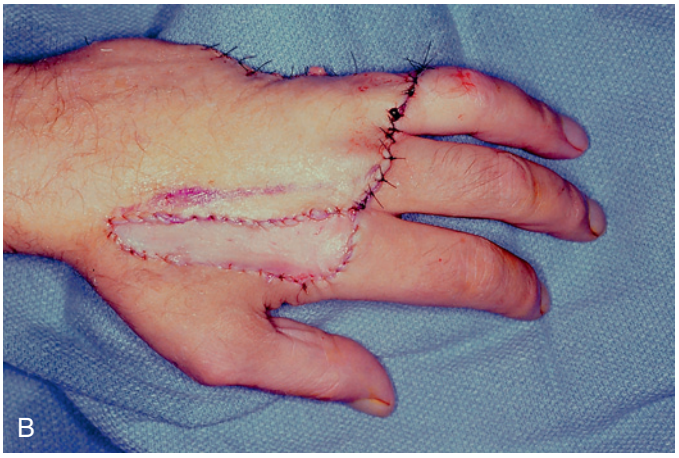

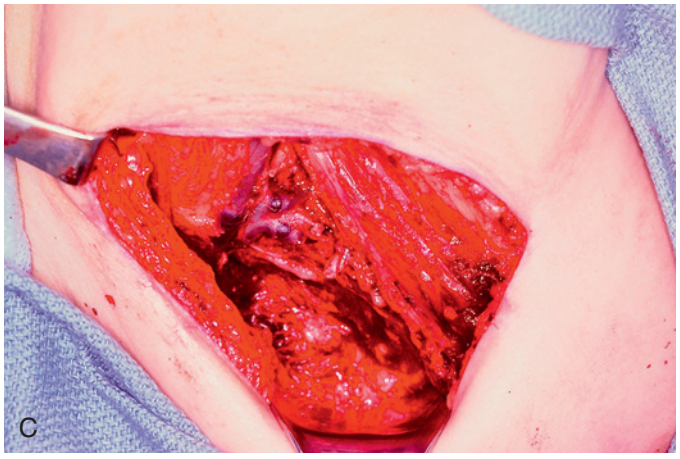

FIGURE 58.40 **A-C,** Merkel cell tumor treated by finger ray amputation, wound closure by dorsal hand transposition flap, and also axillary node dissection.





FIGURE 58.41 **A, B,** Cutaneous lesions of Kaposi sarcoma in a patient with human immunodeficiency virus.

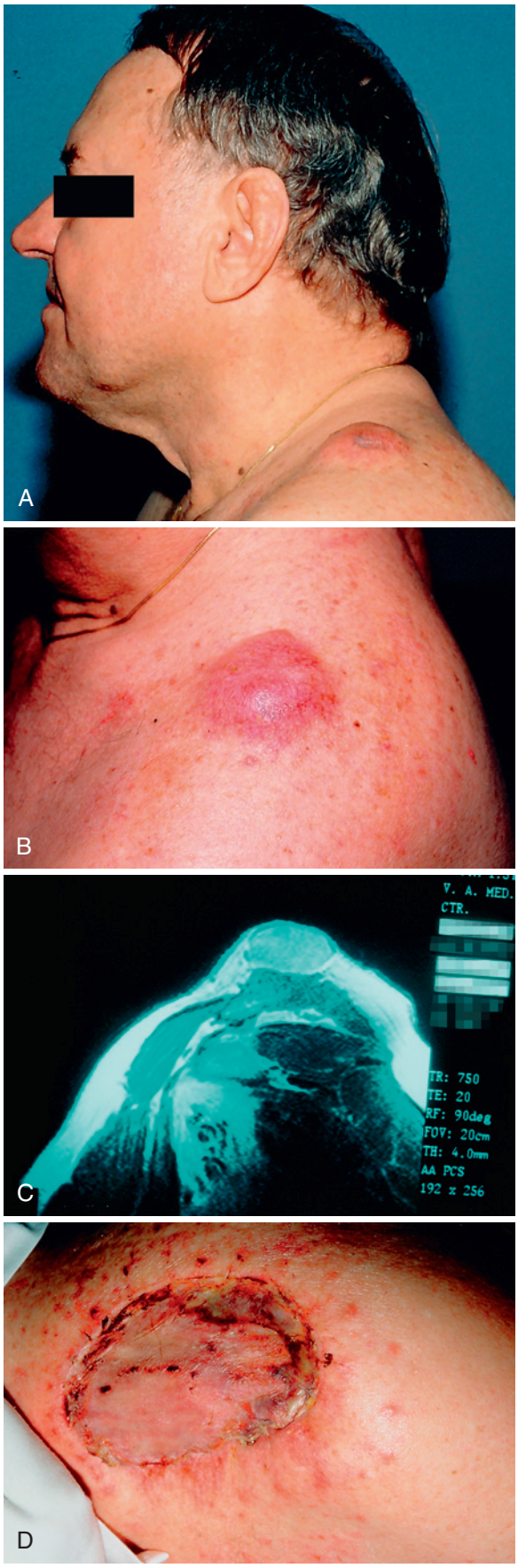

FIGURE 58.42 **A, B,** Dermatofibrosarcoma protuberans of shoulder. **C,** Magnetic resonance imaging scan shows lesion confined to skin and subcutaneous tissue. **D,** Wide lesion excision is followed by split-thickness skin grafting.



FIGURE 58.43 Patient presents with multiple tender fingertip lesions. These were excised and examined histologically and proved to be metastatic renal cell tumors in a patient previously undiagnosed for renal carcinoma.

REFERENCES

1. Abzug JM, Cappel MA: Benign acquired superficial skin lesions of the hand. *J Hand Surg* 37A:378–393, 2012.
2. Anndolu-Brasie R, Patel AR, Patel SS, et al: Squamous cell carcinomas of the skin. In Nouri K, editor: *Skin cancer*, New York, 2008, McGraw-Hill Medical, ch 7.
3. Balch CM, Buzaid AC, Soong S: Final version of the American Joint Committee on cancer staging system of cutaneous melanoma. *J Clin Oncol* 19:3635–3648, 2001.
4. Balch C, Soong S, Smith T: Long-term results of a prospective surgical trial comparing 2 cm vs. 4 cm excision margins for 740 patients with 1–4 mm melanomas. *Ann Surg Oncol* 8:101–108, 2001.
5. Baran R, Mikhail G, Costini B: Distal digital keratoacanthoma: two cases with a review of the literature. *Dermatol Surg* 27:575–579, 2001.
6. Bergman R, Guttman-Yassky E: S and R. Kaposi sarcoma. In Keyvan N, editor: *Skin cancer*, New York, 2008, McGraw-Hill Medical, ch 21.
7. Solomons B: *Lecture notes on dermatology*, ed 3, Oxford, UK, 1973, Blackwell Scientific Publications.
8. Bloom W, Fawcett DW: *A textbook of histology*, ed 9, Philadelphia, 1968, WB Saunders Co, ch 22.
9. Bowne WB, Antonescu CR, Leung DH: Dermatofibrosarcoma protuberans. A clinicopathologic analysis of patients treated and followed at a single institution. *Cancer* 88:2711–2720, 2000.
10. Brodland DG, Zitelli JA: Surgical margins for excision of primary cutaneous squamous cell carcinoma. *J Am Acad Dermatol* 27:241–248, 1992.
11. Cochran AJ, Morton DL: Detection of clinically relevant melanoma metastases requires focused, not exhaustive, evaluation of sentinel lymph nodes. *Am J Surg Path* 30:419–420, 2006.
12. Cooper P: Carcinoma of sweat glands. *Pathol Ann* 22:83–124, 1987.
13. Cruz D: Sweat gland carcinomas: a comprehensive review. *Semin Diag Pathol* 4:38–74, 1987.
14. Cuang K, Kim H, Jeffers L: Lymphangiosarcoma (Stewart-Treves syndrome) in post mastectomy patients. *J Hand Surg* 25:1163–1168, 2000.
15. Dobson J, De Spain J, Hewett J: Malignant potential of actinic keratoses and the controversy over treatment: a patient-oriented perspective. *Arch Dermatol* 127: 1029–1031, 1991.
16. Dubin N, Kopf AW: Multi-variant risk score for recurrence of cutaneous basal cell carcinomas. *Arch Dermatol* 119:373–377, 1983.
17. Emmet AJJ, Austin W, Page G: *The bare fact: the effect of the sun on the skin*, Baltimore, 1988, Williams and Wilkins.
18. English C, Hammert WC: Cutaneous malignancies of the upper extremity. *J Hand Surg* 37A:367–377, 2012.
19. Focht DR, 3rd, Spicer C, Fairchok MP: The efficacy of duct tape vs. cryotherapy in the treatment of verruca vulgaris (the common wart). *Arch Pediatr Adolesc Med* 156:971–974, 2002.
20. Garbe C, Eigentler JK: Diagnosis and treatment of cutaneous melanoma: state of the art 2006. *Melanoma Res* 17:117–127, 2007.
21. Gersenhenwald JE, Morton DL, Thompson JF: Prognostic factors and natural history. In Balch CM, Houghton AN, Sober AJ, et al, editors: *Cutaneous melanoma*, ed 4, St. Louis, 2003, Quality Medical Publishing, ch 2.
22. Giblin AD, Thomas J: Incidence, mortality and survival in cutaneous melanoma. *J Plast Reconstr Aesthet Surg* 60:32–40, 2007.

23. Goepfert H, Dichtel WJ, Medina JE: Perineural invasion in squamous cell carcinoma of the head and neck. *Am J Surg* 148:542–547, 1984.
24. Goldman GD: Squamous cell cancer: a practical approach. *Semin Cutan Med Surg* 17:80–95, 1998.
25. Haase SC, Chung KC: Skin tumors. In Wolfe SW, Hotchkiss RN, Pederson WC, et al, editors: *In: Green's operative hand surgery*, ed 6, Philadelphia, 2011, Elsevier/Churchill Livingstone, ch 64.
26. Harris AO, Levy MI, Goldberg LH, et al: Nonepidermal and appendageal skin tumors. *Clin Plast Surg* 20:115–130, 1993.
27. Ilyas EN, Leinberry CF, Ilyas AM: Skin cancers of the hand and upper extremity. *J Hand Surg* 37A:171–178, 2012.
28. Jacobs GH, Rippey JJ, Altin LM: Prediction of aggressive behavior in basal cell carcinoma. *Cancer* 49:533–537, 1982.
29. Kao G: Carcinoma arising in Bowen's disease. *Arch Dermatol* 122:1124–1126, 1986.
30. Karen JK, Sanchez MR: Skin cancers in HIV patients. In Keyvan N, editor: *Skin cancer*, New York, 2008, McGraw-Hill Medical, ch 29.
31. Kuflik DG: Cryosurgery for skin cancer: 30-year experience and cure rates. *Dermatol Surg* 30:297–300, 2004.
32. Kuijpers DDI, Thissan MR, Berretty PJ: Surgical excision versus curettage plus cryosurgery in the treatment of basal cell carcinoma. *Dermatol Surg* 33:579–587, 2007.
33. Lasa M, Mateo P, Bascon N: Lymphangiosarcoma in a chronic lymphedematous limb: a case report. *Tumor* 81:381–382, 1995.
34. Mantese SA, Diogo PM, Rocha A, et al: Cutaneous horn: a retrospective histopathological study of 222 cases. *An Bras Dermatol* 85:157–163, 2010.
35. Marks R, Gebauer K, Shumack S: Imiquimod 5% cream in the treatment of superficial basal cell carcinoma: results of a multicenter 6-week dose-response trial. *J Am Acad Dermatol* 44:807–813, 2001.
36. Maubec E, Duvillard P, Margulis A, et al: Common skin cancers in porokeratosis. *Br J Dermatol* 152:1389–1391, 2005.
37. Mikhail GR: Subungual epidermosed carcinoma. *J Am Acad Dermatol* 11:291–298, 1992.
38. Morton DL, Cochran AJ, Thompson JF: Sentinel node biopsy for early-stage melanoma: accuracy and morbidity in MSLT-1, an international multicenter trial. *Ann Surg* 242:302–311, 2005.
39. Morton DL, Thompson JF, Cochran AJ, et al: Sentinel-node biopsy or nodal observation in melanoma. *N Engl J Med* 355:1307–1317, 2006.
40. Mosterd K, Thissen MR, van Marion AM, et al: Correlation between histologic findings on punch biopsy specimens in recurrent basal cell carcinoma. *J Am Acad Dermatol* 104:323–327, 2011.
41. Motley R, Kersey P, Lawrence C: Multi-professional guidelines for the management of the patient with primary cutaneous squamous cell carcinoma. *Br J Dermatol* 146:18–25, 2002.
42. Netscher DT, Anous M, Spira M: Premalignant skin conditions, basal cell carcinoma and squamous cell carcinoma. In Cohen M, editor: *Mastery of surgery: plastic and reconstructive surgery*, Boston, 1994, Little Brown and Co, ch 20, pp 309–332,.
43. Netscher DT, Hildreth D, Kleinert HE: Tumors of the hand. In Georgiade GS, Riefkohl R, Levin LS, editors: *Plastic, maxillofacial and reconstructive surgery*, ed 3, Baltimore, 1997, Williams and Wilkins, ch 96.
44. Netscher DT, Leong M, Orengo I, et al: Cutaneous malignancies: melanoma and nonmelanoma types. *Plast Reconstr Surg* 127:37e–56e, 2011.
45. Netscher DT, Spira M: Basal cell carcinoma: an overview of tumor biology and treatment. *Plast Reconstr Surg* 113:74e–94e, 2004.
46. Netscher DT, Spira M, Cohen V: Benign and premalignant skin conditions. In Achauer BM, Eriksson E, Guyuron B, et al, editors: *Plastic surgery: indications, operations and outcomes*, St. Louis, 2000, Mosby, ch. 21.
47. O'Connor EA, Dzwierzynski W: Longitudinal melonychia: clinical evaluation and biopsy technique. *J Hand Surg* 36A:1852–1854, 2011.
48. Parwlik TM, Ross MI, Gershenwald JE: Lymphatic mapping in the molecular era. *Ann Surg Oncol* 11:362–374, 2004.
49. Ranieri JM, Wagner JD, Wench S: The prognostic importance of sentinel node biopsy in the melanoma. *Ann Surg Oncol* 13:927–932, 2006.
50. Rayner CRW, Towers JF, Wilson JSP: What is Gorlin's syndrome? The diagnosis and management of the basal cell nevus syndrome, based on a study of thirty-seven patients. *Br J Plast Surg* 36:62, 1976.
51. Reschly MJ, Messina JL, Zaulyanov LL: Utility of sentinel lymphadenectomy in the management of patients with high-risk cutaneous squamous carcinoma. *Dermatol Surg* 29:135–140, 2003.
52. Robinson JK: Principles of Mohs micrographic surgery. In Cohen M, editor: *Mastery of plastic and reconstructive surgery*, Boston, 1994, Little Brown and Co, ch 21.
53. Rowsell AR, Poole MD, Godfrey AM: Dermatofibrosarcoma protuberans: the problems of surgical management. *Br J Plast Surg* 39:262–264, 1986.
54. Rudolph R, Zelac DE: Squamous cell carcinoma of the skin. *Plast Reconstr Surg* 114:82e–94e, 2004.
55. Sacks JM, Azari KK, Oates S, et al: Benign and malignant tumors of the hand. In Chang J, Neligan PC, editors: *Plastic Surgery*, 3rd ed, vol 6, London, 2013, Elsevier/Saunders, ch 15.
56. Salache SJ, Ammonett RA: Morpheaform basal cell epitheliomas: a study of subclinical extension in a series of 51 cases. *J Dermatol Surg Oncol* 7:387–394, 1981.
57. Samonis G, Mantadakis E, Konoas TC, et al: Merkel cell carcinoma: a case series of twelve patients and review of the literature. *Anticancer Res* 21:4173–4178, 2001.
58. Schwartz R: Keratoacanthoma. *J Am Acad Dermatol* 30:1–22, 1994.
59. Scribener Y, Grossharis ED, Cribier B: Variations of basal cell carcinomas according to gender, age, location and histopathologic subtypes. *Br J Dermatol* 147:41–47, 2002.
60. Simstein NL, Soluggs NK: Merkel cell tumor: two cases. *Int Surg* 83:60–62, 1998.
61. Sober AJ, Balch CM: Method of biopsy and incidence of positive margins in primary melanoma. *Ann Surg Oncol* 14:274–275, 2007.
62. Thai K: Nail apparatus melanoma. *Australas J Dermatol* 42:71–81, 2001.
63. Walls EW: Blood, vascular and lymphatic systems. In Romaines GJ, editor: *Cunningham's textbook of anatomy*, ed 10, London, 1964, Oxford University Press, pp 959–988.
64. Werlinger KD, Upton G, Moore AY: Recurrence rates of primary non-melanoma skin cancers treated by surgical excision compared to electrodesiccation—curettage in private dermatologic practice. *Dermatol Surg* 28:1138–1142, 2002.
65. Witthaut J, Steffens K, Koob E: Reliable treatment of pyogenic granuloma of the hand. *J Hand Surg* 19B:791–793, 1994.
66. Woodward AH, Ivins JC, Soule EH: Lymphangiosarcoma arising in chronic lymphedematous extremities. *Cancer* 30:562–572, 1972.

Bone and Soft Tissue Tumors

Edward A. Athanasian

Acknowledgment: I would like to acknowledge the excellent work of earlier authors who wrote and revised portions of this chapter in previous editions: Alexander C. Angeledes, Gordon B. McFarland, Jr., Waldo E. Floyd III, Richard J. Smith, Clayton A. Peimer, Harold M. Dick, and Owen J. Moy. The principles of management of aggressive and malignant tumors as described in great detail by these authors have changed relatively little. I have attempted to enlarge the focus of the chapter and update patient management principles, which have changed as the effects of adjuvant therapies have become better understood.

The purpose of this chapter is to present the most recent knowledge on specific benign and malignant bone and soft tissue tumors that may appear in the hand. Tumors occurring in the hand and forearm generally have unique growth patterns and potential for metastasis that may be different from those seen elsewhere in the body. Tumors in the hand are relatively uncommon, and most surgeons encounter them infrequently. Knowledge regarding treatment and care of hand lesions is often based on case reports, small case series, retrospective reviews, and a few large general case studies. Data from controlled trials are limited but have advanced the use of chemotherapy and radiation therapy and the treatment of soft tissue sarcoma. At times, the information available is both contradictory and controversial. It is important for the treating surgeon to thoroughly understand the specific characteristics of the tumor being treated, as well as the systemic treatment of the disease. Of greater importance, however, is knowledge and practice of the principles and guidelines for the treatment of patients with tumors.

The reader is strongly encouraged to understand and review the principles of staging, biopsy, resection, and amputation before treating all tumors, particularly those that are malignant. In no other aspect of hand surgery are the implications for uninformed decisions, judgments, or actions more serious than in the treatment of malignant bone or soft tissue sarcomas. Conversely, treatment based on up-to-date knowledge and a thorough understanding of the principles of care for local and systemic cancer maximizes the potential to save the patient's life. Only after this concern has been addressed can one focus on the task of salvaging or reconstructing a useful hand or limb. Regular review of treatment principles before treating patients for malignant tumors is imperative and helps ensure appropriate treatment.

DIAGNOSIS AND MANAGEMENT OF MUSCULOSKELETAL TUMORS

Neoplasms are usually classified into two categories: benign and malignant; in musculoskeletal tissues, malignancies can also be subdivided into low- and high-grade. Cellular growth in benign neoplasms usually proceeds at a much slower rate than in malignant tumors.

Malignant neoplasia is characterized by a rapid growth rate, atypical cellularity, and poor cell differentiation. Local growth is aggressive and infiltrative; there are only "pseudocapsules" through which the tumor must extend to form satellite lesions. Such tumors are likely to spread as blood-borne metastases, and local recurrence rates are high after excision unless a wide margin of normal tissue is included in the resection. Low-grade malignancies grow more slowly and infiltrate early but are less likely to metastasize than to recur locally. *Neither all generic categories nor isolated case illustrations are consistent with these classifications, however.*

Many benign tumors of the hand or forearm require no treatment, can be diagnosed clinically, and are asymptomatic. However, if a lesion increases in size or becomes symptomatic or if the physical or radiographic appearance suggests an aggressive process, appropriate staging studies, including obtaining tissue for diagnosis, must be performed.[38,53,56,134,180,181] Unfortunately, lumps and growths that look innocent may not necessarily be so. Surgeons need to be familiar with the range of possible diagnoses and generate a differential diagnosis for the individual patient under consideration. A physician is not justified in advising a patient that a mass should be "left alone" until the proper diagnosis is established by all appropriate means. Any tumor with an unclear diagnosis on the basis of nonsurgical evaluation should be sampled. If the biopsy proves the tumor to be benign, no further treatment may be necessary. If a malignant or an aggressive nonmalignant lesion is identified, however, further management is required.

Tumors that are symptomatic need to be diagnosed and staged. The clinical and family history, physical characteristics of the tumor, and data from laboratory and imaging studies provide at least the basis of a clinical impression. If the precise

diagnosis is unclear after a complete workup, a carefully planned biopsy is required to avoid the hazards of misdiagnosis and its complications.

CLASSIFICATION AND STAGING OF TUMORS

Management of hand and upper extremity tumors does not differ significantly from management of tumors in other parts of the musculoskeletal system. Correct treatment must always take into consideration the size and location of the growth, its histologic grade and clinical behavior, and its potential for metastases.[38,53,54,115,134,180,181] A thorough understanding of the general principles and guidelines is essential for accurate assessment and staging of tumors.

Histologic Grade and Surgical Staging

The histologic grade (G) of a neoplasm is determined by the malignant characteristics of tissue obtained by biopsy. An accepted classification is as follows:

G0: Benign

Gl: Low grade: few cells, much stroma, little necrosis, mature cells, <5 mitoses per high-power field

G2: High grade: many cells, little stroma, much necrosis, immature cells, more than 10 mitoses per high-power field

Benign tumors can be classified into three stages[53]:

- Latent, stage I tumors do not usually require treatment; they may heal spontaneously or remain unchanged.
- Active, stage II benign neoplasms grow within a limited zone and are contained by natural barriers; if surgery is required, these tumors are most often controlled by intralesional or marginal excision.
- Locally aggressive, stage III benign tumors may both grow and spread beyond natural barriers; excision usually requires a wide surgical margin or en bloc resection for local cure.

To avoid confusion and differences of opinion about malignant bone tumors, it has become important to establish specific grading criteria for tumors. A classification scheme based on a modified staging system for bone sarcomas was established by the American College of Surgeons Joint Committee on Cancer and End Results Reporting in 1977. It was proposed by W. F. Enneking at the University of Florida and accepted by the Musculoskeletal Tumor Society (MSTS) in 1979 (Tables 59.1 and 59.2). Although this staging system was developed for bone sarcomas, it has also been used to describe and stage soft tissue sarcomas, particularly in the orthopedic surgical community. A comparison of the MSTS system and the fourth and fifth editions of the American Joint Committee on Cancer (AJCC) system has found the AJCC system to be more predictive of systemic relapse.[204] The AJCC staging system incorporates grade, size, depth, and the presence or absence of metastasis to determine the final stage of the lesion. This system should be used preferentially for staging of soft tissue sarcomas (Table 59.3).

The pathologist and surgeon must agree on a surgical grade (G1 or G2) of the malignancy based primarily on the histologic features of the tumor and also on its gross pathologic appearance, the clinical setting, and its radiologic appearance. The histologic grade is determined only after careful scrutiny of a representative biopsy specimen by an experienced musculoskeletal pathologist. Clinical and radiologic status are also important parameters for determining the final tissue diagnosis and surgical grade.

The two grades of malignant tumors differ with respect to their rate of metastasis and recurrence: G1 is a low-grade malignancy with a low likelihood of metastasis and frequent local recurrence, and G2 is a high-grade malignancy with frequent blood-borne metastases. The so-called low-grade malignant tumors can also metastasize but are typically less likely to do so early in their course. Assignment of a grade to a particular tumor is neither easy nor exact because grading criteria are not quantifiable. Cellular morphology, anaplasia, necrosis, mitoses,

TABLE 59.1 Surgical Stages

Stage	Grade	Site
IA	Low (G1)	Intracompartmental (T1)
IB	Low (G1)	Extracompartmental (T1)
IIA	High (G2)	Intracompartmental (T1)
IIB	High (G2)	Extracompartmental (T2)
III	Any (G) Regional or distant metastasis (M)	Any (T) Regional or distant metastasis (M)

Adapted from Enneking WF: Staging of musculoskeletal neoplasms. In Uhthoff UK, Stahl E, editors: *Current concepts of diagnosis and treatment of bone and soft tissue tumors*, New York, 1984, Springer-Verlag, pp 1–21.

TABLE 59.2 Surgical Procedures for Extremity Sarcomas

	SURGICAL METHOD			
Margin	Limb Salvage	Amputation	Planes of Dissection	Microscopic Appearance
Intralesional	Debulking, piecemeal excision/curettage	Translesional amputation	Within tumor (palliative)	Tumor at all margins
Marginal	Marginal en bloc excision	Marginal amputation	Within tumor "reactive zone"	Reactive tissue (± microextensions of tumor)
Wide	Wide en bloc excision	Wide through-bone amputation	Through normal tissue but within compartment	Normal tissue (± "skip lesions")
Radical	En bloc resection of entire compartment	Extraarticular disarticulation	Normal tissue extracompartmental	Normal tissue

Adapted from Enneking WF: Staging of musculoskeletal neoplasms. In Uhthoff UK, Stahl E, editors: *Current concepts of diagnosis and treatment of bone and soft tissue tumors*, New York, 1984, Springer-Verlag, pp 1–21.

and tissue of origin can also be influenced by clinical behavior. Tumors that are known to be exceptionally dangerous (e.g., synovial and epithelioid sarcoma) are most properly classified into a higher grade than their histology would indicate. Two other criteria are important: T, which represents the size and site of the tumor; and M, which designates the presence of detectable metastases.

Location (Site)

Regardless of size, if the tumor is limited to a single anatomic compartment, it generally will be resectable. At the same time, it will be possible to preserve the extremity, as is the case with highly malignant tumors involving the distal phalanges and other acral parts. The basis of defining a *compartment* is the recognition that certain natural anatomic barriers exist that will temporarily contain and delay the spread of a pathologic process such as infection and neoplasia. For example, an intraosseous tumor contained by the cortices and intramedullary canal of a tubular bone would be considered intracompartmental. However, if this tumor perforates into the surrounding soft tissues, it would then be considered extracompartmental because it has already crossed a natural barrier. Computed tomography (CT) and magnetic resonance imaging (MRI) enable us to estimate the size and location of a tumor, thereby permitting more accurate preoperative planning than was possible previously.

This concept also applies to soft tissue compartments, but not quite so neatly as with bone tumors. Tumors that involve a flexor tendon in the digit have, in theory, violated the entire compartment of extrinsic muscle. Tumors may have a propensity to spread proximally along the tendon to the muscle, much as a hematoma may track proximally after rupture of a flexor tendon by following the natural barriers of the tendon sheath and muscle fascia.

Metastases

The third criterion for classification of malignant tumors identifies patients in whom the tumor has already metastasized to other sites. The MSTS has three stages, with stage III including all patients with distant metastases, regardless of the other parameters (see Table 59.1). Lymph node involvement is always an important finding in that primary musculoskeletal neoplasms do not commonly spread to regional nodes. Because lymph node metastases develop in less than 5% of patients with sarcomas, the differential diagnosis of extremity tumors with possible nodal metastases must always be expanded to include carcinomas and melanomas. Metastases to lymph nodes are significantly more prevalent with rhabdomyosarcoma, epithelioid sarcoma, clear cell sarcoma, and angiosarcoma.

Once the appropriate staging studies are completed, the surgeon will know the anatomic characteristics (the size or "T") of the lesion and whether metastases (the "M") are absent or present. A differential diagnosis can then be formulated and the biopsy planned.

TABLE 59.3 American Joint Committee on Cancer Staging System for Soft Tissue Sarcomas

	Description
Stage I	
IA	Low grade, small (<5 cm), superficial or deep to fascia
IB	Low grade, large (>5 cm), superficial to fascia
Stage II	
IIA	High grade, small (<5 cm), superficial or deep to fascia
IIB	High grade, large (>5 cm), superficial or deep to fascia
Stage III	High grade, large (>5 cm), superficial or deep to fascia
Stage IV	Any metastasis to lymph nodes or distant sites

EVALUATION PROTOCOL

There are no precise physical characteristics that clearly distinguish aggressive and malignant tumors from benign and reactive lesions. The only definitive test is histologic evaluation of biopsy material. However, because hand tumors can produce such significant dysfunction and because inadequate or unnecessarily aggressive surgery also presents risks, biopsy must be the final step in obtaining a diagnosis. All nonsurgical studies should be completed before surgical biopsy (Figure 59.1).

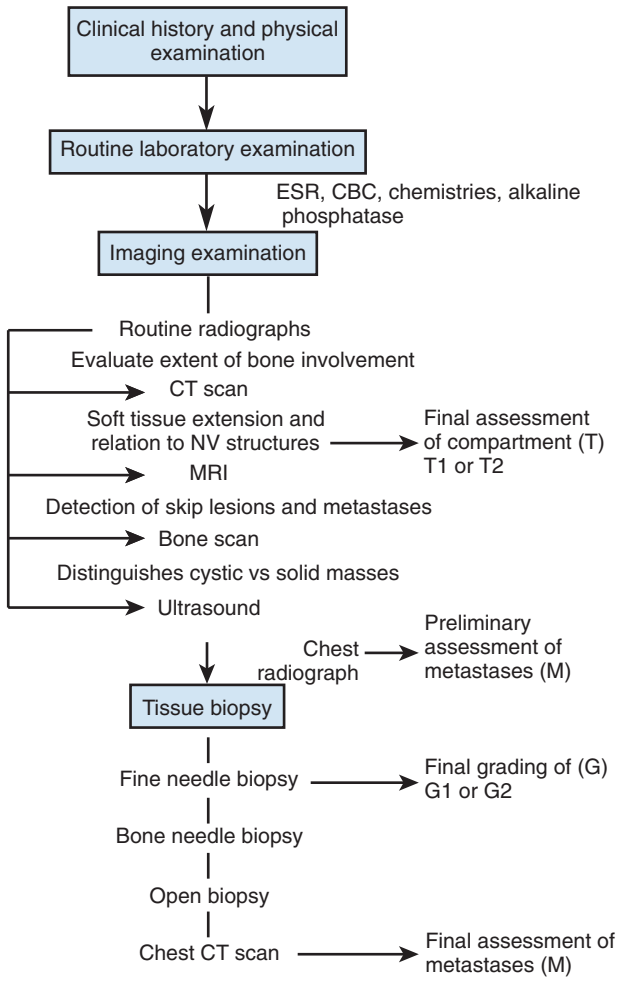

FIGURE 59.1 Suggested evaluation protocol for suspected musculoskeletal neoplasms. *CBC*, Complete blood count; *CT*, computed tomography; *ESR*, erythrocyte sedimentation rate; *MRI*, magnetic resonance imaging; *NV*, neurovascular.

Laboratory Studies

Laboratory studies include determination of the levels of serum calcium, phosphorus, blood urea nitrogen, and creatinine to evaluate the possibility of metabolic bone disease. Serum alkaline phosphatase and lactate dehydrogenase levels are elevated in some malignancies. Serum immunoelectrophoresis assists in determining whether multiple myeloma is present. The hematologic profile and the erythrocyte sedimentation rate are abnormal in the presence of many neoplastic and infectious processes. Urinalysis may detect an occult renal cell carcinoma that can metastasize to the hand. Antinuclear antibodies and rheumatoid factor may be positive in patients who have upper extremity swelling secondary to rheumatoid disease.

Diagnostic Imaging

A variety of diagnostic imaging techniques permit analysis and localization of the size and extent of the lesion and its impingement on normal anatomy. Although imaging does not typically offer a specific diagnosis, it provides important clues in the evaluation, analysis, and workup of a specific patient.

Plain Radiographs

Plain radiographs afford the best possible resolution and detail of bone and adjacent soft tissues. The anatomic region in question should be fully visualized on all radiographs, and this is achieved by taking an adequate number of views. Plain radiographs are initially performed to assess the presence and location of bone involvement. They may also be the most specific radiologic test for bone tumors.

Computed Tomography

Although conventional radiographs offer considerable spatial information, the higher resolution of CT produces images that are specifically useful in localizing small tumors within a bone and in identifying soft tissue extension or calcification within such growths. Because of its ability to discriminate varying densities, CT allows visual separation between the medullary canal, cortex, and surrounding soft tissues and thus often provides critical information concerning anatomic location (T) for tumor staging. Plain chest radiographs are always obtained before performing a biopsy on a suspected malignancy; chest CT scans are useful for staging histologically defined malignant tumors but are not routinely used for prebiopsy screening studies.

Scintigraphy

Radionuclide "bone scan" imaging can be very helpful in detecting primary and metastatic tumors. However, the phenomenon of increased radiopharmaceutical pooling (increased uptake) in a particular bone or soft tissue area is not at all specific or diagnostic. The technique has two time-variable phases. Within minutes after injection, conditions associated with increased vascularity show abnormally high uptake (i.e., trauma, infection, and neoplasia). Later, the isotopes are actively concentrated; in the skeleton, pooling occurs in woven (new) bone, so any process that forms immature bone would be associated with increased uptake on films taken 2 or 3 h after injection. Radioisotope scans are probably the most helpful to demonstrate lesions that may not have been suspected clinically or in anatomic sites not seen on initial images that focused only on the symptomatic region. These findings can be important in patient management, and they have the potential to alter biopsy or therapeutic plans significantly.

Magnetic Resonance Imaging

MRI is a technique that depends on sophisticated computers to produce excellent delineation of soft tissue contrast, as well as images in the axial, coronal, and sagittal planes. For MRI studies, electromagnets generate strong fields that cause cellular nuclei to "wobble" or "vibrate" at specific frequencies. A number of technical factors affect the MRI signal, including echo time (TE), pulse or repetition time (TR), longitudinal or spin-lattice relaxation (T1), and spin–spin relaxation (T2).

The majority of soft tissue tumors have a low signal intensity (i.e., appear darker) on T1-weighted scans and a high signal intensity (i.e., appear brighter or whiter) on T2-weighted studies. Specific problems, such as hematoma, lipoma (or liposarcoma), hemangioma, or conditions that involve hemorrhage into an existing tumor zone, are known to have high signal intensity on Tl-weighted scans. Obviously, the potential value of MRI is diminished in a region recently subjected to biopsy, trauma, or other surgery.

MRI is a superior imaging technique for assessment of the soft tissue extent of disease and is particularly beneficial in the evaluation of soft tissue sarcoma. The extent of intramedullary bone involvement also can be readily determined. This facilitates preoperative planning of the bone transection level during resection and may aid in identification of skip metastases that might otherwise not be identified. High-resolution CT offers the benefit of more accurate assessment of cortical bone involvement and may be the preferred technique for evaluating lesions involving the cortex of a given bone. CT is particularly beneficial in identifying occult osteoid osteomas.

Sonography

Sonograms produce images from a differential pattern of transmitted and received echoes. When compared with CT and MRI, sonography produces less detail with respect to precise anatomic relationships and tumor margins. The echo patterns of solid masses are nonspecific, but fluid-filled lesions can easily be differentiated from solid tumors. Sonograms are extremely inexpensive in comparison to the cost of CTs and MRIs and may be more useful than either for distinguishing reactive and cystic processes. Ultrasound guidance can be particularly useful for core needle biopsy of soft tissue lesions.

Biopsy

Biopsy is the last stage of diagnostic management. Such surgery should be planned as carefully as the definitive operation.[134,180] The exact technique used is influenced by the history, location, and size of the mass, as well as the experience of the surgeon and pathologist.

Needle Biopsy

Core needle biopsy has a limited role in the diagnosis of lesions in the hand and upper extremity. It can be useful in the assessment of subcutaneous lesions or in confirming the histology of a recurrent or metastatic lesion. Needle biopsy produces only a small and often fragmented tissue sample that may be

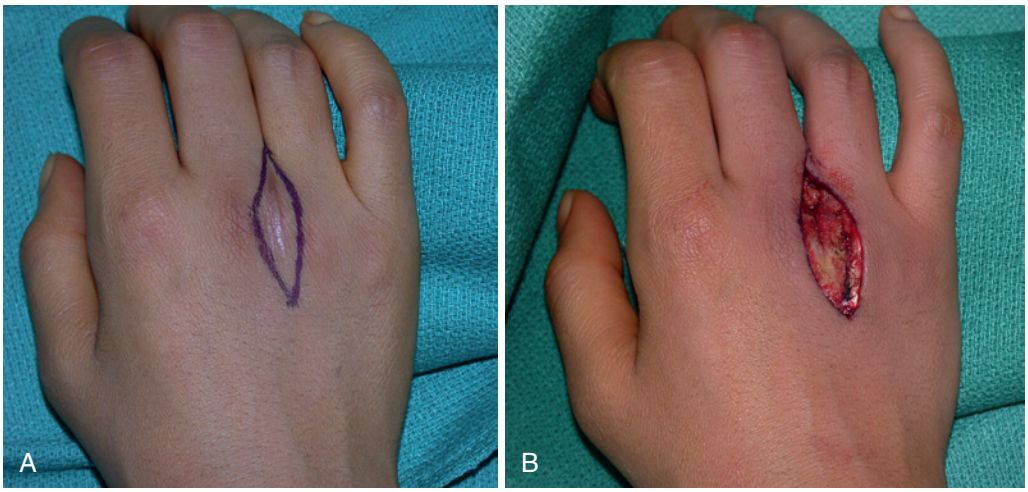

FIGURE 59.2 An open incisional biopsy was performed for a hand lesion. The biopsy site is contaminated with tumor cells **(A)**; the incision is oriented longitudinally and will be excised as part of the definitive procedure performed later **(B)**.

impossible to diagnose or grade accurately. Even if the core biopsy sample seems to clearly be diagnosable, the tissue volume may not be representative of the tumor and could lead to the possibility of overgrading or undermanagement.

Open Biopsy

Open surgical biopsy is a complex procedure, but one that plays a critical role in determining treatment outcome for aggressive and malignant tumors.[134,180,181] During the biopsy, the patient and surgeon must be prepared for the unexpected. Institutions or clinicians who are not prepared or able to complete all diagnostic studies and also provide definitive surgical and adjunctive medical management are best advised to refer patients *before* the biopsy is performed.

Hand surgery is most safely and efficiently performed in a bloodless field. The use of a pneumatic tourniquet is acceptable during both open biopsy and surgical treatment of tumors and neoplasms. Exsanguination of the limb before biopsy is contraindicated before inflation of the tourniquet because of the risk of seeding or dislodging tumor cells. An entirely satisfactory field is achievable by elevating the arm for 1 to 2 minutes before inflating the tourniquet. Likewise, the use of intravenous anesthesia (i.e., Bier block technique), a method that also requires pretourniquet exsanguination, is not appropriate for tumor biopsy or treatment of aggressive bone or soft tissue neoplasms.

A frozen section is necessary at the time that the biopsy is performed to determine whether an adequate specimen has been sampled so that permanent light and special microscopic evaluations can be carried out subsequently. It is rare to find a pathologist who can consistently provide accurate histologic analysis of a frozen specimen dependable enough to begin treatment.[134,181] The definitive treatment plan for malignant lesions is best decided on only after the results of all permanent sections, electron microscopic studies, and special tissue techniques are complete and reported. All biopsy specimens should be cultured, and all cultures should have tissue sent for microscopic examination.

Although plain chest radiographs are taken before biopsy, chest CT is performed to stage a diagnosed lesion. If the tumor is aggressive or malignant, the biopsy tract itself will be contaminated with tumor cells and must later be excised en bloc with the subsequent resection or amputation specimen. Preferred biopsy incisions are therefore longitudinal and carefully placed to permit complete excision of them without having to extend a dissection margin simply to accommodate a badly placed incision. As a simple rule, the biopsy should be placed in line with or immediately parallel to the incision that may be required for later attempted limb salvage (Figure 59.2). Transverse and Bruner-type incisions are specifically to be avoided.

Incisional Biopsy

Incisional biopsy is frequently the most appropriate technique for the diagnosis of bone and soft tissue masses. It requires excision of an adequate tissue sample that is minimally manipulated. Frozen sections are important to determine the adequacy of the specimen. The biopsy incision is located so that it affords the most direct route to the tumor, thereby ensuring that the fewest tissue planes are disturbed or contaminated.

The correct surgical technique for biopsy is different from standard typical surgical dissections. Biopsy involves a direct approach using a longitudinal incision through muscle and other tissues that overlie the mass. Biopsy technique does not include spreading or extensive and vigorous retraction, which has the potential to contaminate a widened area. However, adequate visualization during biopsy, as in any operation, is critical. Because the biopsy tract is contaminated with cells, an approach through a muscle sacrifices only one plane, whereas spreading techniques (i.e., moving muscles aside) contaminate not only the muscle that is retracted but also all surrounding structures. Perfect postsurgical hemostasis is essential to avoid hematoma, which can lead to the spread of cells beyond the primary site and biopsy tract. Once the wound is dry and hemostasis is secure after release of the tourniquet, the wound is closed, not drained. Other than taking steps to avoid pathologic fracture, postbiopsy surgical care is routine while the surgeon awaits the definitive histologic findings.

Excisional Biopsy

Excisional biopsy involves complete removal of a lesion through the reactive zone. An example would be excision of a giant cell

tumor of a tendon sheath or a lipoma. It is a technique that should be reserved for very small lesions (with a diameter of <1-2 cm) to avoid compromising subsequent surgical procedures. Extensive contamination of the operative field occurs with this type of biopsy. If this is done for a large tumor, the extent of contamination may increase the need for soft tissue coverage and increase the risk for both positive margins at definitive resection and subsequent local recurrence. Extensive contamination may preclude subsequent limb salvage and may commit the patient specifically to amputation as a result of the biopsy.

Primary Wide Excision

This type of biopsy requires excision of the tumor with a wide margin or cuff of surrounding normal, nonreactive, healthy tissue. This is an excellent oncologic procedure but requires sacrifice of an extensive amount of normal tissue. Primary wide excision is usually best reserved for very small lesions in which suspicion of malignancy is high and the risk of soft tissue contamination with other forms of biopsy is excessive, as might occur in the carpal tunnel. The decision of when to perform this type of biopsy is generally best made with the assistance of or by a musculoskeletal oncologist.

CRITICAL POINTS *Open Biopsy of Forearm and Hand Tumors*

Indication

- Lesions that cannot be diagnosed as benign on clinical and radiographic grounds.

Technical Points

- Review the case with a pathologist before biopsy and confirm the availability of that person.
- Draw limb salvage incisions or amputation flaps at the time of biopsy.
- Place a longitudinal biopsy incision mark in line with the limb salvage incision.
- Confirm that the biopsy incision will not compromise subsequent amputation flaps.
- Elevate the arm only for exsanguination without using an Esmarch bandage.
- Inflate the tourniquet to ensure a bloodless field.
- Dissect through one anatomic plane or muscle to limit the contamination field.
- Avoid extensive flaps or retraction to limit contamination.
- Incise directly into the tumor to remove a wedge for frozen section and permanent analysis.
- Culture all biopsy specimens.
- Confirm the presence of adequate lesional tissue on the frozen section.
- In most cases, defer definitive treatment of malignant lesions until permanent analysis confirms the diagnosis.
- Obtain perfect hemostasis before closure.
- If a drain is used, it should exit the patient immediately in line with the incision to limit contamination.
- Place sutures close to the wound edges to avoid additional skin contamination.
- Apply a bulky compressive dressing to avoid hematoma.

Postoperative Care

- Limit use of the limb until definitive treatment.

DEFINITIVE TREATMENT

General Plan of Tumor Excision

Benign Tumors

Nonaggressive, benign neoplasms are usually removed simply by marginal or intralesional operations such as curettage. If there is a question about the adequacy of resection of the tissue margins and the diagnosis is already confirmed, a frozen section may be of great assistance for intraoperative sampling of the margins.

Malignant Tumors

In the management of malignancies of the upper limb, preservation of function is secondary to eradication of the disease process. Hand surgeons who undertake management of a neoplasm must have a thorough understanding of the tumor's biologic behavior, its patterns of local and metastatic spread, and its response to radiotherapy and chemotherapy. Radiation therapy and chemotherapy may allow the surgeon to use less radical tumor margins so that amputation can be avoided and function maintained.[78,125] However, the risk of unnecessary sacrifice of tissue must be balanced against the need for adequate resection because local recurrence of sarcoma sometimes carries a grave prognosis. One of the major problems in assessing outcome has been the lack of a common procedural language regarding surgical methods; however, uniform use of the Enneking terminology, as recommended by the MSTS, provides such a means of communication (see Table 59.2).[53]

Treatment should not begin until a neoplasm has been diagnosed definitively and the results of all preoperative studies, including biopsy, are verified. The assumption that a problem can be "handled" by relatively simple extirpation in the absence of complete diagnostic data is neither justified nor defensible. The risks associated with soft tissue extension from a tumor-contaminated field are too great. Because most tumors are benign, cystic, and nonproblematic, the outcome of the few that are aggressive or truly malignant may be disastrous if surgeons become too casual or complacent. When a malignant tumor or aggressive nonmalignant lesion is identified, carefully planned treatment is required not only to preserve the maximal degree of hand function but also to save the patient's life. Function is secondary to survival.[38,70,134,183]

Hand surgeons who seek to treat a specific neoplasm must have not only a general understanding of the concepts and principles of tumor management but also detailed knowledge of the tumor's biology, histologic and clinical behavior, tendency to spread locally and widely, and potential response to adjunctive measures. All these considerations can have a significant bearing on proposed surgical margins and long-term function.[38,125,190] An inadequate resection that permits local recurrence may condemn the patient to a far worse prognosis than would otherwise have occurred.[55]

According to MSTS criteria, compartmental resection and radical excision cannot always be applied to the hand. Most hand tumors occur in spaces rather than in compartments, and although metacarpal excisions may remove a compartment for a stage IA or IIA bone tumor, extirpation of the entire flexor surface or above-elbow amputation would be required to remove the compartment if the neoplasm arose on a digital flexor. Presently, there are no data to support a conclusion that

the MSTS definitions should be applied uniformly to all parts of an acral compartment. Because the flexor tenosynovium is continuous in the thumb and little finger, but not in the index, middle, and ring fingers, there may be differences in management that can be used prudently with such variations in location.

A soft tissue tumor that develops along the dorsum of the wrist requires surgical extirpation of the extensors of several fingers or the thumb (or both), but not necessarily the entire muscle compartment proximally or distally. Functional restoration can be achieved with tendon grafts or transfers or with free muscle flaps. True radical excision may be impractical if function of any kind is to be salvaged in patients with lesions of the hand and forearm, and it may be that a 1- to 2-cm margin of normal tissue, especially with tumors that are sensitive to adjunctive measures, will be safe and allow secondary reconstruction.[158,162,183] The extent of surgical resection for aggressive tumors is dependent on their histologic diagnosis, location, and size. Remote tissue reconstruction, except when provided by microvascular transfer, should be avoided because of the risk of transferring malignant cells using tissue or flap pedicles.

Principles of Excision for Specific Sites

Distal Phalanx

Malignant soft tissue tumors in the distal phalanx commonly involve skin and bone (Figure 59.3). Safe removal may require excision at the distal interphalangeal (DIP) joint; occasionally, a lesser segment may need to be excised when the lesion, such as a nail bed carcinoma, is more superficial and slow growing. A small portion of dorsal or palmar skin might be used as a local flap to cover the middle phalanx after disarticulation of the DIP joint. In such instances, the distal phalanx and DIP joint are sacrificed if the lesion involves or threatens enough tissue while retaining the tissues at a safe distance from the tumor site. Indeed, if the tumor involves both the dorsal and palmar surfaces of soft tissue as well as bone, a more proximal transosseous amputation through the middle phalanx is required. In every case, the proximal end of the excision margin should be sampled and inspected by frozen section at surgery and later by permanent-technique histology to ensure the safety of the level of removal.

Malignant distal phalangeal lesions require removal with an appropriate cuff of contiguous soft tissue. Lower-grade bone tumors can be managed by distal phalangeal amputation that includes a soft tissue cuff 1 to 2 cm proximal to the intraosseous tumor, a level that requires transosseous resection through the middle phalanx. It is unlikely that such lesions can be safely removed by DIP disarticulation alone. Patients with pathologic fractures or extracompartmental extension usually require removal of the finger at or proximal to the proximal interphalangeal (PIP) level or even ray resection.

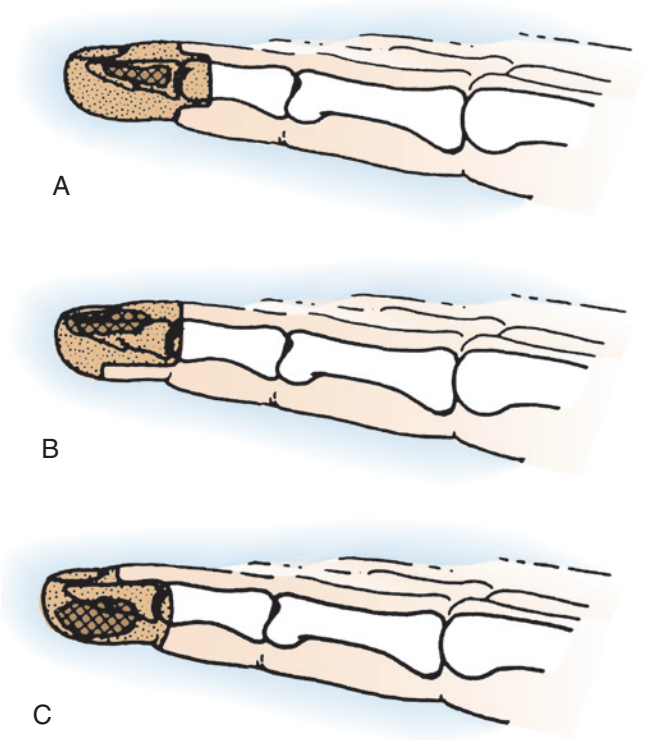

FIGURE 59.3 Malignant lesions of the terminal segment of the finger generally require amputation at or proximal to the DIP joint. **A,** Intraosseous distal phalangeal tumors are amputated at or proximal to the joint along with combined dorsal and volar flap closure. **B,** Dorsal lesions are treated by appropriate tumor excision with volar flap closure. **C,** After removal of a palmar tumor, dorsal flap closure may be possible.

Middle Phalanx

Malignant and aggressive soft tissue tumors in the middle phalanx and those proximal to the region of the DIP joint require amputation at the metacarpophalangeal (MP) joint or metacarpal level or ray resection (Figure 59.4). In this instance, MP joint disarticulation should allow at least a 2- to 3-cm margin of normal tissue; however, functional and aesthetic considerations strongly recommend ray resection (Figure 59.5). In theory, bone tumors involving the proximal and middle phalanges can be excised and replaced with bone graft if the lesion is not aggressive and has not extended into soft tissues. However, ray resection is actually a far more practical and functional alternative if both the proximal and middle phalanges are involved. For malignant tumors that have spread beyond bone because of fracture or slow, progressive extension, ray amputation is clearly indicated. MP joint disarticulation is rarely a safe, practical, functional, or aesthetic choice for treating tumors at these levels.

Thumb lesions are unique. Although lesions distal to the interphalangeal joint are often best treated by amputation,

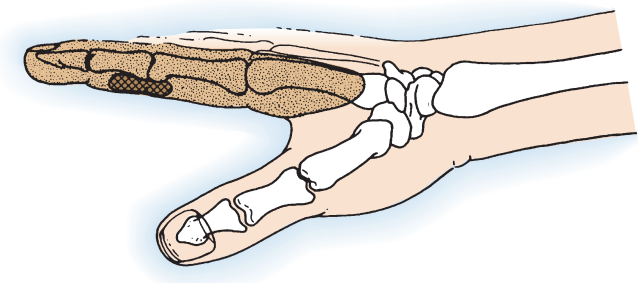

FIGURE 59.4 Tumors of soft tissue at the middle phalangeal and proximal interphalangeal joint level are best treated by ray resection.



FIGURE 59.5 **A,** Axial magnetic resonance imaging demonstrating synovial sarcoma following radiation involving third and fourth metacarpal. **B,** Fourth ray resection was performed with en bloc resection of the diaphyseal third metacarpal. **C, D,** Volar and dorsal incisions for ray amputation and fillet flap marked. Dorsal biopsy tract is incorporated into the dorsal incision. **E, F,** Intraoperative resection. **G, H,** Appearance at closure. **I,** Postoperative radiograph demonstrating third metacarpal reconstruction using fibula graft.

lesions at the proximal phalanx level may be amenable to wide excision and extensive reconstruction. This can be done safely while adhering to the principles of wide excision and subsequent extensive reconstruction, which may require bone and microsurgical soft tissue reconstruction.[141]

First Metacarpal

First metacarpal malignancies can be treated by wide excision and autogenous or allograft replacement (Figure 59.6). Achieving wide margins may require excision of surrounding soft tissues and adjacent joints or bones. Reconstruction with metacarpal allograft, or by fibula or iliac autograft, may be considered in appropriate circumstances. Autografting should be done with a second, separate surgical setup and clean gowns and gloves to avoid cross contamination of the bone donor site. Because osteoarticular allografts may be unstable, arthrodesis may be required at the trapeziometacarpal articulation. Alternatively, suspension may be appropriate if trapezium resection is required.

With extensive soft tissue contamination, more radical resection may be required, including the entire first ray and possibly portions of the web and second metacarpal, to gain a safe margin. If part of the second metacarpal is resected, the "floating index finger" thereby produced can be considered for direct pollicization if sacrifice of the entire second ray is not required.

Finger Metacarpals

Aggressive and malignant bone tumors of the second through fifth metacarpals generally require en bloc bone excision. A more important treatment decision may be whether removal of

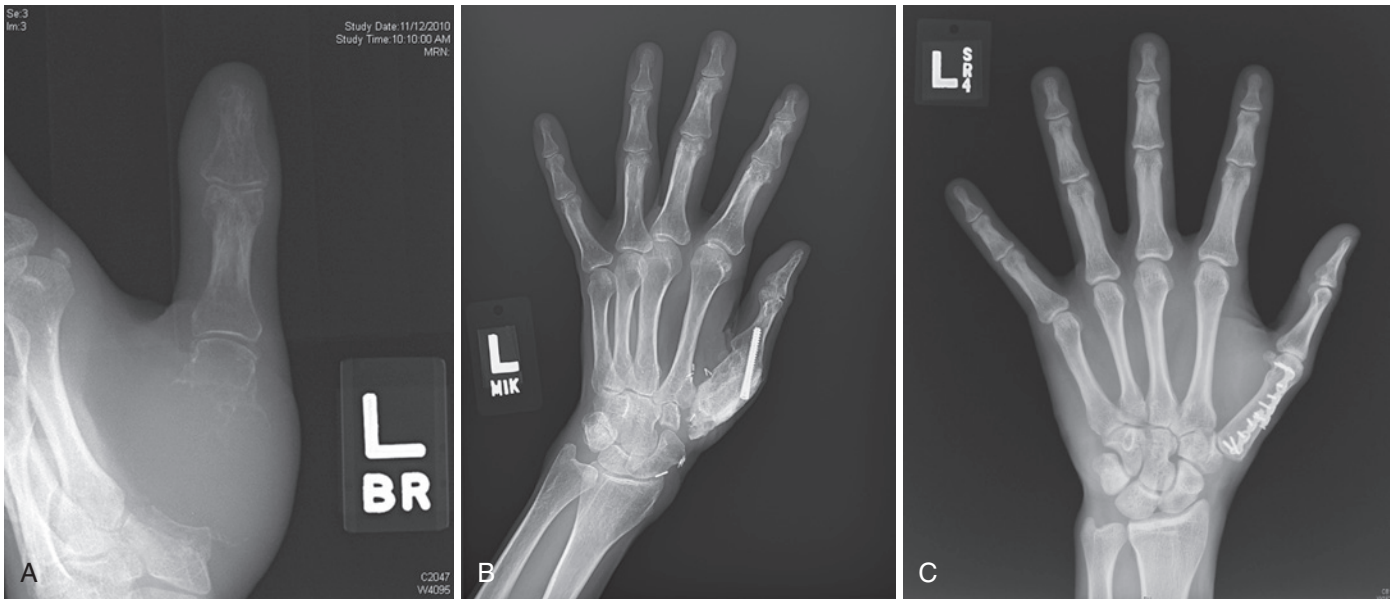

FIGURE 59.6 **A,** A grade 3 giant cell tumor (GCT) of the thumb metacarpal is treated with wide extraarticular resection including the trapezium and base of the proximal phalanx. **B,** Thumb metacarpal is reconstructed with a large iliac crest graft with metacarpophalangeal joint arthrodesis and proximal suspension. **C,** Long-term follow-up of diaphyseal segment reconstruction using iliac crest bone graft for a grade 2 chondrosarcoma. Small blade plates facilitate internal fixation of small periarticular fragments.

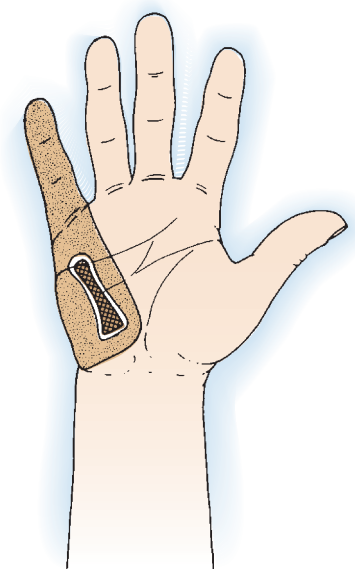

FIGURE 59.7 Malignant tumors of the fifth metacarpal can be treated by ray excision.

one metacarpal alone is possible or whether removal of an entire ray or pair of rays is best. Ray excision is usually best for lesions of the second and fifth metacarpals (Figure 59.7). With the additional consideration of ray transposition, the principles governing removal of the third and fourth rays are no different from those governing the second and fifth. If bone graft has been used for reconstruction, carpometacarpal arthrodesis and MP ligament reconstruction or silicone arthroplasty may be practical. Whatever level is chosen for reconstruction, it is essential that an adequate, safe margin of normal tissue first be excised en bloc with the tumor.

Aggressive tumors of the second through fifth metacarpals that have invaded soft tissue or sustained pathologic fractures often require excision of not only the involved ray but also the contiguous ray or rays radial and ulnar to the involved digit. A malignant tumor of the second metacarpal that extends into soft tissues may necessitate removal of the second and third rays or the first through third rays while preserving the soft tissue of the middle finger as a fillet flap to resurface the radial side of the hand. A similar technique can be used for tumors of the ulnar side of the hand. If the second, third, and fourth rays must be removed, the best strategy is usually to osteotomize and supinate the fifth metacarpal to provide effective oppositional pinch and grasp with the thumb. If a tumor of the fourth metacarpal requires removal of the third through fifth rays, the radial aspect of the middle finger or a fillet of that digit on its radial neurovascular pedicle can be used to close the ulnar side of the hand. Tumors of the fifth metacarpal may require excision of the fourth and fifth rays. Skin coverage may be possible by using a fillet flap from the ring finger.

If a malignant tumor has broken into the midpalm and extends across the metacarpals, removal of all digital rays may be needed to gain an adequate soft tissue margin. Retention of a sensate and relatively mobile thumb may be considerably more aesthetic and functionally satisfactory than a forearm- or wrist-level amputation. However, if a tumor extends proximally from the metacarpal level, a more proximal level of hand, wrist, or forearm amputation is required for safe tumor management.

Soft tissue tumors in the palm or on the dorsum of the hand generally require at least partial hand amputation. If treated by only local or limited excision, the chance of recurrence and metastasis may be enhanced; below-elbow amputation is necessary to treat these larger tumors. It is unusual for an aggressive soft tissue tumor to be adequately removed by a truly local en bloc excision. At a minimum, aggressive soft tissue tumors, such

as bone tumors, require ray resection or removal of multiple rays (Figures 59.8 through 59.10). Central palmar lesions generally require sacrifice of three rays; those on the border are more likely than those in the center to be salvageable by removing just two rays. In the presence of proximal, broader, and larger lesions, all four digits or the entire hand may have to be sacrificed to save the patient.

Wrist and Distal Forearm

Malignancies of the proximal palmar surface of the hand and volar aspect of the wrist often require amputation. A dissection that attempts to "salvage" the median nerve or one or two flexors in the middle of an expanding tumor or reactive zone is only likely to spread the disease. Correct surgical and medical principles for tumor removal and care should be taken (Figures 59.11 through 59.13).

Tumors that arise on the dorsum may allow preservation of the hand if staging studies show that the lesion has not penetrated into the palm and the excision margin verifies a safe plane of normal tissue. Isolated intraosseous carpal lesions that have not invaded soft tissue are rare but can be excised locally. The carpal bones are intraarticular, so the onset of symptoms is generally associated with synovitis and joint invasion; therefore, below-elbow amputation or complete en bloc excision of the entire radiocarpal articulation and carpus is likely to be necessary.

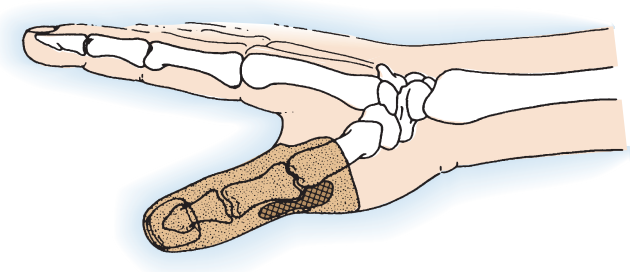

FIGURE 59.8 Malignant soft tissue tumors adjacent to the thumb metacarpophalangeal joint require amputation through the metacarpal. More aggressive and extensive tumors may require removal of the entire ray, possibly contiguous with the second metacarpal.

Growths on the volar aspect of the distal part of the forearm frequently require above- or below-elbow amputation because it is not easy to excise a tumor adequately and still preserve function in and distal to this region after removal of all flexor muscles and tendons, the median and ulnar nerves, and vessels. If a tumor arises in a location that does not specifically involve the ulnar nerve and artery, it may be possible to save a portion of the hand and wrist along with the neurovascular bundle and to consider later reconstruction after longitudinal hemiamputation. Treatment of tumors arising on the radial side of the distal end of the forearm varies according to the size and exact location of the lesion (Figure 59.14). In many situations, as is true of lesions on the volar side, amputation is probably preferable when all criteria are considered. Tumors on the extreme ulnar side of the wrist can be handled in a way that mirrors those on the radial aspect, although lesions in the extreme end of the ulna may be amenable to wide excision of the distal ulna (Figure 59.15).

Intracompartmental lesions within the distal radius or ulna can be treated by wide excision of the bone and arthrodesis or autograft replacement. In such situations, transosseous excision must include biopsy of the medullary canal from the retained segment or segments. When tumors have invaded tissues or crossed compartments extensively, above- or below-elbow amputation may be required.

Wherever a tumor is located, treatment must be individualized to achieve the goal of functional restoration without risking local recurrence and later distant spread. Because of a lack of control over the site and the origin of the neoplasm, the surgeon's responsibility is confined to intelligent management and treatment by adhering to the proper principles of care.

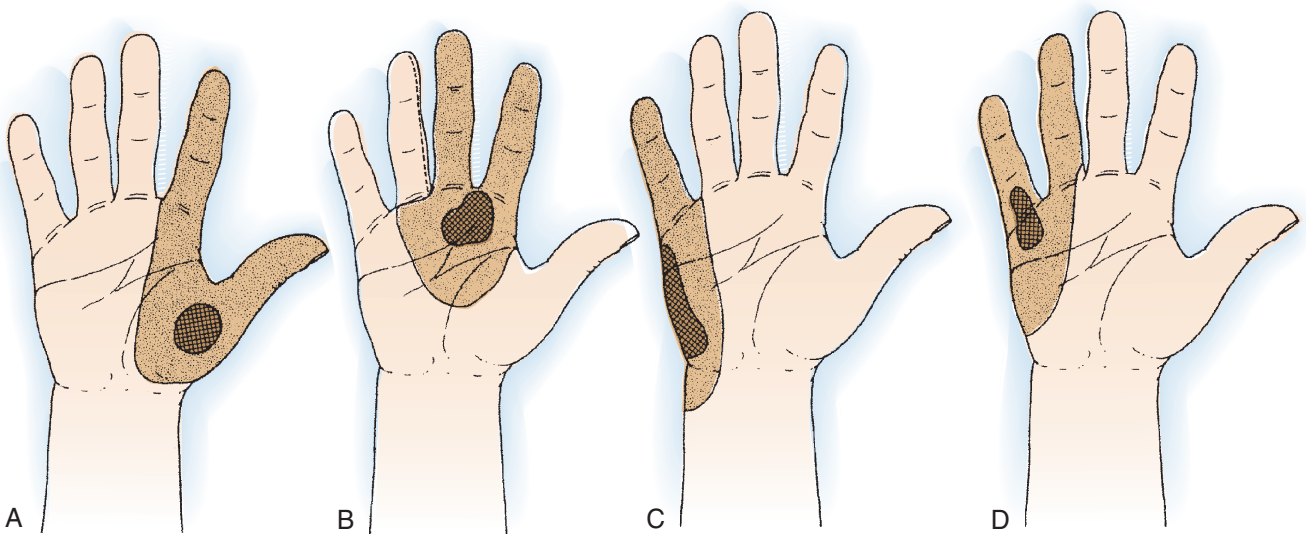

FIGURE 59.9 **A,** Tumors located between the first and second metacarpals may require amputation of both rays for adequate local control. **B,** Tumors between the second and third metacarpals require removal of both rays. **C,** Lesions of the ulnar border of the hand can be treated by resection of the fifth ray and local flap or skin graft closure. **D,** Large and more aggressive lesions or those extending more radially may need removal of both the fourth and fifth rays.

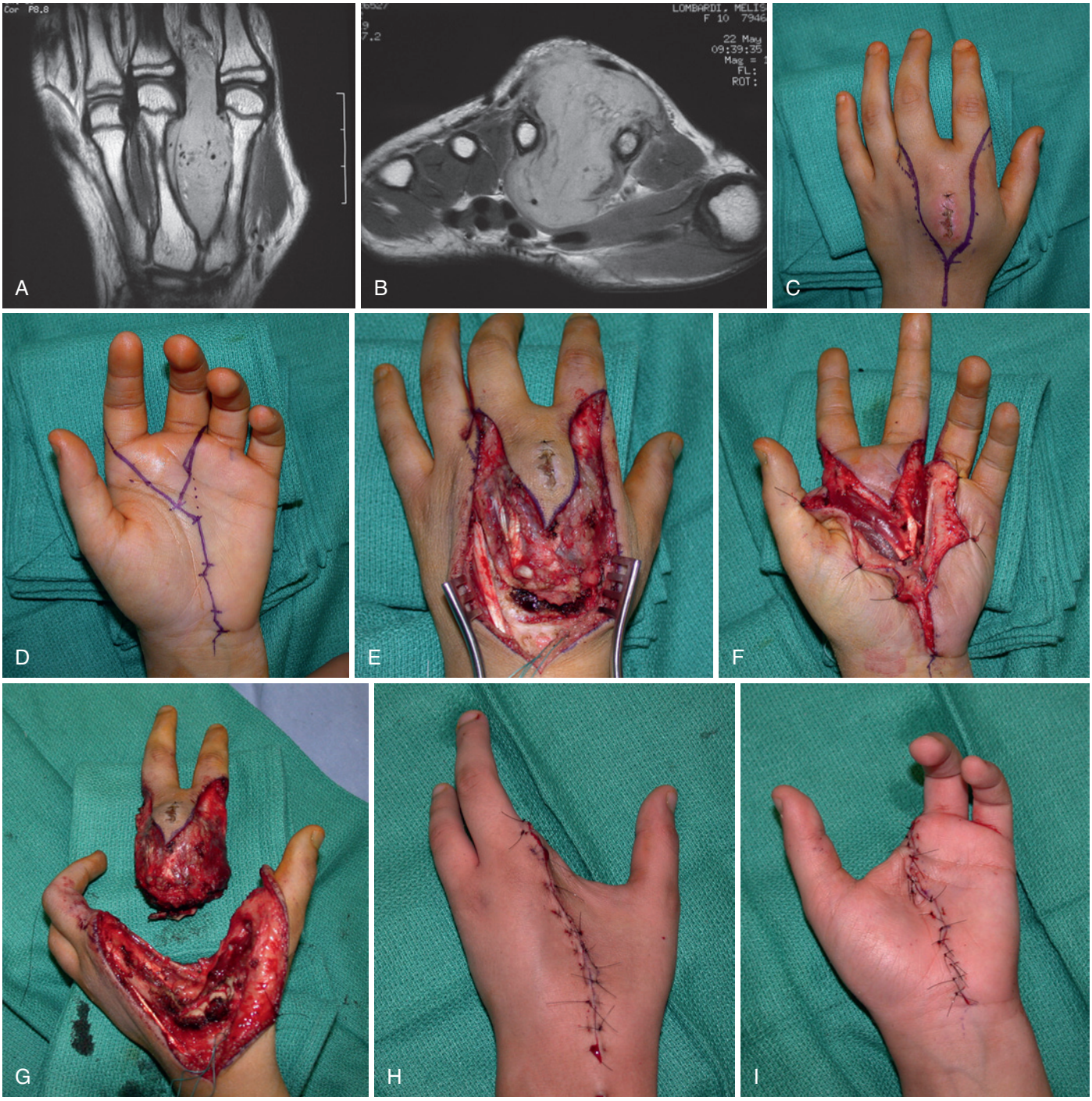

FIGURE 59.10 **A, B,** Magnetic resonance imaging coronal and axial views of a rapidly progressing malignant peripheral nerve sheath tumor. **C-G,** Wide excision required double ray resection of the central rays. **H, I,** Immediate postoperative appearance.

BENIGN SOFT TISSUE LESIONS

Ganglions and Mucous Cysts

Clinical Characteristics

Ganglion cysts are the most common soft tissue tumors of the hand. These mucin-filled cysts are usually attached to the adjacent underlying joint capsule, tendon, or tendon sheath. Ganglions are most prevalent in women and generally occur (70%) between the second and fourth decades of life. They are not rare in children[201] and have been reported from the first to the eighth decades. Ganglions usually occur singly and in very specific locations; however, they have been reported to arise from almost every joint of the hand and wrist (Table 59.4). The less common ganglions are often associated with other conditions of the hand (e.g., bossing of the second and third carpometacarpal joints, de Quervain disease, and Heberden nodes of the DIP joint).

Ganglion cysts have also been reported to cause clinically symptomatic pressure on the median and ulnar nerves of the

hand.[177] Because of their high incidence and prevalence, ganglion cysts should readily be recognized by most hand surgeons. Other conditions that cause diffuse swelling over the dorsum of the wrist, such as extensor tenosynovitis, lipomas, and other hand tumors, also must be considered in the differential diagnosis. The history, physical examination, techniques of transillumination, and aspiration should allow a conclusive diagnosis in most instances.

Patients usually seek medical attention because of the cosmetic appearance of the mass, pain, weakness, and concern for potential malignancy. A specific antecedent traumatic event is present in at least 10% of cases, and repeated minor trauma may be an etiologic factor in their development. There is no obvious correlation with patient occupation. Malignant degeneration has never been reported; however, malignant soft tissue tumors are frequently misdiagnosed as ganglion cysts. Ganglions can appear quite suddenly or develop over a period of several months. They may subside with rest, enlarge with activity, and rupture or disappear spontaneously. Although

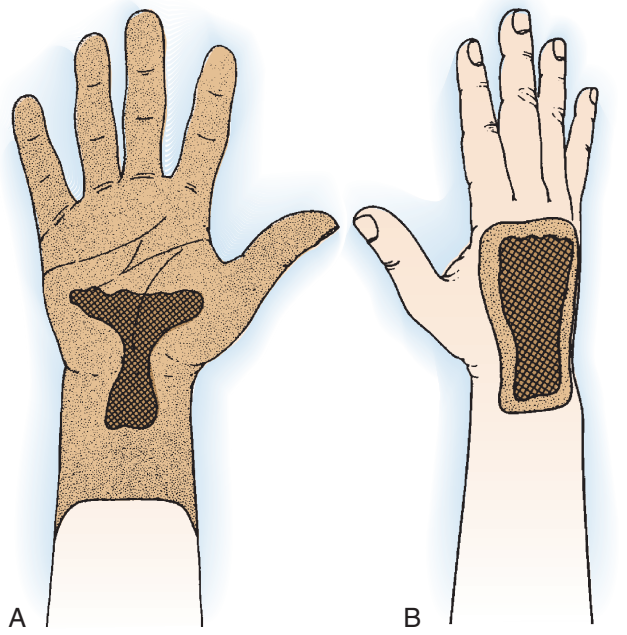

FIGURE 59.11 **A,** Tumors on the proximal volar aspect of the palm often involve the flexor tendons and median and ulnar nerves; forearm- or wrist-level amputation is usually required. **B,** Lesions on the dorsum of the hand may not necessarily invade vital neurovascular structures and can be adequately resected en bloc, followed by secondary reconstruction.

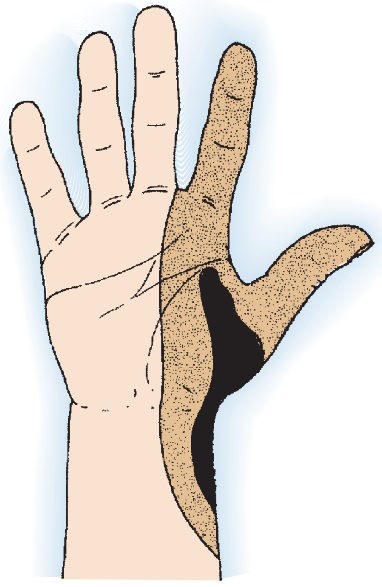

FIGURE 59.13 Aggressive tumors of the radial side of the distal part of the forearm may require amputation of the thumb and index rays, as well as the contiguous radial side of the wrist at a minimum.

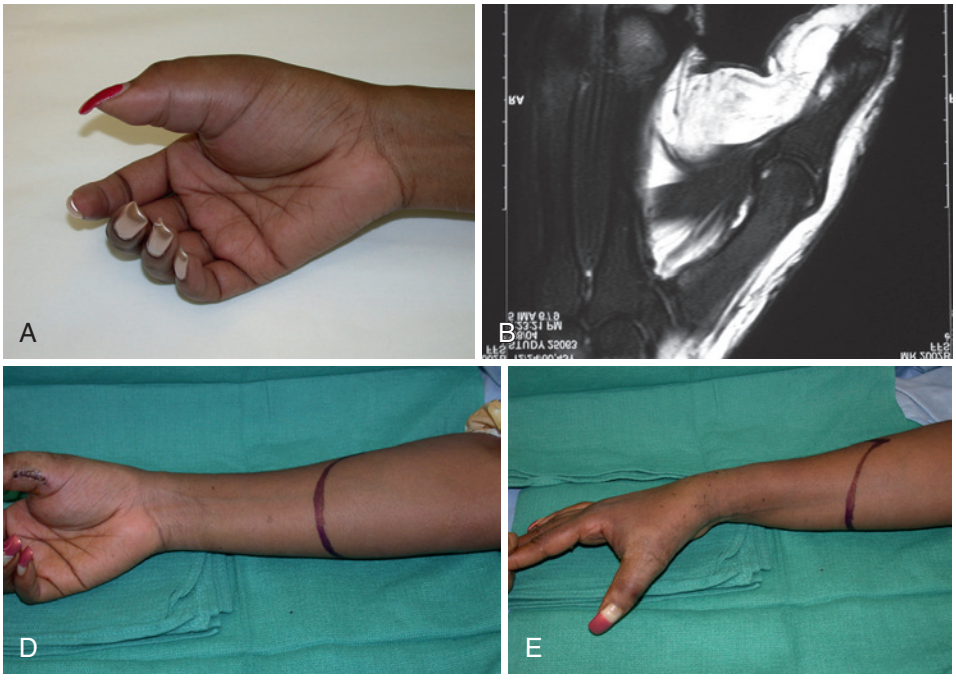

FIGURE 59.12 **A-C,** A myxofibrosarcoma of the thumb with extensive infiltration into the hand rendering hand salvage impossible. **D, E,** The patient was treated by below-elbow amputation.

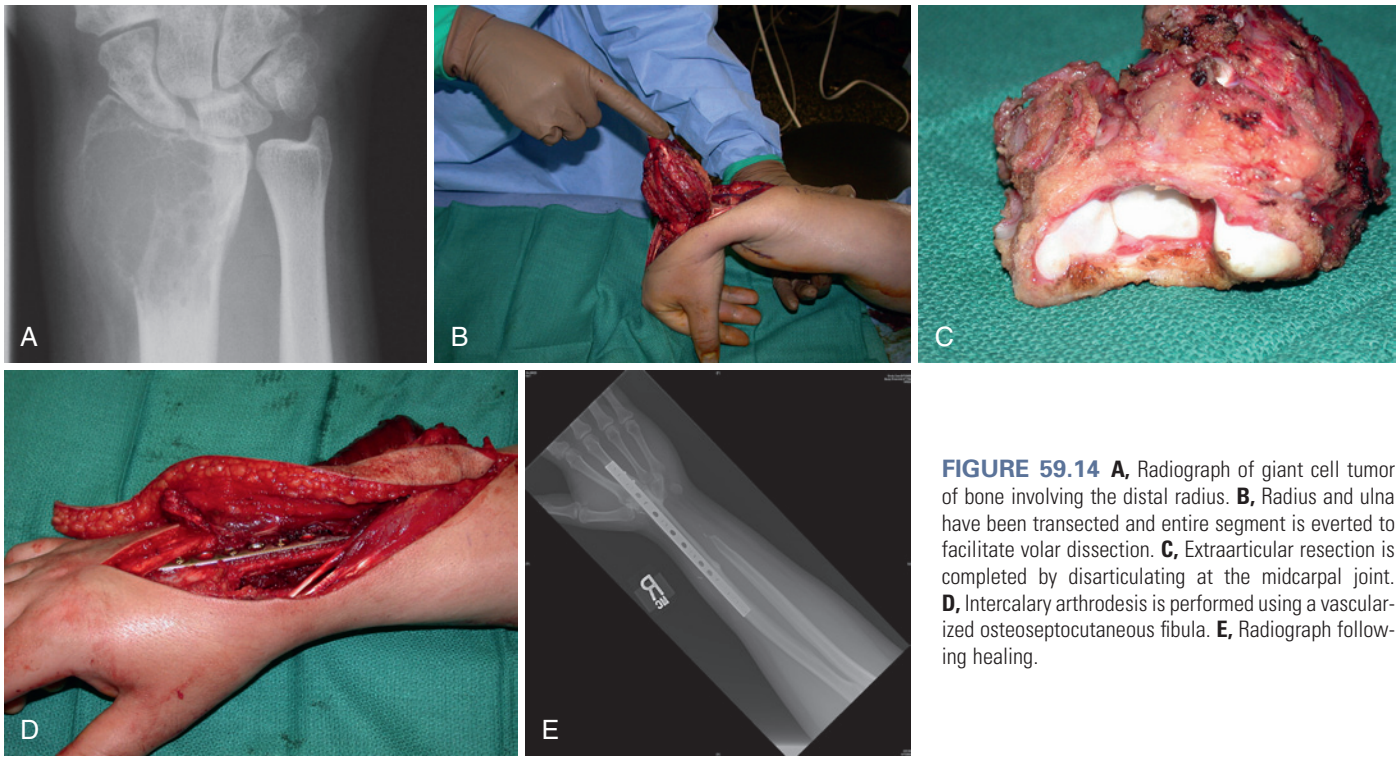

FIGURE 59.14 **A,** Radiograph of giant cell tumor of bone involving the distal radius. **B,** Radius and ulna have been transected and entire segment is everted to facilitate volar dissection. **C,** Extraarticular resection is completed by disarticulating at the midcarpal joint. **D,** Intercalary arthrodesis is performed using a vascularized osteoseptocutaneous fibula. **E,** Radiograph following healing.

TABLE 59.4 Ganglions of the Hand and Wrist

- Dorsal wrist ganglion
- Volar wrist ganglion
- Volar retinacular ganglion (flexor tendon sheath ganglion)
- Mucous cyst (ganglion of the distal interphalangeal joint)
- Other ganglions
- Carpometacarpal boss
- Proximal interphalangeal joint
- Extensor tendon
- Miscellaneous locations
- First extensor compartment (dorsal retinacular ganglion)
- Carpal tunnel
- Ulnar canal
- Intraosseous ganglion

recurrences are infrequent with proper excision,[9,66] >50% may recur if incompletely excised.

Radiographs of the involved region are often unremarkable, although intraosseous cysts are occasionally present at the wrist. Osteoarthritic changes are commonly seen with cysts at the DIP or carpometacarpal joints. Communication between the wrist joint and cyst has been demonstrated with arthrograms but not with cystograms. A one-way valvular mechanism[96] has therefore been postulated to connect the wrist joint to the cyst.

ANATOMY

The microscopic description of ganglions is well known. The main cyst may be single or multiloculated and appears smooth, white, and translucent. The wall is made up of compressed collagen fibers and is sparsely lined with flattened cells without evidence of an epithelial or synovial lining.

The capsular attachment of the main cyst reveals mucin-filled "clefts," which have been shown by serial sections to intercommunicate[9] through a tortuous continuous duct connecting the main cyst with the adjacent underlying joint. The stroma surrounding the intracapsular ducts may show tightly packed collagen fibers or sparsely cellular areas with broken collagen fibers and mucin-filled intercellular and extracellular lakes. No inflammatory reaction or mitotic activity has been noted.

The contents of the cyst are characterized by a highly viscous, clear, sticky, jelly-like mucin made up of glucosamine, albumin, globulin, and high concentrations of hyaluronic acid. In some cases, the mucin may be blood tinged. The contents of the cyst are decidedly more viscous than normal joint fluid.

Pathogenesis

Since Hippocrates offered the first recorded description of "knots" of tissue containing "mucoid flesh," numerous speculative theories with little scientific basis have abounded. This became especially apparent when 18th- and 19th-century anatomists offered the following hypotheses: (1) synovial herniation (Eller, 1746) or rupture through the tendon sheath, (2) synovial dermoid or rest caused by "arthrogenesis blastoma cell nests" or embryonic periarticular tissue (Hoeftman, 1876), (3) new growths from synovial membranes (Henle, 1847), and (4) modifications of bursae or degenerative cysts (Vogt, 1881).

Until recently, the most widely accepted theory, initially postulated by Ledderhose (1893) and popularized by Carp and Stout,[32] was mucoid degeneration. The fibrillation of collagen fibers, accumulation of intercellular and extracellular mucin, and decreased collagen fibers and stroma cells supported this

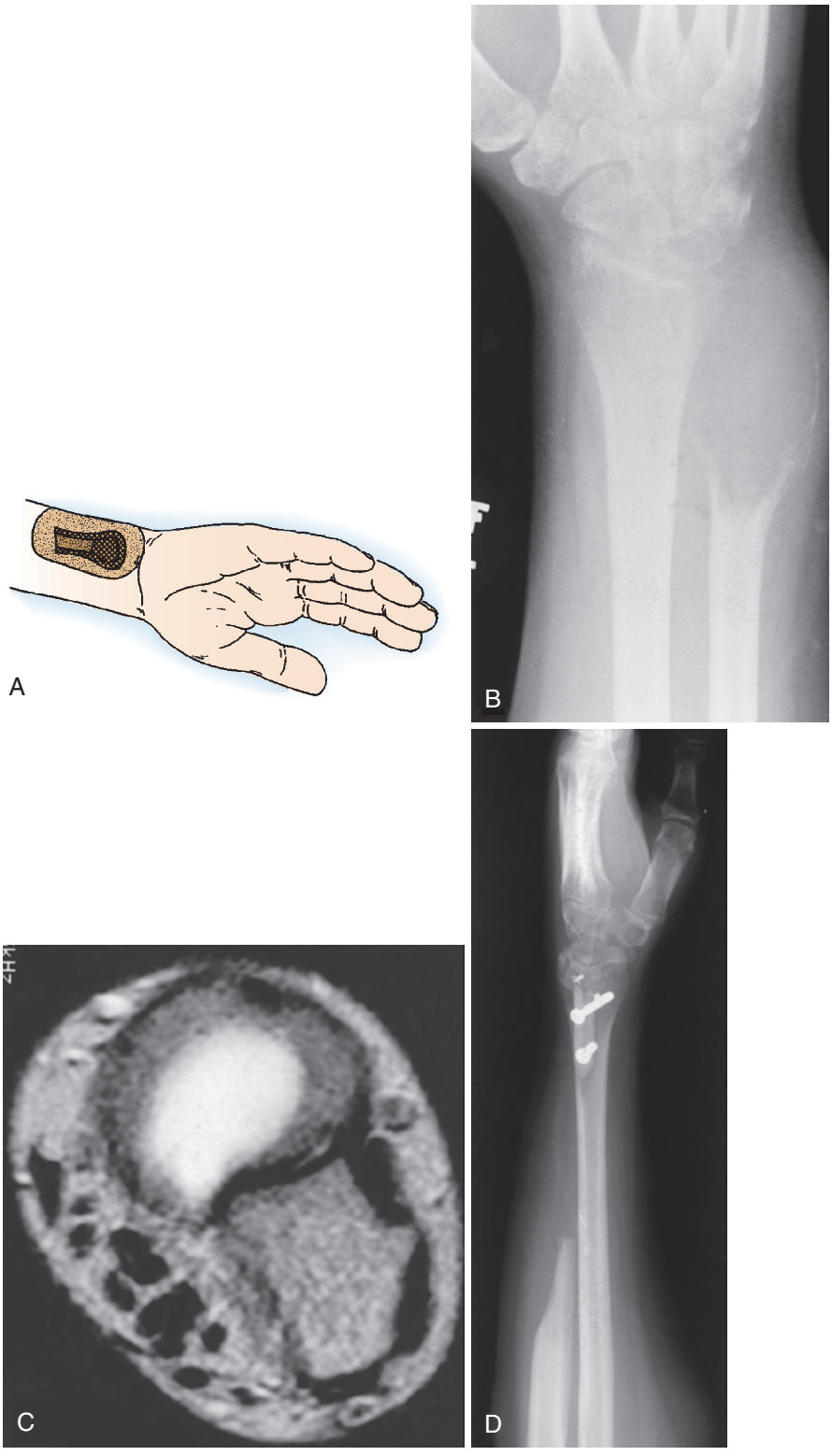

FIGURE 59.15 **A,** Intraosseous tumors of the distal ulna can be managed by en bloc excision. No bone reconstruction is needed in most cases. Tumors with soft tissue extension **(B, C)** may require excision of the ulnar cortex of the radius en bloc with the ulna, as was required with this malignant fibrous histiocytoma. **D,** A portion of the remaining ulna was used to augment the radius and support the lunate facet.

theory. Mucoid degeneration does not, however, explain why the degenerative process is self-limited and solitary and generally occurs in adolescents and young adults and why the fluid recurs after aspiration or incomplete excision.

Nonoperative Treatment

Nonsurgical methods of treatment are usually considered initially because of the limited associated morbidity and possibility of success. Nonsurgical treatment has included digital pressure, injections of hyaluronidase or sclerosing solutions, subcutaneous tenotome dissection, and cross fixation with a heavy suture. Historical folk medicine has mentioned rupture with a mallet or Bible, methods that need not be considered except for their historical interest. Observation has been advocated in the pediatric population because of the high likelihood of spontaneous resolution.[201]

Aspiration of the ganglion, puncture of the cyst wall, and instillation of lidocaine (Xylocaine) and betamethasone (Celestone) into the capsule or tendon sheath attachments reduce the mass and may alleviate symptoms for varying periods.[186] Aspiration may provide long-term relief and has been reported to be effective in 20 to 30% of patients with wrist ganglions. Injection and aspiration of volar wrist ganglions must be approached with caution because of the proximity of the radial artery. Marked subcutaneous atrophy and skin depigmentation may be seen after injection with triamcinolone (Kenalog), which should be avoided.

The most effective nonsurgical treatment is patient reassurance. An explanation of the condition and assurance of its nonmalignant nature are often the only treatment sought or required. Surgery is best reserved for patients with persistently symptomatic ganglions.

Operative Treatment

Open procedures are most commonly done for excision of ganglion cysts. Treatment principles include attempts to minimize scar formation and loss of range of motion. Data on arthroscopic approaches to both dorsal and volar carpal ganglion cysts have been published.[90,130,148,179] The technique appears to be effective with a risk for local recurrence comparable to the historic risk for recurrence after open procedures. Recent comparative studies have evaluated the relative risks and benefits of open versus arthroscopic treatment and demonstrated similar outcomes.[52,101]

Dorsal Wrist Ganglion

Clinical Characteristics. The prototype of all ganglions of the hand is the dorsal wrist ganglion, which accounts for 60 to 70% of all hand and wrist ganglions. The main cyst is usually located directly over the scapholunate ligament (Figure 59.16) and is easily seen and diagnosed. The cyst may occur anywhere else between the extensor tendons, however, and can be connected to the ligament through a long pedicle (see Figure 59.16). Failure to identify this pedicle and excise its attachment to the scapholunate ligament increases the likelihood of recurrence. Careful preoperative palpation of the cyst with digital compression often reveals its extent and the direction of the pedicle. Transillumination or aspiration confirms the diagnosis preoperatively. Although ganglions have been reported in other carpal joints, they are rare and attachments to the scapholunate joint must be ruled out before a dissection is considered complete. Review of the patient's preoperative radiographs to rule out an interosseous component is wise.

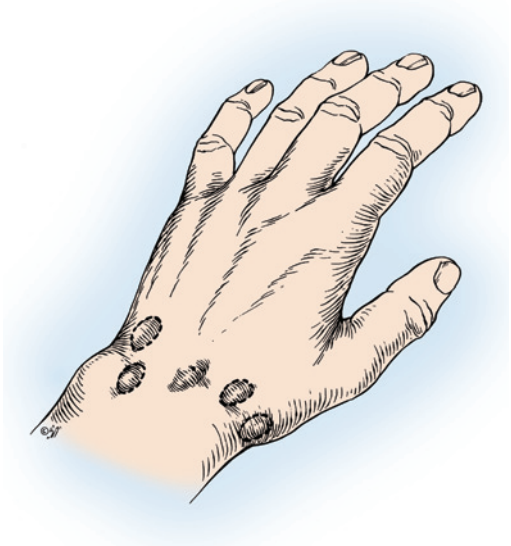

FIGURE 59.16 A few of the many possible locations of dorsal wrist ganglions. The most common site is directly over the scapholunate ligament. The others (*dashed circles*) are connected to the scapholunate ligament through an elongated pedicle. (Copyright © Elizabeth Martin.)



FIGURE 59.17 Transverse incision over the scapholunate ligament **(A)** used to expose the typical dorsal ganglion. An additional incision **(B)** was made to expose a more distant cyst. The main cyst and pedicle are mobilized, passed under the extensor tendons, and delivered through incision at **A**. (Copyright © Elizabeth Martin.)

❖ AUTHOR'S PREFERRED METHOD OF TREATMENT

Operative Technique. Most dorsal ganglions can be approached through a transverse incision over the proximal carpal row, but a modified incision or second transverse incision may be necessary for ganglions not directly over the scapholunate ligament (Figure 59.17). The diagnosis of ganglion cyst should be made before commitment to a transverse incision because this type of incision is not readily incorporated into a limb-sparing

incision in the event of a subsequent diagnosis of a malignant soft tissue tumor. Typically, a dorsal ganglion appears between the extensor pollicis longus and extensor digitorum communis tendons, which are retracted radially and ulnarly, respectively (Figure 59.18).

The main cyst and its pedicle are mobilized down to the underlying joint capsule. With the wrist in volar flexion, the joint capsule is opened along the border of the radius and scaphoid's proximal pole (Figure 59.19). The capsule is elevated and retracted distally to expose the capsular attachments to the scapholunate ligament (Figure 59.20). Smaller intraarticular cysts are often seen attached to the scapholunate ligament. The capsular incision is then continued around the ganglion, but all capsular attachments to the ligament are left intact (Figure 59.21). The capsular incision is extended more laterally if any

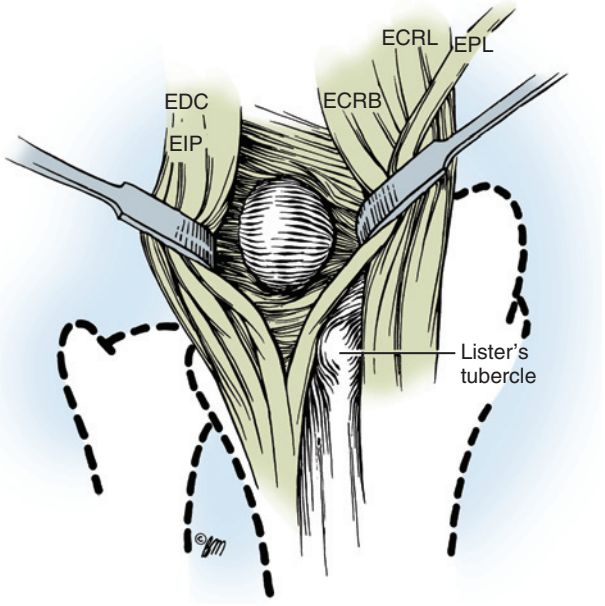

FIGURE 59.18 The dorsal ganglion exposed and mobilized between the extensor pollicis longus (EPL), extensor carpi radialis longus (ECRL), and extensor carpi radialis brevis (ECRB) radially and the extensor digitorum communis (EDC) and extensor indicis proprius (EIP) ulnarly. (Copyright © Elizabeth Martin.)

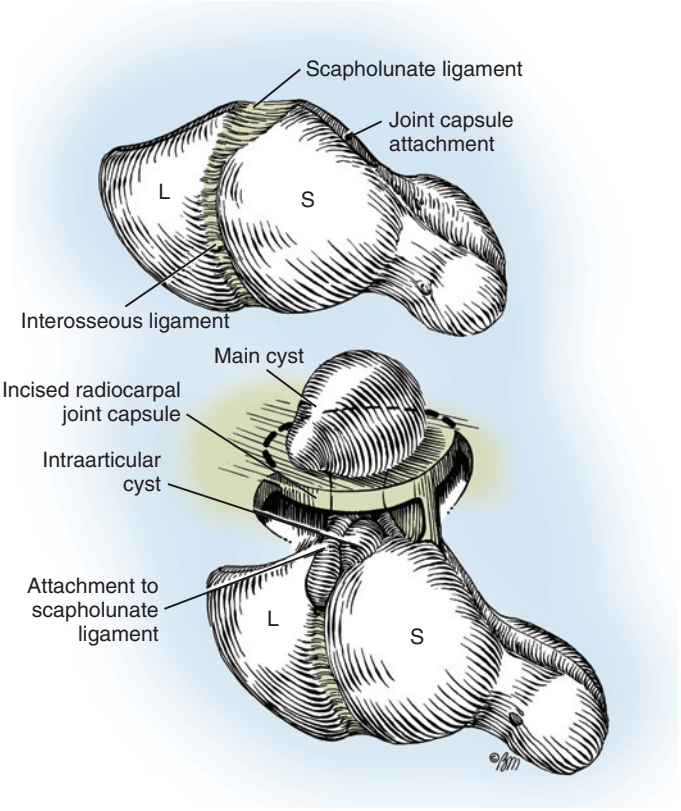

FIGURE 59.20 Schematic representation of the cyst in situ. Attachments to the scapholunate ligament are visualized before final excision (*dashed line*). *L*, Lunate; *S*, scaphoid. (Copyright © Elizabeth Martin.)

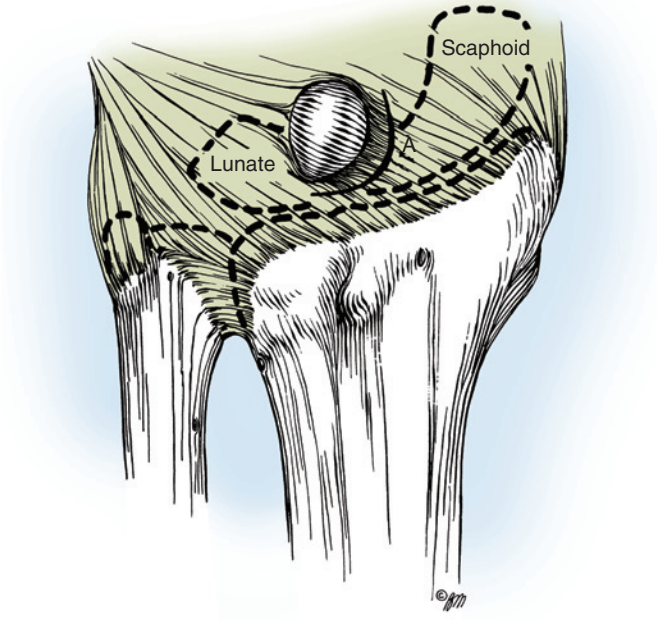

FIGURE 59.19 The initial incision through the joint capsule *(A)* to expose the scapholunate ligament attachments and intracapsular cysts *(B)*. (Copyright © Elizabeth Martin.)

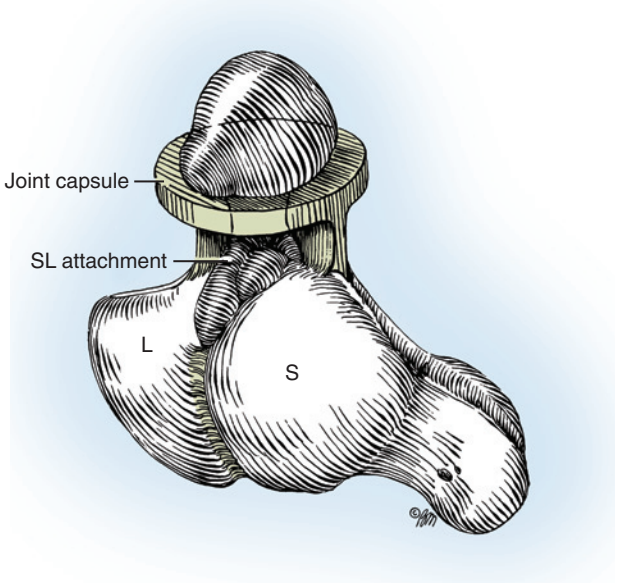

FIGURE 59.21 The ganglion and scapholunate (SL) attachments are isolated from the remaining, uninvolved joint capsule (not shown). *L*, Lunate; *S*, scaphoid. (Copyright © Elizabeth Martin.)

capsular ducts, which can be identified by small amounts of mucin drainage, are encountered during the dissection. The ganglion and its capsular attachments are then tangentially excised off the scapholunate ligament (Figure 59.22).

A small, mucin-filled duct is invariably seen piercing the transverse fibers of the scapholunate ligament. This duct appears to connect the underlying scapholunate joint with the main cyst. Synovial and capsular attachments along the distal margin of the scapholunate ligament are also excised to give an unobstructed view of the head and neck of the capitate (Figure 59.23). If the ganglion ruptures and its anatomic features are lost during the dissection, it should continue until all attachments to the scapholunate ligament have been excised. The excised portion of the joint capsule usually measures approximately 1.0 to 1.5 cm. It is neither necessary nor desirable to cut into the scapholunate ligament, nor is curettage of the scapholunate joint necessary.

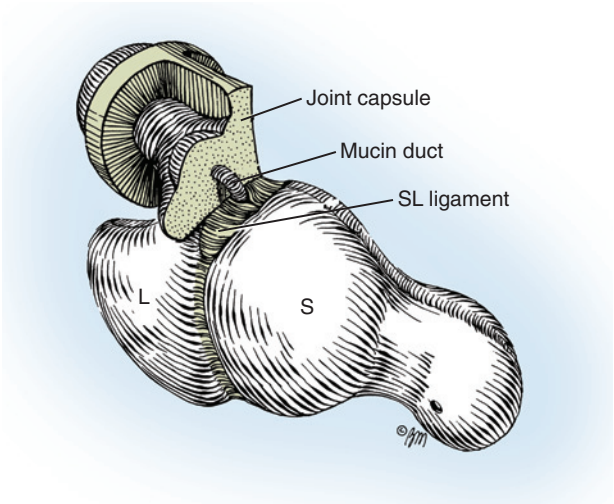

FIGURE 59.22 Tangential excision of the ganglion and attachments off the fibers of the scapholunate (SL) ligament. A minute mucin duct piercing the fibers of the SL is invariably cut during this dissection. *L*, Lunate; *S*, scaphoid. (Copyright © Elizabeth Martin.)

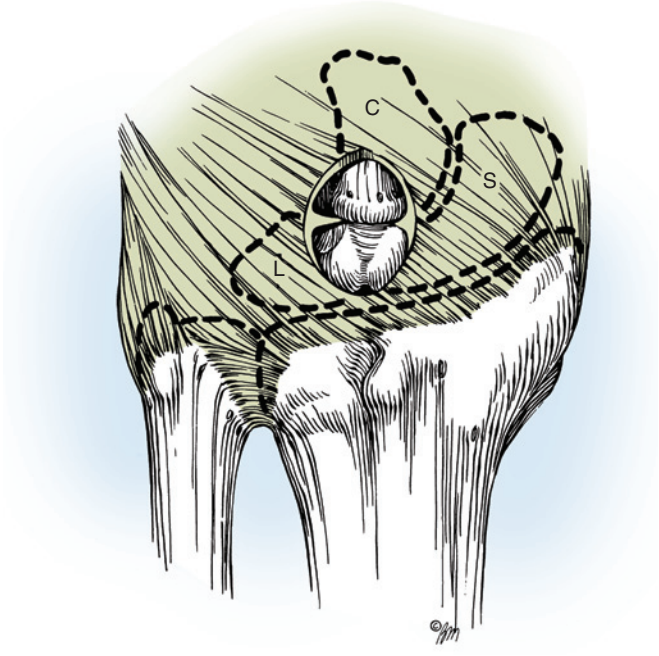

FIGURE 59.23 Completed excision of all attachments to the scapholunate (SL) ligament and the immediate vicinity. Synovial tissue between the ligament and the head of the capitate (C) has also been excised. Note that the SLs remain intact. *L*, Lunate; *S*, scaphoid. (Copyright © Elizabeth Martin.)

The tourniquet is released and hemostasis obtained, then the wound is closed and a dressing applied. Attempts to close the joint capsule either primarily or with fibrous flaps are contraindicated. Subcuticular closure with a monofilament, nonabsorbable pull-out suture may minimize scar formation. Splinting the wrist in slight flexion may reduce postoperative flexion loss.

Postoperative Care. A bulky dressing extending from the proximal part of the forearm to the MP joints is applied and the hand elevated. Early finger motion is encouraged. The dressing and sutures are removed between 7 and 10 days postoperatively. Wrist motion should be initiated and encouraged, especially volar flexion. Hand therapy is continued until a full range of motion has been obtained.

Complications. Early recurrences, the most common complication of ganglion surgery, are usually the result of inadequate and incomplete excision and rarely should occur. Ganglions appearing at the same site years after excision may in fact be new ganglions. Stiffness of the wrist can be avoided by early motion, physical therapy if necessary, and splinting of the wrist in slight flexion during the immediate postoperative period. It is imperative that early volar flexion be stressed. To avoid keloid or hypertrophic scars, longitudinal incisions across the wrist joint should be avoided. Awareness and respect for the sensory branches of the radial and ulnar nerves prevent neuroma formation, which often defies effective treatment. I have not seen avascular necrosis of either the lunate or scaphoid or scapholunate dissociation after the surgical technique just described.[9] Ganglions and sprains of the intercarpal ligaments can occur concomitantly after trauma to the wrist and must be distinguished preoperatively. Identification of concomitant wrist pathology may be facilitated with arthroscopic treatment.

Occult Dorsal Carpal Ganglion

Unlike protruding dorsal ganglions, smaller, occult dorsal ganglions are easily overlooked and can often only be palpated with the involved wrist in marked volar flexion. Comparison with the opposite normal wrist is helpful. An occult ganglion may be the cause of unexplained wrist pain and is disproportionately tender. MRI is useful in confirming the diagnosis and differentiating pain related to scapholunate ligament injury. Dorsal ganglions occasionally do occur in association with an underlying scapholunate diastasis, and they may be blamed for the carpal instability after their excision.

Dorsal prominence of the proximal pole of the scaphoid secondary to intercarpal instability may be confused with a painful occult ganglion and must be diagnosed with appropriate radiographic studies to avoid a delay in proper treatment. Excising the ganglion alone might not alleviate all the patient's preoperative pain. Excision of the posterior interosseous nerve at the level of the radiocarpal joint may help alleviate the pain and add to the patient's postoperative comfort. If other causes of wrist pain and tenderness, especially directly over the scapholunate ligament, can be excluded, an occult dorsal ganglion is best initially treated conservatively by immobilization

and steroid injections directly into the dorsal capsule, which can also aid in diagnosis.

In cases in which further diagnostic studies are necessary, some authors have found the use of MRI and ultrasonography helpful.[153] Chronic tenosynovitis of the extensor tendons can be confused with a dorsal wrist ganglion but can be easily distinguished by the diffuse nature of the swelling and the puckering seen with digital extension, the so-called tuck sign.

Volar Wrist Ganglion

Clinical Characteristics. The second most common ganglion of the hand and wrist is a volar wrist ganglion (18-20%). The majority of volar ganglions occur either directly over the distal edge of the radius or slightly more distally over the scaphoid tubercle. The former arises from the capsular and ligamentous fibers of the radiocarpal joint and occurs under the volar wrist crease between the flexor carpi radialis and abductor pollicis longus tendons (Figure 59.24). The main cyst may be intertwined with bifurcating branches of the radial artery, thus making delicate dissection imperative. The other type of volar ganglion arises from the capsule of the scaphotrapezial joint.

Although volar ganglions may appear small clinically, they can be surprisingly extensive at surgery. Multiloculated cysts extending under the thenar muscles, along the flexor carpi radialis tendon, into the carpal canal, and under the first extensor compartment adjacent to the dorsal branch of the radial artery and as far dorsally as the first web space may be encountered. These extensions can often be appreciated preoperatively by careful palpation and digital compression of the ganglion.

It is important to assess the patency of the radial and ulnar arteries. The Allen test should be performed routinely and ulnar artery occlusion excluded. The surgeon must be aware of the importance of preserving the radial artery, particularly in patients with a radial-dominant circulation.

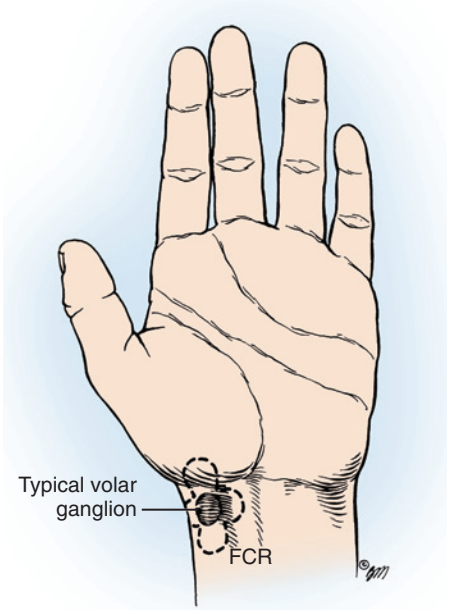

FIGURE 59.24 Typical location of a volar wrist ganglion. Possible subcutaneous extensions (*dashed lines*) are often palpable. *FCR*, Flexor carpi radialis. (Copyright © Elizabeth Martin.)

❖ AUTHOR'S PREFERRED METHOD OF TREATMENT

Operative Technique. Although the surgical technique of excision of a volar ganglion is similar to that for a dorsal ganglion, exposure and precise identification of the capsular attachments of a volar ganglion are more difficult. The incision must be planned to allow for extension into the carpal tunnel or base of the thenar muscles (Figure 59.25). Longitudinal incisions allow for optimal visualization.

With the skin flaps retracted, the forearm fascia is incised longitudinally and the dome of the cyst identified and mobilized. Particular care should be taken to identify and protect the radial artery, which is frequently intimately attached to the wall of the ganglion and may even be completely encircled by the ganglion (Figure 59.26). Loupe magnification aids in this dissection.

The pedicle is traced to the volar joint capsule (usually the scaphotrapezial or radiocarpal ligament). The joint is opened

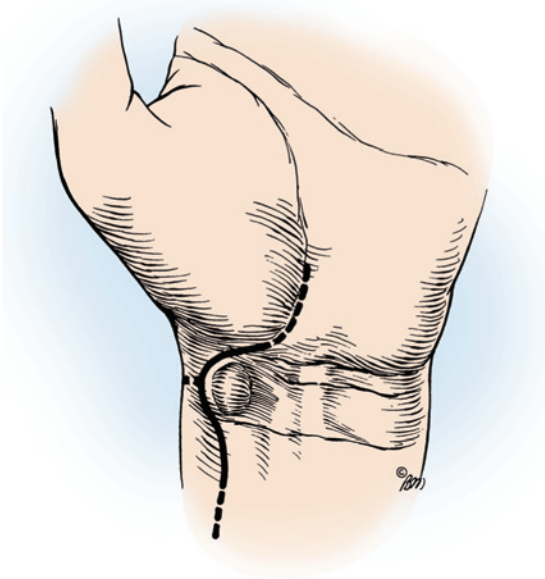

FIGURE 59.25 The usual incision to expose a volar wrist ganglion. Extensions proximally, distally, and even radially are possible (*dashed lines*). Care must be taken to avoid injury to the palmar cutaneous branch of the median nerve if the incision is extended. (Copyright © Elizabeth Martin.)

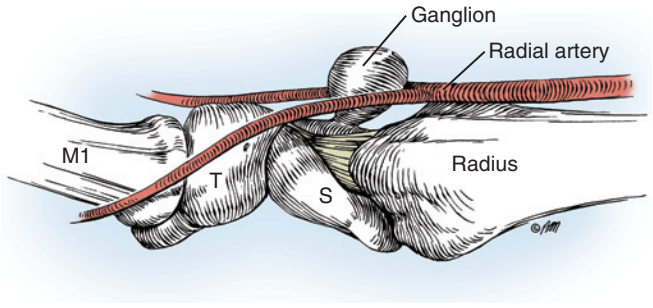

FIGURE 59.26 The usual relationship of the ganglion to the radial artery and volar joint capsule. *M1*, First metacarpal; *S*, scaphoid; *T*, trapezium. (Copyright © Elizabeth Martin.)

and explored and the capsular attachments are excised (approximately 3 ± 4 mm). Once the ganglion has been excised, the surrounding tissues can be compressed digitally to rule out further mucin-filled pockets. If unidentified extensions are present, they must be excised. Hemostasis, wound lavage, and a simple skin closure (preferably subcuticular) complete the operation. Again, capsular closure is unnecessary and only delays early mobilization.

Postoperative Care. A bulky bandage and elevation of the hand ensure early postoperative comfort. Follow-up care is similar to that for dorsal ganglions, and motion of the wrist should begin within the first 2 weeks after surgery.

Complications. The complications are similar to those of dorsal ganglions. Unexpected branches of the radial sensory or lateral antebrachial cutaneous nerves may be injured and lead to troublesome neuromas. Extensions of the routine incision into the carpal canal must avoid injury to the palmar cutaneous branch of the median nerve. Injuries to the radial artery can be repaired microscopically. Some authors recommend leaving a portion of the cyst wall attached to the artery to avoid arterial injury. Stiffness of the wrist is less common than with dorsal ganglions, but it can occur if early motion is not encouraged. Unpleasant scars are not an uncommon problem on the volar aspect of the wrist and often defy "plastic" revisions. Curved incisions appear to consistently provide more attractive scars, especially near the volar wrist creases (see Figure 59.25).

Volar Retinacular (Flexor Tendon Sheath) Ganglion

Clinical Characteristics. The third most common ganglion (10-12%) of the hand is the volar retinacular one, which arises from the proximal annular ligament (A1 pulley) of the flexor tendon sheath. This ganglion is invariably a small (3-8 mm), firm, tender mass palpable under the MP flexion crease (Figure 59.27). The cyst is attached to the tendon sheath and does not move with the tendon. Needle rupture followed by a steroid injection and digital massage to disperse the cyst's contents can frequently delay or obviate the need for surgery. Several attempts at conservative treatment are recommended before surgery, with the patient's understanding that recurrences might happen. The proximity of the digital nerves must be taken into account.

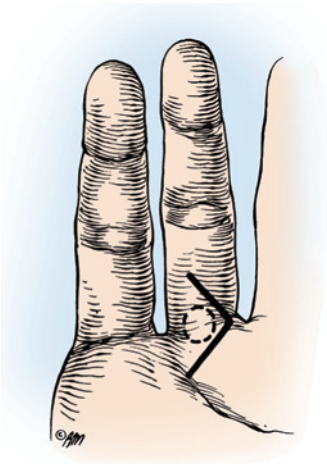

FIGURE 59.27 Volar retinacular ganglion palpable over the proximal tendon sheath and an incision for easy exposure. (Copyright © Elizabeth Martin.)

❖ AUTHOR'S PREFERRED METHOD OF TREATMENT

Operative Technique. The ganglion is approached through an oblique incision over the mass (see Figure 59.27). Transverse incisions do not allow adequate exposure without undue skin traction and are not easily incorporated into an extensile incision, which also must allow identification and mobilization of the radial and ulnar neurovascular bundles. The ganglion can then be traced to the tendon sheath and excised with a small portion of the sheath (Figure 59.28). After skin closure, a simple dressing is applied and early motion allowed.

Mucous Cyst

Clinical Characteristics. A mucous cyst is a ganglion of the DIP joint that generally occurs between the fifth and seventh decades.[39] The earliest clinical sign may be longitudinal grooving of the nail, without a visible mass, caused by pressure on the nail matrix (Figure 59.29). Usually, however, the patient is seen after the cyst has enlarged and attenuated the overlying skin. The 3- to 5-mm cyst typically lies to one side of the extensor tendon and between the dorsal distal joint crease and eponychium. The patient often has Heberden nodes and

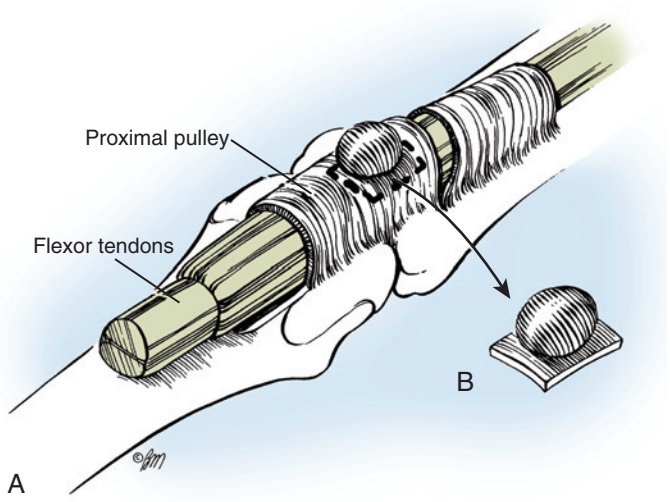

FIGURE 59.28 **A,** Volar retinacular ganglion in situ on the proximal annular ligament (A1 pulley) of the flexor tendon sheath. **B,** Excised specimen with a surrounding margin of tendon sheath. (Copyright © Elizabeth Martin.)

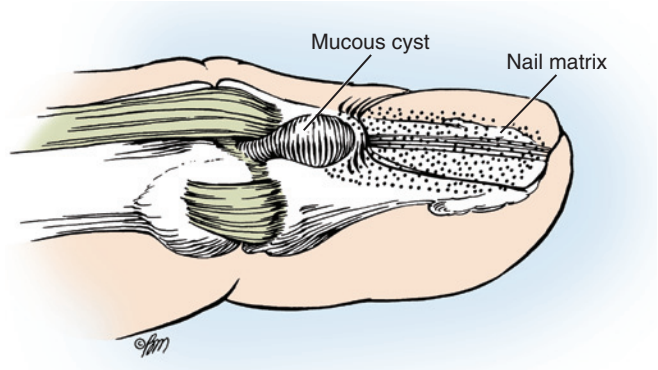

FIGURE 59.29 An early mucous cyst resting on the nail matrix may cause longitudinal grooving of the nail in some cases. (Copyright © Elizabeth Martin.)

radiographic evidence of osteoarthritic changes in the joint. The cyst and osteophytes both should be treated to ensure a satisfactory result.[51]

❖ AUTHOR'S PREFERRED METHOD OF TREATMENT

Operative Technique. The cyst historically has been approached through an "L"-shaped or curved incision (Figure 59.30, *A*), and any attenuated or involved skin that cannot be easily separated from the cyst wall is excised elliptically (see Figure 59.30, *B*). The cyst is mobilized, traced to the joint capsule, and excised with the joint capsule (Figure 59.31, *A*). From a practical point of view, however, all soft tissue between the retracted extensor tendon and adjacent collateral ligament needs to be excised and the DIP joint left exposed (see Figure 59.31, *B*). Care should be taken to not disturb the insertion of the extensor tendon or nail matrix. With the joint extended and the tendon retracted dorsally, the opposite side is explored and occult cysts or hypertrophied synovial tissue is excised. Osteophytes can be excised with a rongeur (Figure 59.32). Skin closure may require rotation and advancement of a dorsal skin flap[112] or a full-thickness skin graft.

An alternative and my current preferred approach is to make a transverse incision centered over the DIP joint. The base of the mucous cyst is identified and excised while leaving the distal and superficial portion of the cyst intact. Osteophytes and joint capsule are excised and the skin closed. The remaining portion of the cyst will involute over the course of several weeks, and the skin complications seen with marginal excision are avoided. I have used this technique since its report by Gingrass and colleagues[79] and have not needed to perform any skin coverage. Patients must be educated preoperatively to expect slow resolution of the cyst. Personal experience has confirmed the results that were published in the report.

Complications. Recurrences may be because of inadequate excision of the ganglion's capsular attachments and failure to recognize extensions of it under the extensor tendon to the opposite side. The underlying arthritic process persists and can result in new ganglion formation. Relief of pressure on the nail matrix by decompression or excision of the ganglion usually restores the nail to its normal appearance. Stiffness rarely causes a functional problem.

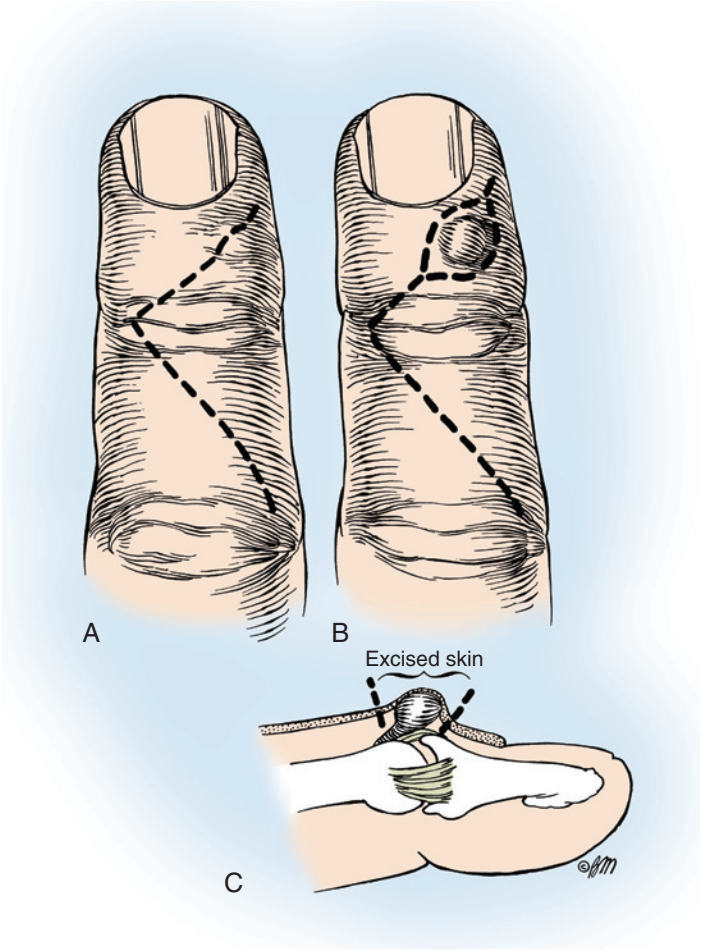

FIGURE 59.30 **A, B,** The cyst without skin involvement and the overlying incision. **C,** Schematic representation of the extent of the elliptic incision when the skin is attenuated. A skin graft or local rotation flap is usually necessary to close the defect. (Copyright © Elizabeth Martin.)

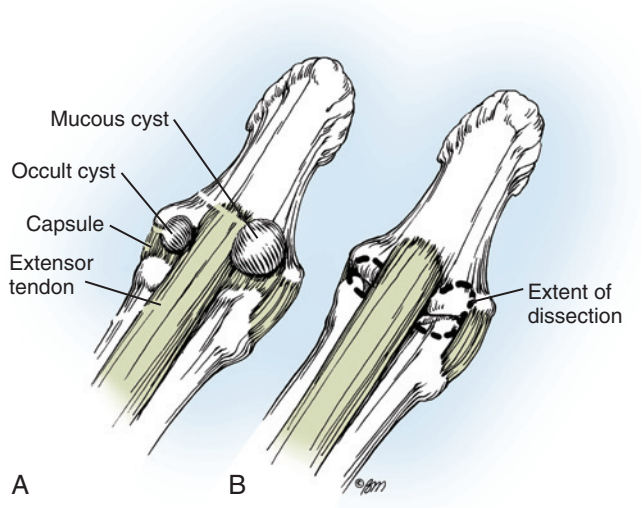

FIGURE 59.31 **A,** The ganglion in situ with its connection to the dorsal joint capsule. A second occult cyst is also illustrated. **B,** The exposed distal interphalangeal joint after excision. (Copyright © Elizabeth Martin.)

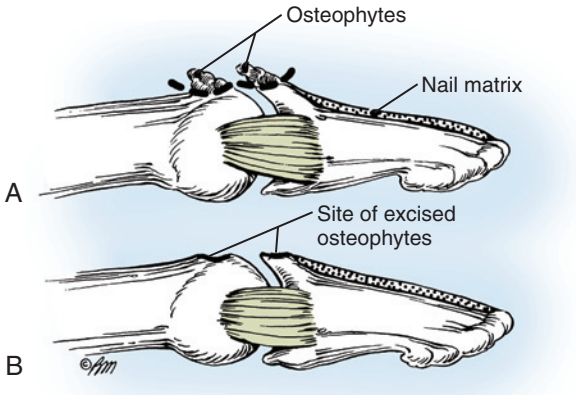

FIGURE 59.32 **A,** The usual osteophytes seen with mucous cysts. **B,** The extent of dissection while avoiding injury to the nail matrix, insertion of the extensor tendon, and articular surface. (Copyright © Elizabeth Martin.)

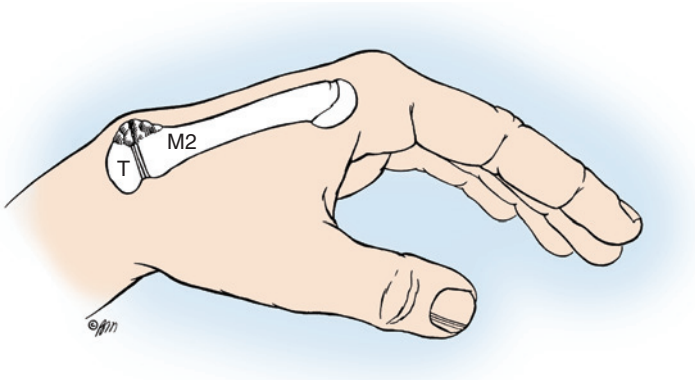

FIGURE 59.33 Carpal boss involving the second carpometacarpal (M2) joint. *T*, Trapezoid. (Copyright © Elizabeth Martin.)

Carpometacarpal Boss

Clinical Characteristics. Dorsal wrist ganglions can be confused with carpal bosses, which are osteoarthritic spurs or prominences that develop at the base of the second or third carpometacarpal joints (or both) (Figure 59.33). A firm, bony, nonmobile, tender mass is visible and palpable at the base of the carpometacarpal joints, especially when the wrist is flexed. Radiologically, the mass is best visualized with the hand in 30 to 40 degrees of supination and 20 to 30 degrees of ulnar deviation ("carpal boss view").

Bosses are more common in women, in the right hand, and between the third and fourth decades. The mass may be asymptomatic, or the patient may complain of considerable pain and aching. A small ganglion is associated with a carpal boss in 30% of cases, thus adding to confusion of it with the more common dorsal wrist ganglion. Every effort should be made to treat the carpal boss nonoperatively. Splinting, nonsteroidal antiinflammatory medications, and ultrasound-guided cortisone injections should be used or strongly considered prior to proceeding with surgery. The potential for persistent symptoms following surgery must be emphasized.

❖ AUTHOR'S PREFERRED METHOD OF TREATMENT

Operative Technique. The mass is approached through a transverse or oblique incision over the bony prominence (Figure 59.34). The extensor digitorum communis and extensor indicis proprius tendons are retracted ulnarward. A ganglion, if present, can be mobilized and excised with its capsular attachments. The osteophytes and carpometacarpal joints are approached through a separate longitudinal incision over each involved joint. Subperiosteal dissection exposes the involved joint to the adjacent osteophytes, which are then excised down to normal cartilage with small osteotomes. The dissection may involve the second and third carpometacarpal joints individually or all four opposing surfaces together (Figure 59.35). The surgical area is palpated through the skin to ensure excision of all palpable prominences. The capsule, periosteum, and any adjacent overlying tendon fibers (extensor carpi radialis longus, extensor carpi radialis brevis) are reapproximated over the joint with a few fine inverting sutures, which should not be palpable through the skin.

Postoperative Care. A cast or splint should be worn for 4 to 6 weeks to allow adequate ligamentous healing and pain relief.

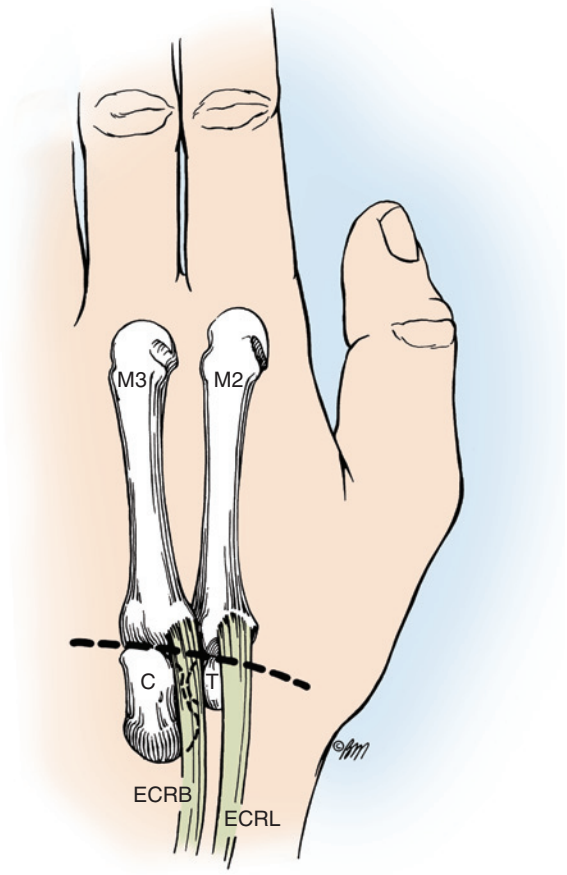

FIGURE 59.34 Incision for excision of a carpal boss, centered over the second (M2) and third (M3) carpometacarpal joints. *C*, Capitate; *ECRB*, extensor carpi radialis brevis; *ECRL*, extensor carpi radialis longus; *T*, trapezoid. (Copyright © Elizabeth Martin.)

Complications. The most common complication is persistence of a mass. Pain may persist unless all abnormal abutting surfaces have been excised. Dorsal wrist ganglions can occur over the carpometacarpal joints and must be distinguished from carpal bosses with an associated ganglion. Avoidance of injury to branches of the radial and ulnar sensory nerves is again stressed.

Ganglions of the Proximal Interphalangeal Joint

Clinical Characteristics. Similar to a mucous cyst of the DIP joint, ganglions also occur dorsally over the PIP joint on either side of the extensor tendon. They arise from the joint capsule and usually pierce the oblique fibers between the central slip and lateral band. These cysts are small (3-5 mm) and tender and may interfere with joint motion.

❖ AUTHOR'S PREFERRED METHOD OF TREATMENT

Operative Technique. A curved or longitudinal incision over the PIP joint exposes the ganglion (Figure 59.36). The lateral margin of the lateral band is released from the transverse retaining ligament and retracted dorsally to expose the PIP joint (Figure 59.37). The pedicle from the main cyst usually can be followed through the extensor system into the joint capsule. A small, elliptic incision through the oblique extensor fibers

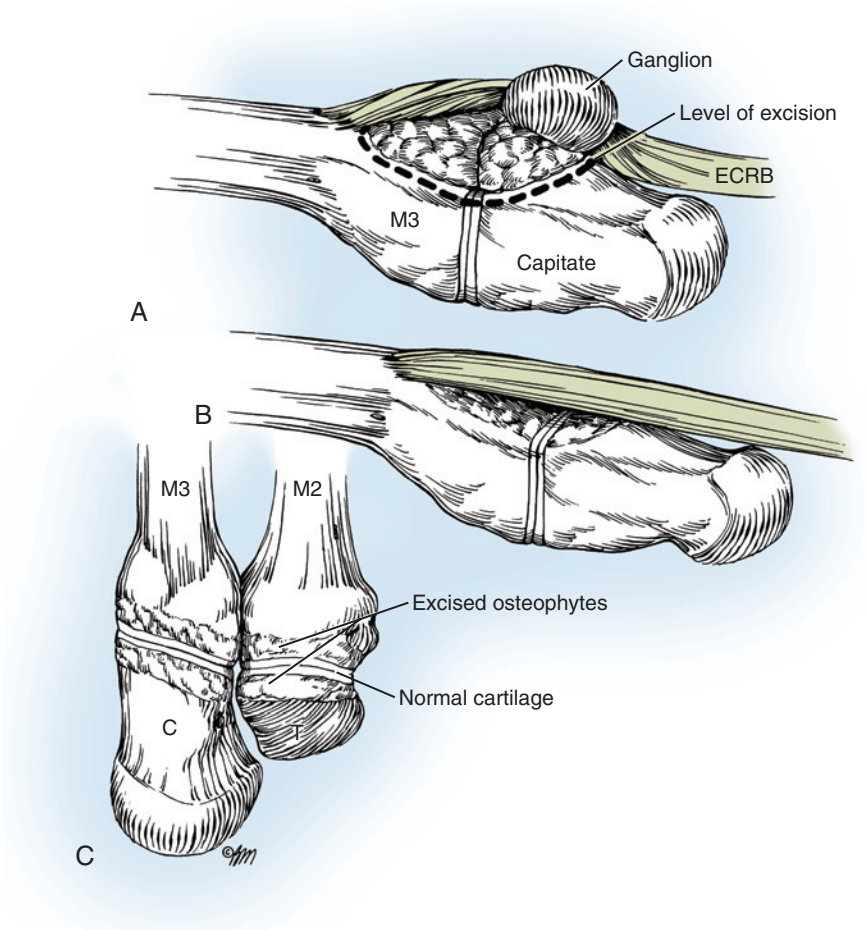

FIGURE 59.35 **A,** Typical carpal boss and associated ganglion. The extent of bony excision is illustrated. **B,** Excised osteophytes with the periosteum and extensor carpi radialis tendon reapproximated. **C,** Exposure after excision of osteophytes involving both carpometacarpal joints (M2 and M3; attached extensor carpi radialis longus and extensor carpi radialis brevis [ECRB] not illustrated). *C,* Capitate; *T,* trapezoid. (Copyright © Elizabeth Martin.)

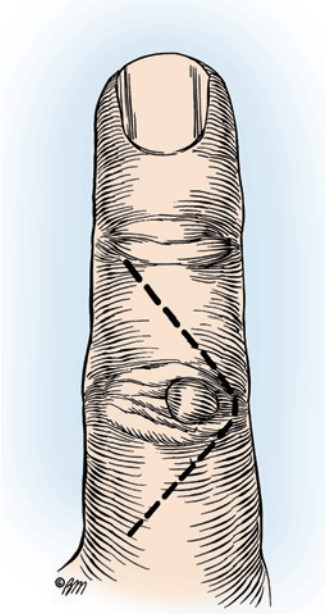

FIGURE 59.36 Dorsal proximal interphalangeal ganglion with a curved skin incision. (Copyright © Elizabeth Martin.)

mobilizes the cyst and pedicle. The entire joint capsule and synovial lining are excised between the collateral ligament and extensor insertion on the middle phalanx.

Postoperative Care. A simple skin closure and dressing followed by early motion are all that is required.

Ganglions of Extensor Tendons

Clinical Characteristics. Ganglions do arise on or within extensor tendons. They typically occur over the metacarpals and are distinguished by their proximal motion with the fingers in extension. They can, however, be confused with dorsal wrist ganglions, carpal bossing, or extensor tenosynovitis. The patient may complain of tenderness, aching, or snapping of the tendon with motion.

❖ AUTHOR'S PREFERRED METHOD OF TREATMENT

Operative Technique. The ganglion is approached through a transverse incision (Figure 59.38), and the intimate broad attachment to the extensor tendon is readily recognized. The ganglion should be dissected off the extensor tendon with all the synovial tissue surrounding the involved tendon. Rupture of the ganglion is difficult to avoid, but recurrences are rare.

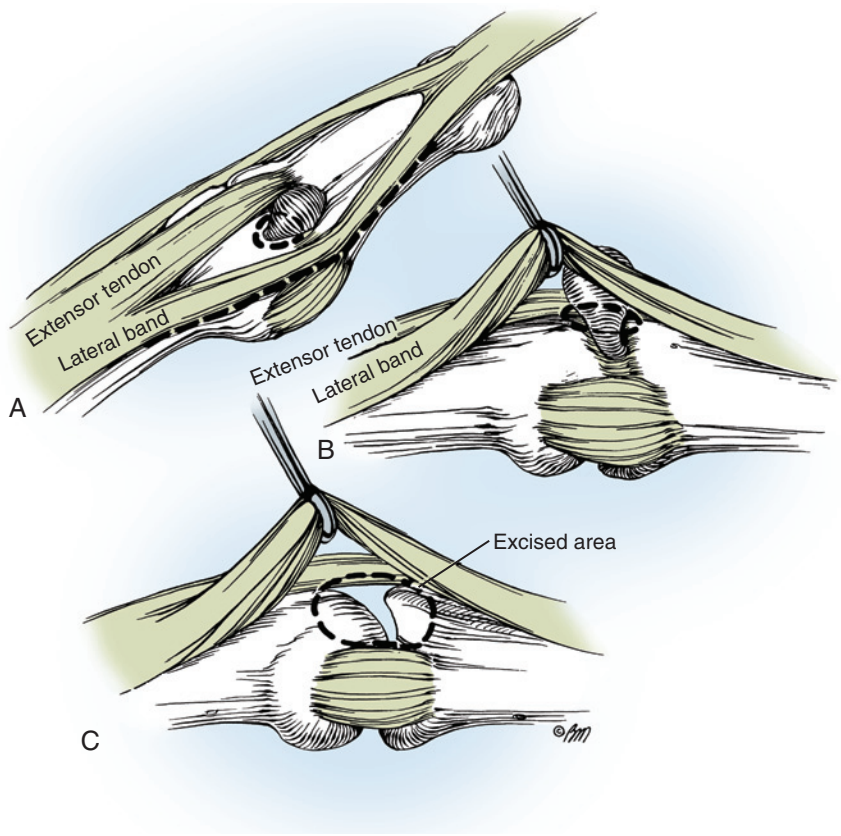

FIGURE 59.37 **A,** Proximal interphalangeal (PIP) ganglion in situ between the extensor tendon and lateral band. An incision along the lateral border of the lateral band and the base of the pedicle is illustrated with a dashed line. **B,** The lateral band has been released and elevated to expose the joint capsule and infratendinous portion of the cyst. **C,** Excision of the cyst and joint capsule reveals the exposed PIP joint. (Copyright © Elizabeth Martin.)

Miscellaneous Locations

Ganglions have been reported to occur in numerous other locations of the hand and wrist and are often associated with various conditions, including those described in the following subsections.

First Extensor Compartment (Dorsal Retinacular) Ganglion. Ganglions attached to the first extensor compartment, similar to volar retinacular ganglions, are seen in patients with acute stenosing tenosynovitis (de Quervain disease) (Figure 59.39). Therefore, in addition to releasing the tendons (see Chapter 56), the involved tendon sheath and the ganglion can be excised. Injury to the radial sensory nerve should be avoided, and a separate compartment of the extensor pollicis brevis may be present and require release.

Carpal Tunnel. Symptoms consistent with compression of the median nerve have been ascribed to ganglions arising from the volar carpus within the carpal canal.[110] A volar wrist ganglion also can extend distally and ulnarward to compress the median nerve. All carpal tunnel releases should be accompanied by exploration of the canal to rule out extrinsic masses, including ganglions.

Guyon Canal/Distal Ulnar Nerve. Ganglions within the ulnar canal (loge de Guyon) can compress the ulnar nerve and cause motor or sensory loss, or both.[177] These ganglions generally arise from joints around the hamate and dissect through the hypothenar muscles or along the motor branch. Ganglions in the palm can lead to isolated atrophy of the first dorsal interosseous muscle. Early excision is imperative and avoids permanent injury to the ulnar nerve.

Intraosseous Ganglions

Although rare and usually an incidental radiographic finding, intraosseous ganglions are increasingly being recognized as a source of wrist pain.[41] Surgical treatment is best delayed, however, until all other possible causes of the patient's discomfort have been excluded. When indicated, curettage and bone grafting adequately treat the condition. Careful exploration of the joint at the time of surgery helps rule out other undiagnosed causes of the patient's symptoms. Communication between the joint cavity and the intraosseous cyst has not been consistently demonstrated (Figure 59.40). The histologic features of intraosseous ganglions are identical to those of their soft tissue counterparts.

Epidermal Inclusion Cysts

Epidermal inclusion cysts are thought to result from traumatic implantation of epithelial cells into the underlying soft tissue or bone.[63,150] The cells grow over an interval of months to years to produce a painless swelling, most commonly in the fingertip. Erythematous and painful lesions have been described. These lesions most frequently occur in the distal phalanx of the left long finger and thumb in men in the third and fourth decades

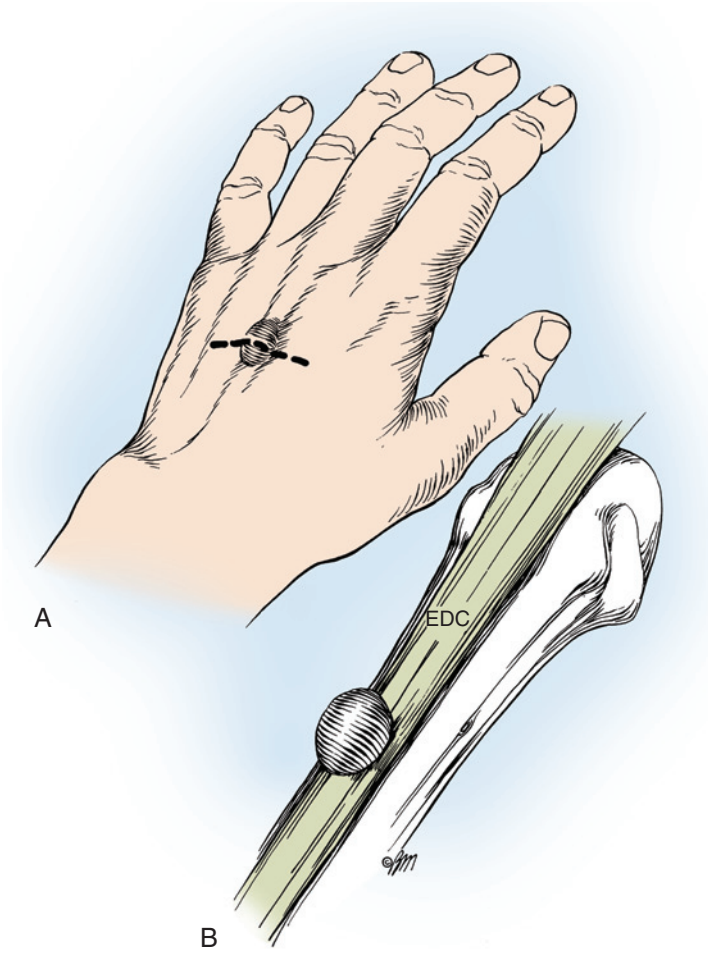

FIGURE 59.38 Extensor tendon ganglion. **A,** The ganglion, tendon, and overlying skin incision. **B,** The ganglion in situ on the extensor tendon. *EDC,* Extensor digitorum communis. (Copyright © Elizabeth Martin.)

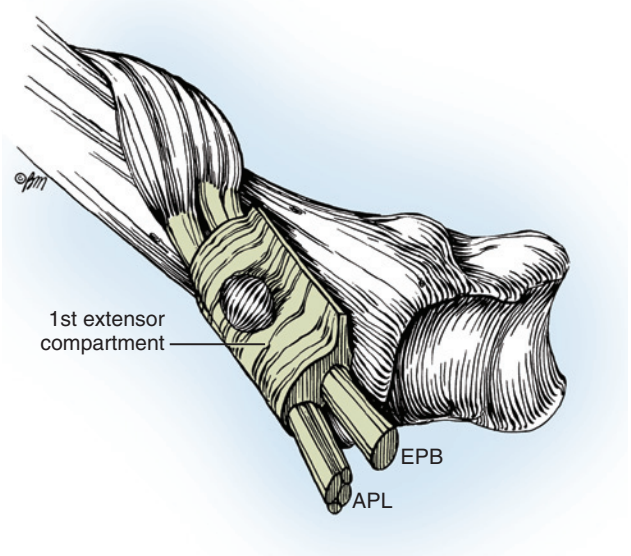

FIGURE 59.39 Dorsal retinacular ganglion. The first extensor compartment with attached ganglion and a separate compartment for the extensor pollicis brevis (EPB) are illustrated. *APL*, Abductor pollicis longus. (Copyright © Elizabeth Martin.)

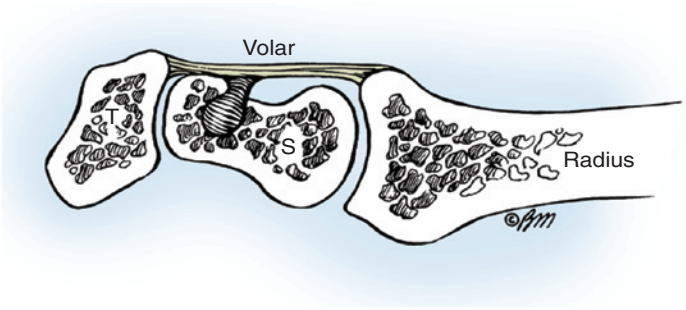

FIGURE 59.40 Intraosseous ganglion of the scaphoid with articular communication. The lesion was treated successfully by curettage and bone grafting. *S,* Scaphoid; *T,* trapezoid. (Copyright © Elizabeth Martin.)

of life. Epidermal inclusion cysts may be seen after traumatic or surgical amputation of the fingertip. Metacarpal involvement is rare, and there are no reported cases occurring in the carpus.

Patients typically note a slowly growing mass on the fingertip or thumb tip, even though a history of trauma (penetrating injury) may not be recalled. When confined to soft tissue, the cyst is usually well circumscribed, firm, and slightly movable. The differential diagnosis can be more difficult when the cyst involves bone, in which case radiographs generally show a well-demarcated lytic lesion (Figure 59.41). Occasionally, cortical penetration can be seen, and the lesion may mimic a malignant or infectious process. More than a fourth of reported lesions have been treated by primary amputation, before pathologic diagnosis, out of concern for an aggressive neoplasm or advanced bone destruction.

Patients with a lytic lesion of the distal phalanx should undergo biopsy before consideration of an ablative procedure. Epidermal inclusion cysts are readily treated by marginal excision or by curettage and bone grafting for lesions involving bone. In rare cases with advanced bone destruction, amputation may be an alternative. Recurrence is uncommon, and malignant transformation has not been reported.

Foreign Body Lesions

Foreign body lesions are traumatic reactive masses rather than true neoplasms. These lesions are a response to implanted foreign material.[8,49,89,173] The tissue's reaction to foreign material varies with the nature of the foreign substance deposited, the anatomic site involved, the duration of the implant, and the presence or absence of tissue hypersensitivity to the material.[89] This response is the host's method of isolating recognized extraneous substances. Glass, wood, and metal are the most common types of particulate matter associated with a foreign body reaction. These lesions are usually relatively superficial in location.

It is important to establish the cause of the lesion because the differential diagnosis includes malignant soft tissue neoplasms. A history of penetrating trauma or identification of a foreign body with radiographs or ultrasonography can provide this information.[8,173] It may be impossible to preoperatively distinguish between an inclusion cyst, a foreign body reaction, or a soft tissue neoplasm. Excisional biopsy of these relatively small lesions allows pathologic analysis and confirmation of the diagnosis and results in a cure for the problem.

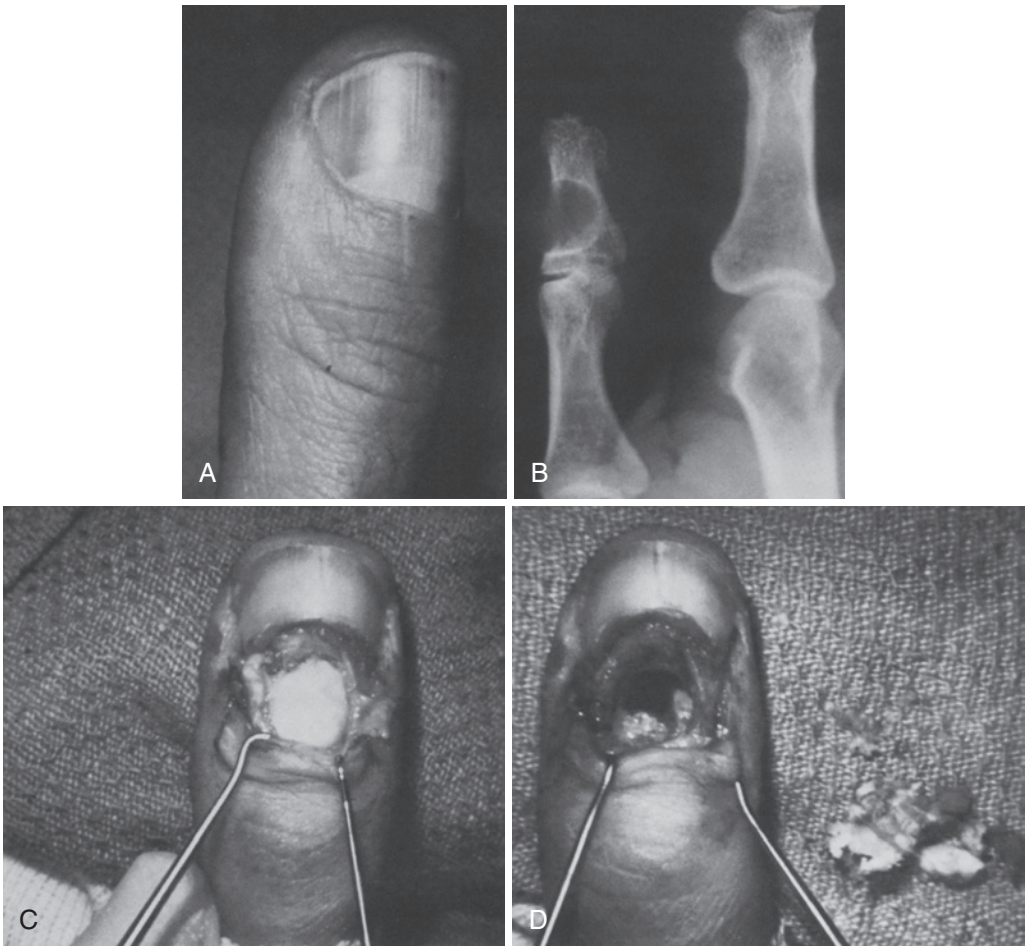

FIGURE 59.41 Epidermal inclusion cyst. A 53-year-old salesman reported that an enlarging deformity of the thumb **(A)** had progressed slowly for some time after a crush injury that occurred at least 18 months earlier. Radiographs showed a well-circumscribed distal phalangeal lesion with a reactive endosteal cortical rim **(B)**, typical of bone reaction to a slowly growing soft tissue tumor. **C, D,** Marginal excision revealed an epidermal inclusion cyst that was successfully treated by removal and phalangeal curettage.

Lipomas

Lipomas are common benign fat tumors that typically occur in several locations in the hand,[14,20,139] most commonly subcutaneously or intramuscularly. Lipomas have been reported to arise in association with tendon sheaths, in the carpal tunnel, in the Guyon canal, and in the deep palmar space. They are soft nontender masses that do not transilluminate. Symptoms of nerve compression may be noted if the tumor is in the deep palmar space or in proximity to a major nerve. Such lesions are frequently present for several years and may grow slowly. When the lesion is subcutaneous, it is readily recognized by its well-demarcated appearance and rubbery consistency. Plain radiographs may reveal a soft tissue shadow, and MRI may be particularly useful by demonstrating signal characteristics that are significantly suggestive of fat, which is often similar to surrounding subcutaneous fat.

Lipomas are usually well demarcated and are readily dissected from surrounding soft tissues, but occasionally the tumor may be immediately adjacent to nerves, thus making dissection difficult. When the patient's physical examination and radiographs are extremely suggestive of a lipoma, a small lesion can be treated by excisional biopsy. Deep lesions, such as those occurring in the carpal tunnel, should be studied preoperatively with MRI. If the signal characteristics are not clearly suggestive of lipoma, a small incisional biopsy should be done to establish the diagnosis and prevent operative contamination of major nerves. Marginal excision of lipomas is generally curative, although recurrence may be seen.

Lipofibromatous Hamartomas

Lipofibromas or lipofibromatous hamartomas are unusual tumors of peripheral nerves that most commonly involve the median nerve when seen in the upper extremity.[91,129] Rare instances of ulnar or radial nerve involvement have been reported.[95] Patients usually complain of slowly progressive swelling in the distal part of the forearm or palm, and symptoms of nerve compression may be present. The mass is most commonly noted in childhood or adolescence and is thought to be congenital or developmental in origin. MRI findings can be diagnostic. Surgical exploration reveals either diffuse fusiform swelling of the nerve without extension into perineural tissues or a more circumscribed area of involvement. The mass is closely associated with the nerve fibers and is not readily dissected free. Attempts at partial excision or interfascicular dissection frequently result in permanent loss of motor or sensory

nerve function and should be avoided in the presence of characteristic MRI findings.[91,161,191] Biopsy of a cutaneous branch of the nerve can be done to confirm the diagnosis if MRI findings are not diagnostic.[161]

Additional surgical treatment is directed only at decompressing the nerve. Spontaneous decrease in tumor size and improved nerve function have been reported after nerve decompression only. If the size of the lesion requires that it be excised, Houpt and associates have advocated complete excision and nerve grafting in children and immediate tendon transfers in adults.[91] Histologic examination of the lesion reveals nerve tissue with surrounding fat cells and a smaller component of fibrous tissue. Long-term follow-up of patients with such lesions has demonstrated slow but progressive loss of nerve function.[129]

Giant Cell Tumors of the Tendon Sheath (Pigmented Villonodular Tenosynovitis)

A giant cell tumor (GCT) of a tendon sheath is a benign soft tissue tumor and is the second most common tumor seen in the hand (after ganglions).[1,83,97,100,104,145] Several terms have been used to describe this lesion, including *localized nodular synovitis, fibrous xanthoma*, and *pigmented villonodular tenosynovitis. Giant cell tumor of the tendon sheath* is not a particularly good term because the lesion does not uniformly contain giant cells and is not necessarily associated with a tendon sheath. The tumor generally occurs on the volar surface of the fingers or hand, although dorsal involvement is not uncommon. There is a propensity for involvement of the radial three digits and the DIP joint region.[145] Clinically, the tumor is most often firm, nodular, and nontender. Because it grows slowly, it may be present for a long time before the patient is seen. A sensory deficit may be present when the lesion occurs in proximity to the digital nerves.

The lesion does not transilluminate, which helps distinguish it from a ganglion. Plain radiographs may demonstrate a soft tissue mass or pressure erosion of underlying bone.[104] Bone invasion, as can be seen with diffuse pigmented villonodular tenosynovitis, is not typical and suggests a more aggressive neoplasm. Actual bone invasion is rare but has been described.[198] Marginal excision is the recommended treatment, although the reported incidence of recurrence is 5 to 50%.[83,145] The high risk for recurrence is thought to be caused by the presence of satellite lesions or incomplete excision. Statistically significant risk factors for local recurrence include degenerative joint disease, location at the DIP joint, and radiographic evidence of pressure erosion.[166] If extensive joint involvement or degenerative changes are seen, arthrodesis may be necessary after excision. Radiation can be considered for multiply recurrent or aggressive lesions.[40] A malignant form of GCT of the tendon sheath has been adequately described.[100]

Schwannomas (Neurilemomas)

Neurilemoma, or schwannoma, is the most common benign nerve tumor occurring in the upper extremity.[50,164,169,189] This lesion arises from Schwann cells and produces a slowly growing, well-circumscribed, eccentric lesion in the peripheral nerve. Neurilemomas are most commonly seen on the flexor surface of the forearm or hand in the fourth, fifth, or sixth decades. Patients most frequently notice a painless mass, but less commonly there may be a neurologic deficit. Palpation or compression of the lesion can produce radiating pain in a specific nerve distribution. The lesion is often mobile in a transverse direction but not longitudinally. It is frequently misdiagnosed as a ganglion and may have a similar consistency.[164,169] MRI can be useful in delineating the lesion, but it may not be possible to distinguish neurilemoma from a neurofibroma or malignant peripheral nerve sheath tumor (Figure 59.42).[189]

Neurilemoma can be dissected free or "shelled out" from the surrounding nerve. Interfascicular involvement may be seen rendering dissection more difficult. Optical magnification and microsurgical techniques have been advocated to reduce the risk for postoperative neurologic deficit. The incidence of postoperative neurologic deficit is approximately 5 to 15%,[182] with a significantly greater risk of a deficit occurring with procedures done after incisional biopsy or recurrence.[50] In the overwhelming majority of cases, the lesion can be completely removed and neurologic symptoms, if present preoperatively, are improved. Recurrence is uncommon. Multiple lesions in a single peripheral nerve have been described. There are rare reports of malignant transformation.[4,74]

CRITICAL POINTS *Excision of Giant Cell Tumor of the Tendon Sheath*

Indications

- Same as for open incision biopsy.
- Suspected giant cell tumor of a tendon sheath.

Technical Points

- Same as for biopsy.
- When diagnosis is confirmed by biopsy or visual inspection, perform a marginal excision.
- Have a low threshold for intraarticular exploration or exploration deep into the volar plate.

Postoperative Care

- Advise the patient of the diagnosis and approximate 30% risk for local recurrence.
- Initiate range-of-motion exercises and remove the sutures at 7 to 10 days.

Neurofibromas

Neurofibromas are benign nerve tumors that arise within nerve fasciculi and are typically more difficult to excise than neurilemomas.[50] Solitary lesions may be seen, but multiple neurofibromas are more common in the setting of neurofibromatosis (von Recklinghausen disease). Symptoms and clinical findings may be similar to those seen with neurilemomas. At surgery, a more prominent nerve fascicle or group of fascicles can be seen entering and exiting the lesion if both proximal dissection and distal dissection are done under magnification.[50] Excision of the lesion requires transection of the entering and exiting fascicles. Postoperative neurologic deficit is more common than after excision of neurilemomas. Progression of motor and sensory nerve deficits has been noted after surgical treatment of plexiform neurofibromas in patients with neurofibromatosis.[50] Surgical treatment of neurofibromas in patients with neurofibromatosis should be reserved for lesions that are growing or producing progressive symptoms. There is a known risk for malignant degeneration of neurofibromas in patients with neurofibromatosis.

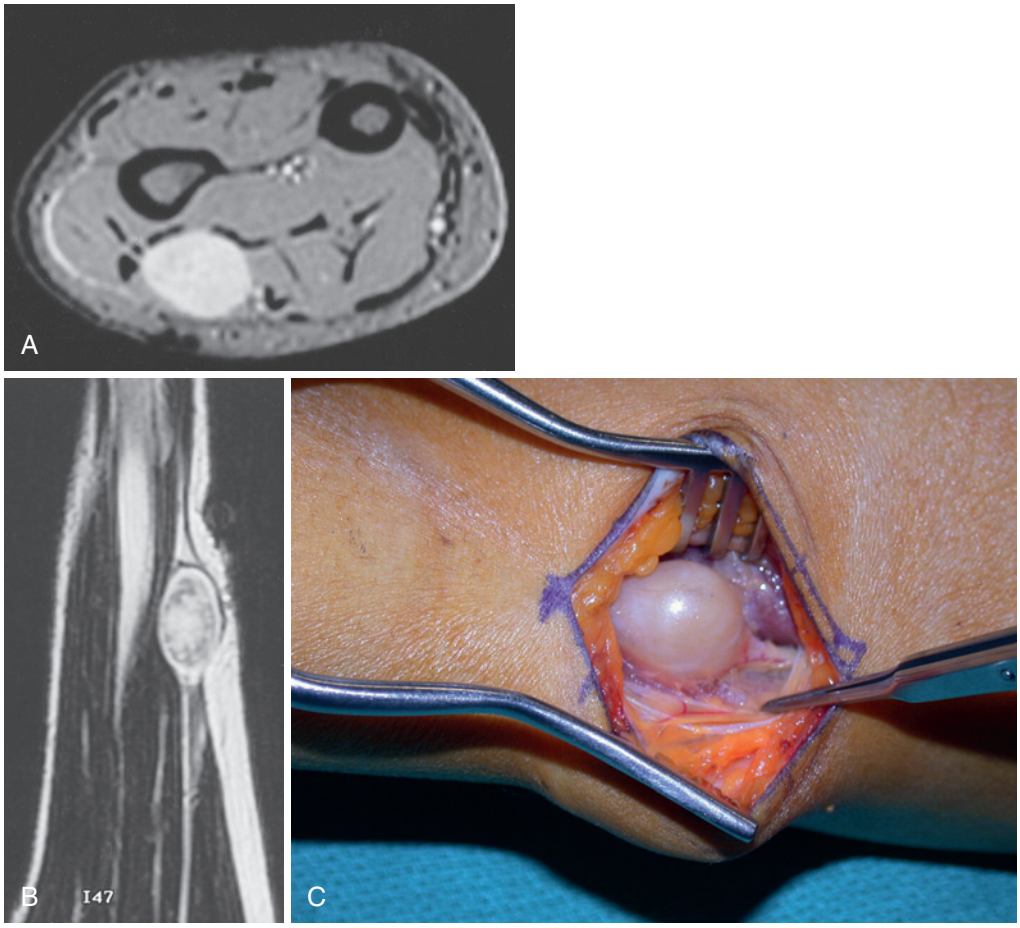

FIGURE 59.42 Axial **(A)** and sagittal **(B)** magnetic resonance images of a neurilemoma arising from the ulnar nerve. Intraoperatively, the lesion was readily dissected from the major portion of the ulnar nerve **(C)**.

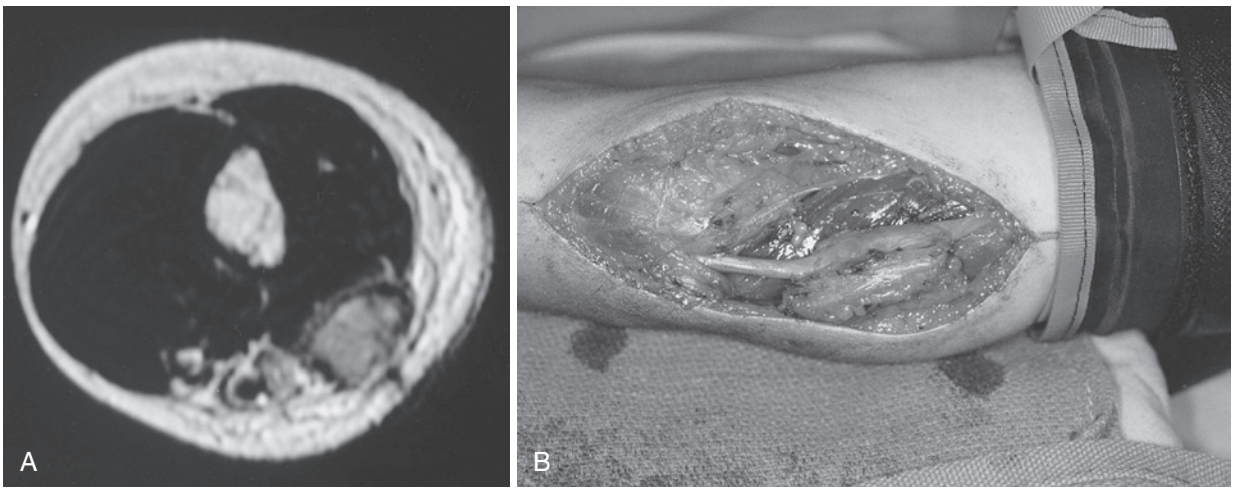

FIGURE 59.43 **A,** Axial magnetic resonance imaging demonstrating a lobulated granular cell tumor arising from the ulnar nerve. **B,** At surgery, the tumor was not able to be separated from the ulnar nerve just proximal to the medial epicondyle.

Granular Cell Tumors (Granular Cell Myoblastomas)

A granular cell tumor is a neoplasm that is rarely seen in the forearm and hand.[58,64,132] This lesion appears to arise from neural elements rather than from myoblasts, as originally believed, and it has been found to occur in close association with nerves (Figure 59.43).[58] Patients usually note a painless mass. Multicentricity has been reported in 10 to 15% of cases. Excision of the tumor has been curative, although there has been no critical analysis of the need for wide margins at excision. A malignant variant of a granular cell tumor has been

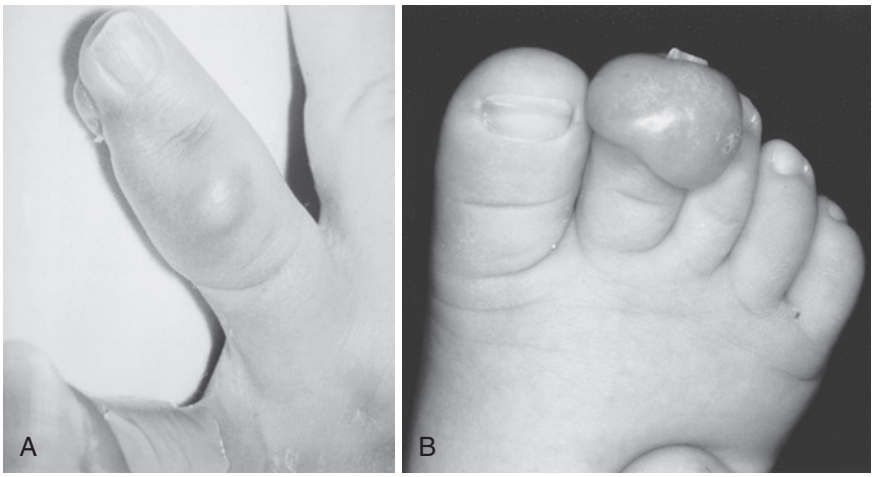

FIGURE 59.44 Digital fibroma during infancy occurs almost exclusively in the fingers **(A)** and toes **(B)**, usually in the first year of life. (Courtesy of Chris Unni, MD.)

reported; it is rare and difficult to distinguish from the benign lesion.[58] Malignant lesions are highly aggressive and require wide excision and consideration of systemic treatment.

Fibromatoses

Digital Fibroma of Infancy

Digital fibroma of infancy is a benign but very aggressive fibrous lesion seen virtually exclusively in the fingers or toes (Figure 59.44), with more than 80% of cases arising before the age of one.[19,61,94] Digital fibroma of infancy generally occurs in the region of the interphalangeal joints of the fingers. The lesions are usually small, dome shaped, skin colored, and painless. The true natural history of this condition is not known. Observation has documented progression with interphalangeal contracture, angular deviation, and bone deformity in severely affected children.[19,61] There are reports of spontaneous resolution of the skin lesions, with some patients having residual deformity.[19] Microscopic evaluation has demonstrated intracytoplasmic inclusion bodies, which has resulted in speculation of a viral or myofibroblast cause of the lesions.

Treatment has included observation, marginal excision, wide excision with coverage, and amputation. No documented cases of metastasis have been reported, but the incidence of local recurrence after excision is approximately 60%. Although no firm treatment guidelines exist, it seems prudent to observe these lesions until spontaneous resolution occurs or early signs of deformity or contracture are seen. Wide excision and skin grafting appear to give the best local control and functional results, but there is a significant risk for local recurrence and even subsequent involvement of adjacent digits.[61]

Juvenile Aponeurotic Fibroma

Fibrous lesions in the hand are commonly seen in childhood and adolescence and are frequently difficult to classify and treat. Juvenile aponeurotic fibroma, or calcifying aponeurotic fibroma, is a benign, aggressive fibrous lesion seen during childhood or adolescence that most commonly affects the palm.[3,34,107,114] This lesion is manifested as a small painless mass, often closely associated with tendons or neurovascular structures. The histologic appearance can be difficult to distinguish from fibrosarcoma.

Wide excision with sparing of functional or vital structures is the recommended treatment, but the recurrence rate has been reported to be higher than 50%.[34] On rare occasion, amputation has been necessary to control the disease. There is one reported case of metastasis after recurrence of juvenile aponeurotic fibroma in the hand, although the metastasis was classified as fibrosarcoma.[114] Local and systemic surveillance should be considered for patients with this lesion. Recurrent lesions can be observed if they do not produce functional impairment and the diagnosis is not in question.[34]

Nodular Fasciitis

Pseudosarcomatous fasciitis, subcutaneous pseudosarcomatous fibromatosis, and *infiltrative fasciitis* are terms that have been used to describe the entity currently called *nodular fasciitis*. It is an uncommon but well-described reactive lesion that is poorly understood and may simulate a sarcoma.[17,187] This lesion most commonly occurs on the volar surface of the forearm and rarely can occur in the hand and digits.[105] Patients usually note a rapidly growing small nodule that has been present for a very short time, frequently less than a month. There may be a history of local trauma and tenderness on palpation. The histologic appearance has been confused with fibrosarcoma and myxoid liposarcoma, which has led to overtreatment.[187] The diagnosis of nodular fasciitis is rarely anticipated preoperatively. The natural history of nodular fasciitis appears to be self-limited. Recurrence after marginal excision should raise the question of an alternative diagnosis because even incompletely excised lesions have not been noted to recur.[17] The most important issue in treating patients with nodular fasciitis is to differentiate this lesion from a soft tissue sarcoma to avoid unnecessary aggressive surgical treatment. Molecular genetic testing of pathologic specimens can assist in establishing a diagnosis as genetic studies have identified frequent presence of the USP6 gene rearrangement by interphase fluorescence in situ-hybridization (FISH).[155]

MALIGNANT SOFT TISSUE LESIONS

Soft Tissue Sarcomas

Soft tissue sarcomas are relatively rare in the hand and forearm.[28] Approximately 12,000 new cases of soft tissue sarcoma are diagnosed each year in the United States and only 15% of them occur in the upper extremity.[120] *The majority of these lesions share a common primitive mesenchymal origin.* For most patients no predisposing risk factor can be identified. Certain environmental and genetic risk factors have been implicated as potential causes of soft tissue sarcoma. Patients exposed to radiation[38] and forestry workers exposed to herbicides may have a higher incidence of soft tissue sarcoma. Genetic factors have been implicated in neurofibromatosis and Li-Fraumeni syndrome.[123]

In previous editions of this chapter, individual types of soft tissue tumors were described on the basis of their presumed cell of origin. It is important to recognize that specific cell origin or tumor differentiation of soft tissue sarcoma has limited value in predicting the behavior of a tumor. The biologic behavior of soft tissue sarcomas can be more accurately predicted by the lesion's histologic grade, which takes into account cell mitotic index, cellularity, tumor necrosis, and anaplasia. The most common histologic subtypes of soft tissue sarcoma seen in the hand are epithelioid sarcoma, synovial sarcoma, and malignant fibrous histiocytoma.[28] Histologic diagnosis can be useful in assessing its propensity for regional lymphatic spread.[68,165,185]

Clinical Picture

The clinical characteristics of the various types of soft tissue sarcomas in the upper extremity and hand can be similar. Most frequently, patients note a painless mass that may have been present for a long time with recent growth.[28,194] Less commonly, a painful mass may be reported. Epithelioid sarcoma is notable for manifestation as an ulcerating nodule that can be mistakenly treated for infection.[185] Soft tissue sarcomas in the hand are frequently misdiagnosed as infection, ganglion, and lipoma. This can lead to inappropriate treatment or to a delay in treatment.

Physical examination of a patient with a suspicious lesion includes careful assessment of size, location, depth, mobility, and relationship to major nerves, vessels, tendons, and bone. Regional lymph nodes are assessed. Plain radiographs are obtained and may demonstrate soft tissue calcification, fat density, or unexpected bone involvement, which can assist in making a diagnosis (Figure 59.45). MRI has become increasingly valuable in defining the pathologic anatomy, determining the local extent of disease, and aiding preoperative planning.

Biopsy

Soft tissue masses that are symptomatic, enlarging, or not readily diagnosed by physical examination should be considered for biopsy. Very small lesions that can be excised with a surrounding cuff of normal tissue can be treated by excisional biopsy before a known diagnosis. Large lesions or lesions in proximity to major nerves, vessels, or tendons are best treated with incisional biopsy. The decision of how to perform the biopsy is particularly important in the hand because of the compact nature of important soft tissues in the wrist and hand. Incisional biopsies or biopsies in which the tumor is inadvertently violated result in contamination of all tissues included in the exposure. Poorly planned biopsies may compromise the ability to perform limb-sparing surgery. It is best to plan the biopsy incision to be in line with or incorporated into the definitive limb salvage or amputation procedure that may be required in the event of a high-grade malignant diagnosis. Transverse, oblique, and zigzag (Bruner) incisions should specifically be avoided.

Staging

After the diagnosis of a soft tissue sarcoma, systemic staging should be done with CT of the chest and axilla. Soft tissue sarcomas of the upper extremity most commonly metastasize to the lungs or regional lymph nodes.[68,74] Lymph node metastasis occurs in less than 5% of soft tissue sarcomas of the extremities, however.[136] Epithelioid sarcoma is a notable exception, with a risk for regional lymph node metastasis as high as 42%.[22,162,165,185] Sentinel lymph node biopsy for epithelioid sarcoma, clear cell sarcoma, angiosarcoma, and rhabdomyosarcoma is currently being investigated and may play a role in the staging of patients with these diseases.[106,131] Soft tissue sarcomas are generally staged on the basis of grade, size, and the presence of metastasis. Prognostic factors that have been incorporated into the AJCC staging system include grade, size, depth, and presence of metastasis.[77] Histologic grade is particularly important in predicting the biologic behavior of the lesion and its risk for metastasis.[118] The tumor should also be staged with the MSTS staging system.[55]

Operative Treatment

Surgery is the primary form of local treatment for patients with soft tissue sarcoma. Treatment of either bone or soft tissue sarcoma requires the surgeon to think and plan for two parts of the operation: resection and reconstruction. At times, a two-team approach may be best. Resection of the lesion is of primary importance. Concerns regarding reconstruction must be given secondary consideration within the context of the particular patient or aggressiveness of the lesion. Compromise of resection margins out of concern for reconstruction increases the risk for local recurrence and may increase the risk for metastasis and death.[28,124,194] Positive margins in the treatment of soft tissue sarcomas in the hand are not readily salvaged or compensated for by the use of external beam radiation and have been found to be predictive of recurrence.[28,194]

The goal of surgery is complete removal of the tumor with a surrounding cuff of normal tissue. Wide excision with 2 to 3 cm of normal tissue surrounding the tumor has been advocated.[118,185] Deliberate sacrifice of major neurovascular structures can often be avoided, provided that there is meticulous attention to dissection, a margin of normal tissue can be obtained, and neurovascular structures are not surrounded by tumor.[118,172] If negative margins cannot be achieved with wide excision, amputation should be very strongly considered. Extensive reconstruction may be required after wide excision of soft tissue sarcomas of the hand. Talbot and colleagues developed an anatomic, site-specific reconstruction algorithm that can help in decision making during complex soft tissue reconstruction after resection of soft tissue sarcomas.[193]

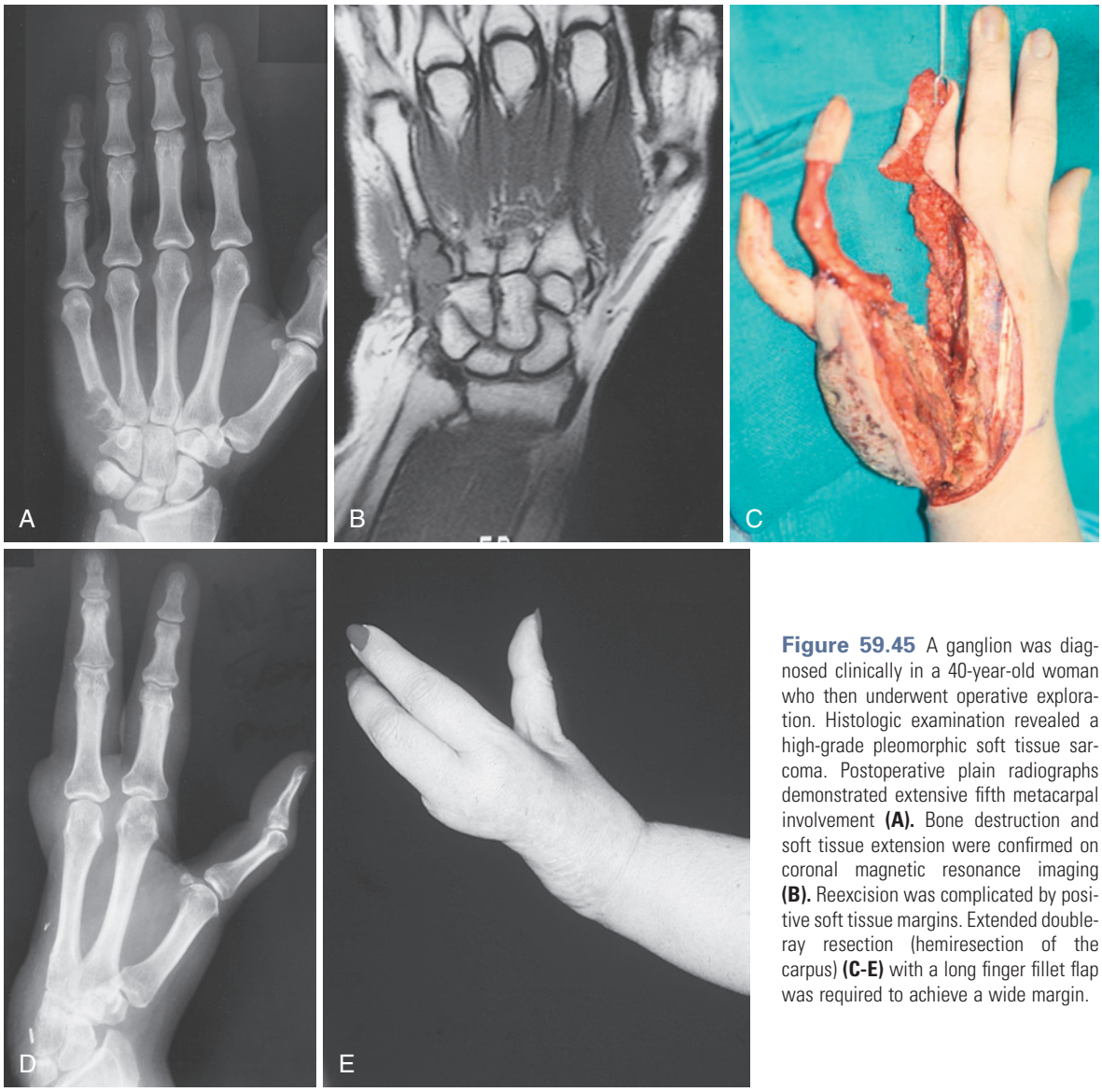

Figure 59.45 A ganglion was diagnosed clinically in a 40-year-old woman who then underwent operative exploration. Histologic examination revealed a high-grade pleomorphic soft tissue sarcoma. Postoperative plain radiographs demonstrated extensive fifth metacarpal involvement **(A).** Bone destruction and soft tissue extension were confirmed on coronal magnetic resonance imaging **(B).** Reexcision was complicated by positive soft tissue margins. Extended double-ray resection (hemiresection of the carpus) **(C-E)** with a long finger fillet flap was required to achieve a wide margin.

After wide excision of a large (>5 cm) high-grade lesion, patients require either brachytherapy* or external beam irradiation in an effort to reduce the risk for local recurrence.[25,26,28,194] Excision of large low-grade lesions should be followed by external beam irradiation. Small (>5 cm) high- or low-grade extremity lesions that can be widely excised may not require adjuvant radiation therapy, although this issue has not been conclusively answered for the hand.[4,28,118,194] Digit, single-ray, or multiple-ray amputation may often be the best solution for patients with soft tissue sarcoma involving the fingers or web space. Wide margins cannot be readily obtained in the digit, and the functional result of amputation may be superior to that of digit salvage and reconstruction. Large lesions or lesions involving the contents of the carpal tunnel may not be amenable to a hand-sparing operation and are frequently best treated with below-elbow amputation.

The role of chemotherapy in the treatment of soft tissue sarcomas in the extremities is still under investigation. Chemotherapy can have a small but real overall survival benefit and may increase the disease-free interval in well-selected patients with extremity lesions.[73] Certain patients with large high-grade lesions may benefit from preoperative chemotherapy in an effort to reduce the size of a lesion to make an unresectable lesion resectable. Patients with large high-grade lesions may be at high risk for metastasis and should be considered for investigational protocols in conjunction with a medical oncologist. Patients initially seen with metastasis can also be candidates for chemotherapy and resection of lung nodules.[74]

*_Brachytherapy_ refers to the use of radioactive implants to deliver radiation over short periods. Small, flexible catheters are implanted at the time of surgery, and beginning about 5 days after surgery, radioactive implants are loaded into the catheters. These implants are left in place for 3 to 4 days during which time high doses of radiation can be delivered directly to the tissue at risk with predictable minimal scatter. Another advantage is that this method dramatically shortens the duration of radiation treatment when compared with external beam therapy (5 weeks). Brachytherapy is more effective for high-grade tumors than for low-grade ones and should not be considered for the latter.

Patients referred after primary excision with positive margins should be strongly considered for reexcision or amputation because the risk for local recurrence in this situation is high.[28,119,194] Patients with metastasis should be treated aggressively locally in the extremity and in the chest, as well as systemically, because survival is possible.[74]

CRITICAL POINTS *Treatment of Forearm and Hand Soft Tissue Sarcomas*

Indications

- Attempted curative treatment of a patient with a soft tissue sarcoma
- Patient able to tolerate limb salvage and reconstruction

Preoperative Evaluation

- Have the pathologic diagnosis confirmed by an experienced pathologist before surgery.
- Complete the staging workup and appropriate consultation before surgery.
- Make a preoperative plan detailing positioning, resection steps, and reconstruction options.

Technical Points

- Mark limb salvage incisions so that they incorporate the previous biopsy tract and any previously contaminated tissue.
- Prioritize tourniquet time to critical portions of the procedure—usually dissection of neurovascular structures.
- Create flaps while leaving the biopsy tract en bloc with the major tumor mass.
- Dissect or sacrifice major nerves and vessels first.
- Leave a cuff of normal, uninvolved, nonreactive tissue covering the major tumor mass.
- Use the nondominant hand to palpate the tumor mass and ensure dissection at least one fingerbreadth from the tumor whenever possible.
- Avoid any contamination from the tumor.
- Take advantage of fascial or compartment boundaries by dissecting on the opposite side of the fascia from the tumor.
- Sacrifice functional tissues, nerves, tendons, vessels, and bone as needed to achieve negative margins.
- Confirm negative margins of resection by assessment of frozen sections.
- Consider a separate reconstruction team, especially with free tissue transfer.
- Use separate isolated fields and clean instruments and clothing for remote tissue harvest for reconstruction.
- Achieve excellent hemostasis before closure.

Postoperative Care

- Confirm the pathologic diagnosis on permanent analysis.

Epithelioid Sarcoma

Epithelioid sarcoma has been reported to be the most common soft tissue sarcoma occurring in the forearm and hand.[22,59,162,165,185] This tumor is notorious for its innocuous appearance, frequent misdiagnosis, propensity for local recurrence, and regional lymph node metastasis. Epithelioid sarcoma is commonly manifested as a painless nodule on the volar surface of the digits or palm that may ulcerate. Misdiagnosis has included infection, Dupuytren nodules, and other types of sarcomas. The extent of local disease is often not evident on clinical or radiographic examination. This tumor is characterized by a tendency to spread proximally along the course of tendons, lymphatics, and fascial planes without respecting fascial boundaries.[162] A high risk for lymph node involvement has been reported, with several authors recommending lymph node dissection.[162,165,185]

Epithelioid sarcoma must be treated aggressively with a true wide excision, radical resection, or amputation. Epitrochlear and axillary lymph node sampling should be strongly considered, even in the absence of clinically or radiographically detectable disease because excision of involved nodes has the potential to be lifesaving. The role of sentinel lymph node biopsy, as opposed to prophylactic lymphadenectomy, is under investigation.[106] Forequarter amputation has resulted in cure of patients with proximally recurrent disease or axillary lymph node involvement.[28] Marginal excision, even when combined with external beam irradiation, has resulted in unacceptably high rates of local recurrence and regional spread and is not a reasonable option for the treatment of epithelioid sarcoma.[185] External beam irradiation or brachytherapy should be done after wide excision of larger lesions. Chemotherapy should be considered for patients with lymph node involvement, metastasis, or recurrence.

Synovial Sarcoma

Synovial sarcoma is a high-grade malignant soft tissue sarcoma that usually arises in proximity to joints, tendons, or bursae.[47,151,171] This tumor most commonly occurs in the region of the carpus and is rarely seen in the fingers. A painless mass over the dorsum of the hand or in the palm, often present for many years, is the most frequent finding and can lead to the false impression that the lesion is benign. Rare intraneural lesions may be heralded by intense radiating pain not usually seen with schwannoma or neurofibroma. Synovial sarcoma can grow very slowly initially, and the patient may give a history of no apparent growth. Any soft tissue mass that is unexplained and not readily diagnosed by physical examination or imaging should be sampled to establish an accurate diagnosis.

Soft tissue calcifications may be seen in 20 to 30% of patients on plain radiographs.[47] The lesion metastasizes to regional lymph nodes in as many as 25% of patients in whom metastasis develops. Although the size of synovial sarcoma has been thought to be an important prognostic factor in general case series,[151] small size may not necessarily be associated with a better prognosis for lesions arising in the hand.[28,47] Studies suggest a benefit from the use of intensive or high-dose chemotherapy, particularly in patients with resectable metastatic disease.[171,184] This tumor is treated as previously discussed for soft tissue sarcomas.

Liposarcoma

Liposarcoma is one of the most common types of soft tissue sarcoma, but it is only rarely seen in the hand.[28,194] Histologic subtypes of liposarcoma include well-differentiated, myxoid, round cell, dedifferentiated, and pleomorphic liposarcoma. Differentiation of liposarcoma into its various subtypes is useful because histologic appearance and tumor grade correlate with clinical behavior, risk for metastasis, and prognosis.[58] Clinically, these lesions can resemble lipomas, but more often they are painful and grow more rapidly. Findings on MRI also may be similar to those for lipoma with the notable exception of greater heterogeneity or lack of suppression on fat suppression sequences (Figure 59.46).

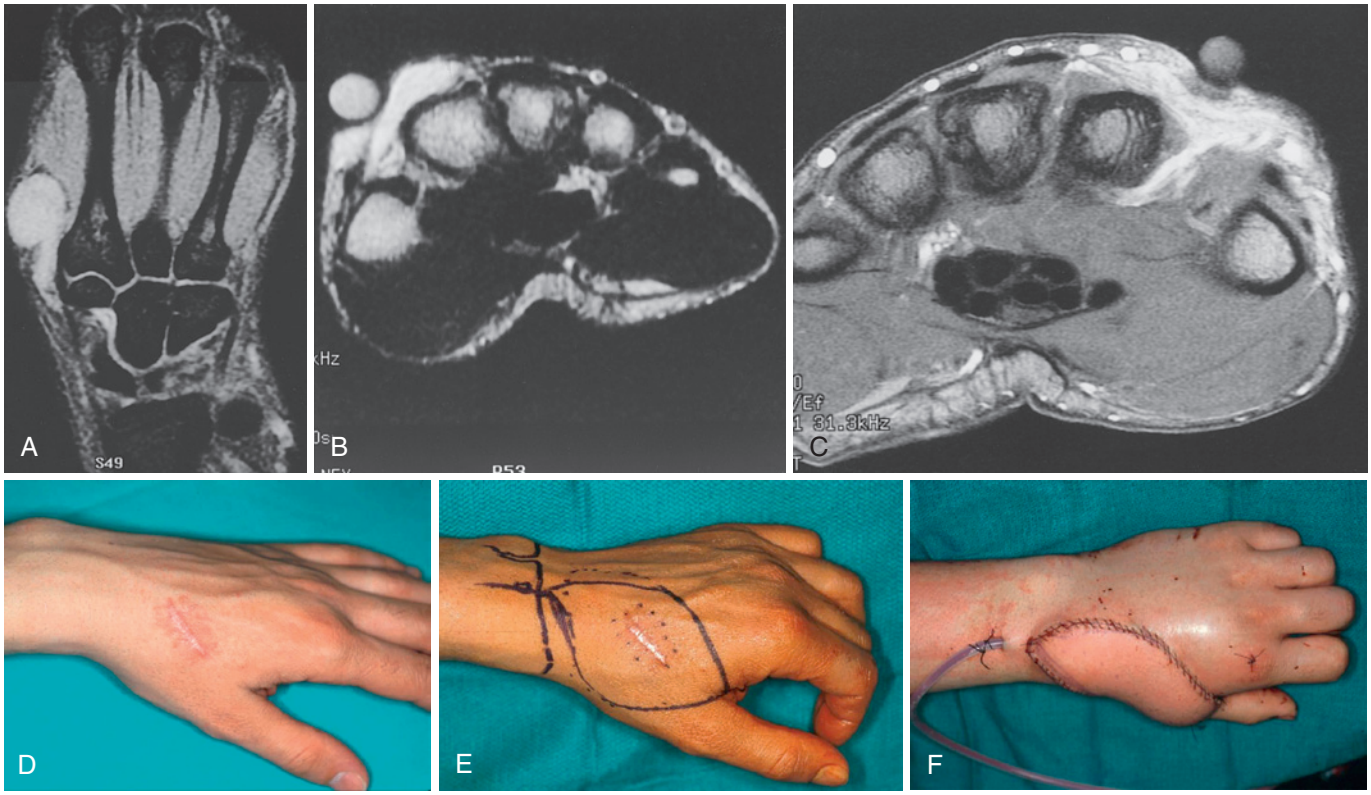

FIGURE 59.46 Preoperative coronal **(A)** and axial **(B)** magnetic resonance imaging (MRI) demonstrating a soft tissue mass with signal characteristics similar to those of subcutaneous fat. After marginal excision for a presumed benign lesion, it was not possible to differentiate residual myxoid liposarcoma, postoperative change, and normal fat on an axial MRI image **(C).** The initial marginal excision biopsy was done through an oblique incision **(D).** The margins were positive. Wide excision **(E)** was done and a lateral arm free flap used for closure **(F).** Reexcision that included a portion of the index metacarpal achieved negative margins.

Any lesion diagnosed preoperatively as lipoma based on the history, physical examination, and radiographic studies should be approached as though it were potentially malignant. Any biopsy or excision should not compromise a subsequent limb salvage operation or amputation. Frozen section diagnosis of fat-containing tumors is difficult, and suspicious lesions are best treated after a malignant diagnosis can be confirmed on permanent sections.

Appropriate treatment of liposarcoma is wide excision and adjuvant radiation therapy for large lesions. Amputation may be necessary if wide margins cannot be achieved, particularly for high-grade lesions. Chemotherapy may be considered for very large high-grade lesions or for patients initially seen with metastasis or in whom metastasis develops.

Fibrosarcoma

Approximately 30% of soft tissue fibrosarcomas occur in the upper extremity, although hand involvement is extremely rare.[70,114] There can be considerable difficulty in making the diagnosis of fibrosarcoma, particularly in children younger than 5 in whom the aggressive histologic appearance of benign fibrous lesions is similar to that of fibrosarcoma. The clinical course of these lesions is different from that of fibrosarcoma in that they are not known to metastasize. Treatment of high-grade lesions in adults includes systemic staging, wide excision, and consideration of irradiation and chemotherapy, as previously outlined for soft tissue sarcomas.

Dermatofibrosarcoma Protuberans

Dermatofibrosarcoma protuberans (DFSP) is an uncommon low-grade malignant soft tissue tumor that may be encountered in the forearm and rarely in the hand (Figure 59.47).[160,174,] This lesion arises in the dermis and most often appears as a painless violet-red plaque or nodule that may have been present for several years. Long-standing lesions may ulcerate or extend deep to subcutaneous tissues to involve muscle, tendon, and fascia. DFSP has a striking propensity for horizontal spread in the dermis and subcutaneous tissues, and there is a notoriously high risk for local recurrence, even after wide excision.

Patients with DFSP must have their disease carefully staged locally before planned excision. MRI is extremely useful in assessing the local extent of disease (see Figure 59.47). Several reports have suggested a 3-cm margin of resection and inclusion of the deep fascia to minimize the risk for local recurrence.[160,174] Retrospective microscopic analysis of resection margins has shown that 75% of lesions can be effectively excised with a 1-cm margin, 80% with a 1.5-cm margin, 85% with a 2-cm margin, and 100% with a 2.5-cm margin.[160] Historically, the risk for local recurrence of DFSP has been 50%. If appropriate wide excision is performed for either primary or recurrent lesions, the incidence of local recurrence is reduced to approximately 12%.[174] The risk for metastasis of this low-grade lesion is less than 5%.[174]

External beam irradiation has been of benefit for improving local control in patients with positive margins, although

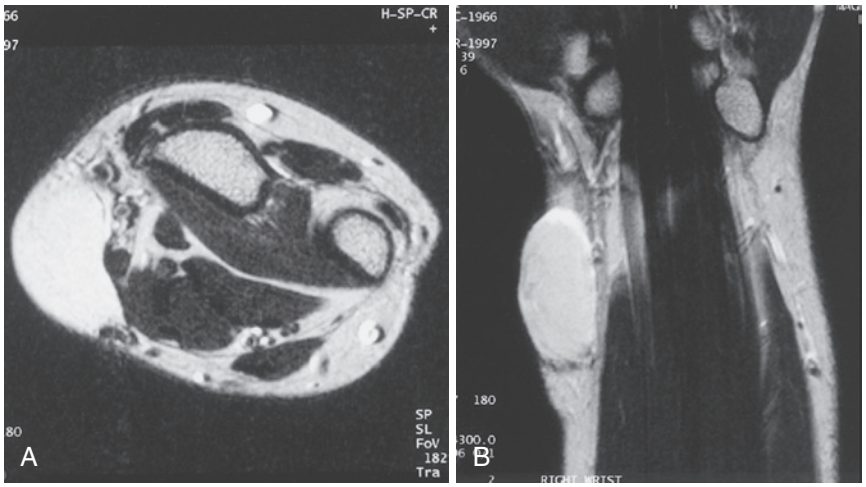

FIGURE 59.47 Axial **(A)** and coronal **(B)** magnetic resonance imaging of dermatofibrosarcoma protuberans abutting the radial artery.

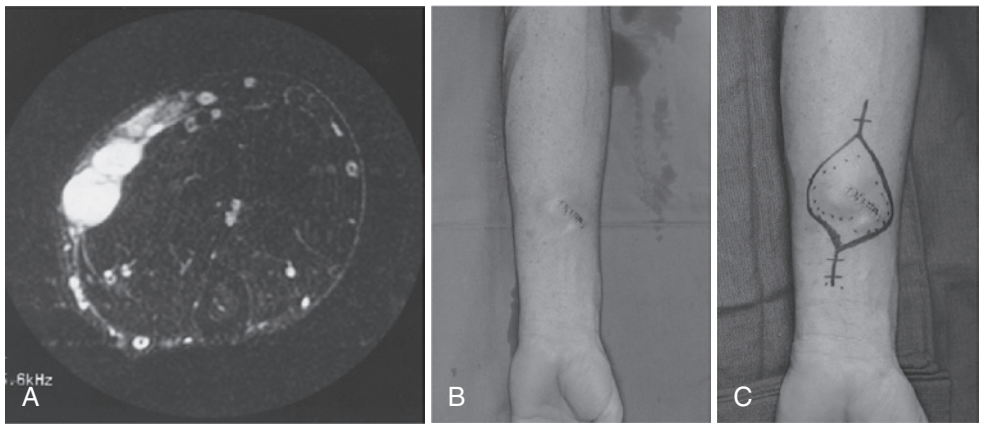

FIGURE 59.48 **A,** Magnetic resonance imaging of malignant fibrous histiocytoma of the forearm. **B,** An oblique incision was used for incisional biopsy. (A straight longitudinal incision would have been better because it is more easily incorporated into a limb-sparing incision at the time of definitive resection.) **C,** The planned wide excision included generous skin margins.

reexcision is generally recommended for those with positive margins. Soft tissue coverage is frequently required after the generous excision of skin needed to achieve appropriate margins. Reports of Mohs micrographic surgery noted excellent short-term local control and may allow surgery with narrower margins.[128,160] Neoadjuvant imatinib may be beneficial in locally advanced or recurrent dermatofibrosarcoma protuberans.[197]

Malignant Fibrous Histiocytoma

There are very few reports of malignant fibrous histiocytoma occurring in the hand, although 19% of lesions arise in the upper extremity, many of which are located in the forearm.[58,92,202] It may arise in the soft tissues or as a primary bone tumor. Bone lesions are lytic on plain radiographs and may arise from a preexisting lesion such as Paget's disease or a bone infarct. Multifocal soft tissue lesions in the hand have been reported. These lesions are best treated by wide excision or amputation (Figure 59.48). Adjuvant radiation therapy is necessary to maximize local control after wide excision of large lesions. There may be a role for chemotherapy in treating very large soft tissue lesions and those arising in bone.

Malignant Peripheral Nerve Sheath Tumor (Neurofibrosarcoma/Malignant Schwannoma)

Malignant peripheral nerve sheath tumor (MPNST) is the accepted term for malignant soft tissue tumors of neural origin, including neurofibrosarcoma, neurosarcoma, and malignant schwannoma.[45,67] Approximately 30% of MPNSTs occur in the upper extremity, with 50% of cases arising in the setting of neurofibromatosis (von Recklinghausen disease). This lesion may be seen as a secondary sarcoma after primary radiation therapy for a different sarcoma or lymphoma.[24,67] MPNST is known for its propensity to grow along peripheral nerves and has an exceptionally high rate of local recurrence, even after amputation. This tumor does not appear to be radiosensitive, nor has chemotherapy been shown to be of benefit.[45,200] Wide excision or amputation has been the recommended treatment. Forequarter amputation may be necessary to achieve local control of brachial plexus lesions. Poor prognostic factors include proximal location of the primary lesion, large tumor size, and neurofibromatosis. The 5-year survival rate for patients with MPNST is approximately 40%, with the poorest prognosis for patients with neurofibromatosis.[67,200]

Rhabdomyosarcoma

Rhabdomyosarcoma is a malignant round cell tumor most frequently seen in childhood, but it is uncommon in the hand.[42,87,127,138] Extremity rhabdomyosarcoma has been associated with a poor prognosis, although upper extremity lesions and distal lesions fare better than lower extremity or more proximal lesions. Alveolar rhabdomyosarcoma is the most common histologic variant seen in the hand and in the past has been thought to confer a worse prognosis. More intensive chemotherapy regimens appear to improve the prognosis for patients with this histologic subtype of rhabdomyosarcoma.[42]

Patient survival in the past 25 years has dramatically improved with the use of effective multiagent chemotherapy and radiation therapy. The extent of disease at initial evaluation and the surgeon's ability to completely remove the lesion with negative margins affect the prognosis.[42,138] Limb-sparing surgery through a wide margin has been recommended for obtaining local control in the setting of multiagent chemotherapy. Marginal surgery or gross total excision has been advocated rather than amputation because of the ability to improve local control with irradiation for patients who do not have wide margins. Extremity rhabdomyosarcoma appears to have a high risk for regional lymph node metastasis, and pathologic evaluation of lymph nodes has been advocated to improve staging and to direct systemic treatment.[68]

Leiomyosarcoma

Leiomyosarcoma is most commonly seen in the viscera and only rarely in the hand.[28,46] This lesion appears to arise in areas of smooth muscle and has been seen in the veins of the hand. There is a report of an apparent benign angiomyoma in the hand recurring as leiomyosarcoma. Some reports have noted a particularly high rate of local recurrence when surgery is not followed by radiation therapy in extremity lesions. Leiomyosarcoma is best treated by wide excision and consideration of adjuvant treatment, as previously outlined for the treatment of soft tissue sarcomas in general.

Clear Cell Sarcoma

Clear cell sarcoma, or malignant melanoma of soft parts, is an uncommon soft tissue sarcoma with a propensity to occur in close association with tendons and aponeuroses.[28,57] It has been confused with metastatic acral lentiginous melanoma. This lesion has been noted to have both a high risk for local recurrence and a potential for regional lymph node metastasis as high as 53%. Regional lymph nodes should be carefully assessed both clinically and radiographically during staging. Strong consideration should be given to regional sentinel lymph node biopsy in patients with clear cell sarcoma. These lesions are best treated as previously outlined for soft tissue sarcomas.

BENIGN BONE TUMORS

Enchondroma

Enchondromas are benign cartilaginous lesions that are the most common primary bone tumors arising from the hand's bones.[15,18,43,62,86,93,126,192] Approximately 35% of all enchondromas develop in the hand, and enchondromas account for as many as 90% of bone tumors seen in the hand.[15,93] Monostotic lesions most commonly occur in the fourth decade, with the majority of lesions developing between the ages of 10 and 40.[93,192] The proximal phalanx is the most common site of involvement, followed by the metacarpal and middle phalanx. The carpus is rarely involved, although enchondromas have been reported in the scaphoid, lunate, and capitate.

Patients with monostotic lesions are most commonly evaluated initially because of either localized swelling, which may be painless, or pathologic fracture associated with minor trauma. Enchondroma can also be diagnosed as an incidental finding on plain radiographs. They typically demonstrate a well-defined lytic lesion, which may be lobulated (Figure 59.49). Matrix calcification may be seen. Soft tissue extension is not typical and is suggestive of a more aggressive neoplasm. The diagnosis of enchondroma in the overwhelming majority of cases can be

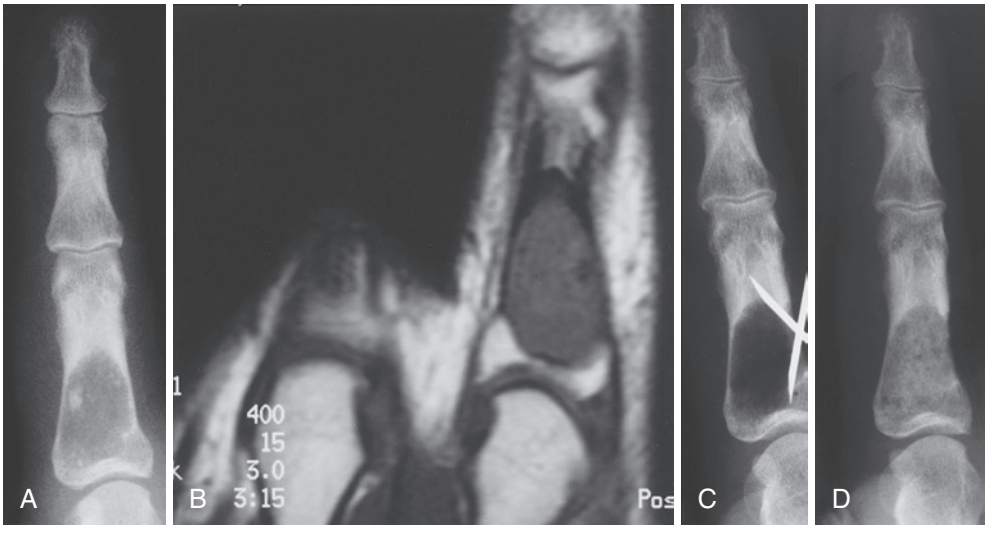

FIGURE 59.49 Enchondroma. A well-demarcated lytic lesion with stippled calcification was seen on radiographs of the proximal phalanx of the index finger **(A).** Magnetic resonance imaging confirmed the intraosseous nature of the lesion **(B).** An open biopsy from ulnar lateral approach confirmed the clinical impression of enchondroma. Intraoperative radiographs after curettage documented complete removal of the lesion **(C)** and complete filling of the cavity with bone graft **(D).**

made with plain radiographs without the need for axial images obtained with CT or MRI.

Small asymptomatic lesions with a typical radiographic appearance can simply be observed. Large or symptomatic enchondromas or lesions that do not demonstrate a characteristic radiographic appearance should be treated by biopsy and curettage. Pathologic fractures can be treated acutely, but the evaluating pathologist should be given the clinical history because the presence of osteoid seen during fracture healing may add confusion to the pathologic diagnosis. Alternatively, the lesion can be treated after the pathologic fracture has healed. There are data to suggest that clinical outcome can be improved if treatment is done after healing of the pathologic fracture.[2]

Enchondromas can be approached dorsally or laterally. The initial biopsy should be done through a limited exposure and the diagnosis confirmed on frozen section before proceeding with wider exposure. Several reports have emphasized the need for thorough curettage, with recurrence being attributed to inadequate curettage. Intraoperative radiographs are useful to be certain of complete removal of all tumor (see Figure 59.49, C). Iliac crest or distal radius bone graft has been most commonly used to fill the defect left after curettage,[15] although fresh frozen or freeze-dried irradiated allograft has been used with similar excellent results reported.[15]

More recently, several authors have reported excellent results with simple curettage without filling the defect with any material.[84,86] Injectable calcium phosphate bone cement has been used to fill the defect in one small series.[205] Although data are limited, whether the cavity is filled with any material does not appear to affect the risk for local recurrence. The latter methods eliminate the morbidity of graft harvest and are an alternative to iliac crest bone graft. There is a small but real risk of disease transmission with allograft. It is not clear whether there is an increased risk for fracture if the cavity is not grafted or whether certain lesions are best excluded from this form of treatment. The incidence of local recurrence after curettage is 4.5 to 7%. Early mobilization can be encouraged in an effort to minimize joint stiffness, provided that there is sufficient residual bone stock and stability. Filling the curetted cavity with methylmethacrylate cement has been advocated to ensure immediate stability and facilitate early motion. Malignant degeneration of monostotic enchondroma to chondrosarcoma, although rare, has been adequately described.[43]

❖ AUTHOR'S PREFERRED METHOD OF TREATMENT

I prefer to expose phalangeal lesions from a lateral approach rather than dorsally to minimize scarring and contamination of the extensor mechanism. My current preference is to fill the curetted cavity with freeze-dried irradiated allograft mixed with the patient's bone marrow. I consider curettage alone in those patients who wish to avoid bone graft. Only rarely do I use local bone graft from the radius or ulna in treating any bone tumor in the hand because of the risk of contamination of the donor field with tumor cells.

Multiple Enchondromatosis (Ollier Disease)

Multiple enchondromatosis, or Ollier disease, is an uncommon, nonhereditary skeletal disorder characterized by the presence of multiple enchondromas or cartilaginous masses in the metaphysis and diaphysis of long bones or short tubular bones of the hands and feet.[93] The disease is usually unilateral or predominant on one side. The enchondromas in Ollier disease can be large and produce significant cosmetic and functional hand deformity, as well as brachydactyly (Figure 59.50). Benign lesions are typically not painful. Growth of the lesion after skeletal maturity, radiographic progression, or the onset of pain should raise the question of malignant transformation. The risk for malignant transformation to chondrosarcoma or osteosarcoma in patients with Ollier disease is approximately 30%.[62,93,126] Histologic confirmation of chondrosarcoma in these patients is difficult and requires correlation with clinical findings and radiographs.[126] Patients with Ollier disease require periodic surveillance with physical and radiographic examination because of the risk of malignancy. Progressive nonmalignant deformity has been treated by diaphysectomy and fibula strut grafting.[62]

CRITICAL POINTS *Treatment of Enchondroma of the Hand Bones*

Indications

- Same as for biopsy
- Lesions at risk for pathologic fracture
- Lesions in which pathologic fracture has previously occurred

Technical Points

- Review the case with a pathologist in advance and confirm availability of that person at time of surgery.
- Draw a limb salvage incision or amputation flaps in the event of a final diagnosis of chondrosarcoma.
- Place the biopsy incision in line with the limb salvage incision or within the amputation field.
- Use radial or ulnar lateral incisions whenever possible.
- Minimize dissection or retraction of the extensor mechanism to minimize postoperative adhesions.
- Consider using Kerrison rongeurs to allow the creation of precise bone windows.
- Confirm the diagnosis of enchondroma on frozen section analysis.
- Place needle markers in the bone cavity and obtain radiographs to confirm adequate curettage.
- Fill the cavity with autograft or allograft, as indicated.

Postoperative Care

- Confirm the diagnosis on permanent analysis.
- Initiate early active or active-assisted range-of-motion exercises under supervision.
- Apply a splint for 6 weeks or as indicated.
- Monitor for local recurrence (4-7% risk).

Maffucci Syndrome

Maffucci syndrome is an extremely rare disease that affects the hands in the majority of cases.[93,121] The radiographic findings in bone are identical to those seen in Ollier disease (see Figure 59.50), but these patients also have multiple hemangiomas, which may be apparent radiographically because of the presence of phleboliths. Patients with this syndrome are also at high risk for the development of both bone and soft tissue sarcomas.[93,121]

Periosteal Chondroma

Periosteal chondroma is an uncommon benign cartilaginous lesion that can occur in the phalanges and be confused



FIGURE 59.50 Multiple enchondromas (Ollier disease).



FIGURE 59.51 **A,** Periosteal chondroma of the proximal phalanx. **B,** Two years after marginal en bloc excision without grafting, normal bone contour has been restored.

radiographically with enchondroma and histologically with chondrosarcoma.[21,120] Periosteal chondroma is most commonly seen in males in the second or third decade. The second most common location for this lesion is the metaphyseal–diaphyseal junction of the phalanges of the hand.[120] Radiographs typically reveal a subperiosteal lytic lesion with erosion of the underlying cortex, buttressing at the proximal and distal extent, and occasionally an overlying rim of sclerosis (Figure 59.51). Histologic examination demonstrates an aggressive-appearing cartilaginous lesion that may be confused with chondrosarcoma. This lesion has a benign clinical course but can recur locally if the overlying periosteum is not excised en bloc with the tumor. Marginal excision is usually curative, with local recurrence rates being less than 4%.[120]

It is important to attempt to make the diagnosis of periosteal chondroma preoperatively based on plain radiographs to treat the lesion appropriately and avoid the unnecessary amputation that has been reported. Periosteal chondroma most often has a characteristic radiographic appearance: external cortical erosion by a lytic unilobular lesion with a faint overlying calcified rim. The differential diagnosis of this lesion includes enchondroma, juxtacortical chondrosarcoma, periosteal osteogenic sarcoma, and subperiosteal aneurysmal bone cyst.

Osteochondroma

Osteochondroma is one of the most common bone lesions seen in the general skeleton, but it is not frequently seen in the hand, except in patients with multiple hereditary exostoses.[35,144] These lesions are osseous growths with a hyaline cartilage cap thought to originate from the physis or regions of tendon insertion.[93] Osteochondromas in the hand are generally seen at the distal aspect of the proximal phalanx during the second or third decade of life.[144] The prominence caused by an osteochondroma can result in cosmetic deformity and impaired function by producing a mechanical block to motion. Angular growth disturbance or rotational abnormalities may be seen, particularly with lesions arising distally in the phalanges. Osteochondromas with a characteristic radiographic appearance that are asymptomatic and do not impair function may be observed. Lesions that produce progressive deformity, pain, or impairment of function should be excised. There is a known risk for malignant transformation of osteochondroma to chondrosarcoma in the general skeleton, but malignant transformation of an osteochondroma in the hand has not been reported.

Bizarre Parosteal Osteochondromatous Proliferation

Osteochondromas are distinct entities and are not related to so-called bizarre parosteal osteochondromatous proliferations.[149] The latter is a benign, large proliferation of bone and cartilage that appears to arise from the cortical surface and lacks continuity with the medullary cavity. It has an aggressive radiographic and histologic appearance and may be confused with parosteal osteogenic sarcoma.[149] Although there is a high risk for local recurrence after marginal excision, wide or radical excision is not necessary because of its benign clinical course.

Subungual Exostosis (Subungual Osteochondroma)

Subungual exostoses are frequently misdiagnosed and may be confused with osteochondromas. This lesion has a cap of fibrocartilage, as opposed to the hyaline cartilage seen with an osteochondroma. Nail removal with excision of the exostosis has been successful in correcting the deformity, without reported recurrence.[35]

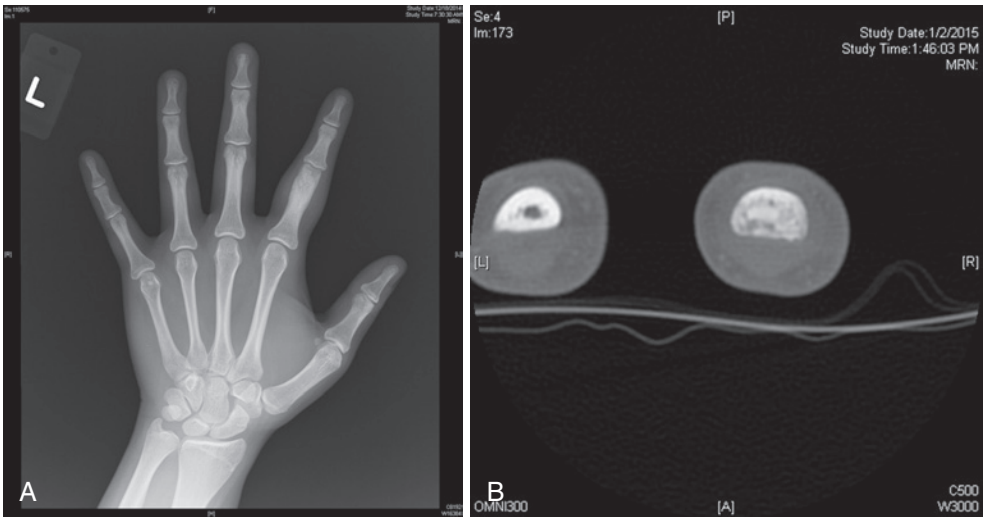

FIGURE 59.52 Osteoid osteoma. **A, B,** A 19-year-old woman was evaluated for a painful proximal phalanx that was dramatically relieved with aspirin. Note the classic sclerotic cortical area with a radiolucent nidus. Complete relief of pain followed local resection of the tumor nidus.

Chondromyxoid Fibroma

Chondromyxoid fibroma is a benign cartilaginous lesion.[78,176,188] Patients may give a long history of mild pain or swelling. Plain radiographs most often reveal a lytic lesion in the metaphyseal region of the bone. In large bones, the lesion is usually eccentric, but in the hand, it is more commonly central. Cortical expansion and the presence of a sclerotic rim are frequent. Pseudotrabeculation may be seen, and matrix calcification is rare in comparison to enchondroma. The lesion is most common before the age of 30, with a male-to-female ratio of 2:1. Curettage and bone grafting have been successful in controlling hand lesions. Recurrence rates of 7 to 25% have been reported with this method of treatment in large case series.[78,176] Local recurrence after curettage and bone grafting for lesions in the hand is uncommon. The most important issue in treating this lesion is making an accurate diagnosis. Chondromyxoid fibroma has been confused with chondrosarcoma in the past because of its aggressive histologic appearance, and amputation has been performed unnecessarily.

Osteoid Osteoma

Osteoid osteoma is a benign bone lesion that has been well described in the hand and distal end of the radius.[7,16,72] Five percent to 15% of osteoid osteomas occur in the hand and wrist,[7,16] most commonly in the proximal phalanx and carpus; involvement of the middle phalanx is rare. Lesions arising in the distal phalanx may be atypical in their findings, with frequent pulp swelling and nail deformity. Radiographs usually demonstrate a lytic lesion rather than the classic appearance of reactive sclerosis surrounding a central lucent nidus.

Patients are typically seen initially in the late second or early third decade of life with a deep, dull ache that is constant and frequently relieved with nonsteroidal antiinflammatory drugs (NSAIDs). Painless osteoid osteomas in the hand do occur, and in these instances the primary complaint is swelling. Osteoid osteoma of the capitate has been reported to cause symptoms of carpal tunnel syndrome, and lesions of the radial styloid have been manifested as de Quervain tenosynovitis.[72] Physical examination usually demonstrates well-delineated tenderness and swelling. The classic radiographic appearance is reactive sclerosis surrounding a central lucency less than 1 cm in diameter (Figure 59.52), although lesions initially seen in an early stage may not show these findings. Diagnosis of hand lesions is frequently delayed, with a mean time to diagnosis of longer than 15 months in two large case series.[7,16] Radionuclide bone scan, tomography, and CT may improve diagnostic accuracy and assist in better defining and localizing the lesion before planned surgical treatment.[16]

Treatment of osteoid osteoma in the hand or carpus has consisted of surgical excision with either curettage of the nidus or en bloc excision. Persistence of the lesion has been reported if the nidus is not completely excised.[7,16] Successful use of percutaneous CT-guided laser photocoagulation has been reported.[206] Radiofrequency ablation may be considered for carefully selected lesions that are not subcutaneous or near major nerves. Successful treatment with prolonged use of NSAIDs has been described for lesions occurring in long bones with a mean symptom duration of 33 months.[113]

There is no large report of this type of treatment for lesions occurring in the hand. Prolonged use of NSAIDs may be an alternative to surgical treatment if the clinical and radiographic findings are strongly supportive of a diagnosis of osteoid osteoma and excision or biopsy of the lesion might produce excessive morbidity. This also may offer an alternative for the treatment of recurrent or residual lesions in which the diagnosis of osteoid osteoma had clearly been established previously.

Osteoblastoma

Osteoblastoma is a rare benign tumor that is usually larger than 2 cm in diameter and is characterized by osteoid and woven bone production.[81,146] The tumor is most frequently found in the posterior elements of the spine. Its histology is similar to that described for osteoid osteoma, but it is important that the tumor be distinguished from osteosarcoma. Differentiation between osteoblastoma and osteoid osteoma is usually based on

location and size. Osteoblastoma is more commonly centered in the medullary portion of bones, whereas osteoid osteomas tend to be cortical, medullary, or subperiosteal in location. Local recurrence may be seen in 20 to 30% of cases after curettage and bone grafting in general case series. Under circumstances in which the lesion has recurred or has become locally destructive, cure may require marginal or wide excision with subsequent reconstruction.

Unicameral Bone Cyst

Unicameral bone cysts are benign, cystic lesions of uncertain etiology that are extremely rare in the bones of the hand and forearm.[30,163,175] Most information on natural history and treatment has been gained from the care of proximal humeral and femoral lesions. Unicameral bone cysts are usually asymptomatic until there has been a pathologic fracture. Radiographs demonstrate a lytic metaphyseal lesion with well-defined borders and septa or minor trabeculations (Figure 59.53). The radiographic differential diagnosis of lesions occurring in the forearm and hand can include enchondroma, aneurysmal bone cyst, and telangiectatic osteogenic sarcoma.

Treatment of unicameral bone cysts has included observation, curettage and bone grafting, drilling, corticosteroid injection, and en bloc excision. Cyst aspiration and corticosteroid injection have become more popular for the treatment of these lesions because of the lower risk for complications and healing rates similar to those attained with curettage and bone grafting.[30,175] Intraosseous injection may need to be repeated several times to achieve partial or complete healing.[175] There is no known risk for malignant degeneration of unicameral bone cysts. Indications for treatment, when a diagnosis has been established, are based on the potential for mechanical failure (fracture) and deformity.

❖ AUTHOR'S PREFERRED METHOD OF TREATMENT

Unicameral bone cysts are sufficiently rare in the hand to warrant biopsy in all suspected cases because accurate radiographic diagnosis of this hand or forearm entity may not be predictable. Although "classic" lesions in the distal radius may be treated by corticosteroid injection, my preference is to treat them with open biopsy, curettage, and bone allograft after frozen section diagnosis. This technique offers the advantage of an accurate pathologic diagnosis and potentially less anesthetics for the patient than may be required with repeated corticosteroid injection.

Aneurysmal Bone Cyst

Aneurysmal bone cysts account for approximately 5% of benign bone tumors, but only 3 to 5% of all aneurysmal bone cysts occur in the hand.[69,137] Hand lesions most commonly occur in the second decade of life, with males and females being equally affected. Metacarpal involvement is more common than phalangeal involvement, and carpal lesions are rare. Its radiographic appearance may be similar to GCT of bone, although more frequently there is an expansile deformity and a thin rim of bone that surrounds the entire lytic lesion (Figures 59.54 and 59.55).[139] Soft tissue extension is uncommon. Although this lesion can be aggressive locally, it is not known to metastasize. The risk for local recurrence may be as high as 60% after curettage and bone grafting of lesions in long bones.[137]

Frassica and coworkers reported the successful use of curettage in six of seven patients, but only three were treated



FIGURE 59.53 Solitary (unicameral) bone cyst in an 18-year-old man with a pathologic fracture through the bone cyst. Biopsy revealed a cavity with fluid present. Treatment consisted of curettage and bone grafting, and the prognosis was excellent.



FIGURE 59.54 Lytic expansile lesion with a surrounding rim of sclerosis typical of an aneurysmal bone cyst.

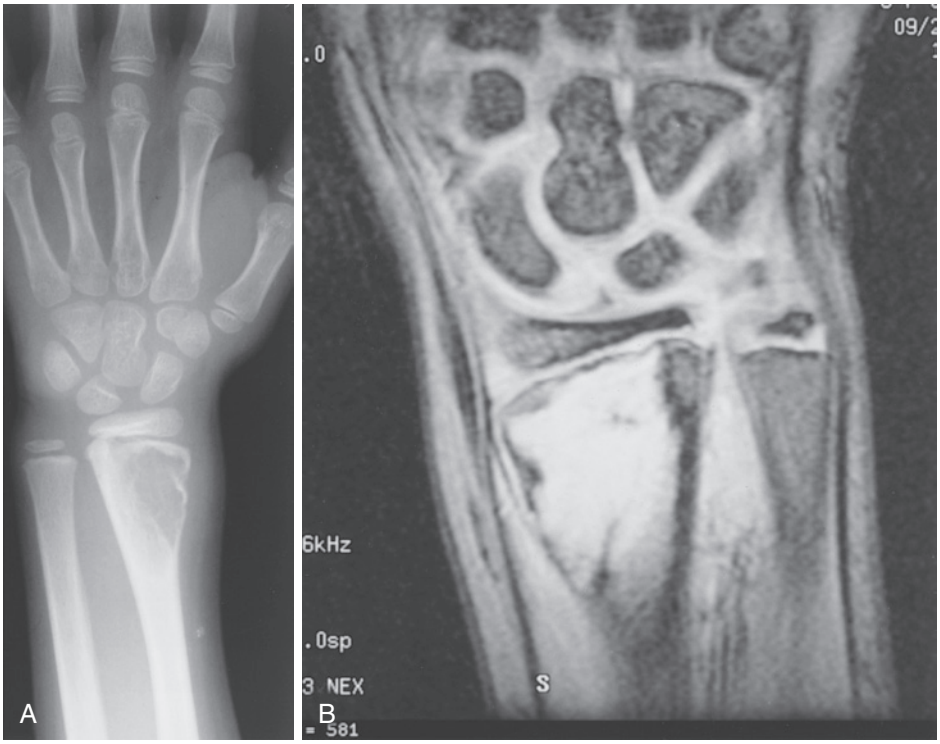

FIGURE 59.55 Aneurysmal bone cyst. **A,** A lytic lesion of the distal radius on a plain radiograph. **B,** Magnetic resonance imaging suggested a fluid-filled lesion. The radiographic interpretation was a unicameral bone cyst, but biopsy revealed an aneurysmal bone cyst. The lesion recurred 2 months after curettage and bone grafting.

effectively at the first operation.[69,139] Marcove and colleagues reported successful local control of 86% of lesions treated by curettage, cryosurgery,[†] and cementation or bone grafting.[137] Cryosurgery has been used successfully to treat recurrent aneurysmal bone cyst in the proximal phalanx. Wide excision has been successful in treating metacarpal lesions, and large distal phalangeal lesions have been treated effectively with amputation.[69]

❖ AUTHOR'S PREFERRED METHOD OF TREATMENT

When performing all incisional biopsies on lytic lesions of the hand bones, I am equipped and prepared to perform cryosurgery immediately after frozen section diagnosis. Most aneurysmal bone cysts can be treated with curettage and bone graft with the knowledge that the majority may require a second curettage and bone graft following recurrence. Cryosurgery, when used as an adjuvant to curettage, has significantly reduced the risk for local recurrence in long bones and has been used successfully for the hand. Recurrent lesions can be treated with a second session of curettage and cryosurgery, provided that there is sufficient bone stock remaining in the affected bone. Wide excision followed by reconstruction is an alternative for large recurrent proximal phalanx or metacarpal lesions. Metacarpal lesions are readily reconstructed with diaphyseal fibula bone graft.

[†]The principle of cryosurgery is to cyclically rapidly freeze the neoplasm or any remaining microscopic disease after curettage, followed by slow warming to room temperature. This produces intracellular crystal formation and cell lysis on rewarming and effectively extends the zone of curettage in a controlled but not precise manner. The technique causes nonselective tissue necrosis based on the temperature produced in the tissues. Rapid freezing is typically accomplished by direct pour or spray of liquid nitrogen into the tumor cavity after the soft tissues have been isolated and protected. A metal or synthetic cryoprobe that circulates liquid nitrogen is an alternative to the direct pour or spray technique.

Giant Cell Tumor of Bone

Although GCT of bone accounts for approximately 5% of benign bone tumors, only 2% of them occur in the hand.[12,13,93] These tumors are considered benign lesions based on their histology, but they may behave in a locally aggressive fashion, metastasize, and ultimately result in death.[12,13,133] Lesions that arise in the bones of the hands have a higher risk for local recurrence after intralesional treatment, have a greater propensity to metastasize than such lesions seen elsewhere in the body, and must be approached with great caution.[12,13,80,152] Local recurrence rates of greater than 80% may be seen after intralesional treatment with curettage, even with the use of phenol as an adjuvant.[12,13] There are several well-documented cases of pulmonary metastases from benign GCTs of bone that developed in the hand.[12,13,133]

GCT of bone generally arises early in the fourth decade of life. The most common locations in the hand are the metacarpals and phalanges, although GCT has been reported in all carpal bones.[12,13,115] A propensity for multicentricity has been reported.[13] Patients have pain and swelling in the affected region or after a pathologic fracture. Radiographs typically demonstrate a lytic lesion with no matrix and indistinct borders, which helps differentiate this lesion from aneurysmal bone cyst (Figure 59.56). Cortical expansion, destruction, and soft tissue extension are common. The epiphyseal and eccentric locations



FIGURE 59.56 Giant cell tumor of bone showing the typical cortical expansion.

typically seen elsewhere in the body are less common in hand lesions because they frequently involve a major portion of the bone at initial evaluation.

Incisional biopsy should be done through a well-planned approach that can later be incorporated into a salvage operation or amputation. Soft tissues must be protected during the biopsy because GCT has a propensity to seed soft tissues, which could result in subsequent soft tissue local recurrence.[12] Proximal carpal lesions have been treated by either curettage or proximal row carpectomy.[12,115] Wide excision has been recommended for distal carpal row lesions.[115] Isolated curettage followed by bone grafting of metacarpal and phalangeal lesions is associated with an unacceptably high risk for local recurrence.[12,13] There are reports of success with the use of curettage, cryosurgery, and bone grafting or cementation for both metacarpal and phalangeal lesions.[136,203]

Metacarpal lesions have been treated successfully by ray amputation or wide excision and reconstruction.[11,13,31] Phalangeal lesions have been treated successfully by amputation or wide excision and reconstruction with toe phalanx transfers.[12,196] External beam irradiation has been effective in the treatment of benign GCT of bone, but radiotherapy is associated with a risk for malignant transformation as high as 8.7%.[168] Malignant GCT of bone that occurs after external beam irradiation is fatal in most cases. Conventional chemotherapy has not been shown to be effective for benign GCT of bone.[133] Denosumab (Prolia) has recently been shown to have a beneficial effect for patients with lung metastases and unresectable primary tumors. Its role in the treatment of primary and metastatic GCT of bone is currently being investigated and defined.[117]

The third most common site of occurrence of GCT in the body is the distal end of the radius.[93] A review of 225 patients with long bone lesions treated by curettage, burring, application of phenol, and packing of the cavity with methylmethacrylate noted a 25% risk for local recurrence.[152] However, when cases arising in the distal radius are selectively reviewed, the risk for recurrence is 50%. In the Memorial Sloan-Kettering Cancer Center series, which included radiographically advanced lesions, the risk for local recurrence was reduced to 22% when curettage was combined with cryosurgery.[178] The most predictable method of local control has been wide excision of the distal radius.[147,178,199] Patients with distal radius lesions appear to be at an increased risk for metastasis.[133] Reconstruction after wide excision has been done with intercalary bone grafting for arthrodesis, articular fibula autograft, articular distal radius allograft, and creation of a one-bone forearm.[147,178,199]

❖ AUTHOR'S PREFERRED METHOD OF TREATMENT

GCT of bone should be approached as a low-grade malignancy when it occurs in the hand and wrist. The disease should be staged after diagnosis with chest radiographs and a bone scan to rule out pulmonary metastasis and multicentric lesions. Phalangeal or metacarpal lesions that perforate the cortex or extend into soft tissues are best treated by amputation or wide en bloc excision and reconstruction. Distal carpal row lesions are best treated by wide excision and limited carpal fusion for reconstruction. Proximal carpal row lesions can be treated by proximal carpal row carpectomy. I would consider performing curettage and cryosurgery for lesions that do not perforate the involved bone and have sufficient remaining bone stock to allow bone grafting. Cryosurgery is associated with significant risks for soft tissue necrosis, wound infection, pathologic fracture, and neurapraxia and should be used only by those experienced with it.[136,140] Isolated curettage and bone grafting or curettage, application of phenol, and bone grafting cannot be advocated for the treatment of GCT of the bones of the hand.

I prefer to treat distal radius lesions that have not perforated the cortex (Campanacci grade I or II lesions) with curettage, burring, cryosurgery, and cementation as long as there is sufficient remaining native bone stock (Figure 59.57). Patients with a single plane-of-palmer perforation may be candidates for intralesional treatment with curettage, cryosurgery, and cementation.[102] Patients with a pathologic fracture or large or multiplane cortical perforation are most predictably treated by wide excision of the distal radius. Reconstruction with an intercalary fibula graft and rigid internal fixation gives the most predictable result.

MALIGNANT BONE TUMORS

Chondrosarcoma

Chondrosarcoma is the most common primary malignant bone tumor that occurs in the hand.[37,43,44,70,75,85,99,103,158,170] This tumor can arise primarily or can develop from a preexistent benign lesion such as an enchondroma or osteochondroma. The lesion usually occurs in patients older than 60 years. The proximal phalanges and metacarpals are the most commonly affected. Only rarely has chondrosarcoma been reported in the distal phalanges or carpus.[70] This lesion often appears as a slowly growing, firm, and painful mass. Radiographs typically reveal a tumor matrix with stippled calcifications, areas of lysis, and poorly defined borders. Extreme cortical expansion,

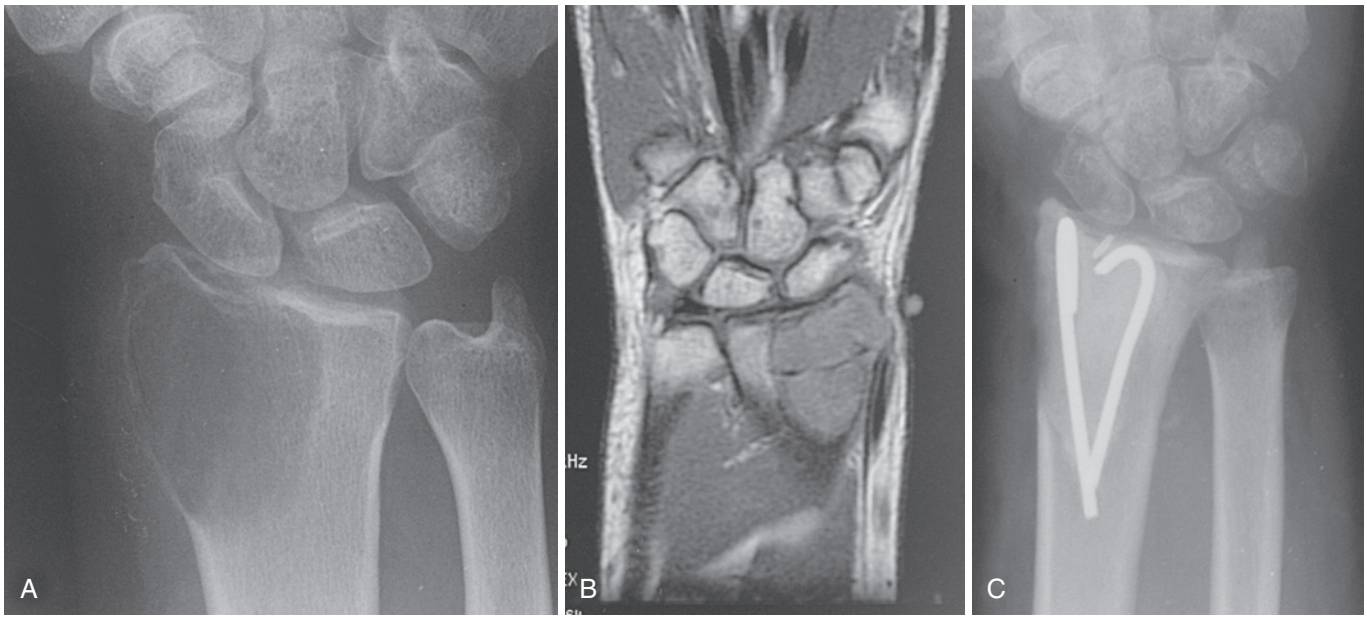

FIGURE 59.57 **A,** An expansile lytic lesion of the distal radius without a reactive sclerotic rim. **B,** Magnetic resonance imaging further delineates the lesion. Open biopsy revealed a giant cell tumor of bone. **C,** A radiograph was taken after curettage, burring, cryosurgery, and cementation with internal Steinmann pin struts.

CRITICAL POINTS *Giant Cell Tumor of Bone*

Preoperative Evaluation
- GCT should be considered a low-grade malignancy.
- Patients should be staged with CT of the chest and a total body bone scan.
- Use MRI to determine the extent of soft tissue contamination.

Indications for Wide Excision or Amputation
- Soft tissue contamination precluding the use of curettage with adjuvant therapy.
- Amputation for the majority of nondistal radius lesions.
- Wide excision for distal radius lesions with perforation of more than one cortex.

Technical Points
- The same as for biopsy or wide excision.

Postoperative Care
- Surveillance for local recurrence or metastasis for 10 years.

perforation, or extension into the surrounding soft tissues helps differentiate this lesion from enchondroma (Figure 59.58, *A, B*).

Even though there are well-documented instances of metastasis and mortality, the majority of chondrosarcomas are low-grade, slow-growing lesions that do not metastasize. The prognosis for patients with chondrosarcoma in general is related to the histologic grade of the lesion, although it is not clear that this principle applies to lesions arising in the hand.[93] The risk of metastasis for lesions occurring in the hand is approximately 10%, and it usually occurs after local recurrence following intralesional treatment.[99]

A well-planned incisional biopsy should be performed for suspicious lesions. It is imperative that the surgeon consult with the pathologist before the biopsy and that the biopsy specimen be reviewed in the presence of the plain radiographs. Interpretation plus diagnosis of cartilaginous lesions in the hand, in particular low-grade chondrosarcoma, is extremely difficult.[44] In general, peripheral cartilaginous lesions (i.e., those in the hand) tend to show greater degrees of cellularity and atypia on histologic examination, although the clinical course is that of a benign lesion. Radiographic findings of an inactive or, alternatively, an aggressive lesion can influence the pathologic diagnosis of cartilaginous lesions, and this has great implications for appropriate treatment. Malignant transformation in the setting of Ollier disease is particularly difficult to diagnose.

Patients suspected of having chondrosarcoma must have their disease staged locally and systemically. Chondrosarcoma most commonly metastasizes to the lungs, and patients should be evaluated with CT of the chest. Currently, chondrosarcoma of the hand bones is best treated surgically with wide en bloc excision or digit or ray amputation. There is investigational interest in intralesional procedures because of the limited metastatic potential of hand lesions.[23] The potential indications for this less aggressive approach remain to be defined. Chemotherapy is not known to be effective for the vast majority of chondrosarcomas. There may be a role for chemotherapy in the treatment of dedifferentiated chondrosarcoma or mesenchymal chondrosarcoma.[71] There is no role for radiation in the treatment of chondrosarcoma arising in the bones of the hand. Patients must be monitored for both local and systemic recurrence because metastasis may become apparent several years after treatment of the primary lesion.

Osteogenic Sarcoma

Osteogenic sarcoma is the most common primary bone tumor seen in children and adolescents, but it only rarely occurs as a primary hand lesion.[33,36,65,70,143,142,154] When it does involve the hand, it may be in older patients in the fourth, fifth, and sixth decades, often arising from a preexisting lesion.[10,33,36,154] Low-grade lesions may be more commonly seen in the hand.



FIGURE 59.58 **A, B,** Chondrosarcoma of the fourth (ring) finger proximal phalanx. Note the poorly defined borders and extension into soft tissues on magnetic resonance imaging.

Survival of patients with osteogenic sarcoma has improved dramatically with the use of systemic chemotherapy, and all patients with high-grade malignant lesions should receive adjuvant chemotherapy.[82,142,143]

Patients with osteogenic sarcoma have a rapidly enlarging firm and painful mass. Plain radiographs may reveal an expansile, sclerotic lesion with malignant new bone formation or with a more lytic or mixed pattern with destruction and a soft tissue mass (Figure 59.59). Parosteal osteogenic sarcoma may appear as a surface lesion with soft tissue involvement. This lesion most commonly occurs in the proximal phalanges and metacarpals.

A well-planned incisional biopsy should be performed while considering the need for subsequent amputation or a limb salvage procedure. After confirmation of the diagnosis, the lesion should be treated by wide en bloc excision or digital or ray amputation. Before modern chemotherapy, hand lesions were thought to have a better prognosis than those occurring elsewhere in the body.[33,36] It is not clear to what extent adjuvant chemotherapy affects the prognosis of patients with hand lesions,[154] but currently adjuvant chemotherapy is considered to be part of a comprehensive treatment plan.[82,142] There is no significant difference in survival with the use of chemotherapy before excision (neoadjuvant) or after excision (adjuvant), although neoadjuvant therapy may improve the quality of resection margins and reduce the risk for local recurrence.[142] There is no role for external beam irradiation in attempted curative treatment of these lesions. Long-term survival after aggressive treatment of local recurrence may be better for lesions occurring in the hand than in general case series, in which the prognosis is extremely poor.

❖ AUTHOR'S PREFERRED METHOD OF TREATMENT

After confirmation of the diagnosis and local and systemic staging, I prefer to immediately initiate neoadjuvant chemotherapy. Although there may be no significant survival benefit with the use of neoadjuvant as opposed to adjuvant chemotherapy, an effective adjuvant in most cases decreases the size of the tumor and reduces surrounding soft tissue edema. This may facilitate wide en bloc excision or improve the quality of margins at amputation. A good response to chemotherapy appears to reduce the risk for local recurrence after wide excision. Analysis of the resection or amputation specimen allows quantitation of response to chemotherapy, which has prognostic significance and can affect postoperative adjuvant treatment plans.[142] After local treatment, chemotherapy should be resumed promptly because a delay in the resumption of it beyond 23 days adversely affects survival.[142] Prolonged local and systemic surveillance for recurrence or metastasis is mandatory.

Ewing's Sarcoma

Ewing's sarcoma is one of the common primary childhood sarcomas of bone but only rarely arises in the hand.[29,48,60,70,98,108,111,116,156,167] This tumor most frequently occurs in the first or second decade of life, with the youngest recorded case occurring in the distal phalanx of a 5-month-old infant. Survival has improved considerably with the use of adjuvant chemotherapy. Local treatment of Ewing's sarcoma in the hand must be done in the context of well-planned and coordinated systemic treatment. [76,98,111,156]

The clinical manifestation of Ewing's sarcoma in the hand is very similar to that seen with infection. Pain, swelling, and erythema are common. A significant soft tissue mass is frequently seen. Signs of systemic illness may be present and include fever and an elevated white blood cell count and sedimentation rate. There are several reports of misdiagnosis and prolonged treatment of presumed infection.[135] The tumor most commonly arises in the metacarpals or phalanges, with extensive soft tissue involvement. There is no well-documented case of this tumor arising in the carpus, and middle phalangeal involvement is rare. Radiographs typically reveal a large lytic, destructive, expansile lesion with associated soft tissue involvement. A mixed lytic and sclerotic appearance may be seen.[167] MRI is particularly useful in delineating the extent of bone and soft tissue involvement that may not be apparent on plain radiographs (Figure 59.60).

Incisional biopsy is indicated for patients with lytic destructive lesions of the bones of the hand. In addition, biopsy must always be strongly considered before the initiation of treatment for presumed deep infection because this is the most common

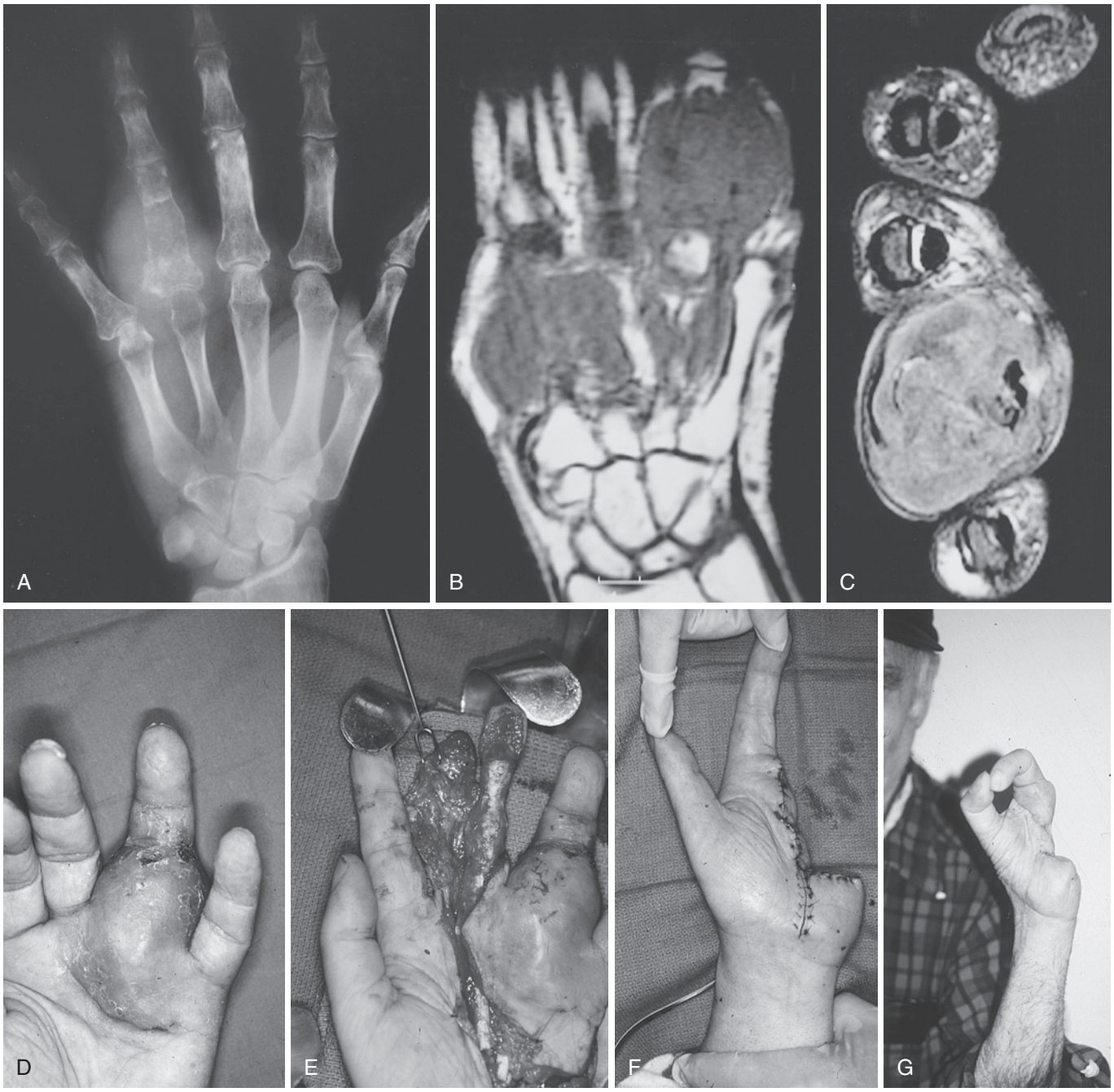

FIGURE 59.59 Osteogenic sarcoma. **A,** Lytic destructive lesion with soft tissue extension in the proximal phalanx of the ring finger. **B, C,** Magnetic resonance imaging demonstrates extensive soft tissue involvement, including the metacarpal head region. This elderly man was unable to tolerate chemotherapy and was treated by triple-ray amputation (long, ring, and small fingers). This very large tumor **(D)** was approached palmarly and dorsally, and closure was facilitated with a fillet flap of the long finger **(E). F,** Appearance after closure. **G,** Useful function.

error in diagnosis. The biopsy must be carefully planned and executed in an effort to avoid additional soft tissue contamination, which may compromise subsequent ablative or limb salvage procedures. The pathologist who will be evaluating the specimen should be consulted in advance, and arrangements should be made to perform cytogenetic analysis because this will improve the accuracy of diagnosis and assist in the diagnosis of particularly difficult cases.

There is considerable controversy regarding the timing and method to be used for obtaining local control of tumors in the hand. The radiation oncology literature supports the use of external beam irradiation to obtain local control in the context of systemic treatment with chemotherapy.[98,111] The hand surgery literature supports the use of ablative surgery with or without the use of external beam irradiation, as well as in the setting of systemic treatment with chemotherapy.[48,60,191] Similar rates of

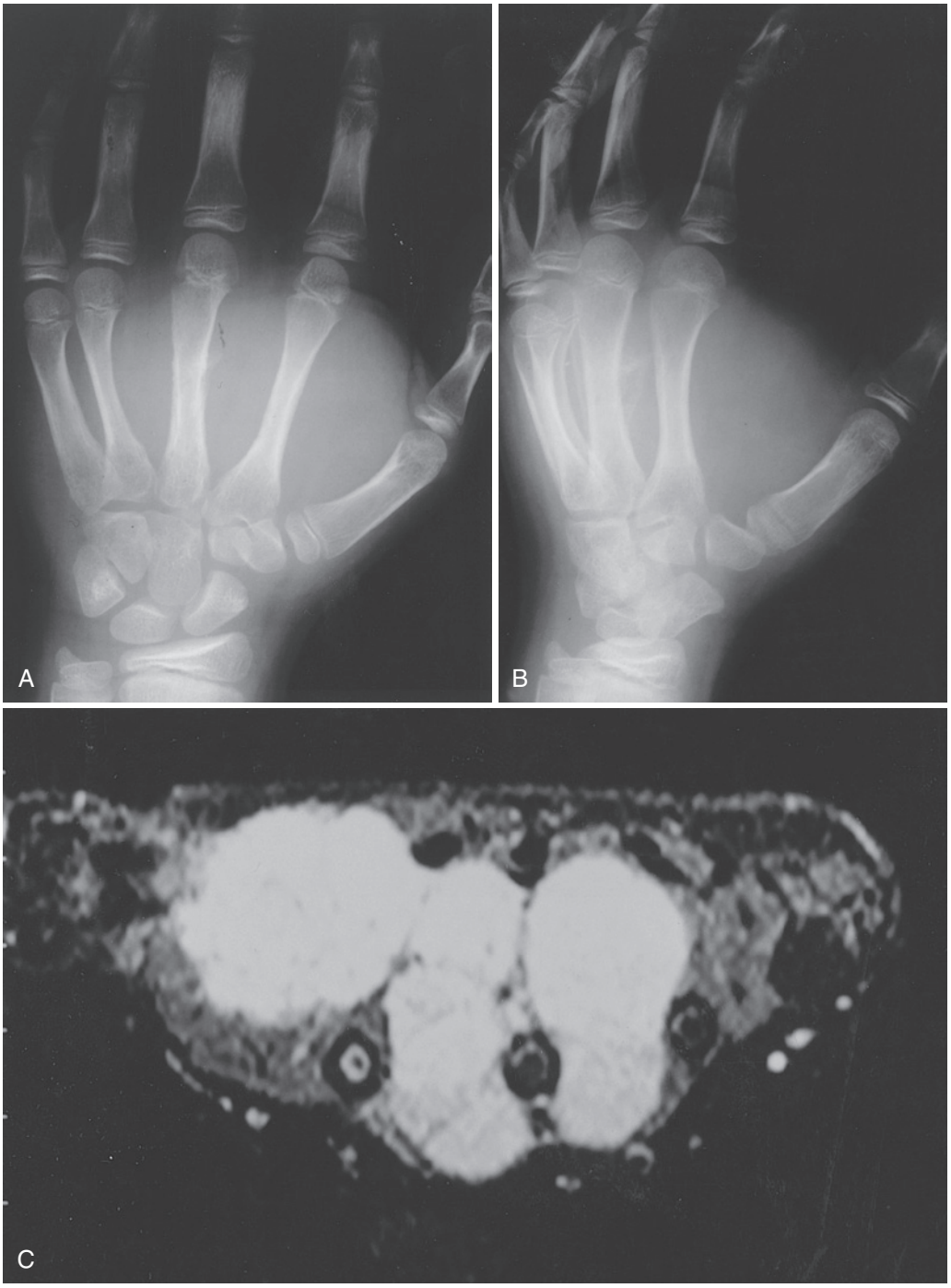

FIGURE 59.60 Ewing's sarcoma. **A, B,** Diaphyseal sclerosis and periosteal new bone formation of the third metacarpal on radiography. **C,** Magnetic resonance imaging demonstrating a large soft tissue mass surrounding the third metacarpal with extensive palmar and radial involvement.

local control with the use of either curative external beam irradiation or surgery have been reported.[159] It is imperative that local control be obtained at the time of primary treatment because local recurrence has been found to be uniformly fatal in some series.[76] Although survival of patients with Ewing's sarcoma occurring in the hand or foot appears to be better than that for patients with more central primary lesions, when cases occurring specifically in the hand are selectively assessed, the rate of survival is similar to that for lesions elsewhere in the body, with the exception of tumors arising in the pelvis.

❖ AUTHOR'S PREFERRED METHOD OF TREATMENT

I prefer the immediate initiation of systemic chemotherapy before definitive local treatment. Ewing's sarcoma is a highly lethal malignancy, and there may be a survival benefit with immediate initiation of systemic treatment without the delay

that can occur after normal postoperative healing or a postoperative complication. In addition, the use of an effective preoperative adjuvant in most cases decreases the size of the tumor and facilitates subsequent surgery. Analysis of the resected specimen provides information regarding the effect of chemotherapy and has implications for additional adjuvant treatment, the possible need for postoperative external beam irradiation, and prognosis. I favor the use of wide en bloc excision or amputation through a wide margin to obtain local control for lesions that occur in the hand. If a wide margin of normal tissue has not been obtained after analysis of the excised specimen, external beam irradiation should be added to the treatment protocol after the completion of chemotherapy.[157] Although external beam radiation may be effective in achieving local control, it could be associated with soft tissue contracture, neuropathy, pathologic fracture, growth inhibition, and radiation-induced malignancy.[122] Wide excision with adequate margins eliminates the need for radiation and avoids the associated morbidity.

Although rates of local control appear to be similar when external beam irradiation is used as primary treatment of Ewing's sarcoma in the hand, the available data are limited. Autopsy studies have documented residual disease at the primary site of malignancy in up to 20% of patients who subsequently died of pulmonary metastases when the primary tumor was treated by external beam irradiation, even in the absence of local clinical recurrence. Local control must be obtained at the time of initial treatment because local recurrence unquestionably adversely affects patient survival.

Metastatic Tumors

Metastasis to the bones of the hand is uncommon.[6,27,88,109] Acrometastases develop in <0.3% of patients with cancer. Metastasis to the hand usually occurs as a rare, preterminal event and is often part of widespread dissemination of the primary malignancy. For as many as 50% of patients with acrometastasis, the lesion can mimic a benign condition or can be the first manifestation of malignancy or metastatic disease.[88]

Although the distal phalanx has previously been noted to be the most common site of metastasis to the hand, the other phalanges and metacarpals can be equally affected. Involvement of the carpal bones is rare. A predilection for involvement of the dominant hand has been noted.[173] Bronchogenic carcinoma of the lung has been reported as the primary malignancy in as many as 50% of cases and is the most common metastatic lesion occurring in men (Figure 59.61).[88] Other reported primary malignancies include renal, esophageal, breast, colon, prostate,

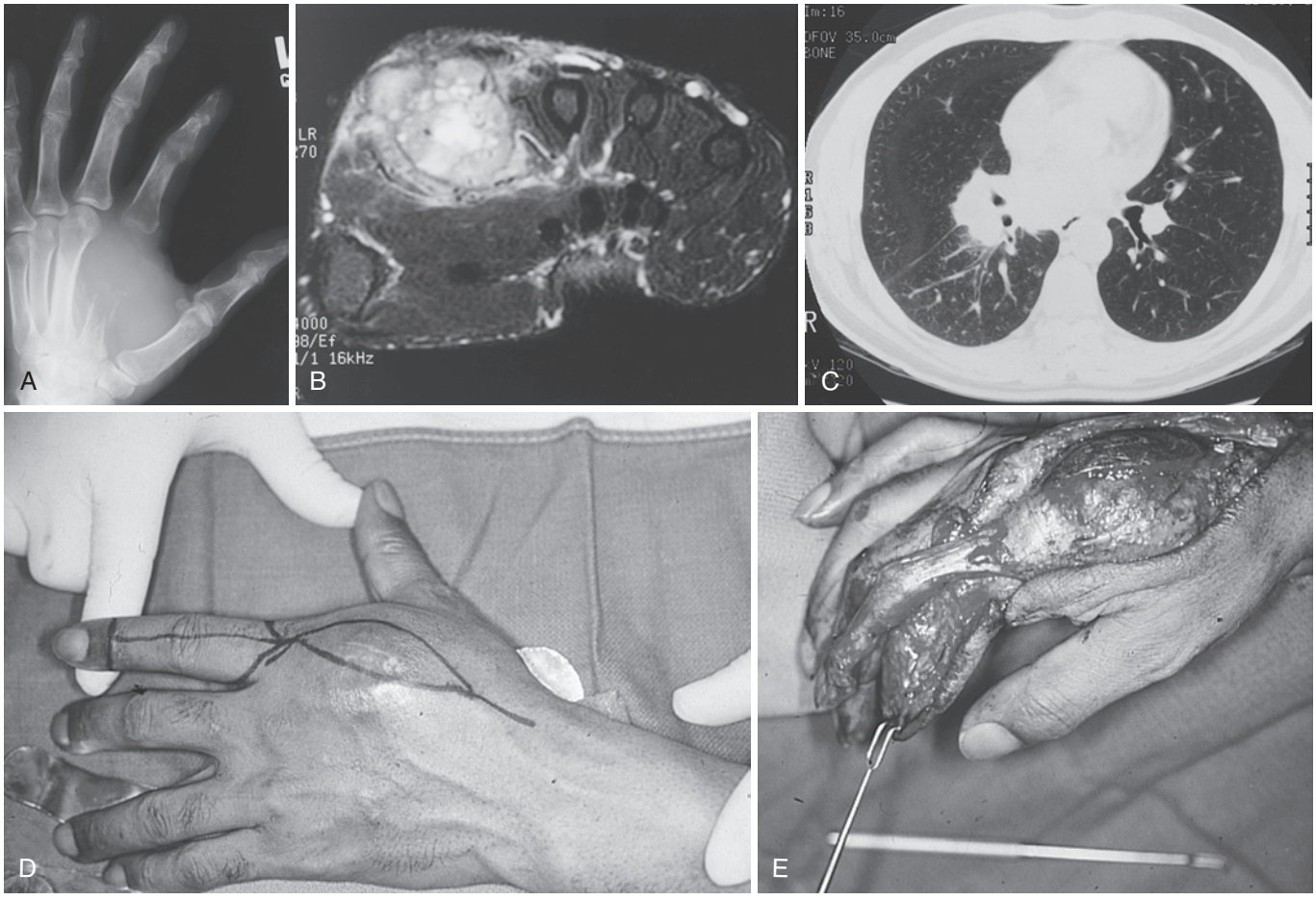

FIGURE 59.61 Metastatic tumor. **A,** In this 46-year-old man with a history of noninvasive bladder cancer and smoking, radiographs demonstrated a destructive lytic permeative lesion of the index metacarpal. **B,** Magnetic resonance imaging documented the extent of soft tissue involvement. **C,** Computed tomography of the chest revealed bilateral masses. An index ray amputation with fillet flap closure was done **(D, E)** after confirmation of the diagnosis of metastatic lung cancer.

thyroid, and bone cancer. In one study the mean time to the development of hand metastases was 16 months after diagnosis of the primary malignancy.[88]

Clinical findings include the typical signs of inflammation—pain, swelling, and erythema—which can lead to an initial clinical diagnosis of infection. Misdiagnosis is common and has included osteomyelitis, felon, gout, rheumatoid arthritis, reflex sympathetic dystrophy, and traumatic fracture.[27,88] Radiographs usually reveal a lytic destructive lesion, although metastatic prostate carcinoma can produce a sclerotic lesion. Extension into adjacent joints is uncommon. Lytic destructive lesions in the bones of the hand should be sampled and cultured without delay in the absence of a known primary malignancy.

Treatment of documented metastases should be directed toward relief of pain and preservation of function. Amputation and ray resection are effective in providing palliation and local control of disease. Although amputation has been done for lesions occurring in the carpus, curettage and packing with methylmethacrylate may offer an alternative method of providing local control of small lesions without the associated morbidity of an amputation in a patient who is terminally ill. External beam irradiation can be used for patients with multiple or inoperable lesions, although pain relief is less predictable.[27] Systemic staging should be done after diagnosis of the metastasis and consideration given to systemic treatment in consultation with an oncologist. The median survival for patients with metastases to the hand is approximately 6 months and is related to the primary malignancy. Early diagnosis may improve morbidity, particularly when the metastasis is the primary symptom of an undiagnosed malignancy.

Treatment of isolated metastasis of renal cell carcinoma to the hand deserves special consideration. Long-term survival and a prolonged disease-free interval have been reported after the resection of isolated metastatic renal cell carcinoma to the extremities.[5,195] A long interval between manifestation of the primary lesion and detection of isolated metastasis, as well as distal extremity metastasis, has been correlated with longer survival. Isolated metastatic renal cell carcinoma to the hand should be approached like that of a primary bone sarcoma.

REFERENCES

1. Abdul-Karim FW, El-Naggar AK, Joyce MJ, et al: Diffuse and localized tenosynovial giant cell tumor and pigmented villonodular synovitis: a clinicopathologic and flow cytometric DNA analysis. *Hum Pathol* 23:729–735, 1992.
2. Ablove RH, Moy OJ, Peimer CA, et al: Early versus delayed treatment of enchondroma. *Am J Orthop* 29:771–772, 2000.
3. Adeyemi-Doro HO, Olude O: Juvenile aponeurotic fibroma. *J Hand Surg [Br]* 10:127–128, 1985.
4. Alektiar KM, Leung D, Zelefsky MJ, et al: Adjuvant radiation for stage IIB soft tissue sarcoma of the extremity. *J Clin Oncol* 20:1643–1650, 2002.
5. Althausen P, Althausen A, Jennings LC, et al: Prognostic factors and surgical treatment of osseous metastases secondary to renal cell carcinoma. *Cancer* 80:1103–1109, 1997.
6. Amadio PC, Lombardi RM: Metastatic tumors of the hand. *J Hand Surg [Am]* 12:311–316, 1987.
7. Ambrosia JM, Wold LE, Amadio PC: Osteoid osteoma of the hand and wrist. *J Hand Surg [Am]* 12:794–800, 1987.
8. Anderson MA, Newmeyer WL, III, Kilgore ES, Jr: Diagnosis and treatment of retained foreign bodies in the hand. *Am J Surg* 144:63–67, 1987.
9. Angelides AC, Wallace PF: The dorsal ganglion of the wrist: its pathogenesis, gross and microscopic anatomy, and surgical treatment. *J Hand Surg [Am]* 1:228–235, 1976.
10. Anninga JK, Picci P, Fiocco M, et al: Osteosarcoma of the hands and feet: a distinct clinco-pathological subgroup. *Virchows Arch* 462:109–120, 2013.
11. Athanasian EA, Bishop AT, Amadio PC: Autogenous fibular graft and silicone implant arthroplasty following resection of giant cell tumor of the metacarpal: a report of two cases. *J Hand Surg [Am]* 22:504–507, 1997.
12. Athanasian EA, Wold LE, Amadio PC: Giant cell tumors of the bones of the hand. *J Hand Surg [Am]* 22:91–98, 1997.
13. Averill RA, Smith RJ, Campbell CJ: Giant-cell tumors of the bones of the hand. *J Hand Surg [Am]* 5:39–50, 1980.
14. Babins DM, Lubahn JD: Palmar lipomas associated with compression of the median nerve. *J Bone Joint Surg Am* 76:1360–1362, 1994.
15. Bauer RD, Lewis MM, Posner MA: Treatment of enchondromas of the hand with allograft bone. *J Hand Surg [Am]* 13:908–916, 1988.
16. Bednar MS, Maywood IL, McCormack RR, Jr, et al: Osteoid osteoma of the upper extremity. *J Hand Surg [Am]* 18:1019–1028, 1993.
17. Bernstein KE, Lattes R: Nodular (pseudosarcomatous) fasciitis, a nonrecurrent lesion: clinicopathologic study of 134 cases. *Cancer* 49:1668–1678, 1982.
18. Bickels J, Wittig JC, Kollender Y, et al: Enchondromas of the hand: treatment with curettage and cemented internal fixation. *J Hand Surg [Am]* 27:870–875, 2002.
19. Bloem JJ, Vuzevski VD, Huffstadt AJC: Recurring digital fibroma of infancy. *J Bone Joint Surg Br* 56:746–751, 1974.
20. Booher RJ: Lipoblastic tumors of the hands and feet: review of the literature and report of thirty-three cases. *J Bone Joint Surg Am* 47:727–740, 1965.
21. Boriani S, Bacchini P, Bertoni F, et al: Periosteal chondroma: a review of twenty cases. *J Bone Joint Surg Am* 65:205–212, 1983.
22. Bos GD, Pritchard DJ, Reiman HM, et al: Epithelioid sarcoma: an analysis of fifty-one cases. *J Bone Joint Surg Am* 70:862–870, 1988.
23. Bovee JV, Van der Heul RO, Taminiau AH, et al: Chondrosarcoma of the phalanx: a locally aggressive lesion with minimal metastatic potential: a report of 35 cases and a review of the literature. *Cancer* 86:1724–1732, 1999.
24. Brady MS, Gaynor JJ, Brennan MF: Radiation-associated sarcoma of bone and soft tissue. *Arch Surg* 127:1379–1385, 1992.
25. Brennan MF: Management of extremity soft-tissue sarcoma. *Am J Surg* 158:71–78, 1989.
26. Brennan MF, Casper ES, Harrison LB, et al: The role of multimodality therapy in soft-tissue sarcoma. *Ann Surg* 214:328–338, 1991.
27. Bricout PB: Acrometastases. *J Natl Med Assoc* 73:325–329, 1981.
28. Brien EW, Terek RM, Geer RJ, et al: Treatment of soft-tissue sarcomas of the hand. *J Bone Joint Surg Am* 77:564–571, 1995.
29. Burgert EO, Jr, Nesbit ME, Garnsey LA, et al: Multimodal therapy for the management of nonpelvic, localized Ewing's sarcoma of bone: Intergroup Study IESS-II. *J Clin Oncol* 8:1514–1524, 1990.
30. Campanacci M, Capanna R, Picci P: Unicameral and aneurysmal bone cysts. *Clin Orthop Relat Res* 204:25–36, 1986.
31. Carlow SB, Khuri SM: Metacarpal resection with a contoured iliac bone graft and silicone rubber implant for metacarpal giant cell tumor: a case report. *J Hand Surg [Am]* 10:275–278, 1985.
32. Carp L, Stout AP: A study of ganglion, with special reference to treatment. *Surg Gynecol Obstet* 47:460–468, 1928.
33. Carroll RE: Osteogenic sarcoma in the hand. *J Bone Joint Surg Am* 39:325–331, 1957.
34. Carroll RE: Juvenile aponeurotic fibroma. *Hand Clin* 3:219–224, 1987.
35. Carroll RE, Chance JT, Inan Y: Subungual exostosis in the hand. *J Hand Surg [Br]* 17:569–574, 1992.
36. Carroll RE, Godwin JT, Watson WL: Osteogenic sarcoma of phalanx after chronic roentgen-ray irradiation. *Cancer* 9:753–755, 1956.
37. Cash SL, Habermann ET: Chondrosarcoma of the small bones of the hand: case report and review of the literature. *Orthop Rev* 17:365–369, 1988.
38. Consensus Conference: Limb-sparing treatment of adult soft-tissue sarcomas and osteosarcomas. *JAMA* 254:1791–1796, 1985.
39. Constant E, Royer JR, Pollard RJ, et al: Mucous cysts of the fingers. *Plast Reconstr Surg* 43:241–246, 1969.
40. Coroneos CJ, O'Sullivan B, Ferguson PC, et al: Radiation therapy for infiltrative giant cell tumor of the tendon sheath. *J Hand Surg [Am]* 37:775–782, 2012.
41. Crane AR, Scarano JJ: Synovial cysts (ganglia) of bone. *J Bone Joint Surg Am* 49:355–361, 1967.
42. Crist WM, Gehan EA, Ragab AH, et al: The Third Intergroup Rhabdomyosarcoma Study. *J Clin Oncol* 13:610–630, 1995.
43. Culver JE, Jr, Sweet DE, McCue FC: Chondrosarcoma of the hand arising from a pre-existent benign solitary enchondroma: case report and pathological description. *Clin Orthop Relat Res* 113:128–131, 1975.
44. Dahlin DC, Salvador AH: Chondrosarcomas of bones of the hands and feet—a study of 30 cases. *Cancer* 34:755–760, 1974.
45. Das Gupta TK, Brasfield RD: Solitary malignant schwannoma. *Ann Surg* 171:419–428, 1970.

46. DeHart MM, Bowyer MW, Silenas R: Leiomyosarcoma of the skin and subcutaneous tissue of the hand and wrist. *J Hand Surg [Am]* 17:481–483, 1992.
47. Dick HM: Synovial sarcoma of the hand. *Hand Clin* 3:241–245, 1987.
48. Dick HM, Francis KC, Johnston AD: Ewing's sarcoma of the hand. *J Bone Joint Surg Am* 53:345–348, 1971.
49. Donaldson JS: Radiographic imaging of foreign bodies in the hand. *Hand Clin* 7:125–134, 1991.
50. Donner TR, Voorhies RM, Kline DG: Neural sheath tumors of major nerves. *J Neurosurg* 81:362–373, 1994.
51. Eaton RG, Dobranski AI, Littler JW: Marginal osteophyte excision in treatment of mucous cysts. *J Bone Joint Surg Am* 55:570–574, 1973.
52. Edwards SG, Johansen JA: Prospective outcomes and associations of wrist ganglion cysts resected arthroscopically. *J Hand Surg [Am]* 34:395–400, 2009.
53. Enneking WF: *Musculoskeletal tumor surgery*, New York, 1983, Churchill Livingstone.
54. Enneking WF: Staging of musculoskeletal neoplasms. In Uhthoff HK, Stahl E, editors: *Current concepts of diagnosis and treatment of bone and soft tissue tumors*, New York, 1984, Springer-Verlag, pp 1–21.
55. Enneking WF, Spanier SS, Goodman MA: A system for the surgical staging of musculoskeletal sarcoma. *Clin Orthop Relat Res* 153:106–120, 1980.
56. Enneking WF, Spanier SS, Goodman MA: Current concepts review: the surgical staging of musculoskeletal sarcoma. *J Bone Joint Surg Am* 62:1027–1030, 1980.
57. Enzinger FM: Clear-cell sarcoma of tendons and aponeuroses: an analysis of 21 cases. *Cancer* 18:1163–1174, 1965.
58. Enzinger FM, Weiss SW: *Soft tissue tumors*, ed 3, St. Louis, 1995, CV Mosby.
59. Erdmann MWH, Quaba AA, Sommerlad BC: Epithelioid sarcoma masquerading as Dupuytren's disease. *Br J Plast Surg* 48:39–42, 1995.
60. Euler E, Wilhelm K, Permanetter W, et al: Ewing's sarcoma of the hand: localization and treatment. *J Hand Surg [Am]* 15:659–662, 1990.
61. Falco NA, Upton J: Infantile digital fibromas. *J Hand Surg [Am]* 20:1014–1020, 1995.
62. Fatti JF, Mosher JF: Treatment of multiple enchondromatosis (Ollier's disease) of the hand. *Orthopedics* 9:512–518, 1986.
63. Fisher ER, Gruhn J, Skerrett P: Epidermal cyst in bone. *Cancer* 11:643–648, 1958.
64. Fisher ER, Wechsler H: Granular cell myoblastoma—a misnomer. *Cancer* 15:936–954, 1962.
65. Fleegler EJ, Marks KE, Sebek BA, et al: Osteosarcoma of the hand. *Hand* 12:316–322, 1980.
66. Flugel M, Kessler K: Follow-up of 425 patients operated for ganglion cysts. *Handchir Mikrochir Plast Chir* 18:47–52, 1986.
67. Foley KM, Woodruff JM, Ellis FT, et al: Radiation-induced malignant and atypical peripheral nerve sheath tumors. *Ann Neurol* 7:311–318, 1980.
68. Fong Y, Coit DG, Woodruff JM, et al: Lymph node metastasis from soft tissue sarcoma in adults: analysis of data from a prospective database of 1772 sarcoma patients. *Ann Surg* 217:72–77, 1993.
69. Frassica FJ, Amadio PC, Wold LE, et al: Aneurysmal bone cyst: clinicopathologic features and treatment of ten cases involving the hand. *J Hand Surg [Am]* 13:676–683, 1988.
70. Frassica FJ, Amadio PC, Wold LE, et al: Primary malignant bone tumors of the hand. *J Hand Surg [Am]* 14:1022–1028, 1989.
71. Frassica FJ, Unni KK, Beabout JW, et al: Dedifferentiated chondrosarcoma: a report of the clinicopathological features and treatment of seventy-eight cases. *J Bone Joint Surg Am* 68:1197–1205, 1986.
72. Fromm B, Martini A, Schmidt E: Osteoid osteoma of the radial styloid mimicking stenosing tenosynovitis: a case report. *J Hand Surg [Br]* 17:236–238, 1992.
73. Frustaci S, Gherlinzoni F, De Paoli A, et al: Adjuvant chemotherapy for adult soft tissue sarcomas of the extremities and girdles: results of the Italian randomized cooperative trial. *J Clin Oncol* 19:1238–1247, 2001.
74. Gadd MA, Casper ES, Woodruff JM, et al: Development and treatment of pulmonary metastases in adult patients with extremity soft tissue sarcoma. *Ann Surg* 218:705–712, 1993.
75. Gargan TJ, Kanter W, Wolfort FG: Multiple chondrosarcomas of the hand. *Ann Plast Surg* 12:542–546, 1984.
76. Gasparini M, Lombardi F, Ballerini E, et al: Long-term outcome of patients with monostotic Ewing's sarcoma treated with combined modality. *Med Pediatr Oncol* 23:406–412, 1994.
77. Gaynor JJ, Tan CC, Casper ES, et al: Refinement of clinicopathologic staging for localized soft tissue sarcoma of the extremity: a study of 423 adults. *J Clin Oncol* 10:1317–1329, 1992.
78. Gherlinzoni F, Rock M, Picci P: Chondromyxoid fibroma: the experience at the Instituto Ortopedico Rizzoli. *J Bone Joint Surg Am* 65:198–204, 1983.
79. Gingrass MK, Brown RE, Zook EG: Treatment of fingernail deformities secondary to ganglions of the distal interphalangeal joint. *J Hand Surg [Am]* 20:502–505, 1995.
80. Gitelis S, Mallin BA, Piasecki P, et al: Intralesional excision compared with en bloc resection for giant-cell tumors of bone. *J Bone Joint Surg Am* 75:1648–1655, 1993.
81. Gitelis S, Schajowicz F: Osteoid osteoma and osteoblastoma. *Orthop Clin North Am* 20:313–325, 1989.
82. Glasser DB, Lane JM, Huvos AG, et al: Survival, prognosis, and therapeutic response in osteogenic sarcoma. The Memorial Hospital experience. *Cancer* 69: 698–708, 1992.
83. Glowacki KA, Weiss APC: Giant cell tumors of tendon sheath. *Hand Clin* 11:245–253, 1995.
84. Goto T, Yokokura S, Kawano H, et al: Simple curettage without bone grafting for enchondromata of the hand: with special reference to replacement of the cortical window. *J Hand Surg [Br]* 27:446–451, 2002.
85. Habal MB, Snyder HH, Jr, Murray JE: Chondrosarcoma of the hand. *Am J Surg* 125:775–776, 1973.
86. Hasselgren G, Forssblad P, Tornvall A: Bone grafting unnecessary in the treatment of enchondromas in the hand. *J Hand Surg [Am]* 16:139–142, 1991.
87. Hays DM, Soule EH, Lawrence W, Jr, et al: Extremity lesions in the Intergroup Rhabdomyosarcoma Study (IRS-1): a preliminary report. *Cancer* 48:1–8, 1982.
88. Healey JH, Turnbull ADM, Miedema B, et al: Acrometastases: a study of twenty-nine patients with osseous involvement of the hands and feet. *J Bone Joint Surg Am* 68:743–746, 1986.
89. Hirsh BC, Johnson WC: Pathology of granulomatous diseases: foreign body granulomas. *Int J Dermatol* 23:531–538, 1984.
90. Ho PC, Lo WN, Hung LK: Arthroscopic resection of volar ganglion of the wrist: a new technique. *Arthroscopy* 19:218–221, 2003.
91. Houpt P, Storm van Leeuwen JB, van den Bergen HA: Intraneural lipofibroma of the median nerve. *J Hand Surg [Am]* 14:706–709, 1989.
92. Hubbard LF, Burton RI: Malignant fibrous histiocytoma of the forearm: report of a case and review of the literature. *J Hand Surg [Am]* 2:292–296, 1977.
93. Huvos AG: *Bone tumors: Diagnosis, treatment, and prognosis*, ed 3, Philadelphia, 1991, WB Saunders.
94. Iwasaki H, Kikuchi M, Mori R, et al: Infantile digital fibromatosis: ultrastructural, histochemical, and tissue culture observations. *Cancer* 46:2238–2247, 1980.
95. Jacob RA, Buchino JJ: Lipofibroma of the superficial branch of the radial nerve. *J Hand Surg [Am]* 14:704–706, 1989.
96. Jayson MI, Dixon AS: Valvular mechanism in juxta-articular cysts. *Ann Rheum Dis* 29:415–420, 1970.
97. Jelinek JS, Kransdorf MJ, Shmookler BM, et al: Giant cell tumor of the tendon sheath: MR findings in nine cases. *AJR Am J Roentgenol* 162:919–922, 1994.
98. Johnstone PA, Wexler LH, Venzon DJ, et al: Sarcomas of the hand and foot: analysis of local control and functional result with combined modality therapy in extremity preservation. *Int J Radiat Oncol Biol Phys* 29:735–745, 1994.
99. Justis EJ, Jr, Dart RC: Chondrosarcoma of the hand with metastasis: a review of the literature and case report. *J Hand Surg [Am]* 8:320–324, 1983.
100. Kahn LB: Malignant giant cell tumor of the tendon sheath: ultrastructural study and review of the literature. *Arch Pathol* 95:203–208, 1973.
101. Kang L, Akelman E, Weiss AP: Arthroscopic versus open dorsal ganglion excision: a prospective, randomized comparison of rates of recurrence and residual pain. *J Hand Surg [Am]* 33:471–475, 2008.
102. Kang L, Manoso MW, Boland PJ, et al: Features of grade 3 giant cell tumors of the distal radius associated with successful intralesional treatment. *J Hand Surg [Am]* 35:1850–1857, 2010.
103. Karabela-Bouropoulou V, Patra-Malli F, Agnantis N: Chondrosarcoma of the thumb: an unusual case with lung and cutaneous metastasis and death of the patient six years following treatment. *J Cancer Res Clin Oncol* 112:71–74, 1986.
104. Karasick D, Karasick S: Giant cell tumor of tendon sheath: spectrum of radiologic findings. *Skeletal Radiol* 21:219–224, 1992.
105. Katz MA, Beredjiklian PK, Wirganowicz PZ: Nodular fasciitis of the hand: a case report. *Clin Orthop Relat Res* 382:108–111, 2001.
106. Kayton ML, Delgado R, Busam K, et al: Experience with 31 sentinel lymph node biopsies for sarcomas and carcinomas in pediatric patients. *Cancer* 1(112):1052–1059, 2008.
107. Keasbey LF: Juvenile aponeurotic fibroma (calcifying fibroma): a distinctive tumor arising in the palms and soles of young children. *Cancer* 6:338–346, 1953.
108. Kedar A, Binlik V, Fishman J: Ewing sarcoma of the hand: literature review and a case report of nonsurgical management. *J Surg Oncol* 25:25–27, 1984.
109. Kerin R: Metastatic tumors of the hand. *J Bone Joint Surg Am* 40:263–277, 1958.
110. Kerrigan JJ, Bertoni JM, Jaeger SH: Ganglion cysts and carpal tunnel syndrome. *J Hand Surg [Am]* 13:763–765, 1988.
111. Kinsella TJ, Loeffler JS, Fraass BA, et al: Extremity preservation by combined modality therapy in sarcomas of the hand and foot: an analysis of local control, disease free survival and functional result. *Int J Radiat Oncol Biol Phys* 9:1115–1119, 1983.
112. Kleinert HE, Kutz JE, Fishman JH, et al: Etiology and treatment of the so-called mucous cyst of the finger. *J Bone Joint Surg Am* 54:1455–1458, 1972.

113. Kneisl JS, Simon MA: Medical management compared with operative treatment for osteoid-osteoma. *J Bone Joint Surg Am* 74:179–185, 1992.
114. Lafferty KA, Nelson EL, Demuth RJ, et al: Juvenile aponeurotic fibroma with disseminated fibrosarcoma. *J Hand Surg [Am]* 11:737–740, 1986.
115. Lane CS, Kuschner SH, Mirra JM: Giant cell tumors in carpal bones. *Orthopedics* 17:181–185, 1994.
116. Laus M, Bertoni F: Malignant tumours of the bones of the hand (from the records of the Rizzoli Institute). *Ital J Orthop Traumatol* 7:279–291, 1981.
117. Lewin J, Thomas D: Denosumab: a new treatment option for giant cell tumor of bone. *Drugs Today* 49:693–700, 2013.
118. Lewis JJ, Brennan MF: Soft tissue sarcomas. *Curr Probl Surg* 33:817–872, 1996.
119. Lewis JJ, Leung D, Heslin M, et al: Association of local recurrence with subsequent survival in extremity soft tissue sarcoma. *J Clin Oncol* 15:646–652, 1997.
120. Lewis MM, Kenan S, Yabut SM, et al: Periosteal chondroma: a report of ten cases and review of the literature. *Clin Orthop Relat Res* 256:185–192, 1990.
121. Lewis RJ, Ketcham AS: Maffucci's syndrome: functional and neoplastic significance: case report and review of the literature. *J Bone Joint Surg Am* 55:1465–1479, 1973.
122. Lewis RJ, Marcove RC, Rosen G: Ewing's sarcoma: functional effects of radiation therapy. *J Bone Joint Surg Am* 59:325–331, 1977.
123. Li FP, Fraumeni JF, Jr, Mulvihill JJ, et al: A cancer family syndrome in twenty-four kindreds. *Cancer Res* 48:5358–5362, 1988.
124. Lin PP, Guzel VB, Pisters PW, et al: Surgical management of soft tissue sarcomas of the hand and foot. *Cancer* 95:852–861, 2002.
125. Lindberg RD, Martin RG, Romsdahl MM, et al: Conservative and postoperative radiotherapy in 300 adults with soft-tissue sarcomas. *Cancer* 47:2391–2397, 1981.
126. Liu J, Hudkins PG, Swee RG, et al: Bone sarcomas associated with Ollier's disease. *Cancer* 59:1376–1385, 1987.
127. Lloyd RV, Hadju SI, Knapper WH: Embryonal rhabdomyosarcoma in adults. *Cancer* 51:557–565, 1983.
128. Loghdey MS, Varma S, Rajpara SM, et al: Mohs micrographic surgery for dermatofibrosarcoma protuberans (DFSP): a single-centre series of 76 patients treated by frozen-section Mohs micrographic surgery with a review of the literature. *J Plast Reconstr Aesthet Surg* 67:1315–1321, 2014.
129. Louis DS, Hankin FM, Greene TL, et al: Lipofibromas of the median nerve: long-term follow-up of four cases. *J Hand Surg [Am]* 10:403–408, 1985.
130. Luchetti R, Badia A, Alfarano M, et al: Arthroscopic resection of dorsal wrist ganglia and treatment of recurrences. *J Hand Surg [Br]* 35:38–40, 2000.
131. Maduekwe UN, Hornicek FJ, Springfield DS, et al: Role of sentinel lymph node biopsy in the staging of synovial, epithelioid and clear cell sarcomas. *Ann Surg Oncol* 16:1356–1363, 2009.
132. Maher DP: Granular cell tumor in the hand. *J Hand Surg [Am]* 12:800–803, 1987.
133. Maloney WJ, Vaughan LM, Jones HH, et al: Benign metastasizing giant cell tumor of bone: report of three cases and review of the literature. *Clin Orthop Relat Res* 243:208–215, 1989.
134. Mankin HJ, Lange TA, Spanier SS: The hazards of biopsy in patients with malignant primary bone and soft-tissue tumors. *J Bone Joint Surg Am* 64:1121–1127, 1982.
135. Marcove RC, Charosky CB: Phalangeal sarcomas simulating infections of the digits: review of the literature and report of four cases. *Clin Orthop Relat Res* 83:224–231, 1972.
136. Marcove RC, Lyden JP, Huvos AG, et al: Giant-cell tumors treated by cryosurgery: a report of twenty-five cases. *J Bone Joint Surg Am* 55:1633–1644, 1973.
137. Marcove RC, Sheth DS, Takemoto S, et al: The treatment of aneurysmal bone cyst. *Clin Orthop Relat Res* 311:157–163, 1995.
138. Maurer HM, Gehan EA, Beltangady M, et al: The Intergroup Rhabdomyosarcoma Study-II. *Cancer* 71:1904–1922, 1993.
139. McFarland GB, Jr, Hoffer MM: Paralysis of the intrinsic muscles of the hand secondary to lipoma in Guyon's tunnel. *J Bone Joint Surg Am* 53:375–376, 1971.
140. Meals RA, Mirra JM, Bernstein AJ: Giant cell tumor of metacarpal treated by cryosurgery. *J Hand Surg [Am]* 14:130–134, 1989.
141. Mehrara BJ, Abood AA, Disa JJ, et al: Thumb reconstruction following resection for malignant tumors. *Plast Reconstr Surg* 121:1279–1287, 2008.
142. Meyers PA, Heller G, Healey JH, et al: Chemotherapy for nonmetastatic osteogenic sarcoma: the Memorial Sloan-Kettering experience. *J Clin Oncol* 10:5–15, 1992.
143. Meyers PA, Heller G, Healey JH, et al: Osteogenic sarcoma with clinically detectable metastasis at initial presentation. *J Clin Oncol* 11:449–453, 1993.
144. Moore JR, Curtis RM, Wilgis EFS: Osteocartilaginous lesions of the digits in children: an experience with 10 cases. *J Hand Surg [Am]* 8:309–315, 1983.
145. Moore JR, Weiland AJ, Curtis RM: Localized nodular tenosynovitis: experience with 115 cases. *J Hand Surg [Am]* 9:412–417, 1984.
146. Mosher JF, Peckham AC: Osteoblastoma of the metacarpal: a case report. *J Hand Surg [Am]* 3:358–360, 1978.
147. Murray JA, Schlafly B: Giant-cell tumors in the distal end of the radius: treatment by resection and fibular autograft interpositional arthrodesis. *J Bone Joint Surg Am* 68:687–694, 1986.
148. Nishikawa S, Toh S, Miura H, et al: Arthroscopic diagnosis and treatment of dorsal wrist ganglion. *J Hand Surg [Br]* 36:547–549, 2001.
149. Nora FE, Dahlin DC, Beabout JW: Bizarre parosteal osteochondromatous proliferations of the hands and feet. *Am J Surg Pathol* 7:245–250, 1983.
150. Oda Y, Hashimoto H, Tsuneyoshi M, et al: Case report 742: interosseous epidermoid cyst arising in the fifth metacarpal bone. *Skeletal Radiol* 21:343–345, 1992.
151. Oda Y, Hashimoto H, Tsuneyoshi M, et al: Survival in synovial sarcoma: a multivariate study of prognostic factors with special emphasis on the comparison between early death and long term survival. *Am J Surg Pathol* 17:35–44, 1993.
152. O'Donnell RJ, Springfield DS, Motwani HK, et al: Recurrence of giant-cell tumors of the long bones after curettage and packing with cement. *J Bone Joint Surg Am* 76:1827–1833, 1994.
153. Ogino T, Minami A, Fukada K, et al: The dorsal occult ganglion of the wrist and ultrasonography. *J Hand Surg [Br]* 13:181–183, 1988.
154. Okada K, Wold LE, Beabout JW, et al: Osteosarcoma of the hand: a clinicopathologic study of 12 cases. *Cancer* 72:719–725, 1993.
155. Oliveira AM, Chou MM: USP6-induced neoplasms: the biologic spectrum of aneurysmal bone cyst and nodular fasciitis. *Hum Pathol* 45:1–11, 2014.
156. Ozaki T, Hashizume H, Kawai A, et al: Ewing's sarcoma of the hand: magnetic resonance images and treatment. *J Hand Surg [Am]* 20:441–444, 1995.
157. Ozaki T, Hillmann A, Hoffmann C, et al: Significance of surgical margin on the prognosis of patients with Ewing's sarcoma: a report from the Cooperative Ewing's Sarcoma Study. *Cancer* 78:892–900, 1996.
158. Palmieri TJ: Chondrosarcoma of the hand. *J Hand Surg [Am]* 9:332–338, 1984.
159. Parida L, Fernandez-Pineda I, Uffman J, et al: Clinical management of Ewing sarcoma of the bones of the hands and feet: a retrospective single-institution review. *J Pediatr Surg* 47:1806–1810, 2012.
160. Parker TL, Zitelli JA: Surgical margins for excision of dermatofibrosarcoma protuberans. *J Am Acad Dermatol* 32:233–236, 1995.
161. Patel ME, Silver JW, Lipton DE, et al: Lipofibroma of the median nerve in the palm and digits of the hand. *J Bone Joint Surg Am* 61:393–397, 1979.
162. Peimer CA, Smith RJ, Sirota RL, et al: Epithelioid sarcoma of the hand and wrist: patterns of extension. *J Hand Surg [Am]* 2:275–282, 1977.
163. Pentimalli G, Tudisco C, Scola E, et al: Unicameral bone cysts: comparison between surgical and steroid injection treatment. *Arch Orthop Trauma Surg* 106:251–256, 1987.
164. Phalen GS: Neurilemomas of the forearm and hand. *Clin Orthop Orthop Res* 114:219–222, 1976.
165. Prat JP, Woodruff JM, Marcove RC: Epithelioid sarcoma: an analysis of 22 cases indicating the prognostic significance of vascular invasion and regional lymph node metastasis. *Cancer* 41:1472–1487, 1978.
166. Reilly KE, Stern PJ, Dale JA: Recurrent giant cell tumors of the tendon sheath. *J Hand Surg [Am]* 24:1298–1302, 1999.
167. Reinus WR, Gilula LA, Shirley SK, et al: Radiographic appearance of Ewing sarcoma of the hands and feet. Report from the Intergroup Ewing Sarcoma study. *Am J Roentgenol* 144:331–336, 1985.
168. Riley LH, Jr, Hartmann WH, Robinson RA: Soft-tissue recurrence of giant-cell tumor of bone after irradiation and excision. *J Bone Joint Surg Am* 49:365–368, 1967.
169. Rinaldi E: Neurilemomas and neurofibromas of the upper limb. *J Hand Surg [Am]* 8:590–593, 1983.
170. Roberts PH, Price CHG: Chondrosarcoma of the bones of the hand. *J Bone Joint Surg Br* 59:213–221, 1977.
171. Rosen G, Forscher C, Lowenbraun S, et al: Synovial sarcoma: uniform response of metastases to high dose ifosfamide. *Cancer* 73:2506–2511, 1994.
172. Rosenberg SA, Tepper J, Glatstein E, et al: The treatment of soft-tissue sarcomas of the extremities: prospective randomized evaluations of (1) limb-sparing surgery plus radiation therapy compared with amputation and (2) the role of adjuvant chemotherapy. *Ann Surg* 196:305–315, 1982.
173. Russell RC, Williamson DA, Sullivan JW, et al: Detection of foreign bodies in the hand. *J Hand Surg [Am]* 16:2–11, 1991.
174. Rutgers EJ, Kroon BBR, Albus-Lutter CE, et al: Dermatofibrosarcoma protuberans: treatment and prognosis. *Eur J Surg Oncol* 18:241–248, 1992.
175. Scaglietti O, Marchetti PG, Bartolozzi P: Final results obtained in the treatment of bone cysts with methylprednisolone acetate (Depo-Medrol) and a discussion of results achieved in other bone lesions. *Clin Orthop Relat Res* 165:33–42, 1982.
176. Schajowicz F, Gallardo H: Chondromyxoid fibroma (fibromyxoid chondroma) of bone: a clinicopathological study of thirty-two cases. *J Bone Joint Surg Br* 53:198–216, 1971.
177. Seddon HJ: Carpal ganglion as a cause of paralysis of the deep branch of the ulnar nerve. *J Bone Joint Surg Br* 34:386–390, 1952.
178. Sheth DS, Healey JH, Sobel M, et al: Giant cell tumor of the distal radius. *J Hand Surg [Am]* 20:432–440, 1995.

179. Shih JT, Hung ST, Lee HM, et al: Dorsal ganglion of the wrist: results of treatment by arthroscopic resection. *Hand Surg* 7:1–5, 2002.
180. Simon MA: Current concepts review—biopsy of musculoskeletal tumors. *J Bone Joint Surg Am* 64:1253–1257, 1982.
181. Simon MA, Enneking WF: The management of soft tissue sarcomas of the extremities. *J Bone Joint Surg Am* 58:317–327, 1976.
182. Siqueira MG, Socolovsky M, Martins RS, et al: Surgical treatment of typical peripheral schwannomas: the risk of new postoperative deficits. *Acta Neuroch (Wien)* 155:1745–1749, 2013.
183. Smith RJ: Complications of surgical treatment of tumors of the hand. In Boswick JA, editor: *Complications in hand surgery*, Philadelphia, 1986, WB Saunders, pp 286–293.
184. Stanelle EJ, Christison-Lagay ER, Healey JH, et al: Pediatric and adolescent synovial sarcoma: multivariate analysis of prognostic factors and survival outcomes. *Ann Surg Oncol* 20:73–79, 2013.
185. Steinberg BD, Gelberman RH, Mankin HJ, et al: Epithelioid sarcoma in the upper extremity. *J Bone Joint Surg Am* 74:28–35, 1992.
186. Stephen AB, Lyons AR, Davis TR: A prospective study of two conservative treatments for ganglia of the wrist. *J Hand Surg [Br]* 24:104–105, 1999.
187. Stout AP: Pseudosarcomatous fasciitis in children. *Cancer* 14:1216–1222, 1961.
188. Strauch RJ, Kleinman WB: Chondromyxoid fibroma of a metacarpal: a case report and review of the literature. *J Hand Surg [Am]* 21:293–295, 1996.
189. Stull MA, Moser RP, Jr, Kransdorf MJ, et al: Magnetic resonance appearance of peripheral nerve sheath tumors. *Skeletal Radiol* 20:9–14, 1991.
190. Suit HD, Proppe KH, Mankin HJ, et al: Preoperative radiation therapy for sarcoma of soft tissue. *Cancer* 47:2269–2274, 1981.
191. Tahiri Y, Xu L, Kanevsky J, et al: Lipofibromatous hamartoma of the median nerve: a comprehensive review and sytematic approach to evaluation, diagnosis, and treatment. *J Hand Surg [Am]* 38:2055–2067, 2013.
192. Takigawa K: Chondroma of the bones of the hand: a review of 110 cases. *J Bone Joint Surg Am* 53:1591–1600, 1971.
193. Talbot SG, Mehrara BJ, Disa JJ, et al: Soft tissue coverage of the hand following sarcoma resection. *Plast Reconstr Surg* 121:534–543, 2008.
194. Terek RM, Brien EW: Soft-tissue sarcomas of the hand and wrist. *Hand Clin* 11:287–305, 1995.
195. Tolo ET, Cooney WP, Wenger DE: Renal cell carcinoma with metastases to the triquetrum: a case report. *J Hand Surg [Am]* 27:876–881, 2002.
196. Torpey B, Faierman E, Lehmann O: Phalangeal transfer for recurrent giant cell tumor of the phalanx of a finger in a nine-year-old child: a case report with forty-one year follow-up. *J Bone Joint Surg Am* 76:1864–1869, 1994.
197. Ugurel S, Mentzel T, Utikal J, et al: Neoadjuvant imatinib in advanced primary or locally recurrent dermatofibrosarcoma protuberans: a multicenter phase II DeCOG trial with long-term follow-up. *Clin Cancer Res* 15:499–510, 2014.
198. Uriburu IJ, Levy VD: Intraosseous growth of giant cell tumors of the tendon sheath (localized nodular tenosynovitis) of the digits: report of 15 cases. *J Hand Surg [Am]* 23:732–736, 1998.
199. Vander Griend RA, Funderburk CH: The treatment of giant-cell tumors of the distal part of the radius. *J Bone Joint Surg Am* 75:899–908, 1993.
200. Wanebo JE, Malik JM, VandenBerg SR, et al: Malignant peripheral nerve sheath tumors: a clinicopathologic study of 28 cases. *Cancer* 71:1247–1253, 1993.
201. Wang AA, Hutchinson DT: Longitudinal observation of pediatric hand and wrist ganglia. *J Hand Surg [Am]* 26:599–602, 2001.
202. Weiss SW, Enzinger FM: Malignant fibrous histiocytoma: an analysis of 200 cases. *Cancer* 41:2250–2266, 1978.
203. Wittig JC, Simpson BM, Bickels J, et al: Giant cell tumor of the hand: superior results with curettage, cryosurgery and cementation. *J Hand Surg [Am]* 26:546–555, 2001.
204. Wunder JS, Healey JH, Davis AM, et al: A comparison of staging systems for localized extremity soft tissue sarcoma. *Cancer* 88:2721–2730, 2000.
205. Yasuda M, Masada K, Takeuchi E: Treatment of enchondroma of the hand with injectable calcium phosphate bone cement. *J Hand Surg [Am]* 31:98–102, 2006.
206. Zouari L, Bousson V, Hamzé B, et al: CT-guided percutaneous laser photocoagulation of osteoid osteomas of the hand and feet. *Eur Radiol* 18:2635–2641, 2008.

60

Vascular Disorders of the Hand

William C. Pederson

Acknowledgment: This chapter was previously written by Dr. Andrew Koman and his associates. The author acknowledges Dr. Koman's scientific approach to the subject and his lifelong body of research into ischemia of the hand. The reader is referred to the chapter in the previous edition if a more scientific background on ischemia of the hand is desired.

Vascular disorders of the hand are relatively uncommon but can pose significant problems for patients suffering from them. Ischemic pain, ulceration, and decreasing hand function because of the foregoing are just some of the problems they face. Proper management of patients can improve their quality of life dramatically and on occasion prevent loss of tissue and potentially even the limb.

ANATOMY

Arterial blood is supplied to the hand through the brachial artery that branches in the proximal forearm primarily into the radial and ulnar arteries. These two major vessels continue down the forearm and supply the major portion of the blood that flows into the hand. The anterior and posterior interosseous vessels can provide flow via collateral circulation in chronic vascular problems; however, these two vessels are much smaller and generally cannot provide adequate oxygenated blood in the case of acute injury to both the radial and ulnar vessels. More recent work has determined that the volar forearm's median artery can provide significant blood flow to the hand, particularly in the case of injury or harvest of the radial artery.[42,47]

Blood supply to the hand was first clearly elucidated by Coleman and Anson in their classic paper,[14] in which they found that most hands have both a "superficial" and a "deep" arch that supplies the fingers. They found that 78% of the hands studied had a "complete" superficial arch, which theoretically allowed normal flow to all the fingers passing through the arch if flow by means of the radial or ulnar arteries was compromised. The ulnar artery flows into the hand on the palmar surface; its terminal portion becomes the superficial arch, while the radial artery courses around the radial volar wrist into the anatomic snuffbox, then it enters the palm via the first webspace. The terminal branches of the radial artery turn into the princeps pollicis and the deep palmar arch (Figure 60.1).

Much has been made of the presence or absence of a complete arch over the years; however, a great deal of clinical experience has shown that acute interruption of flow in either the radial or ulnar artery is extremely unlikely to result in significant ischemia of the hand or fingers.[70] In terms of which vessel provides the dominant circulation to the hand, the results of studies have been variable, with most finding that the ulnar artery is dominant[2,4,19] and others finding that it is the radial.[76] I would think that this point is actually moot because injury to one of the two vessels alone rarely causes any ischemia of the hand.

While the arterial supply to the hand enters primarily on the palmar surface, most of the venous drainage begins on the dorsal fingers and continues on the hand's dorsal surface. The primary arteries of the hand are each followed by two small venae comitantes, the configuration of which actually continues out to the fingers into the digital arteries. The primary drainage of the hand is, however, via the dorsal system, which eventually drains into the cephalic and basilic veins on the forearm and upper arm. Problems with venous drainage of the hand are extremely unusual—with the exception of possible venous thrombosis after replantation—due to the many venous channels available.

ETIOLOGY OF ISCHEMIA

Hand ischemia can result from iatrogenic injury, trauma, or vascular disease. Fortunately, iatrogenic injury is unusual; however, the potential to negatively affect flow to the hand is present in many procedures.[10] An Allen's test should be performed routinely prior to any intervention involving the radial artery (Figure 60.2). Radial artery puncture is a commonly used procedure for harvesting blood to measure gases, and indwelling catheters in the radial artery are commonplace for the monitoring of unstable patients during and after surgery. Although isolated radial artery puncture is exceedingly unlikely to cause ischemia in the hand, indwelling catheters are known to cause permanent ischemic complications in approximately 0.09% of patients.[9]

In the group of patients who develop ischemic problems, studies have shown that surgical intervention is not universally successful, probably due to the severity of vascular disease in the radial artery and the effects of distal embolization from the site of injury[25,79] (Figure 60.3). Depending on the patients' underlying problems, it may be best to manage them with anticoagulation, regional nerve blocks, and possibly intraarterial thrombolytics. The increasing trend toward management of vascular problems with endovascular techniques has led to renewed interest in peripheral artery access, with the radial artery offering a relatively easy way into the arterial system.[74] While early reports minimize the complications of this approach, it remains to be seen whether increasing application of this technique will lead to more ischemic problems in the hand.

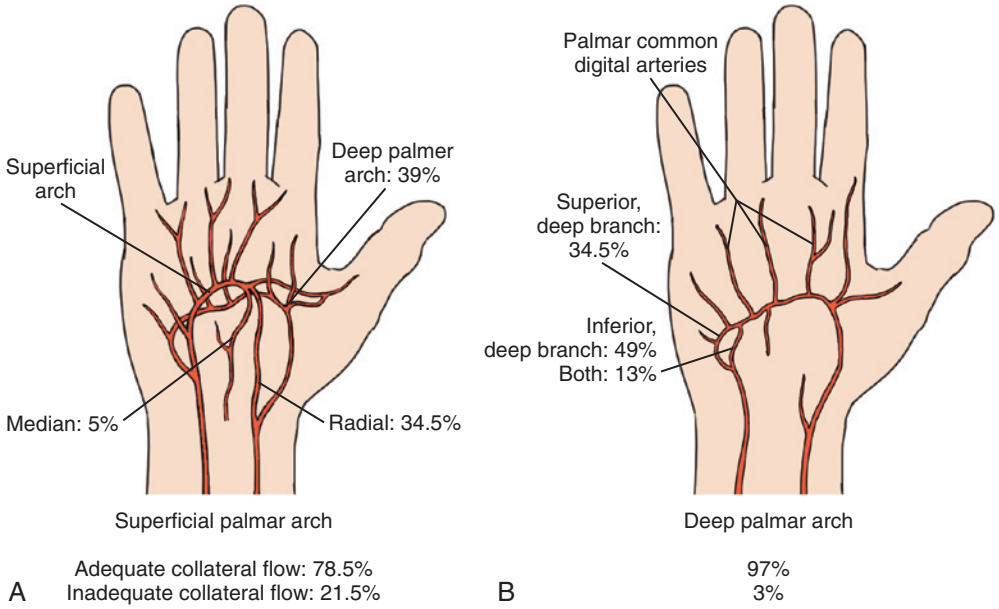

FIGURE 60.1 **A, B,** The superficial palmar arch is "completed" by branches from the deep palmar arch, radial artery, or median artery in 78.5% of patients; the remaining 21.5% are "incomplete." The deep palmar arch is "completed" by the superior branch of the ulnar artery, the inferior branch of the ulnar artery, or both in 98.5% of patients. (Modified from Koman LA, Urbaniak JR: Ulnar artery thrombosis. In Brunelli G, editor: *Textbook of microsurgery*, Milan, Italy, 1988, Masson, 75–83, with permission.)

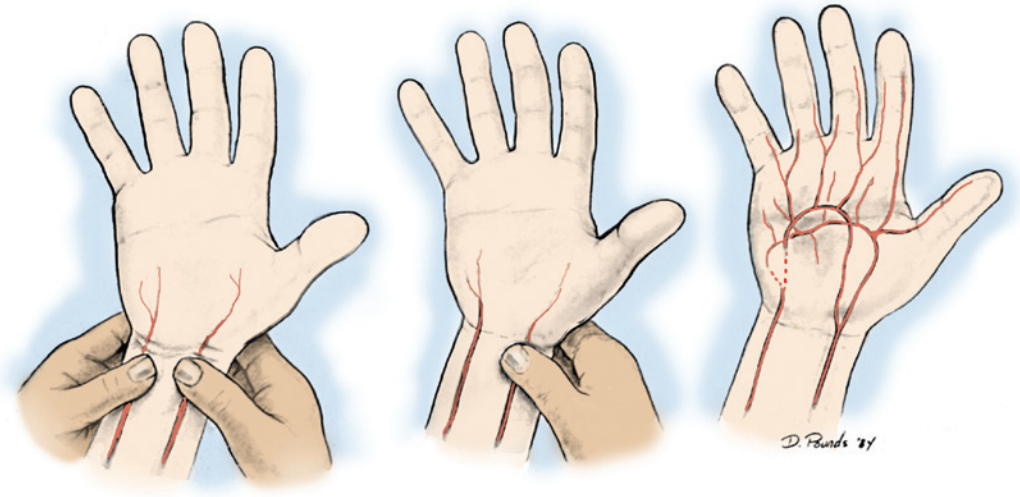

FIGURE 60.2 The Allen test is represented schematically. Blood is exsanguinated from the hand, and both the radial and ulnar arteries are compressed (*left*). After release of the ulnar artery (*middle*), no blood flows through the occluded artery, and the palm remains pale. With release of the radial artery (*right*), the entire hand will fill rapidly through the radial artery if the arch is complete. The order of the testing maneuvers can be reversed to evaluate the radial artery in a similar fashion. The test is best described as: demonstrating flow or no flow through a specific artery. (From Koman LA: Diagnostic study of vascular lesions. *Hand Clin* 1:217–231, 1985, with permission.)

Currently, the radial artery is often harvested for cardiac revascularization and radial forearm flap reconstruction, which also can lead to hand ischemia. The standard to use to avoid problems is the preoperative Allen's test, as noted earlier. Despite the routine use of it, ischemic episodes have been reported after radial artery harvest. This problem can be managed successfully, however, by performing a bypass with the autologous vein to replace the harvested radial artery.

Another iatrogenic cause of ischemia is vascular access in the upper extremity for hemodialysis. This happens in a range of 2 to 5% after a vascular access procedure[56] and can be due to distal embolization or a "steal" phenomenon; in this case, the majority of the arterial flow is diverted across the fistula, leading to ischemia in the distal hand. Often the fistula will have to be banded or even ligated to decrease the shunting of blood from the hand; however, vascular surgeons are usually unwilling to ligate these because of the difficulties of long-term access in dialysis patients. Another option is the so-called "distal revascularization interval ligation," or DRIL, procedure.

In this operation, a vein graft is sewn into the artery above the site of the fistula and the bypass is anastomosed to the distal artery at a level beyond it. The native artery is then ligated just

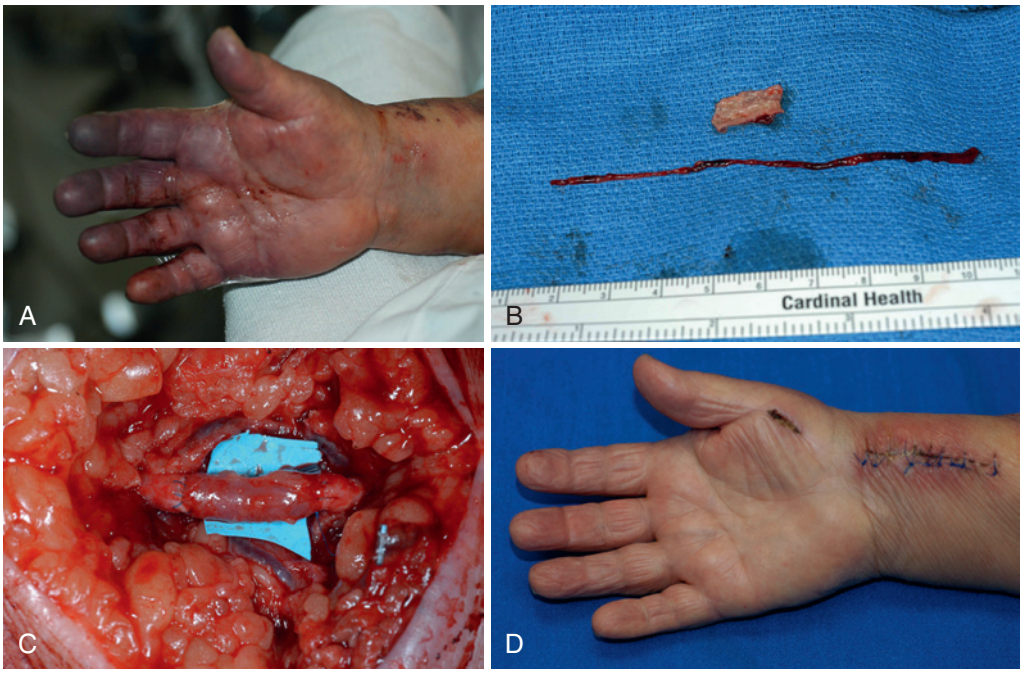

FIGURE 60.3 **A,** View of 82-year-old female's hand 36 hours after attempted radial arterial line placement during surgery. There was no Doppler signal in the distal–radial artery or in the snuffbox. **B,** View of damaged portion of arterial wall removed and thrombus extracted with Fogarty® balloon catheter. Radial artery was heavily calcified. **C,** Radial artery after repair with "Longmire" vein segment patch graft. **D,** View of hand at 2 weeks after repair.

distal to the fistula. This theoretically leads to the hand getting the majority of flow rather than the shunt and is effective in many patients.[71] Diabetic patients on dialysis present other difficulties in that they often develop worsening arteriosclerosis of the upper extremity's vessels and ongoing ischemia; this will be discussed further later.

The other cause of ischemia of the hand is trauma, which can be either an open or a closed injury to forearm and hand vessels. The classic case of a closed injury to the hand's arterial supply is in supracondylar fractures in children.[13] In these patients, displacement of the fracture leads to injury and spasm of the brachial artery, which if not recognized can lead to a compartment syndrome and ultimately a Volkmann ischemic contracture of the flexor muscles. Another fairly common type of closed vascular injury unique to the hand is ulnar artery thrombosis, or "hypothenar hammer syndrome." This injury occurs with closed trauma to the palm of the hand, often when it is used as a hammer or when the hypothenar area suffers a blow.[48] Open injuries, whether by firearms or by lacerations, are particularly common in the forearm and hand. As noted earlier, injury to a single vessel rarely causes acute ischemia but undiagnosed injuries can lead to aneurysm formation and potential distal embolization.

The final cause of ischemia in the hand is intrinsic vascular disease, which can be either arteriosclerotic or vasospastic. They can be seen in combination, which is known as "vasoocclusive" disease. Although Buerger disease has historically been a major cause of arteriosclerotic disease in the upper extremity,[15] in today's world the most common cause is a combination of diabetes and renal insufficiency. This combination of disease processes leads to accelerated occlusive vascular disease in the upper and lower extremities,[35] and it is not uncommon to see patients with bilateral lower-limb amputations appear with critical ischemia of the hand. Likewise, patients with collagen vascular disease (i.e., scleroderma primarily) suffer from vasculitis and vasospastic disease, which can lead to vasoocclusive disease.[61] The patients can present difficult management issues, and surgical intervention, while helpful, often does not provide a long-term solution.

EVALUATION

As with any problem, patients first need to provide a thorough history and undergo a physical examination. Obtaining a medical history, with particular attention to documented diabetes and/or collagen vascular disease, is very important. Obviously, a habit of smoking will have an impact as well. Medical management of the diseases with pharmacologic agents may mitigate some of the symptoms, particularly in those patients with Raynaud disease. The physical exam should pay close attention to the appearance of the hands and the color of the fingers, looking for evidence of ischemia and/or gangrene or ulceration. Likewise, the warmth of the fingers is important and sensation also plays a role, with the potential for sympathetic overactivity in the presence of nerve compression.[29]

The pulses at the elbow and wrist should be felt, and I feel that Doppler ultrasound plays a very important role in the examination of the patient with a vascular disorder. An Allen's test can be done, as described before; however, performing a similar exam with the pencil Doppler may yield much more information. The arch is located with the Doppler, and the radial and ulnar arteries are compressed sequentially at the



FIGURE 60.4 Computed tomographic angiography of palm showing level of detail that can be obtained.



FIGURE 60.5 Arteriogram of patient with recent onset of ischemic symptoms of thumb and index finger. This was read as a normal variant with a large median artery when in fact the patient had suffered thrombosis of the radial artery in the anatomic snuffbox and embolization to the thumb and index finger.

wrist. The Doppler can be moved over the arch as necessary to follow the signal, listening for a change in character or flow. This technique can almost always diagnose the site of arterial occlusion if performed carefully. Likewise, an arterial signal should be heard with the Doppler placed on the pulp of the finger; if it is not, there is a significant problem with flow to that finger.

It should be noted, however, that the presence of an audible Doppler arterial signal in one of the wrist's vessels *is not* an indication of adequate nutritional flow to the hand. By using this simple technique in the office the surgeon usually can diagnose where the occlusion is; however, this information is not adequate for planning a surgical procedure. For this I prefer using computerized tomographic angiography (CTA) or arteriography—the latter if fine detail of the hand's vessels is needed (Figure 60.4).

Others prefer a magnetic resonance angiography (MRA), but I have found that the detail in many of these images is inadequate in terms of knowing exactly where and how significant the problem is. The gold standard, however, remains digital subtraction angiography (DSA). Surgeons must view the vascular studies themselves because the radiologist or vascular specialist may or may not see the lesion.[81] A familiarity with the upper extremity's normal and variant anatomy is essential; however, surgeons who are dealing with vascular problems must evaluate every vascular study, both to review the anatomy and to identify the problem (Figure 60.5).

There are a number of other types of studies that can be done to aid in the diagnosis of vascular problems in the hand. Color-flow ultrasonography can show realtime flow and be used to evaluate an anastomosis, but it is of primary use in the venous system. A commonly performed test to evaluate vasospasm is cold-stress testing, which gives a measure of the vascular system's ability to recover from exposure to cold. In this test digital temperature is measured at baseline and the hand is then placed in cold water (5–8°C) for 5 minutes. Thermistor probes (or laser Doppler) are used to measure the time required for digital rewarming to baseline. A prolonged rewarming response is often seen in women and can be diagnostic of Raynaud's. Likewise, smokers often have a delayed rewarming response.

The digital–brachial index, which is the ratio of the blood pressure as measured in the brachial artery and the finger, can be measured with small blood pressure cuffs. This is similar to the ankle–brachial index, and in the upper extremity any value below 0.7 is felt to designate a significant occlusive problem somewhere in the forearm or hand. Blood flow in the capillary bed can be measured by laser Doppler flowmetry, which can give a quantitative measurement of blood flow at skin level. This can be a useful tool to evaluate the results of treatments, particularly for vasospastic problems; however, this equipment is quite expensive and not available to most practitioners.

Similarly, nailfold capillaroscopy shows morphology and flow at the capillary level but is not of practical use for most surgeons. Many of these sophisticated tests are difficult for the practicing surgeon to perform and do not add much, in my opinion, to decision making in terms of patient management. They, however, can be useful in determining the quality of the outcomes of management. The chapter on vascular problems in prior editions of this textbook (i.e., Chapter 66) has a more thorough and excellent discussion of these modalities and the reader is referred to the earlier edition for more information on this subject.[44]

Historical Review

- Hunter (1704): Ligation of the artery proximal to an aneurysm (popliteal); described traumatic aneurysm
- Raynaud (1862): Described syndrome of peripheral vasospasm
- Mata (1888): Endoaneurysmorrhaphy
- Carrell (1902): Described technique of end-to-end anastomosis of blood vessels
- Murphy (1905): Resection of cervical ribs causing impingement on the brachial artery
- Leriche (1937): Sympathectomy as an effect of excision and ligation of an artery
- Korean conflict (1952): Demonstration of successful arterial repair
- Allen (1962): Description of Allen's test
- Kleinert (1965): Revascularization of the superficial palmar arch
- Flatt (1980): Periarterial digital artery sympathectomy
- Koman (1995): Palmar and wrist sympathectomy for secondary Raynaud's phenomenon

MANAGEMENT

Management of vascular injury or insufficiency in the hand may involve techniques ranging from ligation of the injured vessel to periarterial sympathectomy to complex vein or arterial grafting. Which technique is employed depends on the level of the lesion as well as the cause of the problem. The various techniques used to treat the major causes of ischemia of the hand are discussed in the following subsections.

Open Arterial Trauma

Arterial trauma is reasonably common in the upper extremity and can be due to laceration or closed injury, as noted earlier. Reviews have noted that the majority of these injuries are open (i.e., in the 79% range) and that most were the result of lacerations.[23] The options for management differ somewhat and are discussed here. Open arterial trauma generally requires exploration because there is a wound that needs to be managed, and likewise, injuries to other structures almost always will require repair.

In general, preoperative workup of patients with an open vascular injury is limited to physical examination because a high index of suspicion should be present based on the history and location of the injury. Arterial studies are generally not indicated in open injuries with the exception of gunshot wounds with an otherwise normal examination of motor and sensory systems. It should be noted, however, that clinical studies have demonstrated that up to 50% of vessels with a proximal injury will have a palpable pulse at the wrist.[27] If the limb is well perfused, delay in management of the injury (i.e., beyond 6 h) if the bleeding is controlled and the patient is hemodynamically stable has not been shown to be detrimental.[62] It also has been shown in the military's experience during recent conflicts that temporary arterial shunting is a valuable adjunct in the management of arterial injuries. In such patients, shunts were left in as long as 11 hours and in some cases until definitive repair could be performed. The results between patients who had immediate vascular repair and those shunted showed no significant differences in outcomes.[6]

At the time of exploration, the wound will need to be extended in order to allow exploration and repair of the injured

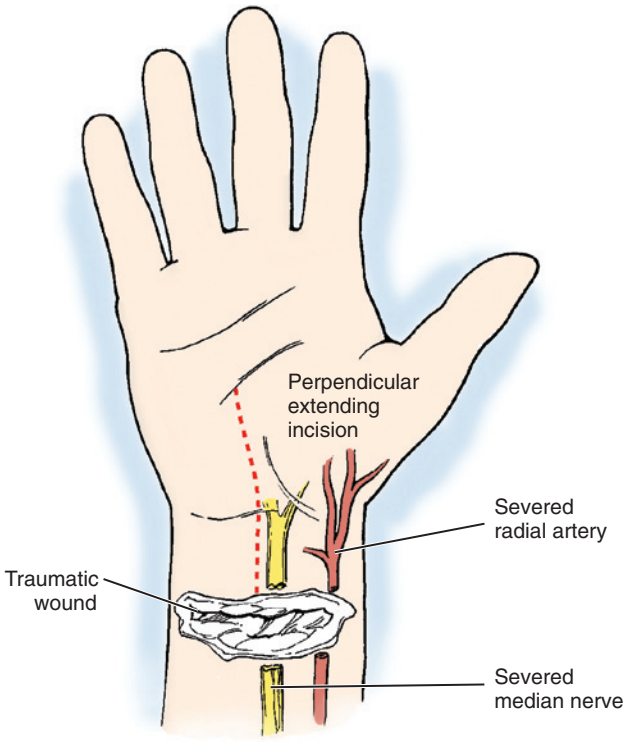

FIGURE 60.6 Schematic representation of treatment of a traumatic wound involving transection of the radial artery and median nerve. During arterial reconstruction, transverse wounds may be extended by perpendicular longitudinal incisions to facilitate exposure and protect repaired structures when wound closure is not possible. (From Koman LA, editor: *Bowman Gray school of medicine orthopaedic manual*, Winston-Salem, NC, 1997, Wake Forest University Orthopaedic Press, with permission.)

structures (Figure 60.6). If the hand is well perfused, a decision needs to be made as to whether repair of the injured vessel is important to the circulation in the hand. The brachial artery can suffer injury from fractures about the elbow, particularly in children with closed supracondylar humeral fractures.[7,73] Such injuries can lead to significant ischemia of forearm muscles and the hand. Studies have demonstrated that single-vessel (i.e., radial or ulnar artery) injuries in the forearm lead to little long-term sequelae even if the injured vessel is simply ligated.[26]

The flow in the remaining vessel has been shown to increase with injury or ligation of the other, and patency rates of repaired single vessels have been shown to be surprisingly low (i.e., in the 50% range), even with proper technique.[28] Arterial injuries combined with median nerve injuries have been shown to lead to increased long-term problems, probably more related to nerve injury than arterial injury. In younger patients and in those with possible vascular compromise from other factors, repair of the radial or ulnar arteries in the forearm almost certainly should be undertaken.

❖ AUTHOR'S PREFERRED METHOD OF TREATMENT: Arterial Vascular Repair

Sharp injuries with complete transection will lead to vessel ends pulling apart, depending on local branches and the surrounding tissue. Cutting injuries usually can be pulled together after careful trimming of the ends of the divided vessel. While forearm vessels can be sewn by most competent hand surgeons

with loupes, studies have shown that a better anastomosis can be performed with a microscope.[68] If there is some tension, a large double clamp (e.g., an Acland or Ikuta[36] microvascular) can be used to take the tension off the repair. A repair should be done in standard microsurgical fashion, and I prefer 8-0 nylon for forearm vessels, and in some cases use 7-0 polypropylene if the vessel is larger. I always use 6-0 or 7-0 polypropylene for the brachial artery and most proximal vessels. If there is a partial injury, which is sharp, it often can be repaired primarily; however, in some instances damage to the vessel of partial injuries (e.g., gunshot wounds) may well require resection of the injured segment and vein grafting.

When a vein graft is necessary, it is probably best (and easiest) to harvest it from the injured arm (Figure 60.7). Although saphenous is an acceptable choice, I have found that it is rather thick-walled and not always the perfect size match for the radial and ulnar arteries in the forearm. There are several maneuvers that can be performed if the vein graft and artery have a circumference mismatch (Figure 60.8). If a vein graft is going to be done, one must resect an adequate segment of the injured artery to be sure that the anastomosis can be performed out of the zone of injury to decrease the rate of thrombosis. Usually, this is fairly obvious, but any portion of the vessel that has suffered bruising, or has signs of intimal separation when viewed under the microscope, should be resected.

An artery with thrombus in it is not be an absolute indication to resect the vessel, as long as the arterial wall does not appear to have suffered damage. After the end is resected, it is probably wise to irrigate the proximal and distal vessels with heparinized saline (generally diluted to 100 units of heparin per milliliter of saline) to decrease the risk of thrombus formation during the time that the clamp is on the artery. Once this is done, I prefer to perform the proximal anastomosis first. When complete, removing the clamp allows the vein graft to fill with blood and both unwind and return to its normal length. After the proximal clamp is removed, the vein is allowed to bleed briefly from the end and is then reclamped. The proper length can then be better estimated than when the vein is empty.

The distal end is trimmed to the proper length if necessary and the distal anastomosis is then performed (Figure 60.9). Once the anastomosis is completed, distal pulses must be checked. A Doppler can be used, but I feel that a palpable pulse is a much better sign of adequate distal flow. The surgeon should be aware that a clot can propagate distally and embolize into the distal artery or even the hand. Familiarity with the techniques of thrombectomy is essential for those performing vascular repairs (see Figure 60.3). Tension on the repair is checked by ranging the wrist and elbow, as disruption of one

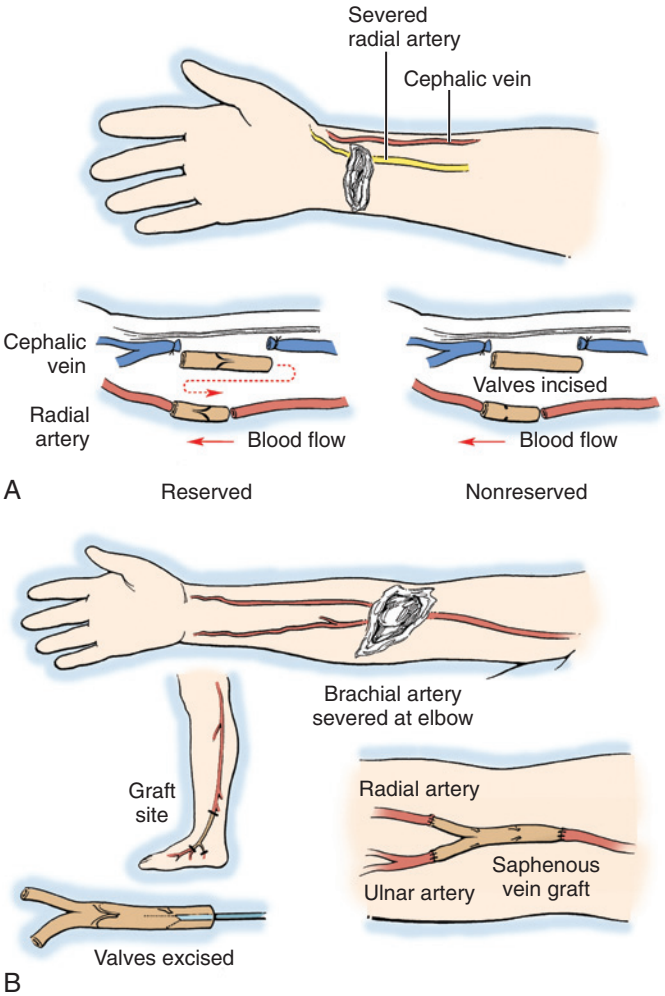

FIGURE 60.7 **A,** Interposition vein grafting may be used to repair damaged arterial segments that would be under tension with an end-to-end repair. Reversed interposition grafts may be obtained from local veins (e.g., cephalic) after reversal. Alternatively, nonreversed veins may be used if the valves are incised (*lower right*). **B,** Severe injuries that involve the brachial artery or the radial and ulnar arteries can be managed by branched vein grafts. Either reversed interposition or nonreversed (with valves incised) interposition vein grafts may be used. (From Koman LA, editor: *Bowman Gray school of medicine orthopaedic manual*, Winston-Salem, NC, 1997, Wake Forest University Orthopaedic Press, with permission.)

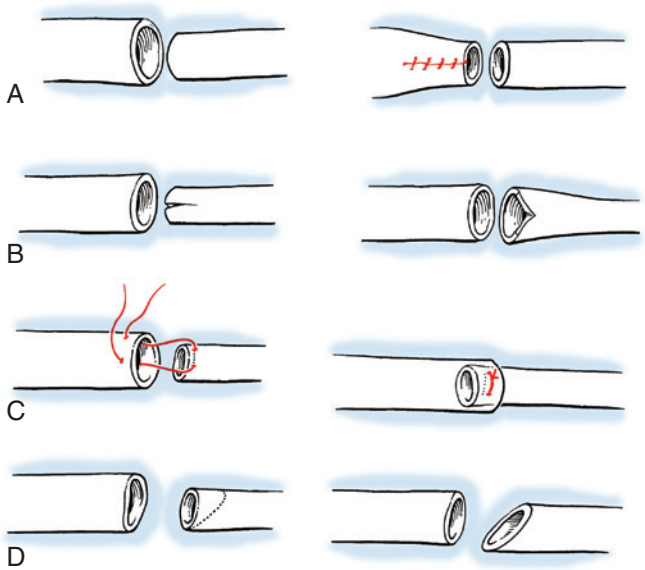

FIGURE 60.8 Mechanisms to overcome size discrepancies during arterial repair. **A,** The larger vessel may have a "V"-shaped portion excised and then be closed. **B,** Conversely, the smaller vessel may be split longitudinally and then expanded to fit the larger vessel. **C,** If the smaller vessel provides proximal inflow, it may be intussuscepted into the larger vessel via a sleeve-type technique. **D,** Small discrepancies can be managed by making a 30-degree angled or beveled cut of the smaller vessel followed by gentle dilation. (From Koman LA, editor: *Bowman Gray school of medicine orthopaedic manual*, Winston-Salem, NC, 1997, Wake Forest University Orthopaedic Press, with permission.)

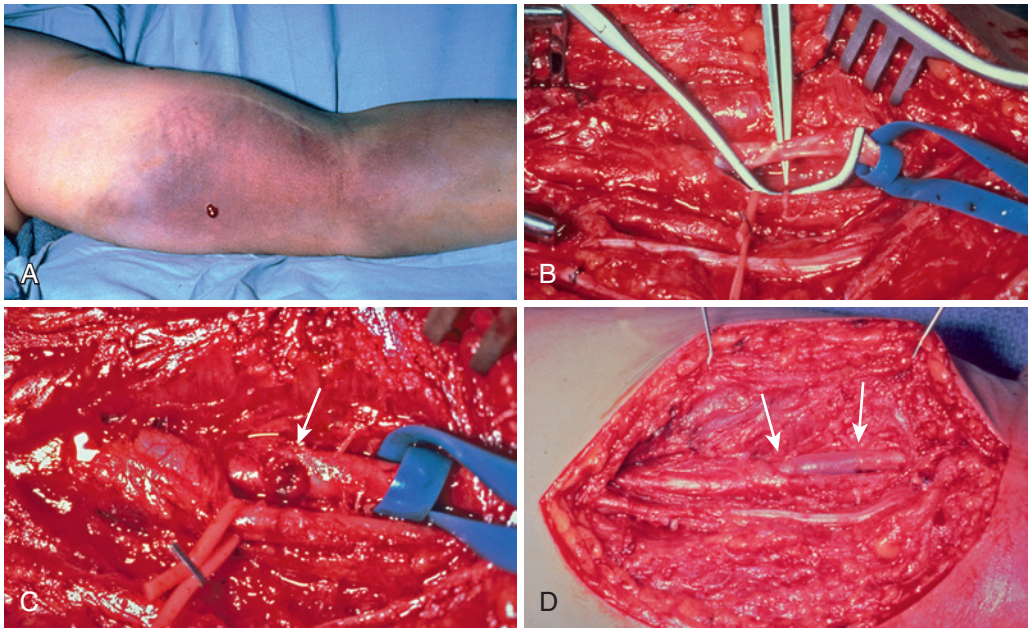

FIGURE 60.9 **A,** Arm of patient after gunshot wound to upper arm. He had no pulses distally. **B,** View of brachial artery after initial exploration. **C,** Brachial artery after dissection with micro forceps through hole in artery. *Arrow* points to clot at site of injury. **D,** Artery after repair with saphenous vein graft. *Arrows* denote two ends of graft.

of the anastomosis with movement of the hand or arm can be catastrophic.

Arterial repairs and arterial vein grafts cannot be left exposed in a wound nor should they be covered just with skin grafts or an allograft. Viable tissue must be placed over repairs to avoid desiccation and disruption of the repair; at times this may necessitate some type of flap. If the wound is large, as in avulsion-type injuries, selection of a vein for grafting may need to incorporate a branch to allow for placement of a free flap over it with arterial anastomosis to the branch of the graft (Figure 60.10).

CRITICAL POINTS ***Vein Grafting of an Arterial Injury***

- Resect wounded artery beyond zone of injury (bruising and/or intimal separation).
- Select appropriate length of forearm vein (i.e., basilic or cephalic), alternatively saphenous.
- Irrigate proximal and distal arteries with heparinized saline.
- Reverse vein graft and repair to proximal artery first, with 7-0 polypropylene or 8-0 nylon.
- Allow vein graft to fill with blood and clamp distally; allows vein to unwind and distend.
- Trim appropriately and perform distal repair.

Postoperative Care After Vein Graft Repair. I generally splint the elbow and/or wrist after vascular repair or vein grafting in the forearm. If the graft is loose, this is probably not necessary; however, based on the contributing trauma and severity of injury, immobilization is probably prudent. Care must be taken to ensure that the splint does not impinge or put pressure on the graft. Systemic anticoagulation has not been shown to be beneficial and in fact can cause bleeding, so this should be avoided—the patient will have received some systemic heparin from the irrigation of the proximal and distal artery that is probably adequate.

Oral aspirin may have some benefit and should be given in a low dose (i.e., 81 mg) daily for 6 weeks. I allow the patient to begin careful movement after about 3 weeks; however, this depends on which other structures (i.e., bone, tendon, nerve) have been injured and the therapy requirements for them if they have been repaired. Patency rates are generally high in upper extremity vascular repairs done with an autogenous vein.[20,23,54]

Complications. The primary complication of arterial repair and/or forearm grafting is thrombosis of the repair or graft. This is unlikely to occur unless the surgeon has failed to resect the damaged vessel or has performed a poor vascular repair. Blowout of a repaired artery or vein graft is not unheard of, however, and can be a catastrophic event and life threatening (see Figure 60.18). There must be coverage of the repaired artery or vein graft with well-vascularized soft tissue. If there is wound breakdown, this must be managed aggressively to prevent infection around the repair or graft as well. "Watchful waiting" is not advisable if there are problems with a repaired vessel.

Closed Arterial Trauma

Although blunt trauma can cause arterial injury anywhere in the upper extremity, the most commonly seen closed trauma is ulnar artery thrombosis in the palm. As noted previously, this is also called hypothenar hammer syndrome; it is seen in patients who suffer trauma to the palm or those who use the ulnar side of the palm as a hammer. Due to its relatively superficial position, the ulnar artery and nerve are easily injured with blunt trauma to the palm (Figure 60.11).

Injuries to the ulnar artery in the Guyon canal can lead to thickening of the vessel wall (with chronic low-grade trauma),

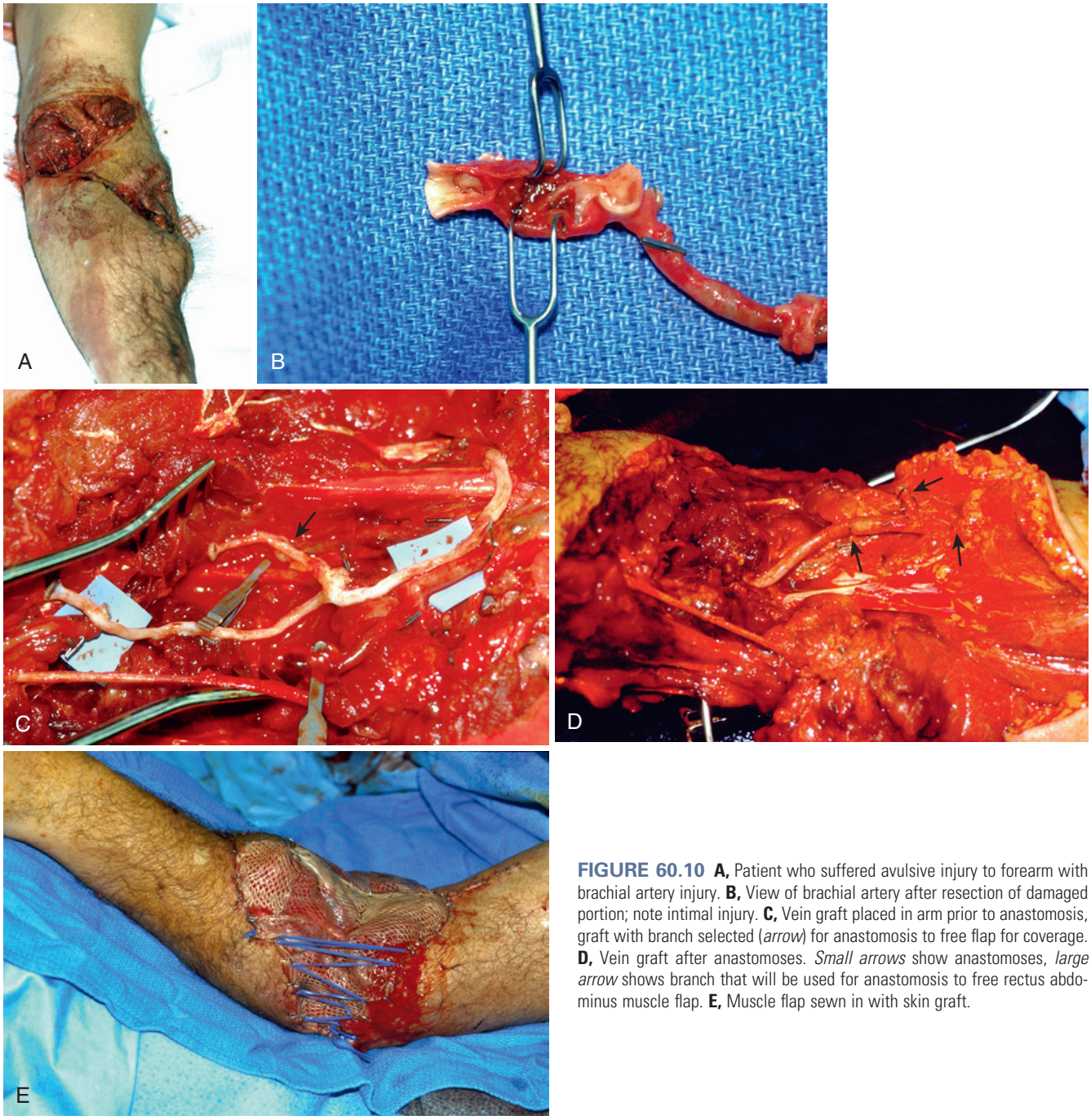

FIGURE 60.10 **A,** Patient who suffered avulsive injury to forearm with brachial artery injury. **B,** View of brachial artery after resection of damaged portion; note intimal injury. **C,** Vein graft placed in arm prior to anastomosis, graft with branch selected (*arrow*) for anastomosis to free flap for coverage. **D,** Vein graft after anastomoses. *Small arrows* show anastomoses, *large arrow* shows branch that will be used for anastomosis to free rectus abdominus muscle flap. **E,** Muscle flap sewn in with skin graft.

disruption of the intima and thrombosis, or even aneurysm formation (Figure 60.12). Regardless of the eventual pathology, these injuries can lead to distal ischemic symptoms, primarily as a result of embolization of thrombus from the site of injury. The incidence of ulnar artery thrombosis is probably underreported; I believe that many individuals may suffer from this and are not particularly symptomatic or fail to seek medical advice due to ongoing excellent perfusion of the hand through the radial artery.

Patients with ulnar artery thrombosis present with ischemic symptoms in the ulnar digits, and in my experience with more than 100 patients with this, the ring finger is involved in nearly half of the patients, with the middle and little fingers involved in closer to one-third (Figure 60.13). The thumb is rarely ischemic in patients with ulnar artery thrombosis. While it has been taught that distal ischemia is due to vasospasm, exploration of a number of these fingers in the past has proven that this is the result of embolization of thrombus (Figure 60.14). These patients frequently complain of paresthesias in the distribution of the ulnar nerve as well because the ulnar nerve can suffer contusion at the time of ulnar artery injury.

Diagnosis usually can be made based on history and physical exam. The patient relates an incident of trauma to the palm with symptoms of digital ischemia of the ring and little finger

following, and there may be ulnar nerve paresthesias as noted earlier. These symptoms may resolve but also may be intermittent after the injury (i.e., due to ongoing embolization of a clot to the distal digits). By the time the patient sees a hand surgeon, the initial symptoms may have resolved to some degree but he or she usually complains of cold intolerance and intermittent color change in the fingers. The office exam obviously should include feeling the pulse at the wrist; however, the ulnar pulse may well be present proximal to the wrist crease. There actually may be a palpable mass in the ulnar palm due to either a large amount of clot in the artery or potentially aneurysmal change as a result of the injury.

I perform a "dynamic" exam with a pencil Doppler as described before. Typically, occlusion of the radial artery at the wrist causes loss of signal over the palmar arch. With this history and exam, arterial studies should be the next step. CT arteriogram is usually sufficient to diagnose ulnar artery thrombosis if the CTA's quality is high; however, if there is any question, a standard arteriogram should be obtained. This is helpful in terms of knowing how far one may need to graft in order to bypass the area of occlusion. Likewise, some patients may develop an aneurysm due to severe intimal injury, which may change treatment options to some degree.

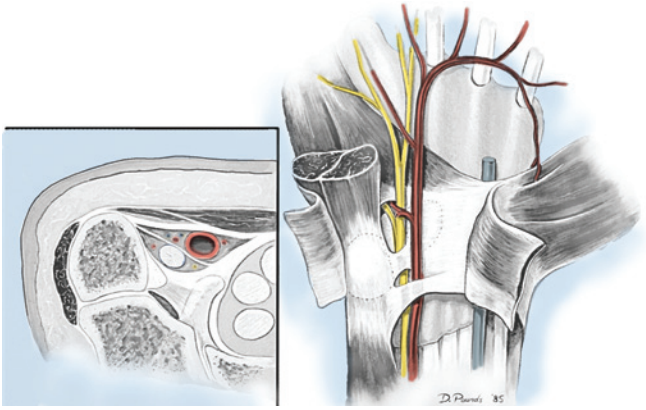

FIGURE 60.11 Schematic drawing of the ulnar artery within the Guyon canal. (From Koman LA, editor: *Bowman Gray school of medicine orthopaedic manual*, Winston-Salem, NC, 1997, Wake Forest University Orthopaedic Press, with permission.)

The pattern of thrombosis is fairly typical and can be seen clearly on an arteriogram of the involved hand. While the original injury is in the palm, over time the thrombus usually propagates back to the dorsal branch of the ulnar artery; it occurs roughly 2 to 3 cm proximal to the volar wrist crease. Likewise, the vessel clots distally to the palmar arch, where the common digital artery to the fourth webspace branches. At both of these points there is still outflow (i.e., from the dorsal–ulnar artery proximal and the palmar arch distally); thus, the initial injury leads to propagation of the clot to these branches (Figure 60.15).

If the patient is seen soon after injury, the area of thrombosis may be smaller as a clot has not had time to propagate proximally and distally. Arteriography also may show a "corkscrew" pattern that implies a damaged artery and in fact may show an aneurysm (Figure 60.16). Some patients can damage the artery enough to lead to development of a large aneurysm that may be palpable. Interestingly, these do not always thrombose but can certainly cause recurrent distal embolization of a clot.

Once the patient is evaluated and thrombosis of the ulnar artery is confirmed, the decision as to how to manage him or her must be made. Patients with minimal symptoms, good flow through the radial artery, and an otherwise normal palmar arch, can be managed medically. If the patient is a smoker, cessation of this activity is nearly mandatory to decrease symptoms. Similarly, calcium channel blockers (CCBs) can be used to decrease symptoms of vasospasm brought on by the clot.[33,83] If the patient is seen early on after the thrombosis, thrombolytic therapy with tissue plasminogen activator can be tried, but success has not been universal in reported cases.[16,80] Management of ulnar artery thrombosis by endovascular techniques also has been reported[1]; however, there is no convincing evidence that it is applicable to arteries at the distal forearm level. Patients with aneurysms of the ulnar artery and those who continue to have symptoms will require surgical intervention.

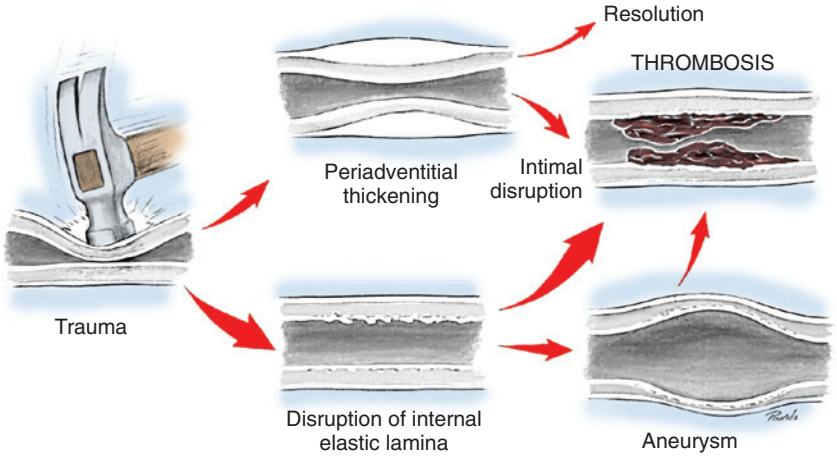

FIGURE 60.12 Mechanisms of occlusion and aneurysm formation in the ulnar artery may include acute or repeated trauma, which may cause direct intimal damage or periadventitial scarring. Periadventitial thickening may constrict the vessel and obstruct flow. Flow may be restored by surgical intervention. Without intervention, additional injury with intimal damage and exposed media may result in thrombosis or aneurysmal dilation, or both. (From Koman LA, editor: *Bowman Gray school of medicine orthopaedic manual*, Winston-Salem, NC, 1997, Wake Forest University Orthopaedic Press, with permission.)

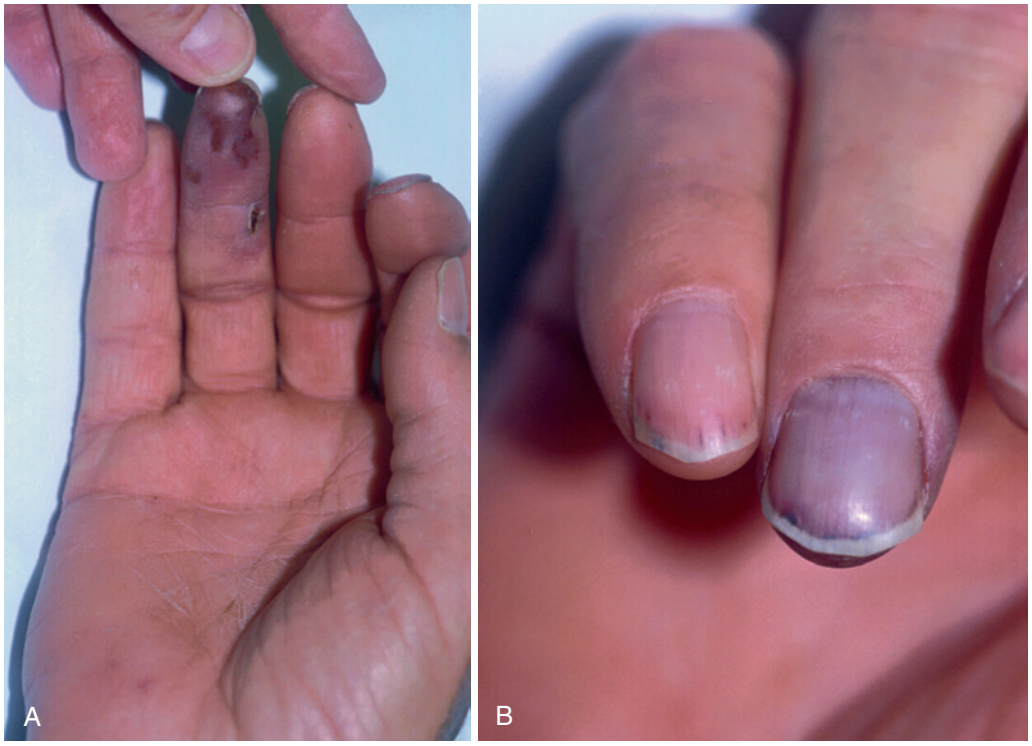

FIGURE 60.13 **A,** View of patient with ulnar artery thrombosis and ischemia of the little and ring fingers. **B,** Nails of same patient showing splinter hemorrhages.

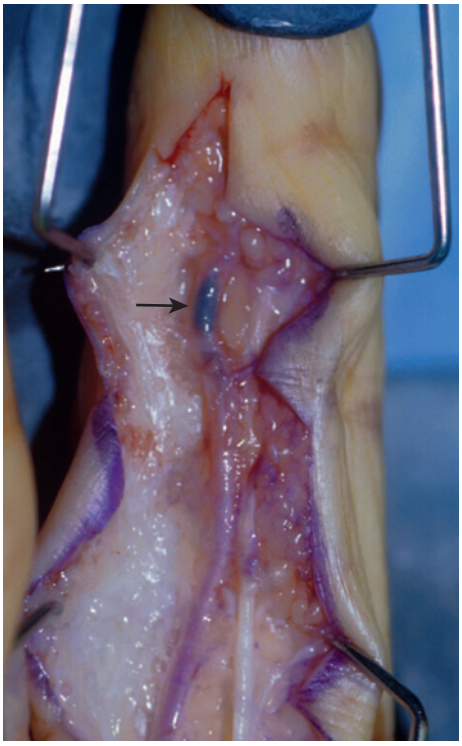

FIGURE 60.14 Digital artery of patient with ulnar artery thrombosis and ischemic symptoms. *Arrow* points to thrombus in ulnar digital artery of little finger.

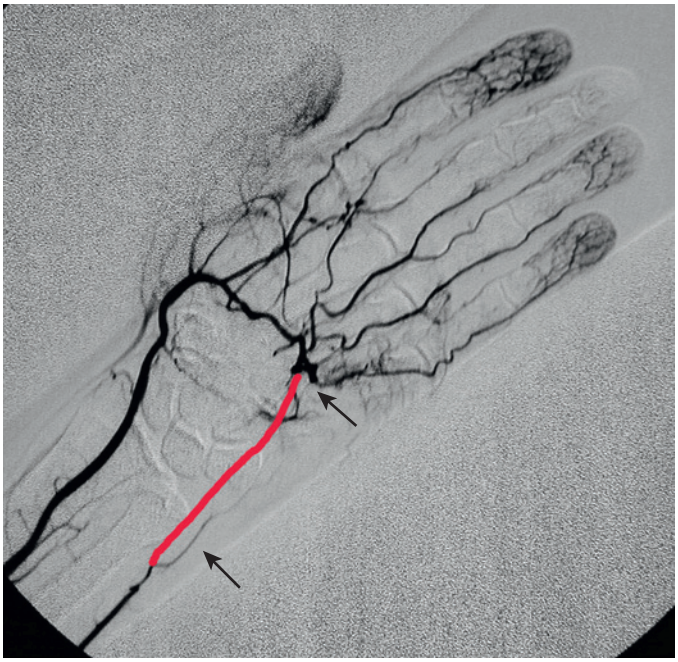

FIGURE 60.15 Arteriogram of patient with ulnar artery thrombosis. *Red line* shows usual course of ulnar artery, *bottom arrow* points to dorsal branch, and *top arrow* points to palmar arch at branching of common digital artery to fourth webspace.

The approach to the ulnar artery via the Guyon canal is standard. A Bruner-type incision is made in the palm over the course of the ulnar artery to the level of the distal palmar crease to allow it to be carried across the palm if necessary. Usually this incision needs to be carried proximally about 3 cm up the distal forearm for access to the ulnar artery at the level of the dorsal branch. While the thrombosed segment of artery can be simply ligated and excised, which accomplishes a "Leriche" sympathectomy, Koman and others have demonstrated that a bypass offers significant improvement over excision.[12,41]

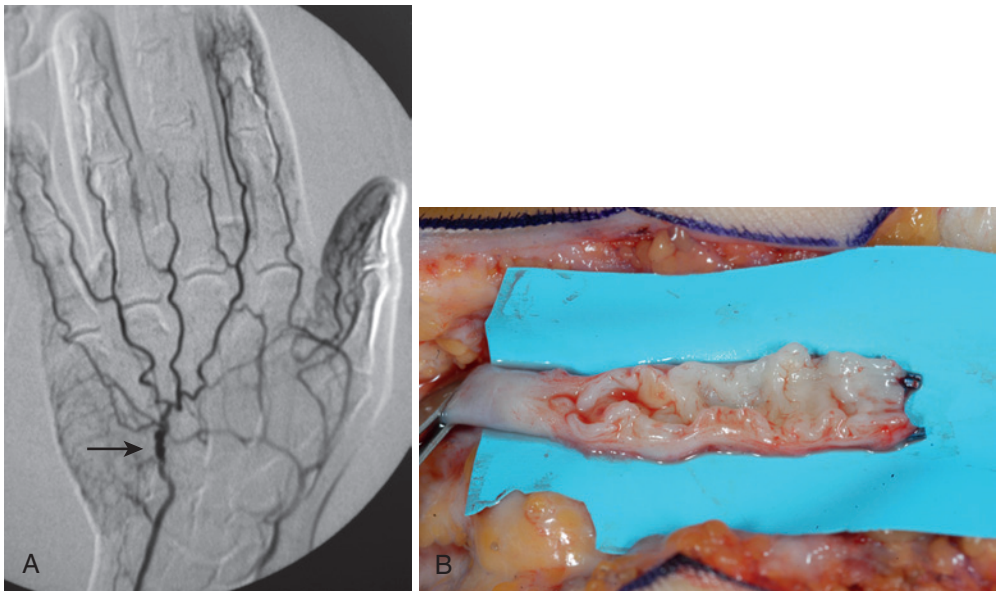

FIGURE 60.16 **A,** Arteriogram of patient with intermittent ischemic symptoms of middle and ring fingers. Aneurysmal change of ulnar artery denoted by *arrow.* Note embolization of digital vessels to middle and ring fingers. **B,** Artery of patient at exploration.

❖ AUTHOR'S PREFERRED METHOD OF TREATMENT: Ulnar Artery Bypass

On occasion, the area of thrombosis is small, the involved artery can be resected, and the ulnar artery repaired primarily, but this is unusual. In most cases, a vein graft is required from the distal forearm to the palmar arch where the common digital artery to the fourth webspace branches off. I prefer to utilize the basilic vein in the mid-forearm to graft the ulnar artery in such cases. This vein offers several advantages over the saphenous in that it is locally available, the wall is not as thick as the saphenous, and the donor site rarely has healing problems. There has been some discussion about the use of arterial grafts for the management of ulnar artery thrombosis, the argument being that an arterial graft may withstand future trauma better than a vein graft and the size match of available arteries—that is, primarily the deep inferior epigastric and descending lateral femoral circumflex.[72,75] Although I have had limited experience with this technique, it would appear to have some merit. The benefits of arterial grafts over standard vein grafts have yet to be proven convincingly, however.[49]

The thrombosed or aneurysmal segment of the ulnar artery is resected back proximally until there is no further thrombus and the intima and medial layers of the vessel wall do not separate when the vessel is cut. The vein is reversed and the technique is as described earlier for traumatic injuries. The distal anastomosis can almost always be performed at the level of the "Y" between the common digital artery to the fourth webspace and the superficial palmar arch (Figure 60.17). Postoperative care is the same as for any venous interposition graft, with attention being paid to avoid kinking of the graft with motion or any pressure on the graft from a splint. I generally do not anticoagulate patients undergoing vein grafting of an ulnar artery thrombosis but give them an 81-mg aspirin daily for at least 6 weeks postoperatively. As noted before, cessation of smoking is essential if ongoing symptoms are to be prevented.

The results of vein grafting of a traumatic ulnar artery thrombosis are generally good,[12,18,33] and my experience has been that there is around a 90% patency rate at 2 years. Even patients who suffer another thrombosis of the ulnar artery do not always become symptomatic again, probably because of the sympathectomy effect of resection of the thrombosed ulnar artery.[33]

Complications. The complications of ulnar artery bypass are the same as those noted after arterial repair or grafting in the forearm. The bypass can thrombose, which can be due to ongoing trauma to the palm, and there is evidence that thrombosis rates of vein grafts increase over time. The rare complication of blowout of the vein graft can be significant but usually is the result of wound-healing problems (Figure 60.18).

The radial artery also can suffer from thrombosis in the hand, and this usually occurs in the anatomic snuffbox over the area of the trapezium (Tq) and under the extensor pollicis longus (EPL).[11,51] The symptoms of this disorder are primarily ischemia of the index finger and occasionally the thumb. The patient also may complain of dull pain in the thenar muscles, which may be a type of claudication from ischemia of the muscles. The etiology of this is unclear, but it would appear to be from trauma to the artery from the overlying EPL tendon. This problem is more common in women than in men, in my experience, and is not usually seen in those with collagen vascular disease. These patients also suffer from embolization of clot into the distal index finger, and ulnar-sided fingers are basically never involved.

Arteriography may in fact show thrombus in the radial artery in the anatomic snuffbox (Figure 60.19). This problem seems to resolve in some patients without the need for further intervention; however, if the radial artery is found to be completely occluded on arteriogram and the patient is suffering from critical ischemia of the finger, treatment with excision of the clotted segment and vein grafting is probably warranted. The cephalic vein is in the field when the radial artery is exposed,

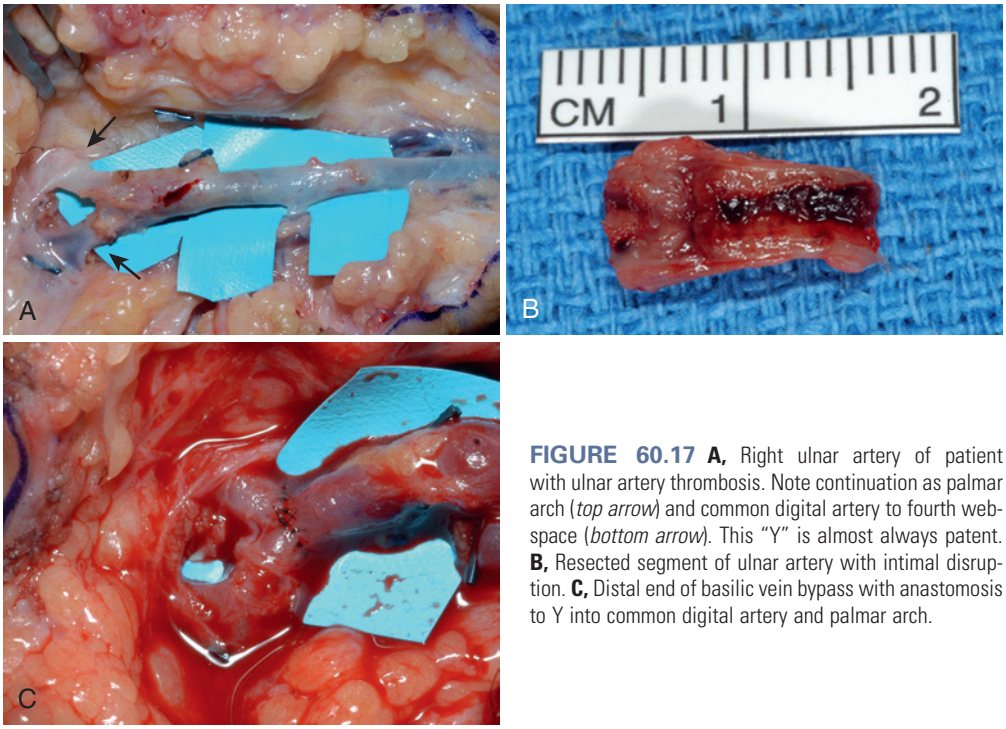

FIGURE 60.17 A, Right ulnar artery of patient with ulnar artery thrombosis. Note continuation as palmar arch (*top arrow*) and common digital artery to fourth web-space (*bottom arrow*). This "Y" is almost always patent. **B,** Resected segment of ulnar artery with intimal disruption. **C,** Distal end of basilic vein bypass with anastomosis to Y into common digital artery and palmar arch.

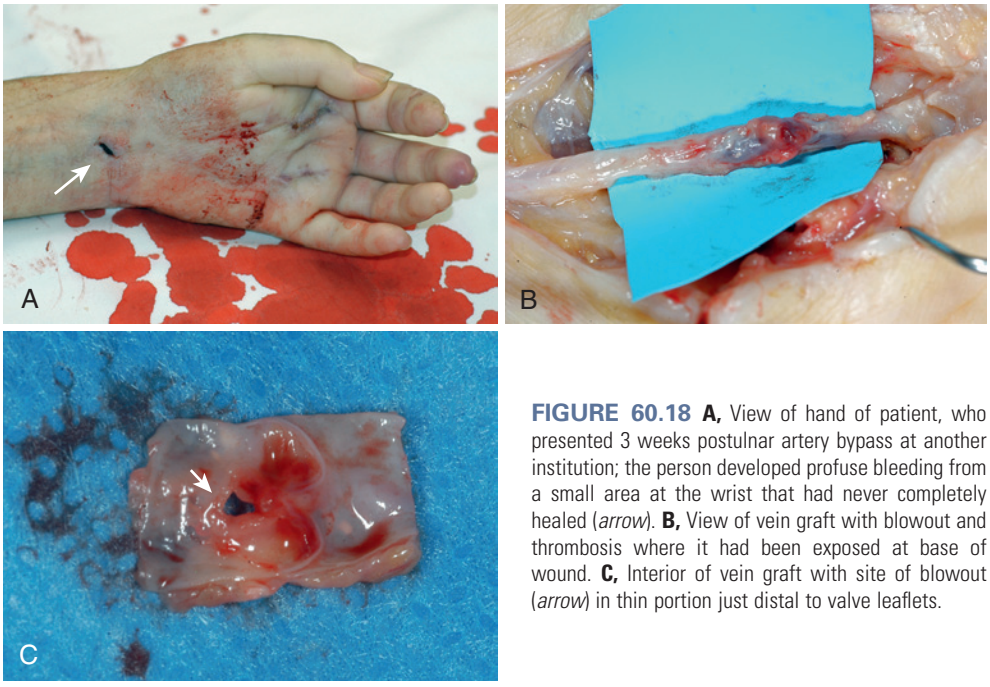

FIGURE 60.18 A, View of hand of patient, who presented 3 weeks postulnar artery bypass at another institution; the person developed profuse bleeding from a small area at the wrist that had never completely healed (*arrow*). **B,** View of vein graft with blowout and thrombosis where it had been exposed at base of wound. **C,** Interior of vein graft with site of blowout (*arrow*) in thin portion just distal to valve leaflets.

and this can be used for the graft. The issue of the EPL tendon pressing on the graft must be addressed, and while the graft may be brought superficial to it, I will usually make a small sling out of a portion of the extensor carpi radialis longus (ECRL) tendon from the base of the second metacarpal to pull the EPL away from the graft (Figure 60.20). Alternatively, the EPL can be freed from its fascial sling at the Lister tubercle and allowed to slide away from the artery proximally.

Vascular Disease

Arterial occlusive disease was not seen frequently in the distal upper extremity 30 to 40 years ago except in patients with Buerger disease. This is a fairly common problem now and is primarily related to the combination of diabetes, renal disease, and often organ transplantation. The need for access for hemodialysis compounds this problem by potentially altering the circulation distal to the site of the arteriovenous fistula. Patients

with collagen vascular disease often suffer from vasospastic disease (see later), but they can also have vascular occlusion from the effects of vasculitis. Today, Buerger disease is an uncommon cause of ischemia of the hand, but it would appear that other disease states leading to critical ischemia of the hand are on the rise. Many patients have already suffered loss of one or both of their lower extremities, and loss of the hand can be devastating from the mobility standpoint. Therefore, I feel that an aggressive approach is warranted for these patients to try and avoid loss of the hand.

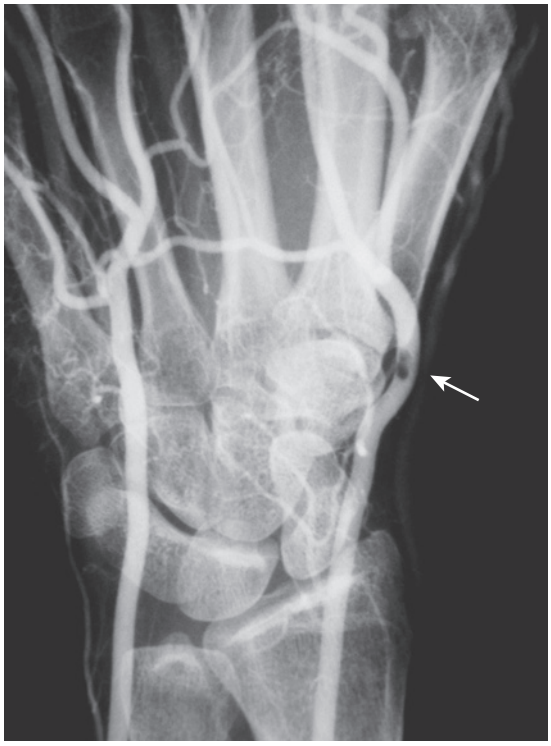

FIGURE 60.19 Arteriogram of patient with symptoms of ischemia of index finger. Note clot (*arrow*) in radial artery in snuffbox under extensor pollicis longus tendon.

Preoperative Evaluation

Patients presenting with ischemia of the hand in the face of vascular disease need a thorough workup. The presence or absence of pulses at the wrist is important, but if absent, they should be sought out with a pencil Doppler. In the absence of a palpable pulse, the presence of a pulse with use of the Doppler is not a sign of adequate nutritive flow to the hand, however. As noted previously, I also use a "dynamic" Doppler to listen to the arch and sequentially occlude the wrist's radial and ulnar arteries. The flow to the fingers should be evaluated for the presence or absence of a signal in the pulp as well. Ischemic, gangrenous, or ulcerated fingers should be noted. Likewise, any previous surgery to the hand and arm should be noted, particularly prior or currently functional vascular access procedures.

The Doppler signal at the wrist should be evaluated with the fistula open and with it occluded with digital pressure to note any improvement in flow with the fistula occluded. Generally, arteriography remains the gold standard for most patients with critical ischemia of the hand because proper evaluation requires good visualization of the forearm vessels, palmar arch, and digital vessels that is difficult to achieve with MRA or CTA. Many patients present from the vascular surgeon with results of an arteriography, but I feel very strongly that the surgeon planning vascular intervention in the hand must view the actual studies.

After exam, all patients who have not had arterial studies should undergo arteriography. Many patients with critical

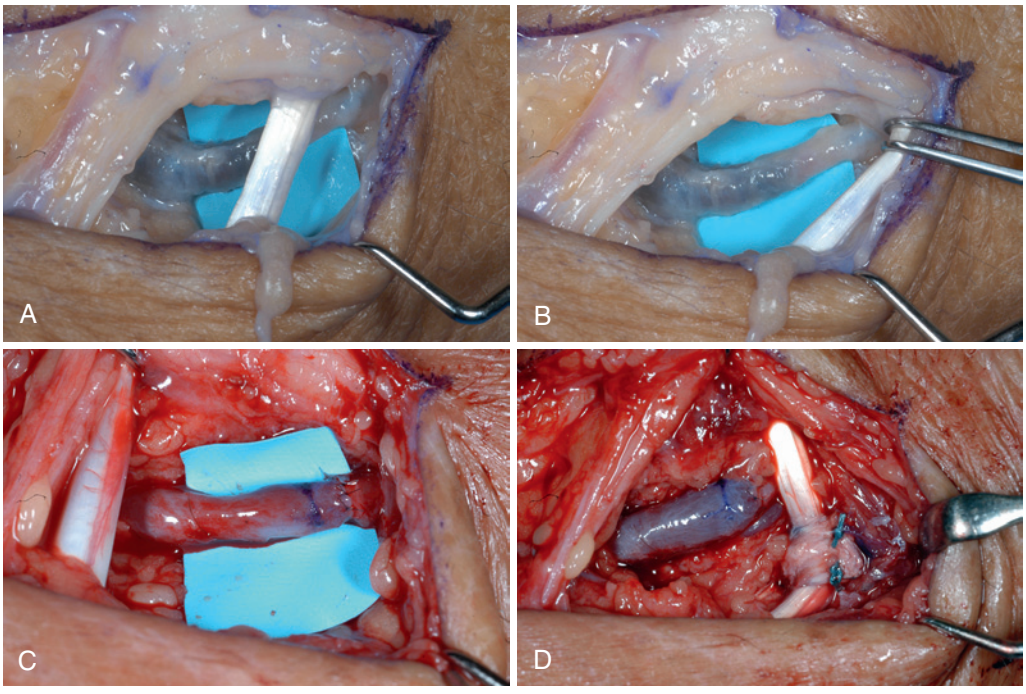

FIGURE 60.20 **A,** View of right radial artery going under extensor pollicis longus (EPL) tendon after thrombosis. Hand is to the right and forearm to the left. **B,** Note thrombus after EPL is moved off of artery. **C,** Repair after excision of thrombosed segment and vein grafting with cephalic vein. **D,** EPL has been pulled off vein graft with a sling made from a portion of extensor carpi radialis longus to the base of second metacarpal.

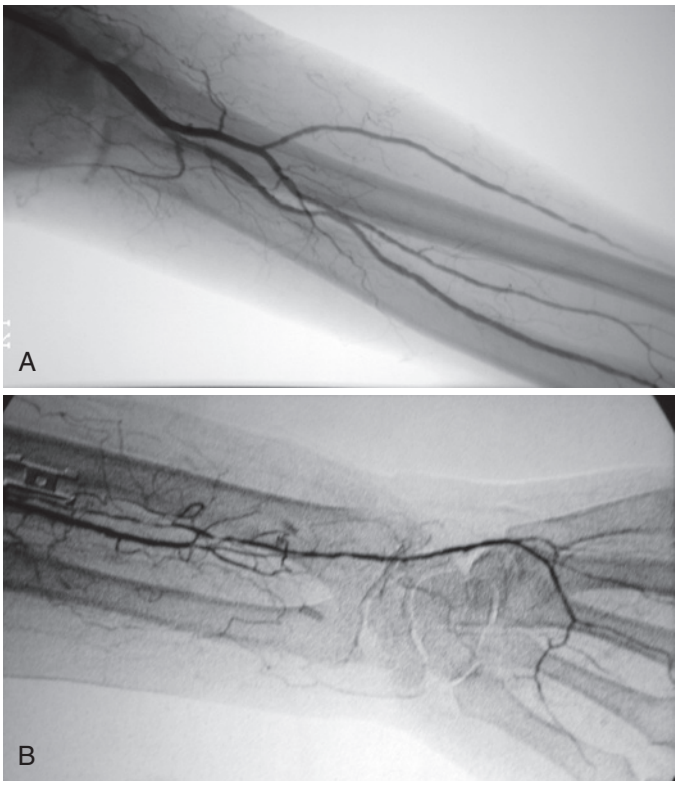

FIGURE 60.21 **A,** Arteriogram of proximal forearm of patient with hand ischemia. Note multiple levels of partial occlusion. **B,** Distal arteriogram of another patient with critical ischemia. While the patient does have flow into the hand through the radial artery, it is fed completely by collaterals. Arteriography is essential to see this level of detail and to know that there is an open distal arch available for potential bypass grafting.

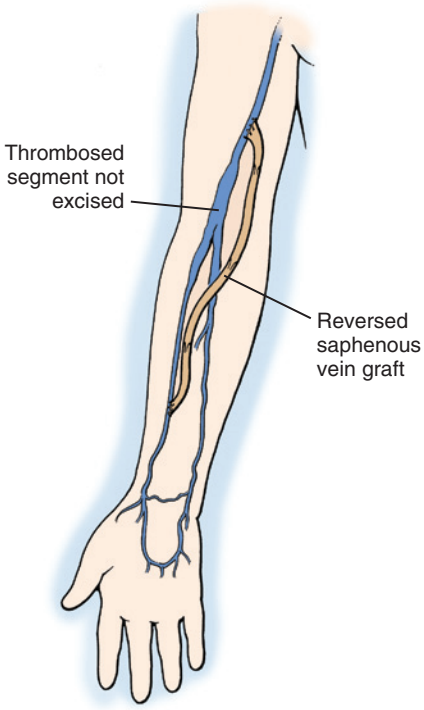

FIGURE 60.22 Technique of local bypass using reversed saphenous vein to go around the occluded segment. (From Koman LA, editor: *Bowman Gray school of medicine orthopaedic manual*, Winston-Salem, NC, 1997, Wake Forest University Orthopaedic Press, with permission.)

ischemia due to complications of diabetes and renal disease will have multiple levels of partial occlusion that can be seen in the forearm vessels on arteriography, and these types of lesion do not lend themselves to a local approach (Figure 60.21). Patients with collagen vascular disease usually have an occlusion limited to the vessels in the distal forearm and/or hand, but the digital vessels may be involved as well. The arteriogram should be used to decide the best approach to improve flow to patients' hand. In the case of ulnar or radial artery thrombosis in the distal forearm and hand, excision of the occluded segment to accomplish a Leriche sympathectomy with bypass grafting usually is indicated. The approach is similar to that discussed earlier for ulnar and radial artery thrombosis.

Patients with multisegment disease require a more aggressive approach. Bypass can be performed in the forearm of occluded areas using saphenous vein grafting very successfully (Figure 60.22). For most patients, however, I feel that going from the proximal brachial artery above all sites of occlusion to an open ulnar or radial artery at the wrist level usually is the most successful option. Patients often have lower-extremity vascular disease and the saphenous may not be available as a result of prior harvesting (e.g., for extremity or cardiac surgery) or because of loss of the lower limb. I have also found that healing of the saphenous donor site in the lower and upper leg can be very problematic in this patient group. The saphenous is quite thick and can present difficulties in anastomosis to the hand's smaller vessels. For all of these reasons, I prefer to do an in situ bypass technique in the hand, generally using the cephalic vein to go from the brachial to the radial artery in the snuffbox if the arch is open (see Figure 60.21, *B*).

❖ AUTHOR'S PREFERRED METHOD OF TREATMENT: In Situ Bypass of the Forearm

I prefer to use the cephalic vein for in situ bypass whenever possible because the radial artery in the snuffbox usually is patent in patients with significant vascular disease.[63-65] The radial artery bifurcates deep in the snuffbox into the princeps pollicis and deep palmar arch; anastomosis usually is done just proximal to this bifurcation. Even with severe calcific arterial disease, there is a segment of the artery just before the bifurcation that is soft enough to sew with a 7-0 or 8-0 suture. Due to the nature of these patients, the cephalic vein may not be patent or partially thrombosed; thus, it is wise to examine this vein prior to undertaking surgical intervention.

In case the cephalic is unusable, the basilic is an option but will not reach the radial artery, so the distal anastomosis must be done to the ulnar arch. In cases in which both of the vessels cannot be used, the reversed saphenous vein remains an option. At times, the only way to be certain about the patency and/or adequacy of these veins is by exploring them, and it must be explained preoperatively to the patient and family that another incision on the leg may be necessary.

An incision is made from over the snuffbox to the antecubital fossa over the brachial artery, largely following the course of the cephalic vein, which is carefully exposed and all branches are sought out. The bigger branches are preserved to allow passage of the valvulotome, while the smaller branches are ligated with little vascular clips. Enough vein is dissected out

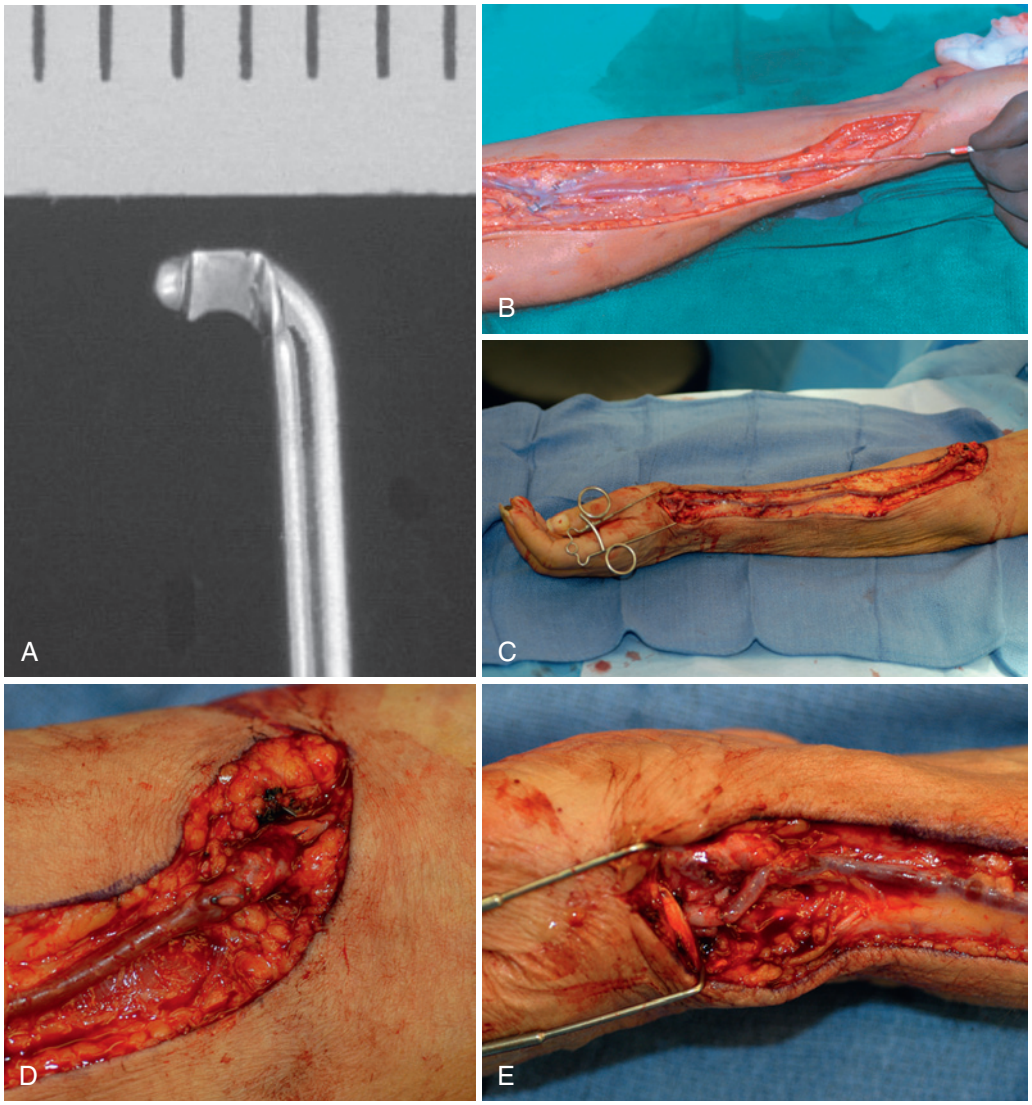

FIGURE 60.23 **A,** Leather-Mills valvulotome: This is the end of the reverse-cutting device that renders the venous valves incompetent. **B,** Valvulotome being passed from distal end of cephalic vein to proximal, and then withdrawn carefully to remove valves. **C,** After completion of brachial–radial bypass with in situ cephalic vein. **D,** Proximal end-to-side anastomosis to brachial artery in antecubital fossa. **E,** Distal end-to-end anastomosis to radial artery in anatomic snuffbox. (From Pederson WC: Revascularization options for terminal distal ischemia. *Hand Clin* 31(1), 2015, Elsevier Scientific, with permission)

proximally and distally to have adequate length for the graft to reach the brachial and radial arteries proximally and distally, respectively. The brachial artery is dissected free in the antecubital fossa, and blue vascular loops are placed on branches to provide proximal and distal control.

Similarly, the radial artery is dissected out from the snuffbox to the site of the bifurcation and an appropriate place for anastomosis is selected (e,g., primarily an area with minimal calcification if this can be located). The larger branches of the cephalic are controlled with small vascular clamps or bulldogs; once the sites for anastomosis are selected proximally and distally, the vein is divided at appropriate sites to allow enough for proximal and distal anastomoses. The vein is then irrigated and the valves are removed carefully with the Leather-Mills valvulotome. This instrument comes in forward-cutting (i.e., antegrade placement) and reverse-cutting (i.e., retrograde placement) styles. I prefer the retrograde reverse-cutting model because it seems to be safer and more able to be controlled (Figure 60.23).

The vein is filled with heparinized saline and the valvulotome is run down the vein distally as far as it will go. It is then withdrawn slowly and resistance is felt as it encounters a valve in the vein. Great care must be taken as the instrument comes to a branch in the vessel, as it can cause a large tear at the site of branching if it catches on it. The valves in the vein are bileaflet; thus, the instrument must be turned 180 degrees and brought back through the area of the valve to cut both leaflets. Once the valves are cut, the vein is irrigated proximally to distally with heparinized saline to make sure all of them have been rendered incompetent. If there is any obstruction to flow, the remaining valve or area of occlusion must be sought out and corrected or the bypass will not stay patent. The valvulotome is passed again carefully and intact valve leaflets located until proximal irrigation goes freely through the graft.

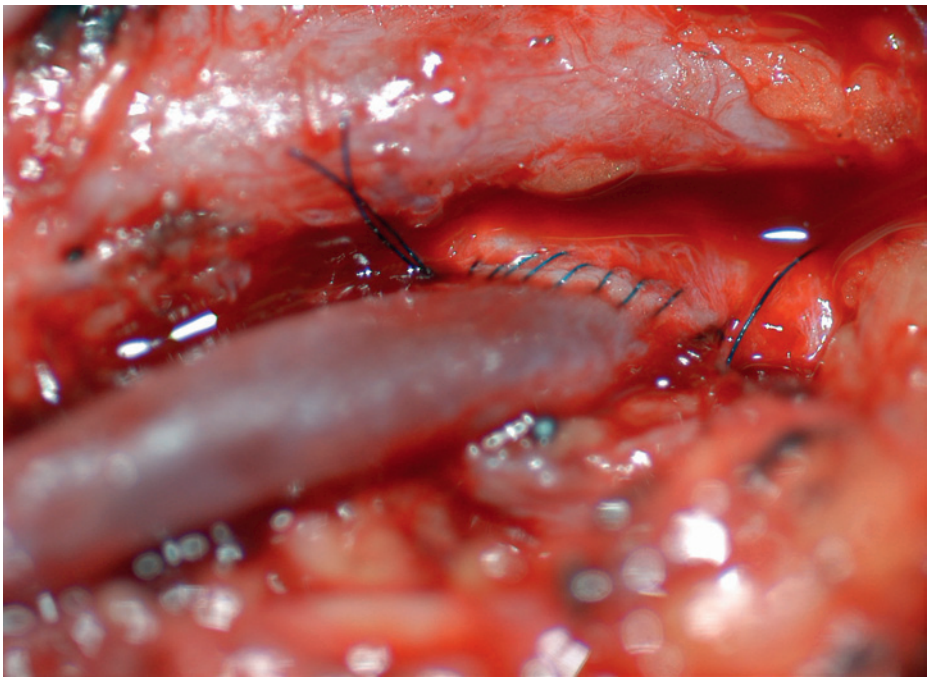

FIGURE 60.24 View of half of end-to-side anastomosis running to brachial artery with 6-0 polypropylene suture.

Likewise, any remaining branches should be checked for and ligated. Once a widely patent graft is ensured, the proximal anastomosis is performed. I prefer to occlude the brachial artery with DeBakey vascular clamps proximally and distally. An arteriotomy in the exposed portion of the brachial artery of the appropriate size is performed with a number 11 scalpel blade. It is preferable to open this up a bit from a simple longitudinal cut to an oblique opening with microscissors or Potts-Smith vascular scissors. Once this is done the artery is irrigated proximally and distally with about 10 cc of heparinized saline to prevent thrombus formation while the artery is clamped. The proximal vein is trimmed appropriately and the anastomosis is usually performed with 6-0 or 7-0 vascular polypropylene. I prefer to use two running sutures with this material on the medial and lateral sides of the arteriotomy (Figure 60.24). Once this is complete, the clamps are removed and the adequacy of flow through the graft is assessed. If there is brisk flow, the distal vein is allowed to "unwind" to remove any twists; this is then secured with a small vascular clamp or bulldog.

After appropriate trimming, the distal anastomosis is performed end-to-end to the radial artery just proximal to its bifurcation in the snuffbox. If the artery is soft, this can be done in standard fashion with an 8-0 nylon microsuture; however, if the artery is heavily calcified, which unfortunately is often the case, the anastomotic technique may need to be modified and a "sleeve" anastomosis performed between the vein graft and the distal artery.[32,84] This is done by placing two 6-0 vascular sutures that are double-armed with needles in the vein graft 180 degrees apart. These sutures are then passed inside-out on the radial artery several millimeters from the site of arteriotomy. The two needles of each suture are passed and then tied on the outside of the artery; this tacks the intima down and pulls the vein inside the artery (Figure 60.25). This can be quite a successful technique in the face of a severely calcified artery.

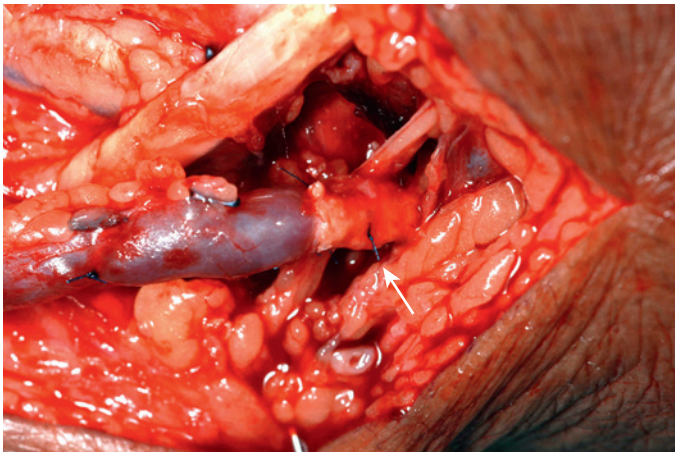

FIGURE 60.25 View of distal sleeve anastomosis between cephalic vein and calcified radial artery. Note two polypropylene sutures are tied on outside of artery (*arrow*).

Once the distal anastomosis is performed, the clamps are removed. Adequacy of flow can be checked by palpating the vein graft for a pulse and listening distally with a pencil Doppler over the arch as well. The graft is again checked for open branches that should be ligated to prevent the formation of arteriovenous fistulae. The arm and hand are arranged to make sure there is no tension or kinking of the graft, which is uncommon with this technique. The wounds are closed and the hand is placed in a soft, bulky dressing. While the hand and forearm are not splinted, use of the arm should be fairly limited for a few weeks until it heals. A more thorough description of this technique is available from other sources.[66]

Complications. The primary complication of in situ bypass is thrombosis of the graft. Fortunately, this is uncommon because,



FIGURE 60.26 View of forearm and hand of patient with long-standing renal disease who underwent in situ bypass 8 years previously for impending loss of his hand. His bypass remained patent for another 5 years when he unfortunately succumbed to his underlying metabolic problems. (From Pederson WC: Revascularization options for terminal distal ischemia. *Hand Clin* 31(1): 2015, Elsevier Scientific, with permission.)

if adequate inflow is provided through the brachial artery and all of the valves are removed, there is a high rate of flow down these grafts. If the graft thromboses, however, there can be severe consequences for the hand, as whatever little flow may have been provided via the radial or ulnar artery (i.e., whichever vessel was used for the distal anastomosis) is now gone. Most of these patients do reasonably well, and it is not uncommon for them to succumb to their basic underlying disease process before the bypass occludes (Figure 60.26).

If arteriography reveals that there is inadequate flow into the arch by way of the radial or ulnar arteries for outflow, an alternative technique for revascularization of the hand is available with arterialization of the venous system. This technique has been found to be useful for patients with no other reasonable option and critical ischemia of the hand.[40,50,65] In the case of poor to no visible outflow to the hand on vascular studies and impending gangrene, this is arguably the best option. The technique is very similar to in situ vein grafting, except that no distal anastomosis is performed and the cephalic or basilic venous system is left intact into the dorsal hand. The valves must be removed as for in situ bypass, but experience shows that the valves distal to the wrist do not need to be cut—attempting this can damage the dorsal venous system that is the basis of how the oxygenated blood reaches the fingers' capillary bed.

It appears that arterial pressure is enough to render the valves in the smaller veins of the dorsal hand incompetent. A branch at wrist level is used to pass the valvulotome, and once the valves are cut, a proximal anastomosis is performed. All branches proximal to the wrist are ligated, however, to prevent proximal arteriovenous fistulae and shunting of blood flow away from the hand. Surgeons can usually detect a Doppler signal in the veins at the metacarpophalangeal level initially, and this usually progresses out to at least the level of the proximal interphalangeal joints after a few weeks. Swelling is not uncommon during the postoperative period, but this usually resolves over a couple of months. One caveat is that this probably should not be attempted in the face of open wounds; as I have had two patients with open wounds who developed severe infections that required amputation of their hands after this procedure.

Management of Vasospastic Disorders

Maurice Raynaud first noted the syndrome of intermittent ischemia of the fingers in a young woman in Paris in the late 1850s and published these findings (along with those of 24 other patients) in his doctoral thesis in 1862. Raynaud was not quite sure what the etiology of this was at the time of his publication. Although the pathophysiology of this condition is much better understood today, treatment for it remains somewhat problematic.

Cold sensitivity is the most common early manifestation of vasospasm and affects up to 10% of the population and up to 30% of premenopausal women.[44] The sympathetic nervous system controls vascular tone in the periphery, and increased tone leads to decreased perfusion that may be physiologic in the face of hypotension or cold temperatures causing thermoregulatory changes. There has been a lot of study of the pathophysiology of this phenomenon, which is beyond the scope of this chapter.[53]

Pathologic hyperactivity of the sympathetic system leads to pathologic decreases in nutritive flow to the digits and eventually can lead to gangrene and ulceration. Koman believes that impending gangrene or ulceration is a sign of distal thrombus and/or thrombosis of one of the main vessels supplying the hand.[44] *Raynaud disease* is vasospasm seen without any underlying systemic disease process while *Raynaud syndrome* is vasospasm seen in conjunction with one of the systemic diseases manifested by vasospasm (e.g., systemic sclerosis). Merritt suggested that the two differentiations of the term be dropped and vasospasm simply be referred to as "Raynaud's," which I think is a practical approach.[52]

Patients presenting with "cold" fingers alone usually do not require any type of medical intervention unless the condition is severe. They can be treated by keeping the fingers warm and avoiding exposure to cold situations. Patients with more severe symptoms that interfere with their daily lives will need a workup and some form of treatment. An evaluation starts with taking a careful history and doing a physical exam. The history should focus on the time course of the symptoms and any other medical conditions that might contribute to the vasospasm. In particular, a history of trauma to the hand should be sought out, as patients with vascular injury (i.e., ulnar or radial artery thromboses) often present with symptoms of vasospasm limited to the involved fingers.

In the absence of previous trauma, evidence of collagen vascular disease should be sought out. I have diagnosed a number of patients over the years with collagen vascular disease who were referred with the primary symptoms of Raynaud's based on history, a physical, and lab work. A thorough evaluation of the vascular system, with pulse and dynamic Doppler exams, should be carried out. The pulp of each finger should be examined with the pencil Doppler because digital artery occlusion may be the underlying issue.

For patients with no signs of vascular occlusion, lab work to screen for inflammatory markers and collagen vascular disease should be ordered, including C-reactive protein (CRP), erythrocyte sedimentation rate (ESR), antinuclear antibody (ANA), and anticentromere antibody (ACA) studies. In the face of positive results, the patient should be referred to a rheumatologist for further evaluation and long-term management of the systemic condition. If there is evidence of thrombosis of the radial or ulnar arteries, the patient should undergo vascular studies (e.g., usually arteriography) to determine the extent of the occlusion.

Nonsurgical Management of Vasospastic Disorders

As noted previously, if there is no impending gangrene or ulceration, many patients can be managed by cold and stress avoidance whenever possible. The use of calcium channel blockers (CCBs) (e.g., nifedipine and diltiazem primarily) have been shown to be beneficial—that is, decreasing the frequency and severity of attacks.[34] A general impression is that CCBs lose some efficacy over time; thus, use of this treatment during the colder months and stopping it when the weather gets warmer seems to be an effective method of managing such patients.

Use of sildenafil also has been shown to have some potential benefits in increasing blood flow and decreasing the severity of Raynaud's episodes, but several patients had to stop treatment because of side effects.[24,31] Controlled studies of a large number of patients are not available for this drug unfortunately, and the drug remains very expensive for the patient because this is an "off-label" use.[8] Patients with more severe symptoms, but without impending ulcers or gangrene, present more difficult management issues. Botulinum toxin (Botox®) injected around the common digital vessels has been shown to improve symptoms in this group of patients and has healed digital ulcers for a few.[53,58,59]

Neumeister and colleagues observed up to a 300% increase in skin blood flow with laser Doppler after Botox injection.[53] It appears to have a reasonable longevity as well, with patients having relief in some studies for many months,[60] whereas some will require reinjection. For patients with occlusion of one of the major vessels, Botox is not likely to give long-term relief. The technique is to inject 10 units (2 cc of reconstituted protein) around each common digital vessel in the palm of each hand. The primary complication of this technique has been intrinsic muscle weakness in some patients, and around 40% of them will require a repeat injection.[59]

Operative Management of Vasospastic Disease

Even though Botox can help with the management of patients with moderately severe symptoms from vasospasm, its long-term efficacy is not entirely clear. Patients with impending gangrene or who already have ulcerations are usually considered candidates for periarterial sympathectomy. It should be stated very emphatically that periarterial sympathectomy is *not* indicated for patients with calcific arterial disease because these vessels are unable to respond to the removal of sympathetic nerves. Thoracoscopic sympathectomy has had some advocates in the past for the management of Raynaud's[17]; however, this has been shown to lead to a rebound hypersympathetic response and is to be avoided in these patients.[44] Periarterial sympathectomy of the arteries of the distal forearm and palm has been shown to be very effective in managing vasospasm in patients who do not do well with nonsurgical therapy.[53,69,82]

Although total flow is not increased, studies have documented that nutritional flow is improved, and there seems to be less arteriovenous shunting, which occurs during vasospasm and deprives the fingers of nutritive blood flow.[43] This procedure is indicated for patients whose ulcers do not heal with conservative treatment and can be effective for ones with occlusion of the ulnar or radial arteries. If surgery is being considered, however, it is prudent to obtain arterial imaging studies to evaluate the patency of the ulnar and radial arteries.

Ulnar artery thrombosis is quite common in patients with collagen vascular disease,[30] and knowledge of the status of the ulnar artery preoperatively can help in planning the best surgical approach. If the ulnar artery is thrombosed, it can be excised in toto to interrupt the sympathetic nerves along the vessel; this accomplishes a so-called "Leriche" sympathectomy.[46] The other option is bypass of the ulnar artery along with periarterial sympathectomy. The long-term patency of venous grafts in patients with underlying collagen vascular disease has been shown to be low, however.[38] Contraindications are relative, and large nonhealing wounds are probably a reason to avoid elective procedures in the hand.

The technique involves stripping of the adventitial tissue off of the arteries, which in turn removes the very small sympathetic connections from the nerves (Figure 60.27). This surgery can be performed with high-powered loupe magnification, but a microscope is used by most surgeons. The areas to be stripped are the radial and ulnar arteries in the distal forearm for 3 to 4 cm, the palmar arch, and common digital arteries distal to the arch (Figure 60.28). If the ulnar artery is thrombosed and excision versus bypass is to be considered, the incision can be extended from the ulnar forearm to include the course of the ulnar artery out to the superficial palmar arch.

All of these vessels are carefully stripped of surrounding perivascular tissue and veins, but care must be taken, particularly in the digital vessels, to avoid damage to the vessel wall by overvigorous stripping. It is preferable to avoid the proper digital arteries in the fingers, as my experience has been that this significantly increases morbidity from this operation in terms of wound-healing problems and stiffness. If an individual finger fails to improve (or gets worse) after forearm and palmar sympathectomy, I will consider performing a limited sympathectomy on the digital arteries over the proximal phalanx.

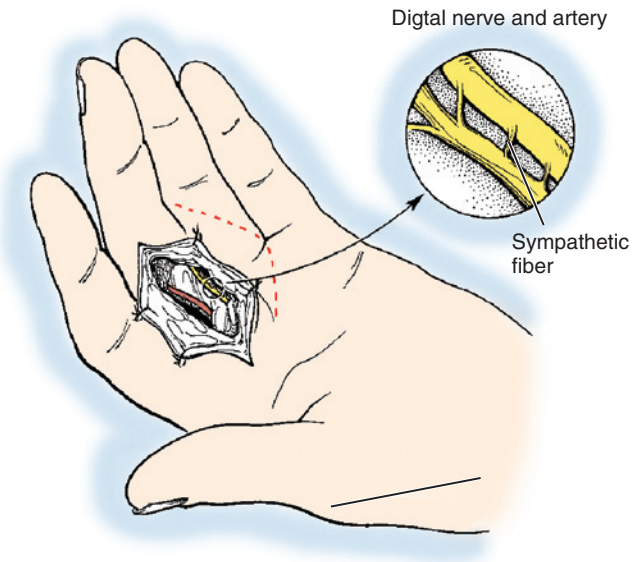

FIGURE 60.27 Digital periarterial sympathectomy (i.e., Flatt-Wilgis technique) is accomplished through a zigzag volar (Bruner) incision. The adventitia is cleaned of sympathetic fibers, and all connections with the accompanying peripheral nerve are transected. The initial dissection is performed under loupe magnification with subsequent dissection visualized with an operating microscope. (From Koman LA, editor: *Bowman Gray school of medicine orthopaedic manual*, Winston-Salem, NC, 1997, Wake Forest University Orthopaedic Press, with permission.)

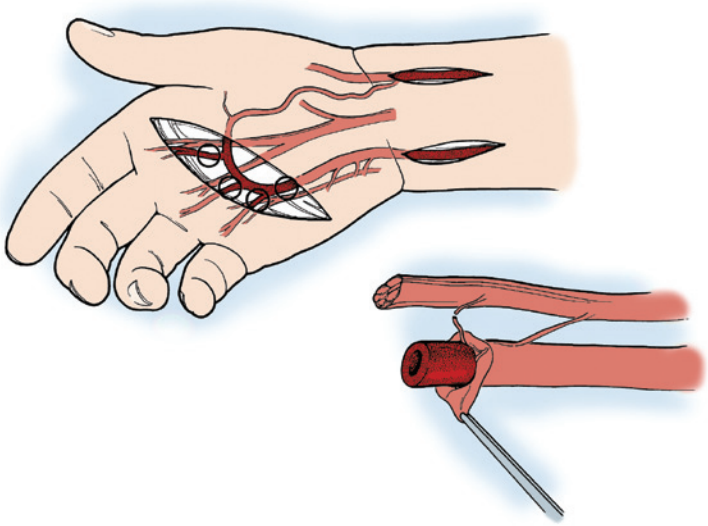

FIGURE 60.28 Schematic representation of periarterial sympathectomy of the hand. Longitudinal incisions are used to expose the radial and ulnar artery, and an oblique incision is used in the palm to expose the superficial arch and the origins of the common volar digital arteries (i.e., the Koman technique). A separate incision (not shown) can be used over the anatomic snuffbox to expose the radial artery. After initial dissection under loupe magnification, the operating microscope is used to strip the adventitial fibers from the vessels and sever connections with parallel peripheral nerves. (From Koman LA, editor: *Bowman Gray school of medicine orthopaedic manual*, Winston-Salem, NC, 1997, Wake Forest University Orthopaedic Press, with permission.)

Ulnar artery bypass can be very helpful, particularly for patients who are stable and quickly develop increasing symptoms and ulceration, which is often due to recent occlusion of the artery.[22] The primary issue is whether these patients benefit long term from bypass of the ulnar artery; it would appear that they do. Experience shows that the two-year patency of venous grafts to the ulnar artery in patients with scleroderma is around 70 to 80%, and it should be noted that those who occlude the grafts generally do not develop acute exacerbation of their symptoms. This is probably the result of the benefit of the sympathectomy effect of excising the diseased and/or occluded artery.

Postoperative Management and Anticoagulation. The use of heparin, low molecular weight heparin, or other acute antithrombotic agents in the perioperative period has been helpful; however, there are no short-term or large studies documenting efficacy. In the setting of grafts, some surgeons use a single dose of 5000 U of heparin at the release of the tourniquet. In subsequent weeks, others have reported the use of warfarin for the first 3 months following the vascular procedure.[82] These measures seem to be used on a case-by-case basis.

❖ AUTHOR'S PREFERRED METHOD OF TREATMENT: Periarterial Sympathectomy

As noted earlier, I feel that periarterial sympathectomy is indicated for patients who have ongoing or worsening symptoms despite conservative measures to manage their vasospasm. The acute development of ulcers usually signals ulnar artery thrombosis. I generally study these patients and if the involved segment of ulnar artery is limited to the very distal forearm and palm, I consider sympathectomy with excision of the ulnar artery. If there is found to be adequate flow from the ulnar artery proximal to the area of occlusion, I perform a bypass as discussed previously. If the segment of ulnar artery thrombosis/thickening goes above the dorsal arterial branch in the forearm, I generally do not perform bypass because, in my experience, long grafts that cross the wrist have a rather poor patency rate. I perform periarterial stripping of the radial and ulnar arteries in the forearm as well as the palmar arch. If the primary symptoms (e.g., ulcers) are on the radial side of the hand, the radial artery in the anatomic snuffbox can also be stripped; this seems to be helpful for some patients.

Aneurysms

Aneurysms in the vessels of the forearm and hand are uncommon and are usually from trauma resulting in a "false" aneurysm due to injury to the vessel wall. These are by far most commonly seen in the ulnar artery secondary to hypothenar hammer syndrome (see before) but can be the result of other traumatic injury as well (Figure 60.29). These patients often present with ulnar nerve symptoms based on compression of the nerve in the palm from the mass of the aneurysm.[55] One also can see aneurysms of the digital vessels as a result of injury. The management of these depends on which vessel is involved and whether ligation and/or excision of the aneurysm will cause ischemia downstream. In the ulnar artery, I feel that usually these should be excised and blood flow restored. On occasion if the aneurysm is small and the artery tortuous, the lesion can be excised and the artery repaired primarily. In most cases, however, a reversed vein graft is required (Figure 60.30). The technique for vein grafting the ulnar artery was discussed previously.

Venous Thrombosis

Deep venous thrombosis in the upper extremity is a rare condition, and it does not always lead to significant symptoms.

Near-total venous occlusion of all the veins in the limb is called "phlegmasia cerulea dolens" and is extremely rare in the hand.[5,39] When coupled with deep venous thrombosis, it can lead to compartment syndrome and potential loss of the limb, however.[3] This syndrome is almost always associated with malignancy or a severe systemic disease state. Management is difficult and often is not successful. Surgical management of the compartment syndrome coupled with anticoagulant therapy may be the only option available. I have treated one patient by exploration, which found every superficial vein in the forearm thrombosed. The vessels in the hand and antecubital fossa were open, however, and a long interposition saphenous vein graft corrected the problem and salvaged the hand.



FIGURE 60.29 Arteriogram of young woman who suffered "minor" stab wound to palm approximately 1 month ago. Now she has a mass in the palm, ulnar nerve paresthesias, and numbness.

Vascular Malformations

Vascular malformations are unusual in the hand and upper extremity. This term can cover a range of lesions from small, low-flow venous malformations to large, pulsatile arteriovenous ones. Abnormalities of the lymphatic system are often seen in conjunction with venous anomalies. True hemangiomas are very rare in the hand and usually are lesions found in children. Hemangiomas are dermal–epidermal lesions that often are involute as the child grows and do not always require treatment. Other vascular malformations may be asymptomatic until they get larger, and it is my impression that thrombosis of an otherwise small and asymptomatic venous lesion often leads to the development of pain. The diagnosis is usually best made with MRI scan of the area; this often can help make the diagnosis and outline the extent of the lesion and its potential involvement of other structures.[67]

If the lesion is asymptomatic, it usually can be left alone. Some patients are effectively treated with a fitted compression glove if the lesion tends to swell when dependent or with activity as it fills with blood. If it is large and potentially affects hand function, treatment should be considered. While sclerosis and embolization are techniques frequently used to good effect in vascular lesions of the head and neck, this approach is problematic in the hand. I have seen permanent nerve injury, as well as loss of digits, after attempted hand sclerosis/embolization has

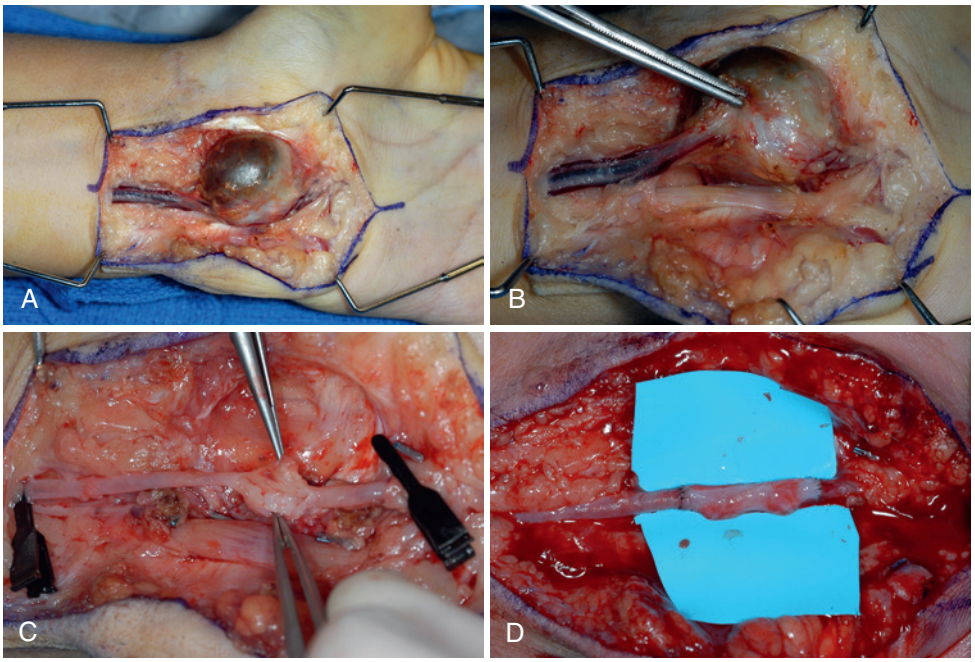

FIGURE 60.30 **A,** Intraoperative view of patient whose arteriogram is shown in Figure 60.29. **B,** Note ulnar nerve compression by aneurysm. **C,** Area of arterial injury after excision of aneurysm. **D,** Repair with reversed basilic vein graft.

happened. If the lesions are markedly symptomatic, I believe that they should be approached surgically.

Upton has vast experience with these lesions and states that the goals of treatment are to completely extirpate the lesion, preserving tendons, bone, nerve, and uninvolved muscle.[78] Vascular supply is then reconstituted as needed with microvascular repairs and vein grafting. His results and those of others have shown that an aggressive surgical approach in symptomatic lesions in all but the worst high-flow lesions leads to acceptable outcomes with low complication rates.[21,37]

Venous malformations are the most common, and excision of these is usually fairly straightforward. The difficulties in dealing with vascular lesions seen in the head and neck are obviated in the hand by the ability to use a tourniquet to limit blood loss. Venous lesions are often seen on or around nerves, and great care should be taken to limit damage to any significant nerve in the hand (Figure 60.31). Although these lesions may recur, surgical excision usually reduces pain and improves function for a significant period of time; thus, a surgical approach that can preserve vascular supply and nerve function is warranted.

High-flow arteriovenous malformations present another set of problems. These patients are often severely symptomatic in terms of pain and disability. The lesions cause proximal shunting of blood flow through large arteriovenous fistulae that leads to distal ischemia. Again, while embolization may be helpful for particularly large lesions, there is a significant risk of loss of tissue distally with this approach. They can be explored very safely and excised with a tourniquet on the upper arm, so blood loss can be minimal. Planning is essential, and I usually prefer to get arteriographic studies for these patients to accurately delineate the extent of the lesion and the involvement of the major vessels of the forearm and hand.

A surgeon should plan to excise the involved abnormal arteries and reconstruct whatever is necessary with vein grafts. Often the other, uninvolved artery will need ligation to decrease the large amount of inflow characteristic of these lesions (Figure 60.32). Ischemic digits are probably best amputated, and results can be very satisfying in terms of decreased pain and improved function for patients. Although such lesions typically recur over time and major amputation is often eventually required, the quality of life for these patients can be improved tremendously for a period of time with aggressive resection and reconstruction.[78]

Glomus Tumors

These tumors are lesions of the glomus body that involves thermoregulation of microvascular blood flow. These tumors make up 1 to 5% of all those in the hand. They can be located nearly anywhere, but in the hand the most common location is in the subungual area.[57] The lesions can be excruciatingly painful, and patients experience pain if any pressure is placed on the lesion and also may have severe cold sensitivity. Any patient with a history of fingertip and/or nailbed pain with marked tenderness of the nail should be evaluated for a glomus tumor of the nailbed. MRI scan is usually diagnostic (Figure 60.33) but sometimes imaging can be negative.[77] Any area of significant pain in the fingers or hand without an obvious cause should include a possible glomus tumor in the differential. Excision is usually curative, and in the most frequent presentation in the nailbed, tumors usually can be enucleated without long-term nail deformity (see Figure 60.33).[45]

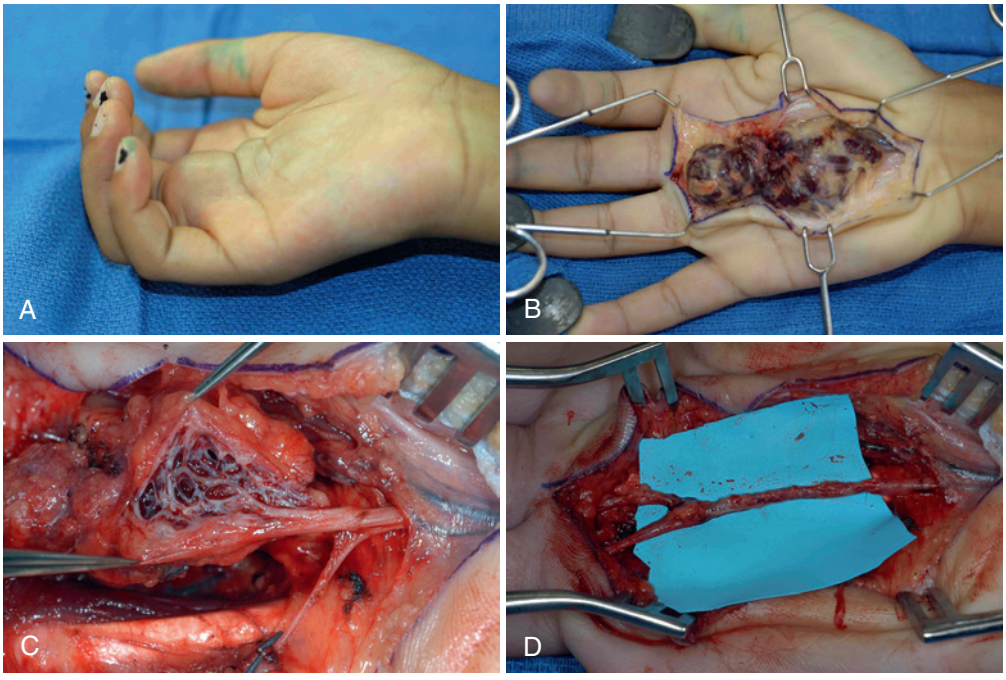

FIGURE 60.31 **A,** View of 8-year-old female's hand with large mass diagnosed on magnetic resonance imaging scan as low-flow venous malformation. **B,** View of lesion after skin incision. **C,** Median nerve with branches involved in lesion that were carefully dissected out of it. **D,** Common digital nerve to third webspace after total resection of lesion.

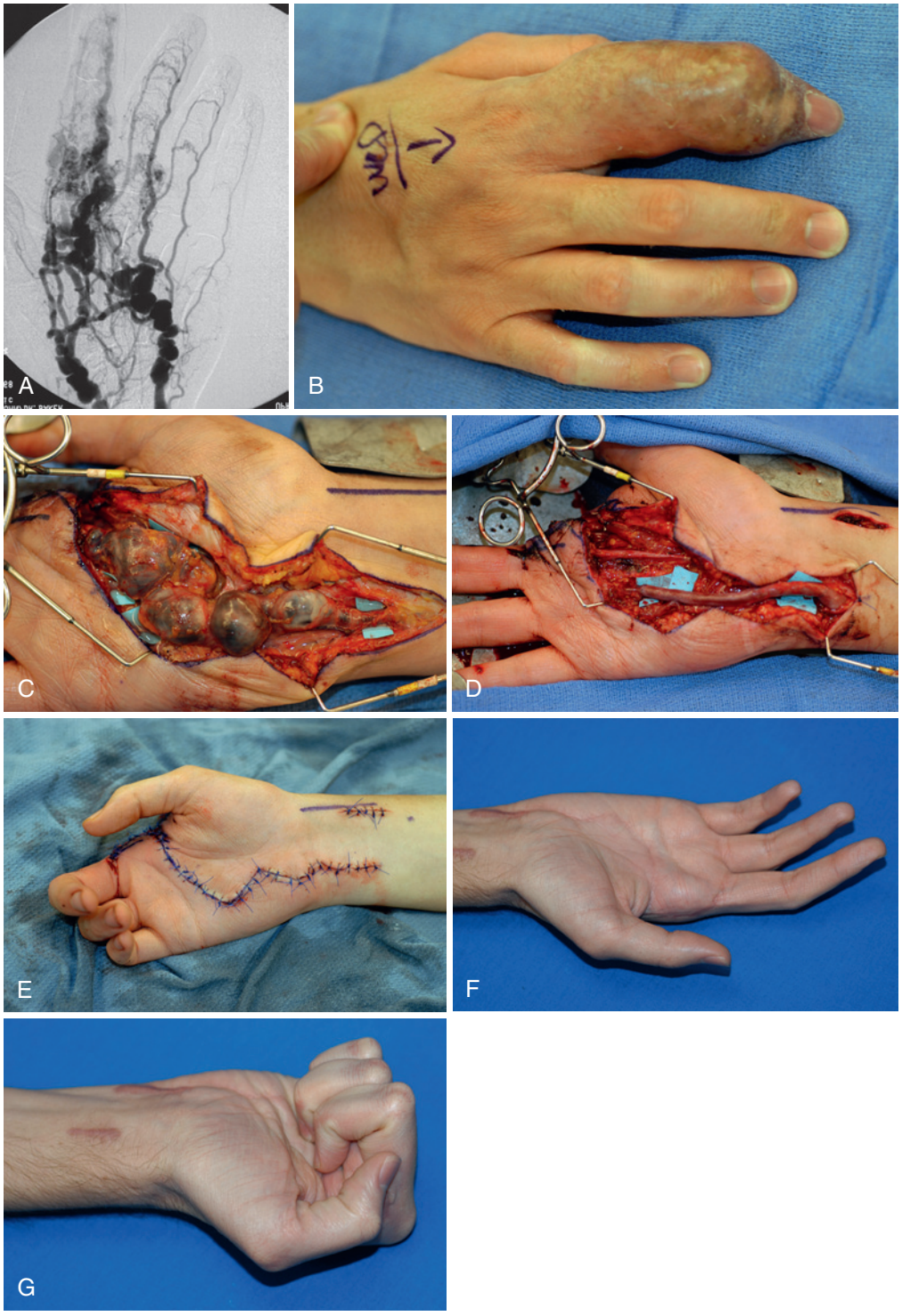

FIGURE 60.32 **A,** Arteriogram of 26-year-old male with long-standing high-flow arteriovenous malformation of right hand. He had severe pain and intermittent ulceration of the index finger. **B,** View of hand, the function of which was very limited with pain and index finger stiffness. The dorsal veins were all pulsatile. **C,** Intraoperative view of ulnar artery after tourniquet was let down briefly. **D,** Hand after reconstruction of ulnar artery with reversed saphenous vein graft. Note side-to-end anastomosis of common digital artery to fourth webspace and end-to-end anastomosis to common digital artery to third webspace. Also note incision for ligation of radial artery. **E,** Hand after closure. **F,** One year follow-up with return of good function, no pain, and no evidence of recurrence. **G,** Flexion at one year.

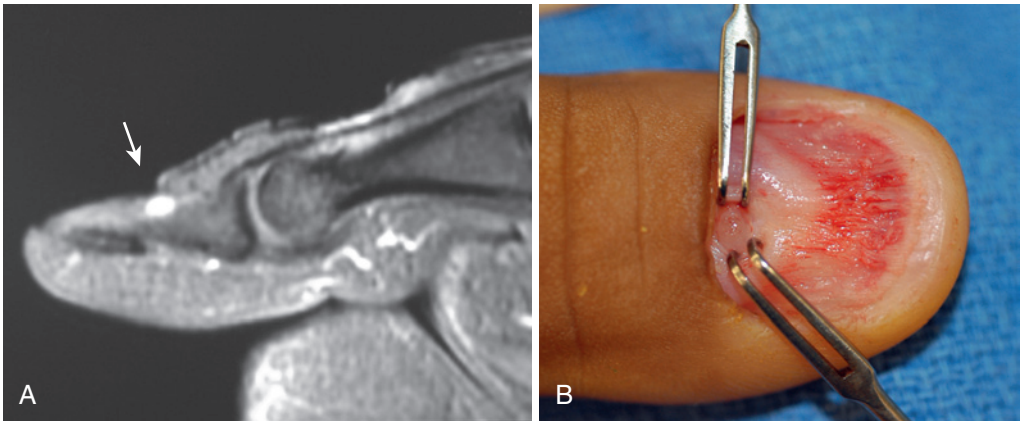

FIGURE 60.33 **A,** Magnetic resonance imaging scan of patient with subungual glomus tumor—lesion marked with arrow. **B,** Exposure via transungual approach. These lesions usually can be shelled out without difficulty.

REFERENCES

1. Abdel-Gawad EA, Bonatti H, Housseini AM, et al: Hypothenar hammer syndrome in a computer programmer: CTA diagnosis and surgical and endovascular treatment. *Vasc Endovascular Surg* 43(5):509–512, 2009.
2. Bataineh ZM, Habbal O, Moqattash ST: Variations in the superficial palmar arch of the hand. *Ital J Anat Embryol* 114(1):11–20, 2009.
3. Bedri MI, Khosravi AH, Lifchez SD: Upper extremity compartment syndrome in the setting of deep venous thrombosis and phlegmasia cerulea dolens: case report. *J Hand Surg [Am]* 34(10):1859–1863, 2009.
4. Bilge O, Pinar Y, Ozer MA, et al: A morphometric study on the superficial palmar arch of the hand. *Surg Radiol Anat* 28(4):343–350, 2006.
5. Bolitho DG, Elwood ET, Roberts F: Phlegmasia cerulea dolens of the upper extremity. *Ann Plast Surg* 45(6):644–646, 2000.
6. Borut LT, Acosta CJ, Tadlock LC, et al: The use of temporary vascular shunts in military extremity wounds: a preliminary outcome analysis with 2-year follow-up. *J Trauma* 69(1):174–178, 2010.
7. Brahmamdam P, Plummer M, Modrall JG, et al: Hand ischemia associated with elbow trauma in children. *J Vasc Surg* 54(3):773–778, 2011.
8. Brueckner CS, Becker MO, Kroencke T, et al: Effect of sildenafil on digital ulcers in systemic sclerosis: analysis from a single centre pilot study. *Ann Rheum Dis* 69(8): 1475–1478, 2010.
9. Brzezinski M, Luisetti T, London MJ: Radial artery cannulation: a comprehensive review of recent anatomic and physiologic investigations. *Anesth Analg* 109(6): 1763–1781, 2009.
10. Chim H, Bakri K, Moran SL: Complications related to radial artery occlusion, radial artery harvest, and arterial lines. *Hand Clin* 31(1):93–100, 2015.
11. Chitte SA, Veltri K, Thoma A: Ischemia of the hand secondary to radial artery thrombosis: A report of three cases. *Can J Plast Surg* 11(3):145–148, 2003.
12. Chloros GD, Lucas RM, Li Z, et al: Post-traumatic ulnar artery thrombosis: outcome of arterial reconstruction using reverse interpositional vein grafting at 2 years minimum follow-up. *J Hand Surg [Am]* 33(6):932–940, 2008.
13. Choi PD, Melikian R, Skaggs DL: Risk factors for vascular repair and compartment syndrome in the pulseless supracondylar humerus fracture in children. *J Pediatr Orthop* 30(1):50–56, 2010.
14. Coleman SS, Anson BJ: Arterial patterns in the hand based upon a study of 650 specimens. *Surg Gynecol Obstet* 113:409–424, 1961.
15. Dargon PT, Landry GJ: Buerger's disease. *Ann Vasc Surg* 26(6):871–880, 2012.
16. De Martino RR, Moran SL: The role of thrombolytics in acute and chronic occlusion of the hand. *Hand Clin* 31(1):13–21, 2015.
17. De Giacomo T, Rendina EA, Venuta F, et al: Thoracoscopic sympathectomy for symptomatic arterial obstruction of the upper extremities. *Ann Thorac Surg* 74(3): 885–888, 2002.
18. Dethmers RS, Houpt P: Surgical management of hypothenar and thenar hammer syndromes: a retrospective study of 31 instances in 28 patients. *J Hand Surg [Br]* 30(4):419–423, 2005.
19. Doscher W, Viswanathan B, Stein T, et al: Hemodynamic assessment of the circulation in 200 normal hands. *Ann Surg* 198(6):776–779, 1983.
20. DuBose JJ, Savage SA, Fabian TC, et al: The American Association for the Surgery of Trauma PROspective Observational Vascular Injury Treatment (PROOVIT) registry: multicenter data on modern vascular injury diagnosis, management, and outcomes. *J Trauma Acute Care Surg* 78(2):215–222, 2015.
21. Ek ET, Suh N, Carlson MG: Vascular anomalies of the hand and wrist. *J Am Acad Orthop Surg* 22(6):352–360, 2014.
22. Fox P, Chung L, Chang J: Management of the hand in systemic sclerosis. *J Hand Surg [Am]* 38(5):1012–1016, 2013.
23. Franz RW, Skytta CK, Shah KJ, et al: A five-year review of management of upper-extremity arterial injuries at an urban level I trauma center. *Ann Vasc Surg* 26(5): 655–664, 2012.
24. Fries R, Shariat K, von Wilmowsky H, et al: Sildenafil in the treatment of Raynaud's phenomenon resistant to vasodilatory therapy. *Circulation* 112(19):2980–2985, 2005.
25. Garg K, Howell BW, Saltzberg SS, et al: Open surgical management of complications from indwelling radial artery catheters. *J Vasc Surg* 58(5):1325–1330, 2013.
26. Gelberman RH, Blasingame JP, Fronek A, et al: Forearm arterial injuries. *J Hand Surg [Am]* 4(5):401–408, 1979.
27. Gelberman RH, Menon J, Fronek A: The peripheral pulse following arterial injury. *J Trauma* 20(11):948–951, 1980.
28. Gelberman RH, Nunley JA, Koman LA, et al: The results of radial and ulnar arterial repair in the forearm. Experience in three medical centers. *J Bone Joint Surg Am* 64(3):383–387, 1982.
29. Hartmann P, Mohokum M, Schlattmann P: The association of Raynaud's syndrome with carpal tunnel syndrome: a meta-analysis. *Rheumatol Int* 32(3):569–574, 2012.
30. Hasegawa M, Nagai Y, Tamura A, et al: Arteriographic evaluation of vascular changes of the extremities in patients with systemic sclerosis. *Br J Dermatol* 155(6):1159–1164, 2006.
31. Herrick AL, van den Hoogen F, Gabrielli A, et al: Modified-release sildenafil reduces Raynaud's phenomenon attack frequency in limited cutaneous systemic sclerosis. *Arthritis Rheum* 63(3):775–782, 2011.
32. Hsieh TY, Huang YH, Chang FS, et al: A secure technique for microvascular anastomosis in arteries with intimal dissection: intimal sleeve fold-over technique. *Ann Plast Surg* 2014.
33. Hui-Chou HG, McClinton MA: Current options for treatment of hypothenar Hammer syndrome. *Hand Clin* 31(1):53–62, 2015.
34. Huisstede BM, Hoogvliet P, Paulis WD, et al: Effectiveness of interventions for secondary Raynaud's phenomenon: a systematic review. *Arch Phys Med Rehabil* 92(7):1166–1180, 2011.
35. Hurton S, Embil JM, Reda A, et al: Upper extremity complications in patients with chronic renal failure receiving haemodialysis. *J Ren Care* 36(4):203–211, 2010.
36. Ikuta Y: Microvascular double clamp type A-II. *J Reconstr Microsurg* 1(1):41–43, 1984.
37. Jacobs BJ, Anzarut A, Guerra S, et al: Vascular anomalies of the upper extremity. *J Hand Surg [Am]* 35(10):1703–1709, 2010.
38. Jones NF, Raynor SC, Medsger TA: Microsurgical revascularisation of the hand in scleroderma. *Br J Plast Surg* 40(3):264–269, 1987.
39. Kaufman BR, Zoldos J, Bentz M, et al: Venous gangrene of the upper extremity. *Ann Plast Surg* 40(4):370–377, 1998.
40. Kind GM: Arterialization of the venous system of the hand. *Plast Reconstr Surg* 118(2):421–428, 2006.
41. Kitzinger HB, van Schoonhoven J, Schmitt R, et al: Hypothenar Hammer syndrome: Long-term results after vascular reconstruction. *Ann Plast Surg* 76(1):40–45, 2016.
42. Knobloch K, Tomaszek S, Busch KH, et al: Palmar microcirculation does not deteriorate 2 years after radial artery harvesting—implications for reconstructive free forearm flap transfer. *Langenbecks Arch Surg* 392(3):315–322, 2007.
43. Koman LA, Smith BP, Pollock FE, Jr, et al: The microcirculatory effects of peripheral sympathectomy. *J Hand Surg [Am]* 20(5):709–717, 1995.

44. Koman LA, Smith BP, Smith TL, et al: Vascular disorders. In Wolfe SW, Hotchkiss RN, Pederson WC, et al, editors: *Green's operative hand surgery*, ed 6, Philadelphia, 2010, Elsevier.
45. Lee W, Kwon SB, Cho SH, et al: Glomus tumor of the hand. *Arch Plast Surg* 42(3):295–301, 2015.
46. Leriche R: Surgery of the sympathetic system. Indications and results. *Ann Surg* 88(3):449–469, 1928.
47. Mansuroglu D, Omeroglu SN, Goksedef D, et al: Does radial artery harvesting cause any changes in the forehand circulation during the postoperative period? An angiographic study. *Anadolu Kardiyol Derg* 4(2):149–152, 2004.
48. Marques E: Ulnar artery thrombosis: hypothenar hammer syndrome. *J Am Coll Surg* 206(1):188–189, 2008.
49. Masden DL, Seruya M, Higgins JP: A systematic review of the outcomes of distal upper extremity bypass surgery with arterial and venous conduits. *J Hand Surg [Am]* 37(11):2362–2367, 2012.
50. Matarrese MR, Hammert WC: Revascularization of the ischemic hand with arterialization of the venous system. *J Hand Surg [Am]* 36(12):2047–2051, 2011.
51. McNamara MG, Butler TE, Sanders WE, et al: Ischaemia of the index finger and thumb secondary to thrombosis of the radial artery in the anatomical snuffbox. *J Hand Surg [Br]* 23(1):28–32, 1998.
52. Merritt WH: Comprehensive management of Raynaud's syndrome. *Clin Plast Surg* 24(1):133–159, 1997.
53. Merritt WH: Role and rationale for extended periarterial sympathectomy in the management of severe Raynaud syndrome: Techniques and results. *Hand Clin* 31(1):101–120, 2015.
54. Mesh CL, McCarthy WJ, Pearce WH, et al: Upper extremity bypass grafting. A 15-year experience. *Arch Surg* 128(7):795–801, 1993.
55. Monacelli G, Rizzo MI, Spagnoli AM, et al: Ulnar artery thrombosis and nerve entrapment at Guyon's canal: our diagnostic and therapeutic algorithm. *In Vivo* 24(5):779–782, 2010.
56. Morsy AH, Kulbaski M, Chen C, et al: Incidence and characteristics of patients with hand ischemia after a hemodialysis access procedure. *J Surg Res* 74(1):8–10, 1998.
57. Netscher DT, Aburto J, Koepplinger M: Subungual glomus tumor. *J Hand Surg [Am]* 37(4):821–823, 2012.
58. Neumeister MW: Botulinum toxin type A in the treatment of Raynaud's phenomenon. *J Hand Surg [Am]* 35(12):2085–2092, 2010.
59. Neumeister MW: The role of botulinum toxin in vasospastic disorders of the hand. *Hand Clin* 31(1):23–37, 2015.
60. Neumeister MW, Chambers CB, Herron MS, et al: Botox therapy for ischemic digits. *Plast Reconstr Surg* 124(1):191–201, 2009.
61. Nihtyanova SI, Brough GM, Black CM, et al: Clinical burden of digital vasculopathy in limited and diffuse cutaneous systemic sclerosis. *Ann Rheum Dis* 67(1):120–123, 2008.
62. Park MJ, Gans I, Lin I, et al: Timing of forearm arterial repair in the well-perfused limb. *Orthopedics* 37(6):e582–e586, 2014.
63. Pederson WC: Surgical techniques for revascularization in the chronically ischemic hand. *Tech Hand Up Extrem Surg* 1(2):103–115, 1997.
64. Pederson WC: Revascularization of the chronically ischemic hand. *Hand Clin* 15(4):629–642, 1999.
65. Pederson WC: Revascularization options for terminal distal ischemia. *Hand Clin* 31(1):75–83, 2015.
66. Pederson WC, Neumeister MW: Reconstruction of the ischemic hand. *Clin Plast Surg* 38(4):739–750, 2011.
67. Petit P: [Imaging in diagnosis and treatment of vascular lesions of the hand]. *Chir Main* 27(Suppl 1):S201–S210, 2008.
68. Rothkopf DM, Chu B, Gonzalez F, et al: Radial and ulnar artery repairs: assessing patency rates with color Doppler ultrasonographic imaging. *J Hand Surg [Am]* 18(4):626–628, 1993.
69. Ruch DS, Holden M, Smith BP, et al: Periarterial sympathectomy in scleroderma patients: intermediate-term follow-up. *J Hand Surg [Am]* 27(2):258–264, 2002.
70. Ruengsakulrach P, Eizenberg N, Fahrer C, et al: Surgical implications of variations in hand collateral circulation: anatomy revisited. *J Thorac Cardiovasc Surg* 122(4):682–686, 2001.
71. Scali ST, Chang CK, Raghinaru D, et al: Prediction of graft patency and mortality after distal revascularization and interval ligation for hemodialysis access-related hand ischemia. *J Vasc Surg* 57(2):451–458, 2013.
72. Smith HE, Dirks M, Patterson RB: Hypothenar hammer syndrome: Distal ulnar artery reconstruction with autologous inferior epigastric artery. *J Vasc Surg* 40(6):1238–1242, 2004.
73. Snyder A, Crick JC: Brachial artery injuries in children. *J Surg Orthop Adv* 22(2):105–112, 2013.
74. Staniloae CS, Korabathina R, Coppola JT: Transradial access for peripheral vascular interventions. *Catheter Cardiovasc Interv* 81(7):1194–1203, 2013.
75. Temming JF, van Uchelen JH, Tellier MA: Hypothenar hammer syndrome: distal ulnar artery reconstruction with autologous descending branch of the lateral circumflex femoral artery. *Tech Hand Up Extrem Surg* 15(1):24–27, 2011.
76. Tonks AM, Lawrence J, Lovie MJ: Comparison of ulnar and radial arterial bloodflow at the wrist. *J Hand Surg [Br]* 20(2):240–242, 1995.
77. Trehan SK, Athanasian EA, DiCarlo EF, et al: Characteristics of glomus tumors in the hand not diagnosed on magnetic resonance imaging. *J Hand Surg [Am]* 40(3):542–545, 2015.
78. Upton J, Coombs CJ, Mulliken JB, et al: Vascular malformations of the upper limb: a review of 270 patients. *J Hand Surg [Am]* 24(5):1019–1035, 1999.
79. Valentine RJ, Modrall JG, Clagett GP: Hand ischemia after radial artery cannulation. *J Am Coll Surg* 201(1):18–22, 2005.
80. Wheatley MJ, Marx MV: The use of intra-arterial urokinase in the management of hand ischemia secondary to palmar and digital arterial occlusion. *Ann Plast Surg* 37(4):356–362, 1996.
81. Wong VW, Katz RD, Higgins JP: Interpretation of upper extremity arteriography: vascular anatomy and pathology. *Hand Clin* 31(1):121–134, 2015.
82. Yee AM, Hotchkiss RN, Paget SA: Adventitial stripping: a digit saving procedure in refractory Raynaud's phenomenon. *J Rheumatol* 25(2):269–276, 1998.
83. Yuen JC, Wright E, Johnson LA, et al: Hypothenar hammer syndrome: an update with algorithms for diagnosis and treatment. *Ann Plast Surg* 67(4):429–438, 2011.
84. Zhang L, Moskovitz M, Baron DA, et al: Different types of sleeve anastomosis. *J Reconstr Microsurg* 11(6):461–465, 1995.

This page intentionally left blank

INDEX

Page numbers followed by "*f*" indicate figures, "*t*" indicate tables, "*b*" indicate boxes, and "*e*" indicate online content.

A
ABCDE acronym, for melanoma, 1977
ABCDEFG procedure (alphabet reconstruction), 1139
Abdominal wall flap, random, for burn deformities, 1944
Abduction, in restoration of thumb-index key pinch, in ulnar nerve palsy, 1058-1059
Abductor advancement, for radial collateral ligament injuries, 309
Abductor digiti minimi (ADM), 138
  transfer of
    in hypoplastic thumb reconstruction, 1292
    in median nerve palsy, 1032-1033, 1033*f*-1034*f*
Abductor pollicis longus (APL)
  imbrication of, for thumb-in-palm deformity, 1112
  transfer of, accessory slip of, 1058, 1058*f*
Abductorplasty, of flexor pollicis longus, for thumb-in-palm deformity, in spasticity, 1111-1112
Abscess
  antibiotic recommendations for, 21*t*
  nerve, in Hansen disease, 106, 109-110, 112-113, 113*f*-114*f*
  shooter's, 51-52
  subaponeurotic space, 37
    treatment for, 38
  subcutaneous space, 37
    treatment for, 38
  web space (collar-button), 37-38, 38*f*-39*f*
    case study, 38.*e*1*b*, 38.*e*1*f*
    treatment for, 38
      preferred method of, 39
Abuse, drug, infections caused by, 51-52
Acanthosis nigricans, 1959-1960
Acid burns, 1948-1949. *see also* Burns
Acid-fast stain, for infections, 65-66, 65*t*
Acquired immunodeficiency syndrome (AIDS), 119-121. *see also* Human immunodeficiency virus (HIV)
  bacillary angiomatosis in, 120-121, 120*f*
  cellular immune responses in, 119.*e*2
  classification and clinical diagnosis of, 119.*e*1-119.*e*2, 119.*e*1*t*
  clinical features of, 119.*e*2
  clinical manifestations of, 119-121
  etiology and epidemiology of, 119
Acquired immunodeficiency syndrome (AIDS) *(Continued)*
  herpes simplex virus in, 120
  indicator conditions, to hand surgery, 119.*e*1*t*
  Kaposi sarcoma in, 121
  treatment of, 121
Acral fibrokeratoma. *see* Digital fibrokeratoma
Acral lentiginous melanoma, 1978
Acral nevi, 1966
Acrosyndactyly, 1227, 1227*f*-1228*f*
  secondary to constriction ring syndrome, 1257
Actinic keratosis, 1972, 1972*f*
Actinobacillosis, 67-68
Actinomycetoma, 70-73
  clinical findings on, 71
  diagnosis of, 72
  etiology and epidemiology of, 70
  microbiology of, 70-71, 71*f*
  treatment of, 72-73
Actinomycosis, 68
Action potential, sensory nerve, in thoracic outlet syndrome, 968
Active stability, of proximal interphalangeal joint, 279
Activity modification, for epicondylitis, 865
Acupuncture, for complex regional pain syndrome, 1817
Acute compartment syndrome, 1763
  diagnosis of, 1765-1767
Acute injury
  in complex traumatic elbow dislocation
    clinical assessment of, 813-814
    imaging of, 814
    treatment of, 818-824
  in longitudinal forearm instability repair, 808
Acyclovir, for herpes simplex virus, 120
Adaptive misalignment, carpal, 463
Adaptive modalities, for complex regional pain syndrome, 1818
Adduction, of thumb, restoration of, 1056-1058
Adductor advancement, for radial collateral ligament injuries, 309
Adductor pollicis, transfer of, in median nerve palsy, 1041
Adenoid basal cell carcinoma, 1974
Adhesion formation, as complication of flexor tendon grafting, 224
Adipofascial flap, 1593
Adjuvant therapy, for heterotopic ossification, 857
Adrenergic compounds, for complex regional pain syndrome, 1813-1814, 1814*t*
Advancement flap(s), 1541-1542, 1547-1550, 1548*f*-1549*f*. *see also* Skin flap(s)
  palmar, for soft tissue defects of thumb, 1676-1677, 1677*b*
    with proximal releasing incision, 1677-1679, 1679*b*, 1679*f*
    without proximal releasing incision, 1677, 1678*f*
  V-Y, 1548-1550, 1549*f*-1551*f*
    in reconstruction of amputated fingertip
      Atasoy-Kleinert volar, 1712-1713, 1713*f*
      Kutler lateral, 1713-1714, 1714*f*
      volar advancement, 1714, 1715*f*
Aeromonas hydrophila, infection with, 1584
Aeromonas species, 48
Afterburn, 1927
Agee single-portal endoscopic technique, for carpal tunnel syndrome, 933-934
Algae infections, 116
Algorithm, management, for pain or paresthesia, 147*f*
Allen test
  for vascular disorders, 2036, 2037*f*
  for vascularity assessment, 1490
Allergic response, to regional anesthesia, 12-14
Allodynia, 1802
  definition of, 1799*t*
Allogeneic bone grafts, 1635-1636
Allograft(s). *see also* Autograft(s); Xenograft
  for mangling injuries, 1510
  of radial head, salvage using, 765
Al-Qattan's classification, of phalangeal neck fractures, 1431-1432, 1433*f*
Amelanotic melanoma, 1980
Amitriptyline, for complex regional pain syndrome, 1812*t*
Amlodipine, for complex regional pain syndrome, 1815*t*
Amniotic band syndrome, 1255-1258, 1256*f*-1257*f*, 1258*b*. *see also* Amniotic disruption sequence
Amniotic disruption sequence, 1255-1258, 1256*f*-1257*f*, 1258*b*

Amoxicillin, for anthrax, 69
Amphotericin B
  for candidiasis, 85
  for coccidioidomycosis, 85-86
  for deep sporotrichosis, 88
  for fungal infections, 79
  spectrum of activity of, 79*t*
Amplitudes, in nerve conduction studies, 929
Amputation
  below-elbow (transradial), 1737
  digital tip, 1709-1717, 1709*f*, 1720*b*
    case study of, 1737.*e*1*b*, 1737.*e*1*f*-1737.*e*3*f*
    cross-finger pedicle flap for, 1714-1716, 1715*f*
    with exposed bone, 1711-1717
    free flaps in, 1717
    island flaps in, 1717
    preferred method of treatment for, 1717, 1722-1723
    with skin or pulp loss only, 1709-1711
    Smith and Albin thenar H-flap in, 1716, 1716*f*
    thenar flap in, 1716
    V-Y flap for
      Atasoy-Kleinert volar, 1712-1713, 1713*f*
      Kutler lateral, 1713-1714, 1714*f*
      volar advancement, 1714, 1715*f*
  of fingers. *see also* Ray amputation
    toe transfer for. *see also* Toe transfer, in finger replacement
      distal digit in, 1646-1647
      multiple-digit in, 1648-1649
      proximal, 1648, 1648*f*-1649*f*
        digit in, 1647-1648
      single digit in, 1646, 1647*f*
  human bites and, 48-49
  interscapulothoracic, 1756, 1757*f*
  limb, major, 1753-1756
    case study of, 1762.*e*1*b*, 1762.*e*1*f*-1762.*e*3*f*, 1762.*e*3*b*
    indications for, 1753, 1754*f*
  lumbrical-plus finger after, 1718
  for macrodactyly, 1282
  for mangling injuries, consideration of skeletal contribution in, 1492-1493
  multiple-digit, 1735-1737, 1735*b*, 1736*f*, 1737*b*
  neuromas after, 1522
  pain management after, 1747-1749
  of perionychium, 323-324, 324*f*-325*f*
  postburn, 1942-1943
  with preservation of basal joint
    composite radial forearm flap for, 1697-1699, 1700*f*, 1699.*e*1*f*
    osteoplastic reconstruction for, 1696-1697, 1697.*e*1*f*
      Gillies "cocked-hat" flap in, 1696, 1697*f*
Amputation *(Continued)*
    two-stage
      stage 1, 1696-1697, 1698*f*
      stage 2, 1697, 1697.*e*1*f*
  pollicization for, index/long finger stump in, 1699-1703, 1702*f*-1704*f*, 1705*b*
  principles of, 1708*b*
  ray, 1719-1730, 1735*b*. *see also* Ray amputation
  replantation after, 1478-1479. *see also* Replantation
  through carpus, 1737
  through distal interphalangeal joint, 1717-1719, 1718*f*
    with disarticulation, 1717-1718
  through phalanx
    middle, 1718-1719, 1719*f*-1720*f*
    proximal, 1719, 1721*f*-1722*f*
  through proximal interphalangeal joint, 1719
  of thumb
    with destruction of basal joint, 1703-1704
    with preservation of basal joint, 1696-1699
    subtotal, 1688-1691
      dorsal rotational flap, 1691-1694
      regional and distant flaps, 1694-1696
      Z-plasty procedures, four flap, 1690-1691, 1690*b*, 1691*f*-1692*f*
    toe transfer for, 1646. *see also* Toe transfer, in thumb replacement
    "Z"-plasty procedures, 1689-1691
      simple, 1689, 1690*f*, 1689.*e*1*f*
  transhumeral, 1754-1756
  transradial, 1753-1754, 1754*f*
  upper extremity, rehabilitation after, 1757-1758
  wrist disarticulation, 1737-1738, 1739*f*
    preferred method of treatment of, 1737-1738
Amputation stump, posttraumatic neuralgia in, 1010.*e*5
Amyloid, deposition of, tendinopathy in, 1906-1907, 1906*f*
Amyoplasia, 1365
Analgesia, definition of, 1799*t*
Anastomosis. *see also* Microvascular surgery
  distal sleeve, for vascular disorders, 2051, 2051*f*
  end-to-end, for vascular disease, 2051, 2051*f*
  end-to-side, for vascular disease, 2051, 2051*f*
  vascular, in toe transfer, 1668
Anatomy, Dupuytren surgery and, 138
Anconeus flap transolecranon approach, to distal humeral fractures, 714-715, 716*f*
Anemia, Fanconi, radial deficiency associated with, 1289, 1290*t*, 1329*t*
Anemones, venomous, 1791-1792
Anesthesia, 1-16
  coronoid fracture-dislocation examination under, 819
  in elbow arthroscopy, 886, 888*f*
  for elbow contracture release, 849
  general, 1
  for humeral fracture fixation, 710-711
  regional, 1-14, 14*b*
    advantages of, 3
    complications of
      allergy as, 12-14
      neurapraxia as, 12, 12*b*
        incidence of, 12
        management of, 12, 13*f*
      sepsis as, 12-14
    contraindications to
      absolute, 1
      relative, 1-2
    disadvantages of, 3
    drugs, commonly used, 4*t*
    equipment for, 4
    historical techniques of, 5-6
      continuous peripheral nerve catheters, 5
      minimum effective dose, 5-6
    indications for, 2-3
      microvascular surgery patients, 2
      patients with rheumatoid arthritis, 3
      pediatric patients, 2
      pregnant patients, 2-3
    intravenous, 10-11
    for limiting use of, 3*b*
    preferred method of, 11-12
    specific blocks, 6-8, 6*f*
      axillary, 8, 8*f*
      infraclavicular, 7-8, 7*f*
      interscalene, 6, 7*f*
      supplementary, 8-11
        at digit, 9-10, 10*f*-11*f*
        at elbow, 8
        at wrist, 8-9, 9*f*
      supraclavicular, 6-7, 7*f*
    toxicity of, 4*b*
    ultrasound-guided, 5, 7*f*
  regional, for complex regional pain syndrome, 1811
  for stiff finger and hand, 340
Anesthetic procedure, for Dupuytren disease, 145
Anesthetic skin patch, for Hansen disease, 104
Aneurysmal bone cyst, 2024-2025, 2024*f*-2025*f*
Aneurysms, 2054, 2055*f*
Angiography. *see also* Arteriography
  prior to free flap transfer, 1577
Angiomatosis, bacillary, AIDS and, 120-121

Angular osteotomies. *see also* Osteotomy
  for forearm fracture malunion, 801-803, 802*f*
Angulation
  after metacarpal fractures, dorsal, 246, 246*f*-247*f*
  after phalangeal fractures
    apex volar, 266, 266*f*
    lateral, 266-267, 266*f*
  after volar plate arthroplasty, 290
Animal(s), venomous, 1788-1795
  caterpillars, 1788, 1789*f*
  cnidarians, 1791-1792, 1792*f*
  fish, 1792-1795, 1793*f*-1794*f*
  sea urchins, 1792, 1792*f*
  snakes, 1789-1791, 1790*f*-1791*f*
  spiders, 1788-1789, 1789*f*
Animal bites, 46-48
  antibiotic recommendations for, 21*t*
Ankylosis, complete, of neuropathic joint, as contraindication to total elbow arthroplasty, 909
Anterior compartment portals, in elbow arthroscopy, 888-890
Anterior drawer test, in midcarpal instability, 460
Anterior (transolecranon) fracture-dislocation, of elbow, 784.*e*13*b*, 784.*e*13*f*-784.*e*14*f*
Anterior transposition, of ulnar nerve, 947
Anterolateral portals, in elbow arthroscopy, 889-890, 890*f*
  distal, 890
  proximal, 889
Anterolateral thigh flap, 1597, 1598*f*
  for burn deformity, 1945
  for mangling injuries, 1513-1515, 1516*f*
Anteromedial portals, in elbow arthroscopy, 888-889
  proximal, 888-889, 889*f*
Anthrax, 56-57, 57*f*, 68-69, 69*f*
  cutaneous, 68-69, 69*f*
    treatment of, 69
Antibiotics, for common infections, 21*t*
Anticoagulation therapy, regional anesthesia and, 2
Anticonvulsants, for complex regional pain syndrome, 1813, 1813*t*
Antidepressants, for complex regional pain syndrome, 1811-1812, 1812*t*
Antifungal agent, activity of, spectrum of, 79*t*
Antiinflammatory medications, for carpal tunnel syndrome, 932-933
Antimony, injection of, for leishmaniasis infection, 117
Antisepsis, for Dupuytren disease, 145
Antituberculous drugs, 100-103, 101*t*
Antivenin, snake, 1789
AO/ASIF classification
  of distal humerus fractures, 703
  of distal radial fracture, 524, 526*f*
Apert syndrome, 1210*f*
  classification of, 1228*t*
  in syndactyly, 1227-1232, 1229*f*
    planning of, groin flaps in, 1228-1230, 1230*f*
Apex volar angulation, as complication of phalangeal fractures, 266, 266*f*
Apical ectodermal ridge (AER)
  in embryogenesis, 1208
  removal of, 1209, 1210*f*-1211*f*
Aponeurosis, of finger, 338.*e*3, 338.*e*5*f*
Arcade of Fröhse, 950-951
Arcade of Struthers, 699, 941, 941*f*
Arcing, 1947
Arm
  compartments of
    release of, 1769, 1769*f*
  mangling injuries of, treatment of, 1515-1519, 1519*f*-1520*f*
  release of, 1770-1771
Arm flap, lateral. *see* Lateral arm flap
Arsenical keratosis, 1972
Artelon implant, for carpometacarpal joint osteoarthritis, 362
Arterial injury, contaminant, 1008
Arterial repairs, in replantation, 1482
Arterial trauma
  closed, 2042-2047, 2044*f*-2046*f*
    complications of, 2046-2047, 2047*f*-2048*f*
    preferred method of treatment of, 2046-2047, 2047*f*
  open, 2040-2042, 2040*f*
    complications of, 2042
    postoperative care after, 2042
    preferred method of treatment of, 2040-2042, 2041*f*-2042*f*
    vein grafting for, 2041, 2041*f*, 2042*b*, 2043*f*
Arterialized venous flaps, 1577
Arteriography, of recipient site, in vascular bone grafting, 1615
Arteriovenous malformations, high-flow, 2056, 2057*f*
Artery(ies). *see also named artery, e.g.*, Radial artery
  defects of, free flaps for, 1609
  preparation of, in toe transfer, 1666
Arthritis. *see also under specific joint*
  posttraumatic, 906, 907*f*
    of elbow, 827
    preoperative assessment of, 906
    preoperative planning of, 906
  psoriatic, 1834-1836
    digital deformity in, 1836, 1836*f*
    thumb deformity in, 1836
    wrist deformity in, 1836
  rheumatoid, 905-906, 906*f*, 1842-1857. *see also* Rheumatoid arthritis
    physical examination of, 905
    preoperative evaluation of, 905-906
    preoperative planning of, 905-906
Arthritis *(Continued)*
  scaphotrapeziotrapezoid, carpal misalignment secondary to, 464
  septic. *see* Septic arthritis
  tuberculous, 96-97, 97*f*
Arthritis mutilans
  arthrodesis for, 1899-1900
  of thumb, 1897
Arthrodesis, 1127
  for arthritis mutilans, 1899-1900
  of carpometacarpal joint, for CMC osteoarthritis
    expected outcomes on, 368
    operative techniques in, 364, 364*f*
    treatment for, 361
  of glenohumeral joint, 1090, 1090*f*
  intercarpal, for wrist arthritis, 690
  of interphalangeal joint, 1899
    distal, 346-349, 349*b*
      author's preferred method of treatment for, 347-349, 348*f*
      complications of, 349
      critical points in, 349*b*
      expected outcomes for, 349
      indications and contraindications of, 346-347
      postoperative management and expectations for, 349
      preoperative planning for, 347
      in rheumatoid arthritis, for swan neck deformity, 1880-1882, 1880*t*
        with screw, 1881, 1881*f*
      studies of, fixation and outcomes, 347*t*
      technique for, 347, 348*f*
    proximal, 349-352
      author's preferred method of treatment for, 350, 351*f*
      complications of, 352
      critical points in, 351*b*
      expected outcomes on, 352
      indications and contraindications for, 349
      postoperative management and expectations for, 350-352
      preoperative planning for, 349
      in rheumatoid arthritis, for swan neck deformity, 1887, 1887*f*
      technique for, 349-350, 350*f*
    of thumb, in ulnar nerve palsy, 1059
  lunotriquetral, 457*b*
  of metacarpophalangeal joint, 352-353, 352*b*
    in spasticity, for swan neck deformity, 1116, 1117*b*, 1117*f*
    for thumb deformities, 1899
    in ulnar nerve palsy, 1059
  midcarpal, 461, 462*f*
  scaphoid-capitate, 448
  scaphoid-lunate-capitate, 448
  scaphoid-trapezium-trapezoid, 447
  scapholunate, 447

Arthrodesis *(Continued)*
of shoulder
for brachial plexus injury, 1190-1192
preferred method of, 1192, 1194*b*, 1194*f*
vascularized allograft fibular construct for, 1622*f*
of thumb, in ulnar nerve palsy, 1059
of wrist, 373-417
after failed total wrist arthroplasty, 404, 404*f*-405*f*
for brachial plexus injury, 1202
capitolunate in, with scaphoid excision, 394-395, 395*f*
history of, 396
with intramedullary pins, critical points in, 404*b*
limited, history of, 377
lunotriquetral, 387-389
indications and contraindications in, 387-388
patients and, 389
pearls, 389, 389*f*
pitfalls of, 389
postoperative management for, 388
preferred method of, 388
osteoarthritis and, common radiographic pattern for, 376, 377*f*
partial fusions of, 377
preoperative assessment of, 374-377
physical examination of, 374
radiographic evaluation of, 374-377, 375*f*-376*f*
radiographic patterns of disease for, 376-377, 377*f*
radiolunate fusion in, 377-380
critical points in, 381*b*
indications for, 377, 379*f*
net analysis of literature in, 380
pitfalls of, 380
postoperative management for, 380
preferred method of, 378-380, 381*f*-382*f*
technique for, 377, 379*f*-380*f*
radioscapholunate in, 385-386
complications of, 375*f*, 386
critical points in, 388*b*
indications and contraindications in, 385, 385*f*
patients and, 386, 388*f*
postoperative care for, 386
preferred method of, 385-386, 386*f*-387*f*
rheumatoid arthritis and
choice of operation in, 1863
complications of, 1867
with metacarpophalangeal joint arthroplasty, 1867-1878
partial fusion in, 1864-1866, 1864*f*
radiographic patterns of, 376-377
tendon transfers in, 1853-1854

Arthrodesis *(Continued)*
scaphocapitate in, 380-385
athletic participation in, 384
contraindications in, 380
critical points in, 384*b*
fixation for, 383, 383*f*
indications for, 383
patients on, 384-385
postoperative expectations in, 384
postoperative management of, 384
preferred method of, 383-384, 383*f*
scapholunate in, 387
scaphotrapeziotrapezoidal fusion in, 389-390
contraindications in, 389
indications for, 389
patients and, 390-391, 392*f*
preferred method of, 390, 391*f*
surgical techniques for, 377-416
alternative techniques for, 390-391
fixation for, alternative methods of, 393-394
total, 395-401
closure in, 399, 401*f*
complications of, 400, 401*f*-402*f*
postoperative management of, 399
preferred method of, 396-399, 396*f*-400*f*
for scapholunate dissociation, 450
triquetrohamate fusion in, 389
Arthrography
of carpal instability, 432
of distal radioulnar joint, 486
of lunotriquetral dissociation, 454
Arthrogryposis, 1365-1390, 1366*f*-1367*f*
diagnostic imaging of, 1366
history of, 1365
patterns of hand deformities in, 1388*t*
pertinent anatomy in, 1367
physical examination for, 1365-1366, 1369*f*
preoperative evaluation of, 1365-1367
surgical procedures for, 1368-1390, 1371*f*
bipolar latissimus dorsi transfer in, 1376-1378, 1378*b*
camptodactyly release in, 1387-1390, 1389*b*
carpal wedge osteotomy, 1380-1382, 1382*b*
elbow extension contracture release in, 1372-1376
humeral external rotation osteotomy in, 1368-1372
radial osteotomy, with and without ulnar osteotomy in, 1378-1380, 1380*b*
thumb reorientation osteotomy and/or metacarpophalangeal chondrodesis, 1383-1387, 1386*b*
thumb contractures in, 1368*t*
treatment of, historical review of, 1370*t*
types of, 1368*t*

Arthrolysis, arthroscopic, for wrist arthritis, 691
Arthropathy, hemophilic, 909
preoperative considerations of, 909
Arthroplasty
of carpometacarpal thumb, for thumb CMC osteoarthritis
expected outcomes on, 368
treatment for, 361-362
distal resection, for scaphoid nonunion advanced collapse, 622-623
of elbow, total, 905-920, 919*b*
complications of, 914-915, 914*f*
contraindications to, 909
for fractures of distal humerus, 906-907, 908*f*
for hemophilic arthropathy, 909
historical review of, 909, 910*t*
mortality rates and, 918
paratricipital exposure for, 711.*e1b*, 711.*e1f*-711.*e2f*
postoperative management and expectations after, 913-918
for posttraumatic arthritis, 906, 907*f*
for primary osteoarthritis, 907-909
for rheumatoid arthritis, 905-906, 906*f*
total replacement in, for distal humeral fractures, 709-710, 710.*e1b*, 710.*e1f*
geriatric, 710.*e1b*, 710.*e1f*
hemihamate, for proximal interphalangeal joint fracture-dislocation, 294
case study on, 315.*e1b*, 315.*e1f*-315.*e2f*
hemiresection-interposition, for radioulnar joint arthritis, 503-504, 504*f*
of metacarpophalangeal joint, 358
of proximal interphalangeal joint, 353-358
complications of, 358, 358*f*
critical points in, 356*b*
expected outcomes on, 356-357
indications and contraindications for, 353
postoperative management and expectations for, 356-358
preferred method of, 354-356, 354*f*-356*f*
preoperative planning of, 353
technique for, 353-354, 354*f*
of radial head, 745
outcome of, 759-760
as preferred treatment, 752-754, 755*f*-756*f*, 756*b*
resection, for carpometacarpal joint osteoarthritis
expected outcomes on, 366-368, 367*t*
as operative technique, 363-364, 363*f*
as treatment, 361
surface replacement, 356-357

Arthroplasty *(Continued)*
for swan neck deformity, in rheumatoid arthritis, 1886-1890, 1886*f*-1887*f*
contraindication to, 1887, 1887*f*
indications for, 1887
outcomes of, 1889-1890, 1890*f*
rehabilitation after, 1889
surgical approaches to, 1887-1889, 1888*f*
of trapeziometacarpal joint, in rheumatoid arthritis, 1900-1901
ulnar head implant, 508-510
operative technique for, 509-510, 509*f*
outcomes of, 510, 510*f*
volar plate, for proximal interphalangeal joint fracture-dislocation, 284
complications of, 290
postoperative management of, 290
preferred method for, 288-290, 289*f*, 290*b*
of wrist, 373-417
total
critical points in, 415*b*
failed, after wrist arthrodesis, 404, 404*f*-405*f*
history of, 405-407
for scapholunate dissociation, 450
Arthroscopic fixation, fracture management by, 899-902
of capitellar fractures, 899, 900*f*
of coronoid fractures, 899-901, 901*f*
of radial head fractures, 902
Arthroscopic osteocapsular arthroplasty, 893
Arthroscopy
of carpal instability, 432
carpometacarpal, for thumb CMC osteoarthritis, 362, 364
of distal radioulnar joint, 487
distraction, for stiff elbow, 856
of elbow, 885-904
advanced procedures of, 903
anesthesia and positioning in, 886, 888*f*
pertinent anatomy and portals in, 886-891, 889*f*
complications of, 903
contracture release in, 849
contributions to, 892*t*
for epicondylitis, 868
historical review of, 891
instrumentation in, 891, 891*f*
for lateral epicondylitis, 897-899, 898*f*
pertinent anatomy in, 886-891, 889*f*
portals in, 886-891, 889*f*
preoperative evaluation in, 885-886
diagnostic imaging in, 886, 887*f*-888*f*
physical examination in, 885
types of operations in, 892-903
Arthroscopy *(Continued)*
for lunotriquetral dissociation, 454
for scapholunate dissociation, 449
of wrist, 653-696
anatomy in, 658-660, 658*f*-661*f*
for arthritis, 689-691
for carpal instability, 661-665
complications of, 694
DRUJ, 660-661
dry, 658
ganglionectomy and, 688-689
general setup for, 653, 654*f*
for interosseous ligament injuries, 661, 661*t*, 662*f*-663*f*
for Kienböck's disease, 691-692, 691*t*, 692*f*
portal placement in, 653-656, 653.*e*1*t*
1-2, 654
3-4, 653-654, 654*f*-656*f*, 653.*e*1*t*
4-5, 653-654, 653.*e*1*t*
6-R and 6-U, 654, 654*f*, 653.*e*1*t*
accessory thumb carpometacarpal, 657-658
distal radioulnar, 657-658, 653.*e*1*t*
midcarpal, 656-657, 653.*e*1*t*
radiocarpal, 653-656, 654*f*-656*f*
scaphotrapeziotrapezoidal, 657
trapeziometacarpal, 657, 658*f*
volar, 655-656, 653.*e*1*t*
small joint, 694.*e*1
for traumatic injuries, 677-687, 677*f*
Class IA, 677, 677*f*
Class IB, 678, 678*f*-679*f*
Class IC, 682-683, 683*f*-684*f*
Class ID, 683, 684*f*
without avulsion, 683-685, 685*f*-686*f*
Arthrosis, after ulnar fractures, 784
Articular bone loss, associated with humeral fractures, 726, 726.*e*1*b*, 726.*e*1*f*-726.*e*6*f*, 726.*e*4*b*
Articular fracture(s)
of distal humerus
classification of, 704-705, 704*f*-705*f*
multiplanar involvement of, 722
variant, 725
of distal radius, management of, 568-573
type III-compression fractures, 571-572
type II-shear fractures, 568-571, 569*f*, 568.*e*14*b*, 568.*e*14*f*-568.*e*19*f*, 568.*e*17*b*
type IV-radiocarpal fracture-dislocation, 572-573, 573*f*, 573.*e*1*f*-573.*e*3*f*, 573.*e*2*b*
type V-combined/complex injury, 573, 574*f*, 573.*e*4*b*, 573.*e*4*f*-573.*e*7*f*
elbow arthroscopy for, 899
of phalanges, 249-251
at base, 249-251, 251*f*-253*f*
in children, 1436-1437
Articular fracture(s) *(Continued)*
preferred method of treatment for, 1437
at condyle, 249, 250*f*-251*f*
at head, 249
in children, 1431
preferred method of treatment for, 1431, 1432*f*
preferred method of treatment of, 251-255, 254*f*-256*f*
at shaft, 251
of radial head, management of, 749, 750*f*-751*f*
Articular loss
complete, 726.*e*4*b*, 726.*e*4*f*-726.*e*6*f*
partial, 726.*e*1*b*, 726.*e*1*f*-726.*e*3*f*
Articular malunion
after metacarpal fractures, 247
after phalangeal fractures, 267
Articular osteotomies, for radial fracture, 580-581, 582*f*, 581.*e*1*b*, 581.*e*1*f*-581.*e*6*f*
Articular surface, of distal humerus, classification of, 703-705
ASMI technique, 837
Aspergillosis, 84-85
Aspirin
after congenital pseudoarthrosis of ulna surgery, 1357
after free flap transfer, 1582
after toe transfer, 1669
Atasoy-Kleinert volar V-Y flap, in reconstruction of amputated fingertip, 1712-1713, 1713*f*
Athletes, scaphoid fractures in, management of, 603
Atypical antidepressants, for complex regional pain syndrome, 1812*t*
Autograft(s). *see also* Allograft(s); Xenograft
for forearm fracture nonunion, 800
hemihamate, for proximal interphalangeal joint fracture-dislocation, 284
outcomes of, 293
postoperative protocol for, 293
preferred technique for, 291-293, 291*f*-294*f*, 293*b*
Autologous blood, injection of, for epicondylitis, 865
Autonomic nervous system, in complex regional pain syndrome
dysfunction of, 1802-1803
evaluation of, 1807
Avanta SR TMC prosthesis, 361-362
Avascular necrosis
after radial head fractures, 761, 761*f*
of capitate, 649
vascularized bone grafting for, 1613
Avulsion fracture(s)
of metacarpal bases, 244
of radius, 527

Avulsion injury(ies). *see also* Mangling injuries
of brachial plexus, free muscle transfer for, 1180-1184
complications of, 1184
donor muscle selection in, 1181-1182
operative technique of, 1181-1183, 1181*f*-1182*f*, 1184*b*
outcome of, 1184, 1184*f*
postoperative protocol for, 1183
subsequent surgery for, 1183-1184
of nail bed, 321, 321*f*
of triceps, 878-881, 879*f*, 881*b*
preferred method of treatment of, 880-881, 880*f*-881*f*
Axial fracture-dislocations, in complex carpal instability, 473-475, 474*f*-475*f*
Axial instability, after radial head fractures, 764-766, 765*f*-766*f*
Axial-pattern flap(s), 1539-1540, 1540*f*, 1574. *see also* Skin flap(s)
distant, 1564-1568
groin, 1564-1568, 1564*f*, 1566*f*-1567*f*, 1568*b*
for mangling injuries, 1511, 1511*f*
regional, 1552-1554
cutaneous, 1554
fasciocutaneous, 1555, 1555*f*. *see also* Fasciocutaneous flap(s)
fillet, 1552-1554, 1554*f*
latissimus dorsi, 1561-1562, 1562*f*, 1563*b*
musculocutaneous, 1561-1562
neurovascular island, 1552-1554, 1553*f*
radial artery forearm, 1555-1558, 1556*f*-1559*f*, 1559*b*
reversed posterior interosseous artery, 1558-1561, 1560*f*
ulnar artery forearm, 1558
transposition, 1543-1545
digital artery island, 1546-1547, 1548*f*
flag, 1545, 1545*f*
kite flap (first dorsal metacarpal artery flap), 1545-1546, 1546*f*
second dorsal metacarpal artery flap, 1546, 1547*f*
Axilla, contractures of, postburn, 1943-1944
Axillary block, 8, 8*f*
Axonal transport, 981
Axonotmesis, 1148, 1010.*e*1-1010.*e*2, 1010.*e*2*t*

B

Bacillary angiomatosis, AIDS and, 120-121, 120*f*
Bacillus anthracis, 56, 68-69. *see also* Anthrax
Bacteria
in Hansen disease, 103-104
in wound, determination of, 1530
Bacterial infections. *see also specific infection*
chronic, 67-77
actinobacillosis, 67-68
actinomycosis, 68
anthrax, 68-69, 69*f*
botryomycosis, 69-70
brucellosis, 70
eight-pack tissue culture for, 65*t*
etiology, diagnosis, and treatment of, 63*t*
mycetoma, 70-73, 71*f*, 72*b*
neutrophilic dermatoses, 75-77, 77*f*
pyoderma gangrenosum, 75-77, 76*f*
syphilis, 73-74, 73*f*
tularemia, 74
yaws, 74-75, 75*f*
of nails, 331, 331*f*
Ballistic injuries, associated with humeral fractures, 726
Ballottement test, 693
Barton fracture, 525*f*, 527. *see also* Radius, distal, fracture of
dorsal, management of, 568, 569*f*-570*f*
Basal cell carcinoma, 1973-1975, 1976*f*
classification of, 1974, 1974*t*, 1976*f*
of perionychium, 334
treatment of, 1974-1975, 1977*f*-1978*f*
Basal cell nevus syndrome. *see* Gorlin syndrome
Basal joint
of thumb
composite radial forearm flap for, 1697-1699, 1700*f*, 1701*b*, 1699.*e*1*f*
osteoplastic reconstruction for, 1696-1697, 1697.*e*1*f*
of thumb, amputation with preservation of, 1696-1699
pollicization for, index/long finger stump in, 1699-1703, 1702*f*-1704*f*, 1705*b*
Basilar styloid fracture, 559-561
Bayne classification, modified, of radial longitudinal deficiency, 1328, 1329*t*
BCC. *see* Basal cell carcinoma
Beals syndrome, arthrogryposis in, 1367*f*
and camptodactyly, 1388
Bell classification, modified, of brachydactyly, 1239, 1241*t*
Below-elbow amputation, 1737. *see also* Amputation
Bending fractures, of radius, 527, 567-568, 568.*e*1*b*, 568.*e*1*f*-568.*e*13*f*, 568.*e*3*b*, 568.*e*7*b*, 568.*e*9*b*, 568.*e*11*b*
Benign juvenile melanoma, 1966
Bennett fracture, 272-273
operative management of, 274*b*
treatment of
complications of, 273
expected outcomes of, 273
preferred method of, 272, 272*f*-273*f*
Biceps
rupture of, 871-878, 878*b*
diagnosis of, 871-872, 872*f*
postoperative treatment protocol after, 877-878
treatment of, 872-873
for acute complete tears, 875-878
complications of, 874
expected outcomes of, 874
for partial tears, 874-875
pertinent anatomy of, 873-874, 873*f*-875*f*
preferred method of, 874-875
single-incision technique in, 875
two-incision repair of, 875-877, 876*f*-878*f*
transfer of, to triceps, in tetraplegic patient, 1127-1129, 1128*f*, 1129*b*
Bicolumnar fractures, of distal humerus, 702, 702*f*
in healthy bone, 721-724, 721*b*
Bier block, 10-11
Bilayer matrix wound dressing, 1711-1712, 1712*f*
Bilhaut-Cloquet procedure, for thumb duplication, 1307, 1307*f*, 1310-1313
Biobrane glove, for burns, 1932, 1932*f*
Biofeedback, for complex regional pain syndrome, 1817
Biologic severity, of Dupuytren disease, 132-133
Biology, Dupuytren surgery and, 138
Biomechanics
in humeral fracture fixation, 719-720
of injured hand, 1492-1495, 1493*f*
case study for, 1492.*e*1*b*, 1493.*e*2*f*, 1492.*e*1*f*, 1493.*e*1*f*, 1492.*e*2*f*, 1493.*e*1*b*
of radial head, 737-740, 739*f*-740*f*
of scaphoid fractures, 590-591
of shoulder, 1186
of thumb opposition, 1026
of wrist, 423-426, 423*f*, 425*f*-426*f*
Biopsy
in Hansen disease
nerve, 106, 108-109
skin, 108, 108*t*
for musculoskeletal tumors, 1990-1992
excisional, 1991-1992
incisional, 1991
needle, 1990-1991
open, 1991, 1991*f*, 1992*b*
of soft tissue sarcoma, 2015
Bioresorbable screw, for scaphoid fractures, 596
Bipolar latissimus dorsi transfer, for arthrogryposis, 1376-1378, 1378*b*
complications of, 1378
contraindications to, 1376
indications for, 1376
postoperative management and expectations after, 1378

Bipolar latissimus dorsi transfer, for arthrogryposis *(Continued)*
preferred method of, 1378
technique of, 1376-1378, 1377*f*
Bipolar transplantation
of latissimus dorsi muscle, 1198
of pectoralis major muscle, 1199-1201
Bisphosphonates, for complex regional pain syndrome, 1815, 1816*t*
Bites
animal, 46-48. *see also specific animal*
antibiotic recommendations for, 21*t*
human, 48-50, 49*f*-50*f*
Blastomycosis, 85
Bleeding, postoperative, after free flap transfer, 1582
Bleomycin, intralesional injection of, for warts, 122-123
Blisters, 1927
Blood, autologous, injection of, for epicondylitis, 865
Blood clotting, perioperative management of, 909
Blood supply
to hook of hamate, 632
of lunate, 638, 640*f*
to perionychium, 318, 319*f*
of radial head, 739
of scaphoid bone, 590, 590*f*
Blood vessels. *see also* Artery(ies)
repair of, in microvascular toe transfer, for hypoplastic digits, 1269
Blue nevus, 1966. *see also* Nevus (nevi)
Body-powered prostheses, 1740, 1740*f*-1741*f*, 1758, 1759*f*
Bone(s). *see also named bone, e.g.*, Humerus
defects of, free flaps for, 1609
exposed, fingertip amputation with, 1711-1717
growth stimulators of, 607
healthy, bicolumnar fractures in, 721-724, 721*b*
heterotopic, after radial head fractures, 764, 764*f*
preparation of, in toe transfer, 1644-1645, 1666
transverse removal of, in cleft hand, 1246
Bone cysts
aneurysmal, 2024-2025, 2024*f*-2025*f*
unicameral, 2024, 2024*f*
Bone graft(s)
for arthritis mutilans, 1900, 1900*f*
conventional, biology of, 1612
corticocancellous, in osteotomies, 577
for distal radius fractures, alternatives to, 546.*e6t*
iliac, 543-546
for Kienbock disease, 643
based on fourth and fifth extensor compartment arteries, 643-644, 643*f*-644*f*
Bone graft(s) *(Continued)*
based on second or third metacarpal, 644, 645*f*
technique for vascularized bundle implantation in, 644-646, 645*f*-646*f*
for mangling injuries, 1500, 1521, 1522*f*
for scaphoid nonunion
1,2 ICSRA in, 617-618, 617*f*-618*f*
Fernandez-Fisk wedge graft, 612-614, 613*f*
Green's modification of Russe technique in, 610-611, 610*f*
harvesting of, percutaneous, 615-616
hybrid Russe procedure in, 611-614, 611*f*-613*f*
Matti technique in, 610-611
Matti-Russe technique in, 610-611
nonvascularized, 610, 610*f*
outcomes of, 618
percutaneous, arthroscopic technique in, 615
postoperative care after, 616
radial, vascular anatomy of, 617
substitute, 615
vascularized, 616-617
from dorsal capsular pedicle, 619, 619.*e1b*, 619.*e1f*-619.*e3f*
from femoral condyle, 619, 620*f*
from iliac crest, 619
pedicled on volar carpal artery, 618-619, 619*f*
from thumb metacarpal, 619
vascularized, 1612-1642
advantages of, 1613
biologic failure of, 1613
biology of, 1612
for carpal defects, 1613-1614
complications of, 1615-1617
donor site in, 1614-1615
complications related to, 1628-1629
exposure and pedicle dissection, 1627
from femoral condyle, 1625-1627, 1626*f*
from fibula, 1613*f*, 1618*f*
following trauma, 1624
from humerus, 1634
from iliac crest, 1620-1621
indications for, 1613-1614
long bone reconstruction and, 1617-1624
manufactured, 1634-1635
medial femoral condyle corticoperiosteal flap harvest, 1627-1628
medial femoral condyle graft aftercare, 1628
medial femoral condyle osteochondral graft harvest, 1628
medial femoral condyle vascularized, 1628, 1628*f*
Bone graft(s) *(Continued)*
pedicle *versus* free flap, 1612
periosteal, 1624-1634
from pisiform, 1634
postoperative monitoring of, 1615
preoperative planning for, 1614-1615
recipient site in, 1614
results of, 1637-1639
from rib, 1634
from scapula, 1634
selection of, 1614-1615
Bone grafting, 792
for ulnar shaft fractures, 796
Bone loss
associated with humeral fractures, 726
segmental, vascularized bone grafting for, 1613
results of, 1621-1624
in thumb deformities, 1899, 1900*f*
Bone scan, 1615, 1615*f*
prior to free flap transfer, 1577
radioactive. *see* Scintigraphy
Bone tumors, 1987-2035
benign, 2020-2026
aneurysmal bone cyst as, 2024-2025, 2024*f*-2025*f*
chondromyxoid fibroma as, 2023
enchondroma as, 2020-2021, 2020*f*, 2021*b*
giant cell tumor as, 2025-2026, 2026*f*-2027*f*, 2027*b*
Maffucci syndrome as, 2021
multiple enchondromatosis as, 2021, 2022*f*
osteoblastoma as, 2023-2024
osteochondroma as, 2022
osteoid osteoma as, 2023, 2023*f*
periosteal chondroma as, 2021-2022, 2022*f*
unicameral bone cysts as, 2024, 2024*f*
malignant, 2026-2032
chondrosarcoma as, 2026-2027, 2028*f*
Ewing's sarcoma as, 2028-2031, 2030*f*
metastatic, 2031-2032, 2031*f*
osteogenic sarcoma as, 2027-2028, 2029*f*
Bone-ligament-bone grafts, scapholunate ligament replacement with, 442-443
Botryomycosis, 69-70
Botulinum toxin (Botox)
for lateral epicondylitis, 865
for shoulder weakness and deformity, in brachial plexus birth palsy, 1410
for spasticity, 1088
for vasospastic disorders, 2053
Boutonnière deformity, 169, 1931, 1940, 172.*e1b*, 172.*e1f*-172.*e2f*
acute, open, 170, 171*b*, 171*f*
preferred method of treatment of, 170-171

Boutonnière deformity *(Continued)*
chronic, closed, 171-172, 174*b*
Curtis staged reconstruction of, 172-174, 173*f*
surgical techniques to, 172-174
exercise program for, 170*f*
lateral band mobilization and relocation for, 172
pathomechanics of, 169*f*
in rheumatoid arthritis, of fingers, 1890-1894
stage I, 1891-1892
extensor tenotomy for, 1891-1892, 1891*f*
stage II, 1892-1893, 1892*f*
stage III, 1893-1894
joint fusion for, 1893-1894, 1893*f*
treatment options for, 1891*t*
tendon grafts for, 172
tenotomy for, 172
of thumb, 1894-1896, 1895*f*
operative treatment
indications for, 1894-1896, 1895*t*, 1896*f*
options of, 1895*t*
Bowen disease, 1972, 1973*f*
Bowing, traumatic, of forearm, 1460-1461, 1461*f*
operations for, 1464
Boxer's fracture, 233-236
closed reduction of, 233-234, 234*f*
open reduction of, 235
operative management of, 237*b*
preferred method of treatment of, 235-236, 235*f*-236*f*
Boyes' preoperative classification, in flexor tendon grafting, 202*t*
Boyes tendon transfer, for radial nerve palsy, 1070-1071, 1071*b*
postoperative management of, 1071
Brachial plexus, 6*f*
anatomy of, 1391, 1392*f*
surgical, 1146, 1147*f*
catheters, 3, 5
Brachial plexus block
axillary and, 8
interscalene and, 6
perivascular, in anticoagulation therapy, 2
supraclavicular and, 6-7
Brachial plexus injury, 1146-1207
after thoracic outlet syndrome surgery, 974-975
classification of, 1146-1148
electrodiagnostic evaluation of, 1153
gunshot causing, 1149
history of, 1150
imaging evaluation of, 1152-1153, 1152*f*
mechanisms of, 1148-1149
neuropathic pain management in, 1203
patterns of, 1149-1150
from penetrating trauma, 1149
Brachial plexus injury *(Continued)*
physical examination of, 1150-1152, 1151*f*-1152*f*
preoperative evaluation of, 1150-1153
pulmonary function tests in, 1153
surgery for
approaches to, 1155-1158, 1155*f*
infraclavicular exploration in, 1157-1158, 1157*f*
supraclavicular exploration in, 1156-1157, 1156*f*
choline acetyltransferase activity in, 1158-1159
considerations for, 1154-1158
contraindications to, 1153-1154
decisions and priorities of repair in, 1159-1160
elbow reconstruction in, 1192-1202
complications of, 1196
free muscle transfer in, 1202, 1202*f*, 1203*b*
latissimus dorsi transfer in, 1197-1198, 1199*f*, 1200*b*
outcomes of, 1196
pectoralis major muscle transfer in, 1198-1202, 1200*f*-1201*f*, 1201*b*
postoperative protocol for, 1196
preferred methods of, 1195-1202, 1195*f*, 1196*b*
triceps-to-biceps transfer in, 1196-1197, 1197*b*, 1197*f*
free muscle transfer in, 1178-1185
indications for, 1153
informed consent for, 1154
intraoperative assessment in, 1158-1159
nerve action potentials in, 1158, 1158*f*
nerve grafting in, 1160-1163, 1161*f*
nerve reimplantation in, 1185
nerve repair in, 1160
nerve transfer in, 1163-1177
neurolysis in, 1160
preparation and positioning for, 1154-1155
shoulder arthrodesis in, 1190-1192
preferred method of, 1192, 1194*b*, 1194*f*
shoulder reconstruction in, 1186
tendon transfer in, 1187
somatosensory and motor evoked potentials in, 1158
timing of, 1154
wrist arthrodesis in, 1202
traction causing, 1148-1149, 1148*f*
Brachial plexus palsy, pediatric, 1391-1424
diagnosis and differential diagnosis of, 1393
elbow in, 1417-1419, 1418*f*
forearm in, 1419, 1420*f*
hand in, 1419-1421
Brachial plexus palsy, pediatric *(Continued)*
natural history of, 1397
nerve surgery for, 1397-1407, 1401*b*
postoperative management for, 1407, 1408*t*
preferred treatment in, 1406-1407
results of, 1399
technique of, 1400-1404
nerve grafting in, 1397, 1398*f*, 1400-1404, 1401*f*-1404*f*
nerve transfers in, 1404-1406, 1405*f*-1407*f*
timing of, 1398
pertinent anatomy in, 1391-1392, 1392*f*
preoperative evaluation of, 1392-1396, 1393*f*, 1394*t*, 1396*b*
secondary musculoskeletal problems in, 1408-1417, 1409*f*
shoulder weakness and deformity in
historical review of, 1411-1412, 1412*b*
operations for, 1412-1416, 1413*f*-1416*f*
expected outcome of, 1417*b*
postoperative management of, 1416-1417
preferred treatment of, 1416, 1417*f*
preoperative evaluation of, 1409-1411, 1410*f*-1412*f*
wrist in, 1419-1421
Brachioradialis, transfer of
to extensor carpi radialis brevis, in cerebral palsy, 1101, 1101*f*
to extensor pollicis brevis, for thumb-in-palm deformity, 1110-1111, 1112*b*, 1112*f*
to flexor pollicis longus, in median nerve palsy, 1043, 1044*f*
in tetraplegic patient
to flexor pollicis longus, 1141
to flexor pollicis longus, in House's one-stage key pinch reconstruction, 1131, 1132*b*, 1134-1135
Brachioradialis muscle flap, for mangling injuries, 1515, 1519*f*
Brachioradialis-splitting approach, to radial tunnel syndrome, transmuscular, 951, 951*f*
Brachybasophalangy, 1238-1239
Brachydactyly, 1238-1243, 1244*b*
Bell classification of, modified, 1239, 1241*t*
clinical features of, 1241, 1242*f*
epidemiologic findings in, 1239
management of, 1241-1243, 1242*f*-1243*f*
pathologic findings in, 1239-1240, 1240*f*
preferred method of treatment for, 1243
syndromes associated with, 1240*t*

Brachymesophalangy, 1238-1239
Brachymetacarpia, 1238-1239, 1241-1242
Brachytelephalangy, 1238-1239
Brachytherapy, 2016
Brand tendon transfer, for radial nerve palsy, 1071, 1071*b*, 1071*f*
Braun prosthesis, 361-362
Bretylium, for complex regional pain syndrome, 1815*t*, 1816
Brown recluse spider venom, 1788
Brucellosis, 70
Brunelli flap, for soft tissue defects of thumb, 1681*f*
Brunelli ligament reconstruction technique, for scapholunate dissociation, 443, 444*b*, 444*f*-446*f*
Bryan-Morrey "triceps-sparing" approach, to distal humeral fractures, 713-714, 714*f*
Buck-Gramcko technique, for short metacarpal lengthening, 1242-1243, 1243*f*
Bundle sutures, completion of, 994*f*
Bunnell intrinsic tightness test, 339, 339*f*
Bunnell repair, of extensor tendon laceration, 158, 159*f*
Bunnell tendon-to-bone pull-out technique, modified, 206, 207*f*
Bunnell's opponensplasty, in median nerve palsy, 1030*f*, 1031
Bunnell's "tendon T" operation, in restoration of metacarpal arch, 1059
Buoy flap, in monitoring of bone grafts, 1615
Bupivacaine, characteristics of, 4*t*
Burns, 1926-1957, 1954*b*
  anatomy in, 1926
  chemical, 1948-1951
    agents and tissue damage by, 1952*t*
    management of, 1949-1951, 1950*f*-1951*f*
  classification of, 1928-1929, 1928*b*, 1929*f*
  complications of, 1935
    early hypergranulation as, 1935
    graft loss as, 1935
  deformities after, 1935-1944
    amputation, 1942-1943
    axillary contractures, 1943-1944, 1944*f*
    boutonnière, 1940
    claw, 1937-1938, 1939*f*
    contractures of the dorsum of the hand, 1940-1941, 1942*f*
    contractures of the thumb, 1938-1939, 1941*f*
    digital flexion contracture, 1939-1940
    elbow contractures, 1943, 1943*f*
    nail bed, 1937, 1939*f*
    prevention of, 1936
Burns *(Continued)*
    treatment of, 1936-1944, 1937*f*-1938*f*
    volume deficiencies and contour irregularities in, 1941-1942, 1942*f*
    web space syndactyly and interdigital contractures, 1938, 1940*f*
  depth of, determination of, 1929
  electrical, 1945-1948
    clinical manifestations of, 1946-1947, 1947*f*
    complications in, 1948
    epidemiologic findings in, 1945
    mechanism and classification of, 1946
    pathophysiologic conditions in, and properties of electricity, 1945-1946
    rehabilitation in, 1948
    treatment of, 1947-1948
      general management in, 1947
      surgical management in, 1947-1948, 1949*f*
  epidemiologic findings in, 1926
  frostbite, 1951-1953
    diagnosis of, 1952
    pathophysiologic findings in, 1952
    treatment of, 1952-1953, 1953*b*
  management of
    anterolateral thigh flaps in, 1945
    control of edema in, 1929
    débridement in, 1933
    escharotomy in, 1929-1930, 1930*f*
    excision and grafting in, 1932-1935, 1933*f*-1934*f*
    flap coverage in, 1934, 1935*f*
    forearm flaps in, 1945
    free serratus fascial flap in, 1945
    groin flap in, 1944
    initial evaluation in, 1927-1931
    lateral arm flap in, 1945
    local wound care in, 1931-1932, 1932*f*
    random abdominal wall flap in, 1944
    splinting in, 1930-1931, 1931*f*
    tensor fasciae latae flap in, 1944-1945
    treatment goals in, 1927, 1928*f*
  pathophysiology of, 1926-1927, 1927*f*
  reconstructive tools for, 1944-1945
  rehabilitation after, 1953-1954, 1953*f*-1954*f*
Bursa, radial and ulnar, infections of, 32-34
Bursitis, tuberculous, 96
Buruli ulcer, 92-93, 93*f*

C

Cadaver triangular ligament, 156*f*
Calcific tendinitis, 57-58, 1905-1906, 1906*f*
Calcinosis, 58*f*, 1840
Calcitonin, for complex regional pain syndrome, 1815, 1816*t*
Calcium channel blockers (CCBs)
  for complex regional pain syndrome, 1814, 1815*t*
  for vasospasm, 2044, 2053
Camitz opponensplasty, in median nerve palsy, 1033-1034, 1034*f*-1035*f*
Camptodactyly release, for arthrogryposis, 1387-1390, 1389*b*
  complications of, 1390
  contraindications to, 1388
  indications of, 1387-1388, 1388*f*-1389*f*, 1388*t*
  postoperative management and expectations after, 1390
  preferred method of, 1389
  technique of, 1388-1389
Cancellous trabeculae, 739
Candidiasis, 85
Capillaroscopy, nailfold, for vascular disorders, 2039
Capillary leak, 1927
Capillary refill, postoperative, in free flap transfer, 1582
Capitate, 660*f*
  avascular necrosis of, 649
  fracture of, 629-631, 629*b*
    in children, 1447, 1447*f*
    incidence of, 625*t*
    mechanism of injury in, 630, 630*f*
    radiographic features of, 630, 631*f*
    treatment of, 630-631, 632*f*
Capitate-lunate instability pattern (CLIP) wrists, 461
Capitate-lunate-hamate-triquetrum fusion, 391-393
  alternative methods of fixation for, 393-394
  contraindications for, 392
  critical points on, 395*b*
  indications for, 391-392, 392*f*
  postoperative management for, 393
  preferred method of, 392-393, 393*f*-394*f*
Capitellum, fracture of, 737, 738*f*. *see also* Humerus, distal, fractures of; Radius, head of, fracture of
  arthroscopic fixation of, 899, 900*f*
  classification of, 703, 703*f*-704*f*
  complex, 725-726, 725.*e*3*b*, 725.*e*3*f*-725.*e*4*f*
  simple, 725
  variant, 725
Capitolunate arthrodesis, with scaphoid excision, 394-395, 395*f*
Capreomycin, dosage of, 101*t*
Capsular contracture, of stiff joint, 339-340
Capsular shrinkage
  arthroscopic, technique for, 693
  for midcarpal instability, 460

Capsulectomy, of distal radioulnar joint contracture
dorsal, 510
outcomes of, 511
volar, 510-511
Capsulodesis
dorsal, in scapholunate dissociation, 442, 442*f*
palmar, of metacarpophalangeal joint, in ulnar nerve palsy, 1049-1050, 1049*f*, 1050*b*
Capsuloligamentous components, of radiocapitellar joint, 813
Capsulotomy
for metacarpophalangeal joint contractures, 341.*e*1
in secondary reconstruction after mangling injury, 1523-1524
Carbamazepine, for complex regional pain syndrome, 1813*t*
Carcinoma, 1959
Cardinal signs, in early diagnosis, for Hansen disease, 105-107
Carpal bone(s). *see also named bone, e.g.*, Scaphoid; Wrist
alignment of, measurement of, in wrist instability, 430, 430*f*-431*f*
distal row of
kinematics of, 423, 423*f*
ligaments of, 422-423
stabilization of, 425
fracture of, 588-652
in children, 1448*b*
incidence of, 625*t*
in mangling injuries, treatment of, 1500
other than scaphoid, 624-649
growth in, 1444
isolated, dislocation of, in complex carpal instability, 475-476, 475*f*
ossification centers of, 1444
proximal row of
kinematics of, 423
stabilization of, 425
stability of, soft tissue structures in, 1444-1445
Carpal collapse
lunotriquetral dissociation with, 451
chronic, treatment of, 456
lunotriquetral dissociation without
acute, treatment of, 455
chronic, treatment of, 455-456, 455*f*-456*f*
Carpal height ratio, measurement of, in wrist instability, 430, 431*f*
Carpal instability, 418, 433-463
analysis of, 433, 433*t*, 434*f*
chart of, 661*t*
chronicity of, 433
classification of, 434
complex, 465
axial fracture-dislocations in, 473-475, 474*f*-475*f*
Carpal instability *(Continued)*
isolated carpal bone dislocations in, 475-476, 475*f*
perilunate dislocations in
dorsal
greater-arc injuries and, 470
lesser-arc injuries and, 465-470, 465*f*-466*f*
treatment of, 465-470
palmar, 472, 474*f*
perilunate fracture-dislocations in, dorsal, 470-472
transscaphoid, 470-471
transscaphoid-transcapitate, 471-472, 472*f*
transtriquetrum, 472, 473*f*
treatment of, 472, 473*f*
radiocarpal dislocations in, 473
as contraindication for capsular release, 691
definition of, 433
diagnosis of, 428-432
arthrography in, 432
arthroscopy in, 432
cineradiography in, 432
clinical examination in, 428
computed tomography scans in, 430-431, 431*f*
magnetic resonance imaging in, 432
measurement of bone alignment in, 430, 430*f*-431*f*
radiological examination in, 428-430
additional views, 429-430, 429*f*
distraction views, 431
routine views, 428-429, 428*f*-429*f*
stress views, 431, 432*f*
ultrasonography in, 432
direction of, 433
dissociative, 434-457
lunotriquetral, 450-457
scapholunate, 434-450. *see also* Scapholunate dissociation
etiology of, 433
location of, 433
mechanics of, 661
nondissociative, 457-463, 458*f*
midcarpal, 459
radiocarpal, 458-459, 458*f*
severity of, 433
wrist arthroscopy for, 661-665
Carpal kinematics, 423-424, 423*f*, 425*f*
Carpal kinetics, 424-426
Carpal ligament(s)
injury to
distal radial fracture associated with, 575
pathomechanics of, 426-428, 427*f*
intrinsic, 421*f*-422*f*, 422-423
Carpal malalignment, defined, 529, 530*f*
Carpal misalignments, 463-464
adaptive, 463
secondary to deformity of distal radius, 463-464
Carpal misalignments *(Continued)*
secondary to deformity of lunate, 464
secondary to deformity of scaphoid, 464
secondary to STT arthritis, 464
Carpal stabilization
ligaments in, 425, 425*f*
muscles in, 425-426, 426*f*
Carpal tunnel, ganglion in, 2009
Carpal tunnel decompression, expected outcome after, 935
Carpal tunnel release, open, 934-935, 934*f*, 935*b*
Carpal tunnel syndrome, 930-935
anatomy of, 930-932, 930*f*-932*f*
management of
nonoperative, 932-933
surgical, revision of, preferred method of, 1822-1823, 1823*f*
provocative tests for, 926*t*
recurrent, 954-955
revision surgery for, 954-955
treatment of, operative, 933-935
Agee single-portal endoscopic technique in, 933-934
Chow two-portal endoscopic technique in, 933
postoperative care after, 935
preferred method of, 934-935, 934*f*, 935*b*
Carpal wedge osteotomy, for arthrogryposis, 1380-1382, 1382*b*
complications of, 1382
contraindications to, 1380-1381
indications for, 1380, 1381*f*
postoperative management and expectations after, 1382
preferred method of, 1382
preoperative planning in, 1381
technique of, 1381, 1382*f*
Carpectomy, proximal row
arthroscopic, 690
for scaphoid nonunion advanced collapse, 623
for scapholunate dissociation, 450
Carpometacarpal boss, 2007
clinical characteristics of, 2007, 2007*f*
complications in, 2007
operative technique for, 2007, 2007*f*-2008*f*
postoperative care for, 2007
Carpometacarpal (CMC) joint(s)
fusion of, in tetraplegic patient, House's one-stage key pinch reconstruction and, 1134, 1135*f*
injuries of, 175
of thumb, 312-315
dislocations of, 312-315
anatomy in, 312, 312*f*
historical review of, 312
postoperative management and expectations in, 314-315

Carpometacarpal (CMC) joint(s) *(Continued)*
preoperative evaluation of, 312-313, 313*f*
treatment of, 313-314
preferred method of, 313, 314*b*, 314*f*
osteoarthritis of, 359-369
anatomy and biomechanics of, 359-360, 360*f*
complications of, 368-369, 369*f*
critical points on, 366*b*
diagnostic imaging of, 359, 359*f*
epidemiologic findings on, 359
evaluation of, 359
expected outcomes on, 366-368, 367*t*
indications and contraindications for, 360-362
operative techniques on, 362-364
physical examination for, 359
postoperative management and expectations for, 366-369
preferred method of treatment for, 364-365, 365*f*-366*f*
treatment for, 360-364
nonoperative, 360-361
other procedures and devices for, 362
Carpometacarpal fracture-dislocations, 244-246
multiple, 245
preferred method of treatment of, 245-246, 245*f*-246*f*
of ring finger, 244
of small finger, 244-245
Carpus. *see also named bone, e.g.*, Scaphoid; Wrist
amputation through, 1737
indications for vascularized bone grafting in, 1624-1625
Cast(s). *see also* Immobilization
postoperative, in tetraplegic patient, 1138-1139
for proximal interphalangeal joint contractures, 340.*e*2
Cast index, 1449, 1453*f*
Casting, for distal radius fractures, 516.*e*1
Cat bites, infection from, 46-47
Catch-up clunk phenomenon, in midcarpal instability, 459
Caterpillars, venomous, 1788, 1789*f*
Catfish, marine and freshwater, venomous, 1792-1793, 1793*f*, 1793.*e*1*f*
Causalgia, 1797
nerve injury and, 1010.*e*3
CBSQ. *see* Cervical Brachial Symptom Questionnaire ("CBSQ")
CCH success, 133
CD4+ T-cell, in acquired immunodeficiency syndrome, 119.*e*1, 119.*e*1*t*
Cellulitis, 17
antibiotic recommendations for, 21*t*
Cement burns, treatment of, 1951
Central hand deficiencies. *see* Cleft hand
Central nervous system, in complex regional pain syndrome, ablative techniques and, 1817
Central slip, 338.*e*5
anatomic integrity of, 155-156, 157*f*
Central slip tenotomy, for swan neck deformity, 1115, 1116*b*, 1116*f*
Centralization
of extensor tendons, 413-414
in management of radial longitudinal deficiency, 1329-1331, 1332*f*
Cerclage wiring
for metacarpal shaft fractures, 239, 237.*e*1*t*
for proximal interphalangeal joint fracture-dislocation, 283-284, 284*f*
postoperative protocol for, 291
preferred method for, 291-293, 291*f*
Cerebral palsy, 1080
Cervical Brachial Symptom Questionnaire ("CBSQ"), 965*f*-967*f*
Cervical incision, transverse, in brachial plexus surgery, 1155-1156, 1155*f*
Cervical nerve(s)
brachial plexus formed from, 1146, 1391, 1392*f*. *see also* Brachial plexus *entries*
C5-C6 injury of, 1149
author's preferred treatment of, 1159
decisions and priorities of repair for, 1159
C5-C7 injury of, 1149
decisions and priorities of repair for, 1159
C5-T1 (pan-plexus) injury of, 1150
author's preferred treatment of, 1160
decisions and priorities of repair for, 1159-1160
C8-T1 injury of, 1149-1150
decisions and priorities of repair for, 1159
Cervical nerve root, impingement of, Spurling test for, 927
Cervical nerve transfer, C7, for brachial plexus injury, 1173-1176, 1175*f*-1176*f*
author's preferred technique for, 1176
complications of, 1176
outcomes of, 1176
postoperative care after, 1176
surgical anatomy in, 1175
Cervical plexus nerves, transfer of, for brachial plexus injury, 1177
Cervical ribs
anatomic variants of, 961*f*
in thoracic outlet syndrome, 963
Cervical spine
involvement of, in rheumatoid arthritis, 1833
in thoracic outlet syndrome, 960*f*
Chang Gung Memorial Hospital, toe transfers at, from 1985-2012, 1672*t*
Charcot-Marie-Tooth disease, 923
CHARGE syndrome, radial deficiency and, 1290*f*, 1290*t*
Chauffeur's fracture, 525*f*, 527
management of, 569-570, 570*f*-571*f*
Cheiralgia paresthetica, 947-948
Chemical burns, 1948-1951. *see also* Burns
agents and tissue damage by, 1952*t*
management of, 1949-1951, 1950*f*-1951*f*
Chemical sympathectomy, for complex regional pain syndrome, 1819-1820
Chemotherapy, extravasation, skin loss due to, 1570
Chevron-type slot graft, for short metacarpal lengthening, 1242-1243, 1242*f*
Children
brachial plexus palsy in, 1391-1424. *see also* Brachial plexus palsy, pediatric
flexor tendon reconstruction in, 223-224, 224*b*
indications of, 223
preferred technique of, 224
hand, wrist, and forearm fractures in, 1425-1475. *see also* Fracture(s), pediatric; Fracture(s), *under specific bone*
regional anesthesia in, 2
scaphoid fracture in, 607-608
trigger digits in, 1916
tuberculous osteomyelitis in, 98
Chloroprocaine, characteristics of, 4*t*
Choke vessels, 1540
Choline acetyltransferase activity, in brachial plexus surgery, 1158-1159
Chondral defects, wrist arthritis and, 689, 690*f*
Chondrodesis, for thumb-in-palm deformity, 1112
Chondrodysplasia
Grebe, 1214, 1215*f*
Hunter-Thompson, 1214
Chondroectodermal dysplasia, postaxial polydactyly in, 1232, 1233*f*
Chondroma, periosteal, 2021-2022, 2022*f*
Chondromyxoid fibroma, 2023
Chondrosarcoma, 2026-2027, 2028*f*
Chow two-portal endoscopic technique, for carpal tunnel syndrome, 933
Chromosome disorders, radial longitudinal deficiency associated with, 1329*t*
Chronic exertional compartment syndrome, 1767-1768
Chronic nerve compression, pathophysiology of, 921-924, 922*f*
Chronic regional pain syndrome, after distal radial fracture, 576

Cineradiography
of carpal instability, 432
of lunotriquetral dissociation, 454, 454*f*
of midcarpal instability, 460
Ciprofloxacin, for anthrax, 69
Circular plate fixation, for scaphotrapeziotrapezoid fusion, 390
Clasped thumb, 1324-1325, 1324*f*, 1325*b*
clinical features of, 1324
treatment of, 1324-1325, 1325*f*
Clavicle
bone loss or nonunion of, vascularized grafting for, 1636
as recipient site, in bone grafting, 1636
Claw-hand deformity
postburn, 1930, 1937-1938, 1939*f*
in ulnar nerve palsy, 1047-1056. *see also* Ulnar nerve palsy
postoperative management of, 1056
surgical correction for, 1048-1056
Burkhalter and strait in, 1054-1055
dynamic tendon transfers in, 1051-1056
extensor carpi radialis longus transfer in
dorsal route of, 1054, 1054*f*
flexor route of, 1055, 1055*f*
extensor indicis proprius and extensor digiti minimi transfers in, 1053-1054
flexor and extensor muscle transfer in, 1054-1056
flexor carpi radialis transfer in, 1055-1056
Fowler's wrist tenodesis in, 1051, 1051*f*
palmar capsulodesis of MP joint (Zancolli) in, 1049-1050, 1049*f*, 1050*b*
palmaris longus four-tail transfer in, 1056
Parkes static tenodesis in, 1050-1051, 1050*f*
Riordan static tenodesis in, 1050
static techniques in, 1048-1051
Stiles-Bunnell procedure in, modified, 1051, 1052*f*
superficialis transfer in, 1051-1053
modifications of, 1051-1053
results of, 1053
Clear cell sarcoma, 2020
Cleft, closure of, first web space release and, 1246-1251, 1246*f*, 1249*f*-1251*f*, 1254*f*
Cleft hand, 1244-1255, 1244*f*, 1255*b*
characteristics of, 1245, 1245*t*
classification of, 1245, 1245*t*
clinical features of, 1245
etiologic findings in, 1244, 1245*t*
surgical treatment for, 1245-1255
in absent thumb deformity, 1251, 1254*f*
Cleft hand *(Continued)*
in cleft deformity, 1246-1251
expected outcomes for, 1255
first web space release and cleft closure in, 1246-1251, 1246*f*, 1249*f*-1251*f*, 1254*f*
indications for surgery, 1245-1246
management of the feet, 1251-1255
Miura and Komada technique in, 1251, 1252*f*
Snow-Littler procedure in, 1248, 1248*f*
surgical management of the progressive deformity in, 1246, 1284*f*
syndactyly release in, 1245*f*, 1246
transverse bone removal in, 1246
in type IIB and III, 1251, 1254*f*
Ueba technique in, 1251, 1253*f*
Clenched fist injury, 48-49, 49*f*
Clinodactyly, 1270-1273, 1271*f*, 1273*b*
classification of, 1271*t*
epidemiologic findings in, 1270-1271, 1272*f*
expected outcomes, 1273
management of, 1272, 1273*f*-1274*f*
preferred technique of, 1272-1273
phalangeal anatomy in, 1271-1272
Clofazimine, for multibacillary Hansen disease, 109
Clonidine, for complex regional pain syndrome, 1814
Closed reduction
cast immobilization with
for lesser-arc injuries, 466-467, 467*f*
for perilunate fracture-dislocations, 470-471
with a cast or splint, of phalangeal shaft fractures, 256-257, 257*f*
of distal radial fracture, 530-531
technique for, 530-531, 531*f*-534*f*
of metacarpal neck fractures, 233-234, 234*f*
percutaneous pin fixation with
for lesser-arc injuries, 467-468, 467*f*
for perilunate fracture-dislocations, 471
percutaneous pinning and
of metacarpal shaft fractures, 237-238, 238*f*
of phalangeal shaft fractures, 257, 258*f*-259*f*
plaster immobilization and, of metacarpal shaft fractures, 237, 237*f*
Closed tendon sheath irrigation, for pyogenic flexor tenosynovitis, 30-31, 30*f*
Clostridial myonecrosis, 56
Cnidarians, venomous, 1791-1792, 1792*f*
Coccidioidomycosis, 85-86
Cold sensitivity, vasospasm and, 2052
Cold-stress testing, for vascular disorders, 2039
Collagenase clostridium histolyticum, enzymatic fasciotomy with, for Dupuytren disease, 140
Collar-button abscess, 37-38, 38*f*
case study, 37-38, 38.*e*1*b*, 38.*e*1*f*
treatment for, 38, 39*f*
preferred method of, 39
Collateral ligament(s). *see also* Radial collateral ligament; Ulnar collateral ligament
anatomy of, 338.*e*1, 338.*e*1*f*
injury to, grading of, 279
lateral (LCL), 830
anatomy of, 813, 832, 832*f*
diagnostic imaging of, 831, 831*f*
instability of
ligament reconstruction for
complications in, 835
contraindications to, 833
indications for, 832-833
outcomes in, 835
postoperative management and expectations of, 835
preoperative evaluation of, 830-831
technique in, 833-835, 834*f*
magnetic resonance image of, 831*f*
physical examination of, 830-831
ulnar, 832
medial (MCL), 830
anatomy of, 813, 836-837, 836*f*
anterior bundle of, 836, 839*f*
diagnostic imaging of, 835-836, 836*f*
instability of
ligament reconstruction for
complications in, 840
contraindications to, 837
indications for, 837
outcomes in, 840
postoperative management and expectations of, 839-840
preoperative evaluation of, 835-836
technique in, 837, 838*f*, 840*f*
magnetic resonance image of, 836*f*
physical examination of, 835
posterior bundle of, 836
transverse bundle of, 836
release of, in metacarpophalangeal joint contracture, 340
Colles' fracture, 524-527, 524*f*, 567
malunited, 579*f*
treatment of, 531*f*
Color, of flap, postoperative, 1582, 1582*f*
Column concept, of distal humeral fractures, 701-703
Columnar classification, of distal radial fracture, 524, 527*f*
"Come-along" flexion splint, for elbow contracture, 857, 858*f*

Comminuted fractures
of capitellum, 703, 704*f*
combined articular and supracondylar, 722, 722.*e1b*, 722.*e1f*-722.*e2f*
minimally, management of, 721-722, 721.*e1b*, 721.*e1f*-721.*e2f*
of radial head, management of, 749, 752*f*-753*f*, 755*f*
supracondylar involvement in, 722
Community-acquired infections (CA-MRSA), methicillin-resistant *S. aureus* (MRSA) and, 18
Compartment pressure, measurement of, 1767*t*
Compartment release, sixth, 511-512
Compartment syndrome, 1763-1772, 1772*b*
acute, 1763
diagnosis of, 1765-1768, 1765*f*, 1766*t*
etiologic findings and incidence of, 1764-1765, 1765*f*
events in recognition and understanding of, 1764*t*
exercise-induced, 1763
exertional, 1763
diagnosis of, 1767-1768
impending, 1763
injuries causing, 1766*b*
localized, 1767*f*
in mangling injuries, 1490
neonatal, 1763-1764, 1764*f*
pathophysiologic findings of, 1765, 1765*f*
pertinent anatomy of, 1768
postoperative, 1
snakebite-induced, preferred method of treatment of, 1791
treatment of, 1768-1772
outcomes and expectations after, 1771-1772
postoperative management and, 1771
preferred method of, 1769
types of, 1763-1764
Complete articular loss, 726.*e4b*, 726.*e4f*-726.*e6f*
Complex fracture, of distal radius, management of, 573, 574*f*, 573.*e4b*, 573.*e4f*-573.*e7f*
"Complex instability of the carpus" (CIC), 465
Complex lateral column fracture, 725.*e3b*, 725.*e3f*-725.*e4f*
Complex posterior olecranon fracture-dislocation, of elbow, 784.*e1b*, 784.*e2f*-784.*e3f*
Complex regional pain syndrome (CRPS), 1797-1827, 1829-1830
Budapest criteria in, 1797, 1799*b*, 1804*t*
clinical definitions of, 1797, 1798*f*, 1805*t*
demographics of, 1801-1802
diagnostic testing for, 1805-1807
Complex regional pain syndrome (CRPS) *(Continued)*
autonomic control in, 1807
endurance testing in, 1809-1810
magnetic resonance imaging in, 1805
pain threshold evaluation in, 1805
radiography in, 1805
scintigraphy in, 1806-1807, 1806*f*
sympathetic blockade in, 1808-1809
thermography in, 1809
historical review of, 1797-1798
mechanical nociceptive focus of, 1804-1805
neural dystrophic focus in, management of, 1820
neural injury of
diagnosis of, 1820-1821
preferred method of treatment of, 1821-1822
surgical management of, 1820-1821
painful median nerve and, management of patients with, 1822*b*
physical examination in, 1803-1804
physiology of, 1798-1801, 1800*f*
psychological factors and effects in, 1802
psychological problems mimicking, 1802
staging of, 1810
symptoms and signs of, 1802-1803, 1803*f*
synonyms for, 1798*b*
terms used in, 1799*t*
treatment of, 1810-1811
acupuncture in, 1817
adaptive modalities in, 1818
adrenergic compounds in, 1813-1814
amputation in, 1824
anticonvulsants in, 1813
antidepressants in, 1811-1812, 1812*t*
biofeedback in, 1817
bisphosphonates in, 1815
calcitonin in, 1815, 1816*t*
calcium channel blockers in, 1814, 1815*t*
chemical sympathectomy in, 1819-1820
CNS ablative techniques in, 1817
corticosteroids in, 1814-1815, 1815*t*
epidural agents in, 1816-1817
free radical scavengers in, 1816
hand therapy in, 1818
implantable devices in, 1817
ketamine in, 1815-1816
level of evidence for, 1817
membrane-stabilizing agents in, 1813
multidisciplinary approach to, 1811
multidisciplinary team approach to, 1818
neuromuscular blocking agents in, 1815
Complex regional pain syndrome (CRPS) *(Continued)*
parenteral medications in, 1815*t*, 1816
patient expectations in, 1818-1819
pharmacologic interventions, 1811
preferred method of, 1818
surgical outcomes and complications in, 1820
surgical sympathectomy in, 1820
types of, 1798*t*
Complex tissue loss, vascularized bone grafting for, 1613
Composite contracture, severe, treatment for, Dupuytren disease and, 143
Composite defects, free flaps for, 1609
Composite flaps, 1577. *see also* Free flap(s)
for mangling injuries, 1515-1519, 1520*f*
Composite rib-serratus anterior-latissimus dorsi osteomuscular flap, 1635*f*
Composite (tension band) wiring. *see also* Tension band wiring
for metacarpal shaft fractures, 239, 237.*e1t*
Compound muscle action potentials (CMAPs), 929
Compression fracture, of radius, 527
management of, 571-572
Compression neuropathy(ies), 921-958
evaluation of, 924-930, 925*f*-926*f*
cutaneous pressure thresholds in, 928
electrodiagnostic studies in, 928-930
electromyography in, 929
light moving touch in, 928
nerve conduction studies in, 929
provocation tests in, 924-927, 926*t*
sensory, 927-928
shoulder and scapular movement in, 927
two-point discrimination in, 928
vibration thresholds in, 928
in Hansen disease, 112, 112*f*
of median nerve, 930-938. *see also* Carpal tunnel syndrome
in elbow and forearm, 935-938, 936*f*, 939*b*
anatomy of, 936
operative technique of, 937-938
postoperative care after, 938
preferred method of, 937-938, 937*f*-938*f*
pathophysiology of, 921-924, 922*f*
double-crush mechanism in, 922-923
longitudinal nerve mobility in, 923
systemic conditions and personal factors in, 923
of radial nerve, 947-949. *see also* Interosseous nerve syndrome, posterior; Radial tunnel syndrome

Compression neuropathy(ies) *(Continued)*
proximal, 953
superficial, 947-949, 948*f*
surgery for previously failed procedures in, 953-956
of ulnar nerve, 938-947. *see also* Guyon canal compression
Compression plating, for radial shaft fractures, 791, 793-794, 795*f*
contouring of, 792
Computed tomographic (CT) myelography, of brachial plexus injury, 1152
Computed tomography (CT)
in brachial plexus birth palsy, 1395-1396, 1408, 1409*f*
of carpal instability, 430-431, 431*f*
of distal radial fracture, 522-523, 523*f*
of distal radioulnar joint, 486, 486*f*
of musculoskeletal tumors, 1990
prior to free flap transfer, 1577
in radioulnar synostosis, 803-804, 804*f*
of scaphoid fractures, 592
Computer adaptive test (CAT), 1395
Computer-aided design and computer-aided manufacture (CAD/CAM), 1761
Concertina deformity, 464
Conduction block, in responses to nerve injury, 983-984
prolonged, 1010.*e*1-1010.*e*2
Conduction studies, of compression neuropathies, 929
Conduit, synthetic, in neuroma, 1014-1019, 1015*b*
Condylar fractures, of phalanges, 249, 250*f*-251*f*
operative management of, 250*b*
Congenital absence, of digits, reconstructive, options for, 1650-1651, 1653*f*
Congenital pseudarthrosis, vascularized bone grafting for, 1624
Conjoined lateral band, 338.*e*3, 338.*e*5, 338.*e*5*f*
Connective tissue
diseases of, 1832-1903. *see also specific disease e.g.*, Rheumatoid arthritis
elements of, 981-982, 981*f*
features of, 982
Conservative wrist, in rheumatoid arthritis, 376, 378*f*
Constriction ring syndrome, 1255-1258, 1256*f*-1257*f*, 1258*b*. *see also* Amniotic disruption sequence
classification of, 1255, 1256*t*
clinical features of, 1255, 1257*f*
etiologic findings in, 1255
management of, 1255-1258
treatment of, 1256-1257
Contagious pustular dermatitis, 123-124, 124*f*
Continuous autonomic blockade, for complex regional pain syndrome, 1817, 1817*f*
Continuous passive motion (CPM), 853
device, for elbow contracture, 857-858
Contracture(s)
of axilla, postburn, 1943-1944, 1944*f*
congenital, 1365
digital flexion, postburn, 1939-1940
of distal radioulnar joint, 510-511
after radial fracture, 582-584
operative technique for, 510-511
outcomes of, 511
of dorsum of hand, postburn, 1940-1941, 1942*f*
Dupuytren. *see* Dupuytren contracture (DC)
of elbow. *see also* Elbow, stiff
in arthrogryposis, 1366
causes and prevention, 843-844, 844*f*
classification of, matching operative plan and, 848-849
duration of, 845
postburn, 1943, 1943*f*
release of
anesthesia for, 849
for arthrogryposis, 1372-1376, 1376*b*
complications of, 1376
contraindications for, 1373
indications for, 1372-1373, 1373*f*-1375*f*
postoperative management and expectations after, 1376
preferred method for, 1376
technique of, 1373-1376, 1375*f*
for fixed deformity, 1092-1093, 1092*b*, 1093*f*
indications for, 847
timing of, 845, 846*f*
extrinsic, assessment of, 339-340
of fingers, after separation of syndactyly, 1221, 1228-1230
first web space
postburn, 1938, 1940*f*
in scleroderma, 1841
flexion, after proximal interphalangeal joint arthroplasty, for fracture-dislocation, 290
intrinsic
after trauma, 343.*e*1-343.*e*2
with muscle fibrosis, 343.*e*2
assessment of, 339-340
of metacarpophalangeal joint
extension, release of, 340-341
late posttraumatic interosseous, 343.*e*1-343.*e*2, 343.*e*2*f*
nonoperative treatment of, 340.*e*1
operative treatment of, preferred method of, 1823-1824, 1824*f*
posttraumatic, 295-296, 296*b*, 296*f*
prevention and correction of, in tendon transfers, 1023
Contracture(s) *(Continued)*
of proximal interphalangeal joint
extension, release of, 341-343, 343*f*
flexion, release of, 341
expectations and outcomes in, 341.*e*2
preferred approach for, 341, 342*f*
late posttraumatic
interosseous, 343.*e*1-343.*e*2, 343.*e*2*f*
intrinsic, 343.*e*1
nonoperative treatment of, 340.*e*1-340.*e*2
release of, in secondary reconstruction, 1523-1524
of shoulder, in arthrogryposis, 1365
of thumb, postburn, 1938-1939, 1941*f*
Volkmann, 1772-1786, 1773*f*. *see also* Volkmann contracture
ischemic, 1764
Conventional graft, 1612
Cooper ligament, 836
Corals, venomous, 1791-1792, 1792*f*
Cord(s), of Dupuytren disease, 129-131
digital, 145
patterns of, 137-138, 137*f*
Cord traction, in procedure, for Dupuytren disease, 146-147
Core decompression, for Kienbock disease, 646
Core sutures, of zone 2 tendon lacerations, 188, 188*f*-189*f*
Coronal shift, 561-563
Coronoid fractures, arthroscopic fixation of, 899-901, 901*f*
Coronoid process
anatomy of, 770-771, 772*f*
fracture of
in complex traumatic elbow dislocation, 815, 816*f*
preferred technique of, 820-822, 821*b*, 822*f*
treatment of, in acute injury, 819-820
treatment of, 780
preferred method of, 782
Corset suture, 158-159
Cortical reorganization, 143
Corticoperiosteal flap, vascularized, in grafting from femur, 1625*f*
Corticosteroids
for complex regional pain syndrome, 1814-1815, 1815*t*
for epicondylitis, 865
for trigger finger, 1908
technique of injection of, 1909-1910, 1917
Cortisone, for complex regional pain syndrome, 1815*t*
Costoclavicular triangle, in thoracic outlet syndrome, 962*f*, 964
Cotton-Loder position, for distal radius fractures, 516.*e*1

Crepitus, in mangling injuries, 1490
CREST acronym, 1839
Cronin's technique, of digital separation, in syndactyly, 1220-1221, 1223*f*, 1225*f*
Cross-arm flap(s), for first web space coverage, 1695-1696, 1695*f*
Cross-finger flap(s), 1550-1552, 1551*f*. *see also* Skin flap(s)
  pedicle, in reconstruction of amputated fingertip, 1714-1716, 1715*f*
  reversed, 1552
  for soft tissue defects of thumb
    dual innervated, 1684, 1685*f*, 1684.*e2f*
    innervated, 1681-1684, 1681*b*
    radial-innervated, 1682-1684, 1683*f*, 1684*b*, 1684.*e1f*
  to thumb, 1680-1681, 1682*f*, 1681.*e1f*
CRPS. *see* Complex regional pain syndrome (CRPS)
Crush injury, 1763
Crush syndrome, 1763
Cryosurgery, 1960-1961, 1961*f*
  for aneurysmal bone cyst, 2025
Cryotherapy, for warts, 122
Cryptococcosis, 86
Crystalline tendinopathy, 1905-1907
  in amyloid deposition, 1906-1907, 1906*f*
  in calcific tendinitis, 1905-1906, 1906*f*
  in gout, 1905, 1905*f*
  in hydroxyapatite deposition, 1906
  in ochronosis, 1907
  in pseudogout, 1906
Cubital tunnel, anatomy of, 941-942, 941*f*
Cubital tunnel syndrome, 940-947
  clinical diagnosis of, 941
  nonoperative management of, 942, 942*f*
  operative treatment of, 942-947
    intramuscular transposition in, 945
    medial epicondylectomy in, 943-944, 943*f*-944*f*
    postoperative care after, 947
    preferred method of, 945-947, 946*f*
    in situ decompression in, 943
    subcutaneous anterior transposition in, 944, 944*f*-945*f*
    submuscular transposition in, 945, 945*f*
  provocative tests for, 926*t*
  recurrent, 955-956
    revision surgery for, 955-956
  surgery of, 948*b*
Culture, of infections, 65, 65*t*
Curettage, 1960, 1961*f*
Curtis staged reconstruction, for boutonnière deformity, 172-174, 173*f*, 174*b*
Curved longitudinal incision, for web space abscess, 38, 39*f*
Curvilinear incision
  for derotational osteotomy, 1415, 1415*f*
  in modified Henry approach, to radial tunnel syndrome, 952
Cutaneous flaps, 1575-1576, 1575*f*. *see also* Skin flap(s)
Cutaneous horns, 1970, 1971*f*
Cutaneous nerve(s)
  grafting of, in brachial plexus reconstruction, 1162
  lateral, grafting of, 997
  medial, grafting of, 997, 997*f*
Cutaneous nerve block, for skin grafting, in outpatient surgery, 1538
Cutaneous nerve dysesthesias, in thoracic outlet syndrome, 975
Cutaneous neuroma, after amputation, 1011*f*, 1010.*e5*
Cutaneous pressure thresholds, in compression neuropathies, 928
Cycloserine, dosage of, 101*t*
Cyst(s)
  bone of. *see* Bone cysts
  epidermal inclusion, 1966-1968, 1969*f*. *see also* Epidermal inclusion cysts
  ganglion, 1997-1998. *see also* Ganglion(s)
  mucous. *see* Mucous cyst
  nail, 328, 328*f*
  phaeomycotic, 84
Cystic basal cell carcinoma, 1974
Cysticercosis, 118

D

Dactylitis, tuberculous, in children, 98
DANE-TJ technique, 837
Dapsone
  for actinomycetoma, 72-73
  for Hansen disease, 103, 109
  for spider bites, 1789
Darrach procedure, 1838
  for radioulnar joint arthritis, 505-506, 506*f*
  for radioulnar joint disability, 582
Dart-thrower's motion, 424
DASH. *see* Disabilities of the Arm, Shoulder, and Hand (DASH)
de la Caffinière prosthesis, 361-362
de Quervain disease, 948, 1916-1919, 1917*f*, 1918*b*, 1919*f*
  treatment of, 1916-1919
    complications of, 1919
    nonoperative, 1916-1917
    preferred method of, 1918-1919
    surgical, 1917-1919
Débridement
  for AIDS, 119-120
  for aspergillosis, 84-85
  of burns, 1933
    electrical, 1948
  for cryptococcosis, 86
  for Hansen disease, 104
    in Lucio reaction, 112
  inadequate, free flap contraindicated in, 1574-1575
  of mangling injuries, 1496-1499, 1499*b*
Débridement *(Continued)*
    case study for, 1499.*e1b*, 1499.*e2f*-1499.*e3f*
    "second-look", 1524
  for mucormycosis, 87-88
  for mycobacterial infections, 91
  of necrotizing soft tissue infections, 55
  for nontuberculous mycobacteria, 103
  for osteoarthritis, 893-897, 896*b*
    indications and contraindications of, 893
    outcomes of, 896-897
    postoperative management of, 894-896
    preoperative planning of, 893
    technique of, 893-894, 895*f*-896*f*
  for osteomyelitis, 43, 46
  for sporotrichosis, 88
  of torn ligament edges, in scapholunate dissociation, 439-440
  for tuberculous arthritis, 96
  for tuberculous osteomyelitis, 100
  for warts, 122
  wound, for free flap transfer, 1578-1579, 1578*b*, 1579*f*
Decompression
  of radial nerve, 949, 949*f*
  in situ, for cubital tunnel syndrome, 943
Deep fibers, 134
Deep finger flexor tendons, in rheumatoid arthritis, rupture of, 1857
Deep head, of interosseous muscles, 338.*e3*, 338.*e5f*
Deep space infections, 34-40, 40*b*
  antibiotic recommendations for, 21*t*
  palmar, 34-36, 34*f*, 35*t*, 36*f*-37*f*
  subfascial, 36-40
Deep transverse intermetacarpal ligament (DTIL), 1723
Deformities, of the hand and fingers, 1217-1288
Dejerine-Klumpke palsy, 1149-1150
Delayed suture, of nerve injury, 994-996, 995*f*-996*f*
Delayed treatment
  clinical assessment of, 814
  imaging of, 814
Delayed union, secondary bone graft for, 1615-1616
Deltoid muscle, posterior, transfer of, to triceps, in tetraplegic patient, 1129, 1130*f*
Demineralized bone matrix (DBM) putty, for scaphoid nonunions, 670, 670*f*
Derby test, for lunotriquetral dissociation, 451
"Dermacarrier", 1534, 1534*f*
Dermadesis, for swan neck deformity, in rheumatoid arthritis, 1882
Dermal lesions, 1966-1968
Dermatitis, pustular, contagious, 123-124, 124*f*

Dermatofibroma, 1966, 1968*f*
Dermatofibrosarcoma protuberans, 1983, 1985*f*, 2018-2019, 2019*f*
Dermatomes, in skin grafting, 1532-1533
Dermatoses, neutrophilic, 75-77
  clinical findings on, 76-77
  diagnosis of, 77, 77*f*
  etiology and epidemiology of, 75-76
  treatment of, 77
Dermofasciectomy, for Dupuytren disease, 139*t*, 142-143, 143*f*
Derotational osteotomy. *see also* Osteotomy
  humeral, for shoulder weakness and deformity, in brachial plexus birth palsy, 1415, 1415*f*
  for proximal radioulnar synostosis, 1351-1352, 1352*f*-1353*f*
Desipramine, for complex regional pain syndrome, 1812*t*
Desmoplastic melanoma, 1980
Dexamethasone
  for de Quervain disease, 1917
  intravenous, for postoperative swelling, 857
Dextran
  after free flap transfer, 1582
  after toe transfer, 1669
Diabetic hand infections, 53-54
Diagnostic imaging, for musculoskeletal tumors, 1990
Diathesis factors, of Dupuytren disease, 132-133
Die-punch fracture, 524, 525*f*
Differential forearm lengthening, for hereditary multiple exostoses of forearm, 1360
Digit(s). *see also* Finger(s); Toe(s)
  absence of, treatment of, 1258
  dislocations and ligament injuries of, 278-317
  distraction of, in absent finger reconstruction, 1262
  Dupuytren disease in, 134-136, 135*f*
  function and mobility of, 338
  multiple amputated, replantation of, 1479
  reduction of, in management of macrodactyly, 1281-1282
  replantation of, 1477, 1484*b*
  separation and resurfacing of, in syndactyly, 1220-1221, 1223*f*-1226*f*
  spasticity in
    examination of, 1084-1085, 1085*f*
    flexor tendon tightness in, operative management of, 1102-1106, 1104*f*
    preferred method of, 1105-1106
  supernumerary, removal of, 1233-1234
  threatened at birth, treatment of, 1255-1256
  venous congestion of, 1482-1483
Digit Widget, for proximal interphalangeal joint contractures, 341, 342*f*
Digital artery, ligation of, in pollicization for thumb hypoplasia, 1295, 1297*f*
Digital artery island flap, 1546-1547, 1548*f*
Digital clawing, in tetraplegia, 1142-1143
  Lasso procedure for, 1142-1143
Digital cords, in planning, for Dupuytren disease, 145
Digital deformity
  in joints, 1840
  in psoriatic arthritis, 1836, 1836*f*
  in scleroderma, 1839-1840, 1839*f*
  in systemic lupus erythematosus, 1838
Digital extension, spasticity in
  operative management of, 1095-1102, 1097*f*, 1097*t*
  treatment of, preferred method of, 1101-1102, 1102*f*-1103*f*
Digital fibrokeratoma, 1966
Digital fibroma, of infancy, 2014, 2014*f*
Digital fibromatosis, infantile, 1968, 1970*f*
Digital flexion, contracture of, postburn, 1939-1940
Digital growth, limiting, in management of macrodactyly, 1278-1281
Digital keratoacanthoma, distal, 1971-1972
Digital nerve(s)
  identification and dissection of, in pollicization for thumb hypoplasia, 1295, 1296*f*
  relationship and distribution of, 10*f*
  repair of, 1481
    preferred method of treatment of, 1009
    results of, 1008-1009
      conduits and homografts for, 1009, 1009*t*
      recovery of sensation after, 1009*t*
  transfer of, in ulnar nerve palsy, 1061
Digital nerve block, 9-10
  subcutaneous, 11*f*
  transmetacarpal, 11*f*
  transthecal, 10*f*
  use of epinephrine in, 10
Digital vein, repair of, 1481
Digital-brachial index, for vascular disorders, 2039
Dimple, in planning, for Dupuytren disease, 145
Direct fovea (DF) portal, for arthroscopy of wrist, 657
Direct muscular neurotization, for nerve injury, 1001, 1001*f*
Direct suture, of nerve injury, 993-994, 994*f*-995*f*
Disabilities of the Arm, Shoulder, and Hand (DASH) score, 924, 975
Disarticulation
  elbow, 1754-1756
  of wrist, 1737-1738, 1753-1754, 1754*f*
Disarticulation *(Continued)*
  preferred method of treatment of, 1737-1738
Dislocation(s). *see also* Fracture-dislocation
  of carpal bones, isolated, in complex carpal instability, 475-476, 475*f*
  of carpometacarpal joint of thumb, 312-315
    anatomy in, 312, 312*f*
    historical review of, 312
    postoperative management and expectations for, 314-315
    preoperative evaluation of, 312-313, 313*f*
    treatment of, 313-314
      preferred method of, 313, 314*b*, 314*f*
  of distal interphalangeal joint, 296-297, 297*f*
  of elbow
    complex traumatic, 813-829. *see also* Elbow, dislocation of
    in radial head fracture, 815, 815*f*
    simple, 818-819
  of epiphysis, in children, 1429, 1430*f*
  infantile, 1413
  of lunate, pathomechanics of, 427-428
  of metacarpophalangeal joint
    anatomy in, 298, 298*f*
    complete (complex), 299
    complications of, 300
    dorsal, 298-300
    outcomes of, 300
    postoperative management of, 300
    preferred method of treatment for, 300, 300*b*
    preoperative evaluation of, 299, 299*f*
    radial collateral ligament rupture in, 300-301
    simple, 299
    surgical techniques for, 299-300
    of thumb, 310-311
      historical perspective on, 310-311
      postoperative management and expectations in, 311
      preoperative evaluation of, 311
      treatment of, 311
    volar, 300
  of proximal interphalangeal joint, 279-293
    acute dorsal, 279-280
    lateral, 280
    posttraumatic fibrosis and contracture in, 295-296
    volar, 280-281
      treatment of, 280-281
  of radial head, congenital, 1347-1349, 1347*t*, 1348*f*-1349*f*, 1350*b*
  in radial head fractures, 737
  of radioulnar joint, distal, 492
  of scaphoid, 475, 475*f*

Dislocation(s) *(Continued)*
of thumb interphalangeal joint, 296-297
of trapezium, 476
of trapezoid, 476
Displaced fracture(s)
with comminution and/or dislocation of elbow, 781
of radial head, 736
without comminution and proximal to midpoint of olecranon (type IIA), 781
Distal forearm injuries, 179, 179.*e*1*b*, 179.*e*1*f*
Distal interphalangeal (DIP) joint, 42-43, 42*f*
amputation of
with disarticulation, 1717-1718
to metacarpophalangeal joint, 1717-1719, 1718*f*
anatomy of, 338.*e*3, 338.*e*3*f*
arthrodesis of, 346-349
author's preferred method of treatment for, 347-349, 348*f*
complications of, 349
critical points in, 349*b*
expected outcomes for, 349
indications and contraindications of, 346-347
postoperative management and expectations after, 349
preoperative planning for, 347
in rheumatoid arthritis, for swan neck deformity, 1880-1882, 1880*t*
with screw, 1881, 1881*f*
studies of, fixation and outcomes, 347*t*
technique for, 347, 348*f*
dislocation of, 296-297, 297*f*
Elson test in, 156
ganglion of, 333, 333*f*-334*f*, 334*b*
Landsmeer's theory in, 157
stiffness of, after volar plate arthroplasty, 290
Distal intrinsic release, 343.*e*1, 343.*e*1*f*
Distal juncture technique, for tendon graft, 208, 209*f*
Distal oblique bundle (DOB), 482
Distal radioulnar joint (DRUJ)
arthroscopy of wrist, 660-661
reconstruction of, for rheumatoid arthritis, 1860-1863, 1861*f*-1862*f*
Distal radioulnar ligament reconstruction, 496-498, 497*f*
Distal segment, of nerve, 984-985, 985*f*
Distal sleeve anastomosis, for vascular disorders, 2051, 2051*f*
Distal tendon juncture, 206, 207*f*
Distal ulnar excision reconstruction, 1860-1863
Distal ulnar resection, 1862*b*
Distant flaps, 1540, 1563-1568
axial-pattern, 1564-1568
groin, 1564-1568, 1564*f*, 1566*f*-1567*f*, 1568*b*
random-pattern, 1563-1564
Distraction osteogenesis, metacarpal lengthening with, in brachydactyly, 1242-1243
Distraction plate fixation, of distal radial fracture, open reduction with, 557-559, 558*f*, 560*f*
Distraction-compression osteogenesis, treatment of nonunion of forearm bones using, 803
Docking technique, 837, 839
Dog bites, infection from, 46-47
Dome osteotomy, physiolysis and, for Madelung deformity, 1342-1344, 1342*f*-1343*f*
Donor muscle, selection of, for free transfers in brachial plexus injury, 1179, 1202
Donor nerve, in brachial plexus reconstruction, selection of, 1161-1162, 1202
Donor site(s)
for flaps, 1540-1541
for free flaps, 1576*t*
morbidity of, after congenital pseudoarthrosis of ulna surgery, 1357
for skin graft
care of, 1538
in managing injuries, 1511
split-thickness, 1531-1532, 1532*t*
for toe transfer
morbidity of, 1670
rehabilitation of, 1671
for vascularized bone grafts, 1614-1615
Donor tendon, 1036
Doppler flowmetry, laser, for vascular disorders, 2039
Dorsal angulation, as complication of metacarpal fractures, 246, 246*f*-247*f*
Dorsal capsule release, arthroscopic arthrolysis and, 691
Dorsal Dupuytren nodules (DDN), 129
signs of, 129-130, 131*f*
treatment of, 143
Dorsal hand skin, 1528, 1529*f*
Dorsal inlay graft, vascularized, placement of, 1632
Dorsal intercalated segment instability (DISI), 418-419
Dorsal interosseous muscle, 338.*e*3, 338.*e*5*f*. *see also* Interosseous muscle(s)
Dorsal paronychial tissue, assessment, of for digit perfusion, 1490, 1490*f*
Dorsal plate fixation, of distal radial fracture, open reduction with, 547-552, 548*f*
Dorsal radiocarpal ligament (DRCL), 421-422
repair of, 665*f*
tears of, 665
Dorsal radiotriquetral ligament, 421-422
Dorsal radius pedicle grafts, specific, 1630-1632
Dorsal retinacular ganglion, 2009, 2010*f*
Dorsal wrist injuries, 178-179
preferred method of treatment of, 179
Dorsum of the hand, contractures of, postburn, 1940-1941, 1942*f*
Double crush phenomenon, nerve injury and, 1-2
Double free muscle transfer, for brachial plexus injury, 1181-1183
Double-barrel flap, vascularized, in grafting from fibula, 1620
Double-crush mechanism, in compression neuropathies, 922-923
Doxepin, for complex regional pain syndrome, 1812*t*
Doxycycline
for actinomycetoma, 73
for anthrax, 69
for syphilis, 74
Drainage, of nerve abscess, 113
Dressing(s)
bilayer matrix wound, 1711-1712, 1712*f*
for burns, 1934
changes and healing by secondary intention, 1709-1711, 1710*f*
in free flap transfer, 1581-1582
postoperative, after syndactyly treatment, 1226-1227
semiocclusive, 1711
Unna boot, 1538
Drug(s). *see also* Multidrug therapy (MDT); *specific drug or drug therapy*
abuse of, infections caused by, 51-52
for complex regional pain syndrome, 1811
outcome of, 1819
parenteral, 1819
resistance to, in Hansen disease, 109
used in regional anesthesia, 4*t*
Drug-susceptibility tests, for infections, 66
"Drunken face" symptom, of snakebite, 1789
Dry arthroscopy
for arthroscopic arthrolysis, 691
for wrist, 658
Duchenne sign, 1046
Dull nail, 330
Duplication
of ring finger, 1234, 1235*f*. *see also* Polydactyly, central
of thumb, 1304-1315
Dupuytren contracture (DC), 128. *see also* Dupuytren disease (DD)
appearance of, 130
treatment of, historical points in, 138, 139*t*

Dupuytren disease (DD), 128-151
associated conditions with, 128-129
demographics, 128-129, 129*f*
diagnostic imaging of, 134
genetic biomarkers of, 129
heritability and, 128
historical review of, 138, 139*t*
pathology of, 136-138, 136*f*-137*f*
physical examination of, 129-131, 130*f*
preoperative evaluation of, 129-134
prevalence of, 129*f*
skin landmarks of, 132, 133*f*
staging in, 131-134
treatment of, recontracture and, 134*t*
types of operations for, 138-143, 139*t*, 148*b*
dermofasciectomy, 142-143, 143*f*
fasciectomy, 140-142
indications and options for, 140*t*
minimally invasive procedures of, 139-140
open surgical procedures and, 140-143, 141*t*
patient instructions in, 144-145
planning in, 145
postprocedure in, 148
procedures of, 145-148
regional fasciectomy, 141-142, 142*f*
segmental fasciectomy, 141-142
Dynadesis, for scapholunate dissociation, 443, 443*f*
Dynamic splints, for joint stiffness, 340.*e*1, 340.*e*1*f*
Dysesthesia(s)
cutaneous nerve, in thoracic outlet syndrome, 975
definition of, 1799*t*
Dysfunctional postures, in factitious disorders, 1828-1829, 1830*f*-1831*f*
Dysplastic nevus syndrome, 1966, 1967*f*
Dystrophic epidermolysis bullosa, syndactyly in, 1231-1232, 1232*f*

E

Early recontracture, of Dupuytren disease, 133-134, 134*t*
Eccrine poroma, 1964
Ecthyma contagiosum, 123-124, 124*f*
Edema
after posttraumatic interosseous contracture, 343.*e*1
control of, in burn management, 1929
"Eight-pack" tissue culture, 65, 65*t*
Elbow
anterior (transolecranon) fracture-dislocation of, 784.*e*13*b*, 784.*e*13*f*-784.*e*14*f*
arthritis of, posttraumatic, 827
arthroplasty of, total, 905-920. *see also* Arthroplasty, of elbow, total
arthroscopy of, 885-904
Elbow *(Continued)*
advanced procedures of, 903
anesthesia and positioning in, 886, 888*f*
complications of, 903
contributions to, 892*t*
for epicondylitis, 868
historical review of, 891
instrumentation in, 891, 891*f*
pertinent anatomy in, 886-891, 889*f*
portals in, 886-891, 889*f*
preoperative evaluation in, 885-886
diagnostic imaging in, 886, 887*f*-888*f*
physical examination in, 885
types of operations in, 892-903
in brachial plexus birth palsy, 1417-1419, 1418*f*
complex posterior olecranon fracture-dislocation of, 784.*e*1*b*, 784.*e*2*f*-784.*e*3*f*
contracture of. *see* Contracture(s), of elbow
disarticulation of, 1754-1756
dislocation of
complex traumatic, 813-829
classification of, 814-817
clinical assessment of, 813-814
complications of, 826-827
definition of, 813
expected outcomes after, 826
functional anatomy in, 813, 814*f*
historical review of, 817-818
imaging of, 814
olecranon fracture-dislocations in, 816-817, 816*f*
patterns of injury of, 814-817
posterolateral rotational injury in, 814-815
postoperative management after, 825-826
preoperative evaluation of, 813-814
in radial head fracture, 815, 815*f*
reconstruction for, 825, 825*f*
treatment options for, 818-825
in acute injuries, 818-824
in delayed treatment, 824-825, 826*b*
varus posteromedial rotational injury in, 817, 818*f*
posterior, with fracture of olecranon process, 784.*e*11*b*, 784.*e*11*f*-784.*e*12*f*
in radial head fractures, 737
simple, 818-819
displaced fractures with comminution and/or dislocation of, 781
epicondylitis of
lateral, 863-864. *see also* Epicondylitis, lateral
medial, 864-865. *see also* Epicondylitis, medial
Elbow *(Continued)*
extension of, in tetraplegic patient, tendon transfer for, 1127-1129
biceps to triceps, 1127-1129, 1128*f*, 1129*b*
posterior deltoid to triceps, 1129, 1130*f*
flexion of, reconstruction of, in brachial plexus injury, 1192-1202
complications of, 1196
free muscle transfer in, 1202, 1202*f*, 1203*b*
latissimus dorsi transfer in, 1197-1198, 1199*f*, 1200*b*
outcomes of, 1196
pectoralis major muscle transfer in, 1198-1202, 1200*f*-1201*f*, 1201*b*
postoperative protocol for, 1196
preferred methods of, 1195-1202, 1195*f*, 1196*b*
triceps-to-biceps transfer in, 1196-1197, 1197*b*, 1197*f*
golfer's, 864. *see also* Epicondylitis, medial
instability of
after release, 855-856, 856*f*
after ulnar fractures, 783, 783*f*
recurrent, after dislocation, 826
instability of, chronic, 830-842
lateral, 830-835
diagnostic imaging of, 831, 831*f*
ligament reconstruction for
complications in, 835
contraindications to, 833
indications for, 832-833
outcomes in, 835
postoperative management and expectations in, 835
preoperative evaluation of, 830-831
technique in, 833-835, 834*f*
pertinent anatomy in, 832, 832*f*
physical examination for, 830-831
medial, 835-840
diagnostic imaging of, 835-836, 836*f*
ligament reconstruction for
complications in, 840
contraindications to, 837
indications for, 837
outcomes in, 840
postoperative management and expectations of, 839-840
preoperative evaluation of, 835-836
technique in, 837, 838*f*, 840*f*
pertinent anatomy in, 836-837, 836*f*
physical examination for, 835
lateral ligamentous anatomy of, 739, 740*f*
mangling injuries of, treatment of, 1515-1519, 1519*f*-1520*f*

Elbow *(Continued)*
poor-quality soft tissues at, as contraindication to elbow arthroplasty, 909
presence of infection at, as contraindication to elbow arthroplasty, 909
spasticity in
examination of, 1084
operative management of, 1090-1093
treatment of, preferred method of, 1091*f*, 1092-1093
stability of, anatomy of, 772-773
stiff
after dislocation, 827
after humeral fracture fixation, management of, 731
arthroscopic release of, 902-903
causes and prevention of, 843-844, 844*f*
history of, 844-845
imaging of, 847-848
pain and, 845
patient history of, 844-845
postoperative management after, 857-858
posttraumatic, categories of, 844*t*
preoperative assessment of, 844-849, 844*t*
assessment of ulnohumeral joint surface after trauma, 847
duration of contracture and timing of release in, 845, 846*f*
examination of ulnar nerve in, 847
motion loss and effect on function in, 845-847
patient's age, 844-845
preoperative discussion prior, 848
treatment of, 843-862
arthroscopic release in, 849
complications of, 859-860
failure to achieve improved motion as, 860
heterotopic ossification as, 859
joint infection as, 859
nerve palsy as, 859
pin tract infections as, 859
recurrent stiffness as, 859
soft tissue deficiencies as, 859
wound necrosis as, 859, 860*f*
contracture release in, anesthesia for, 849, 853*b*
expectations and results of, 858-859
open release in, 849-853
lateral approach to, 852-853
medial "over-the-top" approach, 849, 852*b*
postoperative care, immediate, 853
special circumstances in, 853-856
Elbow *(Continued)*
distal humerus fracture after open reduction with internal fixation, 853-854
distal humerus fracture nonunion, 854
distraction arthroplasty, 856
excessive muscle tightness, 856
head trauma and brain injury, 854, 854*f*
supplementary blocks at, 8
tennis, 863-864. *see also* Epicondylitis, lateral
Elbow pads, for cubital tunnel syndrome, 942
Elderly, distal humeral fractures in, 707-710
open reduction and internal fixation of, 707-709, 709*t*
total elbow replacement for, 709-710, 709*t*, 710.*e*1*b*, 710.*e*1*f*
Electrical injuries, 1945-1948
clinical manifestations of, 1946-1947, 1947*f*
epidemiologic findings in, 1945
mechanism and classification of, 1946
pathophysiologic conditions in, and properties of electricity, 1945-1946
treatment of, 1947-1948
general management in, 1947
surgical management in, 1947-1948, 1949*f*
Electrical stimulation, for spasticity, 1088
Electrically negative neurogenic thoracic outlet syndrome, 960-961
Electrodesiccation, 1961
Electrodiagnostic studies, in compression neuropathies, 928-930
Electromyography (EMG)
in brachial plexus injury, 1153
in compression neuropathies, 929
in neurapraxia, 12
in pediatric brachial plexus palsy, 1396
Electroporation, 1946
Electrosurgery, 1961
for warts, 123
Electrothermal ligament shrinkage
in midcarpal instability, 460
in scapholunate dissociation, 439-440
of scapholunate interosseous ligament, 664, 664*f*
Elevated arm stress test, for thoracic outlet syndrome, 966-967
Ellipsoid universal I wrist design, 406
Elliptical excision, 1961, 1963*f*
Elliptical incision, in removal of supernumerary digits, 1233-1234, 1233*f*
Ellis-van Creveld syndrome, postaxial polydactyly in, 1232, 1233*f*
Elson test, 155-156, 157*f*
Embryogenesis
genes and molecular abnormalities in, 1212-1214
key milestones in, 1209*t*
of limbs, 1208-1215, 1210*f*
musculoskeletal system development in, 1211-1212, 1213*f*
signaling centers in, 1208
signaling pathways during, 1210*t*
systemic considerations, 1214-1215
Emergency treatment, of mangling injuries, 1495-1496, 1496*b*, 1497*f*, 1498*t*
Encapsulation, implant, after metacarpophalangeal joint arthroplasty, 1877-1878
Enchondroma, 2020-2021, 2020*f*, 2021*b*
Enchondromatosis, multiple, 2021, 2022*f*
Endoscopy, for carpal tunnel syndrome
Agee single-portal, 933-934
Chow two-portal, 933
End-to-end anastomosis, for vascular disease, 2051, 2051*f*
End-to-side anastomosis, for vascular disease, 2051, 2051*f*
End-to-side flexor digitorum profundus, tendon juncture of, 220
Endurance testing, in complex regional pain syndrome, 1809-1810
Entubulation, of nerve injury, 999-1000
Envenomation, animals associated with, 1788-1795
caterpillars, 1788, 1789*f*
cnidarians, 1791-1792, 1792*f*
fish, 1792-1795, 1793*f*-1794*f*
sea urchins, 1792, 1792*f*
snakes, 1789-1791, 1790*f*-1791*f*
spiders, 1788-1789, 1789*f*
Enzymatic fasciotomy, for Dupuytren disease, 139*t*
with collagenase clostridium histolyticum, 140
Epicondylectomy, medial, for cubital tunnel syndrome, 943-944, 943*f*-944*f*
Epicondylitis
lateral, 863-864, 871*b*
diagnosis of, 864
etiology, associations, and pathophysiology of, 863
history of, 863
presentation of, 863-864
recurrent, surgical treatment of, 866
surgical treatment of, 866
medial, 864-865, 871*b*
diagnosis of, 864-865
etiology and pathogenesis of, 864
presentation of, 864
surgical treatment of, 867
preferred method of, 868-870, 869*f*-870*f*
treatment of, 865-870
arthroscopic technique of, 868
expected outcomes of, 867

Epicondylitis *(Continued)*
nonoperative, 865-866
preferred method of, 867-868, 867*f*-869*f*
surgical, 866-867
Epidermal inclusion cysts, 1966-1968, 1969*f*, 2009-2010, 2011*f*
Epidermal lesions, 1962-1964
Epidural agents, for complex regional pain syndrome, 1816-1817
Epinephrine, in digital nerve block, 10
Epineural repair, of nerve injury, 994
Epiphyseal bracket resection, 1272, 1274*f*
Epiphyseal dislocation, in children, 1429, 1430*f*
Epiphyseal fracture
of distal phalanx, 248-249, 248*f*
of metacarpals, in children, 1437
preferred method of treatment for, 1437
Epiphyseal transfer, grafting for, 1624
Epiphysiodesis, for macrodactyly, 1278-1281, 1280*f*
Epitendinous suture, of zone 2 tendon lacerations, 188
Epithelioid sarcoma, 2017
Eponychial deformities, 329
Equipment, for regional anesthesia, 4
Erb-Duchenne palsy, 1149
Erb's palsy, 1393
Escharotomy, for burns, 1929-1930, 1930*f*
Essex-Lopresti injuries, 764-765
Essex-Lopresti prosthetic reconstruction, of radial head, 764-765, 765*f*-766*f*
Ethambutol
dosage of, 101*t*
for tuberculosis, 100-101
Ethionamide, dosage of, 101*t*
Etidocaine, characteristics of, 4*t*
Eumycetoma, 70-73
clinical findings on, 71
diagnosis of, 72
etiology and epidemiology of, 70
microbiology of, 70-71
treatment of, 73
Ewing's sarcoma, 2028-2031, 2030*f*
author's preferred method of treatment for, 2030-2031
Excision. *see* Surgical excision
Excisional biopsy
elliptical, 1961
for musculoskeletal tumors, 1991-1992
Exercise(s)
nerve gliding, for carpal tunnel syndrome, 933
"six-pack," for distal radial fractures, 531, 534*f*
Exercise-induced compartment syndrome, 1763
Exertional compartment syndrome, 1763
diagnosis of, 1767-1768
Exostoses
multiple, hereditary, of forearm and elbow, 1357-1362, 1358*f*-1361*f*, 1362*b*
subungual, 2022
Expendable donor, in tendon transfers, 1025
EXT genes, mutations of, 1357
Extension contracture. *see also* Contracture(s)
metacarpophalangeal joint, release of, 340-341
Extension splint, resting, for elbow contracture, 857
Extensor carpi radialis brevis
brachioradialis transfer to, 1101, 1101*f*, 1110-1111, 1112*b*, 1112*f*
extensor carpi ulnaris transfer to, 1099, 1099*b*, 1100*f*
flexor carpi ulnaris transfer to, 1097-1098, 1098*f*, 1099*b*
pronator teres transfer to, 1101, 1101*f*
transfer of
in restoration of thumb adduction, 1056-1057, 1057*f*, 1057*t*
in tetraplegic patient, to brachioradialis, 1131, 1131*f*, 1132*b*
Extensor carpi radialis intermedius, in wrist extension, 152
Extensor carpi radialis longus, transfer of
in median nerve palsy, 1035-1036
to index profundus, 1044, 1044*f*
operative technique for, 1863
to restore wrist balance, in rheumatoid arthritis, 1863
in tetraplegic patient, to flexor digitorum profundus, 1134
in ulnar nerve palsy
dorsal route of, 1054, 1054*f*
flexor route of, 1055, 1055*f*, 1060
Extensor carpi ulnaris, 152, 154*f*, 1863
lateral collateral ligament and, 832
stabilization of, 511-512, 512*f*
tendinitis of, 1921-1922, 1922*f*
surgical treatment, 1922, 1922*f*
tenodesis of, 1140
tenosynovitis and subluxation of, 511-512, 511*f*
operative technique for, 511-512, 512*f*
outcomes of, 512
transfer of
in median nerve palsy, 1034-1035
to restore wrist balance, in rheumatoid arthritis, 1863
wrist spasticity and, to extensor carpi radialis brevis, 1099, 1099*b*, 1100*f*
Extensor compartment artery
fifth, bone grafting using, 1630, 1630*f*
fourth, bone grafting using, 1629-1630
graft, 5 plus 4, 1632
Extensor compartment(s)
first, ganglion of, 2009, 2010*f*
fourth and fifth, stenosis of, 1921
Extensor digiti minimi (EDM), 152, 153*f*
transfer of
in median nerve palsy, 1036, 1036*f*
in ulnar nerve palsy
combined with extensor indicis proprius, 1053-1054
for little finger abduction, 1060, 1060*f*
for metacarpal arch restoration, 1059-1060
Extensor digitorum brevis manus muscle (EDBM), 152, 153*f*
Extensor digitorum communis (EDC), 153-154, 154*f*
in proximal phalanx, 154
spasticity and, flexor carpi ulnaris transfer to, 1099-1100, 1100*b*
tenodesis of, in tetraplegic patient, House two-stage reconstruction and, 1137, 1138*f*
Extensor indicis proprius (EIP), transfer of
to first dorsal interosseous, 1058-1059
in median nerve palsy, 1031-1032, 1032*f*
in restoration of thumb adduction, 1058
in ulnar nerve palsy, combined with extensor digiti minimi, 1053-1054
Extensor pollicis brevis, imbrication of, for thumb-in-palm deformity, 1112
Extensor pollicis longus
in cerebral palsy
rerouting of, for thumb-in-palm deformity, 1110, 1111*b*, 1111*f*
transfer of, for thumb-in-palm deformity, 1110
entrapment, 1921, 1921*f*
in rheumatoid arthritis, rupture of, treatment of, 1850-1851, 1850*f*
in tetraplegic patient
extensor digitorum communis transfer to, 1141
tenodesis of, House's one-stage reconstruction and, 1135, 1135*f*
transfer of, in median nerve palsy, 1037-1040, 1039*f*-1041*f*
alternative, 1040-1041
Extensor proprius tendons, for tendon graft, 206
Extensor retinaculum, pulley reconstruction using, 222
Extensor tendon(s). *see also specific tendon*
anatomy of, 152-157, 152.e1*b*
juncturae tendinum, 152-154, 153*f*
in muscles, 152
variations of, 153
at the wrist level, 152, 153*f*
centralization of, in total wrist replacement, 413-414, 414*f*

Extensor tendon(s) *(Continued)*
of finger, rupture of, 1852-1853, 1854*f*-1855*f*
diagnosis of, 1849-1850, 1849*f*
multiple-tendon, 1852
with metacarpophalangeal joint disease, 1854
reconstruction for, 1852-1857
options for reconstruction in, 1852-1857
in ring and small finger, 1852, 1853*f*
single-tendon, 1851-1852, 1852*f*
treatment of, 1850-1851, 1850*f*, 1851*t*
ganglions of, 2008, 2010*f*
injury to. *see* Extensor tendon injury
long toe, for tendon graft, 205-206
repair of, 1481
in rheumatoid arthritis, of metacarpophalangeal joint
centralization of, 1875-1876, 1875*f*
rupture of, 1850-1851
preferred method of treatment of, 1851
of wrist, tenosynovitis of, 1843-1845
preferred method of treatment of, 1843-1845, 1843*f*-1844*f*
wrist extensors, 1843-1845
complications, 1845
postoperative management, 1845, 1845*f*
Extensor tendon injury, 152-182
treatment of, 158-162, 162*b*
complications in, 161-162
outcomes in, 161, 161*t*
postoperative management in, 160-161, 161*t*
suture repair techniques in, 158-159
zone(s) of, 158, 158*f*
1, distal interphalangeal joint. *see also* Mallet finger injury; Mallet thumb injury
acute, 162-165, 166*b*, 162.*e*1*b*, 162.*e*1*f*
anatomy of, 162
classification of, 162, 163*t*
incidence of, 162
management of, 163
mechanism of, 162
preferred method of treatment of, 164-165, 165*f*
treatment for, 163-164, 164*f*
chronic, 165-166
treatment of, 166-169
postoperative management of, 160
techniques for, repair, 159
2, middle phalanx, 169
postoperative management of, 160
techniques for, repair, 159, 160*f*
3, proximal interphalangeal joint, 169*f*-170*f*, 169.*e*1*b*,
Extensor tendon injury *(Continued)*
169.*e*1*f*-169.*e*2*f*, 172.*e*1*b*, 172.*e*1*f*. *see also* Boutonnière deformity
closed, 171-172
open, 170, 171*f*
lacerations in, 171
postoperative management of, 160, 169-174
preferred method of treatment of, 170-171
techniques for, repair, 159, 160*f*
4, proximal phalanx, 174
postoperative management of, 160
preferred method of, repairs, 174
techniques for, repair, 159, 160*f*
5, carpometacarpal joint, 174-175
postoperative management of, 160
techniques for, repair, 159, 160*f*
6, metacarpal level, 175-177, 178*f*, 175.*e*1*b*, 175.*e*1*f*
chronic, 177
postoperative management of, 160
preferred method of treatment of, 177
techniques for, repair, 159
7, dorsal wrist, 178-179
injuries and rupture in, chronic, 179, 179*f*
postoperative management of, 160
preferred method of treatment of, 179
techniques for, repair, 159
8, distal forearm, 179, 179.*e*1*b*, 179.*e*1*f*
9, proximal forearm, 179-180
Extensor tendon-splitting approach, to radial head, 745-746, 748*f*
Extensors, repetitive contraction of, microtrauma due to, 863. *see also* Epicondylitis, lateral
External fixation
of distal radial fracture, 532-539, 538*f*
augmented, 535-539, 539*b*, 541*f*-542*f*, 535.*e*1*f*
hybrid, 539.*e*1*f*
technique for, 533-535, 539*f*-541*f*
for mangling injuries, 1500, 1502*f*-1503*f*
of metacarpal shaft fractures, 241, 237.*e*1*t*
of proximal and middle phalangeal fracture, 261
of radial shaft fractures, intramedullary rods and, 793, 793*f*-794*f*, 795*b*
External fixator, for segmental metacarpal loss, 244*f*
External fixator pin clusters, 539
Extraarticular intracapsular fractures, of humerus, 702-703, 702*f*. *see also* Humerus, distal
Extraarticular osteotomy. *see also* Osteotomy
for radial fracture, 577, 578*b*, 578*f*-579*f*
Extraoctave fracture, in children, 1435, 1436*f*
Extraosseous nutrient vessels, in bone grafting, 1629-1630
Extraplexal nerve transfers, for brachial plexus injury, 1177
Extrinsic extensors, anatomy of, 338.*e*4-338.*e*5, 338.*e*6*f*
Extrinsic flexor function, restoration of, 1778-1781, 1781*f*
Extrinsic ligaments, of wrist, 420-422, 421*f*

F

Factitious disorders, 1828-1831
differential diagnosis of, 1829-1830
management of, 1830
mistaken diagnoses of, 1829-1830
recognizable, 1828-1829
Fanconi anemia, radial deficiency associated with, 1289, 1290*t*
longitudinal, 1329*t*
Farm yard pox, 123-124, 124*f*
Fasciectomy, for Dupuytren disease, 140-142
comparison of, 141*t*
Fasciitis
necrotizing, 17, 54-55, 54*f*
animal bites and, 48
antibiotic recommendations for, 21*t*
case study, 55.*e*1*b*, 55.*e*1*f*
diabetic hand infections and, 54
fungal, 55, 55*f*
shooter's abscesses and, 51
nodular, 2014
Fasciocutaneous flap(s)
axial-pattern, regional, 1555, 1555*f*
free, 1575-1576. *see also* Free flap(s)
for mangling injuries, 1513, 1514*f*
Fasciotomy
for compartment syndrome, 1764
contraindications to, 1769
indications for, 1769
prophylactic, 1769
for Dupuytren disease, 139*t*, 140
Fat graft, physiolysis and, for Madelung deformity, 1339-1342, 1341*f*
Fat pad sign, in radial head fractures, 734-736, 735*f*
FCR sling suspensionplasty, 363
Feldon's two-pin modification, 1865-1866, 1866*f*
Felon, 25-28, 26*f*, 28*b*
clinical presentation and evaluation of, 25
pertinent anatomy in, 25-26
postoperative management of, 28
treatment for, 26-28
operative, 26, 27*f*, 27*t*
preferred methods of, 26-28
Felty syndrome, in rheumatoid arthritis, 1833

Femoral condyle
bone graft from, for scaphoid nonunion, 619, 620*f*
medial
grafts, 1625-1629
osteochondral graft harvest, 1628
vascularized bone graft from, 1625-1627, 1626*f*
Fernandez-Fisk wedge graft, for scaphoid nonunion, 612-614, 613*f*
FGFR2 gene, mutation of, 1227-1228
Fibrin clot glue, in suturing, 996
Fibroma
chondromyxoid, 2023
digital, of infancy, 2014, 2014*f*
juvenile aponeurotic, 2014
Fibromatosis
of palmar and digital fascia. *see* Dupuytren contracture
subcutaneous pseudosarcomatous, 2014
Fibrosarcoma, 2018
Fibrosis, posttraumatic, of proximal interphalangeal joint, 295-296, 296*b*, 296*f*
Fibrotic band, arthroscopic arthrolysis and, 691
Fibrous histiocytoma, malignant, 2019, 2019*f*
Fibula
anatomy of, 1617
grafting from
for congenital pseudoarthrosis of ulna, 1356
vascularized, 1617-1620, 1617*f*-1618*f*
complications of, 1620, 1620*f*
donor results, 1621, 1622*f*
double-barrel flap in, 1620
with muscle, 1620
osteocutaneous flap in, 1619
in upper extremity, 1622-1623, 1623*f*
with skin flap, 1619
Filarial infection, 117-118
Fillet flap, 1552-1554, 1554*f*. *see also* Skin flap(s)
Finger(s). *see also* Digit(s); Digital *entries*
absence of, 1255-1270, 1270*b*
in constriction ring syndrome, 1255-1258, 1257*f*, 1258*b*
microvascular toe transfer for, 1263-1270, 1265*f*-1268*f*
reconstruction for, 1261-1270
complications of, 1262
distraction of digits in, 1262
free phalangeal transfer in, 1260*f*, 1261-1262
preferred method of, 1262
hand preparation in, 1262, 1262*f*
harvesting of graft in, 1262, 1263*f*
placement of graft in, 1262, 1263*f*
surgical outcomes for, 1270
transposition of rays in, 1245*f*, 1263, 1264*f*
Finger(s) *(Continued)*
in symbrachydactyly, 1258-1260
transverse, acquired causes of, 1261-1270
amputation of. *see also* Ray amputation
multiple-digit, 1735-1737, 1735*b*, 1736*f*, 1737*b*
toe transfer for. *see also* Toe transfer, in finger replacement
distal digit in, 1646-1647
multiple digits in, 1648
proximal digit in, 1647-1648
single digit in, 1646, 1647*f*
aponeurosis of, 338.*e*3, 338.*e*5*f*
bones of. *see* Phalanx (phalanges)
deformities of, 1217-1288, 1879-1894
boutonnière. *see* Boutonnière deformity
claw-hand. *see* Claw-hand deformity
extension of, 154-155
biomechanics of, 158
extensors, 152
rupture of, 1851-1852
fifth, amputation of, preferred method of treatment of, 1732-1733, 1733*f*-1734*f*
flexor tendons of. *see also* Flexor tendon(s)
tenosynovitis of, 1848-1849
preferred method of treatment of, 1848-1849, 1848*f*
hypoplastic, microvascular toe transfer for, in finger absence, 1263-1270, 1265*f*-1268*f*
index
amputation of, 1721-1723, 1723*f*
preferred method of treatment of, 1722-1723, 1724*f*
independent extension of, 153
mangling injuries and, 1493
resection/transplantation of, in distraction procedures, stump of, pollicization of, 1699-1703, 1702*f*-1704*f*, 1705*b*
injury
dorsal, 1737.*e*1*f*
palmar, 1737.*e*1*f*
joints of. *see* Distal interphalangeal (DIP) joint; Interphalangeal (IP) joint; Metacarpophalangeal (MCP) joint(s); Proximal interphalangeal (PIP) joint
little, abduction of, correction of, 1060
long, amputation of, 1723, 1725*f*
without transposition, 1723-1726, 1725*f*-1726*f*
mangling injuries of, treatment of, 1512-1515, 1512*f*-1517*f*
reconstruction of, microvascular toe transfer in, 1263-1270
rheumatoid arthritis of. *see* Rheumatoid arthritis, of fingers
Finger(s) *(Continued)*
ring
amputation of
preferred method of treatment of, 1731-1732, 1732*f*
with transposition of fifth metacarpal, 1732-1733, 1733*f*-1734*f*
duplication of, 1214*f*
restoration of, 1060-1061
suture to middle finger, 1060-1061, 1061*f*
without transposition, 1730-1733
small, amputation of, 1734-1735
preferred method of treatment, 1734-1735, 1735*f*-1736*f*
stiff, 338-344. *see also* Stiffness, of finger and hand
thumb and, restoration of pinch between, in ulnar nerve palsy, index abduction techniques in, 1059
transposition of, long finger, amputation with, 1726-1730, 1728*f*
trigger, 1322, 1323*f*
Finger extension test, resisted, in scapholunate dissociation, 436
Finger flexion
free functional muscle transfer for, 1782*b*
reconstruction of, 1777
tendon transfer for, 1779*b*
Fingernail(s). *see* Nail(s)
Fingertip(s), amputation of, 1709
cross-finger pedicle flap for, 1714-1716, 1715*f*
free flaps in, 1717
island flaps in, 1717
with skin or pulp loss only, 1709-1711
Smith and Albin thenar H-flap in, 1716, 1716*f*
thenar flap in, 1716
V-Y flap(s) for
Atasoy-Kleinert volar, 1712-1713, 1713*f*
Kutler lateral, 1713-1714, 1714*f*
volar advancement, 1714, 1715*f*
Finkelstein sign, in radial nerve compression, 948
First metacarpal osteotomy, for carpometacarpal joint osteoarthritis
expected outcomes on, 366
as operative technique, 362, 362*f*
as treatment, 361
First-degree burns, 1928. *see also* Burns
Fish, venomous, 1792-1795, 1793*f*-1794*f*
Fisher classification, of scaphoid fractures, 593
Fish-mouth incision, for felon, 27*f*, 27*t*

Fixation. *see also* Kirschner pin/wire fixation; Pin fixation; Plate fixation; Screw fixation; Wire fixation
devices for, external, for proximal interphalangeal joint contractures, 341, 342*f*
of Galeazzi-type fracture-dislocations, 792-793, 792*f*
hinged, after elbow contracture release, 855, 855*f*
of humeral fractures
principles in, 717-726, 719*f*, 717.*e*1*b*, 717.*e*1*f*-717.*e*2*f*
sequence of, 724
posterior approach for radial shaft, 790-791, 790*f*-791*f*
of scaphoid fractures
arthroscopy-assisted, 603
mechanics of, 595-596
rigid, 596-597
techniques in, for proximal interphalangeal joint arthrodesis, 350
in toe transfer, 1666-1668
of ulnar fractures, early failure of, 782, 782*f*-783*f*
Fixed-angle implants, in osteotomies, 578
Flap(s)
advancement, 1541-1542, 1547-1550, 1548*f*-1549*f*
"V-Y", 1548-1550, 1549*f*-1551*f*
axial-pattern, 1539-1540, 1540*f*. *see also* Axial-pattern flap(s)
for burns, 1934, 1935*f*
chemotherapeutic extravasation skin loss and, 1570
diamond shaped, in cleft hand surgery, 1247-1248, 1247*f*
distant, 1540, 1563-1568. *see also* Distant flaps
failure in, 1570-1571
salvage of, 1571
fasciocutaneous, 1555, 1555*f*
free, 1575-1576
for mangling injuries, 1513, 1514*f*
free, 1540, 1554
local, 1540-1542. *see also* Local flaps
transposition, 1542. *see also* Transposition flaps
postoperative care for, 1570-1571
preferred method in, 1568-1570, 1568*t*
raising, 1541
random-pattern, 1539. *see also* Random-pattern flap(s)
regional, 1540, 1550-1558. *see also* Regional flap(s)
staging of, 1540
in syndactyly surgery, preferred method of, 1219*f*, 1224-1225, 1226*f*-1227*f*
types of, 1539-1541, 1539*t*
wound preparation for, 1540-1541
Flat (plane) warts, 121
Flatt's classification, of macrodactyly, 1275-1276, 1276*t*
Flexible-hinge silicone arthroplasty, 406
Flexion, of wrist, kinematics in, 423-424
Flexion contractures, after volar plate arthroplasty, 290
Flexion deformity
as complication, of flexor tendon grafting, 225
in proximal interphalangeal joint contractures, 340.*e*2
Flexion splint, "come-along", for elbow contracture, 857, 858*f*
Flexor carpi radialis
tendinitis of, 1922-1923
anatomy of, 1922-1923
treatment of, 1923
nonoperative, 1923
operative technique, 1923
transfer of
for radial nerve palsy, 1071, 1071*b*, 1071*f*
for ulnar nerve palsy, 1055-1056
Flexor carpi ulnaris, transfer of
for radial nerve palsy, 1067-1070, 1067*f*-1069*f*
postoperative management of, 1069
potential problems of, 1069-1070
in spasticity
to extensor carpi radialis brevis, 1097-1098, 1098*f*, 1099*b*
to extensor digitorum communis, 1099-1100, 1100*b*
Flexor digiti quinti, 338.*e*4
Flexor digiti quinti brevis, 338.*e*3
Flexor digitorum longus, for tendon graft, 206
Flexor digitorum profundus (FDP)
anatomy of, 185
avulsion of, 187-188, 187*f*
in rheumatoid arthritis, rupture of, 1856-1857
tendon juncture of, end-to-side, 220, 221*f*
in tetraplegic patient, side-to-side transfer of, 1141
Flexor digitorum superficialis (FDS)
anatomy of, 185, 185*f*
finger in, salvage procedure of, 226
postoperative care of, 226
technique in, 226, 226*f*
FPL reconstruction using, 216.*e*1*f*
insertion, replantation and, 1477, 1478*f*
opponensplasty of, in hypoplastic thumb reconstruction, 1292-1295, 1293*b*, 1293*f*-1295*f*
pulley reconstruction using, 222, 222*f*
in rheumatoid arthritis, rupture of, 1857
tenodesis of, 1737.*e*2*f*
for intrinsic muscle spasticity, 1114
transfer of, 219-220, 220*f*, 220.*e*1*f*
in restoration of thumb adduction, 1057-1058, 1057*f*
Flexor hallucis longus muscle (FHL), 1619
Flexor hinge splint, wrist-driven, 1130-1131, 1131*f*
Flexor origin slide, for Volkmann contracture
complications of, 1785, 1778.*e*1*f*
outcomes of, 1782, 1784*f*-1785*f*
Flexor pollicis brevis (FPB), transfer of, in median nerve palsy, 1041
Flexor pollicis longus (FPL)
anatomy of, 185
lacerations of, 190
loss of, function, 219
in rheumatoid arthritis, rupture of, treatment of, 1856, 1856*f*
in tetraplegic patient
brachioradialis transfer to, 1141
in House one-stage reconstruction, 1134-1135
pronator teres tendon transfer to, 1138
split transfer of, in House's one-stage reconstruction, 1135, 1136*b*, 1136*f*
in thumb-in-palm deformity, in cerebral palsy, abductorplasty for, 1111-1112
transfer of, in median nerve palsy, 1037, 1038*f*
alternative, 1037, 1038*f*-1039*f*
Flexor pronator slide, 1777-1778, 1778*f*, 1780*f*
for Volkmann contracture, 1779*b*
Flexor tendon(s)
anatomy of, 185-186, 185*f*-186*f*
blood supply to, 186, 186*f*
digital, in cerebral palsy, tightness of, 1084-1085, 1085*f*
operative management of, 1102-1106, 1104*f*
of elbow, for spasticity, lengthenings of, 1091-1092, 1091*f*, 1092*b*
fractional lengthening of, for spasticity, 1102-1103, 1104*b*, 1105*f*
ganglion of, volar retinacular, 2005, 2005*f*
grafting of
complications following, 224-226
adhesion formation as, 224
future concepts of, 225-226
infection as, 225
late flexion deformity as, 225
lumbrical-plus finger as, 225
mechanical failure of the implant as, 224
proximal interphalangeal joint as, hyperextension of, 225
pulley disruption as, 224
quadriga syndrome as, 224-225
rupture in, 224
synovitis as, 225, 225.*e*1*f*
extensor indicis proprius tendon harvest in, 206

Flexor tendon(s) *(Continued)*
flexor digitorum longus tendon harvest in, 206, 207*f*
long toe extensor tendon harvest in, 205-206, 206*f*
palmaris longus tendon harvest in, 204, 204*f*
plantaris tendon harvest in, 204-205, 205*f*
single-stage
flexor digitorum profundus and flexor digitorum superficialis tendons disrupted, 202-211, 203*f*, 207*b*
biology of, 203
Boyes' preoperative classification, 202*t*
distal juncture technique of, 209*f*-210*f*, 210
donor for, 203-206
incorporation of, 211
indications for, 202
initial exploration of, 202
placement of, 210
postoperative care of, 211
preferred technique of, 209-210
proximal juncture technique of, 210-211, 210*f*-211*f*
flexor digitorum profundus tendon disrupted, flexor digitorum superficialis tendon intact, 211-212, 212*b*, 214*b*
expectations of, 212
indications for, 211-212, 212*f*-213*f*
postoperative care of, 212
technique of, 212
two-stage, reconstruction, 212-217
alternative techniques in, 213-214, 215*f*
composite tissue transfer methods of, 214
indications for, 212-214
stage I in, 217*b*
postoperative care of, 216
preferred technique of, 214-216, 215*f*-216*f*
stage II in, 218*b*
postoperative care of, 217
technique of, 216-217, 216*f*-218*f*
tissue response to a silicone implant in, 213
issues, in procedure, for Dupuytren disease, 147
pulley system of, 186, 186*f*
repair of, 1481
rupture of
as complication of phalangeal fractures, 269
in rheumatoid arthritis
diagnosis of, 1850
treatment of, 1856-1857, 1856*f*

Flexor tendon(s) *(Continued)*
sheath, proximal portion of, 1723
tenodesis of, for swan neck deformity, in rheumatoid arthritis, 1882-1883, 1882*f*
tenosynovitis of, 1848-1849
antibiotic recommendations for, 21*t*
preferred method of treatment of, 1848-1849, 1848*f*
pyogenic, 28-32, 30*f*-31*f*, 32*b*
septic, 31.*e*1*b*, 31.*e*1*f*
of wrist, tenosynovitis of, preferred method of treatment of, 1848-1849, 1848*f*
"Z" -lengthening of, for spasticity, 1103-1104, 1104*b*
zones of, 185-186, 185*f*
Flexor tendon injury, 183-230
preoperative evaluation of, 183-185, 185*f*
reconstruction of, 199-226
in children, 223-224, 224*b*
indications of, 223
preferred technique of, 224
complications following, 224-226
adhesion formation as, 224
future concepts of, 225-226
infection as, 225
late flexion deformity as, 225
lumbrical-plus finger as, 225
mechanical failure of the implant as, 224
proximal interphalangeal joint as, hyperextension of, 225
pulley disruption as, 224
quadriga syndrome as, 224-225
rupture in, 224
synovitis as, 225, 225.*e*1*f*
grafting of, single-stage, 202-211
patient selection of, 199, 199*f*
pulley system in, 221-223
indications of, 221
postoperative care of, 223
preferred technique of, 222-223, 223*f*
using a flexor digitorum superficialis tendon, 222, 222*f*
using a free tendon graft, 221-222, 222*f*
using artificial materials, 222
using the extensor retinaculum, 222
using the volar plate, 222
secondary, in zones 3, 4, and 5, 219-221
expectations of, 221
indications of, 219
interposition graft of, 219-220, 219*f*
postoperative care of, 221
tenolysis, 199-202, 202*b*
adhesion formation of, agents that may limit, 200
expectations following, 201-202

Flexor tendon injury *(Continued)*
postoperative care following, 201
preferred technique of, 200-201, 201*f*
preoperative evaluation of, 199-200, 200*f*
of thumb, 217-219, 220*b*
indication of, 217-218
staged tendon, 219
technique of, 218-219
repair of
acute, 183-198
complications following, 198
contributions to, 184*t*
expected outcomes of, 195
general principles of, 199*b*
in partial tendon lacerations, 190
rehabilitation after, 195-198
surgical treatment of, 186-194
in tendon lacerations in zones 3, 4, and 5, 190
surgical techniques for, 194
in zone 1 tendon lacerations or avulsions, 187-188, 187*f*, 191*b*
postoperative rehabilitation of, 195-198, 196*f*-197*f*
tendon repair in, 191-194, 194*f*
tendon-to-bone repair, 190, 192*f*-193*f*
in zone 2 tendon lacerations, 188-190, 188*f*-189*f*, 195*b*
postoperative rehabilitation of, 195-198, 196*f*-197*f*
tendon repair in, 191-194, 193*f*-194*f*
Flexor-pronator muscle
origin, slide of, in cerebral palsy
at forearm, 1094-1095, 1094*f*
at wrist and digit, 1102
repair of, in medial "over-the-top" approach, to open release of elbow contracture, 852, 852*b*
Flow-through flap, 1577
Fluconazole
for candidiasis, 85
for coccidioidomycosis, 86
for cryptococcosis, 86
for deep sporotrichosis, 88
for eumycetoma, 73
for fungal infections, 79, 90
of nails, 330-331
for histoplasmosis, 86-87
for paronychia, 81
for protothecosis, 116
spectrum of activity of, 79*t*
for sporotrichosis, 83
Flucytosine
for cryptococcosis, 86
for fungal infections, 79-80
spectrum of activity of, 79*t*
Fluid therapy, after electrical injury, 1947
Fluoroscopy, reduction of screw malposition with, 605

Fluoxetine, for complex regional pain syndrome, 1813*t*
Fluvoxamine, for complex regional pain syndrome, 1813*t*
Foot deformity, in cleft hand, management of, 1251-1255
Forearm
anomalies of, classification of ulnar deficiency based on, 1337*t*
axis of rotation of, 786, 787*f*
in brachial plexus birth palsy, 1419, 1420*f*
compartments of, release of, 1769-1770, 1770*f*-1771*f*
defects of, skin flaps for, 1568-1570, 1568*t*
diaphyseal fractures of, in children, 1458-1471, 1471*b*
epidemiology of, 1459-1460
historical review of, 1462-1464
pertinent anatomy in, 1461-1462
postoperative expectations and management of, 1470-1471
preoperative evaluation of, 1460-1461, 1461*f*-1463*f*
types of operations in, 1464-1471
disorders of, 786-812
distal, musculoskeletal tumors of, excision of, 1996, 1996*f*-2000*f*
fractures of, both bones, 797-798
nonunion and malunion of, 799-803
postoperative management and expectations after, 798
posttraumatic radioulnar synostosis after, 803-804. *see also* Radioulnar synostosis
preferred method of treatment of, 797-798, 798*f*
preoperative evaluation of, 797
removal of hardware from radius and ulna in, 798-799
functional anatomy of, 786, 787*f*
lengthening of, for ulnar deficiency, 1338, 1340*f*
longitudinal axis instability of, 804-809
complications of, 809
interosseous ligament reconstruction in, 808-809
one-bone forearm technique in, 808-809
pertinent anatomy in, 806, 806*f*
postoperative expectations after, 809
preferred methods of, 808-809
prevention of instability in, 806-807
restoration of radius and ulna with radioulnar joint reduction in, 807
malformations and deformities of, 1328-1364
case study for, 1362.*e*1*b*, 1362.*e*1*f*-1362.*e*4*f*
malunions of, 498-500, 499*f*
Forearm *(Continued)*
mangling injuries of, treatment of, 1515, 1518*f*-1519*f*
pronation of, in tetraplegic patient, 1129-1130, 1130*f*
group 0, 1130-1131, 1131*f*
group 1, 1131-1133, 1131*f*-1132*f*, 1132*b*, 1133*t*
groups 2 and 3, 1133-1135, 1133*t*, 1135*f*-1136*f*, 1136*b*-1137*b*
groups 4 and 5, 1135-1140, 1137*f*-1138*f*, 1139*b*, 1140*f*
groups 6 and 7, 1140-1141
group 8, 1141-1142, 1142*f*
group 9, 1142, 1143*f*
as recipient site, in bone grafting, 1636-1637
spasticity in
examination of, 1084
operative management of, 1093-1095
treatment of, preferred method of, 1095, 1096*f*
Volkmann contracture of
restoration of intrinsic function after, 1783
Tsuge classification for, 1774*t*
Forearm compartment syndrome, nerve dysfunction associated with, 1783
Forearm flap(s)
for burn deformities, 1945
composite, for reconstruction of, amputated thumb, 1697-1699, 1700*f*, 1699.*e*1*f*
for mangling injuries, 1513, 1514*f*-1515*f*
radial, 1588-1591, 1589*f*, 1591*b*
anatomy in, 1588-1589
operative technique in, 1589-1591, 1590*f*, 1592*f*
Foreign bodies, infection and, 57-58
Foreign body lesions, 2010
Forequarter amputation, preferred method of treatment for, 1756, 1758*f*
Four-corner fusion, with scaphoid excision, 391
Fourth-degree burns, 1929
Fovea, ulnar, 479, 481*f*
Fovea sign, 489
Fowler's wrist tenodesis, in ulnar nerve palsy, 1051, 1051*f*
Fractional palmar intrinsic lengthening, for swan neck deformity, 1114-1115
Fractional tendon lengthening, for spasticity, 1102-1103, 1104*b*, 1105*f*
Fracture(s)
after metacarpophalangeal joint arthroplasty, 1877
of capitate, in children, 1447, 1447*f*
of carpal bones, 588-652
incidence of, 625*t*
in mangling injuries, treatment of, 1500
other than scaphoid, 624-649
Fracture(s) *(Continued)*
of coronoid process. *see also* Coronoid process, fracture of
in complex elbow dislocation, 815, 816*f*
treatment of, 780
preferred method of, 782
of distal humerus, 906-907, 908*f*
preoperative assessment of, 906-907
of forearm. *see also* Forearm, fractures of
both bones, 797-798
diaphyseal, in children, 1458-1471, 1471*b*
of hamate, 631-634, 633*b*
body of, 634, 634*f*-635*f*
in children, 1447-1448, 1448*f*
hook of, 631-634, 632*f*
blood supply to, 632
clinical and radiographic presentation of, 631-632, 632*f*
postoperative care for, 634
treatment of, 632-634, 634*f*
incidence of, 625*t*
of humerus, distal, 697-733. *see also* Humerus, distal
of lunate, 636-637, 637*b*
incidence of, 625*t*
in Kienbock disease, 639
mechanism of injury in, 637-638, 638*f*
radiographic presentation of, 637-638
treatment of, 638, 639*f*
of metacarpal bones, 231-248
pediatric, 1425-1475
epidemiology of, 1459-1460
of forearm, diaphyseal, 1458-1471
historical review of, 1462-1464
pertinent anatomy in, 1461-1462
postoperative expectations and management of, 1470-1471
preoperative evaluation of, 1460-1461, 1461*f*-1463*f*
types of operations in, 1464-1471
of hand, 1425-1442
epidemiology of, 1425-1426, 1426*f*
historical review of, 1428, 1428*b*
pertinent anatomy in, 1427-1428
preoperative evaluation of, 1426-1427, 1427*f*
types of operations for, 1428-1442
of wrist, 1442-1457
epidemiology of, 1442-1443
pertinent anatomy in, 1444-1445
preoperative evaluation of, 1443-1444
types of operations for, 1445-1457
to perionychium, 322-323, 322*f*-323*f*
of phalanges, 248-270
of pisiform, 634-636, 635*b*, 636*f*
in children, 1448, 1449*f*
incidence of, 625*t*
of radius

Fracture(s) *(Continued)*
distal, 516-587. *see also* Radius, distal, fracture of
at head, 734-769. *see also* Radius, head of, fracture of
at shaft, 786-795. *see also* Radius, shaft of, fracture of
of scaphoid, 426, 588-624
biomechanics of, 590-591
cause of, 588
in children, 607-608
classification of, 592-593, 594*t*
clinical presentation of, 591
delayed presentation of waist fracture in, 603
diagnosis of, 591
distal radius and, fractures of, 603-604
examination of, 591-592
imaging of, 592, 593*f*
incidence of, 588, 589*f*, 625*t*
management of, 594-596
algorithm for, 594*t*
in athletes, 603
at distal pole, 594
incomplete, through waist, 594
mechanics of fracture fixation in, 595-596
at proximal pole, 595
at waist, 595
nonsurgical treatment for, cost of, 605-607
physical examination of, 591, 591*f*
rigid fixation for, 596-597
surgical treatment for, 597-603
arthroscopy-assisted percutaneous fixation in, 603
complications of, 605
cost of, 605-607
dorsal percutaneous Slade technique in, 598
fixation in, palmar percutaneous method of, 601-603, 602*f*
mini-open screw in, palmar approach to, 600-601, 600*f*
open reduction and internal fixation in, 597-598
palmar percutaneous method in, 600
pitfalls for, 601*b*, 601*f*-602*f*
postoperative care, 602-603
preferred, 597-598, 597*f*
waist fracture, displaced, 598-599, 599*f*
stability of, 527-530
stabilization of, 791
stress, after bone grafting, 1616-1617, 1616*f*
of thumb, 270-275
in children, 1439-1442
of trapezium, 626-629, 627*b*, 627*f*
imaging of, 628
incidence of, 625*t*
Fracture(s) *(Continued)*
mechanism of injury in, 626-628, 628*f*
treatment of, 628-629, 628*f*-629*f*
of trapezoid, 636, 636*b*
incidence of, 625*t*
of triquetrum, 427, 624-626, 625*b*
body, 625-626
in children, 1447, 1447*f*
clinical and radiographic features of, 626
dorsal cortical, 624-625, 626*f*
incidence of, 625*t*
patterns of, 624-626
treatment of, 626, 627*f*
volar avulsion, 626
of ulna
complete, surgical treatment of, 1464-1466, 1465*f*-1467*f*
preferred method of treatment of, 1466-1468
distal and midshaft, 795-797
proximal, 770-785
ulnar styloid, 493, 493*f*
Fracture-dislocation
axial, in complex carpal instability, 473-475, 474*f*-475*f*
of carpometacarpal, 244-246
multiple, 245
preferred method of treatment of, 245-246, 245*f*-246*f*
of ring finger, 244
of small finger, 244-245
Galeazzi, fixation of, 792-793, 792*f*
of olecranon process, 774-775, 774*f*-776*f*, 816-817, 816*f*
anterior (transolecranon), 774-775, 775*f*, 784.*e*13*b*, 784.*e*13*f*-784.*e*14*f*
complex posterior, 784.*e*1*b*, 784.*e*2*f*-784.*e*3*f*
posterior, 784.*e*4*b*, 784.*e*4*f*-784.*e*5*f*, 784.*e*6*b*, 784.*e*7*f*-784.*e*8*f*, 784.*e*15*b*, 784.*e*15*f*-784.*e*17*f*, 784.*e*25*b*, 784.*e*25*f*-784.*e*27*f*
posterior Monteggia lesion, 817, 817*f*
transolecranon, 816-817, 816*f*
treatment of, 780, 822-823, 823*f*
hinged external fixation in, 823-824, 824*b*, 824*f*
perilunate, 470-472
transscaphoid, 470-471
transscaphoid-transcapitate, 471-472, 472*f*
transtriquetrum, 472, 473*f*
treatment of, 472, 473*f*
of proximal interphalangeal joint, 281-282, 281*f*
chronic, 293-294
stable, 281-282
tenuously stable, 282
treatment of, 281*f*
preferred method of, 284-294, 284*f*
Fracture-dislocation *(Continued)*
unstable, 282, 282*f*
treatment of, 282-293
cerclage wiring in, 283-284, 284*f*
complications of, 290
dynamic skeletal traction in, 283
extension block pinning in, 283
extension block splinting in, 282-283
hemihamate autogenous grafting in, 284
open reduction with internal fixation in, 283
technique for, 291-293, 292*f*-294*f*, 293*b*
volar plate arthroplasty in, 284
volar, 280
radiocarpal, management of, 572-573, 573*f*, 573.*e*1*f*-573.*e*3*f*, 573.*e*2*b*
transscaphoid perilunate, 604-605, 606*f*-607*f*
unreduced, late treatment of, 472, 473*f*
Fragment-specific classification, of distal radial fracture, 524, 526*f*
Fragment-specific fixation, of distal radial fracture, open reduction with, 552-557, 555*f*-556*f*, 558*b*
Free flap(s), 1540, 1554, 1574-1611
classification of, 1575-1577
composite flaps, 1577
cutaneous flaps, 1575-1576, 1575*f*
muscle and musculocutaneous flaps, 1576
perforator flaps, 1576-1577
venous flaps, 1577
contraindications for, 1574-1575
donor sites for, 1576*t*
failing, saving of, 1583-1585, 1585*b*
leeches for, 1582*f*, 1583-1584
operating room exploration and, 1583-1584
thrombolytic agents and, 1584-1585
indications for, 1574
infection in, 1585
monitoring of, 1582-1583
bleeding in, 1582
capillary refill in, 1582
color, 1582, 1582*f*
other techniques in, 1583
operative technique for, 1578-1582
dressings in, 1581-1582
flap harvesting in, 1580-1581
flap insetting in, 1581, 1581*f*
pedicle dissection in, 1581
peduncle length and accessibility in, 1580
recipient vessels in, 1579-1580
skeletal stabilization in, 1579
skin pattern in, 1579, 1590*f*
tissue defect in, examination of, 1577
wound débridement in, 1578-1579, 1578*b*, 1579*f*
zone of injury, avoiding, 1580, 1600*f*

Free flap(s) *(Continued)*
patient care in, 1582
postoperative care for, 1582-1583
preoperative assessment in, 1577-1578, 1578*f*
angiography prior to, 1577
patient preparation in, operating room, 1578
in reconstruction of amputated fingertip, 1717
selection of, 1608-1609
for artery, defects of, 1609
for bone, defects of, 1609
for composite defects, 1609
for sensation, defects of, 1609
for soft tissue defects, 1608-1609
for tendon, defects of, 1609
specific, 1585-1609
anterolateral thigh, 1597, 1598*f*
groin, 1593-1597, 1595*f*-1596*f*
lateral arm, 1585-1588, 1586*f*-1587*f*, 1588*b*
latissimus dorsi, 1597-1602. *see also* Latissimus dorsi muscle flap
tailored, 1599*f*, 1602-1603
radial forearm, 1588-1591, 1589*f*, 1591*b*. *see also* Radial forearm flap
rectus abdominis, 1604
scapular, 1591-1593, 1593*b*. *see also* Scapular flap
sensory flaps, from first web space of foot, 1605-1608, 1606*f*, 1608*b*
serratus anterior, 1603, 1603*f*
temporoparietal fascial flap, 1604-1605, 1604*f*, 1605*b*
thoracodorsal artery perforator flap, 1602-1603
vascularized, in grafting from fibula, 1619
Free functional muscle transfer, for Volkmann contracture, outcomes of, 1782-1783
Free radical scavengers, for complex regional pain syndrome, 1816
Free serratus fascial flap, for burn deformities, 1945
Freeman-Sheldon syndrome, arthrogryposis in, 1366*f*
Freeze-thawed muscle graft (FTMG), 999
excision of neuroma by, repair and, 1014*b*, 1015*f*
Froment sign, 1046-1047
Frostbite injuries, 1951-1953
diagnosis of, 1952
pathophysiologic findings in, 1952
treatment of, 1952-1953, 1953*b*
Frykman classification, of distal radial fracture, 524.*e*1, 524.*e*1*f*
Full-thickness grafts, 1530-1531. *see also* Skin graft/grafting, full-thickness
Functioning free muscle transfer (FFMT)
for brachial plexus injury, 1152-1153
for Volkmann contracture, complications of, 1785-1786
Fungal infections
chronic, 77-90
classification of, 77-78
cutaneous, 80, 80*f*
deep, 84-89
diagnosis of, 63*t*, 78-79
eight-pack tissue culture for, 65*t*
epidemiology of, 77-78
etiology of, 63*t*, 77-78
newly emerging, 89-90
risk factors associated with, 78*t*
subcutaneous, 80-84
treatment of, 63*t*, 79-80, 79*t*
of nails, 330-331
Fungal necrotizing fasciitis, 55, 55*f*

G

Gabapentin, 969
for complex regional pain syndrome, 1813*t*
Gait analysis, before and after toe transfer, 1670
Galeazzi fracture
in children, 1470
fixation of, 792-793, 792*f*
Gamekeeper's thumb, 306-308, 1897
historical review of, 303
operative treatment of
indications for, 1897
options for, 1897*t*
postoperative management and expectations in, 308
preoperative evaluation of, 306-307
treatment of, preferred method for, 308, 308*b*
types of operations for, 307-308, 307*f*
Ganglion(s), 1997-2010
anatomy of, 1999
arthroscopic excision of, surgical technique for, 688-689, 688*f*-689*f*
in carpal tunnel, 2009
clinical characteristics of, 1997-1999, 1999*t*
of distal interphalangeal (DIP) joint, 333, 333*f*-334*f*, 334*b*
of dorsal wrist, 2001-2003
author's preferred method of treatment for, 2001-2003
clinical characteristics of, 2001, 2001*f*
complications in, 2003
operative technique for, 2001-2003, 2001*f*-2003*f*
postoperative care for, 2003
of extensor tendons, 2008, 2010*f*
of first extensor compartment (dorsal retinacular), 2009, 2010*f*
in Guyon canal/distal ulnar nerve, 2009
intraosseous, 2009, 2010*f*
of occult dorsal carpal, 2003-2004
Ganglion(s) *(Continued)*
pathogenesis of, 1999-2001
of proximal interphalangeal joint, 2007-2008, 2008*f*-2009*f*
treatment of
nonoperative, 2001
operative, 2001
of volar retinacular (flexor tendon sheath), 2005, 2005*f*
of volar wrist, 2004-2005
author's preferred method of treatment for, 2004-2005
clinical characteristics of, 2004, 2004*f*
complications in, 2005
operative technique in, 2004-2005, 2004*f*
postoperative care for, 2005
Ganglionectomy, arthroscopic, of wrist, 688-689
Ganglionic blockade, for complex regional pain syndrome, 1816
Gangrene
of digits and distal palm, 1762.*e*3*f*
gas, 54-56
antibiotic recommendations for, 21*t*
Gangrenosum, pyoderma, 75-77
clinical findings on, 76-77, 76*f*
diagnosis of, 77
etiology and epidemiology of, 75-76
treatment of, 77
Gantzer muscle, 935-936
Gap formation, of zone 2 tendon lacerations, 188-189, 189*f*
Gap index, 1449, 1453*f*
Garrod pads. *see* Dorsal Dupuytren nodules (DDN)
Gas gangrene, 54-56
antibiotic recommendations for, 21*t*
Gate theory, of pain, 1801
Gatifloxacin, dosage of, 101*t*
Geissler technique, for scaphoid fractures, 666-668, 666*f*-668*f*
Gelling, after elbow contracture release, 859
Gender, Dupuytren disease and, 129
General anesthesia, 1
Genetic biomarkers, of Dupuytren disease, 129
Geriatric total elbow arthroplasty, 710.*e*1*b*, 710.*e*1*f*
Germinal matrix, of nails, 318
Giant cell tumors
of bone, 2025-2026, 2026*f*-2027*f*, 2027*b*
of tendon sheath, 2012, 2012*b*
Giant hairy congenital nevi, 1966, 1967*f*
Gigantism anomaly, in macrodactyly, 1276*t*, 1277, 1280*f*
Gillies "cocked-hat" flap, for amputated thumb reconstruction, 1696, 1697*f*
"Gilula's lines", 428, 428*f*

Glenohumeral arthrodesis, in brachial plexus injury, 1192, 1194*b*, 1194*f*
Glenohumeral joint
  arthrodesis of, 1090, 1090*f*
  deformity of, in brachial plexus birth palsy, 1408-1409, 1409*f*
Glomus tumor(s), 2056, 2058*f*
  of perionychium, 334, 335*f*
Gnathostomiasis, 117
Gore-Tex glove, filled with silver sulfadiazine, for burns, 1931, 1932*f*
Gorlin syndrome, 1972-1973, 1974*f*
Gout, 57-58
  tendinopathy in, 1905, 1905*f*
  tophaceous, 58*f*
Gracilis muscle
  dissection of, 1783*f*
  harvest of, for free functioning muscle transfer, in brachial plexus injury, 1179-1180, 1180*f*
  transfer of, 1781
Gracilis muscle flap, for mangling injuries, 1515, 1518*f*
Graft(s)
  bone-ligament-bone, scapholunate ligament replacement with, 442-443
  chevron-type slot, for short metacarpal lengthening, 1242-1243, 1242*f*
  fat, for Madelung deformity, 1339-1342, 1341*f*
  for nail bed, harvest of, 322, 322*f*
  rupture of, as complication, of flexor tendon grafting, 224
  versus tendon transfers, 1065
  toe eponychial, 329
Grafting. *see* Skin graft/grafting
Granular cell tumors, 2013-2014, 2013*f*
Granuloma
  interdigital, 118
  pyogenic, 1970, 1971*f*
  of nails, 332, 332*f*
Grasp
  reconstruction of, free muscle transfer for, after brachial plexus avulsion, 1180-1184
    complications of, 1184
    donor muscle selection in, 1181-1182
    operative technique of, 1181-1183, 1181*f*-1182*f*, 1184*b*
    outcome of, 1184, 1184*f*
    postoperative protocol for, 1183
    prerequisites of, 1181
    subsequent surgery for, 1183-1184
  spasticity and, evaluation of, 1085
Grayson ligament, 134-136
Greater arc injuries, in dorsal perilunate fracture-dislocations, 470
Grebe chondrodysplasia, 1214, 1215*f*
  central polydactyly in, 1234, 1234*f*
Greenstick fractures, 1461, 1462*f*-1463*f*
  operations for, 1464
Groin flap(s), 1564-1568, 1564*f*, 1566*f*-1567*f*, 1568*b*
  for burn deformities, 1944
  in first web space reconstruction, 1228-1230, 1230*f*
  free, 1593-1597, 1595*f*-1596*f*
  for mangling injuries, 1512, 1512*f*-1513*f*
Guepar prosthesis, 361-362
Gunshot injury, to brachial plexus, 1149
Guyon canal
  anatomy of, 939, 939*f*
  ganglions of, 2009
Guyon canal compression, 938-940
  postoperative care in, 940
  preferred treatment of, 939-940, 940*b*
  provocative tests for, 926*t*
  recurrent, 956

H

Hahn-Steinthal fracture, of capitellum, 703, 703*f*
Hairy congenital nevi, giant, 1966, 1967*f*
Hamartomas, lipofibromatous, 2011-2012
Hamate, 660*f*
  fracture of, 631-634, 633*b*
    body of, 634, 634*f*-635*f*
    in children, 1447-1448, 1448*f*
    hook of, 631-634, 632*f*
      blood supply to, 632
      clinical and radiographic presentation of, 631-632, 632*f*
      postoperative care for, 634
      treatment of, 632-634, 634*f*
    incidence of, 625*t*
Hand
  amputee, rehabilitation process of, 1746-1747, 1747*b*
  in brachial plexus birth palsy, 1419-1421
  compartments of, release of, 1770
  defects of, skin flaps for, 1568-1570, 1568*t*
  fractures of, in children, 1425-1442
    epidemiology of, 1425-1426, 1426*f*
    historical review of, 1428, 1428*b*
    pertinent anatomy in, 1427-1428
    preoperative evaluation of, 1426-1427, 1427*f*
    types of operations for, 1428-1442
  mangling injuries of, treatment of, 1512-1515, 1512*f*-1517*f*
  osteoarthritic, treatment of, 345-372
  preparation of, for replantation, 1479
  prosthetics, 1738-1745
  as recipient site, in bone grafting, 1637
  stiffness of, 338-344. *see also* Stiffness, of finger and hand
    after bending fractures, 567-568
  Volkmann contracture of, 1783-1785
Hand preparation
  for free phalangeal transfer, in finger reconstruction, 1262, 1262*f*
  for microvascular toe transfer, of hypoplastic digits, 1267-1268
Hand therapy, for complex regional pain syndrome, 1818
Hand-foot-genital syndrome, 1213-1214
Hangnail, 331
Hansen disease (HD), 103-116
  classification of, 104-105
    lepra reaction in, 111*t*
  clinical, bacteriologic, histologic, and immunologic features of, 105*t*
  clinical pathology of, 104
  diagnosis of, 105-109, 115*b*
    cardinal signs in, 105-107, 106*f*-107*f*
    tests in, 107-109
  for ENL reaction, 110
  epidemiology of, 103
  etiology of, 103
  indications for steroids in, 116*b*
  for lepra reaction, 111*t*
  for Lucio reaction, 110-111
  multibacillary, 109
  nerve abscess in, 112-113, 113*f*-114*f*
  paucibacillary, 109
  treatment of, 109-116
    for compression neuropathy, 112, 112*f*
    for deformities, 114-115, 115*f*
    for nerve abscess, 112-113
    pain in, relief of, 109-113, 110*f*
    preservation of sensation, 113-114
    reactions, 111-112
    rehabilitation in, 115
    resource materials in, 115-116
    restoration of sensibility, 114
    for reversal reaction, 110
Hardware removal, from radius and ulna, after both-bone forearm fractures, 798-799
Harvest technique, in vascularized bone grafting, 1630-1631, 1631*f*
Healing, of scaphoid nonunion, prognosis for, 620-621
Healing time, for phalangeal fractures, 256
Hematoma
  after posttraumatic interosseous contracture, 343.*e*1
  management of, in resection arthroplasty, 363
  in skin grafting, 1537
  subungual, 318-319, 320*f*
Hemiarthroplasty, of wrist, 414-416
Hemiepiphyseal stapling, of distal radius, 1359-1360, 1360*f*
Hemihamate arthroplasty, for proximal interphalangeal joint fracture-dislocation, 294
  case study on, 315.*e*1*b*, 315.*e*1*f*-315.*e*2*f*

Hemihamate autogenous grafting, for proximal interphalangeal joint fracture-dislocation, 284
outcomes of, 293
postoperative protocol for, 293
preferred technique for, 291-293, 291*f*-294*f*, 293*b*
Hemihypertrophic macrodactyly, 1282
Hemipulp flaps, transfer of, from toes to fingers, 1647
Hemiresection-interposition arthroplasty, for radioulnar joint arthritis, 503-504, 504*f*
Hemitrapeziectomy, arthroscopic, technique for, 693-694
Hemophilic arthropathy
preoperative considerations of, 909
total elbow arthroplasty for, 909
Henry approach, to radial tunnel syndrome, 951-952, 951*f*
modified, 952
Heparin
after free flap transfer, 1582
for vasospastic disorders, 2054
Herbert classification, of scaphoid fractures, 593
Herbert screws
for distal humeral fractures, 718
for distal interphalangeal joint arthrodesis, in swan neck deformity, 1881*f*
Herbert-Whipple technique, for scaphoid fractures, 669-670, 669*f*-670*f*
Hereditary motor-sensory neuropathy, 923
Hereditary multiple exostoses, of forearm, 1357-1362
pertinent anatomy in, 1359, 1359*f*
preoperative evaluation for, 1357-1359, 1358*f*
surgical treatment of, 1359-1361, 1360*f*-1361*f*
contraindications to, 1359
postoperative management and expectations after, 1361-1362
preferred technique for, 1362, 1362*b*
Hereditary neuropathy with liability to pressure palsies (HNPP), 923
Heritability, of Dupuytren disease, 128
Herpes simplex virus (HSV) infection
AIDS and, 120
of fingers, 52-53, 52*f*
Herpetic whitlow, 52-53, 52*f*
Heterodigital flap reconstruction, for soft tissue defects of thumb, 1679-1681, 1680*f*
cross-finger flap
dual innervated, 1684, 1685*f*
innervated, 1681-1684, 1681*b*
radial-innervated, 1682-1684, 1683*f*, 1684*b*, 1684.*e*1*f*
to thumb, 1680-1681, 1682*f*, 1681.*e*1*f*
first dorsal metacarpal artery island flap, 1684-1686, 1686*f*
Heterodigital flap reconstruction, for soft tissue defects of thumb *(Continued)*
neurovascular island pedicle flap, 1686-1687, 1688*f*, 1689*b*
Heterotopic bone, after radial head fractures, 764, 764*f*
Heterotopic ossification
adjuvant therapy for, 857
after biceps rupture surgery, 874
after burns, 1943
after elbow contracture release, 859
after elbow dislocation, 826-827
after humeral fractures, 730-731, 730*f*
after radial head fractures, 764
classification of, 803, 804*t*
stiffness of, 784
High-flow arteriovenous malformations, 2056, 2057*f*
High-pressure injection injuries, 57
High-velocity injuries, of radius, 527
Hinged fixation, after elbow contracture release, 855, 855*f*
Hirudo medicinalis, 1584
Histiocytoma. *see also* Dermatofibroma
malignant fibrous, 2019, 2019*f*
Histoplasmosis, 86-87
Hockey-stick incision, for felon, 27*f*, 27*t*
Holstein-Lewis spiral fracture, radial nerve palsy associated with, 1074
Holt-Oram syndrome, 1214
radial deficiency associated with, 1289, 1290*t*
longitudinal, 1329*t*
in triphalangeal thumb, 1315, 1318*f*
Homografts, 1000
for digital nerve repair, 1009
Horner's syndrome, 1149-1150, 1152*f*
in brachial plexus birth palsy, 1393, 1406
Hospital for Sick Children Active Movement Scale (AMS), 1394, 1396*t*
Hotchkiss classification, of radial head fractures, 736, 736*t*
House's reconstruction, in tetraplegic patient
one-stage key pinch, 1134-1135, 1137*b*
brachioradialis to flexor pollicis longus transfer in, 1134-1135
carpometacarpal fusion in, 1134, 1135*f*
extensor pollicis longus tenodesis in, 1135, 1135*f*
split flexor pollicis longus transfer in, 1135, 1136*b*, 1136*f*
two-stage grasp, pinch, and release, 1137-1139, 1139*b*
extensor phase in, 1137-1138
flexor phase in, 1138, 1139*f*
HOX genes, 1213-1214
HOXD13 gene, mutation of, 1234
"H"-type injury, of distal humerus, 702, 702*f*, 718-719. *see also* Humerus, distal
Huber opponensplasty, in median nerve palsy, 1032-1033, 1033*f*-1034*f*
Human bites, 48-50, 49*f*-50*f*
antibiotic recommendations for, 21*t*
wounds, zone 5 injuries, of extensor tendon, 174-175
Human immunodeficiency virus (HIV), 119-121. *see also* Acquired immunodeficiency syndrome (AIDS)
less common malignant tumors and, 1983, 1984*f*
Human papilloma virus (HPV), and verruca vulgaris, 1962
Humeral external rotation osteotomy, for arthrogryposis, 1368-1372, 1371*b*
complications of, 1372
contraindications to, 1368-1370, 1371*f*
indications for, 1368
preoperative planning for, 1370
technique of, 1370, 1372*f*
Humeral graft, for lateral collateral ligament, 833
Humeral tunnel, for lateral collateral ligament, 833, 834*f*
Humerus
distal
anatomy of, 698-699, 699*f*-701*f*
fractures of, 697-733, 906-907, 908*f*
ballistic injuries associated with, 726
bicolumnar, 702, 702*f*, 721-724, 721*b*
bone loss associated with, 726
classification of, 699-705
AO/ASIF, 703
articular fracture patterns in, 703-705, 704*f*-705*f*
capitellum and, 703, 703*f*-704*f*
column concept in, 701-703
trochlear and, 703-704
complications of, 728-731
heterotopic ossification as, 730-731, 730*f*
infection as, 729
nonunion of distal humerus as, 728
nonunion of olecranon osteotomy as, 728-729, 729*f*
stiffness as, 730-731, 730*f*
ulnar neuropathy as, 729-730
considerations and potential pitfalls of, 720-721
elbow stiffness after, 853-854
expectations after, 727-728
fixation principles in, 717-726, 719*f*
historical review of, 705-707, 706*t*, 708*t*
implant biomechanics in, 719-720
operative management of, 707-731
anconeus flap transolecranon approach to, 714-715, 716*f*

Humerus *(Continued)*
anesthesia in, 710-711
Bryan-Morrey "triceps-sparing" approach to, 713-714, 714*f*
in elderly, 707-710
exposures in, 711-717, 711*f*, 718*b*
lateral approach to, 715-717, 717*f*
olecranon osteotomy in, 711-712, 713*f*
open fractures and, 707
open reduction and internal fixation in, 707-709, 709*t*
paratricipital approach to, 711, 712*f*, 711.*e*1*b*, 711.*e*1*f*-711.*e*2*f*
patient position in, 710-711, 710*f*
in polytrauma patients, 707
preferred method of, 720
timing of, 707-711
total elbow replacement in, 709-710, 709*t*, 710.*e*1*b*, 710.*e*1*f*
triceps-reflecting anconeus pedicle approach to, 714, 715*f*
triceps-splitting approach to, 712-713, 713.*e*1*b*, 713.*e*1*f*-713.*e*4*f*
physical examination of, 697
postoperative care for, 726-727
preoperative assessment of, 906-907
preoperative evaluation of, 697-698
radiographic examination of, 697-698, 698*f*-699*f*
simple, 725
supracondylar, 721
transcondylar, 721
unicolumnar, 724-725, 725.*e*1*b*, 725.*e*1*f*-725.*e*2*f*
nonunion of, elbow contracture and, 854
external rotation osteotomy of, for arthrogryposis, 1368-1372, 1371*b*
fractures of, associated with radial nerve palsy, 1074-1076
early, 1074
if no return at longer waiting period, 1075, 1075*f*
nerve exploration in, at 6 to 8 weeks, 1074-1075, 1075*f*
preferred method of, 1075
as recipient site, in vascularized bone grafting, 1636
rotational osteotomy of, 1089, 1089*f*
for ulnar deficiency, 1335, 1338
"Humpback" deformity, scaphoid, 430-431, 464, 1445, 1446*f*
Hunter-Thompson chondrodysplasia, 1214
brachydactyly associated with, 1239-1240
Hutchinson's freckle. *see* Lentigo maligna
Hybrid prostheses, in prosthetics, 1759
Hybrid Russe procedure, in bone graft, for scaphoid nonunion, 611-614, 611*f*-613*f*
Hydrofluoric acid burns, treatment of, 1951, 1951*f*, 1952*t*
Hydrotherapy, for frostbite, 1953
Hydroxyapatite, deposition of, tendinopathy in, 1906
Hyperalgesia, 1802
definition of, 1799*t*
Hyperesthesia, definition of, 1799*t*
Hyperextension, of proximal interphalangeal joint, 294-295
Hypergranulation, early, after burns, 1935
Hyperkeratosis, 1959-1960
Hyperostotic macrodactyly, 1279*f*, 1282
Hyperpathia, 1802
definition of, 1799*t*
Hypodermic needle, 146
Hypoesthesia, definition of, 1799*t*
Hypoglossal nerve transfer, for brachial plexus injury, 1177
Hyponychial deformities, 329-330, 329*f*
Hypothenar hammer syndrome, 2042
Hypothenar muscles, 338.*e*4
Hypothenar space
infections of
characteristics of, 35*t*
treatment for, 36, 37*f*
pertinent anatomy in, 35

I

Iliac bone graft, for distal radial fracture fixation, harvesting of, 543-546
Iliac crest
bone graft from, for scaphoid nonunion, 619
flap, 1620-1621
vascularized grafting from
complications of, 1621
donor results in, 1621
in upper extremity, 1622-1623, 1623*f*
iLIMB digits, 1737.*e*3*f*
Imipramine, for complex regional pain syndrome, 1812*t*
Immobilization, closed reduction with
for lesser-arc injuries, 466-467, 467*f*
for perilunate fracture-dislocations, 470-471
Immune responses, cellular, in AIDS, 119.*e*2
Impaction, ulnar, 582
Impaired vascularity, vascularized bone grafts and, 1615
Impending compartment syndrome, 1763
Implant(s)
Artelon, 362
infections of, 50-51
mechanical failure of, as complication of flexor tendon grafting, 224
in metacarpophalangeal joint, arthroplasty, flexible, 1872-1875, 1872*f*-1875*f*
preferred method of treatment in, 910-913, 912*f*-913*f*
pyrocarbon
for metacarpophalangeal joint arthroplasty, 358
for proximal interphalangeal joint arthroplasty, 357
in radial head arthroplasty, 752-754, 755*f*-756*f*, 756*b*
for rigid fixation, of scaphoid fractures, 596
silastic
for metacarpophalangeal joint arthroplasty, 358
for proximal interphalangeal joint arthroplasty, 357
types of, 909-913, 911*f*
Improved prosthetic control, 1760-1761, 1760*f*
In situ bypass, for vascular disorders, 2049-2052
In situ decompression, for cubital tunnel syndrome, 943
Incision(s)
for complex traumatic elbow dislocation, 824-825
fasciectomy, for Dupuytren disease, 141-142, 142*f*
in operative procedure, to ulnar fractures, 776
in surgical approach
to toe transfer, 1665-1666
to trigger finger, 1910*f*-1911*f*
Incisional biopsy
elliptical, 1961
for musculoskeletal tumors, 1991
Inclination, 419
Inclusion cysts, epidermal, 2009-2010, 2011*f*
Index rotation flap, 1383
Infantile digital fibromatosis, 1968, 1970*f*
Infection(s)
acute, 17-61
anthrax, 56-57, 57*f*
of bite wounds
animal, 46-48
human, 48-50, 49*f*-50*f*
caused by parenteral drug abuse, 51-52
common, 20-22
antibiotic recommendations for, 21*t*
deep space, 34-40, 40*b*
collar-button abscess, 37-38, 38*f*-39*f*, 38.*e*1*b*, 38.*e*1*f*

Infection(s) *(Continued)*
palmar, 34-36, 34*f*, 35*t*, 36*f*-37*f*
subfascial, 36-40
felon, 26*f*-27*f*, 27*t*, 28*b*
flexor tenosynovitis
pyogenic, 28-32, 30*f*, 32*b*
septic, 31.*e*1*b*, 31.*e*1*f*
mallet deformity, 43
osteomyelitis, 43-46, 45*t*, 46*f*, 43.*e*1*b*, 43.*e*1*f*
Parona space, 33
paronychia
acute, 20-22, 20*f*, 22*b*, 22*f*
chronic, 23-25, 24*f*-25*f*, 25*b*
radial bursa, 32-33
in septic
arthritis, 40-41
boutonnière deformity, 43
ulnar bursa, 33
in wrist joint, 41-43, 42*f*, 44*f*
diabetic hand, 53-54
evaluation of, 18-19
general principles of, 17-19
in herpetic whitlow, 52-53, 52*f*
melanoma as, 58.*e*1*b*, 58.*e*1*f*
methicillin-resistant *Staphylococcus aureus*, 18, 18*f*
mimickers of, 57-58, 58*f*
necrotizing, 54*f*-56*f*, 55.*e*1*b*, 55.*e*1*f*
nosocomial, 18
prosthetic and implant, 50-51
in septic thrombophlebitis, 52
types of, 17
principles in, 19, 20*b*
of upper extremity, with HIV, 53
after elbow contracture release
joint, 859
pin tract, 859
after humeral fracture, 729
after metacarpophalangeal joint arthroplasty, 1878
after total elbow arthroplasty, 909, 916-918
after ulnar fractures, 782-783
chronic, 62-127
bacterial, 67-77
etiology, diagnosis, and treatment of, 63*t*
culturing of, 65, 65*t*
isolation in, 66
diagnosis of, 62-64, 63*t*
direct visualization of, by staining, 65-66
drug-susceptibility tests for, 66
evaluation of, 66-67
fungal, 77-90, 78*t*-79*t*
etiology, diagnosis, and treatment of, 63*t*
Hansen disease and, 103-116, 105*t*, 106*f*-107*f*, 110*f*, 111*t*, 112*f*-113*f*, 115*b*
Infection(s) *(Continued)*
laboratory techniques for, 64-67
microbial nucleotide sequences of, detection of, 66
mycobacterial, 90-103, 91*t*
etiology, diagnosis, and treatment of, 63*t*
occupational, 118
parasitic, 116-118
etiology, diagnosis, and treatment of, 63*t*
pathogenic-specific antigens and antibodies for, detection of, 66
protothecal, 116-118
etiology, diagnosis, and treatment of, 63*t*
protozoal, 116-118
etiology, diagnosis, and treatment of, 63*t*
scabies and, 118-119
specimen collection and handling of, guidelines for, 64-65, 65*t*
treatment of, 67, 67*t*
viral, 119-125
etiology, diagnosis, and treatment of, 63*t*
as complication
of flexor tendon grafting, 225
of phalangeal fractures, 269
effect of, on wound healing, 1530
of free flaps, 1585
of perionychium
acute, 330-331
chronic, 331-332, 332*f*
to regional anesthesia, 1
secondary, after burns, 1935, 1936*f*
vascularized bone grafting and, 1624
Infiltrative fasciitis, 2014
Informed consent, for brachial plexus surgery, 1154
Infraclavicular block, 7-8, 7*f*
Infraclavicular brachial plexus, 1146
injury to, 1150
decisions and priorities of repair for, 1160
surgical approach to, 1157-1158, 1157*f*
Infraclavicular nerve block, for contracture release, 849
Inspection, in thoracic outlet syndrome, 964-966, 965*f*-967*f*
Instability
after ulnar fractures, 783, 783*f*
posteromedial varus rotational, 784.*e*9*b*, 784.*e*9*f*-784.*e*10*f*
Intercarpal arthrodesis
limited, for midcarpal instability, 461, 462*f*
for wrist arthritis, 690
Intercarpal fusion, for scaphoid nonunion advanced collapse, 623-624
1,2 Intercompartmental supraretinacular artery
bone grafting using, 1629
for scaphoid nonunion, 1630-1632
inlay graft, vascularized bone graft, 1637
for scaphoid nonunion, 617-618, 617*f*-618*f*
2,3 Intercompartmental supraretinacular artery, bone grafting using, 1629
Intercostal nerve
surgical anatomy of, 1169, 1170*f*
transfer of
for brachial plexus injury, 1169-1172, 1170*f*
to musculocutaneous nerve, 1171, 1171*f*, 1172*b*
complications of, 1172
contraindications to, 1171-1172
outcomes of, 1172
postoperative care after, 1171
Interdigital commissure, release of, in syndactyly, 1219-1220, 1219*f*-1222*f*
Interdigital granuloma, 118
Interdigital pilonidal sinus, barber's, 118
Interfragmentary compression screws, for metacarpal shaft fractures, 240, 240*f*, 237.*e*1*t*
Interligamentous sulcus, 420
Intermediate column
single-fragment fractures of, 571-572, 572.*e*1*b*, 572.*e*1*f*-572.*e*2*f*, 572.*e*3*b*, 572.*e*4*f*-572.*e*6*f*
three- and four-part injuries to, 572
Intermediate fibers, 134
Internal fixation
of radial head fractures, "safe zone" for, 738-739, 739*f*
role of, in vascularized bone grafting, 1637
Internal splint, for radial nerve palsy, 1065
International Association for the Study of Pain (ISAP), 1797, 1799*b*
International classification of surgery, for tetraplegia, 1123*t*, 1133*t*
Interosseous ligament, reconstruction of, in longitudinal forearm instability repair, 808-809
Interosseous membrane (IOM), 482
reconstruction of central band of, 807-808, 807*f*-808*f*
Interosseous muscle(s)
anatomy of, 338.*e*3-338.*e*4, 338.*e*4*f*-338.*e*5*f*
contracture of, posttraumatic, 343.*e*1
dorsal, 1770, 1772*f*
slide of, for intrinsic muscle spasticity, 1113-1114
Interosseous nerve
anatomy of, 936
posterior, 886-887
palsy of, 1064, 1064*f*

Interosseous nerve syndrome
anterior, 937
posterior, 949-952
release of, 953*b*
Interosseous wiring, 259, 260*f*, 259.*e*1*t*
for metacarpal shaft fractures, 239, 237.*e*1*t*
Interphalangeal (IP) joint
distal. *see* Distal interphalangeal (DIP) joint
extensor lag, proximal, as complication of phalangeal fractures, 268-269
in mangling injuries, treatment of, 1493
proximal. *see* Proximal interphalangeal (PIP) joint
in rheumatoid arthritis, boutonnière deformity and, 1898
of thumb
arthrodesis of, in ulnar nerve palsy, 1059
dislocation of, 296-297
Interposition graft, for flexor tendon, 219-220, 219*f*
Interscalene block(s), 6, 7*f*
bilateral procedures and, 2
continuous peripheral nerve catheters and, 5
Interscalene triangle, in thoracic outlet syndrome, 963, 963*f*
Interscapulothoracic amputation, 1756, 1757*f*, 1762.*e*2*f*
Intersection syndrome, 1916, 1920-1921, 1920*f*
Intraarticular anesthetic joint injection, for Dupuytren disease, 148
Intraarticular fractures
of humerus, 701-702. *see also* Humerus, distal
in mangling injuries, treatment of, 1499
Intracarpal pronosupination, 424
Intramedullary fixation
for forearm diaphyseal fracture stabilization, in children, 1465, 1467*f*
of metacarpal shaft fractures, 239-240, 239*f*, 237.*e*1*t*
of proximal and middle phalangeal fracture, 259
Intramedullary implants, 559, 561*f*-562*f*, 559.*e*1*b*, 559.*e*1*f*-559.*e*3*f*
radial, for wrist fractures, 1465, 1467*f*
Intramedullary pins
fusion of, for patients with rheumatoid arthritis, 401-404, 402*f*-403*f*
wrist arthrodesis with, critical points in, 404*b*
Intramedullary rods
of distal and midshaft ulnar fractures, 796
of radial shaft fractures, 793, 793*f*-794*f*, 795*b*
Intramuscular transposition, of ulnar nerve, for cubital tunnel syndrome, 945
Intraosseous ganglion, 2009, 2010*f*
Intraplexal nerve transfers, for brachial plexus injury, 1176-1177
Intravenous regional block, 10-11
Intrinsic lateral band release, for intrinsic muscle spasticity, 1114, 1114*f*
Intrinsic ligaments, of wrist, 421*f*-422*f*, 422-423
Intrinsic muscle, spasticity in, 1085
release or slide of origin of, for thumb-in-palm deformity, 1108-1109, 1108*f*
swan neck deformity and, 1113-1117, 1113*f*
Intrinsic tendons, of metacarpophalangeal joint, in rheumatoid arthritis
crossed transfer of, 1869-1870
release of, 1869, 1869*f*
Intrinsic-minus deformities, 1117-1118
Ion channels, voltage-gated, 980-981
Irrigation, closed tendon sheath, for pyogenic flexor tenosynovitis, 30-31, 30*f*
Ischemia
etiology of, 2036-2038, 2037*f*-2038*f*
metabolic changes after, 1488
Island flap(s)
neurovascular, for soft tissue defects of thumb, 1684-1686, 1686*f*
pedicle, 1540
in reconstruction of amputated fingertip, 1717
Isolated displaced fractures, of radial head fractures, management of, 741-742, 742*f*
Isoniazid
dosage of, 101*t*
for tuberculosis, 100
cutaneous, 92
Itraconazole
for aspergillosis, 84-85
for blastomycosis, 85
for coccidioidomycosis, 86
for cryptococcosis, 86
for deep sporotrichosis, 88
for eumycetoma, 73
for fungal infections, 79, 90
cutaneous, 80
of nails, 330-331
for histoplasmosis, 86-87
for protothecosis, 116
spectrum of activity of, 79*t*
for sporotrichosis, 83, 83*b*

J

Jackson-Pratt drain, 947
Jahss maneuver, 1438
Jellyfish, venomous, 1792, 1792*f*
Jobe technique, modified, 837
Joint(s)
arthroplasty of, 1866-1867, 1867*f*
in mangling injuries
reconstruction of, 1499-1500, 1501*f*-1504*f*, 1502*b*
case study for, 1499.*e*1*b*, 1499.*e*2*f*-1499.*e*3*f*
salvage or fusion of, 1493-1494, 1494*f*
manipulation of, for swan neck deformity, in rheumatoid arthritis, 1879-1890, 1880*t*
measurements, of Dupuytren disease, 132, 132*f*
preoperative evaluation of, 1644-1645
Joint anesthetic injection, for Dupuytren disease, 148, 148*f*
Joint-leveling procedures, for Kienbock disease, 642
Joule's law, 1946
Junctional nevi, 1965-1966
Juncturae tendinum, 152-154
in extensor tendon, 1060
Juvenile aponeurotic fibroma, 2014

K

Kanamycin, dosage of, 101*t*
Kapandji technique, of double intrafocal, wire fixation, for distal radial fracture, 532, 537*f*
Kaposi sarcoma, AIDS and, 121
Keratoacanthoma, 1971, 1972*f*
Keratohyalin, 1958
Keratolytic therapy, for warts, 122
Keratosis
actinic, 1972, 1972*f*
arsenical, 1972
seborrheic, 1964, 1966*f*
Ketamine, for complex regional pain syndrome, 1815-1816
Ketoconazole
for blastomycosis, 85
for deep sporotrichosis, 88
for eumycetoma, 73
for fungal infections, 79
cutaneous, 80
for histoplasmosis, 86-87
for protothecosis, 116
spectrum of activity of, 79*t*
Keyser-Eaton marsupialization, of nail fold, 331-332
Kienbock disease, 639
clinical presentation of, 640
etiologic findings in, 639-648
imaging of, 641
radiographic presentation of, 640, 641*f*
staging of, 640-641, 641*t*
treatment of, 641-647
joint-leveling procedures in, 642
preferred method for, 647-648
of stage I, II or IIIA, with ulnar-negative variance, 641-646

Kienbock disease *(Continued)*
radial-shortening osteotomy in, 642-643, 642*f*
vascularized bone grafting in, 643
of stage I, II or IIIA with ulnar-positive or ulnar-neutral variance, 646
capitate shortening with capitate-hamate fusion in, 646
closing wedge radial osteotomy in, 646, 647*f*
core decompression in, 646
of stage IIIB, 646-647, 648*f*
of stage IV, 647
vascularized bone grafting for, 1624-1625, 1633*f*
lunate, 1638-1639
wrist arthroscopy for, 691-692, 691*t*, 692*f*
Kirner deformity, 1273-1275, 1274*f*, 1275*b*
anatomy in, 1274, 1275*f*
epidemiologic findings in, 1274, 1274*f*
management of, 1274-1275
preferred method of treatment of, 1275
Kirschner pin/wire fixation, 393, 394*f*
of distal humeral fractures, 717
of distal radial fracture, 531
in hemihamate reconstruction, 292-293, 294*f*
for lesser-arc injuries, 467
for metacarpal shaft fractures, 238-239, 238*f*, 237.*e*1*t*
for metacarpophalangeal joint contractures, 341.*e*1
for perilunate fracture-dislocations, 471
for pilon fracture, 283, 283*f*
in pollicization for thumb hypoplasia, 1298-1299, 1300*f*
in proximal interphalangeal joint arthrodesis, in swan neck deformity, 1881-1882
for rigid fixation, of scaphoid fractures, 596
in scapholunate dissociation, 439
sequence of, 724
for ulnar fractures, 777*f*, 778
in wrist arthroscopy, 663
"Kissing" lesions, 1968, 1970*f*
Kite flap, 1545-1546, 1546*f*
Klumpke palsy, 1149-1150
Knuckle pads. *see* Dorsal Dupuytren nodules (DDN)
Kocher approach, to radial head fractures, 745, 747*f*
Kocher-Lorenz fracture, of capitellum, 703, 703*f*
Kocher's lateral approach, to distal humeral fractures, 715, 717*f*
Koebner phenomenon, 374
Krackow stitch
in triceps avulsion repair, 880, 880*f*-881*f*
in two-incision biceps rupture repair, 876, 877*f*
Krackow-Thomas repair, of extensor tendon laceration, 158-159, 159*f*
Krukenberg procedure, for below-elbow transverse failure of formation, 1346
Kutler lateral V-Y flap, in reconstruction of amputated fingertip, 1713-1714, 1714*f*

L

Lacerations
of extensor tendon. *see also* Extensor tendon injury
zone 5 injuries, 174
zone 6 injuries, 177
stellate, of nail bed, 320, 320*f*
Lactation, de Quervain disease of, 1917
Lambda pattern fracture, of distal humerus, 702, 702*f*. *see also* Humerus, distal
Landsmeer ligament. *see* Oblique retinacular ligament (ORL)
Laser Doppler flowmetry, for vascular disorders, 2039
Laser(s), implanted, in monitoring of vascularized
bone grafts, 1615
Lasso procedure, of Zancolli
digital clawing treated with, 1142-1143, 1142*f*
in tetraplegia, 1125*f*, 1141
Late recontracture, of Dupuytren disease, 134, 134*t*
Latency, in nerve conduction studies, 929
Lateral angulation, as complication of phalangeal fractures, 266-267, 266*f*
Lateral approach, to open release, of elbow contracture, 852-853
postoperative care after, 853
Lateral arm flap
anatomy, 1585-1586
for burn deformities, 1945
free, 1585-1588, 1586*f*-1587*f*, 1588*b*
for mangling injuries, 1515, 1517*f*
operative technique in, 1585-1586
Lateral band, 338.*e*3, 338.*e*5*f*
mobilization of
and relocation of, for boutonnière deformity, 172
in swan neck deformity, 1884-1885, 1885*f*
Lateral band tenodesis, for proximal interphalangeal joint subluxation, 294-295
Lateral collateral ligament, repair of, in complex traumatic elbow dislocation, 819
Lateral column fracture, complex, 725.*e*3*b*, 725.*e*3*f*-725.*e*4*f*
Lateral epicondylitis, arthroscopy for, 897-899, 898*f*
Lateral positioning, in elbow arthroscopy, 886, 888*f*
Lateral projection, carpal injury and, 429
Lateral slips, 338.*e*5
Lateral tendon, 338.*e*3, 338.*e*5*f*
Latissimus dorsi muscle
anatomy of, 1599-1601
transfer of
for elbow reconstruction, in brachial plexus injury, 1197-1198, 1199*f*, 1200*b*
for shoulder reconstruction, in brachial plexus injury, 1188
Latissimus dorsi muscle flap, 1561-1562, 1562*f*, 1563*b*
free, 1597-1602, 1598*f*-1601*f*, 1602*b*
tailored, 1599*f*, 1602-1603
for mangling injuries, 1515, 1520*f*
operative technique, 1601-1602
"Law of diminishing returns," in metacarpophalangeal joint extension contracture, 340
Leather-Mills valvulotome, for vascular disorders, 2050, 2050*f*
Leeches
animal bite and, 48
for free flap failure, 1582*f*, 1583-1584
Leiomyosarcoma, 2020
Leishmaniasis infection, 116-117
Lentigo maligna, 1978, 1980*f*
Lentigo simplex, 1965
Lepra reaction, in Hansen disease, 110
classification of, 111*t*
treatment of, 111*t*
Lepromin skin test, for Hansen disease, 107-108
Leprosy. *see* Hansen disease (HD)
Leri-Weill dyschondrosteosis, 1213-1214, 1214*f*
Lesser-arc injuries, in dorsal perilunate dislocations, 465-470, 465*f*-466*f*
Levofloxacin, dosage of, 101*t*
Lichtman classification, of Kienbock disease, 641*t*
Lidocaine
in Bier block, 10-11
characteristics of, 4*t*
for complex regional pain syndrome, 1814*t*
Ligament(s)
definition of, 838
of elbow, 739, 740*f*
reconstruction, for carpometacarpal joint osteoarthritis
operative techniques, 362-363
treatment, 361
of scaphoid, 589-590, 589*f*
Ligamentoplasty, using tendon graft, in scapholunate dissociation, 443-446
Ligamentotaxis, 516.*e*1
Ligamentum subcruetum, 481, 481*f*
Light moving touch, in compression neuropathy evaluation, 928
Limb, threatened at birth, treatment of, 1255-1256

Limb amputation, major, 1753-1756
case study of, 1762.e1b, 1762.e1f-1762.e3f, 1762.e3b
indications for, 1753, 1754f
Limb bud, 1208, 1209f
formation of, 1212b
Limb development
anteroposterior, 1210-1211, 1212f, 1213t
dorsoventral, 1211
during embryogenesis, 1208
key milestones in, 1209t
proximodistal, 1209-1210, 1210f-1211f
spatial axes of, 1209-1211
Limb function, poor, free flap contraindicated in, 1575
Limited open reduction, of distal radial fractures, 536
Lipofibromatosis, macrodactyly associated with, 1276-1277
Lipofibromatous hamartomas, 2011-2012
Lipomas, 2011
Liposarcoma, 2017-2018, 2018f
Liquefaction necrosis, 1948-1949
Little finger
restoration of, 1060-1061
suture to middle finger, 1060-1061, 1061f
Littler flap. *see* Neurovascular island flap
LMB spring finger extension splint, 340.e1f
Local fasciectomy, for Dupuytren disease, 139t
Local flaps, 1540-1542
transposition flaps, 1542
axial-pattern, 1543-1545
flag, 1545, 1545f
random-pattern, 1542
rhomboid, 1543, 1544f
"Z"-plasty, 1542, 1542f, 1543b
four-flap, 1543, 1543f
Localized compartment syndrome, 1767f
Long bone reconstruction, vascularized bone grafting for, 1617-1624
Long toe extensor tendon, for tendon graft, 205-206
Loose body, arthroscopic removal of, 892-893
indications and contraindications of, 892
outcomes of, 893
postoperative management of, 893
preoperative planning of, 892
technique of, 892-893
Lucio reaction, in Hansen disease, 110-111, 111t
Luck classification, of staging, in Dupuytren disease, 131
Lumbrical canal, palmar space infection through, 36
Lumbrical muscles, anatomy of, 338.e4, 338.e6f
Lumbrical-plus finger deformity
after amputation, 1718
as complication of flexor tendon grafting, 225
Lunate, 660f
blood supply to, 638, 640f
bone grafting to, 1632
deformity of, carpal misalignment secondary to, 464
dislocation of, 427-428
fractures of, 636-637, 637b
incidence of, 625t
in Kienbock disease, 639
mechanism of injury in, 637-638, 638f
radiographic presentation of, 637-638
treatment of, 638, 639f
Lunate triquetrum arthrodesis, 457b
Lunate triquetrum dissociation, pathomechanics of, 427
Lunocapitate angle, measurement of, in wrist instability, 430
Lunocapitate dislocation, pathomechanics of, 427-428
Lunotriquetral arthrodesis, 387-389
author's preferred method of treatment for, 388
indications and contraindications for, 387-388
patients and, 389
pearls on, 389f
pitfalls of, 389
postoperative management for, 388
Lunotriquetral dissociation, 450-457
diagnosis of, 451-454
arthrography in, 454
arthroscopy in, 454
cineradiography in, 454
physical examination in, 451-452, 452f
radiographic examination in, 452-454, 452f-453f
pathomechanics of, 450-451, 451f
treatment of, 454-457, 455f-456f
preferred method of, 457
Lunotriquetral ligament, 422, 422f
interosseous, 660f
carpal instability and, 661
tears of, associated with distal radial fracture, 542
Lunotriquetral synchondrosis, 451-452
Lymphangiosarcoma, 1981-1983
Lymphangitis, nodular, differential diagnosis and treatment for, 83, 84t
Lymphatic basins, evaluation of, 1981, 1982f-1983f
Lymphatics, of nail bed, 318
Lymphedema, factitious, 1828, 1829f

M

Macrodactyly, 1275-1285, 1276f-1278f, 1285b
anatomy of, 1278
expected outcomes, 1285
Macrodactyly *(Continued)*
Flatt's classification of, 1275-1276, 1276t
gigantism anomaly in, 1276t, 1277, 1280f
hemihypertrophic, 1282
hyperostotic, 1279f, 1282
management of, 1278-1285, 1280t
amputation in, 1282
limiting digital growth in, 1278-1281
preferred method of, 1281f, 1282-1285, 1283f-1285f
reducing the digit in, 1281-1282
nerve territory-oriented, 1278
progressive, 1276-1277, 1284f
static, 1276-1277
Macules, pigmented, 1965
Madelung deformity, 1213-1214, 1214f, 1339-1345, 1344b, 1345f
bilateral, 1339, 1340f
preoperative evaluation for, 1339, 1340f-1341f
surgical treatment of, 1339-1344
expected outcomes from, 1345, 1345f
preferred technique for, 1344, 1344f
Maestro implant, 407, 407f
Maffucci syndrome, 2021
Magnetic resonance arthrography, for medial collateral ligament, 835-836
Magnetic resonance imaging (MRI)
of biceps rupture, 871-872, 872f
in brachial plexus birth palsy, 1395-1396, 1408, 1409f
of brachial plexus injury, 1152
of carpal instability, 432
in complex regional pain syndrome, 1805
of distal radioulnar joint, 486-487, 487f
of Kienbock disease, 641
for musculoskeletal tumors, 1990
prior to free flap transfer, 1577
of scaphoid fractures, 592
of triceps avulsions, 879, 879f
Malignant fibrous histiocytoma, 2019, 2019f
Malignant peripheral nerve sheath tumor, 2019
Malignant tumors, less common, 1981-1983
dermatofibrosarcoma protuberans as, 1983, 1985f
human immunodeficiency virus (HIV) and, 1983, 1984f
lymphangiosarcoma (Stewart-Treves syndrome) as, 1981-1983
Merkel cell (neuroendocrine) carcinoma as, 1981, 1984f
metastatic tumors as, 1983, 1985f
sweat gland tumors as, 1983
Mallet deformity, 43
Mallet finger injury
acute, 162-165, 166b, 162.e1b, 162.e1f
classification of, 162
incidence of, 162

Mallet finger injury *(Continued)*
mechanism of, 162
type I
management of, 163
nonoperative treatment of, 163
operative treatment of, 163
preferred method of treatment of, 164, 165*f*
type II
management of, 163
preferred method of treatment of, 164
type III
management of, 163
preferred method of treatment of, 164
type IV
complications of, 164
management of, 163-165
nonoperative treatment of, 163-164
operative treatment of, 164, 164*f*
preferred method of treatment of, 164-165
chronic, 165-166
Fowler tenotomy for, 166, 167*f*
preferred treatment of, 168-169
skin imbrication for, 166
spiral oblique retinacular ligament reconstruction for, 168, 168*f*
swan neck deformity associated with, treatment of, 166-169, 169*f*
classification of, 162, 163*t*
Mallet thumb injury, 169
Mallet's classification, of brachial plexus palsy, 1394, 1395*f*
Malone's "golden period", 1758
Malposition, of screws, fluoroscopy and surgical navigation to reduce, 605
Malrotation
after metacarpal fractures, 246-247, 247*f*
after phalangeal fractures, 266
Malunion
of distal radial fracture, 576-582, 578*b*, 579*f*-580*f*
of forearm fractures, 799-803
postoperative management and expectations after, 803
preferred method of treatment of, 800-801
preoperative evaluation of, 799-800, 799*f*-801*f*
rotational or angular osteotomies for, 801-803, 803*f*
of metacarpal fractures, 246-247
articular, 247
of phalangeal fractures, 266, 266.*e*1*b*
articular, 267
osteotomy for, 267*b*
of radial head fractures, 762-763, 762*f*
of radius and forearm, 498-500, 499*f*
Mangled upper extremity. *see* Mangling injuries
Mangling injuries, 1486-1527, 1487*f*
classification of, 1486-1487, 1487*b*
examination of, 1489-1492, 1490*f*-1492*f*
history of, 1489
initial evaluation of, 1489-1492
mechanisms and pathophysiology of, 1487-1489, 1488*f*
principles of, 1486, 1486*b*
treatment of
amputation/skeletal contribution in, 1492-1493
complications of, 1524
emergency, 1495-1496, 1496*b*, 1497*f*, 1498*t*
evolution in, 1495
expected outcomes in, 1524-1525
goals in, 1492-1495, 1493*f*
joints in, 1493-1494, 1494*f*
operative, 1496-1519
debridement/wound excision in, 1496-1499, 1499*b*
nerve repair/reconstruction in, 1508, 1508*b*
skeletal/joint reconstruction in, 1499-1500, 1501*f*-1504*f*
tendon repair/reconstruction in, 1500-1505, 1505*b*
vascular repair/reconstruction in, 1505-1508, 1506*f*-1507*f*, 1508*b*
postoperative management/rehabilitation after, 1519-1521, 1521*b*, 1521*f*
recommended approach to, 1495-1519
secondary procedures in, 1521-1524, 1522*f*-1523*f*, 1524*b*
soft tissue coverage in, 1508-1519, 1509*f*-1510*f*, 1521*b*
of elbow and arm, 1515-1519, 1519*f*-1520*f*
of fingers, hand, and wrist, 1512-1515, 1512*f*-1517*f*
of forearm, 1515, 1518*f*-1519*f*
nerves and, 1495
tendons in, 1494-1495
Maprotiline, for complex regional pain syndrome, 1812*t*
Marine organisms, animal bites and, 47-48
Marsupialization, surgical technique of, for chronic paronychia, 81.*e*1, 81.*e*1*f*
Martin-Gruber anastomosis, between median and ulnar nerves, 1046
Mason classification, of radial head fractures, 736, 736*f*
Matsen's technique, of compartment pressure measurement, 1765
Matti-Russe technique, in bone graft, for scaphoid nonunion, 610-611
Mayo classification, of olecranon fractures, 773-774
Mayo Clinic classification, of distal radial fracture, 524.*e*1, 524.*e*2*f*
Mayo Elbow Performance Score, 707-708
McCabe Cold Sensitivity Severity Scale, 1802
Mechanical failure, of total elbow arthroplasty, 915-916, 916*f*-918*f*
Mechanical passive device, 1737.*e*3*f*
Medial epicondyle, medial collateral ligament on, 839*f*
Medial femoral condyle bone flap, 1637, 1638*f*
Medial femoral condyle corticoperiosteal flap harvest, 1627-1628
Medial femoral condyle osteochondral flap, 1637-1638, 1639*f*
Medial femoral condyle osteochondral graft harvest, 1628
Medial femoral condyle vascularized bone graft harvest, 1628, 1628*f*
Medial "over-the-top" approach, to open release, of elbow contracture, 849-852, 850*f*-851*f*, 852*b*
capsular exposure in
anterior, 851-852
posterior, 850*f*-851*f*, 852
flexor-pronator muscle repair in, 852
patient position and preparation for, 850
postoperative care after, 853
skin incision for, 850-851
superficial exposure for, 850-851
ulnar nerve transposition in, 852
Medial tendon, 338.*e*3, 338.*e*5*f*
Median nerve(s)
anatomy of, variations of, in carpal tunnel syndrome, 930-932, 930*f*-932*f*
compression of. *see also* Carpal tunnel syndrome
in elbow and forearm, 935-938, 936*f*, 939*b*
anatomy of, 936
operative technique of, 937-938
postoperative care after, 938
preferred method of, 937-938, 937*f*-938*f*
injury to, distal radial fracture associated with, 575
repair of, 1008*b*
high, 1007*t*
primary *versus* delayed, 1008, 1008*t*
recovery after, 1005*t*
age and, 1007*t*
factors that affect, 1006-1008
results of, 1005-1008
grading of, 1006*t*
methods of, 1006*t*
in tidy wounds by level, 1007*t*
in war wounds by level, 1010.*e*2*t*
transfer of, to brachialis muscle, in musculocutaneous nerve transfer, for brachial plexus injury, 1167-1169, 1168*f*, 1169*b*

Median nerve block
at elbow, 8
at wrist, 9, 9*f*
Median nerve palsy, 1025-1045
high, 1042-1045
expectations and patient counseling in, 1045
management options in, 1045*b*
preferred method of treatment for, 1044-1045
tendon transfers in, 1026-1036
low, 1025-1042
expectations and patient counseling in, 1042
preferred method of treatment for, 1041-1042
tendon transfers for, 1026-1036
postoperative management of, 1041
for severe nerve deficits, 1036-1041, 1036*f*
thumb opposition in
biomechanics of, 1026
tendon transfers for, 1026-1036
ulnar nerve palsy combined with, 1062, 1063*t*
Medical Research Council grading, of muscle, 1394
in tetraplegia, 1122, 1123*t*
Medications, for rheumatoid arthritis, 905
Melanocytes, 1965-1966
Melanocytic nevus, 1965
Melanoma, 1977-1981, 1980*f*
acral lentiginous, 1978
amelanotic, 1980
benign juvenile, 1966
desmoplastic, 1980
local surgical excisional treatment for, 1980-1981
lymphatic basins in, evaluation of, 1981, 1982*f*-1983*f*
nodular, 1980, 1980*f*
of perionychium, 335, 335*f*
survival rates for, 336
prognosis and staging of, 1980, 1981*t*
subungual, 1978
superficial spreading, 1978, 1980*f*
Melanonychiae, 332-333
Melone classification, of distal radial fracture, 524.*e*1, 524.*e*2*f*
Melonychia, longitudinal, 1966, 1968*f*
Membrane-stabilizing agents, for complex regional pain syndrome, 1813
Meniscus homologue, 482, 482*f*
Mennen's technique, of EPL opponensplasty, 1040-1041
Mepivacaine, characteristics of, 4*t*
Merkel cell (neuroendocrine) carcinoma, 1981, 1984*f*
Meshed grafting, 1533-1534, 1533*f*
preparation of, 1534, 1534*f*
Metacarpal arch, transverse, restoration of, 1059-1060
Metacarpal artery flap
first dorsal, 1545-1546, 1546*f*
second dorsal, 1546, 1547*f*
Metacarpal artery flap, first dorsal, for soft tissue defects of thumb, 1684-1686, 1686*f*
Metacarpal bone(s)
extensor tendon injury over, 175-177, 175.*e*1*b*, 175.*e*1*f*
preferred method of treatment of, 177
of fingers, musculoskeletal tumors of, excision of, 1994-1996, 1995*f*
first, musculoskeletal tumors of, excision of, 1994, 1995*f*
fracture of, 231-248
at base, 244-246
avulsion fractures of, 244
in children, 1439
preferred method of treatment of, 245-246, 246*f*, 1439
in children, 1437-1439, 1439*b*
complications of, 246-248
dorsal angulation as, 246, 246*f*-247*f*
malrotation as, 246-247, 247*f*
malunion as, 246-247
articular, 247
nonunion, 247-248
osteomyelitis, 247
at head, 231-233, 232*f*
preferred method of treatment of, 233
types of, 232*b*
indications for fixation of, 232*b*
at neck, 233-236, 237*b*
in children, 1437-1438
closed reduction of, 233-234, 234*f*
open reduction of, 235
preferred method of treatment of, 235-236, 235*f*-236*f*, 1438
segmental metacarpal loss and, 243-244, 244*f*
preferred method of treatment of, 243-244
at shaft, 236-243
in children, 1438
closed reduction and percutaneous pinning in, 237-238, 238*f*
closed reduction and plaster immobilization of, 237, 237*f*
expected outcomes of, 243
open reduction for, 238-241
cerclage and interosseous wiring in, 239
composite (tension band) wiring in, 238*f*, 239
external fixation in, 241
fracture stabilization techniques in, 237.*e*1*t*
interfragmentary compression screws in, 240, 240*f*
Metacarpal bone(s) *(Continued)*
intramedullary fixation in, 239-240, 239*f*
Kirschner wires in, 238-239, 238*f*
plate fixation in, 240-241
preferred method of treatment of, 241-243, 242*f*, 1438-1439, 1439*f*
stabilization techniques in, 237.*e*1*t*
in mangling injuries, treatment of, 1500
second, vascularized bone graft from, 1634
short, in brachydactyly, lengthening of, 1242-1243, 1242*f*-1243*f*
Metacarpal hand, 1269
reconstruction of, 1649-1650, 1651*f*-1653*f*
type I, 1649, 1650*t*
type II, 1650*t*
Metacarpophalangeal (MCP) joint(s), 42, 1840-1841
anatomy of, 338.*e*1, 338.*e*1*f*
arthrodesis of, 352-353, 352*b*
in spasticity, for swan neck deformity, 1116, 1117*b*, 1117*f*
of thumb, in ulnar nerve palsy, 1059
arthroplasty of, 358, 1879*b*
contractures of
extension, release of, 340-341
late posttraumatic interosseous, 343.*e*1-343.*e*2, 343.*e*2*f*
nonoperative treatment of, 340.*e*1
deformity of, in scleroderma, 1839*f*
dislocations of
anatomy in, 298, 298*f*
complete (complex), 299
complications of, 300
dorsal, 298-300
outcomes of, 300
postoperative management of, 300
preferred method of treatment for, 300, 300*b*
preoperative evaluation of, 299, 299*f*
radial collateral ligament rupture in, 300-301
simple, 299
surgical techniques for, 299-300
volar, 300
extension of, 154-155
extensor tendon in, 155*f*
locked, 301
in mangling injuries, 1494
palmar capsulodesis of, in ulnar nerve palsy, 1049-1050, 1049*f*, 1050*b*
pertinent anatomy and biomechanics of, 346
rheumatoid arthritis of, 1867-1878
ligamentous reconstruction for, 1898-1901
synovectomy for with extensor mechanism reconstruction, 1898

Metacarpophalangeal (MCP) joint(s) *(Continued)*
stiffness of. *see also* Stiffness, of finger and hand
articular surface of, 338-339
examination of, 339
tendon rupture with, multiple tendons in, 1854
of thumb, 301-312
anatomy of, 301-302
dislocations of, 310-311
historical perspective on, 310-311
postoperative management and expectations in, 311
preoperative evaluation of, 311
treatment of, 311
radial collateral ligament injuries in, 308-310
Stener lesion in, 302-303, 303*f*
historical review of, 303
postoperative management and expectations in, 306
treatment of, 303, 304*f*-305*f*, 306*b*
ulnar collateral ligament injuries in
acute, 302-306
chronic, 306-308
volar instability of, chronic, 311-312
Metallic arthroplasty, of radial head, 764
Metaphyseal fracture, bicortical, of distal radius, in children, 1448-1453, 1450*f*-1452*f*, 1454*f*
preferred method of treatment for, 1453-1454
Metaphyseal posterior Monteggia fracture, 784.*e*23*b*, 784.*e*23*f*-784.*e*24*f*
Metaphysis, bending fractures of, 524-527
Metastases, of musculoskeletal tumors, 1989
Metastatic tumors, 1983, 1985*f*
of bone, 2031-2032, 2031*f*
Metatarsal artery, first dorsal
anatomy of, 1606, 1606*f*
in sensory flap from first web space of foot, 1606-1608, 1607*f*
Methicillin-resistant *Staphylococcus aureus* (MRSA), 18, 18*f*
antibiotic recommendations for, 21*t*
Methylprednisolone, for stiff finger, postoperative management of, 341
Mexiletine, for complex regional pain syndrome, 1814*t*
Michigan Hand Outcomes Questionnaire (MHQ), 924
Microbial nucleotide sequences, detection of, 66
Microvascular flow, regulation of, in complex regional pain syndrome, 1807-1808, 1807*f*-1810*f*
Microvascular surgery, regional anesthesia for, 2
Midanterolateral portal, in elbow arthroscopy, 889-890
Midcarpal fusion, scaphoidectomy and, 449-450
Midcarpal joint
instability of, nondissociative, 459
diagnosis of, 459-461
differential diagnosis of, 460-461
pathomechanics of, 459, 459*f*
physical examination in, 460
proximal row, volar, 459-461
radiographic examination in, 460
treatment of, 460-461, 461*f*-462*f*
preferred, 462-463
osseous anatomy of, 420
portals of
for arthroscopic arthrolysis, 691
for arthroscopy of wrist, 656-657, 653.*e*1*t*
Midcarpal ligaments, 422
Midpalmar space
infections of, 34*f*
characteristics of, 35*t*
clinical presentation and preoperative evaluation of, 34-35
treatment for, 36, 37*f*
preferred method of, 39
pertinent anatomy of, 35
Midposterolateral portal, in elbow arthroscopy, 890-891
Milker's interdigital granuloma, 118
Milker's nodule, 123-124, 124*f*
Miller criteria, for extensor tendon function, 161, 161*t*
Mirror hand(s), 1237-1238, 1237*f*, 1238*b*
classification of, 1212*f*, 1213*t*, 1238*t*
etiologic findings, 1237-1238
treatment of, 1238, 1238*f*-1239*f*
Mitsuda reaction, in Hansen disease, 107-108
Miura and Komada technique, in cleft hand surgery, 1251, 1252*f*
Moberg's techniques, in tetraplegia, of passive key pinch reconstruction, 1132, 1132*f*
Mohs micrographic surgery, 1962, 1965*f*
Moles, 1966
Monteggia fracture-dislocation, in children, 1468-1470, 1469*f*-1470*f*, 1469*t*
Monteggia fractures
classification of, 773, 773*f*
metaphyseal posterior, 784.*e*23*b*, 784.*e*23*f*-784.*e*24*f*
posterior (Bado type 2), 773, 773*f*
plate loosening after operative treatment of, 784.*e*28*b*, 784.*e*28*f*-784.*e*29*f*
ulnohumeral instability after, 784.*e*30*b*, 784.*e*30*f*
preoperative evaluation of, 770
treatment of, 780, 780*f*, 781*b*
plate fixation in, 778, 779*f*
Monteggia fractures *(Continued)*
type A posterior, 784.*e*1*b*, 784.*e*2*f*-784.*e*3*f*, 784.*e*15*b*, 784.*e*15*f*-784.*e*17*f*
Monteggia lesion, posterior, 817, 817*f*
classification of, 817
Moray eel, nonvenomous, injury caused by, 1795*f*
Morbidity, donor site, in toe transfer, 1670
Morpheaform (sclerosing) BCC, 1974
Motion
amplitude of, in tendon transfers, 1023-1025
improved, after elbow contracture release, 860
loss of
assessment of, in stiff elbow, 845-847
as complication of phalangeal fractures, 268
Motion protocol, after biceps rupture repair, 878
Motor conduction velocity, for cubital tunnel syndrome, 942
Motor evoked potentials (MEPs), in brachial plexus surgery, 1158
Motor rehabilitation, after toe transfer, 1670-1671
Motor-sensory neuropathy, hereditary, 923
Moxifloxacin, dosage of, 101*t*
Mucormycosis, 87-88, 89*b*
Mucous cyst, 2005-2006
clinical characteristics of, 2005-2006, 2005*f*
complications in, 2006
operative technique for, 2006, 2006*f*
preferred method of treatment for, 2006
Multidisciplinary approach, to complex regional pain syndrome, 1811
Multidisciplinary team approach, for complex regional pain syndrome, 1818
Multidrug therapy (MDT)
for Hansen disease, 109
for mycobacterial tenosynovitis, 95-96
for tuberculosis, 100-103, 101*t*
Multiple enchondromatosis, 2021, 2022*f*
Multiple joints, involvement in rheumatoid arthritis, 905
Multiple warts, 121
Muscle(s). *see also named muscle*
fibula with, in vascularized grafting, 1620
free transfer of
for brachial plexus injury, 1152-1153, 1178-1185
donor muscle selection in, 1179
grasp reconstruction with, 1180-1184
complications of, 1184
donor muscle selection in, 1181-1182

Muscle(s) *(Continued)*
operative technique of, 1181-1183, 1181*f*-1182*f*, 1184*b*
outcome of, 1184, 1184*f*
postoperative protocol for, 1183
prerequisites for, 1181
subsequent surgery for, 1183-1184
operative procedures for, 1179-1185, 1180*f*
for elbow flexion, in delayed cases, 1202, 1202*f*, 1203*b*
prerequisites for, 1178-1179
single-stage, for prehension, 1185, 1185*f*
work capacity of, 1023, 1024*t*
Muscle flaps. *see also specific muscle flap e.g.*, Latissimus dorsi muscle flap
free, 1576
Muscle grading system, Medical Research Council, in tetraplegia, 1122, 1123*t*
Muscle strengthening, for thoracic outlet syndrome, 969-970
Muscle tightness
excessive, elbow contracture with, 856
in spasticity, 1085
Muscle transfer, flexor and extensor, in ulnar nerve palsy, 1054-1056
Muscular neurotization, direct, for nerve injury, 1001, 1001*f*
Muscular release, in spasticity, evaluation of, 1085
Musculocutaneous flap(s), 1561-1562, 1576. *see also* Skin flap(s); *specific muscle flap*
free, 1576, 1597-1602. *see also* Free flap(s)
Musculocutaneous nerve transfer, for brachial plexus injury, 1165-1166, 1165*f*
intercostal nerve to, 1171, 1171*f*, 1172*b*
complications of, 1172
contraindications to, 1171-1172
outcomes of, 1172
postoperative care after, 1171
median nerve transfer to brachialis motor branch in, 1167-1169, 1168*f*, 1169*b*
operative procedure for, 1165
outcomes of, 1166
triceps transfer to axillary nerve in, 1172-1173, 1173*f*-1174*f*
outcomes of, 1174*b*, 1174*f*
ulnar nerve transfer to biceps in, 1166-1167, 1166*f*-1167*f*
outcomes of, 1167, 1167*f*
Musculocutaneous neurectomy, for spasticity, 1090-1091
Musculoskeletal tumors
benign, excision for, 1992
biopsy for, 1990-1992
excisional, 1991-1992
incisional, 1991
needle, 1990-1991
open, 1991, 1991*f*, 1992*b*
definitive treatment for, 1992-1996
diagnosis and management of, 1987-1988
evaluation protocol for, 1989-1992, 1989*f*
excision of, 1993-1996
from finger metacarpals, 1994-1996, 1995*f*
from first metacarpal, 1994, 1995*f*
from phalanx
distal, 1993, 1993*f*
middle, 1993-1994, 1993*f*-1994*f*
from wrist and distal forearm, 1996, 1996*f*-2000*f*
histologic grade and surgical staging of, 1988-1989, 1988*t*-1989*t*
laboratory studies for, 1990
location (site) of, 1989
malignant, excision for, 1992-1993
metastases of, 1989
Musculotendinous components, of radiocapitellar joint, 813
Mycetoma, 70-73
clinical findings on, 71
diagnosis of, 72, 72*b*
differential diagnosis of, 72
etiology and epidemiology of, 70
microbiology of, 70-71
staging of, 71-72, 71*f*
treatment of, 72-73
Mycobacterial infections, 90-103
antituberculous drugs for, multidrug therapy regimens and, 100-103, 101*t*
cutaneous tuberculosis and, 91-92
deep infections and, 93-100, 94*f*-95*f*
eight-pack tissue culture for, 65*t*
etiology, diagnosis, and treatment of, 63*t*
growth rates of, 91*t*
nontuberculous, 90-103
diagnosis and treatment of, 102*t*
subcutaneous tuberculosis and, 92-93, 93*f*
tuberculous, 90-103
Mycobacterial tenosynovitis, 93-96, 94*f*-95*f*
Mycobacterium avium, 91, 93
Mycobacterium haemophilum, 91
Mycobacterium leprae, 92, 103
Mycobacterium marinum, 93, 94*f*
Mycobacterium scrofulaceum, 93, 95*f*
Mycobacterium tuberculosis, 91-93
Mycobacterium ulcerans, 65, 92-93, 93*f*
Myelography
in brachial plexus birth palsy, 1395-1396
of brachial plexus injury, 1152, 1152*f*
Myoblastomas, granular cell, 2013-2014, 2013*f*
Myocutaneous flaps, 1576
Myoelectric devices, in prosthetics, 1759
Myoelectric hands, types of, 1742*f*
Myofascial manipulation, for thoracic outlet syndrome, 969
Myofibroblast, Dupuytren disease and, 131
extracellular matrix, cycle of, remodeling, 136*f*
gene expression of, 136
Myonecrosis, 56, 56*f*

N

Nager syndrome, radial longitudinal deficiency associated with, 1329*t*
Nail(s)
absence of, 326-328, 328*f*
anatomy of, 20-21
dull, 330
germinal matrix of, 318
hooking of, 329, 329*f*
infections of
bacterial, 331, 331*f*
fungal, 330-331
nonadherence of, 326, 327*f*
pincer, 330, 330*f*, 331*b*
split, 326, 326*f*-327*f*
Nail bed
acute injuries of, delayed treatment in, 324
amputation in, 323-324, 324*f*-325*f*
anatomy of, 319*f*
avulsion of, 321, 321*f*
cornified, 328, 328*f*
defect of, 321-322, 322*f*
graft for, harvest of, 322, 322*f*
postburn deformities of, 1937, 1939*f*
repair of, 319-321, 320*f*
scarring of, 325
stellate lacerations of, 320, 320*f*
Nail cysts, 328, 328*f*
Nail fold
infection of
acute, 20-22, 22*b*, 22*f*-23*f*
chronic, 23-25, 24*f*-25*f*, 25*b*
Keyser-Eaton marsupialization of, 331-332
paronychia and, 81
syphilis and, 73-74
treatment of, 81.*e*1
Nail graft, vascularized, in toe transfer flap design and elevation in, 1661-1663
flap designs and elevation, 1661-1663, 1663*f*
indications, 1661, 1662*f*
Nail horns, 1711
Nail ridges, 325-326
Nail spikes, 328, 328*f*
Necrosis
avascular
after radial head fractures, 761, 761*f*
of capitate, 649
vascularized bone grafting for, 1613

Necrosis *(Continued)*
wound, after elbow contracture release, 859, 860*f*
Necrotizing fasciitis, 17, 54-55, 54*f*
animal bites and, 48
antibiotic recommendations for, 21*t*
case study, 55.*e*1*b*, 55.*e*1*f*
diabetic hand infections and, 54
fungal, 55, 55*f*
shooter's abscesses and, 51
Needle biopsy, for musculoskeletal tumors, 1990-1991
Needle depth penetration, 146*f*
Needle fasciotomy, for Dupuytren disease, 139*t*
percutaneous, 140
Needle maneuvers, in procedure, for Dupuytren disease, 146, 146*f*
Needle problems, in procedure, for Dupuytren disease, 147
Needle size, in procedure, for Dupuytren disease, 146
Negative pressure wound therapy
for mangling injuries, 1509, 1510*f*
for skin grafting, 1536
Nerve(s)
anatomy of, 980, 980*f*
conduction studies of, in compression neuropathies, 929
exploration of, in radial nerve palsy with humeral fractures
at 6 to 8 weeks, 1074-1075, 1075*f*
early, 1074
if no return at longer waiting period, 1075, 1075*f*
preferred method of, 1075
gap of, 1007-1008
iatrogenic injuries to, operations for, 1013*t*
issues, in procedure, for Dupuytren disease, 147
longitudinal mobility of, in compression neuropathies, 923
into muscle
implantation of, 1018*f*
translocation of, 1017-1019
preparation of, in toe transfer, 1645, 1666
reconstruction of, in brachial plexus injury
primary, 1154, 1160-1177
secondary, 1154, 1186-1202
reimplantation of, 1185
repair of
in mangling injuries, 1508, 1508*b*
in microvascular toe transfer, for hypoplastic digits, 1269
in radial nerve palsy, 1065
in toe transfer, 1668
Nerve abscess, in Hansen disease, 112-113, 113*f*-114*f*
drainage technique for, 113
treatment of, 112-113
Nerve action potentials (NAPs), in brachial plexus surgery, 1158, 1158*f*
Nerve bed, preparation of, 993
Nerve biopsy, for Hansen disease, 108-109
fine-needle nerve aspiration technique and, 108-109
open, 109
Nerve block(s)
axillary, 8, 8*f*
for complex regional pain syndrome, continuous autonomic, 1817
infraclavicular, 7-8, 7*f*
interscalene, 6, 7*f*
supplementary, 8-11
at digit, 9-10, 10*f*-11*f*
at elbow, 8
at wrist, 8-9, 9*f*
supraclavicular, 6-7, 7*f*
Nerve compression
chronic, pathophysiology of, 921-924, 922*f*
electrodiagnostic studies and, 929-930
Nerve conduction studies, 12
in brachial plexus injury, 1153
Nerve conduction velocity (NCV), 1396
Nerve gliding exercises, for carpal tunnel syndrome, 933
Nerve graft/grafting, 996-999, 999*b*
in brachial plexus birth palsy, 1397, 1398*f*-1399*f*, 1400-1404, 1401*f*-1404*f*
in brachial plexus reconstruction, 1160-1163
allografts in, 1163
coaptation and, 1162-1163, 1162*f*
conduits in, 1163
conventional, 1161-1162, 1161*f*
donor nerve for, 1161-1162
indications for, 1160
operative procedure for, 1160-1161, 1161*f*
other options for, 1162
postoperative care for, 1177
choice of, 996-999, 997*f*-998*f*
for mangling injuries, 1522, 1523*f*
other methods of, 999-1000
postoperative care after, 999
suturing of, 998*f*
tendon transfer *versus*, nerve repair and, for radial nerve palsy, 1065
vascularized, 999
Nerve injury
after radial head fractures, 761
aggravating, 1-2
cause of, 1003
classification of, 982, 982*t*, 984*b*
clinical diagnosis of, 985-991, 986*f*, 990*b*
depth of, 986*t*
digital, repair of, 1008-1009, 1009*t*
preferred method of treatment of, 1009
electrodiagnosis of, 988-989, 988*t*
Nerve injury *(Continued)*
imaging of, 989, 990*f*
lesions in
continuity in, 989-990
distribution and diagnosis of, 1010.*e*1
level of the lesion in, 1002-1003
mangling
evaluation of, 1492
repair/reconstruction of, 1508*b*
restoration of sensation in, 1495
nature of, 1003
level and, 1007
neurologic examination of, 987-988
physical examination of, 986-988, 987*f*
repair of, 979-1022
alternative methods of, 999-1000
closure in, 996
delay in, 1003
effects of, 1005*t*
denervation and reinnervation of, electromyographic findings in, 989*t*
epineurial, 994
exposure in, 991
grafting in, 996-999, 997*f*-998*f*, 999*b*
indications for, 979-982, 980*f*
neurolysis in, 992-993
outcomes of, 1010.*e*2*t*
postoperative care after, 996
recovery after, 1001-1009
factors in prognosis of, 1002-1003, 1003*b*
measurement of, grading and, 1001-1003, 1002*t*
results of, 1003-1009, 1003*t*-1004*t*
grading, 1002*t*
rehabilitation after, 1009-1010, 1010*b*
resection of a damaged nerve of, 991-992
surgical interventions for
considerations before, 990-991
consultation and operative record in, 991
outcomes of, 1010.*e*3-1010.*e*5
techniques of, 991-1001
suturing in, methods of, 993-996
delayed, 994-996, 995*f*-996*f*
direct, 993-994, 994*f*
end-to-end, 993
fibrin clot glue in, 996
responses to, 982-985, 983*f*
conduction block in, 983-984
stretch injury as, 985
Wallerian degeneration in, 984-985
severity of, in war wounds, 1010.*e*1, 1010.*e*1*t*
Tinel sign in, 986, 987*b*
war wounds and, 1010.*e*1-1010.*e*5
Nerve palsy
after elbow contracture release, 859
peripheral, constriction ring associated with, treatment of, 1256

Nerve percussion test, 924
Nerve reconstruction, 1777, 1777*f*
  in brachial plexus birth palsy, 1397-1398
Nerve status
  postoperative, assessment of, 1
  in rheumatoid arthritis, 905
Nerve surgery, for brachial plexus birth palsy, 1397-1407, 1401*b*
  postoperative management for, 1407, 1408*t*
  preferred treatment, 1406-1407
  results of, 1399
  technique of, 1400-1404
    nerve grafting in, 1397, 1398*f*, 1400-1404, 1401*f*-1404*f*
    nerve transfers in, 1404-1406, 1405*f*-1407*f*
  timing of, 1398
Nerve territory-oriented macrodactyly, 1278
Nerve transfer, 1000-1001
  in brachial plexus birth palsy, 1398, 1398*f*-1399*f*, 1404-1406, 1405*f*-1407*f*
  for brachial plexus injury, 1163-1177
    contralateral C7, 1173-1176, 1175*f*-1176*f*
      author's preferred technique for, 1176
      complications of, 1176
      outcomes of, 1176
      postoperative care after, 1176
      surgical anatomy in, 1175
    extraplexal, 1177
    indications for, 1163
    intercostal nerve in, 1169-1172, 1170*f*
    intraplexal, 1176-1177
    musculocutaneous nerve in, 1165-1166, 1165*f*
      intercostal nerve to, 1171, 1171*f*, 1172*b*
        complications of, 1172
        contraindications to, 1171-1172
        outcomes of, 1172
        postoperative care after, 1171
      median nerve transfer to brachialis motor branch in, 1167-1169, 1168*f*, 1169*b*
      operative procedure for, 1165
      outcomes of, 1166
      triceps transfer to axillary nerve in, 1172-1173, 1173*f*-1174*f*
      outcomes of, 1174*b*, 1174*f*
      ulnar nerve transfer to biceps in, 1166-1167, 1166*f*-1167*f*
      outcomes of, 1167, 1167*f*
    postoperative care for, 1177
    spinal accessory nerve in, 1163-1166, 1163*f*
Nerve transfer *(Continued)*
    suprascapular nerve in, 1164-1165, 1164*f*
      outcomes of, 1165, 1165*f*
  in radial nerve palsy, 1075-1076
Neural dystrophic focus, in complex regional pain syndrome, management of, 1820
Neurapraxia, 12, 12*b*, 983-984, 1148
  management of, 12, 13*f*
Neurectomy
  musculocutaneous, for spasticity, 1090-1091
  of ulnar motor, for intrinsic muscle spasticity, 1114, 1115*f*
Neurilemomas, 2012, 2013*f*
Neuritis
  Parsonage-Turner, 936
  silent, in Hansen disease, 114
Neurofibroma, 1968, 1969*f*
Neurofibromatosis, pseudoarthrosis and, 1354, 1355*f*
Neurofibrosarcoma, 2019
Neurologic deficit
  deep flexor compartment with, 1776-1777
  deep flexor compartment without, 1776
  severe, 1777
  superficial flexor compartment with, 1776-1777
Neurolysis
  in brachial plexus birth palsy, 1397
  for brachial plexus injury, 1160
Neuroma(s), 1746*f*, 1748-1749, 1749*f*, 1749*t*
  after amputation, 1011*f*, 1522, 1010.*e*5
  in complex regional pain syndrome, 1822
  peripheral, 1010-1019
    containment of, 1015, 1016*f*
    excision of
      repair and, 1014*b*, 1015*f*
      transposition into muscle and, 1017*b*
    managing, summary of, 1018*b*
    pathophysiology of, 1011-1012
    preferred method of treatment of, 1014
    prevention of, 1012, 1012*f*
    translocation of, 1015-1016, 1016*f*
    transposition of
      into bone, 1016
      into conduit, 1017
      into vein, 1016-1017
    treatment of, 1012-1019
      chemical methods for, 1013
      operations for, 1013-1019, 1013*t*
Neuromuscular blocking agents, for complex regional pain syndrome, 1815
Neuropathic joint, complete ankylosis of, 909
Neuropathic pain, 1010.*e*2-1010.*e*3
  definition of, 1797, 1799*t*
  diagnosis of, 1011*b*
Neuropathy(ies)
  compression. *see* Compression neuropathy(ies)
  hereditary motor-sensory, 923
  ulnar
    after humeral fractures, 729-730
    after ulnar fracture, 783-784
Neurosensory flap, transfer of, from first web space
  flap design and elevation in, 1660-1661
  indications for, 1658-1659, 1660*f*-1661*f*
Neurostenalgia, nerve injury and, 1010.*e*3-1010.*e*4
Neurotization, for brachial plexus injury, 1163
Neurotmesis, 1148
Neurovascular island flap, 1552-1554, 1553*f*
  for soft tissue defects of thumb, 1686-1687, 1688*f*, 1689*b*
Neurovascular spiral bundle, of Dupuytren disease, 138
Neutropenia, 1833
Neutrophilic dermatoses, 75-77
  clinical findings on, 76-77
  diagnosis of, 77, 77*f*
  etiology and epidemiology of, 75-76
  treatment of, 77
Nevus (nevi)
  acral, 1966
  blue, 1966
  giant hairy congenital, 1966, 1967*f*
  junctional, 1965-1966
  melanocytic, 1965
  subungual, 332-333, 332*f*-333*f*
Nifedipine, for complex regional pain syndrome, 1815*t*
Night splinting
  for arthrogryposis, 1380
  for epicondylitis, 865
Night splints, for cubital tunnel syndrome, 942
90-degree abduction external rotation test, 966-967
Nociceptive focus, identification of, in complex regional pain syndrome, 1804-1805
Nociceptive pain, 1797
  definition of, 1797, 1799*t*
Nodular fasciitis, 2014
Nodular lymphangitis, differential diagnosis and treatment for, 83, 84*t*
Nodular melanoma, 1980, 1980*f*
Nodular skin, diffuse, of Dupuytren disease, 130*f*
Nodules
  Dorsal Dupuytren, 129
    pathology of, 136
    signs of, 129-130, 131*f*
    treatment of, 143
  rheumatoid, 1841-1842, 1841*f*

Nonadherence
hyponychial, 329-330
of nails, 326, 327*f*
Nonarticular bone loss, associated with humeral fractures, 726
Nonarticular fractures, of phalanges, 255-256
at neck, 255-256, 256*f*-257*f*
at shaft, 256
expected outcomes of, 264-265
preferred method of treatment of, 261
Nondisplaced fractures, of distal radius, treatment of, 567
Nonmetacarpal hand, multiple-digit amputation, 1648
Nonmicrosurgical coverage, of upper extremity, 1528-1573
flap coverage, local and regional, 1539-1571
skin grafting. *see* Skin graft/grafting
Nonoperative management, of radial head fractures, 741-742, 742*f*
outcome of, 756-758
Nonsteroidal antiinflammatory drugs (NSAIDs), infections and, 19
Nontuberculous mycobacterial infections, 90-103
diagnosis and treatment of, 101, 102*t*
special features of, 101-103
Nonunion
of distal humeral fracture, 728
associated with elbow contracture, 854
of distal radial fracture, 576
of forearm fractures, 799-803
postoperative management and expectations after, 803
preferred method of treatment of, 800-801
preoperative evaluation of, 799-800, 799*f*-801*f*
of metacarpal fractures, 247-248
of olecranon osteotomy, 728-729, 729*f*
of phalangeal fractures, 267-268, 268*f*-269*f*
of radial head fractures, 762
of scaphoid fractures, 588-624
biologic stimulation of, 607
bone graft for, nonvascularized, 610, 610*f*
in children, 1445, 1446*f*
case study for, 1445.*e*1*b*, 1445.*e*1*f*-1445.*e*3*f*
of distal pole, 622
dysvascular, 616-619, 616*f*
evaluation of, 608-609
activity level in, 609
age in, 609
amount of deformity and malalignment in, 608
arthritis in, presence and location of, 609
bone loss in, 608
Nonunion *(Continued)*
comorbidities in, 609
fracture site in, 608
length of time in, 609
pain or dysfunction in, 609
previous treatment in, 608
salvageability of fragment in, 609
vascularity of fragments in, 608
implications of, 590-591, 591*f*
management of, 608-624
preferred method for, 621
open dorsal technique for, 614-615
operative treatment for, 609-619, 609*t*
prognosis for healing in, 620-621
proximal pole, 614-616
treatment for, preferred, 621*t*
unsalvageable proximal pole, 621
vascularized bone grafting for, results of, 1637-1638
without arthritis, 609-611
without substantial bone loss, 609
of ulnar fractures, 783, 784*f*, 784.*e*31*b*, 784.*e*31*f*
No-reflow phenomenon, in mangling injuries, 1488
Nortriptyline, for complex regional pain syndrome, 1812*t*
Nosocomial infections, 18
Notta nodule, in trigger thumb, 1321, 1321*f*, 1915*f*
Nubbin, residual, after suture ligation of ulnar polydactyly, 1233, 1233*f*
Nucleic acid amplification, for infections, 66

O

Oblique fibers, 338.*e*3, 338.*e*5*f*
Oblique retinacular ligament (ORL), 156-157
Occupational infections, chronic, 118
Ochronosis, tendinopathy in, 1907
Ohm's law, 1946
Olecranon fractures, 773-774, 774*f*
posterior dislocation of elbow associated with, 784.*e*11*b*, 784.*e*11*f*-784.*e*12*f*
Olecranon osteotomy, for distal humeral fractures, 711-712, 713*f*, 724*b*
nonunion of, 728-729, 729*f*
technique of, 722-724
Olecranon process
anatomy of, 771-772
fracture-dislocations of, 774-775, 774*f*-776*f*, 816-817, 816*f*
anterior (transolecranon), 774-775, 775*f*
complex posterior, 784.*e*1*b*, 784.*e*2*f*-784.*e*3*f*
posterior, 784.*e*4*b*, 784.*e*4*f*-784.*e*5*f*, 784.*e*6*b*, 784.*e*7*f*-784.*e*8*f*, 784.*e*15*b*, 784.*e*15*f*-784.*e*17*f*, 784.*e*25*b*, 784.*e*25*f*-784.*e*27*f*
posterior Monteggia lesion, 817, 817*f*
Olecranon process *(Continued)*
transolecranon, 816-817, 816*f*
treatment of, 780, 822-823, 823*f*
hinged external fixation in, 823-824, 824*b*, 824*f*
posterior dislocation of elbow associated with, 784.*e*11*b*, 784.*e*11*f*-784.*e*12*f*
Olecranon (type IIA), displaced fractures without comminution and proximal to midpoint of, 781
Ollier disease, 2021, 2022*f*
One wound-one scar concept, of mangling injuries, 1486, 1487*f*
Open biopsy, for musculoskeletal tumors, 1991, 1991*f*, 1992*b*
Open carpal tunnel release, 934-935, 934*f*, 935*b*
Open fractures
in children, 1468
of distal radius, 573-575
Open reduction
of condylar fracture of proximal phalanx, 254*f*
of displaced bicondylar proximal phalangeal fracture, 256*f*
limited, of distal radial fractures, 536
of metacarpal neck fractures, 235
of metacarpal shaft fractures, 238-241, 237.*e*1*t*
with pin fixation, of proximal and middle phalangeal fracture, 258-259, 259.*e*1*t*
for proximal interphalangeal joint dislocation, 280
Open reduction and internal fixation (ORIF)
of coronoid fracture-dislocation, 819-820
of distal humeral fractures, in elderly, 707-709, 709*t*
of distal radial fracture, 547-559, 547*f*
distraction plating technique in, 557-559, 558*f*, 560*f*
dorsal plate approach to, 547-552, 548*f*
fragment-specific fixation in, 552-557, 558*b*
volar plate approach to, 548-552, 549*f*-553*f*, 554*b*
for forearm nonunion, 800-801
for lesser-arc injuries, 468-470, 468*f*, 469*b*, 470*f*
for perilunate fracture-dislocations, 471, 471*f*
of proximal and middle phalangeal fracture, 257, 259*f*-260*f*
for proximal interphalangeal joint fracture-dislocation, 283
outcomes of, 288
postoperative protocol for, 288
preferred method for, 287-288, 288*b*, 288*f*

Open reduction and internal fixation (ORIF) *(Continued)*
of radial head fractures, 743
outcome of, 758
as preferred treatment, 746-750, 750*f*-752*f*, 751*b*
of scaphoid fracture
dorsal approach/mini-open approach to, 597-598
palmar approach to, 599-600
for scapholunate dissociation, 440-442, 441*f*
triceps-splitting, 713.*e*1*b*, 713.*e*1*f*-713.*e*4*f*
Operating room
exploration of, free flap failure, 1583-1584
patient preparation in, preoperative, 1578
Opponens digiti quinti, 338.*e*4
Opponensplasty
for median nerve palsy
high, 1042-1045
brachioradialis-to-FPL transfer, 1043, 1044*f*
complications of, 1044
ECRL-to-index profundus, 1044, 1044*f*
expectations and patient counseling in, 1045
extrinsic transfers in, 1043
preferred method for, 1044-1045
restoration of opposition in, 1043
summary of, 1044-1045, 1045*t*
thumb opposition restoration in, 1043
timing and selection of, 1043
low
abductor digiti minimi (Huber), 1032-1033, 1033*f*-1034*f*
adductor pollicis and flexor pollicis brevis, 1041
Bunnell, 1030*f*, 1031
compromise, for severe nerve deficits, 1036-1041, 1036*f*
expectations in, 1042
extensor carpi radialis longus, 1035-1036
extensor carpi ulnaris, 1034-1035
extensor digiti minimi, 1036, 1036*f*
extensor indicis proprius, 1031-1032, 1032*f*
extensor pollicis longus, 1037-1040, 1039*f*-1041*f*
alternative, 1040-1041
flexor pollicis longus, 1037, 1038*f*
alternative, 1037, 1038*f*-1039*f*
history of, 1026
insertions in, 1027-1029, 1028*f*
management of, 1042*b*
palmaris longus (Camitz), 1033-1034, 1034*f*-1035*f*
Opponensplasty *(Continued)*
patient counseling in, 1026-1027, 1042
postoperative management of, 1041
preferred method of, 1041-1042
prevention and preoperative treatment of contractures prior to, 1027
principles of, 1027
pulley, 1030, 1030*f*
pulley design in, 1027
results of, 1027-1029, 1028*t*, 1029*f*
Royle-Thompson, 1030-1031
selection of motor for transfer in, 1027
standard, 1029-1034
superficialis, 1029-1031
management principles in, 1029*b*
outcomes of, 1042*t*
for tetraplegia, 1138, 1141
Opposition posts, in prostheses, 1740
Optimum timing, in Dupuytren surgery, 139
Oral medications, preferred method of treatment, 1819
Orf infection, human, 123-124, 124*f*
Osseous fibular flap, 1617-1619
Osseous fixation, anticipated, in replantation, 1478
Ossification, centers of, in carpal bones, 1444
Osteoarthritis
after radial head fractures, 763, 763*f*
debridement for, 893-897, 896*b*
indications and contraindications of, 893
outcomes of, 896-897
postoperative management of, 894-896
preoperative planning of, 893
technique of, 893-894, 895*f*-896*f*
of hand, 345
small joints of, 345-358
diagnostic imaging of, 346
historical review on, 346, 347*f*
pertinent anatomy and biomechanics of, 346
physical examination of, 345-346, 346*f*
preoperative evaluation of, 345-346
primary, 907-909
of thumb, 345
carpometacarpal joint of, 359-369
anatomy and biomechanics of, 359-360, 360*f*
complications of, 368-369, 369*f*
critical points on, 366*b*
diagnostic imaging of, 359, 359*f*
epidemiologic findings on, 359
evaluation of, 359
Osteoarthritis *(Continued)*
expected outcomes on, 366-368, 367*t*
indications and contraindications for, 360-362
operative techniques on, 362-364
physical examination for, 359
postoperative management and expectations on, 366-369
preferred method of treatment for, 364-365, 365*f*-366*f*
treatment for, 360-364
wrist arthrodesis and, radiographic patterns of, 376, 377*f*
Osteoblastoma, 2023-2024
Osteochondroma, 2022
of forearm, 1358-1359
location of, 1359, 1359*f*
removal of, 1359-1360
contraindications to, 1359
postoperative management and expectations after, 1361-1362
subungual, 2022
Osteocutaneous fibula, 1613*f*
Osteocutaneous flap, vascularized, in grafting from fibula, 1619
Osteogenesis, distraction, metacarpal lengthening with, in brachydactyly, 1242-1243
Osteogenic sarcoma, 2027-2028, 2029*f*
Osteoid osteoma, 2023, 2023*f*
Osteolysis, 1835-1836
Osteomyelitis, 43-46
classification of, 45*t*
clinical presentation and evaluation of, 45-46, 46*f*
coccidioidal, 85
as complication, of metacarpal fractures, 247
complications of, 46
cryptococcal, 86
fungal, 89
septic joint progression to, 43.*e*1*b*, 43.*e*1*f*
sporotrichal, 88
treatment for, 46
tuberculous, 97-100
in adult, 98-100, 99*f*
in children, 98, 98*f*
treatment of, 100
vascularized bone grafting for, 1613
Osteonecrosis, 639-649
of scaphoid, 1445
Osteoperiosteal sleeve, for split thumbs, 1307-1309, 1309*f*-1310*f*
Osteophyte, 333
Osteoplastic reconstruction, of amputated thumb, with preservation of basal joint, 1696-1697, 1697.*e*1*f*
Gillies "cocked-hat" flap in, 1696, 1697*f*
two-stage
stage 1, 1696-1697, 1698*f*
stage 2, 1697, 1697.*e*1*f*

Osteoplasty, of sigmoid notch and ulna, in chronic radioulnar joint instability, 498, 498*f*
Osteosynthesis, in microvascular toe transfer, for hypoplastic digits, 1269
Osteotomy, 1756
for articular malunion, of phalangeal fractures, 267*b*
closing wedge radial, for Kienbock disease, 646, 647*f*
corrective, for clinodactyly, 1272
derotational
for brachial plexus birth palsy, 1415, 1415*f*
for proximal radioulnar synostosis, 1351-1352, 1352*f*-1353*f*
first metacarpal, for carpometacarpal joint osteoarthritis
expected outcomes on, 366
as operative technique, 362, 362*f*
as treatment, 361
multiple, using three-dimensional modeling, 1344
olecranon, for distal humeral fractures, 711-712, 713*f*, 724*b*
creation of, 722, 723*f*
fixation of, 722-724
nonunion after, 728-729, 729*f*
for radial fracture
articular, 580-581, 582*f*, 581.*e*1*b*, 581.*e*1*f*-581.*e*6*f*
dorsal approach to, 577-578, 579*f*
extraarticular, 577, 578*b*, 578*f*
malunited Smith, 580, 580.*e*4*f*
ulnar-shortening, 580
volar approach to, 578-580, 581*f*, 580.*e*1*b*, 580.*e*1*f*-580.*e*2*f*
Watson's trapezoidal, 580.*e*3, 580.*e*3*f*
radial-shortening, for Kienbock disease, 642-643, 642*f*
rotational
for forearm fracture malunion, 801-803, 802*f*
of humerus, for ulnar deficiency, 1335, 1338
thumb reorientation. *see* Thumb reorientation osteotomy
ulnar-shortening, 501-503, 502*f*, 1455
Outcome score, of Dupuytren disease, 133
Outerbridge-Kashiwagi procedure, 849, 894
Outpatient surgery, in skin grafting, 1538
Overlap syndrome, 1839
Oxacillin-resistant *Staphylococcus aureus* (ORSA), shooter's abscess and, 51

P

Padgett dermatome, 1532-1533, 1532*f*
Paget-Schroetter syndrome, 960, 960*f*
Pain
acute *versus* chronic, 1801, 1801*f*
assessment of, in stiff elbow, 845
Pain *(Continued)*
in complex regional pain syndrome, 1799*t*
definition of, 1799*t*
mediators of, 1800-1801
mediators/receptor control of, 1800-1801
perception of, 1799
physiology of, 1798-1801, 1800*f*
relief of, for Hansen disease, 109-113, 110*f*
sympathetic, definition of, 1799*t*
Pain management
neuropathic, in brachial plexus injury, 1203
postamputation, 1749*b*
Pain questionnaire, 925*f*-926*f*
Pain threshold, evaluation of, in complex regional pain syndrome, 1805
Palm, Dupuytren disease in, 134
Palmar advancement flap(s), for soft tissue defects of thumb, 1676-1677, 1677*b*
with proximal releasing incision, 1677-1679, 1679*b*, 1679*f*
without proximal releasing incision, 1677, 1678*f*
Palmar cutaneous nerve, anatomy of, 936
Palmar fascia, in Dupuytren disease. *see also* Dupuytren disease (DD)
anatomy of, 134, 135*f*
Palmar hand skin, 1528, 1529*f*
Palmar nevi, 1966
Palmar radiocarpal ligaments, 420, 421*f*
Palmar radius pedicle grafts, 1632-1634
Palmar space infections
characteristics of, 35*t*
clinical presentation and preoperative evaluation of, 34-35
pertinent anatomy in, 35
treatment for, 35-36
Palmar ulnocarpal ligaments, 420-421, 421*f*
Palmar V sign, in scapholunate dissociation, 437
Palmaris longus
absence of, 1070
transfer of
to first dorsal interosseous, 1059
in median nerve palsy, 1033-1034, 1034*f*-1035*f*
Palmaris longus four-tail transfer, in ulnar nerve palsy, 1056
Palmaris longus tendon, for tendon grafts, 203-204
Palmer's classification, of triangular fibrocartilage complex lesions, 487*t*, 488*f*
class 1A tear in, 489, 677*f*
class 1B tear in, 489, 678, 678*f*-679*f*
class 1C tear in, 489, 489*f*
class 1D tear in, 489-490, 490*f*
Palpation, in thoracic outlet syndrome, 964-966, 965*f*-967*f*
Palsy
brachial plexus, in children, 1391-1424
cerebral, 1080. *see also* Cerebral palsy
Dejerine-Klumpke, 1149-1150
Erb-Duchenne, 1149, 1393
median nerve, 1025-1045. *see also* Median nerve palsy
peripheral nerve, constriction ring associated with, treatment of, 1256
posterior interosseous nerve, 1064, 1064*f*
radial nerve, 1064-1076. *see also* Radial nerve palsy
ulnar nerve, 1045-1062. *see also* Ulnar nerve palsy
Paneva-Holevich reconstruction, FDS-FDP, 213-214, 215*f*
Pan-plexus (C5-T1) injury, 1150
decisions and priorities of repair for, 1159-1160
Panton-Valentine leukocidin (PVL), methicillin-resistant *S. aureus* (MRSA) and, 18
Pantrapezial degenerative disease, as contraindication for thumb arthroscopy, 693
Paprika sign, 1578
Para-aminosalicylic acid, dosage of, 101*t*
Parasitic infections, chronic, 116-118
etiology, diagnosis, and treatment of, 63*t*
worm, 117-118
Paratricipital approach, to distal humeral fractures, 711, 712*f*, 711.*e*1*b*, 711.*e*1*f*-711.*e*2*f*
Paratricipital exposure, for total elbow arthroplasty, 711.*e*1*b*, 711.*e*1*f*-711.*e*2*f*
Parenteral medications, for complex regional pain syndrome, 1815*t*, 1816
authors' preferred method of, 1819
Paresthesia
definition of, 1799*t*
with needle movement, for Dupuytren disease, 147-148, 147*f*
Parkes static tenodesis, in ulnar nerve palsy, 1050-1051, 1050*f*
Parona space infections, 32-34
clinical presentation and preoperative evaluation of, 33
pertinent anatomy in, 33
postoperative management of, 34
treatment of, 33-34
open, 33-34
preferred method of, 34
Paronychia
acute, 20-22, 22*b*, 22*f*-23*f*
antibiotic recommendations for, 21*t*
chronic, 23-25, 24*f*-25*f*, 25*b*, 81, 81*f*, 81.*e*1*f*
Paronychial fold, formation of, in management of syndactyly, 1221-1222

Parosteal osteochondromatous proliferation, bizarre, 2022
Paroxetine, for complex regional pain syndrome, 1813*t*
Parsonage-Turner neuritis, 936
Partial articular loss, 726.*e*1*b*, 726.*e*1*f*-726.*e*3*f*
Partial hand silicone prosthesis, 1737.*e*3*f*
Partial wrist fusion, for arthritic wrist, 690
Passive key pinch reconstruction, in tetraplegia, 1131-1133, 1132*f*
Passive motion rehabilitation, postoperative, of zone 2 tendon lacerations, 189
Passive stability, of proximal interphalangeal joint, 279
Patient refusal, to regional anesthesia, 1
Patient surveillance, 1960
Patient-Specific Functional Scale (PSFS), 924
Peau d'orange skin, 54
Pectoral nerve transfer, for brachial plexus injury, 1176-1177
Pectoralis minor space, in thoracic outlet syndrome, 964
Pectoralis muscle, transfer of
  for elbow reconstruction, in brachial plexus injury, 1198-1202, 1200*f*-1201*f*, 1201*b*
  for shoulder reconstruction, in brachial plexus injury, 1188
Pediatric Outcomes Data Collection Instrument (PODCI), 1394-1395
Penetrating trauma, to brachial plexus, 1149
Penicillin, for actinomycosis, 68
Penicillin G, for syphilis, 74
Percutaneous needle fasciotomy (PNF), for Dupuytren disease, 140, 143-144
Percutaneous pin fixation, of distal radial fracture, 531-532, 535*f*-537*f*
Percutaneous trigger digit release, 1913-1914, 1913*b*-1914*b*, 1913*t*, 1914*f*
Perforator flaps, 1576-1577
Periarterial sympathectomy, of vasospastic disease, 2053*f*-2054*f*, 2054
Perilunate fracture-dislocations, 427
  dorsal, 470-472
    in complex carpal instability
      greater-arc injuries and, 470
      lesser-arc injuries and, 465-470, 465*f*-466*f*
    transscaphoid, 470-471
    transscaphoid-transcapitate, 471-472, 472*f*
    transtriquetrum, 472, 473*f*
    treatment of, 465-470, 472, 473*f*
      preferred method of, 470
  palmar, 472, 474*f*
  transscaphoid, arthroscopic treatment of, 604-605, 606*f*-607*f*
Perilunate instability
  acute, treatment of, 456
  chronic, treatment of, 456-457, 457*f*
Perionychium, 318-337. *see also* Nail bed
  anatomy of, 318, 319*f*
  complications to, postoperative, 325-330
    absence as, of nails, 326-328, 328*f*
    dull nail as, 330
    eponychial deformities as, 329
    hyponychial deformities as, 329-330, 329*f*
    nail ridges as, 325-326
    nail spikes, cysts, and cornified nail bed as, 328, 328*f*
    nonadherence as, 326, 327*f*
    split nail as, 326, 326*f*-327*f*
  infections of
    acute, 330-331
    chronic, 331-332, 332*f*
  postoperative management of, 324-325
  preoperative evaluation for, 318, 319*f*
  tumors of, 332-336
    benign, 332-334
    malignant, 334-336, 335*f*
  types of operation for, 318-324
    in amputation, 323-324, 324*f*-325*f*
    in avulsion, 321, 321*f*
    in delayed treatment of acute injuries, 324
    in fracture, 322-323, 322*f*-323*f*
    in nail bed defect, 321-322, 322*f*
    in nail bed graft, harvest of, 322, 322*f*
    in nail bed repair, 319-321, 320*f*
    in subungual hematoma, 318-319, 320*f*
Periosteal chondroma, 2021-2022, 2022*f*
Periosteal graft, vascularized, 1624-1634
Peripheral nerve implant, for complex regional pain syndrome, 1817
Peripheral neuroma, 1010-1019
Peripheral ulnar-sided tears
  knotless technique for, 680, 680*f*-683*f*
  Tuohy needle technique for, 678-679
Perivascular blocks, regional anesthesia and, 12
Phaeomycotic cysts, 84
Phalangeal line test, 1427, 1427*f*
Phalanx (phalanges)
  amputation through
    middle, 1718-1719, 1719*f*-1720*f*
    proximal, 1719, 1721*f*-1722*f*
  delta, 1271
  distal
    fracture of, 248-249, 322-323
      in children, 1428-1431, 1431*b*
      classification of, 248.*e*1*t*
      complications of, 249
      epiphyseal, 248-249, 248*f*
      preferred method of treatment for, 1429
      shaft, 248
        in children, 1428-1429
Phalanx (phalanges) *(Continued)*
    tuft, 248
      in children, 1428-1429
  musculoskeletal tumors of, excision of, 1993, 1993*f*
  fracture of, 248-270
    antibiotics in the management of, 270
    articular, 249-251
      at base, 249-251, 251*f*-253*f*
        in children, 1436-1437
        preferred method of treatment for, 1437
      at condyle, 249, 250*f*-251*f*
      at head, 249
        in children, 1431
        preferred method of treatment for, 1431, 1432*f*
      preferred method of treatment of, 251-255, 254*f*-256*f*
      at shaft, 251
    biomechanical testing in, 261.*e*1
    closed reduction and percutaneous pinning in, 257, 258*f*-259*f*
    closed reduction with a cast or splint in, 256-257, 257*f*
    complications of, 266-269
      apex volar angulation as, 266, 266*f*
      entrapment as, 269
      flexor tendon rupture as, 269
      infection as, 269
      lateral angulation as, 266-267, 266*f*
      loss of motion as, 268
      malrotation as, 266
      malunion as, 266, 266.*e*1*b*
        articular, 267
        osteotomy for, 267*b*
      nonunion as, 267-268, 268*f*-269*f*
      proximal interphalangeal joint extensor lag as, 268-269
      shortening as, 267
    displaced
      stable after closed reduction, 261
      unstable after closed reduction, 261-263
        spiral and oblique, 261-262
        transverse, 262-263, 263*f*-265*f*
      unstable and comminuted, 263-264
    external fixation in, 261
    healing time for, 256
    indications for fixation of, 232*b*
    infected, treatment of, 270
    intramedullary fixation in, 259
    at neck, in children, 1431-1434, 1433*f*
      preferred method of treatment for, 1434, 1435*f*
    nonarticular, 255-256
      at neck, 255-256, 256*f*-257*f*
      at shaft, 256
        expected outcomes of, 264-265
        preferred method of treatment of, 261

Phalanx (phalanges) *(Continued)*
nondisplaced and stable, 261
open reduction and internal fixation in, 257
open reduction with pin fixation in, 258-259, 260*f*
plate fixation in, 260-261
screw fixation in, 259-260
at shaft, in children, 1434-1435
preferred method of treatment for, 1435, 1436*f*
surgical approaches in, 257-258, 259*f*-260*f*
of thumb, 270
extraarticular thumb fractures, 270, 270*f*
free transfer of, in absent finger, 1261-1262, 1262*f*
complications of, 1262
in mangling injuries, treatment of, 1499
middle
anatomy of, 154, 156*f*
angulation of, after proximal interphalangeal joint arthroplasty, for fracture-dislocation, 290
fracture of, 249-265
in children, 1431-1437, 1437*b*
musculoskeletal tumors of, excision of, 1993-1994, 1993*f*-1994*f*
proximal
anatomy of, 154, 155*f*
fracture of, 249-265
at base, 265-266
in children, 1431-1437, 1437*b*
unicondylar, operative management of, 250*b*
injuries of, 174
preferred method of, repairs, 174
Phalen test, for nerve compression, 924-927
Phenol burns, treatment of, 1951, 1952*t*
Phenoxybenzamine, for complex regional pain syndrome, 1814, 1814*t*
Phentolamine, for complex regional pain syndrome, 1814
Phenytoin, for complex regional pain syndrome, 1813*t*
Phosphorus burns, white, treatment of, 1951, 1952*t*
Phrenic nerve transfer, for brachial plexus injury, 1177
Physical examination, in rheumatoid arthritis, 905
Physical therapy, after elbow contracture release, 857-858
Physiolysis, for Madelung deformity, 1339-1342
dome osteotomy and, 1342-1344, 1342*f*-1343*f*
fat grafting and, 1339-1342, 1341*f*
Physis(es)
arrest of, 1457
case study for, 1457.*e*1*b*, 1457.*e*1*f*-1457.*e*5*f*
surgical intervention for, 1455, 1457*f*
vascularized bone grafting for, 1613
fibula with, vascularized bone grafting for, 1619-1620
fracture of
in distal phalanges, of children, 1429, 1429*f*-1430*f*
preferred method of treatment for, 1430-1431
in distal radius, of children, 1454, 1455*b*
postoperative expectations and management of, 1455-1457
preferred method of treatment for, 1454-1455, 1456*f*-1460*f*
in middle and proximal phalanges, of children, 1435-1436, 1436*f*
preferred method of treatment for, 1436
Pigmented epidermal lesions, 1965-1966
Pigmented macules, 1965
Pigmented villonodular tenosynovitis, 2012, 2012*b*
Pilomatricoma, 1968, 1969*f*
Pilon fracture, of PIP joint, 282, 283*f*
Pin clusters, external fixator, 539
Pin fixation
of distal radial fracture, 531-532, 535*f*-537*f*
in metacarpophalangeal joint extension contracture, 340
Pin plate, in fragment-specific fixation, 554, 556*f*
Pincer nail, 330, 330*f*, 331*b*
Pinning, extension block, for proximal interphalangeal joint fracture-dislocation, 283
"Pins-and-plaster" technique, for distal radius fractures, 516.*e*1
Pisiform
anatomy of, 419
fracture of, 634-636, 635*b*, 636*f*
in children, 1448, 1449*f*
incidence of, 625*t*
"Pisiform boost splint," for volar instability of the proximal row, 460, 461*f*
Pivot shift test, 830
Plantaris tendon, for tendon grafts, 204-205
Plastic deformation, of forearm, 1460-1461, 1461*f*
operations for, 1464
Plate fixation
of both-bone forearm fractures, 798*b*
circular, for scaphotrapeziotrapezoid fusion, 390
of distal and midshaft ulnar fractures, 796
Plate fixation *(Continued)*
of humeral fractures, 717
of metacarpal shaft fractures, 240-241, 237.*e*1*t*
of Monteggia fractures, 778, 779*f*
of nonunion or malunion of radius or ulna, 803*b*
of proximal and middle phalangeal fracture, 260-261
for proximal interphalangeal joint arthrodesis, 350
of radial shaft, 795*b*
for scaphoid fractures, 597
of ulnar fractures, 778-779, 779*f*, 780*b*, 784.*e*22*b*, 784.*e*22*f*
for wrist arthrodesis, critical points in, 400*b*
Plating systems, locked, 796
Platysma motor branch transfer, for brachial plexus injury, 1177
Poikilothermia, 1766
Poland syndrome, syndactyly in, 1231, 1231*f*
Pollicization, 1295-1299, 1295.*e*1*b*, 1295.*e*1*f*-1295.*e*3*f*
complications of, 1303*t*
of index finger, and removal of hypoplastic triphalangeal thumb, 1320, 1320*f*
of index finger stump, 1699-1703, 1702*f*-1704*f*, 1705*b*
of long finger stump, 1699-1703, 1702*f*-1704*f*
pitfalls of, 1303*t*
procedure of, 1295-1299, 1295*b*, 1296*f*-1301*f*
results of, 1301-1303, 1302*f*
Polydactyly, 1232-1236
central, 1234-1236, 1237*b*
epidemiologic findings, 1234, 1234*f*-1235*f*
treatment of, 1235-1236, 1235*f*-1236*f*
ulnar, 1232-1234, 1232*f*-1233*f*, 1234*b*
classification and treatment of, 1233, 1233*f*
epidemiologic findings, 1232
surgical technique for, 1233-1234, 1233*f*
Polymethyl methacrylate beads, antibiotic-impregnated, 1500, 1504*f*
Polymorphonuclear neutrophils (PMNs), in mangling injuries, 1488, 1488*f*
Polytrauma, distal humeral fractures in, management of, 707
Porokeratosis, 1970, 1971*f*
Poroma, eccrine, 1964
Portal sequence, in procedure, for Dupuytren disease, 146
Portals, for arthroscopy of wrist, 653-656, 653.*e*1*t*
1-2, 654
3-4, 653-654, 654*f*-656*f*, 653.*e*1*t*
4-5, 653-654, 653.*e*1*t*

Portals, for arthroscopy of wrist *(Continued)*
6-R and 6-U, 654, 654*f*, 653.*e*1*t*
accessory thumb carpometacarpal, 657-658
distal radioulnar, 657-658, 653.*e*1*t*
midcarpal, 656-657, 653.*e*1*t*
radiocarpal, 653-656, 654*f*-656*f*
scaphotrapeziotrapezoidal, 657
trapeziometacarpal, 657, 658*f*
volar, 655-656, 653.*e*1*t*
Portuguese man o' war, venomous, 1792*f*
Position of function, 1930-1931
Position of safety, 1930-1931, 1931*f*
Positioning
for complex traumatic elbow dislocation, 824-825
in elbow arthroscopy, 886, 888*f*
Posterior central portal, in elbow arthroscopy, 890
Posterior compartment portals, in elbow arthroscopy, 890-891, 890*f*
Posterior dislocation, of elbow, associated with fracture of olecranon process, 784.*e*11*b*, 784.*e*11*f*-784.*e*12*f*
Posterior drawer test, in midcarpal instability, 461
Posterior interosseous artery flap, reversed, 1558-1561, 1560*f*
Posterior Monteggia fracture
metaphyseal, 784.*e*23*b*, 784.*e*23*f*-784.*e*24*f*
plate loosening after operative treatment of, 784.*e*28*b*, 784.*e*28*f*-784.*e*29*f*
type A, 784.*e*1*b*, 784.*e*2*f*-784.*e*3*f*
ulnohumeral instability after, 784.*e*30*b*, 784.*e*30*f*
Posterior Monteggia lesion, 817, 817*f*
Posterior olecranon fracture-dislocation, 784.*e*4*b*, 784.*e*4*f*-784.*e*5*f*, 784.*e*6*b*, 784.*e*7*f*-784.*e*8*f*, 784.*e*15*b*, 784.*e*15*f*-784.*e*17*f*
failed operative fixation of, 784.*e*25*b*, 784.*e*25*f*-784.*e*27*f*
Posteroanterior (palm down) projection, carpal injury and, 428, 428*f*-429*f*
Posterolateral compartment portals, in elbow arthroscopy, 891
Posterolateral portal, in elbow arthroscopy
distal, 891
proximal, 890
Posterolateral rotatory drawer test, 830
Posterolateral rotatory instability (PLRI), 830
Posteromedial varus rotational instability pattern, 784.*e*9*b*, 784.*e*9*f*-784.*e*10*f*
Postoperative swelling, intravenous dexamethasone for, 857
Posttraumatic arthritis
of elbow, 827
preoperative assessment of, 906
Posttraumatic arthritis *(Continued)*
preoperative planning for, 906
total elbow arthroplasty for, 906, 907*f*
Posttraumatic neuralgia, nerve injury and, 1010.*e*4-1010.*e*5
Postures
abnormal, 923-924, 923*f*
dysfunctional, 1828-1829, 1830*f*-1831*f*
Potassium iodide, for sporotrichosis, 83
Pox, farm yard, 123-124, 124*f*
Prazosin, for complex regional pain syndrome, 1814, 1814*t*
Prednisone
for chronic bacterial infections, 67
in Hansen disease
for lepra reaction, 111*t*
for Lucio reaction, 111-112
for pyoderma gangrenosum, 77
Pregabalin (Lyrica), 969
Pregnancy
de Quervain disease of, 1917
regional anesthesia for, 2-3
Prehension, free muscle transfer for, single-stage, 1185, 1185*f*
Preiser disease, 648-649
Pressure therapy, postburn, 1953, 1954*f*
Pressure thresholds, cutaneous, in compression neuropathies, 928
Prestyloid recess (PSR), 659*f*
Primary arterial coaptation, 1482
Procaine, characteristics of, 4*t*
Profundus tendon, superficialis transfer to, in spasticity, 1104-1105, 1106*f*, 1107*b*
Progressive macrodactyly, 1276-1277, 1284*f*
Progressive recontracture, of Dupuytren disease, 133-134, 134*t*
Pronator, insertion of, release of, 1095
Pronator syndrome, 936-937
Pronator teres
rerouting of, for spasticity, 1095, 1096*b*
transfer of, to extensor carpi radialis brevis, for spasticity, 1101, 1101*f*
Prone positioning, in elbow arthroscopy, 886
Proprioception, wrist, reeducation of, 439
Prosthesis
customized, for mangled hand, 1492, 1493*f*
hand, after amputation, 1738-1745, 1743*f*, 1743*t*-1744*t*, 1745*f*, 1746*b*
types of, 1740-1745, 1740*f*
infections of, 50-51
longevity of, in total elbow arthroplasty, 914
passive, 1758
Prosthetic control, improved, 1760-1761, 1760*f*
Prosthetic designs, 1758-1759, 1759*f*
improved, 1761
Prosthetic rehabilitation
current, 1756-1758
frontiers in, 1759-1761
Prosthetic replacement, of elbow, 905
Prothionamide, dosage of, 101*t*
Prototheca wickerhamii, 116
Protothecosis, 116
etiology, diagnosis, and treatment of, 63*t*
Protozoal infections, chronic, 116-118
etiology, diagnosis, and treatment of, 63*t*
Protriptyline, for complex regional pain syndrome, 1812*t*
Provocative tests
for compression neuropathies, 924-927, 926*t*
for thoracic outlet syndrome, 966-967
Proximal interphalangeal (PIP) joint, 42, 42*f*, 278-296, 1840
amputation through, 1719
anatomy of, 338.*e*1-338.*e*3, 338.*e*2*f*
pertinent, 278, 279*f*, 346
arthrodesis of, 349-352
complications of, 352
critical points in, 351*b*
expected outcomes on, 352
indications and contraindications for, 349
postoperative management and expectations on, 350-352
preferred method of treatment for, 350, 351*f*
preoperative planning for, 349
technique for, 349-350, 350*f*
arthroplasty of, 353-358
complications of, 358, 358*f*
critical points in, 356*b*
expected outcomes on, 356-357
indications and contraindications for, 353
postoperative management and expectations on, 356-358
preferred method of treatment for, 354-356, 354*f*-356*f*
preoperative planning of, 353
technique for, 353-354, 354*f*
arthroscopy of, 694.*e*1
biomechanics of, 346
central slip deficiency of, in tetraplegic patient, 1143
intrinsic tenodesis for, 1143, 1143*f*
central slip of, anatomic integrity of, 155
contractures of
extension, release of, 341-343, 343*f*
flexion, release of, 341
expectations and outcomes in, 341.*e*2
preferred approach for, 341, 342*f*
late posttraumatic
interosseous, 343.*e*1-343.*e*2, 343.*e*2*f*
intrinsic, 343.*e*1

Proximal interphalangeal (PIP) joint *(Continued)*
nonoperative treatment of, 340.*e*1-340.*e*2
treatment for, Dupuytren disease and
needling, 148, 148*f*
severe, 143, 144*f*
deformity, in systemic lupus erythematosus, 1838
dislocations of, 279-293
acute dorsal, 279-280
lateral, 280
posttraumatic fibrosis and contracture in, 295-296, 296*b*, 296*f*
volar, 280-281
treatment of, 280-281
Elson test in, 156
extensor mechanism in, 156*f*
fracture-dislocations of, 281-282, 281*f*
chronic, 293-294
stable, 281-282
tenuously stable, 282
treatment of, 281*f*
preferred method of, 284-294, 284*f*
unstable, 282, 282*f*
treatment of, 282-293
volar, 280
ganglion of, 2007-2008, 2008*f*-2009*f*
hyperextension of, as complication of flexor tendon grafting, 225
injury to, 169-174, 169.*e*1*b*, 169.*e*1*f*-169.*e*2*f*
clinical evaluation of, 279
open, 170
preferred method of treatment of, 170-171
preoperative evaluation of, 278-279
radiographic evaluation of, 278-279, 279*f*
in intrinsic muscle spasticity, 1114
little finger, of Dupuytren disease, 138
rheumatoid arthritis of, 1878-1879, 1879*f*
swan neck deformity in, 1879-1890, 1880*t*
type I, 1879-1883, 1881*f*
type III, 1883-1885
type IV, 1886-1890
synovectomy for, 1878-1879
stiffness of. *see also* Stiffness, of finger and hand
articular surface of, 338-339
examination of, 339
subluxations of, 294-295, 295*f*
Proximal row, wrist
dorsal instability of, 461-462
volar instability of, 459-461
Proximal tendon juncture, 208, 210*f*
Pseudoarthrosis, congenital, of ulna, 1354-1357, 1357*b*
Pseudogout, 57-58
tendinopathy in, 1906
Pseudosarcomatous fasciitis, 2014
Psoriatic arthritis, 1834-1836
digital deformity in, 1836, 1836*f*
thumb deformity in, 1836
wrist deformity in, 1836
Psychological impairment, in tetraplegia, 1126-1127
Psychological problems, mimicking complex regional pain syndrome, 1802
Pterygium, 329
Pulley system
design of, for opponensplasty, 1027
disruption of, as complication of flexor tendon grafting, 224
of flexor tendon, 186, 186*f*
reconstruction of, 221-223, 223*b*
indications of, 221
postoperative care of, 223
preferred technique of, 222-223, 223*f*
using a flexor digitorum superficialis tendon, 222, 222*f*
using a free tendon graft, 221-222, 222*f*
using artificial materials, 222
using the extensor retinaculum, 222
using the volar plate, 222
in toe preparation, 1666
Pull-out sutures, for tendon graft, 207-208, 208*f*-209*f*
Pulmonary function tests, in brachial plexus injury, 1153
Pulp flaps, transfer of, from toes to fingers, 1659-1660
Pulp loss, fingertip amputation with, 1709-1711
Pulsed electromagnetic field (PEMF) therapy, for scaphoid fractures, 607
Pulvertaft end-weave technique, modified, for tendon graft, 210-211, 210*f*
Punch biopsy, 1961, 1963*f*
Pustular dermatitis, contagious, 123-124, 124*f*
Putti sign, 1408
Pyarthrosis, antibiotic recommendations for, 21*t*
Pyoderma gangrenosum, 57-58, 75-77
clinical findings on, 76-77, 76*f*
diagnosis of, 77
etiology and epidemiology of, 75-76
treatment of, 77
Pyogenic flexor tenosynovitis, 28-32, 32*b*
clinical presentation and preoperative evaluation of, 28-29
pertinent anatomy in, 29
treatment for, 29-31
operative, 30-31, 30*f*
preferred methods of, 31, 31*f*
Pyogenic granuloma, 57-58, 58*f*, 1970, 1971*f*
of nails, 332, 332*f*
Pyrazinamide (PZA)
dosage of, 101*t*
for tuberculosis, 100
Pyridoxine, for tuberculosis, 100, 103
Pyrocarbon implant
for metacarpophalangeal joint arthroplasty, 358
for proximal interphalangeal joint arthroplasty, 357

Q

Quadriga syndrome, as complication of flexor tendon grafting, 224-225
Quantitative sudomotor axon reflex test (QSART), 1802-1803

R

Radial artery
anatomy of, 787, 1588-1589
in forearm flap, 1555-1558, 1556*f*-1559*f*, 1559*b*
puncture, 2036
Radial bow, assessment of, 787, 788*f*
Radial bursal infections, 32-34
clinical presentation and preoperative evaluation of, 33
pertinent anatomy in, 32-33
postoperative management of, 34
treatment for
open, 33-34
preferred method of, 34
Radial collateral ligament
anatomy of, 739, 740*f*
injury of, 308-310
anatomy in, 308-309
in metacarpophalangeal joint dislocation, 300-301
postoperative management and expectations in, 310
preoperative evaluation of, 309
treatment of, 309
preferred method of, 309-310, 310*b*, 310*f*
types of operations for, 309-310
Radial deficiency, syndromes associated with, 1289, 1290*t*
Radial forearm flap, 1588-1591, 1589*f*, 1591*b*
composite, for reconstruction of amputated thumb, 1697-1699, 1700*f*, 1701*b*, 1699.*e*1*f*
for mangling injuries, 1513, 1514*f*-1515*f*
operative technique for, 1589-1591, 1590*f*, 1592*f*
Radial head excision
in hereditary multiple exostoses of forearm, 1360
in proximal radioulnar synostosis, 1353

Radial longitudinal deficiency, 1328-1334, 1334*b*
  Bayne classification of, 1328, 1329*t*
  pertinent anatomy in, 1328
  preoperative evaluation of, 1328, 1330*f*
  surgical treatment of, 1329-1334, 1331*f*
    expected outcomes of, 1334, 1335*f*
    postoperative management and expectations after, 1334
    preferred method of, 1333-1334, 1334*f*
    preliminary soft tissue distraction in, 1329-1330, 1331*f*-1332*f*
    ulnar lengthening in, 1329, 1333, 1333*f*
  syndromes associated with, 1328, 1329*t*
Radial lunate ligament, 658-659, 658*f*
Radial midcarpal portal, 660*f*
Radial nerve
  anatomy of, 786-787, 788*f*, 950-951, 951*f*
  compression of, 947-949. *see also* Radial tunnel syndrome
    postoperative care of, 949
    proximal, 953
      operative technique of, 953
      postoperative care of, 953
    superficial, 947-949, 948*f*
  in cross-finger flap, for thumb reconstruction, 1682-1684, 1683*f*, 1684*b*, 1684.*e1f*
  excessive deviation of, after tendon transfer, 1069-1070
  innervation of, 1064*t*
  intermediate zone injuries of, repair of, outcomes of, 1004*t*
  repair of
    effects of delay in, 1005*t*
    recovery after, 1005*t*
    results of, 1003-1005
      grading of, 1003*t*
  restoration of, 1076
    outcome of, 1076
    technique of, 1076
  sensory branch of
    anatomy of, 948, 948*f*
    decompression of, 949, 949*f*
    release of, 950*b*
  superficial, in complex regional pain syndrome, surgical management of, 1821-1822, 1821*f*
Radial nerve block
  at elbow, 8
  at wrist, 9, 9*f*
Radial nerve palsy, 1064-1076, 1064*f*
  associated with fractures of humerus, 1074-1076
    early, 1074
    if no return at longer waiting period, 1075, 1075*f*
    nerve exploration in, at 6 to 8 weeks, 1074-1075, 1075*f*
    preferred method of treatment of, 1075
Radial nerve palsy *(Continued)*
  associated with Holstein-Lewis spiral fracture, 1074
  nerve transfer in, 1075-1076
  nonoperative treatment of, 1064-1065, 1065*f*
  operative treatment of, 1065-1074
    tendon transfers in, 1066-1074, 1067*t*, 1070*b*
      flexor carpi radialis, 1071, 1071*b*, 1071*f*
      flexor carpi ulnaris, 1067-1070, 1067*f*-1069*f*
        postoperative management of, 1069
        potential problems of, 1069-1070
      historical review of, 1066, 1066*f*, 1066*t*
      nerve repair and graft *versus*, 1065
      outcome of, 1072
      preferred method of, 1072-1074, 1073*f*-1074*f*
      superficialis in, 1070-1071, 1071*b*
        postoperative management of, 1071
      timing of, 1065-1066
  patient requirements for, 1064
  secondary, 1074
Radial osteotomy
  articular, 580-581, 582*f*, 581.*e1b*, 581.*e1f*-581.*e6f*
  closing wedge, for Kienbock disease, 646, 647*f*
  dorsal approach to, 577-578, 579*f*
  extraarticular, 577, 578*b*, 578*f*
  malunited Smith, 580, 580.*e4f*
  ulnar-shortening, 580
  volar approach to, 578-580, 581*f*, 580.*e1b*, 580.*e1f*-580.*e2f*
  Watson's trapezoidal, 580.*e3*, 580.*e3f*
  with and without ulnar osteotomy, 1378-1380, 1380*b*
    complications of, 1380
    contraindications to, 1379
    indications for, 1378-1379
    postoperative management and expectation after, 1379-1380
    preferred method of, 1379
    preoperative planning in, 1379
    technique of, 1379, 1380*f*
Radial styloidectomy
  for scaphoid nonunion advanced collapse, 622
  for scapholunate dissociation, 449
Radial translation, 561-563
Radial tunnel syndrome, 949-952
  nerve anatomy in, 950-951, 951*f*
  operative techniques for, 951-952
    anterior (modified Henry) approach to, 952
    posterior (Henry or Thompson) approach to, 951-952, 951*f*
Radial tunnel syndrome *(Continued)*
    postoperative care after, 952
    preferred method of, 952, 952*f*
    transmuscular brachioradialis-splitting approach to, 951, 951*f*
  release of, 953*b*
Radial-to-axillary transfer, 1404, 1407*f*
Radiocapitellar joint, 813
  capsuloligamentous components of, 813
  musculotendinous components of, 813
Radiocarpal joint
  fracture-dislocation of, management of, 572-573, 573*f*, 573.*e1f*-573.*e3f*, 573.*e2b*
  instability of, nondissociative, 458-459, 458*f*
  osseous anatomy of, 419-420
  rheumatoid arthritis of, 1858-1863
    reconstruction of, 1863-1866
      partial, 1864-1866, 1864*f*
    synovectomy for, 1858-1859, 1859*f*
Radiocarpal ligaments
  dorsal, 421-422
  palmar, 420, 421*f*
Radiography
  of capitate fracture, 630
  in complex regional pain syndrome, 1805
  of distal humeral fracture, 697-698, 698*f*-699*f*, 906-907
  of distal radial fracture, 520-523, 521*f*-523*f*, 520.*e1f*
  of distal radioulnar joint, 484-485, 485*f*
  for free flaps, 1577
  of Galeazzi-type fracture-dislocations, 792, 792*f*
  of hamate fracture, hook of, 631-632, 632*f*
  of Kienbock disease, 641, 641*f*
  of lunate fracture, 637-638
  of mangled extremity, 1490, 1491*f*
  plain, for musculoskeletal tumors, 1990
  of proximal interphalangeal joint injury, 278-279, 279*f*
  of radial head fractures, 734-736, 735*f*
  of radioulnar synostosis, 803-804, 804*f*
  of trapezium fracture, 628
  of triquetrum fracture, 626
Radiological examination
  of carpal injury, 428-430
    additional views, 429-430, 429*f*
    distraction views, 431
    routine views, 428-429, 428*f*-429*f*
    stress views, 431, 432*f*
  of lunotriquetral dissociation, 452-454, 452*f*-453*f*
  of midcarpal instability, 460
  of scapholunate dissociation, 436, 437*f*
Radiolunate angle, measurement of, in wrist instability, 430

Radiolunate fusion, 377-380
author's preferred method of treatment for, 378-380, 381*f*-382*f*
critical points in, 381*b*
indications for, 377, 379*f*
net analysis of literature in, 380
pitfalls of, 380
postoperative management for, 380
technique for, 377, 379*f*-380*f*
Radioscaphocapitate (RSC) ligament, 589-590, 589*f*
Radioscaphoid-lunate fusion, and distal scaphoidectomy, 448-449, 449*f*
Radioscapholunate fusion, 385-386
complications of, 375*f*, 386
critical points in, 388*b*
indications and contraindications in, 385, 385*f*
patients and, 386, 388*f*
postoperative care for, 386
preferred method of treatment for, 385-386, 386*f*-387*f*
Radioulnar inclination, kinematics in, 423*f*, 424
Radioulnar joint
distal, 479-515, 480*f*
anatomy of, 479-483, 480*f*-483*f*
arthritis of, 503-507
distal ulnar resection (Darrach procedure) for, 505-506, 506*f*
hemiresection-interposition arthroplasty for, 503-504, 504*f*
Sauvé-Kapandji procedure for, 504-505, 505*f*
stabilization of resected distal ulna in, 506-507, 507*f*
arthrography of, 486
arthroscopy of, 487
biomechanics of, 479-483
computed tomography of, 486, 486*f*
contracture of, 510-511
after radial fracture, 582-584
operative technique for, 510-511
extensor carpi ulnaris in, tenosynovitis and subluxation of, 511-512, 511*f*
operative technique for, 511-512, 512*f*
outcomes of, 512
failed ulnar resection in, 507-508, 507*f*
fracture of, injuries associated with
classification of, 527, 528*f*-529*f*
treatment of, 563, 564*f*-565*f*
instability of
acute, 491-493, 491*f*-492*f*
evaluation of, 492
simple dislocations in, 492
triangular fibrocartilage complex repair (class 1B injury) in, 492-493
ulnar styloid fractures in, 493, 493*f*
Radioulnar joint *(Continued)*
chronic, 494-498, 495*f*
author's preferred treatment for, 496-498, 497*f*
evaluation of, 494
osteoplasty of sigmoid notch and ulna in, 498, 498*f*
outcomes in, 498
treatment for, 494-498, 496*f*
magnetic resonance imaging of, 486-487, 487*f*
physical examination for, 483-484, 484*f*
radiography of, 484-485, 485*f*
radius and forearm malunions in, 498-500, 499*f*
residual disability of, procedures for, 581-582, 583*f*, 584*t*
scintigraphy of, 487
ulnar head implant arthroplasty in, 508-510
operative technique for, 509-510, 509*f*
outcomes of, 510, 510*f*
ulnar impaction syndrome in, 500-503, 500*f*
author's preferred treatment for, 502, 502*f*
evaluation of, 500-501
treatment of, 501-503
partial distal ulnar resection (wafer procedure), 497*f*, 501, 501*f*
ulnar-shortening osteotomy, diaphyseal and metaphyseal, 501-503
ultrasonography of, 485
portals of, for arthroscopy of wrist, 657-658, 653.*e*1*t*
rheumatoid arthritis of, 1858-1863
distal ulnar excision and reconstruction for, 1860-1863
complications of, 1862-1863
synovectomy for, 1858-1859, 1859*f*
Radioulnar ligaments
anatomy of, 481, 481*f*
distal, reconstruction of, 496-498, 497*f*
role of, 482
Radioulnar synostosis, 803-804, 803*f*-804*f*, 804*t*
postoperative management and expectations of, 804
posttraumatic, 1457
preferred method of, 804, 805*f*
proximal, 1349-1354, 1354*b*
classification of, 1351*t*
pertinent anatomy in, 1350
preoperative evaluation of, 1349-1350, 1350*f*-1351*f*
surgical treatment of, 1351-1353
derotation osteotomy in, 1351-1352, 1352*f*-1353*f*
expected outcomes in, 1354
Radioulnar synostosis *(Continued)*
postoperative management and expectations after, 1354
preferred method of, 1353
radial head excision in, 1353
resection in, 1351
Radius
congenital pseudoarthrosis of, 1354-1357, 1357*b*
deformity of, carpal misalignment secondary to, 463-464
distal
anatomy of, 516-520, 518*f*-519*f*
fracture of, 516-587, 671-672
articular, management of, 568-573
bending, 527, 567-568, 568.*e*1*b*, 568.*e*1*f*-568.*e*13*f*, 568.*e*3*b*, 568.*e*7*b*, 568.*e*9*b*, 568.*e*11*b*
carpal ligament injuries associated with, 575
in children, 1448-1455, 1458*b*
preferred method of treatment for, 1448
classifications of, 523-527
AO, 524, 526*f*
associated radioulnar joint injuries in, 527, 528*f*-529*f*
columnar, 524, 527*f*
Fernandez, 524-527, 528*f*-529*f*
fragment-specific, 524, 526*f*
Frykman, 524.*e*1, 524.*e*1*f*
Mayo Clinic, 524.*e*1, 524.*e*2*f*
Melone, 524.*e*1, 524.*e*2*f*
stability in, 527-530
complications of, 575-584
chronic regional pain syndrome as, 576
malunion as, 576-582, 578*b*, 579*f*-580*f*
nonunion as, 576
radioulnar joint contracture as, 582-584
tendon rupture as, 576
eponyms for, 527
evaluation of, 516-523
pertinent anatomy in, 516-520, 518*f*-520*f*
radiographic pathoanatomy in, 520-523, 521*f*-523*f*, 520.*e*1*f*
injuries associated with, 573-575
median nerve injury associated with, 575
metaphyseal, bicortical, in children, 1448-1453, 1450*f*-1452*f*, 1454*f*
preferred method of treatment for, 1453-1454
nondisplaced, treatment of, 567
open, 573-575
operative technique for, 672-676, 672*f*-676*f*
physeal, in children, 1454, 1455*b*

Radius *(Continued)*
postoperative expectations and management of, 1455-1457
preferred method of treatment for, 1454-1455, 1456*f*-1460*f*
radioulnar joint injury associated with, treatment of, 563, 564*f*-565*f*
recognition of patterns in, 523-530, 524*f*-525*f*
scaphoid fracture associated with, 603-604
treatment of, 530-564
arthroscopic reduction and percutaneous fixation in, 541-546, 543*f*
augmented, 535-539, 539*b*, 541*f*-542*f*, 535.*e*1*f*
bone graft substitutes in, 543, 544*t*, 543.*e*1*f*-543.*e*5*f*, 543.*e*2*b*
case-based approach to, 566-567
closed reduction in, 530-531, 531*f*-534*f*
concomitant soft tissue injuries and, 542
in elderly, 566
evidence-based decision making in, 564-573, 565*t*
external fixation in, 532-539, 538*f*
iliac bone graft harvest in, 543-546
open reduction and internal fixation in, 547-559, 547*f*-550*f*
outcomes and expectations in, 575
percutaneous pin fixation in, 531-532, 535*f*-537*f*
rationale for, 516, 517*t*
technique for, 533-535, 539*f*-541*f*
ulnar column instability in, 559-564
preferred method of treatment of, 563-564
malunion of, 498-500, 499*f*
fracture of
in children
complete, surgical treatment of, 1464-1466, 1465*f*-1467*f*
preferred method of treatment for, 1466-1468
single-bone, 1464-1466
in mangling injuries, treatment of, 1500
grafts of, vascular anatomy of, 617
head of
anatomy of, 737-740, 739*f*-740*f*, 772
biomechanics of, 737-740, 739*f*-740*f*
Radius *(Continued)*
congenital dislocation of, 1347-1349, 1348*f*, 1350*b*
preoperative evaluation of, 1347-1348, 1348*f*
surgical treatment of, 1348-1349
expected outcomes for, 1349
preferred method of, 1349
resection in, 1348, 1349*f*
versus traumatic dislocation, 1347*t*
fracture of, 734-769
arthroscopic fixation of, 902
classification of, 736, 736*t*
clinical assessment of, 734, 735*f*
complication of, 761-766
avascular necrosis as, 761, 761*f*
axial instability as, 764-766, 765*f*-766*f*
heterotopic bone as, 764, 764*f*
malunion as, 762-763, 762*f*
nerve injury as, 761
nonunion as, 762
osteoarthritis as, 763, 763*f*
stiffness as, 764, 764*f*
valgus instability as, 764
displaced, 736
elbow dislocation with, complex traumatic, 815, 815*f*
nonoperative management of, 819
operative treatment of, 819, 820*f*
treatment of, 819
evaluation of, 734-740
historical review of, 740-741
imaging of, 734-736, 735*f*-736*f*
injuries associated with, 736-737, 737*f*-738*f*
internal fixation in, "safe zone" for, 738-739, 739*f*
postoperative management and expectations of, 756-766
protocol in, 760-761, 760*f*
treatment of, 780
arthroplasty of, 745, 752-754, 755*f*-756*f*, 756*b*, 759-760
closure in, 756, 757*f*
delayed excision in, 743-744, 744*f*, 759
excision of, 744-745, 750-752, 753*f*, 754*b*
fragment excision in, 743, 746, 748*b*, 749*f*, 758-759
initial, 741, 742*f*
nonoperative, 741-742, 742*f*, 756-758
open reduction with internal fixation in, 743, 746-750, 750*f*-752*f*, 751*b*, 758
operative, 743-756
options in, 741-756, 742*f*
preferred method of, 745-756
primary resection of, 759
Radius *(Continued)*
surgical approach to, 745-746, 746*f*-748*f*
removal of hardware from, after both-bone forearm fractures, 798-799
restoration of length of, with radioulnar joint reduction, for longitudinal forearm instability, 807
shaft of
fracture of, 786-795
bone grafting of, 792
complications in, 795
evaluation of, 786
Galeazzi, fixation of, 792-793, 792*f*
intramedullary rods and external fixation for, 793, 793*f*-794*f*, 795*b*
pertinent anatomy in, 786-787, 788*f*
postoperative management and expectations in, 794-795
preferred method of treatment of, 793-794, 795*f*
preoperative considerations for, 786
stabilization of, 791-792
surgical approaches to, 789-795
anterior, 789-790, 789*f*-790*f*
posterior, 790-791, 790*f*-791*f*
nonunion and malunion of, 799-803
styloid, fracture of, shear, 569-570, 570*f*-571*f*
Radius pedicle grafts, 1629-1634
dorsal, 1629-1632
Random-pattern flap(s), 1539
distant, 1563-1564
for mangling injuries, 1511, 1511*f*
regional, 1550-1552
cross-finger, 1550-1552, 1551*f*
reversed, 1552
division of, 1552
transposition, 1542
Ray(s), transposition of, in absent finger reconstruction, 1245*f*, 1263-1270
Ray amputation, 1719-1730, 1735*b*
of index finger, 1721-1723, 1723*f*
mangling injuries and, 1493
preferred method of treatment of, 1722-1723, 1724*f*
of long finger, 1723, 1725*f*
preferred method of treatment of, 1728-1730, 1729*f*-1731*f*
with transposition, 1726-1730, 1728*f*
preferred method of treatment, 1728-1730, 1729*f*-1731*f*
without transposition, 1730-1733
preferred method of treatment, 1725-1726, 1727*f*-1728*f*
of ring finger, 1730-1733
preferred method of treatment of, 1731-1733, 1732*f*, 1734*f*

Ray amputation *(Continued)*
with transposition of fifth metacarpal, 1732-1733, 1733*f*-1734*f*
without transposition, 1730-1733
of small finger, 1734-1735
Raynaud disease, 2052
Recipient site(s), 1540-1541
for toe transfer, preparation of, 1665-1666
for vascularized bone graft, 1614
Reconstructive wrist, in rheumatoid arthritis, 376, 378*f*
Recontracture, of Dupuytren disease, 133-134, 134*t*
Rectus abdominis muscle flap, 1604
Recurrence assessment, of Dupuytren disease, 133-134, 134*t*
Redisplacement, after volar plate arthroplasty, 290
Reduction and fixation, arthroscopic, for distal radial fracture, 541-546, 543*f*
Reduction-association of the scapholunate (RASL) procedure, for scapholunate dissociation, 446-447, 446*f*
Reflex sympathetic dystrophy, 1012
Regional anesthesia, 1-14
Regional fasciectomy, for Dupuytren disease, 141-142, 142*f*
Regional flap(s), 1540, 1550-1558
axial-pattern, 1552-1554
cutaneous, 1554
fasciocutaneous, 1555, 1555*f*
fillet, 1552-1554, 1554*f*
latissimus dorsi, 1561-1562, 1562*f*, 1563*b*
musculocutaneous, 1561-1562
neurovascular island, 1552-1554, 1553*f*
radial artery forearm, 1555-1558, 1556*f*-1559*f*, 1559*b*
reversed posterior interosseous artery, 1558-1561, 1560*f*
ulnar artery forearm, 1558
random-pattern, 1550-1552
cross-finger, 1550-1552, 1551*f*
reversed, 1552
division of, 1552
for thumb reconstruction, with questionable remaining length, 1694-1696
Rehabilitation
after burns, 1953-1954, 1953*f*-1954*f*
electrical, 1948
after mangling injuries, 1519-1521, 1521*b*, 1521*f*
after metacarpophalangeal joint arthroplasty, 1876-1877, 1876*f*-1877*f*
complications of, 1877-1878
after proximal interphalangeal joint arthroplasty, for swan neck deformity, in rheumatoid arthritis, 1889
after toe transfer
donor site, 1671
motor, 1670-1671
sensory, 1671
for Hansen disease, 115
postoperative, in tetraplegic patient, 1138-1140
Re-Motion implant, 406, 407*f*
surgical technique for, 410-413, 411*f*-414*f*
Reperfusion, 1482
Replantation, 1476-1485
contraindications for, 1476-1477
of digit, 1477, 1484*b*
expected outcomes for, 1483
future directions for, 1483-1484
general considerations in, 1476-1478
emergency management in, 1476
epidemiology in, 1476
patient selection in, 1476-1478
indication for, 1477*f*
intraoperative technique for, 1478-1482
amputated part, preparation of, 1478-1479, 1479*f*
arterial repairs, 1482
digital nerve repairs, 1481
digital vein repairs, 1481
extensor tendon repairs, 1481
flexor tendon repairs, 1481
osseous fixation in, 1481
preparation of the hand, 1479, 1479*f*
reperfusion in, 1482
replantation, 1479-1481
skin closure in, 1482
locating distal veins for, 1481*b*
major, 1480-1481, 1480*f*, 1484*b*
postoperative protocol for, 1482-1483
preparing for, technical considerations in, 1478
Resection
primary, of radial head, outcome of, 759
of pseudoarthrosis of ulna, 1356
of radial head, for congenital dislocation, 1348, 1349*f*
of radial head, outcome of, 759
of synostosis, radioulnar, 1351
Resection arthroplasty, for carpometacarpal joint osteoarthritis
expected outcomes on, 366-368, 367*t*
as operative technique, 363-364, 363*f*
as treatment, 361
Reserpine, for complex regional pain syndrome, 1815*t*
Resisted finger extension test, in scapholunate dissociation, 436
Resisted isometric elbow flexion, 740
Resource materials, for Hansen disease, 115-116
Resting extension splint, for elbow contracture, 857
Restorative wrist, in rheumatoid arthritis, 376, 378*f*
Reticular ligament, reconstruction of, for swan neck deformity, in rheumatoid arthritis, 1883
Retinacular ligament, oblique, 156-157
spiral, reconstruction, technique of, 168, 168*f*
Retroclavicular brachial plexus, 1146
injury to, 1150
Revascularization, of mangled extremity, 1505, 1506*f*-1507*f*
Reversal reaction (leprae type 1), in Hansen disease, 110, 111*t*
Reversed cross-finger flap, 1552
Reversed dart-thrower's motion, 424
Rhabdomyosarcoma, 2020
Rheumatoid arthritis, 1842-1857
arthrodesis, of wrist, complications of, 1867
crossed intrinsic transfer for, 1869-1870
extensor tendon relocation for, 1870, 1870*f*
of fingers, 1876-1877
boutonnière deformity in, 1890-1894
stage I, 1891-1892
extensor tenotomy for, 1891-1892, 1891*f*
stage II, 1892-1893, 1892*f*
treatment options for, 1891*t*
hand deformities, 1835*f*
intrinsic release for, 1869, 1869*f*
medical considerations of, 1833
of metacarpophalangeal joints, 1867-1878
arthroplasty for, 1870-1878
contraindications to, 1871-1872, 1871*f*
extensor tendon centralization in, 1875-1876, 1875*f*
flexible implant, 1872-1875, 1872*f*-1875*f*
indications for, 1871, 1871*f*
options in, 1872
outcome of, 1878
rehabilitation after, 1876-1877, 1876*f*-1877*f*
technical points in, 1876
etiology of, 1867
surgical treatment of
contraindications to, 1868
indications for, 1868, 1868*f*
nodulosis in, 1841-1842
patients with, intramedullary pin fusion for, 401-404, 402*f*-403*f*
physical examination of, 905
preoperative evaluation of, 905-906
preoperative planning of, 905-906
of proximal interphalangeal joint, swan neck deformity in, 1879-1890, 1880*t*

Rheumatoid arthritis *(Continued)*
type I, 1879-1883, 1881*f*
type III, 1883-1885
type IV, 1886-1890
arthroplasty for, 1890*b*
contraindications to, 1887, 1887*f*
indications for, 1887
joint fusion for, 1886
outcome of, 1889-1890, 1890*f*
rehabilitation after, 1889
surgical approaches to, 1887-1889, 1888*f*-1889*f*
regional anesthesia for, 3
soft tissue procedures for, 1880*t*
surgery for
considerations in, 1832-1833
staging hand, 1833-1834, 1834*t*, 1835*f*
swan neck deformity in, 1879-1890, 1880*t*
type I, 1879-1883, 1881*f*, 1899*f*
dermadesis, 1882
distal joint fusion for, 1882
flexor tendon tenodesis, 1882-1883, 1882*f*
retinacular ligament reconstruction for, 1883
with screw, 1881
type II, 1883
intrinsic release for, 1883
type III, 1883-1885
joint manipulation for, 1883
lateral band mobilization for, 1884-1885, 1885*f*
skin release, 1883-1884, 1884*f*
type IV, 1886-1890
synovectomy for, 897, 1868, 1878-1879
with soft tissue reconstruction, 1868
postoperative management of, 1870
techniques of, 1868-1870
tendon rupture in, 1849-1851
extensor
diagnosis of, 1849-1850
with metacarpophalangeal joint disease, 1854
multiple-tendon, 1852
treatment of, 1850-1851, 1850*f*
flexor
diagnosis of, 1850
treatment of, 1856-1857, 1856*f*
options for reconstruction in, 1852-1857
in ring and small finger, 1852, 1853*f*
single-tendon, 1851, 1852*f*
tenosynovitis in, 1842-1849, 1842*f*
anatomy of, 1842-1843
associated with proximal interphalangeal joint stiffness, 1885-1886
preferred method of treatment of, 1843-1845, 1843*f*-1844*f*
Rheumatoid arthritis *(Continued)*
in wrist extensors, 1843-1845
complications, 1845
postoperative management, 1845, 1845*f*
in wrist flexors, 1853-1854
preferred method of treatment of, 1845-1848, 1846*b*, 1846*f*-1847*f*
total elbow arthroplasty for, 905-906, 906*f*
variants of, 1834-1841
of wrist, 1857-1867
arthrodesis of
choice of operation for, 1863
complications of, 1867
with metacarpophalangeal joint arthroplasty, 1867-1878
partial fusion in, 1864-1866, 1864*f*
radiographic patterns of, 376-377
tendon transfers in, 1853-1854
natural history of, 1857-1858, 1858*f*
treatment of, 1858-1863
Rhomboid flap, 1543, 1544*f*
Ribs
cervical
anatomic variants of, 961*f*
in thoracic outlet syndrome, 963
osteochondral autograft reconstruction, of proximal pole, in scaphoid nonunion, 621
vascularized bone graft from, 1634
Rifampin
for cutaneous tuberculosis, 92
dosage of, 101*t*
for multibacillary Hansen disease, 109
for paucibacillary Hansen disease, 109
Riordan static tenodesis, in ulnar nerve palsy, 1050
Rolando fractures, of thumb, 273-275, 274*f*-275*f*
preferred method of treatment of, 274-275
Roos classification, of thoracic outlet syndrome, 961
Roos test, for thoracic outlet syndrome, 966-967, 968*f*
Ropivacaine, characteristics of, 4*t*
ROR2 gene, mutation of, 1239-1240
Rose thorn disease, 82-83, 82*f*-83*f*, 83*b*, 84*t*. *see also* Sporotrichosis
Rotary instability, of scaphoid, 418
Rotational flap(s), 1541-1542
dorsal, for thumb reconstruction, with questionable remaining length, 1691-1694
phalangization of, 1691-1694, 1693*f*-1694*f*, 1694.*e*1*f*
Rotational injury
posterolateral
in elbow instability, 740
posterolateral, in elbow dislocation, 814-815
Rotational injury *(Continued)*
varus posteromedial, in elbow dislocation, 817, 818*f*
Rotational instability pattern, posteromedial varus, 784.*e*9*b*, 784.*e*9*f*-784.*e*10*f*
Rotational osteotomy. *see also* Osteotomy
for forearm fracture malunion, 801-803, 802*f*
of humerus, 1089, 1089*f*
for ulnar deficiency, 1335, 1338
Rothmund-Thomson syndrome, radial longitudinal deficiency associated with, 1329*t*
Royle-Thompson opponensplasty, in median nerve palsy, 1030-1031
Russe classification, of scaphoid fractures, 593
Russe technique, Green's modification of, in bone graft, for scaphoid nonunion, 610-611, 610*f*

S

Sad, hostile, anxious, frustrating, and tenacious (SHAFT) syndrome, 1802
Sagittal band(s), 153
of extrinsic extensors, 338.*e*4
injury, anatomy of, 177*f*
lacerations in, 174
reconstruction of, methods of, 178*f*
rupture, closed, 175, 176*f*
preferred method of treatment of, 175
splint, 177*f*
Salter-Harris fracture
classification of, 1427, 1427*f*
type I, 1429
type II, 1428, 1440-1441
type III, 1428, 1430*f*
of thumb, 1439
type IV, 1428
type V, 1428
Salvage, using allografts, of radial head, 765
Salvage technique/procedures
for free flap failure, 1583-1585, 1585*b*
leeches in, 1582*f*, 1583-1584
operating room exploration and, 1583-1584
thrombolytic agents and, 1584-1585
one-bone forearm technique, for longitudinal forearm instability, 808
for scaphoid nonunion advanced collapse, 622-624
Salvage wrist, in rheumatoid arthritis, 377, 378*f*
Sarcoid, tenosynovitis in, 1907
Sarcoma(s), 1959
Ewing's, 2028-2031, 2030*f*
osteogenic, 2027-2028, 2029*f*
soft tissue, 2015-2020, 2017*b*
biopsy of, 2015
clear cell sarcoma as, 2020

Sarcoma(s) *(Continued)*
clinical picture of, 2015, 2016*f*
dermatofibrosarcoma protuberans as, 2018-2019, 2019*f*
epithelioid, 2017
fibrosarcoma as, 2018
leiomyosarcoma as, 2020
liposarcoma as, 2017-2018, 2018*f*
malignant fibrous histiocytoma as, 2019, 2019*f*
malignant peripheral nerve sheath tumor as, 2019
operative treatment for, 2015-2017
rhabdomyosarcoma as, 2020
staging of, 2015
synovial, 2017
Sauvé-Kapandji procedure
arthrodesis, for radioulnar joint disability, 582, 583*f*
for hereditary multiple exostoses, 1362
for radioulnar joint arthritis, 504-505, 505*f*
for radioulnar joint disability, in rheumatoid arthritis, 1860
Scabies, chronic, 118-119
Scalene injection, diagnostic, for thoracic outlet syndrome, 967
Scaphocapitate arthrodesis, 380-385
athletic participation in, 384
author's preferred method of treatment for, 383-384, 383*f*
contraindications in, 380
critical points in, 384*b*
fixation for, 383, 383*f*
indications for, 383
patients on, 384-385
postoperative expectations in, 384
postoperative management of, 384
Scaphocapitate ligament, 589-590, 589*f*
Scaphocapitate syndrome, 471
Scaphoid
anatomy of
bony and ligamentous, 588-590, 589*f*
vascular, 590, 590*f*
complex injuries of, 603-605
deformity of, carpal misalignment secondary to, 464
dislocation of, 475, 475*f*
distal, resection of, 622-623
excision of
with capitolunate arthrodesis, 394-395, 395*f*
and four-corner fusion, 391-393
author's preferred method of treatment for, 392-393, 393*f*-394*f*
critical points in, 395*b*
fracture of, 426, 588-624
biomechanics of, 590-591
cause of, 588
in children, 607-608, 1442, 1443*f*, 1445, 1445*f*-1446*f*
Scaphoid *(Continued)*
preferred method of treatment for, 1446-1447
classification of, 592-593, 594*t*
clinical presentation of, 591
delayed presentation of waist fracture in, 603
diagnosis of, 591
distal radius and, fractures of, 603-604
examination of, 591-592
imaging of, 592, 593*f*
incidence of, 588, 589*f*, 625*t*
management of, 594-596, 666
algorithm for, 594*t*
in athletes, 603
at distal pole, 594
Geissler technique in, 666-668, 666*f*-668*f*
Herbert-Whipple technique in, 669-670, 669*f*-670*f*
incomplete, through waist, 594
mechanics of fracture fixation in, 595-596
at proximal pole, 595
Slade technique in, 668-669, 668*f*
at waist, 595
nonsurgical treatment for, cost of, 605-607
physical examination of, 591, 591*f*
rigid fixation for, 596-597
surgical treatment for, 597-603
arthroscopy-assisted percutaneous fixation in, 603
complications of, 605
cost of, 605-607
dorsal percutaneous Slade technique in, 598
fixation in, palmar percutaneous method of, 601-603, 602*f*
mini-open screw in, palmar approach to, 600-601, 600*f*
open reduction and internal fixation in, 597-598
palmar percutaneous method in, 600
pitfalls for, 601*b*, 601*f*-602*f*
postoperative care, 602-603
preferred, 597-598, 597*f*
waist fracture, displaced, 598-599, 599*f*
vascularized bone grafting for, 1624
nonunion of, results of, 1637-1638
malunion of, treatment of, 621-622
nonunion of, 588-624
arthroscopic reduction of, 670
biologic stimulation of, 607
bone graft for, nonvascularized, 610, 610*f*
classifications of, 670*t*
of distal pole, 622
dysvascular, 616-619, 616*f*
evaluation of, 608-609
Scaphoid *(Continued)*
activity level in, 609
age in, 609
amount of deformity and malalignment in, 608
arthritis in, presence and location of, 609
bone loss in, 608
comorbidities in, 609
fracture site in, 608
length of time in, 609
pain or dysfunction in, 609
previous treatment in, 608
salvageability of fragment in, 609
vascularity of fragments in, 608
implications of, 590-591, 591*f*
management of, 608-624
preferred method for, 621
open dorsal technique for, 614-615
operative treatment for, 609-619, 609*t*
prognosis for healing in, 620-621
proximal pole, 614-616
treatment for, preferred, 621*t*
unsalvageable proximal pole, 621
without arthritis, 609-611
without substantial bone loss, 609
osteitis of, 648
preparation, for bone grafting, 1631
projection, carpal injury and, 429
Scaphoid nonunion advanced collapse (SNAC), 435, 591
salvage procedures for, 622-624
Scaphoid ring sign, in scapholunate dissociation, 436, 437*f*
Scaphoid shift test, in scapholunate dissociation, 436, 436*f*
Scaphoid-capitate arthrodesis, in scapholunate dissociation, 448
Scaphoidectomy
midcarpal fusion and, 449-450
radioscaphoid-lunate fusion and, 448-449, 449*f*
Scaphoid-lunate-capitate arthrodesis, in scapholunate dissociation, 448
Scaphoid-trapezium-trapezoid arthrodesis, in scapholunate dissociation, 447
Scapholunate advanced collapse (SLAC) wrist, 435
arthroscopy for, 665
Scapholunate angle
increased, in scapholunate dissociation, 436-437, 437*f*
measurement of, in wrist instability, 430
Scapholunate arthrodesis, 387, 447
Scapholunate ballottement test, 436-437
Scapholunate dissociation, 434-450
diagnosis of, 435-436
ballottement test in, 436-437
physical examination in, 435-436
radiological examination in, 436, 437*f*

Scapholunate dissociation *(Continued)*
resisted finger extension test in, 436
scaphoid shift test in, 436
pathomechanics of, 426, 434-435, 435*f*
treatment of, 437-447, 438*b*
preferred method of, 449*f*, 450
Scapholunate interosseous ligament, 658-659, 659*f*
carpal instability and, 661
grade I injury to, 662*f*
grade II injury to, 662*f*
grade III injury to, 662*f*
grade IV injury to, 663*f*
Scapholunate joint
increased space in, 436, 437*f*
Kirschner wire fixation of, 439
reduction-association of, 446-447, 446*f*
Scapholunate ligament, 422, 422*f*
injury to
stage I: partial, treatment in, 438-447, 438*t*
stage II: complete, repairable, treatment in, 438*t*, 440, 440*f*-441*f*
stage III: complete, nonrepairable, normally aligned scaphoid, treatment in, 438*t*, 441-442, 442*f*
stage IV: complete, nonrepairable, reducible flexion deformity of scaphoid, treatment in, 438*t*, 443, 444*f*-445*f*
stage V: reducible carpal collapse, plus instability of radiolunate joint and normal joint cartilage, treatment in, 438*t*, 447, 447*f*-448*f*
stage VI: irreducible carpal collapse, with normal joint cartilage, treatment in, 438*t*, 447
stage VII: with irreducible malalignment and cartilage degeneration, treatment in, 438*t*, 449
interosseous, 589-590, 589*f*
tears of, associated with distal radial fracture, 542
Scapholunate-intercarpal-carpal (SLIC) screw, 663, 663*f*
Scapholunotriquetral tenodesis, 445*f*
Scaphotrapeziotrapezoid arthritis, carpal misalignment secondary to, 464
Scaphotrapeziotrapezoidal fusion, 389-390
alternative techniques for, 390-391
author's preferred method of treatment for, 390, 391*f*
contraindications for, 389
indications for, 389
patients on, 390-391, 392*f*
Scaphotrapeziotrapezoidal joint
portal of, for arthroscopy of wrist, 657
resection arthroplasty of, 693-694
Scaphotrapezoid portal, for arthroscopy of wrist, 657
Scapula
evaluation of, in compression neuropathies, 927
vascularized bone graft from, 1634
Scapular flap, 1554
free, 1591-1593, 1593*b*
anatomy in, 1591, 1593*f*
for mangling injuries, 1515, 1518*f*
operative technique for, 1591-1593, 1594*f*
Scarring
after skin grafting, control of, 1538
of eponychium, 329
of nail bed, 325
postburn, 1953
Schwannomas, 2012, 2013*f*
malignant, 2019
Scintigraphy
in complex regional pain syndrome, 1806-1807, 1806*f*
of distal radioulnar joint, 487
in Kienbock disease, 640
for musculoskeletal tumors, 1990
Sclerodactyly, 1839
Scleroderma, 1839-1840
authors' method of, 1840
calcinosis, 1839
digital deformity in, 1839-1840, 1839*f*
first web contracture in, 1841
proximal interphalangeal joint deformity in, 1838
vascular insufficiency and, 1841
Scratch collapse test, for nerve compression, 927
Screw(s)
bioresorbable, for scaphoid fractures, 596
malposition of, fluoroscopy and surgical navigation to reduce, 605
Screw fixation
in capitate-lunate-hamate-triquetrum fusion, 393-394
of distal humeral fractures, 719
of proximal and middle phalangeal fracture, 259-260
of radial shaft fractures, 793-794, 795*f*
of scaphoid fractures, 596-597, 596*f*
guidewire placement in, 600
length of screw in, 600-601
in scaphotrapeziotrapezoid fusion, 390
sequence of, 724
of ulnar fractures, 778-779, 779*f*, 780*b*
Sea urchins, venomous, 1792, 1792*f*
Seborrheic keratosis, 1964, 1966*f*
Second-degree burns
deep partial-thickness, 1928, 1929*f*
superficial partial-thickness, 1928, 1929*f*
Secretan disorder, 177
Segmental fasciectomy, for Dupuytren disease, 141
Segmental metacarpal loss, 243-244, 244*f*
Selective serotonin reuptake inhibitors, for complex regional pain syndrome, 1812, 1813*t*
Self-report questionnaires, 924
Semipronated (oblique) projection, carpal injury and, 429
Semmes-Weinstein monofilaments, 928
Senile lentigo. *see* Solar lentigo
Sensation
defects in, free flaps for, 1609
preservation of, in Hansen disease, 113-114
Sensibility, restoration of
in Hansen disease, 114
in ulnar nerve palsy, 1061
Sensory evaluation, in compression neuropathies, 927-928
Sensory flaps, from first web of foot, 1605-1608, 1606*f*, 1608*b*
Sensory nerve action potential (SNAP), 929
in thoracic outlet syndrome, 968
Sensory rehabilitation, after toe transfer, 1671
Sentinel lesion, of neonatal compartment syndrome, 1763-1764
Sepsis, regional anesthesia and, 12-14
Septic arthritis, 40-41
clinical presentation and patient evaluation of, 40-41
postoperative management of, 43
treatment for, 41
Septic boutonnière deformity, 43
Septic flexor tenosynovitis, 31.*e*1*b*, 31.*e*1*f*
Septic tenosynovitis, 1907
Septic thrombophlebitis, 52
Serial casting, for proximal interphalangeal joint contractures, 340.*e*2
Serial static splints, for joint stiffness, 340.*e*1, 340.*e*1*f*
Serratus anterior free muscle flap, 1603, 1603*f*
Sertraline, for complex regional pain syndrome, 1813*t*
Seymour fractures, in children, 1429, 1429*f*
Shaft fractures
of metacarpal, 236-243
closed reduction and percutaneous pinning in, 237-238, 238*f*
closed reduction and plaster immobilization of, 237, 237*f*
expected outcomes of, 243
open reduction for, 238-241
cerclage and interosseous wiring in, 239
composite (tension band) wiring in, 238*f*, 239
external fixation in, 241
fracture stabilization techniques in, 237.*e*1*t*

Shaft fractures *(Continued)*
interfragmentary compression screws in, 240, 240*f*
intramedullary fixation in, 239-240, 239*f*
Kirschner wires in, 238-239, 238*f*
plate fixation in, 240-241
preferred method of treatment of, 241-243, 242*f*
of phalanx
distal, 248
nonarticular, 256
expected outcomes of, 264-265
preferred method of treatment of, 261
of thumb, 271-272, 271*f*
SHAFT (sad, hostile, anxious, frustrating, and tenacious) syndrome, 1802
Shave biopsy, 1961, 1962*f*
Shear test, for lunotriquetral dissociation, 451, 452*f*
Shearer's disease, 118
Shearing fracture
of capitellum, 703, 703*f*, 737, 738*f*
of radius, 527
dorsal, isolated, 568, 569*f*-570*f*
management of, 568-573, 569*f*, 568.*e*14*b*, 568.*e*14*f*-568.*e*19*f*, 568.*e*17*b*
Shooter's abscess, 51-52
Shortening, as complication of phalangeal fractures, 267
Shoulder
anatomy of, 1186
arthrodesis of, for brachial plexus injury, 1190-1192
preferred method of, 1192, 1194*b*, 1194*f*
biomechanics of, 1186
contractures of, in arthrogryposis, 1365
examination of, in compression neuropathies, 927
free muscle transfers in, 1178-1179
as recipient site, in vascularized bone grafting, 1636
reconstruction of, in brachial plexus injury, 1186
tendon transfer in, 1187
preferred procedure for, 1189-1190, 1193*f*
spasticity in
examination of, 1084, 1084*f*
operative management of, 1088-1090
treatment of, preferred method of, 1090
stiffness of, after bending fractures, 567-568
weakness and deformity in, in brachial plexus birth palsy, 1408
historical review of, 1411-1412, 1412*b*
Shoulder *(Continued)*
operations for, 1412-1416, 1413*f*-1416*f*
expected outcome of, 1417*b*
postoperative management of, 1416-1417
preferred treatment of, 1416, 1417*f*
preoperative evaluation of, 1409-1411, 1410*f*-1412*f*
Shoulder internal rotation deformity, soft tissue release of, 1088-1089
contraindications to, 1088-1089
indications for, 1088
preoperative planning for, 1089
technique for, 1089
SHOX gene, mutation of, 1339
Shriners Burn Institute, 1529
Shunts, in major replantation, 1480-1481, 1480*f*
Sigmoid notch, 479, 480*f*, 516, 522*f*
osteoplasty of, and ulna, in chronic radioulnar joint instability, 498, 498*f*
Silastic implant
for metacarpophalangeal joint arthroplasty, 358
for proximal interphalangeal joint arthroplasty, 357
Sildenafil, for Raynaud disease, 2053
Silent neuritis, in Hansen disease, 114
"Silhouette" capsulotomy, 584
Silicone sheeting
for burns, 1954
for skin grafting, postoperative care of, 1538
Silver sulfadiazine, glove filled with, for burns, 1931, 1932*f*
Single-column fractures, 701, 701*f*
Single-stage flexor tendon grafting
flexor digitorum profundus and flexor digitorum superficialis tendons disrupted, 202-211, 203*f*, 207*b*
biology of, 203
Boyes' preoperative classification, 202*t*
distal juncture technique of, 209*f*-210*f*, 210
donor for, 203-206
incorporation of, 211
indications for, 202
initial exploration of, 202
placement of, 210
postoperative care of, 211
preferred technique of, 209-210
proximal juncture technique of, 210-211, 210*f*-211*f*
flexor digitorum profundus tendon disrupted, flexor digitorum superficialis tendon intact, 211-212, 212*b*, 214*b*
expectations of, 212
indications for, 211-212, 212*f*-213*f*
postoperative care of, 212
Single-tendon transfer, for radial nerve palsy, 1071-1072
"Six-pack" exercises, for distal radial fractures, 531, 534*f*
Sixth dorsal compartment release, 511-512
Skeletal system, in mangling injuries
evaluation of, 1490
reconstruction of, 1499-1500, 1501*f*-1504*f*, 1502*b*
Skier's thumb, 302-306
Skin, 1528
anthrax in, 68-69, 69*f*
treatment of, 69
chronic paronychia in, 81
treatment of, 81.*e*1, 81.*e*1*f*
closure of
in replantation, 1482
in toe transfer, 1668
on contractures, 340.*e*2
dorsal hand, 1528, 1529*f*
fungal infections of, 80
grafts. *see* Skin graft/grafting
histologic finding of, 1528, 1529*f*
injury of, response to, 1529, 1529*f*
mycetoma in, 71
treatment of, 73
palmar hand, 1528, 1529*f*
pattern of, in free flap transfer, 1579, 1590*f*
preparation of, in toe transfer, 1645
sporotrichosis in, 82, 83*f*
tuberculosis infection of, 91-92
tularemia in, 74
yaws in, 74-75
Skin biopsy, for Hansen disease, 108, 108*t*
Skin flap(s). *see also* Flap(s)
fibula with, 1619
free. *see* Free flap(s)
for paronychial fold formation, in syndactyly, 1221-1222
Skin graft/grafting, 1528-1538
for burns, 1932-1935, 1933*f*-1934*f*
composite, 1709
for digital resurfacing, in syndactyly, 1221, 1225*f*-1226*f*
donor sites for
care of, 1538
in mangling injuries, 1511
filling the defect with, 1536-1537, 1536*f*-1537*f*
full-thickness, 1534-1535, 1535*b*, 1535*f*
choice of graft for, 1535-1536, 1536*f*
technique of obtaining, 1534-1535
general considerations in, 1528-1531
loss of, after burns, 1935
for mangling injuries
donor sites of, 1511
postoperative management of, 1519-1521
type of, 1510
negative pressure wound therapy in, 1536

Skin graft/grafting *(Continued)*
in outpatient surgery, 1538
postoperative care for, 1537-1538
primary closure
in reconstruction of amputated fingertip, 1711
semiocclusive dressings, 1711
skin substitutes for, 1531
skin thickness in, 1531
guidelines for, 1532*t*
split-thickness, 1531-1534, 1533*b*
choice of donor sites for, 1531-1532, 1532*t*
dermatomes for, 1532-1533
Padgett, 1532-1533, 1532*f*
Zimmer air, 1533
harvesting, 1532
meshed. *see* Meshed grafting
split-thickness, in reconstruction of amputated fingertip, 1711
substitution by, 1528-1529
temporary storage of, 1528-1538
timing of, 1530
types of, 1530
Skin lesions, for Hansen disease, 107, 107*f*
Skin loss, fingertip amputation with, 1709-1711
Skin necrosis, after phalangeal transfer, for digital augmentation, 1262
Skin patch, anesthetic, for Hansen disease, 106
Skin protuberances, in constriction ring syndrome, 1257, 1257*f*
Skin release, for swan neck deformity, in rheumatoid arthritis, 1883-1884, 1884*f*
Skin repair, in microvascular toe transfer, 1269
Skin test, lepromin, for Hansen disease, 107-108
Skin tumors, of hand and upper extremity, 1958-1986
anatomy and clinical examination of, 1958-1960, 1959*f*
basal cell carcinoma and, 1973-1975, 1976*f*
classification of, 1974, 1974*t*, 1976*f*
treatment of, 1974-1975, 1977*f*-1978*f*
dermal lesions in, 1966-1968
diagnostic procedures and nonsurgical treatment for, 1960-1961, 1960*f*-1963*f*
epidermal lesions in, 1962-1964
pigmented, 1965-1966
seborrheic keratosis as, 1964, 1966*f*
sweat glands and, 1964
warts as, 1962-1964
malignant, less common, 1981-1983
dermatofibrosarcoma protuberans as, 1983, 1985*f*
human immunodeficiency virus (HIV) and, 1983, 1984*f*
Skin tumors, of hand and upper extremity *(Continued)*
lymphangiosarcoma (Stewart-Treves syndrome) as, 1981-1983
Merkel cell (neuroendocrine) carcinoma as, 1981, 1984*f*
metastatic tumors as, 1983, 1985*f*
sweat gland tumors as, 1983
melanoma, 1977-1981, 1980*f*
local surgical excisional treatment for, 1980-1981
lymphatic basins in, evaluation of, 1981, 1982*f*-1983*f*
prognosis and staging of, 1980, 1981*t*
nonhemangiomatous vascular lesions in, 1968-1970
premalignant, indeterminate behavior lesions and, 1970-1972
actinic keratosis as, 1972, 1972*f*
arsenical keratosis as, 1972
Bowen disease as, 1972, 1973*f*
cutaneous horns as, 1970, 1971*f*
distal digital keratoacanthoma as, 1971-1972
keratoacanthoma as, 1971, 1972*f*
porokeratosis as, 1970, 1971*f*
squamous cell carcinoma, 1975-1977, 1979*f*-1980*f*
surgical lesion excision for, 1962, 1964*f*-1965*f*
syndromal conditions in, 1972-1973
Gorlin syndrome in, 1972-1973, 1974*f*
xeroderma pigmentosum in, 1973, 1975*f*
Skipping lesions, 1946
Slade technique
percutaneous, dorsal, for scaphoid fracture, 598
for scaphoid fractures, 668-669, 668*f*
Slaughterman's interdigital granuloma, 118
Slit-skin smears, for Hansen disease, 108, 108*t*
Slow intermittent passive positioning device, for elbow contracture, 857-858
Smaller-gauge needles, 146
Smith and Albin thenar H-flap, in reconstruction of amputated fingertip, 1716, 1716*f*
Smith fractures, 524-527, 525*f*
malunited, 580, 580.*e*4*f*
Snakes, venomous, 1789-1791, 1790*f*-1791*f*
preferred method of treatment of, 1791
Snow-Littler procedure, in cleft hand surgery, 1248, 1248*f*
"Snuffbox tenderness", 591
Sockets system, 1759
Soft tissue
contractures, 340.*e*2
at elbow, poor-quality, as contraindication to elbow arthroplasty, 909
Soft tissue coverage
in mangling injuries, 1495, 1521*b*
technique of, 1508-1519, 1509*f*-1517*f*
poor, acceptable length and, thumb reconstruction for, 1676, 1676*f*
Soft tissue defects
examination of, prior to free flap transfer, 1577
free flap selection influenced by, 1608-1609
of thumb
heterodigital flaps in, 1679-1681, 1680*f*
palmar advancement flaps in, 1676-1677, 1677*b*
reconstruction of, 1687-1688
Soft tissue deficiencies, after elbow contracture release, 859
Soft tissue distraction, preliminary, in management of radial longitudinal deficiency, 1329-1330, 1331*f*-1332*f*
Soft tissue envelope, in posttraumatic arthritis, 906
Soft tissue flaps, for split thumbs, types III and IV, 1307-1309, 1308*f*
Soft tissue infections, necrotizing, 54-56, 54*f*-55*f*
Soft tissue reconstruction
of midcarpal ligaments, 460-461, 461*f*
of scapholunate ligament, 442
synovectomy with, in rheumatoid arthritis, of metacarpophalangeal joint, 1868
postoperative management after, 1870
Soft tissue release
and balancing, in management of radial longitudinal deficiency, 1331-1333, 1333*f*
of shoulder internal rotation deformity, 1088-1089
contraindications to, 1088-1089
indications for, 1088
preoperative planning for, 1089
technique for, 1089
Soft tissue tumors, 1987-2035
benign, 1997-2014
fibromatoses as, 2014
foreign body lesions as, 2010
ganglions and mucous cysts, 1997-2010, 1999*t*. *see also* Cyst(s); Ganglion(s)
giant cell tumors as, of tendon sheath, 2012, 2012*b*
granular cell tumors as, 2013-2014, 2013*f*
lipofibromatous hamartomas as, 2011-2012

Soft tissue tumors *(Continued)*
lipomas as, 2011
neurofibromas as, 2012
schwannomas (neurilemomas) as, 2012, 2013*f*
malignant, 2015-2020
soft tissue sarcomas as, 2015-2020, 2017*b*
SoftHand prosthetic component (SoftHand Pro), 1740-1741
Solar lentigo, 1965
Solid (nodular) BCC, 1974
Somatosensory evoked potentials (SSEPs)
in brachial plexus surgery, 1158
in thoracic outlet syndrome, 968
Sonography, for musculoskeletal tumors, 1990
Spacer wires, for segmental metacarpal loss, 244*f*
Spastic thumb adductor, insertion of, release of, 1109-1110, 1109*f*, 1110*b*
Spastic thumb intrinsic muscles, release or slide of origin of, 1108-1109, 1108*f*
Spasticity, 1080-1121
botulinum toxin for, 1088
diagnostic testing of, 1085-1086
dynamic electromyography of, 1086, 1087*f*
evaluation of, 1081-1082
imaging of, 1085
of intrinsic muscle, 1085
release or slide of, for thumb-in-palm deformity, 1108-1109, 1108*f*
operative management of, 1088-1118
elbow in, 1090-1093
preferred method of, 1091*f*, 1092-1093
types of, 1090
forearm in, 1093-1095
preferred method of, 1095, 1096*f*
intrinsic muscle spasticity and digital swan neck deformity in, 1113-1117, 1113*f*
preferred method of, 1116-1117
shoulder in, 1088-1090
preferred method of, 1090
types of, 1088
thumb-in-palm deformity in, 1106-1113, 1107*t*
preferred method of, 1112-1113
wrist and digital extension in, 1095-1102, 1097*f*, 1097*t*
preferred method of, 1101-1102, 1102*f*-1103*f*
wrist and digital flexor tightness in, 1102-1106, 1104*f*
preferred method of, 1105-1106
outcome studies of, 1118
physical examination of, 1082-1085, 1082*f*, 1083*t*
in tetraplegia, 1126-1127
Spasticity *(Continued)*
therapy for, 1086-1088, 1088*f*
treatment considerations of, 1081-1086, 1081*f*
Specimen, collection and handling, guidelines for, 64-65, 65*t*
Spiders, venomous, 1788-1789, 1789*f*
Spinal accessory nerve transfer
for brachial plexus injury, 1163-1166, 1163*f*, 1164*b*
to suprascapular, 1404, 1405*f*
Spinal cord stimulation implant, for complex regional pain syndrome, 1817
Spine, cervical, in thoracic outlet syndrome, 960*f*
Spiral bundle, of Dupuytren disease, 145
neurovascular, 138
Spitz nevus. *see* Benign juvenile melanoma
Splenomegaly, 1833
Splint/splinting
for burns, 1930-1931, 1931*f*, 1953, 1953*f*-1954*f*
in camptodactyly release, 1388
for clasped thumb, 1325
dynamic, for joint stiffness, 340.*e*1, 340.*e*1*f*
extension block, for proximal interphalangeal joint fracture-dislocation, 282-283
flexor hinge, wrist-driven, 1130-1131, 1131*f*
for Kirner deformity, 1274-1275
night
for arthrogryposis, 1380
for cubital tunnel syndrome, 942
for epicondylitis, 865
for trigger thumb, 1321
"playing," for ulnar collateral ligament injury, 303
postoperative, for mangling injuries, 1519, 1521*f*
for radial nerve palsy, 1065, 1065*f*
internal, 1065
static
after elbow contracture release, 857
for joint stiffness, 340.*e*1, 340.*e*1*f*
progressive, for joint stiffness, 340.*e*1, 340.*e*1*f*
serial, for joint stiffness, 340.*e*1, 340.*e*1*f*
sugar tong, for distal radial fracture, 531, 532*f*
in thumb reorientation osteotomy, 1383
for trigger finger, 1910
wrist, for carpal tunnel syndrome, 932
Split flexor pollicis longus (FPL) tenodesis, 1059
Split nail, 326, 326*f*-327*f*
Split thumb, 1305
Split-hand/split-foot (SHSF) syndrome, 1244
Split-thickness grafts, 1528-1530. *see also* Skin graft/grafting, split-thickness
Sporotrichosis, 82-83, 83*b*
clinical findings on, 82, 82*f*
deep (extracutaneous), 88
diagnosis of, 82-83, 83*f*, 84*t*
etiology and epidemiology of, 82
treatment of, 83
Spurling test, for cervical nerve root impingement, 927
Spurt test, 1482
Squamous cell carcinoma, 1975-1977, 1979*f*-1980*f*
of perionychium, 334-335, 335*f*
SSEPs. *see* Somatosensory evoked potentials (SSEPs)
"S"-shaped incision, in transmuscular brachioradialis-splitting approach, for radial tunnel syndrome, 951, 951*f*
Stable fractures (type II), nondisplaced, preferred method of, 781
Staphylococcal scalded skin syndrome, 17
Staphylococcus aureus, 17, 1834-1835
methicillin-resistant, 18, 18*f*
Staple fixation
in capitate-lunate-hamate-triquetrum fusion, 393, 394*f*
for scaphoid fractures, 596
in scaphotrapeziotrapezoid fusion, 390
Stapling, hemiepiphyseal, of distal radius, 1359-1360, 1360*f*
Static macrodactyly, 1276-1277
Static splints
for elbow contracture, 857
for joint stiffness, 340.*e*1, 340.*e*1*f*
Static techniques, in ulnar nerve palsy, 1048-1051
Steindler flexorplasty, 1418, 1418*f*
Steindler procedure, modified, for elbow reconstruction, in brachial plexus injury, 1195-1196, 1195*f*, 1196*b*
Stener lesion, 302-303, 303*f*
historical review of, 303
postoperative management and expectations in, 306
treatment of, 303, 304*f*-305*f*, 306*b*
Stewart-Treves syndrome, 1981-1983
Stick-up test, 966-967
Stiffness
after bending fractures, minimization of, 567-568
after humeral fracture, 730-731, 730*f*
after radial head fractures, 764, 764*f*
after ulnar fracture, 784
of finger and hand, 338-344
case study on, 343.*e*3*b*, 343.*e*3*f*-343.*e*7*f*
pathophysiologic findings in, 338, 339*f*
treatment of, 338-343

Stiffness *(Continued)*
evaluation and planning of, 338-340
nonoperative intervention for, 340
operative intervention for, 340-343
recurrent, after elbow contracture release, 859
of thumb, after pollicization, 1303
Stiles-Bunnell procedure, in ulnar nerve palsy, modified, 1051, 1052*f*
Stiletto flap, 1383
Stingrays, venomous, 1793
Straight line of pull, in tendon transfers, 1025
Streptobacillus moniliformis, 47
Streptokinase, for free flap failure, 1585
Streptomycin
for actinomycetoma, 70-73
dosage of, 101*t*
for tuberculosis, 92-93, 100, 101*t*
Stress fractures, after bone grafting, 1616-1617, 1616*f*
Stretch injury, in responses to nerve injury, 985
Styloid
radial, shear fractures of, 569-570, 570*f*-571*f*
of ulna, fracture of, 493, 493*f*
Styloidectomy, radial
for scaphoid nonunion advanced collapse, 622
for scapholunate dissociation, 449
Subaponeurotic space abscess, 37
treatment of, 38-39
Subclavian artery, in thoracic outlet syndrome, 972
Subcoracoid space, in thoracic outlet syndrome, 964
Subcutaneous anterior transposition, of ulnar nerve, for cubital tunnel syndrome, 944, 944*f*-945*f*
Subcutaneous digital nerve block, 9-10, 11*f*
Subcutaneous flap, 1593
Subcutaneous fungal infections, 80-84
classification of, 80-81
paronychia and, chronic, 81, 81*f*, 81.*e*1, 81.*e*1*f*
phaeomycotic cysts and, 84
sporotrichosis and, 82-83, 82*f*-83*f*, 83*b*, 84*t*
Subcutaneous nodules, 1836
Subcutaneous pseudosarcomatous fibromatosis, 2014
Subcutaneous space abscess, 37
treatment of, 38-39
Subfascial space infections, deep, 36-40, 38*f*
clinical presentation and evaluation of, 37-38
pertinent anatomy in, 38
Subfascial space infections, deep *(Continued)*
postoperative management of, 39-40
treatment for, 38-39
preferred method of, 39
Subluxating nerve, 885
Subluxation
of extensor carpi ulnaris, 511-512, 511*f*
of metacarpophalangeal joint, simple, 299
of proximal interphalangeal joint, 294-295, 295*f*
of scaphoid, 435
Submuscular transposition, of ulnar nerve, for cubital tunnel syndrome, 945, 945*f*
Subungual hematoma, 318-319, 320*f*
Subungual melanoma, 1978
Subungual nevi, 332-333, 332*f*-333*f*
Subungual osteochondroma, 2022
Suction drainage, closed, after open release of elbow contracture, 853
Sudeck atrophy, classic, 1805
Sudomotor activity, assessment of, in complex regional pain syndrome, 1808
Sugar tong splint, for distal radial fracture, 531, 532*f*
Superficial basal cell carcinoma, 1974
Superficial displacement, of Dupuytren disease, 138
Superficial fibers, 134
Superficial finger flexor tendons, in rheumatoid arthritis, rupture of, 1857
Superficial head, of interosseous muscles, 338.*e*3, 338.*e*5*f*
Superficial intradermal anesthetic injection, 145
Superficial palmar fascia, anatomy of, in Dupuytren disease (DD), 134
Superficial radial nerve, grafting of, 997
Superficial spreading melanoma, 1978, 1980*f*
Superficialis
harvest of, 1029-1030
opponensplasties, in median nerve palsy, 1029-1031
transfer of
to profundus tendon, in cerebral palsy, 1104-1105, 1106*f*, 1107*b*
in radial nerve palsy, 1070-1071, 1071*b*
postoperative management of, 1071
in ulnar nerve palsy, 1051-1053
modifications of, 1051-1053
results of, 1053
Supine position, in elbow arthroscopy, 886
Supraclavicular brachial plexus, 1146
surgical approach to, 1156-1157, 1156*f*
Supraclavicular nerve block, 6-7
bilateral procedures and, 2
ultrasound-guided, 7*f*
Supracondylar fractures, of distal humerus. *see also* Humerus, distal
management of, 721
Suprascapular nerve transfer, for brachial plexus injury, 1164-1165, 1164*b*, 1164*f*
outcomes of, 1165, 1165*f*
Sural nerve, grafting of, 997, 997*f*
in brachial plexus reconstruction, 1161-1162, 1161*f*
Surface replacement arthroplasty, 356-357
Surgical excision
for burns, 1932-1935, 1933*f*
lesion, 1962, 1964*f*-1965*f*
primary wide, for musculoskeletal tumors, 1992
of radial head, 744-745
delayed, 743-744, 744*f*
outcome of, 759
as preferred treatment, 750-752, 753*f*, 754*b*
of radial head fragments, 743
outcome of, 758-759
as preferred treatment, 746, 748*b*, 749*f*
of ulnar anlage, in management of ulnar deficiency, 1336-1338, 1339*f*
of warts, 123
Suspension system, 1759
Suture
in biceps rupture repair, 877, 878*f*
for extensor tendon laceration repair, 158-159
in triceps avulsion repair, 880, 880*f*-881*f*
Swan neck deformity, 294
classification of, 1880*t*
intrinsic muscle spasticity and, 1113-1117, 1113*f*
treatment of, preferred method of, 1116-1117
in rheumatoid arthritis, of fingers, 1879-1890, 1880*t*
type I, 1879-1883, 1881*f*, 1899*f*
type II, 1883
type III, 1883-1885
type IV, 1886-1890
of thumb, 1896-1897, 1896*f*
operative treatment
indications for, 1896-1897, 1896*t*, 1897*f*
options for, 1896*t*
treatment of, 295*f*
options for, 1880*t*
Sweat gland tumors, 1983
Symbrachydactyly, 1231, 1258-1260, 1261*b*
classification of, 1258-1259, 1258*t*
clinical features of, 1258-1259

Symbrachydactyly *(Continued)*
management of, 1260
in monodactylic type, 1260
in oligodactylic type, 1260
in peromelic type, 1260, 1261*f*
in short finger types, 1260
types of, 1258, 1258*f*
anatomy in, 1259-1260, 1259*f*
Sympathectomy
for complex regional pain syndrome
chemical, 1819-1820
surgical, 1820
summary of role of, 1820
Sympathetic blockade, in complex regional pain syndrome, 1808-1809
Sympathetic nervous system, in complex regional pain syndrome, function of, 1803
Syndactyly, 1217-1227, 1232*b*
in acrosyndactyly, 1227, 1227*f*-1228*f*
in Apert syndrome, 1227-1232, 1228*t*, 1229*f*
classification of, 1217
cleft hand and, 1244, 1245*f*
release of, 1246-1251, 1249*f*-1251*f*
complete, 1217, 1218*f*
complex, 1217, 1218*f*-1219*f*
in dystrophic epidermolysis bullosa, 1231-1232, 1232*f*
epidemiologic findings of, 1217, 1218*f*
expected outcomes for, 1232
incomplete, 1217
management considerations for, 1217-1227, 1218*f*
commissure reconstruction in, 1219-1220, 1219*f*-1220*f*
complications of, 1223
outcome of, 1222-1223
paronychial fold formation in, 1221-1222
preferred method of, 1219*f*, 1223*f*, 1224-1227, 1226*f*-1227*f*
separation and resurfacing of digits in, 1220-1221, 1223*f*-1225*f*
pathologic findings in, 1217
in Poland syndrome, 1231, 1231*f*
preoperative evaluation of, 1217
simple, 1217, 1218*f*
special cases of, 1227-1232
surgery for, 1218
timing of, 1219, 1219*f*
in symbrachydactyly, 1231
web space, postburn, 1938, 1940*f*
Synergism, in tendon transfers, 1025
Synostosis
radioulnar, 803-804, 803*f*-804*f*, 804*t*. *see also* Radioulnar synostosis
tibiofibular, 1356, 1356*f*
Synovectomy
in mycobacterial tenosynovitis, 95
of proximal interphalangeal joint, 1878-1879
for rheumatoid arthritis, 897
Synovectomy *(Continued)*
of metacarpophalangeal joints and, 1868
soft tissue reconstruction
postoperative management after, 1870
techniques of, 1868-1870
of thumb, with reconstruction of extensor mechanism, 1898
of wrist, 1859
for wrist arthritis, arthroscopic, 689-690
Synovial sarcoma, 2017
Synovitis, as complication of flexor tendon grafting, 225, 225.*e1f*
Synpolydactyly, 1213-1214, 1213*f*-1214*f*, 1218, 1234, 1235*f*
treatment of, 1235-1236
Syphilis, 73-74, 73*f*
Systemic lupus erythematosus, 1837-1839, 1837*f*
authors' preferred method of treatment for, 1838
digital deformity in, 1838
proximal interphalangeal joint deformity in, 1838
thumb deformity in, 1838-1839
wrist deformity in, 1837-1838
Systemic sclerosis, 1839

T
"T" fractures, 699, 702, 702*f*. *see also* Humerus, distal
Taenia solium, 118
Tapeworm infection, 118
Targeted-muscle reinnervation (TMR), 1760
Teardrop angle, in distal radial fracture, 520, 521*f*
Telangiectasias, 1968-1970
Temporomandibular joint, involvement of, in rheumatoid arthritis, 1833
Temporoparietal fascial flap, 1604-1605, 1604*f*, 1605*b*
Ten test, of A-beta fibers, 928
Tendinitis
calcific, 1905-1906, 1906*f*
extensor carpi ulnaris, 1921-1922, 1922*f*
flexor carpi radialis, 1922-1923
treatment, 1923
nonoperative, 1923
operative technique, 1923
Tendinopathy, 1904-1925
case study of, 1922.*e1b*, 1922.*e1f*-1922.*e2f*, 1922.*e3f*, 511.*e1f*, 511.*e2f*, 511.*e3f*-511.*e4f*, 1922.*e4f*, 511.*e1b*
crystalline, 1905-1907
in amyloid deposition, 1906-1907, 1906*f*
in calcific tendinitis, 1905-1906, 1906*f*
in gout, 1905, 1905*f*
in hydroxyapatite deposition, 1906
Tendinopathy *(Continued)*
in ochronosis, 1907
in pseudogout, 1906
elbow, 863-884
Tendon(s). *see also named tendon, e.g.*, Flexor pollicis longus (FPL)
adherence, of stiff joint, 339-340
anatomy of, 1842-1843
defects of, free flaps for, 1609
in mangling injuries, 1494-1495
examination of, 1490-1492, 1492*f*
repair/reconstruction of, 1500-1505, 1505*b*
preparation of, in toe transfer, 1645
repair of
in microvascular toe transfer, for hypoplastic digits, 1269
in toe transfer, 1667-1668
rupture of, 863-884
in rheumatoid arthritis, 1849-1851
extensor
diagnosis of, 1849-1850, 1849*f*
with metacarpophalangeal joint disease, 1854
multiple-tendon, 1852
reconstruction for, 1852-1857, 1853*f*
single-tendon, 1851, 1852*f*
treatment of, 1850-1851, 1850*f*
flexor
diagnosis of, 1850
treatment of, 1856-1857
options for reconstruction in, 1852-1857
in ring and small finger, 1852, 1853*f*
Tendon entrapment, 1907-1908
causative factors of, 1907-1908
of fingers and thumb, 1908
histologic findings in, 1907
at wrist, 1920-1923
Tendon graft
for boutonnière deformity, 172, 172*f*
for chronic lateral instability, 833-835
for chronic medial instability, 838
Tendon juncture
distal, 206, 207*f*
proximal, 208, 210*f*
Tendon sheath
anatomy of, 1842-1843
giant cell tumors of, 2012, 2012*b*
Tendon transfer, 1025*b*
combination of EIP and EDC, for pinch, 1058
early, for nerve injuries, 1061
for median nerve palsy, 1025-1045. *see also* Opponensplasty, for median nerve palsy
high, 1042-1045
expectations and patient counseling in, 1045
preferred method for, 1044-1045
summary of, 1044-1045, 1045*t*

Tendon transfer *(Continued)*
low, 1025-1042
expectations and patient counseling in, 1042
postoperative management of, 1041
preferred method of, 1041-1042
for severe nerve deficits, 1036-1041, 1036*f*
in patient with fused wrist, 1853-1854
principles of, 1023-1025, 1186-1190
for radian nerve palsy, 1066-1074, 1067*t*, 1070*b*
flexor carpi radialis in, 1071, 1071*b*, 1071*f*
flexor carpi ulnaris in, 1067-1070, 1067*f*-1069*f*
postoperative management of, 1069
potential problems of, 1069-1070
historical review of, 1066, 1066*f*, 1066*t*
versus nerve grafting, 1065
outcome of, 1072
preferred method of, 1072-1074, 1073*f*-1074*f*
superficialis in, 1070-1071, 1071*b*
postoperative management of, 1071
timing of, 1065-1066
for rheumatoid arthritis, of wrist, 1863
for scapholunate dissociation, 443, 443*f*
for shoulder reconstruction, in brachial plexus injury, 1187
preferred procedure for, 1189-1190, 1193*f*
single, 1025
in tetraplegic patient, 1127
elbow extension, 1127-1129
biceps to triceps, 1127-1129, 1128*f*, 1129*b*
technique, 1140, 1140*f*
in ulnar nerve palsy, dynamic, 1051-1056
for Volkmann contracture, complications of, 1785
Tendon "Z" -lengthening, for spasticity, 1103-1104, 1104*b*
Tendon-to-bone repair
preferred technique of, 190, 192*f*-193*f*
of zone 1 tendon lacerations or avulsions, 187
Tendovaginitis, stenosing, 1907
Tennis elbow, 897
Tenodesis, 1127
flexor, for swan neck deformity, in rheumatoid arthritis, 1882-1883, 1882*f*
flexor digitorum superficialis, for intrinsic muscle spasticity, 1114
lateral band, for proximal interphalangeal joint subluxation, 294-295
Tenodesis *(Continued)*
spiral, in scapholunate dissociation, 447-450, 447*f*-448*f*
in tetraplegic patient
extensor carpi ulnaris, 1140
House's one-stage reconstruction and, 1135, 1135*f*
intrinsic, House two-stage reconstruction and, 1137-1138, 1138*f*
PIP central slip deficiency treated with, 1143, 1143*f*
Zancolli's staged reconstruction for, 1134
three-ligament, in scapholunate dissociation, 443, 444*b*, 444*f*-445*f*
in ulnar nerve palsy
Fowler's wrist, 1051, 1051*f*
Parkes, 1050-1051, 1050*f*
Riordan, 1050
Tenodesis effect, 1426-1427, 1427*f*
Tenolysis
extensor, 340
reconstruction of, in flexor tendon injury, 199-202, 202*b*
adhesion formation of, agents that may limit, 200
expectations following, 201-202
postoperative care following, 201
preferred technique of, 200-201, 201*f*
preoperative evaluation of, 199-200, 200*f*
in secondary reconstruction after mangling injury, 1523-1524
Tenosynovectomy
digital, 1848-1849, 1848*f*
dorsal, 1843-1845, 1843*f*-1844*f*
flexor, 1845-1848, 1846*b*, 1846*f*-1847*f*
volar, 1847*b*
Tenosynovitis
candidiasis and, 85
chronic, 101, 1907
coccidioidal, 85
cryptococcal, 86
defined, 1904
of extensor carpi ulnaris, 511-512, 511*f*
in Hansen disease, 109-110, 110*f*
histoplasmosis and, 86
mycobacterial, 93-96, 94*f*-95*f*
in mycobacterial infections, 90-91
pigmented villonodular, 2012, 2012*b*
proliferative, 1904-1919
in rheumatoid arthritis, 1842-1849, 1842*f*, 1904
anatomy in, 1842-1843
associated with proximal interphalangeal joint stiffness, 1885-1886
in digital flexors, 1848-1849
preferred method of treatment of, 1848-1849, 1848*f*
preferred method of treatment, 1843-1845, 1843*f*-1844*f*
Tenosynovitis *(Continued)*
in wrist extensors, 1843-1845
complications, 1845
postoperative management, 1845, 1845*f*
in wrist flexors, 1845-1848
preferred method of treatment of, 1845-1848, 1846*b*, 1846*f*-1847*f*
in sarcoidosis, 1907
septic, 1907
sporotrichosis and, 88
types of, 66
Tenotomy
for boutonnière deformity, in rheumatoid arthritis, 1891*f*
central slip, for swan neck deformity, 1115, 1116*b*, 1116*f*
tendon, terminal, for boutonnière deformity, 172-174
Tension band wiring, for ulnar fractures, 777, 778*b*, 784.*e*18*b*, 784.*e*18*f*-784.*e*21*f*
Tensor fasciae latae flap, for burn deformities, 1944-1945
Terazosin, for complex regional pain syndrome, 1814, 1814*t*
Terbinafine, for fungal infections of nails, 330-331
Terminal tendon, of interosseous muscles, 338.*e*3, 338.*e*5*f*
"Terry Thomas sign", 436
Tetanus prophylaxis, 19
current guidelines for, 1496, 1498*t*
Tetracaine, characteristics of, 4*t*
Tetracyclic antidepressants, for complex regional pain syndrome, 1811, 1812*t*
Tetraplegia, 1122-1145, 1144.*e*1*b*
diagnostic imaging for, 1124
forearm pronation in, 1129-1130, 1130*f*
group 0, 1130-1131, 1131*f*
group 1, 1131-1133, 1131*f*-1132*f*, 1132*b*, 1133*t*
group 2 and 3, 1133-1135, 1133*t*, 1135*f*-1136*f*, 1136*b*-1137*b*
group 4 and 5, 1135-1140, 1137*f*-1138*f*, 1139*b*, 1140*f*
group 6 and 7, 1140-1141
group 8, 1141-1142, 1142*f*
group 9, 1142, 1143*f*
future areas of research in, 1143-1144
historical review of, 1125, 1126*t*
indications and contraindications to, 1126-1127, 1127*b*
intrinsic reconstruction in, 1142-1143
outcomes of, 1144
pathogenesis of, 1122, 1123*t*
pertinent anatomy in, 1124-1125, 1125*f*
physical examination of, 1123-1124, 1124*f*
preoperative evaluation of, 1122-1124, 1123*t*-1124*t*

Tetraplegia *(Continued)*
psychological impairment in, 1126-1127
spasticity in, 1126-1127
surgery for
digital clawing in, 1142-1143
elbow extension tendon transfer in, 1127-1129
biceps to triceps, 1127-1129, 1128*f*, 1129*b*
international classification for, 1123*t*, 1133*t*
types of operations for, 1127
Thenar crease approach, 35-36, 36*f*
Thenar flap(s), in reconstruction of amputated fingertip, 1716
Smith and Albin, 1716, 1716*f*
Thenar muscle, absence of, in thumb hypoplasia, 1292
Thenar space
infections of, 34*f*
characteristics of, 35*t*
treatment for, 35, 36*f*
preferred method of, 39
pertinent anatomy in, 35
Thermography, in complex regional pain syndrome, 1809
Thigh
anterolateral, free flap from, 1513-1515, 1516*f*, 1597, 1598*f*
anterolateral, free flap from, for burn deformities, 1945
Third-degree burns, 1928-1929, 1929*f*
Thomine coefficient, 133
Thompson APL sling, 363*f*
Thompson approach, to radial tunnel syndrome, 951-952, 951*f*
Thoracic intercostal nerves, transfer of, for brachial plexus birth palsy, 1405-1406
Thoracic outlet, anatomy of, 962, 962*f*
Thoracic outlet syndrome, 959-978
arterial, 959-960, 960*f*
case study in, 977.*e*1*b*
classification of, 959-961
Roos, 961
Wilbourn, 959
clinical findings in, 964
diagnostic studies of, 968, 970*b*
electrodiagnostic evaluation of, 968
epidemiology of, 962, 962*f*
history of, 959
neurogenic, 960
electrically negative, 960-961
true, 960, 961*f*
physical examination of, 964-967, 970*b*
inspection and palpation, 964-966, 965*f*-967*f*
provocative tests for, 966-967
radiologic evaluation of, 968, 970*f*
recurrent, after surgical treatment, 975-976
treatment of, 968-976
Thoracic outlet syndrome *(Continued)*
complications of, 974-975
nonoperative, 968-970, 970*b*
operative, 970-971
recurrent symptoms after, 975-976
preferred method of, 971-976, 971*f*-974*f*
results of, 975-976, 976*f*
venous, 960, 960*f*
Thoracodorsal artery perforator flap, 1602-1603
Thoracodorsal nerve transfer, for brachial plexus injury, 1177
Thoracoepigastric flap, for soft tissue defects of thumb, 1680*f*
Thoracoscopic sympathectomy, for vasospastic disease, 2053
Thrombocytopenia-absent radius (TAR) syndrome, radial deficiency associated with, 1289, 1290*t*
longitudinal, 1329*t*
Thrombolytic agents, for free flaps failing, saving of, 1584-1585
Thrombosis
after toe transfer, 1669
in ulnar artery, 2042, 2045*f*, 2053
venous, 2054-2055
Through-and-through incision, for felon, 27*f*, 27*t*
Thumb
absent, 1255-1270
in cleft hand, management of, 1251, 1254*f*
with acceptable length and poor soft tissue coverage, 1676-1677, 1676*f*, 1677*b*
heterodigital flap in, 1679-1681, 1680*f*
dual innervated, 1684, 1685*f*
first dorsal metacarpal artery, 1684-1686, 1686*f*
innervated, 1681-1684, 1681*b*
radial-innervated, 1682-1684, 1683*f*, 1684*b*, 1684.*e*1*f*
with proximal releasing incision, 1677-1679, 1679*b*, 1679*f*
without proximal releasing incision, 1677, 1678*f*
adduction of, restoration of, 1056-1058
after total amputation with preservation of basal joint, pollicization for, injured digit in, 1699-1703
arthritis mutilans of, 1897
arthrodesis for, 1899-1900
arthrodesis of, in ulnar nerve palsy, 1059
basal joint of
amputation with preservation of, 1696-1699
composite radial forearm flap for, 1697-1699, 1700*f*, 1701*b*, 1699.*e*1*f*
Thumb *(Continued)*
osteoplastic reconstruction for, 1696-1697, 1697.*e*1*f*
pollicization for, index/long finger stump in, 1699-1703, 1702*f*-1704*f*, 1705*b*
carpometacarpal joint of, 312-315
clasped, 1324-1325
contractures of, postburn, 1938-1939, 1941*f*
deformity of, 1289-1292, 1894-1901
pathophysiology of, 1894, 1894*t*
preferred method of treatment of, 1839
psoriatic arthritis in, 1836
secondary to joint destruction, 1897-1901
in systemic lupus erythematosus, 1838-1839
type I, 1894-1896, 1895*f*
type II, 1896
type III, 1896-1897
type IV, 1897
type V, 1897
duplication of, 1304-1315, 1315*b*
classification of, 1304, 1304*t*
clinical features of, 1304-1305, 1306*f*
complications of, 1313-1315
epidemiologic findings in, 1304
general considerations in, 1304-1305
treatment of, 1305-1315
outcomes of, 1310-1313, 1316*f*
in type I or II split thumb, 1305-1307, 1306*f*-1307*f*
in type III or IV split thumbs, 1307-1310, 1308*f*-1313*f*
in type V or VI split thumbs, 1310
in type VII split thumb, 1310, 1313*f*-1316*f*
and first web, classification of ulnar deficiency based on, 1338*t*
flexion, reconstruction of, 1779*b*
flexor tendon reconstruction of, 217-219, 220*b*
free tendon graft in, 218-219
technique in, 218-219
indication of, 217-218
staged tendon reconstruction in, 219
floating, 1291, 1291*f*
fractures of, 270-275
articular, avulsions of, 271
in children, 1439-1442
diaphyseal, in children, 1440
at metacarpal base, 272-273
in children, 1440-1441, 1441*f*
preferred method of treatment for, 1441-1442, 1442*f*
complications of, 273
expected outcomes of, 273
operative management of, 274*b*
preferred method of treatment of, 272, 272*f*-273*f*
at metacarpal head, 271

Thumb *(Continued)*
phalangeal, 270
in children, 1439
preferred method of treatment for, 1439-1440, 1440*f*
extraarticular, 270, 270*f*
Rolando, 273-275, 274*f*-275*f*
preferred method of treatment of, 274-275
at shaft, 271-272, 271*f*
function of, reconstruction of, 1777
heterodigital flap in, neurovascular island flap, 1686-1687, 1688*f*, 1689*b*
hypoplasia of, 1289-1303, 1290*f*, 1304*b*
classification of, 1290-1292, 1290*t*
diagnosis of, 1289
treatment for, 1292-1303
complications of, 1303, 1303*t*, 1304*f*-1305*f*
results of, 1301-1303, 1302*f*
type I, 1290
type II, 1290, 1291*f*, 1290.*e*1*b*, 1290.*e*1*f*-1290.*e*3*f*
type III, 1290, 1291*f*
type IV, 1291, 1291*f*
type V, 1291
interphalangeal joints of, 296-297
mangling injuries of, treatment of, 1493
opposition of
absence of, 1320
biomechanics of, 1026
deficit and deformity in, 1026
in median nerve palsy, tendon transfers for, 1026-1036. *see also* Opponensplasty, for median nerve palsy
history of, 1026
opponensplasty insertions in, 1027-1029, 1028*f*
patient counseling in, 1026-1027
prevention and preoperative treatment of contractures prior to, 1027
principles of, 1027
pulley design in, 1027
results of, 1027-1029, 1028*t*, 1029*f*
selection of motor for transfer in, 1027
osteoarthritic, treatment of, 345-372
with questionable remaining length, 1688-1691
regional and distant flaps for, 1694-1696
"Z"-plasty procedures, 1689-1691
four-flap, 1690-1691, 1690*b*, 1691*f*-1692*f*
simple, 1689, 1690*f*, 1689.*e*1*f*
reconstruction of, 1292-1295, 1293*b*, 1674-1707
after partial or complete traumatic loss, 1675-1704
Thumb *(Continued)*
after total amputation with destruction of basal joint, 1703-1704
after total amputation with preservation of basal joint, 1696-1699
composite radial forearm flap for, 1697-1699, 1700*f*, 1701*b*, 1699.*e*1*f*
case study of, 1705.*e*1*b*-1705.*e*4*b*, 1705.*e*1*f*-1705.*e*4*f*
general considerations in, 1675
historical review of, 1674-1675
microvascular toe transfer in, 1263-1270, 1266*f*
osteoplastic, 1696-1697, 1697.*e*1*f*
postburn, 1942-1943
of soft tissue defects of, 1687-1688
techniques for, 1898-1901
replantation of, 1477*f*, 1481
skier's, 302-306
split, 1305
in tetraplegic patient, control options for, 1141
trigger, 1320-1322
triphalangeal, 1315-1320
Thumb carpometacarpal arthroscopy, 692-694
Thumb metacarpophalangeal joint epiphyseal arthrodesis, for thumb-in-palm deformity, 1112
Thumb reorientation osteotomy, and/or metacarpophalangeal chondrodesis, 1383-1387, 1386*b*
complications of, 1387
contraindications to, 1383
indications for, 1383, 1383*f*
postoperative management and expectations after, 1386-1387
preferred method of, 1385-1386
preoperative planning for, 1383
technique of, 1383-1385, 1384*f*-1387*f*
Thumb-index key pinch, in ulnar nerve palsy, restoration of, 1056-1060
index abduction techniques in, 1058-1059
joint arthrodesis in, 1059
thumb adduction procedures in, 1056-1058
Thumb-index web space, narrowing of, treatment of, 1292, 1293*f*
Thumb-in-palm deformity
classification of, 1107*t*
spasticity in
examination of, 1085, 1086*f*
operative management of, 1106-1113, 1107*t*
preferred method of, 1112-1113
Tibial bone graft, harvesting technique for, 546, 546.*e*1*b*, 546.*e*2*f*-546.*e*5*f*, 546.*e*6*t*
Tibiofibular synostosis, 1356, 1356*f*
Tightrope device, 693.*e*1
Tinel sign, 924
in brachial plexus injury, 1152
in cubital tunnel syndrome, 940-941
in nerve injury, 986, 987*b*
Tissue culture, eight-pack, 65*t*
Tissue damage, chemical agents causing, 1952*t*
Tissue decompression techniques, for electrical injuries, 1947-1948
Tissue defect, examination of, prior to free flap transfer, 1577
Tissue devascularization, in mangling injuries, 1487-1488
Tissue equilibrium, in tendon transfers, 1023
Tissue loss, complex, vascularized bone grafting for, 1613, 1613*f*
Tissue plasminogen activator (t-PA), for free flap failure, 1585
Tissue resistance, in electrical injuries, 1946
Titanium grommets, implant protection with, 1878
Tocainide, for complex regional pain syndrome, 1813, 1814*t*
Toe(s)
dissection of, anatomy in, 1651-1654, 1654*f*
extensor tendon harvest, technique of, 205-206, 206*f*
great, transfer of, in thumb replacement
indications for, 1654, 1655*f*
preferred method of treatment of, 1654-1656
second
toe transfer of, in finger replacement
flap design and elevation, 1656, 1657*f*
indications of, 1656, 1657*f*-1658*f*
preferred method of treatment of, 1663
transfer of, with third toe in adjacent finger replacement, 1663, 1664*f*
third, toe transfer of, in finger replacement, 1663, 1664*f*
second, harvesting of, in microvascular toe transfer for hypoplastic digits, 1268-1269, 1268*f*
Toe transfer, 1643
bone and joint preparation for, 1666
at Chang Gung Memorial Hospital, from 1985-2012, 1672*t*
complications of, 1669
donor site morbidity in, 1670
in finger replacement
after distal digit amputation, 1646-1647
after multiple-digit amputation, 1648

Toe transfer *(Continued)*
after proximal digit amputation, 1647-1648
after single-digit amputation, 1646, 1647*f*
anatomy in, 1651-1654, 1654*f*
combined second and third toes in, 1663-1665, 1664*f*
preferred method of treatment, 1664-1665
combined third and fourth toes in, 1665
combined triple-toe, 1665
first web neurosensory flap, 1660-1661
pulp and hemipulp flaps in, 1647
second toe in, 1656-1657, 1657*f*-1658*f*
flap elevation and design in, 1656, 1657*f*
indications for, 1656, 1657*f*-1658*f*
preferred method of treatment of, 1656-1657
third toe in, 1663, 1664*f*
vascularized nail graft in, 1661-1663, 1662*f*
wraparound flap in, 1657-1658, 1659*f*
flap design of, 1658
indications of, 1657-1658
gait analysis before and after, 1670
general considerations in, 1643-1645
initial care in, 1644-1645
microvascular, for hypoplastic digits, 1265*f*
choice of technique for, 1263-1264
contraindications for, 1266-1267
of great toe, 1269
in hand with no digits, 1266, 1266*f*-1267*f*
indications for, 1264-1265, 1265*f*
presurgical assessment in, 1267
reconstruction of fingers and, 1265-1266, 1266*f*
reconstruction of thumb and, 1265
surgical technique of, 1267-1270
hand preparation in, 1267-1268
nerve repairs, 1269
osteosynthesis in, 1269
postoperative care, 1269
results of, 1269-1270, 1270*f*
retrieving of second toe in, 1268-1269, 1268*f*
secondary surgery, 1270
skin repair in, 1269
tendon repairs in, 1269
vessel repairs in, 1269
nerve preparation for, 1666
outcome of, 1671
postoperative management after, 1668-1669
preoperative evaluation in, 1644-1645, 1644*f*
Toe transfer *(Continued)*
primary *versus* secondary, 1645, 1646*f*
reconstructive options in, 1646-1654
finger amputation and
distal, 1646-1647
multiple, 1648
proximal, 1647-1648
single, 1646, 1647*f*
rehabilitation after, 1670-1671
thumb amputation and, 1646
toe dissection, 1651-1654, 1654*f*
secondary procedures in, 1669-1670
skeletal fixation in, 1666-1667, 1667*f*-1668*f*
surgical techniques of, 1654-1668
combined second and third toes transplantation, 1664*f*
preferred method of treatment, 1664-1665
combined third and fourth toes transplantation, 1663-1665
combined triple-toe transplantation, 1665
first web neurosensory flap in, 1660-1661
great toe transplantation in, total or trimmed, 1654-1656
recipient site preparation, 1665-1666, 1666*f*
second toe transplantation in, partial or total, 1656-1657
second toe wrap around flap in, 1658
tendon and pulley preparation, 1666
third toe transplantation in, 1663, 1663*f*-1664*f*
tendon repair in, 1667-1668
in thumb replacement
great toe in
indications for, 1654, 1655*f*
preferred method of treatment of, 1654-1656
postburn, 1943
skin incisions for, 1665-1666
wraparound flap in, 1657-1658, 1659*f*
flap design in, 1658
indications for, 1657-1658
toe fixation in, 1666-1668
venous preparation for, 1666
Tophi, gouty, 57-58, 58*f*
Topical medications, 1960, 1960*f*
Toronto Test Score, 1394, 1396*t*
Torus fracture, in children, 1448
recommended treatment of, 1448, 1450*f*
Total elbow arthroplasty (TEA), 905-920, 919*b*
complications of, 914-915, 914*f*
contraindications to, 909
for fractures of distal humerus, 906-907, 908*f*
geriatric, 710.*e*1*b*, 710.*e*1*f*
for hemophilic arthropathy, 909
Total elbow arthroplasty (TEA) *(Continued)*
historical review of, 909, 910*t*
mortality rates and, 918
paratricipital exposure for, 711.*e*1*b*, 711.*e*1*f*-711.*e*2*f*
postoperative management and expectations after, 913-918
of posttraumatic arthritis, 906, 907*f*
for primary osteoarthritis, 907-909
for rheumatoid arthritis, 905-906, 906*f*
Total wrist arthrodesis, 395-401
author's preferred method of treatment for, 396-399, 396*f*-400*f*
closure in, 399, 401*f*
complications of, 400, 401*f*-402*f*
postoperative management of, 399
Total wrist replacement, 404-414, 406*f*
centralization of extensor tendons in, 413-414, 414*f*
patients on, 414
preoperative evaluation for, 407
Toxicity
prevention of, 4*b*
systemic, prevention of, 4*b*
Traction, dynamic skeletal, for proximal interphalangeal joint fracture-dislocation, 283
outcomes of, 287
postoperative protocol for, 286-287
preferred method for, 285-287, 285*f*-287*f*, 286*b*
Traction injury, to brachial plexus, 1148-1149, 1148*f*
Transcondylar fractures, of distal humerus. *see also* Humerus, distal
management of, 721
Transfixation pins, for segmental metacarpal loss, 244*f*
Transhumeral amputation, 1755-1756, 1756*f*
with elbow disarticulation, 1754-1756, 1759*f*
Transmetacarpal digital nerve block, 9, 11*f*
Transmuscular brachioradialis-splitting approach, to radial tunnel syndrome, 951, 951*f*
Transolecranon (anterior) fracture-dislocation, of elbow, 784.*e*13*b*, 784.*e*13*f*-784.*e*14*f*
Transolecranon fracture-dislocations, 816-817, 816*f*
Transplantation, toe-to-hand, 1643-1673. *see also* Toe transfer
Transposition flaps, 1542
axial-pattern, 1543-1545
flag, 1545, 1545*f*
random-pattern, 1542
rhomboid, 1543, 1544*f*
"Z"-plasty, 1542, 1542*f*, 1543*b*
four-flap, 1543, 1543*f*

Transradial amputation, 1737, 1754, 1755*f*
with wrist disarticulation, 1753-1754, 1754*f*
Transscaphoid perilunate fracture-dislocations, 470-471
arthroscopy for, 670-671, 671*f*-672*f*
Transscaphoid-transcapitate-perilunate fracture-dislocations, 471-472, 472*f*
Transthecal digital nerve block, 9, 10*f*
Transtriquetrum-perilunate fracture-dislocations, 472, 473*f*
Transverse deficiency, 1345-1346, 1346*b*
evaluation of, 1345-1346, 1346*f*
pertinent anatomy in, 1346
surgical treatment of, 1346
expected outcomes for, 1346
preferred technique for, 1346, 1347*f*
Transverse fibers, of interosseous muscles, 338.*e*3, 338.*e*5*f*
Transverse intercarpal ligaments, 422
Transverse retinacular ligament, 338.*e*5
Trapeziometacarpal joint
degenerative disease of, arthroscopy for, 693
portals of, for arthroscopy of wrist, 657, 658*f*
Trapezium
dislocation of, 476
fractures of, 626-629, 627*b*, 627*f*
imaging of, 628
incidence of, 625*t*
mechanism of injury in, 626-628, 628*f*
treatment of, 628-629, 628*f*-629*f*
Trapezius tendon, transfer of, for shoulder reconstruction, in brachial plexus injury
contralateral lower, 1189, 1191*f*-1192*f*
lower, 1188-1189, 1189*f*-1191*f*
upper, 1187-1188
Trapezoid
dislocation of, 476
fractures of, 636, 636*b*
incidence of, 625*t*
Trapezoidal osteotomy, Watson's, for radial fracture, 580.*e*3, 580.*e*3*f*
Trauma
associated with distal radial fracture, 573
in elbow instability, 830
elbow stiffness caused by, 902-903
Traumatic brain injury, 1080-1081
Traumatic left midcarpal amputation, 1738*f*
Traumatic loss of digits in pediatric hand, 1650-1651
Trazodone, for complex regional pain syndrome, 1812*t*
Triad repair, terrible, 822*b*
Triangular fibrocartilage complex (TFCC), 480-481, 1444-1445
injuries to
class IA, 677*f*
class IB, 678, 678*f*-679*f*
class II, 687-688
Triangular fibrocartilage complex (TFCC) *(Continued)*
radial-sided, knotless repair of, 685, 686*f*-687*f*
treatment of, 676-677
lesions in, 487-491
author's preferred method of treatment for, 490-491, 490*f*
outcomes in, 491
Palmer's classification of, 487*t*, 488*f*
class 1A tear in, 489
class 1B tear in, 489
class 1C tear in, 489, 489*f*
class 1D tear in, 489-490, 490*f*
neurovascular supply to, 483, 483*f*
repair of (class 1B injury), 492-493
Triangular ligament, 156*f*, 338.*e*5
function of, 154
Triceps
advancement and excision of, in ulnar fracture management, 777, 777*b*
avulsions and rupture of, 878-881, 879*f*, 881*b*
preferred method of treatment of, 880-881, 880*f*-881*f*
partial tears of, 880
in tetraplegic patient, biceps transfer to, 1127-1129, 1128*f*, 1129*b*
transfer of
to axillary nerve, in musculocutaneous nerve transfer, for brachial plexus injury, 1172-1173, 1173*f*-1174*f*
outcomes of, 1174*b*, 1174*f*
to biceps, for elbow reconstruction, in brachial plexus injury, 1196-1197, 1197*b*, 1197*f*
Triceps-reflecting anconeus pedicle (TRAP) approach, to distal humeral fractures, 714, 715*f*
Triceps-splitting approach, to distal humeral fracture, 712-713, 713.*e*1*b*, 713.*e*1*f*-713.*e*4*f*
Triceps-splitting open reduction and internal fixation, 713.*e*1*b*, 713.*e*1*f*-713.*e*4*f*
Trigger digits, 1908-1915
in childhood, 1916
classification of, 1908
demographics of, 1908
outcomes of steroid injection for, 1909*t*
pathologic findings of, 1908
Trigger finger, 1322, 1323*f*, 1908
classification of, 1908
demographics of, 1908
splinting in, 1910
surgical treatment of, 1910-1914, 1911*f*
treatment of, 1909-1914
complications, 1914-1915
preferred method of, 1914
surgical, 1917-1919, 1918*f*
open trigger digit release in, 1912-1913, 1912*f*
Trigger finger *(Continued)*
percutaneous trigger digit release in, 1913-1914, 1913*b*-1914*b*, 1913*t*, 1914*f*
skin incisions, 1911-1912, 1911*f*-1912*f*
topographic anatomy, 1911-1912, 1911*f*-1912*f*
technique of injection of, 1917, 1917*f*
Trigger thumb, 1320-1322, 1322*b*
congenital, 1915-1916
treatment, 1915-1916
surgical technique, 1915-1916
incidence and etiologic findings of, 1320-1321, 1321*f*
treatment of, 1321-1322
natural history in, 1321
nonoperative, 1321
surgical, 1321-1322, 1322*f*
Trimethoprim-sulfamethoxazole
for actinomycetoma, 72-73
for tuberculosis arthritis, 97
Triphalangeal thumb, 1315-1320, 1317*f*-1319*f*, 1320*b*
management of, 1318-1319
treatment of, 1319-1320
absence of thumb opposition in, 1320
concomitant anomalies, 1320
extra interphalangeal joint in, 1319-1320
length and angulation in, 1319
thumb/index finger web space, 1320, 1320*f*
Triquetral-hamate portal, for arthroscopy of wrist, 657
Triquetrocapitate ligaments, 423
Triquetrohamate fusion, 389
Triquetrohamate ligaments, 423
Triquetrum, 660*f*
fracture of, 427, 624-626, 625*b*
body, 625-626
in children, 1447, 1447*f*
clinical and radiographic features of, 626
dorsal cortical, 624-625, 626*f*
incidence of, 625*t*
patterns of, 624-626
treatment of, 626, 627*f*
volar avulsion, 626
Triquetrum-ulnar lunate ligaments, plication of, 665
Triscaphe arthrodesis, 389. *see also* Scaphotrapeziotrapezoidal fusion
Trochlear fractures. *see also* Humerus, distal
classification of, 703-704
Trochlear notch, ulnar, anatomy of, 770, 772*f*
Tsuge classification, of Volkmann contracture, 1774, 1774*t*
Tsuge tendon transfer, for radial nerve palsy, 1071, 1071*b*, 1071*f*

Tsuge's procedure, for macrodactyly, 1278-1281, 1280*f*, 1282*f*
Tubed pedicle flap, 1540
Tuberculosis
  cutaneous, 91-92
  multidrug therapy for, 100-103, 101*t*
  subcutaneous, 92-93
Tuberculous arthritis, 96-97, 97*f*
Tuberculous bursitis, 96
Tuberculous osteomyelitis, 97-100, 98*f*-99*f*
Tubiana staging, in Dupuytren disease, 131-132
Tuft fracture
  of distal phalanx, 248
  of phalanx, distal, 1428-1429
Tumors
  bone, 1987-2035
  classification and staging of, 1988-1989
  excision, defects caused by, vascularized bone grafting for, 1623-1624, 1623*f*
  malignant, less common, 1981-1983. *see also* Malignant tumors, less common
  musculoskeletal. *see* Musculoskeletal tumors
  of perionychium, 332-336
    benign, 332-334
    malignant, 334-336, 335*f*
  skin, of hand and upper extremity, 1958-1986. *see also* Skin tumors, of hand and upper extremity
  soft tissue, 1987-2035. *see also* Soft tissue tumors
Tuohy needle technique, for peripheral ulnar-sided tears, 678-679
Turnbuckle splint, for elbow contracture, 857, 858*f*
Two-point discrimination, in compression neuropathies, 928
Two-stage flexor tendon reconstruction, 212-217
  alternative techniques in, 213-214, 215*f*
  composite tissue transfer methods of, 214
  indications for, 212-214
  stage I in, 217*b*
    postoperative care of, 216
    preferred technique of, 214-216, 215*f*-216*f*
  stage II in, 218*b*
    postoperative care of, 217
    technique of, 216-217, 216*f*-218*f*
  tissue response to a silicone implant in, 213

U

Ueba technique, in cleft hand surgery, 1251, 1253*f*
Ulceration, 1840
  factitious, 1828, 1829*f*
Ulna
  congenital pseudoarthrosis of, 1354-1357, 1357*b*
    preoperative evaluation of, 1354, 1354*f*-1355*f*
    surgical treatment of, 1354-1357, 1355*f*-1356*f*
      postoperative management and expectations after, 1357
  coronoid process of, anatomy of, 770-771, 772*f*
  deviation deformity of, in brachial plexus birth palsy, 1420
  distal
    dome (pole) of, 479
    excision of, with radioulnar joint reconstruction, in rheumatoid arthritis, 1860-1863
      complications of, 1862-1863
    fracture of, distal radial fracture with, 1455
    resection of, 505-506, 506*f*
      failed, 507-508, 507*f*
      partial, 497*f*, 501, 501*f*
      stabilization of, 506-507, 507*f*
  distal and midshaft, fractures of, 795-797
    complications in, 797
    direct ulnar fixation of, 796
    intramedullary rods for, 796
    pertinent anatomy in, 795-796, 796*f*
    plate fixation of, 796, 797*b*
    postoperative management and expectations after, 797
    preferred method of treatment of, 796-797
    preoperative evaluation for, 795
    preoperative planning for, 796
  fractures of
    in children
      complete, surgical treatment of, 1464-1466, 1465*f*-1467*f*
        preferred method of treatment for, 1466-1468
      single bone, 1464-1466
    in mangling injuries, treatment of, 1500
  lengthening of, in management of radial longitudinal deficiency, 1329, 1333, 1333*f*
  osteoplasty of, and sigmoid notch, in chronic radioulnar joint instability, 498, 498*f*
  proximal
    anatomy of, 770-773
    fractures of, 770-785
      classification of, 773-775
      complications of, 782-784
        arthrosis as, 784
        early failure of fixation as, 782, 782*f*-783*f*
        infection as, 782-783
        instability as, 783, 783*f*
Ulna *(Continued)*
        nonunion as, 783, 784*f*, 784.*e*31*b*, 784.*e*31*f*
        stiffness of heterotopic ossification as, 784
        ulnar neuropathy as, 783-784
      expected outcome of, 782
      historical review of, 775-776
      operative procedure of, 776-782
        excision and triceps advancement in, 777, 777*b*
        Kirschner wire technique in, 777*f*, 778
        plate and screw fixation in, 778-779, 779*f*, 780*b*, 784.*e*22*b*, 784.*e*22*f*
        preferred method of, 781-782
        screw technique in, 778
        skin incision in, 776
        tension band wiring in, 777, 778*b*, 784.*e*18*b*, 784.*e*18*f*-784.*e*21*f*
      patterns of, 773-775
      postoperative management and expectations of, 782
      postoperative protocol of, 782
      preoperative evaluation of, 770, 771*f*
    removal of hardware from, after both-bone forearm fractures, 798-799
    restoration of length of, with radioulnar joint reduction, for longitudinal forearm instability, 807
    shaft, nonunion and malunion of, 799-803
    styloid of, fractures of, 493, 493*f*
    trochlear notch of, 770-773, 772*f*
Ulnar anlage, excision of, in management of ulnar deficiency, 1336-1338, 1339*f*
Ulnar artery, 2044*f*
  bypass of, 2046-2047, 2047*f*, 2054
    complications of, 2046-2047, 2047*f*-2048*f*
  in forearm flap, 1558
  occlusion and aneurysm formation in, 2044*f*
  thrombosis in, 2042, 2045*f*, 2053
Ulnar bursal infections, 32-34
  clinical presentation and preoperative evaluation of, 33
  pertinent anatomy in, 33
  postoperative management of, 34
  treatment for
    open, 33-34
    preferred method of, 34
Ulnar collateral ligament
  anatomy of, 739, 740*f*
  injury to, in metacarpophalangeal joint of thumb
    acute, 302-306
    chronic, 306-308

Ulnar collateral ligament *(Continued)*
historical review of, 303
open repair technique for, 304-306, 304*f*-305*f*
postoperative management and expectations in, 306
preoperative evaluation of, 302
Stener lesion in, 302-303
treatment of, 303
preferred, 304*f*-305*f*, 306*b*
types of operations for, 304-306
insufficiency of, thumb hypoplasia, treatment of, 1292, 1292*f*
lateral, 832
Ulnar column, instability of, in distal radial fracture, 559-564
preferred method of treatment for, 563-564
Ulnar deficiency, 1334-1339, 1339*b*
classifications of, 1338*t*
pertinent anatomy in, 1335, 1337*t*-1338*t*
preoperative evaluation, 1334-1335, 1336*f*
surgical treatment of, 1335-1339, 1337*f*-1338*f*
excision of ulnar anlage in, 1336-1338, 1339*f*
expected outcomes of, 1339
preferred method of, 1338-1339
rotational osteotomy of humerus in, 1335, 1338
untreated, 1335, 1337*f*
Ulnar detethering, for hereditary multiple exostoses of forearm, 1360-1361
Ulnar deviation, recurrent, after metacarpophalangeal joint arthroplasty, 1877
Ulnar distraction lengthening, for hereditary multiple exostoses of forearm, 1360, 1361*f*
Ulnar fragment, volar, surgical approach to, 555-557, 557*f*
Ulnar head implant arthroplasty, distal, 508-510
operative technique for, 509-510, 509*f*
outcomes of, 510, 510*f*
Ulnar impaction syndrome, 500-503, 500*f*, 582
author's preferred treatment for, 502, 502*f*
evaluation of, 500-501
treatment of, 501-503
partial distal ulnar resection (wafer procedure), 497*f*, 501, 501*f*
ulnar-shortening osteotomy, diaphyseal and metaphyseal, 501-503
Ulnar lunate ligament, 659*f*
Ulnar motor neurectomy, for intrinsic muscle spasticity, 1114, 1115*f*
Ulnar nerve, 1005-1008
after humeral fractures, 729
compression of, 938-947. *see also* Guyon canal compression
distal, ganglions of, 2009
examination of, in stiff elbow, 847
repair of, 1008*b*
distal transfers to, 1008
high, 1007*t*
primary *versus* delayed, 1008, 1008*t*
recovery after, 1005*t*
age and, 1007*t*
factors that affect, 1006-1008
results of, 1005-1008
grading of, 1006*t*
methods of, 1006*t*
methods of, 1006*t*
in tidy wounds by level, 1007*t*
in war wounds, by level, 1010.*e*2*t*
surgical anatomy of, 1166
transfer of, to biceps, in musculocutaneous nerve transfer, for brachial plexus injury, 1166-1167, 1166*f*-1167*f*
outcomes of, 1167, 1167*f*
transposition of, 885
intramuscular, 945
in medial "over-the-top" approach to open release of elbow contracture, 852, 852*b*
subcutaneous anterior, 944, 944*f*-945*f*
submuscular, 945, 945*f*
Ulnar nerve block
at elbow, 8
at wrist, 9, 9*f*
Ulnar nerve palsy, 1045-1062
anomalous innervation patterns in, 1046
claw hand in, 1047-1056. *see also* Claw-hand deformity, in ulnar nerve palsy
clinical signs of, 1046-1047
high, 1060-1062
isolated, preferred method of treatment of, 1061-1062
low, 1047
median nerve palsy combined with, 1062, 1063*t*
pattern of paralysis in, 1046
restoration of function in, 1047
surgical correction for
assessment of outcome in, 1047-1048, 1047*t*, 1048*f*
Bunnell's "tendon T" operation in, 1059
index abduction techniques in, 1058-1059
little finger abduction correction in, 1060
metacarpal arch restoration in, 1059-1060
restoration of sensibility in, 1061
Ulnar nerve palsy *(Continued)*
thumb adduction procedures in, 1056-1058
thumb joint arthrodesis in, 1059
wasted intermetacarpal spaces and, 1061
thumb-index key pinch in, restoration of, 1056-1060
index abduction techniques in, 1058-1059
joint arthrodesis in, 1059
thumb adduction procedures in, 1056-1058
Ulnar neuropathy
after humeral fractures, 729-730
after ulnar fracture, 783-784
Ulnar osteotomy, radial osteotomy with and without, 1378-1380
complications of, 1380
contraindications to, 1379
indications for, 1378-1379
postoperative management and expectation after, 1379-1380
preferred method of, 1379
preoperative planning in, 1379
technique of, 1379, 1380*f*
Ulnar polydactyly, 1232-1234, 1234*b*
classification and treatment of, 1233, 1233*f*
epidemiologic findings, 1232
surgical technique for, 1233-1234, 1233*f*
Ulnar portal, distal, in elbow arthroscopy, 891
Ulnar styloid fixation, 559-561
Ulnar translocation, in radiocarpal instability, 458-459, 458*f*
Ulnar translocation ratio, measurement of, in wrist instability, 430, 431*f*
Ulnar variance, 480
measurement of, in wrist instability, 430
method of perpendiculars for, 485, 485*f*
negative, in stages I, II or IIIA Kienbock disease, 641-646
positive or neutral, in stages I, II or IIIA Kienbock disease, 646
Ulnar-humeral joint, functional anatomy of, 813, 814*f*
Ulnar-shortening osteotomy
for class 1B tear, 490-491, 490*f*
for ulnar impaction syndrome, 501-503, 502*f*
Ulnocapitate ligament, 420-421, 481-482
Ulnocarpal ligaments, 481-482
palmar, 420-421, 421*f*
Ulnocarpal stress testing, 484, 484*f*
Ulnohumeral instability, after posterior Monteggia fracture, 784.*e*30*b*, 784.*e*30*f*
Ulnohumeral joint, surface of, assessment of, in stiff elbow, 847
Ulnotriquetral (UT) ligament, 659*f*
Ultrasonic probes, in monitoring of vascularized bone grafts, 1615

Ultrasonography
axillary block and, 8
for brachial plexus birth palsy, 1411, 1411*f*
of carpal instability, 432
of distal radioulnar joint, 485
infraclavicular nerve block and, 7*f*
regional anesthesia and, 5
supraclavicular nerve block and, 6-7, 7*f*
Undisplaced fractures, of radial head fractures, management of, 741-742, 742*f*
Unicameral bone cysts, 2024, 2024*f*
Unicolumnar fractures, of distal humerus. *see also* Humerus, distal
management of, 724-725, 725.*e*1*b*, 725.*e*1*f*-725.*e*2*f*
Unicolumnar injury, 725.*e*1*b*, 725.*e*1*f*-725.*e*2*f*
Unilateral longitudinal incision, for felon, 27*f*, 27*t*
Universal II implant, 406
surgical technique for, 407-410, 408*f*-411*f*
Unna boot dressing, 1538
Unstable fractures, external fixation for, 535
Upper extremity
amputation, rehabilitation after, 1757-1758
bone defects of, vascularized bone grafting for, 1614
compartments of, 1768*t*, 1771.*e*1*b*
embryology of, 1208-1216, 1209*t*
fibular and iliac crest grafts in, 1622-1623, 1623*f*
loss of, 1756-1757
mangling injuries to, 1486-1527, 1487*f*
nonmicrosurgical coverage of, 1528-1573
Upper limb tension test, for thoracic outlet syndrome, 967, 969*f*
Urokinase, for free flap failure, 1585

V

VACTERL syndrome, radial deficiency associated with, 1289, 1290*t*, 1329*t*
Vacuum-assisted wound closure (VAC), 51
Valacyclovir, for herpes simplex virus, 120
Valgus instability, after radial head fractures, 764
Valgus stress test, 743-744, 744*f*
Valproic acid, for complex regional pain syndrome, 1813*t*
Varus posteromedial rotational injury, in elbow dislocation, 817, 818*f*
Varus rotational instability pattern, posteromedial, 784.*e*9*b*, 784.*e*9*f*-784.*e*10*f*
Varus stress test, 743-744, 744*f*
Vascular anastomoses, in toe transfer, 1668
Vascular lesions, nonhemangiomatous, 1968-1970
Vascular pedicle, 1574
Vascular system
anatomy of, 2036, 2037*f*
disorders of, 2036-2059
arterial
closed, 2042-2047, 2044*f*-2046*f*
complications of, 2046-2047, 2047*f*-2048*f*
preferred method of treatment of, 2046-2047, 2047*f*
open, 2040-2042, 2040*f*
complications of, 2042
postoperative care after, 2042
preferred method of treatment of, 2040-2042, 2041*f*-2042*f*
vein grafting of, 2041, 2041*f*, 2042*b*, 2043*f*
evaluation of, 2038-2039, 2039*f*, 2040*b*
management of, 2040-2056
distal sleeve anastomosis of, 2051, 2051*f*
end-to-end anastomosis of, 2051, 2051*f*
preoperative evaluation in, 2048-2049, 2049*f*
in situ bypass of, 2049-2052, 2050*f*
complications of, 2051-2052, 2052*f*
insufficiency of, in scleroderma, 1840
malformations of, 2055-2056
in mangling injury, repair/reconstruction of, 1505-1508, 1506*f*-1507*f*, 1508*b*
case study of, 1505.*e*1*b*, 1505.*e*1*f*-1505.*e*3*f*
Vascular territory, 1539
Vascularity, of wound, 1530
Vascularized bone grafts. *see* Bone graft(s)
Vascularized composite tissue allotransplantation, 1483-1484
Vascularized medial femoral trochlea osteocartilaginous flap reconstruction, in scaphoid nonunion, 619, 619.*e*4*b*, 619.*e*4*f*-619.*e*5*f*
Vascularized nail graft, in toe transfer flap design and elevation in, 1661-1663, 1662*f*
flap designs and elevation in, 1661-1663, 1663*f*
indications for, 1661, 1662*f*
Vascularized nerve graft, 999
Vasospasm, after toe transfer, 1669
Vasospastic disorders, management of, 2052-2054
nonsurgical, 2053
operative, 2053-2054, 2053*f*-2054*f*
postoperative, anticoagulation and, 2054
Vectors, infections and, 46-58
Vein grafting
for ischemia, 2037-2038
for open arterial trauma, 2041, 2041*f*, 2042*b*, 2043*f*
postoperative care after, 2042
reversed, for aneurysm, 2054, 2055*f*
Vein(s)
dissection of, 1479, 1479*f*
distal, location of, for replantation, 1481*b*
preparation of, in toe transfer, 1666
Venograph, in thoracic outlet syndrome, 968, 970*f*
Venomous injuries
of hand, 1794*b*
management of, 1788-1796, 1795*b*
case study of, 1793.*e*1*b*, 1793.*e*1*f*
Venous flaps, free, 1577
Venous malformations, 2055-2056, 2056*f*
Venous thrombosis, 1482, 2054-2055
Verruca plana, 1962
Verruca vulgaris, 121, 1962. *see also* Warts
of perionychium, 333
Vesicles, anthrax, 68-69, 69*f*
Vessels
preparation of, in toe transfer, 1645
resection of, 1478-1479, 1479*f*
Vibration thresholds, in compression neuropathies, 928
Vibrio infections, 48
Vibrometers, fixed-frequency and variable-frequency, 928
Vickers ligament, in Madelung deformity, 1339
release of, 1339, 1340*f*
Villonodular tenosynovitis, pigmented, 2012, 2012*b*
Viral infections, chronic, 119-125
acquired immunodeficiency syndrome (AIDS) and, 119-121, 119.*e*1*t*
etiology, diagnosis, and treatment of, 63*t*
human orf and, 123-124, 124*f*
Milker's nodule and, 124-125
warts and, 121-123, 122*f*
Viral warts. *see* Verruca vulgaris
Vitamin C, for complex regional pain syndrome, 1811, 1816*t*
Volar advancement V-Y flap, in reconstruction of amputated fingertip, 1714, 1715*f*
Volar approach
for thenar space, 35-36, 36*f*
transverse, 39, 39*f*
zigzag, 38-39, 39*f*
Volar capsulectomy, arthroscopic arthrolysis and, 691
Volar incision, for felon, 27*f*, 27*t*
Volar instability, of thumb metacarpophalangeal joint, chronic, 311-312
Volar intercalated segment instability (VISI), 418-419

Volar interossei, 338.*e*3-338.*e*4
Volar ligament reconstruction, of thumb carpometacarpal joint, technique of, 313-314, 314*f*
Volar plate
  of metacarpophalangeal (MP) joint, 338.*e*1, 338.*e*2*f*
  of proximal interphalangeal joint, 338.*e*2*f*, 340.*e*1, 338.*e*1-338.*e*3
  pulley reconstruction using, 222
Volar plate arthroplasty, for proximal interphalangeal joint fracture-dislocation, 284
  complications of, 290
  postoperative management of, 290
  preferred method for, 288-290, 289*f*, 290*b*
Volar plate fixation, of distal radial fracture, open reduction with, 548-552, 549*f*-553*f*, 554*b*
Volar portals, for arthroscopy of wrist, 655-656, 653.*e*1*t*
Volar proximal interphalangeal dislocations, 280-281
  treatment of, 280-281
    closed, 280-281
    open reduction in, 281
    outcomes of, 281
    preferred method of, 280-281
Volar radial (VR) portal, for arthroscopy of wrist, 655-656
Volar release, 1770
Volar retinacular (flexor tendon sheath) ganglion, 2005, 2005*f*
Volar skin, 1528
Volar surgical approach, for contractures, 341.*e*1, 341.*e*1*f*
Volar ulna (VU) portal, for arthroscopy of wrist, 656
Volar wrist ganglions, arthroscopic excision of, surgical technique for, 688-689, 689*f*
Volar wrist synovectomy, for rheumatoid arthritis, 1847*b*, 1859
Volkmann contracture, 1772-1786, 1773*f*
  classification of, 1773-1774, 1774*f*-1775*f*
  complications of, 1785-1786
  flexor pronator slide for, 1779*b*
  of hand, 1783-1785
  ischemic, 1764
    surgical options for management of, 1776*t*
  late management of, 1785*b*
  moderate, 1778.*e*1*b*, 1778.*e*1*f*
  neonatal, 1763-1764, 1764*f*
  operative treatment of
    bone procedures in, 1775-1776
    soft tissue procedures in, 1776
  outcomes of, 1781-1783
  preferred methods of treatment, 1776-1781
Volkmann contracture *(Continued)*
  severe, 1782.*e*1*b*
  treatment of, 1774-1786
    operative, 1775-1776
Volkmann test, for digital flexor tendon, 1084-1085, 1085*f*
Voltage-gated ion channels, 980-981
von Recklinghausen disease, 2012
"V-Y" advancement flap, 1548-1550, 1549*f*-1551*f*

W
Wafer procedure, for ulnar impaction syndrome, 497*f*, 501, 501*f*
Wafer resection, of ulnar head, arthroscopic, 687-688, 687*f*
Waist fracture, in scaphoid, delayed presentation of, 603
Wallerian degeneration, in responses to nerve injury, 984-985, 984*f*
War Nerve Injuries Clinic (WNIC), 1010.*e*1
Wartenberg syndrome, 948
Warts, 121-123, 1962-1964
  classification of, 121
  common verrucated, 121
  diagnosis, 121
  flat (plane), 121
  multiple, 121
  treatment of, 121-123, 122*f*
  viral, of perionychium, 333
Wasted intermetacarpal spaces, 1061
Watershed, 1540
Watson's trapezoidal osteotomy, for radial fracture, 580.*e*3, 580.*e*3*f*
Web creep, after separation of syndactyly, 1223, 1226*f*
Web space
  abscess of, 37-38, 38*f*
    treatment for, 38, 39*f*
      preferred method of, 39
  Dupuytren disease in, 134
  first
    contracture of
      postburn, 1938, 1940*f*
      in scleroderma, 1841
    cross-arm flap coverage of, 1695-1696, 1695*f*
    of foot
      neurosensory flap, from indication, 1658-1661
      sensory flaps from, 1605-1608, 1606*f*, 1608*b*
    scarring of, after pollicization, 1303
  normal, 1217
  pertinent anatomy in, 38
  in syndactyly, 1217, 1218*f*
  thumb/index
    classification of ulnar deficiency based on, 1338*t*
    narrowing of, 1292, 1293*f*
  in triphalangeal thumb, 1320, 1320*f*
Weck-Goulian knife set, 1532, 1532*f*
Wedge graft, for scaphoid nonunion, 612-614
  anterior, technique of, 614, 614*f*
  arguments against, 614
  Fernandez-Fisk, 612-614, 613*f*
Wedge osteotomy
  for clinodactyly, 1272, 1273*f*
  for Kirner deformity, 1274-1275, 1275*f*
  for Madelung deformity
    dorsal closing, of distal radius and ulnar shortening, 1344
    radial opening, 1344
  for malunited radial fracture, 577
Wedge resection arthrodesis, of wrist, in cerebral palsy, 1102
Weilby sling, 363, 363*f*
Weinstein Enhanced Sensory Test, 928
Weiss-Hastings classification, of unicondylar fractures, 250*f*
White phosphorus burns, treatment of, 1951, 1952*t*
Whitlow, herpetic, 52-53, 52*f*
Wire fixation, double intrafocal, of distal radial fracture, 532, 537*f*
Worm (nematode) infection, parasitic, 117-118
Wound(s)
  bacterial content determination of, 1530
  gunshot, to brachial plexus, 1149
  human bite, zone 5 injuries, of extensor tendon, 174-175
  in mangling injuries, excision of, 1496-1499, 1499*b*
    case study for, 1499.*e*1*b*, 1499.*e*2*f*-1499.*e*3*f*
  preparation of, for flap transfer, 1540-1541
  tissue defects of
    examination of, prior to free flap transfer, 1577
    free flap selection influenced by, 1608-1609
  vascularity of, 1530
Wound care, local, for burns, 1931-1932, 1932*f*
Wound closure, negative pressure therapy for, in mangling injuries, 1509, 1510*f*
Wound healing
  infection on, effect of, 1530
  moist, for burns, 1931
Wound necrosis, after elbow contracture release, 859, 860*f*
W-plasty, in constriction ring surgery, 1256-1257
Wraparound flap procedure, in toe transfer, for finger/thumb replacement, 1658
Wrist, 418-478
  amputation through
    with disarticulation, 1737-1738, 1739*f*, 1753-1754, 1754*f*

Wrist *(Continued)*
preferred method of treatment of, 1737-1738
anatomy of, 419-423, 419*t*
ligamentous, 420-423, 421*f*
osseous, 419-420, 420*f*
arthrodesis of, 373-417. *see also* Arthrodesis, of wrist
combined, 1866-1867, 1867*f*
operative technique for, 1865, 1865*f*
partial, 1864-1865
arthroplasty of, 373-417. *see also* Arthroplasty, of wrist
arthroscopy of. *see* Arthroscopy, of wrist
biomechanics of, 423-426, 423*f*, 425*f*-426*f*
in brachial plexus birth palsy, 1419-1421
deformity of, 1328-1364
in psoriatic arthritis, 1836
in systemic lupus erythematosus, 1837-1838
dislocation of, 465-476
definition of, 465
disorders of, 426-476
diagnosis of, 428-432
pathomechanics of, 426-428
flexion-extension of, kinematics in, 423-424
fracture of, in children, 1442-1457
epidemiology of, 1442-1443, 1443*f*
pertinent anatomy in, 1444-1445
preoperative evaluation of, 1443-1444, 1444*f*
types of operations for, 1445-1457
ganglions of
dorsal, 2001-2003
author's preferred method of treatment for, 2001-2003
clinical characteristics of, 2001, 2001*f*
complications in, 2003
operative technique for, 2001-2003, 2001*f*-2003*f*
postoperative care for, 2003
volar, 2004-2005
author's preferred method of treatment for, 2004-2005
clinical characteristics of, 2004, 2004*f*
complications in, 2005
Wrist *(Continued)*
operative technique in, 2004-2005, 2004*f*
postoperative care for, 2005
hemiarthroplasty of, 414-416
mangling injuries of, treatment of, 1512-1515, 1512*f*-1517*f*
musculoskeletal tumors of, excision of, 1996, 1996*f*-2000*f*
physical examination of, 374
proprioception reeducation of, 439
radioulnar inclination of, kinematics in, 423*f*, 424
range of motion of, 373-374
as recipient site, in vascularized bone grafting, 1637
reconstruction of, with scapholunate/scaphoid nonunion advanced collapse, 391-393
alternative methods of fixation for, 393-394
author's preferred method of treatment for, 392-393, 393*f*-394*f*
contraindications for, 392
critical points on, 395*b*
indications for, 391-392, 392*f*
patients on, 394
postoperative management for, 393
spasticity in
examination of, 1084-1085, 1085*f*
extension of, operative management of, 1095-1102, 1097*f*, 1097*t*
preferred method of, 1101-1102, 1102*f*-1103*f*
flexor tendon tightness in, operative management of, 1102-1106, 1104*f*
preferred method of, 1105-1106
stability, definition of, 433
stabilization of, 425, 425*f*-426*f*
supplementary blocks at, 8-9, 9*f*
tendon entrapment, 1920-1923
total replacement of, 404-414, 406*f*
centralization of extensor tendons in, 413-414, 414*f*
patients on, 414
preoperative evaluation for, 407
Wrist joint, infections of, 41-43
postoperative management of, 43, 44*f*
Wrist splinting, for carpal tunnel syndrome, 932

X
Xenograft. *see also* Allograft(s); Autograft(s)
for mangling injuries, 1510
Xeroderma pigmentosum, 1973, 1975*f*

Y
"Y" fractures, of distal humerus, 699, 702, 702*f*. *see also* Humerus, distal

Z
Zancolli's procedure
Lasso-type, 1142
digital clawing treated with, 1142-1143, 1142*f*
in tetraplegia, 1125*f*, 1141
in ulnar nerve palsy, 1049-1050, 1049*f*, 1050*b*
Zancolli's staged reconstruction, in tetraplegia, 1134
Zigzag incision
in brachial plexus surgery, 1155-1156, 1155*f*
in phalangeal transfer, 1262, 1263*f*
Zimmer air dermatome, 1533
Zone of injury
in extensor tendon, 158, 158*f*
in mangled extremity, 1488-1489
Zone of polarizing activity (ZPA)
in embryogenesis, 1208
in mirror hand, 1237
Z-plasty(ies), 1542, 1542*f*, 1543*b*. *see also* Flap(s)
in constriction ring surgery, 1256-1257
double-opposing, for commissure reconstruction, in syndactyly, 1219-1220, 1220*f*
four-flap, 1543, 1543*f*
for commissure reconstruction, in syndactyly, 1220, 1221*f*
for thumb reconstruction, with questionable remaining length, 1690-1691, 1690*b*, 1691*f*-1692*f*
for thumb-index web space, 1320
for web narrowing, in thumb hypoplasia, 1292, 1293*f*
for thumb reconstruction, 1898
with questionable remaining length, 1689-1691
four-flap, 1690-1691, 1690*b*, 1691*f*-1692*f*
simple, 1689, 1690*f*, 1689.*e*1*f*

This page intentionally left blank